

# **Pocket Atlas of Sectional Anatomy**

## **Volume 2**



# Pocket Atlas of Sectional Anatomy

Computed Tomography and Magnetic Resonance  
Imaging

*Volume 2*

Thorax, Abdomen, and Pelvis

Torsten B. Moeller, M. D.

Am Caritas-Krankenhaus  
Dillingen/Saar  
Germany

Emil Reif, M. D.

Am Caritas-Krankenhaus  
Dillingen/Saar  
Germany

Second Revised Edition

418 Illustrations



Thieme  
Stuttgart · New York 2001

Moeller, Pocket Atlas of Sectional Anatomy, Vol. 2 © 2001 Thieme  
All rights reserved. Usage subject to terms and conditions of license.

Library of Congress Cataloging-in Publication  
Data is available from the publisher

This book is a completely revised and enlarged new edition based on the 2nd German edition published and copyrighted 2000 by Georg Thieme Verlag, Stuttgart, Germany. Title of the German Edition: Taschenatlas der Schnittbildanatomie  
1st German edition 1993  
1st English edition 1994  
1st Japanese edition 1994  
1st Spanish edition 1995  
1st Greek edition 1995  
1st French edition 1996  
2nd German edition 2000

© 1994, 2001 Georg Thieme Verlag  
Rüdigerstrasse 14, D-70469 Stuttgart,  
Germany  
Thieme New York, 333 Seventh Avenue,  
New York, N.Y. 10001 USA

Typesetting by  
primustype Robert Hurler GmbH  
73274 Notzingen, Germany  
Printed in Germany by  
Grammlich, Pliezhausen

ISBN 3-13-125602-8 (GTV)  
ISBN 0-86577-872-8 (TNY)

1 2 3 4 5

*Important Note:* Medicine is an ever-changing science undergoing continual development. Research and clinical experience are continually expanding our knowledge, in particular our knowledge of proper treatment and drug therapy. Insofar as this book mentions any dosage or application, readers may rest assured that the authors, editors, and publishers have made every effort to ensure that such references are in accordance with *the state of knowledge at the time of production of the book.*

Nevertheless, this does not involve, imply, or express any guarantee or responsibility on the part of the publishers in respect to any dosage instructions and forms of application stated in the book. *Every user is requested to examine carefully* the manufacturer's leaflets accompanying each drug and to check, if necessary in consultation with a physician or specialist, whether the dosage schedules mentioned therein or the contraindications stated by the manufacturers differ from the statements made in the present book. Such examination is particularly important with drugs that are either rarely used or have been newly released on the market. Every dosage schedule or every form of application used is entirely at the user's own risk and responsibility. The authors and publishers request every user to report to the publishers any discrepancies or inaccuracies noticed.

Some of the product names, patents, and registered designs referred to in this book are in fact registered trademarks or proprietary names, even though specific reference to this fact is not always made in the text. Therefore, the appearance of a name without designation as proprietary is not to be construed as a representation by the publisher that it is in the public domain.

This book, including all parts thereof, is legally protected by copyright. Any use, exploitation, or commercialization outside the narrow limits set by copyright legislation, without the publisher's consent, is illegal and liable to prosecution. This applies in particular to photostat reproduction, copying, mimeographing or duplication of any kind, translating, preparation of microfilms, and electronic data processing and storage.



*Dedicated to our parents,  
Alfred and Friedel Möller  
Dr. Emil and Edith Reif  
in love and gratitude*



---

## Preface to the Second Edition

The success of the first edition of the Pocket Atlas of Sectional Anatomy was very gratifying. The numerous foreign-language translations, plus the many positive responses and constructive criticisms, motivated us to improve the book further. We realized that significant technological advances had been made since the first edition, especially in sectional imaging procedures (subsecond spiral CT scanning, latest MR imagers). Resolved to go more than just “half way,” we replaced all of the original images and color line drawings with new ones. As a result, this volume is more than just a second edition, more than a revision. It even includes a completely new chapter on vascular and biliary tract imaging.

We retained an important feature of the first edition: a wealth of information presented in a user-friendly form. As before, the material is organized according to a strict format that makes use of multicolored text and small schematic drawings that include special views of the pulmonary and hepatic segments, for example.

Once again, many dedicated colleagues helped us in completing this book. Selecting a few names for special recognition, we express sincere thanks to Brigitte Schild, Pia Saar-Schneider, Sabine Mattil, Monika Bauermann, Andrea Kinsinger, Claudia Zimmer, and Dr. Markus Bach.

Dillingen, October 2000

Torsten B. Möller and Emil Reif

**Contents****Thorax**

---

CT of the Thorax, axial .....	2
MRI of the Thorax, sagittal .....	31
MRI of the Thorax, coronal .....	46
Pulmonary Vessels, MR-Angiography .....	58
MR-Mammography, axial .....	60

**Abdomen**

---

CT of the Abdomen, axial .....	62
MRI of the Abdomen, sagittal .....	110
MRI of the Abdomen, coronal .....	128
Renal Artery, MR-Angiography .....	140
MR-Angiography of the Coeliac Trunk .....	142
MR-Angiography of the Splenic and Portal Veins .....	144
MR-Cholangiopancreatography .....	146

**Pelvis**

---

MRI of the Female Pelvis, axial .....	148
MRI of the Female Pelvis, sagittal .....	160
MRI of the Female Pelvis, coronal .....	170
MRI of the Male Pelvis, sagittal .....	186
MRI of the Male Pelvis, coronal .....	194
MRI of the Prostate, axial .....	204
MRI of the Testes, sagittal .....	208

**Lower Extremity**

---

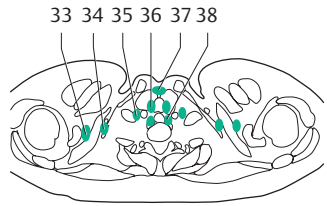
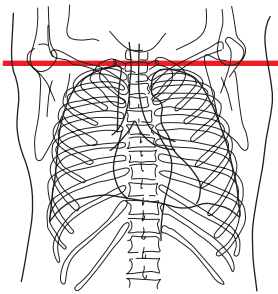
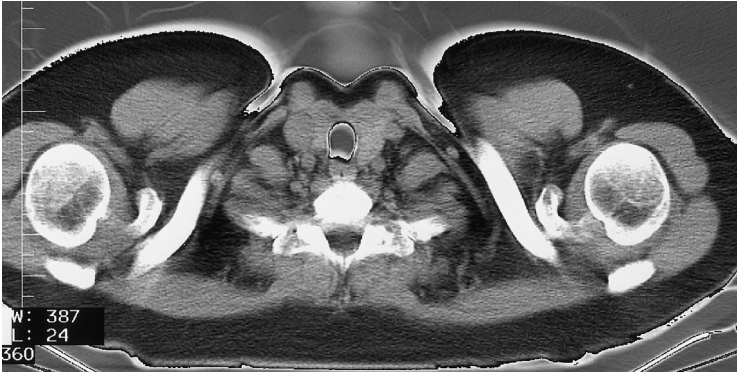
MR-Angiography of the Lower Extremity .....	210
References .....	214
Index .....	215

**Thorax**

**Abdomen**

**Pelvis**

**Lower Extremity**



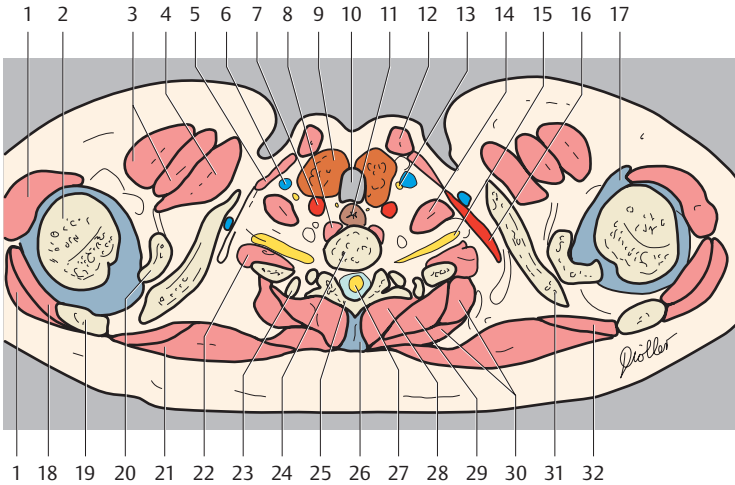
**Segments of the lungs**

**Right Lung**

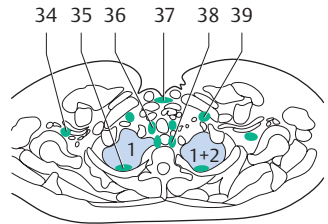
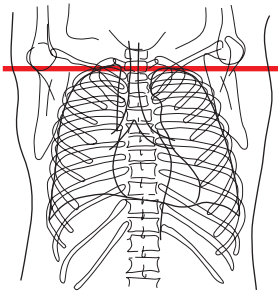
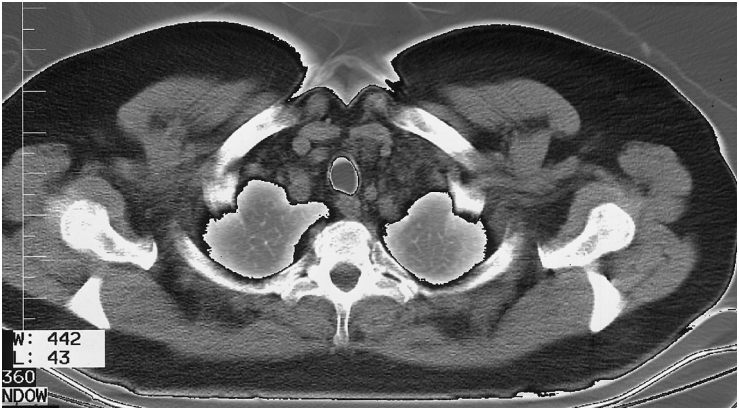
1. Apical segment of upper lobe
2. Posterior segment of upper lobe
3. Anterior segment of upper lobe
4. Lateral segment of middle lobe
5. Medial segment of middle lobe
6. Superior segment of lower lobe
7. Medial basal (cardiac) segment of lower lobe
8. Anterior basal segment of lower lobe
9. Lateral basal segment of lower lobe
10. Posterior basal segment of lower lobe

**Left Lung**

- 1+2. Apicoposterior segment of upper lobe
3. Anterior segment of upper lobe
4. Superior lingular segment
5. Inferior lingular segment
6. Superior segment of lower lobe
7. Medial basal (cardiac) segment of lower lobe
8. Anterior basal segment of lower lobe
9. Lateral basal segment of lower lobe
10. Posterior basal segment of lower lobe



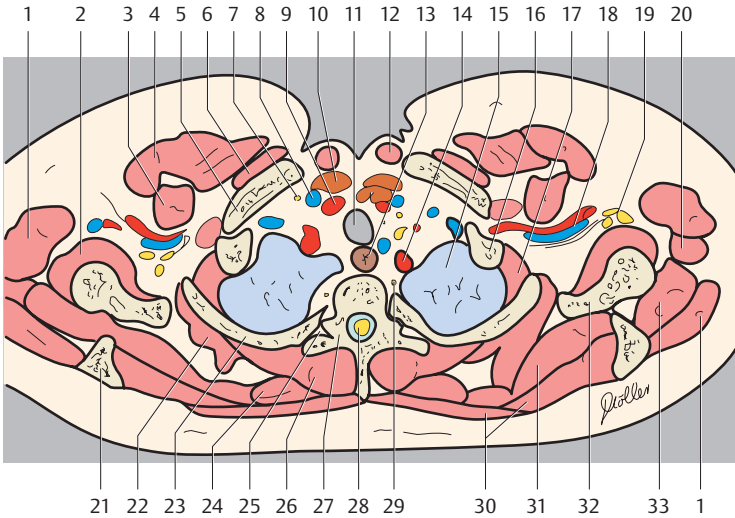
- |                                           |                                           |
|-------------------------------------------|-------------------------------------------|
| 1. Deltoid muscle                         | 20. Coracoid process                      |
| 2. Head of humerus (head of humerus)      | 21. Trapezius muscle                      |
| 3. Pectoralis major muscle                | 22. Medial and posterior scalenus muscles |
| 4. Pectoralis minor muscle                | 23. Costovertebral joint (Rib 1)          |
| 5. Sternothyroid muscle                   | 24. Thoracic vertebra 1                   |
| 6. Internal jugular vein                  | 25. Vertebral arch (lamina)               |
| 7. Internal carotid artery                | 26. Supraspinous ligament                 |
| 8. Longus colli muscle                    | 27. Spinal cord                           |
| 9. Thyroid gland                          | 28. Erector spinae muscle                 |
| 10. Trachea                               | 29. Serratus anterior muscle              |
| 11. Esophagus                             | 30. Rhomboid muscle                       |
| 12. Sternocleidomastoid muscle            | 31. Clavicle                              |
| 13. Vagus nerve (ramus)                   | 32. Supraspinatus muscle                  |
| 14. Anterior scalene muscle               | 33. Supraclavicular lymph nodes           |
| 15. Brachial plexus                       | 34. Subclavicular lymph nodes             |
| 16. Subclavian artery                     | 35. Jugular lymph nodes                   |
| 17. Joint capsule with capsular ligaments | 36. Paratracheal lymph nodes              |
| 18. Infraspinatus muscle                  | 37. Anterior cervical lymph nodes         |
| 19. Spine of scapula                      | 38. Paraesophageal lymph nodes            |



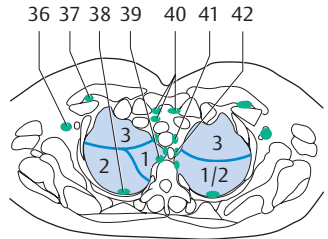
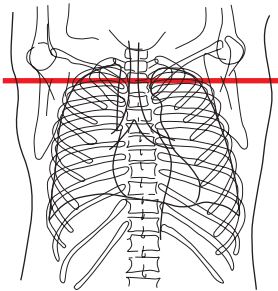
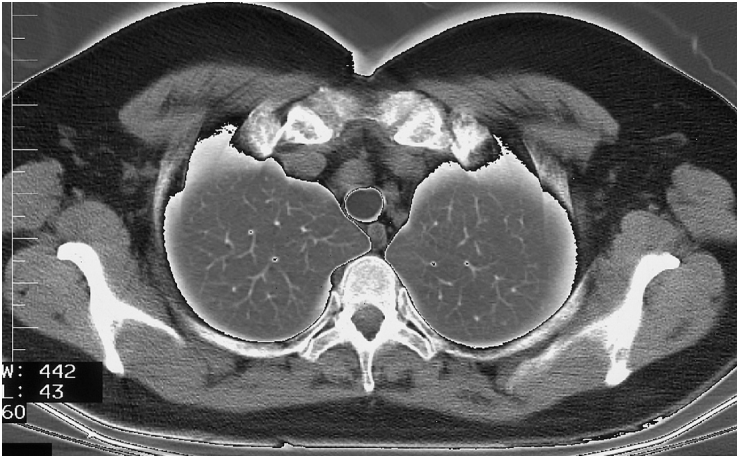
Right Lung  
1. Apical segment of upper lobe

Left Lung  
1+2 Apicoposterior segment of upper lobe





- |                                                    |                                   |
|----------------------------------------------------|-----------------------------------|
| 1. Deltoid muscle                                  | 21. Spine of scapula              |
| 2. Subscapularis muscle                            | 22. Serratus anterior muscle      |
| 3. Pectoralis minor muscle                         | 23. Rib 2                         |
| 4. Pectoralis major muscle                         | 24. Rhomboid muscle               |
| 5. Clavicle                                        | 25. Costovertebral joint          |
| 6. Subclavius muscle                               | 26. Erector spinae muscle         |
| 7. Vagus nerve (ramus)                             | 27. Thoracic vertebra 2           |
| 8. Internal jugular vein                           | 28. Spinal cord                   |
| 9. Internal carotid artery                         | 29. Sympathetic trunk             |
| 10. Thyroid gland                                  | 30. Trapezius muscle              |
| 11. Trachea                                        | 31. Supraspinatus muscle          |
| 12. Sternocleidomastoid muscle                     | 32. Scapula                       |
| 13. Esophagus                                      | 33. Infraspinatus muscle          |
| 14. Subclavian artery                              | 34. Deep axillary lymph nodes     |
| 15. Left lung                                      | 35. Intercostal lymph nodes       |
| 16. Rib 1                                          | 36. Paratracheal lymph nodes      |
| 17. Intercostal muscle                             | 37. Anterior cervical lymph nodes |
| 18. Subclavian artery and vein                     | 38. Paraesophageal lymph nodes    |
| 19. Brachial plexus                                | 39. Jugular lymph nodes           |
| 20. Teres major muscle and latissimus dorsi muscle |                                   |



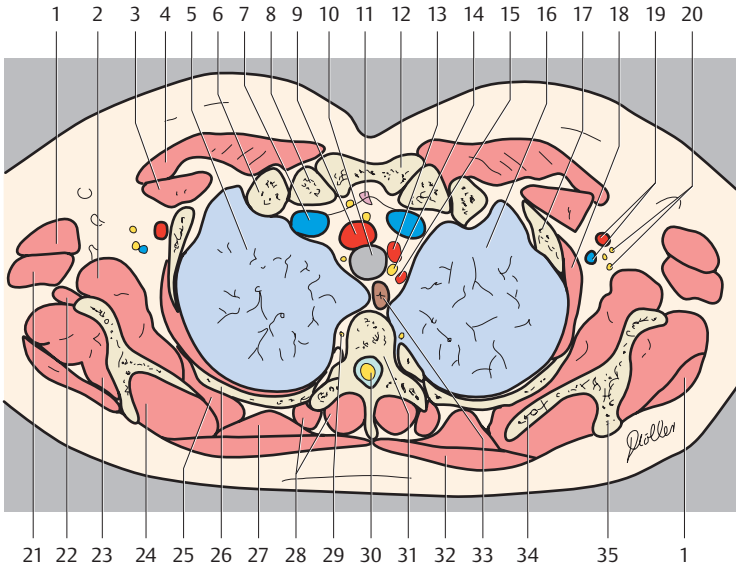
— = Borders of lung segments

Right Lung

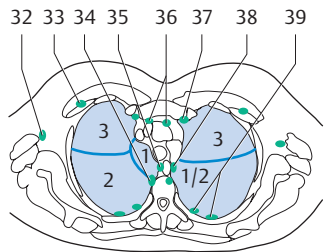
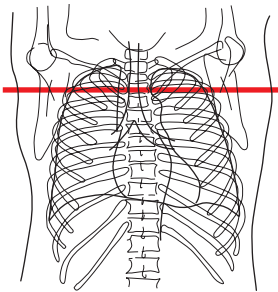
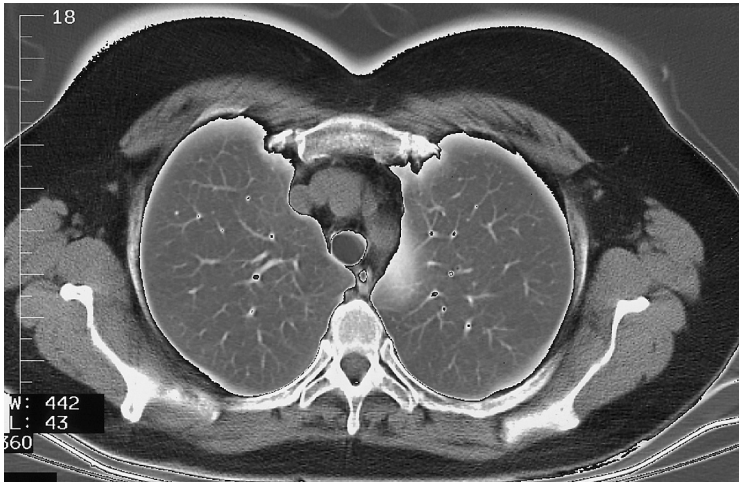
- 1. Apical segment of upper lobe
- 2. Posterior segment of upper lobe
- 3. Anterior segment of upper lobe

Left Lung

- 1+2 Apicoposterior segment of upper lobe
- 3. Anterior segment of upper lobe



- |                                                    |                                        |
|----------------------------------------------------|----------------------------------------|
| 1. Deltoid muscle                                  | 22. Triceps brachii muscle (long head) |
| 2. Subscapularis muscle                            | 23. Infraspinatus muscle               |
| 3. Pectoralis minor muscle                         | 24. Supraspinatus muscle               |
| 4. Pectoralis major muscle                         | 25. Serratus anterior muscle           |
| 5. Right lung                                      | 26. Rib 3                              |
| 6. Rib 1                                           | 27. Rhomboid muscle                    |
| 7. Brachiocephalic vein                            | 28. Erector spinae muscle              |
| 8. Clavicle                                        | 29. Sympathetic trunk                  |
| 9. Brachiocephalic artery                          | 30. Spinal cord                        |
| 10. Trachea                                        | 31. Thoracic vertebra                  |
| 11. Thymus                                         | 32. Trapezius muscle                   |
| 12. Sternum (manubrium)                            | 33. Esophagus                          |
| 13. Left common carotid artery                     | 34. Scapula                            |
| 14. Recurrent laryngeal nerve                      | 35. Spine of scapula                   |
| 15. Left subclavian artery                         | 36. Deep axillary lymph nodes          |
| 16. Left lung                                      | 37. Interpectoral lymph nodes          |
| 17. Rib 2                                          | 38. Intercostal lymph nodes            |
| 18. Intercostal muscle                             | 39. Paravertebral lymph nodes          |
| 19. Axillary artery and vein                       | 40. Anterior mediastinal lymph nodes   |
| 20. Brachial plexus                                | 41. Paratracheal lymph nodes           |
| 21. Teres major muscle and latissimus dorsi muscle | 42. Paraesophageal lymph nodes         |



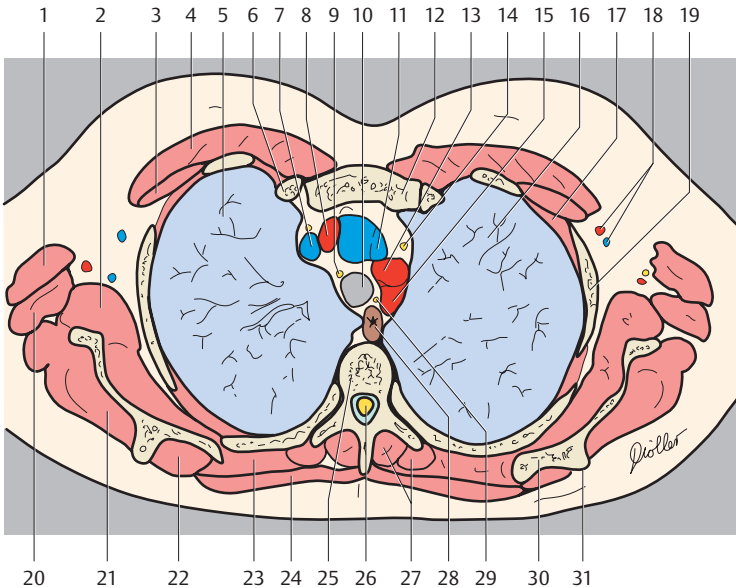
— = Borders of lung segments

Right Lung

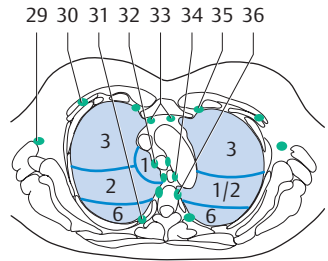
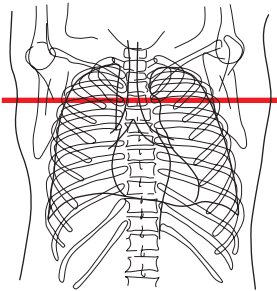
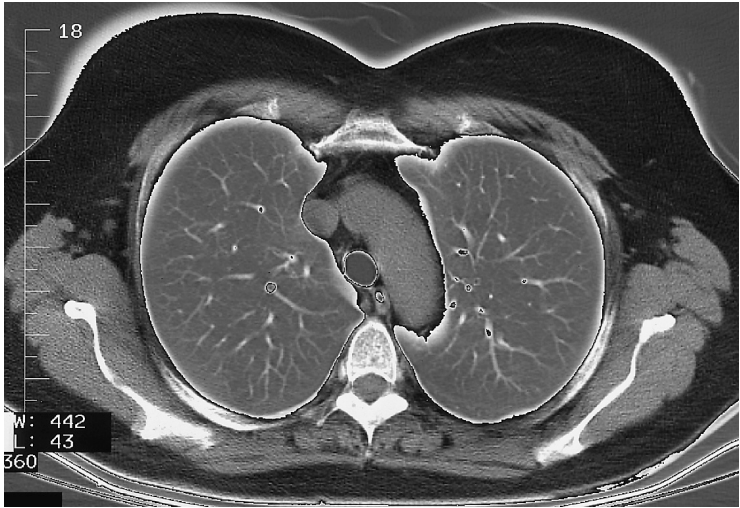
- 1. Apical segment of upper lobe
- 2. Posterior segment of upper lobe
- 3. Anterior segment of upper lobe

Left Lung

- 1+2 Apicoposterior segment of upper lobe
- 3. Anterior segment of upper lobe



- |                                                    |                                      |
|----------------------------------------------------|--------------------------------------|
| 1. Deltoid muscle                                  | 21. Infrapinatus muscle              |
| 2. Subscapularis muscle                            | 22. Supraspinatus muscle             |
| 3. Pectoralis minor muscle                         | 23. Rhomboid muscle major            |
| 4. Pectoralis major muscle                         | 24. Trapezius muscle                 |
| 5. Right lung                                      | 25. Thoracic vertebra                |
| 6. Rib                                             | 26. Spinal cord (thoracic part)      |
| 7. Right brachiocephalic vein                      | 27. Erector spinae muscle            |
| 8. Right brachiocephalic artery                    | 28. Esophagus                        |
| 9. Vagus nerve                                     | 29. Recurrent laryngeal nerve        |
| 10. Trachea                                        | 30. Scapula                          |
| 11. Left brachiocephalic vein                      | 31. Spine of scapula                 |
| 12. Sternum (manubrium)                            | 32. Superficial axillary lymph nodes |
| 13. Left common carotid artery                     | 33. Interpectoral lymph nodes        |
| 14. Phrenic nerve                                  | 34. Paravertebral lymph nodes        |
| 15. Left subclavian artery                         | 35. Paratracheal lymph nodes         |
| 16. Left lung                                      | 36. Anterior mediastinal lymph nodes |
| 17. Intercostal muscle                             | 37. Parasternal lymph nodes          |
| 18. Axillary artery and vein                       | 38. Paraesophageal lymph nodes       |
| 19. Rib                                            | 39. Intercostal lymph nodes          |
| 20. Teres major muscle and latissimus dorsi muscle |                                      |



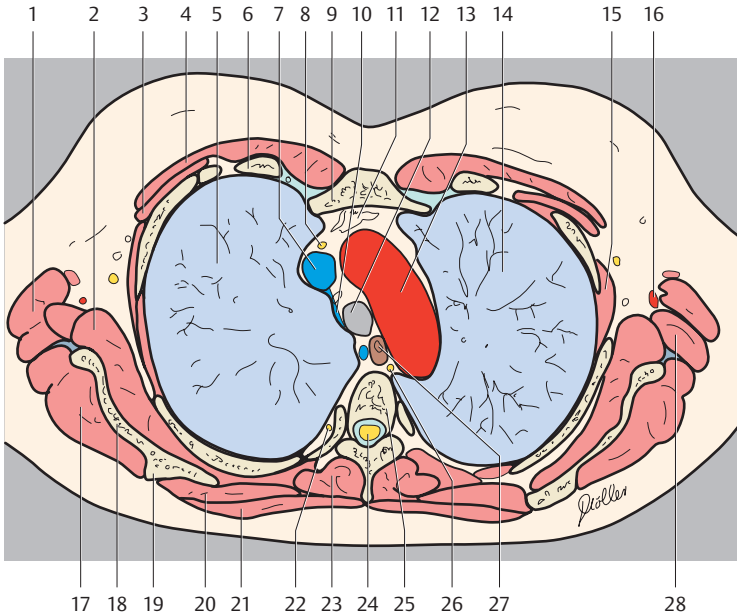
— = Borders of lung segments

#### Right Lung

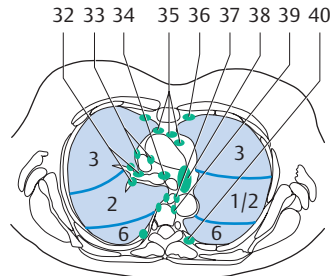
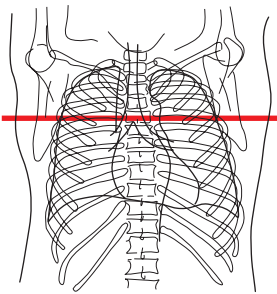
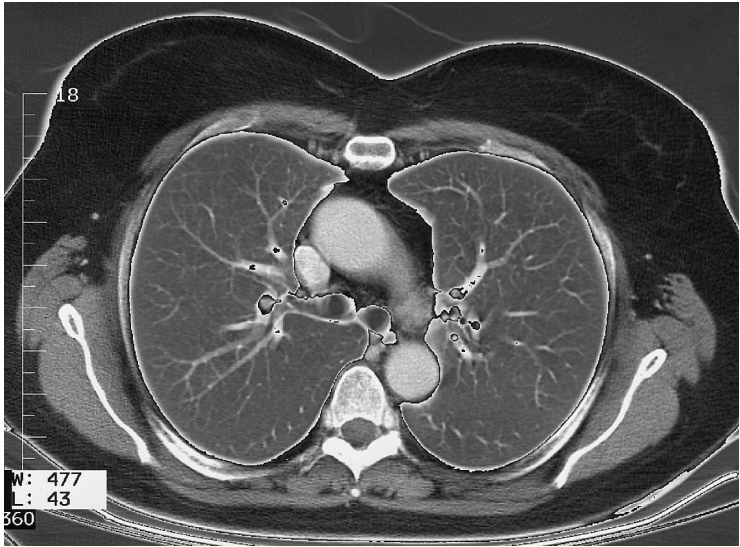
1. Apical segment of upper lobe
2. Posterior segment of upper lobe
3. Anterior segment of upper lobe
6. Superior segment of lower lobe

#### Left Lung

- 1+2 Apicoposterior segment of upper lobe
3. Anterior segment of upper lobe
6. Superior segment of lower lobe



- |                               |                                      |
|-------------------------------|--------------------------------------|
| 1. Latissimus dorsi muscle    | 19. Spine of scapula                 |
| 2. Subscapularis muscle       | 20. Rhomboid muscle major            |
| 3. Pectoralis minor muscle    | 21. Trapezius muscle                 |
| 4. Pectoralis major muscle    | 22. Sympathetic trunk                |
| 5. Right lung                 | 23. Erector spinae muscle            |
| 6. Rib                        | 24. Spinal cord                      |
| 7. Right brachiocephalic vein | 25. Thoracic vertebra                |
| 8. Phrenic nerve              | 26. Thoracic duct                    |
| 9. Sternum (manubrium)        | 27. Esophagus                        |
| 10. Azygos vein               | 28. Teres major muscle               |
| 11. Thymus                    | 29. Superficial axillary lymph nodes |
| 12. Trachea                   | 30. Interpectoral lymph nodes        |
| 13. Aortic arch               | 31. Intercostal lymph nodes          |
| 14. Left lung                 | 32. Paratracheal lymph nodes         |
| 15. Intercostal muscle        | 33. Anterior mediastinal lymph nodes |
| 16. Thoracodorsal artery      | 34. Paraesophageal lymph nodes       |
| 17. Infrapinatus muscle       | 35. Parasternal lymph nodes          |
| 18. Scapula                   | 36. Paravertebral lymph nodes        |



— = Borders of lung segments

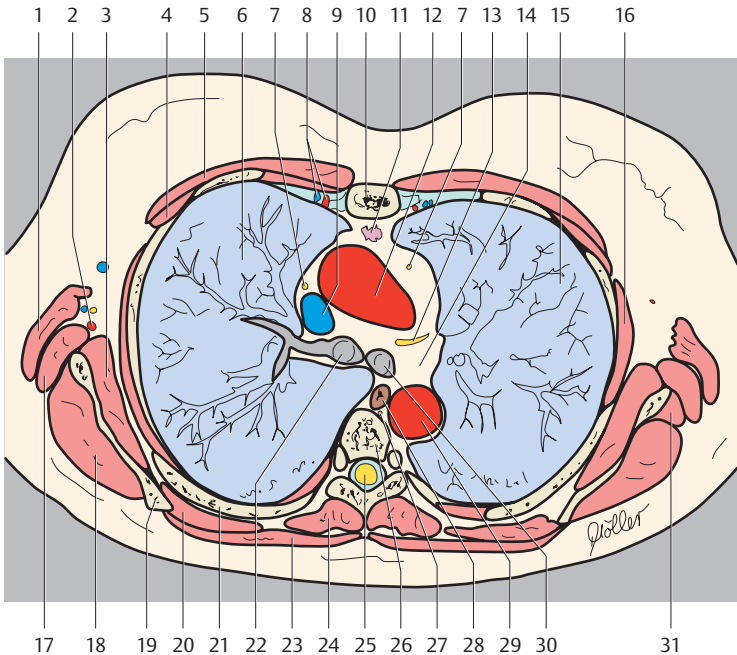
#### Right Lung

- 2. Posterior segment of upper lobe
- 3. Anterior segment of upper lobe
- 6. Superior segment of lower lobe

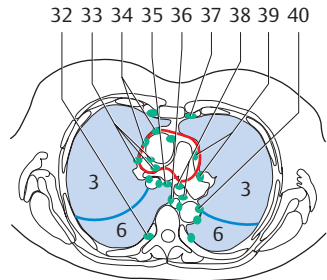
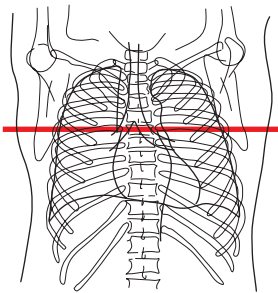
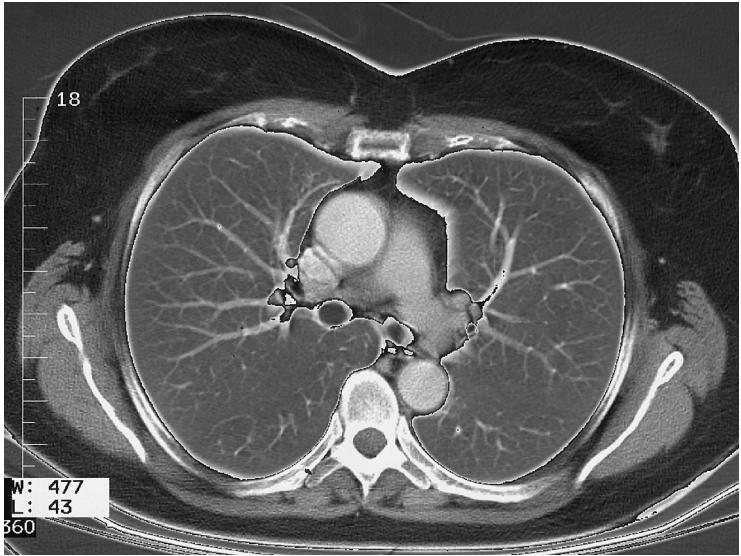
#### Left Lung

- 1+2 Apicoposterior segment of upper lobe
- 3. Anterior segment of upper lobe
- 6. Superior segment of lower lobe





- |                                      |                                                |
|--------------------------------------|------------------------------------------------|
| 1. Latissimus dorsi muscle           | 22. Right main stem bronchus                   |
| 2. Thoracodorsal artery              | 23. Trapezius muscle                           |
| 3. Subscapularis muscle              | 24. Erector spinae muscle                      |
| 4. Pectoralis minor muscle           | 25. Spinal cord                                |
| 5. Pectoralis major muscle           | 26. Thoracic vertebra                          |
| 6. Right lung                        | 27. Thoracic duct                              |
| 7. Phrenic nerve                     | 28. Esophagus                                  |
| 8. Internal thoracic artery and vein | 29. Descending aorta                           |
| 9. Superior vena cava                | 30. Left main stem bronchus                    |
| 10. Sternum (body)                   | 31. Teres minor muscle                         |
| 11. Thymus                           | 32. Tracheobronchial lymph nodes               |
| 12. Ascending aorta                  | 33. Middle mediastinal lymph nodes             |
| 13. Recurrent laryngeal nerve        | 34. Paratracheal lymph nodes                   |
| 14. Aorticopulmonary window          | 35. Anterior mediastinal lymph nodes           |
| 15. Left lung                        | 36. Parasternal lymph nodes                    |
| 16. Intercostal muscle               | 37. Paraesophageal lymph nodes                 |
| 17. Teres major muscle               | 38. Lymph nodes of the aorticopulmonary window |
| 18. Infraspinatus muscle             | 39. Paravertebral lymph nodes                  |
| 19. Scapula                          | 40. Intercostal lymph nodes                    |
| 20. Rhomboid major muscle            |                                                |
| 21. Rib                              |                                                |



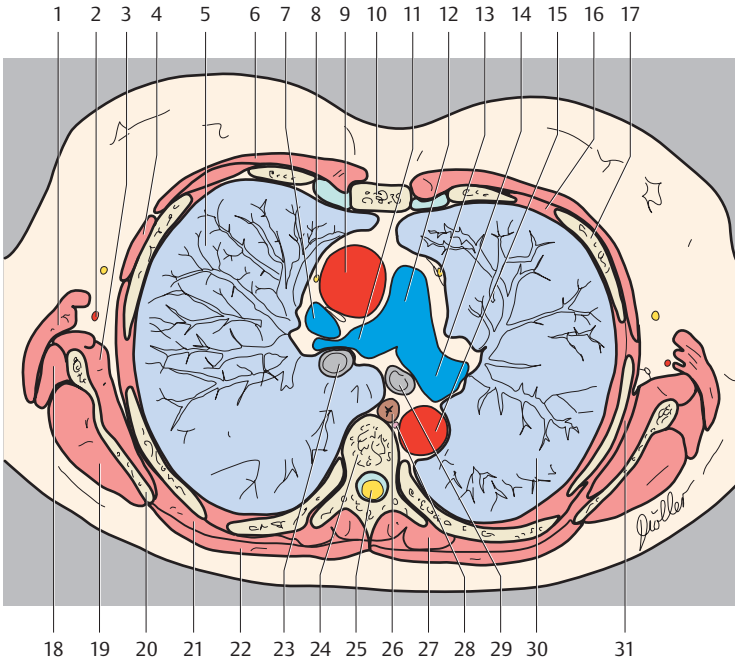
— = Borders of lung segments  
 — = Pericardium

Right Lung

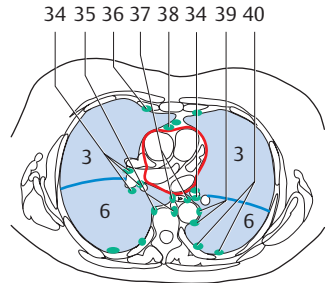
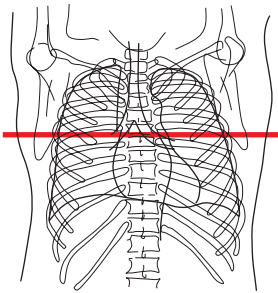
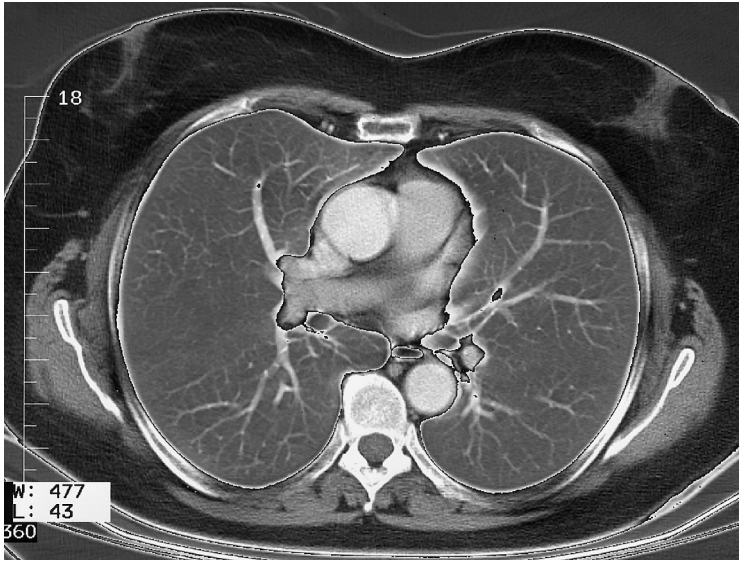
- 3. Anterior segment of upper lobe
- 6. Superior segment of lower lobe

Left Lung

- 3. Anterior segment of upper lobe
- 6. Superior segment of lower lobe



- |                               |                                                |
|-------------------------------|------------------------------------------------|
| 1. Latissimus dorsi muscle    | 22. Trapezius muscle                           |
| 2. Thoracodorsal artery       | 23. Right main stem bronchus                   |
| 3. Subscapularis muscle       | 24. Thoracic vertebra                          |
| 4. Pectoralis minor muscle    | 25. Spinal cord                                |
| 5. Right lung                 | 26. Esophagus                                  |
| 6. Pectoralis major muscle    | 27. Erector spinae muscle                      |
| 7. Superior vena cava         | 28. Thoracic duct                              |
| 8. Phrenic nerve              | 29. Left main stem bronchus                    |
| 9. Ascending aorta            | 30. Left lung                                  |
| 10. Sternum                   | 31. Serratus anterior muscle                   |
| 11. Right pulmonary artery    | 32. Intercostal lymph nodes                    |
| 12. Pulmonary trunk           | 33. Middle mediastinal lymph nodes             |
| 13. Recurrent laryngeal nerve | 34. Anterior mediastinal lymph nodes           |
| 14. Left pulmonary artery     | 35. Paratracheal lymph nodes                   |
| 15. Descending aorta          | 36. Paraesophageal lymph nodes                 |
| 16. Intercostal muscle        | 37. Parasternal lymph nodes                    |
| 17. Rib                       | 38. Bronchopulmonary lymph nodes               |
| 18. Teres major muscle        | 39. Lymph nodes of the aorticopulmonary window |
| 19. Infraspinatus muscle      | 40. Para-aortal lymph nodes                    |
| 20. Scapula                   |                                                |
| 21. Rhomboid major muscle     |                                                |



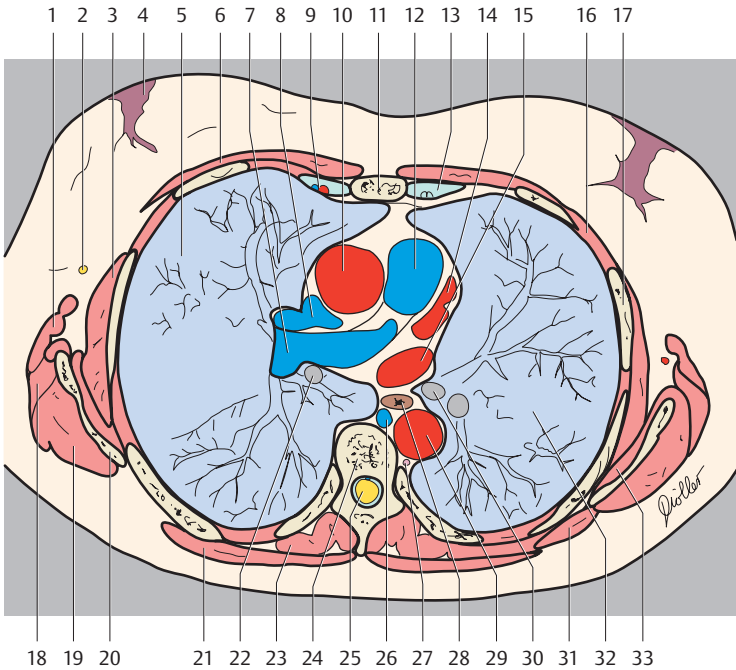
— = Borders of lung segments  
 — = Pericardium

Right Lung

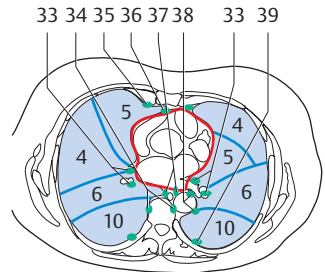
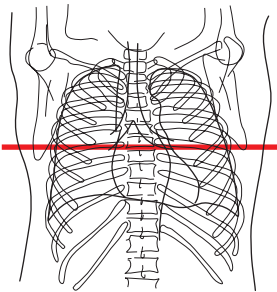
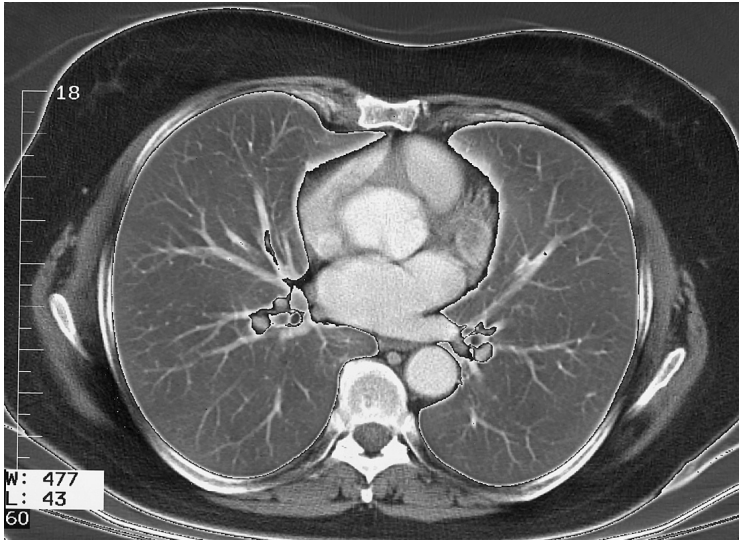
- 3. Anterior segment of upper lobe
- 6. Superior segment of lower lobe

Left Lung

- 3. Anterior segment of upper lobe
- 6. Superior segment of lower lobe



- |                                              |                                      |
|----------------------------------------------|--------------------------------------|
| 1. Latissimus dorsi muscle                   | 21. Trapezius muscle                 |
| 2. Long thoracic nerve                       | 22. Right inferior lobar bronchus    |
| 3. Serratus anterior muscle                  | 23. Erector spinae muscle            |
| 4. Glandular tissue of the breast and nipple | 24. Thoracic vertebra                |
| 5. Right lung                                | 25. Spinal cord                      |
| 6. Pectoralis major muscle                   | 26. Azygos vein                      |
| 7. Right pulmonary artery                    | 27. Thoracic duct                    |
| 8. Superior vena cava                        | 28. Esophagus                        |
| 9. Internal thoracic artery and vein         | 29. Descending aorta                 |
| 10. Ascending aorta                          | 30. Left inferior lobar bronchus     |
| 11. Sternum                                  | 31. Rhomboid muscle major            |
| 12. Pulmonary trunk                          | 32. Left lung                        |
| 13. Rib (costal cartilage)                   | 33. Subscapularis muscle             |
| 14. Left pulmonary vein                      | 34. Bronchopulmonary lymph nodes     |
| 15. Left atrium                              | 35. Paravertebral lymph nodes        |
| 16. Intercostal muscle                       | 36. Parasternal lymph nodes          |
| 17. Rib                                      | 37. Juxtaesophageal lymph nodes      |
| 18. Teres major muscle                       | 38. Anterior mediastinal lymph nodes |
| 19. Infraspinatus muscle                     | 39. Para-aortal lymph nodes          |
| 20. Scapula                                  | 40. Intercostal lymph nodes          |



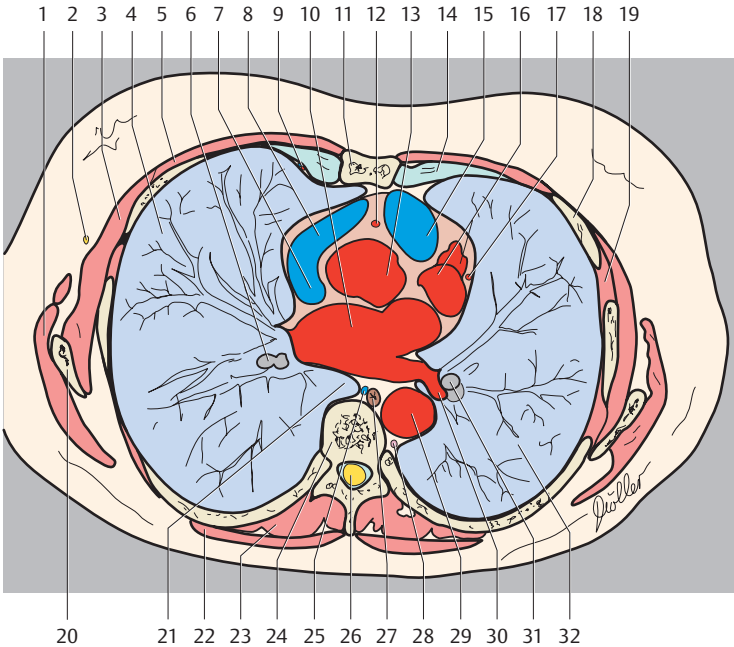
— = Borders of lung segments  
 — = Pericardium

#### Right Lung

4. Lateral segment of middle lobe
5. Medial segment of middle lobe
6. Superior segment of lower lobe
10. Posterior basal segment of lower lobe

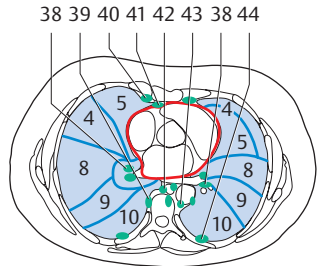
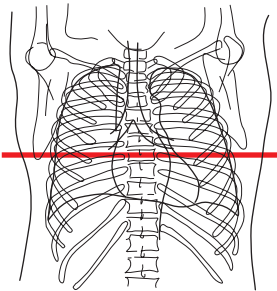
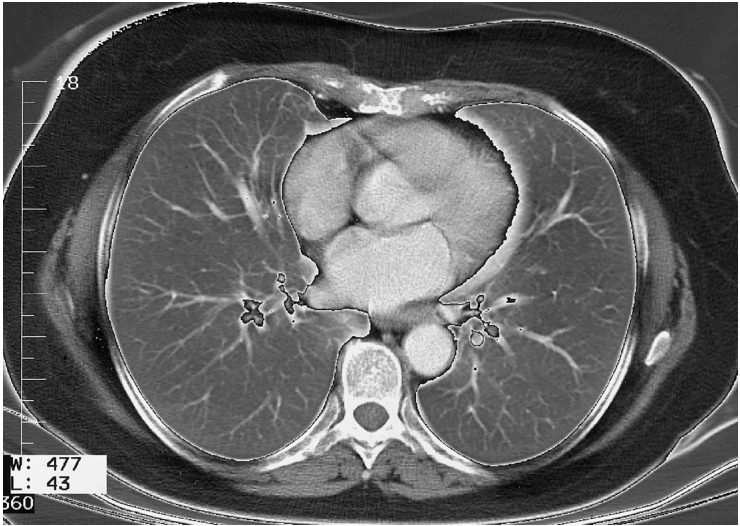
#### Left Lung

4. Superior lingular segment
5. Inferior lingular segment
6. Superior segment of lower lobe
10. Posterior basal segment of lower lobe



- |                                      |                                          |
|--------------------------------------|------------------------------------------|
| 1. Latissimus dorsi muscle           | 21. Right lung in retroesophageal recess |
| 2. Long thoracic nerve               | 22. Trapezius muscle                     |
| 3. Serratus anterior muscle          | 23. Erector spinae muscle                |
| 4. Right lung                        | 24. Thoracic vertebra                    |
| 5. Pectoralis major muscle           | 25. Azygos vein                          |
| 6. Right inferior lobar bronchus     | 26. Spinal cord                          |
| 7. Superior vena cava                | 27. Esophagus                            |
| 8. Right auricle                     | 28. Thoracic duct                        |
| 9. Internal thoracic artery and vein | 29. Descending aorta                     |
| 10. Left atrium                      | 30. Left pulmonary vein                  |
| 11. Sternum                          | 31. Left inferior lobar bronchus         |
| 12. Right coronary artery            | 32. Left lung                            |
| 13. Ascending aorta                  | 33. Bronchopulmonary lymph nodes         |
| 14. Rib (costal cartilage)           | 34. Paravertebral lymph nodes            |
| 15. Conus arteriosus                 | 35. Parasternal lymph nodes              |
| 16. Left ventricle                   | 36. Prepericardial lymph nodes           |
| 17. Left coronary artery             | 37. Juxtaesophageal lymph nodes          |
| 18. Rib                              | 38. Para-aortal lymph nodes              |
| 19. Intercostal muscle               | 39. Intercostal lymph nodes              |
| 20. Scapula                          |                                          |





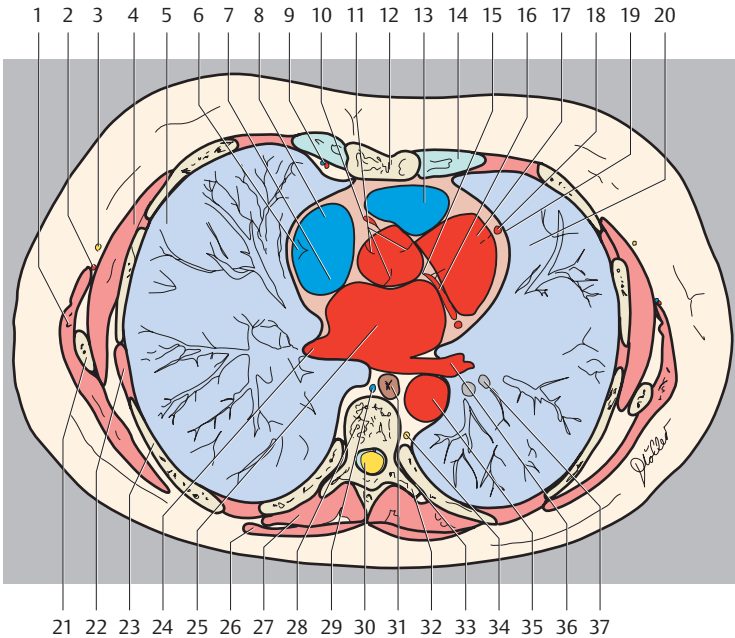
Right Lung

- 4. Lateral segment of middle lobe
- 5. Medial segment of middle lobe
- 8. Anterior basal segment of lower lobe
- 9. Lateral basal segment of lower lobe
- 10. Posterior basal segment of lower lobe

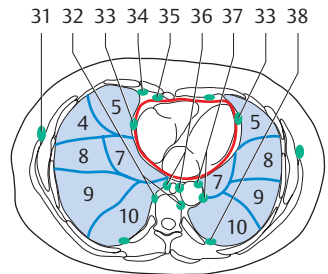
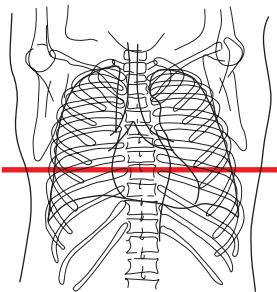
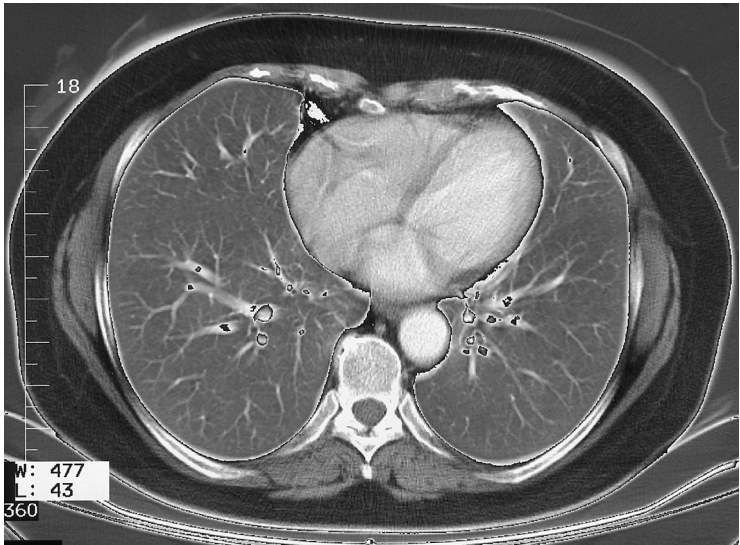
Left Lung

- 4. Superior lingular segment
- 5. Inferior lingular segment
- 8. Anterior basal segment of lower lobe
- 9. Lateral basal segment of lower lobe
- 10. Posterior basal segment of lower lobe





- |                                      |                                  |
|--------------------------------------|----------------------------------|
| 1. Latissimus dorsi muscle           | 23. Rib                          |
| 2. Thoracodorsal artery              | 24. Left pulmonary vein          |
| 3. Long thoracic nerve               | 25. Left atrium                  |
| 4. Serratus anterior muscle          | 26. Trapezius muscle             |
| 5. Right lung                        | 27. Erector spinae muscle        |
| 6. Crista terminalis                 | 28. Thoracic vertebra            |
| 7. Superior vena cava                | 29. Azygos vein                  |
| 8. Right atrium                      | 30. Spinal cord                  |
| 9. Internal thoracic artery and vein | 31. Esophagus                    |
| 10. Right coronary artery            | 32. Transverse process           |
| 11. Aortic valve                     | 33. Costovertebral joint         |
| 12. Sternum                          | 34. Thoracic duct                |
| 13. Conus arteriosus                 | 35. Descending aorta             |
| 14. Rib (costal cartilage)           | 36. Left pulmonary vein          |
| 15. Left coronary artery             | 37. Left inferior lobar bronchus |
| 16. Coronary sulcus                  | 38. Bronchopulmonary lymph nodes |
| 17. Left ventricle                   | 39. Paravertebral lymph nodes    |
| 18. Left coronary artery             | 40. Parasternal lymph nodes      |
| 19. Phrenic nerve and pericardium    | 41. Prepericardial lymph nodes   |
| 20. Left lung                        | 42. Juxtaesophageal lymph nodes  |
| 21. Scapula                          | 43. Para-aortal lymph nodes      |
| 22. Intercostal muscle               | 44. Intercostal lymph nodes      |



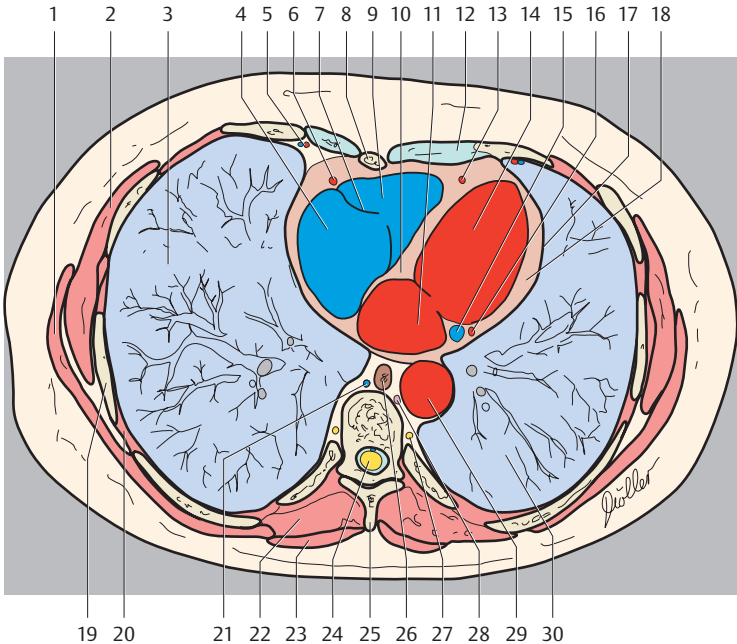
— = Borders of lung segments  
 — = Pericardium

#### Right Lung

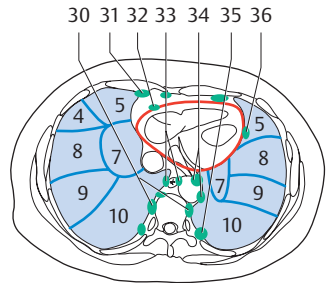
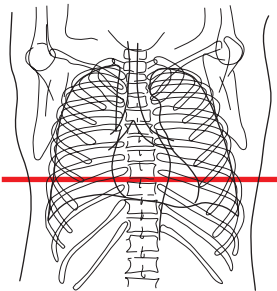
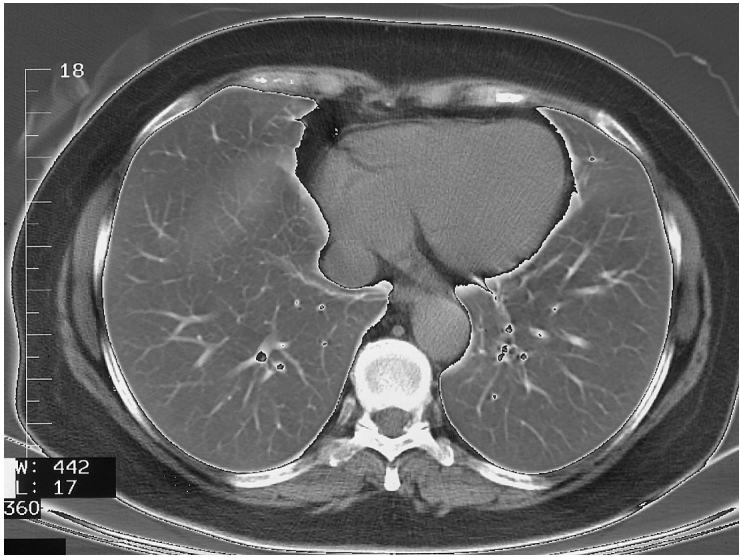
4. Lateral segment of middle lobe
5. Medial segment of middle lobe
7. Medial basal (cardiac) segment of lower lobe
8. Anterior basal segment of lower lobe
9. Lateral basal segment of lower lobe
10. Posterior basal segment of lower lobe

#### Left Lung

5. Inferior lingular segment
7. Medial basal (cardiac) segment of lower lobe
8. Anterior basal segment of lower lobe
9. Lateral basal segment of lower lobe
10. Posterior basal segment of lower lobe



- |                                                    |                                     |
|----------------------------------------------------|-------------------------------------|
| 1. Latissimus dorsi muscle                         | 19. Rib                             |
| 2. Serratus anterior muscle                        | 20. Intercostal muscle              |
| 3. Right lung                                      | 21. Azygos vein                     |
| 4. Right atrium                                    | 22. Erector spinae muscle           |
| 5. Internal thoracic artery and vein               | 23. Trapezius muscle                |
| 6. Right coronary artery                           | 24. Spinal cord                     |
| 7. Right atrioventricular (tricuspid) valve        | 25. Spinous process                 |
| 8. Sternum (body)                                  | 26. Esophagus                       |
| 9. Right ventricle                                 | 27. Sympathetic trunk               |
| 10. Interventricular septum                        | 28. Thoracic duct                   |
| 11. Left atrium                                    | 29. Descending aorta                |
| 12. Rib (costal cartilage)                         | 30. Left lung                       |
| 13. Left coronary artery (interventricular branch) | 31. Paramammary lymph nodes         |
| 14. Left ventricle                                 | 32. Paravertebral lymph nodes       |
| 15. Coronary sinus                                 | 33. Lateral pericardial lymph nodes |
| 16. Left coronary artery (circumflex branch)       | 34. Parasternal lymph nodes         |
| 17. Phrenic nerve and pericardium                  | 35. Prepericardial lymph nodes      |
| 18. Myocardium                                     | 36. Juxtaesophageal lymph nodes     |
|                                                    | 37. Para-aortal lymph nodes         |
|                                                    | 38. Intercostal lymph nodes         |



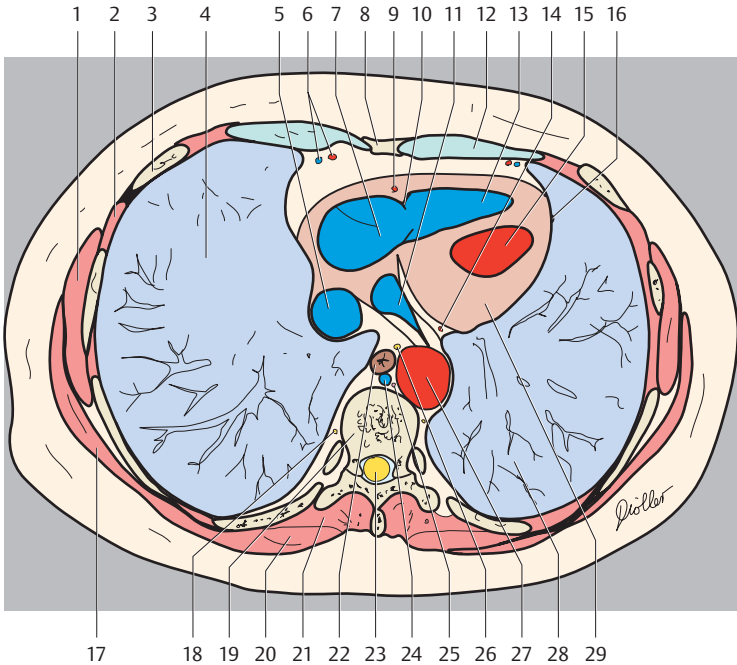
— = Borders of lung segments  
 — = Pericardium

#### Right Lung

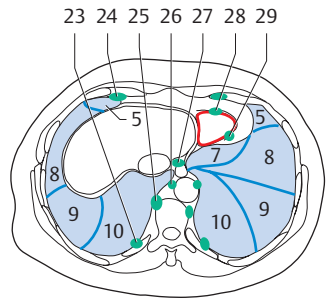
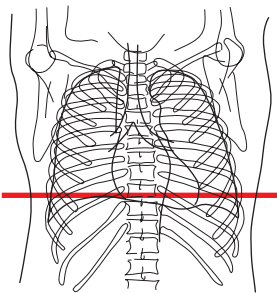
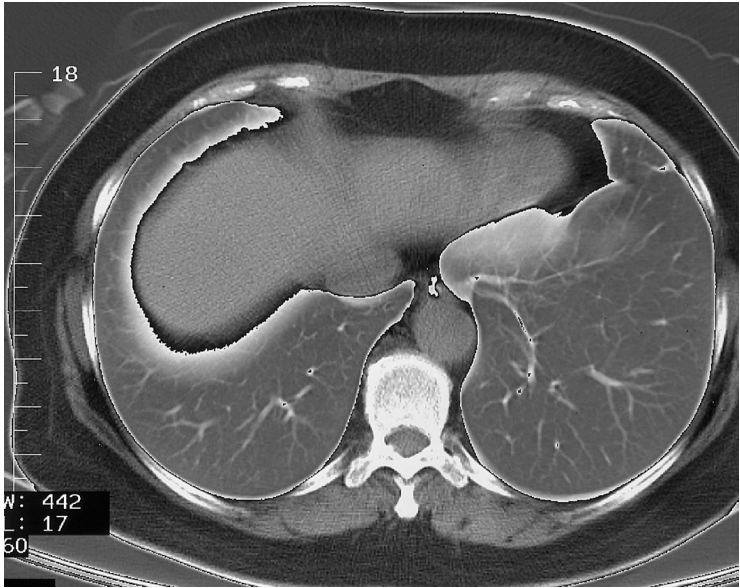
4. Lateral segment of middle lobe
5. Medial segment of middle lobe
7. Medial basal (cardiac) segment of lower lobe
8. Anterior basal segment of lower lobe
9. Lateral basal segment of lower lobe
10. Posterior basal segment of lower lobe

#### Left Lung

5. Inferior lingular segment
7. Medial basal (cardiac) segment of lower lobe
8. Anterior basal segment of lower lobe
9. Lateral basal segment of lower lobe
10. Posterior basal segment of lower lobe



- |                                               |                                      |
|-----------------------------------------------|--------------------------------------|
| 1. Latissimus dorsi muscle                    | 18. Sympathetic trunk                |
| 2. Intercostal muscle                         | 19. Thoracic vertebra                |
| 3. Rib                                        | 20. Trapezius muscle                 |
| 4. Right lung                                 | 21. Erector spinae muscle            |
| 5. Inferior vena cava                         | 22. Esophagus                        |
| 6. Internal thoracic artery and vein          | 23. Spinal cord                      |
| 7. Right atrium                               | 24. Azygos vein                      |
| 8. Xiphoid process                            | 25. Thoracic duct                    |
| 9. Right coronary artery                      | 26. Vagus nerve                      |
| 10. Right atrioventricular (tricuspid) valve  | 27. Descending aorta                 |
| 11. Coronary sinus                            | 28. Left lung                        |
| 12. Rib (costal cartilage)                    | 29. Myocardium of the left ventricle |
| 13. Right ventricle                           | 30. Paravertebral lymph nodes        |
| 14. Circumflex branch of left coronary artery | 31. Parasternal lymph nodes          |
| 15. Left ventricle                            | 32. Prepericardial lymph nodes       |
| 16. Phrenic nerve and pericardium             | 33. Juxtaesophageal lymph nodes      |
| 17. Serratus anterior muscle                  | 34. Para-aortal lymph nodes          |
|                                               | 35. Intercostal lymph nodes          |
|                                               | 36. Lateral pericardial lymph nodes  |



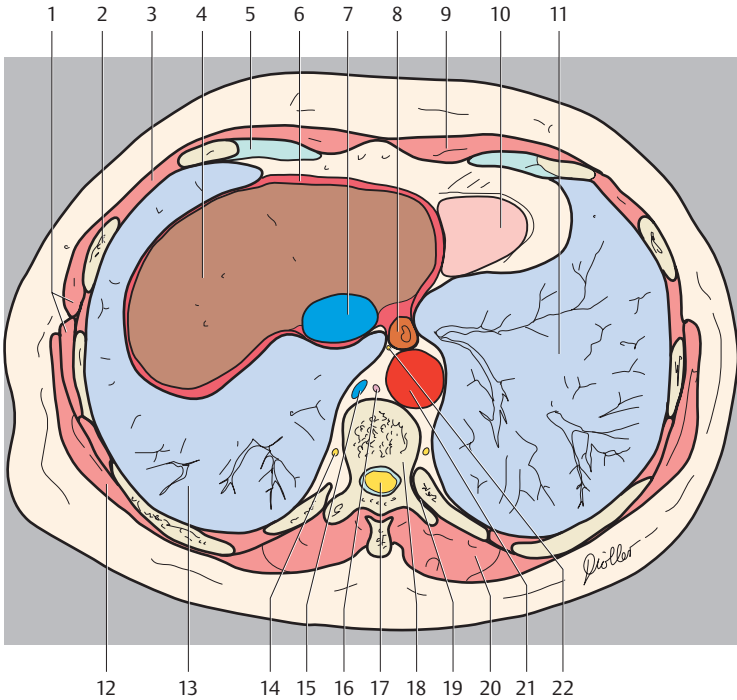
— = Borders of lung segments  
 — = Pericardium

#### Right Lung

- 5. Medial segment of middle lobe
- 8. Anterior basal segment of lower lobe
- 9. Lateral basal segment of lower lobe
- 10. Posterior basal segment of lower lobe

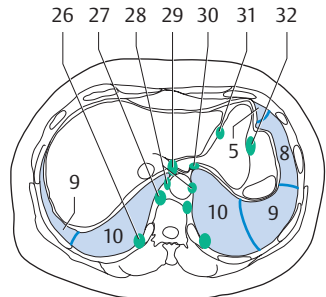
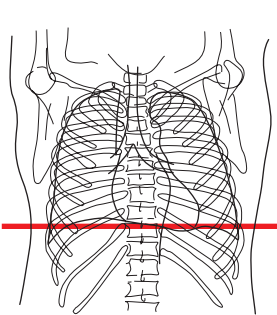
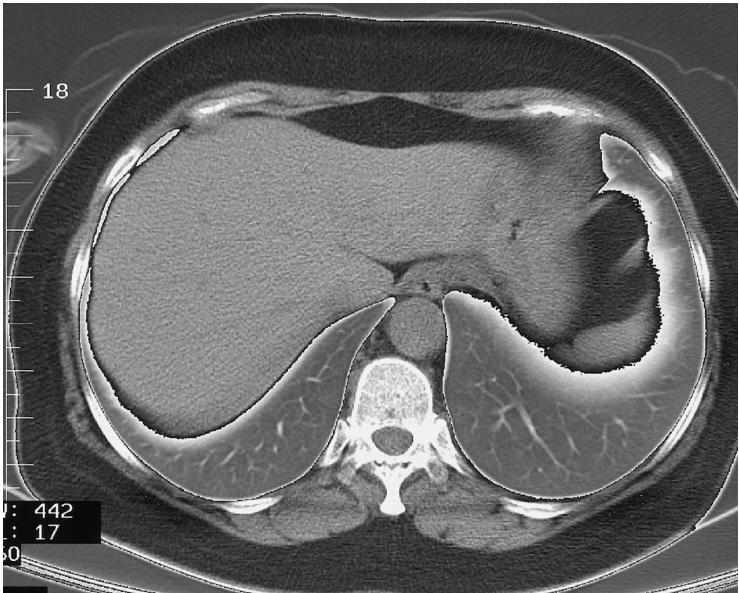#### Left Lung

- 5. Inferior lingular segment
- 7. Medial basal (cardiac) segment of lower lobe
- 8. Anterior basal segment of lower lobe
- 9. Lateral basal segment of lower lobe
- 10. Posterior basal segment of lower lobe



- |                             |                                     |
|-----------------------------|-------------------------------------|
| 1. Serratus anterior muscle | 16. Thoracic duct                   |
| 2. Rib                      | 17. Spinal cord                     |
| 3. Intercostal muscle       | 18. Thoracic vertebra               |
| 4. Liver                    | 19. Costovertebral joint            |
| 5. Rib (costal cartilage)   | 20. Erector spinae muscle           |
| 6. Diaphragm                | 21. Descending aorta                |
| 7. Inferior vena cava       | 22. Vagus nerve                     |
| 8. Esophagus                | 23. Intercostal lymph nodes         |
| 9. Rectus abdominis muscle  | 24. Parasternal lymph nodes         |
| 10. Base of heart           | 25. Paravertebral lymph nodes       |
| 11. Left lung               | 26. Para-aortal lymph nodes         |
| 12. Latissimus dorsi muscle | 27. Superior phrenic lymph nodes    |
| 13. Right lung              | 28. Prepericardial lymph nodes      |
| 14. Sympathetic trunk       | 29. Lateral pericardial lymph nodes |
| 15. Azygos vein             |                                     |





— = Borders of lung segments

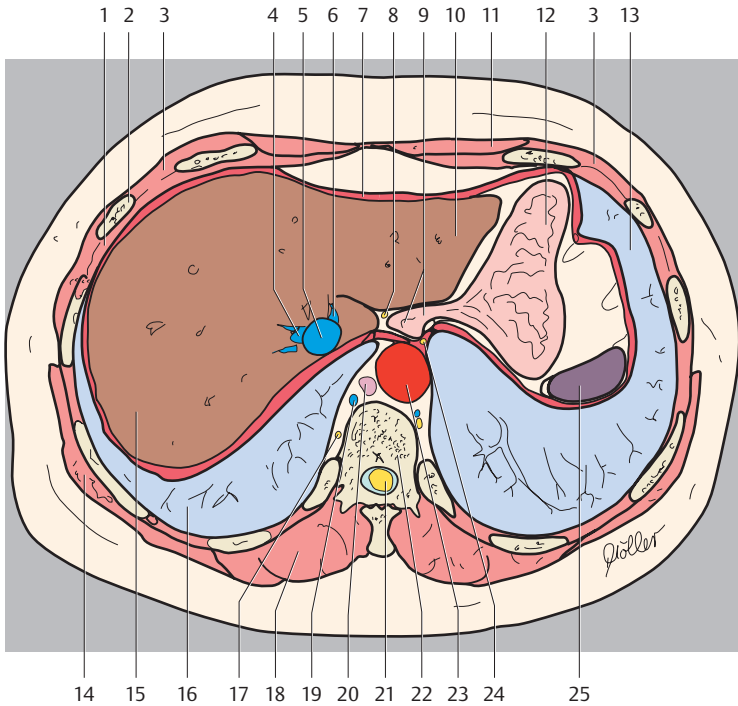
#### Right Lung

- 9. Lateral basal segment of lower lobe
- 10. Posterior basal segment of lower lobe

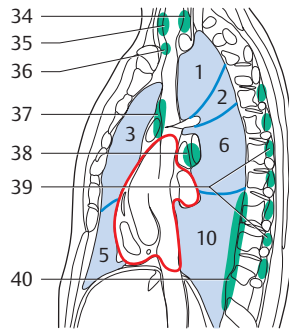
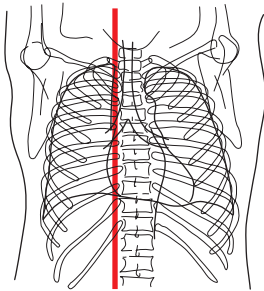
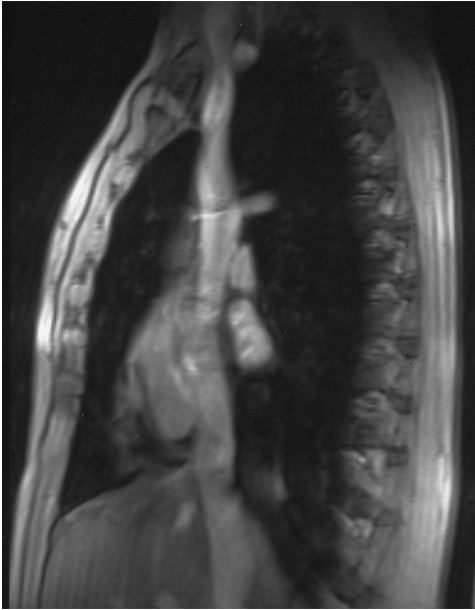
#### Left Lung

- 5. Inferior lingular segment
- 8. Anterior basal segment of lower lobe
- 9. Lateral basal segment of lower lobe
- 10. Posterior basal segment of lower lobe





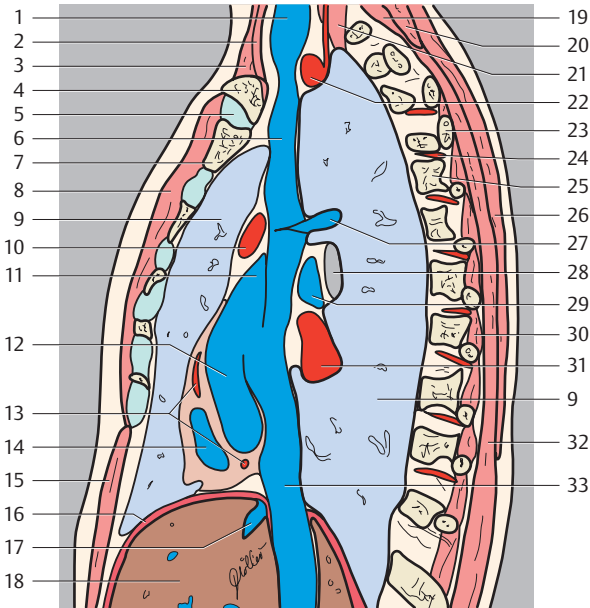
- |                             |                                     |
|-----------------------------|-------------------------------------|
| 1. Intercostal muscle       | 17. Sympathetic trunk               |
| 2. Rib                      | 18. Erector spinae muscle           |
| 3. External oblique muscle  | 19. Azygos vein                     |
| 4. Right hepatic vein       | 20. Thoracic duct                   |
| 5. Inferior vena cava       | 21. Spinal cord                     |
| 6. Left hepatic vein        | 22. Thoracic vertebra               |
| 7. Diaphragm                | 23. Descending aorta                |
| 8. Vagus nerve              | 24. Posterior vagal trunk           |
| 9. Esophagus                | 25. Spleen                          |
| 10. Liver (left lobe)       | 26. Intercostal lymph nodes         |
| 11. Rectus abdominis muscle | 27. Paravertebral lymph nodes       |
| 12. Stomach                 | 28. Para-aortal lymph nodes         |
| 13. Left lung               | 29. Superior phrenic lymph nodes    |
| 14. Latissimus dorsi muscle | 30. Inferior phrenic lymph nodes    |
| 15. Liver (right lobe)      | 31. Right gastric lymph nodes       |
| 16. Right lung              | 32. Left gastroepiploic lymph nodes |



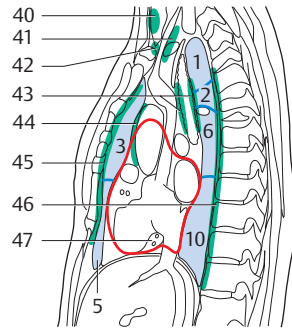
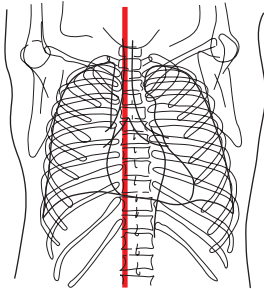
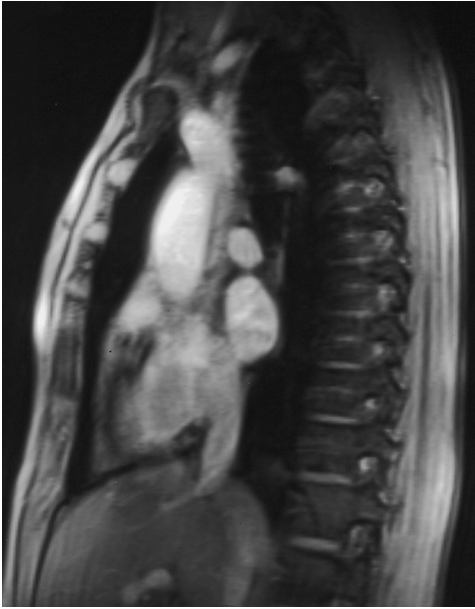— = Border of lung segments  
 — = Pericardium

#### Right Lung

1. Apical segment of upper lobe
2. Posterior segment of upper lobe
3. Anterior segment of upper lobe
5. Medial segment of middle lobe
6. Superior segment of lower lobe
10. Posterior basal segment of lower lobe



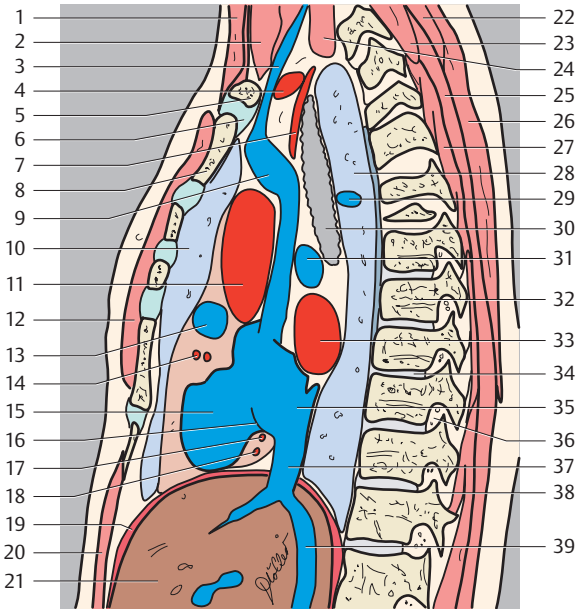
- |                                          |                                       |
|------------------------------------------|---------------------------------------|
| 1. Jugular vein                          | 21. Longus colli muscle               |
| 2. Sternothyroid muscle                  | 22. Subclavian artery                 |
| 3. Sternocleidomastoid muscle            | 23. Rib                               |
| 4. Clavicle                              | 24. Posterior intercostal artery      |
| 5. Sternoclavicular joint                | 25. Vertebra                          |
| 6. Superior vena cava                    | 26. Trapezius muscle                  |
| 7. Sternum                               | 27. Azygos vein                       |
| 8. Pectoralis major muscle               | 28. Right main stem bronchus          |
| 9. Right lung                            | 29. Right pulmonary artery            |
| 10. Ascending aorta                      | 30. Intercostal muscle                |
| 11. Right auricle                        | 31. Pulmonary vein                    |
| 12. Right atrium                         | 32. Erector spinae muscle             |
| 13. Right coronary artery                | 33. Inferior vena cava                |
| 14. Right ventricle                      | 34. Deep cervical lymph nodes         |
| 15. Rectus abdominis muscle              | 35. Superficial cervical lymph nodes  |
| 16. Diaphragm                            | 36. Supraclavicular lymph nodes       |
| 17. Hepatic veins                        | 37. Anterior mediastinal lymph nodes  |
| 18. Liver                                | 38. Bronchopulmonary lymph nodes      |
| 19. Semispinalis capitis muscle          | 39. Posterior intercostal lymph nodes |
| 20. Splenius cervicis and capitis muscle | 40. Paravertebral lymph nodes         |



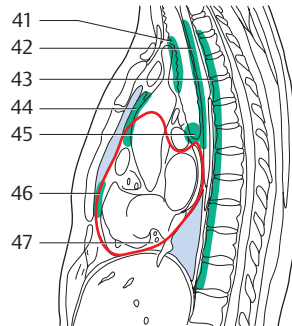
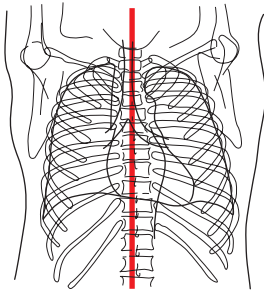
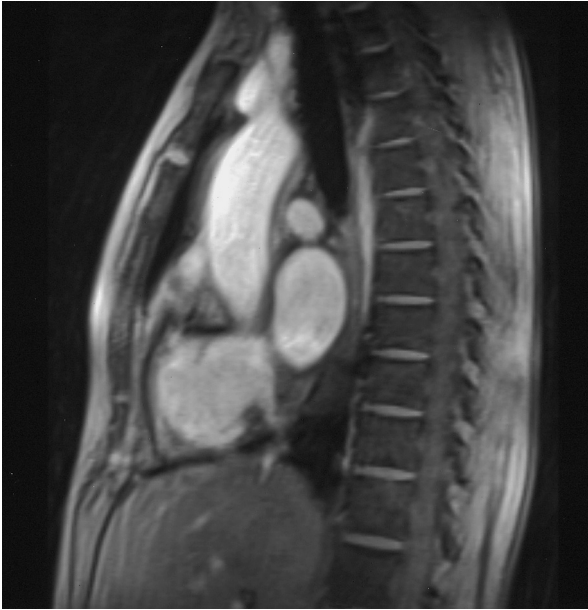
— = Borders of lung segments  
 — = Pericardium  
 (Segments of the lungs, see page 2)

1. Sternocleidomastoid muscle
2. Sternohyoid, sternothyroid and omohyoid muscle
3. Jugular vein
4. Subclavian artery
5. Clavicle

6. Sternoclavicular joint
7. Brachiocephalic trunk
8. Sternum
9. Superior vena cava
10. Right lung
11. Ascending aorta

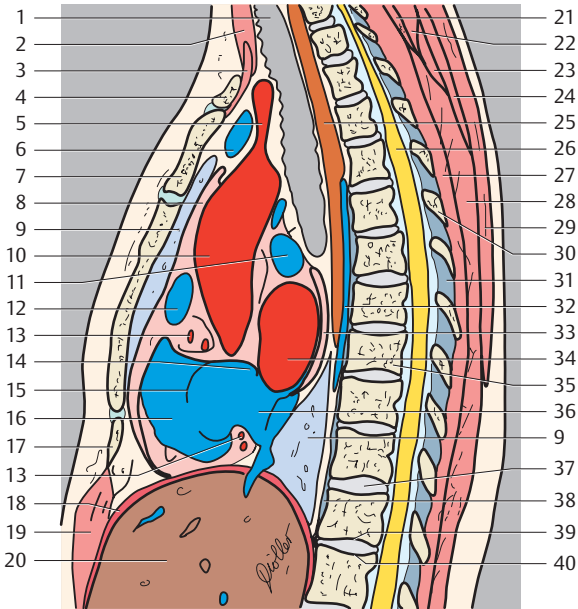


- |                                                               |                                      |
|---------------------------------------------------------------|--------------------------------------|
| 12. Pectoralis major muscle                                   | 28. Right lung                       |
| 13. Right auricle                                             | 29. Azygos vein                      |
| 14. Right coronary artery                                     | 30. Trachea                          |
| 15. Right ventricle                                           | 31. Right pulmonary artery           |
| 16. Right atrioventricular (tricuspid) valve                  | 32. Vertebra                         |
| 17. Right coronary artery (posterior interventricular branch) | 33. Left atrium                      |
| 18. Right coronary artery (terminal branch)                   | 34. Intervertebral space             |
| 19. Diaphragm                                                 | 35. Right atrium                     |
| 20. Rectus abdominis muscle                                   | 36. Foramen                          |
| 21. Liver                                                     | 37. Inferior vena cava               |
| 22. Splenius cervicis and capitis muscle                      | 38. Superior articular process       |
| 23. Semispinalis capitis muscle                               | 39. Hepatic veins                    |
| 24. Longus colli muscle                                       | 40. Thyroid lymph nodes              |
| 25. Erector spinae muscle                                     | 41. Deep cervical lymph nodes        |
| 26. Trapezius muscle                                          | 42. Supraclavicular lymph nodes      |
| 27. Semispinalis thoracis muscle (multifidus muscle)          | 43. Paratracheal lymph nodes         |
|                                                               | 44. Anterior mediastinal lymph nodes |
|                                                               | 45. Parasternal lymph nodes          |
|                                                               | 46. Paravertebral lymph nodes        |
|                                                               | 47. Subpericardial adipose tissue    |

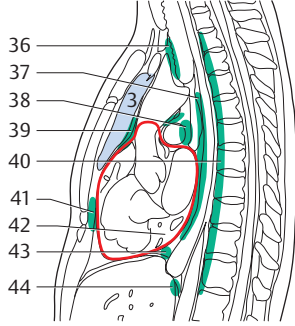
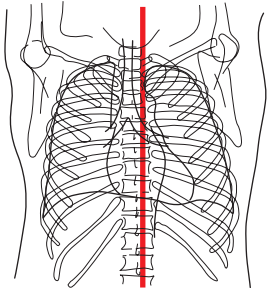
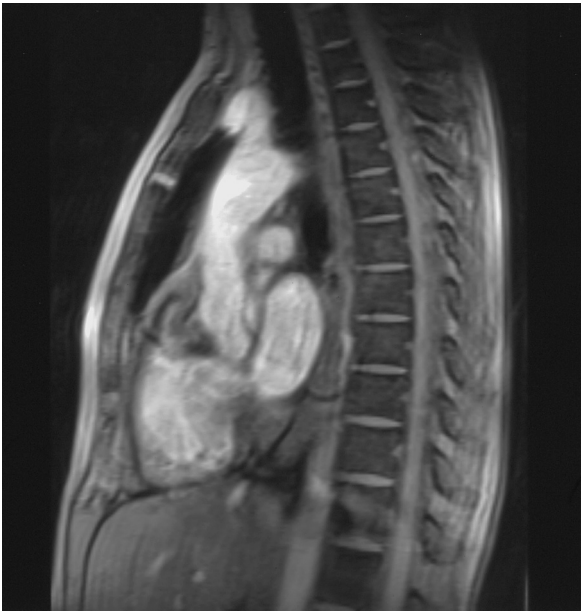


— = Borders of lung segments  
 — = Pericardium

- |                                                |                              |
|------------------------------------------------|------------------------------|
| 1. Trachea                                     | 6. Left brachiocephalic vein |
| 2. Sternocleidomastoid muscle                  | 7. Sternum (manubrium)       |
| 3. Sternohyoid, sternothyroid, omohyoid muscle | 8. Pericardium               |
| 4. Clavicle                                    | 9. Right lung                |
| 5. Brachiocephalic trunk                       | 10. Ascending aorta          |
|                                                | 11. Right pulmonary artery   |



- |                                                          |                                              |
|----------------------------------------------------------|----------------------------------------------|
| 12. Right auricle                                        | 30. Spinosus process (T6)                    |
| 13. Right coronary artery                                | 31. Ligamenta flava                          |
| 14. Interarticular septum                                | 32. Azygos vein                              |
| 15. Right atrioventricular (tricuspid) valve             | 33. Sinus of pericardium                     |
| 16. Right ventricle                                      | 34. Left atrium                              |
| 17. Xyphoid process of sternum                           | 35. Thoracic vertebra (T9)                   |
| 18. Diaphragm                                            | 36. Right atrium                             |
| 19. Rectus abdominis muscle                              | 37. Intervertebral space                     |
| 20. Liver                                                | 38. Anterior longitudinal ligament           |
| 21. Semispinalis capitis muscle                          | 39. Inferior surface of vertebral body (T12) |
| 22. Splenius cervicis muscle and splenius capitis muscle | 40. Superior surface of vertebral body (L1)  |
| 23. Serratus posterior superior muscle                   | 41. Paratracheal lymph nodes                 |
| 24. Rhomboid major muscle                                | 42. Juxtaesophageal lymph nodes              |
| 25. Esophagus                                            | 43. Paravertebral lymph node                 |
| 26. Spinal cord                                          | 44. Anterior mediastinal lymph nodes         |
| 27. Semispinalis thoracis muscle and multifidus muscle   | 45. Tracheobronchial lymph nodes             |
| 28. Erector spinae muscle                                | 46. Prepericardial lymph nodes               |
| 29. Trapezius muscle                                     | 47. Subpericardial adipose tissue            |



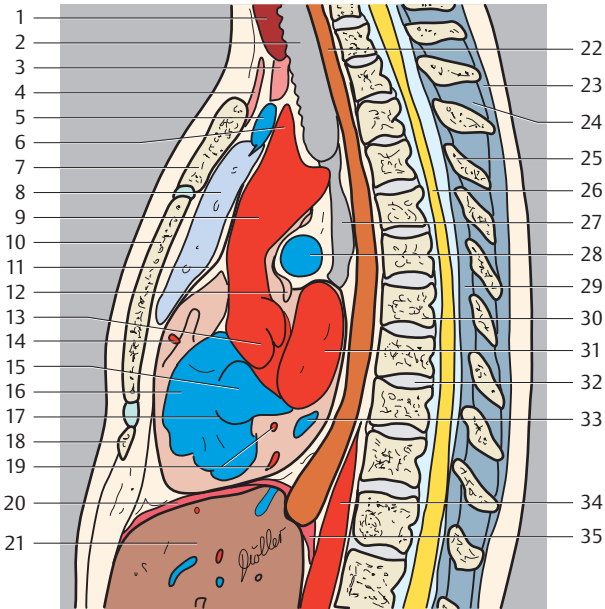
— = Borders of lung segments  
 — = Pericardium

(Segments of the lungs, see page 2)

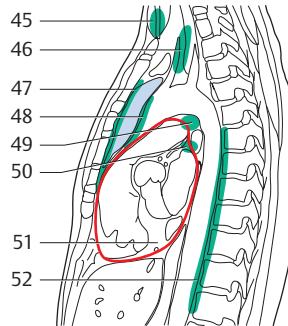
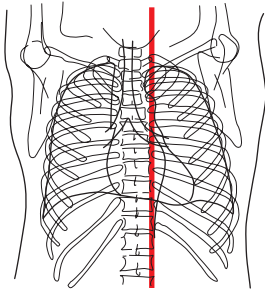
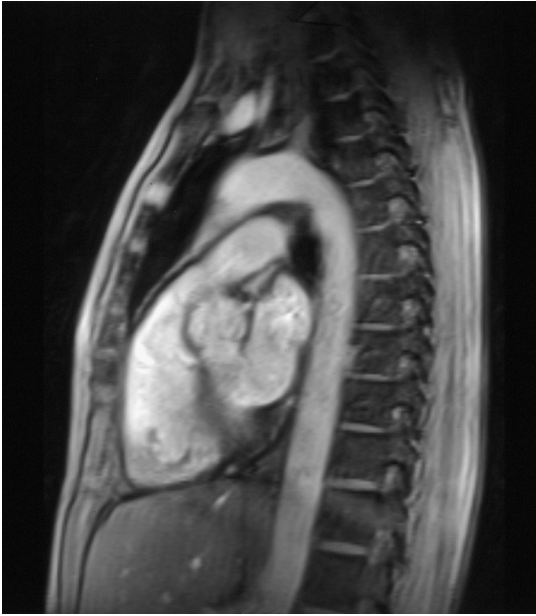
- 1. Thyroid gland
- 2. Trachea
- 3. Sternothyroid muscle
- 4. Sternohyoid muscle and omohyoid muscle
- 5. Left brachiocephalic vein

- 6. Brachiocephalic trunk
- 7. Sternum (manubrium)
- 8. Left lung
- 9. Ascending aorta
- 10. Sternum (body)
- 11. Pericardium





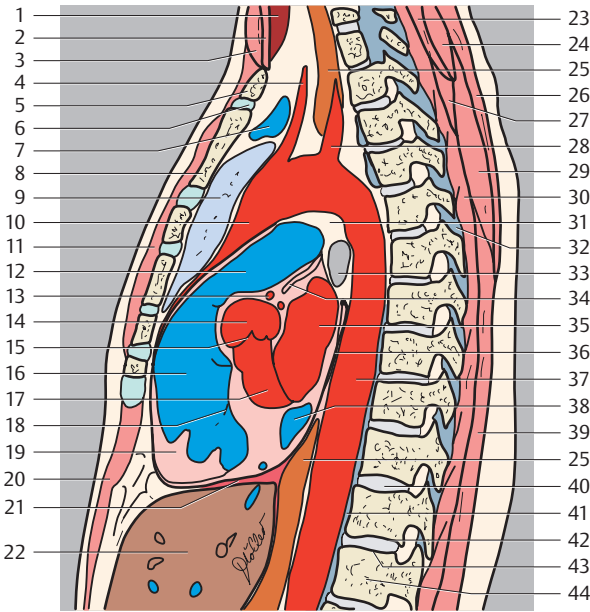
- |                                                                                         |                                      |
|-----------------------------------------------------------------------------------------|--------------------------------------|
| 12. Transverse sinus of pericardium                                                     | 27. Bifurcation of trachea           |
| 13. Aortic bulb and aortic valve                                                        | 28. Right pulmonary artery           |
| 14. Right coronary artery                                                               | 29. Ligamenta flava                  |
| 15. Right atrium                                                                        | 30. Thoracic vertebra                |
| 16. Right ventricle                                                                     | 31. Left atrium                      |
| 17. Right atrioventricular (tricuspid) valve                                            | 32. Intervertebral space             |
| 18. Xiphoid process of sternum                                                          | 33. Coronary sinus                   |
| 19. Right coronary artery (posterior interventricular branch and right marginal branch) | 34. Descending aorta                 |
| 20. Diaphragm                                                                           | 35. Diaphragm (lumbar part)          |
| 21. Liver                                                                               | 36. Paratracheal lymph nodes         |
| 22. Esophagus                                                                           | 37. Juxtaesophageal lymph nodes      |
| 23. Supraspinous ligament                                                               | 38. Tracheobronchial lymph nodes     |
| 24. Interspinal ligaments                                                               | 39. Anterior mediastinal lymph nodes |
| 25. Spinous process                                                                     | 40. Paravertebral lymph nodes        |
| 26. Spinal cord                                                                         | 41. Parasternal lymph nodes          |
|                                                                                         | 42. Subpericardial adipose tissue    |
|                                                                                         | 43. Superior phrenic lymph nodes     |
|                                                                                         | 44. Inferior phrenic lymph nodes     |



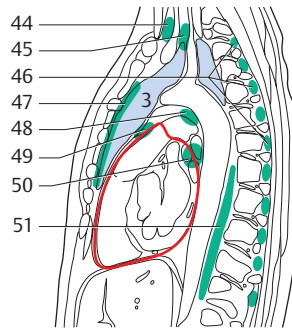
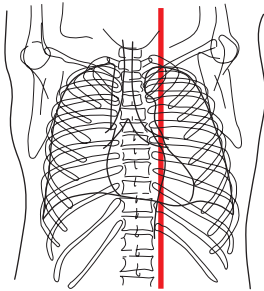
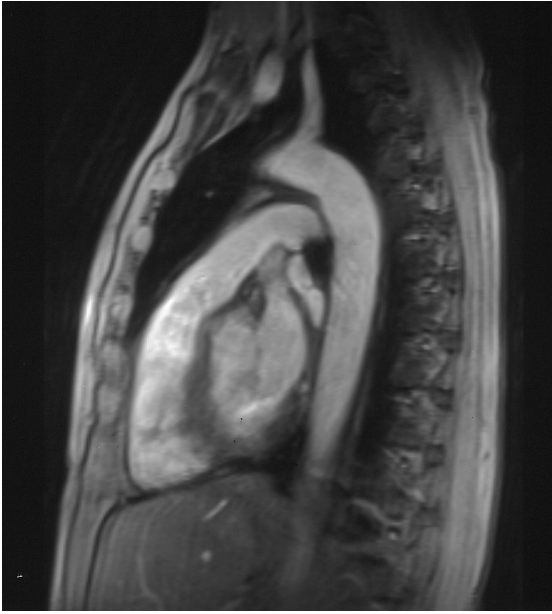
— = Borders of lung segments  
 — = Pericardium

1. Thyroid gland
2. Sternothyroid, sternohyoid, omohyoid muscles
3. Sternocleidomastoid muscle
4. Common carotid artery
5. Clavicle
6. Sternoclavicular joint
7. Left brachiocephalic vein
8. Sternum (manubrium)

9. Left lung
10. Ascending aorta
11. Pectoralis major muscle
12. Pulmonary trunk
13. Left coronary artery
14. Aortic bulb
15. Aortic valve
16. Right ventricle
17. Left ventricle



- |                                                        |                                        |
|--------------------------------------------------------|----------------------------------------|
| 18. Right atrioventricular (tricuspid) valve           | 34. Transverse sinus of pericardium    |
| 19. Anterior papillary muscle                          | 35. Left atrium                        |
| 20. Rectus abdominis muscle                            | 36. Pericardium                        |
| 21. Diaphragm                                          | 37. Descending aorta                   |
| 22. Liver                                              | 38. Coronary sinus                     |
| 23. Semispinalis capitis muscle                        | 39. Erector spinae muscle              |
| 24. Splenius cervicis and capitis muscle               | 40. Intervertebral space               |
| 25. Esophagus                                          | 41. Anterior longitudinal ligament     |
| 26. Trapezius muscle                                   | 42. Inferior surface of vertebral body |
| 27. Posterior serratus muscle                          | 43. Superior surface of vertebral body |
| 28. Subclavian artery                                  | 44. Lumbar vertebra (L1)               |
| 29. Rhomboid major muscle                              | 45. Thyroid lymph nodes                |
| 30. Semispinalis thoracis muscle and multifidus muscle | 46. Deep cervical lymph nodes          |
| 31. Aorticopulmonary window                            | 47. Parasternal lymph nodes            |
| 32. Ligamenta flava                                    | 48. Anterior mediastinal lymph nodes   |
| 33. Left main stem bronchus                            | 49. Bronchopulmonary lymph nodes       |
|                                                        | 50. Tracheobronchial lymph nodes       |
|                                                        | 51. Subpericardial adipose tissue      |
|                                                        | 52. Prevertebral lymph nodes           |

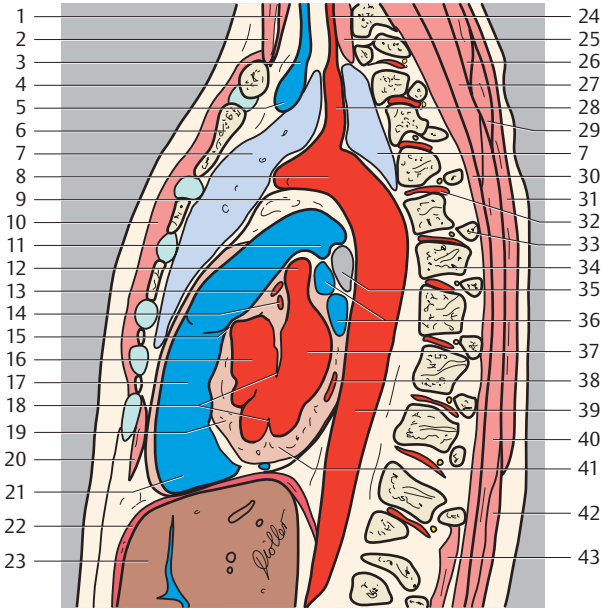


— = Borders of lung segments  
 — = Pericardium

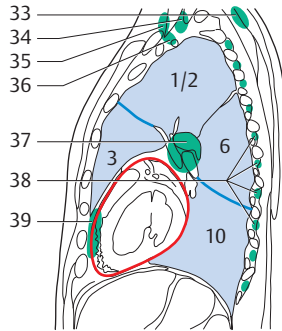
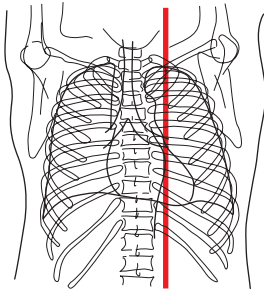
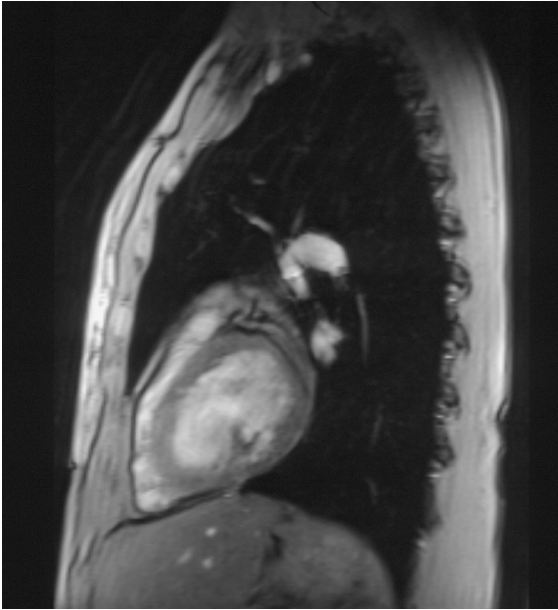
(Segments of the lung, see page 2)

1. Thyroid gland
2. Sternocleidomastoid muscle
3. Left internal jugular vein
4. Clavicle
5. Left brachiocephalic vein
6. Sternum (manubrium)
7. Left lung
8. Aortic arch

9. Aorticopulmonary window
10. Pectoralis major muscle
11. Left pulmonary artery
12. Left auricle
13. Left coronary artery (anterior interventricular branch)
14. Left coronary artery (circumflex branch)



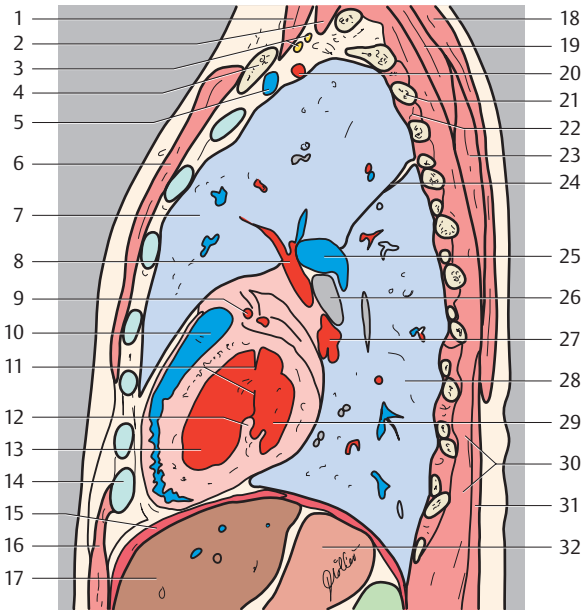
- |                                                                  |                                       |
|------------------------------------------------------------------|---------------------------------------|
| 15. Valve of pulmonary trunk                                     | 32. Posterior intercostal artery      |
| 16. Left ventricle                                               | 33. Head of rib                       |
| 17. Conus arteriosus                                             | 34. Thoracic vertebra                 |
| 18. Left atrioventricular (mitral) valve                         | 35. Left main stem bronchus           |
| 19. Interventricular septum                                      | 36. Pulmonary veins                   |
| 20. Rectus abdominis muscle                                      | 37. Left atrium                       |
| 21. Right ventricle                                              | 38. Coronary sinus                    |
| 22. Diaphragm                                                    | 39. Descending aorta                  |
| 23. Liver                                                        | 40. Erector spinae muscle             |
| 24. Vertebral artery                                             | 41. Myocardium                        |
| 25. Longus colli muscle                                          | 42. Latissimus dorsi muscle           |
| 26. Splenius cervicis and capitis muscle                         | 43. Intercostal muscle                |
| 27. Semispinalis cervicis muscle                                 | 44. Superficial cervical lymph nodes  |
| 28. Subclavian artery                                            | 45. Deep cervical lymph nodes         |
| 29. Serratus posterior superior muscle and rhomboid major muscle | 46. Posterior intercostal lymph nodes |
| 30. Semispinalis thoracis muscle and multifidus muscle           | 47. Parasternal lymph nodes           |
| 31. Trapezius muscle                                             | 48. Aortopulmonal lymph nodes         |
|                                                                  | 49. Anterior mediastinal lymph nodes  |
|                                                                  | 50. Bronchopulmonal lymph nodes       |
|                                                                  | 51. Paravertebral lymph nodes         |



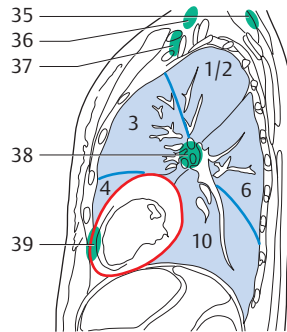
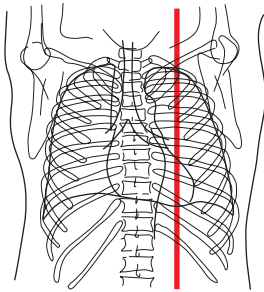
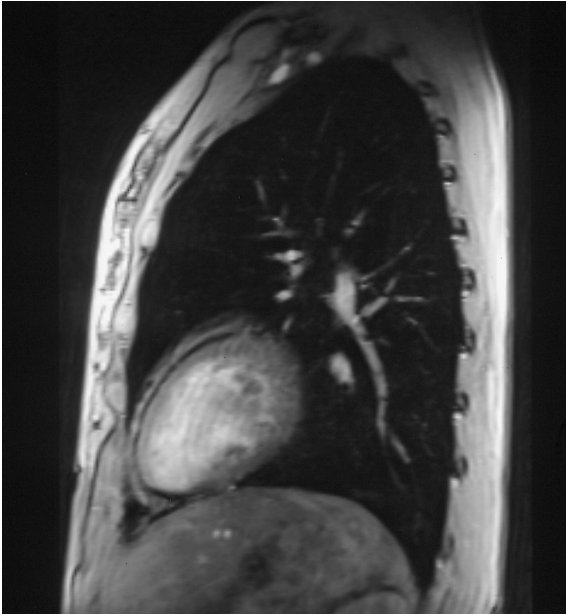— = Borders of lung segments  
 — = Pericardium

**Left Lung**

- 1+2. Apicoposterior segment of upper lobe
- 3. Anterior segment of upper lobe
- 6. Superior segment of lower lobe
- 10. Posterior basal segment of lower lobe



- |                                          |                                                                  |
|------------------------------------------|------------------------------------------------------------------|
| 1. Anterior scalene muscle               | 21. Rib 3                                                        |
| 2. Posterior scalene muscle              | 22. Intercostal muscle                                           |
| 3. Brachial plexus                       | 23. Serratus posterior superior muscle and rhomboid major muscle |
| 4. Clavicle                              | 24. Oblique fissure                                              |
| 5. Subclavian vein                       | 25. Left pulmonary artery                                        |
| 6. Pectoralis major muscle               | 26. Left main stem bronchus                                      |
| 7. Left lung (upper lobe)                | 27. Left inferior pulmonary vein                                 |
| 8. Left pulmonary vein                   | 28. Left lung (inferior lobe)                                    |
| 9. Left coronary artery                  | 29. Left atrium                                                  |
| 10. Right ventricle                      | 30. Semispinalis thoracis muscle and multifidus muscle           |
| 11. Left atrioventricular (mitral) valve | 31. Latissimus dorsi muscle                                      |
| 12. Posterior papillary muscle           | 32. Stomach                                                      |
| 13. Left ventricle                       | 33. Nuchal lymph nodes                                           |
| 14. Costal cartilage (Rib 7)             | 34. Deep cervical lymph nodes                                    |
| 15. Diaphragm                            | 35. Superficial cervical lymph nodes                             |
| 16. Rectus abdominis muscle              | 36. Supraclavicular lymph nodes                                  |
| 17. Liver                                | 37. Pulmonary lymph nodes                                        |
| 18. Trapezius muscle                     | 38. Intercostal lymph nodes                                      |
| 19. Splenius cervicis and capitis muscle | 39. Prepericardial lymph nodes                                   |
| 20. Subclavian artery                    |                                                                  |



— = Borders of lung segment

— = Pericardium

#### Left Lung

1+2. Apicoposterior segment of upper lobe

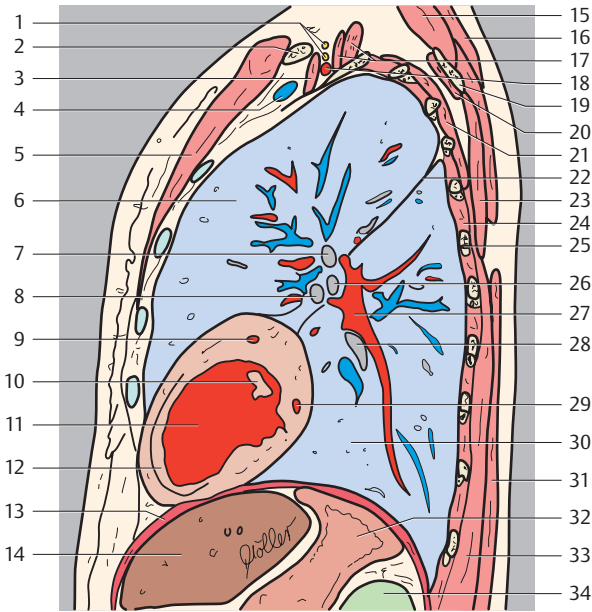
3. Anterior segment of upper lobe

4. Superior lingular segment

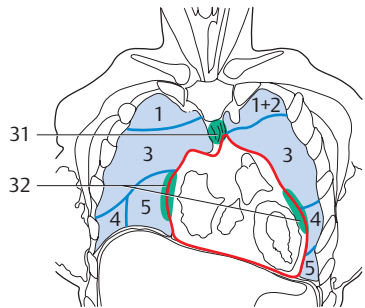
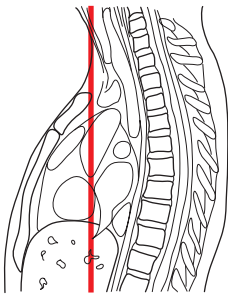
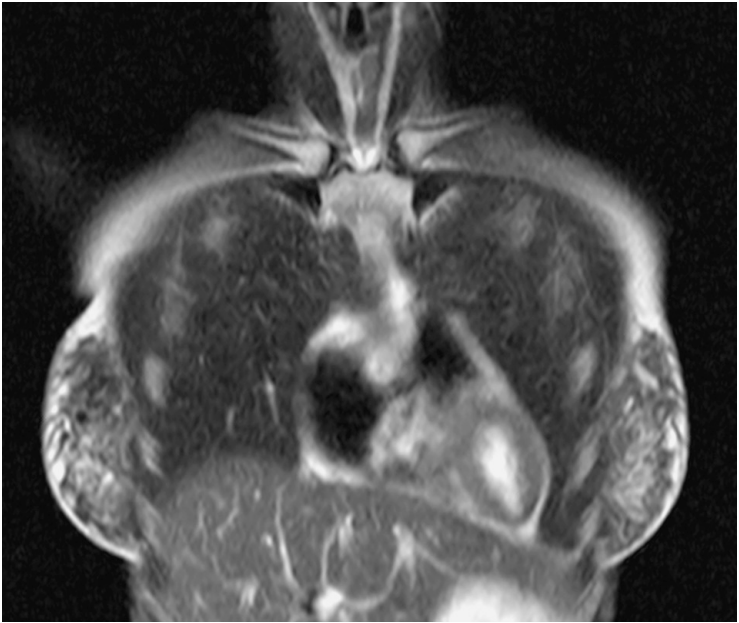
6. Superior segment of lower lobe

10. Posterior basal segment of lower lobe





- |                                                             |                                                        |
|-------------------------------------------------------------|--------------------------------------------------------|
| 1. Brachial plexus                                          | 21. Serratus anterior muscle                           |
| 2. Clavicle                                                 | 22. Oblique fissure                                    |
| 3. Anterior scalene muscle                                  | 23. Rhomboid major muscle                              |
| 4. Subclavian vein                                          | 24. Intercostal muscle                                 |
| 5. Pectoralis major muscle                                  | 25. Rib 6                                              |
| 6. Left lung (upper lobe)                                   | 26. Superior lingular bronchus                         |
| 7. Left superior lobar bronchus                             | 27. Left inferior pulmonary vein                       |
| 8. Inferior lingular bronchus                               | 28. Left inferior lobar bronchus                       |
| 9. Left coronary artery (anterior inter-ventricular branch) | 29. Left coronary artery (circumflex branch)           |
| 10. Anterior papillary muscle                               | 30. Left lung (lower lobe)                             |
| 11. Left ventricle                                          | 31. Latissimus dorsi muscle                            |
| 12. Interventricular septum                                 | 32. Stomach                                            |
| 13. Diaphragm                                               | 33. Semispinalis thoracis muscle and multifidus muscle |
| 14. Liver                                                   | 34. Left kidney                                        |
| 15. Levator scapulae muscle                                 | 35. Nuchal lymph nodes                                 |
| 16. Trapezius muscle                                        | 36. Superficial cervical lymph nodes                   |
| 17. Medial and posterior scalene muscles                    | 37. Supraclavicular lymph nodes                        |
| 18. Subclavian artery                                       | 38. Pulmonal lymph nodes                               |
| 19. Scapula                                                 | 39. Prepericardial lymph nodes                         |
| 20. Posterior serratus muscle                               |                                                        |



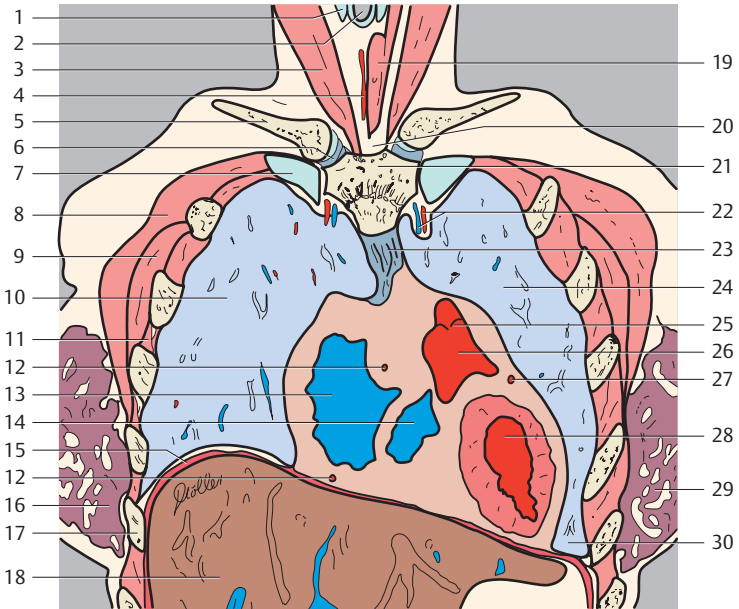
— = Borders of lung segments  
 — = Pericardium

#### Right Lung

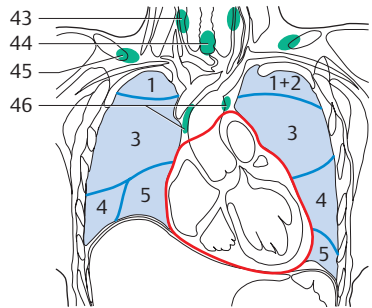
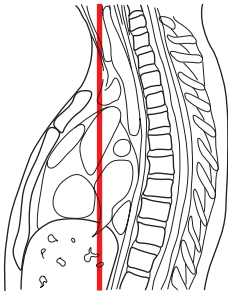
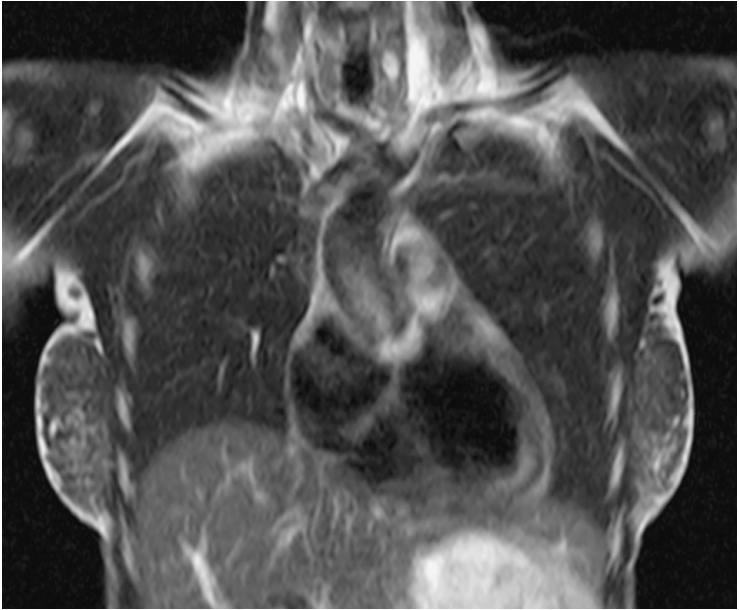
1. Apical segment of upper lobe
3. Anterior segment of upper lobe
4. Lateral segment of middle lobe
5. Medial segment of middle lobe

#### Left Lung

- 1+2. Apicoposterior segment of upper lobe
3. Anterior segment of upper lobe
4. Superior lingular segment
5. Inferior lingular segment



- |                                     |                                                     |
|-------------------------------------|-----------------------------------------------------|
| 1. Thyroid cartilage                | 18. Liver                                           |
| 2. Trachea                          | 19. Omohyoid, sternothyroid and sternohyoid muscles |
| 3. Sternocleidomastoid muscle       | 20. Jugular notch                                   |
| 4. Thyroid ima artery               | 21. Sternum                                         |
| 5. Clavicle                         | 22. Internal thoracic artery and vein               |
| 6. Sternoclavicular joint           | 23. Sternopericardial ligaments                     |
| 7. Rib 1                            | 24. Left lung                                       |
| 8. Pectoralis major muscle          | 25. Valve of pulmonary trunk                        |
| 9. Pectoralis minor muscle          | 26. Conus arteriosus                                |
| 10. Right lung                      | 27. Circumflex branch of left coronary artery       |
| 11. Intercostal muscle              | 28. Left ventricle                                  |
| 12. Right coronary artery           | 29. Left breast (glandular tissue)                  |
| 13. Right atrium                    | 30. Phrenicomedastinal recess                       |
| 14. Right ventricle                 | 31. Anterior mediastinal lymph nodes                |
| 15. Diaphragm                       | 32. Lateral pericardial lymph nodes                 |
| 16. Right breast (glandular tissue) |                                                     |
| 17. Rib 6                           |                                                     |



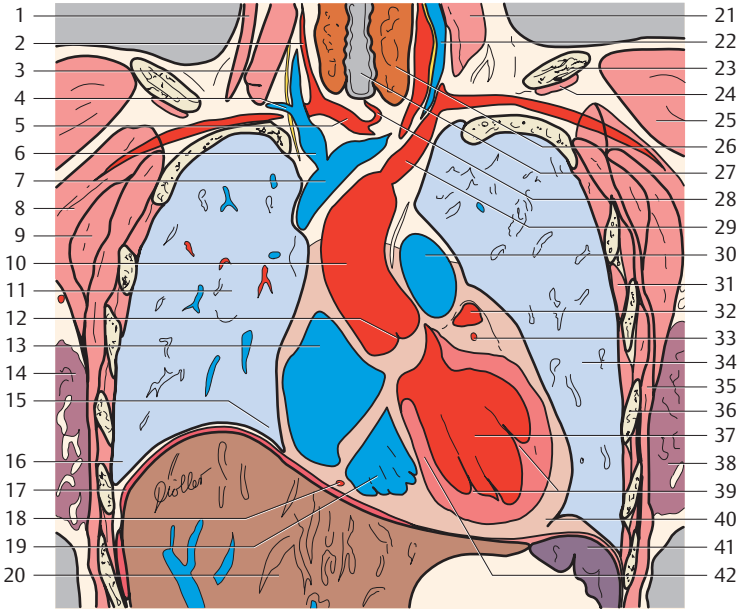
— = Borders of lung segments

— = Pericardium

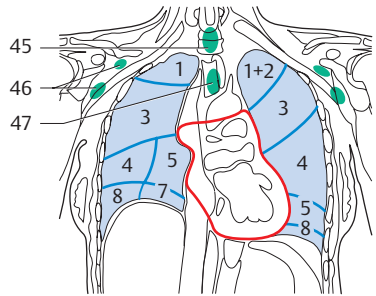
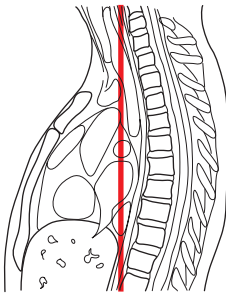
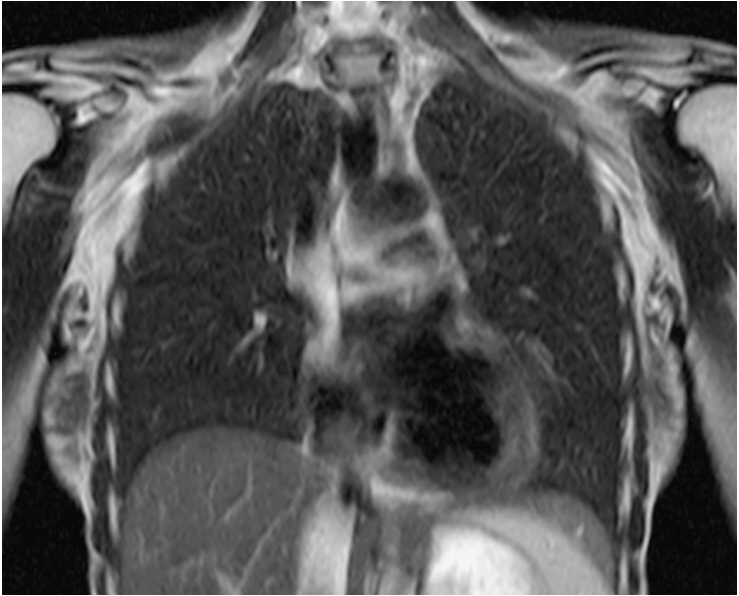
(Segments of the lungs, see page 2)

1. Sternocleidomastoid muscle
2. Right common carotid artery
3. Phrenic nerve
4. Subclavian artery and vein
5. Brachiocephalic trunk
6. Right brachiocephalic vein

7. Superior vena cava
8. Pectoralis major muscle
9. Pectoralis minor muscle
10. Ascending aorta
11. Right lung
12. Aortic valve



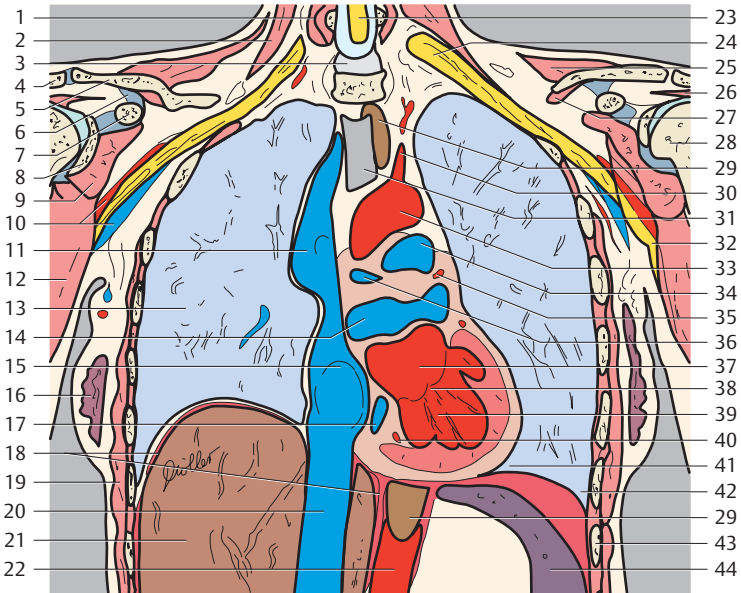
- |                                       |                                               |
|---------------------------------------|-----------------------------------------------|
| 13. Right atrium                      | 31. Intercostal muscle                        |
| 14. Right breast (glandular tissue)   | 32. Left auricle                              |
| 15. Phrenicmediastinal recess         | 33. Circumflex branch of left coronary artery |
| 16. Costodiaphragmatic recess         | 34. Left lung                                 |
| 17. Diaphragm                         | 35. Serratus anterior muscle                  |
| 18. Right coronary artery             | 36. Rib 5                                     |
| 19. Right ventricle                   | 37. Left ventricle                            |
| 20. Liver                             | 38. Left breast (glandular tissue)            |
| 21. Anterior scalene muscle           | 39. Papillary muscle of the left ventricle    |
| 22. Jugular vein and vertebral artery | 40. Apex of heart                             |
| 23. Clavicle                          | 41. Spleen                                    |
| 24. Subclavius muscle                 | 42. Interventricular septum                   |
| 25. Deltoid muscle                    | 43. Superficial cervical lymph nodes          |
| 26. Thyroid gland                     | 44. Paratracheal lymph nodes                  |
| 27. Trachea                           | 45. Supraclavicular lymph nodes               |
| 28. Thyroidea ima artery              | 46. Anterior mediastinal lymph nodes          |
| 29. Left subclavian artery            |                                               |
| 30. Pulmonary trunk                   |                                               |



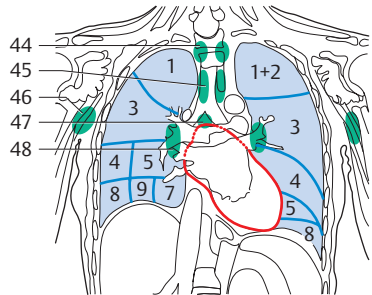
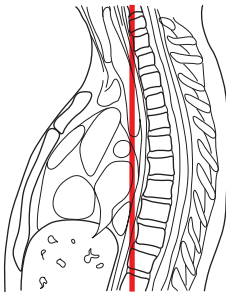
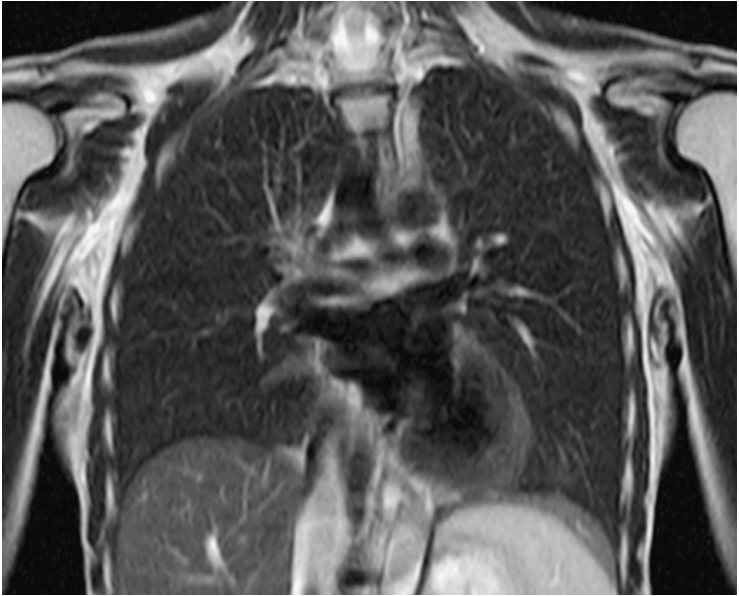
— = Borders of lung segments  
 — = Pericardium

(Segments of the lungs, see page 2)

1. Longus colli muscle
2. Medial und posterior scalene muscles
3. Intervertebral disk and anterior longitudinal ligament
4. Scapula
5. Clavicle



- |                                                      |                                               |
|------------------------------------------------------|-----------------------------------------------|
| 6. Coracoclavicular ligament                         | 27. Subclavius muscle                         |
| 7. Coracoid process                                  | 28. Head of humerus                           |
| 8. Glenoid cavity (articular cavity of the shoulder) | 29. Esophagus                                 |
| 9. Subscapularis muscle                              | 30. Common carotid artery                     |
| 10. Axillary artery and vein                         | 31. Trachea                                   |
| 11. Superior vena cava (with azygos vein)            | 32. Axillary nerve                            |
| 12. Teres major muscle                               | 33. Aortic arch                               |
| 13. Right lung                                       | 34. Pulmonary trunk                           |
| 14. Pulmonary veins                                  | 35. Left coronary artery                      |
| 15. Right atrium (with oval fossa)                   | 36. Right pulmonary artery                    |
| 16. Right breast (glandular tissue)                  | 37. Left atrium                               |
| 17. Coronary sinus                                   | 38. Left atrioventricular (mitral) valve      |
| 18. Diaphragm                                        | 39. Left ventricle                            |
| 19. Serratus anterior muscle                         | 40. Right coronary artery                     |
| 20. Inferior vena cava                               | 41. Sinus phrenicomedialastinalis             |
| 21. Liver                                            | 42. Costodiaphragmatic recess                 |
| 22. Abdominal aorta                                  | 43. Rib 6                                     |
| 23. Spinal cord                                      | 44. Spleen                                    |
| 24. Cervical plexus                                  | 45. Prevertebral lymph nodes                  |
| 25. Trapezius muscle                                 | 46. Superficial and deep axillary lymph nodes |
| 26. Supraspinatus muscle                             | 47. Paratracheal lymph nodes                  |



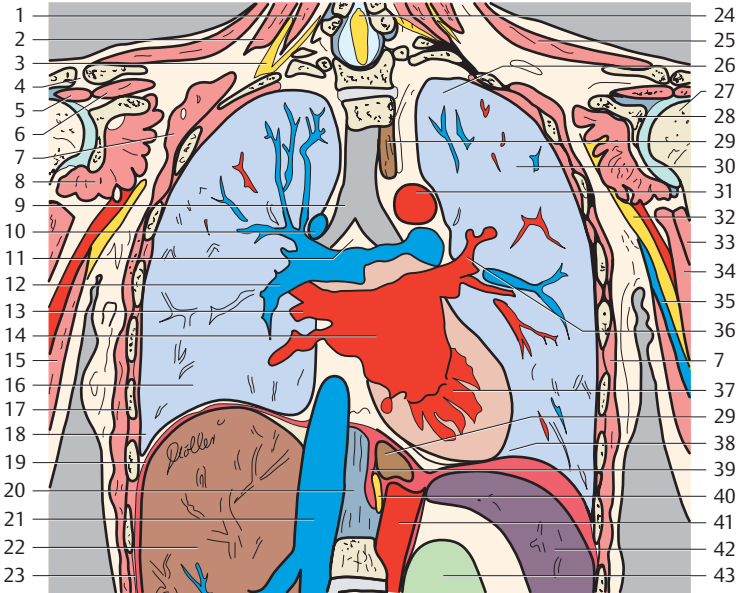
— = Borders of lung segments  
 — = Pericardium

(Segments of the lungs, see page 2)

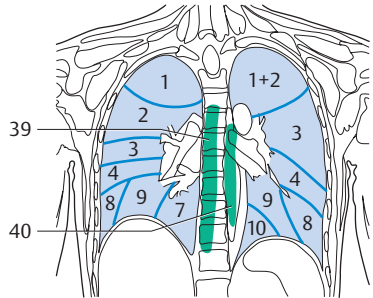
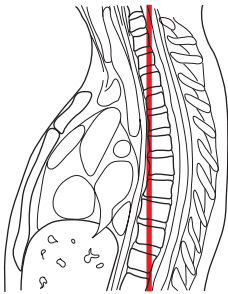
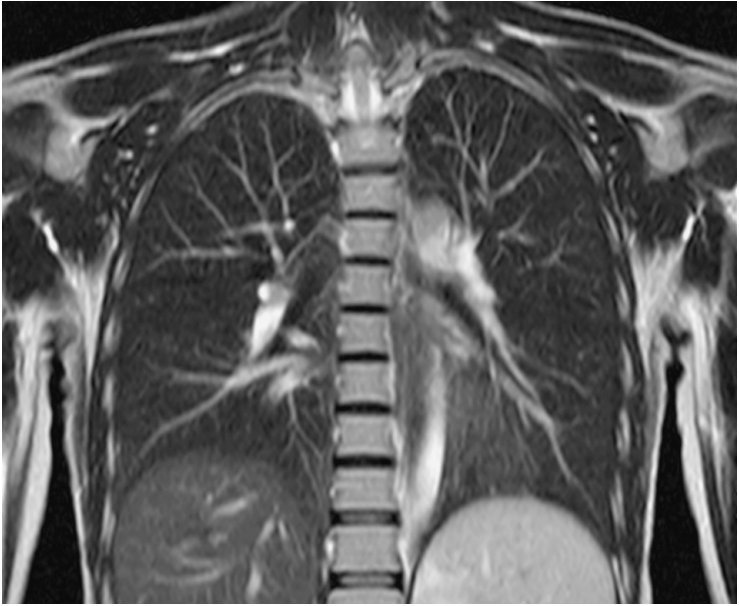
1. Longus colli muscle
2. Posterior scalene muscle
3. Cervical plexus
4. Acromioclavicular joint
5. Infraspinatus muscle
6. Supraspinatus muscle

7. Serratus anterior muscle
8. Subscapularis muscle
9. Trachea
10. Azygos vein
11. Aorticopulmonary window
12. Right pulmonary artery





- |                                                       |                                   |
|-------------------------------------------------------|-----------------------------------|
| 13. Right pulmonary vein                              | 31. Aortic arch                   |
| 14. Left atrium                                       | 32. Median nerve                  |
| 15. Triceps muscle                                    | 33. Biceps muscle                 |
| 16. Right lung                                        | 34. Coracobrachial muscle         |
| 17. Rib 7                                             | 35. Basilic vein                  |
| 18. Costodiaphragmatic recess                         | 36. Left pulmonary vein           |
| 19. Diaphragm                                         | 37. Left ventricle                |
| 20. Anterior longitudinal ligament                    | 38. Phrenicomedial recess         |
| 21. Inferior vena cava                                | 39. Diaphragm                     |
| 22. Liver                                             | 40. Vagal trunk and thoracic duct |
| 23. Intercostal muscle                                | 41. Abdominal aorta               |
| 24. Spinal cord                                       | 42. Spleen                        |
| 25. Trapezius muscle                                  | 43. Kidney                        |
| 26. Apical part of lung                               | 44. Prevertebral lymph nodes      |
| 27. Head of humerus                                   | 45. Paratracheal lymph nodes      |
| 28. Glenoid cavity (articular cavity of the shoulder) | 46. Axillary lymph nodes          |
| 29. Esophagus                                         | 47. Aortopulmonary lymph nodes    |
| 30. Left lung                                         | 48. Bronchopulmonary lymph nodes  |

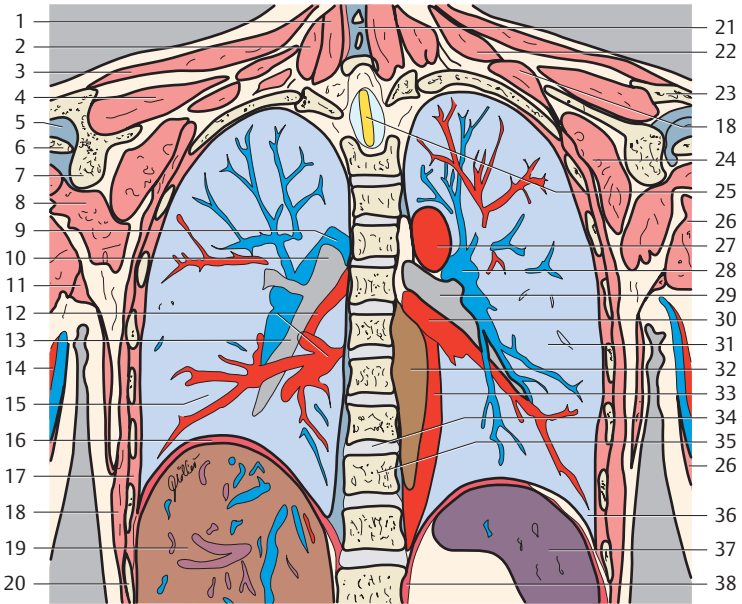


#### Right Lung

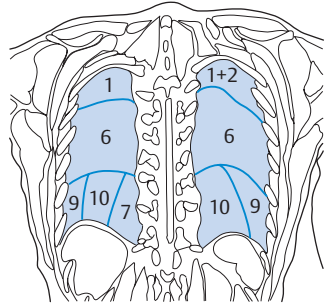
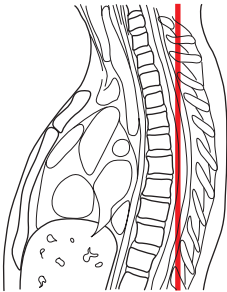
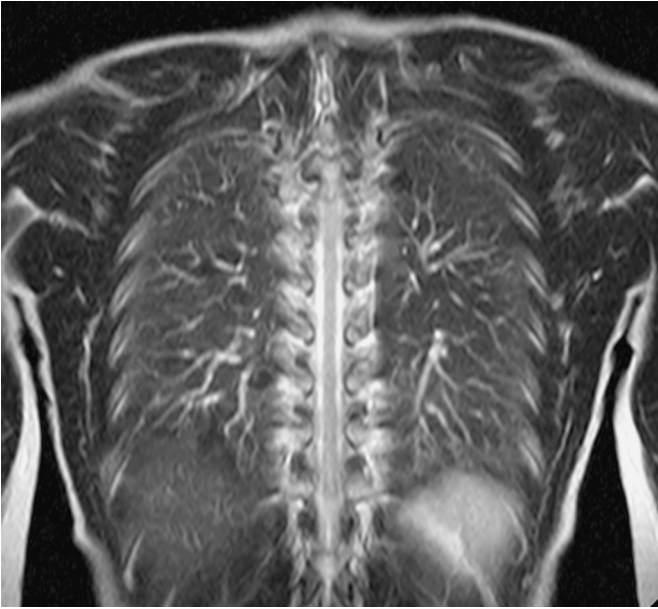
1. Apical segment of upper lobe
2. Posterior segment of upper lobe
3. Anterior segment of upper lobe
4. Lateral segment of middle lobe
7. Medial basal (cardiac) segment of lower lobe
8. Anterior basal segment of lower lobe
9. Lateral basal segment of lower lobe

#### Left Lung

- 1+2. Apicoposterior segment of upper lobe
3. Anterior segment of upper lobe
4. Superior lingular segment
8. Anterior basal segment of lower lobe
9. Lateral basal segment of lower lobe
10. Posterior basal segment of lower lobe



- |                                                      |                                              |
|------------------------------------------------------|----------------------------------------------|
| 1. Multifidus muscle                                 | 21. Spinous process and interspinal ligament |
| 2. Semispinalis cervicis muscle                      | 22. Levator scapulae muscle                  |
| 3. Trapezius muscle                                  | 23. Spine of scapula                         |
| 4. Supraspinatus muscle                              | 24. Subscapularis muscle                     |
| 5. Shoulder (glenohumeral) joint                     | 25. Spinal cord                              |
| 6. Head of humerus                                   | 26. Triceps muscle                           |
| 7. Glenoid cavity (articular cavity of the shoulder) | 27. Aortic arch                              |
| 8. Teres minor muscle                                | 28. Left pulmonary artery                    |
| 9. Right pulmonary artery                            | 29. Left main stem bronchus                  |
| 10. Right main stem bronchus                         | 30. Left pulmonary vein                      |
| 11. Latissimus dorsi muscle                          | 31. Left lung                                |
| 12. Right pulmonary veins                            | 32. Esophagus                                |
| 13. Right inferior lobar bronchus                    | 33. Descending aorta                         |
| 14. Brachial artery and vein                         | 34. Intervertebral disk (T9-T10)             |
| 15. Right lung                                       | 35. Thoracic vertebra (T10)                  |
| 16. Diaphragm                                        | 36. Costodiaphragmatic recess                |
| 17. Intercostal muscle                               | 37. Spleen                                   |
| 18. Serratus anterior muscle                         | 38. Diaphragm                                |
| 19. Liver                                            | 39. Prevertebral lymph nodes                 |
| 20. Rib 10                                           | 40. Juxtaesophageal lymph nodes              |



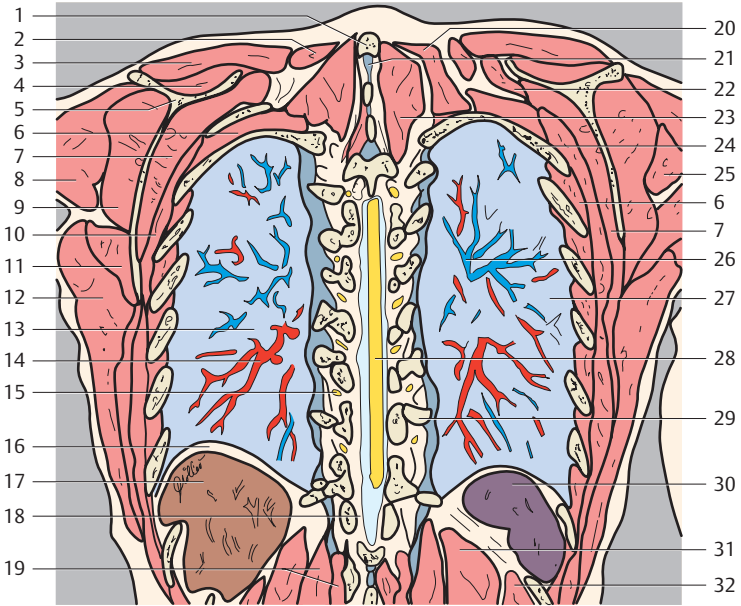
— = Borders of lung segments

#### Right Lung

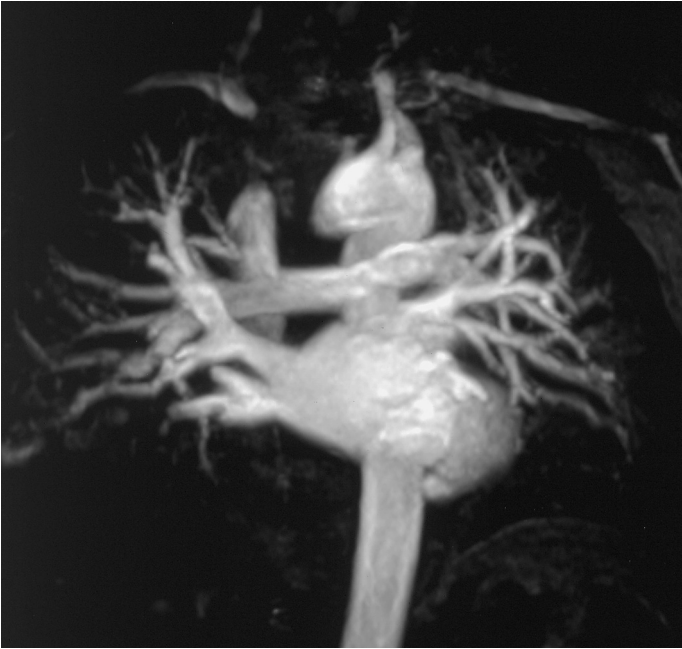1. Apical segment of upper lobe
6. Superior segment of lower lobe
7. Medial basal (cardiac) segment of lower lobe
9. Lateral basal segment of lower lobe
10. Posterior basal segment of lower lobe

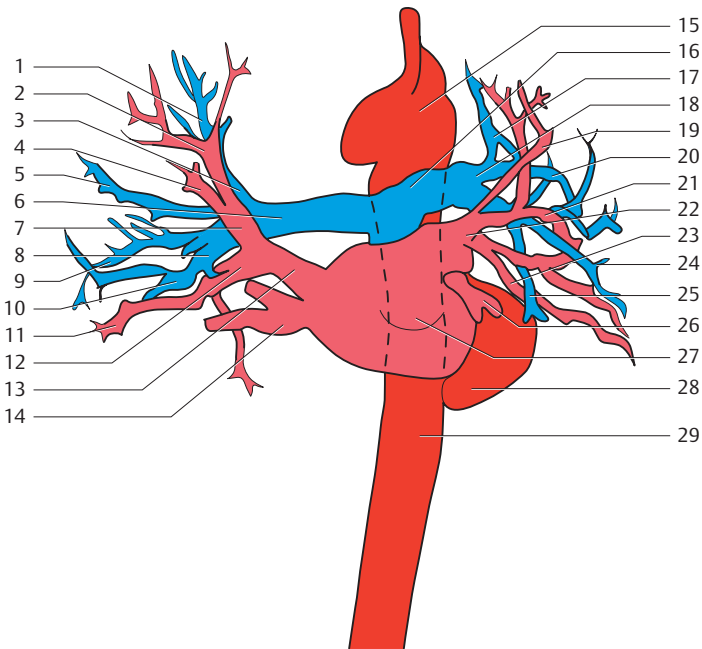
#### Left Lung

- 1+2. Apicoposterior segment of upper lobe
6. Superior segment of lower lobe
9. Lateral basal segment of lower lobe
10. Posterior basal segment of lower lobe

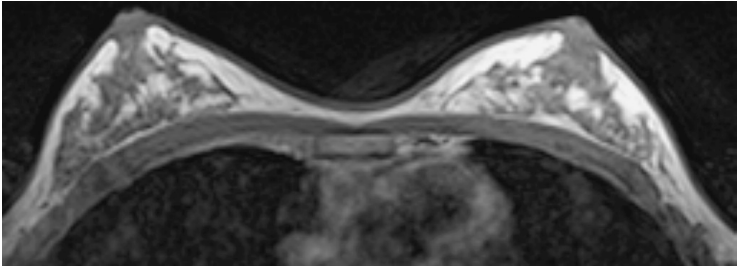


- |                              |                                                        |
|------------------------------|--------------------------------------------------------|
| 1. Spinous process (7)       | 18. Ligamenta flava                                    |
| 2. Splenius cervicis muscle  | 19. Transversospinal muscle (of erector spinae muscle) |
| 3. Trapezius muscle          | 20. Serratus posterior superior muscle                 |
| 4. Supraspinatus muscle      | 21. Interspinal ligaments                              |
| 5. Scapula                   | 22. Levator scapulae muscle                            |
| 6. Intercostal muscle        | 23. Erector spinae muscle                              |
| 7. Subscapularis muscle      | 24. Rib 3                                              |
| 8. Deltoid muscle            | 25. Teres minor muscle                                 |
| 9. Infraspinatus muscle      | 26. Pulmonary arteries                                 |
| 10. Serratus anterior muscle | 27. Left lung                                          |
| 11. Teres major muscle       | 28. Spinal cord                                        |
| 12. Latissimus dorsi muscle  | 29. Rib 9                                              |
| 13. Right lung               | 30. Spleen                                             |
| 14. Right pulmonary veins    | 31. Longissimus muscle                                 |
| 15. Spinal nerve (T9)        | 32. Iliocostalis muscle                                |
| 16. Diaphragm                |                                                        |
| 17. Liver                    |                                                        |

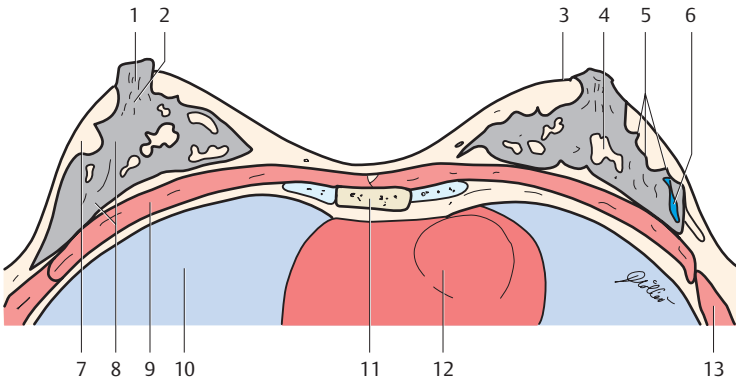




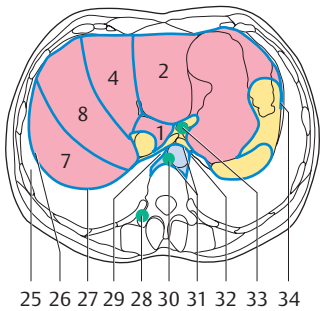
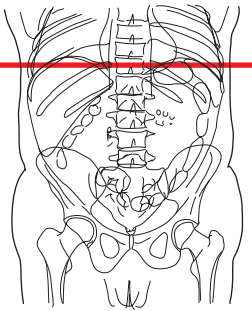
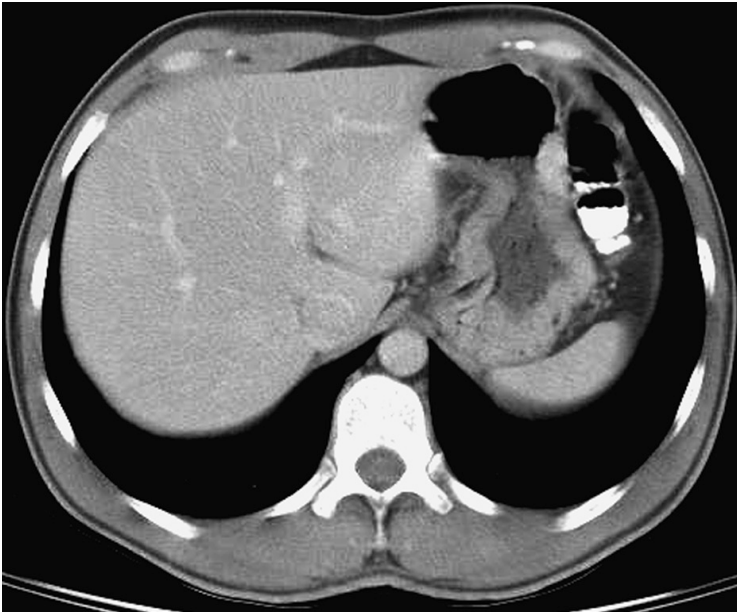
- |                                                                        |                                                               |
|------------------------------------------------------------------------|---------------------------------------------------------------|
| 1. Apical branch to the superior lobe of the right pulmonary artery    | 13. Superior right pulmonary vein                             |
| 2. Apical branch of the superior right pulmonary vein                  | 14. Inferior right pulmonary vein                             |
| 3. Ascending branch of the right pulmonary artery                      | 15. Arch of aorta                                             |
| 4. Posterior branch of the superior right pulmonary vein               | 16. Pulmonary trunk                                           |
| 5. Posterior branch to the superior lobe of the right pulmonary artery | 17. Branches to upper lobe of the left pulmonary artery       |
| 6. Right pulmonary artery                                              | 18. Left pulmonary artery                                     |
| 7. Anterior branch of the right superior pulmonary vein                | 19. Apicoposterior branch of the left superior pulmonary vein |
| 8. Basal part of the right pulmonary artery                            | 20. Lingular branch of the left pulmonary artery              |
| 9. Superior branch to the inferior lobe of the right pulmonary artery  | 21. Anterior branch of the left superior pulmonary vein       |
| 10. Anterior basal branch of the right pulmonary artery                | 22. Left superior pulmonary vein                              |
| 11. Middle lobe branch of the right pulmonary vein                     | 23. Lingular branch of the left superior pulmonary vein       |
| 12. Medial part of the middle lobe branch of the right pulmonary vein  | 24. Lateral basal branch of the left pulmonary artery         |
|                                                                        | 25. Posterior basal branch of the left pulmonary artery       |
|                                                                        | 26. Left inferior pulmonary vein                              |
|                                                                        | 27. Left atrium                                               |
|                                                                        | 28. Left ventricle                                            |
|                                                                        | 29. Descending aorta                                          |



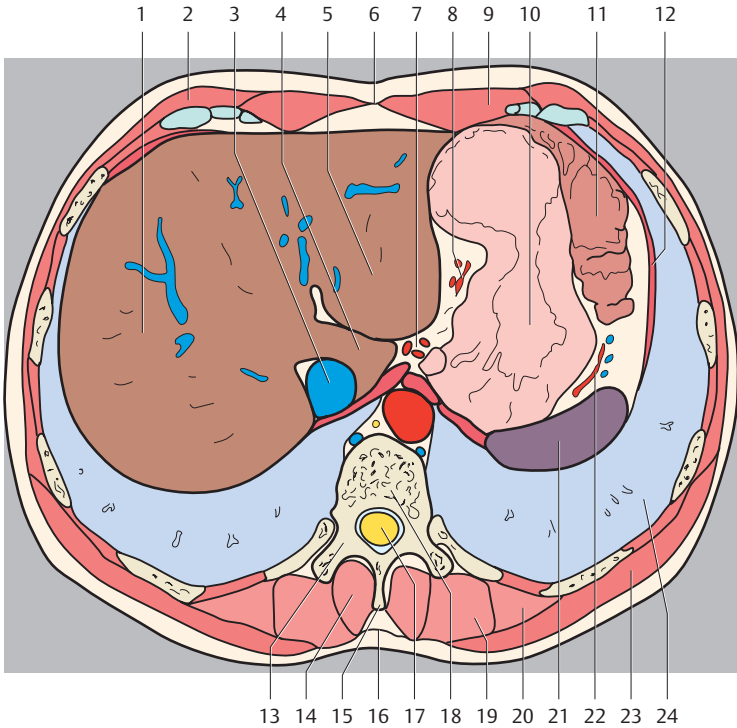




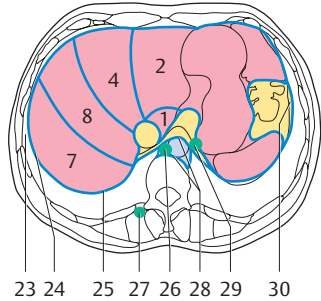
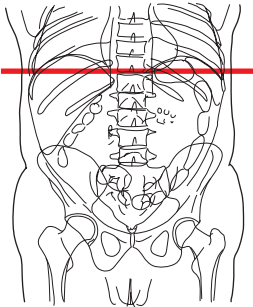
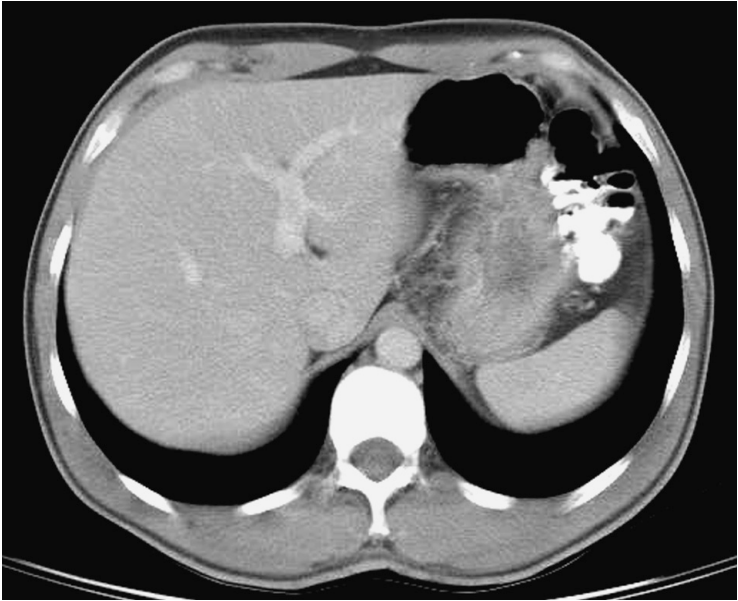
- |                                    |                              |
|------------------------------------|------------------------------|
| 1. Nipple                          | 8. Glandular body            |
| 2. Mammary ducts and areolar ducts | 9. Pectoralis muscle         |
| 3. Skin                            | 10. Right lung               |
| 4. Fatty island                    | 11. Sternum                  |
| 5. Cooper's ligaments              | 12. Heart                    |
| 6. Vein                            | 13. Anterior serratus muscle |
| 7. Subcutaneous fat                |                              |



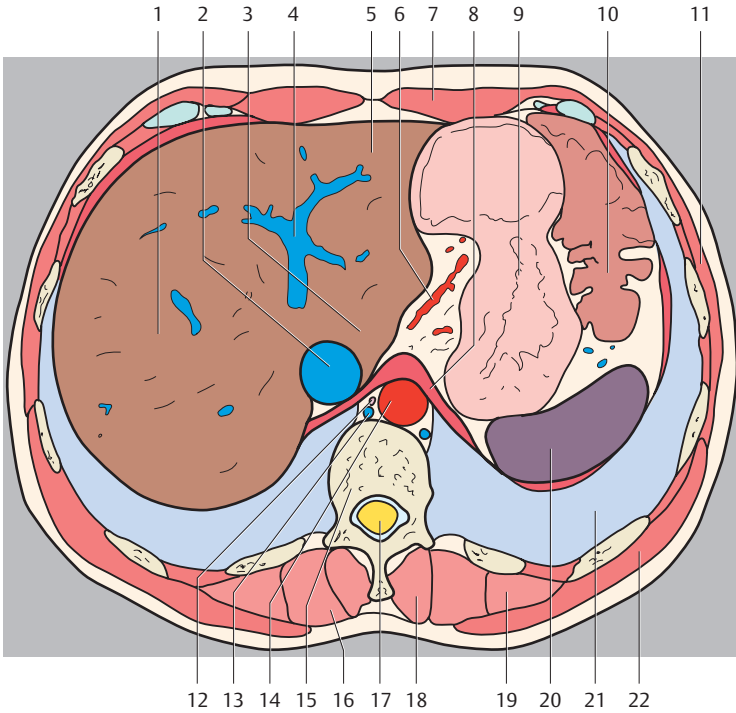
(Numbers indicate liver segments)



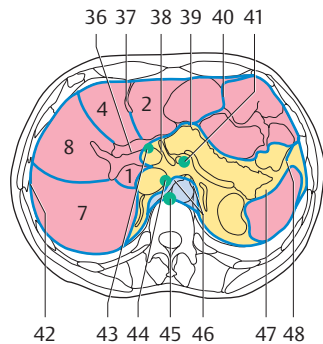
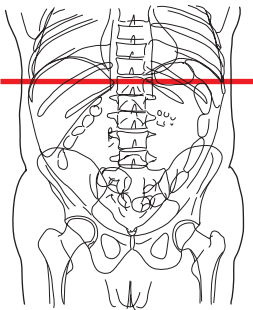
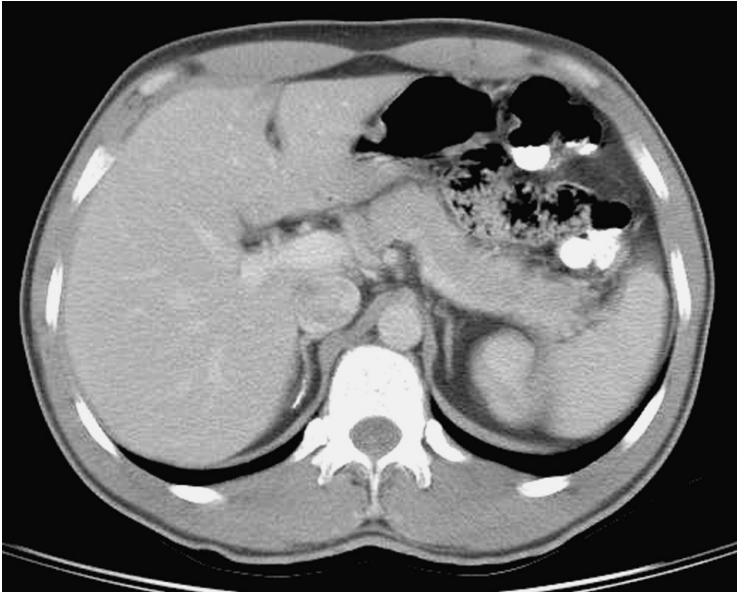
- |                                     |                                        |
|-------------------------------------|----------------------------------------|
| 1. Right lobe of liver              | 19. Longissimus thoracis muscle        |
| 2. External oblique muscle          | 20. Iliocostalis muscle, thoracic part |
| 3. Inferior vena cava               | 21. Spleen                             |
| 4. Caudate lobe of liver            | 22. Posterior gastric artery           |
| 5. Left lobe of liver               | 23. Latissimus dorsi muscle            |
| 6. Linea alba                       | 24. Left lung                          |
| 7. Coeliac trunk                    | 25. Costodiaphragmatic recess          |
| 8. Left gastric artery              | 26. Right subphrenic recess            |
| 9. Rectus abdominis muscle          | 27. Bare area of liver                 |
| 10. Stomach                         | 28. Intercostal lymph nodes            |
| 11. Left colic flexure              | 28. Ostium cardiacum                   |
| 12. Diaphragm                       | 30. Superior diaphragmatic lymph nodes |
| 13. Vertebral arch                  | 31. Posterior mediastinum              |
| 14. Spinalis muscle                 | 32. Cardiac notch                      |
| 15. Spinous process                 | 33. Inferior diaphragmatic lymph nodes |
| 16. Thoracolumbar fascia            | 34. Left paracolic gutter              |
| 17. Vertebral canal and spinal cord |                                        |
| 18. Thoracic vertebra               |                                        |



(Numbers indicate liver segments)



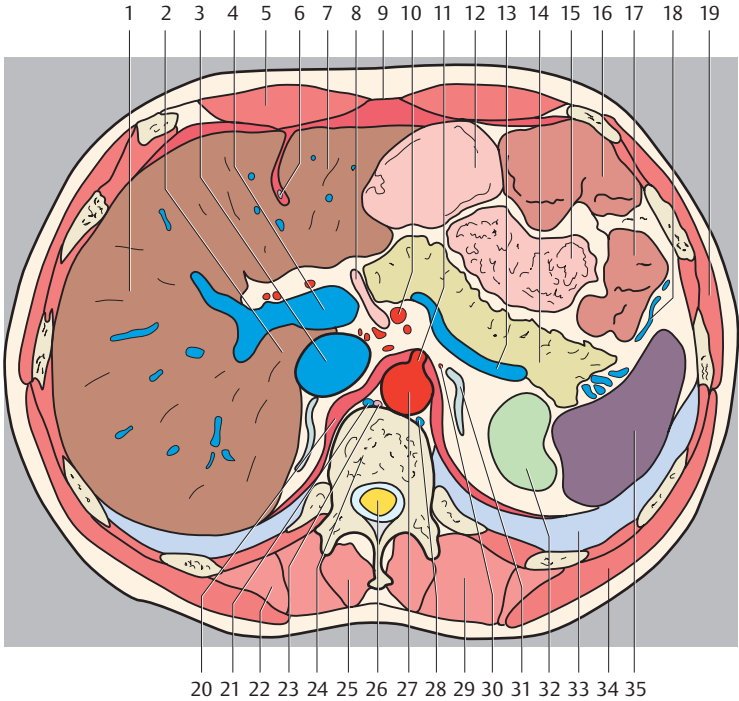
- |                                 |                                        |
|---------------------------------|----------------------------------------|
| 1. Right lobe of liver          | 17. Vertebral canal and spinal cord    |
| 2. Inferior vena cava           | 18. Spinalis muscle                    |
| 3. Caudate lobe of liver        | 19. Iliocostalis muscle, thoracic part |
| 4. Hepatic portal vein          | 20. Spleen                             |
| 5. Left lobe of liver           | 21. Left lung                          |
| 6. Left gastric artery          | 22. Latissimus dorsi muscle            |
| 7. Rectus abdominis muscle      | 23. Costodiaphragmatic recess          |
| 8. Diaphragm                    | 24. Right subphrenic recess            |
| 9. Stomach                      | 25. Bare area of liver                 |
| 10. Left colic flexure          | 26. Superior diaphragmatic lymph nodes |
| 11. External oblique muscle     | 27. Intercostal lymph nodes            |
| 12. Thoracic duct               | 28. Posterior mediastinum              |
| 13. Azygos vein                 | 29. Inferior diaphragmatic lymph nodes |
| 14. Abdominal aorta             | 30. Left paracolic gutter              |
| 15. Thoracic vertebra           |                                        |
| 16. Longissimus thoracis muscle |                                        |



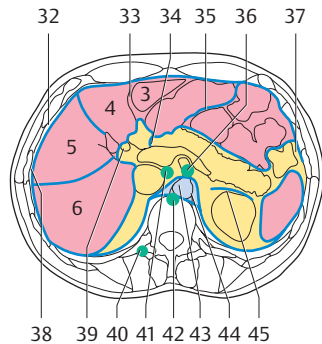
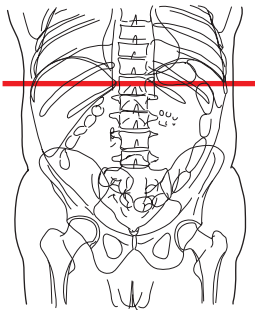
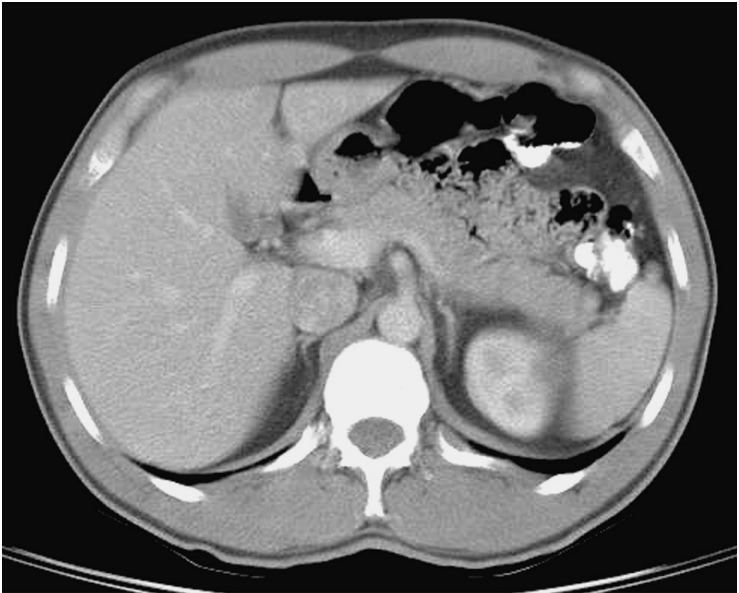
(Numbers indicate liver segments)

1. Liver (right lobe)
2. Caudate lobe of liver
3. Inferior vena cava
4. Hepatic portal vein
5. Rectus abdominis muscle

6. Round ligament of liver
7. Left lobe of liver
8. Duodenum (descending part)
9. Linea alba
10. Superior mesenteric artery



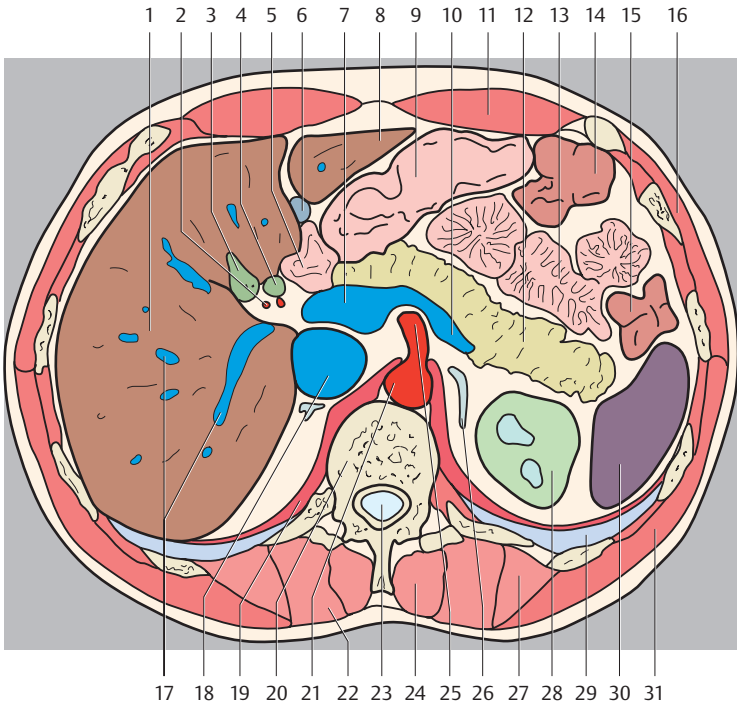
- |                                        |                                        |
|----------------------------------------|----------------------------------------|
| 11. Coeliac trunk                      | 31. Left suprarenal gland              |
| 12. Stomach                            | 32. Left kidney                        |
| 13. Splenic vein                       | 33. Left lung                          |
| 14. Pancreas                           | 34. Latissimus dorsi muscle            |
| 15. Jejunum                            | 35. Spleen                             |
| 16. Transverse colon                   | 36. Hilum of liver                     |
| 17. Descending colon                   | 37. Notch for round ligament           |
| 18. Left colic vein                    | 38. Hepatoduodenal ligament            |
| 19. External oblique muscle            | 39. Epiploic foramen                   |
| 20. Diaphragm                          | 40. Omental bursa/Greater omentum      |
| 21. Azygos vein                        | 41. Pancreatic lymph nodes             |
| 22. Iliocostalis muscle, thoracic part | 42. Right subphrenic recess            |
| 23. Thoracic duct                      | 43. Hepatic lymph nodes                |
| 24. Thoracic vertebra                  | 44. Lumbar lymph nodes                 |
| 25. Spinalis muscle                    | 45. Superior diaphragmatic lymph nodes |
| 26. Vertebral canal and spinal cord    | 46. Posterior mediastinum              |
| 27. Abdominal aorta                    | 47. Hilum of spleen                    |
| 28. Hemiazzygos vein                   | 48. Left paracolic gutter              |
| 29. Longissimus thoracis muscle        |                                        |
| 30. Suprarenal artery                  |                                        |



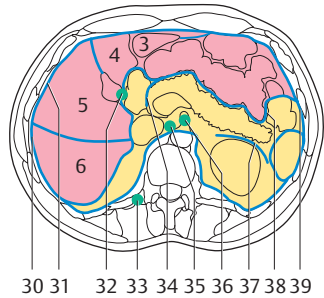
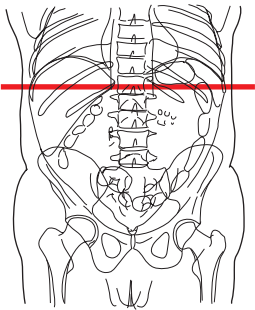
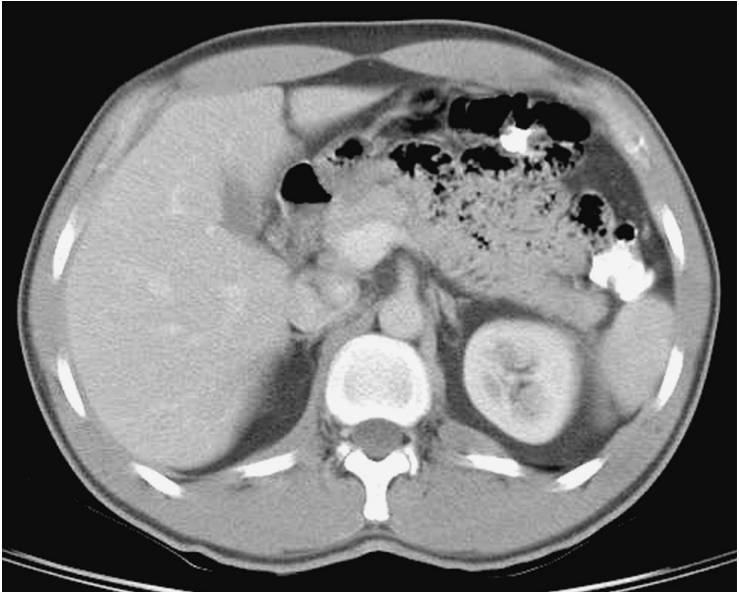
(Numbers indicate liver segments)

1. Right lobe of liver
2. Hepatic artery
3. Gallbladder
4. Bile duct
5. Duodenum (superior part)
6. Round ligament of liver

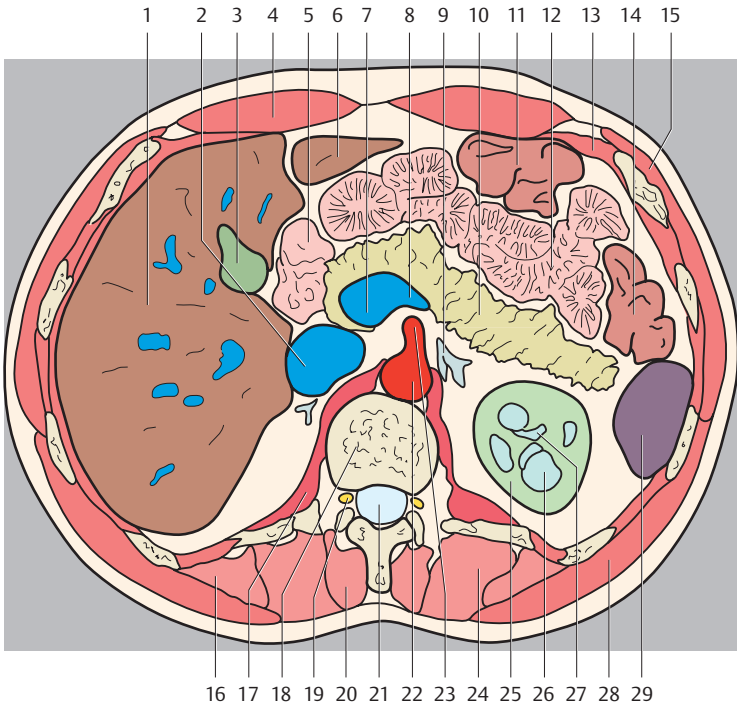




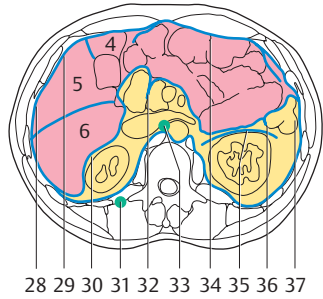
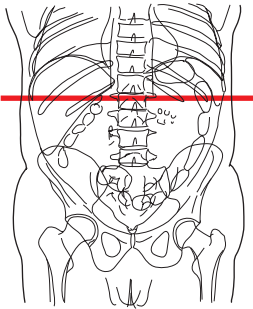
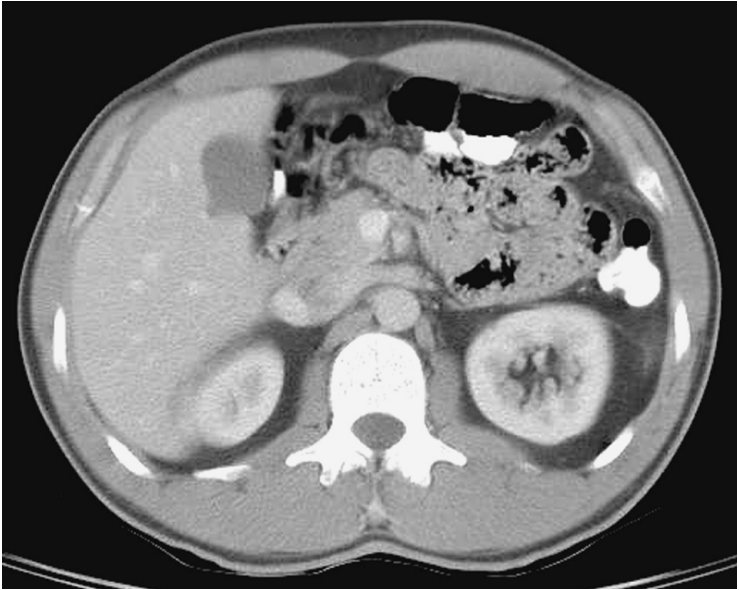- |                                 |                                        |
|---------------------------------|----------------------------------------|
| 7. Hepatic portal vein          | 27. Iliocostalis muscle, thoracic part |
| 8. Left lobe of liver           | 28. Left kidney                        |
| 9. Stomach                      | 29. Left lung                          |
| 10. Splenic vein                | 30. Spleen                             |
| 11. Rectus abdominis muscle     | 31. Latissimus dorsi muscle            |
| 12. Pancreas (tail)             | 32. Right subphrenic recess            |
| 13. Jejunum                     | 33. Notch for round ligament           |
| 14. Transverse colon            | 34. Superior duodenal recess           |
| 15. Descending colon            | 35. Greater omentum                    |
| 16. External oblique muscle     | 36. Superior mesenteric lymph nodes    |
| 17. Hepatic portal vein         | 37. Left paracolic gutter              |
| 18. Inferior vena cava          | 38. Costodiaphragmatic recess          |
| 19. Diaphragm                   | 39. Hilum of liver                     |
| 20. Thoracic vertebra           | 40. Intercostal lymph nodes            |
| 21. Abdominal aorta             | 41. Lumbar lymph nodes                 |
| 22. Longissimus thoracis muscle | 42. Superior diaphragmatic lymph nodes |
| 23. Vertebral canal             | 43. Aortic hiatus                      |
| 24. Spinalis muscle             | 44. Posterior mediastinum              |
| 25. Superior mesenteric artery  | 45. Renal fascia                       |
| 26. Left suprarenal gland       |                                        |



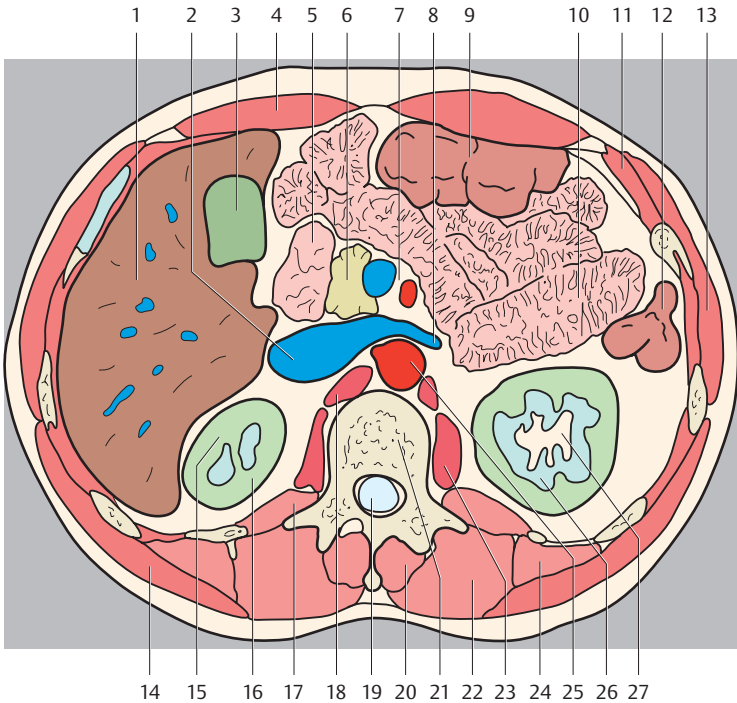
(Numbers indicate liver segments)



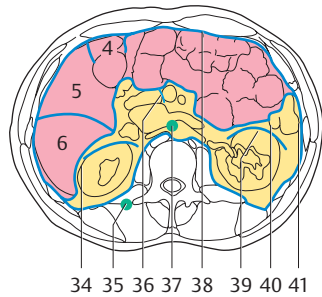
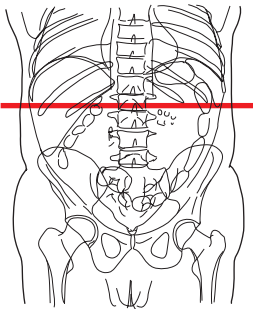
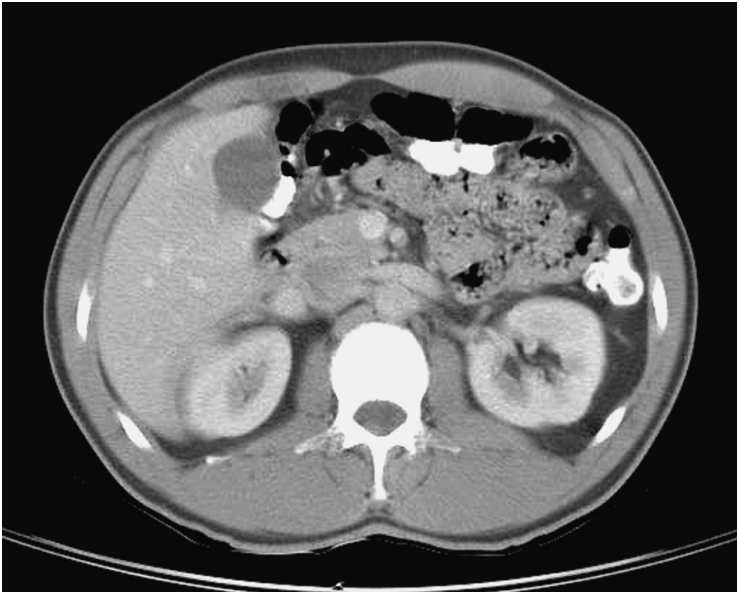
- |                                        |                                     |
|----------------------------------------|-------------------------------------|
| 1. Liver (right lobe)                  | 21. Vertebral canal                 |
| 2. Inferior vena cava                  | 22. Abdominal aorta                 |
| 3. Gallbladder                         | 23. Superior mesenteric artery      |
| 4. Rectus abdominis muscle             | 24. Longissimus thoracis muscle     |
| 5. Duodenum (descending part)          | 25. Left kidney                     |
| 6. Liver (left lobe)                   | 26. Renal pyramids                  |
| 7. Hepatic portal vein                 | 27. Renal sinus                     |
| 8. Splenic vein                        | 28. Latissimus dorsi muscle         |
| 9. Left suprarenal gland               | 29. Spleen                          |
| 10. Pancreas (body)                    | 30. Costodiaphragmatic recess       |
| 11. Transverse colon                   | 31. Subphrenic recess               |
| 12. Jejunum                            | 32. Cystic lymph nodes              |
| 13. Internal oblique muscle            | 33. Intercostal lymph nodes         |
| 14. Descending colon                   | 34. Vestibule of omental bursa      |
| 15. External oblique muscle            | 35. Lumbar lymph nodes              |
| 16. Iliocostalis muscle, thoracic part | 36. Superior mesenteric lymph nodes |
| 17. Diaphragm                          | 37. Renal fascia                    |
| 18. Thoracic vertebra                  | 38. Left mesentericocolic gutter    |
| 19. Spinal nerve                       | 39. Left paracolic gutter           |
| 20. Spinalis muscle                    |                                     |



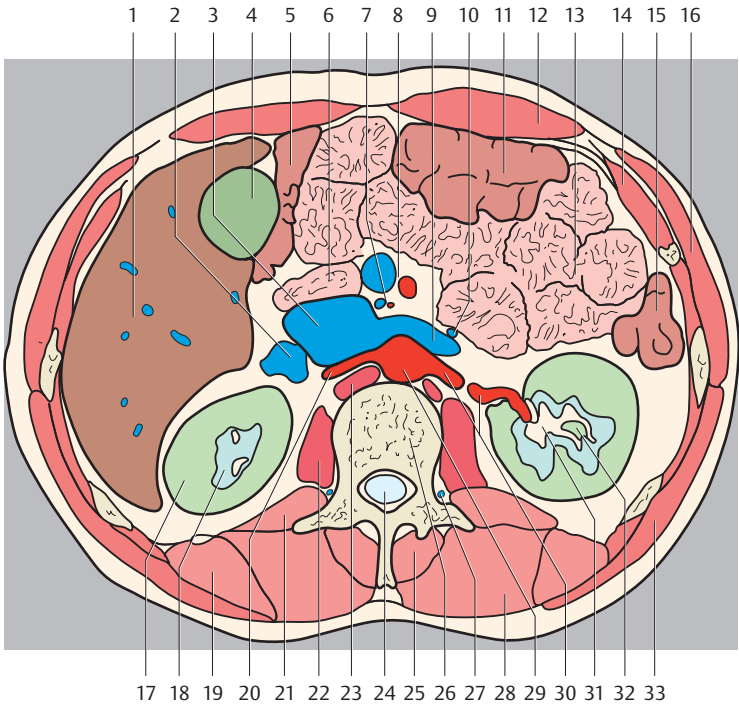
(Numbers indicate liver segments)



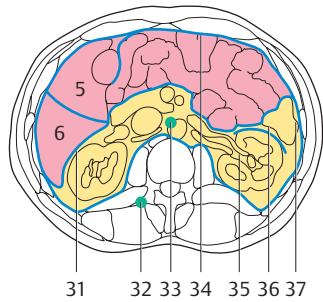
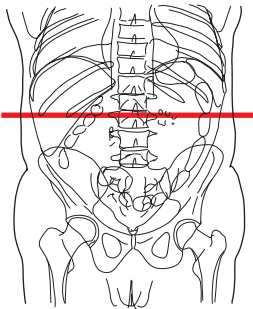
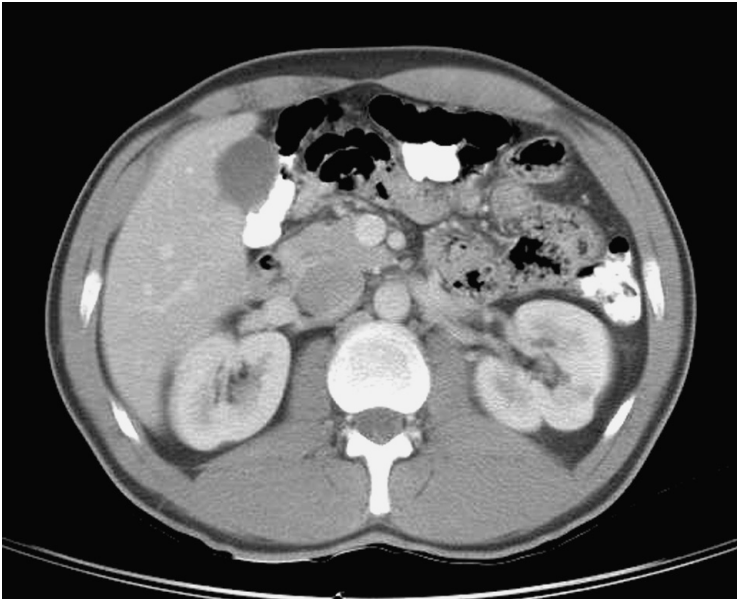
- |                                        |                                                      |
|----------------------------------------|------------------------------------------------------|
| 1. Liver                               | 20. Spinalis muscle                                  |
| 2. Inferior vena cava                  | 21. Thoracic vertebra                                |
| 3. Gallbladder                         | 22. Longissimus thoracis muscle                      |
| 4. Rectus abdominis muscle             | 23. Psoas major muscle                               |
| 5. Duodenum (descending part)          | 24. Iliocostalis muscle, thoracic part               |
| 6. Pancreas (head)                     | 25. Abdominal aorta                                  |
| 7. Superior mesenteric artery and vein | 26. Renal pyramids                                   |
| 8. Left renal vein                     | 27. Renal sinus                                      |
| 9. Transverse colon                    | 28. Costodiaphragmatic recess                        |
| 10. Jejunum                            | 29. Subphrenic recess                                |
| 11. Internal oblique muscle            | 30. Hepatorenal recess                               |
| 12. Descending colon                   | 31. Intercostal lymph nodes                          |
| 13. External oblique muscle            | 32. Inferior duodenal recess                         |
| 14. Latissimus dorsi muscle            | 33. Lumbar lymph nodes                               |
| 15. Renal cortex                       | 34. Greater omentum, omental bursa (inferior recess) |
| 16. Right kidney                       | 35. Renal fascia                                     |
| 17. Quadratus lumborum muscle          | 36. Left mesentericocolic gutter                     |
| 18. Diaphragm                          | 37. Left paracolic gutter                            |
| 19. Vertebral canal                    |                                                      |



(Numbers indicate liver segments)

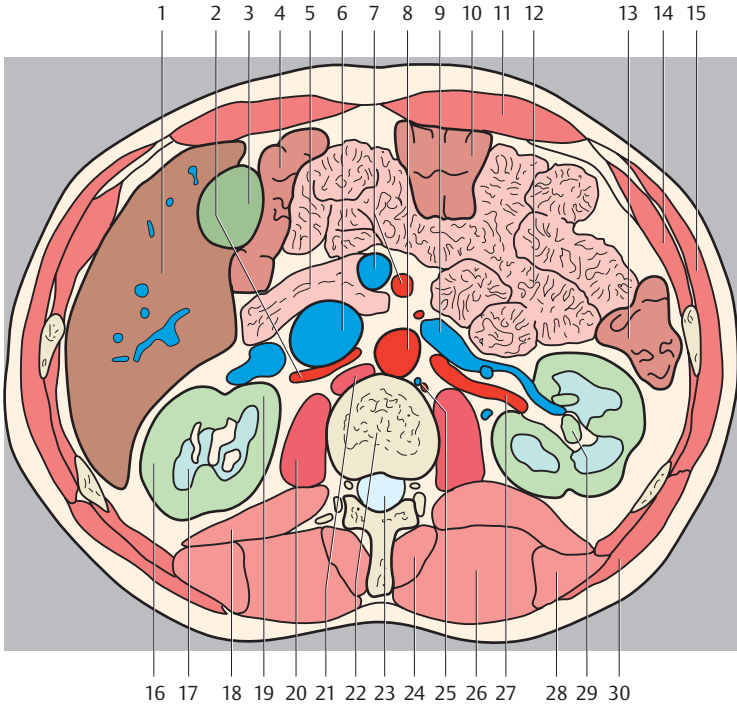


- |                                                 |                                  |
|-------------------------------------------------|----------------------------------|
| 1. Liver                                        | 21. Quadratus lumborum muscle    |
| 2. Right renal vein                             | 22. Psoas major muscle           |
| 3. Inferior vena cava                           | 23. Diaphragm                    |
| 4. Gallbladder                                  | 24. Vertebral canal              |
| 5. Right colic flexure                          | 25. Spinalis muscle              |
| 6. Duodenum                                     | 26. Thoracic vertebra            |
| 7. Inferior pancreaticoduodenal artery and vein | 27. Ascending lumbar vein        |
| 8. Superior mesenteric artery and vein          | 28. Longissimus thoracis muscle  |
| 9. Left renal vein                              | 29. Abdominal aorta              |
| 10. Inferior mesenteric vein                    | 30. Left renal artery            |
| 11. Transverse colon                            | 31. Renal sinus                  |
| 12. Rectus abdominis muscle                     | 32. Renal calices                |
| 13. Jejunum                                     | 33. Latissimus dorsi muscle      |
| 14. Internal oblique muscle                     | 34. Hepatorenal recess           |
| 15. Descending colon                            | 35. Intercostal lymph nodes      |
| 16. External oblique muscle                     | 36. Inferior duodenal recess     |
| 17. Right kidney                                | 37. Lumbar lymph nodes           |
| 18. Renal pyramids                              | 38. Greater omentum              |
| 19. Iliocostalis muscle, thoracic part          | 39. Renal fascia                 |
| 20. Right renal artery                          | 40. Left mesentericocolic gutter |
|                                                 | 41. Left paracolic gutter        |

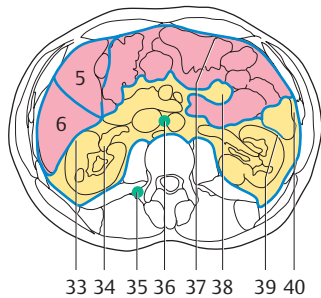
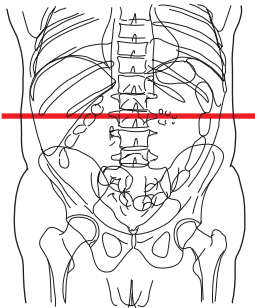
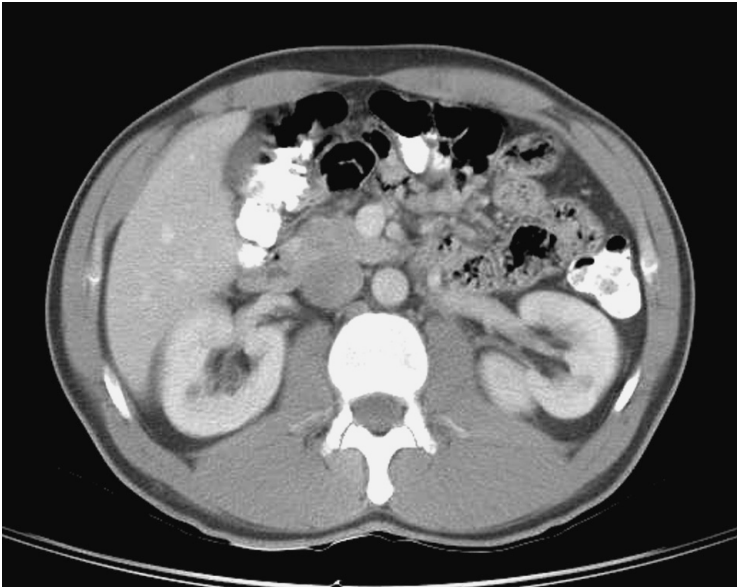


(Numbers indicate liver segments)

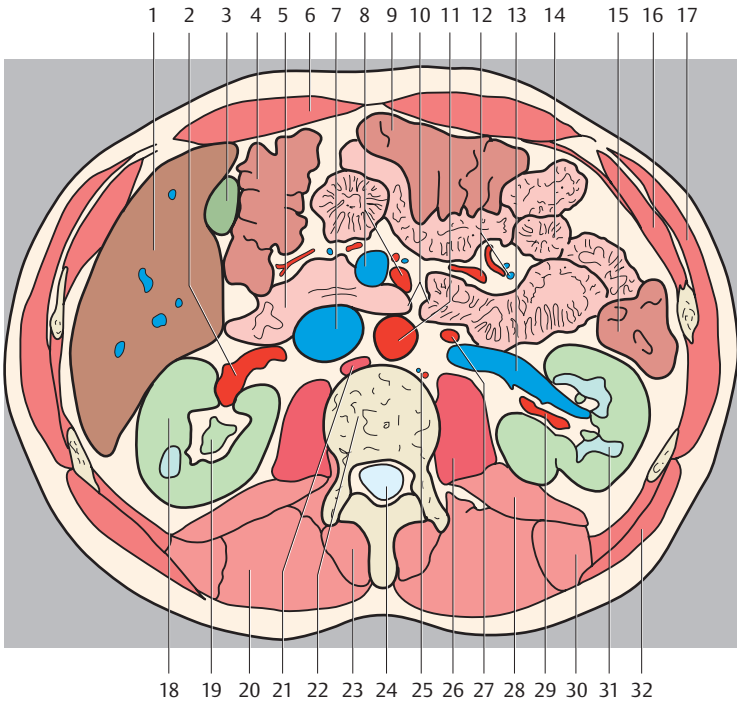




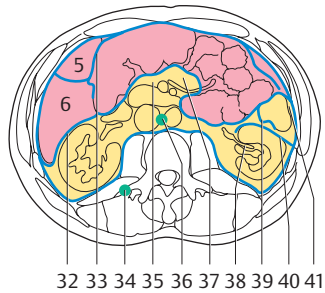
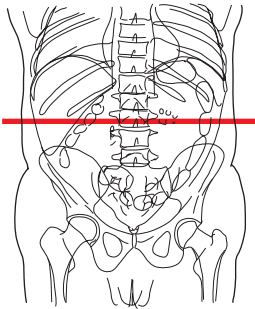
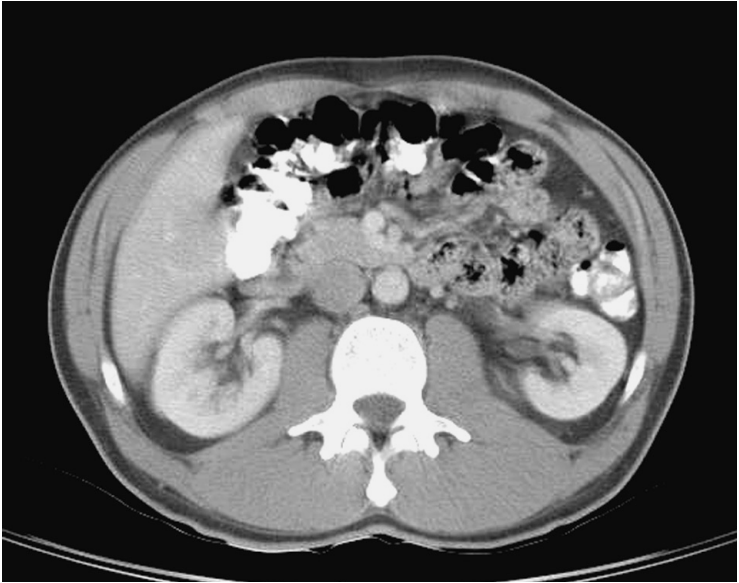
- |                                        |                                  |
|----------------------------------------|----------------------------------|
| 1. Liver                               | 19. Renal cortex                 |
| 2. Right renal artery                  | 20. Psoas major muscle           |
| 3. Gallbladder                         | 21. Diaphragm                    |
| 4. Right colic flexure                 | 22. Thoracic vertebra            |
| 5. Doudenum                            | 23. Vertebral canal              |
| 6. Inferior vena cava                  | 24. Spinalis muscle              |
| 7. Superior mesenteric artery and vein | 25. Lumbar artery and vein       |
| 8. Abdominal aorta                     | 26. Longissimus thoracis muscle  |
| 9. Left renal vein                     | 27. Left renal artery            |
| 10. Transverse colon                   | 28. Iliocostalis muscle          |
| 11. Rectus abdominis muscle            | 29. Renal pelvis                 |
| 12. Jejunum                            | 30. Latissimus dorsi muscle      |
| 13. Descending colon                   | 31. Hepatorenal recess           |
| 14. Internal oblique muscle            | 32. Intercostal lymph nodes      |
| 15. External oblique muscle            | 33. Lumbar lymph nodes           |
| 16. Right kidney                       | 34. Greater omentum              |
| 17. Renal pyramids                     | 35. Renal hilum                  |
| 18. Quadratus lumborum muscle          | 36. Left mesentericocolic gutter |
|                                        | 37. Left paracolic gutter        |



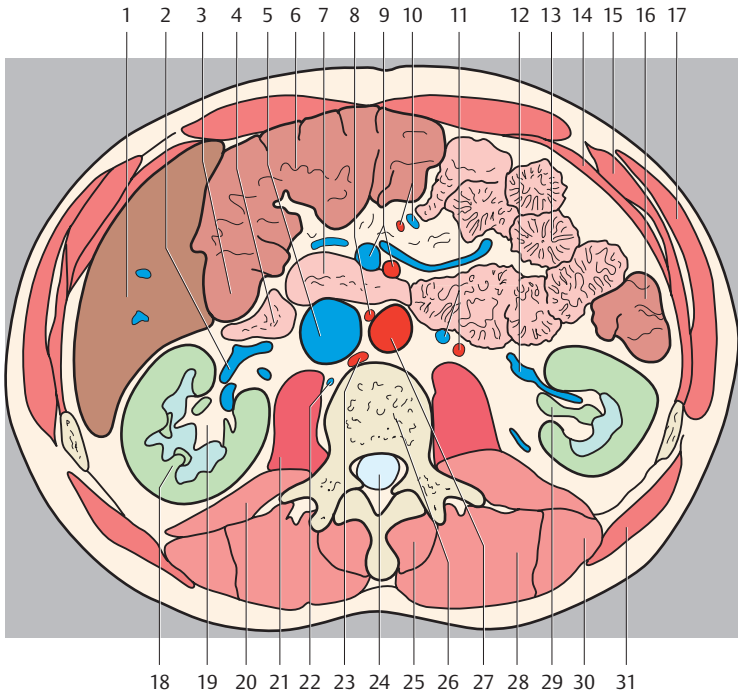
(Numbers indicate liver segments)



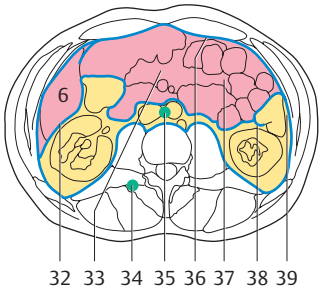
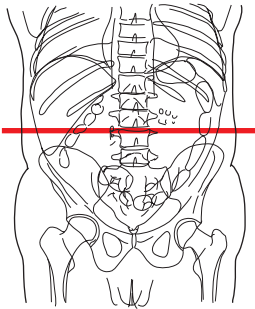
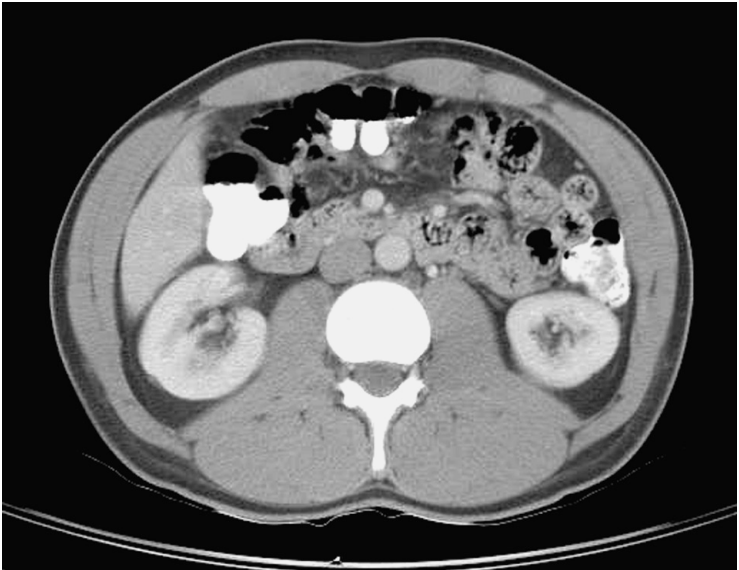
- |                                          |                                  |
|------------------------------------------|----------------------------------|
| 1. Liver                                 | 21. Diaphragm                    |
| 2. Right renal artery                    | 22. Thoracic vertebra            |
| 3. Gallbladder                           | 23. Spinalis muscle              |
| 4. Right colic flexure                   | 24. Vertebral canal              |
| 5. Duodenum                              | 25. Lumbar artery and vein       |
| 6. Rectus abdominis muscle               | 26. Psoas major muscle           |
| 7. Inferior vena cava                    | 27. Left testicular artery       |
| 8. Superior mesenteric artery and vein   | 28. Quadratus lumborum muscle    |
| 9. Transverse colon                      | 29. Left renal artery            |
| 10. Duodenojejunal flexure               | 30. Iliocostalis muscle          |
| 11. Abdominal aorta                      | 31. Renal pyramids               |
| 12. Jejunal and ileal arteries and veins | 32. Latissimus dorsi muscle      |
| 13. Renal vein                           | 33. Hepatorenal recess           |
| 14. Jejunum                              | 34. Renal hilum                  |
| 15. Descending colon                     | 35. Intercostal lymph nodes      |
| 16. Internal oblique muscle              | 36. Lumbar lymph nodes           |
| 17. External oblique muscle              | 37. Greater omentum              |
| 18. Renal cortex                         | 38. Root of mesentery            |
| 19. Renal pelvis                         | 39. Left mesentericocolic gutter |
| 20. Longissimus thoracis muscle          | 40. Left paracolic gutter        |



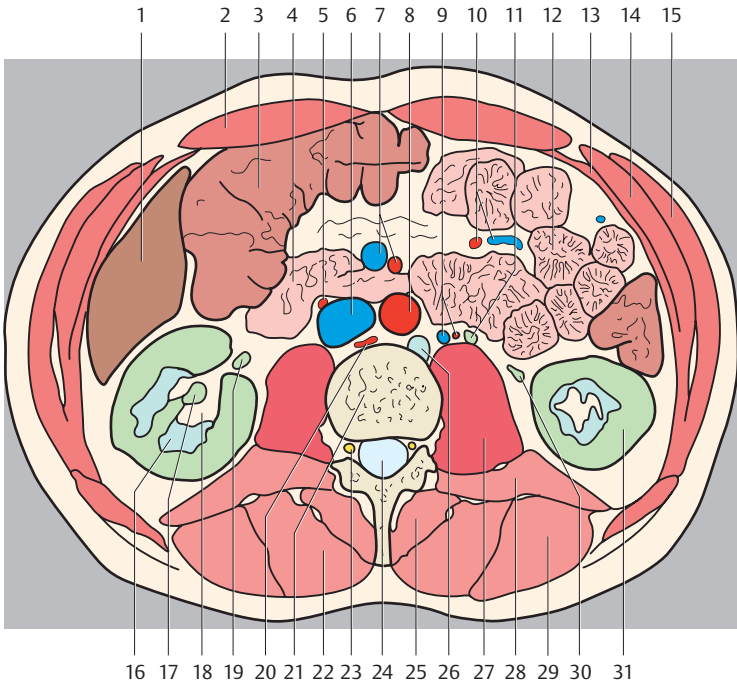
(Numbers indicate liver segments)



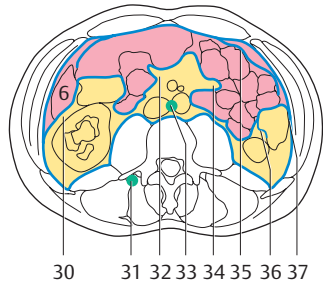
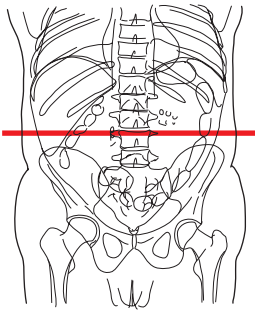
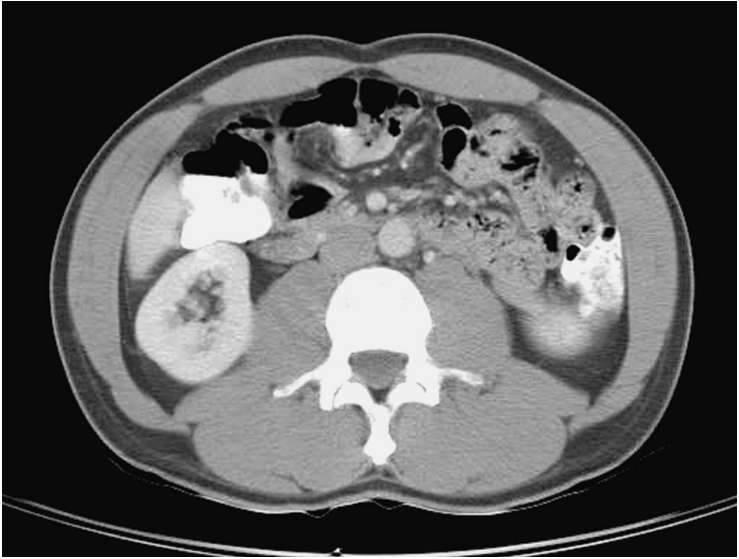
- |                                          |                                  |
|------------------------------------------|----------------------------------|
| 1. Liver                                 | 21. Psoas major muscle           |
| 2. Renal vein                            | 22. Right lumbar vein            |
| 3. Right colic flexure                   | 23. Diaphragm                    |
| 4. Ileum                                 | 24. Vertebral canal              |
| 5. Inferior vena cava                    | 25. Spinalis muscle              |
| 6. Transverse colon                      | 26. Lumbar vertebra              |
| 7. Duodenum                              | 27. Abdominal aorta              |
| 8. Right testicular artery               | 28. Longissimus thoracis muscle  |
| 9. Superior mesenteric artery and vein   | 29. Renal pelvis                 |
| 10. Ileal and jejunal arteries and veins | 30. Iliocostalis lumborum muscle |
| 11. Left testicular artery and vein      | 31. Latissimus dorsi muscle      |
| 12. Renal vein                           | 32. Hepatorenal recess           |
| 13. Jejunum                              | 33. Omental bursa                |
| 14. Transversus abdominis muscle         | 34. Intercostal lymph nodes      |
| 15. Internal oblique muscle              | 35. Transverse mesocolon         |
| 16. Descending colon                     | 36. Lumbar lymph nodes           |
| 17. External oblique muscle              | 37. Mesenterium                  |
| 18. Right kidney                         | 38. Renal hilum                  |
| 19. Renal sinus (adipose tissue)         | 39. Left mesentericocolic gutter |
| 20. Quadratus lumborum muscle            | 40. Renal fascia                 |
|                                          | 41. Left paracolic gutter        |



(Number indicate liver segment)

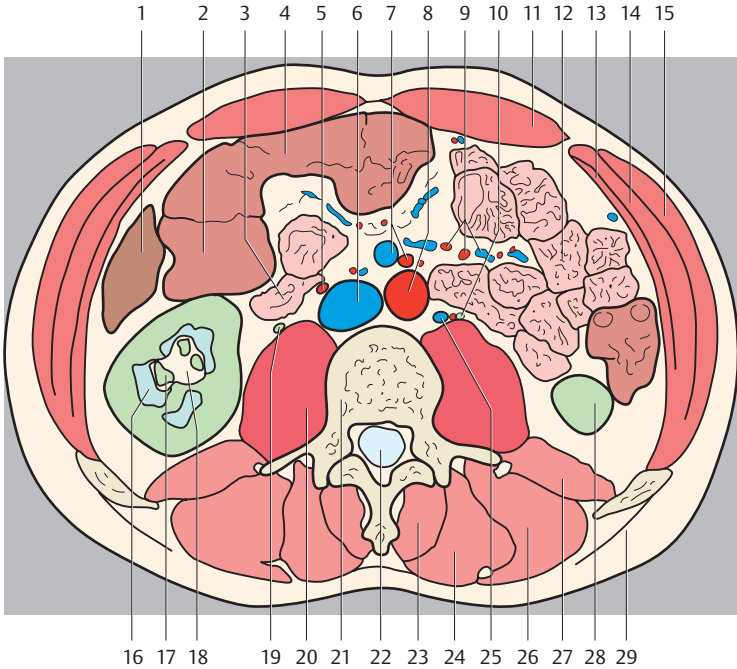


- |                                          |                                  |
|------------------------------------------|----------------------------------|
| 1. Liver                                 | 20. Diaphragm                    |
| 2. Rectus abdominis muscle               | 21. Lumbar vertebra              |
| 3. Ascending colon                       | 22. Longissimus thoracis muscle  |
| 4. Ileum                                 | 23. Nerve root                   |
| 5. Right testicular artery               | 24. Vertebral canal              |
| 6. Inferior vena cava                    | 25. Spinalis muscle              |
| 7. Superior mesenteric artery and vein   | 26. Cisterna chyli               |
| 8. Abdominal aorta                       | 27. Psoas major muscle           |
| 9. Testicular artery and vein            | 28. Quadratus lumborum muscle    |
| 10. Ileal and jejunal arteries and veins | 29. Iliocostalis lumborum muscle |
| 11. Left ureter                          | 30. Left ureter                  |
| 12. Jejunum                              | 31. Left kidney                  |
| 13. Transversus abdominis muscle         | 32. Hepatorenal recess           |
| 14. Internal oblique muscle              | 33. Transverse mesocolon         |
| 15. External oblique muscle              | 34. Intercostal lymph nodes      |
| 16. Renal pyramids                       | 35. Lumbar lymph nodes           |
| 17. Renal pelvis                         | 36. Greater omentum              |
| 18. Renal sinus                          | 37. Mesenterium                  |
| 19. Right ureter                         | 38. Left mesentericocolic gutter |
|                                          | 39. Left paracolic gutter        |

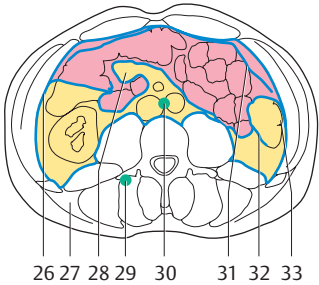
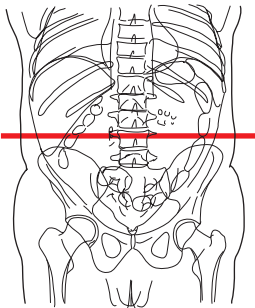
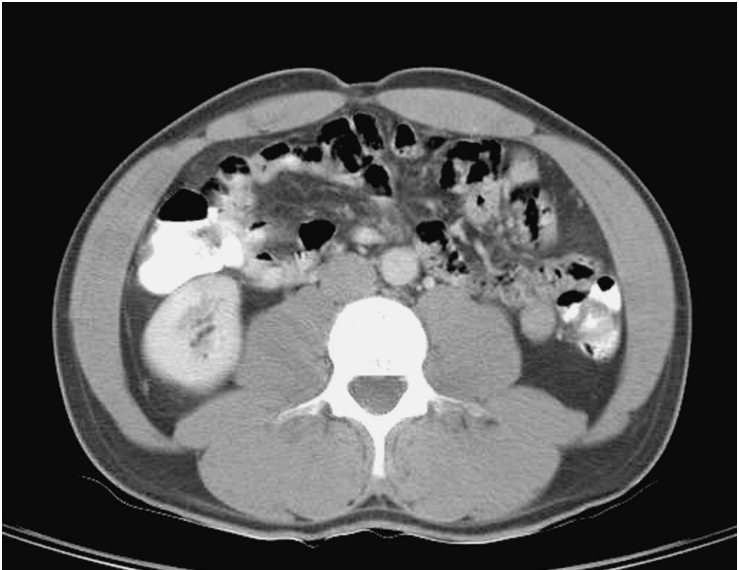


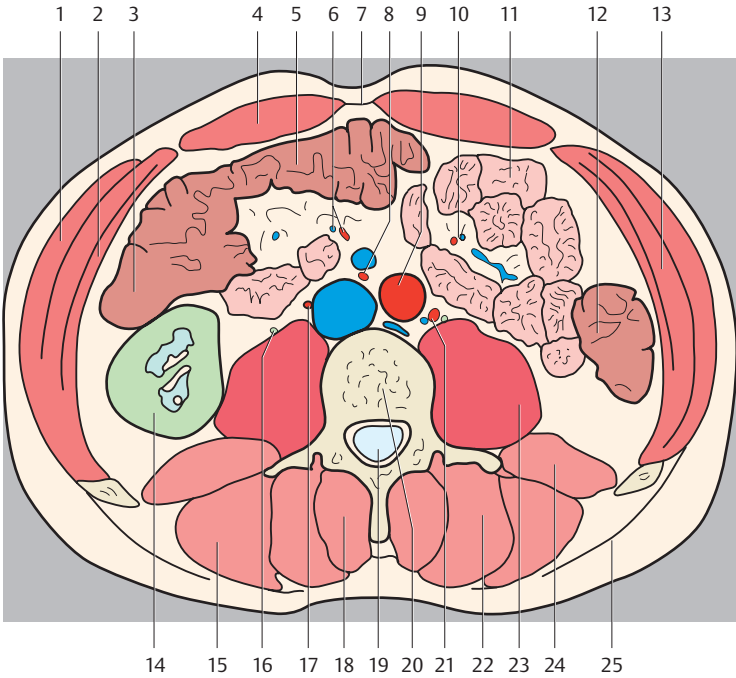
(Number indicate liver segment)



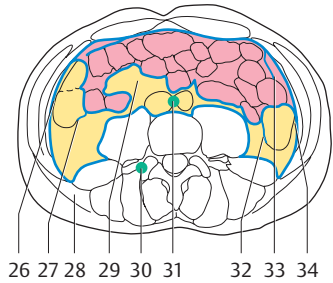
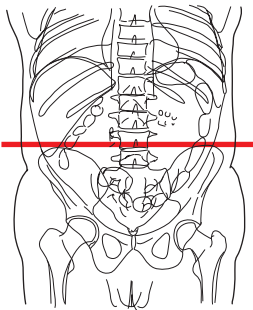
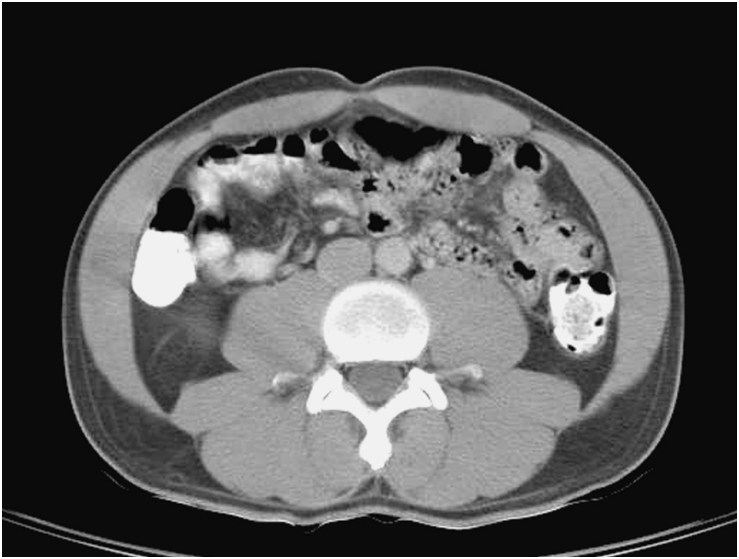

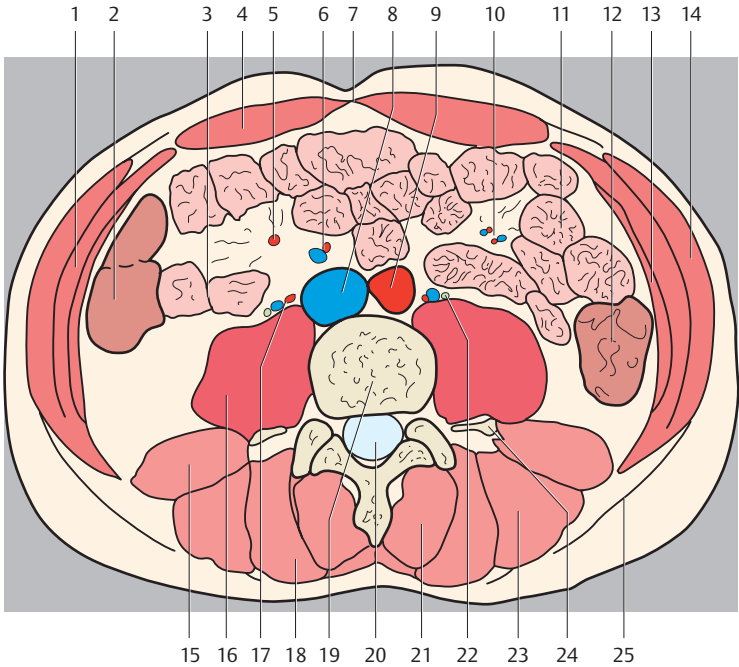
- |                                         |                                     |
|-----------------------------------------|-------------------------------------|
| 1. Liver                                | 19. Right ureter                    |
| 2. Ascending colon                      | 20. Psoas major muscle              |
| 3. Ileum                                | 21. Lumbar vertebra                 |
| 4. Transverse colon                     | 22. Vertebral canal                 |
| 5. Right testicular artery              | 23. Spinalis muscle                 |
| 6. Inferior vena cava                   | 24. Longissimus thoracis muscle     |
| 7. Superior mesenteric artery and vein  | 25. Left testicular artery and vein |
| 8. Abdominal aorta                      | 26. Iliocostalis lumborum muscle    |
| 9. Ileal and jejunal arteries and veins | 27. Quadratus lumborum muscle       |
| 10. Left ureter                         | 28. Left kidney                     |
| 11. Rectus abdominis muscle             | 29. Thoracolumbar fascia            |
| 12. Jejunum                             | 30. Hepatorenal recess              |
| 13. Transversus abdominis muscle        | 31. Intertransversarii muscles      |
| 14. Internal oblique muscle             | 32. Transverse mesocolon            |
| 15. External oblique muscle             | 33. Lumbar lymph nodes              |
| 16. Renal pyramids                      | 34. Mesenterium                     |
| 17. Renal calices                       | 35. Greater omentum                 |
| 18. Renal sinus                         | 36. Left mesentericocolic gutter    |
|                                         | 37. Left paracolic gutter           |



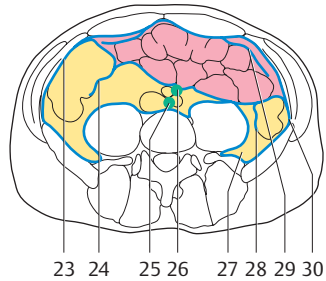
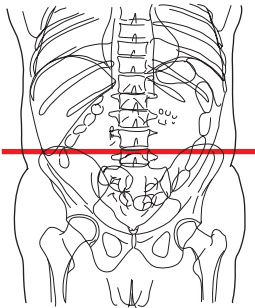
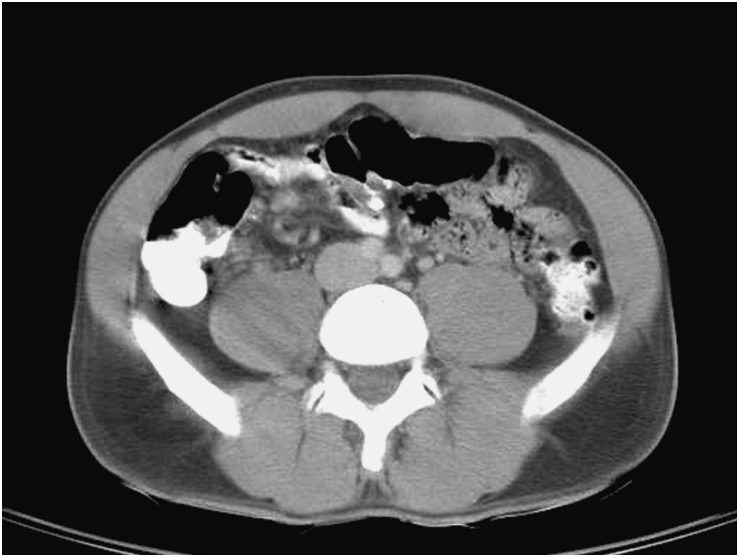

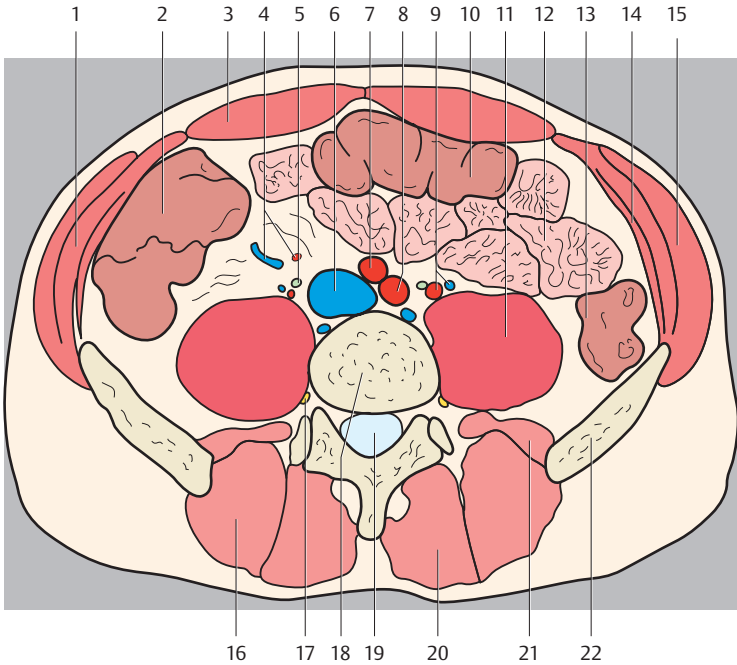
- |                                        |                                     |
|----------------------------------------|-------------------------------------|
| 1. External oblique muscle             | 17. Right testicular artery         |
| 2. Transversus abdominis muscle        | 18. Spinalis muscle                 |
| 3. Ascending colon                     | 19. Vertebral canal                 |
| 4. Rectus abdominis muscle             | 20. Lumbar vertebra                 |
| 5. Transverse colon                    | 21. Left testicular artery and vein |
| 6. Right colic artery and vein         | 22. Longissimus thoracis muscle     |
| 7. Linea alba                          | 23. Psoas major muscle              |
| 8. Superior mesenteric artery and vein | 24. Quadratus lumborum muscle       |
| 9. Abdominal aorta                     | 25. Thoracolumbar fascia            |
| 10. Jejunal arteries and veins         | 26. Right paracolic gutter          |
| 11. Jejunum                            | 27. Lumbar triangle                 |
| 12. Descending colon                   | 28. Transverse mesocolon            |
| 13. Internal oblique muscle            | 29. Intertransversarii muscles      |
| 14. Right kidney                       | 30. Lumbar lymph nodes              |
| 15. Iliocostalis lumborum muscle       | 31. Greater omentum                 |
| 16. Ureter                             | 32. Left mesentericocolic gutter    |
|                                        | 33. Left paracolic gutter           |



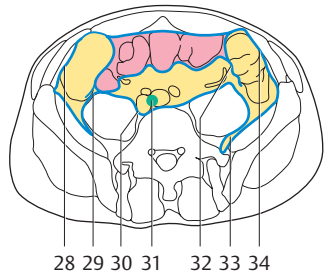
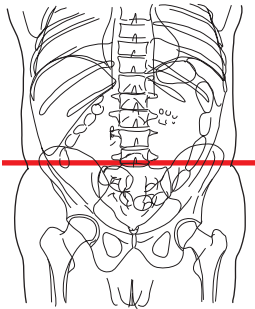
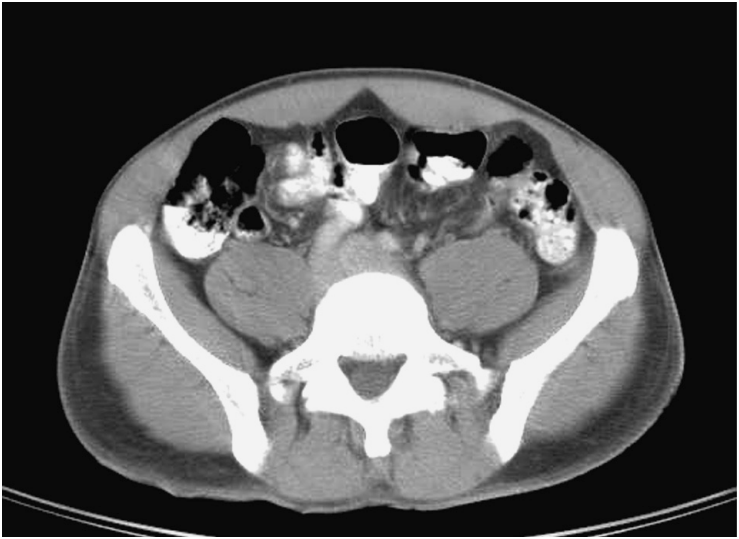

- |                                          |                                           |
|------------------------------------------|-------------------------------------------|
| 1. Internal oblique muscle               | 18. Longissimus thoracis muscle           |
| 2. Ascending colon                       | 19. Lumbar vertebra                       |
| 3. Ileum                                 | 20. Vertebral canal                       |
| 4. Rectus abdominis muscle               | 21. Spinalis muscle                       |
| 5. Right colic artery and vein           | 22. Ureter                                |
| 6. Superior mesenteric artery and vein   | 23. Iliocostalis lumborum muscle          |
| 7. Linea alba                            | 24. Transverse process of lumbar vertebra |
| 8. Inferior vena cava                    | 25. Thoracolumbar fascia                  |
| 9. Abdominal aorta                       | 26. Right paracolic gutter                |
| 10. Ileal and jejunal arteries and veins | 27. Right mesentericocolic gutter         |
| 11. Jejunum                              | 28. Lumbar triangle                       |
| 12. Descending colon                     | 29. Mesenterium                           |
| 13. Transversus abdominis muscle         | 30. Intertransversarii muscles            |
| 14. External oblique muscle              | 31. Lumbar lymph nodes                    |
| 15. Quadratus lumborum muscle            | 32. Left mesentericocolic gutter          |
| 16. Psoas major muscle                   | 33. Greater omentum                       |
| 17. Testicular artery and vein           | 34. Left paracolic gutter                 |

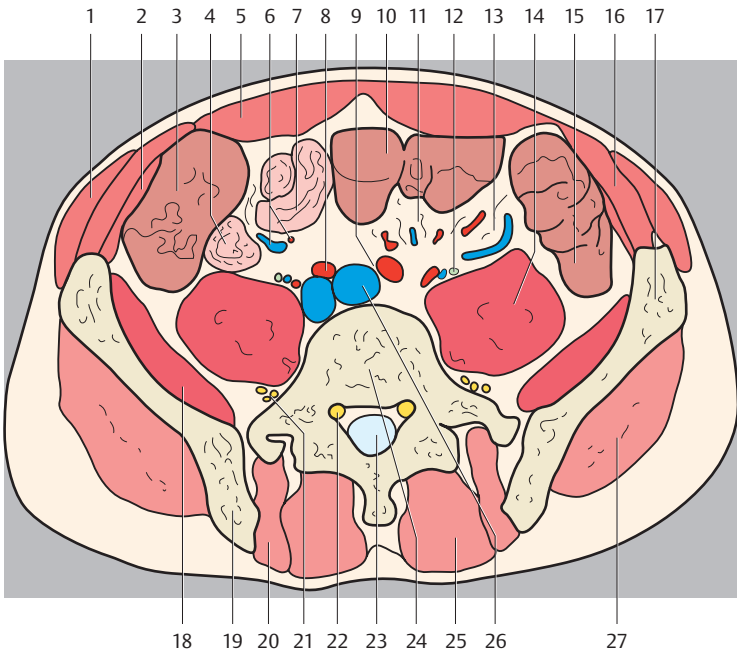




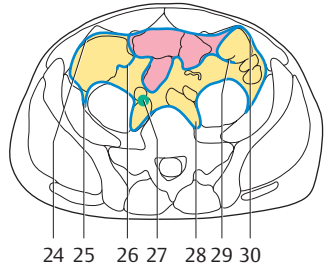
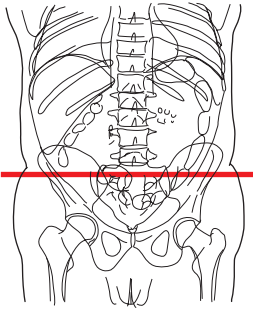
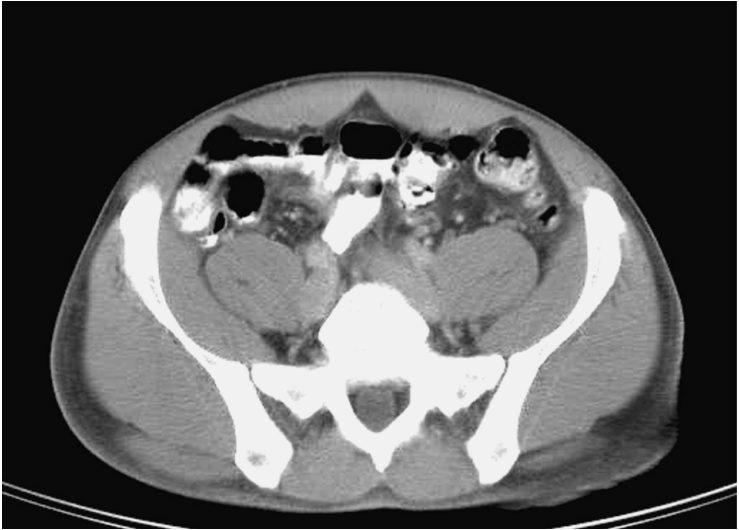- |                                  |                                 |
|----------------------------------|---------------------------------|
| 1. Internal oblique muscle       | 16. Longissimus thoracis muscle |
| 2. Ascending colon               | 17. Femoral nerve               |
| 3. Rectus abdominis muscle       | 18. Lumbar vertebra             |
| 4. Right colic artery and vein   | 19. Vertebral canal             |
| 5. Ureter                        | 20. Spinalis muscle             |
| 6. Inferior vena cava            | 21. Quadratus lumborum muscle   |
| 7. Right common iliac artery     | 22. Ilium                       |
| 8. Left common iliac artery      | 23. Right paracolic gutter      |
| 9. Testicular artery and vein    | 24. Right mesenterocolic gutter |
| 10. Transverse colon             | 25. Lumbar lymph nodes          |
| 11. Psoas major muscle           | 26. Common iliac lymph nodes    |
| 12. Jejunum                      | 27. Gutter of psoas muscle      |
| 13. Descending colon             | 28. Left mesenterocolic gutter  |
| 14. Transversus abdominis muscle | 29. Greater omentum             |
| 15. External oblique muscle      | 30. Left paracolic gutter       |

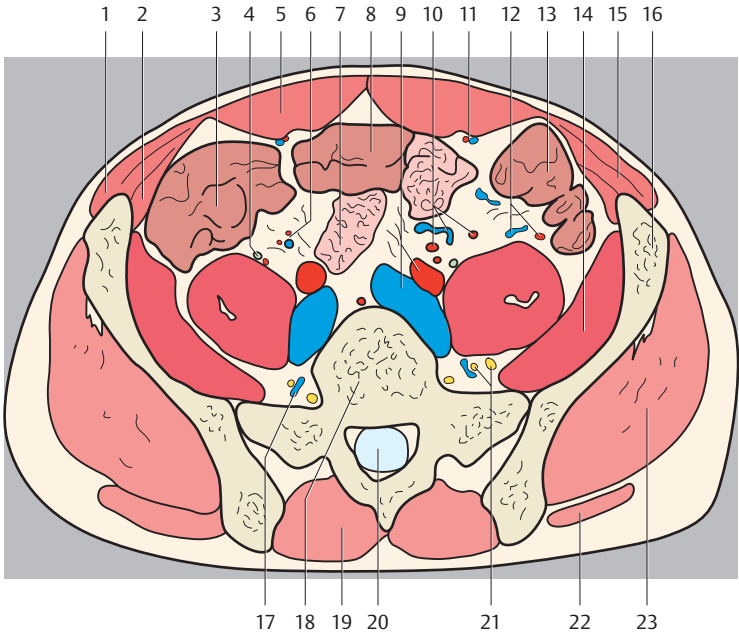




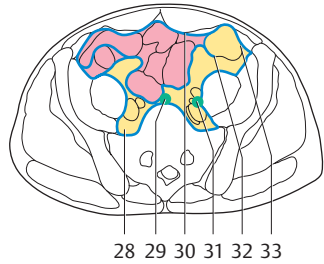
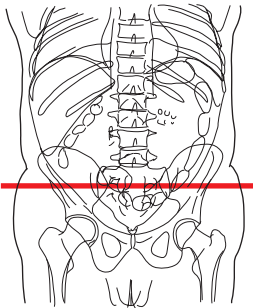
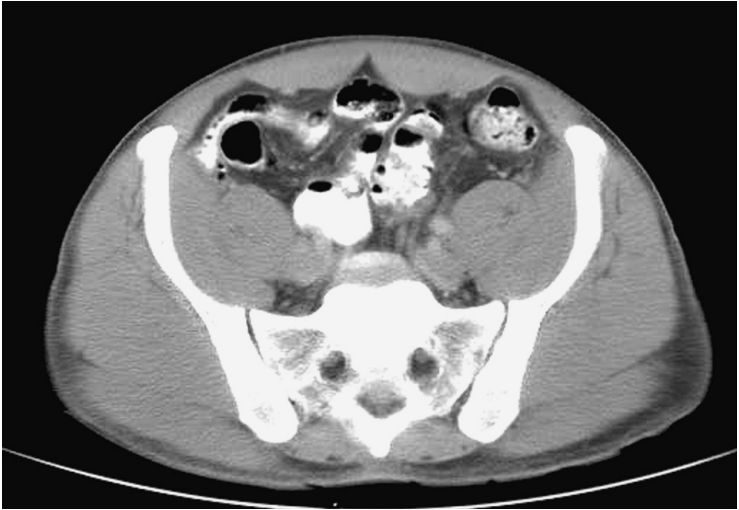


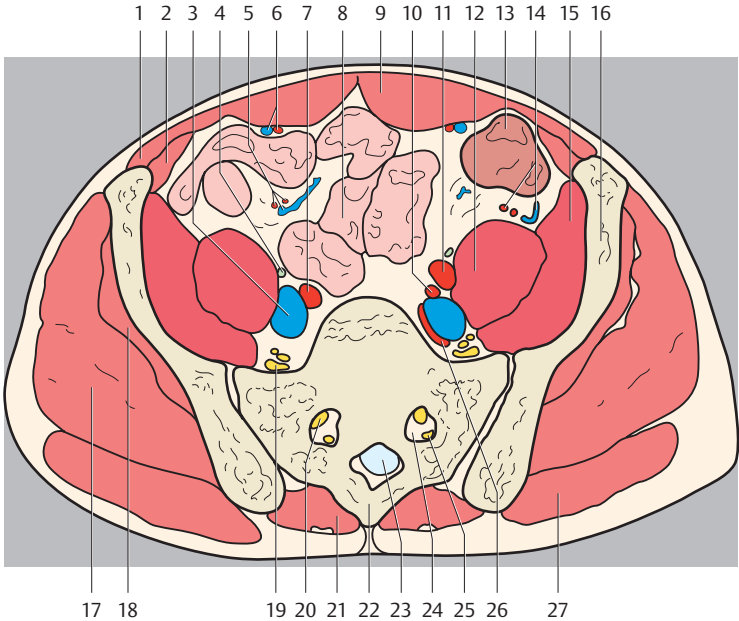
- |                                        |                                   |
|----------------------------------------|-----------------------------------|
| 1. External oblique muscle             | 18. Iliacus muscle                |
| 2. Transversus abdominis muscle        | 19. Ilium                         |
| 3. Ascending colon                     | 20. Longissimus thoracis muscle   |
| 4. Terminal ileum                      | 21. Lumbar plexus                 |
| 5. Rectus abdominis muscle             | 22. Lumbar nerve V                |
| 6. Ileal arteries and veins            | 23. Vertebral canal               |
| 7. Ileum                               | 24. Lumbar vertebra 5             |
| 8. Right common iliac artery and vein  | 25. Spinalis muscle               |
| 9. Left common iliac artery            | 26. Left common iliac vein        |
| 10. Transverse colon                   | 27. Gluteus medius muscle         |
| 11. Middle colic artery and vein       | 28. Right paracolic gutter        |
| 12. Ureter, Testicular artery and vein | 29. Right mesentericocolic gutter |
| 13. Left colic artery and vein         | 30. Medial groove of psoas        |
| 14. Psoas major muscle                 | 31. Common iliac lymph nodes      |
| 15. Descending colon                   | 32. Left mesentericocolic gutter  |
| 16. Internal oblique muscle            | 33. Lateral groove of psoas       |
| 17. Ala of ilium                       | 34. Left paracolic gutter         |



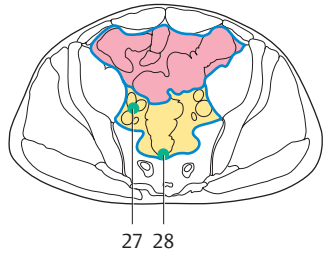
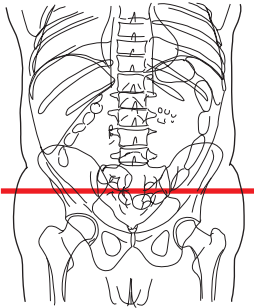
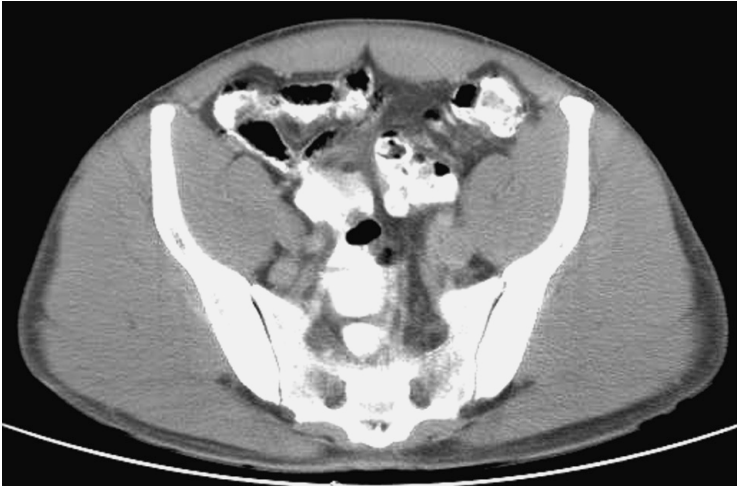


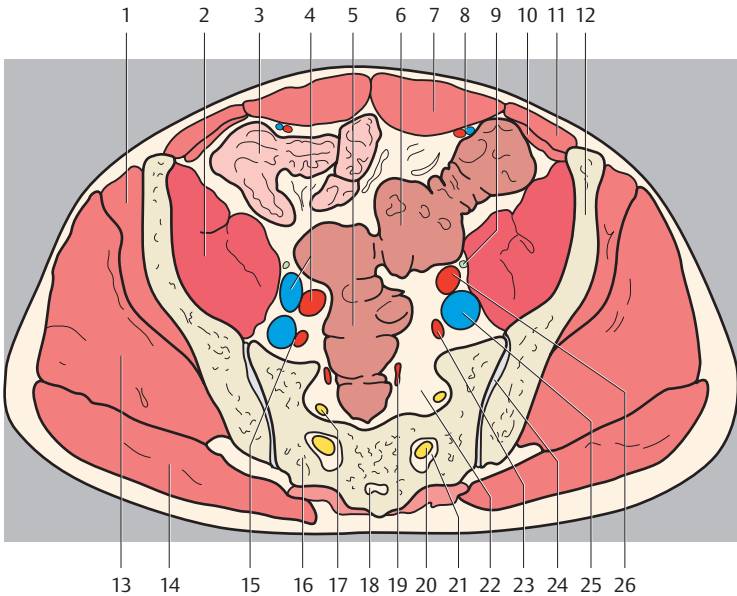
- |                                      |                                    |
|--------------------------------------|------------------------------------|
| 1. External oblique muscle           | 16. Ala of ilium                   |
| 2. Transversus abdominis muscle      | 17. Ascending lumbar vein          |
| 3. Caecum                            | 18. Lumbar vertebra 5              |
| 4. Ureter                            | 19. Spinalis muscle                |
| 5. Rectus abdominis muscle           | 20. Vertebral canal                |
| 6. Right colic artery and vein       | 21. Lumbar plexus                  |
| 7. Ileum                             | 22. Gluteus maximus muscle         |
| 8. Transverse colon                  | 23. Gluteus medius muscle          |
| 9. Left common iliac artery and vein | 24. Right paracolic gutter         |
| 10. Ileal arteries and veins         | 25. Lateral gutter of psoas muscle |
| 11. Epigastric artery and vein       | 26. Right mesentericocolic gutter  |
| 12. Left colic artery and vein       | 27. Common iliac lymph nodes       |
| 13. Descending colon                 | 28. Medial gutter of psoas muscle  |
| 14. Iliacus muscle                   | 29. Left mesentericocolic gutter   |
| 15. Internal oblique muscle          | 30. Left paracolic gutter          |



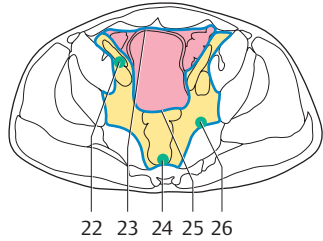
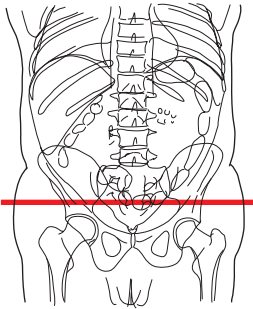
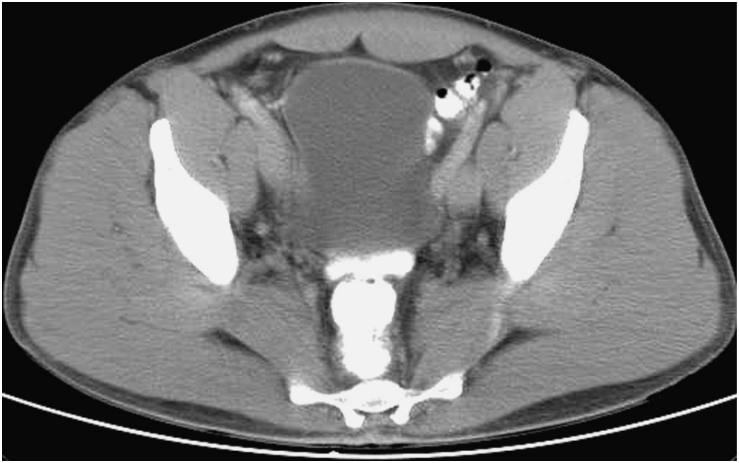

- |                                        |                                  |
|----------------------------------------|----------------------------------|
| 1. Internal oblique muscle             | 18. Gluteus minimus muscle       |
| 2. Transversus abdominis muscle        | 19. Sacral plexus                |
| 3. Common iliac vein                   | 20. Anterior sacral nerve        |
| 4. Ureter                              | 21. Spinalis muscle              |
| 5. Ileal artery and vein               | 22. Sacrum                       |
| 6. Inferior epigastric artery and vein | 23. Vertebral canal              |
| 7. Common iliac artery                 | 24. Sacral foramen I             |
| 8. Ileum                               | 25. Posterior sacral nerve I     |
| 9. Rectus abdominis muscle             | 26. Inferior gluteal artery      |
| 10. Internal iliac artery              | 27. Gluteus maximus muscle       |
| 11. External iliac artery              | 28. Medial groove of psoas       |
| 12. Psoas major muscle                 | 29. Promontorial lymph nodes     |
| 13. Descending colon                   | 30. Greater omentum              |
| 14. Left colic artery and vein         | 31. Common iliac lymph nodes     |
| 15. Iliacus muscle                     | 32. Left mesentericocolic gutter |
| 16. Ilium                              | 33. Left paracolic gutter        |
| 17. Gluteus medius muscle              |                                  |

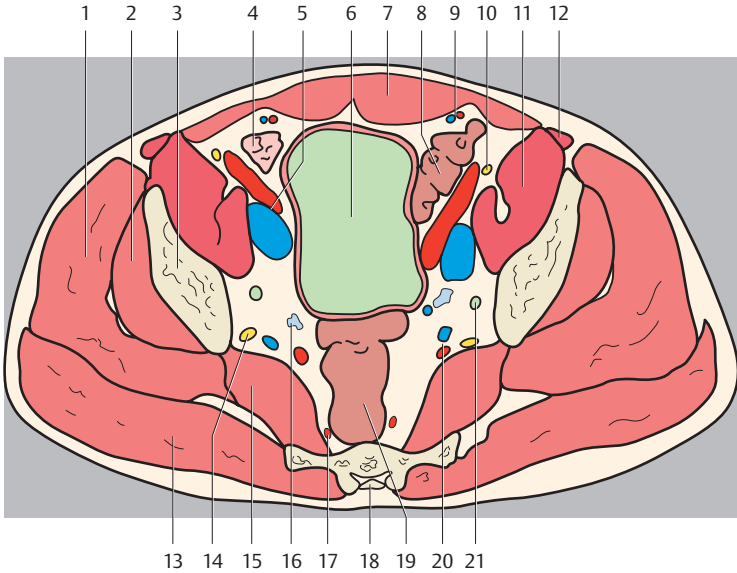




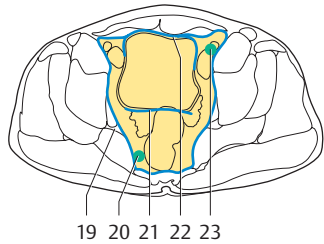
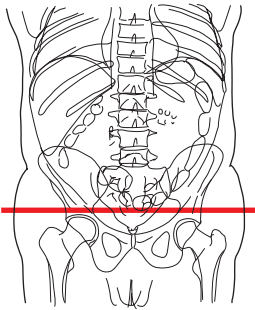
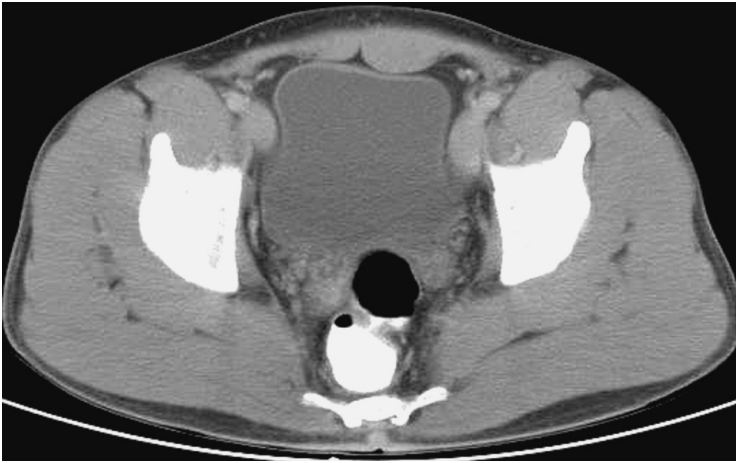- |                                   |                                    |
|-----------------------------------|------------------------------------|
| 1. Gluteus minimus muscle         | 15. Internal iliac artery and vein |
| 2. Iliopsoas muscle               | 16. Sacrum                         |
| 3. Jejunum                        | 17. Sacral nerve II                |
| 4. External iliac artery and vein | 18. Sacral canal                   |
| 5. Rectum                         | 19. Superior rectal artery         |
| 6. Sigmoid colon                  | 20. Sacral nerve III               |
| 7. Rectus abdominis muscle        | 21. Sacral foramen III             |
| 8. Epigastric artery and vein     | 22. Sacral foramen II              |
| 9. Ureter                         | 23. Internal iliac artery          |
| 10. Transversus abdominis muscle  | 24. Sacroiliac joint               |
| 11. Internal oblique muscle       | 25. Common iliac vein              |
| 12. Ala of ilium                  | 26. External iliac artery          |
| 13. Gluteus medius muscle         | 27. Common iliac lymph nodes       |
| 14. Gluteus maximus muscle        | 28. Sacral lymph nodes             |

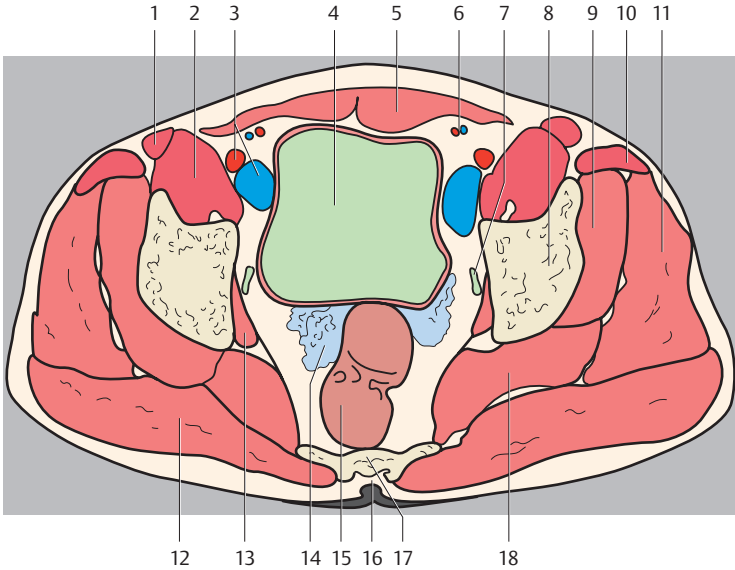




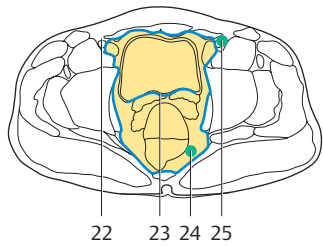
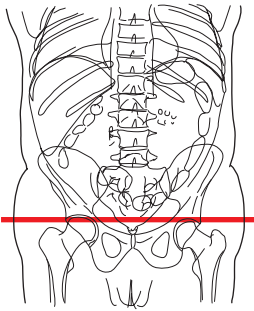
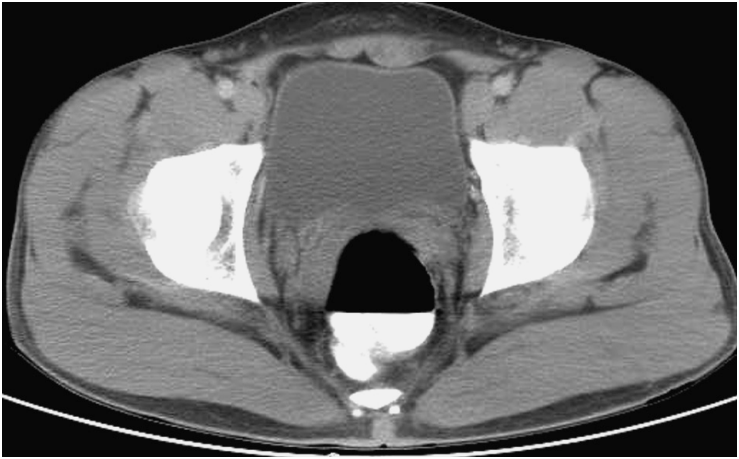

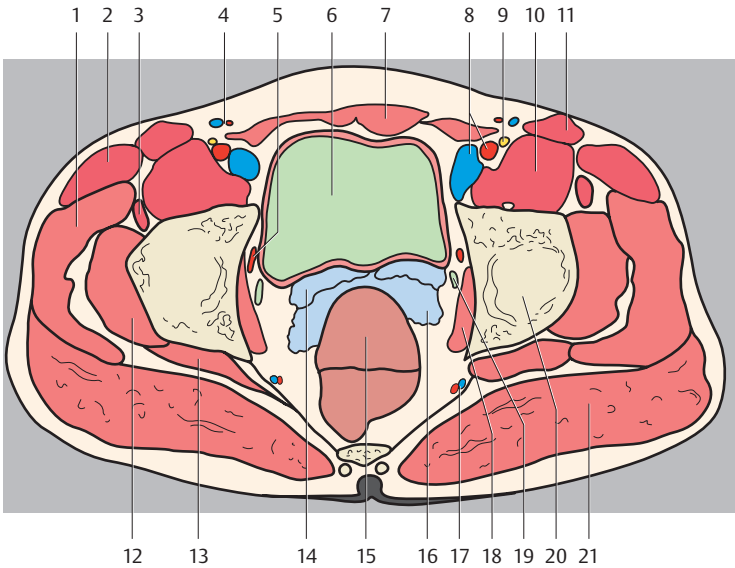
- |                                        |                                    |
|----------------------------------------|------------------------------------|
| 1. Gluteus medius muscle               | 14. Sacral plexus                  |
| 2. Gluteus minimus muscle              | 15. Piriformis muscle              |
| 3. Ilium (body)                        | 16. Seminal vesicle                |
| 4. Ileum                               | 17. Superior rectal artery         |
| 5. External iliac artery and vein      | 18. Sacral canal                   |
| 6. Urinary bladder                     | 19. Rectum                         |
| 7. Rectus abdominis muscle             | 20. Internal iliac artery and vein |
| 8. Sigmoid colon                       | 21. Ureter                         |
| 9. Inferior epigastric artery and vein | 22. External iliac lymph nodes     |
| 10. Femoral nerve                      | 23. Paravesical fossa              |
| 11. Iliopsoas muscle                   | 24. Sacral lymph nodes             |
| 12. Sartorius muscle                   | 25. Recto-vesical pouch            |
| 13. Gluteus maximus muscle             | 26. Inferior gluteal lymph nodes   |



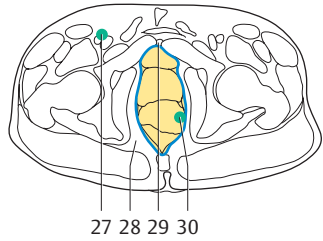
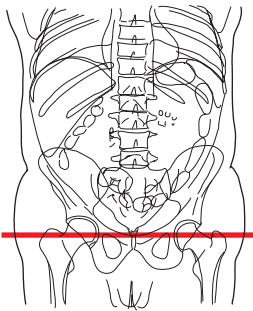
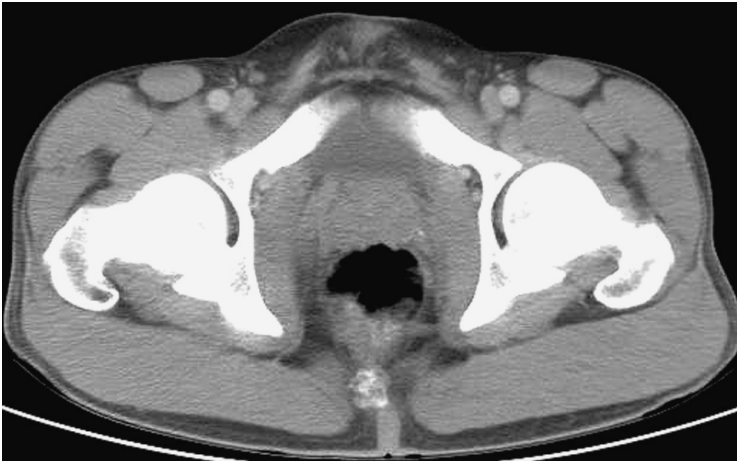

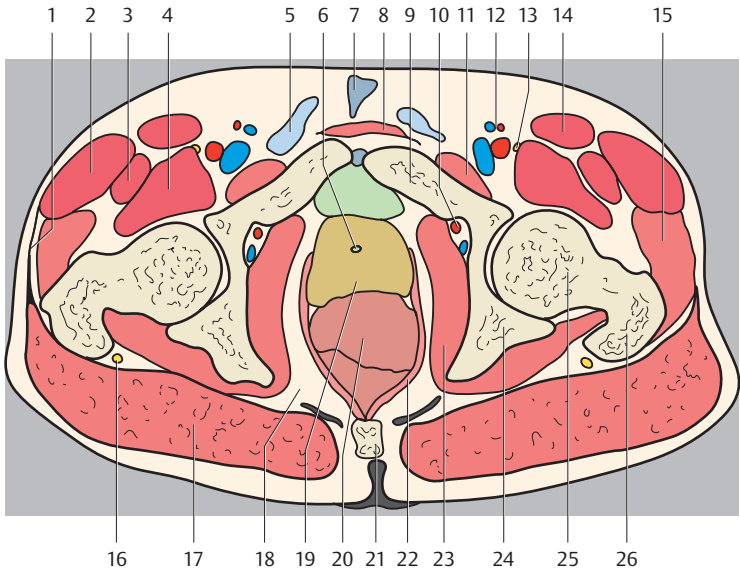
- |                                        |                                |
|----------------------------------------|--------------------------------|
| 1. Sartorius muscle                    | 13. Obturator internus muscle  |
| 2. Iliopsoas muscle                    | 14. Seminal vesicle            |
| 3. External iliac artery and vein      | 15. Rectum                     |
| 4. Urinary bladder                     | 16. Hiatus sacralis            |
| 5. Rectus abdominis muscle             | 17. Sacrum                     |
| 6. Inferior epigastric artery and vein | 18. Piriformis muscle          |
| 7. Ureter                              | 19. Infrapiriform opening      |
| 8. Ilium (body)                        | 20. Pararectal lymph nodes     |
| 9. Gluteus minimus muscle              | 21. Recto-vesical pouch        |
| 10. Tensor fasciae latae muscle        | 22. Paravesical fossa          |
| 11. Gluteus medius muscle              | 23. External iliac lymph nodes |
| 12. Gluteus maximus muscle             |                                |



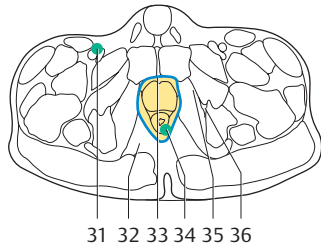
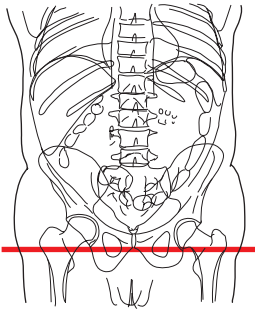
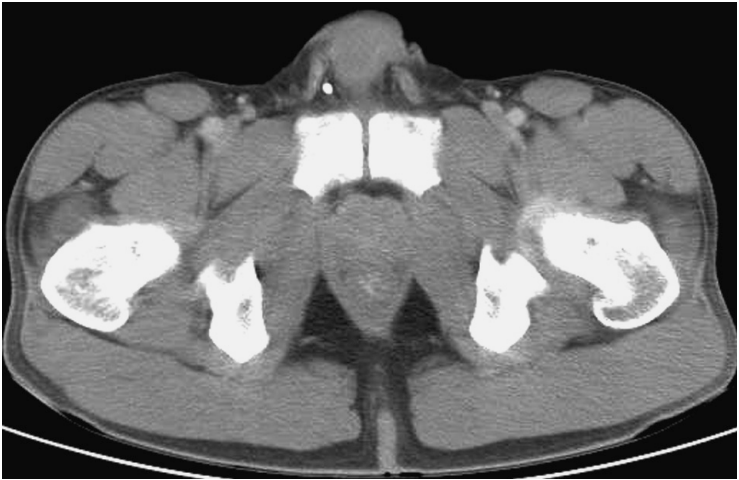


- |                                           |                                      |
|-------------------------------------------|--------------------------------------|
| 1. Gluteus medius muscle                  | 13. Piriformis muscle                |
| 2. Tensor fasciae latae muscle            | 14. Ampulla of ductus deferens       |
| 3. Rectus femoris muscle                  | 15. Rectum                           |
| 4. Superficial epigastric artery and vein | 16. Seminal vesicle                  |
| 5. Obturator artery                       | 17. Inferior gluteal artery and vein |
| 6. Urinary bladder                        | 18. Obturator internus muscle        |
| 7. Rectus abdominis muscle                | 19. Ureter                           |
| 8. External iliac artery and vein         | 20. Ilium (body)                     |
| 9. Femoral nerve                          | 21. Gluteus maximus muscle           |
| 10. Iliopsoas muscle                      | 22. Inguinal canal                   |
| 11. Sartorius muscle                      | 23. Recto-vesical pouch              |
| 12. Gluteus minimus muscle                | 24. Pararectal lymph nodes           |
|                                           | 25. External iliac lymph nodes       |

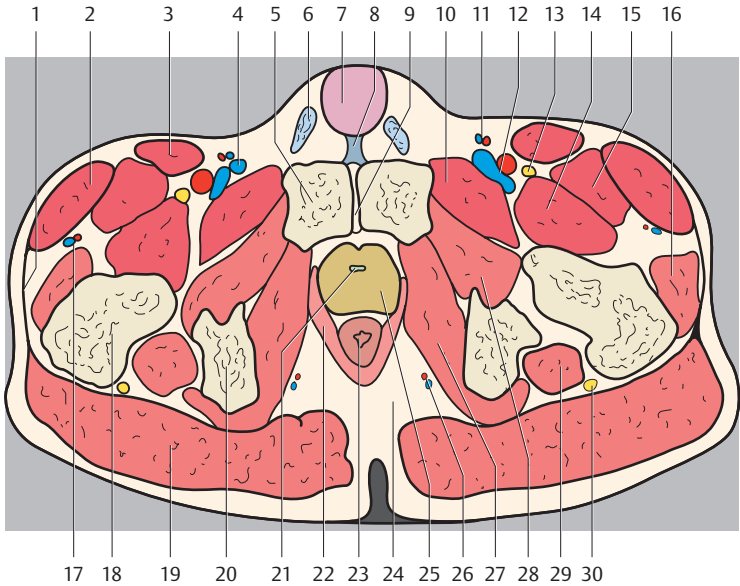




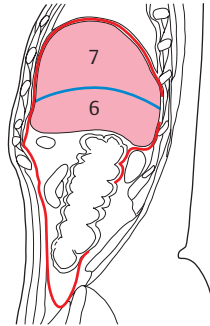
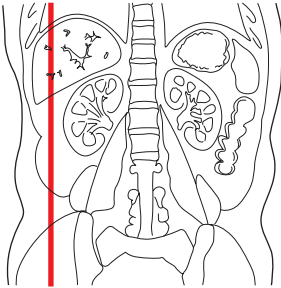
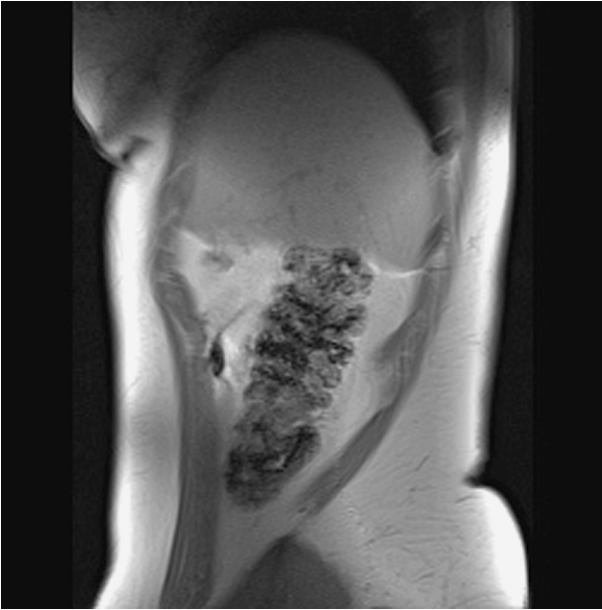
- |                                            |                               |
|--------------------------------------------|-------------------------------|
| 1. Fascia lata                             | 16. Sciatic nerve             |
| 2. Tensor fasciae latae muscle             | 17. Gluteus maximus muscle    |
| 3. Rectus femoris muscle                   | 18. Ischiorectal fossa        |
| 4. Iliopsoas muscle                        | 19. Prostate                  |
| 5. Spermatic cord                          | 20. Rectal ampulla            |
| 6. Urethra                                 | 21. Coccyx                    |
| 7. Suspensory ligament of penis            | 22. Levator ani muscle        |
| 8. Rectus abdominis muscle                 | 23. Obturator internus muscle |
| 9. Pubis                                   | 24. Ischium                   |
| 10. Obturator artery                       | 25. Head of femur             |
| 11. Obturator externus muscle              | 26. Greater trochanter        |
| 12. Superficial epigastric artery and vein | 27. Inguinal lymph nodes      |
| 13. Femoral nerve                          | 28. Ischiorectal fossa        |
| 14. Sartorius muscle                       | 29. Retropubic space          |
| 15. Gluteus minimus muscle                 | 30. Pararectal lymph nodes    |





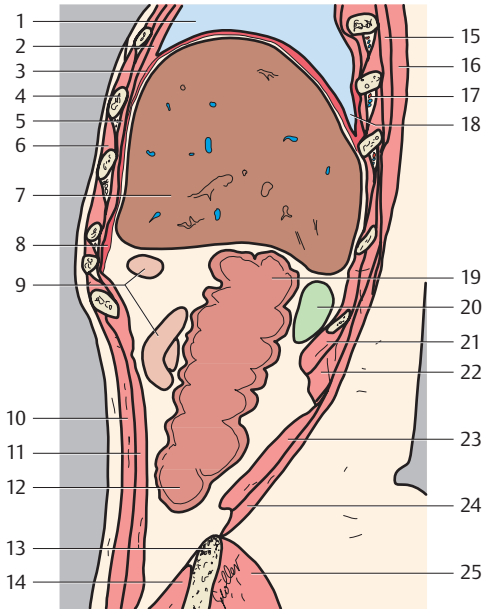


- |                                                |                                    |
|------------------------------------------------|------------------------------------|
| 1. Fascia lata                                 | 18. Femur (intertrochanteric part) |
| 2. Tensor fasciae latae muscle                 | 19. Gluteus maximus muscle         |
| 3. Sartorius muscle                            | 20. Ischium                        |
| 4. Great saphenous vein                        | 21. Urethra                        |
| 5. Pubis (superior ramus)                      | 22. Levator ani muscle             |
| 6. Spermatic cord                              | 23. Rectum                         |
| 7. Root of penis                               | 24. Ischiorectal fossa             |
| 8. Suspensory ligament of penis                | 25. Prostate                       |
| 9. Pubic symphysis                             | 26. Internal pudendal artery       |
| 10. Pectineus muscle                           | 27. Obturator internus muscle      |
| 11. Superficial epigastric artery and vein     | 28. Obturator externus muscle      |
| 12. Femoral artery and vein                    | 29. Quadratus femoris muscle       |
| 13. Femoral nerve                              | 30. Sciatic nerve                  |
| 14. Iliopsoas muscle                           | 31. Inguinal lymph nodes           |
| 15. Rectus femoris muscle                      | 32. Ischiorectal fossa             |
| 16. Gluteus minimus muscle                     | 33. Retropubic space               |
| 17. Lateral circumflex femoral artery and vein | 34. Pararectal lymph nodes         |
|                                                | 35. Obturator membrane             |
|                                                | 36. Obturator canal                |

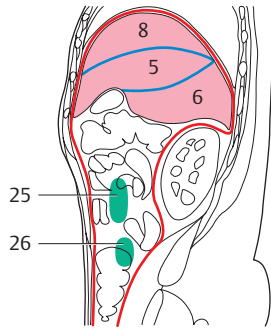
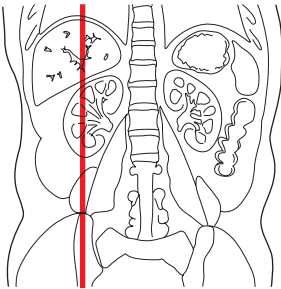
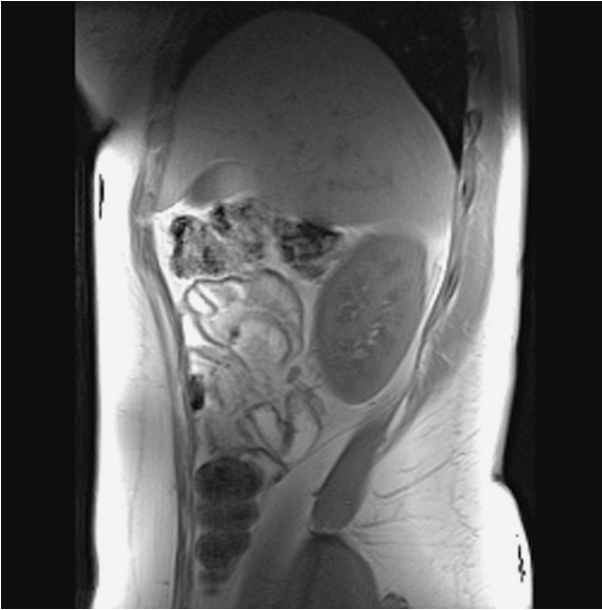

— = Peritoneum

(Numbers indicate liver segments)

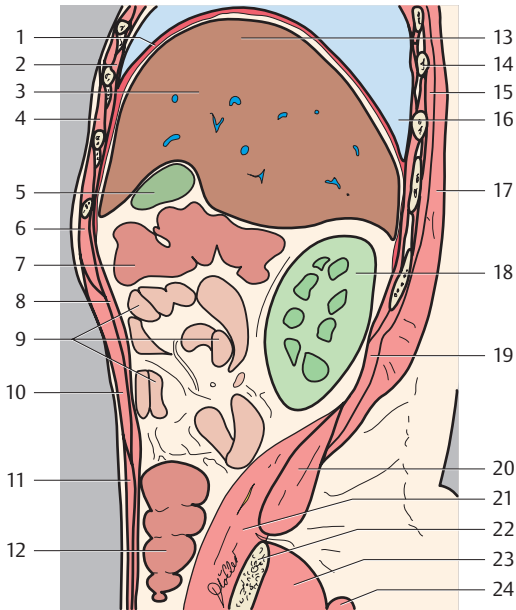


- |                                |                                           |
|--------------------------------|-------------------------------------------|
| 1. Right lung                  | 15. Serratus posterior inferior muscle    |
| 2. Transversus thoracis muscle | 16. Latissimus dorsi muscle               |
| 3. Diaphragm                   | 17. Intercostal artery, vein and nerve    |
| 4. Rib                         | 18. Diaphragm (costodiaphragmatic recess) |
| 5. Internal intercostal muscle | 19. Right colon flexure                   |
| 6. External intercostal muscle | 20. Right kidney                          |
| 7. Liver (right lobe)          | 21. Quadratus lumborum muscle             |
| 8. Diaphragm (costal part)     | 22. Erector spinae muscle                 |
| 9. Small intestine (jejunum)   | 23. Transversus abdominis muscle          |
| 10. External oblique muscle    | 24. External abdominal oblique muscle     |
| 11. Internal oblique muscle    | 25. Gluteus medius muscle                 |
| 12. Cecum                      |                                           |
| 13. Iliac crest                |                                           |
| 14. Iliacus muscle             |                                           |

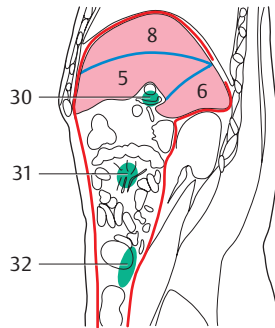
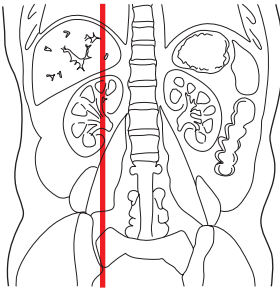
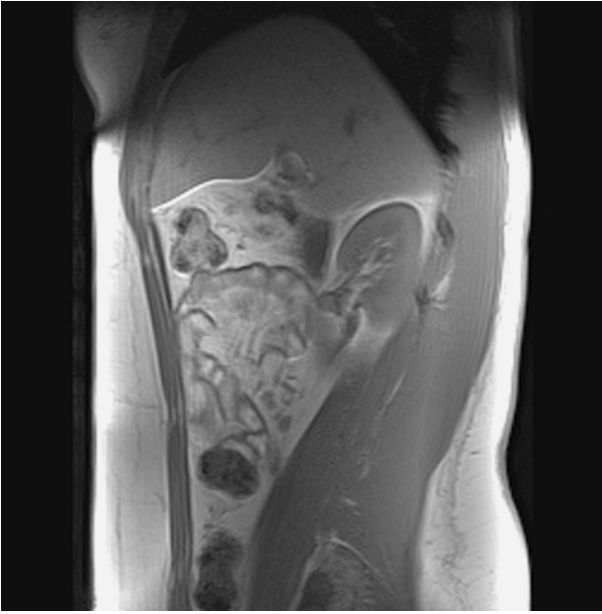


— = Peritoneum

(Numbers indicate liver segments)

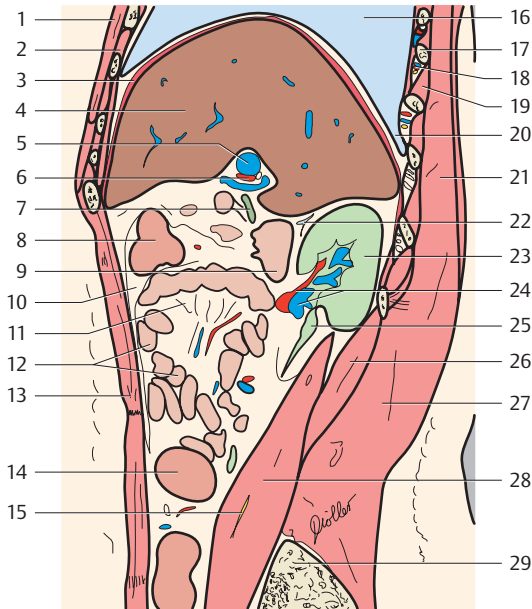


- |                                 |                                        |
|---------------------------------|----------------------------------------|
| 1. Diaphragm                    | 14. Rib                                |
| 2. Internal intercostal muscle  | 15. Erector spinae muscle              |
| 3. Liver (right lobe)           | 16. Costodiaphragmatic recess          |
| 4. External intercostal muscle  | 17. Latissimus dorsi muscle            |
| 5. Gallbladder                  | 18. Right kidney                       |
| 6. Rectus abdominis muscle      | 19. Serratus posterior inferior muscle |
| 7. Transverse colon             | 20. Quadratus lumborum muscle          |
| 8. Transversus abdominis muscle | 21. Psoas major muscle                 |
| 9. Small intestine (jejunum)    | 22. Iliac crest                        |
| 10. External oblique muscle     | 23. Gluteus medius muscle              |
| 11. Internal oblique muscle     | 24. Gluteus maximus muscle             |
| 12. Cecum                       | 25. Mesenteric lymph nodes             |
| 13. Liver                       | 26. Paracolic lymph nodes              |

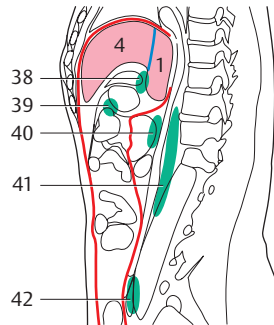
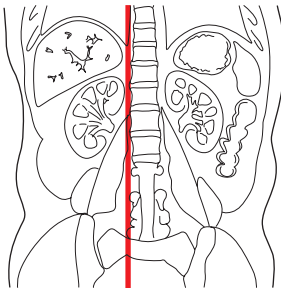
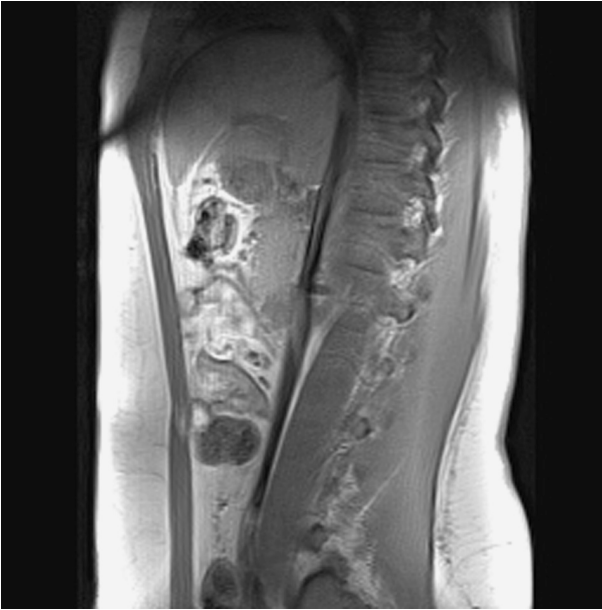

— = Peritoneum

(Numbers indicate liver segments)



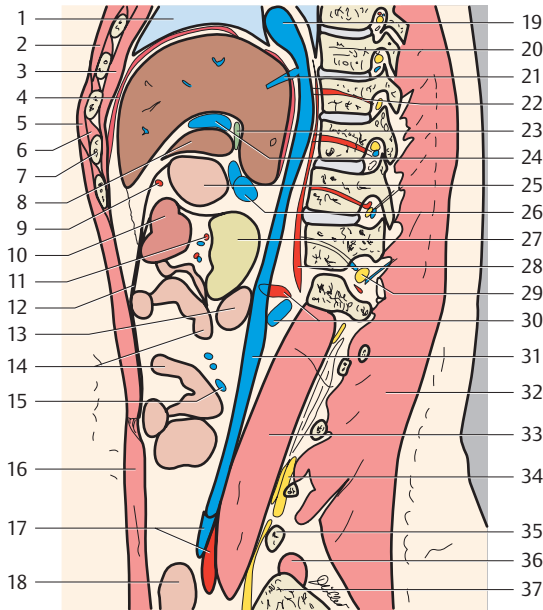
- |                                |                                        |
|--------------------------------|----------------------------------------|
| 1. Pectoralis muscle           | 17. Rib                                |
| 2. Transversus thoracis muscle | 18. Intercostal artery, vein and nerve |
| 3. Diaphragm                   | 19. Intercostalis muscles              |
| 4. Liver (right lobe)          | 20. Costodiaphragmatic recess          |
| 5. Hepatic portal vein         | 21. Latissimus dorsi muscle            |
| 6. Hepatic artery              | 22. Suprarenal gland                   |
| 7. Bile duct                   | 23. Right kidney                       |
| 8. Transverse colon            | 24. Renal artery and vein              |
| 9. Duodenum                    | 25. Ureter                             |
| 10. Greater omentum            | 26. Quadratus lumborum muscle          |
| 11. Mesentery                  | 27. Erector spinae muscle              |
| 12. Small intestine            | 28. Psoas major muscle                 |
| 13. Rectus abdominis muscle    | 29. Iliac spine                        |
| 14. Ascending colon            | 30. Hepatic lymph nodes                |
| 15. Femoral nerve              | 31. Mesenteric lymph nodes             |
| 16. Right lung                 | 32. Paracolic lymph nodes              |



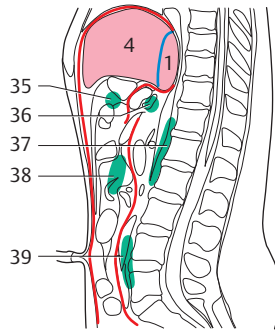
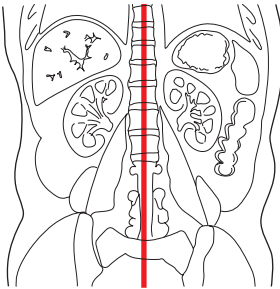
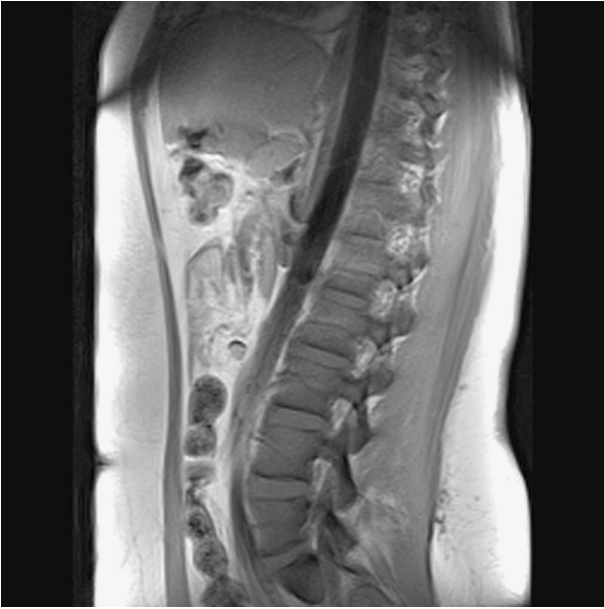— = Peritoneum

(Numbers indicate liver segments)



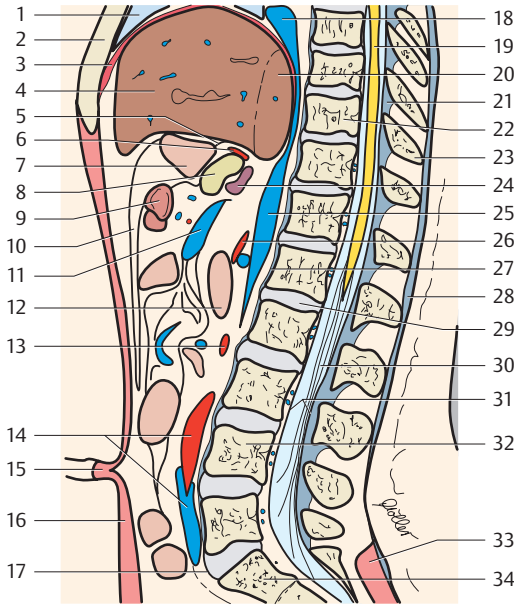


- |                                  |                                       |
|----------------------------------|---------------------------------------|
| 1. Right lung                    | 22. Intercostal artery                |
| 2. Pectoralis muscle             | 23. Bile duct                         |
| 3. Transversus thoracis muscle   | 24. Hepatic portal vein (left branch) |
| 4. Diaphragm                     | 25. Stomach                           |
| 5. External oblique muscle       | 26. Hepatic portal vein               |
| 6. Intercostalis muscles         | 27. Pancreas                          |
| 7. Rib                           | 28. Diaphragm (lumbar part)           |
| 8. Liver (quadrate lobe)         | 29. Nerve root                        |
| 9. Right gastroepiploic artery   | 30. Renal artery and vein             |
| 10. Transverse colon             | 31. Inferior vena cava                |
| 11. Colic artery                 | 32. Erector spinae muscle             |
| 12. Greater omentum              | 33. Psoas major muscle                |
| 13. Duodenum                     | 34. Lumbosacral plexus                |
| 14. Small intestine              | 35. Transverse process (L4)           |
| 15. Jejunal veins                | 36. Quadratus lumborum muscle         |
| 16. Rectus abdominis muscle      | 37. Iliac spine                       |
| 17. Common iliac artery and vein | 38. Hepatic lymph nodes               |
| 18. Small intestine (ileum)      | 39. Gastro-omental lymph nodes        |
| 19. Right atrium                 | 40. Pancreatic lymph nodes            |
| 20. Thoracic vertebra            | 41. Postcaval lymph nodes             |
| 21. Hepatic veins                | 42. Common iliac lymph nodes          |

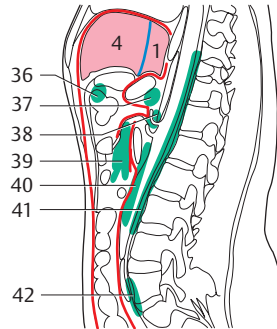
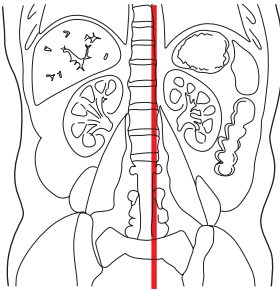
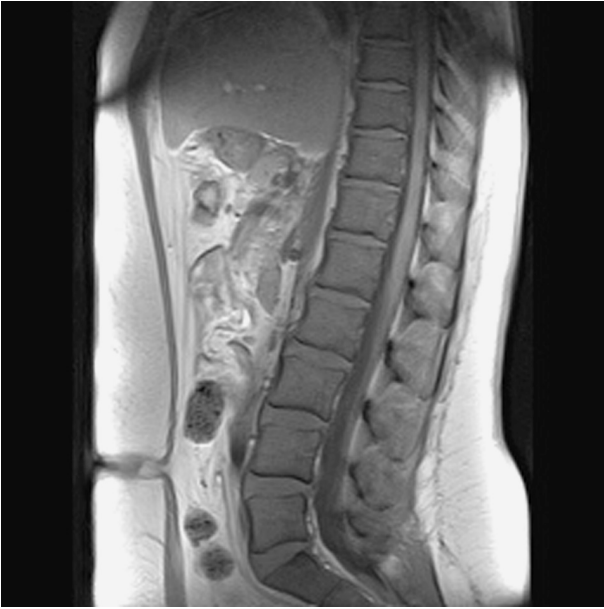


— = Peritoneum

(Numbers indicate liver segments)

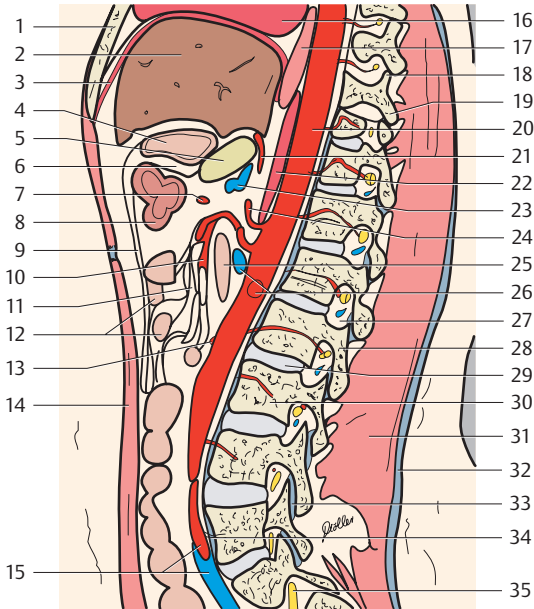


- |                                  |                                    |
|----------------------------------|------------------------------------|
| 1. Lung                          | 21. Ligamenta flava                |
| 2. Sternum                       | 22. Thoracic vertebra (T10)        |
| 3. Diaphragm                     | 23. Spinous process                |
| 4. Liver                         | 24. Hepatic portal vein            |
| 5. Lesser omentum                | 25. Inferior vena cava             |
| 6. Left gastric artery           | 26. Inferior mesenteric artery     |
| 7. Stomach                       | 27. Anterior longitudinal ligament |
| 8. Pancreas                      | 28. Thoracolumbar fascia           |
| 9. Transverse colon              | 29. Intervertebral disk (L1-L2)    |
| 10. Greater omentum              | 30. Cauda equina                   |
| 11. Superior mesenteric vein     | 31. Spinal dura                    |
| 12. Duodenum (descending part)   | 32. Lumbar vertebra (L4)           |
| 13. Inferior mesenteric artery   | 33. Erector spinae muscle          |
| 14. Common iliac artery and vein | 34. Sacrum                         |
| 15. Umbilicus                    | 35. Gastro-omental lymph nodes     |
| 16. Rectus abdominis muscle      | 36. Pancreatic lymph nodes         |
| 17. Promontorium                 | 37. Postcaval lymph nodes          |
| 18. Right atrium                 | 38. Mesenteric lymph nodes         |
| 19. Spinal cord                  | 39. Common iliac lymph nodes       |
| 20. Liver (caudate lobe)         |                                    |

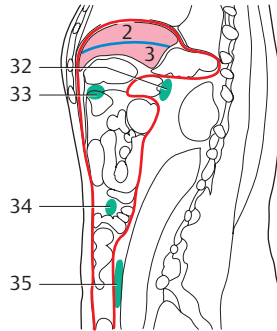
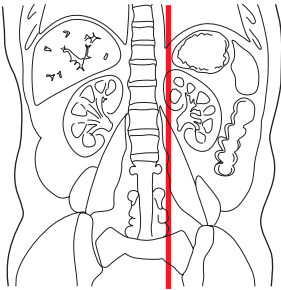
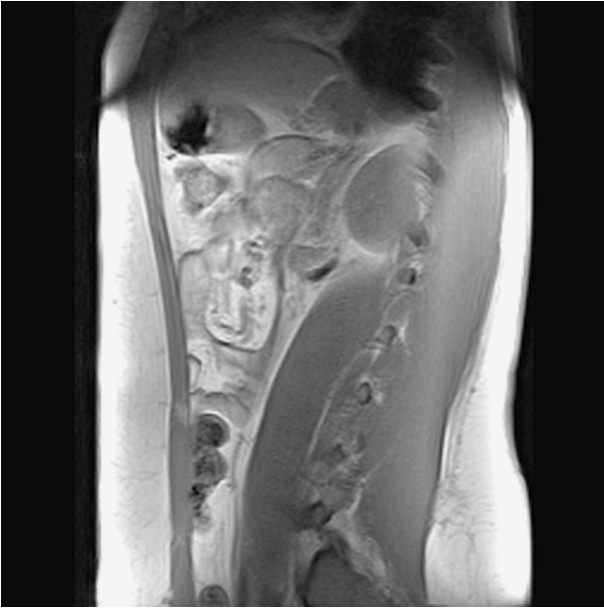

— = Peritoneum

(Numbers indicate liver segments)

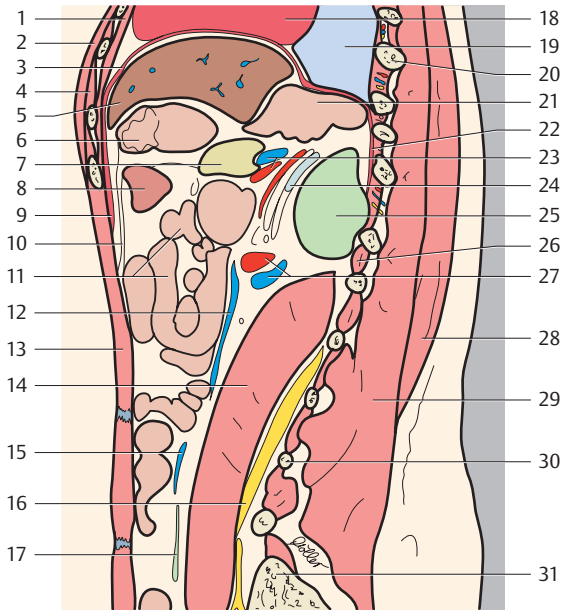


- |                                               |                                    |
|-----------------------------------------------|------------------------------------|
| 1. Sternum                                    | 21. Left gastric artery            |
| 2. Liver                                      | 22. Diaphragm (lumbar part)        |
| 3. Diaphragm                                  | 23. Hepatic portal vein            |
| 4. Stomach                                    | 24. Coeliac trunk                  |
| 5. Pancreas                                   | 25. Duodenum (descending part)     |
| 6. Omental bursa                              | 26. Left renal artery and vein     |
| 7. Middle colic artery                        | 27. Intervertebral foramen         |
| 8. Transverse colon                           | 28. Pedicle                        |
| 9. Greater omentum                            | 29. Intervertebral disk (L2-L3)    |
| 10. Superior mesenteric artery                | 30. Lumbar vertebra (L3)           |
| 11. Mesentery                                 | 31. Erector spinae muscle          |
| 12. Small intestine                           | 32. Thoracolumbar fascia           |
| 13. Inferior mesenteric artery                | 33. Zygapophysial joint            |
| 14. Rectus abdominis muscle                   | 34. Anterior longitudinal ligament |
| 15. Common iliac artery and vein              | 35. Nerve root S1                  |
| 16. Heart                                     | 36. Gastro-omental lymph nodes     |
| 17. Esophagus                                 | 37. Pancreatic lymph nodes         |
| 18. Superior articular process (zygapophysis) | 38. Coeliac lymph nodes            |
| 19. Inferior articular process (zygapophysis) | 39. Mesenteric lymph nodes         |
| 20. Descending aorta                          | 40. Lumbar lymph nodes             |
|                                               | 41. Postcaval lymph nodes          |
|                                               | 42. Common iliac lymph nodes       |

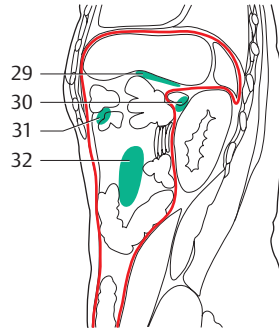
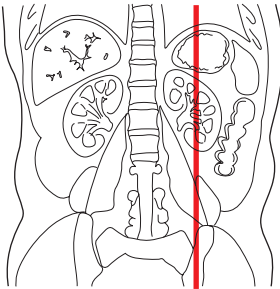
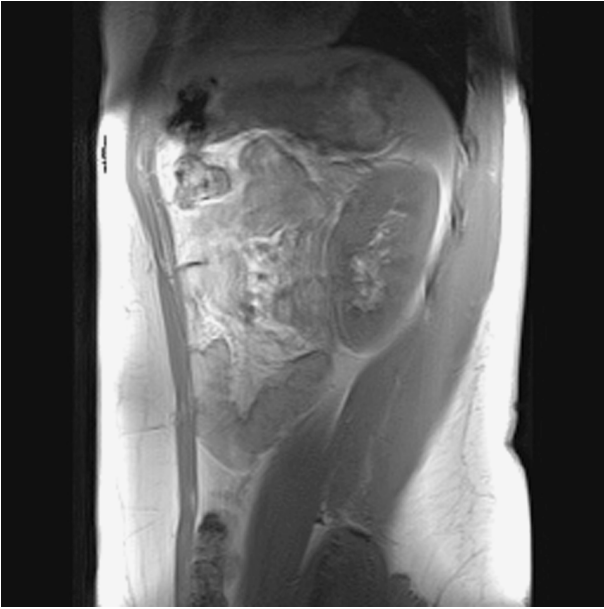

— = Peritoneum

(Numbers indicate liver segments)

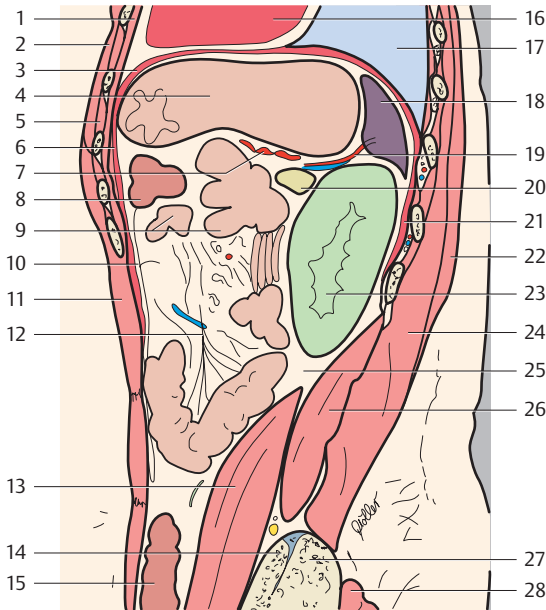


- |                                |                                                 |
|--------------------------------|-------------------------------------------------|
| 1. Transversus thoracis muscle | 20. Rib                                         |
| 2. Pectoralis muscle           | 21. Cardiac part of stomach (cardiac orifice)   |
| 3. Diaphragm                   | 22. Diaphragm (lumbar part)                     |
| 4. Intercostalis muscles       | 23. Splenic artery and vein                     |
| 5. Liver                       | 24. Suprarenal gland                            |
| 6. Stomach (fundus)            | 25. Left kidney                                 |
| 7. Pancreas                    | 26. Intertransversarii muscles (lateral lumbar) |
| 8. Transverse colon            | 27. Renal artery and vein                       |
| 9. Diaphragm (costal part)     | 28. Latissimus dorsi muscle                     |
| 10. Greater omentum            | 29. Erector spinae muscle                       |
| 11. Small intestine            | 30. Transverse process (L3)                     |
| 12. Inferior mesenteric vein   | 31. Iliac crest                                 |
| 13. Rectus abdominis muscle    | 32. Pancreatic lymph nodes                      |
| 14. Psoas major muscle         | 33. Gastro-omental lymph nodes                  |
| 15. Ovarian vein               | 34. Juxtaintestinal lymph nodes                 |
| 16. Lumbosacral plexus         | 35. Common iliac lymph nodes                    |
| 17. Ureter                     |                                                 |
| 18. Heart                      |                                                 |
| 19. Lung                       |                                                 |

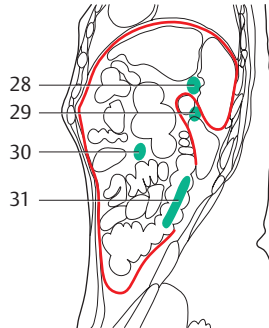
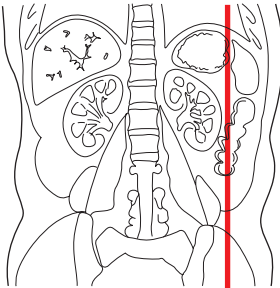
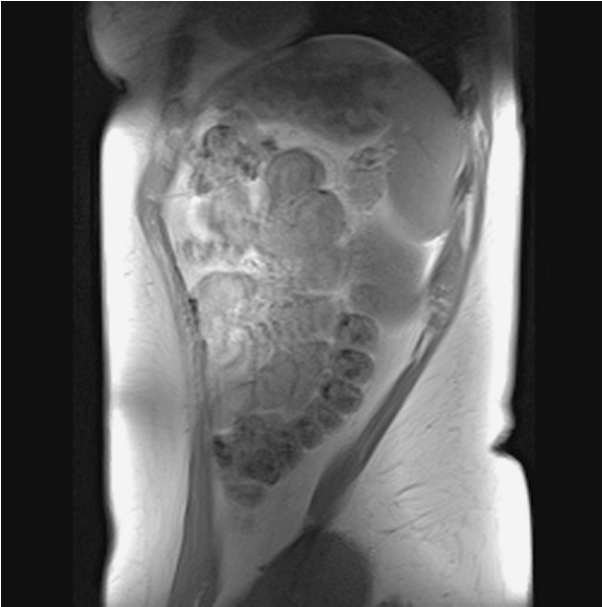


— = Peritoneum

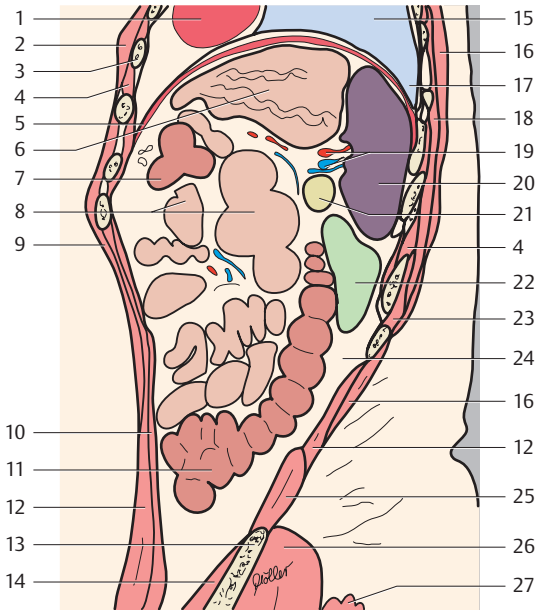




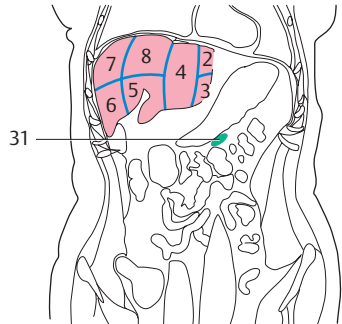
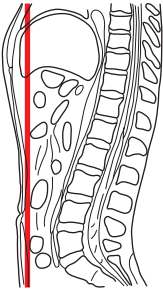
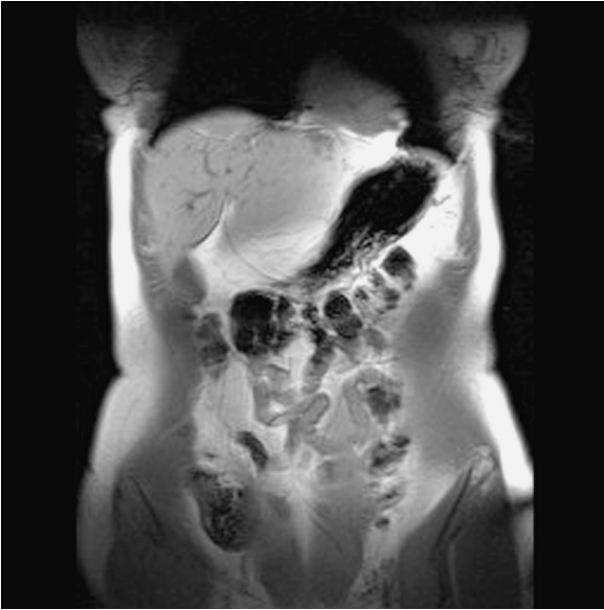- |                                |                                      |
|--------------------------------|--------------------------------------|
| 1. Transversus thoracis muscle | 18. Spleen                           |
| 2. Pectoralis major muscle     | 19. Splenic artery and vein          |
| 3. Diaphragm                   | 20. Pancreas                         |
| 4. Stomach (fundus)            | 21. Diaphragm (lumbar part)          |
| 5. Intercostalis muscles       | 22. Latissimus dorsi muscle          |
| 6. Diaphragm (costal part)     | 23. Left kidney                      |
| 7. Gastric artery              | 24. Erector spinae muscle            |
| 8. Transverse colon            | 25. Fatty capsule of the kidney      |
| 9. Small intestine             | 26. Quadratus lumborum muscle        |
| 10. Greater omentum            | 27. Ilium                            |
| 11. Rectus abdominis muscle    | 28. Gluteus maximus muscle           |
| 12. Mesentery                  | 29. Left gastro-omental lymph nodes  |
| 13. Psoas major muscle         | 30. Pancreatic lymph nodes           |
| 14. Sacrum (ala)               | 31. Right gastro-omental lymph nodes |
| 15. Descending colon           | 32. Juxtaintestinal lymph nodes      |
| 16. Heart                      |                                      |
| 17. Lung                       |                                      |



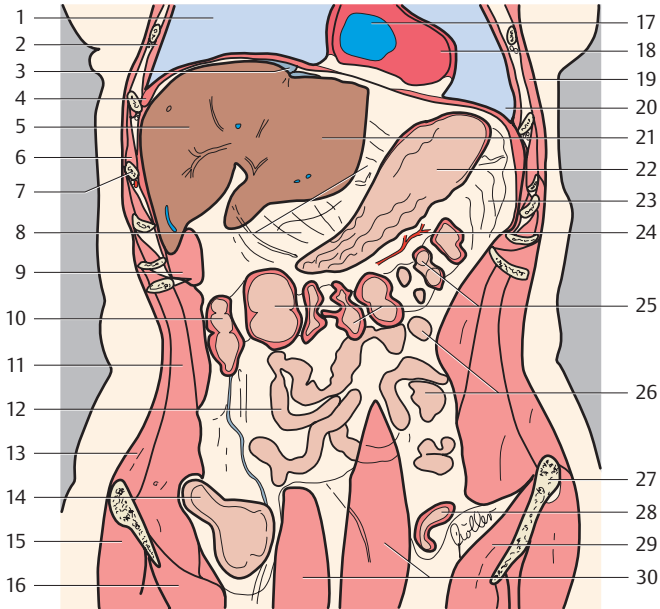
— = Peritoneum



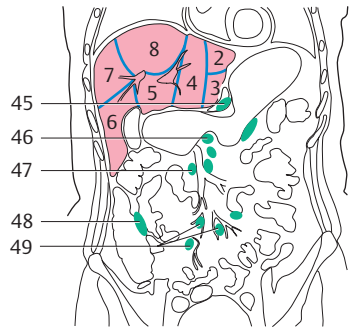
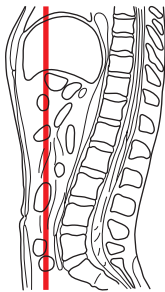
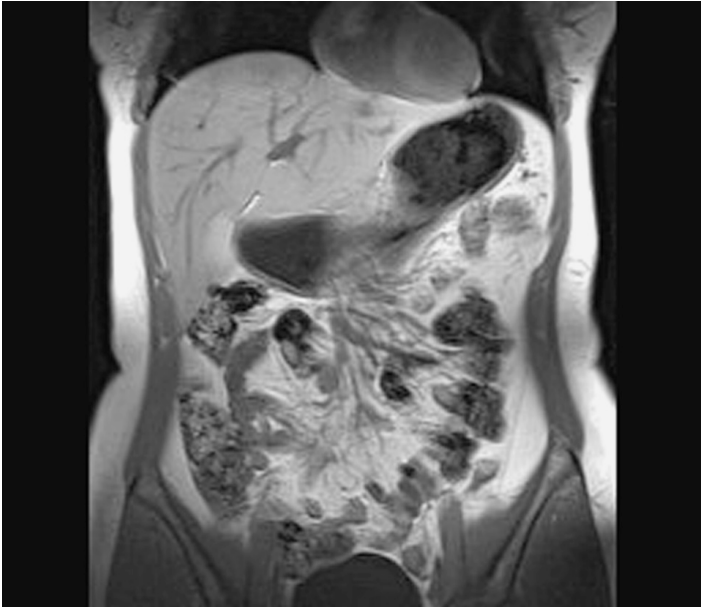
- |                                       |                                                          |
|---------------------------------------|----------------------------------------------------------|
| 1. Apex of heart                      | 17. Costodiaphragmatic recess                            |
| 2. Pectoralis major muscle            | 18. Serratus posterior inferior muscle                   |
| 3. Rib                                | 19. Splenic artery and vein                              |
| 4. Intercostalis muscles              | 20. Spleen                                               |
| 5. Diaphragm                          | 21. Pancreas                                             |
| 6. Stomach                            | 22. Left kidney                                          |
| 7. Transverse colon                   | 23. Erector spinae muscle (iliocostalis lumborum muscle) |
| 8. Small intestine                    | 24. Fatty capsule of the kidney                          |
| 9. External abdominal oblique muscle  | 25. Quadratus lumborum muscle                            |
| 10. Transversus abdominis muscle      | 26. Gluteus medius muscle                                |
| 11. Descending colon                  | 27. Gluteus maximus muscle                               |
| 12. Internal abdominal oblique muscle | 28. Splenic lymph nodes                                  |
| 13. Iliac spine                       | 29. Pancreatic lymph nodes                               |
| 14. Iliacus muscle                    | 30. Juxtaintestinal lymph nodes                          |
| 15. Lung                              | 31. Paracolic lymph nodes                                |
| 16. Latissimus dorsi muscle           |                                                          |



(Numbers indicate liver segments)

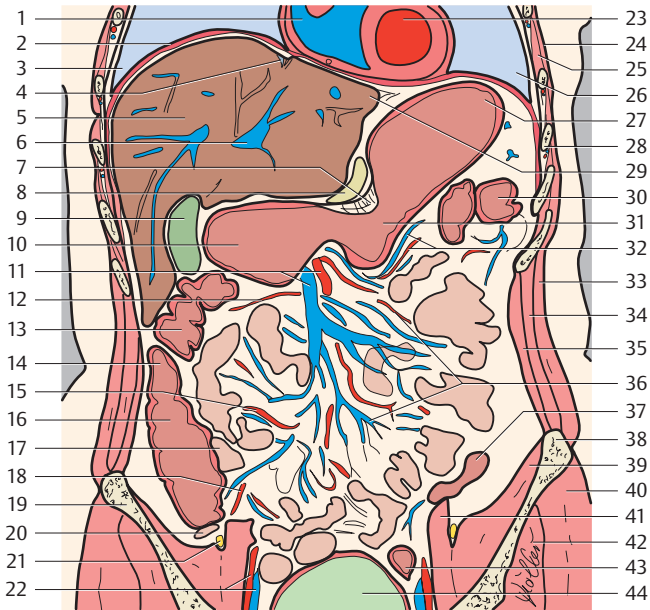


- |                                                                                                     |                                           |
|-----------------------------------------------------------------------------------------------------|-------------------------------------------|
| 1. Right lung                                                                                       | 16. Iliopsoas muscle                      |
| 2. Parietal pleura (costal part) and muscles of thorax (innermost and internal intercostal muscles) | 17. Right ventricle                       |
| 3. Falciform ligament of liver                                                                      | 18. Apex of heart                         |
| 4. Diaphragm                                                                                        | 19. Serratus anterior muscle              |
| 5. Liver (right lobe)                                                                               | 20. Left lung (costodiaphragmatic recess) |
| 6. External intercostal muscle                                                                      | 21. Left lobe of liver                    |
| 7. Rib (7)                                                                                          | 22. Stomach                               |
| 8. Lesser omentum                                                                                   | 23. Greater omentum                       |
| 9. Transversus abdominis muscle                                                                     | 24. Right gastroepiploic artery           |
| 10. Right colon flexure                                                                             | 25. Transverse colon                      |
| 11. Internal abdominal oblique muscle                                                               | 26. Jejunum                               |
| 12. Ileum                                                                                           | 27. Anterior superior iliac spine         |
| 13. External abdominal oblique muscle                                                               | 28. Sigmoid colon                         |
| 14. Cecum                                                                                           | 29. Iliac muscle                          |
| 15. Gluteus medius muscle                                                                           | 30. Rectus abdominis muscle               |
|                                                                                                     | 31. Gastro-omental lymph nodes            |

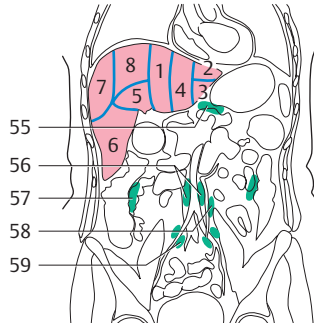
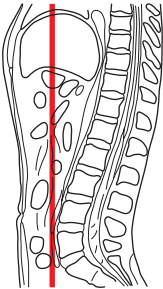
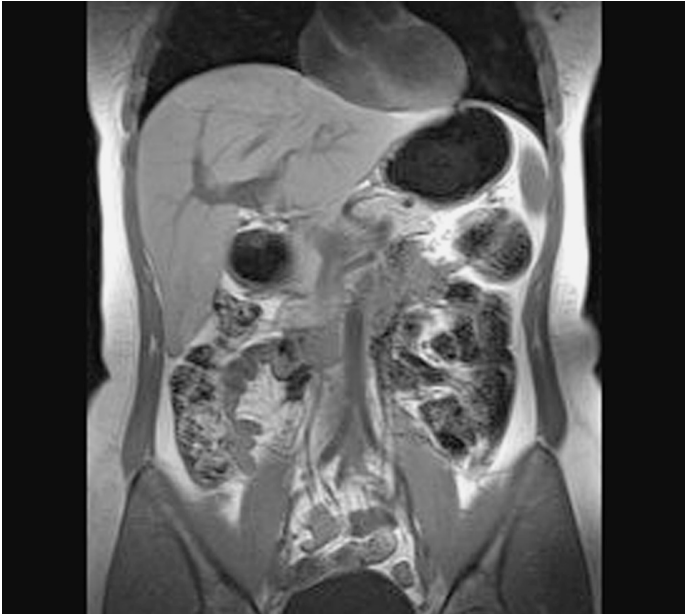

(Numbers indicate liver segments)

1. Right ventricle
2. Diaphragm
3. Right lung (costodiaphragmatic recess)
4. Falciform ligament of liver
5. Right lobe of liver



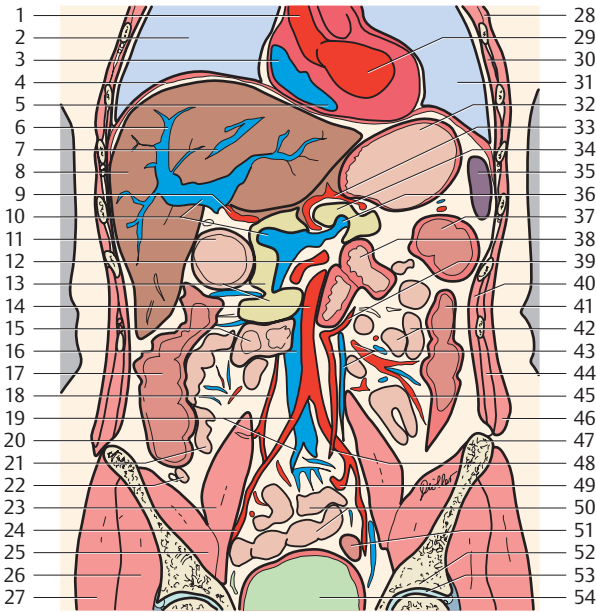
- |                                           |                                         |
|-------------------------------------------|-----------------------------------------|
| 6. Hepatic portal vein                    | 28. Rib (7)                             |
| 7. Omental bursa                          | 29. Left lobe of liver                  |
| 8. Pancreas (body)                        | 30. Left colic flexure                  |
| 9. Gallbladder                            | 31. Stomach (body)                      |
| 10. Stomach (antrum)                      | 32. Left gastroepiploic artery and vein |
| 11. Superior mesenteric artery and vein   | 33. External abdominal oblique muscle   |
| 12. Right colic artery                    | 34. Internal abdominal oblique muscle   |
| 13. Right colon flexure                   | 35. Transversus abdominis muscle        |
| 14. Ascending colon                       | 36. Jejunal and ileal arteries          |
| 15. Ileocolic artery                      | 37. Descending colon                    |
| 16. Cecum                                 | 38. Iliac crest                         |
| 17. Terminal ileum                        | 39. Iliacus muscle                      |
| 18. Appendicular artery                   | 40. Gluteus medius muscle               |
| 19. Ilium                                 | 41. Psoas major muscle                  |
| 20. Vermiform appendix                    | 42. Gluteus minimus muscle              |
| 21. Femoral nerve                         | 43. Sigmoid colon                       |
| 22. External iliac artery and vein        | 44. Urinary bladder                     |
| 23. Left ventricle                        | 45. Gastro-omental lymph nodes          |
| 24. Serratus anterior muscle              | 46. Coeliac lymph nodes                 |
| 25. External intercostal muscle           | 47. Superior mesenteric lymph nodes     |
| 26. Left lung (costodiaphragmatic recess) | 48. Paracolic lymph nodes               |
| 27. Stomach (fundus)                      | 49. Juxtaintestinal lymph nodes         |



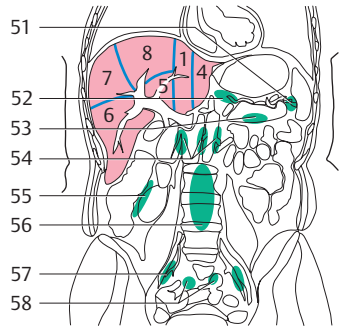
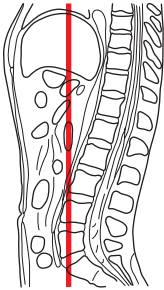
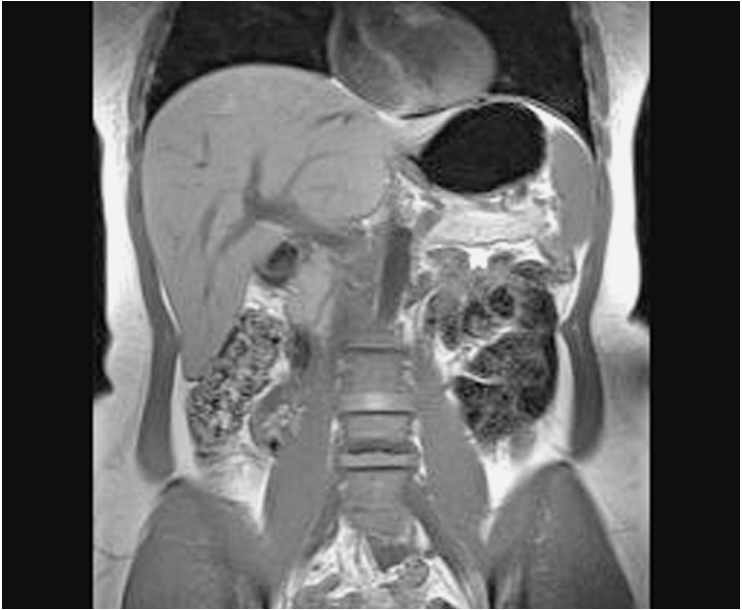(Numbers indicate liver segments)

- |                                       |                                |
|---------------------------------------|--------------------------------|
| 1. Ascending aorta                    | 8. Liver (right lobe)          |
| 2. Right lung                         | 9. Hepatic artery              |
| 3. Right atrium                       | 10. Hepatic portal vein        |
| 4. Diaphragm                          | 11. Stomach (antrum)           |
| 5. Right ventricle                    | 12. Superior mesenteric artery |
| 6. Hepatic portal vein (right branch) | 13. Pancreas (head)            |
| 7. Right hepatic vein                 | 14. Aorta                      |



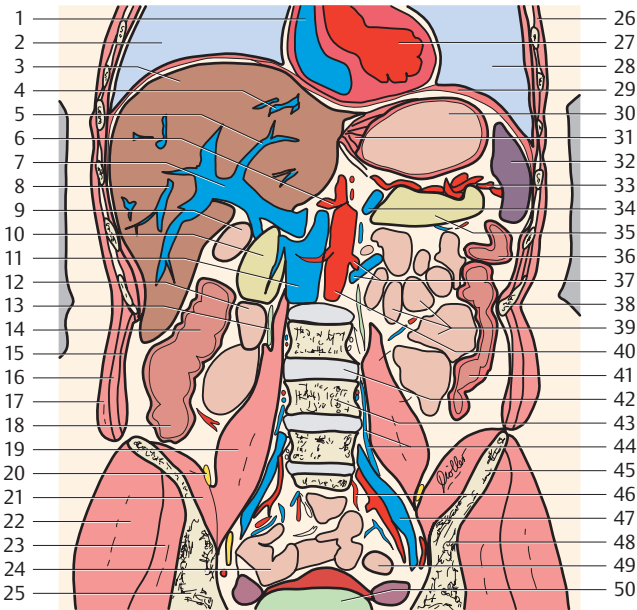


- |                                    |                                                |
|------------------------------------|------------------------------------------------|
| 15. Duodenum                       | 38. Duodenum (horizontal part)                 |
| 16. Inferior vena cava             | 39. Left colic artery                          |
| 17. Ascending colon                | 40. Transversus abdominis muscle               |
| 18. Ileocolic artery               | 41. Descending colon                           |
| 19. Common iliac artery and vein   | 42. Jejunum                                    |
| 20. Ileocecal valve                | 43. Inferior mesenteric artery and vein        |
| 21. Terminal ileum                 | 44. Internal abdominal oblique muscle          |
| 22. Vermiform appendix             | 45. Sigmoid arteries                           |
| 23. Psoas major muscle             | 46. External oblique muscle                    |
| 24. External iliac artery and vein | 47. Iliac crest                                |
| 25. Iliacus muscle                 | 48. Superior rectal artery                     |
| 26. Gluteus minimus muscle         | 49. Internal iliac artery                      |
| 27. Gluteus medius muscle          | 50. Ileum                                      |
| 28. Serratus anterior muscle       | 51. Sigmoid colon                              |
| 29. Left ventricle                 | 52. Ilium (acetabular roof)                    |
| 30. External intercostal muscle    | 53. Hip joint                                  |
| 31. Left lung                      | 54. Urinary bladder                            |
| 32. Stomach (fundus)               | 55. Gastro-omental lymph nodes                 |
| 33. Splenic artery                 | 56. Lumbar lymph nodes (preaortic lymph nodes) |
| 34. Pancreas (body)                | 57. Paracolic lymph nodes                      |
| 35. Spleen                         | 58. Inferior mesenteric lymph nodes            |
| 36. Splenic vein                   | 59. Common iliac lymph nodes                   |
| 37. Left colic flexure             |                                                |

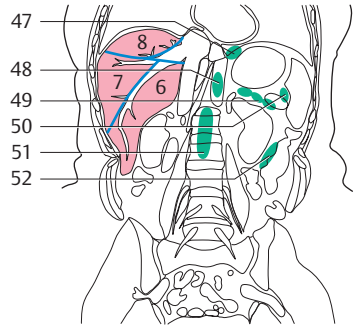
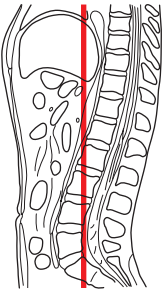
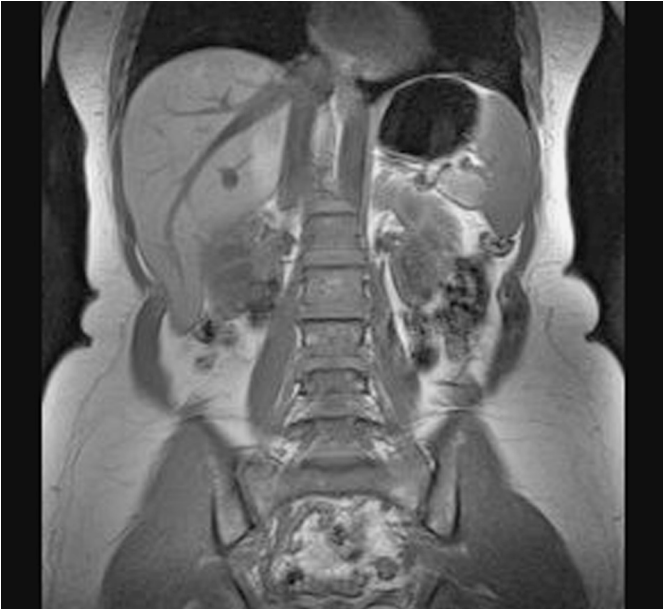

(Numbers indicate liver segments)

1. Right atrium
2. Right lung
3. Liver (right lobe)
4. Hepatic veins
5. Hepatic portal vein (left branch)
6. Coeliac trunk
7. Hepatic portal vein
8. Right hepatic veins

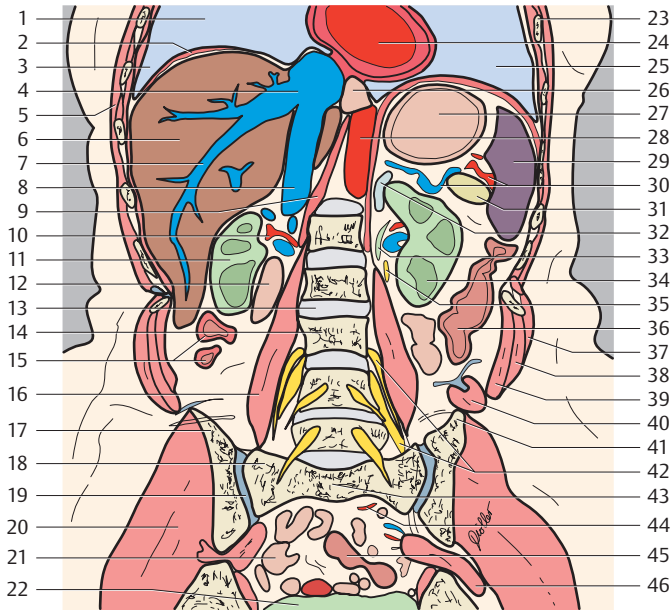


- |                                       |                                    |
|---------------------------------------|------------------------------------|
| 9. Stomach (pylorus)                  | 34. Splenic vein                   |
| 10. Pancreas (head)                   | 35. Pancreas (tail)                |
| 11. Inferior vena cava                | 36. Left colic flexure             |
| 12. Duodenum                          | 37. Left renal artery and vein     |
| 13. Ureter                            | 38. Rib (11)                       |
| 14. Ascending colon                   | 39. Jejunum                        |
| 15. Transversus abdominis muscle      | 40. Abdominal aorta                |
| 16. Internal abdominal oblique muscle | 41. Descending colon               |
| 17. External abdominal oblique muscle | 42. Intervertebral disk (L3-L4)    |
| 18. Cecum                             | 43. Lumbar vertebra (L4)           |
| 19. Psoas major muscle                | 44. Ascending lumbar vein          |
| 20. Femoral nerve                     | 45. Iliac crest                    |
| 21. Iliacus muscle                    | 46. Superior rectal artery         |
| 22. Gluteus medius muscle             | 47. Internal iliac artery and vein |
| 23. Gluteus minimus muscle            | 48. Ilium                          |
| 24. Ileum                             | 49. Sigmoid colon                  |
| 25. Ilium                             | 50. Urinary bladder                |
| 26. Serratus anterior muscle          | 51. Splenic lymph nodes            |
| 27. Left ventricle                    | 52. Gastro-omental lymph nodes     |
| 28. Left lung                         | 53. Pancreatic lymph nodes         |
| 29. Diaphragm                         | 54. Lumbar lymph nodes             |
| 30. Stomach (fundus)                  | 55. Paracolic lymph nodes          |
| 31. Stomach (cardia)                  | 56. Prevertebral lymph nodes       |
| 32. Spleen                            | 57. Internal iliac lymph nodes     |
| 33. Splenic artery                    | 58. Juxtaintestinal lymph nodes    |

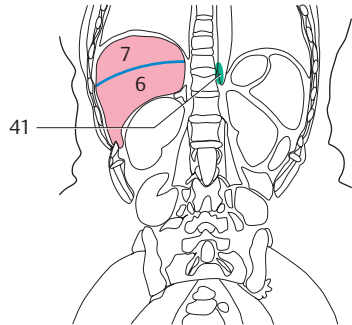
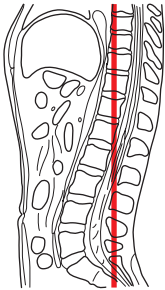
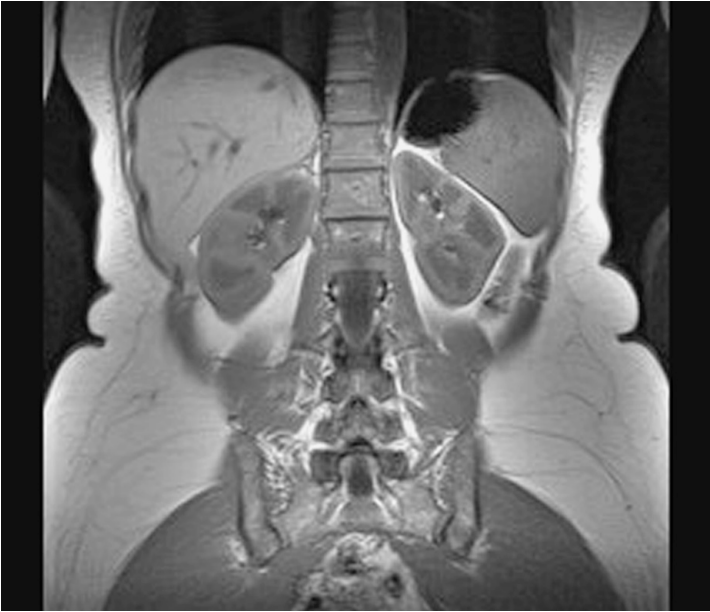

(Numbers indicate liver segments)

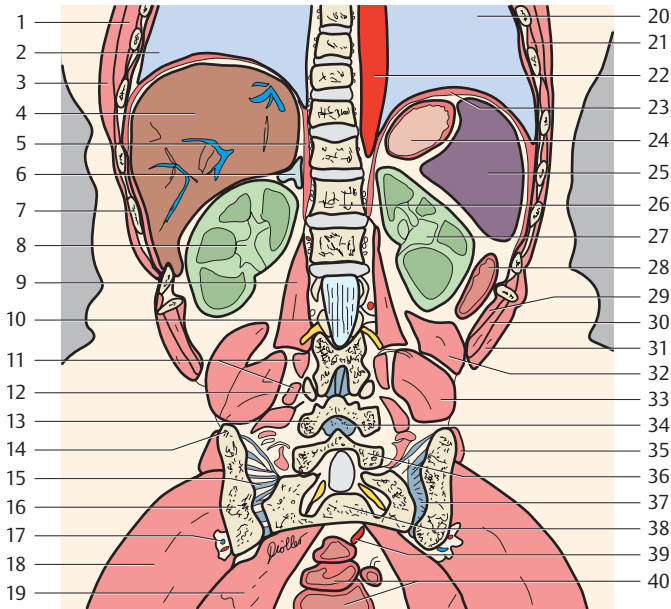
- |                                       |                                        |
|---------------------------------------|----------------------------------------|
| 1. Right lung                         | 8. Inferior vena cava                  |
| 2. Diaphragm                          | 9. Diaphragm (lumbar part, right crus) |
| 3. Costodiaphragmatic recess          | 10. Renal artery                       |
| 4. Hepatic veins                      | 11. Right kidney                       |
| 5. Serratus anterior muscle           | 12. Duodenum (descending part)         |
| 6. Liver (right lobe)                 | 13. Intervertebral disk (L2-L3)        |
| 7. Right hepatic veins (right branch) |                                        |



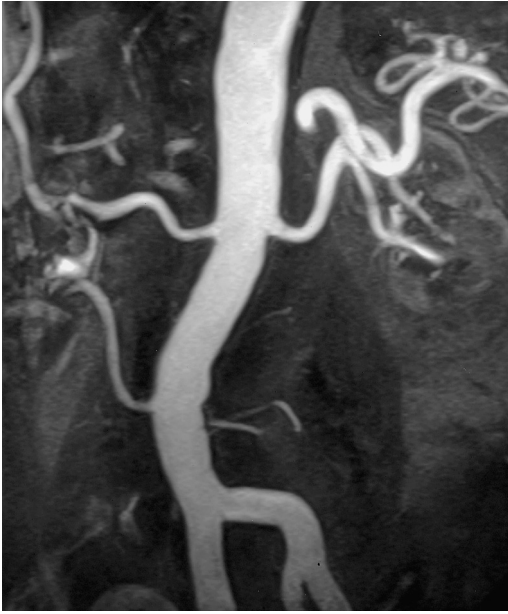- |                                         |                                        |
|-----------------------------------------|----------------------------------------|
| 14. Lumbar vertebra (L3)                | 35. Sympathetic trunk                  |
| 15. Ascending colon                     | 36. Descending colon                   |
| 16. Psoas major muscle                  | 37. External abdominal oblique muscle  |
| 17. Ilium (ala)                         | 38. Internal abdominal oblique muscle  |
| 18. Sacrum (ala)                        | 39. Transversus abdominis muscle       |
| 19. Sacroiliac joint                    | 40. Quadratus lumborum muscle          |
| 20. Gluteus medius muscle               | 41. Iliac crest                        |
| 21. Small intestine                     | 42. Lumbar plexus                      |
| 22. Urinary bladder                     | 43. Sacrum                             |
| 23. Rib (7)                             | 44. Superior rectal artery             |
| 24. Left ventricle                      | 45. Sigmoid colon                      |
| 25. Left lung                           | 46. Piriformis muscle                  |
| 26. Esophagus (hiatus) with vagal trunk | 47. Superior diaphragmatic lymph nodes |
| 27. Stomach                             | 48. Inferior diaphragmatic lymph nodes |
| 28. Descending aorta                    | 49. Pancreatic lymph nodes             |
| 29. Spleen                              | 50. Splenic lymph nodes                |
| 30. Splenic artery and vein             | 51. Prevertebral lymph nodes           |
| 31. Pancreas (tail)                     | 52. Paracolic lymph nodes              |
| 32. Suprarenal gland                    |                                        |
| 33. Ureter                              |                                        |
| 34. Left kidney                         |                                        |



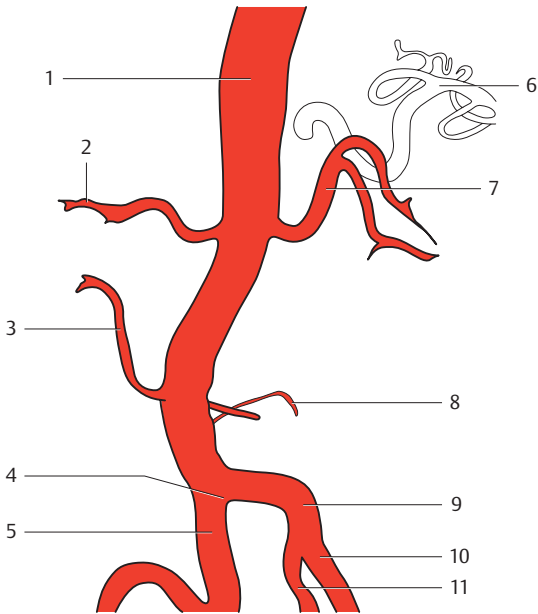
(Numbers indicate liver segments)



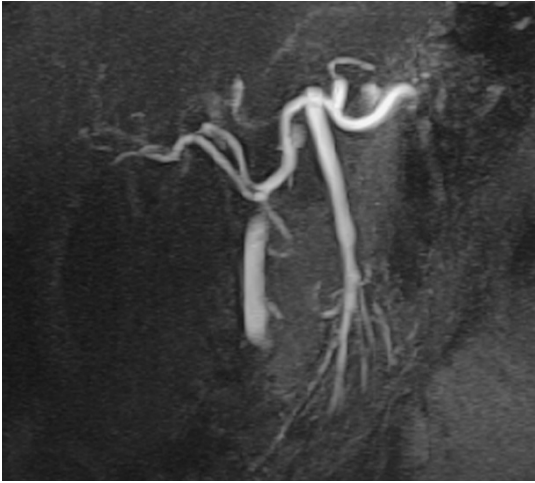
- |                                                       |                                        |
|-------------------------------------------------------|----------------------------------------|
| 1. Serratus anterior muscle                           | 21. External intercostal muscle        |
| 2. Right lung                                         | 22. Thoracic aorta                     |
| 3. Latissimus dorsi muscle                            | 23. Diaphragm                          |
| 4. Liver (right lobe)                                 | 24. Stomach                            |
| 5. Diaphragm (lumbar part, right crus)                | 25. Spleen                             |
| 6. Suprarenal gland                                   | 26. Thoracic vertebra (T12)            |
| 7. Rib (11)                                           | 27. Left kidney                        |
| 8. Right kidney                                       | 28. Descending colon                   |
| 9. Psoas major muscle                                 | 29. Transversus abdominis muscle       |
| 10. Vertebral canal with cauda equina                 | 30. Internal abdominal oblique muscle  |
| 11. Transversospinales muscles                        | 31. External abdominal oblique muscle  |
| 12. Superior articular process (zygapophysis) (of L4) | 32. Quadratus lumborum muscle          |
| 13. Inferior articular process (zygapophysis) (of L4) | 33. Iliocostalis muscle                |
| 14. Iliac crest                                       | 34. Ligamenta flava                    |
| 15. Dorsal sacroiliac ligaments                       | 35. Gluteus medius muscle              |
| 16. Ilium (ala)                                       | 36. Vertebral arch (lamina of L5)      |
| 17. Superior gluteal artery and vein                  | 37. Sacroiliac joint                   |
| 18. Gluteus maximus muscle                            | 38. Sacrum                             |
| 19. Piriformis muscle                                 | 39. Superior rectal artery             |
| 20. Left lung                                         | 40. Rectum                             |
|                                                       | 41. Superior diaphragmatic lymph nodes |

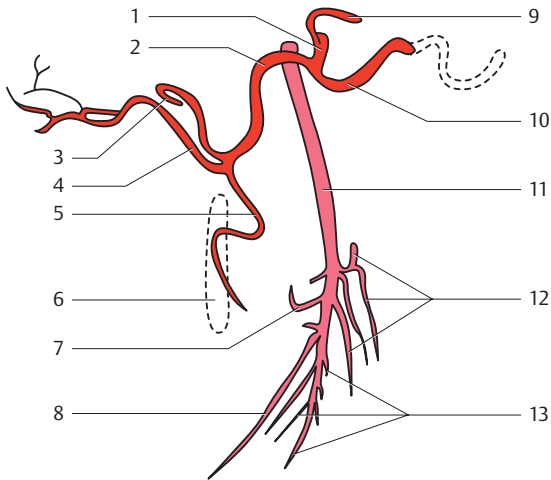




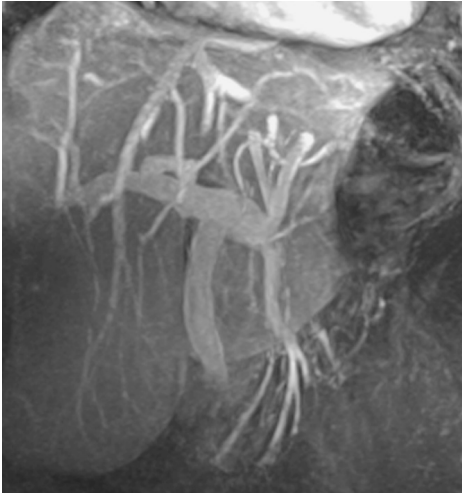


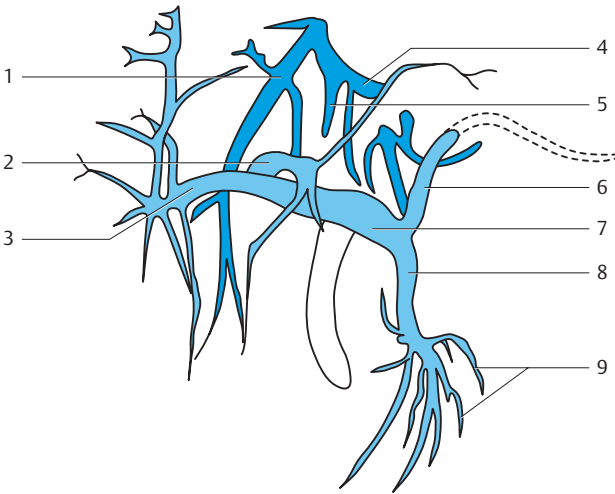
- |                                                 |                             |
|-------------------------------------------------|-----------------------------|
| 1. Abdominal aorta                              | 6. Splenic artery           |
| 2. Right renal artery                           | 7. Left renal artery        |
| 3. Inferior capsular branch of the renal artery | 8. Lumbar arteries          |
| 4. Aortic bifurcation                           | 9. Common left iliac artery |
| 5. Common right iliac artery                    | 10. External iliac artery   |
|                                                 | 11. Internal iliac artery   |



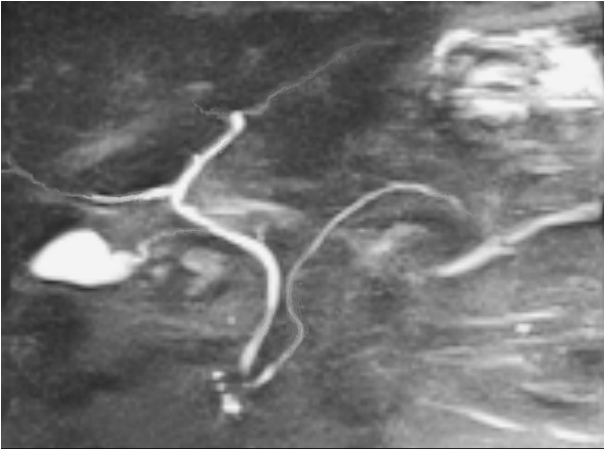


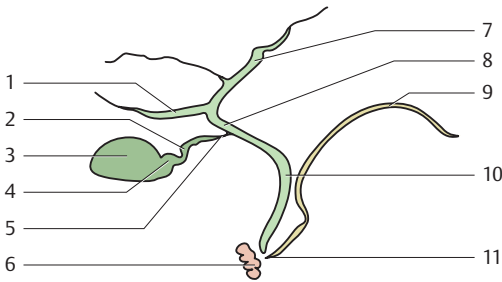
- |                          |                                |
|--------------------------|--------------------------------|
| 1. Coeliac trunk         | 8. ileocolic artery            |
| 2. Common hepatic artery | 9. Left gastric artery         |
| 3. Left hepatic artery   | 10. Splenic artery             |
| 4. Right hepatic artery  | 11. Superior mesenteric artery |
| 5. Gastroduodenal artery | 12. Jejunal arteries           |
| 6. Abdominal aorta       | 13. ileal arteries             |
| 7. Right colic artery    |                                |



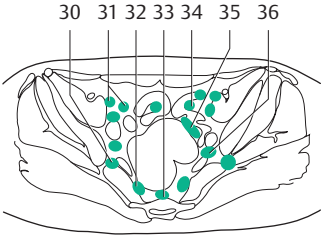
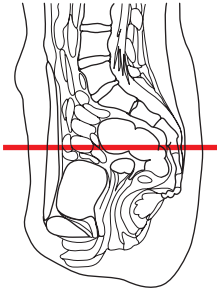
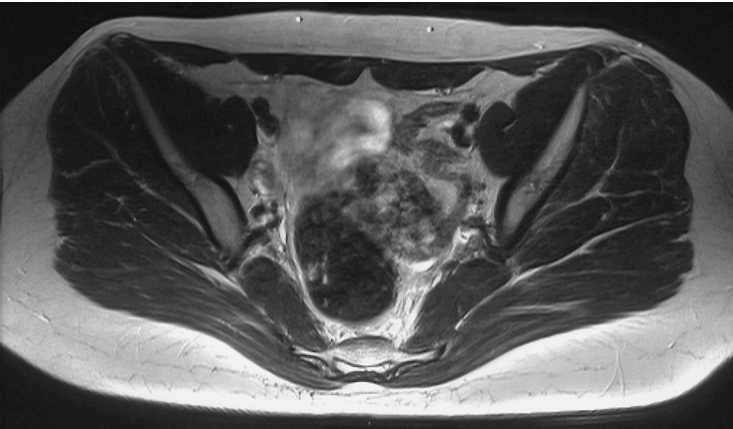


- |                                |                             |
|--------------------------------|-----------------------------|
| 1. Right hepatic vein          | 6. Splenic vein             |
| 2. Left branch of portal vein  | 7. Portal vein              |
| 3. Right branch of portal vein | 8. Superior mesenteric vein |
| 4. Right hepatic vein          | 9. Jejunal and ileal veins  |
| 5. Intermediate hepatic vein   |                             |

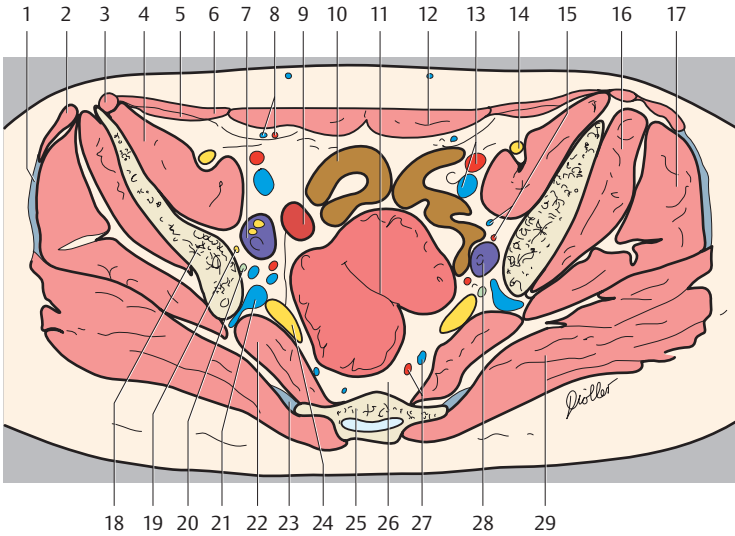




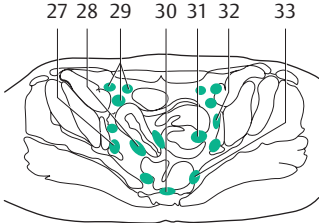
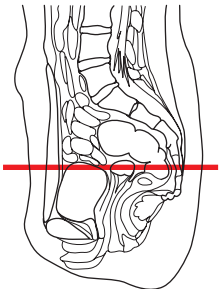
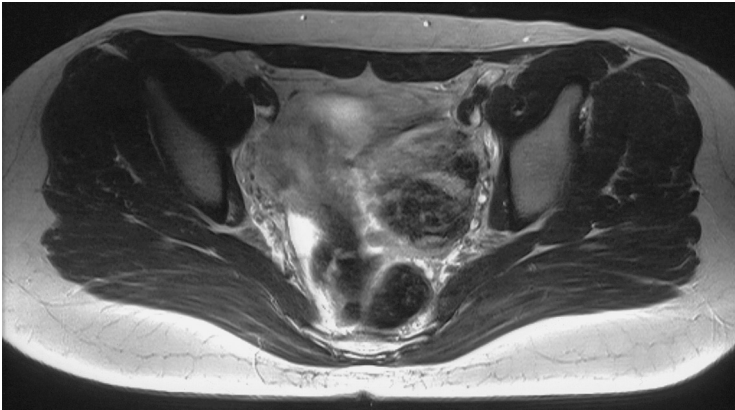
- |                                               |                        |
|-----------------------------------------------|------------------------|
| 1. Right hepatic duct                         | 6. Duodenum            |
| 2. Cystic duct (spiral fold)                  | 7. Left hepatic duct   |
| 3. Body of gallbladder                        | 8. Common hepatic duct |
| 4. Neck of gallbladder                        | 9. Pancreatic duct     |
| 5. Cystic duct (pars flaccida, straight part) | 10. Bile duct          |
|                                               | 11. Duodenal papilla   |

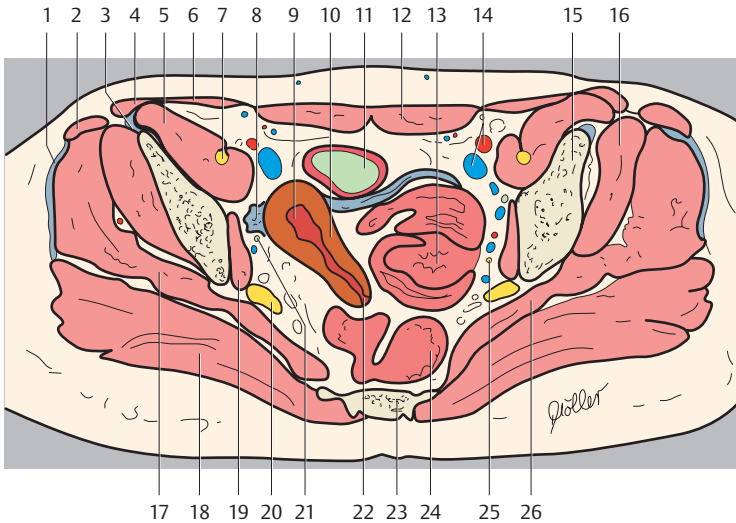




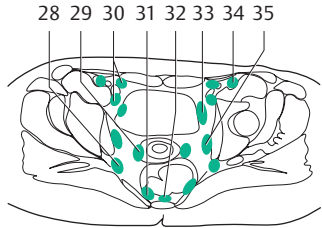
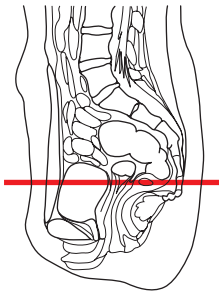
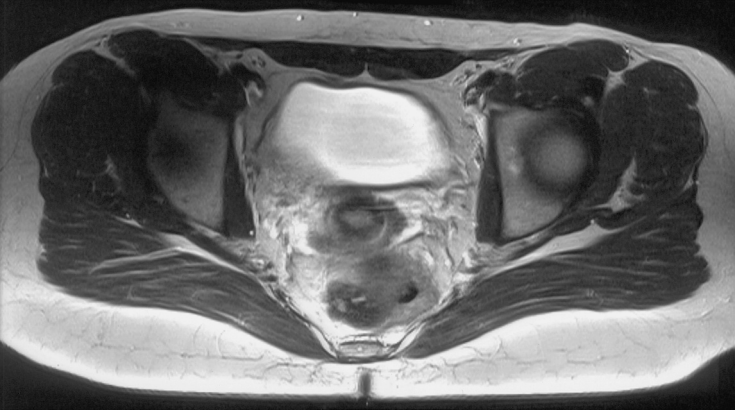


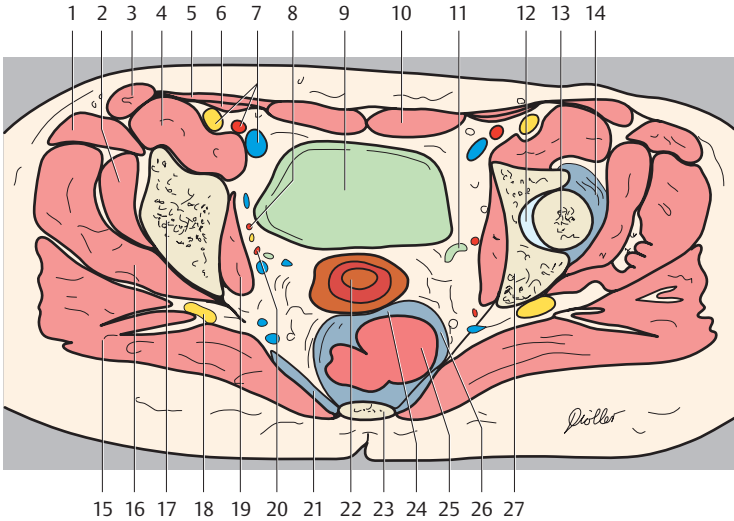
- |                                        |                                                   |
|----------------------------------------|---------------------------------------------------|
| 1. Gluteal aponeurosis                 | 20. Ureter                                        |
| 2. Tensor fasciae latae muscle         | 21. Superior gluteal vein and internal iliac vein |
| 3. Sartorius muscle                    | 22. Piriformis muscle                             |
| 4. Iliacus muscle                      | 23. Sacrotuberous ligament                        |
| 5. Transversus abdominis muscle        | 24. Sciatic nerve                                 |
| 6. Internal abdominal oblique muscle   | 25. Sacrum                                        |
| 7. Right ovary                         | 26. Presacral space                               |
| 8. Inferior epigastric artery and vein | 27. Superior rectal artery and vein               |
| 9. Uterus                              | 28. Left ovary                                    |
| 10. Ileum                              | 29. Gluteus maximus muscle                        |
| 11. Sigmoid colon (distal part)        | 30. Superior gluteal lymph nodes                  |
| 12. Rectus abdominis muscle            | 31. External iliac lymph nodes                    |
| 13. External iliac artery and vein     | 32. Pararectal lymph nodes                        |
| 14. Femoral nerve                      | 33. Sacral lymph nodes                            |
| 15. Ovarian artery and vein            | 34. Juxtaintestinal lymph nodes                   |
| 16. Gluteus minimus muscle             | 35. Paracolic lymph nodes                         |
| 17. Gluteus medius muscle              | 36. Internal iliac lymph nodes                    |
| 18. Ilium                              |                                                   |
| 19. Internal obturator nerve           |                                                   |



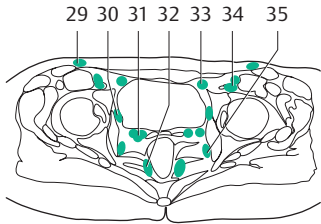
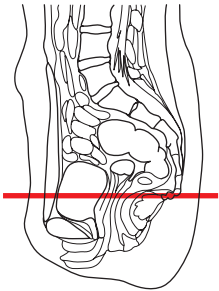
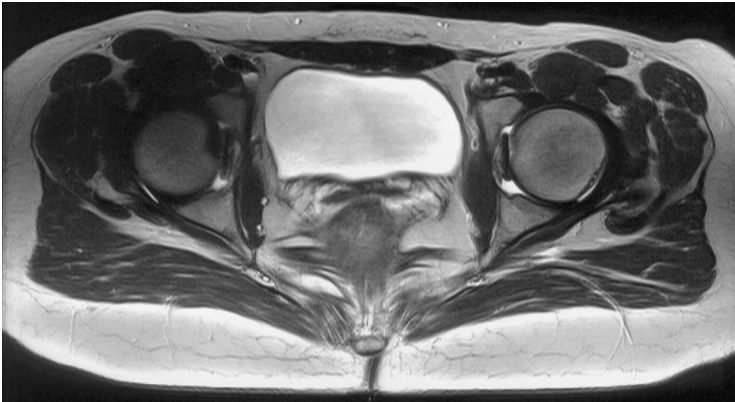


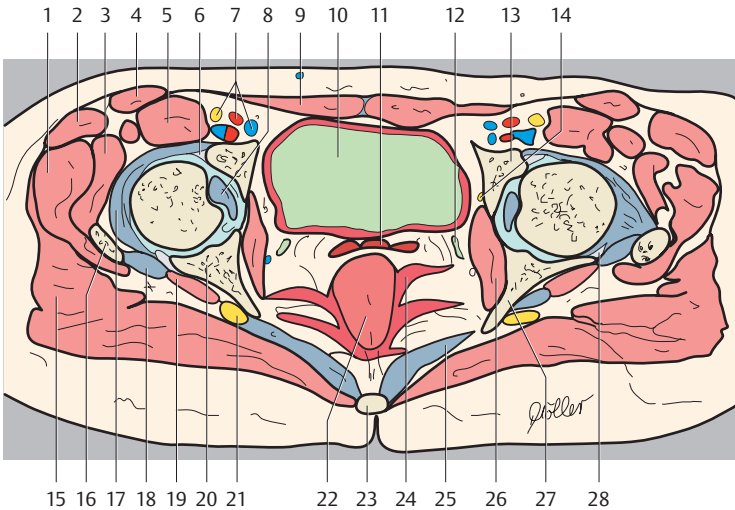
- |                                                                       |                                  |
|-----------------------------------------------------------------------|----------------------------------|
| 1. Gluteal aponeurosis                                                | 17. Gluteus medius muscle        |
| 2. Tensor fasciae latae muscle                                        | 18. Gluteus maximus muscle       |
| 3. Rectus femoris muscle                                              | 19. Obturator internus muscle    |
| 4. Sartorius muscle                                                   | 20. Sciatic nerve                |
| 5. Iliopsoas muscle                                                   | 21. Ureter                       |
| 6. Internal abdominal oblique muscle and transversus abdominis muscle | 22. Uterus (cervix)              |
| 7. Femoral nerve                                                      | 23. Sacrum                       |
| 8. Round ligament of uterus                                           | 24. Rectum                       |
| 9. Uterus (cavity)                                                    | 25. Obturator nerve              |
| 10. Uterus (fundus)                                                   | 26. Piriformis muscle            |
| 11. Urinary bladder                                                   | 27. Superior gluteal lymph nodes |
| 12. Rectus abdominis muscle                                           | 28. Parauterine lymph nodes      |
| 13. Small intestine                                                   | 29. External iliac lymph nodes   |
| 14. External iliac artery and vein                                    | 30. Sacral lymph nodes           |
| 15. Ilium                                                             | 31. Juxta-intestinal lymph nodes |
| 16. Gluteus minimus muscle                                            | 32. Obturator lymph nodes        |
|                                                                       | 33. Pararectal lymph nodes       |



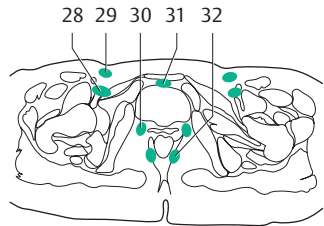
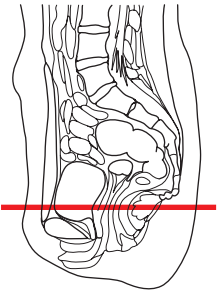
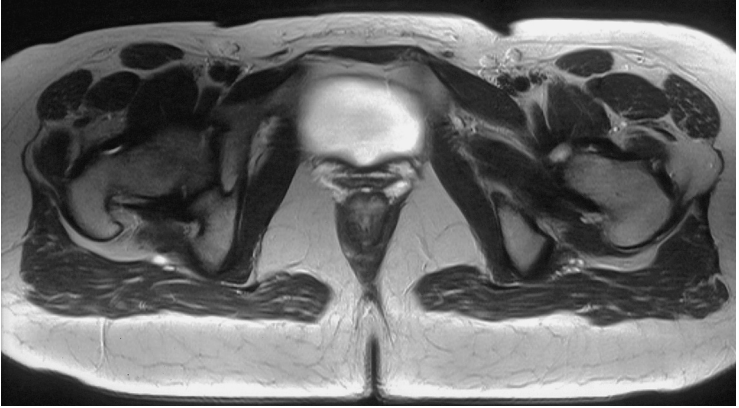

- |                                                          |                                     |
|----------------------------------------------------------|-------------------------------------|
| 1. Tensor fasciae latae muscle and rectus femoris muscle | 18. Sciatic nerve                   |
| 2. Gluteus minimus muscle                                | 19. Obturator internus muscle       |
| 3. Sartorius muscle                                      | 20. Internal iliac artery and vein  |
| 4. Iliopsoas muscle                                      | 21. Sacrospinous ligament           |
| 5. Internal abdominal oblique muscle                     | 22. Uterus (vaginal part)           |
| 6. Transversus abdominis muscle                          | 23. Sacrum                          |
| 7. Femoral nerve and external iliac artery and vein      | 24. Rectouterine pouch (of Douglas) |
| 8. Obturator artery                                      | 25. Rectum                          |
| 9. Urinary bladder                                       | 26. Uterosacral ligament            |
| 10. Rectus abdominis muscle                              | 27. Ilium                           |
| 11. Ureter                                               | 28. Superior gluteal lymph nodes    |
| 12. Hip joint                                            | 29. Parauterine lymph nodes         |
| 13. Head of femur                                        | 30. External iliac lymph nodes      |
| 14. Joint capsule                                        | 31. Pararectal lymph nodes          |
| 15. Gluteus maximus muscle                               | 32. Sacral lymph nodes              |
| 16. Gluteus medius muscle                                | 33. Paravesical lymph nodes         |
| 17. Acetabular roof                                      | 34. Deep inguinal lymph node        |
|                                                          | 35. Obturator lymph nodes           |

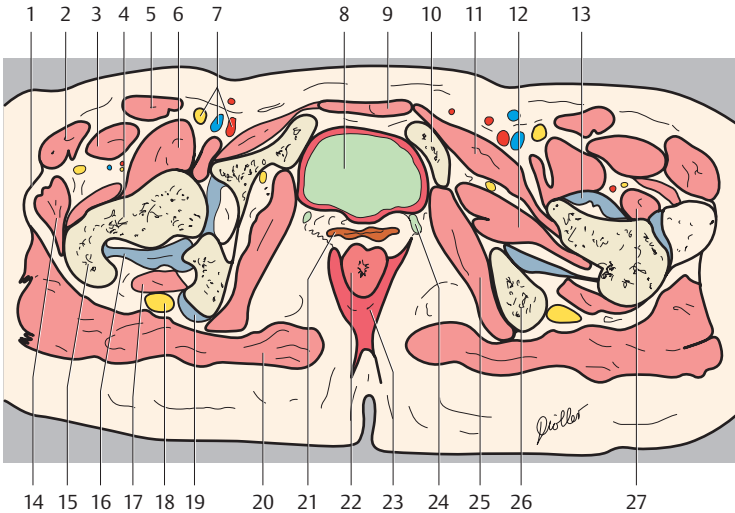




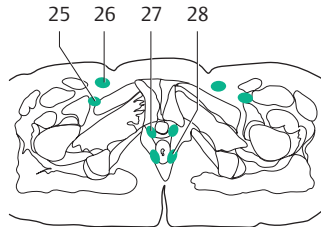
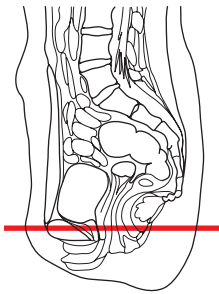
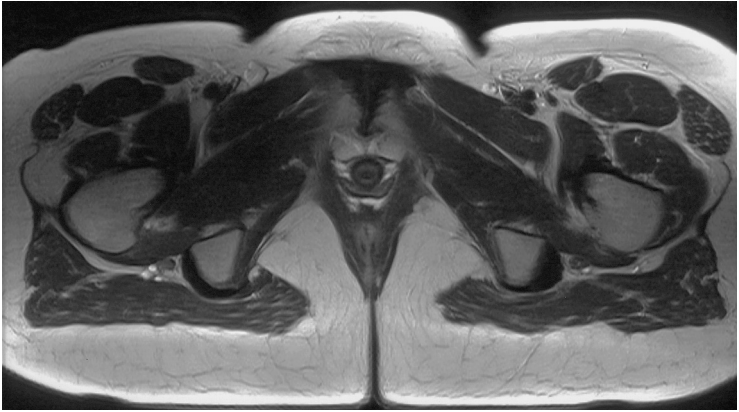- |                                               |                                                     |
|-----------------------------------------------|-----------------------------------------------------|
| 1. Gluteus medius muscle                      | 19. Gemellus superior muscle                        |
| 2. Tensor fasciae latae muscle                | 20. Ilium                                           |
| 3. Gluteus minimus muscle                     | 21. Sciatic nerve                                   |
| 4. Sartorius muscle                           | 22. Rectum                                          |
| 5. Iliopsoas muscle and rectus femoris muscle | 23. Coccyx                                          |
| 6. Acetabular lip (anterior part)             | 24. Levator ani muscle                              |
| 7. Femoral artery, vein and nerve             | 25. Sacrospinous ligament                           |
| 8. Ligament of head of femur                  | 26. Obturator internus muscle                       |
| 9. Rectus abdominis muscle                    | 27. Ischial spine                                   |
| 10. Urinary bladder                           | 28. Acetabular lip (posterior part)                 |
| 11. Vagina                                    | 29. Superficial inguinal lymph nodes                |
| 12. Ureter                                    | 30. Paravesical lymph nodes                         |
| 13. Ilium                                     | 31. Postvesical and parvaginal lymph nodes          |
| 14. Obturator nerve                           | 32. Pararectal lymph nodes                          |
| 15. Gluteus maximus muscle                    | 33. Medial lacunar lymph node (Rosenmüller-Cloquet) |
| 16. Greater trochanter                        | 34. Deep inguinal lymph nodes                       |
| 17. Joint capsule                             | 35. Obturator lymph nodes                           |
| 18. Piriformis muscle (tendon)                |                                                     |

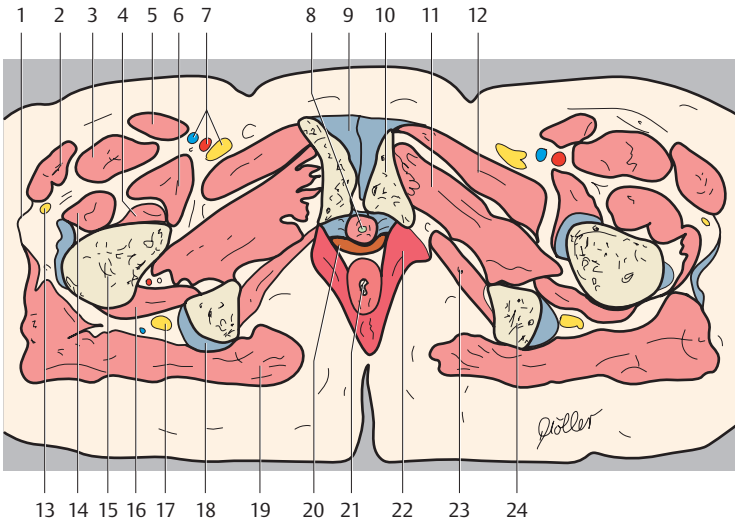




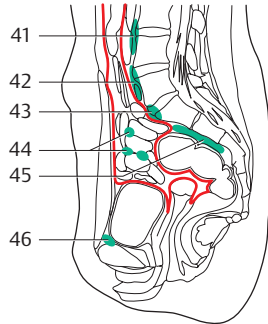
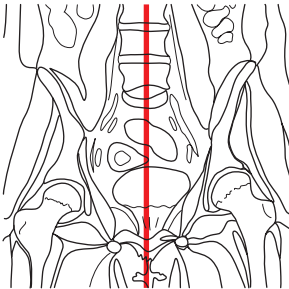
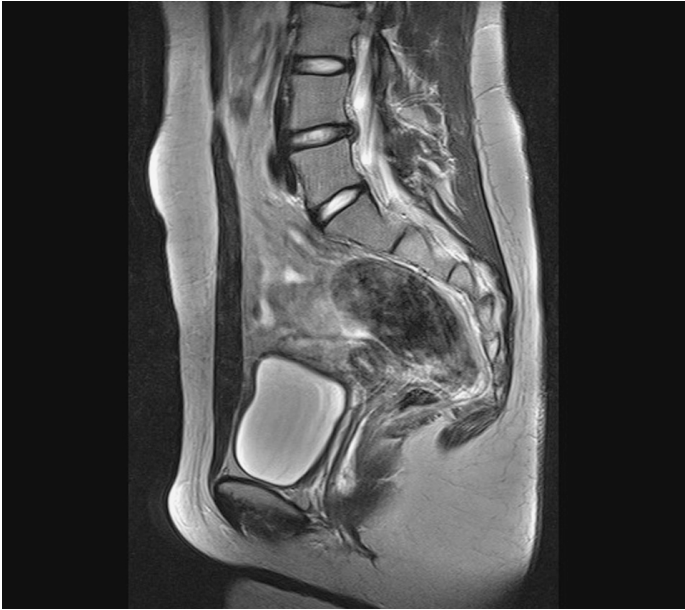

- |                                        |                                             |
|----------------------------------------|---------------------------------------------|
| 1. Iliotibial tract                    | mellus inferior muscles                     |
| 2. Tensor fasciae latae muscle         | 18. Sciatic nerve                           |
| 3. Rectus femoris muscle               | 19. Obturator internus muscle (tendon)      |
| 4. Femur (head)                        | 20. Gluteus maximus muscle                  |
| 5. Sartorius muscle                    | 21. Vagina                                  |
| 6. Iliopsoas muscle                    | 22. Rectum                                  |
| 7. Femoral artery, vein and nerve      | 23. Levator ani muscle                      |
| 8. Urinary bladder                     | 24. Ureter                                  |
| 9. Rectus abdominis muscle             | 25. Obturator internus muscle               |
| 10. Pubis (superior ramus)             | 26. Ischium (tuberosity)                    |
| 11. Pectineus muscle                   | 27. Vastus lateralis muscle                 |
| 12. Obturator externus muscle          | 28. Deep inguinal lymph nodes               |
| 13. Iliofemoral ligament               | 29. Superficial inguinal lymph nodes        |
| 14. Gluteus medius muscle              | 30. Postvesical and paravaginal lymph nodes |
| 15. Greater trochanter                 | 31. Prevesical lymph nodes                  |
| 16. Obturator externus muscle (tendon) | 32. Rectal lymph nodes                      |
| 17. Quadratus femoris muscle and ge-   |                                             |



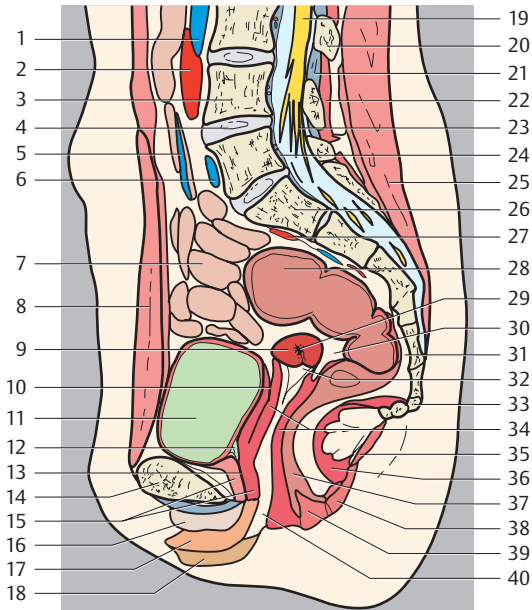


- |                                     |                                                                                   |
|-------------------------------------|-----------------------------------------------------------------------------------|
| 1. Iliotibial tract                 | 16. Quadratus femoris muscle                                                      |
| 2. Tensor fasciae latae muscle      | 17. Sciatic nerve                                                                 |
| 3. Rectus femoris muscle            | 18. Common tendon of biceps femoris, semitendinosus, and semi-membranosus muscles |
| 4. Vastus intermedius muscle        | 19. Gluteus maximus muscle                                                        |
| 5. Sartorius muscle                 | 20. Vagina                                                                        |
| 6. Iliopsoas muscle                 | 21. Rectum                                                                        |
| 7. Femoral artery, vein and nerve   | 22. Levator ani muscle                                                            |
| 8. Urethra                          | 23. Obturator internus muscle                                                     |
| 9. Pubic symphysis                  | 24. Ischium (tuberosity)                                                          |
| 10. Pubis (body)                    | 25. Deep inguinal lymph node                                                      |
| 11. Obturator externus muscle       | 26. Superficial inguinal lymph nodes                                              |
| 12. Pectineus muscle                | 27. Paravaginal lymph nodes                                                       |
| 13. Lateral femoral cutaneous nerve | 28. Pararectal lymph nodes                                                        |
| 14. Vastus lateralis muscle         |                                                                                   |
| 15. Femur                           |                                                                                   |

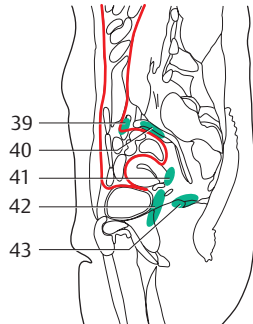
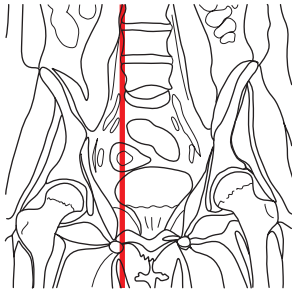
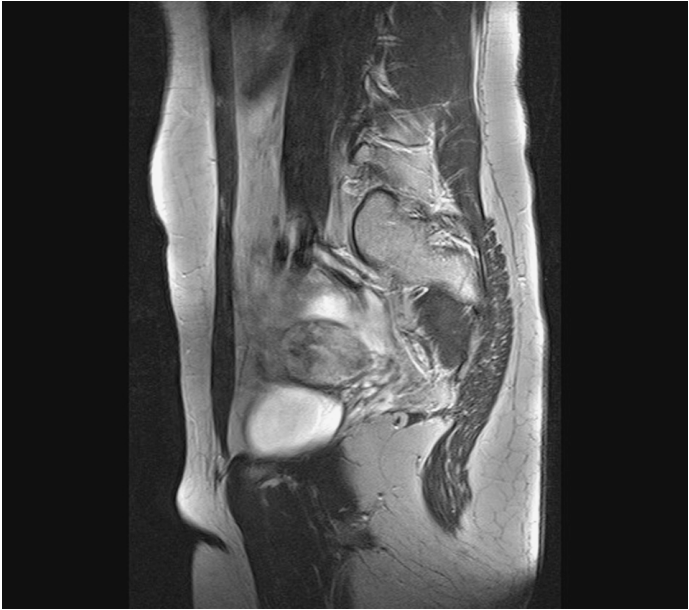

— = Peritoneum

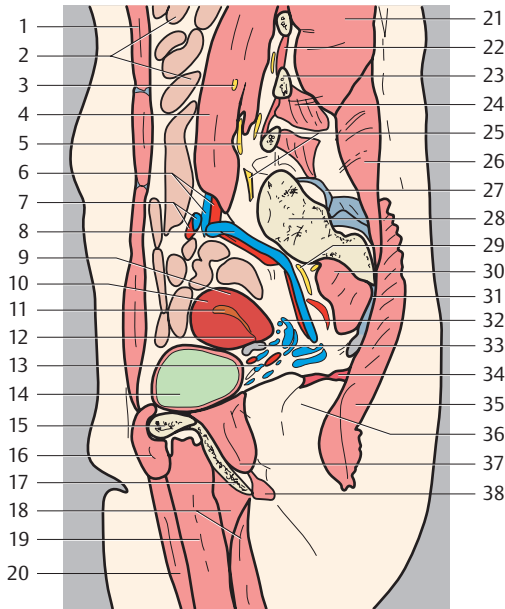
1. Inferior vena cava
2. Aorta
3. Lumbar vertebra (L4)
4. Intervertebral disk L4-L5
5. Jejunal veins



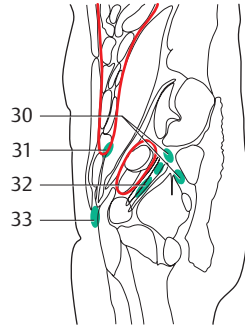
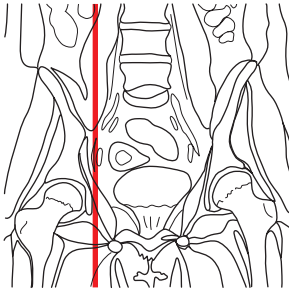
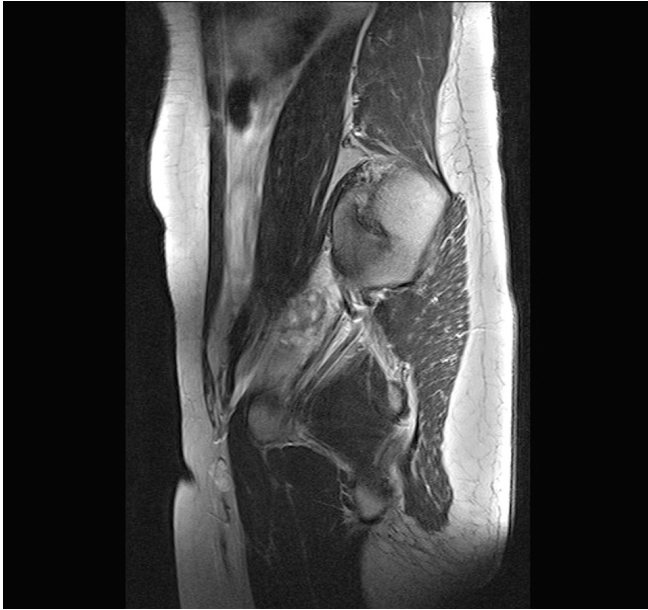- |                                                                   |                                                      |
|-------------------------------------------------------------------|------------------------------------------------------|
| 6. Common iliac vein                                              | 28. Rectum                                           |
| 7. Small intestine                                                | 29. Canalis cervicis                                 |
| 8. Rectus abdominis muscle                                        | 30. Rectouterine pouch (of Douglas)                  |
| 9. Portio                                                         | 31. Presacral space                                  |
| 10. Vesicouterine pouch                                           | 32. Ostium uteri (opening between uterus and vagina) |
| 11. Urinary bladder                                               | 33. Coccyx                                           |
| 12. Internal urethral orifice                                     | 34. Anterior and posterior wall of vagina            |
| 13. Urethra                                                       | 35. Anococcygeal ligament                            |
| 14. Pubis                                                         | 36. Levator ani muscle                               |
| 15. Urethral sphincter muscle and deep transverse perineal muscle | 37. Anal canal                                       |
| 16. Clitoris (body)                                               | 38. External anal sphincter muscle                   |
| 17. Labium minus                                                  | 39. Anus                                             |
| 18. Labium majus                                                  | 40. Vagina                                           |
| 19. Spinal cord                                                   | 41. Prevertebral and lumbar lymph nodes              |
| 20. Spinous process                                               | 42. Common iliac lymph nodes                         |
| 21. Ligamenta flava                                               | 43. Promontorial lymph nodes                         |
| 22. Lumbar interspinal muscles                                    | 44. Juxta-intestinal mesenteric lymph nodes          |
| 23. Cauda equina                                                  | 45. Presacral lymph nodes                            |
| 24. Posterior longitudinal ligament                               | 46. Prevesical lymph node                            |
| 25. Erector spinae muscle                                         |                                                      |
| 26. Sacrum (1)                                                    |                                                      |
| 27. Superior rectal artery                                        |                                                      |



— = Peritoneum

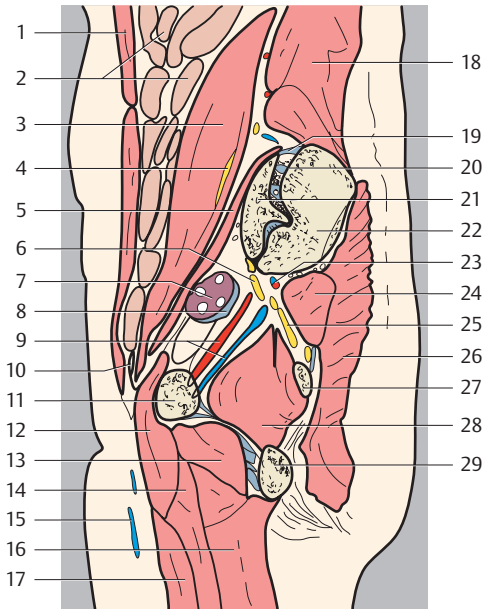


- |                                    |                                     |
|------------------------------------|-------------------------------------|
| 1. Rectus abdominis muscle         | 23. Transverse process              |
| 2. Small intestine                 | 24. Quadratus lumborum muscle       |
| 3. Lateral femoral cutaneous nerve | 25. Lumbar plexus                   |
| 4. Psoas major muscle              | 26. Lumbar iliocostalis muscle      |
| 5. Femoral nerve                   | 27. Dorsal sacroiliac ligaments     |
| 6. Common iliac artery and vein    | 28. Sacrum                          |
| 7. Ovarian artery and vein         | 29. Sacral nerves                   |
| 8. Internal iliac artery and vein  | 30. Piriformis muscle               |
| 9. Uterus (body)                   | 31. Sacrotuberous ligament          |
| 10. Uterus (fundus)                | 32. Uterine venous plexus           |
| 11. Uterus (cavity)                | 33. Round ligament of uterus        |
| 12. Uterus (isthmus)               | 34. Levator ani muscle              |
| 13. Vesical venous plexus          | 35. Gluteus maximus muscle          |
| 14. Urinary bladder                | 36. Ischiorectal fossa              |
| 15. Pubis                          | 37. Obturator internus muscle       |
| 16. Pectineus muscle               | 38. Deep transverse perineal muscle |
| 17. Ischium                        | 39. External iliac lymph nodes      |
| 18. Adductor magnus muscle         | 40. Internal iliac lymph nodes      |
| 19. Adductor brevis muscle         | 41. Parauterine lymph nodes         |
| 20. Adductor longus muscle         | 42. Paravaginal lymph nodes         |
| 21. Erector spinae muscle          | 43. Pararectal lymph nodes          |
| 22. Interspinales lumborum muscles |                                     |

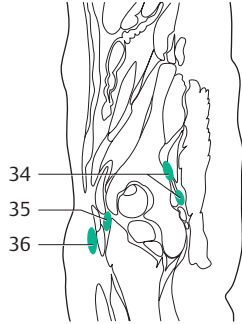
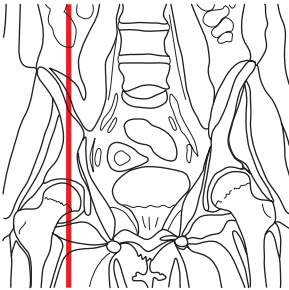
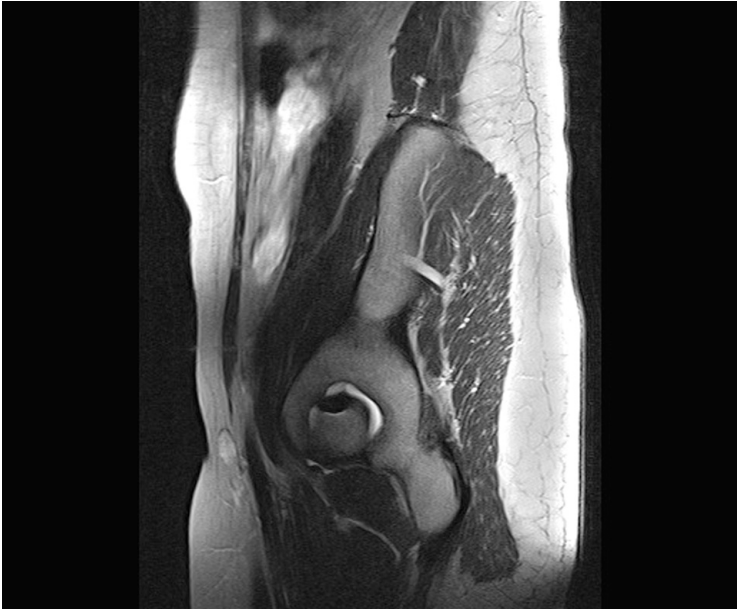

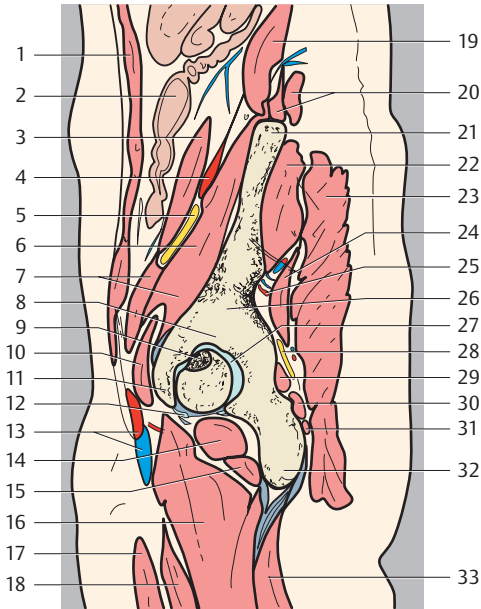
— = Peritoneum



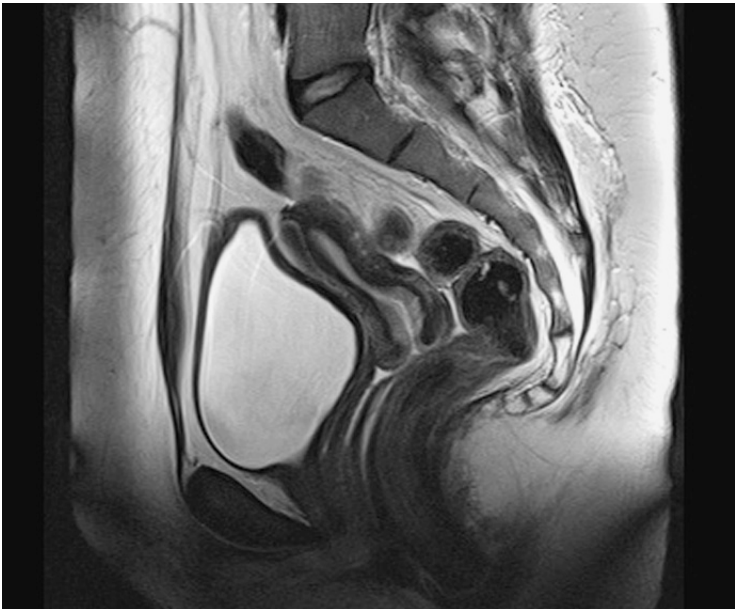


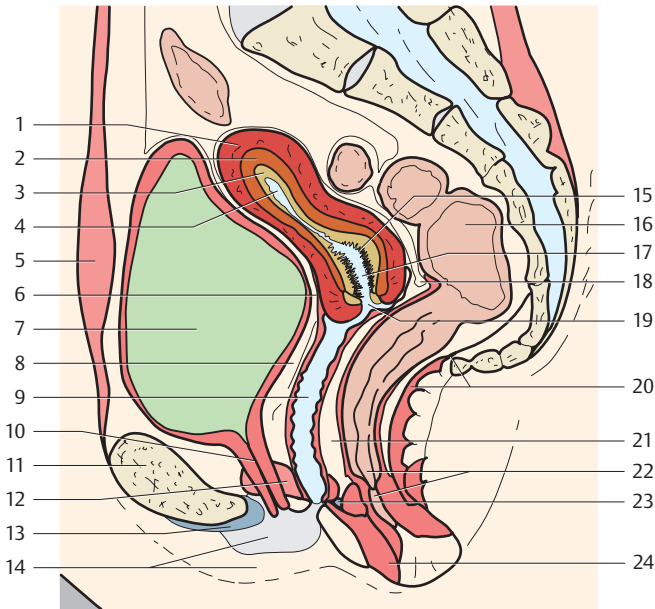
- |                                    |                                      |
|------------------------------------|--------------------------------------|
| 1. Rectus abdominis muscle         | 18. Iliocostalis muscle              |
| 2. Small intestine                 | 19. Dorsal sacroiliac ligaments      |
| 3. Psoas major muscle              | 20. Sacroiliac joint                 |
| 4. Femoral nerve                   | 21. Sacrum                           |
| 5. Iliac muscle                    | 22. Ilium                            |
| 6. Lumbar plexus                   | 23. Superior gluteal artery and vein |
| 7. Ovary                           | 24. Piriformis muscle                |
| 8. Round ligament of uterus        | 25. Sacral nerves                    |
| 9. Obturator artery and vein       | 26. Gluteus maximus muscle           |
| 10. External iliac artery and vein | 27. Ischial spine                    |
| 11. Pubis (superior ramus)         | 28. Obturator internus muscle        |
| 12. Pectineus muscle               | 29. Os ischii (ramus)                |
| 13. Obturator externus muscle      | 30. Gluteal lymph nodes              |
| 14. Adductor brevis muscle         | 31. External iliac lymph nodes       |
| 15. Great saphenous vein           | 32. Obturator lymph nodes            |
| 16. Adductor magnus muscle         | 33. Inguinal lymph nodes             |
| 17. Adductor longus muscle         |                                      |



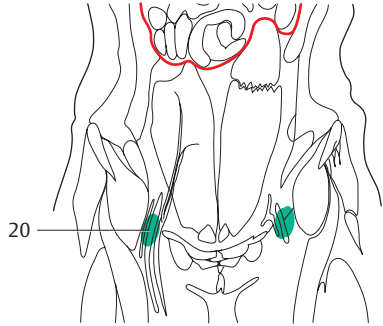
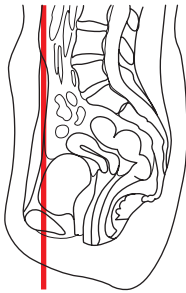
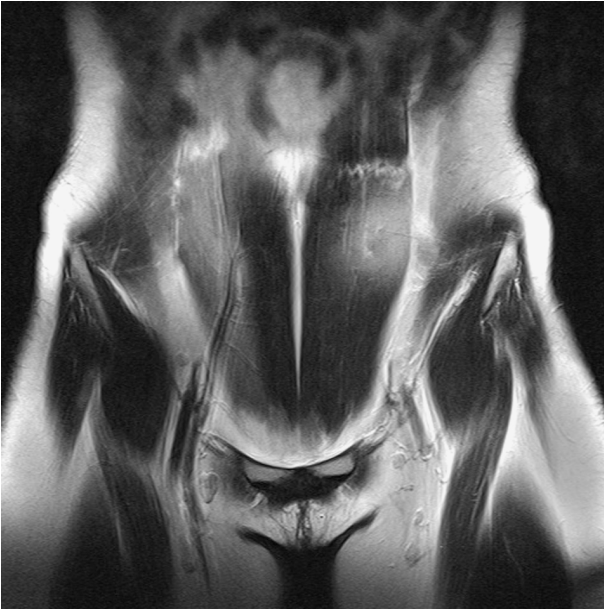

- |                               |                                      |
|-------------------------------|--------------------------------------|
| 1. Rectus abdominis muscle    | 19. Quadratus lumborum muscle        |
| 2. Colon                      | 20. Iliocostalis muscle              |
| 3. Psoas major muscle         | 21. Superior iliac spine             |
| 4. Iliolumbar artery          | 22. Gluteus medius muscle            |
| 5. Femoral nerve              | 23. Gluteus maximus muscle           |
| 6. Iliacus muscle             | 24. Gluteus minimus muscle           |
| 7. Iliopsoas muscle           | 25. Superior gluteal artery and vein |
| 8. Acetabular roof            | 26. Ilium (body)                     |
| 9. Fovea capitis femoris      | 27. Fossa acetabuli                  |
| 10. Pectineus muscle          | 28. Sciatic nerve                    |
| 11. Pubis (body)              | 29. Gemellus superior muscle         |
| 12. Acetabular lip            | 30. Obturator internus muscle        |
| 13. Femoral artery and vein   | 31. Gemellus inferior muscle         |
| 14. Obturator externus muscle | 32. Ischial tuberosity               |
| 15. Quadratus femoris muscle  | 33. Semimembranosus muscle           |
| 16. Adductor magnus muscle    | 34. Gluteal lymph nodes              |
| 17. Adductor longus muscle    | 35. Deep inguinal lymph nodes        |
| 18. Adductor brevis muscle    | 36. Superficial inguinal lymph nodes |

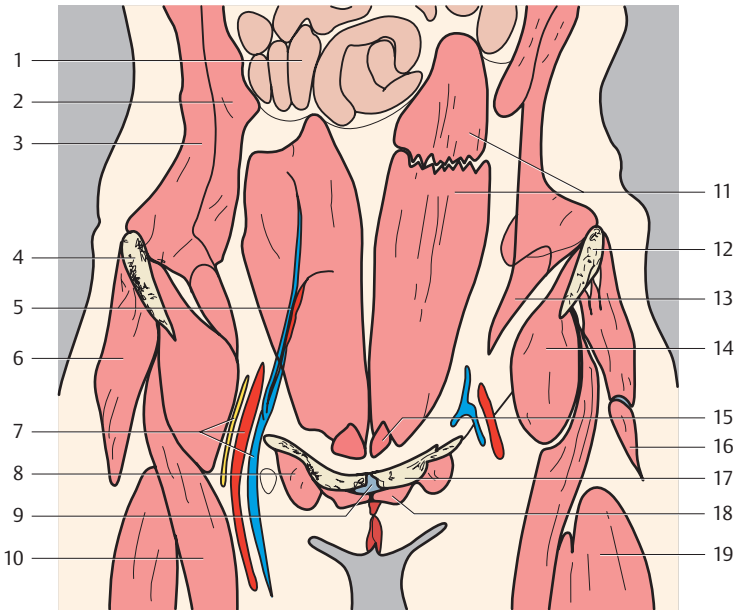




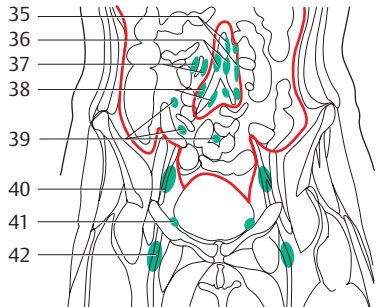
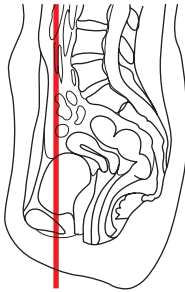
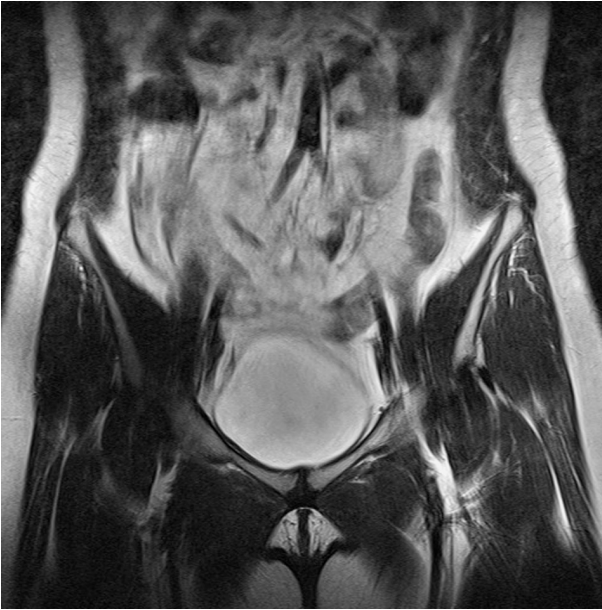- |                                                             |                                                  |
|-------------------------------------------------------------|--------------------------------------------------|
| 1. Body of uterus (myometrium)                              | 14. Labium minus and majus                       |
| 2. Uterus (junctional zone)                                 | 15. Palmate folds (of cervix of uterus)          |
| 3. Uterus (endometrium)                                     | 16. Rectum                                       |
| 4. Uterus (cavity)                                          | 17. Cervical canal                               |
| 5. Rectus abdominis muscle                                  | 18. Rectouterine pouch (of Douglas)              |
| 6. Vesicouterine pouch                                      | 19. Portio                                       |
| 7. Urinary bladder                                          | 20. Anococcygeal ligament and levator ani muscle |
| 8. Fatty layer between urinary bladder, urethra, and vagina | 21. Fatty layer between vagina and rectum        |
| 9. Vagina (wall)                                            | 22. Anal canal and anus                          |
| 10. Urethra                                                 | 23. Perineal body                                |
| 11. Pubis                                                   | 24. External anal sphincter muscle               |
| 12. Deep transverse perineal muscle                         |                                                  |
| 13. Arcuate pubic ligament                                  |                                                  |



— = Peritoneum

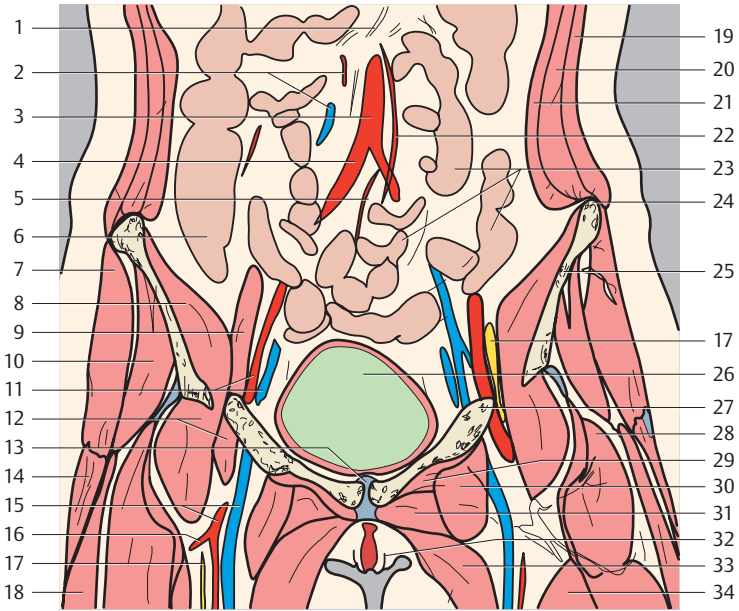


- |                                      |                                     |
|--------------------------------------|-------------------------------------|
| 1. Small intestine                   | 11. Rectus abdominis muscle         |
| 2. Internal abdominal oblique muscle | 12. Ilium                           |
| 3. External abdominal oblique muscle | 13. Transversus abdominis muscle    |
| 4. Anterior superior iliac spine     | 14. Iliopsoas muscle                |
| 5. Superficial epigastric artery     | 15. Pyramidalis muscle              |
| 6. Gluteus medius muscle             | 16. Tensor fasciae latae muscle     |
| 7. Femoral artery, vein and nerve    | 17. Pubis                           |
| 8. Pectineus muscle                  | 18. Adductor longus muscle          |
| 9. Pubic symphysis                   | 19. Vastus lateralis muscle         |
| 10. Rectus femoris muscle            | 20. Superficial inguinal lymph node |

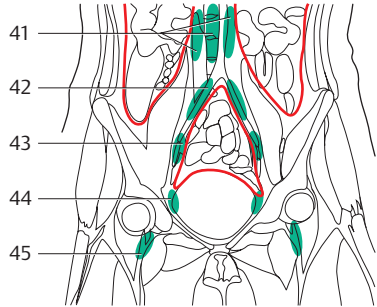
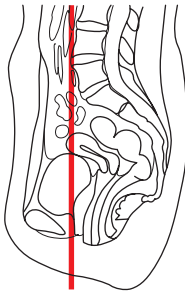
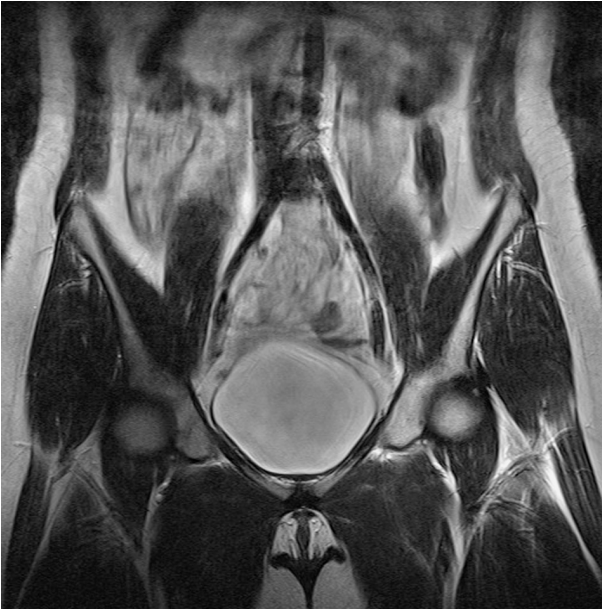

— = Peritoneum

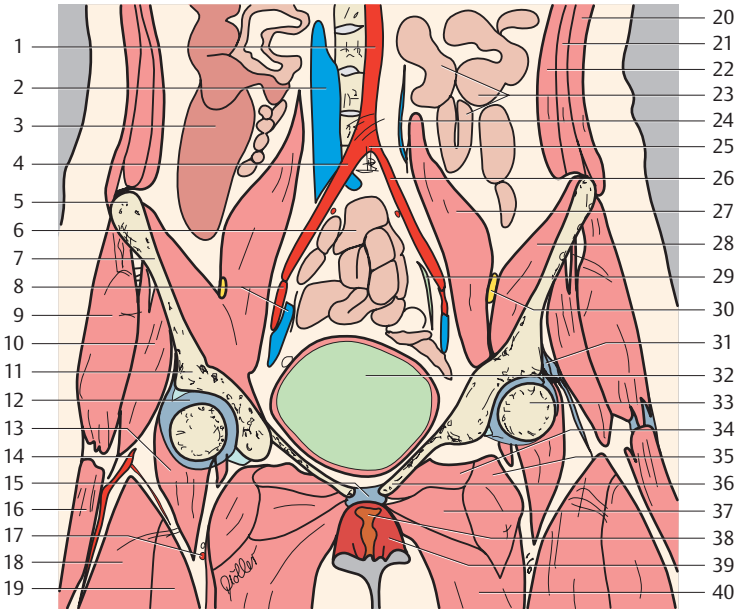




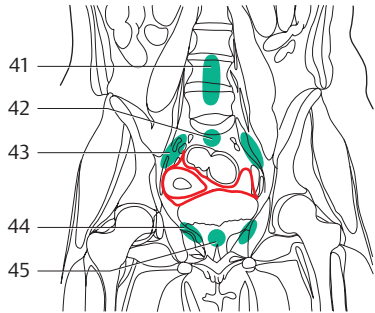
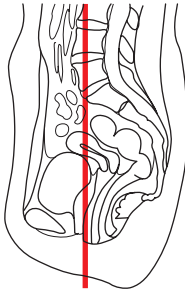
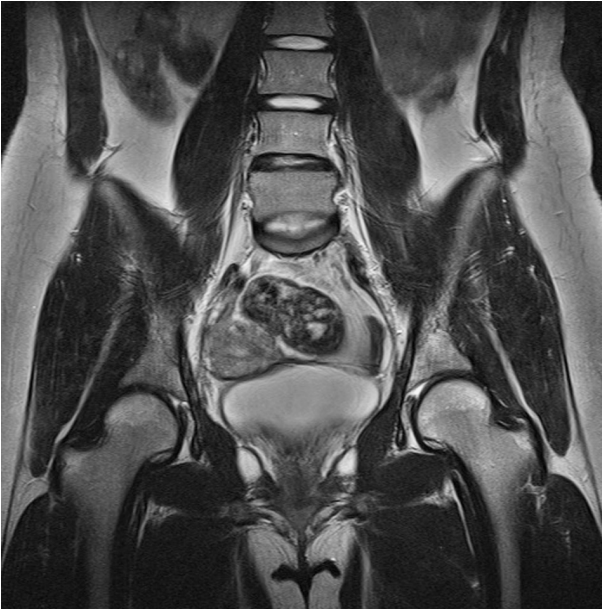
- |                                        |                                     |
|----------------------------------------|-------------------------------------|
| 1. Mesentery                           | 21. Transversus abdominis muscle    |
| 2. Superior mesenteric artery and vein | 22. Inferior mesenteric artery      |
| 3. Abdominal aorta                     | 23. Jejunum                         |
| 4. Right common iliac artery           | 24. Iliac crest                     |
| 5. Sigmoid artery                      | 25. Ilium (ala)                     |
| 6. Ascending colon                     | 26. Urinary bladder                 |
| 7. Gluteus medius muscle               | 27. Pubis                           |
| 8. Iliacus muscle                      | 28. Rectus femoris muscle           |
| 9. Psoas major muscle                  | 29. Obturator externus muscle       |
| 10. Gluteus minimus muscle             | 30. Pectineus muscle                |
| 11. External iliac artery and vein     | 31. Adductor brevis muscle          |
| 12. Iliopsoas muscle                   | 32. Labium majus                    |
| 13. Symphysis                          | 33. Adductor longus muscle          |
| 14. Tensor fasciae latae muscle        | 34. Sartorius muscle                |
| 15. Femoral artery and vein            | 35. Inferior mesenteric lymph nodes |
| 16. Deep artery of thigh               | 36. Lumbar lymph nodes              |
| 17. Femoral nerve                      | 37. Superior mesenteric lymph nodes |
| 18. Vastus lateralis muscle            | 38. Common iliac lymph nodes        |
| 19. External abdominal oblique muscle  | 39. Juxtaintestinal lymph nodes     |
| 20. Internal abdominal oblique muscle  | 40. External iliac lymph nodes      |
|                                        | 41. Paravesical lymph nodes         |
|                                        | 42. Superficial inguinal lymph node |



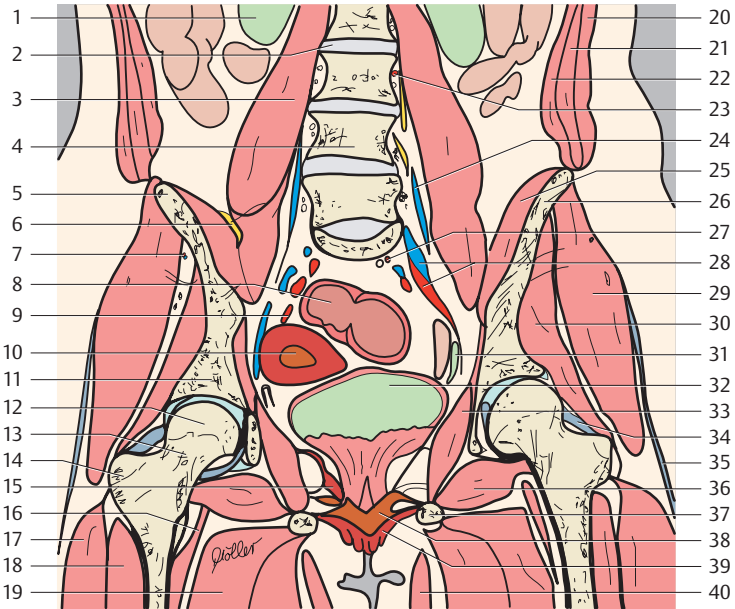
— = Peritoneum



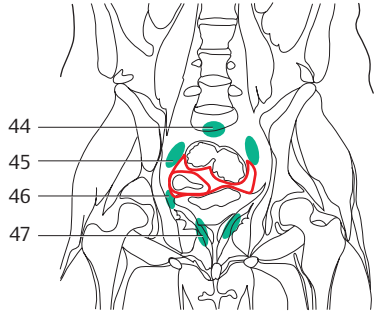
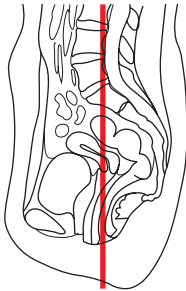
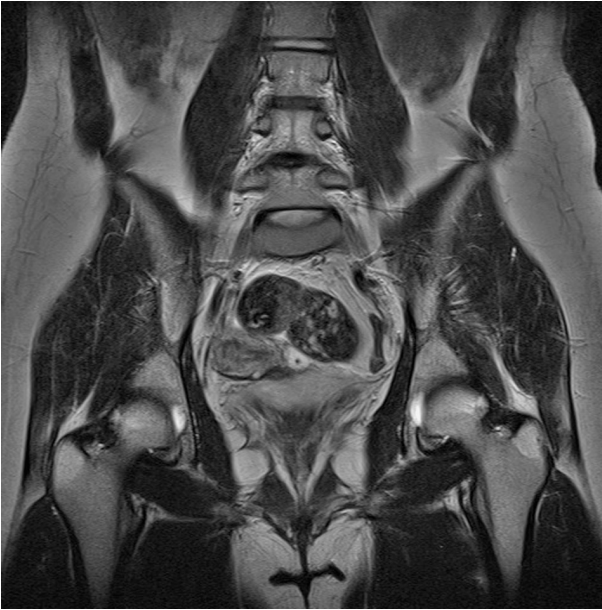- |                                             |                                                                        |
|---------------------------------------------|------------------------------------------------------------------------|
| 1. Abdominal aorta                          | 24. Inferior mesenteric vein                                           |
| 2. Inferior vena cava                       | 25. Aorta (bifurcation)                                                |
| 3. Ascending colon                          | 26. Left common iliac artery                                           |
| 4. Right common iliac artery                | 27. Psoas major muscle                                                 |
| 5. Iliac crest                              | 28. Iliacus muscle                                                     |
| 6. Ileum                                    | 29. Ureter                                                             |
| 7. Ilium (ala)                              | 30. Femoral nerve                                                      |
| 8. External iliac artery and vein           | 31. Common tendon of rectus femoris muscle and vastus lateralis muscle |
| 9. Gluteus medius muscle                    | 32. Urinary bladder                                                    |
| 10. Gluteus minimus muscle                  | 33. Head of femur                                                      |
| 11. Acetabular roof (body of ilium)         | 34. Obturator externus muscle                                          |
| 12. Iliofemoral ligament with joint capsule | 35. Pectineus muscle                                                   |
| 13. Iliopsoas muscle                        | 36. Pubis                                                              |
| 14. Circumflex femoral artery               | 37. Adductor brevis muscle                                             |
| 15. Transverse perineal ligament            | 38. Clitoris (crus)                                                    |
| 16. Tensor fasciae latae muscle             | 39. Labium majus                                                       |
| 17. Deep artery of thigh                    | 40. Adductor longus muscle                                             |
| 18. Vastus lateralis muscle                 | 41. Lumbar lymph nodes                                                 |
| 19. Rectus femoris muscle                   | 42. Common iliac lymph nodes                                           |
| 20. External abdominal oblique muscle       | 43. External iliac lymph nodes                                         |
| 21. Internal abdominal oblique muscle       | 44. Paravesical lymph nodes                                            |
| 22. Transversus abdominis muscle            | 45. Deep inguinal lymph node                                           |
| 23. Jejunum                                 |                                                                        |



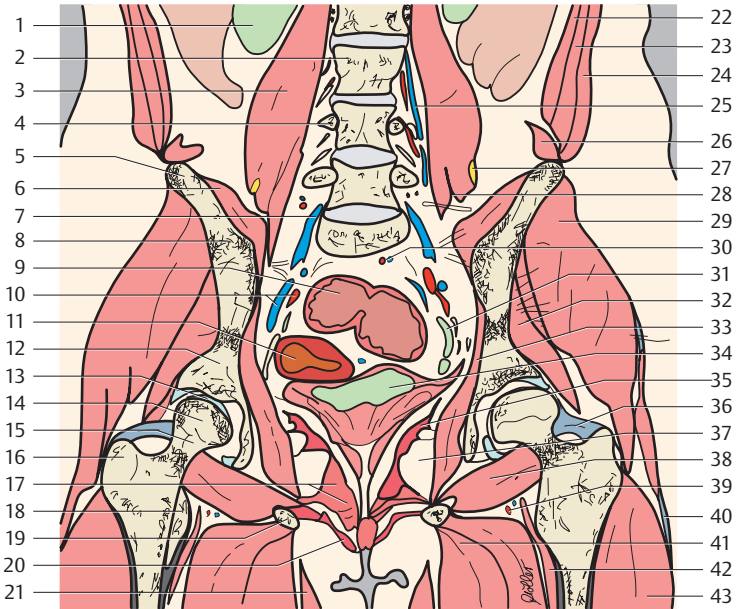
— = Peritoneum



- |                                       |                                     |
|---------------------------------------|-------------------------------------|
| 1. Right kidney                       | 23. Lumbar artery and vein          |
| 2. Intervertebral disk L2-L3          | 24. Iliolumbar artery and vein      |
| 3. Psoas major muscle                 | 25. Iliacus muscle                  |
| 4. Lumbar vertebra (L4)               | 26. Ilium (ala)                     |
| 5. Iliac crest                        | 27. Superior rectal artery          |
| 6. Femoral nerve                      | 28. Internal iliac artery and vein  |
| 7. Superior gluteal artery and vein   | 29. Gluteus medius muscle           |
| 8. Sigmoid colon                      | 30. Gluteus minimus muscle          |
| 9. Uterine artery                     | 31. Ureter                          |
| 10. Uterus (cavum)                    | 32. Urinary bladder                 |
| 11. Acetabular roof (body of ilium)   | 33. Obturator internus muscle       |
| 12. Head of femur                     | 34. Iliofemoral ligament            |
| 13. Neck of femur                     | 35. Iliotibial tract                |
| 14. Greater trochanter                | 36. Obturator externus muscle       |
| 15. Levator ani muscle                | 37. Ischium (ramus)                 |
| 16. Iliopsoas muscle                  | 38. Deep transverse perineal muscle |
| 17. Vastus lateralis muscle           | 39. Labium minus                    |
| 18. Vastus intermedius muscle         | 40. Gracilis muscle                 |
| 19. Adductor magnus muscle            | 41. Prevertebral lymph nodes        |
| 20. External abdominal oblique muscle | 42. Promontorial lymph nodes        |
| 21. Internal abdominal oblique muscle | 43. Internal iliac lymph nodes      |
| 22. Transversus abdominis muscle      | 44. Paravaginal lymph nodes         |
|                                       | 45. Postvesical lymph nodes         |

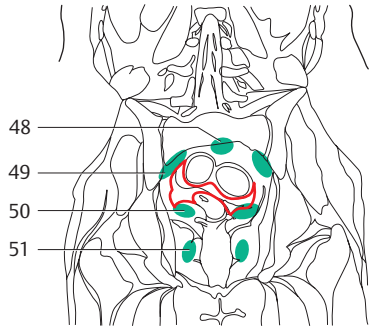
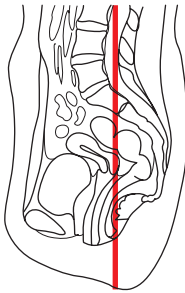
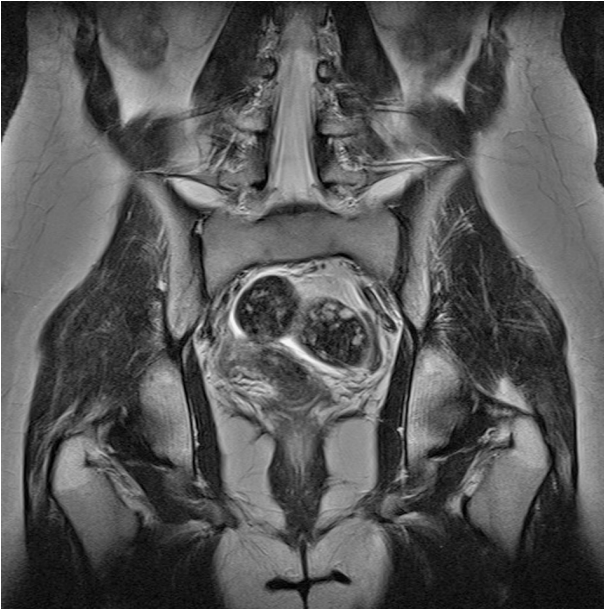

— = Peritoneum



- |                                       |                                      |
|---------------------------------------|--------------------------------------|
| 1. Right kidney                       | 25. Lumbar artery and vein           |
| 2. Lumbar vertebra (L3)               | 26. Quadratus lumborum muscle        |
| 3. Psoas major muscle                 | 27. Femoral nerve                    |
| 4. Transverse process (L4)            | 28. Obturator nerve                  |
| 5. Iliac crest                        | 29. Gluteus medius muscle            |
| 6. Iliacus muscle                     | 30. Superior rectal artery           |
| 7. Ascending lumbar vein              | 31. Ureter                           |
| 8. Ilium (ala)                        | 32. Gluteus minimus muscle           |
| 9. Sigmoid colon                      | 33. Obturator internus muscle        |
| 10. Internal iliac artery and vein    | 34. Urinary bladder                  |
| 11. Uterus (cavity)                   | 35. Levator ani muscle               |
| 12. Acetabular roof (body of ilium)   | 36. Iliofemoral ligament             |
| 13. Hip joint                         | 37. Ischiorectal fossa               |
| 14. Head of femur                     | 38. Obturator externus muscle        |
| 15. Neck of femur                     | 39. Medial circumflex femoral artery |
| 16. Greater trochanter                | 40. Iliotibial tract                 |
| 17. Deep transverse perineal muscle   | 41. Adductor magnus muscle           |
| 18. Lesser trochanter                 | 42. Iliopsoas muscle                 |
| 19. Ischium (ramus)                   | 43. Vastus lateralis muscle          |
| 20. Bulbospongiosus muscle            | 44. Promontorial lymph nodes         |
| 21. Gracilis muscle                   | 45. Internal iliac lymph nodes       |
| 22. Transversus abdominis muscle      | 46. Parauterine lymph nodes          |
| 23. Internal abdominal oblique muscle | 47. Paravaginal lymph nodes          |
| 24. External abdominal oblique muscle |                                      |



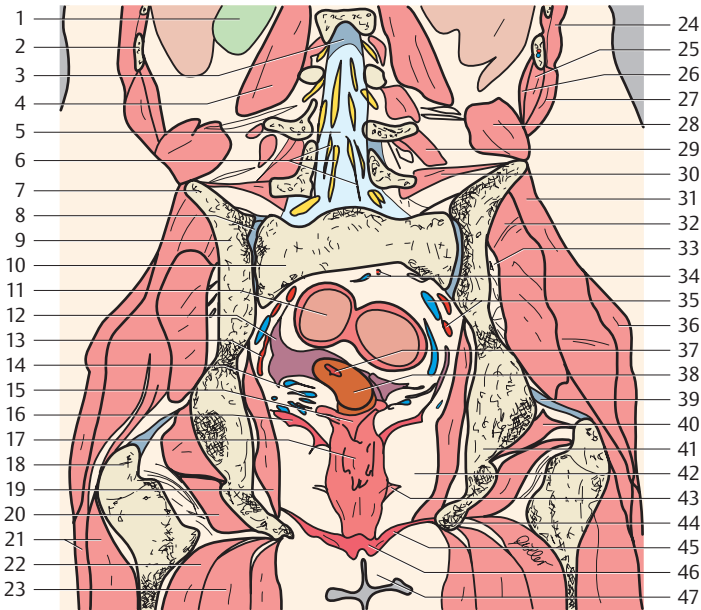


— = Peritoneum

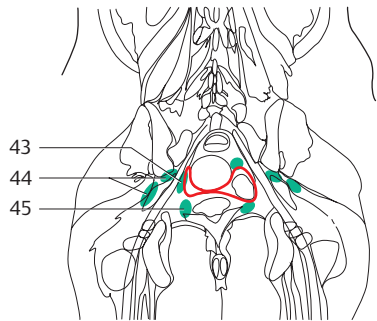
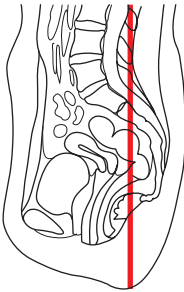
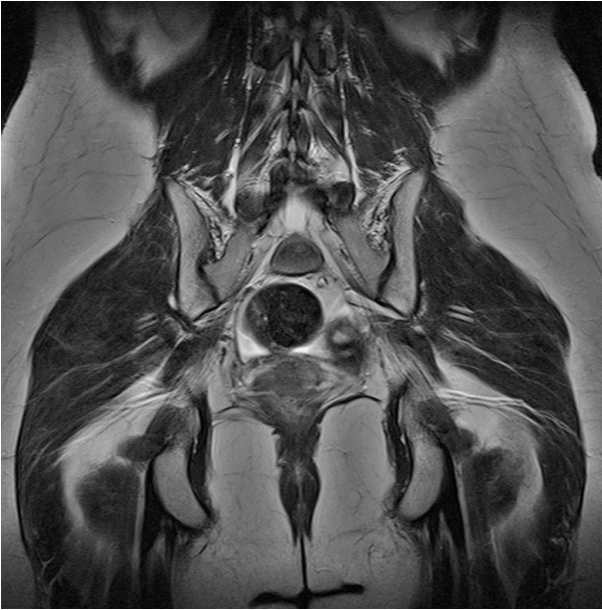1. Right kidney
2. Rib (11)
3. Spinal dura
4. Psoas major muscle
5. Vertebral canal

6. Cauda equina
7. Iliac crest
8. Sacroiliac joint
9. Ilium (ala)
10. Sacrum

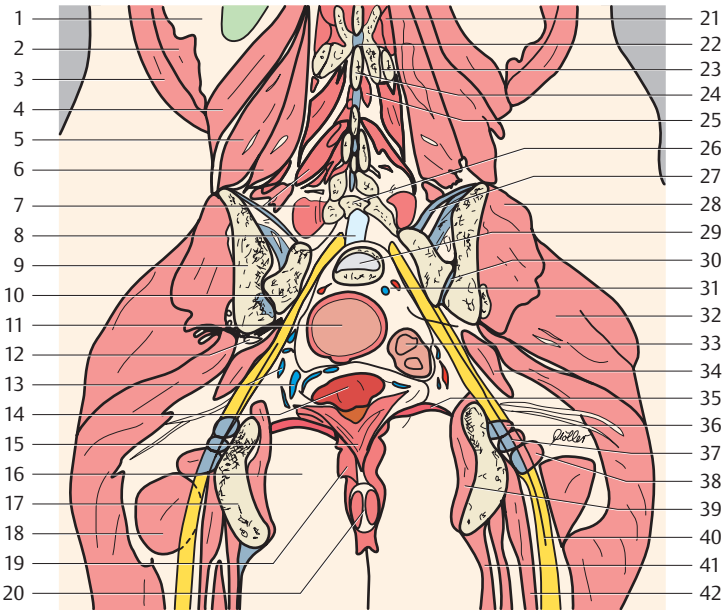




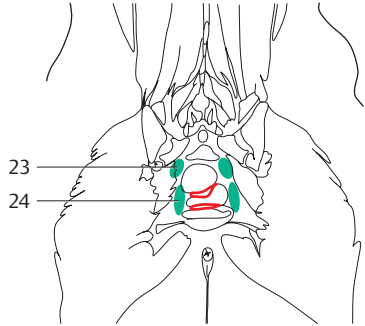
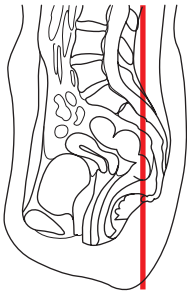
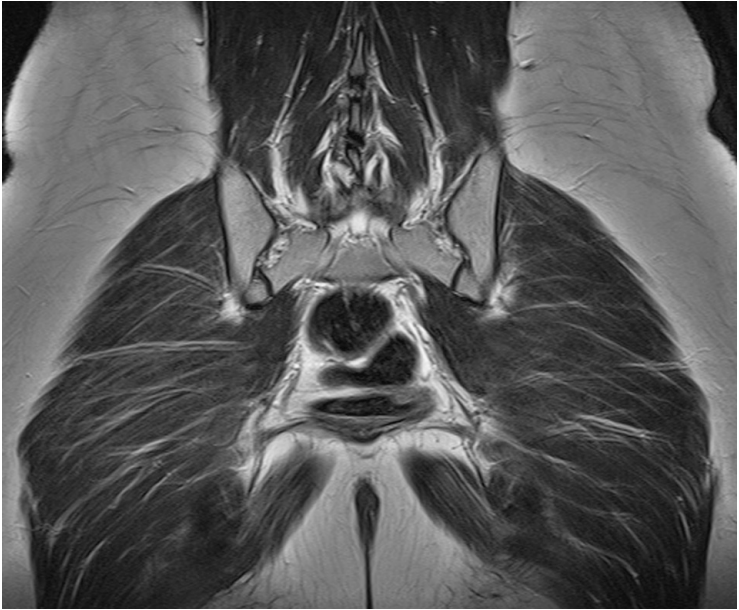
- |                                                                         |                                                            |
|-------------------------------------------------------------------------|------------------------------------------------------------|
| 11. Sigmoid colon                                                       | 31. Gluteus medius muscle                                  |
| 12. Uterine tube (infundibulum)                                         | 32. Gluteus minimus muscle                                 |
| 13. Uterine vein                                                        | 33. Superior gluteal artery and vein                       |
| 14. Uterine venous plexus                                               | 34. Sigmoid arteries and veins                             |
| 15. Vagina (fornix)                                                     | 35. Internal iliac artery and vein                         |
| 16. Levator ani muscle                                                  | 36. Gluteus maximus muscle                                 |
| 17. Vagina                                                              | 37. Cervical canal                                         |
| 18. Greater trochanter                                                  | 38. Cervix of uterus                                       |
| 19. Obturator internus muscle                                           | 39. Iliofemoral ligament                                   |
| 20. Quadratus femoris muscle                                            | 40. Obturator internus muscle                              |
| 21. Vastus lateralis muscle                                             | 41. Ischium                                                |
| 22. Semitendinosus muscle                                               | 42. Ischiorectal fossa                                     |
| 23. Adductor magnus muscle                                              | 43. Pubovaginalis muscle                                   |
| 24. Latissimus dorsi muscle                                             | 44. Ischium (ramus)                                        |
| 25. Internal abdominal oblique muscle                                   | 45. Deep transverse perineal muscle (urogenital diaphragm) |
| 26. Transversus abdominis muscle                                        | 46. Bulbospongiosus muscle                                 |
| 27. External abdominal oblique muscle                                   | 47. Labium minus                                           |
| 28. Quadratus lumborum muscle                                           | 48. Presacral lymph nodes                                  |
| 29. Multifidus muscle and lumbar intertransversarii muscles             | 49. Internal iliac lymph nodes                             |
| 30. Iliolumbar ligament and iliocostalis muscle (erector spinae muscle) | 50. Parauterine lymph nodes                                |
|                                                                         | 51. Paravaginal lymph nodes                                |



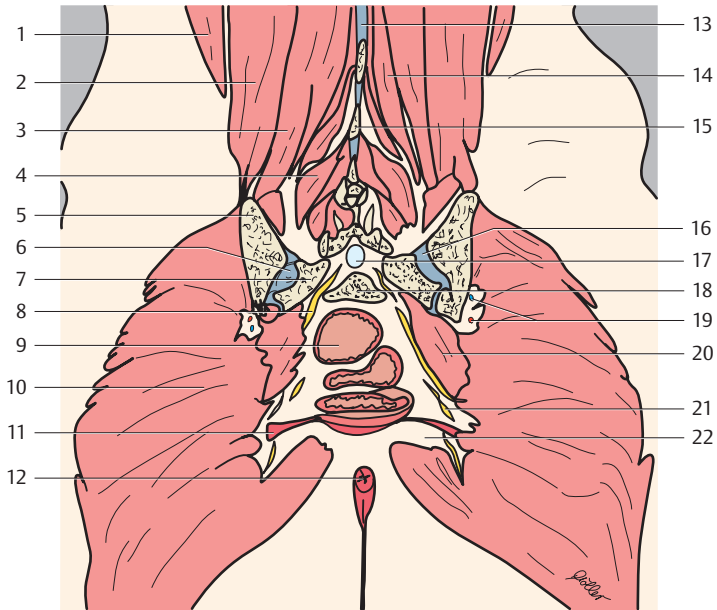
— = Peritoneum



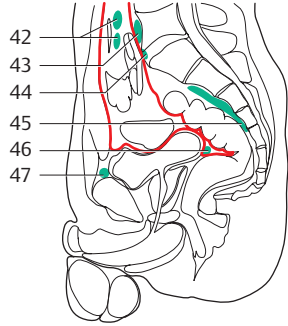
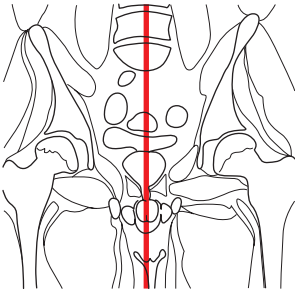
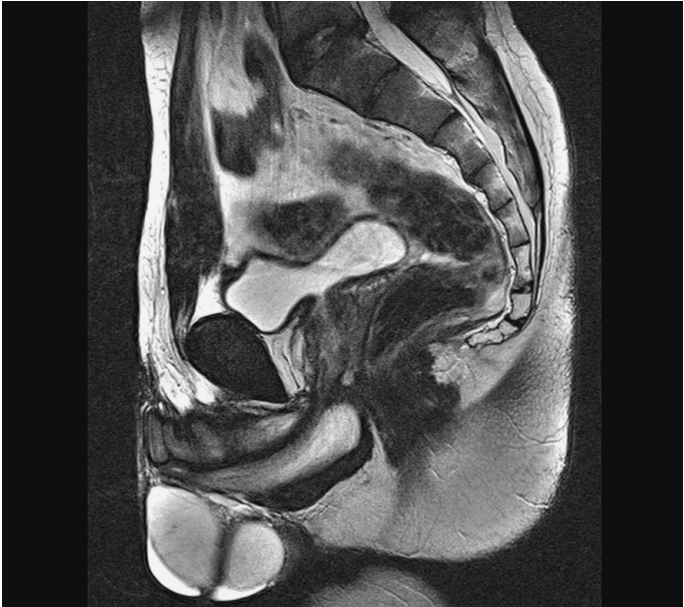- |                                                           |                                        |
|-----------------------------------------------------------|----------------------------------------|
| 1. Fatty capsule of kidney                                | 22. Interspinal ligaments              |
| 2. Serratus posterior inferior muscle                     | 23. Zygapophysial joint                |
| 3. Latissimus dorsi muscles                               | 24. Spinous process                    |
| 4. Quadratus lumborum muscle                              | 25. Interspinalis muscles              |
| 5. Iliocostalis muscle (part of erector spinae muscle)    | 26. Lumbar vertebra 5 (vertebral arch) |
| 6. Longissimus muscle (part of erector spinae muscle)     | 27. Sacroiliac ligaments               |
| 7. Multifidus muscle (part of transversospinales muscles) | 28. Gluteus medius muscle              |
| 8. Vertebral canal                                        | 29. Intervertebral disk S1-S2          |
| 9. Ilium (ala)                                            | 30. Sacroiliac joint                   |
| 10. Sacrum                                                | 31. Sigmoid arteries and veins         |
| 11. Rectum                                                | 32. Gluteus maximus muscle             |
| 12. Superior gluteal veins                                | 33. Sigmoid colon                      |
| 13. Uterine and rectal venous plexus                      | 34. Piriformis muscle                  |
| 14. Vaginal part of uterus                                | 35. Levator ani muscle                 |
| 15. Vagina (posterior wall)                               | 36. Gemellus superior muscle           |
| 16. Ischiorectal fossa                                    | 37. Obturator internus muscle          |
| 17. Ischium                                               | 38. Gemellus inferior muscle           |
| 18. Quadratus femoris muscle                              | 39. Obturator internus muscle          |
| 19. External anal sphincter muscle                        | 40. Sciatic nerve                      |
| 20. Anus                                                  | 41. Semitendinosus muscle              |
| 21. Intertransversarii muscles                            | 42. Adductor magnus muscle             |
|                                                           | 43. Pararectal lymph nodes             |
|                                                           | 44. Gluteal lymph nodes                |
|                                                           | 45. Parauterine lymph nodes            |

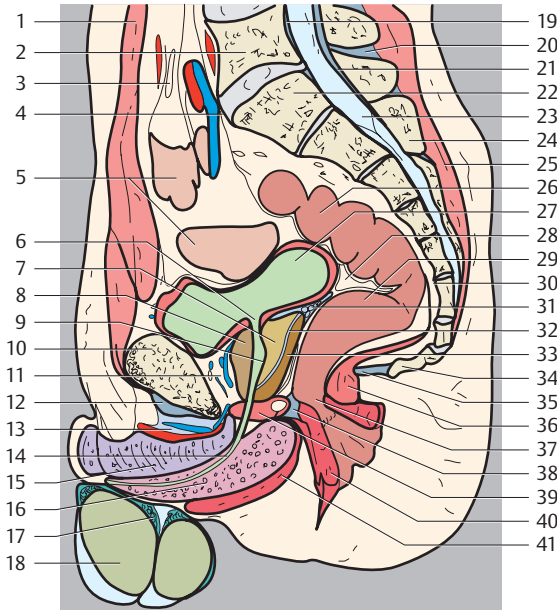


— = Peritoneum

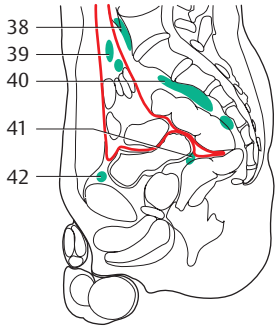
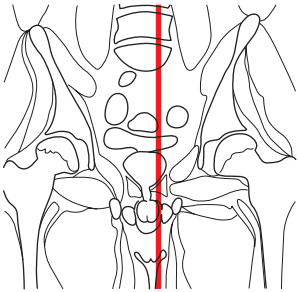
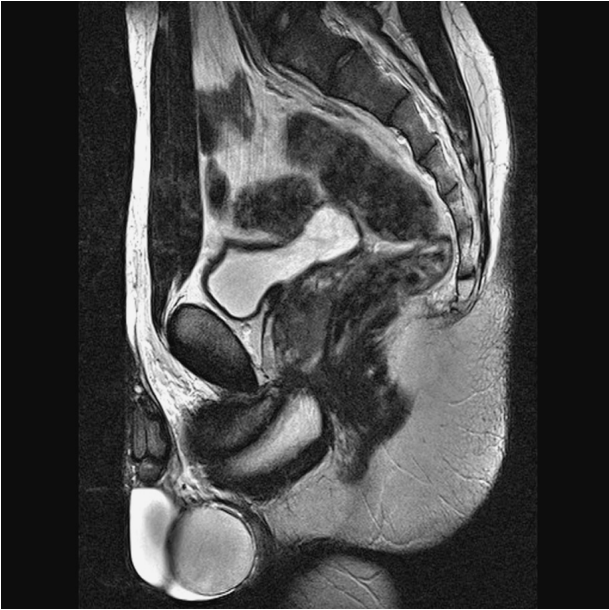

- |                                                        |                                                     |
|--------------------------------------------------------|-----------------------------------------------------|
| 1. Latissimus dorsi muscle                             | 13. Interspinal ligaments                           |
| 2. Iliocostalis muscle (part of erector spinae muscle) | 14. Spinalis muscle (part of erector spinae muscle) |
| 3. Longissimus muscle (part of erector spinae muscle)  | 15. Spinous process                                 |
| 4. Transversospinales muscles                          | 16. Dorsal sacroiliac ligament                      |
| 5. Ilium                                               | 17. Vertebral canal                                 |
| 6. Sacroiliac joint                                    | 18. Sacrum (S2)                                     |
| 7. Sacrum (lateral part or mass of sacrum)             | 19. Superior gluteal artery and vein                |
| 8. Sacral nerves                                       | 20. Piriformis muscle                               |
| 9. Rectum (ampulla)                                    | 21. Inferior gluteal artery, vein, and nerve        |
| 10. Gluteus maximus muscle                             | 22. Ischioanal fossa                                |
| 11. Levator ani muscle                                 | 23. Gluteal lymph nodes                             |
| 12. External anal sphincter muscle                     | 24. Pararectal lymph nodes                          |



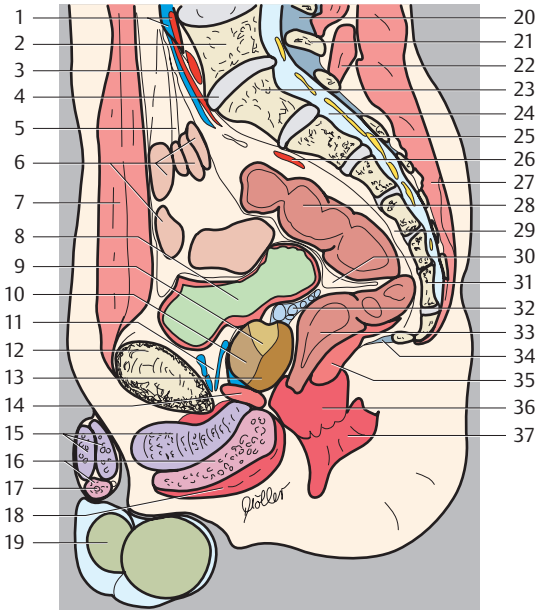


- |                                                               |                                                    |
|---------------------------------------------------------------|----------------------------------------------------|
| 1. Rectus abdominis muscle                                    | 24. Spinous process                                |
| 2. Lumbar vertebra (L5)                                       | 25. Erector spinae muscle                          |
| 3. Mesentery                                                  | 26. Sigmoid colon                                  |
| 4. Promontorium                                               | 27. Urinary bladder                                |
| 5. Small intestine                                            | 28. Rectovesical pouch                             |
| 6. Urinary bladder (internal urethra orifice)                 | 29. Rectum                                         |
| 7. Prostate (central zone)                                    | 30. Presacral space                                |
| 8. Prostate (anterior fibromuscular stroma)                   | 31. Seminal gland                                  |
| 9. Seminal colliculus                                         | 32. Ejaculatory duct                               |
| 10. Pubis                                                     | 33. Prostate, peripheral zone                      |
| 11. Retropubic space with vesical and prostatic venous plexus | 34. Coccyx                                         |
| 12. Arcuate pubic ligament                                    | 35. Anococcygeal ligament                          |
| 13. Suspensory ligament of penis                              | 36. Levator ani muscle                             |
| 14. Urethra                                                   | 37. Anus                                           |
| 15. Corpus cavernosum                                         | 38. Perineal body                                  |
| 16. Corpus spongiosum                                         | 39. Urogenital diaphragm with bulbo-urethral gland |
| 17. Epididymis                                                | 40. External anal sphincter muscle                 |
| 18. Testis                                                    | 41. Bulbospongiosus muscle                         |
| 19. Posterior longitudinal ligament                           | 42. Juxta-intestinal mesenteric lymph nodes        |
| 20. Interspinal ligaments                                     | 43. Prevertebral lymph nodes                       |
| 21. Ligamenta flava                                           | 44. Promontorial lymph nodes                       |
| 22. Sacrum (S1)                                               | 45. Presacral lymph nodes                          |
| 23. Vertebral canal                                           | 46. Postvesical lymph nodes                        |
|                                                               | 47. Prevesical lymph nodes                         |

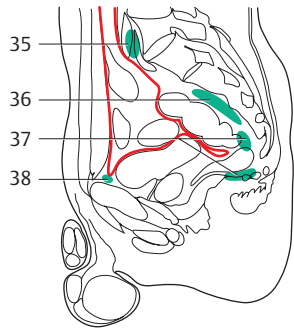
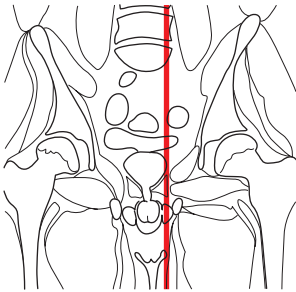
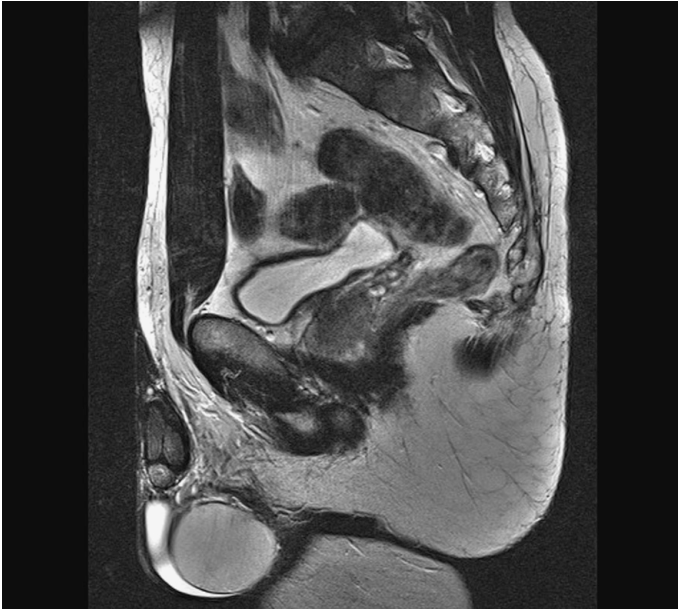


— = Peritoneum

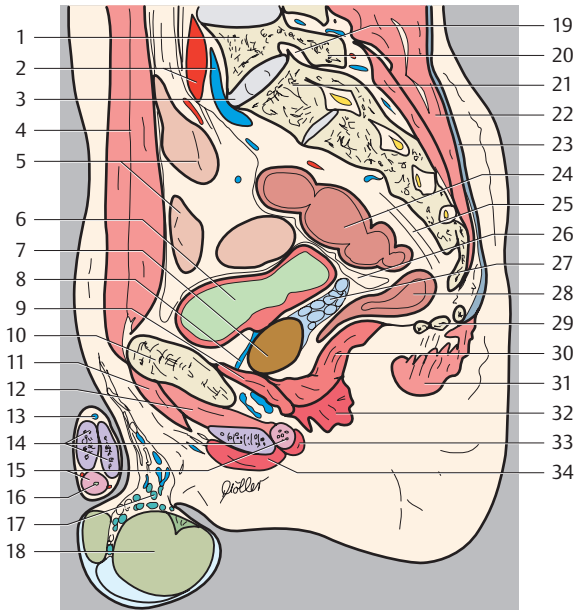




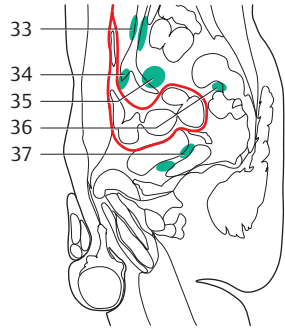
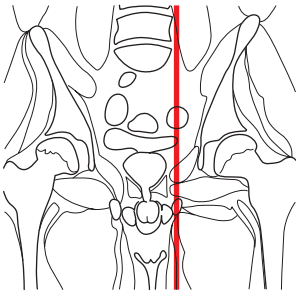
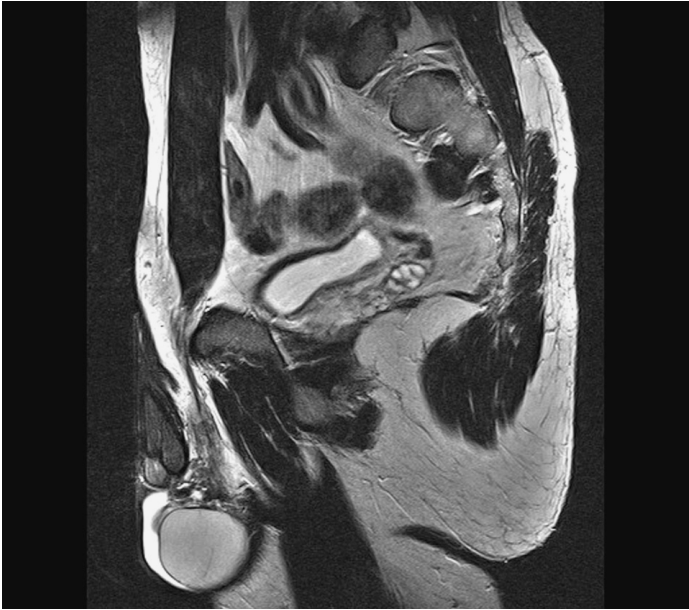- |                                                               |                                                                |
|---------------------------------------------------------------|----------------------------------------------------------------|
| 1. Common iliac artery and vein                               | 23. Sacrum (1)                                                 |
| 2. Lumbar vertebra (L5)                                       | 24. Vertebral canal                                            |
| 3. Internal iliac artery and vein                             | 25. Spinal nerve (part of cauda equina)                        |
| 4. Intervertebral disk L5-S1                                  | 26. Lateral sacral artery                                      |
| 5. Mesentery                                                  | 27. Erector spinae muscle                                      |
| 6. Small intestine                                            | 28. Sigmoid colon                                              |
| 7. Rectus abdominis muscle                                    | 29. Presacral space                                            |
| 8. Urinary bladder                                            | 30. Rectovesical pouch                                         |
| 9. Prostate (central zone)                                    | 31. Coccyx                                                     |
| 10. Prostate (anterior fibromuscular stroma)                  | 32. Seminal gland                                              |
| 11. Retropubic space with vesical and prostatic venous plexus | 33. Rectum                                                     |
| 12. Pubis                                                     | 34. Anococcygeal ligament                                      |
| 13. Prostate (peripheral zone)                                | 35. Levator ani muscle                                         |
| 14. Urogenital diaphragm                                      | 36. External anal sphincter muscle (superficial and deep part) |
| 15. Corpus cavernosum                                         | 37. External anal sphincter muscle (subcutaneous part)         |
| 16. Corpus spongiosum                                         | 38. Common iliac lymph nodes                                   |
| 17. Urethra                                                   | 39. Juxta-intestinal mesenteric lymph nodes                    |
| 18. Bulbospongiosus muscle                                    | 40. Presacral lymph nodes                                      |
| 19. Testis                                                    | 41. Postvesical lymph nodes                                    |
| 20. Ligamenta flava                                           | 42. Prevesical lymph node                                      |
| 21. Spinous process                                           |                                                                |
| 22. Multifidus muscle                                         |                                                                |

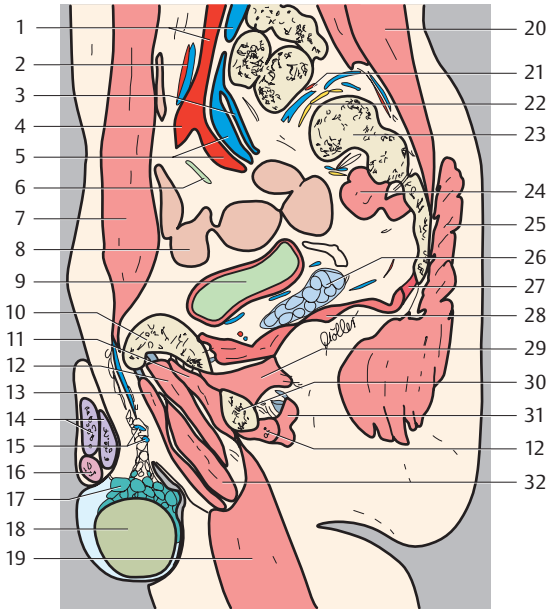


— = Peritoneum

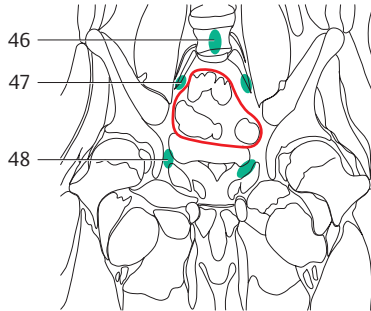
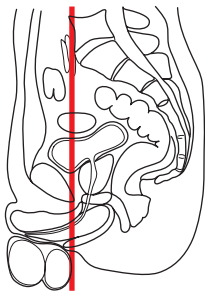
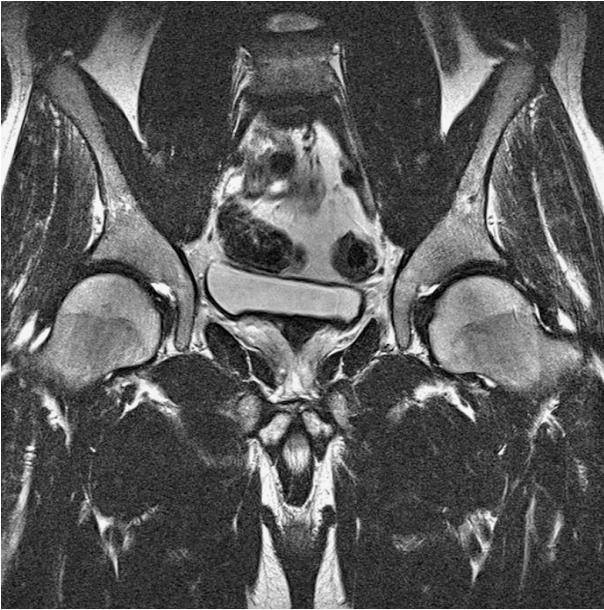


- |                                                              |                                    |
|--------------------------------------------------------------|------------------------------------|
| 1. Lumbar vertebra (L5)                                      | 20. Inferior articular process     |
| 2. Common iliac artery and vein                              | 21. Sacrum (1)                     |
| 3. Intervertebral disk L5-S1                                 | 22. Erector spinae muscle          |
| 4. Rectus abdominis muscle                                   | 23. Thoracolumbar fascia           |
| 5. Small intestine                                           | 24. Sigmoid colon                  |
| 6. Urinary bladder                                           | 25. Presacral space                |
| 7. Prostate, peripheral zone                                 | 26. Rectovesical pouch             |
| 8. Retropubic space with vesical and prostatic venous plexus | 27. Seminal gland                  |
| 9. Urogenital diaphragm                                      | 28. Rectum                         |
| 10. Pubis                                                    | 29. Coccyx                         |
| 11. Adductor brevis muscle                                   | 30. Levator ani muscle             |
| 12. Obturator externus muscle                                | 31. Gluteus maximus muscle         |
| 13. Dorsal vein of penis                                     | 32. External anal sphincter muscle |
| 14. Corpus cavernosum                                        | 33. Bulbospongiosus muscle         |
| 15. Corpus spongiosum                                        | 34. Ischiocavernosus muscle        |
| 16. Urethra                                                  | 35. Common iliac lymph nodes       |
| 17. Epididymis                                               | 36. Presacral lymph nodes          |
| 18. Testis                                                   | 37. Pararectal lymph nodes         |
| 19. Intervertebral foramen                                   | 38. Prevesical lymph node          |

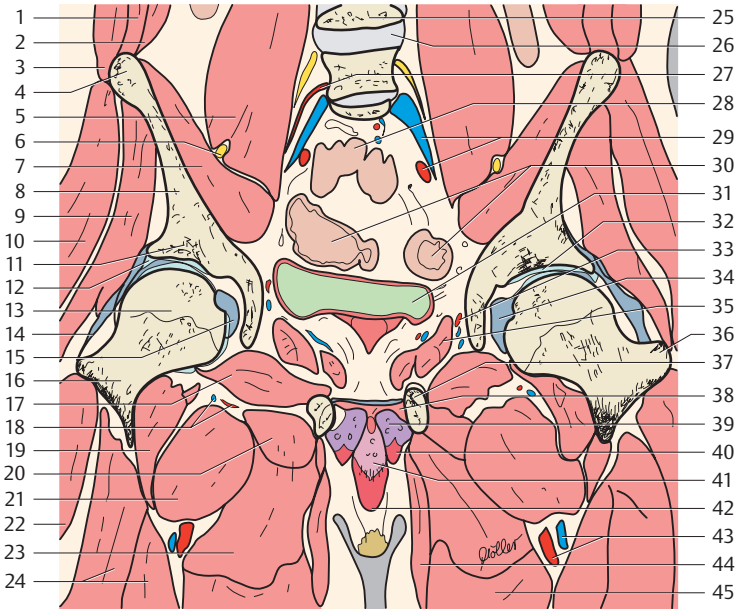




- |                                   |                                             |
|-----------------------------------|---------------------------------------------|
| 1. Common iliac artery and vein   | 20. Longissimus muscle                      |
| 2. Inferior mesenteric artery     | 21. Lateral sacral arteries and veins       |
| 3. Superior gluteal veins         | 22. Sacral nerves                           |
| 4. External iliac artery          | 23. Sacrum (lateral part or mass of sacrum) |
| 5. Internal iliac artery and vein | 24. Piriformis muscle                       |
| 6. Ureter                         | 25. Gluteus maximus muscle                  |
| 7. Rectus abdominis muscle        | 26. Seminal gland                           |
| 8. Small intestine                | 27. Coccygeus muscle                        |
| 9. Urinary bladder                | 28. Levator ani muscle                      |
| 10. Pubis                         | 29. Obturator internus muscle               |
| 11. Obturator externus muscle     | 30. Ischium                                 |
| 12. Adductor magnus muscle        | 31. Semitendineus muscle                    |
| 13. Adductor longus muscle        | 32. Adductor brevis muscle                  |
| 14. Corpus cavernosum             | 33. Common iliac lymph nodes                |
| 15. Inguinal canal                | 34. External iliac lymph nodes              |
| 16. Corpus spongiosum             | 35. Internal iliac lymph nodes              |
| 17. Epididymis                    | 36. Gluteal lymph nodes                     |
| 18. Testis                        | 37. Lateral vesical lymph nodes             |
| 19. Gracilis muscle               |                                             |

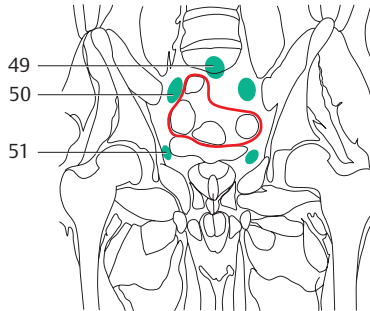
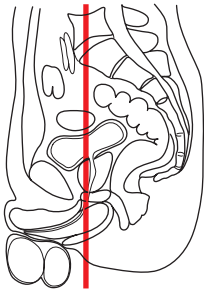
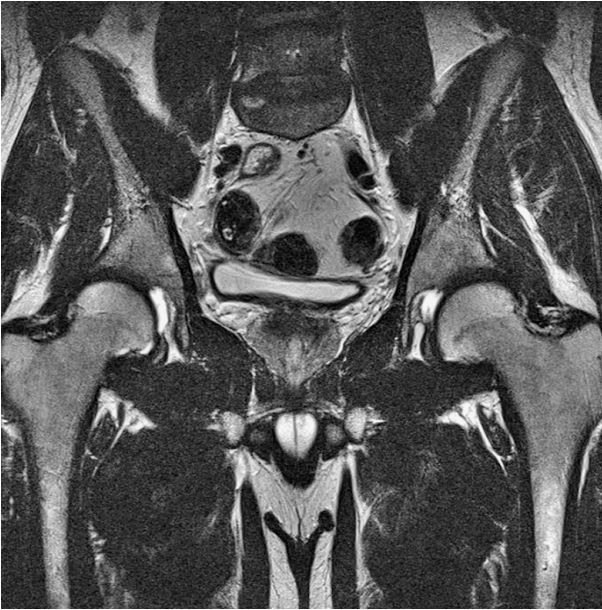

— = Peritoneum



- |                                               |                                  |
|-----------------------------------------------|----------------------------------|
| 1. Internal abdominal oblique muscle          | 24. Vastus intermedius muscle    |
| 2. Transversus abdominis muscle               | 25. Lumbar vertebra 4            |
| 3. External abdominal oblique muscle          | 26. Intervertebral disk L4-L5    |
| 4. Anterior superior iliac spine              | 27. Lumbar arteries              |
| 5. Psoas major muscle                         | 28. Small intestine              |
| 6. Femoral nerve                              | 29. Common iliac artery and vein |
| 7. Iliac muscle                               | 30. Sigmoid colon                |
| 8. Ilium                                      | 31. Urinary bladder              |
| 9. Gluteus minimus muscle                     | 32. Hip joint                    |
| 10. Gluteus medius muscle                     | 33. Obturator artery and vein    |
| 11. Facies lunata acetabuli (acetabular roof) | 34. Fovea for ligament of head   |
| 12. Acetabular lip                            | 35. Obturator internus muscle    |
| 13. Femur (head)                              | 36. Greater trochanter           |
| 14. Iliofemoral ligament                      | 37. Pubis                        |
| 15. Ligament of head of femur                 | 38. Urogenital diaphragm         |
| 16. Neck of femur                             | 39. Corpus cavernosum            |
| 17. Obturator externus muscle                 | 40. Ischiocavernosus muscle      |
| 18. Medial circumflex femoral artery          | 41. Corpus spongiosum            |
| 19. Iliopsoas muscle                          | 42. Bulbospongiosus muscle       |
| 20. Adductor minimus muscle                   | 43. Femoral artery and vein      |
| 21. Pectineus muscle                          | 44. Gracilis muscle              |
| 22. Vastus lateralis muscle                   | 45. Adductor longus muscle       |
| 23. Adductor brevis muscle                    | 46. Prevertebral lymph nodes     |
|                                               | 47. Common iliac lymph nodes     |
|                                               | 48. Lateral vesical lymph nodes  |

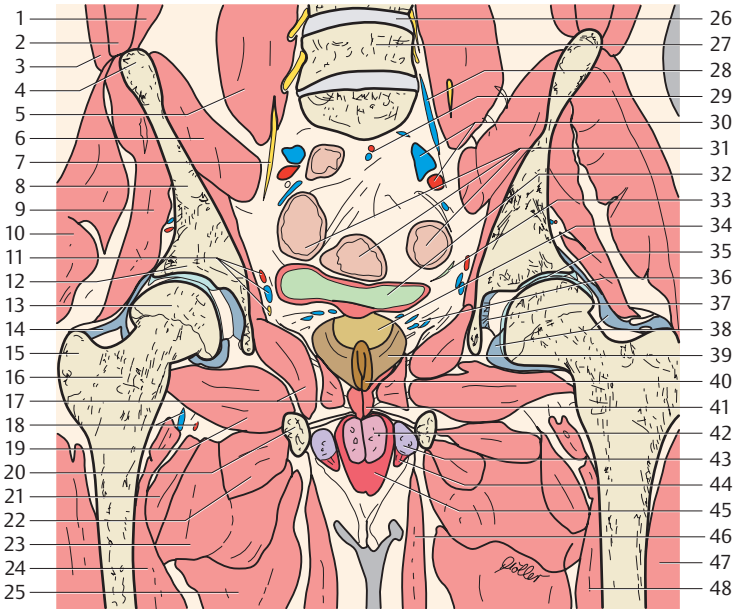




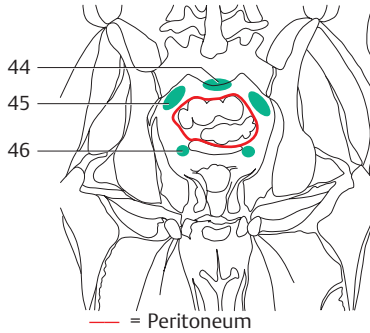
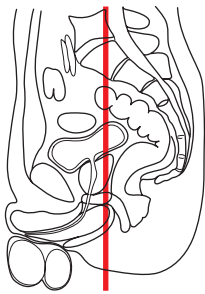
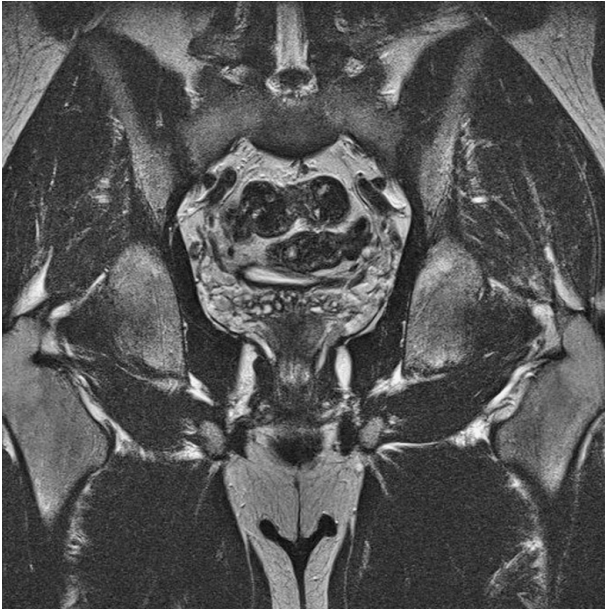
— = Peritoneum

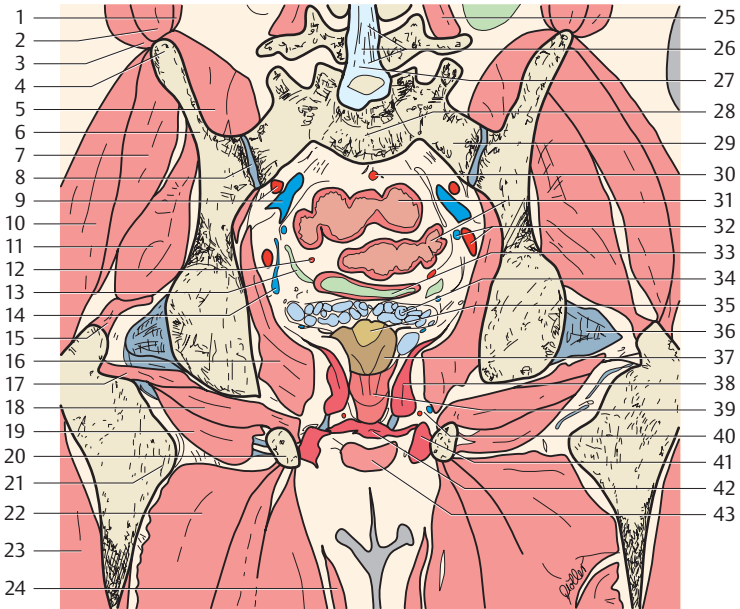
- |                                  |                           |
|----------------------------------|---------------------------|
| 1. Transversus abdominis muscle  | 6. Iliacus muscle         |
| 2. Internal oblique muscle       | 7. Obturator nerve        |
| 3. External oblique muscle       | 8. Ilium                  |
| 4. Anterior superior iliac spine | 9. Gluteus minimus muscle |
| 5. Psoas major muscle            | 10. Gluteus medius muscle |



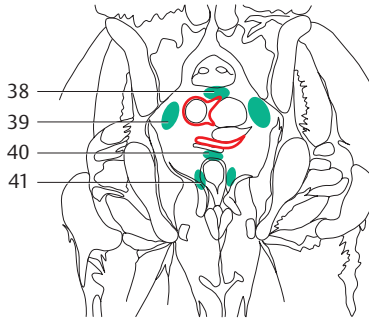
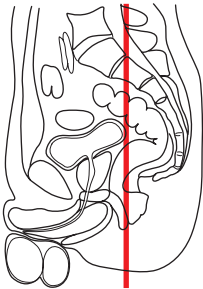
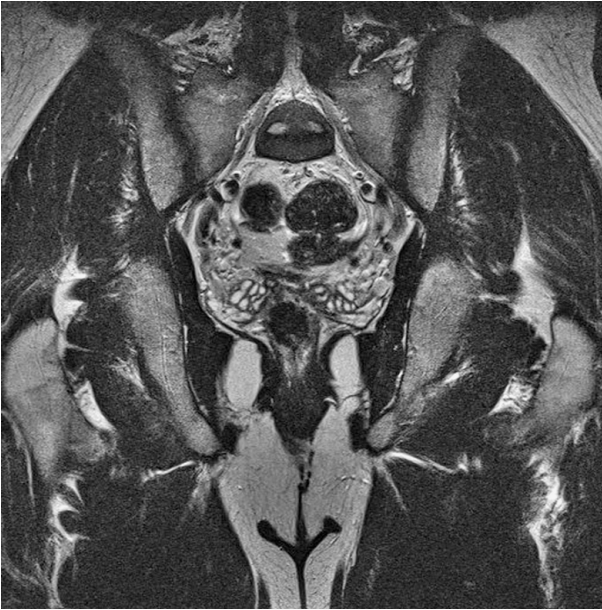

- |                                                      |                                 |
|------------------------------------------------------|---------------------------------|
| 11. Obturator artery, vein and nerve                 | 31. Sigmoid colon               |
| 12. Facies lunata acetabuli (acetabular roof)        | 32. Urinary bladder             |
| 13. Head of femur                                    | 33. Ureter                      |
| 14. Iliofemoral ligament                             | 34. Prostate (central zone)     |
| 15. Greater trochanter                               | 35. Hip joint                   |
| 16. Neck of femur                                    | 36. Prostatic venous plexus     |
| 17. Obturator internus muscle (urogenital diaphragm) | 37. Ligament of head of femur   |
| 18. Medial circumflex femoral artery                 | 38. Orbicular zone              |
| 19. Obturator externus muscle                        | 39. Prostate (peripheral zone)  |
| 20. Pubis                                            | 40. Prostate (transition zone)  |
| 21. Pectineus muscle                                 | 41. Ureter                      |
| 22. Adductor minimus muscle                          | 42. Corpus spongiosum           |
| 23. Adductor brevis muscle                           | 43. Corpus cavernosum           |
| 24. Iliopsoas muscle                                 | 44. Ischiocavernosus muscle     |
| 25. Adductor magnus muscle                           | 45. Bulbospongiosus muscle      |
| 26. Intervertebral disk L4-L5                        | 46. Gracilis muscle             |
| 27. Lumbar vertebra (L5)                             | 47. Vastus lateralis muscle     |
| 28. Ascending lumbar vein                            | 48. Vastus intermedius muscle   |
| 29. Superior rectal artery and vein                  | 49. Promontorial lymph nodes    |
| 30. Common iliac artery and vein                     | 50. Common iliac lymph nodes    |
|                                                      | 51. Lateral vesical lymph nodes |

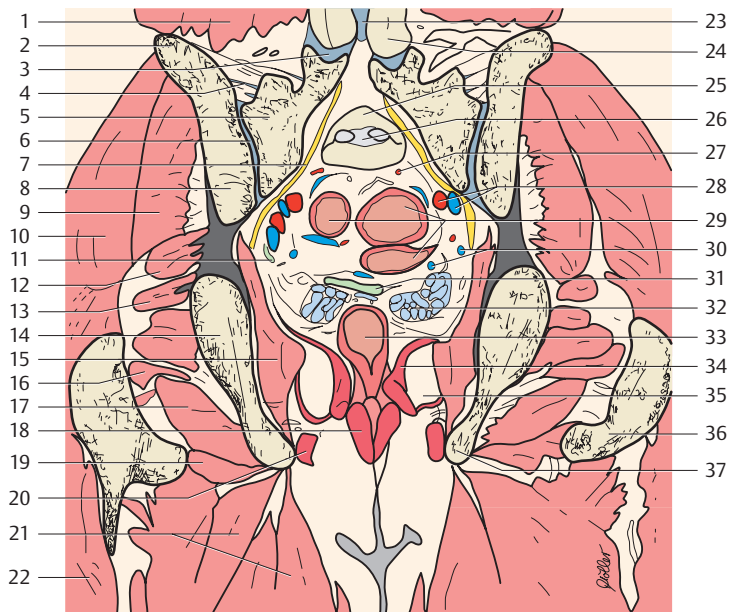




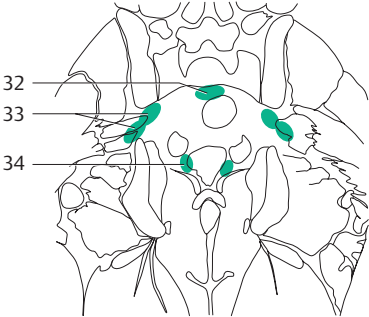
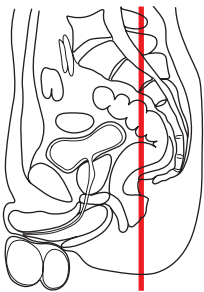
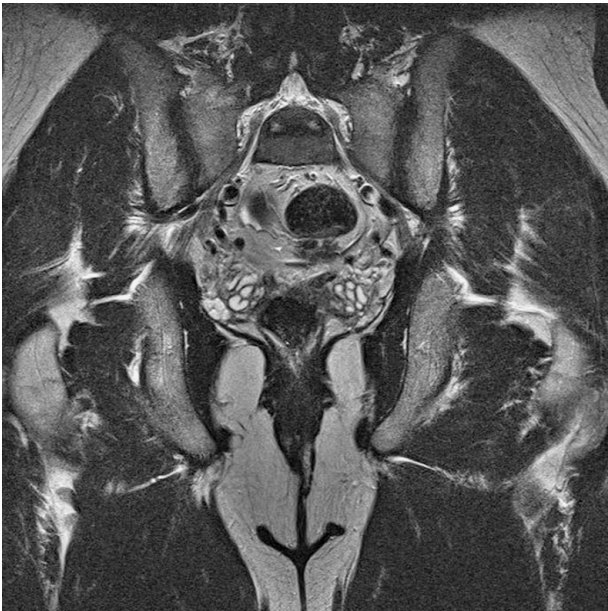- |                                                                         |                                       |
|-------------------------------------------------------------------------|---------------------------------------|
| 1. Transversus abdominis muscle                                         | 23. Vastus lateralis muscle           |
| 2. Internal oblique muscle                                              | 24. Gracilis muscle                   |
| 3. External oblique muscle                                              | 25. Transversospinalis muscles        |
| 4. Iliac crest                                                          | 26. Cauda equina                      |
| 5. Iliacus muscle                                                       | 27. Spinal dura                       |
| 6. Ilium                                                                | 28. Sacrum                            |
| 7. Gluteus medius muscle                                                | 29. Sacrum (ala)                      |
| 8. Sacroiliac joint                                                     | 30. Superior rectal artery            |
| 9. Internal iliac artery and vein                                       | 31. Sigmoid colon                     |
| 10. Gluteus maximus muscle                                              | 32. Obturator artery and vein         |
| 11. Gluteus minimus muscle                                              | 33. Urinary bladder                   |
| 12. Acetabular lip                                                      | 34. Seminal gland                     |
| 13. Ureter                                                              | 35. Prostate (central zone)           |
| 14. Vesical venous plexus                                               | 36. Capsula articularis               |
| 15. Insertion of gluteus minimus and medius muscle (greater trochanter) | 37. Prostate (peripheral zone)        |
| 16. Obturator internus muscle                                           | 38. Levator ani muscle                |
| 17. Gemellus inferior muscle                                            | 39. Rectum (wall)                     |
| 18. Obturator externus muscle                                           | 40. Internal pudendal artery and vein |
| 19. Quadratus femoris muscle                                            | 41. Ischiocavernosus muscle           |
| 20. Ischial tuberosity                                                  | 42. Urogenital diaphragm              |
| 21. Lesser trochanter                                                   | 43. Bulbospongiosus muscle            |
| 22. Adductor magnus muscle                                              | 44. Presacral lymph nodes             |
|                                                                         | 45. Internal iliac lymph nodes        |
|                                                                         | 46. Lateral vesical lymph nodes       |

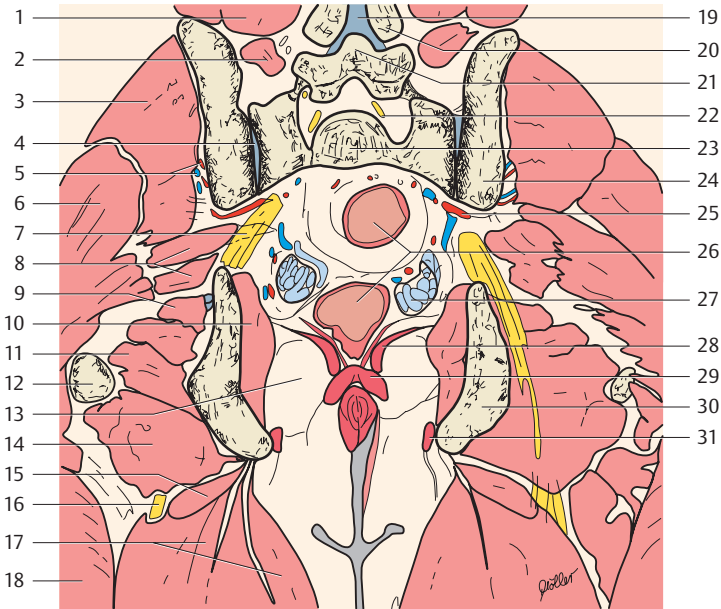


— = Peritoneum



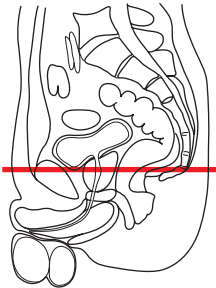
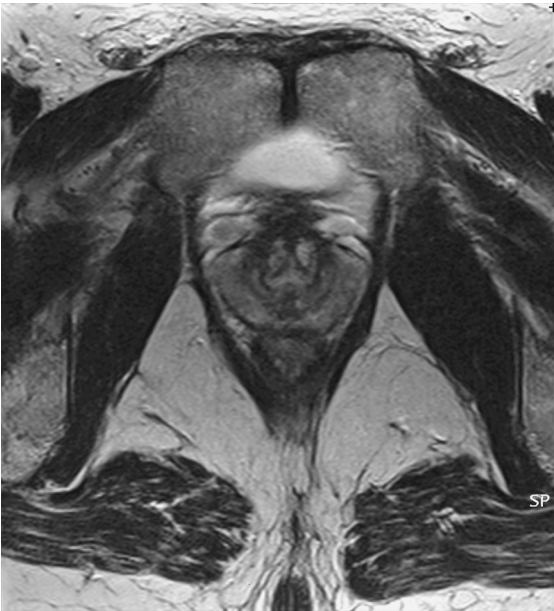- |                                      |                                               |
|--------------------------------------|-----------------------------------------------|
| 1. Quadratus lumborum muscle         | 22. Vastus lateralis muscle                   |
| 2. Iliac crest                       | 23. Spinal dura                               |
| 3. Zygapophysial joint               | 24. Inferior articular process (zygapophysis) |
| 4. Interosseous sacroiliac ligaments | 25. Sacrum (S1)                               |
| 5. Sacrum (ala)                      | 26. Intervertebral disk S1-S2                 |
| 6. Sacroiliac joint                  | 27. Superior rectal artery                    |
| 7. Sacral nerves                     | 28. Internal iliac artery and vein            |
| 8. Ilium (ala)                       | 29. Sigmoid colon                             |
| 9. Gluteus medius muscle             | 30. Vesical venous plexus                     |
| 10. Gluteus maximus muscle           | 31. Urinary bladder                           |
| 11. Ureter                           | 32. Seminal gland                             |
| 12. Piriformis muscle                | 33. Rectum (ampulla)                          |
| 13. Gemellus superior muscle         | 34. Levator ani muscle                        |
| 14. Ilium                            | 35. Ischiorectal fossa                        |
| 15. Obturator internus muscle        | 36. Intertrochanteric crest                   |
| 16. Gemellus inferior muscle         | 37. Ischial tuberosity                        |
| 17. Quadratus femoris muscle         | 38. Presacral lymph nodes                     |
| 18. External anal sphincter muscle   | 39. Internal iliac lymph nodes                |
| 19. Adductor minimus muscle          | 40. Postvesical lymph nodes                   |
| 20. Ischiocavernosus muscle          | 41. Pararectal lymph nodes                    |
| 21. Adductor magnus muscle           |                                               |



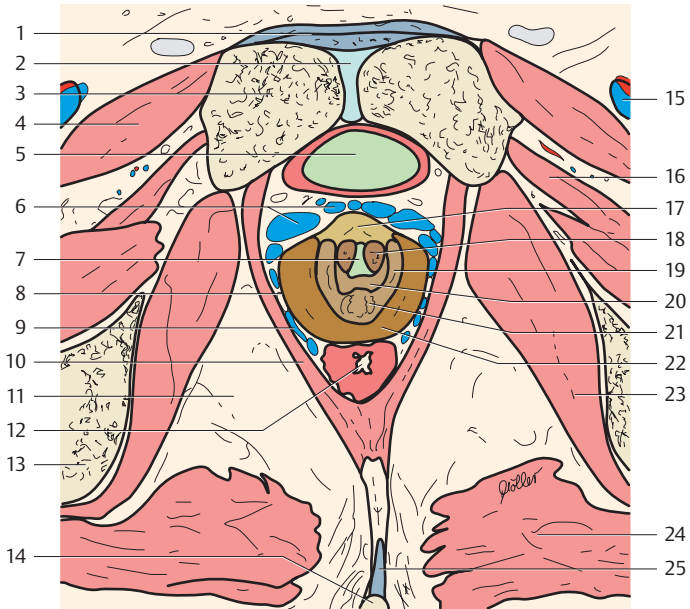


- |                                     |                                                   |
|-------------------------------------|---------------------------------------------------|
| 1. Quadratus lumborum muscle        | 19. Interspinous ligaments                        |
| 2. Multifidus muscle                | 20. Inferior articular process (zygapophysis, L4) |
| 3. Gluteus medius muscle            | 21. Lumbar vertebra (L5)                          |
| 4. Sacroiliac-joint                 | 22. Spinal nerve (L5)                             |
| 5. Superior gluteal artery and vein | 23. Sacrum                                        |
| 6. Gluteus maximus muscle           | 24. Ilium                                         |
| 7. Sacral plexus                    | 25. Internal iliac artery and vein                |
| 8. Piriformis muscle                | 26. Rectum                                        |
| 9. Gemellus superior muscle         | 27. Seminal gland                                 |
| 10. Obturator internus muscle       | 28. Levator ani muscle                            |
| 11. Gemellus inferior muscle        | 29. External anal sphincter muscle                |
| 12. Greater trochanter              | 30. Ischium                                       |
| 13. Ischiorectal fossa              | 31. Ischiocavernosus muscle                       |
| 14. Quadratus femoris muscle        | 32. Presacral lymph nodes                         |
| 15. Adductor minimus muscle         | 33. Gluteal lymph nodes (superior and inferior)   |
| 16. Sciatic nerve                   | 34. Pararectal lymph nodes                        |
| 17. Adductor magnus muscle          |                                                   |
| 18. Vastus lateralis muscle         |                                                   |

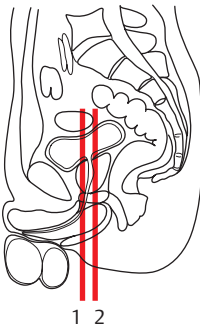
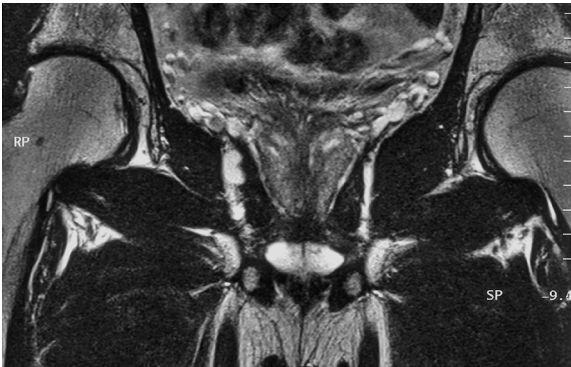
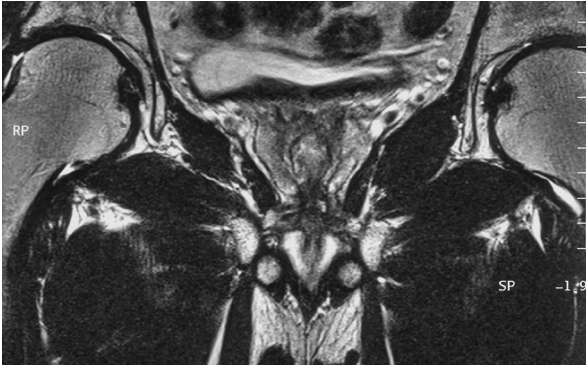




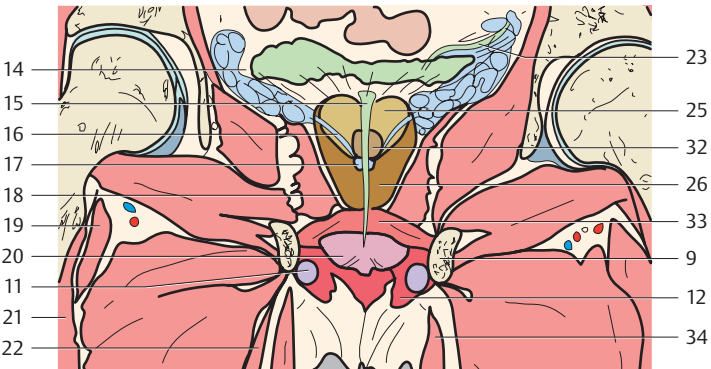
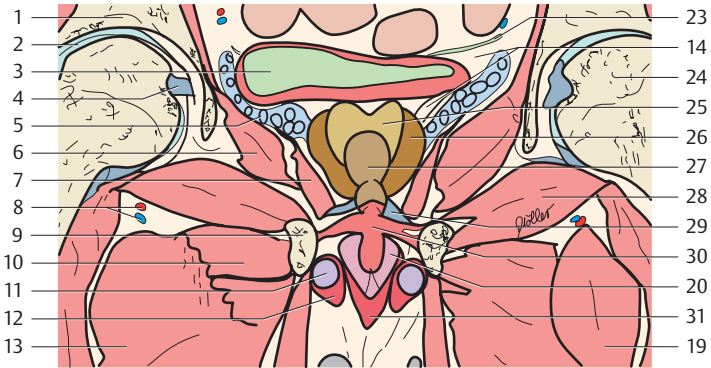




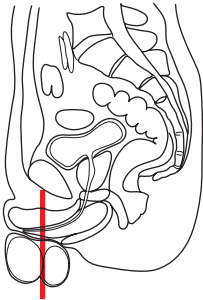
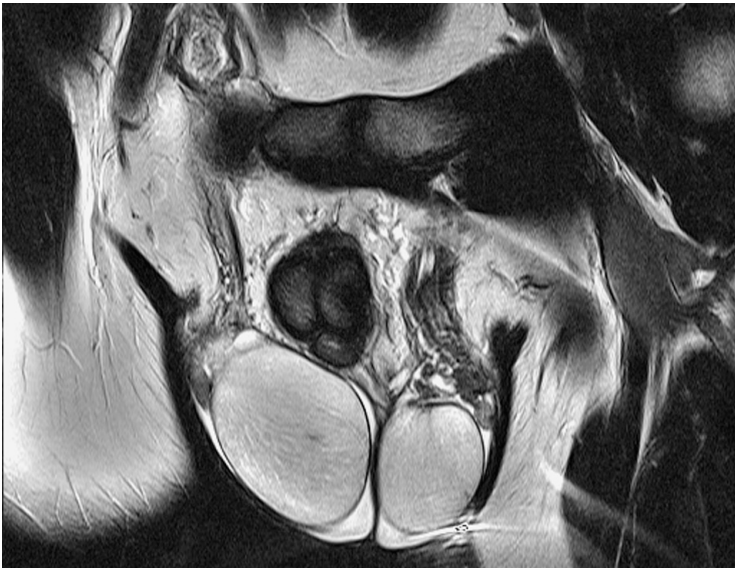
- |                                                                  |                                                                         |
|------------------------------------------------------------------|-------------------------------------------------------------------------|
| 1. Fundiform and suspensory ligaments of penis                   | 15. Femoral artery, vein and nerve                                      |
| 2. Pubic symphysis                                               | 16. Obturator externus muscle                                           |
| 3. Pubis                                                         | 17. Prostate (anterior portion, anterior fibromuscular stroma, Isthmus) |
| 4. Pectineus muscle                                              | 18. Prostate (central portion, transition zone)                         |
| 5. Urinary bladder                                               | 19. Prostate (central portion, central zone)                            |
| 6. Prostatic venous plexus (anterior venous plexus of Santorini) | 20. Prostate (middle lobe with seminal colliculus)                      |
| 7. Urethra                                                       | 21. Ejaculatory duct                                                    |
| 8. Capsule of prostate                                           | 22. Prostate (peripheral zone)                                          |
| 9. Lateral venous plexus (neurovascular bundle)                  | 23. Obturator internus muscle                                           |
| 10. Levator ani muscle                                           | 24. Gluteus maximus muscle                                              |
| 11. Ischioanal fossa                                             | 25. Anococcygeal ligament                                               |
| 12. Anus                                                         |                                                                         |
| 13. Ischium                                                      |                                                                         |
| 14. Coccyx                                                       |                                                                         |

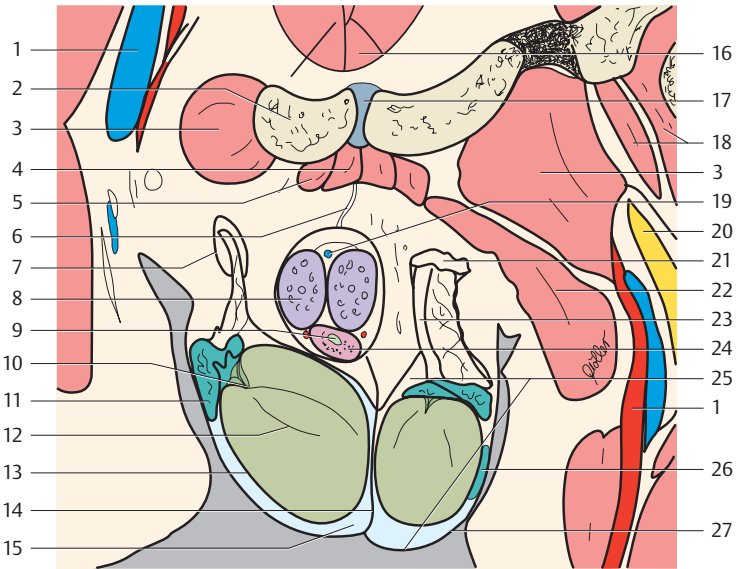


1. Ilium (acetabular roof)
2. Hip joint
3. Urinary bladder
4. Ligament of head of femur
5. Seminal gland

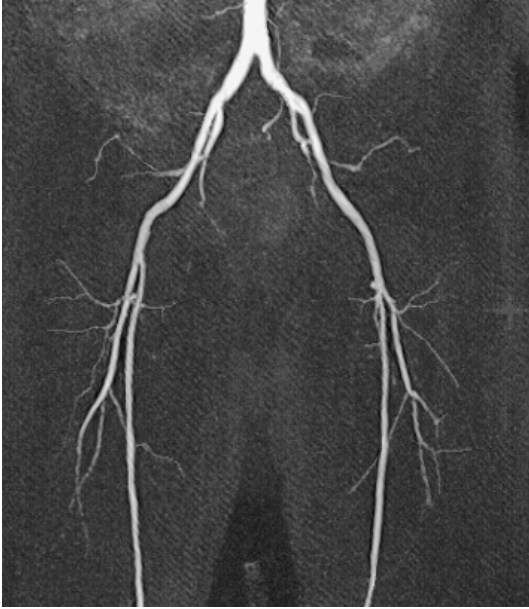


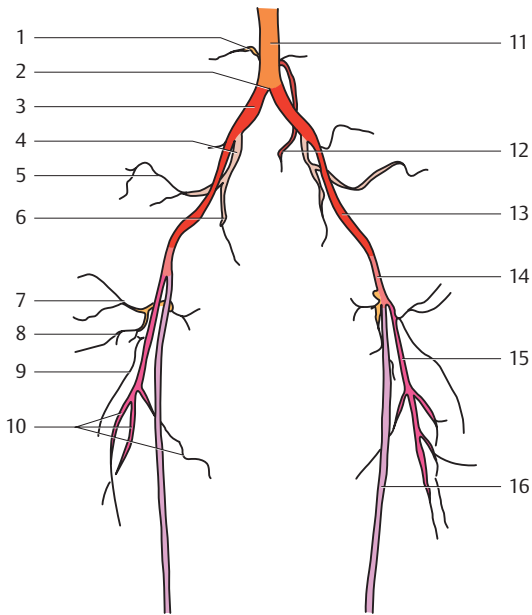
- |                                                             |                                                                  |
|-------------------------------------------------------------|------------------------------------------------------------------|
| 6. Obturator internus muscle                                | 22. Adductor magnus muscle                                       |
| 7. Levator ani muscle                                       | 23. Ureter                                                       |
| 8. Medial circumflex femoral artery                         | 24. Head of femur                                                |
| 9. Pubis                                                    | 25. Central zone of prostate                                     |
| 10. Adductor minimus muscle                                 | 26. Peripheral zone of prostate                                  |
| 11. Corpus cavernosum                                       | 27. Anterior fibromuscular stroma (anterior portion) of prostate |
| 12. Ischiocavernosus muscle                                 | 28. Obturator externus muscle                                    |
| 13. Adductor brevis muscle                                  | 29. Prostatic venous plexus and pubo-prostatic ligament          |
| 14. Lateral venous plexus                                   | 30. Urogenital diaphragm                                         |
| 15. Urethra                                                 | 31. Bulbospongiosus muscle                                       |
| 16. Ejaculatory duct                                        | 32. Prostate (middle lobe with seminal colliculus)               |
| 17. Colliculus seminalis (openings of the ejaculatory duct) | 33. Urethral sphincter muscle and urogenital diaphragm           |
| 18. Capsule of prostate                                     | 34. Gracilis muscle                                              |
| 19. Pectineus muscle                                        |                                                                  |
| 20. Corpus spongiosum                                       |                                                                  |
| 21. Iliopsoas muscle                                        |                                                                  |



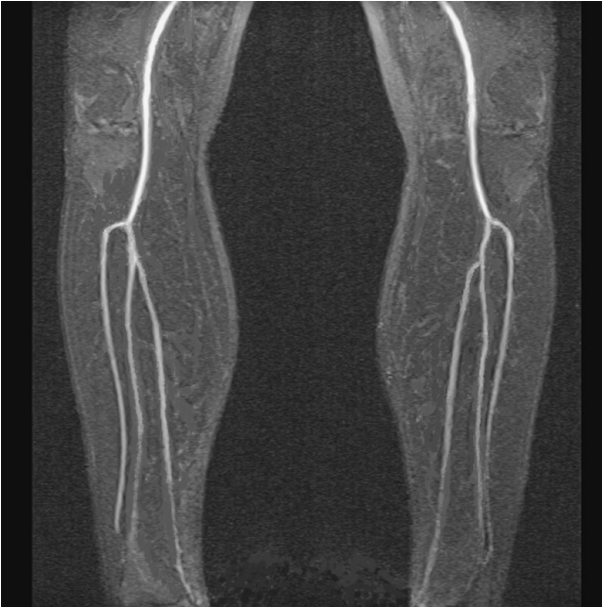

- |                                 |                                                                                  |
|---------------------------------|----------------------------------------------------------------------------------|
| 1. Femoral artery and vein      | 16. Pyramidalis muscle                                                           |
| 2. Pubis                        | 17. Pubic symphysis                                                              |
| 3. Pectineus muscle             | 18. Iliopsoas muscle                                                             |
| 4. Adductor longus muscle       | 19. Deep dorsal vein of penis                                                    |
| 5. Adductor brevis muscle       | 20. Femoral nerve                                                                |
| 6. Suspensory ligament of penis | 21. Spermatic fascia and cremaster muscle                                        |
| 7. Superficial inguinal ring    | 22. Obturator externus muscle                                                    |
| 8. Corpus cavernosum            | 23. Ductus deferens                                                              |
| 9. Urethra                      | 24. Corpus spongiosum                                                            |
| 10. Mediastinum of testis       | 25. Left scrotal cavity                                                          |
| 11. Epididymis (head)           | 26. Epididymis (body)                                                            |
| 12. Septa testis                | 27. Wall of scrotum (with dartos fascia, spermatic fascia, and cremaster muscle) |
| 13. Tunica albuginea            |                                                                                  |
| 14. Septum of scrotum           |                                                                                  |
| 15. Scrotal cavity              |                                                                                  |

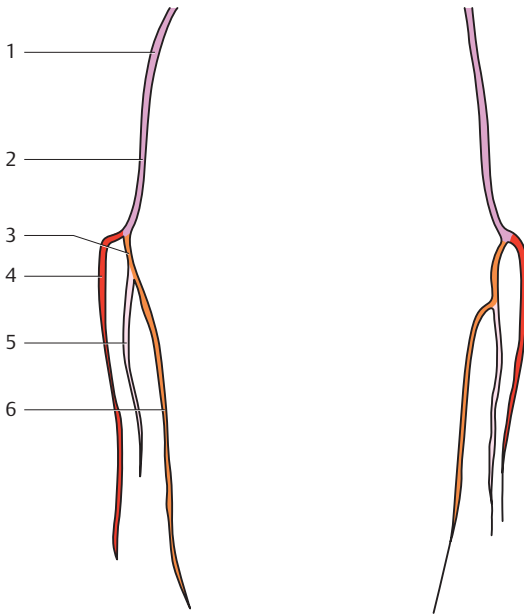




- |                                                          |                                                          |
|----------------------------------------------------------|----------------------------------------------------------|
| 1. Lumbar arteries                                       | 9. Lateral femoral circumflex artery (descending branch) |
| 2. Aortic bifurcation                                    | 10. Deep femoral artery (perforating arteries)           |
| 3. Right common iliac artery                             | 11. Abdominal aorta                                      |
| 4. Right internal iliac artery                           | 12. Superior rectal artery                               |
| 5. Superior gluteal artery                               | 13. External iliac artery                                |
| 6. Internal pudendal artery                              | 14. Common femoral artery                                |
| 7. Lateral femoral circumflex artery (ascending branch)  | 15. Deep femoral artery                                  |
| 8. Lateral femoral circumflex artery (transverse branch) | 16. Superficial femoral artery                           |







1. Superficial femoral artery
2. Popliteal artery
3. Common trunk of posterior tibial artery and peroneal artery

4. Anterior tibial artery
5. Peroneal artery
6. Posterior tibial artery

## References

- Basset, L. W., R. U. Gold, L. L. Seeger: MRI Atlas of the Musculoskeletal System. Deutscher Ärzte-Verlag, Köln 1989
- Beyer-Enke, S. A., K. Tiedemann, J. Görlich, A. Gamroth: Dünnschicht-computertomographie der Schädelbasis, Radiologe 27 1987: 438–488
- Cahill, D. R., M. J. Orland, C. C. Reading: Atlas of Human Cross-Sectional Anatomy. Wiley-Liss 1990
- Chacko, A. K., R. W. Katzberg, A. Mac Kay: MRI Atlas of Normal Anatomy. McGraw-Hill Inc., New York 1991
- El-Khoury, G. Y., R. A. Bergman, E. J. Montgomery: Sectional Anatomy by MRI/CT. Churchill, Livingstone 1990
- Feneis, H.: Pocket Atlas of Human Anatomy, Thieme, Stuttgart 2000
- Han-Kim: Sectional Human Anatomy. Ilchokak, Seoul; Igaku-Shoin, New York – Tokio 1989
- Huk, W. J., G. Gademann, G. Freidmann: MRI of Central Nervous System Diseases. Springer, Berlin 1990
- Kahle, W., H. Leonhard, W. Platzer: Taschenatlas der Anatomie. Thieme, Stuttgart 1999
- Kang, M. S., D. Resnick: MRI of the Extremities: An Anatomic Atlas. W. B. Saunders Company, Philadelphia 1991
- Koritke, J. G., H. Sick: Atlas of Sectional Human Anatomy. Urban & Schwarzenberg, Baltimore – München 1988
- Kretschmann, H.-J., W. Weinrich: Klinische Neuroanatomie und kraniale Bildagnostik, Thieme, Stuttgart 1991
- Leblanc, A.: Anatomy and Imaging of the Cranial Nerves, Springer, Berlin 1992
- Meschan, I.: Synopsis of Radiologic Anatomy. W. B. Saunders Company, Philadelphia
- Middleton, W. D., T. L. Lawson (eds.): Anatomy and MRI of the Joints. Raven Press 1989
- Möller, T. B., E. Reif: MR-Atlas des muskuloskelettalen Systems. Blackwell, Berlin 1993
- Rauber/Kopsch: Anatomie des Menschen. Lehrbuch und Atlas. (Hrsg. U. Leonhardt, B. Tillmann, G. Töndury, K. Zilles). Band 1 Bewegungsapparat. Thieme, Stuttgart 1987
- Richter, E., T. Feyerabend: Normal Lymph Node Topography. Springer, Berlin 1991
- Schnitzlein, H. N., F. Reed Murtagh: Imaging Atlas of the Head and Spine. Urban & Schwarzenberg, Baltimore 1990
- Stark, D. D., W. G. Bradley: Magnetic Resonance Imaging., Mosby, St. Louis 1999
- v. Hagens, G., L. J. Romrell, M. H. Ross, K. Tiedemann: The Visible Human Body. Lea & Febinger, Philadelphia 1991
- Wegener, O. H.: Ganzkörpercomputertomographie. Blackwell, Berlin 1992
- Witzig, H.: Punkt – Punkt – Komma – Strich. Falken Niedernhausen 1991

## Index

### A

- abdomen 62–139
  - axial 62–109
  - coronal 128–39
  - sagittal 110–27
- acetabular lip 155, 157
- acetabular roof 153, 167, 175–9, 195, 206
- acromioclavicular joint 52
- adipose tissue
  - renal sinus 81, 85
  - subpericardial 33–9
- ampulla of ductus deferens 105
- anal canal 161, 169
- anus 132, 160–1, 169, 183, 187, 205
- aorta 132, 160
  - abdominal 51–3, 65–7, 71–89, 141–3, 173–5, 211
  - ascending 13–9, 31–8, 48
  - bifurcation 141, 175, 211
  - descending 13–29, 37–9, 55, 59, 121, 137
  - thoracic 139
- aortic arch 11, 40, 51–9
- aortic bulb 37–8
- aortic hiatus 69
- aortic valve 37–8, 48
- aorticopulmonary window 13, 39–40, 52
- aponeurosis, gluteal 149–51
- appendix, vermiform 131–3
- areolar duct 61
- arteries
  - anterior tibial 213
  - appendicular 131
  - axillary 7–9, 51
  - brachial 55
  - brachiocephalic 7, 9
  - circumflex femoral 175
  - colic 117
  - colic media 121
  - common carotid 7–9, 38, 51
  - common femoral 211
  - common hepatic 143
  - common iliac 97, 117–21, 133, 163, 189–97
    - left 141
    - right 141
  - deep femoral 211
    - perforating arteries 211
  - deep of thigh 173–5
  - epigastric 95–9
  - external iliac 97–105, 131–3, 141, 149, 151–3, 165, 173–5, 193, 211
  - femoral 109, 155–9, 167, 171–3, 195, 205, 209
  - gastric 125
  - gastroduodenal 143
  - hepatic 68, 115, 132, 143
  - ileal 79–97, 143
  - ileocolic 131–3, 143
  - iliolumbar 167, 177
  - inferior epigastric 97, 103, 149
  - inferior gastric 101
  - inferior gluteal 97, 105, 185
  - inferior mesenteric 119–21, 133, 173, 193
  - inferior pancreaticoduodenal 75
  - intercostal 111, 115–7
  - internal carotid 3–5
  - internal iliac 97–101, 133–5, 141, 153, 163, 177–81, 189, 193, 199, 201–3
  - internal pudendal 109, 199, 201
  - internal thoracic 13, 17–25, 47
  - jejunal 79–89, 131, 143
  - lateral circumflex 109
  - lateral femoral circumflex 211
    - ascending branch 211
    - descending branch 211
    - transverse branch 211
  - lateral sacral 189, 193
  - left colic 93–7, 133
  - left common iliac 91–3, 175
  - left coronary 19–21, 38, 45, 51
    - anterior interventricular branch 40, 45
    - circumflex branch 25, 40, 45–9
    - interventricular branch 23
  - left gastric 63–5, 119–21, 143
  - left gastroepiploic 131
  - left hepatic 143
  - left pulmonary 15, 40–3, 55–9
    - lateral basal branch 59
    - lingular branch 59
    - posterior basal branch 59
    - upper lobe 59

- arteries, left pulmonary  
 branches 59  
 left renal 75–9, 121, 135, 141  
 left subclavian 49  
 left testicular 79–85, 87  
 lumbar 77–9, 141, 177–9, 195, 211  
 medial circumflex femoral 179, 195–7, 207  
 middle colic 93  
 obturator 105–7, 153, 165, 195–9  
 ovarian 149, 163  
 peroneal 213  
 common trunk 213  
 popliteal 213  
 posterior gastric 63  
 posterior intercostal 41  
 posterior tibial 213  
 common trunk 213  
 pulmonary 57  
 renal 115–7, 123, 136, 140–1  
 inferior capsular branch 141  
 right colic 87–91, 95, 131, 143  
 right common carotid 48  
 right common iliac 91–3, 173–5, 211  
 right coronary 19, 21–5, 31–5, 49, 51  
 posterior interventricular branch 33, 37  
 right marginal branch 37  
 terminal branch 33  
 gastroepiploic 117, 129  
 right hepatic 143  
 right internal iliac 211  
 right pulmonary 15–7, 31–4, 37, 51–2, 55, 59  
 anterior basal branch 59  
 ascending branch 59  
 basal part 59  
 inferior lobe 59  
 superior branch 59  
 superior lobe 59  
 apical branch 59  
 posterior branch 59  
 right renal 75–9, 141  
 right testicular 81–7  
 sigmoid 133, 173, 181–3  
 splenic 123–7, 133–7, 141–3  
 subclavian 3–9, 31–2, 39–48  
 superficial epigastric 105–9, 171  
 superficial femoral 213  
 superior femoral 211  
 superior gluteal 139, 165–7, 177, 181, 185, 203, 211  
 superior mesenteric 66, 69–89, 121, 131–2, 143, 173  
 superior rectal 99–101, 133–9, 149, 161, 177–9, 197–201, 211  
 superior vesical 199  
 suprarenal 67  
 arteries, testicular 89–93  
 sinister 83  
 thoracodorsal 11–5  
 thyroidea ima 47–9  
 uterine 177  
 vertebral 41–9  
 articular process (zygapophysis) 121, 139  
 inferior 121, 139, 191–203  
 superior 33, 121, 139  
 atrioventricular (mitral) valve  
 left 41–3, 51  
 atrioventricular (tricuspid) valve  
 right 23–25, 33–9  
 atrium  
 left 17–23, 33–43, 51–3, 59  
 right 21–25, 31–7, 47–51, 117–9  
 auricle  
 left 40, 49  
 right 19, 31–5
- B**
- bile duct 68, 115–7, 147  
 brachio plexus 3–7, 43–5  
 brachiocephalic trunk 32–6, 48  
 breast  
 glandular tissue 17, 47–9  
 left 47–9  
 right 47–51  
 bronchus(i)  
 inferior lingular 45  
 left inferior lobar 17–21, 45  
 left superior lobar 45  
 main stem  
 left 13–5, 39–43, 55  
 right 13–5, 31, 55  
 right inferior lobar 17–9, 55  
 superior lingular 45  
 bulbourethral gland 187  
 bursa  
 omental 81, 121, 131

**C**

caecum  
 see cecum  
 canalis cervicis 161  
 capsula articularis 199  
 cardia notch 63  
 cartilage  
 thyroid 47  
 cauda equina 119, 139, 161, 180, 189,  
 199  
 cecum 95, 111–3, 129–31, 135  
 celiac trunk 63  
 cervical canal 169, 181  
 cervical plexus 51, 52  
 cervix  
 uterus 181  
 cisterna chyli 83  
 clavicle 3–7, 31–4, 38–40, 45–50  
 clitoris  
 body 161  
 crus 175  
 coccyx 107, 155, 161, 187–91, 205  
 c(o)eliac trunk 67, 121, 134, 142–3  
 colic flexure  
 left 63–5  
 right 75, 79–81  
 colliculus seminalis 207  
 colon 167  
 ascending 83–93, 115, 131–7,  
 173–5  
 descending 67–81, 89–97, 125–7,  
 131–9  
 sigmoid 99–101, 129–37, 177–83,  
 187–91, 195–201  
 distal part 149  
 transverse 67–81, 85–7, 91–5,  
 113–29  
 conus arteriosus 19–21, 41, 47  
 Cooper's ligament 61  
 coracoid process 3, 51  
 coronary sinus 37–41, 51  
 corpus cavernosum (penis) 187–97,  
 207–9  
 corpus spongiosum (penis) 187–97,  
 207–9  
 costal cartilage 43  
 costodiaphragmatic recess 49–55, 63–  
 73, 113–5, 127, 131–7  
 costovertebral joint 3–5, 21,  
 27  
 crista terminalis 21

cystic duct 147  
 pars flaccida 147  
 spiral fold 147

**D**

dartos fascia 209  
 diaphragm 27–57, 63–83, 111–130, 135–  
 6, 139  
 costal part 111, 123–5  
 costodiaphragmatic recess 111  
 lumbar part 37, 117, 121–5  
 right crus 136, 139  
 urogenital 181, 187–91, 195–9, 207  
 duct  
 ejaculatory 187, 205–7  
 opening 207  
 ductus deferens 209  
 ampulla 105  
 duodenal papilla 147  
 duodenal recess  
 inferior 73–5  
 superior 69  
 duodenojejunal flexure 79  
 duodenum 75–81, 115–7, 133–5, 147  
 descending part 66, 71–3, 119–21,  
 136  
 horizontal part 133  
 superior part 68

**E**

endometrium 169  
 epididymis 187, 191–3  
 body 209  
 head 209  
 esophagus 3–7, 11–29, 35–9, 51–5, 121  
 hiatus 137  
 extremity, lower  
 MR-arterial angiography 210–213

**F**

facies lunata acetabuli 195  
 fascia lata 107–9  
 fascia thoracolumbar 121, 191  
 fatty island 61  
 femur 159  
 head 107, 153, 157, 175–9, 195–7, 207  
 ligament 195–7, 206

femur  
 intertrochanteric part 109  
 neck 177–9, 195–7

fissura oblique 43

flexure

left colic 131–5

right colon 111, 129–31

foramen 33

epiploic 67

intervertebral 121, 191

sacral I 97

sacral II 99

sacral III 99

fossa acetabuli 167

glenoidalis 53

ischioanal 185

ischiorectal 107–9, 179–83, 201–5

paravesical 103

fovea capitis femoris 167

fovea for ligament of head 195

## G

gallbladder 68–79, 113, 131

body 147

neck 147

glandular body 61

glenohumeral joint 55

glenoid cavity 51, 55

groove

medial of psoas muscle 93, 97

gutter

of psoas muscle 91

lateral 95

medial 95

## H

heart 61, 121–5

apex 49, 127–9

base 27

hepatic duct 147

common 147

left 147

right 147

hepatorenal recess 73–85

hiatus sacralis 102

hilum

of liver 67–9

renal 77–81

of spleen 67

hip joint 133, 153, 179, 195–7, 206

humerus

head 3, 51–5

## I

ileum 81–5, 89–93, 97, 117, 133–5, 149  
 terminal 91, 131–3

iliac crest 111–2, 123, 131–9, 173–80,  
 199–201

iliac spine 115–7, 127

anterior superior 129, 171

superior 167

iliotibial tract 157–9, 177–9

ilium 93, 97, 125, 131, 135, 149–55, 165,  
 171, 185, 195–6, 199–206

acetabular roof 133

ala 93–5, 99, 137–9, 173–80, 201

body 101–5, 167, 175–9

infrapiriform opening 103

inguinal canal 105, 193

inguinal canal 193

inguinal ring

superficial 209

interarticular septum 35

interventricular septum 41

intervertebral disk 50

(L1–L2) 119

(L2–L3) 121, 138, 177

(L3–L4) 135

(L4–L5) 160, 195–7

(L5–S1) 191

(S1–S2) 183, 201

(T9–T10) 55

intervertebral space 33–9

intestine

small 111–7, 121–7, 137, 151, 161–5,  
 171, 187–95

ischial spine 155, 165

ischial tuberosity 157–9, 167, 199–201

ischioareolar fossa 163

ischium 107–9, 163, 181–3, 193, 203–5

ramus 177–81

## J

jejunum 67–91, 99, 111–3, 129, 133–5,  
 173–5

jugular notch 47

**K**

- kidney 53, 179–80  
 fatty capsule 125–7, 183  
 left 45, 67–71, 83–5, 123–7, 137–9  
 right 73–7, 81, 87, 111–5, 136, 139, 177

**L**

- labium majus 161, 169, 173–5  
 labium minus 161, 169, 177, 181  
 labrum glenoidale 195  
 ligaments  
 anococcygeal 161, 169, 187–9, 205  
 anterior longitudinal 35, 39, 50, 53, 119–21  
 arcuate pubic 169, 187  
 coracoclavicular 51  
 dorsal sacroiliac 139, 163–5, 185  
 falciform of liver 129–30  
 fundiform of penis 205  
 head of femur 155, 195–7, 206  
 hepatoduodenal 67  
 iliofemoral 157, 175–81, 195–7  
 iliolumbar 181  
 interosseous sacroliliac 201  
 interspinal 37, 55–7, 183–7  
 interspinous 203  
 posterior longitudinal 161, 187  
 puboprostatic 207  
 round 67  
 notch for 67  
 round, of liver 66–8  
 round of uterus 151, 163–5  
 sacroiliac 183  
 sacrospinous 153–5  
 sacrotuberous 149, 163  
 sternopericardial 47  
 supraspinous 3, 37  
 suspensory of penis 107–9, 187, 205, 209  
 transverse perineal 175  
 uterosacral 153  
 ligamenta flava 35–9, 57, 119, 139, 161, 187–9  
 linea alba 66, 87–9  
 liver 27, 31–57, 68, 71–85, 113, 119–23  
 bare area 63–5  
 caudate lobe 63–66, 119  
 falciform ligament 129–30

- hilum 67–9  
 left lobe 29, 63, 66, 69–71, 129–31  
 quadrate lobe 117  
 right lobe 29, 63–5, 111–5, 129–139  
 round ligament 66  
 lobus medius 205  
 lumbar plexus 93–5, 137, 163–5  
 lumbar triangle 87  
 lumbosacral plexus 117, 123  
 lung 119, 123–7  
 apical part 53  
 left 2, 5–27, 36–42, 47–9, 53–7, 63–7, 129–39  
 inferior lobe 43  
 lower lobe 2, 10–28, 42–5, 54–5  
 upper lobe 2, 6–8, 12–6, 42–6  
 right 2, 7–34, 47–8, 51–7, 61, 111, 115–7, 129–30, 134–9  
 lower lobe 2, 12–30, 54–6  
 middle lobe 2, 18–30, 46, 54  
 retroesophageal recess 19  
 upper lobe 2, 6–12, 16, 30, 46, 54–56  
 lymph nodes  
 anterior cervical 3–5  
 anterior mediastinal 7–17, 31–3, 37–41, 47–9  
 of aorticopulmonary window 13–5  
 aortopulmonary 41  
 axillary 53  
 bronchopulmonary 15–21, 31, 39–41, 53  
 coelic 121, 131  
 common iliac 75, 91–9, 117–23, 133, 161, 173, 189–95  
 cystic 71  
 deep axillary 5–7, 51  
 lymph nodes, deep cervical 31–3, 39–43  
 deep inguinal 167, 175  
 deep inguinal 153–9  
 external iliac 101–5, 149–53, 163–5, 173–5, 193  
 gastro-omental 117–23, 129–35  
 gluteal 165–7, 183–5, 193  
 hepatic 67, 115–7  
 inferior diaphragmatic 63–5, 137  
 inferior gluteal 101, 203  
 inferior mesenteric 133, 173  
 inferior phrenic 29, 37  
 inguinal 107–9, 165  
 intercostal 5–29, 43, 63–5, 69–89

## lymph nodes

- internal iliac 135, 149, 163, 177, 179–81, 193, 199–201
- interpectoral 7–11
- jugular 3–5
- juxtaesophageal 17–25, 35–7, 55
- juxtaintestinal 123–31, 135, 149–51, 173
- juxtaintestinal mesenteric 161, 187–9
- lateral pericardial 23–7, 47
- lateral vesical 193–9
- left gastroomental 29
- lumbar 13–5, 71–91, 121, 133–5, 173–5
- medial lacunar 155
- mesenteric 113–15, 119–21
- nuchal 43–5
- obturator 151–5, 165
- pancreatic 67, 117–27, 137
- para-aortal 15–29
- paracolic 113–5, 127, 131–7, 149
- paraesophageal 3–15
- paramammary 23
- pararectal 103–9, 149–59, 163, 183–5, 191, 201–3
- parasternal 11–27, 33, 37–41
- paratracheal 3–11, 15, 33–7, 49–53
- parauterine 151–3, 163, 179–83
- paravaginal 155–9, 163, 177–81
- paravertebral 7–13, 17–37, 41
- paravesical 153–5, 173–5
- postcaval 117–21
- posterior intercostal 31, 41
- postvesical 155–7, 177, 187–9, 201
- preaortic 133
- prepericardial 19–27, 35, 43–5
- presacral 161, 181, 187–91, 199–203
- prevertebral 39, 51–5, 135–7, 177, 187, 195
- prevertebral anal 161
- prevesical 157, 161, 187–91
- promontorial 161
- promontorial 97, 177–9, 187, 197
- pulmonal 43–5
- rectal 157
- right gastric 29
- right gastro-omental 125
- Rosenmüller-Cloquet 155
- sacral 99–101, 149–53
- splenic 127, 137–7
- subclavicular 3
- superficial axillary 9–11, 51

- superficial cervical 31, 41–5, 49
- superficial inguinal 167, 173
- superficial inguinal 155–9, 171
- superior diaphragmatic 63–9, 137–9
- superior gluteal 149–53, 203
- superior mesenteric 59–71, 131, 173
- superior phrenic 27–9, 37
- supraclavicular 3, 31–3, 43–5, 49
- thyroid 33, 39
- tracheobronchial 13, 35–9

**M**

- mammary duct 61
- mammography, MR 60–61
- manubrium of sternum 7–11, 34–40
- mediastinum
  - posterior 63–9
  - of testis 209
- mesentericocolic gutter
  - left 71, 75–89, 91–7
  - right 89–95
- mesentericocolic recess
  - left 73
- mesentery 81–5, 89
- mesentery 115, 121, 125, 173, 187–9
  - root of 79
- mesocolon
  - transverse 81–7
- MRCP 146–7
- muscles
  - adductor brevis 163–7, 173–5, 191–7, 207–9
  - adductor longus 163–7, 171–5, 193–5, 209
  - adductor magnus 163–7, 177–83, 193, 197–203, 207
  - adductor minimus 195–7, 201–3, 207
  - anterior papillary 39, 45
  - anterior scalene 3, 43–5, 49
  - anterior serratus 45, 61
  - anterior superior iliac 195–6
  - biceps 53
  - bulbospongiosus 179–81, 187–91, 195–9, 207
  - coccygeus 193
  - coracobrachial 53
  - cremaster 209
  - deep transverse perineal 161–3, 169, 177–81
  - deltoid 3–9, 49, 57



- erector spinae 3–7, 11, 15–33, 39–41, 57, 111–27, 161–3, 181–91
- external abdominal oblique 111, 127–31, 135–9, 171–81, 195–6
- external anal sphincter 161, 169, 183–7, 191, 201–3
- deep part 189
  - subcutaneous part 189
  - superficial part 189
- external intercostal 111–3, 129–33, 139
- external oblique 29, 63–73, 77–95, 111–113, 117, 133, 199
- gemellus inferior 157, 167, 183, 199–201
- gemellus superior 155, 167, 183, 201–3
- gluteus maximus 95–109, 113, 125–7, 139, 149–59, 163–7, 181–5, 191–3, 199–205
- gluteus medius 93–105, 111–3, 127–39, 149–57, 167, 171–83, 196, 199–203
- insertion 199
- gluteus minimus 97–9, 103–9, 131–5, 149, 153–5, 167, 173–81, 195–6, 199
- insertion 199
- gracilis 177–9, 193–99, 207
- iliacus 93–7, 111, 127–35, 149, 165–7, 173–9, 195–6
- iliocostalis 57, 139, 165–7, 181–5
- thoracic part 63–79
- iliocostalis lumborum 81–9, 127
- iliopsoas 99–109, 129, 151–7, 167, 171–9, 195–7, 207–9
- infraspinatus 3–17, 52, 57
- infraspinous 5
- intercostal 5–31, 41–49, 53–57, 115–7, 125–7
- internal abdominal oblique 127–39, 149–53, 171–81, 195–6
- internal intercostal 111–3, 129
- internal oblique 71–87, 91–9, 111–3, 199
- interspinales lumborum 163
- interspinalis 183
- intertransversarii 123, 183
- ischiocavernosus 191, 195–203, 207
- lateral lumbar 123
- latissimus dorsi 5–29, 41–5, 55–7, 63–81, 111–5, 123–7, 139, 181–5
- levator ani 107–9, 155–63, 169, 177–93, 199–207
- levator scapulae 45, 55–7
- longissimus 57, 183–5, 193
- longissimus thoracis 63–93
- longus colli 3, 31–3, 41, 50–2
- lumbar iliocostalis 163
- lumbar interspinal 161
- lumbar intertransversarii 181
- medial scalene 3, 45, 50
- multifidus 33–5, 39–45, 55, 181–3, 189, 203
- obturator 181
- obturator externus 107–9, 157–9, 165–7, 173–9, 191–9, 205–9
- obturator internus 103–9, 151–9, 163–7, 177–83, 193–7, 201, 205–7
- omohyoid 32–8, 47
- papillary of left ventricle 49
- pectineus 109, 157–9, 163–7, 171–5, 195–7, 205–9
- pectoralis 61, 115–7, 123
- pectoralis major 3–15, 19, 31–3, 40–8, 125–7
- pectoralis minor 3–15, 47–8
- piriformis 101–5, 137–9, 149–51, 155, 163–5, 183–5, 193, 201–3
- posterior papillary 43
- posterior scalene 3, 43–5, 50–2
- posterior serratus 39, 43–5, 57
- posterior serratus superior 35, 41
- psoas 85
- gutter 91
  - lateral 95
  - medial 95
  - medial groove 93, 97
- psoas major 73–97, 113–7, 123–5, 131–9, 163–7, 173–80, 195–6
- pubovaginalis 181
- pyramidalis 171, 209
- quadratus femoris 109, 157–9, 167, 181–3, 199, 201–3
- quadratus lumborum 73–91, 111–7, 125–7, 137–9, 163, 167, 179–83, 201–3
- rectus abdominis 27–35, 39–43, 63–6, 69–71, 75–9, 83–107, 113–29, 149–57, 161–71, 187–93
- rectus femoris 107–9, 151–9, 171–5
- rhomboïd 3–7
- rhomboïd major 9–17, 35, 39–45
- sartorius 101–7, 149–57, 173
- semimembranosus 167

## muscles

- semispinalis capitis 31–5, 39
- semispinalis cervicis 55
- semispinalis thoracis 33–5, 39
- semispileneus cervicis 41
- semispileneus thoracis 41–5
- semitendineus 193
- semitendinosus 181–3
- serratus anterior 3–7, 15–27, 49–52, 55, 129–39
- serratus posterior inferior 111–3, 127, 183
- spinalis 63–97, 185
- splenius cervicis 57
- splenius cervicis and capitis 31–5, 39–43
- sternocleidomastoid 3–5, 31–4, 40, 47–8
- sternohyoid 32–8, 47
- sternothyroid 3, 32–8, 47
- subclavius 5, 49–51
- subscapularis 5–17, 51–7
- supraspinatus 3, 7–9, 51–7
- tensor fasciae latae 103–9, 149–59, 171–5
- teres major 5–17, 57
- teres minor 13, 55–7
- thorax 129
- transversus abdominis 81–99, 111–3, 127–39, 149–53, 171–81, 195–6, 199
- transversus thoracis 111–7, 123–5
- transversospinales 57, 139, 183–5, 199
- trapezius 3–11, 15–25, 31–45, 51–7
- triceps 53–5
- triceps brachii 7
  - long head 7
- urethral sphincter 161, 207
- vastus intermedius 157, 177, 195–7
- vastus lateralis 157–9, 171–81, 195–203
- myocardium 23, 41
  - left ventricle 25
- myometrium 169

## N

## nerves

- anterior sacral 97
- axillary 51
- femoral 91, 101, 105–9, 115, 131, 135,

149, 153–9, 163–7, 171–9, 195, 205, 209

- inferior gluteal 185
- intercostal 111, 115
- internal obturator 149
- lateral femoral cutaneous 159, 163
- long thoracic 17–21
- lumbar V 93
- median 53
- obturator 151, 155, 179, 196–7
- phrenic 9–15, 21–5, 48
- posterior sacral I 97
- recurrent laryngeal 7–9, 13–5
- sacral 163, 185, 193, 201
- sacral II 99
- sacral III 99
- sciatic 107–9, 149–59, 167, 183, 203
- spinal 71, 189
- spinal (L5) 203
- spinal (T9) 57
- vagus 3–5, 9, 25–9
- nipple 61
  - glandular tissue 17
- notch
  - for round ligament 67–9

## O

- oblique fissure 45
- obturator canal 109
- obturator membrane 109
- omental bursa 67, 73
  - vestibule 71
- omentum
  - greater 67–9, 73–9, 83–91, 97, 115–25, 129
  - lesser 119, 129
- orbicular zone 197
- os ischii 165
- ostium cardiacum 63
- ostium uteri 161
- oval fossa 51
- ovary 165
  - left 149
  - right 149

## P

- palmate folds 169
- pancreas 67–73, 117–27

body 131–3  
 head 132, 135  
 tail 137  
 pancreatic duct 147  
 paracolic gutter  
   left 63–91, 95–7  
   right 87–95  
 paravesical fossa 101  
 pedicle 121  
 pelvis  
   female 148–185  
     axial 148–159  
     coronal 170–185  
     sagittal 160–9  
   male  
     coronal 194–203  
     sagittal 186–191  
 penis  
   deep dorsal vein 209  
   dorsal vein 191  
   fundiform ligament 205  
   root 109  
   suspensory ligament 107–9, 187, 205, 209  
 pericardium 20–6, 30, 34–6, 39, 42–4, 50–2  
   transverse sinus 37–9  
 perineal body 169, 187  
 phrenicomedial recess 47–9, 53  
 pleura  
   parietal, costal part 129  
 portio 161, 169  
 presacral space 149, 161, 187–91  
 promontorium 119, 187  
 prostate 107–9  
   anterior fibromuscular stroma 187–9, 205–7  
   anterior portion 205–7  
   axial 204–7  
   capsule 205–7  
   central portion 205  
   central zone 187–9, 197–9, 207  
   isthmus 205  
   peripheral zone 187–91, 197–9, 205–7  
   transition zone 197, 205  
 pubic symphysis 109, 159, 171, 205, 209  
 pubis 107, 161–3, 169–75, 187–97, 205–9  
   body 159, 167

body 167  
   superior ramus 109, 157, 165  
 pulmonary trunk 15–7, 38, 49–51  
   valve 41, 47

## R

rectouterine pouch (of Douglas) 153, 161, 169  
 recto-vesical pouch 101–5, 187–91  
 rectum 99–109, 139, 151–61, 169, 183, 187–91, 203  
   ampulla 107, 185, 201  
   wall 199  
 renal calices 75  
 renal cortex 73, 77–9  
 renal fascia 69–75, 81  
 renal hilum 77–81  
 renal pelvis 77–85  
 renal pyramids 71–85  
 renal sinus 71–5, 81–85  
 retropubic space 107–9, 187–91  
 ribs 3–31, 47–57, 123, 127  
   costal cartilage 23–5, 43  
   eleventh 135, 139, 180  
   fifth 49  
   first 3–7, 47  
   ninth 57  
   second 5–7  
   seventh 43, 53, 129–31, 137  
   sixth 45–7, 51  
   tenth 55  
   third 7, 43, 57  
 root of mesentery 79

## S

sacral canal 99–101  
 sacral plexus 97, 101, 201  
 sacroiliac joint 99, 137–9, 180–5, 199–203  
 sacrum 97–9, 103, 119, 137–9, 149–51, 161–6, 180–3, 189–91, 199, 203  
   ala 125, 137, 199–201  
   lateral part 185, 193  
   (S1) 187, 201  
   (S2) 185  
 scapula 5–21, 45, 50, 57  
   spine 3–11, 55

scrotal cavity 209  
 left 209  
 scrotum  
 septum 209  
 wall 209  
 seminal colliculus 187, 205  
 seminal gland 187–193, 199–203, 206  
 septa testis 209  
 septum  
 interventricular 23, 45, 49  
 of scrotum 209  
 shoulder joint 55  
 articular cavity 51, 55  
 sinus  
 coronary 23–5  
 of pericardium 35  
 sinus subphrenicomedialastinalis 51  
 spermatic cord 107–9  
 spermatic fascia 209  
 spinal cord 3–7, 11–29, 35–7, 51–7, 119,  
 161  
 thoracic part 9  
 spinal dura 180, 201  
 spine of scapula 7–11, 55  
 spinous process 23, 37, 55–7, 63, 119,  
 161, 185–9  
 (T6) 35  
 spleen 29, 49–57, 63–71, 125–7, 133–9  
 hilum 67  
 sternoclavicular joint 31–2, 38, 47  
 sternum 15–21, 31–2, 47, 61, 119–21  
 body 13, 23, 36  
 manubrium 7–11, 34–8, 40  
 xiphoid process 35–7  
 stomach 29, 43–5, 63–9, 119–21, 127–9,  
 137–9  
 antrum 131–2  
 body 131  
 cardia 135  
 cardiac part 123  
 fundus 123–5, 131–5  
 pylorus 135  
 subphrenic recess 71–3  
 right 63–9  
 sulcus  
 coronary 21  
 suprarenal gland 115, 123, 137–9  
 left 67–71  
 sympathetic trunk 5–7, 11, 23–9, 137  
 symphysis 173  
 pubis 205

## T

tendons 157, 175  
 common 157, 175  
 biceps femoris muscle 157  
 rectus femoris muscle 175  
 semimembranosus muscle 157  
 semitendinosus muscle 157  
 vastus lateralis muscle 175  
 testes 187–93  
 medistinum 209  
 sagittal 208–9  
 thoracic duct 11–29, 53, 65–7  
 thoracolumbar fascia 63, 85–9, 119  
 thorax 2–57  
 axial 2–29  
 coronal 46–57  
 muscles 129  
 sagittal 30–45  
 thymus 7, 11  
 thyroid gland 3–5, 36–40, 49  
 trachea 3–11, 33, 36, 47–52  
 bifurcation 37  
 transverse process 21, 117,  
 163  
 lumbar vertebra  
 (L3) 123  
 (L4) 179  
 transverse sinus  
 pericardium 39  
 trigonum lumbale 89  
 trochanter  
 greater (magnus) 107, 155–7, 177–81,  
 195–203  
 lesser 179, 199  
 tunica albuginea 209

## U

umbilicus 119  
 ureter 87–105, 115, 123, 135–7, 149–57,  
 175–9, 197–201, 207  
 left 83–5  
 right 83–5  
 urethra 107–9, 159–61, 187–91, 205–9  
 urethra, internal orifice 161, 187  
 urinary bladder 101–5, 131–7, 151–63,  
 169–79, 189–201, 205–6  
 uterine tube  
 infundibulum 181  
 uterine venous plexus 163

uterus 149  
uterus 169  
  body 163, 169  
  cavity 151, 163, 169, 179  
  cavum 177  
  cervix 151, 181  
  fundus 151, 163  
  isthmus 163  
  junctional zone 169  
  round ligament 151, 163–5  
  vaginal part 153, 183

## V

vagal trunk 53, 137  
  posterior 29  
vagina 155–61, 181  
  anterior wall 161  
  fornix 181  
  posterior wall 161, 183  
  wall 169  
valve  
  ileocecal 133  
  of pulmonary trunk 41, 47  
veins  
  ascending lumbar 75, 95, 135, 179,  
    197  
  axillary 7–9, 51  
  azygos 11, 17–35, 51–2,  
    65–7  
  basilic 53  
  brachiocephalic 7  
    dextra 9  
    sinistra 9  
  common iliac 97–9, 117–21, 133, 161–  
    3, 189, 193–7  
  deep dorsal of penis 209  
  dorsal of penis 191  
  epigastric 95, 99  
  external iliac 99–105, 131–3, 149–53,  
    165, 173–5  
  femoral 109, 155–9, 167, 171–3, 195,  
    205, 209  
  great saphenous 109, 165  
  hemiazzygos 67  
  hepatic 31–3, 117, 134–6  
  hepatic portal 65, 69, 115, 119–21,  
    131–4  
  left branch 117, 134  
  ileal 79–85, 89, 93–97,  
    145  
  inferior epigastric 97, 103, 149  
  inferior gastric 101  
  inferior gluteal 105, 185  
  inferior mesenteric 75, 123, 133, 175  
  inferior pancreaticoduodenal 75  
  inferior right pulmonary  
    59  
  intercostal 111, 115  
  internal iliac 99–101, 135, 149, 153,  
    163, 177–81, 186, 193, 199–203  
  internal jugular 3–5  
  internal pudendal 199  
  internal thoracic 13–25, 47  
  jejunal 79–89, 117, 131, 154, 160  
  jugular 31–2, 49  
  lateral circumflex 109  
  lateral sacral 193  
  left brachiocephalic 34–40  
  left colic 67, 93–7  
  left common iliac 93–5  
  left coronary 21  
  left gastroepiploic 131  
  left inferior pulmonary 43–5, 59  
  left internal jugular 40  
  left pulmonary 17–21, 43, 53–5  
  left renal 73–7, 121, 135  
  left superior pulmonary 59  
    anterior branch 59  
    apicoposterior branch 59  
    lingular branch 59  
  left testicular 81, 85–7  
  lumbar 77–9, 177–8  
  middle colic 93  
  obturator 165, 195–9  
  ovarian 123, 149, 163  
  portal 144–5  
    left branch 145  
    right branch 145  
  pulmonary 31, 41, 51  
  renal 79–81, 115–7, 123  
  right brachiocephalic 11, 48  
  right colic 87–91, 95  
  right common iliac 93  
  right hepatic 29, 135, 145  
    right branch 136  
  right lumbar 81  
  right pulmonary 53–7  
    middle lobe branch 59  
    medial part 59  
  right renal 75  
  right superior pulmonary  
    59

- veins, right
    - anterior branch 59
    - sigmoid 181–3
    - splenic 67–71, 123–7, 133–7, 144–5
    - subclavian 5, 43–8
    - superficial epigastric 105–9
    - superior gluteal 139, 149, 165–7, 177, 181–5, 193, 203
    - superior mesenteric 73–89, 119, 131, 145, 173
    - superior rectal 149, 197
    - superior right pulmonary 59
      - apical branch 59
      - posterior branch 59
    - testicular 89–93
      - sinister 83
    - uterine 181
  - vena cava
    - inferior 25–7, 31–3, 51–3, 63–6, 69–85, 89–91, 117–9, 135–6, 160, 175
    - left 29
    - superior 13–21, 31–2, 48, 51
  - venous plexus
    - anterior, of Santorini 205
    - lateral 205–7
    - prostatic 187–91, 197, 205–7
    - rectal 183
    - uterine 163, 181–3
    - vesical 163, 187–91, 199–201
  - ventricle
    - left 19, 23, 38, 41–53, 59, 131–7
      - myocardium 25
      - papillary muscle 49
    - right 23–5, 31–49, 129–134
  - ventriculus sinister 133
  - vertebrae 31–3
    - lumbar 81–91
      - (L1) 39
      - (L3) 121, 137, 179
      - (L4) 119, 135, 160, 177, 195
      - (L5) 93–5, 183, 187–91, 197, 203
    - transverse process 89
    - thoracic 3–21, 25–9, 37, 41, 63–79, 117
      - (T9) 35
      - (T10) 55, 119
      - (T12) 139
  - vertebral arch 3, 63, 139, 183
  - vertebral body 39
    - inferior surface 39
    - superior surface 39
  - vertebral canal 63–97, 139, 180–9
  - vesicle
    - seminal 101–5
  - vesicouterine pouch 161–9
  - vessels
    - pulmonary 58–59
  - vestibule of omental bursa 71
- X**
- xiphoid process 25
    - sternum 35–7
- Z**
- zygapophysial joint 121, 183, 201
  - zygapophysis 201–3