

UC-NRLF



B 4 096 773


Laboratory Outline
of
Neurology

Herrick & Crosby

Second Edition

Courtney G. Clegg
1942 El Dorado Ave.
Berkeley, Calif.

MEDICAL SCHOOL
LIBRARY



Gift of
Courtney G. Clegg


INTERNET ARCHIVE

Digitized for Microsoft Corporation
by the Internet Archive in 2007.

From University of California Libraries.

May be used for non-commercial, personal, research,
or educational purposes, or any fair use.

May not be indexed in a commercial service.



A LABORATORY OUTLINE
of
NEUROLOGY

By

C. JUDSON HERRICK, Ph. D.

Professor of Neurology in the University of Chicago

and

ELIZABETH C. CROSBY, Ph. D.

Superintendent of Union Schools, Petersburg, Michigan

SECOND EDITION, RESET

QM451
H565
1920

PHILADELPHIA AND LONDON

W. B. SAUNDERS COMPANY

1920

R

Copyright, 1918, by W. B. Saunders Company, Revised, Entirely
Reset, Reprinted, and Recopyrighted, August, 1920

Copyright, 1920, by W. B. Saunders Company



PRINTED IN AMERICA

PRESS OF
W. B. SAUNDERS COMPANY
PHILADELPHIA

PREFACE TO THE SECOND EDITION

THE laboratory course in neurology which is here outlined has grown up in the University of Chicago during the past twenty years. Many teachers have participated in this work and all of these have contributed something of value to the procedure now in use. Acknowledgments cannot be made here to all from whom valuable help has been received; but especial mention should be made of the initial program laid out in 1900 by Doctors Barker and Kyes when they were suddenly confronted with the problem of teaching the anatomy of the brain to a very large class of medical students with practically no equipment and a very limited amount of anatomical material (see the paper by Barker and Kyes cited in the appended Bibliography). The large measure of success which they attained should encourage other teachers whose laboratory equipment is inadequate.

Later Doctors Donaldson and Hardesty elaborated this course, and when the direction of the work was assumed by the senior author in 1907 he received valuable assistance from Doctor Elizabeth H. Dunn in reorganizing the course into the form out of which the present Outline has grown. Professor G. W. Bartelmez has also contributed freely from his own extensive experience. In the year 1915 the Outline was thoroughly revised and privately printed by the authors. In the present work it has been again revised and recast in more general form, which it is hoped may be found more widely useful.

The fundamental purpose of the procedure here outlined is to assist the student as early in his course as possible to formulate his knowledge of the nervous system in terms of the functional significance of the parts. Free use has been made of the methods of functional analysis of the central nervous system which have been developed, chiefly in American laboratories, under the stimulating guidance of researches upon the functional composition of the peripheral nerves; and the experience

in this and numerous other laboratories has demonstrated that a thoroughgoing application of these methods is of the utmost value to the beginning student (cf. Johnston, '06 and '08). In the senior author's Introduction to Neurology ('18) the materials of neurology are organized from this standpoint as an aid in the use of the larger text-books and atlases.

The course in neurology here outlined can be covered by an undergraduate class of properly prepared students in about one-half of a school year, devoting one or two hours each week to lecture and recitation and from six to eight hours to the laboratory. Since, however, many colleges cannot devote as much time as this to the nervous system, the Outline has been so arranged that a selection can be made of those topics for which time and materials are provided. Students of zoölogy and vertebrate comparative anatomy will naturally devote more time to the earlier parts of the Outline (sections 3 to 60) and may omit all of the work on the microscopic structure of the mammalian nervous system.

For several years past there has been offered at the University of Chicago a twelve-weeks course in neurology primarily for students of psychology and education with meager biological preparation. These students make a rather thorough dissection of the nervous system of the dogfish, thus making up in some measure their deficiencies in knowledge of general vertebrate anatomy. This is followed by dissection of the brain of the sheep, with special reference to some of the more important conduction pathways and functional centers, such as the auditory, optic and olfactory tracts, pyramidal tract, cortical localization, etc. Gross human material is freely used for demonstration. Microscopic sections are studied, illustrating the nervous elements, structure of the sense organs, spinal cord, cerebral and cerebellar cortex, and if time permits a few of the conduction pathways within the brain stem.

The course in neurology for medical students at the University of Chicago follows the general histology and a part, at least, of the gross anatomy, and it is, in turn, followed by a laboratory course on the physiology of the nervous system. In this course, which occupies twelve weeks, the students

do most of the work here outlined for the dissection of the dogfish head and sheep and human brains and for the study of the microscopic sections as directed, the sections being supplied from the departmental loan collection. The "optional dissections" of the human brain (sections 102 to 111, 141 to 152) are omitted, or are done by some students in extra time or in a more advanced course.

The second edition has been entirely reset and the references to literature brought up to date. Some other minor changes have been made, in particular new blocks for Figures 5A and 5B, which have been revised by Norris and Hughes in conformity with the latest results of their investigations. Our especial thanks are due to them for their care in this matter and to numerous others whose kindly criticisms have been very helpful.

THE AUTHORS.

CHICAGO, ILL.,
November, 1919.

ANALYSIS OF CONTENTS

| | PAGE |
|---|------|
| I. LIST OF RECOMMENDED COURSES (COURSES I TO VII)..... | 11 |
| II. GENERAL LABORATORY DIRECTIONS (SECTIONS 1, 2)..... | 13 |
| III. DISSECTION OF THE SHARK (SECTIONS 3-29)..... | 16 |
| IV. THE MAMMALIAN NERVOUS SYSTEM..... | 39 |
| 1. Introductory Topics (Sections 30-40)..... | 39 |
| 2. External Anatomy (Sections 41-60)..... | 46 |
| 3. General Directions for Microscopic Material (Sections 61, 62)..... | 59 |
| 4. Internal Structure of the Spinal Cord (Sections 63-68)... | 63 |
| 5. Sympathetic Nervous System (Section 69)..... | 67 |
| 6. The Medulla Oblongata (Sections 70-95)..... | 67 |
| 7. Structure and Connections of the Cerebellum (Sections 96-100)..... | 82 |
| 8. Summary of Spinal, Bulbar, and Cerebellar Tracts and Centers (Section 101)..... | 89 |
| 9. Optional Dissections of the Brain Stem (Sections 102-111) | 93 |
| 10. The Cerebrum (Sections 112-140)..... | 99 |
| 11. Optional Dissections of the Cerebrum (Sections 141-151). | 114 |
| 12. Recapitulation of Conduction Paths (Sections 152, 153).. | 118 |
| V. LITERATURE..... | 119 |

LABORATORY OUTLINE OF NEUROLOGY

I. LIST OF RECOMMENDED COURSES

THE materials of this Outline have been so arranged that the student may select any one of several methods of procedure depending upon the purposes of the study and the time and material at command. The following courses are suggested.

COURSE I. *Comparative anatomy of the vertebrate nervous system. Gross anatomy.*—Begin with the dissection of the dogfish (sections 1 to 29). Other inframammalian types may be dissected according to the same general plan. Johnston's *Nervous System of Vertebrates* ('06) should be read as a guide in these studies; also the comparative anatomies of Kingsley ('17), Wiedersheim ('07), and others. For the mammalian nervous system follow the procedure outlined beyond for the sheep (sections 30 to 59, 69 to 72, 81, 93, 95, 96(a), 100, 112 to 117, 119 to 139). Other mammalian brains may be dissected in the same way.

COURSE II. *Comparative anatomy of the vertebrate nervous system. Microscopic anatomy.*—After the completion of the gross study of one or more vertebrate types as directed in the preceding paragraph, the microscopic study of the same types may be taken up. Directions for the microscopic study of the brains of Ichthyopsida and Sauropsida are not included in this Outline, and indeed this study is tedious and rather difficult for the beginner except under skilled personal direction. Suggestions for microscopic studies of these types are given in Johnston's book ('06). For the microscopic study of the brains of the rabbit and cat the atlases of Winkler and Potter ('11 and '14) are invaluable.

COURSE III. *Gross anatomy of the mammalian brain. Short course.*—For a short course, follow the procedure directed for Course I, omitting the dogfish dissection. Use the brain of the

sheep, beef, dog, or cat as directed in sections 30 to 59, 69 to 72, 81, 93, 95, 96(a), 100, 112 to 117, 119 to 139.

COURSE IV. *Gross anatomy of the mammalian brain. Longer course.*—For a longer course, after the completion of Course III, additional vertebrate types may be used, and the human brain may be thoroughly dissected as directed in sections 102 to 111, 141 to 152.

COURSE V. *Gross anatomy of the human brain.*—Follow through on the human brain the directions given for the brain of the sheep in sections 30 to 59, 69 to 72, 81, 83, 95, 96(a), 100, 112 to 117, 119 to 139. For a more extensive course, add on a second specimen the "optional dissections," sections 102 to 111, 141 to 152.

COURSE VI. *Gross and microscopic anatomy of the human brain.*—If it is desired to make a thorough study of the human brain only, follow the directions given in sections 30 to 153, with or without the "optional dissections" (sections 102 to 111, 141 to 152), using human material throughout.

COURSE VII. *The course for medical students* at the University of Chicago follows the Outline substantially as given in the following pages, omitting all of the "optional dissections" (sections 102 to 111, 141 to 152) and a few other sections, the details varying somewhat from year to year.

II. GENERAL LABORATORY DIRECTIONS

1. The laboratory course here outlined includes the dissection of the nervous systems of several vertebrate types, including man, and the microscopic study of selected portions of the human brain and sense organs. If microscopic preparations of the human nervous system are not available, those from other mammals will answer very well for most purposes. Each student should provide himself with scalpels, scissors, forceps, drawing paper and pencils and one or two orange-wood or bone manicure sticks for blunt dissection and teasing of brain tissue. Compound microscopes must be provided. A simple magnifying lens is also necessary for low-power examination of microscopic sections. (For the requirements of this course the eyepiece of the compound microscope makes a satisfactory substitute for a dissecting lens. Hold the slide to the light and examine it through the inverted ocular.)

2. The point of view from which this Outline has been prepared is the same as that of the senior author's Introduction to Neurology (Philadelphia, 1918), and it is assumed that this book is available for study throughout the course, frequent references being made to it in lieu of full descriptions in the Outline. The first seven chapters of this work should be read early in the course to give the necessary background for the laboratory work. The illustrations in Burkholder's Anatomy of the Brain (second edition, Chicago, 1912) will be found very helpful in the study of the brain of the sheep. Other reference books will be cited throughout the text. The titles of these works are assembled in the Bibliography at the end and the works are referred to in the text simply by the author's name followed by the date of publication. Constant use must be made of standard text-books and atlases of the gross and microscopic anatomy of the human nervous system. The following list includes some of the works of special value for this purpose:

- Bailey and Miller, Embryology ('16).
 Bailey, Histology, 5th edition ('16).
 Barker, Nervous System ('01).
 Bruce, Atlases ('92 and '01).
 Cunningham, Anatomy, Revised 4th edition ('15).
 Edinger, Nervöse Zentralorgane, 8th edition, Bd. I ('11).
 Flatau, Atlas ('99).
 Van Gehuchten, Système Nerveux, 4th edition ('06).
 Gray, Anatomy ('18).
 Herrick, Introduction to Neurology ('18).
 Howell, Physiology, 7th edition ('18).
 Johnston, Nervous System ('06).
 Luciani, Physiology ('15).
 Marburg, Atlas ('04).
 Morris, Anatomy, 5th edition, part III ('14).
 Obersteiner, Nervöse Zentralorgane, 5th edition ('12).
 Piersol, Anatomy ('16).
 Quain, Anatomy, 11th edition ('09).
 Ramón y Cajal, Système Nerveux ('09-'11).
 Rauber-Kopsch, Lehrbuch ('12).
 Reference Handbook of the Medical Sciences, 3d edition, articles on
 the Brain, Cranial Nerves, Ear, End-organs, Spinal Cord, and others.
 Sabin, Atlas ('01).
 Sobotta ('11).
 Spalteholz, Atlas ('09).
 Starling, Physiology ('15).
 Stewart, Physiology ('18).
 Toldt, Atlas ('04).
 Villiger, Brain and Spinal Cord ('12).
 Winkler and Potter, Atlases ('11 and '14).

On technical methods for the study of the nervous system consult the following works:

- Guyer, Animal Micrology, 2d edition ('17).
 Hardesty, Neurological Technique ('02).
 Hardesty, Laboratory Guide for Histology ('08).
 Lee, Arthur Bolles, Microtomist's Vade-Mecum, 7th edition ('13).

On the preparation of laboratory drawings and scientific illustrations for publication see—

- Hardesty, Laboratory Guide for Histology, pp. 1-30 ('08).
 Guyer, Animal Micrology, 2d edition, pp. 159-172 ('17).

A few of the leading neurological journals are listed below. Neurological articles are found also in other journals of anatomy, physiology, and medicine:

- Annali di Nevrologia, Naples.
 Brain, London.
 Folia Neurobiologica, Haarlem.

Journal de Neurologie, Paris (chiefly clinical neurology).
Journal für Psychologie und Neurologie, Leipzig.
Journal of Comparative Neurology, Philadelphia.
Le Névraxe, Louvain (died in the martyrdom of Belgium).
Monatsschrift für Psychiatrie und Neurologie, Berlin.
Neurologisches Centralblatt, Leipzig.

The neurological literature for each year beginning with 1897 is listed and abstracts of the more important articles are given in the Jahresbericht über die Leistungen und Fortschritte auf dem Gebiete der Neurologie und Psychiatrie (Berlin). Numerous other periodical neurological bibliographies are given in the Index Medicus (Washington), Index Catalogue of the Library of the Surgeon General's Office (Washington), Anatomischer Anzeiger (Jena), Centralblatt für Physiologie (Leipzig), and elsewhere.

In this Outline the student's attention is directed especially to those neurological facts which are well established and which are of special significance for the practical understanding of the working of the nervous system in health and disease. Many equally interesting features are not referred to at all; and it should especially be borne in mind that the topics selected are for clearness presented in as schematic a way as possible. The actual relations are in all cases far more complex, and many of these details are as yet imperfectly understood. The student is urged to read, as far as time permits, the larger manuals of neurology and the special articles in the research journals in order to get the simpler and more elementary features of the laboratory study in their proper perspective. This reading should be done topically. As each section of the Outline is studied in the laboratory, the topic there under consideration should be read up as completely as possible from both the anatomical and the physiological standpoints. After some practice in this sort of topical reading, with the aid of the indexes of the works consulted, a large number of books can be abstracted for each topic with small expenditure of time.

III. DISSECTION OF THE SHARK

3. This Outline has been prepared for use with either the smooth dogfish, *Mustelus canis*, or the spiny dogfish, *Squalus acanthias*. It may be adapted with very slight modifications to the skate or any other elasmobranch. The brains and peripheral nerves of the different sharks, skates, and rays exhibit minor differences; but these are not significant for the purposes of this study.

4. *Literature*.—Laboratory directions for the general dissection of the dogfish are given by Kingsley ('07), Marshall and Hurst ('99), and for the allied skate by T. J. Parker ('00). Good figures of the brain of the shark are found in Parker and Haswell's *Zoölogy* ('10, vol. 2, pp. 158-160), in Wiedersheim's *Comparative Anatomy* ('07, p. 209) and in Kingsley's *Comparative Anatomy* ('17, p. 185).

On the structure and functions of the sense organs of fishes the following works may be consulted: Bateson ('90); Berger ('82), Ewart ('93); Garman ('88), Herrick ('03, '03a, '08); Johnson ('17); Lee ('98); Norris and Hughes ('19); Parker and others ('03-'18); Peabody ('97); Sheldon ('09b, '11).

5. The chief *purpose* of the dissection of the fish, as outlined in the following sections, is to secure a clear understanding of the relations between the brain and the other organs of the body. In the fish the brain shows a series of enlargements each of which is directly connected by means of nerves with a particular peripheral organ: the olfactory bulbs with the nose, the optic lobes with the eyes, the acoustic area and cerebellum with the internal ear, the visceral lobe with taste buds, and so on (see Fig. 2 and Herrick, '18, Chap. VII). In the medulla oblongata of this fish there is a series of longitudinal ridges, each of which is connected with a specific type of peripheral end-organs: dorsally is the somatic sensory column, ventrally the somatic motor column, and between these the visceral sensory and motor columns. Here are located the cerebral centers of important reflex systems (see Figs. 2 and 6, Section

23, and Herrick, '18, Fig. 68). The somatic sensory and motor systems enable the animal to react appropriately to external stimuli; the visceral sensory and motor systems effect the internal adjustments of the body, such as swallowing, respiration, digestion, etc.

The fish brain can be clearly seen to owe its form to its physiological connections with peripheral organs. We shall see that similar functional factors are present in shaping the form of the human brain, though much obscured by the elaboration of higher correlation centers in the thalamus, cerebral cortex, etc. In most respects there are instructive resemblances between the adult fish and the human embryo at an early age when gill pouches are present (see Herrick, '18, Figs. 68, 69 and 70).

6. Examine carefully the external form of the head, noting particularly the disposition of the *sense organs and apertures*—mouth, nostrils, gills, spiracles (vestigial gills), endolymphatic ducts (two minute apertures near the midline between the spiracles, by which the internal ears communicate with the exterior). Notice numerous small pores distributed in the skin. These are the openings of subcutaneous sense organs, which are found only in fishes and amphibians and are termed lateral line organs. There are two series of these, the ampullæ of Lorenzini and the lateral line canals. The former are arranged irregularly; the latter comprise four tubes embedded in the deep layer of the skin: supra-orbital, infra-orbital, hyomandibular lines, and the lateral line of the trunk (see Fig. 4). On the lateral line canals see further in Section 18.

7. First open the *pericardial chamber* by a medial-ventral incision from the lower end of the specimen forward to the lower jaw. Note the two-chambered heart, the ventral aorta, and the branches of the latter to the gills (aortic arches). Now complete the ventral incision dorsalward through the lower jaw and floor of the pharynx, opening up the entire length of the mouth cavity back to the esophagus, and spread laterally the ventral walls of the pharynx to expose the inner surfaces of the gills. Next dissect off the skin of the right side of the specimen in the gill region, in each gill noting the cartilaginous gill arch, the feathery gills, the firm gill rakers, the mode of attachment of the gills to the skull, and the clefts between the gills.

Examine the *gills* and determine how they work as organs of respiration, noting the direction of flow of water through them and the mechanism by which this flow is maintained.

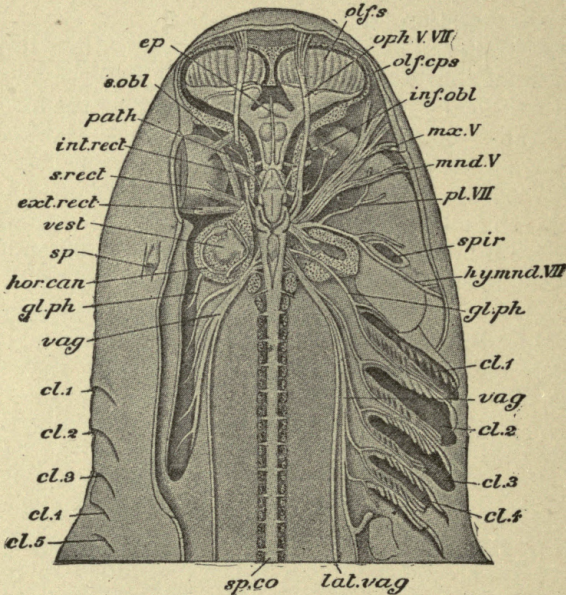


FIG. 1.—Dissection of the brain and cranial nerves of the dogfish, *Scyllium catulus*. The right eye has been removed. The cut surfaces of the cartilaginous skull and spinal column are dotted. *cl.1-cl.5*, Branchial (gill) clefts; *ep.*, epiphysis; *ext.rect.*, external rectus muscle of the eyeball; *gl.ph.*, glossopharyngeal nerve; *hor.can.*, horizontal semicircular canal; *hy.mnd.VII*, hyomandibular branch of the facial nerve; *inf.obl.*, inferior oblique muscle; *int.rect.*, internal rectus muscle; *lat.vag.*, lateral line branch of the vagus nerve; *mand.V*, mandibular branch of the trigeminal nerve; *mx.V*, maxillary branch of trigeminal; *olf.cps.*, olfactory capsule; *olf.s.*, olfactory sac; *oph.V.VII*, superficial ophthalmic branches of the trigeminal and facial nerves; *path.*, trochlear nerve (patheticus); *pl.VII*, palatine branch of facial nerve; *s.obl.*, superior oblique muscle; *sp.*, spiracle; *sp.co.*, spinal cord; *spir.*, spiracle; *s.rect.*, superior rectus muscle; *vag.*, vagus nerve; *vest.*, vestibule. (After Marshall and Hurst, from Parker and Haswell's Zoölogy.)

8. Cut through the skin in the middorsal line and reflect it on the right side as a lateral flap, leaving this flap attached at the lateral border of the head. Locate again the pores of the endo-

lymphatic ducts and avoid injury to these ducts. Now remove the cartilaginous roof of the brain of the right side, beginning at the opening which you will find already made by a cut between the eyes and shaving off the cartilage in thin slices.

9. The *internal ear* lies embedded within the cartilage behind the eyes close to the medulla oblongata under the pores of the endolymphatic ducts (see Fig. 1). The semicircular canals of the ear can be seen through the translucent cartilage. The three canals should be exposed by dissecting away the surrounding cartilage, leaving the membranous canals in place. Demonstrate the ampullæ of the semicircular canals and the connections of each canal with the utriculosaccular chamber. Note the planes in which the canals lie in relation both to each other and to the long axis of the body (cf. the human relations, Herrick, '18, Fig. 85).

Draw the dissection of the membranous labyrinth at this stage of the dissection without removing it from the head. The shape of the utriculosaccular chamber can best be seen while it is still in place, for its delicate walls collapse when removed. The semicircular canals open freely into the dorsal part of the common utriculosaccular chamber, which accordingly corresponds with the human utriculus. In well preserved specimens the recessus utriculi with its sense organ (macula utriculi) may be seen lying ventrally of the superior and horizontal ampullæ. The ventral part of the common chamber corresponds with the human sacculus and in life contains a large ear stone or otolith, which is usually disintegrated in the formalized specimens. In the wall of the sacculus there is a large sensory area, the macula sacculi. There is no cochlea; but from the sacculus a small pouch extends caudo-ventralward. This is the lagena, which contains a sensory area, the macula lagenæ, and represents the rudiment from which the cochlea of higher animals has been developed. Through the translucent walls of the membranous labyrinth the whitish sensory areas can be seen (maculæ and cristæ), and by a little further dissection the branches of the VIII nerve to all of these sensory areas can be demonstrated. The entire membranous labyrinth may now be removed. Compare the internal ear of the dogfish with that of man (see diagram in Herrick, '18, Fig. 91).

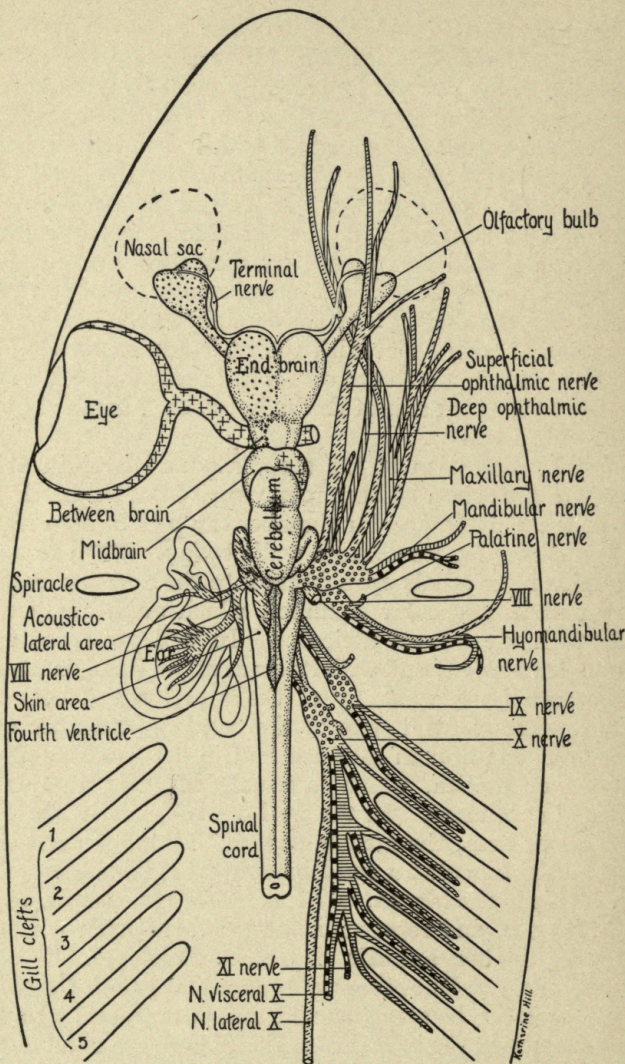
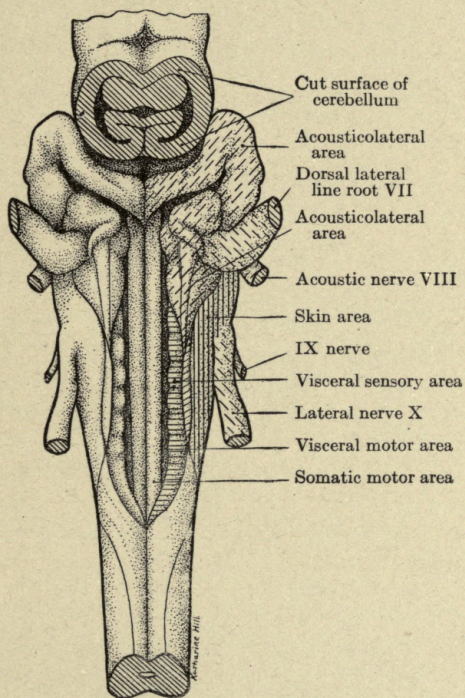


FIG. 2.—Diagram of brain and cranial nerves of the dogfish, *Squalus acanthias*, from above. Natural size. Olfactory part of the brain is marked with coarse dots, the visual apparatus with crosses, the acusticolateral nerves and centers with broken oblique lines, the visceral sensory nerves with horizontal lines, the general cutaneous nerves with vertical lines, and the visceral motor nerves with black and white rectangles.

PLATE I



The medulla oblongata of *Squalus acanthias* seen from above after removal of membranous roof of fourth ventricle; $\times 2$. On the right side the nerve roots and functional areas of the brain are designated by the same conventional markings as in Figs. 2 and 3.

Very complete descriptions and figures of the ears of different species of fishes, including the dogfish, are given by Retzius ('81). On the functions of the ears of fishes, see the papers by F. S. Lee and G. H. Parker cited in the Bibliography. For the mammalian ear see Section 80.

10. Remove the cartilaginous walls of the cranium down to the foramina of the cranial nerves. This can best be done by cutting the cartilage away in thin slices with a sharp knife. The foramen of the slender IV nerve will be first exposed, lying medially of the eyeball and far dorsally. The other foramina lie farther ventrally.

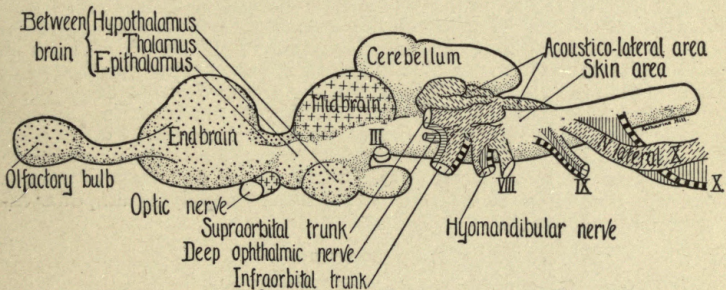


FIG. 3.—The brain of *Squalus acanthias* seen from left side. Designation of nerve roots and brain centers the same as in Fig. 2.

11. Note the membranes (*meninges*) of the brain. The dogfish brain is closely enveloped by a single membrane. Between this and the perichondrium which lines the cartilaginous cranium is a very loose arachnoidal tissue which is not, however, condensed into a definite arachnoid membrane, as in mammals (cf. Section 45).

12. Carefully dissect out the *cranial nerves* and *eye-muscles* of the right side. The optic nerve, eye-muscles, and eye-muscle nerves (III, IV, and VI pairs) are arranged practically as in the human body. Consult your anatomies for names and descriptions and determine the action of each of the eye-muscles. Notice the long ciliary nerves distributed to the eyeball and trace their connections, if possible, with branches of the third and fifth nerves.

DESCRIPTION OF FIGURES 4, 5A, AND 5B

These drawings illustrating the arrangements of the cranial nerve components and ganglia of the dogfish were prepared for us by Dr. H. W. Norris and Miss S. P. Hughes, of Grinnell, Iowa. They are based on an investigation of the cranial nerve components of *Squalus acanthias* by reconstruction from serial microscopic sections. The material used is advanced embryos ("pup" stage), and is probably in all essential respects similar to the adult form. The structures are drawn as seen in flat projection on the median plane and all details shown are drawn true to scale except as noted. The completed research upon which these drawings are based has been published in the *Journal of Comparative Neurology*, vol. xxxi, 1920, pp. 293-402, under the title "The Cranial, Occipital, and Anterior Spinal Nerves of the Dogfish, *Squalus acanthias*." (This is the article referred to in the text and Bibliography as Norris and Hughes, 1919.)

FIG. 4.—Diagram of the lateral line canals and their nerves of *Squalus acanthias*, seen from the side. The ventral portion of the infra-orbital canal is represented as swung ventro-laterally out of its true relation to the other structures. The lateral line canals and their nerves are drawn as they are developed in the advanced embryo ("pup" stage). The exact number of terminal branches of the lateral line nerves supplying the canals is indicated in the drawing. The dots at the ends of the branches indicate the points where they enter the canals. They do not represent separate sense organs within the canals (neuromasts), such as are found in most other fishes. For the form of the sensory epithelium in these canals, see the figures given by Johnson ('17). The ampullæ of Lorenzini are not indicated, but a few of the large nerve trunks supplying ampullæ exclusively are shown (a).

ABBREVIATIONS

- a*, large nerve branches supplying ampullæ of Lorenzini only.
buc. VII, ramus buccalis VII, supplying the greater part of the infra-orbital canal.
chmd., canalis hyomandibularis, innervated by ramus mandibularis externus VII.
cinfro., canalis infra-orbitalis, innervated by rami buccalis VII and oticus VII.
clat., canalis lateralis (main canal of the trunk), innervated by rami supratemporalis X, dorsalis X, and lateralis X.
cmd., canalis mandibularis, innervated by ramus mandibularis externus VII.
cspro., canalis supra-orbitalis, innervated by ramus ophthalmicus superficialis VII.
cspt., canalis supratemporalis (commissural), innervated by ramus supratemporalis X.
ct., canalis temporalis (anterior end of main lateral canal), innervated by ramus supratemporalis IX.
dors. X, ramus dorsalis X, supplying about four end-branches to the main lateral canal of the trunk.
lat. X, ramus lateralis X (main lateral line nerve of the trunk), supplying the greater part of the lateral canal of the trunk.
mde. VII, ramus mandibularis externus VII, supplying the hyomandibular and mandibular canals.
os. VII, ramus ophthalmicus superficialis VII, supplying the supra-orbital canal.
ot. VII, ramus oticus VII, supplying about six end-branches to the posterior end of the infra-orbital canal.
spt. IX, ramus supratemporalis IX, supplying three end-branches in the temporal canal.
spt. X, ramus supratemporalis X, supplying the supratemporal canal and about six end-branches in the anterior part of the main lateral canal.
VIII, nervus acusticus.

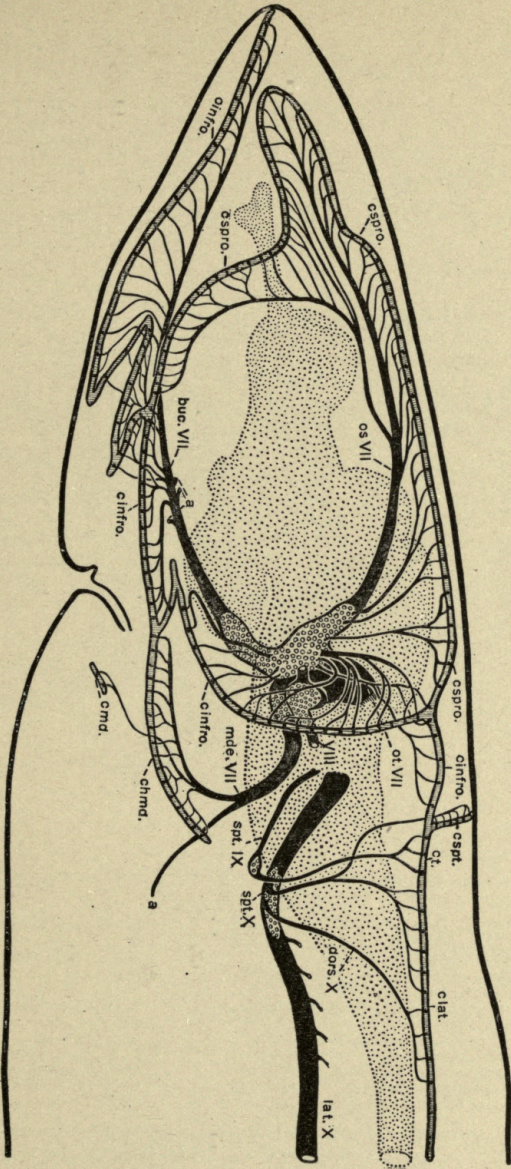






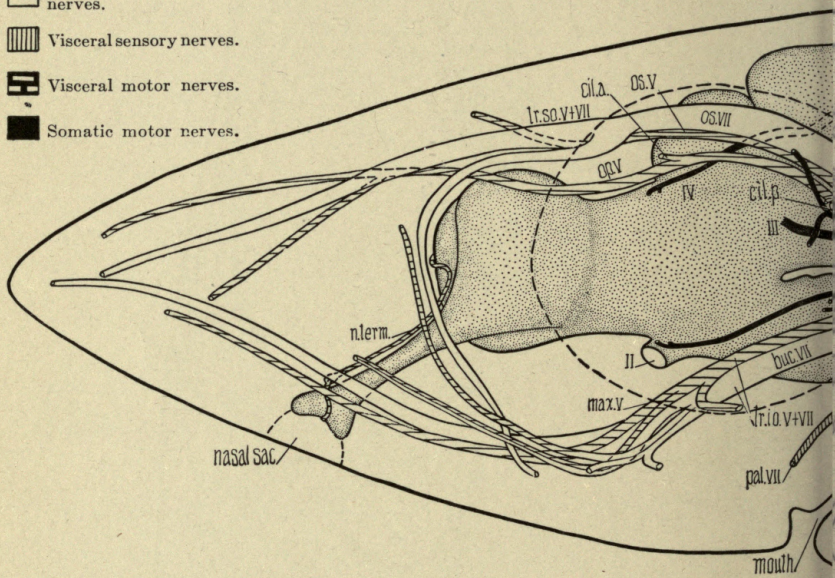


FIG. 4.

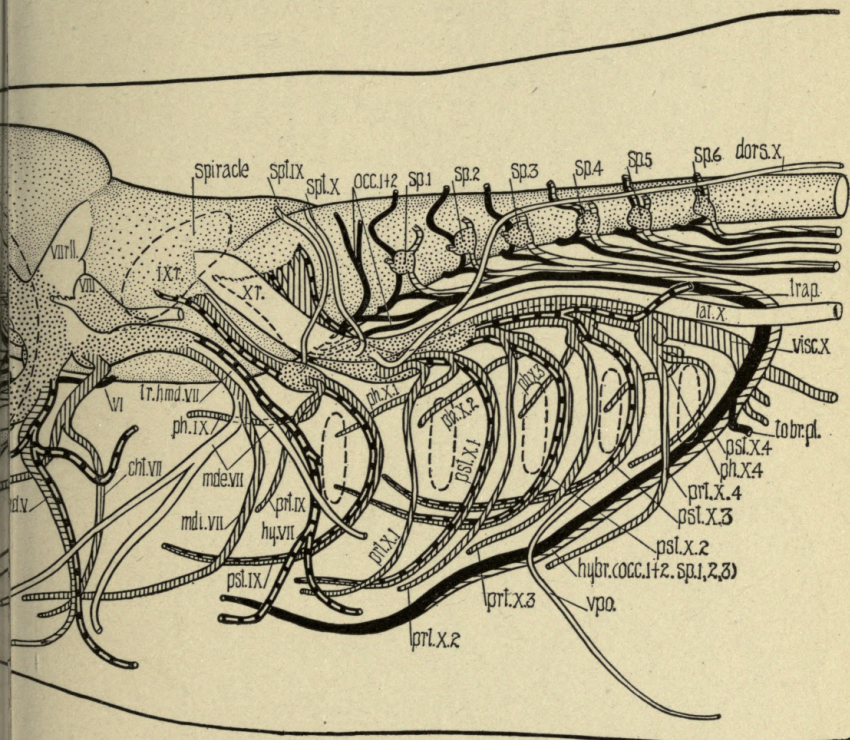
-  Ganglia.
-  Somatic sensory nerves.
-  Lateral line and VIII nerves.
-  Visceral sensory nerves.
-  Visceral motor nerves.
-  Somatic motor nerves.



- buc.VII*, ramus buccalis VII.
- cht.VII*, chorda tympani VII.
- cil.a.*, anterior ciliary nerve.
- cil.p.*, posterior ciliary nerves.
- dors.X*, ramus dorsalis X.
- hybr.* (*occ. 1+2, sp.1, 2, 3*), nervus hypobranchialis.
- hy.VII*, ramus hyoideus VII.
- II*, nervus opticus.
- III*, nervus oculomotorius.
- IV*, nervus trochlearis.
- IXr*, roots of glossopharyngeus.

- lat.X*, ramus lateralis X.
- max.V*, ramus maxillaris V.
- md.v.*, ramus mandibularis externus VI
- mdi.VII*, ramus mandibularis internus VII
- md.V*, ramus mandibularis V.
- n.term.*, nervus terminalis.
- occ.1+2*, occipital nerves.
- op.V*, ramus ophthalmicus profundus V.
- os.V*, ramus ophthalmicus superficialis V.
- os.VII*, ramus ophthalmicus superficialis VII
- pal.VII*, ramus palatinus VII.
- ph.IX*, ramus pharyngeus IX.

FIG. 5A.—Distribution of the nerve components in *Squalus acanthias*, seen from the broken lines. The functional composition of the nerves is



ATIONS

- ph. X. 1-4*, first to fourth ramus pharyngeus X.
- prt. IX*, ramus pretrematicus IX.
- prt. X 1-4*, first to fourth ramus pretrematicus X.
- pst. IX*, ramus posttrematicus IX.
- pst. X 1-4*, first to fourth ramus posttrematicus X.
- sp. 1-6*, first to sixth spinal nerves.
- spt. IX*, ramus supratemporalis IX.
- spt. X*, ramus supratemporalis X.
- to br. pl.*, to brachial plexus.

- trap*, nerve to trapezius muscle.
- tr. hmd. VII*, truncus hyomandibularis VII.
- tr. io. V + VII*, truncus infra-orbitalis V + VII.
- tr. so. V + VII*, truncus supra-orbitalis V + VII.
- VI*, nervus abducens.
- VIII*, nervus acusticus.
- VII r. ll.*, lateral line roots of facialis.
- visc. X*, ramus visceralis (intestinalis) X.
- vpo*, nerve to ventral pit organs.
- X r.*, roots of vagus.

ft side. The outlines of the nose, eye, spiracle and the five gill clefts are indicated by hatched by the conventional symbols printed above the figure.

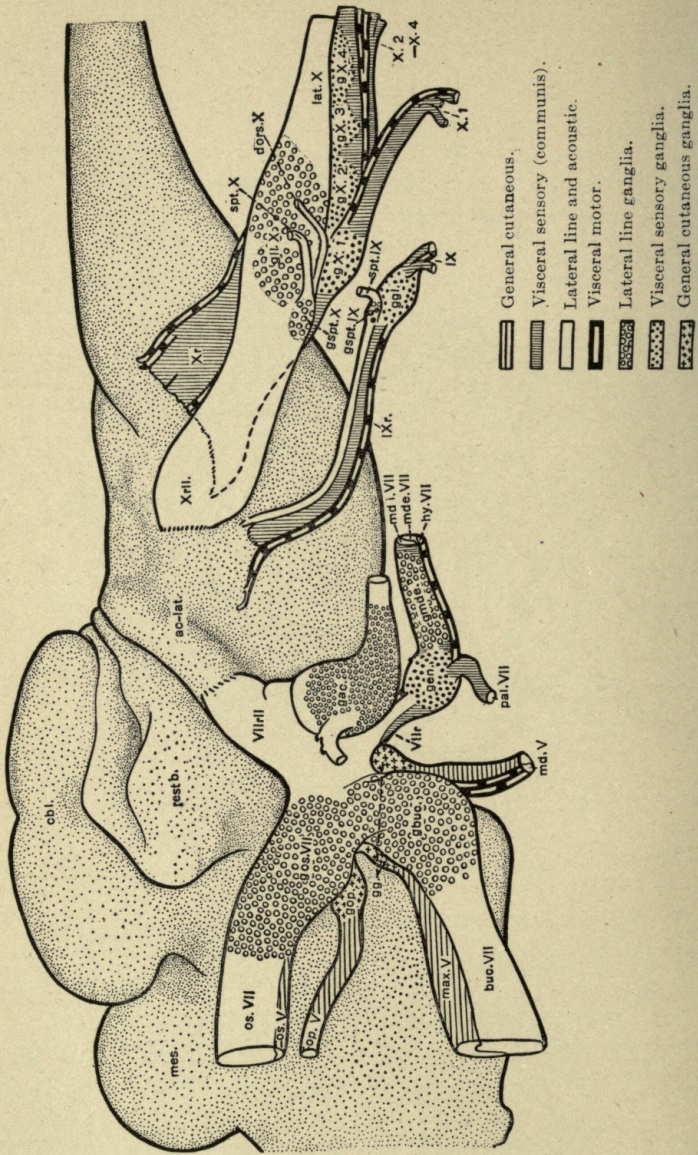


FIG. 5B.

Draw the contents of the orbit as seen from above, including the eye, its muscles, and all nerves which enter the orbit.

13. *The eyeball.*—Remove the eyeball from the orbit by cutting all of its attachments, and dissect the eye. Open the eyeball by a cut around the equator between the cornea and the optic nerve. In the inner half of the eyeball note the three coats—the tough sclerotic, the pigmented choroid, and the grayish-white retina. The retina in preserved specimens is apt to be partly disintegrated and pulled loose from the choroid coat. In the outer half notice the lens and observe its attachment by a delicate suspensory ligament attached to the margin of the eyeball in front of the retina. The space behind the lens is filled with vitreous humor (corpus vitreum); the space in

FIG. 5B.—An analysis of the cranial ganglia of *Squalus acanthias* ("pup" stage). The somatic motor roots are omitted; cf. Fig. 5A. For the significance of the conventional symbols see the accompanying legend.

ABBREVIATIONS

- ac-lat.*, area acustico-lateralis of brain.
buc.VII, ramus buccalis VII.
cbt., cerebellum.
dors.X, ramus dorsalis X.
g ac., ganglion acusticum.
g buc., ganglion of ramus buccalis VII.
gen., ganglion geniculi VII.
gg., ganglion gasseri.
g gl., visceral ganglion of IX.
g ll.X, ganglion of ramus lateralis X.
g mde., lateralis ganglion on hyomandibular trunk.
g op., ganglion of ramus ophthalmicus profundus.
g os.VII, ganglion of ramus ophthalmicus superficialis VII.
g spt.IX, ganglion of ramus supratemporalis IX.
g spt.X, ganglion of ramus supratemporalis X.
g X.1 to g X.4, visceral sensory ganglia on the vagus.
hy.VII, ramus hyoideus VII.
IX, nervus glossopharyngeus.
IX r., roots of nervus glossopharyngeus.
lat.X, ramus lateralis X.
max.V, ramus maxillaris V.
md.V, ramus mandibularis V.
mde.VII, ramus mandibularis externus VII.
mdi.VII, ramus mandibularis internus VII.
mes., midbrain.
op.V, ramus ophthalmicus profundus V.
os.V, ramus ophthalmicus superficialis V.
os.VII, ramus ophthalmicus superficialis VII.
pal.VII, ramus palatinus VII.
rest b., "corpus restiforme" (anterior end of acustico-lateral area).
spt.IX, ramus supratemporalis IX.
spt.X, ramus supratemporalis X.
VII r., roots of facialis proper.
VII r ll., lateral line roots of facialis.
X r., roots of vagus proper.
X r ll., lateral line root of vagus.
X.1 to X.4, first to fourth branchial rami of vagus.

front of the lens and behind the cornea is filled with aqueous humor. The choroid coat is extended in front of the lens to form the iris.

14. Look up the structure of the *human eye* (see Section 135) and compare with that of the dogfish. Note the difference in the shape of the lens in the two cases. In mammals the suspensory ligament is attached to a muscular ridge, the ciliary process, whose ciliary muscles control the accommodation of the lens. In the dogfish the ciliary muscles are feebly developed and there is little, if any, power of accommodation.

The anatomy of the mammalian eye should be studied in formalin hardened and fresh specimens. The ox eye is the most satisfactory, but that of the sheep or pig may be used. Begin the study of the general relations of the parts using a hardened eyeball cut through the optic axis. Identify: cornea, iris, lens, ciliary body, retina, chorioidea, sclera. If fresh material is not available, study the anterior and posterior segments of the eyeball cut transverse to the optic axis just anterior to the equator. See: Cunningham ('15), pp. 806-827; Gray ('18), pp. 1000-1029; Morris ('14), pp. 1051-1081; Piersol ('16), pp. 1436-1483; Quain ('09), Vol. III, Pt. II, pp. 173-264; Rauber-Kopsch ('12), Abteilung VI, pp. 97-170; Sobotta ('11), pp. 247-274; Spalteholz ('09), pp. 770-798; Toldt ('04), pp. 892-910.

If fresh material is available, determine, if possible, whether you have right or left eye by identifying the eyelids, the rudiment of the nictitating membrane (*plica semilunaris*), the *papillæ lacrimales*, the naso-lachrymal duct, the ocular muscles, and the point of entrance of the optic nerve. In the ox the compact group of muscles around the optic nerve inserted into the posterior hemisphere of the eyeball is the *m. retractor bulbi* which is not present in man.

Remove the conjunctiva and the capsule of Tenon (*fascia bulbi*) by making a circular incision around the eyeball just behind the *sulcus scleræ*, carrying it as far as the sclera only and stripping forward and backward to the optic nerve. Look for the trunks of the *venæ vorticosæ* emerging from the sclera and the long and short ciliary nerves (Sobotta, '11,

Fig. 731). Now snip through the sclera near the equator being careful not to injure the dark chorioid tunic. Then put the specimen into water and, separating the sclera and chorioidea, remove the former, at least in part. Brushing away the pigment will serve to demonstrate the venæ vorticosaë. Look for the ciliary nerves. Identify the region of the ciliary body and, cutting away the cornea, expose the iris.

The anterior and posterior hemispheres may now be separated by cutting through the chorioidea and retina and loosening the corpus vitreum from the ciliary region. Study the anterior segment with a hand lense and identify: retina, ora serrata, orbicularis ciliaris, processus ciliaris and iris. By an incision into the capsule of the lens remove the latter and note its shape and consistency. See: Cunningham ('15), Fig. 686; Morris ('14), Fig. 801; Sobotta ('11), Figs. 733-736; Spalteholz ('09), Fig. 840. In the posterior segment identify the papilla optica (blind spot) and retinal vessels. When the retina is stripped off, the pigment layer usually remains adherent to the chorioid. It is partly replaced in the ox by the iridescent tapetum.

If microscopic sections are available study the structure about the iridial angle and the layers of the retina. For details of structure of the retina see Section 135.

15. *Cranial Nerves*.—There are ten pairs of cranial nerves (the XI and XII human nerves are not separately represented). The spinal nerves are much alike, each pair repeating the same functional pattern; but no two cranial nerves have the same functional composition. Accordingly, in studying the cranial nerves it is necessary to determine for each pair of nerves the functional composition of each of its roots and the precise peripheral and central connections of the fibers of each functionally distinct root. This has been done for a sufficient number of vertebrate types to establish a typical vertebrate pattern of cranial nerve components. These functionally defined components are classified in four major groups, somatic sensory and motor and visceral sensory and motor, each of which may be further subdivided. For the discussion of the principles and mode of application of this classification (which is fundamental

to an understanding of the following sections), see Herrick, '18, Chap. IX, and Johnston ('06), Chap. V.

16. The *nerve components of the dogfish* have been carefully studied microscopically by Dr. H. W. Norris and Miss S. P. Hughes, who have very kindly prepared for us the accompanying drawings (Figs. 4 and 5) from a detailed account to be published shortly ('19). The systems of nerve components mentioned at the close of the preceding section are represented in the following cranial nerves of the dogfish:

(1) *Somatic sensory*: II (optic); III, IV and VI (fibers of muscle sense); V (general cutaneous and muscle sense); VII (lateral line fibers); VIII (acoustic and vestibular); IX (lateral line fibers); X (lateral line fibers).

(2) *Somatic motor*: III, IV and VI (eye-muscle nerves) [in man also XII, for tongue muscles, represented in the dogfish by the hypobranchial nerve (Fig. 5A)].

(3) *Visceral sensory*: I (olfactory); VII, IX and X (general visceral and gustatory nerves).

(4) *Visceral motor*: III (ciliary nerves); V (masticatory nerves); VII (nerves of the hyoid musculature [including in man the facial muscles]); IX and X (branchial and general visceral motor nerves).

17. The names of the *cranial nerves* and their chief branches in the dogfish are given for reference in the following list (cf. Figs. 1 to 5). They should be identified in your specimens, but their names need not be memorized. The human cranial nerves show the same general arrangement, save for the absence in man of all components supplying lateral line organs and for the modification of the IX and X pairs resulting from the loss of the gills. See Section 47.

I. N. olfactorius. Passes in very numerous short filaments from the nasal sac on the ventral surface of the snout to the very large olfactory bulb. Associated with this nerve is the slender *nervus terminalis*, running between the nasal sac and the cerebral hemisphere (Figs. 2 and 5A). It passes along the dorsal surface of the olfactory bulb and the medial surface of the stalk of the bulb to enter the cerebral hemisphere near the median plane. See Locy ('05) and McKibben ('14).

II. N. opticus. From the eye to the floor of the brain under the thalamus.

III. N. oculomotorius. From the floor of the midbrain to mm. obliquus inferior and rectus superior, inferior, and medialis.

IV. N. trochlearis. From the roof of the midbrain to m. obliquus superior.

VI. N. abducens. From the floor of the medulla oblongata to m. rectus lateralis.

V and VII. The trigeminus and facialis nerves are so intimately united that microscopic methods are required for their separation. In Figs. 2 and 3 they are drawn very diagrammatically after slight dissection and separation of the roots and ganglia. Their true composition is shown in Fig. 5. The two upper (more rostral) roots of the complex are the sensory and motor V; the lower ones belong to VII. The sensory V root receives its fibers from the skin of the whole head in front of the gill region. The motor V root supplies the jaw muscles; the motor VII root those of the hyoid arch. The sensory VII root (nervus intermedius, or portio intermedia of Wrisberg) receives most of its fibers from taste-buds and the mucous lining of the mouth. The lateral line roots which enter the brain in front of the ear are usually named as parts of the VII nerve; see Section 18.

VIII. N. acusticus. From the labyrinth of the ear to the acoustico-lateral area of the medulla oblongata. The cochlear ramus is absent or rudimentary. A small sensory spot in the sacculle, the lagena, is regarded as the organ from which the cochlear sense organ (spiral organ) of mammals has been differentiated; its nerve, accordingly, is homologous with the cochlear nerve of man.

IX. N. glossopharyngeus. Arises from the oblongata by three roots, two sensory and one motor, passes under the membranous labyrinth of the ear and forks around the first gill cleft. It contains visceral sensory and visceral motor fibers for the innervation of the first gill and also a small lateral line component (r. supratemporalis IX, Figs. 4 and 5).

X. N. vagus. Arises from the oblongata by several roots which form a large trunk from which arise branchial rami to fork around the second to fifth gill clefts (visceral motor and visceral sensory); also r. visceralis vagi for the viscera of the

body cavity farther back (esophagus, stomach, etc.). The r. dorsalis vagi contains lateral line fibers for part of the main lateral canal. The r. lateralis vagi supplies the lateral canal behind the region reached by the r. dorsalis. The r. supratemporalis vagi supplies the anterior end of the lateral canal and the supratemporal canal. All lateral line fibers of the vagus arise by a large root farther forward (rostral) than the other vagus roots.

The human accessory nerve (XI) is represented by a branch of the vagus (Fig. 5A, *trap.*) and the hypoglossus (XII) by fibers of the occipital nerves which enter the hypobranchial nerve.

18. *The acoustico-lateral complex.* The membranous labyrinth and the lateral line organs comprise a complex system of sense organs with many features in common (see Johnston ('06), Chap. VII and S. E. Johnson ('17)). Within the lateral line canals and ampullæ of Lorenzini are found sense organs which resemble those of the internal ear, and the nerves which supply them enter the same part of the brain, the area acustico-lateralis (see Section 22 and Figs. 2 to 5). The sense organs of the sacculæ in fishes are sensitive to sound waves; those of the ampullæ of the semicircular canals assist in maintaining equilibrium; and those of the lateral line organs are sensitive to water vibrations of a slower rate than the sound waves received by the ears, with possibly other functions in addition.

The nerves terminating in the area acustico-lateralis constitute a functional and anatomical system distinct from all other sensory nerves, though peripherally they may be bound up in the same nerve-trunks with other components. They are most closely related with the general cutaneous nerves. They reach their peripheral end-organs through the following nerve trunks (cf. the next section):

(1) For the supra-orbital canal from the supra-orbital trunk (this component of this trunk is called the ramus ophthalmicus superficialis VII).

(2) For the infra-orbital canal from the infra-orbital trunk (this component is called the ramus buccalis VII).

(3) For the hyomandibular canal from the facial trunk or hyomandibular nerve (called the ramus mandibularis externus VII).

(4) For the internal ear from the *nervus acusticus*.

(5) For the lateral line organs of the temporal canal from the *ramus supratemporalis IX*.

(6) For the lateral line canal of the body from the *ramus supratemporalis*, *ramus dorsalis*, and *ramus lateralis X*.

The nerve-fibers of this system which supply the irregularly arranged ampullæ of the head distribute in company with those for the lateral line canals of the head.

19. Many of the *peripheral nerve-trunks* are mixed in the sense that they contain functionally different components. These components may come from roots of several different nerves by anastomoses peripherally of the ganglia. Some of the more important peripheral nerves of the dogfish are as follows:

(1) The supra-orbital trunk, containing the *r. ophthalmicus superficialis V* (general cutaneous) for the skin of the top of the head, and lateral line fibers for supra-orbital lateral line organs (the *r. ophthalmicus superficialis VII*); (2) *r. ophthalmicus profundus V* (general cutaneous), passing through the middle of the orbit, beyond which it anastomoses with the *r. ophthalmicus superficialis V* to supply the skin of the snout (the superficial and deep ophthalmic branches of the *V* nerve together correspond approximately with the ophthalmic branch of the human *trigeminus*); (3) the infra-orbital trunk, passing across the floor of the orbit, below which it divides into the *r. buccalis VII (lateralis)* for infra-orbital lateral line organs, *r. maxillaris V* (general cutaneous) for the skin of the upper jaw, and *r. mandibularis V* (general cutaneous and motor) for the skin and muscles of the lower jaw; (4) *r. palatinus VII* (visceral sensory) for the mucous membrane and taste-buds of the roof of the mouth (represented by the great superficial petrosal nerve of the human body); (5) the hyomandibular trunk, passing behind the spiracular cleft to the region of the hyoid arch and lower jaw, containing the *r. mandibularis internus VII* (visceral sensory) for taste-buds and mucous membrane lining the lower jaw, motor *VII* fibers for muscles of the hyoid arch (*r. hyoideus*), and lateral line fibers for hyomandibular lateral line organs (*r. mandibularis externus VII*). The visceral sensory and motor fibers correspond with the facial trunk of the human body.

The components of these peripheral nerves can be completely separated only by microscopic methods, though a skilful dissector can separate the lateralis components of many of the nerves (see Ewart, '93 and Norris and Hughes, '19). The nerve components of vertebrates are fully described by Johnston ('06 and '09).

20. The gills are visceral structures. Their sensory nerves terminate centrally in the visceral sensory column of the medulla oblongata, and their motor nerves arise from the visceral motor column (see Sections 15 and 23). Each gill cleft has a branchial nerve, as illustrated in Figs. 1, 2, 5A, and 6. The branchial trunk typically divides into: (1) a postbranchial (or posttrematic) nerve, containing visceral sensory and visceral motor components, (2) a prebranchial (or pretrematic) nerve (visceral sensory), (3) a pharyngeal nerve (visceral sensory). The postbranchial division of the IX nerve of fishes is homologous with the human lingual branch, for distribution to the tongue.

The roots of the IX nerve connect with the medulla oblongata a short distance behind the VIII nerve, and the IX nerve itself can be seen, after the dissection of the internal ear, running across the floor of the auditory chamber. Dissect the IX nerve outward and note its division into prebranchial and postbranchial rami.

The roots of the X nerve arise behind those of the IX (except the lateral line root which arises farther forward from the acoustico-lateral area). Dissect the vagus trunk outward and note its division into lateralis and branchial trunks. The latter, after giving off the branchial rami to the second to fifth gills, is continued backward to form the ramus intestinalis and ramus cardiacus.

21. The student should at this time acquire a general familiarity with the arrangement of the human spinal and cranial nerves. The cranial nerves of the dogfish are broadly similar to the corresponding nerves in the human body. Some of the more important differences are as follows: the absence in the dogfish of the XI and XII pairs and of the cochlear branch of the VIII pair (the rudiments of these nerves are present—see Section 17); the presence in the dogfish of functional gills

with corresponding modifications of the IX and X pairs of nerves; the presence in the dogfish of an extensive special system of subcutaneous sense organs structurally (and probably physiologically) related to those of the internal ear. These are the sense organs of the lateral line canals and ampullæ of Lorenzini, for which there is a special system of nerves, the lateralis components of the VII, IX, and X nerves (see Section 18).

Draw the dissection of the brain and cranial nerves, indicating the functional components in each peripheral nerve-trunk by colors in accordance with the scheme given in Section 62 (p. 62), coloring the lateral line nerves the same as the VIII nerve (brown or green).

22. Complete the exposure of the brain, carefully preserving the roots of the cranial nerves.

Now, viewing the brain from above, review the arrangement and physiological composition of the cranial nerves and note particularly the part of the brain with which each peripheral end-organ or group of physiologically similar organs is related. Simple inspection shows that the organs of smell are connected with the olfactory bulbs, and in fact these and almost the whole of the cerebral hemispheres and epithalamus and hypothalamus form the olfactory part of the brain (stippled in Figs. 2 and 3). In the same way the eyes are related with the optic lobes of the midbrain (obliquely cross-hatched in Figs. 2 and 3), the ears and lateral line organs with the acoustico-lateral area (cross-hatched with horizontal lines), and the nerves of general skin sensibility with the general cutaneous area (unshaded). Locate precisely these areas on your specimen.

23. Next carefully remove the membranous roof of the fourth ventricle and study the floor of the fourth ventricle, noting the following structures, passing from the median sulcus laterally (cf. Figs. 2 and 6): (1) a longitudinal ridge marking the position of the fasciculus longitudinalis medialis ("posterior longitudinal fasciculus") and farther ventrally the position of the ventral gray column of the spinal cord and nuclei of the VI, IV, and III cranial nerves—this is the *somatic motor column*; (2) a wide longitudinal groove parallel with the last, below which are found the motor nuclei of the X, IX, VII,

and V cranial nerves—this is the *visceral motor column* and is the forward extension of the lateral gray column of the spinal cord; (3) a longitudinal ridge with a beaded contour, which contains the terminal centers of the visceral sensory components of the X, IX, and VII cranial nerves—the *visceral sensory column*; (4) separated from the last by a deep groove and forming the dorso-lateral wall of the fourth ventricle is the *somatic sensory column*. This column is the continuation of the dorsal gray column of the spinal cord, and its ventral part contains the centers for the general cutaneous nerves of the trunk and head. The dorsal part of this column is the area acustico-lateralis, whose anterior end is greatly enlarged under the cerebellum, with which it is directly continuous. This area receives the VIII and lateral line nerves, and the cerebellum is a specialized derivative of it. The longitudinal groove between columns 2 and 3 is the *sulcus limitans* (cf. the development of the human brain, Section 38). It separates motor centers below (ventrally) from sensory centers lying farther dorsally.

24. From these observations it appears that the brain shows various external thickenings or enlargements, each of which is related to a particular physiological type of end-organ. We may, in fact, recognize a "nose brain," "eye brain," "ear brain," etc., and in addition the cerebellum above these primary sensorimotor centers. There is no cerebral cortex.

25. Draw the medulla oblongata from the dorsal side, twice natural size, after removal of the membranous roof, to illustrate the functional areas in the walls of the fourth ventricle. In this drawing the functional columns should be tinted to correspond with the colors used in the drawing of the peripheral nerves (Section 21). Thus, the acoustico-lateral area will be colored the same as the VIII and lateral line nerves, the general somatic sensory area the same as the general cutaneous nerves, etc. The drawing of the entire brain called for in Section 21 may also be tinted in the same way.

26. The physiologically distinct areas noted in the preceding sections tend to be grouped in larger regions, the pattern of this grouping being determined in part by the primitive segmenta-

tion and development of the brain and in part by physiological convenience.

The brain is separated by a constriction (the isthmus) in front of the cerebellum into the cerebrum in front and the rhombic brain (rhombencephalon) below, the latter being further subdivided into the medulla oblongata and cerebellum. The cerebrum is further subdivided into (1) the midbrain (mesencephalon) containing the optic lobes dorsally and the cerebral peduncles and motor centers for eye movements ventrally, (2) the between-brain (diencephalon) containing thalamus, epithalamus, and hypothalamus, and (3) the end-

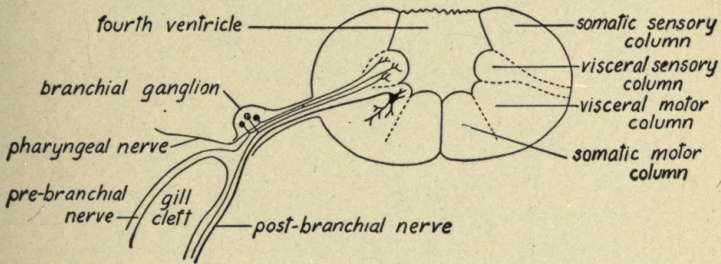


FIG. 6.—Diagrammatic cross-section through the medulla oblongata of the dogfish in the region of the vagus nerve to illustrate the innervation of the gills and the arrangement of the functional columns of the oblongata. The groove between the visceral motor column and the visceral sensory column is the sulcus limitans.

brain (telencephalon) comprising the anterior end of the brain tube, the cerebral hemispheres, and olfactory bulbs. Locate these regions and compare the fuller study of the subdivisions and development of the brain in Section 40.

27. Now remove the brain from the cranial cavity, first carefully cutting the nerve-roots so as to permit their subsequent identification and avoiding injury to the olfactory bulbs in front and the pituitary body on the ventral surface. Examine the ventral surface and complete the study of the parts listed in Section 26.

28. Make a transverse section across the medulla oblongata at the level of the roots of the VIII nerves. Compare this section with a similar one made in the vagus region (Fig. 6) and note the differences.

Draw the transverse section at the level of the VIII nerves and designate on it the structures in the walls of the fourth ventricle enumerated in Section 23.

29. Now divide the entire brain into two lateral halves by a vertical median cut and study the course of the ventricles as thus exposed, noting the narrowing of the fourth ventricle into the aqueduct of Sylvius in the isthmus, its lateral expansion in the optic lobes (optocele), the vertical expansion in the thalamus (third ventricle), and the connection of the latter with the first and second ventricles in the cerebral hemispheres through the foramen of Monró (*foramen interventriculare*) on each side.

IV. THE MAMMALIAN NERVOUS SYSTEM

1. Introductory Topics

30. The directions which follow can be applied to any of the larger mammalian brains. If human brains are available in sufficient numbers, these alone may be used; but in case the available human brains are insufficient in number or poorly preserved, the gross dissections may be made on brains of the sheep, dog, or cat. The brain of the sheep is advised. Heads of freshly killed lambs can usually be procured from the butchers. As soon as possible after the killing the brain should be removed and hardened for a few days before use by immersing it in a 10 per cent. solution of commercial formalin in water. In this solution it may be preserved indefinitely.

To remove the brain, first loosen the top of the skull with a saw and chisel. Hold the head firmly in a vise dorsal side up. First with a saw make a transverse cut from 5 to 10 mm. deep across the top of the head about 1 cm. behind the anterior borders of the bony orbits. Then along each side of the head make an obliquely longitudinal saw cut, beginning just above the occipital condyles and extending forward across the dorsal surface of the head about 2 cm. medial to the inner border of the bony orbit. The lines of these two cuts should follow the curvature of the head and meet in the middorsal plane about 2 cm. in front of the transverse cut already made and the saw should be inclined about 45 degrees downward and inward. Avoid cutting so deeply as to enter the brain substance. Then make a very shallow transverse cut through the cranium immediately above the occipital condyles. With chisel and mallet clip through the occipital condyles behind the cut last made, and also break the remaining bridge of bone medially of each bony orbit. The top of the cranium may now be pried loose with the chisel and lifted off. The dura mater should be cut around with scissors along the line of the cut surface of the skull and the ventral part of the dura left attached to the skull floor. Lift up the brain from the cranial

floor and cut the nerve-roots with a slender scalpel or scissors. Carefully free the anterior and ventral surfaces of the olfactory bulb from the lamina cribrosa of the ethmoid bone, cutting off the filaments of the olfactory nerve. Cut out the hypophysis from its cranial pocket in the sella turcica and leave it attached to the brain by the slender infundibulum. The brain may now be lifted out of the cranial cavity and preserved in formalin.

31. As stated above, most of the dissections described in this Outline can be made on either human or other brains. If brains of the sheep (or dog or cat) are used, specimens and text-book figures of the human brain should be kept constantly at hand for comparison. A certain number of special dissections illustrating particular features should be made in advance and preserved permanently. These should be made, if possible, on human brains and should include, among others, three brains sliced respectively in planes parallel with the transverse, frontal, and sagittal planes of the body. Valuable demonstration specimens may also be made by following out the directions for dissecting the several fiber systems given in the "optional dissections" (Sections 102-111 and 141-152), using a separate brain or half brain for each system. Cunningham and Waterson's Edinburgh University Stereoscopic Atlas is a valuable aid in getting true pictures of the internal structures.

If only one human brain is available for study, it is advised that it be dissected as directed by Dr. Lineback ('15). By this procedure the brain is first divided in the median plane into right and left halves and one of these halves is then further dissected by a single carefully planned incision so as to remove a considerable portion of the cerebral hemisphere from the brain stem and at the same time reveal the internal structure of the hemisphere. The method has the further advantage that the three parts into which the brain is cut can readily be reassembled, so that the specimen can still be used for demonstration of the external form in its entirety.

32. The dissection of many fiber tracts can be carried much farther in well-preserved human brains than is possible in brains of lower animals. Accordingly, there are included in this Outline directions for a certain number of "optional dissections" (Sections 102-111, 141-152), for which human brains

well hardened in formalin are necessary. All of the dissections here outlined, except a few of the "optional dissections" can be made on one lateral half of a single well-preserved human brain and all except the "optional dissections" can be made on the brain of the sheep, though a better mastery of the subject will be obtained by following this first dissection with a second specimen, varying the procedure as may be necessary to bring out any special features desired. If time and material permit, it is recommended that one specimen (either human or sheep) be dissected through as directed and the microscopic preparations studied, and then, with the aid of the experience thus acquired, the more difficult "optional dissections" may be made on a second specimen, the human brain being used in this case. This Outline is prepared with this procedure in mind; but it should be repeated that the directions for the use of the brain of the sheep can be applied to the human brain as well, if this is preferred. A very satisfactory study of the brain can be made on gross material alone if microscopic sections are not at hand, though a few such preparations illustrating the histological elements are very desirable.

The practice at The University of Chicago, where twelve weeks are allotted to the course in neurology, is to provide each student with an entire sheep's brain and one lateral half of a human brain taken from a dissecting-room cadaver. Throughout the study of the external form of the brain both specimens are kept before the student and every part studied is identified on both brains and the differences noted. On this material all of the dissections here outlined can be made, with the exception of some of the "optional dissections," for which the cadaver brains are usually not sufficiently well preserved. A limited number of better preserved formalin hardened human brains are set aside for the use of any students who can give the necessary additional time for the optional dissections, these dissections being made in a review course after the completion of the other work. If, as just suggested, a second specimen of the human brain is dissected, the cerebellum should not be removed as directed in Section 49, thus permitting a more complete dissection of the cerebellar peduncles (see Sections 103-105). This specimen, however, may be divided in the

median plane, for the optional dissections are so planned that all of them can be made on one lateral half of one brain.

33. In the interest of economy, both of material and of the student's time, it is desirable that in the first dissection the order of procedure here outlined be followed exactly. In particular, in the dissection of the sheep (or of the human brain in case this is used for the first dissection) where some of the dissections are to be made on the right side of the brain and some on the left, the dissection must be made on the side directed in order not to interfere with later procedures. The appropriate portion of the Laboratory Outline should be read and text-books consulted before each laboratory exercise, and a certain general familiarity with the parts to be studied thus secured in advance.

Both laboratory and lecture work should be daily supplemented by careful study of the text-books and atlases. But the laboratory notebook is primarily a record of your own observations. The notebook should always show the source of any second-hand matter introduced from text-books and other authorities by way of correlation. Record the observations so far as possible by drawings. Make them neat. See that they are fully and neatly labeled. When for any reason the drawings specified do not record fully or faithfully your observations, supplement them by written notes. These must be written in ink and should be interleaved with the drawings. Each page of drawings should have an appropriate heading. Do not crowd your drawings; avoid especially the promiscuous mixing of unrelated notes on the same page. Excellent directions for laboratory drawing will be found in the first thirty pages of Hardesty's *Laboratory Guide for Histology* ('08) and in Guyer's *Animal Micrology* ('17), pp. 159-172.

34. *Terminology*.—The confusion in the use of terms has been more serious in neurology than in most other departments of anatomy. The only widely used standard is the official list of the German Anatomical Society, commonly referred to as the *B N A* (see Barker's *Anatomical Terminology* and Eycleshymer's *Anatomical Names*), and it is necessary to be familiar with these terms; they should be used in your laboratory notes. Some of our anatomists, however, do not use these terms con-

sistently. Accordingly, the student must be familiar with some other of the more commonly used names also. The *B N A* terms or their English equivalents are used in this Outline, save that dorsal and ventral are substituted for posterior and anterior and that some fiber tracts (notably in the spinal cord) are given names of clearer physiological significance. A list of synonyms of anatomical terms is appended to W. Krause's *Handbuch der Anatomie*, Leipzig, 1905, and a more complete list in Eycleshymer's work ('17) already cited.

35. *Suggestions regarding dissection methods.*—The study of the internal structure of the brain may be made either by tearing or teasing with blunt instruments, or by making series of gross and microscopic sections through the brain in various planes. A surprisingly large amount of detail can be seen in well-prepared gross sections (cf. Barker and Kyes, '00), but the interpretation of this detail is very difficult unless the complex form relations of the parts have been previously determined by other methods of dissection. The gross and microscopic structure of the brain should be correlated so far as possible from the start, and an effort should be made to form some idea, even though imperfect, of the functional significance of every part as soon as it is observed.

Great care must be used in brain dissection. *Do not begin the dissection* until, by the study of the surface anatomy and of figures in text-books and atlases, as well as by reading, you have a clear idea of the relative positions and connections of the deep structures to be dissected. Sharp instruments, such as scalpels and scissors, should be used only when indicated in the directions. Avoid as far as possible the contact of metal with the brain tissue. For teasing, use a sharpened orange-wood or bone manicure stick. Tracts should be dissected out in the direction in which the fibers run, since teasing at right angles breaks the fibers, thus making it impossible to confirm their course, and finally produces an untidy dissection.

36. Parallel with the examination of the gross anatomy of each part of the brain, *microscopic sections* should be studied illustrating its histological structure. These sections should include transverse sections through the spinal cord at four levels (cervical, thoracic, lumbar, and sacral) and a series

through the medulla oblongata and pons. At least six levels of the medulla oblongata should be studied, and more if possible. Similar sections through the midbrain and thalamus are also very desirable, though somewhat more difficult to prepare (cf. Sheldon, '14). The student should also study as many microscopic preparations as possible of special regions of the brain and sense organs, particularly of the spinal cord and the cerebral and cerebellar cortex, illustrating the appearances of particular structures when prepared by the methods of Weigert, Nissl, Golgi, Cajal, Marchi, etc.

37. If microscopic preparations are not available, it will be found practicable to select from the following paragraphs those which apply to the gross material only (see Courses I, III, IV, and V, pp. 11, 12). Gross transverse sections through the human brain at the levels indicated in Section 62 will show many details of internal structure, including the location of the principal gray masses and fiber tracts. In making the gross sections the incisions should be made parallel to each other and at right angles to the long axis of the medulla oblongata as far forward as the midbrain (levels 1 to 9, Section 62). In front of this region the cuts should no longer be made parallel, but so inclined toward each other ventrally as to make each slice somewhat wedge-shaped with the large end of the wedge dorsal. In this way allowance is made for the flexure of the cerebral hemispheres upon the midbrain and the plane of section is kept approximately transverse to the curved long axis of the brain.

Even if microscopic sections through all or a part of the brain stem are available, a brain should be prepared for demonstration purposes by gross section as described above to facilitate the localization of the microscopic sections and their interpretation in terms of the external form of the intact brain.

If the laboratory work is limited to the study of gross material alone, it is recommended that the student read also those sections of the Outline which give directions for the study of microscopic sections, and with the aid of the references given at the close of each section consult in text-books and atlases figures of corresponding sections.

The primary purpose of this study is to gain an understand-

ing of the functional connections of the various parts of the nervous system, and this end should be constantly kept in mind. Daily consultation of reference books in connection with each structure studied in the laboratory is indispensable. The fiber tracts should be related to each other in functional systems of reflex arcs as rapidly as possible. Compare the lists given in the sections devoted to the recapitulation of conduction paths (Sections 101 and 153).

38. *Subdivisions of the brain.*—For convenience of study the central nervous system has been separated somewhat arbitrarily into subdivisions which are more clearly defined in the embryonic brain. These subdivisions should be identified on a series of wax models of developmental stages of the human brain, such as the His models manufactured by Ziegler, and also on the adult brains of man and other mammals.

The following references include accounts of the development of the brain and the principles of its subdivision, together with illustrations of the His models: Bailey and Miller ('16), pp. 532-557; Gray ('18), pp. 733-749; Herrick ('18), Chap. VII; His ('04); Keibel and Mall ('10), Vol. II, pp. 29-106; Piersol ('16), pp. 1059-1063. Almost every text-book of human anatomy and embryology includes some account of these questions and pictures of the models. The official list of *B N A* terms is reprinted in Eycleshymer's *Anatomical Names* ('17) and also a translation of the annotations by Professor His on the neurological terms (pp. 153-174).

39. *Brain of fetal pig.*—Take two pig embryos, about 3 cm. and about 5 cm. in length respectively, which have been preserved in 10 per cent. formalin. Dissect out the brains from the side, or else cut the embryos in the median sagittal plane. The larger embryo can be more conveniently dissected and the smaller one sectioned. They may be stained for five minutes in a dilute solution of methylene-blue (about 1 part in 10,000 parts water) if desired. Determine the five brain vesicles with the aid of a dissecting microscope or a hand lens, draw them, and compare them with the His models and the adult brain. This is the procedure followed in the Anatomical Laboratory of Johns Hopkins University, for which we are indebted to Dr. E. V. Cowdry.

40. Here review the dissection of the fish brain and determine the precise limits of its chief subdivisions in comparison with those of the embryonic human brain. Note particularly the relative size of the cerebral hemispheres in the brains of various animals and that certain other parts of the brain tend to vary with the size of the cerebral cortex (thalamus, pons, cerebellar hemispheres, etc.). These parts are known as cortical dependencies. It should be borne in mind that these gross subdivisions are not functionally independent, but are connected by long tracts of fibers.

2. External Anatomy

41. *Spinal nerves of fetal pig.*—In a fetal pig of 8 or 10 cm. dissect the spinal cord and nerves. First eviscerate the fetus through a median ventral incision. In the dorsal wall of the abdomen note the spinal nerves segmentally arranged and passing out from the midline of the body. Find the sympathetic trunk and its ganglia extending along either side of the vertebral column. Trace the communicating branches (rami communicantes) by slight dissection from the sympathetic ganglia into the body wall to their connections with the spinal nerves. Note nerves radiating from the sympathetic ganglia, many of which go to form the aortic plexus; others cross the vertebral column and connect with ganglia of the opposite side, while still others pass to more distal sympathetic ganglia (cf. Section 69).

Draw the dissection at this stage, showing two or three spinal nerves in position and their connections with the sympathetic ganglia and with the related peripheral nerves.

42. *Spinal cord of fetal pig.*—Now place the fetus on the abdomen with the limbs extended. Make an incision in the dorsal midline along the entire length of the body and remove the muscles and other soft parts adjacent to the vertebral column, working laterally from the midline. Then with bone forceps or strong scissors expose the spinal cord by clipping the neural arches of the vertebræ as close to the intervertebral foramina as possible. Take care to avoid crushing or otherwise injuring the structures lying in the vertebral canal. Examine the meninges of the spinal cord; then expose the cord and dis-

sect several spinal nerves of one side sufficiently to show the spinal ganglia and the adjoining portions of the spinal nerve trunks.

43. Make a transverse section through the fetus in the thoracic region and construct a diagram magnified two or four diameters to illustrate the relations of the spinal cord, spinal nerves, spinal ganglia, and sympathetic ganglia, with their peripheral connections, to the body wall as seen in the transverse section.

44. *Spinal cord, gross structure.*—Note in the intact human spinal cord (*medulla spinalis*) the following external features: the size, shape, length, segmentation, the cervical and lumbar enlargements (*intumescentiæ*), ventral and dorsal nerve roots, ganglia, membranes (*meninges*), *ligamentum denticulatum*. Determine the location of the four transverse sections of the human cord which have been distributed. Review from the text-books the anatomical formation of the spinal column, the relations of the cord segments to their respective vertebræ (Reid's chart), the blood-supply of the spinal cord, its method of suspension in the vertebral canal, and, as far as possible, the relations of the spinal nerve roots to their peripheral distributions.

Cunningham ('15), Figs. 459–465, pp. 517–522, and pp. 685–753; Morris ('14), pp. 752, 756, 771–775, 914, 919–921, 964–974; Quain ('09), Vol. III, Part 1, pp. 58–68; Vol. III, Part 2, pp. 52–148; Piersol ('13), pp. 1021–1028, 1054, 1278, and the following pages; Reference Handbook of the Medical Sciences, 3d ed., Vol. 7, article Spinal Cord; Sobotta ('11), pp. 114–124; Spalteholz ('09), Vol. III, pp. 617–623; Toldt ('04), pp. 752–759 and 810, ff.

45. *Brain membranes.*—Each student should be supplied if possible with a sheep's brain and one lateral half of a human brain. The intact human brain will first be examined by two students at adjacent desks before being cut into halves.

Study the brain membranes (*meninges*) and blood supply of the sheep's brain, especially the circle of Willis (cf. Burkholder, ('12), Plate IV) and the other vessels of the ventral surface, and compare with the human. Review from the reference books the form of the human skull and its foramina with their

contained nerves and blood-vessels; also the arterial and venous blood supply and the lymph spaces of the brain and meninges.

See Cunningham ('15), pp. 667-677 (meninges), pp. 900-908, also pp. 969-976 (blood supply); Gray ('18), pp. 872-880 (Meninges); Morris ('14), pp. 903-924; Piersol ('16), pp. 730-753 (blood supply), pp. 1197-1209 (meninges); Quain ('09), Vol. III, Part 1, pp. 320-339; Sobotta ('11), pp. 188-192. On the cerebro-spinal fluid, see Halliburton ('16); Weed ('14, '17).

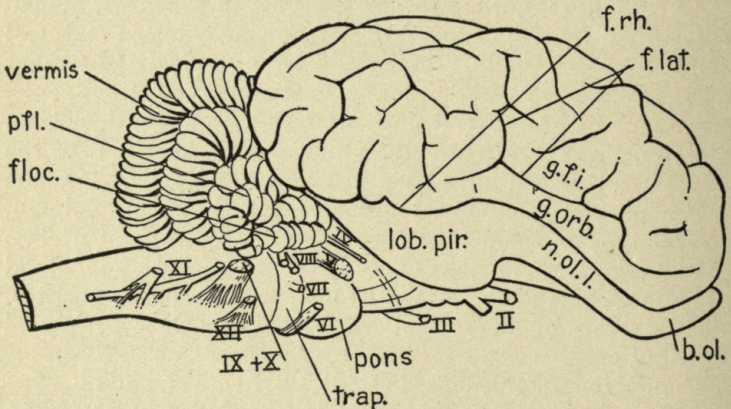


FIG. 7.—The brain of the sheep seen from the right side. Natural size. *b.ol.*, olfactory bulb; *f.lat.*, fissura lateralis (Sylvii); *floc.*, flocculus; *f.rh.*, fissura rhinalis; *g.f.i.*, gyrus frontalis inferior; *g.orb.*, gyrus orbitalis; II to XII, cranial nerves; *lob.pir.*, lobus piriformis (gyrus hippocampi); *n.ol.l.*, nucleus olfactorius lateralis; *pfl.*, paraflocculus; *trap.*, corpus trapezoideum.

46. *Surface anatomy of the brain.*—With the intact human brain and the sheep's brain before you, examine and compare their external forms. Now compare both of these brains with that of the dogfish. Identify in each brain the chief subdivisions referred to in Section 38, so far as these are visible from the surface. After the brain has been cut in two, as directed in Section 58, some of these subdivisions will be more clearly seen. In what parts of the brain do you find the greatest resemblances in the three species; where the greatest differences?

Learn the names of the larger structures visible upon the surface of the brain, omitting the minor subdivisions of the

cerebellum and (for the present) the sulci and gyri of the cerebral cortex, for the study of which see Sections 114 and 115.

On the brain of the sheep see Figs. 7 to 12, and for additional illustrations consult Burkholder ('12) and Fiske ('13); for the human brain consult any standard text-books.

47. *The cranial nerves.*—(a) Locate on both the sheep and the human brains the roots of the twelve pairs of cranial nerves.

(b) The composition of the cranial nerves of the dogfish has been considered in Sections 15 to 19, and this should here be reviewed. Even if the laboratory course has not included the dissection of the dogfish, these sections of the Outline should be read at this time. Chapter IX of Herrick's Introduction ('18) should also be carefully read and the general principles of the analysis of the cranial nerves into functional components mastered: cf. also Herrick ('18), Chapter V. The components of the cranial nerves of a number of vertebrates have been analyzed microscopically. For an excellent summary and discussion of these studies, which are of fundamental importance for the proper interpretation of the human nervous system, see Johnston ('06) and ('09).

(c) Review from the text-books of human anatomy the peripheral distribution of the cranial nerves, giving especial attention to the classification of the various roots of these nerves into functionally similar groups or systems and the peripheral distribution and mode of termination characteristic of each system. In addition to the references cited in the preceding paragraph the following may be consulted: Bailey ('16), pp. 551, 552; Morris ('14), pp. 927, ff.; Reference Handbook of the Medical Sciences, 3d ed., article Cranial Nerves.

(d) *The nervus terminalis.*—This is a slender nerve associated with the olfactory nerve which is not described in most text-books of anatomy, for its presence in the human body has very recently been demonstrated. It has long been known in fishes and can readily be seen in a dissection of the dogfish (cf. Section 17, I). Peripherally this nerve is distributed under the olfactory mucous membrane, but the exact mode of ending has not been determined. Its fibers accompany those of the fila olfactoria, but do not enter the olfactory bulb. In the adult man they pass beyond the olfactory bulb and extend farther

backward, usually in several very slender strands embedded in the pia mater over the gyrus rectus, to enter the brain substance at or near the anterior border of the medial olfactory stria. Ganglion cells are scattered along their peripheral course. The intracranial course of the nervus terminalis can

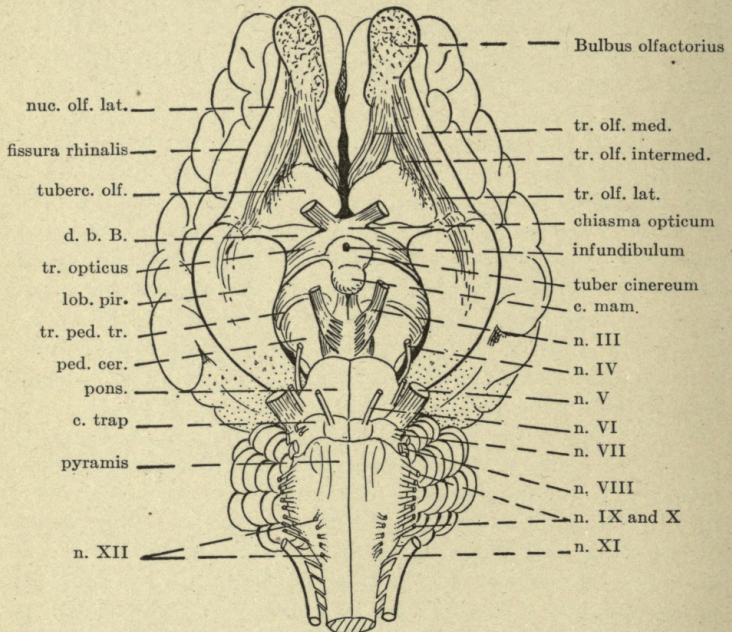


FIG. 8.—The brain of the sheep seen from the ventral side. Slightly reduced. *c.mam.*, corpus mamillare; *c.trap.*, corpus trapezoideum; *d.b.B.*, diagonal band of Broca; *lob.pir.*, lobus piriformis; *n.III* to *n.XII*, cranial nerves; *nuc.olf.lat.*, nucleus olfactorius lateralis; *ped.cer.*, pedunculus cerebri; *tr.olf.intermed.*, tractus olfactorius intermedius; *tr.olf.lat.*, tractus olfactorius lateralis; *tr.olf.med.*, tractus olfactorius medialis; *tr.ped.tr.*, tractus peduncularis transversus; *tuberc.olf.*, tuberculum olfactorium (intermediate olfactory nucleus, part of the anterior perforated space).

usually be seen in a formalinized brain with the aid of a strong magnifying glass.

For recent descriptions of the mammalian nervus terminalis see: Brookover ('14) and ('17); Huber and Guild ('13); Johnston ('13) and ('14); Larsell ('18); McCotter ('13). On the

relation of a special part of the olfactory nerve to the vomeronasal organ (Jacobson's organ) see McCotter ('12) and ('17).

48. *Brain stem and cortex.*—Observe the relations of the cerebral cortex (which makes up the greater part of the cerebral hemispheres) and the cerebellum. With a scalpel cut off a slice about 1 cm. thick from the posterior pole of the left cerebral hemisphere and a similar slice from the left lateral border of the cerebellum. Compare the cut surfaces and observe in each the relations of the superficial gray matter (cortex) to the underlying white matter. The cerebral cortex and cerebellum make up the suprasegmental apparatus, as distinguished from the spinal cord and brain stem, or segmental apparatus; see Herrick ('18), Chap. VII, and A. Meyer ('98), pp. 136–147.

The *isthmus* is a constriction of the brain in front of the medulla oblongata and cerebellum. It divides the brain into *rhombencephalon* and *cerebrum*. The rhombencephalon will be examined before the cerebrum. Each of these subdivisions consists of a basal or segmental part and a suprasegmental part (cerebellum and cerebral cortex respectively). The suprasegmental apparatus overlaps the brain base, or brain stem, whose functions it correlates.

49. *The rhombencephalon.*—In both the human and the sheep's brains observe the mode of attachment of the cerebellum to the medulla oblongata, or bulb. With a scalpel cut these attachments (cerebellar peduncles) on each side, remove the cerebellum, and lay it aside for future study, performing this operation first on the sheep's brain, then on the human. These peduncles should be severed as high up as possible, cutting into the substance of the cerebellum somewhat rather than into the substance of the medulla oblongata. In making this dissection be careful not to injure the delicate membranes lying below the cerebellum and forming the roof of the fourth ventricle. This can readily be accomplished in the sheep's brain. Unless the human brain is well preserved, these membranes may be destroyed in this case.

50. The cavity of the rhombencephalon is the fourth ventricle (*ventriculus quartus* or *fossa rhomboidea*). The cerebellum itself forms the roof of this ventricle for a short

distance between the cerebellar peduncles. In front of this level in the isthmus region the roof is formed by a thin sheet of nervous tissue, the anterior medullary velum (*velum medullare anterius*). Behind this level the roof of the fourth ventricle (*tegmen fossæ rhomboideæ*) is a thin non-nervous membrane, a part of which is highly vascular and much folded; this is the

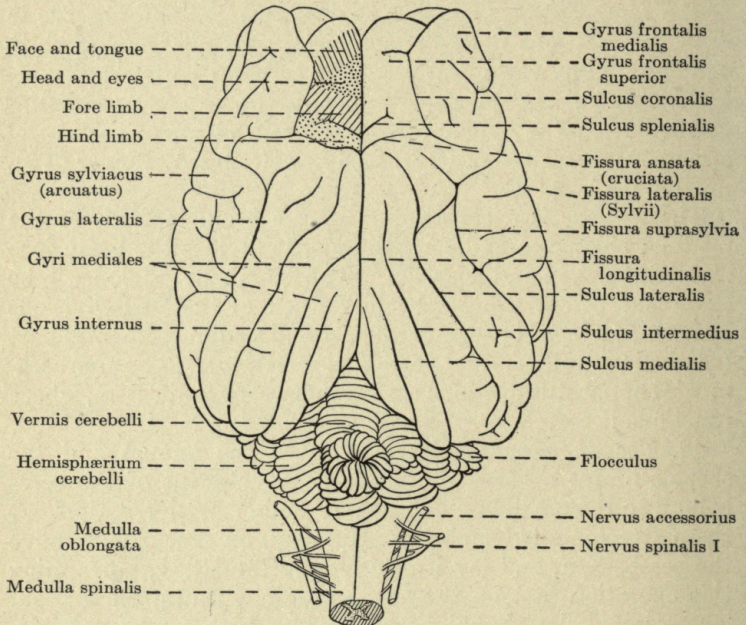


FIG. 9.—The brain of the sheep seen from the dorsal side. Slightly reduced. On the left side the areas of electrically excitable motor cortex are shown after the researches of Simpson and King (1911).

choroid plexus of the fourth ventricle. If this membrane is intact, carefully pick it up with forceps or float it out under water and determine the line of its attachment to the massive wall of the medulla oblongata on each side. This line of attachment is the *tania* of the fourth ventricle (see Fig. 11; Morris ('14), 5th ed., Fig. 639; Sobotta ('11), Figs. 650, 660; Spalteholz ('09), Figs. 695, 703).

Note that immediately behind the cochlear nucleus the tænia turns abruptly to the lateral margin of the medulla oblongata, thus forming the lower boundary of a wide expansion of the fourth ventricle, the *lateral recess*, which extends dorsally over the cochlear nucleus.

51. *The fossa rhomboidea*.—Next remove the membranous roof of the fourth ventricle of the sheep and examine carefully the dorsal, lateral, and ventral surfaces of the medulla oblongata. Identify all the parts named on Figs. 11 and 12.

In the human brain also remove the membranous roof of the fourth ventricle and compare its external form and the sculpturing in the floor of the fourth ventricle with that of the sheep and of the dogfish (Section 23). The following references will aid in the interpretation of the floor of the fourth ventricle: Cunningham ('15), Figs. 477, 479, 482, pp. 542, 544, 550 respectively; Morris ('14), Figs. 631, 640, 647, pp. 802, 814, 821 respectively; Piersol ('16), Figs. 918, 948, 949, pp. 1067, 1097, 1098 respectively; Quain ('09), Fig. 150, p. 136; Rauber-Kopsch ('12), Figs. 113, 114, pp. 99, 100; Reference Handbook of the Medical Sciences, article Brain Anatomy, Vol. II, pp. 283–285; Sobotta ('11), Figs. 659–661; Spalteholz ('09), Fig. 698, p. 630; Toldt ('04), Figs. 1178–1181, pp. 768, 769; Weed ('14a).

52. In all of these cases (dogfish, sheep, embryonic and adult human) there is a deep median sulcus in the floor of the fourth ventricle. Laterally of this is a slender *somatic motor column*, seen as a continuous ventricular ridge in the dogfish, but interrupted in places in man and the sheep. In the latter cases this column (the eminentia medialis, *BNA*) includes the *trigonum hypoglossi*, the *funiculus teres* (see Fig. 11) and the *colliculus facialis* which is sometimes called the eminentia abducentis and below which are the VI nucleus and root-fibers of the VII nerve. In the midbrain the III and IV nuclei also belong in this column, and throughout its length the longitudinal medial fasciculus runs immediately below the ventricular floor (see Section 92).

53. *Visceral motor column*.—In the dogfish the visceral motor nuclei of the cranial nerves form a longitudinal column lying laterally of the somatic motor column and somewhat

deeper. In mammals some of these nuclei appear on the ventricular floor, but most of them lie too deep to be located by surface study. The *ala cinerea* (or trigonum vagi) is an eminence which marks the position of the dorsal motor nucleus of the vagus (general visceral efferent). The special visceral nucleus of the IX and X nerves (nucleus ambiguus) is not visible from the surface. Similarly the visceral motor nuclei of the VII and V nerves lie too deep to be marked on the floor of the ventricle, though root-fibers from the motor VII nucleus form a curious knee-shaped bend (the genu) which forms a part of the colliculus facialis.

54. *Sulcus limitans*.—In embryonic brains there is a longitudinal limiting sulcus which separates the ventro-medial motor columns from the dorso-lateral sensory columns. In the brain of the adult sheep this sulcus is preserved for the entire length of the fossa rhomboidea. It is much deeper in two places than elsewhere, thus forming the *fovea superior* and *fovea inferior* (Fig. 11). The same relations are sometimes found in the adult human brains, though here the middle part of the sulcus limitans is often obliterated by the vestibular nucleus and striæ medullares acustici.

55. *Visceral sensory column*.—In the dogfish (Section 23) the visceral sensory nuclei of the cranial nerves form a longitudinal ridge in the lateral wall of the fourth ventricle. In mammals these nuclei lie deeper in the substance of the medulla and form the nucleus of the fasciculus solitarius (Sections 84 and 110). In one place only this nucleus in man reaches the ventricular surface, viz., in the fovea inferior and the lateral border of the *ala cinerea*, which, accordingly, contains both visceral motor and visceral sensory centers. This implies that the fovea inferior does not mark the exact site of the embryonic sulcus limitans, but lies somewhat laterally of it.

56. *Somatic sensory column*.—In mammals, as in the dogfish, this column of the medulla oblongata contains two clearly separate regions, (1) the general somatic sensory centers and (2) the area acustica (see Section 57). Only the first of these will be considered in this section.

In either the sheep or the human brain an examination of the

spinal cord where it joins the medulla oblongata will reveal on the dorsal surface the fasciculus gracilis and the fasciculus cuneatus. These are composed chiefly of fiber tracts of the spinal proprioceptive system and they enter enlargements lying laterally of the lower end of the fourth ventricle (calamus scriptorius), known respectively as the *clava*, or nucleus of the fasciculus gracilis, and the *tuberculum cuneatum*, or nucleus of the fasciculus cuneatus. Laterally of the tuberculum cuneatum is the *tuberculum cinereum*, a longitudinal ridge formed by the spinal V tract and its nucleus. These three eminences contain centers of general cutaneous and deep sensibility for the trunk, limbs, and head; that is, in the aggregate they form the general somatic sensory column.

57. *The area acustica*.—This is the special somatic sensory column. It comprises the vestibular nucleus in the floor of the fourth ventricle and the cochlear nucleus, a compact crescent-shaped mass of gray matter which encircles the restiform body at the point where the latter turns dorsalward to enter the cerebellum (Fig. 11). The dorsal part of the cochlear nucleus is termed tuberculum acusticum.

58. Now get from the instructor a long, thin brain knife. Special knives for this purpose are sold by the manufacturers of surgical instruments, but a butcher's ham-slicer, to be purchased in the hardware trade, makes a very satisfactory substitute. This is a large butcher knife with a long and very thin, wide blade. Better still is a large steel spatula, or "pill knife," such as druggists use, with both edges ground sharp. With this knife cut the entire brain of the sheep into right and left halves. The incision should pass through the longitudinal fissure between the cerebral hemispheres and should cut through the corpus callosum in the floor of this fissure, and then downward through the entire brain stem. Great care should be taken to make this cut smooth and exactly in the median plane. It should be made with a single long sweep of the knife.

Up to this point two students have examined one human brain. Now repeat on the human brain the division into right and left halves in the same way as in the case of the sheep. Divide also the cerebellum by a median incision. Each student takes one-half of the divided human brain.

59. Examine carefully the cut surfaces of both the human and the sheep's brains, identifying all median structures thus brought into view. Note again the arrangements of the chief subdivisions of the brain referred to in Section 38. For the sheep's brain, see Fig. 10. Similar views of the human brain

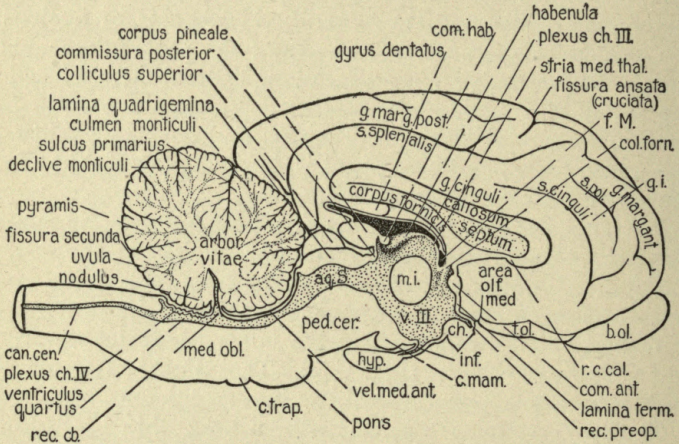


FIG. 10.—Median section of the brain of the sheep. Slightly reduced. The exposed ventricular surfaces are stippled. *Aq.S.*, aqueductus cerebri (Sylvii); *area olf.med.*, area olfactoria medialis or nucleus olfactorius medialis; *b.ol.*, bulbus olfactorius; *can.cen.*, central canal of spinal cord; *ch.*, chiasma opticum; *c.mam.*, corpus mamillare; *col.forn.*, columna fornicis; *com.ant.*, commissura anterior; *com.hab.*, commissura habenularum; *c.trap.*, corpus trapezoideum; *f.M.*, foramen interventriculare (Monroi); *g.i.*, gyrus intermedius; *g.marg.ant.*, gyrus marginalis anterior; *g.marg.post.*, gyrus marginalis posterior; *hyp.*, hypophysis; *inf.*, infundibulum; *lamina term.*, lamina terminalis; *med.obl.*, medulla oblongata; *m.i.*, massa intermedia; *ped.cer.*, pedunculus cerebri; *plexus ch.III.*, plexus chorioideus ventriculi tertii; *plexus ch.IV.*, plexus chorioideus ventriculi quarti; *r.c.cal.*, rostrum corporis callosi; *rec.cb.*, recessus cerebelli; *rec.preop.*, recessus preopticus; *s.pol.*, sulcus parolfactorius; *stria med.thal.*, stria medullaris thalami; *t.ol.*, tuberculum olfactorium (intermediate olfactory nucleus); *vel.med.ant.*, velum medullare anterius; *v.III*, ventriculus tertius.

are pictured by Cunningham ('15), Fig. 477, p. 542; Gray ('18), Figs. 715, 720; Quain ('09), Fig. 132, p. 111; Rauber-Kopsch ('12), Fig. 95, p. 77, Fig. 97, p. 81; Sobotta ('11), Fig. 648; Spalteholz ('09), Figs. 694, 695, pp. 625, 626; Toldt ('04), Figs. 1193–1195, pp. 776, 777.

60. Draw the *median surface* of the human brain (or of the sheep's brain if the human specimen is not well preserved or not cut in the exact median plane), paying particular attention to

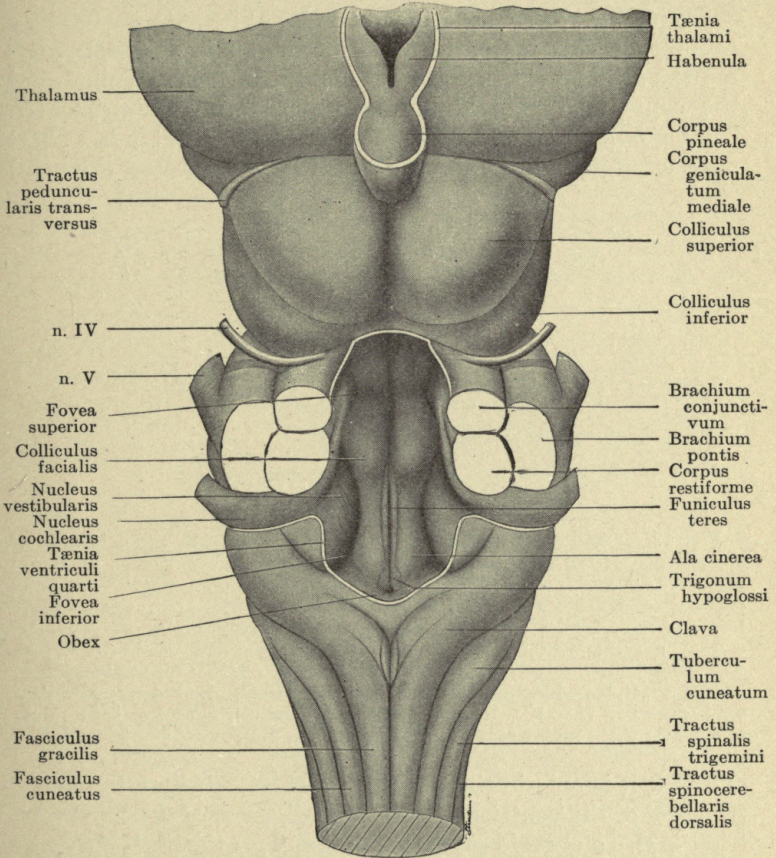


FIG. 11.—The dorsal surface of the medulla oblongata and midbrain of the sheep. $\times 2$.

the extent and boundaries of the ventricles. Trace the ventricular boundaries from the interventricular foramen (of Monro) back to the central canal of the spinal cord. Note especially the thin parts of the ventricular walls: lamina

terminalis, choroid plexus of the third ventricle, anterior medullary velum, and membranous roof of the fourth ventricle (*tegmen fossæ rhomboideæ*), the last two forming the roof of the ventricle above and below the cerebellum respectively.

The *tegmen fossæ rhomboideæ* includes at its anterior border a thin but nervous plate, the posterior medullary velum, bordering the attachment to the cerebellum, and further spinalward the convoluted choroid plexus of the fourth ventricle (cf. Section 50). Notice that the fourth ventricle extends a short distance dorsalward into the cerebellum (*recessus cerebelli*)

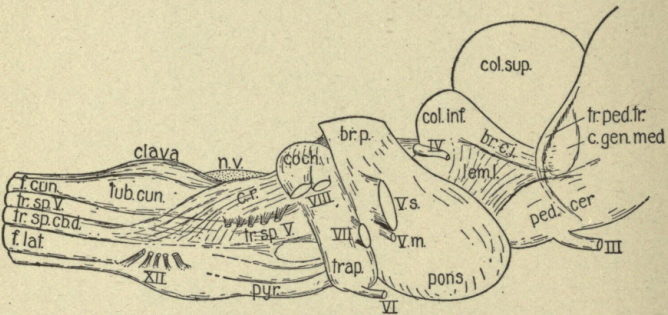


Fig. 12.—The lateral surface of the medulla oblongata and midbrain of the sheep. $\times 1\frac{3}{5}$. *br.c.i.*, brachium of colliculus inferior; *br.p.*, brachium pontis; *c.gen.med.*, corpus geniculatum mediale; *coch.*, nucleus cochlearis; *col.inf.*, colliculus inferior; *col.sup.*, colliculus superior; *c.r.*, corpus restiforme; *f.cun.*, fasciculus cuneatus; *f.lat.*, fasciculus lateralis; *III* to *XII*, cranial nerves; *lem.l.*, lemniscus lateralis; *n.v.*, nucleus vestibularis; *ped. cer.*, pedunculus cerebelli; *pyr.*, pyramid; *trap.*, corpus trapezoideum; *tr. ped. tr.*, tractus peduncularis transversus; *tr.sp.cb.d.*, tractus spino-cerebellaris dorsalis; *tr.sp.V.*, tractus spinalis trigemini; *tub.cun.*, tuberculum cuneatum; *V.m.*, motor root of trigeminus; *V.s.*, sensory root of trigeminus.

and that it is only in this region that the cerebellum forms the true roof of the ventricle. Note that the roof of the third ventricle is also a choroid plexus extending from the pineal body to the interventricular foramen and that a deep fissure, which is outside the brain, extends forward from the region of the tentorium cerebelli between this plexus and the overlying body of the fornix. In the sheep the medial surface of the hippocampus is visible within this fissure (marked "gyrus dentatus" in Fig. 10). Locate the attachment of the choroid plexus of the

third ventricle along the *tenia ventriculi tertii*, or *tenia thalami*, and note also that the plexus itself is continued through the interventricular foramen into continuity with the lateral choroid plexus within the ventricle of the cerebral hemisphere. In a specimen from which the septum pellucidum has been torn away this continuity can be readily observed; but do not at this time attempt further dissection of the lateral choroid plexus (see Section 132).

The *choroid plexuses* of the third and fourth ventricles are commonly referred to, as in the preceding paragraphs, as forming the true roof of the brain cavity in these regions. But according to the more precise usage of the *B N A* each of these structures is really composed of two layers: (1) the *lamina epithelialis*, which is the true brain wall derived from the embryonic neural tube, which here retains its embryonic character as a non-nervous epithelium; (2) the *pia mater*, which is here highly vascular and convoluted. In the *B N A* the term *plexus chorioideus* is applied to this modified pia mater alone.

3. General Directions for Microscopic Material

61. The further study of the spinal cord and brain stem can best be carried out with both gross and microscopic material, though good results can be obtained with either class of material alone. If microscopic preparations are not available, it will be found practicable to select from the following paragraphs those which apply to gross material only. Gross sections through the human brain at the levels indicated below will show many of the details referred to.

62. *Drawings of cross-sections.*—Make an *outline sketch*, ventral side down, of each of four microscopic transverse sections (Weigert method preferred) through the spinal cord taken respectively from the cervical, thoracic, lumbar, and sacral regions; and also select 6 to 12 transverse sections from the series through the brain stem and similarly draw each of these *in outline*. Make these outlines as accurately as possible about six times natural size, or those from the spinal cord and lower part of the medulla oblongata may be magnified 8 diameters and those from the upper levels 4 diameters. The sketches of

the sections should include the outlines of a few only of the more important features, such as the inferior olives, to serve as points of reference. The following levels are recommended:

(1) Upper cervical cord. See Bruce ('92), Fig. 1, Plate XIII; Bruce ('01), Plates I-VIII; Cunningham ('15), Fig. 466; Piersol ('16), Fig. 895, p. 1041; Rauber-Kopsch ('12), Fig. 206, p. 197.

(2) Lower part of decussation of pyramidal tracts. See Bailey ('16), Fig. 333, p. 490; Bruce ('92), Plate III; Cunningham ('15), Fig. 490, p. 558; Piersol ('16), Figs. 920, 921, p. 1069; Quain ('09), Fig. 140, p. 126; Rauber-Kopsch ('12), Fig. 207, p. 197; Sobotta ('11), Figs. 663, 664, p. 172; Spalteholz ('09), Fig. 725, p. 656; Toldt ('04), Fig. 1206, p. 786; Villiger ('12), Fig. 213, p. 238.

(3) Middle of nucleus of fasciculus gracilis including the decussation of the medial lemniscus. See Bailey ('16), Fig. 334, p. 492; Bruce ('92), Plate IV; Cunningham ('15), Fig. 491, p. 559; Piersol ('16), Fig. 922, p. 1070; Quain ('09), Fig. 143, p. 130; Rauber-Kopsch ('12), Fig. 208, p. 198; Sobotta ('11), Fig. 664; Spalteholz ('09), Fig. 726, p. 656; Toldt ('04), Fig. 1208, p. 786; Villiger ('12), Figs. 215, 216, pp. 242-244.

(4) Middle of inferior olive through vagal nuclei. See Bailey ('16), Fig. 335, p. 494; Bruce ('92), Plate VII; Cunningham ('15), Fig. 495, p. 561; Piersol ('16), Fig. 928, p. 1074; Quain ('09), Fig. 146, p. 132; Rauber-Kopsch ('12), Fig. 214, p. 209; Sobotta ('11), Fig. 666; Spalteholz ('09), Fig. 727, p. 657; Toldt ('04), Fig. 1209, p. 786; Villiger ('12), Fig. 219, p. 250.

(5) Roots of VII and VIII nerves. See Bailey ('16), Fig. 340, p. 504; Bruce ('92), Plate IX; Cunningham ('15) Fig. 498, p. 565; Quain ('09), Fig. 163, p. 146; Rauber-Kopsch ('12), Fig. 215, p. 210; Sobotta ('11), Fig. 667.

(6) Colliculus facialis and nucleus of VI nerve. See Bailey ('16), Fig. 342, p. 509; Bruce ('92), Plate XI; Cunningham ('15), Fig. 531, p. 599; Morris ('14), Fig. 652, p. 826; Piersol ('16), Fig. 933, p. 1078; Rauber-Kopsch ('12), Fig. 217, p. 212; Sobotta ('11), Fig. 668; Spalteholz ('09), Fig. 729, p. 658; Toldt ('04), Fig. 1211, p. 787; Villiger ('12), Fig. 225; p. 262.

(7) Roots and nuclei of V nerve. See Bailey ('16), Fig. 343, p. 511; Bruce ('92), Plate XII; Cunningham ('15), Fig. 500, p. 568; Piersol ('16), Fig. 935, p. 1080; Quain ('09), Fig. 164, p.

148; Rauber-Kopsch ('12), Fig. 220, p. 216; Spalteholz ('09), Fig. 730, p. 658; Villiger ('12), Fig. 226, p. 264.

(8) Inferior colliculus. See Bruce ('92), Plate XXIII; Cunningham ('15), Fig. 520, p. 587; Piersol ('16), Fig. 960, p. 1109; Quain ('09), Fig. 212, p. 204; Rauber-Kopsch ('12), Figs. 224, 225, p. 220; Sobotta ('11), Fig. 652; Spalteholz ('09), Fig. 732, p. 659; Toldt ('04), Fig. 1213, p. 788; Villiger ('12), Fig. 229, p. 270.

(9) Superior colliculus. See Bailey ('16), Fig. 355, p. 525; Bruce ('92), Plates XXIV, XXV, XXVI; Cunningham ('15), Fig. 521, p. 587; Edinger ('11), Figs. 220, 227; Morris ('14), Fig. 662, p. 838; Quain ('09), Fig. 213, p. 205; Rauber-Kopsch ('12), Fig. 227, p. 223; Sobotta ('11), Fig. 651; Toldt ('04), Fig. 1215, p. 789; Villiger ('12), Fig. 230, p. 272.

(10) Medial geniculate body and red nucleus. See Luciani ('15), Vol. III, Fig. 244, p. 489; Piersol ('16), Fig. 963, p. 1114; Quain ('09), Fig. 213, p. 205; Rauber-Kopsch ('12), Fig. 228, p. 224; Spalteholz ('09), Fig. 733, p. 660; Toldt ('04), Fig. 1218, p. 791; Villiger ('12), Fig. 231, p. 274.

(11) Middle of thalamus. See Bailey ('16), Fig. 357, p. 533; Piersol ('16), Fig. 967, p. 1120, and Fig. 974, p. 1126; Quain ('09), Fig. 261, p. 261; Rauber-Kopsch ('12), Fig. 127, p. 111; Sobotta ('11), Fig. 646; Toldt ('04), Fig. 1219, p. 792.

(12) Upper part of thalamus behind the anterior commissure. See Quain ('09), Fig. 300, p. 316; Toldt ('04), Fig. 1220, p. 792.

Put each outline on a separate sheet and fill in additional details at a later time as directed below. Study the surface contour of each section drawn, and by comparison with the external form of the cord and brain determine the approximate location of the section. An intact brain or medulla oblongata should be at hand during this comparison. In each outline identify and label every superficial structure which is visible in the gross specimen. The finished drawings will include only selected details of the structures visible in the sections. *Do not complete the drawing* of each cross-section before passing on to the next; but study each fiber tract or nucleus as a whole, following it throughout the series of sections and entering it upon the drawing of each level in which it appears, as directed below, until all the tracts to be studied have been entered upon

the sketches. In these sketches each tract and nucleus should in general be entered on one side only, so as to avoid unnecessary complexity in the finished drawings. In general the ascending tracts should be entered on the right side and the descending tracts on the left side. Of course, tracts which decussate will appear on one side in part of the levels and on the other side in other levels.

The separate tracts and centers may well be drawn in different colors of wax crayons. In the illustrations of the functional analysis of the peripheral nerves in the literature certain systems of nerve components are generally conventionally colored, and on the basis of that usage the following color scheme is suggested. For the basis of the classification employed, see Sections 15 to 19, 47, 52 to 57, 67, and Herrick ('18), Chapters V and IX.

| | |
|--|------------|
| General somatic afferent: | |
| Exteroceptive (general cutaneous)..... | yellow |
| Proprioceptive (muscle sense, etc.) and all afferent cerebellar connections..... | orange |
| Special somatic afferent: | |
| Vestibular (special proprioceptive)..... | brown |
| Auditory (cochlear) and optic..... | green |
| General and special visceral afferent (afferent sympathetic connections, gustatory and olfactory)..... | red |
| General visceral efferent (pre- and post-ganglionic sympathetic fibers)..... | purple |
| Special visceral efferent..... | light blue |
| Somatic efferent, including all efferent cerebellar tracts..... | dark blue |
| Correlation tracts..... | black |

Do not ink the drawings at first, but indicate the outlines of tracts, etc., lightly in pencil; then, when all the sections have been studied as directed in Sections 63 to 101, and the necessary corrections made, review each section and enter upon its drawing any additional details desired, such as the positions of gray centers, nerve-roots, correlation tracts, etc. See that each drawing is fully labeled. Finally, the drawings may be inked in if desired. (For another illustration of this method of laboratory drawing, see Lineback, 1917.)

Throughout the study of the microscopic cross-sections keep in mind the external form of the brain in the region studied and

constantly refer to the intact human brain for the relations of the nerve-roots and other external landmarks.

(During the examination of these sections it will be helpful for the instructor to demonstrate with the projection lantern all of the sections to be studied and point out some of the more important structures. Individual tracts should be followed through the series of sections, passing the entire series in review many times for this purpose.)

4. Internal Structure of the Spinal Cord

63. *General histology of the neuron.*—(a) Procure from the slaughter-house a portion of the spinal cord of a freshly killed beef (the cord of any other one of the larger mammals will answer). Each student should dissect out a small portion of the substance of the ventral gray column (ventral horn) and tease it out with needles on a clean glass slide until it is spread in a thin layer. Cover the fresh tissue with a few drops of a solution of methylene-blue (1 part to 10,000 parts of water) and stain for fifteen minutes. Rinse off the stain, add a drop of water, and cover with a cover-slip. Examine with low and high powers of the microscope and draw a typical neuron with its processes.

(b) Now lay out all of the slides of stained and permanently mounted sections of the spinal cord supplied in the loan collection of microscopic material and examine them to get a general view of its internal structure. Compare sections through the spinal cord prepared by different histological methods (Weigert, Nissl, Golgi, Cajal, etc.) and note which histological elements are best revealed by each of the methods used. Draw on a large scale typical neurons from the ventral gray column from several of these preparations. Look up the technic employed in these methods and the purposes for which each is best adapted. On the study of pathological degenerations and the embryological development of fiber tracts see Section 68 (b) and (c). A thorough neurological study of any part requires the use of several histological methods, since each of them is specific for some elements only of the tissue.

(c) Literature on the neuron: Barker ('10), Chapters I to

IV; Herrick ('18), Chapter III; Meyer ('98); Quain ('09), Vol. 3, Pt. 1, pp. 21-42; Starr, Strong and Leaming ('96).

64. Make a composite drawing of one-half of a section of the spinal cord from Weigert and Nissl (or toluidin blue) sections to show the arrangement of both white matter and nerve-cells. See Herrick ('18), Figs. 57, 58; Morris ('14), Fig. 616, pp. 778, 779; Villiger ('12), Fig. 94, p. 91. Draw the outline and the details of the white matter from a Weigert section and the details of the gray matter from a Nissl section. Label fully all parts, particularly the cell clusters ("nuclei"). Note the relations of the non-nervous elements (ependyma, blood-vessels, connective tissue), neurons, their cell bodies (perikarya) and processes, and the myelinated nerve-fibers. In the gray matter (substantia grisea) identify and designate the columns: *columna grisea ventralis* (ventral horn), *columna grisea lateralis* (lateral horn), *columna grisea dorsalis* (dorsal horn), the *substantia gelatinosa* of Rolando, the *nucleus thoracalis* in the thoracic region (*nucleus dorsalis Clarkii* of the *BNA*, posterior vesicular column of Clarke, Clarke's column), the reticular formation (*formatio reticularis*). Identify the commissures: *commissura ventralis alba*; *commissura ventralis grisea*; *commissura dorsalis*.

The *substantia alba* (white matter) of each side is divided anatomically by the emerging nerve-roots into three portions named respectively *funiculus dorsalis*, *lateralis*, and *ventralis* (Herrick ('18), Fig. 57). These funiculi are further subdivided topographically into fasciculi (*fasc. ventro-lateralis*, etc.) which are usually made up of fibers of diverse sorts. The real units of spinal cord structure are the *tracts*, each of which is composed of fibers of like connections and functions. (Neurologists often use the words *funiculus*, *fasciculus*, and *tract* as synonyms, with resulting confusion.) Your preparations present no anatomical boundaries of the fasciculi and tracts. They have been determined by physiological experimentation and the study of degenerations following pathological lesions.

65. *Neurons of the cord*.—Lay out before you the four outline sketches through the spinal cord in the cervical, thoracic, lumbar, and sacral regions, which have already been drawn. Now in the Nissl (or toluidin blue) sections of the cord note the

distribution of nerve-cells in both the dorsal and ventral gray columns at each of these levels and compare in detail the grouping of the cell bodies in the ventral columns. Draw these groups of cells in the four outline sketches of the spinal cord. The ventro-medial group of neurones supplies the muscles of the back, the dorso-lateral and ventro-lateral groups chiefly the muscles of the limbs, and the intermedio-lateral groups the motor sympathetic fibers (see Barker ('01), pp. 883-914; Bruce ('01); Cunningham ('15), Fig. 467, p. 525; and Fig. 468, p. 529, also summary on p. 527; Curtis and Helmholz ('11); Herrick ('18), Fig. 59; Piersol ('16), Figs. 895-901, pp. 1041-1046; Quain ('09), Fig. 112, p. 78; Rauber-Kopsch ('12), Figs. 35-64, pp. 39-42.

On the neurons of the dorsal gray columns and their connections consult Ramón y Cajal ('09), Vol. I, pp. 307-340.

66. The spinal cord performs two important groups of functions: (1) it contains the central mechanisms of the intrinsic spinal reflexes; (2) it serves as a path of conduction between the sensory and motor spinal nerves and the higher correlation centers of the brain. For a list of the tracts belonging to the second group, see Section 101. Here attention should be directed to the intrinsic reflex connections of the cord. (On this subject see the very interesting cases reported by Riddoch, 1917.) The cell bodies of the neurons involved in these reflexes lie in the gray matter, and their axons form the greater part of the fasciculus proprius, through which reflex impulses are transmitted in both ascending and descending directions between the different levels of the cord. With the aid of your reference books build up a clear picture of the mode of connection of these neurons in typical spinal reflexes. See Herrick ('18), Figs. 60, 61; Herrick and Coghill ('15); Howell ('18), Chapters VII, VIII; Morris ('14), Fig. 610, p. 767; Quain ('09), p. 99; Sherrington ('06), Chapters I to IV, especially the diagram on p. 46; Starling ('15), Chap. VII; Starr, Strong, and Leaming ('96).

67. *Functional analysis of the cord.*—(a) The classification of the functional systems adopted in this work should here be reviewed (see Sections 15 to 19, 47, 52 to 57, and the references there given). The somatic sensory systems include the nerves,

centers, and correlation tracts of general cutaneous and deep sensibility (in muscles, joints, etc.) and in the head the optic, auditory, and cerebellar systems. These are all concerned with the adjustment of the body to its external environment. They fall into two subdivisions: (1) exteroceptive, and (2) proprioceptive (see Herrick ('18), Chapters V and IX; Sherrington ('06) Chapter IV), whose conduction pathways and correlation centers are distinct. The exteroceptive systems respond to external excitations; the proprioceptive systems to excitations arising within the body, but subsidiary to the somatic motor reacting system. The optic and cochlear systems constitute highly differentiated or *special* members of the exteroceptive series, and the vestibular system is similarly a *special* proprioceptive apparatus.

(b) Review now the functional composition of the spinal nerves (see Herrick ('18), Figs. 55 and 56) and master the topographic relations of the internal fiber tracts related to the various functional systems. (The central relations of the visceral sensory components of the spinal nerves are not accurately known.) The primary somatic motor and visceral motor centers of the cord are distinct and are easily recognized in Nissl preparations. The somatic motor neurons lie in the ventral gray column and the visceral motor in the intermedio-lateral column (see Herrick ('18), Fig. 56).

68. (a) Locate with the aid of the reference books the course of the exteroceptive spinal lemniscus tracts for touch, temperature, and pain, and of the proprioceptive systems (dorsal funiculi and spino-cerebellar tracts). See Herrick ('18), Chapter VIII, and especially Figs. 59, 63, and 64; on the general somatic systems Chapter XI should also be read in this connection. Howell ('18), Chap. VIII; Starling ('15), Chap. X.

(b) If pathological preparations illustrating degenerations of spinal cord tracts are available, these should be studied at this time. Consult the larger text-books of neurology, and especially those of neuropathology. (Later sections relating to the tracts of the brain may be illustrated in the same way in any cases where pathological microscopic preparations are available.)

(c) Valuable information regarding the courses of the fiber

tracts of the cord and brain has been gained by embryological methods. Some functional systems of fiber tracts mature earlier than others. Fetal spinal cords of man, pig, or any other mammal taken at successive periods from the age when myelinated fibers first appear up to birth and stained by the Weigert method will demonstrate the sequence of myelination of the spinal tracts. See Barker ('01), pp. 424-437; His ('04).

5. Sympathetic Nervous System

69. At this time the student should consult his reference books and so become familiar with the general pattern of the sympathetic nervous system and its relations with the cerebrospinal system. The sympathetic trunk and its connections with the spinal nerves have already been seen (Section 41). The following references are suggested: Barker ('16), Fig. 552, p. 269; Cunningham ('15), pp. 679-682, 753-767; Edinger ('11), pp. 96-105; Gray ('18), pp. 970-989; Herrick ('18), Chap. XVI; Howell ('18), Chap. XII; Huber ('97); Johnston ('06), Chap. XII; Langley ('00, '00a, and '03); Luciani ('15), Vol. III, Chap. VI, pp. 359-378; Morris ('14), pp. 1026-1047; Piersol ('16), pp. 1353-1375; Quain ('09), pp. 1-3, 13-20; Sobotta ('11), pp. 238-246; Starling ('15), Chap. XIX; Stewart ('18), Chap. XVII.

6. The Medulla Oblongata

70. *The somatic sensory systems.*—(a) Here familiarize yourself from the reference books with the somatic sensory nerve-endings in the skin, subcutaneous tissues, muscle spindles, tendons, joints, etc. See Herrick ('18), Chap. V; Barker ('01), pp. 361-421; Cunningham ('15), pp. 856-866; Piersol ('16), pp. 1014-1020; Quain ('09), Vol. 3, Pt. 1, pp. 44-52; and all works on histology.

(b) Now review again the superficial landmarks of the ventricular and lateral surfaces of the human medulla oblongata, with special reference to the underlying functional columns (see Sections 51 to 57). General somatic sensory fibers for cutaneous and deep sensibility of the head are found in the V, IX, and X cranial nerves (Herrick ('18), Chap. XI), and the special

somatic cochlear (Herrick ('18), Chap. XIII) and vestibular (Herrick ('18), Chap. XII) are represented in the VIII nerve. The connections of these systems will next be taken up, together with the cerebral portions of the spino-cerebral tracts whose spinal parts have already been mentioned. The cerebellum, which is a derivative of the somatic sensory column, will be examined later, and the composition of its peduncles summarized.

71. *The general cutaneous system.*—The cutaneous fibers from the face enter the brain by the V nerve; a smaller number by the IX and X nerves. The cell bodies of these fibers are located respectively in the semilunar (V), superior (IX) and jugular (X) ganglia. The fibers of the sensory V root in part end in the chief sensory V nucleus dorso-medially of the superficial origin of the root, but most of them turn abruptly spinalward and thus form the spinal V tract, whose fibers form an eminence on the lateral surface of the oblongata—the tuberculum cinereum or tubercle of Rolando.

72. *Gross preparation of the spinal V tract.*—On the right half of the brain of the sheep locate the V, IX, and X roots (Figs. 7, 8, 12) and the tuberculum cinereum. Now with a wooden dissector begin at the lower border of the V root and carefully scrape away the transverse fibers of the pons and the trapezoid body until the longitudinal fibers of the spinal V tract lying immediately internal to them are exposed. Continue the dissection spinalward by gently teasing off the superficial external arcuate fibers (see Section 90). Careful scraping in the longitudinal direction with an orange-wood stick sharpened to a slightly rounded chisel edge will readily expose the whole length of the spinal V tract to its terminus in the cervical cord. In its spinal course its fibers become superficial.

A similar dissection can readily be made on the human brain also, though the larger size of the pons makes it necessary to cut through the large mass of the transverse pons fibers below the V root with a sharp knife in order to expose the spinal V fibers. This dissection, however, should not be made on the same specimen which is to be used for the optional dissections of the oblongata (Sections 102–111).

73. *Microscopic study of the V roots.*—In the microscopic

sections find the sensory V root in the pons region (see the references in Section 62 (7)), and follow its fibers backward into the spinal V tract. Only a part of the sensory V root-fibers enter this tract. Others enter the chief sensory V nucleus, which lies dorsally of the spinal V tract at the level of entrance of the fibers of the V nerve and forward (rostrally) of this level. The chief sensory nucleus of the V nerve and the spinal V nucleus (substantia gelatinosa of Rolando), which accompanies the spinal V tract, are the terminal nuclei of the general cutaneous components of the cranial nerves. These nuclei and the spinal V tract should be located and entered in the drawings of all sections in which they occur.

A few general cutaneous fibers enter the spinal V tract and its nucleus from the IX and X roots also, but these are usually not evident in the sections. The motor nucleus of the V nerve will be seen lying medially of the chief sensory V nucleus and it may be drawn in at this time. Golgi sections show that some peripheral sensory V fibers end in the motor V nucleus, thus providing a direct reflex connection between the skin of the face and mouth and the jaw muscles. Neurons of the spinal V nucleus effect the connection between the peripheral cutaneous fibers of the spinal V tract and the motor nuclei of the VII, IX, and X nerves.

74. *Trigeminal lemniscus*.—The ascending secondary fibers from the chief sensory V and spinal V nuclei to the somesthetic nuclei of the thalamus (lateral and related nuclei) form two tracts, both of which are called the trigeminal lemniscus. Their fibers cannot easily be traced in either gross or microscopic preparations.

For diagrams showing the positions of the V nuclei and their connections with other centers in the brain, see Bailey ('16), Fig. 344, p. 512; Herrick ('18), Figs. 64, 71, 73, 75, 77, 78, 81; Gray ('18), Figs. 696–698; Morris ('14), Fig. 654, p. 828; Quain ('09), Vol. 3, Pt. 1, Figs. 170, 171, 172, 175, 176; Villiger ('12), Figs. 163, 164.

75. *The Mesencephalic V root*.—The fibers of this root can easily be recognized in the microscopic sections; see Herrick ('18), Fig. 75, and the references cited in Section 62 (8) and (9). The root-fibers for the motor and chief sensory V nuclei form a

layer of white matter separating these nuclei. From the dorsal border of this layer the fibers of the mesencephalic root can be followed in the series of sections forward and dorsalward to take their positions along the lateral wall of the aqueduct of Sylvius; here they extend through the entire length of the midbrain. These fibers are the innermost myelinated fibers in this region and they are of very large size, though few in number. Most of them are descending fibers arising from the cells of the mesencephalic V nucleus, which can be seen in favorable preparations as a row of large flask-shaped nerve-cells accompanying the tract. Others ascend from cell bodies lying in the semilunar ganglion. This root of the V nerve has often been regarded as motor and is so described in many works; but its sensory character is now well established, though the functions of its ascending and descending fibers are not understood. In the guinea-pig the descending fibers enter the muscular branches for the masseter, pterygoid and temporal muscles (Allen) and probably serve the muscle sense.

See Allen ('19), Herrick ('18), Chap. IX; Johnston ('05); Morris ('14), Fig. 654, p. 828; Otto May and Victor Horsley ('10).

76. *The dorsal funiculi of the cord.*—In the gross specimens both of the human and the sheep's brain identify the fasciculus gracilis and the clava, into which its fibers run to end among the cells of the underlying nucleus of the fasciculus gracilis. Identify also the fasciculus cuneatus and the tuberculum cuneatum, within which lies the nucleus of the fasciculus cuneatus.

Now examine the microscopic sections of the human brain in the region of transition between spinal cord and medulla oblongata and locate all of the structures mentioned in the preceding paragraph. See lists of references under required drawings, Section 62 (1), (2), and (3). Follow the fibers of the fasciculus gracilis and fasciculus cuneatus downward through the four levels of the spinal cord and enter them in your sketches of these levels. Then, beginning at the upper end of the cord, follow these fasciculi upward into their nuclei under the clava and tuberculum cuneatum respectively, where their fibers end. The axons arising from the cells of these nuclei form the medial lemniscus (fillet).

77. *The medial lemniscus.*—These fibers immediately descend from their nuclei to cross ventrally of the ventricle to the other side of the brain, thus forming the decussation of the lemniscus. This tract after its decussation can be followed through the series of sections as far as the thalamus. In the lower part of the medulla oblongata these fibers will be found in the interolivary space near the median plane (Herrick ('18), Figs. 64, 72, 73). They are bounded ventrally by the cortico-spinal (pyramidal) tract, and dorsally by the tecto-spinal tract. Dorsally of the latter is the longitudinal medial fasciculus. At the level of the pons the medial lemniscus begins to turn laterally and in the midbrain it lies dorsally of the substantia nigra (Herrick ('18), Fig. 75). In sections through the midbrain and thalamus these fibers can readily be followed forward to their termination in the lateral and associated somesthetic nuclei of the thalamus (Herrick ('18), Figs. 77, 78, and 79). The medial lemniscus carries general proprioceptive nervous impulses from the spinal cord to the thalamus.

Identify the medial lemniscus in the sections and draw it into the outlines as far forward as the material provided will permit. See, in addition to the figures cited in the previous paragraph, Section 62 (1) to (11); Cunningham ('15), Fig. 579, p. 651; Morris ('14), Fig. 632, p. 803; Piersol ('16), Fig. 964; Sabin ('01), Plates V, VII; Spalteholz ('09), Fig. 752, p. 675; Villiger ('12), Figs. 154, 155, pp. 167, 168. Directions for the dissection of the medial lemniscus of man will be found in Section 108.

78. *The spinal lemniscus.*—The ascending secondary pathway for exteroceptive sensibility (touch, temperature, pain) from the trunk and limbs is the spinal lemniscus, or spino-thalamic tracts. There are two of these tracts in the cord, the tractus spino-thalamicus dorsalis for pain and temperature, and the tractus spino-thalamicus ventralis for touch and pressure (Herrick ('18), Fig. 63). In the medulla oblongata these accompany the ventral spino-cerebellar tract (Herrick ('18), Fig. 73) and in the midbrain they join the lateral lemniscus (Herrick (18), Fig. 75).

It is difficult to demonstrate these tracts in either gross or microscopic material. From your reference books learn their

courses and enter them in the outline drawings of the cross-sections in their appropriate places so far as these can be ascertained.

79. *Summary of secondary general somatic sensory tracts.*—The general somatic sensory centers and tracts of the brain which have now been analyzed comprise the spinal V tract and its nucleus, the chief sensory V nucleus, the mesencephalic V tract and nucleus, the dorsal funiculi and medial lemniscus, and the spinal lemniscus. The centers mentioned receive all fibers of non-visceral cutaneous and deep sensibility from the head, trunk, and limbs except those serving the muscle-sense from the extrinsic eye-muscles. Fibers of this character are present in the III, IV, and VI cranial nerves, but of their central connections nothing is known.

From these primary sensory centers connections are made through the reticular formation (see Section 89) with neighboring motor centers for local reflexes. All ascending tracts of the second order from the primary sensory centers to the thalamus are termed lemnisci. The trigeminal lemniscus and the spinal lemniscus carry exteroceptive nervous impulses (general somatic sensory series). Proprioceptive reactions are served by (1) the dorsal funiculi of the cord and medial lemniscus, (2) vestibular system, and (3) the cerebellar connections. The first of these three belongs in the general somatic sensory series, the second in the special somatic sensory series, while the cerebellum is the general co-ordination center for both of these series.

The papers of Head and his associates (see Head and Thompson ('06), and Head and Holmes ('11)), may profitably be read at this time; also Johnston ('06), Chapter VI.

80. *Organ of hearing.*—If microscopic sections are available, study the cochlea and spiral organ (organ of Corti). Accounts of the structure and functioning of the internal ear may be found in most of the standard text-books. See Bailey ('16), pp. 580-590; Cunningham ('15), pp. 843-854; Herrick ('18), Chap. XIII; Howell ('18), Chap. XX; Morris ('14), pp. 1092-1096; Starling ('15), pp. 505-519; Stewart ('18), pp. 1065-1075. For special reference, the literature cited at the end of Chapter XIII (Herrick, '18) is recommended, particu-

larly the papers of Hardesty ('08a) and ('15), Prentiss ('13), Shambaugh ('07) and ('08), and Van der Stricht ('18).

81. *Gross preparation of the cochlear nerve and its connections.*—In the gross specimens locate the inferior peduncle of the cerebellum (*corpus restiforme*), which connects the dorso-lateral wall of the medulla oblongata with the cerebellum. This is crossed immediately behind the cerebellum by the dorsal cochlear root and nucleus of the VIII nerve (called the tuberculum acusticum). Find this structure in both the human and the sheep's brain. Immediately ventro-laterally of the dorsal cochlear nucleus at the point where the cochlear root of the VIII nerve enters the brain is found the ventral cochlear nucleus.

Root-fibers of the cochlear nerve terminate in both the dorsal and the ventral cochlear nuclei. Fibers of the central acoustic path leave these nuclei by two chief tracts. From the ventral nucleus they enter the trapezoid body (*corpus trapezoideum*), which can be seen in the sheep's brain as a wide transverse band on the ventral surface immediately below the pons. In the human brain these fibers are covered by the fibers of the pons and cannot be seen without dissection of the pons. From the dorsal cochlear nucleus the secondary acoustic path passes medialward along the surface of the floor of the fourth ventricle, thus forming the *striæ medullares acusticæ*, which are very conspicuous in the human medulla oblongata, but less so in the sheep. The further course of the ventral acoustic tract can readily be dissected in the sheep's brain. Having crossed the midplane in the trapezoid body, they enter or pass close to the superior olive and then turn forward to form the chief component of the lateral lemniscus (lateral fillet), which terminates in the inferior colliculus and medial geniculate body.

On the left half of the sheep's brain, which has been divided in the median plane (see Figs. 7, 8, 11, 12) locate the root of the cochlear nerve and its nuclei. The connection of the ventral cochlear nucleus with the trapezoid body farther ventrally can readily be demonstrated. Now observe the relations of the pons and the brachium pontis and of the brachium conjunctivum (superior cerebellar peduncle).

The fibers of the latter will be seen to be directed forward, medialward, and ventralward. On the lateral surface of the

brain (see Fig. 12, *lem.l.*) immediately in front of the pons and more ventrally and superficially than the fibers of the brachium conjunctivum are fibers running from the border of the pons obliquely forward and dorsalward, thus crossing at a right angle the deeper fibers of the brachium conjunctivum. These superficial fibers compose the lateral lemniscus. They occupy a triangular area bounded by the pons behind, the basis pedunculi (pyramidal and cortico-pontile tracts) below, and the corpora quadrigemina above (Herrick ('18), Fig. 45).

Beginning at the cut medial surface, strip back the fibers of the pons as far laterally as the roots of the V nerve. Immediately ventrally of these root-fibers careful teasing with a sharpened wooden instrument will show that some fibers of the trapezoid body turn from the transverse to the longitudinal direction and, passing internal to the pons fibers, reappear on the surface in front of the pons as the lateral lemniscus fibers, to which reference has already been made. At the point where they turn and are covered by the overlying pons fibers a small nucleus of gray matter may be found. This is the superior olive. By gentle teasing the lateral lemniscus fibers may be followed from the level of the pons forward and dorsalward. Some enter the medial geniculate body of the thalamus and some enter the inferior colliculus. The latter are interrupted by a synapse here and the acoustic path is then continued forward through the brachium of the inferior colliculus to enter the medial geniculate body in company with the component first described.

The secondary acoustic path is thus seen to ascend from the cochlear nuclei of one side by way of the lateral lemniscus to the medial geniculate body of the thalamus of the opposite side. Some of these fibers enter the thalamus directly and some are first interrupted by a synapse in the inferior colliculus.

For the dissection of the lateral lemniscus in the human brain, see Section 106.

82. *Microscopic study of the cochlear nuclei and lateral lemniscus.*—Now in the microscopic sections of the human brain stem locate the structures described in the last section (see Section 62 (5)).

Identify the dorsal and ventral cochlear nuclei and the striæ

medullares acusticæ. The fibers of the trapezoid body may not be easily distinguished from the deepest fibers of the pons which lie ventrally of them. The superior olive is a small gray nucleus lying deeper than any of these fibers and laterally of the great medial lemniscus tract (medial fillet). If the lateral lemniscus is not easily identified in this region, locate it in sections at the level of the upper border of the pons and trace it back to the superior olive. In sections through the midbrain the lateral lemniscus can readily be followed to its terminations in the medial geniculate body and inferior colliculus, and the fibers from the later to the medial geniculate body in the brachium of the inferior colliculus are also easily identified. Diagrams illustrating the connections of the cochlear nuclei with other centers of the brain are given in many texts. See Bailey ('16), Fig. 338, p. 500; Herrick ('18), Fig. 96; Morris ('14), Fig. 650, p. 824; Rauber-Kopsch ('12), Fig. 258, p. 269; Villiger ('12); Fig. 165, p. 179.

83. *Nervus vestibularis and its nuclei.*—Locate in your microscopic sections and draw the vestibular root of the VIII nerve and its nuclei (see Section 62 (5) and (6)), viz.:

Nucleus n. vestibuli superior (of Bechterew).

Nucleus n. vestibuli lateralis (of Deiters or nucleus vestibularis magnocellularis).

Nucleus n. vestibuli medialis (of Schwalbe, also called nucleus dorsalis, principal nucleus, and nucleus vestibularis triangularis).

Nucleus n. vestibuli spinalis.

The fibers of the vestibular root pass inward beneath the inferior cerebellar peduncle (restiforme body) and at right angles to its fibers. The vestibular nuclei lie in the floor of the fourth ventricle medially of the restiform body (Herrick ('18), Figs. 86 and 96). All of these nuclei (especially the nucleus medialis) send fibers into the reticular formation of the same and the opposite side for motor reflexes of the oblongata. Find in these sections, if possible, the fibers which pass from the vestibular root and nucleus to the restiforme body and thence into the cerebellum—the cerebellar root of the VIII nerve and the vestibulo-cerebellar tract. These fibers pass directly dorsalward from the upper end of the vestibular nuclei (see Herrick

('18), Fig. 86) and join the restiform body on its medial side. Identify also the vestibulo-spinal tract, passing toward the spinal cord from the lateral and spinal vestibular nuclei. It can be followed downward through the series of sections, lying in the angle between the restiform body and the dorsal vagal nuclei (see Herrick ('18), Fig. 72). Learn its position and enter it in the sketches of the medulla oblongata and cord.

The superior and medial nuclei send fibers into the fasciculus longitudinalis medialis (posterior longitudinal bundle, see Section 92). Enter upon your drawings all of these vestibular tracts which have been observed, including the fasciculus longitudinalis medialis. See Bailey ('16), Fig. 339, p. 502; Howell ('18), Chap. XXI, Jones ('18); Piersol ('16), Fig. 1071, p. 1258; Quain ('09), Fig. 158, p. 141, and Fig. 181, p. 166; Villiger ('12), Fig. 168, p. 182.

We have now completed our first survey of the somatic sensory systems of the spinal cord and the medulla oblongata, except their connections with the cerebellum. These will be taken up after the examination of the visceral sensory and the motor centers of the medulla oblongata.

84. *Visceral sensory system.*—In the microscopic sections identify and draw the fasciculus solitarius and its nucleus. (See Section 62 (4) and (5)). This fasciculus is made up chiefly of root-fibers of the VII, IX, and X cranial nerves carrying both general and special visceral sensory nervous impulses, the special fibers being gustatory in function (Herrick ('18), Fig. 114). Root-fibers of some or all of these nerves may be seen in the sections entering the fasciculus. They arise from the geniculate (VII), petrosal (IX) and nodosal (X) ganglia. Both the general and the special visceral sensory fibers end in the nucleus of the fasciculus solitarius, the gustatory fibers probably in its upper end. In the region of the ala cinerea (Herrick ('18), Figs. 71 to 74) the nucleus is enlarged dorsally and comes to the surface of the floor of the fourth ventricle at the lateral border of the ala cinerea. The fasciculus solitarius and its nucleus correspond with the visceral sensory column seen in the brain of the dogfish (Section 23). For the dissection of the fasciculus solitarius in the human brain see Section 110.

In connection with this section read Herrick ('18), Chap. XVII, and Johnston ('06), Chap. IX.

85. *The organs of taste.*—If microscopic material showing the structure of the taste-buds is available it should be examined in connection with the study of the visceral sensory system (see Bailey ('16), pp. 229–232, 593; Cunningham ('15), pp. 854–856; Piersol ('16), Figs. 1193–1197). There has been much dispute among neurologists regarding the nerve-roots by which taste-fibers reach the brain. The student should become familiar with the various theories (see Cushing ('03), Herrick ('18), Fig. 115, and the accompanying discussion).

86. *Visceral efferent system.*—In the microscopic sections identify and draw the dorsal motor X nucleus under the ala cinerea. See Section 62 (4) and Herrick ('18), Figs. 71 to 74 and 114. This is the general visceral efferent nucleus of the vagus. The general visceral efferent nuclei of the IX and VII nerves are respectively the inferior and superior salivatory nuclei (see Herrick ('18), Figs. 71, 73, and 114). These are not easily identified in the sections. Identify also the nucleus ambiguus (Herrick ('18), Figs. 71 to 74 and 114) and the chief motor nuclei of the VII and V nerves. These are the nuclei of the special visceral motor components. Look for fibers passing out from them into the V, VII, IX, and X nerves. Extending from the nucleus ambiguus downward into the spinal cord is the nucleus of the XI nerve. In the upper levels of the cervical cord these cells form the lateral gray column. Fibers may be seen passing directly lateralward from this nucleus into the spinal roots of the XI nerve.

Sections of the midbrain through the nucleus of the III nerve will show a median group of cells of this nucleus, the nucleus of Edinger-Westphal (see Herrick ('18), Fig. 71) which sends general visceral efferent fibers to the ciliary ganglion.

Visceral reflexes may be effected by short and very simple connections between the afferent visceral sensory fibers terminating in the nucleus of the fasciculus solitarius and the efferent visceral fibers arising from the motor nuclei mentioned in the preceding paragraphs. The neurons of the nucleus of the fasciculus solitarius serve to connect these primary centers (see Herrick ('18), Fig. 113). On the visceral efferent system in general, see Johnston ('06), Chap. XII.

87. *Somatic motor nuclei*.—This system is represented in the III, IV, VI, and XII nerves. These nuclei and the root-fibers arising from them should be drawn in the outlines of the sections (see references under required drawings Section 62; also Bailey ('16), Fig. 354, p. 524; Gray ('18), Fig. 696, p. 781; Herrick ('18), Figs. 71, 75, and 86, and the discussion in Chaps. IX and XI; Johnston ('16), Chap. XI; Morris ('14), Fig. 647, p. 821, pp. 931, 932, Fig. 661, p. 837, Fig. 663, p. 839; Quain ('09), Vol. 3, Pt. 1, Fig. 150, p. 136; Rauber-Kopsch ('12), Fig. 226, p. 281; Villiger ('12), Fig. 162, p. 175).

88. *Correlation fibers of the medulla oblongata*.—Afferent nerve-fibers enter the medulla oblongata by the sensory roots of the V to X cranial nerves and by certain tracts from the spinal cord. Some of these fibers effect secondary connections with the cerebellum as described below; some of the other connections are as follows:

The peripheral general cutaneous fibers from the head are discharged into the chief sensory and spinal V nuclei. The axons of the neurons of these nuclei in part connect with the various motor nuclei of the brain-stem for local reflexes, and in part ascend to the thalamus through the trigeminal lemniscus, as already mentioned.

The central connections of the general proprioceptive fibers of the head are unknown. Probably the mesencephalic V nucleus is related to this system.

The special proprioceptive fibers from the labyrinth are received by the vestibular nuclei, as already described; the axons of these cells reach the various motor nuclei of the bulb, the cerebellum (through the vestibulo-cerebellar tract) and the spinal cord (through the vestibulo-spinal tract). The fasciculus longitudinalis medialis is an important correlation tract for this system (see Section 92).

The chief central pathway from the cochlear nuclei is the lateral lemniscus already studied; but in addition to this there are manifold reflex connections between these nuclei, the nuclei of the trapezoid body, the superior olives, the nuclei of the lateral lemniscus, and the inferior colliculus on one hand and the motor nuclei of the bulb and spinal cord on the other hand. The spinal connection is chiefly through the tecto-spinal tract of the cord (Herrick ('18), Fig. 59).

Visceral reflexes may be effected by short and very simple connections between the nucleus of the fasciculus solitarius and the motor nuclei of the bulb. There is also a visceral lemniscus conducting visceral impulses upward to the diencephalon, but the course of these fibers in the human brain is unknown.

89. *The reticular formation* (see Herrick ('18), Figs. 69, 73, 81, and 83).—In addition to the direct and relatively simple connections between the sensory and the motor nuclei referred to in the preceding sections, there are more diffuse connections for more complex reflexes through the *formatio reticularis*. This is a complex of gray with many bundles of myelinated fibers running through it in the ventro-lateral regions of the medulla oblongata. Locate it in the sections and indicate it in the drawings. This tissue is reached by fibers from all sensory nuclei of the medulla oblongata and the axons of its neurons are distributed to the various motor nuclei. It is the direct continuation of the reticular formation of the cervical cord (see Herrick ('18), Fig. 58, "*processus reticularis*") and its fibers (the *formatio reticularis alba*) are functionally similar to the *fasciculi proprii* of the cord.

90. *Arcuate fibers*.—The correlation fibers just described in part connect various nuclei of the same side of the brain, and in part they cross to the opposite side. The decussating fibers are called arcuate fibers. Some of them cross obliquely through the deeper levels of the oblongata (internal arcuate fibers), while others form a thin but dense layer of obliquely transverse fibers on the extreme outer surface (external arcuate fibers, see Herrick ('18), Fig. 72). Both sorts of arcuate fibers are evident in sections at most levels of the medulla oblongata.

91. *The spino-bulbar tracts*.—Various ascending tracts from the spinal cord to the brain have already been mentioned. Some of these fibers pass through the medulla oblongata to end in the thalamus and the cerebellum. Others, like the *fasciculus gracilis* and *fasciculus cuneatus*, end in the medulla oblongata and, after a synapse here, are continued upward to the thalamus under a different name. The fibers of all of these tracts may give off collaterals into the gray centers of the cord and the correlation centers of the brain stem. Similar fibers reach the midbrain (*tractus spino-tectalis*, see Herrick

('18), Figs. 59 and 75.) These connections serve for reflexes of more complex sorts than can be effected in the spinal cord alone, in contrast with the lemniscus systems terminating in the thalamus and thence connecting with the cerebral cortex, which may serve conscious reactions. The spino-bulbar connections are diffuse and are not readily seen in sections, though physiologically they are important.

92. *The longitudinal medial bundle.*—The fasciculus longitudinalis medialis (the posterior longitudinal bundle) is an important longitudinal motor co-ordination system which can easily be followed in the microscopic sections through the whole length of the midbrain and bulb and downward into the fasciculus proprius of the cord. It is composed of heavily myelinated fibers lying near the median plane immediately ventrally of the ventricle. It has already been noted in connection with the vestibular apparatus (Section 83). If its entire course has not already been entered in the drawings, this should be done now. It arises in front of the III nucleus and is related with all of the motor nuclei of the brain and spinal cord. It is used in conjugate movements of the eyeballs, in vestibulo-oculomotor equilibratory reactions, and in many other reflex movements. See Barker ('01), Fig. 406, p. 617; Bruce ('92), Plate XXVII, Fig. 1; Cunningham ('15), Fig. 524, p. 590; Piersol ('16), Fig. 965, p. 1117.

93. *Dissection of the longitudinal medial bundle.*—On the right side of the divided sheep's brain this tract can be brought to view by gentle scraping in the longitudinal direction on the median cut surface immediately ventrally of the fourth ventricle. In this way the fasciculus can be exposed throughout the entire length of the brain stem.

94. *Microscopic study of the pyramidal tract.*—The tractus cortico-spinalis (fasciculus cerebro-spinalis of the *BNA*), or pyramidal tract, is the great descending voluntary motor path between the motor areas of the cerebral cortex and the lower motor centers. It can be readily identified in the sections through the middle region of the medulla oblongata (see references in Section 62), lying ventrally close to the median plane below the olives. From the level of the olives follow it upward also. Immediately below the pons it forms a sharp projection

on the ventral surface, the pyramid, from which the tract receives its name. Its fibers can be followed into the substance of the pons. Here, as the sections are followed upward, the fibers of the cortico-pontile tracts are added to them, so when they emerge upon the ventral surface of the cerebral peduncle above the pons, the pyramidal fibers form only the middle part of the basis pedunculi, with cortico-pontile fibers on each side of them.

Enter the pyramidal tract in the sketches, consulting Herrick ('18), Fig. 75, for its position in the cerebral peduncle. The following references are also suggested: Bailey ('16), Fig. 331, p. 486; Cunningham ('15), Fig. 480, p. 545; King ('11); Morris ('14), Fig. 664, p. 841, and Fig. 706, p. 897; Piersol ('16), Fig. 1026, p. 1187; Rauber-Kopsch ('12), Figs. 263, 264, pp. 276, 277; Toldt ('09), Fig. 1216, p. 790; Fig. 1229, p. 800; Villiger ('12), Figs. 176, 179, 181, 182.

95. *Dissection of the pyramidal tract.*—The pyramidal tract can readily be dissected in the brains of the sheep and of man. If only one human brain is to be dissected and it is desired to make the optional dissections, this tract should not be exposed in this specimen at this time (see Section 138).

On the right half of the brain of the sheep (see Fig. 8) locate the pyramid on the ventral surface below the pons. Strip the pons fibers back from the cut median surface for a short distance so as to expose the longitudinal pyramidal fibers dorsally of them. In the sheep the pyramidal fibers will be found to interdigitate with those of the trapezoid body and one or the other of these systems will have to be partially destroyed to expose the other. In following the pyramidal tract spinalward, careful teasing will separate its fibers as far down as their decussation, below which they can no longer be dissected. For their spinal course see King ('11).

From the pons upward the pyramidal tract can be dissected through the cerebral peduncle, the number of associated cortico-pontile fibers being much less than in man. The further dissection of the pyramidal tract through the cerebral hemisphere should be deferred (see Sections 138 and 150).

There are many descending systems besides the pyramidal tracts; for an excellent summary of these see Rauber-Kopsch ('12), pp. 275–292.

7. Structure and Connections of the Cerebellum

96. *The cerebellar peduncles.*—There are three of these peduncles: the superior (*brachium conjunctivum*), the middle (*brachium pontis*), and the inferior (*corpus restiforme*).

(a) *Gross Structure.*—The cerebellar peduncles have been severed in both the human and the sheep's brain (Section 49). Examine their cut surfaces on the dorsal aspect of the medulla oblongata (for the sheep see Fig. 11). With the orange-wood stick separate the fibers of the three peduncles from each other on the cut surface and continue the separation of the superior and middle peduncles for 1 cm. or less in a downward direction.

On the left half of the sheep's brain expose the inferior peduncle, or restiform body, by the removal of the cochlear nuclei (cf. Section 81) and tease out its fibers from their cut ends downward along the dorso-lateral border of the medulla oblongata. They cross the fibers of the spinal V tract superficially from their dorsal to their ventral border and continue into the cord as the dorsal spino-cerebellar tract of Flechsig (see Fig. 12).

The fibers of the middle peduncle, or brachium pontis, of the left side were partially dissected when studying the cochlear nuclei (Section 81). Their dissection may now be completed.

The superior peduncle, or brachium conjunctivum, can now be dissected further to its decussation in the cerebral peduncle under the colliculus superior.

For the dissection of the human cerebellar peduncles, see Sections 103–105.

(b) *Microscopic study of the cerebellar peduncles.*—In the microscopic sections locate the inferior cerebellar peduncle (*corpus restiforme*) immediately below its connection with the cerebellum. Following it downward it will be found to receive fibers from the vestibular nucleus (see Section 83) and the inferior olive of the opposite side (*olivo-cerebellar tract*; see Herrick ('18), Figs. 72 and 87).

Some of its fibers can also be followed downward into the spinal cord, where they are known as the dorsal spino-cerebellar tract (*fasciculus cerebello-spinalis* of Flechsig in the *BNA* list). For the courses of this dorsal spino-cerebellar tract (of Flechsig) and of the ventral spino-cerebellar tract (of Gowers) in

the spinal cord and brain stem, see Barker ('01), Chaps. XL and XLI; Bailey ('16), Fig. 345, following p. 512; Herrick ('18), Figs. 59, 63, 73, 83, 87; Morris ('14), Fig. 707, p. 898; Piersol ('16), Fig. 946, p. 1905; Quain ('09), Vol. 3, Pt. 1, Fig. 205, p. 198.

In your sections of the spinal cord and brain stem the fibers of the ventral spino-cerebellar tract cannot be separately recognized. They ascend in the lateral funiculus and in the medulla oblongata accompany the spinal lemniscus fibers lying superficially just dorsally of the inferior olive. In transverse sections of the isthmus region immediately below the decussation of the IV nerves these fibers can be recognized for a short distance on the extreme dorso-lateral surface external to those of the brachium conjunctivum and dorsally of those of the lateral lemniscus. At this point they are turning dorsalward from the brain stem to curve backward into the substance of the cerebellum.

The superior cerebellar peduncle (brachium conjunctivum) can be easily followed in the sections from the cerebellum forward and downward into the midbrain to its decussation under the aqueduct of Sylvius and its termination in the red nucleus (nucleus ruber) of the opposite side (see Morris ('14), Fig. 638, p. 811, and Villiger ('12), Figs. 178, 179, pp. 193, 194).

The brachium pontis is also easily identified in the sections.

All of the cerebellar tracts mentioned in this section should be entered in your drawings of the cross-sections, using reference books to supplement the incomplete demonstrations of their courses which have been possible in your microscopic sections.

(c) *Summary of the cerebellar peduncles.*—(See Herrick ('18), Fig. 87.)

The inferior peduncle (*corpus restiforme*) is composed chiefly of ascending fibers from the great proprioceptive sensory centers of the spinal cord (dorsal spino-cerebellar tract of Flechsig), from the inferior olive (olivo-cerebellar tract), and from the vestibular root and nucleus of the VIII nerve (vestibulo-cerebellar tract).

The middle cerebellar peduncle (*brachium pontis*) is a system of fibers running from the nuclei of the pons to the opposite cerebellar hemisphere. The nuclei of the pons receive impor-

tant descending tracts from the cerebral cortex (cortico-pontile tracts). The fibers of the brachium pontis arise from the nuclei of the pons, thus transmitting nervous impulses derived from the cerebral cortex to the cortex of the opposite cerebellar hemispheres.

The superior peduncle (*brachium conjunctivum*) is the chief efferent pathway from the cerebellum. These fibers arise chiefly from the dentate nucleus (Section 98), enter the mid-brain, and cross to the opposite side under the aqueduct of Sylvius, after which they end in or near the red nucleus (*nucleus ruber*) under the superior colliculus. The superior peduncle also contains ascending fibers from the spinal cord (ventral spino-cerebellar tract of Gowers).

Between the superior peduncles is stretched a thin sheet of nervous tissue, the anterior medullary velum.

97. *Inferior olives, pontile nuclei, arcuate nuclei, substantia nigra.*—These gray centers of the brain stem are all functionally related with the cerebellum. All of these nuclei (except perhaps the arcuate) send fibers to the cerebellar hemisphere of the opposite side (see Strong ('15)). Identify all of these nuclei and enter them in the sketches. The cerebellar connections of the inferior olive (olivo-cerebellar tract, see Herrick ('18), Figs. 72, 83 and 87) and of the pontile nuclei (brachium pontis, see Herrick ('18), Fig. 87) should also be identified and indicated on the sketches. The inferior olives and arcuate nuclei receive internal and external arcuate fibers from the sensory nuclei of the oblongata. The inferior olive receives also a strong tract from the thalamus (central tegmental tract) and a smaller tract from the spinal cord (spino-olivary tract, see Herrick ('18), Fig. 87). These cannot be easily distinguished in the sections. Its chief discharge path is the olivo-cerebellar tract and a smaller one (the olivo-spinal tract) discharges into the spinal cord.

98. *Cerebellar nuclei.*—In addition to the superficial cortical gray matter of the cerebellum there are several deep gray masses. The largest of these is the dentate nucleus lying within each cerebellar hemisphere, from whose neurons most of the fibers of the superior cerebellar peduncle arise. Smaller gray masses are found under the vermis near the roof of the

fourth ventricle. These are the nuclei emboliformis, globosus, and fastigii. These nuclei are not easily seen in a dissection of a sheep's brain, but may readily be found in either gross or microscopic sections of the human brain.

See Cunningham ('15), Figs. 511, 512, and 535; Morris ('14), Figs. 637 and 638; Piersol ('13), Figs. 950 and 951; Quain ('09), Vol. III, Part 1, Figs. 185-189; Rauber-Kopsch ('12), Fig. 105; Sobotta ('11), Figs. 657 and 658; Spalteholz ('09), Fig. 743; Toldt ('04), Figs. 1182-1189.

99. *Microscopic structure of the cerebellar cortex.*—Examine and draw the sections of cerebellar cortex provided, and with the aid of your reference books build up a mental picture of the connections of the different types of cortical neurons. See Herrick ('18), Fig. 89 and the accompanying discussion, and references cited at the end of Section 100.

100. *Structure, subdivision, and functions of the cerebellum.*—Compare the external form of the cerebellum in the fish, sheep, and man, and note that variations in the size of the cerebellar hemispheres are correlated with those of the pons. What are the fiber connections of the pons, and with what remote part of the brain is it in functional connection? Identify the vermis, hemispheres, and flocculus of the cerebellum. *Arbor vitae* is a name given to the appearance of the cerebellar gray and white matter as seen in median section of the vermis. It is separated into two principal subdivisions by the sulcus primarius (Fig. 10).

The cerebellum is a great proprioceptive center of coördination. We have already learned that it is connected by afferent fiber tracts with the primary basal proprioceptive apparatus of the spinal cord and brain stem. And it is also intimately related with the cerebral cortex through the cortico-pontile fiber tracts (Section 96, c). Nervous mechanisms for the performance of all simple reflex and voluntary acts are provided in other parts of the central nervous system; but the participation of the cerebellum is necessary for the performance of all complex movements, especially for equilibration, motor coördination, and the maintenance of muscular tone.

The human cerebellum is subdivided anatomically into a very large number of parts, the names of which are given in all

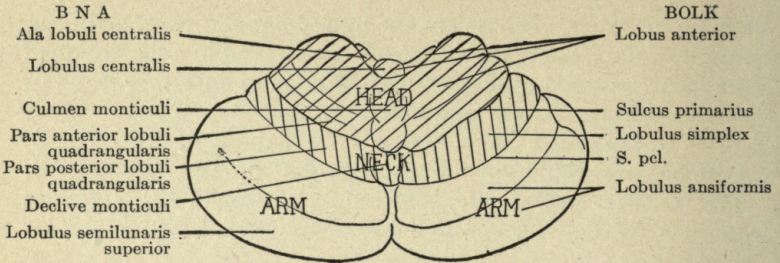


FIG. 13.—The human cerebellum from above.

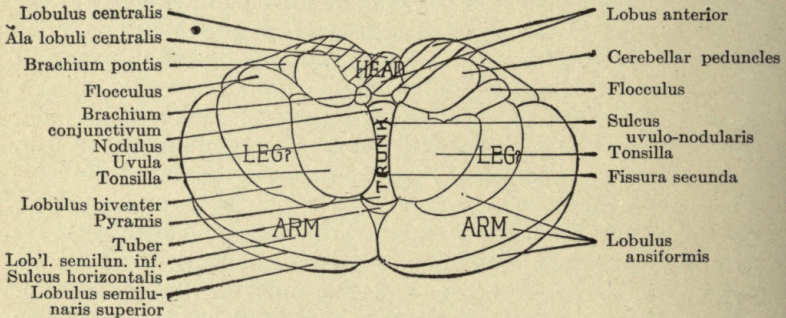


FIG. 14.—The human cerebellum from below.

In these two diagrams the principal subdivisions of the cerebellum are indicated and the *B N A* names are designated at the left. At the right are the names given by Bolk to these structures and one fissure not named by Bolk, the sulcus postclivalis (*S.pl.*), as named by Symington in Quain's Anatomy. The sulcus primarius of Bolk and Kuithan is the same as the furcal sulcus of Stroud, the fissura prima of Elliot Smith, and the sulcus preclivalis of Symington. The lobulus simplex of Bolk extends across the median plane and includes the declive of the *B N A* in the vermis. The tonsilla is Elliot Smith's lobulus paramedianus.

The functional localization within the cerebellar cortex as determined by Bolk, Rynberk, and others is also indicated on the figures. Head movements are controlled in the lobus anterior of Bolk, *i. e.*, all parts in front of the sulcus primarius. The lobus simplex controls neck movements. Arm and leg movements are controlled in the lobus ansiformis and trunk movements in the inferior vermis.

of the larger text-books of anatomy. Recent investigations of the comparative anatomy, comparative embryology, experimental physiology, and pathology of the cerebellum have

revealed a rather obscure type of functional localization within the cerebellum which bears no simple relation to the anatomical subdivisions as defined in the *B N A* tables.

Broadly speaking, there are centers within the cerebellar cortex for muscular coördination and tonic control of the more cephalic parts of the body in the dorsal and rostral parts of the cerebellum. Centers for the similar control of the more caudal muscular complexes extend around the caudal margin of the cerebellum to the inferior surface. Centers for bilaterally coördinated movements of paired groups of muscles are me-

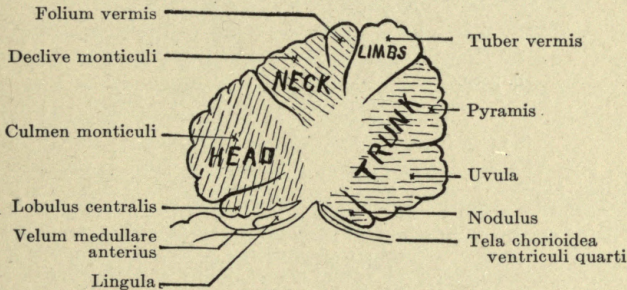


FIG. 15.—A sagittal section through the vermis of the human cerebellum. The *B N A* names of the parts are given and also the functional localization as determined by Bolk, Rynberk, and others. The areas of the head and neck extend lateralward as indicated on Fig. 13. The area for control of movements of the trunk is limited to the inferior vermis. The area for the limbs in the tuber vermis is for the control of coördinated movements of both members of a pair, while the arm and leg areas shown in Figs. 13 and 14 control the separate movements of these limbs.

dian and unpaired. The centers for the motor control of each limb separately lie laterally on the corresponding side of the cerebellum.

The general arrangement of these functional regions is shown in Figs. 13, 14, 15 and 16, though many details are still obscure. In particular, it has not been possible to separate the arm areas from the leg areas in man; but experimental studies on other mammals suggest that the leg area lies inferior to the arm area, as indicated in Fig. 14.

The preceding account of localization of function is based on the studies of Bolk and Van Rynberk. More recently

Ingvar has restudied the question and reached somewhat different conclusions. The type of motor control exercised by the cerebellum is evidently very different from that of the motor centers of the cerebral cortex. The latter determines what movement is to be made; the former appears to be concerned only with the synergic control of the muscles whose activity is called forth by other centers.

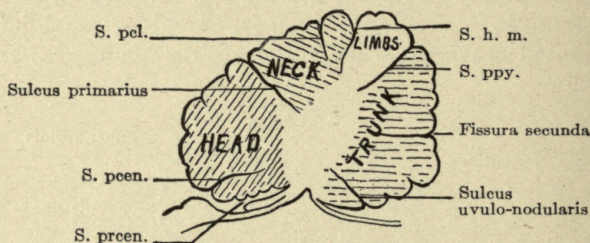


FIG. 16.—The same section shown in Fig. 15 with the names of the cerebellar fissures. Bolk's names are printed in full; others are abbreviated. Between the lingula and the lobulus centralis is the sulcus precentralis (*S.prcen.*) of Symington. Above the lobulus centralis is the sulcus postcentralis (*S.pcen.*) of Symington, or fissura preculminata of Elliot Smith. The sulcus primarius of Bolk is the fissura prima of Elliot Smith and the sulcus preclivalis of Symington. Above the declive is the sulcus postclivalis (*S.pcl.*) of Symington. Between the folium and the tuber is the sulcus horizontalis magnus (*S.h.m.*) of Symington. Between the tuber and the pyramis is the sulcus postpyramidalis (*S.ppy.*) of Symington. Below the pyramis is the fissura secunda of Bolk and Elliot Smith, or sulcus prepyramidalis of Symington. Between the uvula and the nodulus is the sulcus uvulo-nodularis of Bolk or sulcus postnodularis of Symington. For a corresponding section of the cerebellum of the sheep, see Fig. 10.

The nomenclature of the cerebellum is in great confusion, each investigator having developed his own terminology. In Figs. 13, 14, 15, and 16 the *BNA* names are indicated and the names used by Bolk and some other more recent students are given for comparison.

On the structure, connections, and general functions of the cerebellum consult especially the following works: Bailey ('16), pp. 513-520; Cunningham ('15), pp. 570-581; Herrick ('18), Chap. XII; Howell ('18), pp. 233-245; Johnston ('06), Chap. XV; Luciani ('15); Quain ('09), pp. 67-202; Rauber-Kopsch ('12), Schaefer ('00); Spalteholz ('09); Starling ('15),

Chap. XIII; Starr, Strong and Leaming ('96); Strong ('15); Toldt ('04).

The recent investigations bearing on functional localization in the cerebellum (Figs. 13-16) are numerous. See André-Thomas and Durupt ('14); Archambault ('18); Babinski and Tournay ('12); Bárány ('12); Black ('16); Bolk ('06); Howell ('18), p. 243; Ingvar ('18); Jones ('18); Luciani ('15); Van Rynberk ('07 and '12)—critical summaries with full bibliographies; Smith ('03).

8. Summary of Spinal, Bulbar, and Cerebellar Tracts and Centers

101. Now review your sketches of the cross-sections of the spinal cord and brain stem, fixing in mind the entire course of each tract there represented between the thalamus and the lower end of the spinal cord. The individual drawings may also be filled in, if desired, by the addition of other details, and colored (for color scheme see Section 62).

In the accompanying *List of Conduction Pathways* the more important tracts of the brain stem are arranged according to a functional classification, and each neuron of a conduction path is given a separate entry. The tracts of the prosencephalon (thalamus and cerebral hemispheres) have not yet been studied; but their names are entered in the List, printed in black-face type, for future reference.

Using this List as a basis, now prepare a *Table of Conduction Pathways* which may be made up according to the pattern illustrated on page 92, where the first three entries of the List are filled into the Table. The remaining items of the List should also be entered in the Table, giving each entry of the List a horizontal line in the Table. In the first column of the Table in place of the name of the tract we have entered, for economy of space, simply the numerical symbols of the tracts as given in the List.

Not all of the tracts here listed can be demonstrated either by dissection or by the study of microscopic sections of the normal nervous system. Their courses have been demonstrated by a combination of anatomical, physiological, and pathological observations. The data for the Table will, accordingly, be derived partly from your laboratory notes and partly from the reference books.

LIST OF CONDUCTION PATHWAYS

A. ASCENDING (SENSORY) SYSTEMS

I. General Somatic Sensory, Exteroceptive

1. Touch and pressure of trunk and limbs.
 - 1) Peripheral neurons in spinal nerves.
 - 2) Secondary path in spinal lemniscus (tr. spino-thalamicus ventralis).
 - 3) **Tertiary path to cortex (projection tract).**
2. Pain and temperature of trunk and limbs.
 - 1) Peripheral neurons in spinal nerves.
 - 2) Secondary path in spinal lemniscus (tr. spino-thalamicus lateralis).
 - 3) **Tertiary path to cortex (projection tract).**
3. Cutaneous sensibility of head.
 - 1) Peripheral neurons in V, IX, and X cranial nerves.
 - 2) Secondary path in trigeminal lemniscus.
 - 3) **Tertiary path to cortex (projection tract).**

II. General Somatic Sensory, Proprioceptive

1. Muscle sense, etc., of trunk and limbs.
 - 1) Peripheral neurons in spinal nerves and dorsal funiculi.
 - 2) Thalamic secondary path in medial lemniscus.
 - 3) **Tertiary path to cortex (projection tract).**
 - 4) Cerebellar secondary path in dorsal spino-cerebellar tract.
 - 5) Cerebellar secondary path in ventral spino-cerebellar tract.
 - 6) Olivary secondary path in spino-olivary tract (?).

III. Special Somatic Sensory, Proprioceptive

1. Vestibular nerve.
 - 1) Peripheral neurons.
 - 2) Secondary path to cerebellum by vestibulo-cerebellar tract.
 - 3) Secondary path to cord by vestibulo-spinal tract.
 - 4) Secondary path to oculomotor and spinal nuclei by fasciculus longitudinalis medialis.
 - 5) Secondary paths to motor nuclei of bulb by arcuate fibers.

IV. Special Somatic Sensory, Exteroceptive

1. Cochlear nerve.
 - 1) Peripheral neurons.
 - 2) Secondary path from dorsal nucleus, acoustic striæ and lateral lemniscus.
 - 3) Secondary path from ventral nucleus, trapezoid body, and lateral lemniscus.
 - 4) Secondary paths to motor nuclei of bulb and midbrain.
 - 5) Inferior colliculus to thalamus.
 - 6) **Thalamus to cortex (auditory projection tract).**
2. Optic system.
 - 1) **Receptors (rods and cones).**
 - 2) **Granule cells of the retina.**
 - 3) **"Ganglion" cells of retina.**
 - (a) to colliculus superior.
 - (b) to thalamus.
 - 4) **Reflex path colliculus superior to cord (tecto-spinal tract).**
 - 5) **Thalamus to cortex (optic projection tract).**

V. General and Special Visceral Sensory

1. Visceral sensory fibers from sympathetic in spinal nerves.
(Secondary connections unknown.)
2. Visceral sensory and gustatory fibers in VII, IX, and X cranial nerves and fasciculus solitarius.
(Secondary connections unknown.)

B. DESCENDING (EFFERENT) SYSTEMS

I. Visceral Efferent

1. General visceral efferent of spinal cord.
 - 1) Preganglionic neurons in intermedio-lateral column of cord.
 - 2) Postganglionic neurons in sympathetic ganglia.
2. General visceral efferent of brain.
 - 1) Preganglionic neurons in III nucleus for ciliary ganglion.
 - 2) Postganglionic neurons in ciliary ganglion.
 - 3) Preganglionic neurons in superior salivatory nucleus of VII nerve for sublingual and submaxillary glands.
 - 4) Postganglionic neurons in submaxillary ganglion.
 - 5) Preganglionic neurons in inferior salivatory nucleus of IX nerve for parotid salivary gland.
 - 6) Postganglionic neurons in otic ganglion.
 - 7) Preganglionic neurons in dorsal motor nucleus of vagus and adjacent centers for cardiac, respiratory, and other visceral reactions.
 - 8) Postganglionic neurons in various sympathetic ganglia associated with the vagus.
3. Special visceral efferent.
 - 1) Masticatory movements from motor V nucleus.
 - 2) Mimetic movements from motor VII nucleus.
 - 3) Movements of pharynx, larynx, esophagus from the nucleus ambiguus.
 - 4) Movements of shoulder from XI nucleus (primitively visceral but secondarily somatic in type).

II. Somatic Efferent

1. Movements of eyeball from motor III, IV and VI nuclei.
2. Movements of tongue from XII nucleus.
3. Movements of trunk and limb musculature from ventral gray column.
4. Reflex motor paths in cord—fasciculus proprius.
5. Reflex motor paths in brain stem.
 - 1) Equilibratory reflexes in tractus vestibulo-spinalis.
 - 2) Oculomotor and equilibratory reflexes in fasciculus longitudinalis medialis.
 - 3) Optic and acoustic reflexes in tractus tecto-spinalis.
6. Voluntary motor path.
 - 1) Pyramidal tract for somatic motor centers of cord.
 - 2) Peripheral motor neurons of spinal nerves.
 - 3) Fibers associated with pyramidal tract for somatic and special visceral voluntary motor nuclei of brain stem (cortico-bulbar tracts).
 - 4) Peripheral motor neurons of cranial nerves.
7. Cortico-pontile tracts.

C. SUMMARY OF CEREBELLAR CONNECTIONS

1. Afferent.

- 1) Tractus spino-cerebellaris dorsalis.
- 2) Tractus spino-cerebellaris ventralis.
- 3) Tractus vestibulo-cerebellaris.
- 4) External and internal arcuate fibers.
- 5) Central tegmental bundle to inferior olive.
- 6) Spino-olivary tract to inferior olive.
- 7) Tractus olivo-cerebellaris.
- 8) Cortico-pontile tracts to pons.
- 9) Pons to cerebellum by brachium pontis.

2. Efferent.

- 1) Brachium conjunctivum to nucleus ruber.
- 2) Tractus rubro-thalamicus to thalamus and cerebral cortex.
- 3) Tractus rubro-spinalis to cord.
- 4) Tractus cerebello-tegmentalis to reticular formation of brain stem by all three cerebellar peduncles.

TABLE OF CONDUCTION PATHWAYS

| Name | Cells of origin | Location and course | Decussation | Termination | Function |
|----------|-----------------------------|------------------------------------|----------------------------|-----------------------------|--------------------|
| A I 1 1) | spinal ganglion | peripheral nerves and dorsal roots | | dorsal gray column | touch and pressure |
| A I 1 2) | dorsal gray column | ventral funiculus of cord | ventral commissure of cord | lateral nucleus of thalamus | touch and pressure |
| A I 1 3) | lateral nucleus of thalamus | internal capsule | | postcentral gyrus | touch and pressure |
| A I 2 1) | (Table continued) | | | | |

Spaces should be left in the Table for the prosencephalic tracts printed in black face type in the List, and these are to be filled in later in the course, after which the Table will present a complete summary of all of the tracts studied. This will be of value for the final review and correlation (Section 153). The relations of the olfactory tracts are so complex that these may be omitted from the Table and a special table or diagram constructed for them (see Section 130).

This correlation of the anatomical data into functional conduction systems is the most important part of the course and should be done as thoroughly as possible and submitted

for examination at the close of the course, with the laboratory notebooks. So far as possible indicate the source of the stimulus for each fiber system (sense organ, motor areas of cerebral cortex, or associational nucleus, etc., as the case may be), the complete course of the path, the number of neurons involved in the path and their limits, collateral reflex connections, and the organ at which the path terminates.

A useful exercise is to imagine a localized injury which destroys a particular center or tract or group of tracts at some point, and then to determine what symptoms would result from the injury in question.

9. Optional Dissections of the Brain Stem

102. The dissections described in the preceding pages can be performed upon either sheep or human brains, even though the latter be not very well preserved. In the following pages (Sections 103 to 111) directions are given for a more complete dissection of some of the structures of the human brain stem than it is practicable to carry out upon the sheep's brain, and for these dissections well-preserved human brains which have been hardened in formalin are necessary. All of these dissections can be performed on one lateral half of the human brain, save that the connections of the cerebellar peduncles (Sections 103 to 105) within the cerebellum cannot easily be demonstrated in case the cerebellum has previously been removed as described in Section 49.

These dissections, being in some cases more difficult than those previously described, can best be done as a review exercise after completion of the preceding exercises. Upon completion of the dissection of Sections 103 to 111 preserve the specimen for later use (Sections 141 to 151).

103. *Corpus Restiforme*.—Upon lifting up the posterior border of the cerebellum a strong band of fibers is seen leaving the posterior part of the cerebellar peduncle complex to turn backward along the dorso-lateral border of the oblongata. This, the corpus restiforme, is crossed immediately behind the cerebellum by the dorsal root and nucleus of the VIII nerve (tuberculum acusticum). Cut through this cochlear VIII root and reflect its fibers so as to expose the dorsal aspect of the corpus

restiforme, but do not remove the VIII root and nucleus. Locate the vestibular (ventral) root of the VIII nerve. Its fibers pass under the corpus restiforme to enter the vestibular nucleus in the floor of the fourth ventricle medially of the corpus restiforme. Vestibular VIII root fibers pass from the vestibular root into the corpus restiforme and also other fibers of the second order from the vestibular nucleus to its medial border; but their dissection should not be attempted at this time. Trace the restiform body backward and note that it receives external arcuate fibers from the somatic sensory region of the opposite side. At the level of the inferior olive the restiform body receives on its ventral side a large tract from the olive, but this cannot be dissected at this time without destroying the intervening structures ventrally of the restiform body. At the level of the olive the restiform body turns slightly ventralward, crossing superficially the anterior end of the tuberculum cinereum (tubercle of Rolando or spinal V tract), and then passes backward ventrally of the most superficial fibers of the tuberculum cinereum. Dissect out this part of the restiform body and follow it backward into the spinal cord, where it will be seen to form the dorsal spino-cerebellar tract of Flechsig (Section 96). Summarizing the corpus restiforme, this inferior peduncle of the cerebellum is composed chiefly of ascending fibers from the great proprioceptive sensory centers of the spinal cord, the inferior olive, and the vestibular root and nucleus of the VIII nerve.

104. *Brachium pontis*.—At the base of the cerebellum locate the fibers of the brachium pontis, which form the most lateral fibers of the cerebellar peduncles. Beginning at the most ventral part of the pons, gradually tease off the pons fibers, stripping them upward a few at a time into the cortex of the cerebellar hemisphere, and note the way in which those from the anterior (rostral) border of the pons pass obliquely backward ventrally of those from the posterior (caudal) border. Trace these two layers out separately and determine their distribution in the cerebellar hemisphere. In the dissection of the pons be careful to preserve the fibers of the V nerve. The brachium pontis fibers as a whole form two thick layers, the *fibrae superficiales* and the *fibrae profundæ*, separated by the

longitudinal fibers of the pons (pyramidal tract, etc.). The two layers of pons fibers above mentioned belong to the superficial system. Strip off the remaining superficial pons fibers until the longitudinally directed pyramidal tracts are exposed. The fibers of the brachium pontis will be now seen to interdigitate with the fascicles of longitudinal fibers. These fasciculi can be followed forward into the midbrain where they form the most ventral fibers of the pedunculus cerebri. Expose these longitudinally directed fibers for a short distance forward (rostrad) and backward (caudad) of the pons. Do not completely dissect them, but leave them in place for future reference. They will be found to form three chief systems. The most medial and the most lateral bundles of the fiber complex which forms the ventral part of the cerebral peduncle in front of the pons are cortico-pontile tracts from the cerebral cortex to the pontile nuclei (cf. Herrick ('18), Figs. 75, 87), where, after a synapse, their nervous impulses are taken up by the neurons of the pontile nuclei and carried through the brachium pontis to the cortex of the opposite cerebellar hemisphere. The middle bundles of the cerebral peduncle contain the pyramidal tract (tr. cortico-spinalis) which can be dissected through the pons to reappear below on the ventral surface of the oblongata as the pyramid (*pyramis*). Its further course will be dissected later. The chief constituent of the brachium pontis is thus seen to be a system of fibers arising in the pontile nuclei for carrying nervous impulses from the cerebral cortex (by the cortico-pontile tracts) to the cerebellar hemispheres of the opposite side.

105. *Brachium conjunctivum*.—First examine the anterior medullary velum (*velum medullare anterius*), within which near the median plane careful teasing will reveal a thin sheet of fibers.

The brachium conjunctivum (superior peduncle) forms the medial part of the cerebellar peduncle complex at the point where it joins the cerebellum (Fig. 11). Its fibers are directed from the cerebellum forward and downward. Their further dissection in the midbrain (decussation and connection with the red nucleus) will not be taken up at this time. They should, however, be dissected up into the cerebellum, where

they will be seen to connect with the dentate nucleus. This tract is the chief efferent pathway from the cerebellum. Accompanying the tract for the red nucleus are other descending fibers for the motor centers in the reticular formation (tegmentum) of the midbrain and oblongata (tr. cerebello-tegmentalis) which cannot easily be separated from those for the red nucleus (Herrick ('18), Fig. 87).

There is another important component of the brachium conjunctivum, the tractus spino-cerebellaris ventralis of Gowers (see Section 96). At the lower end of the oblongata caudad of the inferior olive this tract, together with the spinal lemniscus, can be recognized, in the gross preparation, lying immediately ventrally of the tr. spino-cerebellaris dorsalis of Flechsig and dorsally and laterally of the olive. Dissect the mixed bundle out in this position and trace it forward. It can be followed to a level near the pons. Its further course (which cannot easily be dissected) is as follows (see Section 107): At about the level of the upper border of the pons the fibers of the ventral spinocerebellar tract separate from the lemniscus fibers and turn abruptly dorsalward, then backward, to enter the brachium conjunctivum. Through the brachium conjunctivum they enter the vermis of the cerebellum medially of the dentate nucleus.

106. *The cochlear nuclei and lateral lemniscus.*—Determine again the positions of the cochlear and vestibular roots of the VIII nerve. Identify the dorsal and ventral cochlear nuclei. Fibers from the dorsal nucleus (striæ medullares acusticæ) can be followed across the floor of the fourth ventricle. At the midline these fibers decussate and pass ventralward to the superior olive of the opposite side. From the ventral cochlear nucleus fibers of the trapezoid body pass ventralward and medialward, at first embedded in the deepest fibers of the pons. They reach the superior olive of the same and the opposite side. They can be dissected, though their separation from the deep fibers of the pons is very difficult. From the superior olive of the opposite side the conduction path which continues both the dorsal and the ventral cochlear pathways (striæ medullares and trapezoid bodies respectively) is the lateral lemniscus, whose fibers terminate in the colliculus

inferior of the midbrain and the medial geniculate body of the thalamus. This portion of the lateral lemniscus can best be dissected from above downward (cf. Sections 81 and 82).

Lift up the occipital pole of the cerebral hemisphere and locate the superior and inferior colliculi on the dorsal surface of the midbrain. Extending backward and downward from the inferior colliculus is a flat ridge formed by the fibers of the lateral lemniscus (Herrick ('18), Fig. 45; Cunningham ('15), Fig. 517). These fibers lie dorsally of those of the cerebral peduncle and superficially of those of the brachium conjunctivum; at the upper border of the pons they turn inward and can be followed downward dorsally of the deep fibers of the pons to the superior olive. This small nucleus is difficult to identify, since its cell bodies are scattered among the fibers, but its position is indicated at the place where the lemniscus fibers turn abruptly medialward. (Compare the next paragraph for the relations of the spinal lemniscus to the lateral lemniscus and Section 82 for the microscopic appearance of this region.)

107. Having traced the fibers of the lateral lemniscus backward to the superior olive, the ventral spino-cerebellar tract (of Gowers) and the spinal lemniscus (see Section 105) may now be traced from the lower border of the pons to the upper border of the superior olive, where they will be seen to accompany the lateral lemniscus from this level forward. The ventral spinocerebellar tract accompanies the lateral lemniscus complex into the midbrain, where its fibers may be seen to separate from the others and to enter the cerebellum by the way of the brachium conjunctivum, lying more superficially than the tract from the dentate nucleus to the red nucleus.

108. *The medial lemniscus.*—Identify again the nucleus of the fasciculus gracilis and the nucleus of the fasciculus cuneatus. These receive proprioceptive fibers from the spinal cord by way of the fasciculus gracilis and fasciculus cuneatus. The cell bodies of these nuclei send their axones to the thalamus by way of the medial lemniscus. In the pons region this lemniscus lies ventrally and medially of the superior olive and medially of the lateral lemniscus, whose fibers it adjoins during their course through the upper pons and midbrain regions.

Identify the medial lemniscus in the region of the superior olive. It will be found as a broad band of longitudinally directed fibers near the midplane immediately dorsally of the deepest fibers of the pons. Tracing them downward they become crowded into the space between the two inferior olives. Under the nuclei of the fasciculus gracilis and fasciculus cuneatus these fibers cross the midplane and then turn abruptly dorsalward in numerous strands to connect with these nuclei of the opposite side.

In the dissection of the medial lemniscus in the medulla oblongata care must be taken not to destroy the pyramidal tract which lies ventrally of it and the fasciculus longitudinalis medialis and tecto-spinal tract which lie dorsally of it.

In the midbrain the medial lemniscus fibers split off from those of the lateral lemniscus shortly before the latter enter the inferior colliculus and the medial geniculate body (Herrick ('18), Fig. 75). The medial lemniscus continues almost directly forward, lying ventrally and medially of the lateral lemniscus, and ends in the lateral and ventral nuclei of the thalamus (Herrick ('18), Figs. 77 and 78), but at this stage of the work it should not be dissected farther forward than the midbrain.

109. *The fasciculus longitudinalis medialis.*—In the medulla oblongata the fibers of the fasciculus longitudinalis medialis (posterior longitudinal bundle) will be found running close to the median plane and immediately under the floor of the ventricle. In the lower parts of the medulla this tract lies dorsally of the medial lemniscus and separated from it only by the tecto-spinal tract, but in the pons region and midbrain these two tracts are far separated. In the dissection of this tract work from the cut median surface lateralward and do not disturb the floor of the fourth ventricle (cf. Sections 92 and 93).

110. *The fasciculus solitarius.*—The fasciculus solitarius can now be dissected out. Locate again the ala cinerea (trigonum vagi) in the floor of the fourth ventricle. This marks the position of the dorsal vagal nuclei. Tease off these superficial gray masses and expose the slender fasciculus solitarius which lies below them. Follow this tract downward and upward to its ends (cf. Section 84).

111. *The pyramidal tract.*—Now complete the dissection of the pyramidal tract (tractus cortico-spinalis) from the pons downward and note the decussating fibers of this tract on the cut median surface at the lower end of the oblongata. These crossed fibers form the lateral cortico-spinal tract of the cord. A small part of the pyramidal tract does not decussate, but descends directly and forms the ventral cortico-spinal tract of the cord (cf. Sections 94 and 95).

10. The Cerebrum

112. *The cerebrum* comprises all parts of the brain in front of the isthmus. It is further subdivided into the *mesencephalon*, *diencephalon*, and *telencephalon*. Like the rhombencephalon, the cerebrum includes a stem portion, or segmental apparatus, and a suprasegmental apparatus (the cerebral cortex).

The brain stem, as a whole, is devoted to the simpler reflex and instinctive activities, while the cerebral cortex serves the higher functions of association. The cerebral hemispheres make up the greater part of the telencephalon. Each cerebral hemisphere comprises cortical and basal or stem portions. The latter includes the olfactory bulb, anterior perforated space (tuberculum olfactorium), septum, corpus striatum, and some other parts. The cortex (pallium) has two great subdivisions, archipallium (old cortex) and neopallium (new cortex). The archipallium attains its maximum development in lower mammals and is chiefly devoted to olfactory correlations. It comprises the hippocampus and part of the gyrus hippocampi (hippocampal lobe or pyriform lobe). The neopallium is non-olfactory cortex and attains its highest development in the human brain. In the sheep also it is more extensive than the archipallium, occupying the convex dorsal surface of the hemisphere.

113. *The midbrain and thalamus.*—On the medial surfaces of the sheep and human brains review the aqueduct of Sylvius, the boundaries of the third ventricle, and the other landmarks in the midbrain and thalamus (see Section 59). On the lateral aspect of the specimens locate the colliculus inferior, colliculus superior, corpus geniculatum mediale, corpus geniculatum laterale (medial, or internal, and lateral, or external, geniculate

bodies), and the pulvinar. In the sheep the lateral geniculate body is not clearly separate from the pulvinar, forming the most ventral part of the eminence which includes both of these structures. The medial geniculate body (Fig. 12) is connected with the inferior colliculus by a clearly defined ridge, the peduncle of the inferior colliculus (*brachium quadrigeminum inferius*). The connection of the lateral lemniscus with the inferior colliculus and medial geniculate body has already been mentioned (Sections 81, 82, and 106). The optic tract is similarly related to the superior colliculus, lateral geniculate body, and pulvinar (Section 136); but the further dissection of this region to expose these connections must be deferred until after the removal of the cerebral hemisphere.

114. Examine the surface of the *human cerebral hemisphere* and locate the lobes and the fissures and gyri given in the following list. The following references will be useful in identifying these parts: Cunningham ('15), Figs. 581, 582, pp. 654, 655, Fig. 585, p. 658, Fig. 589, p. 661; Gray ('18), Figs. 724-728, pp. 817-821; Herrick ('18), Figs. 52, 53, 54, 120; Morris ('14), Figs. 675-679; Piersol ('16), Figs. 984-993, pp. 1138-1152; Quain ('09), Vol. III, Pt. 1, Figs. 255-259, pp. 255-259; Rauber-Kopsch ('12), Figs. 91, 92, 95, 96, pp. 71-78; Sobotta ('11), Figs. 623-634; Spalteholz ('09), Figs. 705-714, pp. 637-644; Toldt ('04), Figs. 1191-1197, pp. 775-779.

lobus frontalis, lobus parietalis, lobus occipitalis, lobus temporalis, insula (island of Reil)
 fissura cerebri lateralis (Sylvii)
 sulcus centralis (fissure of Rolando) and sulcus precentralis
 sulci temporalis superior, medius, and inferior
 fissura calcarina and cuneus
 sulcus cinguli and gyrus cinguli
 fissura collateralis
 gyri frontalis superior, medius, and inferior
 operculum insulae (temporal, parietal, frontal, and orbital parts)
 "Broca's convolution" (the opercular part of the left gyrus frontalis inferior)
 gyrus centralis anterior (precentral gyrus)
 gyrus centralis posterior (postcentral gyrus)

gyri temporalis superior, medius, and inferior
gyrus hippocampi and uncus, fissura hippocampi

115. *The cerebral hemisphere of the sheep.*—Note the arrangement of gyri and sulci in the cerebral hemisphere of the sheep and locate the motor area of the cortex (see Fig. 9, Simpson and King ('11), and King ('11)). Compare this arrangement with that of the human brain and note the differences. On the comparative anatomy of the sulci, see Kappers ('13).

116. *Cortical localization.*—With the aid of the gyri and sulci just listed locate each of the projection centers and association areas on your specimen. The following references may be consulted: Barker ('01), Fig. 657, p. 1037; Barker ('16), Fig. 588, p. 436; Cunningham ('15), Fig. 588, p. 660, Fig. 591, p. 663, also see references under Section 114; Cushing ('08) and ('09); Edinger ('93); Edinger and Fischer ('13); Flechsig ('96); Gray ('18), Figs. 756, 757; Herrick ('18), Figs. 130, 131, 135, 136; Horsley ('09); Howell ('18), Figs. 86–88, pp. 195–197, Fig. 97, p. 222, Figs. 98–101, pp. 227, 228, also discussions in Chap. IX, pp. 192–201, and Chap. X; Leyton and Sherrington ('17); Monakow ('14); Morris ('14), Fig. 703, p. 892, Fig. 704, p. 894; Rauber-Kopsch ('12), Figs. 250, 251, pp. 253, 254; Starling ('15), pp. 434–457; Stewart ('18), pp. 947–975; Villiger ('12), Figs. 118–122, and discussion pp. 123–130.

117. *Gross structure of the cerebral cortex.*—Remove a small rectangular block containing about one square centimeter of cortex from each of the following centers of the human cerebral cortex: visual, auditory, tactile, motor, prefrontal. Cut each block so as to exhibit a section through the cortex strictly perpendicular to the surface and observe with a lens the details of the lamination of the gray and white substance within the cortex. These distinctions are visible only in well-preserved material; cf. Cunningham ('15), pp. 644–647; Herrick ('18), Fig. 122; Quain ('09), Vol. III, Pt. I, pp. 372, 373; and Elliot Smith ('07).

118. *Microscopic structure of the cerebral cortex.*—Study the microscopic sections of the cerebral cortex supplied and note particularly the differences in the lamination of the cells and

fibers in the different regions. See Bailey ('16), pp. 542-549; Barker ('01), Figs. 655, 656, pp. 1034, 1035; Bolton and Moyes ('12); Brodmann ('07); Campbell ('05); Cunningham ('15), Fig. 574, p. 645, and also the references under Sections 114 and 115; Herrick ('18), Chap. XIX; Rauber-Kopsch ('12), pp. 175-186; Villiger ('12), pp. 114-118.

119. *Association tracts of the sheep.*—Now in the sheep's brain by careful teasing examine the arrangement of fibers in the subcortical white matter. Only a part of these fibers are to be studied at this time, and the dissection outlined in this section should not be carried farther than directed. It will require but a short time.

(1) First, along the dorsal border of the medial surface of the hemisphere scrape away the gray matter covering two adjacent gyri. This will bring into view the short associational (arcuate) fibers connecting these gyri. Further teasing will show that similar fibers, lying deeper in the white matter, connect more remote gyri.

(2) Careful dissection of the lateral surface of the hemisphere will show that from other association areas of the cerebral cortex fibers sweep down into the pyriform (hippocampal) lobe, indicating the linking-up of all association areas of the neopallium with the association areas of the archipallium.

(3) The cingulum is a long associational tract running close to the cortex of the medial surface of the hemisphere. In part of its course it runs parallel with the dorsal surface of the corpus callosum. It begins anteriorly in the gyrus subcallosus under the rostrum of the corpus callosum, arches upward at the genu of the corpus callosum, and at its posterior end passes around the splenium of the callosum and then goes downward, forward, and lateralward to the region of the hippocampal gyrus. Begin its dissection above the callosum and follow it in both directions to its termini.

(4) *The corpus callosum.*—These fibers connect all parts of the neopallium of one hemisphere with those of the opposite hemisphere. Break through the middle of the cingulum and tease out a small part of the callosal fibers to their connection with the cortex. Do not disturb the remainder of the callosum at this time.

(5) *The corona radiata*.—This name is given to those fibers which run between the cortex and the underlying parts of the brain stem. Most of them run through the internal capsule of the corpus striatum (see Sections 138, 139, 144, 145, and Herrick ('18), Figs. 77, 79, 80). They include the projection fibers of the great sensory systems from the thalamus, various other thalamo-cortical connections, the voluntary motor cortical tracts (including the pyramidal and cortico-bulbar tracts), and the cortico-pontile tracts. These fibers are named from the fact that they diverge from the upper border of the internal capsule like the rays of a crown. In the dissection at this stage the broken ends of the vertical corona radiata fibers are seen breaking through the transverse sheet of callosal fibers which run at right angles to them. The cingulum and other longitudinal association tracts of the hemisphere run at right angle to both of these systems.

120. *Association tracts of the human brain*.—In the human brain tease away the tissues on the dorsal and lateral walls of the hemisphere and dissect out:

- (1) short association fibers
- (2) fasciculus longitudinalis superior
- (3) fasciculus occipito-frontalis inferior
- (4) fasciculus uncinatus
- (5) fasciculus transversus occipitalis
- (6) fasciculus longitudinalis inferior
- (7) the cingulum

These represent a few only of the more clearly defined association bundles, of which the white matter of the hemispheres is largely made up. While making these dissections note the relations of the fibers of the corpus callosum and of the corona radiata. In well-preserved brains these tracts can be dissected out with great completeness (see Section 141). Even in poorly preserved brains some of them can usually be demonstrated. See: Barker ('01), Chap. LXVII, pp. 1058-1069; Cunningham ('15), Figs. 577, 578, pp. 649, 650; Curran ('09); Gray ('18), Fig. 751; Herrick ('18), Fig. 121; Howell ('15), Fig. 83, p. 185; Morris ('14), Figs. 701, 702, p. 891; Quain ('09), Vol. III, Pt. I, Fig. 323, p. 359; Toldt ('04), Figs. 1230, 1231; Villiger ('12), Figs. 124-127, p. 134.

121. *Rhinencephalon*.—The entire olfactory part of the brain is called the rhinencephalon. This apparatus is so much more highly developed in the sheep than in man that the dissection is much more readily carried out upon this brain. Before undertaking the following dissection look up in the reference books the structure of the olfactory epithelium, nerve and bulb. See Cunningham ('15), p. 623; Herrick ('18), Chap. XV; Howell ('18), pp. 299–305; Villiger ('12), Fig. 116, p. 118. On the *nervus terminalis* see Section 47 (d).

The peripheral olfactory neurons arise from cells lying in the mucous membrane of the nose. These fibers terminate in the olfactory bulb, which is the primary olfactory center of the brain. Here lie the neurons of the second order (mitral cells), whose axons constitute the olfactory tracts, or *striae*, terminating in secondary olfactory centers in the basal parts of the cerebral hemisphere.

These secondary centers in the aggregate are called the area olfactoria and the fibers of the second order terminating in them are called tractus olfactorius (lateralis, medialis, and intermedius). The tracts of the third order are usually named by hyphenated compound words, of which the second member designates the center into which the tract discharges, thus we have the tractus olfacto-habenularis, tractus olfacto-mammillaris, tractus olfacto-corticalis, etc. The tertiary olfactory centers into which these tracts of the third order discharge are arranged in two series: (1) the basal centers of the diencephalon and cerebral peduncle for olfactory reflexes, and (2) the cortical centers in the hippocampus and gyrus hippocampi.

122. *Peripheral olfactory organ*.—If microscopic sections of the nasal epithelium are available, they should be studied at this time. Note that this sensory epithelium differs histologically in important respects from any other in the human body. See Barker ('01), Fig. 208; Herrick ('18), Figs. 36, 103, and 104; Piersol ('16), Figs. 1179, 1180, p. 1415; Quain ('09), Figs. 70 and 71.

123. *Olfactory tracts of the sheep*.—The olfactory fibers of the second order arise from the mitral cells of the olfactory bulb and form the tractus olfactorius, of which there are three parts. For their arrangement in the sheep see Fig. 8.

(1) *Stria olfactoria lateralis* (radix lateralis bulbi olfactorii).—This can easily be dissected out, following the fissura rhinalis from the olfactory bulb to the tip of the gyrus hippocampi (lobus hippocampi, lobus piriformis). In the human brain it runs farther lateralward in the lateral fissure to the border of the insula and then bends sharply medialward and backward to enter the uncus of the temporal lobe.

(2) *Stria olfactoria medialis* (radix medialis bulbi olfactorii).—This can be dissected out and will be found to ascend on the median surface of the hemisphere and to terminate chiefly in the medial olfactory area under the genu of the corpus callosum. This area includes the gyrus subcallosus and septum.

(3) *Stria olfactoria intermedia*.—This lies between the medial and lateral striæ. Part of it can be dissected out directly into the anterior commissure (Burkholder ('12), Plate XIX), within which it decussates to terminate in the anterior perforated space (tuberculum olfactorium) of the opposite hemisphere. This tract can best be dissected by locating the anterior commissure on the median surface of the specimen and then teasing its fibers out as they pass lateralward and forward toward the olfactory bulb. (The anterior commissure contains other fibers besides these, some of which pass between the corpora striata of the two hemispheres and others enter the stria terminalis; see Sections 125 (5) and 132.) A second part of the stria olfactoria intermedia, composed of more scattered fibers, terminates in the region of the anterior perforated space of the same side.

124. *The area olfactoria*.—This area includes the terminal nuclei of the olfactory tracts mentioned in the preceding section.

The area olfactoria lateralis includes the gray matter accompanying the lateral olfactory tract, or the lateral olfactory nucleus (termed by Retzius in the human embryo, lateral olfactory gyrus; see Herrick ('18), Fig. 105), and the part of the temporal lobe reached by the lateral olfactory tract (region of the uncus) and the amygdala. Cf. Section 126 (3).

The area olfactoria medialis includes the gyrus subcallosus (pedunculus corporis callosi), area parolfactoria of Broca and

septum. See Herrick ('18), Fig. 52. It is reached by the medial olfactory tract.

The area olfactoria intermedia lies between the two areas last mentioned and includes the anterior perforated space (in lower mammals the tuberculum olfactorium). It is reached by the intermediate olfactory tract, part of these fibers first decussating in the anterior commissure.

Tracts of the third order arise from all parts of the olfactory area, and these will be considered under two heads: (1) the reflex tracts, and (2) the cortical tracts.

125. *Reflex olfactory tracts*.—These pass from the olfactory area to the brain stem centers in the amygdala, diencephalon, and cerebral peduncle. Most of them can be dissected in the brain of the sheep. See Herrick ('18), Fig. 106.

(1) *Tractus olfacto-mamillaris*.—This is a diffuse collection of fibers from the medial and intermediate olfactory areas passing backward dorsally of the optic chiasma to enter the corpus mamillare. It can be dissected, though with some difficulty on account of the scattered arrangement of its fibers.

(2) *Tractus olfacto-habenularis*.—Fibers originating with those last described can be seen in a careful dissection to separate from them below the interventricular foramen and then to turn dorsalward immediately behind the foramen. They enter the stria medullaris thalami, a strong superficial fiber tract passing across the rostral border of the thalamus and bordering the tænia thalami. This tract is sometimes called the tractus tæniæ; it terminates in the habenula.

(3) *Tractus olfacto-tegmentalis*.—These fibers originate with those of the tractus olfacto-mamillaris, but instead of terminating in the mammillary body they pass on to enter the tegmentum of the cerebral peduncle. They can be dissected, though they are hard to separate from tractus olfacto-mamillaris.

(4) *The olfactory projection tract* of Cajal passes from the lateral olfactory area and amygdala backward into the regions of the mammillary body and cerebral peduncle. We have not been able to dissect these fibers, but they can be demonstrated microscopically.

(5) *Stria terminalis*.—This tract (also called stria or tænia semicircularis) connects the medial olfactory area in the vicin-

ity of the anterior commissure with the amygdala under the uncus, running dorsally of the internal capsule fibers at the line of contact of the thalamus with the cerebral hemisphere. The dissection of this tract should not be made at this time; see Section 132.

(6) *Diagonal band of Broca*.—This is a ridge extending transversely across the ventral aspect of the cerebral hemisphere between the area olfactoria intermedia, or tuberculum olfactorium, and the optic chiasma (Fig: 8). It contains both cells and fibers, the latter connecting the medial olfactory area with the lateral olfactory area. The diagonal band and the stria terminalis contain correlation fibers connecting the same areas, the former running across the extreme ventral surface of the hemisphere and the latter across the extreme dorsal surface of the brain stem along the line of contact of the cerebral hemisphere with the thalamus.

(7) *Tractus mamillo-thalamicus* (tract of Vicq d'Azyr or tractus thalamo-mamillaris).—This tract runs from the corpus mamillare forward and dorsalward to the nucleus anterior of the thalamus. It can readily be dissected by scraping off the ependyma of the third ventricle, beginning in the region of the mammillary body.

(8) *Tractus mamillo-tegmentalis*.—By very slight dissection, beginning in the median plane, this tract can be exposed. It runs from the mammillary body dorsalward and spinalward through the tegmental region under the aqueduct of Sylvius.

(9) *Tractus mamillo-peduncularis*.—This tract arises with the last and runs somewhat farther ventrally in the cerebral peduncle.

(10) *Tractus habenulo-peduncularis* (fasciculus retroflexus, or Meynert's bundle). This tract also can readily be dissected. It runs from the habenula into the ventral part of the cerebral peduncle immediately behind the mammillary body, crossing the tractus mamillo-tegmentalis at a somewhat deeper level (more laterally).

The three tracts last mentioned carry olfactory nervous impulses into the motor centers of the cerebral peduncle. After synapses here the pathways are continued to the lower motor centers.

126. *Cortical olfactory tracts*.—All parts of the olfactory area discharge tracts of the third order into the cerebral cortex (hippocampus and gyrus hippocampi).

(1) *Tractus olfacto-corticalis medialis*.—These fibers ascend from the medial and intermediate olfactory areas close to the median plane between the corpus callosum and the anterior commissure to enter the body of the fornix and fimbria. They are drawn, but not named, in the region marked *S* in Fig. 106 of Herrick ('18). They pass through the fimbria to terminate in the hippocampus (see Section 127).

(2) *Stria longitudinalis medialis* ("nerve" of Lancisius). A few fibers belonging to the same system as the last pass dorsally instead of ventrally of the corpus callosum. By exposing the dorsal surface of the callosum they can be seen curving around the genu, passing backward along its dorsal surface close to the median plane, then curving ventrally around the splenium to enter the underlying hippocampus (see Burkholder ('12), Plates XI and XII). These fibers are accompanied by the thin gray "indusium verum," which is a vestige of an extension of the hippocampus above the callosum which is found in the lowest mammals. See Herrick ('18), Fig. 106, *h. sc.*, and Johnston ('06), Chap. XVIII. These structures are smaller in man than in the sheep, though they may still be recognized. See Cunningham ('15), Fig. 554, p. 626; Morris ('14), Fig. 672, p. 852; Spalteholz ('09), Fig. 715; Toldt ('04), Fig. 1198, p. 780; Villiger ('12), Figs. 32-34, 36, 39.

(3) *Tractus olfacto-corticalis lateralis*.—These fibers arise from the lateral olfactory nucleus and enter the ventrolateral end of the hippocampus in the uncus region of the temporal lobe. They accompany those of the lateral olfactory tract.

The uncus and adjacent parts of the temporal lobe are of transitional type. Forward they merge into the lateral olfactory nucleus, laterally into the neopallium (see Section 112) through the gyrus hippocampi, and medially into the archipallium through the hippocampus (see Section 127).

127. *The hippocampus and fornix*.—When the relations of the olfactory tracts of the sheep already described are clearly in mind, remove the septum pellucidum and look into the lateral ventricle, drawing apart the corpus callosum and the

underlying corpus fornicis (see Fig. 10). Locate the hippocampus in the floor of the posterior horn of the lateral ventricle; also the fimbria and hippocampal commissure (the latter lying in the corpus fornicis and connecting the hippocampi of the two hemispheres). Now cut through the splenium of the corpus callosum, separating the parts last mentioned from the overlying corpus callosum. Working carefully continue this cut laterally and ventrally; cutting from the ventricular wall back into the lobus hippocampi and general cortex along the posterior and outer border of the hippocampus for its entire length downward to the tip of the gyrus hippocampi. Now beginning in the gyrus hippocampi (into which the lateral olfactory tract has already been traced), note carefully the shape and position of the hippocampus and its fiber tract, the fimbria, as you pass toward the midline.

The hippocampus is the chief part of the archipallium, or olfactory cerebral cortex. It is a buried convolution rolled into the lateral ventricle from the ventral and occipital margins of the cortex cerebri along the fissure hippocampi. It is entirely covered by the gyrus hippocampi with which its tissue is confluent. On its ventral side is a subsidiary convolution, the gyrus dentatus (fascia dentata), and it gives rise to a sheet of fibers, the fimbria, which passes forward in the floor of the lateral ventricle to enter the body of the fornix (corpus fornicis, an unpaired mass of fibers under the splenium of the corpus callosum). Here some of the fibers cross to the other side forming the commissura hippocampi, the entire complex forming the lyra. Others descend into the diencephalon as the columna fornicis (Section 129).

128. *The hippocampus*.—Make a cross-section through the hippocampus and lobus hippocampi and draw the cross-section, showing the relation of the fimbria, hippocampus, and gyrus dentatus. Note that this section is not transverse to the whole hemisphere in this region, but only to the hippocampal formation.

129. *Column of the fornix*.—Now from the body of the fornix follow the column of the fornix (columna fornicis), dissecting it out as you go, forward to a position just above the anterior commissure and then backward and ventrally to the mammil-

lary body (see Burkholder ('12), Plate XX). A small part may be seen to turn back immediately behind the interventricular foramen to enter the stria medullaris and so reach the habenula. The column of the fornix consists mainly of fibers passing out of the hippocampus by way of the fimbria into the olfactory correlation centers of the hypothalamus and epithalamus.

The column of the fornix is the efferent projection tract from the olfactory cortical center (hippocampus) to the mammillary body and habenula; that is, it carries motor impulses from the olfactory cortex to the diencephalic olfactory centers. From these latter centers these impulses are carried by the same tracts as those from the subcortical reflex centers; see Section 125 (7) to (10).

130. The following references to figures of the human brain will aid in understanding the relations of the olfactory apparatus of the sheep: Barker ('01), Chap. LII; Cunningham ('15), pp. 623-628, also Fig. 566, p. 637; Gray ('18), Figs. 732, 747, 748; Herrick ('18), Chap. XV; Morris ('14), Fig. 690, p. 877, also pp. 864-873; Piersol ('16), Figs. 1018, 1019, pp. 1180, 1181, Figs. 998-1000, pp. 1158-1161, Fig. 1002, p. 1163, Figs. 1004-1006, pp. 1165-1167; Sobotta ('11), Figs. 634-641.

Master now, by the aid of text-books and diagrams, the olfactory system and its connections and relations as seen in the sheep which is the same in plan as in the human brain. Review the entire dissection, tracing the course of olfactory impulses through the reflex pathways and centers of the basal regions from the nose to the epithalamus and hypothalamus and through the cortical pathways to the hippocampus and thence again to the epithalamus and hypothalamus. This gives a schematic picture of the workings of the entire rhinencephalon. This should be done before further work is undertaken and an analysis of these pathways fully written up.

131. Now cut through the genu of the corpus callosum forward and downward toward the olfactory bulb, thus opening up the anterior horn of the lateral ventricle, which in the sheep is directly continuous with the ventricle of the olfactory bulb. (In the human brain the ventricle of the olfactory bulb is obliterated in the adult.)

132. Beginning now in the gyrus hippocampi at the most

lateral border of the lateral ventricle, note the positions of the *stria terminalis* (*stria* or *tænia semicircularis*), plexus chorioideus of the lateral ventricle and tail of the caudate nucleus. Follow the last three medially and anteriorly, noting carefully their relationships to each other and to the hippocampus, until the anterior end of the head of the caudate nucleus is reached near the region of the anterior perforated space. The *stria terminalis* can be traced forward into the anterior commissure. Tracing the *stria terminalis* backward into the temporal lobe it will be seen to enter the anterior tip of the gyrus hippocampi, where it ends in a small deep gray mass, the *nucleus amygdalæ*. See Cunningham ('15), Figs. 539, 563; Herrick ('18), Figs. 76 and 121; Morris ('14), Figs. 658, 688, 691, pp. 834, 875, 878 respectively; Piersol ('16), see references under Section 130; Quain ('09), Vol. III, Pt. 1, Figs. 228, 233, 294, pp. 224, 229, 294 respectively.

133. Draw the dissection at this stage, as seen from above, showing the form of the lateral ventricle and the structures which form its walls (cf. Burkholder ('12), Plates XIII–XVI).

134. Now pulling carefully so as to tear the tissue slightly, draw away the ventricular wall along the upper border of the caudate nucleus. The internal capsule fibers can now be seen passing downward and backward, lateral to the caudate nucleus. By teasing away the remaining association fibers on the lateral side of the hemisphere the lentiform nucleus (a large gray mass) will be exposed to view and the internal capsule fibers will be seen passing downward and posteriorly between the caudate and lentiform nuclei. By teasing away the gray cell masses of the lentiform nucleus some of the fiber bundles can be seen passing into the cerebral peduncle (*pedunculus cerebri*). Care must be taken not to dissect too deeply and thus injure the underlying thalamus, which lies medially of the posterior part of the internal capsule (cf. Burkholder ('12), Plate XXII).

135. *Retina*.—If microscopic preparations are available, study the histological structure of the retina. From the reference books master the arrangements of its neurons and the course of nervous impulses within it. See Bailey ('16), pp. 561–565; Barker ('01), Chap. XXXVII, pp. 532–543; Cunning-

ham ('15), pp. 814-818; Herrick ('18), Figs. 97-99; Howell ('18), Chap. XVIII. On the general structure of the eye, see Section 14.

136. *Optic system.*—In the sheep dissection remove the hippocampus. Identify the structures on the lateral surface of the thalamus and midbrain: pulvinar, lateral and medial geniculate bodies, superior and inferior colliculi. Follow the optic tract from the chiasma to the thalamic optic centers (pulvinar and lateral geniculate body), where the thalamic optic fibers terminate. Trace other fibers of the optic tract over the surface of the medial geniculate body to the superior colliculus of the midbrain (optic tectum). This is the center for the optic reflexes of accommodation, etc.

By teasing away the gray matter of the pulvinar, optic projection fibers can be followed from the pulvinar to the occipital pole of the cerebral hemisphere. The pulvinar and lateral geniculate body are the thalamic centers, which, through their connections with the cerebral cortex, provide for conscious visual responses. See Bailey ('16), Fig. 358, p. 534; Cunningham ('15), pp. 619, 620; Edinger ('11), Fig. 220, p. 296; Gray ('18), Figs. 773, 774, pp. 882, 883; Herrick ('18), Chap. XIV; Morris ('14), Figs. 655-660, pp. 844, 845, Fig. 670, p. 849; Piersol ('16), pp. 1223-1225; Quain ('09), Vol. III, Pt. I, Figs. 232, 233, pp. 228, 229, Fig. 243, p. 240; Rauber-Kopsch ('12), Figs. 109, 111, 112, 123, 124, 261; Villiger ('12), pp. 172-174.

137. *Auditory system.*—The medial geniculate body of the sheep (thalamic auditory center) and the inferior colliculus (midbrain auditory center) should again be located (Fig. 12), also the arm of the inferior colliculus (brachium quadrigeminum inferius), which is the auditory path between the inferior colliculus and the medial geniculate body.

Auditory projection fibers pass from the medial geniculate body through the internal capsule to the temporal lobe of the cerebral cortex, but these cannot well be separated by dissection in the sheep.

138. *Dissection of the pyramidal tract.*—As the last step of the sheep dissection, by careful tearing down of the fibers follow out some of the internal capsule fibers into the regions of the thalamus, midbrain, and medulla oblongata. Try especially

to work out the cortico-spinal (pyramidal) tract. Although functionally a motor and therefore a descending tract, it can more easily be traced from the oblongata upward to the higher centers. It appears as an eminence (*pyramis*) on the ventral surface of the oblongata below the pons near the midline (cf. Section 95). Its fibers interdigitate with those of the pons, through which the cortico-spinal tract can be traced. It can then be followed along the ventral surface of the mesencephalon through the pedunculus cerebri into the internal capsule. These fibers arise from the cortical neurons of the superior frontal gyrus; see King ('11) and Simpson and King ('11).

139. *Internal capsule*.—From the reference books master the topographic relations of the functional systems of fibers in the internal capsule. For the connections of these tracts in the human brain see the following: Barker ('01), pp. 666–746 and 875–1048; Barker ('16), Fig. 591, p. 442; Cunningham ('15), Figs. 567–573, pp. 638–643, also account on p. 642; Herrick ('18), Figs. 45, 79, 80, 81, 83; Morris ('14), Figs. 692–700, pp. 880–888; Piersol ('16), Figs. 1009–1012, pp. 1170–1174; Spalteholz ('09), Fig. 745; Villiger ('12), Figs. 128–136, pp. 136–143.

140. The dissection of the cerebrum of the sheep's brain, as outlined in the preceding sections, can be completely carried out on one lateral half of the brain. The other half of the specimen can profitably be used for a repetition of the dissection, or it may be cut into a series of transverse or longitudinal slices, in each of which some of the structures already observed may be identified.

Some members of the class may slice this hemisphere in the transverse plane, others in the horizontal, and others in the sagittal, and these specimens may be compared by all members. Compare these sections with transverse sections of the human brain to be supplied by the instructor. Poorly preserved brains which are of small value for dissection by the method of teasing will give excellent gross sections for this study. In these sections look particularly for the continuation of the cerebral peduncle into the internal capsule. Make an especial study of the relations of the internal capsule to the adjacent structures, noting how the corpus striatum is made up of the

lentiform nucleus lying far laterally and the caudate nucleus lying medially and projecting into the lateral ventricle, while the internal capsule appears as a band of white fibers between these two centers and between the lentiform nucleus and the thalamus. In transverse and longitudinal sections of both the sheep and the human brains identify the chief nuclei of the thalamus (Herrick ('18), Fig. 79) and review the relations of the various lemniscus systems to these centers (Herrick ('18), Figs. 77 and 78). The medial and anterior nuclei of the thalamus are seen to be clearly separate from the lateral group of nuclei, including the lateral and ventral nuclei, the pulvinar and the lateral and medial geniculate bodies. The lateral group of nuclei constitute the "neothalamus," or new thalamus and are sources of the thalamic radiations or sensory projection fibers to the cortex. The medial and anterior nuclei belong to the old thalamus and are concerned chiefly with intrinsic thalamic reflexes. Compare these structures as they appear in the transverse sections with their appearance in the longitudinal dissection of the left hemisphere. Try to build up in your mind a three-dimensional picture of the fiber tracts in the sheep's brain, as you have seen them in dissections and gross sections. If microscopic sections through the thalamus and corpus striatum are available, they should be studied in this connection and the account given by Herrick ('18), Chap. X, should be read.

11. Optional Dissections of the Cerebrum

141. *The association tracts.*—The same specimen upon which the dissections outlined in Sections 102 to 111 were made can be used for the following dissections of the cerebrum. The association tracts can be dissected out in great detail, following the procedure directed for the sheep and human in Sections 119 and 120, working carefully with text-book diagrams and descriptions of the chief systems in mind and teasing off the more superficial systems before attempting to study the deeper systems. It will be found that the stronger and more easily isolated association tracts do not connect the projection centers, but the association centers. In view of the fact that in the sheep the association centers are small when compared with

man, the greater ease with which the human association tracts can be isolated by dissection finds its obvious explanation.

142. *The olfactory apparatus.*—Examine the human olfactory bulb and striæ and compare them with those of the sheep. Dissect the olfactory tracts in the way directed for the sheep brain in Sections 123 to 126; but do not continue the dissection as directed in Section 127. In this dissection expose the hippocampus as follows: Lay the specimen down on its median surface and carefully tease off the fibers of the inferior longitudinal fasciculus from the lateral convex surface of the temporal lobe until the inferior horn of the lateral ventricle is opened. The teasing should stop at this point. Now with a probe trace the inferior horn of the lateral ventricle to the anterior end of the temporal lobe and follow the probe with a scalpel cut, thus opening up the inferior horn of the lateral ventricle. Similarly probe from the posterior border of the incision just made backward toward the occipital pole of the hemisphere and follow the probe with a scalpel cut, thus opening the posterior horn of the ventricle in the occipital lobe. Now pull apart the walls of the lateral ventricle as thus opened and locate the hippocampus, a rounded eminence in the floor of the inferior horn of the ventricle. At the point where the inferior and posterior horns of the ventricle join, the hippocampus will be seen to turn sharply medialward. With a scalpel follow the lateral and posterior borders of the hippocampus with a clean cut. This incision must be made carefully, cutting from the ventricle directly outward through the wall of the hemisphere to the brain surface, and must follow the border of the hippocampus closely. It will curve around from the ventral to the medial surface of the hemisphere and finally pass through the splenium of the corpus callosum into the septum pellucidum. Remove the septum pellucidum and review the form of the entire hippocampal formation, including the gyrus dentatus, fimbria, and corpus fornicis. The floor of the inferior horn of the lateral ventricle is formed in part by the hippocampus and fimbria and in part by the membranous plexus chorioideus of the lateral ventricle. Note that this membrane has two lines of attachment to the massive brain walls, one to the free border of the fimbria (the *tænia fornicis*),

and one to the brain stem along the line of contact between the corpus striatum and thalamus (the *tænia chorioidea*). Between these two lines the membrane is folded into the ventricle, thus forming the *fissura chorioidea*. See the references cited in Section 130.

Now repeat on the human the directions outlined for the sheep in Sections 128 and 129.

143. *Stria terminalis*.—The human brain, following the procedure outlined in Section 132, may be further dissected as follows:

Look into the lateral ventricle, as already exposed, and locate the head of the caudate nucleus in the floor of the lateral ventricle above the anterior commissure. Now trace the tail (cauda) of the caudate nucleus backward into the inferior horn of the lateral ventricle where it ends in the vicinity of the nucleus amygdalæ. Also follow the stria terminalis (stria or *tænia semicircularis*), which accompanies the ventral border of the caudate nucleus for its entire length. Some of its fibers can be seen to enter the anterior commissure. This stria is a correlation tract between the nucleus amygdalæ and the medial olfactory area of the same and the opposite side. It marks the boundary between the cerebral hemisphere and the thalamus.

144. *Corpus striatum*.—Remove the hippocampus. Now pull upward on the corpus callosum and upper wall of the lateral ventricle so as to rip off the entire roof of the ventricle, tearing it free from the upper (lateral) border of the caudate nucleus. The lentiform nucleus (Herrick ('18), Fig. 45) will now be visible on the lateral aspect of the specimen, perhaps still covered superficially by the fibers of the external capsule.

145. *Internal capsule*.—The broken ends of the internal capsule fibers will now be seen between the caudate nucleus and the lentiform nucleus of the corpus striatum and between the lentiform nucleus and the thalamus. Examine carefully the relations of the internal capsule to the three gray masses. See the list of references at the end of Section 139.

146. *Nucleus anterior thalami*.—Locate the anterior nucleus of the thalamus (also called nucleus dorsalis) which forms a well-defined eminence at the anterior end of the dorsal aspect

of the thalamus (*tuberculum anterius thalami*), and into which the tractus mamillo-thalamicus (Vicq. d'Azyr's bundle) has been traced (Section 125 (7)). This is a part of the primitive thalamus which, so far as known, has no direct cortical connections; but fibers can be traced by careful teasing directly forward into the head of the caudate nucleus.

147. *Optic connections.*—Trace the optic tract from the optic chiasma to its endings in the colliculus superior (optic tectum) on the one hand and to the pulvinar and lateral geniculate body on the other. The tectum opticum is a mesencephalic center for the unconscious reflex movements of accommodation of the eyes. By carefully teasing away the gray mass of the colliculus superior, fibers can be seen passing down to the region of the floor of the aqueduct of Sylvius, where they effect connections with the nuclei of the III and IV nerves and with the fasciculus longitudinalis medialis. This fasciculus (which has already been dissected out—see Section 109) is a general correlation tract for the eye-muscle nerves and for all visual reflexes. Dissect the optic radiations from the pulvinar to the occipital pole of the cerebral hemisphere. These fibers swing outward, then dorsalward and backward into the cuneus, passing up behind the internal capsule fibers.

148. *Auditory connections.*—The auditory path has already been traced (Section 106) by way of the lateral lemniscus to its thalamic nucleus, the medial geniculate body. Remove the optic tract and pulvinar carefully. Then tease the fibers from the medial geniculate body upward into the internal capsule. They run just in front of the optic radiations and end in the temporal lobe of the cortex.

149. *Somesthetic radiations.*—Carefully tease the lateral and medial lemniscus fibers from the midbrain region, into which they have been traced (Sections 106 and 108), upward into the thalamus. Their terminal nuclei comprise the lateral and ventral nuclei of the thalamus, lying internally of the pulvinar. From these nuclei strands of fibers can be torn upward toward the cortex into the internal capsule. These are the somatic sensory radiations destined for the gyrus centralis posterior.

150. *Pyramidal tract.*—Next tear the pyramidal tract upward from the midbrain floor along the cerebral peduncle into

the internal capsule. These are descending fibers from the gyrus centralis anterior.

151. *Brachium Conjectivum*.—Finally, tear the fibers of the brachium conjunctivum downward to their decussation under the aqueduct of Sylvius. The red nucleus or *nucleus ruber* (where these fibers end after decussating) will be seen immediately in front (cephalad) of this decussation, as a round gray mass about the size of a pea, not far from the median plane. Its rubro-thalamic tracts can readily be seen by teasing forward from the nucleus.

12. Recapitulation of Conduction Paths

152. *Thalamic Nuclei*.—Now make a list of the nuclei of the diencephalon which you have seen and tabulate their fiber connections.

153. Finally, having completed the Table of Conduction Pathways (Section 101) and a table or diagram of the olfactory tracts (Section 130), make a systematic review of each functional system of tracts. For each system get a clear picture of the course of the nervous impulses involved in both the reflex and the cortical functioning of that system. With the intact human brain before you, try to visualize the courses of the fiber tracts in question with reference to the external landmarks.

V. LITERATURE

ALLEN, WM. F. 1919. Application of the Marchi Method to the Study of the Radix Mesencephalica Trigemini in the Guinea-pig, *Jour. Comp. Neur.*, vol. 30, pp. 169-216.

ANDRÉ-THOMAS and DURUPT, A. 1914. Localizations Cérébelleuses, Paris.

ARCHAMBAULT, LA SALLE. 1918. Parenchymatous Atrophy of the Cerebellum, *Jour. Nervous and Mental Disease*, vol. 48, pp. 273-312. Bibliography of 61 titles of works since 1911.

BABINSKI and TOURNAY. 1912. Le Symptomes des Maladies du Cervelet et leur Signification, *Trans. 17. Intern. Congress of Med.*, London, Section XI, Part 1, pp. 51-58.

BAILEY, FREDERICK R. 1916. *Text-book of Histology*, New York.

BAILEY, FREDERICK R. and MILLER, ADAM MARION. 1916. *Text-book of Embryology*, New York.

BÁRÁNY, R. 1912. Lokalization in der Rinde der Kleinhirnhemisphären des Menschen. *Wiener klin. Wochensh.*, Jahrg. 25, No. 52, pp. 2033-2038.

BARKER, LEWELLYS F. 1901. *The Nervous System and Its Constituent Neurons*, New York.

———. 1907. *Anatomical Terminology*, Philadelphia.

———. 1916. *The Clinical Diagnosis of Internal Diseases*, Vol. III, New York.

BARKER, LEWELLYS F., and KYES, PRESTON. 1900. On the Teaching of the Normal Anatomy of the Central System of Human Beings to Large Classes of Medical Students, *Proc. Assoc. Am. Anatomists*, 14th Session, pp. 125-138.

BATESON, W. 1890. The Sense-organs and Perceptions of Fishes, with Remarks on the Supply of Bait, *Jour. Marine Biol. Assoc.*, London, vol. 1, pp. 225-256.

BERGER. 1882. Sehorgane der Fische, *Morph. Jahrb.*, Bd. 8.

BLACK, DAVIDSON. 1916. Cerebellar Localization in the Light of Recent Research, *Jour. Lab. and Clin. Med.*, vol. 1, No. 7.

BOLK, L. 1906. *Das Cerebellum der Säugethiere*, Haarlem and Jena.

BOLTON, J. S., and MOYES, J. M. 1912. Cytoarchitecture of the Cerebral Cortex of the Human Fetus of Eighteen Weeks, *Brain*, vol. 35.

BRODMANN, K. 1907. Die Kortexgliederung des Menschen, *Jour. f. Psychol. u. Neurol.*, Bd. 10.

———. 1909. *Vergleichende Localizationslehre der Grosshirnrinde*, Leipzig.

BROOKOVER, C. 1914. The Nervus Terminalis in Adult Man, *Jour. Comp. Neur.*, vol. 24, pp. 131-135.

———. 1917. The Peripheral Distribution of the Nervus Terminalis in an Infant, *Jour. Comp. Neur.*, vol. 27, pp. 349-360.

BRUCE, ALEXANDER. 1892. *Illustrations of the Nerve Tracts in the Mid and Hind Brain*, Edinburgh.

———. 1901. *A Topographical Atlas of the Spinal Cord*, London.

BURKHOLDER, J. F. 1912. *Anatomy of the Brain*, 2d ed., Chicago.

CAMPBELL, A. W. 1905. *Historical Studies on the Localization of Cerebral Function*, Cambridge.

- COGHILL, G. E. 1913. The Primary Ventral Roots and Somatic Motor Column of *Amblystoma*, *Jour. Comp. Neur.*, vol. 23, pp. 121-144.
- . 1914. Correlated Anatomical and Physiological Studies of the Growth of the Nervous System of Amphibia, *Jour. Comp. Neur.*, vol. 24, pp. 161-233.
- CUNNINGHAM, D. J. 1915. *Text-book of Anatomy*, Revised 4th ed., New York.
- CURRAN, E. J. 1909. A New Association Tract in the Cerebrum. With Remarks on the Fiber Tract Dissection Method of Studying the Brain, *Jour. Comp. Neur.*, vol. 19, pp. 645-656.
- CURTIS, A. H., and HELMHOLTZ, H. F. 1911. The Study of the Anterior Horn Cells of an *Abrachius* and their Relation to the Development of the Extremities, *Jour. Comp. Neur.*, vol. 21, pp. 323-343.
- CUSHING, H. 1903. The Taste Fibers and their Independence of the N. Trigemini, *Johns Hopkins Hospital Bul.*, vol. 14, pp. 71-78.
- . 1908. Removal of a Subcortical Tumor at a Second-stage Operation Without Anæsthesia, *Jour. Amer. Med. Assoc.*, vol. 50, p. 847.
- . 1909. A Note upon the Faradic Stimulation of the Post-central Gyrus in Conscious Patients, *Brain*, vol. 32, pp. 44-54.
- EDINGER, L. 1893. The Significance of the Cortex Considered in Connection with a Report upon a Dog from which the Whole Cerebrum had been Removed by Prof. Goltz, *Jour. Comp. Neur.*, vol. 3, pp. 69-77.
- . 1904. *Vorlesungen über den Bau der nervösen Zentralorgane des Menschen und der Tiere*, 7th ed., vol. 1, Leipzig.
- . 1908. *Idem*, vol. 2.
- . 1911. *Idem*, 8th ed., vol. 1.
- EDINGER, L.; and FISCHER, B. 1913. Ein Mensch ohne Grosshirn, *Pflüger's Archiv*, Bd. 152.
- EWART, J. C. 1893. The Lateral Sense Organs of Elasmobranchs, I, The Sensory Canals of *Lamargus*. *Trans. Roy. Soc.*, Edinburgh, vol. 37.
- EYCLESHYMER, A. C., and SHOEMAKER, D. M. 1917. Anatomical Names, especially the Basle Nomina Anatomica (B N A) with Biographical Sketches (by ROY L. MOODIE), New York.
- FISKE, EBEN W. 1913. *Elementary Study of the Brain*, New York.
- FLATAU, EDWARD. 1899. *Atlas des Menschlichen Gehirns und des Faserverlaufes*, Berlin.
- FLECHSIG, P. 1896. *Gehirn und Seele*, Leipzig.
- GARMAN, S. 1888. On the Lateral Canal System of the Selachia and Holocephala, *Bull. Mus. Comp. Zoöl.*, Harvard, vol. 17.
- VAN GEHUCHTEN. 1906. *Système Nerveux*, 4th ed., Louvain.
- GRAY, HENRY. 1918. *Anatomy of the Human Body*, 20th ed., Philadelphia.
- GUYER, MICHAEL F. 1917. *Animal Micrology*, 2d ed., The University of Chicago Press.
- HALLIBURTON, W. D. 1916. The Possible Functions of the Cerebrospinal Fluid, *Brit. Med. Jour.*, vol. 2, 1916, p. 609.
- HARDESTY, I. 1902. *Neurological Technique*. The University of Chicago Press.
- . 1908. *Laboratory Guide for Histology*, Philadelphia.
- . 1908a. On the Nature of the Tectorial Membrane and Its Probable Rôle in the Anatomy of Hearing, *Amer. Jour. Anat.*, vol. 3, p. 109.

- HARDESTY, I. 1915. On the Proportions, Development, and Attachments of the Tectorial Membrane, *Amer. Jour. Anat.*, vol. 18, pp. 1-73.
- HEAD, HENRY, and HOLMES, GORDON. 1911. Sensory Disturbances from Cerebral Lesions, *Brain*, vol. 34, Parts II and III, pp. 109-254.
- HEAD, HENRY, and THOMPSON, T. 1906. The Grouping of Afferent Impulses within the Spinal Cord, *Brain*, vol. 29, p. 537.
- HERRICK, C. JUDSON. 1899. The Cranial and First Spinal Nerves of Menidia: A Contribution Upon the Nerve Components of Bony Fishes, *Jour. Comp. Neur.*, vol. 9, pp. 153-455.
- . 1903. The Organ and Sense of Taste in Fishes, *Bul. U. S. Fish Commission for 1902*, pp. 237-272.
- . 1903a. On the Morphological and Physiological Classification of the Cutaneous Sense Organs of Fishes, *Am. Naturalist*, vol. 37, pp. 313-318.
- . 1905. The Central Gustatory Paths in the Brains of Bony Fishes, *Jour. Comp. Neur.*, vol. 15, pp. 375-465.
- . 1908. On the Phylogenetic Differentiation of the Organs of Smell and Taste, *Jour. Comp. Neur.*, vol. 18, pp. 157-166.
- . 1918. *An Introduction to Neurology*, 2d ed., Philadelphia.
- HERRICK, C. JUDSON, and COGHILL, G. E. 1915. The Development of Reflex Mechanisms in *Amblystoma*, *Jour. Comp. Neur.*, vol. 25, pp. 65-85.
- HIS, W. 1904. *Entwicklung des menschlichen Gehirns während der ersten Monate*, Leipzig.
- HORSLEY, V. 1909. The Function of the So-called Motor Area of the Brain, *Brit. Med. Jour.*, vol. 2, pp. 125-132.
- HOWELL, W. H. 1918. *Text-book of Physiology*, 7th ed., Philadelphia.
- HUBER, G. C. 1897. *Lectures on the Sympathetic Nervous System*, *Jour. Comp. Neur.*, vol. 7, pp. 73-145.
- HUBER, G. C., and GUILD, S. R. 1913. Observations on the Peripheral Distribution of the Nervus Terminalis in Mammalia, *Anat. Rec.*, vol. 7, pp. 253-272.
- INGVAR, SVEN. 1918. Zur Phylo- und Ontogenese des Kleinhirns nebst einem Versuche zu einheitlicher Erklärung der zerebellaren Funktion und Lokalisation. *Folia Neurobiologica*.
- JOHNSON, S. E. 1917. Structure and Development of the Sense Organs of the Lateral Canal System of Selachians (*Mustelus canis* and *Squalus acanthias*), *Jour. Comp. Neur.*, vol. 28, pp. 1-74.
- JOHNSTON, J. B. 1905. The Radix Mesencephalica Trigemini. The Ganglion Isthmi, *Anat. Anzeiger*, Bd. 27, pp. 364-379.
- . 1906. *The Nervous System of Vertebrates*, Philadelphia.
- . 1908. A New Method of Brain Dissection, *Anat. Rec.*, vol. 2, pp. 345-358.
- . 1909. The Central Nervous System of Vertebrates. *Spengel's Ergebnisse und Fortschritte der Zoologie*, Bd. 2, Heft II, pp. 1-170.
- . 1913. Nervus Terminalis in Reptiles and Mammals, *Jour. Comp. Neur.*, vol. 23, pp. 97-120.
- . 1914. The Nervus Terminalis in Man and Mammals, *Anat. Rec.*, vol. 8, pp. 185-198.
- JONES, ISAAC H. 1918. *Equilibrium and Vertigo*, Philadelphia, Lippincott.

KAPPERS, C. U. ARIËNS. 1913. Cerebral Localization and the Significance of Sulci. Proc. XVII. Intern. Congress of Med., London.

KEIBEL, FRANZ, and MALL, FRANKLIN. 1910. Human Embryology, Philadelphia.

KING, JESSIE L. 1911. The Pyramid Tract and Other Descending Paths in the Spinal Cord of the Sheep, Quart. Jour. Exp. Physiol., vol. 4, No. 2.

KINGSLEY, J. S. 1907. The Dogfish (*Acanthias*), an Elasmobranch, New York, Henry Holt and Co.

———. 1917. Outlines of Comparative Anatomy of Vertebrates, 2d ed., Philadelphia.

KRAUSE, W. 1905. Handbuch der Anatomie des Menschen, Leipzig.

LANGLEY, J. N. 1900. On Axon-reflexes in Preganglionic Fibers, Jour. Physiol., vol. 25, p. 364.

———. 1900a. The Sympathetic and Other Related Systems of Nerves, in Schaefer's Text-book of Physiology, London, pp. 616-696.

———. 1903. The Autonomic Nervous System, Brain, vol. 26, pp. 1-26.

LARSELL, OLOF. 1918. Studies on the Nervus terminalis: Mammals, Jour. Comp. Neur., vol. 30, pp. 1-68.

LEE, ARTHUR BOLLES. 1913. The Microtometist's Vademecum, 7th ed., Philadelphia.

LEE, F. S. 1898. The Functions of the Ear and the Lateral Line in Fishes, Am. Jour. Physiol., vol. 1.

LEYTON, A. S. F., and SHERRINGTON, C. S. 1917. Observations on the Excitable Cortex of the Chimpanzee, Orang-utan, and Gorilla, Quart. Jour. Exp. Physiol., vol. 11, pp. 135-222.

LINEBACK, PAUL E. 1915. A Simple Method of Brain Dissection, Anat. Rec., vol. 9, pp. 387-391, 5 figures.

———. 1917. A Scheme for Drawings in a Course in Embryology, Anat. Rec., vol. 13, pp. 419-423.

LOCY, W. A. 1905. On a Newly Recognized Nerve Connected with the Forebrain of Selachians, Anat. Anz., Bd. 26, pp. 33-63, 111-123.

LUCIANI, LUIGI. 1915. Human Physiology, New York.

MCCOTTER, R. E. 1912. The Connection of the Vomeranasal Nerves with the Accessory Bulb in the Opossum and Other Mammals, Anat. Rec., vol. 6, pp. 299-318.

———. 1913. The Nervus Terminalis in the Adult Dog and Cat, Jour. Comp. Neur., vol. 23, pp. 145-152.

———. 1917. The Vomeranasal Apparatus in *Chrysemys punctata* and *Rana catesbiana*, Anat. Rec., vol. 13, pp. 51-67.

McKIBBEN, PAUL S. 1914. Ganglion Cells of the Nervus Terminalis in the Dogfish (*Mustelus canis*), Jour. Comp. Neur., vol. 24, pp. 437-443.

MARBURG, OTTO. 1904. Atlas des Zentralnervensystems, Leipzig and Wien.

MARSHALL and HURST. 1899. Practical Zoölogy, 5th ed., London.

MAY, OTTO, and HORSLEY, VICTOR. 1910. The Mesencephalic Root of the Fifth Nerve, Brain, Part 130, vol. 33, pp. 175-203.

MEYER, ADOLF. 1898. Critical Review of the Data and General Methods and Deductions of Modern Neurology, Jour. Comp. Neur., vol. 8, pp. 113-148, 249-313.

MONAKOW, C. VON. 1914. Die Lokalisation im Grosshirn und der Abbau der Function durch kortikale Herde, Wiesbaden.

MORRIS. 1914. Human Anatomy, Part III, The Nervous System, Special Sense Organs, 5th ed., Philadelphia.

NORRIS, H. W., and HUGHES, SALLY P. 1919. Cranial Nerve Components in *Squalus acanthias* (forthcoming publication in the Journal of Comparative Neurology.)

OBERSTEINER, HEINRICH. 1912. Anleitung beim Studium des Baues der Nervösen Zentralorgane. 5th ed., Leipzig and Vienna.

PARKER, G. H. 1903. The Sense of Hearing in Fishes, Am. Naturalist, vol. 37, pp. 185-204.

———. 1903a. Hearing and Allied Senses in Fishes, Bul. U. S. Fish Commission for 1902, Washington, pp. 45-64.

———. 1905. The Function of the Lateral Line Organs in Fishes, Bul. of the Bureau of Fisheries for 1904, Washington, pp. 183-207.

———. 1905a. The Stimulation of the Integumentary Nerves of Fishes by Light, Am. Jour. Physiol., vol. 14, pp. 413-420.

———. 1910. Influence of the Eyes, Ears, and other allied Sense Organs on the Movements of the Dogfish, *Mustelus canis* (Mitchell), Bul. Bureau of Fisheries, vol. 29, for 1909, pp. 45-57.

———. 1910a. Olfactory Reactions in Fishes, Jour. Exp. Zool., vol. 8.

———. 1911. Effects of Explosive Sounds, such as those Produced by Motor Boats and Guns, upon Fishes, U. S. Bureau of Fisheries, Document No. 752, pp. 1-9.

———. 1912. The Relation of Smell, Taste, and the Common Chemical Sense in Vertebrates, Jour. Acad. Nat. Sci., Philadelphia, 2 Ser., vol. 15, pp. 221-234.

———. 1912a. Sound as a Directing Influence in the Movement of Fishes. Bul. Bureau of Fisheries, vol. 30 for 1910, pp. 97-104.

———. 1918. A Critical Survey of the Sense of Hearing in Fishes. Proc. Am. Philos. Soc., vol. 57, pp. 1-30.

PARKER, G. H., and VAN HEUSEN, ANNE P. 1917. The Reception of Mechanical Stimuli by the Skin, Lateral-line Organs and Ears in Fishes, especially in *Amiurus*, Am. Jour. Physiol., vol. 44, pp. 463-489.

PARKER, G. H., and SHELDON, R. E. 1913. The Sense of Smell in Fishes, Bul. U. S. Bureau of Fisheries, vol. 32 for 1912 (Doc. no. 775), pp. 33-46.

PARKER, T. J. 1900. A Course of Instruction in Zoötomý (Vertebrata), London, Macmillan and Co.

PARKER, T. J., and HASWELL, W. 1910. Text-book of Zoölogy, London.

PEABODY, J. E. 1897. The Ampullæ of Lorenzini of the Selachii, Zool. Bul., vol. 1, pp. 163-177.

PIERSOL, G. A. 1916. Human Anatomy, 5th ed., Philadelphia.

PRENTISS, C. W. 1913. On the Development of the Membrana Tectoria with Reference to Its Structure and Attachments, Amer. Jour. Anat., vol. 14, pp. 425-459.

QUAIN. 1909. Elements of Anatomy, 11th ed., New York.

RAMÓN Y CAJAL, S. 1909-1911. Histologie du Système nerveux, 2 vols. (vol. I, 1909; vol. II, 1911), Paris.

RAUBER and KOPSCH, FR. 1912. Lehrbuch der Anatomie des Menschen, 9th ed., Abteilung V, Leipzig.

Reference Handbook of the Medical Sciences, 1912, ff., 3d ed. (articles on brain, cranial nerves, ear, end-organs, spinal cord, and others), New York.

RETZIUS, G. 1881. Das Gehörorgan der Wirbelthiere, Stockholm.
 ———. 1896. Das Menschenhirn. Studien in der makroskopischen Morphologie, Stockholm.

RIDDOCH, GEORGE. 1917. The Reflex Functions of the Completely Divided Spinal Cord in Man, Compared with those Associated with Less Severe Lesions, *Brain*, vol. 40, pp. 264-402.

VAN RYNBERK, G. 1907-1908. Die neueren Beiträge zur Anatomie und Physiologie des Kleinhirns der Säuger (critical review), *Folia Neurobiologica*, Bd. I, pp. 46-62, 403-419, 535-551.

———. 1912. Weitere Beiträge zum Localizationsproblem im Kleinhirn (critical review), *Folia Neurobiol.*, Bd. 6, Supplement, pp. 143-170.

SABIN, FLORENCE. 1901. An Atlas of the Medulla and Midbrain, Friedenwald Co., Baltimore.

SCHAEFER, E. A. 1900. *Physiology*, London.

SHAMBAUGH, G. E. 1907. A Restudy of the Minute Anatomy of Structures in the Cochlea with Conclusions Bearing on the Solution of the Problem of Tone Perception, *Am. Jour. Anat.*, vol. 7, pp. 245-258.

———. 1908. The Membrana Tectoria and the Theory of Tone Perception, *Arch. Otolology*, vol. 37, pp. 457-467.

SHELDON, R. E. 1909. The Phylogeny of the Facial Nerve and Chorda Tympani, *Anat. Rec.*, vol. 3, pp. 593-617.

———. 1909a. The Reactions of Dogfish to Chemical Stimuli, *Jour. Comp. Neur.*, vol. 19, pp. 273-311.

———. 1911. The Sense of Smell in Selachians, *Jour. Exp. Zool.*, vol. 10, pp. 51-62.

———. 1914. Paraffine-Weigert Methods for the Staining of Nervous Tissue, with some new Modifications, *Folia Neurobiol.*, Bd. 8, pp. 1-28.

SHERRINGTON, C. S. 1906. *The Integrative Action of the Nervous System*, New York.

SIMPSON, S., and KING, J. LUELLA. 1911. Localization of the Motor Area in the Sheep, *Quart. Jour. Exper. Physiol.*, vol. 4, pp. 53-65.

SMITH, G. ELLIOT. 1903. Further Observations on the Natural Mode of Subdivision of the Mammalian Cerebellum, *Anat. Anz.*, Bd. 23, pp. 368-384.

———. 1907. A New Topographical Survey of the Human Cerebral Cortex, *Jour. Anat. and Physiol.*, vol. 41, pp. 237-254.

SOBOTTA, J. 1911. *Atlas and Text-book of Human Anatomy*, vol. 3, Philadelphia.

SPALTEHOLZ. 1909. *Handatlas der Anatomie des Menschen*, Leipzig.

STARLING, ERNEST H. 1915. *Principles of Human Physiology*, 2d ed., Philadelphia.

STARR, M. A., STRONG, O. S., and LEAMING, E. 1896. *Atlas of Nerve Cells*, New York.

STEWART, G. N. 1918. *Manual of Physiology*, 8th ed., New York.

STREETER, G. L. 1907. On the Development of the Membranous Labyrinth and the Acoustic and Facial Nerves in the Human Embryo, *Amer. Jour. Anat.*, vol. 6, pp. 139-166.

VAN DER STRICHT, O. 1918. The Genesis and Structure of the Membrana Tectoria and the Crista Spiralis of the Cochlea, *Carnegie Inst. of Washington, Contr. to Embryology*, No. 21, pp. 57-86.

- STRONG, O. S. 1915. A Case of Unilateral Cerebellar Agenesis, *Jour. Comp. Neur.*, vol. 25, pp. 361-374.
- TOLDT, CARL. 1904. *An Atlas of Human Anatomy*, Sec. VI, London.
- VILLIGER, E. 1912. *Brain and Spinal Cord* (translated by G. A. Pier-sol), Philadelphia.
- WEED, LEWIS, H. 1914. *Studies on Cerebrospinal Fluid*, *Jour. Med. Research*, vol. 31, pp. 21-117.
- . 1914a. A Reconstruction of the Nuclear Masses in the Lower Portion of the Human Brain Stem, *Carnegie Inst. of Washington*, Pub. No. 191.
- . 1917. The Development of the Cerebro-spinal Spaces in Pig and in Man, *Carnegie Inst. of Washington*, Pub. No. 225.
- WIEDERSHEIM, ROBERT. 1907. *Comparative Anatomy*, 3d English edition, London.
- WILSON, J. G. 1905. The Structure and Function of the Taste-buds of the Larynx, *Brain*, Part CX, vol. 28, pp. 339-351.
- WINKLER, C., and POTTER, ADA. 1911. *An Anatomical Guide to Experimental Researches on the Rabbit's Brain*, Amsterdam.
- . 1914. *An Anatomical Guide to Experimental Researches on the Cat's Brain*, Amsterdam.

INDEX

The references are to pages. Numbers printed in **black-face** type refer to pages with illustrations. A Glossary of the more commonly used neurological terms is combined with the Index of the senior author's Introduction to Neurology.

- ACOUSTIC apparatus. See *Auditory apparatus*.
- Acoustico-lateral system, **20, 21, 23-26**, 32, 33, 36
- Ala cinerea, 54, **57, 76, 77, 98**
- Ala lobuli centralis, **86**
- Amygdala, 105, 111, 116
- Aqueduct of Sylvius, 38, **56, 99**
- Arbor vitæ, **56, 85**
- Archipallium, 99, 109
- Area acustica, 54, 55
- olfactoria, **56, 104-106**
- parolfactoria, of Broca, 105
- Auditory apparatus, of dogfish, **18, 20, 21, 35**
- of mammal, 72, 112, 117
- BETWEENBRAIN. See *Diencephalon*.
- Black substance. See *Substantia nigra*.
- Blood vessels of brain, 47
- Brachium, of colliculus inferior, **58, 100, 112**
- conjunctivum, **58, 82-84, 95, 118**
- pontis, **57, 58, 82-84, 94**
- quadrigeminum inferius, **58, 100, 112**
- Brain of dogfish, **18, 20, 21, 35-38**
- of fetal pig, 45
- methods of dissection, 43, 44
- of sheep, **48, 50, 52, 56, 57, 58**
- removal of, 39
- stem, 51, 99
- subdivisions of, 45
- Broca, area parolfactoria of, 105
- convolution of, 100
- diagonal band of, **50, 107**
- Bulb, olfactory, **20, 21, 48, 50, 56, 99, 104, 115**
- CAPSULE, external, 116
- internal, 111, 113, 114, 116
- Centers, association, 114
- projection, 114
- Cerebellum, 36, 37, 51, 82-89
- localization in, 86-88
- Cerebrum, 37, 51, 99, 114
- Chiasma, optic, **50, 56, 112, 117**
- Cingulum, 102, 103
- Clarke's column. See *Nucleus thoracalis*.
- Clava, 55, **57, 58, 70**
- Cochlea, 72
- Colliculus facialis, 53, **57**
- inferior, **57, 58, 96, 99, 112**
- superior, **56-58, 99, 112, 117**
- Columna fornicis. See *Fornix, column of*.
- Columns of spinal cord, 64
- Commissura, anterior, **56, 105, 116**
- habenularum, **56**
- hippocampi, 109
- posterior, **56**
- superior. See *Commissura habenularum*.
- Components of cranial nerves, **24-26, 29, 30, 49**
- Corona radiata, 103
- Corpus callosum, **56, 102**
- fornicis. See *Fornix, body of*.
- geniculatum laterale. See *Geniculate body, lateral*.
- mediale. See *Geniculate body, medial*.
- mamillare. See *Mammillary body*.
- pineale, **18, 56, 57**
- restiforme. See *Restiform body*.

- Corpus striatum, 113, 116
 trapezoideum. See *Trapezoid body*.
 Cortex, cerebellar, 51, 85
 cerebral, 36, 51, 99, 101
 Corti, organ of. See *Spiral organ*.
 Culmen monticuli, **56, 86, 87**
 Cuneus, 100, 117
 Cutaneous system of dogfish, **20, 21, 35**
 of mammal, 68
- DECLIVE monticuli, 56, 86, 87**
 Dependencies, cortical, 46
 Diencephalon, 37, 99, 118
 Dogfish, 16-38
- EAR of dogfish, **18, 19, 20, 21**
 of mammal, 72
 Eminentia abducentis, 53
 medialis, 53
 Endbrain. See *Telencephalon*.
 Ependyma, 64
 Epiphysis. See *Pineal body*.
 Epithalamus, **20, 37**
 Exteroceptive systems, 66, 72
 Eye of dogfish, **18, 20, 27**
 of mammal, 28
- FASCIA dentata, 109
 Fasciculus, cerebro-spinal. See *Tract, pyramidal*.
 cuneatus, 55, **57, 58, 70, 97**
 gracilis, 55, **57, 70, 97**
 lateralis, **58**
 longitudinalis inferior, 103
 medialis, 35, 76, 80, 98, 117
 superior, 103
 occipito-frontalis inferior, 103
 retroflexus, 107
 solitarius, 54, 76, 98
 of spinal cord, 64
 transversus occipitalis, 103
 uncinatus, 103
- Fibers (fibræ), arcuate, 79, 84, 102
 associational, 102, 103, 114
 profundæ pontis, 94
 projection, 114
 superficiales pontis, 94
 Fillet. See *Lemniscus*.
 Fimbria, 109, 115
 Fish, nervous system of, 16-38
- Fissure (fissura), ansata, **52, 56**
 calcarine, 100
 central, 100
 chorioidea, 116
 collateral, 100
 crucial, **52, 56**
 hippocampal, 101, 109
 lateral, 100
 preculminata, 88
 primaria, 88
 rhinalis, **50**
 of Rolando, 100
 secunda, **56, 86, 88**
 of Sylvius, 100
 Flocculus, **48, 52, 85**
 Folium vermis, **87**
 Foramen, interventricular, 38, **56, 57**
 of Monro. See *Foramen, inter-ventricular*.
 Formatio reticularis. See *Reticular Formation*.
 Fornix, 108-110
 body of, **56, 109**
 column of, **56, 109, 110**
 Fossa rhomboidea. See *Ventricle, fourth*.
 Fovea inferior, 54, **57**
 superior, 54, **57**
 Funiculus of spinal cord, 64, 70
 teres, 53, **57**
- GANGLION, gasserian. See *Ganglion, semilunar*.
 geniculate, 76
 jugular, X, 68
 nodosal X, 76
 petrosal IX, 76
 semilunar, 68
 spinal, 47
 superior IX, 68
 Geniculate body, lateral, **57, 99, 112, 117**
 medial, **57, 58, 97, 99, 112, 117**
 Gills of dogfish, 17, **18, 20, 34, 37**
 Gustatory apparatus. See *Taste*.
 Gyrus, centralis, 100
 cinguli, **56, 100**
 dentatus, **56, 109**
 frontalis, 100
 hippocampi, 99, 101
 lateral olfactory, 105
 subcallosus, 105
 temporalis, 101

- HABENULA, **56, 57, 106**
 Heart of dogfish, 17
 Hemisphere, cerebellar, **52, 85, 95**
 cerebral, **20, 21, 37, 99, 100, 101**
 Hippocampus, 108, 109, 115
 Hypophysis. See *Pituitary body*.
 Hypothalamus, 37
- INDUSIUM, 108
 Infundibulum, **50, 56**
 Insula, 100
 Island of Reil, 100
 Isthmus, 37, 51
- LAGENA of dogfish, 19
 Lamina epithelialis, 59
 quadrigemina, **56**
 terminalis, **56, 57**
- Lateral line organs and nerves, 17,
23-26
- Lemniscus, definition of, 72
 lateral, **58, 73, 74, 96, 97, 117**
 medial, 70, 71, 97, 98
 spinal, 66, 71
 trigeminal, 69
 visceral, 79
- Lingula, **87**
- Lobe (lobus), anterior cerebelli, **86**
 frontal, 100
 occipital, 100
 parietal, 100
 pyriform, **48, 50, 99**
 temporal, 100, 108
- Lobulus ansiformis, **86**
 biventer, **86**
 centralis, **86, 87**
 paramedianus, 86
 quadrangularis, **86**
 semilunaris, **86**
 simplex, **86**
- Localization, cortical, **52, 101**
- Longitudinal medial bundle. See
Fasciculus, longitudinal medial.
- Lyra, 109
- MAMMILLARY body, **50, 56, 106**
 Massa intermedia **56**
- Medulla oblongata, correlation in,
 78
 of dogfish, **20, 26, 35, 36, 37**
 of mammal, **50, 52, 53, 56, 67**
 reference to figures of, 60
 spinalis. See *Spinal cord*.
- Membranes of brain. See *Men-
 inges*.
- Meninges, 21, 46, 47
 Mesencephalon, 37, 99
 reference to figures of, 61
 Meynert's bundle, 107
 Midbrain. See *Mesencephalon*.
 Mitral cells, 104
 Muscles of eyeball, **18, 21**
 Mustelus canis, 16-38
- NASAL organ and nerve. See
Olfactory.
- Neopallium, 99
 Neothalamus, 114
 Nerve, abducens, 31
 accessory, 32
 acoustic, 31, 73
 auditory. See *Nerve, acoustic*.
 cochlear, central connections of,
 73
 cranial, 49
 of dogfish, **18, 20, 21, 23-26, 28-34**
 facial, 31
 glossopharyngeal, 31
 hypoglossal, 32
 of Lancisius, 108
 of lateral lines, **20, 21, 23-26**
 oculomotor, 31
 olfactory, 30
 optic, 30
 spinal, of fetal pig, 46
 terminal, **20, 24, 30, 49**
 trigeminal, 31
 central connections of, 68, 69
 trochlear, 31
 vagus, 31
 vestibular, central connections
 of, 75
- Neuron, 63
 Nodulus, **56, 86, 87**
- Nucleus, ambiguus, 77
 amygdalæ, 105, 111, 116
 anterior thalami, 107, 116
 arcuate, 84
 caudate, 111, 114, 116
 of cerebellum, 84
 cochlear, **55, 57, 58, 73, 74, 96**
 dentate, 84
 dorsalis Clarkii, 64
 dorsal X, 77, 98
 emboliformis, 85
 of fasciculus cuneatus, 97
 gracilis, 97
 solitarius, 76
 fastigii, 85

- Nucleus, globosus, 85
of III nerve, 77
lateral olfactory, **48, 50, 105**
of thalamus, 114, 117
lentiform, 111, 114, 116
motor V, 69, 77
VII, 77
pontis, 84, 95
red, 96, 118
ruber, 96, 118
salivatory, 77
sensory V, 69
of spinal V tract, 69
thoracalis, of Clarke, 64
ventral of thalamus, 114, 117
vestibular, 55, **57, 58, 75, 96**
- OBEX, **57**
- Olfactory apparatus, of dogfish,
18, 20, 21, 24, 25, 35
of mammal, 104-110, 115, 116
organ, 104
- Olive, inferior, 84
superior, 73, 75, 96, 97
- Operculum, 100
- Optic apparatus of dogfish, **18, 20, 21, 27, 35**
of mammal, 112, 117
chiasma, **50, 56, 112, 117**
lobes, 37
- Optocoele, 38
- PALLIUM, 99
- Paraflocculus, **48**
- Peduncle, cerebellar, 51, 82-84
inferior. See *Corpus restiforme*.
medial. See *Brachium pontis*.
superior. See *Brachium conjunctivum*.
cerebral, 37, **50, 56, 58, 95**
of corpus callosum, 105
of inferior colliculus, 100
- Pig, fetal, brain of, 45
spinal cord of, 45
nerves of, 45
- Pineal body, **18, 56, 57**
- Pituitary body, **56**
- Plexus, choroid, definition of, 59
of fourth ventricle, 52, **56, 58**
of lateral ventricles, 59, 111, 115
of third ventricle, **56, 58**
- Pons, **48, 50, 56, 58, 85**
- Posterior longitudinal bundle.
See *Fasciculus longitudinalis medialis*.
- Proprioceptive systems, 66, 72, 85
- Pulvinar, 100, 112, 117
- Pyramid, **50, 58, 113**
- Pyramis cerebelli, **56, 86, 87**
- RADIATIONS, auditory, 117
optic, 117
somesthetic, 117
thalamic, 114
- Recess, cerebellar, **56, 58**
lateral, of fourth ventricle, 53
preoptic, **56**
- Reference books, 14, 15, 119-125
- Restiform body, **57, 58, 82, 83, 93**
- Reticular formation, 64, 72, 79, 96
- Retina, 111
- Rhinencephalon, 104
- Rhombencephalon, 37, 51, 99
- Root, cochlear, 73, 96
mesencephalic V, 69
vestibular, 96
- Rostrum corporis callosi, **56**
- SEGMENTAL apparatus, 51, 99
- Sense organs of fishes, 16, 17
of somatic sensory systems, 67
- Septum pellucidum, **56, 105**
- Shark, 16-38
- Skate, 16
- Smell, apparatus of. See *Olfactory apparatus*.
- Somatic motor system, 17, **24-26, 29, 30, 35, 37, 53, 66, 78**
sensory system, 17, **24-26, 29, 30, 36, 37, 54, 66, 67**
- Space, anterior perforated, 99, 105, 106
- Spinal cord of fetal pig, 46
functions of, 65
human, 47, 64
neurons of, 63-65
sequence of myelination in, 67
- Spiracle, **18, 20, 21, 25**
- Spiral organ, 72
- Squalus acanthias, 16-38
- Stria of Lancisius, 108
longitudinalis medialis, 108
medullares acusticae, 73, 96

- Stria medullares, thalami, **56**, 106,
 110
 olfactory, 104, 105, 115
 semicircularis, 106, 111
 terminalis, 105, 106, 111, 116
 Substantia alba, 64
 gelatinosa, 64, 69
 grisea, 64
 nigra, 84
 Sulcus, cinguli, **56**, 100
 furcal, 86
 horizontalis, **86**, **88**
 limiting, 36, **37**, 54
 postcentralis, **88**
 postclivalis, **86**
 postnodularis, **88**
 postpyramidalis, **88**
 precentralis, **88**, 100
 preclivalis, 86, 88
 prepyramidalis, 88
 primarius, **56**, 85, **86**, **88**
 temporal, 100
 uvulo-nodularis, **86**, **88**
 Suprasegmental apparatus, 51, 99
 Sympathetic nervous system, 46,
 67

 TÆNIA chorioidea, 116
 fornicis, 115
 of fourth ventricle, 52, **57**
 semicircularis, 106, 111, 116
 thalami, **57**, 59
 of third ventricle. See *Tænia*
 thalami.
 ventriculi tertii. See *Tænia*
 thalami.
 Taste, bulbar center of, 76
 nerves of, 77
 organs of, 77
 Tectum, optic, 112, 117
 Tegmen fossæ rhomboideæ, 58
 Tegmentum, 96
 Telencephalon, 37, 99
 Thalamus, **21**, 37, **57**, 99, 114, 118
 reference to figures of, 61
 Tonsilla, **86**
 Tract (tractus), associational, 102,
 103, 114
 central tegmental, 84
 cerebello-tegmental, 96
 cerebro-spinal. See *Tract, py-*
 ramidal.
 cortico-pontile, 85, 95
 Tract (tractus), cortico-spinal. See
 Tract, pyramidal.
 of Flechsig. See *Tract, spino-*
 cerebellar, dorsal.
 general somatic sensory, 72
 of Gowers. See *Tract, spino-*
 cerebellar, ventral.
 habenulo-peduncular, 107
 mamillo-peduncular, 107
 mamillo-tegmental, 107
 mamillo-thalamic, 107, 117
 olfactory, **50**, 104, 115
 olfactory projection, 106
 olfacto-cortical, 108
 olfacto-habenular, 106
 olfacto-mammillary, 106
 olfacto-tegmental, 106
 olivo-cerebellar, 84
 optic, **50**, 100, 112, 117
 projection, 114
 pyramidal, 80, 81, 95, 99, 112,
 117
 spinal trigeminal, **57**, **58**, 68
 spino-bulbar, 79
 spino-cerebellar, dorsal, **57**, **58**,
 83, 94
 ventral, 84, 96, 97
 tæniæ, 106
 thalamo-mammillary, 107
 of Vicq d'Azyr, 107, 117
 rubro-thalamic, 118
 Trapezoid body, **48**, **50**, **56**, **58**, 73,
 75, 96
 Trigonum hypoglossi, 53, **57**
 vagi, 54
 Tuber, cerebelli, **86**
 cinereum, **50**
 vermis, **87**
 Tuberculum acusticum, 55, 73
 anterior thalami, 117
 cinereum, 55, 68
 cuneatum, 55, **57**, **58**, 70
 olfactorium, **50**, **56**, 99, 105, 106

 UNCUS, 101, 105, 108
 Uvula, **56**, **86**, **87**

 VELUM, anterior medullary, 52, **56**,
 58, 95
 posterior medullary, 58
 Ventricle, first and second. See
 Ventricle, lateral.
 fourth, **20**, 35, 36, **37**, 38, 51, 53,
 56

- Ventricle, lateral, 38, 110, 111,
115
third, 38, **56**, 57, 99
- Vermis cerebelli, **48**, **52**, 85
- Visceral apparatus, of dogfish,
20, **21**
- Visceral motor system, 17, **24-26**,
29, 30, 36, **37**, 53, 66, 77
sensory system, 17, **24-26**, 29,
30, 36, **37**, 53, 66, 76
- Visual apparatus. See *Optic ap-
paratus*.

**RETURN TO the circulation desk of any
University of California Library**

or to the

NORTHERN REGIONAL LIBRARY FACILITY

University of California

Richmond Field Station, Bldg. 400

1301 South 46th Street

Richmond, CA 94804-4698

ALL BOOKS MAY BE RECALLED AFTER 7 DAYS

To renew or recharge your library materials, you may
contact NRLF 4 days prior to due date at (510) 642-6233

DUE AS STAMPED BELOW

FEB 26 2008

DD20 12M 7-06

QM451
H57
1920

Herrick, C.J.

55621

Laboratory outline of
neurology, by C.J.Herrick
& E.C.Crosby. 2d ed.

Miles

JAN 23 1947

JAN 20 1947

UNIVERS

