

CORNELL
UNIVERSITY
LIBRARY



GIFT OF

S. H. Gage

Cornell University Library
QM 25.S67 1900a


v.1

Hand atlas of human anatomy,



3 1924 003 110 347

mann



Cornell University Library

The original of this book is in
the Cornell University Library.

There are no known copyright restrictions in
the United States on the use of the text.

HAND ATLAS
OF
HUMAN ANATOMY

BY

WERNER SPALTEHOLZ

EXTRAORDINARY PROFESSOR OF ANATOMY IN THE UNIVERSITY
AND CUSTODIAN OF THE ANATOMICAL MUSEUM AT LEIPZIG

WITH THE ADVICE OF

WILHELM HIS

PROFESSOR OF ANATOMY IN THE UNIVERSITY OF LEIPZIG.

TRANSLATED FROM THE THIRD GERMAN EDITION

BY

LEWELLYS F. BARKER

PROFESSOR OF ANATOMY IN THE UNIVERSITY OF CHICAGO.

WITH A PREFACE

BY

FRANKLIN P. MALL

PROFESSOR OF ANATOMY IN THE JOHNS HOPKINS UNIVERSITY AT BALTIMORE.

VOL. I.

BONES, JOINTS, LIGAMENTS.

LEIPZIG

S. HIRZEL

1900.

WILLIAMS AND NORGATE,

14, HENRIETTA STREET COVENT GARDEN, LONDON
20, SOUTH FREDERICK STREET, EDINBURGH
AND 7, BROAD STREET, OXFORD.

G. E. STECHERT,

IMPORTERS OF BOOKS AND PERIODICALS,
WHOLESALE AND RETAIL,
9, EAST 16TH STREET, NEW YORK.

ALL RIGHTS RESERVED.

Preface.

The appearance of Spalteholz's Atlas a few years ago was welcomed alike by teachers and students of anatomy. So useful is this book to students who desire to study anatomy in the dissecting room that without any effort on my part it has become the favorite aid to the students of anatomy at the Johns Hopkins University. Its value to English and American students not acquainted with the German language is now greatly increased through the admirable translation of the text into English by Professor Barker.

The main object of studying anatomy is to obtain a mental image of the human body rather than to memorize numerous terms as is too often the case in our medical schools, especially in America. When the study of anatomy is transferred from the lecture room, text book and quiz-compend to the dissecting room it becomes one of the best disciplinary studies for medical students and at the same time gives them most useful knowledge by the inductive method of study. In the dissecting room the student obtains the greatest aid from the instructor who teaches him the art of dissection and guides him in methodical study. Next in importance is a good text book which should always be at the student's side in order that he may study the dissection of the body as it proceeds.

The study of anatomy would be relatively easy were the student familiar with the subject before he begins it. The rule that the student should acquire as much knowledge as possible of a region before he begins to dissect it is good but has its limitations because it is only through the work itself that the interest of the student, and thereby his instruction, can be kept up. Just at this time an Atlas proves to be of the greatest value. Pictures of dissections, true to nature, aid the imagination of the student enormously and thus guide his work from the known to the unknown. It follows that the illustrations of an anatomical atlas must be typical, giving all stages of the dissection of the body from its beginning to its completion. The Atlas of Spalteholz meets this requirement. In addition to the superior quality of the illustrations it may be stated that they are all carefully marked with the new anatomical nomenclature.

Making the anatomical terms uniform means much more than simply changing some of the names, for it brings us one step nearer to a knowledge of the normal. In casting the new nomenclature the leading anatomists of the world occupied much of their time in determining the normal and for this reason if for no other the BNA should be adopted. In the translation where the terms used are very different from the old nomenclature the latter are inserted in brackets.

The Atlas speaks for itself. If its reception is as favorable generally as it has been at the Johns Hopkins University it will soon become the standard aid to our students of practical anatomy.

Franklin P. Mall.

Author's preface.

As early as shortly after the appearance of the first part of this atlas, on various sides the wish was repeatedly expressed, among others by my friend Prof. F. P. Mall, to possess an English edition. After some hesitation the publishers have decided to this end, since so distinguished a specialist as Professor Barker has been found ready to prepare this. In order to secure the utmost conformity with the German work, the illustrations have been printed from the original plates, and for the translation, the text of the third German edition, under preparation, was submitted. I myself, moreover, have superintended the proof reading.

In accordance with the plan which I had laid as a foundation for the work, the atlas is intended to embrace the entire descriptive anatomy with the exception of histology, while including so far as possible the relations which are brought out by magnification with strong hand lenses. Thus, likewise, it is intended to have due regard for the field which lies between macroscopic and microscopic anatomy proper. The topographic relations of the organs and especially of the vessels and nerves have been given the utmost consideration attainable within the compass of a book which treats primarily of descriptive anatomy.

In order to increase the clearness of the illustrations, a great part of them have been done in colors so that the parts whose portrayal in the sections is of importance, are brought into prominence by the colors.

The number of drawings necessary is provisionally roughly estimated at about 800, but if necessary this number will be increased.

It is intended, if possible, that the second volume, containing muscles and blood vessels, shall appear in the course of the winter, the third volume containig the viscera, brain, nerves, and sense organs, immediately after its completion in the German edition.

At the end of the atlas a complete index is proposed.

For all illustrations, with unimportant exceptions, new original drawings were made. To the choice of the objects and the production of the drawings the most thoughtful attention was devoted. With regard to the admission and manner of representation of an object, first and foremost, pedagogic principles gave me the decision; where an object appeared difficult a greater number of drawings were made, and vice versa. The illustrations, in all cases, have been faithfully drawn from original preparations, but at the same time no copy of a definite individual case, but always a composite from several sections has been made.

The preparations were made for the most part especially for this purpose and admitted only after many repetitions if the relations did not appear to me

clear enough. Thence it follows that in those cases in which I have given new delineations which departed somewhat from the customary, I did it with full consciousness on the strength of new preparations.

All illustrations are taken from the right half of the body.

As the basis for the technical terms, I have, throughout, made use of the new anatomical nomenclature, BNA, as unanimously adopted by the anatomical association at its IX. meeting in Basel on April 19, 1895 and published with introduction and explanations by W. His. I have held myself strictly to the terms there given and only in a few isolated cases added terms according to my own judgment. Also for the mass of quoted names, the compilation just referred to has served me as a standard; only a few terms will be found missing.

As to the process of reproduction, with a few exceptions the Half-tone was made choice of, because this mechanical method reproduces the original drawing far more accurately than the woodcut.

The drawings of the attachments of muscles were completed from preparations which were made by the deceased Prof. W. Braune himself.

As far as the text is concerned, I undertook only unwillingly the writing of the same, since in my opinion this adjunct too easily permits the idea to be acquired by the student, that this text will suffice for the study of anatomy in general. I have determined ultimately on a supplement to the same if much desired, and then to devote to it the greatest care. My effort was, to give a clear description of the figure, and at the same time an explanation of all the descriptive terms made use of in the figure. In so doing it unintentionally turned out much more detailed than was really necessary in the accompanying text of an atlas, in which, indeed, the illustrations are the essentials; yet it resembles many text books in completeness. And yet again it differs from these in the main points: it is more incomplete in as much as I found it necessary to omit entirely all general matter, and occasionally, if place for the text was wanting, it was necessary that the illustration alone should speak for itself. Consequently the text remains, for the most part, a guide; so it ought not and can in no way render a text book of anatomy unnecessary.

In the part on articulations, I have provided a description of the pure anatomic relations only, and with the exception of the mandibular articulation, intentionally, have nowhere entered into the function of the same; for while the old classification of joints according to the form of the articulating faces has now only partial value, nevertheless a new classification according to the amount of motion possible in life is not yet applicable to all joints.

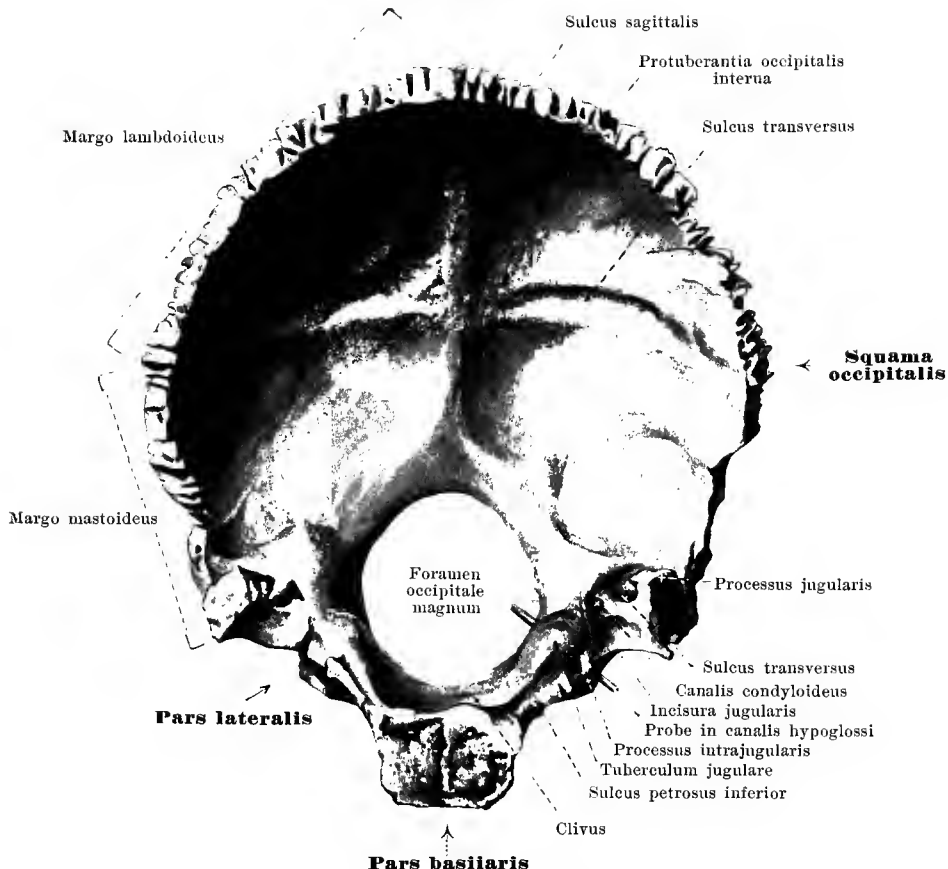
For showing the soft parts, especially the muscles and viscera, for the most part, material carefully hardened in formalin was used.

The data regarding the action of the individual muscles take into account only the influence which the muscles exert on those joints over which they pass.

Werner Spalteholz.

I.

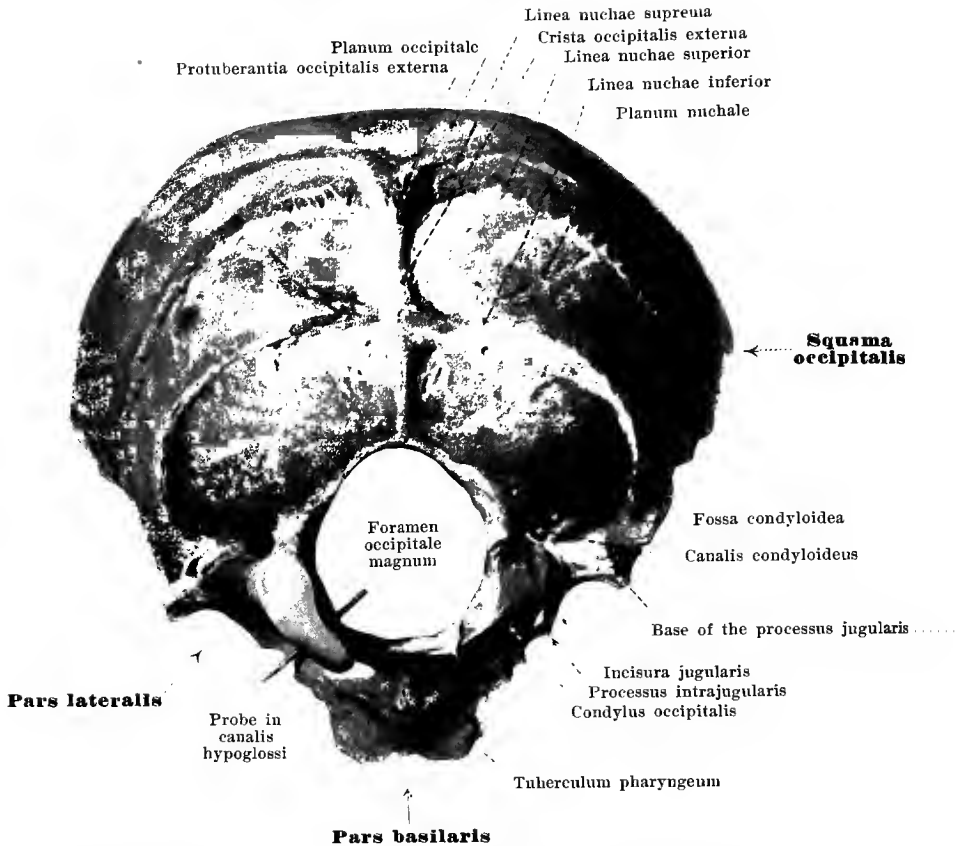
BONES, JOINTS, LIGAMENTS.



I. Occipital bone, *os occipitale*, from in front.

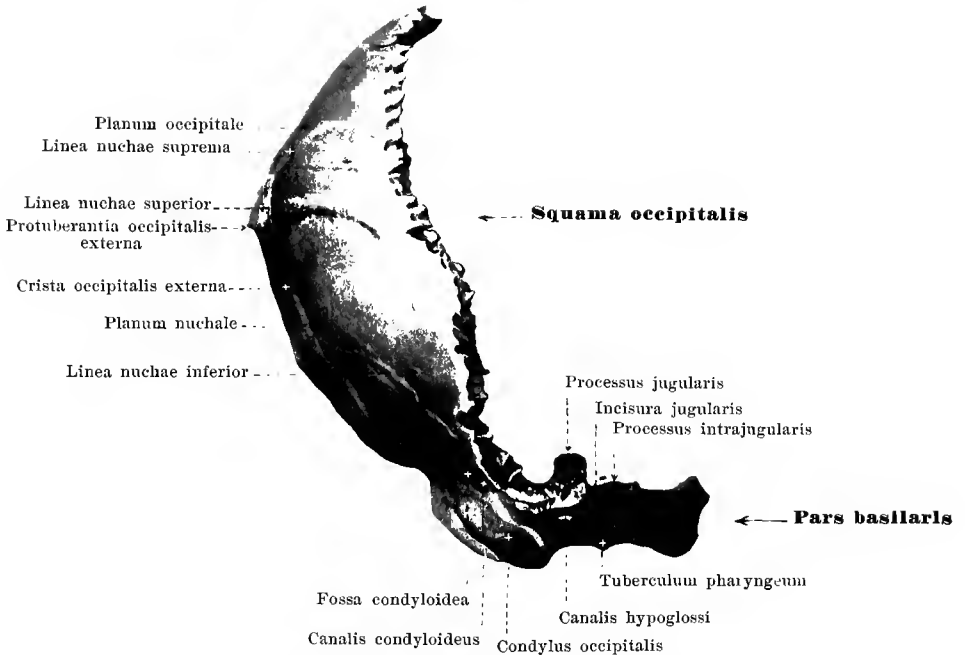
The unpaired **os occipitale** (*occipital bone*) (see also Figs. 2, 3, 55, 56 and 59—66) forms the posterior inferior part of the skull. It is divisible into four parts; an unpaired basilar part (*pars basilaris*); an unpaired squamo-occipital part (*squama occipitalis*) and the paired lateral parts (*partes laterales*). These parts are so arranged around the large occipital foramen (*foramen occipitale magnum*) that the *pars basilaris* lies in front of the foramen, the *squama occipitalis* behind and above it, while the *partes laterales* lie lateral from it. Through the great occipital foramen pass the meningeal rami of the vertebral arteries, the vertebral arteries themselves, the anterior and posterior spinal arteries, the basilar plexus, the nn. accessorii, the roots of the nn. cervicales I, and the medulla oblongata.

The **pars basilaris** presents, up to about the twentieth year of life, a rough surface in front corresponding to its attachment to the body of the sphenoid bone; the union is effected by a layer of hyaline cartilage which ossifies later (*fissura* and *synchondrosis sphenoccipitalis*). The two lateral slightly jagged edges lie upon the posterior angle of the petrous portion of the temporal bone (*fissura* and *synchondrosis petrooccipitalis*); on the upper surface is situated the groove, formed by the two bones in common, corresponding to the *sulcus petrosus inferior* (for the sinus petros. inf.). The posterior border, sharp in the middle, is smooth and concave, and forms the anterior circumference of the for. occip. mag. The superior surface is smooth and slightly concave in a frontal direction; it helps to form the *clivus* inasmuch as it is directly continuous with the posterior surface of the dorsum sellae of the sphenoid. The *clivus* gives support to the pons, the vertebral arteries, the basilar artery and their branches. The inferior surface presents in the median line a small projection, the pharyngeal tubercle (*tuberculum pharyngeum*) (for the attachment of the lig. longitud. ant. and the m. constrictor pharyngis sup.), and also alternating ledges for the m. rectus capitis ant. and the m. longus capitis.



2. Occipital bone, *os occipitale*, from behind.

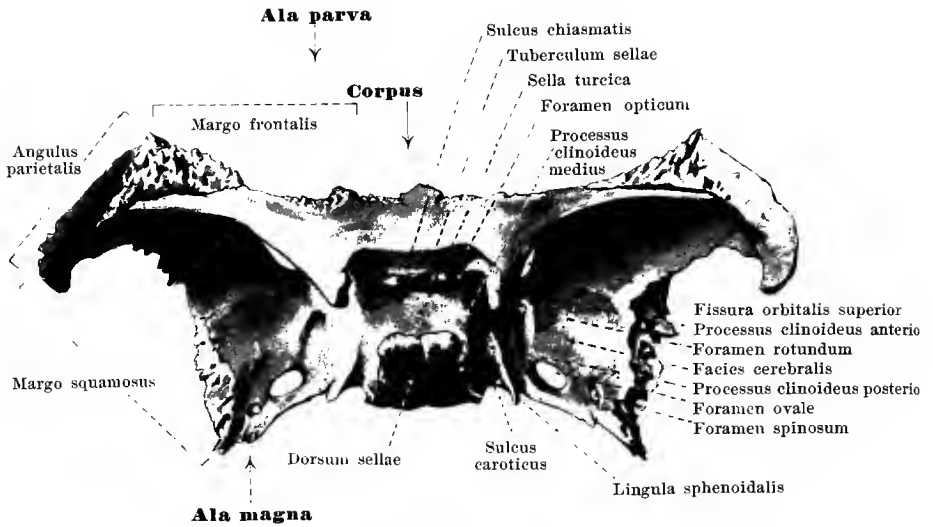
The **partes laterales** form by their medial edges the lateral borders of the great occipital foramen; the anterior portion of the lateral margin is attached to the posterior angle of the petrous portion of the temporal bone and helps to form the *fissura petrooccipitalis*; it presents a smooth concavity, the *incisura jugularis* which is divided by the small *processus intrajugularis* into a larger lateral, posterior, and a smaller medial, anterior fossa which with the corresponding notches of the petrous portion of the temporal bone help to form the similarly divided *foramen jugulare*. The lateral compartment of the jugular foramen gives passage to the internal jugular vein; the medial compartment to the sinus petrosus inf., the n. glossopharyngeus, n. vagus, n. access., gangl. sup. n. glossophar., and the gang. jugul. n. vagi. The posterior part of the lateral border, *margo mastoideus* is rough and unites with the occipital margin of the mastoid portion of the temporal bone (*sutura occipitomastoidea*). At the lateral angle the *processus jugularis* projects upward, being surrounded medianward and behind by the *sulcus transversus* (for the sinus transversus). Medial from this lies the oblong, smooth *tuberculum jugulare* and at the corresponding spot on the inferior surface the oval occipital condyle (*condylus occipitalis*), which is covered with cartilage: it is curved so as to be convex in the sagittal and frontal direction. The long diameters of the right and left condyles converge in front. Between the jugular tubercle and the occipital condyle is seen the short *canalis hypoglossi* (O. T. anterior condyloid foramen); it extends from the great occipital foramen obliquely forward and lateralward and gives passage to the rete canal. hypogl. and the n. hypoglossus. Behind the condyle lies the condyloid fossa (*fossa condyloidea*) with an opening (sometimes absent) known as the *canalis condyloideus* (O. T. posterior condyloid foramen); this canal leads to the sulcus transversus and gives passage to the emissarium condyloideum. On the inferior surface corresponding to the base of the jugular process is the site of insertion of the m. rectus capit. lat. and sometimes a blunt projection, the *processus paramastoideus* (not shown in the figure).



3. Occipital bone, *os occipitale*, seen from right side.

(The direction does not correspond to that of the bone when the skull is in its ordinary position.)

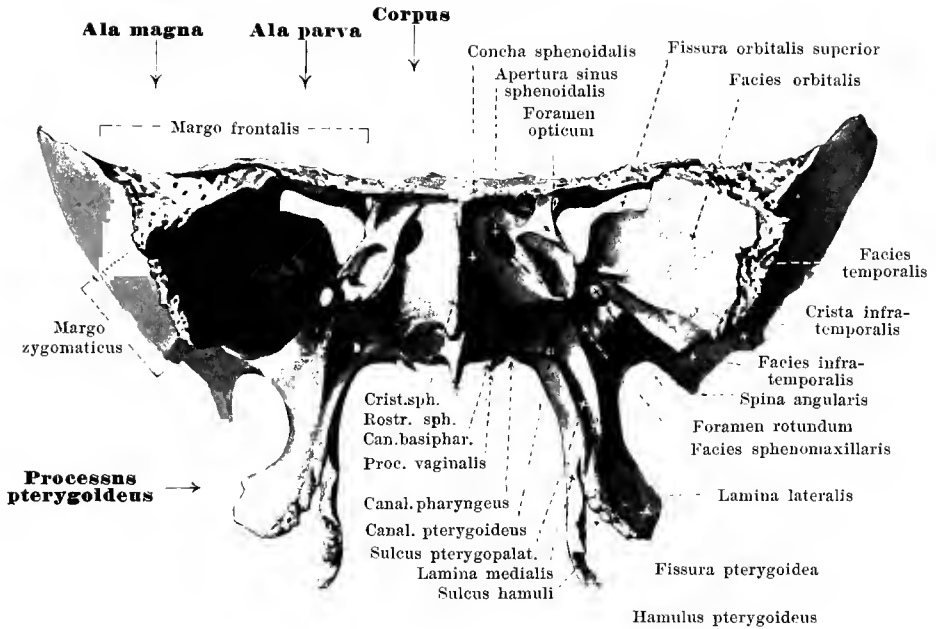
The **squama occipitalis** is curved so as to be convex backward in the sagittal and transverse direction. Its anterior border forms the posterior periphery of the foramen occipitale magnum; the free lateral and superior borders meet in the median plane, the lower portion of each lateral border being slightly serrated as the continuation of the *margo mastoideus* (p. 2); the upper portion of this border is deeply and multiply serrated and is known as the *margo lambdoideus* for union with the occipital margin of the parietal bone (*sutura lambdoidea*). Projecting from the middle of the posterior surface is seen the external occipital protuberance (*protuberantia occipitalis externa*). Extending lateralward from this protuberance on each side are the superior nuchal lines (*lineae nuchae superiores*), convex upward, and above these the less constant supreme nuchal lines (*lineae nuchae supremae*). In the median plane extending toward the foramen magnum is seen the external occipital crest (*crista occipitalis externa*) which gives attachment to the ligamentum nuchae. From about the middle of the crest extend lateralward the two inferior nuchal lines (*lineae nuchae inferiores*), also convex upward. The area for the m. occipitalis above the external protuberance and the supreme nuchal lines is called the occipital plain (*planum occipitale*), while that below the same is designated the nuchal plain (*planum nuchale*) and gives attachment to the mm. trapezius, sternocleidomastoideus, splenius capitis, semispinalis capitis, obliquus capitis superior, recti capitis posteriores. On the anterior surface of the bone at the middle point of the eminentia cruciata nearly corresponding in position to the external protuberance is seen the internal occipital protuberance or *protuberantia occipitalis interna* (for the confluens sinuum; falx cerebri, and tentorium cerebelli). From the internal protuberance arise three well marked grooves: one in the median line passes upward, the *sulcus sagittalis* (O. T. superior longitudinal sulcus) for the sinus sagittalis superior and the falx cerebri; and one lateralward on each side, the *sulcus transversus* (for the sinus transversus; tentorium cerebelli). Of the two transverse sulci the right is usually wider than the left and it alone is continuous with the sulcus sagittalis. A fourth groove or (more often) ridge extends to the foramen magnum and receives the sinus occipitalis.



4. Sphenoid bone, *os sphenoidale*, from above.

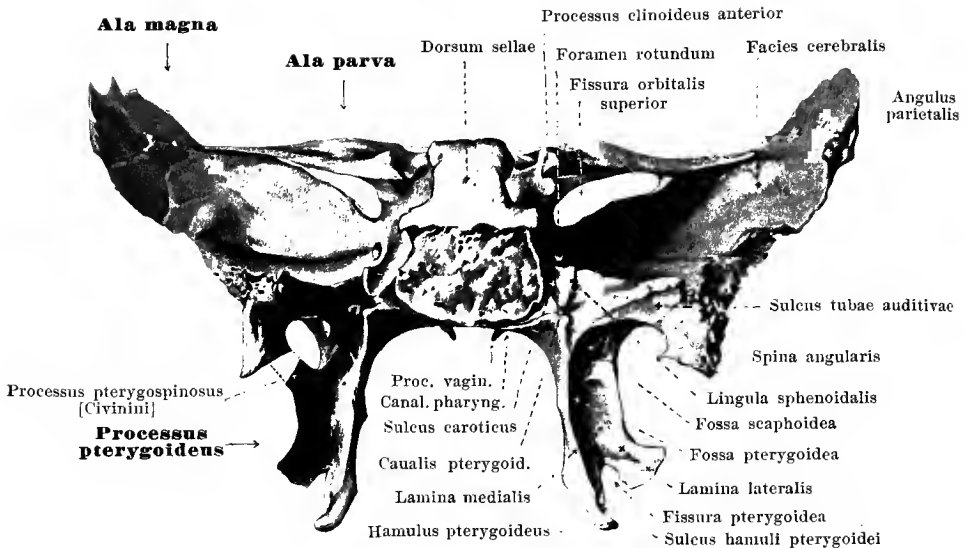
The unpaired **os sphenoidale** (see also Figs. 5, 6, 55, 56, 59, 60, 63—71) lies in the middle of the base of the skull. It is divisible into a middle piece or body (*corpus*) and six processes, known as the two small wings or *alae parvae*, the two large wings or *alae magnae*, and the two pterygoid processes or *processus pterygoidei*; of these the four former are directed lateralward, the two latter, downward.

The **corpus** (*body*) is approximately cubical and contains within it two cavities lined by mucous membrane, the *sinus sphenoidales* (O. T. sphenoidal cells) which are separated from one another by the *septum sinuum sphenoidalium*. The superior surface presents a deep frontally placed groove, the *sella turcica* (for the sinus circularis; hypophysis) with the *fossa hypophyseos* (O. T. pituitary fossa) in the depth. Posteriorly, the sella is overhung by the *dorsum sellae*, which at the angles of its upper free margin presents on each side a small *processus clinoides posterior* (for the tentorium cerebelli); the posterior smooth surface of the dorsum sellae together with the superior surface of the pars basilaris oss. occipitalis forms the *clivus* (for the aa. vertebrales, a. basilaris and its branches; pons). In front of the sella lies the small *tuberculum sellae* or pommel; lateralward and backward therefrom are situated the middle clinoid processes or *processus clinoides medii* (often absent). In front of the tubercle extending transversely on each side to the foramen opticum is the shallow *sulcus chiasmatis* (O. T. optic groove) behind which lies the chiasma opticum. The anterior margin of the superior surface unites with the lamina cribrosa of the ethmoid bone to form the *sutura sphenothmoidalis*. On the lateral surface extending from behind forward, above the region of origin of the large wing is the *sulcus caroticus* (O. T. cavernous groove) for the a. carotis interna and the plexus caroticus internus. Just lateralward from the posterior extremity of this sulcus projects the *lingula sphenoidalis*. The posterior surface of the body unites with the pars basilaris oss. occipitalis (See p. 1). The anterior and a part of the inferior surface are formed by the thin, saucer-shaped, curved *conchae sphenoidales* (O. T. sphenoidal turbinated bones) which, embryologically, properly belong to the ethmoid bone. Each presents lateralward and above an opening, the *apertura sinus sphenoidalis* and, lateralward from this, small depressions which help to close the posterior ethmoidal cells from behind; the lateral border of each concha is connected above with the lamina papyr. oss. ethmoid. (*sutura sphenothmoidalis*); below with the proc. orbit. oss. palat. (*sutura sphenoorbitalis*). In the median plane the conchae and the septum in front form the projecting sphenoidal crest or *crista sphenoidalis* (O. T. ethmoidal crest) for contact with the perpendicular plate of the ethmoid bone; this crest runs out below into a projection, the *rostrum sphenoidale* which is directed downward and lies against the vomer.



5. Sphenoid bone, *os sphenoidale*, from in front.

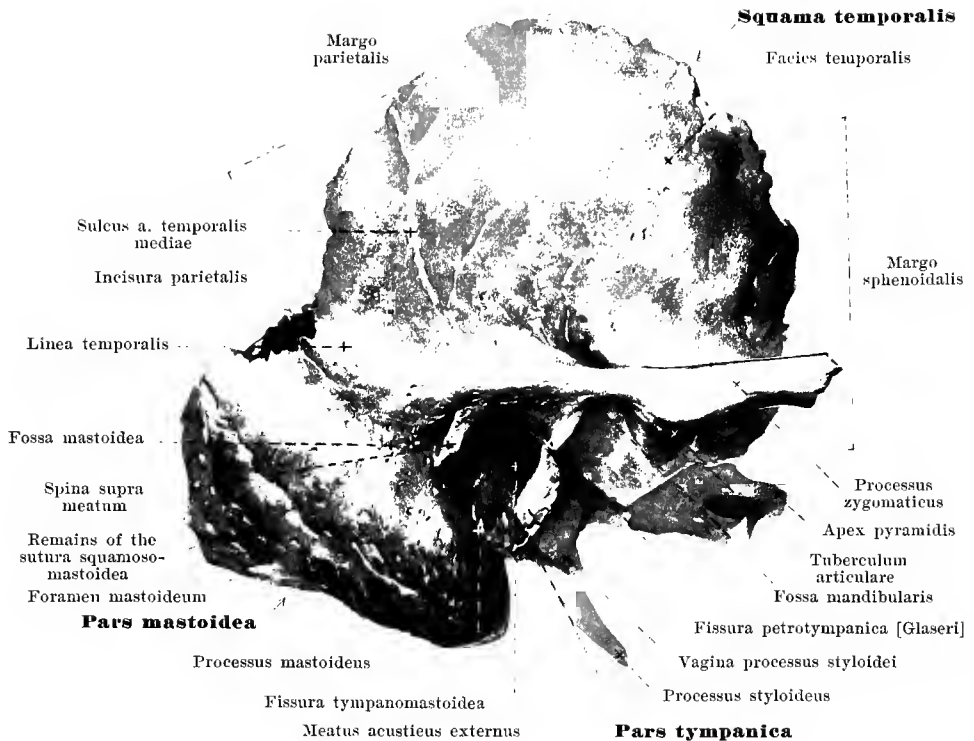
The *alae magnae ossis sphenoidalis* (*large wings of the sphenoid bone*) arise from the lateral surface of the body of the bone and turn first lateralward, then upward and forward. Each possesses an upper, internal, concave surface or *facies cerebralis* and a much divided external surface. Of the latter the quadrangular part which, medianward, is directed forward into the orbit, is called the orbital surface or *facies orbitalis*; its posterior border is smooth and together with the *ala parva* forms the *fissura orbitalis superior* (for the vv. ophthalm. sup. et inf.; nn. oculomot., trochlearis, ophthalm., abducens); the inferior border, also smooth, forms, along with the posterior border of the orbital surface of the maxilla the *fissura orbitalis inferior* (for the a. infraorbital.; v. ophthalm. inf.; nn. zygomat., infraorbit.); the lateral serrated border, *margo zygomaticus*, unites with the frontosphenoidal process of the zygomatic bone to form the *sutura sphenozygomatica*; the lateral superior angle, *margo frontalis*, unites with the orbital portion of the frontal bone and thus helps to form the *sutura sphenofrontalis*. Below the orbital surface and encroaching upon the pterygoid process lies the triangular *facies sphenomaxillaris* (sphenomaxillary surface) which helps to form the fossa pterygopalatina. The rest of the external surface is divided by the *crista infratemporalis* (O. T. pterygoid ridge), passing from before backward, into an inferior, horizontal field or *facies infratemporalis* (for the m. pterygoid. ext.) which looks into the fossa infratemporalis, and a superior vertical field or *facies temporalis* (for the m. temporalis). The posterior border of the latter, *margo squamosus*, is serrated below, somewhat bevelled from without inward above, and serves for apposition with the squama temporalis (*sutura sphenosquamosa*). The uppermost angle (*angulus parietalis*), is bevelled from within and lies upon the angulus sphenoidalis oss. parietalis (*sutura sphenoparietalis*). Passing downward from the most posterior angle of the large wing is the *spina angularis* (O. T. spinous process of the sphenoid) (for the lig. sphenomandibulare; m. tensor veli palatini). In addition, there extends from this point forward and medianward, a short, serrated margin for apposition with the angulus anterior of the petrous portion of the temporal bone (*fissura* and *synchondrosis sphenopetrosa*). Perforating the root of the large wing are three foramina: passing forward from above and behind, to the sphenomaxillary surface is the *foramen rotundum* (for the n. maxillaris); passing downward, from above, to the infratemporal surface is the *foramen ovale* (for the rete foraminis ovalis; n. mandibul.); and the *foramen spinosum* (for the a. mening. med., vv. meningee mediae; n. spinosus, plexus mening.); the latter foramen lies just in front of the most posterior angle and is sometimes incomplete.



6. Sphenoid bone, *os sphenoidale*, from behind.

The *alae parvae ossis sphenoidalis* (*small wings of the sphenoid bone*) arise from the anterior superior part of the lateral surface of the body by two roots which surround the *foramen opticum* (for the a. ophthalmica; n. opticus). They are smooth thin plates of bone which present a superior and an inferior surface; the inferior forms with the orbital surface of the large wing (cf. p. 5) the *fissura orbitalis superior*. The anterior margin, *margo frontalis*, is serrated and lies upon the posterior margin of the pars orbitalis oss. frontalis (*sutura sphenofrontalis*); the posterior margin is smooth and runs out medianward into the strong *processus clinoides anterior*.

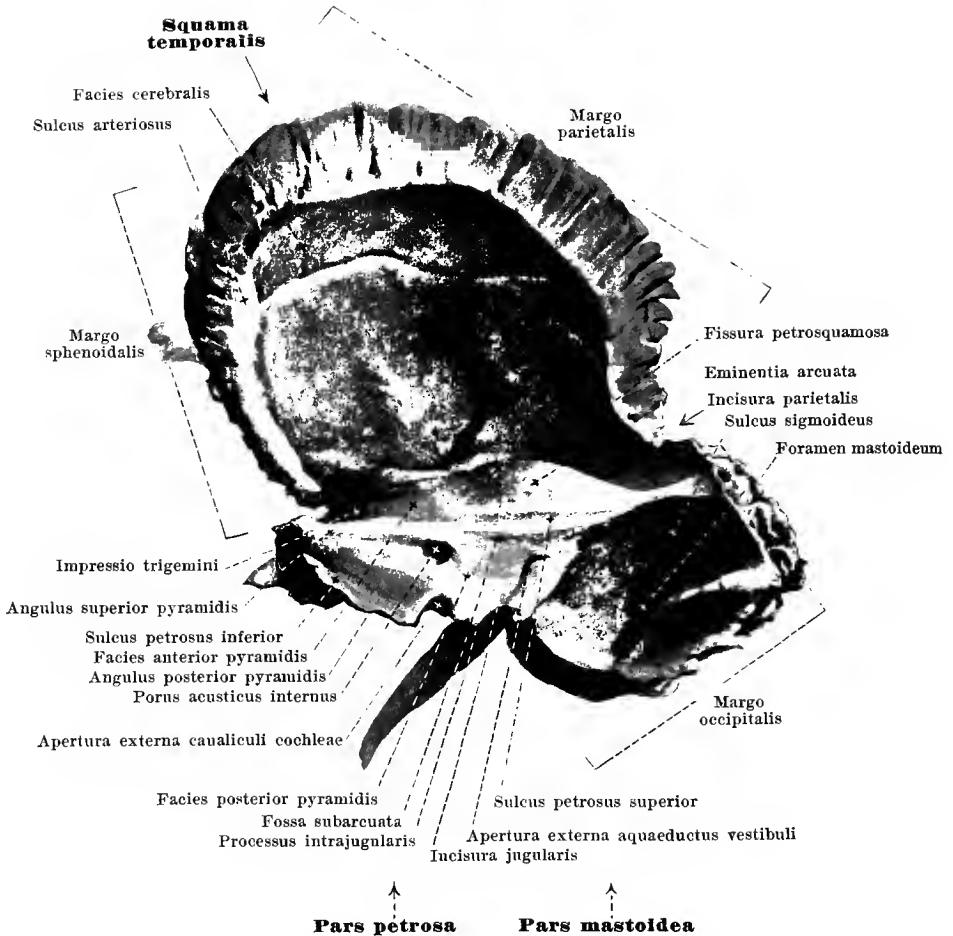
The *processus pterygoidei* (*pterygoid processes*) extend from the point of union of the body and the large wing downward. They are composed of two plates: the shorter and broader, *lamina lateralis proc. pteryg.* (lateral surface for the m. pterygoideus externus); the other narrower and longer, *lamina medialis proc. pteryg.*. The two plates unite anteriorly at an angle, in front of which there extends from above downward the *sulcus pterygopalatinus*; behind, the plates diverge and form the deep *fossa pterygoidea* (for the m. pterygoideus internus); between the two below is a notch with jagged borders, the *fissura pterygoidea*, in which is received the proc. pyramidalis oss. palatini. The lamina medialis runs out below to form the *hamulus pterygoideus* (O. T. hamular process) which is curved lateralward. This process is convex on its lateral surface and is covered with cartilage forming the *sulcus hamuli pterygoidei* (for the tendon of the m. tensor veli palatini). Passing downward over the root of the lamina medialis on the posterior surface is the *fossa scaphoidea* (for the origin of the m. tensor veli palatini). Lateralward from this, encroaching upon the medial surface of the spina angularis lies the *sulcus tubae auditivae* (for the pars cartilaginea tubae auditivae). The lamina medialis gives off from its root the *processus vaginalis*, a small process which extends medianward toward the body; on the inferior surface of this process, either as a closed canal or as a groove which is closed by the proc. sphenoidalis oss. palatini, is the *canalis pharyngeus* (O. T. pterygopalatine canal) (for a small branch of the a. sphenopalatina; rr. nasal. post. sup. lat. gangl. sphenopalat.); between the inferior surface of the body of the bone and the process vaginalis, a canal is sometimes present, the *canalis basipharyngeus* (for the rr. nasal. post. sup. lat. gangl. sphenopalat.). Constantly present, passing through the root of the pterygoid process in a sagittal direction, is the *canalis pterygoideus* [*Vidian*] (O. T. Vidian canal) (for the a. et vv. canal. pteryg.; n. canal. pteryg.); its posterior opening lies below the lingula sphenoidalis, its anterior opening upon the sphenomaxillary surface, medianward and below the foramen rotundum.



7. Right temporal bone, *os temporale*, from without.

The paired **os temporale** or temporal bone (cf. also Figs. 8—15, 55, 56, 63—66) lies between the occipital bone and the sphenoid bone, helping to form both the base of the skull and its lateral wall. Each bone is divisible into four parts; the *squama temporalis*, *pars mastoidea*, *pars petrosa* and *pars tympanica*. Around the *meatus acusticus externus* (external auditory canal) which is open lateralward, these parts are so arranged that the squama is directed upward, the pars mastoidea backward, the pars tympanica forward and downward and the pars petrosa, medianward and forward.

The **squama temporalis** consists essentially of a vertical plate, the free approximately semi-circular border of which is serrated only in its anterior inferior portion, being otherwise bevelled from within; the anterior part of the margin, *margo sphenoidalis*, unites with the large wing of the sphenoid bone to form the *sutura sphenosquamosa*, the posterior, *margo parietalis*, with the margo squamosus oss. parietalis to form the *sutura squamosa*. The lateral surface, *facies temporalis* (for the m. temporalis), is smooth; projecting from the lower part of this surface in front of the external auditory canal is the *processus zygomaticus* (for the lig. temporomandibulare; m. masseter) with two roots of origin; it passes at first horizontally outward, then, turning at a right angle, forward. Between the two roots, directed downward, lies the *fossa mandibularis* (O. T. glenoid cavity) with the *facies articularis*, limited in front by the frontally placed *tuberculum articulare*, the latter being covered by cartilage. On the outer surface of the squama temporalis is seen, passing upward in the posterior part, the *sulcus arteriae temporalis mediae* (for the a. tempor. med.). Running out also from the posterior extremity of the zygomatic process is a ridge, the *linea temporalis*, which curves backward to become continuous with the linea temporalis inferior of the parietal bone. The medial surface of the squama, *facies cerebralis*, presents well marked *juga cerebralia* and *impressiones digitatae* as well as a deep *sulcus arteriosus*.



8. Right temporal bone, *os temporale*, from within.

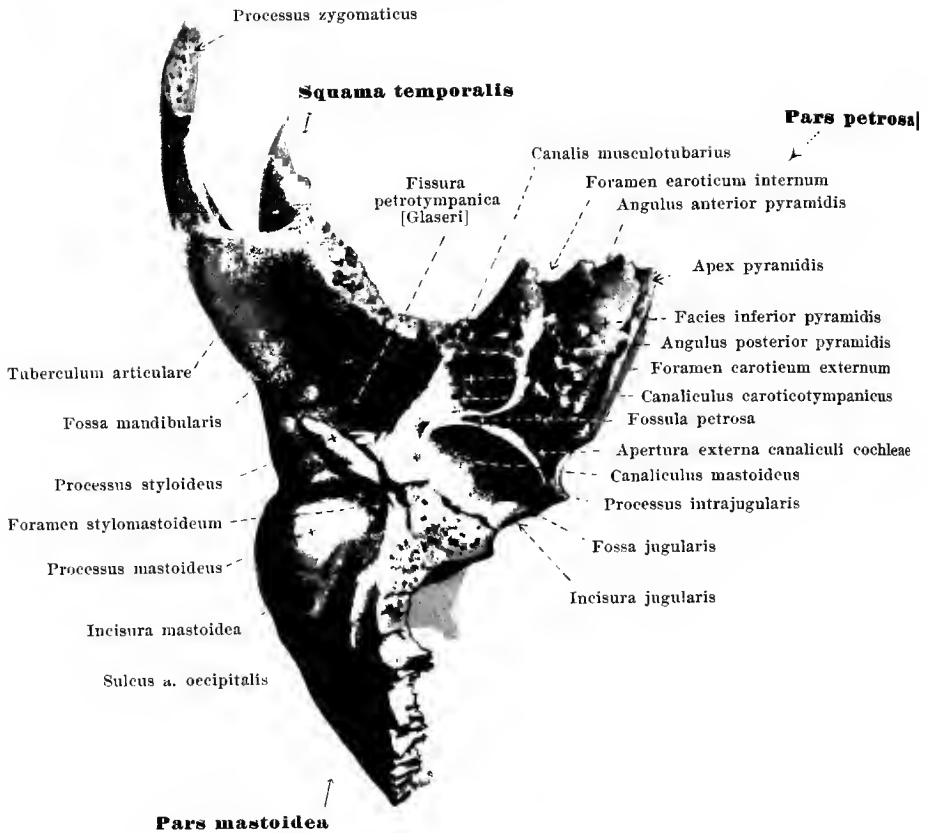
The **pars mastoidea** is a thick conical projection not well developed until adult life. Developmentally it is not an independent part of the bone, but a secondary outgrowth from the lateral and most posterior part of the temporal bone and belongs actually in part to the pars petrosa and in part to the squama temporalis. Its posterior, serrated margin, *margo occipitalis*, comes into apposition with the margo mastoideus oss. occipitalis (*sutura occipito-mastoidea*); the short upper serrated margin forms with the margo parietalis of the squama temporalis an angular indentation, the *incisura parietalis*, in which is received the angulus mastoideus oss. parietalis (*sutura parietomastoidea*); above and in front it goes over into the squama temporalis, in front it adjoins the pars tympanica; the site of junction of the two components is indicated (often very indistinctly in the adult) by the *sutura squamosomastoidea* which runs lateralward, obliquely downward and forward. The lateral surface is convex and slightly roughened (for the attachment of the mm. auricularis posterior et occipitalis), and often presents behind one or several *foramina mastoidea* (for the ramus mastoideus a. occipitalis, emissarium mastoideum) which open on the medial surface in the sulcus sigmoideus. Projecting lateralward from the posterior superior margin of the porus acusticus externus there is frequently found a small spur, the *spina supra meatum*; the surface behind it, often depressed, the *fossa mastoidea*, extends above as far as the linea temporalis and below to the sutura squamosomastoidea, and is perforated by numerous foramina for blood vessels.

A thick process extending downward, the *processus mastoideus* (for the attachment of the mm. sternocleidomastoideus, splenius capitis, longissimus capitis) presents on its medial surface, a smooth depression, the *incisura mastoidea* (O. T. digastric fossa) for the attachment of the digastric muscle, and, further medianward, a groove, the *sulcus arteriae occipitalis* (for the a. occipitalis). The medial surface of the pars mastoidea is fused in front with the pars petrosa; behind, it is free and there presents a deep groove, the *sulcus sigmoideus* (O. T. fossa sigmoidea) (for the sinus transversus). Inside the process are many cavities lined by mucous membrane, the *cellulae mastoideae* (cf. Fig. 11).

The **pars petrosa (pyramis)** is a three-sided pyramid, the base of which is directed lateralward, and is united with the pars mastoidea. It presents for examination three surfaces, a *facies posterior*, a *facies inferior* and a *facies anterior*; at the junctions of the surfaces are the *angulus posterior*, the *angulus anterior*, and the *angulus superior*. The tip, or *apex pyramidis*, is directed medianward and forward, and is inserted in the angle between the occipital bone and the sphenoid bone, leaving, however, an irregular chink, the *foramen lacerum* which is filled by the *fibrocartilago basalis*.

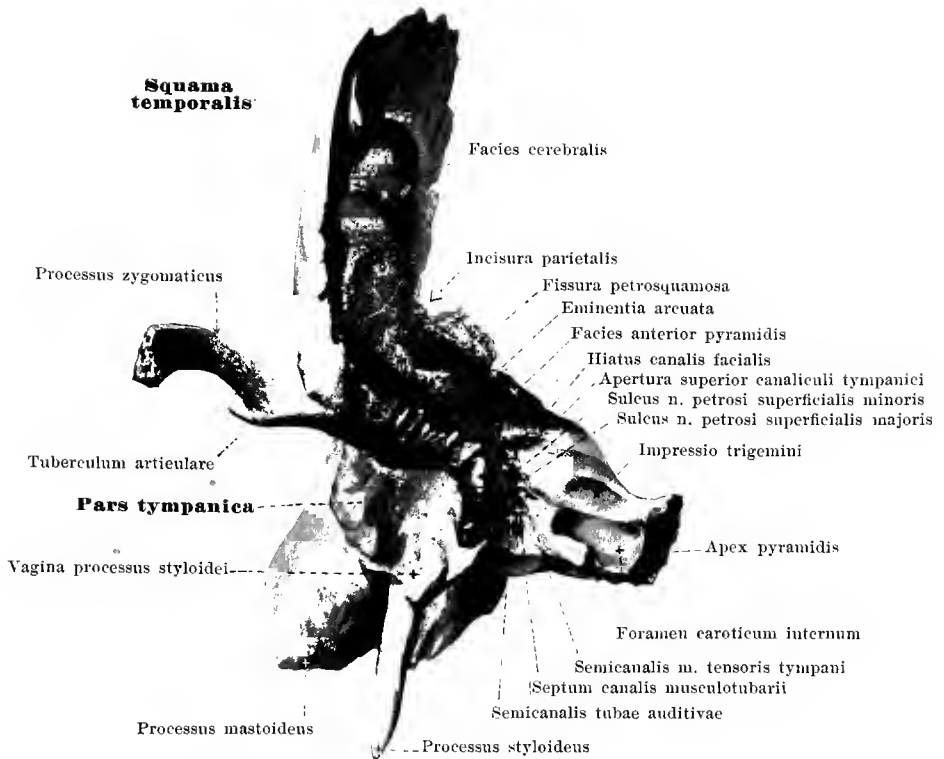
The *facies posterior pyramidis* almost vertical, is bounded above by the *angulus superior* with the *sulcus petrosus superior* (for the sinus petrosus superior; tentorium cerebelli), below by the *angulus posterior*; the latter is rough and unites with the lateral margin of the pars basilaris and the pars lateralis of the occipital bone (*fissura* and *synchondrosis petrooccipitalis*), and contains above at the upper surface of this place of union the *sulcus petrosus inferior* (for the sinus petrosus inferior). At about the middle of the posterior surface a circular opening, the *porus acusticus internus*, leads into the short *meatus acusticus internus* (for the a. and vv. auditivae internae; nn. facialis and acusticus). Above and lateralward close to the superior angle lies the *fossa subarcuata* which, running below the superior semicircular canal, receives a process of the dura mater; this fossa, very well marked in the new-born (see Fig. 15), is usually only slightly indicated in the adult. Still further lateralward and downward is seen the *apertura externa aquaeductus vestibuli* (for the ductus endolymphaticus); it is usually slit-shaped, opening from a dorsolateral direction, and from it a groove runs downward to the incisura jugularis.

The *facies inferior pyramidis* is placed horizontally and is very uneven and rough. In front its boundary is formed laterally by the pars tympanica and medianward therefrom by a free margin, the *angulus anterior*, which unites with the margin of the large wing of the sphenoid bone situated medianward from the spina angularis, to form the *fissura* and *synchondrosis sphenopetrosa*. Behind it is bounded by the *angulus posterior*. A notch, sometimes scarcely noticeable, the *incisura jugularis*, close to the small *processus intrajugularis*, forms with the corresponding *incisura jugularis* of the occipital bone (p. 2), the *foramen jugulare* (lateral compartment for the v. jugularis interna; medial for the sinus petrosus inferior; nn. glossopharyngeus, vagus, accessorius, gangl. superius n. glossopharyngei, gangl. jugulare n. vagi). Just in front of this notch lies the broad *fossa jugularis* (for the bulbus v. jugularis superior) with a small hole, one of the openings of the *canaliculus mastoideus*, and a groove leading to this, the sulcus *canaliculi mastoidei* (for the r. auricularis n. vagi). Just medianward from the jugular fossa near the posterior angle, is seen a funnel-shaped depression, with the *apertura externa canaliculi cochleae* (for the v. canaliculi cochleae).



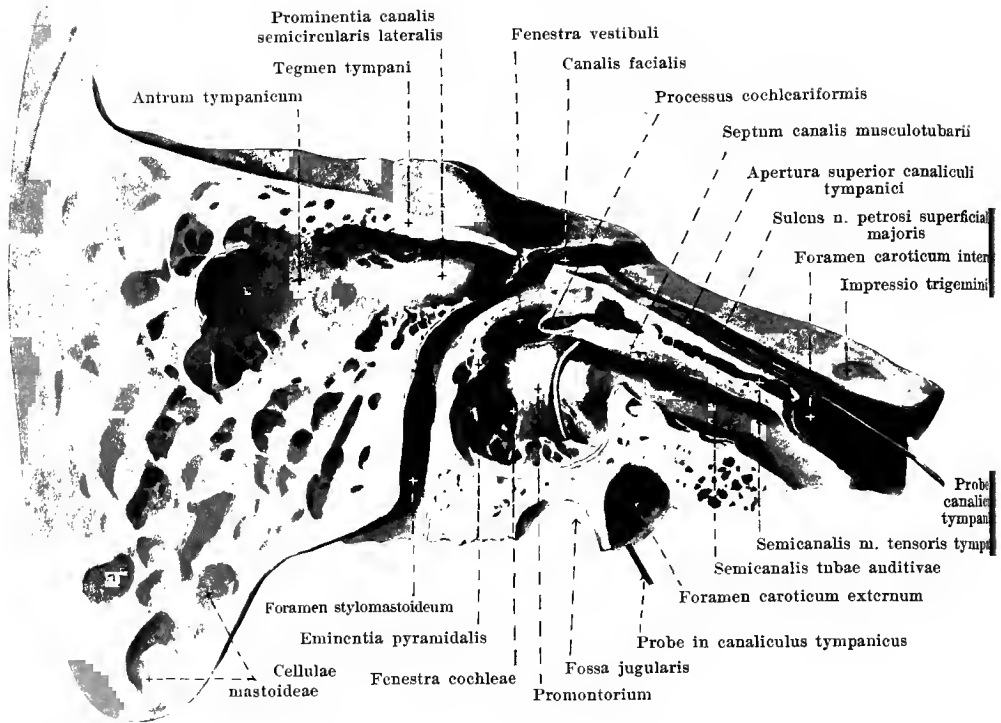
9. Right temporal bone, *os temporale*, from below.

Facies inferior pyramidis (continued). Situated almost exactly in front of the fossa jugularis is a large round opening, the *foramen caroticum externum*, which forms the entrance to the *canalis caroticus* (for the a. carotis interna, plexus venosus caroticus internus; plexus caroticus internus). This canal is curved and passes obliquely from behind and lateralward, forward and medianward through the pyramid, and emerges near the apex by an irregular opening, the *foramen caroticum internum*, partly on the inferior and partly on the superior surface. Near the external carotid foramen can be seen, in the canal, the small openings of the *canaliculi caroticotympanici* (for the r. caroticotympanicus a. carotis internae; nn. caroticotympanici), which pass upward to the middle ear. Between the external carotid foramen, the jugular fossa and the apertura externa canaliculi cochleae lies a small depression, the *fossula petrosa* (for the gangl. petrosus n. glossopharyngei) with a small opening, the *apertura inferior canaliculi tympanici* (for the a. tympanica inferior; n. tympanicus). Situated lateralward and projecting downward and forward is the *processus styloideus* (for the lig. stylomandibulare; mm. stylohyoideus, styloglossus, stylopharyngeus), variously developed in different individuals. Just lateral from this and behind it lies the *foramen stylomastoideum* (for the a. and v. stylomastoidea; n. facialis). Closely attached to the styloid process in front is seen the *vagina processus styloidei* (O. T. vaginal process), the lowest portion of the pars tympanica.



10. Right temporal bone, *os temporale*, from in front.

The *facies anterior pyramidis* is smooth and directed obliquely from behind and above, forward and downward. Laterally it is fused with the squama temporalis through the *fissura petrosquamosa*, where it goes over gradually into the cerebral surface of the squama. The free, rough, anterior margin is the *angulus anterior*; it forms an angle with the *margo sphenoidalis* of the squama in which fits the posterior angle of the large wing of the sphenoid bone. In this angle lies the opening of the *canalis musculotubarius*, directed forward and medianward; this canal is divided, usually incompletely, by means of a leaflet of bone, projecting from its medial wall, the *septum canalis musculotubarii*, into a smaller upper part, the *semicanalis m. tensoris tympani* (O. T. canal for tensor tympani muscle) and a larger inferior part, the *semicanalis tubae auditivae* (O. T. canal for the Eustachian tube). The anterior surface is bounded behind by the *angulus superior* (p. 9). Projecting at a point somewhat lateralward from the middle of the superior surface, near the posterior angle, is the *eminentia arcuata* (O. T. eminence for superior semicircular canal) caused by the *canalis semicircularis superior*. The smooth region a little lateral from this is called the *tegmen tympani* since it covers the *cavum tympani* above. Still further forward two openings can be seen and two grooves running forward from them: the medial opening, *hiatus canalis facialis* (O. T. hiatus Fallopii), leads through a short canal to the *geniculum canalis facialis* and contains the r. petrosus superficialis a. mening. med. and the n. petrosus superfic. maj., the latter passing further forward in the medial groove called the *sulcus n. petrosi superficialis majoris*; the lateral, smaller, opening, sometimes fused with the medial, is known as the *apertura superior canaliculi tympanici* (O. T. opening for smaller petrosal nerve) through which run the a. tympanica superior and the n. petrosus superfic. min. in order to pass further on in the smaller, lateral, groove, the *sulcus n. petrosi superficialis minoris*. On the upper surface near the apex of the pyramid lies the *impressio trigemini* (O. T. depression for Gasserian ganglion) for the n. trigeminus.

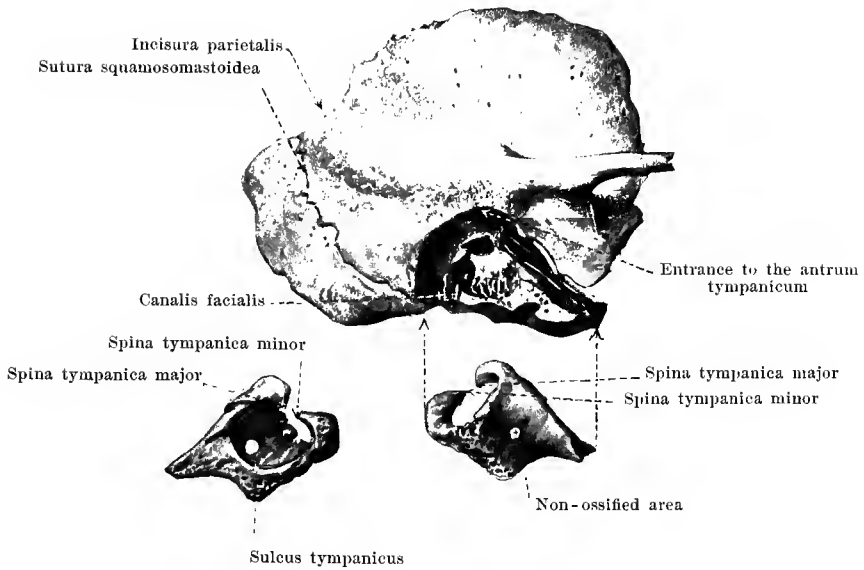


11. Right temporal bone, *os temporale*, cut open, lateral view of medial half of bone. Magnification 2:1.

(The canalis facialis is opened in its entire length.)

The **canalis facialis (Fallopian)** (O. T. Aqueduct of Fallopini) (for the a. and v. stylo-mastoidea, r. petrosus superficialis a. meningae mediae; n. facialis, n. intermedius) begins in the floor of the meatus acusticus internus near the posterior surface of the pyramid, thence passes lateralward, after a short course bends around at a right angle, forming the *geniculum canalis facialis*, and from this point passes backward and then downward. In doing so it lies close to the mastoid wall of the cavity of the tympanum and there forms the *prominentia canalis facialis* (not shown in the figure). It runs at first close beneath the facies anterior pyramidis, then between the fenestra vestibuli and the prominentia canalis semicircularis lateralis, then behind the eminentia pyramidalis to terminate in the *foramen stylomastoideum*. From the geniculum canalis facialis which, in the new-born (Fig. 15) lies free upon the anterior surface of the pyramid, a short canal passes medianward and forward to the *hiatus canalis facialis* (O. T. hiatus Fallopii) (for the r. petrosus superfic. a. mening. med.; n. petrosus superficialis major); another very delicate canal runs to the upper part of the canaliculus tympanicus; behind the eminentia pyramidalis a little lateral branch is given off to enter this eminence and below it arises the *canaliculus chordae tympani* which leads into the middle ear (see Organ of Hearing), and receives the canaliculus mastoideus.

The *canaliculus tympanicus* (below for the a. tympanica inferior, above for the a. tympanica superior; besides for the n. tympanicus and n. petrosus superficialis minor) begins with the *apertura inferior* in the depth of the *fossula petrosa*, arrives in the cavum tympani on its inferior wall, runs over the promontorium in the *sulcus promontorii*, perforates the processus cochleariformis and then passes in a curved direction in the bone, forward and upward to the *apertura superior canaliculi tympanici* on the upper surface of the pyramid; in this upper part it receives a delicate canal coming from the geniculum canalis facialis.



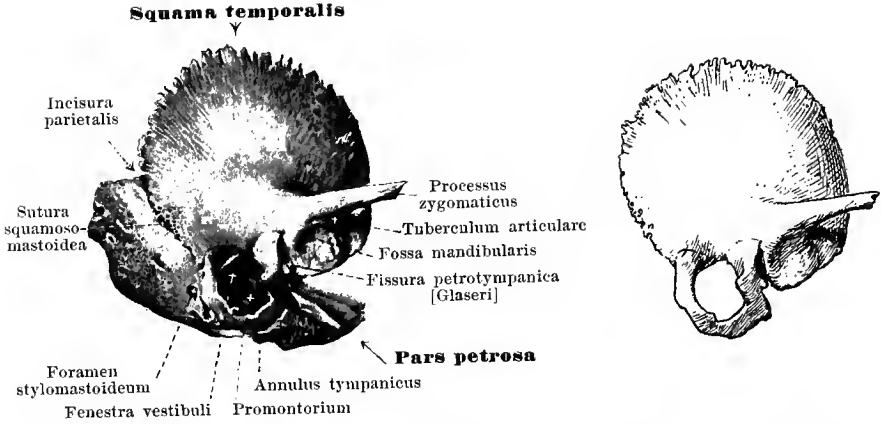
12. Right temporal bone, *os temporale*, at the 7th or 8th year of life, seen from without and somewhat from below.

(The pars tympanica has been shelled out and drawn separately in the lower part of the figure; on the right it is seen from the outside, on the left from within.)

The *canaliculi caroticotympanici* (for the r. caroticotympanicus a. carotis internae; nn. caroticotympanici superior et inferior) usually two in number, are openings or short canals which pass from the posterior wall of the canalis caroticus immediately over the foramen caroticum externum to the cavum tympani and open in the latter on its anterior wall (see Organ of Hearing).

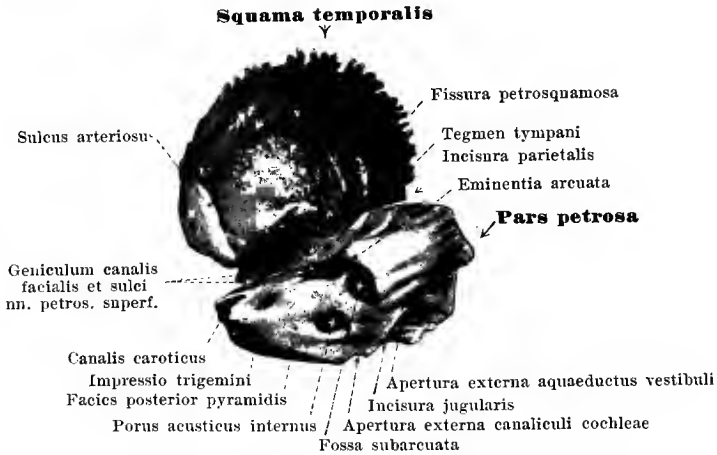
The **pars tympanica**, a platelet of bone hollowed out behind and above in the form of a groove, a nearly flat plate in front and below, presents normally, during the early years of life, a non-ossified portion. The pars tympanica forms the whole inferior anterior and a part of the posterior wall of the *meatus acusticus externus* as well as the *porus acusticus externus*. The posterior limb of the groove lies upon the anterior surface of the proc. mastoideus and often forms there the *fissura tympanomastoidea*. The anterior limb of the groove is attached to the inferior margin of the squama temporalis just behind the fossa mandibularis; lateralward it is fused for a short distance with the squama, but medianward there exists between the two a narrow platelet of bone which proceeds from the anterior margin of the facies anterior pyramidis and which, with the pars tympanica, forms the *fissura petrotympanica* [Glaseri] (O. T. Glaserian fissure). The latter presents several small openings for the a. tympanica anterior, vv. tympanicæ, chorda tympani and the lig. mallei anterioris. Below, surrounding the root of the styloid process from in front like a sheath, is a process called the *vagina processus styloidei* (O. T. vaginal process).

The superior posterior surface of the pars tympanica is smooth and contains near its anterior medial extremity a groove, bounded by two ridges, the *sulcus tympanicus* (for the membrana tympani), the plane of which is inclined obliquely forward, downward and medianward; at each of the upper angles of the pars tympanica it runs out into a small pointed extremity, the anterior being called the *spina tympanica major*, the posterior, the *spina tympanica minor*. The space between these two spines is not entirely filled up by the attachment of the pars tympanica to the squama temporalis; on the contrary, there remains an indentation called the *incisura tympanica* [Rivini] (see Organ of Hearing).



13 and 14. Right temporal bone, *os temporale*, from the newborn child, seen from without.

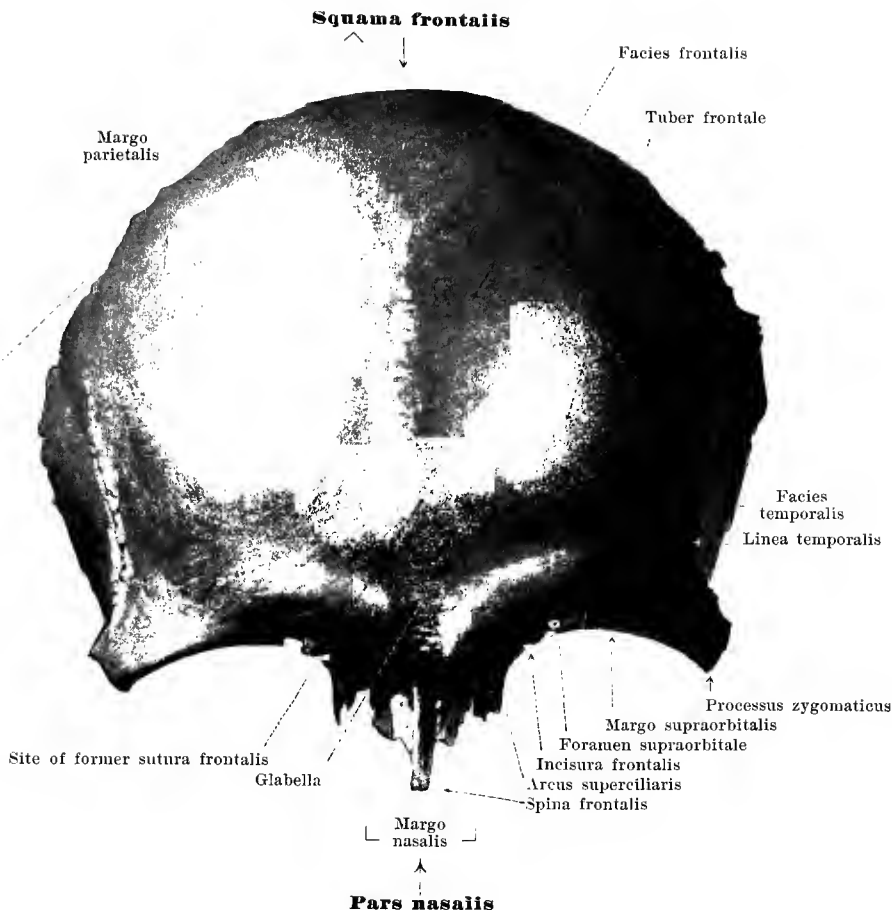
(13: complete, 14: squama temporalis and annulus tympanicus alone.)



15. Right temporal bone, *os temporale*, from newborn child, seen from within.

The *os temporale* consists in the foetus of three parts, *pars petrosa*, *squama temporalis* and *pars tympanica*; in the newborn it is still divided into all three or into only two parts according as the *squama temporalis* and *pars tympanica* still remain separated or have united with one another. The *pars tympanica* in the newborn is a flat semicircle, the *annulus tympanicus*; it is open above and contains in its concavity the *sulcus tympanicus* (see p. 13); out of it the *pars tympanica* ultimately develops in that it grows out chiefly in a lateral direction to form a groove.

In the newborn no actual *proc. mastoideus* exists. The *foramen stylomastoideum* lies on the lateral surface of what is later to be the *pars mastoidea*. The *proc. styloideus* is still cartilaginous. On the posterior and anterior surface of the pyramid the size of the *fossa subarcuata* (p. 9) and the site of the *geniculum canalis facialis* (pp. 11—12) not yet bridged over by bone, are striking features; accordingly, a hiatus *canalis facialis*, in the sense in which it exists in the adult, is absent in the newborn.

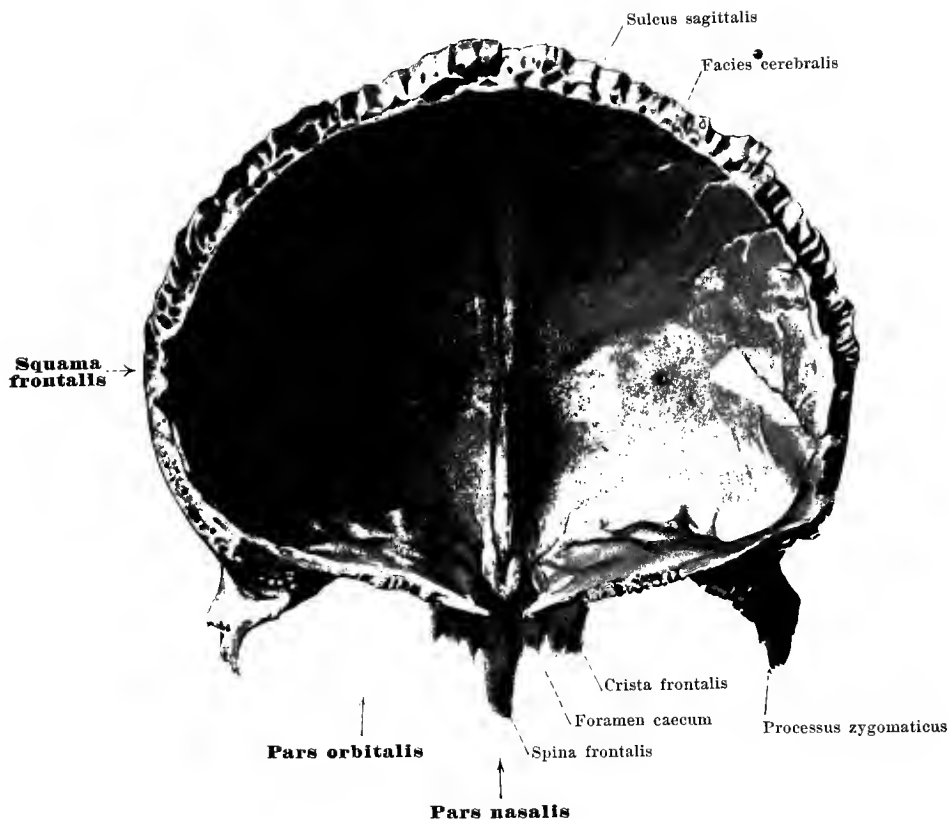


17. Frontal bone, *os frontale*, from in front.

The unpaired **os frontale** (*frontal bone*) (see also Figs. 17, 18, 55—58, 61—66, 68—71, and 73) closes the cerebral skull in front and lies above the facial skull. It has four parts, the unpaired *squama frontalis* and *pars nasalis*, and the paired *partes orbitales*.

The **squama frontalis** is curved sagittally and transversely so as to be convex in front. Its largest posterior serrated margin, *margo parietalis*, unites with the frontal margins of the parietal bone to form the *sutura coronalis*. The inferior boundary is formed in the middle by the *pars nasalis*, lateral from this on each side by the *margo supraorbitalis*; the latter runs out lateralward into the *proc. zygomaticus*, which unites, by means of a rough surface, with the *proc. frontosphen.* of the zygomatic bone to form the *sutura zygomaticofrontalis*.

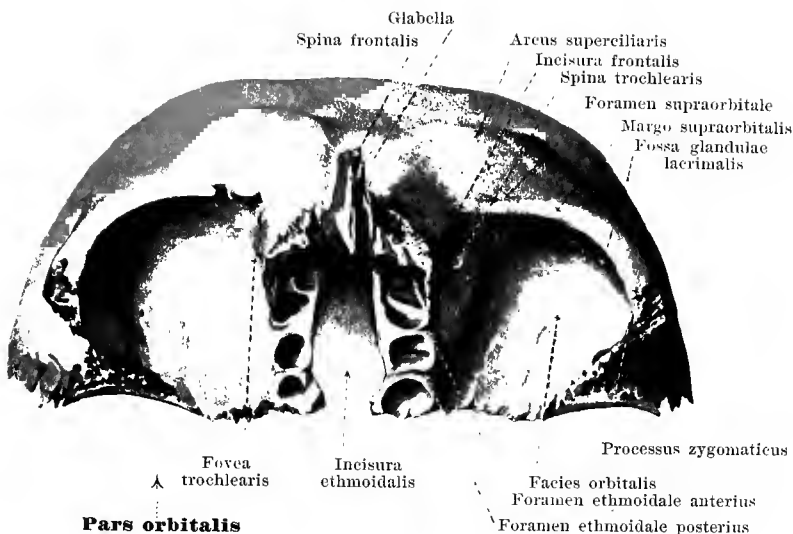
In the medial part of the *margo supraorbit.* there is often a shallow notch, *incisura frontalis* (rarely a *foramen frontale*) (for the a. frontalis; r. frontal. n. frontal.) and lateralward from this a *foramen supraorbitale* or an *incisura supraorbitalis* (for the a. supraorbit.; n. supraorbit.). The anterior, convex surface, *facies frontalis*, is smooth and sometimes presents, in the median plane, signs of the *sutura frontalis* (always present at birth); lateralward from this on each side lies the *tuber frontale* (O. T. frontal eminence) and lateralward from this the *linea temporalis*, ascends backward and upward from the zygomatic process, bounding the flat, nearly sagittally placed, *facies temporalis* (for the m. temporal.). Close to the inferior border, near the median plane on each side, begins a ridge, *arcus superciliaris* (O. T. superciliary ridge), which passes upward and lateralward, flattening as it proceeds; the depressed surface lying between the medial ends of these ridges is called the *glabella*.



17. Frontal bone, *os frontale*, from behind.

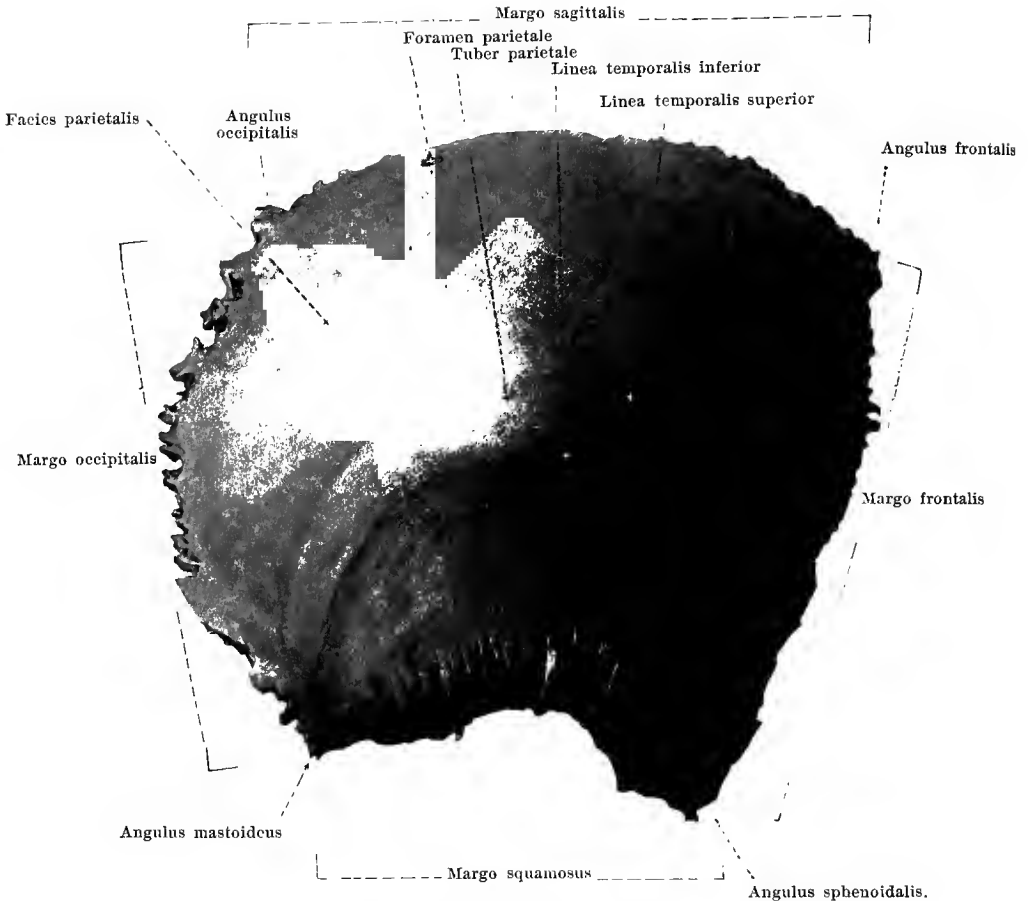
The concave posterior surface of the **squama frontalis** forms a part of the *facies cerebrialis* (O. T. internal surface) of the frontal bone. In the median plane in the upper part, is a shallow groove, *suleus sagittalis* (for the sinus sagittalis superior; falx cerebri); out of its lower end develops a narrow, usually markedly projecting sharp ridge, the frontal crest or *crista frontalis* (for the falx cerebri), which, below, forms the anterior boundary of the foramen caecum.

The term **pars nasalis** is applied to the part projecting somewhat from the inferior margin of the squama frontalis in the middle; it separates the two partes orbitales from one another. In front it is bounded by the slightly serrated *margo nasalis*, to which the nasal bone is attached on each side (*sutura nasofrontalis*); immediately adjacent is attached the proc. frontalis maxillae (*sutura frontomaxillaris*). The posterior free margin is the anterior part of the *incisura ethmoidalis*; it unites with the anterior margin of the lamina cribrosa oss. ethmoidalis and forms a part of the *sutura frontoethmoidalis*. Obliquely downward and forward from the inferior rough surface projects the *spina frontalis* (O. T. nasal spine). It is rough in front for the further attachment of the nasal bones and of the frontal processes of the maxillae; its posterior, partly smooth, partly rough, surface is applied medianward to the crista galli and lamina perpendicularis oss. ethmoidalis, lateralward to the medial wall of the ethmoidal labyrinth; between these the posterior surface helps to form also the anterior wall of the nasal cavity. On the upper surface, close behind the inferior extremity of the crista frontalis, lies the entrance (usually formed by the frontal bone alone) to the foramen caecum, a canal which grows smaller as it descends and ends blindly in the apex of the spina frontalis; it contains only a process of the dura mater. The spina frontalis is also perforated by a small canal which extends from behind and above, forward and downward, and gives passage to the n. ethmoid. ant.



18. Frontal bone, *os frontale*, from below.

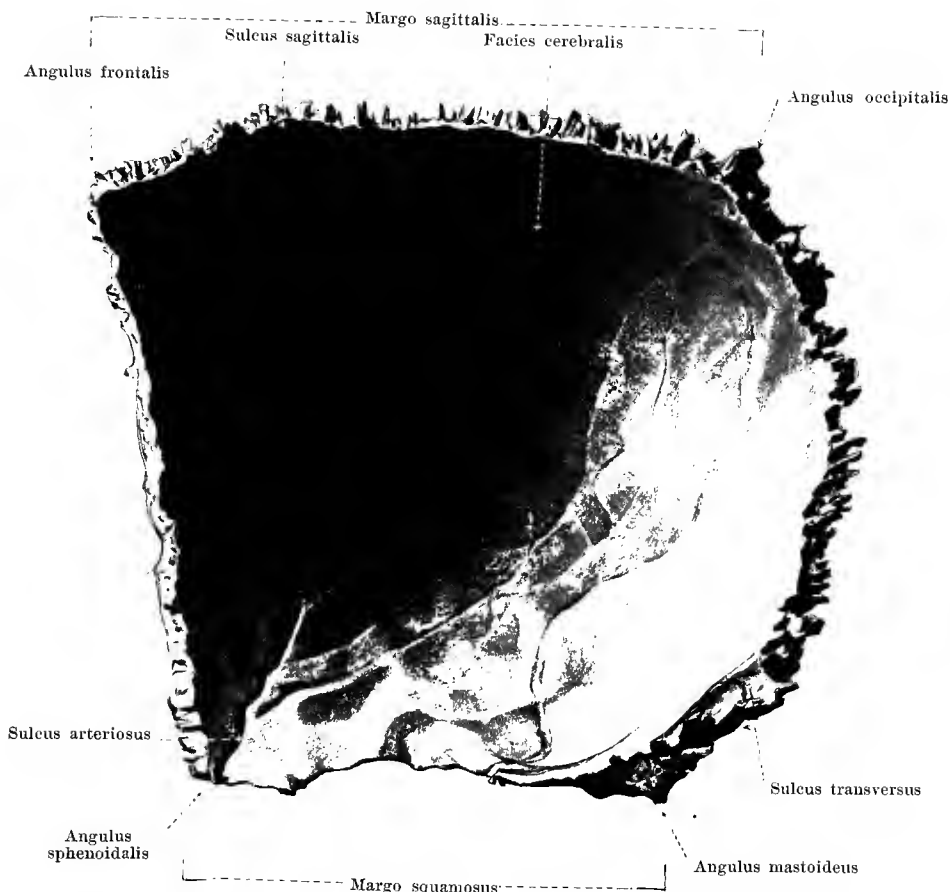
The **partes orbitales** pass at a right angle from the inferior margin of the squama frontalis backward and are separated from one another by the quadrangular *incisura ethmoidalis* cutting in from behind. The anterior boundary is formed by the *margo supraorbitalis*; the lateral by the *processus zygomaticus*. The posterior margin is slightly serrated medianward for union with the ala parva oss. sphenoid., and is continuous lateralward toward the proc. zygomat. with a triangular rough surface for contact with the margo frontalis of the ala magna oss. sphenoid. (*sutura sphenofrontalis*); behind this surface lies a variable, narrow, sickle-shaped, smooth field, which along with the ala parva oss. sphenoid. helps to form the middle fossa of the skull. The medial border, bounding the *incisura ethmoidalis*, is only slightly rough and forms with the lateral margin of the lamina cribrosa oss. ethmoid. a part of the *sutura frontoethmoidalis*. Near this margin a rough ridge runs lateralward to which are attached in front the os lacrimale by the *sutura frontolacrimalis*, behind the lamina papyracea oss. ethmoid. by a part of the *sutura frontoethmoidalis*. The oblong field lying between this ridge and the medial border is irregularly divided by thin transverse ridges, lies upon the upper surface of the ethmoidal labyrinth and helps to cover the cellulæ ethmoidales from above; two grooves, running frontally, form with corresponding grooves of the ethmoidal labyrinth the *foramen ethmoidale anterius* (for the a. ethmoid. ant.; n. ethmoid. ant.) and the *foramen ethmoidale posterius* (for the a. ethmoid. post.; n. ethmoid. post., rr. orbital. gangl. sphenopalat.). The inferior surface of the pars orbit., *facies orbitalis*, is smooth and presents near its medial anterior angle a small depression, the *fovea trochlearis* (and occasionally near it a small spur, *spina trochlearis*) (for the trochlea m. obliqui oculi super.); in the lateral portion, bounded in front by the margo supraorbit., lateralward by the proc. zygomat., lies the *fossa glandulae lacrimalis* (for the glandula lacrim. sup.). The upper surface, *facies cerebralis*, presents strong juga cerebralia and impressiones digitatae. At the junction of the partes orbitales with the squama frontalis the bone contains within it, the *sinus frontales* or frontal sinuses, cavities between the plates of the partes orbitales and the squama of varying width and lined by mucous membrane. They are subdivided by the *septum sinuum frontalem*, which usually diverges somewhat from the median plane; the entrances lie in the anterior medial angles of the partes orbitales.



19. Right parietal bone, *os parietale*, from without.

The *os parietale* (*parietal bone*) (see also Figs. 20, 55, 56, 61—66) is paired and helps to form the roof and lateral wall of the skull. It is a quadrangular, flat, saucer-shaped bone with an external, convex *facies parietalis* and an internal, concave *facies cerebralis*.

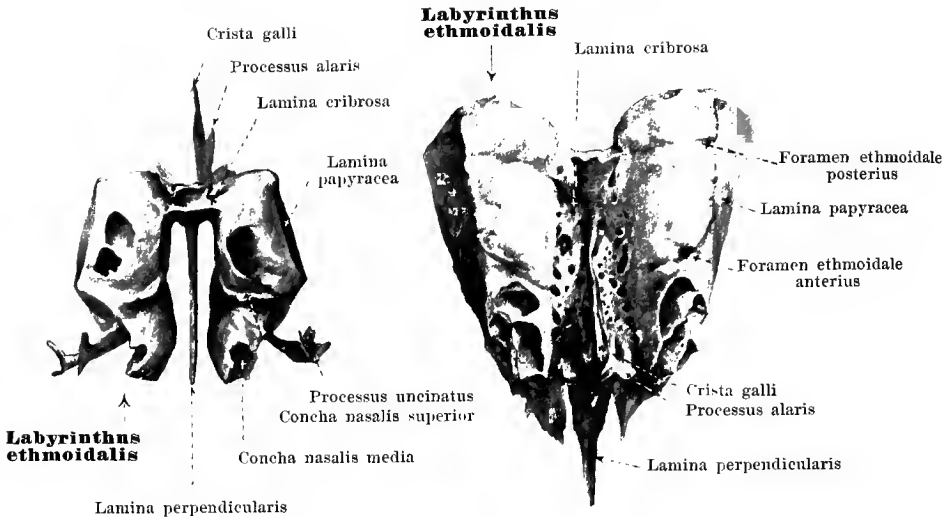
The bone has four margins, and four angles. The posterior convex margin, *margo occipitalis*, is deeply serrated and unites with the margo lambdoideus oss. occip. to form the *sutura lambdoidea*. The inferior margin, *margo squamosus*, is concave and bevelled from without; it is attached to the margo parietal. oss. tempor. (*sutura squamosa*). The anterior, slightly concave margin, *margo frontalis*, is serrated and unites with the margo parietal. oss. front. to form the *sutura coronalis*, and the upper straight, markedly serrated margin, *margo sagittalis*, forms with the same margin of the opposite parietal bone the *sutura sagittalis*. The anterior superior angle, *angulus frontalis*, lies in the middle of the *sutura coronalis* and adjoins the frontal bone; the posterior superior *angulus occipitalis*, adjoins the upper extremity of the squama occipitalis. The posterior inferior angle, *angulus mastoideus*, is inserted in the incisura parietal. oss. tempor. and forms there with the upper margin of the pars mastoid. oss. tempor., the *sutura parietomastoidea*. The anterior inferior angle, *angulus sphenoidalis*, is bevelled from without, attached to the angul. pariet. of the ala magna oss. sphenoid. and forms with this the *sutura spheno-parietalis*.



20. Right parietal bone, *os parietale*, from within.

The *facies parietalis* is more or less markedly bulged out in the middle; this projection is called the *tuber parietale*. Below it runs the *linea temporalis inferior*, convex above, which begins at the margo frontalis as a continuation of the *linea temporalis oss. frontalis* and goes over at the angulus mastoideus into the *linea temporalis oss. temporalis*; it itself and the field beneath give origin to the *m. temporalis*. Concentric with it runs generally a less marked *linea temporalis superior*, which ends at the margo occipitalis; to it are attached the *fascia temporalis* and the *galea aponeurotica*. Close to the margo sagittalis there is often, near the angulus occipitalis, an opening, the *foramen parietale* (for the *r. meningeus a occipitalis*, *emissarium parietale*).

On the *facies cerebralis* along the margo sagittalis runs a groove, completed by apposition with the parietal bone of the other side, the *sulcus sagittalis* (for the *sinus sagittalis sup.*; *falx cerebri*), into which the *foramen parietale* usually opens. Over the inner surface of the angulus mastoid. runs a short broad flat groove, the *sulcus transversus* (O. T. groove for lateral sinus) (for the *sinus transvers.*). At the angulus sphenoid. is found a deep *sulcus arteriosus*, sometimes for a short distance an actual canal, otherwise several shallower ones, for branches of the *a. mening. med.* In addition the *facies cerebralis* presents *impressiones digitatae* and *juga cerebralia* and also frequently, especially in older people, near the *sulcus sagittalis*, *foveolae granulares* [*Pacchioni*] (O. T. *Pacchionian* depressions).



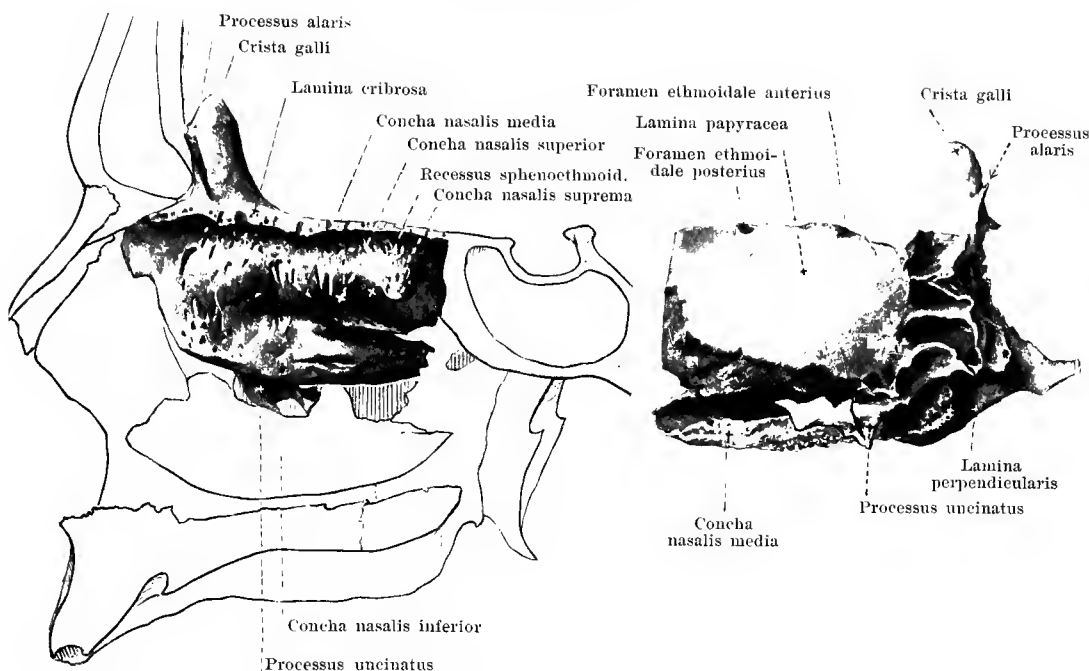
21 and 22. Ethmoid bone, *os ethmoidale*.

From behind, somewhat schematic.

From above.

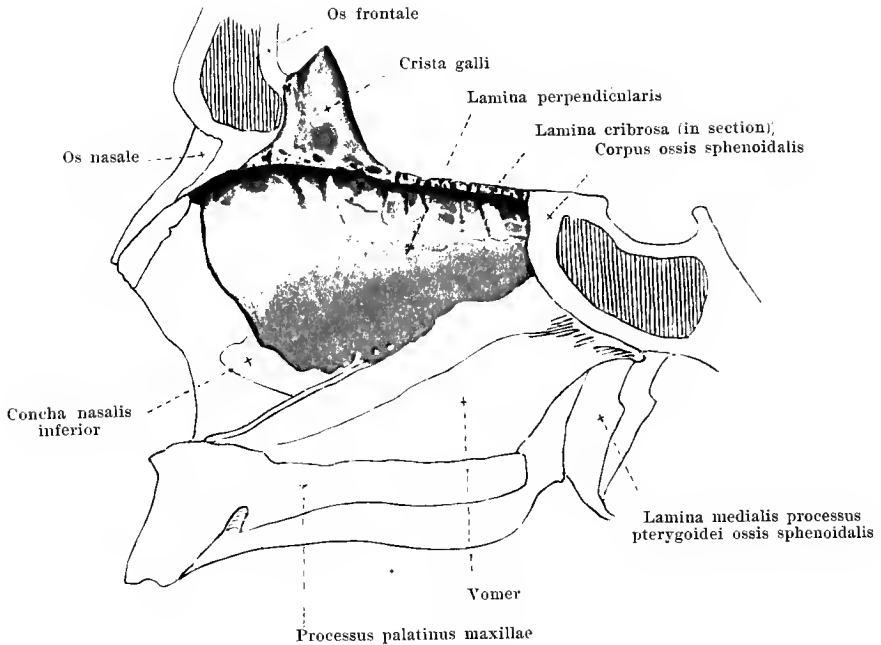
The *os ethmoidale* (*ethmoid bone*) (see also Figs. 23—25, 63, 64, 65—70, 73—75) is unpaired, helps in part to close the most anterior portion of the cerebral skull below, but reaches with its main mass deep down into the facial skull and helps to form the nose and orbit. It consists above of a transversely placed oblong plate, the *lamina cribrosa*; from the under surface of this extending downward in the median plane is the *lamina perpendicularis* and from each of its two lateral borders hangs the *labyrinthus ethmoidalis*.

The *lamina cribrosa* (*cribriform plate*) lies horizontally, fills the incisura ethmoidalis *oss. frontalis* completely and thus forms at the anterior and the two lateral margins a part of the *sutura frontoethmoidalis*; the posterior margin lies on the anterior border of the upper surface of the body of the sphenoid bone (*sutura sphenoeethmoidalis*). The cribriform plate presents on its upper surface in the median plane a ridge which becomes elevated in front to form the oblong *crista galli* or cork's comb (for the *falx cerebri*); this is higher in front than behind and often contains bone-marrow spaces; it is attached to the *pars nasalis* and *crista frontalis oss. frontalis*, usually by means of the two small, laterally directed *processus alares*, and completes the entrance to the foramen caecum *oss. frontalis* when this is incomplete. The cribriform plate is perforated by numerous foramina, the larger of which are arranged chiefly in two rows, one medial and one lateral, and which are continued in small grooves on the *lamina perpendicularis* and on the medial surface of the labyrinth; they give passage to the *nn. olfactorii*. A small slit lateralward from the anterior part of the *crista galli* receives the *a.* and the *n. ethmoidalis anterior*.



23 and 24. Right ethmoidal labyrinth, *labyrinthus ethmoidalis*.
 From within. From without.

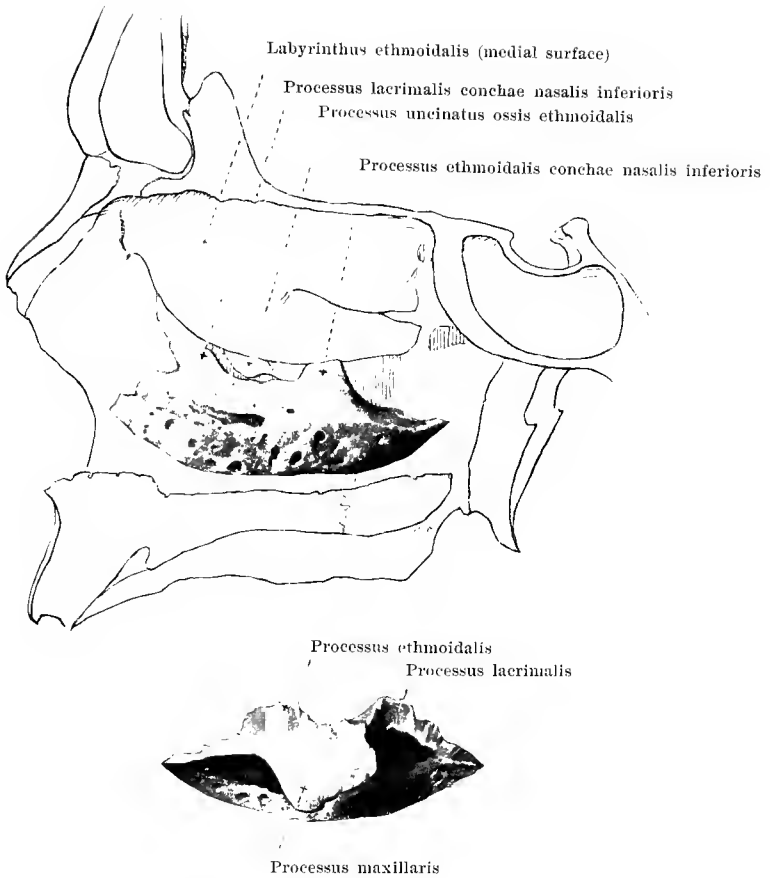
Each *labyrinthus ethmoidalis* (O. T. *lateral mass of ethmoid*) is oblong and quadrangular in shape and is connected only above and medianward with the lateral border of the lamina cribrosa. Inside it is divided by delicate platelets of bone into the numerous *cellulae ethmoidales* (ethmoid cells) lined by mucous membrane. They communicate with one another and are closed completely by the wall of the ethmoid bone only on the medial and lateral surface; otherwise they are partly open and become closed cavities only by the attachment of adjacent bones; in front the pars nasalis oss. frontalis and proc. frontalis maxillae, lateralward by the os lacrimale and corpus maxillae, behind by the proc. orbitalis oss. palatini, corpus oss. sphenoidalis and conchae sphenoidales, above by the pars orbitalis oss. frontalis; spread out on the latter surface of union are the *foramen ethmoidale anterius* (for the a. ethmoid. ant.: n. ethmoid. ant.) and the *foramen ethmoidale posterius* (for the a. ethmoid. post.: rr. orbit. gangl. sphenopalat.). The lateral wall of the labyrinth, *lamina papyracea* (O. T. *os planum*), is oblong, quadrangular, and unites in front with the os lacrimale, below with the corpus maxillae (*sutura ethmoideomaxillaris*), behind with the proc. orbital. oss. palat. (*sutura palatoethmoidalis*) and the corpus oss. sphenoid. (*sutura sphenothmoidalis*), above with the pars orbital. oss. front. (*sutura frontoethmoidalis*). The medial wall is vertical, is very rough, and much perforated. Its anterior margin is attached to the posterior surface of the spina frontalis oss. frontalis, its posterior border to the anterior surface of the concha sphenoidalis; the inferior thickened border hangs down free, bends around somewhat lateralward, and thus forms the *concha nasalis media* (middle turbinated bone); above this in the posterior part is a deep notch (*meatus nasi superior*, upper nasal passage) and above this a similar, concha-like plate of bone, bent so as to be convex medianward, the *concha nasalis superior* (superior turbinated bone); further backward and upward lies usually still another turbinated bone, the *concha nasalis suprema*, separated from the preceding by a groove, the *recessus sphenothmoidalis*. Lateralward from the anterior extremity of the concha media, a sickle-shaped process, the *processus uncinatus* (O. T. *unciform process*), directed backward, becomes separated from the inferior wall; at its extremity it rolls around lateralward, and below or behind this place unites with the proc. ethmoidalis conchae nasalis inferioris.



25. Ethmoid bone, *os ethmoidale*, *lamina perpendicularis*, from the left.

The **lamina perpendicularis** or *perpendicular plate* is quadrangular with unequal sides; at its upper border in the median plane it is in large part united to the inferior surface of the lamina cribrosa; it hangs down perpendicularly and free between the two labyrinths and thus forms a part of the bony nasal septum. At its upper margin it presents small grooves which are continuations of the medial foramina of the lamina cribrosa. The upper border is attached in front to the posterior surface of the spina frontalis oss. frontalis (*sutura frontoethmoidalis*); the posterior margin unites with the crista sphenoidalis oss. sphenoidalis (*sutura sphenoeethmoidalis*), the inferior with the anterior margin of the vomer, the anterior with the cartilaginous nasal septum.

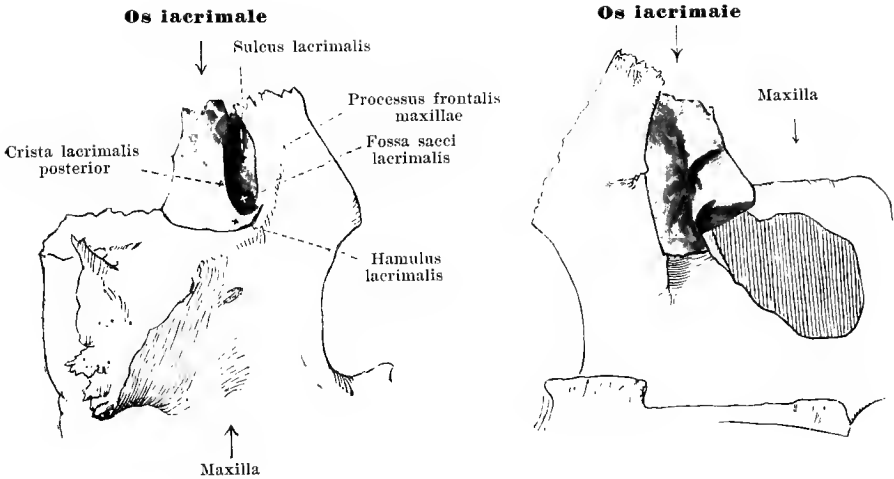
Deviations of the lamina perpendicularis as a whole or in single spots from the median plane are very frequent.



26 and 27. Right inferior turbinate bone, *concha*

Above, from within. *nasalis inferior.* Below, from without.

The **concha nasalis inferior** (*inferior turbinate bone*) (see also Figs. 68, 73, and 74) is paired; it lies on each side in the lower part of the lateral wall of the nasal cavity and is placed sagittally in its longest diameter. It is oblong, very porous, bent so as to be convex medianward, and hangs downward as a free mass from its upper attached margin. The inferior border is much thickened and lateralward somewhat rolled. The upper thinner margin is attached in front to the crista conchalis maxillae and gives off close behind this point the *processus lacrimalis*, directed obliquely upward and forward, which unites with the inferior margin of the os lacrimale (*sutura lacrimoconchalis*); somewhat further backward the broad *processus maxillaris* projects lateralward and downward, so as to lie on the inferior circumference of the hiatus maxillaris; above this broad process arises the narrower, more irregular *processus ethmoidalis* which passes upward to unite with the *processus uncinatus* oss. ethmoidalis. The most posterior part of the upper margin is attached to the crista conchalis oss. palatini.

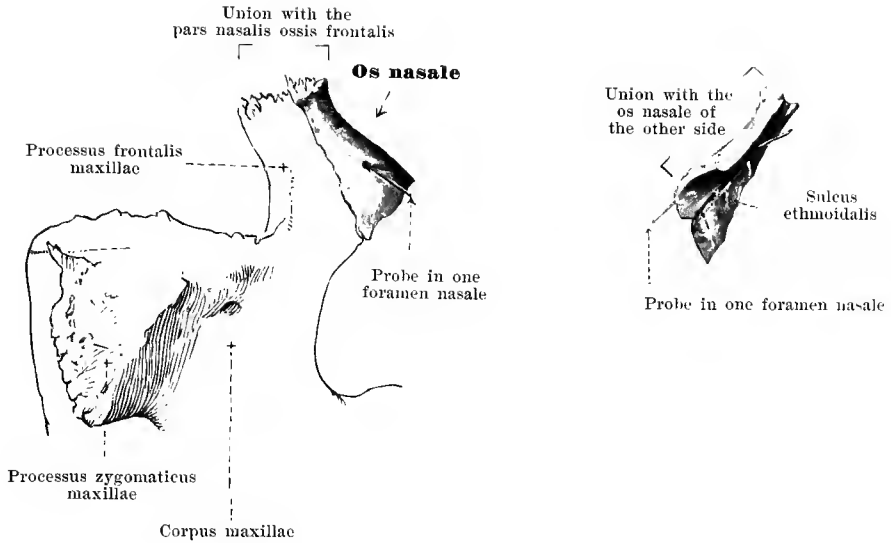


28 and 29. Right lachrymal bone, *os lacrimale*.

From without

From within.

The **os lacrimale** (*lachrymal bone*) (see also Figs. 68—70, 73, and 74) is a paired, oblong, quadrangular, thin platelet of bone, the size of a finger nail, and lies in the anterior part of the medial wall of the orbit. The upper margin unites with the pars orbitalis oss. frontalis (*sutura frontolacrimalis*); the posterior margin with the anterior border of the lamina papyracea oss. ethmoidalis; the inferior margin behind with the medial margin of the facies orbitalis of the corpus maxillae (*sutura lacrimomaxillaris*), in front with the proc. lacrimalis conchae nasalis inferioris (*sutura lacrimoconchalis*); the anterior margin with the margo lacrimalis of the proc. frontalis maxillae (*sutura lacrimomaxillaris*). The medial surface is tolerably flat, lies from without on the anterior part of the lateral wall of the ethmoidal labyrinth and so closes the anterior ethmoidal cells; the lateral surface is divided by a crest extending from above downward, the *crista lacrimalis posterior* (O. T. lachrymal crest) (for the origin of the pars lacrimalis m. orbicularis oculi), into a smaller posterior level area and a larger anterior concave area, *sulcus lacrimalis*; the latter forms with the sulcus lacrimalis of the proc. frontalis maxillae, the *fossa sacci lacrimalis* (for the sacculus lacrimalis). From the inferior extremity of the crista lacrimalis posterior proceeds the somewhat variable *hamulus lacrimalis* (O. T. hamular process) lateralward, forward and downward; it is inserted in the incisura lacrimalis on the medial anterior margin of the orbital surface of the body of the maxilla.

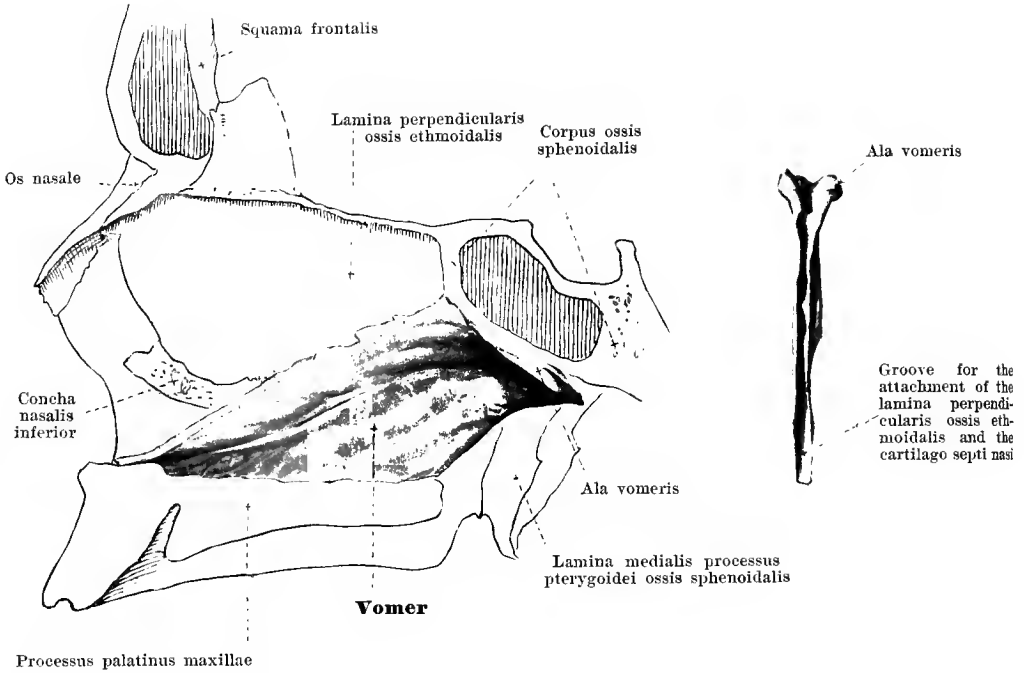


30 and 31. Right nasal bone, *os nasale*.

From without

From within.

The **os nasale** (*nasal bone*) (see also Figs. 57, 58, 68, 73—75) is paired and forms with that of the other side the root of the nose and the upper part of the back of the nose. It is a small, oblong, quadrangular bone thicker and narrower above, thinner and broader below. The nasal bones of the two sides are attached to one another by their medial, slightly serrated borders to form the *sutura internasalis*; the upper serrated border unites with the *margo nasalis* of the *pars nasalis oss. frontalis* to form the *sutura nasofrontalis*; the lateral, somewhat bevelled margin forms with the anterior margin of the *processus frontalis maxillae* the *sutura nasomaxillaris*; the inferior, bevelled, irregularly serrated margin unites with the lateral nasal cartilage; in the macerated skull, however, it lies free and helps to bound the *apertura piriformis*. The anterior surface is smooth and usually slightly curved like a saddle. The posterior surface in its upper portion is attached from in front to the *spina frontalis oss. frontalis*; in its lower portion it is smooth and helps to form the bony part of the anterior wall of the nasal cavity; there is seen also the *sulcus ethmoidalis* (O. T. groove for nasal nerve) (for the *n. ethmoidalis anterior*). The nasal bone is often perforated by one or several small openings, *foramina nasalia*.

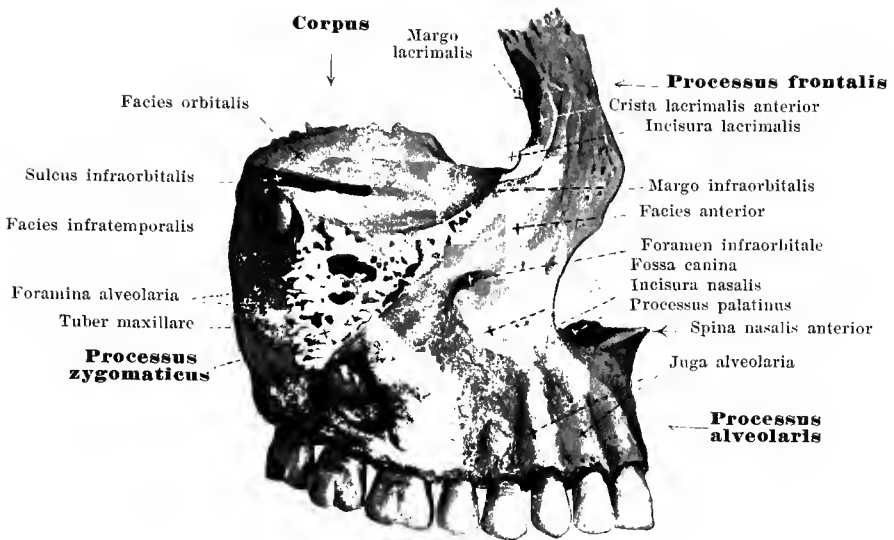


32 and 33. Plough-share bone, *vomer*.

From the left.

From in front.

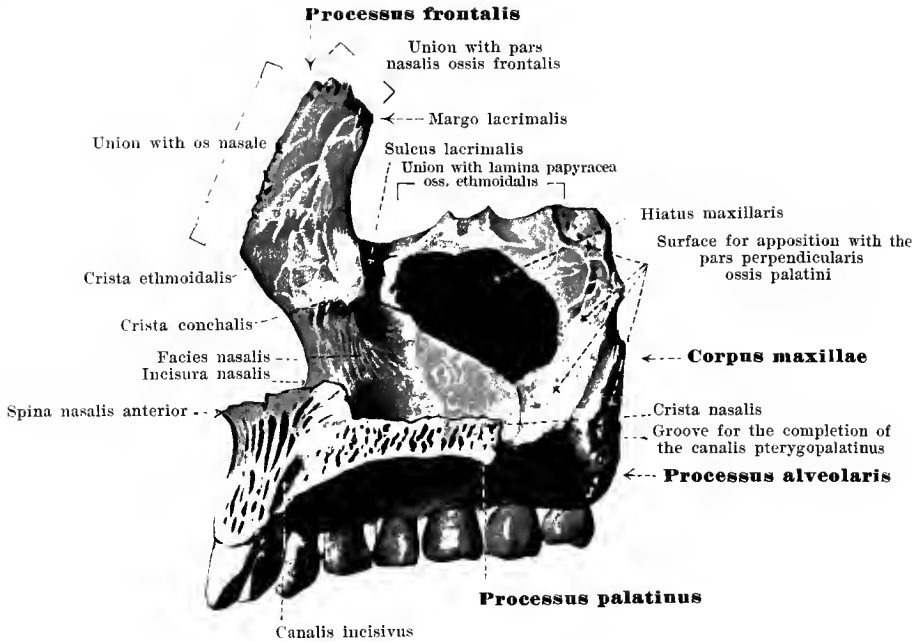
The **vomer** (*plough-share bone*) (see also Fig. 75) is an unpaired, oblong quadrangular, flat bone which lies in the median plane and forms the posterior part of the nasal septum. It is usually bent somewhat to one side, but never at its posterior margin. Its upper margin is broad and is split into two thick laterally directed leaves (*alae vomeris*), each of which is attached by its free margin to the proc. vaginalis of the proc. pterygoideus oss. sphenoidalis and to the proc. sphenoidalis oss. palatini. The two wings of the vomer leave a groove between them in which is placed the rostrum sphenoidale. The posterior margin is smooth, thin and lies free. The inferior margin is sharp and serrated, and adjoins the crista nasalis of the united palate bones and upper jaw bones. The anterior margin, which is also the upper, is somewhat thickened and hollowed out to form a groove; it unites behind with the inferior margin of the perpendicular plate of the ethmoid bone, in front with the cartilaginous nasal septum.



34. Right upper jaw bone, *maxilla*, from without.

The *maxilla* (*O. T. superior maxillary bone*) (see also Figs. 35, 36, 55—60, 67—75) is paired, lies in the upper anterior part of the facial skull and is divisible into a *corpus* or body and four processes of which two, the *processus frontalis* and *processus zygomaticus*, belong to the upper part, while the two others, the *processus alveolaris* and the *processus palatinus*, belong to the lower part.

The *corpus* or *body* is quadrangular in shape and contains within it a large cavity, *sinus maxillaris* (*O. T. antrum* of Highmore) lined by mucous membrane, the entrance to which, *hiatus maxillaris*, is situated on the nasal surface. The upper surface, *facies orbitalis* (*planum orbitale*) is smooth, triangular, directed obliquely forward, outward and downward and forms the floor of the orbit; its medial border unites behind with the lamina papyracea oss. ethmoid. (*sutura ethmoideomaxillaris*), in front with the lacrymal bone (*sutura lacrimomaxillaris*); the anterior border is smooth medianward, lying free as the *margo infraorbitalis*, while lateralward it is serrated and goes over into the proc. zygomaticus; the posterior border is for the most part smooth, lies free, and forms with the inferior margin of the orbital surface of the large wing of the sphenoid running parallel to it, the *fissura orbitalis inferior* (for the a. infraorbit., v. ophthalm. inf.; m. zygomat., infraorbit.). From this point forward on the upper surface extends a groove (*sulcus infraorbitalis*) closed by periosteum, which gradually becomes deeper and is continued into the *canalis infraorbitalis* (both for the a. infraorbit.; n. infraorbit.); branching off from this are the very minute *canales alveolares* (for the aa. alveol. sup. ant.; rr. alveol. sup. medius et anteriores n. infraorbit.), which run within the anterior wall of the body of the bone. Upon and beneath the posterior medial angle of the facies orbitalis is attached the proc. orbital. oss. palat. (*sutura palatomaxillaris*). The posterior surface, *facies infratemporalis* (*O. T. zygomatic surface*), looks into the fossa infratemporalis and pterygopalatina, is slightly rough, often bulged out (*tuber maxillare*) and there gives origin to parts of the mm. pterygoideus externus and internus; it presents from two to three small *foramina alveolaria*, which lead into canals passing forward, the *canales alveolares* (*O. T. posterior dental canals*) (for the a. alveol. sup. post.; m. alveol. sup.). The anterior surface, *facies anterior* (*O. T. external or facial surface*), presents above the *foramen infraorbitale* the opening of exit of the *canalis infraorbit.*; beneath it a variable depression, *fossa*

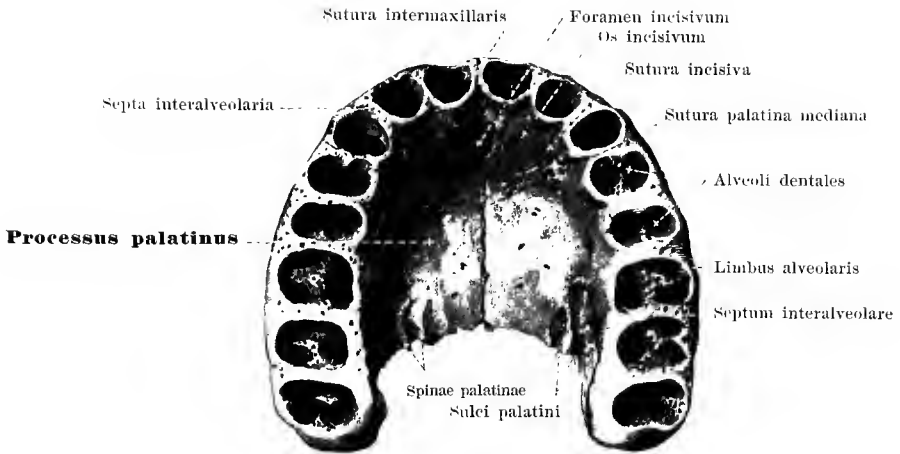


35. Right upper jaw bone, *maxilla*, from within.

The *facies nasalis* of the **corpus maxillae** is placed sagittally and helps to form the lateral wall of the nasal cavity. A large opening in it, the *hiatus maxillaris*, leads into the *sinus maxillaris* (O. T. antrum of Highmore). The slightly rough field behind the hiatus has attached to it the *facies maxillaris* of the *pars perpendicularis oss. palatini* and presents usually a smooth perpendicular groove for the completion of the *canalis pterygopalatinus*. In front of the hiatus in the upper part passing downward from the posterior margin of the *proc. frontalis* is the *sulcus lacrimalis* which is closed to form the *canalis nasolacrimalis* (O. T. lachrymal groove) by the attachment to it medianward of the *os lacrimale* above and the *proc. lacrimalis conchae nasalis inferioris* below. In front of this the *crista conchalis* (for union with the upper border of the *concha nasalis inferioris*) runs approximately horizontally forward. The anterior margin, *incisura nasalis*, helps to bound the *apertura piriformis*.

The **processus frontalis** (O. T. *nasal process*) ascends in front from the upper margin of the *facies nasalis* and *facies anterior*. Its upper, thick, serrated margin lies upon the *pars nasalis oss. frontalis* (*sutura frontomaxillaris*); the anterior, sharp, slightly serrated margin unites with the *os nasale* (*sutura nasomaxillaris*). The posterior broad margin presents a groove, *sulcus lacrimalis*, which leads downward on the *facies nasalis* of the body (vide supra); it is bounded medianward by the *margo lacrimalis*, to which is attached the anterior margin of the *lacrymal bone* (*sutura lacrimomaxillaris*), lateralward by the slight *crista lacrimalis anterior*, which goes over into the *margo infraorbitalis*; behind this point of transition is situated the *incisura lacrimalis*, in which is placed the *hamulus lacrimalis oss. lacrimalis*. The lateral surface is smooth; on the medial, running from behind forward, is the *crista ethmoidalis* (for apposition with the anterior extremity of the medial surface of the labyrinth).

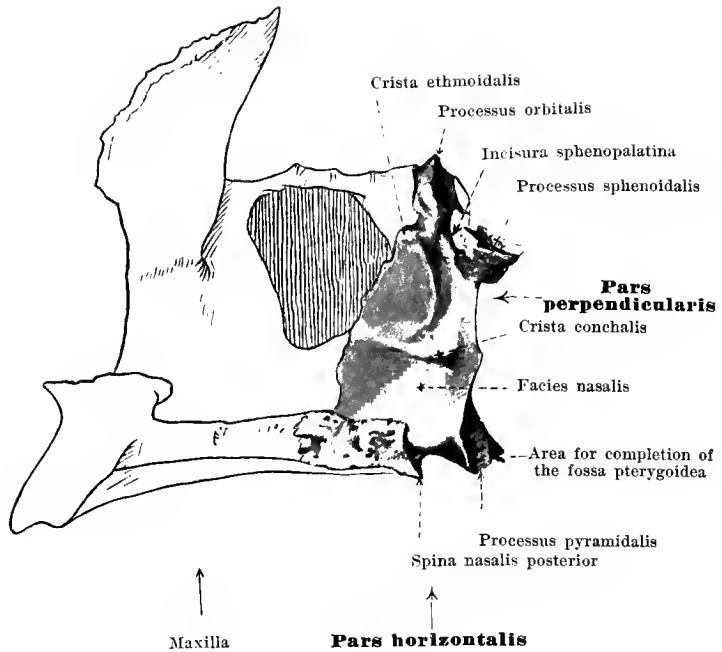
The short, broad **processus zygomaticus** (O. T. *malar process*) proceeds from the lateral upper angle of the body of the upper jaw and is usually hollowed out in its base



36. The two upper jaw bones, *maxillae*, united, from below.

The **processus palatinus** is a transversely placed plate of bone which goes off medianward from the inferior margin of the *facies nasalis* and helps to form the bony septum between the nasal and the buccal cavity. At the medial rough margin the two maxillae unite with one another to form the *sutura palatina mediana*; above the same on each maxilla runs a ridge, *crista nasalis*, the union of the two ridges serving for the attachment of the vomer and the cartilage of the septum of the nose. The posterior margin lies on the anterior border of the *pars horizontalis oss. palatini* (*sutura palatina transversa*). The upper surface is smooth and slightly concave in frontal direction; the inferior surface is rougher and presents near the posterior extremity usually two *sulci palatini* (for the branches of the *a. palatina major*) bounded by small ridges, *spinae palatinae*.

The **processus alveolaris** is dependent in its development on that of the teeth and extends downward like an arch convex in front and externally, concave behind and internally, from the lower margin of the body. The broader, free, inferior margin, *limbus alveolaris*, contains eight tooth cavities, *alveoli dentales*, which are separated from one another by the *septa interalveolaria*; they have wide mouths and grow narrower in the depth; they are exact impressions of the corresponding roots of the teeth. The anterior surface of the *proc. alveolaris* presents oblong projections, *juga alveolaria*, corresponding to the anterior five alveoli. The portion of the bone lying most medianward including the most anterior two (incisor-teeth) alveoli and the corresponding part of the *proc. palatinus* represents what is in the foetus a special bone (*os incisivum*) which fuses early with the rest of the bone; remains of the suture originally present at the site of union, the *sutura incisiva*, are usually distinct in the new-born, sometimes also in the adult; medianward they extend, arch-like, backward to an unpaired opening, *foramen incisivum*, situated on the inferior surface of the combined *proc. palatini*; from it proceeds upward the symmetrically forking *canalis incisivus* (for branches of the *a. palatina major*, branches of the *n. nasopalatinus*) and ends on the upper surface of each *proc. palatinus* by an opening on each side. The two *processus alveolares* unite in the

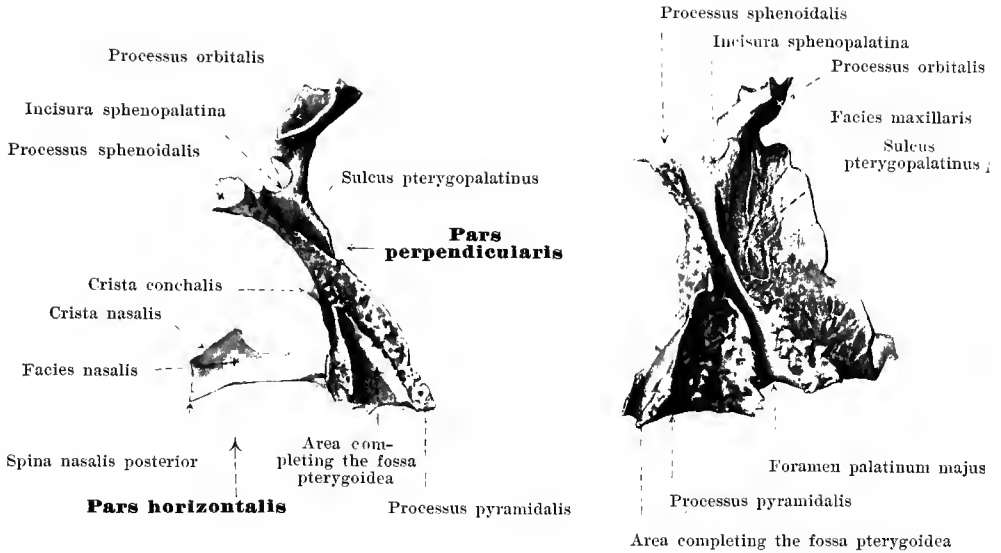


37. Right palate bone, *os palatinum*, from within.

The paired **os palatinum** (*palate bone*) (see also Figs. 38, 39, 59, 50, 68—70, 72—74) lies in the posterior part of the nasal cavity and there forms a part of the floor of the same (of the hard palate) and of the lateral wall. It presents for examination a *pars horizontalis* and a *pars perpendicularis*.

The **pars horizontalis** (*O. T. horizontal plate*) is very similar to the proc. palatinus maxillae, only shorter; the upper surface (*facies nasalis*), is smooth and slightly concave; the lower surface (*facies palatina*), is somewhat rough and presents near the posterior margin a small sickle-shaped elevated surface for the attachment of the *m. tensor veli palatini*. The anterior, slightly serrated margin lies on the posterior border of the proc. palatinus maxillae and forms with this the *sutura palatina transversa*. The medial margin unites with the corresponding border of the bone of the other side and forms the posterior part of the *sutura palatina mediana*; on the upper surface of this border the *crista nasalis* (for union with the vomer) projects upward and runs out behind into the *spina nasalis posterior*. The posterior margin is smooth and concave.

From the lateral part of the posterior margin projects backward the strong *processus pyramidalis*. It is inserted from in front into the *fissura pterygoidea* oss. sphenoidalis and helps, with a smooth area on its posterior surface, to complete the inferior part of the *fossa pterygoidea*. The external, rough surface unites with the posterior portion of the corpus maxillae just above the eighth alveolus. The medial, smooth surface looks into the nasal cavity. The inferior surface belongs to the lower surface of the hard palate and contains usually three openings, of which the *foramen palatinum majus* lies furthest forward, the others, *foramina palatina minora*, lie further backward. These are the outlets of the *canales palatini* (for the aa. palatinae major et minores; nn. palatini) which sometimes open lateral-

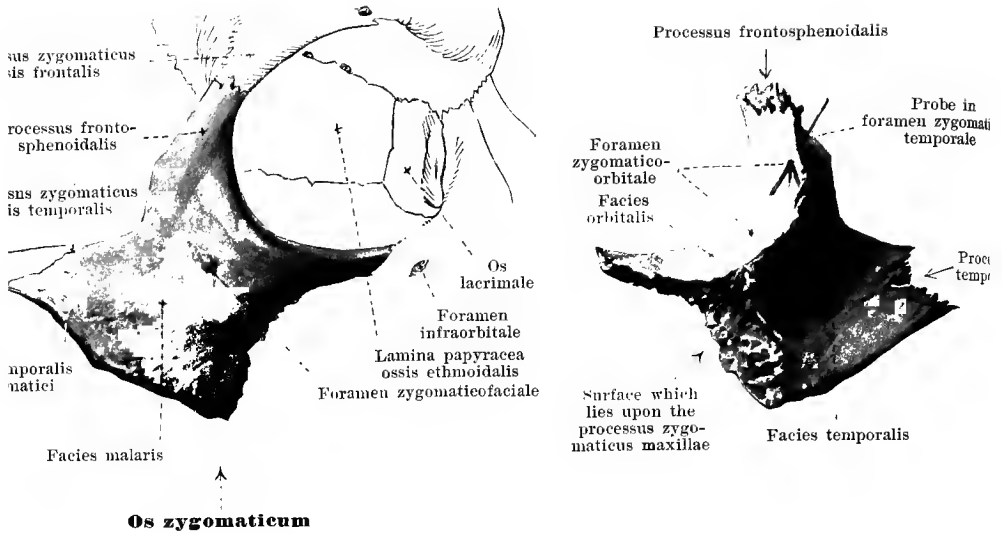


38 and 39. Right palate bone, *os palatinum*.

From behind.

From without.

The **pars perpendicularis** (O. T. *vertical plate*) ascends as a thin leaf of bone vertically upward from the lateral margin of the pars horizontalis. The medial *facies nasalis* is smooth and presents two ridges extending from before backward, an upper, shorter, *crista ethmoidalis* (O. T. superior turbinated crest), for the attachment of the concha nasalis media, and a lower, *crista conchalis* (O. T. inferior turbinated crest), for union with the concha nasalis inferior. The lateral surface, *facies maxillaris*, is for the most part rough and unites with the posterior, rough portion of the facies nasalis corporis maxillae, so that it covers over a portion of the hiatus maxillaris from behind; it is attached behind to the anterior margin and the medial surface of the lamina medialis proc. pterygoidei oss. sphenoidalis. Between these two areas, extending from above downwards, is the smooth, shallow *sulcus pterygopalatinus*. Through the attachment of the facies maxillaris to the two bones mentioned this forms together with the sulcus pterygopalat. of the proc. pteryg. oss. sphenoidalis and a groove on the upper jaw bone, above, the *fossa pterygopalatina*, open lateralward (for the aa. maxill. int., palat. descendens, sphenopalat.; nn. zygomat., sphenopalat., alveol. sup., infraorbit.; gangl. sphenopalat.), below, the *canalis pterygopalatinus* (O. T. posterior palatine canal) (for the a. palat. descendens; nn. palat., rr. nasal. post. inf. gangl. sphenopalat.), closed also externally by the proc. pterygoideus oss. sphenoid. and the upper jaw; it is continued below into the *canales palatini* (for the aa. palatinae major et minores; nn. palat.) which usually run in the proc. pyramidalis alone. From the upper margin of the pars perpendicularis extend two processes, the *processus sphenoidalis* bent somewhat backward and markedly medianward, which lies on the inferior surface of the body of the sphenoid and on the ala vomeris, and the *processus orbitalis* forward and somewhat lateralward. The latter is bulged out and contains a small cavity which helps to close the posterior ethmoidal cells. Its lateral, smooth surface forms the most posterior part of the floor of the orbit; in front and below it meets the facies orbitalis corporis maxillae (*sutura palatomaxillaris*), in front and above the lamina papyracea oss. ethmoid. (*sutura palatoethmoidalis*), behind and above the anterior margin of the lateral surface of the body of the sphenoid (*sutura sphenoorbitalis*); behind and below it lies free and helps in part to form the medial portion of the *fissura orbitalis inferior*, in part it looks into the fossa sphenopalatina. Between the proc. sphenoid. and the proc. orbital. lies the



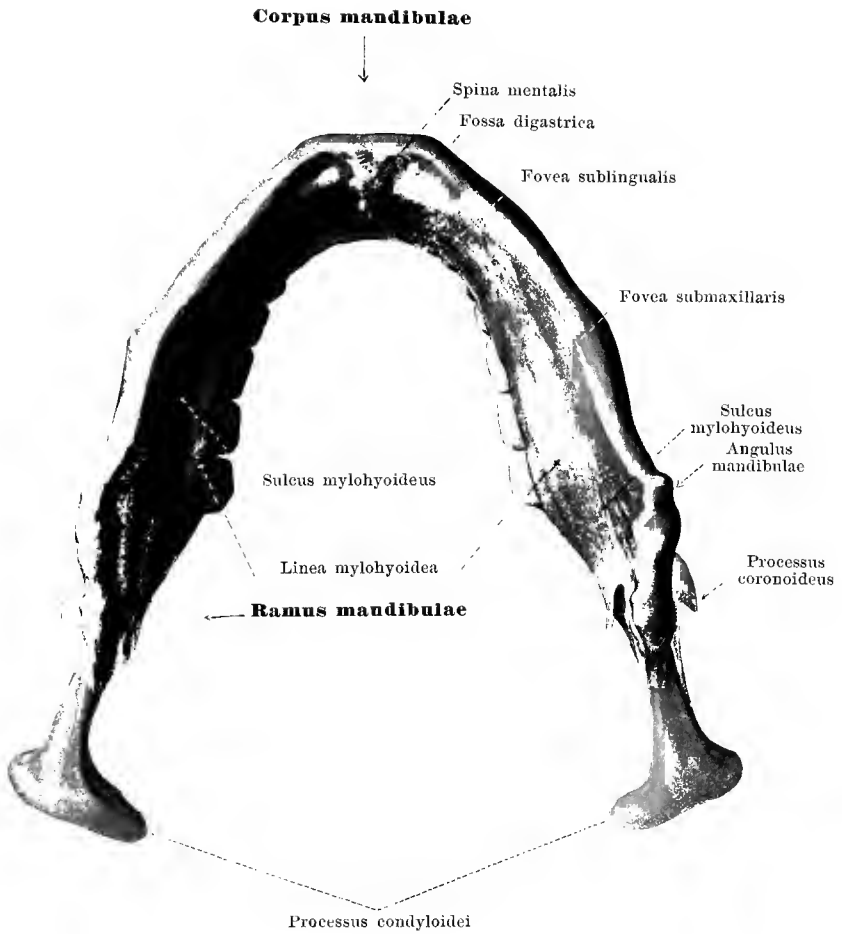
40 and 41. Right yoke bone, *os zygomaticum*.

From without

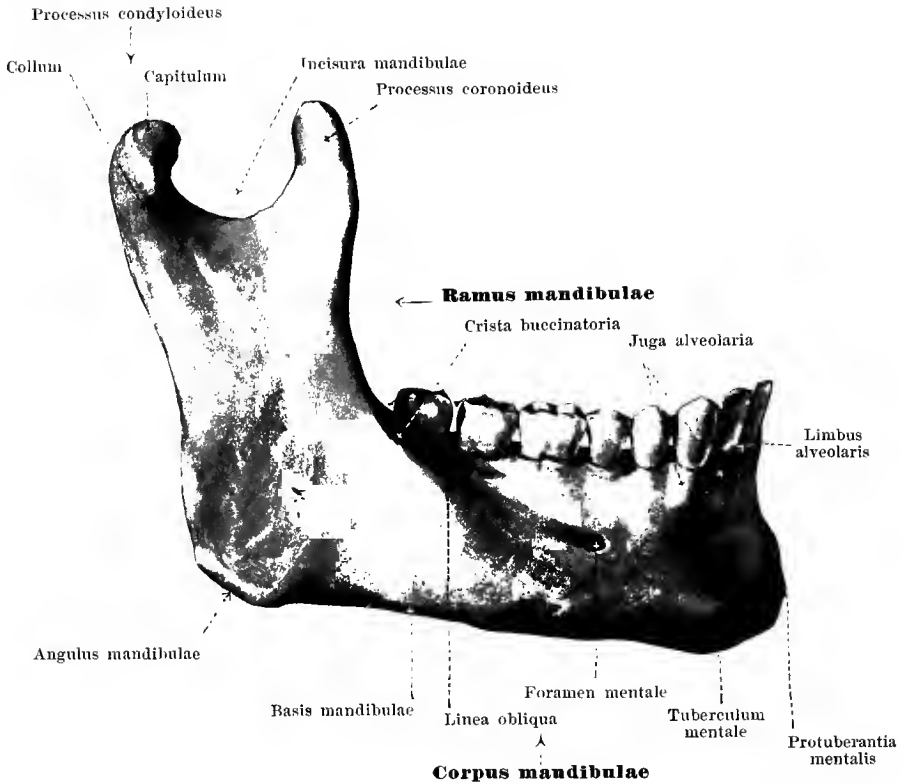
From within.

The **os zygomaticum** or *yoke bone* (O. T. malar bone) (see also Figs. 55—60, 69—72), is paired and lies in the lateral part of the facial skull. It has three surfaces. The laterally directed *facies malaris* is quadrangular, fairly smooth, markedly convex and presents the *foramen zygomaticofaciale* (O. T. malar foramen). The concave *facies orbitalis*, directed medianward and forward, helps to form the lateral and inferior wall of the orbit and meets the *facies malaris*, forming a markedly curved concave margin, which below completes the *margo infraorbitalis*, and above forms the lateral margin of the aditus orbitae. The medial inferior margin of the *facies orbitalis* unites with the lateral angle of the *facies orbitalis corporis maxillae* (*sutura zygomaticomaxillaris*) and forms in half the cases the lateral boundary of the *fissura orbitalis inferior*; the medial upper margin lies upon the *margo zygomaticus* of the *ala magna ossis sphenoidalis* (*sutura sphenozygomatica*). On the *facies orbitalis* can be seen the single or double *foramen zygomaticoorbitale* (O. T. temporo-malar canals), the entrance to a bifurcating canal (sometimes double from the beginning), the divisions of which perforate the bone and end on the *facies malaris* and the *facies temporalis* (for the r. *zygomaticofacialis* et r. *zygomaticotemporalis* n. *zygomatici*). The *facies temporalis* looks downward and medianward, is curved so as to be markedly concave and forms the anterior part of the *fossa temporalis*. Here the *foramen zygomaticotemporale* is visible; medianward it adjoins a rough surface for broad union with the *proc. zygomaticus corporis maxillae* (*sutura zygomaticomaxillaris*).

At the upper angle of the *facies malaris* lies the *processus frontosphenoidalis* (O. T. frontal process), in front for union with the *proc. zygomaticus ossis frontalis* (*sutura zygomaticofrontalis*), behind with the large wing of the sphenoid (vide supra). From the posterior angle of the bone goes off the slim *processus temporalis* (O. T. zygomatic process), which



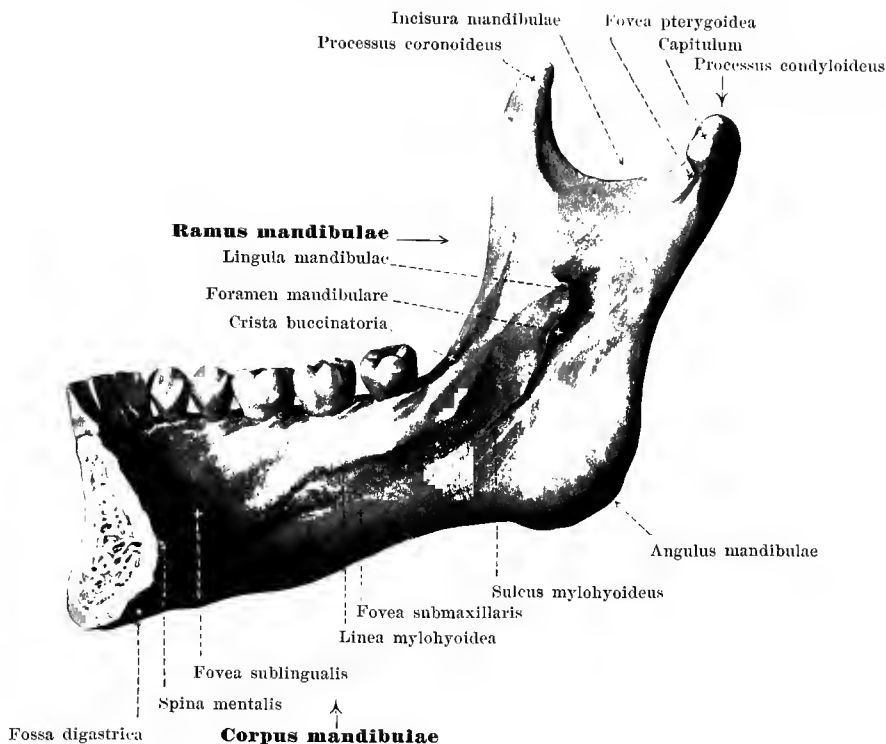
42. Lower jaw bone, *mandibula*, from below.



43. Lower jaw bone, *mandibula*, right half, from without.

The **mandibula** (*lower jaw bone*), (O. T. inferior maxillary bone) (see also Figs. 42, 44—50, 57, and 58) is unpaired and forms the inferior anterior part of the facial skull. It consists of the parabolically curved *corpus*, and two *rami*, which ascend from the ends of the corpus.

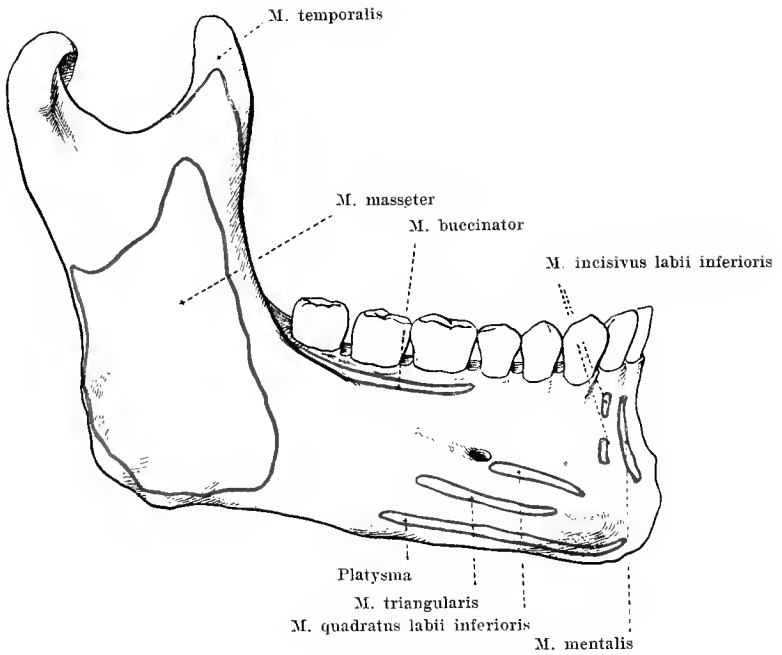
The **corpus mandibulae** (*body of lower jaw*) consists originally of two halves united with one another in the median plane, the union taking place in the first year of life. The point of union is often indicated by a groove. Each half represents a mass of bone which is higher than it is thick, and curved in front so as to be markedly convex externally. Its inferior margin, *basis mandibulae*, is somewhat thickened and rounded; close above this, near the median plane, is situated the somewhat roll-shaped, transversely placed *protuberantia mentalis* (O. T. mental process), which, lateralward, runs out into the *tuberculum mentale*. Somewhat lateralward and upward from the latter a round *foramen mentale* (for the a. mentalis; n. mentalis) is visible; it is usually situated below the alveolus of the second prae-molar, about half-way between the base and the upper margin. Beneath it, or somewhat further back, begins the *linea obliqua* (O. T. external oblique line) extending obliquely upward to the anterior margin of the ramus. The upper part of the body, *pars alveolaris*, dependent in development upon that of the teeth, is bounded above by a narrow border, the *limbus alveolaris*. It contains on each side eight, altogether then sixteen, *alveoli dentales* which are separated from one another by thin *septa interalveolaria*; the alveoli are wide at the opening and become narrower in the depth, being exact impressions of the roots of the teeth which they hold. Oblong projections, *juga alveolaria*, usually caused by the three anterior alveoli only, are observable on the outer surface. The medial surface of the corpus presents, close to the



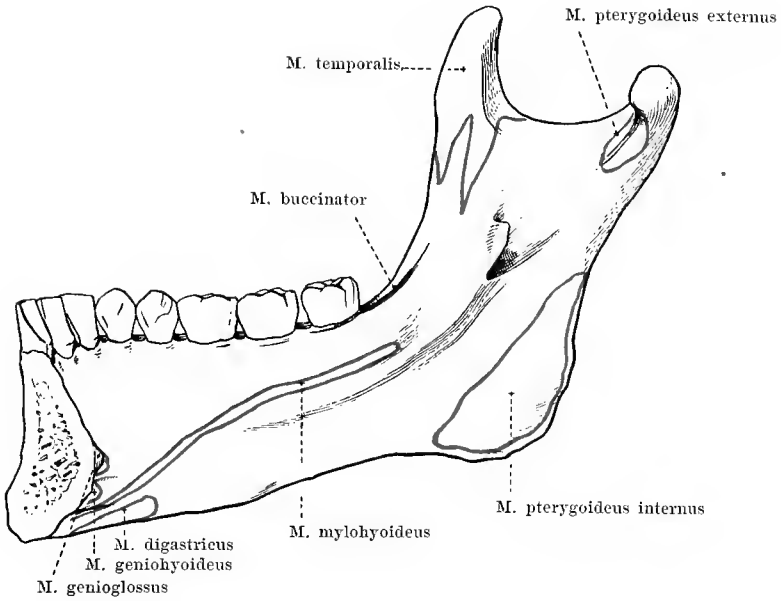
44. Lower jaw bone, *mandibula*, right half, from within.

Above the fossa digastrica on each side begins the *linea mylohyoidea* (O. T. internal oblique line) (for the mm. mylohyoid., mylopharyng.), which ascends obliquely backward to the medial surface of the ramus. Above the medial part of the latter lies the *fovea sublingualis* (O. T. sublingual fossa) (for the gland. subling.), usually distinctly marked; beneath the lateral portion, often less well indicated, the *fovea submaxillaris* (O. T. submaxillary fossa) (for the gland. submax.). Extending forward, just below the lateral part of the linea mylohyoid., is the *sulcus mylohyoideus* (for the r. mylohyoid. a. alveol. inf.; n. mylohyoid.).

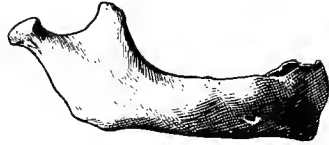The **ramus mandibulae** (O. T. perpendicular portion) is a broad plate of bone which extends from the posterior end of the body perpendicularly upward or obliquely backward. Its posterior, thicker margin forms with the basis corporis the *angulus mandibulae*; its anterior margin begins lateralward at the posterior end of the linea obliqua, medianward at the last alveolus, with a small triangular surface on which is often visible the *crista buccinatoria* (for the m. buccinat.). The lateral surface is smooth, the medial presents about its middle an opening, *foramen mandibulare* (O. T. inferior dental foramen), which is bounded medianward by a small leaflet of bone, the *lingula mandibulae*. Below the for. mandibul. begins the *sulcus mylohyoideus* and in it the *canalis mandibulae* (O. T. inferior dental canal) (for the a. alveol. inf.; n. alveol. inf.) which extends, within the spongiosa of the bone, arch-like, downward and forward as far as the median plane; before reaching this, however, it opens also on the external surface at the foramen mentale. The upper end of the ramus supports two processes separated from one another by the *incisura mandibulae* (O. T. sigmoid notch); the anterior, *processus coronoideus*, (for the insertion of the m. temporal.) is bent backward somewhat hook-like, the posterior, *processus condyloideus*, serves for articulation of the lower jaw with the rest of the skull and supports a roller-like *capitulum mandibulae*, covered over



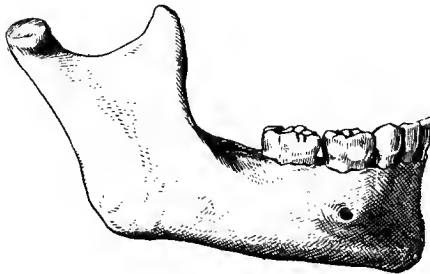
45. Lower jaw bone, *mandibula*, right half, from without, showing muscular attachments.



46. Lower jaw bone, *mandibula*, right half, from within, showing muscular attachments.

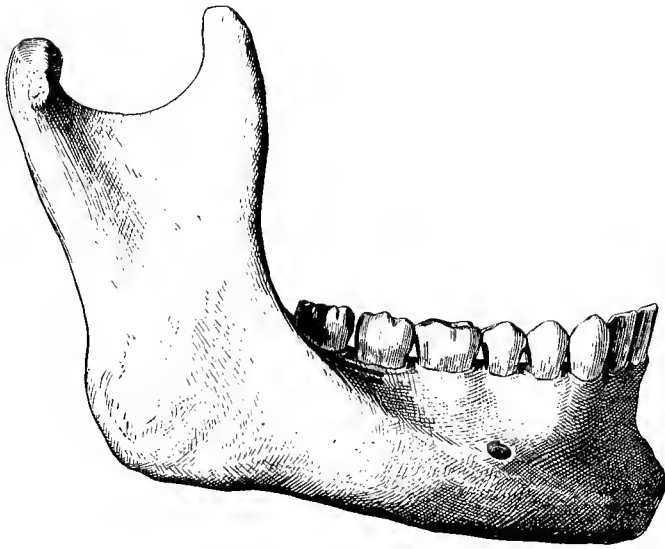


47. Newborn.

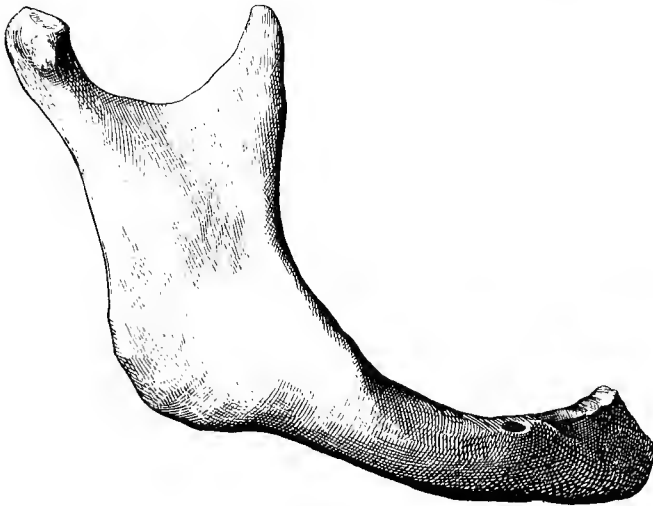


48. 6—7 year old child.

47—50. Lower jaw bones, *mandibulae*,
at different ages of life, figures drawn to uniform scale.

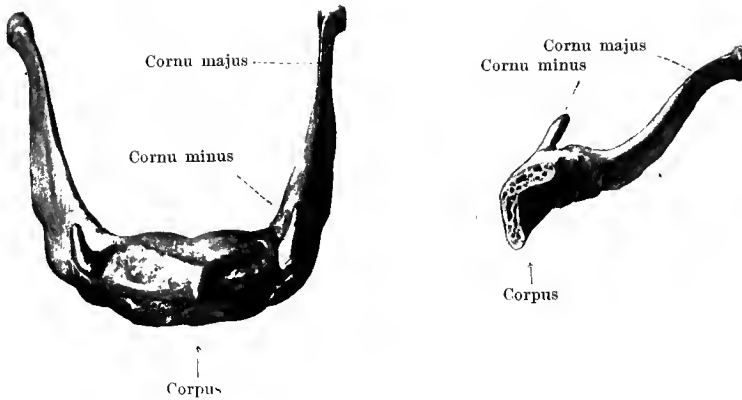


49. Adult.



50. Old age.

47—50. Lower jaw bones. *mandibulae*.



51 and 52. Hyoid bone, *os hyoideum*.

From above.

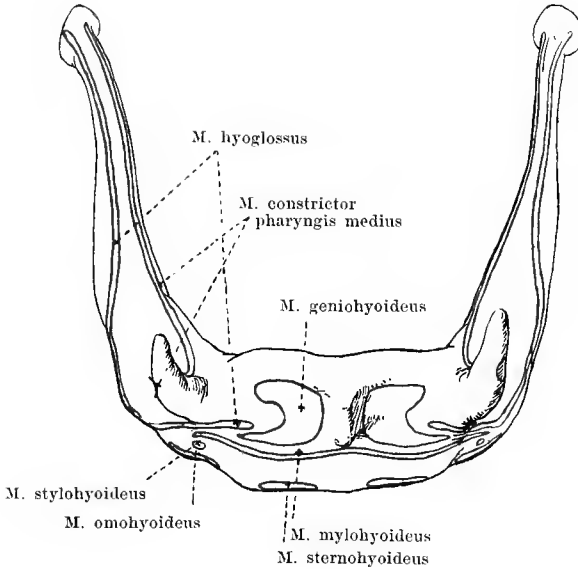
Right half, from the left.

The **os hyoideum** (*hyoid bone*) lies as an unpaired, horse-shoe-shaped bone behind and below the lower jaw between the muscles, without direct connection with the other bones. It is divisible into a middle piece or *corpus*, two *cornua majora* and two *cornua minora*.

The **corpus** (*body*) is a transversely placed oblong plate with an anterior surface, bent so as to be convex in front and above, and a concave posterior surface. The anterior surface presents variously developed ridges for the muscular attachments, the posterior is smooth. At the lateral ends are small fossae, below for union with the *cornua majora*, above for the *cornua minora*.

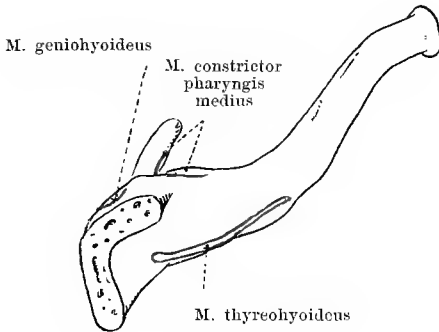
The **cornua majora** are thin, laterally flattened plates of bone, longer than the body. They are placed horizontally or directed obliquely upward, are united in front with the body by means of a narrow plate of cartilage or by a small joint with a joint cavity and a tight capsule. Behind, each ends in a small button-like projection.

The **cornua minora** are small pieces, sometimes remaining cartilaginous, which are attached above near the point of union of the body and the *cornua majora*, either by means of a small joint with joint cavity and loose capsule or by ligamentous union only. They are surrounded by the end of the *ligamentum stylohyoideum* (see Fig. 555), a thin round elastic fibrous ligament which extends from the *processus styloideus* *oss. tempor.* interwoven in the deep layer of the cervical fascia. Sometimes it contains masses of bone, the single pieces being more or less separated from one another. The *processus styloideus*, the *lig. stylohyoideum* and the *cornu minus* *oss. hyoid.* arise from the second branchial arch of the foetus.

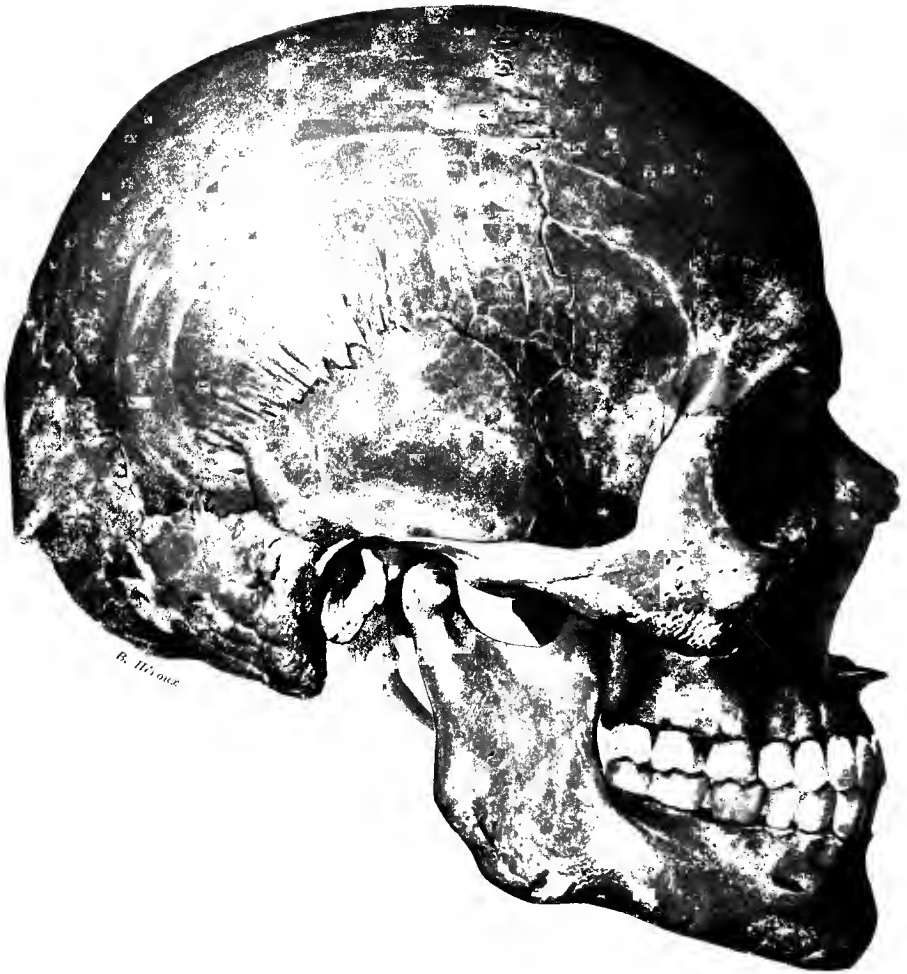

53. Hyoid bone, *os hyoideum*, from above, with muscular attachments.

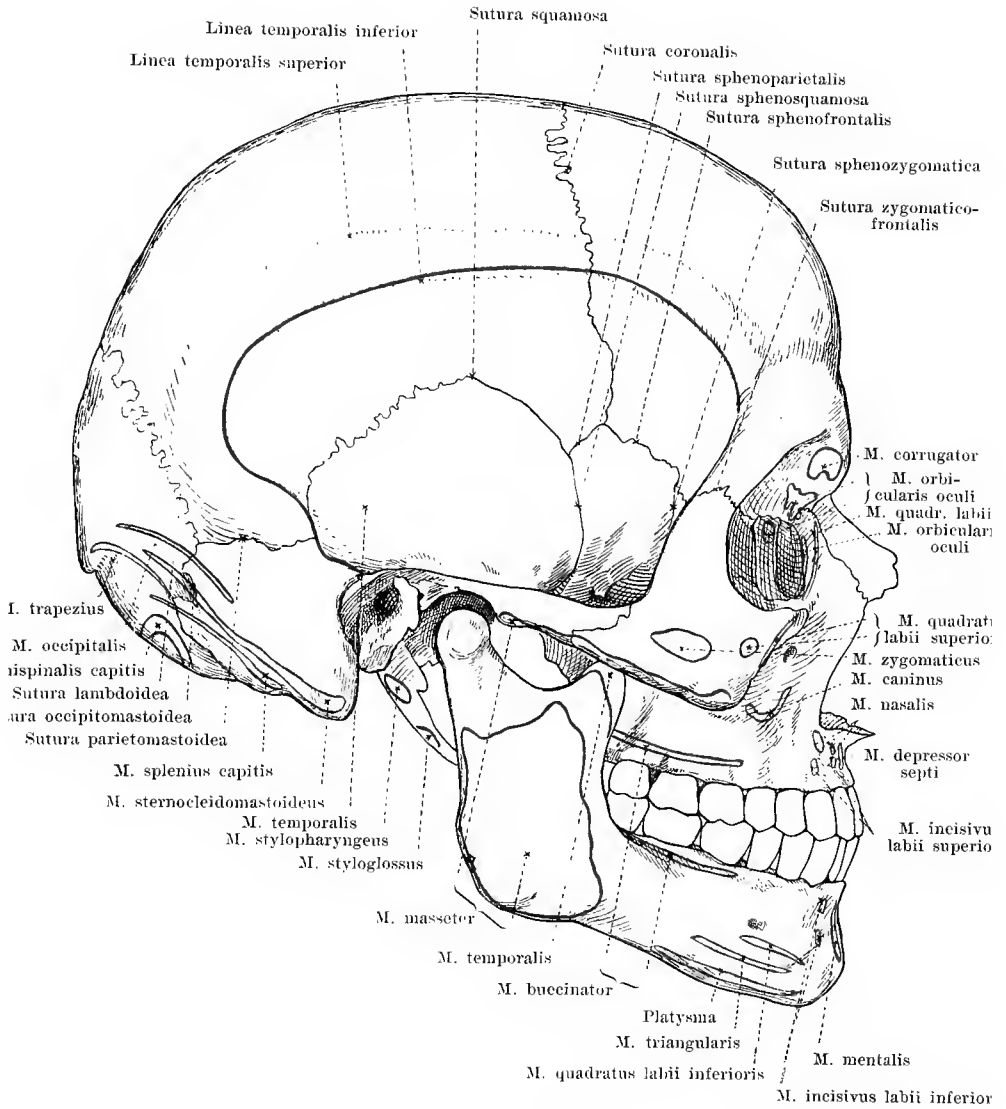
Magnification 3 : 2.



54. Hyoid bone, *os hyoideum*, right half, from the left, with muscular attachments.



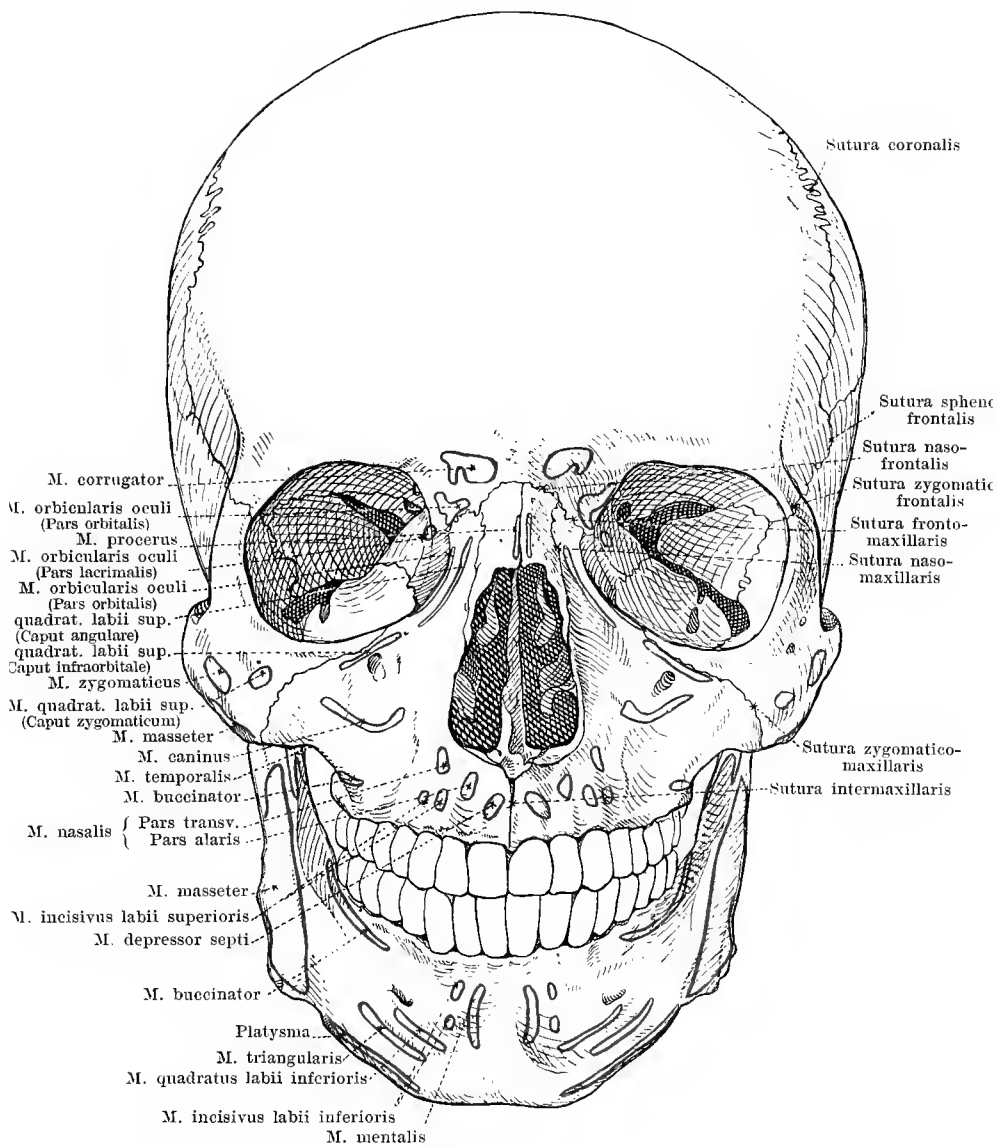
55. Skull, from the right.



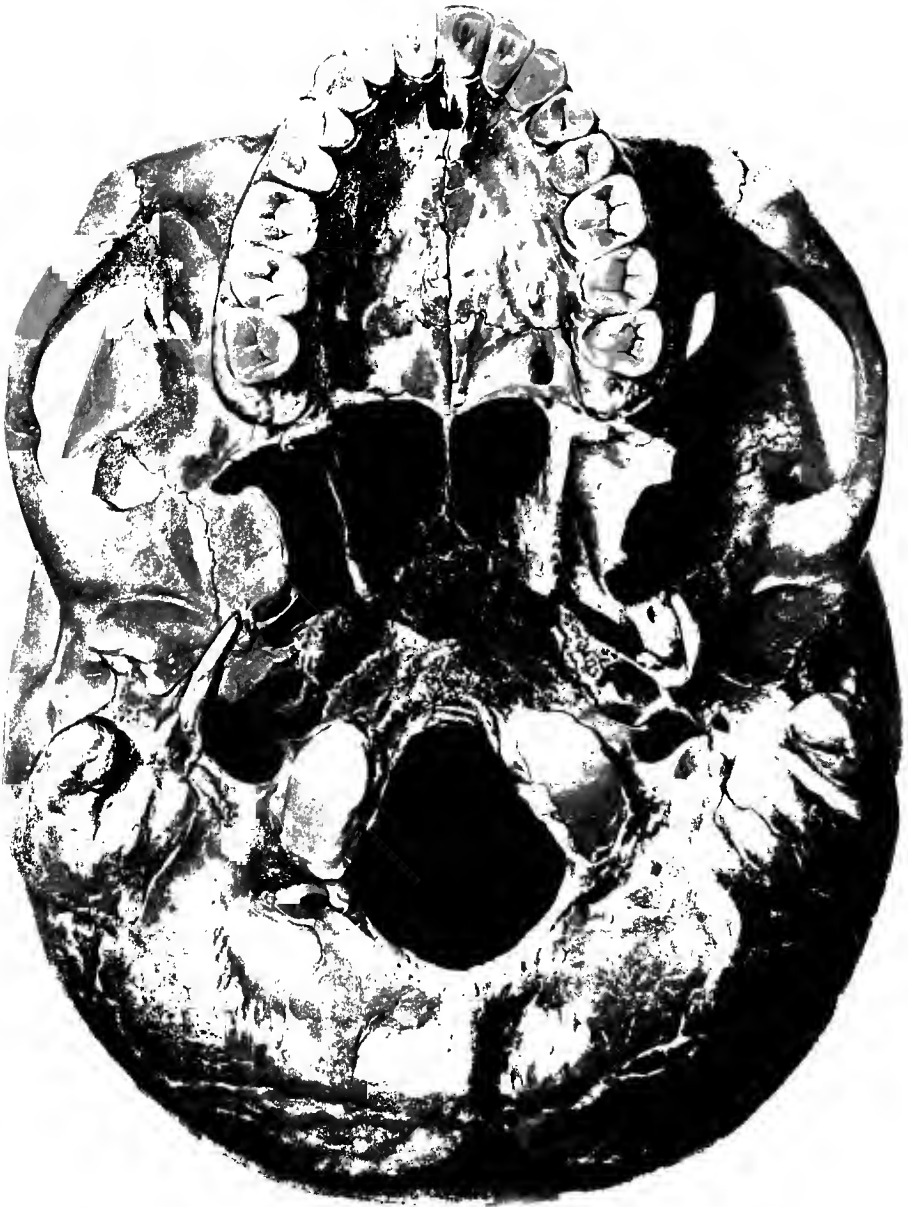
56. Skull, from the right, with muscular attachments.



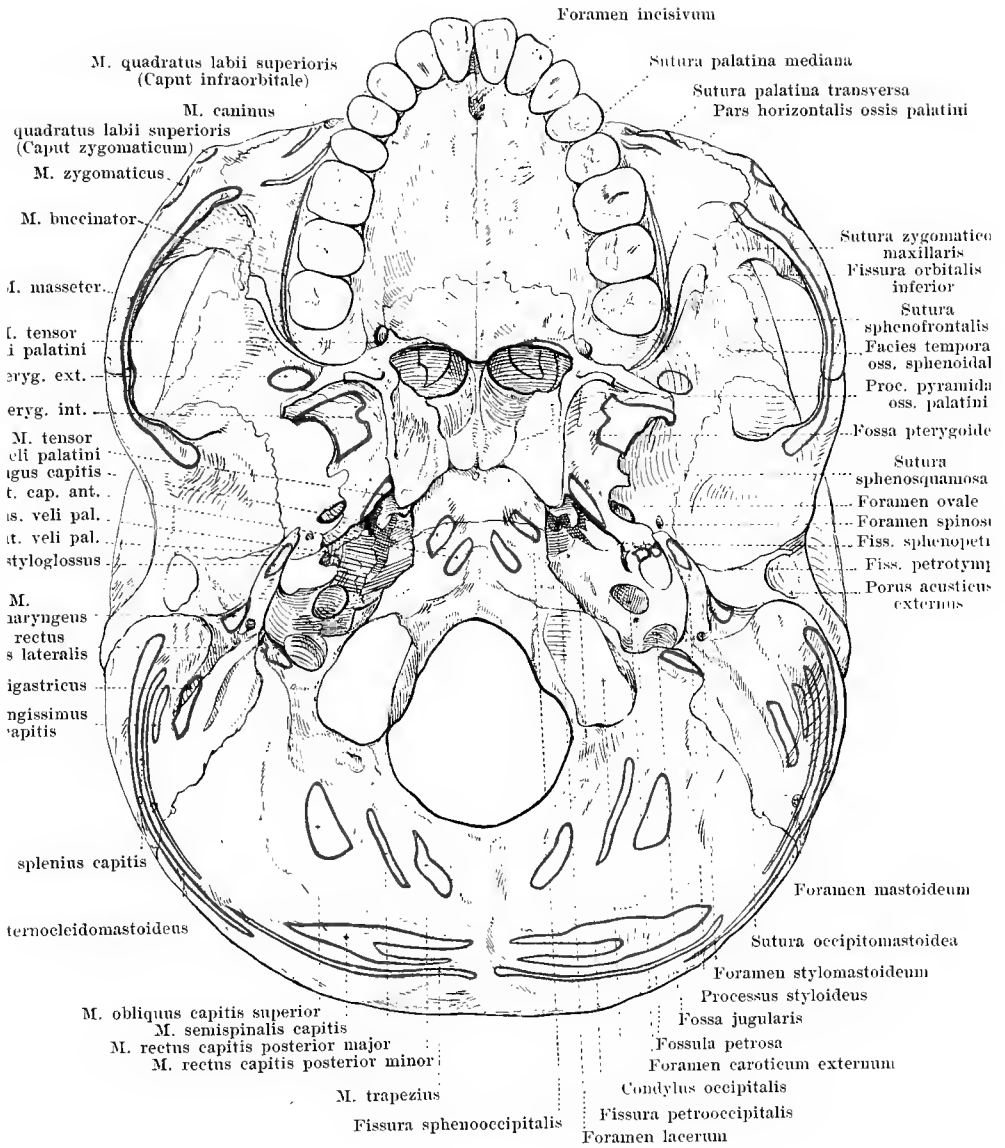
57. Skull, from in front.



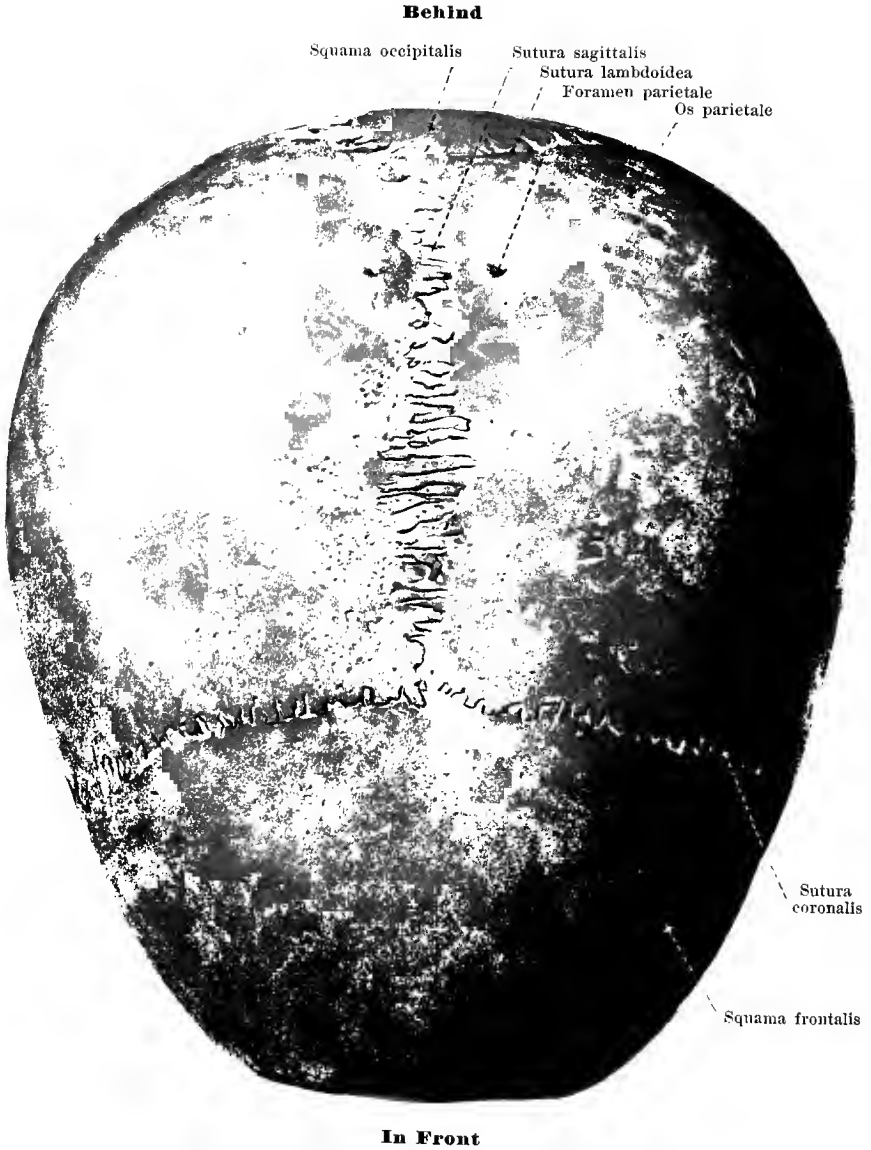58. Skull, from in front, with muscular attachments.



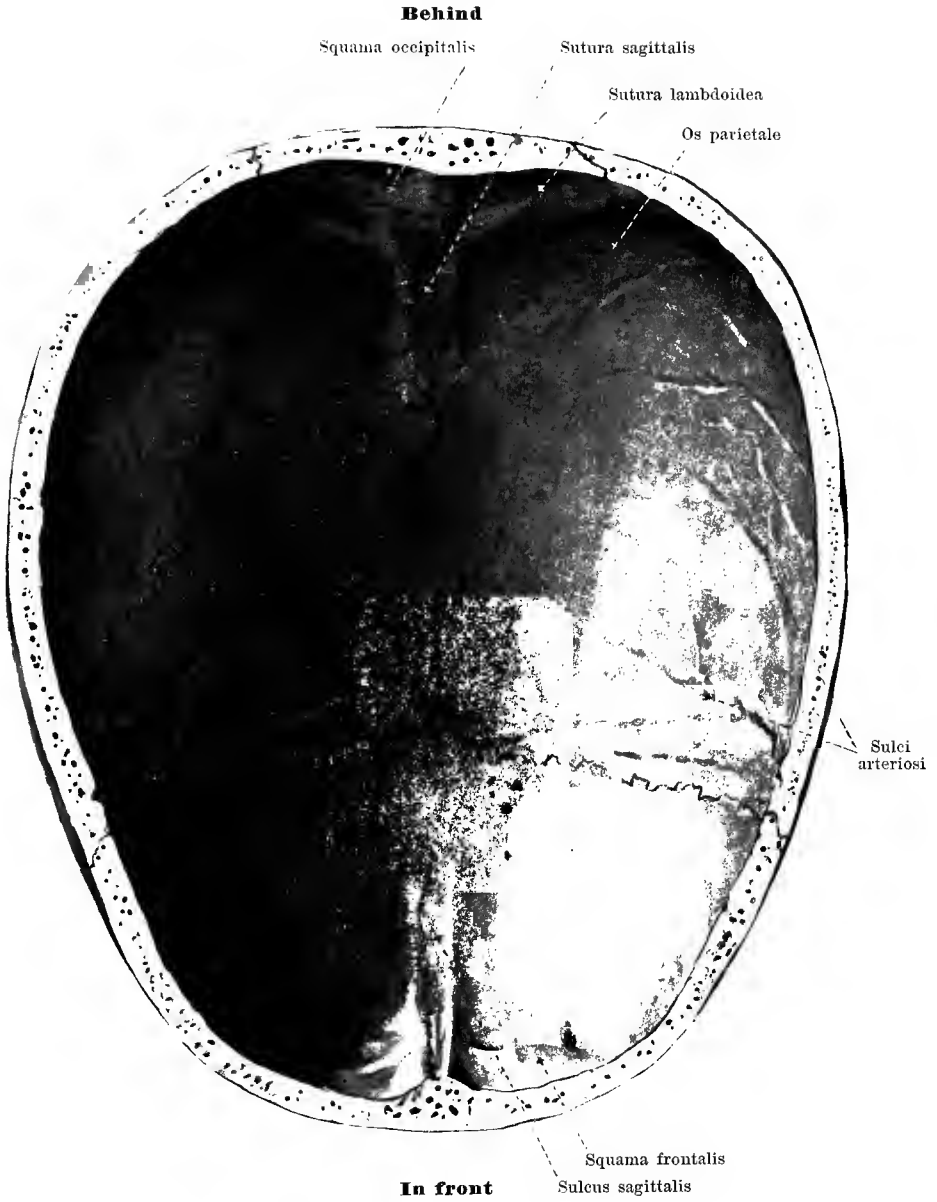59. Base of the skull. from without. *basis cranii externa.*



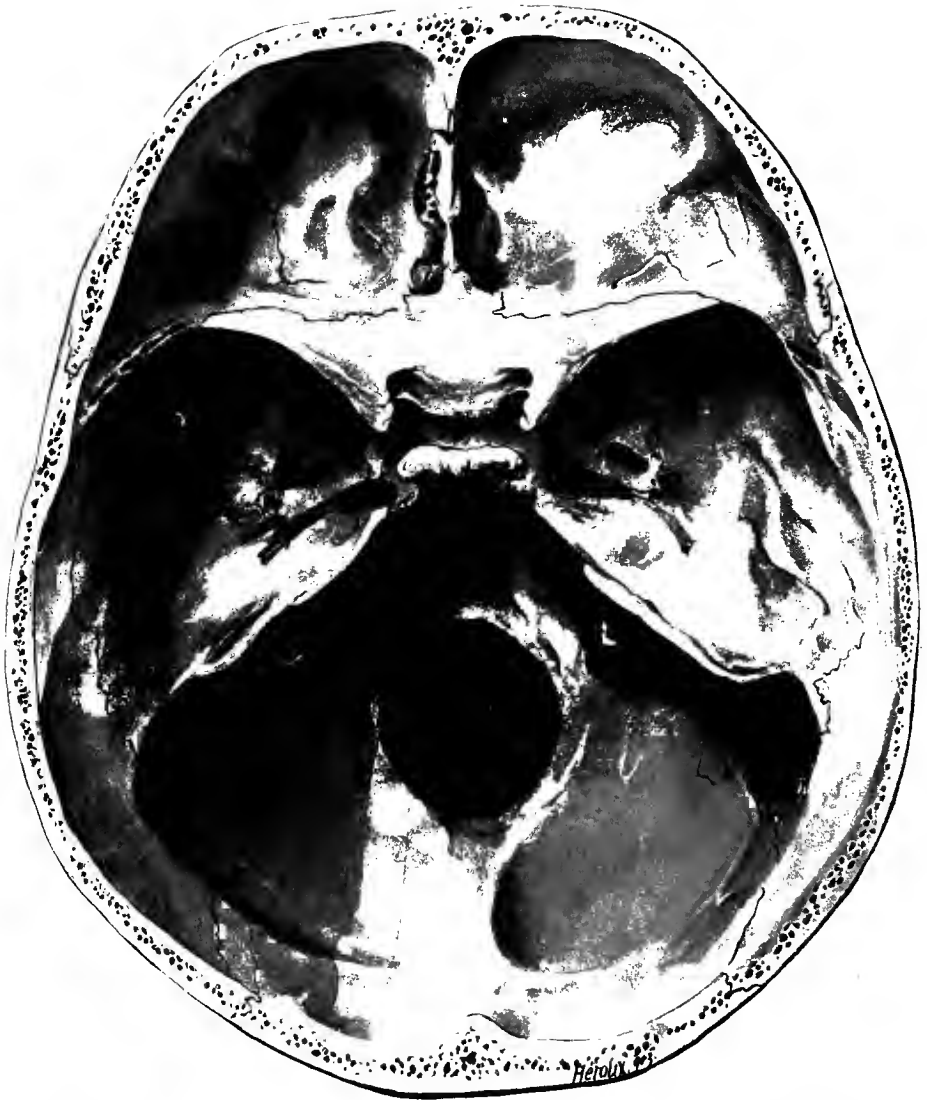
60. Base of the skull, from without, *basis cranii externa*, with muscular attachments.



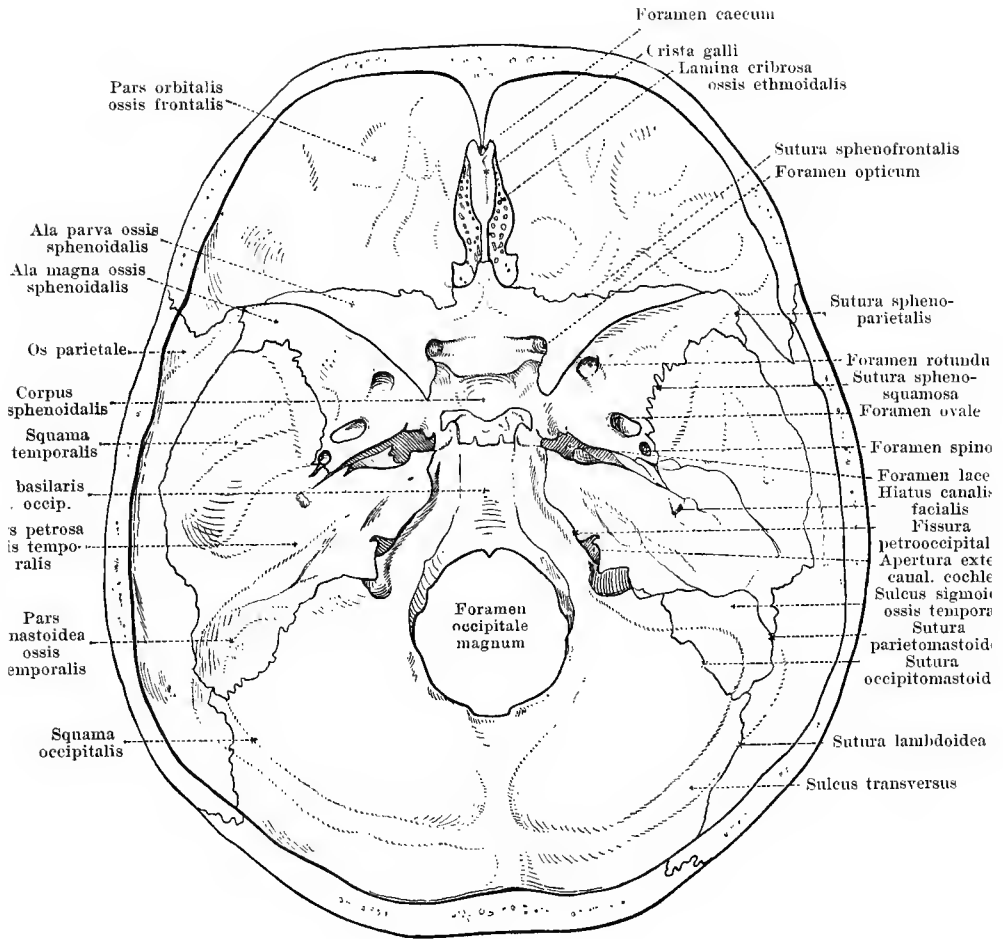
61. Skull, from above.



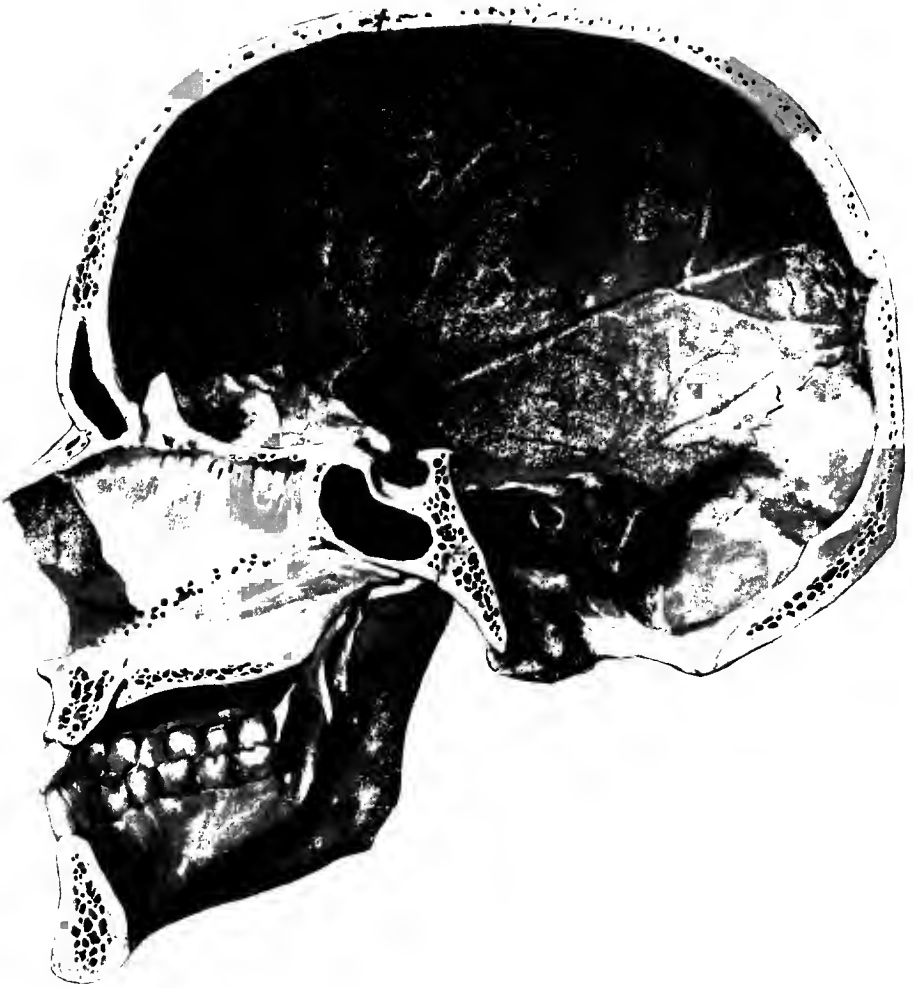62. Skull cap, from within.



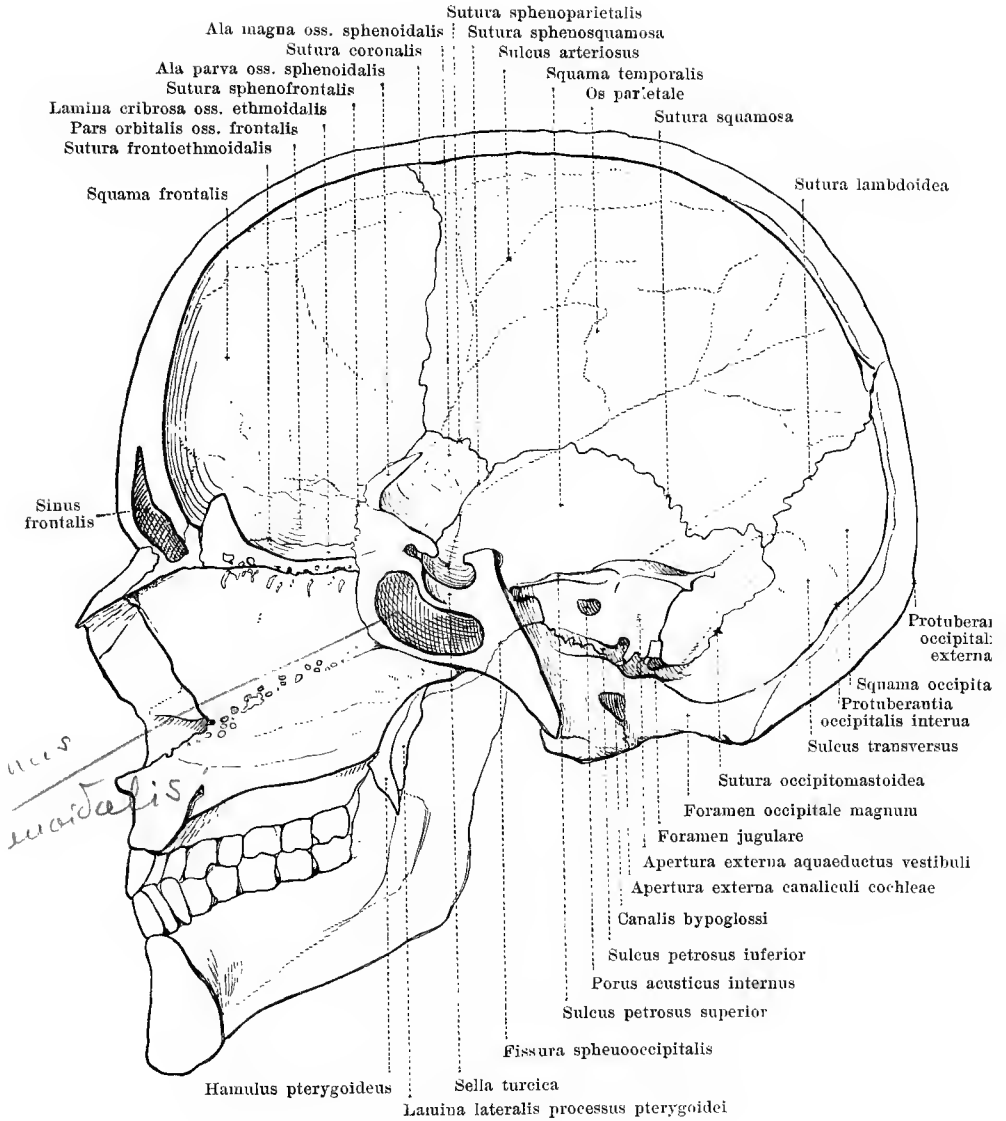
63. Base of the skull, from within, *basis cranii interna*.



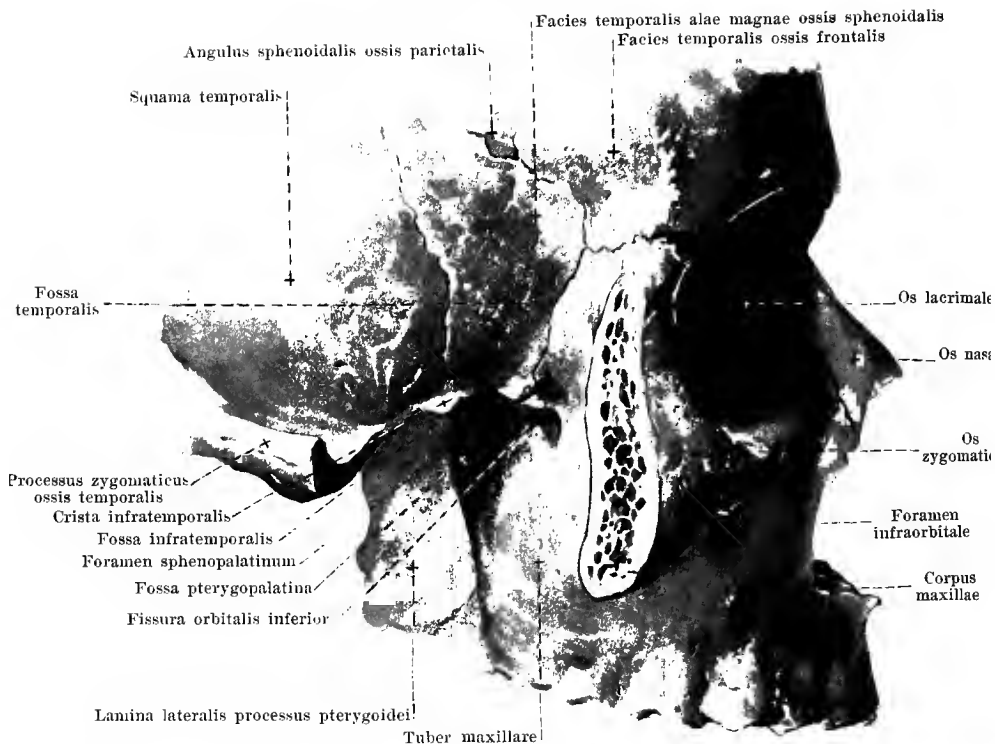64. Base of the skull, from within, *basis cranii interna*, with names of various parts.



65. Median section of the skull, from the left.



66. Median section of the skull, from the left, with names of various parts.

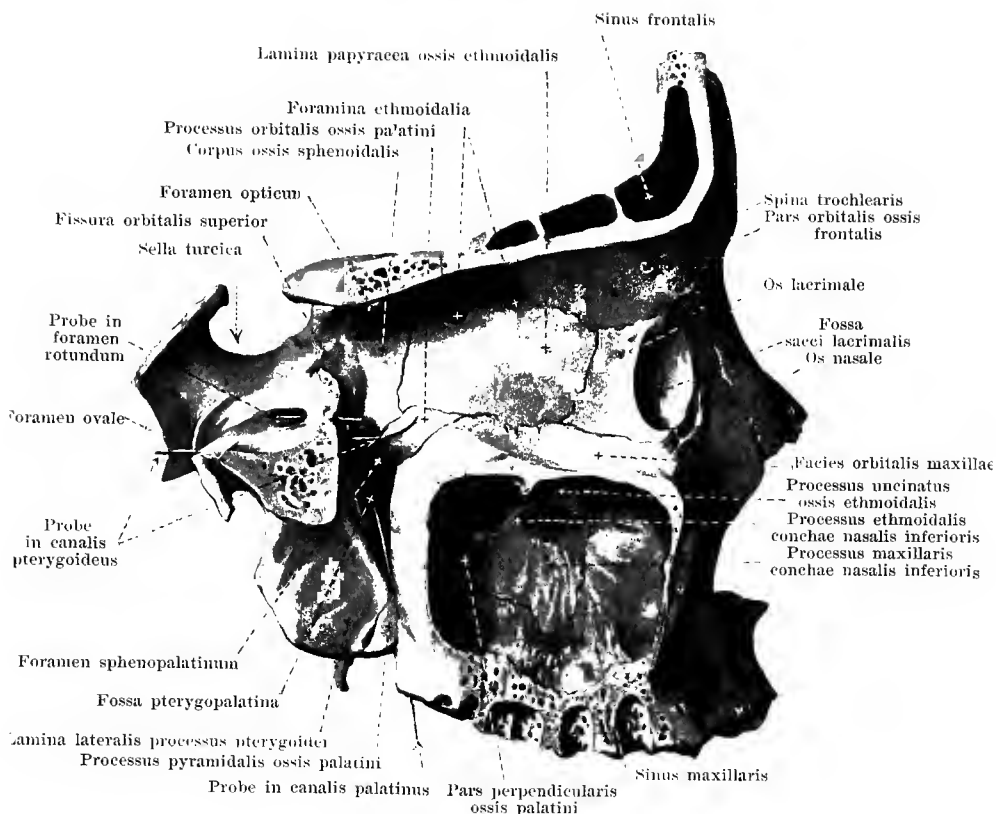


67. Right temporal fossa, *fossa temporalis*, from without.

(The arcus zygomaticus has been partially sawed away.)

The **fossa temporalis** lies on each side on the lateral surface of the skull and is, for the most part, open lateralward. Its medial surface is formed by the most inferior part of the facies parietal oss. pariet., by the facies tempor. squamae tempor., the facies tempor. oss. front., and the facies tempor. of the ala magna oss. sphen.; the anterior surface by the facies tempor. oss. sphen. and the facies tempor. oss. zygom.; the external wall by the arcus zygom. Below and medianward it goes over into the fossa infratempor.. On the medial-surface run the *sutura squamosa* (between squama tempor. and margo squamos. oss. pariet.), the *sutura sphenosquamosa* (between squama tempor. and margo squamos. oss. pariet.), the *sutura sphenoparietalis* (between angul. sphen. oss. pariet. and angul. pariet. alae magnae oss. sphen.), the *sutura coronalis* (between margo front. oss. pariet. and margo pariet. oss. front.), the *sutura sphenofrontalis* (between pars orbital. oss. front. and margo front. alae magnae oss. sphen.) and the *sutura zygomaticofrontalis* (between proc. zygom. oss. front. and proc. frontosphen. oss. zygom.); on the anterior surface, the suture last mentioned and the *sutura sphenozygomatica* (between os zygom. and margo zygom. alae magnae oss. sphen.); on the lateral surface the *sutura zygomaticotemporalis* (between proc. tempor. oss. zygom. and proc. zygom. oss. tempor.). On the anterior wall lies the foramen zygomaticotemporale.

The **fossa infratemporalis** (O. T. zygomatic fossa) lies on each side below and medianward from the arcus zygom., goes over above into the fossa tempor. and is open behind and below. Its upper wall is formed medianward by the facies infratemp. of the ala magna oss. sphen., the anterior oblique wall by the facies infratempor. maxillae and the facies tempor. oss. zygom., the lateral wall by the ramus of the lower jaw and the medial by the lamina lat. proc. pteryg.. On the anterior surface the *sutura zygomaticomaxillaris* (between os zygom. and proc. zygom. maxillae) is visible. At the junction of the anterior and medial sur-



38. Right pterygopalatine fossa, *fossa pterygopalatina*, from without.

(The main portion of the ala magna oss. sphenoid., of the lateral part of the corpus maxillae and of the pars orbit. oss. front. have been removed by a sagittal section, so that the medial wall of the sinus maxillaris and of the orbit is visible.)

The **fossa pterygopalatina** (O. T. sphenomaxillary fossa) lies, deeply concealed, between the bones medianward from the fossa infratemporalis. It is united with the latter by a sickle-shaped space, broad above, narrow below, which is closed below and lateralward by periosteum. Its medial wall is formed by the lateral surface of the pars perpendicularis oss. palatini, its upper wall by the lateral portion of the inferior surface of the body of the sphenoid, the posterior by the sphenomaxillary surface of the ala magna oss. sphenoidalis and by the anterior surface of the processus pterygoideus, the anterior by the most posterior margin of the corpus maxillae and by the processus orbitalis oss. palatini. Below it narrows to become the *canalis pterygopalatinus* which is continued into the canales palatini oss. palatini and opens at the foramina palatina majus et minora on the under surface of the hard palate; in addition, delicate canals pass between the facies maxillaris of the pars perpendicularis oss. palatini and the facies basalis corporis maxillae obliquely forward and downward into the nose. On the anterior wall connection is made with the orbit by means of the fissura orbitalis inferior, with the anterior

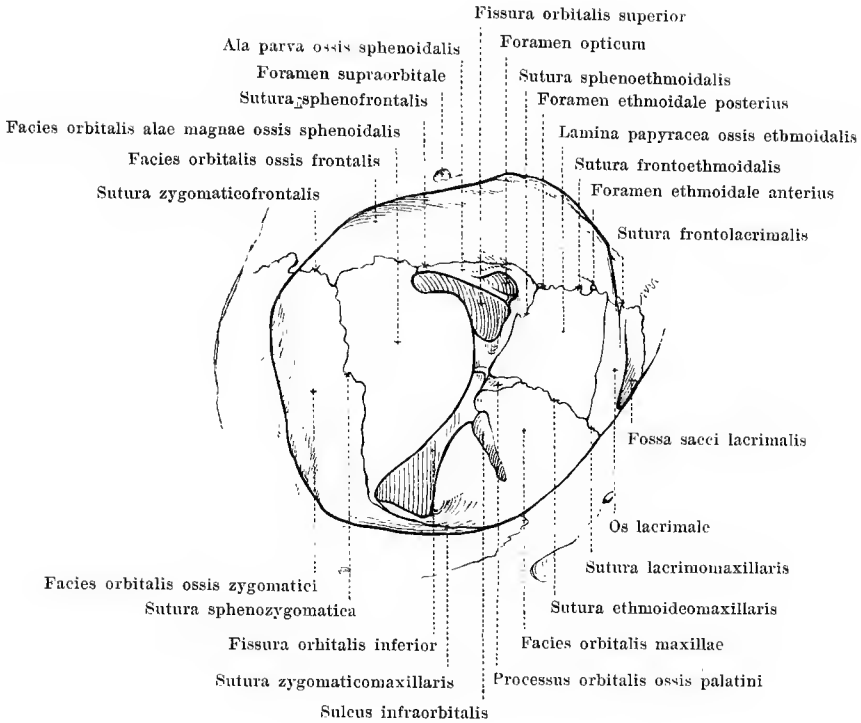


69. Right orbital cavity, *orbita*, from in front.

Magnification 5 : 4.

The **orbita** (*orbital cavity*) lies on each side in the upper part of the facial skull and, above, adjoins the cerebral skull. It opens in front by a wide mouth, *aditus orbitae*, behind this widens suddenly in its lateral half and then narrows gradually from before backward. Its shape, in front, is that of a four-sided, behind, that of a three-sided, pyramid, since the medial and the inferior wall form in front an obtuse angle with one another, while further back, they lie almost in one plane. The axes of the two orbital cavities (from the middle of the anterior opening to the middle of the foramen opticum) converge behind to the region above the sella turcica and are in addition inclined, in front, somewhat downward.

The opening of entrance, **aditus orbitae**, is more or less quadrangular with rounded corners. The upper margin, *margo supraorbitalis*, is formed by the margo supraorbitalis and processus zygomaticus oss. frontalis, the medial by the pars nasalis oss. frontalis and the processus frontalis maxillae, the inferior, *margo infraorbitalis*, by the corpus maxillae and os

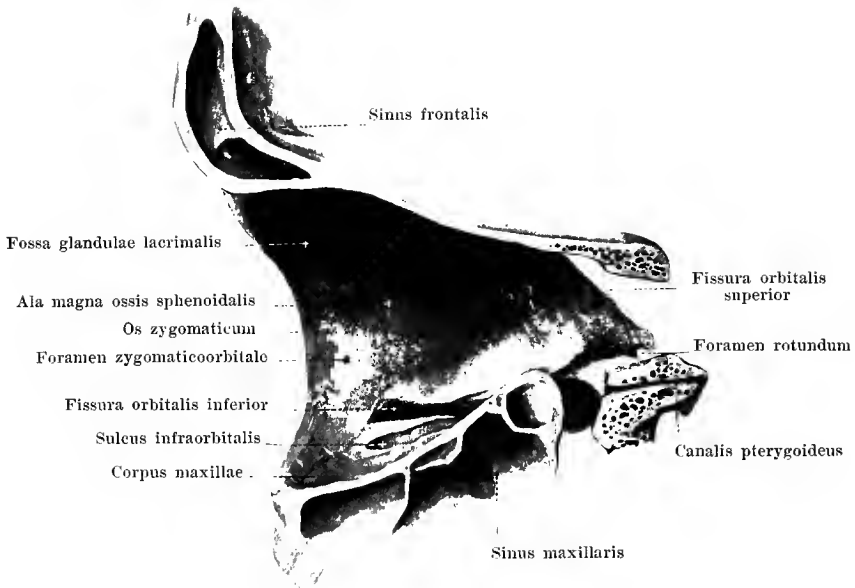


70. Right orbital cavity, *orbita*, from in front.

Outline drawing with explanation of Fig. 69. Magnification 5 : 4.

The walls of the orbit go over into one another, usually with rounded angles, and are lined by a thin periosteum, the *periorbita*.

The medial wall, **paries medialis** (see also Fig. 68), is placed nearly sagittally. It is composed of the os lacrimale, the lamina papyracea oss. ethmoidalis and the lateral surface of the corpus oss. sphenoidalis. It presents the *sutura lacrimomaxillaris* (between os lacrimale and proc. frontalis maxillae), the *sutura frontolacrimalis* (between os lacrimale and pars orbitalis oss. frontalis), the *sutura frontoethmoidalis* (between pars orbitalis oss. frontalis and os ethmoidale) as well as the *sutura sphenoethmoidalis* (between os ethmoidale and corpus oss. sphenoidalis). Near the anterior margin lies the fossa sacci lacrimalis which is continuous below with the canalis nasolacrimalis. At the junction of the medial with the upper wall go off the foramina ethmoidalia anterius et posterius, of which the anterior leads constantly into the skull cavity upon the lamina cribrosa oss. ethmoidalis, the posterior also to the same

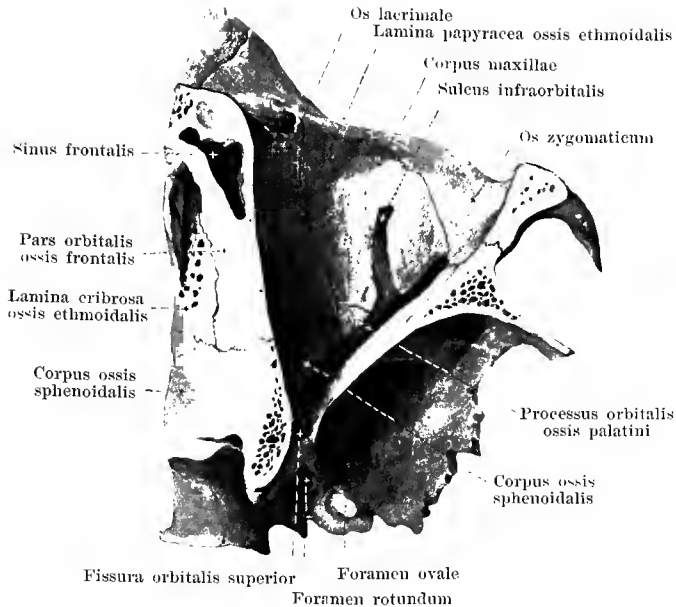


71. Right orbital cavity, *orbita*, lateral wall, from the left.

(The medial part of the orbit has been removed by an approximately sagittal section.)

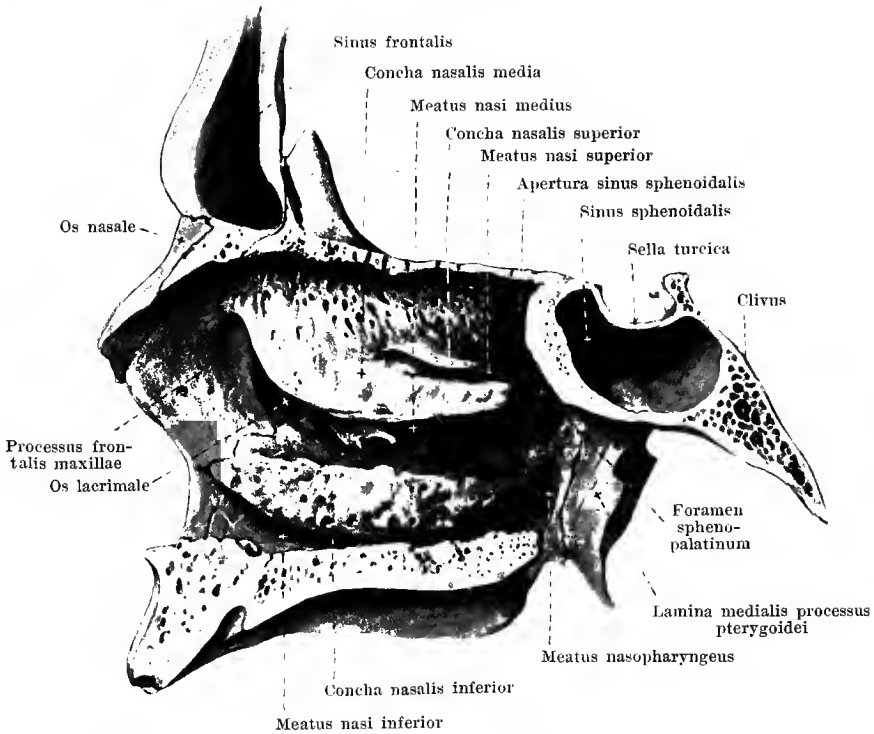
The upper wall of the orbit, **paries superior**, (see also Figs. 69 and 70) is horizontal and is formed by the pars orbitalis oss. frontalis and the ala parva oss. sphenoidalis; it is smooth and slightly concave. A part of the *sutura sphenofrontalis* is visible between these two bones. In addition it contains in front and lateralward the fossa glandulae lacrimalis, in front and medianward, the fovea and occasionally the spina trochlearis.

The lateral wall, **paries lateralis**, is vertical and inclined from in front and lateralward obliquely downward and medianward. It is composed of the facies orbitalis oss. zygomatici, the facies orbitalis of the ala magna oss. sphenoidalis, partly also of the medial surface of the processus zygomaticus oss. frontalis. Between these bones run the *sutura sphenozygomatica* (between os zygomaticum and ala magna oss. sphenoidalis), the *sutura zygomatico-frontalis* (between processus frontosphenoidalis oss. zygomatici and processus zygomaticus oss. frontalis), as well as the *sutura sphenofrontalis* (between ala magna oss. sphenoidalis and pars orbitalis oss. frontalis). Here can be seen also the single or double foramen zygomatico-orbitale which leads to the facial surface and to the fossa temporalis, and the *fissura orbitalis superior* (O. T. sphenoidal fissure or foramen lacrum anterius). The latter is found on the boundary between the lateral and the superior wall and occupies the whole medial half of the same: it is narrow and acute-angled lateralward and broadens medianward usually suddenly.



72. Right orbital cavity, *orbita*, inferior wall, from above.

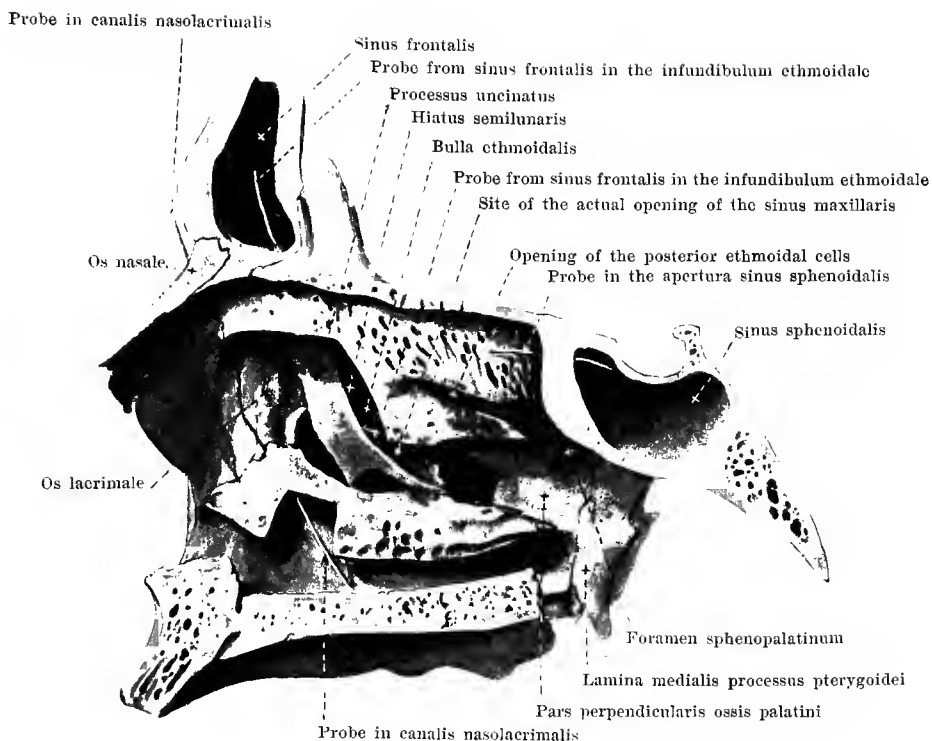
The inferior wall of the orbit, **paries inferior**, is inclined somewhat obliquely downward, forward and lateralward. It is formed chiefly by the *facies orbitalis corporis maxillae*, besides, lateralward, by a part of the *facies orbitalis oss. zygomatici*, and behind by the *processus orbitalis oss. palatini*. At the boundary between the inferior and the medial wall one sees the *sutura lacrimomaxillaris* (between *os lacrimale* and *corpus maxillae*), the *sutura ethmoideomaxillaris* (between *os ethmoidale* and *corpus maxillae*), the *sutura palatoethmoidalis* (between *os ethmoidale* and *proc. orbitalis oss. palatini*), the *sutura sphenoorbitalis* (between *corpus oss. sphenoidalis* and *processus orbitalis oss. palatini*), besides, near the posterior angle, the *sutura palatomaxillaris* (between *corpus maxillae* and *processus orbitalis oss. palatini*) and near the lateral margin the *sutura zygomaticomaxillaris* (between *processus zygomaticus maxillae* and *os zygomaticum*). It is united by bone with the lateral wall only in the anterior half, but is separated from it in the posterior half by the *fissura orbitalis inferior* (O. T. sphenomaxillary fissure). This slit, running between the posterior margin of the *facies orbitalis corporis maxillae* and the inferior margin of the *facies orbitalis alae magnae oss. sphenoidalis*, is, lateralward, closed either by a small process of one of these two bones or by the *os zygomaticum*. The slit is often broader lateralward than medianward and leads externally into the *fossa infratemporalis*, internally into the *fossa pterygopalatina*. It is connected at its medial extremity by a groove with the *fissura orbitalis superior* and is for the most part closed by tough connective tissue and periosteum. At about its middle begins the *sulcus*



73. Nasal cavity, *cavum nasi*; right lateral wall, from the left.

The *cavum nasi* (*nasal cavity*) is unpaired and lies in the middle and upper part of the facial skull. It consists of the nasal cavity proper and the accessory cavities which surround the former above, lateralward and behind; these accessory cavities are the *sinus frontales* (in front and above), the *cellulae ethmoidales* (lateralward almost in the whole depth), the *sinus sphenoidales* (behind and above) and the *sinus maxillares* (lateralward).

The **lateral wall** is nearly sagittal, but somewhat inclined from above and medianward downward and lateralward. It is formed in front by the medial surface of the proc. frontalis maxillae, in front and in the middle by the facies nasalis corpor. maxillae, further by the os lacrimale, by the medial wall of the labyrinthus ethmoidalis, by the concha nasalis inferior, by the facies nasalis of the pars perpendicularis oss. palatini and by the medial surface of the lamina medialis of the proc. pterygoideus oss. sphenoidalis. From these bones hang down free the three conchae nasales (turbinated bones) which cover over partially medianward three oblong fossae, the *nasal passages*. The *meatus nasi superior* (*upper nasal passage*), between the concha nasalis superior and media of the os ethmoid., is the shortest and narrowest, present only in the posterior half of the nasal cavity; it descends somewhat obliquely toward the upper circumference of the foramen sphenopalatinum. The *meatus nasi medius* (*middle nasal passage*), between the concha media and the concha inferior, reaches from the anterior margin of the middle concha as far as the region of the foramen sphenopalatinum. The *meatus nasi inferior* (*inferior nasal passage*), between the concha nasal. inferior and the inferior wall of the nasal cavity, is the longest and at the same time the most capacious. Lateralward from the septum, medianward from the conchae there remains a slit-shaped space between which extends through the whole height of the nasal space, the *meatus nasi communis*. The part of the cavity situated on each side behind the posterior ends of the conchae is called the *meatus nasopharyngeus*; it is bounded above by the inferior surface of the body of the sphenoid, the ala vomeris, the proc. vaginalis of the proc. pteryg. oss. sphenoid. and the proc.

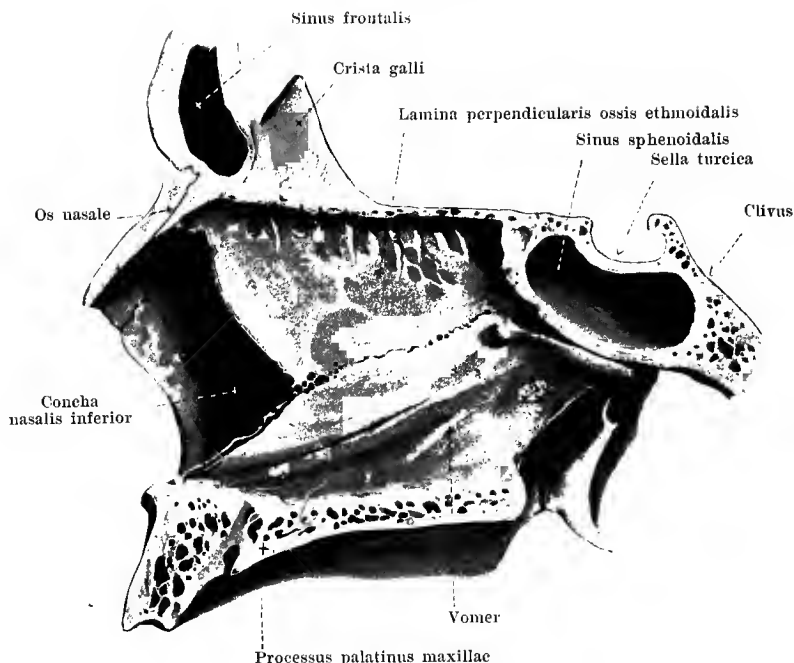


74. Nasal cavity, *cavum nasi*, right lateral wall, from the left.

(The middle and inferior turbinated bones have been partially removed.)

In the *meatus nasi inferior*, near the anterior end, lies the lower opening of the *canalis nasolacrimalis*. This goes out from the fossa sacci lacrimalis and is formed lateralward and in front by the sulcus lacrimalis of the corpus and of the proc. frontalis maxillae, medianward and behind by the sulcus lacrimalis oss. lacrimalis and the proc. lacrimalis conchae nasalis inferioris; it is directed from above downward and at the same time somewhat from before backward.

Into the *meatus nasi medius* opens the sinus maxillaris. The opening does not correspond to the whole hiatus maxillaris of the upper jaw bone, for this is essentially narrowed by the overlapping of the neighboring bones, namely, by the pars perpendicularis oss. palatini from behind, the proc. maxillaris conchae nasalis inferioris from below, the proc. ethmoidalis conchae nasalis inferioris and the proc. uncinatus oss. ethmoidalis in the middle. The actual opening lies lateralward from the proc. uncinatus at the bottom of a narrow oblong fossa (*infundibulum ethmoidale*), which extends along the proc. uncinatus upward and forward, widens like a funnel and opens above into the sinus frontalis, but in addition receives the openings from the anterior ethmoidal cells; besides this connection between the frontal and nasal cavities there is also a second just medianward from the processus uncinatus. Projecting downward into the infundibulum ethmoidale from the outside there is usually a vesicular ethmoidal cell the *bulla ethmoidalis*: the narrow sickle-shaped slit between this and the upper



75. Nasal cavity, *cavum nasi*.

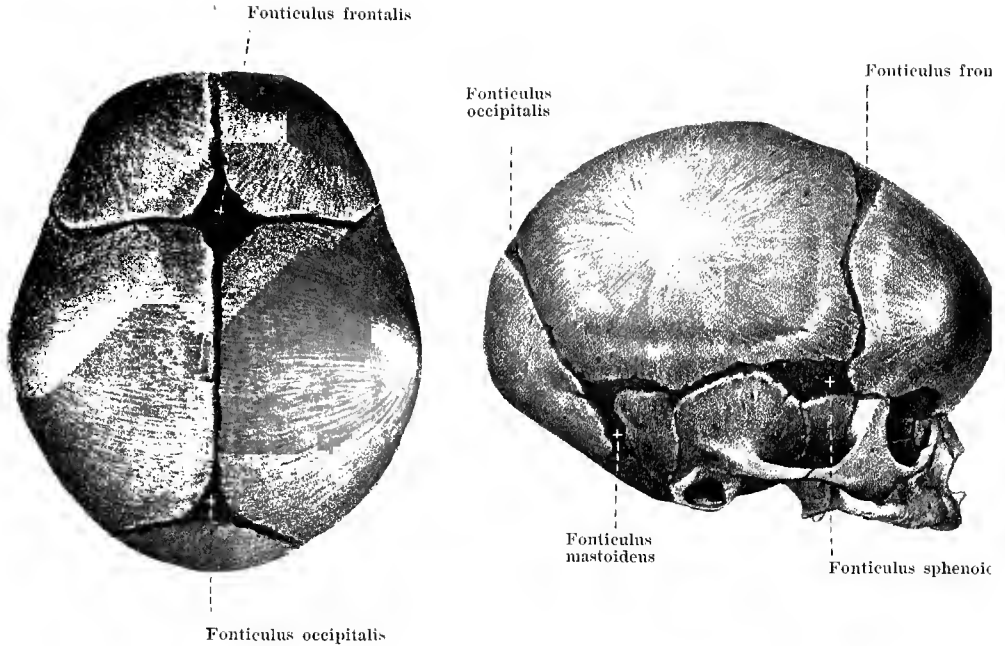
Bony nasal septum, *septum nasi osseum*, from the left.

The **upper**, narrowest **wall of the nasal cavity** is formed by the lamina cribrosa oss. ethmoidalis; the **lower**, broader **wall** by the slightly concave upper surface of the processus palatini maxillae and the partes horizontales oss. palatini.

The **anterior wall** of the nasal cavity proper is bony above only and is there formed by the spina frontalis of the pars nasalis oss. frontalis and the ossa nasalia; below it presents the *apertura piriformis* (O. T. anterior nares), opening toward the facial surface. This is "pear-shaped", narrow above, broad below and is surrounded above by the free margins of the ossa nasalia, lateralward by the incisurae nasales of the upper jaw bones, below by the ossa incisiva and the spina nasalis anterior.

The **septum nasi osseum** (*bony nasal septum*), which, within, subdivides the nasal cavity, lies in the median plane and is usually somewhat deflected toward one side or the other. This deviation, however, is never met with at the posterior margin. The septum begins in front, behind the apertura piriformis, by a deep notch which is filled up by the cartilago septi nasi, ends free behind at the posterior boundary of the nasal cavity and otherwise extends without essential interruption from the upper to the lower wall. Its upper part is formed by the lamina perpendicularis oss. ethmoidalis, the lower by the vomer. Above it unites in front with the spina frontalis of the pars nasalis oss. frontalis and with the lamina cribrosa oss. ethmoidalis, behind with the crista sphenoidalis and the rostrum sphenoidale; below it lies on the crista nasalis of the united maxillary and palate bones.

The nasal cavity is connected on its upper wall by the openings of the lamina cribrosa with the skull cavity and by the foramina ethmoidalia with the orbit; on its lateral wall by the canalis nasolacrimalis with the orbit, by the foramen sphenopalatinum with the fossa



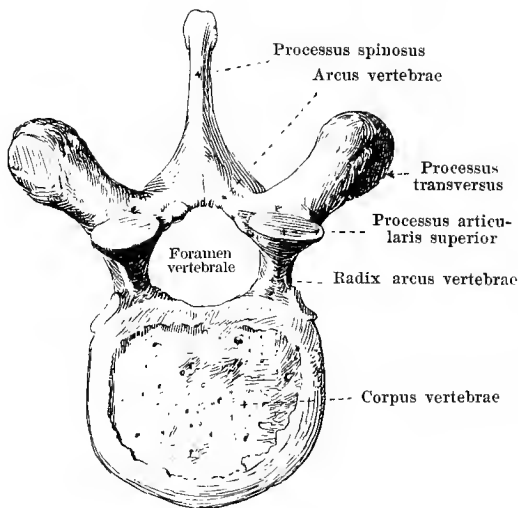
76 and 77. Skull of the new born child, magnification 1 : 2.

View from above.

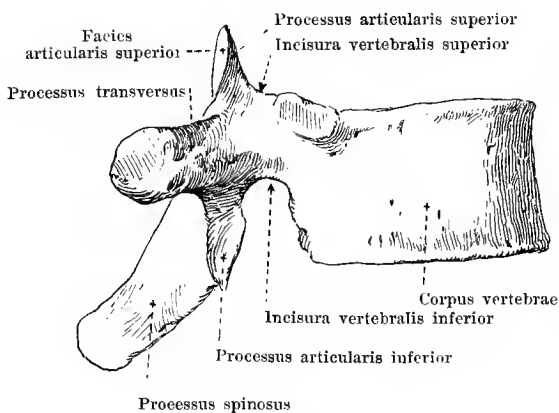
View from the right.

A part of the bones of the skull are originally laid down in cartilage and represent the *primordial cranium* (chondro-cranium); these are the os occipitale (without the upper part of the squama), the os sphenoidale, the os temporale (without the squama and the pars tympanica), the os ethmoidale, the concha nasalis inferior, the os hyoideum and the small bones of the ear. All other bones of the skull arise as *roof bones* (bones of the vault) and *parietal bones* in that the bony substance forms in membrane, the membranous skull-capsule surrounding the brain above, in front, behind, and at the sides. At birth there are still non-ossified remains of this membrane in the regions in which the bones of the skull meet, there being narrower stripes along what are later to be the bony sutures, larger areas where several bones meet with one another. These latter regions are called the **fonticuli** (*fontanelles*) and are six in number; two unpaired and two paired. Of the unpaired the largest, quadrangular, *fonticulus frontalis [major]* lies at the junction of the suturæ coronalis, sagittalis and frontalis, the small, triangular *fonticulus occipitalis [minor]* at the apex of the squama occipitalis, where the suturæ lambdoideae and the sutura sagittalis meet. Of the paired fontanelles, the anterior, oblong *fonticulus sphenoidalis* lies at the apex of the large wing of the sphenoid, bounded by the angulus parietalis of the ala magna oss. sphenoidalis, by the squama temporalis oss. temporalis, the angulus sphenoidalis oss. parietalis, and the squama frontalis oss. frontalis; the posterior, more irregular *fonticulus mastoideus* is situated below the anulus mastoideus

78 and 79. Vertebra, *vertebra* (10th thoracic vertebra, somewhat schematically represented).



from above



from the right

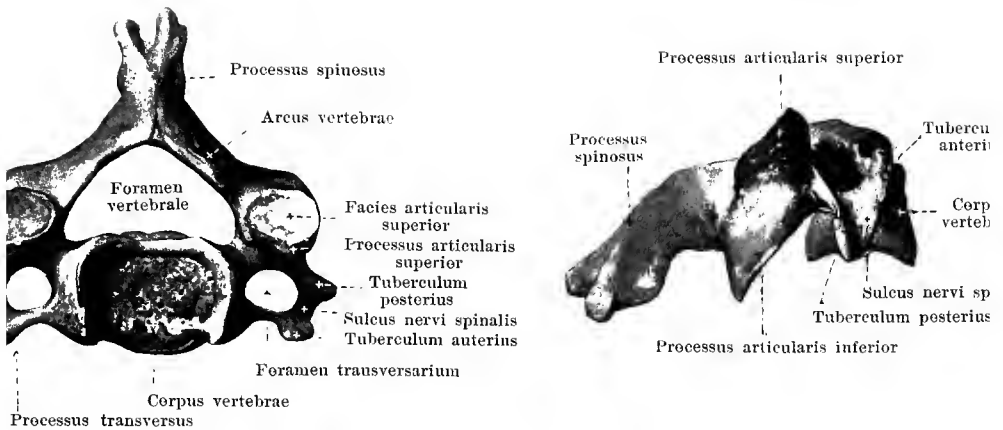
The **columna vertebralis** (*vertebral column* or *spine*) extends from the base of the skull as far as the lower end of the trunk. It consists of the single *vertebrae* superimposed upon one another; these are divisible, according to the regions in which they lie, into *vertebrae cervicales*, *vertebrae thoracales*, *vertebrae lumbales*, *vertebrae sacrales*, and *vertebrae coccygeae*.

Each **vertebra** is approximately ring-shaped and consists of an anterior, thick body, *corpus vertebrae*, and a feebler, flat arch, *arcus vertebrae*; the two include between them a wide opening, the *foramen vertebrale*. The sum of all the vertebral foramina forms the *canalis vertebralis* (spinal canal).

The **corpus vertebrae** (*vertebral body*) possesses an upper and a lower surface by means of which it is connected with neighboring vertebrae; these surfaces are somewhat rough, flat or slightly depressed. The anterior and the lateral surfaces are convex in the horizontal, somewhat concave in the vertical direction; the posterior surface, which forms the anterior boundary of the foramen vertebrale, is approximately flat and presents especially large foramina nutricia.

The **arcus vertebrae** (*vertebral arch*) begins at the body by a narrow root, *radix arcus vertebrae* (O. T. pedicle); above this lies the shallower *incisura vertebralis superior*, below it the deeper *incisura vertebralis inferior*;

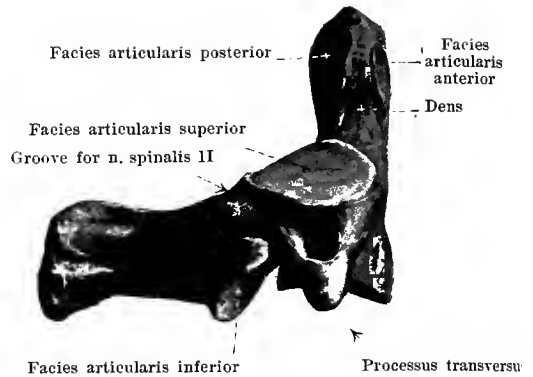
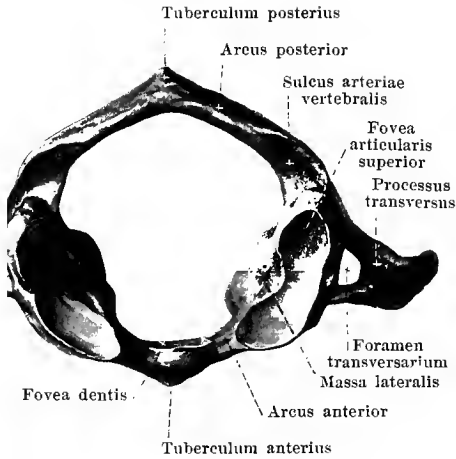
the intervertebral notches of two adjoining vertebrae unite to form one *foramen intervertebrale* (for the passage of vessels and nerves). Close behind these, passing upward on each side is the *processus articularis superior* with the *facies articularis superior*, which generally looks backward, while passing downward is the *processus articularis inferior* with the *facies articularis inferior* which generally looks forward; between these, directed lateralward, is the



80 and 81. Fourth cervical vertebra,
From above. *vertebra cervicalis IV.* From the right.

Each of the *seven vertebrae cervicales* (*cervical vertebrae*) (see also Fig. 85) has a low *body* which, as seen from above, is quadrangular with rounded angles. The upper surface is concave in frontal, slightly convex in sagittal direction, the lower exactly the reverse. The *foramen vertebrale* is very wide and triangular. The *processus articulares superiores et inferiores* are placed very obliquely; their *facies articulares* are smooth or slightly arched, the *superiores* look backward and upward, the *inferiores* forward and downward. The *processus spinosi* are usually short and split into two spurs. The form of the *processus transversi* is especially characteristic for the cervical vertebrae. These arise in front of the *processus articulares*, are short and directed lateralward. On the upper surface, each presents a deep groove, *sulcus nervi spinalis*, which runs out from the *incisura vertebralis superior* and separates, at the tip of the transverse process, the *tuberculum anterius* from the *tuberculum posterius*. In the region of the groove is situated also the *foramen transversarium* (in the upper six cervical vertebrae for the a. and v. vertebralis). The part of the *processus transversus* situated in front of the *foramen transversarium* with the *tuberculum anterius* is partially homologous with a rib and is accordingly also called the *processus costarius*; it may be so developed on the seventh cervical vertebra that it actually forms a *cervical rib* (see Fig. 96, No. 4).

The first cervical vertebra, *atlas*, the second, *epistropheus*, and the seventh, *vertebra*

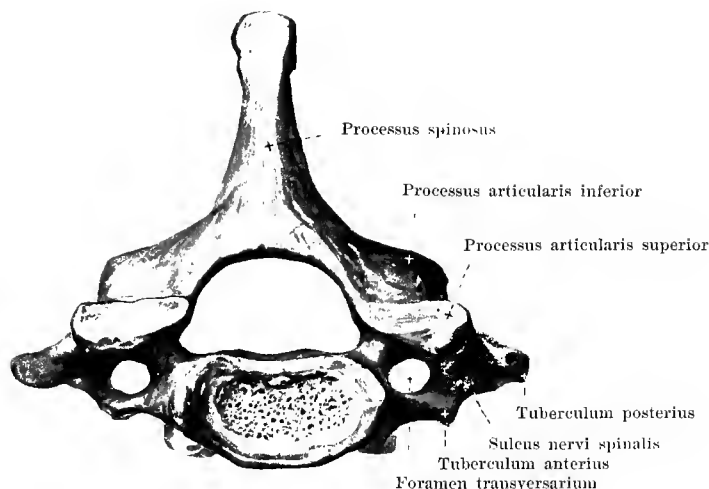


82. Atlas,
from above.

83. Epistropheus
(O. T. axis), from the right.

The **atlas** is especially characterized by the fact that it lacks the main mass of the body. The only representative of a body is a narrow mass of bone in front, *arcus anterior*, which presents, in the middle on its anterior surface, a small *tuberculum anterius*, on its posterior surface a flat *fovea dentis*, covered with cartilage. The arch proper, here called *arcus posterior*, is narrow, roundish and presents, in the middle behind, in place of the processus spinosus, a small *tuberculum posterius*. Between the two arches lie the *massae laterales*; each lateral mass possesses above an oval, concave articular surface, *fovea articularis superior*, for articulation with the condylus occipitalis (oss. occipitalis), below a flat, rounded *facies articularis inferior* for articulation with the epistropheus. Lateral from each *massa lateralis* the *processus transversus* projects far lateralward; it is devoid of sulcus. n. spinalis and of tubercles. Running out from the *foramen transversarium* is a groove which leads behind the *massa lateralis* on the upper surface of the *arcus posterior* to the *foramen vertebrale*, the *sulcus arteriae vertebralis* (for the a. and v. vertebralis; n. suboccipitalis). *Incisurae vertebrales* are absent in the form in which they occur in the other cervical vertebrae (vide infra).

The **epistropheus** (O. T. axis) is especially characterized by a thick cone, *dens* (*tooth*) (O. T. odontoid process), which ascends from the upper surface of the body; this presents, both in front and behind, a small, flat surface, covered with cartilage, *facies articularis anterior* and *posterior* and ends above in a blunt tip. Near the toothshaped process on the lateral part of the body lie the slightly convex *facies articulares superiores*, directed obliquely lateralward and upward. The *processus articulares inferiores* and *spinosus* show no especial deviations; the *processus transversus* lack the *tubercula anterius* and *posterius* as well as the *sulcus n. spinalis*. The *incisura vertebralis inferior* is present and situated as in the other cervical vertebrae, i. e. in front of the *processus articularis*. An exactly corresponding *incisura*



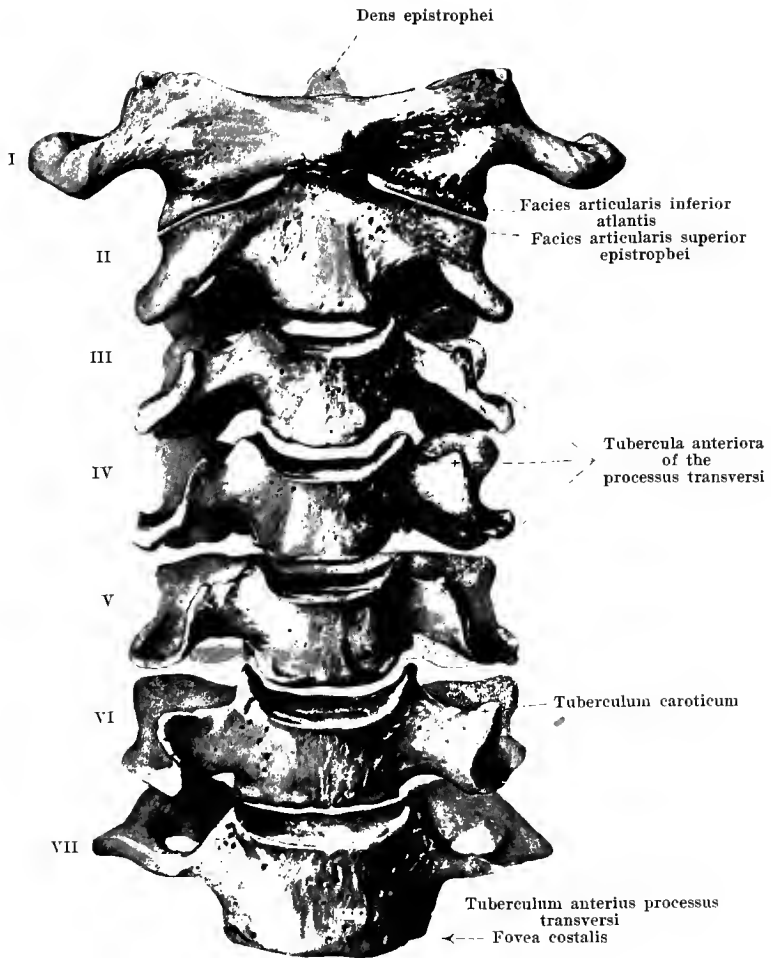
84. Seventh cervical vertebra, *vertebra prominens*.

From above.

The **seventh cervical vertebra** is characterized by an especially long, powerful, non-bifurcated processus spinosus, which on palpation of the spine from above is usually the first to be distinctly felt; it is accordingly named the **vertebra prominens**. It has in addition longer processus transversi; its foramen transversarium is sometimes absent, it is nearly always small, is sometimes subdivided and often serves for the passage of the v. vertebralis.

On the lower margin of the lateral surface of the body a *fovea costalis* is usually present for articulation with the head of the first rib.

The part (processus costarius, see p. 65) situated in front of the foramen transversarium, is sometimes slightly movable, forming the so-called *cervical rib*, in which case its length may vary greatly (see Fig. 96, No. 4).

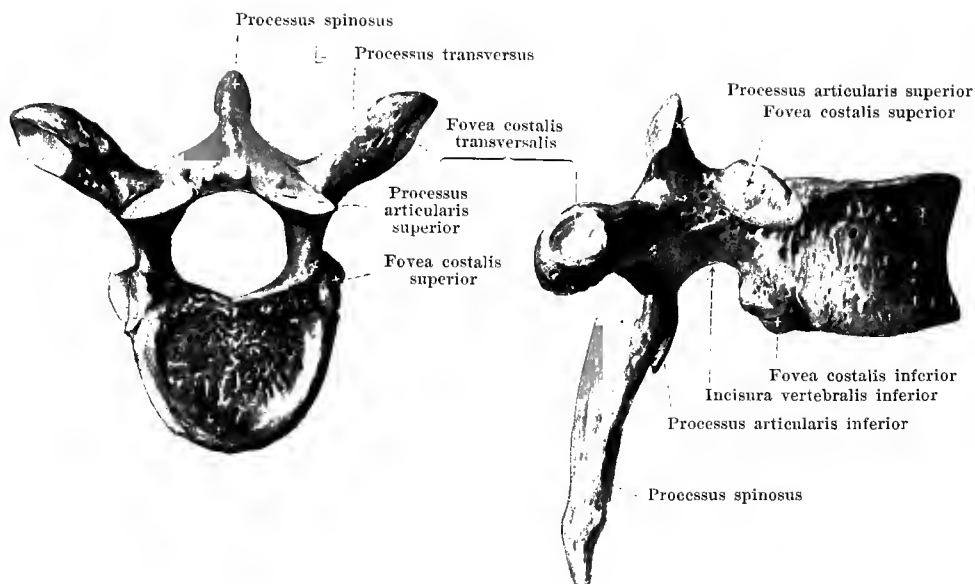


85. Cervical spine, *vertebrae cervicales*, from in front.

The bodies of the *cervical vertebrae* grow gradually broader from above downward. The adjacent surfaces of the same are so curved that the under surface of each vertebra always fits into the upper surface of the next vertebra below.

The processus transversi on the whole diminish gradually in length from the seventh upward as far as the second vertebra; then follow immediately the widely projecting processus transversi of the atlas. The tubercula anteriora of the processus transversi increase in size from the third to the sixth vertebra; those of the sixth vertebra are called the *tubercula carotica*; on the seventh vertebra they are only feebly developed (see also Fig. 84).

The processus spinosi are short from the second to the (fifth or) sixth cervical vertebra.

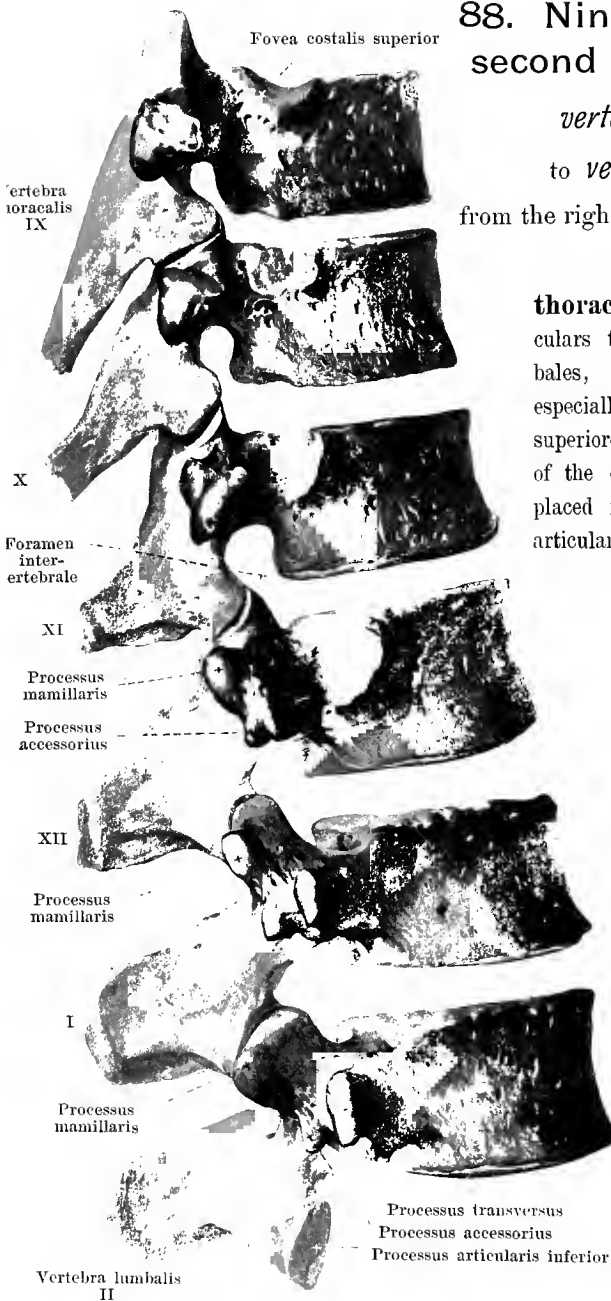


86 and 87. Sixth thoracic vertebra, *vertebra thoracalis VI.*

From above.

From the right.

The *twelve vertebrae thoracales* (*thoracic vertebrae*, O. T. dorsal vertebrae) possess broad *bodies*. The connecting surfaces of the bodies are flat and on the upper and lower vertebrae are described as bean-shaped, on the middle vertebrae as more heart-shaped. The *foramen vertebrale* is narrow and rounded. The *processus articulares* stand nearly frontally, their *facies articulares* are slightly curved and form parts of the mantle of a cylinder, the axis of which is situated in front of the body; the *facies articulares superiores* look backward, the *facies articulares inferiores* forward. The *processus transversi* arise between the *processus articulares*, are very powerful and directed obliquely backward and lateralward. On the anterior surface of their lateral extremity they present a small fossa covered with cartilage, the *fovea costalis transversalis* (O. T. facet for tubercle of rib) for articulation with the *tuberculum costae*; they are absent from the eleventh and twelfth, sometimes also from the tenth vertebra. The *processus spinosi* are long, triangular, apical and directed more or less markedly downward; the middle ones cover one another like tiles of a roof. The small articular surfaces which lie on the lateral surfaces of the bodies of the vertebrae, just in front of the roots of the vertebral arches, are special peculiarities of the thoracic vertebrae. On the nine upper vertebrae two of these are present on each bone, one larger at the upper margin, *fovea costalis superior* (O. T. demifacet for head of rib) and one smaller on the lower margin, *fovea costalis inferior*; each *fovea costalis inferior* forms with the *fovea costalis superior* of the next vertebra below and with the *intervertebral disc* lying



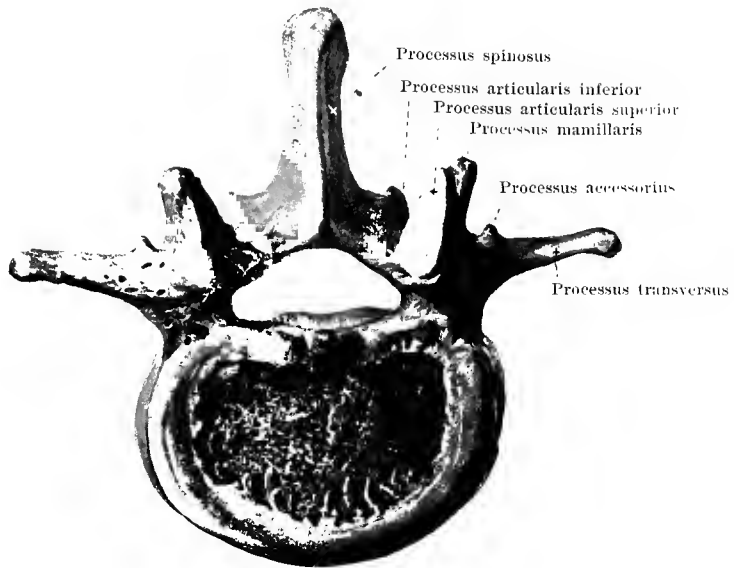
88. Ninth thoracic to the second lumbar vertebra,

vertebra thoracalis IX
to *vertebra lumbalis II*,

from the right and somewhat from behind.

The lower two **vertebrae thoracales** approach in many particulars the form of the *vertebrae lumbales*, the twelfth thoracic vertebra especially. The *processus articulares superiores* of the latter are, like those of the other thoracic vertebrae, usually placed nearly frontally; their *processus articulares inferiores* on the contrary, like those of the lumbar vertebrae, nearly sagittally. This change in the direction of the *processus articulares* may occur even at the eleventh thoracic vertebra.

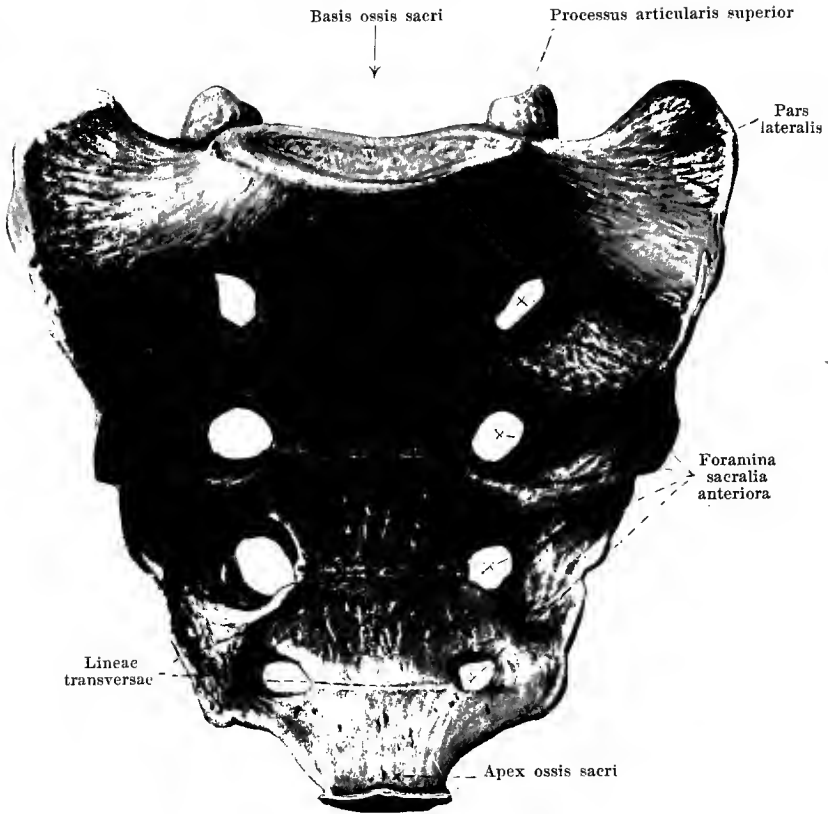
Further, on the posterior surface of the *processus transversi* and *articulares superiores* small projections are present which resemble in form and position the *processus mamillares* and *accessorii* of the lumbar vertebrae; these are usually distinctly marked on the twelfth thoracic vertebra, less so on the eleventh and tenth. The *processus transversi* are short and directed markedly backward.



89. Third lumbar vertebra, *vertebra lumbalis III*, from above.

The *five vertebrae lumbales* (*lumbar vertebrae*) (see also Fig. 85) are higher and broader than the cervical and thoracic vertebrae. Their *bodies* have flat connecting surfaces, varying from a bean-shaped to a transversely oval form. The *foramen vertebrale* is narrow and triangular. The *processus articulares* are vertical; their *facies articulares* lie nearly in sagittal planes; the *facies articulares superiores* are concave behind and hollowed out medianward, the *facies articulares inferiores* are convex in front and lateralward, so that the two belong to a cylinder-mantle, the axis of which is situated behind the *processus spinosus*; every two *processus articulares superiores* surround the *processus articulares inferiores* of the next vertebra above as an axle-box does an axle. On the posterior margin of the *processus articularis superior* a blunt bony mass, the *processus mamillaris*, projects backward. The *processus spinosi* are flat and high, pass straight backward, end in a swollen extremity and are often bent hook-like, downward. The *processus transversi* arise in front of the *processus articulares*; they are thin, flat and directed only slightly backward. They are considered from their largest part to be homologues of the ribs; the corresponding part is accordingly also designated as the *processus costarius*; this is sometimes especially large on the first lumbar vertebra and united by a joint with the rest of the process; it is then called a *lumbar rib* (see Fig. 96, No. 8). On the posterior surface of the root of the transverse process, lateral from and below the *processus mamillaris*, a small, variably developed nodule, the *processus accessorius*, projects backward.

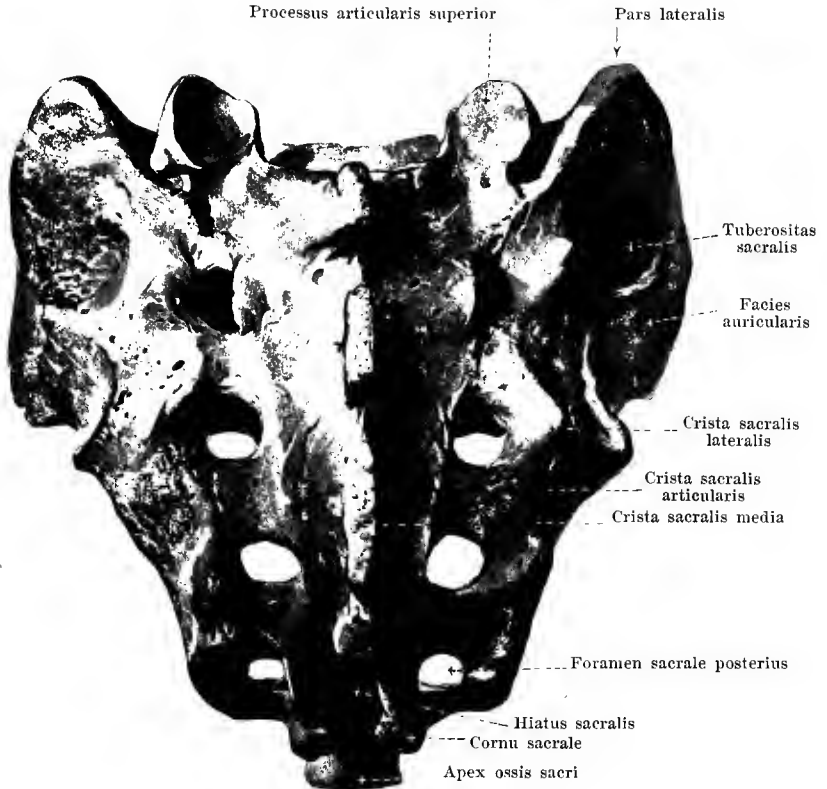
Bones of the Spine.

90. Sacrum, *os sacrum*, from in front and below.

The *five vertebrae sacrales* are distinctly separated from one another in youth only; in the adult they are fused to a single bone, the **os sacrum** (see also Figs. 91—93), which is situated below the lumbar vertebrae and is the largest and broadest bone of the vertebral column.

The os sacrum is wedge-shaped, broad above (*basis*), pointed below (*apex*); its sagittal diameter also diminishes essentially from above downward. Its anterior inferior surface, *facies pelvina*, looking into the pelvis, is concave, its posterior upper surface, *facies dorsalis*, is convex.

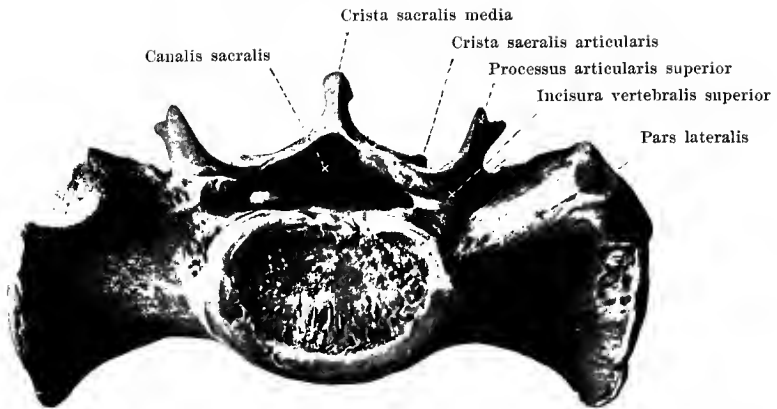
The anterior inferior surface, **facies pelvina**, is in general smooth and concave. In the middle, four *lineae transversae* are to be seen, lines corresponding to the places where the five individual bodies of the sacral vertebrae have grown together. Lateral from them on each side lying in a vertical series over one another are the four *foramina sacralia anteriora*, which behind and medianward lead into the *canalis sacralis* (see Fig. 92^a), but, lateralward, run out into grooves on the anterior surface of the partes laterales. The foramina sacralia anteriora diminish in size from above downward; below the last one, near the apex ossis sacri, is a notch which is closed by the processus transversus ossis coccygis and by the ligamentum sacrococcygeum laterale to form a fifth foramen sacrale. The *apex ossis sacri*



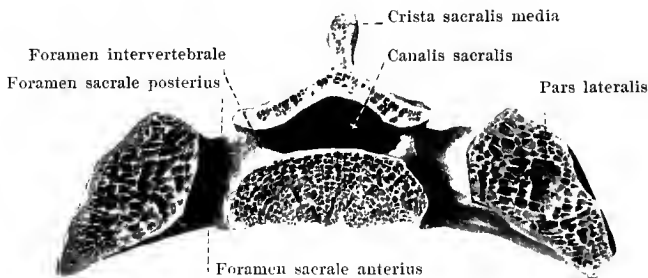
91. Sacrum, *os sacrum*, from behind and above.

The **facies dorsalis ossis sacri** is very rough and convex from above downward. On it five rows of processes and projections run downward, almost parallel to one another. The middle row, *crista sacralis media*, has resulted from the fusion of the processus spinosi; it is most marked, represents often an uninterrupted ridge, but is frequently incomplete. Lateralward on each side lie the *cristae sacrales articulares*; they are to be considered as the processus articulares fused with one another and usually project only moderately above the surface. Lateralward from these, separated from them by the foramina sacralia posteriora, are the *cristae sacrales laterales*; they arise from the fusion of the processus transversi and are usually more distinctly marked than the cristae sacrales articulares. The four *foramina sacralia posteriora* like the anterior, are situated on both sides in nearly parallel rows; they lead (see Fig. 92^a) forward and medianward into the canalis sacralis, forward and downward to the foramina sacralia anteriora.

Corresponding to the upper end of the cristae sacrales articulares two completely developed *processus articulares superiores* pass vertically upward; their facies articulares superiores are directed medianward and backward and articulate with the corresponding surfaces of the fifth lumbar vertebra. From the lower end of the cristae sacrales articulares the two small



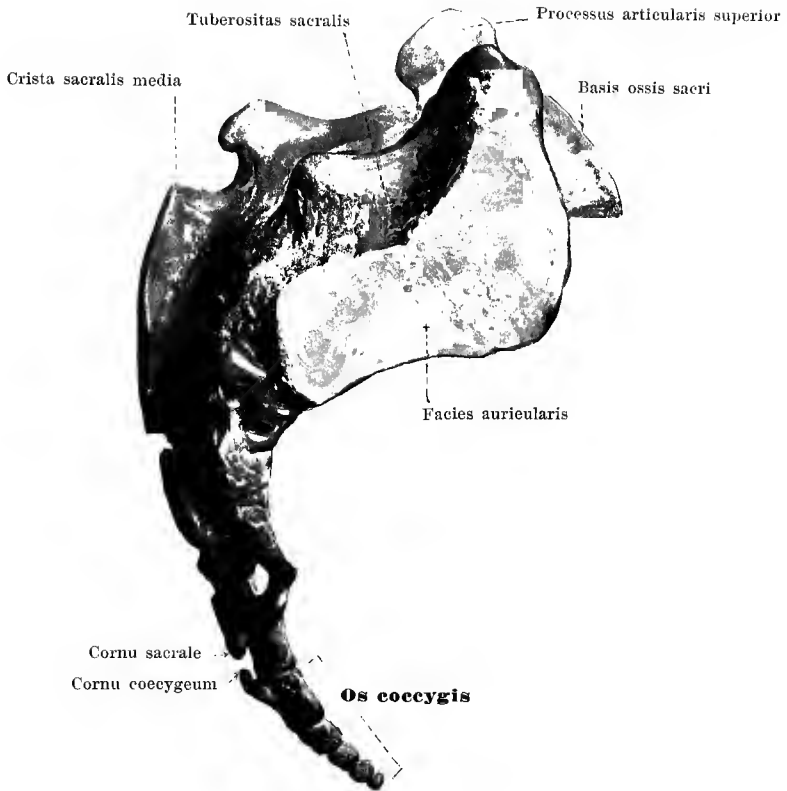
92. Sacrum, *os sacrum*, from above.



92^a. Transverse section through the sacrum
at the level of the second pair of foramina sacralia.

The anterior upper surface of the sacrum, **basis ossis sacri**, contains in the middle a somewhat projecting, transversely oval, flat surface with which the body of the fifth lumbar vertebra is connected by means of an intervertebral disc. Behind this lies the upper, triangular opening of the *canalis sacralis* which passes through the sacrum from above downward and reaches its lower extremity in the hiatus sacralis on the posterior surface, a little above the apex; within the bone going off from it on each side are four short canals (*foramina intervertebralia*) which are continued H-shaped into the foramina sacralia anteriora and posteriora. Lateralward from the upper opening of the canalis sacralis the *processus articulares superiores* (see p. 73) project upward; in front of them lie the *incisurae vertebrales superiores*. The lateral portions of the basis ossis sacri are smooth, somewhat concave and form the anterior, upper limiting surfaces of the partes laterales ossis sacri.

Through the union of the fifth lumbar vertebra with the sacrum there arises, at the

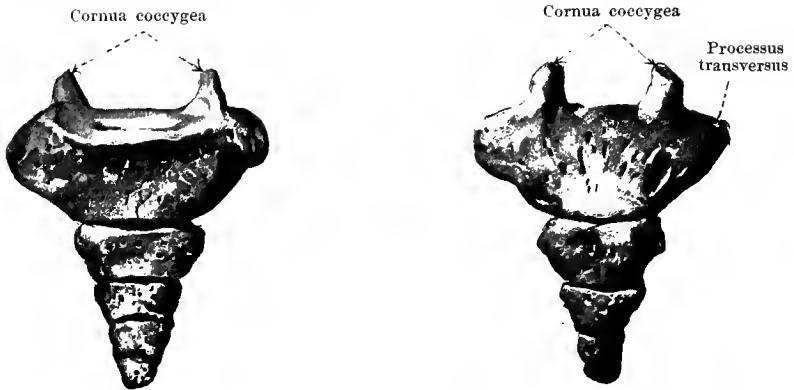


93. Sacrum and coccyx, *os sacrum* and *os coccygis*.

From the right.

The portions which lie lateralward from the foramina sacralia are called the **partes laterales ossis sacri**; they have arisen through fusion of the transverse processes and of rudiments of ribs (on the upper three vertebrae). The partes laterales grow much narrower from above downward and present on the upper part of their free lateral surfaces an uneven joint surface, *facies auricularis*, covered with cartilage, for union with the hip bone; it is formed in the main by the first sacral vertebra, less by the second and least by the third. Behind the facies auricularis lies a markedly roughened surface, *tuberositas sacralis*, to which are attached the ligamenta sacroiliaca interossea.

Sometimes the uppermost vertebra of the sacrum is fused laterally with the pars lateralis only in one-half, while on the other half it has a shape similar to that of a lumbar vertebra; such a transition form is called a *lumbosacral vertebra* (see Fig. 96, No. 11).



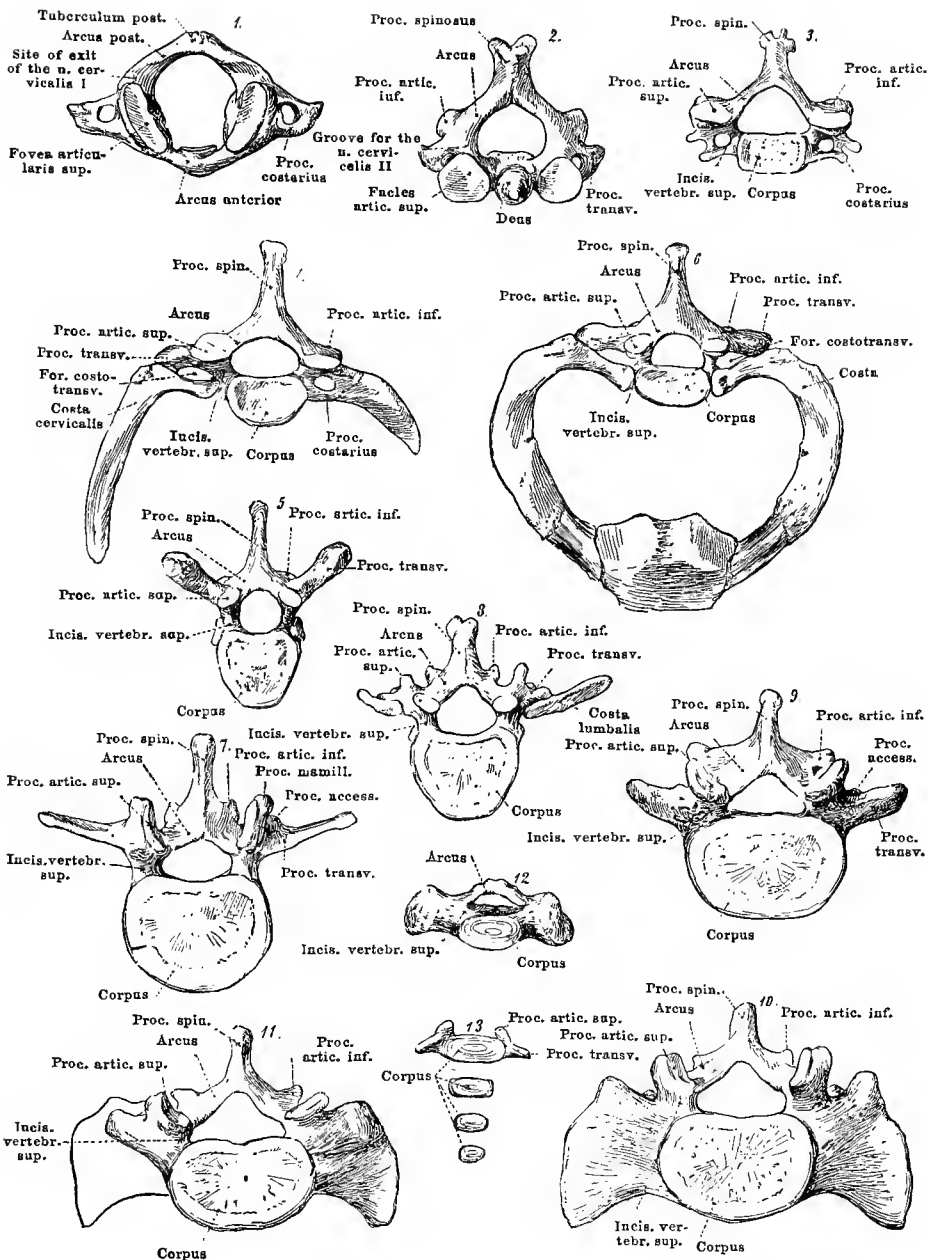
94 and 95. Coccyx, *os coccygis*.

From in front.

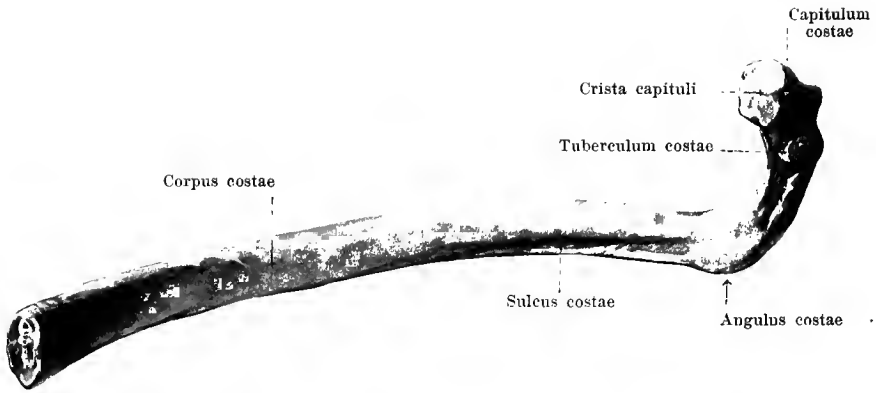
From behind.

The **os coccygis** lies as a small, triangular bone at the lower end of the vertebral column below the sacrum. It consists of from four to five rudimentary *vertebrae coccygeae*, of each of which the body only, as a rule, is present. The first possesses still two small, transversely directed *processus transversi* and in place of the *processus articulares superiores* two *cornua coccygea* directed upward. The succeeding vertebrae diminish in size from above downward and represent actually only small oblong or spherical pieces of bone.

The upper surface of the coccyx is united with the tip of the sacrum by the *symphysis sacrococcygea* (see p. 162). The first, second and third coccygeal vertebra are usually united with one another by a layer of fibro-cartilage, the third, fourth and fifth by bony substance. Deviations occur very often in that the connections between the first three or that between the coccyx and sacrum ossify.



96. Collection of different vertebrae and vertebral varieties to illustrate the morphological value of the single parts (after Quain).



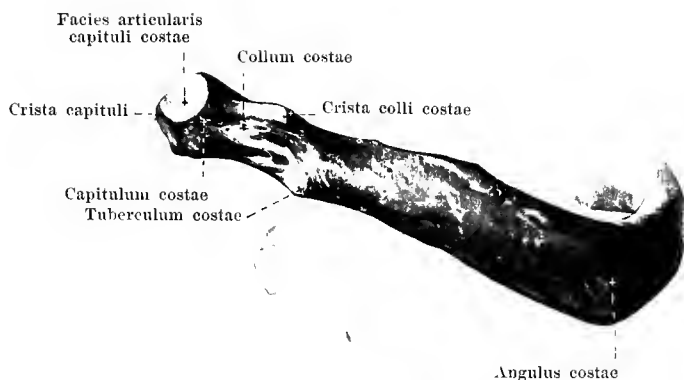
97. Seventh rib of right side, *costa VII*, from within.

The *twelve costae (ribs)* (see also Figs. 105—107) are thin, partly bony, partly cartilaginous masses which go out on each side from the lateral surfaces of the thoracic vertebrae and which, forming an arch which is convex lateralward, help to bound the thoracic cavity. Each thoracic vertebra corresponds to a pair of ribs; they are numbered from above downward.

The upper seven (sometimes eight) pairs of ribs are fastened directly to the sternum in front near the median plane and are distinguished as *costae verae* (true ribs) from the lower five (sometimes four) pairs of ribs, the *costae spuriae* (false ribs), which are indirectly connected with the sternum or else end free.

Each rib consists of a longer posterior bony portion, *os costale*, and a shorter, anterior, cartilaginous portion, the *cartilago costalis*.

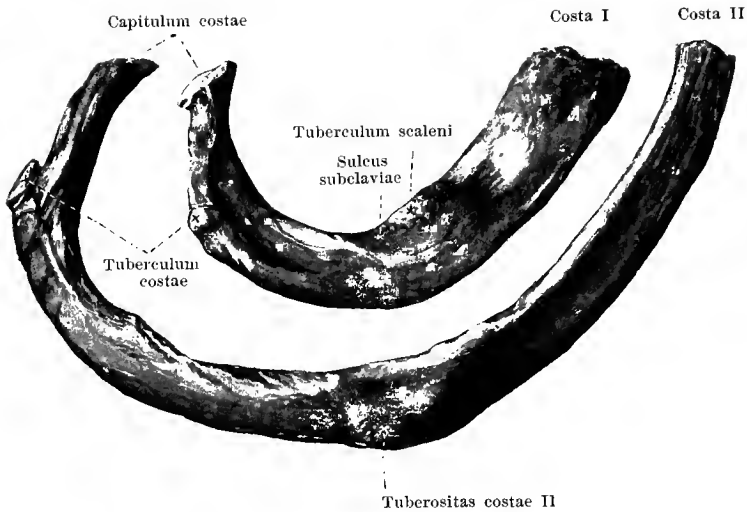
Each rib is somewhat expanded at its vertebral end so as to form the *capitulum costae* (head of the rib); this possesses a small *facies articularis capituli costae*, covered over with cartilage, which is divided, on the ribs from the second to the tenth, by a transverse ridge, *crista capituli*, into an upper smaller and a lower larger surface. By means of these joint surfaces the heads of the ribs articulate with the foveae costales of the bodies of the vertebrae. The portion of the bone adjoining the capitulum is somewhat narrowed, *collum costae* (neck of the rib), on the upper ribs more distinctly than on the lower; the neck presents on its upper margin a longitudinal ridge, *crista colli costae*, which is continued lateralward upon the shaft and is absent only from the first and the last ribs; at its lateral extremity a small nodule, *tuberculum costae*, projects backward and downward; this possesses a small *facies articularis tuberculi costae*, covered with cartilage, for articulation with the fovea costalis



98. Eighth rib of right side, *costa VIII*, from behind.

The middle piece or shaft of the rib, **corpus costae**, forms lateralward from the tuberculum costae an angle which is directed backward and downward, the *angulus costae*. This lies on the first rib close to the tubercle; on succeeding ribs it is situated ever more lateralward; it is most marked on the middle ribs and is absent from the last two ribs. The body of the rib is a flat plate of bone with an internal and an external smooth surface; the external surface is directed vertically in the middle ribs, markedly upward in the uppermost ribs, more downward in the lowermost (see Figs. 105—107). The curvature of a whole rib is double, since in the first place the surface of the shaft is bent so as to be convex lateralward and in the second place, its upper edge is curved so as to be concave or ω -shaped. On the internal surface near the lower margin runs the *sulcus costae* (for the v. and a. intercostalis); it begins at the tubercle, is most marked behind and becomes lost in front; on the first and last ribs it is absent or only slightly indicated. The anterior extremity is less broadened and ends in a rough depressed surface for the reception of the costal cartilage.

The **cartilago costalis** (*costal cartilage*) (see Fig. 105) has in general the same shape as the rib. It unites in front with the sternum or is attached to the cartilage of the next rib above. The cartilages increase in length from the first to the seventh; from this on they decrease so that the cartilage of the eleventh and twelfth ribs are only short pointed pieces. The first two costal cartilages only follow the same direction as the bony parts of their ribs, the others are more or less curved upward at their anterior extremities.

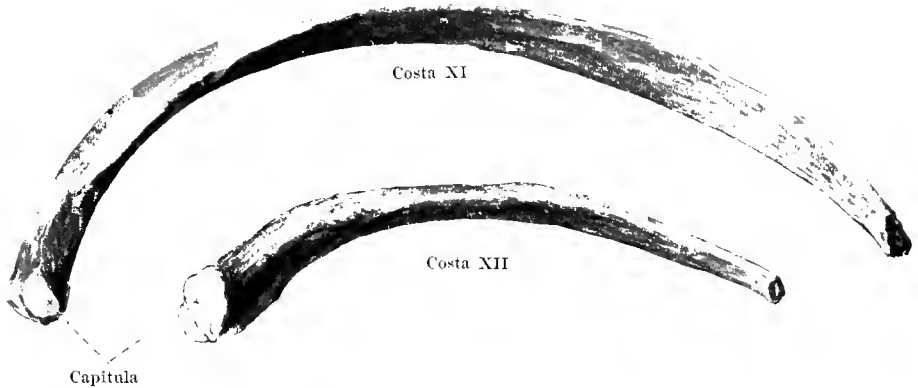


99 and 100. First and second ribs of right side,
costae I et II, from above and without.

The first two ribs present certain peculiarities.

The **costa I** (see also Figs. 105 and 107) is on the whole directed equally obliquely forward and downward and possesses an upper surface directed somewhat lateralward and a lower directed somewhat medianward. On the upper surface a little in front of the middle, near the medial border is a small nodule (sometimes only a roughening), *tuberculum scaleni [Lisfranci]* (for the attachment of the m. scalenus anterior); a very shallow furrow in front of this serves for the v. subclavia, a curve behind this, the *sulcus subclaviae*, for the a. subclavia is usually somewhat more distinctly marked. Behind the latter lies another roughened area for the m. scalenus medius.

The **costa II** (see also Figs. 105 and 107) resembles the other ribs in its form much more than it does the first rib. On its lateral surface, somewhat in front of the middle, is a roughened area, the *tuberositas costae II* (for the attachment of various

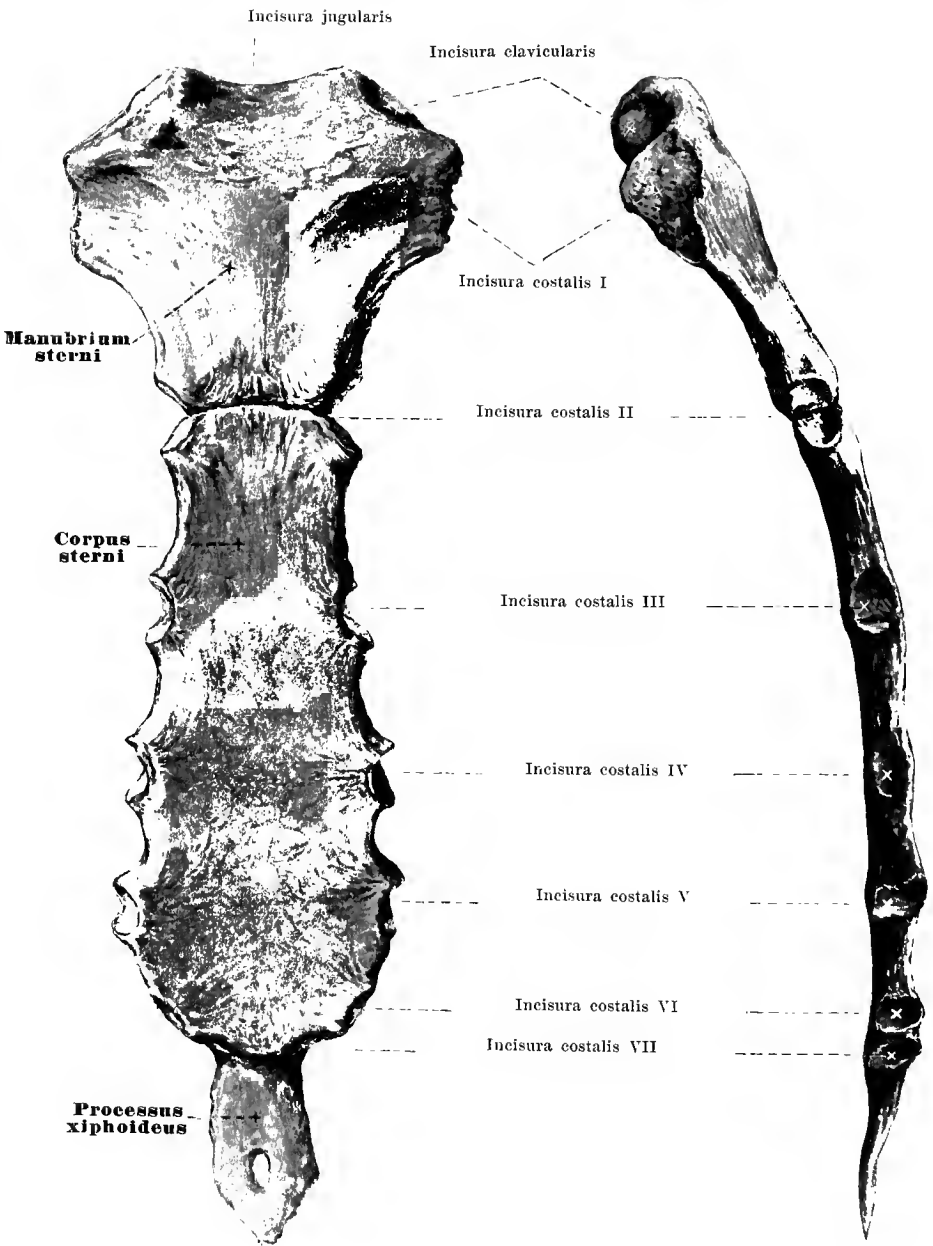


101 and 102. Eleventh and twelfth ribs of right side, *costae XI et XII*, from below.

The **costa XI** is like the **costa XII** (see also figures 106 and 107), a delicate bone in which there can be sharply made out only a small *capitulum* behind without *crista capitali*; the *collum costae* and *tuberculum costae* are practically absent as are also the *angulus costae* and the *sulcus costae*. The two ribs are, in their whole length, directed nearly evenly obliquely downward and curved so as to be almost evenly convex lateralward and backward. The cross section shows rounded angles: in front the ribs become sharper and possess generally only a small cartilaginous tip. They form no joint union with the other ribs; but end free between the abdominal muscles.

The twelfth rib is very variable.

Between every two adjacent ribs is an intercostal space, **spatium intercostale** (see Figs. 105—107). Its form resembles that of the adjacent ribs and varies with their shape and position.



103 and 104. Breast bone, sternum.

The **sternum** (*breast bone*) (see also figures 105 and 107) lies as an unpaired oblong plate of bone in the median plane and helps to form the anterior wall of the thorax. It extends in general somewhat obliquely from behind and above, forward and downward and corresponds in position to the spine from the third to the ninth thoracic vertebra. Three parts are distinguishable: *manubrium sterni*, *corpus sterni* and *processus xiphoideus*, the parts being separated from one another by layers of cartilage which, however, in advanced age may ossify and lead to fusion.

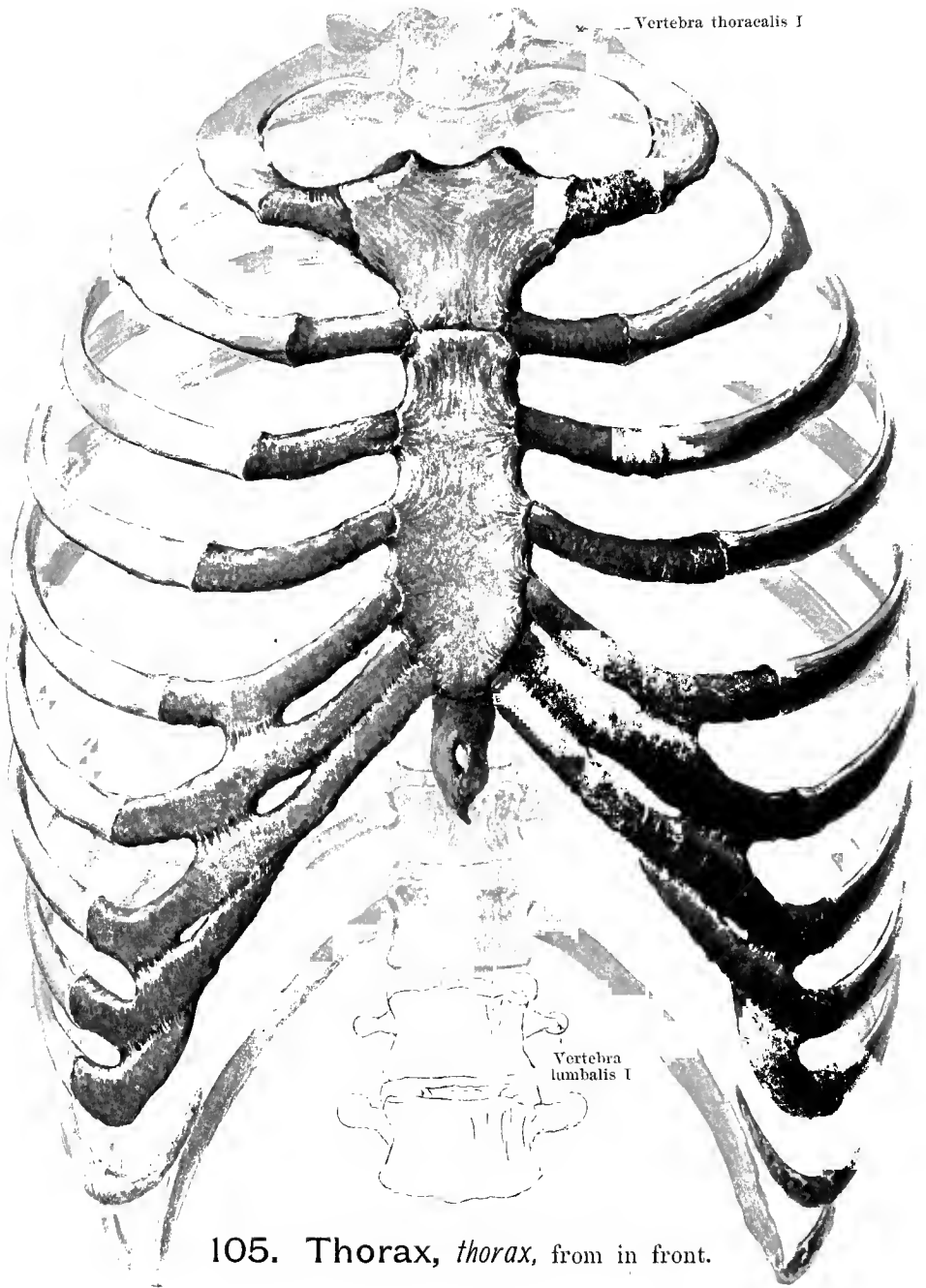
The **manubrium sterni** is the broadest part, especially above; below it becomes somewhat narrower; its anterior surface is slightly convex, its posterior, flat. At the upper margin in the middle is a flat notch, *incisura jugularis* (O. T. presternal notch); near this, at the upper angle on each side, is a somewhat deeper depression covered with cartilage, the *incisura clavicularis*, for articulation with the facies articularis sternalis clavicularum.

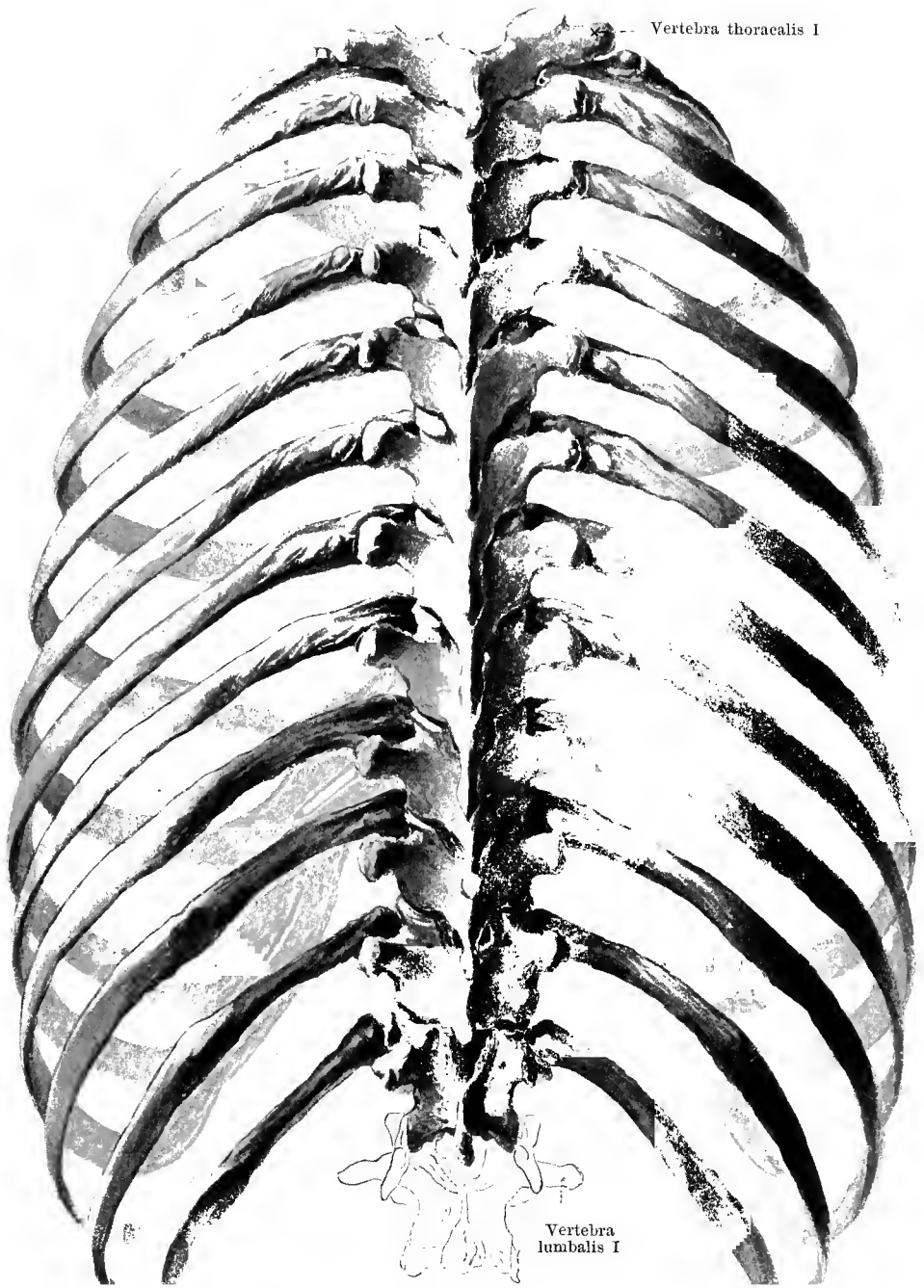
The **corpus sterni** (O. T. gladiolus) is the longest portion; above and below it is somewhat narrower than in the middle; its anterior surface, *planum sternale*, and its posterior surface are flat. The manubrium and corpus are somewhat movable upon one another where they are united at the *synchondrosis sternalis*; at the point of junction, whether the joint exists or even when it has become ossified, there is often an angle, *angulus sterni*, which can be felt as a transverse ridge projecting forward beneath the skin.

The **processus xiphoideus** (O. T. ensiform process) forms the lower extremity; it is thin, longer than it is broad, very irregular in shape, often bifurcated or perforated by an opening and remains for a long time wholly or partially cartilaginous. Only late in life does it begin to become ossified inside and to fuse with the body.

On each lateral surface of the manubrium and corpus are seven (sometimes eight, see p. 78) notches, *incisurae costales*, for the upper seven (eight) ribs. The first is rough, the others are covered with cartilage. The first notch is in the manubrium just below the *incisura clavicularis*; the second at the point of union of manubrium and corpus, each forming a half of it; the third on the corpus nearly in the middle of the whole length of manubrium + corpus; the fourth to the seventh (eighth) in the lower half, so that the inferior notches are closer and closer together, the two lowest often being fused to one; the seventh (and eighth) situated at the junction of the corpus with the *processus xiphoideus* may be situated partially in front of the latter.

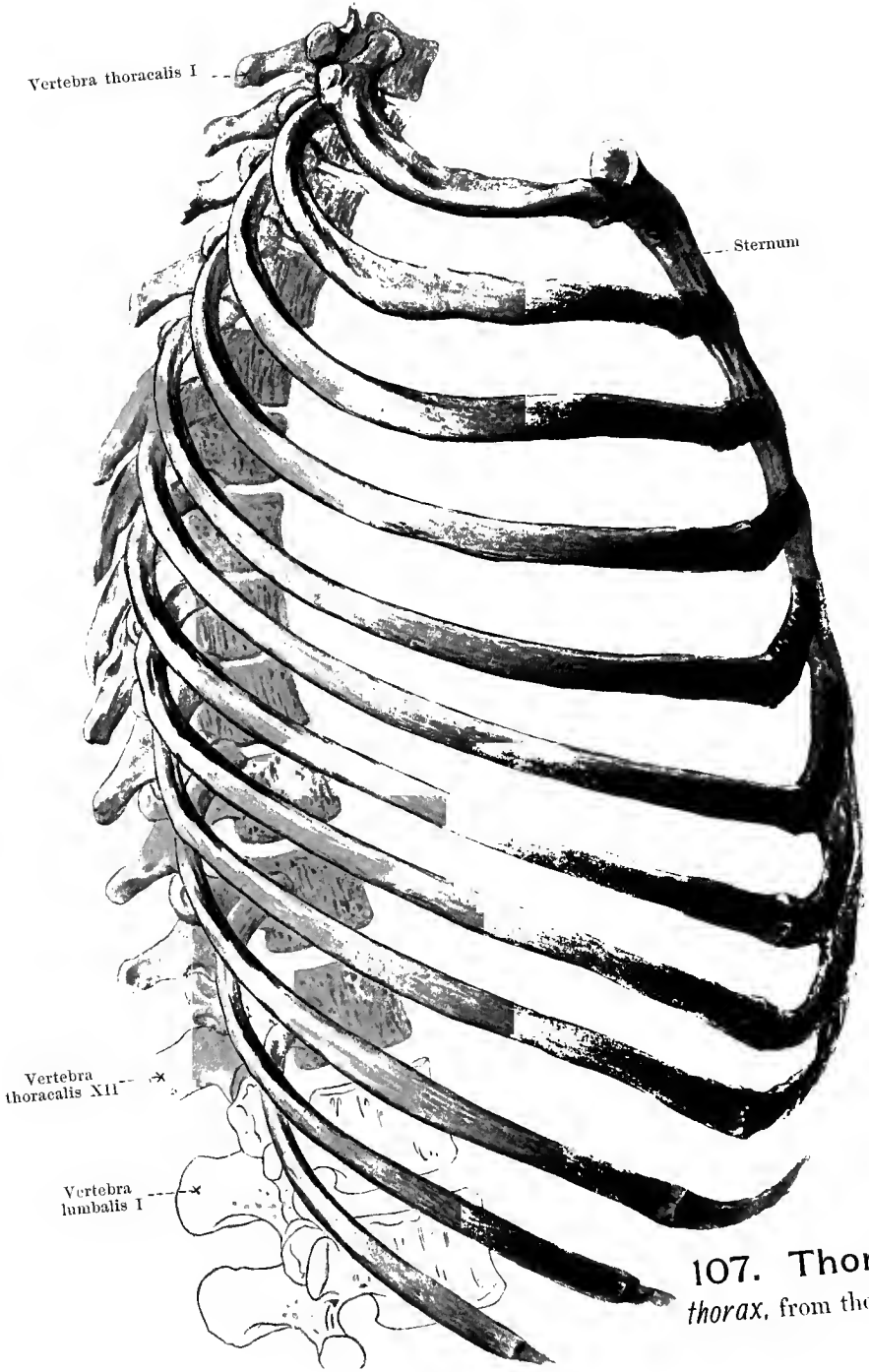
In the female, other things being equal, the corpus sterni is shorter than in the male; accordingly, the female sternum is, on the whole, shorter and looks relatively broader and plumper.



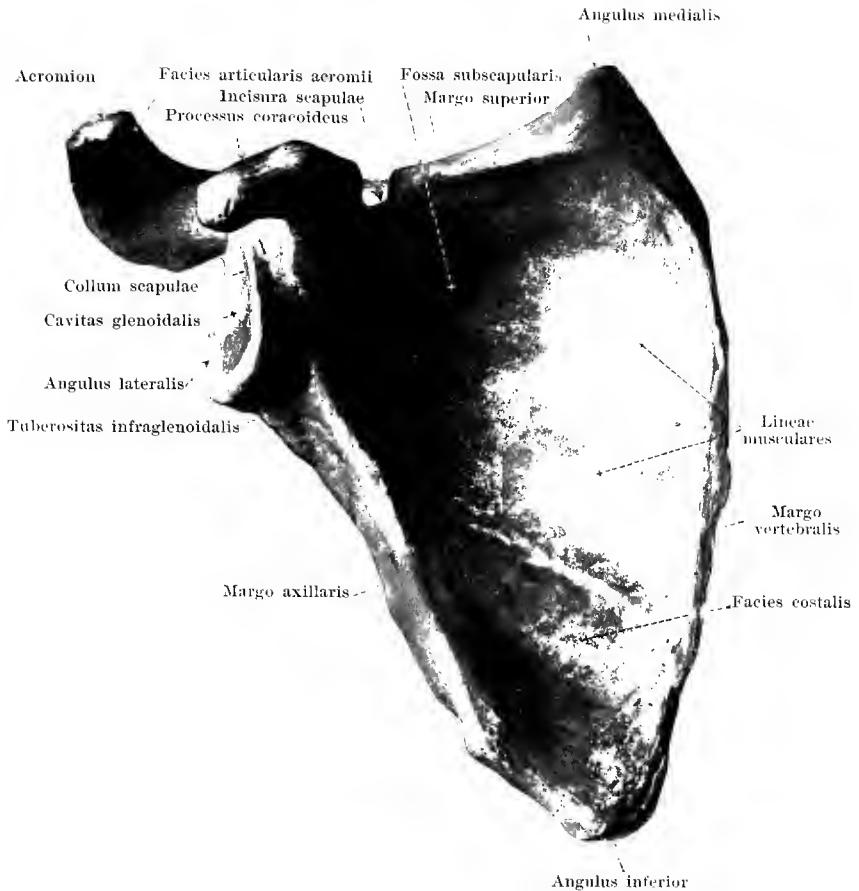


Vertebra thoracalis I

Vertebra lumbalis I



107. Thorax
thorax, from the rig

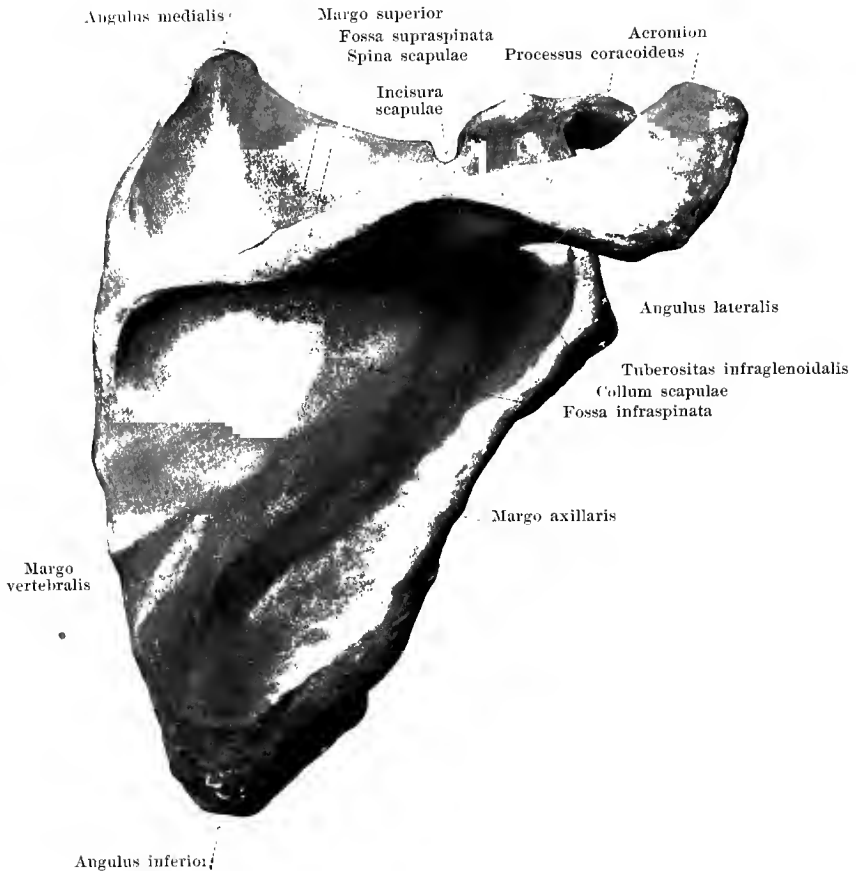


108. Right shoulder blade, *scapula*, from in front.

The **scapula** (*shoulder blade*) (see also figures 109—112) is a broad, flat, thin, triangular bone which lies upon the upper part of the wall of the thorax so that the lateral angle projects lateralward over the thorax; its medial margin, when the arm is hanging down, runs nearly parallel to the median plane and extends from the second or third to the seventh or eighth rib. It lies freely movable between the muscles and is connected by joints lateralward with the clavicle and with the humerus only.

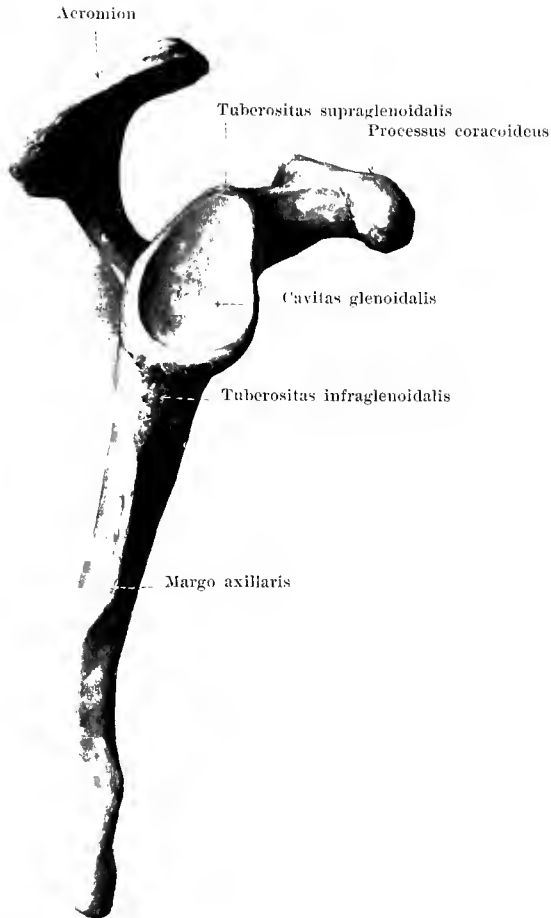
The shoulder blade has three margins: the thin, shortest, upper, *margo superior*, which presents on its lateral extremity a notch, the *incisura scapulae* (O. T. suprascapular notch), the longest, medial margin, *margo vertebralis*; the thick, lateral margin, *margo axillaris*. These margins meet in three angles; the blunt, thick *angulus inferior*, the sharper, thinner *angulus medialis* (O. T. superior angle) and the *angulus lateralis* (O. T. anterior angle); the latter supports the surface for articulation with the humerus (see p. 89).

The anterior surface, **facies costalis**, is markedly concave in its upper lateral part,



109. Right shoulder blade, *scapula*, from behind.

The posterior surface of the shoulder blade, **facies dorsalis scapulae**, is convex and subdivided by a bony projection, *spina scapulae*, which ascends about at the junction of the upper with the middle third, into the upper smaller, deeper *fossa supraspinata* and the lower, larger, flatter *fossa infraspinata*. The spina scapulae is low where it begins at the margo vertebralis and develops gradually to a very powerful high plate of bone which possesses an upper surface, directed also somewhat forward, and a lower surface, looking also somewhat backward. The free margin is broad. A strong process (the *acromion*) goes off from the side of it, first lateralward, then forward; it looks flattened out in its most anterior part and presents an upper and a lower surface; near its apex it presents medianward a small oval *facies articularis acromii* for articulation with the facies articularis acromialis claviculae.

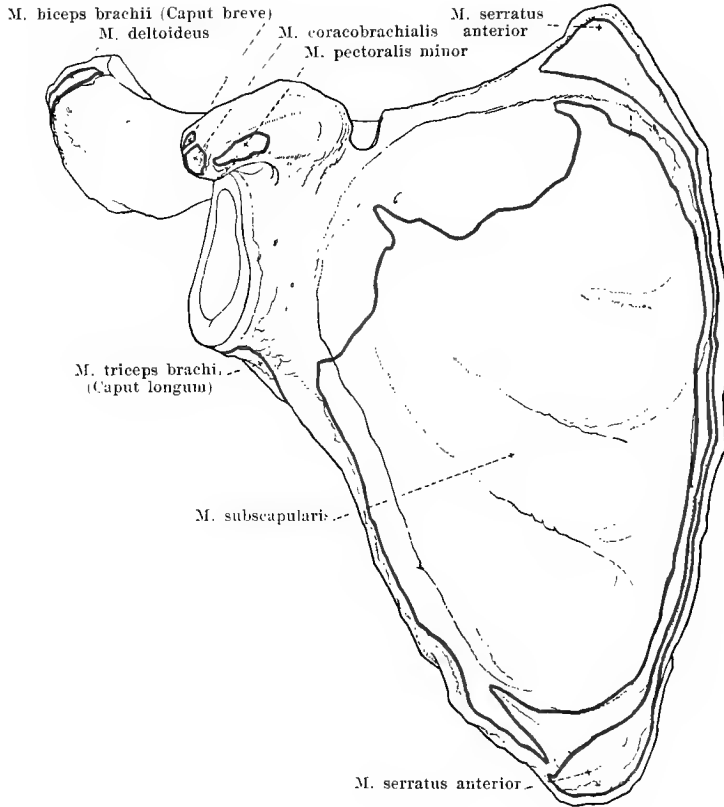


110. Right shoulder blade, *scapula*, from without.

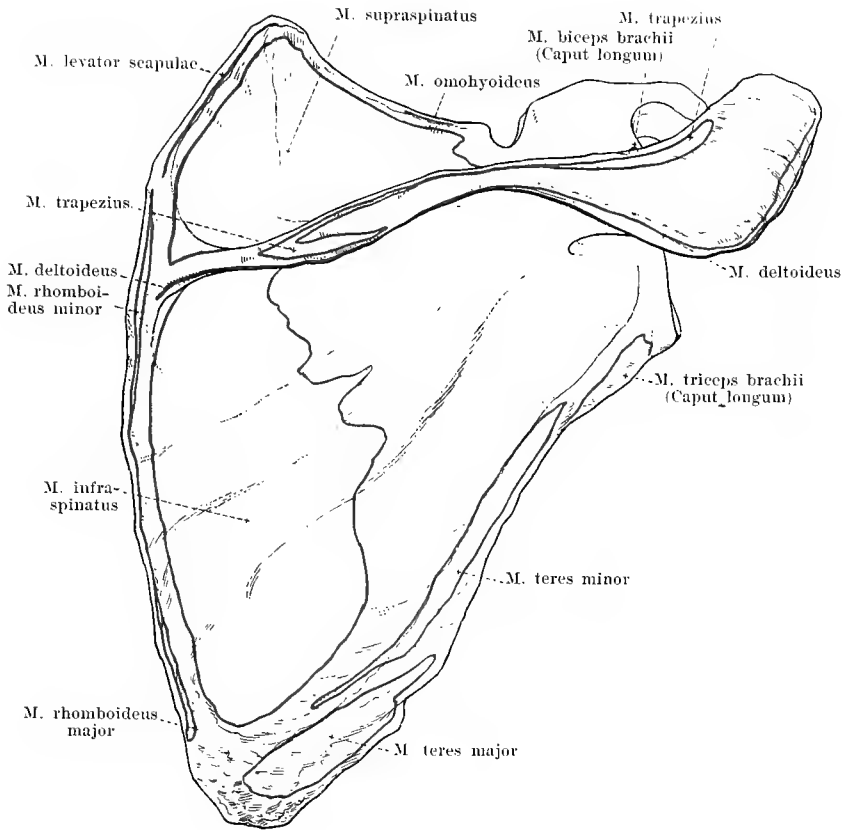
The **angulus lateralis scapulae** becomes markedly broader externally and is marked off from the rest of the shoulder blade by a shallow groove or neck, *collum scapulae*. The surface which is turned lateralward, the *cavitas glenoidalis*, is somewhat concave and is covered with cartilage; it is nearly oval in shape and is broader below than above; there is a slight indentation in the upper part of the anterior margin. A roughness just above this, the *tuberositas supraglenoidalis* (O. T. supraglenoid tubercle), gives origin to the caput longum m. bicipitis; another, larger, below it, at the uppermost end of the margo axillaris, *tuberositas infraglenoidalis* gives origin to the caput longum m. tricipitis.

Between the cavitas glenoidalis and the incisura scapulae, arising from the margo superior, is the *processus coracoideus* (*crow's beak process*); it is thick, rounded, runs first forward and upward, and then, making a marked hook-like curve forward and lateralward, ends in a blunt tip.

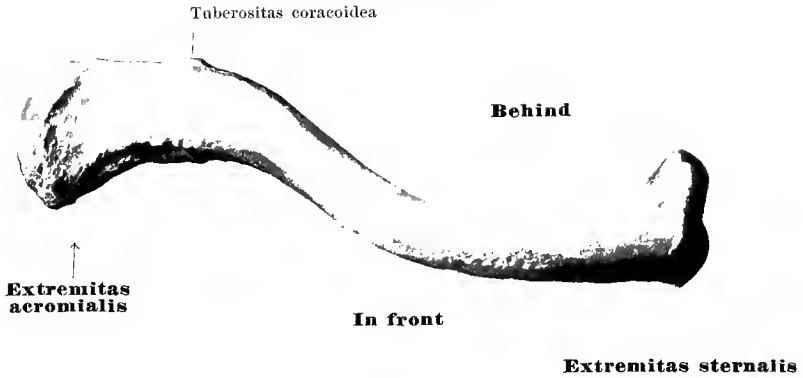
Bones of the Upper Extremity.



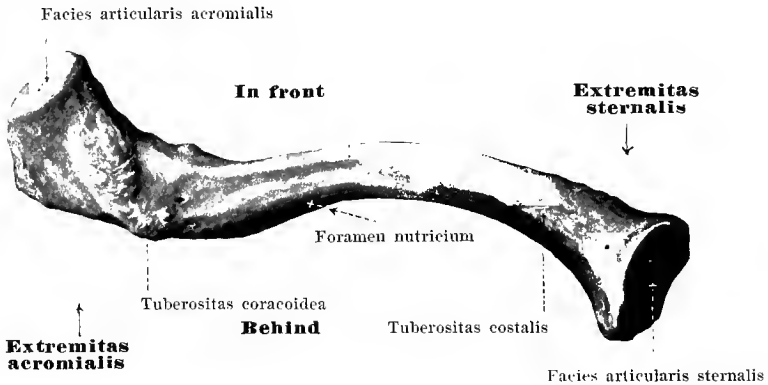
III. Right shoulder blade, *scapula*, from in front,
with the muscular attachments.



112. Right shoulder blade, *scapula*, from behind, with the muscular attachments.



113. Right collar bone or clavicle, *clavicula*, from above.

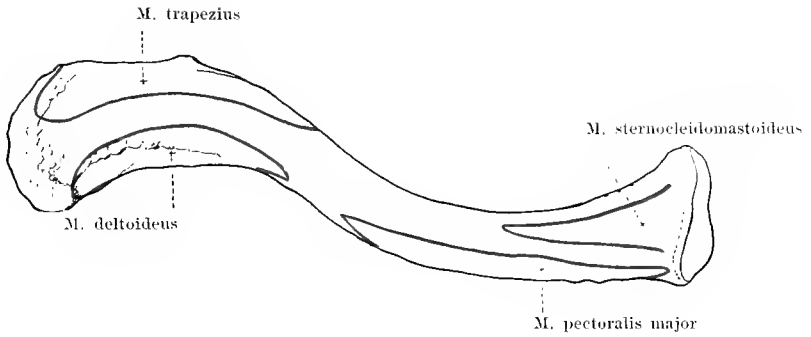


114. Right collar bone or clavicle, *clavicula*, from below.

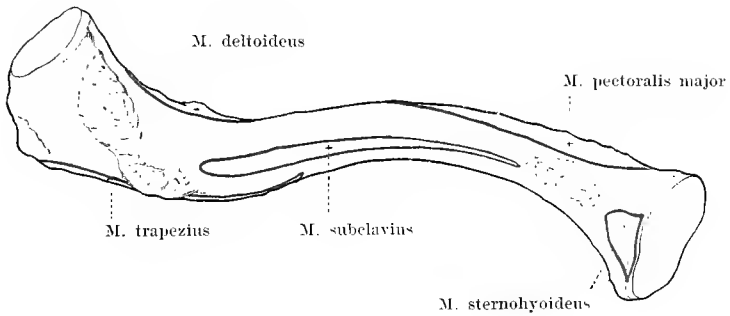
The **clavicula** (*key, clavicle or collar bone*) is a short, strong, cylindrical bone bent α -like which runs transversely in front of the first rib, going out on each side from the upper end of the sternum, and is attached at its lateral extremity to the acromion scapulae.

It is divisible into a shaft and two extremities: that directed toward the sternum, *extremitas sternalis*, and that looking toward the scapula, *extremitas acromialis*.

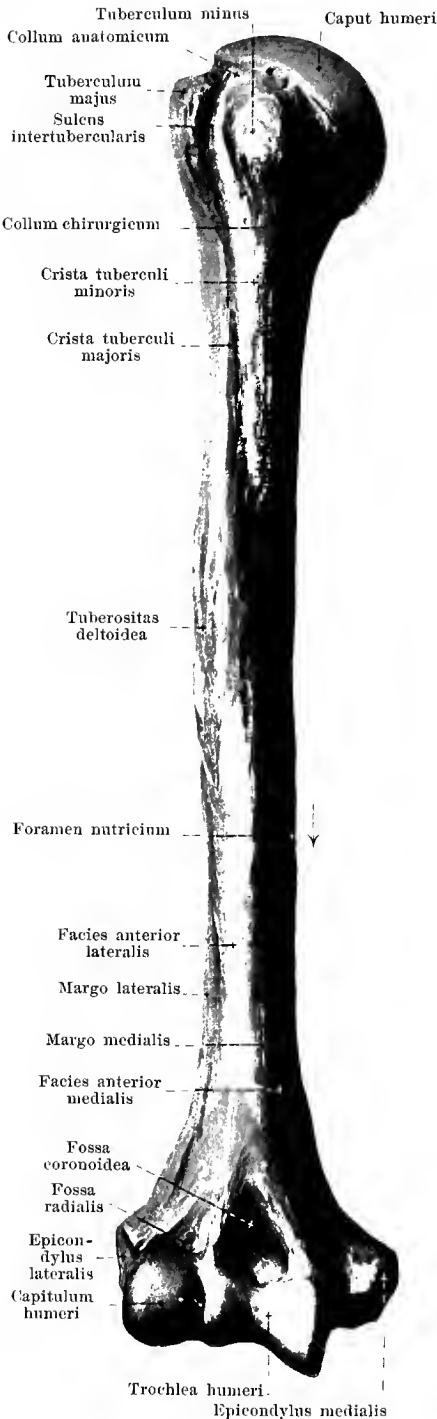
The shaft is bent convexly forward in its medial half; in its lateral half convexly backward. It is triangular with rounded angles especially medianward. The extremitas sternalis ends with the approximately triangular, curved *facies articularis sternalis* covered with cartilage, which lies in the incisura clavicularis sterni. Somewhat lateralward from it, at the junction of the inferior with the posterior surface, the *tuberositas costalis* (O. T. Impression for rhomboid ligament) (for the lig. costoclaviculare) is visible. The extremitas acromialis is somewhat broadened and is flattened from above downward; at its extreme end it is turned somewhat forward and supports there the small, oval, flat *facies articularis acromialis* for articulation with the facies articularis acromii scapulae. Just medianward, near this, on the lower surface lies the oblong, rough *tuberositas coracoidea* (O. T. impression for coroid ligament) (for the lig. coracoclaviculare).



115. Right collar bone or clavicle, *clavicula*, from above with the muscular attachments.



116. Right collar bone or clavicle, *clavicula*, from below with the muscular attachments.



117. Right humerus, *humerus*, from in front.

The **humerus** (*upper arm bone*) (see also figures 118—122) is a long cylindrical bone which articulates above with the shoulder blade, below with the bones of the forearm. It is divisible into a body or shaft, *corpus humeri*, and two extremities.

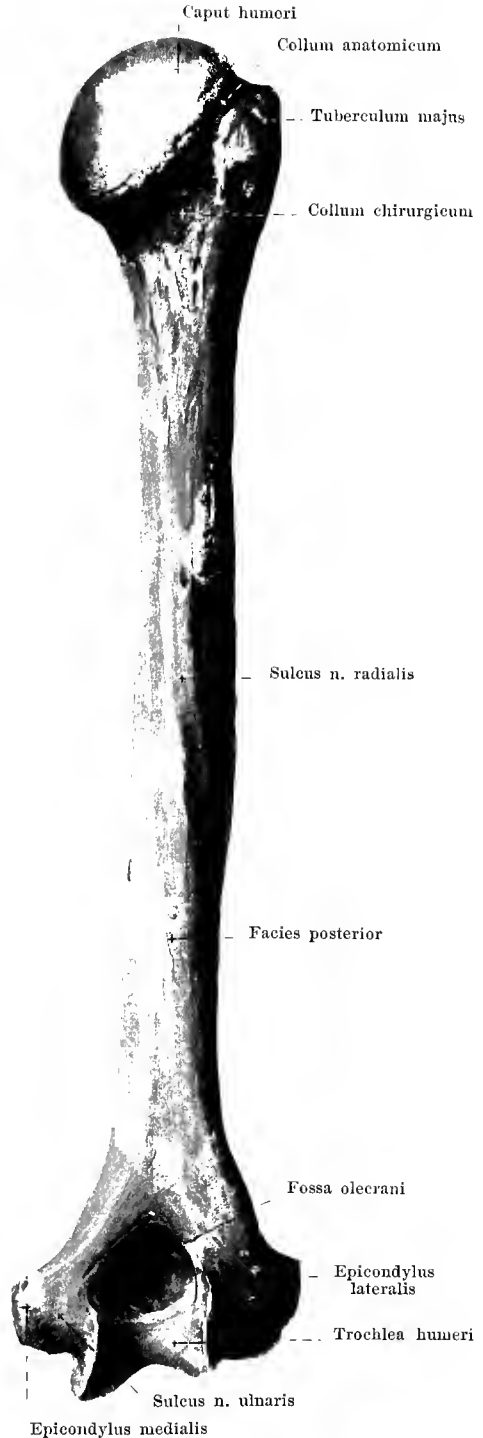The **corpus humeri** (*shaft*) is more cylindrical above, distinctly triangular below; its surfaces are called the *facies posterior*, the *facies anterior medialis* (O. T. internal surface) and the *facies anterior lateralis* (O. T. external surface); the posterior surface is separated from the two anterior surfaces by the *margo medialis* (O. T. internal border) and the *margo lateralis* (O. T. external border) both of these being especially sharp and prominent below. On the *facies anterior lateralis* somewhat above the middle is a broad rough surface, *tuberositas deltoidea* (for the m. deltoideus); behind this, on the posterior surface lies a shallow groove, the *sulcus nervi radialis* (O. T. musculospiral groove) (for the n. radialis), which begins on the medial margin and descends like a long drawn-out spiral to the lateral margin. A large *foramen nutricium* is often noticeable near the middle on the medial margin; it leads into a *canalis nutricius* directed distalward.

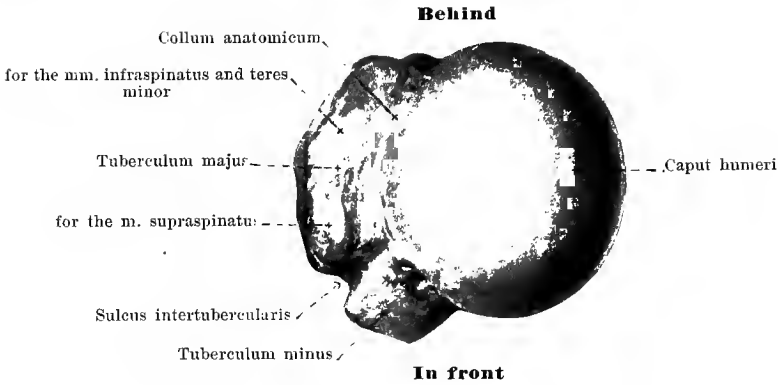
The **upper extremity** is broadened and supports the *caput humeri* which is covered with cartilage; this is nearly hemispherical and directed upward and medianward. It is separated from the rest of the bone by a constriction, the *collum anatomicum* (anatomical neck). Close to this lie two eminences: directed exactly lateralward is the *tuberculum majus* (O. T. greater tuberosity), in front of this directed forward, the *tuberculum minus* (O. T. lesser tuberosity); running forward and downward from both of these are ridges, the *crista tuberculi majoris* (O. T. posterior bicipital ridge) and the *crista tuberculi minoris* (O. T. anterior bicipital ridge). Between the tubercula and the cristae runs the deep *sulcus intertubercularis* (O. T. bicipital groove) (for the tendon of the caput longum m. bicipitis). At the junction of the upper extremity with the *corpus humeri* lies the *collum chirurgicum* (*surgical neck*).

118. Right humerus, *humerus*, from behind.

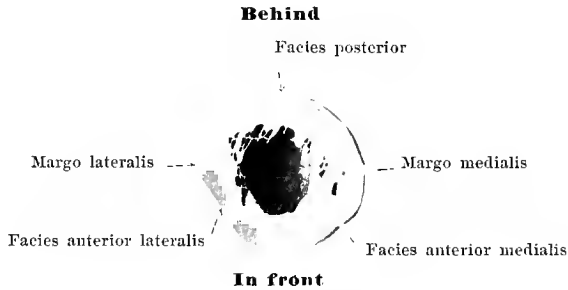
The lower extremity of the **humerus** is somewhat thinner but broader than the shaft. From each side of it projects a rough eminence, the *epicondylus medialis* (O. T. internal condyle) and the *epicondylus lateralis* (O. T. external condyle). These lie in the lines of continuation of the margo medialis and the margo lateralis and give attachment to muscles and ligaments of the elbow joint. The epicondylus medialis is the larger and presents on its posterior surface a shallow groove, *sulcus nervi ulnaris* (for the n. ulnaris).

Between the two epicondyles lies a joint surface, covered with cartilage, for articulation with the bones of the forearm. It consists of a medial, roller-shaped surface, *trochlea humeri* (for articulation with the ulna), which extends also upon the posterior surface, and of a lateral, smaller *capitulum humeri* (O. T. capitellum or radial head) (for articulation with the radius), shaped like the segment of a sphere, which is not continued upon the posterior surface. Above the trochlea, both in front and behind, is a deep depression; that in front is called the *fossa coronoidea*, that behind, the *fossa olecrani*; between the two the bone is very thin and may be absent. On the anterior surface, above the capitulum humeri, lies the smaller *fossa radialis*. These three depressions are not covered with cartilage.

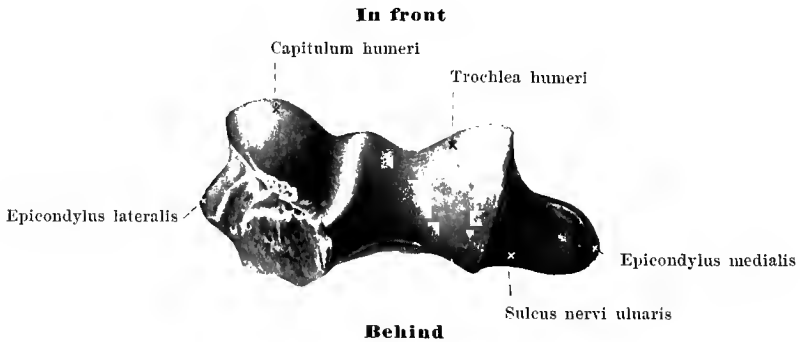




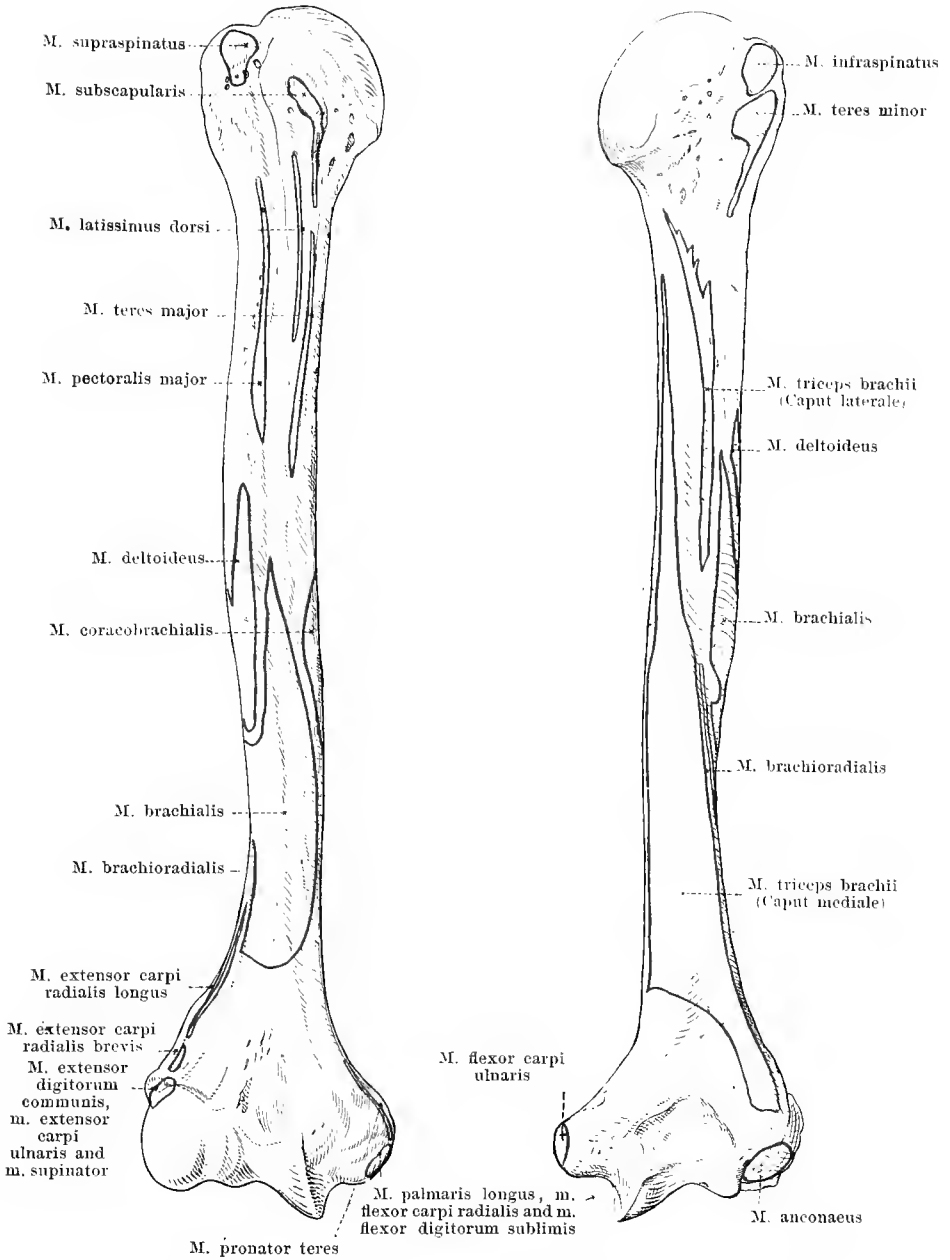
119. Right humerus, *humerus*, upper extremity, from above.



119^a. Transverse section through the lower half of the right humerus.



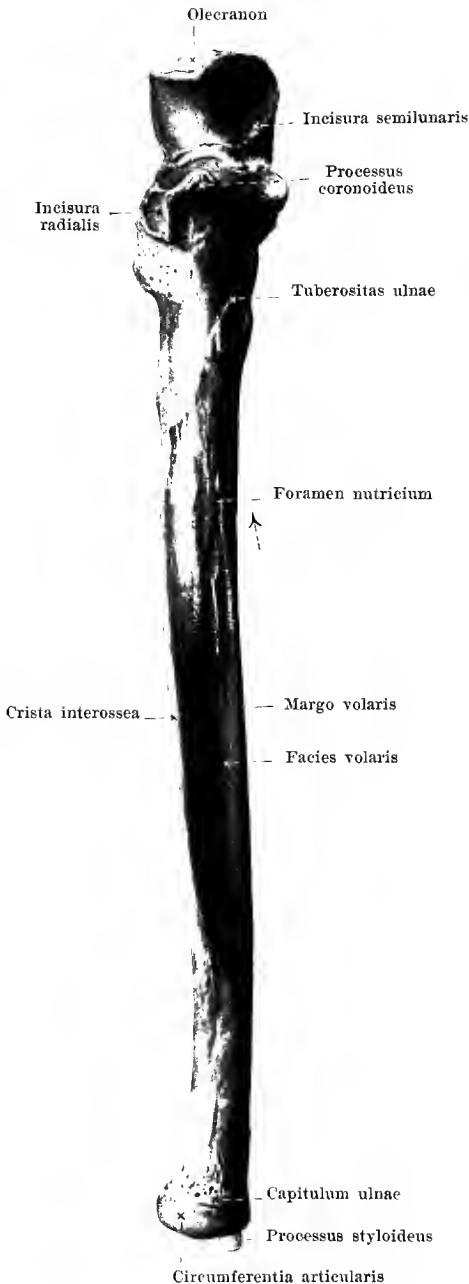
120. Right humerus, *humerus*, lower extremity, from below.



121 and 122. Right humerus, *humerus*, with muscular attachments.

From in front.

From behind.



123. Right ulna, *ulna*, from in front.

The **ulna** (see also Figs. 124, 127—129, 146) is a long, cylindrical bone which is thicker at its upper than at its lower extremity. It lies on the side of the forearm corresponding to the little finger, is united above by a joint with the upper arm, below, only indirectly, with the carpus; it is united by joints with the radius both above and below.

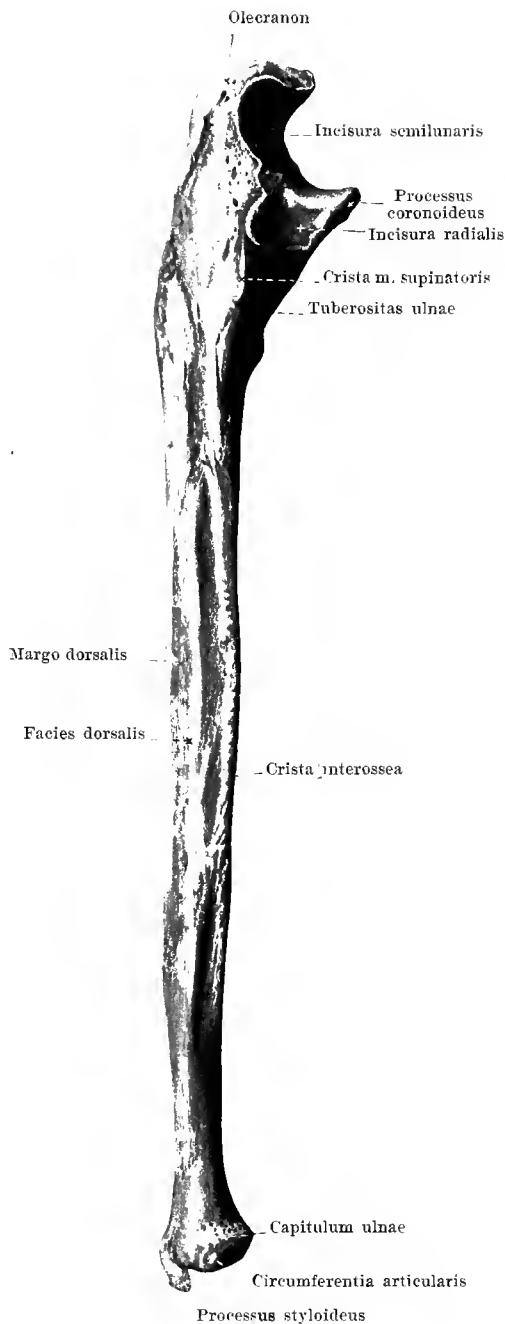
It is divisible into a shaft or *corpus*, and two extremities.

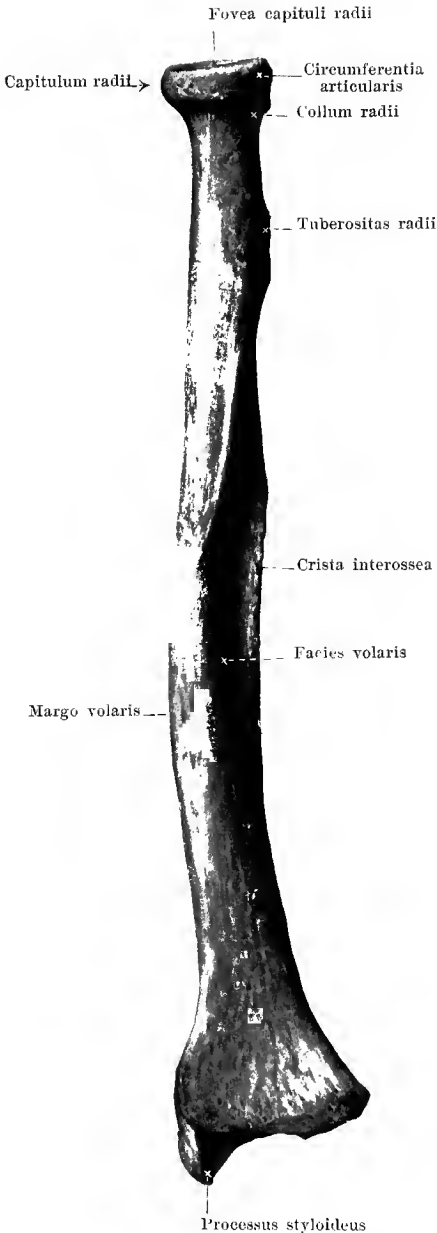
The shaft, **corpus ulnae**, is bent slightly so as to be convex toward the side of the little finger and is triangularly prismatic. Of its three surfaces, the *facies medialis* (O. T. internal surface) on the side corresponding to the little finger is narrow; it goes over at the rounded *margo volaris* (O. T. anterior border) in front and the *margo dorsalis* (O. T. posterior border) behind, into the broader *facies volaris* (O. T. anterior surface) and *facies dorsalis* (O. T. posterior surface). These meet radialward in the sharply projecting *crista interossea* (O. T. external or interosseous border). A *foramen nutricium* often lies near the *crista interossea* at the middle of the length of the volar surface and leads into a *canalis nutricius* directed proximalward.

124. Right ulna, *ulna*, from the radial side.

The **upper extremity** of the **ulna** is thickened and ends with a rough strong process, the *olecranon*; beneath it, projecting from the volar surface, is the strong *processus coronoideus*. Between these two processes lies a deep notch, covered with cartilage, the *incisura semilunaris* (O. T. greater sigmoid cavity), in which the trochlea humeri is received. On the radial side of the proc. coronoideus the smaller, slightly concave, *incisura radialis* (O. T. lesser sigmoid cavity) (for the capitulum radii) is visible. Passing obliquely backward and downward from this is a sharp bony ridge, the *crista m. supinatoris* (for the origin of the m. supinator). Somewhat below the proc. coronoideus lies a broad rough surface for the attachment of the m. brachialis, the *tuberositas ulnae*.

The **lower extremity** is narrower and forms a small rounded head, *capitulum ulnae*. This is covered with cartilage on its distal surface as well as in the larger part of its circumference, the *circumferentia articularis* (for the incisura ulnaris radii). On the side corresponding to the little finger, the small blunt *processus styloideus* projects distalward.





125. Right radius, *radius*, from in front.

The **radius** (*spoke*) (see also Figs. 126 — 129, 146) is a long cylindrical bone, thickened at its lower end which occupies the side of the forearm corresponding to the thumb. It articulates above with the upper arm, below enters into the joint between the bones of the forearm and those of the wrist and rotates above and below on the ulna.

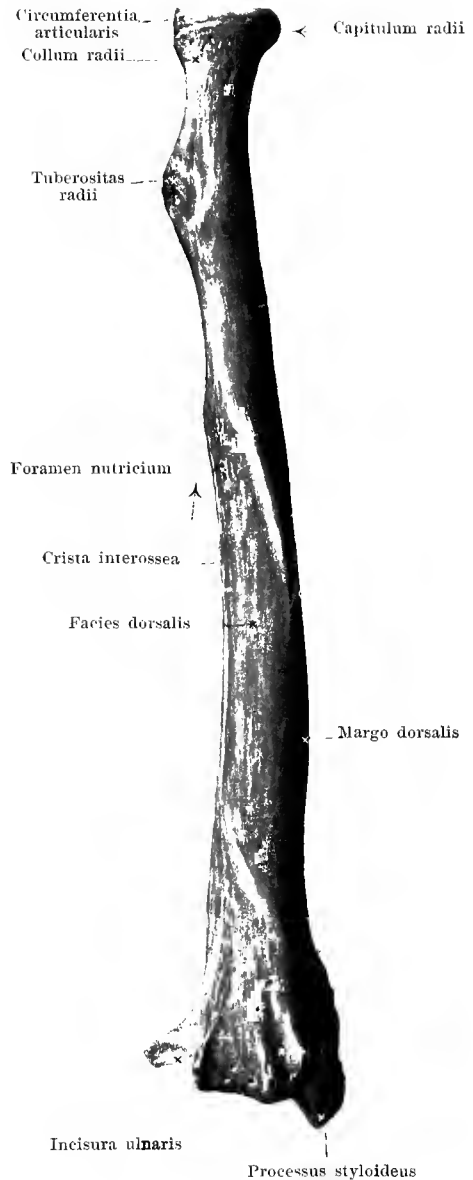
It is divisible into a shaft or *corpus* and two extremities.

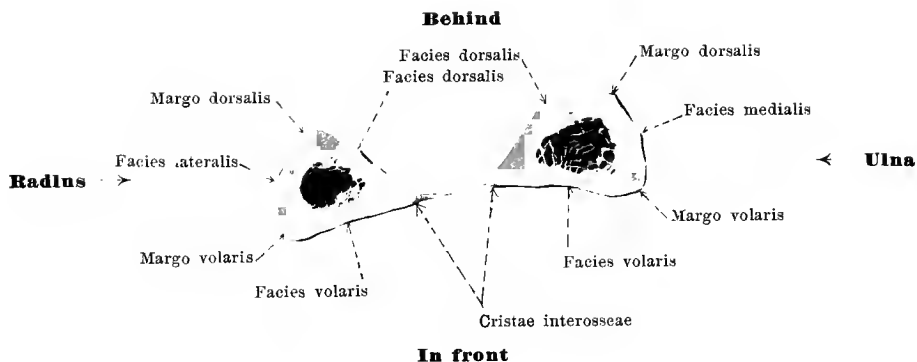
The **corpus radii** or shaft is bent so as to be somewhat convex toward the thumb side and is triangularly prismatic. The narrowest of its three surfaces, *facies lateralis* (O. T. external surface) is directed toward the thumb side; it adjoins at the rounded *margo dorsalis* (O. T. posterior border) behind and the *margo volaris* (O. T. anterior border) in front, the broader *facies dorsalis* (O. T. posterior surface) and *facies volaris* (O. T. anterior surface). The ulnar angle formed by these two surfaces is especially sharp and is called the *crista interossea* (O. T. internal or interosseous border). A *foramen nutricium* is often visible at a spot corresponding to that on the ulna; the *canalis nutricius* is directed proximalward.

126. Right radius, *radius*, from behind.

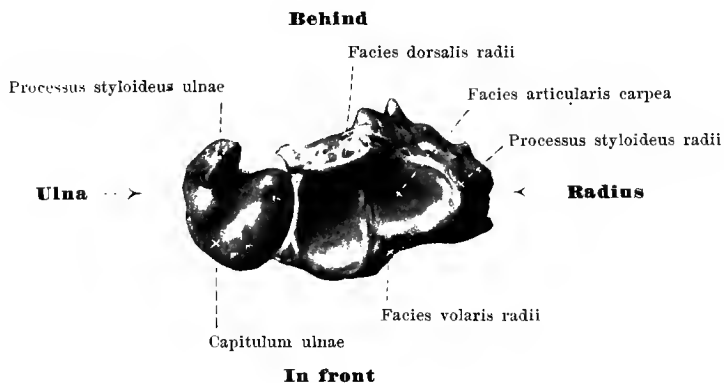
The **upper extremity of the radius** supports the button-shaped *capitulum radii* (head); this is for the most part covered with cartilage and proximalward presents a small flat depression, *fovea capituli radii* (for articulation with the capitulum humeri); its circular periphery covered with cartilage, *circumferentia articularis*, moves in the incisura radialis ulnae. Just below the capitulum the bone is narrowed to form a neck, *collum radii*, and close below this spot, projecting ulnarward and volarward, is the *tuberositas radii* (O. T. bicipital tuberosity) (for the attachment of the m. biceps brachii).

The **lower extremity** is markedly broadened. Its anterior surface is smooth and slightly concave; its posterior surface is subdivided by several longitudinal ridges into grooves for tendons (see Fig. 129). The distal terminal surface, *facies articularis carpea*, covered with cartilage, is slightly concave and triangular; it is subdivided, usually distinctly, into a triangular radial part (for the os naviculare) and a quadrangular ulnar part (for the radial portion of the os lunatum). On the ulnar side is a small notch covered with cartilage, the *incisura ulnaris* (O. T. sigmoid cavity) (for the capitulum ulnae). Projecting distalward from the angle on the thumb side is the short blunt *processus styloideus*.





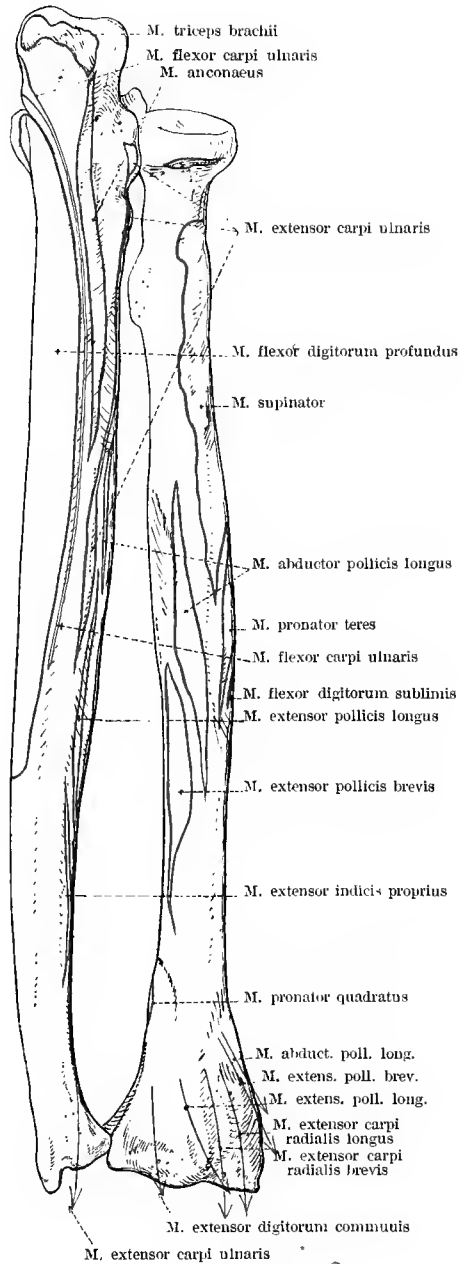
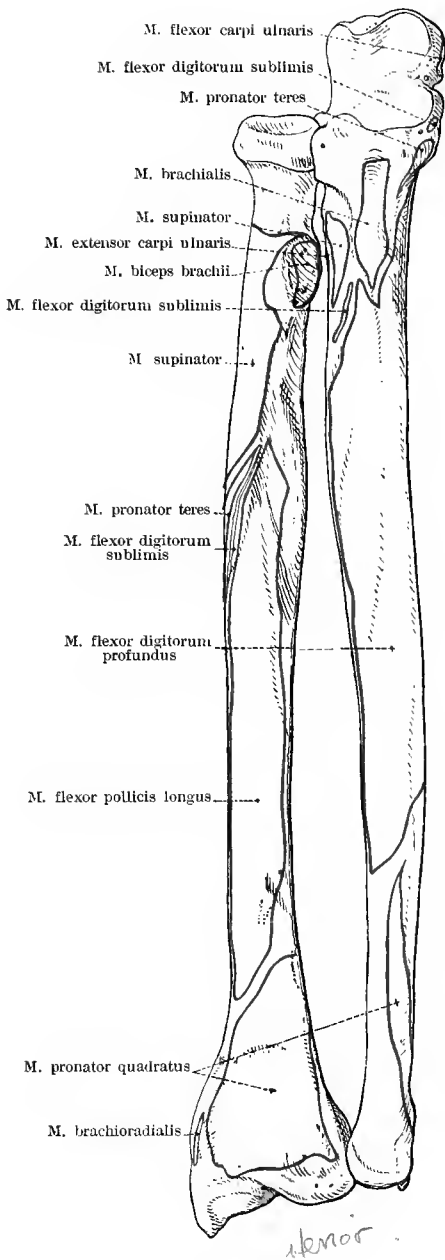
127^a. Transverse section through the middle of the bones of the right forearm.



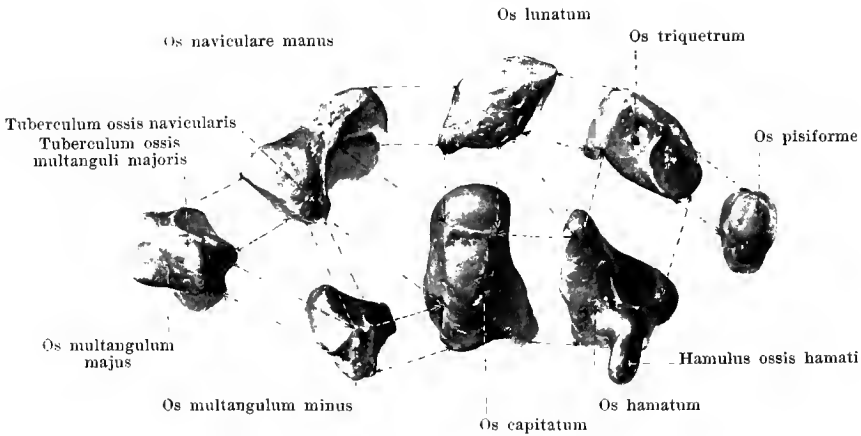
127. Lower extremity of the bones of the right forearm, from below.

The lower extremity of the bones of the forearm (see also Fig. 146) which forms the articulation with the carpus, presents on its distal surface the *facies articularis carpea radii* and the *capitulum ulnae*. The former articulates directly with the os naviculare manus and the radial part of the os lunatum. The capitulum ulnae on the contrary does not touch the ulnar part of the os lunatum and the os triquetrum, situated distalward from it, directly, but is separated from them by a discus articularis.

On the sides of this surface the two *processus styloidei* are visible.



128 and 129. Bones of the right forearm,
 with the muscular attachments,
 from the surface corresponding to the hollow of the hand. from the side corresponding to the back of the hand.



130—137. Bones of the right carpus, *ossa carpi*, shown singly, from the volar surface.

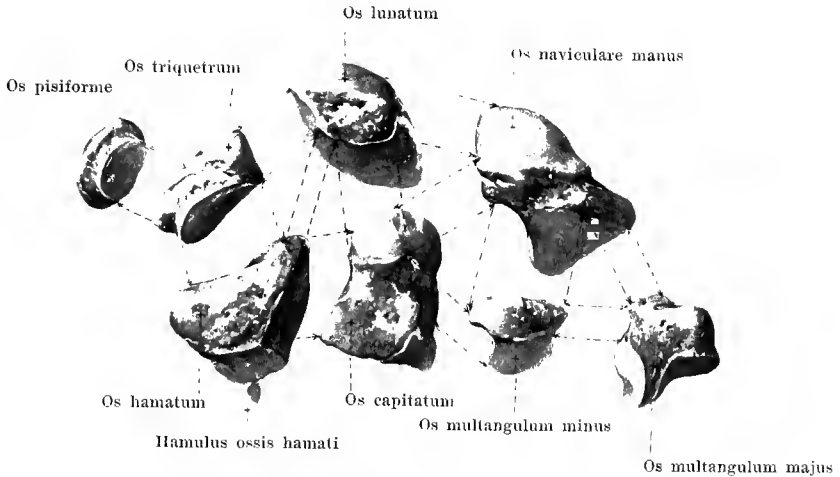
The eight **ossa carpi** (*wrist bones*) (see also Figs. 138—146, 148, 149) are arranged in two transverse rows of four each: the proximal (numbered from the thumb side) consists of the *os naviculare manus*, *os lunatum*, *os triquetrum*, *os pisiforme*; the distal of the *os multangulum majus*, *os multangulum minus*, *os capitatum*, *os hamatum*.

The **os naviculare manus** (O. T. scaphoid bone) presents proximally a convex articular surface (for the radius), on its distal surface, a convex articular surface (for the *ossa multangula majus et minus*), on the ulnar surface distalward a concave surface (for the *os capitatum*) and proximalward a small flat articular surface (for the *os lunatum*). On the volar surface lies the *tuberculum ossis navicularis*.

The **os lunatum** (O. T. semilunar bone) presents proximally a markedly convex articular surface (for the radius and for the *discus articularis* of the joint formed by the forearm with the hand), distally, a markedly concave articular surface (for the *os capitatum* and the *os hamatum*); radialward and ulnarward lie small flat articular surfaces for the *os naviculare* and the *os triquetrum*.

The **os triquetrum** (O. T. cuneiform bone) has proximally a small, convex articular surface (for the *discus articularis* of the joint formed by the forearm with the hand), distally, a large concave-convex surface (for the *os hamatum*), radialward, a small flat one (for the *os lunatum*) and on the volar surface a small, flat, rounded articular surface (for the *os pisiforme*).

The **os pisiforme** is a small, egg-shaped bone which dorsalward presents a small, flat, rounded articular surface (for the *os triquetrum*).



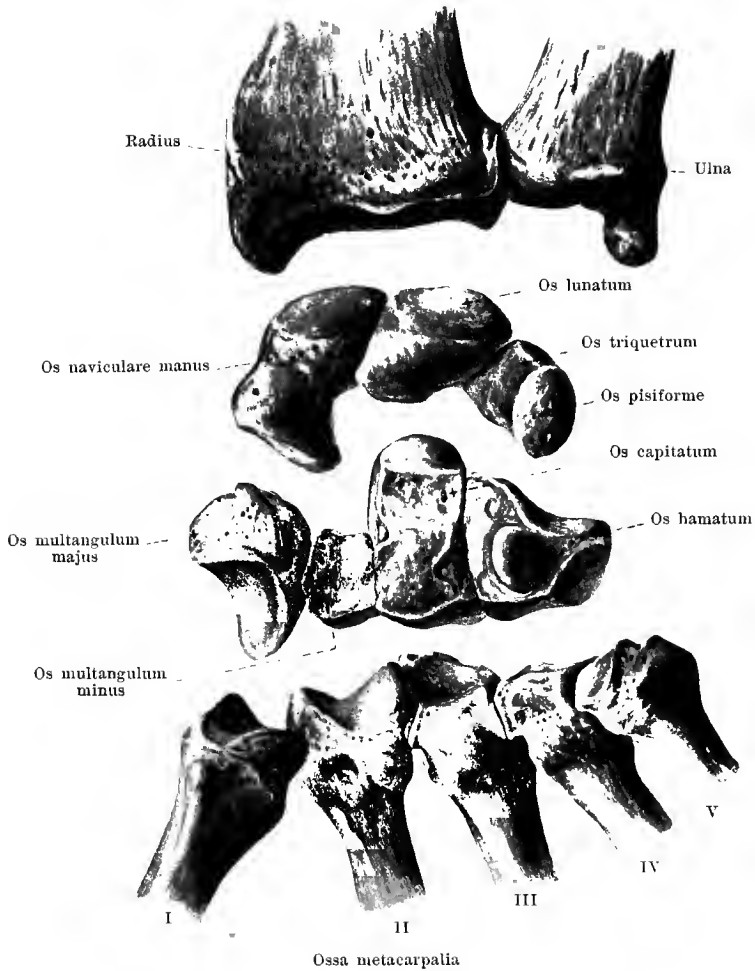
138—145. Bones of the right carpus, *ossa carpi*,
shown singly, from the surface.

The **os multangulum majus** or large multangular bone (O. T. trapezium) has proximally a slightly concave articular surface (for the os naviculare), distalward a saddle-shaped surface (for the os metacarpale I), ulnarward a small surface (for the os metacarpale II) and a somewhat larger, concave surface (for the os multangulum minus). On the volar surface is a small projection, *tuberculum ossis multanguli majoris*, and ulnarward from it a groove (for the tendon of the m. flexor carpi radialis).

The **os multangulum minus** or small multangular bone (O. T. trapezoid bone) presents proximally a slightly concave articular surface (for the os naviculare), distalward a flat saddle-shaped surface (for the os metacarpale II); on the radial surface has a slightly convex articular surface (for the os multangulum majus), on the ulnar a feebly concave surface (for the os capitatum).

The **os capitatum** (O. T. os magnum) is inserted in its proximal part into the deep concavity formed by the os naviculare and the os lunatum. It supports there a markedly convex articular surface (for the os lunatum), distalward a tripartite, flat, articular surface (for the ossa metacarpalia II, III, IV); radialward are convex articular surfaces for the os naviculare and the os multangulum minus, ulnarward a flat articular surface for the os hamatum.

The **os hamatum** or hook bone (O. T. unciform bone) presents a large, convex-concave articular surface (for the os lunatum and the os triquetrum) directed proximally and at the same time ulnarward; distally is a double articular surface (for the ossa metacarpalia IV, V) and radialward a single, flat, articular surface (for the os capitatum). On the volar surface a flat somewhat curved process projects upward, the *hamulus ossis hamati* (O. T. unciform process).

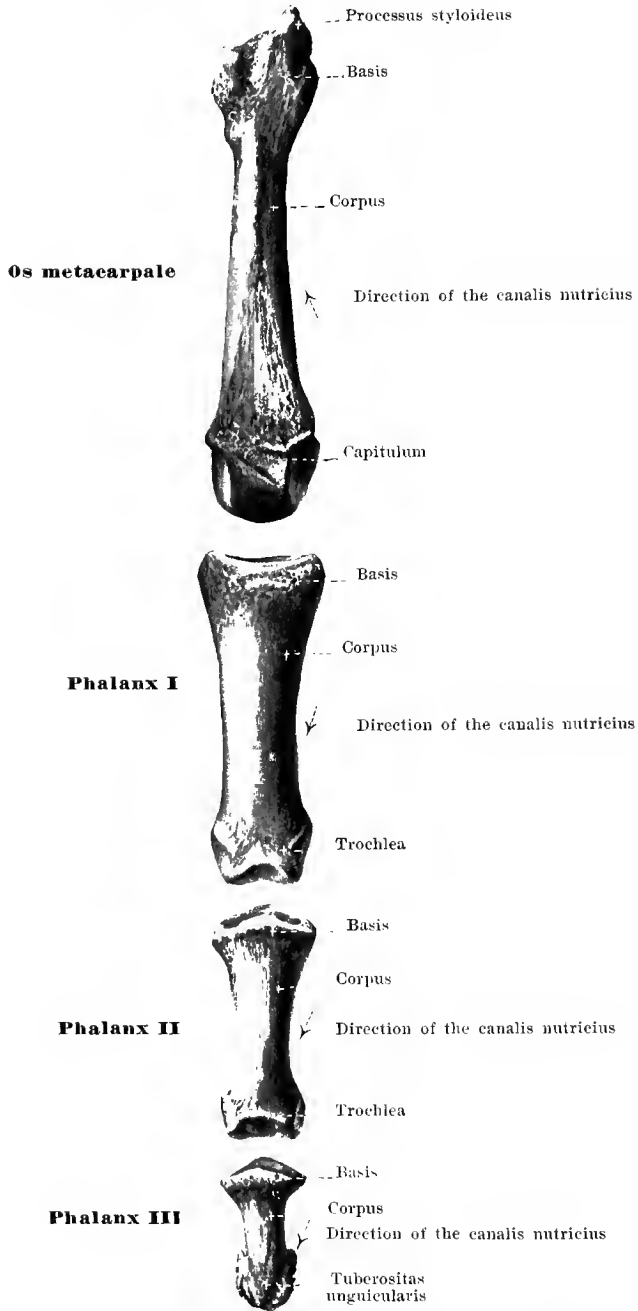


146. Right wrist and neighboring bones, in transverse rows, separated from one another, from the volar surface.

The **first carpal row** (see also Fig. 240), considered as a whole, has proximalward an elongated oval, markedly convex, articular surface, in the formation of which participate the os naviculare and the os lunatum especially, the os triquetrum to a less extent; the os naviculare and the radial part of the os lunatum articulate with the facies articularis carpea radii, the ulnar part of the os lunatum and the os triquetrum with the discus articularis situated below the capitulum ulnae. The os pisiforme takes no part in the articulation with the bones of the forearm nor in that with the second carpal row, but is simply attached, volarward, to the os triquetrum. Distalward the first carpal row is bounded by a surface, the radial portion of which (formed by the os naviculare) is convex and projects markedly distalward, and its ulnar portion (formed by the ossa naviculare, lunatum, triquetrum) represents a depression markedly hollowed out proximally.

The **second carpal row** (see also Fig. 240) ends proximalward in a surface, the radial portion of which (formed by the ossa multangula majus et minus), is concave and its ulnar part (formed by the os capitatum and os hamatum) represents a head projecting markedly proximalward. These proximal surfaces are impressions of the corresponding distal surfaces of the first carpal row. The distal boundary of the second row is formed by a wavy surface in which the ossa metacarpalia are deposited; furthest radialward lies the saddle-shaped surface for the os metacarpale I (formed by the os multangulum majus) after this comes the surface for the os metacarpale II (formed by the ossa multangula majus et minus, os capitatum): then the surface for the os metacarpale III (formed by the os capitatum), then the surface for the os metacarpale IV (formed by the os capitatum and the os hamatum) and finally, the surface for the os metacarpale V (formed by the os hamatum).

The **carpus** (*wrist*) (see Figs. 148 and 149) is on the whole almost quadrangular, and narrower proximally than distally. It is besides curved so as to be somewhat convex dorsalward and, accordingly, volarward forms a groove which is made deeper by the fact that the radial and the ulnar sides are somewhat elevated; radialward are the tuberculum ossis navicularis and the tuberculum ossis multanguli majoris which together form the *eminentia carpi radialis*; ulnarward the os pisiforme and the hamulus ossis hamati project upward and form the *eminentia carpi ulnaris*. The groove bounded by the two eminentiae carpi is called the *sulcus carpi*; it is converted into a complete *canalis carpi* by the ligamentum carpi transversum which extends between the eminentiae: through this canal go the tendons, vessels and nerves to and from the fingers.



147. Metacarpal bone and phalanges of the third finger of the right hand, *os metacarpale III et phalanges digiti III*, from the dorsal surface.

The five **ossa metacarpalia** (see also Figs. 146, 148—151) are short cylindrical bones, each of which is divisible into a shaft, or *corpus*, a proximal extremity, *basis*, and a distal extremity, *capitulum*. The whole bone is curved, so as to be slightly convex toward the back of the hand.

The *corpus* or shaft is triangular so that one side looks dorsalward, the other two radial- and ulnarward; the latter surfaces meet in an angle directed volarward. On the volar surface is a large *foramen nutricium*, which leads into a *canalis nutricius* directed in the thumb distalward, in the second to the fifth finger, proximalward.

The *basis* is somewhat broadened and presents on its proximal surface an articular surface for connection with the carpus, between the second and the fifth finger also small articular surfaces on the radial and ulnar surface for the neighboring metacarpal bones. The basis ossis metacarpalis I, has a saddle-shaped joint surface (for the os multangulum majus) but no lateral articular surfaces. On the basis ossis metacarpalis III, from the radial part of the dorsal surface, a blunt process, the *processus styloideus ossis metacarpalis III*, projects toward the carpus. The basis ossis metacarpalis V presents proximalward a slightly saddle-shaped articular surface and a flat articular surface on the radial side.

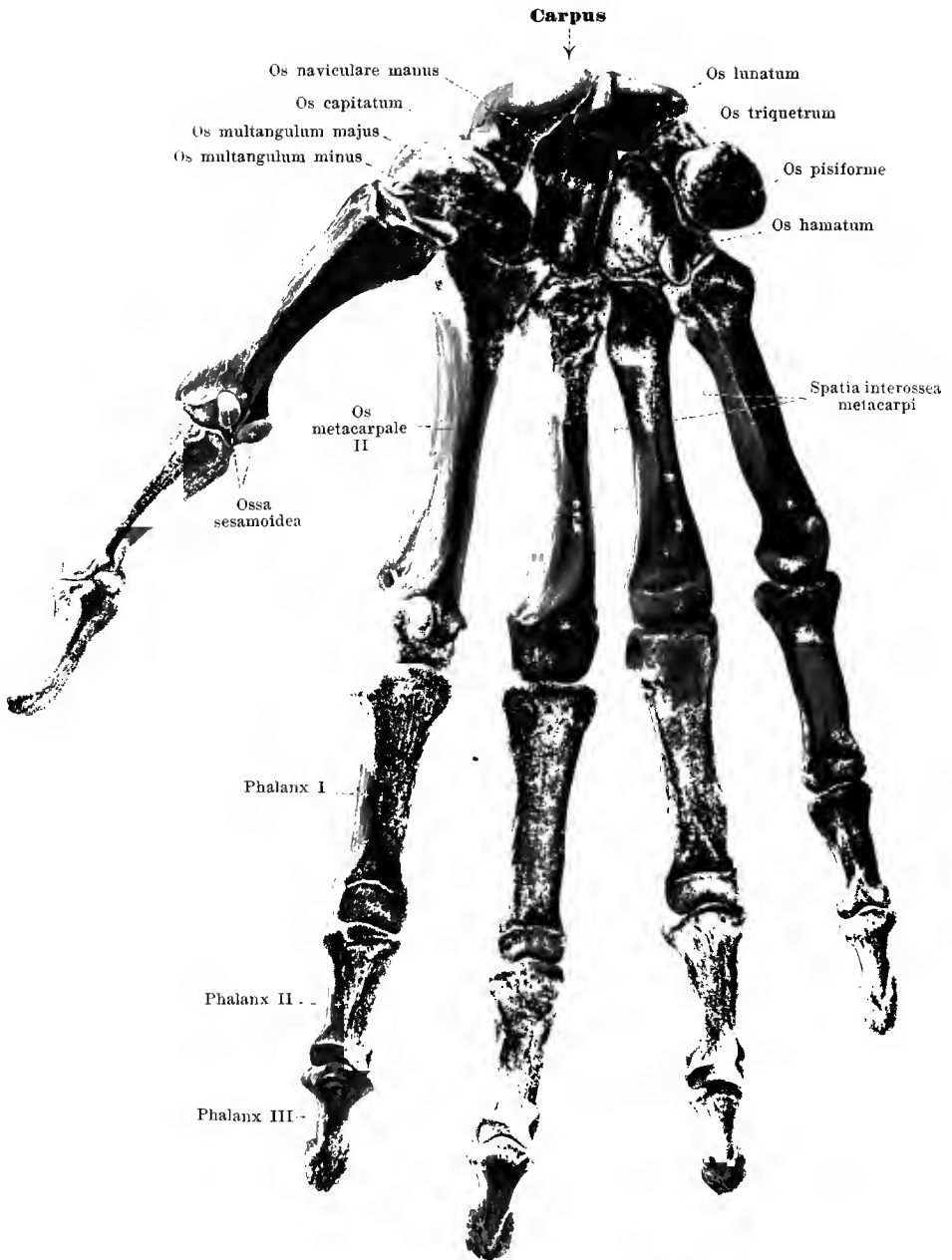
Each *capitulum* possesses a spherical articular surface, covered with cartilage, which extends upon the volar more than upon the dorsal surface. On the two sides there are depressions and roughened areas for the ligaments of the joint.

The four spaces lying between the ossa metacarpalia (see Figs. 148 and 149) are called *spatia interossea metacarpi*. The first, between thumb and index finger is the broadest. They are all filled out by the mm. interossei.

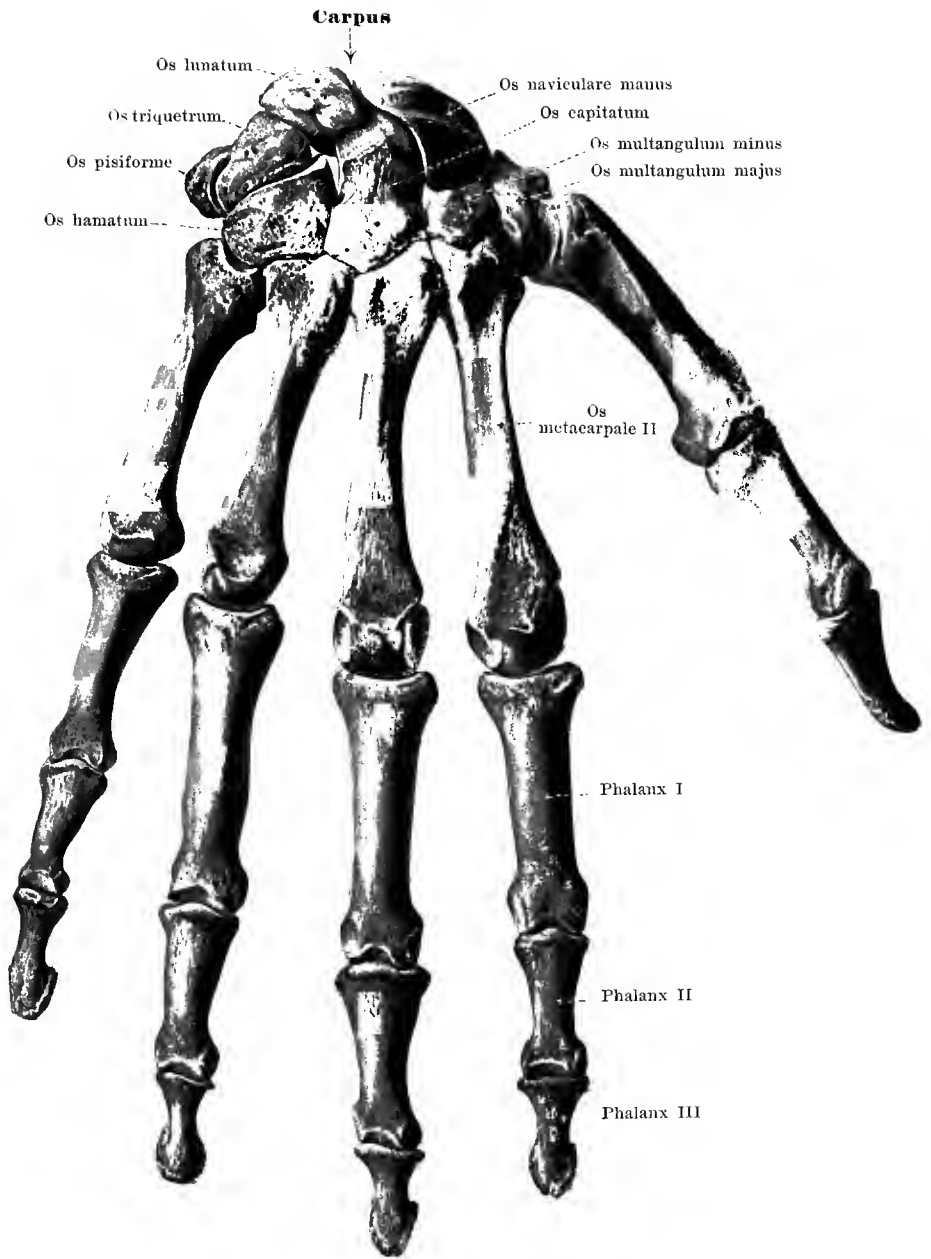
The **phalanges digitorum** (see also Figs. 148 and 149) are three in number from the second to the fifth finger; while on the thumb there are two; they are called *phalanx prima*, *secunda*, *tertia*. Each *phalanx* is a short cylindrical bone which is divisible into a shaft or *corpus*, a proximal end, *basis*, and a distal end.

The *corpus* is flat volarward and curved dorsalward so as to be convex in transverse direction. A large *foramen nutricium* on its volar surface leads into a *canalis nutricius* directed distalward. The *basis* is somewhat broadened and possesses a deep articular surface, covered with cartilage, which on the first phalanx is simple, on the others is divided by a ridge. The distal end of the first phalanx of the thumb and also of the first and second phalanx of the remaining fingers has a *trochlea*, a small transverse roller surface covered with cartilage, with a groove in the middle; on the sides lie small depressions for the attachment of the ligaments of the joint. On the terminal phalanx the distal end is transformed to a broad flat rough area, the *tuberositas unguicularis*.

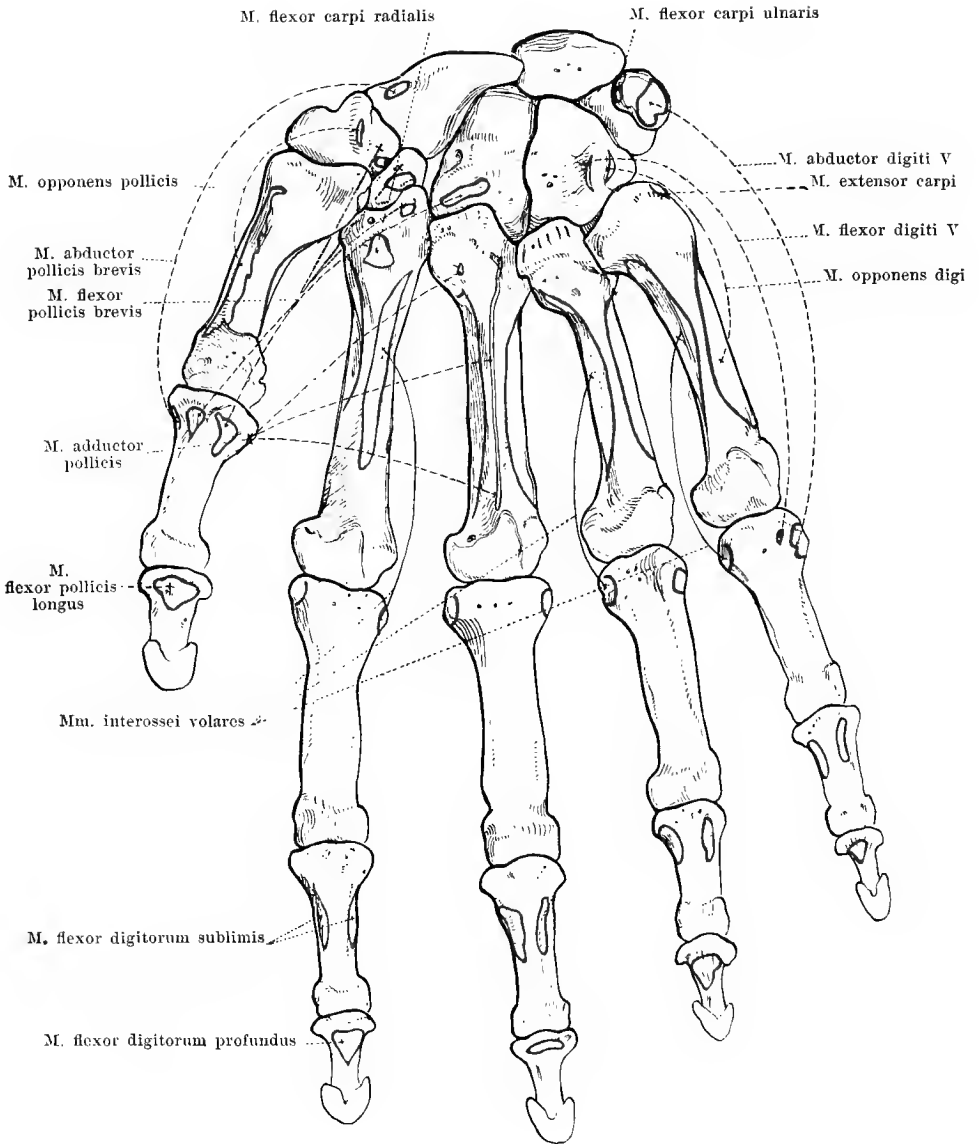
Ossa sesamoidea (*sesamoid bones*) (see Fig. 148) are small masses of bone which, embedded in tendons or ligaments, lie upon the other bones. There are constantly five or almost constantly five such on the volar surface, two at the metacarpophalangeal joint of the thumb, one at the interphalangeal joint of the thumb and one each at the metacarpophalangeal joint of the second and of the fifth finger.



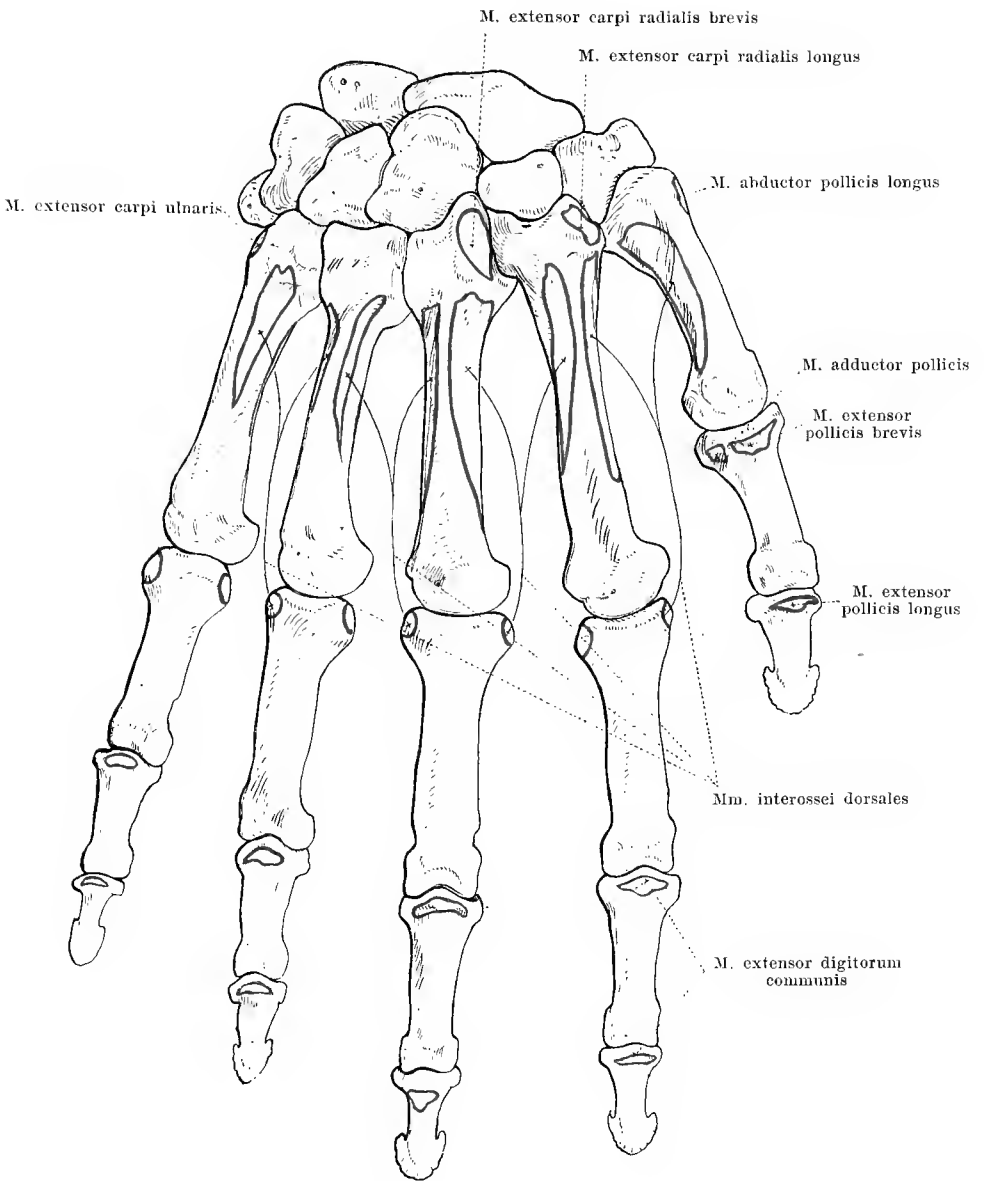
148. Bones of the right hand, *ossa manus*,
 from the volar surface.



149. Bones of the right hand, *ossa manus*, from the dorsal surface.

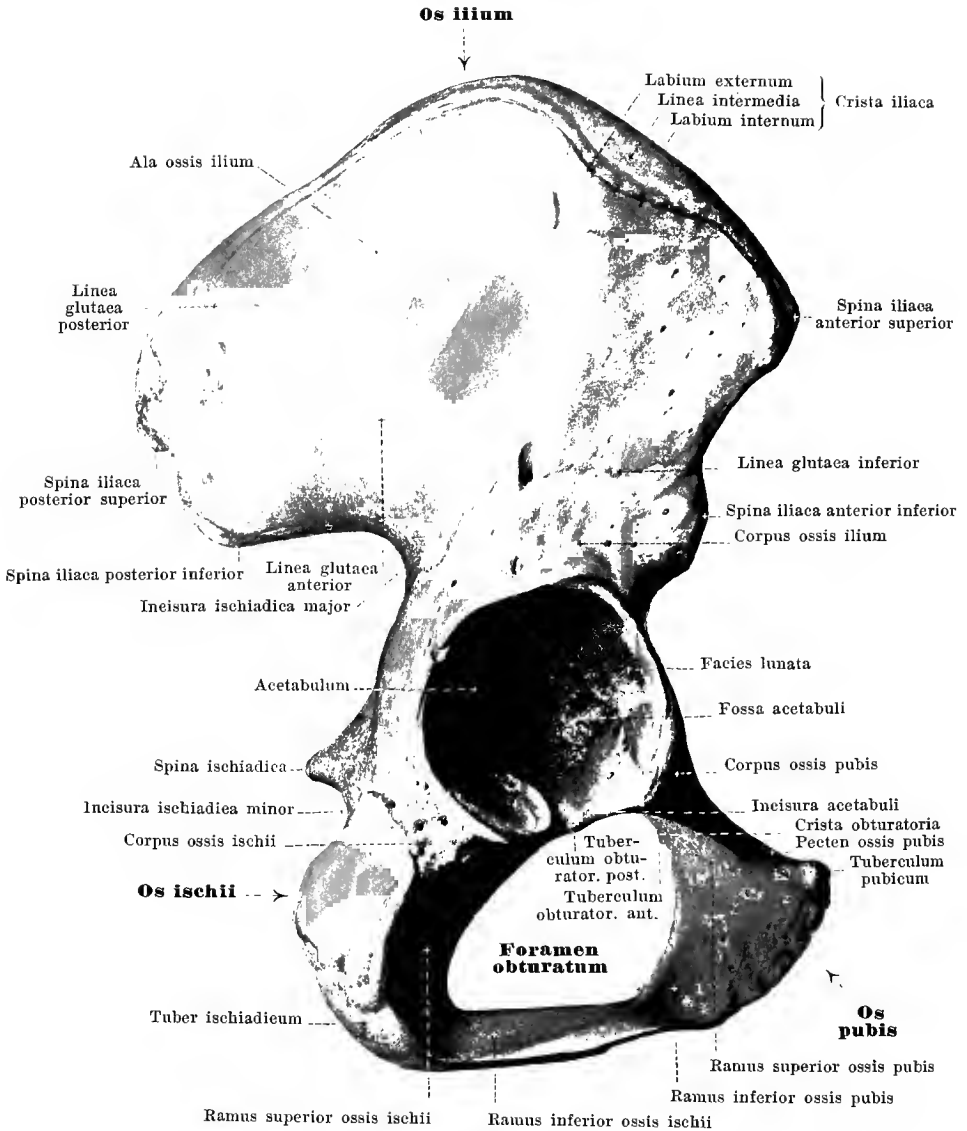


150. Bones of the right hand, *ossa manus*, from the volar surface, with the muscular attachments.



151. Bones of the right hand, *ossa manus*,
from the dorsal surface, with the muscular attachments.

(Beckler)

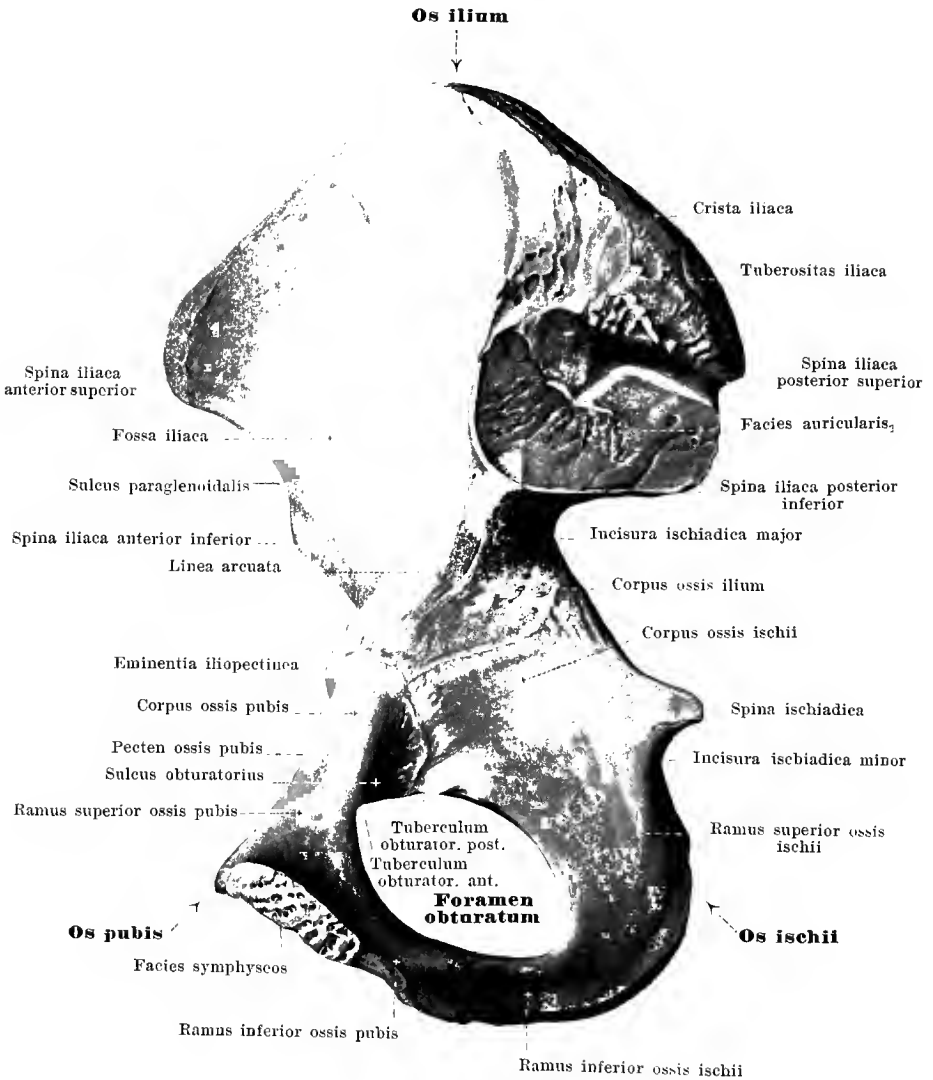


152. Right hip bone, *os coxae*, from without.

The **os coxae** (*hip bone*) (O. T. *os innominatum*) (see also Figs. 153—167) is paired, lies in the lowermost part of the trunk, and forms there with the same bone of the other side and with the sacrum a firm broad bony ring upon which the vertebral column rests above and with which, externally, the bones of the thigh are connected.

Each os coxae is composed of three pieces, separated until about the age of puberty: the *os ilium* which is directed upward and backward, the *os ischii*, which is directed downward and the *os pubis* which is directed forward and downward. These three constituents meet somewhat below the middle of the hip bone. At this spot on the external surface lies a wide deep fossa, the *acetabulum*. This is surrounded by a high bony wall which presents below a broad notch, the *incisura acetabuli*; in the bottom of the acetabulum a large rough spot is visible, the *fossa acetabuli*, which is surrounded in front, above and behind by a horse-shoe-shaped concave surface, the *facies lunata*, covered with cartilage. The acetabulum serves for articulation with the femur. In youth the places where the three bones unite are visible as a Y-shaped seam, the middle point of which is situated in the fossa acetabuli.

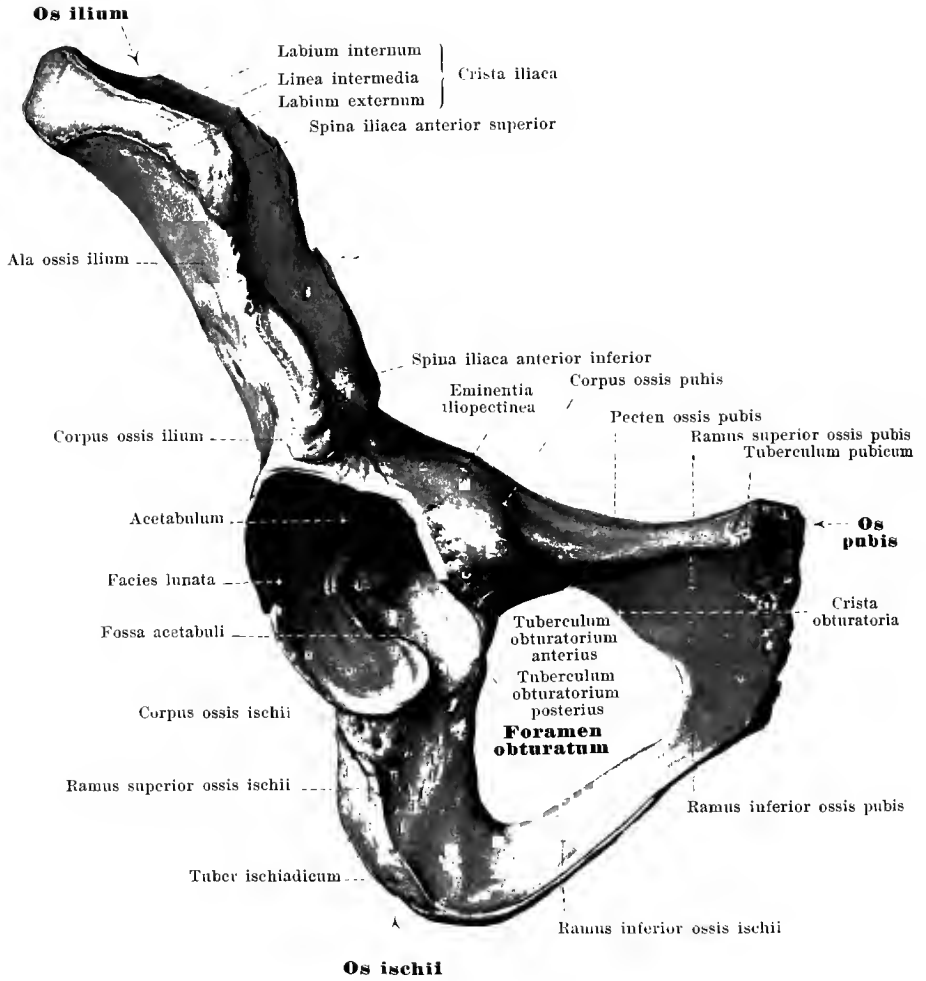
The **os ilium** helps to form the acetabulum by means of its thick and broad lower part, the *corpus ossis ilium* (vide supra); the upper part is a broad, in places very thin, somewhat wavy bony plate which bends backward, upward and lateralward and is called the *ala ossis ilium*. The corpus and ala are separated from one another by the *linea arcuata* a curved rounded bony ridge descending obliquely from behind and above, forward and downward. The free margin of the ala ossis ilium is curved like the letter S, being concave in front and medianward and behind and lateralward, besides it is markedly broadened; it is called the *crista iliaca* (*iliac crest*). On it the places of attachment of the abdominal muscles are marked as ridges, namely as *labium externum* and *labium internum* on the external and internal angle of the crest and as *linea intermedia* between these two. The crest ends in front in a blunt projection, *spina iliaca anterior superior*; below this the margin is narrower, somewhat concave and presents a second less marked projection, *spina iliaca anterior inferior*; below this it goes over into the corpus ossis pubis and there forms with the latter the *eminentia iliopectinea*. The iliac crest ends behind at the *spina iliaca posterior superior*; below it, separated by a small notch, lies the *spina iliaca posterior inferior* (sometimes indistinct), and still lower is a deep notch involving also the corpus ossis ischii, the *incisura ischiadica major* (O. T. great sacro-sciatic notch). The medial surface of the ala is for the most part, smooth, slightly concave, the *fossa iliaca*: behind it is an uneven portion, the anterior S-shaped half of which, *facies auricularis*, covered with cartilage, unites with the facies auricularis ossis sacri, while its posterior very rough half, *tuberositas iliaca*, serves chiefly for the attachment of the ligamenta sacroiliaca interossea. The facies auricularis is not infrequently partially surrounded in front and behind by a groove, the *sulcus paraglenoidalis*, which serves for the attachment of the deep fibrous bands of the ligamenta sacroiliaca. The external surface of the ala is fairly smooth, and curved so as to be partly concave, partly convex. It presents three rough ridges, convex upward and backward, the shortest of which, the *linea glutaea inferior* (O. T. inferior curved line), lies just above the acetabulum; above and behind this is the *linea glutaea anterior* (O. T. middle curved line) which is the longest of the ridges and extends from the incisura ischiadica major to the spina iliaca anterior superior; and above this the shorter *linea glutaea posterior* (O. T. superior curved line) runs from the spina iliaca posterior inferior to the crista iliaca.



153. Right hip bone, *os coxae*, from within.

The **os ischii** (O. T. ischium) helps by its thicker upper part or body, the *corpus ossis ischii*, to form the acetabulum. At the anterior margin of this, below the *incisura acetabuli*, there is not infrequently a small projection, *tuberculum obturatorium posterius*; from its posterior margin the strong, sharp *spina ischiadica* (O. T. spine of ischium) projects backward and somewhat medianward. The deep notch between the *spina ischiadica* and the *spina iliaca posterior inferior* is called the *incisura ischiadica major* (O. T. great sacro-sciatic notch); a second notch, the *incisura ischiadica minor* (O. T. lesser sacro-sciatic notch), below the *spina ischiadica*, between this and the *tuber ischiadicum*, is flatter and covered with cartilage.

Extending backward and downward from the body or corpus is the triangularly prismatic *ramus superior ossis ischii*; the surface of this, directed backward and lateralward, is rough and much thickened; it forms the *tuber ischiadicum* (O. T. tuberosity of the ischium). From the lower end of the *ramus superior* in front the thinner flat *ramus inferior ossis ischii* (O. T. ascending ramus) goes off, nearly at a right angle; it extends forward and upward and fuses with the inferior extremity of the *ramus inferior ossis pubis*.

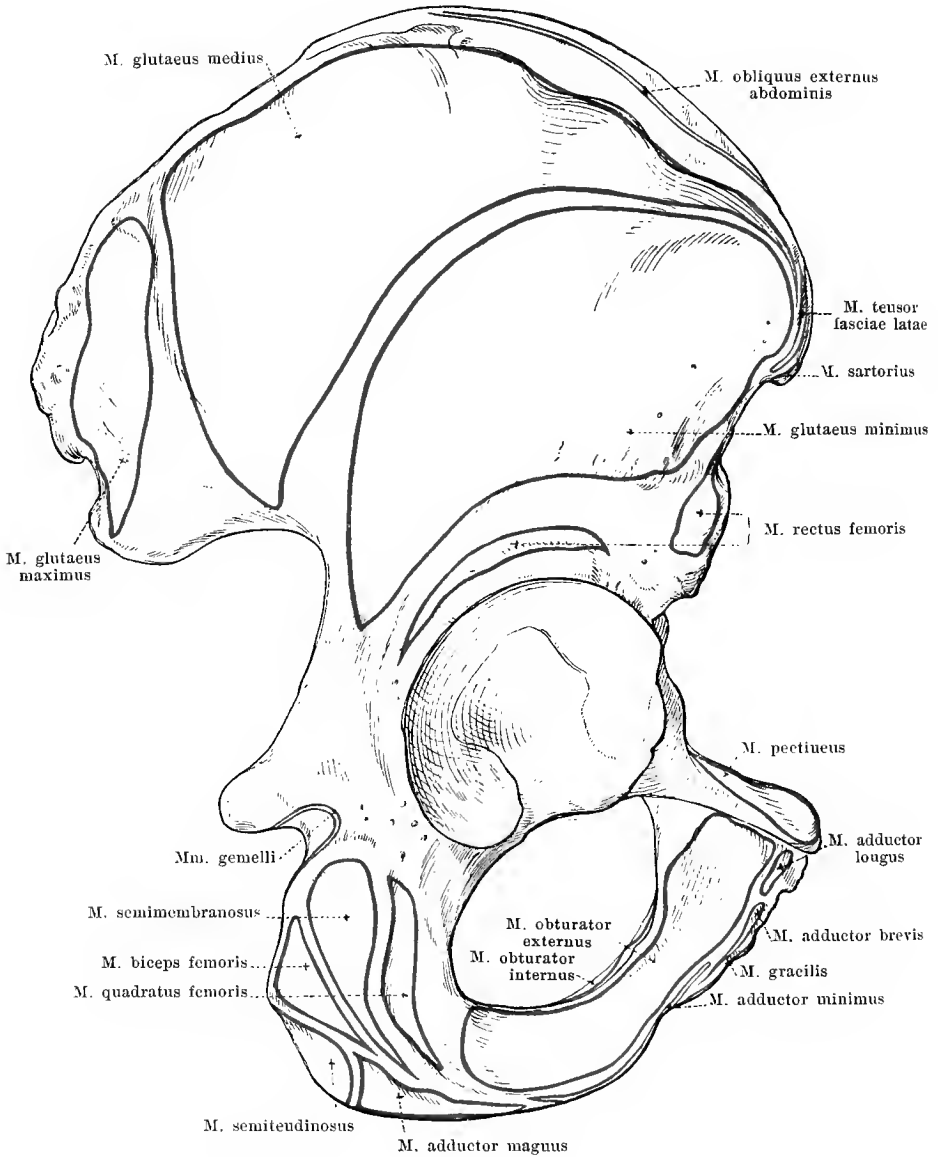


154. Right hip bone, *os coxae*, from in front and below.

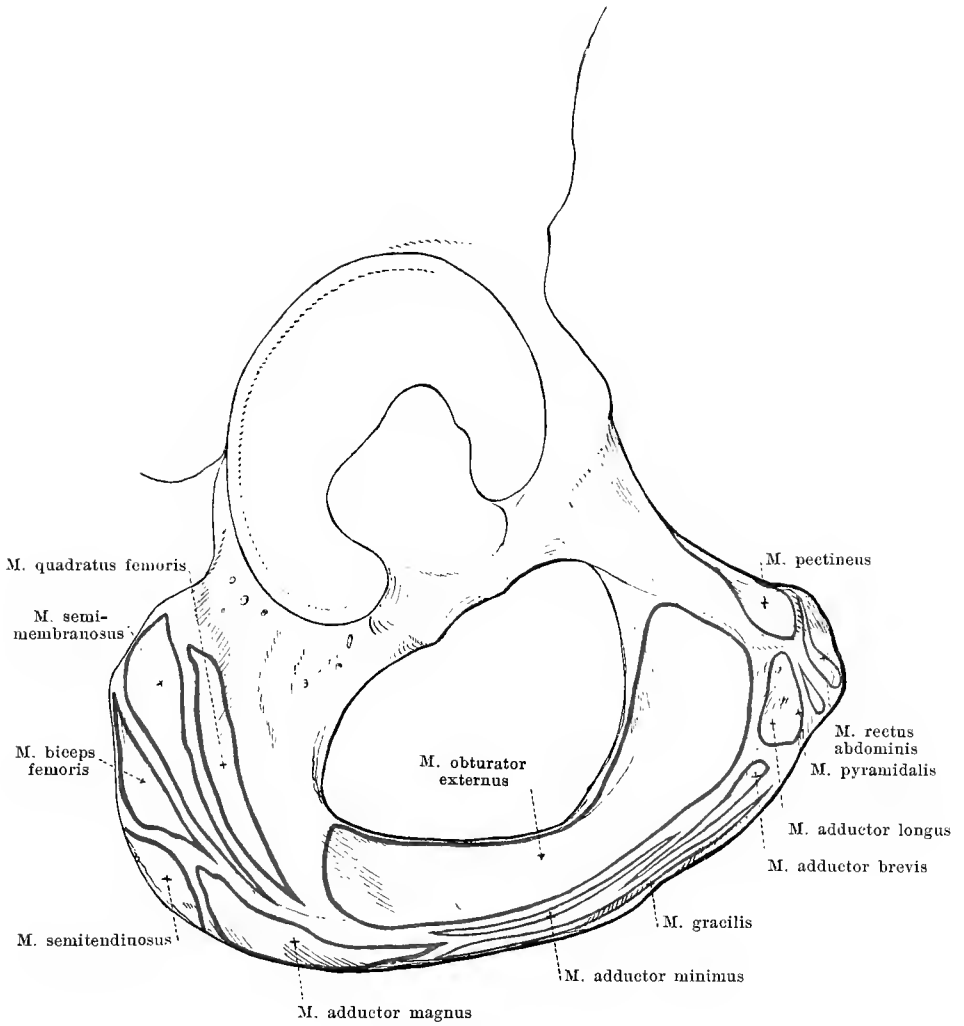
The **os pubis** helps, with its thicker upper lateral portion, the *corpus ossis pubis*, to complete the acetabulum. Medianward and somewhat in front of this portion lies a rough projection, *eminentia iliopectinea*, formed by the os pubis and the os ilium in common. Extending forward, downward and medianward from the corpus (*body*) is the *ramus superior ossis pubis*. It is triangular and grows narrower from the outside in. Its posterior surface is smooth and somewhat concave. Its superior, somewhat convex surface is directed at the same time obliquely lateralward and forward, is broad at its beginning at the acetabulum and at the *eminentia iliopectinea* and is narrow, where it ends, medianward; the posterior margin of this surface, *pecten ossis pubis*, projects in part to form a ridge, is continued behind and lateralward into the *linea arcuata ossis ilium* and forms with it and the projection between the *facies pelvina* and *basis ossis sacri* the *linea terminalis* of the pelvis; the anterior border arises from the *incisura acetabuli*, is rounded, slightly concave and ends near the median plane at a small rough projection, the *tuberculum pubicum* (O. T. spine of os pubis). The lower surface looks medianward at the same time forward and is continued lateralward into a groove, *sulcus obturatorius*, which ascends obliquely lateralward, backward and upward on the lower surface and ends on the inner surface; the sharp bony border below by which this surface and groove are bounded medianward is called the *crista obturatoria* and presents a small projection, *tuberculum obturatorium anterior*. The *ramus superior* ends medianward with an oval rough surface, *facies symphyseos* (O. T. symphysis pubis), for connection with the pubic bone of the other side.

The *ramus inferior ossis pubis* is the narrow, flat piece of bone which extends from the medial end of the *ramus superior* downward and lateralward and unites with the upper end of the *ramus inferior ossis ischii*.

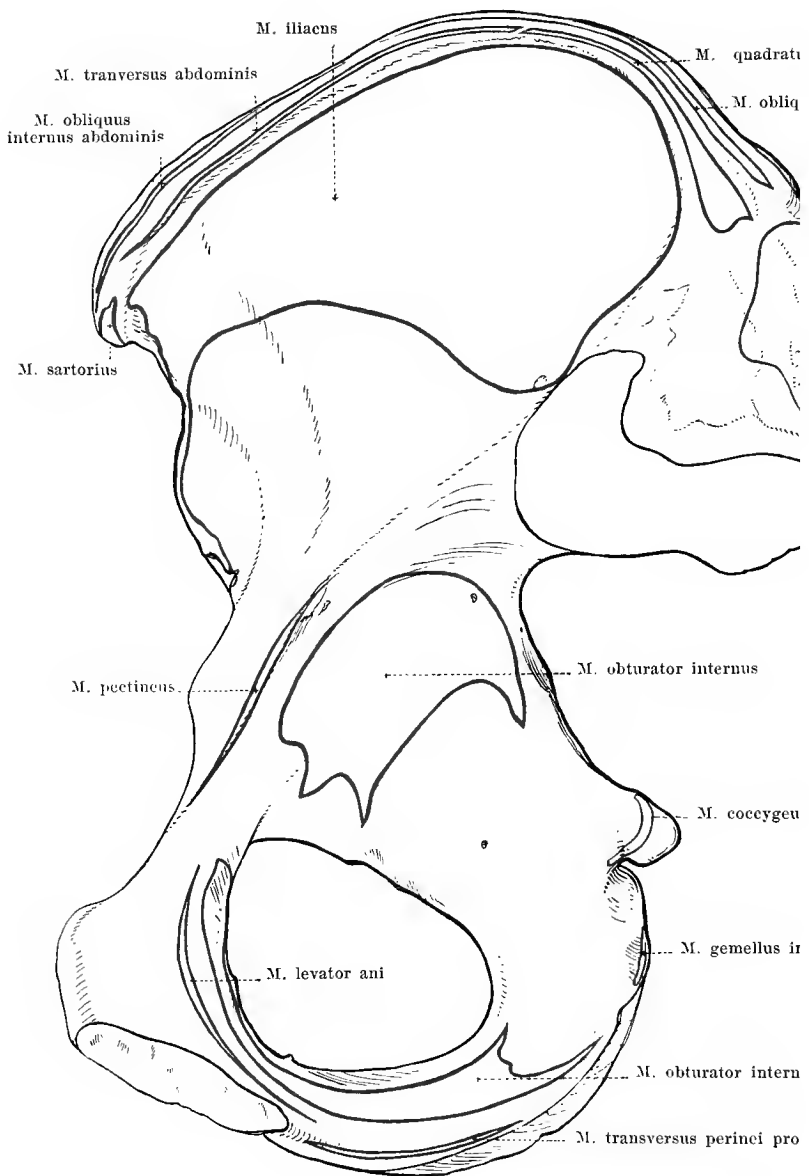
The **foramen obturatum** is a large triangularly oval opening which is bounded by the os ischii and the os pubis on all sides. Its margin is everywhere sharp, except in the upper lateral angle where the *sulcus obturatorius* is situated. The *foramen obturatum* is closed in the fresh pelvis by a thin membrane, *membrana obturatoria* (see Fig. 246) whose uppermost transverse bands are stretched out between the two *tubercula obturatoria*; the space thus left behind corresponds in its course to the *sulcus obturatorius* and is called the *canalis obturatorius* (for the a. and v. *obturatoria*; n. *obturatorius*).



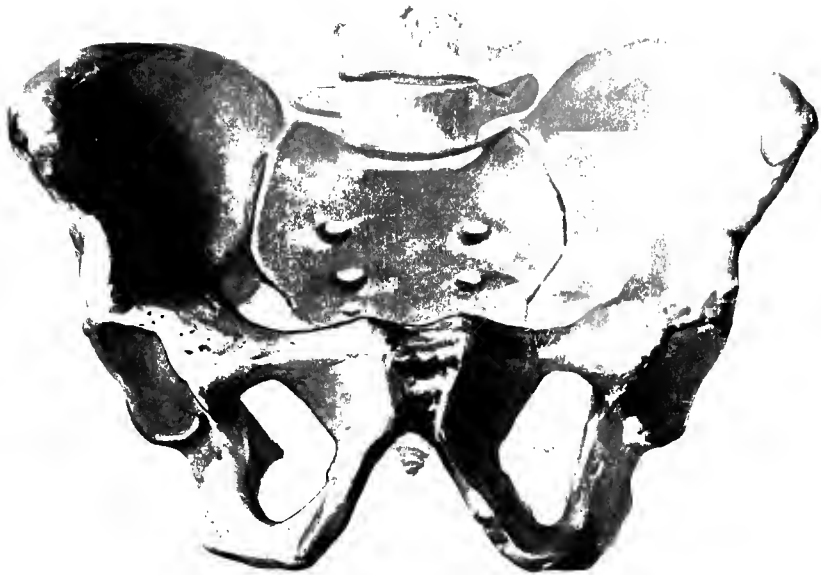
155. Right hip bone, *os coxae*, from behind and without, with the muscular attachments.



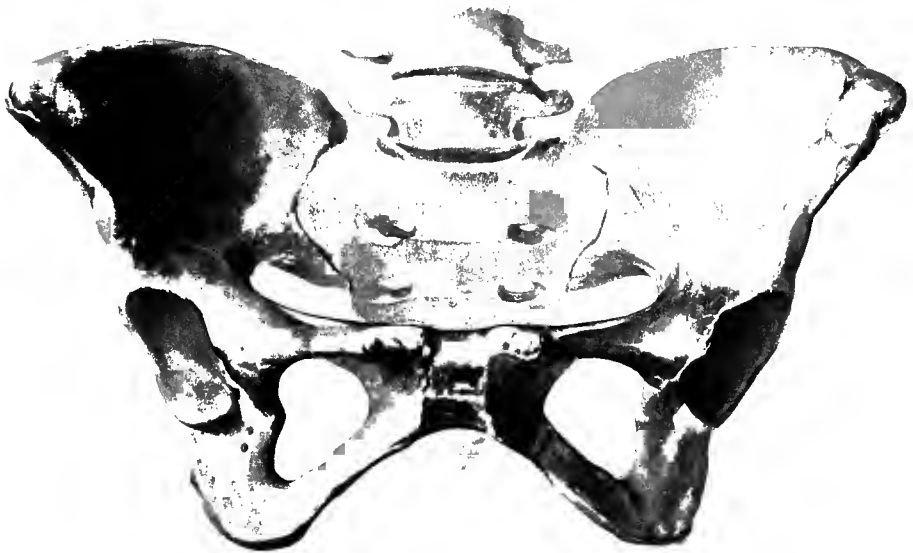156. Right hip bone, *os coxae*, from in front and without and somewhat from below, with the muscular attachments.



157. Right hip bone, *os coxae*, from within with the muscular attachments.



158. Male pelvis, *pelvis*, from in front and below.



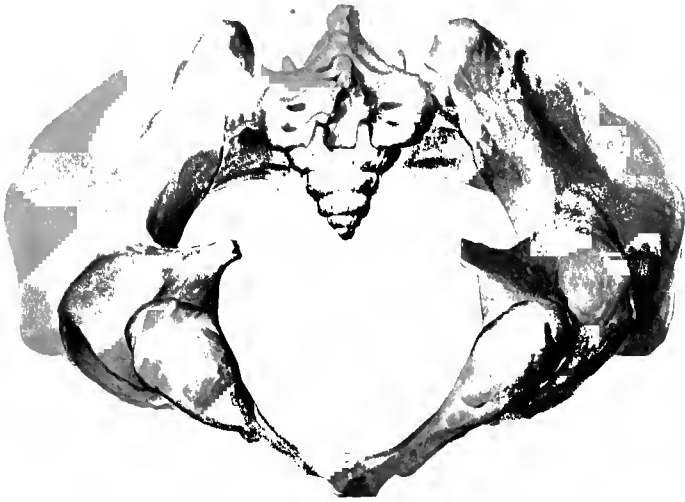159. Female pelvis, *pelvis*, from in front and below.



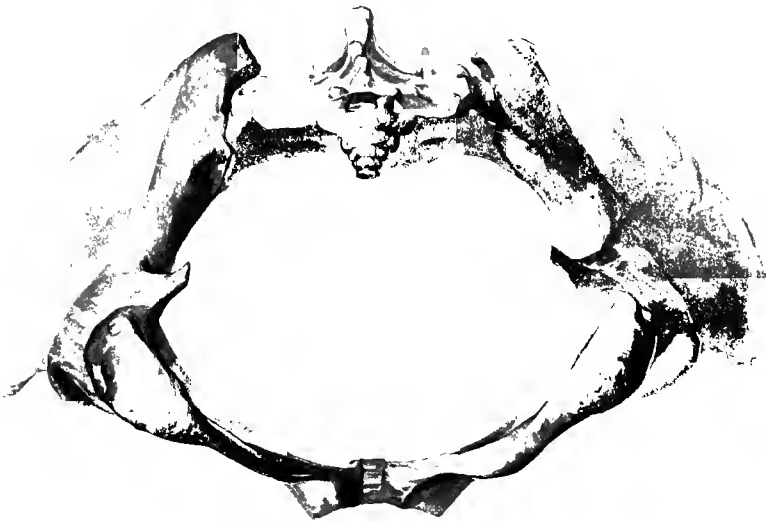
160. Male pelvis, *pelvis*, from in front and above.



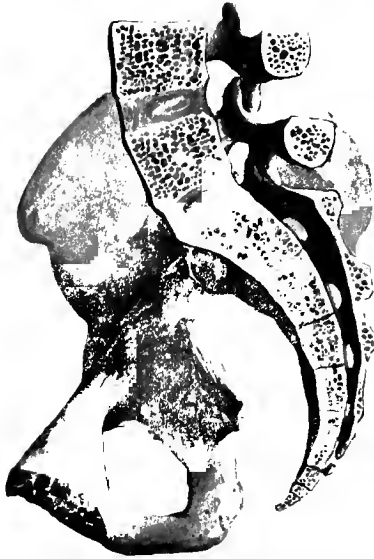161. Female pelvis, *pelvis*, from in front and above.



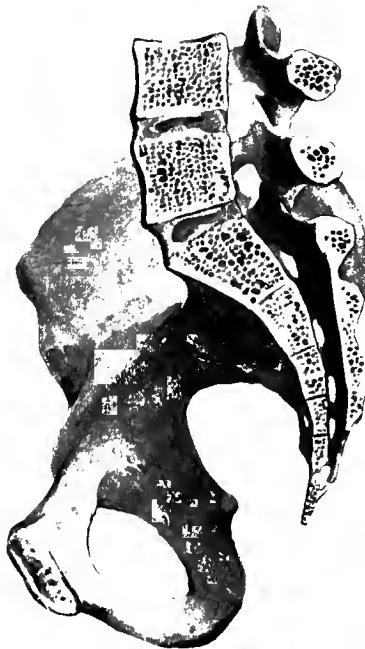162. Male pelvis, *pelvis*, from below and behind.



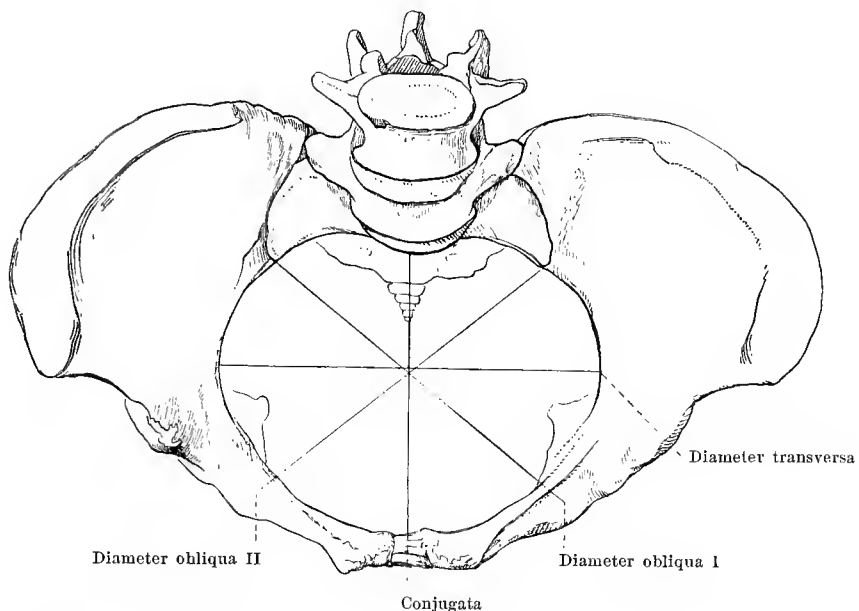
163. Female pelvis, *pelvis*, from below and behind.



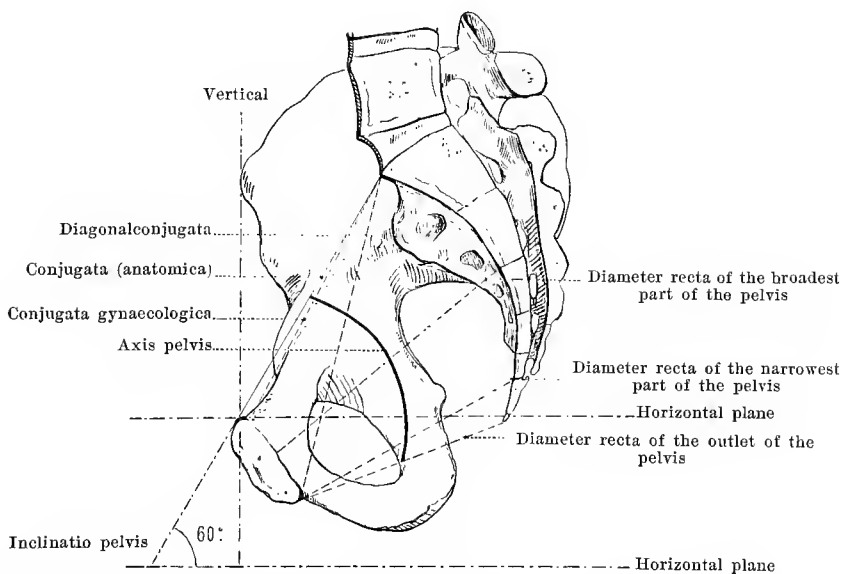
164. Male pelvis, *pelvis*, median section, right half, from the left.



165. Female pelvis, *pelvis*, median section, right half, from the left.



166. Female pelvis, *pelvis*, from in front and above, with pelvic diameters.



167. Female pelvis, *pelvis*, median section, right half, from the left, with pelvic diameters.



168. Right thigh bone, *femur*, from in front.

The **femur** (see also Figs. 169—177) (*thigh bone*) is the longest cylindrical bone of the human body and lies in the thigh; it articulates above with the acetabulum of the hip bone, below with the tibia and is so situated that its long axis is oblique in that the two thigh bones converge toward one another at their lower extremities.

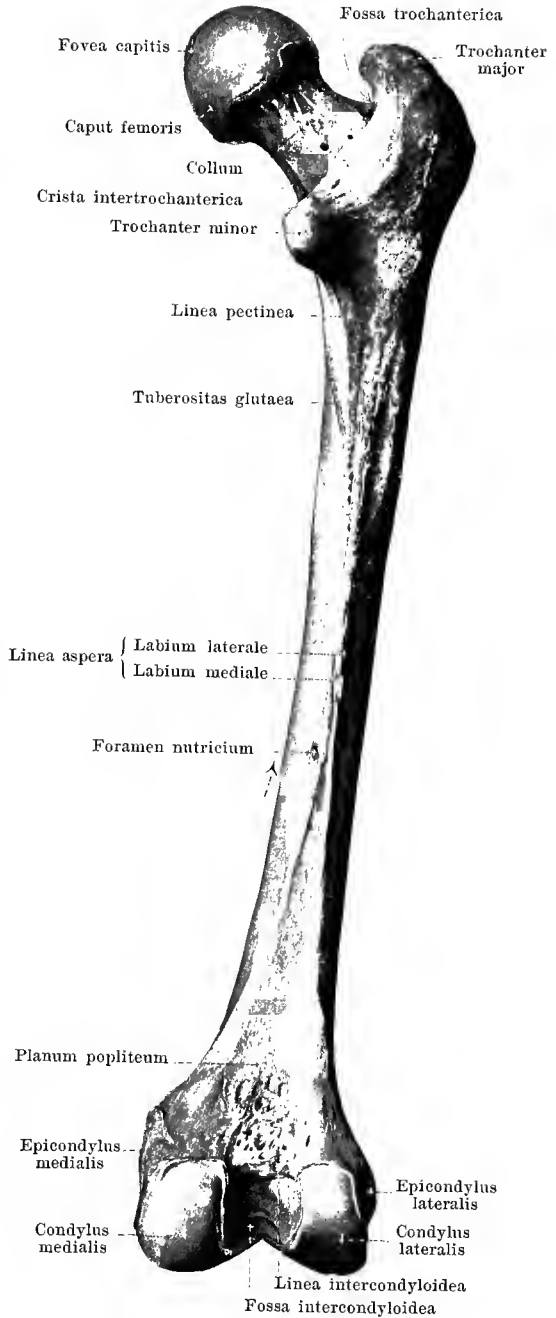
The thigh bone is divisible into a shaft or *corpus*, and two extremities.


The **corpus femoris** (*shaft*) is curved so as to be slightly convex in front and is nearly triangularly prismatic. Its anterior surface is very convexly curved in transverse direction and goes over without sharp limit into the two lateral surfaces which are also directed backward; these latter meet in the middle behind in a rough ridge, *linea aspera*, on which two lips are distinguishable, an external, *labium laterale*, and an internal, *labium mediale*. Below and above, these two lips diverge: below they go to the two condyles and leave between them a flat, triangular field, *planum popliteum* (O. T. popliteal space). Above, the medial lip extends partly toward the trochanter minor and forms a tolerably distinct ridge, *linea pectinea*, in part it bends below the trochanter minor forward and upward and is continued into the linea intertrochanterica; the lateral lip turns outward and goes over into an oblong rough field, *tuberositas glutacea*, which sometimes projects like a comb as the so-called *trochanter tertius*.

In the middle of the linea aspera can be seen usually one large or several smaller *foramina nutriticia*, which lead into *canales nutriticii*, directed proximalward.

169. Right thigh bone,
femur, from behind.

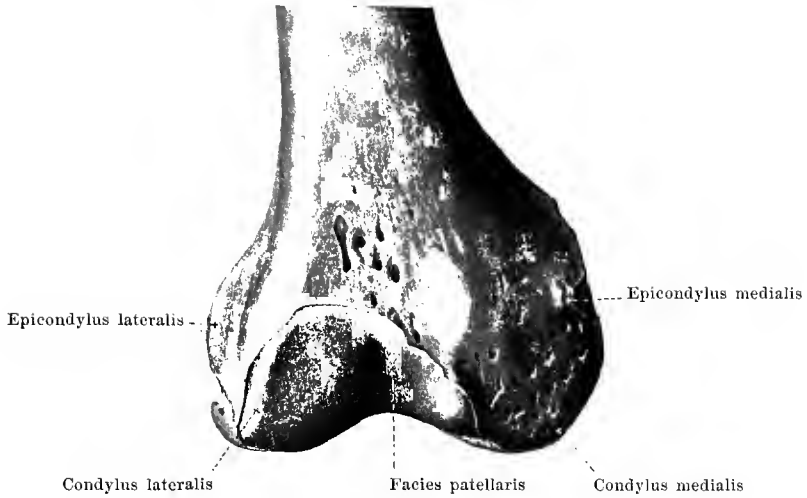
The **upper extremity of the femur** supports the *caput femoris* (*head*), covered with cartilage, which is directed obliquely inward and upward and possesses medianward a small rough depression, the *fovea capitis femoris*. The head includes about three-fourths of the surface of a sphere. It sits upon the *collum femoris* (*neck*) which looks flattened out from before backward; the long axis of the neck is directed obliquely medianward and upward. At the place where the neck is united with the shaft there are two large projections from the posterior surface, the *trochanter major* and the *trochanter minor*. The trochanter major projects directly backward and upward and possesses on its medial surface, below the blunt tip which is bent medianward, a deep fossa, *fossa trochanterica* (O. T. digital fossa). The trochanter minor is situated lower down and looks also medianward. The *crista intertrochanterica* (O. T. intertrochanteric line), in part very markedly projecting, connects the two trochanters on the posterior surface. The much less prominent *linea intertrochanterica* (O. T. spiral line) runs on the anterior surface of the bone obliquely downward and medianward from the trochanter major, turns backward below the trochanter minor and becomes lost in the labium mediale of the linea aspera.



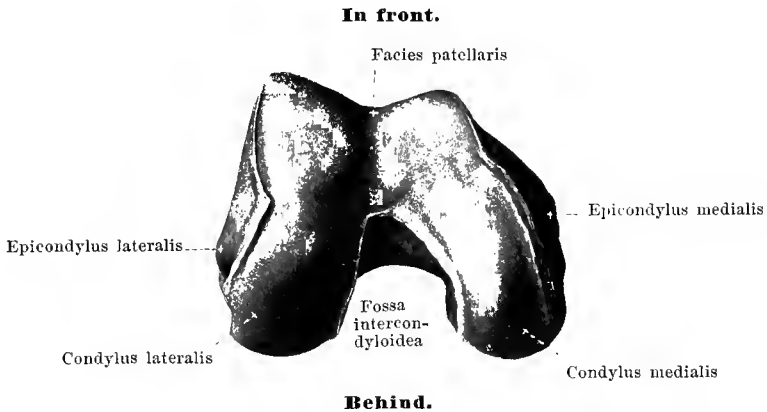


170. Right thigh bone, *femur*, from within.

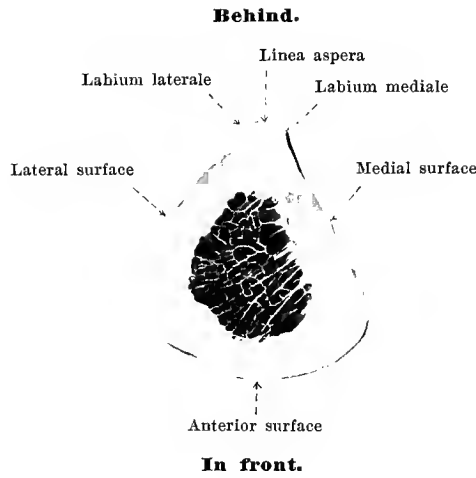
The **inferior extremity of the femur** is thickened and runs out into two strong *condyli* (*condyles*), covered with cartilage, which are especially developed backward, where they are, however, separated from one another by a deep notch, the *fossa intercondyloidea*. The *condylus medialis* (O. T. inner condyle) is larger than the *condylus lateralis* (O. T. outer condyle); both, on account of the oblique position of the thigh bone, are situated in the same horizontal plane in the body; the lateral condyle projects further forward in front than does the medial. Both are covered with cartilage behind, beneath, and in front, run together in front to form a common surface, the uppermost part of which, *facies patellaris*, is hollowed out in the middle like a groove and receives the patella when the knee is extended. The surface, covered with cartilage, is curved so as to be markedly convex in the sagittal direction. The lateral surfaces of the condyles are rough and each presents a prominent nodule, the *epicondylus medialis* (O. T. inner tuberosity) on the condylus medialis and the *epicondylus lateralis* (O. T. outer tuberosity) on the condylus lateralis. The fossa intercondyloidea is rough and bounded above toward the planum popliteum by the *linea intercondyloidea*.



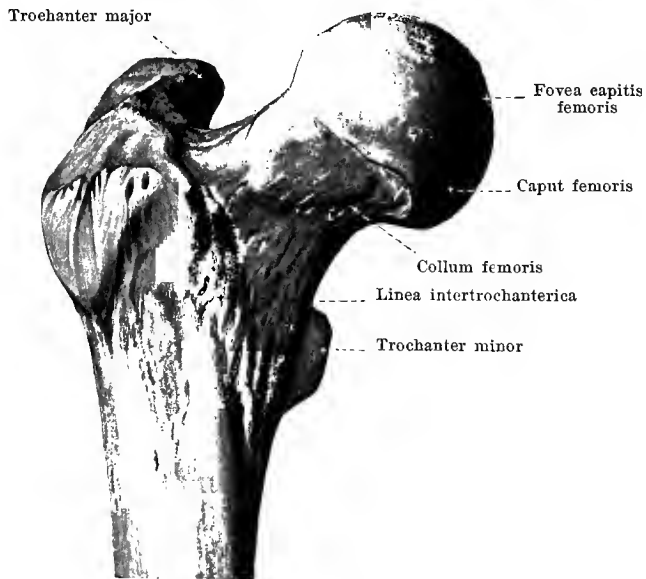
171. Right thigh bone, *femur*, inferior extremity, from in front.



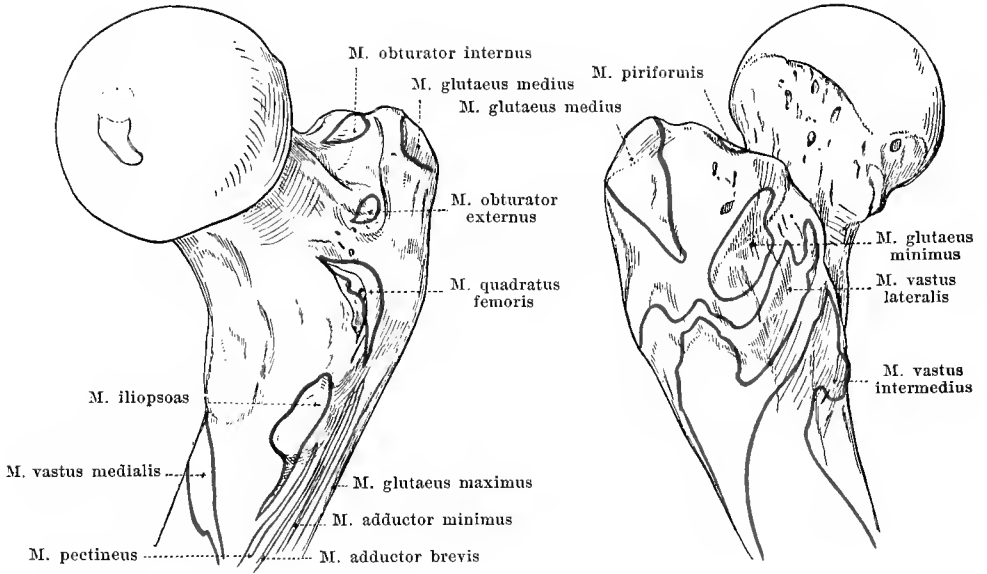
172. Right thigh bone, *femur*, inferior extremity, from below.



172^a. Transverse section through the middle of the right thigh bone.



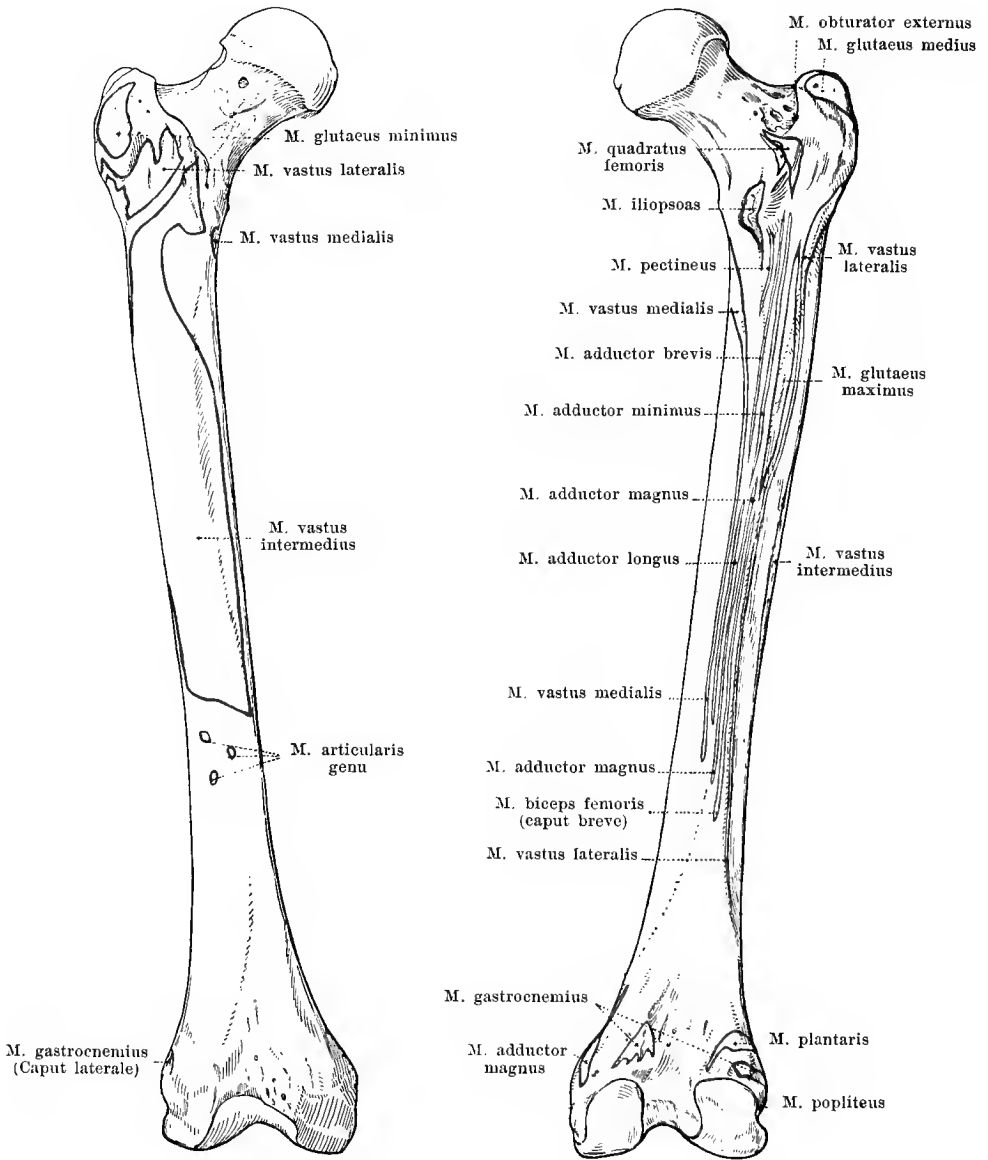
173. Right thigh bone, *femur*, upper extremity, from in front.



174 and 175. Right thigh bone, *femur*, upper extremity, with the muscular attachments.

From behind and within.

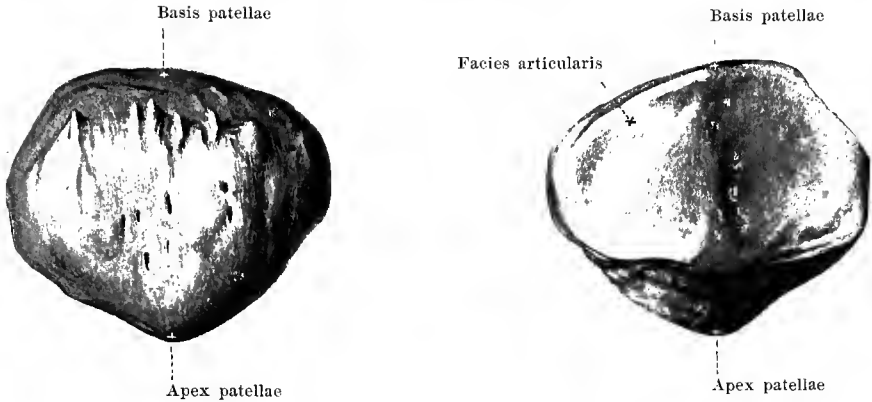
From in front and without.



176 and 177. Right thigh bone, *femur*, with the muscular attachments.

From in front.

From behind.

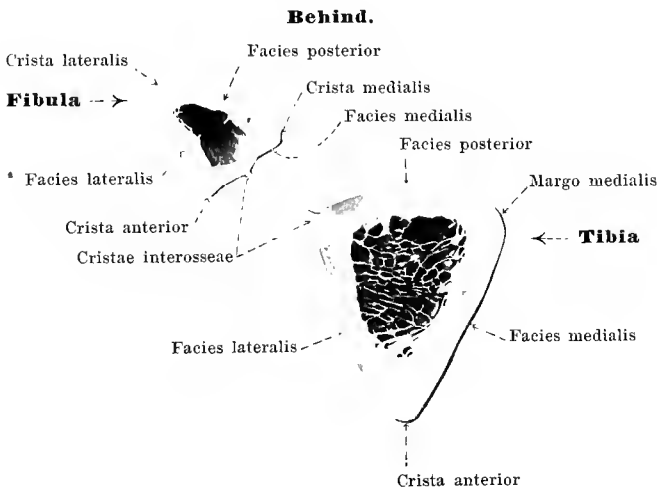


178 and 179. Right patella, *patella*.

From in front.

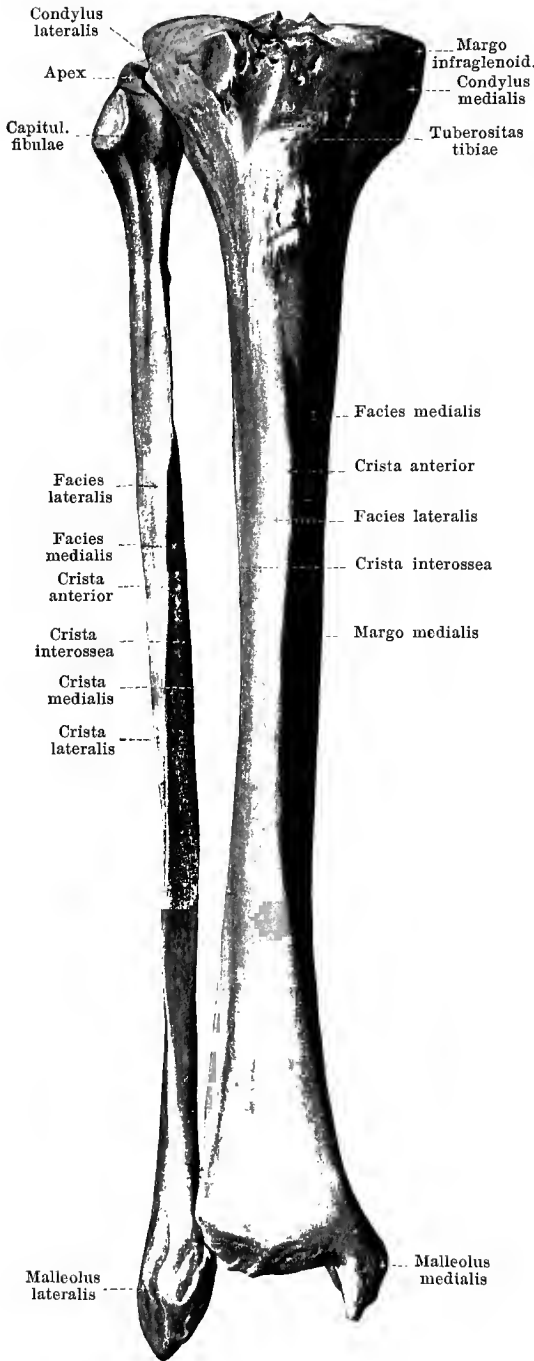
From behind.

The **patella** (*knee-cap*) is a flat, rounded bone, which is intercalated as a large sesamoid bone in the terminal tendon of the m. quadriceps femoris, and is situated in front of the lower extremity of the femur. The upper end is the broader, *basis patellae*, the lower end is somewhat pointed, *apex patellae*, the margins are but little sharpened. The anterior surface is rough. The posterior surface is for the most part covered with cartilage, *facies articularis*, and divided by a longitudinal projection into a somewhat larger lateral and a somewhat smaller medial part; when the knee is extended it lies on the facies patellaris femoris and in movements of flexion at the knee joint glides downward and backward between the two joint-condyles of the femur in front of the fossa intercondyloidea.



180^a. Transverse section through the middle of the bones of the right leg.

180. Right shin bone and calf bone, *tibia* and *fibula*, from in front.



The **tibia** (*shin bone*) (see also Figs. 180^a, 181—185) is a long, strong cylindrical bone and lies in the medial portion of the leg; it articulates above with the femur, below with the tarsus and also, above and below, with the fibula. It is divisible into a shaft or *corpus* and two extremities.

The **corpus tibiae** (*shaft*) is triangularly prismatic, possesses a posterior, nearly flat surface, *facies posterior*, a smooth, somewhat convex surface looking forward and medianward, *facies medialis*, and a slightly concave surface directed forward and lateralward, *facies lateralis*. Of the three borders where the surfaces meet, the anterior, *crista anterior*, is the sharpest; the laterally directed *crista interossea* is less sharp, while the medial, *margo medialis*, is rounded off. At the uppermost part of the posterior surface a rough ridge, *linea poplitea* (popliteal line), extends obliquely from above and lateralward, downward and medialward. At the junction of the upper and middle thirds there is behind usually a large *foramen nutricium* which leads into a distally directed *canalis nutricius*.

The **upper extremity of the tibia** is broadened markedly to form on the two sides the tibial condyles, *condylus medialis* (O. T. internal tuberosity) and *condylus lateralis* (O. T. external tuberosity). Each of these possesses a proximally directed, triangularly oval, somewhat depressed *facies articularis superior*, covered with cartilage; between the two lies a rough surface, broader in front and behind, which is elevated in the middle to form the *eminentia intercondyloidea* (O. T. spinous process) where it ends in two small spurs, the *tuberculum intercondyloideum mediale* and the *tuberculum intercondyloideum laterale*. The area in front of the eminence is called the *fossa intercondyloidea anterior*, that behind it the *fossa intercondyloidea posterior*. The surface covered with cartilage is continued on each side for a certain distance upon the eminence. On the outer circumference of the *facies articularis superior* the bone falls suddenly as the *margo infraglenoidalis*. Below this, at the upper end of the *crista anterior*, a rough broad, projecting spur is visible, the *tuberositas tibiae* (O. T. tubercle); at about the same level on the posterior lateral part of the condylus lateralis lies a small, flat, oval articular surface for the capitulum fibulae, *facies articularis fibularis*.

181. Right shin bone and calf bone, *tibia* and *fibula*, from behind.

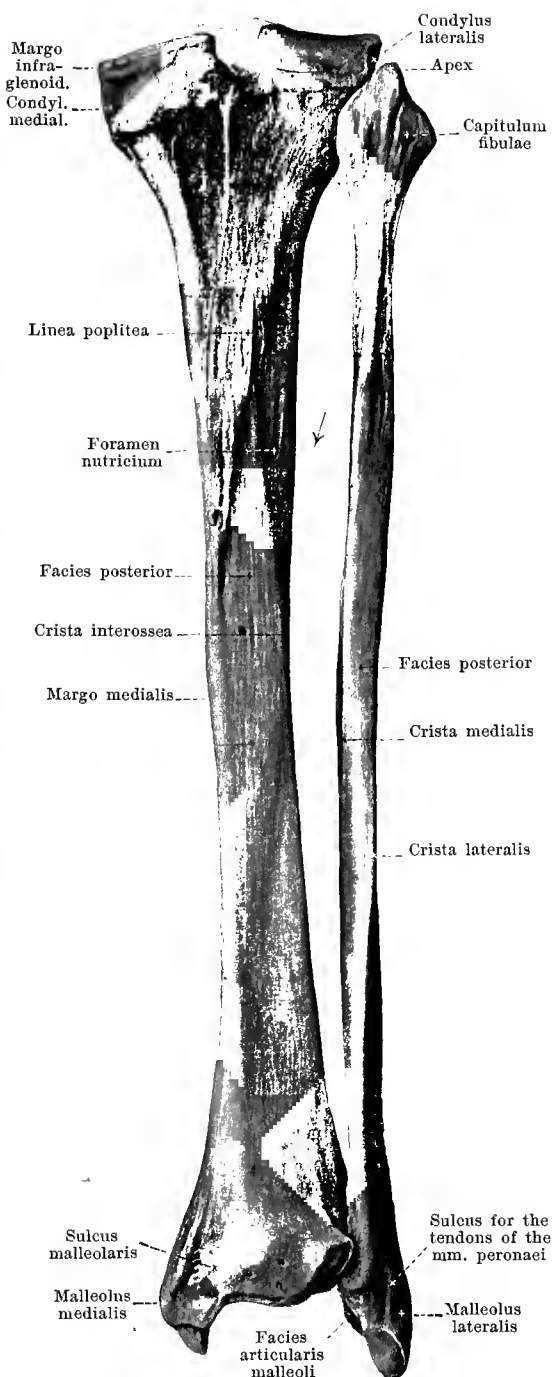
The **inferior extremity of the tibia** is quadrilateral, but not much broadened; the lateral surface is somewhat concave below, *incisura fibularis*, for the attachment of the malleolus lateralis fibulae; medianward a strong blunt process passes downward, *malleolus medialis* (O. T. internal malleolus), which on its medial surface is somewhat rough, on its lateral surface (*facies articularis malleolaris*), is covered with cartilage; on the posterior surface near the malleolus a shallow furrow extends downward, *sulcus malleolaris* (for the tendon of the m. tibialis posterior). The surface directed distalward, *facies articularis inferior* (for the talus) is slightly concave, quadrangular, and covered with cartilage.

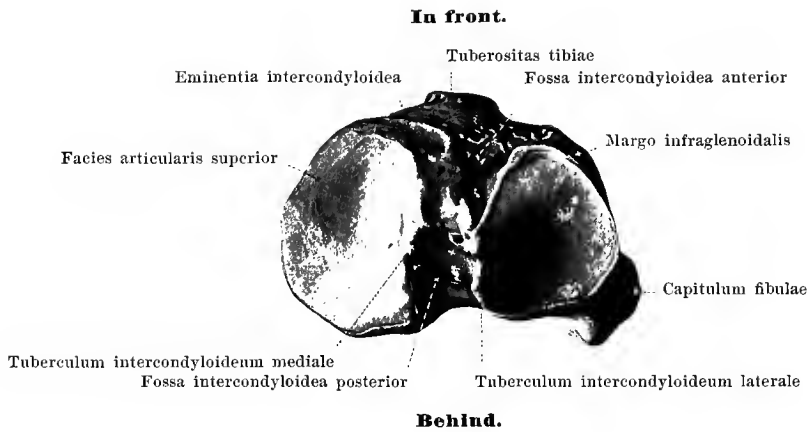
The **fibula (calf bone)** (see also Figs. 180^a, 180, 182—185) is a long, thin cylindrical bone situated in the lateral part of the leg and connected above with the tibia, below with the tibia and the tarsus. It is divisible into a shaft or *corpus*, an upper extremity, *capitulum* and a lower extremity, *malleolus lateralis*.

The **corpus fibulae** or *shaft* is nearly triangularly prismatic in shape, but appears at the same time twisted on its long axis. It presents a posterior surface, *facies posterior*, an anterior medial, *facies medialis*, and an anterior lateral, *facies lateralis*. They are separated from one another by three borders; the sharpest looks forward, *crista anterior*, the second is directed medianward, *crista medialis* and the third lateralward, *crista lateralis*; further, running down over the medial surface is the *crista interossea*, of markedly variable development. In the middle of the posterior surface a *foramen nutricium* leads into a *canalis nutricius* which runs distalward.

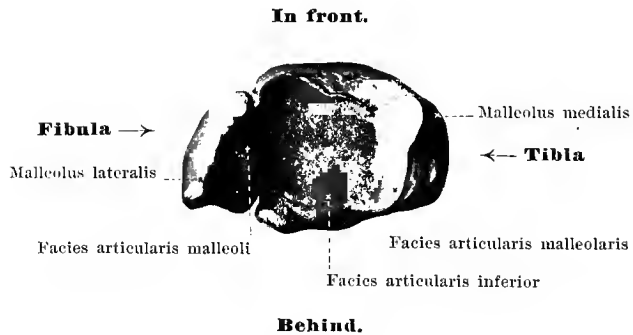
The **capitulum fibulae (head)** is somewhat thickened, runs out proximally into a blunt tip, *apex capituli fibulae*, and supports on its medial anterior surface a small flat joint surface, *facies articularis capituli*.

The **malleolus lateralis** (O. T. external malleolus) is thickened, projects further downward than the malleolus medialis and ends in a blunt tip. On its medial surface it is covered with cartilage, *facies articularis malleoli*, and, above this surface, lies in the *incisura fibularis tibiae*. The other surfaces are rough; on the posterior surface a shallow furrow for the tendons of the mm. peronei is visible.

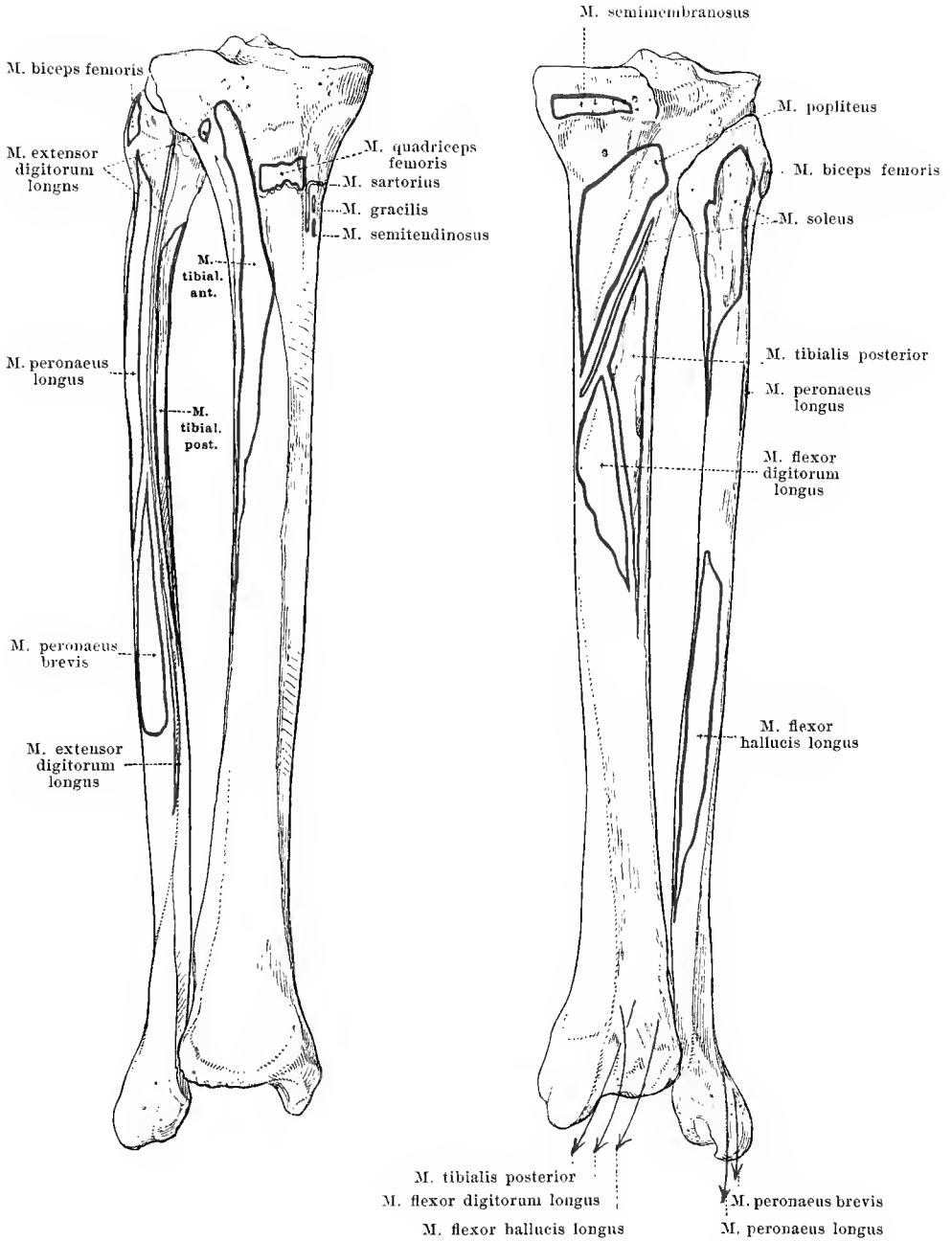




182. Right tibia and fibula,
from above.



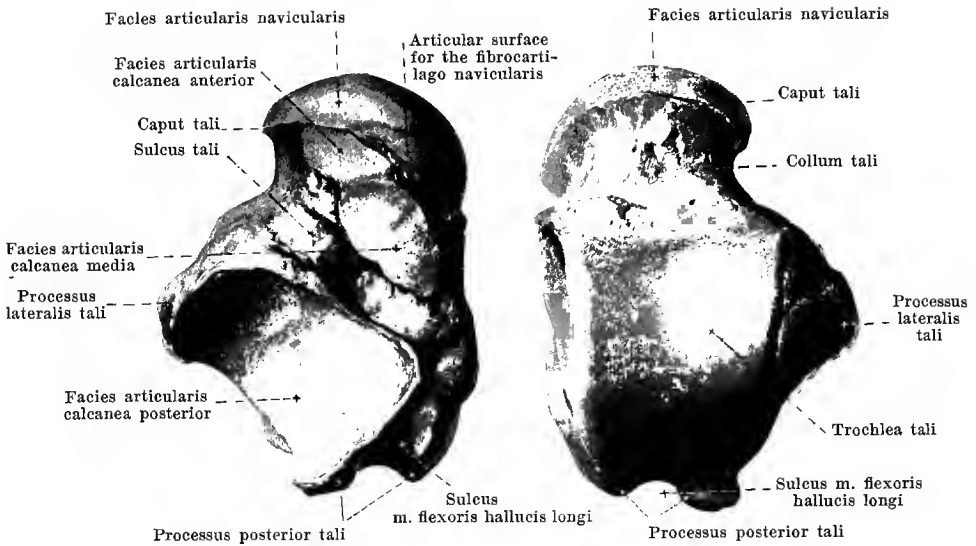
183. Right tibia and fibula,
from below.



184 and 185. Right tibia and fibula, *tibia et fibula*, with the muscular attachments.

From in front.

From behind.



186 and 187. Right ankle bone, *talus* (O. T. astragalus).

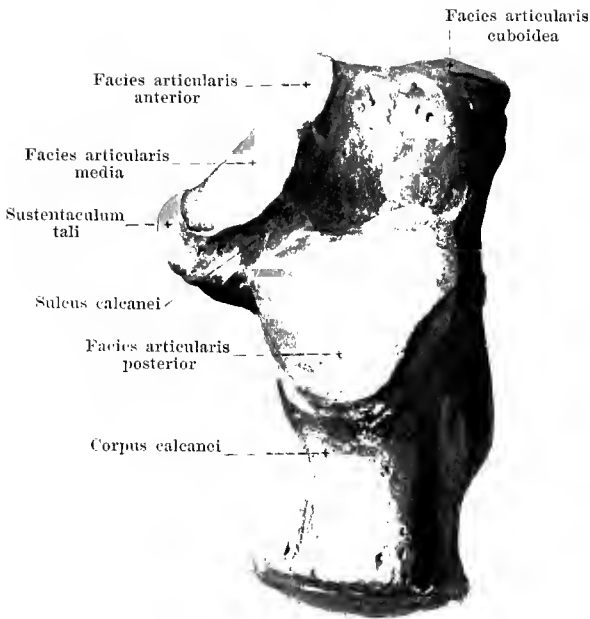
From below.

From above.

The **tarsus** (*root of the foot*) (see also Figs. 198—203) is composed of the seven *ossa tarsi*: *talus*, *calcaneus*, *os naviculare pedis*, *ossa cuneiformia primum, secundum, tertium, os cuboideum*; the four last mentioned lie distalward close to one another; the three first mentioned proximalward partly over one another, so that the bones of the leg are not united with several bones of the tarsus, but only with that situated uppermost, namely, the talus.

The **talus** (*ankle bone*) (O. T. astragalus) (see also Figs. 193—203) is divisible into a body, *corpus tali*, and a head, *caput tali*, attached in front; between the two lies a constricted part, the *collum tali*.

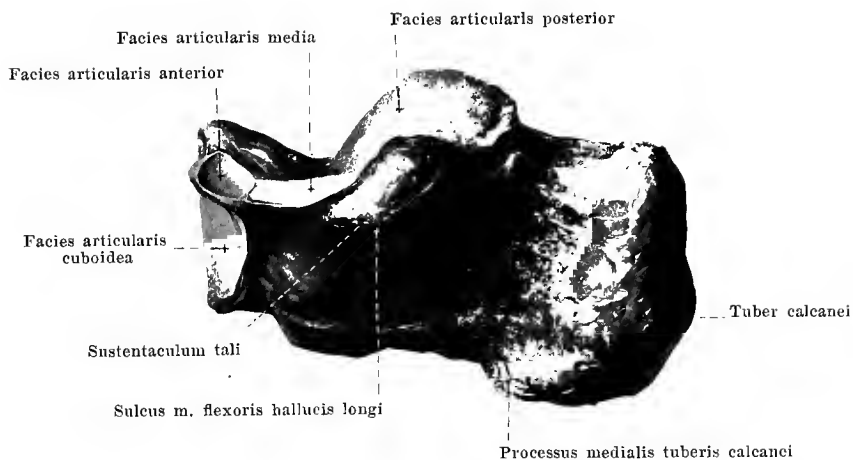
The corpus tali supports on its upper surface the broad *trochlea tali*; this is covered with cartilage above, *facies superior*, curved so as to be markedly convex from before backward and slightly concave in transverse direction; it possesses a large, triangular, lateral surface, *facies malleolaris lateralis* (see Fig. 198) covered with cartilage, from which a process, *processus lateralis tali*, passes off lateralward and downward; the medial surface of the trochlea has above only a narrow *facies malleolaris medialis* (see Fig. 199); it is covered with cartilage. The lower surface of the ankle bone possesses three articular surfaces, covered with cartilage, for the calcaneus: a posterior, largest, markedly concave, *facies articularis calcanea posterior*, as well as (separated therefrom by a deep, rough groove, *sulcus tali*) two nearly flat, smaller, *facies articulares calcaneae media et anterior*, of which the most anterior lies upon the caput tali. On the posterior margin of the body a blunt process, *processus posterior tali*, is visible which is divided by a groove, *sulcus m. flexoris hallucis longi* (for the tendon of the m. flexor hallucis longus) into a smaller, medial and a larger, lateral projection; the latter is sometimes an independent bone (*os trigonum*) and then is connected by connective tissue only with the remaining bone (it is not shown in the figure). The head presents in front an oval, transversely directed, markedly convex articular surface, *facies articularis navicularis* (for the os naviculare); adjacent to this, below and medianward, is another oblong surface for the lig. calcaneonavicular plantare, or the fibrocartilago navicularis.



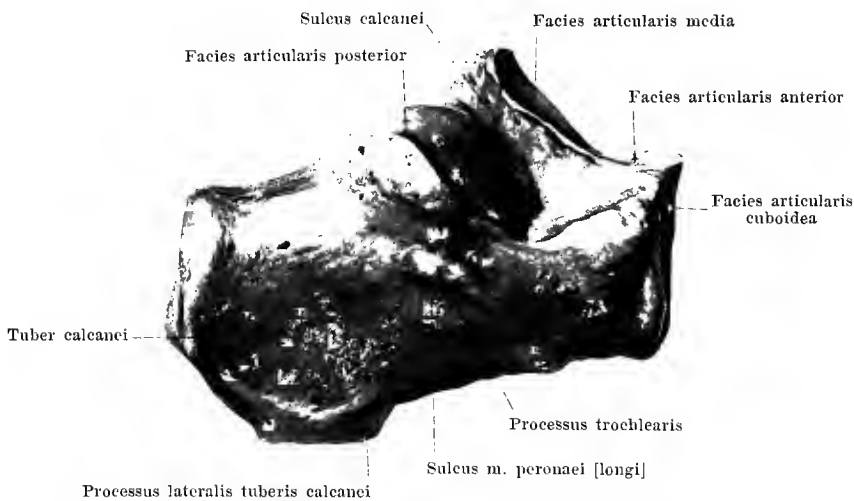
188. Right heel bone, *calcaneus*, from above.

The **calcaneus** (*heel bone*, O. T. *os calcis*) (see also Figs. 189, 190, 198—203) is the largest tarsal bone, lies below the ankle bone and at the same time projects beyond it behind. It possesses a quadrilaterally prismatic body, *corpus calcanei*, and an anterior extremity.

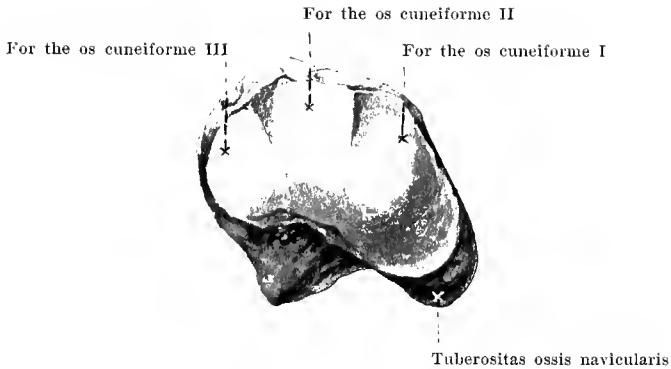
The *corpus calcanei* becomes thickened behind to form the *tuber calcanei*, from which two rough broad projections pass downward, the *processus medialis tuberis calcanei*, and the *processus lateralis tuberis calcanei* (see Fig. 201). The upper surface has three articular surfaces covered with cartilage for the talus; about in its middle an oblong, markedly convex, *facies articularis posterior*, in front and medianward two smaller, almost flat, *facies articulares media et anterior*; the latter are separated from the posterior by a rough deep groove, *sulcus calcanei*; the middle rests upon a medially projecting piece of bone, *sustentaculum tali*, which presents on its inferior surface a groove, the *sulcus m. flexoris hallucis longi* (for the tendon of the *m. flexor hallucis longus*). The margin of this projection directed medianward is usually rough, sometimes, however, partly smooth or hollowed out like a groove; on it glides the tendon of the *m. flexor digitorum longus* on its way to the sole of the foot. On the lateral surface of the heel bone there is often a small projection, *processus trochlearis*; below which runs a groove, the *sulcus m. peronei [longi]* (for the tendon of the *m. peroneus longus*). The anterior surface of the calcaneus is directed also medianward, is quadrilateral with rounded corners, curved so as to be saddle-shaped and covered with cartilage to form the *facies articularis cuboidea* (for the *os cuboideum*). The *sulcus calcanei* and *sulcus tali* form together the *sinus tarsi*, a canal which, open lateralward, grows markedly narrower as it extends medianward.



189. Right heel bone, *calcaneus*, from within.

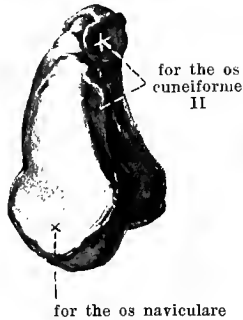
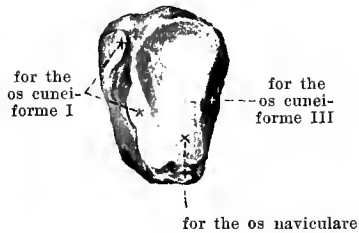
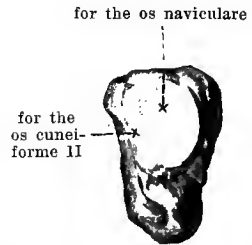


190. Right heel bone, *calcaneus*, from without and somewhat from above.



191. Right scaphoid bone, *os naviculare pedis*, from in front.

The **os naviculare pedis** (*scaphoid bone*) (see also Figs. 198—203) is oval, flattened from before backward and lies in front of the talus on the medial side of the tarsus. It possesses proximally a markedly concave articular surface covered with cartilage for the caput tali, distalward a convex surface covered with cartilage and divided by two ridges into three parts for the three cuneiform bones. The lateral surface supports, usually, a small articular surface for the os cuboideum. The upper surface is rough, convex and slopes markedly toward the medial side. Medianward on the lower surface the broad rough *tuberositas ossis navicularis* projects downward.

Os cuneiforme I**Os cuneiforme II****Os cuneiforme III**

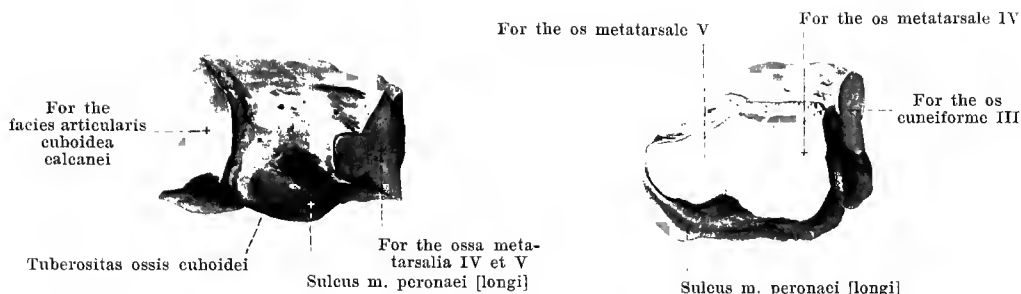192—194. The three cuneiform bones of the right side, *ossa cuneiformia primum, secundum, tertium*, from behind.

The *ossa cuneiformia primum, secundum, tertium* (*wedge bones*) (see also Figs. 198—203) are wedge-shaped; they lie distal from the os naviculare and are numbered beginning at the medial border of the foot.

The **os cuneiforme primum** (O. T. internal cuneiform bone) is the largest with the base of the wedge directed plantarward; it has more the form of an inverted comma. The posterior surface is triangularly rounded, and covered with cartilage (for the os naviculare). The medial surface, turned also upward, is rough and possesses in front and below an oblique flat groove in which lies the tendon of the m. tibialis anterior being separated from the bone by the bursa subtendinea m. tibialis anterioris. The anterior surface is covered with cartilage, bean-shaped (for the os metatarsale I); the lateral surface has an anterior, small articular surface (for the os metatarsale II) and a posterior (for the os cuneiforme II).

The **os cuneiforme secundum** is the smallest with the base of the wedge directed dorsalward. The posterior triangular surface, covered with cartilage, serves for the attachment of the os naviculare, the anterior surface, covered with cartilage, for the os metatarsale II; on the medial and lateral surfaces are small articular surfaces for the neighboring cuneiform bones.

The **os cuneiforme tertium** has the base of the wedge looking dorsalward. Its posterior, rounded surface, covered with cartilage, is attached to the os naviculare, the anterior to the os metatarsale III; medianward it possesses a small, anterior articular surface for the os metatarsale II and a larger, posterior for the os cuneiforme II; lateralward it supports a small articular surface for the os cuboideum.



195 and 196. Right cuboid bone, *os cuboideum*.

From the side.

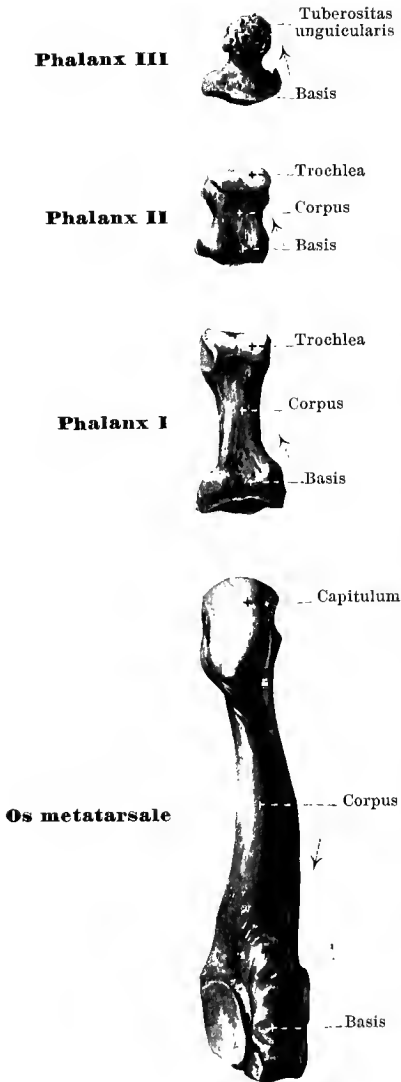
From in front.

The **os cuboideum** (*cuboid bone*) is very irregularly cuboidal in shape and lies in front of the calcaneus and on the lateral side of the tarsus. It is longer medianward than lateralward.

Its posterior surface, covered with cartilage, is directed also lateralward, is quadrangularly rounded, curved so as to be saddle-shaped (for the *facies articularis cuboidea calcanei*); its distal surface supports two rounded quadrangular articular surfaces (for the *ossa metatarsalia IV et V*) separated by a slight ridge; its medial surface shows a small articular surface for the *os cuneiforme III* and usually also one for the *os naviculare*. The upper and lateral surface is rough. The lower surface presents an oblong bulging, the *tuberositas ossis cuboidei*, above the anterior smooth portion of which, covered lateralward with cartilage, (*sulcus m. peronei [longi]*) the tendon of the *m. peroneus longus* glides. In front of the tuberosity is a rough groove extending obliquely medianward and forward.

197. Metatarsal bone and phalanges of the second toe of the right side, *os metatarsale II et phalanges digiti secundi*, from the plantar aspect.

(The arrows indicate the direction of the canales nutricii.)



The five *ossa metatarsalia* (*metatarsal bones*) (see also Figs. 198—203) are short cylindrical bones in which can be distinguished a shaft or *corpus*, a proximal end, *basis*, and a distal end, *capitulum*. On the whole they are curved so as to be somewhat convex dorsalward.

The *corpus* is triangularly prismatic so that one side looks dorsalward, the other two lateral and medianward; the latter meet in the border directed plantarward. A *foramen nutricium* situated plantarward corresponds to the one in the hand (see p. 109).

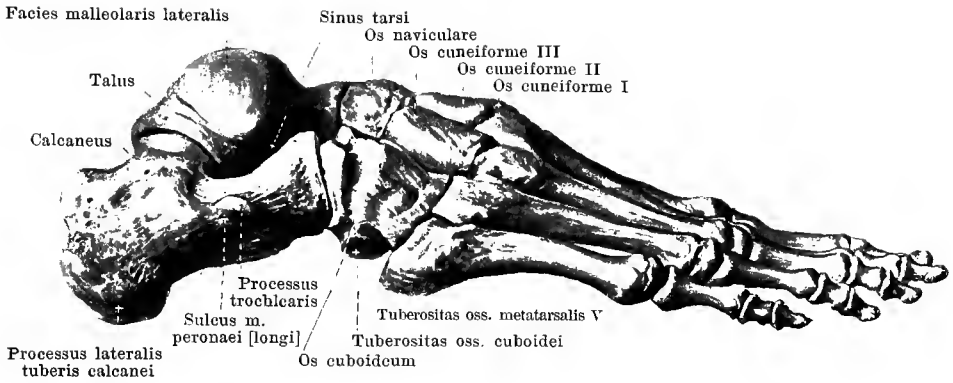
The *basis* is somewhat broadened, supports on its proximal side an articular surface for connection with the tarsus and from the second to the fifth toe also small articular surfaces at the sides for the neighboring metatarsal bones. The *basis ossis metatarsalis I* possesses a large concave, bean-shaped articular surface (for the *os cuneiforme I*), but no lateral articular surfaces; on the plantar surface a blunt nodule, *tuberositas ossis metatarsalis I*, projects lateralward (see Fig. 201). Projecting from the side of the *basis ossis metatarsalis V* backward is a strong process, the *tuberositas ossis metatarsalis V* (see Figs. 198, 200, and 201).

The *capitulum* is flattened laterally, possesses a spherical articular surface, covered with cartilage, which extends further upon the plantar than upon the dorsal surface. At the sides are rough areas for the articular ligaments.

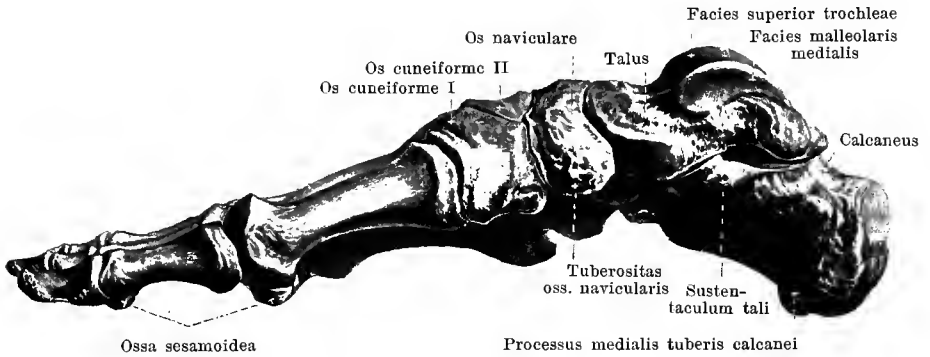
The four spaces between the *ossa metatarsalia*, *spatia interossea metatarsi*, (see Figs. 200 and 201) correspond to the *spatia interossea metacarpi* (see page 109).

The *phalanges digitorum* correspond in number, arrangement and form as well as in the relations of their *foramina nutricia* entirely to those of the hand (see p. 109), except that they are all essentially shorter.

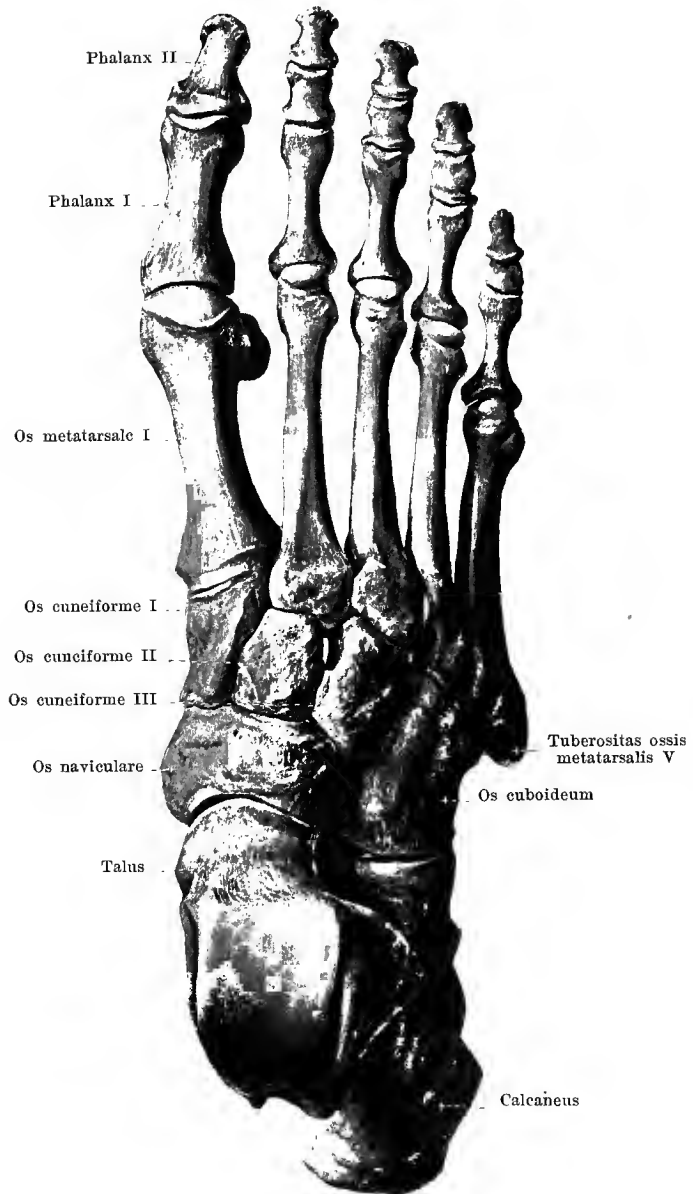
As to *ossa sesamoidea* (*sesamoid bones*) (see Fig. 201), two are constantly found at the metatarsophalangeal joint of the great toe, a third less constant, at the interphalangeal joint of the same toe; a fourth is situated in the tendon of the *m. peronaeus longus* in front of the lateral angle of the *tuberositas ossis cuboidei* and a fifth sometimes in the tendon of the *m. tibialis posterior* below the *fibrocartilago navicularis*.



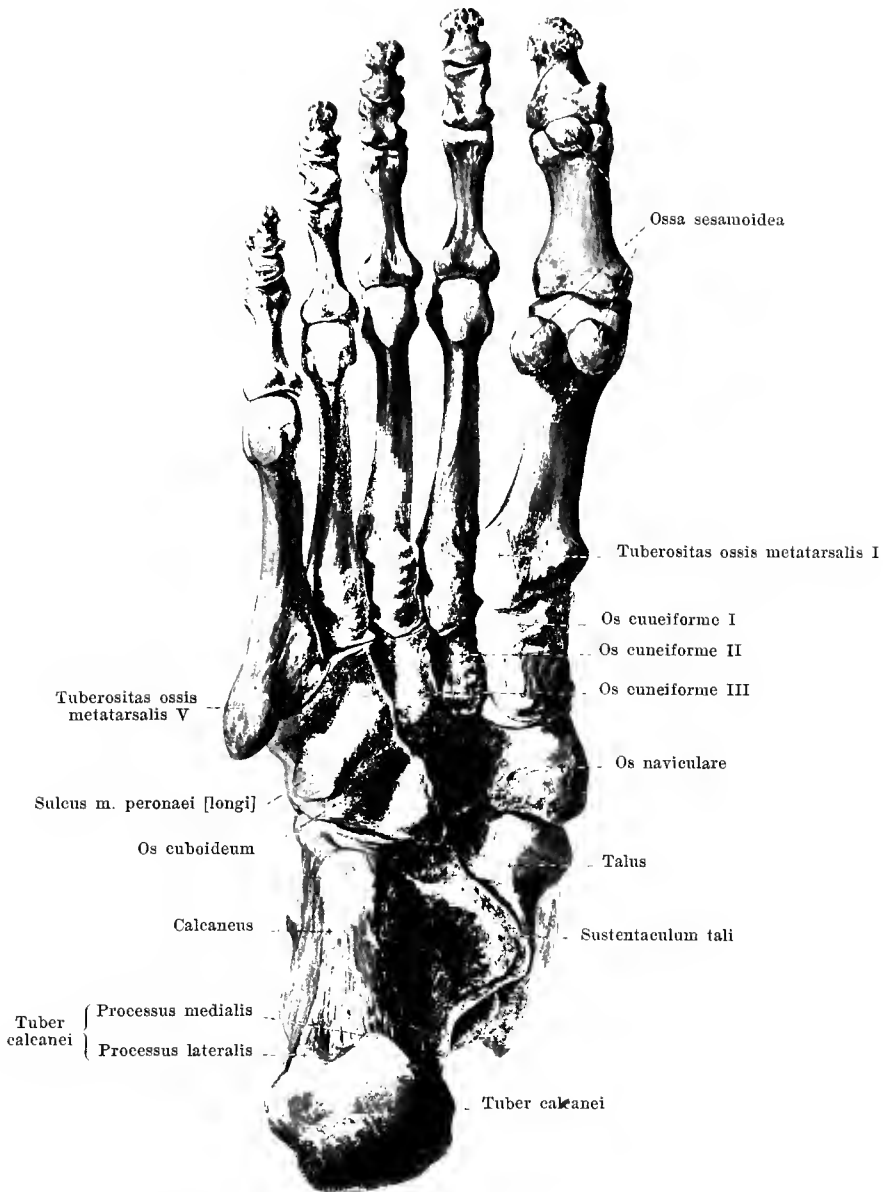
198. Bones of the right foot, *ossa pedis*,
from the lateral aspect.



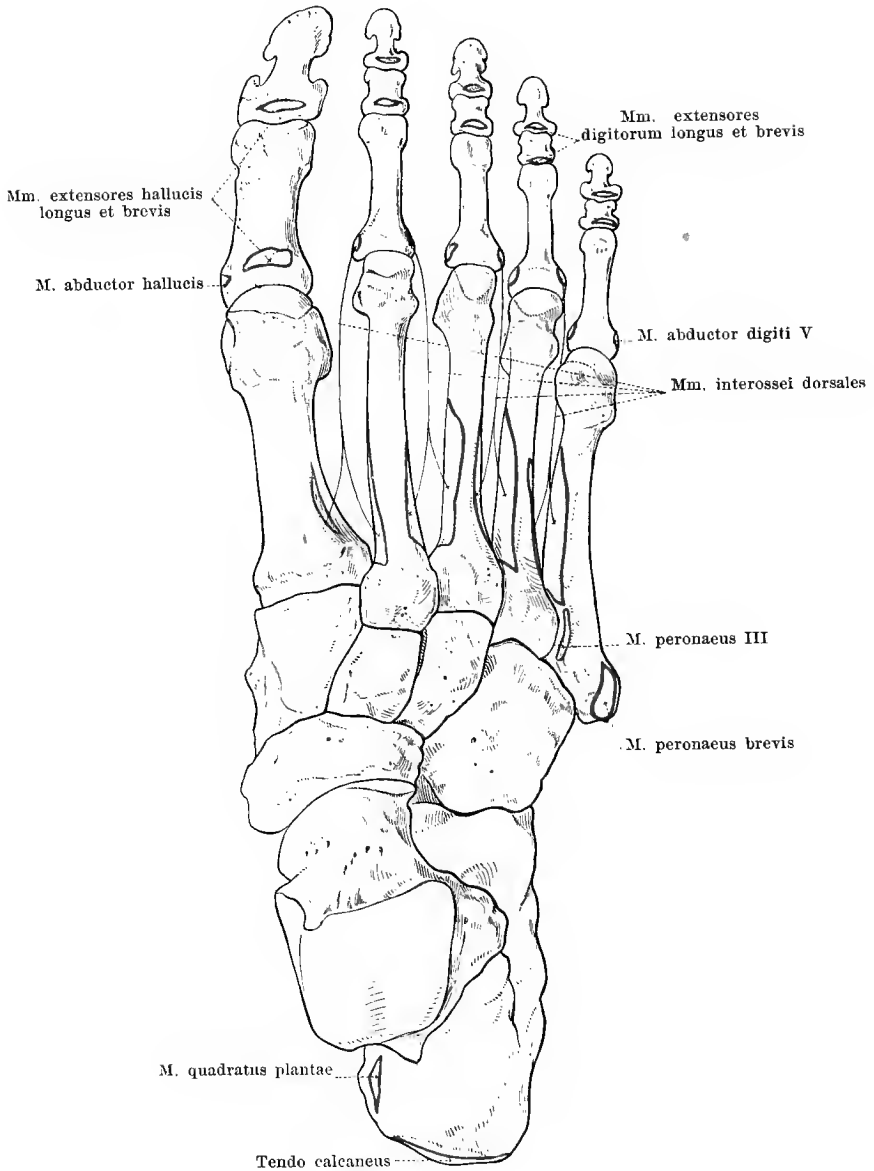
199. Bones of the right foot, *ossa pedis*,
from the medial aspect.



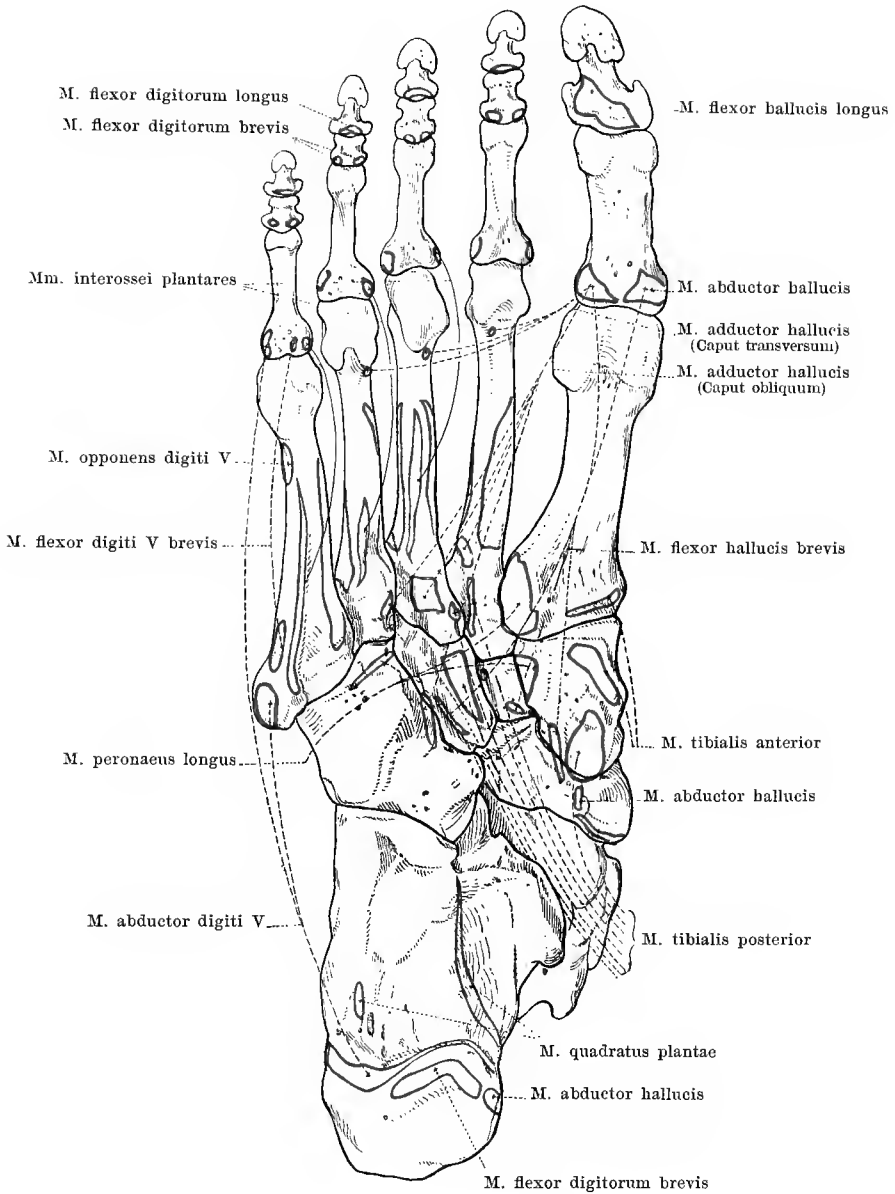
200. Bones of the right foot, *ossa pedis*,
viewed from the back of the foot.



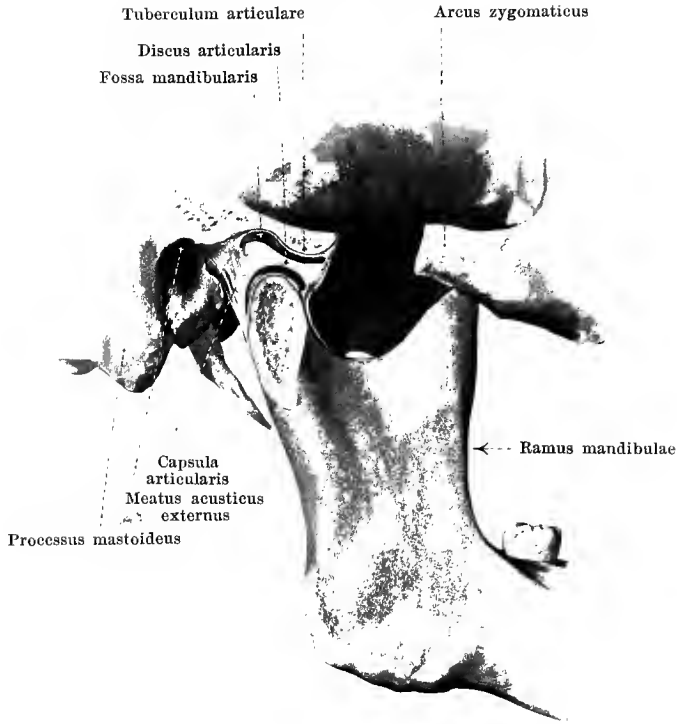201. Bones of the right foot, *ossa pedis*,
viewed from the sole of the foot.



202. Bones of the right foot, *ossa pedis*, with the muscular attachments, viewed from the back of the foot.



203. Bones of the right foot, *ossa pedis*, with the muscular attachments, viewed from the sole of the foot.



204. Jaw joint of right side, *articulatio mandibularis*, from without.

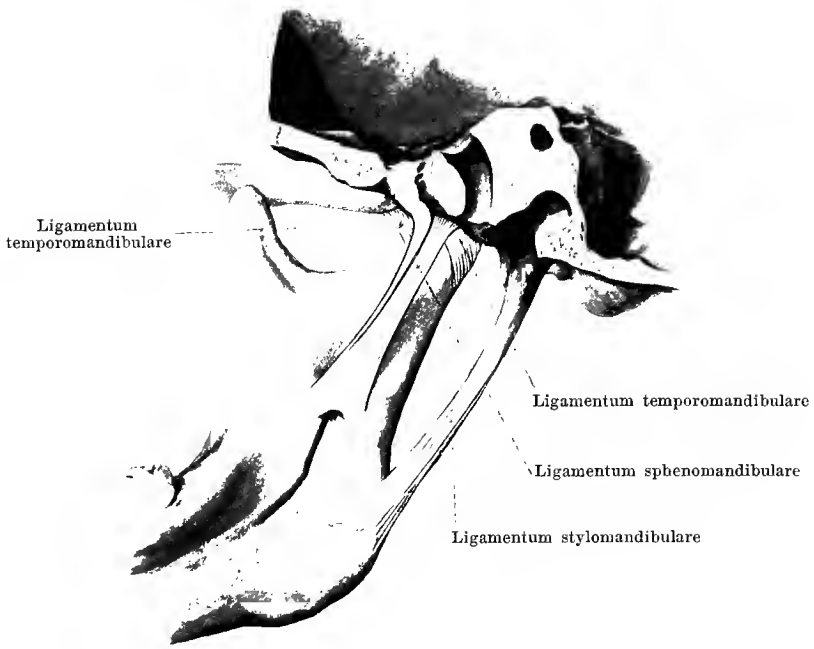
(The arcus zygomaticus and the processus condyloideus mandibulae have been partially removed; the parts have been somewhat separated from one another.)

By means of the **articulatio mandibularis** (*joint of the jaw*) (O. T. temporo-maxillary articulation) (see also Figs. 205—207) the lower jaw is movably connected with the rest of the skull. The capitulum of the processus condyloideus mandibulae on each side rests on the posterior slope of the tuberculum articulare in the fossa mandibularis ossis temporalis. The facies articularis extends into the fossa mandibularis not quite as far as the fissura petrotympanica where it is for the most part covered by connective tissue and only in its most anterior portion covered with cartilage; in front it goes over upon the tuberculum articulare which is covered with cartilage and does not end until its anterior slope is reached. Between the processus condyloideus on the one side and the fossa mandibularis and tuberculum articulare on the other is inserted a connective tissue disc, *discus articularis* (O. T. interarticular fibrocartilage), which is thinner in the middle, thicker in front and behind and about of the shape of a biconcave transversely placed plate. The *capsula articularis* (O. T. capsular ligament) is loose and is stretched from the circumference of the facies articularis of the fossa mandibularis and of the tuberculum articulare to the upper margin of the discus articularis, as well as from the lower border of the latter to the collum (neck) of the processus condyloideus mandibulae. In this way two joint cavities, completely separated from one another, are formed, an upper and a lower, which are separated from one another by the articular disc.



**205. Jaw joint of right side, *articulatio mandibularis*,
from without.**

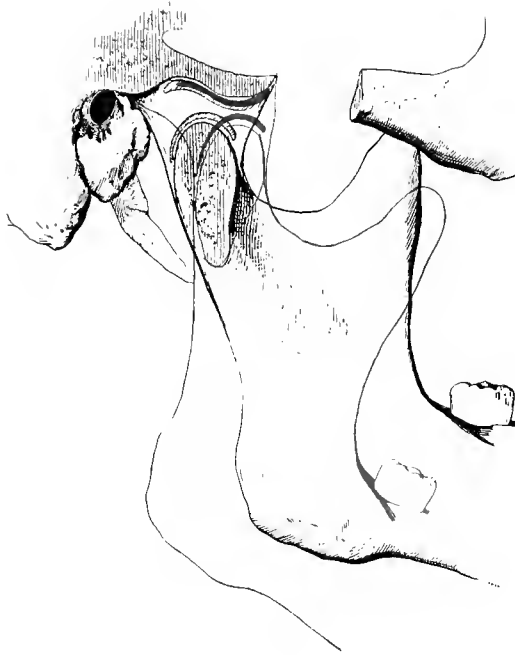Passing obliquely from in front and above backward and downward, as a strengthening ligament of the capsula articularis, is the *ligamentum temporomandibulare*. It arises on the lateral surface (O. T. External lateral ligament) by a broad base at the root of the processus zygomaticus ossis temporalis and is fastened to the collum (neck) of the processus condyloideus mandibulae; medianward a weaker fibrous band proceeds from the region of the fissura petrotympanica to the collum processus condyloidei mandibulae (see Fig. 206).



**206. Jaw joint of right side, *articulatio mandibularis*,
from within.**

On the medial side of the jaw joint the *ligamentum sphenomandibulare* proceeds from above and behind, downward and forward. It arises from the spina angularis ossis sphenoidalis and from the fissura petrotympanica ossis temporalis and ends with a broad insertion at the lingula mandibulae. It is separated from the medial fibrous band of the ligamentum temporomandibulare and from the processus condyloideus mandibulae by a space through which runs the a. maxillaris interna with the veins accompanying it (see page 449) and the n. auriculotemporalis.

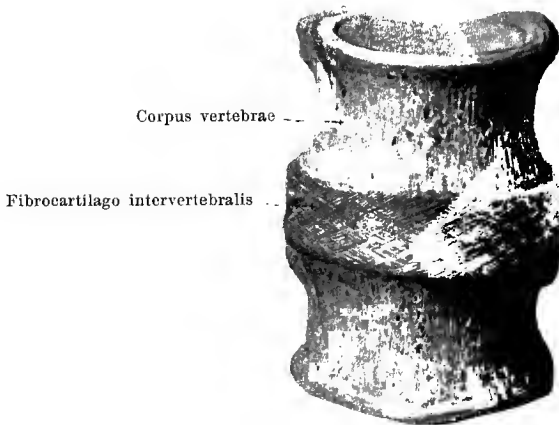
The *ligamentum stylomandibulare* (O. T. Stylo-maxillary ligament) arises in common with the ligamentum stylohyoideum (see p. 40) from the processus styloideus, runs obliquely forward and downward and is fastened by broad attachment to the inner side of the angulus mandibulae. It is only a band of the fascia buccopharyngea (see p. 247) and has nothing to do with the joint of the jaw.



**207. Jaw joint of right side, *articulatio mandibularis*,
from without; somewhat schematic.**

The position of the lower jaw when the mouth is shut is indicated in black; when the mouth is wide open in red.

When the mouth is closed the capitulum of the processus condyloideus is in contact with the posterior slope of the tuberculum articulare and the anterior portion of the fossa mandibularis; when the mouth is wide open it stands somewhat in front of the deepest point of the tuberculum articulare; in both cases, however, the capitulum is separated from the points of the temporal bone mentioned by the discus articularis.




208. Intervertebral disc, *fibrocartilago intervertebralis*, with the adjacent vertebral bodies, from in front.

The **ligamenta columnae vertebralis** (*spinal ligaments*) consist of the *fibrocartilagine intervertebrales* between every two vertebral bodies, of the *capsulae articulares*, which unite the *processus articulares inferiores* of each vertebra with the *processus articulares superiores* of the next vertebra below, and of ligaments which are stretched out between the arches and between the processes of the same name of every two adjacent vertebrae, namely: *ligamenta flava*, *ligamenta intertransversaria*, *ligamenta interspinalia*; besides the latter there are still a number of ligaments present which extend over the whole spinal collum or at least over the largest part of the same: *ligamentum supraspinale*, *ligamentum longitudinale anterius* and *ligamentum longitudinale posterius*.

The **fibrocartilagine intervertebrales** (*intervertebral discs*) (see also Figs. 209—210) are flat fibrocartilaginous discs which lie between the adjacent surfaces of every two successive vertebrae; to these surfaces they are very firmly attached by a thin layer of hyaline cartilage. They have the shape of the adjacent vertebral body but are somewhat larger so that at the edges they project somewhat over this.

In the cervical and lumbar part of the vertebral column (see Fig. 210) they are somewhat higher in front than behind. The total number of intervertebral discs present down to the sacrum is 23; the uppermost is situated between the second and third cervical vertebrae, the lowermost between the fifth lumbar vertebra and the sacrum (see also page 162).

On the five lower cervical vertebrae there is usually, on each side, between the bent up lateral part of the upper surface of each vertebral body and the adjoining portion of the intervertebral discs, a small joint cavity with a *capsula articularis* (see Fig. 215).

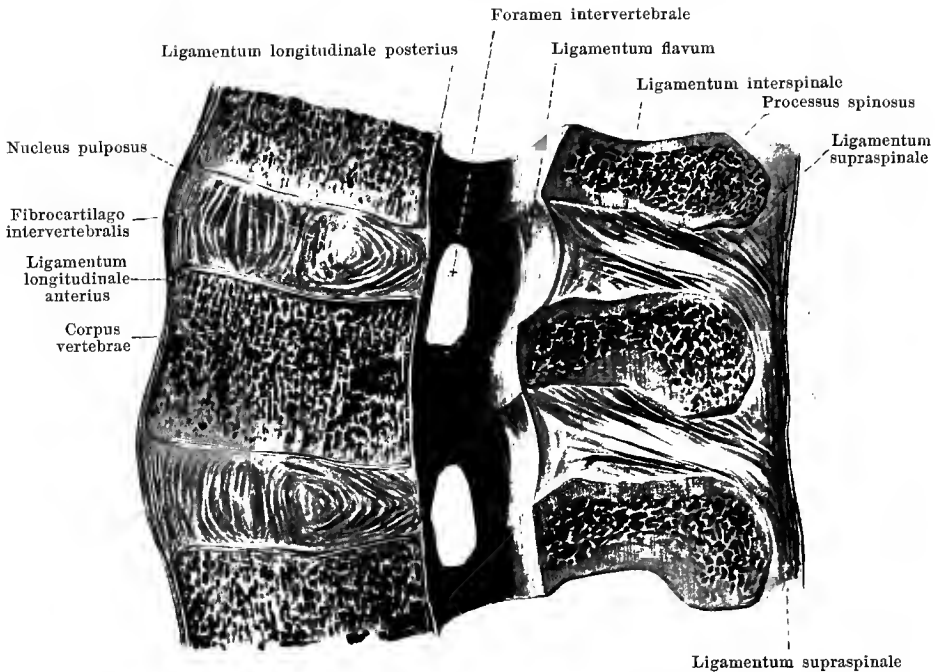


**209. Intervertebral disc, *fibrocartilago intervertebralis*,
cut through horizontally. Magnification 3 : 2.**

Each **fibrocartilago intervertebralis** consists of a firmer external portion, *annulus fibrosus*, and a softer centre, *nucleus pulposus*.

The **annulus fibrosus** is composed of concentric layers of connective tissue fibres which are arranged like the leaves of an onion; inside each layer the fibre bundles cross one another in network-like fashion (see Fig. 208); in the depth the connective tissue layers are less sharply separated from one another and alternate with layers of very soft fibrocartilage.

The **nucleus pulposus** consists essentially of a very soft mass of fibrocartilage with irregular connective tissue bands and contains the remains of the embryonic chorda dorsalis; it is separated but not sharply from its surroundings and lies nearer the posterior circumference of the intervertebral disc (see Fig. 210). In the uninjured spinal column its constituents are under high pressure so that on cutting through the disc they project markedly.



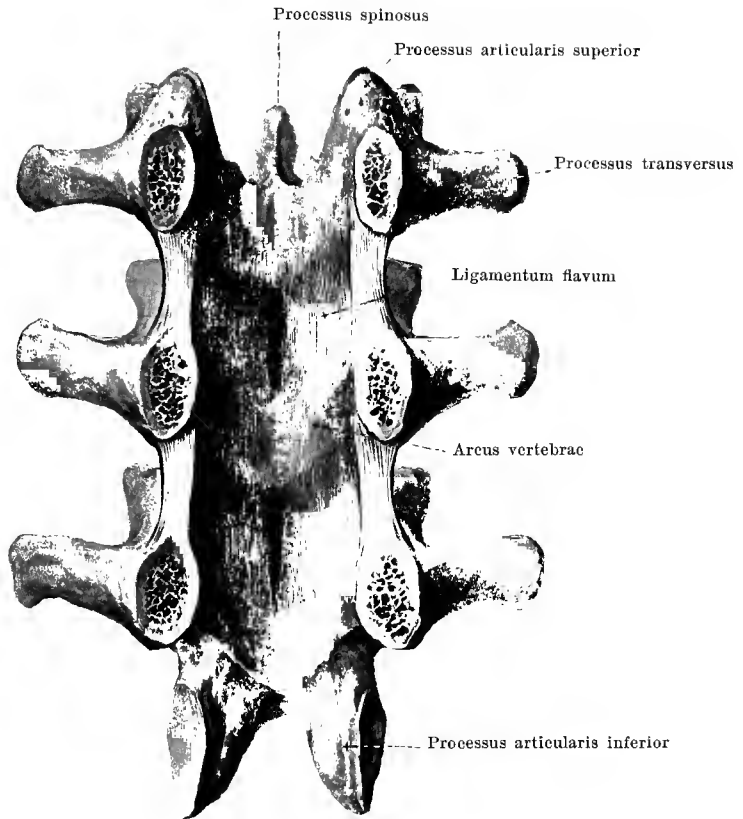
210. Median section of a piece of the lumbar spinal column, right half of sections, viewed from the left.

A median section of a **fibrocartilago intervertebralis** permits the excentric position of the nucleus pulposus to be especially distinctly recognized and besides shows that the connective tissue layers which compose the annulus fibrosus are bent so as to be somewhat convex forward; behind, on the other hand, they are much stronger and are sharply bent backward; in the middle of the disc the direction of curvature can be variable.

The **capsulae articulares** (see Fig. 220) are stretched out between the borders of each adjacent pair of processus articulares. They are looser on the cervical than on the thoracic and lumbar vertebrae.

The **ligamenta interspinalia** are flat bands of tissue which extend between the borders of each adjacent pair of processus spinosi. They are most strongly developed on the lumbar vertebrae, feeblest on the cervical vertebrae. In general the fibres are directed from above downward and backward.

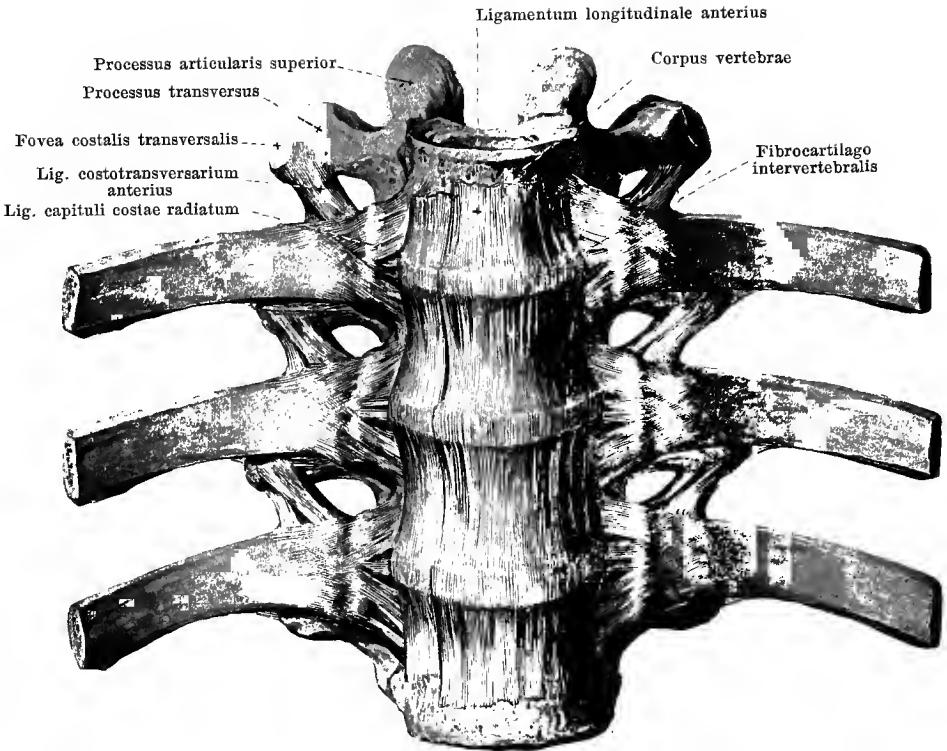
The **ligamenta intertransversaria** (see Figs. 223 and 224) are rounded, thinner bands which run between the borders of every adjacent pair of processus transversi. They are strongest in the lumbar and thoracic spine, feeble, sometimes doubled on the cervical vertebrae; they may be entirely absent from the latter. The fibres are directed from above downward.



211. Vertebral arches with ligamenta flava, from in front.

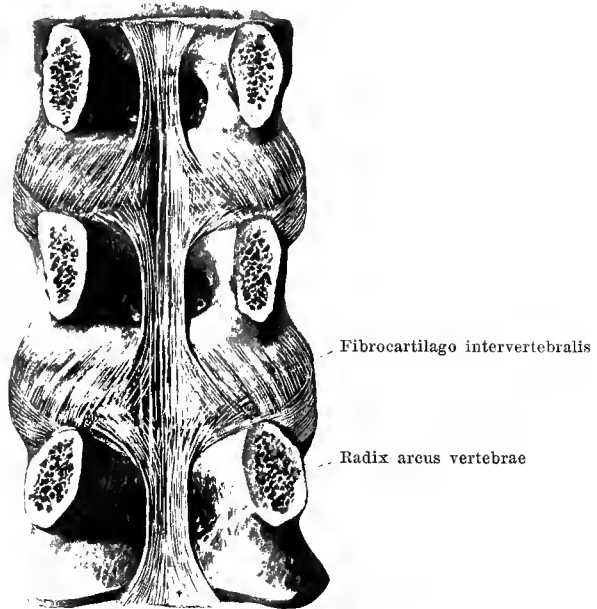
(The vertebral arches have been sawed off at their roots and the vertebral bodies removed.)

The **ligamenta flava** (see also Fig. 210) are broad flat bands stretched out between the arches of every two adjacent vertebrae and always proceed from the front surface of the higher arch to the upper edge of the lower. They are especially strong and long on the lumbar and become feebler towards the cervical vertebrae. Their fibres run in a vertical direction; in the median plane they are divided into two halves by a narrow groove. They consist almost exclusively of elastic fibres and are accordingly of a yellow color; hence the name. The band is not present in this form between the occipital bone and the atlas, nor between atlas and axis; at the former place is the *membrana atlantooccipitalis posterior* (see page 164), at the latter a thin membrane of connective tissue, which is strengthened only by isolated yellow stripes of elastic fibres (see Fig. 216).



212. Spinal column with ligaments, from in front.

The **ligamentum longitudinale anterius** descends on the anterior and lateral surfaces of the bodies of the vertebrae. It begins as a narrow tough band at the tuberculum pharyngeum ossis occipitalis (see Figs. 215 and 221), is fastened to the tuberculum anterius atlantis, then goes to the anterior surface of the epistropheus and thence to all of the bodies of the vertebrae as far as the upper part of the facies pelvina ossis sacri; where it becomes lost in the periosteum. From the epistropheus on, it becomes ever broader as it passes downward, is intimately connected with the vertebral bodies and the fibrocartilagine intervertebrales and is divisible more or less distinctly into three stripes, a broader one in the middle and a narrower one on each side. On the lumbar spine there arise from it the (tendinous) crura of the pars lumbalis diaphragmatis (lumbar portion of the diaphragm).



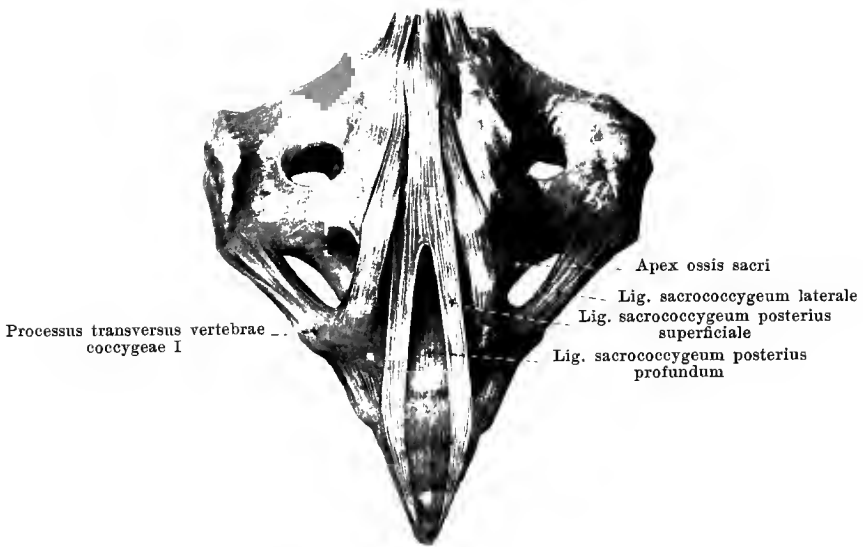
Ligamentum longitudinale posterius

213. Vertebral bodies with ligaments, from behind.

(The vertebral arches have been sawed off at their roots.)

The **ligamentum longitudinale posterius** (O. T. posterior common ligament) (see also Figs. 220 and 221) runs on the posterior surface of the vertebral bodies down inside the *canalis vertebralis*. It begins as an extraordinarily thin, broad layer upon the *clivus* and is united as far as the third cervical vertebra with the *membrana tectoria*, behind which it descends, and with the *dura mater*. From the third cervical vertebra on it becomes narrower and stronger behind each vertebral body but at each *fibrocartilago intervertebralis* broader, and is at the same time especially firmly connected with the latter. It ends in the upper part of the *canalis sacralis*. In it can be made out deeper bands, lying near the vertebral bodies, which are short and connect the vertebrae which are close to one another, and superficial, long bands which extend over long distances; it is the latter alone which form the uppermost part of the ligament behind the *membrana tectoria* (see p. 168).

The **ligamentum supraspinale** (O. T. supraspinous ligament) (see Fig. 210) is a powerful, narrow ligament. It extends downward behind the tips of the spinous processes, becomes narrower between the same and fuses there with the *ligamenta interspinalia*. At the tips of the *processus spinosi* it is separated from the bone by a thin layer of fibrocartilage. The *ligamentum supraspinale* begins at the *processus spinosus* of the seventh cervical vertebra where it is connected with the *ligamentum nuchae*, and ends below at the *crista sacralis media*.



214. Ligaments between the sacrum and the coccyx, from behind.

The connection between the sacrum and the coccyx (**symphysis sacrococcygea**) is mediated by a thin fibrous disc; similar fibrous discs are usually present also between the first, second and third coccygeal vertebrae; the connection, however, can also be bony here as is the rule between the third, fourth and fifth coccygeal vertebrae.

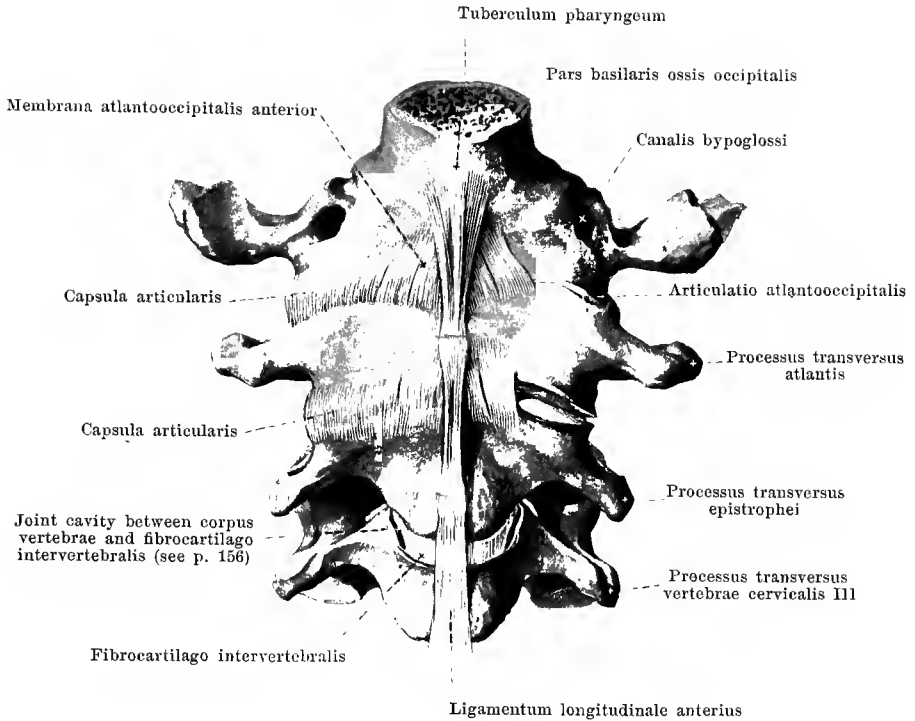
A number of ligaments also are present which are to be considered as modifications of those of the other vertebrae.

The *ligamentum sacrococcygeum anterius* (= lig. longitudinale anterius) (see Figs. 243 and 670) consists of two thin fibrous bands which extend on the anterior surface from the tip of the sacrum to the coccygeal vertebrae, crossing over one another in part; below it is attached to the m. levator ani (see page 608).

The *ligamentum sacrococcygeum laterale* (= lig. intertransversarium) runs on each side from the lower end of the crista sacralis lateralis to the processus transversus of the first coccygeal vertebra, bounds externally the notch situated lateral from the apex of the sacrum and so helps to form a fifth foramen sacrale.

The *ligamentum sacrococcygeum posterius profundum* (= lig. longitudinale posterius), lies as a thin plate immediately upon the posterior surface of the combined bodies of the sacral and coccygeal vertebrae and is connected in part with the following ligament.

The *ligamentum sacrococcygeum posterius superficiale* consists of several fibre-bands which extend on the one hand from the lower end of the crista sacralis media downward to the posterior surface of the coccyx and at the same time close the hiatus sacralis more or less completely; on the other hand, the fibre-bands extend between the cornua sacralia and the cornua coccygea. Narrow spaces between the single bands serve for the passage of the n. sacralis V and the n. coccygeus. The ligament corresponds partly to the ligamenta flava, partly to the capsulae articulares.

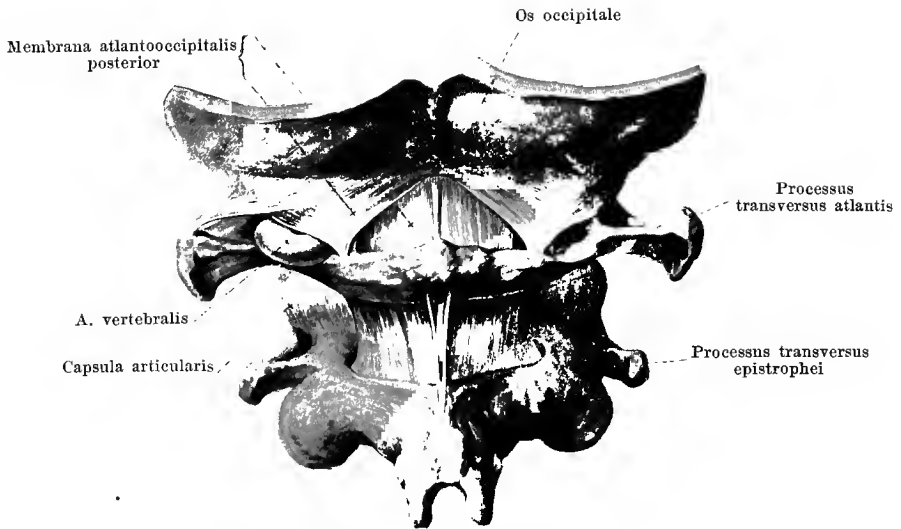


215. Occipital bone and first three cervical vertebrae with ligaments, from in front.

(The joints have been partially opened.)

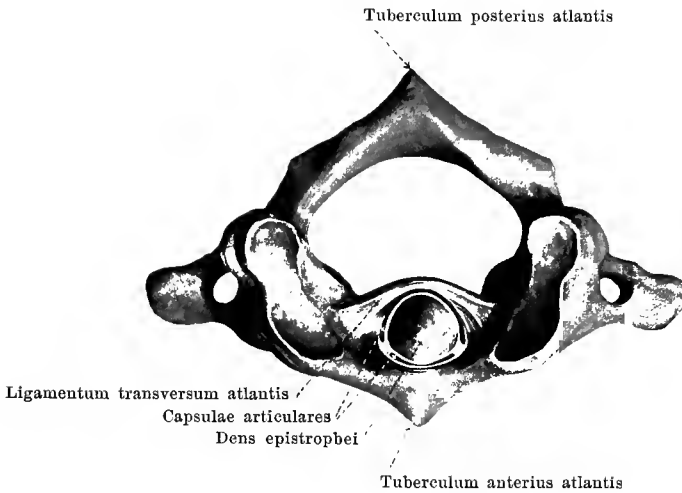
The **articulatio atlantooccipitalis** (*occipital joint*, O. T. articulation of the atlas with the occipital bone) (see also Figs. 216 and 219) is formed so that the condyli occipitales move in the foveae articulares superiores atlantis. Between the borders of these cartilaginous joint surfaces are stretched the loose *capsulae articulares* (O. T. capsular ligaments). The interspaces between the arches of the atlas and the occipital bone are filled up by the *membranae atlantooccipitales*.

The **membrana atlantooccipitalis anterior** (O. T. anterior occipitoatlantal ligaments) extends as a flat, tough band between the pars basilaris ossis occipitalis and the arcus anterior atlantis; its fibres run essentially vertically. In the middle it is fused with the uppermost part of the ligamentum longitudinale anterius, at the borders with the capsulae articulares.



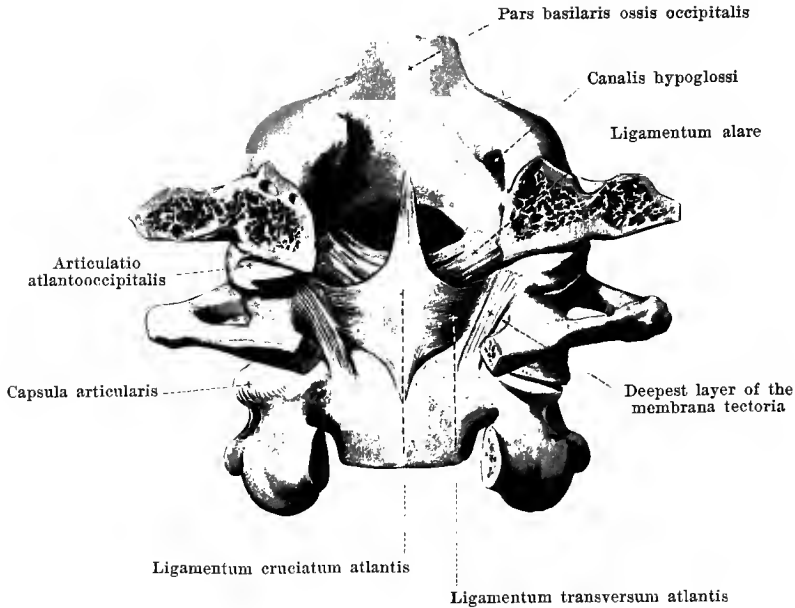
216. Occipital bone, first and second cervical vertebrae with ligaments, from behind.

The **membrana atlantooccipitalis posterior** (O. T. posterior occipito-atlantal ligament) (see also Fig. 221) goes from the posterior circumference of the foramen occipitale magnum to the arcus posterior atlantis. Its middle, vertically running part is extraordinarily thin and firmly fused with the dura mater. Its lateral part consists of stronger fibrous bands; they extend obliquely lateralward and are fastened there to a fibrous arch which bridges over the sulcus a. vertebralis and transforms it into a canal, through which pass the a. and v. vertebralis and the n. suboccipitalis.



217. Atlas and epistropheus, with ligaments, from above.

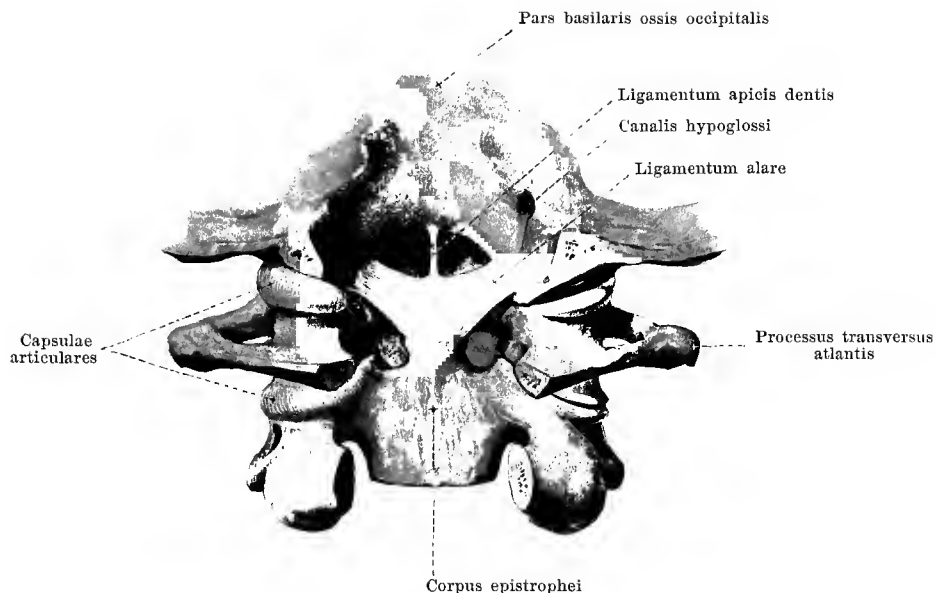
The **articulatio atlantoepistrophica** (*joint for rotation of head*, O. T. articulation of the atlas with the axis) (see also Figs. 218—221) is formed in that the *facies articulares inferiores atlantis* move upon the *facies articulares superiores epistrophei* and that, at the same time, the *dens epistrophei* turns with its two *facies articulares*, like an axle in its axle-box, in the cylindrical space which is bounded in front by the *arcus anterior atlantis*, behind by the powerful *ligamentum transversum atlantis*. All the joint surfaces mentioned, though widely separated from one another, belong therefore to one and the same joint. Between the border of each inferior joint-surface of the atlas and the upper joint-surface of the epistropheus are stretched loose *capsulae articulares* (O. T. capsular ligaments); there is also a similar joint-capsule between the border of the *fovea dentis atlantis* and the *facies articularis anterior epistrophei*, as well as between the circumference of the *facies articularis posterior epistrophei* and the anterior surface of the *ligamentum transversum atlantis*.



218. Occipital bone, first and second cervical vertebrae with ligaments, from behind.

(The part of the occipital bone situated behind the middle of the foramen occipitale magnum and the arches of the cervical vertebrae have been removed; most of the membrana tectoria has been removed. The joint slits are partly opened.)

Among the essential constituents of the **articulatio atlantoepistrophica**, the *ligamentum transversum atlantis* (O. T. the transverse ligament) may first be mentioned. This tough, flat ligament (see also Figs. 217 and 221) goes behind the dens epistrophei, has a broad origin from the medial surface of one massa lateralis atlantis and is similarly fastened on the other side; it is curved so as to be convex behind and contains in the middle fibrocartilaginous deposits. On its anterior surface it is separated by a small joint cavity from the odontoid process; on its posterior surface it is united loosely with the membrana tectoria. From the middle of its upper margin a thinner bundle of fibres runs vertically upward to the anterior circumference of the foramen occipitale magnum and from the inferior margin one runs downward to the posterior surface of the body of the second cervical vertebra. These fibre-bands together with the ligamentum transversum atlantis make up the *ligamentum cruciatum atlantis* (O. T. cruciform ligament).

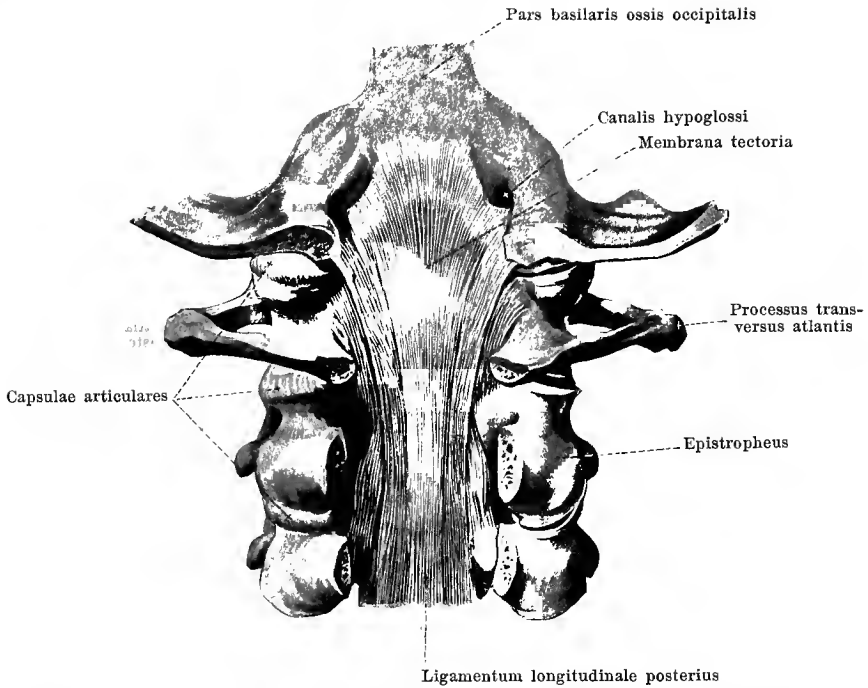


219. Occipital bone, first and second cervical vertebrae with ligaments, from behind.

(The part of the occipital bone situated behind the middle of the foramen occipitale magnum and the arches of the cervical vertebrae have been removed; the membrana tectoria and the ligamentum cruciatum atlantis have been completely removed. The right joint slits are opened.)

The **articulatio atlantoepistropheica** is strengthened by the *ligamenta alaria* (O. T. odontoid or check ligaments) (see also Fig. 218). These consist on each side of a strong, flat-rounded fibre bundle which extends from the lateral surface of the dens epistrophei obliquely upward and lateralward to the medial surface of the condylus occipitalis where it is attached. They are situated therefore, in front of the ligamentum cruciatum atlantis.

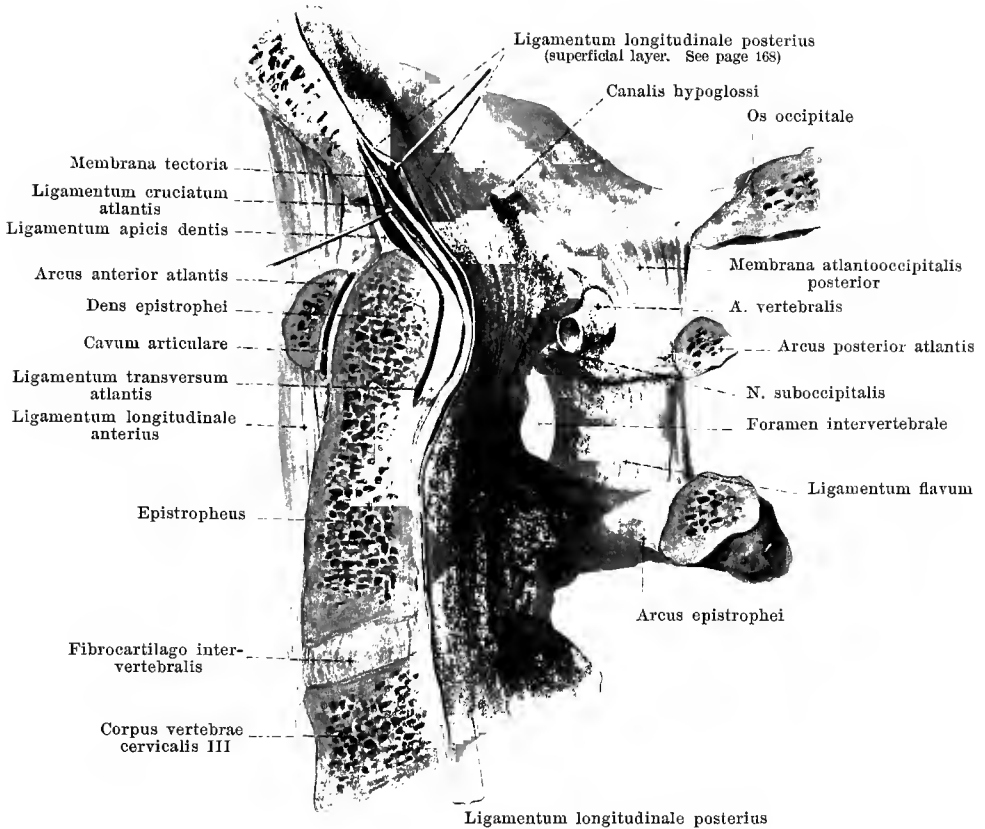
Also in front of the ligamentum cruciatum atlantis, in front of its upper vertical limb, a thin rounded band, *ligamentum apicis dentis*, (O. T. ligamentum suspensorium) extends in the median plane from the tip of the odontoid process to the anterior circumference of the foramen occipitale magnum (see also Fig. 221). It is mechanically insignificant and only important because it arises from the uppermost part of the embryonic chorda dorsalis.



220. Occipital bone and first three cervical vertebrae with ligaments, from behind.

(The part of the occipital bone situated behind the middle of the foramen occipitale magnum and the arches of the cervical vertebrae have been removed; the most superficial, thin layer of the ligamentum longitudinale posterius has also been removed. The right joint slits are opened.)

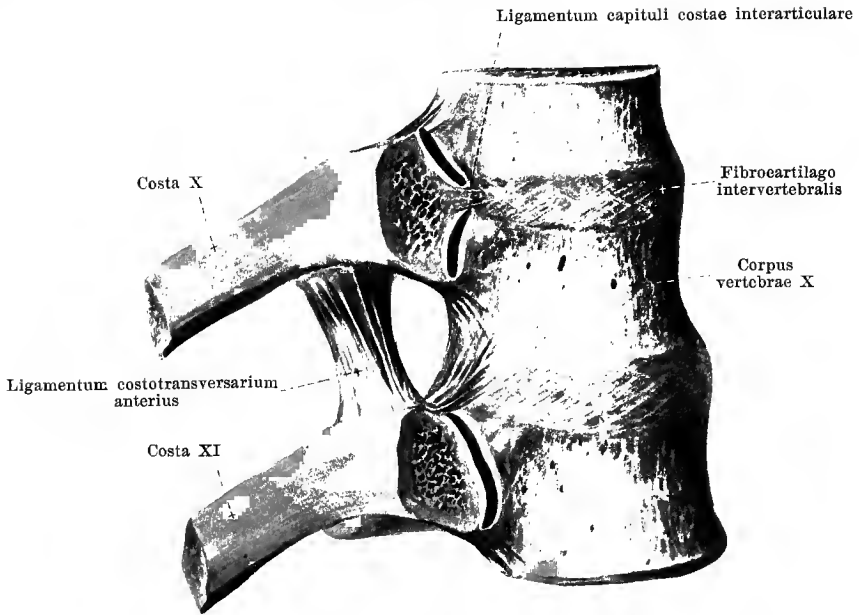
The **articulatio atlantoepistrophica** is covered behind by the *membrana tectoria* (O. T. occipito-axial ligament) (see also Fig. 221). This lies as a broad, quadrangular fibrous plate behind the ligamentum cruciatum atlantis, is loosely connected with it and is separated from the dura mater of the canalis vertebralis by a very thin fibrous layer which is considered as a continuation of the superficial long bands of the ligamentum longitudinale posterius, while the membrana tectoria itself is looked upon as the especially strongly developed uppermost part of the deep, short-fibred layer of the ligamentum longitudinale posterius (see p. 161). The membrana tectoria arises from the posterior surface of the clivus as well as from the anterior and lateral circumference of the foramen occipitale magnum where it is broadest; its fibres converge downward and become fastened in several strands to the posterior surface of the body of the epistropheus. Short bands of fibres between the atlas and the epistropheus are attached in the depth, lateralward, to the membrana tectoria (see Fig. 218).



221. Median section through the occipital bone and first three cervical vertebrae with ligaments; right half of section, viewed from the left, somewhat schematic; magnification: 4 : 3.

(The ligamentous masses have been partially separated from one another.)

Enumerated from before backward the ligaments of the **articulatio atlantooccipitalis** and the **articulatio atlantoepistrophica** lie behind one another as follows: ligamentum longitudinale anterius with the membrana atlantooccipitalis anterior, ligamentum apicis dentis, ligamentum cruciatum atlantis, membrana tectoria, ligamentum longitudinale posterius (superficial layer), membrana atlantooccipitalis posterior.

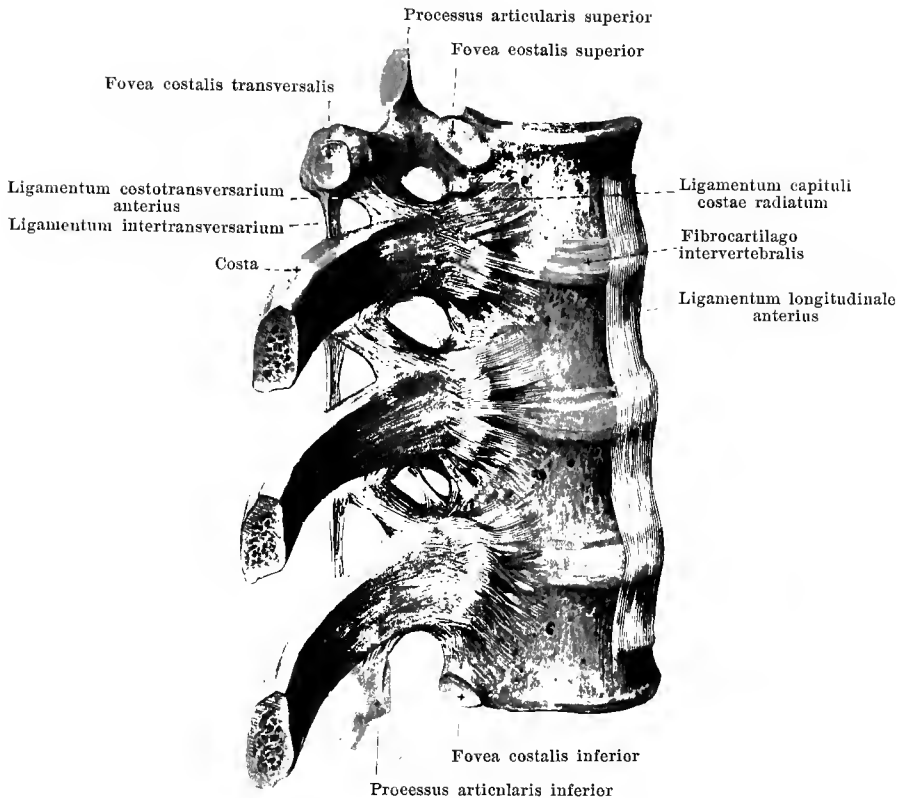


222. Tenth and eleventh ribs and corresponding vertebral bodies with their ligaments, viewed from the right.

(The most anterior layer has been sawed off from the heads of the ribs; the parts have been somewhat separated from one another. The ligamentum longitudinale anterius has been removed.)

The **articulationes costovertebrales** (*articulations of the ribs with the vertebrae*) (see Fig. 225) are the moveable connections between the ribs and the thoracic vertebrae. Each rib is articulated at two points; the capitulum costae moves in the foveae costales of the bodies of the vertebrae (*articulationes capitulorum*) and at the same time the tuberculum costae rotates in the fovea costalis transversalis (*articulationes costotransversariae*). Both together form mechanically one joint.

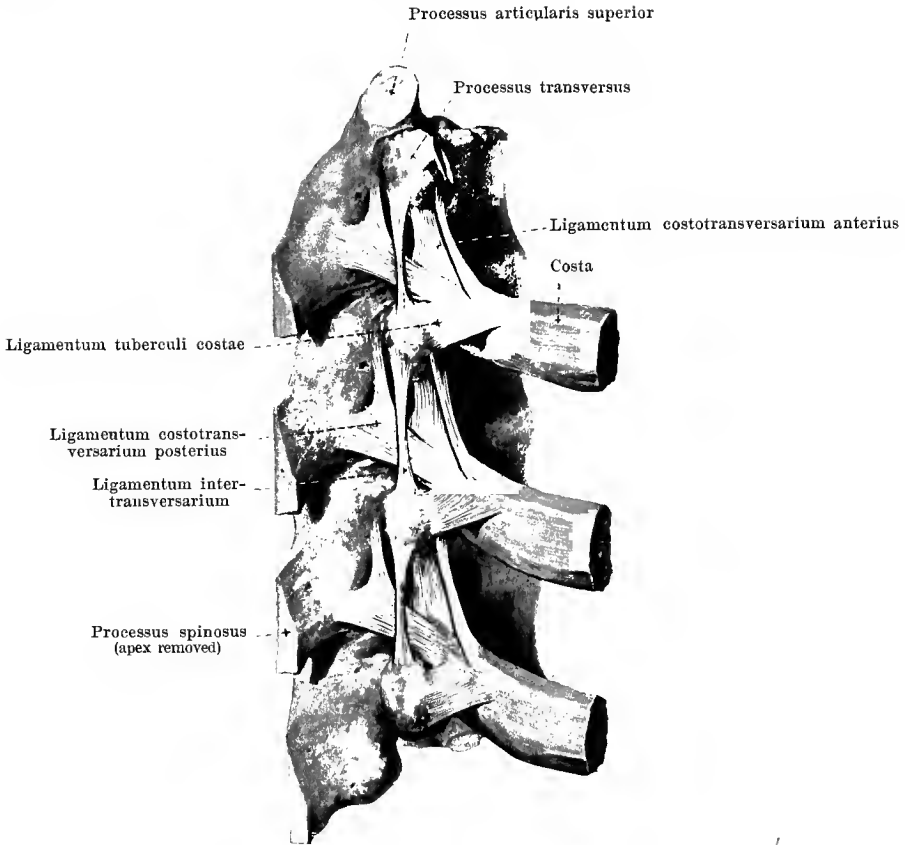
In the **articulationes capitulorum** (*articulations between the heads of the ribs and the vertebrae*) (see also Figs. 212, 223 and 225) each capitulum costae lies with its facies articularis in the corresponding foveae costales of the vertebral bodies, so that, for example, the capitulum of the sixth rib rests in the fovea costalis inferior of the fifth thoracic vertebra, in the fovea costalis superior of the sixth thoracic vertebra and in a depression in the intervertebral disc lying between the two. On the second to the tenth rib, a *ligamentum capituli costae interarticulare* (O. T. interarticular ligament) extends from each crista capituli to the fibrocartilago intervertebralis, and usually separates two special joint cavities, with their *capsulae articulares* from one another. The eleventh and twelfth ribs unite each with one vertebral body only and accordingly possess always only one capsula articularis each.



223. Ribs and corresponding vertebrae, with ligaments, viewed from the right.

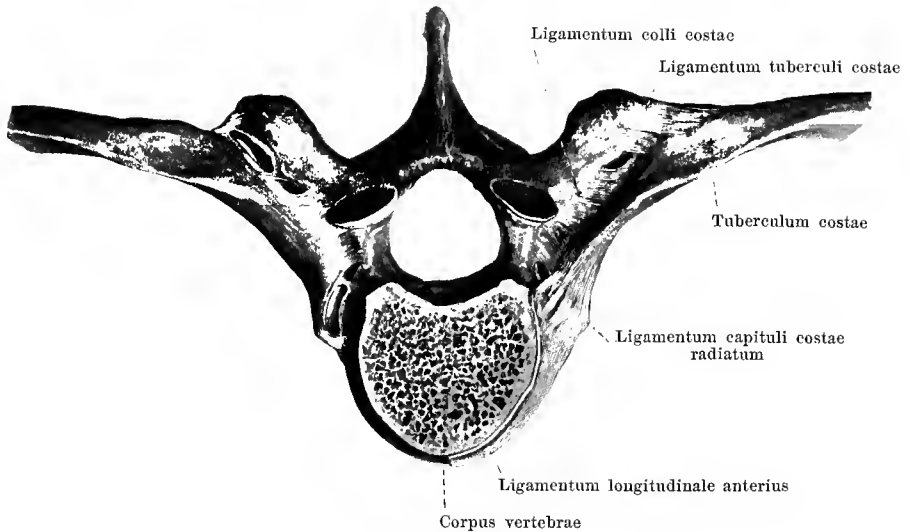
(The lateral portion of the ligamentum longitudinale anterius has been removed.)

On the anterior surface of each of the **articulationes capitulorum**, the broad flat *ligamentum capituli costae radiatum* (O. T. anterior costovertebral or stellate ligament) (see also Figs. 212 and 225) extends from the head of the rib to the lateral surfaces of the corresponding vertebral bodies and fibrocartilago intervertebralis; the fibres diverge medianward and are partly covered over by the lateral portions of the ligamentum longitudinale anterius.



224. Ribs and corresponding vertebrae with ligaments, viewed from behind and somewhat from the right.

The **articulationes costotransversariae** (see also Figs. 212, 222, 223, 225) are formed on the first to the tenth rib by the apposition of each *facies articularis tuberculi costae* to the *fovea costalis transversalis* of the vertebra pertaining to the rib, so that for example, the tubercle of the sixth rib is connected with the transverse process of the sixth thoracic vertebra. The margins of the cartilaginous joint surfaces are connected by *capsulae articulares*. Extending as a strengthening ligament from the under surface of the next transverse process above is the strong, quadrangular *ligamentum costotransversarium anterius*, which passes obliquely downward and medianward to the *crista colli*; behind this the feebler, triangular *ligamentum costotransversarium posterius* runs from the root of the *processus spinosus* and from the root of the *processus transversus* of the next vertebra above obliquely lateralward and downward to the posterior surface of the *collum costae* and to the region above the *tuberculum costae*.

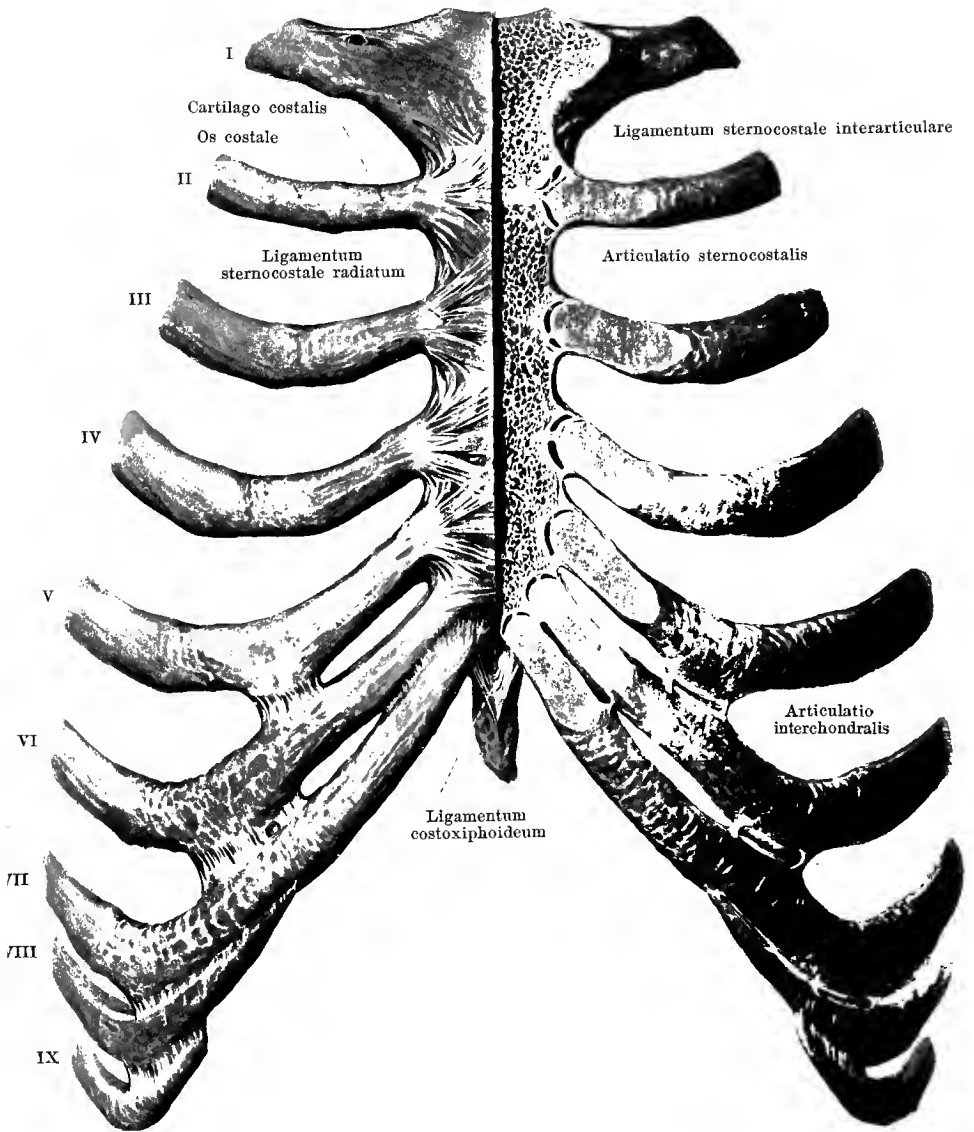


225. Ribs and corresponding vertebra with ligaments, from above.

(The body of the upper of the two vertebrae connected with the rib has been sawed through transversely. On the right side the joint slits have been opened.)

The following strengthening ligaments of the **articulationes costotransversariae** have yet to be considered:—the *ligamentum tuberculi costae*, which extends as a quadrangular ligament behind the joint from the tip of the processus transversus to the posterior surface of the tuberculum costae (see also Fig. 224), as well as the *ligamentum colli costae*. The latter is short, broad, and stretched out horizontally between the posterior surface of the collum costae and the anterior surface of the processus transversus of the corresponding vertebra. The fibres run obliquely backward and medianward from the rib. This ligament fills the space between the anterior surface of the processus transversus and the posterior surface of the collum costae, the *foramen costotransversarium*, almost completely except for chinks in the anterior and posterior part.

On the eleventh and twelfth rib the tuberculum costae does not touch the processus transversus of the vertebrae, and the joint cavity of the articulatio costotransversaria is absent as is also the capsula articularis; corresponding to this the two ligaments of this joint are somewhat modified.



226. Sternum and ribs with ligaments, from in front.

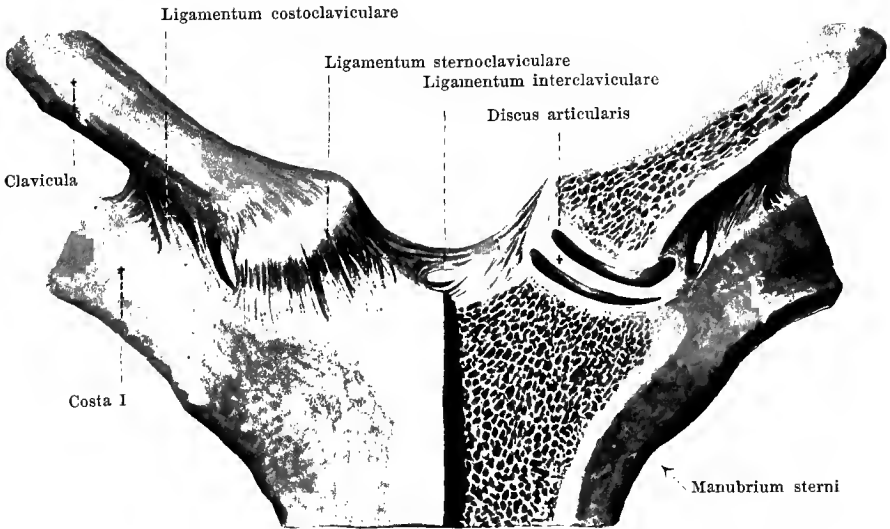
(In the left half of the figure the most anterior layer has been removed and the joint slits have been opened; the parts are separated somewhat from one another on the left side.)

The anterior extremities of the seven upper costal cartilages are attached directly to the incisurae costales of the sternum, **articulationes sternocostales** (*articulations of the cartilages of the ribs with the sternum*); the cartilage of the first rib fuses usually directly with the sternum, while for the cartilages of the second to the seventh rib there are usually present slit-shaped joint cavities and *capsulae articulares*. A *ligamentum sternocostale interarticulare* (O. T. interarticular chondrosternal ligament), which extends from the medial end of the second costal cartilage to the cartilaginous (or bony) junction of the manubrium with the corpus sterni, makes constantly two separate joint cavities for this joint. In the other joints there are often similar fibrous strands, which, however, lead usually only to incomplete division of the joint cavities. The joint capsules are strengthened on the anterior surface by strong, on the posterior by weak, *ligamenta sternocostalia radiata* (O. T. anterior and posterior chondrosternal ligaments), which extend from the ends of the costal cartilages, diverging to the sternum; the anterior of these interweave with those of the other side to form a tough layer. This layer, ensheathing the sternum in front and behind, is called the *membrana sterni*.

The eighth and ninth rib are attached usually (see p. 78) each with the anterior end of its cartilage to the cartilage of the next rib above. In these places as well as sometimes at other places on the fifth to the ninth costal cartilage, where contact between the cartilages or cartilaginous processes takes place, small joint slits and joint capsules are present, the *articulationes interchondrales*.

The anterior extremity of the tenth costal cartilage is united by a loose ligamentous band with the ninth; no such connection of the eleventh with the twelfth rib exists.

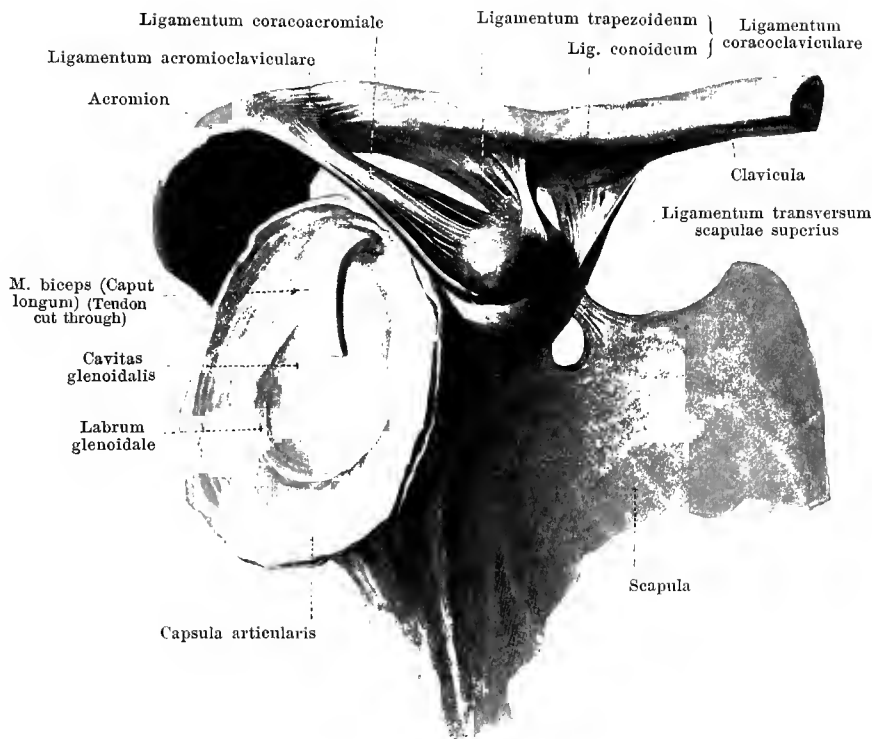
From the lowermost end of the corpus sterni and from the anterior surface of the sixth and seventh costal cartilage strand-like bands go off obliquely medianward to the anterior surface of the processus xiphoideus, the *ligamenta costoxiphoidea* (O. T. chondroxiphoid ligaments). They are connected with the anterior leaf of the vagina musculi recti abdominis.



227. Clavicle, sternum and first rib, with ligaments, from in front.

(On the left half the most anterior layer has been removed; the parts forming the joints are somewhat separated from another.)

The **articulatio sternoclavicularis** (*sternoclavicular joint*) arises from the fact that the *extremitas sternalis claviculae* with its *facies articularis sternalis*, covered with cartilage, lies in the *incisura clavicularis sterni* which is also covered with cartilage, the two being separated only by the *discus articularis* (O. T. interarticular fibrocartilage); the latter is thickened above, medianward and behind, and separates two special joint cavities with *capsulae articulares* from one another. On the anterior surfaces of the joint the broad *ligamentum sternoclaviculare* extends from the clavicle down to the sternum. In addition, the rounded, unpaired *ligamentum interclaviculare*, concave above, stretches out between the medial extremities of the two clavicles over the *incisura jugularis sterni*. The *ligamentum costoclaviculare* (O. T. rhomboid ligament), a powerful ligament, consisting of several layers, goes from the *tuberositas costalis claviculae* to the upper margin of the first costal cartilage.



228. Right clavicle and shoulder blade with ligaments, from without and somewhat from in front.

(The medial half of the clavicle has been sawed off. The shoulder joint has been opened and the head of the humerus removed. Of the shoulder blade only the lateral portion has been drawn.)

The three **ligaments of the shoulder blade** extend between segments of bone which are not moveable upon one another; they accordingly serve only as a supplement of the bony structure.

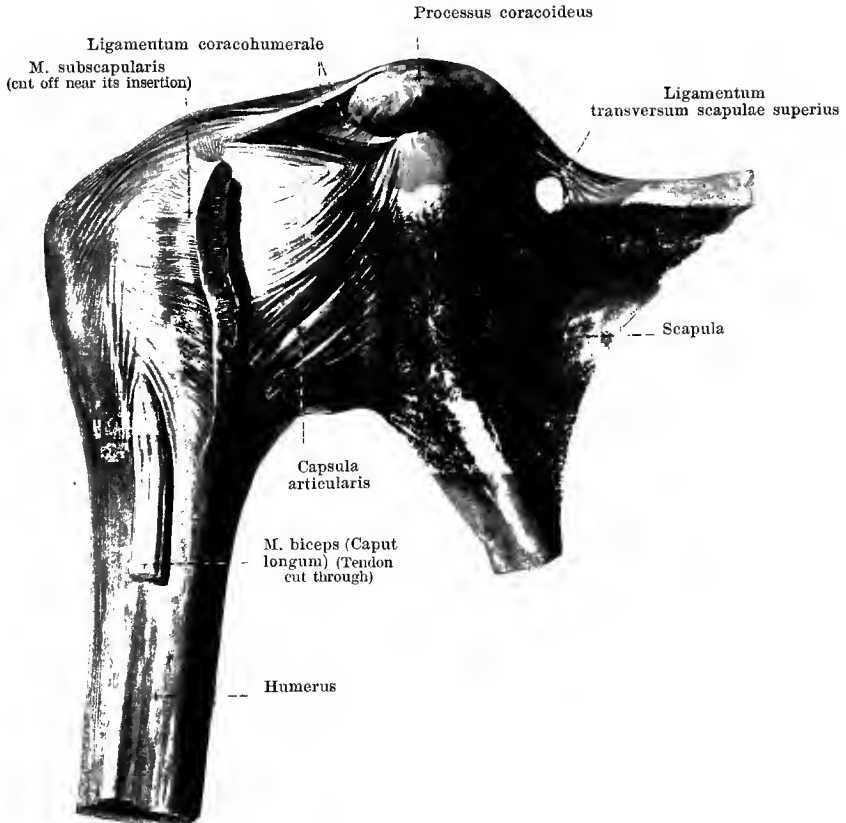
The *ligamentum coracoacromiale* (*coracoacromial ligament*) is strong, broad, oblong, quadrangular and extends above the shoulder joint from the anterior surface of the acromion to the posterior surface of the processus coracoideus.

The *ligamentum transversum scapulae superius* (see also Figs. 229 and 231) is thin and flat; it is stretched out over the incisura scapulae and transforms this into a foramen through which pass the v. transversa scapulae and the n. suprascapularis (the a. transversa scapulae generally runs over the same).

The *ligamentum transversum scapulae inferius* (see Fig. 230) is thin and round; it extends from the root of the acromion to the posterior margin of the cavitas glenoidalis, over the collum scapulae. Through the space between ligament and bone runs the a. transversa scapulae.

In the **articulatio acromioclavicularis** the facies articularis acromialis claviculae is united with the facies articularis acromii (rarely with intercalation of a disc of fibro-cartilage, *discus articularis*). From the margins of the joint surfaces stretches out a *capsula articularis*, strengthened on the upper surface by the broad *ligamentum acromioclaviculare*.

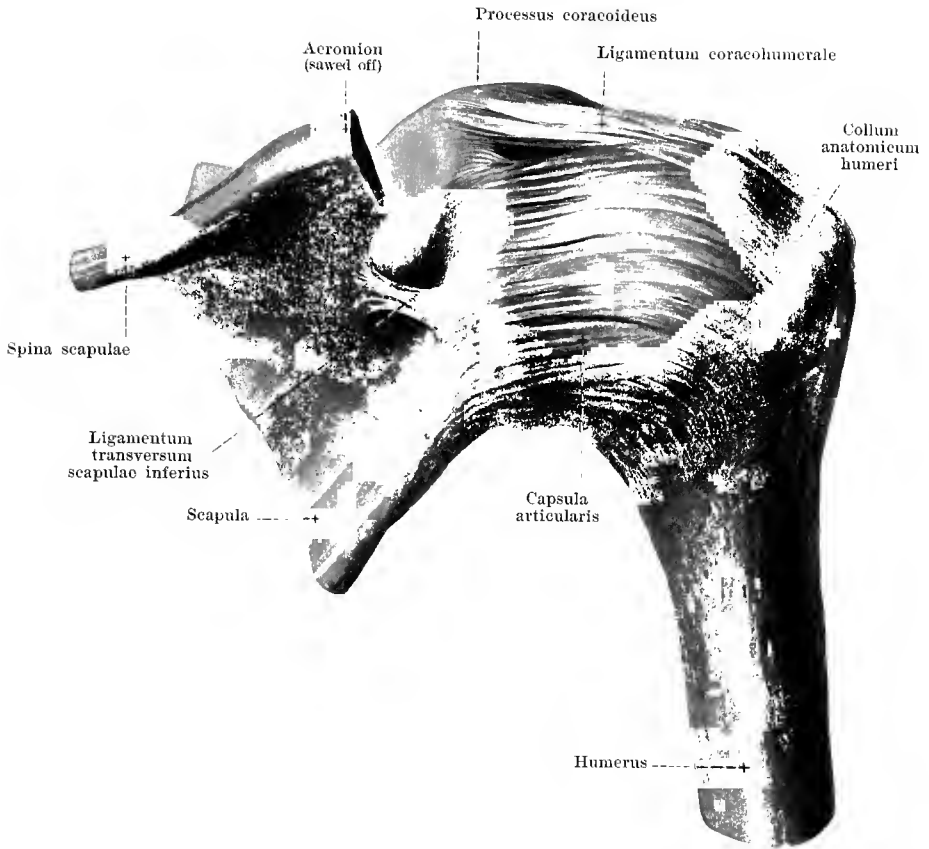
Between the tuberositas coracoidea claviculae and the upper surface of the processus coracoideus scapulae extends the broad, powerful *ligamentum coracoacilaviculare*; its anterior, lateral, quadrangular part is called the *ligamentum trapezoidem*, its posterior medial, triangular part, broader above, more apical below, the *ligamentum conoideum*; between the two there is often a bursa, bursa ligamenti coracoacilavicularis (see Fig. 345).



229. Right shoulder joint, *articulatio humeri*, from in front.

(The bursa m. subscapularis is not shown. Of the shoulder blade only the lateral part has been drawn in.)

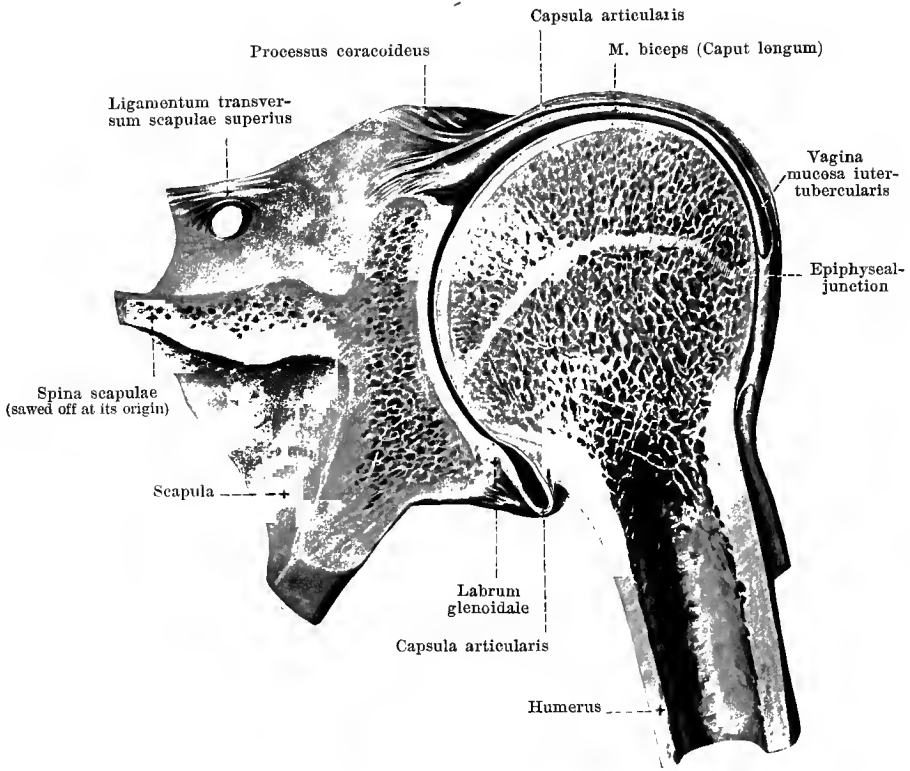
The *articulatio humeri* (*shoulder joint*) (see also Figs. 228, 230 and 231) is formed in that the caput humeri moves upon the cavitas glenoidalis scapulae. The articular surface of the shoulder blade is enlarged by means of a fibrocartilaginous ring, *labrum glenoidale* (O. T. glenoid ligament), which is attached to the margin of the cavitas glenoidalis. From the outer side of this fibrocartilaginous projection a wide and loose *capsula articularis* extends to the collum anatomicum humeri and bridges over the upper end of the sulcus intertubercularis. The mm. subscapularis, supraspinatus, infraspinatus, running close by the joint, are firmly attached to the capsule near their insertions to the humerus. The stratum fibrosum of the capsule consists essentially of laterally directed fibre bands which form somewhat thicker layers in front and below.



230. Right shoulder joint, *articulatio humeri*,
from behind,

(The acromion has been sawed off. Of the shoulder blade only the lateral portion has been drawn in.)

The *ligamentum coracohumerale* (see also Fig. 229) is shown as an especial strengthening ligament of the **articulatio humeri**. This arises from the lateral border of the processus coracoideus below the ligamentum coracoacromiale, is there separated from the capsule by loose tissue, but then sinks into the capsule and radiates out into its upper and posterior wall toward the tuberculum majus.



231. Right shoulder joint, *articulatio humeri*.

Frontal section through the same, from behind.

(The vagina mucosa intertubercularis has not been opened in its whole length. Of the shoulder blade only the lateral portion has been drawn.)

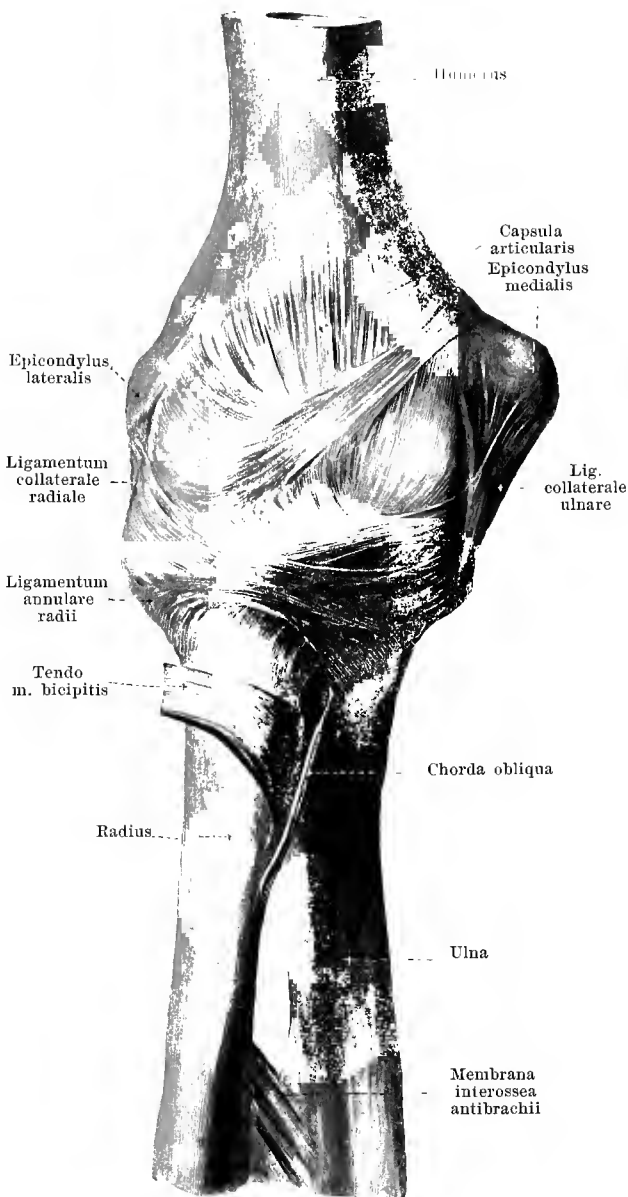
The **articulatio humeri** possesses regularly two bulgings of its capsula articularis. The one bulging, *bursa m. subscapularis* (see also Fig. 346) lies between the upper part of the m. subscapularis and the joint capsule, is ovale and extends to below the root of the processus coracoideus; it is connected with the joint cavity by an opening situated a little below the ligamentum coracohumerales.

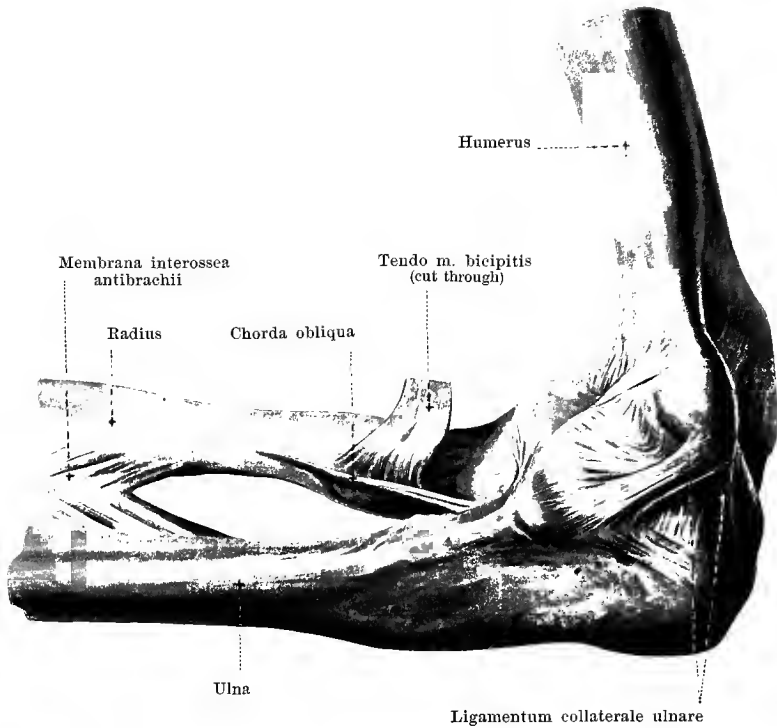
The second bulging of the capsula articularis is the *vagina mucosa intertubercularis* (see also Fig. 346). It surrounds the tendon of the caput longum m. bicipitis as a tubular cylindrical canal, is in free communication at its upper extremity with the joint cavity and lies close to the bone in the region of the sulcus intertubercularis which is covered with cartilage above; it ends in the form of a blind sac in the region of the collum chirurgicum where the stratum synoviale of the capsule is reflected upon the tendon of the m. biceps, covering over part of the same as it runs inside the joint cavity.

232.

Right elbow joint,
articulatio cubiti,
from in front.

The **articulatio cubiti** (*elbow joint*) (see also Figs. 233 to 236) is the articulation between the humerus and the bones of the forearm. Here three different joints are included in one common *capsula articularis*: — (1) the *incisura semilunaris ulnae* glides upon the *trochlea humeri* (*articulatio humeroulnaris*); (2) the *fovea capituli radii* rotates on the *capitulum humeri* (*articulatio humeroradialis*); (3) the *circumferentia articularis radii* moves in the *incisura radialis ulnae* (*articulatio radioulnaris proximalis*). The *articulatio humeroulnaris* takes part in the movements between the upper arm and the forearm only, while the *articulatio radioulnaris proximalis* serves exclusively for the movements between the two bones of the forearm; the *articulatio humeroradialis* on the other hand, takes part in both movements.

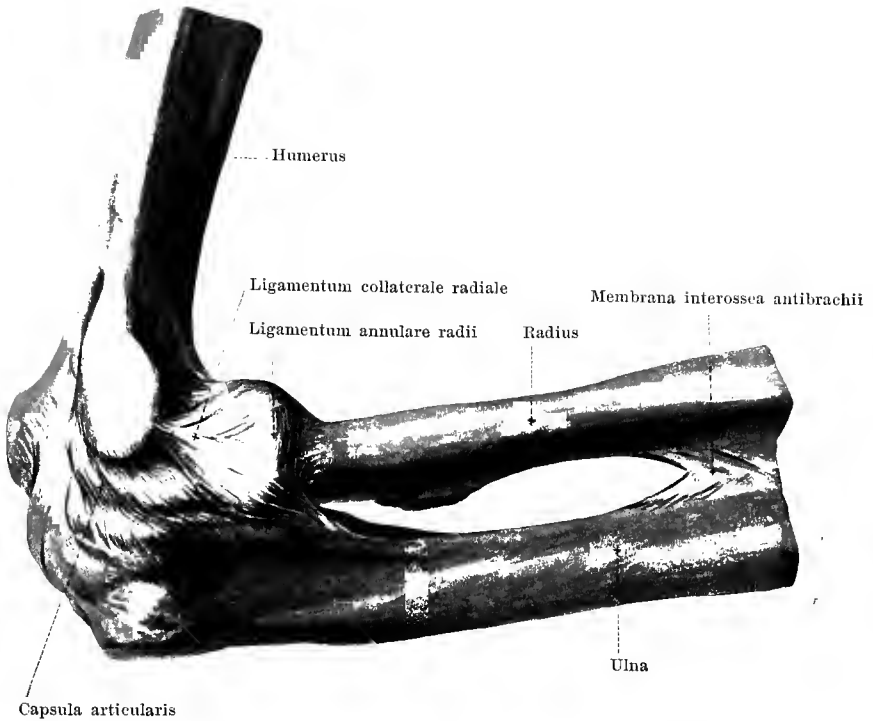




233. Right elbow joint, *articulatio cubiti*, from the ulnar side.

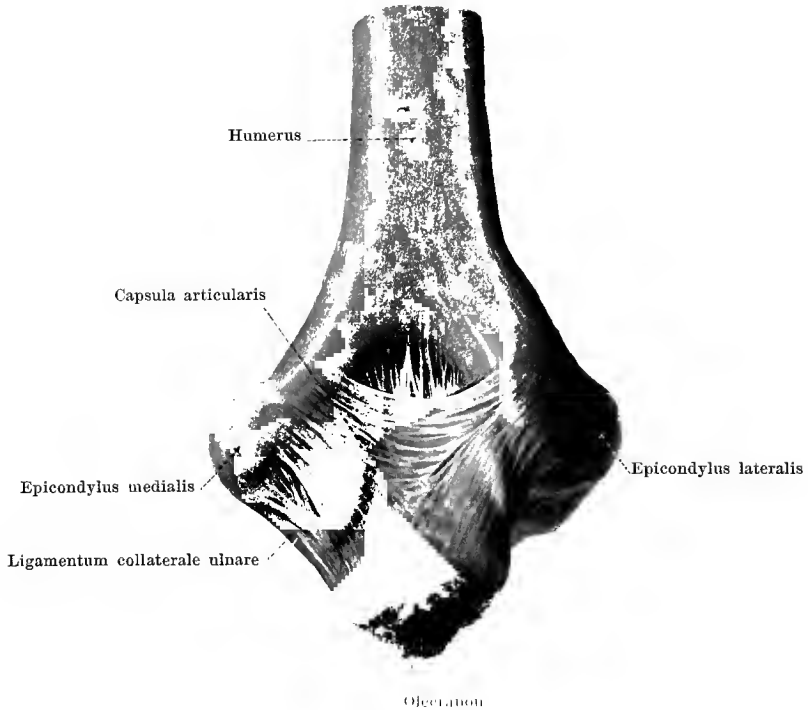
The *capsula articularis* of the **articulatio cubiti** is tolerably wide and proceeds from the humerus in front and behind in a line convex above; this place of origin lies in the middle in front close above the fossa coronoidea and fossa radialis, behind in the upper part of the fossa olecrani; on the sides it runs distalward from the two epicondyls. On the ulna the capsule is attached in the whole circumference of the incisura semilunaris and incisura radialis beyond the margin of the surface covered with cartilago; to the radius it is fastened around the collum radii, about in the middle between the lower margin of the capitulum and the tuberositas radii. The narrow bulging of the capsule between the incisura radialis ulnae and the circumferentia articularis radii extending distalward is called the *recessus sacciformis*.

The powerful, flat, triangular *ligamentum collaterale ulnare* (O. T. internal lateral ligament) (see also Figs. 232 and 235) is to be mentioned as an especial strengthening ligament on the ulnar side; it extends from the epicondylus medialis humeri, its fibres diverging to the ulnar margin of the incisura semilunaris ulnae.



234. Right elbow joint, *articulatio cubiti*,
from the radial side.

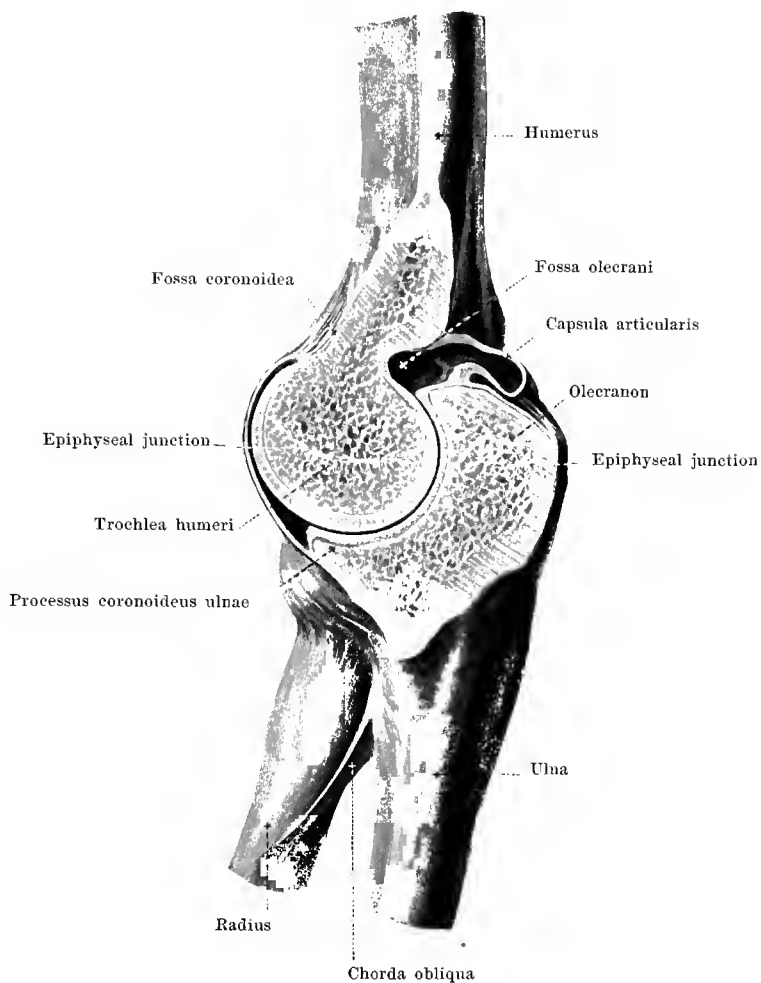
The **articulatio cubiti** possesses as a second strengthening ligament on its radial side the *ligamentum collaterale radiale* (O. T. external lateral ligament) (see also Fig. 232). This arises as a strong bundle on the epicondylus lateralis humeri and divides into two diverging fibre bands of which one goes in front of, the other behind the capitulum radii; they are attached to the ulna partly in front of the incisura radialis, partly behind it and to the radial margin of the incisura semilunaris; distalward they reach as far as the level of the collum radii. The space between the diverging limbs of this ligament is filled up by fibres which surround the capitulum and collum radii circularly and which partially unite with the limbs mentioned, partially are fastened separately to the ulna in front and behind the incisura radialis; these circular fibre bands are most markedly developed at the distal part and are grouped together there especially, under the name, *ligamentum annulare radii* (O. T. orbicular ligament) (see also Fig. 237), but they are only artificially, not sharply, separable from the others.



235. Right elbow joint, *articulatio cubiti*, from behind.

(The forearm is flexed at a right angle on the upper arm.)

The *capsula articularis* of the **articulatio cubiti** reaches on the upper arm behind, in the middle as far as the upper part of the fossa olecrani, on the sides as far as the lower part of the epicondylus medialis and lateralis. Especial strengthening ligaments in the posterior wall of the fibrous capsule will not be described. The upper part of the fossa olecrani contains a thick mass of fat close to the capsule between it and the tendon of the *m. triceps brachii*.



236. Right elbow joint, *articulatio cubiti*,

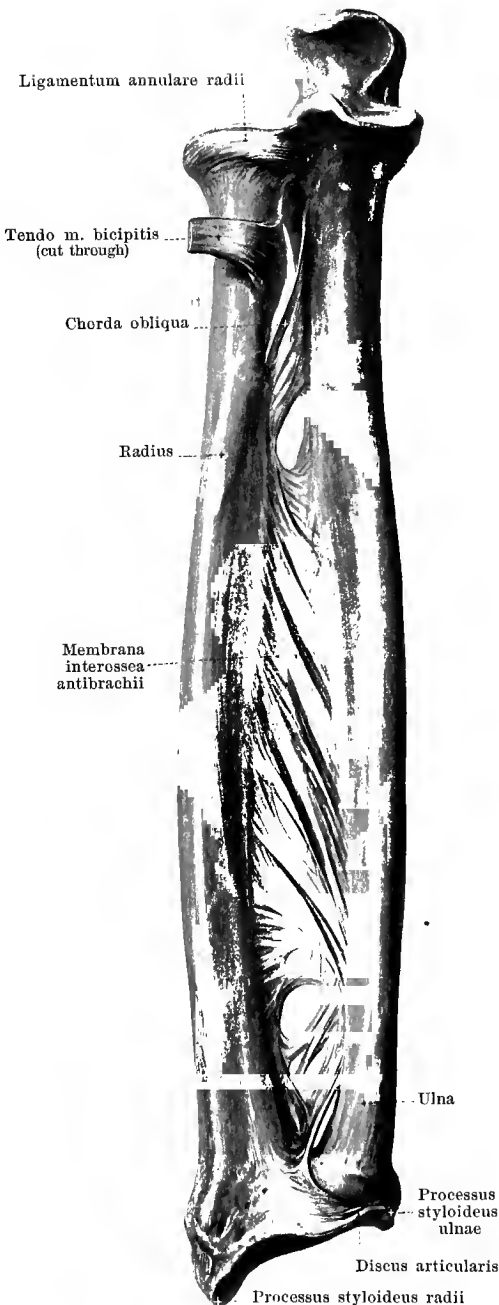
cut through at right angles to the axis of the trochlea humeri, from the ulnar side.

(The joint cavity on the anterior surface is not struck at the spot in which it extends furthest upward; the latter corresponds about to the dotted line leading into the fossa coronoidea.)

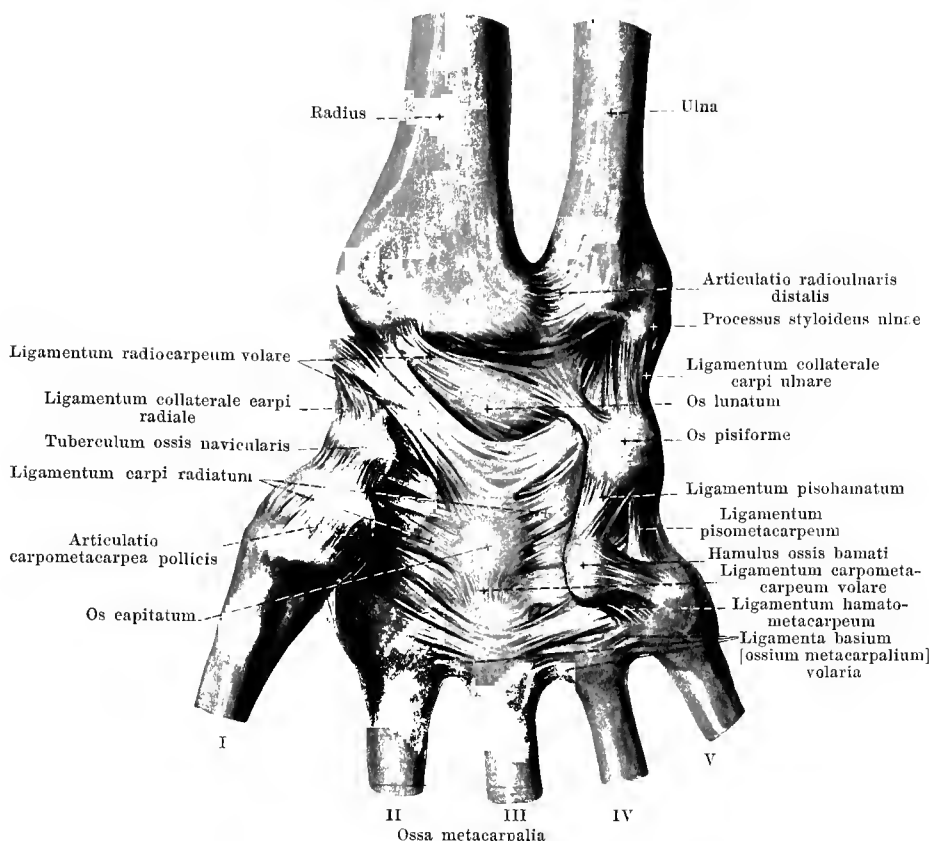
In the **articulatio cubiti** the olecranon ulnae comes to lie in the fossa olecrani humeri when the forearm is extended; when the forearm is flexed, on the contrary, the processus coronoideus ulnae enters the fossa coronoidea humeri and the capitulum radii enters the fossa radialis. During life, however, it is unusual to have the movements of extension and flexion go so far that the projections of the forearm bones mentioned touch the corresponding depressions of the humerus; the movements are checked before this occurs.

237.

Bones of the right forearm, with ligaments, from the volar surface.



The joint union between the two bones of the forearm, the **articulatio radioulnaris** is divisible spatially into two portions: these are the *articulatio radioulnaris proximalis* (O. T. superior radioulnar articulation) between the circumferentia articularis of the capitulum radii and the incisura radialis ulnae (see p. 181) and the *articulatio radioulnaris distalis* (O. T. inferior radioulnar articulation), between the incisura ulnaris radii and the circumferentia articularis of the capitulum ulnae. The latter joint is surrounded by a loose *capsula articularis*. This arises on the radius and ulna from the margin of the cartilaginous surfaces and fuses distalward with the margin of the *discus articularis*, a triangular plate of fibrocartilage which has a broad attachment to the ulnar margin of the incisura ulnaris radii and becoming narrow is fastened to the tip of the processus styloideus ulnae (see also Fig. 240). The blind-sac-like bulging of the joint capsule extending proximalward between the circumferentia articularis of the capitulum ulnae and the incisura ulnaris radii is called the *recessus sacciformis* (see Fig. 240). The articulationes radioulnares proximalis et distalis, in a mechanical sense, form together one joint. The space between the two bones of the forearm is almost completely filled up by the *membrana interossea antibrachii* (*interosseous membrane*). This powerful fibrous sheet is stretched out between the cristae interossee of the radius and of the ulna, is separated proximalward by a large, distalward by a narrow space from the corresponding joint, and possesses several irregular openings for the passage of vessels and nerves; the fibre bands run in the main obliquely and extend from the radius distalward toward the ulna. In addition the *chorda obliqua* (O. T. oblique ligament) (see also Figs. 232 and 233) extends as a thin rounded fibrous band from the region of the tuberositas ulnae obliquely downward to the region of the tuberositas radii.



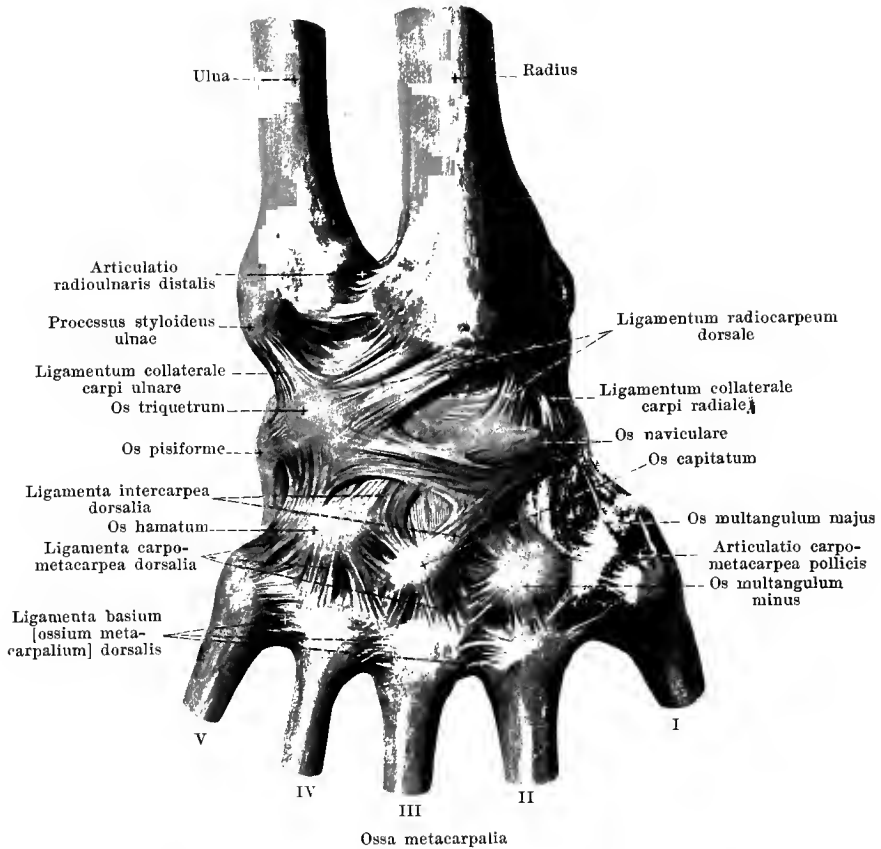
238. Joints of the right hand, *articulatio manus*, from the volar surface.

The **articulatio manus** (*joint of the hand*) (see also Figs. 239 and 240) is divisible into the *articulatio radiocarpea* and the *articulatio intercarpea*.

In the formation of the *articulatio radiocarpea* (*wrist-joint*) the proximal joint surfaces of the ossa naviculare, lunatum, triquetrum move upon the *facies articularis carpea* of the radius and upon the distal surface of the *discus articularis*. Its wide loose *capsula articularis* is attached to the circumference of the articular surfaces. It is strengthened by the *ligamentum collaterale carpi radiale* (O. T. external lateral ligament) which extends from the *processus styloideus radii* to the *os naviculare*, and by the *ligamentum collaterale carpi ulnare* (O. T. internal lateral ligament) which extends from the *processus styloideus ulnae* to the *os triquetrum*. On the volar surface runs also the broad *ligamentum radiocarpum volare* (O. T. anterior ligament) which arises from the *processus styloideus* and from the volar margin of the *facies articularis carpea* of the radius and goes in several bundles to the *ossa naviculare, lunatum, triquetrum, capitatum*.

The *articulatio intercarpea* connects and permits motion among the bones of the wrist; the individual bones are connected among one another by small *capsulae articulares*. On the volar surface there are several strengthening ligaments, short, flat, almost transversely directed, *ligamenta intercarpea volaria* (O. T. palmar ligaments); of these, those which radiate out from the *os capitatum* to the adjoining bones are grouped together as the *ligamentum carpi radiatum*.

In the formation of the *articulatio ossis pisiformis*, the dorsal surface of the *os pisiforme* glides upon the volar surface of the *os triquetrum*; a small, loose *capsula articularis* connects the borders of these surfaces. From the *os pisiforme*, the powerful *ligamentum pishamatum* goes to the *hamulus ossis hamati*; the *ligamentum pisometacarpeum* to the *basis ossis metacarpalis III—V*, both ligaments being really continuations of the tendon of the *m. flexor carpi ulnaris*.



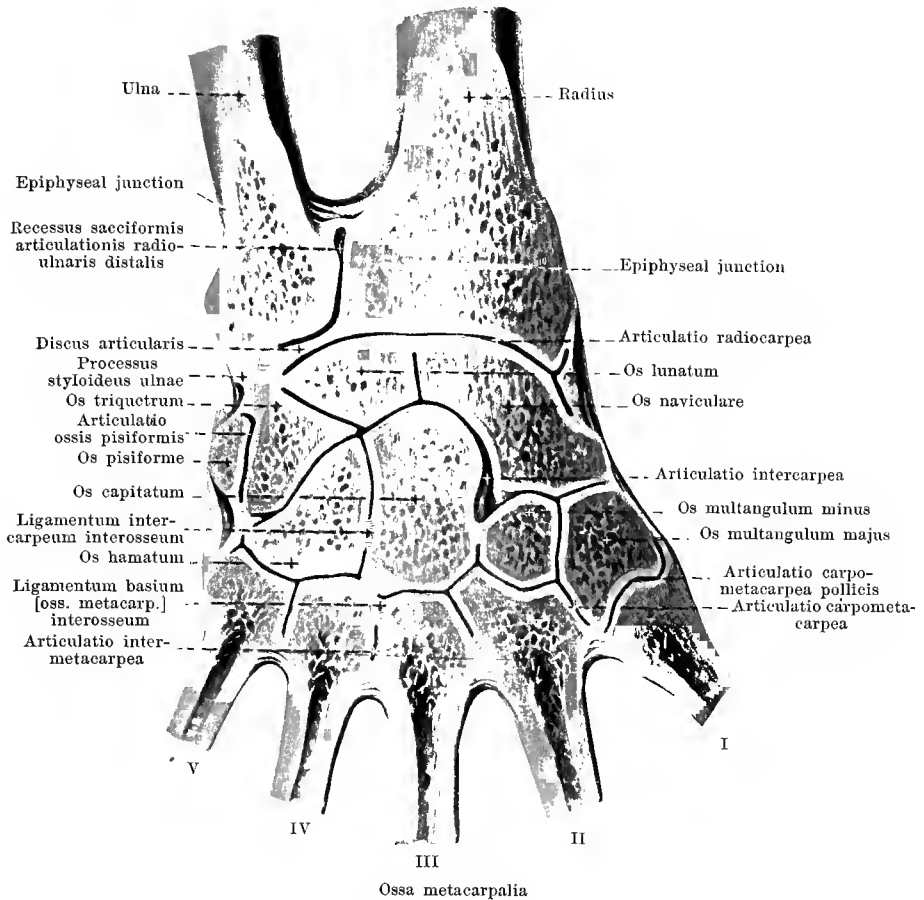
239. Joints of the right hand, *articulatio manus*, viewed from the back of the hand.

Articulatio manus (continuation). On the dorsal surface, the capsule of the *articulatio radiocarpea* is strengthened by the *ligamentum radiocarpeum dorsale* (O. T. posterior ligament) which goes from the dorsal margin of the *facies articularis carpea radii* in different divisions to the bones of the first row of the carpus.

The *articulatio intercarpea* possesses on the dorsal surface several short strengthening ligaments, *ligamenta intercarpea dorsalia* (O. T. dorsal ligaments), which run usually transversely.

The *articulationes carpometacarpeae* (*carpometacarpal articulations*) are formed on the one side by the distal surfaces of the bones of the second row of the carpus, on the other side by the proximal surfaces of the *ossa metacarpalia*. Several short perpendicular and oblique ligaments on the volar and dorsal surfaces, *ligamenta carpometacarpea dorsalia et volaria* (O. T. dorsal and palmar ligaments) serve to their *capsulae articulares* as strengthening ligaments; of the latter, that situated furthest ulnarward extends from the *hamulus ossis hamati* to the *basis ossis metacarpalis V* and is called the *ligamentum hamatometacarpeum* (see Fig. 238).

The *articulationes intermetacarpeae* (*articulations of the metacarpal bones with one another*) have their origin in that the proximal ends of the second to the fifth metacarpal bones can move upon one another by means of their lateral surfaces which are covered with cartilage. Their *capsulae articulares* are strengthened by short transversely directed fibre bands, *ligamenta basium [ossium metacarpalium] dorsalia et volaria* of which there are four on the back of the hand, but only three in the hollow of the hand (the ligament between the *os metacarpale I* and *II* is absent) (see also Fig. 238).



240. Joints of the right hand, *articulatio manus*, from the back of the hand.

(The surface of a frozen hand has been filed off until the joint cavities have been opened.)

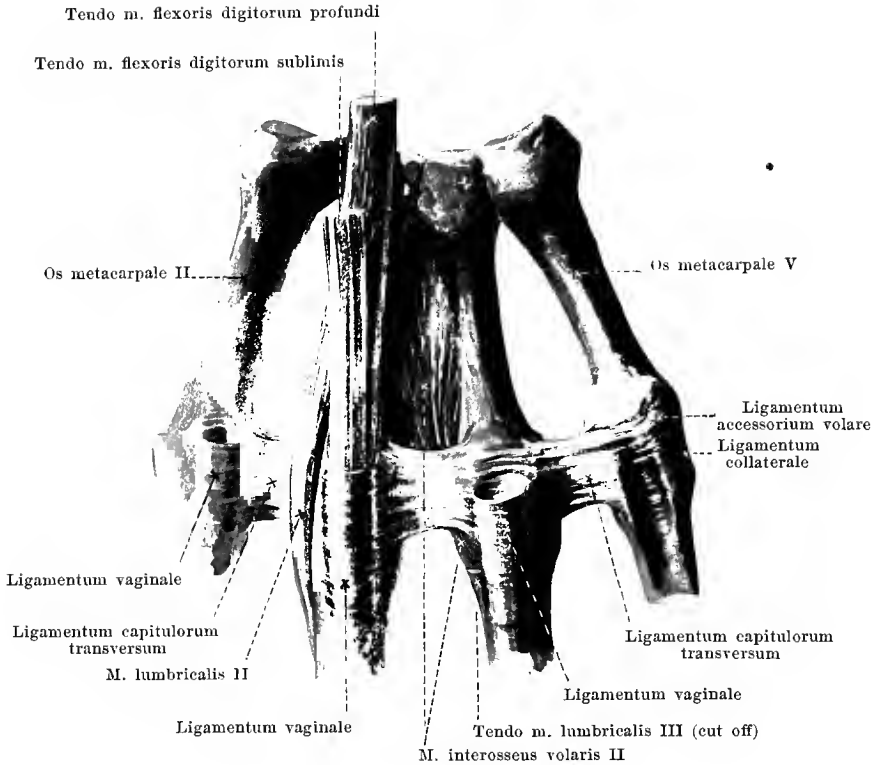Articulatio manus (continuation). The joint cavity of the *articulatio radiocarpea* is connected neither with that of the *articulatio radioulnaris distalis* nor with that of the *articulatio intercarpea*.

The slits between the individual joint surfaces of the bones which together form the *articulatio intercarpea* are usually all connected not only with one another, but also with the joint cavities of the *articulationes carpometacarpeae* and *intermetacarpeae* of the second and third fingers. Short, strong *ligamenta intercarpea interossea* extend in the depth in a transverse direction between the neighboring wrist bones of the same row.

The joint cavity of the *articulatio ossis pisiformis* is usually separated from the others.

In the *articulationes carpometacarpeae* of the second and third finger the joint slits are usually connected not only with those of the *articulatio intercarpea*, but also with those of the *articulationes intermetacarpeae* between the second, third and fourth finger; the *articulationes carpometacarpeae* and the *articulatio intermetacarpea* of the fourth and fifth fingers are usually separated from the others, the *articulatio carpometacarpea pollicis* always.

The three *articulationes intermetacarpeae* possess, in the depth, short, transverse *ligamenta basium [ossium metacarpalium] interossea*. The joint capsules go off from the margins of the surfaces covered with cartilage.



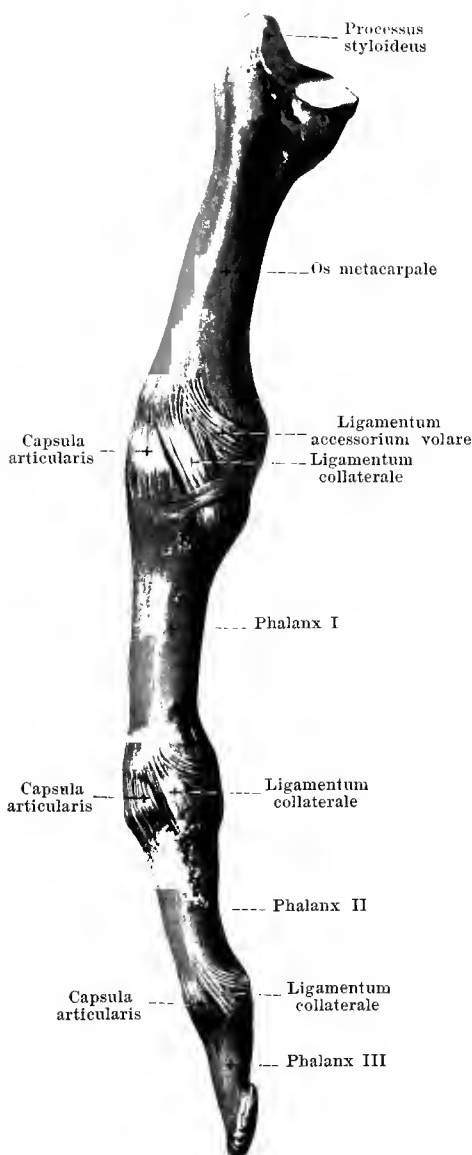
241. Metacarpal bones and first phalanges of the second to the fifth finger of the right hand with ligaments, from the volar surface.

In the formation of the **articulationes metacarpophalangeae** the base of each phalanx I moves upon the capitulum of the os metacarpale. A tolerably loose *capsula articularis* connects the margins of the surfaces covered with cartilage.

Between the heads of the second to the fifth os metacarpale a flat powerful *ligamentum capitulorum [ossium metacarpalium] transversum* (O. T. transverse metacarpal ligament) stretches out transversely over the distal end of the corresponding spatium interosseum metacarpi on the volar surface. It is partially fastened to the lateral surface of the capitulum; in part it goes over into the volar portion of the joint capsule and there connects with the ligamentum accessorium volare; in part it helps to form the ligamenta vaginalia for the flexor tendons of the fingers. The ligament separates the distal portions of the mm. interossei from those of the mm. lumbricales in that the former run dorsalward from it, the latter volarward.

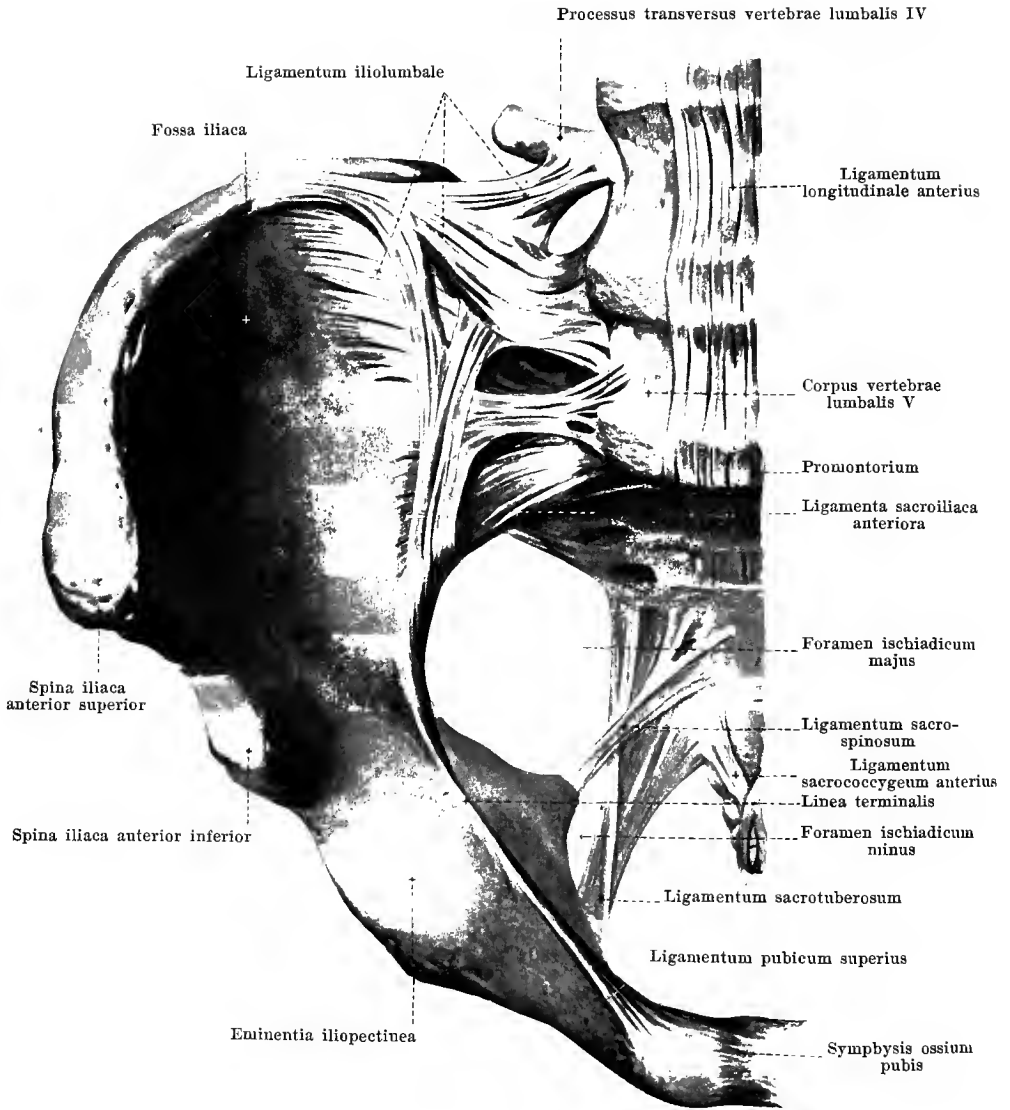
242.

Metacarpal bone and phalanges of the third finger of the right hand with ligaments, from the radial side.



The **articulationes metacarpophalangeae** possess a *ligamentum collaterale* (O. T. lateral ligament) as a strengthening ligament, one on the radial and one on the ulnar side which extends from the lateral surface of the capitulum ossis metacarpalis obliquely distalward and volarward to the base of the first phalanx. In addition, a *ligamentum accessorium volare* (O. T. transverse metacarpal ligament) with one limb on each side to the capitulum ossis metacarpalis just volarward from the ligamentum collaterale runs arch-like to the volar surface of the joint, broadening as it goes; there the two limbs unite so that the whole ligament resembles a loop; on the volar surface it is united with the ligamentum capitulorum transversum (see Fig. 241).

In the formation of the **articulationes digitorum manus** (*finger joints*) the base of each phalanx II is moveably connected with the trochlea of each phalanx I and in the same way the base of each phalanx III with the trochlea of each phalanx II. In the first finger (thumb), only one such joint is present; in the second to the fifth finger always two. Loose *capsulae articulares* connect the margins of the cartilaginous joint surfaces with one another and are strengthened by powerful *ligamenta collateralia* (O. T. lateral ligaments) which run to the radial and ulnar side in a manner entirely analogous to that in the articulationes metacarpophalangeae.



243. Ligaments of the right half of the pelvis, from in front and somewhat from above.

The **pelvic bones** are connected by means of two joints: — the paired *articulatio sacroiliaca* and the unpaired *symphysis ossium pubis*.

In the **articulatio sacroiliaca** (see also Figs. 244 and 245) the *facies auricularis ossis sacri* and the *facies auricularis ossis ilium* of each side are in contact. A short, tight *capsula articularis* connects the margins of the cartilaginous surfaces; it is strengthened on the anterior surface by the *ligamenta sacroiliaca anteriora*, which, considered as a whole, run as broad thin fibre plates from the upper and anterior surface of the *pars lateralis ossis sacri* transversely to the inner surface of the ilium and are there attached in the periphery of the *linea arcuata*, eventually also in the *sulcus paraglenoidalis*.

The *ligamentum iliolumbale* (O. T. iliolumbar ligament) (see also Fig. 244), must also be regarded as a strengthening ligament (in the wider sense) for this joint. This forms a powerful flat fibre band which has its origin from the *processus transversus* of the fifth (partially also, as in Fig. 243, of the fourth) lumbar vertebra; one part of the fibres extends from there to the posterior portion of the *crista iliaca*, another larger part broadens out on the inner surface of the *ala ossis ilium* and on the upper surface of the *pars lateralis ossis sacri*.

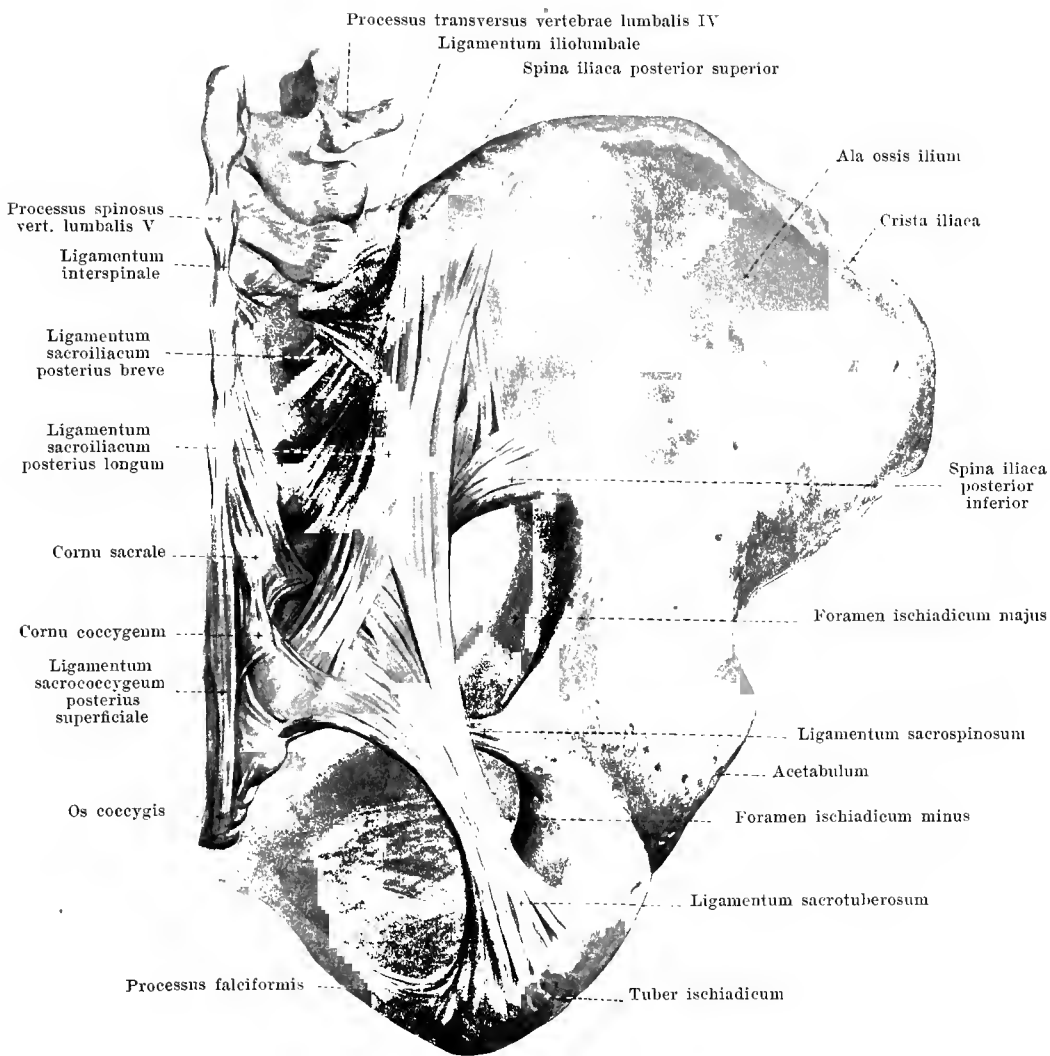
The **articulatio sacroiliaca** is strengthened on the posterior surface by the *ligamenta sacroiliaca interossea* (see also Fig. 245) and the *ligamenta sacroiliaca posteriora brevia et longum*. The latter form the broad mass of fibre bands, only indistinctly separated from one another, which ascend obliquely from the region of the crista sacralis lateralis of the sacrum toward the ala ossis ilium; they are attached there chiefly to the spina iliaca posterior superior; of these the fibrous bands which come from the region of the second and third sacral vertebra are called the *ligamentum sacroiliacum posterius breve*, those from the region of the fourth sacral vertebra, the *ligamentum sacroiliacum posterius longum*. These ligaments cover over the *ligamenta sacroiliaca interossea* completely from behind and lie close upon them.

Of great importance for the form and firmness of the pelvis are also the **ligamentum sacrotuberosum** and the **ligamentum sacrospinosum** (see also Fig. 243).

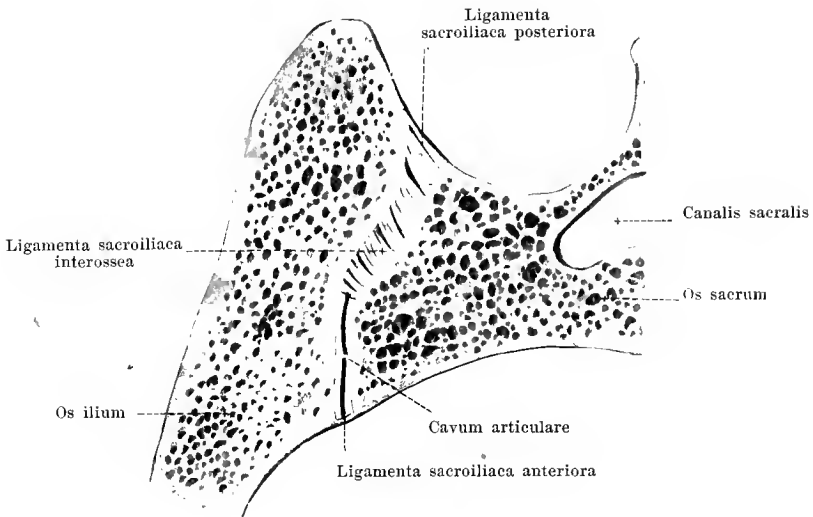
The *ligamentum sacrotuberosum* (O. T. posterior or great sacrosciatic ligament) arises broad and thin from the spinae iliaceae posteriores superior et inferior as well as from the lateral margin of the sacrum and of the two upper coccygeal vertebrae; it is accordingly intimately connected in its upper part with the *ligamenta sacroiliaca posteriora*. The fibres converge to form a strong flat ligament which extends obliquely forward, downward and lateralward and becomes attached to the medial surface of the tuber ischiadicum where it again broadens out; a narrow band which extends as a continuation of some fibre bundles from this point along the medial margin of the ramus inferior ossis ischii, is called the *processus falciformis* (O. T. falciform ligament).

The *ligamentum sacrospinosum* (O. T. anterior or lesser sacrosciatic ligament) is essentially thinner than the preceding; it arises on the lateral margin of the lower portion of the sacrum and of the upper coccygeal vertebrae, extends past the anterior surface of the *ligamentum sacrotuberosum* forward and lateralward, narrowing as it goes, and is attached to the spina ischiadica; at the point where it crosses the *ligamentum sacrotuberosum*, it fuses with it. The *ligamentum sacrospinosum* forms, with the m. coccygeus (see p. 328), a common mass of variable composition; sometimes the connective tissue structures predominate, sometimes the muscle bundles.

The *ligamentum sacrotuberosum*, as well as the *ligamentum sacrospinosum*, stretches out medianward from the two incisurae ischiadicae (or between them) so that these notches are transformed into foramina which are surrounded partly by bone, partly by ligaments; the incisura ischiadica major becomes the rounded quadrangular *foramen ischiadicum majus* (O. T. great sacrosciatic foramen), the incisura ischiadica minor the triangular *foramen ischiadicum minus* (O. T. lesser sacrosciatic foramen) (see also Fig. 243).



244. Ligaments of the right half of the pelvis, from behind.

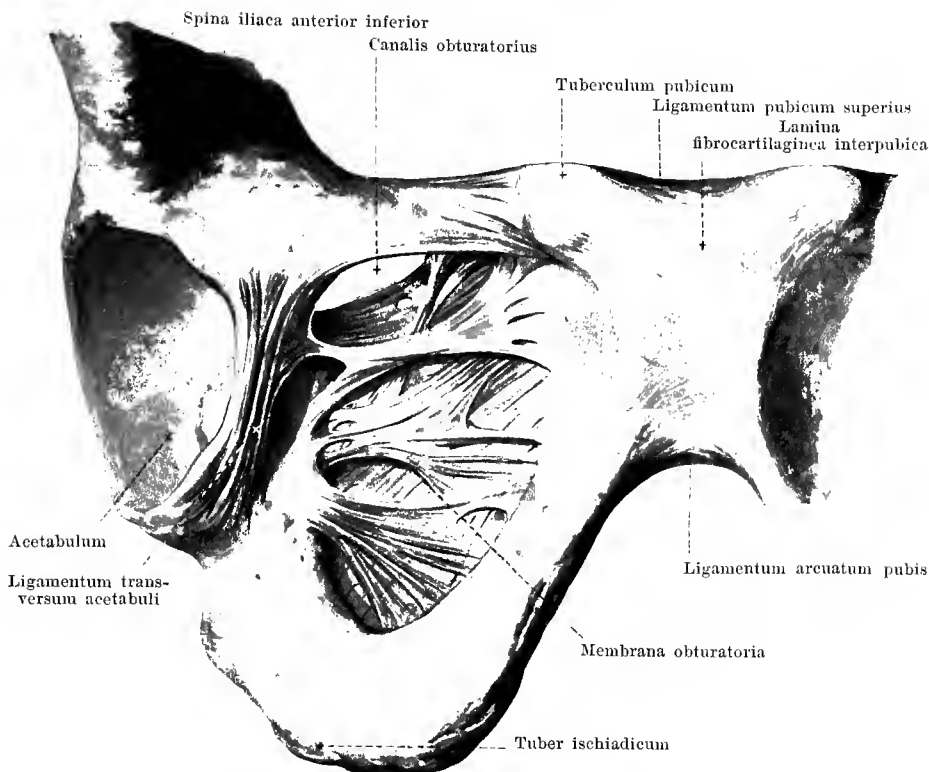


245. Articulatio sacroiliaca dextra, frontal section.

Posterior half of section, from in front.

The **articulatio sacroiliaca** possesses an unevenly curved joint slit; the adjoining articular surfaces are completely covered by cartilage and smooth, but they present several irregular projections which fit in to corresponding depressions of the other bone.

On the dorsal surface there are present, as strengthening ligaments, the *ligamenta sacroiliaca interossea*. Under this name are included the mass of short fibre bands which are covered over completely behind by the *ligamenta sacroiliaca posteriora* and which extend obliquely upward and backward from the *tuberositas sacralis* [ossis sacri] to the *tuberositas iliaca* [ossis ilium], eventually, also to the *sulcus paraglenoidalis*; they fill completely the irregular depression which is situated behind the joint cavity between these two rough surfaces, and are not visible in the uninjured joint.

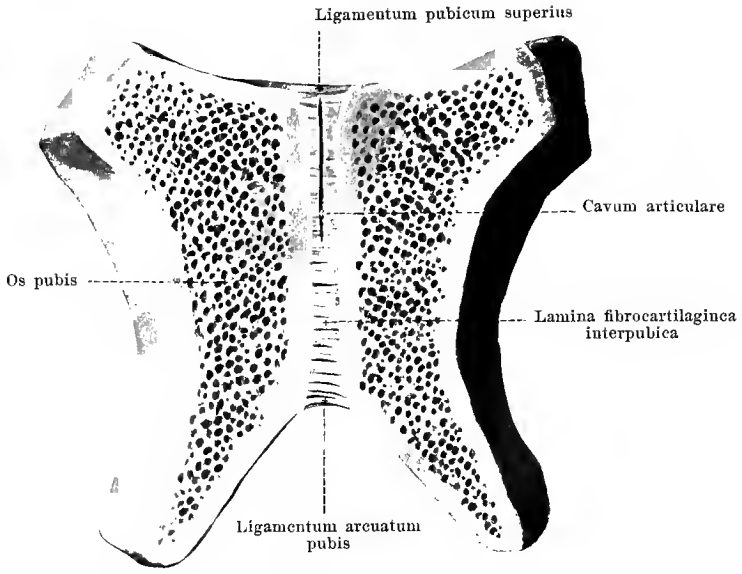


246. Symphysis pubis and right half of pelvis with ligaments, from in front and below.

(Only those fibres of the labrum glenoidale which form the ligamentum transversum acetabuli have been retained.)

The **membrana obturatoria** is usually a thin fibre plate which almost completely closes the foramen obturatum. The fibres arise from the margins of the foramen, coming in the lower and posterior part from the posterior surface of the same. The direction of the fibres is usually transverse. The uppermost bands stretch out below the sulcus obturatorius between the tubercula obturatoria and transform this groove into the short *canalis obturatorius* (for the a. and vv. obturatoriae; n. obturatorius).

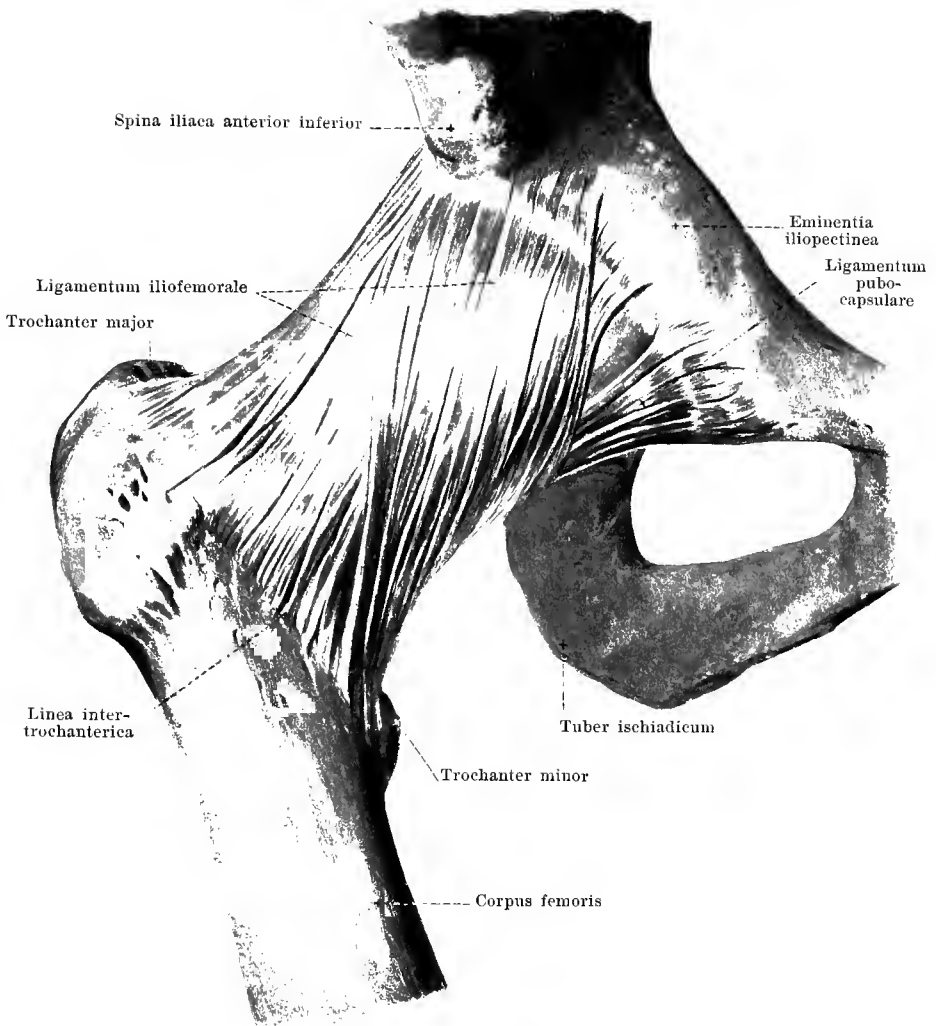
In the unpaired **symphysis ossium pubis** (see also Fig. 247), the two pubic bones are united with one another in the median plane. Between the opposing rough facies symphyseae, which are covered over with a layer of hyaline cartilage, is intercalated a fibrocartilaginous disc (*lamina fibrocartilaginea interpubica*) (O. T. interpubic disc). This projects somewhat on the posterior surface as a narrow ridge; in front it broadens essentially and is covered by a layer of decussating fibres which are connected with the tendons of the mm. recti abdominis. The uppermost, transverse fibre layer stretches out between the upper margins of the rami superiores of the pubic bones or rather between the tubercula pubica, and is called the *ligamentum pubicum superius*; lateralward it is continued like a ridge upon the pecten ossis pubis (see Fig. 243) and there gives origin to a part of the m. pectineus. The sharp-angled triangular fibrous band which extends from the ramus inferior of one pubic bone to that of the other on the lower margin of the symphysis and which, above, is fused with the fibrocartilaginous disc, is called the *ligamentum arcuatum pubis* (O. T. subpubic ligament).



247. Symphysis pubis, opened by a frontal section.

Posterior half, viewed from in front.

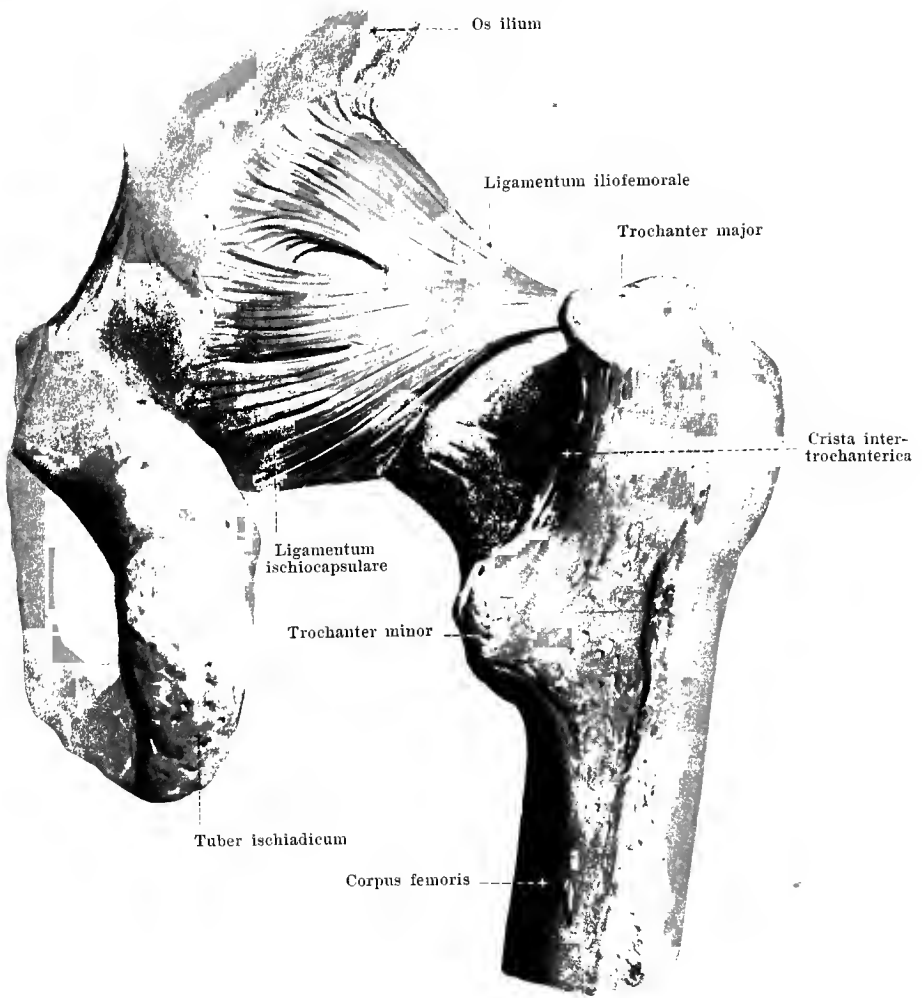
The **symphysis ossium pubis** contains in most cases within its *lamina fibrocartilaginea interpubica* a small medianly situated joint slit which lies nearer the posterior margin than the anterior and extends almost over the upper half of the fibrocartilaginous mass. The strands of fibrocartilage run in the depth, mostly transversely, between the two layers of hyaline cartilage and are seen on median section to consist of concentrically arranged circular layers. Cartilage and fibrocartilage are very firmly united with one another.



248. Right hip joint, *articulatio coxae*, from in front.

In the formation of the *articulatio coxae* (*hip joint*) (see also Figs. 249—252) the caput femoris moves upon the facies lunata of the acetabulum. The latter is enlarged by means of a high three-cornered fibrocartilaginous ring, *labrum glenoidale* (O. T. cotyloid ligament) (see Figs. 250 and 252) which sits with its broad base upon the border of the acetabulum and bridges over the incisura acetabuli as the *ligamentum transversum acetabuli*; this has also a broad attachment to the margins of the incisura acetabuli and is connected with the fibres of the membrana obturatoria (see Fig. 246).

The *capsula articularis* (see Fig. 252) is strengthened on the anterior surface by the strong triangular *ligamentum iliofemorale*. It arises below and near the spina iliaca anterior inferior, broadens gradually and is fastened to the linea intertrochanterica in its whole length. The *ligamentum pubocapsulare* (O. T. pubofemoral ligament) lies on the medial, inferior side of the joint, comes from the corpus and ramus superior ossis pubis and runs partly to the upper margin of the trochanter minor, partly to the capsule in the same region.

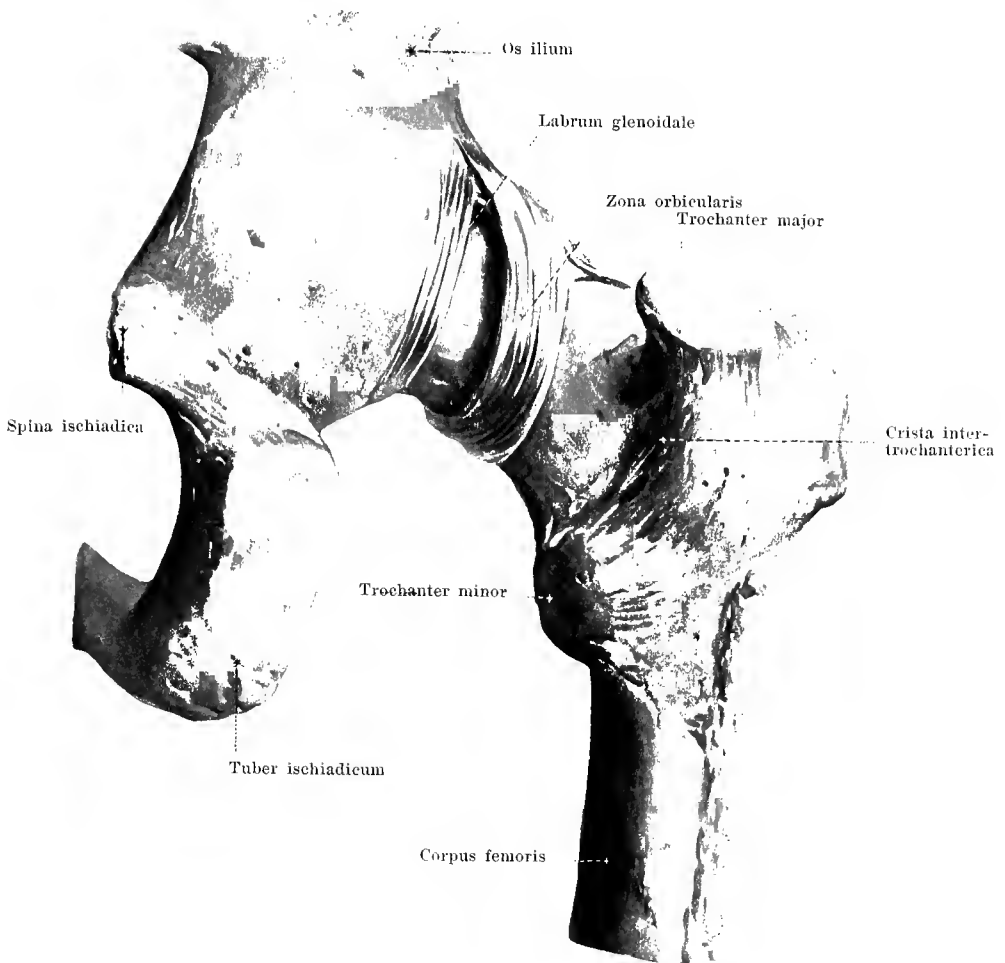


249. Right hip joint, *articulatio coxae*,
from behind.

(The joint capsule, except for the strengthening ligaments, has been removed.)

The **articulatio coxae** possesses, as a strengthening ligament of the posterior wall of the capsule, the *ligamentum ischiocapsulare*. This broad, thick ligament arises externally along the margin of the acetabulum in the whole extent of the corpus ossis ischii; its fibres converge somewhat, run obliquely upward and lateralward and become attached for the most part to the zona orbicularis; part of them reach even to the anterior margin of the trochanter major.

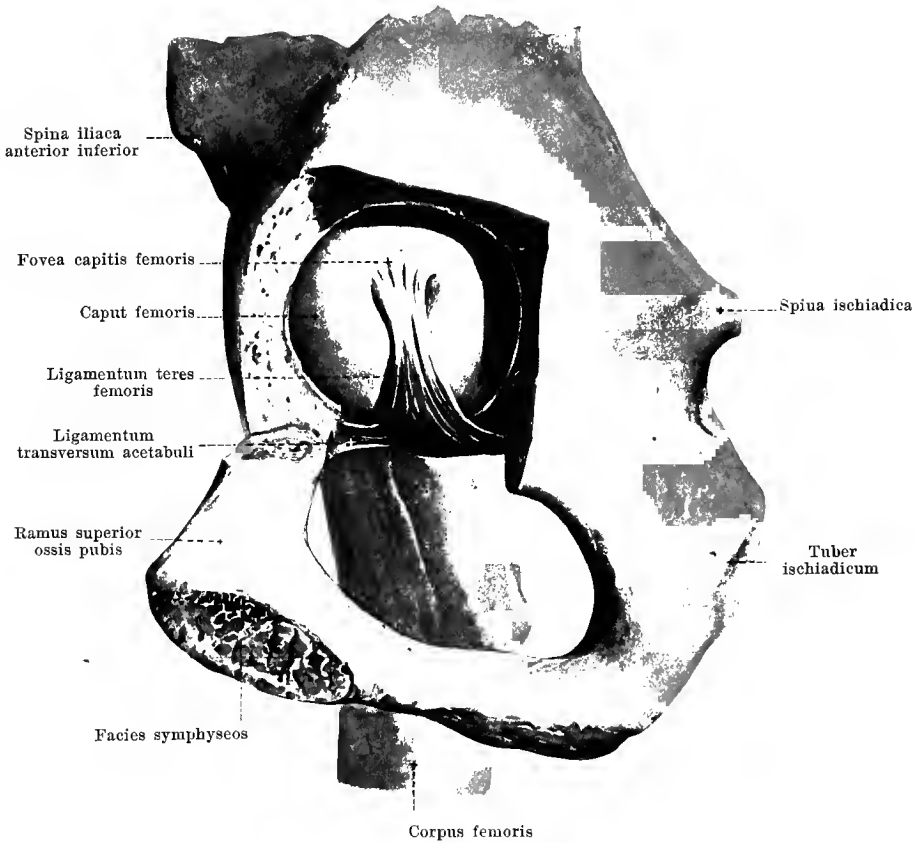
Between the ligamenta iliofemorale, pubocapsulare and ischiocapsulare, the capsule is essentially thinner in three places; these places correspond to the points where the bones forming the acetabulum fuse with one another.



250. Right hip joint, *articulatio coxae*,
from behind.

(The superficial layer of the capsule and the ligamentum ischiocapsulare have been removed.)

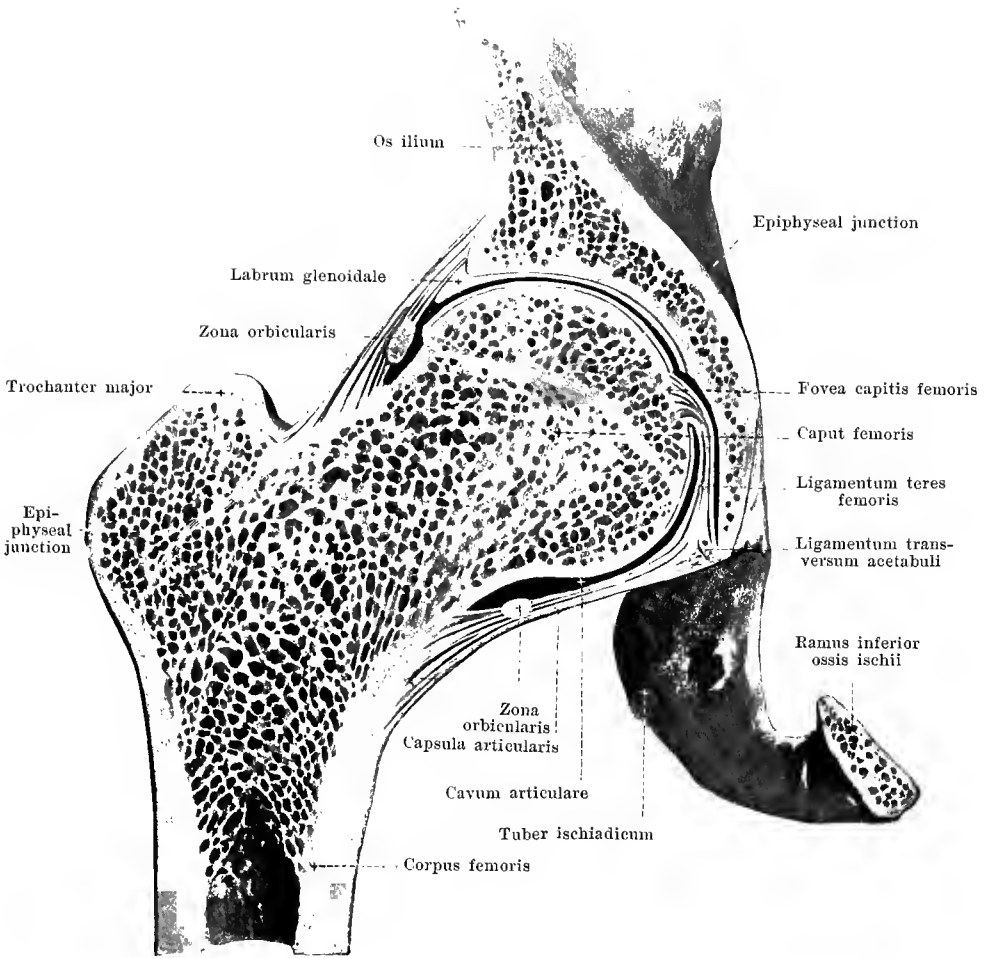
The capsule of the *articulatio coxae* is strengthened in the depth by the *zona orbicularis* (see also Fig. 252). This band of fibres, covered over completely by the other ligaments, but connected with them, is strongest and most distinct above, behind and below; it surrounds the neck of the femur like a ring and is connected above with the bone below the spina iliaca anterior inferior. It extends therefore, essentially like a loop, from this point, downward in front of the neck, then behind the same and thence, back again, upward to its starting point: its lateral margin is formed of fibres which run purely circularly.



251. Right hip joint, *articulatio coxae*,
from the medial side.

(The bottom of the acetabulum has been chiselled away sufficiently to make the head of the femur visible.)

Hidden inside the **articulatio coxae** is the *ligamentum teres femoris* (see also Fig. 252). This flatly rounded ligament arises by a broad origin in the neighborhood of the incisura acetabuli and from the ligamentum transversum acetabuli, becomes narrow above and is attached in the fovea capitis femoris. It lies in the fossa acetabuli between its floor and the medial inferior surface of the head of the femur so that the posterior margin of the ligament, when the body is upright, is approximately vertical in direction. The ligamentum teres is covered over by the stratum synoviale of the capsula articularis.

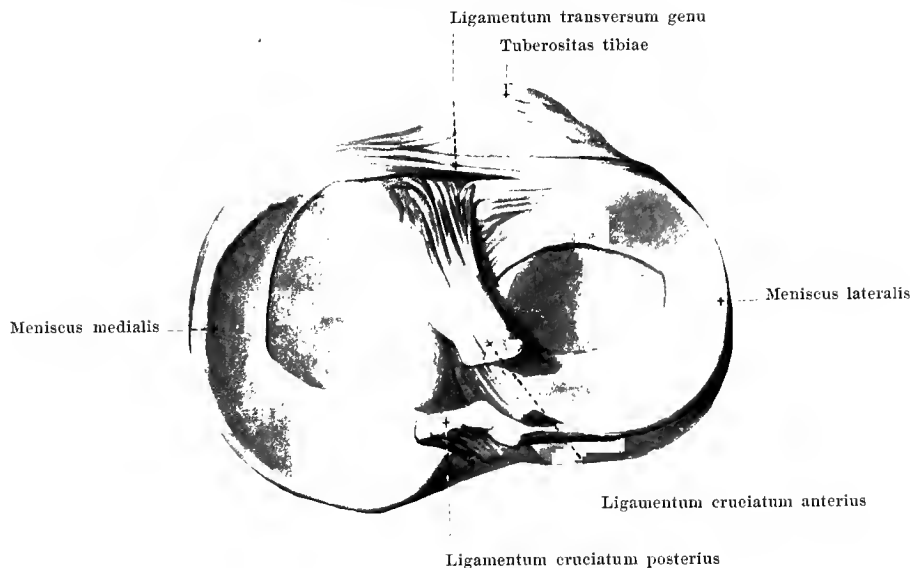


252. Right hip joint, *articulatio coxae*.

Frontal section through the same. Posterior half of section, viewed from in front.

(The joint surfaces have been somewhat pulled apart.)

The *capsula articularis* of the *articulatio coxae* arises at the margin of the acetabulum, chiefly outside the labrum glenoidale so that this lies more or less completely within the joint cavity. The capsule is attached to the femur in front close above the linea intertrochanterica, behind to the neck of the femur medianward from the crista intertrochanterica in a line parallel to the latter so that somewhat more than the medial half of the posterior surface of the neck of the femur looks into the joint capsule. The stratum synoviale of the capsule is continued upon the ligamentum teres and encloses this like a sheath. The fossa acetabuli is almost completely filled up by masses of fat, synovial villi and the ligamentum teres.



253. Right knee joint, *articulatio genu*.

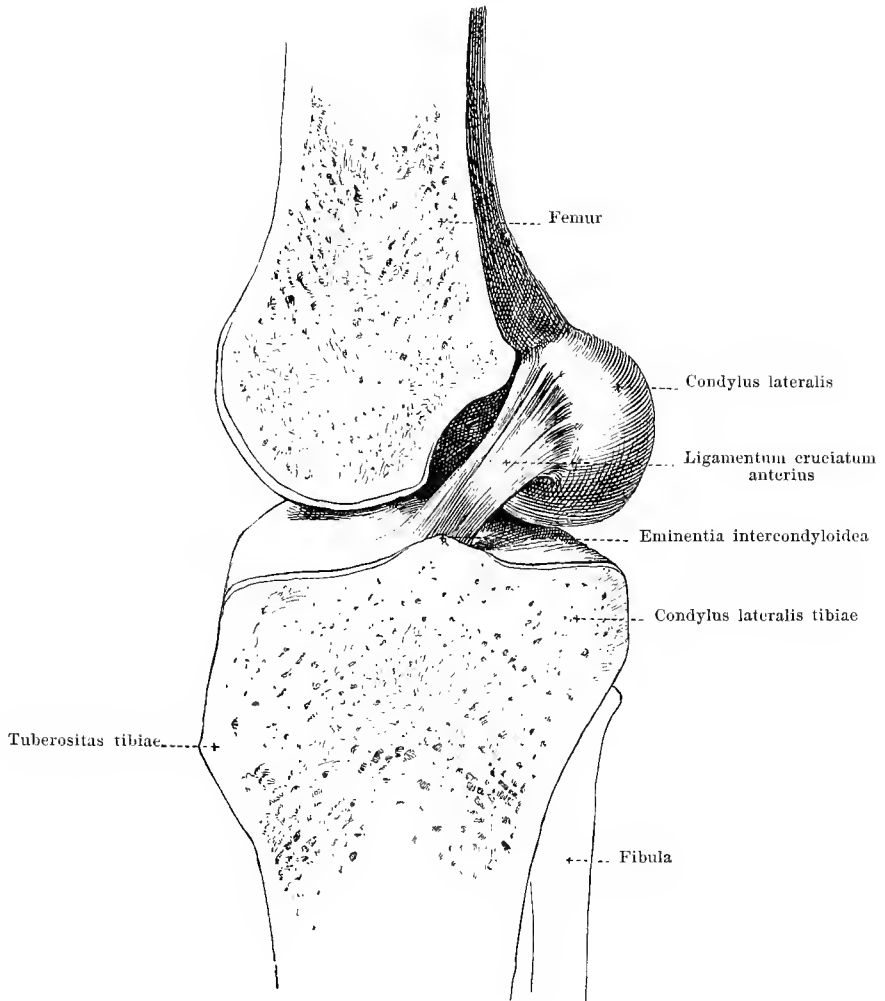
Tibia with cartilaginous discs, from above.

In the formation of the **articulatio genu** (*knee joint*) (see also Figs. 254—261) the two condyli femoris move upon the condyli tibiae. Within the *capsula articularis* enclosing the joint, between the two bones, two sickle-shaped fibrocartilaginous discs are intercalated, the *meniscus lateralis* and the *meniscus medialis* (see also Figs. 255—257 and 260). These are firmly connected at their extremities, by connective tissue strands, with the tibia. Each meniscus is triangular on cross section (see Fig. 260); its narrowest side looks outward and is fused with the capsule, the two other smooth sides lie one on the condylus tibiae, the other on the condylus femoris; these two sides meet in a sharp concave margin.

The *meniscus lateralis* (O. T. external semilunar fibrocartilage) is somewhat shorter and more circular; it arises anteriorly close in front of the eminentia intercondyloidea tibiae, directly in front of the tuberculum intercondyloideum laterale, and is fastened by its posterior extremity to the posterior slope of the eminentia intercondyloidea, chiefly to the tuberculum intercondyloideum mediale.

The *meniscus medialis* (O. T. internal semilunar fibrocartilage) is longer, broader, and more sickle-shaped; it arises anteriorly in front of the fossa intercondyloidea anterior from the margo infraglenoidalis and is attached behind in the fossa intercondyloidea posterior.

Between the most anterior points of the two menisci is stretched out the thin rounded *ligamentum transversum genu* (see also Figs. 255 and 256), which is composed of connective tissue.

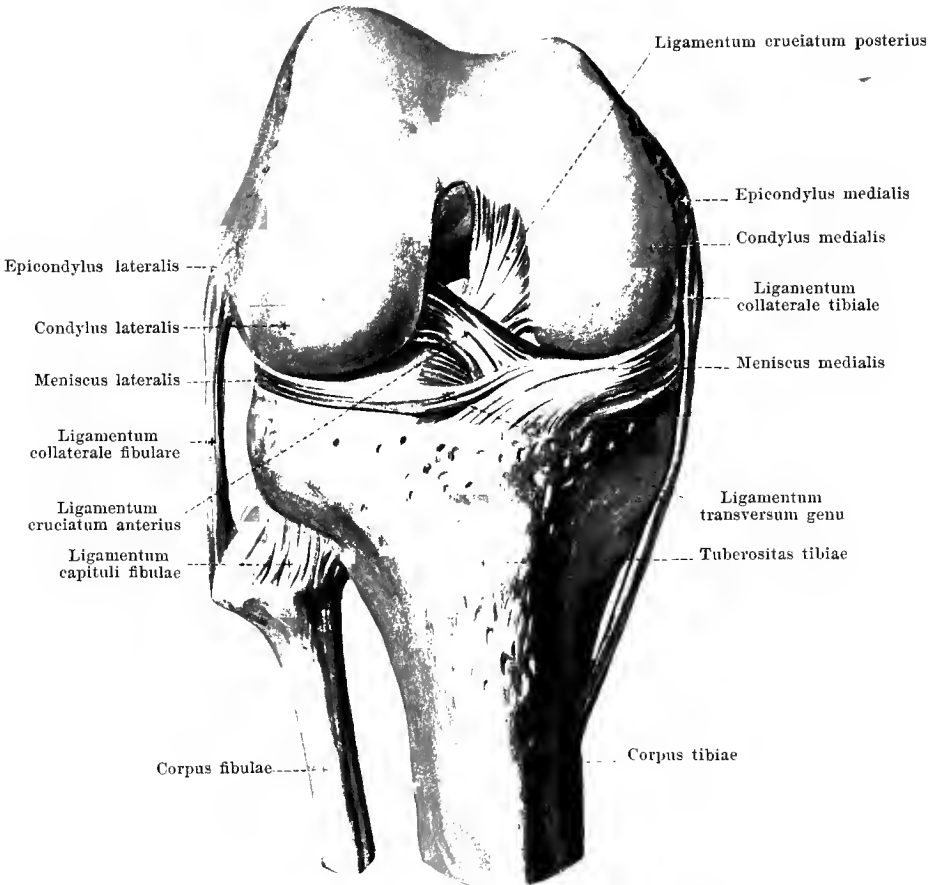


254. Right knee joint, *articulatio genu*.

Sagittal section at about the middle of the joint. Lateral half, viewed from the medial side; somewhat schematic.

(The meniscus lateralis has been removed.)

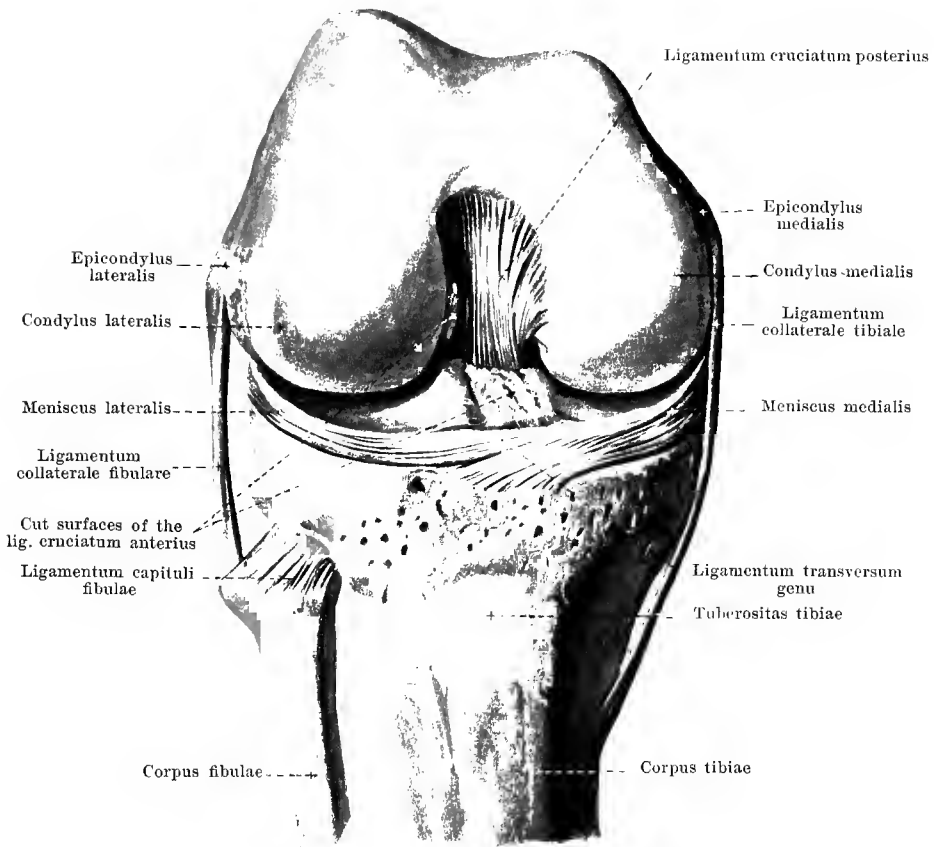
The **articulatio genu** has inside it the *ligamenta cruciata genu anterius et posterius*. Each of these goes from the surface turned toward the fossa intercondyloidea of one condylus femoris downward to the region of the eminentia intercondyloidea tibiae; in the extended position the anterior ligament is directed obliquely forward, the posterior somewhat obliquely backward. Together they assume the form of an X and are connected by loose connective tissue and fat not only with one another, but also with the posterior wall of the capsula articularis. They are ensheathed by synovial membrane.



**255. Right knee joint, *articulatio genu*,
from in front.**

(The knee is flexed at a right angle; the patella and the capsule of the joint have been removed.)

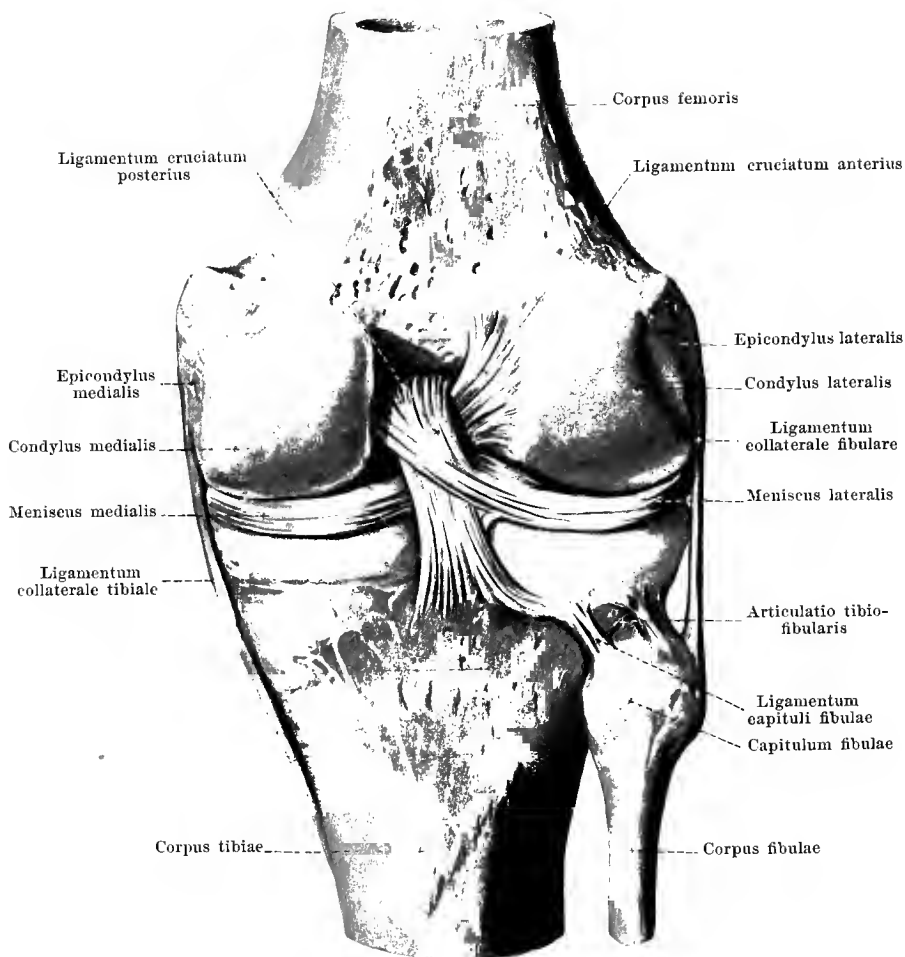
In the *articulatio genu* the *ligamentum cruciatum anterius* (O. T. anterior or external crucial ligament) (see also Figs. 253, 254, and 257) has a broad origin on the non-cartilaginous, medial surface of the condylus lateralis femoris, near its posterior margin. From there on it becomes narrower, passes as a flatly rounded bundle obliquely forward, downward, and medianward and is attached especially to the tuberculum intercondyloideum mediale and in the fossa intercondyloidea anterior tibiae.



256. Right knee joint, *articulatio genu*,
 from in front.

(The knee is flexed at a right angle; the patella and the capsule of the joint have been removed, the ligamentum cruciatum anterius has been cut off short at its points of attachment.)

The *ligamentum cruciatum posterius* (O. T. posterior or internal crucial ligament) (see also Figs. 253, 255, and 257) of the **articulatio genu** lies behind the ligamentum cruciatum anterius, crosses the same and is somewhat stronger. It has a broad origin from the lateral surface of the condylus medialis femoris close to its anterior and inferior margin, narrows to a flatly rounded cord and passes somewhat obliquely downward, backward, and lateralward to the fossa intercondyloidea posterior tibiae and to the posterior surface of the tibia; one band of fibres, arising in the medial portion, runs behind the ligament obliquely lateralward to the posterior part of the meniscus lateralis (see Fig. 257).



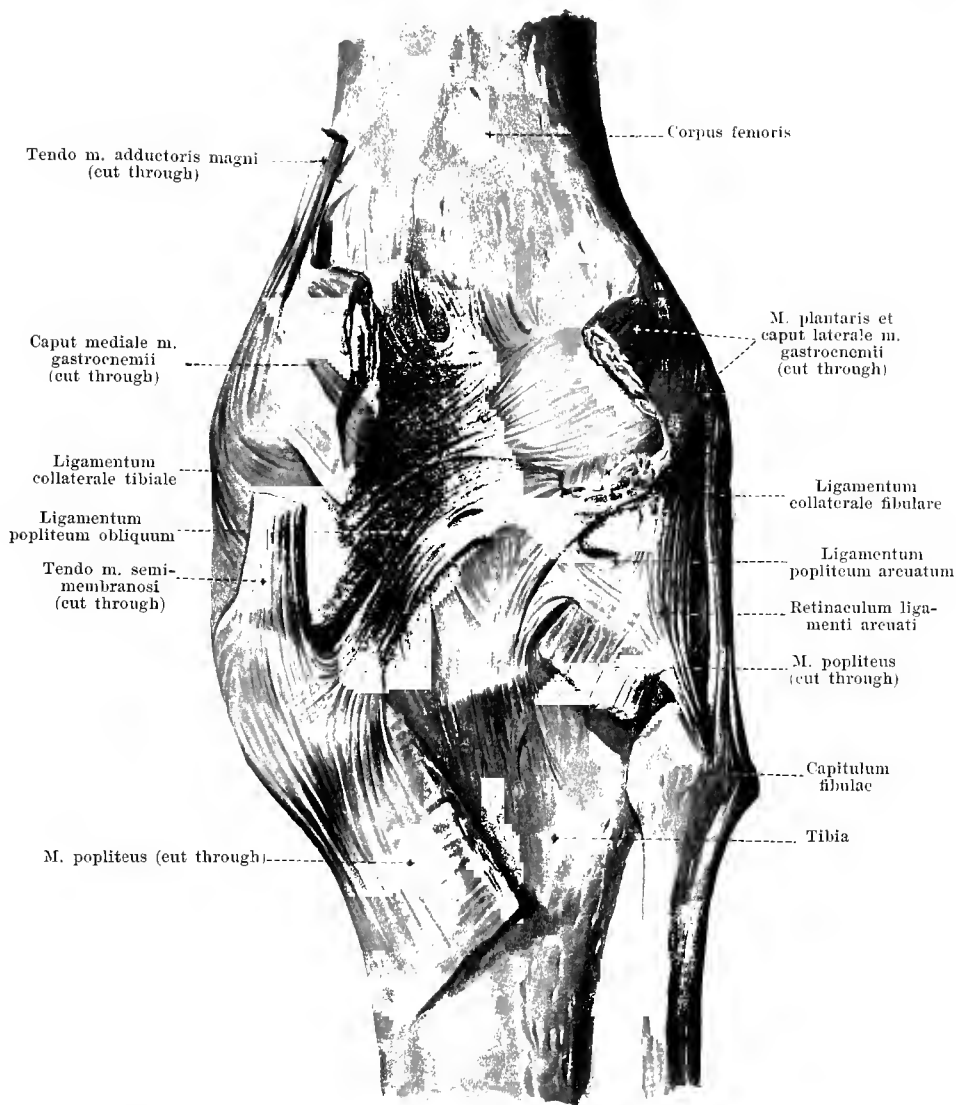
257. Right knee joint, *articulatio genu*, from behind.

(The capsule, except for the strengthening ligaments, has been removed.)

Articulatio genu (continuation). The ligaments which serve to strengthen the capsule laterally are called the *ligamenta collateralia fibulare et tibiale* (see also Figs. 255, 256, 258, 261).

The *ligamentum collaterale fibulare* (O. T. long external lateral ligament) is a rounded fibrous cord, which, when the knee is extended, is stretched out tight from the epicondylus lateralis femoris to the lateral surface of the capitulum fibulae. It is separated by fatty tissue from the capsule of the joint and from the meniscus lateralis.

The *ligamentum collaterale tibiale* (O. T. internal lateral ligament) is a broader, flat ligament which extends from the epicondylus medialis femoris to the medial portion of the margo infraglenoidalis and thence further downward. It is interwoven in the wall of the capsule and is partly attached also to the meniscus medialis. Below, it covers over the a. genu inferior medialis, which lies directly upon the bone.

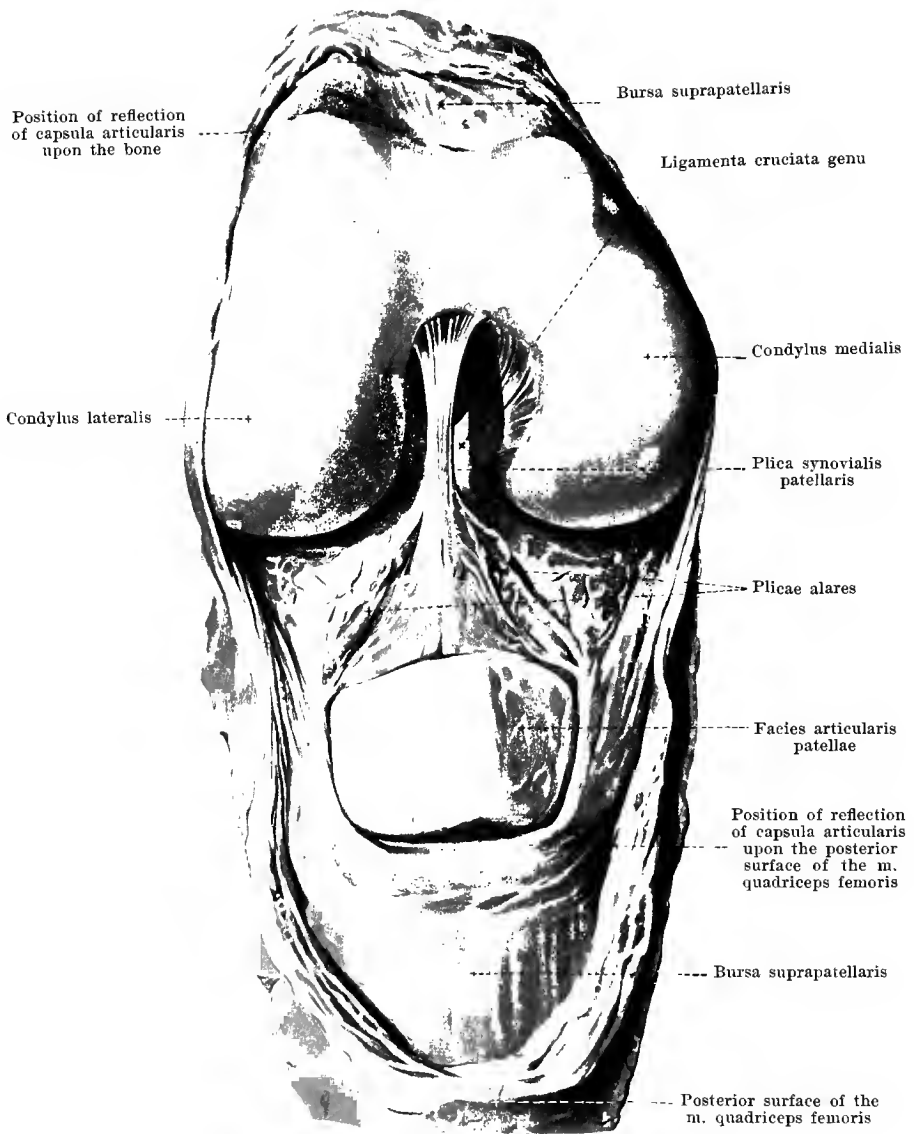


258. Right knee joint, *articulatio genu*, from behind.

(The muscles partially fused with the capsule have been cut off, close to their attachment.)

The *articulatio genu* has, on the posterior surface, the following strengthening ligaments: The powerful, flat *ligamentum popliteum obliquum* (O. T. posterior ligament) extends from the region of the condylus lateralis femoris obliquely medianward and downward; its fibres become lost, partially descending in the wall of the capsule and in the fascia of the m. popliteus, partially by bending around upward and going over into the tendon of the m. semimembranosus.

The *ligamentum popliteum arcuatum* is a horse-shoe shaped band of fibres, concave above, which arises in the region of the epicondylus lateralis and becomes lost in the middle of the posterior wall of the capsule below the ligamentum popliteum obliquum. From the convex circumference of the ligament the *retinaculum ligamenti arcuati* goes off with two converging limbs; it has a narrow attachment to the capitulum fibulae; from the same place, also, a part of the m. popliteus arises.

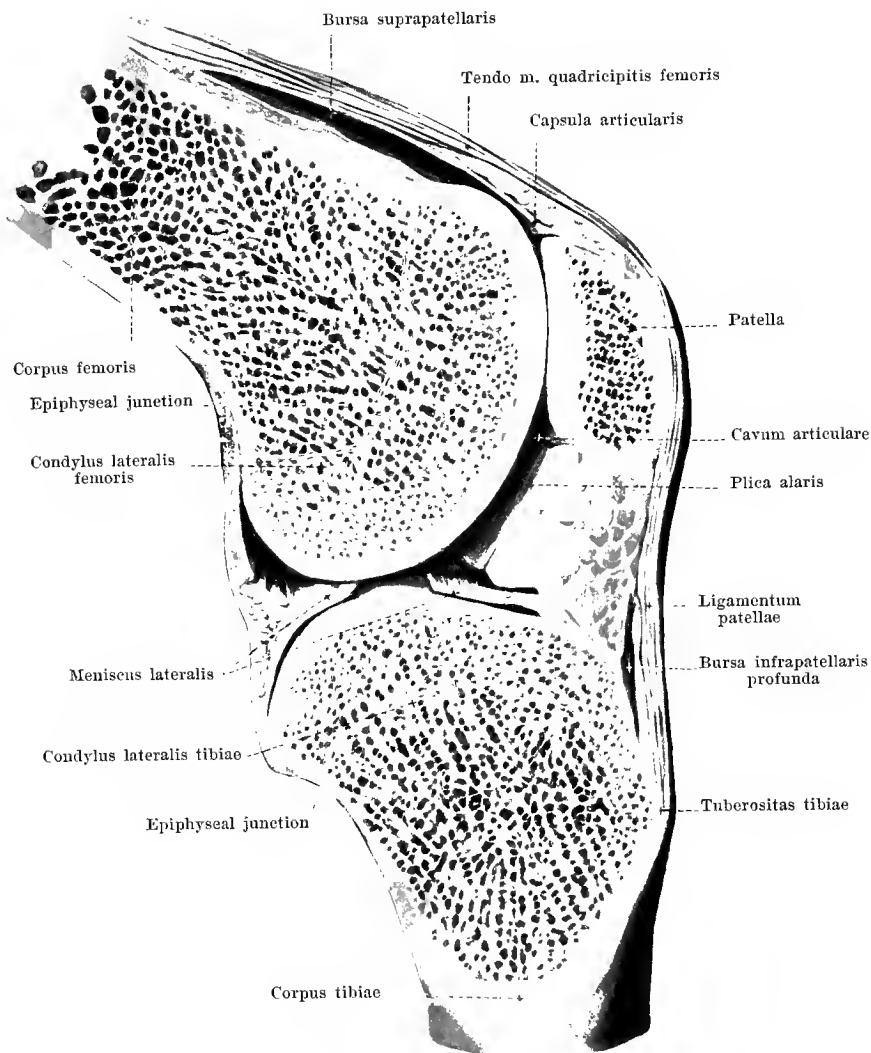


259. Right knee joint, *articulatio genu*, from in front.

(After cutting through the capsula articularis close to the bone the tendinous expansion of the m. quadriceps femoris along with the patella have been turned down in front; the knee is flexed.)

The *capsula articularis* of the **articulatio genu** extends over the posterior surface of the common tendon of the m. quadriceps femoris in front close above the patella and goes over at the border of the patella upon the latter so that the whole *facies articularis patellae* looks into the joint cavity. Thence the capsule runs as a loose membrane separated by abundant fatty tissue from the *ligamentum patellae* and from the adjoining parts of the *retinacula patellae* (see Figs. 260 and 261) to the upper margins of the two menisci and to the inferior attachment of the *ligamentum cruciatum anterius*. It then encloses the two *ligamenta cruciata genu* in a common sheath and goes over at the posterior margin of the *ligamentum cruciatum posterius* into the posterior wall; thus the two *ligamenta cruciata genu* form with the surrounding synovial membrane a sort of wall of separation which is shoved in from behind into the joint cavity, dividing this, behind, into a medial and a lateral compartment. From the medial and lateral margin of the *facies articularis patellae* project two prominent, fatty, synovial folds, *plicae alares* (O. T. *ligamenta alaria*) which converge below. At the angle of union of the same there arises a simple, larger fold, the *plica synovialis patellaris* (O. T. *ligamentum mucosum*), which extends backward, in a sagittal direction, free through the joint cavity to become attached at the lowermost margin of the *fossa intercondyloidea femoris*; this ligament is extraordinarily different in individual cases; it often contains fat lobules inside it.

The joint cavity is continued upward in the majority of cases directly into the *bursa [mucosa] suprapatellaris*. This large bursa lies between the anterior surface of the lower end of the femur which has only a slight covering of fat and the posterior surface of the common tendon of the m. quadriceps femoris (see Figs. 260 and 261); it is intimately fused with the latter and separated from the joint cavity, usually only incompletely and indistinctly, by a projecting fold (see Fig. 261); in rare cases it is completely shut off and then no connection exists between the two cavities.



260. Right knee joint, *articulatio genu*.

Sagittal section through the condylus lateralis femoris.

Medial half of section, from the lateral side.

(The knee is slightly flexed; the joint surfaces have been pulled a little apart.)

The *capsula articularis* of the **articulatio genu** passes in front from the posterior surface of the tendon of the m. quadriceps femoris (see p. 211) to the anterior surface of the femur above the joint tuberosities, covers their cartilaginous surfaces completely and goes over at the sides only a little beyond the margin of the cartilage so that it leaves the region of the epicondyli free (see Fig. 261).

To the tibia the capsule is attached around the margo infraglenoidalis, a little below the margin of the cartilaginous joint surfaces; thence it goes to the lower margin of each of the two menisci, lines its lower and upper surfaces and from its upper margin passes upward, partly to the posterior surface of the patella and of the tendon of the m. quadriceps femoris (see p. 211), partly to the point of reflection on the femur.

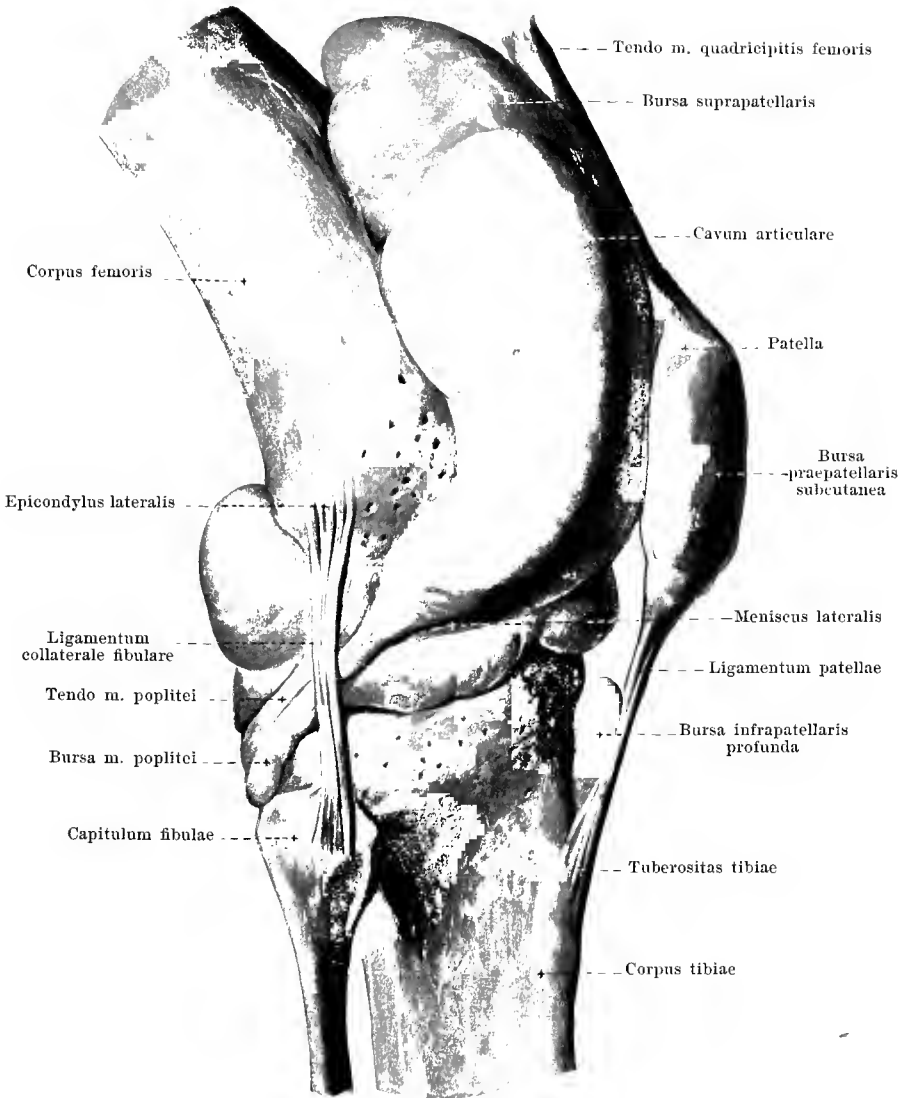
The *ligamentum patellae* (see also Fig. 261) is a flat, very strong ligament, which goes off from the lower margin and the anterior surface of the patella and, narrowing slightly, becomes attached to the tuberositas tibiae; it is separated from the capsula articularis by thick masses of fat. The ligament is partially a direct continuation of the tendinous fibres of the m. quadriceps femoris running over the patella and can accordingly be considered as the terminal tendon of this muscle; in this sense the patella itself has to be thought of as a large sesamoid bone intercalated in this tendon.

The *cavum articulare* of the **articulatio genu** is in open communication regularly with the *bursa [mucosa] musculi poplitei*. This tube-like pocket extends downward and backward on the lateral side in front of and below the tendon of origin of the m. popliteus; it opens into the joint by a narrow slit above the meniscus lateralis, between this and the tendon of the m. popliteus, but possesses usually in addition a second communicating opening below the meniscus; it is sometimes connected also with the articulatio tibiofibularis.

For the *bursa suprapatellaris* see p. 211.

In front of the patella are three bursae: the *bursa praepatellaris subcutanea* in the subcutaneous connective tissue in front of the fascia lata (see also Fig. 375), the *bursa praepatellaris subfascialis* behind the fascia lata (not figured), between it and the tendinous expansion of the m. quadriceps femoris, and the *bursa praepatellaris subtendinea* between the tendon of the m. quadriceps and the anterior surface of the patella (not figured). In most cases only one of these three bursae praepatellares occur; sometimes two or three exist over one another in which event they usually communicate freely with one another; the size of these bursae differs much.

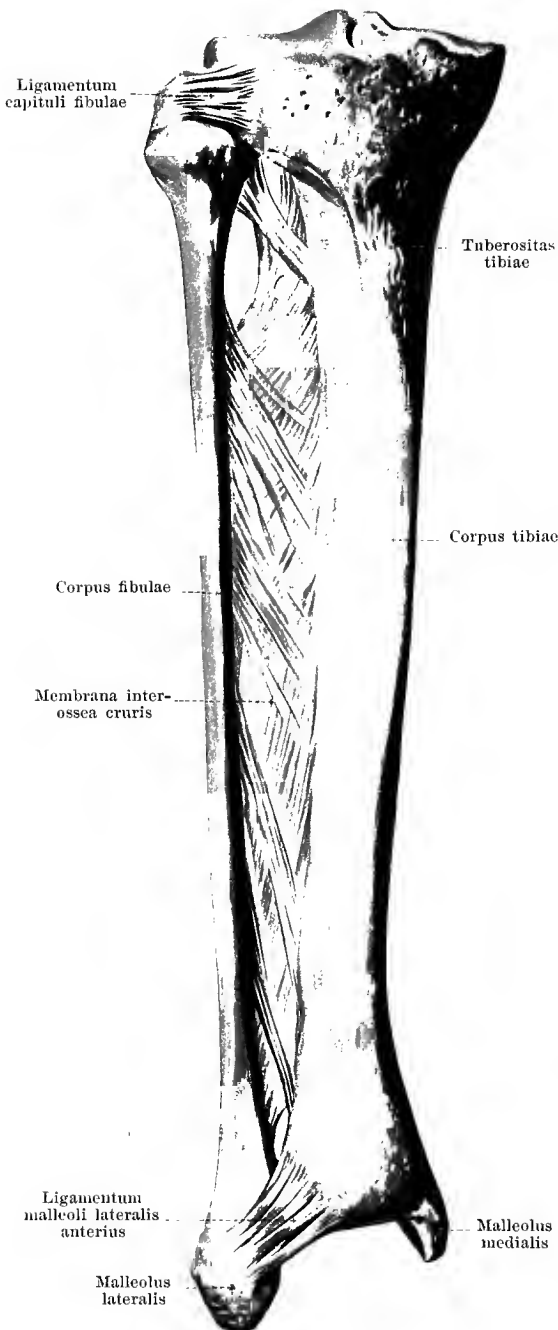
The *bursa infrapatellaris profunda* (see also Fig. 260) lies between the posterior surface of the ligamentum patellae and the anterior surface of the tibia. It is separated from the cavity of the knee joint by masses of fat and communicates with it only very rarely.



261. Right knee joint, *articulatio genu*,
from the lateral surface.

(The joint cavity and several bursae have been injected with a stiffening medium and then dissected out.)

262. Ligaments of the right leg, from in front.

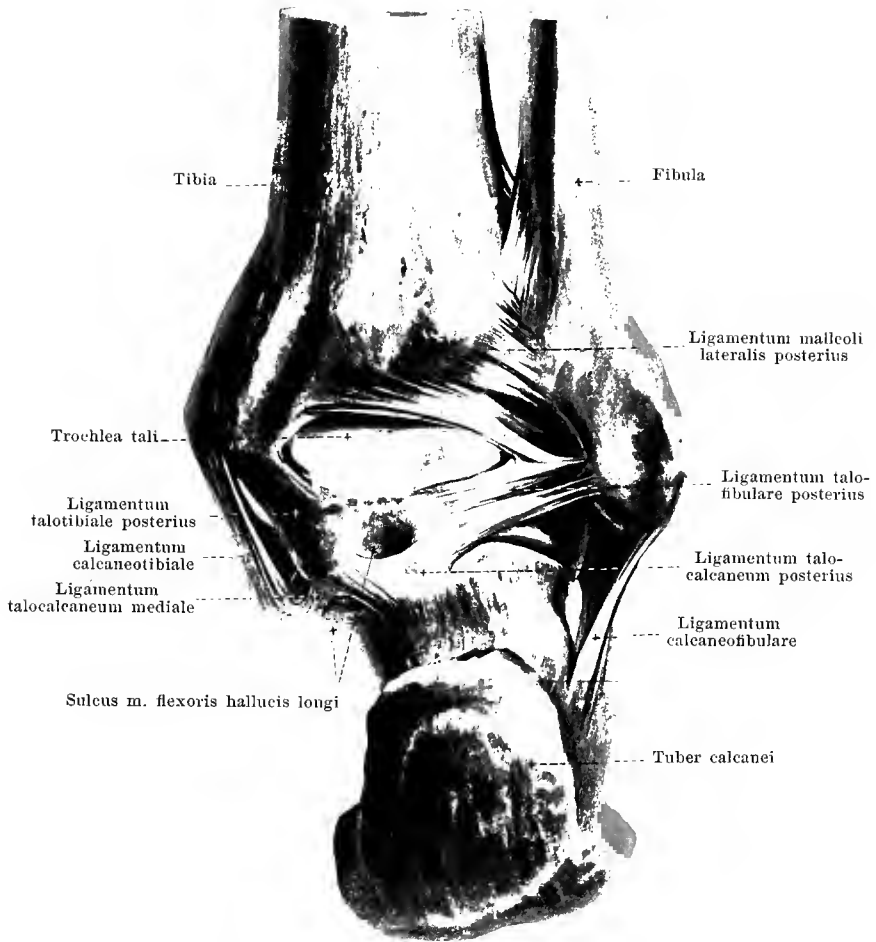


The tibia and fibula are united by two joints, one above and one below, besides throughout nearly their whole length by the *membrana interossea cruris*.

The **articulatio tibiofibularis** (O. T. superior tibiofibular articulation) (see also Figs. 255—257) arises through the apposition of the *facies articularis capituli fibulae* and the *facies articularis fibularis tibiae*. The tight *capsula articularis* arises from both bones generally close to the margin of the cartilaginous surface. On the anterior surface and often also on the posterior, a strengthening ligament, the *ligamentum capituli fibulae*, (O. T. anterior and posterior superior tibiofibular ligaments) runs transversely or somewhat obliquely lateralward and downward. In addition the *ligamentum collaterale fibulare* and the *retinaculum ligamenti arcuati* of the knee joint are to be regarded as strengthening ligaments (in the wider sense) for the articulatio tibiofibularis. The joint communicates sometimes with the bursa [mucosa] m. poplitei and through this indirectly with the knee joint.

The **membrana interossea cruris** (O. T. middle tibiofibular ligament or interosseous membrane) is stretched out as a broad lamella between the *cristae interossee* of the tibia and fibula. The fibres usually assume a course descending toward the fibula. Above, between the membrane and the articulatio tibiofibularis, there remains a large opening for the passage of vessels and nerves.

The **syndesmosis tibiofibularis** (O. T. inferior tibiofibular articulation) (see also Figs. 263, 264 and 271) is the moveable union between the medial surface of the *malleolus lateralis* (above the *facies articularis malleoli*) and the *incisura fibularis tibiae*. The bony surfaces opposed to one another are not covered by joint cartilage, but only by periosteum with a fatty substratum in parts; between the two, projecting upward from the articulatio talocruralis is a small slit-shaped pocket. In front and behind a strong ligament runs transversely over the joint, the *ligamenta malleoli lateralis*. The *ligamentum malleoli lateralis anterius* extends as a flat cord from the region in front of the *incisura fibularis tibiae* obliquely downward to the anterior surface of the *malleolus lateralis*.

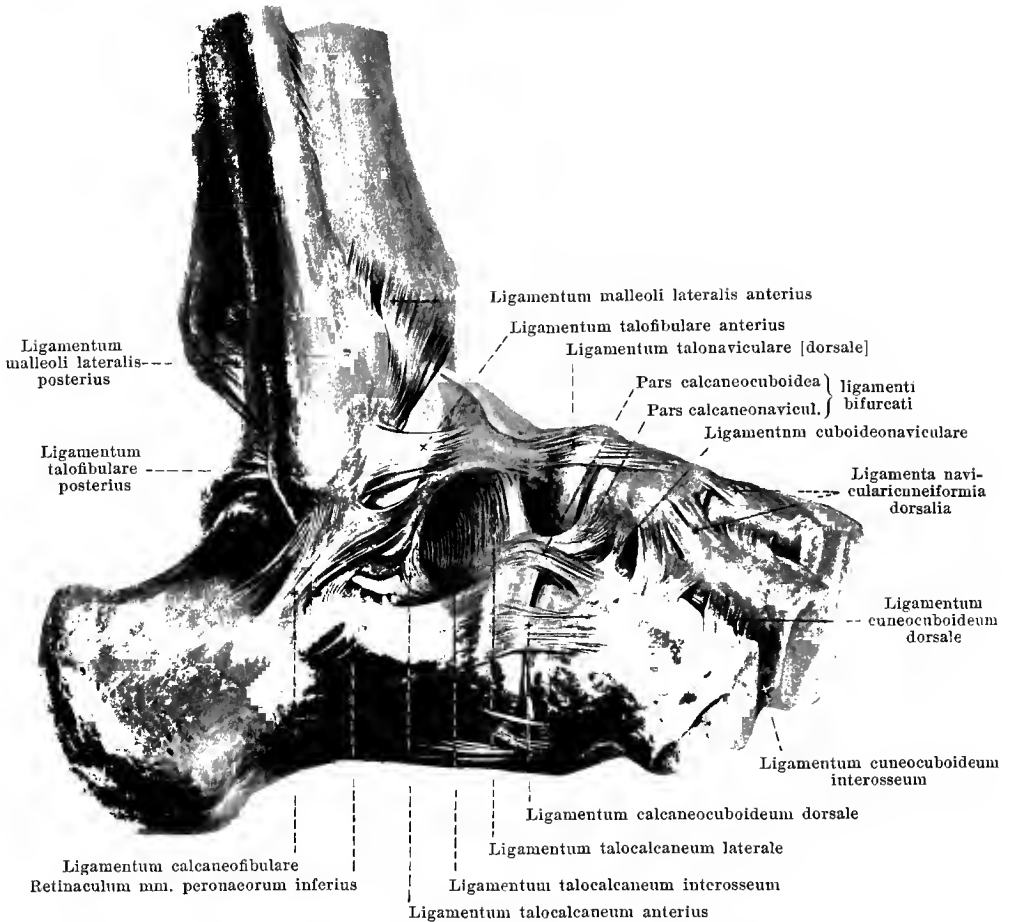


263. Joints of the right foot, *articulationes pedis*, from behind.

(The capsulae articulares have been removed except for the strengthening ligaments.)

Syndesmosis tibiofibularis (continuation). The *ligamentum malleoli lateralis posterius* has a broad origin from the region behind the incisura fibularis tibiae and from the posterior margin of the facies articularis inferior tibiae and goes obliquely downward to the posterior surface of the malleolus lateralis; its lower fibres help to enlarge and deepen the joint cavity for the trochlea tali.

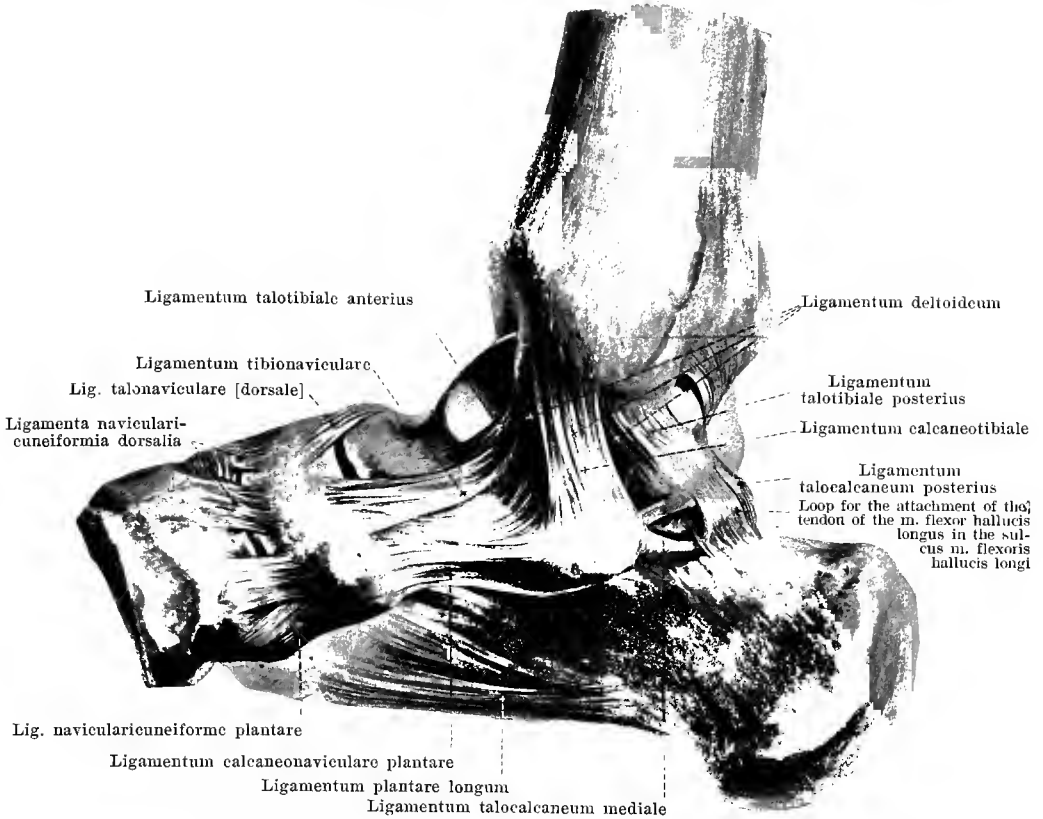
In the formation of the **articulatio talocruralis** (*ankle-joint*) (see also Figs. 264 and 265) the trochlea tali moves in the joint cavity formed by the distal end-pieces of the tibia and fibula; here the facies superior tali glides upon the facies articularis inferior tibiae, the facies malleolaris lateralis tali upon the facies articularis malleoli fibulae and the facies malleolaris medialis tali upon the facies articularis malleoli tibiae; the two malleoli thus embrace the trochlea tali from two sides. The *capsula articularis* arises everywhere close to the margin of the cartilaginous surfaces: only in front of the facies articularis superior tali does it cover a part of the collum tali which is free from cartilage; at the sides the capsule is tight; in front and behind it is looser. Lateralward and medianward very powerful strengthening ligaments, *ligamenta talofibularia et calcaneofibulare* and *ligamentum deltoideum*, go from the two malleoli to the ankle bones (see pages 218 and 219).



264. Joints of the right foot, *articulationes pedis*, from the lateral surface.

(The metacarpal bones have been removed as well as the capsulae articulares with the exception of their strengthening ligaments.)

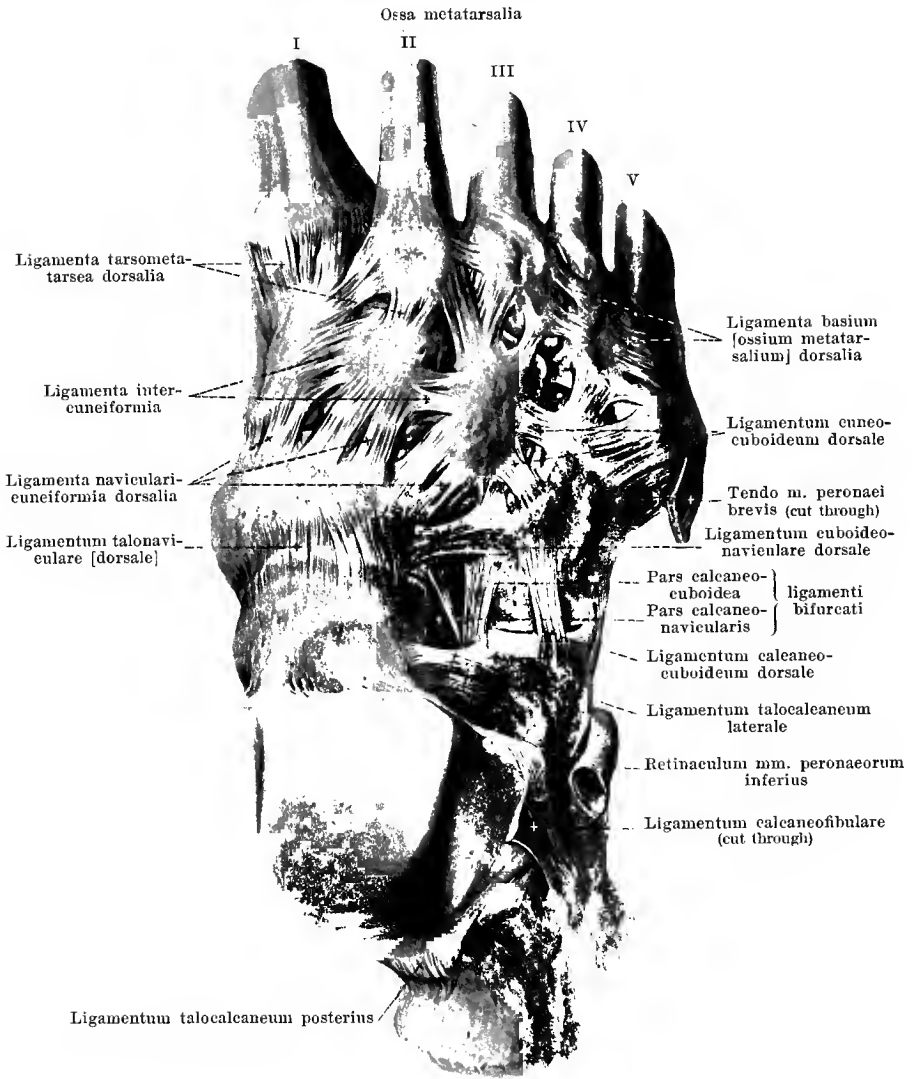
Articulatio talocruralis (continuation). The *ligamentum talofibulare posterius* (O. T. posterior fasciculus of external lateral ligament) (see Fig. 263) arises at the malleolus lateralis [fibulae] behind the facies articularis malleoli and extends, flat, obliquely medianward and downward to the region of the lateral projection from the processus posterior tali. The *ligamentum talofibulare anteriorius* (O. T. anterior fasciculus of external lateral ligament) goes from the anterior surface of the malleolus lateralis medianward to the lateral surface of the collum tali. The *ligamentum calcaneofibulare* (O. T. middle fasciculus of external lateral ligament) (see also Figs. 263 and 266) runs as a flat-rounded cord from the tip of the malleolus lateralis obliquely downward and backward to the lateral surface of the calcaneus; its outer surface forms a shallow groove in which glide the tendons of the mm. peronaei.



265. Joints of the right foot, *articulationes pedis*, from the medial surface.

(The specimen has been prepared as for Fig. 264.)

Articulatio talocruralis (continuation). The *ligamentum deltoideum* (O. T. deltoid or internal lateral ligament + the anterior and posterior tibiotarsal ligaments) is an unequal-sided quadrangular ligamentous mass which has a narrow origin on the medial surface of the malleolus medialis [tibiae] and has a broad attachment to the talus, calcaneus and os naviculare. This ligament is composed of several layers and is divisible, according to the lower attachment of its fibres, into the *ligamenta talotibialia*, the *ligamentum calcaneotibiale* and the *ligamentum tibionaviculare*. The *ligamentum talotibiale posterius* (O. T. posterior tibiotarsal ligament) (see also Fig. 263) is a thick, broad band of fibres which arises behind the tip of the malleolus medialis and is attached to the talus close behind and below the facies malleolaris medialis of the trochlea, in front of the medial projection of the processus posterior tali. The *ligamentum talotibiale anterius* (O. T. anterior tibiotarsal ligament) for the most part hidden below the ligamenta calcaneotibiale and tibionaviculare, is short and narrow and goes off from the tip of the malleolus medialis just in front of the preceding and has a somewhat broad attachment below the anterior portion of the facies malleolaris medialis of the trochlea tali. The *ligamentum calcaneotibiale* (O. T. internal lateral ligament) (see also Fig. 263), the most superficial part of the ligamentum deltoideum, has a broad origin on the medial surface of the malleolus medialis and runs downward to the posterior margin of the sustentaculum tali of the calcaneus. The *ligamentum tibionaviculare* has a broad attachment to the medial surface of the malleolus medialis just above the ligamentum talotibiale anterius and, broadening, goes to the dorsal and medial surface of the os naviculare as well as to the medial margin of the ligamentum calcaneonaviculare plantare: at its origin and behind it is partially hidden beneath the ligamentum calcaneotibiale. The ligamenta talotibiale posterius and calcaneotibiale form, medianward, a groove for the tendon of the m. tibialis posterior.



266. Joints of the right foot, *articulationes pedis*, viewed from the back of the foot.

(The ossa metatarsalia have been sawed through in the middle, the capsulae articulares have been removed except for the strengthening ligaments.)

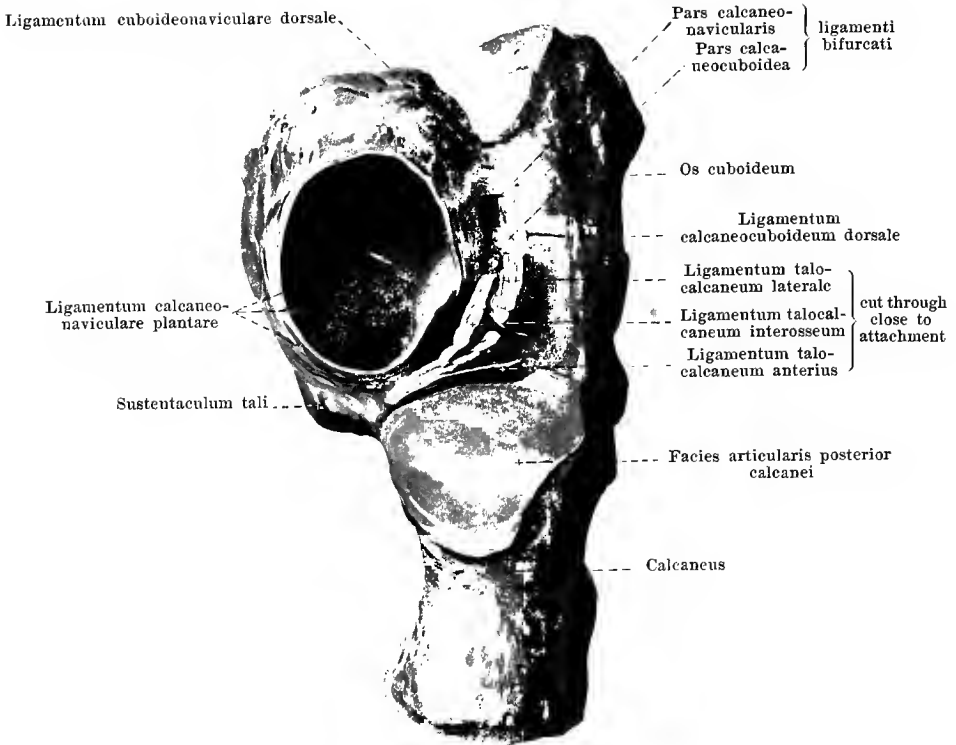
In the formation of the **articulationes intertarsae** (O. T. articulations of the tarsus) each individual ankle bone can move with its cartilaginous joint surface upon the corresponding surfaces of the neighboring tarsal bones. The *capsulae articulares* of the individual joints thus arising (see Fig. 271) are strengthened usually by short fibrous bands.

Between the talus and the calcaneus are found five **ligamenta talocalcanea** (O. T. ligaments connecting the os calcis and the astragalus): (1) the *ligamentum talocalcanaeum posterius* (O. T. posterior calcaneoastragaloid ligament) (see also Figs. 263 and 265), goes from the lateral projection of the processus posterior tali to the upper surface of the calcaneus immediately behind the facies articularis posterior; (2) the *ligamentum talocalcanaeum anterius* (see Figs. 264 and 267) is a broad band of fibres which is stretched out in the sinus tarsi behind the ligamenta talocalcanea laterale et interosseum, on the anterior side of the articulation talocalcanea (see p. 222 Text), between the lower surface of the talus and the upper surface of the calcaneus, immediately in front of the facies articularis posterior; (3) the *ligamentum talocalcanaeum mediale* (O. T. internal calcaneoastragaloid ligament) (see Figs. 263, 265, and 269) is a narrow bundle which extends from the medial tubercle of the processus posterior tali almost horizontally to the posterior margin of the sustentaculum tali of the calcaneus; (4) the *ligamentum talocalcanaeum laterale* (O. T. external calcaneoastragaloid ligament) (see also Figs. 264 and 267) has a broad origin from the lateral and inferior surface of the collum tali and runs at the entrance into the sinus tarsi obliquely downward, forward and lateralward to the upper surface of the calcaneus; (5) the *ligamentum talocalcanaeum interosseum* (O. T. interosseous ligament) (see Figs. 264 and 267), fills up the sinus tarsi and consists of several broad, usually short, bands of fibres which go from the sulcus tali to the sulcus calcanei; in front it is partially covered over and sometimes only indistinctly separable from the ligamentum talocalcanaeum laterale. The sinus tarsi contains also masses of fat and in these, near the ligamentum talocalcanaeum, there is often a bursa, the *bursa sinus tarsi* (not figured).

On the back of the foot are the following **ligamenta tarsi dorsalia**: the *ligamentum talonaviculare [dorsale]* (O. T. superior astragalonavicular ligament) (see also Figs. 264 and 265) extends as a broad ligament from the upper surface of the collum tali to the upper surface of the os naviculare; the *ligamentum bifurcatum* (see also Figs. 264, 267, and 271) has a broad origin near the anterior margin of the dorsal surface of the calcaneus in front of the ligamentum talocalcanaeum laterale and divides fork-like into the stronger *pars calcaneonavicularis* (O. T. superior or external calcaneonavicular ligament), reaching wide into the depth, which is attached to the posterior lateral angle of the os naviculare, and into the *pars calcaneocuboidea* (O. T. internal calcaneocuboid ligament) which goes to the upper surface of the os cuboideum; the *ligamentum calcaneocuboideum dorsale* (O. T. external calcaneocuboid ligament) (see also Figs. 264 and 267) runs lateralward from the preceding from the upper surface of the calcaneus to the upper surface of the os cuboideum; the *ligamentum cuboidconaviculare dorsale* (see also Figs. 264 and 267) stretches out between the upper surfaces of the os naviculare and the os cuboideum; the *ligamenta navicularicuneiformia dorsalia* (see also Figs. 264 and 265) are from four to five fibrous bands which extend from the dorsal surface of the os naviculare to the upper surfaces of the three cuneiform bones; the two *ligamenta intercuneiformia dorsalia*, sometimes still further subdivided, pass transversely from the dorsal surface of one cuneiform bone to that of the adjoining bone; the *ligamentum cuneocuboideum dorsale* (see also Fig. 264) is a ligament (frequently divided) extending from the upper surface of the third cuneiform bone to that of the cuboid bone.

The **articulationes tarsometatarsae [Lisfranci]** (O. T. tarsometatarsal articulations) are strengthened by six (or more) short *ligamenta tarsometatarsae dorsalia*; these extend upon the dorsal surface of the ossa cuneiformia and from the os cuboideum straight or obliquely forward to the bases ossium metatarsalium; in this way the second metacarpal bone is connected with all three cuneiform bones.

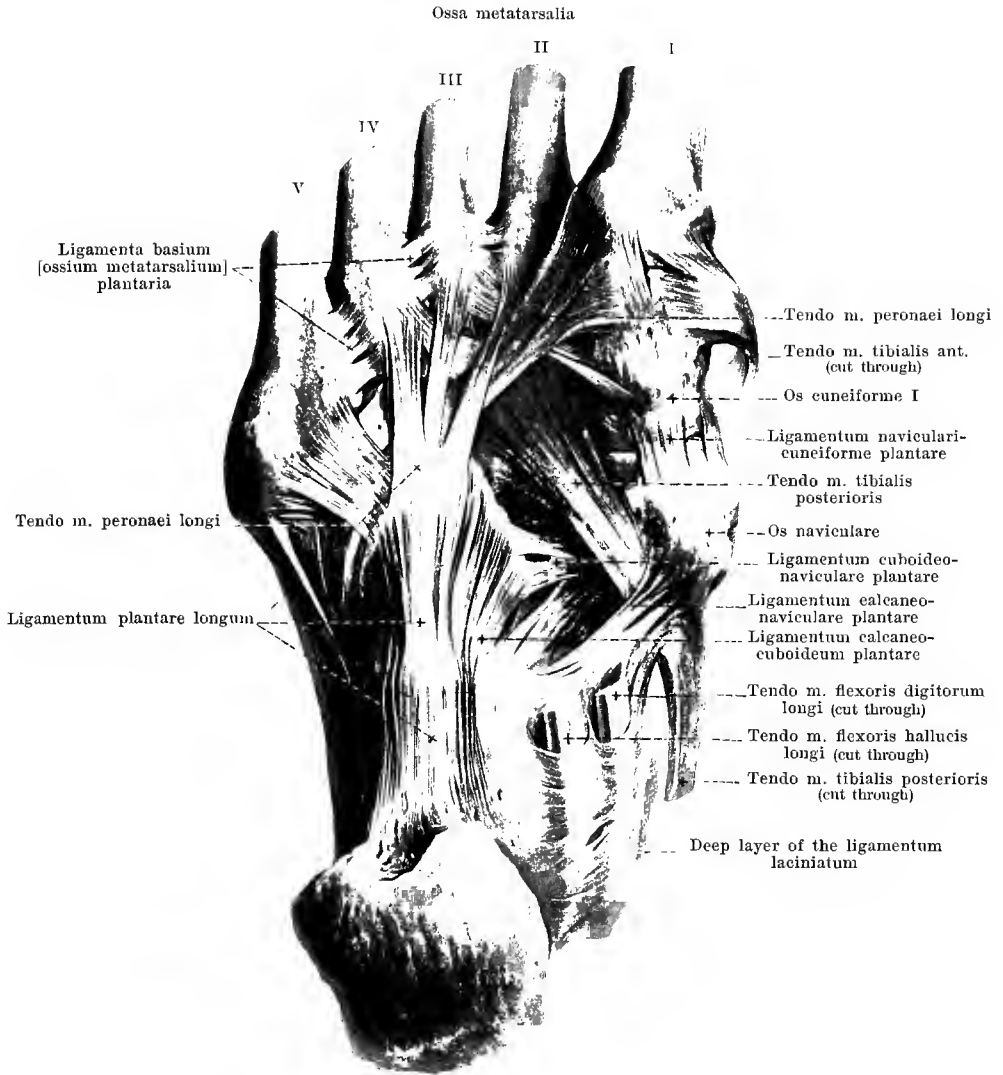
The **articulationes intermetatarsae** (O. T. articulations of the metatarsal bones with each other) possess three *ligamenta basium [ossium metatarsalium] dorsalia* which are stretched out transversely between the dorsal surfaces of the proximal ends of the second to the fifth os metatarsale.



267. Joints of the right foot, *articulationes pedis*, viewed from the back of the foot.

(The talus has been removed as have also the cuneiform bones and the metacarpal bones, the capsulae articulares have been removed except for the strengthening ligaments.)

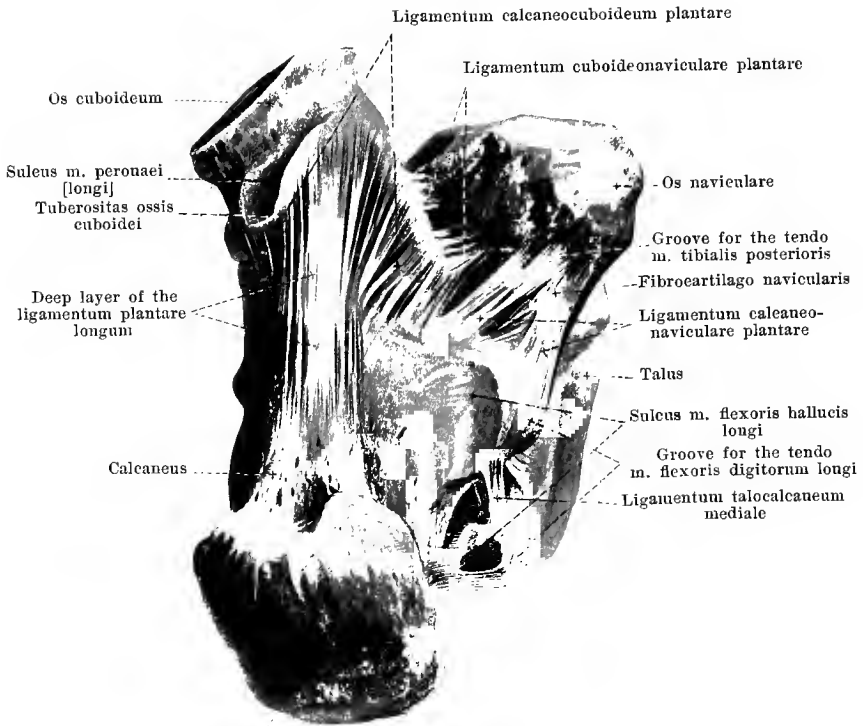
The talus is moveably united with the calcaneus and with the os naviculare with constant formation of two separate joint cavities (see also Fig. 271). The posterior joint cavity is situated between the facies articularis calcanea posterior of the talus and the facies articularis posterior of the calcaneus; this union is called the **articulatio talocalcanea**; its *capsula articularis* goes off from the bone usually near the margins of the cartilaginous surfaces; the strengthening ligaments belonging here are the ligamenta talocalcanea posterius, anterius et mediale (see p. 221). The anterior joint cavity lies between the facies articulares calcaneae media et anterior of the talus and the facies articulares media et anterior of the calcaneus as well as between the facies articularis navicularis of the talus and the proximal joint surface of the os naviculare; besides, the joint concavity is made still more complete for the caput tali by means of the ligamentum calcaeonaviculare plantare (see p. 224) and the fibrocartilago navicularis enclosed in this, as well as by the pars calcaeonavicularis ligamenti bifurcati (see p. 221); this anterior joint union is known as the **articulatio talocalcaeonavicularis**; its most anterior portion is also known separately as the **articulatio talonavicularis**; its *capsula articularis* leaves the bones for the most part near the margins of the cartilaginous surfaces; lying close upon the capsule, as a strengthening ligament of the same, is the ligamentum talonaviculare [dorsale] (see p. 221) while the ligamenta talocalcanea laterale et interosseum (see p. 221) are separated from it by masses of fat; in addition, the ligamentum calcaeonaviculare plantare and the pars calcaeonavicularis ligamenti bifurcati have to be designated as strengthening ligaments.



268. Joints of the right foot, *articulationes pedis*, viewed from the sole of the foot.

(The ossa metatarsalia have been sawed through in the middle, the capsulae articulares with the exception of the strengthening ligaments have been removed.)

Of the **ligamenta tarsi plantaria** in the sole of the foot the strongest is the *ligamentum plantare longum* (O. T. long calcaneo-cuboid or long plantar ligament) (see also Fig. 269). It is very broad and powerful, arises from the lower surface of the calcaneus in front of the tuber calcanei and extends with its main mass to the tuberositas ossis cuboidei. As a continuation of its most superficial bundles it sends thin diverging fibrous strips to the proximal ends of the ossa metatarsalia which bridges over the groove for the tendon of the m. peroneus longus.

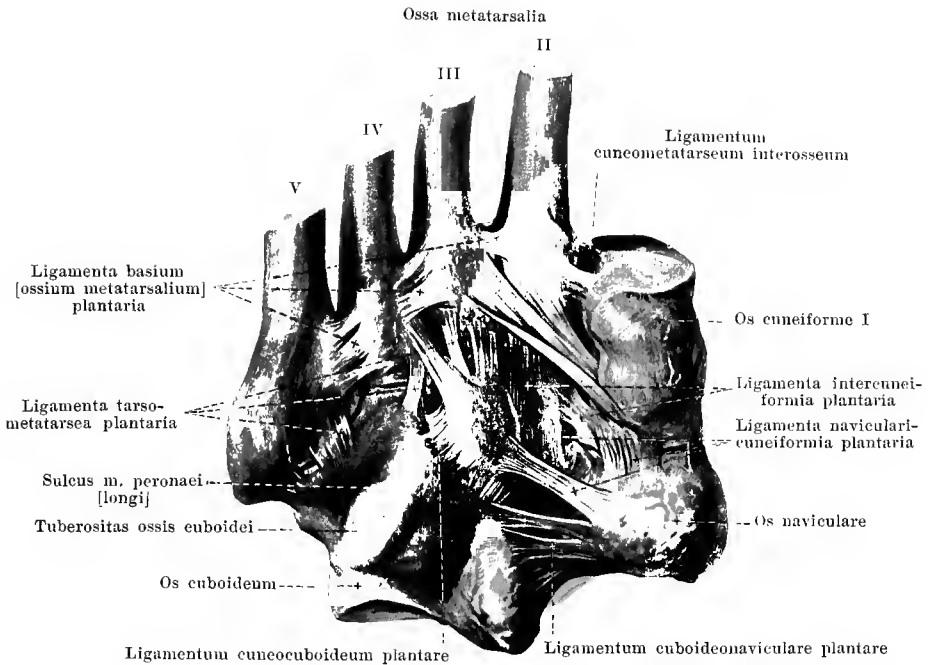


269. Joints of the right foot, *articulationes pedis*, viewed from the sole of the foot.

(The cuneiform bones and the metacarpal bones have been removed, the superficial layer and the most anterior processes of the ligamentum plantare longum have been cut off, the capsulae articulares except the strengthening ligaments have been removed.)

Ligamenta tarsi plantaria (continuation). The *ligamentum calcaneocuboideum plantare* (O. T. short calcaneocuboid or short plantar ligament) (see also Fig. 265) is a broad band of short fibres which go from the anterior end of the lower surface of the calcaneus to the lower surface of the os cuboideum; they are partially covered by the ligamentum plantare longum which lies more superficially and is more or less intimately fused with it.

The *ligamentum calcaneonaviculare plantare* (O. T. inferior calcaneonavicular ligament) (see also Figs. 265, 267 and 268) arises as a thick, broad mass of fibres from the anterior and medial margin of the sustentaculum tali of the calcaneus and is fastened to the posterior end of the inferior and medial surface of the os naviculare. The ligament, the bands of which extend essentially from behind forward and connect dorsalward with the ligamentum tibio-naviculare, forms a trough which is concave upward and lateralward (see Fig. 267); its upper concave surface is lined by synovial membrane, belongs to the articulatio talocalcaeonavicularis and forms a part of the socket for the caput tali (see p. 222). At the junction of the inferior with the medial surface a slightly curved fibro-cartilaginous disc, *fibrocartilago navicularis*, is enclosed. The medial, inferior surface of the ligament is hollowed out to form a shallow groove and serves for the reception of the tendon of the m. tibialis posterior.



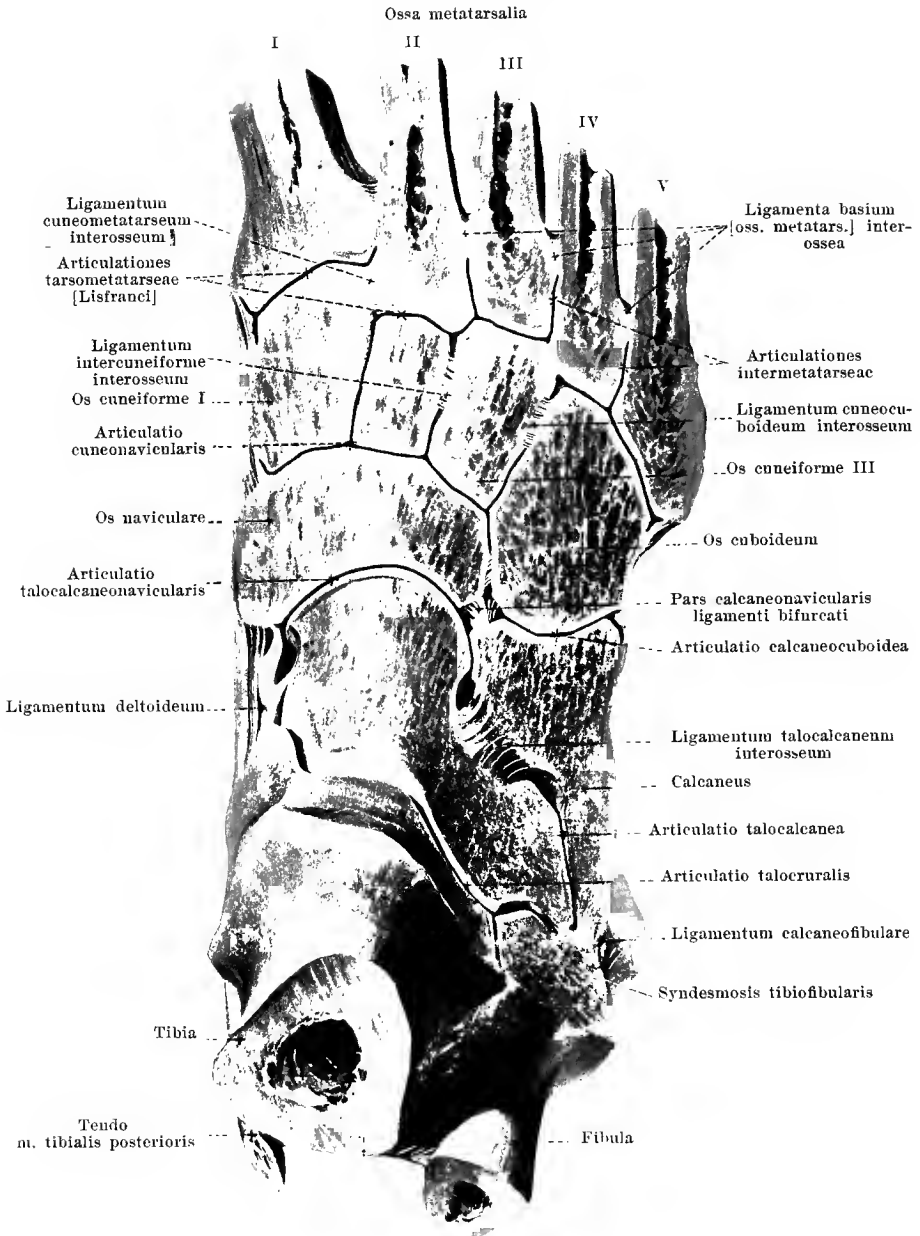
270. Joints of the right foot, *articulationes pedis*,
viewed from the sole of the foot.

(The calcaneus and talus have been removed at the so-called *articulatio tarsi transversa* [Choparti]. The os metatarsale I has been completely excised, the ossa metatarsalia II—V have been sawed through in the middle; the capsulae articulares, with the exception of the strengthening ligaments, have been removed.)

Ligamenta tarsi plantaria (continuation). The *ligamentum cuboconaviculare plantare* (see also Figs. 268 and 269) stretches out between the plantar surfaces of the os cuboideum and the os naviculare. The *ligamenta navicularicuneiformia plantaria* (see also Figs. 265 and 268) are three short bands of fibres passing directly or obliquely forward, which extend from the plantar surface of the os naviculare to the plantar surfaces of the ossa cuneiformia. The two *ligamenta intercuneiformia plantaria* run as short fibre bundles transversely between the plantar surfaces of the ossa cuneiformia. The *ligamentum cuneocuboideum plantare* goes as a broad band from the under surface of the os cuneiforme III obliquely lateralward and backward to the plantar surface of the os cuboideum.

The **articulationes tarsometatarsae** [Lisfranci] have a large number of strengthening ligaments, *ligamenta tarsometatarsae plantaria*, which, partly shorter, partly longer, run on the plantar surface from the ossa cuneiformia and from the os cuboideum to the bases ossium metatarsalium.

The **articulationes intermetatarsae** are strengthened by three *ligamenta basium [ossium metatarsalium] plantaria* (see also Fig. 268) which spread out on the plantar surface transversely between the proximal ends of the second to the fifth metatarsal bone.



271. Joints of the right foot, *articulationes pedis*,
from the back of the foot.

(The surface of a frozen foot has been filed off until the joint cavities have been opened.)

Articulationes pedis. The joint cavities of the *articulatio talocalcanca* and of the *articulatio talocalcaneonavicularis* (see p. 222) are completely closed off not only from one another, but also from the neighboring joint cavities; the *articulatio talonavicularis* is only a part of the *articulatio talocalcaneonavicularis*.


In the formation of the *articulatio calcaneocuboidea* the facies articularis cuboidea of the calcaneus moves upon the proximal joint surface of the os cuboideum; its *capsula articularis* arises close to the margins of the cartilaginous surfaces; the joint cavity is not connected with adjoining ones. The *articulatio calcaneocuboidea* and the *articulatio talonavicularis* are also designated in common by the name *articulatio tarsi transversa* [*Chopart*].

The *articulatio cuneonavicularis* is the joint between the distal surface of the os naviculare and the proximal surfaces of the ossa cuneiformia; the *capsula articularis* surrounds these joint surfaces but in addition also those by which the ossa cuneiformia articulate with one another and those by which the os cuboideum glides upon the os cuneiforme III and on the os naviculare; the capsule is attached everywhere close to the margin of the cartilaginous surfaces. The joint cavity is connected as a rule, between the first and second cuneiform bones with the cavity of the *articulatio tarsometatarsae* of the os metatarsale II (and through this also with that of the os metatarsale III); short ligaments extend in the depth between the cuneiform bones and also between the third cuneiform bone and the cuboid bone: two *ligamenta intercuneiformia interossea* and one *ligamentum cuneocuboideum interosseum*.

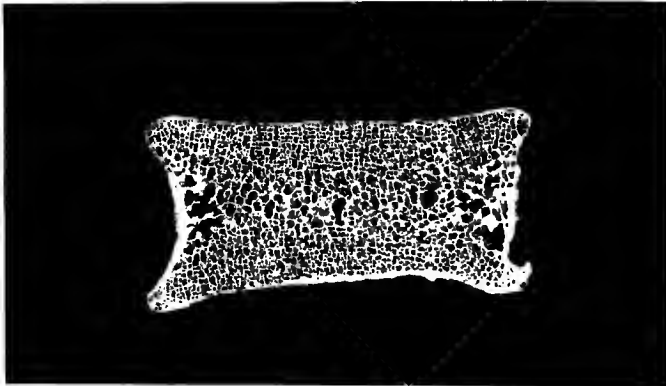
In the formation of the *articulationes tarsometatarsae* [*Lisfranci*] the proximal joint surfaces of the bases ossium metatarsalium are in contact with the distal joint surfaces of the ossa cuneiformia and of the os cuboideum. The places of junction form, in general, a surface convex from the medial toward the lateral side, which suffers interruption at the os cuneiforme II, in that the os metatarsale II reaches further proximalward than the others. Usually three separate joint capsules are present: The first between the os cuneiforme I and os metatarsale I, the second between the ossa cuneiformia II et III and the ossa metatarsalia II et III, the third between the os cuboideum and ossa metatarsalia IV et V; the joint cavity of the second is usually connected with that of the *articulatio cuneonavicularis*. From the lateral surface of the os cuneiforme I and from the medial surface of the os cuneiforme III short *ligamenta cuneometatarsae interossea* (see also Fig. 270) run in the depth to the adjoining surfaces of the basis ossis metatarsalis II.

The *articulationes intermetatarsae* are formed in that the proximal ends of the second to the fifth os metatarsale are in contact, with the cartilaginous surfaces opposed to one another. The joint slits communicate with those of the corresponding *articulatio tarsometatarsae*; the *capsulae articulares* arise from the bone close to the margin of the cartilaginous surfaces. Four *ligamenta basium [ossium metatarsalium] interossea* extend, in the depth, between the neighboring surfaces of the bases ossium metatarsalium.

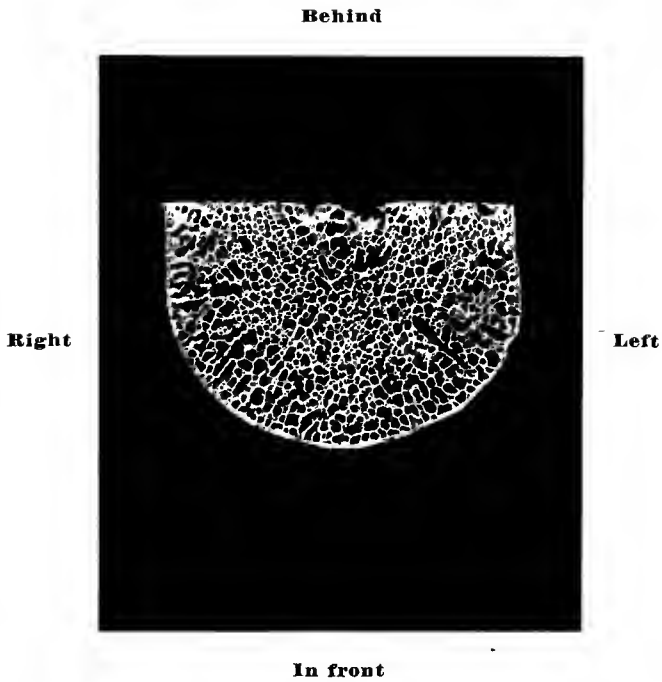
The *articulationes metatarsophalangeae* and the *articulationes digitorum pedis* (O. T. articulations of the phalanges) present as regards their capsules and ligaments, essentially the same relations as do the corresponding joints in the hand (see Figs. 241 and 242).

Above**Behind****In front****Below**

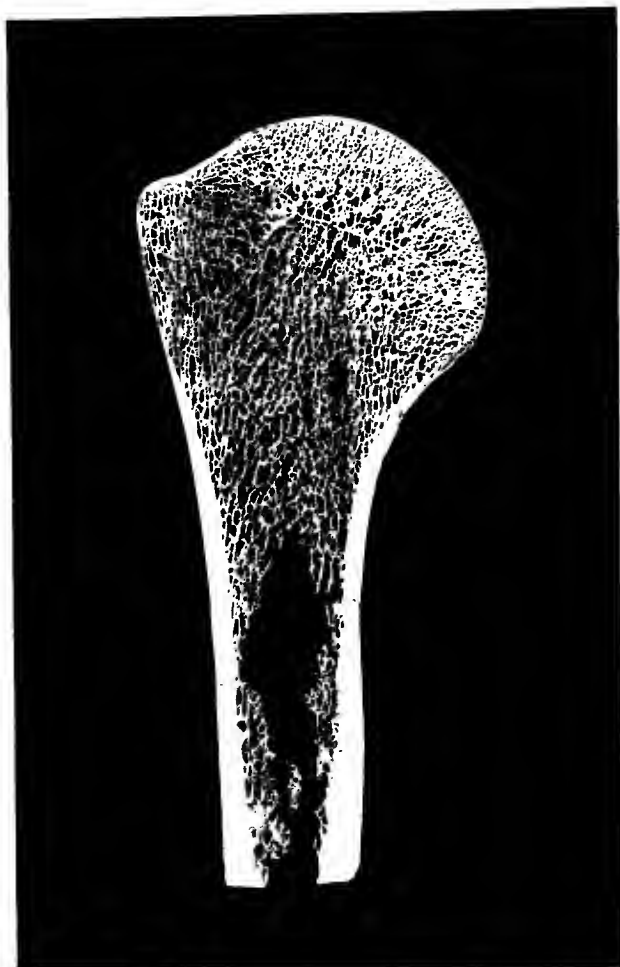
272. Lumbar vertebra, *vertebra lumbalis*,
ground sagittal section, from the side.

Above**Right****Left****Below**

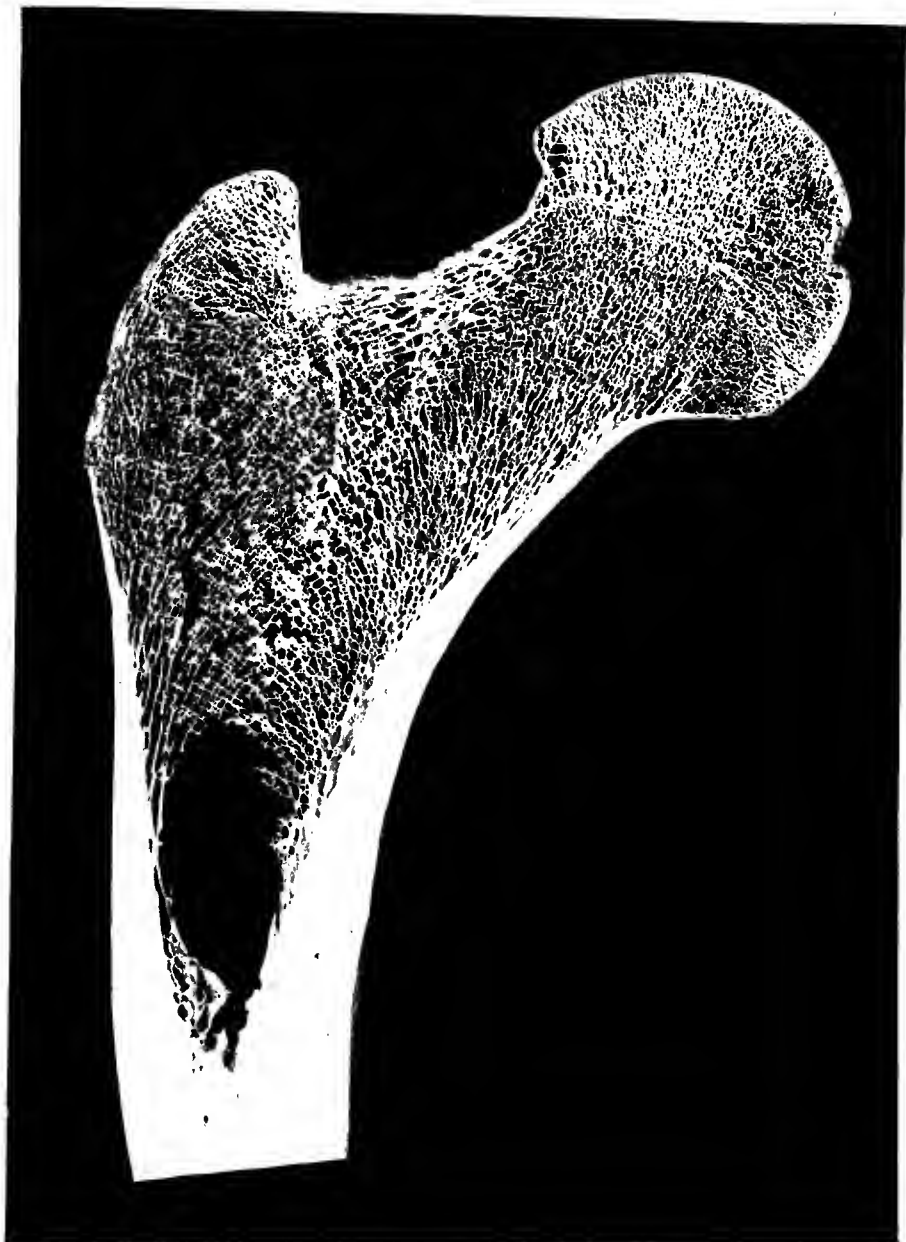
273. Lumbar vertebra, *vertebra lumbalis*,
ground frontal section, from in front.



274. Lumbar vertebra, *vertebra lumbalis*,
ground horizontal section, from above.

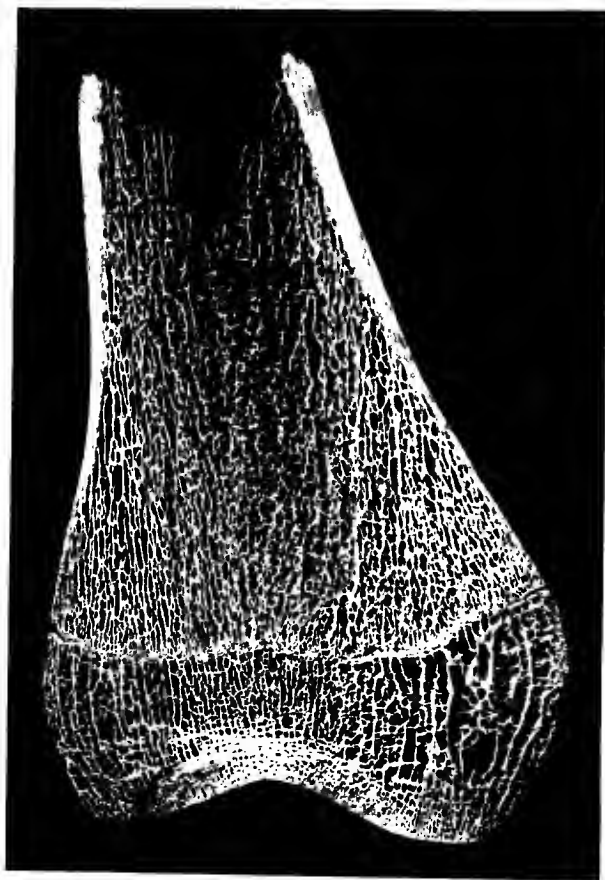


275. Right upper arm bone, *humerus*, upper extremity, ground frontal section, from in front.



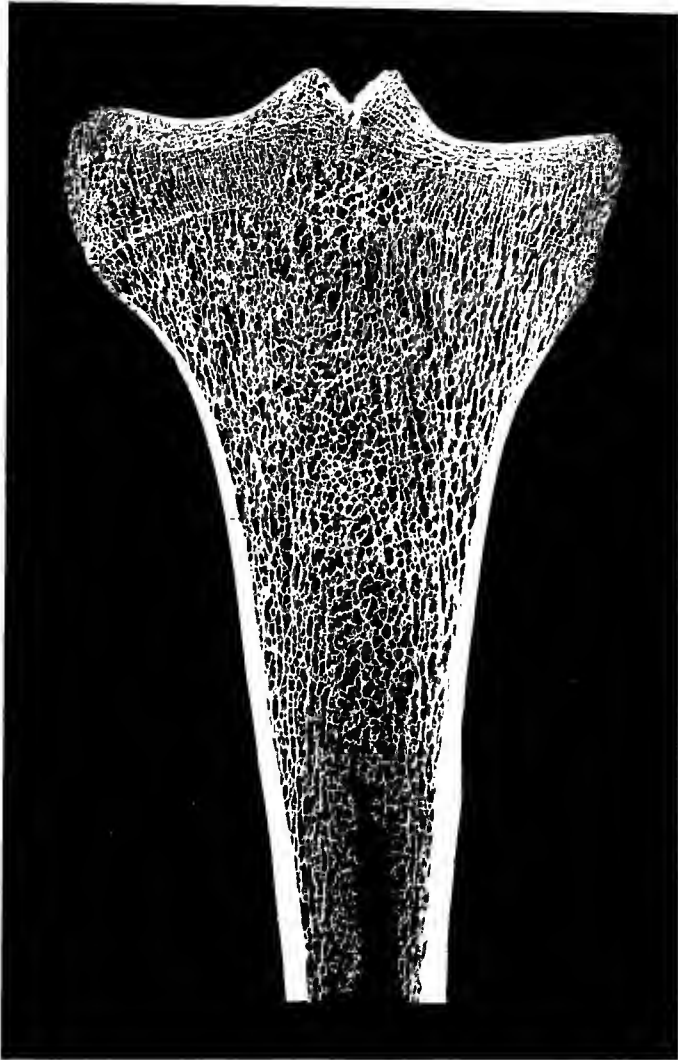
276. Right thigh bone, *femur*, upper extremity,
ground frontal section, from in front.

Epiphyscal
junction — Y

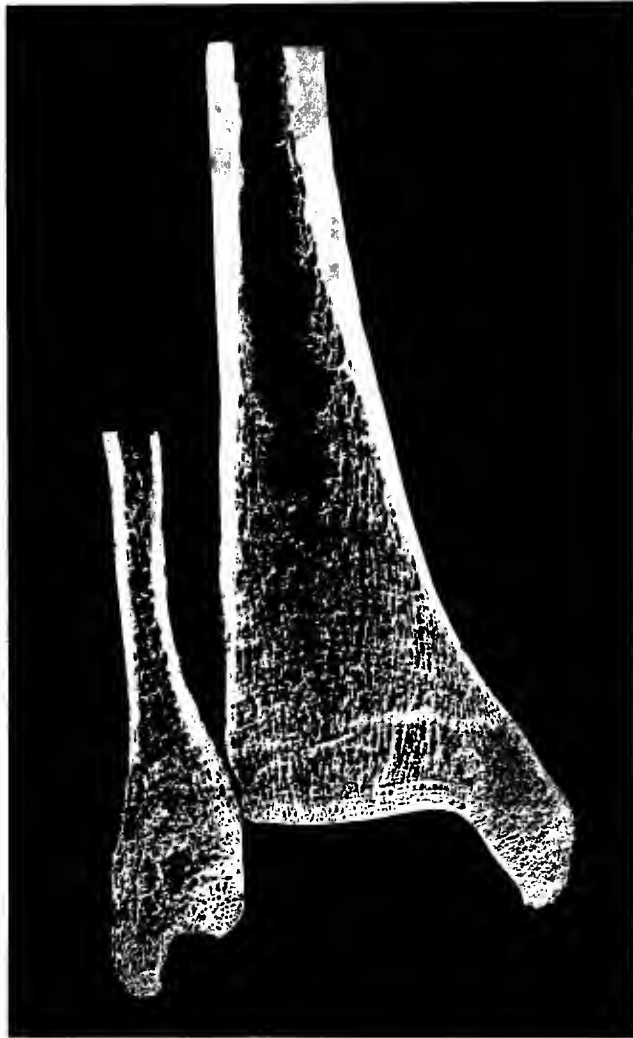


277. Right thigh bone, *femur*,
inferior extremity,
ground frontal section, from in front.

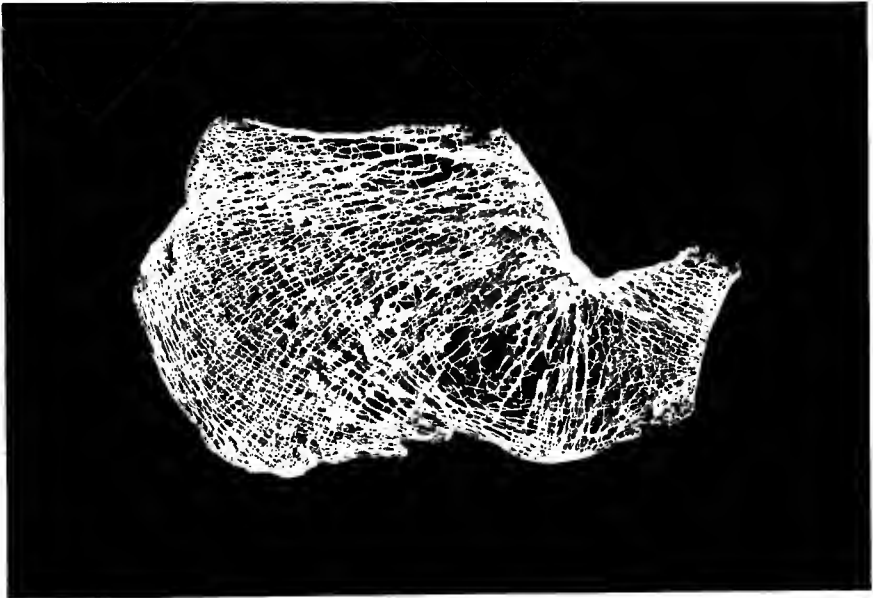
Epiphyseal
junction y



278. Right shin bone, *tibia*, upper extremity,
ground frontal section, from in front.



279. Right shin bone and calf bone,
tibia and *fibula*, inferior extremity,
ground frontal section, from in front.



280. Right heel bone, *calcaneus*,
ground sagittal section, viewed from the side.

Printed by Fischer & Wittig, Leipzig.

