

ANATOMY

FIFTH EDITION

By

Mabel H. Palmer, D. C., Ph.C.

Professor of Anatomy in The
Palmer School of Chiropractic

1923

PUBLISHER:
THE PALMER SCHOOL OF CHIROPRACTIC
CHIROPRACTIC FOUNTAIN HEAD
Davenport, Iowa, U. S. A.



Yours practically yours
Mabel Palmer

PREFACE TO FIFTH EDITION

In the Fifth Edition of this text-book, there have been some appreciable changes made.

Several new illustrations of the nervous system have been added. This is the work of Dr. S. J. Burich, professor of Neurology and Chemistry at the Palmer School of Chiropractic.

New matter has been added to many of the subjects throughout the text; detail of others has been enlarged upon, thus giving the student a more comprehensive knowledge of the work, and typographical and other errors made in the preparation of former editions have been corrected.

In reiteration, this text-book has been prepared primarily for the Chiropractic student and the practitioner in the field. For this reason it has been condensed as much as possible, eliminating much of the technical nomenclature found in most of the present day text-books on this subject. Present day authors have adopted, almost entirely, the Anglicized form of the BNA, while in this text-book the BNA form, when used, is in connection with the old terms. However, for the convenience and satisfaction of the reader, most of the terminology is given in the more common synonyms of the nomenclature of the fine old masters of anatomy. For elaborate and detailed description the student may use other texts for reference.

MABEL H. PALMER, *D. C., Ph. C.*

PREFACE TO THIRD AND FOURTH EDITIONS

In the third and fourth editions of Anatomy, perhaps no appreciable changes are noted, as in the second edition, but omissions and duplications have been carefully considered and care has also been exercised to correct the errors which were found in the completion of the previous edition.

PREFACE TO SECOND EDITION

The first edition of this text-book has been favorably received, and its most cordial reception is much appreciated by the author. It, therefore, makes possible the issuing of a second edition.

Because the first edition was published such a short time ago, it seems unnecessary to make any particular alterations in, or to attempt a revisal of its text. In issuing a second edition the chapters have been carefully reviewed, errata and omissions noted in the first attempt have been corrected and kindly criticisms have received willing attention. New plates have been added, the subject matter has been enlarged, and minor changes have been introduced thruout the text wherever the subject matter could be improved.

In this as well as in the first edition, I have kept in mind the original principle; that is, to give to the Chiropractic profession an anatomy that will be used, not only by the student to make the study of anatomy more interesting and simplified, but that the practitioner in the field may find it a valuable reference in his daily work.

PREFACE TO FIRST EDITION

When it was suggested and urged, by Chiropractors, that I prepare a text-book of Anatomy—at this, a time when good text-books are in abundance—I did not accept without due reflection as to the nature of the demand for such a work, so my thought has been to produce a book which would supply the wants of students only, and not one for the finished anatomist.

This book represents a compilation of my lectures, given during the past nine years, and it is because of the interest which my classes have shown that I have thus consented to have the notes reproduced in book form. This volume is largely the result of information and knowledge acquired during my years of teaching and in its preparation I have consulted such ancient and modern books as I could obtain, and have gleaned from them much information.

The fundamental principle of this work has been to avoid any unusual presentation of the subject which would make the recognition of well known relations more difficult for the student, and to limit the material to what is essentially necessary from a Chiropractic viewpoint. Its object is to place Chiropractic on a more scientific basis by offering to the profession an anatomy presenting the subject as it is taught at the Fountain Head of Chiropractic.

So this work is offered, not with the desire to supplant other valuable works, but with the hope of promoting among Chiropractors a better knowledge of the human body, which has been called the “temple of God.”

Knowledge is the birthright of every being, and knowledge of no other subject is more useful than that of the human organization—the brain guided by the Universal Intelligence which governs it. Man is a being of such proportions and complexity as to completely baffle description, and I shall not attempt it here, whether he is spirit or matter, or both; but we do know that he has a body which is constructed on strictly mechanical principles, and controlled by an All Wise Intelligence. It is my aim to lay particular stress upon this bodily structure, so that one may gain a better and more general knowledge of its nature.

It is to be regretted that anatomy loses so much in consequence of the want of a definite nomenclature, but I am of the opinion that the student's attention soon wearies of technicality, whether written or spoken, and I have, therefore, made use of such terms as experience has shown to be the most easily understood and remembered, and therefore I have tried by eliminating as many difficult terms as possible, though using as many new and old terms as I deemed advisable to make this anatomy serviceable to all.

In the last few pages of the book will be found a collection of words with their definitions with which the author sincerely hopes the student will familiarize himself. This will be of value to the student in his work throughout the school year.

There is little scope for originality in the writing of a text-book on anatomy, for every structure has been so often and so well

described that I cannot expect to do better than have my predecessors and thus I am gratefully indebted to such great masters and authorities as Cunningham, Sobotta and McMurrich, Morris, Piersol and contributors of Gray.

The anatomy of the nervous system is, however, taken up in a manner different from that followed by other anatomists, and the metric system, as taught in Chiropractic, has been closely followed, so that the practitioner in the field may find the book of value in his daily work.

The illustrations are from Sobotta and McMurrich's work and Bock's Atlas of Human Anatomy, with a few original illustrations and outlines from the students of the P. S. C., reproduced from cuts made by the Columbian Engraving Company, of Chicago, and I take this opportunity of expressing my appreciation for permission to use the illustrations which appear in the book.

The author desires to thank Dr. S. J. Burich, professor of Chemistry and Neurology, in The Palmer School of Chiropractic, for his cooperation in the chapters of the spinal and cranial nerves; and Dr. Sterling Cooley for the use of Bock's Human Atlas on Anatomy, from which many of the plates were made, and especially do I wish to thank Mr. J. K. Cheney for his courtesy, untiring interest and valuable assistance during the preparation of this text.

To the printer, Rogers & Hall Co., of Chicago, I wish to express my appreciation of their generous support and consideration during the publication of the book, and to the many students of the P. S. C. and to practitioners in the field, I gratefully acknowledge their kindly words of appreciation, their loyal support and patience in the production of this work.

DEDICATION

In grateful appreciation of the constant inspiration which has made possible this work, and because of the pride which I know he will take in its production, I dedicate to my loving companion, Dr. B. J. Palmer, this first book of Chiropractic Anatomy.

ANATOMY

Anatomy originally signified to cut apart or dissect, and is a term given to that branch of natural science which deals with the study of the structure, or framework, of the body.

A great deal can be said of the importance of anatomical knowledge, which is universally conceded to be the foundation of a study of the organism of living things.

To study anatomy, with the least labor and the greatest profit, the student should read the complete description of each structure and learn from it the Histology, Morphology and Biology of each tissue. As a teacher, I have endeavored to impress this upon the minds of my students, that the body itself is, and always will be, the best book on Anatomy. The subject resolves itself into the following subdivisions of Anatomy:

Comparative—A comparison of the structure of lower vertebrates with that of man.

Surgical—A more careful study of certain parts on account of surgical importance.

Pathological—Presents a morbid structure, altered by incoordination.

General—Includes everything relating to the structure of organs of the body.

Human Anatomy—Or man's body, consists of a combination of several systems and each system is made up of a set of organs. Each organ is built up of many tissues, which in turn consist of elements. Human Anatomy is, therefore, divided into several sciences or studies, as follows:

Osteology—study of bones.

Syndesmology and Arthrology—joints and ligaments.

Myology—muscle attachments, and coverings.

Angiology—blood vessels.

Neurology—nerves and brain.

Splanchnology—viscera. This includes adenology, the study of glands.

Genesiology—reproductive organs of male and female.

Osteology, the first division, embraces the study of the bony framework of the body, the skeleton. There are two parts to be considered in the study of the skeleton. The **endo-skeleton** includes those parts most internal, the splanchnic skeleton, not visible, for the bones are covered by soft parts. The **exo-skeleton** is external, and includes the nails, teeth, hair, feathers, scales, horns, hoofs, etc., all of which are derived from the dermoid system. The term skeleton (dried) is applied to all parts which remain after the softer parts of the body have been removed, and includes not only bones, but cartilages and sometimes ligaments.

Bone is developed by two methods—namely: by **parostosis**, or **intra-membranous** development from membrane, and this includes most of the flat bones; secondly, by **chondrostosis**, or **intra-cartilag-**

ANATOMY

inous development from cartilage, and all the other bones of the body are developed by this latter method.

Bone is composed about equally of water and solids. The solids consist of **organic** or animal matter, one-third or 33-1/3 per cent, consisting of gelatine, vessels and fat, which gives toughness and elasticity to the bone; and of **inorganic** or mineral matter, two-thirds or 66-2/3 per cent, composed mostly of phosphate, carbonate of calcium, lime and salts, which gives hardness and rigidity to the bone.

In young children the relative amount of animal matter is much greater, so that in them the bones are very tough and elastic, but not very hard, and therefore, not capable of bearing much weight. In old age there is a relatively large amount of earthy matter present. The bones of old persons, therefore, are very hard and brittle, but not very tough and elastic; hence the frequency of fractures in old persons from slight causes.

Bone is the chief supporting tissue of the body, and is of hard, or compact, tissue externally, and of cancellous, or spongy, tissue internally. It is connective tissue of a white-fibrous nature, so calcified and structurally modified as to become osseous tissue. The interior of long bones is hollow, forming the medullary canal. On a transverse section of bone, a number of holes will be observed, averaging 1/500 of an inch in diameter, and surrounded by a series of concentric circles, consisting of an interrupted series of dark spots. These openings are called **Haversian canals**. They transmit vessels, and are seen to be surrounded by a series of concentric rings, termed **lamellae**, while the dark spots reveal themselves as cavities in the bone, called **lacunae**, communicating with each other and with the central Haversian canal by means of delicate lines, called **canaliculi**, and this aggregation of structures form an **Haversian system**. Each Haversian canal communicates either directly or indirectly with the marrow cavity of the bone and with the periosteum, so that both the internal and external parts of bone contain nutrient vessels passing to all parts of each Haversian system.

Periosteum (**peri**-around, **osteo**-bone) is a dense, fibrous, serous, connective-tissue membrane, investing the surfaces of bones excepting, when at its articular surfaces, cartilage is substituted. It consists of two layers—an outer and an inner. The fibers of the outer layer are arranged closely, and it is quite dense, while the inner layer consists chiefly of numerous elastic fibres and bone-forming cells, known as the osteoblasts. These cells take an important part in the formation of bone during its growth. Periosteum receives the insertions of tendons and ligaments and serves for the distribution of the vessels which enter the bone thru small foramina on its surface. It also takes part in ossification and regeneration of bone. When the periosteum is stripped from a bone the uncovered portion is liable to necrosis and exfoliation.

Endosteum is the vascular and delicate connective-tissue-lining of the medullary and cancellous cavities of bones. A **center of ossification** is the point where the mineral matter is first deposited and is called the **primary center**. Some bones are developed from a single center while others have several, for example; the sacrum has thirty-five centers of ossification, the humerus seven, and the femur five.

Bone Marrow is found in both the young and adult, and there are two varieties, the **yellow** and the **red**. **Yellow marrow** occurs in the shaft of adult long bones and has blood-vessels, fat, cells and a network of fibrous tissue. Its yellow color is due to the fat, constituting 95 per cent, its other elements comprising albumins, and 1% of water and salts. **Red marrow** contains less fat and is less solid matter, being composed of 72% of water, 2% of fat, 22% of albumoids and 4% of salts, and is found in the diploe of the cranial bones, in the cancellous tissue of the vertebrae, ribs, and sternum and in the extremities of long bones.

Cartilage is a non-vascular structure found in various parts of the body, and is a gristly or white elastic substance, and a supporting tissue in which the intercellular substance predominates and yields chondrin upon boiling. Cartilages are surrounded by a dense connective tissue membrane, called the **perichondrium**, in which small blood-vessels ramify. According to the structure of the matrix, cartilage is divided into **hyaline cartilage**, **white fibro-cartilage** and **yellow** or **elastic fibro-cartilage**. Besides these varieties, met with in the adult human subject, there is a variety called **cellular cartilage**, which is composed almost entirely of cells, sometimes united by a fine network of tissue.

Hyaline cartilage consists of a gristly mass of a firm consistence, with considerable elasticity and of a bluish white color, which has a granular or homogenous matrix like ground glass, with little fibrous tissue; *articular cartilage*, *costal cartilage*, *temporary cartilage* and some of the *respiratory cartilages* are of the hyaline variety.

Articular cartilage is a thin layer of hyaline cartilage found on the joint-surfaces of bones, *costal cartilage* is that form which connects the true ribs with the sternum, *temporary cartilage* is any cartilage which is normally destined to become changed into bone, and the *respiratory* are those found along the course of the respiratory tract.

White fibro-cartilage is any tough and elastic cartilage of which the matrix contains a considerable amount of white fibrous tissue **white fibro-cartilage** is arranged into four groups—the *interarticular*, *connecting*, *circumferential* and the *stratiform*.

The *interarticular* fibro-cartilage is any movable plate of fibro-cartilage, lying between opposed joint surfaces, as the acromio-clavicular, the intervertebral, the intercoccygeal, the sterno-clavicular, and the wrist and knee joints. *Connecting fibro-cartilage* is any disk of fibro-cartilage which attaches opposing bones to each other, being the cartilage interposed between the two bony surfaces.

The *circumferential fibro-cartilage* is any fibro-cartilage forming a rim about a cavity, as the glenoid cavity of the shoulder joint and the cotyloid cavity of the hip joint, and therefore circumferential fibro-cartilages serve to deepen normally these cavities. *Stratiform fibro-cartilage* is such as lines the bony grooves in which certain tendons are placed.

Yellow or **elastic fibro-cartilage** is any cartilage of which the matrix is mainly a network of yellow fibers. It is found in the external ear, Eustachian tube, and epiglottis, also in the cornicula laryngis and cuneiform cartilages of the larynx.

ANATOMY

The blood-vessels of bone are small arteries derived from the nutrient vessels of the periosteum, supplying principally the compact bone, while larger blood-vessels, called perforating vessels, pass directly thru the bony shaft and supply the marrow. On account of its greater vascularity and greater nerve supply, a broken bone heals more rapidly than a torn tendon or ligament, or than does a broken cartilage. The veins emerge thru numerous openings near the articular ends of long bones, or they may follow the artery thru its opening, in either compact or cancellous tissue.

Nerves are distributed freely to the periosteum, and they accompany the artery into the interior of the bone; they are most numerous in the articular extremities of long bones, in the vertebrae and in large flat bones.

The **epiphysis** is a plate of cartilage, developed from a center of ossification distinct from that of the shaft or body of the bone. It remains separated until the growth of the bone is completed, when it ossifies with the **diaphysis**, the part which grows between two epiphyses, and forms the main portion of a bone (shaft of a long bone and the body in an irregular bone). An **apophysis** is a bony process, or outgrowth, which does not have a separate center of ossification. It is attached for a time to the principal part of the bone, by cartilage, but later it becomes united with it.

As to differences of bones we find they are smoother, lighter, more elastic and smaller in the female than in the male.

There are 206 bones in the body, exclusive of the sesamoid and sutural bones. Of these, 197 are the articulate bones, the remaining nine bones include the six ossicles of the ears, the hyoid bone and the two patellae.

Bones are divisible into four classes, **long**, **short**, **flat** and **irregular**. The **long bones**, found chiefly in the extremities, form a system of levers, sustaining the weight of the trunk, and providing the means of locomotion. The **short bones** are found mainly where compactness, elasticity, and limited motion are the principal requirements. **Flat bones** serve as a special protection for the viscera, and provide broad surfaces for muscular attachment. **Irregular bones** constitute a group of peculiar form, often very complex, and are found chiefly where great pressure, and little flexion, is the requirement. There are 90 long bones, namely: the clavicle (2), brachium (2), radius (2), ulna (2), femur (2), tibia (2), fibula (2), metacarpals (10, five for each hand), metatarsals (10, five for each foot), and phalanges (56, fourteen for each hand and foot, forming the fingers and toes). The short bones are 30 in number and include the carpals (16, eight for each hand), and the tarsals (14, seven for each foot). The flat bones number 38, and are the occipital (1), frontal (1), vomer (1), sternum (1), parietal (2), nasal (2), lacrimal (2), scapulae (2), ribs (24), and the innominate bones (2). The irregular bones are 39 in number, namely: the vertebrae (24), sacrum (1), coccyx (1), temporal (2), ethmoid (1), sphenoid (1), inferior turbinated (2), superior maxillary (2), palatal (2), malar (2), and the mandible (1).

Bones not classified are: The **Wormian** or **sutural** bones, found at the junction of two or more of the cranial sutures, where, during

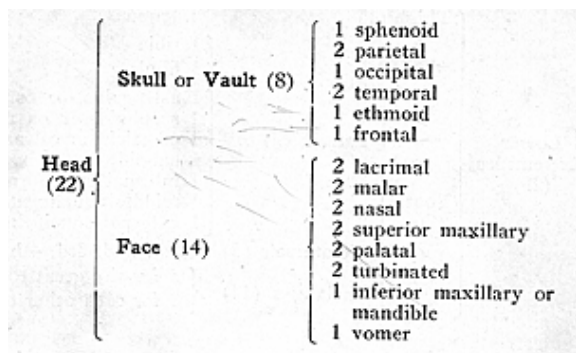
ANATOMY

infancy, a membranous interval existed, known as fontanelle, these bones from their triangular form are often called **ossa triquetra**; the **hyoid** bone, located at the base of the tongue; the **patella**, a flat triangular bone placed at the front of the lower end of the femur, and probably a sesamoid bone; the **sesamoid** bones, small seed-like bones of fibro-cartilage developed in the substance of tendons, playing over a joint-surface; the **ossicles** of the ear, minute bones of the tympanum or middle ear, namely: the stapes, incus and malleus.

There are 34 single, or mesial bones, namely: The frontal, sphenoid, ethmoid, occipital, vomer, mandible, hyoid, sternum, the 24 vertebrae, sacrum and coccyx. The surfaces of bones are variously modified by enviroing conditions. Pressure at the extremities causes enlargement, and movement renders them smooth. Certain characteristic articular processes on bones are known as **heads** and **condyles**. **Heads** are convex, smooth projections, with a constriction or a neck beneath; **condyles** are double projecting processes, and may have a constriction or a neck.

Some of the non-articular processes are **trochanters**, short projecting levers, near articulations, to facilitate rotation of the bone on its long axis; **tuberosities**, roughened, or blunt, broad prominences; **tubercles**, similar to the above, but smaller; and **spines** and **spinous processes**, more or less pointed projections. Slightly elevated ridges of bone are **crests**, when these ridges are narrow and pronounced they are called **lines** and **borders**. Some of the articular cavities of bone are the **cotyloid**, resembling a deep cup; **glenoid**, when they have a shallow cup form; **trochlear**, pulley-like; **facet**, when smooth like one of the surfaces of a cut gem; and **sigmoid** when S shaped. The principal non-articular cavities are the **fossae**, shallow depressions, **sinuses**, deep cavities communicating with the exterior by small openings being larger within than at the entrance; **grooves**, long narrow depressions; **fissures**, cracks; **notches**, deficiencies of the edges of bones; and **foramina**, minute canals, or openings, traversing bones for the entrance and the exit of blood-vessels and nerves.

Bones are classified as those of the **head** (22), the **trunk** (53), the **upper extremities** (32), and the **lower extremities** (29).



ANATOMY

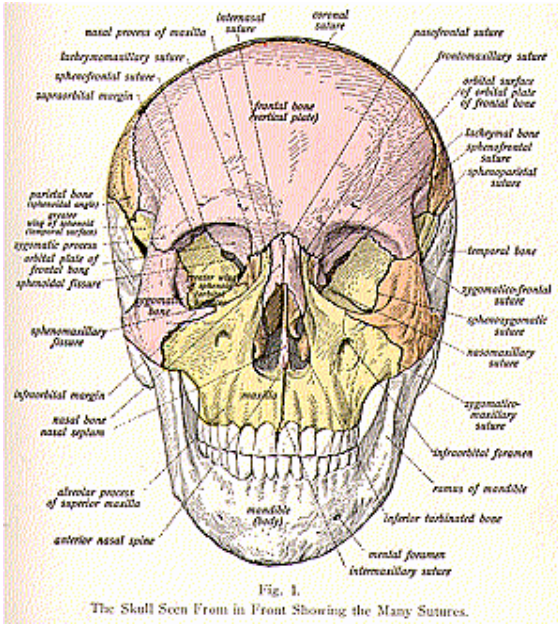
Trunk (53)	Thorax (25)	{ 1 sternum { 24 ribs, or costae
	Spine (24)	{ 7 cervical vertebrae { 12 dorsal, or thoracic, vertebrae { 5 lumbar vertebrae
	Pelvis (4)	{ 1 sacrum { 1 coccyx { 2 ossa innominata
Upper Extremities (32)	Shoulder (2)	{ 1 clavicle { 1 scapula
	Arm (1)	1 brachium, or humerus
	Forearm (2)	{ 1 radius { 1 ulna
	Hand (27)	{ 1 scaphoid, or navicular { 1 semilunar, or os lunatum { 1 cuneiform, or os triquetrum { 1 pisiform { 1 trapezium, or great multangular { 1 trapezoid, or small multangular { 1 os magnum, or capitate bone { 1 unciform, or os hamatum
	Carpals (8)	{ 1 scaphoid, or navicular { 1 semilunar, or os lunatum { 1 cuneiform, or os triquetrum { 1 pisiform { 1 trapezium, or great multangular { 1 trapezoid, or small multangular { 1 os magnum, or capitate bone { 1 unciform, or os hamatum
	Metacarpals (5)	1st, 2nd, 3rd, 4th, 5th.
	Phalanges (14)	{ 2 for each thumb { 3 for each finger
	Thigh (1)	1 femur
	Leg (2)	{ 1 tibia { 1 fibula
	Foot (26)	{ 1 astragalus, or os talus { 1 scaphoid, or os navicular { 1 os calcis, or calcaneum { 1 cuboid { 1 internal cuneiform { 1 middle cuneiform { 1 external cuneiform
Lower Extremities (29)	Tarsals (7)	{ 1 astragalus, or os talus { 1 scaphoid, or os navicular { 1 os calcis, or calcaneum { 1 cuboid { 1 internal cuneiform { 1 middle cuneiform { 1 external cuneiform
	Metatarsals (5)	1st, 2nd, 3rd, 4th, 5th.
	Phalanges (14)	{ 2 for the great toe { 3 for each other toe

ANATOMY

THE SKULL

(Illustrations Nos. 1, 2 and 3.)

The skull is the skeleton of the head and face. Viewed from above, the skull presents an oval outline, with the broader end behind, the bones being connected to each other by means of sutures. A **suture** is a seam, or line of junction between adjacent cranial, or facial, bones. The important sutures at the vertex of the skull are the



metopic or the **frontal suture**, which is the median fissure in the frontal bone just above the glabella; the **sagittal suture**, situated between the two parietal bones; the **coronal** or **fronto-parietal suture**, lying between the frontal and two parietal bones; and the **lambdoid suture**, formed between the parietal and the occipital bones.

The more important regions are the **bregma**, which indicates a

point on the surface of the skull at the junction of the coronal and sagittal sutures; the **lambda** is the point, at the posterior part, where the lambdoid and sagittal sutures meet, and is situated about 2-3/4 inches above the external occipital protuberance; the **obelion** is the point on the sagittal suture where it is crossed by a line which connects the parietal foramina; the **pterion**, or region of the sphenoparietal suture, is situated about 1-1/4 inches behind the external angular process of the frontal bone, and about 1-3/4 inches above the zygomatic arch, being the point of junction of the temporal, sphenoid, frontal and parietal bones, the **asterion**, a point where the parietomastoid, occipitomastoid and lambdoid sutures meet, is situated about 2 inches behind the auricular point (the center of the external auditory meatus), very nearly in line with the upper border of the zygomatic arch; and the **inion**, which is the external occipital protuberance.

The **sutures** at the sides of the skull receive the names of the **spheno-parietal, squamo-parietal, masto-parietal, front-malar** and the **fronto-sphenoidal**. Those found at the base are the **basi-sphenoidal**, the **petro-occipital**, two **masto-occipital**, two **petro-sphenoidal**, and the two **squamo-sphenoidal**. The basi-sphenoidal suture is formed by the junction of the basilar surface of the occipital bone with the posterior surface of the body of the sphenoid; in early life a thin plate of cartilage exists between these bones, but in the adult they become fused into one. The **facial sutures** are numerous, but the only one receiving a special name is the **transverse**, which extends from one external angular process of the frontal bone to the other on the opposite side, joining that bone with the malar, the sphenoid, the ethmoid, the two nasal, the maxilla and the lacrimal.

The **Orbital Cavities** are two pyramid cavities, with their bases directed forward and outward and their apices backward, and inward. Their inner walls are nearly parallel, but their outer walls diverge so as to be nearly at right angles with each other. Seven bones enter into the formation of the orbit, namely: the frontal, sphenoid, ethmoid, palate, malar, lacrimal, and the maxilla. The *roof* of the orbit is formed by the orbital plate of the frontal bone anteriorly, and the lesser wing of the sphenoid posteriorly. The inferior wall or *floor* is formed by the orbital plate of the maxilla, the orbital process of the malar and by the palate bones. The *outer wall* is formed by the orbital surface of the greater wing of the sphenoid and the malar, the *inner wall* which is narrow, is formed from before backward by the nasal process of the maxilla, the lacrimal, the os plenum of the ethmoid, and the body of the sphenoid.

The inner wall is the smallest of the four, and is traversed by three vertical sutures, one between the nasal process of the maxilla and the lacrimal; a second one between the lacrimal and the ethmoid, and a third between the ethmoid and the sphenoid. The apex of each orbit corresponds to the optic foramen, a circular orifice which transmits the optic nerve and the ophthalmic artery. The *orbital cavity communicates* with the *cranial cavity* behind by the *optic foramen* and the *sphenoidal fissure*; with the *nasal fossa* thru the canal of the *nasal duct*, and with the *zygomatic* and *spheno-maxillary fossae* by the

spheno-maxillary fissure. Besides these larger openings, the orbital cavity has five other foramina—the infraorbital, malar, temporal, and the anterior and posterior ethmoidal, canals which open into, or lead from, each cavity.

The **Nasal Fossae** are two irregular cavities situated on either side of the middle line of the face, extending from the base of the cranium to the roof of the mouth. They are separated from each other by a thin medial vertical septum, the **septum of the nose**, formed by the perpendicular plate of the ethmoid and by the vomer. There are fourteen bones which form the nasal fossae, namely, the frontal, sphenoid, ethmoid, two lacrimal, two palatal, two superior maxillary, two turbinated, two nasal and the vomer. The nasal fossae open in front by the *anterior nasal aperture* and communicate above with the *frontal sinus* behind with the *spheroidal, maxillary* and *ethmoidal sinuses*. Also each fossa communicates with the orbital cavity by the *lacrimal groove*; with the mouth by the *anterior palatine canal*; with the cranium by the *olfactory foramina*; with the spheno-maxillary fossa by the *spheno-palatine foramen*, they often communicate with each other by an aperture in the septum. The outer walls of each fossa present three irregular longitudinal passages, formed by three projecting bony plates, called the **superior, middle** and the **inferior meatuses**. The **superior meatus** lies between the superior and the middle turbinated bones (processes of the ethmoid), the **middle meatus** occupies the posterior two-thirds of the wall, and lies between the middle and inferior turbinated bones: the **inferior meatus** lies between the inferior turbinated bone and the nasal floor, and extends the whole length of the outer wall.

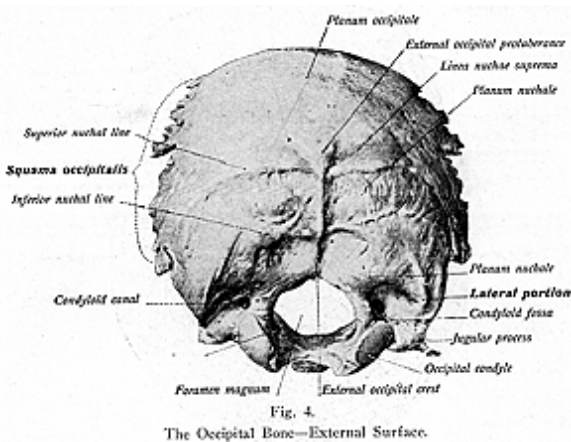
The **Temporal Fossa** is situated in the lateral region of the skull and is formed by parts of the frontal, sphenoid, temporal parietal and malar bones. Each fossa is marked out upon the skull-cap by the temporal ridge, which extends in a curved line from the external angular process of the frontal bone to the zygomatic process of the temporal bone. Each fossa is bounded *anteriorly* by the frontal, the malar, and the greater wing of the sphenoid; *above* and *behind* by the temporal ridge; *below* by the pterygoid ridge, on the greater wing of the sphenoid; *externally* by the zygomatic arch. The temporal fossa opens, below, into the zygomatic fossa, and is filled by the temporal muscle. It is traversed by grooves for the distribution of the temporal artery.

The **Zygomatic Fossa** is bounded *anteriorly* by the superior maxilla; *superiorly*, by the pterygoid ridge of the sphenoid, and by the under part of the squamous plate of the temporal; *behind*, by the posterior pterygoid process, *below*, by the alveolar border of the maxilla; **internally**, by the external pterygoid plate, and **externally**, by the ramus of the lower jaw, and by the zygoma.

The **Spheno-Maxillary Fossa** is bounded, *above*, by the under surface of the body of the sphenoid, in *front*, by the superior maxillary bone; *behind*, by the pterygoid process of the sphenoid; and *internally*, by a vertical plate of the palatal, with its orbital and sphenoidal processes. Five foramina open into the spheno-maxillary fossa, namely:—the posterior palatine, pterygo-palatine and the vidian canals the foramen rotundum and the spheno-palatine foramen; these openings

posterior fontanelle is found between the two parietal bones and the superior part of the occipital, behind and below. The closure of this space should take place about the second month after birth. The **two anterior lateral fontanelles** are situated at the angle of the parietal bone, where it joins with the frontal, sphenoid and temporal bones, and should close from two to three months after birth. The **posterior lateral spaces** or **fontanelles** lie between the parietal, temporal and occipital bones and should close one or two years after birth. Cunningham says, "at birth the face is proportionately small as compared with the cranium, constituting about one-eighth of the bulk of the latter.

"In the adult, the face equals at least half of the cranium. About the age of puberty the development and expansion of some of the air-sinuses, more particularly the frontal sinus, leads to characteristic differences in form in both the head and face. In old age the skull usually becomes lighter and the bones thinner, the alveolar borders of the maxillae and mandible become absorbed owing to the loss of the teeth. This gives rise to a flattening of the vault of the hard palate



and an alteration in the form of the mandible, whereby the mandibular angle becomes more obtuse."

THE BONES OF THE HEAD

The **skeleton of the head**, or the bones of the head, are known as the skull and face. The bones of the **cranium** are the bones of the skull after the mandible has been removed. The **calvaria** is the skull cap. Bones of the skull and their location are as follows:—

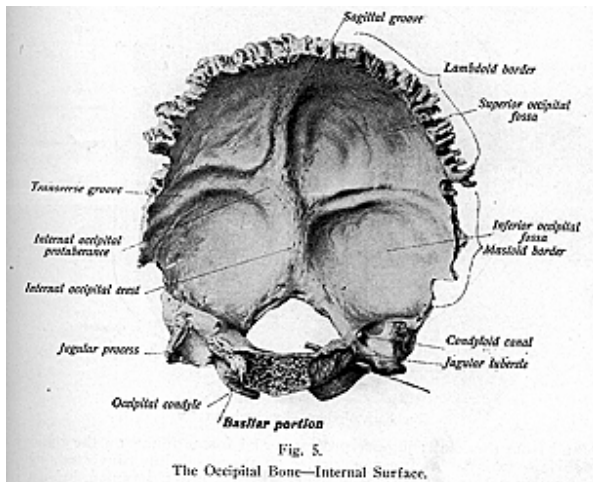
Occipital—(occiput, base) at the posterior and inferior part of the skull; **frontal**—(frons) at the superior and upper portion of the skull; **parietal**—(parietes) on the sides, forming the superior and lateral walls, or sides, of the cranium, or skull; **temporal**—(tempus, time) on either side, at the lower and inferior portion of the skull; **sphenoid**—(wedge-like) at the base of the skull; and the **ethmoid**—(sieve-like) anterior and superior to the sphenoid, and inferior to the frontal bone.

THE OCCIPITAL BONE

(Illustrations Nos. 4 and 5.)

The **Occipital Bone (os occipitale)** is a flat bone located at the posterior and inferior part of the skull; it presents two surfaces and four borders. On the **external surface**, which is convex and smooth, are found the following parts for description:—

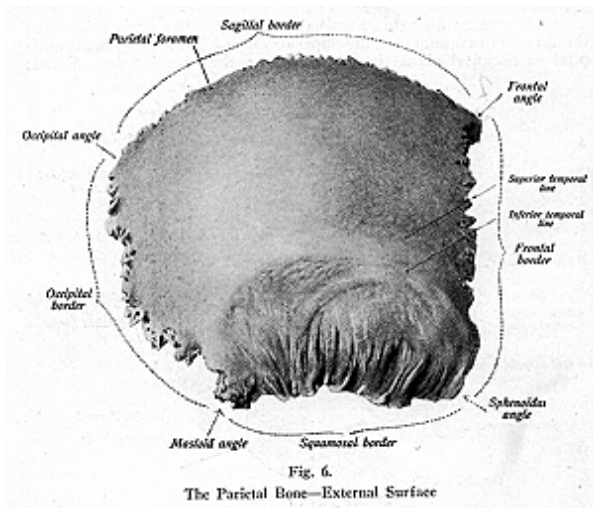
The **plenum nuchale** or **nuchal plane**, the outer surface between the foramen magnum and the superior curved line; the **plenum occipital** or **occipital plane** the surface above the superior curved line;



the **external occipital protuberance**—a small rough prominence between the superior and inferior borders on the external surface, which differs in individuals, often quite prominent and forming a small osseous tumor; the **external occipital crest**—a vertical ridge on the external surface, leading from the external occipital protuberance

OSTEOLOGY

to the foramen magnum; the **superior** and **inferior curved lines**, or **superior** and **inferior nuchal lines**, are linear ridges on the external surface, not very distant from each other and serving for the attachment of muscles; the **foramen magnum**—a large opening thru which the spinal cord passes, and around which the marginal surface is uneven and rough, due principally to the close attachment of the dura mater, the external covering of the brain; two **condyles**, prominent pieces of bone, differing in individuals, sometimes found even and flat, again convex, or dividing into articular processes, but, in most bones, elongated, flattened surfaces articulating with the superior articulating facets of the atlas; the **tubercles**—small prominences on the inner surface of each condyle for the attachment of the check ligaments, the **anterior** and **posterior condyloid foramina**—two foramina, anterior and posterior to the condyles, which transmit vessels and nerves to



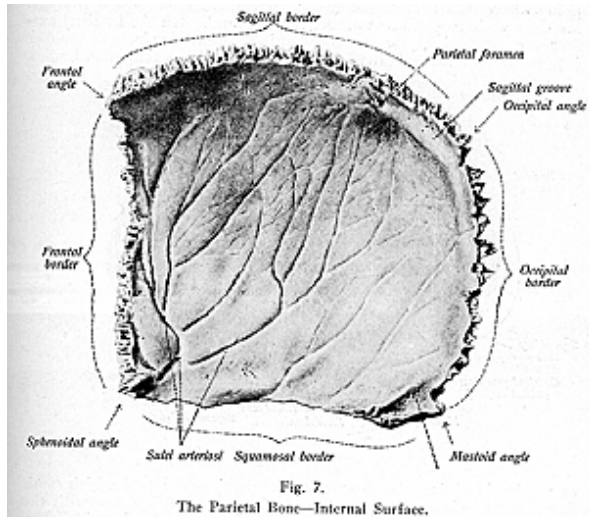
and from the skull; **jugular processes** and **fossae** found on the outer surface external to the condyles, each process being converted, by junction with a portion of the temporal bone, into a foramen, known as the **jugular foramen** or **foramen lacerum posterius**, thru which pass the jugular vein and nerve trunks; and the **basilar process**, a plate of bone, broad and quadrilateral in form, which extends anteriorly from the foramen magnum. On its upper surface is a depression called the **basilar groove** on which the medulla rests; on its under surface is a

OSTEOLOGY

small spicula of bone, known as the *pharyngeal spine*, for the attachment of the superior constrictor muscle of the pharynx.

The **internal surface** of the occiput is concave. Four fossae, or cavities, two superior and two inferior, are here formed by the **crucial ridge**. The two superior occipital fossae contain the occipital lobes of the cerebrum, while the two inferior fossae contain the two lobes of the cerebellum. All of the cranial bones have depressions, or fossae, which the convolutions of the brain follow.

On the internal surface are found the following parts for description: the **internal occipital protuberance** is a small tubercle, almost on a level with the external occipital protuberance, altho placed a little higher, and is the central point of the crucial ridge; the **torcular**



Herophili (the wine press of Herophilus) is a groove, or depression, a little below the internal occipital protuberance, where there is a confluence of a number of venous sinuses, the **transverse groove** passes outward on each side to the lateral angle and lodges the lateral sinuses, its margins affording attachment for the tentorium cerebelli a covering for the brain.

The occipital bone is developed in two ways—from membrane and from cartilage. The occipital bone articulates with the two parietal, two temporal, the sphenoid bone, and with the atlas. Muscles at-

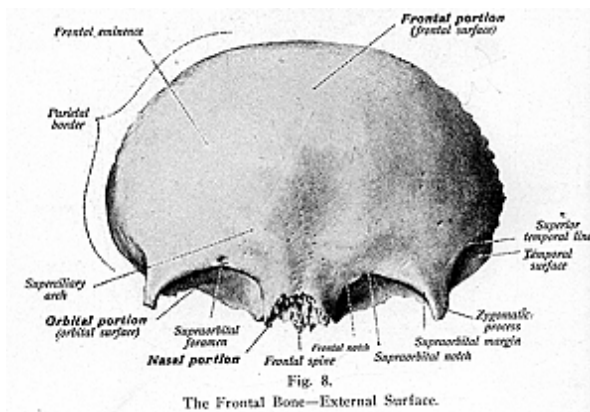
OSTEOLOGY

tached to the occipital bone are the occipito-frontalis, trapezius, sterno-mastoid, complexus, splenius, the obliquus capitis superior, rectus capitis posticus major and minor, superior constrictor of the pharynx, rectus capitis anticus major and minor, and the rectus capitis lateralis.

THE PARIETAL BONE

(Illustrations Nos. 6 and 7.)

The **Parietal Bones (os parietale)** are two flat bones, quadrilateral in form, situated at the superior and lateral sides of the skull, and forming the walls of the skull. Each bone presents for study—on the **external surface**—a **parietal eminence**, a slight eminence, also the point where its ossification begins; **parietal ridge**, or **temporal ridge**, for the attachment of one muscle, the temporal. On the **internal surface** are depressions for the convolutions of the brain, and smaller depressions for the lodgment of small glands, the pacchionian bodies,



or arachnoid villi, and a **groove** for the meningeal artery which rami-fies along the inner surface. The parietal bone articulates with the opposite parietal, the occipital, temporal, frontal and sphenoid bones.

THE FRONTAL BONE

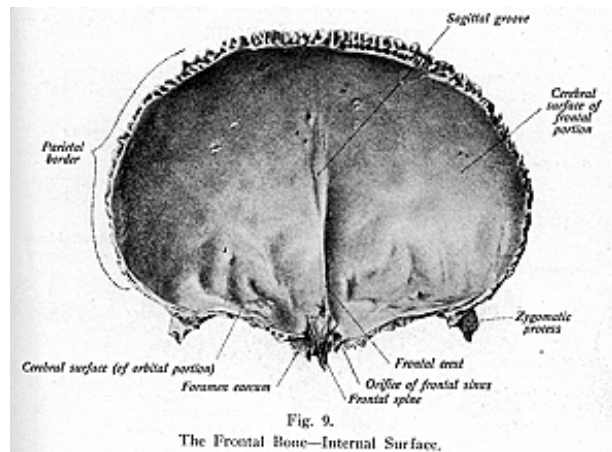
(Illustrations Nos. 8 and 9.)

The **Frontal Bone (os frontale)** is a flat bone, located at the anterior and superior part of the skull, consisting of two principal parts, the orbital and frontal, or the vertical and horizontal portions.

The frontal bone presents for study the following—on the **external surface**; the **interfrontal suture**—a seam or ridge formed by the

OSTEOLOGY

fusion, in early life, of the two symmetrical halves of the bone; the **frontal eminences**, on either side of the centers of the horizontal or upper portion, and that to be the center of ossification; **superciliary arches**, two curved broad ridges on which are mounted the eyebrows and between the superciliary ridges is an elevation called the **glabella** or **nasal eminence**; **supraorbital arches**, two curved **prominent arches** which form the upper boundary of the orbit and separate the vertical from the horizontal portion of the bone; the **external** and **internal angular processes** (called also the **zygomatic processes**), two sharp processes of bone at the outer and the inner angle of each arch, the external being the more prominent, and the **supraorbital notch**, an indentation, on the inner margin of each arch, which is converted into a foramen, the *supra-orbital foramen*, by a small band of tissue—the



transverse ligament derived from the muscles covering the anterior portion of the head.

On the orbital portion of the bone are found the **orbital cavities**, two concave depressions whose walls protect the eyeball, on the outer margin of each cavity is a hollow depression which lodges the lacrimal gland, and, on the inner surface, a small depression for the attachment of the trochlear muscle, the **nasal spine** is a sharp pointed process which extends outward, from the frontal bone, and articulates with the nasal bones; and the **frontal sinuses**, two in number, are openings formed where the frontal articulates with the nasal bone, forming the air sinuses which open into the nose.

On the **internal surface** are the following: a **crest**, a ridge which gives attachment to the falx cerebri; a **sagittal groove**, which lodges

OSTEOLOGY

the longitudinal sinus, a large vein of the skull; **depressions** and **elevations** for convolutions of the brain and for the Pacchionian bodies; also the **foramen caecum**, a blind opening, found between the frontal bone and the ethmoid, where the crest of the frontal terminates. This foramen, when present, transmits a small vein from the mucous membrane of the nose to the superior longitudinal sinus.

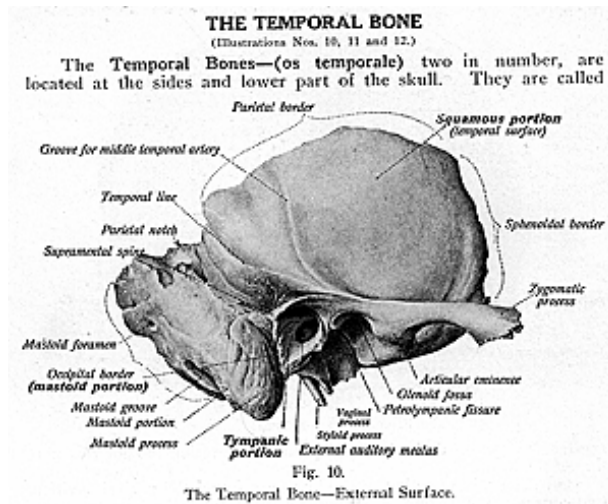
The frontal bone articulates with the two malar, two parietal, sphenoid, ethmoid, two nasal, two superior maxillary, and the two lacrimal bones. Muscles attached to the frontal bone are: the temporal, corrugator supercilii, the orbicularis oculi, and the occipito-frontalis.

The frontal bone, aside from forming the forehead, helps in the formation of the orbits. Each orbit consists of 7 bones, and the two orbits of 11 bones, namely: the frontal, sphenoid, ethmoid, two lacrimal, two superior maxillary; two palatal, and two malar.

THE TEMPORAL BONE

(Illustrations Nos. 10, 11 and 12.)

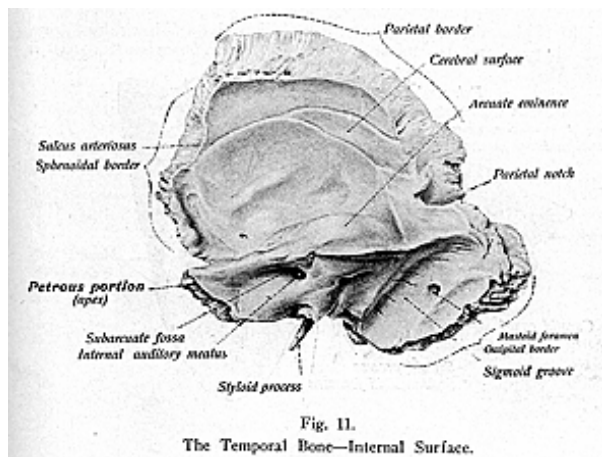
The **Temporal Bones**—(**os temporale**) two in number, are located at the sides and lower part of the skull. They are called



“temporal” because it was that that the hair turned gray first at that place. Each bone presents for study three descriptive parts—**squamous**, scale-like, **mastoid**, nipple-like, and the **petrous**, stony part. The **squamous** is the thinner part, scale-like in form, and made up of an external and an internal layer, having little connective tissue within. The **mastoid** part is nipple-shaped, usually rough, and is sometimes perforated with many openings on its outer surface. The **petrous** portion is the hard, dense, ivory-like part containing the greater part of the middle and inner ear.

OSTEOLOGY

Other points for study on the bone are the following: a **temporal ridge** on the squamous portion, for the temporal artery, also for the temporal muscle; the **zygoma**, a broad arch-shaped piece of bone, which projects anteriorly to articulate with the zygomatic process of the malar; the **glenoid fissure**, a groove underneath the zygoma; **glenoid fossa**, a depression also beneath the zygoma, for the articulation of a process known as the condyle of the mandible; the **styloid** and **vaginal process**, sharp and pen-like in form, each usually about 1/2 to 1 inch in length and giving attachment to muscles and ligaments; the **external auditory meatus**, a canal seen on the external surface, partly in the squamous and partly in the mastoid portions of the bone, leading to the middle ear; **digastric groove**, a deep groove on the posterior surface of the mastoid process, for the attachment of the posterior belly of the digastric muscle; **occipital groove**, below the digastric groove for the occipital artery; **tympanic** or **mastoid antrum**,



a recess in the mastoid process, communicating with the tympanum; **mastoid cells**, air cells, which extend from the antrum into the mastoid process in a downward and backward direction, they also extend forward over the roof of the external auditory meatus and inward for a certain distance into the petrous portion; and the **supra-mental spine** is a sharp scale of bone which gives attachment to a part of the cartilage of the external ear.

On the petrous portion is found the **opening of the carotid canal**, for the internal carotid artery and plexus, the **internal auditory meatus**, which transmits the 7th and 8th pairs of cranial nerves and the auditory artery; the **jugular fossa**, a depression for the sinus of the

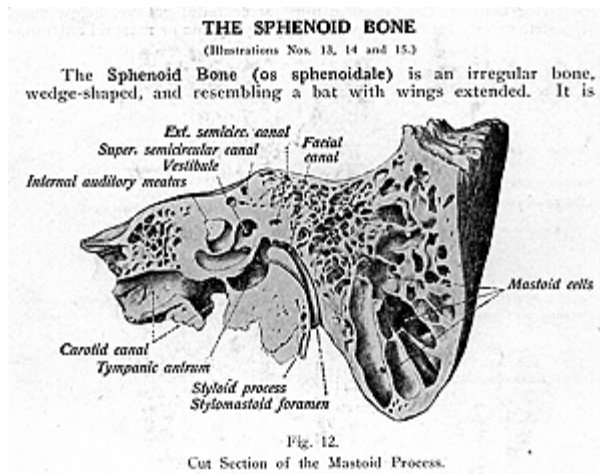
OSTEOLOGY

internal jugular vein, and which, when joined with the occipital bone, forms the **jugular foramen; subarcuate fossa**, a fossa in the posterior inner surface beneath the protrusion of the semicircular canal; an **arcuate eminence**, an eminence on the upper surface marking the location of the superior semicircular canal; and the **facial canal** or **aqueduct of Fallopius**, a canal for the facial nerve in the petrous portion. Numerous other openings, foramina, depressions, and eminences are found on this bone. The temporal bone articulates with the occipital, the parietal, the sphenoid, the malar and the mandible. Muscles attached to the temporal bone are the following: the temporal, masseter, epicranium, sterno-mastoid, splenius capitis, trachelo-mastoid, digastric, retrahens aurem, tensor tympani, levator palati, stapedius, stylo-glossus stylo-hyoid and the stylo-pharyngeus.

THE SPHENOID BONE

(Illustrations Nos. 13, 14 and 15.)

The **Sphenoid Bone (os sphenoidale)** is an irregular bone, wedge-shaped, and resembling a bat with wings extended. It is

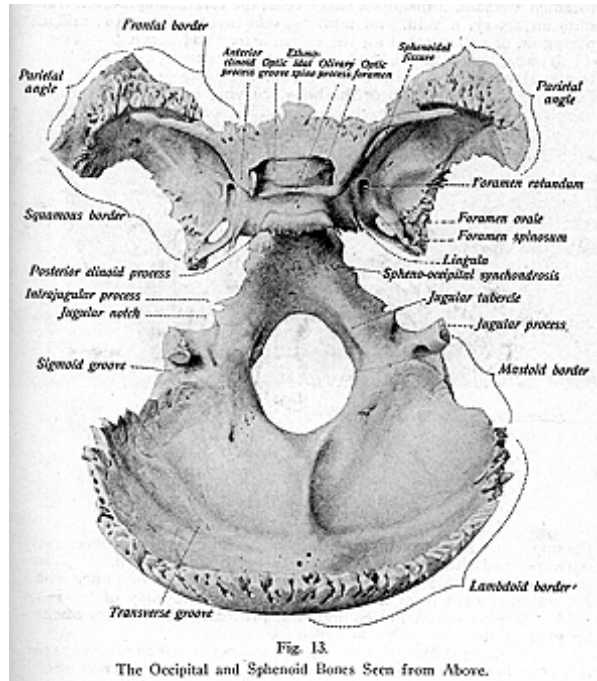


located at the base of the skull, anterior to the occipital, posterior to the frontal and the ethmoid, with the temporal on either side. It enters into formation of the cranial, orbital and nasal cavities. For descriptive parts it has a **body**, **two greater wings**, **two lesser wings** and **two pterygoid processes** or **plates**.

The **body** is placed in the median line, cuboid in shape, hollowed out in the interior and containing cavities called the **spheroidal sinuses**, or spheroidal cells. It presents on its upper surface an **ethmoidal spine** articulating with the ethmoid; a **vaginal process**, a process of bone on the inferior surface of the body running inward from the base of the pterygoid plate, it articulates with the ala of the vomer, and on

OSTEOLOGY

the inferior surface of this process is a groove, which is converted by a process of bone on the palate bone, into a canal, called the **pterygo-palatine canal** for the passage of the pharyngeal nerve and pterygo-palatine artery, the **olive**, a smooth oval-shaped eminence; an **optic groove** for the optic nerve, and the **sella turcica** (turkish saddle), a depression which lodges a gland known as the pituitary body. The posterior portion of the sella turcica, called the **dorsum sellae**, is somewhat curved and forms a complete septum. Four sharp processes, the **clinoid processes**, two anterior and two posterior, are found



at the front and back part, or wall, of the sella turcica; the **clivus** (a slope) is a bony surface, which slopes down from the sella turcica; this is sometimes called the basilar process of the sphenoid, it unites

with the basilar process of the occipital bone, and lodges a band of fibers of the brain, called the pons Varolii.

On either side of the body are the following openings:—**optic foramen**, transmits the optic nerve, and the ophthalmic artery; **spheroidal** or **superior orbital fissure**, or foramen lacerum anterius, an elongated opening, transmits the 3rd and 4th branches of the 5th and 6th cranial nerves, also branches of arteries, **foramen rotundum**, transmits the maxillary division of the 5th cranial nerve; **foramen ovale**, transmits the mandibular division of the 5th nerve and a small artery; **foramen Versalii**, transmits a small vein; the **foramen spinosum** transmits an artery, a vein, and numerous filaments of nerves; and the **pterygoid** or **vidian canal** for the vidian artery and nerve.

The sphenoid bone has two **greater wings**, also called the **temporal wings**. These are two broad, wing-like processes of bone, extending from the sides of the body, curving upward, outward and backward. A portion of each wing receives some of the convolutions of the cerebrum. They are rough on either side. The two **lesser** or **orbital wings** are thin, triangular processes of bone extending from

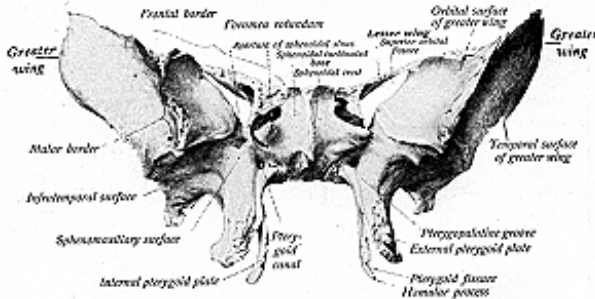


Fig. 14.
The Sphenoid—External Surface.

the upper and lateral portions of the body. They project transversely outward, and their two roots encircle the optic foramen. The two **pterygoid processes** or least wings are small pieces of bone, which extend downward from the lateral portions of the body of the sphenoid. They terminate in two hook-like processes known as the **hamular processes**.

On the anterior portion are two processes called the **lingulae**, two ridges of bone, found in between the body and the greater wings, to which are attached small tendons and ligaments. There are two grooved pieces of bone which contain air sinuses, lined with mucous membrane, and these communicate with the nasal fossae. A ridge, or crest, known as the **ethmoidal crest**, or **spheroidal crest**, articulates

OSTEOLOGY

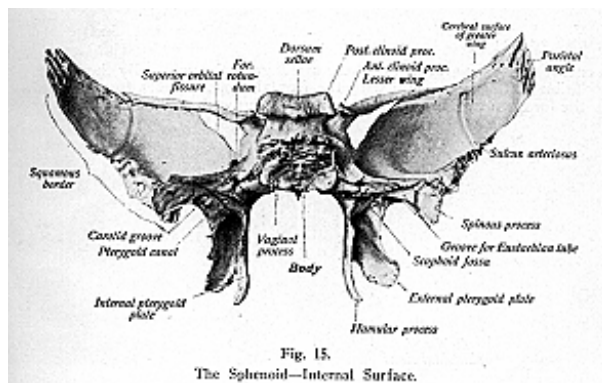
with the cribriform plate of the ethmoid bone, and assists in forming the nasal septum. The sphenoid bone articulates with all of the cranial bones and with five of the facial bones, the two malar, two palatal and the vomer. To the sphenoid bone are attached the six pairs of the orbital muscles, the temporal, external and internal pterygoid, the muscles of mastication, the superior constrictor of the pharynx, the tensor palati, and the laxator tympani.

THE ETHMOID BONE

(Illustrations Nos. 16, 17 and 18.)

The **Ethmoid Bone (os ethmoidale)** is so named from its form and shape, ethmoid meaning "sieve-like." It is an irregular bone lying anterior and superior to the sphenoid, between the orbits, and it helps in the bone formation of the orbits, and of the nasal fossae. The parts of which the bone is composed are the two **lateral masses**, or **labyrinths**, the **perpendicular plates** and the **horizontal plates**.

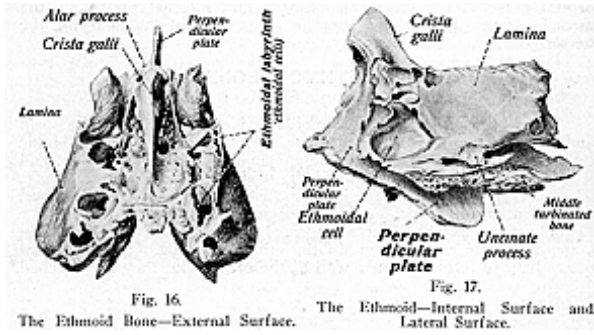
The two **lateral masses** are formed of curved, hollowed-out thin bone, and their cavities contain the **ethmoidal cells**. Their orbital plates help to form the inner wall of the orbits, and they are notched



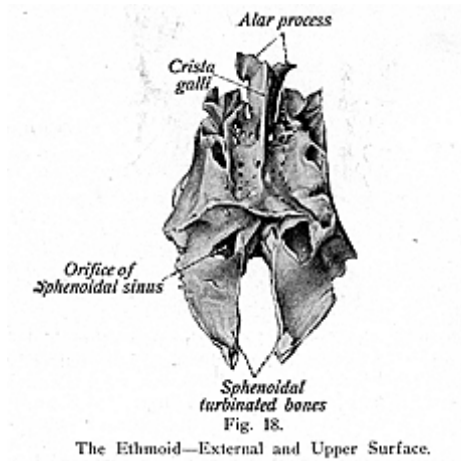
above to form, with the frontal bone, the two ethmoidal foramina. The superior and middle turbinated processes, large curved pieces of bone, bound the superior meatus of the nose, and are considered by some as detached pieces of the turbinated bones. On the outer side of each lateral mass is a thin, smooth, oblong plate of bone, called the **os plenum** or **orbital plate**, it forms the principal part of the inner wall of the orbit. Immediately beneath this plate of bone, is an irregular hook-like layer of bone called the **unciform** or **uncinate process**, which closes the upper part of the orifice of the antrum.

OSTEOLOGY

The **perpendicular plate** is a vertical plate, running from before backward, and forms part of the septum of the nose. It is usually inclined to one side, and projects into the cranial cavity as the **crista galli**. The perpendicular plate is grooved for filaments of the olfactory



nerves, and has attached to it the cartilage of the nose. By the articulation of the crista galli with the frontal bone, it gives formation to the foramen caecum, a sinus communicating with the nasal fossae.



The **crista galli** is so named from its fancied resemblance to a cock's comb. It gives attachment to a process of the dura mater, called

OSTEOLOGY

the falx cerebri, on a level between the orbits. The **cribriform plate** lies horizontally at the sides of the crista galli. It is concave for the olfactory bulbs, and is perforated for the olfactory nerves and some small vessels. The olfactory nerves are fifteen or twenty in number on each side, and small perforations of the ethmoid bone form the openings thru which they pass from the mucous membrane of the nose.

The ethmoid articulates with thirteen bones of the skull, this number includes two cranial bones, the sphenoid and frontal, and eleven bones of the face; the two nasal, two palatal, two superior maxillary, two lacrimal, two turbinated and the vomer. There are no muscles attached to the ethmoid.

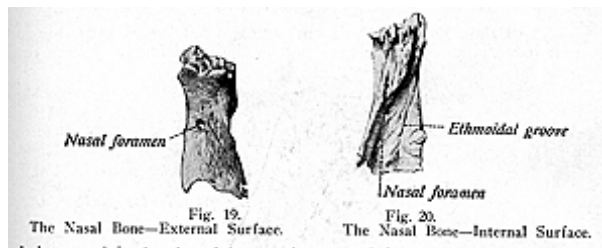
THE BONES OF THE FACE

The **bones of the face** are fourteen in number: (2) **nasal**, (2) **palatal**, (2) **inferior turbinated**, (2) **malar**, the **vomer**, (2) **superior maxillary**, (2) **lacrimal** and the **mandible**.

THE NASAL BONE

(Illustrations Nos. 19 and 20.)

The **Nasal Bones (os nasale)** are two small, oblong bones, situated at the upper part of the face. They form the bridge of nose, and assist in the formation of the nasal fossae. The **inter-nasal** suture separates the two bones. Each bone is thicker above and broader



below, and is developed in membrane and from a single center. A small foramen, for the nasal nerve, is found at the center of each bone. It is known as the **nasal foramen**. Each bone articulates with the frontal, the ethmoid, the superior maxillary, and its opposite fellow-nasal. There are no muscles attached to the nasal bones, except possibly a few fibers from the occipito-frontalis.

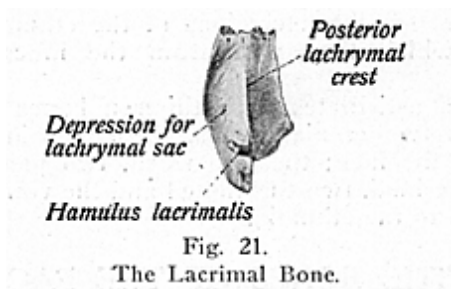
THE LACRIMAL BONE

(Illustration No. 21.)

The **Lacrimal Bones (os lacrimale)** are two small bones, the smallest of the facial bones, situated at the front of the inner wall of the orbit, being extremely thin and delicate. Each bone presents for

OSTEOLOGY

study the following: The **external**, or **orbital surface**, which is divided by a vertical ridge, the **lacrimal crest**, into two unequal portions. The anterior, the smaller part is deeply grooved to form the **lacrimal sulcus**, which lodges the lacrimal sac and forms the commencement

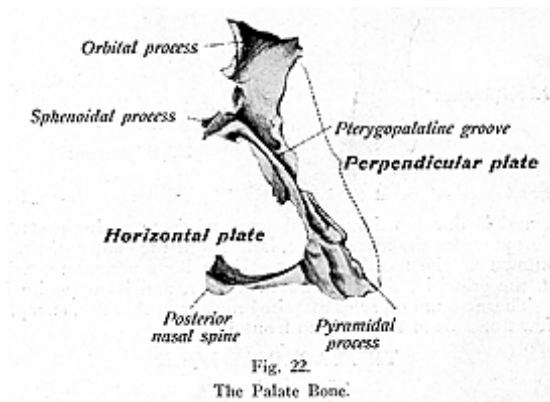


of the nasal duct. The portion behind the ridge is smooth and forms part of the inner wall of the orbit. The ridge gives attachment to the tensor tarsi, and terminates inferiorly in a hook-like process the **hamulus**, which curves forward and completes the superior orifice of the nasal canal. The lacrimal bone articulates with the frontal, ethmoid, superior maxillary, and the turbinated bones. It gives attachment to one muscle, the tensor tarsi, or Homer's muscle. The lacrimal is developed from membrane and from one center, which appears in the third or fourth month of intra-uterine life.

THE PALATE BONE

(Illustration No 22.)

The **Palate Bones (os palatum)** are two flat bones, very thin in some parts, situated at the back part of the nasal fossa, between the



maxillae. They form the posterior part of the hard palate, from the lateral walls of the nasal fossae, and assist in the formation of the floor and outer wall of the nose, the roof of the mouth, the floor of the orbit

and the inner wall of the antrum. Each bone consists of a **vertical plate**, a **horizontal plate**, and **three processes**: the **spheroidal** the **orbital** and the **pyramidal**.

The **vertical** or **perpendicular plate** is oblong, and is directed upward and a little inward. It presents a **superior turbinated crest** and an **inferior turbinated crest**, for the attachment of the middle and the inferior turbinated bones, between which lies a groove for the middle and inferior nasal meatus. Another deep groove is found on the external surface, forming the posterior palatine canal, by articulating with the superior maxillary. This transmits the descending palatine vessels and the anterior palatine nerve. The **horizontal** or **palatal plate** is smooth, concave from side to side on the upper surface, and forms the back part of the nasal fossa. Its inferior surface completes the hard palate behind, and presents a ridge on the posterior part, for the attachment of the tensor palati muscle.

The **spheroidal process** of the palate bone surmounts the posterior border of the perpendicular plate, and is slightly incurved. It presents three surfaces and three borders. The superior or spheroidal surface is grooved and articulates with the inferior surface and with the vaginal process, of the sphenoid. The groove on this surface with that on the under surface of the vaginal process, forms the **pterygo-palatine canal**. The internal or nasal surface is scooped out, and forms part of the outer wall of the nasal fossa. The external or the speno-maxillary surface forms a part of the inner wall of the speno-maxillary fossa. The anterior border forms the posterior boundary of the speno-palatine foramen, a space between the orbital and spheroidal processes of the palate bone. The posterior border is serrated and articulates with the internal pterygoid plate of the sphenoid. The internal border articulates with the ala of the vomer.

The speno-palatine notch is situated between the orbital and spheroidal processes and is converted into a foramen usually by the inferior surface of the body of the sphenoid.

The **orbital process** is placed on a higher plane than the spheroidal process and surmounts the anterior border of the perpendicular plate. It presents six surfaces: of these, three are articular surfaces. The superior is the upper surface and forms a part of the orbital cavity. The external is the speno-maxillary surface. The anterior is the maxillary surface and is continuous with the external surface of the perpendicular plate and articulates with the back part of the orbital surface of the superior maxillary. The internal is the ethmoidal surface, which articulates with the lateral masses of the ethmoid bone. The posterior surface or the spheroidal surface is serrated and articulates with the front of the body of the sphenoid and communicates with the spheroidal cells thru the spheroidal air sinuses. The inferior or nasal surface is continuous with the internal surface of the perpendicular plate and forms part of the outer wall of the nasal fossa at its upper and back part, where it overhangs the groove for the superior meatus.

The anterior border of the palate bone is thin and rough and presents a leaf-like projection on the perpendicular plate, called the **maxillary process** which closes the lower and back part of the opening of

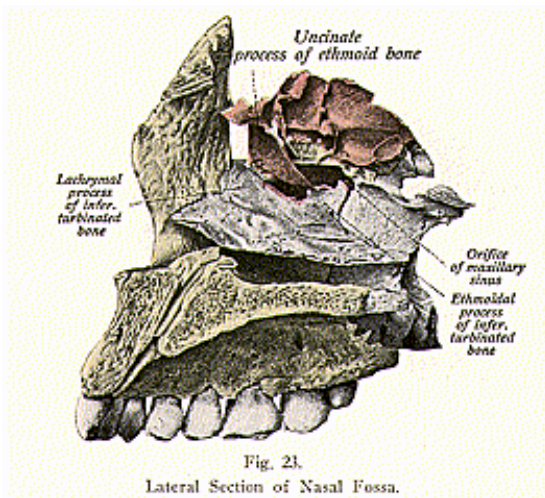
OSTEOLOGY

the antrum of Highmore. Superiorly it articulates with the ethmoid and inferiorly with the superior maxilla. The posterior border is free, curved and sharp, giving attachment to the soft palate. The **pyramidal** or **pterygoid process** is a tuberosity which projects backward, downward and outward from the meeting of the horizontal and perpendicular plates. Internally it is thick and broad, for articulation with its fellow of the opposite side, forming a continuation of the crest of the palatal process of the superior maxilla, and supporting the vomer. The palate is ossified in membrane from a single center, and at birth the two palates are nearly equal in length. Each articulates with the vomer, inferior turbinate, ethmoid, sphenoid, the superior maxillary bones, and with the opposite palate. The muscles attached to the palate bone are the tensor palati, internal pterygoid, azygos uvulae, and the superior constrictor of the pharynx.

THE TURBINATED BONE

(Illustration No. 23.)

The **Turbinated Bones (middle and inferior concha)** are two irregular bones, one on each side of the nasal fossae, hanging into the



cavity in such a way as to separate the middle meatus of the nose from the inferior meatus. Each may be regarded as a detached portion of the lateral mass of the ethmoid, with which it is closely related. Each turbinated is a thin, spongy bone, curled upon itself like a scroll, hence its name turbinated, and has for study **three processes**: the **lacrimal process**, at the front of the upper border, is small and pointed, and articulates with the anterior inferior angle of the

lacrimal bone and, by its margins, with the groove on the back of the nasal process of the maxilla, and thus assists in forming the nasal duct, the **ethmoidal process**, a broad thin plate at about the center of the bone, ascends to join the unciform process of the ethmoid; the **maxillary process**, a thin layer of bone curving downward and outward, hooks over the edge of the orifice of the maxillary sinus, which it narrows below, and this process fixes the turbinated bone firmly to the outer wall of the nasal fossa. The turbinated bone articulates with the ethmoid, lacrimal, palate and the superior maxillary. Each bone is developed from one center in cartilage. No muscles are attached to them.

THE SUPERIOR MAXILLAE

(Illustrations Nos. 24 and 25.)

The **Superior Maxillary Bones**, or the **Maxillae** are two in number, irregular in form, and unite to form the upper jaw. Each consists of a hollow **body** and **four processes**. They each support the maxillary teeth, take part in the formation of the floor of the orbit, the roof of the mouth, the outer wall of the nasal fossae, and enter into the formation of the zygomatic and speno-maxillary fossae.

The **body** is cuboidal in form, and hollowed out in its interior to form a large cavity, the **maxillary sinus**, or **antrum of Highmore**. It presents four surfaces—an external or facial, a posterior or zygomatic, a superior or orbital and an internal or nasal.

The external or facial surface is directed forward and outward and presents inferiorly five ridges, coinciding with the roots of the incisor, canine and bicuspid teeth, of which that of the canine is conspicuous and is called the canine ridge. Just above these eminences for the incisor teeth is a depression, the **incisive** or **myrtiform fossa**. External to this fossa is a larger and deeper fossa called the **canine fossa**, and above this is the **infraorbital foramen**, the termination of the infraorbital canal which transmits the infra-orbital vessels and nerves.

The posterior or zygomatic surface is situated behind the malar process and separated from the facial surface by a strong ridge of bone. Toward its center it presents several apertures leading to canals in the substance of the bone; they are called posterior dental canals. At the lower part of the zygomatic surface is a rounded eminence, the maxillary tuberosity which is especially prominent after the growth of the wisdom tooth.

The superior or orbital surface is triangular, smooth and slightly concave and it forms the greater part of the floor of the orbit. This portion of the bone is known as the orbital plate. It presents the infraorbital groove which, commencing at the posterior border in a notch, ultimately becomes converted into the infraorbital canal. The internal border of the orbital surface presents behind the nasal process, the lacrimal notch which receives the lacrimal bone.

The internal or nasal surface forms part of the outer wall of the nasal fossa and it presents the opening of the antrum of Highmore, in front of which is a deep lacrimal groove which is converted posteriorly and internally into the lacrimal canal. The **maxillary sinus** or **antrum**

OSTEOLOGY

is a cavity which varies much in size, but in most cases is very small. The apex of the sinus, directed outwardly, is formed by the malar process, and its base is formed by the outer wall of the nose. Its walls are very thin and correspond to the facial, orbital and zygomatic surfaces of the body of the bone. Its floor is formed by the alveolar processes of the superior maxillary, and its roof corresponds to the orbital plate. The inner wall has a large irregular aperture, thin and ragged, which communicates with the nasal fossae. In the articulated skull, this cavity communicates with the middle meatus of the nasal cavity, generally by two small apertures left between the ethmoid and turbinated bones.

The **antrum** is an air chamber, lined with mucous membrane, a prolongation of the Schneiderian membrane of the nose. In its inte-

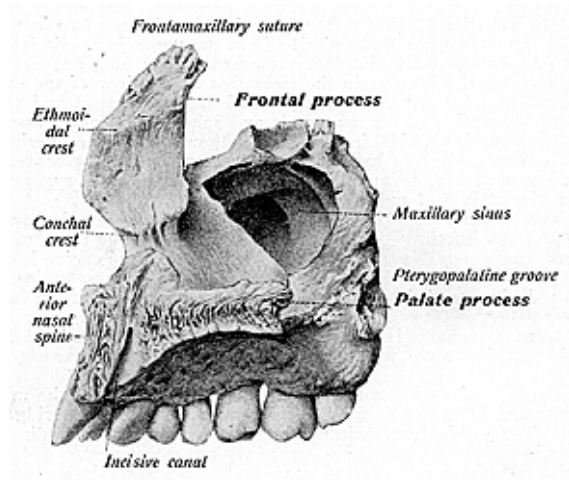


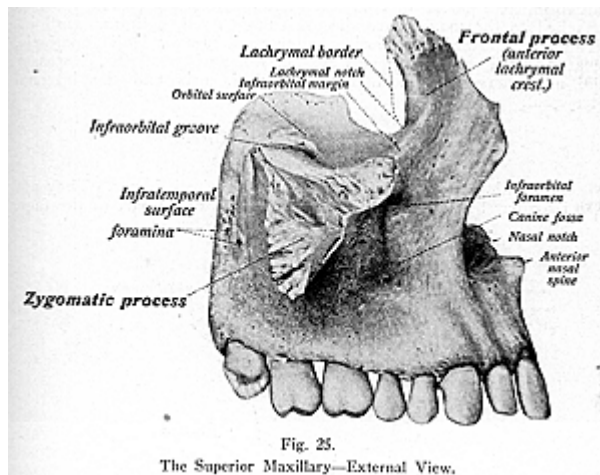
Fig. 24.
The Superior Maxillary—Internal View.

rior are several projecting laminae of bone, which form septa, resembling the sinuses of the cranium. Its floor is usually very uneven, due to prominences corresponding to the roots of the molar teeth. In most cases the bone tissue separating the teeth from the sinus is very thin, and in some cases the roots project uncovered into the sinus. This cavity is usually a single cavity, but, occasionally, specimens are seen in which it is divided by bony septa into chambers. The roof of the antrum presents, near its anterior aspect, a thick piece of bone which is hollow and corresponds to the infra-orbital canal. The bone is very vascular; its arteries are numerous and large, and are derived

OSTEOLOGY

from the infra-orbital, alveolar, descending palatine, naso-palatine, ethmoidal, frontal, nasal and facial vessels.

The **malar** or **zygomatic process** is a rough, triangular eminence, concave on its facial and zygomatic surfaces, and is roughly serrated, above, for the malar bone. The **nasal** or **frontal process** is thick and triangular, rising upward, inward and backward from the nasal angle of the maxilla. Its anterior border is thin and serrated, for articulation with the nasal bone, while the posterior border is thick and grooved, for the lacrimal duct. Superiorly, it articulates with the frontal and, by a rough surface, with the ethmoid. The **palatal process** is situated on the internal surface of the body from which it projects horizontally inwards, and with its fellow it forms three-fourths of the hard palate and forms the floor of the nasal fossa. The **alveolar process**



is thick and spongy, with eight cavities, of varying lengths, in which the teeth are lodged. These cavities have wide mouths, and gradually narrow as they pass into the substance of the bone, forming exact impressions of the corresponding teeth. The pit for the canine tooth is deepest, while those for the molars are widest, and are subdivided.

When the bones of the two sides are placed in apposition, a large diamond-shaped fossa may be seen in the middle line of the hard palate immediately behind the incisor teeth. This is the anterior palatine fossa, presenting four openings by which the nasal fossa communicates with the mouth; the **foramina of Scarpa**, for the transmission of the naso-palatine nerves, and the **foramina of Stenson**, which transmit some terminal branches of the superior palatine artery to the nasal

fossa, they also contain the remains of Jacobson's organ. The inner border of the palatal process is thicker in front than behind, and is raised above into a ridge, the **nasal crest**, which, with the corresponding ridge in the opposite bone, forms a groove for the reception of the vomer. In front, this crest rises to a considerable height, and is named the **incisor crest**.

The superior maxillary articulates with the frontal, ethmoid, nasal, lacrimal, malar, the turbinated, palate, vomer, and with the opposite maxilla, sometimes with the sphenoid, with its greater wing and pterygoid process. The bone develops very early in life, immediately after the clavicle and the mandible, by four to six centers, the exact number of ossific centers being uncertain because of its early development. If the two palatal processes partially or completely fail to unite, a partial or complete cleft palate results. The muscles attached to the maxilla are the orbicularis oculi, obliquus oculi inferior, levator labii superioris alaeque nasi, levator labii superioris, levator anguli oris, compressor nasi, dilator naris posterior, depressor alae nasi, masseter, buccinator, orbicularis oris and the internal pterygoid.

THE MALAR BONE

(Illustrations Nos. 26 and 27.)

The **Malar** or **Zygomatic Bones** are the cheek bones. They are two irregular bones situated at the upper and outer part of the face,

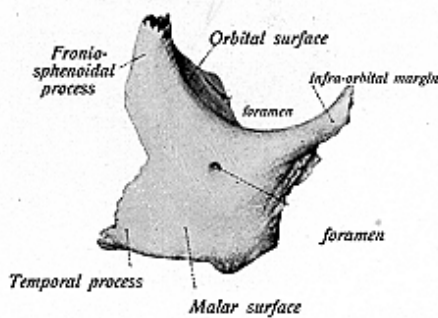


Fig. 26.
The Malar Bone—External Surface.

and forming the prominence of the cheeks. Each bone is quadrangular in shape, forms parts of the outer wall and floor of the orbit, and parts of the temporal and zygomatic fossae. It presents for study the external and internal surface, four processes and four borders. The external surface is convex and smooth and presents near its center a prominence, the **malar tuberosity**; it also presents one or two small orifices, **malar foramina**, for the transmission of the malar nerves and vessels. The internal surface is concave, forms the anterior boundaries

OSTEOLOGY

of the temporal and zygomatic fossae, and articulates with the superior maxillary bone.

The malar bone has four processes the **superior** or **fronto-sphenoidal**, which is the most prominent, and is serrated; the **orbital process**, a thick, strong plate which projects backward from the orbital margin of the bone, being smooth and concave internally, where it forms part of the floor of the outer wall of the orbit; the **zygomatic** or **posterior process** is long, narrow and serrated, and articulates with the zygomatic process of the temporal bone; the **maxillary process** is blunt, points downward and articulates with the superior maxillary. The borders are: the **orbital**, the longest, extending from the frontal to the orbital process; the **temporal border**, thick and rounded, extending from the frontal to the zygomatic process; the **masseteric border**, thick and rough, completing the lower edge of the zygomatic arch, and giving origin to the masseter muscle, and the **maxillary border**, which is rough and concave, and is connected by a suture with the maxilla. The malar is developed in membrane from three

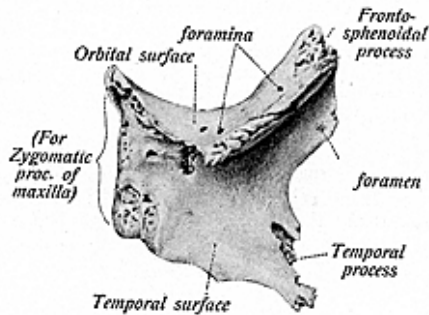


Fig. 27.
The Malar Bone—Internal Surface.

centers; it articulates with the frontal, sphenoid, temporal and the superior maxillary. The muscles attached are the masseter, temporal, levator labii superioris, and the zygomaticus major and minor.

THE VOMER

(Illustration No. 28.)

The **Vomer** is a flat bone, shaped like a plowshare, and is a single bone placed vertically between the nasal fossae. It forms the lower part of the nasal septum. It is thin, and usually bent somewhat to one side. Its superior border is the thickest part of the bone, is expanded laterally into two alae, and is deeply grooved for the rostrum of the sphenoid. The anterior border is grooved for the vertical plate of the ethmoid, and for the nasal septal cartilage. The inferior border is received into the groove formed by the nasal crest of the superior maxillary and the palate bones. The posterior border is free,

OSTEOLOGY

smooth and covered by mucous membrane, concave, thick above and thin below. It separates the nasal fossae behind. The vomer articulates with the sphenoid, ethmoid, the maxillae, and palate bones, and with the cartilage of the septum.

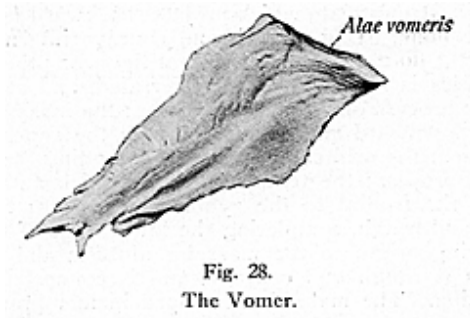


Fig. 28.
The Vomer.

The vomer is developed in membrane, from two centers, in the form of two separate laminae, which coalesce early in life, but ossification is not complete until puberty. There are no muscles attached to it. The vomer is often deflected to one or the other side, more frequently the left, and so it may curtail the cavity of the nasal fossa to which it is deflected.

THE MANDIBLE

(Illustration Nos. 29 and 30.)

The **Inferior Maxillary**, or the **Mandible**, forms the lower jaw, and is the largest and the strongest bone of the face. It supports

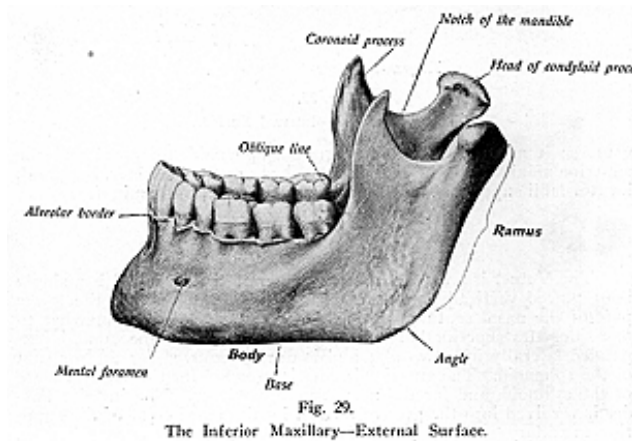
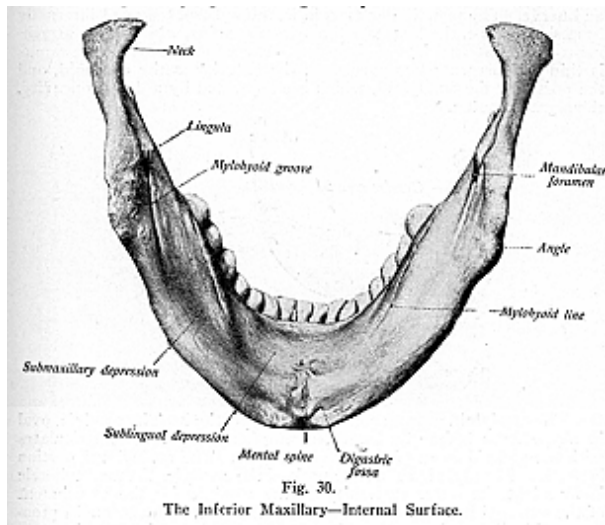


Fig. 29.
The Inferior Maxillary—External Surface.

OSTEOLOGY

the lower teeth, and presents for study: a **body**, which is horse-shoe shaped, being convex from side to side externally, concave on the internal surface; on its external surface, in the median line, is found the **symphysis**, a vertical ridge marking the junction of the two halves of the bone. This ridge ends below in an elevation on the chin, known as the **mental protuberance**, the lower part of which is depressed in the center, and raised on either side to form the **mental tubercle**. On the external surface of the body, at the side of the symphysis and below the incisor teeth, is a shallow depression, the **incisor fossa**, giving attachment to the levator menti muscle. More externally, below the interval and midway between the upper and the lower margins, is the **mental foramen** for the exit of the mental vessels and nerve. The internal surface, at the back of the symphysis, presents four projections, called the **genial tubercles**, giving attachment to the genio-hyo-glossi and genio-hyoidii muscles.



Upon either side of the genial tubercles is an oval depression, **sublingual fossa**, lodging the sublingual gland; beneath the fossa is a depression, the **digastric fossa**, rough on both sides, giving attachment to the anterior belly of the digastric muscle. Extending obliquely upward and backward, from the sublingual fossa is an internal oblique line—the **mylo-hyoid ridge**—for the same named muscle, and beneath its edge is an oblong depression, the **submaxillary fossa**, for the submaxillary gland. The superior border of the body is

hollowed out into numerous cavities, **alveoli**, for the reception of the teeth. These cavities are sixteen in number and vary in depth. They are conical in shape and form exact counterparts of the roots of the teeth which they contain. The inferior border of the body is thick and rounded, and presents, where the body joins the ramus, a shallow groove for the facial artery, where it turns upward onto the face.

The **rami** (the right and left ramus) are two ascending, flattened plates of bone, which join the body at right angles, and each presents for examination four borders, two surfaces and two processes. The external surface is flat and marked with ridges, and gives attachment to the masseter muscle. The internal surface presents, near its middle, an oblique canal, the **mandibular foramen** or **inferior dental canal**, which traverses the bone downward and forward in the substance of the ramus, and terminates at the mental foramen on the external surface of the body. It transmits the inferior dental vessels and nerve. The mandibular margin is, most often, bounded internally by a sharp spine, the **lingula**, or **mandibular spine**, which gives attachment to the internal lateral ligament. The upper border of the ramus is thin and presents two processes, the anterior is the **coronoid**, and the posterior the **condyloid**, which are separated by a deep concavity, the **sigmoid notch**.

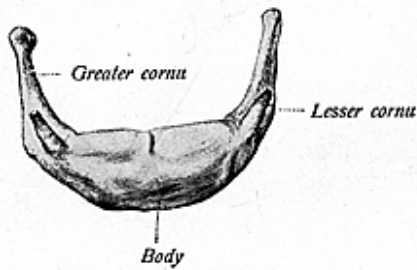


Fig. 31.
The Hyoid Bone.

The **condyloid process** consists of two portions. The **condyle**, oval in shape from before backward, strengthened by ridges, articulates with the glenoid fossa of the temporal bone. The constricted portion beneath the condyle is called the **neck** of the condyle. A small tubercle is found at the outer extremity of the condyle for the attachment of the external lateral ligament of the lower jaw. The **coronoid process**, a thin flat eminence, continued upwards from the anterior part of the ramus, gives attachment to the temporal and masseter muscles. The **sigmoid notch** is a semilunar excavation separating the two processes, and is crossed by the masseteric nerve and vessels.

The mandible articulates with the glenoid fossae of the temporal bones. It is the second bone of the skeleton to ossify, and is developed by several centers, most often six in number. The mandible gives attachment to fifteen pairs of muscles, namely: the masseter

OSTEOLOGY

internal and external pterygoid, temporal, genio-hyoid, mylo-hyoid, genio-hyo-glossus, digastric, the superior pharyngeal constrictor, the levator menti, depressor anguli oris, the depressor labii inferioris, orbicularis oris, the buccinator, and the platysma myoides.

The mandible undergoes certain changes. At birth the bone consists of two halves, united only by the fibrous tissue forming the symphysis menti, and their osseous union is not complete until the second year. The body becomes elongated after the first dentition, and the ramus forms, with the body of the mandible, an obtuse angle of 140 degrees, while in the adult the angle formed is nearly a right angle. The mental foramen is opposite the second bicuspid, not being altered after the first dentition. In old age, after the fall of the teeth, the alveolar portion is absorbed, the angle formed by the ramus and the body again becomes very obtuse, and the dental canal is near the upper surface. In old age the neck of the condyle is short and bent backward, while the condyle is nearly in the same horizontal line with the body of the bone.

THE HYOID BONE

(Illustration No. 31.)

The **Hyoid Bone**, or **os hyoideum**, or **lingual bone**, an unclassified bone grouped with the bones of the head, is situated at the anterior part of the neck between the chin and the thyroid cartilage. It supports the tongue, and gives attachment to numerous muscles. It is suspended, from the lower extremities of the styloid processes of the temporal bones, by ligamentous bands, the stylo-hyoid ligaments. It has for study, a **body**, two **greater cornua** and two **lesser cornua**.

The **body**, quadrilateral in shape, forms the central part of the bone, and is placed transversely. Its anterior surface is convex, and at its central point is a tubercle, the **hyoid tubercle**. The posterior border is concave and is directed downward and backward, separated from the epiglottis by the thyro-hyoid membrane and some loose connective tissue. The **greater cornua** project backward from the lateral surfaces of the body. The **lesser cornua** are attached at the junction between the body and the greater cornua, and ligaments are attached to both the greater and lesser cornua. The hyoid bone is developed from five or six centers, in cartilage. Ossification begins in the early months of intra-uterine life, but the greater cornua and the body do not unite until middle life. The small cornua rarely unite with the body, and then only in advanced age.

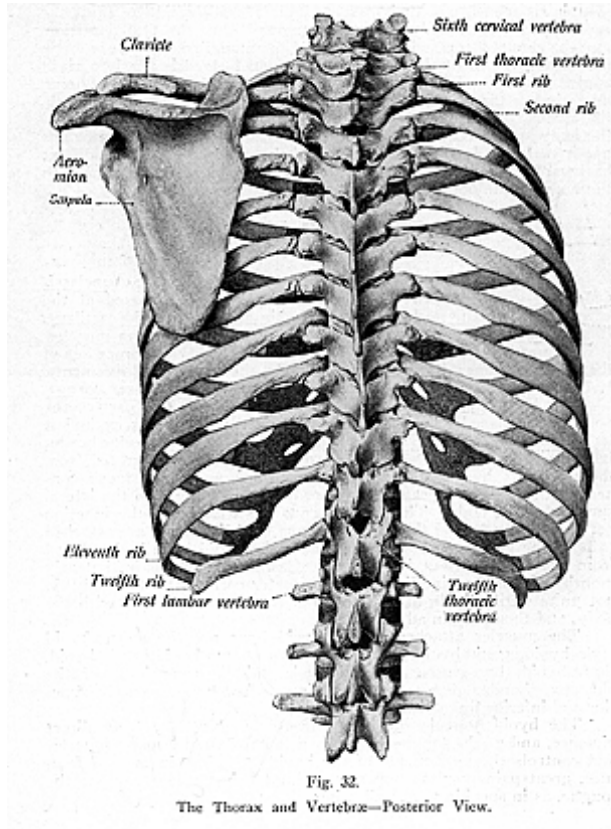
The muscles attached to the hyoid bone are the sterno-hyoid, mylo-hyoid, genio-hyoid, genio-hyo-glossus, omo-hyoid, stylo-hyoid, thyro-hyoid, hyo-glossus, the digastric, middle constrictor of the pharynx, chondro-glossus, and sometimes a few fibers from the superior and inferior lingualis.

The hyoid bone is sometimes fractured, generally from direct violence, and as the tongue is attached to the bone by many muscles and controls the movements of the hyoid, therefore in case of fracture, great pain results upon any attempt being made to move the tongue, as in speaking or swallowing.

BONES OF THE TRUNK

(Illustrations Nos. 32 and 33.)

According to customary outline, the bones of the trunk are classified as those of the **thorax**, **spine** and **pelvis**. The **thorax**, or **chest** (coat of mail), is an osseo-cartilaginous cage, and forms the large



OSTEOLOGY

splanchnic cavity which lodges and protects the chief organs of respiration and circulation. It is formed by the bodies of the thoracic vertebrae behind, the twelve pairs of ribs laterally, and the sternum in front. It is conical in shape, narrowed above, broader below, flattened from before backward. This cavity contains the trachea, bronchi, lungs, heart, aorta and its primary branches, the internal mammary vessels, the venae cavae, pulmonary arteries and veins, part of the carotid and subclavian arteries, innominate veins, the pneumogastric phrenic and splanchnic nerves, the esophagus thoracic duct, thymus gland, and numerous lymphatic vessels and glands.

THE STERNUM

(Illustration No. 34.)

The **Sternum**, or breast bone, is a flat bone situated in the median line of the front of the chest. It consists of three parts, or segments, called the **manubrium**, **gladiolus** and the **ensiform**, or **xiphoid appendix**. This bone has been likened to an ancient sword, the first piece, or manubrium, representing the handle of the sword, the gladiolus, the body or blade; and the ensiform process, or appendix, representing its point. In the young subject the sternum consists of six pieces, they are known as sternebrae. The first always remains separate, while the four next segments unite to form the gladiolus, and the lowest, the ensiform process, remains as cartilage until an advanced age.

The **manubrium** is the broadest and thickest part of the bone, and has upon its upper border a notch, the **interclavicular, epi-sternal** or **jugular notch**. Upon either side are facets for the first and second ribs, and, at the upper end, an oval articular surface for the reception of the clavicle. The **gladiolus**, the second piece, is long, narrow and thin, and on its lateral borders are series of facets, for articulation with the second to the seventh ribs, inclusive. The **ensiform cartilage**, or **xiphoid appendix**, is the thin, elongated process, which projects downward between the cartilages of the seventh rib. As stated before, it is mostly of cartilage until old age, but it is subject to many variations in form. It may be broad, or pointed, extremely thin, or bifid or it may be perforated by a foramen, and it may also be bent forward or backward, or deflected to either side.

The muscles attached to the sternum are the pectoralis major, sterno-mastoid, sterno-hyoid, sterno-thyroid, the rectus abdominis the external and internal oblique, the transversalis, diaphragm and the triangularis sterni). The sternum articulates with the two clavicles and, on either side, with the seven costal cartilages.

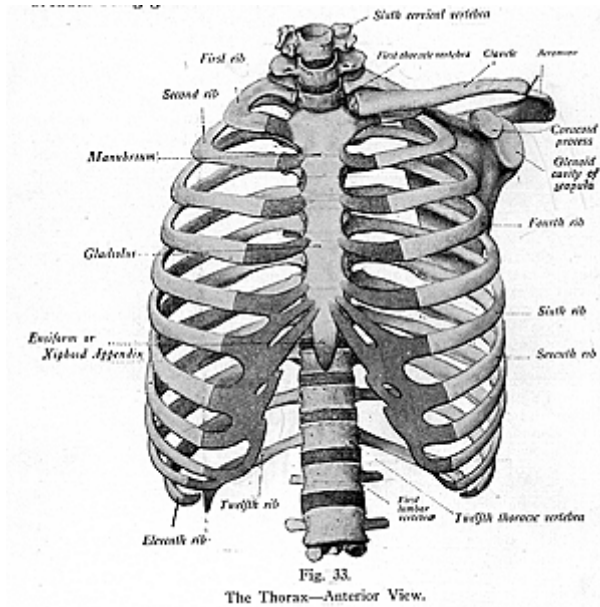
THE RIBS

(Illustrations Nos. 35 and 36.)

The **Ribs (Costae)** are twelve in number on each side. They are narrow, flattened, elastic bones, and form the chief part of the walls of the thorax. They are classified as the **true ribs**, seven on each side, and the **false**, five on each side. The last two pairs of these are known as the **floating ribs**. The number of pairs may be increased by the development of a cervical or a lumbar pair, or may be dimin-

OSTEOLOGY

ished by the absence of the last pair of floating ribs. The ribs increase in length from the first to the seventh, and decrease from the seventh to the twelfth. They also vary in their direction, the upper ones being more oblique than the lower. The ribs are situated one below the other in such a manner that spaces are left between them and each space is called an **intercostal space**. The length of these spaces corresponds to the length of the ribs and their cartilages, their breadth being greater in front than behind.

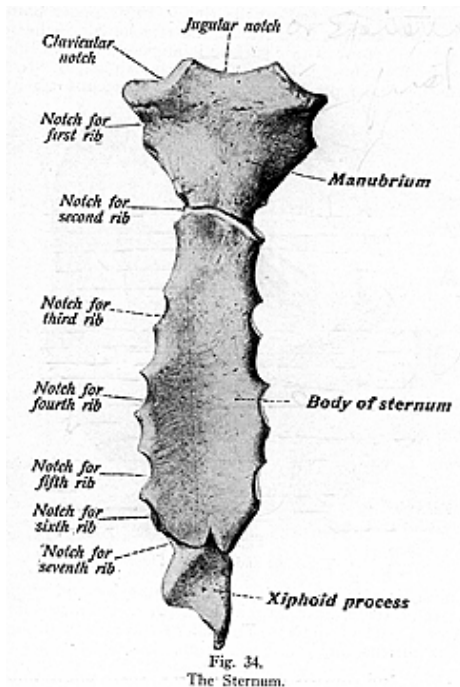


A **Typical Rib** consists of a **head**, **neck**, **shaft**, **angle**, and a **tuberosity**. Each rib has a **posterior** or **vertebral extremity**, and an **anterior** or **sternal extremity**.

The **head** (except of the first, eleventh and twelfth ribs) is marked by two facets for the articulation with the costal cavity, formed by the junction of the bodies of two contiguous thoracic vertebrae. These two facets are separated by a crest, which is connected, by an intra-articular ligament, with an intervertebral disc. The neck, about one inch in length, is flattened and extends forward

OSTEOLOGY

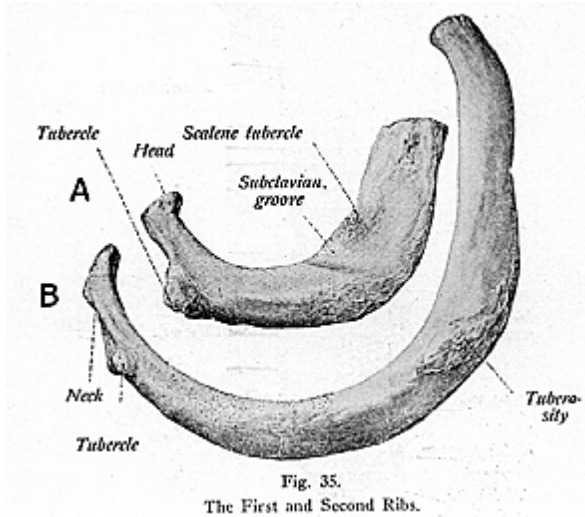
from the head to the tubercle. It is roughened upon its upper anterior border, for the middle costo-transverse ligament, and is perforated by numerous foramina. The **tubercle** is situated at the junction of the base of the neck with the shaft. It presents a facet for articulation with the transverse process of the next lower vertebra, and a rough surface for the posterior costo-transverse ligament.



The shaft is curved and presents for examination two surfaces and two borders. Excepting the first and the second ribs, the shaft is convex externally, its upper border is rounded and affords attachment to the internal and external intercostal muscles. The lower border is grooved, thin and sharp, and gives attachment to the external intercostal muscles. And though, at first, the curve is in the same plane with the neck, yet it quickly turns forward at the **angle**, a point on the posterior surface of the shaft. The **anterior** or **sternal extremity**

presents an oval cupped depression for the reception of the costal cartilage. The internal surface is concave and presents, near its inferior border, the **subcostal** or **costal groove**, which lodges the intercostal vessels and nerves.

The **peculiar ribs** are the **first, second, tenth, eleventh** and **twelfth**. The first is peculiar because it is the shortest, broadest, flattest, strongest and most curved of all the ribs. On its upper border is a rough surface, the **scalene tubercle**, for the attachment of the scalenus anticus muscle; in front of this surface is a groove for the subclavian vein, and a groove behind it lodges the subclavian artery. It has one facet on the head and presents no angle. The **second rib** is longer



than the first, is also flattened, and its tuberosity and angle nearly coincide. It presents, near its middle, a rough eminence for the attachment of a part of the first and all of the second digitations of the serratus anticus, and for the attachment of the scalenus posticus muscle. The **tenth** rib is distinguished by having only a single facet on its head, for articulation with the body of the tenth dorsal vertebra. The **eleventh** and **twelfth** ribs also have one facet of rather large size on the head. They are further distinguished by having no tuberosity, no angle, no neck and no subcostal groove. Their anterior extremities are pointed and free. The eleventh and twelfth ribs are known as the **floating ribs** or the **vertebral ribs**, they being attached at the posterior, or vertebral, extremity only. The ribs and the sternum consist of cancellous tissue internally, and of compact bone externally.

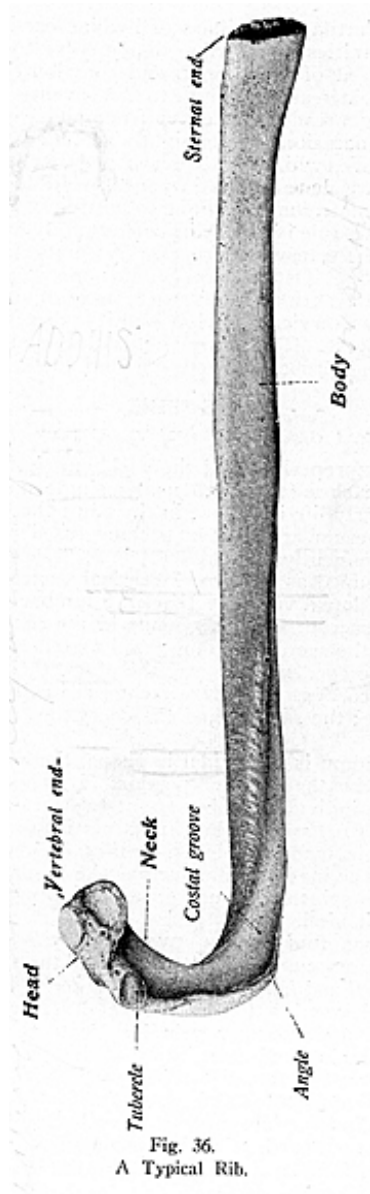


Fig. 36.
A Typical Rib.

OSTEOLOGY

The **Costal Cartilages** are bars of hyaline cartilage, attached to the anterior extremities of the ribs. They serve to prolong the ribs forward to the front of the thorax, and contribute elasticity to the chest wall. They increase in length to the seventh and then become shorter, and their breadth decreases from above downward. The upper seven, and occasionally the eighth, cartilages are connected to the cartilages above, while the eleventh and twelfth are free. The costal cartilages are more elastic in youth, while in old age they become of a deep yellow, and are prone to ossify. A **cervical rib** is not uncommon, but as a rule is of small size and rarely extends far beyond the extremity of the transverse process. A number of specimens may be seen in the P. S. C. Osteological Studio; one, in particular, is very nearly of the same length as the first rib, its head articulates with the body of the seventh cervical vertebra, and its tubercle articulates with the transverse process. It has a well defined neck, and its shaft shows a ligamentous band, probably where it joined the first rib.

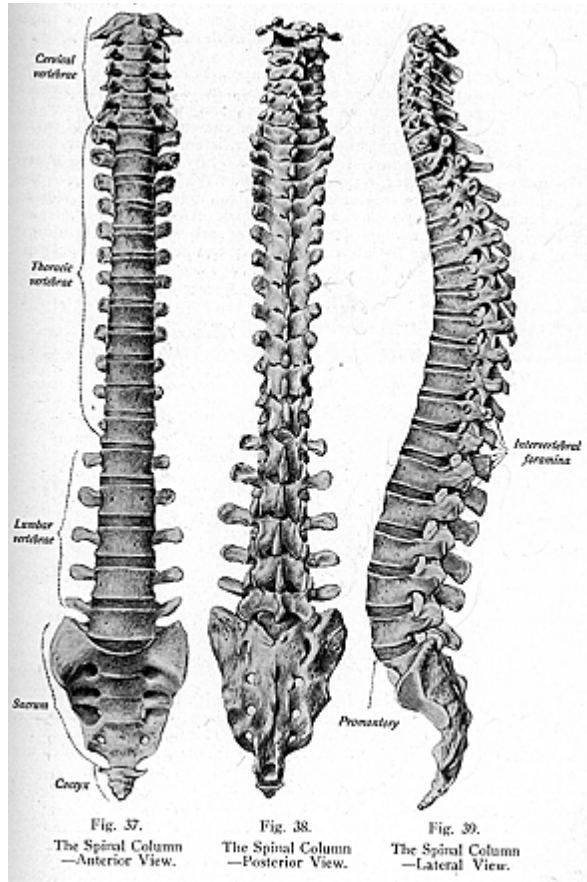
THE SPINE

(Illustrations Nos. 37, 38 and 39.)

The **Spine**, improperly called the backbone, is formed of a series of bones called **vertebrae** (turning bones), a single one being a **vertebra**. The number in early life is 33, but in the adult there are only 26 vertebrae, for the sacrum and coccyx become fused into single pieces. There are 24 permanently movable vertebrae. The total number of 33 segments are grouped as follows: 7 **cervical vertebrae** (pertaining to cervix, neck), 12 **dorsal vertebrae** (back), 5 **lumbar vertebrae** (loin), 5 **segments** in the **sacrum** and 4 **segments** in the **coccyx**. In the adult the five pieces in the sacrum become fused together and so also do the four pieces in the coccyx; they are, therefore, then classified as one sacrum and one coccyx. The 24 vertebrae are called the movable or the true vertebrae; the sacrum and the coccyx are the immovable, or false vertebrae.

A **Spinal Column** is pyramidal in shape, the base downward and the apex formed by the superior portion. It is usually one-third of the height of the individual, being about two feet and two, or three, inches in length. All animals known as vertebrate have a spine like man's; for example, mammals, birds, reptiles and fishes. Those forms of life known as the invertebrate, such as the mollusk, the oyster and the snail, have no spines, but such structural formation as is adapted to the life of their kind.

The spine has **four curves, two primary, and two secondary curves**. The **primary curves** are the *dorsal* and the *pelvic*. The **secondary** are the *cervical* and *lumbar curves*. The *dorsal curve* extends from the second dorsal vertebra to the twelfth dorsal vertebra, the *pelvic curve* extends from the sacro-vertebral angle to the coccyx, and both these curves are maintained even in the supine position. The *cervical curve* extends from the second cervical vertebra to the second dorsal vertebra, the *lumbar curve* extends from the twelfth dorsal vertebra to the sacro-vertebral angle. These curves are called secondary because they are brought into use immediately when one assumes an upright position. The spinal column forms a single support for the head and trunk, and is

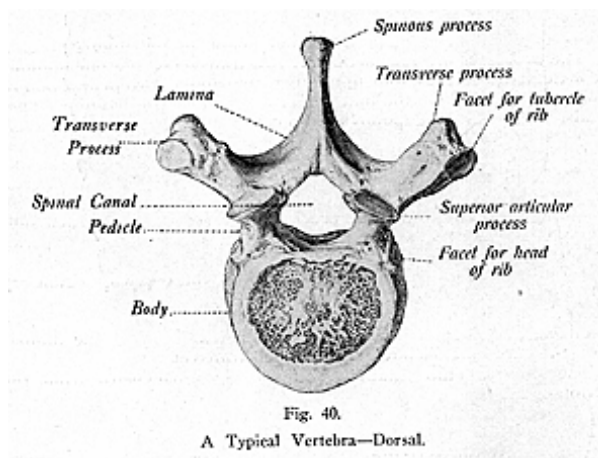


OSTEOLOGY

a strong walled canal guarding the spinal cord. It is the central line-shaft of man, it holds the body erect, and is the base from which the trunk muscles act. It permits of all motion such as flexion, extension, rotation and counter extension.

A **Typical Vertebra** (Fig. 40) is composed of a **body, neural arch, seven processes, two pedicles** and **two laminae**. Each vertebra is perforated by many openings for the transmission of vessels and nerves, which pass to the interior of the bone for the supply of all its parts.

The **body** or **centrum**, the largest part, is convex anteriorly from side to side, but posteriorly it is flat and slightly concave from above downward. The **bodies**, or **centra**, differ in the various parts of the spine. In the cervical region they are smaller, broader from side to side than from before backward. The upper surface is concave transversely, and presents a projecting lip on each side. In the dorsal region the bodies are flat above and below, are heart-shaped and pre-



sent facets and demi-facets for articulation with the heads of the ribs. In the lumbar region the bodies are flattened, or slightly concave, above and below, and are kidney-shaped. The upper surfaces of the bodies are rough for the intervertebral discs, or cartilages, which are shock absorbers interposed between the bodies of the vertebrae.

The **pedicles** are two short, thick pieces of bone, which project backward, one on either side, from the upper part of the body of the vertebra, at the line of junction of its posterior and lateral surfaces. The concavities above and below the pedicles are the vertebral notches, the lower ones being usually the deeper. When the vertebrae are in normal position, the four opposing notches of each contiguous pair of pedicles form two intervertebral foramina (openings), which

OSTEOLOGY

communicate with the spinal canal, and transmit the spinal nerves and blood-vessels.

When a subluxation exists, the bone partially occludes these openings, and the nerves are pressed upon. This prevents the free and uninterrupted passage of the nerve impulse and impression, the consequence being a lack of function in the tissues and organs in which the affected nerve terminates; thus arises a necessity for the correction of the articulating position of those bony segments.

The **laminae** are two, comparatively broad, plates of bone. In the articulated spine, the laminae are imbricated, overlapping one another thruout the whole length of the spine. They connect the spinous process with the pedicles, and their borders are rough for the attachment of ligaments and muscles. They complete the neural arch by fusing together, in the middle line behind, and enclose a foramen, the **spinal foramen, spinal canal, or vertebral canal**, which serves for the protection of the spinal cord. The spinal foramen is largest and triangular in the cervical region, smallest and round in the thoracic region, of medium size and triangular shape in the lumbar region.

The **processes** are **four articular, two transverse** and **one spinous**. The **articular processes**, four in number, two above, two below, and on either side, spring from the junction of the pedicles and laminae. They are also called the **zygapophyses**. The superior pair, the pre-zygapophyses, project upward, with their articular surfaces directed backward in the cervical region, backward and outward in the dorsal, and backward and inward in the lumbar region; while the lower or inferior pair, the post-zygapophyses, are exactly the reverse of the upper pair in each region. The **transverse processes** project, one from each side, at the point where the laminae join the pedicles, between the superior and inferior processes, and they serve for the attachment of muscles and ligaments. The transverse processes in the cervical region are bifid, and perforated by a foramen, the vertebral foramen, for the vertebral vessels and nerves, in the thoracic region they are thick and strong and have articular facets for the ribs; and in the lumbar region they are long, slender, and directed transversely outward.

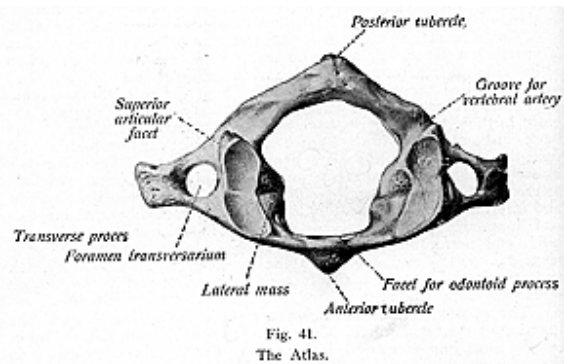
The **spinous** (thorn-like) **process** projects backward from the junction of the two laminae. Chiropractors consider the spinous process the most important descriptive part of the vertebrae, because it is the primary object of spinal palpation, and serves as the lever with which to adjust the vertebra. The spinous processes in the cervical region are bifid, short and horizontal, and in the thoracic region are long, triangular and directed obliquely downward, while in the lumbar region the spines are thick, broad and quadrilateral, and terminate in a rough uneven border.

The **peculiar vertebrae** are the **first, the second and seventh**, also the third and sixth cervical vertebrae the first, ninth, tenth, eleventh and the twelfth dorsal vertebrae. The fifth lumbar vertebrae might also be considered as having distinguishing features. The first cervical vertebra is most peculiar because it has neither body nor spinous process.

The **Atlas** (Fig. 41) the first vertebra, is so named because it supports the globe, or head. The chief peculiarities of this bone are that

OSTEOLOGY

it has neither body nor spinous process. The atlas is ring-like and consists of an **anterior arch**, a **posterior arch** and **two lateral masses**. The **anterior arch** is a curved plate of bone which connects the antero-internal parts of the lateral masses. It presents on its anterior surface about its centre, a conical prominence, called the anterior tubercle, which gives attachment at either side to a portion of the longus colli muscle. The posterior surface presents at its centre a circular concave facet, called the **odontoid facet** or **fovea dentalis**, for the articulation of the odontoid process of the axis. The **posterior arch**, since there is no spinous process, cannot ordinarily be palpated. If it can be palpated it denotes an abnormal development of the posterior tubercle, or a very pronounced posterior condition of the atlas. But if no tenderness is felt, and function is unimpaired, the prominence of the tubercle is not pathological, only a peculiarity. (In the P. S. C. Studio many specimens may be seen.) The atlas has no body, it being, supposedly, usurped by the odontoid process of the axis. The absence of the body

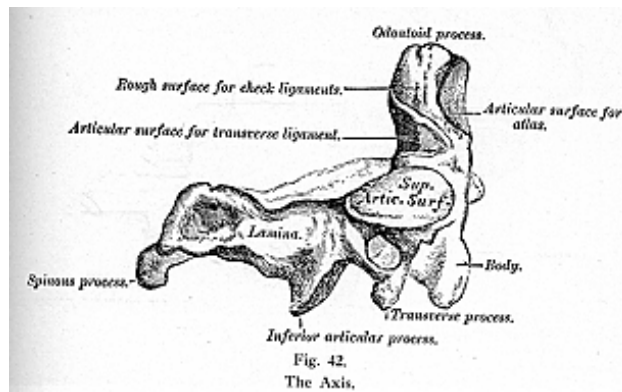


makes the atlas thinner, and permits of freer motion of the head on the spinal column, in accordance with the general rule that the smaller the vertebra the greater the arc of its mobility. Its articulating facets are inclined planes which spontaneously reduce the concussion which would otherwise occur when the condyles were, even slightly, forced downward. The facets of the atlas, and axis, are anterior to the place of exit of the spinal nerves, elsewhere the facets are posterior to the intervertebral foramina.

There are two **lateral masses**, which are the most bulky and solid parts of the atlas, and they support the weight of the head. They present two articulating processes above, and below. The two superior are of large size, oval and concave, and approach each other in front, but diverge behind. They are directed upward, and a little

OSTEOLOGY

backward, each forming a sort of a cup for the condyle of the occipital bone, and they are admirably adapted to the nodding movements of the head. Sometimes they show very little concavity and are indented, in which cases they are divided into two unequal parts, and then permit of but slight movement of the head. Just below, and on the inner margin of, each lateral mass is a **tubercle** for the attachment of the transverse ligament, which stretches across the ring of the atlas and divides it into two unequal parts. The anterior, the smaller, portion receives the odontoid process of the axis, the posterior portion transmits the spinal cord and its membranes. While each of the other vertebrae has a spinous process, the atlas presents merely the two processes of bone, the laminae, forming an **arch**. The transverse processes of the atlas are prominent, of large size and project directly outward and downward from the lateral masses, and serve for the attachment of special muscles which assist in rotating the head. They are long, not bifid and are perforated at their base by a canal

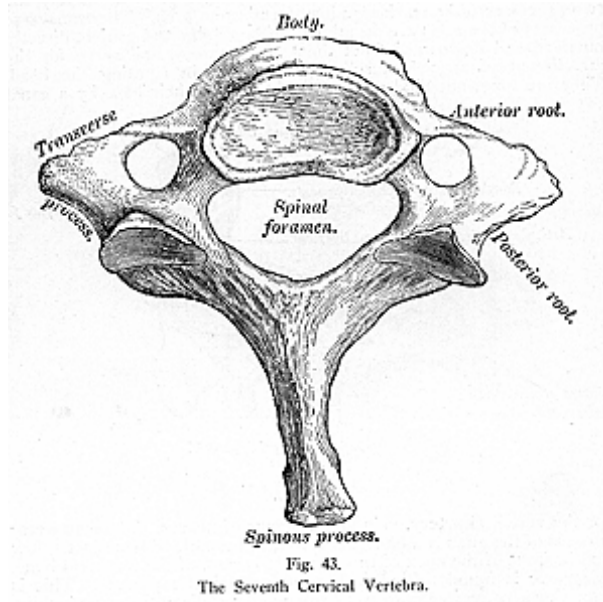


for the vertebral artery, vein and a plexus of nerves. The transverse process of the atlas can be felt as a rounded nodule of bone just below and in front of the apex of the mastoid process, of the temporal bone. A groove is found behind each superior articular process. This is sometimes converted into a foramen by a delicate bony spiculum.

The **Axis (Epistropheus)** (Fig. 42) the second cervical vertebra, is so named from forming the pivot upon which the first vertebra (atlas), carrying the head, rotates. The most distinctive characteristic of the axis is the strong prominent process, tooth-like in form, hence the name **odontoid**, which arises perpendicularly from the upper surface of the body. The body is deeper in front than behind, and is prolonged downward anteriorly so as to overlap the upper and fore-part of the next vertebra. The odontoid process presents two articulat-

OSTEOLOGY

ing surfaces, one, of an oval form, in front, for articulation with the atlas, another, behind, for the transverse ligament. The apex is pointed and gives attachment to the odontoid, or check, ligaments which limit the rotation of the head, these ligaments being attached to the condyles of the occipital bone. In hanging, or in dislocation the transverse ligament is broken. The pedicles of the axis are broad and strong, also the laminae are exceptionally strong, being thick and prismatic on cross section, while the transverse processes are very small; but the spinous process is of large size, very strong, deeply channeled on its under surface and presents a bifid, tubercular extrem-



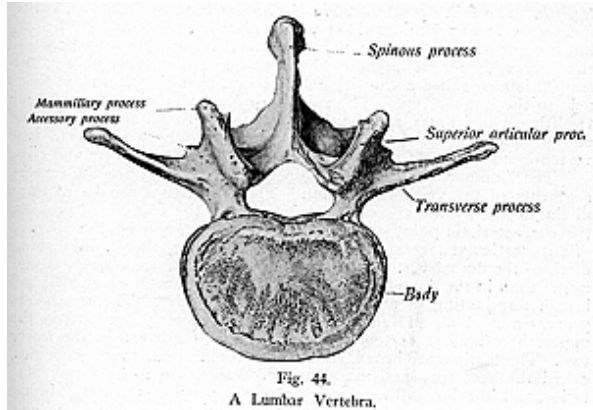
ity, for the attachment of muscles which serve to rotate the head upon the spine.

The **Seventh Cervical Vertebra**, the **Vertebra Prominens**, is so-called because of its very long, and prominent, spinous process. This process is thick, nearly horizontal in direction and not, as a rule bifurcated, but terminates in a single large tubercular eminence. Its transverse processes are usually of large size and, occasionally, the anterior root of the transverse process exists as a separate bone and

OSTEOLOGY

attains to large size. It is then known as a *cervical rib*, or *homologous rib*. The antero-posterior measurement of the body exceeds that of other cervical vertebrae and the transverse foramen is of small size and does not transmit the vertebral vessels, tho the vertebral vein may pass thru it. The seventh vertebra is also called a transitional vertebra, because it possesses certain characteristic features of both the cervical and the dorsal vertebrae. (See Fig. 43.)

The **third cervical vertebra**, is the smallest of all the vertebrae and is placed more anteriorly than are the other cervical vertebrae.



McClellan says, "It is the weakest point, not only of the neck, but of the entire spine." Its laminae are very light, and most often fractured. Its spinous process is the shortest of all the vertebrae, and is felt with difficulty unless the neck is flexed, but the shortness of the spinous process permits of freer movements in the cervical region. Its transverse processes are not so thick as are those of the vertebrae lower in the spine.

The remaining cervical vertebrae, namely, the fourth and fifth and sixth have parts in common with each other, as well as with the third, but the sixth often displays an enlargement of the anterior tubercle on the transverse process, called the *carotid tubercle* (*Chassaignac's tubercle*), from the circumstance that the carotid artery may be compressed against it.

The **Dorsal**, or **Thoracic, Vertebrae** bodies are heart-shaped, and are intermediate in size between that of the cervical and lumbar vertebrae, increasing in size from above downward. The dorsal vertebrae may be at once recognized by the presence, on the sides of the body, of one or more facets, or half facets, for the heads of the ribs. (See figure 40.)

OSTEOLOGY

Their laminae are broad and thick and overlap one another, like tiles of a roof. The spinal foramen is small. The spinous processes are long, triangular, directed obliquely downward, and terminate in a tubercular extremity. The transverse processes arise from the same part of the arch as do the posterior roots of the transverse processes in the neck, and are situated behind the articular processes and pedicles. They present a clubbed extremity, which has on its tip a smooth, concave surface for articulation with the rib next above.

The peculiar dorsal vertebrae are the *first, ninth, tenth, eleventh* and *twelfth*. The **first dorsal vertebra** is peculiar because it has an entire facet above, and a demi-facet below, the *ninth* has no demi-facet below but has one above; the *eleventh* has no facet on the transverse process, the process being rudimentary, but has one entire facet above; the *twelfth* is also called a transitional vertebra, changing from the thoracic to the lumbar type. The spinous processes of the eleventh and twelfth are horizontal, and the one whole facet, placed upon the bodies and pedicles, is the only point of articulation between these two vertebrae and the ribs, hence the mobility of both vertebrae and ribs.

The **Lumbar Vertebrae** (see illustration No. 44), are the largest segments of the vertebral column. These vertebrae can be at once distinguished by the absence of a foramen in the transverse process the characteristic point of the cervical vertebrae, and by the absence of any particular facets on the sides of the bodies, the distinguishing mark of the dorsal vertebrae. The spinal foramina are triangular and larger than in the dorsal region. The spinous processes are thick and broad, terminating in a rough and uneven border. The transverse processes are long and slender, directed transversely outward in the upper three lumbar vertebrae, but slant a little upward in the lower two. The laminae are broad, short and strong. Four more processes, called the **accessory** and **mamillary processes**, are to be found posterior, and inferior, to the superior articular processes of each lumbar vertebra. These are called, by some anatomists, the true transverse processes. The external ones are known as the costal processes, they being homologues of the ribs. In man these processes are comparatively small, but in some animals they attain considerable size and serve to lock the Vertebrae closely together.

The fifth lumbar vertebra is characterized by having a body much thicker in front than behind, and it takes on the form of the first segment of the sacrum. The spinous process is small, and the interval between the inferior articulating processes is wide. The transverse processes of this vertebra are larger and thicker than those of the other lumbar Vertebrae, and spring from the body as well as from the pedicles.

The bodies of all the Vertebrae are composed of light, spongy cancellous tissue, having a thin coating of compact tissue on their external surfaces, perforated by numerous orifices for the passage of vessels. The vertebral bodies are separated from each other by plates of fibro-cartilage, the inter-vertebral discs. Each of the ordinary vertebrae is developed by four centers of ossification, one for each lamina and its processes, and two for the body. At twenty-one years of age a thin, circular epiphyseal plate of bone is formed from the lay-

OSTEOLOGY

ers of cartilage situated on the upper and under surfaces of the body, and these are formed from two additional centers of ossification. All these become joined and the bone is completely formed between the twenty-fifth and the thirtieth year of life.

The muscles attached to the atlas are the longus colli, rectus capitis anticus minor and rectus capitis posticus minor, obliquus capitis superior and inferior, levator anguli scapulae, the inter-transversales and the splenius colli; attached to the axis are the longus colli, splenius colli, transversalis colli, semi-spinalis colli, levator anguli scapulae, scalenus medius, the inter-transversales, the interspinales, multifidus spinae, the obliquus capitis inferior and the rectus capitis posticus major. Attached to the other vertebrae are the longus colli, rectus capitis anticus major, the three scaleni muscles (anticus, medius and posticus), the psoas muscles (magnus and parvus), the diaphragm, quadratus lumborum, internal abdominal oblique and the transversalis abdominis, the trapezius and the latissimus dorsi, levator anguli scapulae, rhomboid muscles (major and minor), serratus posticus superior and inferior splenius capitis and colli, erector spinae, spinalis dorsi (often absent), transversalis colli, cervicalis ascendens, complexus, trachelo-mastoid, biventer cervicis, semi-spinalis dorsi and colli, the multifidus spinae, rotatores spinae, the supra-spinales, interspinales, inter-transversales and the levatores costarum.

The **sacrum** and **coccyx** consist, at an early period of life, of nine separate pieces which are united in the adult to form two bones, five entering into formation of the sacrum, and four into that of the coccyx.

THE SACRUM

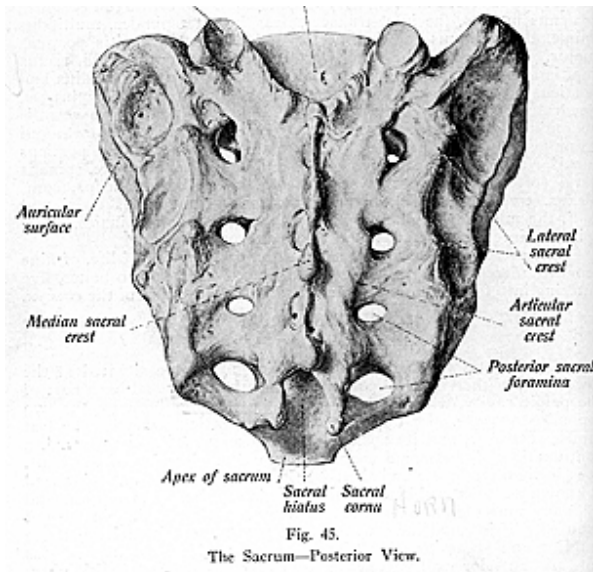
(Illustrations Nos. 45 and 46.)

The **Sacrum** (sacred) is a large triangular bone situated at the lower part of the vertebral column, and at the upper and back part of the pelvic cavity, where it is inserted like a wedge between the two innominate bones. Its upper part, or **base**, articulates with the last lumbar vertebra, and its **apex** with the coccyx. The sacral canal, a continuation of the spinal canal, runs thru the interior of the bone. It is incomplete below and the resulting interval in its posterior wall is known as the **sacral hiatus**, this space is covered by membrane and by many muscular fibers, so the structures contained therein are not exposed. This canal lodges the sacral nerves, and from it open the anterior and posterior sacral foramina, thru which the nerves pass out. Its anterior wall is concave from above downward and slightly so from side to side, and in its middle are **transverse ridges**, or **lines** showing the former division of the bone into five separate pieces. The portions of bone intervening correspond to the bodies of the vertebrae. On either side are four openings, the anterior sacral foramina, which correspond to the intervertebral foramina in other regions of the vertebral column, and these transmit the anterior divisions of the first four sacral nerves. On the upper surface or corresponding to the first segment, is a projecting lip called the **promontory** or **sacral prominence**.

The exterior posterior surface of the sacrum is convex and narrower than the anterior, and in the middle line are three or four

OSTEOLOGY

tubercles, which represent the rudimentary spinous processes of the sacral vertebrae forming the **median sacral crest**. The first of these processes is the most prominent. The second and the third may be confluent, and the fourth is often absent. Flanking the spines are the laminae, those of the fourth and fifth sometimes being deficient, and outside of the laminae are the rows of rudimentary transverse proc-

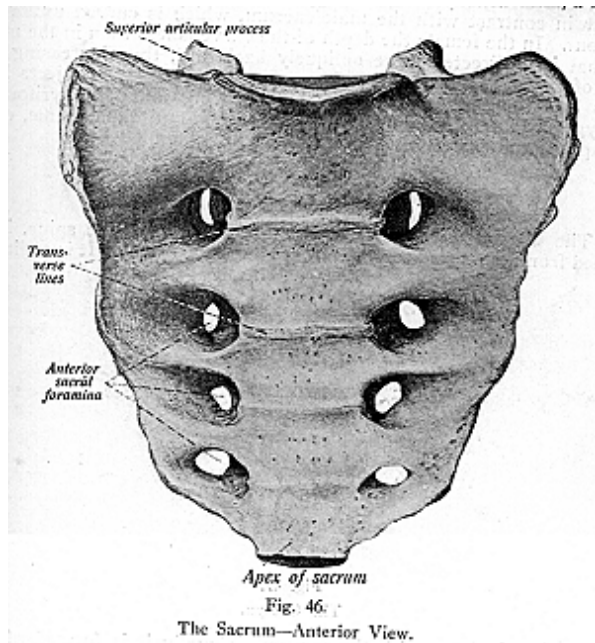


esses, which may be as prominent as those of the other vertebrae. They appear, more often, as tubercles on either side, and, therefore, form the **tubercular ridge**, or the **articular sacral crest**. On either side of the spine is seen a broad groove, the **sacral groove**, lodging the origin of the erector spinae muscle, and external to the laminae are a series of small eminences which represent the articular processes of the vertebrae above.

The first pair of superior articulating processes is large for articulation with the last lumbar vertebra, the second and third are small and the fourth and fifth are usually blended together. They are situated on either side of the sacral canal and assist in forming the **sacral**

OSTEOLOGY

cornua (lateral margins prolonged downward from the laminae of the fourth and fifth segments of the sacrum). Immediately external to the articular processes are the posterior sacral foramina, four on each side. They are smaller than are the anterior, and give exit to the primary divisions of the first sacral nerves. The lateral margins, or surfaces, of the sacrum are broad above, but converge into an edge below. Its upper half presents in front, for articulation with the ilium, a broad



ear-shaped surface which is known as the **auricular surface**. It is rough for the attachment of the posterior sacro-iliac ligaments, in the recent state being coated with cartilage. The **base** of the sacrum is broad and expanded, and is directed upward and forward. It presents, in the middle, an oval articular surface, which is connected with the under surface of the body of the last lumbar vertebra. On either side of the articular plate is a broad and flat triangular surface of bone, which extends outward and is called the **ala** of the sacrum. It supports the psoas magnus muscle and lumbo-sacral cord, and is continuous on each side with the iliac fossa. It also gives attachment to a few of the fibers of the iliacus muscle.

The **apex** of the sacrum is directed downward, and slightly forward, and presents a small oval concave surface for articulation with

OSTEOLOGY

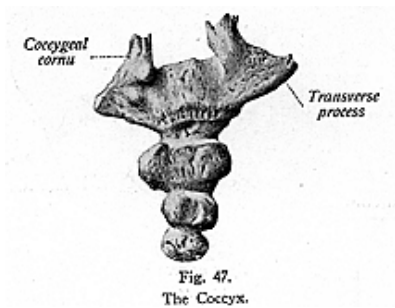
the coccyx. The sacrum ossifies from thirty-five centers, which appear between the eighth fetal week and the twentieth year. Complete ossification and fusion occurs between the twenty-fifth and thirtieth years. The sacrum articulates with the last lumbar vertebra, coccyx, and ossa innominata.

The sacrum in the female is shorter and broader than in the male, and is usually flattened above and somewhat abruptly curved below in contrast with the male sacrum, which is curved uniformly thruout. In the female the depth of the curve is less than in the male, so that it is directed more obliquely backward, thus increasing the size of the pelvic cavity, tho the sacro-vertebral angle projects less. This bone gives attachment to the following muscles, pyriformis, coccygeus, gluteus maximus, latissimus dorsi, multifidus spinae, erector spinae, and sometimes the extensor coccygis.

THE COCCYX

(Illustration No. 47.)

The **Coccyx** (os coccygis), the last segment of the spine, is so named from its fancied resemblance to a cuckoo's beak. It is rudimen-



tary and articulates with the sacrum. Usually it is formed of four small triangular segments of bone, tho it may have either three or five segments which have a tendency to become fused together. These segments have rudimentary spinous and transverse processes, also a spinal canal, but the nerves, after passing thru the inferior part of the sacrum, spread out and surround the coccyx instead of having exit thru openings similar to the intervertebral foramina. The coccyx, like other vertebrae, may require chiropractic adjustment.

The coccyx presents, for examination, an **anterior** and a **posterior surface**, the **base**, **apex** and **cornua**. The **base** is the widest part, and articulates above with the sacral apex. The **cornua**, on either side of the base, project upward from the first segment for articulation with the sacral cornua, their junctions completing the fifth sacral foramina, for the posterior branches of the nerves. The **apex** is rounded and,

OSTEOLOGY

occasionally, bifid, or turned to one side. Rudimentary bodies, also rudimentary transverse and articular processes, may be seen on the first two segments. The coccyx is developed from four centers, one for each segment. The segments are usually united between the twenty-fifth and thirtieth year of life. Often, at a late period of life, the coccyx becomes ankylosed to the apex of the sacrum.

The muscles attached to the coccyx are the coccygeus, the gluteus maximus, extensor coccygis, sphincter and, and the levator ani.

THE INNOMINATE BONES

(Illustrations Nos. 48 and 49.)

The **Bones Which Form the Pelvis** are the two **innominate bones**, the **sacrum**, and the **coccyx**.

The **Innominate Bones, Ossa Coxae, Hip Bones, or Ossa Innominata**, are two flat bones which enter into formation of the pelvis. The pelvis is a conoidal cavity, open above and below, which supports and contains part of the intestines, and part of the urinary and generative organs. It also serves as a fixed point, for the articulation of the lower limbs, the attachment of their muscles and the execution of their movements. It supports, behind, the vertebral column, and is sustained before by the femoral bones. The pelvis is divided, into the **true** and the **false pelvic cavities**, by an oblique plane passing thru the prominence of the sacrum and the upper margin of the symphysis pubis, called the *ilio-pectineal-line* or *plane*. The *false pelvis* is that expanded portion of the cavity which lies above the iliopectineal line, and between the iliac fossae, and constitutes a part of the abdomen proper. The *true pelvis* is that part of the pelvic cavity which is situated below the ilio-pectineal line, is smaller than the false pelvis, but its walls are more perfect. It forms the pelvic girdle proper and consists of a brim or inlet, a cavity and an outlet.

There are marked differences between the male and female pelvis. In the male the bones are heavier, rougher and stronger, the inlet is heart-shaped, the symphysis deeper, pubic arch narrower and more pointed, the obturator, or thyroid foramen, is oval, the sacrum narrower and more curved, and the capacity of the true pelvis of the male is less. In the female pelvis, which is lighter, the bones are more slender, iliac fossa is shallow, true pelvis is wider, inlet more oval, pubic arch wider and more rounded, muscular impressions are slightly marked, obturator foramen triangular, sacrum wider and less curved, the capacity of the true pelvis is greater, and the several diameters are universally greater.

The *inlet* of the pelvis, or the superior circumference, forms the brim of the pelvis, and is bounded, anteriorly, by the crest and spine of the pubic bone on each side, posteriorly by the anterior margin of the base of the sacrum, and laterally by the ilio-pectineal lines. The inlet has three diameters, an antero-posterior or conjugate diameter, which extends from the upper border of the symphysis pubis to the promontory of the sacrum, and measures 4 to 4-1/2 inches in the female and about 4 inches in the male; transverse diameter extends across the greatest width of the inlet, extending from one ilio-pectineal line

OSTEOLOGY

to the opposite side, and its average measurement is 5-1/4 inches in the female and about 5 inches in the male, the oblique diameter extends from one sacro-iliac articulation to the ilio-pectineal eminence of the opposite side, and its average measurement is 5 inches in the female and approximately 4-1/4 inches in the male.

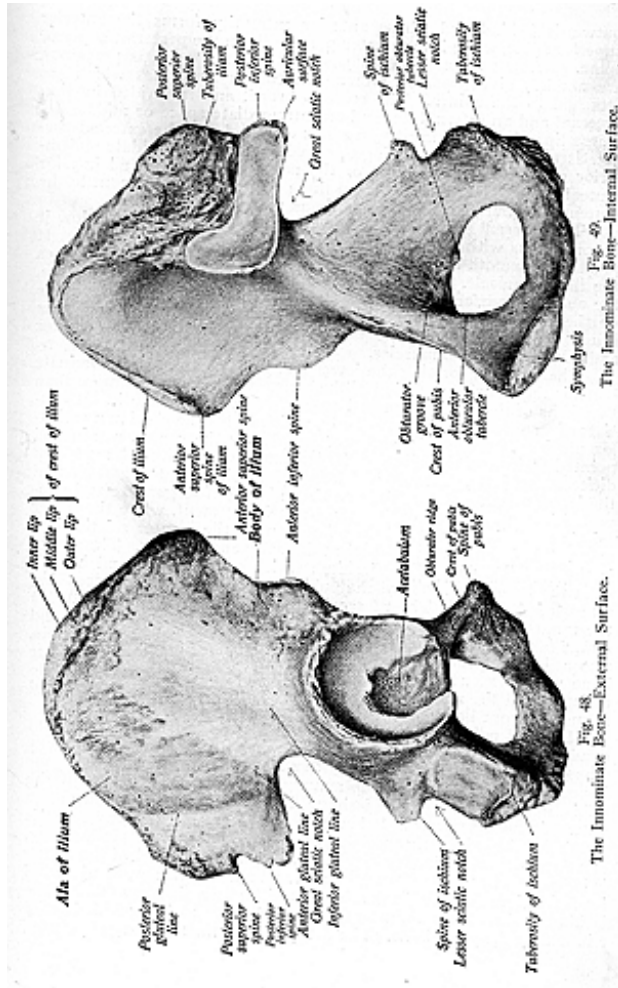
The *cavity* is bounded in front by the bodies and rami of the pubic bones, behind by the sacrum and coccyx, and on either side by an extensive osseous plane corresponding to the inner surface of the body of the ischium, also by that portion of the ilium which is below the ilio-pectineal line. The antero-posterior or conjugate diameter of the cavity in the female extends from the center of the symphysis pubis to the upper margin of the third sacral segment, and measures about 5 inches; the transverse diameter, from a point corresponding to the lower margin of the acetabulum on one side to the corresponding point on the other, measures approximately 5 inches in the female but less in the male; the oblique diameter, from the center of the great sacro-sciatic foramen on one side to the center of the obturator membrane on the other, measures 5-1/4 inches in the female. The cavity contains, in the recent subject, the rectum, bladder and some of the organs of generation.

The *outlet* of the pelvis forms the lower aperture of the pelvis and measures antero-posteriorly, on account of the mobility of the coccyx, 5 inches in the female and 4-3/4 inches in the male; the transverse diameter of the outlet measures 4-3/4 inches in the female but less in the male; the oblique diameter is 4-1/2 inches in the female, but about 4 inches in the male. The outlet of the pelvis is very irregular and is bounded posteriorly by the coccyx, laterally by the ischial tuberosities. The anterior boundary is formed by the rami of the pubes and ischia.

The axes of the pelvis are important in obstetrics. The axis of the brim is indicated by a straight line drawn from the umbilicus to the apex of the coccyx; the axis of the outlet by a line drawn from the first bone of the sacrum to the entrance of the vagina. An imaginary curved line which indicates the direction of the canal of the pelvis has occasionally been termed the curve of Carus from an obstetrician's description of the curve in question. The axis of the cavity intersects planes having different inclinations and is necessarily curved, the concavity being directed forward. It is described as, "the perpendicular of a line drawn from the middle of the symphysis pubis to the center of the sacro-coccygeal curve."

For descriptive parts, the **innominate bone** consists of three main divisions, separated in early life, and known as the **ilium**, **ischium** and the **pubis**. The innominate bones articulate with the sacrum, behind, and with each other anteriorly. The ilium, ischium and the pubes meet together to form a large cup-like cavity, the **acetabular cavity** or the **acetabulum**, which is situated near the middle of the outer surface of the bone.

The **ilium** is the superior expanded part of the bone which forms the upper two-fifths of the acetabulum. It presents for study, two **surfaces**, the external and the internal, also a **crest** which is the surmounting part of the ilium, concave inwards in front and concave



outwards behind and whose anterior extremity forms the **anterior superior spine**, while it terminates posteriorly in the **posterior superior spine**. Below the anterior and posterior superior spinous processes are notches giving partial attachment to the structures which are attached to the spines. The crest is broad, and is divided into an **external** and an **internal** lip, and an intermediate space or middle lip. These lips give attachment to a series of muscles. The external surface is traversed by three ridges, called the **superior, middle and inferior gluteal or curved lines**, or the posterior, anterior and inferior gluteal lines. The spaces between these ridges give attachment to the gluteus maximus, medius and minimus muscles.

The internal surface is bounded above by the crest and below it is continuous with the pelvic surface of the os pubis and ischium. It presents a smooth concave surface called the **iliac fossa** which lodges the iliacus muscle. Behind the iliac fossa is an ear-shaped surface the **auricular surface**, which articulates with a similar shaped surface on the side of the sacrum. The posterior portion of this surface is rough for the attachments of the sacro-iliac ligaments and the erector and multifidus spinae muscles.

The **ischium**, forming the lower and back part of the innominate bone, is the strongest portion of the bone. It forms a little more than two-fifths of the acetabulum and proceeds downward from it. It consists of a somewhat triangular **body**, which forms the chief non-articular portion of the pelvis, and presents, below the center, a thin and pointed eminence, the **spine of the ischium**, more or less elongated in different subjects. Above, and below the spine are the **greater** and the **lesser sciatic notches**, the one above being of larger size and converted into a foramen by the lesser sciatic ligament, while the lesser sciatic notch is converted into a foramen by the greater sciatic ligament. The bone consists also of a **tuberosity** and a **ramus**. The **ramus** is the flattened part of the ischium which runs upward and inward from the tuberosity, toward the pubis, and joins with the descending ramus of the pubis. The **tuberosity** is that portion of bone between the ramus and the body, and it forms a rough, thick eminence, and serves for the attachment of several muscles. The **pubis**, or **os pubis**, also called the pectineal bone, is that anterior part of the innominate bone which extends inward and downward from the acetabulum to articulate, in the middle line, with the bone of the opposite side, and forms the front boundary of the true pelvic cavity.

Each os pubis consists of a **body**, which is broad and somewhat quadrilateral in shape, and a **crest** forming a short horizontal ridge whose inner surface is oval, rough and articular. It forms, with the bone of the opposite side, the **symphysis pubis**. The **ramus** of the pubis, like the ramus of the ischium, is thin and flattened, and passes outward and downward. It becomes narrower as it descends, and is rough for the origin of muscles. The **acetabulum**, or **cotyloid cavity**, is a deep, cup-like, circular depression in which the head of the femur is lodged, and consists of an articular, and a non-articular, portion. To its formation the ilium contributes a little less than two-fifths, the ischium a little more than two-fifths, and the remaining fifth is contributed by the pubic bone. The **obturator foramen** is a large aperture,

OSTEOLOGY

situated between the pubis and the ischium. Its margins are thin, and serve for the attachment of the obturator membrane. The **obturator membrane**, sometimes called the **obturator ligament**, is a thin layer of interlacing fibers which closes the obturator foramen. It is attached to the ramus of the pubis and ischium posteriorly, and to the margins of the foramen externally, internally and below. In the male the obturator foramen is larger and oval in form, in the female it is triangular. Its sharp circumference closes the opening except at the obturator groove superiorly, where the membrane converts that groove into a fibro-osseous canal for passage of the obturator nerves and vessels.

Muscles attached to the innominate bone are the following: tensor fasciae latae, latissimus dorsi, transversalis abdominis, quadratus lumborum, sacro-spinalis, internal abdominal oblique, external abdominal oblique, gluteus maximus, medius and minimus, rectus femoris, iliacus, pyriformis, rectus abdominis, pyramidalis, obturator internus and externus, transversus perinaei, gemelli superior and inferior, levator and, coccygeus, biceps femoris, semitendinosus, semi-membranosus, adductor longus, magnus and brevis, pectineus, gracilis and ischio-cavernosus.

THE BONES OF THE UPPER EXTREMITY

The **Bones of the Upper Extremity are classified** as the **shoulder, arm, forearm and hand**. The shoulder, also known as the shoulder girdle, is composed of the **clavicle** and **scapula**.

THE CLAVICLE

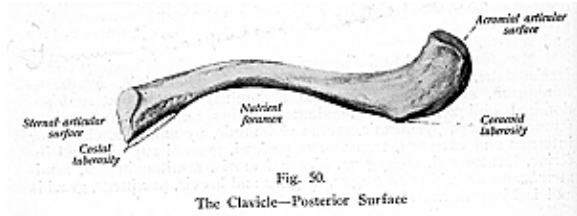
(Illustrations Nos. 50 and 51.)

The **Clavicle**, or collar bone, is a long bone, curved like the italic letter *f*, and is situated above the first rib, at the upper and anterior part of the thorax. It extends outward and backward, from the upper border of the sternum to the acromion process of the scapula. The clavicle connects the upper limb with the trunk, the inner end resting on the sternum and first costal cartilage, while the outer end is associated with the scapula in all its movements. It firmly supports the scapula and prevents it from falling inward on the chest, while at the same time it allows of great latitude of motion in the arm.

The clavicle is flattened, from above downward, is thin and rough, and presents two curves. The inner curve is convex forward, and extends over two-thirds of the bone, while the outer curve, concave forward, is smaller and exists only on the outer part. The upper surface is flat and rough, and is marked by several impressions for the attachment of the deltoid and trapezius muscles. The **internal**, or **sternal**, end of the clavicle is triangular in form, and presents an articular surface directed inward, downward and a little forward. This end articulates with a facet placed on the upper border of the manubrium of the sternum thru an interposed fibro-cartilage. The **outer** or the **acromial end** is directed outward and forward, and presents a smooth oval articular facet directed slightly downward for

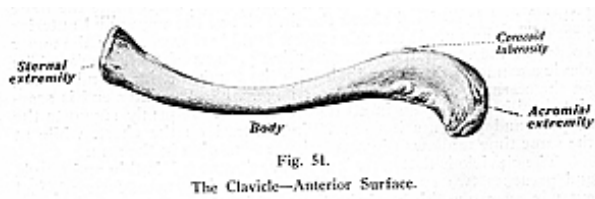OSTEOLOGY

the acromion process of the scapula. On the posterior border, and a little beneath, is the **conoid tubercle** or **coracoid tuberosity**, a small rough eminence for the attachment of the conoid ligament; on the anterior border is another tubercle, the **deltoid tubercle**, for the deltoid muscle. The under surface of the middle portion presents the **subclavian groove**, for the attachment of the subclavius muscle. Beneath the posterior border of the sternal end is the **costal tuberosity** and the



rhomboid depression, the latter about an inch in length. Both give attachment to the rhomboid ligament.

The clavicle consists, externally, of a compact layer of bone, much thicker in the middle and gradually thinning out toward its two extremities. The clavicle has no true medullary canal. The bone is developed from two centers, one for the shaft and outer extremity and one for the sternal end. This bone begins as membrane, but the ossification quickly extends into the underlying cartilage. It is therefore a compound bone. The primary center begins very early, one of



the earliest centers to appear in any of the bones of the body, at about the sixth week of embryonic life. The clavicle articulates with the scapula, and with the sternum and first costal cartilage. An intra-articular fibro-cartilage is interposed between the clavicle and sternum, in this articulation.

The muscles attached to the clavicle are the sterno-mastoid trapezius, pectoralis major, deltoid, subclavius, the sterno-hyoid and sometimes the sterno-thyroid, also the platysma myoides. The clavicle is often fractured, about as frequently as any other bone in the body,

due to its being slender and superficial, and because it is especially exposed to violence by being the only bony connection between the upper limb and the trunk.

THE SCAPULA

(Illustrations Nos. 52 and 53.)

The **Scapula**, or shoulder blade, is a large flat bone, triangular in shape, and situated at the upper and posterior part of the thorax, extending between the second and the seventh ribs. It presents, for study, **two surfaces, three angles and three borders**. The **anterior** or **ventral surface** is deeply concave, and forms the **subscapular fossa**, which presents some transversely oblique ridges for the attachment of the tendinous insertions of the subscapular muscle. The outer third of the surface is smooth, while internally, in front of the upper and lower angles, are two small flat areas, excluded from the subscapular fossa by lines, and joined by a ridge which runs close to the internal border. This ridge gives attachment to the serratus anticus muscle.

The **posterior** or **dorsal surface** is arched from above downward but is generally convex from side to side. It is divided by a prominent plate of bone—the **spine**—into two unequal parts. The hollow portion above the spine is called the **supra-spinous fossa**, and lodges the supraspinatus muscle. The portion below the spine is known as the **infraspinous fossa**, which is three times as large as the supra-spinous fossa. It gives origin to the infra-spinatus muscle, and presents an anterior, or marginal surface, divided into two surfaces by an oblique line at the junction of the lower and middle thirds. The lower of these is for the teres major and the upper for the teres minor muscles. The two fossae are separated, but communicate thru the great scapular notch at the outer border of the spine. Thru this notch, the supra-scapular nerve and artery are transmitted from one fossa to the other.

The **spine** is a strong triangular plate of bone, attached obliquely to the dorsum of the scapula and directed backward and upward, and separates the two fossae (supra-spinous and infra-spinous), it commences at the vertebral border known as the apex, and gradually becomes more prominent, it thus forms a subcutaneous **crest**, to which is attached the trapezius. The base, which is directed outward, corresponds to the neck of the scapula. The crest presents two lips—a superior for the insertion of the trapezius, and an inferior lip for the origin of the deltoid. Externally the crest is continued into the **acromion process**, or the **acromion**. This is a large, triangular, flattened process, directed at first a little outward, then curving forward and upward so as to overhang the glenoid cavity. It gives attachment along its outer margin to the deltoid, along its inner margin to the trapezius also, by its apex, to the coraco-acromial ligament. It has on its inner margin, behind the apex, an articular facet for articulation with the clavicle.

The **superior border** of the scapula is the shortest and thinnest of the three borders. It is concave and presents, at its outer part, the **supra-scapular notch**, which is converted, by a ligament, into a foramen for the transmission of the supra-scapular nerve.

OSTEOLOGY

The **external** or **axillary border** is the thickest of the three, and extends from the lower margin of the glenoid cavity to the inferior angle of the bone. Near its junction with the glenoid cavity there is a rough surface, about an inch in length, the **infra-glenoid tubercle**, which gives attachment to the triceps brachii muscle. In front of this tubercle is a longitudinal groove, which extends along the upper two-thirds of the border, and gives attachment to a part of the subscapularis muscle. To the inferior third of this border, thin and sharp, is attached the teres major and the subscapularis. The **internal** or **ver-**

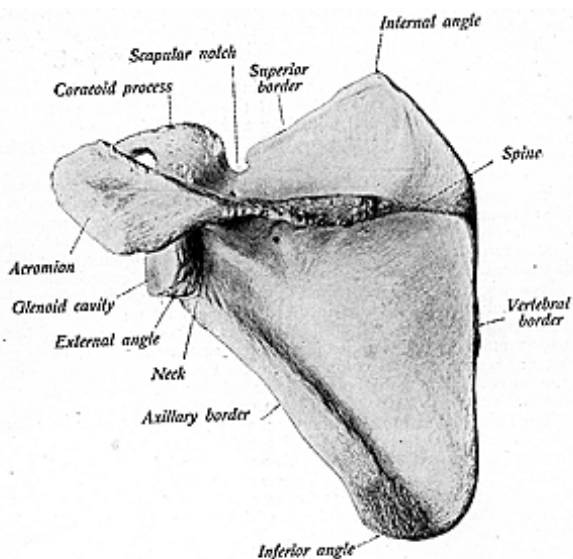


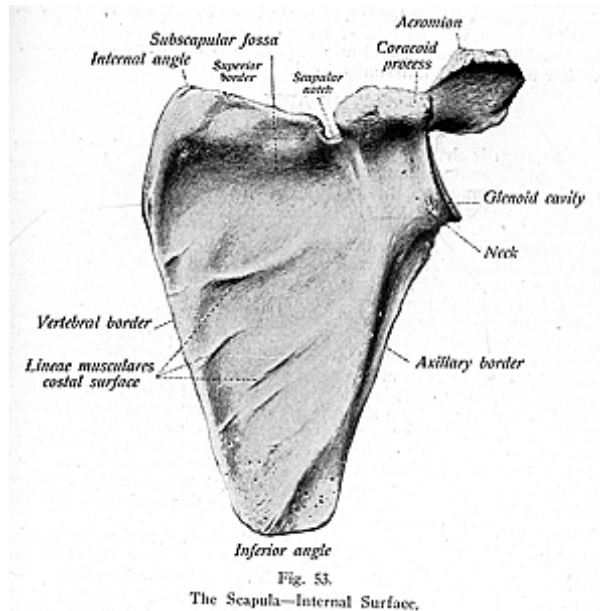
Fig. 52.
The Scapula—External Surface.

tebral border is the longest and presents an anterior lip, a posterior lip, and an intermediate space. The anterior lip affords attachment for the serratus anticus; the posterior lip for the supra-spinatus and infra-spinatus muscles; and the intermediate space for the rhomboideus major and minor, and for a few fibers of the levator anguli scapulae.

The **superior** or **internal angle** is formed by the junction of the superior and internal borders. It is thin and smooth, forms the highest part of the body of the scapula, and gives attachment to the serratus

OSTEOLOGY

anticus and the levator anguli scapulae. The inferior angle is thick, rounded and rough, and gives attachment to the teres major and, often, to a few fibers of the latissimus dorsi. The **external angle** forms the expanded portion and is that part of the bone known as the **head** of the scapula. This head presents a shallow pyriform articular cavity, the **glenoid cavity**, and is supported by a somewhat constricted portion, the **neck**. The **glenoid cavity** receives the head of the brachium. Its



margin is raised and affords attachment to the glenoid ligament, which deepens the cavity. On the upper portion of the margin is a rough surface, the supra-glenoid tubercle, from which arises the long tendon of the biceps brachii muscle. Projecting upward from the neck of the scapula is the **coracoid process**, a short thick projection that to resemble a crow's beak. It is directed at first upward and inward, then passes forward and outward, and attached to it are the pectoralis minor, the coraco-brachialis and the biceps brachii muscles, also the conoid and coraco-acromial ligaments. The scapula is developed from seven centers, one for the body, two for the coracoid process, two for

OSTEOLOGY

the acromion process, one for the vertebral border, and one for the inferior angle. Often the upper part of the glenoid cavity may be ossified from a separate center. Sometimes nine centers are given. Ossification is completed by the twenty-fifth year. The acromion process may not unite with the spine by bony union, but by a gliding joint with synovial membrane.

The scapula articulates with the clavicle and brachium, and gives attachments to the following muscles: the supra-spinatus and infra-spinatus, subscapularis, deltoid, trapezius, omohyoid, serratus anticus, rhomboideus major and minor, coraco-brachialis, biceps brachii, triceps brachii, teres major and minor, pectoralis minor, and sometimes to a few fibers of the latissimus dorsi.

THE ARM

(Illustrations Nos. 54 and 55.)

The **Arm** is that part of the upper extremity extending between the shoulder and the forearm, and consists of a single bone, the **brachium**, or **humerus**. It is the longest and largest bone of the upper extremity, and articulates above with the scapula, below with the radius and ulna. The brachium presents, for study, a **shaft**, or **body**, and an **upper** and a **lower extremity**. The **shaft** of the brachium is almost cylindrical above, prismatic and flattened below and presents three borders, anterior, external and internal, and three surfaces, external, internal and posterior. The **anterior border** extends from the front of the greater tuberosity above to the coronoid fossa below and separates the internal from the external surface. About its centre it forms the anterior boundary of the rough **deltoid impression**. The **external border** runs from the back part of the greater tuberosity to the external condyle. It is smooth and indistinct above, but is interrupted in the middle by a shallow groove, the **musculo-spiral groove**, for the musculo-spiral nerve and the superior profunda artery. Internal and external to the groove are margins for the outer and inner heads of the triceps brachii muscle. The outer border becomes curved and prominent, outwardly, to form the **external supra-condylar ridge**, which affords attachment, in front for the supinator longus and the extensor carpi radialis longus muscles.

The **internal border** extends from the lesser tuberosity to the internal condyle, and is marked on its upper part by a ridge forming the inner lip of the bicipital groove, which receives the insertion of the teres major muscle. At about the center of the inner border is an impression for the coraco-brachialis. The inferior third of this border is raised into a slight ridge, the **internal supra-condylar ridge**, which, is prominent below and has, attached to it, the brachialis anticus and the triceps brachii muscles. The **external surface** is smooth above, rough in the middle, where it forms the **deltoid tubercle** with a large impression below, the **deltoid impression**, for the deltoid muscle. The lower part of this surface gives attachment to the outer part of the brachialis anticus. The **internal surface** is narrow at its upper part, it forms the floor of the bicipital groove, and to it is attached the latissimus dorsi muscle. The lower part of this surface is smooth and shallow, but the middle part is rough, giving attachment

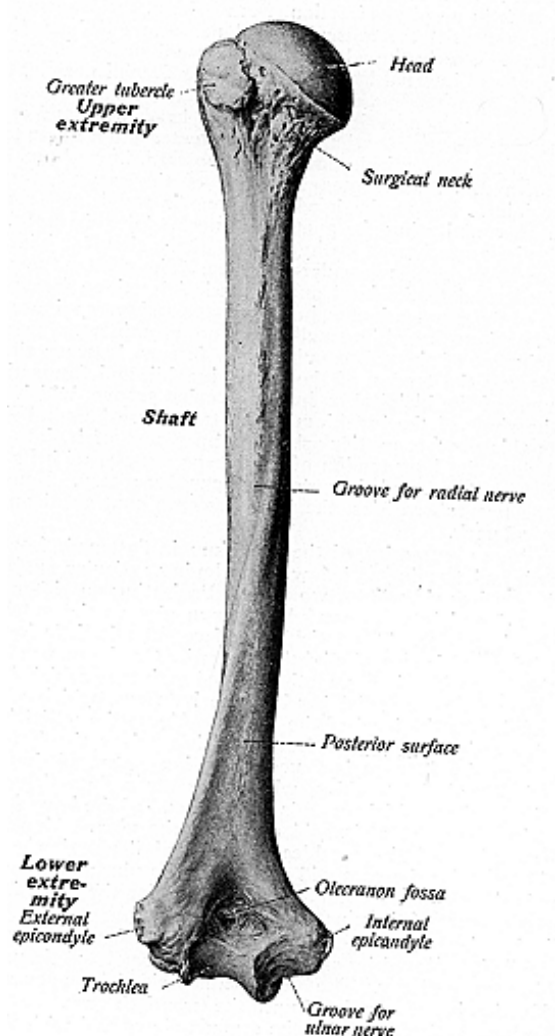


Fig. 54.
The Humerus—Posterior Surface.

to the coraco-brachialis muscle. The **posterior surface** is somewhat twisted, runs in a spiral direction, from behind, downward and forward, and transmits the musculo-spiral nerve and the superior profunda artery. Nearly the whole of the external surface is covered by the external and internal heads of the triceps brachii muscle, the two heads being separated by the musculo-spiral groove.

The upper extremity is formed by the **head, neck** and a **greater** and **lesser tuberosity**, sometimes called a **greater** and a **lesser tubercle**. The **head** is nearly hemispherical, facing upward, inward and slightly backward, and, with the glenoid cavity of the scapula, forms the shoulder joint. Below the head, the bone is rough and somewhat constricted, constituting the **anatomical neck**. The circumference of the neck gives attachment to the capsule of the shoulder-joint, and is perforated by numerous vascular foramina. The **greater tuberosity** is situated external to the head and is marked by three facets for the insertion of the supra-spinatus, infra-spinatus and teres minor muscles. The **lesser tuberosity**, altho smaller, is more prominent. It serves for the attachment of the subscapularis. A furrow, between the tuberosities, lodges the tendon of the biceps brachii, and forms the commencement of the **bicipital** or **intertubercular groove**, which extends along the shaft of the brachium. The transverse humeral ligament converts this groove, particularly the upper part of it, into a canal which lodges the long tendon of the biceps muscle, with its tube of synovial membrane, and the anterior circumflex artery. Immediately below the two tuberosities, the bone becomes contracted and forms the **surgical neck**.

The lower extremity of the brachium is flattened, from before backward, and terminates below in a sloping articular surface, subdivided by a low ridge into two parts. Projecting on either side are the **external** and **internal condyles**, known also as the **external** and **internal epicondyles**. The articular surface extends little lower than the condyles and is curved slightly forward. On the outer portion of the articular surface is a smooth rounded eminence which is known as the **capitulum**, or **radial head** of the humerus, which articulates with a cavity on the head of the radius. Above the radial head is a slight depression, the **radial fossa**, which receives the head of the radius when the forearm is flexed. The inner part of the articular surface is called the **trochlea**, which presents a deep depression, a pulley-like surface, which extends over the end of the bone for articulation with the greater sigmoid cavity of the ulna. Above, on the anterior surface of the trochlea, is an oval depression called the **coronoid fossa** for the coronoid process of the ulna, on the posterior surface is the **olecranon fossa**, a deep hollow for the reception of the olecranon process of the ulna.

The interior of the brachium is hollowed out for a large medullary canal, while its extremities are composed of cancellated tissue covered by a thin compact layer. The brachium is ossified from seven centers, its ossification is not completed until the twentieth year.

The bone articulates with the scapula above and with the radius and ulna below. It gives attachment to twenty-four muscles: the supra-spinatus, infra-spinatus, teres major and minor, pectoralis ma-

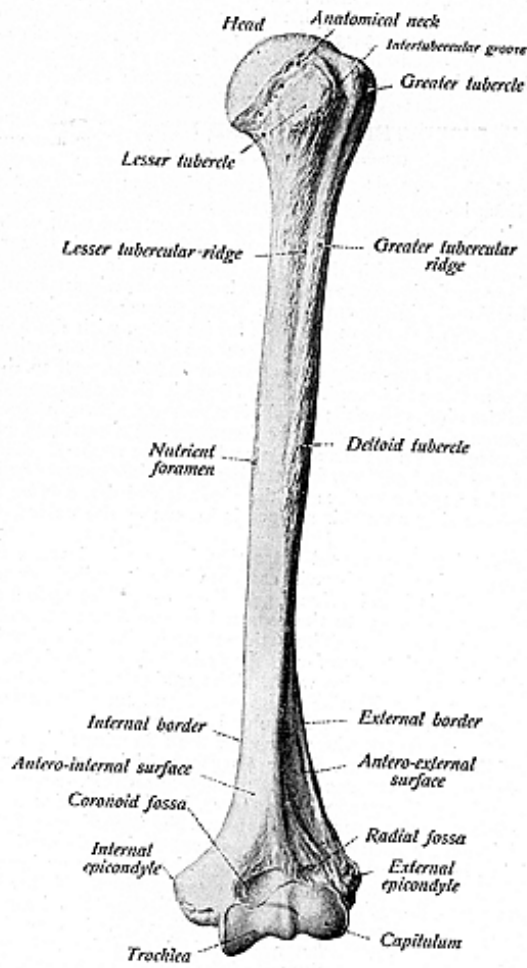


Fig. 55.
The Humerus—Anterior Surface.

OSTEOLOGY

jor, deltoid, latissimus dorsi, tricep brachii, brachialis anticus, coraco-brachialis, subanconeus, subscapularis, pronator radii teres, supinator longus, flexor carpi radialis, flexor sublimis digitorum, palmaris longus, flexor carpi ulnaris, extensor carpi radialis longior, extensor carpi radialis brevior, extensor communis digitorum, extensor minim) digit), extensor carpi ulnaris, anconeus and the supinator brevis.

THE RADIUS AND ULNA

(Illustrations Nos. 56, 57, 58 and 59.)

The **Radius** and the **Ulna** form the forearm and are two long bones. Each has for study a **shaft**, or **body**, and **two extremities**, the **distal** and **proximal ends**. These bones run parallel with each other.

The **Radius** is prismatic in form, slightly curved, larger below where it articulates with the carpal bones, and is shorter than the ulna. For descriptive parts the radius has the following: a **head**, which is cylindrical and slightly cupped on its upper surface, articulates with the radial head of the humerus and, by its sides, with the lesser sigmoid cavity of the ulna, the neck of the radius is the constricted part beneath the head, the **bicipital tuberosity** is below, and to the inner side of the neck and is rough behind where it gives attachment to the tendon of the biceps brachii; the **shaft** presents a sharp internal **interosseous border** for the interosseous ligament, and a nutrient, or medullary foramen is seen on its middle and anterior surface. A ridge is seen on its external surface, for attachment of the pronator radii teres muscle. The anterior surface of the shaft is called the *volar surface* and the sharp ridges on this surface is known as the volar border or ridge.

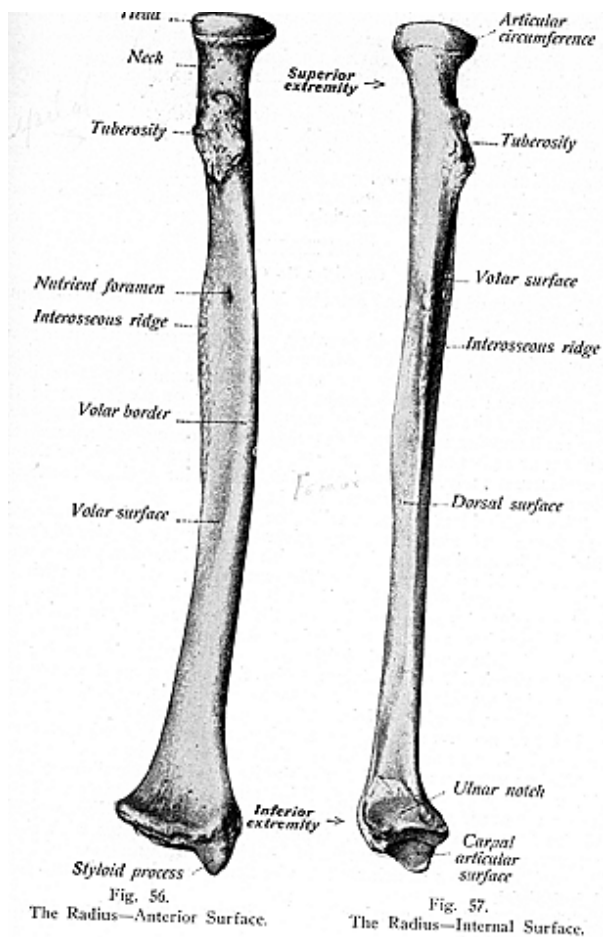
The **distal end**, or **carpal extremity**, has, on its lower surface, a shallow depression, the **sigmoid cavity**, where it articulates with the ulna. Externally is found a sharp, pen-like process, the **styloid process**, which gives attachment to the external lateral ligament, and to the supinator longus muscle. The articular surface of this distal end is divided by a ridge into two facets for articulation with the semilunar and scaphoid bones of the wrist. The radius articulates with the humerus above, with the ulna on its lateral and superior surfaces, and with the scaphoid, semilunar and ulna below.

Muscles attached to the radius are the following: biceps brachii, flexor sublimis digitorum, flexor longus pollicis, supinator brevis, pronator quadratus, extensor ossis metacarpi pollicis, extensor brevis pollicis, supinator longus, pronator teres, brachialis anticus.

The **Ulna**, or the **Elbow Bone**, forms the inner bone of the forearm and is longer than the radius. It enters into formation of the elbow joint, but it is excluded from the wrist-joint by an intra-articular fibro-cartilage. The ulna presents for study the following: the **olecranon process**, or the **olecranon**, a saddle-shaped articular prominence, at the upper extremity, forms the elbow. It is curved forward and is received into the olecranon fossa of the brachium. Its posterior surface is rough for the attachment of the triceps tendon; the **coronoid process** projects forward below the olecranon process and fits into the coronoid fossa of the brachium, its upper surface forming part of the

OSTEOLOGY

greater sigmoid cavity, or semilunar notch. This cavity lies between the processes, and is divided by a vertical ridge into two unequal parts and it articulates with the trochlear surface of the brachium, the **lesser sigmoid cavity or radial notch,** is smaller, lies external to the



OSTEOLOGY

coronoid process, is oval and concave, and receives the head of the radius; the **shaft** is large and prismatic above, small and rounded below, and, like the radius, has a sharp **interosseous border** and a **nutrient foramen**. The head of the ulna, the **capitulum**, is its distal end, and articulates, by its outer surface, with the sigmoid cavity of the radius below, and with the fibro-cartilage of the wrist-joint; the **styloid process** is the projecting piece upon the head, and presents an apex, which gives attachment to the internal lateral ligament of the wrist-joint. The ulna articulates with the brachium and radius above, and with the radius below.

Muscles attached to the ulna are the following: triceps brachii, anconeus, flexor carpi ulnaris, brachialis anticus, pronator teres, flexor profundus digitorum, flexor sublimis digitorum, pronator quadratus, flexor carpi ulnaris, flexor longus pollicis (sometimes), extensor carpi ulnaris, supinator brevis, extensor ossis metacarpi pollicis, extensor longus pollicis, and extensor indicis.

THE HAND

(Illustration No. 60.)

The **Bones of the Hand** are classified as the **Carpus**, **Metacarpus** and the **Phalanges**.

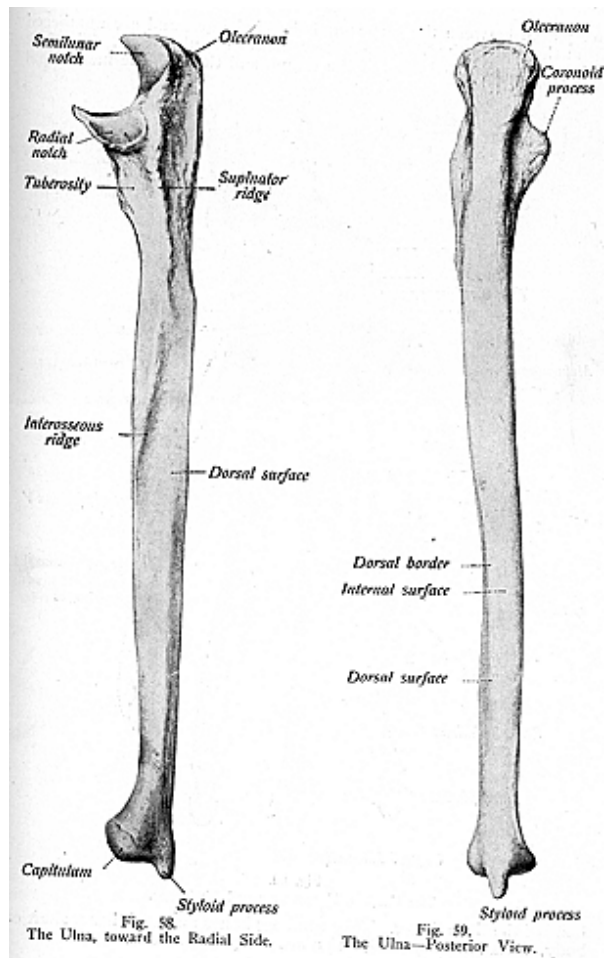
The **Carpus** are eight in number, and are arranged in two rows of four each, and named from without inward. Those of the proximal row are named the **scaphoid** or **os naviculare**, **semilunar** or **os lunatum**, **cuneiform** or **os triquetrum**, **pisiform** or **os pisiforme**; in the distal row are the **trapezium** or **os multangular major**, the **trapezoid** or **os multangular minor**, the **os magnum** or **os capitatum**, and the **unciform** or **os hamatum**. Nearly all carpal bones have either five or six surfaces, namely, the proximal, distal, posterior or dorsal, anterior, palmar or volar, and the external and internal.

The scaphoid articulates with the radius, trapezium, trapezoid, os magnum and semilunar, and gives attachment to the abductor pollicis. The semilunar articulates with the radius, os magnum, unciform, scaphoid and cuneiform. The cuneiform articulates with the pisiform, the semilunar and unciform bones and is separated from the ulna by an interior-articular fibro-cartilage. The pisiform articulates with the cuneiform only, and it gives attachment to the flexor carpi ulnaris and abductor (minim) digit) muscles. The trapezium articulates with the scaphoid, trapezoid, and the first and second metacarpal bones, and gives attachment to the abductor pollicis, opponens pollicis and the flexor brevis pollicis. The trapezoid articulates with the scaphoid, os magnum and the trapezium and the second metacarpal bone, and gives attachment to one muscle, the flexor brevis pollicis.

The os magnum articulates with the scaphoid, semilunar, trapezoid, unciform and the second, third and fourth metacarpal bones. The os magnum gives attachment to the adductor obliquus pollicis and the flexor brevis pollicis. The unciform articulates with the os magnum, cuneiform, semilunar and fourth and fifth metacarpal bones. The unciform gives attachment to the flexor carpi ulnaris and flexor (minim) digit).

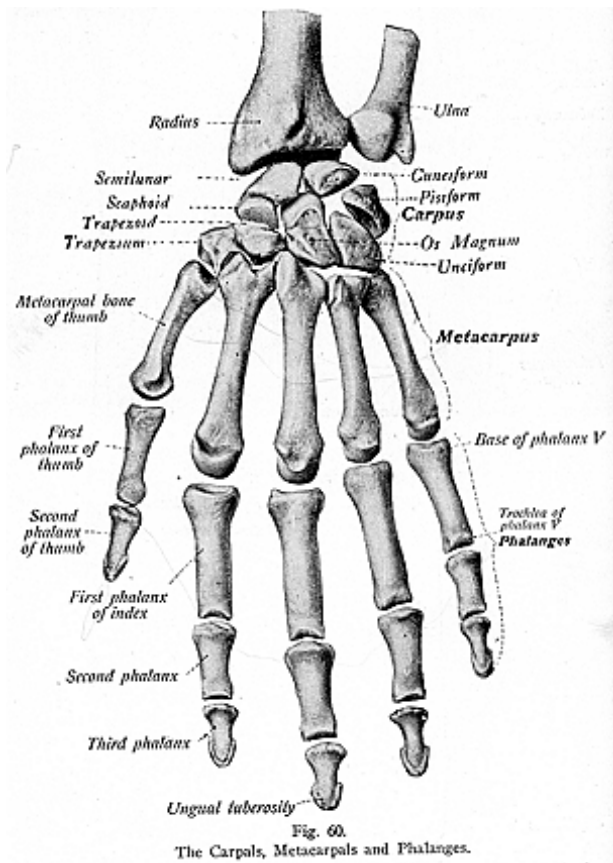
The **Metacarpus** consists of the five metacarpal bones, which

OSTEOLOGY



OSTEOLOGY

are placed between the carpus and the phalanges and are numbered from the first to the fifth, from the radial to the ulnar side. The first being the metacarpal bone of the thumb and the fifth the metacarpal



bone of the little finger. They are long bones and each has a **shaft** or **body**, a **head** or **distal end**, and a **base** or **proximal end**.

OSTEOLOGY

The metacarpal bones articulate with each corresponding phalanx and the 1st metacarpal articulates with the trapezium; the 2nd with the trapezium, trapezoid, os magnum and third metacarpal bones; the third, with the os magnum, and 2nd and 4th metacarpal bones; the fourth, with the os magnum, unciform and 3rd and 5th metacarpal bones; and the 5th with the unciform and the fourth metacarpal.

The muscles attached to the metacarpal bones are the following: opponens pollicis, flexor brevis pollicis, extensor ossi metacarpi pollicis, flexor carpi radialis, extensor carpi radialis longior and brevior, abductor obliquus pollicis, flexor carpi radialis, adductor pollicis, extensor carpi ulnaris, flexor carpi ulnaris, opponens minimi digiti, and the 1st, 2nd, 3rd and 4th dorsal interossei and 1st, 2nd and 3rd palmar interossei.

The **Phalanges**, or finger bones, are fourteen in number, two for the thumb and three for the lesser fingers. They, also, are long bones and each has a **shaft**, a **base** or **upper extremity**, and a **distal extremity**. The distal extremities of the first and second phalanges have condyles, but the last row, or distal row, have rough tubercles on their palmar surface for attachment of the pulp of the fingers. The terminal phalanx of each finger and toe is called the **ungual phalanx**, and is convex on its dorsal surface where it presents an enlargement called the **ungual tuberosity**. The phalangeal articulations are as follows: the first row articulates with the metacarpal bones and the second row of phalanges; the second row articulates with the first and third rows, and the third row articulates with the second row. The muscles attached to the phalanges are the extensors, flexors, adductors and abductors of the fingers.

THE BONES OF THE LOWER EXTREMITY

The **Bones Which Form the Lower Extremity** are the **femur** (the thigh), the **tibia**, **fibula** and **patella** (the leg), the **tarsus**, **metatarsus** and the **phalanges** (the foot).

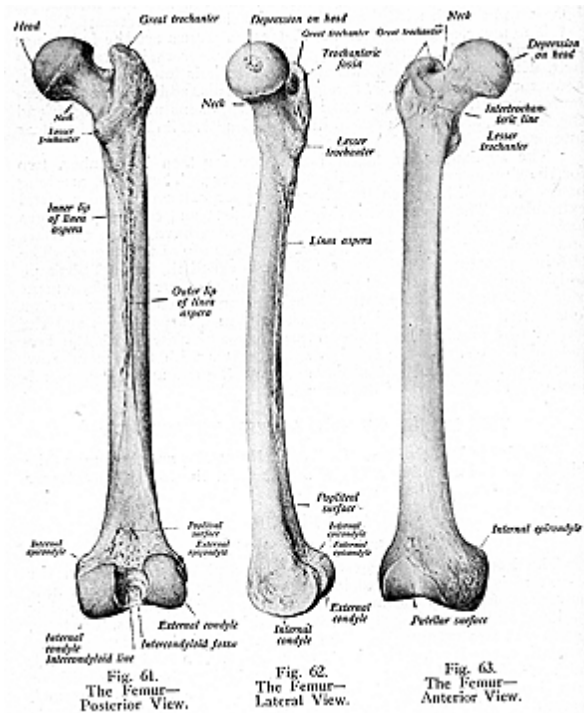
THE FEMUR

(Illustrations Nos. 61, 62 and 63.)

The **Femur** is the largest, strongest and longest bone in the body, and is inclined toward its fellow to bring the knee joint near the center of gravity during walking. It is found between the pelvis and knee, and forms the only bone of the thigh. It presents, for study, a **shaft** and **two extremities**. The **upper extremity** has a large globular portion, the head. This is directed upward, inward and forward, and has, behind and below its center, a depression, the fossa capitis or teres depression for the ligamentum teres. The neck is flattened, pyramidal, and joins the head with the shaft, and, in the adult male forms an obtuse angle with the shaft. The neck also presents numerous foramina for the transmission of blood-vessels and nerves. The **tuberosities** are eminences, called the **trochanters**, the **greater** and the **lesser trochanters**. The **greater trochanter** is a large irregular eminence directed upward, outward and backward, it being very rough, for the attachment of muscles. The **lesser trochanter** is small and

OSTEOLOGY

conical, projects from the lower back part of the base of the neck, and receives the insertion of muscles. The **anterior** and **posterior intertrochanteric lines** connect these two processes, the posterior line being the more prominent. Another line, known as the **linea quadrata**,



is frequently seen to begin at about the middle of the trochanters, for the attachment of the quadratus femoris muscle.

The **shaft** is broad and cylindrical at both extremities, narrow and triangular at its center, and is curved slightly forward. It is smooth on its anterior surface, but a rough line, the **linea aspera**, is found on the posterior surface. This line is a prominent longitudinal

OSTEOLOGY

ridge, and has an external and internal lip, and an intermediate space. On the lower third of the shaft, the lips of the linea aspera bifurcate, and are prolonged to the condyles as the external and internal supracondylar ridges and enclose there a smooth space called the **popliteal space** or **fossa**, also known as the **trigonum femoris**.

The lower extremity presents two **condyles**, the **external** and the **internal**. They are smooth, convex from before backward and from side to side, and they articulate with the tibia. Separating the two condyles is the **inter-condyloid notch**, and to its sides are attached two ligaments, the crucial ligaments. In front, the condyles form a continuous articular surface, the **trochlea**, over which the patella glides. The outer, as well as the inner, condyle presents an **epicondyle**, a tuberosity, which gives attachment for the external and internal lateral ligaments. The femur is one of the bones to ossify early. It follows the clavicle, the mandible being first. The femur articulates with the acetabular cavity of the innominate bone, above, with the tibia and patella, below. Muscles attached to the femur are: gluteus maximus, medius and minimus, obturator externus and internus, crureus, gemellus superior and inferior, vastus externus, vastus internus, psoas magnus, piriformis, iliacus, quadratus femoris, adductor longus, magnus and brevis, biceps femoris, pectineus, subcrureus, gastrocnemius, plantaris, popliteus. The femur of the female is smoother than in the male; the angle formed by the neck with the shaft is greater; the bones are farther apart above, more sloped inwards, and nearer to each other than in the male.

THE PATELLA

(Illustrations Nos. 64 and 65.)

The **Patella**, or **rotula**, is the knee cap. It is a flat triangular bone, classified with the sesamoid bones in its mode of development. It is placed at the front and lower end of the femur. Its anterior surface is roughened, the posterior surface is divided by a vertical ridge into two smooth facets for the trochlea of the femur, its **apex** gives attachment to the ligamentum patellae, its superior and lateral borders serve for the attachment of several muscles, the quadriceps extensor muscle the external and internal vasti muscles, the rectus femoris and crureus.

The **Bones of the Leg** are the **tibia** and the **fibula**. The **patella**, also, may be classed as one of the leg bones.


THE TIBIA

(Illustrations Nos. 66, 67 and 68.)

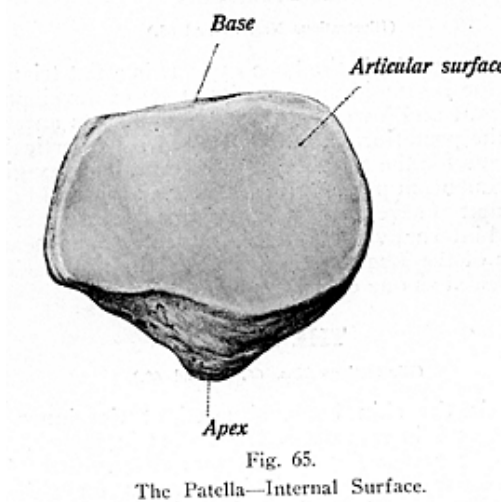
The **Tibia** is the shin bone, situated at the inner and front part of the leg, and is second to the femur in length. The tibia presents for study a **head**, **shaft** and **two extremities**. The **upper extremity** is known as the head, it presents on either side an enlargement of bone called the **lateral tuberosities**, an external and internal, sometimes called the **external** and **internal condyles**, which bear, upon their upper surfaces, smooth concave ovoidal facets for the femoral condyles; a **spine** is found between the tuber-

OSTEOLOGY

osities; and a **tubercle**, or **tuberosity**, for the ligamentum patella, is found below in the mid-line in front of the head. The **shaft** is prismoidal and has three borders. The **anterior** border is called the **crest**,



or **shin**; the **external** is the **interosseus border**; and the **internal**, directed toward the fibula, is styled the **soleus border**. The posterior

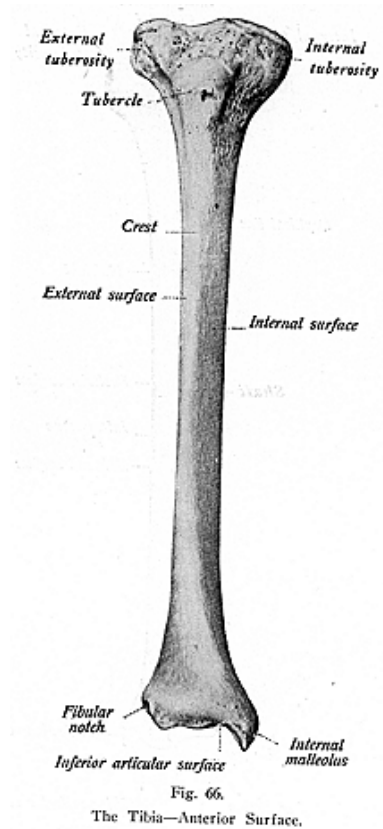


surface presents, at its upper part a prominent ridge, the **oblique line of the tibia**, or **popliteal line**, for the attachment of muscles.

The **lower extremity** of the tibia is smaller than the upper. It has

OSTEOLOGY

an inferior concave surface for the astragalus, and an external rough surface, the **fibular notch**, for articulation with the fibula. Projecting downward internally is the **internal malleolus** which articulates, by



its outer surface, with the side of the astragalus. The tibia articulates with the femur, fibula and astragalus. To the tibia are attached

OSTEOLOGY

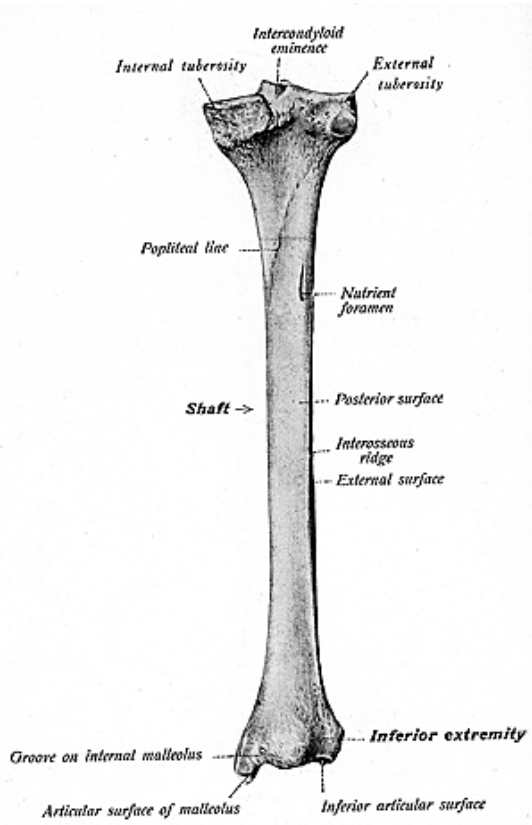


Fig. 67.
The Tibia—Posterior Surface.

OSTEOLOGY

the following muscles: semimembranosus, semitendinosus, biceps femoris, sartorius, gracilis, tibialis anticus, tibialis posticus, popliteus,

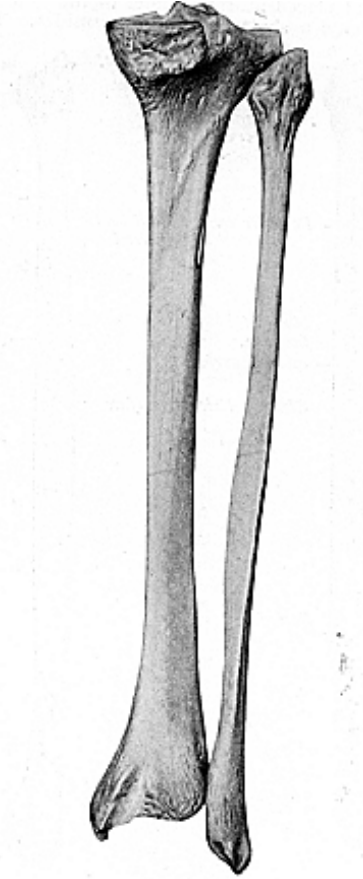
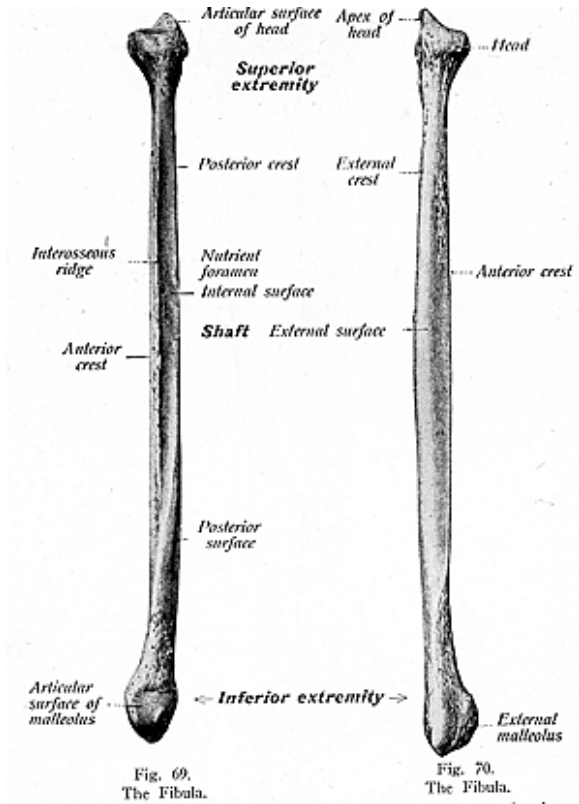


Fig. 68.
The Tibia and Fibula Together in Situ.

the quadriceps extensor muscle, extensor and flexor longus digitorum peroneus longus (sometimes), and the fibers of the tensor fascia femoris are indirectly attached thru the ilio-tibial band.

THE FIBULA

The **Fibula** or **Peroneal Bone** (see illustrations Nos. 69 and 70) is long, slender, and placed nearly parallel to the tibia. Like other long bones it presents a **shaft** and **two extremities**. The **head**, or



upper end, articulates by a flattened facet with the external tuberosity of the tibia, and is prolonged upward, behind, into an apex, forming the **styloid** process, for the attachment of the external lateral ligament of the knee joint and the biceps femoris muscle. The **shaft** is tri-

OSTEOLOGY

angular and twisted, and has **four borders** and **four surfaces**, namely: the *antero-external*, *antero-internal*, *postero-external* and *postero-internal borders*, and the *anterior*, *posterior*, *internal* and *external surfaces*. On the lower extremity is an **external malleolus**, longer than the internal malleolus of the tibia, and this process articulates with the astragalus. The fibula articulates with the tibia and the astragalus. To the fibula are attached the following muscles: biceps femoris, soleus, peroneus longus, brevis and tertius, tibialis posticus extensor longus digitorum, extensor hallucis, and flexor longus hallucis.

THE FOOT

(Illustrations Nos. 71 and 72.)

The **Bones of the Foot** include the seven **Tarsals**, namely: the **calcaneum** or **os calcis**, the **astragalus** or **os talus**, the **cuboid**, the **scaphoid** or **os navicular**, and the **external**, **middle** and **internal cuneiform**; the five **metatarsal** bones, first, second, third, fourth and fifth; and the 14 **phalanges**.

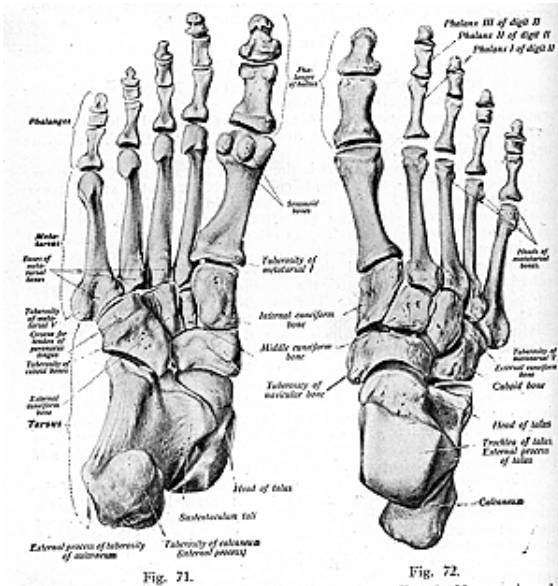
The **calcaneum** or **os calcis** is the largest and strongest of the tarsal bones and it is known as the heel bone. It is situated at the lower and back part of the foot and serves to sustain the weight of the body to the ground, and serves for the attachment to the tendo Achillis. It presents a superior, inferior, anterior, posterior, and an external and internal surface for examination. On its internal surface is a prominence of bone, called the *sustentaculum tali*, to which is attached a part of the tendon of the tibialis posticus and the posterior slip of the deltoid ligament. The os calcis articulates with the two bones, the astragalus and cuboid, and to this bone is attached the tibialis posticus, muscles which form the tendo Achillis, adductor hallucis, adductor minimi digiti, flexor brevis digitorum, extensor brevis digitorum and flexor accessorius; the astragalus articulates with the tibia, fibula, os calcis and scaphoid; the cuboid articulates with the os calcis, external cuneiform and the 4th and 5th metatarsal bones and gives attachment to a slip from the tendon of the tibialis posticus and the flexor brevis hallucis; the scaphoid articulates with the astragalus and the three cuneiform bones and sometimes with the cuboid and it gives attachment to part of the tibialis posticus muscle.

The cuneiform bones: the first or internal articulates with the scaphoid, middle cuneiform, 1st and 2nd metatarsal bones, and gives attachments to the tibialis anticus and posticus and peroneus longus muscles, the second or middle cuneiform articulates with the scaphoid internal and external cuneiform, and second metatarsal bone, and gives attachment to the tibialis posticus; the external cuneiform articulates with the scaphoid, cuboid, middle cuneiform and 2nd, 3rd and 4th metatarsal bones and it gives attachment to the tibialis posticus and flexor brevis hallucis muscles.

The **Metatarsal** bones have prismatic **shafts**, which present **two extremities**. The first metatarsal is shorter and heavier than the others and articulates with the internal cuneiform and second metatarsal and gives attachment to the tibialis anticus and the peroneus longus and first interosseous; the second metatarsal articulates with the internal, middle and external cuneiform, the third metatarsal, and

OSTEOLOGY

sometimes with the first metatarsal, and gives attachment to the adductor hallucis, tibialis posticus, first and second dorsal interossei, and peroneus longus (sometimes); the third metatarsal articulates with the external cuneiform second and fourth metatarsal bones, and gives attachment to the adductor hallucis, tibialis posticus, second and third dorsal and first plantar interossei; the fourth metatarsal with the cuboid, third metatarsal, fifth metatarsal and external cunei-



form, and gives attachment to the adductor hallucis, tibialis posticus and third and fourth dorsal, and second plantar interossei; the fifth metatarsal bone articulates with the cuboid and fourth metatarsal, and it gives attachment to the peroneus brevis and tertius, flexor minimi digiti, adductor hallucis, fourth dorsal, and third plantar interossei. The **Phalanges** of the foot are fourteen in number, two segments

OSTEOLOGY

for the great toe, and three for the lesser toes. Their distal ends, like those of the phalanges of the hand, are expanded and rough for the support of the pulp of the toe, and for the support of the nails. The phalangeal articulations are as follows: the first row articulates with the metatarsal bones behind and second phalanges in front; the second row of the four outer toes with the first and third phalanges; of the great toe with the first phalanx; the third row of the four outer toes, with the second phalanges. To the phalanges of the foot are attached the extensors, flexors, abductors and adductors of the toes.

SYNDESMOLOGY AND ARTHROLOGY

Syndesmology is that branch of anatomy which treats of ligaments.

Arthrology is that branch which is the study of joints and articulations.

An **Articulation** is a junction between, or the union of, bones which are movable when indirectly united and immovable when directly united.

A **Joint** is a place, or part, where two things, or parts, are joined together, or united, such as the union of two or more smooth or even surfaces admitting of a close fitting or junction, whether movable or immovable; or a joint is the part, or the arrangement or mechanism of the part, where two bones of a body are joined, especially when so as to admit of motion.

A **Ligament** is a tough band of fibres which binds bones together. The ligaments consist of bands of various forms, which serve to connect the articular extremities of bones. They are composed mainly of coarse bundles of very dense, white fibrous tissue, placed parallel with, or closely interlaced with, one another, presenting a white shining silvery aspect. A ligament is pliant and flexible to allow of the utmost perfection of movement, but it is strong and tough to withstand the most severely applied force, and so is well adapted to serve as the connecting medium between the bones. Some ligaments consist entirely of yellow elastic tissue, as the ligamenta subflava and the ligamentum nuchae, and in these cases it will be observed that the elasticity of the ligament is intended to act as a substitute for muscular power. Some of the ligaments support viscera. Some are folds of fascia, and still others are the indurated folds of peritoneum, or the relics of disused fetal organs.

Joints, articulations and ligaments are classified as being of the head, trunk, or extremities.

The **tissues** which enter into formation of a joint are:—*bone, cartilage, ligaments, synovial membrane, muscles, blood-vessels and nerves.*

Joints have various kinds of motion, such as flexion, extension, adduction, abduction, rotation and circumduction.

Synovial Membrane, or Stratum Synoviale, is a basement membrane which secretes a viscid, glairy, transparent, alkaline secretion, resembling the white of an egg, serous in character and often called the joint oil. There are three kinds of synovial membrane: the **articular**, which covers the articular ends of bone, lubricating the joints; the **bursal**, forming closed sacs (bursae), interposed between the surfaces which move upon each other, as in the extremities; and the **vaginal**, which lines fibro-osseous canals where tendons glide, serving as a sheath for the tendon. Synovial bursae are frequently found in places other than the interior of joints. They are developed for the purpose of reducing friction in such places as between the skin and prominent subcutaneous projections of bone, as at the point

of the elbow, or where the patella glides over the femur, or, they may be found wherever a group of tendons play.

The articulations are classed in three divisions:—**Synarthrosis**, the immovable; **Amphiarthrosis**, partly movable, having limited motion; and the **Diarthrosis**, the freely movable.

The **Synarthroses**, which have no cartilage, are subdivided into the **suture vera** (true seam), **suture notha** (false seam), **schindyleses**, **gomphoses**, and **synchondroses**. These include all those articulations in which the surfaces of the bones are in almost direct contact, and are fastened together by connective tissue. Such have no appreciable motion, no synovial membrane, nor cartilage, and are the joints found between the bones of the cranium and face, excepting the temporo-mandibular joint.

Examples of the synarthroses are the **suture vera**, which are further subclassed as *dentata* (tooth-like), the inter-parietal suture *sutura serrata* (saw-like), the interfrontal suture, and the *sutura limbosa* (bevelled), as the fronto-parietal suture; and the **suture notha**, which are also subclassed as the *sutura squamosa* (*overlapping*), the temporo-parietal suture, and the *sutura harmonia* (*direct apposition*), the inter-maxillary suture; a **schindylesis** is found where a plate of bone is received between two portions of another, as the articulation of the sphenoid with the vomer, or of the vomer between the two maxillae and the palate bones; the **gomphosis** (socket like) is that form of an articulation seen where the teeth are received into their alveoli; the **synchondrosis** is a union of bones by fibro-cartilage, a temporary form of joint, since the cartilage becomes bone before adult life. This form is found in epiphyseal lines and between the occipital and the sphenoid at, and for some time after birth. (See Fig. 13.)

The **Amphiarthroses** have limited motion, and represent the joints in which the surfaces are connected by discs of fibro-cartilage. They are subdivided into the **symphyses**, and the **syndesmoses**. A **symphysis joint** is that form of articulation found where two surfaces are connected by fibro-cartilage. Examples are the joints between the bodies of the vertebrae, the inter-sternal joints, and the symphysis pubis. A **syndesmosis** joint is formed where the surfaces of bones are united by interosseous ligaments. Examples of the syndesmoses are the middle radio-ulnar, the middle tibio-fibular, the middle inter-metacarpal, and the middle inter metatarsal joints.

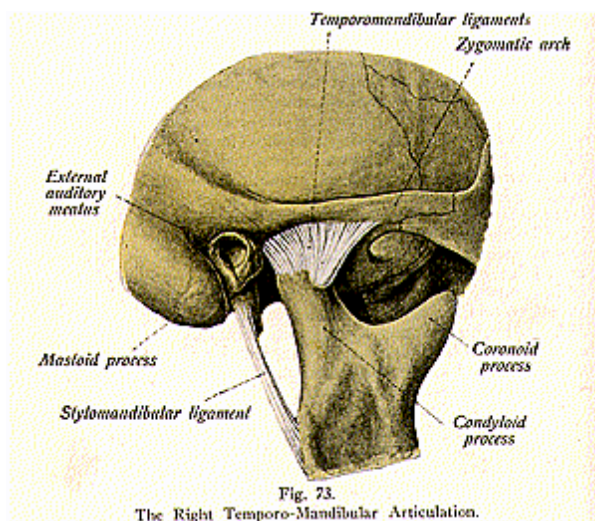
The **Diarthroses** are the movable joints. They always have synovial membrane and cartilage, and are subdivided into the **enarthrosis** or **ball-and-socket joints**, the **ginglymus** or **hinge joint**, the **trochoides** or **pivot joints**, the **condyloid joints**, the **reciprocal reception** or **saddle joint**, and the **arthrodia** or **gliding joints**. An **enarthrodial**, or **ball-and-socket**, joint is found where there is motion in all directions, and in this form a large globular head fits into a cup-like cavity. Examples of the enarthroses are the hip and shoulder joints. A **ginglymus**, or **hinge joint**, is found where motion is limited to two directions, backward and forward; examples of this form of articulations are the temporo-mandibular joint, the elbow, knee, ankle, wrist and the inter-phalangeal joints.

The **trochoides**, or **pivot joints**, are found where a pivot is fitted

into a ring, or a rotary joint turns within a ring, as in the superior radio-ulnar and the atlanto-axial joints. The **condyloid joints** are found where condyles enter into formation of the joint, or where an oval head is received into an elliptical cavity, and examples are the elbow, knee, occipito-atlantal, and the temporo-mandibular joints.

The **reciprocal reception**, or **saddle-joint**, has the saddle-shaped surfaces, that is, where two articular surfaces are convex in one direction and concave in the other. The only true example of this form of joint is the carpo-metacarpal joint of the thumb.

The **arthrodia**, or the **gliding joints**, are found where two plane surfaces glide over each other, and examples are the inter-carpal,



the inter-tarsal joints, the ribs with the vertebrae, and the articulations of the articulating surfaces of the vertebrae.

The interior of the joint, the muscle moving it, and the skin over the insertions of the muscle, are all supplied by the same trunk, or trunks, of nerves.

THE ARTICULATION OF THE LOWER JAW

(Illustration No. 73.)

In describing an articulation the following outline will be of assistance to the student. The *classification* of the joint, the *sub-classification*, the *bones which form the joint*, the *ligaments* which hold the bones together and the *kind of synovial membrane* found in that particular kind of an articulation.

The articulations of the head belong to the synarthrodial joints, excepting only the **temporo-mandibular articulation**. It is a diarthrodial joint, and is subclassed as a ginglymus, an arthrodial and a condyloid joint. This joint is formed by the temporal and mandible, between the condyle of the lower jaw and the glenoid fossa of the temporal bone.

The **ligaments** which hold these parts together are the **external lateral**, extending from the tubercle of the zygoma of the temporal bone to the outer side of the neck of the condyle of the lower jaw; the **internal lateral** ligament, from the spine of the sphenoid to the dental foramen of the mandible; the **stylo-mandibular**, from the styloid process of the temporal bone to the angle of the mandible; and the **capsular**, which passes between the mandible and the temporal bones, near the margins of the glenoid fossa and the neck of the lower jaw, and which consists of ligamentous fibres, thick at the back part of the joint. This joint has two **synovial membranes** with an interarticular fibro-cartilage between them.

ARTICULATIONS OF THE TRUNK

1. **Vertebral**—between the vertebrae.
2. **Atlanto-axial**—between the atlas and axis.
3. **Occipito-atlantal**—between the occipital bone and atlas.
4. **Occipito-axial**—between the occipital bone and axis.
5. **Costo-vertebral**—between the ribs and the vertebrae.
6. **Costo-chondral**—between the ribs and the costal cartilages.
7. **Intersternal**—between the segments of the sternum.
8. **Spino-pelvic**—between the spine and pelvis.
9. **Inter-pelvic**—between the pelvic bones.

THE ARTICULATIONS OF THE UPPER EXTREMITY

1. **Sterno-clavicular**—between the sternum and the clavicle.
2. **Coraco-clavicular**—between the scapula and clavicle.
3. **Acromio-clavicular**—between the scapula and clavicle.
4. **The scapula proper**—between parts of the scapula.
5. **Shoulder Joint**—between the brachium and scapula.
6. **Elbow Joint**—between the radius, ulna and brachium.
7. **Superior radio-ulnar**—between the radius and ulna.
8. **Middle radio-ulnar**—between the radius and ulna.
9. **Inferior radio-ulnar**—between the radius and ulna.
10. **Wrist joint** between the radius, scaphoid and semilunar bones.
11. **The intercarpal joint**—between the carpal bones.
12. **The carpo-metacarpal**—between the carpal and metacarpal bones.
13. **Metacarpo-phalangeal**—between the metacarpal and the phalanges.
14. **Inter-phalangeal**—between the phalanges

THE ARTICULATIONS OF THE LOWER EXTREMITY

1. **The Hip Joint**—between the femur and the innominate bone.
2. **Knee Joint**—between the femur, tibia and patella.

3. **Superior tibio-fibular**—between the tibia and fibula.
4. **Middle tibio-fibular**—between the tibia and fibula.
5. **Inferior tibio-fibular**—between the tibia and fibula.
6. **Ankle joint**—between the tibia, fibula and astragalus.
7. **Intertarsal**—between the tarsal bones.
8. **Tarso-metatarsal**—between the tarsal and metatarsal bones.
9. **Metatarso-phalangeal**—between the metatarsal bones and the phalanges.
10. **Interphalangeal**—between the phalanges.

THE VERTEBRAL ARTICULATIONS

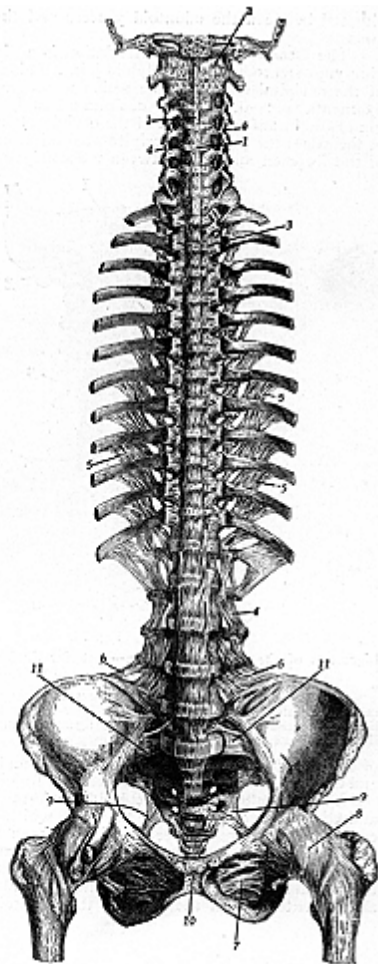
The **Vertebral Articulations** are formed by the adjacent surfaces of the bodies of the vertebrae, the articular, spinous, and transverse processes, and they are connected by the following ligaments:

Anterior common ligament—lies over the anterior surfaces of the bodies; **posterior common ligament**—lies over the posterior surfaces of the bodies, **ligamenta subflava**—yellow elastic ligaments connecting the laminae, from the internal surface of the one above, to the upper edge of the one below; **supra-spinous**—connecting the tips of the spinous processes, **inter-spinous**—found between the spinous processes; **inter-transverse**—short fibres connecting the transverse processes; **capsular**—surround the articular processes, and are lined with synovial membrane; the **ligamentum nuchae**—the upper thickened portions of the supra-spinous ligament, extending from the seventh cervical spinous process to the external occipital protuberance forming in man merely a strip of fibres, but in the lower animals serving to sustain the weight of the head; and the **intervertebral** connecting **fibro-cartilage**, or **disc**, attached firmly to the upper and lower surfaces of the bodies of the vertebrae, except the atlas and the axis. They are known as the circumferential cartilages, and are pulpy and elastic in the center. The intervertebral discs are adherent, by their surfaces, to a thin layer of hyaline cartilage which covers the upper and lower surfaces of the bodies of the vertebrae, and in which, in early life, the epiphyseal plates develop.

The **Atlanto-Axial Articulation**, a diarthrodial joint, is subclassed as an arthroial and a pivot joint. It is formed between the atlas and the odontoid process of the axis. Its **ligaments** are: the two **anterior atlanto-axial**, between the lower front border of the atlas and the front of the axis, the **posterior atlanto-axial**, from the posterior inferior edge of the ring of the atlas to the superior edge of the axis both these ligaments appear to be continuations of the anterior and posterior ligaments; the **capsular ligament** surrounds the articulating surfaces, each lined with synovial membrane; the **transverse ligament** stretches between the tubercles on the inner surface of each lateral mass of the atlas. This ligament divides the spinal foramen into two portions, the anterior part contains the odontoid process, and the posterior the spinal cord and its membranes. Passing upward and downward from the transverse ligament are two bands, from which it is named the **cruciform** or **cruciate ligament**. A **synovial membrane** is

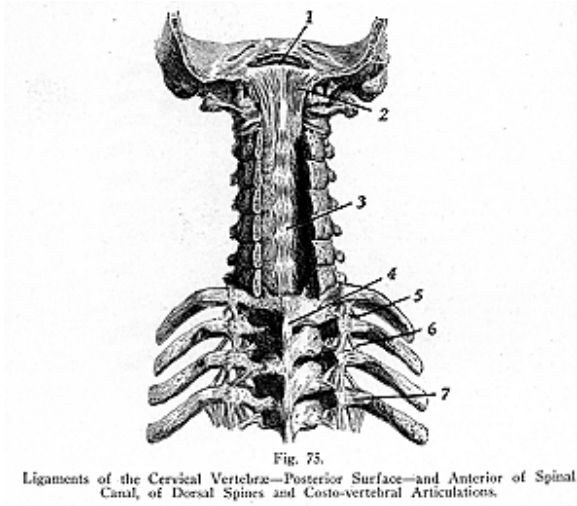
Fig. 74.
Ligaments of the
Vertebrae, Sternal
End of Ribs, Pelvis
and Iliacmoral
Articulation — An-
terior Surface.

1. Anterior common ligament.
2. Anterior occipito-atlantoid ligament.
3. Costo-vertebral ligament.
4. Intertransverse ligament.
5. Intercostal ligament.
6. Iliolumbar ligament.
7. Obturator ligament.
8. Capsular ligament.
9. Lesser sciatic ligament.
10. Inter-pubic ligament.
11. Sacrotitac ligament.



situated between the odontoid process and the anterior arch of the atlas.

The **Occipito-Atlantal Articulation** is a diarthrodial joint, also a ginglymo-arthrodial and condyloid joint. It is formed by the condyles of the occipital bone and the articular processes of the atlas. The **ligaments** are:—the **anterior occipito-atlantal**, from the anterior margin of the foramen magnum of the occipital bone, to the anterior arch of the atlas; the **posterior occipito-atlantal**, from the posterior margin of the foramen magnum between the condyles, to the posterior arch



of the atlas; two **capsular ligaments** surround the articular surfaces, and are lined with synovial membrane. (Illustration No. 76.).

The **Occipito-Axial Articulation** is formed by the occipital bone and the odontoid process of the axis, which do not articulate with each other but are connected with ligaments. The **ligaments** are: the **occipito-axial** or **occipito-cervical ligament**, extends upward from the axis to be attached to the basilar process of the occipital bone; the **lateral ligaments**, or **check ligaments**, or **alar ligaments (ligamenta alaria)**, extend from the sides of the odontoid process to the inner

edge of the occipital condyles; the **middle odontoid ligament**, or **ligamentum suspensorium**, extends from the apex of the odontoid process to the anterior margin of the foramen magnum. (Illustration No. 76.).

ARTICULATIONS OF THE RIBS WITH THE VERTEBRAE

The **Costo-Vertebral Articulations** (illustrations Nos. 74 and 75) are each a double arthrodioid joint, between the head of the rib and the bodies of the two adjoining vertebrae, except in the 1st, 10th, 11th and 12th ribs, which articulate with but one vertebra each. The **ligaments** are, the **anterior costo-vertebral**, or **stellate**, or **radiate**, which consists of three bundles or slips, of fibers, extends from the head of the rib to the sides of the bodies of two adjacent vertebrae and to the intervening intervertebral disc; the **intra-articular** is situated in the in-

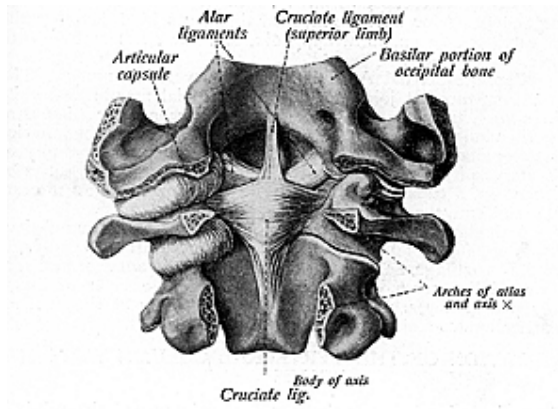


Fig. 76.

View Showing the Articulations Between the Occiput, Atlas and Axis.

terior of the joint from the head of the rib to the intervertebral disc; and the **capsular** surrounds the articular surfaces.

The **Costo-Transverse Articulations** are arthrodioid, ten in number, found between the tubercles of the first ten ribs and the transverse processes of the vertebrae next below. The **ligaments** are the **anterior**, **middle** and **posterior costo-transverse**. The **anterior costo-transverse ligament** extends from the neck of the rib, to the side of the transverse process of the vertebra next above; the **middle costo-transverse ligament**, from the neck of the rib, to the anterior surface of the transverse process of the vertebra next below; the **posterior costo-transverse ligament**, from the tubercle of the rib, to the summit of the transverse process of the vertebra next below. The **capsular ligament**

is a thin membranous sac, attached to the circumference of the articular surfaces. It encloses a **synovial membrane**.

ARTICULATION OF THE RIBS WITH THE CARTILAGES

The **Costo-Chondral** and **Inter-Chondral Articulations** connect the costal cartilages with the ribs and with each other; with the ribs by a depression on the end of each rib, and held there by a continuity of periosteum and perichondrium.

ARTICULATIONS OF THE STERNUM AND ITS CARTILAGES

The **Interchondral Articulations**, classed as **arthrodia**, are found between the edges of the cartilages, from the fifth to the ninth, and sometimes to the tenth, costal cartilages. These articulations are surrounded by articulate capsules lined with synovial membrane. The **anterior** and **posterior chondro-xiphoid** ligaments bind together the xiphoid cartilage, or ensiform appendix, and the sixth and seventh cartilages.

The **Chondro-Sternal Articulations** are seven in number. The first is a synarthrodial joint and has no synovial membrane, while the others are arthrodial. They are formed between the cartilages of the true ribs and the sternum. Each has four **ligaments**, the **anterior** and **posterior chondro-sternal**, which radiate from the front and posterior surfaces of the true ribs to the anterior and posterior surfaces of the sternum, a **capsular**, around the articulations, and an **interarticular**, found between the articulations.

The **Articulation of the Sternum**, found between the manubrium and gladiolus, forms an amphiarthrodial joint, united by a single piece of fibro-cartilage, and further connected by the **anterior** and **posterior sternal ligaments**. These latter consist of a layer of longitudinally placed fibres, which blend with the fibres of the anterior and posterior chondro-sternal ligaments.

ARTICULATION OF THE VERTEBRAL COLUMN WITH THE PELVIS

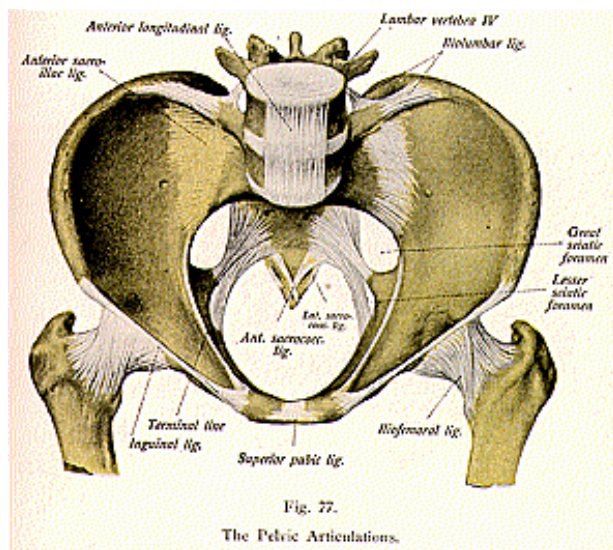
The articulation between the vertebral column and the pelvis is called the **spino-pelvic articulation**. It is formed between the last lumbar vertebra, the sacrum, and the innominate bones. The ligaments which connect the 5th lumbar vertebra with the sacrum are similar to those which connect the segments of the vertebral column with each other. These include the downward continuation of the anterior and posterior common ligaments, the intervertebral substance found between each two articulating segments, the ligamenta subflava, connecting the arch of the last lumbar vertebra with the posterior border of the sacral canal, the inter- and supra-spinous ligaments, and the capsular ligaments.

The **ligaments** which hold the 5th lumbar vertebra to the sacrum and to the innominate bone are short thick bands, the **lumbo-sacral** and the **ilio-lumbar** ligaments. The **lumbo-sacral** ligament extends from the front of the transverse process of the 5th lumbar vertebra, to the lateral and anterior surface of the sacrum. The **ilio-lumbar**

ligament extends from the tip of the transverse process of the 5th lumbar vertebra, to the crest of the ilium.

ARTICULATIONS OF THE PELVIS

The **Sacro-Iliac Articulations** (illustrations Nos. 77 and 78) are **syndesmoses**, found between the articular surfaces of the ilium and sacrum. The ligaments are the **anterior sacro-iliac**, thin bands of fibers connecting the anterior surfaces of the sacrum and ilium; the **posterior**



sacro-iliac, a strong ligament uniting their posterior borders together; and the **interosseus ligament**, the strongest of all, passing between the contiguous rough surfaces of the sacrum and ilium. The **ligaments** connecting the sacrum and the ischium, on each side, are the **great** and the **lesser sacro-sciatic ligaments**. The **great sacro-sciatic ligament**, or **sacro-tuberosum**, the posterior ligament, is situated at the lower and back part of the pelvis. It consists of a thick, triangular, flat band of fibres extending from the inferior and posterior spine of the ilium and the posterior margins of the sacrum and coccyx to the inner margin of the tuberosity of the ischium, thence it is extended forward along the inner margin of the ramus, forming the **falciform ligament**, or **processus falciformis**.

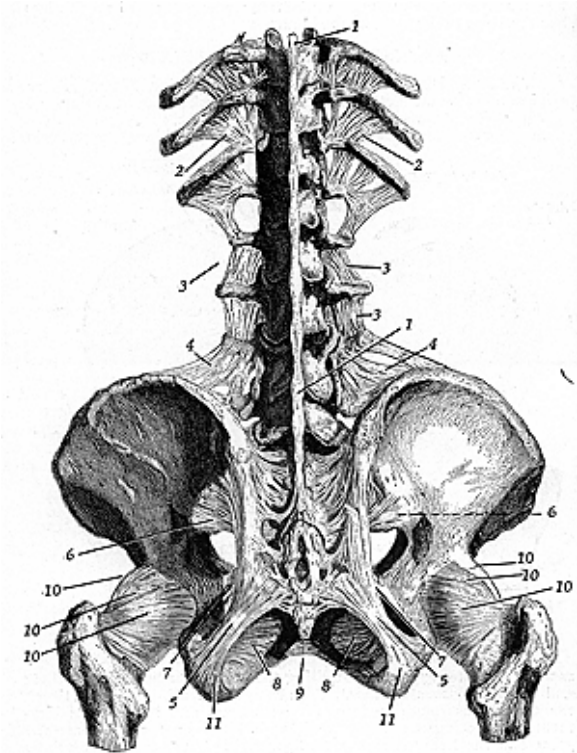


Fig. 78.
Posterior Ligaments of Spinal Column, Pelvis and Ilio-Femoral Articulations.

The great sciatic ligament converts the lesser sciatic notch into a foramen, thru which pass the tendon of the obturator internus muscle, the obturator nerve, and the internal pudic vessels and nerve.

The **lesser sciatic**, or **sacro-spinosum, ligament**, smaller and shorter than the great sciatic, is attached to the lateral margin of the sacrum and the coccyx, and extends to the apex of the spine of the ischium. It converts the great sciatic notch into a foramen, thru which pass the tendon of the piriformis muscle, superior gluteal vessels and nerve, the inferior gluteal nerve, internal pudic vessels and nerve, and the sciatic vessels and nerves.

The **Articulation of the Sacrum and the Coccyx** is an amphiarthrodial joint formed between the oval surface of the apex of the sacrum and the base of the coccyx. The **ligaments** are the **anterior sacro-coccygeal**, a continuation of the anterior common ligament, the **posterior sacro-coccygeal**, a continuation of the posterior common ligament, and a portion of which corresponds to the ligamenta subflava, the **lateral sacro-coccygeal**, or **intertransverse**, which connects the transverse process of the coccyx to the lower lateral angle of the sacrum on each side, and lastly the **inter-articular fibro-cartilages**, interposed between the bodies of the segments of the sacrum and coccyx, like those between the vertebrae.

The **Pubic Articulation** is an amphiarthrodial joint, of the symphysis class, and is formed by the junction of the two pubic bones with each other. The **ligaments** are the **anterior pubic**, which passes across the front of the articulation, the **posterior pubic**, a few thin fibres which unite the two pubic bones posteriorly, the **supra-pubic**, connecting the two pubic bones superiorly, the **infra-pubic**, a thick band connecting the two pubic bones below, and the **interpubic disc**, consisting of a disc of fibro-cartilage connecting the surfaces of the pubic bones in front.

THE ARTICULATIONS OF THE UPPER EXTREMITY

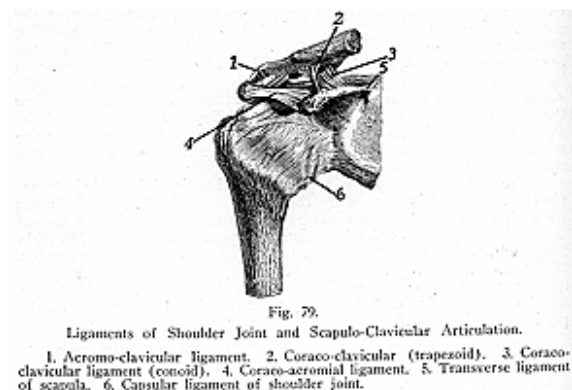
(Illustrations Nos. 79, 80, 81, 82, 83 and 84.)

The **Sterno-Clavicular Articulation** is an arthrodial joint, formed by the sternal end of the clavicle in its articulation with the sternum and the cartilage of the first rib. The joint has an interarticular fibro-cartilage, and the **ligaments** are: the **anterior** and **posterior sterno-clavicular**, strengthening the anterior and posterior parts of the joint; the **capsular**, surrounds the articular margins; the **interclavicular ligament** is a flattened band which varies in thickness, and extends from the posterior superior angle of the inner extremity of each clavicle, to the upper margin of the sternum; and the **costo-clavicular**, or **rhomboid ligament**, is rhomboid in form, and stretches from the upper border of the first costal cartilage to a depression on the under surface of the clavicle.

The **Acromio-Clavicular Articulation** is an arthrodial joint, formed by the outer extremity of the clavicle and the acromion process of the scapula, it rarely has an inter-articular fibro-cartilage, and often has only one synovial sac. The **ligaments** are the **superior acromio-clavicular**, and the **inferior acromio-clavicular**, composed of fibers which unite the articulating surfaces of the joint anteriorly and

posteriorly, and form a complete capsule around the joint; and the **coraco-clavicular**, composed of the **conoid** and **trapezoid** ligaments. The **conoid ligament** is attached to the rough impression at the base of the coracoid process, and extends to the conoid tubercle of the clavicle; the **trapezoid ligament** extends from the upper surface of the coracoid process, to the oblique line on the under surface of the clavicle.

The **Ligaments of the Scapula** are the **coraco-acromial** and the **transverse**. The **coraco-acromial** is a triangular band, attached by its apex to the summit of the acromion process, and to the whole length of the outer border of the coracoid process. This ligament completes



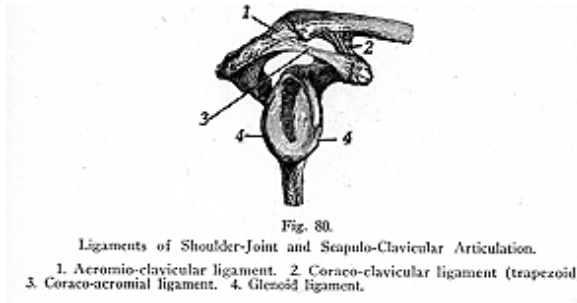
the vault partially formed by the coracoid and acromion processes, for the protection of the head of the humerus.

The **transverse ligament**, or **suprascapular ligament**, a thin and flat band, converts the **suprascapular** notch into a foramen. The suprascapular nerve passes thru the foramen, the suprascapular vessel passes over the ligament. An additional ligament, the **inferior**, or **spino-glenoid**, is a very slender ligament, which stretches from the outer border of the spine to the outer margin of the glenoid cavity and, when present, forms an arc, under which the suprascapular vessels and nerve pass on their way to the infra-spinous fossa.

The **Shoulder Joint** is diarthrodial, and is subclassed as a ball-and-socket, or enarthrodial joint. The bones which form it are the head of the brachium and the glenoid cavity of the scapula. The **ligaments** are the **capsular**, **coraco-humeral**, **transverse**, and the **glenoid**. The **capsular** ligament extends from the margin of the glenoid cavity above, to the anatomical neck of the humerus below, and completely encircles the articulation. The **coraco-humeral**, consisting of a broad

band of fibres, arises from the outer border of the coracoid process and passes obliquely downward and outward to the front of the great tuberosity of the humerus, being intimately united with the capsular, and strengthening the upper part of the capsular ligaments.

The **glenoid ligament**, triangular on section, is a dense fibro-cartilaginous rim attached around the margin of the glenoid cavity, which it deepens, also protecting the edges of the bone. It is continuous above with the long head of the biceps muscle. The **transverse ligament**, a prolongation of the capsular ligament, is a broad band of fibrous tissue, passing from the greater to the lesser tuberosity of the humerus, it converts the bicipital groove into a canal, and serves to hold the tendon of the biceps brachii in position. The **gleno-humeral**, superior and middle and inferior are small bands extending from the margin of the glenoid cavity, to the lesser tuberosity and



anatomical neck of the humerus. These ligaments are known as supplemental bands of the capsular ligaments and old terms for them are *Flood's*, and *Schlem's* ligaments.

The **synovial membrane** is reflected, from the margins of the glenoid cavity, over the fibro-cartilaginous rim surrounding it, and upon the anatomical neck of the humerus as far as the articular margin. It gives a synovial sheath to the long tendon of the biceps brachii, which passes thru the capsular ligament. Numerous bursae exist between the joint capsule and the tendons of several surrounding muscles. The movements of the joints are not regulated by the capsule (whole primary office is not to maintain apposition but to limit motion), so much as by the surrounding muscles and atmospheric pressure.

The shoulder joint is capable of movement in every direction, flexion, extension, abduction, adduction, circumduction and rotation. Some of the peculiarities of the shoulder joint, are:—the large size of the head of the humerus, compared with the depth of the glenoid cavity; the thinness and great laxity of the capsule, which, if fully distended, would accommodate a bulk twice as large as the head of the

humerus; the length of the humerus, affording a very long leverage; and the exposed position of the shoulder. All of these circumstances favor dislocation, and render this joint a more frequent subject of accident than is any other joint in the body.

The **Elbow Joint** is a diarthrodial joint, and subclassed as a ginglymo-arthrodioid, and condyloid joint. It is formed by the lower end of the humerus, in its articulation with the greater sigmoid cavity of the ulna and the head of the radius. The **capsular** ligament is the principal ligament, it surrounds the joint, while its thickened portions are usually described as distinct ligaments under the following

names: **anterior**, **posterior**, **external lateral** and **internal lateral**. The **anterior ligament** extends from the internal condyle and front of the humerus, above the radial and coronoid fossae, to the anterior surface of the coronoid process of the ulna, and to the orbicular ligament of the radius, the **posterior ligament** extends from the posterior and lower end, of the humerus to the olecranon process of the ulna, the **external lateral** is attached, above, to the external condyle of the humerus, below the orbicular ligament and to the outer and upper margin of the ulna; the **internal lateral ligament**, by two parts, an anterior and a posterior, extends from the internal condyle of the humerus, to the coronoid and olecranon process of the ulna.

The **synovial membrane** is very extensive. It covers the articular surface of the humerus, lines the coronoid and olecranon fossae, and forms a pouch between the lesser sigmoid cavity, internal surface of the orbicular ligament, and the radius. Pads of fat lie between folds

of the synovial membrane in its relation to the coronoid, olecranon and radial, fossae.

The **Superior Radio-Ulnar Articulation** is a trochoides, or pivot joint, and is formed by the head of the radius and the lesser sigmoid cavity of the ulna, its synovial membrane is continuous with that of the elbow joint. Only one **ligament** is found here, the **orbicular ligament**, or **ligamentum annulare radii**, or **annular ligament** of the elbow joint, as it is sometimes called. This ligament is a strong flat band of fibres which surrounds four-fifths of the head of the radius, and holds it in firm position. It is attached to the margins of the

lesser sigmoid cavity of the ulna, and to the external lateral ligament of the elbow joint.

The **Middle Radio-Ulnar Articulation** is formed by the shafts of the radius and ulna, which do not touch each other but are connected by the **oblique** and the **interosseous ligaments**. The **oblique ligament** is a slender band of fibres which extend from the tubercle at the base of the coronoid process of the ulna, to the shaft of the radius a little below the bicipital tuberosity. The **interosseous** ligament passes obliquely downward and inward, from the interosseus ridge of the radius to that of the **ulna**.

The **Inferior Radio-Ulnar Articulation** is a pivot joint, and is formed by the head of the ulna, in its articulation with the sigmoid cavity, on the inner side of the lower end of the radius. The **liga-**

ments which hold this joint in place are three in number. The **anterior** and **posterior radio-ulnar ligaments** are usually described as portions of the capsular ligament, and extend, respectively, between the two anterior margins and two posterior margins of the articular surfaces. The **triangular fibro-cartilage** is triangular in shape and separates the head of the ulna from the wrist joint. It is attached, by its apex, to a depression lying between the styloid process of the ulna and the head of that bone, by its base, to the margin of the radius below the sigmoid cavity. Both articular surfaces are covered with **synovial mem-**

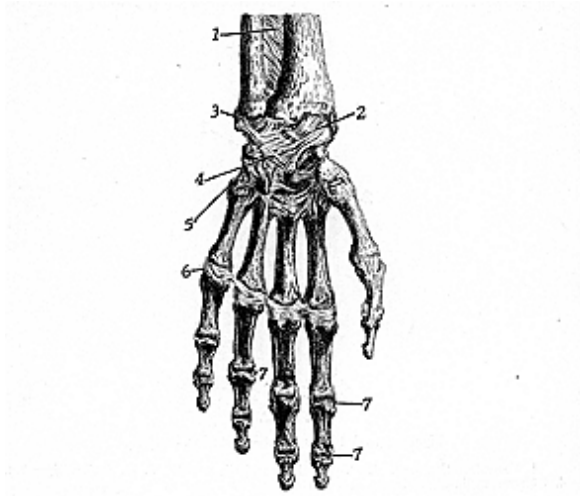


Fig. 83.

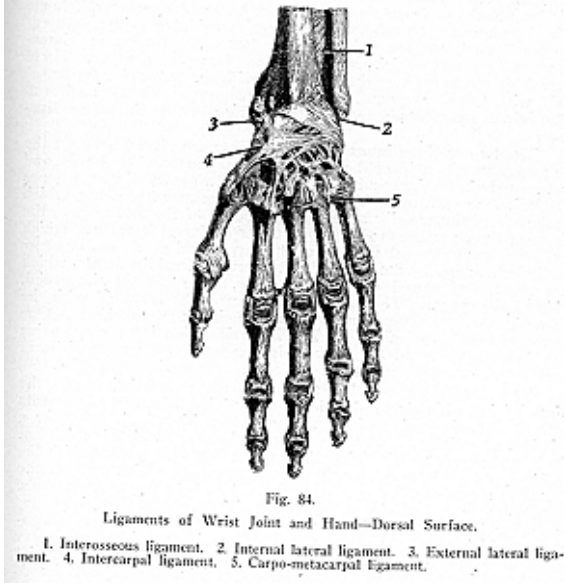
Ligaments of Wrist Joint and Hand—Anterior Surface.

1. Interosseous ligament. 2. Anterior radio-carpal ligament. 3. Triangular cartilage. 4. Anterior carpal ligament. 5. Anterior carpo-metacarpal ligament. 6. Metacarpo-phalangeal ligament. 7. Interphalangeal articulation.

brane. This is very loose, and lines the anterior and posterior ligaments, and, between the radius and ulna, it forms a loose cul-de-sac known as the *recessus sacciformis*.

The **Wrist Joint** is diarthrodial, and ginglymo-condyloid. It is formed by the lower end of the radius, and the triangular fibro-cartilage, articulating with the scaphoid, semilunar and cuneiform carpal bones, all of which latter form the condyles. The articular surface

of the radius and the articular disc form the cavity. The **capsular ligament** is divided into four ligaments, the **external lateral**, which extends from the styloid process of the radius to the scaphoid; **internal lateral**, from the styloid process of the ulna, by two slips to the pisiform and cuneiform bones; the **anterior ligament**, from the anterior margins of the radius and ulna, to the scaphoid, semilunar and cuneiform, sometimes some fibres are attached to the os magnum; the **posterior ligament**, or **dorsal ligament**, is attached to the posterior border



of the radius, and to the posterior surfaces of the scaphoid, semilunar and cuneiform bones. The **synovial membrane** lines the inner surface of the ligaments, it is loose, and lax, and presents numerous folds.

The **Inter-Carpal Articulations** are diarthrodial, mostly arthrodial, and consist of the joints between the bones of the first row those between the bones of the second row, and the articulations of the two rows with each other.

The **ligaments** which connect the scaphoid, semilunar, and cunei-

form, of the first row, are the **dorsal, palmar** and **interosseous ligaments**. The dorsal ligaments, placed transversely behind the bones of the first row, connect the scaphoid and semilunar, and the semilunar and cuneiform; the **palmar ligaments** connect the scaphoid and semilunar, the semilunar and cuneiform, and are placed on the palmar surface of the carpus; the **interosseous** ligaments, two or three in number, connect the semilunar with the scaphoid, and with the cuneiform. The **capsular ligament** is a thin membrane which connects the pisiform to the cuneiform bone. Two **palmar ligaments** connect the pisiform to the unciform, and to the base of the fifth metacarpal bone. The four bones of the second row, the trapezoid, trapezium, os magnum and unciform, are united by the **dorsal, the palmar** and **interosseous ligaments**, which extend from one bone to the other. These **dorsal ligaments** connect the trapezium with the trapezoid, the trapezoid with the os magnum, and the os magnum with the unciform. The **palmar ligaments** have a similar arrangement on the **palmar surface**.

The two or three **interosseous ligaments** are placed between the os magnum and unciform, between the os magnum and trapezoid, and between the trapezium and trapezoid. The two rows of carpal bones are united to each other by the anterior or **palmar ligaments**, which extend from the anterior surface of the bones of the first row, to the front of the os magnum; by the **posterior** or **dorsal ligaments**, which extend from the dorsal surfaces of the carpus and pass from one row to the other; and by the **exterior** and **interior lateral ligaments**, which are short, and placed one on the ulnar, the other on the radial, side of the carpus. These ligaments connect the scaphoid with the trapezium, and the trapezium with the cuneiform and unciform. One **synovial membrane** of the intercarpal articulation is very extensive and is common to all the carpal joints except between the pisiform and the cuneiform, where there is a separate synovial membrane.

The **Carpo-Metacarpal Articulations** are arthrodial, except the thumb joint, which is a saddle-joint. This joint enjoys all movements except that of rotation of the metacarpal on its axis, it possesses a distinct synovial sac, and has a capsular ligament, which is thick but loose and surrounds the joint. The other four metacarpals, with the adjacent carpal bones, have the **dorsal ligaments**, which connect the carpal and metacarpal bones on their dorsal surfaces, the **palmar ligaments**, on the anterior surfaces of the joints, except the third metacarpal which has three ligamentous slips, and the **interosseous ligaments**, which connect the os magnum, and unciform, with the adjacent surfaces of the third and fourth metacarpal bones. One synovial membrane is common to all the metacarpal joints, and synovial sacs may be found between the articulations.

The **Articulations of the Metacarpal Bones** with each other are arthrodial joints at their articulate extremities and interosseous joints between their contiguous surfaces. The arthrodial joints are formed by the carpal extremities of the four inner metacarpal bones, articulating with one another at either side by small surfaces covered with cartilages and held together by the **dorsal** and **palmar** ligaments with **synovial membrane** between the facets. The **interosseous ligaments**

are narrow fibrous bands which pass across from the inner border of the shaft of one bone to the other.

The **Metacarpo-Phalangeal Articulations** are condyloid joints formed by the rounded heads of the metacarpal bones, and the shallow cavities in the extremities of the first phalanges, and each has an **anterior** and two **lateral ligaments**.

The **Interphalangeal Articulations** are ginglymus joints, the **ligaments** are the **anterior** and the two **lateral ligaments**, and each joint has a capsule.

THE ARTICULATIONS OF THE LOWER EXTREMITY

The **Hip Joint** (see illustrations Nos. 74 and 78) is diarthrodial, and is a true ball-and-socket, or enarthrodial, joint. It is formed by the head of the femur and the acetabulum of the innominate bone. The **ligaments** are the **ilio-femoral**, the **ligamentum teres**, the **cotyloid**, **transverse** and the **capsular**.

The **ilio-femoral**, or **Y ligament**, is the strongest ligament in the body. It is attached to the anterior inferior spine of the ilium and by two fasciculi, in an inverted Y shape manner, to the anterior intertrochanteric line of the femur. This ligament is sometimes called the accessory ligament of the hip joint. The **ligamentum teres**, or **round ligament**, is not round, but flattened and triangular. It is formed of white fibrous tissue, and extends from a depression on the head of the femur, the teres depression, into the margins of the cotyloid cavity, and is there attached to the transverse ligament by two bands. The **cotyloid ligament** is a fibro-cartilaginous ring, is attached around the acetabular cavity, serving to deepen the cavity and, at the same time, it protects the edges of the bone and fills up the inequalities of its articular surface. The **transverse ligament**, a ligamentous band, is that part of the cotyloid ligament which crosses the cotyloid notch, and converts this notch into a foramen, which transmits nutrient vessels to the joint.

The **capsular ligament** is a strong, dense capsule. It is attached to the acetabular margins, to the neck of the femur, to the anterior inter-trochanteric line, and is reflected, like a tube, up to the head of the femur. The capsule is strengthened by three bands,—the *ilio-femoral* band (previously described), the *ischio-capsular* band, a sheet of fibers extending from the ischium to the lower part of the joint, and lastly, the *pubo-capsular*, which consists of a few fibres extending from the pubes to the front and lower part of the capsule. The **synovial membrane** is extensive, it invests almost all of the head and neck of the femur, covers the other ligaments of the joint, and lines the cavity of the acetabulum.

The **Knee Joint** (illustrations Nos. 85 and 86) is diarthrodial chiefly a hinge joint, but it is partly arthrodial because the condyles enter into its formation. The bones which form it are the condyles of the femur and the head of the tibia below, and the patella in front. Its **synovia**, the most extensive of any in the body, sends a prolongation over the front of the femur for two or three inches, also over the condyles, epicondyles, semilunar fibro-cartilages, and the head of the tibia. Numerous fatty pads are found between the folds of synovial

membrane, and serve as pads to fill the spaces between the skin and the patella, between the skin and the ligamentum patellae, between the fascia and the insertion of the quadriceps muscle, between the tendons of the hamstring muscles, between the tendons and the capsule of the knee joint, and between the periosteum of the patella and the tendons of the surrounding muscles and the tibia. The bursa above the patella receives the name of the subcutaneous prepatellar bursa, and that below the patella, the subcutaneous infrapatellar bursa.

The **ligaments** of the knee joint are **six extrinsic** or **external**, and **six intrinsic** or **internal, ligaments**. The **external ligaments** are the **anterior** or **ligamentum patellae**, the **posterior** or **ligament of Win-**

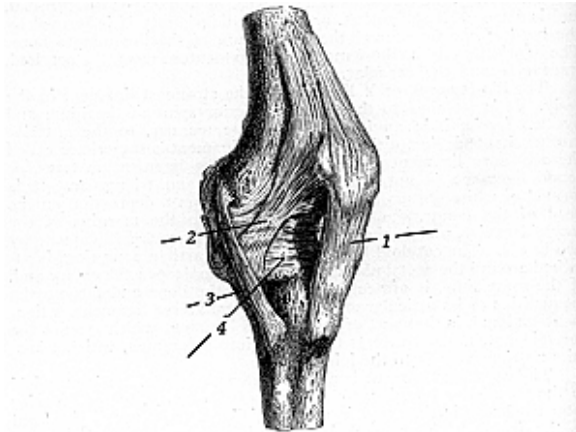


Fig. 85.
Ligaments of Knee Joint—Anterior Surface.

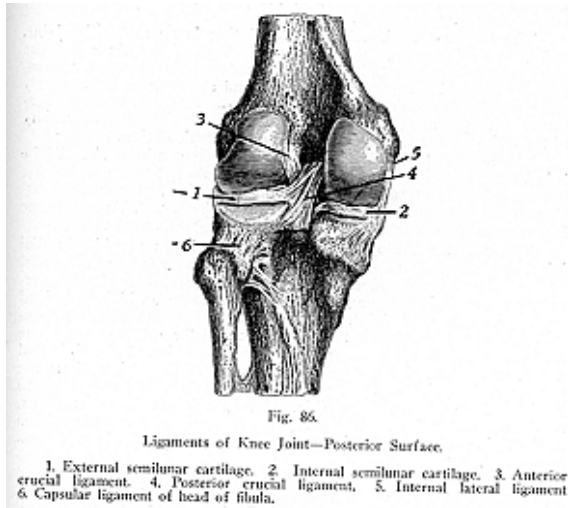
1. Ligamentum patellae. 2. Internal fibers of ligamentum patellae. 3. Internal lateral ligament. 4. Capsular ligament.

slow, the **internal lateral**, the **two external lateral** and the **capsular**. The **internal ligaments** are the **anterior** and **posterior crucial ligaments**, the **two semilunar fibro-cartilages** (internal and external), the **transverse**, and the **coronary ligaments**.

The **ligamentum patellae**, or **anterior ligament** of the knee joint, is about three inches long and one inch broad. It is attached to the apex of the patella, and to the lower part of the tubercle of the tibia; the **posterior ligament** extends from the upper margin of the intercondyloid notch of the femur to the posterior margin of the tibia; the

internal lateral ligament, from the internal epicondyle of the femur, to the inner tuberosity of the tibia and to the internal semilunar fibro-cartilage; the **external lateral ligaments** are two in number, the **long**, or **anterior**, is a rounded cord attached to the external epicondyle of the femur above, and to the end of the fibula below, while the **short**, or the **posterior**, is attached, above to the outer, lower and back part of the tuberosity of the femur, below to the styloid process of the fibula; these ligaments are also known as the tibial and fibular collateral ligaments.

The **crucial ligaments** are two in number, and cross like the limbs of the letter X. They are covered in front and at the sides by



synovial membrane. The **anterior crucial ligament** is attached to a depression in front of the spine of the tibia, and to the inner surface of the back of the outer condyle of the femur; the **posterior crucial ligament** extends from the back part of the depression behind the spine of the tibia, and the popliteal notch, to the outer surface of the inner condyle; the **semilunar fibro-cartilages**, or the **menisci**, are two curved fibro-cartilages, situated between the articular surfaces, which serve to deepen the surface of the head of the tibia, for articulation with the condyles of the femur.

Both surfaces are covered with synovial membrane. Each fibro-cartilage is attached to a depression, one in front and one behind the spine of the tibia and they are attached to the head of the tibia by the coronary ligaments, connected to one another, in front, by the **transverse ligament**, a small thin band of fibers, which passes from one cartilage to the other. The **coronary ligaments** are portions of the capsular ligament, they connect the circumference of each of the semilunar fibro-cartilages with the margin of the head of the tibia. Below the patella, stretching from the front of the joint to the front of the inter-condyloid notch, is a triangular fold of the synovial membrane, called the **ligamentum mucosum**, from whose sides extend, upward and outward to the sides of the patella, the fringe-like folds termed the **ligamenta alaria**.

The **Superior Tibio-Fibular Articulation** is an arthrodial joint and is formed between the facets on the head of the fibula and the outer tuberosity of the tibia. The **ligaments** are the **capsular**, a membranous sac which surrounds the joint and strengthens it anteriorly and posteriorly; the **anterior superior** and the **posterior superior ligaments**, which connect the head of the fibula with the outer tuberosity of the tibia. A synovial membrane lines this articulation.

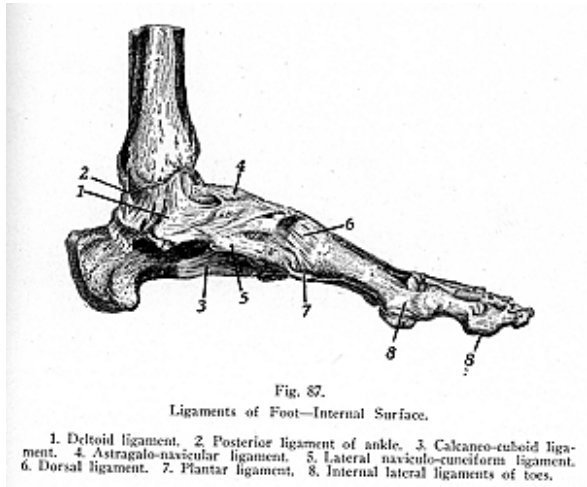
The **Middle Tibio-Fibular Articulation** is a syndesmosis. While it is formed by the shafts of these bones they do not touch each other but are united by an **interosseous membrane** which separates the muscles on the front from those on the back of the leg. This membrane is perforated in numerous places for the passage of small vessels.

The **Inferior Tibio-Fibular Articulation** is an amphiarthrodial joint, and is a syndesmosis, formed by the rough surfaces of the distal ends of the tibia and fibula. These surfaces are covered with cartilages and a limited amount of synovial membrane, which is derived from that of the ankle joint. The **ligaments** are, the **anterior** and **posterior inferior tibio-fibular**, the **transverse** and the **interosseous**. The first two are attached between the adjacent margins of the tibia and fibula, on the anterior and posterior aspects of the articulation; the **transverse** is a narrow band passing from the external malleolus, to the internal malleolus, of the tibia, behind the joint; the **interosseous**, short and strong, is attached between the contiguous rough surfaces of the tibia and fibula, and is continuous above with the interosseous membrane.

The **Ankle Joint**, or the **Tibio-Tarsal Articulation** (illustrations Nos. 87 and 88), is a diarthrodial, and a ginglymus joint, formed by the lower ends of the tibia and fibula, by their malleoli, with the astragalus. The **ligaments** are the **anterior, posterior, internal** and **external lateral ligaments**. The **anterior ligament** connects the anterior articular margins of the tibia and fibula, with the rough upper surfaces of the astragalus; the **posterior ligament**, thin and sometimes defective, is attached to the posterior margins of the tibia and astragalus; the **internal lateral, or deltoid ligament**, extends from the lower border of the internal malleolus to the three adjacent tarsal bones, the astragalus, the scaphoid and the os calcis. The deltoid ligament is strong, consists of two sets of fibres, the superficial and the deep, and is cov-

ered by the tendons of the tibialis posticus and the flexor longus digitorum muscles.

The **external lateral ligament** is composed of three fasciculi, the anterior, posterior and middle, and so is considered by some authorities as three distinct ligaments, namely; the **anterior fasciculus**, astragalo-fibular, or talo-fibular, which passes from the front of the external malleolus to the anterior surface of the astragalus, the **posterior fasciculus**, or posterior astragalo-fibular, deep seated and extending from the posterior part of the external malleolus to the posterior surface of the astragalus, and the **middle fasciculus**, or calcaneo-fibular, the longest of the three, which passes from the apex of the external malleolus, downward and backward, in the form of a rounded cord, to the outer surface of the calcaneus, or heel bone. The synovial mem-



brane, which lines the inner surface of the articulation, is often projected proximally for a short distance between the tibia and the fibula.

The **Tarsal Articulations**, or the **Intertarsal Articulations**, are mostly arthrodial joints, and are found between the os calcis and astragalus; cuboid and scaphoid; between the astragalus and scaphoid; between the scaphoid and the cuneiform bones; between the scaphoid and cuboid; between the articulations of the cuneiform bones with each other, and between the external cuneiform and the cuboid. Between the os calcis and astragalus is a capsule, while the bones are

united by the **external, internal, anterior** and **posterior calcaneo-astragaloid** ligaments, and by the **interosseous**.

The os calcis and cuboid joint has the **superior**, the **internal**, the two **plantar** (long and short), and **calcaneo-cuboid** ligaments. The superior is sometimes known as the dorsal calcaneo-cuboid ligament and the internal as the interosseous ligament. The os calcis and scaphoid, as a rule, do not articulate with one another, but are connected by **two ligaments**—the **superior** and **inferior calcaneo-scaphoid** ligaments. The astragalus and scaphoid articulation has only one ligament the **superior astragalo-scaphoid** ligament. The scaphoid is

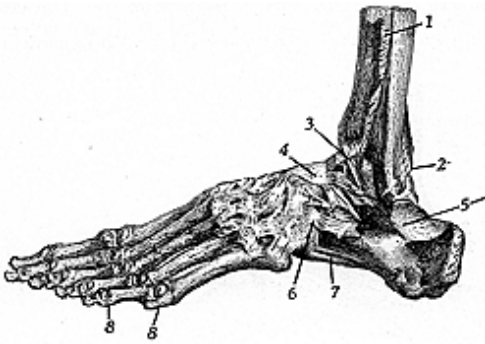


Fig. 88.
Ligaments of Foot—External and Dorsal Surfaces.

1. Interosseous membrane. 2. Posterior tibio-fibular ligament. 3. Anterior tibio-fibular ligament. 4. Dorsal astragalo-navicular ligament. 5. External lateral ligament of ankle. 6. Calcaneo-cuboid ligament. 7. Plantar ligament. 8. External lateral ligament of toes.

connected to the three cuneiform bones and to the cuboid, the three cuneiform bones are connected to each other, and the external cuneiform is connected to the cuboid, by the **dorsal**, the **plantar** and the **interosseous ligaments**. The synovial membrane of these joints is part of the tarsal synovial membrane.

The **Articulations of the Metatarsal Bones** with each other, except the first, are arthrodial and interosseous joints. The articular extremities of the metatarsal bones forming the gliding joints and the interosseous borders of the shafts of the bones forming the syndesmoses. These joints are connected together at their bases by the **dorsal** and **plantar ligaments** with the **interosseous** ligaments found between the shafts. The movement permitted in the tarsal ends of the metatarsal bones is limited to a slight gliding of the articular surfaces upon one another, therefore these surfaces are covered with articular

synovial membrane. The base of the first metatarsal is not connected with the base of the second by any ligament, it resembles the thumb in this respect.

The **Metatarso-Phalangeal** and the **Inter-Phalangeal Articulations** correspond to those in the hand—each having a **plantar** and **two lateral ligaments**. The metatarso-phalangeal articulations are condyloid joints and the inter-phalangeal articulations are ginglymus joints.

MYOLOGY

Myology is the study of muscles. The muscles are the movers of the body, and are formed of reddish fibres, endowed with the power of contractility, and so packed and arranged as to give symmetry of form and rapidity of motion. Muscles form the red flesh of the body, and are divided into two classes, the **voluntary**, the striped or striated, and the **involuntary** or the non-striped or non-striated, so named from the appearance of the fibers as seen under the microscope. The **voluntary**, or the striped or skeletal, variety consists of primary fasciculi about 1/400 of an inch in diameter, such fasciculus is formed by a number of fibrillae separated from each other by the endomysium enclosed in individual tubular sheaths, the **sarcolemma**, each secondary bundle of these is surrounded by a sheath, the **epimysium**, its component fasciculi are connected together by a delicate tissue, the **edomysium**. This variety of muscle tissue forms the voluntary muscles and are under the partial control of educated intelligence, tho not entirely so, while the involuntary are under the sole control of the Innate Intelligence. **Non-striated** muscle tissue consists of numerous elongated spindle-shaped cells held together in bundles by a cement-substance, and these bundles are arranged in layers or flattened bands bound together by areolar tissue. It is this kind of muscle that is found forming the contractile coats of the intestine, stomach, bladder, esophagus, arteries and veins, lymphatics, urethra, ducts of glands, the iris, ciliary body, etc.

It is estimated that there are 682 muscles in the body. Muscles are attached to bones, cartilages, ligaments, and to the skin, by **tendons aponeuroses** or **fasciae**. A **tendon** is a white, glistening, round, or flattened cord, composed of white inelastic fibrous tissue, almost without blood supply, and serves to connect the muscles with the structures to be moved. **Aponeuroses** are white, shining, gristly membranes, flattened, or ribbon-shaped tendons, and serve the same purpose. When the tendinous attachment forms a broad sheet it is called an aponeurosis.

Muscles are attached by two ends, and these attachments are called the **origin** and **insertion**. The **origin** is the attachment which remains stationary, or is the fixed and central point, from which the muscle acts, while the **insertion** is the movable point, that to which the muscle is attached or directed, the terminal point; but in many muscular acts the part usually described as the insertion becomes the fixed point, and the origin the movable one, for some muscles can act in either direction and others have double origins and single insertions, as the Epicranius, Digastric, the Omo-hyoid, and the Diaphragm. Muscles act upon the joints over which they pass and so their actions can usually be inferred from their attachments.

Fasciae are laminae of fibrous or fibro-areolar tissue investing soft tissue. Fascia varies in thickness and strength and is found in all regions of the body, serving as a band to cover the more delicate organs. It contains fat and is found beneath the skin over the whole

body; cutaneous vessels and nerves transverse it on their way to and from the skin.

The fasciae have been sub-divided into two groups, the **superficial** and the **deep**. **Superficial fascia** is a sheet of areolar tissue and contains fat; it is found immediately beneath the skin and connects the skin with the deep or aponeurotic fascia. **Deep fascia** is a dense inelastic, strong, fibrous, bluish membrane found beneath the superficial fascia, and covers the muscles, being thickened in the region of some of the joints where it binds down the muscles or tendons in their proper places. Also, in some instances, deep fascia provides attachment for the muscles and sends septa in amidst the tissue to cover the muscles, vessels, nerves and gland. The fibers of the deep fascia are placed parallel to one another and are thickened in unprotected places, such as upon the most external muscles of the limb and, of course, would be thinner upon the inner muscles. Certain cutaneous muscles are situated within the superficial fascia, while the deep fascia binds muscles down into a shapely mass, and tends to preserve the form of the parts, since partitions of it descend between the various muscles to become attached to the periosteum of the bony framework. *Vaginal synovial membranes*, line grooves and sheath tendons which pass over the bones or ligaments, and are found between the tendons of muscles, to facilitate movement. Bursae are also found above tendons where the fascia and skin cover subcutaneous bony points.

Muscles are arranged, according to the general divisions of the body, as those of the *cranium*, *face* and *neck*, those of the *trunk*, of the *upper extremity*, and of the *lower extremity*. Muscles differ in size considerably as is shown by the Gastrocnemius, which is from 2 to 2-1/2 inches thick and forms the chief bulk of the back of the leg; the fibres of the Sartorius are two feet in length, while of the Stapedius, in the ear, the fibres are not more than two lines in length. There is, also considerable variation in the arrangement of the fibres of certain muscles, and again they vary extremely in their form. In the limbs they are of considerable length, especially the more superficial ones the deep ones are generally broad, in the trunk they are broad, flattened and expanded, forming the parietes of the cavities which they enclose.

In some parts of the body the fibres run parallel, or are obliquely arranged, and converge like the plumes of a pen to one side of a tendon which runs the entire length of the muscle, or the fibres run perpendicularly, or fibres may alternate with series of tendinous bands. We also have muscles in which the fibres are arranged in curved bundles, in one or more planes, forming a sphincter. Muscles whose fibres are long and few have great range of action, but little strength, while those muscles whose fibres are short and more numerous are possessed of great power.

Muscles are named according to their *location*; as the temporal, tibialis, subscapularis, radialis, abdominalis; *direction*, oblique, transversalis and the rectus; *shape*, the deltoid, trapezius and the rhomboid; *use*, flexors, extensors, abductors, rotators, levators, compressors, tensors, corrugators; *number of divisions*, biceps, triceps, quadriceps;

and *points* of attachment, sterno-hyoid, sterno-mastoid, and the occipito-frontalis.

MUSCLES OF THE HEAD

(Illustration No. 89.)

The muscles of this set, which are known as the muscles of expression, include the muscles of the scalp, extrinsic muscles of the ear, muscles of the eyelids, nose and mouth. All these are supplied by the facial nerve, while the mandibular division of the fifth cranial nerve supplies the muscles of mastication.

The **Occipito-Frontalis**, or **Epicranius**, is a broad muscle which consists of two flat fleshy bellies, one on either side, connected by a flat intermediate tendon. **Origin**, its posterior belly from the outer two-thirds of the superior curved line of the occipital bone and from the mastoid process of the temporal; its anterior belly arising from the aponeurosis of the muscles of the forehead, that is, the orbicularis oculi, corrugator supercilii and the pyramidalis nasi; **insertion** is into the aponeurosis, or galea aponeurotica, which covers the vertex of the skull; **action**, it raises the eyebrows, wrinkles the skin of the forehead and moves the skin of the scalp backward and forward, **nerve supply**, the facial.

The *epicranial aponeurosis* covers the upper part of the vertex of the skull and is attached posteriorly, between the divisions of the occipital bellies, to the external occipital protuberance and the superior curved line; in front it forms a short and narrow prolongation between the frontal portions, and its lateral edges are firmly attached to the auricular muscles. This is a two-bellied muscle, and is known as one of the muscles of expression.

MUSCLES OF THE EAR

The **Auricular Muscles**, the **Attrahens Aurem**, **Attollens Aurem** and **Retrahens Aurem**, are three muscles placed immediately beneath the skin around the pinna of the ear. In man the external ear is capable of very slight voluntary motion and therefore the muscles are almost rudimentary, while in the lower animals these muscles are large and important.

The **Attrahens Aurem**, **origin**, from the lateral edge of the aponeurosis of the epicranium; **insertion**, into the front of the ear, **action**, to draw the pinna forward; **nerve supply**, facial, the temporal branch.

The **Attollens Aurem**, **origin**, from the occipital-frontalis aponeurosis, **insertion**, into the upper part of the ear; **action**, to raise the pinna; **nerve supply**, facial.

The **Retrahens Aurem**, **origin**, from the mastoid process of the temporal bone; **insertion**, into the lower part of the concha; **action**, is to retract the external ear; **nerve supply**, facial, the posterior auricular branch. These three muscles are also known as the auricularis posterior, superior and anterior, and in man they possess very little action.

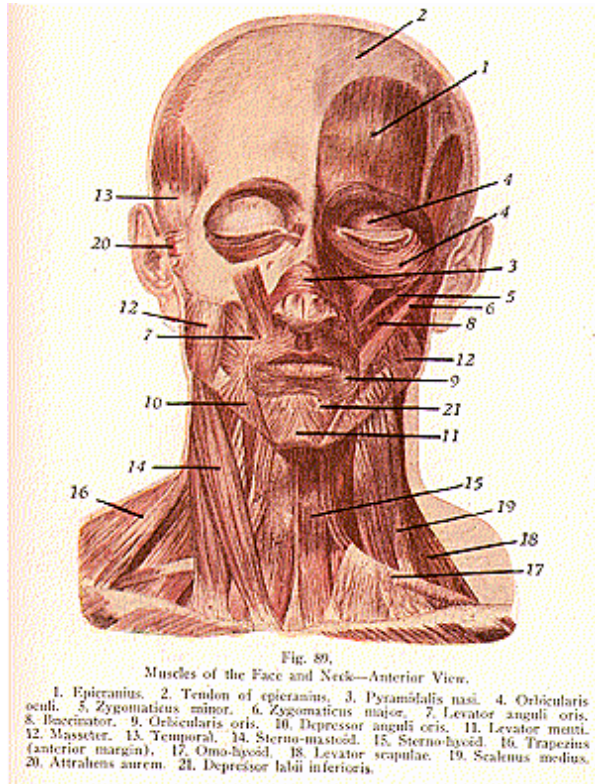
The **Helicis Major** and **Minor** are muscles of the pinna, called the

MYOLOGY

intrinsic muscles of the pinna, and serve to render tense the skin of the auditory canal.

The **Tragicus** and the **Antitragicus**, the **Transversus Auriculæ** and the **Obliquus Auriculæ**, other muscles of the pinna are attached to the tragus, the antitragus, the helix and the concha of the external ear.

The muscles of the middle ear are the **Stapedius**, which depresses and retracts the stapes, the **Laxator Tympani**, which relaxes the mem-



brane of the tympanum, and the **Tensor Tympani**, which draws tense the membrane.

THE PALPEBRAL REGION

The muscles in this set are the **Orbicularis Oculi**, or **Palpebrarum**, the **Corrugator Supercilii**, **Levator Palpebrae** and the **Tensor Tarsi**.

The **Orbicularis Oculi** is a sphincter muscle which surrounds the eyelids in the form of a loop. **Origin**, from the internal angular process of the frontal bone, from the nasal process of the superior maxillary bone and from the tarsal ligaments; **insertion**, into the skin of the eyelids, surrounding the circumference of the orbit, spreading out over the temple and downward over the cheek, blending with the epicranium and corrugator supercilii; **action**, closes the eyelids; **nerve supply**, facial.

The **Corrugator Supercilii** is a small muscle which **arises** from the inner end of the superciliary ridge of the frontal bone, its fibers pass upward and outward and are **inserted** into the skin of the eyebrows; **action**, wrinkles the skin by drawing the eyebrows downward and inward, producing the vertical wrinkles of the forehead; **nerve supply**, facial. It is called the frowning muscle.

The **Levator Palpebrae**, **origin**, from the lesser wing of the sphenoid bone; **insertion**, into the upper tarsal cartilage; **action**, is to raise the upper lid, therefore a direct antagonist of the orbicularis oculi; **nerve supply**, facial.

The **Tensor Tarsi**, or **Homer's Muscle**, **origin**, from the crest of the lacrimal bone; **insertion**, into the tarsal cartilages or plates; **action**, compresses the tear sac; **nerve supply**, the facial.

THE ORBITAL REGION

The **Rectus Superior**, **Rectus Inferior**, **Rectus Internus**, **Rectus Externus**, the **Obliquus Oculi Superior** and **Obliquus Inferior**, constitute the set of muscles which moves the eyeball.

The **Rectus Superior**, and **Inferior**, **Externus** and **Internus**, **arise** from a tendinous ring surrounding the optic foramen and from the *ligament of Zinn*, which serves as the annular ligament of origin which is common to the rectile muscles of the eye, and which is attached to the edge of the optic foramen and to the inner part of the sphenoid fissure. All these are **inserted** into the sclerotic coat of the eyeball their **action** is to rotate the eyeball upward and downward, inward and outward; **nerve supply**, the third and sixth cranial nerves.

The **Obliquus Oculi Superior** **arises** a little above the inner margin of the optic foramen and terminates in a rounded tendon attached to the trochlear fossa near the internal angular process of the frontal bone. This tendon is reflected backward, outward and downward beneath the rectus superior, to the outer part of the globe of the eye and is **inserted** into the sclerotic coat; **action** is to rotate the eyeball downward and inward; **nerve supply**, the fourth cranial.

The **Obliquus Oculi Inferior**, **origin**, from the orbital plate of the superior maxillary ; **insertion**, into the sclerotic coat, **action**, rotates the eyeball upward and outward; **nerve supply**, the oculo-motor.

NASAL REGION

Pyramidalis Nasi, the **Levator Labii Superioris Alaeque Nasi**, the **Dilator Nares Anterior** and **Posterior**, the **Compressor Nasi**, the **Compressor Narium Minor** and the **Depressor Alae Nasi**.

The **Pyramidalis Nasi** is a small triangular-shaped muscle, **origin**, from the occipito-frontalis; **insertion**, into the compressor nasi, **action**, depresses the eyebrows by drawing down their inner angle, and produces transverse wrinkles over the bridge of the nose; **nerve supply**, facial.

The **Levator Labii Superioris Alaeque Nasi** is a thin, triangular muscle at the side of the nose; **origin**, from the nasal process of the superior maxillary; **insertion**, into the cartilage of the wing of the nose and into the upper lip; **action**, to elevate the upper lip and dilate the nostril; **nerve supply**, the facial. This muscle possesses marked influence over the facial expression, and is the principal factor in the expression of contempt.

The **Dilator Nares Anterior** and **Posterior** are two small slips placed on the lateral margin of the nostril, and are **inserted** into the skin near the nostril; their **action** in ordinary breathing is to resist the tendency of the nostrils to close from atmospheric pressure, by dilating the nostril; **nerve supply**, facial.

The **Compressor Nasi**, **origin**, from the superior maxillary bone **insertion**, into the fibroid cartilage of the nose; **action**, to compress the nostrils; **nerve supply**, facial.

The **Compressor Narium Minor**, **origin**, from the cartilage of the wing of the nose; **insertion**, into the skin at the end of the nose **action**, compresses the sides, and thus dilates the nostril; **nerve supply**, facial.

The **Depressor Alae Nasi** is a short muscle, **origin**, from the incisive fossa of the superior maxillary bone; **insertion**, into the septum and ala of the nose; **action**, to narrow the nostril or contract it; **nerve supply**, facial.

SUPERIOR MAXILLARY DIVISION

The **Levator Labii Superioris**, **Levator Anguli Oris**, **Zygomaticus Major** and **Minor**.

The **Levator Labii Superioris**, **origin**, from the lower margin of the orbit; **insertion**, into the upper lip; **action**, to lift and protrude the upper lip; **nerve supply**, facial.

Levator Anguli Oris, **origin**, from the canine fossa of the upper maxillary, **insertion**, into the angle of the mouth; **action**, raises the angle of the mouth and draws it in; **nerve supply**, facial.

The **Zygomaticus Major** and **Minor**, **origin**, from the malar bone; **insertion**, into the angle of the mouth; **action**, to raise the lip outward and upward; **nerve supply**, facial.

THE MANDIBULAR REGION

The **Levator Labii Inferioris**, **Depressor Labii Inferioris**, and **Depressor Anguli Oris**.

The **Levator Labii Inferioris**, also called **Levator Menti**, is a small bundle of fibres, the **origin**, from the incisive fossa of the mandible; **insertion**, into the skin of the chin; **action**, raises the lower lip and wrinkles the chin; **nerve supply**, facial.

Depressor Labii Inferioris or **Quadratus Menti**, **origin**, from the external oblique line of the mandible; **insertion**, into the skin of the lower lip; **action**, depresses lower lip; **nerve supply**, facial.

The **Depressor Anguli Oris**, or **Triangularis Menti**, **origin**, from the external oblique line of the mandible, **insertion**, into the angle of the mouth; **action**, depresses the angle of the mouth; **nerve supply**, facial.

BUCCAL REGION

The **Orbicularis Oris**, **Buccinator**, and the **Risorius**.

The **Orbicularis Oris** is a sphincter occupying the lips and being continuous with the muscles converging at the mouth, which muscles contribute many of its fibres. Its own fibres **arise** from the nasal septum, and from the superior and inferior maxillary borders; **insertion**, fibres radiate to join with those of other adjacent muscles, forming the sphincter of the mouth; **action**, closes the mouth; **nerve supply**, facial.

The **Buccinator**, **origin**, from the alveolar edges of the maxillary bones and from the pterygo-maxillary ligament, **insertion**, into the orbicularis oris, that is, it mingles with the other muscles at the angle of the mouth; **action**, compresses the cheeks and retracts the angle of the mouth; **nerve supply**, facial.

The **Risorius** is the laughing muscle, **origin**, from the fascia covering the muscles of the side of the face; **insertion**, into the angle of the mouth; **action**, retracts the angle of the mouth; **nerve supply**, facial. If the risorius draws the angle of the mouth too far outward it produces the unpleasant expression which is sometimes seen in tetanus and which is known as the risus sardonicus (sardonic grin).

THE TEMPORO-MANDIBULAR REGION

The **Masseter**, **Temporal**, the **External Pterygoid** and the **Internal Pterygoid** are known as the muscles of mastication.

The **Masseter**, **origin**, from the zygomatic arch, and from the malar process of the superior maxillary bone, **insertion**, into the angle, ramus, and coronoid process, of the mandible; **action**, used in chewing; **nerve supply**, tri-facial.

The **Temporal** is a broad, radiating muscle, **origin**, from the temporal fossa and fascia, **insertion**, into the coronoid process, **action** sets the mouth, and retracts the jaw; **nerve supply**, tri-facial.

The **External Pterygoid**, **origin**, from the external pterygoid plate and the great wing of the sphenoid; **insertion**, into the condyle of the mandible; **action**, draws the lower jaw forward, and hence is called the triturating (grinding) muscle of mastication; **nerve supply**, tri-facial, the mandibular branch.

The **Internal Pterygoid**, **origin**, from the pterygoid plate of the sphenoid, and a groove of the palatal bone; **insertion**, into the inner

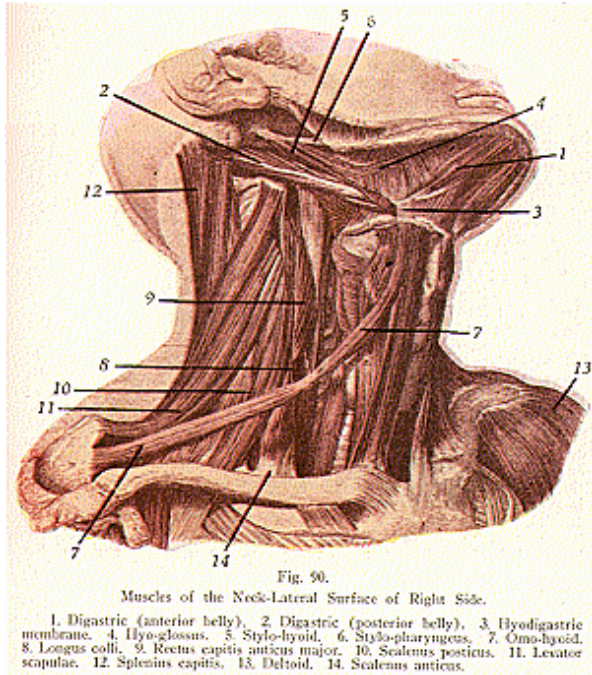
MYOLOGY

surface of the ramus and angle of the lower jaw; **action**, raises, and draws forward, the lower jaw; **nerve supply**, tri-facial branch.

MUSCLES OF THE NECK

(Illustrations Nos. 90, 91, 92 and 93.)

These are divided into those of the **superficial cervical region**, the **supra-hyoid region**, **infra-hyoid region**, **lingual region**, **pharyngeal**



region, **palatal region**, the **anterior and lateral vertebral region**, and the muscles of the **larynx**. These muscles are covered by the **superficial and deep fasciae**.

The **Superficial Cervical Fascia** is a thin aponeurotic layer which

can hardly be described as separate membrane. It invests the platysma myoides muscle.

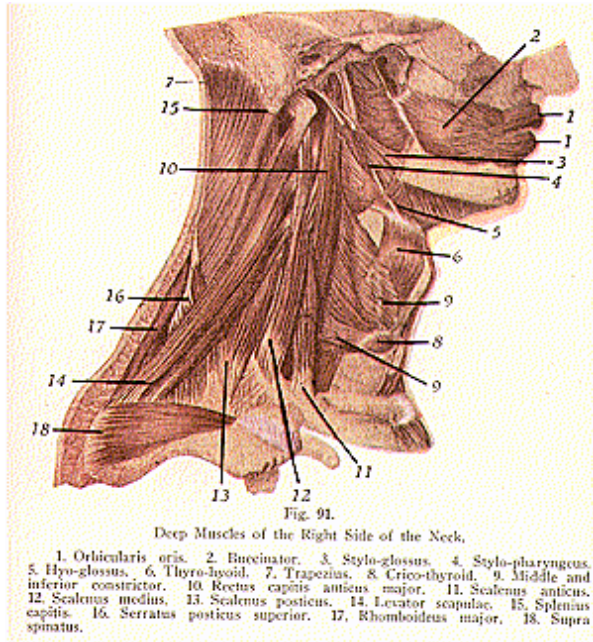
The **Deep Fascia** is a well-marked sheet of connective tissue, which lies beneath the platysma and forms a complete covering for the muscles of the neck. It gives off, from its deeper surface, numerous thin layers which surround the various structures of the neck. This fascia also forms a sheet for the carotid vessels, and is attached behind to the ligamentum nuchae. It forms a thin investment for the trapezius muscle, and extends over to the posterior border of the sterno-mastoid, where it begins to assume the appearance of a facial membrane. In line with the middle of the neck, it is attached to the symphysis menti and to the hyoid bone. Above, this fascia is attached to the superior curved line of the occiput, to the mastoid process of the temporal, and to the body of the mandible. From here it is reflected over the parotid gland and blends with the fascia covering the muscles of mastication. Below, the cervical fascia is attached to the acromion process of the scapula, to the clavicle, and to the upper part of the sternum. By its extensive distribution it forms the sheath which covers the tendons of the omo-hyoid and the large vessels of the neck. It passes inward behind the deep vessels to the front of the three vertebral muscles, and at this point the fascia extends above, to the base of the skull, where it is fixed; below, it is continued into the thorax, thus forming the posterior limit of a fibrous compartment which contains the larynx, trachea, thyroid gland, pharynx and the esophagus. After being continued downward into the thorax thus far, in front of the esophagus and trachea, it becomes lost upon the upper part of the epicardium. Its posterior boundary in the thorax lies anterior to the vertebral column.

The **Platysma Myoides** is the most superficial muscle of the neck. Its **origin** is from the skin and subcutaneous tissue over the pectoralis major and deltoid muscles, on a line extending from the cartilage of the second rib to the tip of the acromion process. Its fibres are directed upward and inward; the **insertion** is into the skin and subcutaneous tissue of the lower part of the facial muscles, the mouth and lower lip; **action** wrinkles the skin of the neck and depresses the mouth and lower lip. It is a muscle of expression and, therefore is supplied by the facial nerve.

The side of the neck presents a somewhat quadrilateral outline known as the **quadrilateral space**. This space, or area, in the neck is bounded, *above*, by an imaginary line drawn from the angle of the jaw to the mastoid process of the temporal bone, *below*, by the clavicle, *anteriorly*, by the median line of the neck, from the lower part of the chin to the sternum, and *posteriorly*, by the trapezius. The **sterno-mastoid** muscle divides this space into two triangles, an **anterior** and a **posterior triangle**. The **anterior triangle** of the neck is bounded in front by the middle line of the neck, that is, a line extending from the chin to the sternum, behind by the anterior border of the sternomastoid muscle; its base, directed upward, is formed by the lower border of the body of the mandible and a line drawn from the angle of that bone to the mastoid process. The triangle is covered by the skin, superficial fascia, the platysma myoides and deep cervical fascia.

MYOLOGY

The anterior triangle is divided into three triangles, by the anterior belly of the omo-hyoid muscle inferiorly and by the two bellies of the digastric superiorly. These three subdivisions, from below upward, are called the *muscular*, *carotid* and the *digastric*, or *submaxillary*. The **posterior triangle** of the neck lies behind the sterno-mastoid muscle. It is bounded in front by the sterno-mastoid; behind by the trapezius; its base the middle third of the clavicle and the apex is at the superior curved line of the occipital bone where the sterno-mastoid and trapezius may meet. It is covered by skin, superficial and deep fasciae, and for a short distance inferiorly by the platysma



myoides. The posterior triangle is subdivided into two smaller triangles, the *occipital*, the upper triangle and the *subclavian*, or *supra-clavicular*, the lower triangle.

The **Sterno-Mastoid**, or **Sterno-Cleido-Mastoid**, **origin**, by two

heads, from the sternum and clavicle; **insertion**, into the mastoid process of the temporal bone, and the outer two-thirds of the superior curved line of the occipital bone; **action**, depresses and rotates the head and flexes the head and neck; **nerve supply**, spinal accessory and cervical nerves.

THE INFRA-HYOID REGION

The **Sterno-Hyoid**, **origin**, from the upper part of the sternum and inner part of the clavicle; **insertion**, into the body of the hyoid bone, **action**, depresses the larynx; **nerve supply**, upper cervical.

The **Sterno-Thyroid**, **origin**, from the posterior surface of the sternum and cartilage of the first rib; **insertion**, into the wing of the thyroid cartilage; **action**, depresses the thyroid cartilage and so depresses the larynx; **nerve supply**, hypoglossal.

The **Thyro-Hyoid**, **origin**, from the oblique line of the sides of the thyroid cartilage; **insertion**, into the greater horn and body of the hyoid bone; **action**, raises and changes the form of the larynx; **nerve supply**, hypoglossal.

The **Omo-Hyoid** is a two-bellied muscle the **origin**, from the upper border of the scapula; **insertion**, into the body of the hyoid bone, being held down by a tendinous loop to the clavicle and first rib; **action**, to retract and depress the hyoid bone, also contracts the cervical fascia; **nerve supply**, upper cervical.

THE SUPRA-HYOID REGION

The **Digastric** is also a two-bellied muscle, united by an intermediate, rounded tendon; **origin**, from the digastric groove of the temporal bone, and the anterior belly from the digastric fossa of the mandible; **insertion**, by a central tendon, into the body of the hyoid bone, **action**, to elevate and retract the hyoid bone and tongue; **nerve supply**, facial and inferior dental.

The **Stylo-Hyoid**, **origin**, from the styloid process of the temporal bone, **insertion**, into the body of the hyoid bone; **action**, to draw the hyoid and tongue upward and backward; **nerve supply**, facial.

The **Mylo-Hyoid**, **origin**, from the mylo-hyoid ridge of the mandible; **insertion**, into the hyoid bone; **action**, raises the hyoid bone, forms the floor of the mouth and aids in depressing the jaw; **nerve supply**, inferior dental.

The **Genio-Hyoid**, **origin**, from the inferior genial tubercle of the lower jaw; **insertion**, into the hyoid bone; **action**, lifts the hyoid bone and aids in depressing the jaw; **nerve supply**, hypoglossal.

THE LINGUAL REGION

The **Genio-Hyo-Glossus**, **origin**, from the superior genial tubercle of the mandible, **insertion**, into the hyoid bone and under-surface of the tongue; **action**, retracts, depresses and protrudes the tongue and raises the hyoid bone; **nerve supply**, hypoglossal.

Hyo-Glossus, **origin**, from the body of the hyoid bone and its cornua; **insertion**, into the side of the tongue; **action**, is to depress the side of the tongue and retract it; **nerve supply**, hypoglossal.

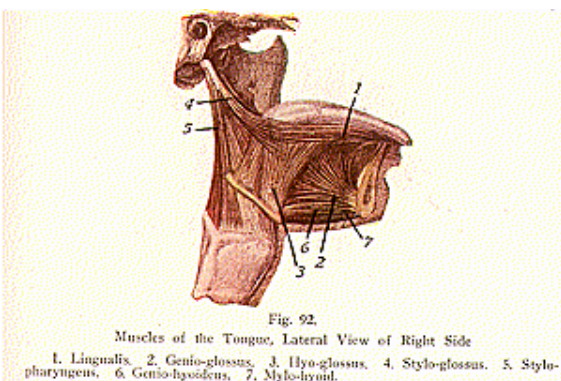
MYOLOGY

The **Stylo-Glossus, origin**, from the styloid process and the stylo-maxillary ligament; **insertion**, into the side of the tongue; **action**, to draw the tongue upward and backward; **nerve supply**, hypoglossal.

The **Chondro-Glossus, origin**, from the inner side of the lesser cornu of the hyoid bone; **insertion**, into the substance of the tongue; **action**, raises the tongue upward and backward; **nerve supply**, hypoglossal. This muscle is often given as a part of the hyoglossus.

The **Palato-Glossus** is one of the muscles of the tongue which serve to draw its base upward. **Origin**, from the anterior surface of the soft palate; **insertion**, into the dorsum and side of the tongue; **action**, to raise the back of the tongue, and to constrict the fauces; **nerve supply**, a branch of the spinal accessory.

The **Lingualis** forms the bulk of the tongue, lies between the hyoglossus and genio-hyo-glossus on either side, and has four sets of fibres the *superior, inferior, transverse* and *vertical*. These fibres are found along the borders of the tongue and are **inserted** into the tip,



the edges and the upper surface of the tongue; **action** of these muscles shortens the tongue, narrows and stretches it, lifts its edges and flattens the tip; **nerve supply**, the hypoglossal, it being the motor nerve of the tongue.

MUSCLES OF THE PHARYNX

The muscles of the pharynx are the **Superior, Middle** and **Inferior Constrictors**, the **Stylo-Pharyngeus, Palato-Pharyngeus** and the **Salpingo-Pharyngeus**.

The **Superior Constrictor** is the thinnest of the constrictors, and is situated at the upper part of the pharynx; **origin**, from the palate

bone, internal pterygoid plate, the pterygo-maxillary ligament, the alveolar process of the lower jaw, and the side of the tongue; **insertion**, into the fibrous rapine of the pharynx; **action**, contracts the pharynx, as in swallowing; **nerve supply**, pharyngeal plexus. This muscle is prolonged by means of a fibrous aponeurosis to a spine on the basilar process of the occipital bone. The interval between the two attachments of this aponeurosis, where there is a deficiency of muscle fibres, is closed by a portion of the pharyngeal aponeurosis, and this interval is called the **sinus of Morgagni**.

The **Middle Constrictor** is a flattened, fan-shaped muscle; **origin**, from the cornua of the hyoid bone, and from the stylo-hyoid ligament; **insertion**, into the fibrous rapine of the pharynx; **action**, contracts the pharynx; **nerve supply**, the pharyngeal plexus.

The **Inferior Constrictor** is the thickest and most superficial of the constrictors; **origin**, from the cricoid and thyroid cartilages; **insertion**, into the fibrous rapine of the pharynx; **action**, same as the other constrictors; **nerve supply** branches from the pharyngeal plexus, glosso-pharyngeal and recurrent laryngeal.

The **Stylo-Pharyngeus**, **origin**, from the styloid process of the temporal bone; **insertion**, into the side of the pharynx and posterior border of the thyroid cartilage; **action**, raises and dilates the pharynx; **nerve supply**, glosso-pharyngeal and the pharyngeal plexus.

The **Salpingo-Pharyngeus**, **origin**, from the inferior part of the Eustachian tube, near its orifice; **insertion**, into the posterior part of the palato-pharyngeus muscle; **action**, to raise the upper and lateral part of the pharynx; **nerve supply**, the spinal accessory. This muscle is more often described with the muscles of the palatal region.

MUSCLES OF THE PALATAL REGION

The muscles of the palatal region are the **Levator Palati**, **Tensor Palati**, **Azygos Uvulae**, the **Palato-Pharyngeus** and **Palato-Glossus** (previously described).

The **Levator Palati**, **origin**, from the petrous portion of the temporal bone and the Eustachian tube; **insertion**, into the posterior surface of the soft palate; **action**, raises the soft palate; **nerve supply**, the branch of the spinal accessory thru the pharyngeal plexus.

The **Tensor Palati**, **origin**, from the scaphoid fossa, spine of the sphenoid, at the base of the internal pterygoid plate, outer side of the Eustachian tube, and reflected around the hamular process of the sphenoid; **insertion**, into the anterior surface of the soft palate by an aponeurosis, and to the upper surface of the palate bone; **action**, renders the soft palate tense; **nerve supply**, branch from the inferior maxillary nerve thru the otic ganglion.

The **Azygos Uvulae**, **origin**, from the anterior nasal spine of the palate bones; **insertion**, into the uvula; **action**, raises the tip of the uvula; **nerve supply**, spinal accessory thru the pharyngeal plexus.

The **Palato-Pharyngeus**, **origin**, from the soft palate on each side of the uvula, and passes to the front of the tonsil; **insertion**, into the posterior border of the thyroid cartilage and the side of the pharynx;

MYOLOGY

action, closes the posterior nares and the facial orifice; **nerve supply**, spinal accessory thru the pharyngeal plexus.

MUSCLES OF THE ANTERIOR VERTEBRAL REGION

The muscles of the anterior vertebral region are the **Rectus Capitis Anticus Major** and **Minor**, the **Rectus Capitis Lateralis**, and the **Longus Colli**.

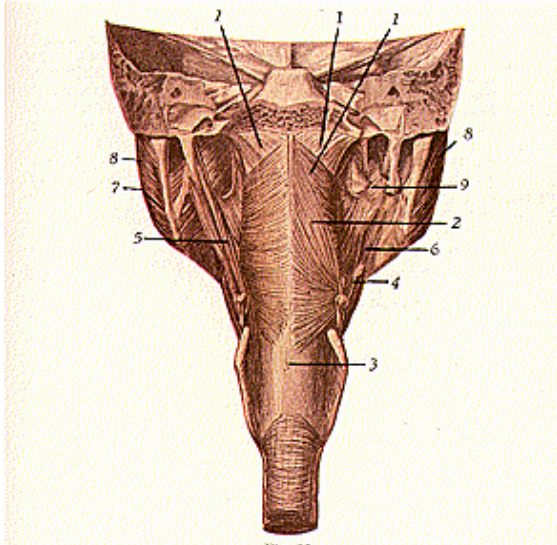


Fig. 93.
Muscles of the Back of the Pharynx and Inferior Maxilla.
1. Superior constrictor, 2. Middle constrictor, 3. Inferior constrictor.
4-5. Stylo-pharyngens, 6. Mylo-hyoid, 7. Internal pterygoid, 8. Masseter.
9. Buccinator.

The **Rectus Capitis Anticus Major**, or **Longus Capitis**, **origin**, from the transverse processes of the third, fourth, fifth and sixth cervical vertebrae; **insertion**, into the basilar process of the occipital bone; **action**, flexes the head, slightly rotates it, and aids in supporting the head; **nerve supply**, first and second cervical nerves.

The **Rectus Capitis Anticus Minor**, **origin**, from the transverse process and lateral mass of the atlas, **insertion**, into the basilar process of the occipital bone; **action**, flexes and aids in supporting the head, **nerve supply**, first and second cervical.

The **Rectus Capitis Lateralis**, **origin**, from the transverse process of the atlas; **insertion**, into the jugular process of the occipital bone; **action**, to flex the head laterally; **nerve supply**, same as the two last described.

The **Longus Colli** lies on the anterior aspect of the cervical, and upper thoracic, vertebrae; it is a long muscle, flat in the middle, narrow and pointed at each extremity, and consists of three parts, the *upper oblique*, *lower oblique* and *vertical portions*. The *upper oblique*, **origin**, from the transverse processes of the third to the fifth cervical vertebrae, **insertion**, into the atlas; the *lower oblique*, **origin**, from the bodies of the first to the third dorsal, **inserted**, into the transverse processes of the fifth and sixth cervical vertebrae; and the *vertical portion*, **origin**, from the bodies of the first three dorsal and last three cervical vertebrae, **inserted** into the bodies of the second to fourth cervical vertebrae, **action** of all 3 parts, to flex and support the cervical vertebrae; **nerve supply**, lower cervical.

THE LATERAL VERTEBRAL REGION

The muscles of the lateral vertebral region contain the deep lateral muscles of the neck, the **Scalenus Anticus**, **Medius** and **Posticus**.

The **Scalenus Anticus** (so named scalene, having uneven sides). **Origin**, from the transverse processes of the third to sixth cervical vertebrae; **insertion**, into the scalene tubercle on the first rib; the **Scalenus Medius**, **origin**, from the transverse processes of the lower six cervicals; **insertion**, into the first rib, close to the scalenus anticus; and the **Scalenus Posticus**, **origin**, from the transverse processes of the lower two or three cervical vertebrae; **insertion**, into the outer border of the second rib, **action**, the scaleni muscles elevate the first and second ribs and are, therefore, respiratory muscles, but they often take their fixed point from below, and, then, flex the neck laterally and support the head; **nerve supply**, the cervical nerves from the fourth to seventh inclusive, also the first dorsal nerves.

THE MUSCLES OF THE LARYNX AND EPIGLOTTIS

These are a series of muscles which act upon the vocal cords, to help bring about the production of voice.

The **Crico-Thyroid**, **origin**, from the front, and side, of the cricoid cartilage; **insertion**, into the thyroid cartilage, at the lower and inner border; **action**, renders the vocal cords tense; **nerve supply**, superior laryngeal.

The **Crico-Arytenoideus Posticus**, **origin**, from the back of the cricoid cartilage; **insertion**, into the outer angle of the base of the arytenoid cartilage; **action**, opens the glottis by rotating the arytenoid, **nerve supply**, recurrent laryngeal.

The **Crico-Arytenoideus Lateralis**, **origin**, from the side of the cricoid cartilage: **insertion**, into the angle, and external surface, of the

arytenoid cartilage; **action**, closes the opening of the glottis by rotating the arytenoid cartilage; **nerve supply**, the recurrent laryngeal.

Arytenoideus, **origin**, from the base, and outer border, of the arytenoid cartilage; **insertion**, into the apex of the other arytenoid cartilage; **action**, closes the posterior part of the glottis; **nerve supply**, recurrent laryngeal.

The **Kerato-Cricoideus** is occasionally found and, when present, its **origin** is from the lower border of the cricoid cartilage; **insertion**, into the inferior cornu of the thyroid; **action**, possibly steadies one cartilage upon the other, tho it is usually found only on one side. Another muscle is also sometimes found, known as an anomalous one, the **Triticeo-Glossus**, **origin**, from the side of the thyro-hyoid ligament; **insertion**, into the side of the tongue, no particular action is given.

The **Thyro-Epiglottideus**, **origin**, from the thyroid cartilage; **insertion**, into the sacculus laryngeus and aryteno-epiglottidean folds; **action**, depresses the epiglottis and compresses the saccule, **nerve supply**, recurrent laryngeal.

The **Aryteno-Epiglottideus Superior**, **origin**, from the apex of the arytenoid cartilage; **into** the aryteno-epiglottidean folds; **action**, to constrict the opening of the larynx; **nerve supply**, recurrent laryngeal.

The **Aryteno-Epiglottideus Inferior**, **origin**, from the anterior part of the arytenoid cartilage, **insertion**, into the anterior surface of the epiglottis; **action**, compresses the saccule; **nerve supply**, recurrent laryngeal.

THE MUSCLES OF THE TRUNK

(Illustration No. 94.)

These muscles are arranged into four groups, of the **Back**, **Thorax**, **Abdomen**, and **Perineum**.

The **Muscles of the Back** are arranged into sets, the superficial and deep, and are covered with **Superficial** and **Deep Fasciae**.

The **Superficial Fascia** is found beneath the skin, is a layer of considerable thickness, and contains nerves and vessels, also a considerable amount of fat, and is continuous with the superficial fascia in other parts of the body.

The **Deep Fascia** of the back is a dense fibrous layer, thin and membranous, but firm, which covers the superficial muscles, forming sheaths for them and, therefore, is attached, above, to the superior curved line of the occipital bone, at the middle, to the spines of the cervical, dorsal and lumbar vertebrae; on either side extends over to the spine of the scapula, the clavicle, to the axilla, and the abdominal wall; and, below, to the iliac crest, and to the spines of the lumbar and sacral vertebrae.

The **Deep Fascia of the Neck** is known as the **cervical** or **nuchal fascia**, which is not especially strong. The fascia in the thoracic and lumbar regions is termed the **vertebral aponeurosis** and becomes considerably thickened. The lower part of the fascia of the back becomes continuous with the fascia late and gives origin to the latissimus

dorsi and serratus posticus inferior. It lies behind the erector spinae, where it forms the posterior sheath.

The **Cervical Fascia** lies under cover of the platysma myoides, and forms a complete investment for the neck. It is attached superiorly to the external occipital protuberance, to the superior curved line, the mastoid process of the temporal bone, body of the mandible, and is prolonged upward, ensheathing the parotid and submaxillary glands. A thickened part of the sheath (*parotid fascia*), which covers the parotid gland, is attached to the styloid process, and to the angle of the mandible. It forms a strong band, termed the stylo-mandibular ligament, and separates the parotid from the sub-maxillary gland. Below, the cervical fascia is attached to the acromion process, the clavicle, and to the manubrium of the sternum. Here the cervical fascia splits into two layers, the superficial, and the deep layer. The former completely invests the neck, in the form of a collar, while the deep invests the muscles, viscera, chief blood-vessels and nerves. The most important portions are derived from that layer of the superficial which forms the posterior wall of the sheath of the sternomastoid muscle, and they are named the **carotid**, **pretracheal**, and **prevertebral**, all of which have an intimate initial connection.

The **carotid fascia** forms a strong sheath for the large vessels of the neck, in which are enclosed the carotid artery, internal jugular vein, the vague, and descending cervical nerves.

The **pretracheal fascia** extends inward in front of the carotid vessels, assists in forming the carotid sheath, and passes forward bellied the depressor muscles of the hyoid bone, in which situation it splits, to ensheath the thyroid body, trachea and esophagus; it then passes to the median line, where it is continuous with the pretracheal lamina of the opposite side. This fascia is attached, superiorly, to the hyoid bone, inferiorly it descends over the trachea and the blood-vessels, into the superior mediastinum of the thorax, where it blends with the fibrous layer of the pericardium; this layer is fused, on either side, with the prevertebral layer.

The **prevertebral fascia** extends inward behind the carotid vessels, and assists in forming the carotid sheath. It passes in front of the prevertebral muscles, and forms a posterior limit of a compartment which contains the larynx, trachea, thyroid gland, pharynx, and the esophagus. This fascia is attached superiorly to the styloid process, jugular process, and base of the occipital bone, inferiorly it is continued down into the thorax.

The *bucco-pharyngeal fascia* is a thin layer which covers the constrictors of the pharynx, and the buccinator. It is connected later-

Fig. 94.

Muscles of the Trunk, Pelvis, Upper Part of Thighs and Arms—Posterior View.

1. Epicranius (anterior belly). 2. Orbicularis oculi. 3. Attolens aurem.
4. Retrahens aurem. 5. Attrahens aurem. 6. Masseter. 7. Epicranius (posterior belly). 8. Sterno-mastoid. 9. Splenius capitis. 10. Splenius colli. 11. Complexus.
12. Levator scapulae. 13. Trapezius. 14. Rhomboideus minor. 15. Rhomboideus major. 16. Latissimus dorsi. 17. Serratus posticus inferior. 18. Serratus anticus.
19. Interspinales. 20. Sacro-lumbalis (erector spinae). 21. External abdominal oblique. 22. Internal abdominal oblique. 23. Gluteus maximus. 24. Gluteus

MYOLOGY

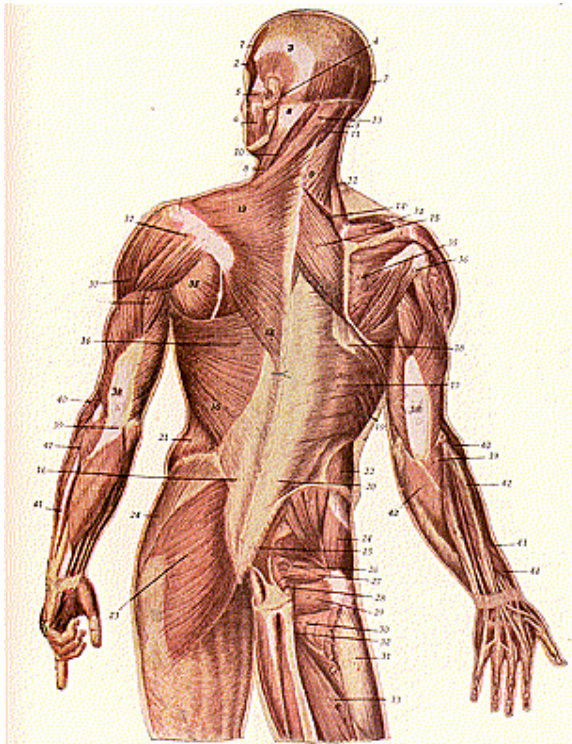


Fig. 94.

medius. 25. Piriformis. 26. Gemellus superior. 27. Obturator internus.
 28. Gemellus inferior. 29. Quadratus femoris. 30. Obturator externus. 31. Vastus
 externus. 32. Semimembranosus. 33. Adductor magnus. 34. Supra spinatus.
 35. Infra spinatus. 36. Teres minor. 37. Deltoid. 38-39. Triceps brachii.
 40. Supinator longus. 41. Extensor carpi ulnaris. 42. Extensor communis digi-
 torum. 43. Abductor longus pollicis. 44. Extensor brevis pollicis.

ally with the prevertebral fascia and, between these lateral attachments, is separated from the prevertebral fascia by an intervening space, the *retro-pharyngeal space*. This space contains loose areolar tissue and unites the two fasciae, it extends as high as the base of the skull and, below, is continuous with the posterior mediastinum of the thorax.

The **Vertebral Aponeurosis** is attached, in the median line—to the spinous processes of the thoracic vertebrae, externally, to the angles of the ribs; it is continuous with the intercostal and lumbar fascia below; it blends, above, with the deep fascia of the neck.

The **Lumbar Fascia** or **Aponeurosis** is the posterior aponeurosis of the transversalis abdominis muscle. It is composed of *three laminae* the *anterior*, *middle* and the *posterior*, only the latter of which is exposed in this region. The *anterior layer* is attached to the roots of the transverse processes of the lumbar vertebrae, the *middle layer*, to the tips of the transverse processes of the lumbar vertebrae, and both form the fascia covering the quadratus lumborum muscle; the *posterior layer* is of considerable strength and is attached to the spines of the lumbar and sacral vertebrae, and to the posterior outer lip of the iliac crest. The anterior layer is fixed, below, to the ilio-lumbar ligament and the iliac crest, while above it is thickened to form the external arcuate ligament of the diaphragm. The middle layer is attached—above to the last rib, below to the iliac crest. The dorsal layer is continued above as the vertebral aponeurosis, inferiorly it is fixed to the crest of the ilium, and above to the spines of the vertebrae and the angles of the ribs.

MUSCLES OF THE BACK

(Illustrations Nos. 94, 95 and 96.)

The Muscles of the Back may be subdivided into five, or seven, layers; for the convenience of the student we will give both classifications.

The First Layer.

Trapezius, and latissimus dorsi.

The Second Layer.

**Levator anguli scapulae.
Rhomboides major.
Rhomboides minor.**

The Third Layer.

**Serratus posticus superior.
Serratus posticus inferior.
Splenius capitis
Splenius colli**

Fig. 95.
Deep Muscles of the Neck and Back

1. Biventer cervicis. 2. Complexus. 3. Trachelo-mastoid. 4. Transversalis colli. 5. Cervicalis ascendens. 6. Erector spinæ (ilio-costalis). 7. Longissimus dorsi. 8. Erector spinæ (sacro-lumbalis). 9. Spinalis dorsi. 10. Spinalis colli. 11. Semi-spinalis dorsi. 12. Levatores costarum. 13. Intercostales. 14. Obliquus capitis superior.

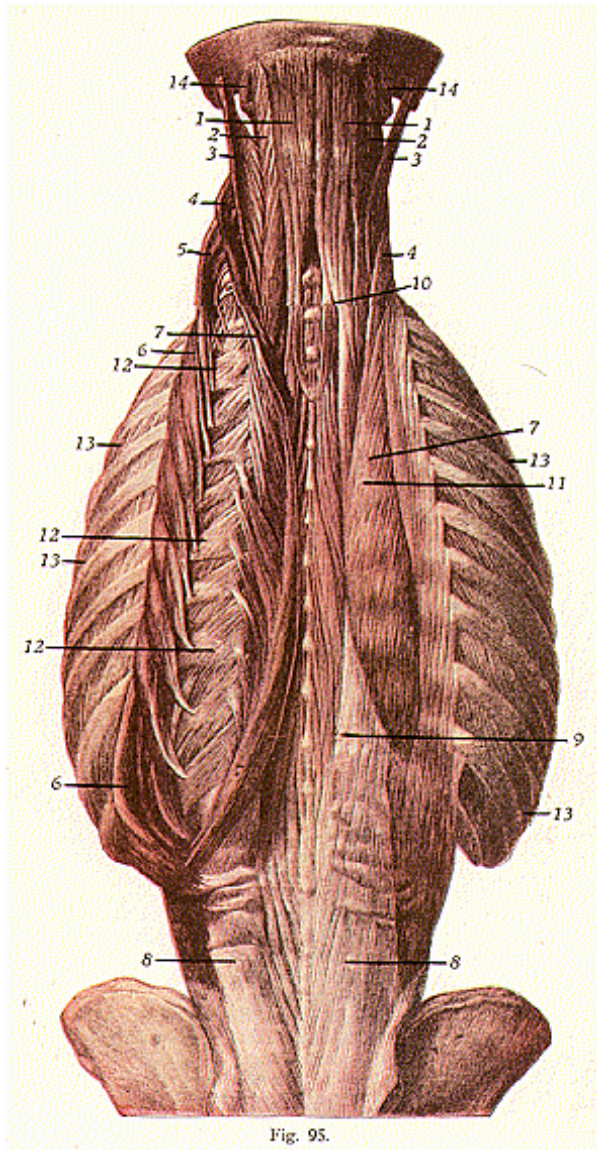


Fig. 95.

MYOLOGY

The Fourth Layer.

Erector spinae, with its subdivisions:
sacral, lumbar, dorsal and cervical.
Ilio-costalis.
Musculus accessorius.
Longissimus dorsi.
Spinalis dorsi.
Cervicalis ascenders.
Transversalis cervicis or colli.
Trachelo-mastoid.
Complexus.
Biventer cervicis.
Spinalis colli.

The Fifth Layer.

Semi-spinalis dorsi.
Semi-spinalis colli.
Multifidus spinae.
Rotatores spinae.
Supra-spinales.
Inter-spinales.
Extensor coccygis.
Intertransversales.
Rectus capitis posticus major.
Rectus capitis posticus minor.
Obliquus capitis inferior.
Obliquus capitis superior.

According to the subdivision into seven layers or groups.

First Layer.

Trapezius.
Latissimus dorsi.

Second Layer.

Levator anguli scapulae.
Rhomboideus major.
Rhomboideus minor.

Third Layer.

Serratus posticus superior.
Serratus posticus inferior.

Fourth Layer.

Splenius capitis.
Splenius colli or cervicis.

Fifth Layer.

Sacro-spinal mass, and semi-spinal mass.
Sacro-spinal mass-erector spinae.
Ilio-costalis lumborum.
(Sacro-lumbalis.)
Ilio-costalis dorsi.
Ilio-costalis cervicis.
(Old term—cervicalis ascenders.)
Longissimus dorsi.
Longissimus cervicis.
(Old term—transversalis colli.)

MYOLOGY

Longissimus capitis.

(Old term—trachelo-mastoid.)

Semi-spinal mass.

Spinalis dorsi.

Spinalis cervicis or colli.

Semi-spinalis capitis.

(Old term—complexus, and biventer cervicis.)

Semi-spinalis dorsi.

Semi-spinalis colli or cervicis.

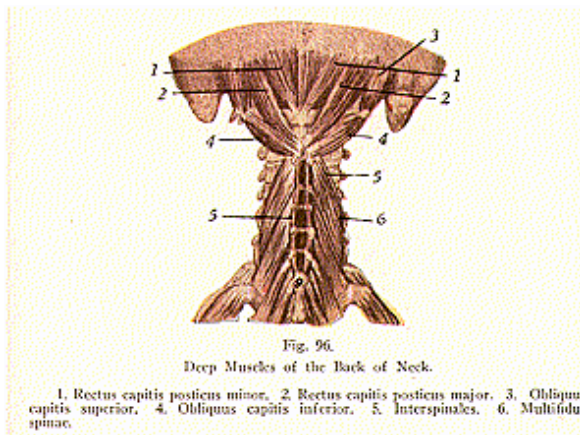
Sixth Layer.

Multifidus spinae.

Rotatores spinae.

Interspinales.

Intertransversales.



Supraspinales.

Extensor coccygis.

Seventh Layer.

Rectus capitis posterior major.

Rectus capitis posterior minor.

Obliquus capitis superior.

Obliquus capitis inferior.

Thus we see, the first and second layers correspond in the two classifications, the third and fourth are subdivided in the seven layer

classification, but are considered as one layer (the third) in the five-layer classification. One-half of the fifth in the seven-layer classification is the fourth layer in the five-layer division, the sixth layer is part of the deep layer in the first classification, and the seventh layer has the sub-occipital muscles, considered as in the deep, or fifth, layer in the first classification.

Trapezius. This muscle is so named because, along with its fellow, it presents the four-sided appearance of a trapezium. **Origin**, from the inner third of the superior curved line of the occipital bone, the ligamentum nuchae, the spines of the cervical and all the dorsal vertebrae, and from the corresponding portion of the supraspinous ligaments; **insertion**, into the outer third of the posterior and upper surface of the clavicle, the inner margin of the acromion process, the whole length of the superior border of the spine of the scapula; **action**, draws the head downward and backward, retracts the scapula and braces-back the shoulder. If the head is fixed, the upper part of the trapezius will elevate the point of the shoulders as unsupported weights, when the lower fibres serve as the fixed point, it depresses the shoulder. If the shoulders are fixed, both trapezii will act together and draw the head directly backward; if only one muscle acts the head is drawn to the corresponding side; **nerve supply**, spinal accessory and branches from the cervical plexus.

Latissimus Dorsi, origin, from the spinous processes of the lower six dorsal, and those of the lumbar and sacral vertebrae, from the dorsal layer of the lumbar fascia, from the external lip of the crest of the ilium, from the three or four lower ribs, and sometimes by a few fibres from the spine of the scapula; **insertion**, into the bicipital groove of the humerus; **action**, draws the arm downward backward and inward. If the arm is fixed, this muscle raises the lower ribs and assists in forcible respiration. When the muscle acts from its insertion, it raises the pelvis and trunk toward the outstretched arms, as in the act of climbing. This muscle draws the raised arm downward and backward, producing at the same time internal rotation, as when the hands are crossed behind the back; **nerve supply**, long subscapular and lower cervical nerves.

Levator Anguli Scapulae, origin, from the transverse processes of the first four cervical vertebrae, **insertion**, into the superior angle and posterior border, of the scapula; **action**, raises the angle of the scapula, thereby rotating the bone and depressing the point of the shoulder; **nerve supply**, branches of the cervical plexus.

Rhomboideus Major, origin, from the spinous processes of the second to fifth dorsal vertebrae; **insertion**, into the vertebral border of the scapula, between the root of its spine and the inferior angle, by a tendinous expansion, which is firmly attached to the inferior angle; **action**, draws the scapula backward and upward, and rotates the bone so as to depress the point of the shoulder; **nerve supply**, lower cervical.

Rhomboideus Minor, origin, from the spinous processes of the seventh cervical and first dorsal vertebrae and the ligamentum nuchae; **insertion**, into the smooth surface at the root of the spine of the scapula; **action**, same as the rhomboideus major; **nerve supply** same.

Serratus Posticus Superior, origin, from the ligamentum nuchae, the spines of the 7th cervical and of the two or three upper dorsal vertebrae, and the supra-spinous ligaments; **insertion**, into the upper borders and outer surfaces of the second to fifth ribs, a little beyond their angles; **action**, elevates the ribs in inspiration; **nerve supply**, lower dorsal.

Serratus Posticus Inferior, origin, from the spinous processes of the last two dorsal and three upper lumbar vertebrae, **insertion** into the lower borders of the four lower ribs: **action**, depresses the lower ribs in expiration; **nerve supply**, lower dorsal nerves.

Splenius Capitis and Colli, made up of two slips, originally constituting a single muscle, divided at its insertion into two parts; the **origin**, from the spinous process of the seventh cervical vertebra the ligamentum nuchae, the spines of the six upper dorsal vertebrae and the supra spinous ligament; **insertion** of **splenius capitis**, into the mastoid process of the temporal bone, and into the occipital bone below the outer third of the superior curved line; **insertion** of the **splenius colli**, into the transverse processes of the two or three upper cervical vertebrae, **action**, to draw the head backward and downward and flex the neck to its own side, the face being turned to the same side, **nerve supply**, lower cervical, and upper dorsal nerves.

Erector Spinae (illustrations Nos. 95 and 96) **origin**, from the spines of the last two dorsal, of all the lumbar and sacral vertebrae sacro iliac groove, and posterior part of inner lip of crest of the ilium; **insertion**, is represented by the parts, or columns, into which it divides; the **ilio-costalis**, inserted *into* the angles of the six or seven lower ribs; the **musculo-accessorius**, *into* the angles of the six upper ribs, the **cervicalis ascenders**, *into* the transverse processes of the 4th, 5th and 6th cervical vertebrae; **longissimus dorsi**, *into* the lumbar transverse processes and the accessory tubercles of their articular processes, into the transverse processes of the thoracic vertebrae, and into the lower ten ribs, external to their tubercles; **transversalis colli**, *into* the transverse processes of the cervical vertebrae, from the 2nd to the 6th inclusive; **trachelo-mastoid**, *into* the mastoid process of the temporal bone; **spinalis dorsi**, *into* the spinous processes of the 4th to 8th dorsal vertebrae; **spinalis colli**, *into* the spinous process of the axis, sometimes also of the 3rd and 4th cervical vertebrae, **complexus** *between* the superior and inferior curved lines of the occipital bone (the **biventer cervicis** is usually blended with this muscle, constituting its inner portion, by an elongated tendon between its two fleshy bellies). **Action** of the erector spinae and its many parts; holds the spine erect, bends the body backward, steadies the head and neck and fixes them in an upright position, flexes the neck, extends the head, and depresses the ribs, as in expiration; **nerve supply**, cervical, dorsal and lumbar nerves.

Semi-Spinalis Dorsi, origin, from the transverse processes of the 6th to 10th dorsal vertebrae; **insertion**, into the sides of the four upper dorsal, and of the 6th and 7th cervical, vertebrae.

Semi-Spinalis Colli, origin, from the five or six upper dorsal transverse processes; **insertion**, into the 2nd, 3rd, 4th and 5th cervical

spinous processes; **action**, these semi-spinales muscles are extensors and lateral flexors of the vertebral column, also hold the spine erect; **nerve supply**, cervical and upper-dorsal nerves.

Multifidus Spinae, origin, from the back of the sacrum, posterior superior spine of the ilium, sacral groove, deep surface of the tendon of the erector spinae, inner lip of the iliac crest, sacro-iliac ligament, mammillary tubercles of the lumbar vertebrae, transverse processes of the dorsal vertebrae, and the articular processes of the lower four cervical vertebrae; **insertion**, into the spines of the vertebrae, from root to tip, that is, each fasciculus passes obliquely upward and inward into the whole length of the spinous process of a vertebra above, up to and including that of the 2nd cervical; **action**, assists the erector spinae in holding the spine erect, rotates the spine, and it rests the other muscles by successive contraction and relaxation of its separate fasciculi; **nerve supply**, branches of the spinal nerves.

Rotatores Spinae, origin, from the transverse processes of the dorsal vertebrae, the 2nd to the 12th inclusive; **insertion**, into the laminae of the next vertebra above; **action**, rotates the vertebrae towards the opposite side; **nerve supply**, branches of the spinal nerves.

Inter-Spinales consists of short bundles placed between the spinous processes of the contiguous vertebrae, connecting the spinous processes, **origin**, from the under surface, near the apex of the spines of the vertebrae; **insertion**, into the posterior part of the upper surface of the spinous process below; **action**, to support the spinal column, and extend the vertebrae; **nerve supply**, branches of the spinal nerves.

Inter-Transversales, placed between the transverse processes of the vertebrae; **action**, lateral flexors of the vertebral column; **nerve supply**, branches of the spinal nerves.

Supraspinales, consist of bundles of fibres attached to the tips of the spinous processes in the cervical region.

Extensor Coccygis, arises from the last segment of the sacrum or the first of the coccyx; **insertion**, into the tip of the coccyx; **action**, extends the coccyx; **nerve supply**, sacral branches.

Rectus Capitis Posticus Major, origin, from the spinous process of the axis; **insertion**, occipital bone, below its inferior curved line; **action**, rotates the head and draws it backward; **nerve supply**, sub-occipital.

Rectus Capitis Posticus Minor, origin, from the lateral mass of the atlas; **insertion**, into the rough surface beneath the curved line of the occipital bone; **action**, rotates the head and draws it backward; **nerve supply**, sub-occipital.

Obliquus Capitis Superior, origin, from the transverse processes of the atlas, **insertion**, between the occipital superior and inferior curved lines, **action**, to rotate the head and draw it backward; **nerve supply**, sub-occipital.

Obliquus Capitis Inferior, origin, from the spinous process of the axis; **insertion**, into the transverse processes of the atlas; **action**, rotates the atlas and the head; **nerve supply**, sub-occipital.

MYOLOGY

Muscles attached to the spine are the following:—

Latissimus dorsi	Complexus
Trapezius	Rotatores spinae
Levator anguli scapulae	Supraspinales
Rhomboideus major	Interspinales
Rhomboideus minor	Intertransversales
Serratus posticus superior	Semi-spinalis colli
Serratus posticus inferior	Semi-spinalis dorsi
Splenius capitis and colli	Multifidus spinae
Erector Spinae	Rectus capitis posticus major
Ilio-costalis	Rectus capitis posticus minor
Longissimus dorsi	Obliquus capitis superior
Spinalis dorsi	Obliquus capitis inferior
Cervicalis ascendens	Scalenus anticus
Transversalis colli	Scalenus medius
Levatores costarum	Scalenus posticus
Rectus capitis anticus major	Psoas magnus
Rectus capitis anticus minor	Psoas parvus
Longus colli	Quadratus lumborum
Rectus capitis lateralis	Transversalis abdominis
Trachelo-mastoid	Diaphragm

The internal abdominal oblique and the iliacus are attached to the lumbar fascia. To the sacrum and coccyx are attached, the pyriformis, coccygeus, extensor coccygis, gluteus maximus, the sphincter and, and the levator and.

MUSCLES OF THE THORAX

(Illustrations Nos. 97 and 98.)

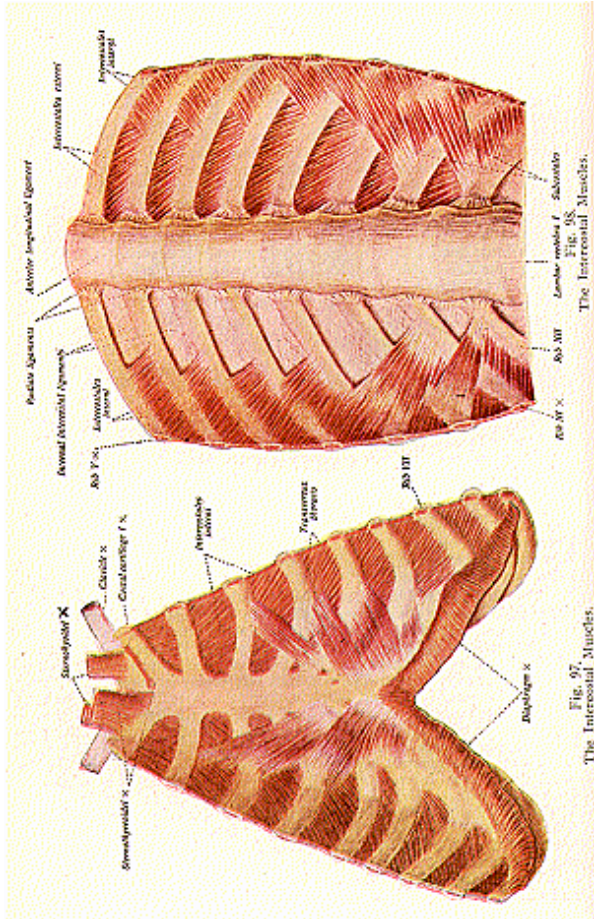
External intercostals	Triangularis sterni
Internal intercostals	Levatores costarum
Infra-costales, or sub-costals	Diaphragm

The **Intercostal Fascia** is a thin, but strong, layer of connective tissue which covers the external and internal intercostals, it lies across the intercostal spaces and spans intervals in the muscle fibers.

External Intercostals are eleven in number. They stretch across all the intercostal spaces from the lower border of one rib to the upper border of the next. Their strands are largely interspersed with strands of connective tissue. **Origin**, from the lower border of each rib, the fibres passing downward and anteriorly; **insertion**, into the upper border of the rib below; **action**, raise the ribs in inspiration; **nerve supply**, intercostals.

Internal Intercostals, also eleven in number, lie immediately beneath the external intercostals and, like those, extend across all of the intercostal spaces. **Origin**, from the inner lip of the inferior border of the rib, the fibres passing downward and posteriorly, extending from the angle of the rib to the sternum; **insertion**, into the upper border of the rib below; **action**, depress the ribs in expiration; **nerve supply**, intercostals.

The **action** of the intercostals has given rise to much discussion and difference of opinions. Some authorities claim that the external



MYOLOGY

and internal intercostals both act as elevators of the ribs and are, therefore, muscles of inspiration. Hamberger states that the external intercostals are the elevators, while the internal intercostals are the depressors, of the ribs. According to Hutchinson, the external intercostal muscles and the interchondral portions of the internal intercostals, act as elevators of ribs and are, therefore muscles of inspiration, while the interosseous portions of the internal intercostals act as depressors of the ribs and are, therefore, muscles of expiration. Gray states that the external intercostal elevates the rib below, and that it is the action of the internal intercostal which is in dispute, for the reason that Haller, long ago, taught that the internal acts together with the external intercostal, as inspiratory, while later investigators have endeavored to show that they act as expiratory muscles. Others believe that the intercostals contract simultaneously, and serve merely as strong septal supports which prevent the intercostal spaces from being pushed out, or drawn in, during respiration.

The **Subcostals**, or **Infra-Costales**, **origins** are 10 in number, small slips from the inner surface of each rib near its angle; **insertion**, into the inner surface of the 1st, 2nd or 3rd rib below, **action**, depress the ribs in expiration, **nerve supply**, intercostals.

Triangularis Sterni or **Transversus Thoracis**, **origin**, from the lower part of the side of the sternum, from the inner surface of the ensiform cartilage, and from the cartilages of the fifth, sixth and seventh ribs, **insertion**, into the lower border, and inner surface, of the 2nd, 3rd, 4th, 5th and 6th costal cartilages. The **insertion** takes place by separate slips, and one or two of the upper slips may be partially attached to the rib itself, **action**, used in expiration, by depressing the anterior extremities of the ribs; **nerve supply**, intercostals.

Levatores Costarum are 12 pairs of fan-shaped muscles, **origin**, from the transverse processes of the 7th cervical to 11th dorsal vertebrae; **insertion**, into the upper surface of the rib next below, between the tubercle and angle of the rib; **action**, raise the ribs; **nerve supply**, intercostals.

THE DIAPHRAGM

(Illustration No. 99.)

The **Diaphragm** (partition or wall) is a dome-shaped musculo-fibrous septum which separates the thoracic and abdominal cavities. It consists of fibers radiating from the lower border of the thorax and upper lumbar vertebrae, toward a central tendinous area, the **central**, or **cordiform, tendon**. The upper surface of the diaphragm forms the floor of the thoracic cavity, and is in contact with the pleurae and pericardium. Below, the diaphragm is largely invested by peritoneum, and is in relation with the liver, stomach, spleen, kidneys, suprarenals, duodenum, pancreas, inferior vena cava and the coeliac axis. **Origin** from the posterior surface of the ensiform cartilage, inner surface of the cartilages of the six or seven lower ribs, the ligamenta arcuata (external and internal arcuate ligaments), and by its crura from the bodies of the lumbar vertebrae; **insertion**, into the central tendon from

all sides; **action**, the great muscle of respiration and expulsion; **nerve** supply, right and left phrenic.

The **central tendon**, or **cordiform tendon**, is much elongated from side to side, convex in front, and concave behind. It is divided into three leaf-like divisions and, therefore, is described as being **trefoil** shaped. It forms the centre of the dome of the diaphragm, and to its borders the muscular fibres slope upward from their several points of origin. The fibres intersect one another at various angles, and unite into straight and curved bundles, their arrangement affording additional strength.

The **ligamenta arcuata** are ligaments, five in number; external right and left, internal right and left, and middle. The **external arcuate ligament**, also called the external lumbo-costal arch, is a thickening of the upper parts of the anterior wall of the sheath of the quadratus lumborum and lumbar fascia, and extends from the last rib to the tip of the transverse process of the first lumbar vertebra.

The **internal arcuate ligament**, or the internal lumbo-costal arch, is a thickening of the upper part of the sheath of the psoas magnus, and arches from the tip of the transverse process of the first lumbar vertebra, to the sides of its body.

The **middle arcuate ligament** is a fibrous band which connects the innermost tendinous fibres of the right and left crura, on a level with the lower border of the body of the twelfth dorsal vertebra, it arches over the aorta.

The **crura** are strong, thick, musculo-tendinous bundles, fleshy above and tendinous below, the left being the smaller, shorter, and the more posterior of the two. They are situated on the bodies of the lumbar vertebra, each side of the aorta. The **right crus** arises from the bodies of the four upper lumbar vertebrae, and the **left crus** arises from the two or three upper lumbar vertebrae. The muscular fibres of the crura pass upward in a diverging manner, to be inserted into the posterior border of the central tendon.

The diaphragm is the principal muscle of respiration. During respiration the lower ribs are fixed and from these and the crura the muscle fibres contract and draw the central tendon downward and forward. When the muscular part contracts, it descends, pushing the abdominal viscera downward and increasing the capacity of the thorax, so that the lungs may expand. The diaphragm is also a muscle which aids in all efforts of expulsion, such as sneezing, laughing, crying, micturition, emesis and defecation, and it becomes one of the principal muscular agents at the time of parturition.

The **openings in the diaphragm** are three large, and several smaller ones. The *aortic opening* is situated in the middle line between the upper portions of the crura, opposite the fibro-cartilage of the 12th dorsal and 1st lumbar vertebrae; it transmits the aorta, thoracic duct, and azygos vein. The *esophageal opening* is situated at the level of the 10th dorsal vertebra, in the fleshy part of the muscle, is elliptical in form, and lies in front, and a little to the left, of the aortic opening. It transmits the esophagus, the vague, or pneumo-gastric, nerve, and small branches of the esophageal arteries, from the gastric artery. The *vena caval opening* is situated in the central tendon close to its

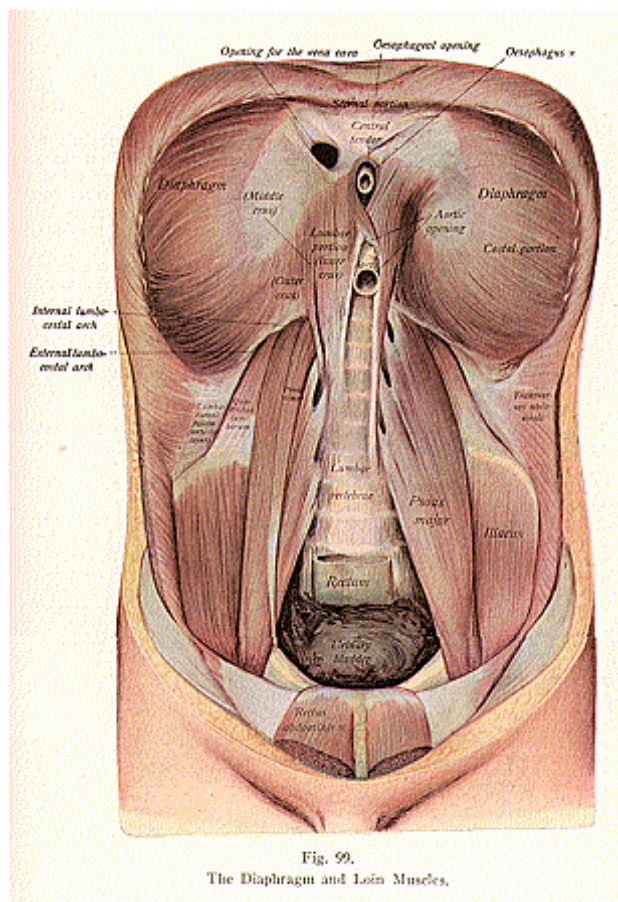


Fig. 99.
The Diaphragm and Loin Muscles.

posterior border. This is the highest opening, situated about on level between the 8th and 9th dorsal vertebrae, one inch to the right of the median plane; it transmits the inferior vena cava, and some small lymphatics from the liver.

The fibers of the crura decussate before reaching the central tendon, and each crus, in its tendinous portion, is perforated by the greater and lesser splanchnic nerves.

The other foramina transmit the superior epigastric vessels, the musculo-phrenic vessels, some of the lower intercostal nerves, branches of the sympathetic system, and some of the smaller veins.

The *muscles used in ordinary or tranquil respiration* are the scaleni (anticus, medius and posticus), the external and internal intercostals, triangularis sterni, subcostals, levatores costarum, serratus posticus superior and inferior, and the diaphragm.

The *accessory muscles or extraordinary muscles of respiration* are the quadratus lumborum, pectoralis major, serratus anticus, sterno-mastoid, latissimus dorsi, infra-hyoid, the abdominal muscles, and many of the extensors of the vertebral column.

The above named muscles, with the trapezius, levator angulae scapulae, rhomboideus major and minor, the subclavius, omo-hyoid, and pectoralis major and minor, are used in forced respiration.

MUSCLES OF THE ABDOMINAL WALL

Muscles of the abdominal Wall are the **External Oblique, Internal Oblique, Transversalis, Rectus** and the **Pyramidalis** (illustration No. 100).

The **Fasciae of the Abdomen** consist of two layers, the **superficial** and the **deep layers**.

The **Superficial Fascia** of the anterior wall of the abdomen extends from Poupart's ligament to a line drawn transversely, from the anterior superior iliac spine, to the linea alba. It resembles the superficial fascia which forms the common body-covering, and contains cutaneous vessels and nerves, and a certain amount of fat. As this layer approaches the groin, it is divisible into two layers, the **superficial** and the **deep layer**.

Fig. 100.

Muscles of the Trunk, Pelvis, Upper Part of Thigh and Upper Extremity—
Anterior View.

1. Epicraniius. 2. Pyramidalis nasi. 3. Attolens aurem. 4. Attrahens aurem. 5. Orbicularis oculi. 6. Levator labii superioris alaeque nasi and compressor nasi. 7. Levator labii superioris. 8. Zygomaticus minor. 9. Zygomaticus major. 10. Levator anguli oris. 11. Masseter. 12. Buccinator. 13. Triangularis menti. 14. Depressor labii inferioris. 15. Levator menti. 16. Orbicularis oris. 17. Platysma myoides. 18. Sterno-mastoid. 19. Sterno-hyoid. 20. Scaleni. 21. Pectoralis major. 22. Pectoralis minor. 23. Subclavius. 24. Serratus anticus. 25. External abdominal oblique. 26. Linea alba. 27. Rectus abdominis. 28. Aponeurosis of rectus abdominis. 29. Pyramidalis abdominis. 30. Internal oblique. 31. Poupart's ligament. 32. Intercolumnar fibres. 33. Internal portion of Poupart's ligament. 34. External abdominal ring. 35. Internal abdominal ring. 36. Inguinal canal. 37. Deltoid. 38. Coracobrachialis. 39. Short head of biceps brachii. 40. Long head of biceps brachii. 41. Biceps brachii. 42. Subscapularis. 43. Brachialis anticus. 44. Inner head of triceps brachii. 45. Pronator teres. 46. Supinator longus. 47. Flexor carpi radialis. 48. Palmaris longus. 49. Flexor carpi ulnaris. 50. Flexor communis digitorum.

MYOLOGY

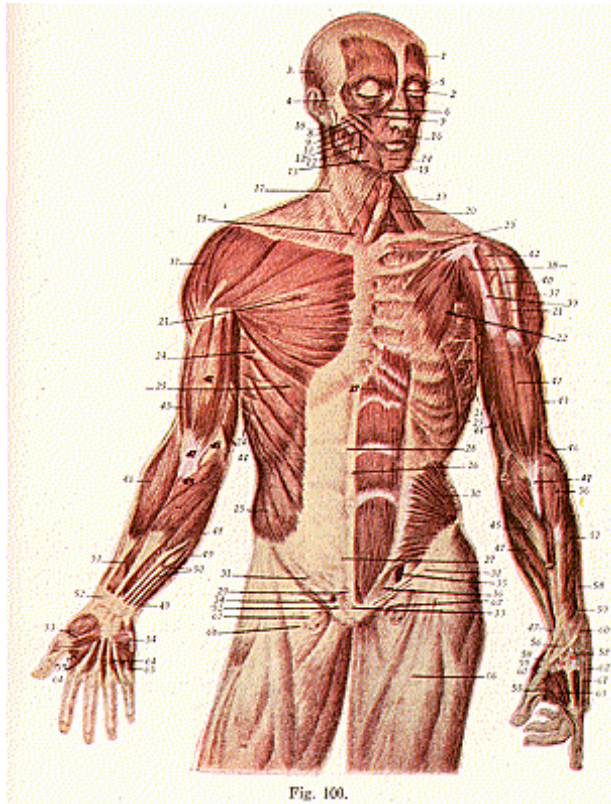


Fig. 100.

51. Flexor longus pollicis. 52. Annular ligament of wrist. 53. Abductor pollicis. 54. Palmaris brevis. 55. Adductor pollicis. 56. Extensor carpi radialis longus. 57. Extensor carpi radialis brevis. 58. Extensor ossis metacarpi pollicis. 59. Extensor brevis. 60. Extensor longus pollicis. 61. Extensor indicis. 62. Extensor communis digitorum. 63. Abductor indicis. 64. Lumbricales. 65. Abductor of little finger. 66. Fascia femoris. 67. Femoral ring. 68. Falciform process of fascia lata.

The **superficial**, or **subcutaneous**, layer or the **fascia of Camper**, is composed of areolar tissue, containing adipose tissue in its meshes. When traced upward it blends with the deep layer, above the level of the line connecting the anterior superior iliac spine with the linea alba. When followed inwardly, it is continuous with the corresponding layer of the opposite side. In a downward direction it is freely continuous with Poupart's ligament, and with the subcutaneous layer of the superficial fascia of the front of the thigh. When traced downward and inwardly, it passes along the spermatic cord into the scrotal wall and over the penis, and helps to form the dartos of the scrotum; as it passes to the scrotum it changes its character, becoming thin, while muscular fibres replace its adipose tissue. From the scrotum it may be traced backward and found to be continuous with the superficial fascia of the perineum. In the female, this fascia passes along the round ligament of the uterus, into the labia majora.

The **deep layer** of the superficial fascia, or the **fascia of Scarpa**, is a strong membrane, but is thinner in structure and contains yellow elastic tissue. It is separated from the superficial layer by the superficial epigastric vessels, but its deep aspect is loosely connected, by areolar tissue, to the subjacent aponeurosis of the external oblique muscle. Above, this fascia fuses with the superficial layer, below it is carried down over Poupart's ligament, blending with the fascia lata. It is carried down over the penis, fusing with the superficial layer, and over the spermatic cords of the scrotum, where it also fuses with the superficial layer; behind the scrotum it is continuous with the similar deep layer in the perineum. In the female this fascia is continued into the labia majora, while in the middle line it is firmly bound down, by fibrous bands, to the linea alba, and to the symphysis pubis.

The **Deep Fascia** of the abdomen resembles that of other parts of the body in that it is membranous. It invests the external oblique muscle, and is well marked, laterally, where the external is fleshy, but where it approaches the aponeurosis of the muscle, it becomes thin and delicate, and ultimately disappears.

The **External Abdominal Oblique**, or **Obliquus Externus Abdominis**, is situated on the side, and front, of the abdomen. It is the largest of the abdominal muscles, being broad, and its fibres pass obliquely downward and forward. **Origin**, from the lower 8 ribs, by 8 fleshy digitations (finger-like slips); **insertion**, into the anterior half of the outer lip of the crest of the ilium, into the ensiform cartilage, the linea alba, spine and crest of the pubes; **action**, compresses the viscera flexes the thorax on the pelvis, and vice versa, and assists the diaphragm in all forms of expulsion and respiration; **nerve supply**, lower intercostals.

The **Aponeurosis** of the **External Abdominal Oblique** is a strong membranous aponeurosis, the fibres are directed downward and inward. It joins with the aponeurosis of the opposite muscle and covers the whole anterior abdominal wall. The aponeurosis attains its greatest width, and strength, at and below the level of the anterior superior iliac spine; it is narrowest opposite the umbilicus. Above, this aponeurosis gives origin to the pectoralis major, below, some of

its fibres are attached to the symphysis pubis, while others pass deeply thru the middle line, to be attached to the crest and ilio-pectineal line of the opposite side; and is here called the *triangular fascia*.

Parts of the aponeurosis, aside from the triangular fascia just mentioned, are the **linea alba**, **Poupart's ligament**, **Gimbernat's ligament**, the **external abdominal ring**, and the **intercolumnar fibres**.

Linea alba (white line) is a tendinous band, extending from the ensiform cartilage to the symphysis pubis. It is a strong, dense, fibrous band, about one-half inch broad at its upper part, above the umbilicus, but it becomes narrow below. It is formed by the decussation of the aponeurosis of the abdominal muscles of the opposite sides, except the recti muscles, and this line serves to strengthen the wall. The anterior abdominal wall is thinner and less vascular along the linea alba, than at any other part. This line is, therefore, selected for such operations as supra-public lithotomy, ovariectomy, etc. The umbilical opening is a fibrous ring, formed (in the linea alba) by its fibres, and filled with scar tissue. In the adult the umbilicus is a cicatrix, but in the foetus it transmits vessels and ducts.

Poupart's ligament, or the **ligamentum inguinale**, is an infolded, thickened, tense tendon, which extends from the anterior superior spine of the ilium to the spine of the pubes. This aponeurotic band gives partial attachment, on its outer part, to the internal oblique and transversalis muscles. Its inner half gradually widens, at its attachment to the os pubis, and lies beneath the spermatic cord, forming here a bundle of fibres to form the side of the external ring. An expansion of Poupart's ligament from the pubic spine to the ilio-pectineal line, a distance of one inch, is called the **ligamentum lacunae**, or **Gimbernat's ligament**, more prominent in the male than in the female. The outer margin of Gimbernat's ligament is concave, thin, sharpened and wiry, and lies in contact with the crural sheath, forming the inner boundary of the crural, or femoral, ring. Its deep margin corresponds to the ilio-pectineal line, and is continuous with the fascia lata, while its superficial surface is continuous with Poupart's ligament.

The **external abdominal ring**, or the **subcutaneous inguinal ring**, is an opening in the aponeurosis of the external oblique, and is situated immediately above, and to the outer side of, the pubic spine. It is triangular in form, the apex upward and the base downward; it serves to transmit the spermatic cord in the male, and the round ligament of the uterus in the female. The opening is of considerable extent, but its edges are drawn together, in the natural condition, so that no opening is perceptible; these edges are strengthened by a number of arched or curved fibres, called the **intercolumnar fibres** which arise from Poupart's ligament and stretch across the external ring, the opening in the aponeurosis. The external ring is from one to one and one-half inches in length; its breadth, at the base, about one-half inch.

The margins of the external abdominal ring are called the *pillars* or *columns*. The *external pillar*, or *crus inferior*, is the stronger of the two pillars, and is that part of Poupart's ligament which is fixed to the pubic spine. It is curved on the upper part, its concavity lodging the spermatic cord, or the round ligament. The *internal pillar*, or *crus*

superior, is a thin straight band formed by the fibres of the aponeurosis of the obliquus externus, and is attached to the front of the symphysis pubis. The intercolumnar fibres, or intercrural fibres, increase the strength of the lower part of the aponeurosis and prevent a divergence of the pillars from each other. As the intercolumnar fibres pass across the external abdominal ring they are connected together by fibrous tissue, thus forming the **intercolumnar fascia**, sometimes called the **external spermatic fascia**; it forms a tubular sheath which lies upon the spermatic cord.

The **triangular fascia**, also known as the **ligament of Colles**, or the **ligamentum inguinale reflexum**, is situated beneath the spermatic cord and behind the internal pillar of the external abdominal ring, and lies in front of the conjoined tendon. Its fibres are derived from the external oblique aponeurosis of the opposite side and, having crossed the linea alba, they take insertion into the spine and crest of the pubes.

Petit's triangle, or the **trigonum lumbale**, is only present when the latissimus dorsi and external oblique do not meet. It is situated above the center of the iliac crest, is bounded in front by the external oblique, behind by the latissimus dorsi, below, by the crest of the ilium, and its floor is formed by the internal oblique. In this situation a lumbar hernia may occur, or a lumbar abscess may find its way thru it. It is a weak point, easily located in jujitsu.

The **Internal Oblique**, or **Obliquus internus abdominis**, lies internal to the external oblique, and most of its fibres pass upward and forward across those of the external oblique. **Origin**, from the lumbar fascia, the anterior two-thirds of the middle lip of the crest of the ilium, and the outer half of Poupart's ligament; **insertion**, into the six lower ribs, ensiform cartilage, linea alba, and the crest of the pubes by the conjoined tendon which it forms with the transversalis; **action**, compresses the viscera, flexes the thorax on the pelvis, and vice versa, and assists the diaphragm in its various acts of expulsion, and in respiration, **nerve supply**, lower intercostals.

The **Transversalis Abdominis** is the deepest muscle of the abdomen, its fibers pass transversely forward. **Origin**, from the spine and transverse processes of the lumbar vertebrae, the anterior two-thirds of the inner lip of the crest of the ilium, and the external one-half of Poupart's ligament; **insertion**, into the ensiform cartilage, the linea alba, pectineal line, and the crest of the pubes by the conjoined tendon of the internal oblique and transversalis; **action**, compresses the viscera, flexes the pelvis on the thorax, and vice versa, and assists the diaphragm in all forms of expulsion and respiration, **nerve supply**, lower intercostals, and branches from the ilio-hypogastric and ilio-inguinal nerves.

The **conjoined tendon** is the tendon which gives a common insertion to the internal oblique and the transversalis muscles. It is composed of the fused parts of the aponeuroses of these two muscles and is inserted into the front of the pubic crest, and into the pectineal line for a distance of one inch. The tendon is formed principally by the transversalis, which extends for one inch along the ilio-pectineal line while the internal oblique extends along that line for only one-half

inch. The conjoined tendon varies greatly in development, and in many cases is hardly distinguishable. It lies behind the external abdominal ring, and thus strengthens what would otherwise be a weak part of the abdominal wall. The conjoined tendon is often divided into two parts, an outer portion known as the *ligament of Hesselbach*, and an inner portion, the *ligament of Henle*.

The external oblique, internal oblique and transversalis, cross each other at different angles, the external passing downward, the internal upward, and the transversalis horizontally forward; thus they form an intricate lattice work, which renders the abdominal wall very strong, and is a powerful safeguard against hernial protrusions.

The **Cremaster Muscle** is a thin layer of a series of loops which descend over the testes and the spermatic cord. It **arises** from the inner part of Poupart's ligament, where its fibres are continuous with the internal oblique and the transversalis, and is found only in the male. These loops at the upper part are short, but become in succession longer, the longest reaching the testicle. They are united by areolar tissue, and form a covering for the testes, called the cremasteric fascia. The **action** of this muscle is to support and raise the testes, **nerve supply**, genito-crural.

The **Fascia Transversalis** is situated underneath the transversalis abdominis muscle. It is of greatest strength over the lower abdominal wall and is separated from the peritoneum by a thin layer of extraperitoneal areolar fatty tissue. *Anteriorly*, it is continuous with the fascia of the quadratus lumborum, and extends over the fat which covers the posterior surface of the kidney; *superiorly* it blends with the fascia of the diaphragm; and *inferiorly* it is continuous with the iliac fascia, along the crest of the ilium and the posterior outer half of Poupart's ligament. Here this part of the fascia joins with the iliac fascia, and the two form a canal which contains the deep circumflex vessels. Anterior to the femoral vessels, it is carried distally into the thigh, and forms the anterior wall of the femoral sheath; internal to them, it is attached to the pubis and the ilio-pectineal line. Beneath Poupart's ligament the transversalis fascia is strengthened by a band of fibrous tissue, which is loosely connected to Poupart's ligament, and is known as the *deep femoral arch*. This is prolonged over the spermatic cord and testis, as the **infundibuliform fascia**. The spermatic cord in the male, and the round ligament of the uterus in the female, pass thru this fascia, the point where they pass thru is called the **internal abdominal ring**.

The **internal abdominal ring**, or the deep abdominal ring, is situated in the fascia transversalis, at a point midway between the anterior superior spine of the ilium and the symphysis pubis, about one-half inch above Poupart's ligament. It is an oval opening one-half inch long, which transmits the spermatic cord in the male, and the round ligament of the uterus in the female. Externally, this opening is not visible, because the fascia transversalis is prolonged from the margins of the aperture, around the spermatic cord, as the **infundibuliform**, or **internal spermatic fascia** which encloses the cord and the testis.

The **inguinal canal**, or **spermatic canal**, is an oblique passage,

about one and one-half inches in length, placed parallel with Poupart's ligament, slightly above it, and directed downward, forward and inward. It begins at the internal abdominal ring, at which point the cord enters, and terminates at the external abdominal ring. It is bounded, in front, by skin, superficial fascia, the aponeurosis of the external oblique, and part of the internal oblique; behind, by the triangular fascia, the conjoined tendon, the transversalis fascia, subperitoneal tissue, and the peritoneum; below, by the union of the transversalis fascia with Poupart's and Gimbernat's ligaments; and superiorly, by the arched fibres of the internal oblique and transversalis muscles.

An interval, found in this region, is known as **Hesselbach's triangle**, which is situated at the lower part of the anterior abdominal wall, above the inner half of Poupart's ligament. It is bounded externally, by the deep epigastric vessels, internally by the outer border of the rectus abdominis, inferiorly, by the inner half of Poupart's ligament. The apex corresponds with the point where the deep epigastric vessels pass beneath the outer border of the rectus abdominis. Its floor is formed by the transversalis fascia and the conjoined tendon. The inguinal canal is opposite the lower part of the triangle, and therefore a direct inguinal hernia enters the inguinal canal from the internal side of the epigastric vessels, pushing the floor of the triangle with it.

The **Rectus Abdominis, origin**, from the pubic crest and symphysis, **insertion**, into the cartilage of the 5th, 6th and 7th ribs; **action**, compresses the viscera, flexes the thorax upon the pelvis, and vice versa, and assists the diaphragm in expulsion and respiration; **nerve supply**, lower intercostals.

This muscle is long and flat, and extends the whole length of the abdomen, its fibres are directed upward, upon either side of the linea alba. It is narrow below where it has two heads for attachment, but it becomes broad above. Below the umbilicus the two muscles are very near each other, the interval between them being not more than one-eighth of an inch. Each muscle is marked by three tendinous intersections or inscriptions; the **lineae transverse**, which cross it in a somewhat irregular manner at certain intervals—one at the level of the umbilicus, a second one opposite the tip of the ensiform cartilage, and the third between these two; at the outer border of these lines is a similar line, placed vertically, the **linea semilunaris**, formed by the aponeurosis of the internal oblique at its point of division. These are the remains of the septa which separated the primitive muscle-segments and, by some, they are regarded as indicating the abdominal ribs of certain animals, such as the crocodile. These fibres blend with the anterior wall of the sheath of the rectus, but do not blend with its posterior wall.

The rectus muscle is enclosed in a sheath called the *rectus sheath*, which is formed by the aponeurosis of the oblique and transversalis. When the aponeurosis of the internal oblique arrives at the outer margin of the rectus, it divides into two lamellae, one of which passes in front of the rectus, blending with the aponeurosis of the trans-

versalis; and these, joining at its inner border, are inserted into the linea alba.

The **Pyramidalis, origin**, from the front of the pubic crest; **insertion**, into the linea alba half-way to the umbilicus; **action**, renders tense the linea alba; **nerve supply**, lower intercostals and ilio-hypogastric.

The muscles of the posterior abdominal wall are the **Quadratus Lumborum, Psoas Magnus** and **Psoas Parvus** and the **Iliacus**. The last three named muscles, however, are more often considered with the muscles of the lower extremity and will be described later.

The **Quadratus Lumborum, origin**, from the ilio-lumbar ligament and the adjacent two inches of the crest of the ilium; **insertion**, into one-half of the lower border of the last rib and the tips of the transverse processes of the lumbar vertebrae. Occasionally, there are fibres which arise from the tips of the transverse processes of the lower lumbar vertebrae, when this is the case, the inserting fibres pass upward to the tips of the transverse processes of the upper lumbar vertebrae, by tendinous slips, and to the lower border of the last rib; **action**, flexes the chest laterally and forward, and aids in forced respiration; **nerve supply**, lower dorsal and upper lumbar.

This muscle is encased in a sheath, called the **Fascia of the Quadratus Lumborum**, the anterior wall of which is formed by the anterior layer of the lumbar fascia; the posterior wall by the middle layer of the same fascia. That portion of this fascia which extends, from the transverse process of the first lumbar vertebra, to the lower part of the last rib, constitutes the external arcuate ligament of the diaphragm.

THE MUSCLES AND FASCIA OF THE PELVIC OUTLET

(Illustration No. 101.)

The **Muscles** and **Fasciae** of the **Pelvic Outlet** are those structures which form the floor of the pelvis. The muscles of this region are situated in the ischio-rectal space, and in the perineum. The tuberosity of the ischium can be felt (on either side) as can also the ischio-pubic ramus, but the great sciatic ligament cannot be felt, on account of the thickness of the lower border of the gluteus maximus muscle. The tip of the coccyx is very accessible to the finger.

The **perineum** practically corresponds with the outlet of the pelvis, and is a lozenge-shaped structure between the pubic arch, the tip of the coccyx, and the tuber-ischii on either side. It is a structure where the genital organs turn forward and the rectum turns backward. It is conveniently divided into two parts by a line connecting the ischial tuberosities, each division being triangular. The anterior division represents the uro-genital, or urethral, division and the perineum proper; the posterior, the ischio-rectal, or anal, division. The *central; tendinous point of the perineum* is a fibrous point, thickened in the middle line of the pelvic outlet, between the urethra and the rectum, and about one inch anterior to the anus; at this point the muscles of the perineum converge so that, by the contraction of these muscles which extend in opposite directions, it serves as a fixed point.

The **Pelvic Fascia** is a thin, strong membrane which lines the

wall of the pelvic cavity, being directly continuous with the transversalis fascia, in front, and with the iliac fascia at the sides. It arises, on either side, from the attachment of these fasciae, upon the posterior surface of the pubic and the contiguous portion of the brim of the pelvis; and from the obturator foramen just above the attachment of the obturator internus muscle. At the posterior border of the obturator internus muscle, it continues as a much thinner layer to the pyriformis muscles, (where it is called the pyriformis fascia), and to the coccygeal muscles and the sacral plexus of nerves, behind the internal iliac vessels, to the front of the sacrum. It descends upon the pelvic wall until it receives the tendinous attachment of the levator ani muscle, which forms a dense curved white line extending from the symphysis pubis to the spine of the ischium. This line is an important landmark for it indicates the position of a separation of the pelvic fascia into two layers, the inner layer known as the *rectovesical* fascia and the outer layer, which becomes the *obturator fascia*.

The *recto-vesical* fascia descends over the pelvic surface of the levator ani muscle and is attached to the lower portions of the viscera, namely; in the male, to the bladder, prostate gland and the rectum; and in the female, to the bladder, the vagina, the neck of the uterus and the rectum. These expansions constitute the true ligaments of the pelvic viscera, so called because they serve to support these organs and in a measure to maintain them in their proper positions. The *obturator fascia* descends on the inner surface of the obturator internus muscle, forming the sheath for the internal pubic vessels and nerves, and is attached to the pubic arch, to the tuberosity of the ischium, and to the great sacro-sciatic ligament. Anteriorly, this fascia stretches across between the rami and the pubes, being continuous with the similar fascia from the opposite side, and forms the sub-pubic fascia or the posterior layer of the triangular ligament.

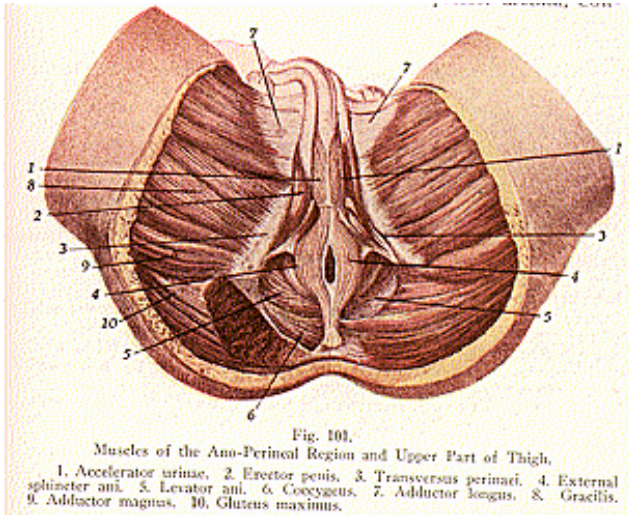
The **Fascia of the Perineum** consists of two layers, the superficial and the deep, as in the other regions of the body. The *superficial* or *subcutaneous layer* is thick, loose, areolar in texture, and contains much adipose tissue in its meshes. In front, it is continuous with the dartos of the scrotum; continuous behind with the subcutaneous areolar tissue surrounding the anus; and on either side with the same fascia on the inner side of the thigh. The *deep layer* of the *superficial fascia* is thin, strong, and aponeurotic in character, and is attached to the anterior border of the ramus of the ischium as far as the ischiatic tuberosities; internally, the fascia of one side is continuous with that of the other side, along the middle line. This fascia serves to bind down the muscle of the root of the penis, and is continuous with the dartos of the scrotum, with the fascia of the penis, and with the deep layer of the superficial fascia of the abdomen.

The **deep perineal fascia** is more often known as the **triangular ligament** or **uro-genital diaphragm**. It is prolonged over the levator ani muscle as a thin fascia called the *ischio-rectal fascia*.

The **triangular ligament** or deep perineal fascia, of the male and female perineum, is a deep triangular band of fascia which is stretched across the pubic arch, so as to close in the front part of the outlet of the pelvis, and is composed of two layers, the superficial and the deep

MYOLOGY

layers, or the fasciae, inferior and superior, of the uro-genital diaphragm. The fascia inferior, or superficial layer, is the lower thickened part, triangular in form, one and a half inches in depth, its sides attached to the pubic arch, its base is fused with the fascia superior, or deep layer, its apex is directed forward, and is separated from the subpubic ligament by an oval aperture which transmits the dorsal vein of the penis to the prostatic plexus, and in the female, the dorsal vein of the clitoris. The fascia superior of the uro-genital diaphragm or the deep layer, is connected laterally with the sides of the pubic arch and fascia, and in front and posteriorly with the inferior or superficial layer, between the two fasciae are found the membranous part of the urethra, its sphincter, fibres of the compressor urethra, Cow-



per's glands, the pudic vessels, artery, veins and nerves of the clitoris, part of the urethra, the compressor urethrae muscles, and the glands of Bartholin. The triangular ligament or deep perineal fascia in the female is not so strong as in the male. It is attached to the pubic arch and is divided in the middle line by the aperture of the vagina; its posterior border is continuous, as in the male, over the levator ani muscle, and is known also as the ischio-rectal fascia.

The **perineal body** is peculiar to the female perineum. It is triangular in form, one and one-half inches in breadth, and bounded in front by the posterior wall of the vagina, behind, by the anterior wall of the anal canal, and inferiorly by the skin. The perineal body is a

thickening of connective tissue, mixed with elastic tissue and a few muscular fibres, it serves as a support to the posterior wall of the vagina and, during parturition, it becomes greatly stretched, but its elastic tissue usually guards it against rupture.

THE MUSCLES OF THE PELVIC OUTLET

These muscles are described as the muscles of the perineum of the male, or female, and the muscles of the ischio-rectal region.

The **Muscles of the Perineum in the Male** are the **Transverse Perineal**, the **Accelerator Urinae**, **Erector Penis** and the **Compressor Urethrae**.

The **Transverse Perineal**, or **Superficial Transversus Perinaei**, **origin**, from the tuberosity of the ischium; **insertion**, into the central tendon of the perineum; **action**, to draw tense the central tendon; **nerve supply**, pudic.

Accelerator Urinae, **origin**, from the central tendon and from the median rapine, which is continued forward from that point toward the symphysis pubis; **insertion**, into the triangular ligament, and into the bulb, and spongy and cavernous portions of the penis; **action**, ejects the urine and semen, and aids in erection; **nerve supply**, pudic.

Erector Penis, or **Ischio-Cavernosus**, **origin**, from the tuberosity and ramus of the ischium, and the crus penis; **insertion**, into the sides and under-surface of the crus penis; **action**, maintains erection; **nerve supply**, pudic.

Compressor Urethrae, **Sphincter Urethrae**, or **Deep Transversus Perinaei**, **origin**, from the rami of the ischium and pubis, **insertion**, into the opposite muscle, by a median rapine, after encircling the membranous portion of the urethra. At the middle line the muscle divides into two layers, which, passing above and below the membranous part of the urethra, form a sphincter muscle to it; **action**, to constrict the membranous part of the urethra, also plays a part at the end of micturition, and assists the accelerator urinae in expelling the urine and semen, **nerve supply**, internal pudic.

The **Muscles of the Perineum in the Female** are the **Transverse Perineal**, **Sphincter vaginae**, **Erector Clitoridis**, and the **Compressor Urethrae**.

The **Transverse Perineal**, **origin**, from the tuberosity and ramus of the ischium; **insertion**, into the central tendon of the perineum **action**, a tensor, serves to fix the central tendinous point of the perineum, **nerve supply**, pudic.

Sphincter Vaginae, or **Bulbo-Cavernosus**, **origin**, from the central tendon; **insertion**, into the clitoris; **action**, constricts the vagina, thus diminishing its size; **nerve supply**, pudic.

Erector Clitoridis, or **Ischio-Cavernosus**, **origin**, from the tuberosity and ramus of the ischium; **insertion**, into the sides and under surface of the crus clitoridis; **action**, erects the clitoris; **nerve supply**, pudic.

Compressor Urethrae, or **Deep Transversus Perinaei**, from the junction of the rami of the ischium and pubis, **insertion**, into the opposite muscle, and into the wall of the vagina behind the urethra; **action**, compresses the urethra; **nerve supply**, pudic.

Muscles of the **Ischio-Rectal Region** are the **Corrugator Cutis Ani**, the **External and Internal Sphincter Ani**, **Levator Ani** and the **Coccygeus**.

The **Corrugator Cutis Ani**, **origin**, from the submucous tissue within the anus; **insertion**, into the skin surrounding the anus; **action**, wrinkles the skin around the anus; **nerve supply**, sacral nerves, hemorrhoidal branches.

External Sphincter Ani, **origin**, from the tip of the coccyx and the fascia near it; **insertion**, into the central tendon of the perineum; **action**, closes the anus; **nerve supply**, sacral nerves and hemorrhoidal branches.

Internal Sphincter Ani, consists of circular unstriated fibres of the intestine, is placed one inch above the anus, forms a circular ring around the rectum, and assists the external sphincter in closing the anus.

A third sphincter of the rectum is often mentioned, the **sphincter of Hyrtl**, or **s.-tertius**, which consists of an incomplete band of muscular fibres in the rectum a few inches above the anus.

Levator Ani, **origin**, from the body and ramus of the pubis, from the pelvic fascia, and the spine of the ischium; **insertion**, into the rectum, coccyx, and central tendon of the perineum; **action**, supports the rectum, vagina and bladder, assists in forming the floor of the pelvis, also aids in defecation; **nerve supply**, sacral nerves.

Coccygeus, **origin**, from the spine of the ischium and the lesser sciatic ligament; **insertion**, into the side and last segment of the coccyx; **action**, supports and raises the coccyx, and assists in forming the floor of the pelvis; **nerve supply**, sacral nerves. The coccygeus with the levator ani muscle forms that portion of the floor of the pelvis called the *pelvic diaphragm*.

The **sphincter vesicae** consists of thick muscular fibres, derived from the middle coat around the neck of the urinary bladder and the commencement of the urethra, beyond which point they are continuous with the muscular tissue of the prostate gland in the male and with the muscular wall of the urethra in the female. They assist in closing the internal orifice of the urethra. The **internal os uteri** in the female consists of circular fibres of the middle coat of the uterus, which form a distinct sphincter around the internal os, the internal orifice of the cervical canal. Another sphincter, of widely different location which may be described here, is the **sphincter pupillae**, or **s.-iris**, which consists of muscular fibres and surrounds the pupillary margin of the iris, it contracts the pupil.

A summary of the **Sphincters**, **Compressors**, **Corrugators** and **Tensors**.

Sphincters.

Orbicularis oculi, **orbicularis oris**, **external sphincter** and, **internal sphincter** and, **sphincter vaginae** (female), **sphincter vesicae**, **sphincter urethrae** (male), **internal os uteri** (female), **sphincter pupillae**, or **sphincter iridis**, and the **pyloric sphincter**.

Corrugators.

Corrugator supercilli, **pyramidalis nasi**, the **epicranius**, **corrugator**

cutis ani, platysma myoides, the palmaris brevis, and the levator labii inferioris.

Tensors.

Tensor tarsi, tensor palati, pyramidalis abdominis, tensor fascia femoris, tensor tympani, psoas parvus, palmaris longus, transversus perinaei, crico-thyroid, subanconeus, and the heliis major and minor.

Compressors.

The external oblique, internal oblique, transversalis, rectus abdominis, compressor urethrae, sphincter vaginae (female), compressor sacculi laryngis, compressor narium, compressor narium minor, tensor tarsi, and the buccinator.

MUSCLES OF THE UPPER EXTREMITY

The **Muscles of the Upper Extremity** are grouped as those of the **anterior and lateral thoracic regions, the shoulder, arm, forearm and hand.** (See illustration Nos. 94 and 100.)

The **Fascia of the Pectoral, or Thoracic, Region** is arranged in two layers, the **superficial** and the **deep**. The **superficial fascia** is a loose, thin sheet of areolar tissue, containing fat, and continuous with the superficial fascia of the neck and abdomen.

The **deep fascia** is attached, above, to the clavicle, and forms a thin membrane closely adherent to the surface of the pectoralis major at the lower border it becomes continuous with the **axillary fascia**, toward the centre it is attached to the sternum, and at the side it becomes continuous with the fascia covering the shoulder, axilla and thorax. As a deep layer of this fascia there arises a well defined sheet known as the **clavi-pectoral fascia**, which encloses the subclavius muscle; it is then continued downward to the upper border of the pectoralis minor. There it divides into two sheets which enclose that muscle and, at its lower margin, unite to form a single sheet which becomes continuous with the axillary fascia, close to the axillary border of the pectoralis major. A portion of this fascia, which intervenes between, is termed the *coraco-clavicular, or costo-coracoid, membrane*. It is prolonged laterally along the upper border of the pectoralis minor over the upper portion of the axillary vessels, to the coracoid process.

An aponeurotic band, called the **lacertus fibrosus**, extends from the tendon of the biceps to the forearm, it is the *bicipital fascia*.

The **axillary fascia** is a firm sheet which extends across, from the lower border of the pectoralis major, to that of the latissimus dorsi and teres major, forming the floor of the axilla. Laterally it passes over the deep fascia of the arm, medially into the fascia covering the serratus anticus and, near the border of the pectoralis major, has inserted into it the downward continuation of the fascia which encloses the pectoralis minor.

The **Axilla** is a pyramidal space located at the upper, and lateral part of the chest, and inner side of the arm. The *anterior boundary* is formed by the pectoralis major and minor; the *posterior boundary*, by the subscapularis, teres major and latissimus dorsi; the *inner side* or wall by the four ribs, the intercostal muscles and the serratus anticus; the *outer wall* is formed by the upper part of the humerus and by the common origin of the coraco-brachialis and biceps brachii. Pass-

ing thru the axillary space, are axillary vessels and nerves, brachial plexus of nerves, long thoracic artery and nerve, intercostal nerve branches, cephalic vein, subscapular vessels and nerves, smaller arteries and veins, lymphatic glands, areolar tissue and fat.

The **Pectoralis Major** is a large, broad muscle, situated at the upper and fore part of the thorax and in front of the axilla, **origin**, from the sternal end of the clavicle, one-half the breadth of the sternum, and from the cartilages of the true ribs; its fibres radiate into three slips, the clavicular, sternal and brachial, terminating in a flat tendon; **insertion**, is into the pectoral ridge or the external bicipital ridge of the humerus; **action**, to draw the arm forward, inward, and across the chest, also aids in forced respiration; **nerve supply**, anterior thoracic.

The **Pectoralis Minor** is found beneath the pectoralis major **origin**, from the cartilages of the third, fourth and fifth ribs; **insertion**, into the coracoid process of the scapula; **action**, depresses the front of the shoulder and lowers the scapula; **nerve supply**, anterior thoracic.

The **Subclavius** is a small triangular muscle, placed between the clavicle and first rib, the **origin**, from the first rib and its cartilage **insertion**, into the groove (subclavian) on the under surface of the clavicle; **action**, draws the clavicle downward and forward, and assists in forced respiration; **nerve supply**, lower cervical.

The **Serratus Anticus**, or **Magnus**, is a thin quadrilateral muscle situated between the ribs and scapula, at the upper and lateral part of the thorax. **Origin**, from the eighth upper ribs by nine digitations (finger-like slips), the second rib having two slips; **insertion**, into the vertebral border of the scapula; **action**, raises the scapula, brings the scapula forward, and assists in respiration; it is called the pushing muscle and, in lower animals is known as the sling-muscle; **nerve supply**, posterior thoracic.

The **Deltoid** is a large, thick triangular muscle of the shoulder and received its name from its resembling the Greek letter delta, inverted. The **origin**, from the inferior lip of the spine of the scapula, from the outer margin of the acromion process, the outer third, and upper surface of the clavicle, **insertion**, into the middle of the outer side of the shaft of the humerus, into a triangular rough prominence the deltoid tubercle, **action**, to raise the arm, at right angles to the body, and aid in carrying it forward and backward; **nerve supply**, the circumflex.

The **Subscapularis** is a muscle which fills up the subscapular fossa, its **origin**, from the inner two-thirds of the subscapular fossa **insertion**, into the lesser tuberosity of the humerus; **action**, rotates the humerus inward; **nerve supply**, subscapular.

The **Supraspinatus** occupies the supraspinous fossa. **Origin**, from the inner two-thirds of the supraspinous fossa; **insertion**, into the greater tuberosity of the humerus; **action**, supports the shoulder joint and assists the deltoid in raising the arm; **nerve supply**, suprascapular.

The **Infraspinatus** occupies the greater part of the infraspinous fossa. The **origin**, from the inner two-thirds of the infraspinous fossa of the scapula; **insertion**, into the greater tuberosity of

the humerus, by a tendon which is closely connected with the capsule of the shoulder joint, separated only by a synovial bursa. **Action**, rotates the humerus outward and extends it; **nerve supply**, suprascapular.

The **Teres Major** is a thick, flat muscle, it lies at the lower border of the superior wall of the axilla. **Origin**, from the dorsal surface of the inferior angle of the scapula; **insertion**, into the internal ridge of the bicipital groove of the humerus, **action**, draws the arm downward and backward, and rotates it inwardly, the same as does the latissimus dorsi; **nerve supply**, subscapular.

The **Teres Minor** is a long, narrow muscle, which lies along the lower border of the infraspinatus, and on the posterior surface of the capsule of the shoulder. The **origin**, from the upper two-thirds dorsal surface of the axillary border of the scapula; **insertion**, into the greater tuberosity of the humerus; **action**, rotates the arm outward and extends it, thus assisting the infraspinatus; **nerve supply**, circumflex.

MUSCLES OF THE ARM

The muscles of the arm are the **Coraco-Brachialis**, **Biceps Brachii**, **Brachialis Anticus**, **Triceps Brachii**, and the **Subanconeus**.

The **Deep Fascia of the Arm** (Illustration No. 102) completely invests the arm, and forms a thin, loose, membranous sheath, which sends down inter-muscular septa to separate the muscles from each other. This fascia is attached to the clavicle, the acromion process, and spine of the scapula, and is continuous with the fascia of the shoulder and axilla and, below, with the fascia of the forearm; it is attached to the olecranon process and to the epicondyles.

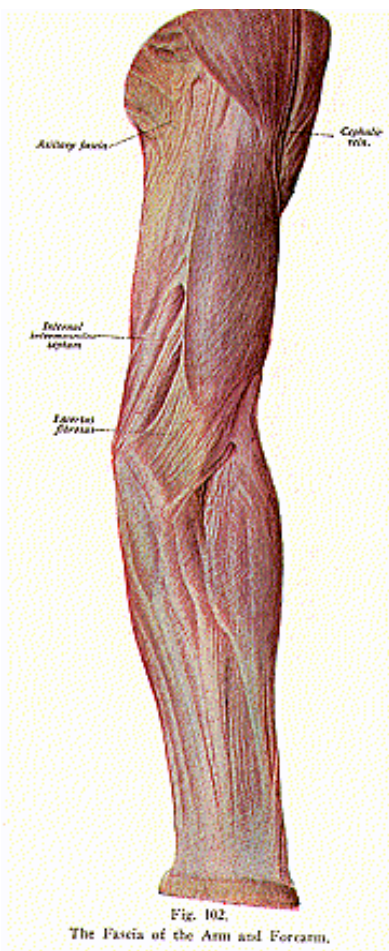
The **Coraco-Brachialis** lies on the anterior upper and inner part of the arm. The **origin**, from the apex of the coracoid process of the scapula; **insertion**, into the middle of the inner surface of the shaft of the humerus, **action**, draws the humerus inward and forward, and raises it, **nerve supply**, musculo-cutaneous.

The **Biceps Brachii**, or **Biceps Flexor Cubiti**, is a long, slender muscle, on the anterior surface of the arm and extending its whole length, it is divided above into two parts, or heads. The **origin**, by its short head, from the apex of the coracoid process; by its long head, from the upper margin of the glenoid cavity of the scapula; **insertion**, into the bicipital tuberosity of the radius, at its posterior part; **action**, flexes, and supinates, the forearm, and renders the fascia of the forearm tense, **nerve supply**, musculo-cutaneous.

The **Brachialis Anticus** is a broad muscle which covers the lower front half of the humerus. **Origin**, from the lower front half of the shaft of the humerus; **insertion**, into the coronoid process of the ulna; **action**, flexes the forearm; **nerve supply**, musculo-cutaneous and musculo-spiral.

The **Triceps Brachii**, or **Triceps Extensor Cubiti**, is situated on the posterior surface of the arm, extending its whole length; it divides, above, into three divisions or heads. The **origin**, by the long head, from the lower margin of the glenoid cavity; by the external head, from the posterior surface of the humerus, above the musculo-spiral

MYOLOGY



groove; and by the internal head, from the posterior surface below the musculo-spiral groove. **Insertion**, into the olecranon process of the ulna, **action**, extends the forearm, and is the direct antagonist of the biceps brachii; **nerve supply**, musculo-spiral.

The **Subanconeus**, **origin**, from the humerus, above the olecranon fossa, **insertion**, into the posterior ligament of the elbow; **action**, draws tense the synovial sac over the posterior ligament of the elbow joint; **nerve supply**, musculo-spiral.

MUSCLES OF THE FOREARM

The **Muscles of the Forearm** are classified as those of the anterior, posterior, and lateral regions, and are divided into a superficial and a deep layer.

The superficial layer.

Pronator teres
Flexor carpi radialis
Flexor carpi ulnaris
Flexor sublimis digitorum
Palmaris longus
Supinator longus (Brachio-radialis)
Extensor carpi radialis longus
Extensor carpi radialis brevis
Extensor communis digitorum
Extensor minimi digiti (extensor digiti quinti proprius)
Extensor carpi ulnaris
Anconeus

The muscles of the deep layer.

Flexor profundus digitorum
Flexor longus pollicis
Pronator quadratus
Supinator brevis
Extensor ossis metacarpi pollicis or abductor pollicis longus
Extensor brevis pollicis
Extensor longus pollicis
Extensor indicis

A space, or fossa, is located at the anterior and inferior part of the brachium, known as the **cubital fossa**, or the **antecubital fossa**. It is a triangular hollow, on the anterior aspect of the elbow, formed *externally*, by the brachio-radialis (the supinator longus), *internally*, by the pronator radii teres. Its *base* is upward and is formed by an imaginary line between the condyles; the *apex* lies where the brachio-radialis and pronator radii teres cross. Its *roof* is of skin, the superficial fascia; its *floor* is formed by the brachialis anticus and supinator brevis. This space contains the brachial artery, the accompanying veins, the radial and ulnar arteries and veins, the median and musculo-spiral nerves, the tendon of the biceps brachii, and fat.

The **Fascia of the Forearm** invests the forearm, and is continuous with the fascia of the arm. Strengthened by an expansion from the tendon of the triceps, it is attached to the dorsal surface and olecranon process of the ulna, and sends in septa between the muscles. It also

becomes continuous with the fascia of the hand, and is thickened at the wrist. There it forms a band, the **annular ligament**, which holds the tendons in position and assists in binding together the bones.

The **annular ligament** consists of an anterior and a posterior division. The anterior part is very thick and strong, and is attached internally, to the pisiform bone and to the hook of the unciform (os hamatum); externally it is attached to the tuberosity of the scaphoid (navicular) and to the inner part of the anterior surface of the trapezium (great multangular). The posterior division of the annular ligament is longer, but weaker, than the anterior division, and is attached, internally, to the styloid process of the ulna, and to the cuneiform (triquetrum) and pisiform bones; externally, to the margin of the radius. The tendons which are enclosed in this ligament, are ensheathed in synovial membrane.

The **Pronator Teres**, or **Pronator Radii Teres**, lies obliquely across the front part of the forearm. The **origin**, by two heads from the coronoid process of the ulna, and from the internal condyle of the humerus, by a common tendon (common, also, to other associated muscles); and from the fascia of the forearm and an intermuscular septum, separating it from the muscles beneath; **insertion**, by means of a flat tendon, 1-1/2 inches broad, into the outer side of the shaft of the radius; **action**, pronates the forearm (a rotation of the hand so that the palm is turned down), and also assists in flexion of the elbow joint; **nerve supply**, median.

The **Flexor Carpi Radialis** lies on the inner side of the pronator teres, **origin**, from the internal condyle, by the common tendon, and from the intermuscular septa; **insertion**, into the metacarpal bone of the index finger; **action**, flexes the wrist, abducts it and helps to pronate the hand; **nerve supply**, median.

Flexor Carpi Ulnaris, **origin**, by two heads; one from the internal condyle of the humerus by a common tendon and intermuscular septum, the other head from the olecranon process of the ulna, **insertion**, into the pisiform and the fifth metacarpal; **action**, flexes the wrist and adducts it; **nerve supply**, ulnar.

Flexor Sublimis Digitorum (Flexor Perforatus), **origin**, by three heads, 1st, from the internal condyle by the common tendon, and intermuscular septum, 2nd, from the coronoid process of the ulna, 3rd, from the oblique line of the radius; **insertion**, by four tendons, into the sides of the second phalanges of the four inner fingers; **action**, flexes the second phalanges; **nerve supply**, the median.

The **Palmaris Longus** lies along the ulnar side of the forearm, **origin**, from the internal condyle of the humerus by the common tendon, and from the fascia and muscular septa; **insertion**, into the annular ligament and palmar fascia; **action**, to render tense the palmar fascia by stretching it; **nerve supply**, median.

The **Palmar Fascia** forms a common sheath which invests the muscles of the hand; it protects vessels, nerves and tendons which lie deep to it. It is triangular in form, lies in the palm of the hand, and is attached to the anterior division of the annular ligament, to the roots of the four inner fingers, to the skin of the palm and creases of the fingers, and to the lateral surfaces of the metacarpal bones at their

distal extremities. On the radial side, it blends with the sheath of the tendons which form the ball of the thumb; on the ulnar side, it is attached to the muscles of the little finger.

The **Supinator Longus**, or **Brachio-Radialis**, is the most superficial muscle of the radial side of the forearm, **origin**, from the external condyle of the humerus by the common tendon, and from the fascia and intermuscular septum; **insertion**, into the styloid process of the radius; **action**, supinates the hand, so that the palm faces upward. This muscle, tho it is called a supinator, is a flexor of the forearm, acting most directly when the limb is in a state of semipronation, therefore, it may act both as a supinator and a pronator; **nerve supply**, musculo-spiral.

The **Extensor Carpi Radialis Longus** lies on the radial side, and back, of the forearm, **origin**, from the external condyloid ridge of the humerus by the common tendon, and from the fascia and intermuscular septa, **insertion**, into the base of the metacarpal bone of the index finger; **action**, extends and abducts the wrist; **nerve supply**, musculo-spiral.

The **Extensor Carpi Radialis Brevis** is shorter than the preceding, **origin**, from the external condyle by the common tendon, and from the fascia and intermuscular septa; **insertion**, into the base of the third metacarpal bone; **action**, to extend and abduct the wrist; **nerve supply**, posterior interosseous.

The **Extensor Communis Digitorum** is situated at the back of the forearm, toward the radial side, **origin**, from the external condyle of the humerus by the common tendon, and from the fascia and intermuscular septa; **insertion**, into the second and third phalanges of the fingers by four slips; **action**, extends, first the fingers, then the wrist, then the elbow; **nerve supply**, posterior interosseous.

The **Extensor Minimi Digiti**, or the **Extensor Digiti Quinti Proprius**, is a slender muscle lying along the middle of the back of the forearm, **origin**, from the external condyle of the humerus by the common tendon and from the fascia and intermuscular septa, **insertion**, into the phalanges of the little finger; **action**, extends the little finger, **nerve supply**, posterior interosseous.

The **Extensor Carpi Ulnaris** is the most superficial muscle on the ulnar side of the forearm, **origin**, from the external condyle by the common tendon from the fascia and intermuscular septa, and from the posterior border of the ulna; **insertion**, into the base of the fifth metacarpal bone; **action**, extends and abducts the wrist; **nerve supply**, posterior interosseous.

The **Anconeus** is a small triangular muscle, which lies on the radial side of the posterior part of the elbow, **origin**, from the external condyle of the humerus; **insertion**, into the olecranon process and upper part of the posterior surface of the ulna; **action**, extends the forearm, therefore assists the triceps brachii; **nerve supply**, musculo-spiral.

The **Flexor Profundus Digitorum** is situated on the ulnar side of the forearm beneath the superficial flexors. **Origin**, from the upper 3/4 of the inner and anterior surface of the shaft of the ulna, the interosseous membrane and coronoid process; **insertion**, into the distal

phalanges; **action**, to flex the last phalanges; **nerve supply**, ulnar and anterior interosseous.

The **Flexor Longus Pollicis** (named from the Latin term pollex—the thumb) is situated on the radial side of the forearm; **origin**, from the anterior surface of the radius, its middle 1/3, and from the coronoid process of the ulna; **insertion**, into the last phalanx of the thumb; **action**, flexes the thumb; **nerve supply**, anterior interosseous.

The **Pronator Quadratus** lies at the distal end of the forearm, a small flat quadrilateral muscle, **origin**, from the lower 1/4, and anterior border, of the ulna; **insertion**, into the lower 1/4, and anterior border, of the radius; **action**, pronates and rotates the hand; **nerve supply**, anterior interosseous.

The **Supinator Brevis** is a broad muscle, found around the upper third of the radius, and forms part of the floor of the cubital space, **origin**, from the external condyle of the humerus, the orbicular and external lateral ligaments, and from the oblique line of the ulna; **insertion**, into the neck of the radius, bicipital tuberosity, and oblique line of the radius; **action**, supinates the hand; **nerve supply**, posterior interosseous.

The **Extensor Ossis Metacarpi Pollicis**, or **Abductor Pollicis longus**, lies deeply in the middle third of the forearm, **origin**, from the posterior shaft of the ulna and radius, and from the interosseous membrane; **insertion**, into the base of the first metacarpal bone of the thumb; **action**, to carry the thumb outward and backward from the hand; **nerve supply**, posterior interosseous.

Extensor Brevis Pollicis, or **Extensor Primi Internodii Pollicis** **origin**, from the posterior surface of the shaft of the radius at its distal end, and from the interosseous membrane, **insertion**, into the base of the first phalanx of the thumb; **action**, extends the proximal phalanx of the thumb and, by its continued action, helps to extend and abduct the wrist; **nerve supply**, posterior interosseous.

The **Extensor Longus Pollicis**, or **Extensor Secundi Internodii Pollicis**, is much larger and longer than the preceding muscle, **origin**, from the posterior shaft of the ulna and the interosseous membrane **insertion**, into the last phalanx of the thumb; **action**, extends the last phalanx of the thumb, and, by its continued action, helps to extend and abduct the wrist; **nerve supply**, posterior interosseous.

Extensor Indicis, **origin**, from the posterior surface of the shaft of the ulna, beginning at the middle third and reaching to near the lower end of the bone, and from the interosseous membrane, **insertion**, into the second and third phalanges of the index finger; **action**, to extend the index finger; **nerve supply**, posterior interosseous.

MUSCLES OF THE HAND

The **Muscles in the Hand** are **Abductors**, **Adductors**, **Flexors**, and **Extensors**, or the **Interosseous Muscles**; that is, of the muscles found between the metacarpal bones, those between the metacarpals and phalanges, and those between the phalanges. They are covered by the thin **interosseous fascia**, derived from the palmar fascia.

The **Abductor Pollicis**, or **Abductor Pollicis Brevis**, **origin**, from the trapezium (great multangular), the scaphoid (navicular), and

from the annular ligament; **insertion**, into the radial side of the base of the first phalanx of the thumb; **action**, draws the thumb from the median line, abducts it; **nerve supply**, median.

Opponens Pollicis, **origin**, from the palmar surface of the trapezium (great multangular) and the annular ligament; **insertion**, into the radial side of the metacarpal bone of the thumb, **action**, draws the metacarpal bone inward over the palm, so as to turn the ball of the thumb toward the fingers; **nerve supply**, median.

Flexor Brevis Pollicis, **origin**, from the trapezium (great multangular), the annular ligament, and first metacarpal bone; **insertion**, into the base of the first phalanx of the thumb by two tendons, each containing a sesamoid bone; **action**, flexes and adducts the first phalanx of the thumb; **nerve supply**, median and ulnar.

The **Adductor Pollicis** lies deeply in the radial half of the palm; between its converging roots the radial artery enters the palm.

This muscle has two heads or portions, the **oblique portion**, **origin** from the palmar surfaces of the trapezium and trapezoid (great and lesser multangular), from the os magnum (capitatum), from the bases of the 2nd, 3rd, and 4th metacarpals, and from the ligaments connecting these bones, the **transverse head**, from the palmar surface of the shaft of the 3rd metacarpal and the fascia covering the interossei in the 2nd and 3rd spaces. These heads join and are **inserted** by a tendon into the ulnar side of the base of the 1st phalanx of the thumb **action**, to draw the thumb and its metacarpal toward the palm; **nerve supply**, ulnar.

The **thenar eminence** is the ball of the thumb, and is formed by the abductor pollicis, the opponens pollicis, flexor brevis pollicis and the adductor pollicis, the short muscles of the thumb, the **hypothenar eminence** is the ball of the little finger and is formed by the palmaris brevis, abductor minimi digiti, flexor brevis minimi digiti and the opponens minimi digiti, the short muscles of the little finger.

The **Palmaris Brevis** is a thin muscle placed beneath the skin on the ulnar side of the hand. **Origin**, from the annular ligament and the palmar fascia; **insertion**, into the skin on the inner border of the palm; **action**, to wrinkle the skin of the palm; **nerve supply**, ulnar.

The **Abductor Minimi Digiti**, or **Abductor Digiti Quinti**, is situated on the ulnar side of the palm of the hand, **origin**, from the pisiform bone; **insertion**, into the ulnar side of the first phalanx of the little finger; **action**, draws the little finger from the median line, also assists in flexing the metacarpo-phalangeal joint; **nerve supply**, ulnar.

The **Flexor Brevis Minimi Digiti**, or **Flexor Digiti Quinti Brevis** lies on the radial side of the palm of the hand. **Origin**, from the unciform bone (hamatum); **insertion**, into the first phalanx of the little finger; **action**, draws the little finger from the middle line of the hand also assists in flexing its first phalanx; **nerve supply**, ulnar.

The **Opponens Minimi Digiti**, or **Opponens Digiti Quinti**, is placed under the two preceding muscles, **origin**, from the unciform bone (hamatum) and the annular ligament; **insertion**, into the whole length of the fifth metacarpal bone; **action**, draws forward the fifth metacarpal bone so as to deepen the hollow of the hand; **nerve supply**, ulnar.

The **Lumbricales** are four fleshy bundles, their **origin**, from the flexor profundus digitorum; **insertion**, into a tendinous expansion of the extensor communis digitorum; **action**, aid in flexion and extension, **nerve supply**, median and ulnar.

The **Dorsal**—(three in number) and the **Palmar Interossei** (four in number), are named from occupying the intervals between the metacarpal bones. The **dorsal interossei** are the abductors; the fingers which they abduct are the index, middle and ring fingers; the middle finger, having two abductors, can be drawn to either side of the middle line of the hand which line passes thru the center of the middle finger; the **palmar interossei** are the adductors; they adduct the index, ring and little fingers.

MUSCLES OF THE LOWER EXTREMITY

(Illustrations Nos. 104 and 105.)

The **Muscles of the Lower Extremity** are subdivided into regional groups, just as are those of the upper extremity, and are classified as those of the **iliac region**, the **thigh**, **hip**, **leg** and **foot**.

The **Iliac Fascia** is a thin fascia covering the psoas and iliacus muscles, and is prolonged, behind the femoral vessels, into the thigh as the posterior wall of the femoral sheath. Above the level of the iliac crest, it is in relation only to the psoas magnus, and the part covering the muscle is spoken of as the psoas sheath. Superiorly, it is thickened and forms the internal arcuate ligament of the diaphragm, which arches between the tip of the first lumbar transverse process and the side of the body of that vertebra. Internally, it is attached to the intervertebral discs and the margins of the bodies of the lumbar vertebrae, to the alae of the sacrum, and to the brim of the true pelvis; externally, near the tips of the transverse processes of the lumbar vertebrae, it blends with the anterior layer of the lumbar fascia, which covers the quadratus lumborum and the whole length of the inner lip of the crest of the ilium. Below the level of the iliac crest, the iliac fascia covers the iliacus, as well as the psoas magnus, and inferiorly it is continuous with the transversalis and the pubic part of the fascia late of the thigh.

The **Psoas Magnus** lies on the posterior wall of the abdomen **origin**, from the bodies, transverse processes, and intervertebral discs of the 12th dorsal and of all the lumbar vertebrae; **insertion**, into the lesser trochanter of the femur; **action**, flexes the thigh on the pelvis, and vice versa, coming into play when walking, ascending stairs, or in the act of stooping, also it rotates the thigh outwardly; **nerve supply**, lumbar branches.

The **Psoas Parvus**, not always present, lies in the abdomen on the anterior surface of the psoas magnus, **origin**, from the bodies transverse processes, and intervertebral discs, of the last dorsal and first lumbar vertebrae; **insertion**, into the ilio-pectineal line, and iliac fascia; **action**, draws tense the iliac fascia; **nerve supply**, lumbar branches.

The **Iliacus** lies in the iliac fossa, it is a flat, triangular muscle, which fills up the whole of the fossa, **origin**, from the iliac fossa, inner margin of the crest of the ilium, ilio-lumbar ligament, base of the sacrum, from the anterior superior and inferior spines of the ilium and

from the notch between them; **insertion**, into the lesser trochanter of the femur; **action**, flexes the thigh on the pelvis, and vice versa, assisting the psoas magnus; **nerve supply**, anterior crural.

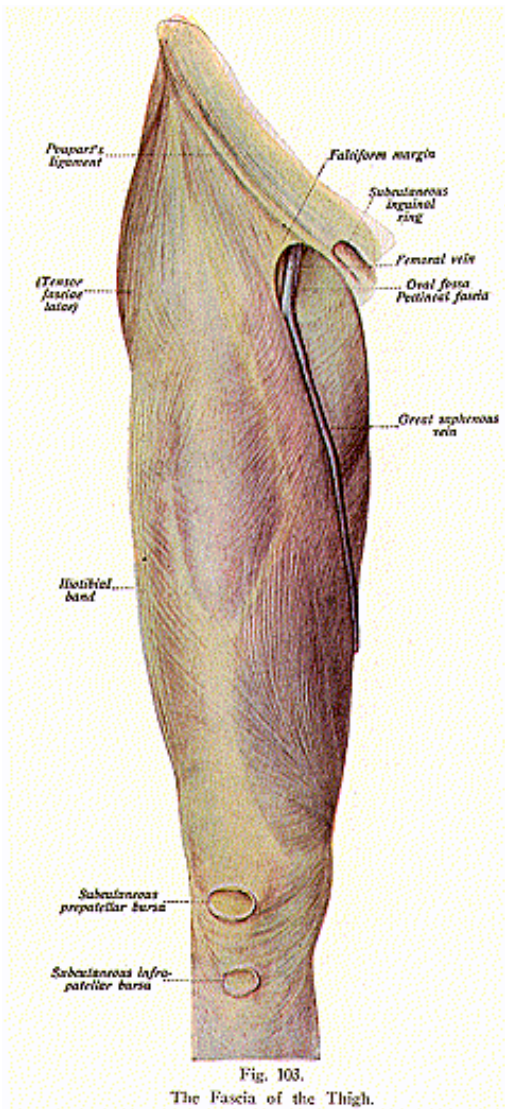
MUSCLES OF THE ANTERIOR PART OF THE THIGH

The **Muscles on the Anterior Part of the Femur**, are the **Tensor Fascia Femoris**, the **Sartorius**, **Subcrureus** and the **Quadriceps Extensor Tendon**, the latter includes the **rectus femoris**, **vastus externus** and **internus**, and the **crureus**.

The **Superficial Fascia** of the **Thigh** forms a continuous layer over all the whole of the thigh, is thickest on the inner side and particularly in the groin, and consists of areolar tissue. It is divisible into two layers—the *subcutaneous* and the *deep*; the *subcutaneous layer* is fatty, and when traced upward becomes continuous with the fascia of the abdomen. In between the two layers, are the superficial vessels and nerves. The *deep layer* is a very delicate membrane, best marked on the inner side of, and beneath, the long saphenous vein, so that vessel, also, lies between it and the subcutaneous layer. It is adherent to fascia late below Poupart's ligament, covers the saphenous opening in the fascia lata, being closely united to the margins of the opening, and is connected to the sheath of the femoral vessels. The portion of the fascia which covers the saphenous opening is called the *cribriform fascia*, because it presents foramina, for the passage of the long saphenous vein and numerous blood-vessels and lymphatics.

The **Deep Fascia of the Thigh, or the Fascia Lata** (Illustration No. 103) is a very strong fibrous membrane, which forms a continuous tubular sheath, swathing the muscles in this region. It is attached, above, to Poupart's ligament as far inward as the pubic spine, and to the outer lip of the crest of the ilium, behind, to the margins of the sacrum and coccyx; internally, to the descending ramus of the os pubis, to the ramus and tuberosity of the ischium, and to the lower border of the great sciatic ligament. The fascia late extends below to the parts around the knee joint, that is, to the condyles of the femur, the tuberosities of the tibia, the head of the fibula, to the lateral borders of the patella, and around the back part of the knee joint, covering the popliteal space. That portion of the outer side of the fascia late which extends from the forepart of the iliac crest, to the anterior part of the external tuberosity of the tibia, the head of the fibula and the capsule of the knee, forms a thick strong band and is spoken of as the **ilio-tibial band (tractus ilio-tibialis)**.

From the deep surface of the fascia late are given off two strong, intermuscular septa, which are attached to the whole length of the linea aspera and pass between the muscles to form a part of their muscular sheaths. There is an opening in the fascia lata, for the passage of the long saphenous vein and other smaller vessels, and this is termed the **saphenous opening**. It is situated upon the front of the thigh, below and outside the pubic spine, and just below the inner third of Poupart's ligament. It is an oval opening, about 1-1/2 inches in length, its breadth about 1/2 inch; it is covered by a portion of the innermost layer of the superficial fascia, called the cribriform fascia.



The **Femoral Sheath** is formed by the fascia lining the interior of the abdomen; by the fascia transversalis anteriorly, and by the fascia iliaca posteriorly. It is prolonged into the thigh around the femoral vessels for 1-1/2 inch before fusing with their coats. This sheath extends from Poupart's ligament to a point 1-1/2 inches below it, its outer wall is straight but the inner wall is oblique, being sloped downward and outward. Within the sheath are two septa, the external and internal, both of which extend from the anterior to the posterior wall; the external septum lies close to the outer side of the femoral vein, and the internal septum close to its inner side. By means of these two septa, the interior of the sheath is divided into three distinct compartments, the outer, middle and inner. The outer compartment contains the common femoral artery and a branch of the genito-crural nerve, for a short distance at its upper part where the nerve lies external to the artery; the middle compartment contains the femoral vein and the deep femoral glands; the inner compartment a narrow interval, is called the **femoral canal**, it contains a deep femoral gland and some adipose tissue, and exists as a distinct canal only when the sheath is separated from the vein by dissection or by pressure, as in a tumor or hernia; a femoral hernia always enters the thigh thru the femoral canal. The outer border of the sheath is pierced by the femoral nerve, its inner border by the long saphenous vein.

The **femoral or crural canal**, then, is the inner compartment of the femoral sheath, and is about 1/2 inch in length and extends from the femoral ring to the saphenous opening. The *anterior wall* is formed by the fascia transversalis, the *posterior wall* by the fascia iliaca, the *inner wall* by the junction of the fascia transversalis and the fascia iliaca and the *outer wall* by the internal septum within the sheath.

The **crural or femoral ring** is the mouth or proximal end of the femoral canal, and opens into the abdomen; it is oval in form, and larger in the female than in the male. The ring is situated close to the outer side of the base of Gimbernat's ligament. Its position may be ascertained by drawing a line from the pubic spine horizontally outward across the front of the thigh, then take a point in this line fully one inch to the outer side of the pubic spine. The ring is bounded anteriorly by Poupart's ligament; posteriorly, by the pectineal line and pectineus muscle; internally, by the base of Gimbernat's ligament; and externally, by the upper extremity of the internal septum within the femoral sheath.

Tensor Fascia Femoris, origin, is from the anterior superior spine and outer crest of the ilium; **insertion**, into the fascia lata a little beyond the great trochanter; **action**, renders tense the fascia lata; **nerve supply**, sacral, the gluteal branch.

The **Sartorius** is the longest muscle in the body, a long, flat ribbon-like muscle, it lies superficially on the front of the thigh **origin**, from the anterior superior spine of the ilium, and the notch below; **insertion**, into the upper inner surface of the shaft of the tibia; **action**, flexes the leg upon the thigh, thigh upon the pelvis, rotates the thigh outward and at the same time crosses the legs and is therefore known as the tailor's muscle; **nerve supply**, anterior crural.

The **Quadriceps Extensor** includes four of the muscles located on the anterior part of the thigh; it forms a large fleshy mass which ends in a single tendon attached to the patella and, thru this and the ligamentum patellae, acts upon the tuberosity of the tibia; by expansions it blends with the capsule of the knee joint. The muscles which form this tendon, called the common tendon, are the **vastus externus**, **vastus internus**, **rectus femoris**, and the **crureus**.

The **Vastus Externus**, or **Lateralis**, is the largest unit of the quadriceps extensor, and lies on the outer and lateral side. **Origin**, from the anterior intertrochanteric line, great trochanter, and upper half of the outer lip of the linea aspera; **insertion**, by the common tendon into the tubercle of the tibia after surrounding the patella; **action**, extends the leg; **nerve supply**, anterior crural.

The **Vastus Internus**, or **Medialis**, lies on the inner side of the thigh; **origin**, from the anterior intertrochanteric line, inner lip of the linea aspera, its whole length, and from the spiral line, a line leading from the inner side of the neck of the femur to the linea aspera; **insertion**, by the common tendon into the tubercle of the tibia after surrounding the patella; **action**, extends the leg; **nerve supply**, anterior crural.

The **Rectus Femoris** is situated in the centre of the anterior region of the thigh, **origin**, by two heads, from the anterior inferior spine of the ilium, and from the brim of the acetabulum; **insertion**, by the common tendon into the tubercle of the tibia after surrounding the patella; **action**, extends the leg; **nerve supply**, anterior crural.

The **Crureus**, or **Vastus Intermedius**, is sometimes considered, not as a separate muscle, but as that part of the vastus internus which is covered by the rectus femoris; however, a narrow interval is found extending upward from the inner border of the patella between the two muscles, and here they can be separated as far as the anterior intertrochanteric line, **origin**, from the upper two-thirds of the shaft of the femur, the anterior intertrochanteric line, and outer lip of the linea aspera, its lower half, **insertion**, by the common tendon into the tubercle of the tibia after surrounding the patella; **nerve supply**, anterior crural.

The **Subcrureus**, or the **Articularis Genu**, is a small muscle usually distinct from the crureus but occasionally found forming a portion of it, being then the lowest and deepest portion of the crureus. When considered as an independent muscle it has its **origin**, from the lower part of the shaft of the femur; **insertion**, into the synovial capsule of the knee joint; **action**, draws up the capsule during extension of the knee; **nerve supply**, anterior crural.

The muscles on the inner side of the femur, are the **gracilis**, **pectineus**, and three **adductors**, namely the **adductor longus**, **brevis** and **magnus**.

The **Gracilis** is the most superficial muscle of the inner side of the thigh, being flat and strap-like in the upper third of the thigh, thick and narrow in the middle third, and long, narrow and thin in the lower third, separated from the internal lateral ligament of the knee joint by a bursa; **origin**, from the margin of the symphysis and the descending ramus of the os pubis; **insertion**, into the upper inner

surface of the shaft of the tibia below the tuberosity; **action**, flexes the leg, rotates it inward and adducts the thigh; **nerve supply**, obturator.

The **Pectineus** is a flat four-sided muscle, it lies on the anterior inner and upper side of the thigh; **origin**, from the ilio-pectineal line and the spine of the os pubis; **insertion**, into the rough line leading from the lesser trochanter to the linea aspera; **action**, flexes the thigh upon the pelvis, adducts and rotates the thigh outward; **nerve supply**, anterior crural.

The **Adductor Longus** is the most superficial of the three adductors, a flat triangular muscle, and has its **origin** from the front of the os pubis close to the crest and the symphysis, **insertion** into the linea aspera, its middle third; **action**, adducts and flexes and rotates the thigh outward; **nerve supply**, obturator.

The **Adductor Brevis** is situated behind the adductor longus and pectineus; **origin**, from the body and descending ramus of the os pubis, between the points of attachment of the gracilis and obturator externus, **insertion**, into the upper part of the linea aspera; **action**, adducts and flexes the thigh, and rotates it outward; **nerve supply**, obturator.

The **Adductor Magnus** is triangular and fan-shaped, and is the powerful adductor of the thigh; **origin**, from the rami of the os pubis and ischium, and the outer and under surface of the tuberosity of the ischium; **insertion**, into various parts of the femur, namely: to the rough line leading from the great trochanter to the linea aspera, to the whole length of the linea aspera, to the internal condyle and to the internal epicondylar ridge; **action**, adducts the thigh, rotates it outward and extends it. In consequence of the obliquity of the insertion of the adductor muscles into the linea aspera they rotate the thigh outward.

The adductors come into action in riding horseback, enabling the rider to grasp the saddle with his thighs, hence the adductors are called the "rider's muscles;" **nerve supply**, obturator and the great sciatic. At the lower part where the adductor magnus is attached to the epicondylar ridge, the attachment is interrupted for the passage of femoral vessels into the popliteal space or fossa. This opening, found in the adductor magnus muscle, must not be confused with the adductor, or Hunter's canal.

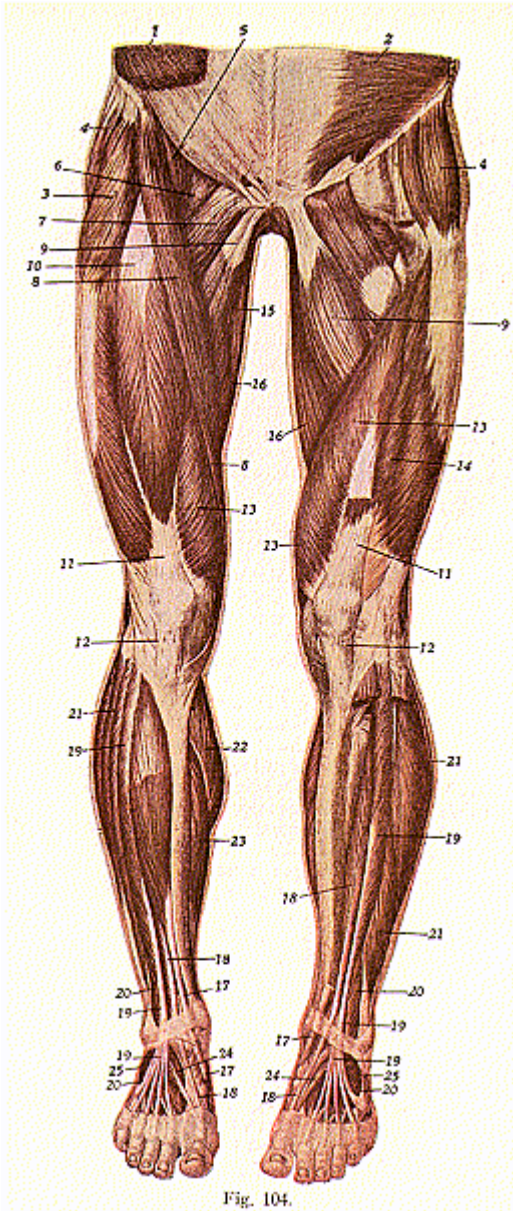
In the upper and forepart of the thigh is a triangular space called **Scarpa's triangle** or the **femoral trigone**; its *outer* boundary is the sartorius ; its *base*, Poupart's ligament (inguinal ligament); its *inner* boundary is the inner border of the adductor longus; its *floor* is

Fig. 104.

Muscles of the Anterior Surface of the Lower Extremities.

1. External abdominal oblique. 2. Transversalis abdominis. 3. Tensor fascia femoris. 4. Gluteus medius. 5. Iliacus. 6. Psoas magnus. 7. Pectineus. 8. Sartorius. 9. Adductor longus. 10. Rectus femoris. 11. Quadriceps extensor tendon. 12. Ligamentum patella. 13. Vastus internus. 14. Vastus externus. 15. Gracilis. 16. Adductor magnus. 17. Tibialis anticus. 18. Extensor longus hallucis. 19. Extensor longus digitorum. 20. Peroneus tertius. 21. Peroneus longus. 22. Gastrocnemius. 23. Soleus. 24. Extensor brevis hallucis. 25. Extensor brevis digitorum.

MYOLOGY



formed by the psoas magnus, iliacus, pectineus, adductor longus, and a small part of the adductor brevis. Its *roof* is formed by the skin, superficial fascia and fascia lata. The *contents* of the *triangle* are as follows:—Common femoral artery and its branches, upper part of the femoral vein and its tributaries, the anterior crural nerve with its divisions and their branches, and some fat and lymphatics.

At the apex of the femoral trigone is the beginning of a canal, **Hunter's canal** or the **adductor canal**, (so named because John Hunter was the first surgeon who tied the superficial femoral artery in this part of its course, for popliteal aneurism, in 1785). It extends from Scarpa's triangle to the femoral opening in the adductor magnus muscle, having the vastus internus on its outer side, the adductor longus and magnus on its inner side; it is covered by a strong aponeurosis which extends transversely from the vastus internus across the femoral vessels to the adductor longus and magnus. The aponeurosis is weak over the upper half of the canal, but over the lower part is strong. The contents of Hunter's canal are the femoral artery and vein, enclosed in their own sheath and the long or internal saphenous nerve.

MUSCLES OF THE GLUTEAL REGION

The **Muscles of the Hip**, or **Gluteal Region**, are the **Gluteus Maximus**, **Medius** and **Minimus**, the **Pyriformis**, **Obturator Internus** and **Externus**, **Gemellus Superior** and **Inferior**, and the **Quadratus Femoris**.

The **superficial fascia of the gluteal region** is very thick and is filled with fat. It is continuous, over the iliac crest, with the superficial fascia of the back of the trunk, while the **deep fascia** forms a part of the fascia lata. As it passes over the gluteus medius it is dense; over the fleshy part of the gluteus maximus it is thin; in passing from the gluteus medius onto the gluteus maximus, it straps down the upper border of the latter muscle.

The **Gluteus Maximus** is the coarsest and heaviest muscle of the body and is the thick fleshy mass which forms the prominence of the buttock. Several synovial bursae are found beneath the muscle; between the lower border of the muscle and the tuberosities of the ischium, between the muscle and the great trochanter, and between the tendon of this muscle and the upper part of the vastus externus, just below the great trochanter. **Origin**, from the superior curved line and crest of the ilium, from the posterior surface of the lower part of the sacrum and the side of the coccyx, from the aponeurosis of the erector spinae, and the great sacro-sciatic ligament, **insertion**, into the fascia late and the rough line leading from the great trochanter to the linea aspera; **action**, rotates, abducts, and extends the thigh; **nerve supply**, inferior gluteal.

The **Gluteus Medius** lies in the upper and anterior part of the buttock **origin**, from the ilium, between the superior and inferior curved lines; **insertion**, into the great trochanter; **action**, rotates abducts, and extends the thigh; **nerve supply**, superior gluteal.

The **Gluteus Minimus** is under cover of the gluteus medius, and

has its **origin**, from the ilium, between the middle and inferior curved lines and, behind, from the margin of the great sacrosciatic notch; **insertion**, into the great trochanter; **action**, rotates, abducts and extends the thigh; **nerve supply**, superior gluteal.

The **Pyriformis** is a flat pyramidal muscle, found partly in the pelvis and partly at the back part of the hip joint; **origin**, from the front of the sacrum, margin of the great sciatic notch, and great sciatic ligament; **insertion**, into the great trochanter; **action**, rotates the thigh outward; **nerve supply**, sacral. This muscle passes out of the pelvis thru the great sciatic foramen, along with the superior gluteal vessels and nerves, also the sciatic and pudic vessels and nerves.

The **Obturator Internus** is situated, like the pyriformis, partly within the pelvis and partly at the back of the hip joint; **origin**, from the internal margin of the obturator foramen and membrane, **insertion**, into the inner surface of the great trochanter, after passing out of the pelvis thru the lesser sciatic foramen; **action**, rotates the thigh outward; **nerve supply**, obturator.

The **Obturator Externus** lies deeply on the front of the pelvis, and passes below and behind the neck of the femur; **origin**, from the inferior and outer surface of the obturator foramen, and membrane; **insertion**, into the great trochanter, in the digital fossa at its base; **action**, rotates the thigh outward; **nerve supply**, obturator.

The **Gemellus Superior** and **Inferior** are two small muscles, one above and one below the tendon of the obturator internus, the superior has its **origin** from the spine of the ischium, **insertion**, into the great trochanter; the **origin**, of the inferior, from the upper tuberosity of the ischium; **insertion**, into the great trochanter; **action**, of the gemelli, to rotate the extended thigh and abduct it when flexed; **nerve supply**, sacral.

The **Quadratus Femoris** is a short, flat muscle, it lies in the lowest part of the buttock; **origin**, from the tuberosity of the ischium, **insertion**, into the line which crosses the posterior intertrochanteric line—the linea quadrata; **action**, rotates the thigh outward; **nerve supply**, sacral.

THE MUSCLES OF THE POSTERIOR PART OF THE THIGH

The **Muscles** of the **Posterior Part** of the **Thigh** are the **Biceps Femoris**, **Semitendinosus**, and **Semimembranosus**.

These muscles are known as the **hamstring muscles**. The word “ham” is derived from a term meaning curved or crooked; this term has been applied to the muscles of the popliteal space, because that space is situated behind the crook, curve or bend, of the knee, later, the word “ham” came to be applied to the whole of the thigh, hence the name hamstring, which is given to the muscles of that region.

The **Biceps Femoris** is a large muscle, situated in the back, and to the outer part, of the thigh, and is the lateral boundary of the popliteal space; **origin**, by two heads, the long head from the tuberosity of the ischium, the short head from the outer lip of linea aspera;

insertion, into the outer side of the head of the fibula, and a few fibres into the outer tuberosity of the tibia; **action**, flexes the leg and when the knee is semiflexed, rotates the leg outward; **nerve supply**, great sciatic.

The **Semitendinosus** has a very long tendon, and is situated at the posterior and inner part of the thigh; **origin**, from the tuberosity of the ischium; **insertion**, into the upper and inner surface of the tibia; **action**, flexes the leg; **nerve supply**, great sciatic.

The **Semimembranosus**, so called because its greater part is of membranous origin, is situated at the back and inner part of the thigh, **origin**, from the tuberosity of the ischium, above the two preceding muscles; **insertion**, into the inner tuberosity of the tibia, and here the tendon gives off fibrous expansions, one to the outer condyle of the femur, and another downward to the fascia of the popliteus muscle; **action**, flexes the leg; **nerve supply**, great sciatic.

The tendons of the semitendinosus, semimembranosus, gracilis and sartorius; form the **internal hamstring**, and they are all inserted close together, into the upper part of the inner surface of the shaft of the tibia; the biceps femoris forms the **external hamstring**, and is inserted into the outer tuberosity of the tibia and outer side of the head of the fibula. These muscles draw the leg back, as in walking and running, and, therefore, are called the running muscles.

The rotators of the hip joint are sixteen in number, as follows: the three adductors—longus, magnus and brevis, the two obturators—externus and internus, the two gemelli—superior and inferior, the three glutei—maximus, medius and minimus, and the pyriformis, pectineus, psoas magnus, iliacus, sartorius and the quadratus femoris.

MUSCLES OF THE LEG

The **Muscles and Fascia of the Leg** are those found on its anterior posterior, and outer and inner parts, and are invested in a heavy sheath of fascia, a part of it being the prolongation of the fascia late of the thigh and this is attached around the knee joint, the fascia is also attached superiorly to the head of the fibula and to the external tuberosity of the tibia, lower part of the patella, ligamentum patellae, the tubercle and the front of the internal tuberosity of the tibia. At the ankle the deep fascia is attached to the external and internal malleoli and forms ligaments, which hold the tendons in position. This fascia helps to bind together the bones of the leg and, over the shin bone, it becomes closely incorporated with the periosteum. The part of the

Fig. 105.

Muscles of the Posterior Surfaces of the Pelvis and Lower Extremities

1. Gluteus maximus. 2. Gluteus medius. 3. Pyriformis. 4. Gemellus superior. 5. Obturator internus. 6. Gemellus inferior. 7. Quadratus femoris. 8. Obturator externus. 9. Biceps femoris (upper). 10. Biceps femoris (lower). 11. Tendon of biceps femoris. 12. Semitendinosus. 13. Semimembranosus. 14. Adductor magnus. 15. Opening in adductor magnus. 16. Gracilis. 17. Sartorius. 18. Vastus externus. 19. Popliteus. 20. Gastrocnemius. 21. Gastrocnemius (external part). 22. Gastrocnemius (internal part). 23. Plantaris. 24-25. Tendo Achillis. 26. Soleus. 27. Peroneus longus. 28. Peroneus brevis. 29. Flexor longus hallucis. 30. Tibialis posticus. 31. Flexor longus digitorum.

MYOLOGY

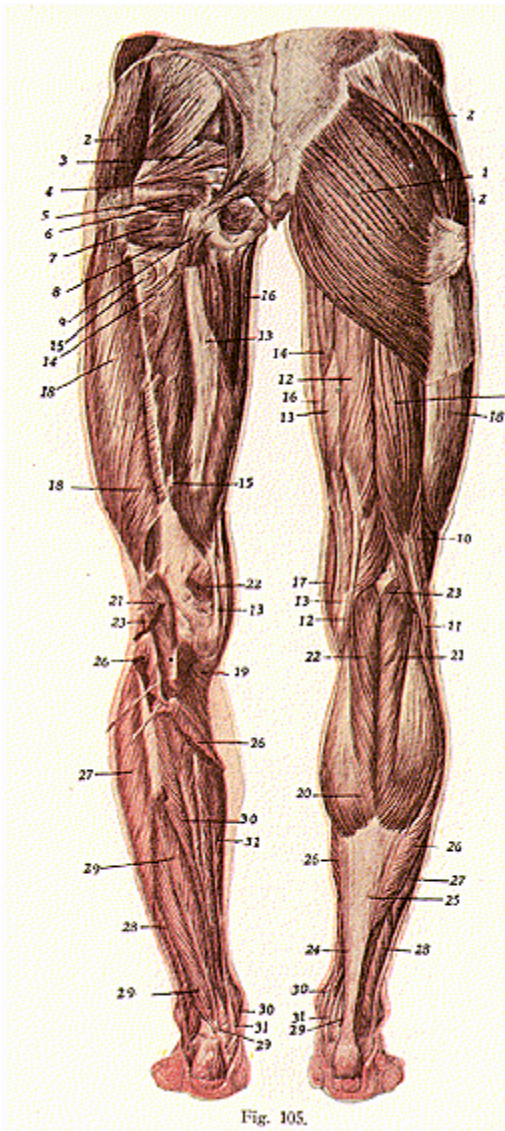


Fig. 105.

fascia behind the knee joint presents an opening for the passage of the short saphenous vein. The fascia in the posterior part is thin, but over the front and outer parts of the leg, especially in the upper half, it attains considerable strength and density. In the region of the knee-joint, it receives strong fibres from the tendons of the quadriceps extensor and the hamstring.

At the back part of the knee-joint is a space called the **popliteal space**, which extends upward to the junction of the upper three-fourths and the lower one-fourth of the thigh. It is a diamond-shaped space, bounded, *externally*, by the biceps femoris, and *internally*, by the semitendinosus, semimembranosus, gracilis, sartorius, and by the internal head of the gastrocnemius; its *roof* is formed by integument; its *floor*, by the lower part of the posterior surface of the shaft of the femur, upper end of the tibia, and by the fascia covering the popliteus muscle, and the space is covered in by the fascia lata. The *contents* of this space are the popliteal artery and its branches, popliteal vein and its tributaries, the termination of the short saphenous vein, the internal and external popliteal nerves and their branches, part of the sciatic nerve, branch of the obturator nerve, some lymph glands and a considerable amount of fat.

The **Muscles of the Leg** are the **Tibialis Anticus**, **Peroneus Tertius**, **Extensor Longus Hallucis**, **Extensor Longus Digitorum**, **Gastrocnemius**, **Soleus**, **Plantaris**, **Popliteus**, **Flexor Longus Hallucis**, **Flexor Longus Digitorum**, **Tibialis Posticus**, **Peroneus Longus**, and the **Peroneus Brevis**.

The **Tibialis Anticus**, or **Flexor Tarsi Tibialis**, is situated on the outer side of the tibia, it is thick and fleshy at its upper part, but quite tendinous below; **origin**, from the outer tuberosity and upper part of the external surface of the shaft of the tibia, from the interosseous membrane, deep fascia, and the intermuscular septum; **insertion**, into the inner and under surface of the internal cuneiform bone, and into the base of the metatarsal bone of the great toe; **action**, flexes and inverts the foot, that is, elevates the inner border of the foot; **nerve supply**, anterior tibial.

The **Peroneus Tertius** is sometimes given as a detached portion of the extensor longus digitorum; **origin**, from the anterior surface of the shaft of the fibula, in its lower fourth, the interosseous membrane fascia, and intermuscular septum; **insertion**, into the dorsal surface of the fifth metatarsal bone; **action**, flexes and everts the foot; **nerve supply**, anterior tibial.

Extensor Longus Hallucis (from the Latin, "hallus," great toe), or the **Extensor proprius Hallucis**, is a thin elongated flattened muscle which lies between, and partly hidden by, the tibialis anticus; **origin**, from the anterior surface of the fibula, its middle two-fourths, and the interosseous membrane; **insertion**, into the base of the last phalanx of the great toe; **action**, to extend the great toe; **nerve supply**, anterior tibial.

The **Gastrocnemius**, **Soleus** and **Plantaris**, form the calf of the leg, a large, powerful, muscular mass on the posterior part of the tibia and fibula, forming the **Triceps Suræ**, (sure, calf), all uniting to form a common tendon, **tendo-Achilles**, for insertion. These muscles

are the chief extensors of the foot at the ankle joint; they possess considerable power, and are constantly called into use in standing, walking, dancing and leaping.

The **Gastrocnemius** is the largest and is so named because it forms the belly of the leg. It arises by two heads; **origin**, of the external head—from the condyles of the femur of the internal head—from the supra-condylar ridges. The two bellies form a flat tendon, which joins the soleus, and plantaris when present, at the centre of the leg to form the **tendo-Achillis**, to be **inserted** into the posterior surface of the os calcis; **action**, raises the heel, thus extends the foot, and slightly rotates it. The gastrocnemius also flexes the knee. **Nerve supply**, internal popliteal.

The **Soleus**, a flat muscle, so named from its resemblance to a sole-fish, lies beneath the gastrocnemius; **origin**, from the posterior surface of the head, and upper third of the posterior surface of the shaft, of the fibula, and the oblique line and inner border of the tibia **insertion**, the tendon joins with that of the gastrocnemius at the center of the back of the leg, to form the tendo-Achillis which is inserted into the posterior surface of the os calcis; **action**, raises the heel and extends the foot; **nerve supply**, internal popliteal.

The **Plantaris** is sometimes absent but when present acts as a very weak auxiliary to the gastrocnemius; **origin**, from the lower part of the linea aspera and the posterior ligament of the knee joint; **insertion**, by a common tendon with the gastrocnemius and soleus, into the posterior surface of the os calcis; **action**, extends the foot and slightly flexes the leg; **nerve supply**, internal popliteal.

The **Tendo-Achillis** was so called from the mythological account of Achilles, the Greek hero, whose death is alluded to in the Odyssey. By dipping him in the River Styx, his mother made him invulnerable except only in the heel, by which she held him and here he was finally fatally wounded by an arrow shot by Paris. This tendon is the thickest and strongest tendon in the body, being about six inches in length, it extends from the center of the back of the leg to the prominence of the heel, and is inserted into the middle of the posterior surface of the os calcis. It is covered by the fascia and the integument, a bursa intervening between the tendon and the fascia; the tendon is separated from the deep muscles and vessels by a considerable interval, filled up with areolar and adipose tissue.

The **Popliteus** is a thin triangular muscle, which forms the floor of the popliteal space. **Origin**, from the outer condyle of the femur and the posterior ligament of the knee joint; **insertion**, into the oblique line of the posterior surface of the tibia; **action**, flexes the leg and rotates the flexed leg inward; **nerve supply**, internal popliteal.

The **Flexor Longus Hallucis** is situated on the fibular side of the back of the leg and in the sole of the foot; **origin**, from the lower two thirds of the shaft of the fibula internally, the interosseous membrane, deep fascia, and intermuscular septum, **insertion**, into the base of the last phalanx of the great toe; **action**, flexes the great toe and extends the foot; **nerve supply**, posterior tibial.

The **Flexor Longus Digitorum** is situated on the tibial side of the leg; **origin**, from the posterior surface of the shaft of the tibia, below

the oblique line, **insertion**, into the last phalanges of the four lesser toes; **action**, flexes the phalanges and extends the foot; **nerve supply**, posterior tibial.

The **Tibialis Posticus** lies between the flexor longus hallucis and digitorum; **origin**, from the posterior surface of the shaft of the tibia and the fibula, the interosseous membrane, deep fascia and intermuscular septa; **insertion**, into the tuberosity of the scaphoid and the internal cuneiform, and, by expansions given off to the other cuneiform bones, cuboid, os calcis, and the bases of the 2nd, 3rd and 4th metatarsals, **action**, extends the foot, inverts the foot, i. e., turns it inward, contributes in a material degree to the support of the longitudinal arch of the foot, and so helps to guard against the condition known as flat foot. **Nerve supply**, posterior tibial.

The **Peroneus Longus** lies superficially in the front of the calf; **origin**, from the head, and upper two-thirds of the shaft, of the fibula, the deep fascia, and intermuscular septa; **insertion**, into the metatarsal bone of the great toe, and into the internal cuneiform, having crossed the sole of the foot; **action**, extends and everts the foot, i. e., turns it outward; **nerve supply**, musculo-cutaneous, a branch of the external popliteal.

The **Peroneus Brevis** lies anterior to and beneath the longus, and is shorter and smaller than it. **Origin**, from the outer surface of the lower two-thirds of the shaft of the fibula, also from the deep fascia and intermuscular septa; **insertion**, into the base of the metatarsal bone of the little toe, **action**, extends the foot. The peronei muscles, when they take their fixed point below, serve to steady the leg upon the foot, especially is this the case when standing upon one leg. **Nerve supply**, musculo-cutaneous, a branch of the external popliteal.

MUSCLES OF THE FOOT

The **Fascia of the Foot** is classified as the **superficial** and the **deep**. The superficial fascia of the sole is traversed by a fibrous band which divides the fat into lobules, which lie beneath the skin and form a thick pad. The skin of the sole is characterized by great thickness over the bony prominences of the heel and over the balls of the toes in which situations bursae are frequently developed.

The **Deep Fascia of the Foot** is called the **Plantar Fascia**, and is connected to the skin by the fibrous processes, which enclose and support the lobules of fat of the superficial fascia. The plantar fascia is thickened on the toes, where it forms sheaths, and this fascia is the densest of all the fibrous membranes. The fascia on the dorsum of the foot is a thin membranous layer continuous above with the anterior margin of the annular ligament, it becomes gradually lost, opposite the heads of the metatarsal bones, and on each side blends with the lateral portions of the plantar fascia; it forms sheaths for the tendons placed on the dorsum of the foot. The fibrous bands or thickened portions of the deep fascia of the leg, around the ankle joint, form the **annular ligaments** of the ankle joint; they serve to confine, and maintain in position, the strong tendons in that region, and are three in number, the anterior, external, and internal.

The *anterior annular ligament*, or *ligamentum transversum cruciatum*, is attached to the lower ends of the fibula and tibia, to the os calcis and the plantar fascia, it binds down the extensor tendons as they descend on the front of the tibia and the fibula. The *internal annular ligament* or the *ligamentum laciniatum* extends from the inner malleolus of the tibia to the os calcis, and converts a series of grooves into canals, lined by synovial membrane for the passage of the flexor tendons and vessels into the sole of the foot. The *external annular ligament* or the *peroneal retinaculum* extends from the outer malleolus to the os calcis, and binds down the peronei tendons, which are enclosed in one synovial sac.

The **Extensor Brevis Digitorum** is the only muscle on the dorsum of the foot; **origin**, from the upper and outer surfaces of the os calcis, and anterior annular ligament; **insertion**, into the first phalanx of the great toe and the outer sides of the tendons of the 2nd, 3rd, and 4th toes; **action**, extends the toes. **Nerve supply**, anterior tibial.

The **Abductor Hallucis** lies along the inner side of the sole. **Origin**, from the os calcis, internal annular ligament and the plantar fascia; **insertion**, into the inner side of the first phalanx of the great toe; **action**, to abduct the great toe from the imaginary line of the foot which passes thru the center of the second toe, and also flexes the metatarso-phalangeal joint of the great toe; **nerve supply**, internal plantar

The **Abductor Minimi Digiti**, or **Abductor Digiti Quinti**, lies along the outer border of the foot. **Origin**, from the outer tubercle of the os calcis, plantar fascia and intermuscular septum; **insertion**, into the outer side of the phalanx of the little toe; **action**, abducts the little toe, **nerve supply**, external plantar.

The **Flexor Accessorius**, or **Quadratus Plantae**, lies deep to the posterior part of the flexor digitorum brevis, being an accessory to that muscle; **origin**, from the outer and inner surfaces of the os calcis; **insertion**, into the tendon of the flexor longus digitorum; **action**, flexes the toes; **nerve supply**, external plantar.

The **Lumbricales** of the foot are four in number; **origin**, from the tendons of the flexor longus digitorum, **insertion**, into the first phalanx of the four lesser toes; **action**, flex the toes; **nerve supply**, internal and external plantar.

The **Flexor Brevis Hallucis** lies along the plantar surface of the first metatarsal bone; **origin**, from the under surface of the cuboid and external cuneiform bones; **insertion**, into both sides of the first phalanx of the great toe; **action**, flexes the great toe; **nerve supply**, internal plantar.

The **Adductor Hallucis**, **origin**, by 2 heads, a transverse and oblique portion, called the **Adductor Obliquus Hallucis** and the **Adductor Transversus Hallucis**, from the tarsal ends of the three metatarsal bones; **insertion**, into the outer side of the base of the first phalanx of the great toe; **action**, to adduct the great toe, and draw all the toes together, **nerve supply**, external plantar.

The **Flexor Brevis Minimi Digiti**, or **Flexor Digiti Quinti Brevis**, lies on the metatarsal bone of the little toe; **origin**, from the base of the fifth metatarsal bone; **insertion**, into the base of the first phalanx

MYOLOGY

of the little toe; **action**, flexes the little toe; **nerve supply**, external plantar.

The **Interossei** muscles in the foot are similar to those in the hand, and are seven in number, the **three plantar** and the **four dorsal**. The plantar muscles are seen only in the sole, but the dorsal muscles are seen on the dorsum of the foot as well as in the sole.

The **Plantar Interossei—origin**, from the inner and under surfaces of the three outer metatarsal bones; **insertion**, into the inner sides of the first phalanges of the same toes.

The **Dorsal Interossei—origin**, from the surfaces of the adjacent metatarsal bones; **insertion**, into the outer sides of the bases of the first phalanges of the corresponding toe; **action**, the plantar interossei are the adductors, the toes which they adduct being the third, fourth and fifth; the dorsal interossei are the abductors, the toes which they abduct being the second, third and fourth; **nerve supply**, external plantar.

THE BLOOD-VASCULAR SYSTEM

Angiology is the anatomy of the blood-vessels and lymph-vessels. The **blood-vascular system** comprises the heart, blood-vessels, and their contained fluid—the blood. The heart is the central organ and by its contraction the blood is pumped thru the body by a series of tubes—the **arteries**—then to minute vessels—**arterioles**—into close meshed vessels—**capillaries**—then into **venules** and **veins**, and back again to the heart, constituting the circulation of blood.

There are three systems considered in the blood system:—The **greater**, or the **systemic**, which is the circulation from the left ventricle, thru the body generally and back to the heart, entering the right auricle by the pre- and the post-cava, and by the coronary veins; the **lesser** or the **pulmonary**, which is the circulation of the blood from the right ventricle, thru the lungs and back again to the heart, entering the left auricle by the pulmonary veins; and the **fetal** circulation, the circulation as it exists before the child is born. Parts or divisions of the systemic, are the *portal*, or that of the liver; and the *renal*, or that of the kidney.

The lymphatic system consists of a series of vessels, conveying the lymph; these delicate vessels have transparent walls, formed of the same coats as are the arterial walls, they possess valves, and are found in all parts of the body except the nails, hair, cartilage and cuticle; at various points along their course these lymph-vessels present many small, solid, round or oval, granular bodies, the lymphatic glands. (More thoroughly considered in following pages.)

Valves are infoldings or reduplications of the inner lining of the heart and blood vessels. They are usually arranged in pairs, and are semilunar in form; their convex borders are continuous with the vessel wall and their free borders are turned toward the heart. They do not interfere with the flow of blood onward, but do prevent any backward flow; they also help to sustain the column of blood in all vessels in which there is an upward flow. Each valve consists of a fold of the inner layer, strengthened by connective tissue. Valves are more numerous in veins than in arteries; as a general rule, the wall of the vein is dilated above each valve into a shallow pouch or sinus, so that when veins are distended they assume a nodulated appearance.

Capillaries are the intermediate vessels between the arterioles and venules, and are disposed in the form of a network; they measure about 1/50 of an inch in length and 1/2000 to 1/3000 of an inch in diameter. Their walls are simple and, in the smallest capillaries, consist principally of elongated elastic endothelial cells. Capillaries are arranged in meshed networks, the nature and character of which differ in different tissues.

THE HEART

(Illustrations Nos. 106, 107 and 108.)

The **Heart** is a hollow muscular organ, situated between the lungs, obliquely in the chest behind the gladiolus, and corresponds to the vertebrae—from the 5th to the 8th dorsal—and from the 2nd to the 6th costal cartilages. In shape, it is an irregular and flattened cone, having a base, apex and two surfaces. The **base** is upward, backward and to the right, and corresponds to a line drawn across the sternum on a level with the upper border of the third right rib and the lower border of the second left costal cartilages; the base extends one-half inch to the right of the sternum and one inch to the left of it. The **apex** is downward, forward and to the left, corresponding to the fifth intercostal space, three and one-half inches from the middle line of the sternum. In adults, the heart measures 5 inches in length, 3-1/2 inches in breadth, 2-1/4 inches in thickness; its weight in the male is 10 to 12 ounces and in the female a little less. The heart increases in weight and size up to an advanced period of life, and normally a certain amount of fat is found upon its surface, increasing as age advances.

Further descriptive parts of the heart are the four cavities into which the organ is divided; the **right** and **left auricles**, and the **right** and **left ventricles**, each being lined by a delicate, thin, smooth membrane—the **endocardium**—which gives a glistening appearance to the surface and enters into formation of the segments of the valves in the heart—the **mitral**, **tricuspid**, and the **semilunar**; each cavity is capable of containing about the same amount of fluid, from three to four ounces. The heart is divided into the two parts, the right or the pulmonary side and the left or the systemic, and a thick muscular septum is found between the auricles and between the ventricles, these septa are named the inter-auricular and inter-ventricular, respectively. The auricles are separated from the ventricles by the muscular, auriculo-ventricular septum.

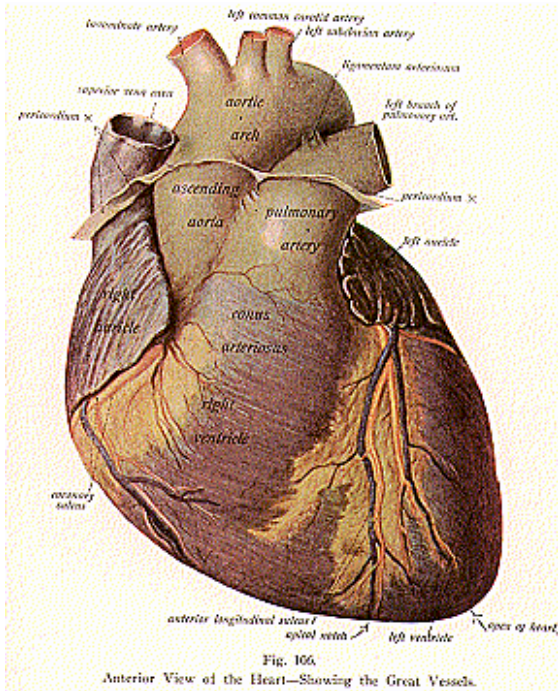
THE AURICLES AND VENTRICLES

The **Auricles** are the receivers, they are the upper cavities, have smooth internal walls, and have thinner muscular walls than do the ventricles. The large posterior part of each auricle is called the **atrium**, receiving chamber, while projecting forward from the anterior and upper part of each atrium there is an **auricular appendix**, a small, conical, muscular pouch, the margins presenting a dentated edge; these right and left auricular appendices are ear-shaped; the internal surfaces of their walls are marked by a number of muscular elevations, arranged as closely set vertical parallel bands, which look like the teeth of a comb, from which resemblance they receive the name **musculi pectinati**.

The **Ventricles** are the propellers, that is, they send the blood from the heart; they are the lower cavities, have thicker walls than the auricles, are triangular in shape, and have the **chordae tendineae**, and the **columnae carnae**.

THE BLOOD-VASCULAR SYSTEM

The right auricle is the larger of the two auricles, its walls are thinner and the right auricular appendix is shorter, broader, and less curved, than the left appendix, but is more deeply notched on its margin. Into the right auricle opens the pre-cava, or superior vena



cava; it opens at the upper and back part of the auricle and has no valve. It returns the blood from the upper half of the body. The post-cava, or inferior vena cava, is larger than the pre-cava and opens into the lowest part of the auricle, the opening being guarded by the

Eustachian valve. This vein returns the blood from the lower half of the body.

The **coronary sinus** opens into the auricle between the inferior **vena cava** and the auriculo-ventricular orifice, and is protected by an incomplete valve, the **coronary** or the valve of **Thebesius**; the coronary vein returns the blood from the substance of the heart. The opening between the right auricle and the right ventricle is the **auriculo-ventricular** or the **tricuspid orifice**, an oval aperture, situated in the lower and the anterior part of the atrium, in front of the orifice of the inferior vena cava with the intervention of the opening of the coronary sinus; three fingers, the index, middle and the ring fingers, held close together and side by side, could be passed thru the tricuspid orifice without difficulty. Thru this opening the blood passes from the right auricle into the right ventricle; the opening is guarded by a valve—**tricuspid**—which is composed of three cusps or segments covered with endocardium, they project into the cavity of the ventricle and are triangular in form. The auricular cusps are smooth but their ventricular surfaces are roughened by the chordae tendineae, which are attached to the margins.

These are numerous foramina, the **foramina of Thebesius**, which are found in the walls of both the right and the left auricles, some of them are merely depressions, while others are the orifices of minute veins which return the blood directly from the heart muscle substance. At the lower part of the right auricle, in the auricular septum is an oval depression called the **fossa ovalis**, which corresponds to the situation of the foramen ovale in the fetus, an opening by which the auricles communicated before birth, and which closes almost immediately after birth.

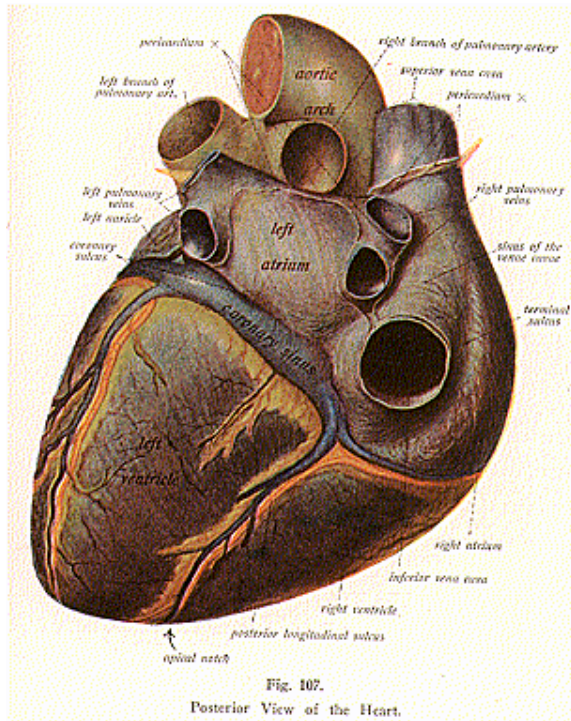
Into the left auricle, open the three, or four, pulmonary veins which bring the arterial blood from the lungs; they open into the upper part of the posterior surface of the left auricle, two on either side of its middle line, and they have no valves.

The opening between the left auricle and the left ventricle is the **mitral**, or **bicuspid**, orifice, situated in the anterior part of the floor of the atrium, below and to the left of the aortic orifice. Thru the mitral valve the blood passes from the left auricle into the left ventricle. It is oval in form and could admit two fingers held side by side and in close contact. It is smaller than the tricuspid orifice and is guarded by the **mitral** or **bicuspid valve**, which consists of two cusps, in the same way that the tricuspid valve guards the opposite side, it also is formed by the infoldings of the lining membrane, and to the cusps are attached the chordae tendineae.

The ventricles differ, in that the right ventricle is triangular in shape, forms the greater part of the anterior external surface, while the left ventricle is conical in form, is longer, forms most of the posterior surface, and its walls are three times as thick as are those of the right ventricle; this can be easily accounted for, by the fact that the left ventricle is concerned with the systemic circulation, while the right ventricle has to do with the pulmonary circulation and the latter involves a much shorter circuit, therefore less powerful muscular contractions are sufficient to propel the blood thru it.

THE BLOOD-VASCULAR SYSTEM

The openings in the right ventricle are the auriculo-ventricular, between the right ventricle and the right auricle; and the opening for the pulmonary artery, which is circular in form, is situated at the base, the upper part, of the cavity, and is guarded by the right **semilunar** or



pulmonary valve. The pulmonary artery, altho it conveys venous blood from the heart to the lungs for oxygenation, is called an artery because it carries blood away from the heart. The openings in the left ventricle are two in number; one opens into the aorta, and the other, the auriculo-ventricular orifice, lies between the left auricle and the

left ventricle. The aorta is the large artery that, thru its branches, carries the blood from the heart to all parts of the body and it is guarded by a valve, the **aortic** or left **semilunar valve**.

The heart is composed of muscular tissue, which is known as the **myocardium** and it is enclosed in a conical sero-membranous sac, the **pericardium**.

The **Pericardium** consists of two layers, the parietal and the visceral, between which is a secretion of a thin fluid, serous in character, in sufficient amount to moisten the surface and thus lessen friction during the heart movements. The outer or parietal layer of the pericardium is a fibrous layer, and is strong and dense; inferiorly, it is attached to the central tendon of the diaphragm, superiorly it ensheaths the great vessels connected with the base of the heart, with the single exception of the inferior vena cava. This outer layer is also attached to the sternum, by two fibrous bands, known as the superior and inferior sterno-pericardial ligaments; the superior fibrous band is attached to the manubrium, and the inferior one to the ensiform cartilage. On each side it is intimately related to the pleura, and in front and on the sides to the costal fascia. Above, the fibrous layer not only blends with the external coats of the great vessels, but it is continuous with the pretracheal layer of the deep cervical fascia.

The inner layer or the visceral, also called the **epicardium**, is serous in structure; it lies within the walls of the pericardium and serves to line them. It is a typical serous membrane, containing endothelial cells, it thus gives to the surface of this layer a smooth polished appearance. In the course of pericarditis it is this inner layer of the pericardium which becomes dry and roughened.

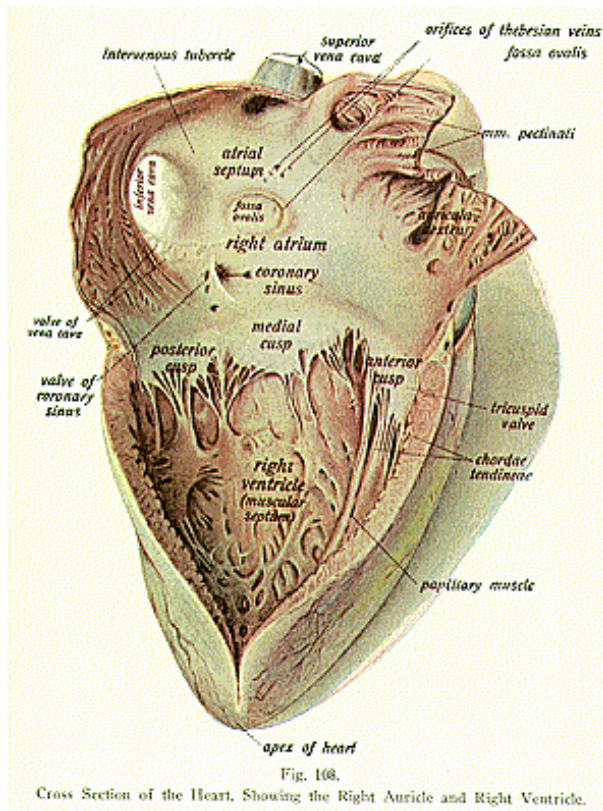
The **Endocardium**, the lining of the heart, is a smooth delicate membrane, covered on its internal surface by endothelium. It consists of a connective-tissue basement membrane containing elastic fibres, and is continuous, thru the arterial and venous orifices, with the tunica intima of the vessels; it also enters into formation of the segments of the auriculo-ventricular and semilunar valves. The walls of the interior of the ventricles are elevated into muscular bands called the **columnae carnae**; these project into the cavities, and, by their reticular arrangement, render the interior walls very irregular.

According to the manner of their attachment, the columnae carnae are classified in three sets, as simple elevations, which are attached to the wall thruout their entire length, as well as at their extremities, some are attached to the wall only at their extremities, being free elsewhere; those of the third set are attached at one extremity only. Those of this last set are called the **musculi papillares**. They are conical in shape, their bases are attached to the wall of the ventricle and their free extremities are connected with a number of filiform processes, called the **chordae tendineae**. These are delicate tendinous cords, which are connected at one extremity with the wall of the ventricle by the musculi papillares or the papillary muscle, and, at the other extremity, with the cusps of the auriculo-ventricular valve. When the ventricle contracts, the musculi papillares also contract, and, by tightening the chordae tendineae, they prevent the segments

THE BLOOD-VASCULAR SYSTEM

of the auriculo-ventricular valve from being driven too far upward into the auricle.

The valves in the heart are the **tricuspid** and **bicuspid**, previously



described as being between the auricles and ventricles, the **pulmonary**, **aortic**, **valve of Thebesius** or the **coronary valve**, and the **Eustachian valve**. The **pulmonary valve** guards the opening into the pulmonary

THE BLOOD-VASCULAR SYSTEM

artery, the large vessel which carries the blood from the right ventricle to the lungs. It consists of three semilunar segments, two anterior and one posterior, which are formed by reduplications of the lining membrane of the ventricle, strengthened by interposed fibrous tissue. The wall of the artery, opposite each segment of the valve, presents a recess, or dilation, and these recesses are called the **sinuses of Valsalva**.

The **aortic valve** guards the orifice of the large artery, which leaves the left ventricle, and consists of three semilunar segments, similar to those of the pulmonary valve in their mode of attachment, two are posterior and one anterior, but the cusps are larger and stronger than in the pulmonary valve. The interior of the wall of the aorta, also, presents three well-marked dilations or recesses; each recess is placed opposite to a segment of the valve, and they form the **sinuses of Valsalva**, which are larger than those at the origin of the pulmonary artery. The aortic valve serves to prevent regurgitation of the blood from the aorta into the left ventricle during the elastic recoil of the arterial wall.

The **Coronary Valve**, or **Valve of Thebesius**, is a semilunar fold of the lining membrane of the right auricle, guarding the orifice of the coronary sinus. It prevents a regurgitation of blood into the sinus during the contraction of the auricle.

The **Eustachian Valve** is found between the anterior margin of the inferior vena cava and the auriculo-ventricular opening. It is larger in the fetus, at which time it serves to direct the blood of the inferior vena cava thru the foramen ovale. In the adult, this valve is rather rudimentary and is a crescentic fold of endocardium, which varies in size and sometimes presents several small openings.

The heart substance is supplied by the right and left coronary arteries, branches from the ascending aorta, the veins accompany the arteries and terminate in the right auricle. The pericardium receives the blood supply from the pericardial branches from the thoracic aorta. The **nerve supply** to the heart is by branches from the cardiac plexus, being derived principally from the second dorsal pair of spinal nerves, emitting thru the 9th intervertebral foramina.

THE ARTERIES AND VEINS

Arteries (so named because they were supposed to be filled with air) are the blood-vessels which, except the pulmonary artery and the umbilical artery, carry the oxygenated blood, the pure red blood; they leave the heart, are dense and elastic tubes, are noncollapsible, they stand full and open after death, have no valves, have *venae comites* (accompanying veins), anastomose freely (communicate with each other), are less numerous than veins, have branches, are smaller than veins, have thick walls and are deep seated.

Veins are the blood-vessels which, except the pulmonary and the umbilical veins, carry blood containing carbon dioxide, the blue or impure blood; they enter the heart, or carry the blood toward the heart, are not elastic, tubes are collapsible (that is, they collapse when the vessel is cut), they have valves except the deeper veins, anas-

THE BLOOD-VASCULAR SYSTEM

tomose more freely, are more numerous, have tributaries, are of larger size than are the arteries, have thinner walls and lie more sub-cutaneously than do arteries. A dilated channel for venous blood is called a sinus; these are found chiefly in the cranium, but we have also the coronary sinus of the heart, all are progressively widening spaces. In the skull, the sinuses have no true wall, but run in grooves between the two layers of the dura mater.

Vasa Vasorum are small blood-vessels which carry the blood to the larger blood-vessels and are distributed, as a fine network, in their external coats. They are usually branches from some neighboring artery, their favorite situation being the external coat within which they ramify, breaking up into capillaries that in the larger vessels invade the adjacent tunica media. The blood from the vessel wall is collected by small veins that accompany the nutrient arteries, or, as in the case of veins, empty directly into the venous trunk in whose walls they course.

Nerves distributed to the walls of the blood-vessels, especially to the arteries, are numerous. They form a plexus of nerves which surrounds the vessel where these nerve fibers penetrate the vessel wall, and end among the muscle-fibres.

Arteries and veins have **three coats**—the **outer**, or the **tunica adventitia**, which is fibrous; the **middle**, or the **tunica media**, a muscular coat; and the **inner**, the **tunica intima**, which is serous. The tunica adventitia is the fibrous coat, and consists of fibro-elastic tissue; the tunica media is composed of small muscular fibres and some yellow elastic tissue, which prevents the arteries from collapsing; and the tunica intima is a serous coat, it consists of endothelial cells resting upon a lining membrane. In the veins, the middle coat is a thinner coat and therefore is weaker than the middle coat of the arteries, so veins do not stand open when divided, as do the arteries.

Arteries are distributed to the different parts of the body, as a series of small tubules called **arterioles** and, taken together, they are like a highly ramified tree; the artery forms the common trunk and, from it, branches are given off, which pass to nearly every part of the body; they terminate in the tissue as a network, called the **capillaries**. From the capillaries the veins begin, thru small vessels, the **venules**, which pass toward the heart, constantly increasing in size as they receive tributaries or join other veins. The arteries, and likewise the veins, in their distribution, communicate with one another, thus forming what is called an **anastomosis** or **inosculation**; these communications take place between both the large and small vessels. The most important of the anastomoses will be described.

THE PULMONARY ARTERY AND VEINS

(Illustration No. 109.)

The **Pulmonary Artery** is a short, thick vessel which, by means of its right and left divisions, carries the venous blood from the right ventricle to the lungs. It is about two inches in length, and one and one-half inches in diameter; it is a wide vessel and is, therefore, an example of an artery which conveys venous blood. It arises from the

left side of the right ventricle, on a level with the upper margin of the third left costal cartilage, in front of the aorta. It passes upward and backward and after a course of about two inches divides, about on a level with the intervertebral substance between the fifth and sixth thoracic vertebrae, into the right and left branches.

The **Right Pulmonary Artery** is longer and larger than the left branch, it passes outward to the right and divides into two branches, an upper and a lower, which are distributed to the right lung.

The **Left Pulmonary Artery** passes outward to the left and divides into two branches, which are distributed to the left lung. The terminal branches of the pulmonary artery are described elsewhere with the anatomy of the lung. A small fibrous cord, the *ligamentum arteriosum*, which is the remains of an important vessel, peculiar to fetal life, the *ductus arteriosus*, is connected to the root of the left pulmonary artery and connects that vessel to the arch of the aorta.

The **Pulmonary Veins**, tho called veins, carry arterial blood from the lungs to the heart, they enter the left auricle on its posterior aspect. The right pulmonary veins are larger and longer than those of the left side.

THE AORTA

(Illustration No. 109)

The **Aorta** or **Arteria Magna** is the largest artery and is the main systemic arterial trunk. The term aorta signifies "arising from." It **begins** at the upper part of the left ventricle, passes upward to the second costal cartilage, then arches backward to the left side over the root of the left lung, then descends within the thorax on the left side of the vertebral column, enters the abdominal cavity by the aortic opening in the diaphragm, and **ends** opposite the fourth lumbar vertebra in the two common iliac arteries. For convenience of study, the aorta is divided into the *ascending aorta*, the *arch*, and the *descending aorta*, the last being again divided into the thoracic and the abdominal aorta, from the position of these parts.

The **Ascending Aorta** is about two inches in length, it **commences** at the base of the left ventricle, on a level with the lower border of the third costal cartilage; thence it passes upward and to the right, and **ends** at the upper border of the second costal cartilage. The **branches** of the ascending aorta are the **right** and **left coronary**, or **coronary dextra** and **coronary sinistra**, two vessels which arise near the beginning of the aorta and supply the heart.

The **Right Coronary Artery** is about the size of a crow's quill and passes forward between the pulmonary artery and the right auricular appendix; it divides into two main branches, the **transverse** and

Fig. 109.

Principal Arteries and Veins of the Neck, Thorax and Upper Extremities with Deep Blood-Vessels of the Abdominal Cavity.

1. Superior vena cava. 2. Ascending aorta. 3. Pulmonary artery. 4. Arch of aorta. 5. Innominate artery. 6. Right common carotid. 7. Right subclavian artery. 8. Left common carotid. 9. Left subclavian artery. 10. Left innominate vein. 11. Right innominate vein. 12. Internal jugular. 13. External jugular. 14. Subclavian

THE BLOOD-VASCULAR SYSTEM

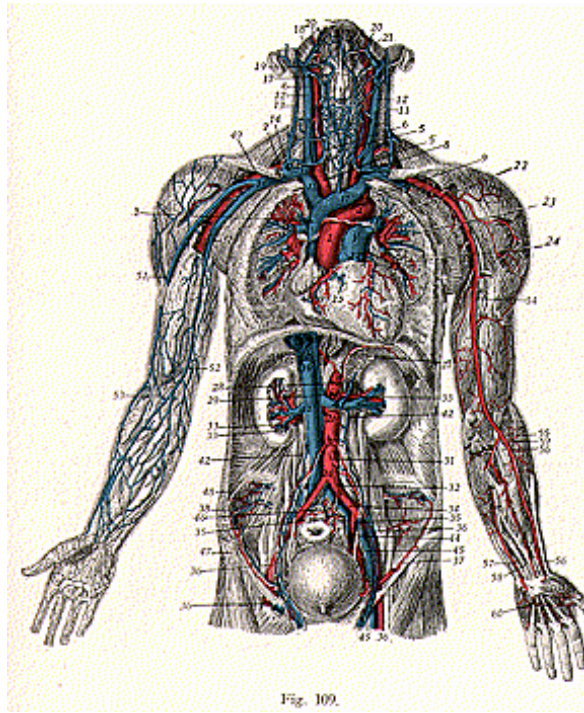


Fig. 109.

vein. 15-16. Junction of internal jugular and subclavian veins. 17. Superior thyroid vein. 18. Trunk of facial vein. 19. Superior thyroid vein. 20. Facial vein. 21. Branch of facial artery. 22. Pulmonary artery. 23. Pulmonary vein. 24. Left coronary vein. 25. Right coronary artery. 26. Abdominal aorta. 27. Phrenic artery. 28. Coeliac axis. 29. Superior mesenteric artery. 30. Spermatic artery. 31. Inferior mesenteric artery. 32. Hemorrhoidal artery. 33. Renal artery. 34. Common iliac artery. 35. Internal iliac artery. 36. External iliac artery. 37. Circumflex iliac artery. 38. Ilio-lumbar artery and vein. 39. Inferior vena cava. 40. Hepatic veins. 41. Renal vein. 42. Spermatic vein. 43. Common iliac vein. 44. Internal iliac vein. 45. External iliac vein. 46. Sacra media artery and vein. 47. Inguinal nerve. 48. Ilio-lumbar nerve. 49. Axillary artery. 50. Axillary vein. 51. Cephalic vein. 52. Basilic vein. 53. Median vein. 54. Brachial artery. 55. Bifurcation of brachial artery. 56. Radial artery. 57. Ulnar artery. 58. Common interosseous artery. 59. Muscular arteries. 60. Palmar arteries.

the **descending branches**. The right coronary artery supplies the right auricle, both ventricles, the septum, the root of the pulmonary artery, and the root of the aorta.

The **Left Coronary Artery** is larger than the right; it also gives off the **transverse** and **descending branches**, and supplies the left auricle, both ventricles, and sends a few twigs to the pulmonary artery and to the aorta. The right and left coronary arteries form an anastomosis at the apex of the heart, thru the descending branches of each artery, and it is called the **coronary anastomosis**.

The **Arch** of the aorta, or the **Transverse aorta**, **commences** at the level of the upper border of the second costal cartilage on the right side, is about 2 inches in length, and passes upward, then backward, and **terminates** on the left side of the body of the fourth dorsal vertebra; there it becomes continuous with the descending aorta.

There are three **branches** of the arch of the aorta, namely, the **innominate**, **left common carotid** and the **left subclavian** arteries; they arise in this order, from before backward and from right to left.

The **Innominate Artery**, **Arteria Anonyma** or the **Brachio-Cephalic Artery**, is the largest artery given off from the arch, and it **arises** from the arch on a level with the upper border of the second costal cartilage, in front of the left common carotid; it **terminates** at the upper border of the right sterno-clavicular joint, where it divides into the right common carotid and the right subclavian arteries. The innominate is from 1 to 2 inches in length, and its direction is upward and outward. There are no constant branches of the innominate, but occasionally a small branch is given off, the **thyroidea ima**, which when present, passes to the lower part of the thyroid gland, which it supplies; this vessel has been found to spring from the arch.

The **Descending Aorta** is about 12 inches in length and is divided into the **thoracic** and the **abdominal aorta**.

The **thoracic aorta** begins at the left side of the lower border of the 4th dorsal vertebra, and **terminates** at the aortic opening in the diaphragm, in front of the body of the 12th dorsal vertebra. The **abdominal aorta** extends from this point to a point opposite the body of the 4th lumbar vertebra, where it bifurcates into the two common iliac arteries. The **branches** of the thoracic aorta are the **pericardial**, **bronchial**, **esophageal**, **posterior mediastinal**, and the **intercostals**; these are the vessels which supply the greater part of the thoracic viscera, the lungs, the covering of the heart, the mediastinum, the ribs, etc.

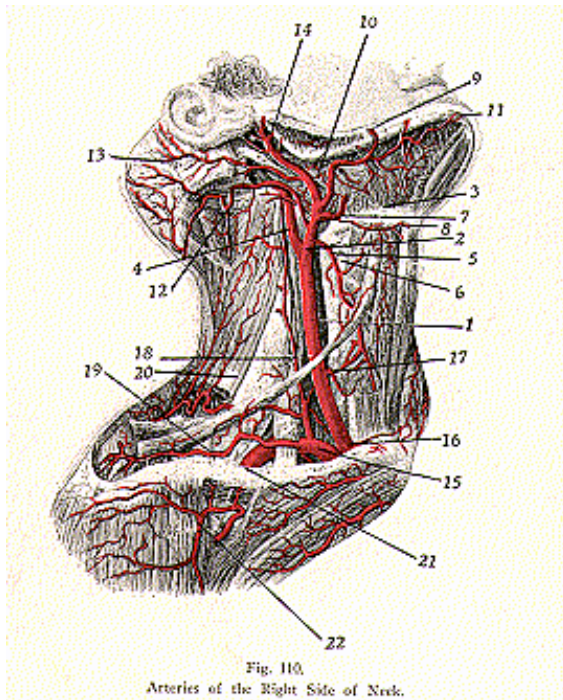
The **branches** of the **abdominal aorta**, are the **phrenic** (right and left); **coeliac axis**, which in turn gives off the *gastric*, *hepatic* and the *splenic arteries*, the **superior mesenteric**; the **supra renals** (right and left); the **renals** (right and left); **spermatic** in the male, and in the female the **ovarian** (right and left); the **inferior mesenteric**; four to eight **lumbar branches**; and the **middle sacral**. These branches supply the greater part of the abdominal viscera, the stomach, liver, spleen intestines, kidneys, suprarenal capsules, etc.

THE BLOOD-VASCULAR SYSTEM

ARTERIES OF THE HEAD, NECK AND UPPER EXTREMITIES

(Illustrations Nos. 110 and 111.)

The **Common Carotid Arteries** are the chief arteries of the head and neck, but differ in their origin and in their length; the **right common carotid** arises from the innominate artery, with the right sub-



1. Right common carotid. 2. Bifurcation of right common carotid. 3. Cervical branches. 4. Internal carotid. 5. Superior thyroid. 6. Superior laryngeal. 7. Lingual. 8. Hyoid branches. 9. Facial artery (maxillary branch). 10. Palatine. 11. Submental. 12. Occipital. 13. Posterior auricular. 14. Temporal artery. 15. Subclavian. 16. Right common carotid. 17. Inferior thyroid. 18. Ascending cervical. 19. Suprascapular. 20. Transversalis colli. 21. Axillary. 22. Anterior thoracic.

clavian, at the sternoclavicular joint, and divides into an **external** and an **internal carotid** at the upper border of the thyroid cartilage, opposite the 4th cervical vertebra; it supplies the right side of the face and neck, while the **left common carotid** is longer and arises from the arch of the aorta, to the left of the innominate. It also divides into the external and internal carotids, at the same place as does the right carotid, and supplies the left side of the face and neck.

The common carotids pass obliquely upward and are separated from each other by the trachea, the thyroid gland, pharynx and the larynx; each carotid is enclosed in a sheath derived from the deep cervical fascia, which also encloses the internal jugular vein and the pneumogastric nerve. Each common carotid rests upon the anterior tubercle of the transverse process of the sixth cervical vertebra, called Chassaignac's tubercle, the carotid artery may be compressed at this point and such compression is used by some drugless healers for arresting pain in the head.

The **External Carotid Artery**, two and a half inches in length, is given off, with the internal carotid, from the common carotid artery at the upper border of the thyroid cartilage; it extends upward and forward and then inclines backward to the space between the neck of the condyle of the mandible and the external auditory meatus. There it gives off its terminal branches, which supply the superficial parts of the skull and the deep parts of the face.

The branches are: **superior thyroid**, which arises below the hyoid bone and gives off numerous muscular branches, also the *sterno-mastoid*, the *crico-thyroid*, the *superior laryngeal* and the *hyoid*; the **lingual**, which runs to the under surface of the tongue, gives off the *hyoid*, *dorsalis linguae*, *sublingual* and the *ranine* arteries to the parts named, the **facial**, or **external maxillary**, gives off ten branches, the *ascending palatine*, *tonsilar*, *submaxillary*, *submental*, *inferior labial*, *inferior coronary*, *superior coronary*, *lateral nasal*, *angular*, and numerous *muscular* branches. These arteries supply the tonsils, lips, cheeks, salivary glands, palate, lower part of the nose and the orbit, also the muscles attached to many of the bones of the face; the **occipital** lies in the occipital groove of the temporal bone and gives off the *sterno-mastoid*, *auricular*, *meningeal*, *mastoid*, *princeps cervicis*, or the *ramus descendens*, *muscular* and *cranial* branches, the **auricular** runs beneath the parotid gland to the groove between the cartilage of the ear and the mastoid process, and gives off the following branches: *parotid*, *auricular*, *stylo-mastoid*, and *occipital*; the **ascending pharyngeal** has the *pharyngeal*, *meningeal*, and *prevertebral* branches. The **superficial temporal** and the **internal maxillary** branches are the terminal branches of the external carotid; the **superficial temporal** divides into an *anterior* and a *posterior* branch, *posterior* and *middle temporal*, the *orbital* and *facial*; the **internal maxillary** is the large terminal branch, and gives off the *pterygoid*, *maxillary* and *spheno-maxillary* branches, and these divide into smaller branches, the deep auricular, tympanic, middle meningeal, small meningeal, the inferior dental, the deep temporal, pterygoid, alveolar, infraorbital, superior palatine, spheno-palatine, the buccal, masseteric and the vidian.

The **Internal Carotid Artery** (illustration No. 112) is given off,

THE BLOOD-VASCULAR SYSTEM

with the external carotid artery, from the common carotid at the upper border of the thyroid cartilage and passes vertically upward to the under surface of the petrous portion of the temporal bone. Here it enters the carotid canal, and, after transversing the canal, it enters the cranial cavity. For study it is divided into the **cervical**, **petrous**, **cavernous** and the **cerebral** portions. The **cervical part** of the internal carotid extends from the level of the upper border of the thyroid cartilage to the carotid canal, and runs upward in front of the transverse processes of the upper three cervical vertebrae. The **petrous portion** of the internal carotid is contained within the carotid canal of the petrous portion of the temporal bone and lies in front of the cochlea and the tympanum, and as it bends it has the Eustachian tube on its anterior and outer side. The **cavernous portion** lies within the cavernous sinus, which occupies the cavernous groove on the side of the body of the sphenoid bone, and passes forward and inward to the anterior clinoid processes of the sphenoid; while the **cerebral portion**, beginning at the side of the clinoid process, passes between the optic and the oculomotor nerves to the anterior perforated space at the base of the brain and gives off its terminal branches.

The **branches** of the **petrous portion** are the *tympanic* and the *vidian*; of the **cavernous portion**, the *arteriae receptaculi*, the *anterior meningeal* and the *ophthalmic* arteries; the **cerebral portion** has the *anterior cerebral*, *middle cerebral*, the *posterior communicating* and the *anterior choroid*. The *tympanic* and the *vidian branches*, given off from the petrous portion, supply the mucous membrane of the middle ear, the roof of the pharynx and the Eustachian tube. There are no branches given off from the cervical part.

The **branches** of the cavernous portion supply the anterior part of the dura mater, the walls of the cavernous and inferior petrosal sinuses, the pituitary body, lacrimal gland, eyelids, the ciliary muscles and the iris, the forehead, the retina, the choroid and the sclerotic coats, also the mucous membrane, cartilages, and skin, of the nose. The *branches* of the *ophthalmic artery* are the *lacrimal*, which supplies the lacrimal gland, eyelids and conjunctiva, also branches to the malar bone, the temporal fossa and to the cheek; the *supraorbital* supplies the skin and muscles of the forehead, the superior oblique muscle, and the inner angle of the eye; the anterior and posterior *ethmoidals* supply the ethmoidal cells, the meninges of the brain, and the skin of the nose; the *palpebral* supplies the eyelids; the *frontal* supplies the skin, the muscles and periosteum of the skull; the *nasal*, to the lacrimal sac, root of the dorsum of the nose; the *ciliary* branches, long, short and anterior ciliary, fourteen or fifteen branches, which supply the choroid coat, ciliary processes, maxillary muscles, conjunctiva and the sclerotic coat and the iris; the *arteria centralis retinae*, or the central artery of the retina, pierces the optic nerve and runs forward in its substance, and enters the globe of the eye thru the porus opticus; and *muscular branches* to the oblique and recti muscles of the eyeball.

The **cerebral portion**, with the *anterior* and *middle cerebral*, the *posterior communicating*, and the *anterior choroid* branches, supply the brain and form an important anastomosis, at the base of the brain, with

the terminations of the basilar artery. The *anterior cerebral artery*, from the cerebral portion of the internal carotid artery, passes forward and across to the anterior perforated space, at the base of the brain, and communicates with the opposite anterior cerebral by the *anterior communicating artery*. From this point the two vessels run side by side and curve around the genu of the corpus callosum and then terminate, by passing backward, where they join the posterior cerebral arteries, forming an anastomosis, after supplying the anterior or frontal portion of the brain; the *middle cerebral artery*, of large size, sinks into the Sylvian fissure at the side and the base of the brain and traverses in an outward direction, giving off the ganglionic, frontal, parietal and temporal branches; the *posterior communicating artery* runs backward and anastomoses with the posterior cerebral, a branch of the basilar artery; the *anterior choroid artery*, is given off from the internal carotid, and passes backward and outward between the temporal lobe and the crus cerebri and enters the lateral ventricle, where it supplies the deep parts of the cerebrum, and, in the lateral ventricle, helps to form the choroid plexus.

The *posterior cerebral arteries*, right and left, are the terminal branches of the basilar at the upper border of the pons Varolii; each passes at first outward beneath the crus cerebri, then winds round the outer side of the crus, and thus reaches the interior of the occipital lobe. It gives off along its course ganglionic, cortical and posterior choroid branches (tho the latter may be given off with the anterior choroid from the middle cerebral artery).

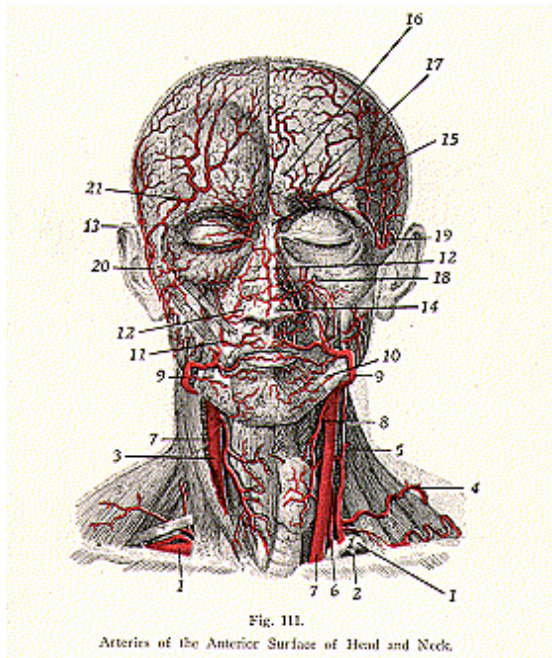
The **Circle of Willis**, or **Circulus Arteriosus**, or the **Polygon of Willis** (see illustration 112) is an important arterial circle at the base of the brain, forming a communication between the subclavian and internal carotid arterial systems. It is not actually a circle, tho it is so named, but has seven sides and seven angles, and it surrounds the posterior perforated space and encloses the optic chiasma. Because of this anastomosis, between the main trunks of the carotids and the vertebrals, neither side of the brain can be prevented from receiving a supply of blood by pressure upon, or by the blocking of, any two of the main trunks. The **formation of the circle is as follows**:—the two vertebrals, given off from the subclavian, unite to form the **basilar** which divides into the two posterior cerebrals; the internal carotid, from its cerebral portion, gives off the anterior cerebral, the middle cerebral, and the posterior communicating; the anterior cerebrals are united anteriorly by the anterior communicating artery, they are joined to the middle cerebrals, and to the posterior cerebrals by the posterior communicating, thus completing the circle.

The **Anterior Triangle of the Neck** (previously described) has subdivisions known as the **muscular**, **carotid** and the **submaxillary triangles**. In the **muscular triangle** are the following structures: the common carotid artery, internal jugular vein and the vagus nerve, lateral lobe of the thyroid gland, the trachea and the larynx; in the **carotid triangle** are the lower parts of the external and the internal carotid arteries and the upper part of the common carotid, also the origins of the superior thyroid, the lingual, facial, and occipital arteries, some tributaries of the internal jugular vein, the hypoglossal

THE BLOOD-VASCULAR SYSTEM

and spinal accessory nerves, and some cervical glands; the **submaxillary** or the **digastric triangle** contains some of the submaxillary gland, the facial artery and vein, a part of the parotid gland, a part of the hypoglossal nerve, and the posterior auricular artery, a branch of the external carotid artery.

The **Posterior Triangle of the Neck** is subdivided into the **occip-**



1. Subclavian artery. 2. Internal mammary. 3. Common carotid. 4. Transverse colli. 5. Ascending cervical. 6. Inferior thyroid. 7. Common carotid. 8. Superior thyroid. 9. Facial, labial branch. 10. Labial artery, inferior branch. 11. Labial artery, superior branch. 12. Nasal artery. 13. Angular branches. 14. Nares arteries. 15. Palpebral artery. 16. Frontal artery. 17. Supraorbital artery. 18. Infraorbital artery. 19. Deep temporal. 20. Superficial temporal. 21. Superficial temporal.

ital and **subclavian triangles**. The contents of the **occipital**, are the superficial branches of the cervical plexus, the spinal accessory nerve, a small part of the occipital artery, and some deep cervical glands; in the **subclavian** triangle are the following: the greater part of the outer third of the subclavian artery, the lower portion of the external jugular vein, the transverse colli artery and vein, the nerve trunks of the brachial plexus, the supra-scapular and posterior thoracic nerves, and occasionally a part of the subclavian vein is seen in this space, and some lymph nodes.

The **Subclavian Arteries** differ, like the common carotids, in their length and mode of origin.

The **Left Subclavian Artery** is about four and a half inches in length, and is given off from the arch of the aorta, behind the left common carotid, on a level with the fourth thoracic vertebra, it ascends vertically to the root of the neck and then arches outward and ends in the axillary at the outer border of the first rib.

The **Right Subclavian Artery**, about three inches in length, arises from the innominate with the right common carotid, at the sternoclavicular joint, and terminates in the axillary artery at the outer border of the first rib; each subclavian artery is divided by the tendon of the scalenus anticus muscle into three portions, that portion internal to the muscle, that behind the muscle, and that external to it. This tendon also intervenes between the subclavian artery and the subclavian vein. The **branches** of the **subclavian artery** are the **vertebral, thyroid axis, internal mammary** and the **superior intercostal**.

The **Vertebral Artery** is the largest branch of the subclavian. It passes upward and enters the foramen of the transverse process of the sixth cervical vertebra, it then ascends thru this foramen and thru the foramina of the transverse processes of all the vertebrae above this, after passing thru the transverse process of the atlas, it winds backward and behind the articular process and runs in a deep groove on the upper surface of the posterior arch of the atlas, then pierces the dura mater and enters the skull thru the foramen magnum, joining its fellow of the opposite side at the lower border of the pons Varolii, which corresponds to the clivus of the sphenoid bone, to form the basilar artery. The **branches** are the *lateral spinal*, passing to the spinal cord and its membranes; the *muscular*, to the deep muscles of the neck; *posterior meningeal*, to the dura mater at the posterior part; the *anterior spinal*, and *posterior spinal*, which supply the membranes and substance of the cord, the *posterior cerebellar*, which supplies the under surface of the cerebellum; and the *bulbar* arteries, which pass to the medulla.

The **Basilar Artery** is formed by the vertebrales, and gives off the following **branches**: the *transverse*, to the pons; the *internal auditory*, to the internal ear; the *anterior, inferior* and *superior cerebellar*, to the cerebellum; and the *posterior cerebral artery*, the terminal branch of the basilar, which passes to the under surface of the cerebrum, the temporal and occipital lobes.

The **Thyroid Axis**, given off from the subclavian artery, arises near the inner border of the scalenus muscle, and runs upward for a short distance and divides into three **branches**; the *inferior thyroid*,

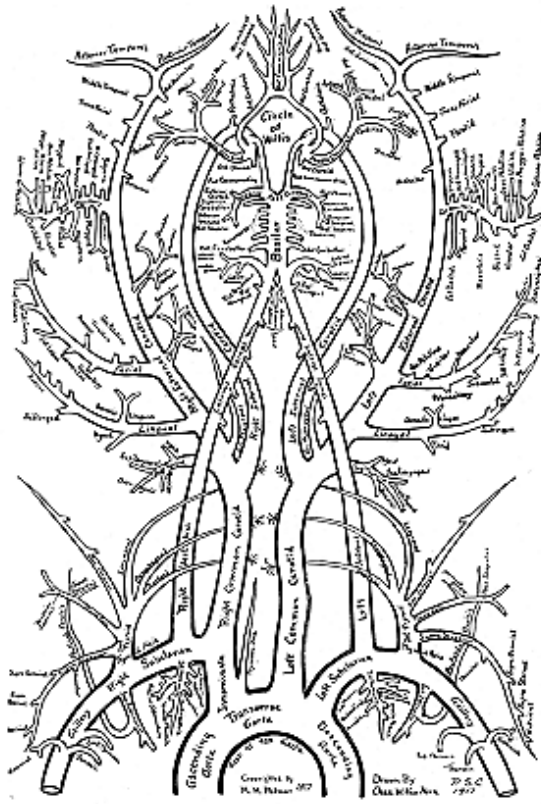


Fig. 112.
Arteries of the Head. Circle of Willis.

transverse cervical and *suprascapular*. The *inferior thyroid* passes upward and inward in a tortuous manner in front of the vertebral, and reaches the lower part of the lateral lobe of the thyroid body; here it breaks up into its terminal branches and anastomoses with the superior thyroid from the external carotid artery.

The *branches* of the *inferior thyroid* are the muscular, ascending cervical, inferior laryngeal, tracheal and esophageal. The *transverse cervical or colli* passes transversely outward in front of the scalenus anticus muscle and phrenic nerve, and enters the subclavian triangle, it then passes beneath the trapezius muscle, reaches the levator anguli scapulae and divides into the superficial cervical and the posterior scapular, which supply the first and second layers of the muscles of the back and the scapula, anastomosing with other terminal branches from the axillary; the *suprascapular artery* passes downward and outward, and passes to the upper border of the scapula, in company with the suprascapular nerve, and gives off the following *branches*: the *muscular*, to the sterno-mastoid and subclavian muscles; the *suprasternal*, to the upper part of the sternum; *supra-acromial*, to the acromion process; *articular*, to the shoulder joint; *ventral* to the front of the scapula; and the *supra-* and *infra-spinous*, to the scapular fossae and muscles.

The **Internal Mammary Artery**, given off from the subclavian runs downward and slightly forward, and ends opposite the seventh rib in the *superior epigastric* and *musculo-phrenic* arteries. Its **branches** are the *comes nervi phrenici*, or *pericardio-phrenic*, or *superior phrenic*, which accompanies the phrenic nerve and supplies the pleura, pericardium and diaphragm; the *mediastinal*, to the areolar tissue, thymus and the pericardium; *pericardiac*, to the pericardium; *sternal branches* to the posterior surface of the sternum; the *rami-intercostals*, two to the intercostal muscles; the *perforating*, which pierce the internal intercostals and the membrane, and supply the pectoralis major muscle, the skin and the mammary gland. In females these last named branches are of large size during lactation.

The *superior epigastric*, given off as a terminal branch with the musculo-phrenic from the internal mammary, descends between the ensiform cartilage and the costal portions of the diaphragm, and enters the sheath of the rectus abdominis, lies first behind the muscle but afterward enters it and anastomoses with the deep epigastric artery of the external iliac. Along its course it gives off the muscular, phrenic metasternal, anterior cutaneous, peritoneal and hepatic branches. The *musculo-phrenic artery*, given off as a terminal branch with the superior epigastric from the internal mammary, passes obliquely downward and outward behind the 7th, 8th and 9th costal cartilages and, about on a level with the 10th rib, it perforates the diaphragm and terminates in the lateral wall of the abdomen, and anastomoses with the lateral epigastric branch of the deep circumflex iliac artery. It gives off intercostal and muscular branches.

The **Superior Intercostal** is given off from the subclavian artery, from the posterior part of the vessel, and furnishes the first and second intercostal arteries to the first and second intercostal spaces their distribution being similar to that of the succeeding aortic intercostal arteries. A large branch of the superior intercostal is the

deep cervical, which supplies the complexus, semispinalis colli muscles and other adjacent muscles, anastomosing with the princeps cervicis of the occipital, from the external carotid.

The **Axillary Artery**, a continuation of the subclavian, **begins** at the outer border of the first rib, and **terminates** at the lower border of the teres major muscle or the internal bicipital ridge of the humerus, where it becomes the brachial. The axillary artery is crossed by the pectoralis minor muscle and is thus divided into three parts—the first part lies above, the second part behind, and the third part lies below the muscle. This artery passes thru the axillary space, enclosed, with the axillary vein and the brachial plexus of nerves, in a fibrous sheath, the axillary sheath which is continuous with the cervical fascia and at its commencement, is quite deep seated, but near its termination it becomes superficial, being covered only by the skin and the fascia. The **branches** of the axillary artery are the **superior thoracic**, **acromio-thoracic**, the **long thoracic**, the **alar thoracic**, the **subscapular**, and the **anterior** and the **posterior circumflex**.

The **superior thoracic artery** supplies the pectoral muscles and the thoracic wall; the **acromio-thoracic** supplies the deltoid, serratus anticus, and the subclavius, the **long thoracic**, or the **external mammary**, supplies the serratus anticus, the pectoral muscles, mammary gland and sends branches to the axilla—the long thoracic, or external mammary, anastomoses with the internal mammary and with the intercostal arteries, the **alar thoracic** supplies the areolar tissue of the axilla; the **subscapular** supplies the parts of the subscapular fossa, the teres muscles, a part of the deltoid and triceps muscles, the **anterior** and **posterior circumflex** arteries supply the shoulder joint, and form the anastomosis of the shoulder joint. The posterior circumflex is the larger of the two, and both vessels give off small branches to the deltoid muscle.

The **Brachial Artery** is a continuation of the axillary, at the bicipital ridge of the humerus, it passes down the inner and anterior part of the arm; at about one-half inch below the elbow joint it divides into the radial and the ulnar arteries. The brachial artery is at first internal to the humerus, but it gradually inclines to the front of the bone, at the elbow it is equally distant from the two condyles. It is for the most part superficial, being only slightly overlapped by the coraco-brachialis and the biceps brachii muscles, but at the bend of the elbow it sinks deeply into the cubital space, and is covered by fascia. The brachial artery occupies the middle line of this space dividing, opposite the neck of the radius, into the radial and ulnar arteries.

The **branches** of the brachial artery are the **superior profunda**, **inferior profunda**, **nutrient**, **muscular** and **anastomotica magna**. The **profunda branches** supply the deep parts of the arm, that is, the triceps muscle, both above and below, and send off nutrient branches which enter the bone. They anastomose with each other, and the superior profunda anastomoses with the posterior circumflex, the radial recurrent, and the anastomotica magna; the inferior profunda anastomoses with the ulnar recurrent and the anastomotica magna. The **nutrient** branches supply the bone, while the **muscular** branches

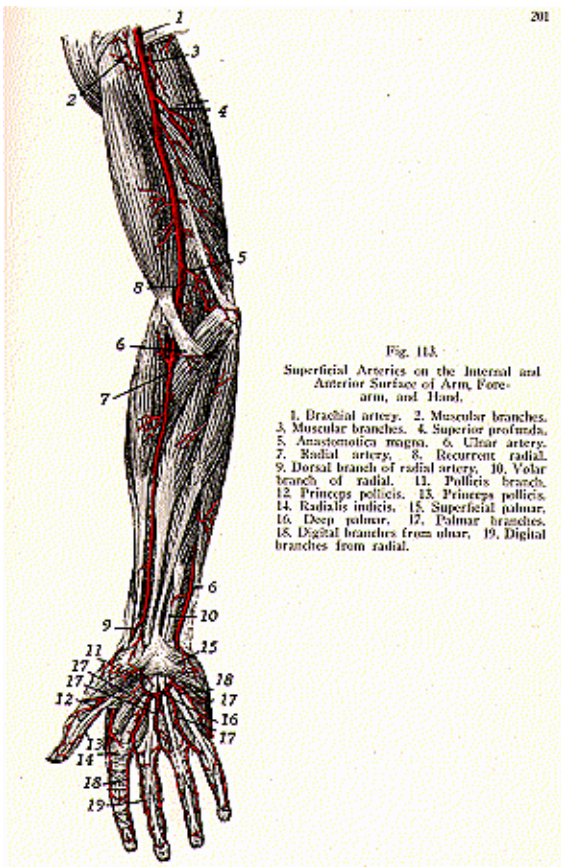
supply the following muscles; the coraco-brachialis, biceps brachii, and the brachialis anticus. The **anastomotica magna** forms an extensive anastomosis around the elbow joint, giving off the anterior and posterior branches, which anastomose with the superior and inferior profunda branches, also with the anterior and posterior ulnar recurrent arteries.

The **Radial Artery** (illustrations Nos. 113 and 114) is given off, with the ulnar artery, from the bifurcation of the brachial, one-half inch below the elbow joint, and extends along the radial side of the forearm to the wrist, to the apex of the styloid process; it then winds backward, around the carpus, and passes to the space between the metacarpal bones of the thumb and the index finger, and reaches the palm, where it forms the *deep palmar arch*, anastomosing here with the profunda branch from the ulnar artery.

The **branches** of the **radial artery** are the **radial recurrent, muscular, anterior and posterior radial carpal, superficialis volae, metacarpal, dorsales, pollicis and indicis**, the **princeps pollicis, radialis indicis, perforating, palmar interosseous** and the **palmar recurrent**. The **radial recurrent** supplies the elbow joint and the muscles in close proximity, and anastomoses with the superior profunda branch of the brachial artery, the **muscular** arteries are numerous branches distributed to the radial side of the forearm; the **anterior and posterior radial carpal** supply the articulations of the wrist and the carpus. The anterior radial carpal anastomoses with the anterior carpal branch of the ulnar artery, while the posterior radial carpal anastomoses with the posterior carpal branch of the ulnar.

Numerous interosseous and digital branches are given off from these vessels and form the anterior and posterior **carpal arches** at the wrist joint; the **superficial volar** arises near the wrist and ends in the muscles of the ball of the thumb; **metacarpal** or interosseous, the **first dorsal interosseous** supplies the adjoining sides of the index and middle fingers, and forms an anastomosis with the two other dorsal interosseous arteries from the posterior radial carpal artery; the **dorsalis pollicis** runs along the sides of the posterior aspect of the thumb; the **dorsalis indicis**, along the lateral side of the index finger; **princeps pollicis** runs along the palmar aspect of the thumb, and forms an arch from which branches are distributed to the skin and the subcutaneous tissue of the thumb; the **radialis indicis** runs along the radial side of the index finger to its extremity; the **perforating** pass to the 2nd, 3rd and 4th inter-metacarpal spaces, and anastomose with the dorsal interosseous arteries; the **palmar interosseous**, three or four in number, run from the deep palmar arch to the 2nd, 3rd and 4th interosseous spaces, near the clefts of the corresponding fingers they terminate and anastomose with the digital branches of the superficial arch; the **palmar recurrent** branches are few and of small size, they arise from the deep palmar arch, pass to the front of the wrist, and supply the carpal articulations, they anastomose with the anterior carpal from the radial carpal.

The **branches** of the **ulnar artery** are the **anterior and posterior ulnar recurrent, anterior and posterior interosseous, muscular, anterior and posterior ulnar carpal, profunda**, and the **superficial palmar**



arch. The **anterior** and **posterior ulnar recurrent branches** are given off below the elbow joint, the anterior rises higher than does the posterior. The anterior passes upward and inward, the posterior backward and inward, they anastomose with the profunda and anastomotica magna of the brachial and supply the elbow joint and the neighboring muscles of the joint; the **interosseous** is about one inch long and is a common trunk which divides into two branches, the *anterior* and *posterior interosseous*.

The *anterior interosseous* passes down on the front of the interosseous membrane and, at the upper border of the pronator quadratus, it divides into two terminal branches and supplies both bones of the forearm; the *posterior interosseous* gives off, near its origin, the interosseous recurrent to the elbow joint, and then passes between the upper border of the interosseous membrane and the oblique ligament, at the lower part it ends in articular branches at the wrist joint; **muscular** branches are distributed to the muscles along the ulnar side of the forearm; the **anterior** and **posterior, ulnar carpals** anastomose with the corresponding branches of the radial carpal artery; the **profunda** anastomoses with the termination of the radial artery and joins the deep palmar arch; the superficial palmar arch is a continuation of the ulnar artery in the hand—four digital branches are given off from the arch.

The **Superficial Palmar Arch** arches across the palm under the cover of the palmar aponeurosis, and is formed by the part of the ulnar artery which lies in the palm of the hand, which anastomoses with the radialis indicis from the radial artery.

The **Deep Palmar Arch** is formed by the radial artery, which anastomoses with the deep palmar or profunda branch from the ulnar and lies upon the carpal ends of the metacarpal bones and the interossei muscles.

The **Anterior Carpal Arch** is formed by the anastomosis of the anterior carpal of the radial with the anterior carpal of the ulnar, in front of the wrist.

The **Posterior Carpal Arch** is formed by the anastomosis of the posterior carpal of the radial with the posterior carpal of the ulnar artery.

THE DESCENDING AORTA

The **Descending Aorta** (see illustration No. 109) is divided into two portions, the **thoracic** and the **abdominal**.

The **Thoracic Aorta begins** as a continuation of the arch, at the lower border on the 4th dorsal vertebra; it passes along the anterior surface of the vertebral column and **terminates** at the aortic opening in the diaphragm, which is opposite the body of the 12th dorsal vertebra, becoming continuous with the abdominal aorta. The **branches** are the **pericardial, bronchial, esophageal, posterior mediastinal** and the **intercostal**. The **pericardial** supplies the **pericardium**; **bronchial**, the lung tissue; **esophageal**, the esophagus; **posterior mediastinal**, the small glands and areolar tissue in the mediastinum; the **intercostal** arteries are usually nine pairs, and run to the intercostal spaces, to-

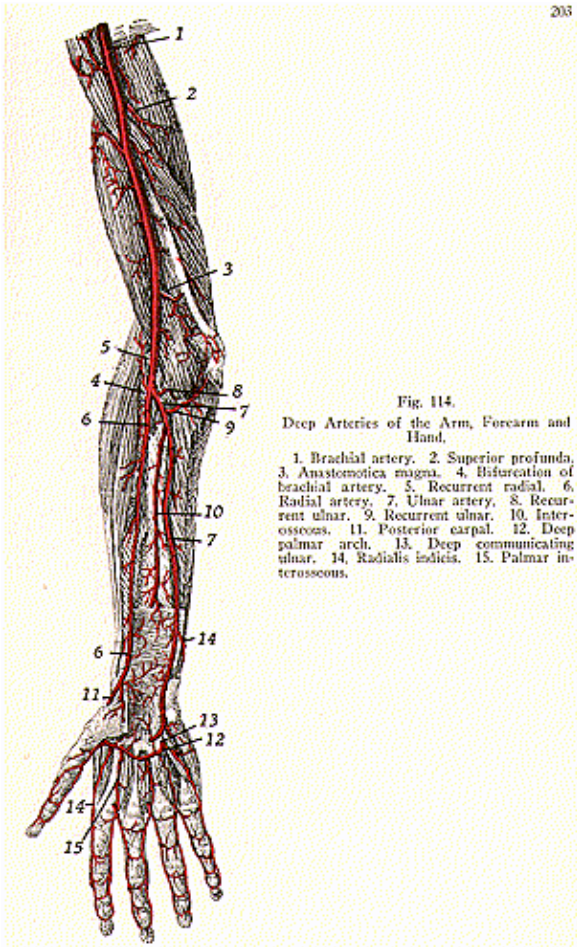


Fig. 114.
Deep Arteries of the Arm, Forearm and Hand.

1. Brachial artery. 2. Superior profunda. 3. Anastomotica magna. 4. Bifurcation of brachial artery. 5. Recurrent radial. 6. Radial artery. 7. Ulnar artery. 8. Recurrent ulnar. 9. Recurrent ulnar. 10. Interosseous. 11. Posterior carpal. 12. Deep palmar arch. 13. Deep communicating ulnar. 14. Radialis indicis. 15. Palmar interosseous.

ward the angle of the upper rib, thence, lying in the subcostal groove, they anastomose with intercostal branches of the internal mammary and with the thoracic branches of the axillary. The intercostals supply the intercostal muscles, the ribs, mammary gland, pectoral muscles, and the vertebrae, spinal cord, dorsal muscles and the skin.

The **Abdominal Aorta begins** at the aortic opening of the diaphragm, which is opposite the front of the body of the 12th dorsal vertebra, at the left of the vertebral column it **terminates** opposite the body of the fourth lumbar vertebra, by dividing into the right and left common iliacs. The length of the abdominal aorta is about five inches. It lies in the epigastric and umbilical regions, where it lies deeply behind the peritoneum; its direction is downward, with a slight inclination to the left. **Its branches** are the **phrenic, coeliac axis, superior mesenteric, inferior mesenteric, suprarenal, renal, spermatic** or the **ovarian, lumbar and middle sacral**.

The **right and left phrenic** arise near the beginning of the aorta, most often above the coeliac axis, they are usually called the right and left inferior phrenic to distinguish them from the superior phrenic of the internal mammary. Each vessel passes to the under surface of the diaphragm and divides into two branches, an internal and an external, one passes to the front of, and the other to the side of, the thorax and diaphragm, and sends a few branches to the suprarenals; the internal phrenic anastomoses with the superior phrenic and the musculo-phrenic of the internal mammary, while the external anastomoses with the intercostal arteries.

The **Coeliac Axis** is a short, thick trunk about one-half inch in length, which is given off from the abdominal aorta just below the 12th dorsal vertebra, behind the peritoneum, above the pancreas. Its direction is straight forward and it divides into three large branches, the **gastric, splenic** and the **hepatic**. The **gastric, or coronary artery**, is the smallest branch of the coeliac axis, and passes upward and to the left as far as the lesser curvature of the stomach till it reaches the cardia where it distributes branches to the esophagus and anastomoses with the esophageal branches of the thoracic aorta; other branches supply the cardiac end of the stomach, anastomosing with the branches of the splenic artery. It continues its course upon the lesser curvature to the pyloric end and gives off branches to the anterior and posterior surfaces of the stomach, and anastomoses with the pyloric branches of the hepatic.

The **hepatic artery** is intermediate in size between the gastric and the splenic, tho in the fetus it is the largest of the three branches of the coeliac axis. This vessel runs forward and to the right and divides at the portal fissure of the liver into two branches, the *right* and the *left hepatic*, supplying the corresponding lobes of the liver. Its *branches* are the *pyloric*, to the pyloric end of the stomach there anastomosing with the gastric; and the *gastroduodenalis*, which gives off the right gastro-epiploic and the superior pancreatico-duodenal. The right gastro-epiploic passes along the greater curve of the stomach, it sends off branches to both the anterior and posterior surfaces of the stomach and anastomoses with the left gastro-epiploic from the splenic artery; the superior pancreatico-duodenal runs to the

right and then downward, between the duodenum and the pancreas, supplying both, and anastomoses with the inferior pancreatico-duodenal, from the superior mesenteric artery.

The **splenic artery** is the largest branch of the coeliac axis. It passes by a very tortuous course to the left, along the superior border of the body of the pancreas, and, on reaching the front of the left kidney, it breaks up into several splenic branches, which enter the spleen thru the hilum. The *branches* of the splenic artery are, the *pancreatic*, large and small, which supply the pancreas; the *left gastro-epiploic*, arises near the spleen and runs in the gastro-splenic ligament to the left end of the stomach and then runs along the greater curvature, it gives off branches to both the anterior and the posterior surfaces of the stomach, and anastomoses with the right gastro-epiploic, from the gastro-duodenal, from the hepatic; the *vasa brevia* are from five to seven small branches which are distributed to the greater curvature and fundus of the stomach, they anastomose with branches of the gastric artery.

The **Superior Mesenteric Artery** arises from the front of the aorta, below the coeliac axis, posterior to the pancreas and, opposite the first lumbar vertebra, it takes a curved course and forms an arch, its convexity being to the left, and **ends** in the right iliac fossa by anastomosing with one of its own branches—the ileo-colic branch. The *branches* are the *inferior pancreatico-duodenal*, which runs to the right between the pancreas and the duodenum, supplying both of these structures and anastomosing with the superior pancreatico-duodenal, from the gastro-duodenal from the hepatic, the *vasa*, or *rami intestini tenuis*, or the *intestinal arteries*, are usually twelve to fifteen in number and run toward the intestine between the layers of the mesentery. They divide and anastomose, forming arterial arcades, which, by their junction with the contiguous branches, give rise to primary arches, and from these convexities smaller branches are given off, which act in a similar manner and give rise to secondary arches. This disposition of arteries goes on so as to form three or four or even five arches, and these vessels supply the jejunum and the ileum; the *ileo-colic* artery is the lowest branch given off from the superior mesenteric artery, it supplies the ileum, caecum, the vermiform appendix and the ileo-caecal valve; the *right colic* passes to the ascending colon and divides into two branches, a descending, which anastomoses with the ileo-colic, and an ascending branch, which anastomoses with the middle colic; the *middle colic* supplies the transverse colon, and divides into right and left branches, which anastomose with the right and left colics and also with the right and left gastro-epiploics.

The **Inferior Mesenteric Artery** arises from the left side of the abdominal aorta, one and a half inches above its bifurcation, and runs down and to the left, behind the peritoneum, and **ends** in the superior hemorrhoidal artery. The inferior mesenteric supplies the descending colon, the sigmoid flexure, and the upper part of the rectum, and gives off the following *branches*: *left colic*, *sigmoid* and *superior hemorrhoidal*. The *left colic* divides into an ascending branch, which anastomoses with the middle colic from the superior mesenteric, and into a descending branch, which anastomoses with the upper sigmoid artery: the

sigmoid arteries are two or three in number and run across the ureter and the psoas muscles, and supply the sigmoid colon and part of the descending colon; the *superior hemorrhoidal* is a continuation of the inferior mesenteric, it runs half way down the rectum and divides into two branches, which sink into its substance and anastomose with the middle and inferior hemorrhoidal arteries from the anterior trunk of the internal iliac.

The **Supra Renal Arteries** arise from either side of the aorta, and supply the supra-renal capsules.

The **Renal Arteries**, right and left, are two large trunks given off from the sides of the aorta, they pass to the kidneys, entering the hilum of each kidney.

The **Spermatic Arteries**, in the male, right and left, pass thru the inguinal canal and supply the testes. Small branches from the spermatic anastomose with the artery of the vas deferens, from the superior vesical, from the internal iliac. Each spermatic artery gives off the **cremasteric arteries** which supply the cremaster muscle and tissues.

The **Ovarian Arteries**, in the female, supply the ovaries, the uterus, the skin of the labia and of the groin. The ovarian arteries anastomose with the uterine, from the internal iliac artery.

The **Lumbar Arteries** are usually eight in number, four from each side, they run backward and outward upon the bodies of the upper four lumbar vertebrae. Each divides into a dorsal and a spinal branch. The dorsal passes backward between the transverse processes and is distributed to the muscles and to the skin of the loin: while the spinal branch enters the vertebral canal and is distributed to the spinal cord and its covering, as well as to the wall of the canal.

The **Middle Sacral Artery** or **Sacra Media** is a small vessel, which arises just at the bifurcation of the aorta and passes along the anterior part of the two lower lumbar vertebrae, the sacrum and the coccyx, to end in branches supplying the coccygeal body. Other minute branches also are given off. The middle sacral artery anastomoses with the lateral sacral from the internal iliac.

The **Common Iliac Arteries extend** from the bifurcation of the aorta at the 4th lumbar vertebra, to the level of the lumbo-sacral articulation, where each divides into an **External** and **Internal Iliac**. The right common iliac is longer than the left, and passes more obliquely across the body of the last lumbar vertebra. Each artery rests upon the lower half of the body of the fourth and upon the whole length of the body of the fifth lumbar vertebra. There are no named branches given off from the common iliacs, but a few twigs pass to the ureters, the psoas magnus, the peritoneum, and surrounding areolar tissue.

The **Internal Iliac Artery**, or the **Hypogastric Artery**, arises from the bifurcation of the common iliac artery at the lumbo-sacral joint It is about one and one-half inches in length and **extends** to the upper margin of the great sacro-sciatic notch, and there divides into an **anterior** and **posterior trunk**, which supply the walls and viscera of the pelvis, the buttocks, generative organs, and the inner side of the

thigh. The **anterior trunk** gives off the following **branches**:—*superior vesical, middle vesical, inferior vesical, middle hemorrhoidal, obturator, internal pudic, sciatic*, also the *uterine* and *vaginal* in the female. From the **posterior trunk** of the internal iliac, are given off the *ilio-lumbar, lateral sacral* and the *gluteal branches*.

The *superior vesical artery* is the remaining pervious part of the vessel known as the hypogastric artery in the fetus. This vessel sends branches to the upper part of the bladder, to the vas deferens and to the ureter, and anastomoses with the inferior and middle vesical arteries, the *middle vesical* supplies the base of the bladder and the seminal vesicles, the *inferior vesical* passes to the base of the bladder, the prostate gland, and seminal vesicles, and anastomoses with the middle and the superior vesical arteries; the *middle hemorrhoidal* is distributed to the rectum, and anastomoses with the superior and inferior hemorrhoidal arteries, it also gives branches to the seminal vesicles and to the prostate gland; the *obturator artery* passes, thru the canal in the obturator membrane, to the thigh and divides into an external and an internal branch, and these vessels supply the ilium, the iliacus muscle, the bladder, back of the pubes, also the obturator externus, pectineus, the adductors, and the gracilis, also the muscles attached to the tuberosity of the ischium and to the hip joint; the *internal pudic artery* or *pudendal artery*, is distributed to the external generative organs, is larger in the male and it gives off the following *branches*:—*muscular*, to the levator and, obturator internus, pyriformis and coccygeus; the *inferior hemorrhoidal*, to the muscles and integument of the anal region; the *superficial* and *transverse perineal*, to the scrotum and to the muscles and integument of the perineum in the male, and to the labiae and the perineum in the female; the *artery of the bulb* supplies the bulb of the urethra and sends a small branch to Cowper's gland in the male, and, in the female, to the bulb of the vestibule and the erectile tissue of the vagina; the *profunda penis*, to the penis; and, in the female, the *profunda clitoridis*, to the clitoris.

The *dorsal artery* of the penis in the male, and of the *clitoridis* in the female, passes to the dorsum of the penis, or to the clitoris, the *sciatic* or *inferior gluteal* artery supplies the back of the pelvis, and leaves the pelvis, with the pyriformis muscle, thru the great sacro-sciatic foramen. It gives off branches to the pyriformis, coccygeus, levator and, the rectum, bladder, seminal vesicles, prostate gland, articular branches to the hip joint, and the cutaneous branches to the skin of the buttock and back of the thigh.

From the **posterior trunk** of the **internal iliac**, are given off the following *branches*:—*ilio-lumbar*, supplies the iliacus, the ilium, the gluteal and the posterior abdominal muscles; the *lateral sacral*, superior and inferior, which supplies branches to the contents of the sacral canal and to the muscles and skin on the dorsum of the sacrum, and the *gluteal*, which divides into a superficial and a deep branch to the glutei muscles, supplies the skin over the sacrum and the hip joint, also a few nutrient branches to the ilium.

ARTERIES OF THE LOWER EXTREMITY

The **External Iliac Artery** (illustrations Nos. 115 and 116), larger than the internal iliac, is from three and one-half to four inches in length. It **arises** from the bifurcation of the common iliac, and **extends** from the lumbo-sacral joint to the middle of Poupart's ligament, where it is continued as the femoral artery. The **branches** of the external iliac, are the **deep epigastric** and the **deep circumflex iliac** arteries.

The **deep epigastric artery** arises from the inner side of the external iliac, about one-fourth inch above Poupart's ligament, and passes inward between Poupart's ligament and the lower border of the internal abdominal ring. It then changes its course and passes upward and inward and perforates the sheath of the rectus muscle, and, about two inches above the umbilicus, it ends in terminal branches, which anastomose with the branches of the superior epigastric artery. The branches along its course, are the *cremasteric, pubic, muscular, cutaneous, peritoneal* and its terminal branches. The **deep circumflex iliac artery** arises opposite the epigastric and passes along the crest of the ilium, at about its middle, it pierces the fascia of the transversalis and, at its termination, it anastomoses with the iliolumbar, gluteal, lumbar branches and with the superficial circumflex iliac.

The **Femoral Artery** (illustrations Nos. 115 and 116) **begins** as a continuation of the external iliac, at the middle of Poupart's ligament and runs thru the femoral trigone (Scarpa's triangle, described with muscles) and thru Hunter's canal (adductor canal), it **ends** at the opening in the adductor magnus, which is at the junction of the middle with the lower third of the thigh, where it becomes the popliteal artery. The femoral artery, at the upper part of the thigh, lies in front of the hip joint; in the lower part it is in close relation with the inner side of the shaft of the femur.

The artery and vein are enclosed in a strong fibrous sheath, for the first inch and a half of the vessel, called the *femoral sheath*. In the upper third of the thigh, it lies within the femoral trigone. The **branches** of the femoral are the **superficial epigastric**, supplying the inguinal glands, fascia and skin, and anastomosing with the deep epigastric from the external iliac; the **superficial circumflex iliac**, to the skin of the groin, and supplying glands, it anastomoses with the deep circumflex iliac from the external iliac; the **superficial** and the **deep external pudic**, to the skin of the abdomen, penis, and scrotum in the male, and to the labia in the female, it anastomoses with the internal pudic of the internal iliac; **muscular**, to the sartorius and vastus internus; **profunda femoris** (the deep femoral artery), arises posteriorly about one or two inches below Poupart's or the inguinal ligament, it descends to the lower third of the back of the thigh and gives off the following *branches*, the *external circumflex*, or *lateral circumflex* supplies the muscles on the front of the thigh, the *internal circumflex* or *medial femoral circumflex*, supplies the hip joint and muscles on the front of the thigh, the adductor muscles, and the gracilis; and **perforating** arteries to the flexor muscles and to the adductors of the thigh; the **anastomotica magna** or the **genu supreme**, arises from

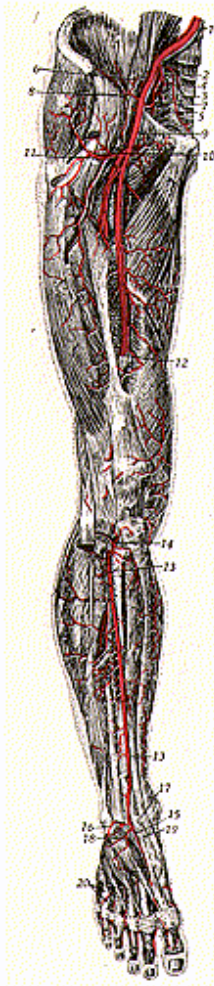


Fig. 115.

Arteries on the Anterior Surface of Pelvis, Thigh, Leg, and Foot of the Right Upper Extremity.

1. Right common iliac artery. 2. Internal iliac artery. 3. Lateral sacral artery. 4. Superior gluteal artery. 5. Inferior gluteal artery. 6. External iliac artery. 7. Deep epigastric artery. 8. Deep circumflex iliac artery. 9. Femoral artery. 10. Profunda femoris artery. 11. External circumflex artery. 12. Femoral artery thru Hunter's canal. 13. Anterior tibial artery. 14. Recurrent tibial artery. 15. Dorsalis pedis artery. 16. External malleolar. 17. Internal malleolar. 18. and 19. Tarsal arteries. 20. Interosseous arteries.

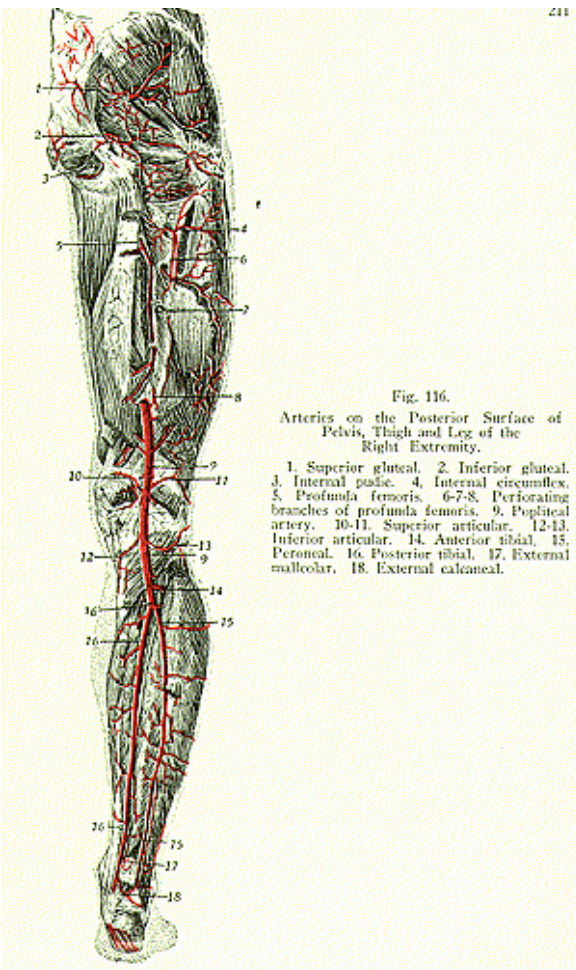
the femoral artery before it passes thru the adductor canal (Hunter's canal), and immediately divides into two branches, a superficial and a deep branch, which anastomose around the knee joint with the articular branches of the popliteal artery, and supply the knee joint.

The **Popliteal Artery** is a continuation of the femoral artery and **begins** at the middle of the thigh, passing behind the knee joint between the two condyles of the femur. It **ends** at the lower border of the popliteus muscles, where it **divides** into an **anterior** and **posterior tibial artery**. The division takes place on a level with the lower border of the tubercle of the tibia, and fully one and one-fourth inches below the level of the upper surface of the head of the tibia. The vessel at first passes downward and outward until it reaches the middle of the femur, then it takes a straight course downward between the condyles of the femur and finally sinks beneath the heads of the gastrocnemius. The popliteal artery passes thru the popliteal space or fossa (previously described) and it is crossed by the popliteal vein and the internal popliteal nerve, it gives off the following **branches**:—**superior** and **inferior muscular** branches to the adjacent muscles; **cutaneous** to the skin, and **articular** (superior, inferior and middle), or the **genu superior, inferior** and **middle**, to the knee joint. The articular branches anastomose with the anastomotica magna of the femoral around the knee joint.

The **Anterior Tibial Artery** arises, with the posterior tibial artery from the bifurcation of the popliteal, at the lower border of the popliteus muscle; it **ends** at the front of the ankle joint or the bend of the ankle joint, midway between the malleoli, where it becomes superficial and is known as the dorsalis pedis. The **branches** of the anterior tibial; the **posterior recurrent**, to the back of the knee joint; **anterior recurrent**, to front of knee; **superior fibular**, to the neck of the fibula and the muscles attached; the **muscular** and **cutaneous** to muscles and skin; and the **external** and **internal malleolar**, to the inner and outer part of the ankle.

The **Dorsalis Pedis Artery** is a continuation of the anterior tibial at the ankle, and, passing along the tibial side of the foot to the back part of the first inter-metatarsal space, it dips down into the sole, and **ends** by joining the plantar arch. The **branches** are the **tarsal, interossei, or metatarsal, digital**, the **dorsalis hallucis** or the first **dorsal interosseous**, all to the adjacent sides of the great and second toes; and the **communicating** or **plantar digital** branch, which joins with the external plantar from the posterior tibial artery, to complete the plantar arch.

The **Posterior Tibial Artery** is a larger vessel than the anterior tibial, and, given off with the anterior tibial from the popliteal at the lower border of the popliteus muscle and between the inner part of the ankle and heel, it divides into the **internal** and **external plantar arteries**. In the upper part of the leg, the posterior tibial, (over the interval between the tibia and the fibula), is situated between the superficial and deep muscles, then it approaches the inner side of the leg, lying behind the tibia; in the lower part it becomes superficial to the inner side of the tendo Achillis. The **branches** are the **peroneal**, which passes along the back part of the fibular side of



THE BLOOD-VASCULAR SYSTEM

the leg and gives off, as branches, the *muscular*, *nutrient*, *communicating*, the *external calcaneal*, also the *anterior* and the *posterior peroneal branches*; the **nutrient**, passes to the muscles upon the back of the leg; the communicating branch passes to a communicating branch of the posterior tibial; the **internal calcaneal** passes to the inner surface of the os calcis, and anastomoses with the external plantar artery.

The **Internal Plantar Artery**, or the **Medial Plantar Artery**, runs along the inner side of the foot and great toe; it gives off *cutaneous articular* and *digital branches*, and ends by anastomosing with its digital branch.

The **External Plantar Artery**, or the **Lateral Plantar Artery**, is larger than the internal plantar. Arising, with the internal plantar, from the posterior tibial, it passes across the plantar aspect of the foot and curves inward to the interval between the bases of the first and the second metatarsal bones, there it anastomoses with the plantar digital branch or with the communicating branch from the *dorsalis pedis*, completing the plantar arch.

The **Plantar Arch** is formed by the lateral or external plantar and the *dorsalis pedis*, thru the communicating branch or plantar digital branch of the latter. The arch, besides distributing numerous branches to the muscles, integument and fasciae of the foot, gives off the perforating branches. These pass thru the outer interosseous spaces between the head of the dorsal interossei muscles and the digital branches, supplying both sides of the three outer toes and the outer side of the second toe; while the plantar digital, or the communicating, supplies the adjacent side of the great and second toes.

THE FETAL CIRCULATION

(Illustration No. 117.)

The **Fetal Circulation** is that circulation which is carried on in the fetus. We will describe vascular structures peculiar to the fetus, also the changes which take place when the child is born.

The placenta is a round, flat organ, within the uterus, which establishes communication between the mother and child by means of the umbilical cord. The placenta is the fetal organ of circulation, respiration, nutrition and excretion. It is a circular mass, about seven inches in diameter, about one inch in thickness, and weighs about sixteen ounces. It consists of a modified part of the chorion of the fetus, and develops villi which become a part of the modified mucous membrane of the womb. The maternal and fetal blood streams do not intermingle but there is between them an interchange of dissolved substances by diffusion. The placenta is attached to the fetus by the umbilical cord and is usually expelled after the young is born, constituting the chief part of the after-birth. The umbilical cord (*funiculus umbilicalis*) consists of areolar tissue and whitish filaments. It contains the umbilical vein and arteries, thru which the blood is carried to the fetus (by the umbilical vein) and returned to the placenta (by the umbilical artery).

The umbilical vein, carrying oxygenated blood, enters the abdomen at the umbilicus and passes to the under surface of the liver, where it gives off two or three branches to the right and left lobes of

the liver, while a small branch continues outward, under the name of the **ductus venosus**, to join the hepatic vein at the point of junction of that vessel with the inferior vena cava. So the blood from the placenta reaches the inferior vena cava in two ways, directly by means of the ductus venosus, and indirectly by means of the hepatic veins after having circulated thru the liver. This freshly oxygenated blood of the inferior vena cava, becomes mixed with blood returning from the lower extremities and from the wall of the abdomen; it enters the right auricle, and, guided by the Eustachian valve, passes thru the **foramen ovale** into the left auricle, where it becomes mixed with a small quantity of blood returned (by the pulmonary veins) from the lungs, as yet unexpanded.

From the left auricle the blood passes into the left ventricle, and from the left ventricle into the aorta, by whose branches it is distributed, almost entirely, to the head and upper extremities; some goes to the substance of the heart by the coronary arteries, and a small quantity is carried into the descending aorta, where it mixes with the venous blood entering the descending aorta by the **ductus arteriosus**. From the head and the upper extremities, the blood is returned, by tributaries, to the superior vena cava, thence to the right auricle where it becomes mixed, to a limited degree, with the blood from the inferior vena cava; from the right auricle it is carried into the right ventricle, from the right ventricle it is driven into the trunk of the pulmonary artery.

The lungs of the fetus are inactive, so only a small quantity of blood passes to them, while the greater part of the blood from the right ventricle is carried to the aorta thru the ductus arteriosus. This vessel joins the aorta at a point beyond the origin of the left subclavian artery, so none of its blood enters the three great vessels—the innominate, left common carotid or left subclavian—which spring from the arch of the aorta. The whole of it descends within the descending aorta and is distributed to the abdominal and pelvic viscera and to the lower extremities. From those parts a certain portion returns to the heart by the post cava, tho a larger portion is conveyed by the hypogastric arteries to the placenta.

The **hypogastric arteries**, right and left, are prolonged from the common iliacs to the fetal umbilicus, thru which they leave the body of the fetus, and, under the name of the **umbilical arteries**, they pass along the umbilical cord to be distributed to the placenta. They convey venous blood from the fetus to the placenta, and the blood is cleared, in the placenta, by osmosis to and from the uterine and the ovarian arteries of the mother.

The **changes at birth**: Respiration is established and the lungs become active, after which time they perform their office as respiratory organs; the **pulmonary arteries** enlarge greatly in order to carry all the blood in the pulmonary trunk to the lungs; the **placental circulation** is entirely arrested; the **foramen ovale**, between the right and left auricles, becomes occluded when the valvular edges are pressed together by pressure of the blood coming in thru the pulmonary veins, this closure is usually complete by the tenth day after birth; in the place of this opening we then find the **fossa ovalis** as seen on the inner

wall of the right auricle; the **ductus arteriosus**, which connects the trunk of the pulmonary with the arch of the aorta, begins to contract and becomes transformed into a fibrous cord, called the **ligamentum arteriosum**, and is attached to the pulmonary artery or to the aorta; the **ductus venosus**, becomes transformed into a fibrous cord, called the **ligamentum venosum**, which occupies the fissure for the ductus venosus of the liver, then that portion of the umbilical vein within the fetus dwindles to a fibrous cord and becomes the **round ligament** of the liver, it requires from two to five days after birth for the ductus venosus and the umbilical vessels to change, the **hypogastric** or **umbilical arteries** change, in that the portion from the side of the bladder to the umbilicus becomes a fibrous cord, tho the remaining part, from the trunk to the internal iliac, remains as the superior vesical artery this taking place from the second to the fifth day after birth; the **Eustachian** valve is of large size during fetal life and is associated with the orifice of the post cava at the posterior part of the right auricle. It is a crescentic fold of the endocardium, and is so situated as to direct the blood, entering the right auricle by the post cava, to the foramen ovale; after birth this valve becomes rudimentary and has no further importance. The lungs of the fetus, prior to birth, are placed at the back of the thorax, against the spine. They feel solid and would at once sink if placed in water.

Arterial anastomoses of greatest importance, include the following:

The **coronary anastomosis**. The right and left coronary arteries branches of the ascending aorta, form an anastomosis at the apex of the heart.

Thyroid anastomosis. The superior thyroid, a branch of the external carotid, anastomoses with the inferior thyroid, a branch of the thyroid axis, which in turn arises from the subclavian.

The **princeps cervicis** or the **ramus descendens**, a branch of the occipital, from the external carotid, anastomoses with the vertebral from the subclavian, and with the profunda cervicis, a branch of the superior intercostal, from the subclavian.

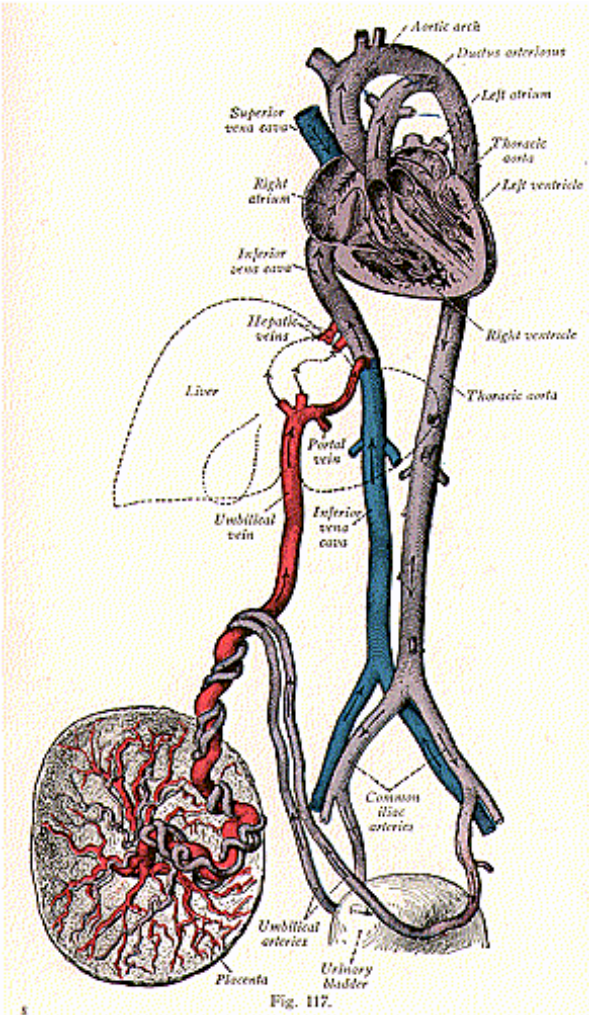
The **shoulder joint anastomosis**. The anterior and posterior circumflex, branches of the axillary, form an anastomosis around the head of the humerus; the suprascapular, from the thyroid axis, the latter from the subclavian, anastomoses with the subscapular, a branch of the axillary, and with the posterior scapular, from the transversalis colli, from the thyroid axis.

The **anastomosis** of the **elbow joint**, is formed by the superior profunda, which gives off a posterior articular branch which anastomoses with the radial recurrent, a branch of the radial; the anastomotica magna anastomoses with the superior profunda, with the inferior profunda, also with the anterior branches from the brachial and with the posterior ulnar recurrent from the ulnar artery.

Fig. 117.

Plan of the Fetal Circulation. Vessels carrying arterial blood are colored red those carrying venous blood, blue, those carrying mixed blood, violet. The blood stream from the umbilical vein through the liver is indicated by dotted lines.

THE BLOOD-VASCULAR SYSTEM



The **anastomosis** of the **hip joint**. The deep circumflex iliac from the external iliac anastomoses with the superficial circumflex iliac of the femoral; the gluteal and sciatic branches of the internal iliac anastomose with the internal and external circumflex, branches of the profunda femoris of the femoral artery, forming the crucial anastomosis, the obturator branch of the internal iliac anastomoses with the internal circumflex of the profunda femoris of the femoral, the transverse branch of the internal circumflex anastomoses with the sciatic, with the external circumflex, and with the perforating branches from the crucial anastomosis, behind the junction of the neck of the femur with the great trochanter.

The **anastomosis** of the **knee joint**. The genu supreme, or anastomotica magna, a branch of the femoral, anastomoses with the articular branches of the popliteal; the descending branch of the external circumflex of the profunda femoris anastomoses with the anterior recurrent branch of the anterior tibial.

The **longest anastomosis in the body** is found between the subclavian and the external iliac, in the following manner: the superior epigastric, a branch of the internal mammary, from the subclavian, anastomoses with the deep epigastric of the external iliac.

The **gastric anastomosis** is formed by the gastric branches of the gastric artery, which pass to the front and back of the stomach where they anastomose with the gastro-epiploic branches of the splenic and with the gastro-duodenal from the hepatic artery, these large trunks being branches of the coeliac axis; the right and left gastro-epiploic branches form an anastomosis at the great curvature of the stomach.

The **mesenteric anastomosis**. The superior mesenteric gives off the middle colic, the right colic and the ileo-colic, which anastomose with each other and with the left colic, a branch of the inferior mesenteric.

The **hemorrhoidal anastomosis** is formed by the superior hemorrhoidal, from the inferior mesenteric, in its anastomosis with the middle and inferior hemorrhoidal, from the anterior trunk of the internal iliac.

The **uterine-ovarian anastomosis** is formed by the ovarian, a branch of the abdominal aorta, in its anastomosis with the uterine, a branch of the anterior trunk of the internal iliac. This anastomosis is also called the Byron Robinson anastomosis.

The **vesical anastomosis** is formed by the superior, middle and inferior arteries—branches from the anterior trunk of the internal iliac.

The **circle of Willis**, or the **polygon of Willis**, is formed at the base of the brain by branches of the vertebral and internal carotid arteries. The two vertebrals are given off from the subclavian and unite to form the basilar, which ends in the posterior cerebrals, these are united to the internal carotid by the posterior communicating arteries; the internal carotid also gives off the anterior cerebrals which are united by the anterior communicating artery—thus completing the circle.

THE ARTERIES OF THE SPINAL CANAL AND SPINAL CORD

The **arteries of the spinal canal** are the vessels which enter the spinal canal thru the intervertebral and sacral foramina. In the *cervical region* they are branches of the vertebral and deep cervical arteries; in the *thoracic* and *lumbar regions* they are derived from branches of the intercostal and lumbar arteries; and in the *sacral region* they come from the lateral sacral arteries.

In the **spinal canal** each spinal artery divides into three branches, namely: the *neutral* or *central* or the *lateral spinal* arteries which pierce the dura mater, and supply the meninges and the nerve roots, and anastomose with the anterior and posterior spinal arteries of the cord; and the *anterior* and *posterior parietal* branches to the bodies, laminae, pedicles, and other surface parts of the vertebrae.

The arteries of the **spinal cord** are the *anterior spinal artery*, the *posterior spinal arteries* right and left, and the *lateral spinal* arteries. The anterior spinal arteries are branches which pass along the front of the cord in the median line, the *posterior spinal* descends on the side of the cord, one part going to the front of, and the other behind, the posterior nerve roots. These are reinforced by branches from the lateral spinal arteries, and these extend over the entire length of the cord. From these chains, branches are freely given to the pia mater and thru it to the cord, which anastomose with the ascending and deep cervical, from the thyroid and superior intercostal and from the lumbar branches.

THE VEINS

Veins are vessels which return the blood to the heart from the capillaries of the body, and are classified as **superficial**, **deep**, and as sinuses.

The **Superficial Veins**, or **Subcutaneous Veins**, usually do not accompany the arteries and as a rule lie between layers of the superficial fascia; they terminate in the deep vessels, anastomose freely and the veins of the superficial set have their lining membrane so arranged as to form semilunar reduplications or valves set in pairs opposite one another, to prevent the backward flow of blood.

The **Deep Veins** accompany the arteries, enclosed in the same sheath, and are given the same names. The secondary arteries of the deep set, such as the brachial, radial, ulnar, etc., have two veins each, called the **venae comites**.

The **Sinuses**, another set of veins, are the venous channels of the skull, differing from veins as to structure but serving the same purpose. They are formed by a separation of the layers of the dura mater, and are lined with endothelium.

The **Pulmonary Veins**, previously described, begin in the capillaries of the lungs, and convey oxygenated blood to the left auricle.

The **Systemic Veins** include all veins tributary to the **superior** and **inferior vena cavae**, and the **coronary sinus**. There are many veins that have no valves, in this class are the deep or internal veins the venae cavae, the hepatic, portal, renal, uterine, ovarian, vertebral spinal and the pulmonary veins.

The **Cardiac Veins** open into the right auricle of the heart. The **great cardiac** or the left **coronary vein**, **begins** at the apex of the heart and passes along the anterior interventricular groove to the base of the ventricles, it then curves to the back of the heart and **opens** into the left extremity of the coronary sinus; it receives tributaries carrying blood from the walls of the left auricle and both ventricles. The **small cardiac vein**, or the right **coronary vein**, runs in the groove between the right auricle and ventricle, and opens into the right extremity of the coronary sinus; it receives the blood from the posterior walls of the right auricle and ventricle. The **middle cardiac vein** begins at the apex of the heart and ends in the coronary sinus near its right extremity; the **anterior** and **posterior cardiac** veins open directly into the right auricle; the **oblique atrii sinistri** or the **oblique cardiac vein** (vein of Marshall) ends in the middle of the sinus; the **venae cordis minimae** or **veins of Thebesius** return the blood from the substance of the heart, and open directly into the heart cavities.

THE VEINS OF THE HEAD AND NECK

These are subdivided into the veins of the **interior** of the **cranium** and of the **diploe**, the veins of the **exterior** of the **head** and **face**, and the veins of the **neck**, the **veins of the skull**, the **sinuses** and the **cerebral** veins, **emissary** veins, and those of the **diploe**.

The **Veins** of the **Diploe** are situated in the cancellated tissue between the outer and inner tables of the skull and are exposed after removal of the outer plate. They are destitute of valves and are arranged in the form of a network from which the blood is returned by four diploic veins on either side, namely—the frontal, the anterior and posterior temporal, and the occipital. These terminate partly in extra-cranial veins, and partly in the intra-cranial venous sinuses and meningeal veins.

The **Emissary Veins** are vessels which pass thru foramina in the cranial wall and serve to establish communications between the intra-cranial venous sinuses and the extracranial veins. The principal emissary veins are as follows:—mastoid, nasal, condyloid, occipital, frontal and parietal; the openings for these vessels are the mastoid foramen, parietal foramen, condyloid foramina, and openings in the sphenoid bone.

Meningeal Veins accompany the meningeal arteries in the outer layer of the dura and empty into the neighboring sinuses.

The **Sinuses** are blood-channels or spaces situated between the two layers of the dura mater, and are as follows:

Superior sagittal or the **superior longitudinal sinus**, **inferior sagittal** or the **inferior longitudinal**, **straight** or **rectus** or **tentorial sinus**, **occipital**, **circular**, **lateral sinuses** (two), **superior petrosal** (two) **inferior petrosal** (two), **cavernous** (two), **spheno-parietal** (two) and the **basilar** or **transverse sinuses** (several).

The **Superior Longitudinal** or **Sagittal** is situated in the median line, and commences at the foramen caecum, it extends upward, backward and finally downward, and is attached to the margin of the falx cerebri. It ends at the right side of the internal occipital pro-

tubérance, in a depression which contains the confluence of the sinuses, the **torcular Herophili** (confluens sinuum). The superior longitudinal sinus increases in size as it passes backward, its shape is triangular, and it receives the superior cerebral veins, some of the meningeal veins, and numerous veins from the diploe; it communicates with the scalp, the veins of the roof of the nose and with the spaces in the dura into which the Pacchionian bodies project.

The **Inferior Sagittal Sinus** lies in the posterior two-thirds of the lower edge of the falx cerebri, and its direction is backward; it opens into the front part of the straight sinus, at the anterior edge of the tentorium cerebelli. It receives tributaries from the lower part of the falx cerebri and adjacent parts of the mesial surfaces of the cerebral hemispheres.

The **Straight** or **Rectus Sinus** is situated at the junction of the falx cerebri and the tentorium cerebelli. It is dilated at the internal occipital protuberance and is continued into the left lateral sinus. Its terminal dilation is connected with the torcular Herophili by a transverse vessel; it receives, along its course, the vein of Galen, some of the superior cerebellar veins and tributaries from the falx and tentorium cerebelli.

The **Occipital Sinus**, situated within the falx cerebelli along its attachment to the internal occipital crest, is small and is formed by the union of several small veins around the margin of the foramen magnum, one of which joins the lateral sinus. It communicates with the spinal veins and receives some of the inferior cerebellar veins. Superiorly, the occipital sinus opens into the torcular Herophili; it receives tributaries from the falx cerebri and the inferior surface of the cerebellum, and it establishes a communication between the commencement and termination of the lateral sinuses.

The **Circular Sinus** surrounds the pituitary body in the sella turcica of the sphenoid. It is formed by two transverse sinuses, the anterior and posterior inter-cavernous, which connect the two cavernous sinuses; one passes in front of and the other behind the pituitary body and form a venous circle around the pituitary body.

The **Lateral Sinuses** are two in number—right and left. Each sinus extends from the internal occipital protuberance to the jugular foramen, and, with the inferior petrosal sinus, forms the jugular vein.

The **right lateral sinus** is, as a rule, the direct continuation of the superior longitudinal sinus, and the **left lateral sinus** is the continuation of the straight sinus; they are frequently of unequal size. The lateral sinus of each side receives the superior petrosal sinus—some superior and inferior cerebral veins; some from the diploe, and oftentimes some veins from the internal ear. The course of the lateral sinus may be indicated on the exterior by drawing a line horizontally outwards from the external occipital protuberance to the base of the mastoid process, on a level with the external auditory meatus, then downward in a curved manner to the tip of the mastoid process.

The **Superior Petrosal Sinus** (right and left) is situated along the superior border of the petrous part of the temporal bone, and lies within the attached margin of the tentorium cerebelli; it begins

at the cavernous sinus, ends in the lateral sinus, connects the cavernous and the lateral sinuses, and receives tributary veins from the cerebellum, the diploe, and from the middle ear.

The **Inferior Petrosal** (right and left) occupies the groove at the junction of the basilar process of the occipital bone with the petrous part of the temporal bone; it commences at the back part of the cavernous sinus and passes backward and outward to the jugular foramen, where it is joined by the lateral sinus to form the internal jugular vein. It receives tributary veins from the inferior surface of the cerebellum and from the internal ear.

The **Cavernous Sinus** (right and left) is so named because the interior of each is broken up by fibrous filaments which give it a reticular appearance. Each sinus is situated on the side of the body of the sphenoid bone, and extends from the sphenoid fissure to the apex of the petrous portion of the temporal bone. It receives the ophthalmic vein and the spheno-parietal sinus in front, and some of the inferior cerebral veins. It communicates with its fellow by the intercavernous sinuses, and with the lateral sinus by means of the superior petrosal sinus.

The **Spheno-Parietal Sinuses** are two in number—the right and left. Both are of small size and are situated one on the inferior surface of either lesser wing of the sphenoid bone. They take their origin from the meningeal veins and receive blood from the diploe of the skull and terminate in the anterior part of the cavernous sinus.

The **Basilar Sinus** or the **Transverse Sinus** consists, in reality, of a plexus of veins. It is situated within the dura mater over the basilar process of the occipital bone, extending as low as the anterior margin of the foramen magnum; its component veins communicate with the anterior spinal veins, and also serve to connect the two inferior petrosal sinuses.

The **veins** of the **brain** are the *ganglionic*, *basilar* and the *cortical veins*.

The **Cerebral Veins** are remarkable for the absence of valves, and, on account of the extreme thinness of their coats, they have no muscular tissue. The cerebral veins are classified as the **superficial** and the **deep**.

The **superficial** or **cortical veins**, occupy the surface of the cerebrum and cerebellum. The veins of the cerebrum ramify upon the surface, being lodged in the fissures between the convolutions; they receive tributaries from the substance of the brain, and are divisible into two sets—the superior and inferior cerebral veins. The superficial veins of the cerebellum are also divided into two sets—the superior and inferior cerebellar veins. They occupy the surface of the cerebellum, and all terminate in some of the various sinuses.

The **deep cerebral veins**, or the **veins** of **Galen**, are two in number. In their course they gather the blood from the interior of the brain, from the choroid plexus, from the velum interpositum and the corpus striatum. In the region of the third ventricle they unite to form a **common vein of Galen**, the **vena cerebri magna**, about one-half inch long. This passes out of the tela choroidea and opens into the straight sinus. These veins are sometimes called the **ganglionic** or

THE BLOOD-VASCULAR SYSTEM

central veins. The **deep cerebellar veins** bring the blood from the interior of the cerebellum and empty into the superficial cerebellar veins.

The **Basilar Vein** collects the blood from the under surface of the cerebrum and feeds the petrosal; cavernous, and lateral sinuses, The **veins of the pons** come from the under surface of the pons and

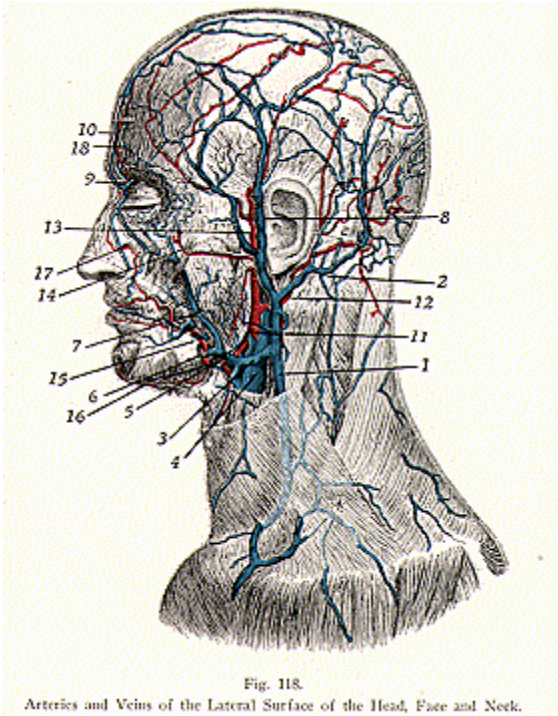


Fig. 118.

Arteries and Veins of the Lateral Surface of the Head, Face and Neck.

1. External jugular. 2. Occipital vein. 3. Facial vein. 4. Internal jugular. 5. Facial vein. 6. Labial vein. 7. Angular vein. 8. Temporal vein. 9. Ophthalmic vein. 10. Frontal vein. 11. External carotid artery. 12. Posterior auricular artery. 13. Superficial temporal artery. 14. Facial vein. 15. Facial artery and labial vein. 16. Submental artery. 17. Angular artery. 18. Frontal artery.

empty into the basilar vein and superior petrosal sinus, or they may join the cerebellar. The **veins of the medulla oblongata** communicate with the veins of the spinal cord and join with the inferior petrosal and occipital sinuses.

THE VEINS OF THE HEAD, NECK AND FACE

The veins of the head, neck and face are: **Frontal, Supraorbital, Angular, Facial, Superficial temporal, Internal Maxillary, Temporomaxillary, Posterior auricular, Occipital.** (Illustrations Nos. 118 and 119).

The **Frontal** and the **Supra-Orbital Veins** unite near the middle line of the forehead to form the angular vein. They receive small tributaries from the veins of the forehead and the dorsum of the nose.

The **Angular Vein**, formed by the frontal and supra-orbital veins, runs downward toward the root of the nose and **ends** in the facial vein. They receive veins from the eyelid and the side of the nose.

The **Facial Vein commences** above the inner canthus of the eye and passes downward and outward over the body of the mandible. It **unites** with the temporo-maxillary vein to form the common facial, which empties into the internal jugular opposite the body of the hyoid bone. The facial vein receives numerous tributaries from the mouth, lips, cheek, lower eyelid, palate, tonsil, tongue, submaxillary gland, and parts around the chin.

The **Superficial Temporal begins** on the side of the head near the vertex of the skull, by anterior and posterior branches, which unite and are joined by the middle temporal above the zygoma. These vessels pass thru the substance of the parotid gland and **unite** with the internal maxillary to form the temporo-maxillary. The superficial temporal, therefore, receives tributaries from the temporal region and adjoining parts of the frontal and parietal regions, the supraorbital region, and the parotid gland.

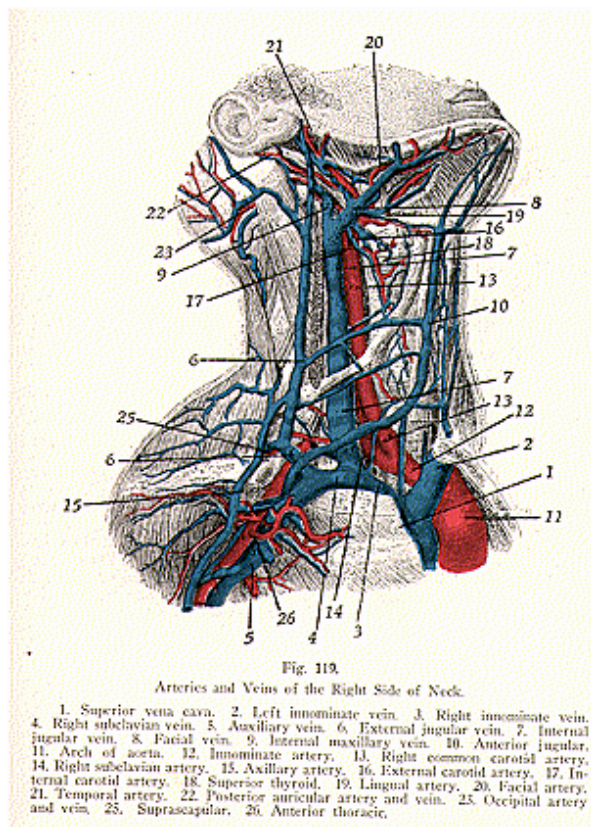
The **Internal Maxillary** is a short trunk, formed by a plexus of veins—the pterygoid plexus—composed of the meningeal, deep temporal, pterygoid, masseteric, buccal, alveolar, palatine, superior and inferior dental, auricular, tympanic, and infra-orbital veins. The internal maxillary joins with the superficial temporal to form the temporo-maxillary vein.

The **Temporo-Maxillary Vein** is **formed** by the union of the superficial temporal and the internal maxillary above the zygoma, and descends in front of the ear; in the substance of the parotid gland it divides into an anterior and a posterior division. The anterior joins the facial vein; the posterior is joined by the posterior auricular and becomes the external jugular vein.

The **Posterior Auricular Vein drains** the posterior parts of the temporal and parietal regions. It descends posterior to the ear and joins the posterior division of the temporo-maxillary to form the external jugular.

The **Occipital Vein drains** the occipital and posterior parietal regions and **ends** in the sub-occipital triangle. It terminates in a plexus of veins which is drained by the vertebral and deep cervical

THE BLOOD-VASCULAR SYSTEM



1. Superior vena cava. 2. Left innominate vein. 3. Right innominate vein. 4. Right subclavian vein. 5. Axillary vein. 6. External jugular vein. 7. Internal jugular vein. 8. Facial vein. 9. Internal maxillary vein. 10. Anterior jugular. 11. Arch of aorta. 12. Innominate artery. 13. Right common carotid artery. 14. Right subclavian artery. 15. Axillary artery. 16. External carotid artery. 17. Internal carotid artery. 18. Superior thyroid. 19. Lingual artery. 20. Facial artery. 21. Temporal artery. 22. Posterior auricular artery and vein. 23. Occipital artery and vein. 24. Suprascapular. 25. Anterior thoracic.

veins. Occasionally it communicates with the external jugular, or it may terminate in the internal jugular vein.

The **Veins of the Neck** receive the blood from the head and face. They are the **External Jugular, Anterior Jugular, Posterior Jugular, Internal Jugular, Innominate Veins,** and **Superior Vena Cava.**

The **External Jugular Vein** or **Vena Jugularis Externa** is **formed** by the union of the temporo-maxillary and the posterior auricular veins, in the substance of the parotid gland, behind the angle of the mandible; it **drains** the greater part of the blood from the exterior of the skull and the deep parts of the face. The external jugular runs down the side of the neck, crosses the sternomastoid muscle, and lies in the subclavian triangle; it pierces the deep cervical fascia, and **terminates** in the subclavian vein at the sternal end of the clavicle. Its course lies to the outer side of, or in front of, the scalenus anticus muscle. **Tributaries** to the external jugular are the **anterior jugular, posterior jugular, supra-scapular,** and **transverse cervical veins.** It is provided with valves at its termination, as well as for a distance of about one and one-half inches above this point.

The **Anterior Jugular Vein commences** in the roof of the sub-maxillary triangle near the hyoid bone; it is **formed** by the union of small veins from the lower lip and the chin—the submental, inferior labial and mental veins—and **terminates** in the external jugular. The anterior jugular has no valves, and this vein may be divided into more than one anterior jugular.

The **Posterior Jugular Vein** is **formed** by veins in the superficial tissues of the upper and back part of the neck. It runs across the roof of the posterior triangle and **ends** in the external jugular at about the middle of the neck.

The **Internal Jugular Vein,** or **Vena Jugularis Interna,** **commences** in the jugular foramen at the base of the skull; it is formed by the union of the lateral and inferior petrosal sinuses, and **terminates** behind the inner end of the clavicle by joining with the subclavian to form the innominate vein. The internal jugular **drains** the interior of the cranium and the superficial parts of the face and neck. A dilation found at its origin is known as the *sinus* or *bulb*, or the *gulf* of the *internal jugular*. This vein passes vertically, lying first on the outer side of the internal carotid artery, and subsequently on the outer side of the common carotid artery, the pneumogastric nerve being interposed in each case, and all these structures are enclosed within the carotid sheath. The **tributaries** of the internal jugular are the **facial, lingual, pharyngeal, superior and middle thyroid, occipital,** and **cochlear veins.** The internal jugular vein is of considerable size, but varies in different individuals. Each internal jugular is provided with a pair of valves, which are usually placed about an inch above its termination.

The **lingual veins commence** on the dorsum, sides, and under surface of the tongue; each receives the **ranine vein,** a tributary which commences at the tip of the tongue. The lingual returns the blood from the tongue, and **ends** in the internal jugular vein.

The **pharyngeal veins commence** in the pharyngeal plexus on the wall of the pharynx. They receive along their course the dural,

meningeal, and sphenopalatine veins, and **terminate** in the internal jugular vein.

The **superior** and **middle thyroid veins** accompany the corresponding arteries, receiving the laryngeal and crico-thyroid veins. They collect the blood from these parts and from the thyroid gland, larynx and trachea, and terminate in the internal jugular vein.

The **Innominate Veins**, or the **Venae Anonymae**, or **Brachio-Cephalic Veins**, are two in number, the right and left, and are **formed** by the junction of the internal jugular and subclavian veins, behind the inner border and sternal end of the clavicle. The two innominate veins then pass downward, the right innominate, one inch in length, and the left innominate two and one-half inches in length; at the lower border of the first costal cartilage the two **innominates unite** to form the **superior vena cava**. There are no valves in the innominate veins.

The **tributaries** of each vein are the **vertebral, inferior thyroid, internal mammary**, and the **superior intercostal** veins. The right innominate vein lies superficially and external to the innominate artery; the left innominate passes between the upper part of the manubrium and between the innominate, left common carotid and left subclavian arteries.

The **Vertebral Veins** are **formed** in the occipital triangle from a number of small veins which arise from the intra-spinal veins, forming a plexus; they leave the upper end of the vertebral canal, descending in the transverse processes of the cervical vertebrae, and at the lower part of the neck each vertebral **empties** into its corresponding innominate vein. Along its course it receives tributaries from the deep muscles, from the spinal plexuses and from other parts of the neck.

The **Inferior Thyroid Veins**, from two to four in number, **commence** from a plexus of veins in front of the trachea, and receive the esophageal, tracheal and laryngeal vein; they end in the innominate veins.

Internal Mammary Veins (Mammaria Interna) are two to each internal mammary artery. They lie on either side of the artery, follow the course of the artery, and are formed by the venae comites of the musculo-phrenic and superior epigastric arteries. In their course they receive **tributaries** from the **intercostals**, the **sternum** and the **pleura**. The internal mammary veins unite to form a single trunk, which terminates in the innominate vein.

The **Superior Intercostal Veins**, right and left, drain the blood from the upper intercostals, and end usually in the innominate veins. These veins are the posterior divisions of the superior intercostals.

The **Superior Vena Cava**, or the **Pre-Cava**, is about three inches in length and is **formed** by the right and left innominate veins at the lower border of the cartilage of the first rib, close to the sternum, on the right side. It pierces the pericardium and **terminates** in the upper part of the right auricle, opposite the upper border of the third right costal cartilage. The superior vena cava **drains** the whole of the upper half of the body. Among its **tributaries** are the **azygos** and **pericardiac** veins.

THE VEINS OF THE UPPER EXTREMITY

(Illustration No. 109.)

The **Veins** of the **Upper Extremity** are divided into two sets: the **superficial** and the **deep**. The **superficial veins** are placed close beneath the skin, between the two layers of the superficial fascia. In the hand they begin by the digitals, and these empty into the interosseous veins; these into the palmar veins, which form a plexus upon the palmar fascia in the palm of the hand, and these veins form the superficial radial and ulnar veins. The names of the superficial veins of the hand, forearm and arm, are the **anterior** and **posterior ulnar, common ulnar, radial, median, median cephalic, median basilic**, the **basilic** and the **cephalic**. They all have valves.

The **Anterior and Posterior Ulnar Veins** commence on the anterior and posterior surface of the ulnar; they arise from the superficial veins of the hand, and **form** a common trunk, the **common ulnar**, at the bend of the elbow.

The **Common Ulnar Vein**, a short trunk, **formed** by the anterior and posterior ulnar, **unites** with the median basilic to **form** the basilic vein.

The **Radial Vein** commences from the superficial veins of the hand, passes along the radial side of the forearm and, at the bend of the elbow, unites with the median cephalic to form the cephalic vein.

The **Median Vein**, or **Median Cubital Vein** is formed by a few veins which originate in the plexus in front of the wrist, its course is upward, in front of the forearm. At the bend of the elbow it **divides** into two trunks, the **median cephalic** and the **median basilic**, which diverge from each other as they ascend.

The **Median Basilic**, the larger of these two, passes thru the cubital space and, at the internal condyle of the humerus, joins the common ulnar to form the basilic.

The **Median Cephalic**, a smaller vessel, passes thru the cubital space and, near the external condyle, joins the radial, to form the cephalic vein.

The **Basilic Vein**, **formed** by the union of the median basilic and ulnar, passes along the inner side of the arm to the bicipital groove of the humerus, and is continued as the axillary vein.

The **Cephalic Vein** is formed by the union of the median cephalic and the radial, and passes along the outer side of the biceps brachii. Just below the clavicle it **terminates** in the axillary vein.

The **deep veins** of the **upper extremity** follow the course of the arteries and are the **venae comites**; they possess more valves than do the superficial veins.

The **Deep Veins** are the **digital, interosseous, deep palmar veins, brachial veins, axillary vein**, and the **subclavian vein**.

The **Digital Veins** begin in the hand; they **form** the **interosseous** and **palmar** veins. These latter terminate in the **deep radial** and **deep ulnar** veins, which join, at the bend of the elbow, to form the venae comites of the brachial artery.

The **Brachial Veins** lie one on either side of the brachial artery, and join the axillary vein. These veins have numerous anastomoses not only with each other, but also with the superficial set. The

brachial veins receive the blood from tributaries corresponding in name with the branches given off from the brachial artery.

The **Axillary Vein** is the **continuation** of the basilic vein, and lies to the inside of the axillary artery, it **terminates** beneath the clavicle, under the name of the subclavian. The axillary receives the brachial and cephalic, and **drains** those parts which are supplied by the axillary artery.

The **Subclavian Vein**, the continuation of the axillary vein, extends from the lower border of the first rib to the inner end of the clavicle, there it **joins** with the internal jugular to **form** the innominate vein. The subclavian vein lies in front of the subclavian artery with the scalenus anticus muscle between. The subclavian vein **receives** the **external jugular** as its only constant tributary, tho it may receive the anterior jugular and a branch from the cephalic. At its termination it has a valve.

THE SPINAL VEINS

The **Spinal Veins** are arranged in four sets:

The **dorsi-spinal**, or the **extra-spinal**, those on the exterior of the spine, **meningo-spinal** or **rachidian**, or the **intra-spinal**, those in the interior of the **canal; venae basis vertebrarum**, the veins of the bodies of the vertebrae; **medulli-spinalis**, the veins of the spinal cord.

The **Dorsi-Spinal Veins** form a plexus around the spines, processes and laminae of the vertebrae; they **empty** into the vertebral, the intercostal, lumbar and sacral veins, in their respective regions.

The **Meningo-Spinal**, or the **Anterior** and **Posterior Longitudinal**, form two longitudinal plexuses which run the whole length of the spinal canal, situated between the dura mater and the wall of the spinal canal. They **empty** into the dorsi-spinal veins and into the vertebral, intercostal, lumbar and sacral veins, in their various regions.

The **Venae Basis Vertebrarum** are the veins of the bodies of the vertebrae; they are contained within the cancellated tissue of the vertebral bodies, and communicate with the dorsi-spinal and meningo-spinal veins.

The **Medulli-Spinal Veins** are the veins of the spinal cord. They lie within the substance of the pia mater and arachnoid, and form venous chains and plexuses on the surface of the cord; they **empty** into the cervical, intercostal, lumbar and sacral veins, in the corresponding regions.

The **Azygos Veins** are three in number; they collect the blood from the intercostal spaces, the lumbar region, the lungs, esophagus, pericardium and the mediastinum. They may also **connect** the superior and the inferior venae cavae.

The **Vena Azygos Major**, or the **Right Azygos**, **commences** in the abdomen, by a branch of the lumbar veins, sometimes from the right renal vein and sometimes from the inferior vena cava, it enters the thorax thru the aortic opening in the diaphragm, and ends in the superior vena cava, just before the superior vena cava enters the pericardium. The vessels tributary to the right azygos, are the right

lower intercostals, the **left azygos**, or the **azygos minor**, the **right bronchial**, **esophageal**, **mediastinal** and the **pericardial veins**.

The **Azygos Minor**, or the **Left Lower Azygos**, or the **Hemiazygos**, begins in the abdomen from the left lumbar or renal veins, and enters the thorax by piercing the left crus of the diaphragm; it crosses the vertebral column and **ends** in the right azygos, having **drained** the **intercostals**, esophageal and the mediastinal.

The **Left Upper Azygos** or **Accessory Azygos** is formed by a junction of the fourth to the seventh or eighth left posterior intercostal veins at the level of the seventh dorsal vertebra. It crosses the vertebral column from left to right and ends in the azygos major. It sometimes receives the left bronchial vein, tho the accessory azygos may be wanting entirely.

The **Intercostal Veins** are eleven in number on either side and each lies in the subcostal groove above the corresponding artery from the aorta the intercostal veins are divided into an **anterior** and a **posterior division**. The **anterior intercostal veins** are tributaries of the internal mammary or of the musculo-phrenic; the **posterior intercostals** terminate in the innominate, vertebral, azygos major and minor.

THE VEINS OF THE LOWER EXTREMITY

The **Veins** of the **Lower Extremity** are subdivided like those of the upper extremity into two sets, the **superficial** and the **deep**. The **superficial veins** are situated beneath the skin between the layers of fascia, while the **deep veins** accompany the arteries, forming the venae comites of those vessels. Both sets of vessels have valves, but they are more numerous in the deep than in the superficial set.

The **Superficial Veins** are the **Digitals**, which form the **Interosseous**; these form a plexus situated in the superficial structure of the dorsum of the foot, across the distal parts of the metatarsals forming an arch. The veins of the arch terminate in the **long** and the **short saphenous veins**, the chief superficial veins of the lower extremity.

The **Long Saphenous**, or **Great Saphenous**, or **Internal Saphenous** commences at the inner side of the dorsum of the foot, from the plexus of the veins forming the arch; it passes in front of the internal malleolus along the inner side of the leg behind the internal condyle of the femur, and enters the thigh, then turns to the front of the thigh, superficial to the sartorius, and passes thru the **saphenous opening** in fascia lata. It terminates in the femoral vein, an inch and a half below Poupart's or the inguinal ligament. The long saphenous has several valves, from ten to fifteen, which are more numerous in the thigh than in the leg. The long saphenous drains the superficial parts of the foot, also the inner and superficial parts of the leg and thigh; it receives **tributaries** known as the **cutaneous**, **superficial external iliac**, **superficial epigastric**, and the **pudic veins**.

The **External Saphenous**, or the **Short Saphenous**, or **Small Saphenous**, commences at the outer side of the dorsum of the foot from a plexus of veins, and passes behind the external malleolus, up

the middle of the back part of the leg, and **ends** in the popliteal vein in the popliteal space between the two condyles. The short saphenous **drains** the superficial part of the outer side of the foot and leg, and has from six to twelve valves. It receives **tributaries** from the back part of the leg.

The **Deep Veins** of the **Lower Extremity** accompany the arteries and their branches and are called the **venae comites**, beginning in the foot as the **external** and the **internal plantar**, which unite to form the **posterior tibial**; likewise the **dorsalis pedis** continues upward, to form the **anterior tibial vein**, the anterior and the posterior tibial commences at the lower border of the popliteus muscle and pass between the fibula and tibia, thru an oval aperture above the interosseous membrane and form by their junction there the popliteal. The **popliteal** passes thru the popliteal space, thru the opening in the adductor magnus muscle, and **terminates** in the femoral vein. The popliteal vein receives, along its course, **tributaries** which drain the parts supplied by the popliteal artery.

The **Femoral Vein** begins at the end of the popliteal, at the opening in the adductor magnus muscle in the lower third of the thigh, and accompanies the femoral artery thru the upper two-thirds of the thigh, thru the Adductor, or Hunter's, canal and thru the femoral trigone (Scarpa's triangle). A little to the inner side of, and below, Poupart's (the inguinal) ligament, the femoral **becomes** the external iliac vein. The **tributaries** of the femoral vein are: the **venae comites** of the **anastomotica magna artery**, at the lower end of the adductor canal; the **venae comites** of each of the **muscular branches** of the superficial femoral artery; the profunda femoris vein, at a point about 1-3/4 inches below Poupart's ligament; the **long saphenous vein**, at a point about 1-1/2 inches below Poupart's ligament. Thus the femoral vein **drains** the parts that are supplied by the femoral artery.

The **External Iliac** receives the **deep epigastric**, the **deep circumflex iliac**, and **small pudic veins**. The **deep epigastric vein** is formed by a union of the venae comites of the deep epigastric artery; the **deep circumflex iliac vein** is formed by the **venae comites** of the similarly named artery, both veins join the external iliac vein about 3/4 of an inch above Poupart's ligament.

The **Internal Iliac Vein**, or **Hypogastric Vein**, **begins** at the upper part of the great sciatic notch; it is formed by the venae comites of the branches of the internal iliac artery, and **terminates** at the lumbosacral joint, by joining with the external iliac vein to form the common iliac vein. The **tributaries** of the internal iliac vein correspond to the branches of the internal iliac artery, and are the **gluteal, sciatic, internal pudic, obturator, hemorrhoidal plexus, uterine** and **vaginal plexus, vesical plexus, prostatic plexus**, the **dorsal veins** of the **penis**, and the veins of the clitoris.

The **Common Iliac Veins** are **each formed** by the union of the external and internal iliac veins at the lumbo-sacral joint, they pass obliquely upward toward the right side, and, opposite the body of the fifth lumbar vertebra, they **unite** to form the **Inferior Vena Cava**. The **right common iliac** is shorter than the left and passes almost vertically, while the **left common iliac vein** is longer **than the right**,

and ascends very obliquely from left to right. The common iliac veins are usually destitute of valves. They receive along their course the lateral sacral and the ilio-lumbar veins.

The **Inferior Vena Cava** or **Post Cava** returns the blood to the heart from all parts below the diaphragm. It is 8 inches in length and **commences** opposite the body of the 4th or 5th lumbar vertebra, a little to the right of the middle line, it is formed by the union of the right and left common iliac veins, and it **terminates** at the posterior and inferior angle of the right auricle of the heart. It ascends along the right side of the aorta, and, having reached the liver, rests in a groove on its under surface, the fissure for the inferior vena cava. There it is covered by a piece of liver substance, the *pons hepaticus*. It then passes thru the vena caval opening in the diaphragm, on a level with the 8th dorsal vertebra, and then passes forward and inward for about an inch, where, piercing the pericardium, it opens into the lower and back part of the right auricle. It is guarded by the **Eustachian valve**, rudimentary in the adult—but of larger size in fetal life. The **tributaries** of the inferior vena cava are:—**hepatic veins, right spermatic** or **ovarian, right** and **left renals, supra-renals, phrenic** and the **right** and **left lumbar** veins.

The **Hepatic Veins** drain the liver; they have their beginnings in the substance of the liver, by capillaries from the hepatic arteries and the portal system; from these capillaries, form intra-lobular and then sub-lobular veins which eventually form three large trunks of hepatic veins. These pass to the posterior surface and open into the inferior vena cava, situated in the fissure at the back part of the liver.

Spermatic Veins receive tributaries from the testes and the epididymis, and help form the spermatic cord by forming a large plexus, the *spermatic* or the *pampiniform plexus*—at the internal abdominal ring; they first form as two veins which accompany the artery in the abdomen, and finally they unite to form one vein. The right spermatic enters the inferior vena cava on the right side; the left spermatic enters the left renal vein.

Analogous to the spermatic in the male are the **ovarian** veins in the female, which form a plexus in the broad ligament near the ovary and about the Fallopian tube; they communicate with the uterine plexus and terminate in the same way as do the spermatic veins in the male. The ovarian and the uterine veins both become greatly enlarged during pregnancy.

The **Renal Veins** are large, are placed in front of the renal arteries and terminate in the inferior vena cava. They are formed by tributaries which issue from the hilus of the kidney. The **left renal vein**, about two inches in length, is longer than the right, is higher and crosses in front of the aorta, it receives the left suprarenal and left spermatic or ovarian veins. The **right renal vein**, shorter than the left, about one inch long, crosses to the inferior vena cava; it terminates in the right side of the vena cava, a little below the left renal.

Lumbar Veins collect the blood from the lateral and posterior walls of the abdomen, particularly from the muscles and skin of the loin and the lumbar portion of the spinal cord.

The **Suprarenal Vein** on the right side ends in the vena cava; on the left side it ends in the left renal, or sometimes the left phrenic vein; the suprarenals drain the suprarenal bodies.

The **Phrenic veins**, two in number, the venae comites of the phrenic arteries, enter the upper end of the vena cava, tho the left phrenic usually ends in the renal or suprarenal.

The **Portal System** is formed by the **superior mesenteric, inferior mesenteric, the gastric, splenic and the cystic** ; it includes all the veins which drain the blood from the intestines, spleen, stomach, gall-bladder and pancreas. The two largest veins—the **superior mesenteric** and the **splenic**—form the **portal vein**; they join behind the head of the pancreas, which point corresponds to a point on a level with the second lumbar vertebra. It is about 3 inches in length and enters the portal or transverse fissure of the liver. Unlike other veins, the portal vein carries mixed blood and ends like an artery, by breaking up into branches, first into two branches, then they subdivide until they end in the capillaries of the substance of the liver; from these capillaries the blood is carried to the intra-lobular and the sub-lobular veins which end in the hepatic veins, these end in the inferior vena cava. There are no valves in the portal vein nor in its tributaries.

The **Superior Mesenteric Vein** is formed by tributaries which return the blood from those parts of the intestinal canal which are supplied by the superior mesenteric artery. The veins which empty into the superior mesenteric are the veins of the small intestine, also the ilio-colic, right colic, middle colic, the right gastro-epiploic and veins from the pancreas.

The **Inferior Mesenteric Vein** drains the parts supplied by the inferior mesenteric artery; veins which empty into the inferior mesenteric are the sigmoid veins and the left colic vein.

The **Gastric Vein** passes along the lesser curvature of the stomach as far as the esophagus; it receives the blood from both surfaces of the stomach, and some tributaries from the esophagus, then it turns to the right and opens into the portal vein.

The **Splenic Vein** is formed by four or five large branches, which emerge from the spleen. It is of large size and passes from left to right, behind the pancreas, where it lies below the splenic artery. The veins which empty into the splenic are: the vasa brevia, those small vessels which drain the fundus and the greater curvature of the stomach; the left gastro-epiploic vein; also several pancreatic veins and, as a rule, the inferior mesenteric vein.

The **Cystic Vein** drains the gall bladder and empties into the right branch of the portal vein.

THE LYMPHATIC SYSTEM

(Illustration No. 120.)

The **Lymphatic System** is considered with the blood-vascular system because of the similarity of its vessels to the blood-vessels, in that the lymphatic vessels carry a fluid, possess valves, pass in a definite direction, are arranged in two sets—the superficial and the deep, they also accompany the blood-vessels and anastomose freely; the largest lymph-vessels, like the blood-vessels, have three coats, styled the outer, middle and inner.

The **Lymphatics** are delicate, transparent vessels, that carry a colorless fluid, they have three coats, like those of arteries and veins, but their walls are not so thick. They are found thruout the greater part of the body, are more numerous than arteries or veins and they converge to form two main trunks, the **right** and **left lymphatic ducts**. The valves produce a characteristic knotted or beaded appearance, are also of semilunar form and are placed at shorter intervals than are the valves in the veins.

The **Lymph Spaces** are found thruout the body. They vary in size and are the tissue spaces, consisting of areolar tissue, lace-like, over which the lymph-vessels are distributed; they are known as the subdural, inter-pleural, inter-peritoneal, perivascular spaces, etc., and are lined by endothelium. Over these spaces the vessels pass and communicate with their cavities by small openings in the lymphatic walls, called **stomata**.

The **Lymphatic Vessels** in the intestines are called the **Lacteals**, because the fluid carried by them is somewhat milk-like in appearance.

Along the course of the lymphatic vessels are numerous nodular **collections, Lymphatic Glands**, and these are named according to the region in which they are found. The glands are small, solid, round or oval glandular bodies, situated in the course of the vessels, and are found chiefly at the root of the lungs, in the mesentery, coeliac region of the abdomen, along the great vessels, in the axilla, neck, at the front of the elbow, groin and popliteal space. A majority of the glands are pinkish-gray in color, but the bronchial glands are black-

Fig. 120.

Thoracic Duct, Lymphatics of Trunk, Pelvis and Upper Extremities.

1. Superior vena cava. 2. Right innominate vein. 3. Left innominate vein. 4. Internal jugular vein. 5. External jugular vein. 6 Subclavian vein. 7. Subclavian artery. 8. Common carotid artery. 9. Facial artery. 10. Facial vein. 11. Temporal artery and vein. 12. Axillary artery. 13. Brachial artery. 14. Cephalic vein. 15. Basilic vein. 16. Median vein. 17. Ulnar artery and vein. 18. Radial artery and vein. 19. Interosseous artery and vein. 20. Abdominal aorta. 21. Common iliac artery. 22. Femoral artery. 23. Inferior vena cava. 24. Azygos vein. 25. Long saphenous vein. 26. Receptaculum chyli. 27. Left thoracic duct. 28. Right thoracic duct. 29. Cervical thoracic vessels. 30. Axillary thoracic plexus. 31. Brachial thoracic plexus. 32. Superficial lymphatics of arm and forearm. 33. Deep lymphatics

THE LYMPHATIC SYSTEM

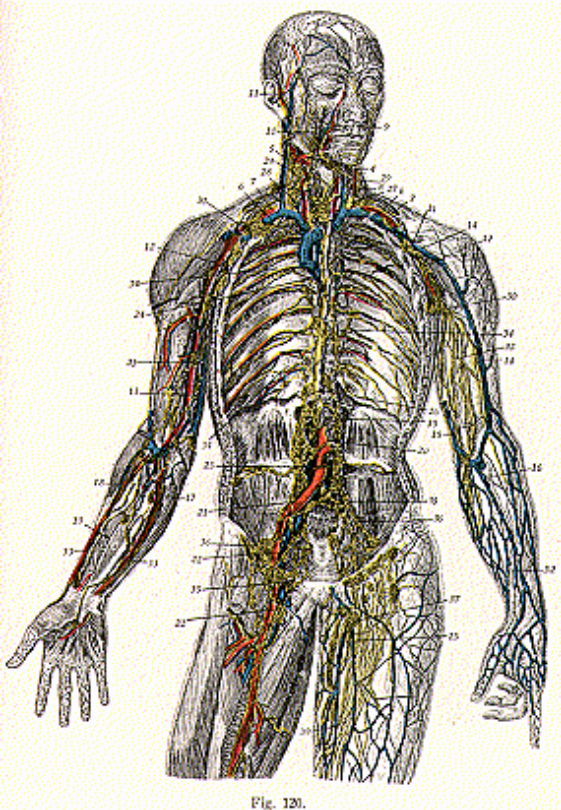


Fig. 120.

of forearm. 34. Intercostal lymphatics. 35. Lumbar lymphatics. 36. Iliac lymphatics. 37-38. Superficial and deep inguinal plexus. 39. Saphenous plexus.

THE LYMPHATIC SYSTEM

ened, the hepatic are yellow and the splenic are brown. Each gland has a localized depressed area, the *hilus* or *sinus*, and is enclosed in a capsule of fibrous tissue from which trabeculae are sent inward, forming alveoli, in which lies the gland-pulp or lymphoid tissue; this tissue consists of reticulate, its meshes being filled with lymph cells. The glands vary in size, some being no larger than the head of a pin, while others may be as large as a bean or even an olive. They lie embedded in the connective tissue, some immediately beneath the skin, but nearly always at the side of the great blood-vessels, and seldom are they found singly, usually in groups of from two to fifteen. There are few lymph glands in the limbs, but they are very numerous in the head, neck and the trunk.

Hemolymph Nodes or **Haemal Lymph** exist in various regions, but are most common in the abdomen; they do not differ from the other lymphatic glands except in that they are deep red instead of pink, because they contain, in their sinuses, blood.

THE LYMPHATIC GLANDS AND VESSELS OF THE HEAD AND NECK

(Illustration No. 121.)

The **Glands** of the **Head** are the **occipital**, at the back of the **head**; **post auricular**, near the mastoid process; **anterior auricular**, external to the parotid gland; parotid, seen in and around the parotid gland; **facial**, which are called the **maxillary** if in regions around the orbits, the **mandibular** if on the anterior surface of the mandible, and the **buccal**, if on the surface of the buccinator; **lingual**, between the genio-glossis and the hyo-glossis muscles; the **submaxillary**, in the submaxillary fossa, near the ramus of the lower jaw; **submental**, below the chin; **retro-pharyngeal**, one on either side of the upper part of the pharynx, opposite the axis, and the **superficial** and **deep cervical glands**.

The **superficial cervical glands** are located along the external jugular vein, around the superficial tissues of the ear and neck, in front of the larynx and trachea, in the submaxillary region, and above the hyoid bone. The **deep cervical glands** are found under cover of the sterno-mastoid, along the carotid sheath, above the clavicle, at the roots of the brachial plexus and around the internal jugular vein the back of the neck and scalp, in the palate, esophagus, larynx, tonsils, tongue and in and about the thyroid gland.

The **Lymphatic Vessels** of the **Head** and **Neck** are named practically the same as are the veins which many of them accompany, being the **temporal, auricular, occipital, lingual, superficial facial, deep facial, submaxillary, submental, parotid, retro-pharyngeal** and **thyroid lymphatics**. These drain the parts of the face and neck; the **cerebral** and **meningeal** drain the regions of the cranium and the neck, and in the neck are continuous with the lymphatic vessels of the face.

THE LYMPHATIC GLANDS AND VESSELS OF THE UPPER EXTREMITIES

The **Lymphatic Glands** of the **Upper Extremity** are classified as superficial and deep. The superficial are few in number and are found

THE LYMPHATIC SYSTEM

beneath the skin or in the subcutaneous tissue; the **deep ones** are quite numerous and among the principal deep glands are the **axillary**. These are from ten to fifteen in number, are of large size and are situated in the axilla, lying in chains along the border of the pectoralis major muscle. They are arranged as the **brachial**, or **lateral**, on the

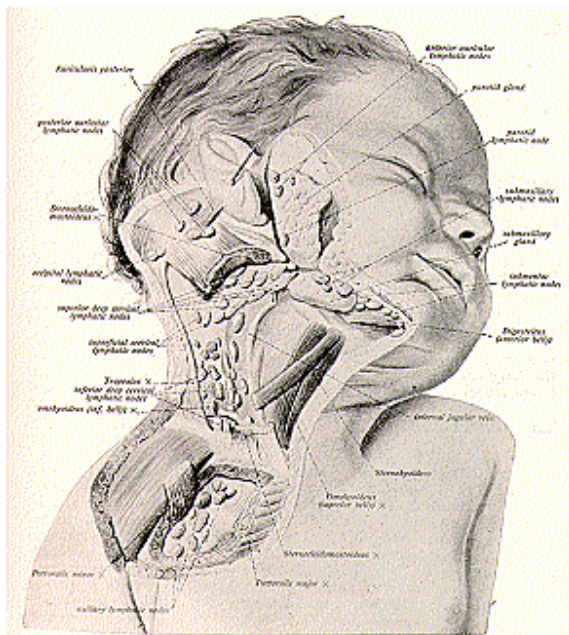


Fig. 121.
The Lymphatic Nodes of the Right Side of Head and Neck of Child.
floor of the axilla; the **pectoral**, between the pectoralis muscles and the serratus anticus; and the **subscapular**, along the border of the subscapularis muscle and along the subscapular artery.
The **Lymphatic Vessels of the Upper Extremity** are also classi-

floor of the axilla; the **pectoral**, between the pectoralis muscles and the serratus anticus; and the **subscapular**, along the border of the subscapularis muscle and along the subscapular artery.

The **Lymphatic Vessels of the Upper Extremity** are also classi-

THE LYMPHATIC SYSTEM

fied as the **superficial** and the **deep**. They accompany the veins and **arteries**; the **superficial** accompany the deep veins, while the **deep** lymphatic vessels accompany the arteries; they begin in the plexuses and convey the lymph from the skin, muscles, bones, ligaments, etc., and empty into the axillary glands.

THE LYMPHATIC GLANDS AND VESSELS OF THE LOWER EXTREMITY

(Illustration No. 122.)

The **Glands** in the **Lower Extremity** are arranged in about the same manner as are those of the upper extremity; that is, as the **superficial** and the **deep**; the **superficial** lie in the subcutaneous tissue, but there are few of this class below the groin, they being the anterior tibial and popliteal; all these are small. The anterior tibial glands are found in the anterior surface of the interosseous membrane; the popliteal are found in the fat of the popliteal space or fossa.

The **inguinal glands** are arranged in two sets, the **superficial** and the **deep inguinal** glands. The **superficial** are from ten to twenty in number, are of large size and are placed below Poupart's ligament and along the upper part of the long saphenous vein, close to where it passes thru the saphenous openings in fascia lata. The **deep** inguinal glands are from three to five in number and are placed under fascia lata and on the inner side of the femoral vein.

The **Lymphatic Vessels** of the **Lower Extremity** are also in two sets, the **superficial** and the **deep**. The **superficial** lie in the superficial fascia and are classed as the *external* and the *internal*, along the long and short saphenous veins; the **deep** accompany the deep blood-vessels, passing into the lymphatic glands of the popliteal fossa.

THE LYMPHATIC GLANDS AND VESSELS OF THE PELVIS AND ABDOMEN

The **Glands** of the **Pelvis and Abdomen** are the **external iliac**, **internal iliac**, the **common iliac** and the **lumbar glands**, the **coeliac glands**, **vesical**, **rectal**, **sacral**, **mesenteric** and the **para-uterine glands**.

The **external** and **internal iliac glands** form chains around the external and internal iliac vessels; the **common iliac**, about the common iliac artery; the **lumbar glands** lie in front of the lumbar vertebrae, along the aorta and inferior vena cava and close to the psoas magnus and quadratus lumborum; these lumbar glands are quite numerous and are known as the *lateral aortic*, the *pre-aortic* and the *retro-aortic* glands; the **coeliac glands** are about twenty-five in number; they surround the coeliac axis and lie in front of the aorta, and they are known as the *gastric*, anterior and posterior, *pericardial* at the cardiac end of the stomach, the *pyloric* or *subpyloric*, at the end of the gastro-duodenal artery, *hepatic*, in the portal fissure, *splenic*, accompanying the splenic artery, and are situated along the upper border and behind the pancreas, and the *cystic*, placed at the neck of the gall bladder; the **vesical glands**, in the retro-pubic fat at the front of the bladder; the **rectal** in the wall of the rectal ampulla; the **sacral**, along the inner side of the

THE LYMPHATIC SYSTEM

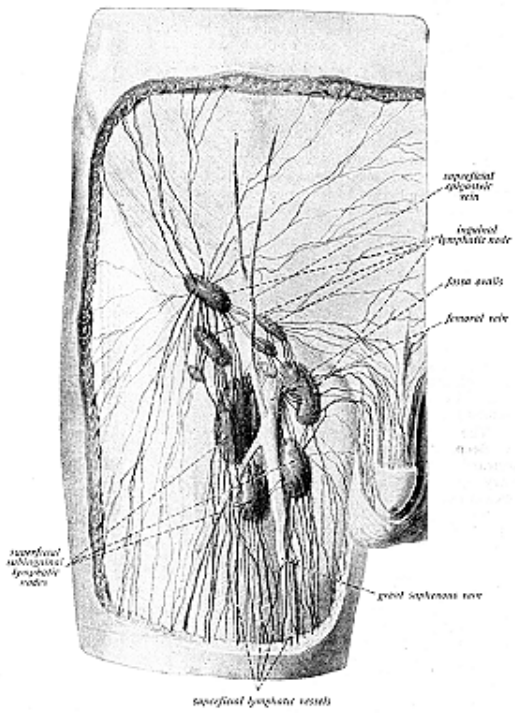


Fig. 122.

The Lymphatic Vessels and Nodes of the Thigh, Inguinal Region and External Genitalia.

THE LYMPHATIC SYSTEM

anterior sacral foramina; the **mesenteric** glands **lie between** the **layers** of the mesentery and are about one hundred and fifty to two hundred in number; they are arranged as *superior* and *inferior mesenteric glands*, those of the superior class predominating in numbers; the **para-uterine glands** are found in the folds of the broad ligament, at the **side** of the cervix.

The **Lymphatic Vessels** of the **Abdomen** and **Pelvis** are classed as **superficial** and **deep**. The **superficial** follow the course of the superficial blood vessels and pass into the superficial inguinal glands; the **deep** vessels run along the principal blood-vessels, most of them accompany the blood-vessels and therefore receive the same names while those of the abdomen proper are associated with the glands of the liver, the pancreas, spleen, kidneys, the stomach and the intestines.

The lymphatics of the penis, scrotum, perineum and gluteal region follow the course of the superficial blood-vessels, while those of the bladder, rectum, uterus, kidney, liver, stomach, spleen and pancreas, testes and ovaries are the deep and the visceral lymphatics.

THE LYMPHATIC GLANDS AND VESSELS OF THE THORAX

The **Lymphatic Glands** of the **Thorax** are found in the thoracic wall, the **intercostal** in the intercostal spaces, the **internal** mammary along the internal mammary artery, the **anterior** and **posterior** mediastinal in their respective mediastinal regions, anterior and posterior mediastinum, also containing the bronchial, at the bifurcation of the trachea and the roots of the lungs, the **cardiac glands** are found in front of the transverse aorta and receive the lymph from the heart, the thymus gland and from the pericardium.

The **Lymphatic Vessels** of the **Thorax** are the **superficial** and the **deep**, and they drain the thoracic viscera; that is, the heart, pericardium, lungs, pleura, thymus gland and esophagus, the mammary glands, the diaphragm and the intercostal spaces. These vessels end in the axillary, tracheo-bronchial and mediastinal glands.

The **Thoracic Duct** or **Left Lymphatic Duct** is the main channel, it being the common lymph-trunk that conveys the bulk of the lymph from all parts of the body, excepting only the right upper extremity, right side of the head, neck and thorax, right lung, the right side of the heart and convexity of the liver. **It begins in** the abdomen as a triangular dilatation, the **receptaculum chyli**, on the front of the body of the second lumbar vertebra. It enters the thorax thru the aortic opening in the diaphragm, and in the mediastinum it crosses behind the aorta at the fourth dorsal vertebra; opposite the upper border of the seventh cervical vertebra it curves downward and ends where the internal jugular and subclavian veins unite. The thoracic duct is from 15 to 18 inches in length and is dilated both at its origin and at its termination. It has three **coats**, an *external coat*, composed of areolar tissue with elastic fibers and bundles of muscular fibers; a *middle coat* consisting of a longitudinal layer of connective tissue with elastic fibers and several layers of muscular tissue arranged obliquely, longitudinally and transversely; and an *internal coat* con-

THE LYMPHATIC SYSTEM

sisting of a layer of flattened endothelial cells similar to those found in the arteries. The thoracic duct is provided with valves, more numerous in the upper part, formed by infoldings of the inner lining of the vessel; these valves prevent a backward flow of the fluid.

The **Right Lymphatic Duct** is a short trunk, about one-half inch in length, smaller in size than the left thoracic duct, which lies at the right side of the root of the neck, along the inner border of the scalenus anticus muscle. It is formed by vessels which receive the lymph from the right side of the heart and convexity of the liver, the right upper extremity, right lung, right side of the thorax, head and neck. The right lymphatic duct terminates at the point where the right subclavian and right internal jugular veins unite, being guarded by a set of valves.

The **Receptaculum Chyli**, or the **Reservoir** or **Cistern of Pacquet**, is a dilated area, being the commencement of the thoracic duct. It is situated deeply at the upper part of the posterior abdominal wall, in front of the bodies of the first and the second lumbar vertebrae; it has the aorta on its left side and slightly in front, the right azygos vein on its right side, and is overlapped by the right crus of the diaphragm. It is somewhat elliptical, being about one-sixth inch broad at its widest part and about 2 inches in length. Superiorly it becomes narrower and is continued as the thoracic duct, which enters the thorax thru the aortic opening of the diaphragm. It receives the following afferent vessels from below upward, the right and left lumbar lymphatic trunks, from the lumbar glands, the intestinal lymphatic trunks, from the mesenteric glands, and often the coeliac vessels from the coeliac glands.

The fluid carried in the lymphatic vessels is called lymph, and is a transparent, slightly yellow or straw-colored fluid. It coagulates, is more dilute than plasma of the blood or the cerebro-spinal fluid, which is a serous fluid, or serum. Lymph contains proteins, salts and extractives, and contains as much fibrin as does blood, but less albumen. Therefore, the lymph vessels merely collect and convey the lymph, while the lymph glands serve, in part, as filters, and in part as the sources of origin of some of the lymph corpuscles. These corpuscles are called lymphocytes and become the white corpuscles of the blood stream. The lymphatic glands serve as intermediate agents to the serous fluid.

THE ORGANS OF VOICE AND RESPIRATION

The **Thorax** (coat of mail) is also called the chest, and forms one of the largest splanchnic cavities. It lodges and protects the chief organs of respiration and circulation.

The **mediastinum**, or the **inter-pleural space**, is a space in the thorax between the sternum and spine, and between the two lungs; it contains all the thoracic viscera except the lungs, and is divided into two parts for description—an *upper*, above the level, and a *lower*, below the level, of the pericardium. The *lower* portion is further subdivided into the *anterior*, *middle* and *posterior mediastinum*. The *superior mediastinum* contains the origins of the sterno-hyoid and sterno-thyroid muscles, the lower extremities of the longus colli muscles, the arch of the aorta, innominate artery, left carotid and left subclavian arteries, also the upper part of the superior vena cava, the innominate veins, left superior intercostal vein, the cardiac and phrenic veins, the vague, trachea, esophagus, thoracic duct, thymus gland, cardiac, phrenic and left recurrent nerves, and lymphatic glands.

The *anterior mediastinum* is bounded in front by the sternum, behind by the pericardium, and laterally by the pleura; it contains several lymphatic glands and vessels, also some small branches from the internal mammary artery, and a quantity of loose connective tissue. The *middle mediastinum* is the broadest part and contains the heart and pericardium, also the ascending aorta, the bifurcation of the trachea, and the pulmonary vessels. The *posterior mediastinum* is an irregular triangular space running parallel with the vertebral column bounded in front by the pericardium, behind by the vertebrae, from the fourth to the twelfth inclusive; it contains the descending aorta, the azygos veins, the esophagus, thoracic duct, some lymphatic glands, the vagus and splanchnic nerves.

The **Organs Which Form the Respiratory Apparatus** include the **nasal passages**, the **pharynx**, **larynx**, **trachea**, **bronchi**, **lungs** and the **pleura**.

In giving the structure of an organ, the following outline may be followed and will be of great assistance to the student, particularly so with the organs of respiration and digestion: the **definition**, **location**, **size**, **weight** or **capacity**, **color**, **texture**, **descriptive parts**, **coats**, and the **parenchyma** or working parts of the organ (particularly of glands), also the **blood** and **nerve supply**. Here and there thruout this book are found references to the nerve-supply of certain parts. Two versions are given, viz: the usual medical path, and the unusual Chiropractic nerve-tracing path. We use the term “unusual” because it disputes the usually recognized medical authorities. As an anatomy aims to state facts only, it still leaves the *reasons* why open to further study, all of which reasons can be had by referring to B. J. Palmer’s works, where the subject is treated exhaustively. The nerve-distribution, together with the intimate connection between subluxated vertebrae and pathological tissues, the vertebral-organic con-

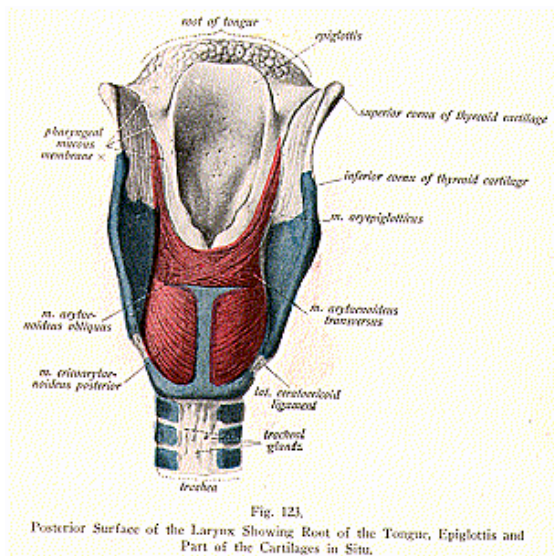
THE ORGANS OF VOICE AND RESPIRATION

nection, are in Vol. 2 of The Science of Chiropractic, by B. J. Palmer, under the subject of the "Meric System."

LARYNX

(Illustrations Nos. 123, 124 and 125.)

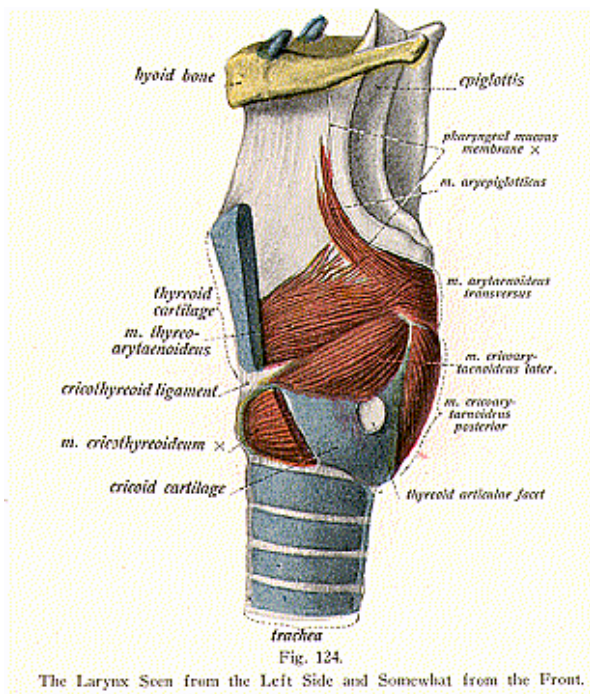
The **Larynx** is the organ of voice, and is a musculo-membranous cartilaginous box, especially moulded for the production of voice.



It is placed at the upper part of the air passage, at the top of the trachea, between the trachea and the base of the hyoid bone; it is covered by the thyroid gland on either side, is located at the base of the tongue and at the upper and fore part of the neck, and lies opposite the fourth, fifth and sixth cervical vertebrae, tho it is placed higher in females, and is higher during childhood. Superiorly it opens into the pharynx and below into the trachea. On its either side are the great vessels, and it forms part of the boundary of the pharynx, behind.

THE ORGANS OF VOICE AND RESPIRATION

The larynx is broad above, where it presents the triangular box, is flattened behind and at the sides and, below, it is narrow and cylindrical; it is subcutaneous in the middle line, being covered only by skin and cervical fascia, but laterally it is overlaid by the insertions of the sterno-hyoid, sterno-thyroid, thyro-hyoid and omo-hyoid muscles. The position of the larynx is influenced by the movements of the head and neck, so that it is elevated when the head is thrown backward, and is depressed when the chin is carried downward toward the chest. Again, by placing the fingers upon it during deglutition, it will be



seen that the larynx moves to a very considerable extent. Pharyngeal muscles are attached to it and help bring about these movements.

Changes in the position of the larynx are noticed while singing, high notes elevate, and low notes depress, the organ. The position of the larynx is not the same, however, at all periods of development and growth. In the early stages of growth, all the thoracic viscera undergo

THE ORGANS OF VOICE AND RESPIRATION

a gradual lowering and the larynx follows with these; the permanent position of the larynx is not reached until puberty is attained; more marked difference is found between the earlier and later positions of the larynx in the male than in the female. In the male, at puberty, the larynx increases greatly, while the length of the glottis, or cavity, is nearly doubled; all its cartilages enlarge, the thyroid cartilage especially. This cartilage forms a prominence in front, in the middle line of the neck, and is called the **pomum Adami (Adam's apple)**.

The **structure** of the larynx is complicated. It consists of a framework composed of *cartilages*, held together by *ligaments* and moved by *muscles*; it contains a cavity across which are stretched two elastic

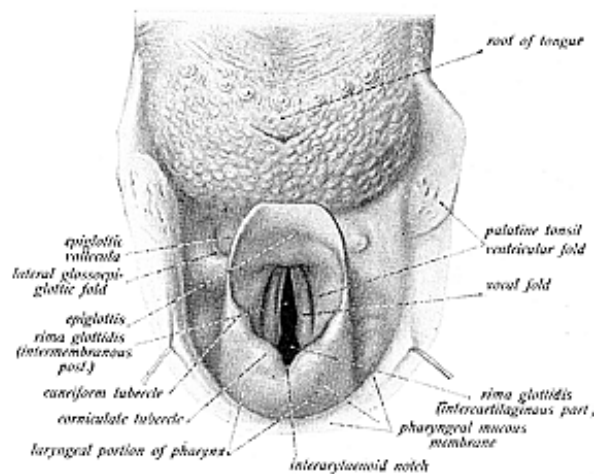


Fig. 125.

The Larynx Seen from Behind and Above, also Showing the Root of the Tongue

cords, the *vocal cords*. The cavity is lined with mucous membrane and in certain places there are masses of mucous glands. There are *twenty ligaments* of the larynx; eight extrinsic, connecting the larynx to the tongue, hyoid bone and trachea; and twelve intrinsic, binding the cartilages together.

The mucous membrane of the larynx is continuous, above, with the pharynx and, below, with the trachea; it is covered with stratified, ciliated, and columnar epithelium; the posterior surface of the epiglottis is covered by the stratified squamous variety.

The **cartilages are nine** in number—**three single** and **three pairs**.

THE ORGANS OF VOICE AND RESPIRATION

The single cartilages are the **thyroid**, **cricoid** and the **epiglottis**; the paired ones are the **arytenoids**, the **cuneiform** cartilages, and the **cornicula laryngis**. The epiglottis, cornicula laryngis and the cuneiform

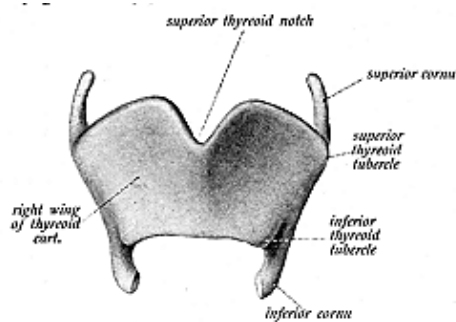


Fig. 126.
The Thyroid Cartilage—Front View.

cartilages are of yellow fibro-cartilage; the thyroid, cricoid, and the arytenoids are of *hyaline cartilage*, and these last mentioned begin to ossify as early as the 21st year, and are completely ossified in advanced age.

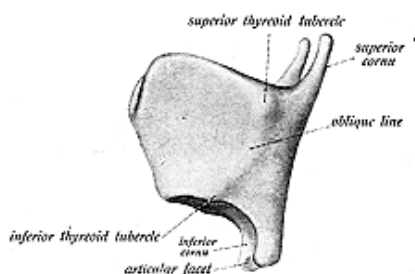


Fig. 127.
The Thyroid Cartilage—Lateral View

The **thyroid cartilage** (illustrations Nos. 126 and 127), the largest, a shield-like hyaline cartilage, and consists of two lateral *lamellae* or *alae* which unite at an acute angle in front, forming a projection, the *pomum Adami*, which is more prominent in the male than in the

THE ORGANS OF VOICE AND RESPIRATION

female. These two lamellae are quadrilateral and converge in front, but diverge widely behind. The inner surfaces of the lamellae are smooth and give attachment to the true and false vocal cords, to muscles and to ligaments. The outer surface, by an oblique ridge, gives attachment to the sterno-thyroid, thyro-hyoid and the inferior constrictor muscles. The upper border presents a deep triangular

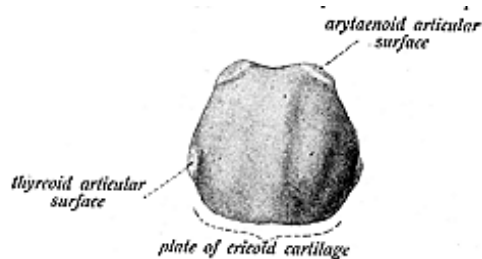


Fig. 128.

The Cricoid Cartilage—Seen from Behind.

cleft, the **thyroid notch**, which gives attachment to the thyro-hyoid membrane. The lower border of the thyroid is connected, mainly, with the cricoid cartilage by the crico-thyroid membrane; its posterior borders are thick and rounded, and terminate, above, in the **superior cornua**, and below in the **inferior cornua**; this lower posterior border gives attachment to the stylo-pharyngeus and palato-pharyngeus muscles, and to the thyro-hyoid ligament; the inferior cornua articulate with the cricoid cartilage, each cornu articulating by a small facet.

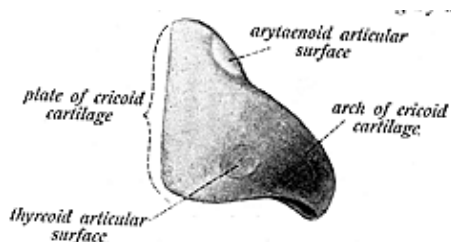


Fig. 129.

The Cricoid Cartilage—Lateral View.

The **cricoid cartilage** (illustrations Nos. 128 and 129), is signet-ring shaped, is the second largest in size, is hyaline, and is thicker and stronger than all the others; it forms the lower and back part of the larynx, and articulates, above, with the thyroid and with the arytenoids on either side. The anterior portion of the cricoid is narrow, and measures vertically about one-fifth of an inch; it affords attachment to the crico-thyroid and inferior constrictor muscles. Its posterior portion is broad and gives attachment to the fibers of the esophagus and, on either side, to the crico-arytenoideus muscle; its

THE ORGANS OF VOICE AND RESPIRATION

lower border is connected with the first tracheal ring by a fibrous membrane.

The **epiglottis** (illustration No. 130), of yellow fibro-cartilage, is a thin, flexible, cartilaginous lid; it is placed behind the tongue and body of the hyoid bone and in front of the superior aperture of the larynx. It shuts, like a lid, over this aperture during deglutition.

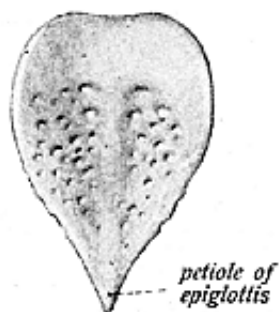


Fig. 130.

The Epiglottis.

The epiglottis is leaf-shaped, and stands bolt-upright between the base of the tongue and the superior aperture of the larynx. Its base is free and curves forward toward the base of the tongue; its apex is attached to the angle of the thyroid by the thyro-epiglottic ligament. The anterior or lingual surface, where it faces the base of the tongue is covered by mucous membrane, which, when taken away, presents numerous perforations and is indented by pits; glands are lodged in these pits, while blood-vessels and nerves pass thru the openings.

The **arytenoids** (illustrations Nos. 131 and 132), are so called

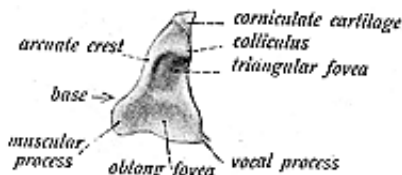


Fig. 131.

The Arytenoid Cartilage—Posterior View.

from their fancied resemblance to the mouth of a pitcher. They are two in number, and are placed on the upper border of the cricoid, at the back of the larynx; each has the form of a three-sided pyramid and measures about one-half inch in height. They are hyaline cartilages, each has three surfaces, three borders, a base and an apex; they give attachment to the thyro-arytenoideus, to the arytenoideus, crico-arytenoideus muscles, and to the vocal cords; their bases articulate with the cricoid, and their apices with the cornicula laryngis.

The **cuneiform cartilages**, or the **cartilages of Wrisberg**, are two rod-shaped elongated pieces of yellow elastic cartilage and are placed, one on each side, in a fold of mucous membrane, which extends from

THE ORGANS OF VOICE AND RESPIRATION

the apex of the arytenoid cartilage to the side of the epiglottis, just in front of the arytenoids. On the surface of each cartilage is seen a collection of mucous glands, which tend to make the cartilages stand out in relief under the mucous membrane.

The **cornicula laryngis**, or the **cartilages of Santorini**, are two small conical nodules of yellow elastic cartilage, located at the summit of the arytenoids with which they articulate; they serve to prolong the arytenoids backward and forward.

The **cavity** of the **larynx** extends from the superior aperture of the larynx to the lower border of the cricoid cartilage. The **vocal cords** form an imperfect diaphragm, dividing the cavity into two parts; between the cords is a narrow, triangular interval or chink called the **rima glottidis** and this is less than an inch in length and about half an inch in breadth. To differentiate the glottis from the rima glottidis, tho they are considered as the same by many, it might be convenient to describe the glottis as being all of that part of the cavity, or aperature, of the larynx, which is concerned in voice-produc-

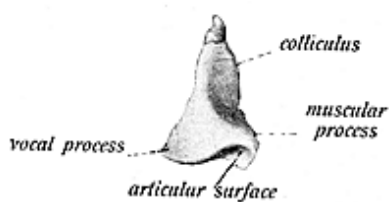


Fig. 132.

The Arytenoid Cartilage—Anterior View.

tion; the rima glottidis is only the interval or chink between the vocal cords. The part of the cavity above the vocal cords is sometimes called the vestibule and is broad and corresponds to the interval between the alae of the thyroid cartilage, and it contains the false vocal cords; the inferior part of the cavity becomes more circular and is continuous with the tube of the trachea.

The **vocal cords** are folds of yellow elastic tissue, arranged in two sets, the *superior* or the *false*, and the *inferior* or the *true*, *vocal cords*. The *false vocal cords* are two thick folds of mucous membrane, which extend from front to back, along the lateral walls of the laryngeal cavity; they are widely separated from each other, so that the true vocal cords are visible on looking into the larynx from above. The cords of this superior set are called the false vocal cords, for they are not directly concerned in the production of voice. The *true* or the *inferior vocal cords*, two bands of yellow elastic tissue covered with mucous membrane, are attached in front to the angle of the thyroid cartilage below the false vocal cords, and behind to the base of the arytenoids.

The ventricle of the larynx is an oval or oblong depression on each side of the larynx between the true and the false vocal cords; it leads up into the caecal pouch, called the **sacculus laryngis**, or the **laryngeal pouch**. This pouch is a membranous sac, situated between the true vocal cords and the inner surface of the thyroid cartilage.

THE ORGANS OF VOICE AND RESPIRATION

It contains 60 to 70 glands, lodged in the areolar tissue, and when the muscles of the larynx compress the saccule, the secretion it contains is poured over the surface of the vocal cords and lubricates their surfaces. This saccule is also called the Sinus of Morgagni.

The vocal cords are the agents by means of which voice is produced. **Voice** is sound produced by air driven from the lungs, throwing the ligaments of the glottis into vibration. This function is called phonation. Here is an evidence of the intellectual superiority of man, for in the lower animals phonation is limited to the production of a simple sound. In man it is modified by motion of the tongue, lips and teeth, and the glottis is the space over which the vibrations travel, and is likened to a reed instrument, as the clarinet.

Articulate voice has been produced even after removal of the tongue, but is indistinct. Singing voice is not confined to the larynx for the pharynx is also concerned. Notes produced in the latter constitute the pharyngeal or falsetto voice. The width and shape of the rima glottis vary with the movements of the vocal cords during respiration and phonation.

The **blood supply** to the larynx is carried by the superior laryngeal and crico-thyroid, branches from the superior thyroid, a branch from the external carotid, and by the inferior laryngeal from the inferior thyroid; the veins bear the same name, and open into the internal jugular and the lingual. The **nerves supplying** it are the superior and the recurrent laryngeal, and these nerves convey nerve fibres derived from the sixth cervical pair of spinal nerves. It is these latter fibres which are subject to pressure at their foraminal exits.

THE TRACHEA

(Illustration No. 133.)

The **Trachea**, or **Windpipe**, is a muco-cartilaginous-membranous-elastic tube, cylindrical in form, anteriorly and laterally, posteriorly it is flattened, so that it does not press upon the esophagus over which it lies. The trachea is 4-1/2 inches in length, and from 3/4 to 1 inch in diameter; it extends from the lower end of the larynx, from a point opposite the fifth or sixth cervical, and ends opposite the fourth dorsal vertebra, where it bifurcates into the two bronchi. The trachea consists of about 16 to 20 cartilaginous rings, which are incomplete posteriorly. They serve to keep the tube permanently open, for the transmission of air, and are embedded in fibrous tissue which also connects their contiguous borders. They are shaped like the letter C, and each ring forms rather more than two-thirds of a circle being flat externally and convex internally.

The trachea occupies a mesial position and its direction is downwards with an inclination backwards, it is lined with mucous membrane, which is continuous above with that of the larynx, and below with that of the bronchi. This lining shows a basement membrane surmounted by columnar ciliated epithelium, and containing numerous mucous glands, called the **tracheal glands**. The lower end of the trachea is fixed in position, this being a necessary provision to prevent a dragging upon the roots of the lungs during the movements of the head and neck. It is a very elastic tube, so that it stretches when

THE ORGANS OF VOICE AND RESPIRATION

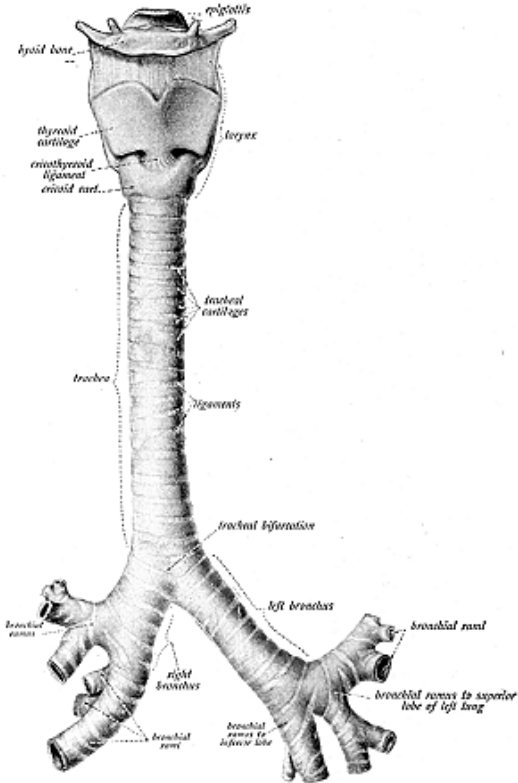


Fig. 133.
The Trachea and Bronchi.

THE ORGANS OF VOICE AND RESPIRATION

the head is thrown backward, and, when the chin is depressed, the length of the trachea is diminished by the recoil of its wall. The trachea is larger and longer in the male than in the female. The trachea may be absent, the bronchi springing directly from the larynx.

The **blood supply** is carried to the trachea and bronchi by the tracheal branches from the inferior thyroid, from the thyroid axis, and by the bronchial from the thoracic aorta; the veins are tributaries from the thyroid axis and bronchial veins; the **nerves** are branches from the vague, and laryngeal plexus. They convey fibres derived from the sixth cervical and first dorsal pairs of spinal nerves, and it is these latter fibres that are subject to pressure.

THE BRONCHI

(Illustration No. 134.)

The **Bronchi** are two muco-musculo-cartilaginous tubes. They resemble the trachea and extend from its bifurcation to the lungs where they divide and subdivide into bronchial tubes. The bronchi

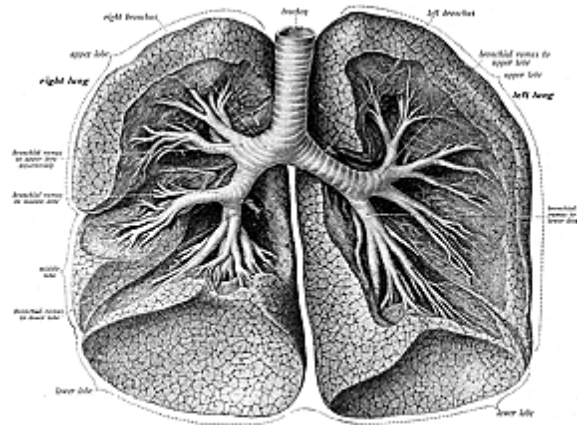


Fig. 134.

The two lungs shown with the lower part of the trachea and the bronchi, with the branches of the bronchi being exposed by cutting away the lung tissue.

lose their rings at about the second or third division and, like the trachea, are cylindrical and firm in front, but are flattened posteriorly. The **right and left bronchi** differ in length, in width, and as to the direction which they pursue. Each bronchus is given off at the bifurcation of the trachea, at a level corresponding to the fourth or fifth dorsal vertebra. The right bronchus is the shorter, wider and more vertical in direction, passing downward and outward; it is about one

THE ORGANS OF VOICE AND RESPIRATION

inch in length, and contains six to eight cartilaginous rings. The left bronchus is narrower, longer, and descends more obliquely. It is two inches in length, and has from nine to twelve rings. The right bronchus lies more nearly in the median line than does the left, so there is a tendency for foreign bodies, when dropped into the trachea, to fall into the right bronchus.

At the roots of the lungs the bronchi subdivide into two branches or rami, the bronchial tubes, corresponding to the primary lobes of the lungs. The lower branch of the right bronchus sends off a small branch to the third lobe on that side.

The bronchi, upon entering the lungs, divide and subdivide thruout the entire organ, forming **respiratory bronchioles, then terminal bronchioles**, forming the **atria**, then the **infundibula**, or **air sacs**, which contain the **air cells** or **alveoli**. Within the lobes of the lungs the cartilages of the bronchi are not imperfect rings, but consist of thin lamellae, varying in form and size; at their terminal divisions the bronchi becomes wholly membranous. The fibrous coat is continued upon the smallest ramifications of the bronchi, the muscular coat exists in the form of a continuous layer of annular fibers; the mucous coat lines the bronchi thruout, and is covered with columnar ciliated epithelium.

THE PLEURAE

The Pleurae are two delicate serous sacs, which enclose the lungs. Each pleura encloses one lung, as far as its root, and is reflected over the pericardium, the diaphragm and the inner surface of the thorax. That part of the membrane, reflected over the surface of the lung substance, and dipping into the fissures between the lobes, is called the **pulmonary** or the **visceral pleura**, that part which lines the inner surface of the thorax is known as the **parietal** or **costal pleura**. The **space** between these two layers is called the **cavity of the pleura**; it is not, however, a real cavity unless the lung becomes collapsed. Between the two layers is found a serous fluid which facilitates motion of the lung.

Beginning at the sternum, the **parietal pleura** is reflected over the costal cartilages, over the inner surface of the ribs, posteriorly upon the bodies of the dorsal vertebra, inferiorly over the upper surface of the diaphragm, and superiorly to the cervical fascia; so it forms a series of membranous reflections called the **pleural ligaments**; the *cervical pleura* or *capula pleura*, above; the *costal pleura*, covering the costal arches; the *diaphragmatic pleura*, over the diaphragm; and the *mediastinal* reflected to the vertebral wall. The pleura is composed of a thin, connective-tissue stratum, in which the bundles of fibres cross each other in various directions and are intermixed with a considerable quantity of elastic tissue. The inner surface of the pleura is covered with endothelial cells. Many blood-vessels and nerves traverse the membrane.

THE LUNGS

(Illustrations Nos. 135, 136 and 137.)

The Lungs are the essential organs of respiration and occupy the greater portion of the chest cavity. They are two in number,

THE ORGANS OF VOICE AND RESPIRATION

the right and left. They are placed one in each side of the thorax, and are separated from each other by the heart and other contents of the mediastinum. They extend from the clavicle to the tenth or eleventh dorsal vertebra, or to the ninth or tenth costal cartilage. The lungs are of soft, spongy, elastic, flexible, compressible, and dilatable substance; they crepitate when pressed between the fingers, will float

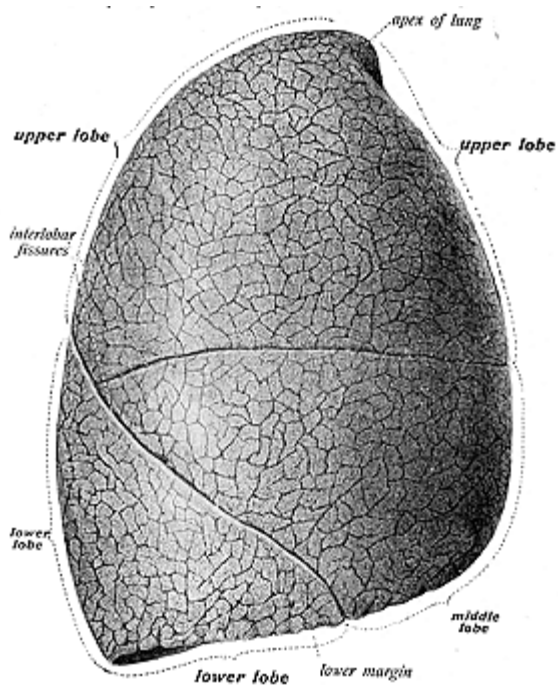


Fig. 133.
Lateral Surface of the Right Lung.

in water, and collapse when the chest cavity is opened, and then retain about one-third of their original size. Their **color** varies according to age and circumstances; in the adult they are of a dark slate-color having a mottled appearance, and in subjects living in smoky cities, or about coal mines, they become black. The coloring matter consists of carbonaceous substances which become deposited

THE ORGANS OF VOICE AND RESPIRATION

in the areolar tissue near the surface. In youth the lungs are rose-pink, the fetal lungs are hard and will sink; they lie against the spine as two small, hard lumps, but when respiration has been established the lungs entirely fill all of the unoccupied space of the pleural cavity.

The lungs, according to their mode of development, are classed as glands. The weight of both lungs, including their normal contents,

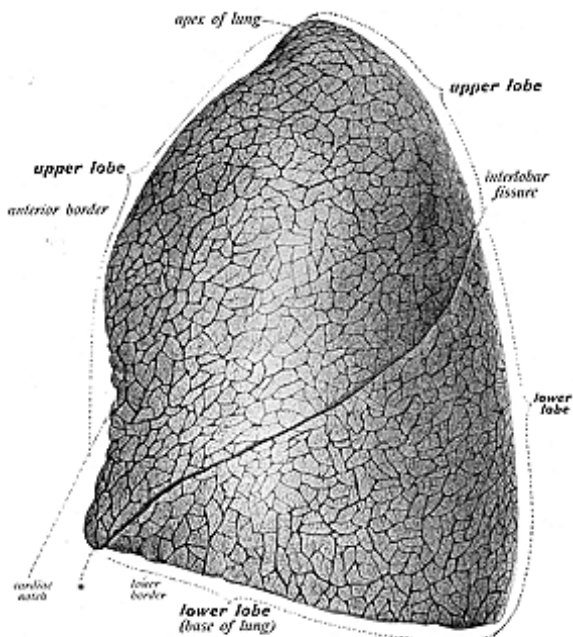


Fig. 136.
Lateral Surface of the Left Lung.

is forty-one ounces, the right lung being somewhat heavier than the left. Each lung is conical in shape, and has for **descriptive parts** the **apex, base, root, two borders**, anterior and posterior, and **two surfaces**, external and internal. Each lung is divided into lobes; the right lung has three and the left lung two lobes. Differences are found in the structure of the two lungs; the right lung has three lobes, made so by two deep fissures, the **interlobar fissures**, and the left lung has two

THE ORGANS OF VOICE AND RESPIRATION

lobes and one fissure; the right lung is larger and heavier, weighing 22 ounces; the right lung is also broader than the left, owing to the inclination of the heart to the left side, and it is shorter by almost an inch, for the reason that the diaphragm rises higher on the right side to accommodate the liver.

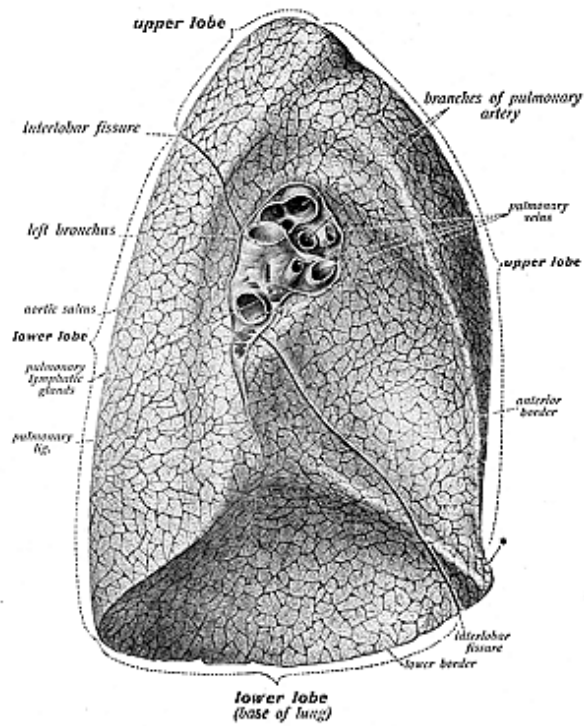


Fig. 157.
Median Surface of the Left Lung.

The apex of each lung forms a tapering cone in the neck situated behind the sterno-mastoid muscle and rising out of the thoracic cavity into the root of the neck for about one and one-half inches above the level of the first rib. The **base** is broad and concave, and

rests upon the convex surface of the diaphragm. The **root consists** of a bronchus, the pulmonary artery and veins, the bronchial arteries and veins, lymphatics and their lymph nodes, together with the pulmonary plexus of nerves; all these are connected by areolar tissue and enclosed by the pleura. The root is found a little above the middle of the inner surface of each lung and nearer its posterior than its anterior border, and by this root the lung is connected to the heart and the trachea.

The **anterior border** of either lung is sharp and thin, and overlaps the pericardium; the **posterior border** is rounded and broad, and is received into the deep cavity formed on either side of the spinal column; the **external surface** or the **thoracic** or **costal surface** is smooth and convex, is marked by a fissure, and conforms to the form of the cavity of the chest, being deeper behind than in front; the **internal** or the **mediastinal surface** is concave and presents, in front, a depression for the heart. Behind is a deep fissure—the **hilum**—which gives attachment to the root of the lung and which is, therefore, the depression where the vessels enter and leave the organ.

The lungs are composed of an external serous coat, the visceral layer of the pleura which invests the lung as far as its root, and the subserous elastic areolar tissue, together with the pulmonary substance or the parenchyma.

The subserous tissue invests the whole organ and extends inward between the lobules; it cannot be separated from the lung tissue without lacerating the substance. The **parenchyma**, or true lung-tissue, consists of lobes, divided into **lobules**, each consisting of the **terminal bronchioles**, the **atria**, **air sacs**, **air cells**, **blood-vessels**, **nerves** and **lymphatics** and held together with **areolar tissue**. A **lobule** is a miniature lung, which varies in size from 1/8 inch to 1-1/5 inches; it is composed of a terminal bronchiole, or bronchial tube, with a dilation called the atrium (the entry), from which the air sac or infundibulum extends, like a blind pouch, containing the air-cells or the alveoli; these are small, polyhedral alveolar recesses, measuring about 1/100 of an inch in diameter; they are lined by pavement epithelium and are separated from the blood flow by membrane. The pulmonary vessels, thru the capillaries, form a plexus around the air-cells for the absorption of oxygen and the emission of carbonic dioxide. The capacity of the lungs is 350 cubic inches; two-thirds of a pint of air is inhaled and exhaled at every inspiration and expiration.

After every breath, foreign matter composed of soot and atmospheric dust, is inhaled, but only a small proportion of it reaches the lung tissue; the greater part of it becomes entangled in the slimy mucus, which coats the mucous membrane of the larger air passages, and is gradually gotten rid of along the cilia of the lining epithelium.

The bronchial **arteries supply** the lung tissue, and the bronchial **veins** drain the organs; while the pulmonary arteries carry the venous blood to the air cells for aeration, and the pulmonary veins return the blood to the heart to be carried thruout the various parts of the body.

The **nerves** to the lungs are from the anterior and the posterior pulmonary plexuses. They convey nerve fibres derived from the third dorsal pair of spinal nerves.

ORGANS OF DIGESTION

The **Organs of Digestion** constitute that part of splanchnology, the organs of which form the digestive apparatus; the greater part of these are located in the abdomen, the largest of the three splanchnic cavities. The cranial cavity, the smallest splanchnic cavity, contains the brain, and the thorax, the second largest cavity, contains the lungs, heart, etc. A **viscus** is an internal organ, and the viscera include any of the contents of the cranial or the thoracic or abdominal or pelvic cavities. The **digestive apparatus** consists of the **alimentary canal** and the **accessory organs**, or they may be classified as the *oral cavity*, the *foregut*, *midgut*, *hindgut*, and the *appendages* which perform functions of ingestion, mastication, insalivation, deglutition, gastric digestion, elaboration, assimilation, intestinal digestion, colic digestion and elimination.

The **alimentary canal** is a muco-musculo-membranous tube, about thirty feet in length, and extends from the mouth to the anus, it is lined thruout with mucous membrane, and consists of the **mouth, pharynx, esophagus, stomach, small and large intestines**; the **accessory organs** are the **tongue, teeth, salivary glands, the liver, spleen and pancreas**. The primary organs above the diaphragm are the mouth, pharynx and esophagus; those below the diaphragm are the stomach, small and the large intestines. The secondary organs above the diaphragm are the tongue, teeth and salivary glands; the secondary organs below the diaphragm are the liver, spleen and pancreas.

THE MOUTH

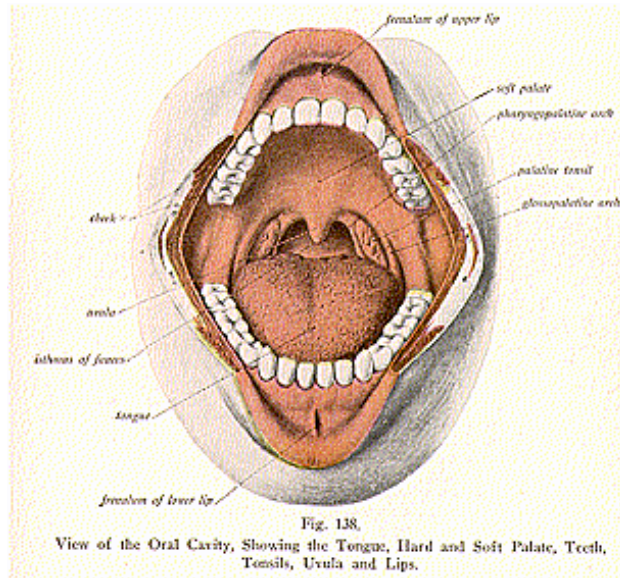
(Illustration No. 138.)

The **Mouth** is located at the commencement of the alimentary canal and is called the **oral cavity**. It is an oval-shaped cavity in which the mastication and insalivation of food takes place. It consists of two parts—the outer and smaller portion, or the *vestibule*, and the inner or larger part, called the *cavity proper*. The *vestibule* is that slit-like space between the lips and cheeks, externally, and the gums and teeth internally. It is attached, in front, to the lips by the *frenulum* or *froenum*, a fold of mucous membrane, and receives its secretion from the parotid gland and from numerous mucous glands embedded in the mucous membrane. The *cavity proper* is bounded superiorly by the hard and soft palates, forming the roof; below by the tongue and mucous membrane, forming the floor; behind, by the soft palate, uvula and the fauces, and laterally and anteriorly, by the cheeks and the alveolar processes of the upper and lower jaws.

The **Lips** are two fleshy folds which surround the orifice of the mouth, and consist of skin externally and mucous membrane internally; between these two layers are the muscular fibres of the orbicularis oris, depressor anguli oris, and of the levator anguli oris;

THE ORGANS OF DIGESTION

also the coronary vessels, and some areolar tissue, fat and glands. The **labial glands** are small racemose, mucous glands, resembling the salivary glands in structure; they are round and of the size of a pea, and are found between the mucous membrane and the muscular fibres; they open by small orifices on the mucous membrane. Each lip is connected, to the middle line of the gum of the corresponding jaw, by a fold of mucous membrane called the **fraenum** or **frenulum**; of the upper lip it is called the fraenum labii superioris, and of the lower lip, the fraenum labii inferioris. The lips, at the angle of the mouth, become continuous.



The **Cheeks** (buccae) form the sides of the face and are continuous in front with the lips. They are composed of skin externally, of mucous membrane internally; between the skin and membrane are mucous glands, fat, blood-vessels and nerves, also the buccinator, masseter, zygomaticus major and minor, and the risorius muscles, together with the fascia covering these muscles. The glands are called the **buccal glands**; they resemble the labial glands, but are smaller and open upon the mucous membrane by tiny ducts.

The Palate (see illustration No. 140) forms the roof of the mouth,

THE ORGANS OF DIGESTION

and consists of two divisions, the **hard** and the **soft palate**. The **hard palate** is bounded in front and on the sides by the alveolar arches and the gums; it forms the anterior two-thirds of the roof, being continuous behind with the soft palate, and is, itself, formed by the superior maxillary and palate bones, covered by dense fibrous tissue and mucous membrane. The membrane is hard, thick, corrugated and pale in color, it has, contained along its median line, a linear ridge, the **palatine rapine**, which terminates in front of the soft palate in a small papilla, the opening into the anterior palatine fossa.

The **soft palate** or the **velum pendulum palati**, often called the *veil of the palate*, forms the posterior one-third of the palate and hangs suspended from the hard palate, forming an incomplete septum between the mouth and the pharynx, it consists of a fold of mucous membrane, which encloses muscular fibres, vessels, nerves, adenoid tissue and mucous glands. The soft palate terminates posteriorly and externally in a free margin, and it is usually relaxed and pendant.

The **Uvula** (little grape), (which is not to be confused with the soft palate), is a small, conical-shaped, pendulous body, which varies in size in different individuals; it hangs from the middle of the posterior border of the soft palate. The uvula consists of the azygos muscle, an aponeurosis, mucous glands and connective tissue, and is covered with mucous membrane.

Arching downward and outward upon either side, in a diverging manner, from the base of the uvula, are two prominent folds of mucous membrane, called the **anterior** and **posterior pillars** of the **fauces**, or **palatine arches**; the space between the fauces is called the **isthmus** of the fauces, a passage which leads from the oral cavity to the pharynx. The **anterior pillars** or **glosso-palatine arches**, run downward and outward and forward to the sides of the base of the tongue, and are formed by the projection of the palato-glossi muscles covered by mucous membrane; the posterior **pillars** or **pharyngo-palatine arches**, arch downward, outward and backward to the sides of the pharynx, and are formed by the projection of the palato-pharyngei muscles covered by mucous membrane. Between the anterior and posterior pillars is an interval which contains the tonsils. The mucous membrane of the soft palate is thin, and contains numerous glands, called the **palatine glands**, which pour their secretion on the surface of the mucous membrane. The **isthmus of the fauces** is that space thru which the mouth communicates with the pharynx, and is bounded by the free margin of the soft palate above, below by the back of the tongue, and on each side by the pillars and the tonsils. A cleft soft palate may be found, and in this, the uvula or the hard palate may also be involved; if the fauces are cut, a flabby or "S" sound is given.

THE TONSILS, OR THE AMYGDALAE

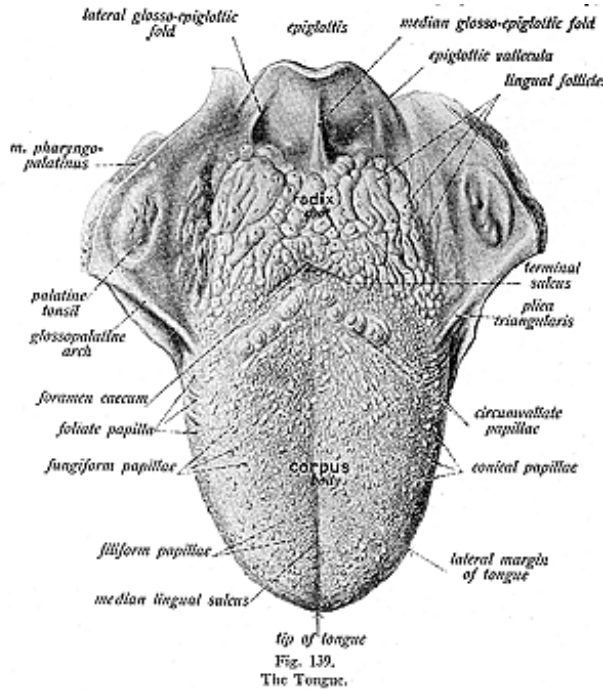
(Illustration No. 138.)

The **Tonsils (Palatine Tonsils)** are two prominent almond-shaped bodies, compound tubular glands, situated on either side of the fauces, between the anterior and posterior pillars of the fauces. The tonsils stand out as oval enlargements covered by mucous membrane; they

THE ORGANS OF DIGESTION

vary in size, in individuals, but an average tonsil measures about 1 inch in length, about 3/4 of an inch from before backwards, and about 1/2 inch from within outwards.

Each tonsil has from 15 to 20 orifices or openings, which lead from tubules into recesses or **crypts** lined with mucous membrane, which extends into the lymphoid tissue, from which the cells form a secretion: this secretion is transparent, of a thin grayish consistency,



and oozes out upon the surface, on pressure, and lubricates the isthmus of the fauces during deglutition. This secretion acts as a source for the supply to the mouth and pharynx, of phagocytes, small organisms, which destroy bacteria entering the mouth. The tonsil lies in close relation to the internal carotid artery, about an inch from it, and is separated from the artery by the superior constrictor muscle.

THE ORGANS OF DIGESTION

The **pharyngeal tonsil**, differentiating from the **palatine tonsils**, is a small accumulation of lymphoid tissue on the posterior wall of the naso-pharynx and it extends from the body of the sphenoid down as far as the margin of the occipital bone, close to the Eustachian tube; an enlargement of the pharyngeal tonsil is often confused with adenoids in children, and sometimes it entirely fills the cavity. A **submerged tonsil** is one which is wholly or partially hidden by the anterior pillars of the fauces, so that no enlargement can be recognized.

The **arteries** which supply the tonsils are branches from the lingual and facial, also the ascending pharyngeal and internal maxillary from the external carotid; **veins** accompany the arteries and terminate in a plexus which eventually reaches the external jugulars; the **nerves** are derived from the cervical plexus, anatomists claim, thru the glosso-pharyngeal and the sphenopalato ganglion, but chiropractors give the 6th or 7th dorsal pairs of spinal nerves emitting from the 13th and 14th intervertebral foramina, for it is these spinal nerves that are subject to pressure which causes incoordination in the region of the tonsils.

THE TONGUE AND GUMS

(Illustration No. 139.)

The **Tongue** is concerned in the digestive apparatus for the part it plays in the process of mastication, in salivation and deglutition, but is more often considered with the organs of special sense. It is a muscular organ consisting of extrinsic and intrinsic muscles, placed in the floor of the mouth it is attached to the hyoid bone and thruout the interval between the lateral portions of the lower jaw.

(For structure see the tongue, special sense organ.)

The **Gums (gingiva)** serve to fix the teeth, and are composed of dense fibrous membranes, of firm red tissue. They are continuous with the mucous membrane of the vestibule of the mouth, and are connected to the periosteum of the alveolar processes and surround the necks of the teeth, being covered by a smooth vascular mucous membrane, which is remarkable for its limited sensibility.

THE TEETH

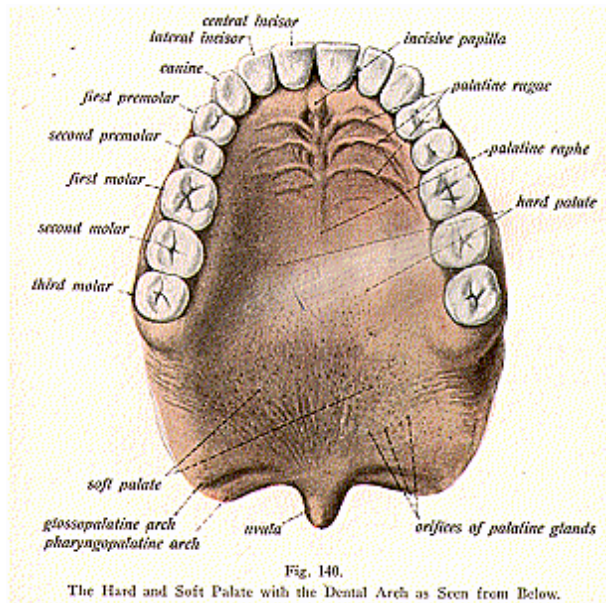
(Illustrations Nos. 140 and 141.)

The **Teeth** are used to reduce the food to fragments and so they perform the process of mastication in digestion; they are divided into two sets, namely, the **temporary** and the **permanent**, which make their appearance at different periods of life. The **first set** or the **temporary, milk or deciduous, teeth** make their appearance from the sixth month on, altho in rare instances children are born with **teeth**, and it is not uncommon to find the temporary set starting in the third month after birth. There are twenty in number of the temporary set—the *four incisors, two canines, and four molars* in each jaw. The **second** or the **permanent teeth** appear about from the seventh year up to the twenty-first year, and are thirty-two in number namely, the *four incisors (cutting), two central and two lateral, the two*

THE ORGANS OF DIGESTION

canines (dog teeth), improperly called the stomach teeth; the *four bicuspid*s, having two points or cusps and *six molars* (grinders). The last four molars to appear in the full set are called the wisdom teeth.

Each tooth consists of a **crown** or **body**, that part which projects above the gums; a **root** or **fang**, that part which is embedded in the alveolus, entirely concealed and the apex of the fang having an opening for blood-vessels and nerves; the neck, that constricted portion between the root and the crown; and the **pulp cavity**, which occupies



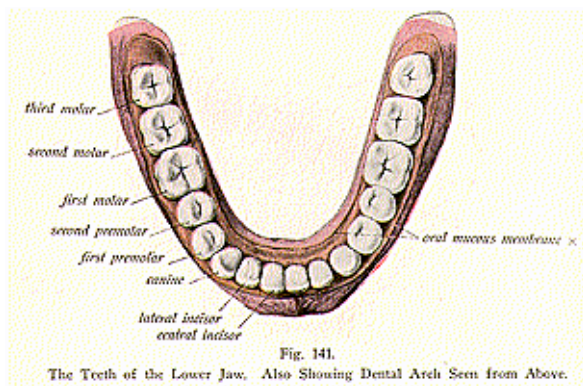
the central cavity. The **substance** of a tooth consists of the **ivory** or **dentine**, the **enamel**, the **cement** or **cortical substance**, and the **pulp**.

The **ivory** or **dentine** forms the principal mass of the tooth, and in its centre is the pulp cavity; dentine is composed of minute wavy tubes and bears a resemblance to bone, but contains less of animal, and more of earthy matter. The dentine has a striated appearance, the striations which curve outward from the pulp cavity toward the deep aspects of the enamel and cement.

THE ORGANS OF DIGESTION

The **enamel** is the hardest part, and covers the exposed part of the crown—its thick or grinding surface. It is exceedingly hard, due to the fact that it contains no animal matter, and protects the dentine. The **cement**, or the **crusta petrosa**, covers the dentine and encloses the root or fang; it consists of true bony tissue, containing lacunae and canaliculi. The **root** of the tooth is maintained in its alveolus by the dental periosteum, which covers the cement and lines the walls of the alveolus, being continuous with the gum at the neck of the tooth. The **pulp cavity** is the central chamber of the tooth and contains the pulp, which is very vascular and sensitive and consists of a matrix of connective-tissue, with blood-vessels, nerves and cells, the vessels and nerves gaining entrance thru the apex of the fang. **Molar glands**, are two or three large buccal glands, whose ducts open near the last molar tooth.

The teeth are **supplied** by branches from the internal maxillary **arteries**, and drained by the same named **veins**; most anatomists



claim the **nerves** come from the anterior and posterior dental branches of the maxillary and mandibular divisions of the fifth nerve, but Chiropractors have established the fact of innervation of the teeth by the fourth cervical spinal nerves, for the reason, the latter fibres are subject to pressure at their foraminal exits and thus cause inco-ordination in the parts they supply.

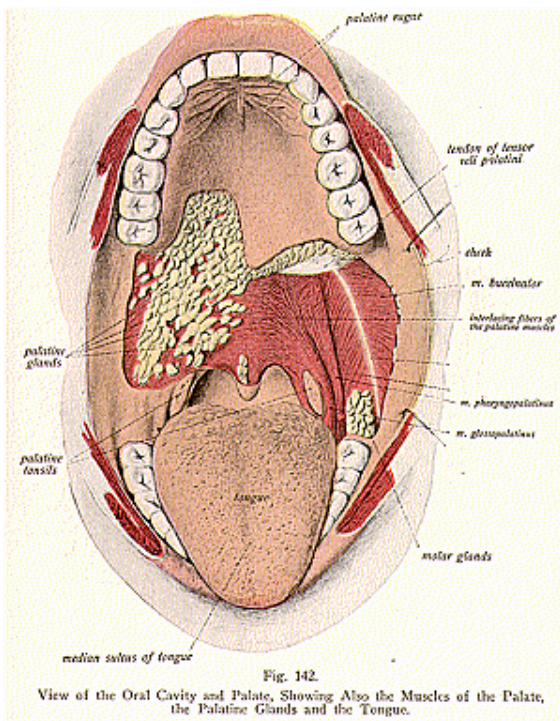
THE SALIVARY GLANDS

(Illustrations Nos. 143 and 144.)

The **salivary glands** are six glands, three on each side of the median line of the face, which secrete saliva and communicate with the mouth by ducts; they are named the **parotid**, **submaxillary** and

THE ORGANS OF DIGESTION

the **sublingual** glands. Other glands, which also open into the mouth are called the oral glands, namely, the labial, buccal, palatine, uvular, lingual and the tonsils (previously described). The salivary glands are compound racemose glands; the parotid is a serous gland; the

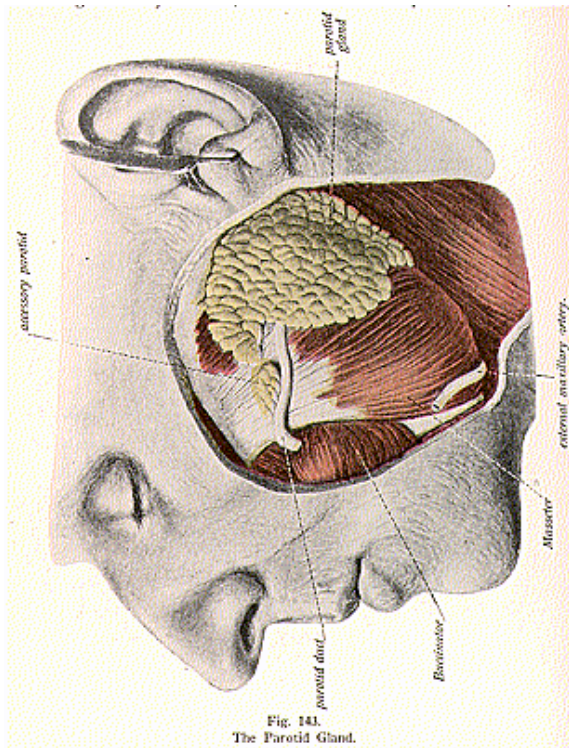


submaxillary a mixed, that is, both serous and mucous; and the sublingual is a mucous gland.

The **Parotid** (illustration No. 143) is the largest of the three glands; is a serous gland, and is situated on the side of the face,

THE ORGANS OF DIGESTION

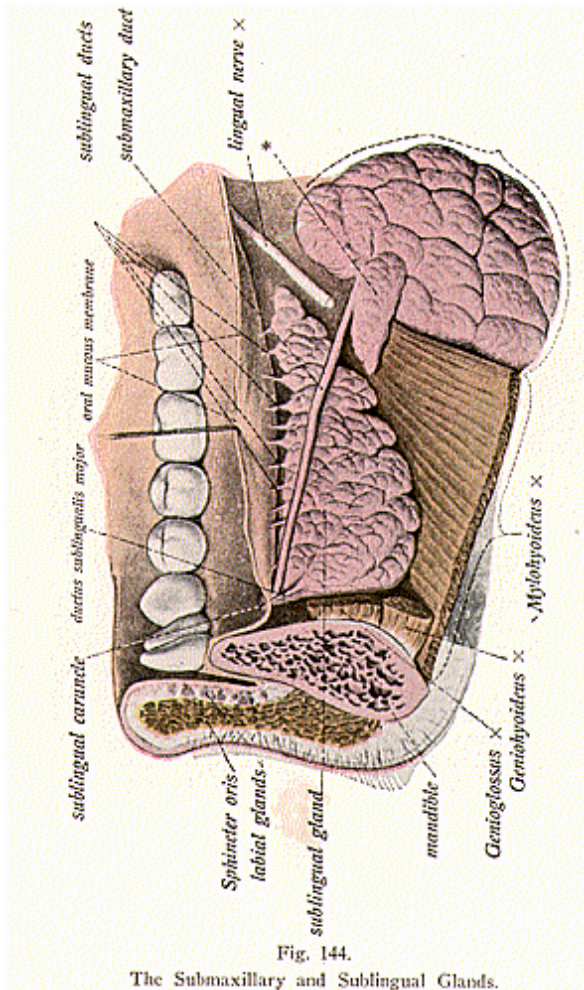
immediately in front of and below the external ear, it lies between the zygoma above, the mastoid process and the external meatus behind, the angle of the jaw below, and the ramus of the jaw in front; ante-



riorly it is covered by the masseter muscle. Important blood-vessels pass thru its substance, including the external carotid artery and its divisions and terminations embedded in the gland. The parotid is

THE ORGANS OF DIGESTION

grayish-yellow in **color**, is triangular in shape, and weighs from 1/2 to 1 ounce. It consists of numerous smaller lobules, compactly arranged, and each lobule ramifies as branches of a tree into dilated ends, called the alveoli (small secreting sacs or cavities). These alveoli are com-



posed of secreting cells, blood-vessels, nerves and ducts, and areolar tissue, which connects all parts together.

The **duct** of the parotid gland is called **Stenson's duct**, and is

THE ORGANS OF DIGESTION

about 2-1/2 inches in length. It commences by small tubes in the substance of the gland, crosses the masseter muscle and pierces the buccinator muscle, and opens on the inner surface of the cheek by a small orifice opposite the second molar tooth of the upper jaw. The canal is about the size of a crow-quill and is lined with mucous membrane of the short columnar epithelium type; its walls consist of an external or fibrous coat containing contractile fibres.

The **socia parotidis**, or **accessory parotid** is a detached portion of the parotid gland, which occasionally exists as a separate lobe, just beneath the zygomatic arch. When a duct is present of this gland, it empties into the parotid or Stenson's duct.

The **Submaxillary Gland** (illustration No. 144), a muco-serous gland, is situated under the jaw, in the submaxillary triangle of the neck, resting in the submaxillary fossa of the mandible; the lower part of the gland is covered by the skin, superficial fascia, the platysma myoides muscle, and the deep fascia of the neck.

The submaxillary gland weighs about two drachms, is of a yellowish white **color**, is composed of lobes and lobules; it is next in size to the parotid, and is irregular in form and loosely arranged; the submaxillary gland is enclosed in a capsule which is derived from the deep cervical fascia. Its excretory duct is called Wharton's duct and is about 2 inches in length, its walls being thinner than those of the parotid duct. Wharton's duct enters the mouth at either side of the fraenum of the tongue by a narrow orifice on the summit of a small papilla.

The **Sublingual Gland** (illustration No. 144) is a mucous gland found under the tongue in the sublingual fossa, close to the symphysis, and is the smallest of the salivary glands. It is flattened, narrow and shaped like an almond; it is grayish-white in **color** and weighs about one drachm. In structure it is similar to the parotid and submaxillary glands, but its lobules are fewer in number and more loosely arranged. The sublingual has from 10 to 20 ducts, the **ducts of Rivinus**, which nearly all open separately into the oral cavity upon the floor of the mouth; some join Wharton's duct, often two or more join and form a single duct, this then receives the name of **Bartholin's duct**, which opens directly into the submaxillary duct.

The **Blood supply** to the salivary glands is by branches from the external carotid, thru the lingual and the facial; the veins empty into the external jugular. Anatomists claim the **nerves** are derived from the facial, great auricular and the lingual, Chiropractors have established the fact of their innervation by the sixth or seventh pairs of dorsal spinal nerves, emitting thru the 13th and 14th intervertebral foramina.

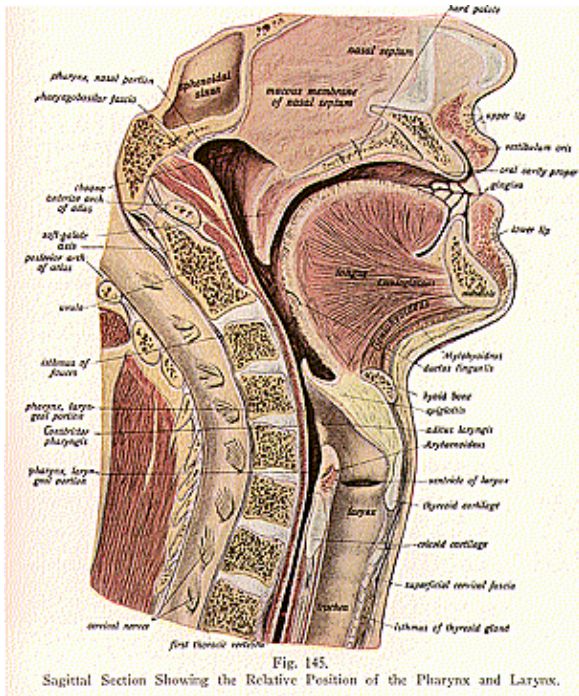
THE PHARYNX

(Illustration No. 145.)

The **Pharynx** is a muco-musculo-membranous tube, about 4-1/2 inches in length, and about 1-1/2 inches in width at its widest part. Located behind the larynx it extends from the basilar process of the occipital bone to the lower border of the cricoid cartilage, opposite the **5th cervical vertebra**, where it terminates in the **esophagus**; its

THE ORGANS OF DIGESTION

base is upward and its **apex** downward. Its base is attached to the periosteum of the basilar process of the occipital bone and to the petrous portion of the temporal bone, its apex to the esophagus. Posteriorly the pharynx is connected, by loose areolar tissue, with the cervical portion of the vertebral column and muscles, the longus colli



and recti antici muscles; anteriorly the pharynx is attached to the Eustachian tube, parts of the sphenoid bone (the pterygoid), the base of the tongue, the hyoid bone, thyroid and cricoid cartilages; laterally it is attached to the styloid processes and the muscles attached thereto. It is in close relation with the common carotid, the internal

THE ORGANS OF DIGESTION

carotid artery and internal jugular veins. When at rest, the anterior and the posterior walls are nearly together, but above the larynx they leave a channel for air. There are **seven openings** into it; the two *posterior nares*, which communicate with the cavities of the nose, two *Eustachian tubes*, which communicate with the middle ear, the *mouth*, *larynx* and the *esophagus*.

The pharynx has **three coats**. The *outer* coat is muscular and consists of the superior, middle and inferior constrictors, the stylo-pharyngeus, the palato-pharyngeus and the salpingo-pharyngeus; the *middle* coat is fibrous and is situated between the mucous and the muscular coats, it is thick above, and here acquires great strength and firmness, where it is attached to the base of the occipital bone, and petrous portion of the temporal and the Eustachian tube, and the sphenoid bone; it forms strong fibrous bands called the *pharyngeal aponeurosis*, and presents posteriorly a fibrous band, called a rapine, giving attachment to the constrictor muscles. The *inner* coat is mucous, being covered with ciliated epithelium down to the level of the floor of the nares, below this point it has the squamous epithelium; this mucous coat contains numerous mucous glands. The mucous coat is continuous with the linings of the nares, Eustachian tubes, the mouth and the larynx.

The **blood supply** to the pharynx is thru the ascending pharyngeal, the superior thyroid and internal maxillary, three branches from the external carotid, the veins empty into the external jugular. The **nerves** are derived from the pharyngeal plexus. This plexus conveys nerve fibres from the sixth or seventh pair of dorsal spinal nerves emitting thru the 13th and 14th intervertebral foramina. It is these fibres which are subject to pressure at their foraminal exits.

THE ESOPHAGUS

(Illustration No. 146.)

The **Esophagus** (I carry to eat), or the food gullet, is a muco-musculo-membranous tube, which extends from the apex of the pharynx to the stomach. Commencing at the lower border of the cricoid cartilage, opposite the fifth or sixth cervical vertebra, it passes along the front of the spine thru the diaphragm by the esophageal opening, and terminates in a somewhat expanded part called the **cardia**, at the cardiac opening of the stomach, opposite the tenth or eleventh dorsal vertebra.

It lies between the trachea and the vertebral column, and its direction is vertical. It is 9 inches in length and, when contracted, about one-half inch in diameter; when fully dilated its diameter approximates one inch or more. There are **three coats** of the esophagus, the *external* or muscular, consisting of longitudinal and circular fibres of considerable thickness; the *middle* coat is of areolar tissue which loosely connects the muscular and the mucous coats; the *inner* coat is mucous, thick, of reddish color above, tho paler below, and is thrown into longitudinal folds when the tube is empty. Mucous glands, most numerous at the cardiac opening, are scattered thruout the tube and open on its inner surface by small ducts.

THE ORGANS OF DIGESTION

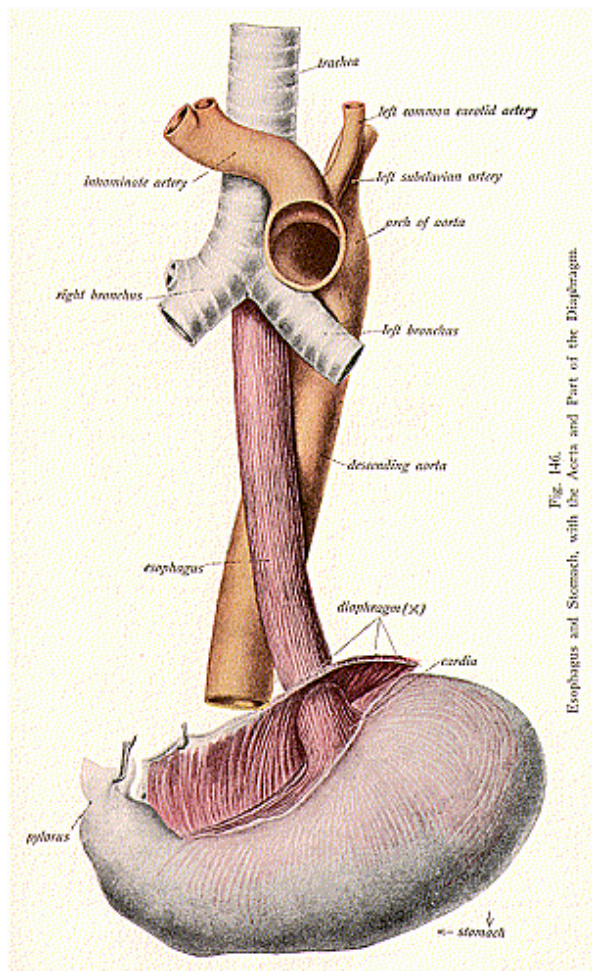


Fig. 146.
Esophagus and Stomach, with the Aorta and Part of the Diaphragm.

THE ORGANS OF DIGESTION

There are **three descriptive parts** of the esophagus, the *cervical*, extending to the opening in the thorax, the *thoracic*, from the second dorsal vertebra to the tenth, and the *diaphragmatic*, from about 1 inch above the diaphragm to where the esophagus passes thru the diaphragm. An abdominal portion is present only when the stomach is empty and the esophagus is pulled down, this portion is then covered for about one-half inch with peritoneum. There are three **constrictions** of the esophagus, one at the beginning of the tube, one where the left bronchus crosses it, and the third where the esophagus passes thru the diaphragm. The **arteries** to the esophagus **are** from branches of the thoracic aorta, and the **veins** empty into the vena azygos minor. The **nerves** are branches from the esophageal plexus and these nerves **convey** nerve fibres derived from the sixth or seventh dorsal pairs of spinal nerves, emitting thru the 13th and 14th intervertebral foramina. It is these spinal nerve fibres which are subject to pressure.

THE ABDOMEN

(Illustration No. 147.)

The **Abdomen** (put away or conceal) is the largest cavity in the body and extends from the diaphragm to the levator ani muscles; it is arbitrarily divided into the upper or larger part, the abdomen proper, and the lower or smaller portion, the pelvis; the brim of the pelvis marks the imaginary boundary line between them, and, tho we treat each as a separate cavity, the student must keep in mind that they are not structurally separate, for the viscera are everywhere in close contact. The abdomen is oval in form and the vertical measurement greatly exceeds the transverse. The abdomen proper is bounded by muscles and fascia, and varies in capacity and shape, according to the condition of the viscera, age and sex. It is bounded **above** by the diaphragm, which separates the thoracic cavity from the abdominal cavity; in **front** it is bounded by the abdominal muscles and ribs; **behind** by the bodies of the dorsal and lumbar vertebrae, the psoas and quadratus lumborum muscles; and **below** by the brim of the pelvis.

The abdomen **contains** the stomach, small and large intestines, liver, spleen and gall bladder, the kidneys, adrenals, and ureters, the abdominal aorta, inferior vena cava, the thoracic duct receptaculum chyli, the bladder, when distended, and the uterus during pregnancy. The organs are covered by an extensive and rather complicated membrane, the **peritoneum**. The abdomen is artificially divided into **nine regions** by means of two horizontal and two vertical lines with their corresponding planes. The horizontal lines extend from the level of the cartilages of the 10th ribs, called the *subcostal plane*, the other from the highest point of the crests of the iliac bones, called the *intertubercular* line; the two vertical lines extend from the cartilages of the 8th ribs to the middle of Poupart's ligament. The nine regions thus outlined are named the **right** and **left hypochondriac**, the **right** and **left lumbar** or **renal**, and the **right** and **left inguinal**, the **epigastric**, **mesogastric** or **umbilical** and the **hypogastric regions**.

There are eight openings in the abdominal walls for the passage of structures to or from, and these are: the **umbilical**, for the fetal

THE ORGANS OF DIGESTION

umbilical vessels, which after birth leave a depression filled with scar tissue, forming the umbilicus; the **vena caval**, for the passage of the

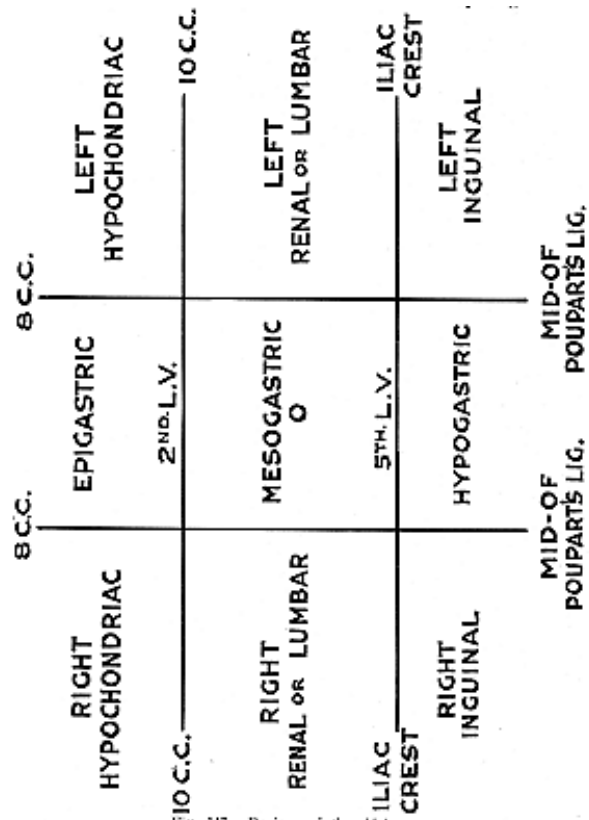


Fig. 247. Regions of the Abdomen.

inferior vena cava; the **aortic**, for the aorta; the **esophageal**, for the esophagus; the two **internal abdominal rings**, one on each side for the

THE ORGANS OF DIGESTION

spermatic cord in the male and the round ligament in the female, and the two **femoral** openings for the passage of the femoral vessels. In the pelvis are the urethral and rectal openings and, in the female, also the vaginal.

THE PERITONEUM

(Illustrations Nos. 148, 149 and 150.)

The **Peritoneum (tunica serosa)** is a serous membrane which lines the abdominal parietes, and invests, more or less completely, most of the viscera. It is composed of two layers, the **visceral** and the **parietal**, and between the two layers is a serous fluid, so the contiguous surfaces are smooth and moist. In the male, the peritoneum forms a closed sac, but in the female the fringed extremities of the Fallopian tubes open into the peritoneal cavity. In the female, the peritoneum, upon leaving the rectum, passes to the posterior wall of the vagina, the upper part of which it covers; from this it is continued up over the posterior surface and fundus of the uterus, and down on the anterior surface as far as the junction of the cervix and body; here it passes from the uterus to the bladder, which it partly covers in the male, and is then carried to the anterior abdominal wall. Normally it secretes only sufficient moisture to lubricate its surface and to facilitate the movements of the contained viscera during the changes in size and form which they undergo.

For convenience, the peritoneum is divided into the **greater** and the **lesser sac**, the greater sac extends over the anterior two-thirds of the liver, behind and above the stomach; the lesser sac extends behind and below the liver and the stomach. The opening between the greater and the lesser sacs is merely a constricted portion called the **foramen of Winslow**.

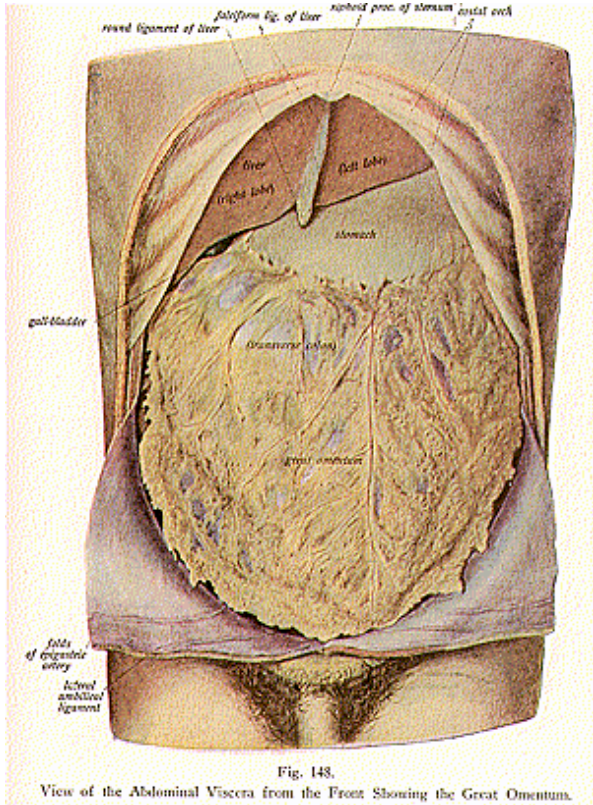
The **parietal layer** lines the walls of the cavity of the abdomen, it is loosely connected with the fascial lining of the abdomen and pelvis, but closely attached to the diaphragm on its under surface, the **visceral layer** is reflected over the viscera, and is covered by a layer of flattened endothelial cells which secrete the fluid to keep the parts moist. It gives a glistening, highly-polished appearance to the deep surfaces of the abdominal wall and to the exposed viscera, and its **chief uses are**, *to unite* the layers of the abdominal walls together, *to connect* the viscera to these walls and to one another in such a loose manner that their distention and relaxation may not be interfered with, which would be the case if the peritoneum were firm and rigid, and to *act* as a storehouse for fat, and *to form* sheaths for the blood-vessels and nerves.

The peritoneum forms certain reflections or folds which are called **omenta**, **mesenteries** and **ligaments**, and the **cul-de-sacs** or **pouches**. Any fold of peritoneum that connects the stomach with any organ takes the name **omentum**; the **omenta** are **three in number** the **greater** or **gastro-colic** omentum, the **lesser** or **gastro-hepatic**, and the **least** or **gastro-splenic** omentum.

The **greater omentum** is a fold of peritoneum which hangs down like an apron from the greater curvature of the stomach, over the transverse colon and the coils of the small intestine to a considerable extent, but does not always spread over the intestines; it is found

THE ORGANS OF DIGESTION

loaded with fat, and the functions of the great omentum are as follows:—it acts as a movable and easily adjustable packing material



capable of filling all temporarily produced spaces in the abdomen; it prevents the passage of the small intestine up into the stomach

THE ORGANS OF DIGESTION

chamber, and helps keep them from becoming entangled there; it is a storehouse for fat; is a protection for the abdominal viscera and

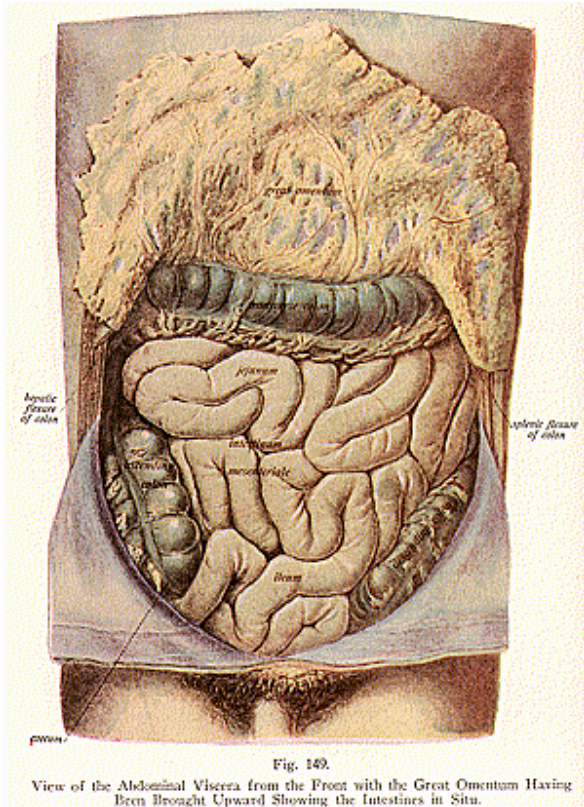


Fig. 149.

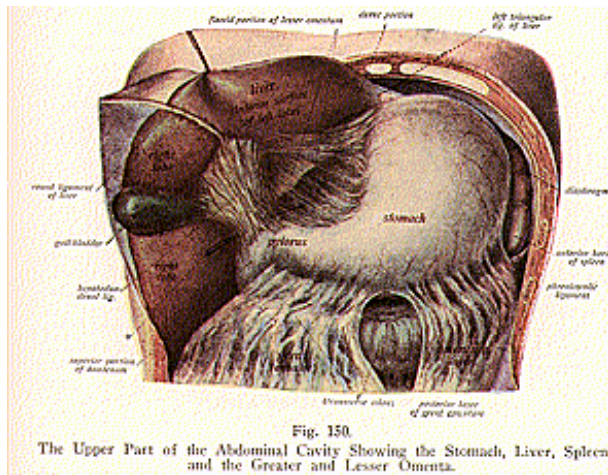
View of the Abdominal Viscera from the Front with the Great Omentum Having Been Brought Upward Showing the Intestines in Situ.

being freely movable can pass to almost any part of the abdomen; it keeps the intestines warm; and prevents many forms of hernia by

THE ORGANS OF DIGESTION

refusing to be pulled down. The **lesser omentum**, or the **gastro-hepatic omentum**, is a double fold of peritoneum, which extends from the lesser curvature of the stomach to the transverse fissure of the liver; the **least omentum**, or the **gastro-splenic omentum**, is that fold of peritoneum which connects the stomach with the spleen, and is continuous below with the great omentum.

Any fold of peritoneum attached to the intestines is called a **mesentery**. The subdivisions of the mesenteries are the **mesentery proper** and the **meso-colon**. The **mesentery proper connects** the jejunum and the ileum to the posterior abdominal wall; it serves to retain the small intestines in position, and contains, between its layers, the mesenteric vessels and nerves. The **meso-colon** is a fold of peritoneum which holds the large intestine in place and attaches it to the posterior



wall of the abdomen; it is subdivided into the following portions named for the parts each holds in place: the *meso-appendix*, a fold of peritoneum which holds two-thirds of the appendix in place; the *meso-coecum*, holding the caecum to surrounding parts; the *transverse meso-colon*, connecting the transverse colon to the posterior abdominal wall; the *sigmoid meso-colon*, which attaches the sigmoid colon to the iliac fossa; and the *meso-rectum*, the upper part, or ampulla, of the rectum, to the front of the sacrum.

The **ligaments of the peritoneum** are formed by 17 or 18 folds of peritoneum which connect the viscera, other than the intestines, to each other and to the abdominal or pelvic walls, they are named as follows; the **gastro-phrenic**, from the stomach to the diaphragm: the

four hepatic, two laterals, one from either side of the liver to the diaphragm; the coronary, from the posterior surface of the liver to the diaphragm; the falciform, suspensory or broad, from the under surface of the diaphragm to the liver; the hepato-renal, from the under surface of the liver to the kidney, the **lieno-renal**, from the spleen to the kidney; the **lieno-phrenic**, from the spleen to the diaphragm; the **five vesical**, an anterior, a posterior, two laterals and the suspensory; the **six uterine**, two vesico-uterine, two rectal uterine, and two laterals, the latter are called the broad ligaments; also the **phreno-colic** might be mentioned, from the diaphragm to the colon. During life and in the uncut corpse, the peritoneal cavity is air-tight; it is the surgeon's knife that makes it accessible.

Retro-peritoneal fossae are recesses of peritoneum, forming **cul-de-sacs** or **pouches**, the one found between the folds of the duodenum is called the **duodenal**; the **pericaecal** around the **caecum**, the **intersigmoid**, between the coils of the sigmoid colon; the **recto-vesical**, between the rectum and the bladder; the **vesico-pubic**, between the bladder and the pubes; the **recto-vaginal** or **sac of Douglas**, in the female, between the rectum and vagina, and the **vesico-uterine**, between the bladder and uterus.

Reflections of the peritoneum cover the kidneys, the supra renals, and the pancreas, and form the serous capsules of these organs.

THE STOMACH

(Illustrations Nos. 151 and 152.)

The **Stomach (gaster)** is one of the principal organs of digestion, and is a muco-musculo-membranous sac, situated between the termination of the esophagus and the beginning of the small intestine. It is pear-shaped and is known as the dilated portion of the alimentary canal. Its form varies with varied conditions, according to sex, age and degree of distention. At birth it is scarcely larger than a hen's egg, and in shape it pretty closely corresponds to that of the adult, but is placed more nearly vertical than in later life. When the stomach is empty it is elongated and slender, and forms almost a right angle at its pyloric end. After death the tissues immediately become soft and flaccid, bag-like, and the walls are flat and relaxed, for there is then no muscular tonicity. When food enters, the stomach expands, the greater the amount of food the greater the expansion, when the food leaves, the stomach gradually relaxes, is contracted rather than collapsed. When the stomach is distended it assumes the form of an irregular pear, somewhat flattened, and the pyloric end is directed backward, the liver is pushed to the right side, and often the apex of the heart is tilted upward, in the extreme distention the pyloric end may pass below the epigastric into the hypogastric and left lumbar regions. The stomach changes position in respiration, moving slightly upward and downward with the diaphragm and the abdominal muscles.

The stomach extends from the diaphragmatic end of the esophagus, at a point opposite the 7th left costal cartilage, and at the level of the 11th dorsal vertebra, to the duodenum at the pylorus, opposite the 8th right costal cartilage; it lies with about 1/3 of it to the left of

THE ORGANS OF DIGESTION

the median line, in the left hypochondriac and epigastric regions, between the liver, diaphragm and the spleen.

Its **size** varies, but when moderately distended it measures from three to six inches, from cardiac to pyloric end, from 9 to 12 inches across the greater curvature, and 4 inches in diameter; its capacity in the adult is from 5 to 8 pints, in the newborn about 1 ounce.

The **descriptive parts** are the **greater** and **lesser curvature**, the **fundus**, and the **cardiac** and **pyloric orifices**. The **greater curvature** is the lower border, it is convex, is the more anterior border, and is connected to the colon by the greater omentum; the **lesser curvature**, the upper border, is concave and is attached to the liver by the lesser omentum. The fundus, the large end, is directed upward and is attached to the spleen by the gastro-splenic omentum. The **cardiac orifice** is situated at the left end of the lesser curvature and is behind the 8th left costal cartilage at a point one inch to the left of the

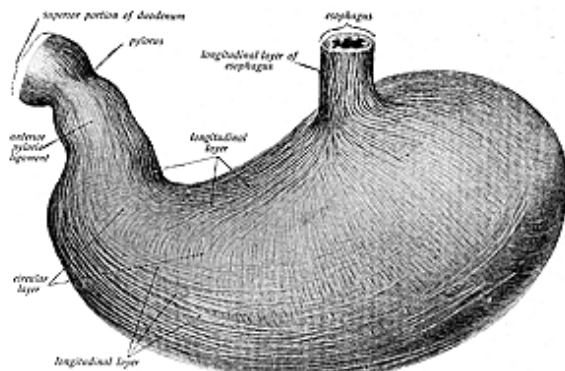


Fig. 151.
The Stomach, Showing the Muscular Layers.

sternum; this is the opening by which the esophagus communicates with the stomach. The dilated portion, just where the esophagus enters the stomach, is known as the *cardia*. The **pyloric orifice** is situated at the right end of the stomach, being about on a level with the upper border of the first lumbar vertebra, and just to the right of the linea alba; this is the opening by which the stomach communicates with the duodenum, and the aperture is guarded by a valve called the pyloric valve. The valve is a muscular ring, formed by the circular fibres of the middle coat of the stomach, and forms a well-defined sphincter, called also the **pyloric sphincter**.

The stomach has four coats (illustrations Nos. 151, 152 and 153); the **outer**, a **serous coat**, is derived from the **peritoneum**; the **middle**

THE ORGANS OF DIGESTION

coat is muscular, consisting of three sets of fibres, the most external of which are arranged longitudinally, those of the middle layer being circular. From these the pyloric sphincter is formed. The fibres of the internal layer are arranged obliquely. The **sub-mucous** coat lies beneath the muscular coat and consists of areolar tissue and blood-vessels and nerves; the sub-mucous coat connects the muscular and mucous coats. The **mucous** coat is smooth, thick and velvety, honey-comb-like in appearance, and when contracted lies in folds. At the pyloric end the mucous membrane is thick and pink, but is red and thin at the cardiac end. The honey-comb appearance is produced by the mouths of the glands, which open on the surface; the rugae are the longitudinal folds into which the mucous membrane is thrown; they

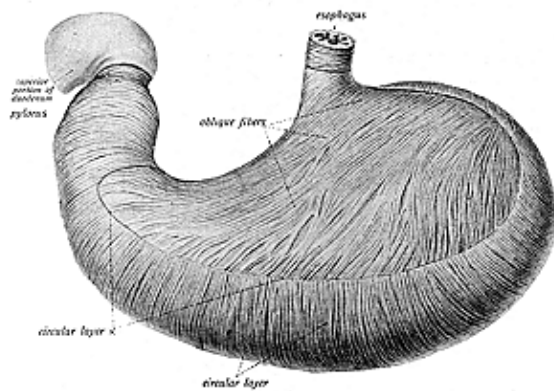


Fig. 152.

The Stomach Seen from the Front, Showing the Oblique and Circular Fibres.

are prominent when the stomach is empty, but are entirely obliterated when the organ is distended.

The **function** of the stomach is to serve as a receptacle in which the food may accumulate after its passage thru the esophagus, and in it take place some of the earlier processes of digestion, resulting in the conversion of the food into a soup-like mixture, called **chyme**. This action is made possible by the numerous glands in the stomach. These glands are known as: the **pyloric**, found at the pyloric end and quite numerous; the *cardiac glands*, situated all over the stomach, but most numerous at the cardiac end; and the *fundus glands*, scattered over the stomach. These are also called the peptic glands. Other glands, scattered between these glands named, are concerned in the manufacture of the gastric juice. These gastric juices may

THE ORGANS OF DIGESTION

be excessive or deficient in quantity. Their action is definite and putrefaction of food in the stomach does not occur after the gastric juice has acted upon the food.

The **blood supply** to the stomach is thru the gastric, pyloric, and right and left gastro-epiploic arteries, branches and sub-branches from the coeliac axis; the veins terminate in the portal system. The **nerve supply** is by branches from the vagus and from the gastric plexus. They convey nerve fibres derived from the sixth, seventh and eighth dorsal pairs of spinal nerves, emitting thru the 13th, 14th

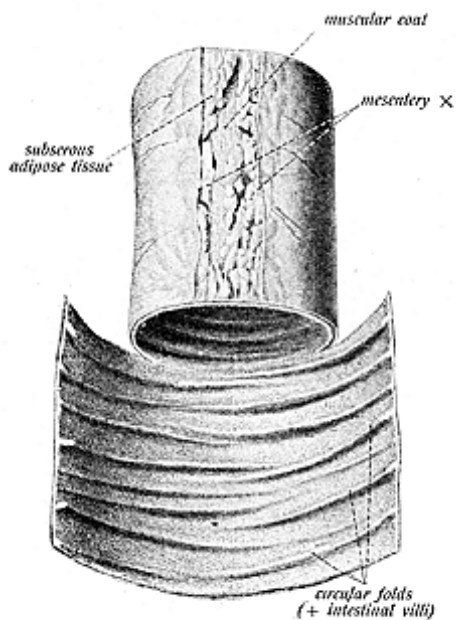


Fig. 154.
A Portion of the Jejunum Showing the Mucous Lining.

and 15th intervertebral foramina respectively. It is these spinal nerves, when interfered with at their foraminal exits, which causes incoordination in the gastric region.

The stomach of ruminants (the ox, sheep, goat, CONY, llama) have four compartments for the reception and maceration of food. Of these four compartments the rumen, or first stomach, is the largest, reaching the enormous capacity of forty gallons in the ox; it is

THE ORGANS OF DIGESTION

divided into four sac-like pouches by two muscular band-like girdles, whose function is to contract on the contents and to render assistance in the mechanical process of returning the cud for further mastication, the rumen is covered with glands. The reticulum is the second gastric reservoir and is the smallest compartment; the omasum, the third, is a little larger than the reticulum; and the abomasum corresponds to the stomach of other animals and needs no further description.

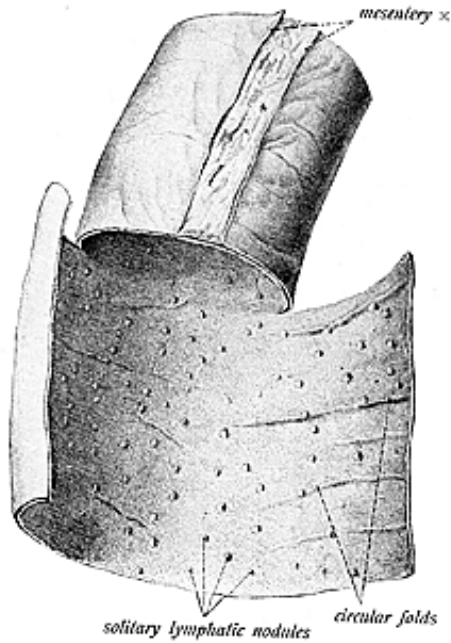


Fig. 155.

A Portion of the Ileum, Showing the Mucous Lining.

An average man daily consumes 5-1/2 lbs. of food and drink. This amounts to nearly one ton of solid and liquid nourishment annually.

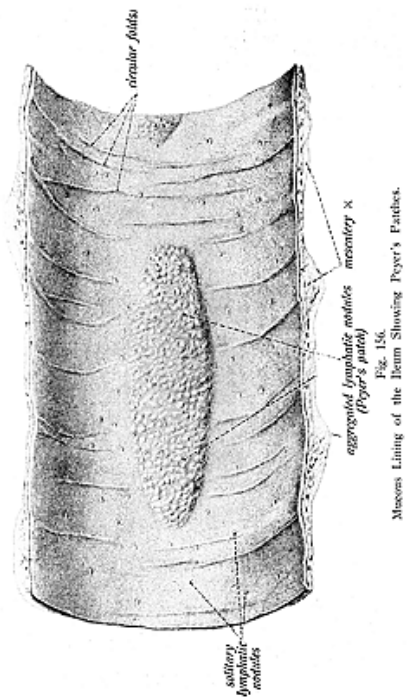
THE SMALL INTESTINE

(Illustrations Nos. 154 and 155.)

The next part of the alimentary canal, below the stomach, is the **small intestine**, the mid-gut or bowel (see illustration No. 149), and

THE ORGANS OF DIGESTION

it is a muco-musculo membranous tube, about 20 feet in length. It is located in the mesogastric region; begins at the pyloric end of the



stomach and terminates at the opening of the caecum, in the right iliac fossa; thus it occupies the greater part of the central portion of the abdominal cavity. It has, for descriptive parts, three divisions,

THE ORGANS OF DIGESTION

namely, the **duodenum** (twelve fingers' breadth), the **jejunum** (empty), and the ileum (coiled), and these parts are attached to the spine by the mesenteric portion of the peritoneum.

The **duodenum** is the shortest and most fixed part of the small intestine; it is ten inches in length, its diameter being from 1-1/2 to 2 inches. It has no mesentery, but is invested by a covering of the peritoneum. It is horse-shoe shaped, being divided into four sections: a superior, a descending, a transverse, and an ascending portion. It surrounds the head of the pancreas. Into the descending portion open two ducts, the common bile duct and the pancreatic duct, this part of the duodenum is most often found stained after death, since it lies next to the gall-bladder.

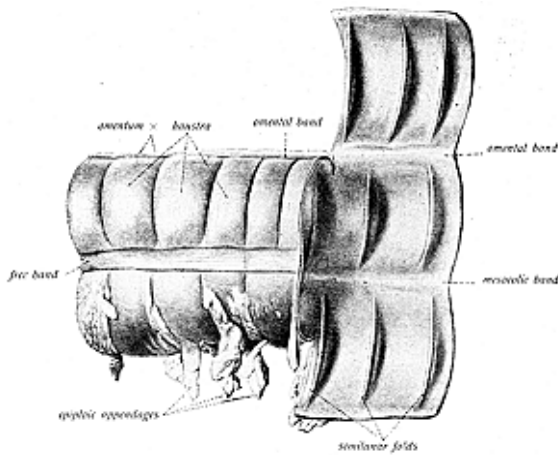


Fig. 157.
Part of the Transverse Colon Seen from the Front and Below, Showing Both the Outer and Inner Coats.

The jejunum, the second part, is the most vascular, is wider weighs more, and is about 9 feet in length, comprising about $\frac{2}{5}$ of the remaining length of the small intestine; there is scarcely a visible external mark, other than its greater vascularity, to distinguish it from the ileum, tho both have certain internal characteristic features, for thruout their length the jejunum and ileum undergo a gradual change from their beginning to their termination. The ileum is the lowest portion, is about 1-1/4 inches in diameter, about 11 feet in

length, and is named from its numerous coils and convolutions; it lies to the right of the jejunum. Its coats are thinner than are those of the other parts of the intestine, it terminates in the right iliac fossa by opening into the large intestine, at the ileo-caecal valve. The **capacity** of the small intestines is from 16 to 18 pints.

There are **four coats**, similar to those of the stomach—the **serous**, **muscular**, **sub-mucous** and **mucous** coats. The **serous** coat is derived from the peritoneum; the **muscular**, consisting of fibres arranged longitudinally and circularly; the **sub-mucous**, being an areolar coat uniting the muscular and mucous coats; and the **mucous** coat, which contains the villi, the valvulae conniventes, also numerous glands. The **villi** are minute vascular masses of mucous membrane, which give to its surface a soft, velvety appearance. They project from the surface of the mucous membrane thruout its whole extent, their total number is said to be about four millions. They are most numerous in the lower part of the duodenum and in the jejunum. They vary in length from 1/30 to 1/40 inch, and each villus is an elevation consisting of adenoid tissue, a capillary network of blood-vessels muscular tissue and numerous branchings of nerve-fibrils, covered by columnar epithelium. The villi are leaf-shaped in the duodenum oval in the jejunum, and thread-like in the ileum. The villi play an important part in the process of absorption.

The **valvulae conniventes** (shutting valves), also called the **valves of Kerkring**, are circular valvular folds which retard the food as it passes along, and affords a more extensive area for absorption. They are arranged in a spiral formation, and first appear at about the upper end of the second part of the duodenum, at a distance of from one to two inches from the pylorus. They exist as straggling folds until they reach the ileum, where they become smaller and very irregular and finally disappear just beyond the center of the ileum.

The **glands** found on the mucous membrane are termed **Brunner's glands**, **crypts of Lieberkuhn**, **solitary glands**, and **Peyer's patches** (Illustration No. 156). Brunner's glands are small conglomerate tubular masses found in the duodenum, very numerous near the pylorus, and are also found in the first part of the jejunum; they are small flattened granular bodies, resembling a racemose gland, and each opens upon the surface by a small secretory duct. The **crypts of Lieberkuhn**, or follicles, are found all over the small intestine, as well as in the large intestines; they are simple tubular glands having a crypt or tubular depression, a small sac which opens upon the surface by a small circular aperture. These orifices appear as minute dots between the villi. The **solitary glands** are small, white, round or oval lymphoid bodies of the size of a millet seed, scattered thruout the intestine; occasionally a few are seen in the duodenum. They are few and small in the jejunum; are largest and most numerous at the lower part of the ileum.

Peyer's patches or **glands** are aggregations of solitary glands and are most developed during digestion; there are from 20 to 30 patches, they measure from 1/2 to 4 inches in length, and from 1/2 to 1 inch in breadth, being placed lengthwise in the intestine; they are well marked in young persons, but towards middle life they fade

THE ORGANS OF DIGESTION

away, and in old persons are distinguishable only as discolored portions of the mucous membrane. In intestinal fevers they are ulcerated.

Sometimes there is found connected with the lower part of the ileum about two or three feet from its ending a blind tube or diverticulum, called *Meckel's diverticulum*, about two inches in length and of the same width as in the portion of the intestine of which it is a part. Sometimes a part of it is open, while the rest remains as a shrunken fibrous cord; in other cases it is large. It is usually found at a right-angle to the small intestine, or it may take any other direction; also,

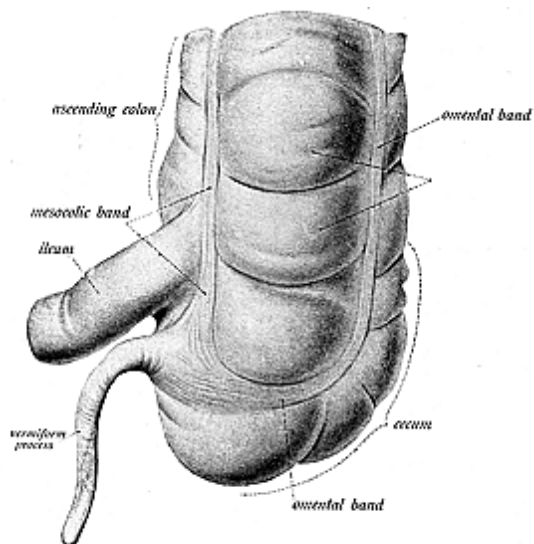


Fig. 188.
The Cecum and Vermiform Appendix.

it may be attached to the abdominal wall by a fibrous cord. It is the remains of the vitelline duct, which in fetal life connects the embryonic yolk-sac and alimentary canal.

The **blood supply** to the intestines is thru the mesenteric vessels from the abdominal aorta, the veins terminate in the portal system. The **nerves** are branches from the mesenteric plexus. They convey nerve fibres from the first and second lumbar pairs of spinal nerves, and it is these fibres which are subject to pressure at their foraminal exits.

THE LARGE INTESTINE

(Illustrations Nos. 157 and 158.)

The **Large Intestine**, or bowel, is a muco-musculo-membranous tube, five feet in length, and extends from the ileum, terminating at the ileo-caecal valve, to the anus; the large intestine surrounds the small intestine and differs from the small in that it is sacculated is wider, but shorter, and its capacity is from 5 to 8 pints; it consists of the following **descriptive parts**: the **caecum**, the **colon** and the **rectum**.

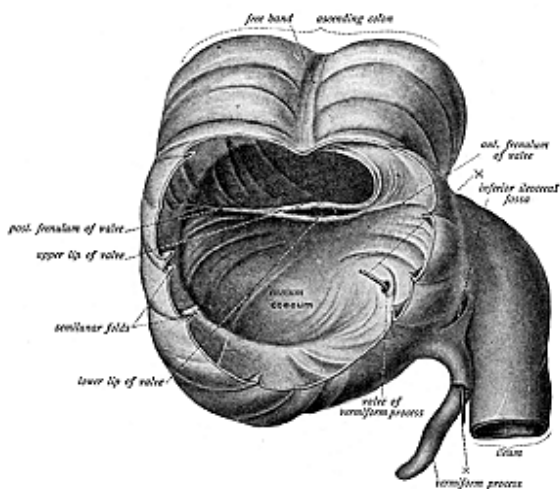


Fig. 159.
The Caecum and Appendix Opened, Showing the Ileo-Caecal Valve.

The caecum (illustrations Nos. 159 and 160), or intestinal caecum, the **blind gut**, **cul-de-sac**, or **caput caecum coli**, is a blind pouch, situated below the ileo-caecal valve, in which the large intestine commences; the blind portion is directed downward and the open end is directed upward. The caecum is situated almost all in the right iliac fossa and right inguinal region, and is covered by a fold of peritoneum, called the meso-caecum. Its size varies, but averages about 3 inches in width and 25/2 inches in length. It has **three openings**: one into the ileum, one into the colon, and one into the appendix. When the caecum is empty it is covered by the coils of the ileum, and when

THE ORGANS OF DIGESTION

distended, it comes in contact with the anterior abdominal wall, and at the same time descends as low as the outer half of Poupart's ligament. Its mucous membrane resembles that of other parts of the large intestine. In carnivorous (flesh eating) animals the caecum is slightly developed, while in the herbivorous (herb eating) animals the caecum is extremely large.

The **Vermiform Appendix** is found only in man, in the higher apes, in the wombat, and often in certain rodents. The appendix is a long, slender, worm-like, musculo-membranous tube of the size of a goose quill, and lined with mucous membrane; it is given off from the inner side of the posterior wall of the caecum, behind and below the ileum, and varies from 1-1/2 to 9 inches in length; in rare instances

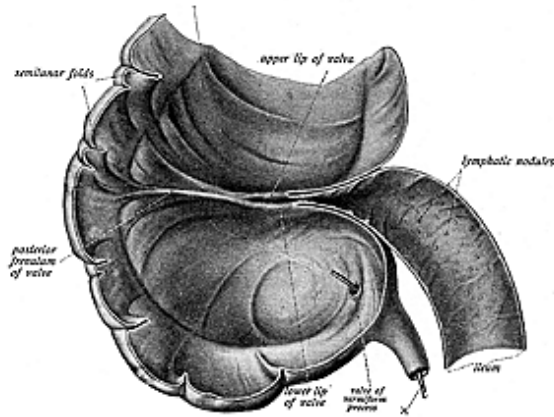


Fig. 160.

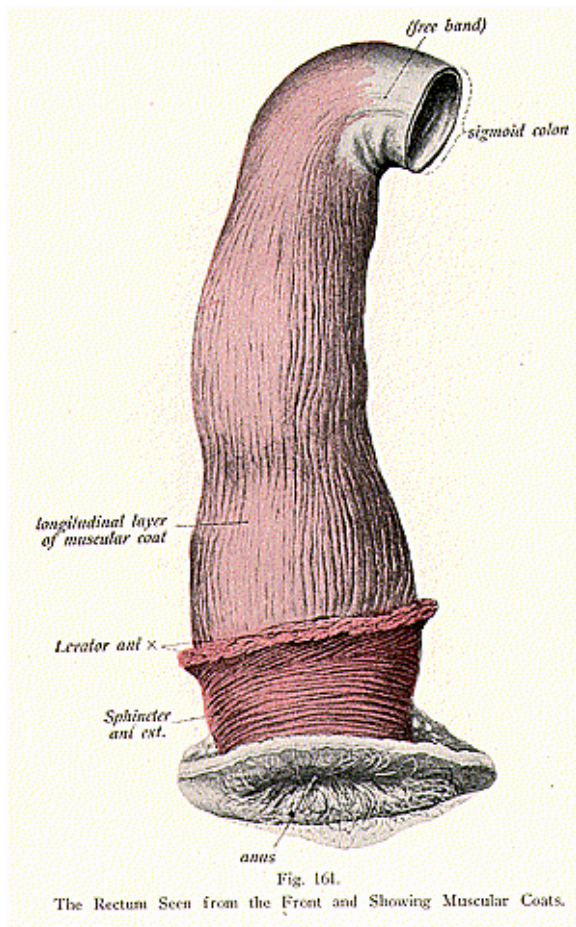
The Caecum and the Terminal Part of the Ileum Divided.

its length may be 18 inches, but the average length is about 3 inches. It is directed upward and backward and is held in place by the meso-appendix; its growth continues to the 24th year. It is yellowish pink in **color**, and soft and smooth to the touch; its **coats** are the same as of the intestine. The mucous coat has glands, and lines a canal which extends the whole length of the tube. The glands give off a secretion of an oily consistency, which is carried into the caecum; the entrance to the appendix is guarded by the **valve of Gerlach**, not always present and never perfect.

At the present day the appendix is treated with the utmost rigor and not only is it hastily taken away, should the least pain occur, but there seems to be no hesitation in deliberately removing it when the

THE ORGANS OF DIGESTION

health is perfect. Seemingly then the appendix is a useless organ, but this opinion is certainly not held by all, and especially is the idea discountenanced by the Chiropractor, for he believes that the vermiform appendix has an important function to perform in the secretion



of a special liquid, a “hormone,” which has the effect of causing the evacuation of intestinal residue thru contractile or peristaltic movements of the large intestine, while this secretion poured from the appendix into the caecum empties that portion of the intestinal canal.

The vermiform appendix throws forth a slimy alkaline lubricant, which, when united with the other intestinal fluids, dissolves the white of an egg in from three to ten minutes. The appendix, then, instead of being the degenerate and, therefore, dangerous vestige of a once active viscus, is still a secreting gland and an efficient aid in the complicated process of digestion.

The **ileo-caecal valve**, or **valve of Bauhin**, guards the entrance from the small intestine and projects into the caecum; the opening appears like a transverse double slit, formed of two crescentic mucous folds, made strong by circular muscular fibres; the valve is covered with villi toward the ileum, but is smooth toward the caecal side. When the caecum or the large intestine are distended, this valve-like fold prevents a reflux into the small intestine; it is known, however that a large enema, distending the bowel, may in part pass the valve and enter the small intestine; the valve offers resistance, but a certain amount of pressure will overcome it.

The **Colon** comprises the **ascending**, **transverse**, **descending** and **sigmoid colon**. The **ascending colon** begins from the caecum in the right inguinal region, passes upward thru the right lumbar and hypochondriac regions, forming a sharp turn there below the liver known as the hepatic flexure; thence it continues onward as the **transverse colon**, which passes transversely across the abdomen, thru the epigastric and mesogastric regions, and ending at the lower border of the spleen, where it forms another bend called the **splenic flexure**; thence it continues downward as the descending colon, thru the left **iliac fossa**, where it is known as the **sigmoid colon**, which is so very much convoluted as to form the **sigmoid flexure**, being curved like the letter S. The colon ends at the commencement of the **rectum**. The freedom of movement of the sigmoid flexure renders it liable to become twisted, for the gut, because of its great weight when loaded with feces, may fall over the gut below and so form a knot.

The colon has **three coats**. The **outer** coat is serous, derived from the peritoneum, the **middle** coat is muscular, and the **inner** coat is mucous. There are three chief characteristics of the large intestine—the **sacculations**, the **taeniae** and the **appendices epiploicae**. The **sacculations** are pouches produced by the taeniae, which shorten the tube; when the bands are removed, the tube can be lengthened and its sacculated character becomes lost. The **taeniae** are longitudinal bands of muscular fibres, arranged in three flat bands; these bands constitute the heavier parts of the muscular coat, which does not form a uniform layer over the whole surface of the large intestine, but collects into these bands, which are about one-half inch in width, and they shorten the colon. These taeniae are called the *taenia mesocolica*, a muscular band extending longitudinally thruout the length of the colon, corresponding to the insertion of the mesentery; the *taenia libera* opposite the previous one; and the *taenia omentalis*, corresponding to the place of adhesion of the omentum to the transverse colon. The taeniae arise from the caecum,

at the base of the vermiform appendix, and extend along the several parts of the intestines as far as the rectum, where they spread out and form a continuous covering, completely surrounding that part of the bowel. The **appendices epiploicae** are peritoneal pouches containing fat. They protrude from the peritoneal coat at irregular intervals.

The Rectum (straight) (illustrations Nos. 161 and 162) is not straight, but curves with the sacrum, and it is the termination of the large intestine. The rectum begins at the left sacro-iliac articulation and ends at the anus, it is 8 inches in length, is not sacculated, and passes downward and backward and to the right to the level of the third sacral vertebra, where it then lies in the middle line. It has a **superior** or **sacral portion**, and an **inferior portion**, also called the **anal canal**. The upper part is dilated and is called the **ampulla**; this is the only part covered by peritoneum, and it receives the name of the meso-rectum. The **anal portion** is the lower part and terminates in a circular opening called the **anus** (circle). Here the skin is corrugated and pigmented, and contains hairs, sebaceous and sudoriferous glands.

The **coats** of the rectum are the **serous**, found only in the upper portion. The **muscular coat**, which consists of an external layer of longitudinal, and an internal circular layer of muscular fibres. The longitudinal fibres form a complete layer spread all around the rectum; the circular fibres form a continuous covering and become thickened below, and so give rise to the *sphincter ani*. The **submucous coat** is composed of areolar tissue and connects the muscular and mucous coats in a very loose manner, so that the latter is thrown into a number of temporary folds when the rectum is empty. The **mucous coat** is thick and pale in color, and when the lower part of the rectum is contracted its mucous membrane is thrown into a number of folds; some of these folds are longitudinal in direction and constitute, near the anus, the *columns of Morgagni* or the *rectal columns*; these are 1/2 inch in length, are 5 to 10 in number, and when contracted are most prominent. Between these columns are grooves or folds, called *valves*, known as the *rectal valves* or *sinuses*, they serve to check or hold in check the descending load of feces, and operate to give gradual escape rather than sudden discharge. When the anus is closed the skin lies in radial folds, but under extreme dilation the orifice may admit a good sized hand.

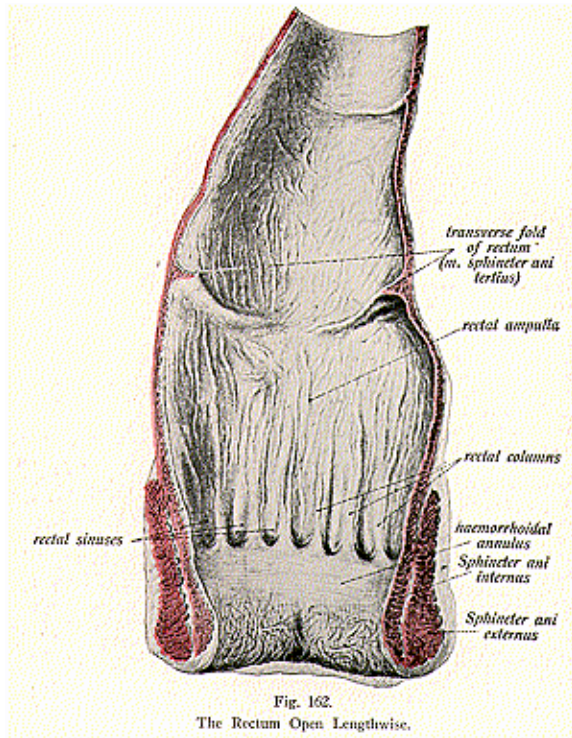
The **perineum** is a triangular space in the pelvic cavity between the ischii, where the rectum turns backward and the genital organs forward; in the female the anal canal is separated from the lower end of the vagina by a fibro-muscular body, called the perineal body.

The crypts of Lieberkuhn and simple follicles are glands found in the large intestine, the crypts being longer and more numerous than in the small intestine. Owing to the absence of the villi, the surface of the mucous lining of the large intestine is smooth, but is raised into crescentic folds corresponding to the intervals between the external sacculations. The mucous membrane is thickly set with the openings of simple tubular glands of large size, also with solitary

THE ORGANS OF DIGESTION

glands which are scattered irregularly over the entire colon, but are most abundant in the appendix and the caecum.

The **blood supply** to the large intestine is thru the mesenteric arteries: to the rectum, thru the hemorrhoidal vessels, and the



veins empty into the portal system (the hemorrhoidal into the internal iliac vein). The **nerves** are derived from the mesenteric and hemorrhoidal plexuses. They convey nerve fibres derived from the lumbar plexus formed by branches from the fourth and fifth lumbar pairs of spinal nerves. It is these spinal nerve fibres which are subject to

THE ORGANS OF DIGESTION

pressure interference which causes such disorders as are found in the large intestine.

The intestinal juice, or *succus entericus*, acts upon the secretions carried to the small intestines from the stomach and the liver, and acts upon any food which may have passed unaltered by the other secretions.

THE LIVER. (HEPAR)

(Illustrations Nos. 163 and 164.)

The Liver, one of the organs of digestion and the largest gland in the body, is situated in the upper part and right-hand side of the abdominal cavity, occupying almost all the right hypochondriac and epigastric regions and extending into the left hypochondriac region. It is a lobulated tubular gland, very large in the fetus, and weighing in the adult male from fifty to sixty ounces. Its limiting borders correspond to 1/2 inch below the right nipple, below the tip of the 10th rib, and 1 inch below the left nipple, above, it is in relation with the diaphragm; below, with the stomach, transverse colon, and the right kidney; behind it are the vertebral column, the aorta and the vena cava; in front is the chest wall. To a very large extent the liver lies under cover of the lower ribs and costal cartilages of the right side of the ensiform cartilage, and beneath the 6th, 7th and 8th costal cartilages of the left side; it is accurately molded on the under surface of the diaphragm, and moves with respiration. It measures from 9 to 12 inches in various directions and is approximately 3 inches thick. Its **color** is dark reddish-brown; it is of a soft, solid consistency, firm to the touch, but friable and easily lacerated.

Few organs vary in size more than does the liver. According to varying stages of digestion it enlarges or diminishes in proportion to the fullness or emptiness of the adjacent viscera, for while the liver has its own intrinsic shape, yet it is capable of modification within certain limits by varying pressure of surrounding parts. Long continued pressure, as in tight lacing, alters its shape, and in addition to the fact that the liver ascends and descends at every expiration and inspiration, it also changes slightly when the body is raised from a reclining to an erect posture; sometimes, even without any evident cause, the liver and the diaphragm are found to occupy a higher or lower position than usual.

For **descriptive parts** it has **upper** and **under surfaces**, an **anterior**, and a **posterior border**, **five lobes**, **five fissures**, **five ligaments** and **five sets of vessels**. The **upper surface** is convex and fits under the vault of the diaphragm, the **under surface** is concave and uneven, and is in relation with the stomach, the duodenum, the hepatic flexure of the colon, the right kidney and the suprarenal capsule.

The whole surface thruout the organ presents a number of impressions, formed by and named for those organs which rest against the liver. These are known as the gastric impression, where the stomach is in contact; the colic impression for the hepatic flexure; the renal, for the kidney; the duodenal, for the duodenum; and the impression formed by the gall-bladder. There is also a rounded eminence, the omental tuberosity, named for the omenta.

The **lobes** of the liver are five in number—the **right lobe**, the

THE ORGANS OF DIGESTION

left lobe, the **lobus quadratus** or the quadrate lobe, the **lobus caudatus** and the **lobus Spigelii**; the last three are parts of the right lobe and are found on the under surface of the lobe. The **right lobe** is larger than the left, is quadrilateral in form, and is located wholly in the right hypochondriac region. The **left lobe** is smaller, is flattened, and

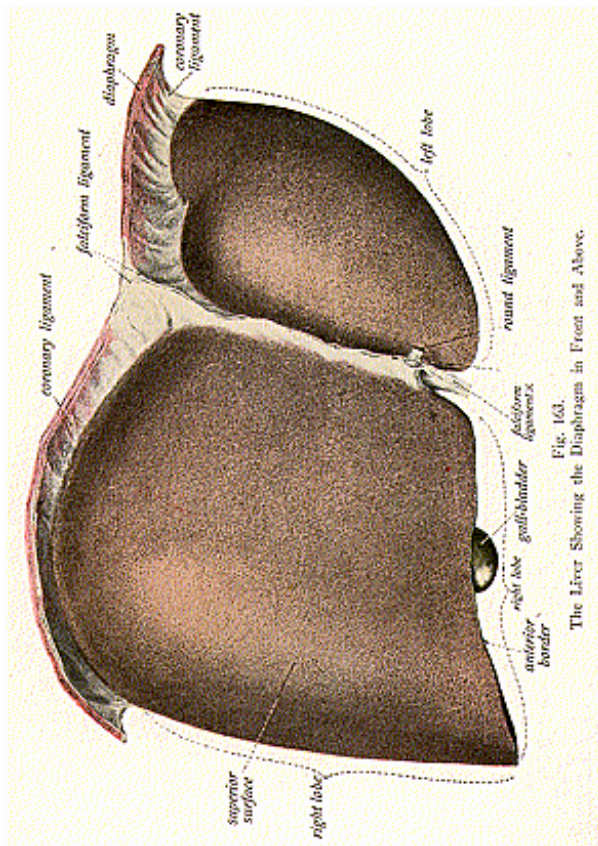


Fig. 163.
The Liver Showing the Diaphragm in Front and Above.

is situated in the epigastric and left hypochondriac regions. The **lobus quadratus**, or the square-shaped lobe, is situated on the under surface of the right lobe, and is in contact with the pyloric end of the stomach and with the first part of the duodenum. The **lobus caudatus**, or the tailed lobe, is a narrow portion of liver substance and it also is situated on the under surface of the right lobe; it separates the fissure for the gall-bladder from the fissure for the vena cava. The **lobus Spigelii** is situated on the posterior surface of the right lobe behind the portal fissure.

The **fissures** which divide the liver into five lobes are also five in number and are seen upon the posterior and the inferior surfaces; they resemble the letter H, being clefts or grooves which extend around the organ and lodge certain structures. The **longitudinal fissure** separates the right and left lobes, and is formed by the first two of the five fissures; its anterior part is called the *umbilical fissure* and contains the obliterated umbilical vein; its posterior part is called the *fissure for the ductus venosus*, and is a groove lodging the obliterated ductus venosus which later exists as a fibrous cord; the **transverse** or **portal fissure**, is short and deep, about two inches in length, and extends across the under surface of the left portion of the right lobe. It is sometimes called the gateway to the liver, because it lodges the portal vein, the hepatic artery and nerves, the hepatic duct, and numerous lymphatics; the **fissure** for the **gall-bladder** is a shallow fossa on the under surface of the right lobe, and contains the gallbladder; the **venal caval fissure**, on the posterior surface, lodges the inferior vena cava, which is here covered by a portion of liver substance called the *pons hepaticus*.

The **ligaments** also are five in number, four **are** peritoneal folds and the fifth is formed by the obliterated umbilical vein. The **suspensory**, or **broad**, or **falciform, ligament** is a double fold of peritoneum, attached to the under surface of the diaphragm and to the posterior sheath of the right rectus muscle to within one inch of the umbilicus it separates the right and left lobes; the **coronary ligament connects** the posterior surface of the liver to the diaphragm; the **round ligament**, or **teres ligament**, is a fibrous cord extending from the umbilicus to the under surface of the liver, and the **two lateral ligaments** right and left, extend from the liver to the diaphragm.

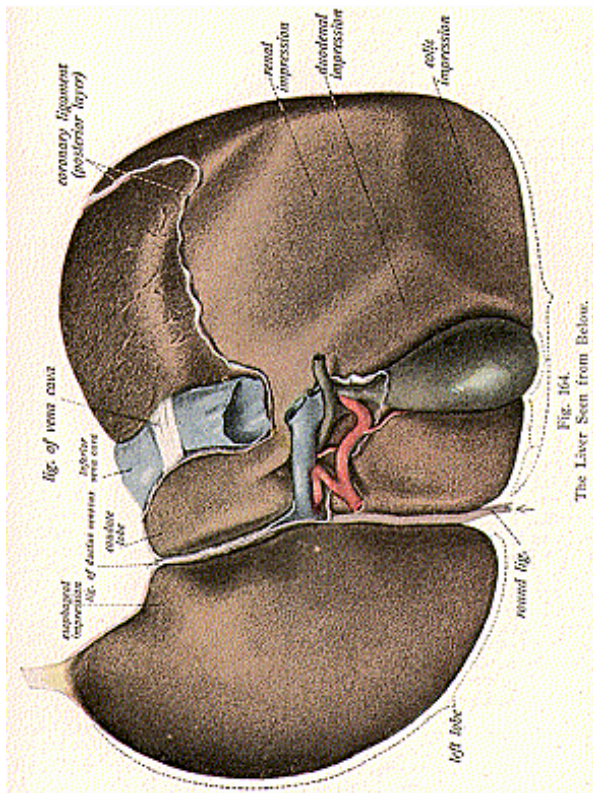
There are **five sets of vessels** connected with the liver; they are the hepatic artery and vein, the portal vein, the hepatic duct, and the lymphatics.

The liver has an external serous coat, derived from the peritoneum, which covers the greater part of the organ; beneath the serous coat is a fibrous coat, called the *Glisson coat*, consisting of areolar tissue, which at the portal fissure surrounds the hepatic artery, hepatic duct, and portal vein, and forms the *Capsule of Glisson*.

The **parenchyma** of the organ consists of lobes and lobules, held together by fine areolar tissue, blood-vessels, ducts and nerves. The lobules form the chief mass of the organ and are small granular bodies about the size of a millet seed, one-twentieth to one-tenth of an inch in diameter, very irregular in outline and closely packed together. Each lobule is composed of a mass of hepatic cells which form the

THE ORGANS OF DIGESTION

secretion; the ducts by which the secretion is carried away, the blood vessels conveying the blood to and from the organ, the lymphatics accompanying the blood-vessels, and the nerves, form a plexus.



The hepatic cells form the secretion and this secretion is gathered into minute vessels called the *intercellular biliary passages* or the *bile canaliculi* or *bile capillaries*; it is then gathered into *interlobular ducts* from between the lobules, these forming the *right* and the *left hepatic*

ducts from the right and the left lobes; the union of these two ducts forms the *main hepatic* duct about two inches in length, which passes out thru the portal fissure of the liver and joins with the cystic duct to form the **common bile duct**.

The **common bile duct** or the **ductus communis choledochus**, is about 3 inches in length and about one-fourth of an inch in diameter; it is a fibro-muscular tube lined with mucous membrane and conveys bile to the small intestine. It empties its contents into the descending part of the duodenum at a point about four inches from the pylorus; the common bile duct often joins the pancreatic duct to form the ampulla of Vater at their duodenal extremity, tho they may open separately into the duodenum.

Function of the liver—It forms and secretes the bile, and its property is to convert the glycogen stored away in the liver into sugar as required by the body, it also has the property of assisting the pancreatic juice in converting chyme into chyle for absorption in the intestine. Bile acts as a natural laxative and exerts some antiseptic influence in preventing the decomposition of food while in the intestinal canal. It is a secretion and an excretion, which is constantly being formed and discharged, a portion of it being held in reserve in the gall bladder, and poured out abundantly as soon as food enters the intestine; the amount secreted every 24 hours is two and one-half pounds or about one and one-half pints. The food when reached by the bile, is changed from a grayish mass to a yellowish mixture and it takes usually from three to five hours to digest an average meal. If the ductus communis choledochus is obstructed, the feces contain large quantities of undigested fats, the stools become hard, and death usually ensues in a short time, from absorption of the putrefied products. The liver is the largest of the digestive glands and plays a very important part in the metabolism of both the carbohydrates and nitrogenous materials.

The hepatic artery conveys the blood to the liver from the coeliac axis, and divides into numerous branches which pass to the capsule of the liver, to the walls of the interlobular vessels, and to the outer coats of the ducts, these arterial branches form a minute plexus between the lobules. The portal vein, formed by the junction of the splenic and the superior mesenteric veins, carries mixed blood; it passes thru the portal fissure and ramifies thru the liver like an artery ending in minute capillaries around the cells. The hepatic veins three in number, convey the blood from the liver to the inferior vena cava. The **nerve supply** to the liver is thru the hepatic plexus, derived from the coeliac plexus. The fibres from this plexus are derived from branches from the fourth dorsal pair of spinal nerves, emitting thru the 11th intervertebral foramina. It is these fibres which are subject to pressure that causes incoordination in the liver.

The **Gall-Bladder** (illustration No. 165) is a reservoir for bile. It is a muco-musculo-membranous sac, is pyriform in shape, and is situated on the inferior surface of the right lobe of the liver. It occupies the depression or fissure for the gall-bladder, close to the anterior border, and is directed obliquely downward and forward. It is from 3 to 4 inches in length, about 1 inch in width, and holds 1

THE ORGANS OF DIGESTION

ounce or perhaps a little more. It has, **four descriptive parts**, a **body**, **fundus**, **neck** and **duct**. The **body** is directed upward, backward and to the left, and rests upon the right end of the transverse colon and the first part of the duodenum. The **fundus**, which is round, touches the anterior wall opposite the 9th costal cartilage, close to the rectus abdominis muscle, and is covered by peritoneum. The **neck** is the

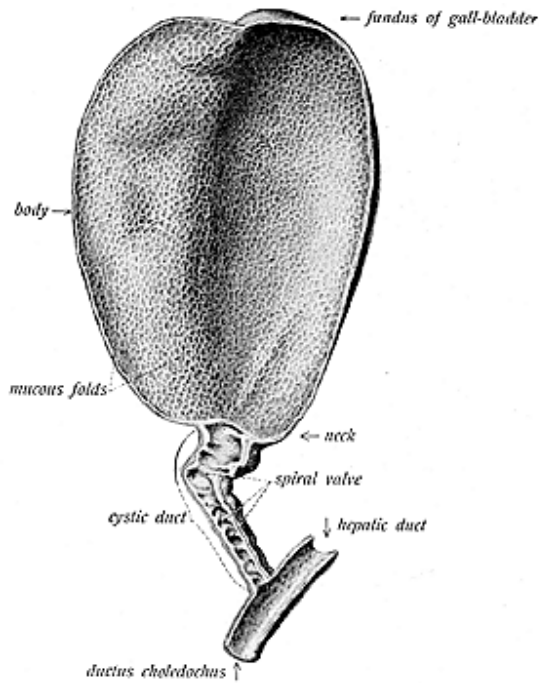


Fig. 165.
The Internal Surface of the Gall Bladder and Duct.

constricted portion and is curved like the letter S and it is continued into the cystic duct.

The gall-bladder has **three coats**; the **outer coat**, sero-fibrous, is derived from the peritoneum; the **middle** is muscular and its fibres run transversely and longitudinally; the **inner** coat is mucous and is not smooth, but, like the stomach, contains minute rugae, which allow for the distention of the sac, the mucous membrane is covered with columnar epithelium, the glands secreting a thick viscid substance. The

THE ORGANS OF DIGESTION

cystic duct is about 1 1/2 inches long and its diameter is about one-twelfth of an inch. It contains a series of folds of mucous membrane, which being spirally arranged, are called **spiral valves** or the **valves of Heister**; they moderate the flow of bile in and out of the reservoir. The cystic duct joins the hepatic duct to form the common bile duct, which ends in the small intestine.

The **blood supply** to the gall-bladder is from the cystic artery, a branch from the hepatic artery, and the veins empty into the right branch of the portal vein.

The **nerve supply** is thru the hepatic plexus from the fourth dorsal trunk of nerves.

The **biliary apparatus**, then, consists of the liver, the gland which secretes the bile; the hepatic duct, conveying the secretion away from the organ, the gall-bladder, which serves as a reservoir for the bile; the cystic duct which empties the sac, and the common bile duct, conveying the bile to the intestine. In the intestine, the bile mixes with the secretions from the stomach and pancreas and thus assists in the process of digestion, known as elaboration and assimilation.

THE PANCREAS

(Illustration No. 166.)

The **Pancreas** (all flesh) is a compound racemose gland and is called sweetbread when used as food. It is often called the abdominal salivary gland, because of its close resemblance to the true salivary glands. It is **located** behind the stomach, and in front of the first lumbar vertebra; it lies transversely across the vertebral column and is found in the epigastric, the mesogastric and hypochondriac regions; its greater part rests in the epigastric region, and only a small portion is located in the left hypochondriac region. It is 6 inches long, 1-1/2 inches wide, and 1-1/2 inches thick, it weighs about 3-1/2 ounces.

It is reddish-white in the living individual but grayish in the cadaver; it is soft in texture, long and irregular in shape, like a dog's tongue. It is covered with so thin a reflection from the peritoneum that the outline of the lobules may be seen thru the capsule, this capsule dips into the interior and so unites the various lobules together. For **descriptive parts** the pancreas has a **head, neck, body** and **tail**. The **head forms** its right extremity, is shaped like the head of a hammer, and lies in the loop of the duodenum seemingly bent downward; it lies in front of the aorta, inferior vena cava, the common bile duct and the right crus of the diaphragm.

The **body** of the pancreas extends from the head of the gland to the spleen, anterior to it are the transverse colon and the posterior wall of the stomach; posterior to it are the aorta, the inferior vena cava, the crura of the diaphragm, the left kidney, suprarenal capsule and the origin of the thoracic duct. The neck is about an inch in length and forms the connecting link between the head and the body of the gland. The tail is the left extremity, it lies above the left kidney, and is the narrowest portion of the pancreas. The pancreas is a compound racemose gland and so is composed of lobules, which are loosely arranged and held together by loose areolar tissue.

The *lobules* are reddish-white structures, consisting of groups of alveoli, which are saccular dilations arranged like a bunch of grapes;

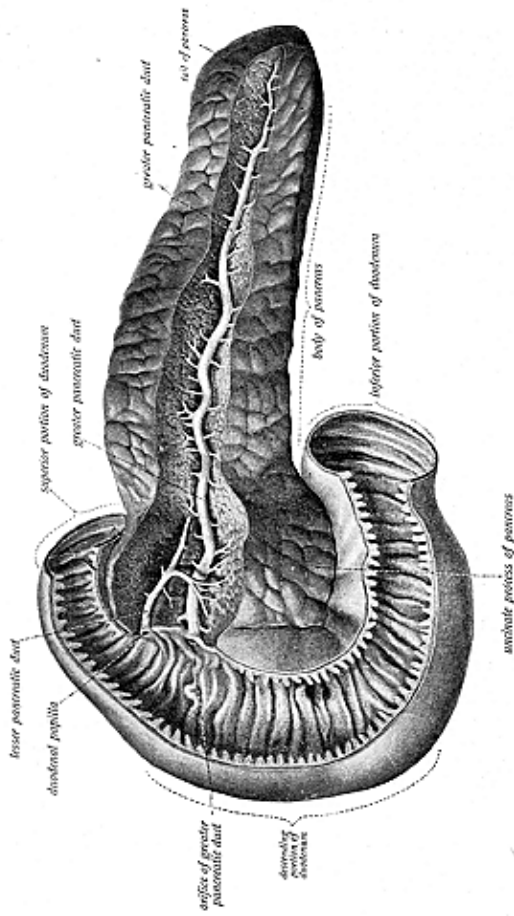


Fig. 166.
The Pancreas and Duodenum.

THE ORGANS OF DIGESTION

these alveoli or acini are long and tubular, terminating in caecal pouches, and are made up of secreting cells, blood-vessels, nerves, lymphatics, and ducts. The smaller ducts convey the secretion to a central duct, which begins at the tail end and becomes larger as it passes thru the center of the gland; all along its course it receives the secretions from the lobules, and is called the **pancreatic** duct or the duct of **Wirsung**. It is buried in the substance of the gland and appears as a thin, whitish tube, about the size of a goose-quill; it opens into the descending portion of the duodenum, close to the common bile duct and often in common with it.

The **Islands of Langerhans** are irregular structures in the pancreas; they are composed of spindle-shaped cells, the **cells of Langerhans**, which are smaller than the ordinary secreting cells and are found within the centers of the alveoli, they being continuous with the cells of the junctional duct. They are more numerous in the splenic end, or tail of the pancreas, than elsewhere. These masses are thot to have a part in the metabolism of carbohydrates and are considered as cells which constantly contain an internal secretion; the theory is advanced that these cells, forming the Islands, alone secrete trypsinogen.

It is not uncommon to find an **accessory pancreas**, called sometimes the **uncinate process** of the pancreas, it being a series of isolated lobules lying close to the head of the pancreas, usually detached, and having an excretory duct called the **accessory pancreatic duct** or **duct of Santorini**; this is usually small and empties into the main pancreatic duct.

The **blood supply** to the pancreas is thru the pancreatic arteries arising from the hepatic and the splenic, and thru the superior mesenteric arteries; the veins bear the same names and empty into the portal system. The **nerves** are derived from the coeliac plexus, and fibres from this plexus are derived from branches from the eighth dorsal pair of spinal nerves, emitting thru the 15th intervertebral foramina.

The pancreas furnishes a secretion which is used in the process of digestion for assimilation and elaboration, the secretion resembles saliva in many respects, and is known as *pancreatin* or *pancreatic juice*. It has four ferments, which are known as *trypsin*, which acts upon the proteids; *steapsin*, acting upon fats; *myopsin*, on albumens; and *amylopsin*, on the starches.

A *ferment* is an agent, in any of the various parts of the alimentary canal, which exerts a special action on the food as it passes along; there are two kinds of ferments—the unorganized, forming the enzymes of the digestive juices; and the organized, found in yeast-plants, bacteria and fungi. They are substances which produce chemical changes in other substances, without themselves being changed.

THE SPLEEN

(Illustration No. 167.)

The **Spleen (lien)**, is a so-called ductless gland, the largest of this class of glands in the body, and is situated in the left hypochondriac region, between the fundus of the stomach and the diaphragm, and

THE ORGANS OF DIGESTION

above the left kidney; its upper and inner part extends into the epigastric region. It is not visible from the front. It moves with respiration and with the movements of the stomach. It varies in **size**,

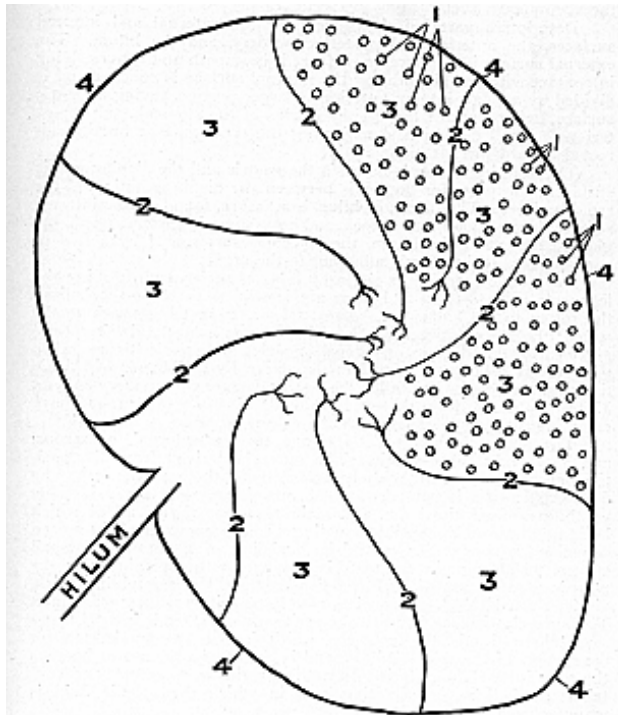


Fig. 167.
Cross Section of the Spleen.
1. Follicles or Secreting Sacs. 2. Trabeculae. 3. Areolae or Spaces. 4. Capsule.

being usually 5 inches long, 3 inches wide and 1-1/2 inches thick; it weighs about 7 oz. Its size and weight are liable to extreme variations at different periods of life, in different individuals, and in the same individual under different conditions. It is increased in size during digestion and varies accordingly, being enlarged in highly fed, and

THE ORGANS OF DIGESTION

small in starved, animals, it has been known to weigh from 18 to 20 ozs. It is oblong and flattened, of soft, brittle consistency, and is highly vascular; it is of a dark, purple, bluish **color**, the darkest of all the abdominal viscera.

Descriptive parts of the spleen are the **external** and **internal surfaces**, the **anterior** and **posterior borders**, and the **hilum**. The **external surface** is the **phrenic surface**; it is smooth and convex, lying in contact with the diaphragm; the **internal surface** is concave and is divided by a ridge, into an anterior or larger portion having a gastric surface, being directed toward the fundus of the stomach, and a posterior or smaller portion, constituting the renal surface because directed toward the left kidney.

The **anterior border** is between the gastric and the diaphragmatic surfaces; the **posterior border** is between the diaphragmatic and the renal surfaces. The **hilum**, or **hilus**, is a fissure, found on the internal surface, for the lymphatic vessels and nerves passing from, and to, the gland. Except at the hilum, the spleen is surrounded by a fold of peritoneum, it being firmly adherent to the organ.

The gland is held in position by folds of peritoneum forming the ligaments of the spleen and these are known as the *lieno-renal*, from the spleen to the kidney; the *gastro-splenic*, from the stomach to the spleen; the *spleno-colic*, from the spleen to the colon; and the *spleno-phrenic*, to the diaphragm. Small nodules of splenic tissue, when present, are usually connected to the spleen by thin bands of splenic tissue; these nodules are called the *supernumerary* or *accessory spleens*. They vary in size from that of a pea to the size of a walnut, and have essentially the same structure as the spleen proper.

The spleen is invested by **two coats**—an **external**, or **serous** and an internal fibro-elastic. The outer is derived from the peritoneum, it is thin and closely attached to the one beneath; the fibro-elastic coat is composed of fibrous tissue, with a considerable admixture of elastic tissue, and plain muscular tissue, all of which build up a strong, distensible covering. The **framework** of the spleen resembles a sponge-like material, consisting of a number of small spaces, which contain the material known as the splenic pulp, the pulp is a soft mass of dark, reddish-brown color, resembling thick, viscid, clotted blood. It consists of cells and intercellular substance. The fibro-elastic coat, beneath the peritoneal coat, sends inward many small fibrous bands, the *trabeculae*; which form a spongy skeleton for the support of the *splenic pulp*, found in the *areolae*, the spaces between the trabeculae. The pulp is of a netlike, reticular structure, and contains the follicles or secreting sacs in which the splenic fluid is manufactured.

Here and there are round or oval masses, enlargements, which on a cross section appear as grayish specks in between the splenic pulp; these are called the **Malpighian bodies**, or **corpuscles**, which vary in size and are localized expansions of the lymphoid tissue surrounding the arterioles.

The spleen, for a long time, was considered a gland of unknown function, yet not altogether a useless organ; therefore, many fancied functions have been given to the spleen, among them the following:

It was considered the seat of anger, "By the gods! ye shall digest the venom of your spleen." It is now considered to be the grave of the red corpuscles, and the birthplace of the white corpuscles. It has been said to be the place of origin of the ganglionic nerve cells, for it was thot to possess some mysterious influence over the mind.

It has been suggested that the spleen is concerned in the production of uric acid. A substance found in the spleen contains substances from which uric acid or xanthin may be readily formed by the action of the spleen-tissue itself. Herzon states that, "the spleen furnishes a true internal secretion which possesses a special affinity for the pancreas, the protrypsin of which it transforms into trypsin."

The spleen and the Islands of Langerhans are thot to be functionally united in the formation of a ferment, which is able to digest albumoid bodies.

Hirschfield sums up the splenic function as follows: "In man the organ makes the blood elements—lymphocytes and large mononuclears. The entrance of these into the circulation has not yet been observed. In anemias, leukemias and infectious diseases the spleen can form erythrocytes and granulocytes. The organ under normal conditions destroys erythrocytes and the hemoglobin becomes the bilirubin of the liver. The spleen regulates iron metabolism as well as hemoglobin metabolism. It is the regional lymph node of the blood and, generally speaking, destroys all particulate bodies which have fulfilled their uses, as well as foreign particles which have reached the blood, including bacteria. It also is the source of bacteriolysins, etc. For these reasons it always enlarges during infections. The spleen also exerts a regulating action on the formation of erythrocytes in the bone marrow, and **it has certain relations to digestion not yet understood.**"

Chiropractors have for the following reasons long maintained that the spleen furnishes a secretion, which is used in the process of digestion. The gland enlarges immediately when food is received into the stomach, and becomes congested at the moment when the stomach discharges chyme into the duodenum; it decreases to its normal size three to four hours after a meal, and again increases in size from the fourth to the fifth hour, the same as does the pancreas. In splenectomized animals, the bymogen (a mother ferment) accumulates in the gland-cells of the pancreas during a period of fasting, but it becomes rapidly and copiously transformed into trypsin only in the presence of renewed activity of the spleen and in direct proportion to its dilatation, so it would seem feasible that the spleen produces an internal secretion, a substance unknown to the average physiologist, which transforms inert zymogen, already deposited in the pancreas, into active trypsin, to pass into the secretion of that gland; for always in proportion to splenic dilatation is the action of trypsin in the pancreas.

Again—in artificial digestions the pancreatic juice alone, or mixed with an infusion of a contracted spleen, digests nothing or almost nothing, while the same pancreatic secretion, to which has been added the infusion of an engorged spleen, digests rapidly and copiously.

More recent investigations has shown that the spleen, like the

THE ORGANS OF DIGESTION

liver and some other organs, contains special enzymes, by whose action the split products of the nucleins may be converted to uric acid; it is probable therefore that this latter substance is constantly formed in the spleen and is carried to the secretions concerned in the process of digestion, thus the added secretions of the spleen assist very materially in the process not only of gastric, but also of intestinal digestion.

The muscular activity of the spleen, due to the action of its muscular capsule and trabeculae which causes it to contract and expand, is under the dominion of the nervous system; the **nerves** which supply the organ are derived from the splenic plexus. The fibres from this plexus are branches derived from the ninth dorsal pair of spinal nerves. It is these spinal nerves which are subject to pressure interference and causes incoordination in the spleen. The **blood supply** comes from the splenic artery, a branch from the coeliac axis, the splenic vein drains the spleen, and terminates in the portal system.

THE DUCTLESS GLANDS

A **Gland** is an organ for secreting and excreting a substance or substances to be used in, or eliminated from, the body, and among the various forms of glands are found the following: **simple tubular**, which may or may not be coiled, as the sweat glands of the skin; **sacculated glands**, as the sebaceous glands; when there are several sacs we have the **racemose gland**, as the salivary glands; **compound tubular**, as the testes, **lobulated**, as the liver, and then the **ductless glands**. This last class includes a number of organs said to be ductless tho forming an internal secretion, but not having any certain excretory duct, as do the liver, pancreas, etc.; from such the secretion leaves the gland by other channels.

All glands produce a secretion, and each must have its excretion so there must be some kind of a duct system, else the organ would become clogged and useless. The ductless glands, therefore, constitute a transitional serous tissue, with a specific cellular structure and chemical activity especially adapted to the performance of a definite function. These secretions are of the greatest importance to the metabolism of our economy, being very essential for the activity of all tissues, this subject is more thoroly discussed in connection with the serous circulation. The secretion of a ductless gland acts upon the incoming urea and converts it into a substance or essence having a chemical production, which is used in the general metabolism of the body.

The **so-called ductless glands** are the **spleen**, previously described the **supra-renal capsules**, the **thyroid**, **para-thyroids**, **thymus gland**, the **pineal**, **pituitary** and **Pacchionian bodies**. The *carotid*, *coccygeal* as well as the *para-sympathetic* bodies are sometimes classed as ductless glands, but they do not have the same structure and do not functionate similarly.

The general **structure** of one ductless gland might be applied to nearly all the glands in this group, in that they are surrounded by a serous capsule, derived from the surrounding serous membrane, be it the peritoneum, the meninges of the brain, or the fascia of the muscle;

THE ORGANS OF DIGESTION

beneath this outer coat is a fibro-elastic coat, which sends into the gland numerous fibrous bands separating its various lobes or lobules, or forming the framework for others; and within these lobules, or between the spaces, is found the glandular substance, which, of course, differs in the various glands.

THE SUPRARENAL CAPSULES

(Illustration No. 168.)

The **Suprarenal Capsules**, or **Suprarenal Glands**, the **Adrenals**, the **Atrabiliary Capsules**, or the **Renal Glands**, are two flattened bodies, the right one triangular in form and the left one semilunar; they are **located** above and in front of either kidney, are yellowish in **color**, and vary in **size**, but usually measure 1-1/2 inches in length, a little less in width, and 1/4 of an inch in thickness; each **weighs** about 1-1/2 drachms. They were called atrabiliary capsules because Galen and other ancient physicians claimed they secreted black bile, causing melancholia and mania.

These glands are comparatively larger in the fetus and so some

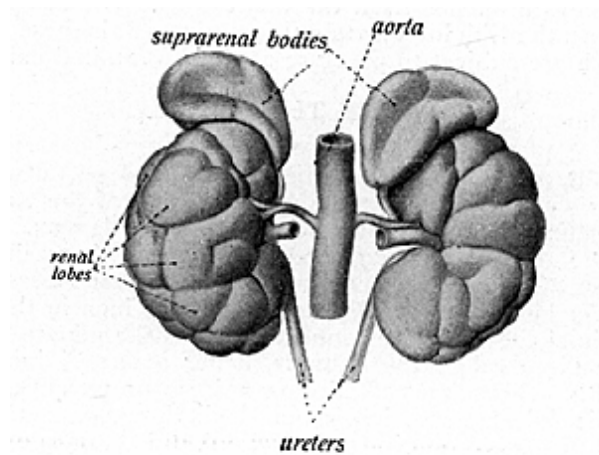


Fig. 168.

The Kidneys with the Supra-Renal Capsules.

authorities give their importance as being limited to the period of fetal existence. Each capsule is covered with a reflection from the peritoneum and from the transversalis fascia, which form the outer coat; beneath this is a fibrous capsule, which is quite thin and closely adherent to the substance, and which sends inward numerous trabeculae to form a supporting stroma. The **substance proper** of the gland is known as the **cortical portion**, which is composed of masses of cells, with channels between them, having a yellow tint; the inner portion is the **medullary portion**, which consists of a fibrous stroma, with bundles of connective tissue collected together and numerous granular cells, being pulpy, soft in consistency, and of a reddish-brown color, and having blood-vessels and nerves intermingled amidst the substance. Each gland has a hilum, which is a small depressed area

THE ORGANS OF DIGESTION

on the anterior surface, which lodges and transmits the vessels to and from the organ.

The impairment of the functions of the adrenal system involves a corresponding loss of resistance to the effects of all kinds of toxins, poisons and venoms, surgery has demonstrated that the adrenals have a secretion necessary to life for the removal of both the glands soon results in death, while so long as one adrenal is normal, life may continue, at least so long as any morbid condition affecting this organ intrinsically or extrinsically is not sufficiently advanced to interfere with its physiological functions. The removal of one of these glands is manifested by the generally progressive loss of muscular tonicity.

The adrenals secrete a fluid which acts upon the incoming urea, passing it thru a necessary transformation, and creating a fluid which is carried further on for use in the serous circulation.

The **blood supply** to the adrenals is from the suprarenal arteries, branches of the abdominal aorta, and the veins terminate in the inferior vena cava. Sometimes the left supra renal vein empties into the left renal vein. The **nerves** are derived from the renal plexus which conveys branches from the tenth dorsal pair of spinal nerves, emitting thru the 17th intervertebral foramina. It is these spinal nerve fibres which are subject to pressure at their foraminal exits.

THE THYROID

(Illustration No. 169.)

The **Thyroid Gland** is another ductless gland, **situated** at the front and side of the neck, at the upper portion of the trachea, being in close relation with the thyroid cartilage of the larynx. It is placed between the thyroid cartilage and the 5th or 6th tracheal ring; it **weighs** about 2 ounces and consists of **two lateral lobes**. Each lobe is about 2 inches in length, 1-1/4 inches wide, 3/4 inch in thickness, and is conical in shape; they are connected across the middle by a narrow transverse piece called the **isthmus**, being about 1/2 inch in length and breadth. Sometimes a third or middle or **pyramidal** lobe, not constant, is found. It arises from the isthmus, ascends from the upper part of the isthmus in front of the thyroid cartilage in the direction of the hyoid bone and sometimes reaches the hyoid bone, being attached to it. The thyroid body is covered by a serous capsule derived from the deep cervical fascia, and beneath this capsule is a fibrous capsule, which is thin and closely adherent and projects into the substance or framework, forming the septa. The lobes consist of lobules, made up of numerous closed vesicles, which are connected together by areolar tissue and are surrounded by a network of capillary blood-vessels and nerves.

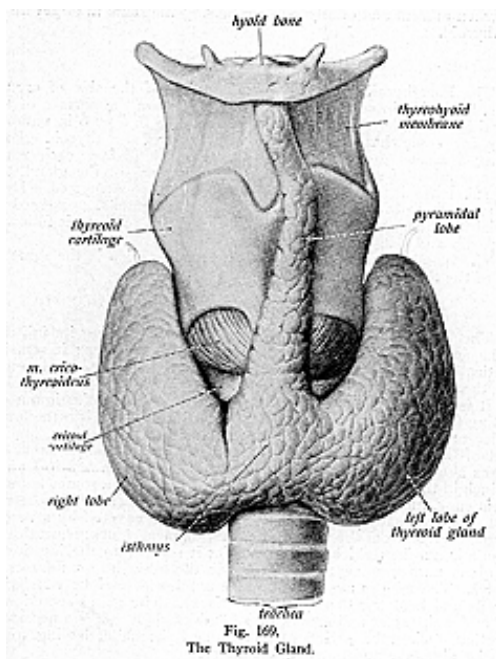
These vesicles are oval or spherical and each is lined with a single layer of columnar or cubical epithelium; they contain a yellow glairy fluid, glue-like, called the **colloid material**.

Authorities differ as to the function of the thyroid, some claiming it to be a gland which sustains the functional activity of the pituitary body and that with the adrenals it constitutes a system thru which cardiac action, respiration and general cellular oxidation are maintained. Also, that an infusion of thyroid extract stimulates growth,

THE ORGANS OF DIGESTION

but fails to enhance mental development in idiots; and again, that a too rapid growth leads to a softened condition of the bones, which results in the bending of those bones which have to bear weight.

The removal of the thyroid, if not fatal, results in bone-softening, and cretinism, while impairment of the functions of the gland are expressed in myxedema and goitre. Thus we conclude that the thyroid secretes one of the secretions necessary for the general meta-



bolism of the body, receiving from the incoming serum materials which are necessary for its nutrition, and giving in return its secretion for use further on in the system.

The **blood supply** to the thyroid is thru the thyroid anastomosis, from the superior and inferior thyroid arteries; the veins bear the same

THE ORGANS OF DIGESTION

names, and empty into the internal jugular and innominate veins. The **nerves** form a plexus about the gland, being branches from the sixth dorsal pair of spinal nerves and sometimes branches from the sixth cervical pair of spinal nerves, emitting thru the 13th and the 6th intervertebral foramina, respectively.

Accessory thyroids are isolated masses of thyroid tissue, situated near the thyroid, sometimes mentioned only as embryonic remains but when present and of any size are usually the same in structure as the thyroid.

THE PARATHYROIDS

The **Parathyroids** are two round bodies, of the size of orange seeds, brownish in color, and are embedded upon the surface of the lateral lobes of the thyroid gland; they may be 3, 5 or 6 in number. They are somewhat the same in structure as the thyroid gland, having a serous capsule covering them, which divides each gland into a number of spaces containing the substance of the gland, tho this substance is softer in consistency than in the thyroid. Most observers regard the parathyroids as distinct glands, possessed of special functions, and the removal of all or a part of them is followed by spasms and symptoms of tetanus.

The **blood** and **nerve** supply of the parathyroids is the same as that of the thyroid gland.

THE THYMUS

The **Thymus Gland** is a temporary organ, obtaining its full size at the end of the second year, when it ceases to grow; it remains practically stationary until puberty, at which period it rapidly degenerates, tho it does not entirely disappear.

It is **situated** in the upper part of the anterior mediastinum, extending from the level of the 4th costal cartilage upward to the lower border of the thyroid gland; it lies behind the manubrium, and in front of the anterior surface of the pericardium and aortic arch. It **weighs** about 1/2 of an ounce and measures about 2 inches in length, 1/3 inch in thickness, and 1-1/2 inches in width; it is of a somewhat soft consistency, and of a pinkish-gray **color**. It consists of **two lateral lobes**, which usually differ in size, and they are covered by a serous capsule derived from the surrounding serous membranes; beneath this capsule is another which is fibro-elastic; it sends into the interior of the gland numerous septa, which divide the lobes into a number of lobules. The lobules are made up of a number of vesicles consisting of cells and held together by areolar tissue. The gland secretion is of a milky character and somewhat resembles chyle. It is a necessary secretion during the period of lactation of the child, having to do with its digestive and nutritive functions.

This gland gradually disappears, so that in old age it is hardly discernible. In the adult it becomes penetrated by fatty tissue, and is usually replaced by a fatty body, containing the remains of the original gland and retaining its shape.

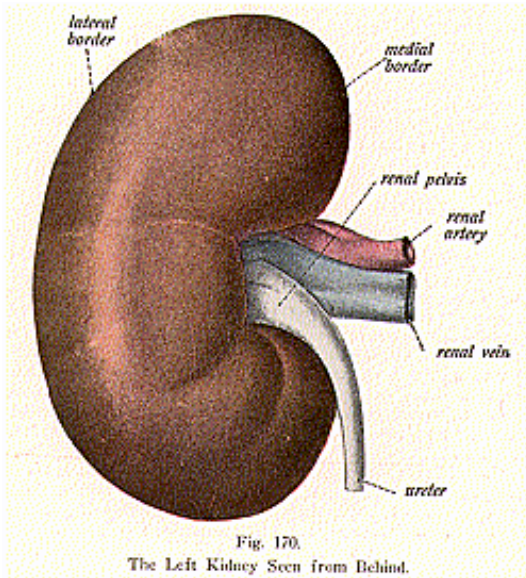
The **blood supply** is thru arteries **derived** from the internal

THE ORGANS OF DIGESTION

mammary and thyroid branches. The **nerves** are branches from the sixth dorsal and sixth cervical pairs of spinal nerves, emitting thru the 13th and 6th intervertebral foramina, respectively.

THE PINEAL GLAND

The **Pineal Gland (Epiphysis Cerebri)** is a small, reddish body, conical in shape, of about the size of a cherry stone, and located in the posterior part of the roof of the third ventricle of the brain. It is covered by the velum interpositum, a thin membrane derived from the pia mater. It is said to be large in the child, and larger in the female than in the male; it is a gland whose secretions are of a magne-



sia and lime character and, therefore, its secretion is sometimes called the brain sand. The pineal gland consists of a mass of tubular follicles filled with numerous cells which have a gritty substance within them. The function of this curious little body is not definitely known, but in birds, it is supposed to be associated with their homing instinct. For a long time it was considered as a rudimentary eye, owing to the fact that in reptiles it is suspended as from a stalk. By others it has been thought to be a remnant of an important sense, as it was in the pineal gland that Descartes placed the seat of the soul.

THE PITUITARY BODY

The **Pituitary Body (Hypophysis Cerebri)** is a small, reddish body, it weighs 5 to 10 grains, is oval in form, and is situated in the sella turcica of the sphenoid bone, where it is held in place by a process of dura mater—the diaphragma sellae. This process covers the pituitary and has a small opening in its centre, thru which the infundibulum, leading from the third ventricle of the brain, passes and constitutes one of the means by which the ventricles communicate with the spaces of the brain.

It is composed of **two lobes**, an anterior and a posterior lobe, closely attached and covered by a serous capsule; the elastic fibres from the capsule form tiny septa and divide the lobes into **lobules**; these are made up of tubules; lined with epithelium, held together by areolar tissue, and surrounded by a plexus of blood-vessels and nerves. Their secretion is phlegm-like in character, is carried into the system thru the serous fluids, and so plays an important part in the general metabolism of the body.

The **blood supply** comes from the pituitary vessel, branches of the internal carotid, the **nerves** are derived from those which supply the base of the brain.

THE PACCHIONIAN BODIES

The **Pacchionian Bodies**, or the **Arachnoid Villi**, are numerous whitish or purple-colored projections, grouped into clusters of variable size; they are **located** in the depressions of the cranial bones—Pacchionian depressions—on the outer surface of the dura mater, and are also **called Luschka's villi**. They are not usually visible in infancy, but increase in size from the seventh year and quite rapidly as age advances. These bodies are the thickened projections of the arachnoid membrane, and are classed with the ductless glands as to their function—they act as absorptive agents and serve to regulate the pressure of the cerebro spinal fluid in the subarachnoid space and in the ventricles; they constitute channels thru which the subarachnoid fluid can be drained away, or replenished.

The **Carotid** and **Coccygeal** are two small lymphoid bodies found, respectively, at the bifurcation of the carotid artery, and at the tip end of the coccyx; in structure they are similar to the ductless glands, yet are closely allied to the lymphatic glands or nodes.

The **Parasympathetic Bodies** were discovered in 1901, and there are from 1 to 6 of them; they are situated anterior to the abdominal aorta, at the level of the third or fourth lumbar vertebra.

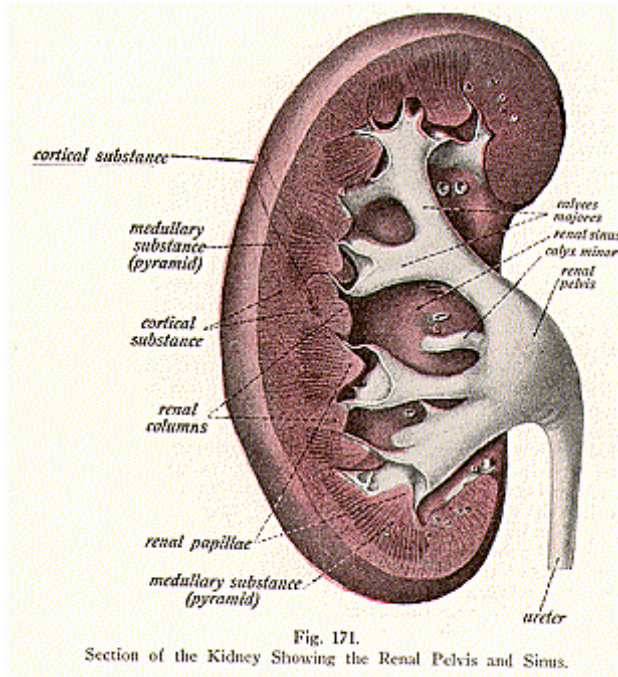
THE KIDNEYS

(Illustrations Nos. 170, 171 and 172.)

The **Kidneys** are compound tubular glands, two in number, right and left, which are **situated** at the back part of the abdomen near the spinal column; they extend from the upper border of the twelfth dorsal vertebra to the third lumbar vertebra, in the right and left hypochondriac regions, the right kidney being lower than the left.

THE ORGANS OF DIGESTION

They lie in a mass of fat called the *perirenal fat*, which differs from other fat, it being soft, delicate and of a light yellow color. Each kidney is 4-1/2 inches long, 2-1/2 inches wide, and 1 inch, or a little more thick; **each weighs** from 4-1/2 to 6 ounces. The kidney has the characteristic form of a flattened bean, is reddish-brown in **color**; the organ is not a solid body, but contains a cavity called the **renal sinus**, and has at its internal margin a deep fissure by which the vessels enter and leave. The kidney rests upon the psoas magnus and quadratus lumborum muscles, upon the tendon of the diaphragm, and the trans-



versalis muscle. In the adult, numerous ridges, facets and depressions are seen, they being the remains of the linear areas called lobes in the fetus.

Now the kidney is not held in place by any distinct ligaments or special folds of peritoneum, but its fixation, to a large extent, depends upon the pressure and the counter-pressure which is exerted upon it by neighboring structures, also upon its connections with the renal fascia. The kidneys differ in size, not only in different individuals, but

also in the same individual. There may be an entire absence of one kidney, or one kidney may be diminished in size, in which case there is a proportionate increase in the size of the other organ. It is not unusual to find the kidneys higher than normal and the number may be increased to three, the additional organ being lateral or median in position. The capsule of the kidney may be very loose, giving rise to the condition known as movable or floating kidney.

The kidney is not covered by any special fold of peritoneum, but receives a reflection from the peritoneum, which forms the serous capsule of the organ and is known as the **tunica-serosa**. For descriptive parts the kidney has a **hilum**, an **anterior** and a **posterior surface**, the **superior** and the **inferior extremities**, the **sinus** and the **external** and **internal borders**.

The **hilum** is a fissure leading into the cavity, or sinus, of the organ and transmits the renal vessels, nerves and the ureter. The **anterior surface** of the right kidney is in contact with the suprarenal capsule, the right lobe of the liver, ascending and transverse colon; the anterior surface of the left kidney, with the suprarenal capsule, the spleen, and the splenic flexure of the colon. The **posterior surface** is directed backward and lies upon the diaphragm, the lumbar aponeurosis, the psoas and transversalis muscles. The **superior extremity** is thick and rounded and is capped by the suprarenal capsule. Its **inferior extremity** is smaller and thinner, and, in the normal position, extends to within two inches of the crest of the ilium. The **renal sinus** is the central cavity of the kidney to which the hilum leads. The **external border** is convex and faces the posterior lateral border of the abdomen; the **internal border** is concave and opens into the sinus.

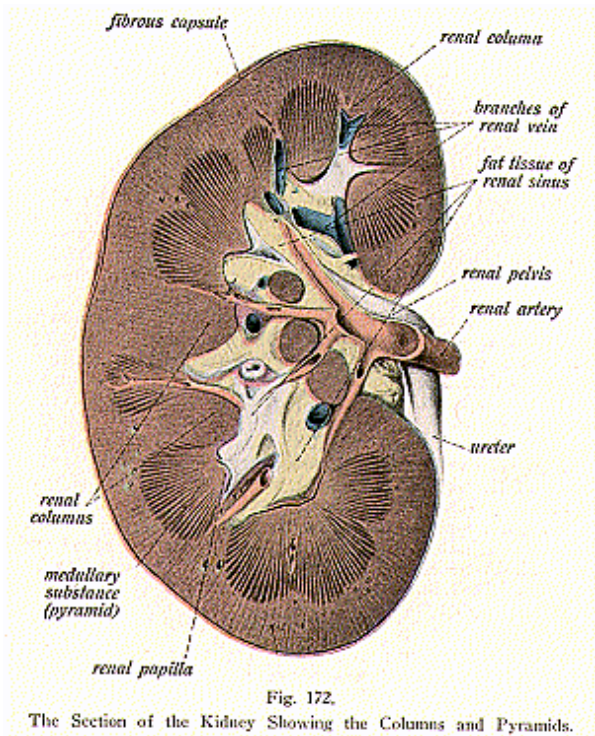
When a kidney is cut into halves (illustration No. 172) by a longitudinal incision carried from the outer to the inner border, it is seen to be composed of two parts—the **cortical** and the **medullary portions**. The **cortical portion** is the glandular, investing part, bright reddish-brown in color, is soft and easily lacerated, and is about 1/2 inch deep; it is found beneath the serous capsule, and sends prolongations between the **Malpighian pyramids**; these prolongations are called the **cortical columns**, or **renal columns**, or **columns of Bertin**; the portions over the bases of the pyramids are the cortical arches. The **cortical substance** consists of small reddish bodies (**Malpighian**), and convoluted tubules, embedded in a fibrous stroma (bed), which contains vessels and nerves.

The **medullary portion** is made up of red-colored, striated cone-shaped masses, consisting of a large number of diverging tubules bound together by fibrous tissue, containing vessels and nerves. These cone-shaped masses are made up of a number of pyramids called the **pyramids of Malpighi**, their apices converging towards the center, where they form prominent papillae, called the **renal papillae**; these papillae project into the interior of the **calices**, which lead into the cavity or **sinus**. The cortical and medullary substances are dissimilar in appearance, but similar in structure. The medullary portion is the collecting portion of the uriniferous tubules, arranged in pyramids. These pyramids vary in number from eight to eighteen, the average number being about twelve. The **bases** of these pyramids are **directed**

THE ORGANS OF DIGESTION

towards the circumference, while their apical parts are called the papillae, which, as was just stated, project into the sinus.

The **Malpighian bodies** or **corpuscles** or the **glomeruli** (small ball), appear as small dark spots, which represent the beginnings of the uriniferous tubules; each Malpighian body consists of a tuft, a pouch-like commencement, formed of a plexus of vessels and nerves. They are very much convoluted and are held together by connective



tissue. Each body measures about 1/120 of an inch in diameter. A capsule, called the **capsule of Bowman**, surrounds the tuft, and is a delicate supporting membrane.

The **uriniferous tubules** or **canals**, or **tubuli uriniferi**, commence in the cortical portion of the kidney at the Malpighian corpuscle, and pursue a very circular course thru the cortical and the medullary portion, they open at the apex of the pyramid, emptying their contents into the calices of the kidney.

THE ORGANS OF DIGESTION

In their course they present many alterations in shape and direction. At their junction with the Malpighian corpuscle they have a constricted portion called the **neck**; then the tube becomes convoluted and forms of **proximal** or the first convoluted tubule; from here the tubule takes a spiral direction and forms the **spiral tube**. Then, as it enters the Malpighian pyramid, the tubule suddenly becomes very narrow, and forms the **descending limb of Henle's loop**, or the descending tubule; from here, taking a sharp bend, it forms a loop called **Henle's loop**. It then retraces its course into the pyramid, in which it becomes quite enlarged and as it passes upward, it forms the **ascending limb of Henle's loop**, where it then re-enters the cortex, becoming narrow. It then forms a zigzag, or very irregular, tubule called the **distal convoluted tubule**, which leads into a **straight tubule** which unite to form the ducts of Bellini and end where each opens on the apex of the papilla; thru these openings the urine passes into a **calix**. Connective tissue holds together these tubules, which are cone-shaped masses of over a thousand in number, consisting of a basement membrane lined with epithelium, which varies in the different parts of the tubules. If the surface of a papilla is examined, it is seen to be studded with from 16 to 20 openings; in the fresh kidney, pressure being made, a fluid will be seen to exude from these depressions, for they are the orifices of the uriniferous tubules.

The calices (singular-calix), are cup-like tubes surrounding the renal papillae; they empty into the renal pelvis.

The **pelvis of the kidney** or **renal pelvis** is a dilated portion of the ureter and is flattened from before backward it divides into two or three funnel-shaped divisions called the **infundibula** or the **large calices**.

The function of the kidney is to separate from the serous tissue, materials, which when transformed constitute urine. It is that ending place of the serous circulation where by the osmosing of urea thru its texture converts their substance into that known as urine.

The **blood supply** to the kidney is thru the renal artery, a branch from the abdominal aorta; the renal vein drains the gland and ends in the inferior vena cava. The **nerve supply** is by branches from the 10th, 11th and 12th dorsal pairs of spinal nerves.

THE URETERS

The **Ureters are two** tubes which convey the urine from the kidney to the bladder; they are pale-colored, thick-walled ducts, about 14 or 16 inches in length. The lumen of the ureters is of the size of a goose-quill. They begin about opposite the first lumbar vertebra, and pass obliquely downward along the abdominal wall to the sides of the wall of the bladder, where each duct opens by a constricted orifice into the bladder. The ureters have **three coats—an outer fibrous**, continuous with the capsule of the kidney; a middle coat, made up of **muscular** tissue, consisting of an external longitudinal layer, a middle circular, and another layer of longitudinal fibres, and an **inner, mucous** coat, covered with transitional epithelium.

The ureter passes downward, inward and forward, and lies upon the psoas muscle; it crosses the common iliac artery, passes behind the

THE ORGANS OF DIGESTION

ileum on the right side and the sigmoid colon on the left side. In the female, the ureters pass along the upper part of the vagina and the sides of the neck of the uterus. The urine passes from the pelvis of the kidney, the dilated portion of the ureter, into the bladder; it does not flow at any fixed rate; nor does it enter the bladder at regular intervals; but on the contrary, it drops into the bladder every minute or two. The papillae at each orifice form a valve-like arrangement which closes, and, in the dead subject, form a semilunar fold called the valvulae ureteris. The openings of the two ureters into the bladder, when the organ is empty, are about one inch apart.

The **blood supply** to the ureters is by branches from the renal, the internal iliac, and the vesical arteries; the renal veins, leaving thru the hilum, empty into the inferior vena cava. The **nerve supply** is the same as that of the kidney.

The **bladder** and the **urethra** will be considered with the generative apparatus, as to the differences found between the male and female organs.

MUCOUS AND SEROUS MEMBRANES

Membranes are thin, sheet-like tissues, more or less elastic, varying in their structure and useful properties. They absorb or secrete fluids, connect certain parts of the body, separate, envelope, or form certain organs, or act as partitions between **two fluids** or **gases**, permitting them to mingle.

Mucous membranes are soft and velvety, and have on their free surface, cells for absorption or motion, and in their substance, follicles which secrete mucus for lubricating purposes.

Serous membranes facilitate the motion of the organs they envelop (abdominal digestive organs, the lungs and heart) by reason of the serum they secrete; they also maintain the shape of these organs.

Allied to the serous membranes are the synovial membranes lining the movable joints. By reason of their smoothness and by the aid of their lubricating serum the ends of bones move readily upon one another.

A **Mucous Membrane** so-called on account of the mucous fluid by which it is constantly lubricated, consists of a lining of epithelial cells on a basement membrane, which is the elastic, cellular, and secreting membrane upon which the epithelial cells rest; these flattened epithelial cells, with the connective tissue cells, enter into the formation of mucous membrane, as also do fibres, blood- and lymph-vessels. These membranes line cavities which communicate with the exterior of the body, such as the alimentary canal, respiratory and the uro-genital system.

The mucous membranes are attached to the surrounding structures by a sub-mucous layer of areolar tissue. The latter varies in thickness and density, consequently, the firmness of the union between the mucous and sub-mucous layers differs greatly in various localities. Usually the attachment is loose and readily permits changes in position and tension, which in the relaxed condition is often thrown into numerous folds or rugae, as in the stomach, gallbladder, etc. In other places the folds are permanent and are not effaced by the distention of the organ; an example of such arrangement is seen in the valvulae conniventes of the small intestine.

A **Serous Membrane** is transparent and thin. One surface adheres to other textures, the other is smooth, polished and moistened by a fluid. This membrane resembles an areolar membrane and consists of a lining of endothelial cells, elastic fibres, blood-vessels and nerves, and this membrane secretes a serous fluid which is viscid and is more of a lubricant than mucous. It is found lining cavities which are enclosed and do not communicate with the external such as the pleural, pericardial, and peritoneal cavities, also the cavities of joints and of the brain.

It is claimed that these cells on the serous membrane can produce a secretion that clots, and that in this manner adhesions are quickly formed to prevent the spreading of peritoneal infections; and secondly, that these serous-membrane cells act as phagocytes which feed upon bacteria, destroying them and thus act as scavengers.

SEROUS CIRCULATION

Serous Circulation is an original theme, and my aim is to present these thoughts as briefly, yet as lucidly, as possible. The subject is covered minutely in Volume II, under circulations, and by Dr. B. J. Palmer himself; so it will be my purpose, in these few pages, to present the subject as a finishing touch to the subject of the organs of digestion. I do not only suggest to the student, but urge, that he supplement the reading of the following article, by a careful study of Serous Circulation in Vol. II, also the lecture upon the "Wet and Dry Man," which will be found in the same volume.

The Serous Circulation was at one time a pet dogma of Dr. B. J. Palmer's, but it is now being recognized by scientists more generally. We, as Chiropractors, take great pride in the fact that the establishing of a **serous circulation** belongs to Chiropractic and is due to B. J. Palmer, who labored long and hard to prove that there is no other function so absolutely necessary to the maintenance of life as is the Serous Circulation. Discovered in the winter of 1905, it has provided a reasonable solution of the problem of many abnormal symptoms that were until then unsolved, and contrary to the history of many ideas which become great, this discovery was not accidental, but was evolved by clinical deductions, drawn from personal observation and study of the symptom groups observed in those cases which Dr. Palmer has so aptly described as the Wet and Dry Man. The Serous Circulation is, therefore, the outcome of months of study. By way of explanation, the discovery (if you will) came about in this way: Certain patients entering the clinic of the Palmer School of Chiropractic presented peculiar conditions. As usual, there was asked the question "why" and, after consulting Butler, Osler and a dozen other authorities in the library, no reason for, nor explanation of, those conditions could be found. As in hundreds of other like questions, Dr. Palmer was compelled to answer the why himself.

A brief outline of the human circulations might better clear the atmosphere for the addition of this one great circulation.

Air circulation is effected when air is carried to the air sacs of the lungs, passing thru a series of tubes which end around the air cells of the lungs. The blood circulation, which begins in the left ventricle, is established when the blood is carried thru the aorta, the large artery, to be distributed to all parts of the body; it courses from arteries to arterioles, to capillaries, to venules, to veins, and back to the right auricle of the heart, by the Pre and Post Cava and the coronary sinus; then to the right ventricle, thence thru the pulmonary artery to the lungs, where the exchange of CO₂ and O takes place. The **nerve circulation**, which starts in the brain, from its various centres, conveys mental impulses thru efferent nerves to the tissue cell and thru afferent nerves again to the brain. The **lymphatic circulation** arises in lymph spaces thruout the body, and in the lacteals, with their milk-colored stream of chyme which is carried to the recepta-

SEROUS CIRCULATION

culum chyli, and has really no definite ending other than in the tissue and the subclavian veins, where the principal ducts terminate.

In its broadest lines the serous circulation may be described as embracing the entire fluid element of the physical body. This fluid element is constantly being placed, eliminated, and replaced, in approximately equal volume. It constitutes more than two-thirds of all the bodily tissues taken as a whole.

The reception, distribution and elimination of this fluid element must, therefore, be accorded a position of prime importance in any comprehensive study of the human anatomy.

We have, then, to state that, in the broadest sense, the serous circulation embraces the circulation of fluid within the blood-vascular system, within the lymphatic system, and also the circulation of all serum of the body outside of these well defined and definitely enclosed channels.

In its limited sense we may here, for convenience, describe the serous circulation as it exists outside of the blood-vessels and outside of the lymphatic vessels.

The serous circulation begins wherever and whenever the serous fluid passes out from, or exists outside of, the lymphatic and blood-vascular systems. A considerable part of its origin is had from the stomach, and from the small and large intestines, but it may be said to have its origin in any of the tissue cells which line or surround the alimentary tract. This is true, because fluids enter the body by this tract, and such fluids become serum whenever and wherever they are absorbed by the tissue cell. When so absorbed and transformed into serum, it has already entered into, and become a part of, the serous circulation, to be carried to, thru, and from, all the tissues and glands of the body; it bathes each tissue cell, contributes necessary nourishment to it, and carries from the tissue cell its remaining original elements and also such elements as may have been contributed to the serous fluid by each cell so bathed.

The serum of the serous circulation is the original conveyor of all nutrition of the body; together with a much smaller percentage of solids, it forms the blood and the lymph and, by osmosis, the serum of the blood and lymph may again and again pass thru the vascular walls to alternately bathe the tissue cells outside of those fixed channels, and return to those channels.

It completes a circulation to, thru, and from, the tissue of all glands of the body and might be called a glandular circulation, for all glands are greatly concerned in contributing to and taking from its fluids, the kidney being particularly involved. The **basis**, then, of this circulation is the glandular and interconnective and supportive tissues, for all these tissues are connected, thus form a chain, and are **inter-communicative**.

Each glandular secretory product issues direct to some specific end, or helps to form another element of other composition. Serous Circulation is the chemical-agent, and re-agent, maker of man. The blood circulation conveys O to, and CO₂ from, the tissues and, just as in the serous and lymph circulations, mental impulses are necessary to enable each or any of the three circulations to accomplish its own

particular function. The **serum of the serous circulation** is neither lymph nor blood, altho both lymph and blood have an abundance of serum in their composition.

Serum is the whey, the clear portion of any animal liquid when separated from its more solid constituents; for example, it is the clear liquid which separates in the clotting of blood. Prick the skin, if you will, and you will find a flow of blood for a period, then a flow of liquid, which is not blood; they are alike only in their fluid constituents, which are the same in the serum of the serous circulation, and in the serum of the blood. This is serum, or it is serum in a transitional change.

Lymph is a transparent, slightly yellow or straw-colored liquid, alkaline in reaction, which fills the lymphatic vessels and passes, in a definite direction, thru channels provided with valves like those of blood-vessels, and having the same coats and walls as do the arteries and veins. Lymph is more dilute than either plasma or the cerebro-spinal fluids. Lymph contains proteins, salts, and extractives; coagulates because it contains as much fibrin as does blood, but it contains less albumin and more water, while under the microscope it is seen to contain corpuscles. The **lymphatic system** is an intermediate system, wherein the refuse serum from all over the body is gathered and poured into the blood stream to be utilized elsewhere by the absorption from it of some substance which is of value in helping to sustain the glandular system.

There are two main divisions of the serous circulation. The **intra- and inter-cellular circulations** and **five steps** might be given: (1) **transformation**, the forming of food into serum; (2) **serous**, the lacteals sap it up from the small intestine, (3) **ureac** or **ureal**, in which serum is carried to the glands, takes substance to, and from, them and is then finally carried to the kidneys and to the skin for ultimate excretion; (4) **reninogen**, serous circulation thru the suprarenal capsules; and (5) the **urine**, the kidneys.

Serous circulation establishes a circulatory system between glands; **direct**, by circulation to and from the cell; and by **osmosis**, thru the cell. Glands known as "ductless" are much concerned in this circulation. The **spleen**, which is the largest, has been much discussed and many functions have been given to it. We know it is a gland, and that it has no main canal or duct like the liver or pancreas, yet, it enlarges during digestion and, like all glands, furnishes a secretion which is used in the body, or is eliminated from the body. Whether the secretion is carried by a canal or otherwise may not be decided, but there must be an outlet for the organ, else it would become clogged. The necessary fluids and solids enter the individual cell of the gland by inter-cellular and intra-cellular serous-circulation channels. Secretions and excretions must reach their final destination by the same channels.

The blood-vascular and lymphatic circulations must deliver and collect their respective portions of the glandular secretion and excretions thru the same serous-circulation channels. The quantity or place of such reception has not been determined, but the serous fluid of the body is constantly passing into, from, and between all living

SEROUS CIRCULATION

tissue cells, hence the great scope and importance of this most comprehensive of all circulations of the body.

The same principle applies to the other ductless glands; the **adrenals** furnish a secretion which received the name of black bile and we find many untoward manifestations resulting from a removal of the glands, particularly the loss of muscular tonicity; the **pineal** gland, located in the third ventricle of the inter-brain, furnishes a secretion of a magnesia and lime character; the **pituitary**, located in the sella turcica of the sphenoid bone, secretes a substance of phlegm-like character; the **arachnoid villi**, or Pacchionian bodies, located in depressions of the parietal, frontal, or temporal bones, serve as absorptive agents; the **thyroid**, situated in front and at the sides of the neck, contains a yellow, glairy, or glue-like fluid called colloid material, the removal of these glands results in cretinism and myxedema, they are thought to furnish a secretion resembling iodine; the **thymus gland**, tho only a temporary structure, attains its full size as early as the second year, when it ceases to grow, but during that time it secretes a substance, milk-like in character and furnishing a chemical during the lactation period, necessary for the nutrition of the child; and the **parathyroids**, two round bodies of the size of orange seeds, imbedded upon the surface of the lateral lobes of the thyroid gland, are possessed of special functions, for the removal of them is followed by spasms. Among other secreting glands are the simple, serous and mucous glands of the secreting membranes, also the synovial, lymphatic, and lacrimal glands.

Many are the problems of secretions and excretions but the serous circulation clears up many of these problems which had never before been satisfactorily solved, thoroly understood, nor explained.

Serous circulation is to man what the sap system is to the tree, a direct circulation to the cell and between cells by osmosis; it is a seeping process, slow to be sure, for there are many millions of cells involved, and any circumscribed area may readily be involved in an excess or lack of this serum. The tissue cell expands, grows and functions only when favorably supplied and nourished by the serum; like the vegetable cell, it lies dormant or decays in arid and swampy soils. Each cell acts as the absorber of its own sap, or of its own serum. Man is inclined to recognize only the more prominent chemical changes going on in the body, yet he should regard the many less prominent chemical changes which frequently are so minute that the eye does not see, nor can the mind readily conceive of them.

This idea makes the individual areas a specific study and gives to each cell its individual cellular activity, as regards the serous circulation. While this circulation is general, yet its utilization becomes specific to each cell. Look for that agent or element which expands every living cell, and water, in one form or another, will be found as that agent. No vegetable substance can be named which will not expand, if placed in water; as for instance the sponge, bean, wood or corn. Take a bulb plant, the hyacinth; it represents little until placed in water, but what a beautiful flower then evolves. Water in the ground, is absolutely necessary for the development of vegetable life, and why should man be different? We know that two-

SEROUS CIRCULATION

thirds of the bodily weight is of water, which, when transformed, becomes serum. In blood we have a predominating proportion of serum; lymph contains serum, while the lymph nodes or glands may be said to be the intermediate agents between the lymph and serum.

Water is the most important of the inorganic constituents as it is indispensable to life. It is present in all tissues and fluids without exception; from 99 per cent in saliva to 80 per cent in blood, 75 per cent in muscle, and 2 per cent in the enamel of the teeth, hard and dense as is that adamantine substance.

Remove the moisture from a body by cremation, and the ashes remaining can be put into a small urn as dust. Seven-eighths of the substance of even the brain is water, therefore, how essential to us must be the study of that fluid substance which constitutes a two-thirds part of our bodies. Its entry into all tissues, its passage thru, or its absorption by, all parts constitutes the serous circulation, and can only be explained as a serous circulation.

The serous circulation begins thruout the alimentary tract, principally in the small intestine, which is the true distributor and converter of nutrients from the inside outward; it is at this point that water, mixed with the juices of solid foods, which have been digested, is converted into serum. The watery fluid content of the alimentary tract is known as a serum after having seeped, by osmosis, thru the walls of the small intestine into the serous tissues. Serous Circulation begins in the process of osmosis, this clear liquid conveying nutrition to all parts of the body. Each gland receives, from the incoming urea or serum, that which is necessary for its nutrition and function, and in turn gives to this fluid the chemical it manufactures, for the use of other glands and tissues.

Each gland is invested by a serous-capsule covering. Bones are covered by periosteum and bones atrophy and die if the periosteum be scraped from the bone; cartilage has the perichondrium; muscles have fascia, the lungs the pleurae; the heart, the pericardium; brain and spinal cord have the meninges for a covering; and the abdomen has the peritoneum. Thru these capsules, which invest the organs, is the fluid transmitted, not by a series of ducts but by minute canals or canaliculi. The period from the time the fluid leaves the intestines, until it reaches the tissue, may vary from twenty-four to forty-eight or even to seventy-two hours, depending upon the parts or areas involved.

The serous circulation ends principally in the kidneys and in the skin, but it may be said to end wherever and whenever the serous fluid ceases to be a useful part of the tissues of the body and enters a definite channel for elimination from the body. If the living body is immersed in an ice cold bath, the pores close like so many gates; if a turkish bath is taken, then the perspiration is profuse from the inside outward. The kidneys serve as the filters, but all glands are, like component parts of a chain, each depending on the other for its maintenance; thus in parotitis the salivary glands are closely related to other glands, for in the incoordination of the parotid glands, other glands are similarly affected. The elimination of waste material is

SEROUS CIRCULATION

accomplished principally thru the kidneys, in the form of urine, and thru the skin, in the form of perspiration.

The relation of the secretion of the skin to that of the kidneys is a very close one. Thus, copious secretions of urine, or water-evacuations from the alimentary canal, coincide with dryness of the skin; while abundant perspiration and scanty urine are conditions which usually exist coincidentally. Adaptative departures from the normal secretions must follow any and every interference with the action of the kidneys, whether that interference results in an excess of, or in a lack of, secretion and excretion. In the conditions known as uremia, when the kidneys excrete little or no urine, an increased quantity and percentage of urea is thrown off from the body in the sweat; the sputum and saliva also contain urea under those circumstances. In some cases of uremia, when the skin excretes so abundantly and the sweat dries on the skin, the patient is covered with a coating of urea crystals; so the sweat, like the urine, must be regarded as an excretion, formed by various secretory cells, and conveyed to the skin for the purpose of elimination.

Previous to going to the kidneys, a small portion of the urea goes thru the suprarenal capsules, whose function it is to extract certain chemical substances from the urea, thus is conferred upon those organs the function of making a specific substance which is necessary for the maintenance of muscular tonicity. Very limited and poor would be digestion, if the nutritive fluids were not acted upon by this fluid. It is an absolute necessity.

May, 1917, in the Rockefeller Institute, Doctor Meltzer brought forth this idea and, as nearly as I can, I will quote him: "The students were practicing sero-therapy and, by injections of adrenalin, strich-nine, morphine, and other drugs, into the mucous membrane of the eye, various demonstrations and remarkable symptoms were observed, showing the distribution of the drugs takes place thru the spaces separating the tissues and thru the fluids other than those of the blood and lymph which fills these spaces, thus giving more or less a connected system of communication thruout the entire body." Now the main function of the kidneys is to osmose urea thru its texture, converting it into urine. The true secreting part of the kidney thus serves as a filtering apparatus.

The term excretion is better than secretion when applied to the kidney, for the constituents of the urine are not actually found in the kidney; the kidney is simply the place where they are picked out from the serous tissues and eliminated from the body. Every secreting apparatus consists essentially of a layer of secreting cells, arranged around a central cavity, and they take from the serum the necessary material and transform it into a secretion which they pour into the cavity. Investigate the structure of the kidneys, which complete the circuit of the serous circulation; they are like two sponges contracting and expanding, and by this principle they draw urea, after it has passed thru the successive stages, from serum to urea. The investment of each kidney by a serous capsule allows the urea to pass thru this sheath, which is the end of the channels thru which the circulation is maintained. It moves thru, and glides into, the interior structure

SEROUS CIRCULATION

of the kidney, eventually reaching the pelvis of the kidney into which the urine gathers; here the urine represents the final waste. Likewise of the skin, the sudoriferous and sudoriporous glands are like many little vacuums, sucking the serum, which as urea has by this time become waste, to be given off thru the pores of the skin.

The propelling force of serum is thru the muscularis mucosae or direct muscular contractions, all along the path which gives to it a specific movement, all of which combined makes a definite, direct, and specific set of movements thruout the serous body. Serous circulation is the nutrient conveyer but, like a circle, is unable to be described as to a single fixed point of commencement or of termination. Every gland and tissue is doing its particular work, which work bears a common relationship to the work of every other gland. The **secretions**, as a rule, consist of substances which do not pre-exist in proper form in the membranes; their production requires special cells and a process of elaboration for their formation, e. g., the liver cells for the secretion of bile, the mammary gland cells for the formation of milk, etc. The **excretions**, on the other hand, commonly consist of substances which exist ready formed after the organ has taken from the serum what is needed.

If for any cause the gland is unable to get substances from which to form its secretions, as occurs in abnormal conditions, when the serous circulation is in excess or not enough in the excretory organ, the separation of a normal, or excessive, excretion is prevented, and an accumulation of the serous fluid ensues; this frequently escapes thru the tissues and may then be detected in the various fluids of the body. If the kidneys be removed the urea, which would ordinarily go to the kidneys, accumulates in the serous circulation. But this is never the case with the secretions, for after the removal of the special organ by which each of the fluids is manufactured, the secretion is no longer found.

Therefore, to recapitulate, we have the blood circulation, which conveys O to and CO₂ from the tissue, the lymph circulation, an intermediate circulation between blood and serum, for the lymphatic vessels accept from the glands any substance which becomes a refuse thru the serous circulation, and the serous circulation, which begins in the small intestine and absorbs serum and ends at the kidney and the skin, meanwhile going into and becoming a part of every structure of your body.

SPECIAL SENSE ORGANS

The **Organs of Special Sense** are five in number; the **tongue**, of the special sense of taste; the nose, the special sense of smell; the eye, the special sense of sight; the ear, the special sense of hearing; and the **skin**, the organ of the special sense of touch. Other senses not classified as special are the *spiritual, equilibrium, muscular pressure, the sense of heat and cold, transmission, impression, perception, intellectual, imaginative, memory, sexual and moral*; these latter are more generally known as general-sensations and are distributed thruout the body. Often the senses are classed as internal and external senses—the internal including such faculties as intellectuality, memory and morality, etc.; while the external senses include such faculties as feeling, seeing and hearing.

A **Sense** is a faculty possessed by animals, of receiving impressions from natural objects, or a faculty of perceiving impressions thru certain organs. Aristotle brot out the idea of the five special senses, and said that all other senses, aside from the special, were demonstrations of the soul. Bichat defined a sense as “the property possessed by living bodies of receiving impressions, whether the individual be conscious or not, if conscious the sensibility is known as animal sense and if not conscious, organic.” Referring to the vegetable world, minutely, the sense of sight, smell, thirst and hunger is not thot to belong to its units, altho they do absorb, exhaust and secrete; yet we cannot state this as a known fact. The human mind may never be able to fathom many of nature’s innermost secrets. Chiropractic results would indicate that we are only beginning to learn the first fundamental principles of the metabolism of the animal body. The human mind had not previously realized that the educated mind itself, was a manifestation of an Innate Intelligence which controls the metabolism of its corporeal abode.

An **organ of sense** is an instrument by which the mind is brot into relation with external objects.

THE NOSE

(Illustration No. 173.)

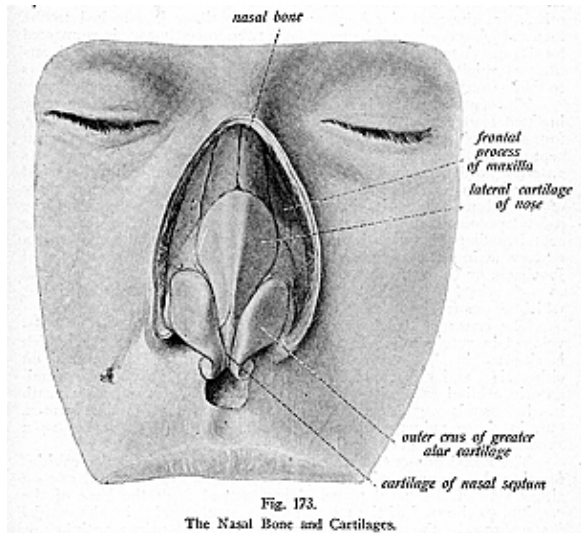
The **Nose** is the peripheral organ of the sense of smell, and is called the **organ olfactorum**. It consists of an external portion, the *outer nose*, and the *internal cavity*, comprising the *nasal fossae*, which together constitute the *cavum nasi*.

The nose occupies the middle and anterior portion of the face, and projects from the center of the face immediately above the upper lip. It extends downward from its root, which joins the forehead. The nose protects the lungs from the inhalation of gases by its muscular responsiveness to its innately controlled nerves, and it discriminates as to properties of food; therefore, it very materially

SPECIAL SENSE ORGANS

assists the organ of taste, and also serves as a part of the respiratory tract.

The nose is triangular in form, and is composed of a framework of **bones** and **cartilages**, acted upon by **muscles**. It is lined by **mucous membrane**, is covered by skin, and contains many arteries, veins and nerves. The external nose has for **descriptive parts** the **base**, **root**, **apex** or **point**, the **anterior nares** or the **nostrils**, the **dorsum**, the **bridge**, and the **alae** or **wings**. The bony framework consists of the nasal bones and the nasal processes of the maxillae, the **cartilages** are the *two upper lateral*, the *two lower lateral*, and the *cartilage of the septum*.



The **base** is directed downward and is perforated by two elliptical openings, the **anterior nares** or the **nostrils**. Within these is a dilated portion, called the **vestibule**, which extends as a small pouch toward the point and is lined with numerous short stiff hairs, called the **vibrissae**. These hairs arrest the passage of foreign substances which may be carried by the current of the air intended for respiration; they protect the nasal cavity and respiratory tract.

The **root** is the upper angle, connected directly with the forehead; the **apex** or the point, is the tip or the free extremity of the nose; the

dorsum is formed by the lateral surfaces, joining in the middle line; the **bridge** is the upper part of the dorsum covered by the nasal bones; and the **ala** or the **wing** is an expanded portion which forms the lateral margin of either naris, and above each ala is a furrow, the **alar sulcus**.

The skin of the nose is thin and moves freely over the dorsum and root, but is thick and adherent over the tip and over the alae; here it contains a number of sebaceous glands, their openings being quite distinct.

The **cartilages** of the nose are five in number. The two **upper lateral cartilages**, situated immediately below the nasal bones, are triangular in form. Their anterior borders are continuous with each other, but the posterior border of each cartilage is attached to the lower sloping border of the nasal bone; the lower border is connected by fibrous tissue to the upper margins of the **two lower lateral cartilages**, which are situated below the upper pair. Each is bent so as to lie in front, and on each side, of the nostril, which it keeps open.

The **septal cartilage** is placed in the medial plane, tho it is usually inclined to one side, most frequently to the left. It is an irregular, four-sided plate of cartilage, and forms a large part of the nasal septum anteriorly, completely separating the nasal fossae in front. Its anterior border is thickest above and is connected with the nasal bones; its posterior border is connected with the perpendicular plate of the ethmoid, and its inferior border, with the vomer and the palatal processes of the maxillae. Along the inferior border of the septal cartilage, between it and the anterior border of the vomer, is a narrow strip of cartilage, sometimes two, called the **cartilage of Jacobson**, or the **vomerine cartilage**. These cartilages are connected to each other, and to the surrounding bones, by tough fibrous tissue, which allows free movement between them.

The *organ of Jacobson* is rudimentary in man, but is well developed in ruminantia. It takes the form of a blind pouch, which is situated in the lower and anterior part of the septum nasi on either side, and this pouch extends upward and backward to terminate in a blind extremity with the **cartilage of Jacobson underneath** it. Jacobson's organ does not seem to perform any function in man, but, in those animals where it is well developed, it serves as a supplementary organ of smell.

The **Nasal Fossae** (illustration No. 174) are two irregular cavities forming the cavum nasi, situated in the middle of the face, one on either side of the nasal plane. They extend from the base of the cranium to the roof of the mouth, and are surrounded by the cranial Fossae above, by the orbital cavities laterally, and by the mouth below. They open in front, when the soft parts are in place, by two openings, the **anterior nares**; they terminate behind in the naso-pharynx by the **posterior nares**. The two fossae are separated from each other by a partition, called the **septum nasi**, which is partly osseous and partly cartilaginous. The boundary line between the bony and cartilaginous portions of the nasal cavity is called the **limen nasi**.

Each fossa presents a *roof*, *floor*, and an *inner* and an *outer wall*. The **bones** which form the two fossae are fourteen in number, the *frontal*, *sphenoid*, *ethmoid*, two *lacrimal*, two *palatal*, two *superior maxil-*

SPECIAL SENSE ORGANS

lary, two *turbinated*, two *nasal* and the *vomer*. The *roof* of each fossa is formed by the frontal, sphenoid, ethmoid, palatal, nasal, superior maxillary, and the vomer. The *floor* is smooth and concave from side to side, and is formed by the superior maxillary and the palatal bones. The *inner wall* is the septum nasi, formed chiefly by the perpendicular plate of the ethmoid bone and the vomer, tho the rostrum of the sphenoid, and parts of the frontal and nasal, palatal, and the maxillary bones contribute to its formation. The *outer wall*, very irregular, is formed by the superior and middle conchae of the ethmoid bone, by the inferior turbinated, the sphenoid and the palatal, also by parts of the nasal, maxillary and lacrimal bones.

In some animals of higher order of development than fishes, the nasal fossae opens anteriorly by the nostrils into the mouth; in some

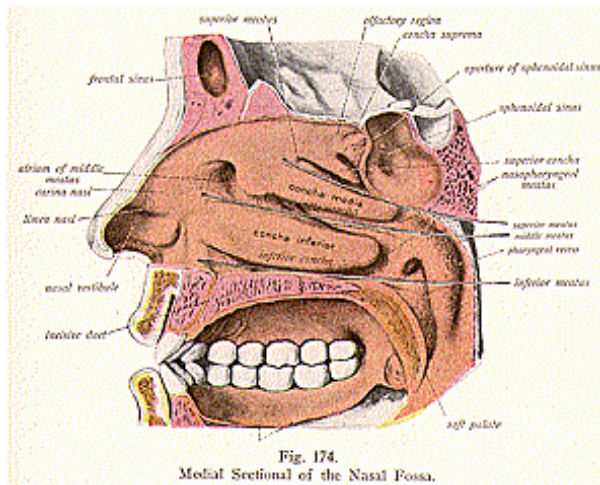


Fig. 174.
Medial Sectional of the Nasal Fossa.

lower orders of life the nasal cavities are represented by small sacs on the sides of the head in front of the eyes, and there would then be no communication with the mouth and no function in respiration.

The **outer wall** of each fossa forms irregular, longitudinal passages, called a **superior**, **middle** and an **inferior meatus**.

The **superior meatus** is the smallest of the three, as well as the highest and most posterior. It is situated toward the back part of the outer wall of each nasal fossa, and lies between the superior and inferior turbinated processes of the ethmoid; it is quite short and is directed obliquely forward and upward. Into it open the posterior ethmoidal cells and the sphenopalatine foramen.

The **middle meatus** is longer than the superior and lies about in the center, but above the turbinated bone and external to the middle turbinated process of the ethmoid bone. At its anterior part it turns upward and is continued into a passage known as the **infundibulum**, which communicates with the anterior ethmoidal cells.

The **inferior meatus**, the longest of the three meatuses, lies between the turbinated bone and the floor of the nasal fossa; near its anterior part is the lower orifice of the lacrimal canal, which lodges the nasal duct.

Opening into the various parts of the nasal fossae, and communicating directly with them, are a number of recesses, or hollow cavities, known as **sinuses**. The fossae communicate above with the frontal sinus, thru the infundibulum, a passage between the middle meatus and the ethmoid cells; behind, with the **spheroidal sinus**, thru the sphenoid-ethmoidal recess; with the **maxillary sinuses** on the outer wall; and with the **ethmoidal sinuses** on either side. Each fossa also communicates with the **orbital cavity**, by the lacrimal groove; with the mouth, by the anterior palatine canal, or incisive duct, with the **cranium**, by the olfactory foramina; and with the **spheno-maxillary fossa**, by the sphenopalatine foramen.

In the living subject, the openings known as the **nares** are very small, while the inferior turbinated bones appear very large, because the mucous membrane is very thick around these parts. The **anterior nares** are the orifices by which the nasal fossae open on the face thru the anterior nasal aperture, while the **posterior nares** are situated at the posterior extremities of the nasal fossae, between the pterygoid processes of the sphenoid, and they communicate with the naso-pharynx.

Each naris is bounded externally by the internal pterygoid plate of the sphenoid; internally by the posterior border of the vomer, inferiorly by the palatal bone; and superiorly by the vaginal process of the sphenoid, by the ala of the vomer, and by the spheroidal process of the palatal bone.

The **sense of smell** resides in the mucous membrane lining the upper portion of the nasal fossae, where the olfactory nerve-filaments are distributed.

The *mucous membrane lining the outer nose* is continuous with the skin externally, and with the mucous membrane of the nasal fossae internally.

The *mucous membrane which lines the nasal fossae*, called the **pituitary** or **Schneiderian**, or **olfactory**, a highly vascular and sensitive mucous membrane, is continuous with that of the pharynx, Eustachian tube, tympanum and mastoid cells, and with that of the accessory nasal cavities, that is, the frontal, ethmoidal, maxillary and spheroidal sinuses, and with the lacrimal sac, nasal duct and with the conjunctiva.

The *mucous membrane over the conchae or turbinated bones*, also on the septum, is thick and spongy, but over the floor and meatus it is comparatively thin. In the vestibule, where the lining membrane is skin, the epithelium is of the stratified squamous variety; in the respiratory region, as well as in the air sinuses; it is stratified col-

SPECIAL SENSE ORGANS

ummar ciliated epithelium, while the epithelium in the olfactory region is of the non-ciliated columnar variety.

The *olfactory mucous membrane* is thick and pulpy and has a yellowish-brown color, due to pigment in the epithelial cells. It contains a dense plexus of olfactory nerve-fibres and many serous glands, which are known as the *glands of Bowman*. The epithelium is thick and of the nonciliated columnar variety, its free surface being covered by a delicate limiting membrane; the cells are of two kinds, the **supporting** and the **olfactory** cells. The **supporting** or the **sustentacular cells** are long columnar nucleated cells, and between these are the **olfactory cells**, which are elongated and spindle-shaped.

The *olfactory hairs* are fine, delicate, hair-like filaments which project from the surface of the olfactory cells.

The olfactory nerves are fifteen to twenty in number on each side, and, after leaving the inferior surface of the olfactory bulb at the base of the brain, they pass thru the olfactory foramina in the ethmoid bone, and so reach the upper part of the nasal fossa, where they are distributed over the mucous membrane. Anatomists claim that the nerves of ordinary sensation are nasal branches derived from the ophthalmic and from the superior maxillary division of the fifth cranial, but Chiropractic clinical findings prove the **nerve supply to** be largely from the branches of the third and fourth cervical pairs of spinal nerves.

The **arteries** of the nasal fossae are the ethmoidal from the ophthalmic, sphenopalatine and the infra-orbital branches from the internal maxillary, and the **veins** form plexuses and are drained by the facial, the ethmoidal, and the sphenopalatine veins.

THE TONGUE

(Illustrations Nos. 125, 138, 139 and 142.)

The **Tongue** is the special organ of the sense of taste, also an organ of speech, and assists in mastication, deglutition and insalivation. The name is synonymous with *lingua* or *glossa*; and it is also used interchangeably with the word *language*, on account of its usefulness in articulation. It is a movable muscular organ which changes its shape with every movement, and at every muscular contraction it becomes shorter. In man, the tongue is soft and fleshy, in birds it is chiefly hard and horny. In snakes it is forked, and serves as a tactile organ and not as a sting, as many suppose. In other animals, such as toads and chameleons, it is free at its hind end so as it can suddenly protrude to catch insects with its sticky surface. In fishes it is hard and immovable.

The tongue is **situated** in the floor of the mouth between the portions of the lower jaw, and extends from the hyoid bone to the lower incisor teeth; when at rest the average tongue is three and one-half inches in length. It consists of two sets of muscles; the *extrinsic*, holding the organ to surrounding parts; and the *intrinsic*, the fibres of the organ itself, consisting of both educated voluntary and educated involuntary muscle fibres.

The tongue has for **descriptive parts**—the **body**, **base** or **root**

(**radix**), the **apex** or **tip**, the **fraenum**, the **dorsum**, **sides** or **margins**, and an under surface.

The **body** (*corpus*), forms the great bulk of the organ; the **base** or **root**, its back part is connected to the hyoid bone, the **apex**, or tip, is the anterior free extremity, it is thin and narrow and lies against the lower incisor teeth; the **fraenum** is a vertical fold of smooth mucous membrane which holds the tongue in contact with the floor of the mouth; the **dorsum** is the upper surface and is convex from before backward, presenting, over its anterior two-thirds, a vertical median depression, or rapine, **median lingual sulcus**, which divides the tongue into two symmetrical halves. The dorsum terminates posteriorly in a depression, the **foramen caecum**. The **margins**, or the **lateral sides**, are free; a triangular fold called the plica triangularis is found where the glosso-palatine arch joins the lateral border of the tongue. The **under surface** is connected to the lower jaw by the genio-hyo-glossus and to the mucous membrane in the floor of the mouth by the **fraenum linguae**, or **frenulum**.

The tongue is covered with a mucous membrane, which is thick on the dorsum, but on the under surface is thin and contains numerous mucous glands. The mucous membrane covering the pharyngeal portion of the tongue, is destitute of papillae, but is freely provided with follicles similar to those of the tonsils, and with mucous glands. The follicles are arranged upon the walls as crypts, the mouths of which open upon the surface. The mucous membrane in this region forms the glosso-epiglottidean fold or frenum epiglottidis, which is placed in the middle line. On either side of this fold, between it and the fold between the epiglottis and pharynx, is a pouch or depression called the **vallecula**. A characteristic feature of the tongue is the **papillae**, small projections on the mucous membrane, which give to the tongue its roughness.

Under certain conditions these papillae differ, for they may be soft, hard, rough or smooth, dry or moist. They are distributed thickly over the surface and vary in size, form and location. They are called the **circumvallate papillae** or the **papillae maxillae**, the **fungiform** or **papillae mediae** and the **filiform** or **papillae minillae**, while, scattered over the surface, between the other papillae, are the **simple papilla**, which are microscopical in size.

Foliate papilla are projections (rudimentary in man), arranged in folds on the anterior pillars of the fauces.

The **circumvallate papillae** are circular in form, of large size but few in number, being only about eight or twelve. They lie mostly in depressions, and are arranged in a V-shaped manner at the base of the tongue. These are also sometimes called the **vallate papillae**, for they form a circular elevation around a trench or deep depression and thus form a vellum (rampart).

The **fungiform papillae** are scattered over the sides and tip of the tongue, being few over the dorsum. They are mushroom-shaped, are round and enlarged at the surface, but taper at their deep ends.

The **filiform** or **conical papillae** are conical in form, and are the most numerous. They are arranged in more or less parallel, closely-set rows over the anterior two-thirds of the dorsum of the tongue;

SPECIAL SENSE ORGANS

they have a number of thread-like processes which project from their apices. The various papillae are from 1/20 to 1/12 of an inch in length, are mostly submerged and lie in depressions, they consist of connective tissue and are covered with squamous epithelium. Within the circumvallate and fungiform papillae are small bodies, called the taste-buds, these are flask-shaped and oval, like an acorn, and consist of nests of epithelial cells, blood-vessels and nerves. These taste-buds are also met with on the anterior surface of the soft palate, on the posterior aspect of the epiglottis, and on the anterior pillars of the fauces.

Each taste-bud consists of a base, which rests in the mucous membrane and gives passage to a nerve fibre by an orifice. The superficial end is narrow and presents a **gustatory pore**, by which it communicates with the oral cavity and thru which the distal process of a gustatory cell projects. The wall of the taste-bud is composed of flattened, nucleated epithelial cells, called the **sustentacular cells**. These are pointed at either end, and cohere by their edges very much like the staves of a barrel. The interior of the taste-bud contains a bundle of **gustatory cells**; these form a bulging body, with two processes, the inner being continuous with the nerve fibre at the base of the bud, while the outer or distal passes to the gustatory pore and ends in a cilium, the *gustatory* or *taste-hair*.

Anatomists claim the chorda tympani from the 7th nerve, also the lingual, a branch of the glosso-pharyngeal, are the nerves of the special sense of taste; also that the hypoglossal is the motor nerve, and that the lingual, a branch of the 5th nerve, is the nerve of ordinary sensation. Chiropractors consider the **nerve supply** to the tongue, as coming thru branches from the sixth and seventh dorsal pairs of spinal nerves, for it is these spinal nerve fibres, which are subject to pressure interference at their foraminal exits, and thus cause incoordination in the parts they supply.

The **arteries** of the tongue are branches from the external carotid the **veins** are tributaries to the lingual, facial and ascending pharyngeal branches. The lingual artery is the largest and gives off, as branches, the ranine and sublingual; the ranine passes to the inferior surface, immediately external to the line of insertion of the genio-hyoglossus muscle, and anastomoses with its fellow beneath the tip.

The sense of taste can be cultivated and more highly developed than any other organ. Sweet-taste sensation is from the tip, bitter from the base, saline from all parts, acid, sour, metallic, and alkaline taste sensations arise from the sides of the tongue.

THE EYE

(Illustrations Nos. 175, 176 and 177.)

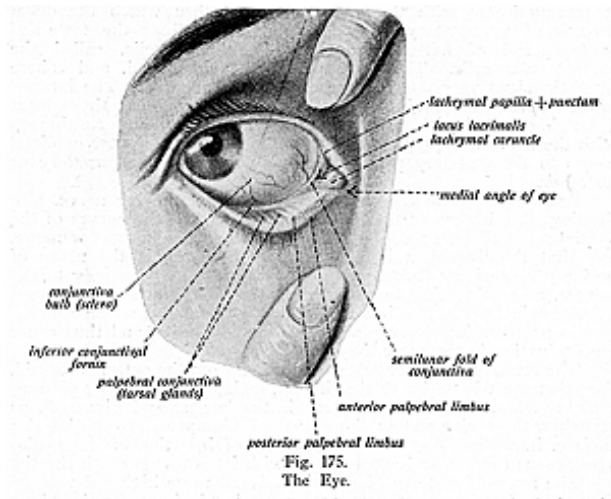
The **eyeball** is the organ of vision, the special sense of sight, and is situated in the anterior portion of a cavity, known as the orbit. It is securely protected from injury, while at the same time its position is such as to afford a most extensive range of vision.

The eye (Latin term "oculus") has been called the window of the soul, and, in describing this organ of vision, the term eyeball is

SPECIAL SENSE ORGANS

used in preference to the term eye. It is movable in the orbit and is acted upon by four straight, and by two oblique, muscles. The eyeball is embedded in a cushion of fat and is held in position by the ocular muscles, the conjunctiva, the optic nerve, and by the eyelids. It is partly surrounded by a thin, membranous sac or capsule, **Tenon's capsule**. The eyeball is flattened from before backward, so its transverse diameter is the longest of the three diameters, and measures almost an inch.

The **Orbits** are two cavities which are pyramidal in shape, and each cavity is formed of seven bones—the *frontal*, *sphenoid*, *ethmoid*, *palatal*, *lacrimal*, *superior maxillary* and the *malar*. It is the large size of these cavities, deprived of their peculiarly expressive organs, which gives to the dry skull its ghastly appearance.

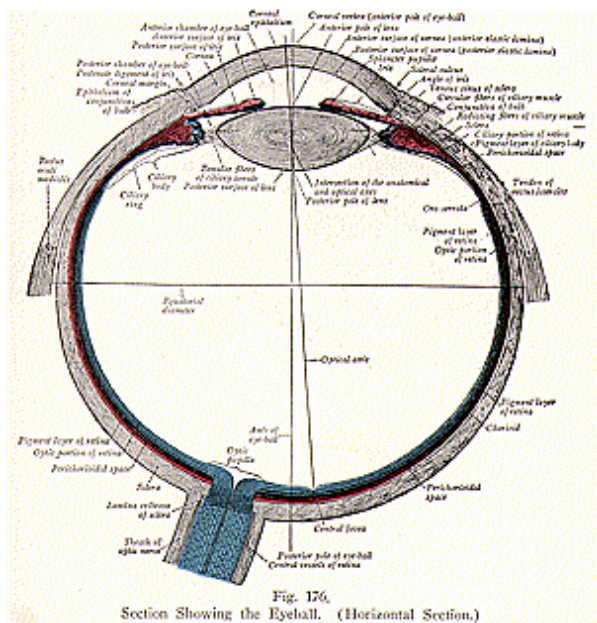


Tenon's capsule consists of a thin membranous sac isolating the eyeball and allowing free movement. It arises from the optic foramen behind, to become lost upon the sclerotic coat and conjunctiva in front, having a visceral layer for two-thirds of the globe and a parietal layer lining the fatty cushion in which the eye rests. It forms a socket in which the eyeball plays, both layers of the capsule being lined by flattened endothelial cells. The two layers enclose a space which contains fluid; the space is known as *Tenon's space*, which is broken up into a reticulum by processes of connective tissue passing between the capsule of Tenon and sclerotic coat. The straight and oblique muscles pierce the capsule and receive sheaths from it. Below and in front, the sheaths of the rectus

SPECIAL SENSE ORGANS

muscles extend as fibrous expansions which run from the malar to the lacrimal bone; they are called the *check ligaments*. If only one band is present it is called the *suspensory ligament*, for it is slung like a hammock, being expanded in the center and narrow at its extremities. The popularly so-called large eyes owe their seemingly larger size to a greater prominence of the globe and a wider fissure between the eyelids.

For **descriptive parts**, the eyeball has **three coats** and **three refracting media**.



The coats of the eyeball are the external, middle and internal. The **external coat** is comprised of the **sclera** and **cornea**; the **middle coat** is made up of the **choroid**, **iris**, and the **ciliary body**; the **internal coat** is formed by the **retina**.

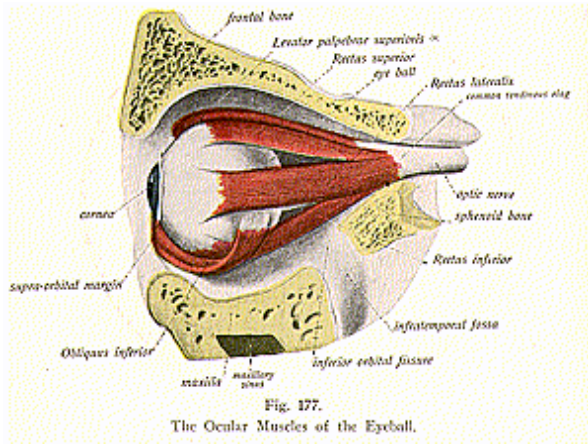
The **refracting media** are also three in number, the **aqueous humor** filling the anterior and posterior chambers; the **crystalline lens**; and the **vitreous body**, filling the posterior four-fifths of the globe.

SPECIAL SENSE ORGANS

The **External Tunic** of the eyeball is formed by the **sclera** and **cornea**.

The **sclerotic coat** is an opaque, hard, fibrous, unyielding, firm structure forming five-sixths of the external covering of the eyeball; the greater part of it forms a cover for the posterior part of the eye.

The **cornea** constitutes the remaining, anterior, one-sixth, of the external covering; in texture it is a horny substance, forming a transparent membrane. The sclerotic coat has received its name from its extreme density and hardness, and it is this coat that gives shape and protection to the refracting media, it also affords attachment for the muscles that move the eyeball. Although of a bluish color, it is popularly called the white of the eye. The external surface is white, but the internal surface is stained a brown color and is marked by grooves, which contain the ciliary vessels and nerves. It is thicker



behind than in front, and is continuous in front with the cornea, which it slightly overlaps.

The sclerotic coat is composed of fibrous tissue, mixed with elastic fibres and connective tissue corpuscles. The fibres are arranged in bundles which are disposed longitudinally and transversely, interlacing with one another. The thickness of the sclerotic coat varies, but is usually about $\frac{1}{25}$ of an inch posteriorly and $\frac{1}{60}$ of an inch anteriorly. At its posterior part, the optic nerve pierces the sclera. The *optic entrance*, thru which the nerve passes, is situated slightly toward the nasal side.

The tissues connecting the inner and outer layers of the sclera, about the optic entrance, separate to form a number of openings for

the passage of the fasciculi of the optic nerve and this network is called the *lamina cribrosa*; the largest one of these openings transmits the arteria centralis retinae to the interior of the eyeball. A small canal, the **canal of Schlemm (sinus venosus sclera)** is found at the junction of the sclerotic coat and the cornea; it communicates externally with the scleral veins, and internally, with the anterior chamber of the eyeball, thru numerous openings, called the **spaces of Fontana**.

Nerves to the sclerotic coat are the ciliary nerves which are few in number. The **arteries** and **veins** are short branches, from the ophthalmic artery, the tributaries to the ophthalmic vein.

The **cornea** is the anterior, transparent, thickened part of the external coat. It is not quite circular, its transverse measurement being slightly greater than the vertical and it fits into the sclerotic coat just as a crystal fits into the case of a watch.

The **cornea consists of five layers**; from without inward, they are the *anterior* or the *epithelial layer*, the *anterior elastic layer*, the *substantia propria*, the *posterior elastic layer*, and the *posterior endothelial layer*.

The *anterior epithelial layer*, or the *conjunctival layer*, consists of stratified epithelium. It is hard and is made up of several layers of cells, the deepest cells being columnar, next the polyhedral, and the most superficial strata consist of several layers of squamous cells; the surface of the cornea would be dry and horny like keratin if it were not constantly bathed by the secretion from the conjunctiva.

The *anterior elastic layer*, or *membrane of Bowman*, is a thin, firm, elastic layer consisting mostly of extremely closely interwoven fibrils. It resembles the corneal tissue of the fibrous layer of the substantia propria, being closely connected with this latter substance; it contains no corpuscles.

The *substantia propria* is the substance proper of the cornea forming its main part. It is fibrous, tough, and unyielding, being composed of modified connective tissue, arranged in about sixty laminae superimposed one upon the other; these layers are held together by a cement-substance in which are small spaces called corneal spaces, communicating with each other by very delicate canaliculi.

The *posterior elastic layer*, or *membrane of Descemet*, or *Demours*, covers the posterior surface of the substantia propria. It is a structureless, elastic, brittle, and extremely thin, membrane which is not rendered opaque by water, alcohol or acids; it has a tendency to roll upon itself when separated from the cornea proper. The posterior elastic layer at its circumference breaks up into fibres, the most posterior fibres passing in a radiating and reticular manner into the iris to form the *ligamentum pectinatum iridis*. Little spaces or intervals exist between the fibres and these are called the spaces of Fontana, which communicate internally with the anterior chamber and externally with the canal of Schlemm.

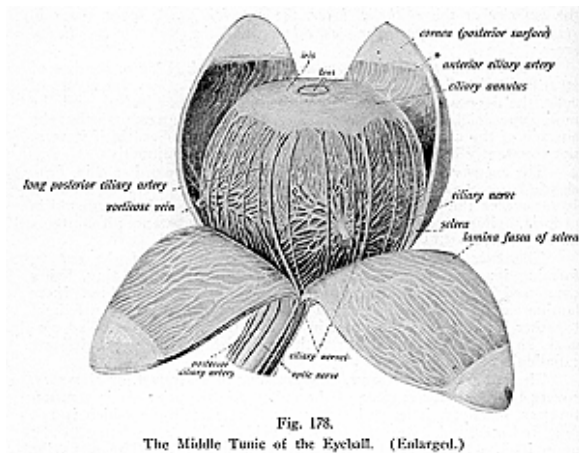
The *endothelial layer* is the most posterior layer, it consists of one layer of cells, which are transparent, flattened and polygonal, and resemble the cells lining other serous cavities.

SPECIAL SENSE ORGANS

The **Middle Coat** is formed by the **choroid**, the **ciliary body**, and the **iris**. (See Illustration 178.)

The **choroid** lies internal to the sclera, it is vascular and pigmented. Its inner surface is covered, like a camera, by a dark substance called the obscure (dark chamber). The choroid is a thin chocolate-brown membrane, which invests 5/6 of the globe, terminating in front at the ciliary body, and blending to form the ciliary processes; it consists of connective tissue, blood-vessels and branched pigment cells.

It is composed of two layers, which are named, from without inward; the *lamina suprachoroidea*, composed of delicate non-vascular lamellae, each of which is made up of elastic fibres, arranged in a reticular manner. The *choroid-proper layer*, really consists of two layers, the *external* or *lamina vasculosa*, and the *internal* or the *lamina chorio-capillaris*. The *lamina vasculosa* is composed of branches of the



short ciliary arteries and veins, between which are numerous pigment cells; the *lamina chorio-capillaris*, or *tunica Ruyschiana*, the internal layer, consists of a very fine capillary plexus, formed by the short ciliary vessels. A small space exists between the choroid and the sclera called the *perichoroidal space*.

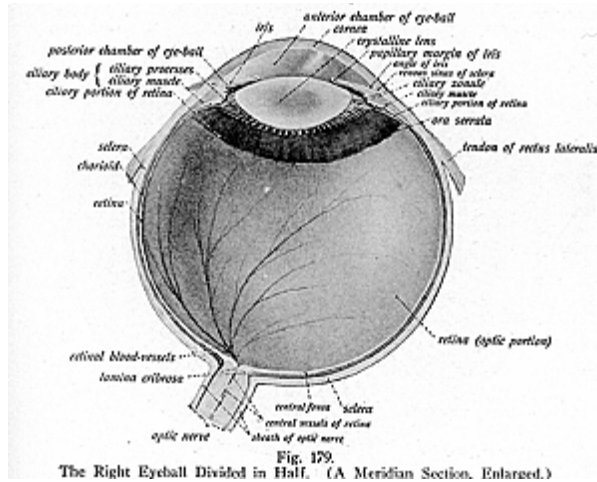
The **tapetum** is a name applied to the iridescent pigment epithelium of the choroid membrane of certain animals, which give to their eyes the property of shining in the dark, called also the tapetum lucidum.

SPECIAL SENSE ORGANS

The choroid coat is also pierced by the optic nerve and at this point it is firmly adherent to the sclera. Like the sclerotic coat, it is thicker behind than in front. The dark coloring absorbs all the loose scattered rays that might confuse the image.

The **ciliary body** is that part of the middle coat which lies between the choroid and the iris, and is formed of the *ciliary muscle*, *ciliary processes*, and the *orbiculus ciliaris*.

The *ciliary muscle* or *muscle of Bowman* is a grayish, triangular band of unstriped muscular fibres about one-eighth of an inch broad lying between the choroid and the iris. It is thick at the front and thin behind and consists of circular and radiating fibres, the latter being more numerous and arising from the deep surface of the sclero-corneal



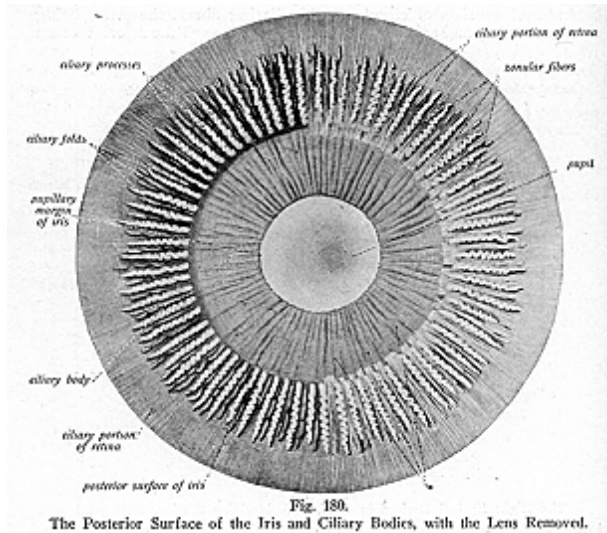
junction to pass backward to the choroid, opposite the ciliary processes; the circular fibres are internal and pursue a circular course around the insertion of the iris. When the ciliary muscle contracts it draws the choroid forward, and thereby relaxes the suspensory ligaments of the lens. It is the muscle of accommodation, and adjusts the eye to the vision of near objects.

The *ciliary processes* are 60 to 80 folds which form a circle by the folding and plaiting of the choroid at its anterior margin; these folds are received between the corresponding folds of the suspensory ligament of the lens. They are similar in structure to the choroid, and consist of large and small processes which alternate, the larger being about one-tenth of an inch long, and forming a sort of a plaited frill

SPECIAL SENSE ORGANS

around the iris, they contain ciliary glands. On their posterior surfaces or deep surfaces, the processes are covered by the *pars ciliaris retinae*, layers of the dark pigment cells, which are prolonged from the pigmentary layer of the retina, and is continuous with the *pars iridica retinae* or the uvea on the posterior surface of the iris.

The *orbiculus ciliaris* is a narrow zone, about 1/6 inch wide, which lies immediately in front of the anterior part of the choroid, and with which it is continuous. It presents plications which are radially disposed, and it separates the ciliary processes from the ora serrata of the retina.



The **Iris** is a thin, circular, colored, contractile curtain which is suspended in the aqueous humor between the cornea and the crystalline lens, it is perforated by an almost circular aperture, called the pupil, which serves for the transmission of light.

Iris was the name of the rainbow, and the iris of the eye received its name from its varied colors in different individuals. Its posterior surface is covered with a black substance called the *pars iridica retinae*, or *uvea*, because of its resemblance to the pulp of a black grape. The pigment granules form the coloring of the iris. In dark eyes many granules are present, in the blue eye there are few granules, while in the pink or the albino, there is no pigment.

SPECIAL SENSE ORGANS

The *iris* is about 1/6 inch wide, 1/100 inch thick, and consists of radiating and circular muscular fibres, and of a fibrous stroma, which is made up of a layer of endothelium, connective-tissue of branched cells, blood-vessels and nerves, and pigment granules. The layer of endothelium covers the anterior surface of the iris, and is continuous with the endothelium which lines the posterior elastic layer of the cornea. The muscular fibres of the iris are arranged in two sets—the circular and radiating. The circular fibres form a ring around the pupil and constitute the *sphincter pupillae*, while the radiating fibres converge from the ciliary margin of the iris towards the pupillary margin, where they blend with the circular fibres, the radiating fibres form the *dilator pupillae*. The iris by its power of expansion and contraction regulates the quantity of light admitted thru the pupil. This opening in living individuals varies in size, under the influence of light and in efforts at accommodation, it being small when objects are near, and large when objects are at a distance. In the light the pupil contracts and in the dark it dilates.

The *membrana pupillaris* is a delicate, transparent, vascular membrane which occludes the pupil in fetal life; it usually disappears shortly before birth by gradual absorption from the center towards the circumference.

The *ligamentum pectinatum iridis* is the suspensory ligament of the iris, and connects the iris with the cornea. This ligament consists in reality of the fibres of the posterior elastic layer, which pass in a radiating and reticular manner into the iris, thus uniting the cornea and the iris; the spaces between the fibres are called the *spaces of Fontana*, thru which the canal of Schlemm communicates with the anterior chamber of the eyeball. The **arteries** of the middle coat of the eyeball are branches from the ciliary vessels, the **veins** accompany the arteries. The **nerves** are branches from the 4th cervical pair of spinal nerves.

THE RETINA

The **Inner Tunic** of the eyeball is the **retina**. It is the nerve tunic a delicate membrane made up of many nerve fibres, formed by a membranous expansion of the optic nerve elements as it spreads out. Upon its surface the images of external objects are received. It is soft in consistency, translucent, and of a pinkish-gray color. Its internal surface is in contact with the hyaloid membrane, which encloses the vitreous body; its external surface is in contact with the choroid coat, posteriorly it receives the fibres of the optic nerve and anteriorly it ends in a jagged or notched margin, the **ore serrate**. Here its nervous elements terminate, but its pigmentary layer is continued over the deep, or posterior, surfaces of the ciliary processes and over the back of the iris, forming there the *pars ciliaris retinae* and the *pars iridica retinae*, respectively.

The retina consists of ten layers, two of them are the boundary **membranes**, the **membrana limitans interna**, which covers the retina on its **internal surface**; and the **membrane limitans externa**, a membrane formed of retinal connective tissue, perforated by numerous openings.

The layers therefore from within outwards are:

1. **Membrana limitans interna.**
2. **Stratum opticum**, or the **layer of nerve-fibres.**
3. **Ganglionic layer**, or the **layer of nerve-cells.**
4. **Inner molecular**, or **inner plexiform layer.**
5. **Inner nuclear**, or **granular layer.**
6. **Outer molecular**, or **plexiform layer.**
7. **Outer nuclear**, or **granular layer.**
8. **Membrana limitans externa.**
9. **Jacob's layer**, or the **layer of rods and cones.**
10. Pigmentary layer, or **tapetum nigrum.**

The **membrane limitans interna** is a transparent membrane formed of retinal connective tissue, lying in contact with the hyaloid membrane of the vitreous body; the **stratum opticum** is a layer of nerve-fibres from the optic nerve, extending from the optic disc to the ore serrate; the **ganglionic layer** is a single layer of large flask-shaped cells; the **inner molecular** or **plexiform layer** is made up of a reticulum of fibrils which mix with the cells of the ganglionic layer; the **inner nuclear** or granular layer consists of cells arranged in three kinds, the bipolar, amacrine and cells of Muller; the **outer molecular** or **plexiform layer** is thinner than the inner molecular layer, and is a dense network of minute fibrils; the **outer nuclear** or **granular layer** consists of small granules which are continuous with the rods and cones of Jacob's layer; the **membrane limitans externa**, intervenes between the outer nuclear layer and Jacob's membrane; the layer of rods and cones or **Jacob's layer** is the perceptive portion of the retina, and is composed of rods and cones known as the visual cells, which are arranged perpendicularly to the surface, each composed of an outer and an inner portion joined by a cement-substance.

The rods are cylindrical and the cones flask-shaped; the former are much more numerous, are longer and narrower than the cones. Both, however, are placed perpendicularly. The rods and cones are continued at their inner ends thru the membrane limitans externa into rod-fibres and cone-fibres, which belong to the outer nuclear layer, while the outer ends project into the pigmentary layer. The rods and cones are the terminal organs of the optic nerve fibres. On the outer surface of the rods is found a coloring matter known as the *visual purple* or *rhodopsin*, which soon fades or bleaches when exposed to sunlight.

The **pigmentary layer**, or the **tapetum nigrum**, is the most external layer of the retina, and is in close contact with the choroid coat. It consists of a layer of cells which contain pigment, and often is described with the choroid. At the ore serrate the nerve layers of the retina terminate; abruptly, but the retina is continued onward as a single layer of elongated columnar cells covered by the pigmentary layer; this prolongation is known as the *pars ciliaris retinae*. The connective tissue which unites all the layers, is a fenestrated, sponge-like membrane, called, the *membrane* or the *fibres of Muller*, composed of numerous sustentacular fibres which constitute the supporting tissue of the retina.

The **macula lutea**, or the **yellow spot**, is an oval, yellowish spot,

exactly in the center of the posterior part of the retina, which corresponds to the axis of the eye. Here vision is most perfect. The macula lutea has a minute central depression called the **fovea centralis**, the retina here being exceedingly thin. The point where the optic nerve enters is called the **optic disk** and lies about 1/8 inch internal to the yellow spot; it is often called the **blind spot**, for it is the only portion of the retina where the sense of vision is wanting. The margin around the disk is elevated and known as the **optic papilla**.

THE REFRACTING MEDIA

The **Refracting Media**, thru which the rays of light pass, are three in number: the **aqueous humor**, the **vitreous body**, and the **crystalline lens**.

The **aqueous humor** occupies the space between the cornea and the front of the crystalline lens, which space is divided by the iris into two communicating chambers, an **anterior** and a **posterior**. It is a clear, serous fluid of alkaline reaction, filling the anterior and posterior chambers; it is composed of water, about 96 per cent; albumen, 1 per cent, sodium chlorid and extractives, about 3 per cent.

The **anterior chamber** is the space bounded anteriorly by the cornea, and posteriorly by the iris and central portion of the crystalline lens enclosed within its capsule. It communicates with the spaces of Fontana and with the canal of Schlemm. The **posterior chamber** is only a narrow interval or chink between the peripheral part of the iris and the ciliary processes. The anterior and posterior chambers are completely separated in the fetus.


The **vitreous body** occupies about four-fifths of the space within the eyeball, and is situated between the crystalline lens and the retina. It is transparent, has the consistency of thin jelly, and is composed of 98.5 per cent water, the balance consisting of some salts and a trace of albumen; it is enclosed in a delicate, transparent membrane, the **hyaloid membrane**. This membrane is in close contact with the retina except anteriorly, in which latter situation it presents an excavation called the **fossa patellaris**, into which the posterior surface of the crystalline lens is received. The tiny elastic fibres of the hyaloid membrane are prolonged into the vitreous body and divide it into compartments, in which are contained the fluid. On a cut section, according to Hanover, it shows lamellae arranged like an orange, there being about 180 of these lamellae.

In the center of the vitreous body, running from the entrance of the optic nerve to the posterior surface of the lens, is a canal, the **canal of Stilling** or the **hyaloid canal**, also called the **canal of Cloquet**, which is filled with fluid; it is lined by a prolongation of the hyaloid membrane, and, in the fetus, transmits a branch of the arteria centralis retinae, called the hyaloid artery, which supplies the capsule of the lens.

The **Zonula of Zinn** or the **zonula ciliaris** is the thickened portion of the hyaloid membrane which is situated in front of the serrate of the retina. From this point it extends inward behind the ciliary processes toward the equator of the crystalline lens, and behind the ciliary processes it presents radial folds with intervening

SPECIAL SENSE ORGANS

depressions. These depressions receive the ciliary processes, and the radial folds are separated from the intervals between the ciliary processes by spaces which communicate with the posterior chamber of the eye. As the zonula of Zinn approaches the equator of the lens it divides into three layers—the anterior, the middle and the posterior. The anterior layer being the thickest, passes over the ciliary body and constitutes the **suspensory ligament** of the lens, which is attached to the anterior wall of the capsule of the lens not far from the equator. When the radiating fibres of the ciliary muscle contract, the suspensory ligament is relaxed and the convexity of the anterior surface of the lens is increased. The middle layer consists of a few scattered fibres which pass to the equator of the lens and the posterior layer lines the fossa patellaris on the anterior aspect of the hyaloid membrane. Behind the suspensory ligament of the



lens is a sacculated canal which surrounds the equator of the lens and is called the **canal of Petit**, which communicates with the posterior chamber of the eye.

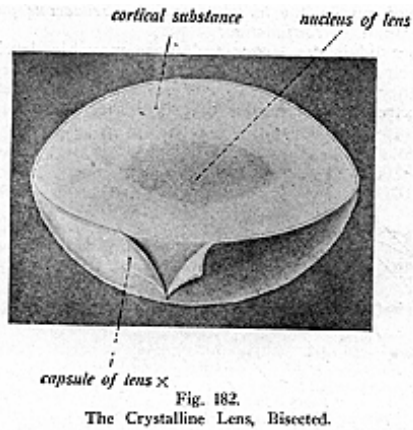
The **crystalline lens** (illustrations Nos. 181 and 182) is a solid double convex, transparent body, more convex posteriorly than in front, enclosed in a capsule and held in place by the **suspensory ligament**. It lies immediately behind the pupil, in front of the vitreous body, surrounded and slightly overlapped by the ciliary processes. The posterior surface is received into the patellar fossa on the anterior aspect of the vitreous body. The periphery is related to the suspensory ligament, the canal of Petit and the ciliary processes. The lens is composed of water, albuminous matter, fat, and cholesterin. The center of the anterior and posterior surfaces is known as the anterior and posterior *poles*; the surfaces meet in a rounded border, the *equator*.

The lens, when hardened, is seen to consist of a series of concentric layers; the external layer is soft in consistency, but the succeeding ones gradually become firmer. The central portion constitutes a hardened nucleus. The laminae are arranged concentrically, and after boiling or the immersion in alcohol, they may be peeled off

SPECIAL SENSE ORGANS

like the coats of an onion. The laminae consist of numerous layers, composed of six disc-sided fibres with serrated margins, which fit accurately one with the other.

The **capsule of the lens** is a transparent, brittle, and highly elastic membrane, which surrounds and encloses the lens; when torn, the edges roll up, with the outer surface to the inside. Its anterior wall is thicker and more elastic than the posterior, and it measures about 1/2000 inch thick in front and 1/6000 inch behind. In the adult the lens is non-vascular, but in the fetus it receives the hyaloid artery, which reaches it thru the canal of Stilling. The crystalline lens varies at different ages. In fetal life the lens is pink in color,



almost spherical, semitransparent, and soft in consistency; in the adult the lens is biconvex, has no color, is transparent and of hard consistency, while in old age, the lens is inclined to become flattened, has a yellowish color, it loses its transparency and increases in its density.

THE APPENDAGES OF THE EYE

(Illustrations Nos. 183 and 184.)

The appendages of the eye consist of the **eyebrows**, the **eyelids**, the **conjunctiva**, and the **lacrimal apparatus**, which is composed of the *lacrimal gland* and *duct*, the *lacrimal sac* and the *nasal duct*.

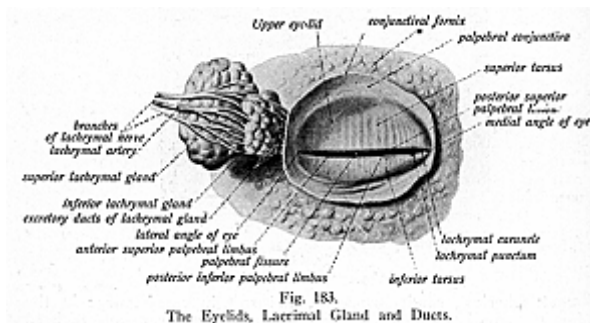
The **eyebrows**, or the **supercilia**, are two arched eminences of skin surmounting the upper margins of the orbits; from each side grow several rows of short hairs placed obliquely on the surface. They are situated on the superciliary ridge of the frontal bone, and extend from the side of the root of the nose to the temple, their inner extremity being more prominent than the outer. They are connected beneath with the orbicularis oculi, the corrugator supercillii, and the occipito-frontalis muscles; these muscles, to a certain extent, control

SPECIAL SENSE ORGANS

the amount of light admitted to the eye. The short, stiff hairs with which they are covered, are directed from within outward and have most always the color of the hair of the head. They entangle foreign bodies, as well as lessen the force of blows; they also serve as an ornament to the countenance and are said to direct the perspiration from the eye.

The **eyelids** (see illustrations Nos. 175 and 183) are two thin, movable folds placed in front of the eyes. By their closure they protect the eyes from injury by foreign objects, and from the influence of too great light. They are composed of the following structures, in order from without inward *Skirt, superficial fascia, areolar tissue, fibres of the orbicularis oculi muscle, the tarsal plate, large sebaceous glands, blood-vessels, nerves, and the conjunctiva.*

The upper lid is the larger and more movable, having its own elevator muscle, the levator palpebrae. The two lids are separated from each other by an elliptical interval called the **palpebral fissure**, the lateral extremities or angles of this fissure are called the outer



and the **inner canthus**. The **internal canthus** is prolonged inward toward the nose, leaving the triangular space between the lids and the globe, known as the **lacus lacrimalis** (lacrimal lake), which is the beginning of the lacrimal canal. In this canal there is a small body called the **caruncula lacrimalis**. In this region the eyelids are separated from the eyeball by a vertical semilunar fold of the conjunctiva called the **plica semilunaris**.

On the margin of each lid is a small conical elevation, called the **lacrimal papilla**, its apex being pierced by a small opening, the **punctum lacrimale**, which gives passage to a **minute duct** from the lacrimal canal, which conveys tears thru the nasal duct into the inferior meatus of the nose.

The **skin** of the eyelid is very thin and at the ciliary margins of the eyelids it becomes continuous with the conjunctiva,—the mucous membrane of the eye. The superficial fascia and areolar tissue is also thin, loose, and devoid of fat. The fibres of the orbicularis oculi form

a very delicate, pale sheet in each lid. The **tarsal plate** or **cartilage** is a thin, elongated plate of dense connective tissue, about an inch in length, placed one in each lid next to the conjunctiva; they contribute to the form and support of the lid. The superior tarsal plate is larger and thicker than the lower, and gives attachment to the levator palpebrae muscle. Each tarsal plate is connected to the malar bone by an external tarsal ligament, and to the nasal process of the superior maxillary by an internal tarsal ligament, often called the tendo oculi.

The **sebaceous glands** are called the **Meibomian** or **tarsal glands**. They are situated on the internal surface of each tarsal plate, and lie between the plate and the conjunctiva. These glands are about thirty in number in the upper lid, and about twenty in the lower lid, being arranged in parallel rows. Each gland opens by an independent orifice, discharging its secretion upon the free edge of the lids and thus preventing their adhesion, by lubricating the margins of the eyelids. The Meibomian glands are the largest sebaceous glands in the body.

The **eyelashes** are attached to the free edges of the lids and serve as protection, acting as a picket guard for the organ of vision; they assist, also, in diminishing the intensity of light. The eyelashes on the upper lid are more numerous and longer than those on the lower lid; they curve upward, while the lower eyelashes curve downward. Numerous openings for the sebaceous glands are found near the attachment of the eyelashes.

The **conjunctiva** is the mucous membrane which lines the inner surfaces of the eyelids, it is reflected over the front of the sclerotic coat and the cornea, and consists of two parts—the **ocular** and the **palpebral** portions.

The **palpebral part** is thick, opaque and vascular; it presents numerous papillae, containing glands. The **ocular** or the **bulbar part**, thin and transparent, is loosely attached to the globe by subconjunctival areolar tissue; it contains only a few blood-vessels, the whiteness of the sclera being unaffected by it. The corneal conjunctiva is very thin and consists only of epithelium.

The **caruncula lacrimalis** or **lacrimal caruncle**, is a small, conical, reddish, spongy body, situated at the inner angle; it occupies the space called the **lacus lacrimalis**. It consists of a group of follicles, sebaceous and sweat glands, and upon it grow a few delicate hairs. This little body is the source of the whitish secretion which accumulates at the inner angle of the eye. On the outer side of the caruncula is the small semilunar fold of conjunctiva, the **plica semilunaris**, which corresponds to the membrane nictitans, or the third eyelid, in birds.

THE LACRIMAL APPARATUS

(Illustrations Nos. 183 and 184.)

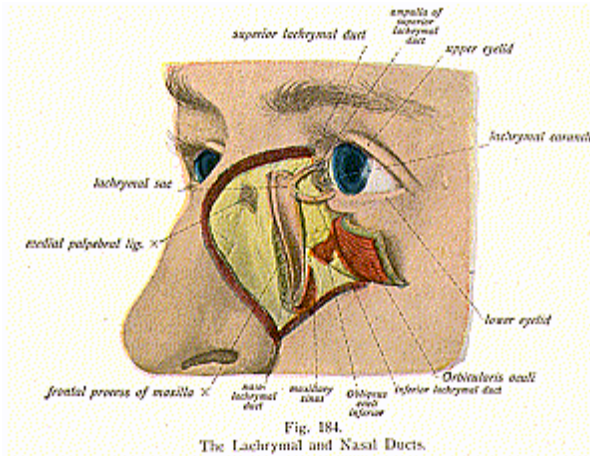
The **Lacrimal Apparatus** consists of the **lacrimal gland** which secretes the tears; the **lacrimal ducts**, which convey the fluid to the surface of the eye which bathes the eyeball; the **lacrimal sac**, and the **nasal duct**.

The **lacrimal gland** is an oval, compound racemose gland, of the size and shape of an almond; it is located at the anterior and outer

SPECIAL SENSE ORGANS

part of the orbit superiorly, and lies in a depression on the inner side of the external angular process of the frontal bone. Its upper surface is convex and its under surface is concave, in adaptation to the eyeball. The ducts, which issue from both sides, are about twelve in number, and open by minute orifices, placed in a row on the upper and outer part of the palpebral conjunctiva. The tears are taken up by the puncta, thence they pass thru the lacrimal canals into the lacrimal sac, and then into the nasal duct, thus reaching the inferior meatus of the nose.

The **lacrimal canals** or the **lacrimal ducts**, are two minute canals—



a superior and an inferior, which commence at the punctum lacrimale on the summit of each lacrimal papilla. They are situated on the inner margin of each lid, lined with mucous membrane, continuous with the conjunctiva, and are about $\frac{1}{3}$ of an inch long and $\frac{1}{25}$ of an inch in diameter. The two canals open into the lacrimal sac, either close together or by a common orifice, the two slips of the tensor tarsi muscle being closely related to their sides.

The **lacrimal sac** is the flattened, ovoidal, sacciform dilation of the upper part of the nasal duct, lodged in a groove formed by the lacrimal bone and the nasal process of the superior maxillary, thru this groove the tears are carried from the lacrimal canal to the nasal duct, to enter the inferior meatus of the nose. The sac is composed of fibro-elastic tissue which adheres closely to the periosteum of the bones. It is lined by mucous membrane, continuous thru the lacrimal canals with the mucous lining of the conjunctiva, continuous also,

SPECIAL SENSE ORGANS

thru the nasal duct, with the nasal mucous membrane. The epithelial lining is of the columnar variety, and, here and there, the cells contain cilia. The walls are covered by the tensor tarsi muscle, and in front is the tendo oculi attached to the ridge of the lacrimal bone.

The **nasal duct** is a membranous canal which extends from the lower end of the lacrimal sac to the anterior part of the inferior meatus of the nose. It is about 3/4 of an inch in length, and about 1/8 of an inch in diameter. Its direction is downward, backward and outward, it being contained in an osseous canal formed by the superior maxillary, lacrimal, and turbinated bones; it is lined with mucous membrane, continuous with the conjunctiva above and with the pituitary membrane below. A valve-like fold is sometimes found at the termination of the nasal duct; when present it is called the *valve of Hasner*, and guards the somewhat expanded terminal opening of the duct.

The **blood supply** to the eyelids, conjunctiva and lacrimal apparatus, is carried by branches from the ophthalmic, from the internal carotid artery, anastomosing with branches from the temporal, lacrimal, facial, and angular branches from the external carotid.

The **nerve supply** to the eyelids is by branches from the 4th cervical pair of spinal nerves; the nerves to the conjunctiva and lacrimal apparatus are under the direct control of the 10th, 11th and 12th dorsal pairs of spinal nerves, thru their control of the serous circulation, in combination with branches from the 4th cervical pair of spinal nerves.

THE EAR

The **Auditory Apparatus** is lodged in the petrous, mastoid and tympanic portions of the temporal bone, and is divisible into three parts: the **external ear**; the **middle ear**, or the **tympanum**; and the **internal ear**, or **labyrinth**.

The **external ear** consists of the *auricle* or the *pinna*, and the *externa auditory canal*; the **middle ear** or **tympanum comprises** the *membrana tympani*, the *cavity* of the *tympanum*, the *mastoid cells* and the *Eustachian tube*, *ossicles* and *muscles*; the **internal ear**, or the **labyrinth**, contains the *vestibule*, the *semicircular canals*, the *cochlea*, and the *auditory nerve*.

THE EXTERNAL EAR

(Illustration No. 185.)

The **auricle** or **pinna** (wing), the pavilion of the ear, is attached to the side of the head, midway between the forehead and the occiput; it is oval in form, with the large end upward. It consists, mostly, of a plate of yellow elastic fibro-cartilage covered by skin, which is thin and adheres closely to the fibro-cartilaginous plate; the skin contains sweat and sebaceous glands, and is provided with short, downy hairs. The plate of cartilage imparts firmness and elasticity to the pinna, which is also provided with ligaments and intrinsic muscles.

The foundation of the pinna is an expanded layer of fibro-cartilage, so disposed in ridges as to concentrate and direct the waves of sound into the external auditory meatus, with which it is continuous; the cartilage is deficient at certain points, such intervals being filled up by dense fibrous tissue. The pinna presents great variations,

SPECIAL SENSE ORGANS

it being smaller and more firmly molded in the female than in the male.

The auricle has the following parts for study: the *helix* (tendrils of a vine) is the outer, curved, prominent rim of the auricle; the *anti-helix*, a curved ridge parallel with and in front of the helix, this bifurcates above, so as to enclose a triangular depression, the *fossa triangularis*; the *concha* (concave shell), a deep cavity, which leads into the external auditory meatus; the *cymba conchae*, being the upper part of the concha: the *tragus* (a goat), bearded in old persons, is the

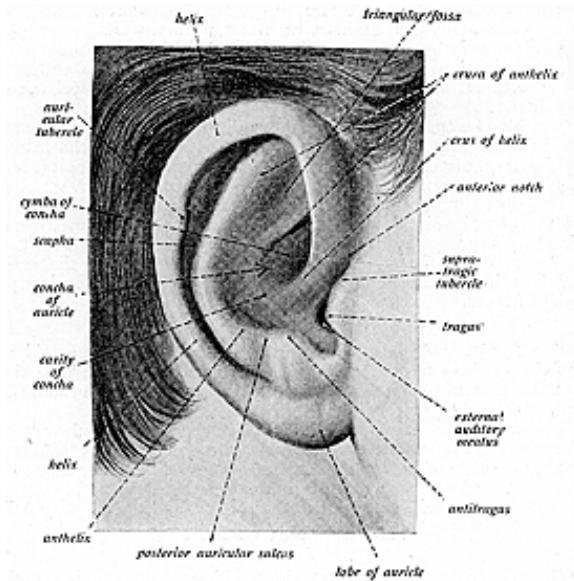


Fig. 185.
The External Ear.

pointed prominence in front of the concha, bearing on its under surface tufts of hair, the *tragi*; the *antitragus* is a small tubercle opposite the tragus, separated by a deep notch, the *incisura intertragica*; the *scaphoid fossa*, a narrow, curved depression between the helix and the anti-helix, and another triangular depression between the crura of the anti-helix, which is known as the *triangular fossa*; the *lobule*, or *lobe*, is a soft pendulous portion, formed of fat and connective tissue, and enclosed by integument. Sometimes the lobule does not hang freely, but is adherent. An *ear-point*, or the *tubercle of Darwin*, is frequently seen on the postero-superior margin of the helix, pointing forward, where the

SPECIAL SENSE ORGANS

helix is turned downward; this tubercle receives the name of the auricular tubercle and is prominent in monkeys.

The **external auditory canal**, or **meatus**, extends from the bottom of the concha to the membrane tympani. It is an osseo-cartilaginous, oval, cylindrical canal about 1-1/4 inches in length; it is first directed obliquely forward, upward and inward; it then passes again forward and downward, having two constrictions. It is lined with skin, which is closely adherent to the perichondrium and periosteum, and it contains hair follicles, sebaceous, and ceruminous glands.

The **ceruminous glands** are of a brownish color, and they secrete a substance called cerumen, the ear-wax, which lubricates the lining of the canal, and is thot to be offensive to insects. The lumen of the canal is influenced by the movements of the lower jaw.

The **muscles** of the **external ear** are classified as the *extrinsic* and *intrinsic*. The *extrinsic* are the *attollens*, *atrahens* and *retrahens aurem*. They move the pinna upward, forward and backward. The *intrinsic* extend between various parts of the auricle, and are the *helices major* and *minor*, the *tragicus*, *antitragicus*, *transversus auricularae*, and the *obliquus auricularae*. The **arteries** to the outer ear are branches from the anterior and the posterior auricular arteries and the temporal; the veins are tributaries from the external carotid, temporal and the occipital. The **nerves** are given by anatomists as branches from the facial, the vague, and the mandibular division of the fifth cranial, but Chiropractors give the nerve supply as being from the cervical plexus, by branches direct from the first, second and the third cervical nerves, for it is these cervical nerve fibres which are subject to pressure at their foraminal exits that causes incoordination in the parts they supply.

THE MIDDLE EAR

(Illustrations Nos. 186 and 187.)

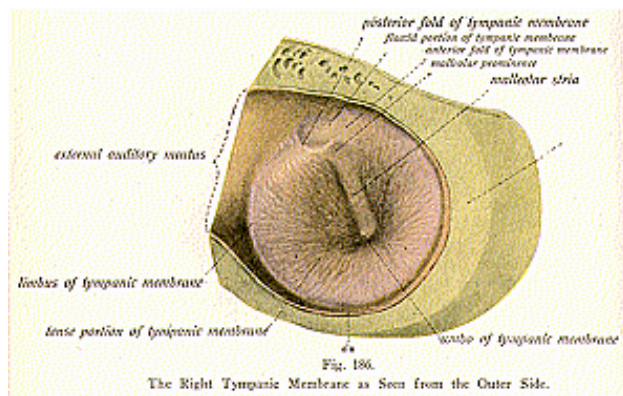
The **Middle Ear** or **Tympanum** is a space, within the petrous part of the temporal bone, which lies between the membrane tympani externally and the outer wall of the internal ear or labyrinth internally. It consists of the **membrane tympani**, the **cavity** of the **tympanum**, the **ossicles** and muscles, **Eustachian tube**, and the **mastoid cells**.

The **tympanum** is an irregular cavity measuring about 1/2 inch antero-posteriorly, 1/3 inch vertically, and 1/5 inch transversely. Situated in the petrous bone, compressed laterally, it is placed above the jugular fossa; it has the carotid canal in front, and the mastoid cells behind, the external auditory meatus externally and the labyrinth internally; it is separated from the external passage by a thin membrane called the **membrane tympani**; this cavity has a roof, a floor, an outer and inner wall, an anterior and a posterior wall.

The **membrane tympani** (Illustration No. 186), also called the drum-head, forms the outer wall of the tympanum, and is an oval, thin, translucent membrane, placed obliquely at the bottom of the external auditory meatus; it is composed of 3 **layers**, called the *external*, *middle* and *internal layers*. The *external cutaneous* layer, is very thin and is derived from the integument of the external auditory meatus; it is a squamous epithelium, contains no glands, and

SPECIAL SENSE ORGANS

is freely provided with blood-vessels and nerves. The *middle layer* or *fibrous layer*, forms the proper substance of the membrane and consists of fibrous tissue, constituted by two sets of fibres—the radiating and the circular. The radial fibres lie beneath the cutaneous layer and radiate from the handle of the malleus; the circular fibres are situated within the radial fibres and are most numerous toward the circumference of the membrane. The *internal*, or mucous layer, of the membrane tympani faces inward, forward and downward, and is continuous with the mucous membrane of the tympanum; it is covered by a single layer of squamous epithelium. The membrane is of a pearl color, but this depends mostly upon the condition of the mucous lining—the part receiving the light. At the apex of the malleolar handle there is seen a bright reflection, triangular in outline and called the *cone of light* or the *light-spot*, which has a dark



central portion, the *umbo* or shadow, due to the concavity of the exterior surface of the membrane. The *malleolar stria* is a stripe on the membrane tympani from the malleolar prominence to the umbo, caused by the handle of the malleus.

The **ossicles** of the ear (Illustration No. 188) are three small bones, forming a movable chain which connects the middle ear with the labyrinth; they serve to convey the vibrations of the membrane across the cavity of the tympanum, to the internal ear.

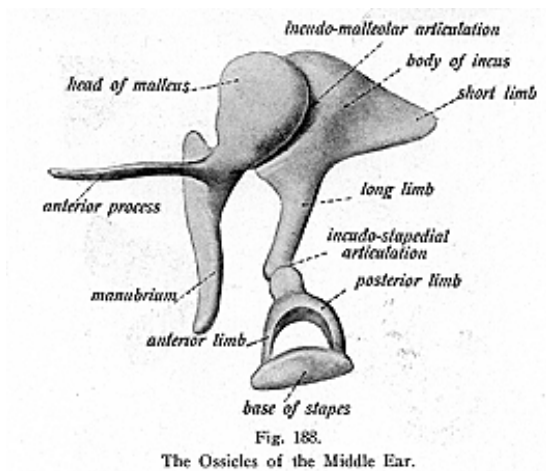
The bones are called ossicles, the smallest bones in the body, and named according to their shape, the **malleus**, **incus**, and the **stapes**. They are articulate and, because of their minute size and cartilaginous composition, are seldom preserved after the cadaver is dissected.

SPECIAL SENSE ORGANS

the drum; it passes thru a fissure, the Glasserian fissure, and is attached to the spinous process of the sphenoid.

The **malleus**, or the **hammer**, is composed of a *head*, *neck*, *handle* and two *processes*, namely, the *long* and the *short*. The *head* is the upper, enlarged, rounded end, and articulates with the incus, presenting a saddle-shaped facet directed obliquely downward and inward; the *neck* is the constricted part below the head; the *handle*, or the manubrium, affords attachment to the tensor tympani muscle, the *long process* (when present) is slender and springs from the front of the neck. It is lodged in the Glasserian fissure and is fastened by a bony or ligamentous attachment; the *short process* is situated below the long process and is fastened to the middle layer of the drum head.

The **incus** or **anvil** has a *body*, which is thick and articulates with the malleus; it also has *two processes*, a *long* and a *short*. The *long process* terminates in a rounded end which articulates with the head of the stapes; the *short process* is tipped with cartilage, and articulates



with a depression on the posterior wall of the tympanum. It is also attached to the margin of the opening into the mastoid cells.

The **stapes**, or **stirrup**, presents a *head*, which articulates with the long process of the incus; a *neck*, receiving the head of the insertion of the stapedius muscle; a *footpiece* or *base* somewhat oval, which is connected with the margins of the fenestra ovalis, and the *two crura*, anterior and posterior, which spring from the neck and are attached to the base of the stapes near its extremities.

The **ligaments** of the **ossicles** are found between the synovial joints, between the malleus, incus and the stapes; they connect the ossicles to the walls of the tympanic cavity and are five in number,

the *anterior, superior* and *external ligaments* of the *malleus*, the *posterior ligament* of the *incus*, and the *annular ligament* of the *stapes*.

The **Eustachian** or **auditory tube** is a canal about 1-1/2 inches in length, 1/3 inch in diameter, thru which the tympanum communicates with the pharynx. It is an osseo-cartilaginous canal, directed inward and forward from the anterior wall of the tympanum to the nasopharynx. The osseous part is about 1/2 inch in length and represents the lower part of the canal, situated in the angle between the petrous and squamous portions of the temporal bone. The cartilaginous part is about 1 inch in length and lies in a groove between the great wing of the sphenoid and the petrous portion of the temporal bone. At first it is narrow, but it gradually enlarges so as to resemble a trumpet; it is a triangular plate of elastic fibro-cartilage, folded on itself above to leave a deficiency below which is filled by fibrous and muscular tissue. The tube is lined with ciliated mucous membrane, which is continuous with that of the tympanum on the one hand and with that of the pharynx on the other; thick below and thin above, it contains mucous glands and some adenoid tissue near its lower end, forming there *Gerlach's tonsil*. The **isthmus** is the narrowest part of the tube, and is found at the junction of the osseous and the cartilaginous portions.

The tube communicating with the pharynx permits equal air pressure on both sides of the tympanic membrane, it carries away mucous secretions and permits of the renewal of air within the cavity of the tympanum. To it are attached the tensor palati, the levator palati fibres, and the dilator tubae muscles. The Eustachian tube is opened during deglutition by the salpingo-pharyngeus and dilator tubae muscles. Sometimes a valve is found at the opening into the pharynx, tho it is usually a rather imperfect one.

The interior of the mastoid portion contains a number of cavities, lined with mucous membrane, called the **mastoid air cells**. These open into an irregular chamber known as the **mastoid** or **tympanic antrum**, which is situated at the upper part of the posterior wall of the tympanum. The antrum is lined by mucous membrane, continuous with that lining the cavity of the tympanum. The cells extend from the antrum into the mastoid portion in a backward and downward direction, and are varied in regard to number and size, some being large and irregular, others representing spaces of cancellous bone and usually containing marrow.

The **arteries** of the tympanum are branches from the internal maxillary, the auricular, and from the internal carotid, thru the tympanic, stylo-mastoid, petrosal and the Vidian vessels, which form an arterial circle on the margin of the membrane tympani; the **veins** terminate in a plexus, which end in the superior petrosal.

Anatomists give the nerves to the tympanum as branches from the facial, glosso-pharyngeal, and from the otic ganglion, but Chiropractors give the **nerve** supply to the middle ear as branches from the first, second and third cervical pairs of spinal nerves, for it is these cervical nerve fibres which are subject to pressure interference which causes incoordination in the middle ear.

SPECIAL SENSE ORGANS

THE INTERNAL EAR

(Illustrations Nos. 189, 190 and 191.)

The **Internal Ear** or **Labyrinth** is the essential part of the organ of hearing; it is known as the **labyrinth**, from its shape, it being a place of many turnings, the exit of which is not easily discovered.

The **labyrinth** consists of **two parts**, the **osseous labyrinth** and the **membranous labyrinth**.

The **Osseous Labyrinth** lies internal to the tympanum within the petrous portion of the temporal bone, and consists of the **vestibule**, the central cavity; the semi-circular canals, three bony tubes behind the vestibule; and the **cochlea**, in front of the vestibule.

The **vestibule** of the **osseous labyrinth** is the common central cavity with which all parts of the ear communicate. It is placed behind the cochlea, in front of the semi-circular canals, and internal to the tympanum. It is oval in shape, and about 1/5 of an inch from before backward, as well as from above downward, but its diameter is less from without inward.

On the outer wall, or the tympanic side, of the vestibule is the **fenestra ovalis** or **fenestra vestibuli**, an oval opening which is occupied by the base of the stapes and its annular ligament. The inner wall presents anteriorly a depression called the **fovea spherica** or **fovea hemispherica**, or **recessus sphericus**, a small circular depression which lodges the saccule, and is perforated by several minute holes from ten to fifteen in number, for the passage of the filaments of the auditory nerve; the perforated plate is called the macula cribrosa.

Behind and above the fovea spherica or recessus sphericus, is a ridge called the **crista vestibuli**; posteriorly this ridge bifurcates and, between its two divisions, there is a small depression, called the **recessus cochlearis**, which is perforated for the passage of about eight or ten filaments of the auditory nerve.

The **aqueductus vestibuli** is a small canal at the back part of the crista vestibuli, it transmits a small vein and contains a tubular prolongation of the lining membrane of the vestibule, ending in a pouch located between the layers of the dura mater, in the cranial cavity.

The roof of the vestibule presents an oval depression, called the **fovea elliptica** or **hemielliptica**, or **recessus ellipticus**, which lodges the utricle; it is pierced by foramina for the passage of the nerves to the ampullae of the superior and external semi-circular canals. The fovea elliptica is separated from the fovea spherica by the crista vestibuli. The vestibule communicates anteriorly with the scale vestibuli of the cochlea, posteriorly it presents five openings of the semi-circular canals.

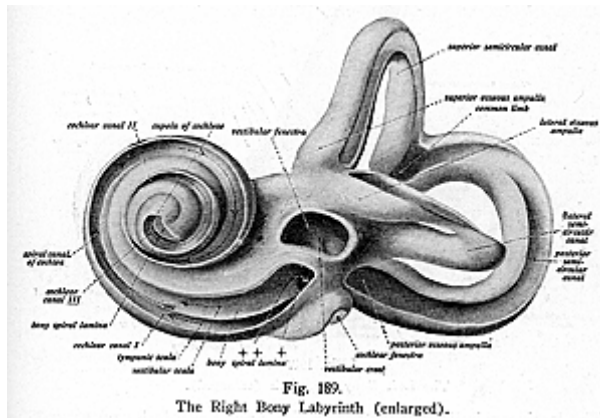
The **semi-circular canals** are three curved, bony tubes compressed from side to side and each describing the greater part of a circle. They are of unequal length, but have a uniform diameter of 1/30 of an inch; each canal lies in a plane at a right angle to the other two and presents at one end the **ampulla**, of nearly double the diameter of the tube. They open by five orifices into the vestibule and each takes a separate direction; they are called the **superior**, **posterior** and **lateral** semi-circular canals, the non-ampullary ends of the

SPECIAL SENSE ORGANS

superior and posterior canals being united, so that these two ends open by a common orifice.

The **superior semi-circular canal** is about one inch long and lies in a vertical position, and transversely as regards the long axis of the petrous portion of the temporal bone; the **posterior semi-circular canal**, the longest of the three, is also vertical and is arched backward, nearly parallel to the posterior surface of the petrous portion of the temporal bone; the **lateral semi-circular canal** is the shortest of the three canals, about 1/5 inch in length; it is placed horizontally, its arch being directed outward and backward.

The **cochlea** forms the anterior part of the labyrinth. It is situated in front of the vestibule, is conical in shape and consists of a tube coiled spirally upon itself like a snail's shell. Its apex is directed outward, forward and downward toward the upper and front part of the inner wall of the tympanum, its base corresponds to the



bottom of the internal auditory meatus, and is perforated by numerous foramina for the passage of the cochlear nerve, a branch of the auditory nerve. The cochlea is about 1-1/2 inches long, gradually diminishing in size from base to apex.

The **modiolus** is the central pillar or axis of the cochlea and extends from the base to the apex of the cochlea, being a central conical axis perforated by numerous canals for arteries and veins, and for filaments of the cochlear branch of the auditory nerve. The apex terminates in a delicate expanded lamella, like a funnel divided longitudinally, called the **infundibulum**.

A canal, the spinal canal, is the space between the modiolus and the outer wall of the cochlea. It is about 1/12 inch in diameter and

SPECIAL SENSE ORGANS

1-1/3 inches long and makes two and one-half spiral turns round the modiolus. The spiral portion is directed from left to right in the right ear, from right to left in the left ear. Each canal terminates at the apex of the cochlea in a cul-de-sac, the **cupola**. It presents 3 openings, one, the fenestra rotunda, communicates with the tympanum, altho in the recent state this opening is closed by the *membrana tympani secundaria*; the second opening leads into the vestibule; while the third opening is the aperture of the aqueductus cochleae.

An osseous, shelf-like plate, called the **lamina spiralis**, projects from the modiolus half way across the spiral canal and is formed of two bony lamellae which divide the canal incompletely into two passages, the upper, the **scale vestibuli**, and a lower, the **scale tympani**; between the lamellae are numerous canals for the nerve fibers.

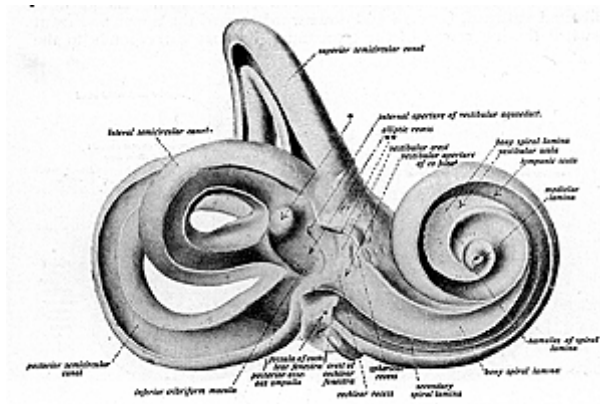


Fig. 190.
The Left Bony Labyrinth (enlarged).

The lamina spiralis extends across the canal towards its outer wall for about half its width, and in the recent state the remainder of the distance is completed by the basilar membrane.

Winding around the modiolus near the apex, the lamina spiralis terminates in a hook-like process, the **hamulus**; it is defective in the last half turn of the cochlea, leaving an aperture called the **helicotrema**, a space which unites the scale vestibuli and the scale tympani.

The **aqueductus cochleae**, a minute canal at the lower end of the scale tympani, transmits a small vein from the cochlea to the inferior petrosal sinus and establishes a communication between the scale tympani and the subarachnoid space of the brain.

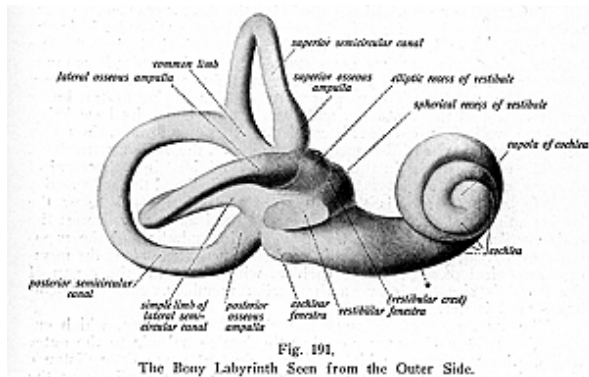
The **Membranous Labyrinth** is situated within the bony, or osseous, labyrinth and receives the terminal branches of the auditory

SPECIAL SENSE ORGANS

nerve. It consists of the **vestibule**, which contains the **utricle** and the **sacculle**; the **membranous semi-circular canals** within the **osseous semi-circular canals**; and the **membranous cochlea**, within the **osseous cochlea**.

The **vestibule** contains two membranous sacs, the **utricle** and the **sacculle**, which are in close contact and communicate indirectly; each sac contains a fluid called **endolymph** and calareous matter of minute crystals of calcium carbonate bound together by delicate tissue in which ramify minute fibres of the auditory nerve. These crystals form the *otoliths*, or *ear stones*. The membranous labyrinth is separated from the periosteal lining of the osseous labyrinth by a fluid called the **perilymph**.

The **Utricle** is the larger of the two sacs, of an oblong form, laterally compressed, and into it the membranous semi-circular canals open. It occupies the upper and the back part of the vestibule, a



portion of it lying in the fovea elliptica and the part below it. The floor and anterior wall of that part which is lodged in the fovea elliptica is much thicker than elsewhere and forms a thickened spot, called the **macula acustica utricularis**, which receives the filaments of the auditory nerve, it is here that the otoliths are formed.

The **sacculle**, smaller than the utricle, is somewhat oval in form; it lies in front of the utricle, and occupies the fovea spherica. It is surrounded with perilymph and communicates indirectly, by a short canal, with the utricle, which joins a similar canal given off from the sacculle. These ducts are called the *ductus utriculi* and the *ductus sacculi*; when the two ducts join they form the **ductus endolymphaticus**. This duct ends in a blind pouch on the posterior surface of the petrous portion of the temporal bone, where it is in close contact with the dura mater.

The anterior wall of the saccule presents a circular thickened spot, similar to that on the utricle called the **macula acustica saccularis**, where the filaments of the auditory nerve are distributed.

The **membranous semi-circular canals** are contained within the osseous semi-circular canals and are, in number, shape and form, the same as the osseous canals, tho their diameter is only about one third as great; they are attached to the osseous canals by numerous tiny fibrous bands. Each membranous canal, like the osseous canals, presents, at one end, an enlargement, the **ampulla**, and they open by five orifices into the utricle. Each canal, as well as the utricle and saccule, has three *coats* or *layers*, namely, an outer or a loose fibrous layer containing blood-vessels and pigment cells; the middle layer, thicker, translucent, and resembling the hyaloid membrane of the eyeball; and the inner layer, containing polygonal nucleated epithelial cells.

The **membranous cochlea**, called also the **ductus cochlearis** or the **scale media**, consists of a spirally arranged tube, enclosed within the osseous cochlea; it completes the deficiency which is left by the lamina spiralis, for, as has been stated, the lamina spiralis extends only part of the distance between the modiolus and the outer bony wall of the cochlea. The membranous cochlea begins at the lower anterior part of the vestibule, and enters the cochlea, its base being the outer wall of the cochlea; it consists of two membranes, the upper being the **membrane of Reissner**, and the lower, the **basilar membrane**.

The cochlear tube in the recent state is divided into three spiral passages, called the *scala tympani*, the *scala vestibuli* and the *scala media*.

The *scala tympani* is the portion of the spiral canal below the lamina spiralis of the osseous cochlea and the basilar membrane; the *scala vestibuli* is that portion above the lamina spiralis and the membrane of Reissner; the *scala media* or the *ductus cochlearis* is the membranous spiral passage of the cochlea, which contains the **organ of Corti** and is situated between the basilar membrane and the membrane of Reissner.

The **membrane of Reissner** is a delicate membrane, which extends from the periosteum covering the lamina spiralis to the outer wall of the cochlea, to which it is attached at some little distance above the basilar membrane; it separates the scale media from the scale vestibuli, forming the roof of the scale media, and is made up of a very delicate connective-tissue membrane, lined on each side with squamous epithelium.

The **basilar membrane** is a thin membrane which stretches from the free edge of the lamina spiralis to the outer wall of the cochlea; it separates the scale media from the scale tympani; completes the septum between the scale vestibuli and the scale tympani; the two scarce communicate with each other thru the opening of the helicotrema at the apex of the cochlea. The basilar membrane forms the floor of the scale media and supports, on its upper surface, the **organ of Corti**. The inner part of the basilar membrane is very thin and is called the *zona arcuata* on which rests the organ of Corti; the outer part, thicker and striated, is the *zona pectinata*. The under surface of the basilar membrane is covered by a layer of vascular connective

tissue, and one of the vessels is larger than the others, it lies below the spiral organ of Corti and receives the name of the *vas spirale*.

The **organ of Corti (papilla spiralis)** is a complex structure formed of a series of over three thousand arches, formed of cells, some rod-like and others are epithelial hair cells. They appear at first sight, as numerous papillae, but on close observation are arranged in two rows; they consist of the **rods of Corti**, the **auditory or hair cells**, the **cells of Deiters**, the **cells of Hensen and Claudius**, the **lamina reticularis** and the **membrane tectoria**.

The **rods of Corti** are arranged in two rows, the inner and the outer rows, each being inclined toward another so that they meet at their opposite extremities to form a series of arches roofing over a space called the *tunnel of Corti*. The upper end of the inner rod resembles the upper end of the ulna and the upper end of the outer rod resembles a swan's head. The inner rods are about 6,000 in number the outer rods 4,000, and each rod consists of a *head*, the upper part, and a *foot-plate* or *base*, with an intermediate portion between, called the *canal of Corti*.

The **auditory hair-cells** are epithelial cells with stiff, hair-like cilia; the outer hair-cells, which are external to the outer rods, number about 12,000 and are arranged in four rows. The inner hair-cells are 3,500 in number and present a single row internal to the inner rods. Each hair-cell contains about twenty fine hairless which are arranged in crescent form. Between the rows of the outer hair-cells are rows of supporting cells, called the **cells of Deiters**, which expand slightly and form the phalangeal (beak-like projections) processes, the lamina reticularis. The **cells of Hensen** consist of five or six rows of columnar cells to the outer side of Deiters, cells, and other columnar cells, lying to the outer side of Hensen's cells, are called the **cells of Claudius**.

The **lamina reticularis** is a delicate layer which is perforated by rounded holes. It extends from the inner rods of Corti to the cells of Hensen, and is composed of phalangeal processes, arranged in rows, connected together and to the heads of the outer rods, forming rings thru which pass the free ends of the hair-cells.

The **membrane of Corti**, or the **tectoria membrane**, is an elastic membrane covering the organ of Corti but not touching it, it extends from the upper surface of the lamina spiralis near, and external to the lower attachment of the membrane of Reissner, to the outer hair cells.

The **auditory nerve** or the **acoustic nerve**, the special nerve of the sense of hearing, divides, within the internal auditory meatus, into an anterior or cochlear and a posterior or vestibular nerve. The vestibular division divides into branches which pass thru minute openings at the upper back part of the meatus and, entering the meatus and vestibule, are distributed to the utricle, saccule and to the ampulla of the semi-circular canals. The cochlear division gives off numerous branches to the hair-cells of the organ of Corti, and filaments of the cochlear nerve, winding round the modiolus, form a plexus or ganglion, called the *ganglion spirale* or the *ganglion of Corti*.

SPECIAL SENSE ORGANS

The **nerve supply** to the inner ear is had by branches from the first, second and third cervical pairs of spinal nerves.

By the help of the external ear, the vibrations of air are concentrated upon the tympanic membrane and set it vibrating. The chain of bones in the middle ear transmits these vibrations to the internal ear, where, wholly or chiefly thru the cells in the organ, they are received by the afferent fibres of the auditory nerve which spread out over the basilar membrane. The **arteries** to the inner ear are the internal auditory artery from the basilar, which gives off the vestibular and the cochlear branch; and the stylomastoid, from the posterior auricular. The **veins** accompany the arteries and empty into the lateral and petrosal sinuses.

“Physiologists recognize there is a well defined sixth sense, known as the sense of **orientation** or **equilibration**. Its seat is in the semi-circular canals of the inner ear, very ingeniously constructed to do that for which they were intended; they are controlled by the vestibular division of the acoustic nerve. The theory advanced is as follows: the semi-circular canals, consisting of semi-circular tubes almost at right angles to one another, are full of clear liquid. They enable a person to tell what position he is in, even tho he be blind or paralyzed. By some peculiar process, not well understood, but probably involving a variation in the pressure produced by the liquid in the canals, on the nerve fibres as the body assumes different positions, they warn us when we are about to lose our equilibrium and give us the consciousness of being in any particular position which we may assume.

“A peculiar thing in this connection, and one that had a great deal to do with the final discovery of the use of the organs, is the following: On divers occasions, steeple-jacks and workmen employed on high buildings found that they had lost their nerve and could no longer persuade themselves to go very far from the ground. On trying to work at their old trades, they would have a dizzy feeling and would not be able to sit upright, at great heights, for any length of time. On examination by physicians, it was determined that their semi-circular canals were diseased, and that, consequently, their sense of equilibrium had been partly lost.” (See center of equilibrium.)

THE SKIN

(Illustration No. 192.)

The **Skin** is the principal seat of the sense of touch, it forms the body-covering, and is continuous with the mucous membrane at the orifices of the alimentary and other canals. It acts as a protective coat, is a medium for expression of body temperature, and is a respiratory, excretory and absorptive organ. It contains the peripheral ending of the sensory nerves.

It is a common covering for the body and is a very elastic structure which varies in thickness in different parts of the body, being thinnest at the prepuce and at the junction of the eyelids, while it is thickest over the back of the neck and shoulders, on the palms of the hands and on the soles of the feet. The color depends on the pigment granules; it is deepest in color in the genital regions, over the mam-

mary glands, axilla, also in parts exposed to air, light, and to extreme temperatures. It also varies according to age, it being yellow, thin and dry in old age, while in youth it is of a pinkish hue. Exposure to climatic conditions changes the color of the skin, it being deepest and thickest when exposed to all kinds of weather and temperature, such as are found in the tropics; thus in the various races of people we find them divided into the white, black, yellow, red and brown.

The color of the skin is, also affected in certain diseases, in jaundice it is yellow, while in Addison's disease it is brown, and in anemia, perfectly colorless. The skin is movable, but it is attached closely to underlying structures so that on the scalp, palms, soles of the feet, and on the outer portion of the ear, it is said to be immovable. It appears to be smooth, but on close examination it is made up of depressions, folds, many openings, creases and furrows. It also contains hairs of various lengths.

About the joints are folds of skin, called temporary folds or wrinkles, created by the contractions of superficial muscles. The facial wrinkles of advancing years are principally due to habitual expression and to a loss of skin elasticity, a dimple is a pit or depression due to an adhesion of the superficial surface to the parts beneath.

The **skin** consists of the **epidermis** or **cuticle**; and the **derma**, **cutis vera**, or **corium**.

The **epidermis** or **cuticle** is the superficial layer, and is composed of epithelial cells of stratified epithelium, called non-nucleated because at the surface its cells lose their nuclei. The cuticle contains no blood-vessels, and is composed mostly of epithelial cells; its deepest layer is columnar, and is the softest. Accurately molded upon the papillary layer of the derma, it forms a covering of the true skin.

The **cuticle** is made up of **two layers**, the *superficial or horny*; and the *deep* or *Malpighian layer* or *rete mucosum*. The horny layer is formed by several layers of non-nucleated scaly cells which contain *keratin*. These are constantly being rubbed off and replaced by cells from the Malpighian layer, which cells become richer in keratin as they approach the surface.

The **epidermis** is further subdivided into five layers, named from without inward, and known as the *horny epithelial layer*, containing cells without nuclei, the *stratum lucidum*, consisting of a layer of flat cells, closely packed, in which traces of flattened nuclei may be found; the *stratum granulosum*, softer and made up of flattened spindle-shaped cells, containing granules which consist of a substance called eleidin, an intermediate substance in the formation of keratin; the *stratum mucosum*, or the *rete mucosum*, formed of numerous layers of cells containing pigment granules and connective tissue, and the *stratum germinativum*, sometimes termed the basilar layer or stratum cylindricum, composed of soft cells of a prickle cell type embedded in a cement containing the original seed cells, separated from the papillary layer of the derma by a homogeneous basement membrane.

The **derma** or **corium** or **true skin**, is the deep layer and is a tough, flexible and highly elastic tissue, protecting subjacent parts.

SPECIAL SENSE ORGANS

It is the chief organ of the sense of touch, excretion is effected by its various glands, absorption also takes place from its surface. It is derived from the mesoderm and therefore consists of connective tissue and elastic fibres. It contributes elasticity to the skin and is the seat of the sense organs.

The **corium** or **true skin** is composed of **two layers**—the **papillary** and the reticular. The papillary layer is situated just beneath the stratum germinativum of the epidermis and presents a number of minute conical projections, or eminences (both vascular and nerve papillae), averaging 1/100 inch in length. These eminences are scattered irregularly in slightly sensitive parts, but are arranged in parallel curved lines, forming ridges, in highly sensitive organs. The papillae are fine strands of connective tissue, they project from the corium beneath and enter into depressions of the epidermis; they are large in the palms, and at the tips of the fingers and toes. The papillae contain the ducts of the sweat, and sebaceous, glands, also the tactile corpuscles, where touch is most highly developed.

The **reticular layer** of the derma, or the corium, serves to hold the skin to the parts beneath it contains interlacing bands of white fibrous tissue, some yellow tissue fibres, unstriped muscular fibres, lymphatics, blood-vessels and nerves, hair follicles, fat and glands.

The **nerves** of the skin terminate both in the epidermis and in the corium; they vary in different parts of the body, being numerous where the sense of touch is acute and fewer in number where sensibility is less. The nerves of the skin form a plexus on the papillary layer of the corium and end in bulbous enlargements of their own extremities, also in *end-bulbs*, *touch corpuscles*, and *Pacinian bodies*.

End-bulbs or end-buds, are ovoid or sphenoid bodies, found chiefly in certain parts of the mucous membrane, at the ends of sensitive nerves. *Tactile corpuscles* are found in the papillae of the skin of the hand, foot, forearm, lips, nipples, etc. *Pacinian bodies* consist of sets of small corpuscles surrounding the terminations of sensory nerves, in the subcutaneous cellular tissue of the fingers and toes. Other fibrils are distributed to the hair-follicle, and still other nerves pass to the muscular coat of the blood-vessels and to the arrectores pilorum muscles of the hair follicle.

THE APPENDAGES OF THE SKIN

(Illustration No. 192.)

The **Appendages of the Skin** are the **nails**, the **hairs**, the **sebaceous** and **sudoriferous glands**.

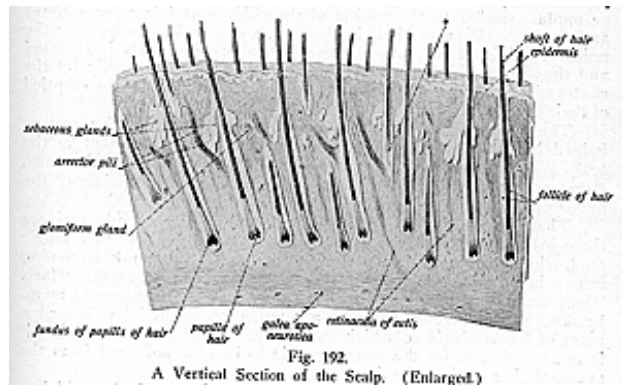
The **Nails** are flattened, horny, elastic structures, covering the dorsal portion of the last phalanges of the fingers and the toes. They are convex externally and concave within, and consist of a *body*, the chief mass, which lies upon the nail bed; the *root*, that part embedded in a groove of the skin; and the *lateral margin*, or the *ungual wall*, which is overlapped by skin. The unguinal wall is also called the nail wall. The *matrix* is that portion beneath the nail and from which the nail is produced ; it is very vascular, therefore the color seen thru it, which is pinkish white with the exception of a small semilunar area near the root. This more opaque portion is called the *lunula* or the *lunette* (half moon); it is less vascular.

SPECIAL SENSE ORGANS

The nails resemble epidermis in chemical composition, but they contain more carbon and sulphur. Hoofs, horns, claws, scales, etc., in the lower animals correspond to nails in man, being the thickened layers of the epidermis, principally of the stratum lucidum, only varying in thickness and being differently shaped. The nails support the fingers and toes, and protect them against hard bodies; they are also useful in laying hold of small bodies.

The **Hairs** are modifications of the epidermis, and are found everywhere in the skin, except on the palms of the hands, soles of the feet, the nipples, and the inner surface of the prepuce. The hairs in the different parts of the body are known as follows: of the **head**, *capilla*; the **eyebrows**, *supercilia*; the **beard**, *barba*; of the **ears**, *tragi*; in the **nostrils**, *vibrissa*; the **eyelashes**, *cilia*, of the **axilla**, *hirci*; of the **pubis**, the *pubes*; the small woolly hairs on the **skin** are known as the *lanugo*.

Hairs vary in length, thickness, and in color in different parts of the body and in different races of mankind. In the eyelashes they



are short, and on the head they are of considerable length, the hairs of the pubic region and of the beard are remarkable for their thickness. Straight hairs are stronger than curly hairs and present on transverse section an oval outline, while curly hairs appear flattened. If the hair-follicle, which commences on the surface of the skin with a funnel-shaped opening, passes inward in an oblique manner then there is found a straight hair, but if in a curved direction, the hair is curly.

A **hair** consists of a *root*, a *shaft* and a *point*. The *root* is that bulbous part lodged at the bottom of an involution of the epidermis and corium, called a *hair-follicle*, which sometimes extends into the subcutaneous cellular tissue, and into which open from two to five sebaceous glands. The *shaft* is the portion projecting from the surface,

it consists of a fibrous central path, or *medulla* and a cortical substance, constituting the chief part of the hair and lying next to a layer of thin, flat cells, the true cuticle of the hair.

The *medulla* is absent in fine hairs and in those of young children. It is composed of polyhedral cells and contains pigment granules, fatty tissue and air spaces, while the *cortex* consists of elongated cells which unite to form flat fusiform cells, between which are found minute spaces, those in dark hair containing pigment granules; the outer hair membrane or true *cuticle* is made up of a number of thin flattened overlapping cells; the *point* consists only of the cortex and cuticle.

The hairs are erected by smooth muscle fibres called the *arrectores pilorum*, which arise from the superficial layer of the corium and are inserted into the outer surface of the hair follicle below the entrance of the sebaceous gland duct; they are placed on the side toward which the hair slopes, and by their action elevate the hair. At the bottom of the hair follicle is a small conical vascular eminence or papilla, similar to the papilla of the skin, containing nerve fibres and vessels. When the hair is elevated, a depression forms over the point of origin of the muscles, the skin about the parts is elevated and thus goose-skin or goose-flesh is formed; it is probably by the contraction of these muscles that the sebaceous glands are emptied of their oil.

The **Sebaceous Glands** are small sacculated glandular organs lodged in the substance of the corium. They are abundant in the scalp and face, and are numerous around the apertures of the anus, nose, mouth and external ear; they are wanting in the palms of the hands and soles of the feet.

The largest of these glands are found in the eyelids and are there called the Meibomian glands. Each gland consists of a single duct, which terminates in a cluster of small secreting pouches opening into a hair-follicle, sometimes they open upon the general surface. These clusters of pouches or sacs, are composed of a transparent membranous capsule which encloses a number of epithelial cells and a mass of fat or oil-tissue which constitutes the sebaceous material; it is not uncommon for the larger glands to become enlarged from the accumulation of the secretion.

The **Sudoriferous** or **Sweat Glands** are the media by which a great part of the gaseous and aqueous materials are given off from the body. They are small, reddish, lobular, coiled glands, each having a single duct and coil situated in the deepest part of the corium or in the subcutaneous cellular tissue, opening on the free surface between the papillae by a spiral duct. The duct has two coats; an external fibro-cellular, which is continuous with the corium; and an internal epithelial lining, continuous with the epidermis.

Each gland consists of an elongated tube, the deeper portion of which forms the secretory duct and is coiled in the subcutaneous tissue in the form of an ovoid or spherical ball, termed the *glomerulus*. The duct is called the *ductus sudoriferous* and opens into a pore, called the *porus sudoriferous*.

SPECIAL SENSE ORGANS

It is said there are nearly two and one-half millions of these glands in the body, and that their apertures on the surface constitute an evaporating area of only about eight square inches, making over two million openings in the skin which act as outlets for sweat; each perspiratory duct is 1/4 inch in length, and the aggregate length of the whole number would be about nine miles. The glands are relatively few in number on the back of the trunk in comparison to its area (about 400 to the square inch), but are extremely numerous in other parts, such as on the palm of the hand (here about 2,000 to the square inch); the contents of the sweat glands are mostly the waste of the serous fluid, tho the larger glands contain colored granules and cells within the fluid.

GENESIOLOGY

Urinogenital and Reproductive Organs of the Male and Female

The **Pelvis** is peculiarly constructed so that it serves not only to protect the viscera which it contains and to support some of the viscera of the abdomen, but also to transmit the weight of the body to the lower extremities; it also affords attachment to the muscles which steady the trunk and move the thighs. The cavity of the pelvis is that part of the general abdominal cavity below the level of the ilio-pectineal line, which divides the pelvis into a true and a *false pelvis*. The *false pelvis* is practically the lower part of the abdominal cavity, and corresponds to the hypogastric region, with the right and left ilia of the innominate bones and the iliac fossae forming its side and floor. The *true pelvis* is the space below the ilio-pectineal line and forms the pelvic cavity proper. The pelvis, in the male, contains the following viscera: the bladder, the rectum, pelvic colon, the prostate gland, lower portions of the ureters, the prostatic portion of the urethra, the seminal vesicles, and part of the two vasa deferentia. The female pelvis contains the bladder, rectum, pelvic colon, urethra, uterus, vagina, the broad ligaments, the round ligaments, the Fallopian tubes, the ovaries and their ligaments, besides these organs, both contain many blood-vessels, forming plexuses, and many large trunks of nerve fibres. The bladder and urethra will be considered first on account of the dissimilarity between these organs in the male and female.

THE BLADDER

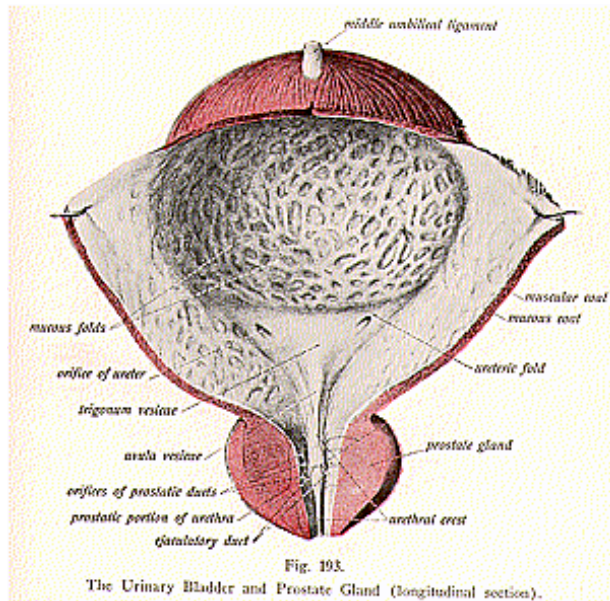
(Illustrations Nos. 193 and 194.)

The **Bladder** is the temporary reservoir for urine, and differs according to position, sex, age and shape. In position, the bladder lies in the pelvic cavity between the pubes and the rectum in the male; between the pubes and the cervix uteri and part of the vagina in the female. In infancy it is cone-shaped and extends above the pubic bones into the hypogastric region; in the adult it is cup-shaped or triangular when empty, it is ovoid when distended. In the female the bladder has, in front of it, a quantity of loose areolar tissue and fat which allows the organ to be pressed upward and forward, in pregnancy, by the gravid womb. When the bladder is empty or moderately distended it lies entirely within the cavity of the pelvis, but when it is fully distended, its apical part rises, above the level of the symphysis pubis, into the hypogastric region for at least two or three inches. When greatly distended it reaches the umbilicus, and may extend even a little higher.

The bladder is a muco-musculo membranous sac, and when moderately distended it measures about 5-1/2 by 4-1/2 by 3 inches. Its

capacity is one pint (16 oz.), tho it is said to be comfortably filled when it contains from 6 to 10 ounces. Its capacity varies considerably, even in health, depending very much upon the habits of the individual.

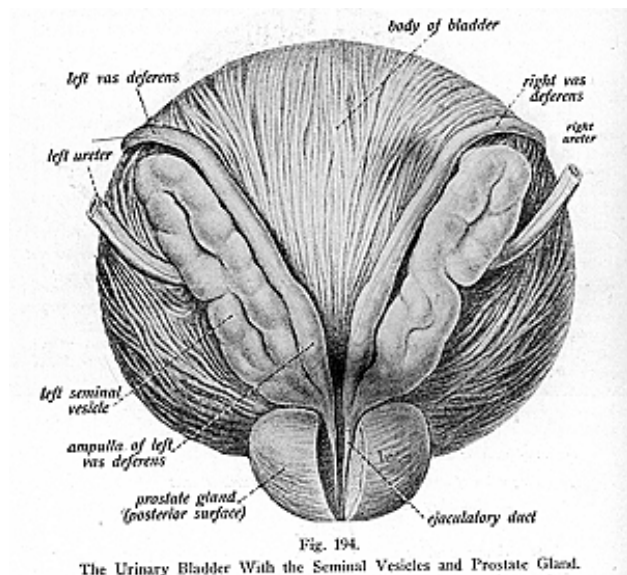
For **descriptive parts**, the bladder has a **summit**, a **base** or **fundus**, a **cervix** or **neck**, and a superior, anterior, posterior, and two lateral surfaces. The summit is connected to the umbilicus by a fibromuscular cord, the urachus or middle umbilical ligament, the upper



part of the obliterated umbilical vessel; the **base**, or **fundus**, is directly backward and downward toward the rectum, is partly covered by peritoneum, and extends forward and downward, where it terminates in a funnel-shaped portion, the **neck**. In the male, the neck of the bladder is embraced by the prostate gland, and terminates in the urethra, while in the female the lower portion is adherent to the anterior wall of the vagina.

The **superior surface** is directed upward and is usually related to coils of the intestine, also to the uterus in the female. The anterior

surface is directed toward the pubes, the **posterior surface** is in relation with the rectum in the male, and with the uterus and the upper part of the vagina in the female. The **two lateral surfaces** are covered with peritoneum. The neck of the bladder is no true tapering point, but represents the lower constricted part which is continuous with the urethra, and is situated at the meeting of the base and the inferior surface. As has been stated, it is surrounded by the prostate gland in the male. The bladder is held in place by five true and five false **ligaments**. The five **true ligaments** include the *anterior* or *pubo-vesical*, consisting of two folds extending from the bladder to the pubes; the *two lateral*, passing from the sides of the organ to the pelvic walls;



and the *urachus* or *middle umbilical ligament*, extending from the summit to the umbilicus. The five **false ligaments** are formed by peritoneal folds, and include the *two posterior ligaments*, which extend from the bladder to the rectum in the male, and from the bladder to the sides of the uterus in the female; the *two lateral*, two folds which pass to the sides of the pelvis, blending with the iliac fascia; and the *superior* or *suspensory ligament*, which extends from the summit of the bladder and is carried over the urachus to the umbilicus.

The bladder has four **coats**—the **outer coat** is serous, derived from the peritoneum; the second coat is **muscular**, the **muscular fibres** of the external layer being arranged longitudinally, those of the internal layer are circular fibres, and these latter fibres are continued to form the sphincter vesicae, the **submucous coat**, of areolar tissue, is the third coat and serves to unite the muscular and the mucous coats; the inner coat, the **mucous coat**, is transitional epithelium, and contains mucous follicles and racemose glands. The membrane of the mucous coat is smooth and thin, and is thrown into numerous folds or rugae when the bladder is empty. These folds are over the entire inner surface with the exception of a smooth triangular space at the base; this triangular surface, known as the **trigone vesicae**, is of pale color, always remains smooth, and prevents the possibility of an entire closure of the orifices of the urethra and ureters.

The ureters pass obliquely downward along the wall of the abdomen from the kidneys and pierce the sides of the bladder, where they terminate at the base of the trigone, they terminate about two inches apart and about 1-1/2 inches above the urethral opening. Sometimes thin, crescentic, valvular folds are found at the termination of either ureter and these are called the *valvulae ureteris*. The **uvula vesicae** is a small elevation of thickened submucous tissue which is found at the anterior and lower part of the bladder and extends to the urethral opening.

The **blood supply** to the bladder is carried by branches from the superior, middle and inferior vesical arteries, by branches from the anterior trunk of the internal iliac and by a few branches from the obturator and lateral sacral arteries, veins having the same names drain the part and empty into the internal iliac vein. The **nerve supply** is by branches from the hypogastric plexus. The fibres which are subject to pressure interference at their exit from the intervertebral foramina are those which pass into this plexus from the 23rd and 24th intervertebral foramina.

Incoordinations arising in the tissues of the bladder are occasioned by pressure upon those nerve fibres which enter the plexus from the fourth and fifth lumbar pairs of spinal nerves.

THE URETHRA

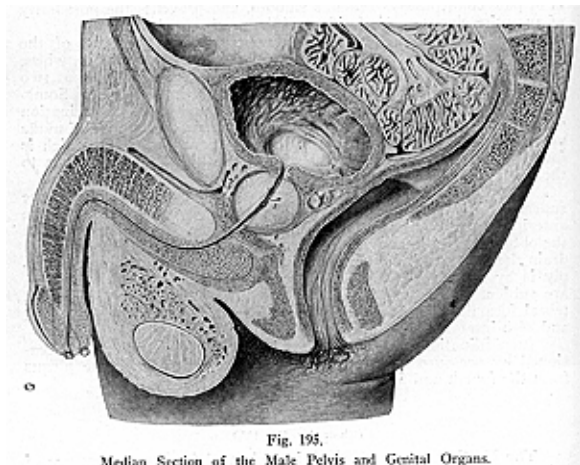
(Illustration No. 195.)

The **Urethra (to pass urine)** is a channel for the conveyance of urine to the outside world, in the male it also serves for the exit of the seminal products. The male urethra is longer and more curved than that in the female, being about 8 to 9 inches long, while the female urethra is about 1-1/2 inches in length. In the female it is more dilatable, so that stones or other foreign matter can, as a consequence, be removed from the female bladder with greater facility.

The **male urethra commences** at the urethral orifice at the neck of the bladder, and terminates at the glans penis in a vertical fissure called the **meatus urinarius**, the male urethra lies mostly within the penis and is divided into three divisions or parts for description, the **prostatic**, the **membranous**, and the **spongy** or **pendulous portions**.

The **prostatic part** (see illustration No. 193) is the widest and

most dilatable part of the canal and lies within the pelvic cavity, between the lateral lobes of the prostate gland, next to the bladder. It is about 1-1/4 inches in length, is inclined to be spindle-shaped, and is collapsed except during the passing of fluids. Upon the middle of its floor is a broad and prominent elevation, about 3/4 of an inch in length, and this is called the *crest* or *verumontanum* or *caput gallinaginis*, from its fancied resemblance to the head of a woodcock. Just below and in front of the crest, below the most prominent part, is an opening, a blind recess or blind pouch, called the **sinus pocularis**. This little pouch is often found to be prolonged into the lateral lobes of the prostate gland, and it has, therefore, been considered to be homologous to the uterus of the female; it is also called the **masculine**



uterus. The ejaculatory ducts empty into the urethra at the side of the sinus pocularis.

The mucous membrane of the prostatic urethra is surrounded, externally, by the inner circular muscular fibres of the prostate, it is covered internally by transitional epithelium. The length, and to a less degree, the curvature of the prostatic portion depends on the amount of distention of the bladder and rectum. Into the floor of the prostatic portion, empty the numerous **ducts** from the prostate gland.

The **membranous portion** of the urethra is the shortest and narrowest portion, it is also more firmly fixed and is the least dilatable

portion of the passage. It is about $\frac{3}{4}$ of an inch long and extends from the apex of the prostatic portion to the spongy portion, it lies about 1 inch behind and below the infra-pubic ligament, its direction is downward, and slightly forward, and it describes a curve which looks upward toward the lower part of the symphysis pubis. This portion is surrounded by the fibres of the compressor urethra muscle. Cowper's Glands are found on each side, and the ducts from these glands usually empty into the membranous part of the urethra, tho they may terminate in the spongy portion. The walls of the duct are very thin.

The **spongy portion** or **pendulous portion** is the longest, about 6 inches in length, and is so called from its being contained in the corpus spongiosum. It extends from the membranous portion to the meatus urinarius, and presents two dilatations; one posterior, at the upper end called the *bulb*, 1-1/2 inches in length; the other anterior at the lower end, the *fossa navicularis*, about 1/2 inch long. At the lower portion, at the meatus urinarius, the calibre of the canal is diminished and has at its sides two small lips, this being the narrowest part of the entire canal. The spongy portion, at its commencement, is directed forward for a short distance, then bends downward, thus describing a curve at a point about 2 inches from its commencement.

The mucous membrane of the spongy portion is provided with elastic tissue, is very vascular, and contains columnar epithelium, except at the glans penis—the extremity—where it is of the stratified squamous variety. Outside of the mucous membrane is the submucous coat, a vascular erectile layer, which contains two layers of plain muscular tissue, the longitudinal and circular muscle fibres. External to the submucous coat is a plexus of vessels which, together with the mucous coat, the erectile tissue, and the submucous coat, form the corpus spongiosum, that part of the penis which encloses the urethra.

The mucous membrane contains numerous glands, the *glands of Littre*; other mucous glands open into the surface by small blind recesses, called the *lacunae of Morgagni*, and if the ducts of Cowper's glands open into the spongy, instead of into the membranous, portion they end by small orifices into the bulb. The urethra, therefore, has three **coats**, the **inner** or the **mucous**, the **submucous** and the **muscular coat**, the latter consists of longitudinal and circular muscle fibres, both layers being directly continuous with the muscular layers of the bladder and aiding in the sphincteric action of the urethral muscles.

The **Female Urethra** is about 1-1/2 inches in length and extends from the neck of the bladder to the meatus urinarius. It is more simple in arrangement, is wider than the male urethra, and is embedded in the anterior wall of the vagina. Its external opening is situated near the anterior margin of the vagina, about one inch behind the clitoris, and is surrounded by a prominence of mucous membrane. The walls are thick, but the structures are softer than those surrounding the male urethra. The female urethra also has three **coats**; the **muscular**, which is continuous with that of the bladder, is made up of circular and longitudinal fibres together with the compres-

sor urethrae, which surrounds the canal as in the male urethra. The **mucous coat** is pale in color and is continuous with that of the bladder and vulva; it is thrown into numerous folds, one of which is often quite prominent and resembles the verumontanum in the male urethra. The **erectile coat** consists of a thin layer of spongy erectile tissue and lies beneath the mucous coat. Around the external orifice of the female urethra are numerous mucous glands.

THE MALE ORGANS OF REPRODUCTION

(Illustration No. 196.)

The **Male Organs of Reproduction** are the **prostate gland**, **Cowper's glands**, the **penis**, the **testes** and their **coverings** and **ducts**, and the **seminal vesicles**.

THE PROSTATE AND COWPER'S GLANDS, AND THE PENIS

(Illustration No. 197.)

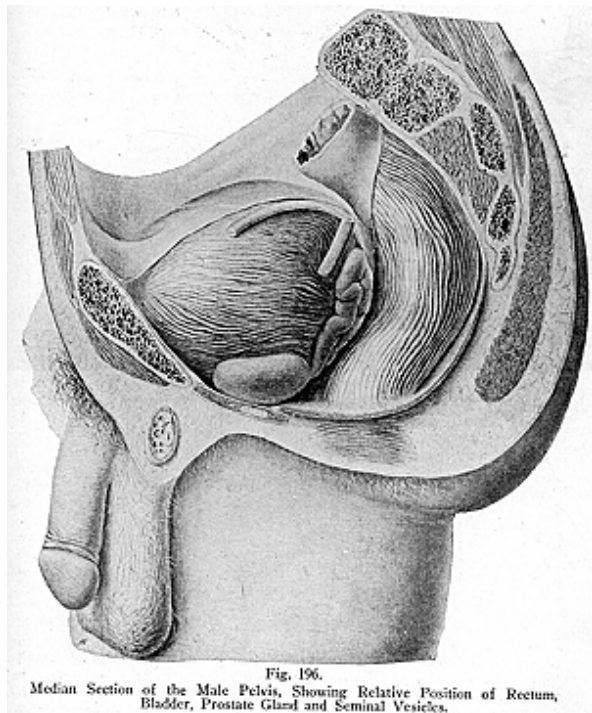
The **Prostate Gland (to stand before)** is partly a glandular and partly a muscular body which surrounds the neck of the male bladder and the commencement of the urethra. It is situated in the pelvic cavity behind the lower part of the symphysis pubis; its posterior surface rests upon the rectum and, therefore, it can be distinctly felt thru the rectum, especially when enlarged, as it becomes in old age. It varies much in **size**, but its average measurements may be given as follows: the transverse diameter or the longest diameter at the base is about 1-1/2 inches; the vertical diameter from base to apex is about 1-1/4 inches; from the anterior to the posterior, about 3/4 inch. The weight is approximately 3/4 oz.

The prostate is firm in consistency and in shape and color it resembles a horse-chestnut. It consists of **two lateral lobes**, which are of equal size and form the chief bulk of the gland, but often a middle or a third lobe is present. This is a small band or eminence placed between the lateral lobes immediately in front of the bladder. This so-called middle lobe, which is often absent in the adult, is merely a connecting band between the lateral lobes, unless it is hypertrophied, and then it extends up to the posterior and lower end of the bladder. Superficially the prostate is separated from the bladder by deep lateral grooves directed downward and forward, and by a narrow groove which is horizontal. The prostate is enveloped by a thin but firm fibrous capsule, derived from the surrounding pelvic fascia. It forms a sheath for the gland and encloses in its meshes numerous follicular pouches which form the gland tissue.

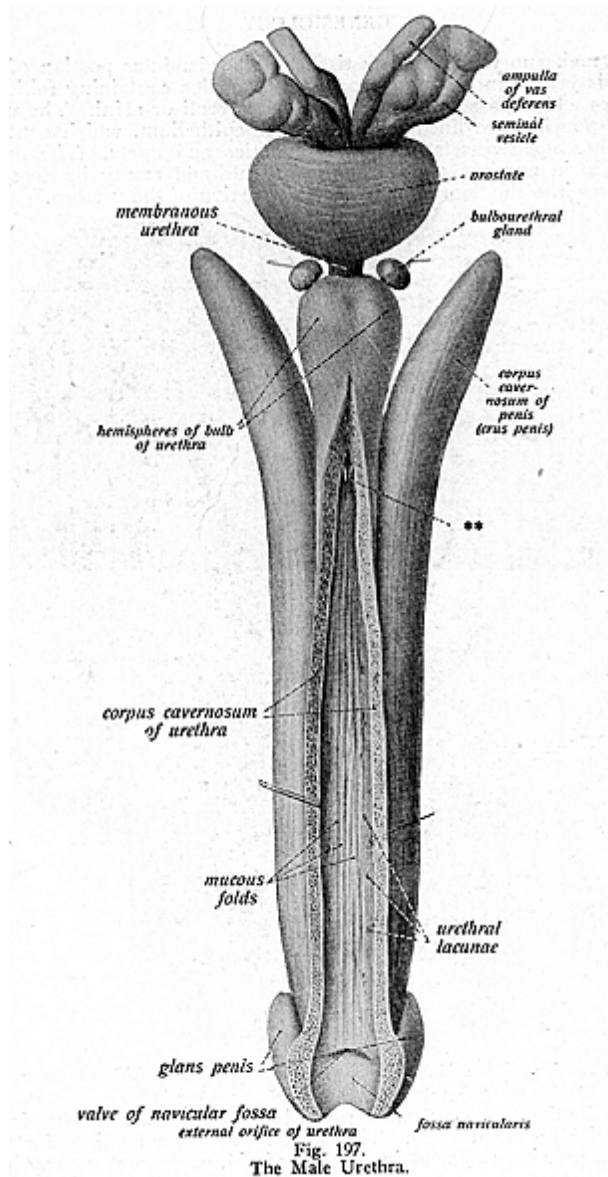
The muscular tissue is densest at the base of the gland, that next to the bladder becoming loose and spongy toward the apex of the organ. The muscular fibres, which form the muscular tissue, consist principally of a mesh of unstriped muscle fibres continuous with the dense capsule; the fibres are partly longitudinal, partly transverse and circular; they pervade the gland in a decussating manner and so form trabeculae. In between the meshes are found numerous small racemose glands, which form the gland tissue. The trabeculae divide the gland into a number of incomplete lobules, about 50 in number,

GENESIOLOGY

which make up the glandular tissue. The glandular portion of the gland is yellow in color and consists of lobules containing follicular pouches which possess branched tubular alveoli or acini. The walls of the pouches are lined with columnar epithelium, which contains the cells, blood-vessels, nerves, lymphatics and ducts. The ducts, about 20 in number, pass thru the capsule and empty by separate apertures into the floor of the prostatic portion of the urethra.



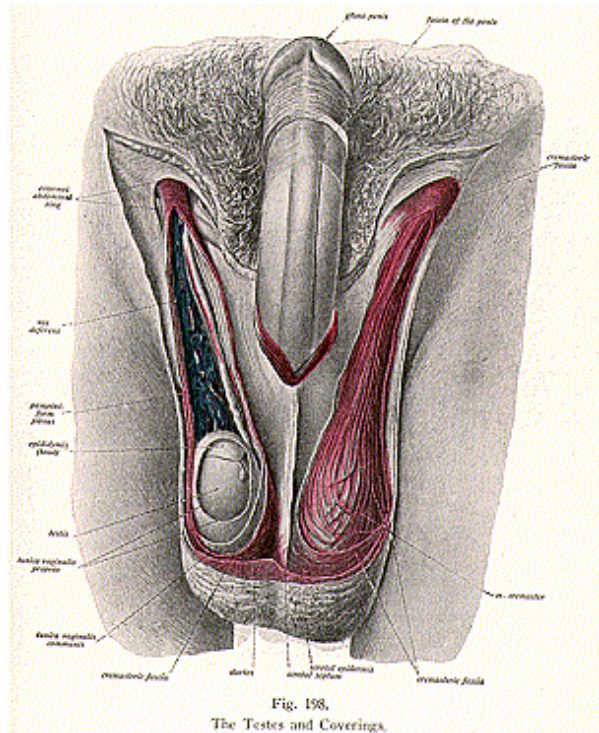
The **function** of the prostate gland is to secrete a fluid to lubricate the interior of the urethra. This fluid serves as a medium for the sperm to pass thru or float in. It is a viscid, opalescent serous fluid



GENESIOLOGY

alkaline in reaction. In old age the gland frequently hypertrophies, and calcareous concretions then form and lie embedded in the gland.

The **blood supply** to the gland is carried by branches from the internal iliac artery, also by the internal pudic and hemorrhoidal



vessels; the veins are tributary to the internal iliac vein. The **nerves** are branches from the hypogastric plexus. They convey many fibres derived from the third, fourth and fifth lumbar pairs of spinal nerves, emitting thru the 22nd, 23rd or 24th intervertebral foramina, and it

is these spinal nerve fibres which are subject to pressure at their foraminal exits.

Cowper's Glands, called also the **bulbo-urethral glands**, are **two** little round whitish-yellow bodies, the size of peas, below the membranous portion of the urethra and enclosed in the fibrous sheath of the compressor urethrae muscle. Their existence is constant, but they gradually diminish in size as age advances. They are racemose mucous glands of quite firm consistency and are usually lobulated. The fibrous capsule forms a covering for each gland and sends into the gland, trabeculae, which divide the gland into lobules; each gland has an excretory duct about an inch in length, running beneath the mucous membrane and opening into the membranous or the bulbous urethra. The secretion from these glands is that to be concerned in neutralizing the acid secretions in this portion of the urethra.

The **Penis** (illustrations Nos. 198 and 199) is the organ of copulation and consists of three cylindrical compartments of erectile tissue. These compartments are the **two corpora cavernosa** and the **corpus spongiosum**; the latter encloses the urethra and is situated beneath and between the two corpora cavernosa. The entire organ is ensheathed by peculiarly thin and extensible skin, which is continued from the pubes and the scrotum.

For **descriptive parts** the penis has a **root**, **body**, and a **glans penis** or the extremity. The root is attached to the border of the pubic arch by two strong fibrous processes, the crura of the corpora cavernosa, the **body** is that part between the root and the extremity, and when the organ is flaccid, the body is cylindrical in form, when expanded it appears as a three-sided column surmounted by the glans, which is shaped like a dome with a rounded summit and a broad base. The **body** is covered by the integument and contains in its interior the urethra. The skin covering it is thin, loose, dark colored, and free from fat, and, at the lower extremity, forms the loose and movable **prepuce** or the **foreskin** by doubling upon itself so as to enclose and protect the glans. The skin fold which connects the under surface of the glans and the lower part of the meatus with the prepuce, is called the **fraenum preputii**. The skin is modified over the glans by the absence of a proper subcutaneous tissue and it is firmly attached to the underlying structure, becoming continuous with the mucous membrane of the meatus; here it is furnished with numerous vascular and sensitive papillae.

The **corpora cavernosa** are two cylindrical tubes placed side by side, and constitute more than two-thirds of the bulk of the organ, and chiefly determine its shape when it is distended. They are composed of erectile tissue, and each is enclosed in a fibrous capsule of interlacing fibres. The tubes are in close contact, for the anterior three-fourths, presenting a median groove for blood-vessels and nerves while at their back part they separate from each other and form two strong tapering processes called the crura. Each crus begins by a club-shaped process in front of the tuberosity of the ischium and the rami of the pubes.

The **corpus spongiosum** surrounds the urethra and is composed of erectile tissue similar to that of the corpora cavernosa; it is situated

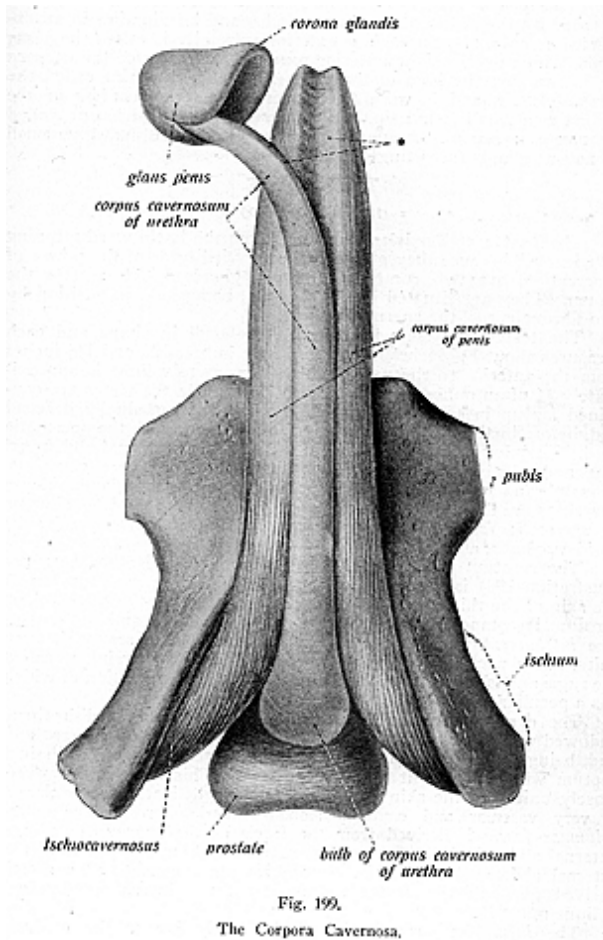


Fig. 199.
The Corpora Cavernosa.

on the inferior surface, between the crura of the corpora cavernosa and expands behind to form the urethral bulb, and anteriorly to form the glans penis. The bulb is the rounded enlargement, being surrounded by the accelerator urine muscles and terminating in an expanded cap-like structure. The exterior extremity is called the **glans penis**, which overlaps the anterior rounded extremity of the corpora cavernosa. At the base of the glans is a wheel-like rim called the *corona glandis*, and between the converging anterior borders of the corona is a small round tip, which presents a vertical fissure called the *meatus urinarius*. Around the corona glandis are numerous small sebaceous glands (secreting glands).

THE TESTES

(Illustration No. 200.)

The **Testes**, or **Testicles**, so named from the Latin word meaning a “witness,” because they give evidence of virility or of the power of procreation, are two compound tubular glands which secrete the semen. They are situated in the scrotum, being held in position by two fibrous cords, the **spermatic cords**.

The testes, grayish white bodies, are oval in shape and each measures about 1-1/2 inches in length, 1 inch in breadth, and 1-1/4 inches from the anterior to the posterior; their average weight is approximately 3/4 of an ounce. At an early period of life the testes are contained far up in the abdominal cavity, but they gradually descend and, before birth, pass to the inguinal canal along with the spermatic cord. They leave the abdomen thru the canal and external abdominal ring, and pass into the scrotum, carrying with them several coverings of membrane and fascia which form the coats of each gland. These **coverings** are the *skin* and the *dartos* of the scrotum; the *intercolumnar* or *spermatic fasciae*; *cremasteric fascia*, *infundibuliform fascia*; the *tunica vaginalis*; and the *tunica albuginea*.

The **scrotum** (originally spelled “scortum,” a leather bag, see illustration 198) is a cutaneous pouch, formed by a prolongation of the skin of the thigh and the perineum, and contains the testes. The scrotum is composed of two layers, the integument and the dartos. The *integument* is thin and loose, it contains a few scattered, crisp hairs, has a peculiar color, is thrown into numerous wrinkles called the rugae and is provided with sebaceous glands, the secretion of which has a peculiar odor.

The *dartos* (“skinned”) is a thin loose layer of reddish tissue endowed with contractility; it forms the proper tunic of the scrotum, and, being the inner layer of the scrotum, it sends inward a distinct septum which divides it into two cavities. This layer is, however, closely united to the skin externally and is a delicate areolar tissue, is very vascular and contains smooth muscle fibres. The *intercolumnar fascia* is derived from the fascia of the aponeurosis of the external abdominal oblique muscle, extending from the pillars of the external abdominal ring. The *cremasteric fascia* consists of a sheath derived from the cremaster muscle, from the internal abdominal oblique muscle.

The *infundibuliform fascia*, which loosely invests the cord, is

derived from the transversalis muscle. The *tunica vaginalis* is the serous covering which surrounds the testicle, being a process of peritoneum which has been cut off from the general peritoneal cavity in the descent of the testes. It consists of two layers, the visceral portion and the parietal portion. The visceral layer is the primitive peritoneum which covered the testes while contained in the abdominal cavity, it is inseparably united to the tunica albuginea, and covers the epididymis as well as the testes. The parietal layer is stronger than the visceral layer, and extends upon the cord for a short distance below the testicle, lining the scrotum; its inner surface is lined

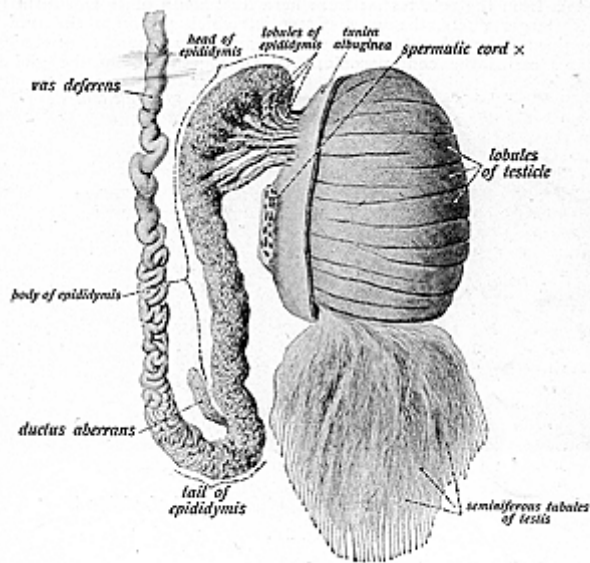


Fig. 200.
The Testis, Epididymis and Part of the Vas Deferens.

with endothelial cells. The interval between the two layers is called the cavity of the tunica vaginalis.

The *tunica albuginea* is a dense, inelastic membrane formed of white fibrous tissue; the fibres interlace in every direction, forming the trabeculae which divide the gland into numerous lobules. This covering encapsulates the testicle and, at the back part of the gland, is projected for a short distance into its substance, forming an incomplete septum, the *corpus Highmorianum* or the *mediastinum testis*.

The **parenchyma** (illustrations Nos. 201 and 202) of the testes

consist of an enormous number of much convoluted tubules which completely fill the intervals between the septa. The tubules are known as the **seminiferous tubules**, being about 800 or 900 in number, from 1/300 to 1/200 of an inch in diameter, and convoluted to form 300 conical **lobules**. Each tubule is about two feet in length when unravelled. Each **lobule** contains from two to four tubules, its base being directed towards the circumference of the testes, the apex towards the mediastinum.

The **tubules** unite to form 20 or 30 large ducts called the **vasa recta**, these ducts enter the mediastinum and with numerous blood-vessels form the **rete testis**; from here they again unite and form 12 to 20 larger ducts, the **vasa efferentia**, which perforate the tunica albuginea. Here they become enlarged and form a number of conical masses called the **coni vasculosi**, which together form the globus

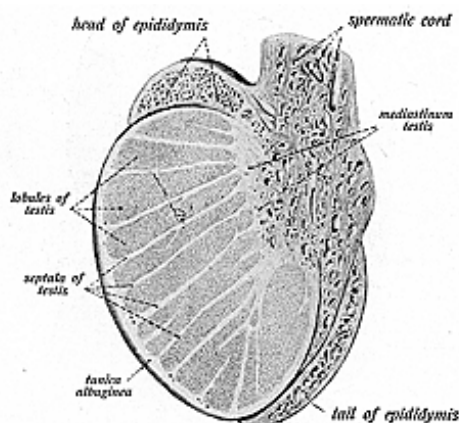


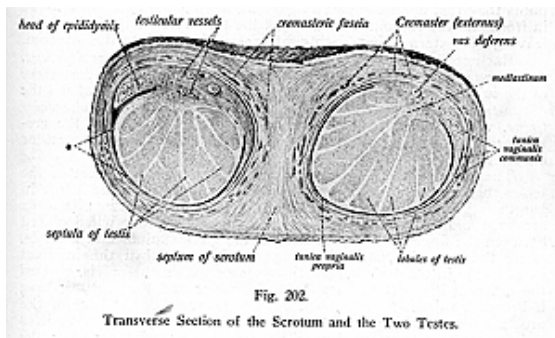
Fig. 201.
Longitudinal Section of the Testis.

major of the epididymis. Each **conus vasculosus** is 6 to 8 inches in length, and the diameter is about 1/3 of an inch, it gradually decreases from the testis to the epididymis.

The tubules are a pale gray in color in early years, but are inclined to become yellow later in life, due to the fat which is found between the lobules. The tubules look like fine silken threads, they do not anastomose, but are very much convoluted and so, when divested of the coverings, they appear like fine threads wound one around the other. Each tubule has a basement membrane which contains a lining of several layers of epithelial cells, also a layer of cubical, transparent, nucleated cells are called the lining cells and

within the lining cells are two or three layers of spheroidal cells, which ultimately become converted into the **spermatozoa**. These little organisms lie with their heads buried between the more deeply placed cells and their long tails projecting free into the long lumen of the tubule. The vasa recta are lined with cubical epithelium; the vasa efferentia and the coni vasculosi contain the ciliated columnar variety.

The secretion formed in the testes is known as **semen**, in which float the **spermatozoa**, **minute** elongated particles with a *head* or nucleus, a *body* or the middle piece, and a *tail*, resembling in shape and motion the tadpole. The spermatozoa are formed in the seminiferous tubules and are carried in the semen thru the vasa recta, to the vasa efferentia, to the coni vasculosi; then into the canal of the epididymis into the vas deferens and thru the inguinal canal, within the spermatic cords, to the seminal vesicles and enter there the duct of the seminal vesicles, or pass immediately into the ejaculatory duct if seminal emission is in progress. The distance passed by the spermatozoa before being eliminated by the urethra is approximately 24 feet, and



these organisms are themselves perfectly inactive in making this passage.

The supply of spermatozoa is extensive, in man there are 60,000 spermatozoa to each cu. millimeter of semen. During copulation the spermatozoa are discharged probably from the whole length of the vas deferens by peristaltic contraction of this duct, and not solely from the seminal receptacle, as formerly supposed. The **semen** is a whitish fluid of alkaline reaction and characteristic odor, containing water, proteids, salts and nitrogenous substances. The testes physiologically exert a marked influence on the development of the body. They are actively engaged in the production of spermatozoa and are essential for the act of copulation.

THE EPIDIDYMIS

The **Epididymis** (illustration No. 200) is a small, grayish, oblong body placed on the posterior surface of the testes, it is made up of a single convoluted tube occupying a small area, but, when unravelling, measuring 20 feet in length and about 1/16 inch in diameter. It has for descriptive parts an upper enlarged portion or the head, called the **globus major**; the middle or central portion, the **body**; and the lower end, the smaller tapering portion, the **globus minor**, where it terminates in the vas deferens. The **globus major** is formed by the coni vasculosi, the **body** consists of the convolutions of the tube, and the **globus minor** ends in a single tube—the vas deferens.

The testes are held in position by two cord-like structures which form the suspensory ligaments of the testes and are called the **spermatic cords**; the left testicle hangs a little lower than the right one. These cords are about four inches in length and extend from the back of the testicle to the internal abdominal ring; the cords pass thru the inguinal canal, thru the external abdominal ring, and near the pubis they rest upon Poupart's ligament, having the external oblique in front and the conjoined tendon and the transversalis behind. After leaving the external ring, each cord passes directly into the scrotum.

Each cord consists of the following structures: the *vas deferens*, the *spermatic artery*, *spermatic vein*, the *cremasteric artery*, the *artery of the vas*, the *spermatic nerve plexus*, *branch of the ilio-inguinal* and the *genito-crural nerve*, the *vas aberrans* (sometimes), *lymphatics*, and *areolar tissue*, which holds these various structures together, having the cremasteric, intercolumnar, and infundibuliform fasciae for the coats or coverings.

The **vas deferens** is the seminal duct, the excretory duct of the testes, being a continuation of the epididymis, it is about 2 feet in length and its canal is very small and lined with epithelium; its walls are hard and dense, and the duct feels like a whipcord when placed between the fingers. It commences at the globus minor and ascends, along the posterior part of the spermatic cord, thru the inguinal canal to the internal abdominal ring, passes within the pelvis, crosses the external iliac artery between the bladder and the rectum; here it becomes enlarged and sacculated, but narrows at the base of the prostate gland, where it joins with the duct of the seminal vesicles and forms the *ejaculatory duct*. The vas deferens has three *coats*, the outer, which is an areolar coat, the middle or the muscular coat, made up of an external longitudinal layer, and a middle or circular layer; and the inner coat is a mucous coat, pale in color and arranged in small longitudinal folds. This coat contains a double layer of tall ciliated cells.

The spermatic artery and vein accompany the vas within the cord. The **vas aberrans** or **ductus aberrans** is a small blind tube which is found at the lower end of the globus minor along with the vas deferens. It is an unusual tube, not always present and seldom extends more than to the external abdominal ring.

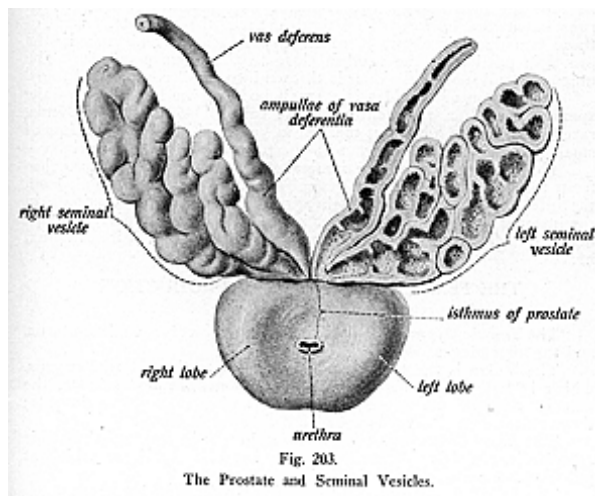
The **blood supply** to the testes and the epididymis is carried by branches from the spermatic artery; the veins form a plexus, called the pampiniform plexus. The chief veins empty into the inferior

vena cava or into the renal vein. The **nerves** are derived from the spermatic plexus; the nerve fibres from this plexus are derived from branches from the third, fourth and fifth lumbar pairs of spinal nerves, emitting thru the 22nd, 23rd and 24th intervertebral foramina, and it is the latter fibres which are subject to pressure at their foraminal exits that causes incoordination in these organs.

SEMINAL VESICLES

(Illustration No. 203.)

The **Seminal Vesicles** are two hollow, sacculated, membranous pouches, situated between the base of the bladder and the front of



the rectum. They serve as reservoirs for the semen, as well as forming a secretion to be added to the secretion of the testicles. They are about 2 inches in length, and are partly covered by peritoneum. Each vesicle tapers at the lower end and forms a duct called the *duct of the seminal vesicle*, which unites with its corresponding vas deferens to form the **ejaculatory duct**. The seminal vesicles are considered by some authorities to be dilated parts of the vasa deferentia, the seminal ducts and not true glands. Each vesicle consists of a single coiled tube, having minute diverticula within its lumen. The vesicle is lined with columnar epithelium, and the diverticula contain goblet cells, which may be regarded as concerned in pro-

ducing the peculiar fluid within these sacs. This secretion is of importance, probably, not only in diluting the secretion of the testicle and supplying the medium favorable for the motility of the spermatic filaments, but also in completing the volume of fluid necessary for efficient ejaculation.

The seminal vesicles have three **coats**, an external or **serous**; the **middle** or **muscular**, arranged like the vas deferens in two layers, the longitudinal and the circular; the inner coat is **mucous**, containing reticular ridges, and thus appears honey-combed, containing cells forming a secretion which, when added to the semen carried from the testes, aids to keep the sperm alive while contained in the reservoir. The duct of the seminal vesicle joins the vas deferens at the base of the prostate gland and forms the **ejaculatory duct**, which runs downward between the lateral lobes of the prostate. Each of these two ducts is about 3/4 of an inch in length, and ends in the prostatic portion of the urethra close to the sinus pocularis. The mucous membrane in the duct is thrown into small complicated folds.

The **Organ of Giraldes** is a small body at the lower end of the spermatic cord, a rudimentary body, called also the **paradidymis**, rarely seen in the adult but marked in young children; it consists of small tubules, and is analogous to the parovarium in the female.

The **blood supply** to the seminal vesicles is carried by branches from the middle and inferior vesical and middle hemorrhoidal, from the internal iliac artery, veins bearing the same name terminate in the internal iliac vein. The **nerves** are derived from the pelvic plexus, being branches from the third, fourth and fifth lumbar pairs of spinal nerves.

THE FEMALE ORGANS OF REPRODUCTION

(Illustration Nos. 204 and 205.)

The **Female Organs of Reproduction** are the **vulva, vagina, uterus**, and the appendages.

The **Vulva** is the term generally applied to the external organs, which include the **mons veneris**, the **labia majora** and **minora**, the **clitoris**, **external orifice of the vagina**, and the **meatus urinarius**; these external genital parts are also called the pudenda.

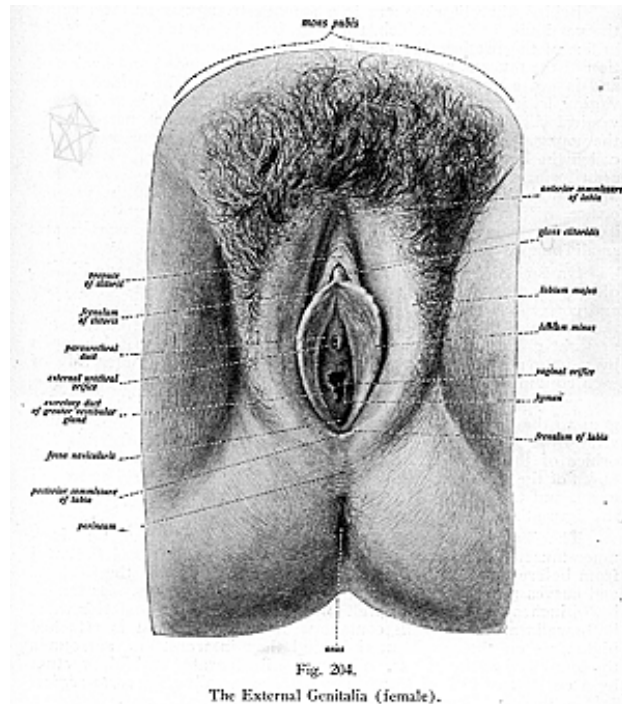
The **Mons Veneris** is a rounded eminence in front of the pubic symphysis, and is made up of a collection of fatty tissue which at puberty becomes covered with hair.

The **Labia, Majora and Minora**, are two folds of integument extending from the mons veneris to the perineum, the more external and larger lips are called the **majora**, while the internal and smaller are termed the **labia minora**; they correspond to the scrotum in the male. The labia are prominent longitudinal cutaneous folds, made up of integument externally, and modified skin internally, between which are found areolar tissue, fat, vessels, nerves and glands. The labia meet in front and form the *anterior commissure*, and nearly meet behind to form the *posterior commissure* at the anterior boundary of the perineum.

The **labia majora** commence in front at the anterior commissure and blend beneath the pubes, diminishing below, and about an inch

GENESIOLOGY

above the anus join and form the posterior commissure. Within the latter there is a small transverse fold, called the **fourchette** or the **frenulum**; the space between it and the posterior commissure is called the **fossa navicularis**. The external skin of the labia majora is provided with hairs and sebaceous glands, but the internal surface resembles mucous membrane, being smoother, thinner and moist.



The **labia minora** are the two smaller folds, called the *nymphae*, which are situated internally to the majora. They commence half way between the commissures, and, as they approach the anterior commissure, they blend and form a hood-like covering for the clitoris. The structure of the labia minora differs from that of the majora in that they do not contain fat.

The **Clitoris** is a small erectile organ situated within the anterior commissure, analogous to the penis in the male, and about 1-1/2 inches in length; it is attached to the rami of the os pubis by two crura and a suspensory ligament. The free extremity is called the **glans clitoris**, and is a small rounded eminence consisting of soft spongy erectile tissue, blood-vessels and nerves.

Behind the clitoris there is a smooth triangular surface, called the **vestibule**, back of which, about an inch below the clitoris, is the orifice of the urethra, the meatus urinarius, surrounded by an elevation of the mucous membrane. The meatus is rounded and puckered, and is not a vertical slit like that of the penis. The orifice of the vagina is just below the meatus and, when closed, appears as a vertical slit, becoming elliptical when expanded. It is narrowed in the young woman by the presence of a thin fold of mucous membrane, called the **hymen**, which is very variable in development. It may be cribriform, crescentic, perforated, fringed, or it may consist of two lips; but ordinarily it extends across the lower part of the vaginal orifice, with a crescentic border directed upward. After its rupture its borders appear scalloped, and form the *carunculae myrtiformes* small rounded eminences.

On each side of the posterior part of the vagina is a round body, often two may be found, reddish in color, about the size of a bean and corresponding to Cowper's glands in the male. They are called the **glands of Bartholin**, or the **sub-urethral glands**, and, like the sub-urethral glands in the male, they are racemose glands. They open by a long single duct, external to the hymen, on the inner side of each labium minus.

The sphincter vaginae or the bulbo-cavernosus muscle, is analogous to the accelerator urinae in the male, it consists of fibres which arise from the central tendon of the perineum, and surrounds the orifice of the vagina. At the central tendon of the perineum, the fibres of the sphincter vaginae and those of the external sphincter ani unite, and the two muscles together present somewhat the form of the figure 8.

The **Vagina** extends from the vulva to the uterus. It is a muco-musculo-membranous canal, cylindrical in form and flattened from before backward. It lies between the rectum and the bladder, and curves upward, conforming to the axis of the pelvis. Its length is 2-1/2 inches on its anterior wall and 3-1/2 inches on the posterior wall; both walls are usually in contact with each other. It is attached higher up on the cervix uteri behind than in front, and surrounds the lower end of the uterus. The vagina is separated from the rectum by a cul-de-sac derived from the peritoneum, called the *recto-vaginal fold*, or the *sac of Douglas*.

The vagina consists of a muscular coat composed of a layer of erectile tissue, the fibres being arranged in two layers, a longitudinal and a circular layer. External to the muscular coat is a layer of connective tissue which contains anastomosing blood-vessels and nerves; internal to the muscular coat is another layer, which is mucous

GENESIOLOGY

membrane. In the upper part of the vaginal canal, the mucous membrane is smooth and is continuous with that of the uterus, while in the lower part of the canal it is roughened, due to the presence of a series of transverse ridges, known as the rugae, formed by contraction of the longitudinal fibres of the muscular coat. The mucous membrane is of a pinkish color and covered with numerous conical papillae; it has a thick lining of stratified squamous epithelium and contains glands which are more numerous at the upper end of the canal, near to the neck of the uterus.

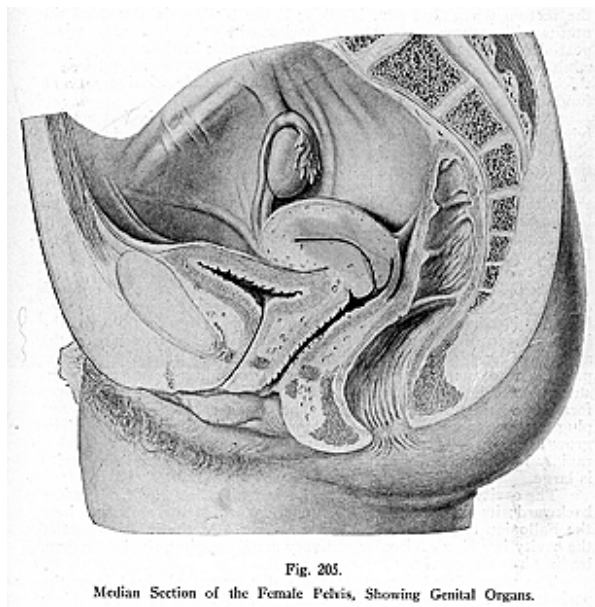


Fig. 205.
Median Section of the Female Pelvis, Showing Genital Organs.

The **blood supply** to the vagina is carried by branches from the internal iliac, thru the vaginal artery; the veins bear the same names and end in the iliac vein. The **nerve supply** is had by branches from the hypogastric plexus. The nerve fibres from this plexus consisting of fibres from branches derived from the third, fourth or fifth lumbar pairs of spinal nerves.

THE UTERUS

(Illustration No. 206.)

The **Uterus** is the organ of gestation, it receives the fecundating ovum, develops and supports it, and becomes the principal agent of expulsion at the time of parturition. It is situated in the pelvic cavity between the rectum and the bladder, opening below into the vagina; the upper part of the organ is on a plane a little below the brim of the pelvis. It may often be deflected to the right side, by pressure of the sigmoid flexure of the colon where it terminates in the rectum when that part is filled; if the bladder is distended the uterus will assume a pronounced backward curve. The uterus is a pear-shaped organ and is also called the womb; in the non-pregnant adult it is about 3 inches in length, 2 inches in breadth, and 1 inch thick, and weighs about 1-1/2 ounces. It has **four descriptive parts**, a **fundus**, **body**, **cervix** and a **cavity**.

The upper, convex part is called the fundus, which is that portion lying below the pelvic brim; the **body** is about 2 inches in length, oblong in shape, its anterior surface is the vesical surface, the posterior surface looks toward the rectum, and the superior angles are situated at the points of entrance of the Fallopian tubes, forming there the **cornua**. The body of the organ narrows at the lower part and forms the **neck**, which is the lower rounded constricted portion spindle-shaped, and measuring a trifle over an inch in length; it lies partly above the vagina and partly within it, and, therefore, consists of two parts—the *vaginal* and the *supra-vaginal portions*.

Around the vaginal portion is a circular opening called the *mouth of the womb* or the *os externum*, which is enclosed by two convex borders, forming the lips. In women who have borne children, the inner margin of the external os uteri is very irregular, while in the absence of past parturition it is smooth. The *supra-vaginal* portion projects into the cavity of the os uteri, opening by a small constriction called the *os internum*, where the fibres of the circular layer form the sphincter of the uterus. The cervix is closed by a mucous plug during pregnancy and remains so until labor begins. The growth of the organ is slow until puberty, then it seems to develop rapidly for a time and in women who have borne children the cavity is large.

The **cavity of the uterus** is small, triangular, flattened from before backward; its lateral angles are funnel-shaped at the apex and here the Fallopian tubes enter by minute orifices. At the inferior part of the cavity is a single, circular and very small opening, the internal os, leading into the cervix.

The uterus has three **coats**, the **outer, serous, derived** from the peritoneum, is called the perimetrium; the middle coat is muscular; and the **inner is a mucous coat**. The **middle coat, muscular**, forms the bulk of the organ, and is composed of unstriped muscular fibres, with blood-vessels, nerves and areolar tissue. The fibres are arranged in three layers, the *external* is a thin layer made up of fibres which run longitudinally, found beneath the peritoneum; the *middle layer* consists of an oblique, a longitudinal, and a transverse set of fibres, also the middle layer is arranged in two hollow cones whose apices sur-

The **broad ligaments** are two large folds **stretched between** the sides of the uterus and the lateral walls of the pelvis, dividing the cavity into two portions, in the anterior part are contained the urethra, bladder and vagina; in the posterior part is found the rectum. Between the folds of the broad ligaments are found the following: The Fallopian tubes, the ovaries, the round and the ovarian ligaments, the two parovaria, connective tissue, blood-vessels and nerves.

The **round ligaments**, or the **teres ligaments**, are **two cord-like** structures, 4 or 5 inches in length; each extends from the superior angle of the uterus, passes forward and outward thru the internal abdominal ring, thru the inguinal canal and thru the external ring, to the labia majora, where it becomes lost in the fatty tissue of the corresponding labium major. Each cord consists of muscular tissue, some fibrous and areolar tissue, blood-vessels and nerves, enclosed in a fold of peritoneum derived from the broad ligaments, which fold, in the fetus, is prolonged into the inguinal canal as a tubular process called the canal of Nuck.

The **uterus undergoes changes** at puberty, the menstrual period, at time of pregnancy, during pregnancy, after parturition, at the menopause period, and in old age. At puberty the uterus rapidly enlarges and acquires adult characteristics; the body of the organ now grows faster than the cervix, and at this time assumes its normal position within the pelvis. Periodic changes are attendant upon the function of menstruation and are accompanied by changes in the condition of the uterine walls; this takes place every twenty-eight days, between the ages of 14 and 45, and is known as the menstrual period. At this time there is a change occurring which results in the periodic shedding of the mucous membrane of the lining of the uterine cavity. The organ becomes somewhat enlarged owing to the flow of blood in the vessels, the external os is rounded and the lips are swollen about it. The mucous membrane thickens, becomes softer and of a dark color, and when it gets to the point of swelling or rupture of the blood-vessels, a hemorrhage takes place lasting from two to five days, sometimes seven days. The amount which is discharged varies between two and eight ounces. Some authors claim that, by the process of bleeding the walls of the uterus are made raw and that if an impregnated ovum arrives it will adhere to the wall.

At pregnancy the changes are very remarkable. The organ gradually enlarges and rises against the anterior abdominal wall **where it** can be felt as a large ovoidal mass extending into the umbilical region. It also increases rapidly in size and length so that instead of the length being 3 inches, it becomes, about the eighth month, between 8 or 9 inches or even more. The normal weight is 1-1/2 ounces and it acquires the weight of two pounds, and at this time it changes from spherical form to oval. The muscular fibres hypertrophy and the uterus, on account of its weight, seems to drop into the pelvic cavity, it then rises again and reaches as high as the epigastric region, then gradually descends into the pelvis.

The length of the cervical portion of the organ is not altered during pregnancy and the canal does not dilate until labor begins. During pregnancy the glands, found at the cervix, swell and secrete

an unusual amount of mucus, this closes the cervical canal, and is not removed until labor begins. The walls of the uterus lose their compact texture, to become loose and extensible, until the time of birth when they are extremely thin. After parturition the uterus returns to its usual size in a very short time, tho the cavity is always larger, the external os is more marked, the muscular fibres and ligaments are more clearly defined. At menopause the uterus ceases to functionate, and gradually and slowly atrophies. In very old age the walls become pale in color, the ligaments become hard and rigid, and the internal and the external os are entirely obliterated.

The **blood supply** to the uterus is carried by branches from the ovarian, from the abdominal aorta, and by the uterine from the anterior trunk of the internal iliac; these arteries form an extensive

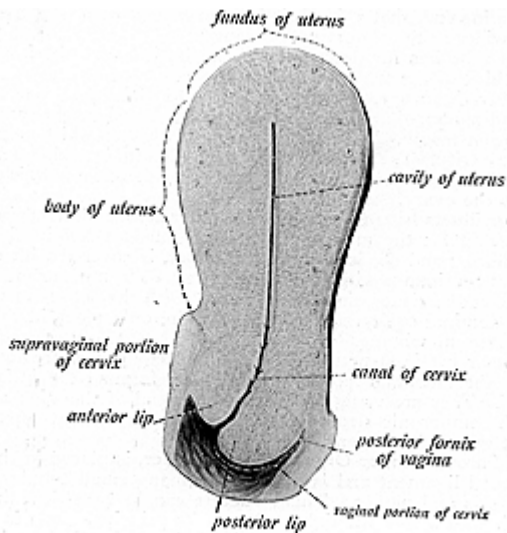


Fig. 207.
A Sagittal Section of the Uterus and the Upper Part of the Vagina.

anastomosis, called the uterine-ovarian anastomosis. The vessels are very tortuous and, during pregnancy, enlarge and form sinuses.

The **nerves** are derived from the hypogastric plexus. **Other** anatomists claim they are derived from the third and fourth sacral nerves, but Chiropractors, by nerve tracing and by established clinical results, find the nerve supply includes fibres derived from the third, fourth and fifth lumbar pairs of spinal nerves. These fibres are readily subject to pressure interference which causes such disorders as are found in this organ. Adjustments given during pregnancy are essential.

THE APPENDAGES OF THE UTERUS

(Illustration No. 208.)

The **Appendages of the Uterus** include the **Fallopian tubes**, the **ovaries**, the **ovarian ligaments**, the **round ligaments**, and the **organ of Rosenmuller**. These structures, with considerable loose connective tissue, blood-vessels and nerves, are all enclosed in the folds of the broad ligaments.

The **Fallopian Tubes**, or the **Oviducts**, are two tubes which convey the ova from the ovary to the uterine cavity. They are found in the broad ligaments, and extend from the upper end of the uterus to the sides of the pelvis; these tubes are 4 inches in length and about 1-1/16 inches in diameter; each tube is such a very narrow structure at the uterine end, that a fine bristle can scarcely pass thru the canal, but it is wider at the abdominal opening.

Each tube has for **descriptive parts** the **isthmus**, the inner constricted third of the tube; the **ampulla**, the dilated larger part which curves over the ovary, and includes one-half of its total length, and the **infundibulum**, the trumpet-shaped outer, ovarian, expanded end, with its open mouth, the *ostium abdominale opening* which opens into the pelvic cavity. The margin of the infundibulum is broken up into a number of fringed processes called the *fimbriae*; one of which is attached to the ovary.

The oviducts **have three coats**, the **outer serous**, **derived** from the broad ligaments, the **middle muscular**, formed of longitudinal and circular fibres, and the **inner**, a **mucous coat**, is covered with ciliated epithelium continuous with that of the uterus. The mucous membrane lining the canal, comes directly in contact with the serous membrane of the abdominal cavity, and is probably the only place in the body where these membranes do come together. Often one or more peduncles or cystic structures, delicate and elongated, are found attached to the fimbriated portion of the tube, forming the *hydatids of Morgagni*. They are vestiges of the anterior end of the Wolffian duct, one of the embryonic structures which precedes the development of the adult generative organs.

The **Parovarium**, or **Organ of Rosenmuller**, is placed in the folds of the broad ligament and is made up of many small tubules, a few blood-vessels and nerves. This structure can be seen thru the peritoneum if held before the light. One of its principal ducts is known as Gartner's duct; it is represented in the male by the canal of the paradidymis.

THE OVARIES

(Illustrations Nos. 206 and 208.)

The **Ovaries** are the reproductive glands in the female, two in number, and are analogous to the testes in the male. They contain the ova and are located in the folds of the broad ligament, behind and below the fimbria of the oviduct, which clasp the surface of the ovary, placed one on either side of the uterus; each ovary is attached to the uterus by the ovarian ligament and by the mesovarium. Each gland is oval, or almond-shaped, about the size of the last phalanx of

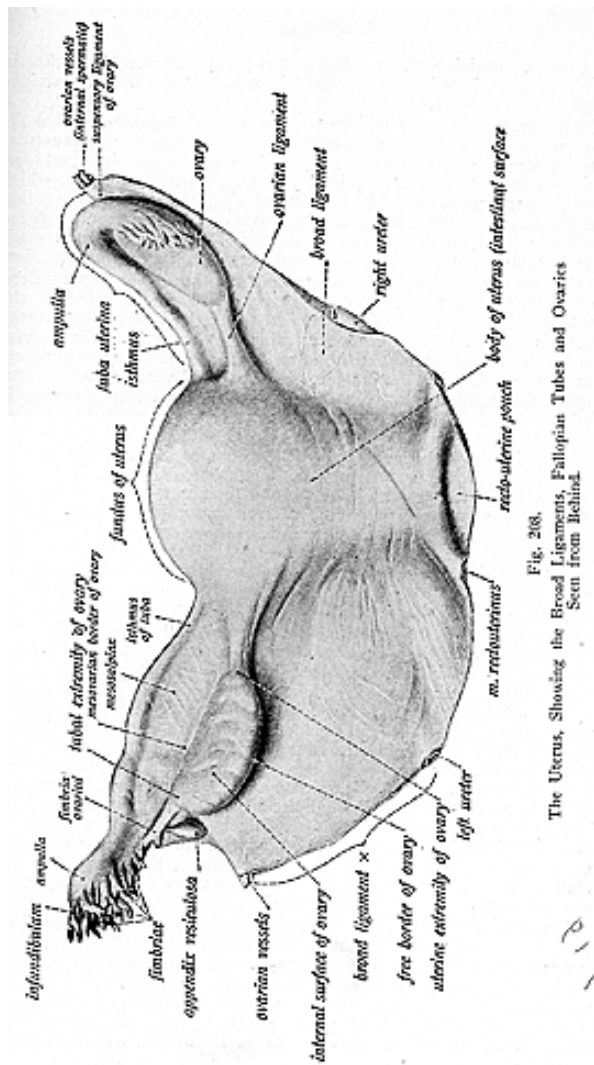


Fig. 208.
 The Uterus, Showing the Broad Ligaments, Fallopian Tubes and Ovaries
 Seen from Behind.

the thumb, grayish-pink in **color**, and measures about 1-1/2 inches in length, 3/4 of an inch in width, and 1/4 inch in thickness. Each weighs about one-half ounce.

The ovaries are attached to the uterus by a ligament called the ligament of the ovary, a cord-like structure consisting of muscular tissue; anteriorly the ovary is attached to the broad ligament, and superiorly to the fimbria by the mesovarium, a peritoneal fold, which holds the ovary in place. The position of the ovaries varies according to the position of the uterus, and thus it would be differently placed in different individuals. It is said that after the first pregnancy the ovary becomes changed and seldom resumes quite its original position.

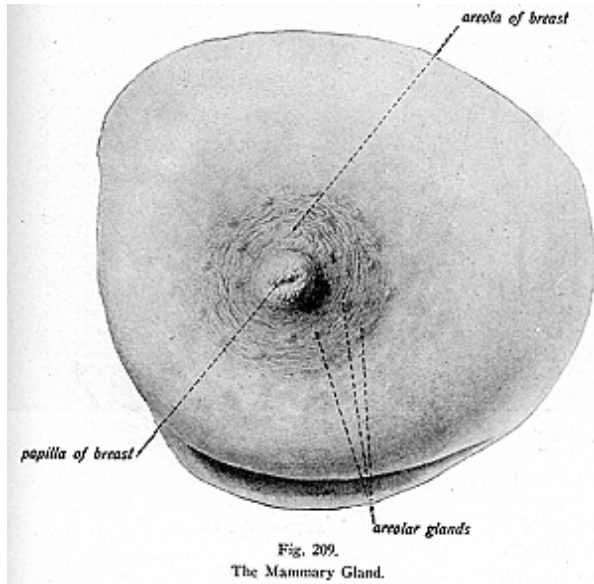
For **descriptive parts** the ovary has **two surfaces, two borders, and two extremities**. The **surfaces** are called the **internal** or the **mesial**, which is related to the Fallopian tube; the **external, or lateral**, surface is related to the groove in which it lies, called the *ovarian fossa*, in the broad ligament; the **anterior** border is straight and presents a depression for the entrance of the blood-vessels and nerves; the **posterior border** is convex and free. The **superior extremity** is called the tubal end, being attached to the fimbria of the Fallopian tube and connected here with a fold of peritoneum which passes upward to join the peritoneum over the psoas muscle. This fold is sometimes called the suspensory ligament of the ovary, it is continuous with the outer part of the broad ligament, and contains the ovarian vessels and nerves. The **inferior extremity**, or the uterine end, is connected with the superior angle of the uterus by the ligament just mentioned, the ligament of the ovary. The attachment of this ligament is behind and a little below the uterine end of the Fallopian tube.

The ovaries consist of a dense, soft, reddish, fibrous stroma in which numerous **Graafian follicles** are embedded. Externally the capsule of the ovary is covered by modified peritoneum having columnar cells of a dull white appearance. In childhood, the surface of the ovary is smooth and even, of a delicate shell pink or white appearance, but, after repeated rupture of the Graafian follicles, the surface becomes fringed or pitted, and is of a reddish-gray color. These **Graafian follicles** or vesicles are also called the **ovisacs** because they contain the ova, and are found all over the ovary. The **stroma** consists of numerous spindle cells, with connective tissue, and abundant blood-vessels and nerves. The follicles appear as transparent vesicles and number more than 70,000 at birth. Their diameter increases from 1/1000 of an inch in diameter to the size of a currant when ready to rupture. When the larger follicles are matured, they approach the surface and at each menstrual period one or more of them ruptures. The ovum then escapes into the Fallopian tube.

Microscopically each ovisac or follicle is seen to consist of an external fibro-vascular coat, connected with the stroma by a vascular network; and an internal coat or capsule, called the *ovicap-
sule*, lined with a layer of nucleated cells, the *membrana granulosa*. The ovi-
capsule contains a transparent albuminous fluid, the *liquor folliculi*, sup-
porting the ovum. The cells are heaped-up around the ovum, and, at
that part where the ovary seems to be thickened, where the ma-

tured cells are massed together, is found the *discus proligerus* (producing disk), in which the ovum is ensheathed. The development of the Graafian follicles, and of its contained ova, continues without interruption from puberty to the end of the fruitful life of the woman. They begin to form before birth. At puberty the vesicles develop in great numbers and their ova are capable of fecundation.

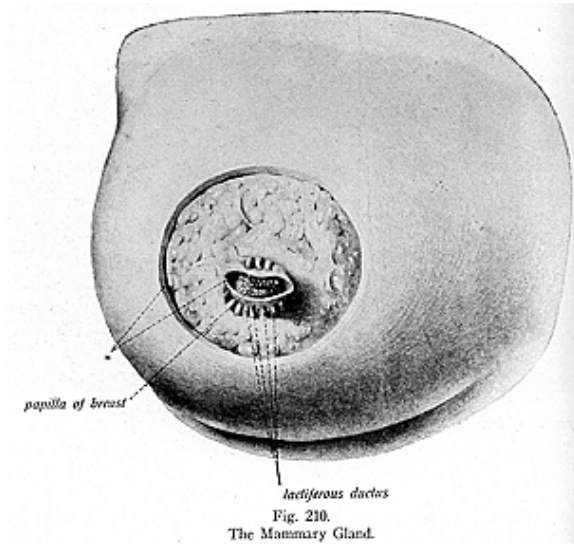
The **human ovum** is a spherical mass of protoplasm 1/100 of an inch in diameter, just visible to the naked eye, consisting of a *vitelline membrane*, or the cell wall; a *vitelline yolk* which contains a nucleus, the *germinal vesicle*; and the *germinal spot*. The ovum corresponds to a typical cell with all its parts.



The ova are liberated from the ovary by periodical compression of one or more of the Graafian follicles, and, as they drop from the ovary, the fimbriated portions of the Fallopian tube seems to catch the ova as they fall, and then conduct them to the uterus; or the ova may drop into the abdominal cavity and perish; or they may be wafted toward the open end of the tube by means of motion set up by the ciliated epithelium, upon which the cilia are directed toward the tube; or the fimbriated end of the tube may clasp the surface of

the ovary and draw the ovum into the tube by peristalsis. If the uterus is not capable of impregnation these ova are thrown off as dead cells, and are carried out as an excretion. But when the ovum is fecundated or when it meets the male sperm, called the spermatozoon, it adheres closely to the walls of the uterus and seems to embed itself in the mucous membrane; the two elements when fused become known as to the embryo. It is said that an ovum requires from 7 to 10 days to pass from the ovary to the uterus.

The *corpus luteum*, is an irregular yellow spot seen on the surface of the ovary at the site of a ruptured Graafian vesicle; these spots differ in appearance sufficiently to indicate whether it is a *true* or *false corpus luteum*. The *true corpus luteum*, or that of pregnancy, is



single and increases in size up to a certain point. It does not disappear before the eighth month and often not until after delivery. Sometimes it occupies the greater part of the ovary, while the *false corpus luteum* is that variety which is found following the ordinary menstruation. It is much smaller and disappears in about a month from the time of its appearance.

The **ovaries change** at puberty, for up to that period their surfaces are smooth and pinkish white, but after the **rupture** of the

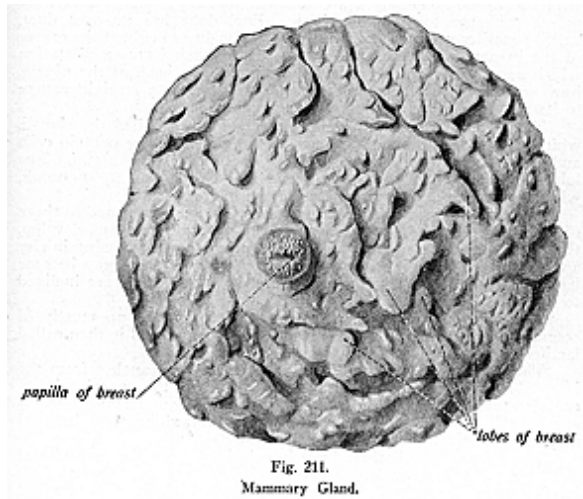
Graafian follicles their surfaces become pitted or puckered and their color becomes a grayish hue. At menopause they cease to functuate and their surfaces show deep pits; the glands gradually become smaller so that in old age they are quite small and hard.

The **blood supply** to the ovaries is carried thru anastomoses between the uterine and ovarian vessels. The **nerve supply** is the same as that of the uterus.

THE MAMMARY GLANDS

(Illustrations Nos. 209, 210 and 211.)

The **Mammary Glands**, or the **Mammae**, or breasts, are considered with the organs of reproduction for the part they play in the process



of lactation; that is, they secrete the milk for the child. Mammae exist in both sexes, being small and usually rudimentary in the male. In the female they are hemispherical eminences situated on either side of the chest, upon the pectoralis major muscle and in the superficial fascia; they extend from the second or third to the seventh rib.

The mammary glands, as to structure, are compound racemose glands, their size and weight differ at different periods of life and in different individuals. The outer surface of each gland is convex and presents, just below the center about the fourth rib, a small conical prominence, the **nipple**, containing a number of papillae. The

nipple is surrounded by a light colored area called the **areola**, which in the young girl is of a rose color, but after impregnation it enlarges and its color becomes darker, often black in the later stages of pregnancy; this color diminishes as soon as lactation is over, but is never entirely lost.

The skin over the areola presents a number of small projections due to the presence of sebaceous glands, which are often called the *glands of Montgomery*. The mammary glands consist of about 20 lobes, and these in turn consist of lobules, with areolar tissue and fat all these are connected by a fibrous stroma. The entire gland is ensheathed by the splitting of the superficial pectoral fascia into laminae which send processes into the interior of the gland and support the lobes. The lobes are inclined to be pyramidal and their apices converge toward the nipple. Each lobe has its own duct, called a **lactiferous duct** (milk bearing). The ducts begin at the center of the breast and pass to the areola, where each forms a dilatation which serves as a reservoir for the milk; at the base of the nipple, however, they again become contracted and pursue a straight course to its summit, where they open by several orifices.

The lobules are made up of a cluster of tubes, called the alveoli, which represent the secreting parts of the gland. They contain cells and fat globules during the functional activity of the organ. The lobes are surrounded by fatty tissue and by a capillary network, which occupies the intervals between the lobules.

The mammary glands undergo changes which correspond to those of the uterus, that is, they enlarge as the generative organs develop, they pass thru corresponding changes at pregnancy, increasing in size and the areola changing in color; after pregnancy they may become larger or they may diminish in size, and in old age they are inclined to become flabby and often atrophy.

The male breast is a small, flat structure, made up mostly of connective tissue, tho in some instances it develops and is then called lactiferous, during the time it secretes milk.

The **blood supply** to the glands is carried by branches from the internal mammary artery, the axillary, and from the superior intercostals; the veins bear the same names, and form an anastomosis around the base of the nipple, ending in the axillary and internal mammary veins.

The **nerves** are thoracic branches derived from the second and third dorsal pairs of spinal nerves, emitting thru the 9th and 10th intervertebral foramina. There is no physiological or anatomical connection between the mammae and the generative organs, yet we find corresponding changes taking place in these organs; the explanation of this, given **Chiropractically**, is that the sexual lobe in the brain sends forth the impulses to the mammary glands and simultaneously to the generative organs, which in turn begin preparation for the process, or their part in the process of reproduction; and thus also would there be a close relation at other times than at the time of pregnancy, for the glands also are affected previous to, and during the menstrual period.

HERNIA

Hernia is a term meaning to sprout or shoot forth, and signifies a protrusion of any viscus from its natural cavity. Any one of the three splanchnic cavities may be involved—the cranial, thoracic, or abdominal, including the pelvic cavity, but surgeons generally confine it to protrusion of the viscera from the cavity of the abdomen. It is called a rupture and may be defined as any tumor formed by the displacement of a viscus or any portion of a viscus which has escaped from its natural cavity by some aperture and projects externally; unless otherwise specified, hernia means—abdominal hernia. Herniae have been arranged according to the organ affected or the region where found, also according to the openings involved, or the viscera included in them. Herniae most frequently make their appearance at the groin, navel, labia pudendi, and upper and fore-part of the thigh.

Abdominal herniae are remarkable for their frequency, their variety, and for the dangers attending them, they are produced by the protrusion of the viscera of the abdomen thru natural or accidental apertures in the parietes of the abdominal cavity.

The organs most frequently involved in abdominal herniae are the intestines and the epiploon. These herniae have been divided according to the apertures by which they escape. First, inguinal hernia exists when the viscera protrude from the inguinal region, canals, etc., these are sometimes designated as a bubonocoele when small, and as a scrotal hernia in men, or as a vulvar or pudendal hernia in women when they extend to the labia majora. **Inguinal herniae** are of two kinds, the *external* or *oblique*, and the *internal* or *direct*.

In an **oblique inguinal hernia** the tissues involved will be the skin, superficial fascia, inter-columnar fascia, cremasteric fascia, infundibular fascia, subserous cellular tissue and the peritoneum forming the sac, then the contents of the tumor.

1. A **direct**, or **internal inguinal hernia** is one in which the protrusion passes thru the parietes of the abdomen, opposite the external ring, thru some part of Hesselbach's triangle, while in **indirect inguinal hernia** the protruding parts pass downward thru the canal, thru both rings, and the neck of the sac lies to the outer side of the epigastric artery. 2. **Crural**, or **femoral hernia**, as it is generally called, is one which is found issuing thru the crural ring or canal. 3. **Obturator** or **infrapubic hernia** is found when the viscera escapes thru the obturator foramen, which gives passage to the infrapubic vessels and nerves. 4. **Ischiatic** or **sciatic hernia** is that form of hernia found when the protrusion occurs thru either of the sciatic notches, or foramina. 5. **Umbilical hernia** is one in which the bowel or omentum protrudes thru the abdominal wall under the skin of the umbilicus. 6. **Epigastric hernia** occurs in the linea alba or thru a muscular rent in the upper portion of the abdomen. 7. **Hypogastric hernia** occurs below the umbilicus in **linea alba**. 8. **Perineal hernia** is found when the protrusion takes place thru the levator ani muscle,

HERNIA

and appears at the perineum. 9. **Vaginal hernia** is found when the contents protrude into the vagina. 10. **Diaphragmatic hernia** is a protrusion thru the diaphragm. 11. **Inguino-femoral** is a double hernia combining both an inguinal and a femoral hernia. 12. **Ventral hernia** is found when the escaped loop of the intestine passes thru the abdominal wall at any point other than thru the normal rings or at the umbilicus.

The prolongation of the hernial sac in various directions within the abdominal walls is called **intra-parietal** or **inter-muscular**.

The herniae are likewise distinguished according to the contents which are found forming them; for example, the **enterocele**, a hernia containing a portion of the intestines; **epiplocele**, containing omentum only; **gastrocele** is a hernia of a portion of the stomach; **splenocele**, tumor of the spleen; **hepatocele**, carrying the lesser omentum only or a hernia of the liver; **cystocele**, hernia of the bladder; **cardiocele**, of the heart; **proctocele**, of the rectum, **orchiocele**, of the testicle; **bubon-ocele**, an inguinal hernia.

The term "cele" is a suffix which denotes a swelling or a hernia of the part signified by the main word. Others of the 150 varieties of hernia that might be mentioned are: **caecal hernia**, one that contains the caecum or a part of it; **cerebral hernia**, the protrusion of the brain substance thru the skull; **concealed hernia**, one that is not perceptible on palpation; **infantile hernia**; **interstitial**, one which lies between the two layers of the abdominal wall; **hernia of the iris**; **lumbar hernia in the loin**, **mucosal hernia** of the mucous membrane of the intestine, thru an opening in the muscular coat, **ovarian hernia**, a protrusion of the ovary, **Petit's hernia**, hernia thru the Petit's triangle; **sliding or slipping hernia**, a hernia of the colon in which portions are drawn into, or slip into, a hernial sac, by the inclusion of the sac of the parietal peritoneum to which it is attached; **synovial hernia**, a protrusion of the inner lining membrane thru the stratum fibrosum of a joint capsule; **umbilical hernia**, which may be congenital, the viscera with the omenta protrude thru the opening of the umbilicus. This classification, altho not exhaustive by any means, will serve as a basis for those structures most concerned in the production of the special, as well as the more common, herniae.

A hernia is said to be reducible when the protruded bowel can be restored to its natural cavity by the aid of pressure, etc. properly applied; and irreducible when adhesions or its bulk oppose its return. The reduction may be prevented by adhesions formed at the neck of the sac, or by an accumulation of fecal matter, or by edema. When the aperture, giving passage to the hernia, causes more or less constriction of the protruded portion, the hernia is said to be incarcerated, and, if the constriction cannot be removed, the hernia soon becomes strangulated.

The seat of stricture in a strangulated oblique inguinal hernia is apt to be: 1st, at the internal ring; 2nd, in the inguinal canal by constricted fibres of the internal oblique or transversalis muscles; 3rd, at the external ring, providing it is not at the thickened neck of the sac, the most usual site in old hernia.

The *tissues involved* in a hernia, besides the omenta or viscera

HERNIA

are the superficial fascia, blood-vessels, nerves, the deep fascia, the labia majora, the scrotum, etc. The *inguinal canal* passes downward and inward for an inch and a half, parallel with Poupart's ligament, and lodges the spermatic cord in the male and the round ligament in the female. It is formed between the aponeuroses of the internal oblique, external oblique, and transversalis muscles; commencing at the internal or deep abdominal ring and terminating at the external or superficial ring. The *internal ring* is an oval opening midway between the anterior superior spine of the ilium and the spine of the pubis, about 1/2 inch above Poupart's ligament. It is bounded above and externally by the arched fibres of the transversalis and internal oblique muscles; internally by the epigastric vessels. From its circumference the infundibular fascia passes onto the spermatic cord or round ligament. The *external ring* is an oblique, triangular opening in the aponeurosis of the external oblique muscle, just above the crest and to the inner side of the spine of the pubes. From base to apex it measures about 1 inch, and 1/2 of an inch transversely. It is bounded above and in front by the curved intercolumnar fibres; below by the crest of the pubes; and on each side by the free borders of an aponeurosis, called the internal and external columns or pillars of the ring. From the margin of the ring the *intercolumnar fascia* passes onto the cord or round ligament.

The inguinal canal has, anteriorly, the skin, superficial fascia, aponeurosis of the external oblique, and the outer one-third of the internal oblique muscle. Posteriorly, it is bounded by the triangular fascia of the abdomen, the conjoined tendon, transversalis fascia, sub-peritoneal tissue, and the peritoneum. Superiorly, it is bounded by the arched fibres of the internal oblique and transversalis muscles; inferiorly, by the union of the transversalis fascia with Poupart's and Gimbernat's ligaments.

Poupart's ligament is the infolded, thickened margin of the aponeurosis of the external oblique muscle, it extends from the anterior superior spine of the ilium to the pubes, from which it is reflected a short distance along the pectineal line, forming *Gimbernat's ligament*. The *triangular fascia* of the abdomen is an oblique band of fascia or tendinous fibres arising from the external oblique aponeurosis of one side to be inserted into the pubic crest and the pectineal line of the opposite side: it passes inward beneath the spermatic cord, behind the inner pillar and in front of the conjoined tendon. The *cremasteric fascia* consists of a series of muscular loops, connected by areolar tissue, investing the spermatic cord; it is supposed to be derived from the internal oblique muscle during the descent of the testicle, and, of course, is absent in the female. The *conjoined tendon* is formed by the joining of the transversalis and internal oblique muscles, it is attached to the spine and crest of the pubes, the anterior part or space where the fibres spread is called Hesselbach's triangle; the posterior space is known as Henle's triangle.

The *femoral or crural canal* lies beneath and posterior to Poupart's ligament, and to the inner side of the femoral vein and Gimbernat's ligament. It is from 3/5 of an inch to one inch in diameter, is larger in the female than in the male. **Femoral** hernia, for this reason, is

HERNIA

most frequently met with in women. Its site is situated below and internal to the internal abdominal ring, therefore the seat of femoral hernia is the upper and fore-part of the thigh. The protruded intestine passes out at the same opening thru which the larger blood-vessels are transmitted to the thigh, hence the hernia is under Poupart's ligament.

In the various forms of **internal hernia**, the sac of Douglas, the recto-vesicle, or vaginal and intersigmoid fossae, are involved, also the foramen of Winslow.

Prolapses are classified and named about the same as herniae, that is, according to the region involved and the character of the same. If muscular tissue becomes flabby, it drops and this is known technically as prolapsed muscles. A prolapsus may be found without a hernia, but never a hernia without a prolapsus.

The danger attending operations for hernia is greater than in the treatment of prolapses; yet ruptures as great or greater occur to internal viscera, and individuals survive these conditions for years, altho, if surgical means were used, the patient could not survive the shock resulting from an operation intended to correct the condition.

Each tissue has a certain elasticity and expansive power, but it is an excess demand upon this elasticity that makes each and every hernia a possibility. If the mesenteric tissue supporting the various divisions of the bowel is enfeebled, then a prolapsus of the bowel will occur. If, in addition to this, the abdominal muscles weaken and allow the weight of the prolapsed organ to press against the weakened walls, then at some opportune time, when the individual is in a cramped, stooped, or strained position, a hernia will result. These conditions may have existed for days, weeks, months or years, before it was observed or recognized. The cause may have preceded the recognized condition by years. The subluxation that made possible the prolapsed condition could have existed for months before the test of strength came which showed the normal resistance was absent. The original cause remains the same, the lack of current from the brain to the tissues that are needing it. The physical representative of this cause could have been palpated at any time after its creation, before the muscles became relaxed; after the organs had prolapsed, or after the hernia was observed, its adjustment could have taken place at any stage and would have prevented the condition from becoming worse.

Therefore, the Chiropractor is able to correct subluxations which, if continued, may cause the unnecessary loss of hundreds of lives. If the abdominal muscles are powerful, vigorous, solid and secure, then a prolapsus of any or all internal organs will not create a hernia. If the internal viscera and organs maintain their normal position and remain in a state of normal tonicity, they will be better able to stand the daily strain that man sees fit to impose upon them, also, the abdominal muscles will be relieved of the unnecessary weight, and hernia will not readily occur.

Predisposing conditions for hernia are: occupations that necessitate much muscular effort, particularly if in lifting heavy weights, or if exerted while the person is in a stooping posture; unusual res-

piratory efforts, in which the diaphragm augments the outward pressure of the abdominal viscera; diseases which produce rectal or vesical pain or spasmodic contraction; or respiratory diseases, producing chronic or violent coughing or inspiratory obstruction. The decreased resistance of the whole abdominal wall may be due to debilitating illness, to old age, abdominal tumors, repeated pregnancies, to muscular atrophy, excessive corpulence, straining at stool, or it may be due to emaciation.

Hernia is very common during the first year of life, due to the existence of developmental defects; among these might be mentioned the presence in the abdomen of portions of the pelvic organs, increasing intra-abdominal pressure; or the habitual flexion of the side of the abdomen, relaxing the tissues about the hernial orifices, or any extreme shortness of the inguinal canal. The increase in frequency of hernia, as puberty approaches, is due to the more active habits of life and the assumption of occupations often laborious.

Hernia is more frequent in males because of structures connected with the male genitalia are more often the subject of developmental defects; also the inguinal canal in the female is narrower (containing the round ligament) and longer, and for these reasons offers less opportunity for the descent of the viscera.

Reasons attributed for a hernia upon the right side of the body, at all ages and in both sexes, are: The great bulk and weight of the liver; to right-sidedness in walking and lying; to the greater strain on the muscles of the right side caused by right-handedness, and to the inclination from the left to the right of the mesentery of the small intestine as it descends. However, these reasons do not completely suffice, for the question might be asked, why is Bell's palsy more often on the right side? Now the **cause** of the various forms of herniae is an interference with the current of mental impulses flowing to the parts involved, which obstructions are due to nerve impingement, occasioned by vertebral subluxation. This prevents starved tissue from expressing its normal functions.

The question could be broadened to the extent of acknowledging that every tissue, or cell, must receive its normal innervation, otherwise the value of that tissue is lost.

The following are a few of the many remarkable cases of hernia which have come under the care of the Chiropractor, with a history of results obtained in each case:—Dr. B. brought a child into the P. S. C. clinic. She had been operated upon for appendicitis, and the drainage tube had not been properly drawn, therefore a rent was present in the abdominal wall. The skin and peritoneum were healed, but an open space between the muscles allowed a tumor, of about the size of an ordinary fist, to protrude. After adjustments of six weeks, the place was examined by a prominent physician and surgeon, and no trace could be found of the rent in the muscle, not even the remains of a cicatrix in the muscle. Another case, Mr. R., had been ruptured for 19 years and presented an inguino-femoral hernia. He took adjustments for 3 months; altho working right along in a stooping posture, he had been able to take his truss off at the end of three weeks after beginning the adjustments. A Mrs. H., 62 years of age,

HERNIA

reports that, after a violent spasmodic cough, she had had a spontaneous rupture of the parietes. The rent was four inches in length, extending along the linea alba, and thru it protruded a mass of omentum. She was adjusted and completely recovered.

Another case reported was that of a rupture of immense size, protruding from a spot weakened by a former abscess. The opening was in the abdominal wall outside of the internal abdominal ring, and was large enough so that the writhings of the intestines were plainly visible thru the walls of the pouch. This condition yielded readily to the adjustments, and the hernia was entirely reduced within a period of 6 months.

A case of Mrs. D., a woman of 50 years, showed a large lobulated tumor protruding from the abdominal wall and the umbilicus, the veins covering it were prominent and distended; the circulation of the skin was defective, giving it a bluish appearance. The vermicular contraction of the small intestine could be seen at a distance. The tumor was soft and velvety to the touch. She told of many previous attempts made to reduce it, all of which had been exceedingly painful. On percussion, the note over the bulk was tympanitic, and dull at the base. The distal portion contained a part of the small intestine instead of the colon, which is the most frequent occupant; the umbilicus was completely obliterated. She stated it was her belief that this hernia was caused by the weakening of the abdominal wall from a blow, and she thought that the protrusion came from an aperture near the umbilicus, tho it happened so early in her childhood she could not quite remember. Under adjustments the viscera were about normally placed, and in her last report in the clinic, she stated she now had none of the inconvenience she had endured for so many years before.

The question is often asked, "If a bowel protruded and there was a strangulated hernia, would you advise it to be replaced by hand, also would you advise a patient to wear a truss while having adjustments?" In our experience we have never yet found it necessary to use local measures in such cases. The desired results are accomplished, more accurately and better, thru vertebral adjustments. The adjustment must be given exactly right, in order to immediately release the abdominal form of contraction upon the outside and create a normal drawing inward of the internal organs, and you will find that this correction of the one subluxation, that is making the two different points of expression; then, in proportion as this pressure is released on both cables of nerves, the fullest expression is allowed to the parts, so that the kinks of the bowels will recede and in proportion as that bowel goes back will those fibres heal.

A vertebral **subluxation is the cause** of every hernia and the zone or area of the subluxation in the spine will inevitably correspond to the zone of the place of existence of the hernia.

THE NERVOUS SYSTEM

The **Nervous System** is composed of the **brain**, the **spinal cord**, **all the nerves**, the **ganglia** and **plexuses**; classified under the subdivisions of the cerebro-spinal or central nerve system, and the peripheral nerve system, which, because its intimate association with, and control by, the central system was then unknown, has been improperly styled the Sympathetic system.

Under the **cerebro-spinal** or **central nerve system** are classified the **brain** and **spinal cord**, **cranial** and **spinal nerves**. The **peripheral nerve** system is made up of two gangliated cords extending from the base of the brain to the tip of the coccyx, the various gangliated plexuses, and the periphery nerves. All these anatomical divisions comprise the **brain system**, while its two principal functional divisions are the **Innate** and the **Educated nervous systems**. Just in what manner and in what part of the brain the line of division between the two is found, cannot be stated; for each part of the brain is dependent upon the other for the manifestation of the various functions of the body. The Innate and the Educated brain are intimately connected together, and connected also with all other parts of the body by a main nerve trunk, known as the spinal cord.

Each brain is divisible into many *lobes*, each of which is composed of abundant *cells*, each one of which has a *fibre* or a *fibrilla* which goes to a point where it meets similar processes of other cells of the brain, and all these fibres collect into a large cable of nerves, called the **spinal cord**, which in turn gives off thirty-one pairs of spinal nerves. Each spinal nerve consists of a bundle of fibres which go to the peripheral tissues of the body, so that the brain is in direct connection at all times with every functioning cell group of the body while life exists.

The brain, therefore, is the seat of all intelligence in the body the habitat of Innate Intelligence, which is the director of all functions in the body, from the time of birth to the dissolution of the physical and the mental, which is death. The brain is the place from which the mental currents, which control all functions of the body, emanate and flow to all parts of the body, to each tissue cell, the brain constitutes the beginning and the ending of the one great cycle, called life.

Nerve tissue consists of **cells**, the gray **matter**; **nerve fibres**, the white matter, and neuroglia. Nerve-cells, like all other cells in the body, consist of a mass of protoplasm with or without a cell wall and having, at or near their center, a nucleus (a kernel) and, within the nucleus, a nucleolus (little kernel), which is sometimes peculiarly clear and brilliant. Leading from the body of a nerve-cell or, as we prefer, exclusively from the brain cell, is a prolongation, called a nerve fibre. This may or may not have a covering, if it has a covering it is called a **medullated nerve fibre**, but if the sheath is absent it is called a **non-medullated fibre**. **Neuroglia** is the delicate, web-like

THE NERVOUS SYSTEM

supporting tissue of the nervous system. It consists of a fine meshwork tissue made up of *glia cells* and *glia fibres*.

Cell bodies vary in size from 1/3000 to 1/200 of an inch in diameter; they vary in shape and in the number of processes given off, from the unipolar and bipolar, to multipolar types, the latter being a pyramidal cell that to be confined to the brain.

A nerve cell with its chief prolongation and minor processes is called a **neuron** or **neurone**, the prolongation constituting a nerve fibre; a collection of many nerve fibres becomes known as a **nerve**, which is a rounded or flattened cord. These nerve fibres are the medium thru which the brain is brot in relation with the balance of the bodily tissue; they are classified as **afferent** and **efferent nerve fibres**.

In the prolongation as it leaves the cell-body, a thin, shining, transparent thread is seen; this forms its core and is the medium over which impulses and impressions travel; it is called the **axis-cylinder** or **axone**. The axone, together with its individual sheath, constitutes a nerve fibre; the sheath may be one of myelin or it may be merely a membrane of condensed fibrous tissue, the axone frequently possesses both these coverings.

Axones may vary in length from a fraction of a millimetre to the equal of a man's stature, so that, despite the delicacy of the axone, its bulk may be many times greater than that of the cell body from which it proceeds. The function of the axis-cylinder is to conduct impulses and impressions, and the axis-cylinder is composed of many fibrils; so it follows that such a cylinder may conduct more than one impulse. These in turn reach different tissues thru different collaterals. Just as the nerve is frequently composed of a great number of axis-cylinders, so also is the axis-cylinder composed of a multitude of fibrils.

If a nerve fibre is covered by a thick sheath of fatty substance it is known as a **medullated** or a **myelinic fibre**, and when this covering is absent it is **non-medullated** or an **amyelinic fibre**. A thin, serous membrane usually covers the axones of both these varieties, and is called the primitive sheath or the **neurolemma**.

A **medullated nerve fibre** is a soft, transparent thread (axon or axone), surrounded by a white fatty substance, the *white substance of Schwann* or the *medullary sheath*, the latter being surrounded by the primitive sheath, the **neurolemma**. At regular intervals, along the course of the medullated fibre, constrictions are found, called the *nodes of Ranvier*, the portions between are known as the *internodes*. On the inner surface of the neurolemma is an oval nucleus, these nuclei are found along the whole length of the nerve fibre. The **medullary sheath**, the covering of the axis-cylinder, consists of fat and neurokeratin, which latter, on burning, gives the odor of burnt bone; it is this medullary sheath that gives the white color to the nerves and forms the white matter of the brain. The absence of the neurolemma in the brain and cord accounts for the pulpy consistency and soft nature of the tissue, for the neurolemma gives strength to the nerve fibres.

A bundle of nerve fibres is called a funiculus, the fibres being held together by a delicate connective tissue called the *endoneurium*;

THE NERVOUS SYSTEM

this in turn is surrounded by a sheath called the *perineurium*. Several funiculi bound together by a connective-tissue sheath, called the *epineurium*, form a nerve. Nerves are cords, they are the conveyers of the impulses and the impressions, and are the conducting elements of the nervous system and serve to bring nerve cells into relationship with each other and with the various tissues of the body.

Nervi nervorum are small nerve fibres passing to the larger nerves, and are to the nerves what the vasa vasorum are to the blood-vessels.

Nerves do not anastomose as do the blood-vessels; if they did there would be a confusion of the impulses and impressions along the nerve fibre, for each brain cell has its message to convey by its cable, the nerve fibre, to the receiver, the tissue cell.

A **ganglion** is usually mentioned as a knot-like enlargement along the course of a nerve fibre, supposed to be an independent brain or a centre for the formation of nerve power; but Chiropractors consider a ganglion as a small crossing place of nerves, consisting of a collection of cells at a point where the fibres meet, here they form a knot-like enlargement, but not for the dispensation of nerve power.

A **plexus** is a large crossing place of nerves and anastomosing blood-vessels, forming a reticulum.

Nerve centers, said to be from 63 to 83 in number, are described as being collections of nerve cells to which external impressions are carried, and from whence impressions or reflexes are sent out; but if that were literally true, then there would be no apparent necessity that these centres be in direct communication with the brain. A **centre** is the localization of a particular part or the middle point or centre of physiological activity, hence any plexus may be called a centre. These are fully considered with the peripheral nervous system. The more recent and better informed authorities on the subject of the human anatomy are expressing, more and more, their assurance that the brain is the agent thru which is expressed a complete control over every functional expression of the entire body. Chiropractic has accomplished much in demonstrating this truth.

The **brain** and **its coverings** will be considered first, then the **spinal**, cord and its **membranes**, followed by the **nerves**, **plexuses**, **ganglia** and the **peripheral system**.

THE MENINGES

The **brain** and the **spinal cord** are covered by three **membranes**, known also as the meninges; they are the **dura mater**, the most external covering; the **pia mater**, the innermost covering; and the **arachnoid**, which is found between these two.

The **Dura Mater (hard mother)** is a thick, inelastic, bluish-white membrane, which lines the interior of the skull and forms its internal periosteum, as well as a covering for the brain substance; thus it consists of two layers, the outer is called the *endosteal*, the inner the *meningeal layer*. The outer layer, rough and fibrillated, is attached to the internal surface of the cranial bones and, at the margin of the foramen magnum, it becomes continuous with the spinal dura mater. The cranial dura mater is more firmly adherent to the bones

forming the base of the skull than over the vault of the cranium. The adhesions to the vault of the cranium are most firm along the course of the sutures. The internal surface of the cranial dura mater, smooth and covered with a layer of endothelial cells, is the layer which sends strong fibrous processes or partitions into the cranial cavity and subdivides it partially into compartments, for the support and protection of the brain. These partitions are four in number, namely, the **falx cerebri**, **falx cerebelli**, the **tentorium cerebelli**, and the **diaphragma sellae**.

The **dura mater** of the brain differs from the dura mater of the cord, in that the dura of the cord forms a loose sheath which is separated from the bony walls by loose connective tissue, containing blood-vessels and fat; the interval is known as the **epidural space**.

The **falx cerebri (falx, sickle)** is a sickle-like process and occupies the great longitudinal fissure, where it lies between the two cerebral hemispheres. It is attached anteriorly, where it is narrow, to the crista galli of the ethmoid bone, posteriorly, where it is broad, to the internal occipital protuberance, blending with the upper surface of the tentorium; superiorly it is attached in the median line to the frontal and parietal bones and to the upper part of the occipital bone. Its upper part contains the superior longitudinal sinus; its lower part, which is concave, contains the inferior longitudinal sinus.

The **falx cerebelli** is a smaller sickle-shaped process placed below the tentorium cerebelli, extending forward between the two cerebellar hemispheres, it is attached to the internal occipital crest, and bifurcates below into two divisions, which are traced forward on each side of the foramen magnum.

The **tentorium cerebelli (stretcher)** is a process of the dura forming a partition between the cerebrum and the cerebellum, and covering the upper surface of the cerebellum. It extends from the internal occipital protuberance, over to the petrous portion of the temporal bone, and anteriorly to the posterior clinoid process of the sphenoid bone, being continued over the pituitary body as the **diaphragma sellae**. The **diaphragma** is pierced at its centre for the passage of the infundibulum.

The **Arachnoid Membrane (web-like)** is the middle covering of the brain, lying between the dura and the pia mater, and separated from the dura mater by the subdural space. The arachnoid is a very thin, delicate membrane, resembling a spider's web, it loosely surrounds the brain and furnishes sheaths for the cranial nerves. It does not dip into the fissures, except the longitudinal fissure, where its general course follows the convolutions into that fissure. The interval between the arachnoid and the dura mater is called the **subdural space** and it contains cerebro-spinal fluid sufficient to moisten the surfaces. It is not a space, for it contains a spongy tissue and thickened projections of the arachnoid, which form the *arachnoid villi* or the *Pacchionian bodies*. These are numerous white or purple projections or villi, usually collected into clusters of variable size and found on the under surface of the dura mater, situated along the course of the superior longitudinal sinus. They lie in slight depressions on the inner surface of the cranial bones, the Pacchionian

THE NERVOUS SYSTEM

depressions; some of them are situated along the lateral and straight sinuses. These bodies are classed with the ductless glands, each is a localized projection of the arachnoid, which serves as an absorptive agent, to regulate the cerebro-spinal fluid, constituting channels for the fluid to be carried from, or to, the subdural space.

The **Pia Mater (tender mother)** is the most internal covering of the brain, it consists of a fine areolar serous membrane, which not only covers the brain, following the convolutions and dipping into the fissures, but it also lines the ventricles of the brain. Here it forms the vascular membrane, which, in the lateral and the fourth ventricle, is known as the choroid plexus; and, in the third ventricle, as the velum interpositum or the tela choroidea superior. Upon the surface of the hemispheres, where it covers the convolutions, it contains the ramifications of many blood-vessels, which extend into the cerebral substance.

The interval between the arachnoid and the pia mater is known as the **subarachnoid space**. It is not an uninterrupted space, for it is crossed by delicate trabeculae of connective tissue which form a reticulum, and it is in the meshes of this tissue that the cerebrospinal fluid is contained. This space is small on the surface of the hemispheres, where the arachnoid and the pia mater are in close contact, but in other localities the two membranes are more or less widely separated by intervals, called *cisternae*. The *cisterna magna*, which lies between the posterior part of the inferior surface of the cerebellum and the dorsal surface of the medulla, is of large size, for here the arachnoid passes from the cerebellum to the medulla, being widely separated from the pia mater; it is continuous, thru the foramen magnum, with the posterior part of the subarachnoid of the spinal cord. The *cisterna pontis* is situated on the anterior surface of the pons, and contains the basilar artery.

Other *cisternae* are found in various positions and all communicate freely with one another. The fluid in the subarachnoid space is the cerebrospinal fluid, it consists of a clear, pure liquid, alkaline in reaction, saline to the taste; the greater part of it is water, the remaining smaller portion consisting of solids of animal and mineral nature. The subarachnoid space communicates with the ventricles thru openings in the fourth ventricle, thru the infundibulum and thru perforations in the floor of the lateral ventricles.

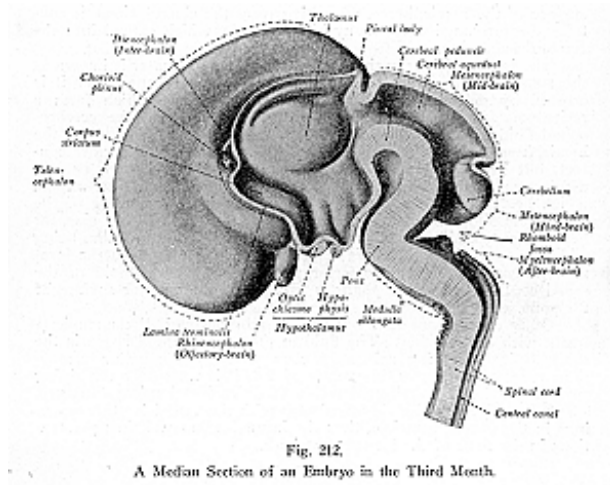
THE BRAIN

The Brain is that part of the cerebro-spinal axis which is located in the cranial cavity; its descriptive parts are the **cerebrum**, the **cerebellum**, the **medulla oblongata**, and the **pons Varolii**.

Describing the early development of the brain, Cunningham's Anatomy gives its formation as follows: "No definite trace of the nervous system is present until the primitive streak has formed and the embryonic area has passed from a circular to an elongated form. Then an area of thickened ectoderm, the neural plate, appears in the anterior part of the area. It commences a short distance posterior to the anterior end of the area and its posterior extremity embraces the anterior end of the primitive streak. Its lateral margins fade

THE NERVOUS SYSTEM

gradually into the surrounding ectoderm, and in the earliest stages cannot be definitely defined; but as the elongation of the plate continues, coincidentally with the elongation of the embryonic area, the lateral margins of the plate are elevated as the mesoderm beneath them thickens, and so they become distinct. As the lateral margins of the neural plate are raised the plate is necessarily folded longitudinally, and the sulcus so formed is called the neural groove. Each side wall of the neural groove, formed by the corresponding half of the neural plate, is a neural fold. At a very early period the neural folds unite anteriorly to form the anterior boundary of the neural groove, and somewhat later they unite posteriorly, caudal to the neurenteric



canal, and cross the anterior end of the primitive streak. After the lateral boundaries and the anterior and posterior extremities of the neural groove are defined, the lateral margins of the neural folds converge until they meet and fuse in the median plane, and the neural groove is thus converted into the neural tube, with the cavity forming the canal.”

The brain is developed from the cephalic portion of the neural tube, which undergoes enlargement and is divided by constrictions into the **anterior**, the **middle**, and the **posterior primary vesicles**. The anterior vesicle is the **forebrain**, or the **proencephalon**; the middle vesicle is the **midbrain**, or the **mesencephalon**; and the third vesicle

is the **hindbrain**, or the **rhombencephalon**. Subsequently, the anterior and posterior primary vesicles or the proencephalon and the rhombencephalon become subdivided, each into two vesicles, and they then became known as the secondary vesicles. Thus the entire development gives rise to five vesicles, named the *first, second, third, fourth* and *fifth vesicles*, in this order from before backwards. The first vesicle forms the **telencephalon**; the second, the **diencephalon**, or the **thalamencephalon**; the third, the **mesencephalon**; the fourth, the **metencephalon**; and the fifth vesicle forms the **myelencephalon**.

From the telencephalon, the anterior vesicle of the proencephalon, are developed the cerebral hemispheres, the lateral ventricles, the anterior part of the third ventricle, the olfactory bulbs and tracts, the corpus callosum, the corpus striate and the fornix.

From the **diencephalon**, the posterior vesicle of the proencephalon are developed the posterior portion of the third ventricle, the optic thalami, the pineal gland, the tuber cinereum, the infundibulum, the pituitary body, the optic nerve and the optic tracts.

From the **mesencephalon**, the midbrain, are developed the crura cerebri, the aqueduct of Sylvius and the corpora quadrigemina.

From the **metencephalon**, the anterior vesicle of the rhombencephalon, are developed the cerebellum, the pons Varolii and the anterior or upper part of the fourth ventricle.

From the **myelencephalon**, or the posterior vesicle of the rhombencephalon, are developed the medulla oblongata and the posterior or lower part of the fourth ventricle.

The first secondary vesicle, the **telencephalon**, sends out hollow protrusions, one on either side, from the fore-part of its lateral surface; these grow rapidly, spread out and extend forward, laterally, and backward, over the sides of the first and second vesicles, forming large cavities which become the lateral, or first and second ventricles. From each of these, prolongations take place, one forward and outward; the second, backward and inward; while the third passes backward, outward and downward, then turns forward and inward. These prolongations form the anterior, the lateral, and the posterior horns of the lateral ventricles. The lateral ventricles communicate with each other by an opening, which, in the later development of the brain, is known as the foramen of Monro.

The second vesicle, the **diencephalon**, becomes elongated from before backward and compressed laterally so as to form the greater part of the third ventricle, which opens above into the lateral ventricles, thru the same opening by which the lateral ventricles communicate, the foramen of Monro.

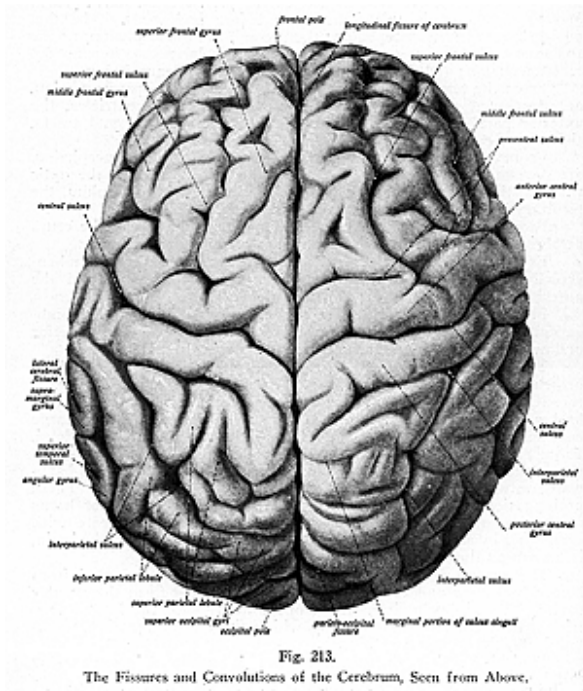
The third vesicle, the **mesencephalon**, is converted into a narrow canal, the *iter a tertio ad quartum ventriculum*, and becomes later known as the aqueduct of Sylvius, which unites the third and the fourth ventricles.

The fourth vesicle, the **metencephalon**, becomes widened and assumes a triangular form, and at the same time it is flattened from above downward; it forms the anterior part of the fourth ventricle.

The fifth vesicle, the **myelencephalon**, undergoes changes like those of the fourth vesicle and so forms the posterior part of the tri-

THE NERVOUS SYSTEM

angle which forms the posterior part of the fourth ventricle; at the lower end, where the apex of the triangle is directed downward, a constriction is found from which the central canal of the spinal cord is prolonged thruout its entire length.



The brain is of soft consistency and conforms in size and shape with the anterior of the skull or the brain case. Its mass is, to some extent, related to the size of the body, but it is modified by the degree of mental development of the individual to whom it belongs, the intelligence probably depending upon the quality rather than upon the quantity of the organ.

During the intra-uterine life the development of the brain is very active, and at birth it is relatively of large size, of a soft pulpy consistency, presenting an approximation in form and relations to the adult brain. It grows rapidly up to the seventh year, weighing at that period 40 ounces, it becomes gradually firmer, increasing slowly until about the age of forty; its full growth is considered to have been attained between forty and fifty years of age.

The weight of the brain varies, but the average human brain weighs 48 to 50 ounces. The cerebrum in the adult weighs approximately 43 oz.; the cerebellum 5 oz.; the pons and the medulla 1 oz. or a little less. The heaviest brain recorded is given as having weighed 63-3/8 oz. The brain of an idiot is long and tapering, and seldom weighs more than 23 oz. The brains of the lower races of mankind show a lower average weight than that of the European races.

The cerebrum (illustrations Nos. 213 and 214) is that part of the brain in which the complexity of convolutions depends on the grade of intelligence of the individual. In lower animals the corpus callosum is almost wanting; birds have a smooth cerebral surface and very large optic lobes, while the brains of many vertebrate have no distinct parts as in man. The brain of man is actually larger than that of any other animal however large, with the exceptions of the elephant and the whale. Vertebrates of past geological periods had, as a rule, very small brains compared to those of their living representatives.

The brain consists of **gray** and **white matter**. The **gray matter**, or the cineritious or vesicular matter, is composed mainly of nerve cells, it forms the **cortex** and is situated principally on the surface, but in addition to the cells of the cortex there are masses of gray matter in the interior of the brain.

The **white matter**, or **medullary** or **tubular substance**, is made up of nerve fibres situated in the interior, serving to connect the gray portions and to bring them into relation with the spinal cord, thru the pons and the medulla. The **white matter** of the cerebrum consists of *three sets of fibres*: the *projection fibres* or *peduncular fibres* pass either to or from the cord connecting the hemispheres with the medulla and the pons; the *commissural* or *transverse fibres* connect the two hemispheres together; and the *association fibres* connect different structures in the same hemisphere.

In man, the largest of the parts of the brain is the cerebrum, which is composed of two ovoid lateral masses, called the right and left hemispheres. They are located in the cranial cavity, occupying the depressions of the frontal, temporal, and parietal bones, also the depressions of the upper half of the occipital bones, and of the superior part of the sphenoid bone.

The **right** and the **left hemispheres** are separated by a long, deep fissure, called the **longitudinal** or intercerebral fissure. They are united by a thick band of white substance, forming the **corpus callosum**. Each hemisphere has an external layer of gray matter, and its surface is raised into irregular ridges called **gyri** or **convolutions**, a single convolution is called a **gyrus**. These convolutions are separated by clefts or grooves called the **fissures** or **sulci**; a single fissure

THE NERVOUS SYSTEM

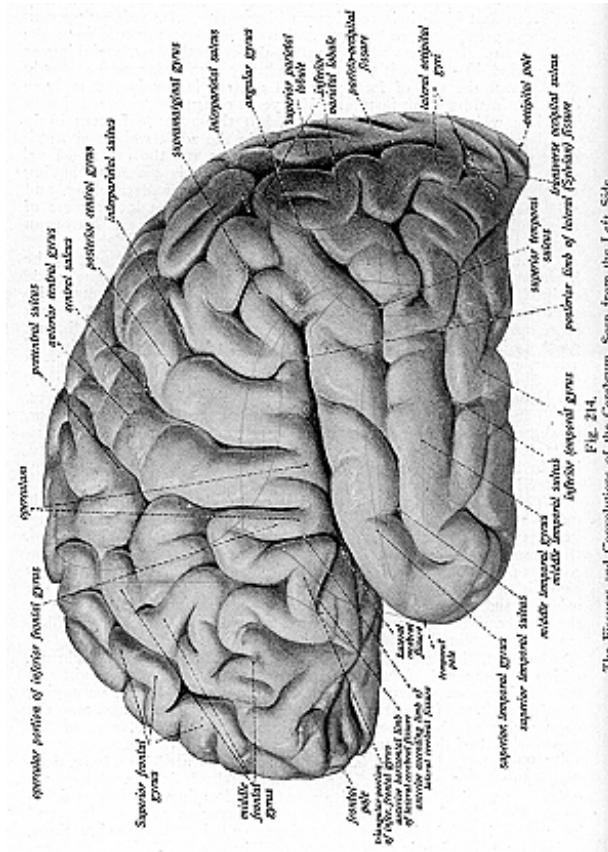


Fig. 214. The Fissures and Convulsions of the Cerebrum, Seen from the Left Side.

is called a **sulcus**. The sulci are of two kinds, while the number, as well as the depth, of the sulci appears to bear a close relation to the intellectual power of the individual. In the child the convolutions are simple and the sulci are shallow. The gyri and the sulci are not uniform in all brains, nor are they symmetrical as to corresponding parts of the opposite sides. By their arrangement, the convolutions are adapted to increase the amount of gray matter without occupying much additional space.

The **cerebrum** (illustration No. 215) presents a superior surface, convex from before backward and from side to side, which corresponds to the inner surface of the skull. The inferior surface, or under surface or the base of the encephalon, occupies the anterior and middle fossae of the skull and it presents from before backward the following structures: In the middle line are the longitudinal fissure, the peduncles of the corpus callosum, the lamina cinerea, the optic commissure, tuber cinereum, infundibulum, the pituitary body, corpora albicantia, posterior perforated space, the pons Varolii, and the medulla oblongata. On either side of the middle line are found the frontal lobe, the olfactory lobe and tract, the anterior perforated space, the fissure of Sylvius, the optic tract, the crus cerebri, and the temporal lobe (all of these being parts of the cerebrum); and one hemisphere of the cerebellum. The cranial nerve roots are also found at the base of the brain and may be brought to view with the other structures previously mentioned when the entire brain is removed from the skull case.

STRUCTURES AT THE BASE OF THE ENCEPHALON

(Illustrations Nos. 215 and 216.)

The **longitudinal fissure** is the **intercerebral fissure** and separates the frontal lobes anteriorly, and the occipital lobes posteriorly; and by this fissure the cerebrum is divided into the two hemispheres.

The **peduncles** of the **corpus callosum** are seen on each side of the median line in the longitudinal fissure, being the place at the base of the brain where the corpus callosum terminates by a concave margin, from there the peduncles pass backward, where each meets the corresponding outer root of the olfactory tract.

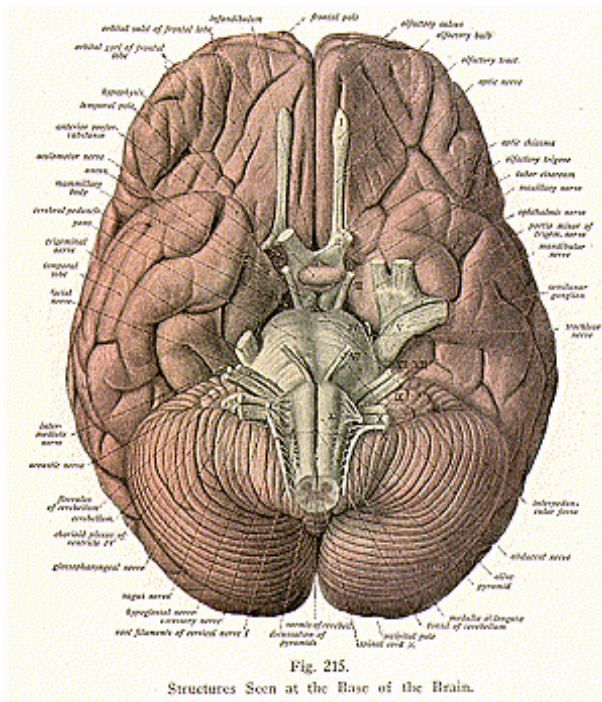
The **lamina cinerea** is a thin layer of gray matter extending upward into the longitudinal fissure, continuous on each side with the other gray matter at the base of the brain.

The **optic commissure**, or the **optic chiasma** or **optic chiasm**, is the point of junction of the optic tracts. The **optic commissure** or the **optic chiasma** or **chiasm** is a quadrilateral-shaped interval, which rests upon the olivary eminence and upon the optic groove of the sphenoid bone. It is seen at the base of the brain, and lies in front of the tuber cinereum and infundibulum, with the anterior perforated space on either side; its superior surface is connected with the lamina cinerea, and it is intimately related to the anterior part of the third ventricle. It is a commissure or decussation of the optic nerve fibres, which form the optic tracts.

The **tuber cinereum** is an eminence of gray matter situated be-

THE NERVOUS SYSTEM

tween the optic tracts, it extends from the optic commissure in front to the corpora albicantia behind. It is connected to the surrounding parts of the cerebrum, is composed of gray matter, and forms a part of the floor of the third ventricle. The tuber cinereum, with the infundibulum, pituitary body, corpora albicantia and the posterior



perforated space, form an oblong area, called the *interpeduncular space*.

From the middle of the under surface of the tuber cinereum a conical tubular process projects, called the **infundibulum**, which pierces the diaphragma sellae, and is attached to the pituitary body. Its canal is hollow and funnel-shaped, it communicates with the third ventricle and enters the floor of that cavity.

The **pituitary body or the hypophysis cerebri**, is a small reddish-gray, bi-lobed organ situated in the sella turcica of the sphenoid bone; it is fully described with the ductless glands.

The **corpora albicantia**, sometimes called **corpora mamillaria**, are two small, round, white masses each about the size of a pea, placed side by side and united together. They are formed mainly by the anterior pillars of the fornix, which, after descending to the base of the brain, are twisted upon themselves to form loops.

The **posterior perforated space** or the **pons Tarini**, or **locus perforatus posticus**, is a whitish-gray area behind the corpora albicantia, with the pons behind and the crura on either side; it forms part of the floor of the third ventricle. This space is perforated by small orifices, for the passage of branches of the posterior cerebral and posterior communicating arteries, as well as a few nerve fibres.

The **pons Varolii** is a mass of white fibres, it connects the medulla below with the crura cerebri above (described with the hindbrain).

The **medulla oblongata** is a pyramidal mass of gray and white matter, and is called the intra-cranial spinal cord or the spinal bulb. It connects the spinal cord, the pons, the cerebellum, and the cerebrum. (It also is described with the hindbrain.)

The **frontal lobe** is located at the anterior part of the cerebrum its under surface is seen on either side of the middle line of the base of the brain.

Beneath the frontal lobe is the **olfactory lobe**, or the **olfactory bulb**, which is small in man, but generally is well developed in the lower animals, in which species it consists of a distinct extension of the cerebral hemisphere. This lobe consists of the *olfactory bulb*, the *olfactory tract*, and the *olfactory trigone*; these form the anterior olfactory lobule, while the anterior **perforated space** represents the posterior olfactory lobule. The enlarged anterior extremity, the **olfactory bulb**, is an oval mass of reddish-gray color, its upper surface is in contact with the orbital surface of the frontal lobe, its under surface rests upon the upper one-half of the cribriform plate of the ethmoid bone; from its under surface are given off the olfactory nerves, which extend to the mucous membrane of the nose.

The **olfactory tract** is a white band which extends backward from the olfactory bulb; both the tract and bulb occupy the olfactory sulcus, which is on the back part of the orbital surface of the frontal lobe. Posteriorly the tract divides into two roots, an inner and an outer, which diverge and enclose between them an area of gray matter, the **olfactory trigone**. The inner root of the tract passes inward in a curved manner behind the area of Broca, and then passes into the convolutions of the limbic lobe; the outer root passes backward and enters the posterior part of the limbic lobe.

The **anterior perforated space (locus perforatus anticus)** on each side of the optic commissure is a gray area, perforated for the passage of vessels into the floor of the lateral ventricle. This space is bounded posteriorly by the optic tract, and is partially concealed by the temporal lobe, which overlaps it.

The **fissure of Sylvius** is a fissure which separates the frontal lobe from the temporal lobe.

THE CEREBRAL HEMISPHERES

The **Right and Left Cerebral Hemispheres** (see illustration No. 213) form the cerebrum, being separated by the **longitudinal fissure**. Each hemisphere is ovoid in shape and presents *two extremities*, the anterior and the posterior; and three *surfaces*, the *external*, *internal* and the *inferior surfaces*. The anterior extremity is thick and rounded; its most projecting part is called the *frontal pole*. The posterior extremity is narrow and pointed, and its most projecting part is called the *occipital pole*.

The *external surface* of each hemisphere is convex and fills the concavity of the corresponding half of the cranial vault. The *internal surface* is flat and vertical, and forms the lateral boundary of the great longitudinal fissure; for the most part it is in contact with the falx cerebri. The *inferior surface* is irregular and rests in front on the anterior and middle fossae of the base of the skull; behind, it rests upon the cerebellum.

Each hemisphere consists of seven **lobes**, formed by six clefts or fissures, and the names of the lobes are as follows: the frontal, the **parietal**, the **temporal**, the **occipital**, the **central**, the **limbic** and the **olfactory lobes**. The fissures are known as the **fissure of Sylvius**, the **fissure of Rolando**, the **parieto-occipital**, the **calloso-marginal**, the **collateral** and the **circular fissures**.

The **Frontal Lobe** is of large size, it is separated from the temporal lobe by the fissure of Sylvius, and from the parietal lobe by the fissure of Rolando. It has three surfaces—the external, the internal, and the inferior, or under surface, also called the orbital surface. The **convolutions**, or **gyri**, of the frontal lobe, as seen on the external surface, are called the **superior**, the **middle**, the **inferior frontal** or the *convolution of Broca*, and the **anterior central** or the **ascending frontal convolution** or **precentral gyrus**. These convolutions are formed by three **sulci** or **fissures**, namely: the **precentral sulcus**, running upward thru the lobe and limiting a convolution which lies between it and the fissure of Rolando, called the **ascending frontal convolution**; the **superior** and **inferior frontal sulci**, running forward and downward and dividing the remainder of the surface into the **superior**, **middle** and **inferior frontal convolutions**.

The mesial or internal surface of the frontal lobe presents a single curved convolution, the **marginal gyrus**, which is continuous with the superior frontal gyrus, but anteriorly it is broken up by one or more sulci. The **marginal gyrus** or **convolution**, found on the mesial or internal surface of the frontal lobe, bounds the longitudinal fissure on the middle aspect of the hemisphere, and is separated from the corpus callosum by the calloso-marginal fissure. The posterior part of the marginal convolution is almost completely detached and forms the *paracentral lobule*, which contains the upper end of the fissure of Rolando. This lobule is oval in form and is distinguished as the **paracentral gyrus** or **convolution**; it represents the junction of the upper ends of the ascending frontal and ascending parietal lobes. The **superior frontal convolution** is narrow and is in relation to the longitudinal fissure, it borders on the anterior part of the corpus callosum internally.

The **middle frontal convolution** is broad, and lies between the superior and inferior frontal sulci. It extends to the under surface and is there known as the orbital convolution; it is usually connected with the ascending frontal or the precentral gyrus by an *annectant gyrus*, (connecting or joining gyrus.)

The **inferior frontal convolution** is below the middle frontal and is in relation to the Sylvian fissure. It is sometimes called the **convolution of Broca** from the fact that in 1861 Broca discovered that it was the centre for language.

The **anterior central** or the **ascending frontal convolution**, is a small, simple convolution separated from the other three convolutions by the precentral sulcus in front and by the fissure of Rolando behind. The **precentral fissure** or **sulcus**, running more or less parallel with the fissure of Rolando, together with the **superior frontal** and the **inferior frontal sulci** which extend forward from the precentral sulcus, divide the frontal lobe into the four convolutions just described.

The inferior or orbital surface of the frontal lobe rests on the orbital plate of the frontal bone, it contains three convolutions formed by the **orbital** or the **tri-radiate sulcus**. The convolutions are named from their positions, the **internal orbital gyrus**, the **anterior orbital gyrus** and the **posterior orbital gyrus**.

The **orbital sulcus** or **fissure** is of variable form and consists of three limbs, the inner, outer, and the transverse. The inner limb is separated from the olfactory sulcus by the internal orbital gyrus; the outer limb is curved and has, external to it, the orbital part of the inferior frontal gyrus; while the transverse limb passes, in a more or less curved manner, between the inner and outer limbs.

The **internal orbital gyrus** presents a well marked groove, the *olfactory sulcus*, for the olfactory tract. The internal portion of this gyrus is called the *gyrus rectus*, which lies between the olfactory sulcus and the mesial border, being continuous with the marginal gyrus. The **anterior orbital gyrus** is situated in front of the transverse limb of the orbital sulcus. The **posterior orbital gyrus** lies behind the transverse limb of the orbital sulcus.

The **frontal lobe**, where the visual centres react in consciousness, extends from the angular gyrus over the occipital lobe and adjoining portions of the temporal and parietal lobes. It is the centre for speech, and for the memories of odors and taste; it is also the seat of perception and of the knowledge of things in space. The anterior part seems to be related to the highest processes of the mind. Lesions in this locality are generally followed by proportionate mental deterioration. In the posterior extremity of the frontal lobe are found the centres which are devoted to muscular sense, they being the centres which control the voluntary movements of the body; that is, of the eye, the face, the trunk, and of the limbs.

The **Parietal Lobe** occupies the upper and lateral portions of the hemisphere of the cerebrum, it is found between the fissure of Rolando and the external part of the parieto-occipital fissure; it arches over a branch of the fissure of Sylvius. There are four principal **convolutions** of the parietal lobe, namely: the **superior parietal**, the

inferior parietal, the **ascending parietal** or the **posterior central**, and the **quadrate convolution** or lobe. There are two principal fissures of the parietal lobe, namely, the intraparietal sulcus and the **postcentral sulcus**. The **superior parietal** and the **inferior parietal convolutions** are separated by the **intraparietal sulcus**, they are usually continuous with the convolutions of the occipital lobe, by bridges of gray matter, called the *annectant convolutions* or *gyri*.

The **inferior parietal convolution** usually consists of two portions, the *angular* and the *supra-marginal convolutions*. The *supra-marginal gyrus* or *convolution* arches round the ascending extremity of the posterior limb of the fissure of Sylvius; it is continuous in front with the ascending parietal gyrus, behind with the angular gyrus, and posteriorly and inferiorly with the first or superior temporal gyrus. The *angular gyrus* or *convolution* arches round the ascending extremity of the first or superior temporal sulcus; it is continuous with the second or middle temporal convolution and is connected with the occipital lobe by an *annectant gyrus*.

The **ascending parietal gyrus** or **posterior central gyrus** arches round the ascending extremity of the second temporal sulcus and is continuous with the third or inferior temporal gyrus. It is situated immediately behind the fissure of Rolando, which separates it from the ascending frontal or precentral gyrus in front of that fissure, it lies parallel to the ascending frontal gyrus with which it is connected below the fissure of Rolando, these two convolutions completely surround the fissure of Rolando and form the Rolandic area of the cerebral cortex. The quadrate convolution is found on the middle or internal surface of the parietal lobe; it is of small size, of quadrilateral outline and, from its situation above the cuneate lobe of the occipital lobe, it is often called the *precuneus lobule* or convolution.

The **intra-parietal sulcus** is found between the superior and inferior parietal convolutions, the ascending portion of the sulcus separates off a convolution, the ascending parietal; and the remaining portion separates the other two convolutions, the superior and inferior parietal convolutions.

The **post-central sulcus**, only slightly marked, is sometimes considered as a branch of the intra-parietal sulcus, being given off where the ascending portion of this sulcus turns backward. It is situated immediately behind the fissure of Rolando which separates it from the ascending frontal gyrus in front of that fissure.

The **parietal lobe** is said to be the centre for morals and, therefore, is only slightly developed in the lower animals.

The **Temporal Lobe** is sometimes called the **temporo-sphenoidal lobe**; it is separated from the frontal lobe by the **fissure of Sylvius**. The temporal lobe is prominent and of large size, and its gyri are three in number the **superior temporal**, the **middle temporal** and the **inferior temporal convolutions**; its **sulci** are two in number, the **first** and the second temporal sulci.

The superior surface of the temporal lobe or the **opercular surface** is concealed within the fissure of Sylvius and is directed towards the central lobe. It is the external surface of the temporal lobe which is, divided into the three convolutions: the **superior** or **first temporal**,

the **middle** or **second temporal**, and the **inferior** or **third temporal convolutions**; arranged in horizontal tiers, by two fissures called the **first** and the **second temporal sulci**.

The temporal lobe is bounded superiorly by the horizontal portion of the posterior limb of the fissure of Sylvius and by a line prolonging this limb backwards to meet the posterior boundary of the parietal lobe; anteriorly it is bounded by the stem of the fissure of Sylvius, which separates it from the orbital area of the frontal lobe; posteriorly it is continuous with the occipital lobe, but is separated externally by the extremity of the external part of the parieto-occipital fissure, and inferiorly by a line which corresponds with the portion of the limbic lobe which lies below the splenium of the corpus callosum. Inferiorly it is separated from the hippocampal convolution by the collateral fissure. The temporal lobe is somewhat pyramidal, the rounded apex being directed forward. The apical part forms the *temporal pole*, and it overhangs, from behind, the stem of the fissure of Sylvius.

The **first temporal** or **superior convolution** is situated between the horizontal limb of the fissure of Sylvius and the first temporal sulcus; it is continuous behind with the supra-marginal convolution of the parietal lobe. The **middle** or the **second temporal convolution** lies between the first and second temporal sulci, and is continuous posteriorly with the angular and middle occipital convolutions. The **inferior** or the **third temporal convolution** lies below the second temporal sulcus posteriorly it is continuous with the lower part of the external surface of the occipital lobe and is prolonged on to the under surface of the temporal lobe where it is limited internally by a small sulcus called the **third temporal sulcus**.

The **first temporal sulcus** runs from before backward thru the temporal lobe, parallel with the horizontal limb of the Sylvian fissure, from which circumstance it is often called the *parallel sulcus*. It commences near the temporal pole and posteriorly it turns upwards into the parietal lobe where the angular gyrus arches round it.

The **second temporal sulcus** takes the same direction as the first but is situated below it, and it is usually broken up into two or more parts by annectant gyri. Posteriorly it turns upwards into the parietal lobe.

The **occipito-temporal sulcus** or the **third temporal sulcus** extends from near the occipital pole behind, to near the anterior extremity of the temporal lobe in front, but is usually broken up into parts by *annectant gyri*.

The inferior surface, or the tentorial surface, of the temporal lobe presents, in addition to the third temporal or occipito-temporal sulcus, the occipito-temporal gyrus, which latter is sometimes called the *fourth temporal* or *subcollateral convolution*. This gyrus is situated between the occipito-temporal sulcus and the collateral fissure, and extends from the occipital to the temporal pole, being a convolution which connects the occipital and the temporal lobes. The *subcalcarine convolution* or *lingual gyrus* is a narrow area which lies between the calcarine fissure above and the posterior part of the collateral fissure below and it is continuous in front with the hippocampal convolution of the limbic lobe.

The **temporal** lobe is the center for hearing, smell and taste, and in this lobe are found also a few visual fibres.

The **Occipital Lobe** lies behind the parietal and the temporal lobes, and forms the posterior part of the cerebral hemisphere. The occipital lobe is pyramidal in form; it presents an apex and an external, internal, and an inferior surface. The apex forms the posterior extremity or the occipital pole. On the external surface are found the three convolutions, the **superior occipital, middle occipital** and the **inferior occipital convolutions**, which are subdivided as such by the **superior** and **inferior occipital sulci** or **fissures**. These convolutions are continuous with the convolutions of the occipital and temporal lobes.

The **superior occipital convolution** or **gyrus** is situated above the superior occipital sulcus; the **middle occipital convolution** is situated between the superior and inferior occipital sulci; and the **inferior occipital convolution** is situated below the inferior occipital sulcus. These convolutions are connected to the convolutions of the parietal and temporal lobes by *annectant gyri*.

The **superior occipital sulcus** or **fissure**, also called the **transverse occipital sulcus**, is formed by the bifurcation of the posterior end of the intra-parietal sulcus, and it separates the superior occipital convolution from the middle occipital convolution. The **inferior occipital sulcus**, or **middle sulcus** as it is sometimes called, or the **lateral occipital sulcus**, is smaller than the superior sulcus and is situated on the lateral and external surface of the occipital lobe. Extending from behind forward it separates the middle occipital convolution from the inferior convolution.

The medial or internal surface of the occipital lobe presents a somewhat triangular-shaped convolution known as the **cuneate lobule**, or as the **cuneus**. It is situated between the calcarine fissure and the parieto-occipital fissure. A small gyrus, called the *gyrus lingualis* or the *infracalcarine gyrus*, is situated between the calcarine fissure above and the posterior part of the collateral fissure below. It becomes narrow anteriorly and joins the hippocampal gyrus. The surface of the occipital lobe which rests upon the tentorium, is composed chiefly of two convolutions, the inner one of which blends with the hippocampal convolution of the limbic lobe; the outer one is the occipital part of the occipito-temporal convolution. Both are continuous with the convolutions on the under surface of the temporal lobe. The inferior surface or tentorial surface of the occipital lobe presents the posterior part of the occipito-temporal gyrus, internal to which is the posterior part of the collateral or occipito-temporal fissure, and internal to this again there is the lower portion of the lingual gyrus of the temporal lobe.

The **occipital lobe** is the seat of vision, that is, of image and memory, and there are a few auditory impressions received here as well.

The **Central Lobe** or the **Island of Reil**, or the **Insula**, is situated deeply within the Sylvian fissure, and is concealed from view by the convolutions which bound this fissure. This lobe consists of a triangular cluster of convolutions, which are almost surrounded by

a deep fissure called the **limiting** or the **circular sulcus**, separating it from the parietal, frontal and temporal lobes.

The central lobe consists of a **pre-central** and a **post-central lobe**, separated by the central sulcus, which runs backward and upward almost in line with the fissure of Rolando. The pre-central lobe is further divided into three or four short convolutions (*gyri breves*) arranged side by side upon the triangular mass, and appearing, when exposed, very much like the fingers of the hand when closed upon the palm.

The **opercula insulae** are the parts of the cerebral hemispheres which bound the three limbs of the fissure of Sylvius and overhang the insula or the central lobe. They are four in number: The *fronto-parietal operculum* forms the upper lip; the *temporal operculum* forms the lower lip; the *frontal operculum* lies between the ascending and anterior limbs of the Sylvian fissure; and the *orbital operculum* is that part found on the orbital surface of the frontal lobe.

The central lobe and the corpus striatum represent the stem of the cerebral hemisphere, whilst the remainder of the hemisphere is known as the brain mantle or the pallium. The internal or mesial relation of the central lobe is the claustrum, internal to which are, in succession, the external capsule, the lenticular nucleus, the internal capsule, and the caudate nucleus, seen in the floor of the lateral ventricle.

The **central lobe** is considered the centre of speech, containing the throat impressions.

The **Limbic Lobe** is known as the *grande lobe limbique* and, according to Gray, "this lobe was introduced in 1878 by Broca, and under it are included two convolutions namely, the callosal and the hippocampal which together arch round the corpus callosum and the hippocampal fissure. These are separated on the morphological ground that they are well developed in animals possessing a keen sense of smell (osmatic animals), such as the dog and fox."

The limbic lobe is situated on the internal or mesial surface of the cerebral hemisphere and, as previously stated, it is composed of two convolutions, namely, the **callosal gyrus** or **gyrus fornicatus**, and the **hippocampal gyrus**; which are so arranged as to almost form a complete ring round the corpus callosum.

The **callosal convolution**, or **gyrus fornicatus**, or the **gyrus cinguli**, is intimately related to the corpus callosum, around which it arches. It commences at the anterior perforated space below the rostrum of the corpus callosum, and it terminates below the splenium of that body. The callosal gyrus is separated from the corpus callosum by the callosal sulcus; it is separated from the marginal convolution of the frontal lobe by the **calloso-marginal fissure**; and it is separated from the quadrate convolution of the parietal lobe by the posterior branch of the calloso-marginal fissure.

The **hippocampal convolution** or **hippocampal gyrus**, extends from a point below the splenium of the corpus callosum to the anterior perforated space. It is bounded externally by the anterior part of the collateral fissure, which separates the uncus of the limbic lobe from the temporal lobe. Internally it is bounded by the hippocampal or dentate fissure. It is separated from the occipito-temporal con-

volution on the under surface of the collateral fissure. It forms the floor of the middle horn of the lateral ventricle, terminating anteriorly in a hook-like process, the *uncus*.

The **cingulum** is a tract of long association fibres, which tract is connected with the limbic lobe, these fibres are regarded as connecting the gyri of the limbic lobe with the cerebral cortex. The **hippocampal fissure** or the **dentate fissure**, commences behind the splenium of the corpus callosum, where it is continuous with the callosal sulcus. It is directed forwards, lying between the gyrus dentatus above and the hippocampal gyrus below; it terminates within the uncus of the hippocampal gyrus. The hippocampal or the dentate fissure, being complete, gives rise to the elevation, in the descending cornu of the lateral ventricle, called the *hippocampus major*.

The **dentate convolution**, or **gyrus dentatus**, is situated above the hippocampal gyrus and below the fimbria, and is separated from the hippocampal gyrus by the hippocampal fissure. The dentate gyrus is narrow and its free margin is notched, hence its name dentate. It commences behind the splenium of the corpus callosum and is directed forward above the hippocampal gyrus into the curve of the uncus. The **fimbria** is a prolongation of the posterior pillars of the fornix. It is situated above the gyrus dentatus, from which it is separated by a small sulcus. Posteriorly it turns upwards around the posterior extremity of the optic thalamus, and so becomes continuous with the posterior pillars of the fornix. Anteriorly it enters the uncus.

The **Olfactory Lobe**, located at the base of the encephalon, has been previously described with the structures at the base of the brain.

The **Fissure of Sylvius**, which is the first fissure to appear in the course of development, commences on the inferior surface of each hemisphere, at the anterior perforated space, in a depression called the vallecule Sylvii. It is a deep cleft which is overhung posteriorly by the frontal part of the temporal lobe. This fissure separates the orbital surface of the frontal lobe from the temporal lobe. The Sylvian fissure divides into three limbs; the anterior-horizontal, the anterior-ascending, and the posterior-horizontal limbs. The anterior-horizontal limb, as well as the anterior-ascending limb, pass upward and forward into the frontal lobe; the posterior-horizontal limb, the longest, passes backward and terminates in the parietal lobe.

The **Fissure of Rolando**, also known as the **central sulcus of Rolando**, separates the frontal from the parietal lobe. It is located on the superior surface of each hemisphere, extending from the longitudinal fissure downward and forward toward the fissure of Sylvius. The fissure of Rolando forms two bends or curves, the upper or superior genu, and the lower or inferior genu. The superior genu is concave forward and upward, and the inferior genu is directed backward.

The **Parieto-Occipital Fissure** is situated about two inches behind the upper end of the fissure of Rolando, it separates the parietal from the occipital lobe. It is composed of two limbs, the external and the internal limbs. The external limb is found on the outer surface of the hemisphere, commencing at the posterior extremity of the brain and the fissure of Rolando, and passing transversely outward

THE NERVOUS SYSTEM

and downward for about $\frac{3}{4}$ of an inch. The internal limb appears as a deep cleft on the internal surface of the hemisphere. It runs downward and forward to join the calcarine fissure, a short distance behind the splenium of the corpus callosum.

The **Calloso-Marginal Fissure** is situated on the internal surface of the hemisphere. It separates the marginal convolution of the frontal lobe from the gyrus fornicatus, or the callosal convolution, of the limbic lobe. The marginal gyrus lies above the fissure, and the callosal convolution below it.

The **Collateral Fissure** or the **Occipito-Temporal Fissure** is situated on the inferior surface of the hemisphere. It is below and posterior to the calcarine fissure and, commencing near the occipital pole, it extends forward to near the temporal pole. It separates the temporal lobe from the hippocampal convolution of the limbic lobe.

The **Calcarine Fissure** is a deep cleft which commences on the internal aspect of the occipital lobe, usually by branches. It passes first forward and then downward, and terminates in the limbic lobe beneath the splenium of the corpus callosum. This fissure separates the cuneus convolution of the occipital lobe from the gyrus lingualis or the lingual convolution of the same lobe.

The **Circular** or **Limiting Fissure** is situated within the fissure of Sylvius, and surrounds the convolutions which form the central lobe. It is composed of three parts—the superior part separates the central lobe from the frontal and the parietal lobes; the inferior part separates the central lobe from the temporal lobe; and the anterior part separates the central from the frontal lobe.

THE INTERIOR OF THE CEREBRUM

(Illustration No. 217.)

If the upper part of each hemisphere is removed, a section of the cerebrum shows it consists of gray substance externally forming the cortex, and a white nerve tissue internally, the medulla. The white matter is an oval-shaped centre of white substance surrounded on all sides by narrow margins of gray matter which presents an equal thickness in nearly every part.

The **corpus callosum** makes up a great part of this white matter on the internal surface. It is known as the great commissure of the brain. It is an arched mass of white matter, situated at the bottom of the longitudinal fissure, and is made up of transverse fibres connecting the cerebral hemispheres. It is thicker in front and behind than at its centre, and attains its greatest thickness posteriorly where more fibres cross in it than elsewhere, on account of there being larger portions of the hemispheres behind it than in front of it. The corpus callosum is about four inches long, and extends to within one inch and a half of the anterior extremity, and two inches and a half of the posterior extremity, of the cerebrum. It is about one-third of an inch thick, and is widest behind, varying from three-fourths of an inch to one inch in width at that part.

The superior surface of the corpus callosum is related to the falx cerebri and is covered by a thin layer of gray matter. Anteriorly

THE NERVOUS SYSTEM

it is bent upon itself and passes at first downward and then backward. The bent portion in front is called the *genu*, while that portion which curves backward to the base of the brain is termed the *rostrum*

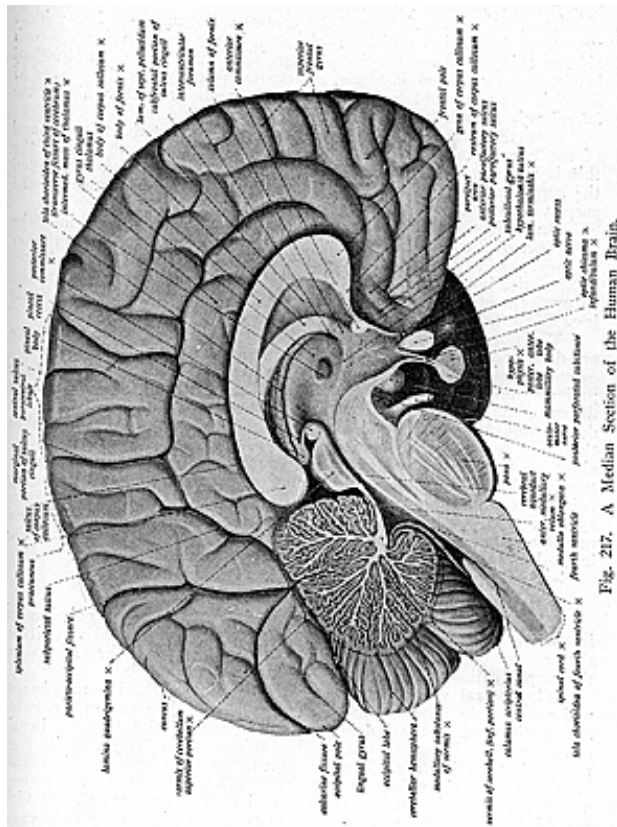


Fig. 217. A Median Section of the Human Brain.

or the beak. Posteriorly, the corpus callosum forms a thick rounded fold called the *splenium* or pad.

The lowest part of the rostrum, as it descends, becomes thinner

THE NERVOUS SYSTEM

and is attached by its lateral margins to the frontal lobes. The rostrum joins with the lamina cinerea, and terminates posteriorly in two white bands, called the *peduncles* of the *corpus callosum*, which disappear in the fissure of Sylvius.

Upon the upper surface of the corpus callosum there is a middle groove or depression called a **rapine** and, in the recent state, on each side of this rapine are readily distinguished two white, longitudinal bands, called *striae longitudinale*, sometimes spoken of as the nerves of *Lancisi*. Parallel and external to these bands are other fibres, the *lateral striae (taenia tecta)*.

A small gyrus, the **geniculate gyrus**, is found at the anterior end of the corpus callosum. The striae of each side, together with the thin layer of gray matter, represent a rudimentary convolution called the **supra-callosal gyrus**, which is found on the upper surface of the corpus callosum.

On each side the fibres of the corpus callosum extend into the substance of the hemispheres and traverse them in a radiating manner as they pass to the cerebral cortex, the fibres from the central portion of the body, and from the upper part of the splenium of the corpus callosum, which pass forward to the temporal lobe, form what is called the *tapetum* (spread out like a carpet).

The fibres of the cerebrum which form the medullary substance are described as the *longitudinal* or the *association fibres*; the *transverse* or *commissural fibres*; and the *projecting* or the *peduncular fibres*. Much patience and critical study has been given to the unravelling of the fibres of the brain and spinal cord, and many conclusions have been drawn and observations recorded. These conclusions have been that there are sets of nerve-centres and nerve-paths, thru which impressions are transmitted to and from the periphery, and to and from the gray cortical surface of the hemispheres; the common understanding being that nerve centres are located along various parts of the nervous system. Chiropractically considered, the centres of all physical and moral actions, as well as of all the motor and sensory areas, are located in the cortical substance of the cerebrum.

THE TELEENCEPHALON

The **telencephalon**, or anterior vesicle of the proencephalon or **forebrain**, consists of the cerebral hemispheres, the lateral ventricles, the anterior part of the third ventricle, the olfactory bulbs and tracts, the corpus callosum, the corpora striate, and the fornix.

The **lateral ventricles** are cavities of the cerebral hemispheres, and are two in number, the right and left. They are of irregular shape, situated in the inner and lower parts of the cerebral hemisphere, and each occupies about two-thirds of the length of its corresponding hemisphere. They are lined with ependyma, a thin membrane covered by ciliated epithelium. They contain more or less serum, cerebro-spinal fluid. Each lateral ventricle communicates with the third ventricle by an opening, the *foramen of Monro*; they communicate with each other only thru the foramen of Monro, save when the septum is ruptured, as in cases of serous effusion.

Each lateral ventricle consists of a body and three prolongations,

termed the **anterior, middle** and **posterior cornua**. The body, or central part of the lateral ventricle, is situated in the lower part of the parietal lobe, while the cornua extend respectively into the frontal, temporal, and the occipital lobes.

The **anterior cornua** of the lateral ventricles curve outward from each other into the substance of the frontal lobes around the caudate nucleus of the corpus callosum. This cornu is bounded above by the corpus callosum, and below by a prominent enlargement, which is the large extremity of the caudate nucleus of the corpus callosum.

The **descending** or **middle cornua** are the largest of the prolongations of the cavities of the lateral ventricles. They each pass downward into the temporal lobe toward the base of the brain, curving backward, outward and downward, round the back of the optic thalamus, they then pass forward and inward round the crura cerebri, resembling somewhat the horns of a ram and so are sometimes called the *cornua Ammonis*. The roof of each descending cornu is formed chiefly by the corpus callosum and the narrow part or tail of the caudate nucleus. The taenia semicircularis is also prolonged into a roof, and extends forward into the deep end of the cornu where it presents a mass of gray matter, the *amygdaloid nucleus*. The floor of the descending cornu presents the following parts: the *hippocampus major*, the *pes hippocampi*, *eminentia collateralis* or *pes accessorius*, *fimbria hippocampi* and the *choroid plexus*.

The *hippocampus major* is a long, white, rounded eminence about two inches in length, which follows the curve of each descending cornu and occupies the principal part of its cavity. It enlarges as it descends and, beneath the amygdaloid nucleus, it terminates in four or five small elevations with intervening depressions, and is called the *pes hippocampi* (so named from its fancied likeness to the paw of an animal). The hippocampus major is formed by the reduplication of the hippocampal convolution, produced by the dentate or hippocampal fissure on the inner or mesial surface of the cerebral hemisphere.

The *eminentia collateralis* or *pes accessorius* is a white eminence situated in the angle between the descending and posterior cornua of the lateral ventricles. It is produced by the inward protrusion of the collateral fissure on the inferior surface of the cerebral hemisphere.

The *fimbria* is the prolongation of the posterior pillar of the fornix and represents a band of white matter along the median edge of the hippocampus major, to which it is attached.

The *choroid plexus* will be described with the structures forming the floor of the cavity of the lateral ventricle.

The **posterior cornua** of the lateral ventricles are not always equally developed in both hemispheres and may be absent. They usually curve backward into the substance of the occipital lobes. The roof of the posterior cornu and its outer wall are formed by the corpus callosum (tapetum). The inner wall has a claw-shaped eminence of white matter, the *hippocampus minor*, also called the *calcar avis*, which is produced by the inward protrusion of the calcarine fissure. The body of the lateral ventricle presents several objects of interest, and these are described as the structures forming the *roof*, the *floor*, an *inner wall* and an *outer wall*.

to the upper surface of the corpus callosum; the *floor* by the fornix, corpus fimbriatum, choroid plexus, optic thalamus, taenia

semicircularis and the corpus striatum, and the *outer wall* by the caudate nucleus, the internal capsule, the lenticular nucleus and the external capsule. These structures will be described in their respective places.

The **septum lucidum** or **septum pellucidum** forms the inner wall of each lateral ventricle. It is a delicate, almost translucent, vertical partition, situated between the anterior cornua of the lateral ventricles; above, it is attached to the under surface of the corpus callosum. It is triangular, being broad in front and narrow behind. It consists of two layers, the outer surface of each layer facing the corresponding ventricle, the inner surface being directed towards its fellow. A narrow interval is found between the two laminae, and this enclosed space is called the **fifth ventricle**. This space can hardly be called a cavity or ventricle unless distended with fluid, a condition which may occur in dropsy of the brain.

The *floor* of each lateral ventricle presents the following structures, in order from within outward: the *fornix*, *corpus fimbriatum choroid plexus*, *optic thalamus*, *taenia semicircularis*, and the *corpus striatum*.

The **fornix** is a band of white, longitudinal fibres. It lies beneath the corpus callosum, with which it is connected posteriorly, but from which it is separated anteriorly by the septum lucidum. It is composed of two lateral halves, united in the median line to form the *body* of the *fornix*; but in front and behind they are separated from each other, and these form an anterior and a posterior prolongation, known as the anterior and posterior *pillars* or *crura* of the *fornix*. The body is the central portion, it is triangular, being narrow in front where it is continuous with the anterior pillars, and broad behind, where it is prolonged into the posterior pillars. The upper surface of the fornix is connected anteriorly with the septum lucidum and posteriorly with the corpus callosum, while laterally it forms part of the floor of each lateral ventricle. The under surface rests directly upon the velum interpositum, which separates it from the third ventricle.

The *anterior pillars* or the *anterior crura* of the *fornix* are two round bundles of white matter, which curve downward from the front of the body of the fornix, being slightly separated from each other by a narrow interval. They leave the corpus callosum at about the position of the foramen of Monro, traversing the gray matter on the sides of the third ventricle. Upon reaching the base of the brain, each pillar becomes twisted in the form of a loop, somewhat resembling the figure 8; and the curve, which the fibres of each anterior pillar take at the base of the brain, forms the *corpus albicans* (white body) of that side. Extending from this body, the fibres of the anterior pillar terminate in a bundle of fibres, called the bundle of Vicq d' Azyr, which passes upward and backward into the optic thalamus.

The *posterior pillars* or *posterior crura* of the *fornix* are prolongations of the posterior part of the body on either side. They are flattened bands, which, at their commencement, adhere to the under surface of the corpus callosum, but subsequently curve outward and

downward round the posterior extremity of the optic thalamus and enter the descending cornua of the lateral ventricles. Here they come in contact with the hippocampus major, upon the surface of which some of their fibres spread out, while the rest of the fibres are prolonged along the inner concave borders of the hippocampal convolutions, as narrow bands of white matter, called the *fimbriae* or *taeniae hippocampi*. As the two posterior pillars diverge from each other, they enclose between them a small triangular space, which is traversed by a number of transverse and oblique fibres, and which from its fancied resemblance to an ancient lyre, is called the *lyra*.

A commissure, known as the *anterior commissure* of the *fornix* is a round bundle of white fibres, which crosses the anterior pillars in front. Its fibres pass thru the adjacent corpora striate and extend into the temporal lobes, and it is in this way that the temporal lobes are connected. The anterior commissure serves also to connect the two olfactory bulbs, fibres passing from the one side to a corresponding structure on the other side.

The **corpus fimbriatum** or **fimbria**, has already been mentioned as the prolongation of the posterior pillar of the fornix. It is placed to the outer side of the fornix, below the choroid plexus, and is attached by its deep surface to the hippocampus major as it passes thru the descending cornu of the lateral ventricle. It consists of a thin, fringed body, a thin, flattened and delicate band, situated along the concave edge of the hippocampus major.

The **choroid plexus** is a membranous and vascular duplicature of the pia mater, situated in the floor of each of the lateral ventricles; posteriorly it is prolonged into the descending cornu. It is a loose, fringe-like structure, receiving the ramifications of the choroid vessels; it is fixed to the tela choroidea or velum interpositum by one edge, but is loose and floating at the other. The choroid plexus of the lateral ventricle is continued into the third ventricle and there forms the velum interpositum. It is the upper surface of the optic thalamus, which enters into formation of the floor of the lateral ventricles, and these structures will be described later with the interbrain.

The **taenia semicircularis** is a grayish, semi-transparent band of white fibres, situated in the groove separating the optic thalamus from the corpus striatum in the lateral ventricle. The fibres are continued anteriorly into the anterior pillars of the fornix, and posteriorly into the descending cornu of the lateral ventricle, apparently losing themselves in that cavity. At the foramen of Monro, the fibres of the taenia semicircularis pass partly in front of and partly behind the anterior commissure of the fornix, and they are regarded as terminating in the region of the anterior perforated space.

The **corpus striatum** has received its name from the fact that when the structure is cut, a mixture of white and gray substance is seen, giving it a striped appearance. It is a large ovoid mass, situated in front and on the outer side of the lateral ventricle, and composed of two collections of gray matter: the *caudate nucleus*, the intra-ventricular portion of the corpus striatum; and the *lenticular nucleus*, the extra-ventricular portion. Between these two nuclei there is a thick tract of white fibres which constitute the *internal capsule*. On

the outer side of the lenticular nucleus, there is another lamina of white matter, called the *external capsule*. The *caudate nucleus* is a pyriform mass of gray matter; its larger and round end is directed forward, projecting into the anterior cornu of the lateral ventricle. The smaller and narrow end is directed outward and backward in the floor of the body of the lateral ventricle, where it lies on the outer side of the optic thalamus, separated from it by the taenia semicircularis. Its most external end or tail is continued into the roof of the descending cornu of the lateral ventricle, being prolonged in the roof as far as the *amygdaloid nucleus*, in which it terminates.

The *lenticular nucleus* is a semilunar mass of gray matter, embedded in the white matter of the cerebral hemisphere, and lies on the outer side of the caudate nucleus, being separated from it by the internal capsule. It does not extend as far forward or backward as does the caudate nucleus, and it receives its name from the fact that, when divided horizontally, it presents the appearance of a bi-convex lens.

When a section is made thru the centre, the lenticular nucleus presents a triangular outline, the base being directed toward the island of Reil, and having the external capsule in loose connection with it, while the internal surface is in contact with the internal capsule. In such a section the nucleus is seen to be transversed vertically by two white bands called the *medullary laminae*, which divide it into three zones. The outer and largest zone is called the *putamen* (shell), and is of a dark reddish color; the inner two zones, somewhat yellowish in color, are together known as the *globus pallidus*, constituting the pale interior of the nucleus. The gray matter of the caudate and lenticular nuclei comes to the surface at the base of the brain in the region of the anterior perforated space, where it is continuous with the gray matter of the cerebral cortex.

The *internal capsule* is a broad, thick band of white matter, which lies internal to the lenticular nucleus and separates it from the caudate nucleus.

As seen in a horizontal section, each internal capsule is somewhat abruptly curved, with its convexity forward; the bend is called the genu. The part of each capsule in front of the genu is called the anterior limb and this, forming about one-third of the capsule, separates the lenticular from the caudate nucleus. The portion behind the genu is the posterior limb, which forms about two-thirds of the entire capsule, and it separates the lenticular nucleus from the optic thalamus. The internal capsule is composed largely of projection fibres, derived from the crus cerebri, which are continued thru it to the cortex of the cerebral hemispheres. The fibres of the anterior limb are derived from the frontal region, those of the genu are derived from the Rolandic area of the cerebral cortex as they pass on their way thru the crista of the crura cerebri; the fibres of the posterior limb are from the temporal and occipital lobes. There are also fibres passing from the cortex to the thalamus and to the pons, as well as to the cerebellum. The fibres diverge in a radiating manner on their way to the cerebral cortex, forming the *corona radiata*.

The *external capsule* is a layer of white matter situated on the

THE NERVOUS SYSTEM

outer side of the lenticular nucleus, where it lies between that nucleus and the claustrum. It is thinner than the internal capsule, with which it is continuous behind.

The fibres of which the external capsule is composed are probably derived from the crus cerebri, from the anterior commissure, and from the optic thalamus.

The *claustrum* (barrier) is a thin layer of gray matter, situated on the outer surface of the external capsule. It lies embedded in the white matter which occupies the region between the lenticular nucleus and the central lobe. It is regarded as an isolated portion of the gray matter of the central lobe or island of Reil.

The *outer wall of the lateral ventricle* is formed by the corpus striatum, and the parts of it have just been described.

The **foramen of Monro** or the **interventricular foramen**, is a Y-shaped opening which leads from the lateral ventricles above, into the third ventricle below. It is situated at the back part of the anterior pillars of the fornix, and slightly above the anterior commissure. Some authorities consider that there are two foramina, the right and left, but the short branches which form the letter Y are accepted by most authors as forming only the one opening. By means of the foramen of Monro the lateral ventricles communicate with the third ventricle and, thru that ventricle, with each other. The choroid plexuses of the lateral and third ventricles also becomes continuous with each other thru this foramen.

The **fifth ventricle** or the **ventricle of the septum lucidum** is a narrow, cleft-like interval between the two layers of the septum lucidum. It is a closed space and therefore does not communicate with any other ventricle, except by osmosis of the fluid thru its walls. The ventricle, however, contains very little fluid.

THE DIENCEPHALON

The **diencephalon**, also known as the **thalamencephalon**, is the **interbrain** (see illustrations No. 217 and 219). It consists of the structures around the third ventricle. The interbrain corresponds to the structures developed from the second cerebral vesicle; it is connected above and in front with the forebrain or the telencephalon, behind, it is connected with the mesencephalon or the mid-brain.

The **third ventricle** is the cleft or interval which is situated in the median line between the optic thalami. It is entirely concealed from view, for it is covered by the cerebral hemispheres; to expose the ventricle, it is necessary to remove the corpus callosum, the fornix, and the velum interpositum.

The third ventricle communicates with the lateral ventricles above by the foramen of Monro and with the fourth ventricle below by the aqueduct of Sylvius. The **cavity** presents a *roof*, *floor* and *two lateral walls*, also an *anterior* and a *posterior boundary*. The *roof* is the *velum interpositum* (interposed veil), with the fornix above that.

The **velum interpositum** or the **tela choroidea superior**, in contradistinction to the tela choroidea inferior of the fourth ventricle consists of two layers of the pia mater, which is prolonged into the in-

terior of the brain. It is traversed by numerous arteries, the choroidal arteries, and by the veins of Galen. The velum interpositum is triangular; the apex is situated behind the anterior pillars of the fornix at the foramen of Monro, and the base lies beneath the splenium of the corpus callosum. On either side, the velum interpositum is projected into the lateral ventricles and appears as a convoluted fringe, and there forms the choroid plexuses of the lateral ventricles.

The *floor* of the third ventricle is sloped downward and forward, and the structures which form it lie in an area called the *interpeduncular space*, at the base of the brain. They are named, from before backward; the optic commissure, tuber cinereum, corpora albicantia, posterior perforated space, and the tegmenta of the crura. These structures have been previously described with the structures at the base of the brain.

The *lateral walls* of the third ventricle are formed by the **optic thalami**, large oblong masses of gray matter which, for the most part, lie obliquely on the sides of the third ventricle, with their long axes directed outward and backward. They embrace the crura cerebri and their upper surfaces project into the floors of the lateral ventricles. The optic thalami (so named, for it was thought they were the chambers of vision) are composed mainly of gray matter, with their free surfaces covered with a thin layer of white matter. The gray matter is arranged in two masses, the outer and inner nuclei, which are partially separated by the white strata or layers, which traverse the gray matter and are called the *medullary laminae*. The internal medullary lamina is formed by the fibres which separate the nuclei; the outer medullary lamina is that layer of white matter which forms a coating on the outer surface of the optic thalamus.

The outer and lateral nucleus, the largest, is situated between the internal and external medullary laminae, and extends backward into the *pulvinar*, the inner or mesial nucleus is connected with the corresponding nucleus of the opposite side thru the middle commissure of the third ventricle.

Each side-wall is slightly convex, so that in the middle of the ventricle the two lateral walls of the optic thalami are almost in contact; they are united here by a fragile band of gray matter, called the *middle commissure*, which is soft and is almost always broken in examining the brain.

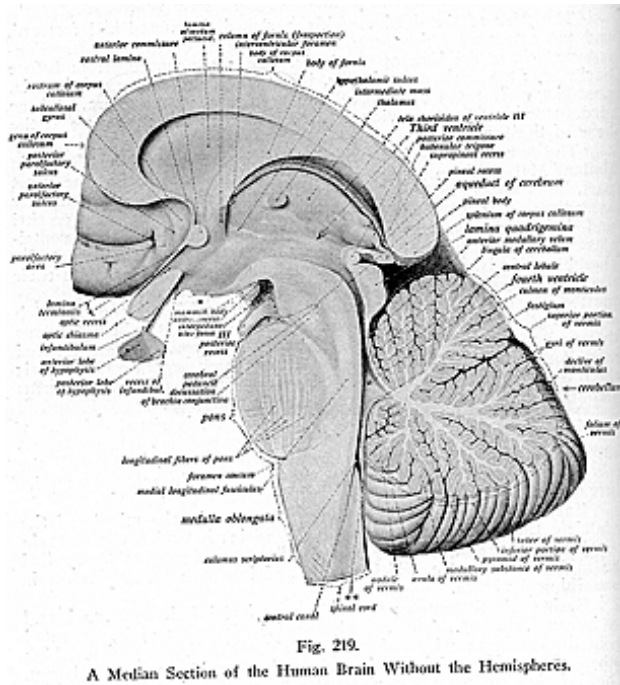
Each optic thalamus presents a superior, inferior, external, and an internal surface. The superior surface is free and is separated from the caudate nucleus of the fourth ventricle by a groove, which lodges the taenia semicircularis and a vein from the corpus striatum. The inferior surface rests upon the tegmenta of the crura. The external surface is directly related to the internal capsule, which separates it from the lenticular nucleus. Many fibres emerge from the external surface and enter the internal capsule on their way to the cerebral cortex. The internal surface is smooth and faces its fellow of the opposite side, with which it is connected by the middle commissure; it forms the lateral wall of the third ventricle.

The optic thalami are said to give rise to the motor tracts concerned with instinctive movements, such as those of an emotional

THE NERVOUS SYSTEM

nature. The thalami act also as a relay station for the various tracts which convey sensations of pain, touch, and temperature from the body. It transmits and receives impulses from the cerebral cortex.

The *anterior extremity* of either optic thalamus is marked by a prominence called the *anterior tubercle*, which enters into the body of the lateral ventricle; the *posterior extremities* diverge outwardly



from each other and each presents a well marked enlargement, called the *posterior tubercle* or the *pulvinar* (cushion).

Below and external to the posterior extremity, or pulvinar, are four eminences of gray matter, called the **corpora geniculata internum** and **externum**, according to their position. The **external geniculate body** is the larger unit of the pair in which the optic tract commences, and is connected internally with the upper quadrigeminal body by a white band called the *anterior* or *superior brachium*; the **internal geni-**

THE NERVOUS SYSTEM

culate body, a small oval mass, is merely a tubercle inserted into the bend formed by the external geniculate body, and is attached to the lower quadrigeminal body by a similar white band, the *inferior* or *posterior brachium*.

The **posterior commissure** of the third ventricle is a cord-like band of white fibres, which is situated at the back part of the third ventricle, into the posterior boundary of which it enters. It overlies the superior part of the aqueduct of Sylvius. This commissure connects the optic thalami posteriorly, and the fibres of the one side decussate with the fibres of the opposite side and terminate in a club-shaped mass of gray cells, called the *ganglion habenulae*. This ganglion is placed in a small triangular space, the *trigonum habenulae*, situated in front of the upper quadrigeminal body, on the anterior surface of the optic thalamus.

The pineal body or epiphysis cerebri, described with the ductless glands, is situated at the back part, and hangs from the roof, of the third ventricle, behind and above the posterior commissure. It occupies a depression between the two superior quadrigeminal bodies and is attached by a *peduncle* or *stalk* (*habenula conarii*) of white matter extending from the pineal recess, which is a hollow or depression in the pineal gland.

THE MESENCEPHALON

The **mesencephalon** is the **midbrain**. It is the constricted portion of the brain, about three-quarters of an inch in length, between the proencephalon or the forebrain, in front and the rhombencephalon or hindbrain, behind. It is called the **isthmus cerebri**, and serves to connect the pons Varolii with the interbrain and with the cerebral hemispheres.

The mesencephalon, in early fetal development, is one of the primary cerebral vesicles and from it are formed the **crura cerebri** below, and the corpora quadrigemina above, its cavity remaining as the aqueduct of Sylvius. The direction of the interbrain is downward and backward. In front and above, it is continuous with the inter-brain and below with the pons. Its two surfaces, dorsal and ventral, are free but concealed, for the greater part of the midbrain is hidden by the cerebral hemispheres. The ventral surface is brought to view by drawing aside the temporal lobes of the hemispheres, and here are seen two white bands of white matter, the **crura cerebri**, which emerge from the pons and, as they pass forward and outward, diverge and enter the inner and under part of each hemisphere. The corpora quadrigemina are seen on the dorsal surface when exposed. The two surfaces of the midbrain meet on the side, being separated by a deep furrow, which runs forward and upward.

The **crura cerebri**, **pedunculi cerebri** or **cerebral peduncles**, form the ventral portion of the mesencephalon. They are two in number, a right and a left crus cerebri, and they appear as two large rope-like strands of white matter, which emerge from the cerebral hemispheres and enter the pons Varolii. At the place where the crus enters the cerebral hemisphere it is embraced externally by the optic tract.

Each crus is composed of two parts—the *dorsal* and *ventral*. The *dorsal portion*, called the *tegmentum*, is prolonged upwards into the region of the optic thalamus and consists of ascending fibres; while the *ventral portion* of the crus is known as the *crusta* or *pes* or *basis pedunculi*, and is composed mostly of descending fibres. These two parts are separated from each other by a mass of gray matter, called the *substantia nigra*, the separation being indicated on either side by a groove, called the *lateral sulcus*.

The *tegmentum* passes from the thalamic region into the cerebral cortex and the *crusta* becomes continuous with the internal capsule, being the fibres which descend from the cerebral cortex.

The *tegmentum* is, as stated, the dorsal portion of the crus cerebri, and consists of longitudinal fibres, intersected by curved and transverse fibres, with gray matter in the intervening spaces. This arrangement is prolonged upward and forms a reticulated membrane called the *formatio reticularis*, similar to the same named structure in the pons and in the medulla, with which it is continuous.

In some parts of the *tegmentum* the fibres are arranged in bundles or tracts and are grouped as follows:—*superior cerebellar peduncle*, *posterior longitudinal bundle*, and the *fillets*, the *lateral* and the *middle fillet*.

The *superior cerebellar peduncle* consists of fibres which lie on either side of the middle line of the *tegmentum*, and which, as they pass thru it, cross to the opposite side. Here each bundle comes in contact with a collection of gray matter, which has a reddish color and is known as the red *nucleus*, or the nucleus of the *tegmentum* or *nucleus ruber*. The superior cerebellar peduncle of one side, therefore, connects the cerebellar hemisphere of that side with the cerebral cortex of the opposite side, the red nucleus and the optic thalamus being interposed in the course of most of its fibres.

The *posterior longitudinal bundle*, or *Meynert's fasciculus*, is composed of large nerve fibres. It lies on either side and close to the median line, on the dorsal aspect of the *tegmentum*, just below the aqueduct of Sylvius. These fibres are prolonged upwards from the columns of the cord, they pass thru the side of the medulla, enter the pons and, from there, pass into the *tegmentum*; from there they are prolonged upwards thru the entire length of the midbrain. The fibres of this bundle receive fibres from the superior quadrigeminal body of the opposite side, decussating with those of the opposite side to form the *commissure of Meynert*.

The *fillets* are two tracts, also called **lemnisci**, and named the *lateral fillet* and the *medial fillet*. They are tape-like, white bands found on the outer side of the superior cerebellar peduncles; they begin in the spinal cord and pass between the two olivary bodies, extending thru the *tegmentum* of the crus and the middle of the pons. The *lateral fillet* consists of fibres which are prolonged from the pons upward to the midbrain, where the upper fibres pass to the dorsal portion of the *tegmentum*, to the upper quadrigeminal body, and to the occipital portion of the cerebrum; the lower fibres pass to the ventral part of the *tegmentum* and to the lower quadrigeminal body. The *middle* or *mesial fillet* is that portion of the fillet that passes from the pons up-

ward, where it enters the tegmentum; its fibres pass thru the optic thalamus, and terminate in the cerebral cortex.

The *crusta*, or *pes*, is the ventral portion of the crus cerebri, and it is separated from the tegmentum, the dorsal portion of the crus, by a mass of gray matter, called the *substantia nigra*. Each crusta consists of longitudinal bundles of white matter and is continuous with the internal capsules of each corpus striatum, from where it extends to the cerebral cortex. Some authors group the fibres of the crusta as two sets—the *pyramidal* and *cortico-pontine*, with the latter arranged in two strands, the *fronto-pontine* and the *temporo-pontine*. The *fronto-pontine* strand arises from fibres of the cortex of the frontal lobe, and the *temporo-pontine* strand contains fibres from the cortex of the temporal lobe. Both strands, with the pyramidal fibres, which traverse the internal capsule, occupy the inner part of the crusta.

The *substantia nigra* is a deeply pigmented mass of gray matter crescentic or semilunar in transverse section, which separates the tegmentum, the dorsal portion of the crus cerebri, from the crusta or pes, the ventral portion of the crus cerebri.

The **corpora quadrigemina (colliculi)** are four rounded eminences which form the dorsal portion of the mesencephalon. They are placed two in front and two behind, separated from each other by a transverse groove, called the *crucial depression* or *groove*. They are situated beneath the splenium of the corpus callosum, behind the third ventricle and posterior commissure, and are composed of white matter externally and gray matter within. They were formerly called the optic and auditory lobes, for it was that they gave origin to the optic and auditory nerves. They are relatively small in man, altho their size in most animals bears relation to the power of sight. In birds there is only one pair of the quadrigeminal bodies, and in early fetal life there is one pair also. They are oval in form. The anterior or upper pair (*colliculi superiores*), sometimes called the *nates*, are the larger and are of a darker gray color than are the posterior pair. The latter are known as the lower pair (*colliculi inferiores*) and are called the *testes*. From the outer side of each of these bodies a white band, called the *brachium*, extends forward and outward. Each *superior* or *anterior brachium* extends, from the anterior or upper quadrigeminal body, outward and backward to the external geniculate bodies and optic thalamus. The *inferior* or *posterior brachium* passes upward from the posterior or lower quadrigeminal body to the internal geniculate bodies.

The **upper quadrigeminal bodies** consist of four layers, namely: the *stratum zonale*, a thin layer of white matter placed superficially, the fibres being fine and arranged longitudinally; the *stratum cinereum*, a layer of gray matter, semilunar in shape and thick at the centre and embedded in a network of fine nerve fibres; *stratum opticum*, gray matter having nerve fibres in between; and the *stratum lemnisci*, a deep layer of gray matter which is derived from the fillet, and, like the stratum opticum, is composed of fibres intersecting the gray.

The **lower or posterior quadrigeminal body** of each side is composed of a central nucleus of gray matter, which is almost completely surrounded by white fibres. Because the fibres are connected with

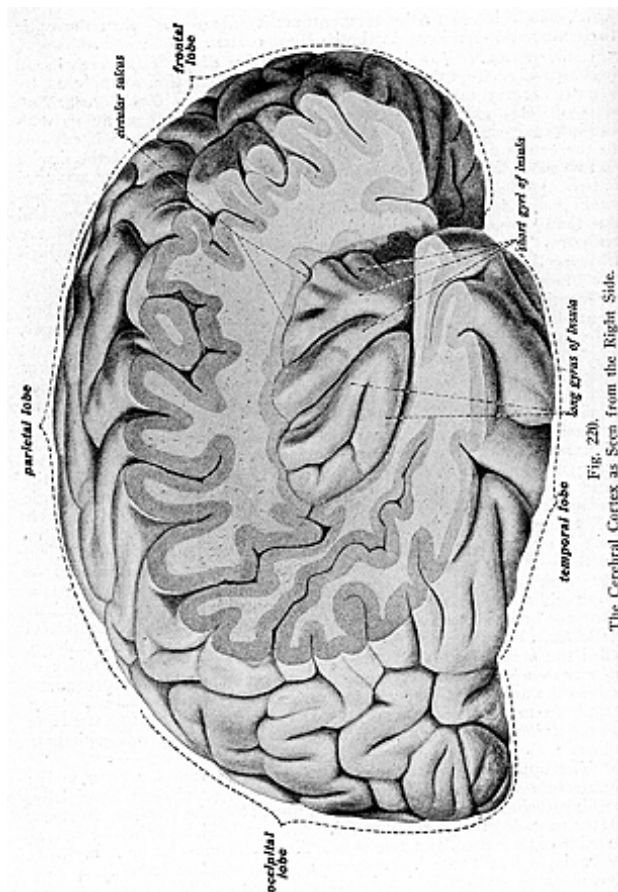


Fig. 220
The Cerebral Cortex as Seen from the Right Side.

the auditory tract, the lower quadrigeminal body is regarded as associated with the auditory apparatus.

The **aqueduct of Sylvius** or **Iter a Tertio ad Quartum Ventriculum**, is a narrow passage about half an inch in length, which leads

THE NERVOUS SYSTEM

thru the mesencephalon from the third to the fourth ventricle. It is lined by columnar ciliated epithelium and is surrounded by a layer of gray matter, called the gray matter of the aqueduct. This is continuous, superiorly, with the gray matter of the floor and lateral walls of the third ventricle and inferiorly with that which covers the floor of the fourth ventricle. The aqueduct of Sylvius is the persistent remains of the cavity of the mesencephalon.

GENERAL STRUCTURE OF THE CEREBRAL HEMISPHERES

The **cerebrum** consists of *gray* and *white matter*, the **gray matter** forming a continuous covering for the entire hemisphere, dipping into the sulci or fissures, so as to cover the opposed surfaces of the gyri or convolutions, as well as the bottom of the sulci. It is thicker over the superficial surfaces of the gyri than at the bottom of the sulci, and attains its greatest thickness (1/6 inch) over the central lobe, while it is thinnest (1/10 inch) over the occipital lobe.

The **cortex** is composed of nerve cells embedded in a matrix of neuroglia, and leading from the cells are nerve fibres, which are arranged in two groups—the *vertical* or *radial* and the *tangential* or *horizontal*. The nerve cells vary in shape and size, and are arranged in four layers which are as follows, from without inwards: the *molecular layer*, the *pyramidal layer*, first the small cells and then the large cells, and the layer of *polymorphous* cells.

The *molecular layer* (*stratum zonale*), the most superficial, is composed of fibres arranged transversely and its cells are triangular or fusiform in shape. The cells contain numerous dendrites, their long axes parallel with the surface.

The *pyramidal layers* represent the next two layers and are composed of pyramidal cells, which contain granular pigment, and they constitute the chief part of the cerebral cortex. The layer of small pyramidal cells is narrow, but the large pyramidal cells are often of considerable thickness; both types of cells having long dendrites. There is no mark of distinction between these two layers.

The *polymorphous layer* is the deepest layer. The cells of this layer are very irregular and their dendrites become a part of the white matter within. In addition to the above named cells, two other kinds of cells are met with in the cerebral cortex, namely; the *cells of Golgi*, nerve cells with very short processes, which are also seen in the posterior horns of the spinal cord; and the *cells of Martinotti*, whose axis-cylinders pass towards the surface and enter the molecular layer of the cortex, where they form, with the cells of that layer, an extensive arborization.

The nerve-fibres of the cortex, as stated, are arranged in radiating and horizontal bands. The *radial* or *vertical bands* issue from the medullary substance within, traverse the polymorphous and pyramidal layers, and terminate in the cerebral cortex; while the *horizontal* or *tangential fibres* form several strata, known as the *superficial tangential fibres*, which occupy the superficial part of the molecular layer; the *band of Bechterew*, a layer of fibres which is situated between the stripes of Baillarger and the horizontal fibres; the *band of Baillarger*, which is a layer of the cerebral cortex, made up of short, delicate

THE NERVOUS SYSTEM

fibres parallel to the surface, may be seen by the naked eye in the region around the calcarine fissure, where it is known as the bundle of Vicq d' Azyr; the *terminal fibres* of the anterior pillars of the fornix after they form the corpora albicantia, the two white bodies at the base of the brain; and the *deep tangential fibres*, which are situated in the deep part of the horizontal layer.

The **white matter** of the **cerebrum**, or the **medullary centre**, consists of nerve fibres arranged in bundles, with neuroglia between them. The fibres pursue different courses, and are arranged in three groups, namely: the *projection fibres*, the *commissural fibres*, and the *association fibres*.

The **projection** or **peduncular fibres** are the longitudinal fibres which connect the hemispheres with the pons, medulla and cerebellum. They are composed of both afferent and efferent fibres, and form the crura cerebri or cerebral peduncles.

The **commissural fibres** are disposed transversely, and serve to connect the gray matter of one hemisphere with that of the other. They constitute the corpus callosum, the lyra, and the anterior and posterior commissures of the fornix.

The **association fibres** serve to connect different parts of the cortex of the same hemisphere. They not only unite adjacent convolutions, but pass between more distant parts in the same hemisphere and therefore they are known as the *long* and *short association fibres*.

The *long association fibres* pass between portions of the gray cortex, which are some distance from each other. They are arranged in bundles, as follows:—the *superior longitudinal fasciculus*, which extends from the frontal to the occipital lobe; the *inferior longitudinal fasciculus*, connecting the occipital and temporal lobes, its fibres being disposed upon the outer walls of the posterior and descending cornua of the lateral ventricle; the *perpendicular fasciculus*, connecting the inferior parietal gyrus with the occipito-temporal gyrus, the *uncinate fasciculus*, connecting the frontal and temporal lobes; the *cingulum*, connected with the limbic lobe and its fibres connecting the gyri of the limbic lobe with the cerebral cortex; and the *occipito-frontal fasciculus*, connecting the frontal with the occipital and temporal lobes.

The *short association fibres* pass between contiguous gyri, extending in their course across the bottom of the sulci.

THE FUNCTION OF THE CEREBRUM

The **cerebrum** is the only part of the brain, in man, where the afferent impulses react in consciousness or are interpreted by the innate mind. It contains the centres where afferent impulses of the peripheral end-organs are received to give rise to mental impressions. It also contains the centres from which impulses proceed, by means of the power of the will, to various portions of the body and thus control the movements, which are the expressions of desires of the mental state; they being the centres of motion, sense, hearing, sight, smell and taste, and the seat of consciousness, intellect, judgment and ideation. All physical and moral actions have their perceptive centres somewhere in the cortical substance of the cerebrum. An animal may

THE NERVOUS SYSTEM

live after the removal of a portion of its cerebral hemispheres, but it will be insensible to peripheral disturbance and incapable of exercising volition.

THE RHOMBENCEPHALON

The **rhombencephalon** is the **hindbrain**. It comprises the **cerebellum**, **pons Varolii**, and the **medulla oblongata**. The cerebellum, the pons Varolii, and the upper half of the fourth ventricle comprise the *metencephalon*, that part of the rhombencephalon which is developed from the fourth cerebral vesicle, while the lower part of the fourth ventricle and the medulla oblongata form the *myelencephalon*, that part derived from the fifth cerebral vesicle. The fourth ventricle is formed from both the metencephalon and myelencephalon.

THE CEREBELLUM

(Illustrations Nos. 221, 222 and 223.)

The **cerebellum** or little brain occupies the inferior occipital fossae of the skull. It lies beneath the posterior parts of the hemispheres beneath the occipital lobes of the cerebrum, from which it is separated by a fold of the dura mater, called the *tentorium cerebelli*. It is posterior to the medulla oblongata and to the pons Varolii.

It consists of white and gray matter, the white matter being situated in the interior, where it constitutes the *medullary substance*, the gray matter being spread over the surface as the *cortex*. The *cortical substance* of the cerebellum is darker in color than that of the cerebrum and it is arranged in parallel curved folds, with intervening fissures, which gives it a laminated or foliated appearance. The fissures vary in depth and subdivide the surface into lobules.

The cerebellum is oblong and flattened from above downward the greatest diameter being from side to side. It measures 3-1/2 to 4 inches transversely, 2 to 2-1/2 inches from before backward, and about 2 inches in thickness; it weighs 5 ounces. The cerebellum is composed of two large lateral portions and a middle portion, called the **vermiform process**, or **worm** or **central lobe** or **vermis**. All these are of the same structure and are continuous with each other.

The two hemispheres present a large and deep fissure, the **horizontal** or **transverse fissure**. It passes, from the front of the pons horizontally round the free margin of the hemisphere to the middle line behind. It separates the hemispheres of the cerebellum into an upper and a lower portion. The space between the two hemispheres, below, is called the *vallecula* or *valley*. In front, in the median line, is a notch, the anterior *cerebellar notch* (*incisura cerebelli anterior* or *semilunaris*), which is wide and separates the two hemispheres, it contains the lower pair of the quadrigeminal bodies and the superior peduncles. On the posterior surface, in the median line, is the *posterior cerebellar notch* (*incisura marsupialis*), which is deep and narrow, and separates the cerebellar hemispheres behind. The internal occipital protuberance projects into the notch, which also contains the falx cerebelli.

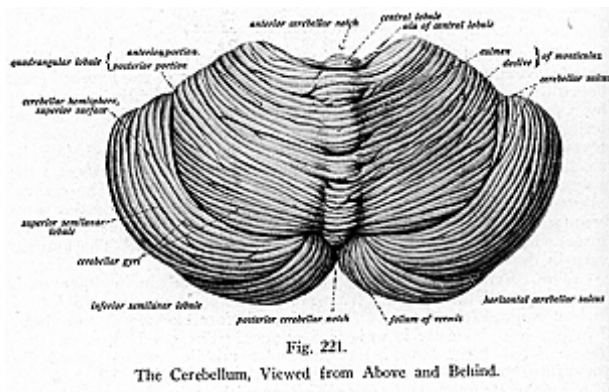
The superior surface of the hemispheres of the cerebellum pre-

THE NERVOUS SYSTEM

sents four fissures, which are named from their position in relation to the central lobe, or worm. These **fissures** are the **pre-central, post-central, pre-clival** and **post-clival**; they divide the upper surface of the cerebellum into five **lobes**, namely: the **frenulum, ala lobuli centralis, anterior crescentic lobe, posterior crescentic lobe** and **posterior superior lobe**. The latter three lobes are also called the **semilunar lobes**.

The lobes of each hemisphere are continuous with the subdivisions of the superior vermis, with the exception of the **lingula**. This lobe is deeply placed and consists of three or four folia, tongue-shaped, with small ridges extending into it from the superior cerebellar peduncles. The lamellae or folia may be continued on either side over the peduncle and when this is the case, the prolongation is known as the **frenulum**, seen upon the superior surface of the cerebellar hemisphere.

The **ala lobuli centralis** is a continuation of the lamellae which

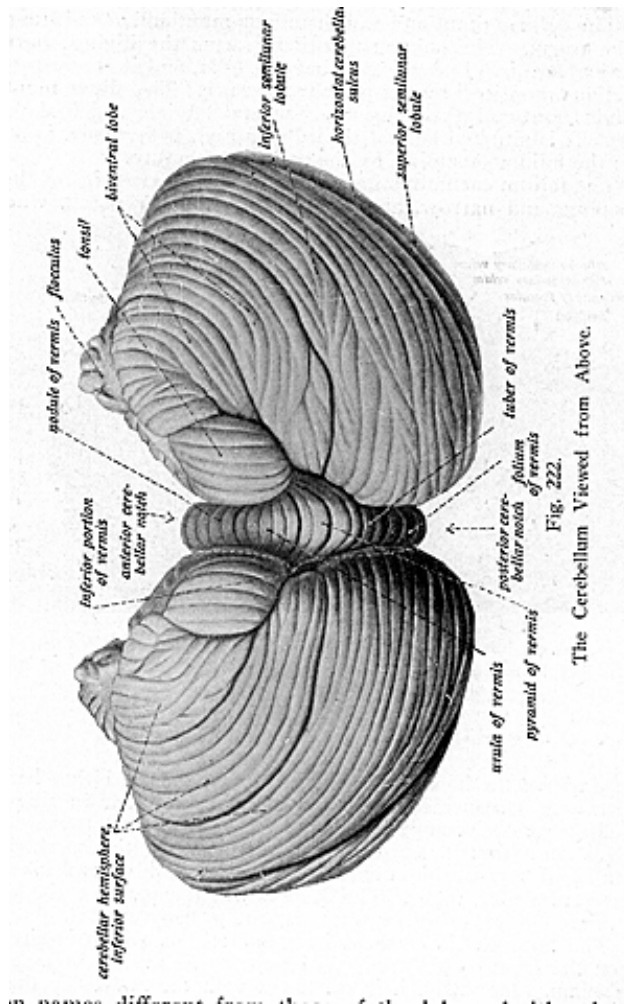


form the central lobe or lobulus centralis, from which it is prolonged for a limited distance round the anterior part of the hemisphere, in the region of the anterior notch. The **anterior crescentic lobe** is continuous with the culmen monticuli; the **posterior crescentic lobe** is continuous with the clivus monticuli, and is separated from the anterior crescentic lobe by the pre-clival fissure. These two lobes constitute the greater part of the superior surface of the lateral hemispheres. The **posterior superior lobe** corresponds to the folium cacuminis, but is more extensive than the latter.

The **superior surface of the worm** or **middle lobe** is expanded and is called the superior vermis. This extends from the anterior notch to the posterior notch, where it forms a laminated elevation which is higher in front than behind; the projecting prominent part is known as the **monticulus cerebelli**. The folia on the surface of the superior

THE NERVOUS SYSTEM

vermis are thicker than in the surface of the lateral hemispheres; it is from its appearance, being worm-like, that the central lobe has received its name. The five lobes on the superior surface of the worm



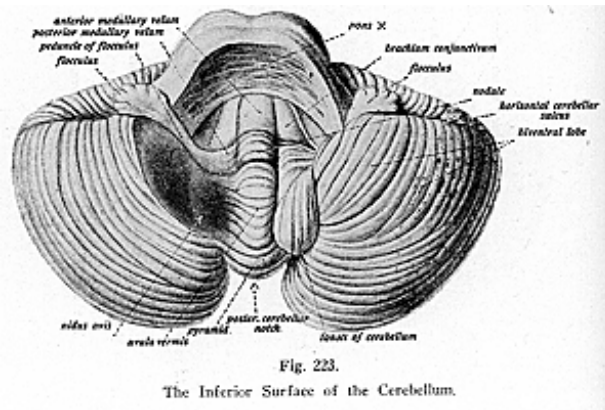
are given names different from those of the lobes of either lateral hemisphere. They are named, from before backward: the **lingula**, **lobulus centralis**, **culmen monticuli**, **clivus monticuli** and the **folium cacuminis**.

THE NERVOUS SYSTEM

The **lobulus centralis** or **central lobe** is small in size, quadrilateral in shape, and lies at the bottom of the anterior notch; it is separated from the lingula, previously described, by the **pre-central fissure** and from the culmen monticuli by the post-central fissure.

The **culmen monticuli** and the **clivus monticuli** constitute the bulk of the worm. The **culmen monticuli** forms the highest part of the superior vermis. It consists of several folia, and it is separated from the clivus monticuli by the **pre-clival fissure**. The **clivus monticuli** or **declivis monticuli** also consists of several laminae which slope downward. It is situated behind the culmen and, posteriorly, is separated from the folium cacuminis by the **post-clival fissure**.

The **folium cacuminis** forms the posterior extremity of the worm. It is long and narrow, and lies at the posterior notch, where it is



placed above the horizontal fissure. It expands in either hemisphere into a lobe of considerable size, which is semilunar in shape and is called the **posterior superior lobe**.

The **inferior surface of the hemispheres** of the cerebellum presents the **flocculus**, the **amygdala** or **tonsil**, the **biventral lobe** and the **posterior inferior lobule**. The **fissures** which separate these lobes are: the **post-nodular**, **pre-pyramidal** and the **post-pyramidal**.

The **flocculus** is a small, irregular lobule, which is situated between the front of the biventral lobe and the middle peduncle of the cerebellum. Internally, it is connected with the nodule by the *inferior medullary velum*.

The **amygdala** or **tonsil** is a round mass, seen between the uvula and the biventral lobule. It is separated from the flocculus by the **post-nodular fissure** and from the biventral lobe by the **post-pyramidal**

THE NERVOUS SYSTEM

fissure. It is situated between these two lobes in a depression which is called the *nidus avis* (*bird's nest*).

The **biventral lobe** consists of several curved folds, triangular in shape and divided by a sulcus into two portions, an outer and inner; hence the term biventral. This lobe has the *slender* or *gracile lobe*, a part of the posterior-inferior lobe, to its outer side; and the amygdala on its inner side.

The **posterior-inferior lobe**, or **lobule**, is situated at the back part of the under surface of the hemisphere. It is divided into the *slender* or *lobulus gracilis* and the *inferior semilunar lobe* by the *post-gracile fissure*, which is a prolongation forward and outward from the post-pyramidal fissure.

The **inferior surface of the worm** known as the **inferior vermis**, presents from before backward the following: the **nodule**, **uvula**, **pyramid** and **tuber valvulae**.

The **nodule** forms the anterior part of the inferior vermis and consists of several folia which are partly concealed by the uvula. It forms a part of the roof of the fourth ventricle and can only be seen after the structures of the fourth ventricle have been separated, that is, the cerebellum from the pons and medulla. The nodule is connected on either side with the flocculus of either hemisphere, by a thin band of white matter called the *inferior* or *posterior medullary velum*. The nodule is separated from the uvula by the **post-nodular** fissure.

The **uvula** is triangular, the base directed backward, and consists of several laminae in front of the pyramid and between the amygdalae or tonsils of the hemispheres. It is separated from the hemisphere on either side by a deep groove, the *sulcus valleculae*. A ridge of gray matter, notched at intervals and called the *furrowed band*, lies at the bottom of the sulcus and, as it crosses, it connects the uvula to the amygdala on either side. The uvula is separated from the pyramid by the **pre-pyramidal fissure**.

The **pyramid** is cone-shaped, consisting of several folia and forms the largest part or the prominence of the worm on the lower surface. It is situated in front of the tuber valvulae and is separated from that lobe by the **post-pyramidal fissure**, and separated from the cerebellar hemisphere by the sulcus valleculae. Laterally it is connected with the biventral lobe of each hemisphere by a band of gray matter, similar to the furrowed band just described.

The **tuber valvulae** (**tuber posticum** or **tuber vermis**) is of small size and forms the posterior part of the inferior vermis. It consists of several folia prolonged into the corresponding hemisphere, into the posterior-inferior lobule, with which it becomes continuous.

THE WHITE AND GRAY MATTER OF THE CEREBELLUM

The **white matter of the cerebellum** forms a solid mass, situated in the centre, and is known as the medulla. The gray matter is found in two situations; it is spread over the white matter, disposed superficially on the surface, where it is known as the **cortex**; and it also forms the collection of gray matter in the interior.

If a sagittal section of one of the hemispheres is made, it will be seen to consist of a mass of white matter in the center, forming a core,

which seems to send off-shoots into the lobules, and, embedded in its midst, a mass of gray matter called the *corpus dentatum*. When a cross section is made of the hemisphere, the white mass appears to have radiating branches, upon which the gray cortical substance is infolded; this gives the appearance of the trunk and branches of a tree, and receives the name of the *arbor vitae* (*tree of life*). The white matter of the cerebellum consists of the projection fibres, forming the **superior, middle and inferior peduncles** or **crura**, and the **fibres proper** of the cerebellum.

The **superior peduncles**, or **brachia conjunctiva**, leave the hemispheres, first passing upward, on the lateral aspect of the dorsal surface of the pons, in a converging manner toward the corpora quadrigemina, where they form the sides of the upper part of the floor of the fourth ventricle. At the same time they extend upward and, by their convergence, project over the floor of the ventricle and so take part in the formation of the roof of that cavity.

The two superior peduncles have an interval between them, which is, however, closed by a thin transparent layer of white matter, called the *superior medullary velum* or *valve of Vieussens*. The velum, like the inferior medullary velum, forms a thin layer of tissue and is seen in the roof of the fourth ventricle. On entering the inferior quadrigeminal bodies, the superior peduncles pass beneath them and enter the mesencephalon.

The **middle peduncles**, or **brachia pontis**, are of large size. They consist of a mass of bundles of fibres, which are made up of both afferent and efferent fibres, extending from between the two hemispheres to the pons Varolii.

The **inferior peduncles** connect the cerebellum with the medulla and form the restiform bodies of the medulla oblongata. Each inferior peduncle, after leaving the medulla as the restiform body, lies for a short distance on the dorsal aspect of the pons Varolii and thereafter enters the corresponding hemisphere of the cerebellum.

The **fibres proper** consist of *commissural* and *association* or *arcuate* fibres. The former fibres cross the middle line to connect the opposite halves of the cerebellum, while the latter fibres connect adjacent laminae with each other.

The **gray matter** of the cerebellum, as stated, is found in the cortex and in the interior, there forming the nuclei of the cerebellum. These consist of four paired nuclei, situated opposite each other on either side of the mid-line. These include the *dentate nucleus*, the *nucleus emboliformis*, *nucleus globosus*, and the *roof nucleus* (*nucleus fastigii*). The *dentate nucleus* is a collection of gray matter, situated within the white matter of each hemisphere; it is similar to the olivary nucleus in the medulla. The *nucleus emboliformis* is a small mass of gray matter between the dentate nucleus and nucleus fastigii; the nucleus fastigii lies in the white substance of the worm close to the midline, the *nucleus globosus*, a flat mass of gray matter, lies in the cerebellar hemisphere, close to the median line, internal to the nucleus emboliformis and the nucleus fastigii. The latter helps in the formation of the roof of the fourth ventricle.

The **gray matter of the cortex** is composed of two layers, an outer

THE NERVOUS SYSTEM

molecular layer, which consists of numerous cells and small branching nerve fibres; and an inner granular layer; made up of granule nerve-cells and fibres, and, because the granule-cells give to this layer a reddish-brown color, it sometimes receives the name of the rust-colored layer. In between the outer and inner layers is an incomplete stratum of large, branched cells, called the *cells* or *corpuscles of Purkinje*. **These cells** project into the outer layer, but rest upon the inner layers as a basement membrane.

The **function of the cerebellum** has been determined by physiological observations to be the co-ordination of muscular contraction, for the purpose of maintaining equilibrium of the body. Many authorities claim it is an auxiliary organ and not essential for life. When the cerebellum is operative, it is said to relieve the mind of any special attention to the matter of equilibrium, its absence or failure to act imposes upon the mind a duty of which it is continually conscious, in order to maintain equilibrium. Persons must then pay attention to the muscles or stagger about. An animal can do without the cerebellum, as has been demonstrated. Immediately after removal, the subject is unable to move about but, after strenuous effort, is able to do so. The cerebellum appears to be the centre for the regulation of the output of motor impulses, and causes the contraction of proper sets of muscles, at a certain time and to a proper degree. I have heard it stated by physicians that the larger or better developed the cerebellum is in the individual, the better the chance for life. Prognosis of a case is often based upon the degree of development of the base of the brain, since persons having a highly developed cerebellum seem to recover quickly and are not so often sick. It is stated that children with an abnormally large cerebrum are delicate, never as robust as when the two parts of the brain are well balanced, or when the cerebellum is above par. And, thus, observation has taught US that the cerebellum is in truth the *tree of life*.

THE PONS VAROLII

(Illustrations Nos. 215, 216 and 217.)

The **pons Varolii** (bridge of Varolius, named from Constantio Varolius of Bologna) is a band of fibres, situated above the medulla oblongata and between the hemispheres of the cerebellum. The pons with the cerebellum forms that part of the hindbrain or rhombencephalon which forms the **metencephalon**. It rests upon the clivus of the sphenoid, that plate of bone found between the basilar process of the occipital bone and the dorsum sellae of the sphenoid. It is 1 inch long, 1 inch thick, and 1-1/2 inches wide. It is the organ of conduction, which joins with the cerebrum above, by the crura cerebri; with the cerebellum behind, by the peduncles, and with the medulla below, by the fibres direct from that organ.

The pons **presents four surfaces**: a *ventral* or *anterior*, a *dorsal* or *posterior*, a *superior*, and an *inferior surface*. The *ventral surface* rests upon the upper border of the clivus of the sphenoid. It is convex from side to side and from above downward, and has a transversely striated appearance, due to the disposition of its fibres. It presents a shallow groove, in its middle line, which lodges the basilar artery.

THE NERVOUS SYSTEM

The *dorsal surface* is directed toward the cerebellum. It is covered with ependyma; it forms the upper part of the floor of the fourth ventricle; and is covered by gray matter, which is continuous with the gray matter of the medulla. The *superior surface* is arched, being higher at its centre than on its sides, and the crura are seen emerging from it. The *inferior surface* is straight, and here are seen the 6th, 7th and 8th cranial nerves.

Internally the pons is composed of a **ventral**, or **basilar portion**, and a **dorsal portion**. The **ventral part** is the larger part and consists of bundles of transverse and longitudinal fibres, with gray matter interspersed between. The **dorsal portion**, called the **segmental portion**, consists of two symmetrical halves, divided by a median line; these halves may be regarded as an upward continuation of the pyramids from the medulla oblongata.

A section of the **ventral** or **basilar portion** of the pons will show that it is mainly composed of white transverse fibres, crossed by longitudinal fibres which form a solid compact mass consisting of two large bundles, one on either side, representing the middle peduncle of the cerebellum; the transverse fibres connect the pons to the cerebellum. The longitudinal fibres pass from the medulla below, where they are seen in the pyramids, to the cerebrum above. They produce the prominences on each side of the pons and are continued upward where they are collected into bundles and there form the crura cerebri. These fibres are arranged in layers, having gray matter variously disposed among them, especially in that part of the pons which assists in forming the fourth ventricle and where many of the cranial nerves are seen to pass from its sides. The **segmental** or **dorsal portion**, as stated, consists principally of a prolongation of the reticular membrane of the medulla oblongata. Inferiorly are numerous transverse fibres, which extend thru the central portion of the pons and form a path for some of the nerves. For the reason that these fibres form an irregular four-sided body, it receives the name of *corpus trapezoides*. The gray matter on the segmental portion of the pons consists of numerous isolated nuclei, which consist of smaller masses of gray matter, and, lying close to the nuclei, are seen the superficial points of origin of the cranial nerves.

The pons is a bridge of nerve fibres, which cross from the medulla below, to the cerebrum above, and to the cerebellum behind.

THE MEDULLA OBLONGATA

(Illustrations Nos. 215, 216, 217, 229 and 230.)

The **medulla oblongata** (oblong marrow), called the **bulb** or **intracranial spinal cord**, is that part of the hindbrain or rhombencephalon which forms the **myelencephalon**. It is called the bulb, for it represents the upward continuation of the spinal cord; it extends from the lower margin of the foramen magnum to the lower border of the pons. It is the lowest part of the brain and its ventral surface rests on the basilar groove of the occipital bone; its dorsal surface is received into a fossa between the cerebellar hemispheres, its direction being upward and forward. The medulla is 1 inch in length, 3/4 of an inch in

THE NERVOUS SYSTEM

breadth, and 1/2 inch in thickness. With the pons, it weighs less than an ounce. It is pyramidal in form, being wider above than below, where it corresponds to the spinal cord.

The medulla oblongata consists of white and gray matter. The outer part consists of white and gray matter, the former being arranged on the outer part in long, slender bundles, while the gray matter is found in the interior. But, unlike that of the spinal cord where it is arranged in a solid compact form, the gray matter of the medulla is scattered thruout its entire substance and is found in small masses, constituting nuclei. The white matter of the medulla is formed of tracts or bundles, known as the **funiculus gracilis**, the **funiculus cuneatus**, and the **restiform bodies**; all of these being associated with the spinal cord. The gray matter consists of a network of interlacing fibres, containing nerve-cells and being traversed by white nerve fibres; this network is called the *formatio reticularis*. Gray matter lies in a thick layer around the central canal in the closed part of the medulla, and on the floor of the fourth ventricle in the open part also in the nucleus gracilis and nucleus cuneatus, the olivary nuclei and in the arcuate nucleus.

The decussation of the pyramids, and the divergence of the lateral tracts of the medulla, cause a change in the arrangement of the gray matter in the upper part of the medulla, from the characteristic disposition of the gray matter of the spinal cord. The anterior horns of the cord become separated from the mass of gray matter, owing to the decussation of the fibres from the lateral tracts, and, behind the olivary bodies, form the lateral nuclei. The rest of the gray matter of the anterior horns in this locality is broken up into the interlacement of fibres, the *formatio reticularis*, which is situated behind the pyramid of the olivary body.

The medulla consists of two symmetrical halves and its surface is marked, in the middle line, in front and behind, by an *anterior* and a *posterior median fissure*. These are continuous with the anterior and posterior fissures of the spinal cord. The *anterior median fissure* extends as high as the lower border of the pons, where it ends in a blind recess or cul-de-sac, called the *foramen caecum*. The *posterior median fissure* extends only over the lower part of the medulla, and expands into the floor of the fourth ventricle, at a level with the lower part of the medulla, called the *calamus scriptorius* (writer's pen). The lower half of the medulla contains a prolongation of the central canal of the cord which opens, at the *calamus scriptorius*, into the lower part of the fourth ventricle. This part of the ventricle becomes known as the closed part, while the upper half of the medulla is known as the open part.

The medulla oblongata is made up of three columns, like those of the cord; the **anterior**, the **posterior**, and the **lateral columns**.

The **anterior columns** of the cord become continuous with the anterior columns of each lateral half of the medulla, where each forms a pyramid. The **posterior column** becomes the posterior part of the pyramid, or the restiform body of the medulla; the lateral column of the cord is the lateral tract or **lateral column** of the medulla. **Therefore**, each half of the medulla oblongata consists of four longitudinal

masses, namely, the **pyramids**, the **lateral columns** or **tracts**, **olivary bodies**, and the **restiform bodies**.

The **pyramids** are two pyramidal bundles of white matter placed one on either side of the anterior fissure and separated from the olivary body by a sulcus. The two pyramids, a right and a left, consist of fibres which are continued upward from the spinal cord, and each pyramid is divided inferiorly into two parts, a small external part and an internal part of large size. The external part is composed of fibres which constitute the direct pyramidal tract of the anterior column of the spinal cord, and these are continued directly upward thru the pons to the cerebrum. The internal portion is made up of fibres continuous with the crossed pyramidal tract of the lateral column of the cord.

These fibres, in the medulla, cross to the opposite side, the intercrossing taking place in the lower part of the anterior fissure of the medulla, at the upper border of the atlas, just at the entrance into the skull. This intercrossing is called the *decussation of the pyramids*, and usually involves three-fourths of the fibres of the medulla.

Each pyramid enters the pons and is traced, thru its substance, to the point where they form the fibres of the *crura cerebri*. The *crura* serve to bring into relation the pons and the cerebrum.

The **lateral columns** form the sides of the medulla, and are continuations of the fibres direct from the lateral columns of the spinal cord. At the lower part of the medulla, each lateral column forms a single slender bundle and is called there the *lateral tract*. Superiorly each lateral column presents an oval enlargement, called the **olivary body** or eminence, which is separated from the pons by a deep transverse groove.

The **olivary bodies**, therefore, are two prominent oval masses each being 1/2 inch long and about 1/5 inch thick, situated on the outer side of the pyramids. Each olive is separated from the pyramids by a groove, the *sulcus lateralis anterior*, out of which ten to twelve fine, flattened nerve filaments emerge and unite into two cords, forming the 12th cranial or hypoglossal nerve. Between the olivary body and the restiform body is the *sulcus lateralis posterior*, in which a large number of nerve fibres can be seen, grouped into two sets, which form the 9th cranial or glosso-pharyngeal nerve, and the 10th cranial or vagus nerve.

The olivary body below is limited by a bundle of fibres, called the *superficial arcuate* or *arciform fibres*, which loop around it from the pyramid and enter the restiform body. The other portion of the lateral column of the medulla, aside from the tracts and olivary bodies, are the three tracts or groups of fibres called the *funiculus cuneatus* the *funiculus of Rolando*, and the *funiculus gracilis*.

The *funiculus cuneatus* is a collection of fibres on the outer side of the *funiculus gracilis*, continuous below with the tract of Burdach from the posterior column of the spinal cord; above, it is continuous with the restiform body. The *funiculus Rolando* forms a longitudinal prominence on the outer side of the lower part of the medulla. It blends with the cuneate funiculus and so is of ten called the *lateral cuneate funiculus*. The *funiculus gracilis* is the direct prolongation of

THE NERVOUS SYSTEM

the fibres of the tract of Goll. It is a narrow, white cord, placed along the posterior border of the restiform body, extending parallel to the posterior median fissure. When the funiculi reach the lower part of the medulla, at the level of the calamus scriptorius, each becomes enlarged. The enlargement formed by the funiculus gracilis is called the *clava* (stick), which becomes lost in the restiform body. A corresponding enlargement is formed by the funiculus cuneatus and this is called the *cuneate tubercle*. As the medulla opens out at the calamus scriptorius to form the lower part of the floor of the fourth ventricle the clavae diverge, and the central canal of the spinal cord appears in the angle between them.

Within the olivary body are collections of gray matter called the *olivary nuclei*, and beneath the funiculus gracilis and the funiculus cuneatus, as well as beneath the clava, there is in each case an elongated nucleus of gray matter. These collections of gray matter are called the *nucleus gracilis* and *nucleus cuneatus*, respectively.

The **restiform bodies** are seen on the upper and posterior part of the medulla. They are the largest prominences of the medulla and form the visible portion of the posterior column of the medulla. They are oblong in shape and whitish in appearance, they pass upward on either side of the fourth ventricle and enter the cerebellum forming its inferior peduncles.

The restiform bodies, with the funiculi gracilii and cuneatii, form the posterior part of the medulla and form part of the floor of the fourth ventricle. These structures with the opening-out of the posterior median fissure and the central canal of the spinal cord display in the floor of the fourth ventricle the gray matter of the medulla, which is continuous with the gray matter of the spinal cord.

The **arcuate** or **arciform fibres** are found in the upper part of the medulla and are arranged in two sets—the *superficial* and the *deep*. The *superficial arcuate fibres* or the external set, emerge from the anterior median fissure and cross the pyramid, then take a curved course around the olivary body and pass upwards into the restiform body. As they cross the olivary body they receive some of the internal or *deep arciform fibres*, which come to the surface on the inner side of the olivary body. Small, isolated masses of gray matter are located among the superficial arcuate fibres. The transverse fibres of the formatio reticularis are the *internal* or *deep arcuate fibres*, which arise from the cells of the nucleus gracilis and nucleus cuneatus on their deep aspects. They pass forward and inward in a curved manner to the median rapine of the medulla. Here they cross to the opposite side decussating with those which come from that side immediately above the level of the decussation of the pyramids, but on a more posterior plane.

The medulla oblongata is the intra-cranial spinal cord, and serves to conduct impulses from the brain, and impressions to the brain. It is an organ of conduction as is the spinal cord. The gray matter of the medulla does not lie in independent centres but, like the gray matter of the cord, it consists of groups of nerve cells along the nerve fibres. The cell groups are held together by neuroglia. Eight pairs of cranial nerves, from the 5th to the 12th, inclusive, are seen to pass from the sides of the medulla.

THE FOURTH VENTRICLE

The **fourth ventricle** of the brain is situated between the pons Varolii and the cerebellum and medulla. It is a diamond-shaped cavity, somewhat lozenge-shaped, being broadest at its central part, and smaller above and below. It lies in a plane below the level of the base of the cerebrum and terminates below in the point known as the calamus scriptorius (writing reed or pen). It communicates, above, with the third ventricle by the iter a tertio ad quartum ventriculum (way from the third to the fourth ventricle) or aqueduct of Sylvius, and below it is continuous with the central canal of the spinal cord.

The *posterior wall* or the *roof* of the fourth ventricle, is formed by the superior peduncles of the cerebellum, the superior and inferior medullary velum, and by the tela choroidea inferior. The *anterior wall* or *floor* is formed by the dorsal surfaces of the medulla and the pons. *Each side* is formed by long, curved and narrow prolongations of the ventricular cavity carried laterally from its widest part, and curving round the upper-part of the corresponding restiform body.

The *cavity* is bounded by two triangular sheets of membrane, with their bases in contact. The sides of the upper triangle are formed by the convergence of the superior peduncles of the cerebellum. The sides of the lower triangle are formed by the divergence of the funiculi gracilis and cuneatus and the restiform body of the medulla, on either side.

The *cavity* presents *four angles*—a *superior angle*, which reaches as high as the pons and corresponds with the opening of the aqueduct of Sylvius into the fourth ventricle. The *inferior angle* is called the calamus scriptorius and it is at this angle where the central canal of the spinal cord, after traversing the lower or closed part of the medulla, opens into it. Its lateral angles are formed by the prolongations of the ventricles laterally between the medulla and the cerebellum, and in these situations form the lateral recesses.

The structures which form the *roof* of the ventricle are named from above downward, and are: the **superior peduncles** of the cerebellum, which, as they emerge from the substance of the cerebellar hemispheres, pass upward and forward and form the lateral boundaries of the upper half of the fourth ventricle, the **superior medullary velum** or **valve of Vieussens**, a thin layer of white matter, which is continuous with the white matter of the cerebellum and extends between the converging peduncles and bridges over the interval between them, and so completes the roof of the ventricle above; the **inferior medullary velum**, a strip of white substance, which is continuous with the white matter of the cerebellum, and unites the flocculus of each hemisphere with the nodule. This velum, as it passes from the cerebellum, becomes a very delicate layer of tissue, covered with pia mater, and closes—in the fourth ventricle. The **tela choroidea inferior** is the choroid plexus of the fourth ventricle and is a layer of pia mater, which covers the fourth ventricle posteriorly.

There are three oval perforations found in the choroid plexus. One in the median line, situated a little above the calamus scriptorius, is called the **foramen of Majendie**; the other two are placed, one on

each side, in the lateral recess of the ventricle and are known as the **foramina of Key** and **Retzius**. By means of these three openings the cavity of the fourth ventricle communicates with the subarachnoid space. The fluid found in this space is cerebro-spinal fluid, the same as that found in the lateral and third ventricles of the cerebrum. It serves to equalize the pressure and is the serum which permeates every part of the body, but, in the serous cavities, collects in quantities. Thus, in the brain cavities, it passes freely from one ventricle to the other thru openings provided for it. In the instance of the fourth ventricle, the fluid in the cavity communicates with the space between two of the coverings, the arachnoid and the pia mater.

The lining of the ventricle, known as the **ependyma** (the choroid plexus is a thickening of this membrane in the roof of the cavity) is continuous with that of the floor of the cavity; but, before this takes place, there are three layers of white matter which project over it for a short distance and they are named, the **obex**, and the **right** and **left taenia** or **ligula**. The **obex** is a thin layer of white matter, containing thickened membrane, which gives it a rather gray color, found at the point of the calamus scriptorius. The **taenia** or **ligula**, one on either side, is a narrow band of white matter which extends from the lateral recess above, nearly to the calamus scriptorius below and projects over the ependyma of the roof for a short distance.

The *floor* or the *ventral wall* of the fourth ventricle, formed by the dorsal surface of the pons and the medulla, is rhomboidal in form and is widest opposite the middle peduncles of the cerebellum. The entire floor is covered by a thick layer of gray matter continuous with that which surrounds the central canal of the spinal cord and of the lower part of the medulla. This gray layer is covered by ependyma and the ependymal cells are continuous with those which line the central canal. Above, the ependyma is continuous with that of the third ventricle, thru the aqueduct of Sylvius.

For convenience, the floor is divided into two portions, the *upper* or *pontine*, and the *lower* or *medullary*. The *upper portion* is bounded laterally by the superior peduncle of the cerebellum. The *lower portion* is bounded laterally and from below upwards, by the clava, the cuneate tubercle, and restiform body. These structures form the sides of the fourth ventricle. The floor is also traversed at its widest part by numerous bundles of fibres called the **striae medullares** or **acusticae**. These fibres pass outward over the restiform body and divide the floor into two triangles. In the upper part, which corresponds to the dorsal portion of the pons, is a slight depression called the *fovea superior*, and between it and the median groove is a well marked prominence, called the *eminentia cinerea* or *teres*, which is produced by the underlying bundle of fibres.

The **locus caeruleus** is a small area above the fovea superior which presents a bluish tint thru the thin stratum covering it. This color is due to a group of pigment cells, known as the *substantia ferruginea*. Nerve fibres are seen emerging from the side of the locus caeruleus.

In the lower portion or triangle of the floor of cavity, is seen a triangular depression, the *fovea inferior*. It is shaped like an arrow head. Its apex is directed toward the striae and the lateral angles

THE NERVOUS SYSTEM

of its base are prolonged into grooves, which diverge. Between these two diverging grooves is a triangular, ash-colored area called the *trigonum vagi*, which corresponds with the nuclei seen in the vagus and glosso-pharyngeal nerves. A second and third nuclei are seen close to the fovea inferior, and these are called the *trigonum hypoglossi* and *trigonum acustici*, in the midst of which are seen the hypoglossal and auditory nerves.

THE MEMBRANES OF THE SPINAL CORD

(Illustration No. 224.)

The **Spinal Cord** is that part of the nervous system which is contained within the spinal canal. It extends from the foramen magnum, at the base of the brain, to the second lumbar vertebra, for which distance it is wholly bound together, from there it spreads out in a fan-shaped arrangement, called the **cauda equina**, and terminates in a long, slender filament, called the **filum terminale**, attached to the tip of the coccyx.

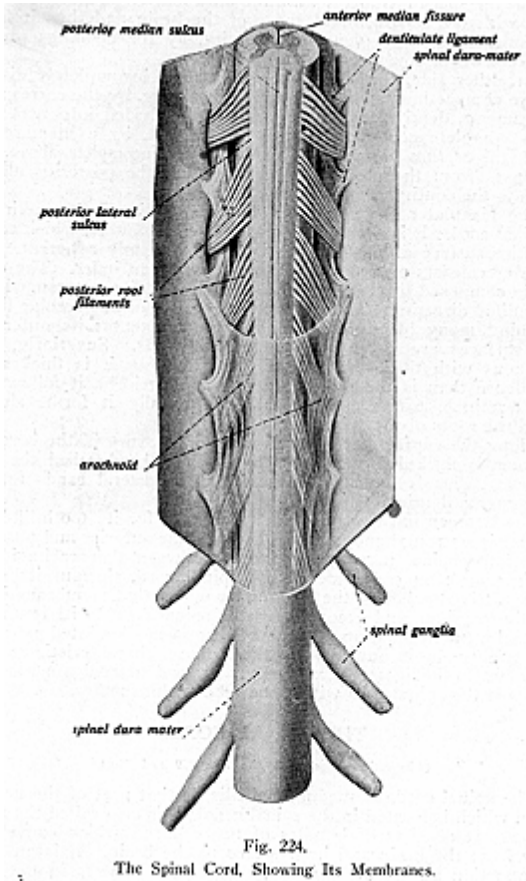
Three **membranes**, called the meninges, envelop the spinal cord and receive the same names as have the coverings of the brain; the **dura mater**, the **arachnoid** and **pia mater**.

The **most external covering** is the **dura mater** (hard mother or nourisher). It is a strong, fibrous membrane, forming a firm fibrous tube or theca, which extends from the margin of the foramen magnum, the axis, and the third cervical vertebra, where it is continuous with the endosteal layer of the dura mater of the brain, to the back of the body of the second or third sacral segment. It forms a loose sheath, which surrounds the spinal cord, but is separated from the walls of the spinal canal by an interval known as the **epidural space**, which contains plexuses and loose areolar tissue. This dura mater of the cord is prolonged, on either side, thru the intervertebral foramina in the form of sheaths around the roots of the spinal nerves. In structure, the dura mater is a fibrous, semi-transparent membrane, nearly white in color, thick and very resistant. Its internal surface is covered by a layer of endothelial cells; some blood-vessels and nerves traverse the membrane. The dura mater of the cord consists of only one layer, while that of the brain is composed of an outer and inner layer, it does not form the periosteum of the spinal canal, it does not send septa into the cord, and its layers do not form venous sinuses, as in the brain.

The **arachnoid** (spider-web in form) is a very delicate membrane surrounding the spinal cord, in the form of a tube, which lies between the dura mater and the pia mater. It is a colorless, transparent membrane and is made up of delicate interlacing fibres arranged in several layers. Both its external and its internal surfaces are covered by endothelial cells. Superiorly, it is continuous with the intra-cranial arachnoid, and, at either side, is prolonged over the roots of the nerves, and, like the dura mater, forms a sheath for them as they pass out toward the intervertebral foramina. Between the arachnoid and the dura mater is an intervening space, called the

THE NERVOUS SYSTEM

subdural space; it contains a small amount of fluid, which moistens the opposed endothelial surfaces.



Between the arachnoid and the pia mater is a wider interval, named the **subarachnoid space**. It is crossed by delicate trabeculae of connective tissue, which are arranged in a reticular manner, and

THE NERVOUS SYSTEM

within its meshes is found cerebro-spinal fluid in sufficient abundance to expand the arachnoid membrane and to completely fill up the whole of the space included within the dura mater. It communicates above, with the subarachnoid space of the brain and thus it freely communicates with its ventricular cavity, by the openings present in the roof of the fourth ventricle.

On either side, the subarachnoid space is incompletely divided into two compartments, an anterior and posterior, by the corresponding ligamenta denticulata. Posteriorly, it is divided into two more or less complete compartments, right and left, by a membranous septum, the *septum posticum*. This septum is incomplete above. Its fibres pass from the pia mater, as it crosses the posterior median fissure, to the contiguous part of the arachnoid.

The **pia mater** (soft mother) is the most internal covering of the spinal cord. It is a very delicate, serous membrane, which covers the entire surface of the cord, to which it is firmly adherent. The pia mater consists of two layers, an outer and an inner. The outer layer is composed of connective tissue, with its fibres arranged in a longitudinal direction. The inner layer consists of fine areolar tissue containing many blood-vessels and nerve filaments; its outer and inner surfaces are covered by endothelial cells. Superiorly, it is continuous with the pia mater of the brain, but it is thicker and more dense than is the pia of the brain. Inferiorly, it follows the filum terminale to its destination, and laterally it forms sheaths around the roots of the spinal nerves.

Along the course of the anterior median fissure of the cord the pia mater is thickened and forms a glistening band called the *linea splendens*. This is similar in structure to the lateral bands forming the ligamenta denticulata.

The **ligamentum denticulatum** (so named for its tooth-like projections) is a strong band, situated between the anterior and posterior roots of the spinal nerves. It extends between the arachnoid and the pia mater, on each side of the spinal cord, thruout its entire length. It is attached to the dura mater where that membrane issues from the cranium, and accompanies the spinal cord to its extremity. Its attachment to the dura mater takes the form of pointed processes about twenty-one in number, and these give a characteristic serrated appearance to the ligament externally. These dentate ligaments serve to support the spinal cord within the tube of dura mater.

THE SPINAL CORD

(Illustrations Nos. 225, 226, 228, 229 and 230.)

The **spinal cord**, or **medulla spinalis**, is that part of the nervous system which is located in the spinal canal; it is also called the spinal marrow. It consists of bundles of nerve fibres, which convey impulses from the brain and impressions to the brain. It is an organ of conduction and is the means by which the centres in the brain are brot into relation with the tissue cells, by means of the nerves which leave the side of the vertebral canal thru the intervertebral foramina.

THE NERVOUS SYSTEM

The spinal cord is about 18 or 19 inches in length and is a continuation of the medulla oblongata. It commences at the foramen magnum of the occipital bone, and descends in the vertebral canal as low as the second lumbar vertebra, where it terminates in a tapering portion, called the **conus medullaris**. From here a number of nerves spread out to form the **cauda equina**, so called from its resemblance to a horse's tail. From the lower end of the cone, a slender glistening thread, called the **filum terminale**, about 6 inches in length, is continued downward between the bundles of the lumbar, sacral and coccygeal nerves of either side; it is attached to the dura mater lining the canal of the sacrum, and ends at the back of the coccyx. As far as the second sacral segment, it is situated within the theca, but, at that level, it pierces the theca, from which it receives an

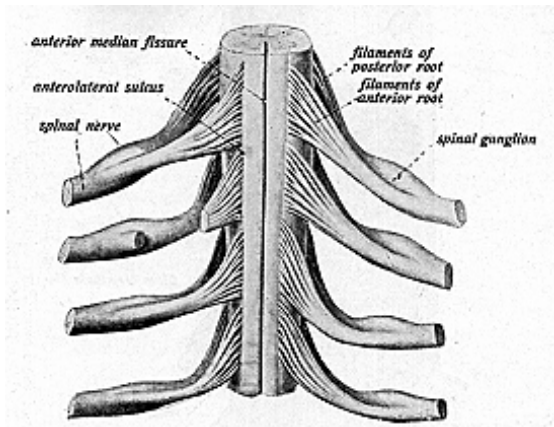


Fig. 225.

Spinal Cord, Showing the Anterior and Posterior Nerve Roots.

investment, and then passes to be attached to the back of the first coccygeal segment. Here it blends with the periosteum. For some distance the filum terminale contains, in its centre, a prolongation of the central canal of the spinal cord. It is also composed of pia mater, prolonged downward from the conus medullaris, and reinforced by fibres derived from the lower portions of the ligamenta denticulata and linea splendens. Its lower part is purely fibrous.

The filum terminale serves to fasten the spinal cord to the coccyx and thus holds the cord in situ.

The **cauda equina** is the terminal division of the spinal cord, which, at about the level of the second lumbar vertebra, is separated into a mass of separate nerves, having a resemblance to a horse's tail, hence the name. It is composed of the lumbar, sacral and coccygeal nerves of each side, together with the filum terminale, which lies in the median line between them.

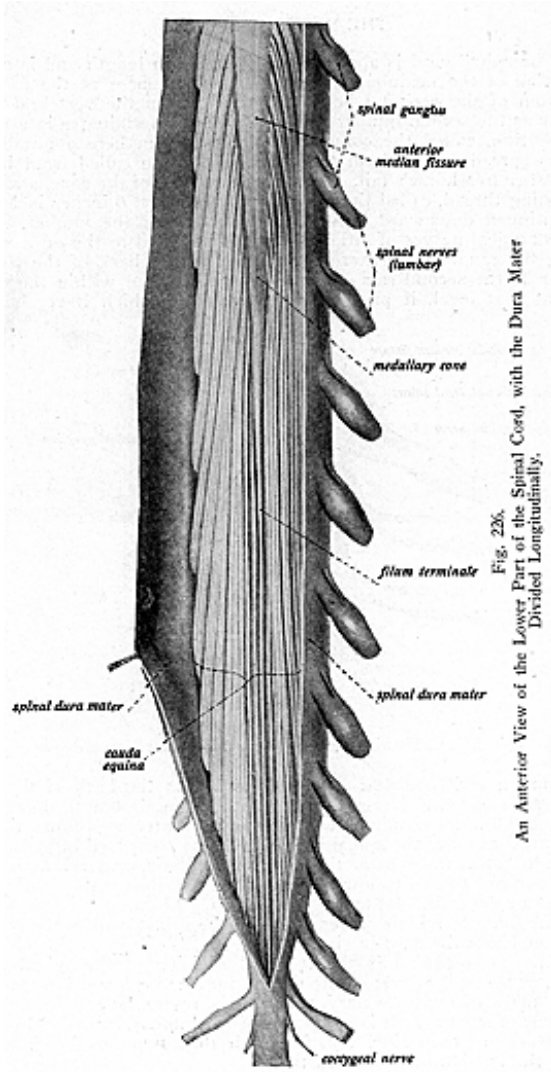


Fig. 226.
An Anterior View of the Lower Part of the Spinal Cord, with the Dura Mater Divided Longitudinally.

THE NERVOUS SYSTEM

The spinal cord does not fill the spinal canal, in which it is contained, tho it does not lie naked in the canal, but is enveloped by the membranes previously described. It lies loosely in the canal, its investing membranes being separated from the surrounding bony walls by areolar tissue and a plexus of vessels. Its position in the spinal canal varies with the degree of curvature of the spine. The cord, being of smaller dimensions than the spinal canal, is relieved from pressure during the ordinary movements of the vertebral column.

The spinal cord is cylindrical in form, but is slightly flattened from before backward, tho it varies in different regions. In the cervical region, on a cross section, it is transversely oval; in the thoracic region, nearly circular; and in the lumbar region it is still more circular than in the thoracic region.

It presents two well marked enlargements, which are known as the **cervical** and **lumbar enlargements**, and these swellings correspond to the large nerve trunks, which branch out to the upper and lower extremities.

The **cervical** or **brachial enlargement** extends from the third cervical vertebra to the first or second dorsal vertebra, it being largest opposite the sixth cervical vertebra. The **lumbar enlargement** is situated opposite the tenth, eleventh and twelfth dorsal vertebrae. Below the twelfth, where it reaches its maximum diameter, the cord gradually tapers to form the conus medullaris.

The spinal cord weights about one and one-half ounces, and on cross section it measures about half an inch, tho it varies in the cervical, dorsal and lumbar regions, being greatest in the cervical region.

The cord is partially divided by two longitudinal fissures, in front and behind, which nearly reach its centre; they are called the **anterior** and **posterior median fissures**. These fissures divide the cord, incompletely, into two symmetrical halves.

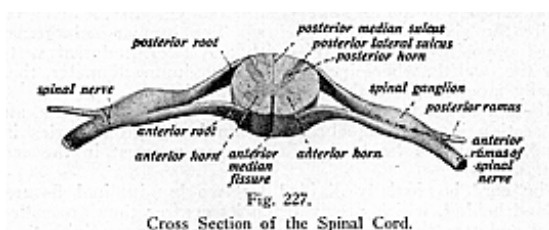
The **anterior median fissure** is the wider, and extends thru about one-third of the substance of the cord to a transverse layer of white matter, called the **anterior white commissure**, which connects the anterior parts of the two halves of the cord; the fissure contains a fold of pia mater.

The **posterior median fissure**, altho so named, is not an actual fissure like the anterior, and does not contain a fold of pia mater. It is the space between the posterior halves of the cord and extends thru about half the substance of the cord to the **posterior gray commissure**, which lies at the bottom of the fissure. There is also upon each side of the cord a posterior lateral groove, fissure or sulcus, which corresponds to the line of entrance over the posterior roots of the spinal nerves. It extends to the posterior cornu of the gray matter in the spinal cord. An anterior lateral groove or sulcus, not as distinct as the posterior groove, indicates the line of emergence of the anterior roots of the spinal nerves. By means of these fissures, the white portion of the cord is marked out into the anterior, lateral and posterior columns, on each side; these are continued upward into the medulla and there form the pyramids, lateral tracts, and restiform bodies.

THE NERVOUS SYSTEM

On a transverse section (Illustration No. 227) the cord will be found to be nearly solid, being composed of white substance externally, enclosing gray matter internally and so arranged that it forms two crescent-shaped masses. These are joined by transverse bands of gray matter, forming the letter H, which form the gray commissure of the cord. Running thru the centre of the commissure, the whole length of the cord, is a minute canal, called the **central canal of the cord**, or the **ventricle of the cord**, which is just barely visible to the naked eye.

This canal opens, above, into the fourth ventricle at the calamus scriptorius, and terminates below. Opposite the first sacral segment it becomes enlarged, and from this point it is prolonged for some distance into the filum terminale and here ends in a closed extremity called the cul-de-sac. This canal is lined by ciliated epithelium and columnar cells, which are known as *ependymal cells*, and surrounded by neuroglia; it contains some cerebro-spinal fluid. In fetal life this canal served for the purpose of transmitting the fluids from the ventricles of the brain thruout the length of the cord, and was filled with



well defined columnar ciliated epithelium, but, in the adult, the space is almost closed and most of the cilia disappear. In the adult, the canal has more of a gelatinous appearance, tho some fluid is still found in the interval. The central canal represents the lumen of the neural tube, from which the spinal cord is developed.

THE WHITE MATTER OF THE SPINAL CORD

The **white matter of the spinal cord** forms a coating on the surface of the cord, and consists of white nerve fibres enclosed in a sheath of neurokeratin and embedded in neuroglia. These fibres form into groups or bundles running longitudinally and transversely, forming ascending and descending tracts; they also form other tracts which are known as the anterior, lateral and posterior columns of the cord.

The **tracts in the cord** are grouped as follows: the **projection pathways**, those which convey impulses and impressions to or from the cord; the **association pathways**, connecting different parts of the cord together; and **commissural pathways**, which connect the two sides of the cord with each other. The very complicated courses of the nerve-fibres of the spinal cord, to and from the medulla and thence to the brain, have been most laboriously studied and there is yet much to be determined regarding them. The following arrangement has

been determined only by experiment, by dissection, and from observation of pathological changes. Its acceptance by most anatomists does not, by any means, prevent the Chiropractor from modifying the arrangement to conform to facts which may be proved by his nerve tracing and clinical observation. (For further and more detailed study of the statement just given, see lectures on Nerve Tracing, and Majors and Minors, by Dr. B. J. Palmer.)

The **anterior column of the cord** is situated between the anterior median fissure and the anterior nerve roots; the **lateral column** is the area between the anterior and the posterior nerve roots, and the **posterior column** is the region between the posterior median fissure and the posterior nerve roots.

The **anterior column** consists of a vertical set of fibres, which form two well-defined tracts, namely: the **direct** or **anterior pyramidal tract** and the **anterior ground bundle**.

The **lateral column** consists of the following tracts: the **direct cerebellar tract**, the **tract of Gowers**, the **crossed** or **lateral pyramidal tract**, the **lateral ground bundle**, and the **lateral limiting tract**.

The **posterior column** consists of the following: the **tract** or **column of Goll**, the **tract of Burdach**, and the **tract of Lissauer**.

The **direct** or **anterior pyramidal tract**, sometimes called the **column of Turck**, is a bundle of fibres, which lies close to the anterior median fissure. It is traced superiorly into the medulla, where it forms the outer portion of the pyramid; and from there its fibres are traced into the pons, then to the crura cerebri, into the internal capsule of the corpus striatum, and finally to the Rolandic area of the cerebral cortex of the same side. In the cord, these fibres descend and cross at intervals in the anterior white commissure to the opposite column, where they enter the gray cornu, from which the fibres of the anterior nerve roots arise.

The **anterior ground bundle** forms the greater part of the anterior column. It surrounds the anterior nerve roots and is continuous with the lateral bundle. Its fibres consist of longitudinal, commissural or association fibres, and pass between the segments of the cord, at different levels; they also unite the groups of cells in the gray matter of the cord, and form the anterior nerve roots before leaving the cord.

The **direct cerebellar tract** is found in the lateral column, in its posterior part, and consists of large fibres which are seen passing, from the spinal cord, thru the medulla to the restiform body, and then to the cerebellum. This tract is stated by Morat to convey a certain portion of the tactile impulses towards the cerebellum; it also contains fibres which are concerned in the correct performance of certain movements of coordinated efforts.

The **tract of Gowers**, or the **indirect cerebellar tract**, is situated in front of the direct cerebellar and crossed pyramidal tracts. The fibres from this tract can be traced thru the medulla and pons into the cerebellum, thru the superior peduncle, where the fibres are seen in the vermis superior of the cerebellum; other fibres, carried thru the superior peduncles, pass on toward the cerebral cortex, via the crura cerebri from the pons, and are considered as fibres which convey voluntary motor impulses.

THE NERVOUS SYSTEM

The **crossed pyramidal tract**, also known as the **lateral pyramidal tract**, is situated in the posterior part of the lateral column of the cord. It consists of fibres which can be traced from the central and frontal lobes of the cerebral cortex, to the internal capsule of the corpus striatum, thru the crura to the pons, then to the medulla, and down thru the cord. They form the nerve roots in the cord, and leave the cord, below, at variable points, in the anterior roots of the spinal nerves. These are the fibres which form the decussation of the pyramids in the medulla.

The **lateral ground bundle** is continuous with the anterior ground bundle. It consists of longitudinal association fibres, commissural fibres and transverse fibres, the latter set belong to the anterior nerve roots of the spinal nerves. The fibres from this tract, as well as from the anterior ground bundle, are commissural and their function is given as that of co-ordination of muscular power. Fibres from this tract may be traced thru the optic thalamus from the pons to the parietal lobe of the brain. A small bundle, called the **lateral limiting area**, is situated between the gray matter and the crossed pyramidal tract and lateral ground bundle, and is more often considered with the ground bundle and so is concerned in the commissural fibres.

The **column of Goll** lies close to the posterior median fissure and includes a small tract called the *comma tract*; this lies internal to the posterior gray cornu, and its fibres are seen in the posterior nerve roots. The column of Goll is formed of fibres, which form the posterior nerve roots; they can be traced superiorly to the medulla where they form the funiculus gracilis of the medulla in the floor of the fourth ventricle. The **column of Burdach** is placed between the posterior gray cornu and the column of Goll. Its fibres are traced to the funiculus cuneatus in the same region. They are exceedingly long tracts and are seen forming the posterior nerve roots of the spinal nerves. The fibres from these tracts are said to be concerned in muscle and tactile sense.

The **tract of Lissauer**, a small tract, is situated on the posterior surface and is formed by fibres of the posterior roots of the spinal nerves. The **tract of Helwig**, or **olivospinal tract**, is found on the anterior surface, and is formed by the anterior roots of the spinal nerves. Both of these tracts can be traced to the substantia gelatinosa of Rolando in the fourth ventricle.

THE GRAY MATTER OF THE SPINAL CORD

The **gray matter of the spinal cord** consists of a fibrous stroma, within which the nerve elements are distributed. These elements consist of nerve cells, which lie in small spaces; they are traversed by the medullated and non-medullated nerve fibres and blood-vessels, and are held together by neuroglia.

The gray matter occupies the central portion of the cord and, in any traverse section, is arranged in two irregular crescentic masses. Their convex borders are turned toward each other and the two parts are united by a narrow band of gray matter, called the **gray commissure**, the arrangement presenting the letter H. The gray

THE NERVOUS SYSTEM

matter lies at the bottom of the posterior median fissure and presents, in its centre, a minute opening, the **central canal** (previously described).

The part of the commissure, in front of this canal, is the **anterior gray commissure**; the part behind is known as the **posterior gray commissure**. In front of the anterior gray commissure is a transverse band of white matter, called the **anterior white commissure**, which lies at the bottom of the anterior median fissure.

Each crescentic mass has an anterior and posterior projecting part, called **horns** or **cornua**; an **anterior** or **ventral**, and a **posterior** or **dorsal cornu**.

Each anterior cornu is short and thick, and stops short of the surface of the cord, being separated from the surface by white matter. It projects toward the ventro-lateral surface, from which emerge the anterior roots of the spinal nerves.

Each posterior horn or **cornu** is slender and nearly reaches the surface of the cord. At its base, it is connected with the rest of the gray substance and is here called the *cervix cornu*, it then enlarges into the main part of the cornu and forms the *caput cornu*; the tapering portion near the surface is called the *apex cornu*. It projects into the fissure occupied by the posterior roots of the spinal nerves. The caput, as well as the apex, of the cornu, is surrounded by a semitransparent gelatinous material, called the *substantia gelatinosa*.

Within the centre of the concavity of each crescentic mass, the gray matter projects outward into the lateral column, in the form of a network of small white and gray fibres, and is here called the *formatio reticularis*, from its reticular appearance.

In some parts of the cord, the gray matter at the base of the posterior horn on its inner side, is seen to form a triangular projection, formed of a collection of cells. The projection is called *Clark's column*.

The gray matter varies in amount in different parts of the cord being present in largest quantity in the lumbar and cervical enlargements.

The cells in the gray matter are grouped into columns, called the anterior or ventral column, situated in the anterior cornu of the gray matter; the **lateral cell column**, in the lateral cornu of gray matter; and the **posterior cell column**, in the posterior gray cornu and known there as **Clark's column**.

NERVES

(Illustrations Nos. 228, 229 and 230.)

A **Nerve** is a bundle of fibres. These fibres emanate from the many centres in the brain. They converge toward the base of the skull, where they form the spinal cord, pass down thru the spinal canal, and give off thirty-one pairs of nerves to the various parts of the body. These nerves leave the neural canal in pairs, thru the intervertebral foramina, and pass to all parts of the body, they are all alike in structure but differ as to function. The one carrying or conveying the mental impulses from the brain to the tissue is called

THE NERVOUS SYSTEM

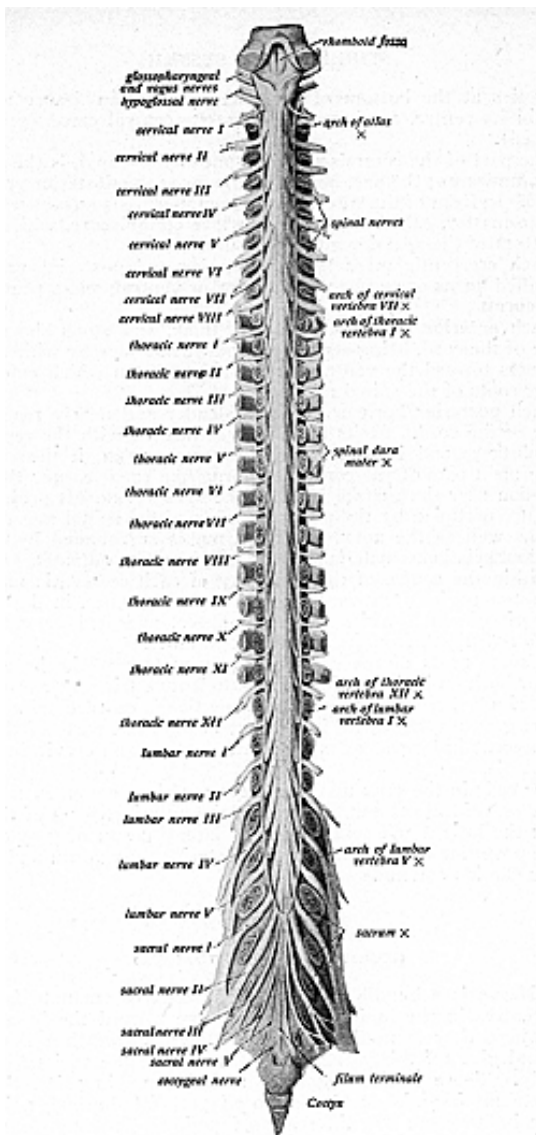


Fig. 228.

Spinal Cord with Nerves (Arranged According to Anatomy).

the **efferent nerve**, and the one carrying the mental impulse from the tissue back to the brain is called the **afferent nerve**.

Any interference with the normal action of the nerves in carrying the life current, deranges their function and thereby deranges the function of the organs to which they carry the life current. Deranged functions are diseases and are caused by the pressure exerted by displaced vertebrae impinging the nerves; therefore, deranged functions can only be made normal by having the displaced segments replaced, giving free and normal action to the nerves. A live nerve, like a "live wire," is made so by the current sent thru it (thru the wire from the dynamo and thru the nerve from the brain); each may be said to have function.

A subluxation that pinches or presses upon a nerve may be likened to a rheostat on a live wire. The rheostat interferes with the current that passes, or would pass, thru the wire, it resists, keeps back the current, changes the functions of the wire, also of the motor or lamps on that wire.

Innate Intelligence has control over every tissue cell in the human body. Educated Intelligence has control over a very small portion, namely the muscular system; Innate guides the rest, every tissue cell, in the nine primary functions. These functions are as follows: **motor, sensation, secretion, excretion, calorific, nutrition, expansion, reparation** and **reproduction**.

Motor function has to do with muscular tonicity; **sensory function** has to do with sensation; **secretory** is that function which has to do with the formation of the fluids manufactured in the glands thruout the body; **excretory** is that which has to do with the elimination of any material or fluid found in the body which is of no value or is poisonous to the body; **calorific**, the heat; **nutrition** is that function which has to do with the anabolism of the body; the **expansion** is that function which has to do with the growth of new tissue; **reparation** is that function concerned in replacing the used or exhausted cells in the body with new ones; and **reproduction** is that function which has to do with the production of the species.

Any interference with the transmission of energy will result in a lack of function in that part thru which the affected nerves ramify. The function affected will be the one whose activity is interfered with by the nerve compression, which has reduced the amount of current below the amount required to maintain its normality. These interferences result in a general incoordination of the functions of the body.

Anatomy gives a sufficient knowledge of the twelve cranial nerves, that is, it gives their origins, paths and functions. Anatomy also tells us that many of these have their exit thru foramina at the base of the skull, but it does not tell us that any have their exit thru the foramen magnum or other parts thru and into the spinal cord so that they may have exit thru any intervertebral foramina. No such paths are given for any of the cranial nerves. B. J. Palmer says: "If anatomy is correct as to the origin, paths, and exit, of the twelve cranial nerves, they have paths and exits thru the cranial

THE NERVOUS SYSTEM

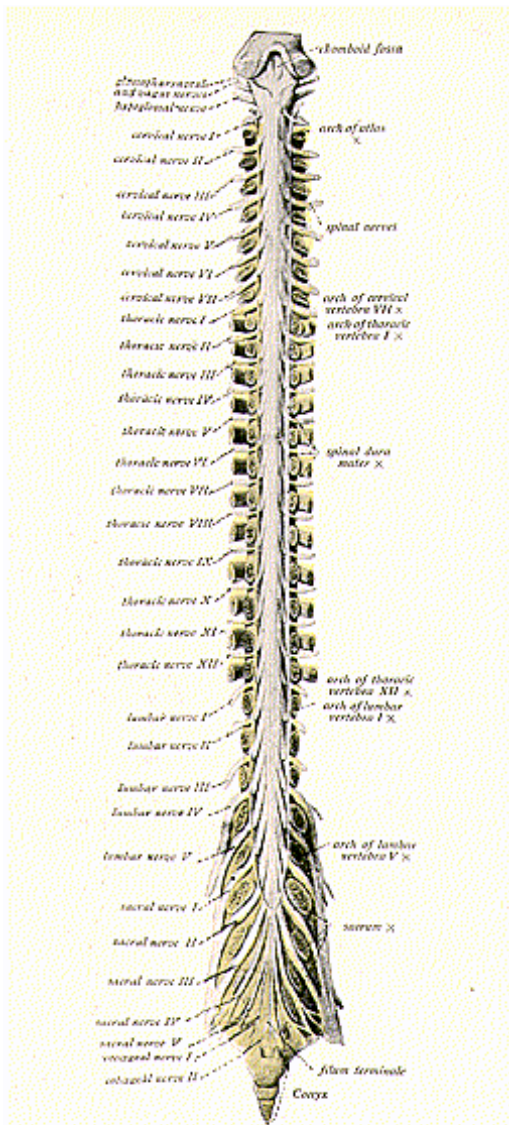


Fig. 229.
Spinal Cord with Nerves, According to the Meric System.

THE NERVOUS SYSTEM

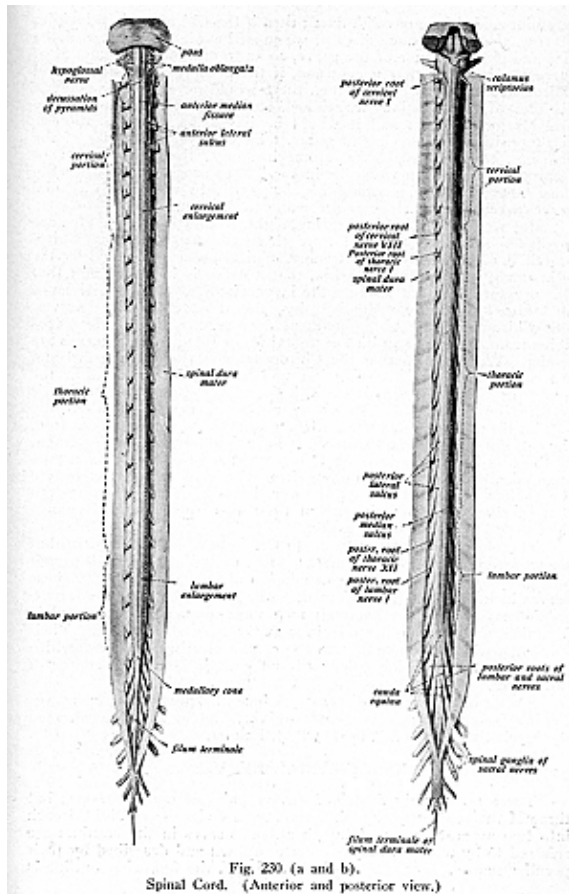


Fig. 230 (a and b).
Spinal Cord. (Anterior and posterior view.)

THE NERVOUS SYSTEM

foramina and these are solid, fixed; then if the Chiropractic principles be true, that, to produce disease, we must have a diminution of the size and circumference of the nerve, so as to diminish the amount of current going thru that nerve; and, if the premises of anatomy and Chiropractic both be correct, then there would never be any possible disorder of the functions mentioned, such as smelling, moving the eyeballs, or hearing; and it would be impossible to have abscess, decomposition or decaying of gums, tetanus, or any disorder of the pharynx, tongue, esophagus, stomach, lungs, liver, diaphragm or respiration, because it would be impossible to produce pressure upon these nerves. A man would be comparatively well if his cranial nerves were doing their duty according to Anatomy.”

But we find that man’s hearing, sight, respiration, teeth, etc., are involved. No one is exempt from these common diseases. Chiropractic has proved, by nerve tracing, clinical observation, and by the adjustment of a specific vertebra, that a nerve is impinged and that this pressure does not produce the incoordination of the functions of all those structures supplied by the twelve cranial nerves. The Chiropractor by his adjustment does restore sight. He traces fibres from the eye to an intervertebral foramen, and these nerves are tender. We find also that the Chiropractor can adjust the 3rd and 4th dorsal vertebrae and function will be thereby restored in the lungs; or adjust the 6th, 7th or 8th dorsal vertebrae and function is restored in the stomach. There are no known nerves—anatomically—from the 4th cervical vertebra to the eye; there are no nerves from the 6th dorsal vertebra to the eyeball, which control the movement of the sets of muscles around the eyeball, neither are there nerves anatomically known, that radiate from the 12th dorsal vertebra to the eyelids or glands around the eye, but Chiropractic has proven that specific adjustment in any of these three places would change the incoordination to coordination.

Therefore the cranial nerves do not form a distinct system, but are an arrangement of fibres of the spinal nerves, such as will permit of a proper distribution and transmission of mental impulses. These nerves include fibres direct from the spinal nerves and they enter the cranial cavity thru the foramen magnum, jugular fossae, condyloid foramina, and many other openings at the base of the brain. Their filaments, within the skull, form the communicating branches, which in turn form the various plexuses and ganglia along the course of the nerves.

For an outline of the diseases produced by pressure upon nerves leading from various zones, and the vertebrae to be adjusted, read the Meric System, Vol. 2, by Dr. B. J. Palmer.

THE CRANIAL NERVES

There are usually described twelve pairs of cranial nerves, but three of these, namely the fifth, seventh and eighth are divided each into two separate parts. Though all the nerves in the cranium are referred to by number, they are better known and described by their peculiar names. For reason of convenience, the following outline is

THE NERVOUS SYSTEM

given, showing their number, name, distribution, superficial origin, function, and their point of exit from the cranial cavity.

No.	Name.	Distribution	Superficial Origin	Function	Exit
I.	Olfactory	Olfactory nasal epithelium	Olfactory bulb	Smell	Cribriform plate of ethmoid
II.	Optic	Retina	Optic chiasma	Sight	Optic foramen
III.	Oculomotor	Muscles of the eye, ciliary body, iris	Cvura cerebri	Motor of eye muscles	Sphenoidal fissure
IV.	Trochlear	Superior oblique	Posterior to crura cerebri	Motor of superior oblique	Sphenoidal fissure
V.	Trigeminal	Face, mouth and scalp	Gasserian ganglion	Sensory	Sphenoidal fissure Foramen ovale Foramen rotundum
	Masticator	Muscles of mastication	Pons	Motor	Foramen ovale
VI.	Abducens	External rectus	Between pyramids and pons	Motor of external rectus	Sphenoidal fissure
VII.	Facial	Facial muscles	Medulla	Motor	Stylomastoid foramen
	Glossopharyngeal	Tongue, palate, salivary glands	Medulla	Sensory and motor	Stylomastoid foramen
VIII.	Acoustic or Auditory	Internal ear	Between the olivary and restiform bodies	Hearing	Does not leave cranial cavity
	Cochlear Vestibular	Semicircular canals, utricle, saccule	Between the olivary and restiform bodies	Equilibrium	Does not leave cranial cavity
IX.	Glossopharyngeal	Tongue, palate, pharynx	Between the olivary and restiform bodies	Motor and sensory	Jugular foramen
X.	Vagus	Esophagus, larynx, pharynx, heart, trachea, lungs	Between the olivary and restiform bodies	Sensory and motor	Jugular foramen
XI.	Spinal Accessory	Neck and shoulder muscles, pharynx, larynx and heart	Spinal cord and medulla	Motor	Jugular foramen
XII.	Hypoglossal	Tongue muscles	Between the olivary bodies and pyramids	Motor	Hypoglossal foramen

THE OLFACTORY NERVES

The **olfactory** are the **first pair of cranial nerves**, known as the nerves of special sense of smell. Anatomically this pair of nerves arises by three striae, which are known as the medial, intermediate and lateral. The three striae form the structure known as the trigonum olfactorium. Issuing from the union of these three striae is a flat narrow band of fibres, which is termed the olfactory tract, lying in an excavation of the brain substance, known as the olfactory fissure. The fibres of this band converge toward an enlargement, which is known as the olfactory bulb, found resting upon the cribriform plate of the ethmoid bone; thru the openings of this plate the peripheral fibres,

THE NERVOUS SYSTEM

eighteen to twenty in number on each side, issue forth into the olfactory region of the nose.

The medial stria is a narrow band and merges with the adjacent cerebral surfaces. The intermediate is not very distinct and cannot always be traced out, but seems to have its origin in the gray matter of the anterior perforated space. The lateral strict is the continuation of the limen insulae (that portion of the brain lying between the base and the island of Reil). If you were to lift up this entire structure, you would find that the three striae, which form the tract, diverge over a small pyramidal elevation, the base of which forms the trigonum proper and is found directly in front of the anterior perforated space.

The filaments, which arise from the oval-shaped olfactory bulb, are prolongations or axones of the olfactory cells, and are found in the superior turbinated process of the ethmoid bone and in the corresponding portion of the nasal septum. By the naked eye they are distinguished from the respiratory filaments on account of their brownish color. The lower extremities of these small fila, form minute plexuses and are arranged into two groups, the inner and the outer. The inner group is larger and is spread over the upper third of the nasal septum, while the outer set is distributed over the superior turbinated process and the surface of the ethmoid bone in front. All these fibres appear, at the lower extremity, to be in direct connection with, or a direct continuation of, the deep extremities of the olfactory cells.

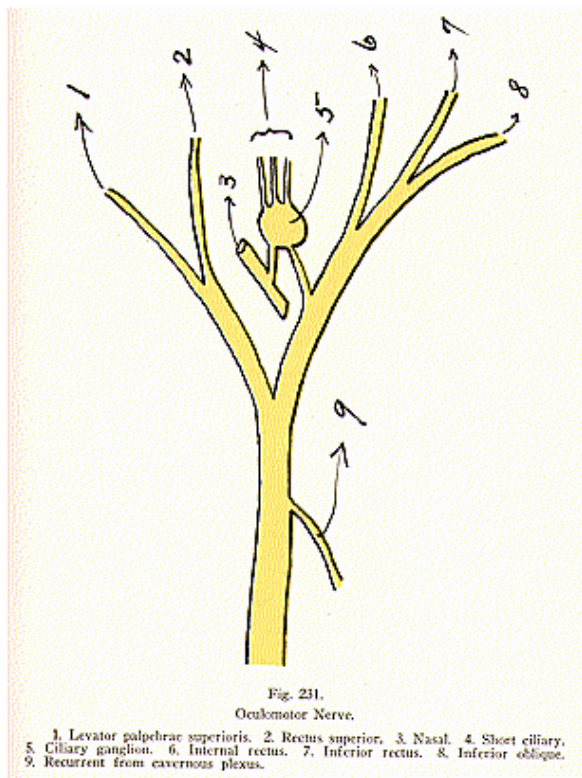
The olfactory nerves differ from other nerves in that they are composed entirely of amyelinic fibres, meaning fibres which have no medullary sheath or white substance of Schwann, but consist of axis-cylinders with a nucleated sheath in which there are more nuclei than the ordinary amyelinic fibres possess. Impressions from the olfactory mucous membrane pass to the olfactory glomeruli, thence thru the central fibres of connection into the brush work of mitral cells, and, from these, thru the central fibres of conduction into the brain substance. Gaseous elements come in contact with the bipolar cells of the mucous membrane and afferent impulses are set up, which traverse the nerve fibres from the periphery to the brain, where interpretation takes place, and Innate thus becomes aware of the quality of the exciting agent.

THE OPTIC NERVES

The **second pair of cranial nerves** is known as the optic, or the nerves of special sense of sight; passing from the optic chiasma or commissure, thru the optic foramen, into the posterior part of the eyeball, their fibres spread over the sensitive membrane of the retina.

The optic chiasma is a white quadrangular plate in which are found the inter-retinal fibres, the decussating fibres and the intercerebral. The straight or longitudinal fibres have nothing to do with the formation of the optic commissure, but pass from the outer half of the retina directly thru the lateral optic tract into their nuclei of origin. The decussating fibres pass from the inner half of the retina, thru the optic commissure, and down thru the lateral tract of the opposite side. The inter-retinal fibres pass from one retina, thru the

THE NERVOUS SYSTEM



THE NERVOUS SYSTEM

optic commissure, to the retina of the opposite side. The inter-cerebral fibres pass from one medial geniculate body to the other, on the opposite side of the median line. These fibres form the medial portions of the two optic tracts and, tho they pass thru the optic commissure, have apparently nothing to do with vision. The lateral optic tract, which arises to the outside of the crus cerebri, is the visual tract and is comprised of the straight and decussating fibres.

The fibres of vision arise in nests of gray matter cells or nuclei in the substance of the brain, known as the pulvinar, the lateral geniculate bodies, and the superior quadrigeminate bodies. These nuclei are, in turn, connected by fibres of optic radiation to gray matter cells, located in the occipital lobes of the cerebral hemispheres. There exists yet another connection, and this one is between the nuclei of vision and those from which arise the oculomotor, trochlear and abducent nerves. These three nerves are directly connected with the cavernous plexus, from whence the peripheral cord of fibres passes into the superior border of the superior cervical ganglion, which ganglion is connected with the first four cervical nerves, by the rami communicantes. Tho this connection is seemingly very indirect, yet it exists as an anatomical communication between the spinal nerves of the upper cervical region and the optic fibres of vision. These fibres of vision have their numerous endings directly connected with the rods and cones of the retina.

THE OCULO-MOTOR NERVES

(Illustration No. 231)

The **third pair of nerves** is known as the **oculomotor** or **motor oculi**, supplying all the orbital muscles with exception of the superior oblique and the external rectus. Thru their connection with the ciliary or lenticular ganglion, which is located upon the nasal nerve, posterior to the eye-ball, these nerves also supply the sphincter of the iris and the ciliary body.

The oculomotor nerves are large, firm and cylindrical, and have their superficial origin in the oculomotor groove along the ventral middle border of the crura. From this point they can be traced backward, thru the tegmentum of the crura, to the oculomotor ganglia situated in the ventral portion of the aqueduct of Sylvius, adjacent to the superior quadrigeminate bodies. Each nucleus of these nerves is said, physiologically, to consist of smaller groups of cells; each cell, or rather the fibres originating from it, controlling particular muscles of the eyeball.

As the oculomotor nerves emerge from the brain substance, they carry with them a prolongation of the pia mater and arachnoid membranes. Each passes between the superior and posterior cerebral arteries, piercing the dura mater in front of the clinoid process of the ethmoid bone, and thence along the outer wall of the cavernous sinus above the other orbital nerves.

Each oculomotor nerve is divided into two parts, known as the *superior* and *inferior*, both entering thru the spheroidal fissure below the trochlear and the upper two branches of the ophthalmic division of the trigeminus. Both divisions are located between the two heads

THE NERVOUS SYSTEM

of the external rectus muscle. The nasal nerve passes between them. The *superior division* is the smaller, and again subdivides into two branches, which pass inward over the optic nerve and supply the superior rectus and levator palpebrae superioris muscles.

The *larger inferior division* is divided into three branches, one passes beneath the optic nerve to the internal rectus; another to the inferior rectus; and the third and longest division, forward between the inferior and external recti to the inferior oblique. Before dividing into its three branches it gives off a short, thick root that communicates with the lenticular ganglion.

In its course thru the cavernous sinus, the oculomotor nerve receives one or two filaments from the cavernous plexus and, thru these, a means of communication is established with the cervical nerves, similar to that described in connection with the optic, only more direct.

THE TROCHLEAR NERVES

The **fourth pair of cranial nerves** is known as the **trochlear**. They arise on either side from nuclei in the floor of the mid-brain aqueduct on a level with the inferior quadrigeminate bodies. Each passes somewhat outward, then inward, and crosses over to form the trochlear decussation, and enters the orbit thru the sphenoidal fissure. It is the highest nerve in the orbit, passes above the origin of the levator palpebrae superioris muscle, and enters the superior oblique. In the outer wall of the cavernous sinus, it forms a communication with the cavernous plexus and the ophthalmic division of the trigeminal. In the sphenoidal fissure, it very often gives off a branch which helps to form the lacrimal nerve. It also gives off a recurrent branch, which passes backward and divides into two or three filaments that may be traced as far back as the lateral sinus.

The trochlear, like the second and third cranial nerves, communicates with the upper cervical nerves thru the branch from the cavernous plexus.

THE TRIGEMINAL NERVES

(Illustrations Nos. 232 and 233.)

The **fifth, trigeminal, or bifacial, is the largest** of all cranial nerves; it is said to resemble the spinal nerves, having motor and sensory roots, also a large ganglion on the sensory division. It is the sensory nerve of the head and face, and the motor nerve of the muscles of the face, principally those of mastication. The ventral root is the motor, and very much smaller than the dorsal sensory root. This nerve arises from the upper border of the pons; the two roots being separated by a few transverse fibres. The small root consists of only three or four bundles, while the large root consists of between seventy and one hundred bundles. The deep termination of the sensory portion is in the lower sensor nucleus, forming the ascending root of the nerve passing upward and uniting with fibres from the upper sensor nucleus. The motor root arises partly from a nucleus in the lower part of the fourth ventricle, and partly from nerve cells at the side of the aqueduct these fibres forming the descending root. These two roots pass

THE NERVOUS SYSTEM

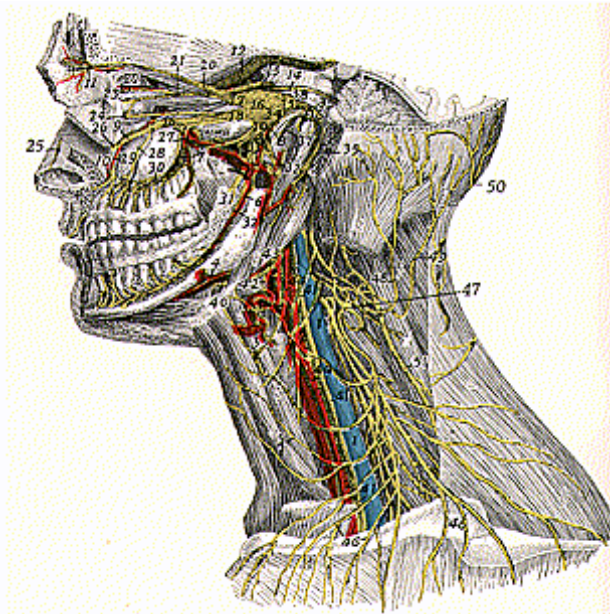


Fig. 232.

Distribution of the Deep Nerves of the Head, Neck and Orbit.

1. Internal jugular vein. 2. Common carotid artery. 3. Superior thyroid artery.
4. Facial artery. 5. Cervical cutaneous branch. 6. Inferior alveolar artery. 7. Superior alveolar artery and nerve. 8. Middle meningeal artery and nerve. 9. Infra-orbital artery and nerve. 10. Anterior alveolar artery and nerve. 11. Supra-orbital artery and nerve. 12. Optic nerve. 13. Oculomotor nerve. 14. Trochlear nerve.
15. Trifacial nerve. 16. Gasserian ganglion. 17. Ophthalmic branch. 18. Maxillary branch. 19. Mandibular branch. 20. Frontal nerve. 21. Lacrimal nerve.
- 22-23. Lacrimal nerve, external and internal branch. 24. Subcutaneous malar branch.
25. Ethmoidal nerve. 26. Infra-orbital nerve. 27. Alveolar nerve. 28. Middle alveolar nerve. 29. Anterior alveolar nerve. 30. Superior dental nerves. 31. Ninth nerve. 32. Inferior alveolar nerve. 33. Otic ganglion of the auricular nerves.
34. Branches between the otic ganglion and the petrosal ganglion. 35. Facial nerve.
36. Facial ganglia. 37. Chorda tympani. 38. Superficial vidian nerve. 39. Digastric nerve. 40. Hypoglossal nerve. 41. Vagus nerve. 42. Superior laryngeal nerve.
43. Hypoglossal nerve. 44. Ramus descendens. 45. Subcutaneous colli. 46. Supra-clavicular nerve. 47. Cervical plexus. 48. Great auricular nerve. 49. Occipitalis minor.
50. Occipitalis major.

forward below the tentorium, which bridges the notch on the inner part of the superior border of the petrous portion of the temporal bone. They run, between the bone and dura mater, to the apex of the petrous portion, where the sensory fibres enter the large **semi-lunar ganglion**; the motor passing beneath the ganglion, without having any connection.

The **semi-lunar, or Gasserian ganglion, is a large ganglion lodged** in the cavum Meckeli, near the apex of the petrous portion of the temporal bone. It is crescentic in shape and closely adherent, with its upper surface, to the dura mater. It receives, on its inner side, filaments from the carotid plexus and gives off small branches to the tentorium cerebelli and dura mater. From its anterior convex portion, emit three large branches, namely: the *ophthalmic, superior maxillary* and *inferior maxillary*.

The **ophthalmic nerve** is the first division and sensory in function. It supplies the cornea, ciliary muscle, iris, lacrimal gland, part of the mucous lining of the nasal fossa, and the integument of the eyelids, eyebrows, forehead and nose. It is the smallest of the three divisions, a short, flat band arising from the upper part of the Gasserian ganglion. It passes along the outer wall of the cavernous sinus below the oculomotor and trochlear, and, just before entering the orbital cavity thru the spheroidal fissure, divides into the *frontal, lacrimal* and *nasal*.

The *frontal nerve* is the largest of the three ophthalmic division; and seems to be a continuation of the main part of the nerve. It enters the orbit, thru the spheroidal fissure, and runs forward between the levator palpebrae superioris muscle and the periosteum. Midway in the orbit, it gives off the supra-trochlear and supra-orbital branches.

The *supra-trochlear*, the smaller branch, passes above the pulley of the superior oblique muscle, and gives off a descending filament which joins with the infra-trochlear branch of the nasal. It then leaves the orbit, between the pulley and the supra-orbital foramen, curves up and ascends beneath the corrugator supercilii and occipito-frontalis, gives off small branches that supply the integument of the lower part of the forehead, and sends branches to the conjunctiva and skin of the upper eyelid.

The *supra-orbital branch* passes thru the supra-orbital foramen, and here gives off the **palpebral filaments** to the upper eyelid. It ascends upon the forehead and terminates in **cutaneous** and **pericranial** branches. The cutaneous are two in number and supply the cranium as far back as the vertex. They are situated beneath the occipito-frontalis; the inner branch being in the frontal portion of the muscle, the outer in the aponeurosis. The **pericranial**, are distributed to the pericranium, over the frontal and parietal bones.

The *lacrimal nerve* is the smallest of the three branches of the ophthalmic nerve, and joins with a small filament from the trochlear nerve. It passes forward in a sheath of dura mater and enters, thru the narrowest part of the spheroidal fissure, into the orbit. It runs along the upper part of the external rectus muscle, communicating with the temporomalar branch of the superior maxillary. It enters the lacrimal gland and gives off small filaments, which supply the

gland and conjunctiva. It pierces the superior palpebral ligament and terminates in the upper eyelid, uniting with filaments of the facial nerve. The lacrimal nerve is sometimes absent and, in that case, the temporal branch of the superior maxillary takes its place.

The *nasal nerve* is larger than the lacrimal, smaller than the frontal. It enters the orbit thru the spheroidal fissure, between the two heads of the external rectus, passes across the optic nerve, beneath the superior rectus and superior oblique, to the inner wall of the orbit. From here it passes thru the anterior ethmoidal foramen, entering the cranial cavity, passes thru a groove in front of the cribriform plate, down thru a slit by the side of the crista galli into the nose, where it gives off the **internal** and **external branches**.

The **internal branch** supplies the mucous membrane of the fore-part of the septum. The **external branch** runs in a groove on the inner surface of the bone, supplies the mucous membrane of the outer nasal wall as far down as the inferior turbinated process, leaves the cavity of the nose between the nasal bone and the upper lateral cartilage, passes below the compressor nasi and supplies the integument of the ala and tip of the nose, also joining with the facial nerve. Before passing out from the orbital cavity it gives off several branches.

The **ganglionic** branch arises from the nasal nerve between the two heads of the external rectus and passes into the posterior border of the ciliary ganglion. The **long ciliary** branches are three in number, given off more anteriorly, in about the region where the nasal crosses the optic. They pierce the posterior part of the sclera, run between it and the choroid, and are distributed to the ciliary muscle, the iris and cornea. The third branch is the **infra-trochlear**. It runs along the upper border of the internal rectus muscle, receives a filament from the supra-trochlear and then passes to the inner angle of the eye, supplies the eyelids, side of the nose, conjunctiva, lacrimal sac and the caruncula lacrimalis.

The **ophthalmic, lenticular** or **ciliary ganglion** is a small flattened ganglion, reddish-gray in color and about the size of a moderate pin-head, situated at the posterior part of the orbit where it lies flattened upon the outer sides of the optic nerve. It is usually in close contact with that nerve and is enclosed in a quantity of loose fat. Posteriorly it receives three roots called the long, short and middle, and anteriorly the short ciliary nerves pass forward from it.

The **superior maxillary**, or the maxillary, is the middle division of the tri-facial nerve. It passes horizontally forward and leaves the cranium thru the foramen rotundum. Crossing the sphenomaxillary fossa, it enters the orbit thru the sphenomaxillary fissure, then appears upon the face at the infra-orbital foramen. Its terminal lies beneath the levator labii superioris muscle, where it divides into a great many branches. For purposes of discussion, the branches are divided into four groups: those given off in the cranium; in the sphenomaxillary fossa; in the infra-orbital fissure; and those of the face.

The *meningeal* is given off near the origin of the superior maxillary and accompanies the meningeal artery, supplying the dura mater of the central portion of the base of the skull.

The *orbital* is the first branch that arises in the sphenomaxillary

fossa and divides into the *temporal* and *malar*. The *temporal nerve* passes in a groove of the malar bone and enters the temporal fossa. It pierces the temporal muscle about an inch above the zygoma and is distributed over the temple, communicating with the facial and a branch of the inferior maxillary. It gives off a slender branch that passes to the outer angle of the orbit. The *malar nerve* passes along the inferior angle of the orbit, emerges thru the foramen in the malar bone, thru the orbicularis muscle, and supplies the prominent part of the cheek, where it becomes the subcutaneous malae. It receives branches from the superior maxillary, namely, the facial and palpebral.

The *sphenopalatine* are two in number and descend to the sphenopalatine ganglion.

The *posterior superior dental* arise just before the nerve enters the infra-orbital canal. They are usually two in number and pass downward to the tuberosity of the maxilla. They give off several small branches to the gums and mucous membrane of the cheek, enter the posterior dental canal, communicate with the middle dental nerve and give off small filaments to each molar tooth.

The *middle superior dental* is one of the third division given off in the back part of the infraorbital canal. It runs forward in a special canal and supplies the two bicuspid teeth. Above the root of the bicuspid tooth, is the *Valentin ganglion* where it forms the communication with the posterior dental nerve. Its connection with the anterior branch is called *Bochdalek's ganglion*.

The *anterior superior dental* is a large branch and divides into a series of small fibres, which supply the incisor and canine teeth. It communicates with the middle dental and also gives off a nasal branch, which supplies the mucous membrane of the forepart of the meatus, joining with the nasal branches from the sphenopalatine ganglion.

The branches of the fourth division of the maxillary nerve are the *palpebral*, *nasal* and *labial*. The *palpebral branches* pass upward beneath the orbicularis palpebrarum muscle and supply the conjunctiva of the lower eyelid, uniting with the facial nerve. The *nasal branches* pass inward and supply the side of the nose, and join with the nasal of the ophthalmic division. The *labial branches*, the largest of this last division, are distributed thru the integument of the upper lip the mucous membrane of the mouth, and the labial glands. All the above branches are joined by filaments from the facial nerve, forming the infraorbital plexus.

Meckel's ganglion, also called the **spheno-palatine ganglion**, is deeply placed in the sphenomaxillary fossa; it is triangular in shape, of a reddish-gray color, and is situated below the superior maxillary nerve; it has motor, sensory and peripheral roots. Its sensory root is received thru the sphenopalatine branches of the superior maxillary; its motor root is derived from the large superficial petrosal nerve; and its peripheral connection thru the carotid plexus. The two latter branches form the **vidian nerve**, which enters the superior posterior part of the ganglion.

The **branches of Meckel's ganglion** are divided into the *ascending* or *orbital*, *descending* or *palatal*, *internal* or *nasal*, and *posterior* or *naso-*

THE NERVOUS SYSTEM

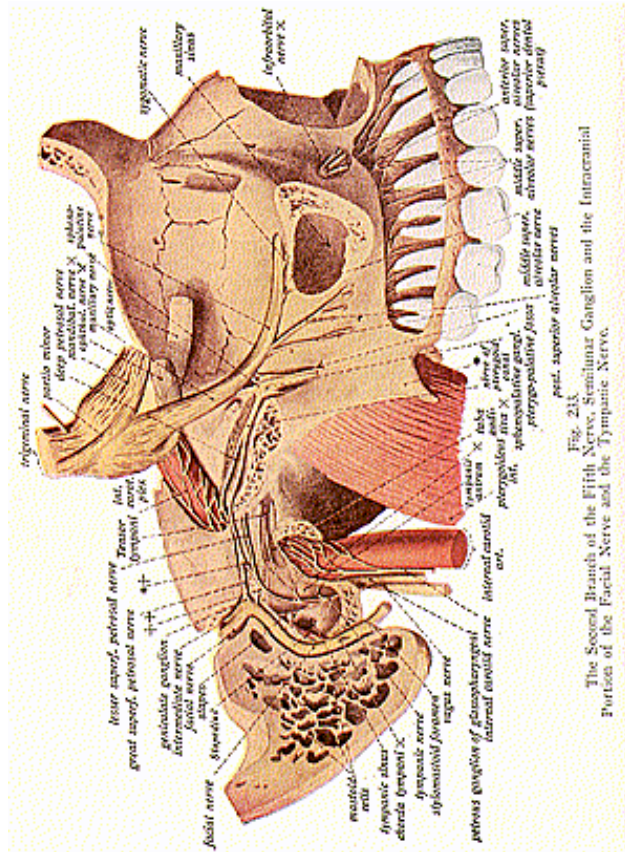


Fig. 213
The Second Branch of the Fifth Nerve, Semilunar Ganglion and the Intracranial Portion of the Facial Nerve and the Tympanic Nerve.

pharyngeal. The branches of the first division are very small filaments that supply the superior and inferior tarsal muscles and the membrane of the posterior ethmoidal and spheroidal sinuses. The *palatine branches* are divided into the posterior, middle and anterior. The anterior, supplies the hard palate and unites, in front, with the nasal nerve. The middle palatine supplies the uvula, tonsil and soft

palate. The posterior, supplies principally the soft palate. The middle and posterior, join with the glosso-pharyngeal and form the plexus about the tonsil. The *internal branches* are the *superior nasal* and *nasal palatine*, distributed over the back part of the nasal fossa. The *posterior branch* is distributed in the mucous membrane of the upper part of the pharynx, behind the Eustachian tube.

The **inferior maxillary** is the lowest division of the tri-facial nerve and is spoken of as the **mandibular**. It is distributed to the teeth and gums, the temple, external ear, lower part of the face and lips, to the muscles of mastication, and to the tongue. It is the largest of the three divisions of the tri-facial, being formed by a large sensory, and a small motor root. It leaves the cranium, thru the foramen ovale, and divides into the anterior and posterior branches. Before its division, it gives off a recurrent meningeal and the internal pterygoid. The internal pterygoid nerve is a long, slender branch and supplies the internal pterygoid muscle.

The **anterior branch** of the inferior maxillary is the smaller of the two and receives nearly all the branches or fibres of the motor root. The branches that supply principally the muscles of mastication, are the *masseteric*, *deep temporal*, *buccal*, and *external pterygoid*. The *deep temporal* divides into the anterior and posterior, and supplies the surface of the temporal muscle. The *buccal* divides into the superior and inferior; the superior supplies the integument and the upper part of the buccinator muscle; the inferior supplies the inferior portion of the muscle and also the mucous lining of the cheek, and joins with the facial nerves.

The *masseter branch* passes above the external pterygoid, behind the tendon of the temporal muscle, crosses the sigmoid notch, and gives off a branch to the temporo-mandibular joint.

The *external pterygoid nerve* is usually derived from the buccal, but may be given off as a separate branch from the inferior maxillary.

The **posterior division** of the inferior maxillary is the larger and is, for the greater part, a sensory nerve, altho it receives a few motor filaments. It divides into three branches, namely: the *auriculo-temporal*, *lingual* and *inferior dental*. The *auriculo-temporal* usually arises by two roots, between which passes the meningeal artery. It goes to the inner side of the neck and mandible, turns upward between the external auditory canal and condyle of the mandible, under the parotid gland and divides, at about the zygoma, into two temporal branches. It communicates with the otic ganglion and with the facial nerve.

The branches of the auriculo-temporal are the **anterior auricular**, **articular**, **parotid**, **superficial temporal**, and **filaments** given off to the external auditory meatus. The anterior auricular branches, usually two in number, supply the upper part of the pinna, also the skin of the helix and tragus. The parotid branches innervate the parotid gland. The superficial temporal branches accompany the temporal artery to the vertex of the skull, supply the temporal region and communicate with the facial and the temporo-malar filaments. The branches that pass to the external auditory meatus are two in number, found between the bony and cartilaginous portion, supplying

THE NERVOUS SYSTEM

the lining of the meatus and sending a small filament to the membrana tympani.

The *lingual nerve*, supplying the mucous membrane and the papillae of the anterior two-thirds of the tongue, lies deeply in the tissue of the tongue and communicates with the inferior dental, the hypoglossal and the submaxillary ganglion. Its branches of distribution supply the sublingual gland, the mucous membrane of the tongue, and portions of the mouth.

The *inferior dental* division is the largest of the three branches of the inferior maxillary nerve. It passes, between the internal lateral ligament and the ramus of the mandible, into the dental canal, thru here as far as the mental foramen, where it divides into two branches, the incisor and mental. The incisor supplies the canine and incisor teeth, the mental supplies the molar and bicuspid. There are two other branches, given off from the inferior dental, namely the mylohyoid and mental. The mylohyoid passes under the muscle and supplies the anterior part of the digastric. The mental gives off two or three small branches, one supplies the skin of the chin, another the mucous membrane of the lower lip.

The trigeminal nerve is connected directly with the spinal nerves in the upper cervical region. The ophthalmic is joined in the cavernous sinus by branches from the cavernous plexus. It also communicates with the oculomotor and abducent, which in turn are connected with cervical nerves. The middle division communicates with the carotid plexus and the facial nerve. The mandibular division also communicates with the facial and, thru the otic ganglion, with the peripheral plexuses. Aside from the above mentioned connection the ganglia associated with the trigeminal are connected to the glosso-pharyngeal. Thru this and its several communications with the facial and motor oculi, its branches supply many important organs.

The **otic** or **Arnold's ganglion**, is a small oval-shaped, reddish body, situated below the foramen ovale, on the inner surface of the inferior maxillary nerve. It is connected to the internal pterygoid by two or three small filaments. It communicates with the glosso-pharyngeal, thru the small superficial petrosal nerve, and also communicates here with the facial. It is connected to the peripheral system by a filament from a plexus that surrounds the middle meningeal artery. From the ganglion is given off the spheroidal filament to the vidian nerve. It gives off the tensor palati and tensor tympani branches.

The **sub-maxillary ganglion** is small and fusiform in shape, situated above the sub-maxillary gland. It is joined to the lingual nerve by two small filaments, and communicates with peripheral branches around the facial artery. Its branches of distribution are several, arising from the lower border of the ganglion; they supply the mucous membrane of the mouth, the submaxillary and sublingual glands, also portions of the tongue.

THE ABDUCENS NERVES

The **sixth pair of cranial nerves** is known as the **abducens** or abducent, and supply the external recti muscles of the eyeball. Each

THE NERVOUS SYSTEM

nerve arises, superficially, between the pons and the pyramid, having the deep origin in the floor of the fourth ventricle, close to the median line. There are said to be fibres from the nucleus of the sixth nerve passing to the oculomotor on the opposite side, which then are carried to the internal rectus muscle. Thus we may say that the **external** and the **internal** recti muscles receive impulses from the same nucleus. The sixth nerve pierces the dura mater at the base of the sphenoid bone, runs thru a notch below the clinoid process and enters the cavernous sinus. It enters the orbit, thru the spheroidal fissure passes between the heads of the external rectus muscle, and is distributed on the ocular surface of this muscle. This nerve is joined by several filaments from the cavernous plexus and by a branch from the ophthalmic division of the trigeminus, thus establishing communication with the cervical spinal nerves.

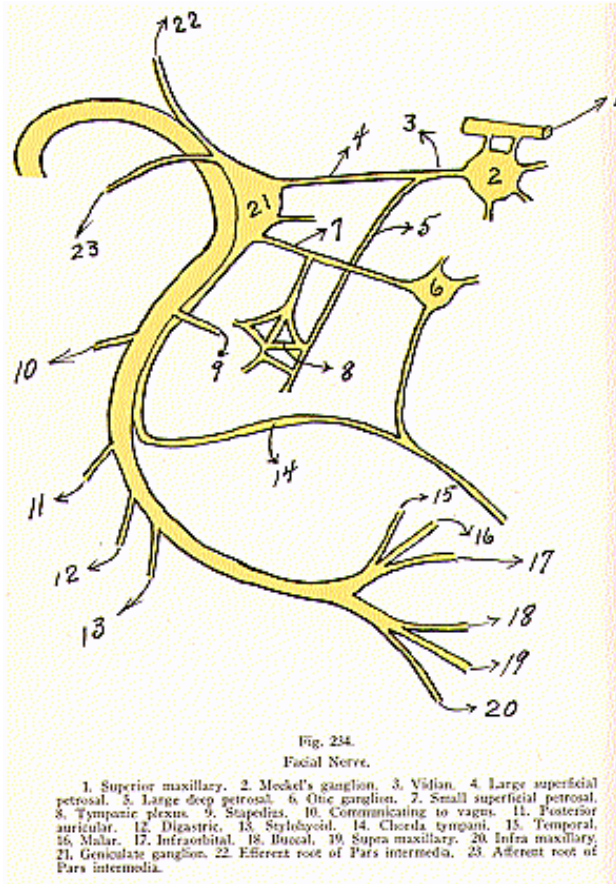
THE FACIAL NERVES

(Illustration No. 234.)

The **seventh nerve** is known as the **facial**. It is the motor nerve of the muscles of expression, of the platysma, the buccinator, the muscles of the external ear, the posterior part of the digastric and the stylohyoid. It arises, superficially, from the medulla, between the olivary and restiform bodies; its deep origin is found in the floor of the fourth ventricle. The branches of communication of the facial nerve may be arranged in the following way: In the internal auditory meatus, it unites with a branch of the acoustic, also called the auditory; from the geniculate ganglion it connects with the sphenopalatine ganglion by the large superficial petrosal, and with the otic ganglion by the small superficial petrosal. It gives off the intermediate nerve, which ends in the glosso-pharyngeal nerve; also a branch that passes to the sublingual ganglion and one that leads to the tympanic plexus. It communicates, in the Fallopian aqueduct with the auricular branch of the vagus and, at its exit from the stylomastoid foramen, with the glosso-pharyngeal. Behind the ear it receives a branch from the small occipital, and communicates in the neck with the superficial cervical. At the point where the facial nerve changes its direction in the aqueduct of Fallopius, is a reddish gangliform swelling, the **geniculate ganglion**.

The **branches of distribution** within the Fallopian aqueduct are the *tympanic* and the *chorda tympani*. The *tympanic* arises from the nerve opposite the pyramids and supplies the stapedius muscle. The *chorda tympani*, given off at the back of the tympanum, passes down along the lingual nerve where, seemingly, it receives fibres from the otic ganglion; thence passing downward, it gives off efferent branches to the sub-maxillary ganglion and to the sub-lingual gland. The remaining nerves of distribution are given off at its exit from the stylo-mastoid foramen. They are the *posterior auricular*, *digastric* and *stylohyoid*. The *auricular nerve* divides into the auricular and occipital branches. The auricular supplies the small muscles on the cranial surface of the pinna. The occipital, or larger branch, passes along the superior curved line of the occipital bone and supplies the occipito-frontalis. The *digastric* usually arises in common with the stylohyoid

THE NERVOUS SYSTEM



THE NERVOUS SYSTEM

branch. It divides into several filaments, which supply the posterior part of the digastric muscle; one piercing the muscle and uniting with the glosso-pharyngeal. The *stylohyoid* supplies the stylohyoid muscle.

On the face, the branches of the seventh nerve are divided into the **temporo-facial** and **cervico-facial**.

The **temporo-facial** are the *temporal*, *malar* and *infra-orbital*. The *temporal branches* supply the muscles of the ear, and join with the branches of the temporo-malar, from the superior maxillary; and also with the auriculo-temporal, from the inferior maxillary. The anterior branches supply the occipito-frontalis and corrugator supercilii, and join with the supra-orbital and lacrimal branches of the ophthalmic. The *malar branches* pass to the outer angle of the orbit, join with the filaments of the lacrimal nerve, and supply the lower eyelid and the orbicularis palpebrarum muscle. These fibres unite with the malar branch of the superior maxillary. The *infraorbital* are the superficial and the deep. The superficial supply the muscles of the face and the pyramidalis nasi; and join with the infra-trochlear and nasal branches of the ophthalmic. The deep ones supply the levator labii muscles and give off small branches to the nose. These form the infra-orbital plexus, by joining with the infra-orbital of the superior maxillary and with the buccal branches of the cervico-facial.

The **cervico-facial division** is comprised of the *buccal*, *supra-maxillary* and the *infra-maxillary*. The *buccal branches* cross the masseter, supply the buccinator and the orbicularis oris, and join with the infra-orbital branches of the temporo-facial division and with filaments from the inferior maxillary. The *supra-maxillary* supplies the muscles of the lower lip and integument of the chin, communicating with the mental branch of the inferior dental. The *infra-maxillary* forms a series of arches over the side of the neck in the supra-hyoid region. It communicates with cervical nerves from the cervical plexus and supplies the platysma myoides.

THE AUDITORY NERVES

Each **auditory** or **eighth cranial nerve**, also called the **acoustic** nerve, is composed of two distinct sets of fibres, which are very closely blended together. The two divisions are the **cochlear** and the **vestibular**. The fibres of the **cochlear nerve** are the axones of the bipolar cells that terminate in the hair cells of the organs of Corti, and are the nerves of the special sense of hearing. The **vestibular nerve** innervates the semi-circular canals, utricle and saccule. At its periphery it is divided into the utriculo-ampullar and the sacculo-ampullar. The upper branch divides into the utricular, the superior ampullar, and the lateral ampullar. The lower branch divides into the posterior ampullar and the saccular branches.

THE GLOSSOPHARYNGEAL NERVES

The **ninth cranial nerve** is the **glossopharyngeal** and is distributed over the tongue, pharynx, fauces and tonsils. Its superficial origin is by three or four filaments from the upper part of the medulla

THE NERVOUS SYSTEM

oblongata. It leaves the skull at the central part of the jugular foramen, and passes below the styloid process of the temporal bone to the lower border of the stylo-pharyngeal muscle. It has two ganglia, or enlargements, in the region of the jugular foramen: the upper, smaller one, known as the jugular; the lower, as the petrous ganglion, or Ganglion of Andersch.

The ninth nerve is connected to the vagus by a branch from the lower or petrous ganglion; and this, in turn, is connected with the superior cervical ganglion of the peripheral system. A branch arising from the trunk of the nerve below the petrous ganglion, communicates with the facial nerve. The branches of distribution of the nerve proper are: the *tympanic*, *carotid*, *pharyngeal*, *muscular*, *tonsillar* and *lingual*.

The *tympanic branch* arises from the petrous ganglion, ascends to the tympanum and divides into small filaments, forming the tympanic plexus. The *carotid branches* descend, with the internal carotid artery, communicating with the pharyngeal branch of the vagus and with branches of the peripheral system. The *pharyngeal branches* three or four in number, unite with the pharyngeal of the vagus and peripheral fibres to form the pharyngeal plexus, which gives off small filaments that supply the muscles and mucous membrane of the pharynx. The *muscular branch* supplies the stylopharyngeus muscle. The *tonsillar branches* form the tonsillar plexus, and give off branches to the soft palate and the fauces; they communicate with the palatine nerve. The *lingual branches* are two in number; one supplies the circumvallate papillae and the mucous membrane of the posterior part of the tongue; the other branch communicates with the lingual nerve.

THE PNEUMOGASTRIC NERVES

The **tenth nerve** is known as the **vagus** or **pneumogastric**. Its distribution is more extensive than that of any other cranial nerve. It is composed of both motor and sensory fibres, and supplies the organs of voice, respiration, the pharynx, esophagus, stomach and heart.

It arises, superficially, by eight to ten filaments, between the olivary and restiform bodies. It emerges from the skull thru the jugular foramen, where it accompanies the spinal accessory in a sheath of dura mater. In this part it presents the superior or jugular ganglion. To this ganglion is connected the spinal accessory, by one or two filaments. Below the foramen it forms the inferior ganglion to which the principal part of the spinal accessory fibres are joined and are from here distributed. Some few filaments are continued with the vagus and form a part of the recurrent laryngeal and cardiac nerves.

The vague, on each side, passes vertically down the neck, between the internal carotid and jugular veins, to the thyroid cartilage, and then, between the jugular vein and the common carotid artery, to the root of the neck. The right vagus crosses the subclavian artery, to the trachea and the root of the right lung, where it assists in

forming the posterior pulmonary plexus; from thence two cords descend upon the esophagus, where they divide and communicate with branches of the other side, forming the esophageal plexus. Below this plexus, the nerves are collected into a single bundle, running along the back part of the esophagus, and, entering the abdomen, are distributed over the posterior surface of the stomach and are found joining with the left side of the solar plexus.

The **left vagus nerve** enters the thorax, between the left carotid and subclavian arteries, crosses the arch of the aorta and passes behind the root of the lung, and helps to form the posterior pulmonary plexus; farther down it unites with the branch of the opposite side, to assist in forming the esophageal plexus. It passes from here to the anterior portion of the stomach, distributing filaments over the fundus and others along the lesser curvature. Some few fibres pass to the gastrohepatic omentum, there joining other nerves, together forming the hepatic plexus.

The **branches of distribution** are divided into three classes: those in the jugular fossa; those in the neck; and those in the abdomen. Of the first division there are the *meningeal* and the *auricular*. The *meningeal* is a recurrent filament that passes to the dura mater lining the poster part of the base of the skull. The *auricular branch* is joined by a filament from the glosso-pharyngeal and above the facial canal, gives off an ascending branch that joins with the facial. The continuation of this nerve passes between the mastoid process and the external auditory meatus. Here it divides into two filaments, one communicating with the posterior auricular nerve, the other innervating the back part of the pinna and the posterior part of the external auditory meatus.

The first branch of the second division is the *pharyngeal*. It is the principal motor nerve of the pharynx. It divides into several filaments, and, together with fibres of the glossopharyngeal and other nerves, forms the pharyngeal plexus, from which branches are distributed to the mucous membrane, soft palate and tensor palati muscle. Here it gives off a small filament that joins with the hypoglossal nerve. The superior pharyngeal nerve receives a branch from the superior cervical ganglion, and divides into the internal and the external branches. The external is the smaller and supplies the crico-thyroid muscle; it communicates with the superior cardiac nerve. The internal laryngeal and pharyngeal supply the mucous membrane of the larynx, some branches to the epiglottis and base of the tongue.

The *inferior recurrent* is the motor nerve of the larynx. On the right side, it arises in front of the subclavian artery on the left, in front of the arch of the aorta. It gives off several filaments, known as the cardiac, that unite with the cardiac fibres of the vagus proper and the peripheral. It gives off the esophageal branches to the muscular coat of the esophagus; tracheal branches to the trachea, and pharyngeal branches to the inferior constrictor muscles of the pharynx. The cervical cardiac branches arise at the upper and lower parts of the vague, in the cervical region. The superior ones communicate with the cardiac of the peripheral system and form a part of the deep cardiac plexus. The inferior branches help to form the

THE NERVOUS SYSTEM

deep cardiac plexus, and also send some filaments to the superficial cardiac plexus.

The first nerves of the third division are the *thoracic cardiac* branches, on the right and left sides. On the right, they communicate with the recurrent laryngeal; on the left, they terminate in the deep cardiac plexus.

The *anterior pulmonary branches* are two or three in number, distributed over the anterior portion of the root of the lung; communicating with filaments from other nerves, they form the anterior pulmonary plexus. The *posterior pulmonary branches*, distributed over the posterior root of the lung and joined by filaments from the third and fourth thoracic ganglia, together form the posterior pulmonary plexus. The **esophageal branches** are given off below, and above, the **pulmonary branches**; they form, from opposite sides, the esophageal plexus.

The **gastric nerve** forms the terminal filaments of the vague. On the right side, it is distributed over the posterior part of the stomach and sends branches to the coeliac plexus, splenic plexus and renal plexus. On the left side, it is distributed over the anterior portion of the stomach. Here it unites with filaments from the right nerve also with peripheral fibres, and gives off branches that pass thru the lesser omentum to the hepatic plexus.

THE SPINAL ACCESSORY NERVES

The **eleventh** or **spinal accessory nerve** consists of two parts: one the accessory to the vague, the other the spinal portion. The vagal accessory is the smaller part, arising, superficially, by three or four filaments below the origin of the vague. It is connected, in the jugular foramen, to the upper ganglion of the vague, passes thru the foramen and is distributed to the pharyngeal and laryngeal regions, in company with similar branches of the vague.

The spinal portion of this nerve arises from the lateral portion of the cord, as low down as the sixth cervical nerve. It passes upward thru the foramen magnum, then out thru the jugular foramen, where it receives filaments from the vagal accessory. It passes thru the sterno-mastoid muscle and gives off branches to this muscle. It receives filaments from the second and third cervical nerves, and, beneath the trapezius muscle, it forms a plexus with fibres from the third and fourth cervical nerves, from this plexus being distributed to the muscle.

THE HYPOGLOSSAL NERVES

The **twelfth** or **hypoglossal** is the motor nerve of the tongue. It arises by several filaments, from ten to fifteen in number, between the pyramid and olivary body, its deep origin being found in the floor of the fourth ventricle. The filaments of this nerve are collected into bundles. In some cases the hypoglossal foramen is double and in such cases the two parts of the nerve are separated by a small piece of bone. The nerve is first deeply placed below the internal carotid artery and connected with the vague. Below the digastric muscle, it

becomes superficial. It communicates with the vague, close to its exit from the skull, and with a small nerve from the pharyngeal plexus.

Branches of communication with the peripheral are from the superior cervical ganglion; also, somewhat lower down, small fibres from the first and second cervical nerves connect with it. It also communicates with a branch of the lingual. Its branches of distribution are the **meningeal, descendens hypoglossi, thyrohyoid** and **muscular**. The meningeal branches pass to the dura mater of the posterior fossa of the base of the skull. The descendens hypoglossi is a long, slender filament, consisting mainly of fibres which pass to it from the first and second cervical nerves. This nerve gives off branches to the sternohyoid, sternothyroid and omohyoid muscles. The thyrohyoid is a small branch that supplies the thyrohyoid muscle. The muscular branches pass to various muscles in the hyoid region, and small, slender filaments pass to the intrinsic muscles of the tongue.

COMMUNICATIONS OF THE LAST SIX CRANIAL NERVES

The **seventh** or **facial nerve** communicates with the auditory and the pars intermedia, in the inner auditory meatus. It connects, by the large superficial, with the sphenopalatine or Meckel's ganglion; with the otic ganglion, by the small superficial petrosal. These branches to the above ganglia are derived from the geniculate ganglion of the facial nerve. It also communicates with the auricular branches of the vague, with the ganglion of the trunk of the vague, with the great auricular from the anterior cervical plexus, with the small occipital from the ascending division of the anterior cervical plexus, and with superficial cervical nerves. With the mandibular branch of the trifacial, this nerve establishes a communication thru the auriculotemporal; and, aside from this communicates with all three divisions of the fifth nerve by means of its peripheral fibres.

The **auricular nerve** receives filaments from the pars intermedia and gives off communicating branches to the geniculate ganglion of the facial.

The **ninth** or **glossopharyngeal** communicates with the tympanic plexus, the auricular branch of the vague, and with the superior cervical ganglia of the peripheral system. Aside from the above three communications, it establishes another with the facial just at its exit from the stylomastoid foramen.

The **vagus nerve** communicates, by branches from the ganglia of the root, with the peripheral system and with the glossopharyngeal and spinal accessory nerves. By filaments from the ganglia of the trunk, it communicates with the superior cervical ganglia, with the spinal accessory, with the hypoglossal and with a cervical loop between the first and second cervical nerves.

The **eleventh** or **spinal accessory** communicates, by a small branch, with the ganglion of the root; and, by a large branch, with the ganglion of the trunk of the vague. After establishing communication with the vague, the spinal accessory portion of it communicates with nerves from the cervical region that supply the sternomastoid and trapezius muscles.

The **twelfth**, or **hypoglossal nerve**, communicates with the ganglion of the trunk of the vague, the superior cervical ganglion, and with the first cervical loop. At its periphery in the tongue, its fibres form a plexus with those of the lingual nerve.

SPINAL NERVES

(Illustrations Nos. 228, 229 and 235.)

The **spinal nerves** are thirty-one pairs in number, divided into seven cervical,* twelve dorsal, five lumbar, five sacral and two coccygeal. Sometimes the second coccygeal is found wanting, making only thirty pairs. The first pair of the spinal nerves arises between the occipital bone and the atlas; the last pair, the coccygeal, is formed by small fibres arising from the last sacral nerves. The last four sacral nerves emit thru the sacral foramina, while the first coccygeal nerve comes out at the lower extremity or apex of the sacrum. All the remaining spinal nerves emerge thru the intervertebral foramina.

The **first pair** of spinal nerves is given off at right angles to its point of origin in the spinal cord, while the exit of the second pair is a little lower than its origin, and so with every succeeding pair. As we progress down the cord the distance becomes greater and greater between the point of exit from the cord and the point of exit from the spinal canal. The lowest point of the cord is reached in the lower dorsal and upper lumbar regions; from this point of termination, the nerves emitting from the lumbar, sacral, and coccygeal foramina are given off from the spinal cord. This arrangement of nerve fibres is known as the cauda equina or horse's tail, because of the manner in which they are spread out and separated, one from another.

There are, principally, two kinds of nerve fibres comprising the spinal nerves, known as the **motor** and **sensory**. The **motor nerves** are spoken of as the efferent or descending, while the other class is

***Author's Note.**—It seems of advantage to deviate from the customary recognition of eight cervical pairs of nerves, and we take the liberty of so doing in order that the vertemere may in every case consist of a vertebra and its corresponding superior pair of spinal nerves. (See Mere and Vertemere.)

Fig. 235.

Anterior View of the Pons, Medulla, Spinal Cord, Spinal Nerves

1. Internal carotid artery. 2. Internal jugular vein. 3. Intercostal arteries and veins. 4. Pons Varolii. 5. Trifacial nerve. 6. Abducens nerve. 7. Facial and auditory. 8. Glosso-pharyngeal nerve. 9. Accessory nerve. 10. Pneumogastric nerve. 11. Hypoglossal nerve. 12. Ramus descendens of hypoglossal nerve. 13. Medulla. 14. Decussation of pyramids. 15. The cervical part of the spinal cord. 16. Thoracic portion, spinal cord. 17. Bulbous expansion of spinal cord. 18. Filum terminale. 19. Cervical nerve. 20. Eighth cervical nerve. 21. Cervical plexus. 22. Brachial plexus. 23. First dorsal nerve. 24. 12th dorsal nerve. 25. Intercostal nerve. 26. Lumbar nerve. 27. Fifth lumbar nerve. 28. Lumbar plexus. 29. Anterior crural nerve. 30. Ilio-inguinal nerve. 31. Ilio-hypogastric nerve. 32. Inguino-cutaneous. 33. Obturator nerve. 34. Sacral nerve. 35. Fifth sacral nerve. 36. Sacral plexus. 37. Coccygeal nerves. 38. Divisions from spinal nerves. 39. Superior cervical ganglion. 40. Middle cervical ganglion. 41. Inferior cervical ganglion. 42. Thoracic ganglia. 43. Lumbar ganglion. 44. Sacral ganglion. 45. Coccygeal ganglion. 46. Connecting nerves. 47. Great sacro-sciatic. 48. Inguinal nerve

THE NERVOUS SYSTEM

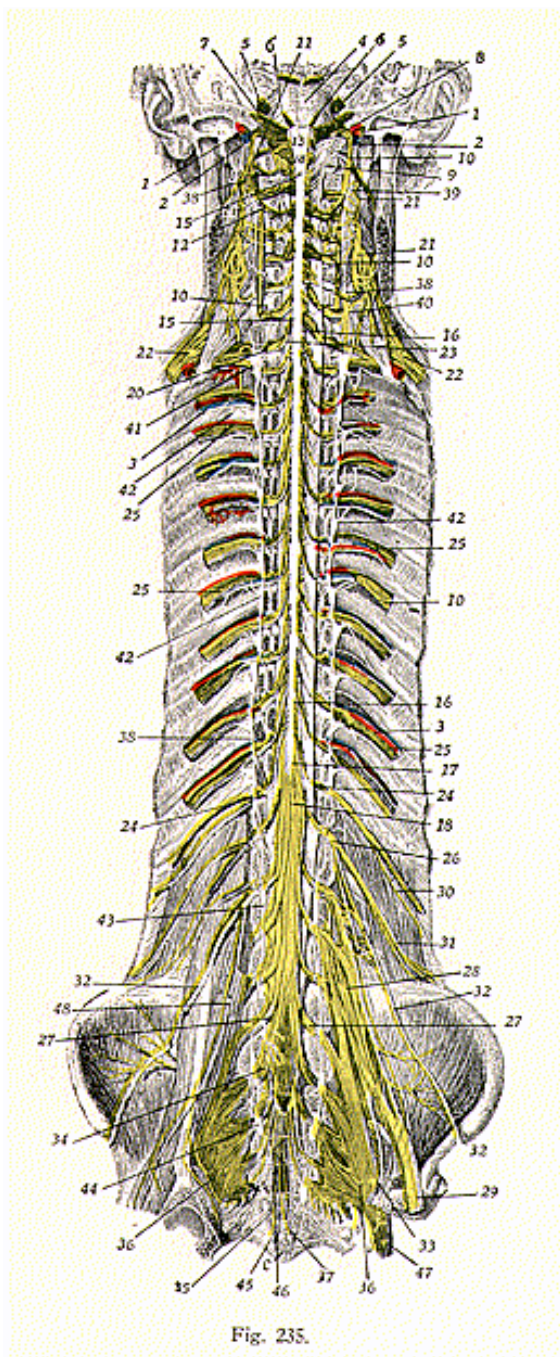


Fig. 235.

known as the **afferent** or **ascending**. The first kind are prolongations of the brain-cell, extending to tissue cell; while the second carry impulses in the opposite direction. All the spinal nerves have their origin in the cerebral hemispheres and pass down in converging bundles thru the crura cerebri into the pons, thence to the medulla, some crossing here and others continuing in a straight course downward thru the foramen magnum into the spinal cord.

Each **spinal nerve** is formed from **two roots**, the **anterior** and **posterior**. The **anterior** or **motor roots** arise from the anterior, short horns of the spinal cord, while the **posterior** or **sensory** have their origin in the posterior, long horns. Along the entire surface of the spinal cord, over the anterior and the posterior horns, there arise numerous minute fibres. Those in the region of a certain foramen are gathered, those on the posterior to form the posterior root and those on the anterior to form the anterior root, and the two are united to form a spinal nerve, emitting from a single foramen on either side.

After each of these single nerves emits thru the intervertebral foramen, it divides into two branches, known as the anterior and posterior primary. Sometimes these branches are known as the internal and external.

POSTERIOR DIVISIONS OF THE SPINAL NERVES

(Illustration No. 236.)

All the **posterior divisions of the spinal nerves** further bifurcate, into **internal** and **external branches**, except the first cervical, fifth sacral, and two coccygeal.

The **first cervical posterior root** is larger than the anterior one and emits between the occipital bone and the atlas. It supplies the oblique muscles and the complexus, also giving off a small filament to connect with the posterior division of the second nerve.

The *posterior division of the second cervical nerve* is also larger than the anterior, and divides into internal and external branches. The internal branch forms the great occipital, which joins with the third posterior division. The **great occipital** pierces the integument at the base of the skull and supplies the scalp over the posterior, as far as the vertex. The great occipital gives off the transverse auricular, back of the pinna, which supplies the external auditory canal and the pinna. The external division supplies muscles in the posterior upper part of the neck.

The *posterior division of the third cervical nerve* is smaller than that of the first and larger than that of the second. The internal division becomes the third or **least occipital**, while the external is **muscular**.

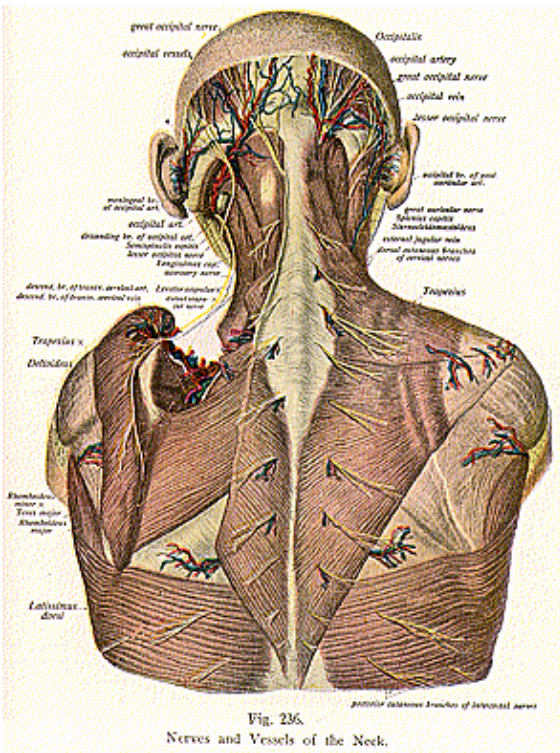
The first three posterior divisions are connected by a series of loops forming the **posterior cervical plexus**.

Each of the last four cervical and the first dorsal posterior divisions is bifurcated into internal and external branches, supplying the posterior and external lateral muscles of the neck.

The *posterior divisions of the dorsal nerves* are all smaller than the corresponding anterior divisions, but increase somewhat in size from the first to the twelfth. Each of these nerves divides into internal and external branches, and gives off a cutaneous filament, arising from

THE NERVOUS SYSTEM

the posterior primary of the upper six, and from the **external divisions** of the lower six. All these branches are principally for the supply of muscles and skin over the posterior thoracic region.



The *posterior divisions of the lumbar nerves* diminish in size from above downward and all divide into internal and external branches. The four upper external divisions give off cutaneous filaments.

THE NERVOUS SYSTEM

The *sacral nerves* also diminish in size from above downward, the last four emitting thru the posterior sacral foramina and the first at the base of the sacrum. The first four of these nerves are divided into internal and external portions and, at their points of exit from the sacrum, are connected by a series of loops, thus giving rise to the **posterior sacral plexus**. The last sacral and the first coccygeal nerves do not divide, but unite with each other, and then with the second coccygeal, to form the posterior sacro-coccygeal nerve.

ANTERIOR DIVISIONS OF THE SPINAL NERVES

(Illustration No. 237.)

The **anterior primary divisions** are, for the most part, larger than the posterior, and supply the lateral and anterior portions of the trunk; also the upper and lower extremities. In the dorsal region they run independently of each other, but in the other regions of the spine they form intricate plexuses.

The *anterior primary divisions of the first four cervical nerves* unite to form the anterior cervical plexus, which is found opposite the first four cervical vertebrae, resting upon the levator anguli scapulae and scalenus medius muscles, covered over by the sterno-cleido-mastoid muscle.

The **branches** of this plexus are divided into two groups, namely: the **superficial** and the **deep**. The superficial are further sub-divided into the *ascending*, *transverse* and *descending*. Of the ascending branches we have the **small occipital** and **great auricular**.

The **small occipital**, or **occipitalis minor**, perforates the deep fascia and runs upward behind the ear, communicating with the great occipital, great auricular, and the posterior auricular division of the seventh, or facial cranial nerve. It is divided into three branches known as the *occipital*, *mastoid* and *auricular*. The *occipital* supplies the integument at the posterior part of the base of the skull; the *mastoid* supplies the integument covering the mastoid process of the temporal bone; and the *auricular* supplies the external ear.

The **great auricular**, or **auricularis magnus**, is the largest of the ascending branches. It passes beneath the platysma myoides muscle, to the parotid gland and communicates with the seventh or facial nerve. It divides into three branches, known as the *auricular*, *mastoid* and *facial*. The *auricular* supplies the ear, and, by small filaments communicates with the vague. The *mastoid* supplies the integument behind the ear, over the region of the mastoid process. The *facial* passes to the angle of the mouth.

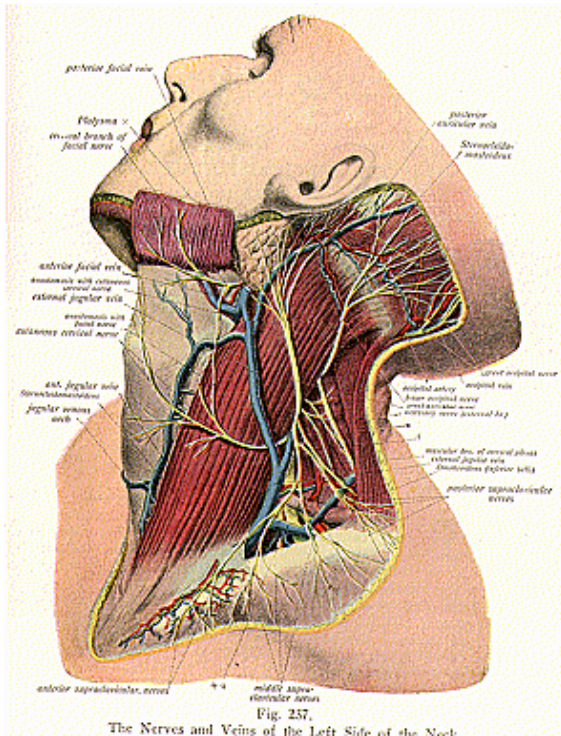
Of the descending branches there are the **sternal**, the **acromial** and the **clavicular**. The **sternal branches** supply the sternal and clavicular attachments of the sterno-cleido-mastoid muscle and the sterno-clavicular joint. The **clavicular branches** supply the pectoral and deltoid muscles, and communicate with the intercostals. The **acromial branches** supply the outer surface of the trapezius and the integument of the upper and back part of the shoulder.

Of the **deep branches of the anterior** cervical plexus we have several small filaments that communicate with the vague, hypoglossal and other nerves. The deep muscular, supply the anterior and lateral

THE NERVOUS SYSTEM

recti muscles. Of this division, there are also the communicantes hypoglossi, which consist of two small branches that unite to join the descendens cervicalis.

The **phrenic nerve** of the muscular division is known as the **inter-**



nal respiratory nerve of Bell, and arises, chiefly, from the fourth cervical nerve. It descends to the root of the neck, across the front of the scalenus anticus muscle, passes over the first part of the sub-

THE NERVOUS SYSTEM

clavian artery and enters the thorax near the origin of the mammary artery. In the thorax, it descends in front of the root of the lung, between it and the pericardium, to the diaphragm, where its filaments are distributed.

The right phrenic nerve is situated more deeply and is shorter than the left. Branches from this nerve form a ganglion, from which they are distributed to the phrenic plexus. On the left, there is no ganglion and the branches communicate directly with the phrenic plexus. Both the right and the left phrenic nerves give off branches of distribution to the lungs and pleura.

Many muscular branches of this division are distributed to the sterno-cleido-mastoid, trapezius, levator anguli scapulae, the scalenus medius, and deltoid muscles.

THE BRACHIAL PLEXUS

(Illustrations Nos. 238, 239, 240 and 241.)

The **brachial plexus** is an intricate interlacement of nerve fibres formed by the union of the anterior primary divisions of the three lower cervical, and the greater part of the first and second dorsal, nerves. This plexus extends from the lower side of the neck to the axilla and divides, opposite the coracoid process, into numerous branches which supply all the structures of the upper extremity. All the nerves, forming this plexus, are of a general size, which is usually uniform, but the communication between them varies in different individuals so that no one definite plan can be given to this arrangement. The **plexus** consists usually of **three trunks**, the **upper** formed by the fifth and sixth cervical nerves, the **middle** by the seventh cervical, and the **lower** by the first and second dorsal branches. As they pass beneath the clavicle, each trunk divides into anterior and posterior parts. The anterior portions of the middle and upper trunks unite to form the outer cord; the anterior portion of the lower trunk forms the inner cord; while the posterior portions all unite to form the posterior cord.

The *branches of distribution of the brachial plexus* are divided into the **supra-** and the **infraclavicular divisions**. Of the **supraclavicular** division we have the *communicating* and the *muscular branches*. The *communicating branch*, with the phrenic, is derived usually from the fifth cervical or from a loop between the fifth and sixth, joining the phrenic on the anterior scalenus muscle.

The *muscular branches* are seven in number. The first is the *posterior scapular*. It arises from the fifth cervical, passes beneath the levator anguli scapulae and supplies the rhomboid muscles.

The **external respiratory nerve of Bell** or **posterior** or **long thoracic**, supplies the serratus magnus muscle. This nerve is very long and usually arises by roots from the fifth and sixth cervical nerves, sometimes from the seventh cervical nerve. It passes down behind the brachial plexus, along the side of the thorax, to the lower border of the serratus magnus.

The **suprascapular** nerve arises from the trunk formed by the fifth and sixth cervical nerves, passes out beneath the trapezius and omo-hyoid muscles, enters the suprascapular fossa, thence around the

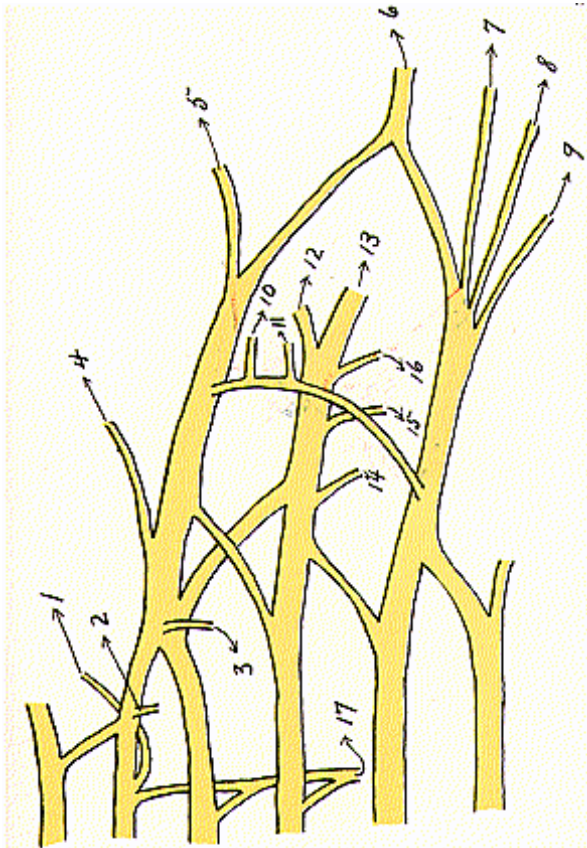


Fig. 238.

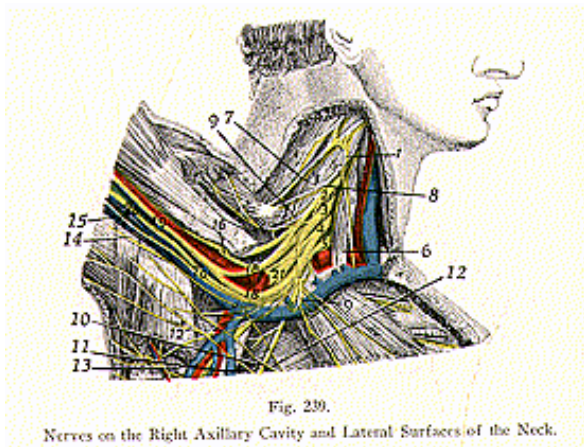
Brachial Plexus.

1. Rhomboid, 2. Root of Phrenic, 3. Subclavian, 4. Suprascapular, 5. Musculo-cutaneous, 6. Median, 7. Ulnar, 8. Internal cutaneous, 9. Lesser internal cutaneous, 10. External anterior thoracic, 11. Internal anterior thoracic, 12. Circumflex, 13. Musculo-spiral, 14. Superior subscapular, 15. Middle subscapular, 16. Inferior subscapular, 17. Posterior Thoracic. (External respiratory nerve of Bell.)

THE NERVOUS SYSTEM

external border of the spine of the scapula, to the infraspinous fossa. From the supraspinous fossa it gives off two filaments, one to the spinatus muscle, the other to the shoulder joint and to the scapula.

The **infraclavicular branches** are divided into those of the outer, inner and posterior cords. They are sometimes classified according



1. Fifth cervical nerve. 2. Sixth cervical nerve. 3. Seventh cervical nerve. 4. Eighth cervical nerve. 5. First dorsal nerve. 6. Phrenic nerve. 7. Cervical branch to levator scapulae. 8. Supraascapular nerve. 9. Long thoracic nerve. 10. Anterior branch of thoracic nerve. 11. External thoracic nerve. 12. Internal cutaneous nerve. 13. Subscapular nerve. 14. Internal cutaneous. 15. Middle cutaneous. 16. Musculo-cutaneous and perforating branch. 18. Median nerve. 19. Median nerve. 20. Ulnar nerve. 21. Musculo-spiral nerve.

to the regions they supply, as follows: those to the thorax, those to the shoulder, those to the arm, forearm and hand.

The **anterior thoracic** are two in number, and supply the pectoral muscles. They are called the *internal* and *external*. The *external thoracic nerve*, the larger of the two, originates from the outer cord of the brachial plexus, which is formed directly from fibres of the fifth, sixth and seventh nerves. It passes inward across the axillary artery and is distributed to the under surface of the pectoralis major muscle, and communicates by a filament with the internal thoracic nerve.

The *internal thoracic* nerve arises from the inner cord, its fibres coming mainly from the first and second dorsal nerves. It passes behind the axillary artery, under the pectoralis minor muscle, where it divides into several small filaments.

Of the nerves of the shoulder we have the **subscapular** and the **circumflex**. The **subscapular** are three in number and arise from the

posterior cord of the brachial plexus. The upper is the smallest and supplies the lower border of the subscapularis muscle. The **middle**, which is spoken of as the long subscapular, is the largest of the three. It passes along the posterior wall of the axilla and is distributed thru the latissimus dorsi. The **lower** or **inferior subscapular** enters the axillary border of the subscapularis and terminates in the teres major.

The **circumflex nerve** supplies the integument of the shoulder, the shoulder joint and some of the muscles of this region. It arises from the posterior cord of the brachial plexus and its fibres are traced to the fifth and sixth cervical nerves. It passes to the lower border of the subscapularis muscle, then thru the quadrilateral space, and divides into the upper and lower branches. The upper branch passes around the surgical neck of the humerus, beneath the deltoid muscle, supplying it and giving off cutaneous branches that ramify thru the integument of this part. The lower branch gives off filaments to the teres minor and the back portion of the deltoid. It pierces the deep fascia of the posterior lower two-thirds of the deltoid and the head of the triceps. Before its division into the upper and lower branches, it gives off an articular filament to the shoulder joint.

Of the nerves of the arm, we have first the musculo-cutaneous, which arises from the outer cord of the brachial plexus and is traced back to the fifth, sixth and seventh nerves. It passes between the biceps and the brachialis anticus muscles, to the outer side of the arm thence around the outer border of the tendon of the biceps, perforating here the deep fascia and becoming the cutaneous. In its course it gives off branches to the muscles that it passes. A small branch passes thru the nutrient foramina, into the humerus. The *cutaneous portion* of this nerve divides into an **anterior** and a **posterior division**. The **anterior** passes down, along the radial border of the forearm, to the wrist, and supplies the integument over the outer one-half of the anterior portion. At the wrist joint, it pierces the deep fascia and supplies the carpus, from here passing to the ball of the thumb and terminating in cutaneous filaments. It communicates with the radial and a branch of the median. The **posterior branch** passes down, along the back of the radial part of the forearm, to the wrist. It communicates with the radial and supplies the integument of the forearm and the wrist.

Next we have the **internal cutaneous nerve**, which is one of the smallest branches of the plexus. It arises from the inner cord, passing down on the inner side of the axillary artery, then along the brachial. Its fibres are derived from the first and second dorsal nerves. It gives off, near the axilla, a cutaneous nerve which supplies the covering of the biceps muscle. The anterior branch is the larger of the two, descending on the anterior surface of the ulnar side of the forearm distributing branches to the integument of parts over which it passes. The posterior branch passes over the internal condyle of the humerus, to the back of the forearm. It communicates, above the elbow, with the lesser internal cutaneous, and, above the wrist, by a cutaneous branch with the ulnar.

The **lesser internal cutaneous nerve**, or **nerve of Wrisberg**, is distributed to the inner side of the arm, it is the smallest of the branches

THE NERVOUS SYSTEM

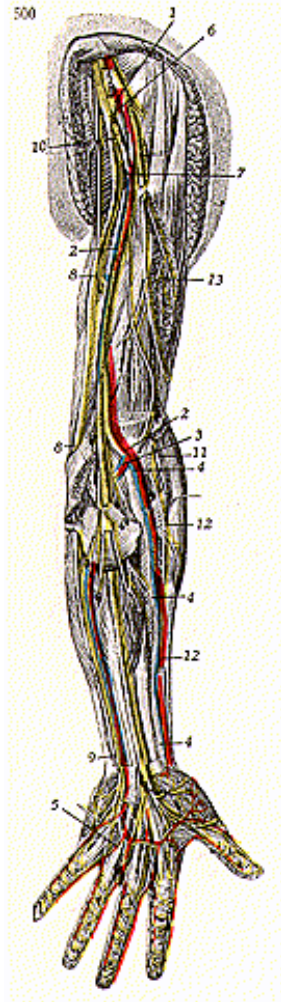


Fig. 240.

Nerves on the Anterior Surface of the Left Upper Extremity (Deep).

1. Axillary artery. 2. Brachial artery and vein. 3. Ulnar artery and vein. 4. Radial artery and vein. 5. Superficial palmar artery and nerve. 6. Axillary nerve. 7. Median nerve. 8. Ulnar nerve. 9. Ulnar branches to both sides of little fingers. 10. Musculo-spiral nerve. 11. External interosseus nerve. 12. Radial nerve. 13. Musculo-cutaneous nerve.

THE NERVOUS SYSTEM

of the brachial plexus, receiving its fibres from the second thoracic. It descends along the inner side of the brachial artery and supplies the lower third of the arm.

The **median nerve** extends along the middle of the arm to the forearm and the hand, it lies between the ulnar and the radial. It arises by two roots, one from the outer, and the other from the inner, cord of the brachial plexus. These unite in front of the axillary artery. The median nerve receives filaments from the sixth and seventh cervical nerves, and also from the first and second dorsal. It passes first to the outside of the brachial artery, then across this vessel, and is found on the inside of the bend of the elbow. It passes down the forearm, between the two heads of the pronator teres muscle, to within about two inches above the annular ligament, where it becomes superficial. From here it passes thru the carpal canal, beneath the annular ligament, to the palm of the hand. In the arm, the median nerve sometimes gives off a branch, which passes to the elbow joint. In the forearm its branches are the *muscular*, *anterior interosseous* and the *palmar cutaneous*. The *muscular branches* are given off at the elbow joint, and supply the muscles of the forearm, superficially.

The *anterior interosseous* supplies the deep muscles on the front of the forearm. The *palmar cutaneous* arises in the lower part of the forearm, pierces the fascia above the annular ligament, and divides into two branches. The *outer* supplies the skin of the ball of the thumb; the inner, the integument of the palm of the hand. The digital branches are five in number, placed superficially to the digital artery. Opposite the first phalanx, each nerve gives off a branch that communicates with a similar branch of the dorsal digital nerve.

The **ulnar nerve** is situated along the inner side of the arm, and is distributed to the muscles and integument of the forearm and hand. It arises from the inner cord of the brachial plexus, in common with the inner head of the median; its fibres may be traced to the first and second dorsal nerves. Near its origin, this nerve lies on the inner side of the axillary artery as far down as the middle of the arm. Here it pierces the muscles and runs obliquely across the internal head of the triceps, descending to the groove between the internal condyle and the olecranon process. In the forearm, it has a straight course: its upper half, hidden by muscle; its lower half, by skin and fascia. At the wrist, it crosses the annular ligament on the outer surface of the pisiform bone, and, beyond this point, divides into the superficial and the deep palmar.

The branches of the ulnar nerve are divided into two sets: those in the forearm, and those in the hand. Of the branches in the forearm, we have the *articular*, *muscular* and *cutaneous*. Of those in the hand, we have the *superficial* and the *deep palmar branches*.

The *articular branches* to the elbow joint are several in number, they are very small filaments, which arise from the nerve as it lies in the groove between the condyle and the olecranon process. The *muscular branches* are two in number and are found arising somewhat below the elbow joint. Of the *cutaneous branches* we have the *palmar* and the *dorsal*. The *palmar* is given off about the middle of the forearm,

THE NERVOUS SYSTEM

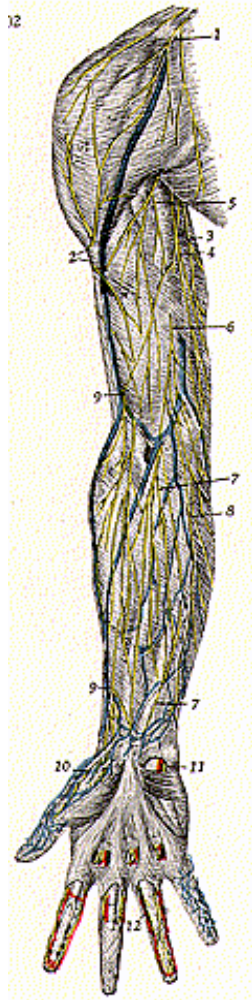


Fig. 241.

Nerves on the Anterior Surface of Right Upper Extremity.

1. Supraclavicular nerve. 2. Cutaneous branch of the axillary nerve. 3-4. Cutaneous branch of median nerve. 5. Cutaneous branch of the median nerve. 6. Lesser internal cutaneous nerve. 7. Palmar cutaneous nerve. 8. Cutaneous branch of ulnar nerve. 9. Cutaneous branch of musculo-cutaneous nerve. 10. Branch of ulnar nerve. 11. Digital nerves. 12. Digital nerves.

and, just above the annular ligament, it pierces the integument, to end in small filaments over the palm of the hand. The *dorsal* cutaneous arises about two inches above the wrist and gives off filaments to each finger. The *superficial palmar* are found on the inner side of the hand terminating in digital branches and communicating with filaments from the median. The *deep palmar branches* are distributed to the interosseous spaces of the hand, supplying the muscles and fascia.

The **musculo-spiral** is the largest nerve of the brachial plexus and supplies muscles of the back part of the arm and forearm. It arises from the posterior cord of the brachial plexus, receiving its main filaments from the sixth and seventh cervical and first dorsal nerves. At its commencement it is placed behind the axillary artery and behind the upper part of the brachial. It winds around, from the inner to the outer side of the humerus, in the musculo-spiral groove, and, at the external condyle, divides into the **radial** and **posterior interosseous**. Other branches of the musculo-spiral nerve are the *muscular* and *cutaneous*. The *muscular* are several in number, and supply all the muscles of the upper extremity. They comprise the internal, external, posterior and collateral branches. The *cutaneous* branches are **three** in number, one internal and two external.

The **radial nerve** passes along the front of the radial border of the forearm, and, at the outer border, divides into two branches. The *external branch* is small and supplies the ball of the thumb, joining with branches of the musculo-cutaneous. The *internal branch* communicates, above the wrist, with the musculo-cutaneous and also with branches from the ulnar. It divides into four digital branches that supply the thumb and the next three fingers. The **posterior interosseous nerve** is a small nerve that presents an enlargement near the wrist, over the carpus, where it divides into several filaments that supply structures in the hand.

The nerves, in each mere or zone of the spinal nerves, emanate above the vertebra in the same zone, the tissues being supplied with currents thru this pair of nerves.

A Mere is, in Chiropractic, applied to the human body, to designate one of the superimposed layers of tissue, which go to make up the human mechanism. A **vertemere** includes one vertebra and the spinal nerves emitting next above it; as, for example, the **atlas vertemere**, or the **first vertemere**, would include the first pair of nerves emitting between the atlas and the occipital bone. Diseases which may be caused by the subluxation of the atlas would result from pressure upon the first or second pairs of spinal nerves; incoordination may result from pressure upon either or any of the nerves of these first and second pairs alone, or may be caused by a combination of pressure upon these nerves and upon spinal nerves in other regions of the spine.

The **second vertemere**, or the **second meric zone**, would correspond to the second cervical vertebra and the nerves which emit between the first and second cervical vertebrae. The **twenty-fourth meric zone** or **vertemere**, includes those nerves emitting between the twenty-third and twenty-fourth vertebrae. The twenty-fifth zone includes the

THE NERVOUS SYSTEM

sacrum as found in adult life, the twenty-sixth zone includes that limited area surrounding the coccyx.

The **first pair of cervical nerves** corresponds to the 1st vertemere, and supply the brain, optic tract and commissure, the cranial bones, scalp, atlas and upper parts of the ear and forehead.

The **second pair of cervical nerves** from the 2nd vertemere, supply many of the same structures as do the first pair of cervical nerves, the brain, ear and portions of the face and neck.

The **third pair of cervical nerves**, in the 3rd vertemere, supply the nasal passages, retina, teeth, orbit and the cheek.

The **fourth pair of cervical nerves**, in the 4th vertemere, supply the eye, teeth, nasal passages, gums, bones of the face, tissues of the nose, the nasopharynx, posterior nares, Eustachian tube, the middle and inner ear and the hyoid bone.

The **fifth pair of spinal nerves** the 5th vertemere, supply the retina, nose, face, teeth, posterior and lateral neck muscles, and the hyoid bone.

The **sixth pair of cervical nerves** the 6th vertemere, supply the neck and adjacent tissues, the superior part of the shoulders, anterior part of the arm, and the upper part of the bronchi.

The **seventh pair of cervical nerves**, the 7th vertemere, supply the posterior neck muscles, upper part of the arm, forearm and hand, and trachea, and upper part of the bronchi.

THORACIC OR DORSAL NERVES

The **thoracic or dorsal nerves** are twelve in number on each side. The roots of the dorsal nerves are of small size and vary but slightly from the 2nd to the last. Both roots are very slender, the posterior roots vary slightly exceeding the anterior, in thickness. They gradually increase in length from above downward and, in the lower part of the dorsal region, attain considerable size as they branch out to the corresponding organs. Each nerve divides into an anterior and posterior root and, as they leave the spine, form a network of fibres, known as ganglia, where they meet other communicating branches.

ANTERIOR DIVISIONS OF THE THORACIC NERVES

Of the so-called primary thoracic nerves there are twelve on each side.

The first nerve divides into two branches. The larger branch helps in the formation of the brachial plexus. The smaller branch is the first intercostal and usually terminates in a cutaneous branch at the anterior part of the thorax. At its exit from the spine it is connected to the adjacent ganglion of the peripheral system, as are all the other primary divisions, by a communicating branch. It is also very often connected to the second thoracic by a slender filament.

The second, third, fourth, fifth and sixth thoracic anterior divisions are classed under the head of **thoracic intercostals**. At the back of the thorax they are found between the pleura and the intercostal membrane. Farther on to the side they are found somewhat deeper and in the anterior portion they lie between the pleura and the inner wall of the anterior muscles.

In their course these nerves give off several small filaments, the principal one seemingly having its origin at about the middle of the nerve. This one receives the name of the **lateral cutaneous** and divides into an *anterior* and *posterior branch*. Both of these branches are superficial, one reflected forward and the other backward. At the anterior each intercostal thoracic becomes the anterior cutaneous.

The lateral nerve of the second intercostal is much larger than any of the other lateral nerves and receives the name of the **intercostal humeral**. This nerve supplies the inner and back part of the arm, and communicates with a filament of the musculospiral.

The seventh, eighth, ninth, tenth, eleventh and twelfth nerves are known as the **thoraco-abdominal intercostals**. Their distribution is similar to that of the upper thoracic nerves and all in great measure supply muscles both posteriorly of the thorax and anteriorly of the abdomen.

The **first pair of thoracic nerves** correspond to the 8th vertemere and supply the shoulder, arm, forearm and hand, bronchi, upper ribs and sternum.*

The **second pair of thoracic or dorsal nerves** correspond to the 9th vertemere and supply not only the muscles of the surrounding area, but also the heart, pericardium, aorta, bronchi, the forearm, hand, and the structures in the immediate vicinity of the 2nd rib.

The **third pair of dorsal nerves** correspond to the 10th vertemere and supply the lungs, pleurae, lower part of heart, mammary glands, and the 3rd rib.

The **fourth pair of thoracic nerves, in the 11th** vertemere, supply the liver, gall-bladder, bile duct, 4th pair of ribs and lower portion of the lungs, as well as the muscles in the immediate region of the 4th dorsal vertebra.

The **fifth pair of thoracic nerves** correspond to the 12th vertemere and supply, beside the muscles previously mentioned, the 5th pair of ribs; it is a general excessive-heat zone.

The **sixth pair of thoracic nerves**, in the 13th vertemere, supply the stomach, esophagus, pharynx, glands of the throat, eyeball, pupil and the 6th pair of ribs.

The **seventh pair of dorsal nerves** correspond to the 14th vertemere and supply approximately the same structures as do the nerves of the 6th pair.

The **eighth pair of dorsal nerves in the 15th** vertemere, supply the pancreas, upper part of the spleen, diaphragm, duodenum, omenta, and 8th pair of ribs; they blend with the 14th and 16th vertemeres.

The **ninth pair of dorsal nerves** correspond to the 16th vertemere and supply the 9th pair of ribs, the spleen, duodenum, and omenta; they blend with 15th mere.

***Author's Note.**—It seems of advantage to deviate from the customary recognition of eight cervical pairs of nerves, and we take the liberty of so doing, in order that the vertemere may in every case consist of a vertebra and its corresponding superior pair of spinal nerves.

THE NERVOUS SYSTEM

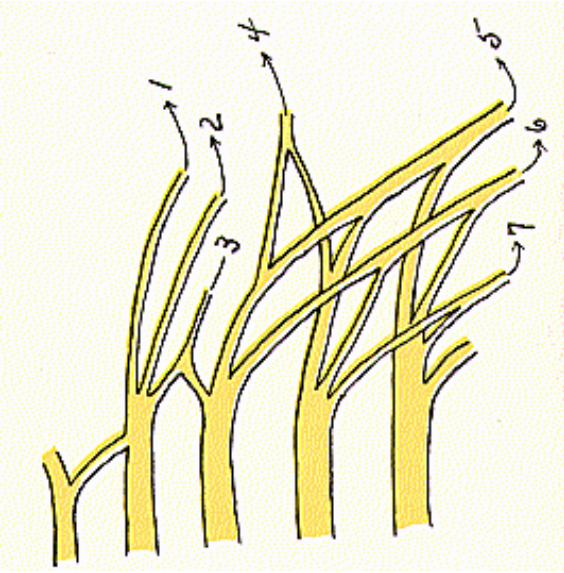


Fig. 242.
Lumbar Plexus.

1. Ilio-hypogastric. 2. Ilio-inguinal. 3. Genito-Femoral. 4. External cutaneous.
5. Anterior Crural. 6. Obturator. 7. Obturator accessory.

THE NERVOUS SYSTEM

The **tenth pair of dorsal nerves**, in the 17th vertemere, supply the suprarenal glands, upper part of the kidney, eyelids, and the 10th pair of ribs.

The **eleventh pair of dorsal nerves**, in the 18th vertemere, supply the kidneys and their kindred structures.

The **twelfth pair of dorsal nerves** correspond to the 19th vertemere and supply the 12th pair of ribs, lower portion of the kidneys, end of the spinal cord, ureters, and exercise a control over the serous circulation.

LUMBAR PLEXUS

(Illustrations Nos. 242, 243 and 245.)

The **anterior divisions** of the lumbar, sacral and coccygeal nerves form the lumbo-sacral plexus, which, for convenience, is divided into the **lumbar, sacral and pudendal plexuses**.

The **lumbar plexus** is formed by the four lower lumbar nerves and a filament of the first lumbar pair. In the beginning, the plexus is narrow but branches out, below, where it is joined, by the lumbosacral cord, to the sacral plexus. This plexus is found in the posterior part of the psoas magnus muscle, anterior to the lumbar transverse processes. The formation of this plexus is not the same in all instances, and differs from the brachial in that it is not as intricate an interlacement.

As stated above, the second lumbar nerve receives a branch from the first lumbar nerve. Its upper, larger portion divides to form the **ilio-hypogastric** and **ilio-inguinal**. One branch from the lower portion of the second lumbar nerve communicates with the third lumbar. The remainder of the second, which is inferiorly located, unites with a branch from the upper part of the anterior division of the third, to form the **genito-crural**. The third, fourth and fifth nerves divide into anterior and posterior divisions. The remainder of the anterior division of the third, which does not help to form the genito-crural unites with the anterior division of the fourth and a part of the fifth to form the **obturator**. The remaining portion of the anterior part of the fifth, communicates with the lumbo-sacral pair of nerves. The posterior divisions of the third and fourth, divide. The smaller portions unite to form the **external cutaneous**. The larger posterior portions of the third and fourth join with the posterior part of the fifth, to form the **femoral** or **anterior crural**. Sometimes there is found an accessory obturator and, if it exists, it is formed from filaments of the fourth and fifth nerves.

The **ilio-hypogastric nerve** pierces the transversalis muscle, above the crest of the ilium. It divides into the *iliac* and *hypogastric*. The *iliac* is distributed in the gluteal region, behind the lateral cutaneous branch of the first lumbar nerve. The *hypogastric* pierces the aponeurosis of the external oblique, about an inch above the external abdominal ring, and is distributed in the hypogastric region.

The **ilio-inguinal nerve**, smaller than the ilio-hypogastric, passes across the quadratus lumborum, pierces the internal oblique and emerges thru the external abdominal ring, and is distributed to the inner part of the thigh and the external generative organs.

The **genito-crural nerve** passes thru the psoas magnus muscle, emerges at the inner border of it, between the fourth and fifth lumbar vertebrae, and, below this point, divides into the *genital* and *femoral*. The genital passes thru the internal abdominal ring and supplies the cremaster muscle. In the female it is lost on the round ligament. The *femoral* passes below Poupart's ligament to the thigh.

The **external cutaneous nerve** passes below Poupart's ligament into the thigh, and divides into the *anterior* and *posterior branches*. The anterior passes as far as the knee and becomes a part of the patellar plexus. The *posterior branch* is distributed down as far as the middle of the thigh.

The **obturator nerve** emerges from the psoas muscle, at the top of the pelvis, and passes, from here, thru the obturator foramen to the thigh, where it divides into the *anterior* and *posterior branches*. The *posterior*, gives off an articular branch to the hip joint; and the *anterior*, a branch to the knee joint.

The **femoral** or **anterior crural nerve** is the largest nerve of the lumbar plexus. It passes below Poupart's ligament into the thigh, where it becomes somewhat flattened and divides into *anterior* and *posterior branches*. In the abdomen, it gives off a few muscular branches. The anterior division of the nerve gives off the *middle* and *internal cutaneous*, also *muscular branches*. The *middle cutaneous* passes down as far as the knee joint and helps in the formation of the patellar plexus.

As posterior divisions, we have the **muscular, articular** and **long saphenous**. The **muscular branches** supply the quadriceps, rectus femoris, vastus internus and externus, and crureus. The **articular branches** are those to the hip joint and three to the knee. The **long saphenous** is the largest cutaneous nerve of the femoral. It passes along the internal border of the tibia, and, about two-thirds of the way down, divides into two branches, one terminating in front of the ankle, the other in the great toe. It distributes its fibres to the skin of the thigh, leg and foot, passing in front of the ankle to go as far as the great toe.

The **first pair of lumbar nerves** corresponds to the 20th vertemere and, besides the muscles mentioned, they supply the upper part of the small intestines, the peritoneum, the loins, and ureters.

Fig. 243.

Nerves on Anterior Surface of Lower Extremity.

1. Abdominal aorta. 2. Common iliac artery. 3. Internal iliac artery 4. Femoral artery. 5. Femoral vein. 6. Long saphenous vein. 7. Short saphenous vein 9. Lumbar plexus. 10. Anterior crural nerve. 11. Obturator nerve. 12. Branch of femoral nerve. 13. Inguinal nerve. 14. External-cutaneous nerve. 15. Long saphenous nerve. 16. Cutaneous branch of femoral nerve. 17. Cutaneous branches of saphenous nerve. 18. Ilio-hypogastric nerve. 19. Ilio-inguinal nerve. 20. Muscular branches of anterior crural nerve. 21. Superficial peroneal nerve. 22-23. Cutaneous branches to the dorsum of the foot. 24. Cutaneous branch of anterior crural nerve. 25. Deep peroneal nerve 26. Peroneal nerve (internal branch). 27. Peroneal nerve (external branch).

THE NERVOUS SYSTEM

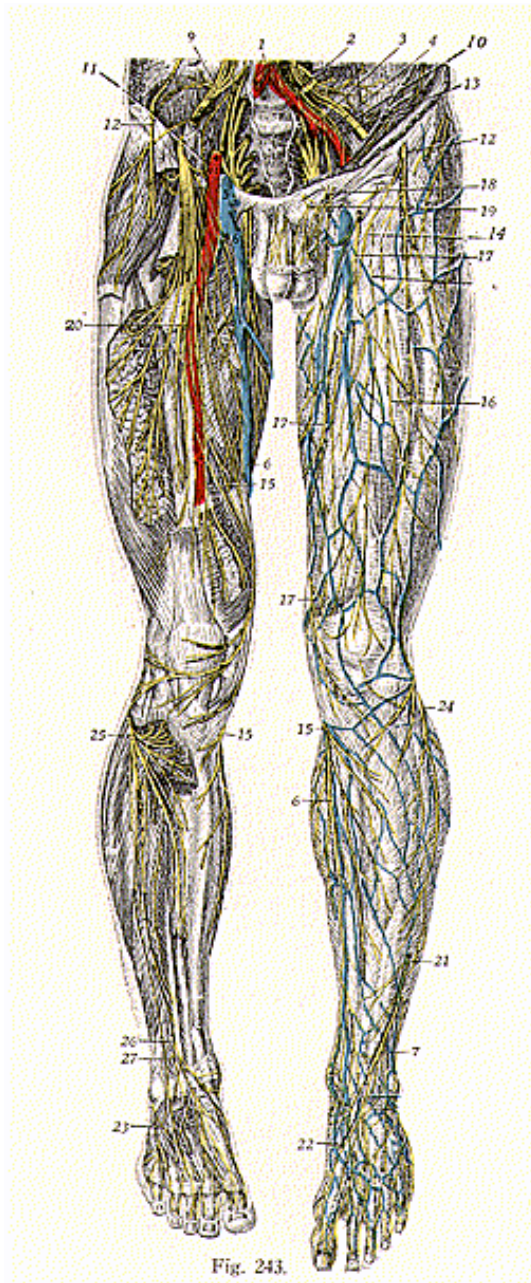


Fig. 243.

The **second pair of lumbar spinal nerves**, in the 21st vertemere, supply the small intestines, vermiform appendix, peritoneum, ovaries and caecum, as well as the muscles previously mentioned.

The **third pair of lumbar nerves**, in the 22nd meric zone, supply the bladder, testes, prostate gland, ovaries, uterus, broad ligaments, lower part of the small intestines, vermiform appendix, caecum, colon, abdominal muscles, thigh muscles and the knee.

The **fourth pair of lumbar nerves**, in the 23rd vertemere, supply the large intestines, posterior part of the thigh, the leg and foot, the bladder, innominate bone, and the uterus, vagina, prostate gland and rectum.

The **fifth pair of lumbar nerves** correspond to the 24th meric zone and supply the rectum, uterus, and the buttocks.

SACRAL PLEXUS

(Illustrations Nos. 244 and 245.)

The **lumbo-sacral cord** is formed by a few fibres from the fourth lumbar and all the fibres of the fifth lumbar nerves, together with the first sacral and portions of the second and third sacral nerves, it forms the **sacral plexus**.

Branches from the posterior divisions are the **superior and inferior gluteal, great sacro-sciatic, internal popliteal** and a **muscular branch** to the pyriformis muscle. Branches from the anterior portion are the **quadratus femoris, obturator internus, articular, external popliteal** and **muscular**.

The **superior gluteal nerve** arises, by three roots, from the fourth and fifth lumbar and first sacral nerves. It passes backward and outward to the buttocks, under cover of the gluteus maximus, outward over the gluteus minimus, and ends in the tensor vaginae femoris. This nerve supplies the gluteus medius and minimus muscles.

The **inferior gluteal nerve** arises, by three roots, from the fifth lumbar and the upper two sacral nerves. It breaks up at its periphery into several small branches, which supply the gluteus maximus muscles.

The **pyriformis nerve** arises from the posterior portion of the first and second, sometimes only the second sacral, enters the substance of the pyriformis muscles which it supplies.

The nerve which supplies the short head of the biceps is given off from the upper part of the great sciatic. Its fibres are traced back to the fifth lumbar and the first two sacral nerves. It passes along the outer side of the peroneal nerve from which it separates in about the middle of the thigh.

Fig. 244.

Nerves on Posterior Surface of Lower Extremity.

1. Short saphenous vein. 2. Posterior tibial artery and vein. 3. Gluteal nerves. 4. Posterior cutaneous branch from femoral. 5. Inferior gluteal cutaneous branches. 6. Saphenous nerve. 7. Saphenous nerve. 8. Peroneal nerve. 9. Tibial nerve. 10. Cutaneous branches to the heel, sole and foot. 11. Superior gluteal nerve. 12. Inferior gluteal nerve. 13. Pudic nerve. 14. Great sciatic nerve. 15. Branches from sciatic nerve. 16. Great sciatic nerve. 17. Peroneal nerve. 18. Tibial nerve. 19. Peroneal nerve.

THE NERVOUS SYSTEM

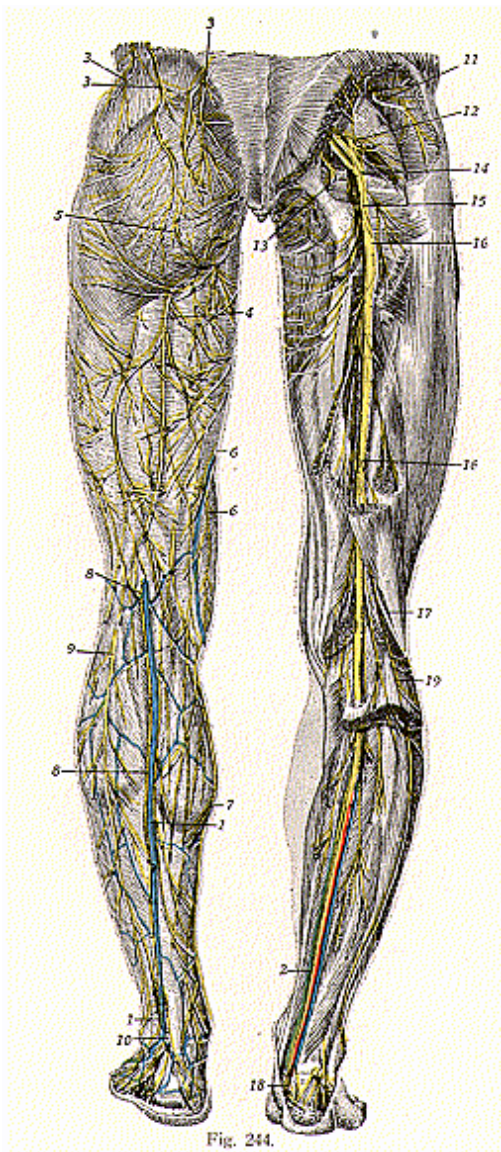


Fig. 244.

The **great sacro-sciatic nerve** is the largest **nerve** of the sacral plexus; in fact, it is the largest nerve cord in the body, measuring about 3/4 of an inch broad. It is formed by the 4th and 5th lumbar nerves, with the 1st, 2nd and 3rd sacral nerves. It passes out of the pelvis, thru the great sciatic foramen, and descends between the great trochanter and tuberosity of the ischium. It then passes down the middle line of the back of the thigh, under cover of the long head of the biceps femoris, and, about at the junction of the middle and lower thirds, it is divided into the **internal** and **external popliteal nerves**. The great sciatic has *articular branches*, which supply the hip joint; and *muscular branches*, which are distributed to the flexors of the leg and to the adductor magnus muscle.

The **internal popliteal** or **tibial nerve** arises from the fourth and fifth lumbar, and the upper three sacral nerves. It is the larger of the two branches of the great sciatic, and descends along the posterior of the thigh to the lower border of the popliteus muscle, where it becomes known as the **posterior tibial**. Its branches are the *articular*, *muscular* and the *communicating tibial*.

The *articular branches* supply the knee joint, and are usually three in number.

The *muscular*, are usually four or five in number and supply the gastrocnemius, plantaris, soleus, and popliteus muscles.

The *communicating tibial* is a cutaneous nerve, which joins with the communicating fibular, to form the **sural** or **short saphenous nerve**. The **sural nerve** passes to a point between the external malleolus and the os calcis. It divides into the posterior and anterior branches. The posterior gives rise to the lateral calcaneal branches. The anterior division passes round the external malleolus, and supplies the integument along the outer side of the foot and the little toe. In the leg, it communicates with branches of the small sciatic and, on the dorsum of the foot, with the musculo-cutaneous.

The **posterior tibial** is the continuation of the internal popliteal from the lower border of the popliteus muscle. It passes along the posterior of the leg, round the internal malleolus, and divides into the **internal** and **external plantar**.

The branches of the posterior tibial are the *muscular*, *internal calcaneal* and *articular*.

The *muscular branches* arise from the upper portion of the nerve and supply the soleus, tibialis posticus, flexor longus hallucis, and the flexor longus digitorum.

The *internal calcaneal* supplies the integument of the heel and the inner side of the foot; the *articular branches* supply the ankle joint.

The **internal plantar** gives off digital branches to the great toe, second and third toes, and one branch to the inner side of the fourth toe. Along its course, the *internal plantar* also gives off some cutaneous filaments, which supply the integument of the sole of the foot, muscular branches, supplying the abductor hallucis and the flexor brevis digitorum; *articular branches*, to the articulation of the tarsal and metatarsal bones. Each of the digital branches mentioned above, also give off cutaneous and articular filaments, for the supply of the articulations and skin of the toes.

THE NERVOUS SYSTEM

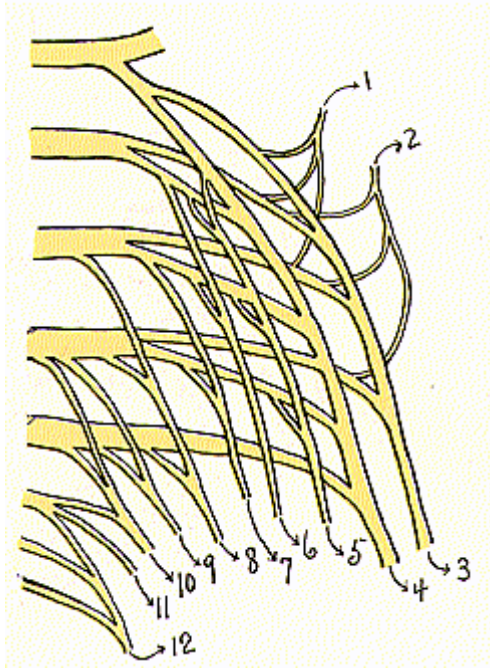


Fig. 245.
Sacro-Pudendal Plexus.

1. Superior gluteal. 2. Inferior gluteal. 3. External popliteal. 4. Internal popliteal. 5. Quadratus femoris. 6. Obturator internus. 7. Pyrformis. 8. Small sciatic. 9. Perforating cutaneous. 10. Pudic. 11. Perineal. 12. Anterior sacro-coccygeal.

THE NERVOUS SYSTEM

The **external plantar is the smaller** of the two and it is this which completes the supply of mental impulses to the digits and to the skin of the sole of the foot. It is divided into the *superficial* and *deep branches*. The superficial branch divides into two digital filaments; while the deep branch is muscular and supplies all the interosseous spaces except the fourth, also some of the minor muscles of the foot.

The **external popliteal** or **common peroneal nerve**, arises from the fourth and fifth lumbar and the first and second sacral nerves, it descends to the internal of the popliteal space, along the inner margin of the biceps femoris muscle, down to the head of the fibula, and divides into the **anterior tibial** and **musculo-cutaneous**. The **anterior tibial** descends to a point in front of the ankle, where it divides into the *internal* and *external branches*. The *external branch* divides into three interosseous filaments, which supply the tarsal, metatarsal and phalangeal joints of the second, third and fourth toes. The *internal branch* passes to the inner side of the dorsum of the foot, and, at the first interosseous space, divides into two dorsal digitals. Before its division, it gives off the interosseous branch, which supplies the metatarso-phalangeal joint of the great toe. Before the division of the anterior tibial into the internal and external branches, it gives off *muscular filaments* to the tibialis anticus, extensor longus digitorum, extensor proprius hallucis and peroneus tertius muscles, also one *articular* nerve to the ankle joint.

The branches of the **common peroneal nerve**, previous to its division, are the *articular* and *cutaneous*. The *articular*, are three in number, two of these supply the outer side of the knee joint, the other supplies the anterior of the joint.

The *cutaneous* nerves, usually two or three in number, supply the integument along the back and outer sides of the leg. The largest one of these branches is known as the fibular communicating, which, together with the tibial communicating, forms the short saphenous nerve.

The **musculo-cutaneous nerve**, or **superficial peroneal**, supplies the muscles on the fibular side of the leg and the integument of the dorsum of the foot. In its course, it gives off muscular branches to the peroneus longus and brevis, and cutaneous fibres to the lower part of the leg. The two terminal divisions of the musculo-cutaneous, are the *medial dorsal* and the *intermediate dorsal*. The *medial dorsal* divides into two dorsal digital filaments, one supplying the inner side of the great toe, the other the adjacent sides of the second and third toes.

The *intermediate dorsal*, also, divides into two dorsal digital nerves, supplying the adjacent sides of the third and fourth toes, also the outer sides of the fourth and fifth toes.

PUDENDAL PLEXUS

(Illustration No. 245.)

The **pudendal plexus** is made up of branches from the second and third sacral, all of the fourth and fifth sacral, and the coccygeal nerves. The **branches of distribution** of this plexus are the **small sciatic**, **perforating cutaneous** and **pudic nerve**.

The **small sciatic nerve** supplies the integument of the perineum and the back part of the thigh and leg. It is formed by branches from

the second and third nerves of the sacral plexus. Some of its fibres pass out of the pelvis, thru the great sacro-sciatic foramen, then beneath the gluteus maximus muscle, and, at the lower border of that muscle, pass, beneath the fascia lata, and over the long head of the biceps, to the lower part of the popliteal region, where they pierce the fascia and become cutaneous. Branches of the small sciatic nerve are all cutaneous, and are known as the *gluteal*, *perineal* and *femoral*.

The *gluteal cutaneous* consists of filaments, which pass over the border of the gluteus maximus and supply the skin over the muscle. The *perineal cutaneous* are branches, distributed to the skin at the upper and inner side of the thigh on its posterior aspect. One long branch, the pudendal, also called the nerve of Soemmering, pierces the fascia late and passes beneath the superficial fascia of the perineum, to be distributed to the integument of the scrotum, in the male, and the labia in the female.

The *femoral cutaneous* branch consists of numerous filaments, which are distributed to the posterior and the inner and outer sides of the thigh, to the skin covering the popliteal space, and to the upper part of the skin of the leg.

The **perforating cutaneous nerve** distributes its fibres to the skin of the back of the thigh, as low as the knee joint.

The **pudic nerve** is one of the terminal branches of the sacral plexus and derives its fibres from the second, the lower branches of the 3rd, and the upper branch of the 4th, sacral nerves. It leaves the pelvis thru the great sacro-sciatic foramen, crosses to the back part of the spine of the ischium, then passes thru the small sacro-sciatic foramen, pierces a sheath of the obturator fascia, and enters the ischio-rectal fossa. It then divides into three branches, namely: the *inferior hemorrhoidal nerve*, the *perineal*, and the *dorsal nerve of the penis*.

The *inferior hemorrhoidal* or the *ano-coccygeal nerve* passes, inward, across the ischio-rectal fossa to the region of the anus, and distributes its fibres to the external sphincter muscle and to the integument around same. The *perineal nerve* is the larger, and accompanies the superficial perineal artery in the perineum, dividing into *cutaneous* and *muscular branches*. The *cutaneous branches*, an anterior and a posterior, distribute their fibres to the skin of the scrotum; in the female, these nerves supply the labia majora. *Muscular branches* are distributed to the muscles of the pelvic outlet.

The *dorsal nerve of the penis* is the deepest division of the pudic nerve, it runs, forward of the inner margin of the ramus of the os pubis, between the superficial and deep layers of the triangular ligament. It accompanies the dorsal artery of the penis, between the layers of the suspensory ligament, and is distributed to the dorsum of the penis as far as the glans and prepuce. In the female, the dorsal nerve is small and supplies the clitoris. The sacrum forms the 25th vertemere, and the nerves, emitting next above its base supply the rectum, anus, buttocks, uterus, the thigh and parts of the leg and foot.

The 26th meric zone includes that limited area surrounding the coccyx—the coccygeal veterbrae (one, two, three or four). The nerves which emit from the coccygeal foramina are not usually considered as being subject to pressure.

SYMPATHETIC NERVOUS SYSTEM

Many anatomists, and with them many physiologists, divide the nervous system into two complete and distinct systems; the one known as the cerebro-spinal system and the other the sympathetic system, each being entirely independent of the other. These authorities claim that the cerebro-spinal system takes part in the functions of the so-called animal life or that of relation, and the sympathetic nervous system in the functions of the vegetative life or that of nutrition. If this were true the human organism would represent two lives, the one animal and the other vegetative. Morat states the following: "Regarding the internal organs, such as the heart, the lungs, and the intestine, it becomes obvious that they are intended for maintenance of life, for nutrition; on the other hand, the organs of sense, the apparatus of expression and of external movement are adapted for the relationship of the animal with the medium which surrounds it and especially with the living world. But the line of division is not fixed at the immediately visible organs. Every cell, every organized part, presents it once again in its more restricted area; in every cell indeed there is a portion of the protoplasm which is especially concerned with its maintenance and conservation, and another portion which discharges the social function with regard to other cells, bringing them into relation with itself. And if ever analysis shall penetrate still further into the organization of this complex being, the cell, the same division will apply to every differentiated portion of this miniature organism. In short, animal life and vegetative life are not two separate things, but two different aspects of the functions of the living organization, aspects which are encountered in every system of complicated organs when they are analyzed."

Of late years the sympathetic system is no longer taught as an independent system, as is shown by the following paragraph from Cunningham's Anatomy: "The sympathetic nervous system comprises a pair of elongated gangliated trunks, extending through the whole length of the body from the base of the skull to the coccyx connected to the peripheral spinal nerves by one series of nerves, and to the viscera by another series. At the cephalic end each sympathetic trunk passes into the cavity along with the internal carotid artery, on which it forms plexuses, and thereby forms complex relations with certain cerebral nerves. At their caudal ends the two sympathetic trunks are joined together by fine filaments and unite with the coccygeal ganglion.

"The sympathetic system is essentially depended on and subservient to the spinal nervous system. It distributes efferent fibres from the peripheral spinal nerves to (a) the viscera and vessels of the splanchnic area, and (b) through recurrent (gray) rami to vessels, glands, and involuntary muscles, in the course of the somatic (those to the body wall and to the limbs) divisions of the spinal nerves. It further collects and transmits to the cerebro-spinal system afferent fibres from the viscera."

Here, also note the following from Piersol's Human Anatomy: "The sympathetic portion of the peripheral nervous system differs

from that already described—the spinal and the cranial nerves—in being particularly concerned in carrying efferent and afferent impulses to and from the thoracic and abdominal organs (collectively termed the splanchnic area), in contrast to the great somatic (skeletal) masses of voluntary muscle. Whilst the paths of the afferent or sensory impulses conducted from the splanchnic area differ in no important respect from those formed by the cerebro spinal nerves, the efferent or motor paths are peculiar (a) in supplying the involuntary and cardiac muscle and the glandular tissue, and (b) in consisting of at least two, sometimes of more, links between the source of the impulse (the spinal cord) and the structure upon which it is expended. It is evident therefore that the sympathetic system consists of a complex of spinal and sympathetic fibres intermingled with groups of ganglion-cells.

“The sympathetic system serves to receive, rearrange and distribute the visceral filaments of the cerebro-spinal nerves, and to complete, by the interposition of one or more of its especial neurones, the path for the impulses brought by such fibres to the objective organs.” But it is not so very long ago that Cunningham as well as Morris Gray, Eckley, Spalteholtz and others, gave distinct differences between the cerebro-spinal and the sympathetic systems. (For quotations from these authorities see *Science of Chiropractic*, Vol. 2: *The Sympathetic Nervous System*.)

But Chiropractors have always maintained, from the very beginning of the Science, that the two systems are continuous one with the other. The sympathetic nervous system is given as an arrangement to permit of rearrangement and transmission of impulses, and as being in direct communication with the fibres from the spinal cord.

All fibres arise from the brain, and pass out thru the large cable of nerves which is the spinal cord, and these nerves make their exit thru the intervertebral foramina, at each side of the spine, branching thruout all portions of the body.

Reasons of convenience have been given, by anatomists, for the distinction made in the two systems. The brain and the spinal cord which are enclosed in an osteo-fibrous cavity, form the central system, and the sympathetic trunk forms the peripheral nerves.

Morat further states: “Experiment has convincingly shown that the sympathetic system communicates with the cord and therefore with the brain itself, with which it effects an exchange of impulses. Thus the division of nerves into those of nutrition and those of exterior relation is inaccurate and the terms which define it are deceptive. The great sympathetic is a sort of spinal cord, or a portion of the spinal cord, disseminated in the nutritive apparatus.”

The **sympathetic nervous system** is considered to be a double chain of nerves, forming a cord on either side of the spine, extending from the base of the brain to the tip of the coccyx, where the two trunks unite and form an enlargement, called the ganglion.

The sympathetic cord is situated partly in front of and laterally to the vertebral column, and along its course are the **cervical** and **splanchnic ganglia**. It further consists of **three great plexuses** situated in front of the spine, in the thoracic, abdominal and pelvic

THE NERVOUS SYSTEM

cavities; and of **smaller ganglia**, situated in relation with the abdominal viscera, and of **numerous nerves** from the gangliated cord.

One particular thing is characteristic of the sympathetic nervous system, the fibres are smaller and there is a notable disposition to form plexuses and ganglia in the chain, but why not? Being located immediately in front of great areas of physiological activity, they represent an extensive blood and nerve supply to the organs surrounding them.

The sympathetic cord, on either side, has as many ganglia as there are vertebrae, and there are as many nerve trunks, passing from its side, as there are intervertebral foramina ; but, in the cervical region, these coalesce and form three groups of fibres, which are given the names of the three pairs of **cervical ganglia**.

The twelve dorsal pairs, being branches from the dorsal nerves, form the **dorsal ganglia**; the four lumbar branches correspond to the lumbar portion of the spine; and the sacral branches form the sacral portion of the cord. Except in the neck, each ganglion corresponds to the vertebra against which it lies. In the cervical region, they are situated in front of the transverse processes of the cervical vertebrae; in the dorsal region, in front of the heads of the ribs; in the lumbar region, on the sides of the bodies of the vertebrae; and in the sacral, in front of the sacrum.

The **cervical portion of the sympathetic cord** is placed upon the muscles in front of the vertebrae, and fibres from these nerves are traced to the brain, ears, eyeball, nasal passages, teeth, the posterior lateral neck muscles, the larynx and thyroid gland. Fibres from the superior cervical ganglia are continued along the carotid artery into the brain and there form the carotid plexus.

The **sympathetic cord in the thoracic region** is given as located in front of the necks of the ribs and consists of collections of nerves which pass to the upper extremities, the heart, pericardium, lungs and pleurae, liver, pharynx, eyeballs, stomach, pancreas, diaphragm, spleen, suprarenals, kidneys, and to the ureters.

The **abdominal and sacral portions of the sympathetic cord** are placed in front of the bodies of the vertebrae and sacrum, and send fibres to the kidneys, ureters, small and large intestines, to most of the sex organs, to the rectum and, with the sacral portion of the cord, supply the lower extremities.

The **superior cervical ganglia** are formed by the union of branches from the 1st, 2nd, 3rd and 4th pairs of cervical nerves. Branches from the 5th and 6th form the **middle cervical ganglia**; and branches from the 7th cervical and the 1st and 2nd dorsal form the **inferior cervical ganglia**. In the dorsal region they are grouped as follows: branches, from the 6th, 7th, 8th and 9th dorsal divisions of nerves, form the **great splanchnic plexus**; the 10th and 11th form the **lesser splanchnic**, and branches from the 12th dorsal nerve form the **least splanchnic ganglia**.

Branches of nerves, called **branches of communication**, are given as the nerve fibres which pass directly from the spinal nerves to the branches which form the gangliated cord, known as the sympathetic cord of the nervous system.

The three great plexuses are named according to the region they

occupy in the splanchnic cavities of the body. They are the **cardiac**, in the chest; solar or epigastric, in the abdomen; and the hypogastric, in the pelvis. Each consists of large nerve-trunks and numerous blood-vessels, which pass to the corresponding viscera in each cavity.

The **cardiac plexus** is situated at the base of the heart, and smaller plexuses, found at the side of the cardiac plexus, are called secondary plexuses. These consist of groups of nerve fibres, which cross each other, along with anastomosing blood-vessels. The cardiac plexus is formed by branches which pass to and from the heart. Secondary plexuses from the cardiac plexus are the *coronary*, passing between the aorta and the pulmonary artery supplying the heart substance the *pericardial* plexus, consisting of branches which are distributed to the pericardium; and the *pulmonary* plexus, which is divided into right and left pulmonary divisions, each of which enters the hilus of the corresponding lung, to supply the lung. These nerves, from the cardiac plexus, can be traced from the 9th zone which corresponds to the 2nd and 3rd dorsal pairs of spinal nerves.

The **epigastric** or **solar** or **coeliac plexus**, called by some anatomists the **abdominal brain**, is placed behind the stomach, in front of the aorta, where this artery gives off its coeliac axis branch, in front of the crura of the diaphragm, about opposite the 1st or 2nd lumbar vertebra. It is the largest of all the plexuses and its fibres are distributed to the largest organs of the body. Secondary plexuses, or those found to the side of the solar plexus, are: the *hepatic*, consisting of hepatic fibres and blood-vessels, passing to the liver and gallbladder; the *splenic plexus*, consisting of fibres which pass to the spleen, pancreas and stomach; *gastric plexus*, formed of fibres passing to the stomach and to the lower end of the esophagus, *phrenic plexus* fibres to and from the diaphragm; *renal plexus*, large nerve fibres which are distributed to the kidney; *supra-renal plexus*, fibres which pass to the supra-renal gland; *superior* and *inferior mesenteric plexuses* made up of fibres which are distributed to the large and small intestines; *spermatic plexus*; nerve-filaments which accompany the spermatic vessels to the testes, in the female it is called the *ovarian plexus* and its fibres consist of those which pass to the ovaries and uterus.

The fibres which form the solar plexus and the secondary plexuses, can be traced from the dorsal and lumbar pairs of spinal nerves from the 4th dorsal pair to, and including, the 4th lumbar pair of nerves; these comprise areas within, and including, the 11th to the 23rd zones.

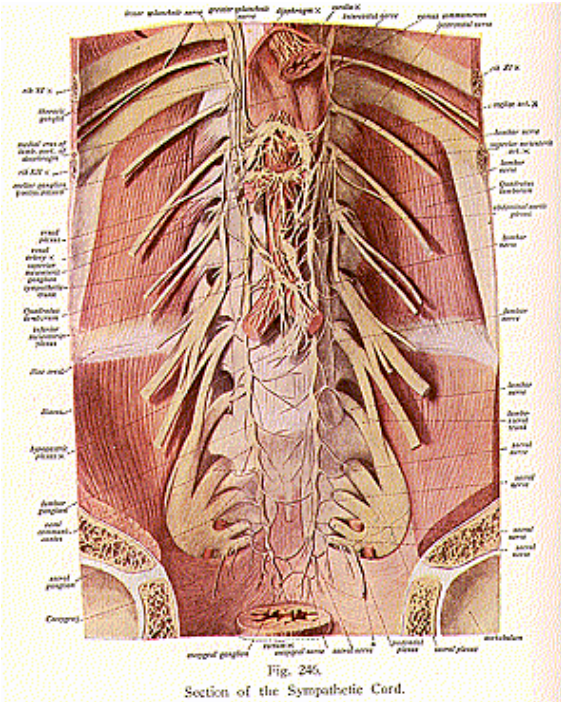
The **hypogastric** or **pelvic plexus** is formed of nerve fibres and blood-vessels which are found in front of the sacrum, where the aorta bifurcates into the two common iliac arteries, and at the junction of the iliac veins, where they form the inferior vena cava.

The fibres from the hypogastric plexus are distributed to the rectum, where they form the *hemorrhoidal plexus*, to the prostate gland, neck of the bladder and seminal vesicles, where they form the *prostatic plexus*; to the uterus and structures in the folds of the broad ligaments, where they form the *uterine plexus*; and to the walls of the vagina and urethra in the female, where these fibres form the *vaginal plexus*. The fibres, which form the hypogastric plexus and

THE NERVOUS SYSTEM

secondary plexuses, can be traced to the 3rd, 4th and 5th lumbar pairs of spinal nerves, which comprise the 22nd to the 24th zones inclusive.

The following from Gray may be of interest to the Chiropractor in meeting questions regarding visceral nerve supply: "In the forma-



tion of a plexus the component nerves divide, then join, and again subdivide in such a complex manner that the individual funiculi become interlaced most intricately; so that each branch leaving a plexus may contain filaments from each of the primary nervous

THE NERVOUS SYSTEM

trunks which form it. In the formation also of smaller plexuses at the periphery of the body there is a free interchange of the funiculi and primitive fibres. In each case, however, the individual filaments remain separate and distinct, and do not inosculate with one another.”

REFLEXES AND CENTRES

The history of the reflex is as follows: “Long ago it had been remarked that certain movements which were altogether involuntary ensued as a response to sensitive or censorial excitations. The phenomenon had been observed and recorded by Montaigne and Descartes; it appears that Astruc had already described it as reflex (1743); but, according to Longet it is to Prochaska (1784) that the first experimental data concerning the question are due. He was the first to observe the movements of response of the decapitated frog when its skin is irritated; he attributed these movements to a phenomenon which was centered in the small spinal cord, and which he designated by the name which it has since preserved: ‘impressionum sensoriarium in motorias reflexio’; he saw clearly the simple relation which exists in this case between sensation and movement. He compared to these facts the involuntary acts which are observed in man, such as winking of the eyelids, sneezing, coughing, vomiting, following censorial or sensory impression which is rather active and unexpected or extra-functional, and also the movements of the limbs induced by irritations of the skin during sleep or in apoplectic patients, as being movements, so to speak, independent of consciousness and of the will. Voluntary movement is nothing more than the elaborated form of reflex action; muscular movement is itself merely a differentiated form of organic movement usually hidden and invisible.”

Morat says: “The word reflex signifies return of the impulse towards its point of departure by passing thru that which is known as a center. But according as the impulse penetrates more or less deeply into the central masses of the nervous system, according as it reaches the medulla oblongata, the basal ganglia, or even the cerebral cortex, the reflex act becomes continually more complicated, without ceasing to be fundamentally a phenomenon of the communication and transmission of the impulse through a chain of elements Hence there is, between the simplest and the most complicated actions of the nervous system, a continuity which causes the second to take origin from the first by an insensible graduation. This is why it is said that the function of the nervous system, regarded as a whole, as well as in detail, is merely a reflex phenomenon. The reflex act is, under any circumstances, the simplest image which he can imply in order to characterize this totality of action.”

“The simple, ordinary reflex has the aspect of a purely mechanical movement of transmission. Consciousness and spontaneity appear to be totally absent from it; on the other hand, this spontaneity and this consciousness seem to characterize the actions which require the intervention of the superior portions of the nervous system, and especially of the cerebral cortex. Hence the reflex act has been, and is, opposed to the voluntary act. In practice, however, this opposition is based on the condition that it is not regarded as absolute.”

“As often as the impulse is communicated from one nerve element to another which follows it, there is reflexion of this impulse in a most general sense of the word, whatever may be its point of departure and its point of termination.”

Reflex actions are those performed without consciousness. The Chiropractor recognizes no reflex action in the living, thinking body. However, those functions, which occur in living bodies, which are construed as reflex actions, can be better interpreted in the following language and thereby meet the conditions best understood by him: An impression, in a certain tissue or area, is carried by an afferent nerve to the brain, where innate intelligence interprets the impression. Such an impression is carried as an impulse back, by an efferent nerve, to the point in the tissue, where the impression produced the activity. It is not a question of what is, because that which is being analyzed, is the same in both instances, it is the question of how it is accomplished, that gives rise to the two differences of opinions.

So called reflexes have been classified as simple and complicated. Among the more common are the following: **abdominal reflex**, consisting of the contraction of the abdominal muscles, caused by stroking the skin on the side of the abdomen, from the edges of the ribs; **Achilles reflex**, a contraction of the calf-muscles when the Achilles tendon is tapped, the foot being slightly flexed; **plantar reflex**, tickling the sole of the foot and causing a contraction of the toes; **patellar reflex**, the knee-jerk, contraction of the abductor muscles of the thigh when the tendon of the patella is tapped, while the patient is lying on his back. **Cranial reflexes**, one of these being the **palatal reflex** which is the act of swallowing, following the tickling of the palate, **laryngeal reflex**, cough produced by muscular action when the throat and larynx are irritated, and a number of others, as when tickling, pricking, pinching or gently scratching the surface; **nasal reflex**, sneezing and crying when the mucous membrane of the nose is irritated; closure of the eyelids when the conjunctiva is touched or when suddenly exposed to a **bright light** ; **pupillary reflex**, the accommodation of the pupil when exposed to sudden light; **labial reflex**, the quivering of the lip of a sleeping babe, which occurs on tapping near the angle of the mouth.

Do not these demonstrations prove that Innate is trying to adapt itself to the circumstance? For a blow on any organ calls for adaptative processes—a blow on the solar plexus would produce great responsiveness upon the part of the Innate mind, which would adapt its powers to the circumstances, be they great or small. Also, adaptations are the results of an intelligent thinking individuality, which has the ability to control bodily functions.

This adaptation causes a withdrawal of the parts when they come in contact with objects foreign to them, and when the nerve is not impinged to a point of causing pain; merely a slight pressure on the nerve causes the skin to retract or the knee to jerk, demonstrating the fact that Innate, realizing the possible injury that might be done to the organs or parts involved, thus protects the tissues by adapting her intellectual forces to the condition of material things.

A centre represents the localization of a particular part, or the

middle point, or centre of physiological activity, or the concentration of such actions in the specific locality.

Chiropractically speaking, all the centres are contained in the brain, and all impressions must be carried there to be interpreted and sent forth as an impulse, from the area where the interpretation takes place, to the tissue involved. As Dr. B. J. Palmer says, in *Reflex Action*: “At the central end of every brain fibre is its Innate brain cell, and it there receives external impressions, puts them thru an intellectual cross-examination—interpretation—so that the extension (nerve) can transmit, to the periphery, an intelligent impulse denoting character, that directs where it should go and what it must do, then we have an intelligent response (not a ‘reflection or duplicature’ of what went inward) to the external appeal for help.”

Authorities, except Chiropractors, consider a centre as a collection of nerve cells, to which external impressions are carried and whence impulses are sent out, and therefore they are considered as brains, being regions of gray matter in which the anatomical and functional bonds of union between elements and systems are established. Not all of these seeming centres are located in the brain, many of them are located in the spinal cord and the medulla. Take the vaso-motor nerves for an example, they form a system which presides, not merely over the circulation, but also over other analogous functions, and these nerves are considered as radiating from the vasomotor centre in the medulla and spinal cord—that is, the impression is said to be received there and the impulse sent from the centre for the control of the circulatory system.

About 63 centres are given and of these the following may be mentioned: **cilio-spinal**, a centre in the lower part of the cervical portion of the spinal cord regulating the dilation of the pupil; **cardiac centre**, parts of the inferior cervical and superior dorsal regions of the spinal cord, which exert excitomotor action on the heart; **coughing centre**, nervous centre connected with coughing, in the medulla above the respiratory centre; **defecation centre**, a nervous centre at the level of the fifth lumbar vertebra controlling defecation; **respiratory centre**, a region in the medulla or floor of the fourth ventricle for inducing and coordinating the movements of respiration; **vomiting centre**, located in the medulla, controlling this action; trophic centre, centre presiding over nutrition, seated in the gray matter of the spinal cord and sympathetic system, **deglutition centre**, for the control of swallowing; **peristaltic centre**, a centre in the medulla, controlling the peristaltic action of the intestines; **salivary centre**, located in the floor of the fourth ventricle regulating the secretion of saliva; **sneezing centre**, in the medulla, sending nerves to the expiratory muscles; **micturition centre**, situated in the lumbar enlargement, controlling the bladder and inhibiting the tension of the vesical sphincter; **accelerating centre**, a centre in the medulla which sends accelerating fibres to the heart ; **parturition centre**, a centre for the contraction of the uterus and for fetal expulsion, located opposite the first and second lumbar vertebrae; **knee-jerk centre**, a musculo-tendinous reflex centre in the cord, at the level of the 3rd and 4th lumbar vertebrae, **abdominal centre**, a collection of gray matter in the cord, between the 6th and

THE NERVOUS SYSTEM

11th dorsal vertebrae, known as a cutaneous reflex, **convulsion centre**, a centre in the medulla, in the floor of the fourth ventricle, its stimulation causing convulsions; and the **sweat centre**, a centre in the spinal cord controlling perspiration.

These and many other centres are considered automatic or without consciousness. The digestion of food, healing of wounds, mending of fractures, are all considered as automatic and the functions for such intelligent actions are relegated to the numerous centres of the body, from whence the impression was received and the impulse sent forth to the tissue.

But Chiropractic teaches a direct system, which is given us by Innate Intelligence, in which every fibre leads from the tissue to the brain-cell, or vice versa. The brain-cell receives its impressions, the fibre transmits impulses and the impulses are interpreted or expressed in tissue cells.

In the brain is located each specific lobe, which contains specific cells, where every interpretation takes place and where responsive action is intellectual. There, then, is a direct, specific adaptation and the cell that needs the impulse is the one only that receives it. For "Reflex Action and the Sympathetic Nervous System," considered from all angles and given in detail, read and study the lectures on these subjects in *The Science of Chiropractic*, Vol. 2, by Dr. B. J. Palmer.

The following lecture was given at the P. S. C. Lyceum, 1917. In response to the many requests for a copy thereof, I herewith append the article:

IS THERE A CEREBRAL HEAT CENTRE?

I once saw this question in a medical magazine and the thought immediately came to me—why should such a question be asked? It then set me thinking and viewing the question from all angles. When I tried to find some centre not located in the brain, I immediately began my search thru various sources, and in many ways, for an answer to the question, "If all functions, both physical and mental, emanate from the brain, why should a heat-regulating centre be doubted?" And also, "If by various demonstrations and clinical observations or tests, other centres have been proven to be located in the cerebrum, where would this heat centre be found, and what would be its duty?"

The centralization of nerve fibres in the brain, forms a system of varying complexity, which co-ordinates the functions, and such a centralization is called a centre. This term is applied to those regions of the gray matter, in which anatomical and functional bonds are established between certain cells in the brain and certain cells in the tissue.

Among the better known, most important, and much discussed centres (about 63 are found in the body) are the **cilio-spinal, cardiac, coughing, deglutition, auditory, hiccough, mastication, respiratory, sweat, sneezing, secretory, excretory, trophic, tactile, gustatory** and **sleep**; each of these represents a central point of physiological activity. Take the vaso-motor nerves for an example. They form a

systematized assemblage of nerve fibres and cells, which preside, not merely over the circulation, but also over other analogous functions.

The **brain**, or **encephalon**, that portion of the nervous system which occupies the cranial cavity, is made up of the cerebrum, cerebellum, the medulla, and the pons Varolii. The cerebrum is located in the antero-superior part of the cranium, the cerebellum, below and posterior to the cerebrum, reposes in the inferior occipital fossae; the pons rests upon the clivus, a plate of bone, back of the sella turcica of the spheroid, the medulla corresponds to the basilar process of the occipital bone. These parts, together with the spinal cord and all the nerves, constitute the nervous system, or the brain system, as we prefer to call it. I will not here attempt a detailed description of all of these parts, but only of those concerned in a description of a few of the more important centres to be discussed. Since disorders of the brain arise from extra-cranial causes, it is my purpose to explain the centres which control all these functions in the entire body, incoordination of which functions, from an anatomical viewpoint, results from anatomical displacements.

The brain consists of gray and white matter. In man, the largest of the parts of the brain is the cerebrum, which constitutes over 80 per cent of the weight of the entire brain. It is divided into two hemispheres by a long fissure—the inter-cerebral or the longitudinal fissure. The hemispheres are connected by a large mass of white matter, called the corpus callosum. Each hemisphere has an external layer of gray matter, known as the cortex, while its interior is called the medullary substance. The surface of each hemisphere is raised into irregular ridges, called gyri or convolutions, which are separated by **fissures** or **sulci**.

Each hemisphere consists of **seven lobes**—the **frontal**, **parietal**, **occipital**, **temporal**, **limbic**, **central**, and the **olfactory**. The first four lobes correspond to the cranial bones; while the fissures which separate these four lobes—the **fissure of Rolando**, **fissure of Sylvius**, and the **parieto-occipital fissure**, correspond to the sutures formed by the junction of the frontal, parietal, temporal and occipital bones. The **limbic lobe** consists of three or four convolutions, arching round the corpus callosum; the **central lobe** is a triangular cluster of convolutions, which are found in the depths of the Sylvian fissure; the **olfactory lobe** is located at the anterior and base of the brain, and from it are given off the nerve filaments of the sense of smell.

Also each hemisphere contains a cavity—the **lateral ventricle**; and a small cavity, below and posterior to it, called the **third ventricle**. These ventricles communicate with each other and contain a serous fluid—the cerebro-spinal fluid. The structures found around the lateral ventricles are placed as follows: the roof of the cavity is the corpus callosum, a large mass of white tissue; the septum lucidum forms the inner ventricular wall; while the choroid plexus, the fornix, and the corpus striatum, consisting of the lenticular and caudate nuclei, and the external and internal capsules, form its floor and outer wall.

Of the third ventricle, the velum interpositum forms the roof the optic thalami form the sides; and the floor is formed by the pos-

THE NERVOUS SYSTEM

terior perforated space, the tuber cinereum the corpora albicantia and the pituitary body. These structures will suffice to pass in mental reviews, the parts which contain the centres of the body.

Each lobe of the cerebrum consists of several convolutions, and these, by the complexity and depth of their fissures, determine the grade of the intelligence of the individual. In the lower vertebrates many convolutions are wanting, while other parts are more highly developed, such as the olfactory lobe in animals possessing a keen sense of smell, and the optic lobes in birds. In the child, the convolutions are simple and the fissures are shallow. The lobes are made up of an external gray substance, consisting of cells; while leading from the cell-tissue are white nerve fibres, also in each lobe are found aggregations of cells, which compose a certain area, or a central point or localization of activity, called a **centre**. From these centres the nerve-fibres emanate, to pass to their destination, to the periphery cells in the various parts of the body.

The **cerebrum** is the only part of the brain in man where afferent impulses react in consciousness or are interpreted by the innate brain. It contains the various centres where afferent impulses of peripheral end-organs are received and give rise to the mental impressions. It is the place which contains the centres from which impulses proceed by means of the power of the will, to the various portions of the body and thus control their movements, these centres give rise and expression to the desires of the mental ego, being the seat of consciousness, intellect, judgment, language, emotion and ideation.

In the **frontal lobe**, therefore are located the centres which control the voluntary movements of the body, of the eyes, face, trunk and limbs. Also it is where the visual centres react in consciousness, and is the centre of speech; it is also in this lobe that we have a knowledge of things in space.

The **parietal lobe** is the centre of morals and of the higher physical functions; it is but slightly developed in the lower animals.

The **occipital lobe** is the seat of vision, that is, of imagery and memory. It also receives a few auditory impressions.

The **temporal lobe** is the centre of taste and smell. It is especially well developed in the lower animals.

The **central lobe** is the centre of speech, receiving the throat impressions and we find this lobe highly developed in orators.

The **limbic lobe**, not a "lobe" in the sense of comprising a definite segment of the hemisphere as do the other lobes, but its convolutions seem to be devoted to the functions of smell.

The **olfactory lobe** is the centre of the sense of smell, and this lobe is highly developed in the fox, dog, etc. In many cases the olfactory lobe forms almost one-half of the entire mass of the forebrain of the cerebrum. The small armadillo spends its entire time burrowing in the soil, and creeping about the foliage of the forests. For choosing its food and for finding it, it therefore depends on the sensory apparatus of the sense of smell.

In the ape, the prehensile hand requires a much greater development of true physical centres for the upper extremities, than is found in the small creature that lives by wallowing. This special develop-

ment of particular centres occurs in all species. For example, the elephant possesses an especially large facial area, which is entirely wanting in the rhinoceros and the tapir. If nothing were known of the source of the wonderful ability of the elephant to use its trunk in such various ways, it might be concluded, from the presence of the large facial area, that all the muscles capable of such special function were located entirely in this area.

A large head does not necessarily mean a large brain, for, by contrast, we find enormous brains, or rather, weighty brains, are found contained in comparatively small craniums, and powerful skulls show only a normal development of the brain. The human brain weighs approximately 48 to 50 ounces. However, by the addition of cells, the convolutions increase; and, by increased depth of the fissures, the cortical gray substance greatly increases, without occupying additional space in the cranium. Therefore, while the cerebrum is used as a measure of the sum total of intelligence, yet uncommonly heavy brains may appear in individuals who do not rank very high intellectually; on the other hands, relatively low weights have been found in brains of prominent men.

Anyone endowed with enormous visual memory, or visual imaginations, together with all the intellectual attributes that characterize the great artist, might occupy a position entirely unique, and would probably show an increased development of the occipital lobe. The same may be said of a musician, and here, in all probability, we have to do with an increase of the convolutions of the temporal lobe.

The brain of the ape is surprisingly similar, in regard to convolutions, to that of man. That which especially distinguishes it from man, however is the development of the convolutions in the frontal and central lobes. They are much shorter and often exhibit mere rudiments of many of the convolutions found in these areas of the human brain. It is highly probable that this is the anatomical expression of the inferior intelligence of the ape, particularly of the utterly undeveloped faculty of articulate speech. As we probably owe the perfection of our intelligence to our faculty of speech (not as individuals, but as a race) the reason for the inferior development of the entire frontal lobe in apes may, perhaps, be found in the imperfect development of the most anterior convolution of that lobe.

It is not so very long ago that anatomists manifested little interest, and physicians none at all, in the study of the conformation of the cerebral surface. Nor it is so very long ago since order was brot out of the seeming chaos of the convolutions, and clear and accurate illustrations took the places of those plates of which an author once remarked that they "resembled a dish of macaroni more than the brain." Interest was first actively stimulated in regard to the human brain only after physiology had shown that extirpations and the freezing of certain portions of the brain, had interfered with the various working and demonstrations of the functions of the body.

I will briefly mention a few of these experiments: by a removal of the tactile area, intelligence is absolutely ruined; for neither by touch, hearing, sight, or smell can the animal be induced to perform

any intelligent act. The resultant conditions might be considered as one of dementia.

By the removal of the visual area, physical blindness appears; the frontal area removed results in the absence of many of the voluntary acts, both in muscular movement and in speech, particularly in articulate speech. Mental inferiority is especially pronounced.

When the parietal area is removed, the animal presents serious anomalies, particularly when, in an unfamiliar place and after ascending a stairway, it is entirely incapable of descending and is not able to "give a paw."

Dr. B. J. Palmer, in his superior meric system of Volume II, elaborates in detail on the pathological conditions resulting from pressure upon nerves and the consequent shutting off of a percentage of interpretation, which then takes place in the corresponding brain lobes, presiding over each set of functions.

In man, the expression of ideas is conveyed by conventional signs and by acquired movements. There is, on the other hand, an expression of the emotions by movements of which we are not aware, constituting a kind of unlearned universal language; this language exists from birth and is found even in those animals whose organizations approach our own, principally in the domesticated animals.

Emotion is shown in the face, by the contraction of one or more muscles, which, arising from a fixed insertion on the skull, displace certain portions of the skin, either hollowing it into wrinkles or by removing those already existing and thus changing the expression

Among the many emotions displayed are: attention to external objects—that is characterized by an elevation of the eyebrow and of the upper eyelid, while at the same time transverse folds are formed on the brow, producing an expression of surprise, but which, if exaggerated, produces an expression of horror.

Reflection is a state of mind which causes the attention to be concentrated internally; to the exclusion of all external impressions; and is shown by a lowering of the eyebrow and an obliteration of its curve, while, at the same time, the lines on the forehead disappear.

Pain, both physical and moral, is shown by a fold of the eyebrow, which is raised upwards and outwards by the contraction of the corrugator supercilli. Menace is shown by a lowering of the inner half of the eyebrows and by transverse folds across the root of the nose, by the contraction of the pyramidalis muscle. In laughter, the commissure of the lips is drawn upwards and outwards, the skin of the cheeks become more prominent and forms folds radiating toward the external angle of the eye—crow's feet—and this enlarges the shadow below this angle and almost gives rise to the belief that the eyelid has changed its position.

The facial expression of weeping is the opposite to that of laughter, as far as regards the direction impressed on the commissure and on the folds of the mouth. Disdain, scorn and disgust, derive their expression from modifications of the position of the lips. The conventions of civilized life oblige us to restrain the manifestations of our emotions, but this restraint is incomplete and allows an involuntary revelation of our internal sentiments to occur, more or less

THE NERVOUS SYSTEM

distinctly; thus even the faintest of indications of such emotions become very expressive.

No anatomical or physiological explanation has been attempted, to explain the many centres controlling these emotions (they are called clinical phenomena), but Chiropractors know that the brain is the great centre from which all impulses are conveyed and interpreted, causing all tissues to act, at a certain time and to a proper degree.

Cellular activity declares itself, very generally, by a more or less apparent movement. It is rendered evident, still more generally, by a development of heat. The muscle which contracts and the capsular muscular tissue surrounding the secreting glands also contracts, and both become warmer; the one more than the other, but both to a sensible degree.

This development of heat is, like movement itself, an evidence of the activity of the organs and of the nerves which preside over them. To these nerves, then, which directly influence thermogenesis, is given the name **calorific** or **thermic nerves**. The development of heat, which is molecular vibration, is merely one of the many aspects of cell-function and it follows, therefore, that all nerves connected with heat production are **thermic nerves**, radiating from a **thermal** or a **heat centre** in the brain just as all other functions arise from their corresponding centres.

It must be equally true of this function, as it is of all others, that there is a centre for the regulation of heat, and that this function makes use of a special system of coordinated nerves in order to obtain a fixed temperature. The impingement of a thermic nerve diminishes or increases the bodily temperature; also a fixed thermic or calorific level may be maintained by compensation of the motor nerves in spite of variations of external temperature.

The indisputable fact that a nearly constant bodily temperature is maintained within the organism by an accurate balance of heat production and heat loss is, to say the least, highly suggestive of some regulatory process on the part of the whole nervous system. Many authors contradict the statement that this function of temperature regulation can be specially localized in any particular part of the nervous system, so that it would be possible to speak of a heat centre in the same way we speak of a respiratory, vaso-motor, or secretory centre. This has been said to be improbable because heat centres have been thought not to exist above the bulb, but Sajous says, "heat centres are found precisely along the path of the fibres from the pituitary body and therefore are called pituitary nerves. Ott, Tangle and others, all record instances where, in experimentation, they have obtained a marked rise of temperature six hours after puncturing the tuber cinereum, a structure at the base of the brain. Harris states, "in order to establish that the rise of temperature did not originate from the pituitary body, that puncturing the floor of the lateral ventricle clearly shows a rise in body temperature."

In the basal ganglia in the floor of the lateral ventricle is the caudate nucleus, an elongated comet-shaped mass of gray matter, lying between the upper part of the temporal lobe and the junction of

THE NERVOUS SYSTEM

the central and parietal lobes. In this structure are located a number of short fibres, which play an important part in the coordination of those fibres which affect bodily temperature, and those needed to adapt the parts to an increased respiration and sweating. These brain centres with their fibres may, like the other structures in the brain, be influenced by cold, heat and drugs. These agents cannot alter the nature of the responses of these brain cells or elements or fibres, they can only be claimed to effect qualitative changes, which are called stimulation or depression.

The reason for, or the proof of, the location of this centre within the caudate nucleus is obtained from observations made of cooling the corpus striate area, in which is located the caudate nucleus; this causes respiratory exchanges and heat production. If heat be centrally applied to the same area, an opposite effect is produced. The facts would indicate that a central localization of heat-regulation must exist since the character of the effects is diametrically opposite to the nature of the stimulus.

Although I do not now recall the names of the authors, I clearly remember a statement issued by some of our best universities in medicine, that a cerebral heat centre cannot be confirmed, stating that the facts at their disposal were too meager to warrant any definite localization of the heat-regulating functions. Chiropractic teaches, however, that all centres are located in the brain, for Chiropractors deal with the impressions transmitted between brain-cell and periphery, and with the Innate Intelligence, which interprets these expressions. The brain is the generator, transformer and converter of mental impulses, and in the cerebral portion of the brain are these areas located; also from the cerebrum, with the assistance of the cerebellum, the pons and the medulla, are the fibres transmitted to eventually reach the parts for which they are intended. When no interference exists along the circuit, the brain works in completely harmonious order, for the fulfillment of the duty for which it was originally intended—a complete cycle—health.—MABEL H. PALMER.

GLOSSARY

- Abdo'men. To hide or conceal.
Abdu'cens. Drawing away.
Abduct. To draw away from the medium line.
Abnormal'ity. Not normal.
Accel'erator. Hastener.
Acetab'ulum. Named after vessel for holding vinegar.
Ac'inus. Grape-like.
Acro'mion. The summit of the shoulder.
Acus'ticus. Pertaining to sound.
Adduct. To draw toward.
Ad'enoid. Like a gland
Adhe'sion. Union of two surfaces.
Ad'ipose. Fatty.
Af'ferent. From tissue to center.
Ala. Wing-like.
Al'ba. White.
Al'bicans. White.
Albugin'ea. Whitish.
Alve'olar. Socket-like.
Am'nion. The inner layer of membrane which envelops the fetus in the uterus.
Ampu'lla. Flask-shaped, dilated end.
Amyg'dala. Almond-like.
Anab'olism. Constructive cellular activity.
Anal'ogous. Similar organ in function but different in structure.
Anastomo'sis. Communication of vessels.
Anco'neus. Pertaining to the elbow.
An'gio. Prefix denoting relation to a vessel
Angle. A sharp bend formed by the meeting of two borders or surfaces.
Ankylo'sis. Bony union of two bones which are normally separate.
Anom'aly. Marked deviation from the hair-like normal.
An'nular. Like a ring.
Ante or anti. In front of or before.
An'tero. Short form of anterior.
Ante'riad. Toward the anterior surface of the body.
An'ticus. Anterior.
An'trum. Cava or cavity.
A'nus. A ring.
A'pex. Tip or extremity.
Apon'euro'sis. Expansion of a tendon.
Apoph'ysis. A process or swelling on a bone.
Appen'dix. Something attached to an organ.
A'qua. Water.
Arach'noid. Web-like.
Articulate. Curved or arched.
Are'ola. A small open place.
Arthro'dia. Gliding.
Ary'tenoid. Form of pitcher.
As'pera. Rough.
Asym'metry. Lack of proper proportions.
A'trium. A hall, (pl.) ATRIA.
At'rophy. Decrease in the size of an organ. Wasting away
Au'ditory. Pertaining to the sense of hearing.
Auris or auric'ular. Ear.
Axilla. The armpit
Az'ygos. Without a fellow, single.
Bas'ilar. Pertaining to the base or under surface.
Bi. A prefix signifying two or twice.
Bi'ceps. Two heads.
Bicor'nate. Having two horns.
Biol'ogy. Study of organisms.
Biven'ter. Having two bellies.
Bra'chium. Arm or the humerus.
Brev'is Short.
Bron'chus. Windpipe.
Buc'ca. Cheek.
Cacu'men. Top or apex.
Cadav'er. Dead body.
Cae'cum. Blind pouch.
Ca'lices. Plural of calix.
Ca'lix. A cup or goblet.
Callo'sum. Hard or thick.
Calva'rium. Skull-cap.
Can'cellous. Having cells.
Can'thus. Corner of the eye.
Capil'lary. A vessel,
Capitell'um. A small head.
Ca'put. Any head-like structure.
Car'dia, or car'diac. Refers to the heart.
Car'dinal. Chief or principal.
Cau'dad. Toward the tail extremity.
Cau'dal, caudate or cauda. Pertaining to a tail.
Cen'trad. Toward the center of the body.
Centrum. pl. CENTRA. The body of a vertebra. The center of any body or structure.
Ceph'alad, cephal'ic. (1) Toward the head. (2) Pertaining to the head.
Cer'vix. The neck or a neck-like part.

GLOSSARY

- Chias'ma, or chi'asm. Two lines placed as in an X.
- Chon'dral. Referring to cartilage.
- Chor'da. Cord-like.
- Cho'roid, or cho'rioid. Like skin.
- Ci'lia. Hair-like.
- Cine'reus. Grayish or ash-colored.
- Claus'trum. A bolt, barrier or inclosure.
- Cleft. A fissure.
- Cleido. Pertaining to the clavicle.
- Cli'noid. Like a bed post.
- Clit'oris. To enclose.
- Cli'vus. A slope.
- Col'ic. Pertaining to the colon.
- Coll'oid. Glue-like.
- Collum. The neck.
- Co'mes. A companion.
- Con'cha. A shell.
- Con'dyle. Knuckle.
- Congen'ital. Existing at or before birth.
- Co'noid. Cone-like.
- Convolut'ed. Rolled together.
- Cor'acid. Like a crow's beak.
- Cord'iform. Heart-shaped.
- Cor'nea. Horny.
- Cor'nu, pl. cornua. Horn-like projection.
- Cor'onary. Incircling.
- Cor'onoid. Like a crooked beak.
- Cor'pus. A body.
- Cor'tex. The bark or outer covering.
- Cos'tal. Pertaining to a rib.
- Cot'yloid. Cup-shaped.
- Cox'a. The hip.
- Crest. Surmounting-part of an organ.
- Crib'riform. Sieve-like.
- Cri'coid. Like a ring.
- Cris'ta. The crest.
- Cru'cial. Shaped like a cross.
- Cru'ra. Leg-like structures.
- Cru'ral. Pertaining to the leg.
- Cu'bitus. The forearm.
- Cul'men. Ridge.
- Cu'neate. Wedge-shaped.
- Cu'pola. A dome.
- Cuta'neous. Pertaining to the skin.
- Cys'tic. Pertaining to a cyst or to the urinary bladder
- Decid'uous. Falling away.
- Def'erens. Carrying away.
- Del'ta. Like the Greek letter delta.
- Dem'i. Half.
- Den'tate. Tooth-like.
- Dex'ter or dex'tra. On the right side or hand.
- Di. Prefix meaning two or twice.
- Di'a. Through or between.
- Dias'tole. Relaxation of the heart.
- Digas'tric. Two bellied.
- Dig'it. Finger or toe.
- Disloca'tion. Removal from proper place.
- Dis'tal. Farthest from the head; oppo- site of proximal.
- Dor'sal, or dor'sum. Back.
- Ec'tal, or ec'tad. Toward the external.
- Ec'tomy. To cut out.
- Ef'ferent. From center to peripheral tissue.
- Em'issary. Sent out.
- Enceph'alon. The brain.
- En'do. Prefix meaning within.
- En'siform. Sword-like.
- En'tal, or en'tad. Toward the center or interior.
- En'tero. A prefix referring to the in- testine.
- Ep'i-. Upon or over.
- Epip'loon. The fetal peritoneum.
- E'vert. To turn outwardly.
- Ex'tra. Outside of, or beyond.
- Extrin'sic. External.
- Fac'et. Smooth articular surface.
- Fal'ciform. Sickle-like.
- Falx. Sickle.
- Fascic'ulus. A small bundle.
- Fenes'tra. An opening, like a window.
- Fi'bro. Prefix relating to fibers or fibrous tissue.
- Fib'ula. A clasp.
- Fil'iform. Like a thread.
- Fi'lum. A thread.
- Fim'briated. Fringed.
- Floc'culus. Flaky shreds.
- Fol'ium or fol'ia. Leaf-like.
- Foll'icle. A small bag.
- Fontanell'e. A little fountain.
- For'nicate. Shaped like an arch.
- For'nix. An arch.
- Fos'sa. A shallow depression.
- Fourchett'e. A fork.
- Fo'vea. Smooth depression.
- Fron'tal. Front.
- Fun'dus. The base or part of a hollow organ remotest from its mouth.
- Fun'giform. Mushroom-shaped.
- Funic'ulus. A cord-like structure.
- Gang'lion. A knot.
- Gas'ter, or gastric, or gastro. Pertain- ing to the stomach.
- Gemell'us. Double or paired.
- Gem'inus. Double or two fold.
- Ge'nio. Refers to the chin.
- Genic'ulate. Knee-like.
- Gen'ito. Refers to the genital organs.
- Ge'nu. The knee or any structure bent like a knee.
- Glabel'la. Smooth.
- Gladi'olus. A sword.
- Glen'oid. Shallow.
- Glo'bus. A sphere or ball.
- Glomer'ulus. A small ball of thread.
- Glos'sa, or glos'so. Refers to the tongue.
- Glott'is. Narrow opening between two parts, as between vocal cords.
- Glu'teal. Pertaining to the buttock.

GLOSSARY

- Grac'illis. Slender.
 Gus'tatory. Pertaining to taste.
 Gy'rus. A circle or a crook, a convolution in the brain.
- Haben'ula. Any frenum or rein-like structure.
 Hal'lucis. Belonging to, or of the great toe.
 Hal'lus, hallux. The great toe.
 Ham'ular. Hook-shaped.
 He'lix. Coiled or spiral.
- Hem'i. Prefix signifies half.
 Hemorrhoid'al. Pertaining to the rectum.
 He'par, hepatic or hepato. Refers to the liver.
 Her'nia. A rupture.
 Hia'tus. An opening or gap.
 Hi'lum. A depression for the entrance and exit of vessels, nerves and ducts of an organ.
 Hi'lus. Same as hilum.
 Hippocam'pus. A sea horse.
 Homol'ogous. Like another structure or organ, common to a number of organs.
 Hy'aline. Glassy.
 Hydat'id. Watery vesicle.
 Hymen. A thin skin or membrane.
 Hyoid. Like the Greek letter U.
 Hyper. Above or excessive.
 Hypo-. Prefix signifying deficiency, below or beneath.
 Hys'tero-. A prefix denoting some relation to the uterus.
- Ileum. Twisted or coils. The distal portion of the small intestine.
 Ileo. Relating to the ileum.
 Ilium. The flank. The wide upper portion of the innominate bone.
 Ima. Within.
 Impar. Unequal.
 Incus. Anvil.
 Infra. Below.
 Infundib'ulum. Funnel-shaped.
 In'guinal. The groin.
 In'nate. Born with or within.
 In'sula. An island.
 Inter-. Between.
 Interos'eous. Between bones.
 Interstitial. Pertaining to or situated in the small intervals of a tissue.
 Intra-. Within.
 Intrin'sic. Internal.
 Invert. To turn in.
 I'ris. Rainbow.
 Ischia'tic. Refers to the hip.
 Iter. A passage or way.
- Jeju'num. Empty.
 Ju'gular. Throat or neck.
- Katab'olism. Destructive cellular activity.
 Ker'ato-. Horny.
 Ky'phos. Humpback.
 Kypho'sis. A posterior curvature.
- La'bium. Lip.
 Lac'rimal. Pertaining to tears.
 Lac'teal. Pertaining to milk.
 Lactif'erous. Milk carrying.
 Lacu'na. A hollow or cavity.
 Lat'ero. Prefix denoting one side, lateral.
 Lam'ina. A small plate.
 Lamel'la. A small plate or thin leaf.
 La'ta or latum. Broad.
 Latiss'imus. Broadest.
 Lat'eral. Pertaining to the side.
 Li'eno. Pertaining to the spleen.
 Lig'ula. A strap.
 Lig'ature. A thread or wire for tying a vessel.
 Limbo'sa. Over-lapping.
 Lim'bus. A border.
 Lin'ea. A line.
 Lin'gual. Refers to the tongue.
 Lin'gula. A little tongue.
 Lon'gus. Long.
 Lordo'sis. An anterior curvature.
 Longis'simus. Longest.
 Lum'bar. Pertaining to the loin.
 Lum'bricoid. Like an earth-worm.
 Lum'bus. Loin.
 Lu'men. The cavity of a tubular structure.
 Lu'nar. Refers to the moon.
 Lu'nula. A little moon.
 Lu'teum. Muddy, like clay.
 Lymphat'ic. Lymph.
- Mac'ula. A spot.
 Mag'nus. Large.
 Ma'lar. Pertaining to the cheek.
 Male'olus. A mallet.
 Mal'leus. A hammer or mallet.
 Mam'ma. A breast.
 Man'dible. Lower jaw.
 Manu'brium. Handle.
 Mas'toid. Nipple-like.
 Max'illary. Pertaining to the upper or lower jaw.
 Max'imus. Greatest.
 Mea'tus. A passage or canal.
 Mediasti'num. The middle. A mediastinum septum or partition.
 Medul'la. Marrow.
 Menin'ges. Membranes.
 Menis'cus. A crescent.
 Men'tal. Pertaining to the chin.
 Me'sial. Internal.
 Mes'o or medio-. Middle.
 Me'siad. Toward the middle.
 Meta-. Change, transformation or exchange. After or next.

GLOSSARY

- Metab'olism. Constructive and destructive cellular activities.
- Metro-. Prefix relating to the uterus.
- Metop'ic. Referring to the forehead.
- Micro-. Prefix signifying small size.
- Min'imus. Smallest.
- Modi'olus. The hub of a wheel. Central pillar of the cochlea.
- Mo'lar. Grinder.
- Montic'ulus. A small mountain.
- Mu'co. Prefix referring to mucus.
- Multif'idus. Divided into many parts
- Mu'cous. Relating to mucus.
- Multi-. Prefix meaning many.
- Myr'tiform. Like a myrtle-berry.
- Mye-. Marrow, most always refers to the spinal cord.
- Myo-. Prefix referring to muscle.
- Na'res, or Na'si. Refers to the nose.
- Navic'ular. Boat-shaped. The scaphoid bone.
- Neph'ro. Prefix pertaining to the kidney.
- Neph'ros (Greek). A kidney.
- Ner'vi. Nerve.
- Neu'ral. Pertaining to a nerve.
- Neu'ro. Prefix signifying relation to a nerve.
- Neurog'lia. Nerve glue.
- Nic'titans. Winking.
- Nu'cha. The nape of the neck.
- Nu'chae. Pertaining to the nape of the neck.
- Nu'cleus. A kernel.
- Oc'ular. Pertaining to the eyeball.
- Oc'ulo. Pertaining to the eyeball.
- Oid. Suffix, denoting likeness or resemblance.
- Olfac'tory. Pertaining to the sense of smell.
- Omo-. Pertaining to the shoulder.
- Oper'culum. Lid or cover.
- Op'tic. Pertaining to the eye, to vision.
- O'ris. Of the mouth.
- Os. Mouth or opening.
- Ora. Plural of same. Also a border or margin.
- Os. Bone.
- Ossa. Plural of same.
- Osmo'sis. Diffusion of fluid thru a membrane.
- Os'seous. Bony.
- Os'teo. Prefix pertaining to bone.
- Ova'rio-. Prefix, referring to the ovary.
- Oxyn'tic. Producing acid.
- Palmar. Pertaining to the palm.
- Pal'pebra. An eyelid.
- Papil'la. A small nipple-like elevation.
- Para-. Near, by the side of, or beside.
- Paren'chyma. The working part of an organ.
- Pari'etal. Wall.
- Par'vus. Small.
- Pectin'eal. Pubic.
- Pectoria'lis. Pertaining to the breast.
- Pec'tus. The breast or chest.
- Peri-. Around or surrounding.
- Perine'um. Pelvic diaphragm.
- Peristal'sis. Worm-like motion.
- Perone'al. Pertaining to the fibula.
- Pes, (pl) PE'DES. Pertaining to a foot.
- Pet'rous. Hard or stony.
- Phren'ic, or Phreno. Refers to the diaphragm.
- Plan'tar. Pertaining to the sole of the foot.
- Pleu'ra. A side or rib.
- Plex'us. Twining or a network.
- Pli'ca. A fold.
- Pneu'mo. Refers to the lung, air in any part.
- Pol'licis. The thumb.
- Pol'y. A prefix meaning many.
- Pons. A bridge.
- Poplite'al. (L. POPLES, ham.) Pertaining to the posterior surface of the knee.
- Portal. A gateway.
- Post. Following, or behind.
- Post-axial. Situated behind an axis.
- Pos'ticus. Posterior.
- Post-natal. After-birth.
- Pre-. Before.
- Pre-axial. In front of the transverse axis of the body.
- Pre-natal. Previous to birth.
- Pri'mus. First.
- Pro-. Prefix denoting forward or before.
- Profun'dus. Deep.
- Prone. Lying face downward.
- Prox'imal. Nearest the trunk center or medium line.
- Pseu'do. False.
- Pso'as. The loin.
- Pter'ygoid. Wing-like.
- Pubes. Hair on the external genitalia.
- Pu'bic. Pertaining to the pubes.
- Puden'dal. Pertaining to the external genital parts of the female.
- Pul'mo. A lung.
- Pulvi'nar. A couch or cushion.
- Pylor'ic. A gate-keeper.
- Quadra'tus. Square.
- Quadri-. A prefix meaning four.
- Quad'riceps. Having four heads.
- Quadrigem'inus. Fourfold.
- Rac'emose. Like a cluster of grapes.
- Ra'dius. A spoke of a wheel.
- Ra'mus. A branch.
- Raph'e. A seam, ridge or furrow.
- Receptac'ulum. A receptacle.
- Rec'tus. Straight.

GLOSSARY

- Recurrent. Running back.
 Re'flex. A turning backward.
 Re'flux. Return flow.
 Regurgita'tion. Reflux or return flow.
 Re'nal. Refers to the kidney.
 Ren'iform. Kidney-shaped.
 Res'tiform. Like a rope.
 Re'te, pl. re'tia. A net or meshwork.
 Ret'rahens. Drawing back.
 Re'tro. Prefix signifying backward.
 Ri'ma. A cleft or chink.
 Ros'trum. A beak.
 Ru'gae. Wrinkles.
- Sac. A bag-like organ.
 Sag'ittal. Like an arrow.
 Sal'pinx. A trumpet or tube.
 Saph'enous. Manifest.
 Sca'la. Like a staircase.
 Scale'nus. Of uneven sides.
 Sca'phoid. Like a boat.
 Scapula. A spade.
 Sciat'ic. Pertaining to the hip.
 Sclerot'ic or sclerosis. Hard.
 Scolio'sis. Lateral curvature.
 Seba'ceous. Like suet or tallow.
 Secun'dus. Second.
 Sel'la. Saddle.
 Semi-. A prefix denoting half.
 Sem'inal. Referring to the semen.
 Sen'sory. Pertaining to sensation.
 Sep'tum. A dividing wall or partition.
 Sero-. Prefix referring to serum or serous.
 Serra'tus. Saw-like.
 Se'rum. Whey.
 Ses'amoid. Seed-like.
 Sig'moid. Shaped like the letter S.
 Sin'ister or Sin'istra. The left side.
 Si'nus. A cavity or opening, larger within than at the entrance.
 So'leus. Pertaining to the sole or bottom of the foot.
 Sper-ma. Seed or semen.
 Spermat'ic. Referring to the semen.
 Sphe'noid. Wedge-like.
 Sphinc'ter. Closing tight.
 Spi'nal. Pertaining to the spinal column.
 Spine. Sharp or thorn-like.
 Spi'ral. Twisted.
 Splanch'nic. Referring to the viscera.
 Sple'nium. A bandage or compress.
 Squa'mous. Scale-like.
 Stape'dius. A stirrup.
 Stel'late. Like a star.
 Sto'ma, pl. STO' MATA. Mouth or pore.
 Sty'loid. Pen-like.
 Sub-. A prefix signifying under, or beneath or almost or near.
 Subfla'va. Somewhat yellow.
 Subli'mis. Superficial.
 Subluxa'tion. A partial dislocation.
 Sul'cus. A groove or furrow.
- Superfic'ial. Near the surface.
 Supernu'merary. Exceeding the normal number.
 Supi'ne. Lying flat on back.
 Supra-. Above.
 Su'ral. Pertaining to calf of the leg.
 Su'ture. A seam.
 Sym'physis. The line of junction and fusion between bones originally separate.
 Syn-. With, together with.
 Syno'via. Joint oil.
 Sys'tole. The contraction of the heart.
- Tac'til (e). Pertaining to touch.
 Tae'nia. Flat band.
 Tal'ipes. Club-foot.
 Ta'lus. Ankle-bone.
 Tan'gent. Touching, especially at a single point.
 Tangen'tial. Resembling a tangent.
 Tar'sus. Instep.
 Tegmen'tum. A covering.
 Tem'poral. Pertaining to time.
 Ten'don. From the Latin word tendo—
 I stretch.
 Te'res. Round or rounded.
 Ter'tius. Third.
 Thal'amus. A bed-chamber.
 The'ca. A cover, case or sheath.
 Thy'roid. Like a shield.
 Tor'cular. A wine-press.
 Trabec'ulae. Fibrous septa which extend into an inclosed substance.
 Tra'chea. Rough.
 Trap'ezium. A four-sided figure.
 Tre'foil. Having three leaves.
 Tri-. Prefix denoting three.
 Tri'ceps. Having three heads.
 Trigem'inous. Triple.
 Trigo'num. A triangle.
 Trique'trum. Three cornered.
 Troch'lear. Pulley-like.
 Tro'choid. Wheel-like.
 Tro'phic. Pertaining to nutrition
 Tu'ba. A trumpet or tube.
 Tu'bercle. A small uneven eminence.
 Tuberos'ity. A large, broad, uneven prominence.
 Tu'nic. A covering or coat.
- Umbili'cus. The navel.
 Umbo-. A boss or knob.
 Un'cifform. Hook-like.
 Un'cinat. Furnished with a hook.
 Un'gual. Relating to the nail.
 Uni-. Signifies one or single.
 Uro-. Prefix relating to urine or urinary organs.
 Urinif'erous. Urine-carrying.
 U'tricle. A little womb.
 U'vula. "Little grape."

GLOSSARY

Vagi'na. A sheath.
Va'gus. Wandering.
Val'vula. A little valve.
Vas. A vessel.
Va'sa. Plural of vast.
Ve'lum. A veil.
Ven'tral or Ven'trad. Front.
Ven'tricle or ven'triculus. A little belly.
Ventro-. Prefix pertaining to a belly.
Ver'miform. Like a worm.
Ver'tebra. From verto, to turn.
Ver'tex. Crown or head.
Ves'ical. Pertaining to the urinary bladder.

Ves'tibule. Oval cavity at entrance.
Vestig'ial. A trace of vestige.
Vil'lus. A shaggy hair or club-faced tuft.
Vis'cera. The internal organs.
Viscus. Any internal organ
Vitel'lus. The yoke of an egg.
Vit'reous. Like glass.
Vo'la. The palm or sole.
Volar. Pertaining to the palm or sole.
Vorticosae. Latin. "Coiled."
Xi'phoid. Like a sword.

INDEX

	Page		Page
Abdomen	270	Ampullar nerve	485
boundaries of	270	Amygdala of cerebellum	446
fasciae of	142	Amygdaloid nucleus	429
triangular	146	Amygdalae	258
lymphatic vessels of	236	Anal, canal	290
lymphatics of	236	orifice	290
muscles of	142	valves	290
regions of	270	Anastomosis, of arteries	214
veins of	231	of veins	217
walls of, apertures in	270	Anastomatica magna of brachial	200
Abdominal aorta	190-204	Anastomatica magna of femoral	208
aortic plexus of nerves	519	Anatomy, classification of	1
ring, external	145	definition of	1
internal	147	descriptive terms of	1
Abducent nerve	482	Anconeus muscle	160
Abductor, hallucis muscle	177	Angiology, definition of	179
minimi digiti muscle, foot	177	Angular artery	192
hand	162	gyrus	421
pollicis longus muscle	161	vein	222
Accelerator urinae muscle	152	Ankle-joint	108
Accessory, obturator nerve	507	synovial membrane of	109
organs of digestion	256	Anococcygeal nerves	515
pubic artery	207	Antecubital fossa	158
Acetabulum	58-59	Antihelix of ear	348
transverse ligament of	105	Antitragicus muscles	349
Acoustic nerve	359-485	Antitragus of ear	348
Acromial artery	199	Antrum of Highmore	29
nerve	494	mastoid	19-353
region, muscles of	154	Anus	290
Acromioclavicular articulation	97	Aorta	188
ligaments	98	abdominal	190-204
Acromion process	63	arch of	190
Adam's apple	243	ascending	188
Adductor, brevis muscle	168	descending	190-202
longus muscle	168	thoracic	190-202
magnus muscle	168	transverse	190
hallucis muscle	177	Aortic branches	188-190
pollicis muscle	162	lymph nodes	236
transversus, hallucis muscles	177	opening of diaphragm	140
pollicis muscle	162	valve	186
Adrenal capsule	305	Aponeuroses	112
Adrenal gland	305	epicranial	114
Air, sacs	251-255	of external oblique	144
sinus, frontal	17	of internal oblique	146
Ala of sacrum	55	lumbar	130
Alae of ethmoid	24	pharyngeal	268
of nose	326	vertebral	130
Alar cartilage, sulcus	326	Apophysis of bone	4
Alimentary canal	256	Apparatus—	
tract, development of	256	auditory	347
Alveolar artery	192	biliary	298
process of maxillae	31	digestive	256
Alveoli of lungs	251	lacrimal	345
of mandible	36	respiratory	240
Ampulla of Fallopian tube	392	urinary	366
of rectum	290	Appendices epiploicae	290
of semicircular canals	354-358		

INDEX

	Page		Page
Appendix, ensiform	39	Artery or Arteries (Continued)—	
vermiform	287	carpal	202
xiphoid	39	cerebellum	196
Appendages of eye	343	cerebral	193
digestive	256	anterior	194
skin	362	middle	194
uterus	392	posterior	194
Aquaeductus, cochlea	356	cervical	198
vestibuli	354	choroid	194
Aqueduct of midbrain	440	ciliary	193
Aqueous, chamber	341	circle of Willis	194
humor	341	circumflex	199-208
Arachnoid, of brain	408	of clitoris	207
villi	310-408	coats of	187
spinal	456	coeliac axis	204
Arbor vitae	448	colic	205
Arch, of aorta	190	colli	198
carpal	202	comes nervi phrenici	198
femoral, deep	147	communicating, anterior	194
palmar, deep	202	posterior	194
superficial	202	of cornea	335
plantar	212	coronary	188
supraorbital	17	cremasteric	208
Arcuate fibres	452	cricothyroid	192
of medulla oblongata	452	definition of	186
ligaments	140	digital	200-212
Areola of mammary gland	398	dorsalis hallucis	210
Arm, bones of	66	indicts	200
fascia of	156	linguae	192
muscles of	156	pedis	210
Arrectores pilorum	364	pollicis	200
Arteria centralis retinae	193	epigastric	198-208
magna	188	deep	208
princeps cervicis	192	superficial	208
Arteriae receptaculi	193	superior	198
Arterioles	179	ethmoidal	193
Artery or Arteries	179-186	facial	192
acromial	199	femoral	208
of ala	199	fibular superior	210
alveolar	192	frontal	193
anastomoses	214-215	of gall-bladder	296
aorta, abdominal	190-204	gastric	204
arch of	190	gastroduodenal	204
ascending	188	gastroepiploic	205
descending	190-202	genu, of knee-joint	210
thoracic	190-202	suprema	208
arteria receptaculi	193	gluteal	207
auricular	192	of head	191
axillary	199	of heart	188
basilar	196	hemorrhoidal	205-207
of bladder	369	hepatic	204-296
of bones	4	of hip-joint	208
brachial	199	hyoid	192
brachiocephalic	190	hypogastric	206-213
of brain	193-194	iliac, common	206
bronchia	202	deep circumflex	208
buccal	192	external	208
of bulb	207	internal	206
calcaneal	212	superficial circumflex	208
carotid, common	191	ileocolic	205
external	192	iliolumbar	207
internal	102	infraorbital	192

INDEX

	Page		Page
Artery or Arteries (Continued)—		Artery or Arteries (Continued)—	
innominate	190	pulmonary	187
intercostal	198	pyloric	204
interosseous, foot	210	radial	200
hand	200	radialis indicis	200
recurrent	202	ranine	192
ulnar	202	recurrent, palmar	200
of kidneys.....	314	radial	200
of knee-joint.....	210	tibial	210
labial coronary	192	ulnar	202
lacrimal	193	renal	206
of large intestines.....	291	of retina	193
laryngeal	192	sacral, lateral	207
lingual	192	middle	206
of liver.....	296	of salivary glands	266
lumbar	206	sciatic	207
malleolar	210	of seminal vesicles.....	207
mammary, internal.....	198	sigmoid	205
masseteric	192	of small intestines.....	205
maxillary, external	192	spermatic	206
internal	192	spheno-maxillary	192
mediastinal	202	spinal	217
meningeal, anterior	192	of spinal cord.....	217
from ascending pharyngeal.....	192	splenic	205
from occipital	192	sphenopalatine	192
mesenteric	205	sternomastoid	192
musculophrenic	198	of stomach.....	204
nasal	192-193	stylo-mastoid	192
of neck	191	subclavian	196
obturator	207	sublingual	192
occipital	192	submaxillary	192
ophthalmic	193	submental	192
orbital	192	subscapular	199
ovarian	206	superficialis volae.....	200
palatine	192	superior-hyoid	192
palpebral	193	supraorbital	193
pancreatic	205	suprarenal	206
pancreaticoduodenal	205	suprascapular	198
parotid	192	temporal	192
of penis	207	thoracic	202
pericardial	202	thyroid, axis.....	196
perineal	207	inferior	196
peritoneal	208	superior	192
peroneal	210	thyroidea ima.....	190
petrosal	193	tibial, anterior	210
pharyngeal	192	posterior	210
phrenic	204	of tongue	192
plantar	212	tonsilar	192
of pleura.....	198	tympanic	193
popliteal	210	ulnar	200
prevertebral	192	umbilical	213
princeps cervicis	192	of upper extremity	191
pollicis	200	uterine	207
profunda clitoridis.....	207	vaginal	207
femoris	208	vasa brevia.....	205
inferior	199	vertebral	196
penis	207	vesical	207
superior	199	vidian	193
of prostate gland.....	207	Arthrodia	88
pterygoid	192	Arthrology	86
pudic	207	Articular cartilage	3
pudendal	207		

INDEX

	Page		Page
Articulations	86	Attrahens aurem muscle.....	114
acromioclavicular	97	Auditory, apparatus	347
of atlas with axis	90	canal	349
with occipital bone	90	hair cells	359
of axis with occipital bone	92	meatus, external.....	19-349
of carpal bones	103	internal	19
carpometacarpal	104	nerve	359-483
chondro-sternal	94	tube	353
costotransverse	93	Auricle of ear	347
costovertebral	93	of heart	180
costo-chondral	94	Auriculoventricular	182
of elbow-joint.....	100	Axilla	154
of hip-joint	105	Axillary artery	199
inter-carpal	103	fascia	154
inter-chondral	94	lymph nodes	235
inter-phalangeal	105-111	space	154
inter-tarsal	109	Axis	49-196-204
of knee-joint.....	105	cylinder	406
of lower extremity	105		
metacarpal	104	B	
metacarpo-phalangeal	105	Band of Vicq d' Azyr	431
of hand.....	105	of Baillarger	441
of metatarsal bones with each		of Bechterew	441
other	110	ilio-tibial	164
metatarso-phalangeal	111	Barba	363
of foot	111	Bartholin, duct of.....	266
of pelvis	95	glands of.....	496
of pubic bones.....	97	Basilar, artery.....	196
radiocarpal	103	groove	14
radio-ulnar	101	membrane	358
of ribs with their cartilages.....	94	process	14
with vertebrae	93	sinus	220
sacroiliac	95	vein	221
of sacrum, and coccyx.....	97	Basilic vein.....	226
and ilium	95	Bechterew, band of	441
of scapula.....	98	Bell, respir. nerve of, external.....	496
scapuloclavicular	97	internal	495
of shoulder-joint.....	98	Biceps, brachii muscles	156
spino-pelvic	94	femoris muscle	171
sternoclavicular	97	flexor cubiti muscle.....	156
of sternum	94	Bicipital, groove	68
tarsal	109	tuberosity	70
tarsometatarsal	110	Bicuspid, teeth.....	261
temporomandibular	89	valve	182
tibiofibular	108	Biliary apparatus.....	298
tibiotarsal	108	Bile	296
of trunk	89	duct	296
of upper extremity.....	97	“Bird’s nest” of cerebellum	447
of vertebral column	90	Biventral lobe	447
with pelvis	94	Bladder	366
of wrist-joint	102	arteries of.....	369
Arytenoid cartilage	246	ligaments of	368
Arytenoideus muscles.....	127	nerves of.....	369
Astragalus	83	structure of	366
Atlanto-axial ligaments	90	trigone of	369
Atlanto-odontoid joint	90	veins of	229
Atlas	47	Blind spot	341
articulation of, with occipital bone	92	Blood-vascular system.....	179
with axis	90	Bodies, carotid.....	310
transverse ligament of.....	90	parasympathetic	310
Atria	255	quadrigeminal	437-439
Atollens aurem muscle.....	114		

INDEX

	Page		Page
Body, ciliary	337	Bone or Bones (Continued)—	
coccygeal	310	occipital	13
geniculate	436	os calcis	83
olivary	452	os coxae	57
pineal	309	ossification of	2
pituitary	310	palate	25
thyroid	306	parietal	16
vitreous	341	patella	77
Bone or Bones—		pelvic	57
apophysis of	4	of pelvis	6-57
of arm	6-66	periosteum of	2
astragalus	83	peroneal	82
atlas	47	phalanges of foot	6-84
axis	49	of hand	6-75
blood-vessels of	3	processes on	5
calcaneum	83	pubis	60
calcification of	2-4	radius	70
canaliculi of	2	ribs	39
carpus	6-72	sacrum	53
chemical composition of	2	scapula	63
classification of	4-5-6	sesamoid	5
clavicle	61	sexual differences of	4
coccyx	56	shin	77
collar	61	short	4
compact	2	shoulder, blade	63
covering	2	girdle	61
of cranium	12	single bones	5
development of	2	skull	5-12
endosteum	2	spheroid	20
ethmoid	23	spine	6-44
of face	5-25	sternum	39
femur	75	superior maxillary	29
fibula	82	sutural	4
flat	4	tarsal	6-83
of foot	83	temporal	18
of forearm	6-70	thigh	6-75
frontal	16	of thorax	38
of hand	6-72	tibia	77
of head	5-12	trunk	6-38
hip	57	turbinated	28
humerus	66	ulna	70
hyoid	37	of upper extremity	6-61
ilium	58	vertebrae	44
innominate	57	vomer	33
irregular	4	Wormian	4
ischium	60	Bowman, capsule of	313
of jaw	29-34	glands of	329
lacrimal	25	muscle of	337
of leg	6-77	Brachial artery	199
lingual	37	fascia	154
long	4	plexus of nerves	496-497
of lower extremity	6-75	veins	226
malar	32	Brachialis anticus muscle	156
mandible	34	Brachiocephalic artery	190
marrow	3	veins	225
maxilla	29	Brachioradialis muscle	160
metacarpus	6-72	Brachium	66-437
metatarsal	6-83	Brain	405-409
nasal	25	cerebellum	443
nerves of	4	coverings of	407
not classified	4	development of	410
number of	4	meninges of	407

INDEX

	Page		Page
Brain (Continued)—		Canal or Canals (Continued)—	
weight of	413	obturator	61
Breast bone	39	palatine, anterior	10
Bregma	7	posterior	10
Broca's convolution of	420	of Petit	342
Bronchi	250	pterygopalatine	10
Bronchioles, respiratory	251	sacral	53
Bronchus	250	of Schlemm	335
Buccinator muscle	118	semicircular, bony	354
Buccopharyngeal fascia	128	membranous	358
Bulb, of internal jugular vein	224	spermatic	147
olfactory	417	spinal	47
urethral	371	of Stilling	341
Bulbocavernosus muscles	152	of vermiform appendix	287
Bundle, Lissauer's	464	uriniferous	313
Turck's	463	vertebral	47
Vicq d' Azyr	431	vidian	10
Burdach, column of	464	Canaliculi of bone	2
Bursa or bursae about knee-joint	106	Canine, fossa	29
of elbow joint	101	teeth	260
of hip-joint	105	Canthi of eyelids	344
of knee-joint	106	Capilla	363
patellae	106	Capillaries	179
of shoulder-joint	99	Capsular ligaments of—	
Bursal synovial membrane	86	atlanto-axial	90
		chondro-sternal	94
C		costo-vertebral	93
Cacuminal lobes	446	elbow-joint	100
Caecum	286	hip-joint	105
Calamus scriptorius	454	inter-carpal	103
Calcaneal nerves	512	knee-joint	105
Calcaneum	83	occipito-atlantal	92
Calcarine fissure	426	shoulder-joint	99
Calcification of bone	2	sterno-clavicular	97
Calices, majores	314	superior tibio-fibular	108
minores	314	temporo-mandibular	89
Calix	314	of vertebrae	90
Callosal gyrus	424	wrist-joint	103
Calvaria	12	Capsule of Bowman	313
Camper, fascia of	144	of crystalline lens	342
Canal or Canals, adductor	170	Glisson's	294
alimentary	256	of Tenon	332
anal	290	Caput cecum coli	286
auditory	349	gallinaginis	370
carotid	19	Cardia	277
central, of spinal cord	462	Cardiac glands	278
of Cloquet	341	nerves, cervical	490
crural	166	orifice	277
dental	36	plexus of nerves	494
for Eustachian tube	353	veins	218
femoral	166	Carotid—	
Haversian	2	arteries, common	191
Hunter's	170	external	192
hyaloid	341	internal	192
infraorbital	29	cavernous portion of	193
inguinal	147	cerebral portion of	193
lacrimal	346	cervical portion of	193
malar	32	petrous portion of	193
mandibular	36	bodies	310
of nasal duct	347	canal	19
orifice of	347	fascia	128
		ganglion	486

INDEX

	Page		Page
Carotid (Continued)—		Cell or Cells (Continued)—	
glands	310	of Hensen	359
plexus	518	of Langerhans	300
sheath	128	mastoid	353
triangle	121-194	nerve	405
tubercle	51	olfactory	329
Carpal arch	202	Purkinje	449
bones	72	splenic	302
Carpus	72	supporting	329
articulations of	103	sustentacular	329-331
ligaments of	103	Cement of teeth	262
Cartilage	3	Centers or centres	407-522
articular	3	Cerebellum	443
arytenoid	246	“bird’s nest” of	447
cornicula laryngis	247	cortex of	447
costal	44	fibres of	448
cricoid	245	fissures of	443
cuneiform	247	flocculus of	446
elastic	3-246	folia of	446
epiglottis	246	function of	449
epiphyseal	4	gray matter of	448
fibro-cartilage	3-246	lingula	444
hyaline	3-244	lobes of	444
of Jacobson	326	nuclei of	448
of larynx	243	peduncles of	448
of nose	326	structure of	443
of pinna of ear	347	vermis of	443
of Santorini	247	worm of	443
septal	326	Cerebral artery—	
tarsal	344	anterior	194
thyroid	244	middle	194
of trachea	248	posterior	194
vomarine	326	cortex	441
of Wrisberg	246	gyri	413-419
Caruncula lacrimalis	344	hemispheres	419
Carunculæ myrtiformes	386	lobes	419
Cauda equina	459	peduncles	437
Cavernous sinuses	220	veins	220
Cavity or Cavities, cotyloid	58-60	Cerebrospinal fluid	428
fourth ventricle	454	Cerebrum	413-415-419
glenoid	65	function of	442
larynx	247	Cervical, curve of vert. column	44
of lateral ventricle	428	enlargement of spinal cord	461
of mouth	256	fascia	128
nasal	326	ganglia	518
oral	256	lymph nodes	234
orbital	8	nerves	492
pelvic	57	pleura	251
of pelvis	57	plexus of nerves	492
pulp	261	rib	51
sigmoid, of ulna	71	vertebrae	51
of thorax	37	seventh	51
of uterus	388	Cervix uteri	388
Cell or Cells, air, mastoid	353	Chassaignac’s tubercle	51
auditory hair	359	Check ligaments	92
cerebral cortex	441	Check ligaments	92
of Claudius	359	Cheeks	257
of Deiters	359	Chemical composition of bone	2
ependymal	462	Chest, see Thorax.	
glia	406	Chiropractic Features—	
gustatory	331	application of, to study of an-	
hair	359	atomy	Preface

INDEX

	Page		Page
Chiropractic Features (Continued)—		Circulation—	
adjustments, coccygeal	56	of air	317
adjustments during pregnancy	391	of blood	179-317
adjustments, hernia	402	fetal	212
adjustments, spine	47	lymphatic	232 317
appendicitis	287	nerve	317-406
axis-cylinder, subdivisions of	406	serous	317
centres, brain	523 526	systemic	179
of moral actions	526	Circumflex arteries	199-208
cerebral heat centre	524	Cisterna, magna	409
nerve	407-523-526	of Pacquet	239
circulations, air	317	pontis	409
blood	179-317	Clark's column	465
lymphatic	232-317	Clastrum	434
nerve	317-406	Clava	453
serous	317	Clavicle	61
cranial nerve paths	470	Clavicular nerve	494
disease	467-470	Clavipectoral fascia	154
distribution of spinal nerves	490	Clitoris	386
ductless glands	304	frenulum of	385
educated brain	405	nerves of	515
functions, nine primary	467	Clival lobes	444
ganglia	407	Clivus	21
innate brain	405-442	Coccygeal—	
Innate Intelligence	405-442-467-522	body	310
membrane—		ganglion	517
mucous	316	gland	310
serous	316	nerves	514
mere	503	plexus of vertebra	56
nerve, pressure-interference	467-503	Coccygeus muscle	153
nerves, spinal	490	Coccyx	56
nerve supply to parts of organs, see		Cochlea	355
index for part or organ.		bony canal of	355
nervous system	405	membranous canal of	358
nine primary functions	467	Coeliac, artery	204
palpation of spine	47	plexus of nerves	519
reflex action	522	Colic arteries	205
serous circulation	317	Collar-bone	61
subluxations	47	Collateral circulation (see anaste-	
sympathetic system	517	moses) .	
vertemere	503	Colles, fascia of	146
Chorda tympani	483	Colliculi	439
Chordae tendineae	180-184	Colon	289
Choroid	336	flexures of	289
artery of	194	mucous membrane of	290
nerves of	339	sigmoid flexure of	289
plexuses of fourth ventricle	455	splenic flexure of	289
of lateral ventricles	432	Column, of Burdach	464
of third ventricle	435	Clark's	465
vein	220	of Goll	463
Chyme	278	lateral, of medulla	451
Chyle	296	Morgagni	290
Cilia	363	Spinal	44
Ciliary, arteries	193	Turck	463
body	336	Columnae carneae	184
ganglion	478	Common, bile duct	296
muscle	337	carotid artery	191
nerves	478	facial vein	222
processes	337	iliac arteries	206
Cingulum	425	veins	229
Circle of Willis	194	Commissures of spinal cord	461
Circular sinus	219	Commissure, anterior	461

INDEX

	Page		Page
Commissure (Continued)—		Corona (Continued)—	
Meynert	438	radiate	433
middle	435	Coronary, arteries	188
posterior	437-461	ligament of knee-joint	106
Communicantes hypoglossi nerve	495	plexus of nerves.....	519
Communicating artery, anterior.....	194	sinus	182
posterior	194	valve	182
Complexus muscle	135	veins	218
Compressor, narium minor muscle	117	Coronoid fossa.....	68
urethrae muscle	152	Coronoid process of mandible	36
Condyles of bones	14-36-68-77	Corpora, albicantia	417
Condylloid foramen.....	14	cavernosa	376
process of mandible	36	mamillaria	417
Confluence of sinuses	219	quadrigemina	439
Conjugate diameter of pelvis.....	57	Corpus, albicans	417
Conjunctiva	345	callosum	426
nerves of.....	347	genu of.....	427
Conoid ligament.....	98	peduncle of	428
Constrictor muscles.....	123-268	rostrum of	427
Conus vasculosus	380	splenium	427
Conus medullaris.....	459	tapetum of	428
Convolution or convolutions—		dentatum	448
angular	421	fimbriatum	432
of Broca	420	Highmorianum	379
callosal	424	luteum	396
central lobe.....	423	spongiosum	376
dentate	425	Corpus striatum	432
frontal lobe.....	419	Corpus trapezoides	450
hippocampal	424	Corpuscles—	
limbic lobe	424	Malpighian	302-312
occipital lobe.....	423	Pacinian	362
parietal lobe	420	Purkinje	449
quadrate	421	renal	312
subcalcarine	422	splenic	302
subcollateral	422	tactile	362
supra marginal	421	touch	362
temporal	421	Corrugator cutis ani muscle	153
Coracoacromial ligament.....	98	supercilli muscle.....	116
Coracobrachialis muscle.....	156	Cortex, cerebral.....	441
Coracoclavicular ligament.....	98	cerebellum	448
Coracohumeral ligament	98	of kidneys.....	312
Cord, gangliated	517	Corti—	
spermatic	382	canal of.....	359
spinal	458	ganglion	359
vocal	247	membrane of	359
Corium, or skin	362	organ of	359
Cornea	334	rods of	359
arteries of.....	335	tunnel of	359
layers of	335	Costal—	
nerves of.....	477	cartilages	44
spaces	335-339	pleura	251
Cornicula laryngis	247	Costosternal articulations.....	94
Cornua ammonis	429	Costotransverse articulations	93
Cornua, of coccyx	56	ligaments	93
of hyoid.....	37	Costovertebral, articulations	93
of lateral ventricles.....	429	ligament	93
of thyroid cartilage.....	245	Cotyloid, cavity	60
sacral	55	ligament	105
of spinal cord	465	notch	105
of uterus	388	Cowper's glands	376
Corona—		Cranial region, muscles of	114
glandis	378	nerve.....	470

INDEX

	Page		Page
Cranium, bones of	12	Cutaneous Nerve (Continued)—	
Cremaster muscle	147	internal	499
Cremasteric, arteries	208	lesser	499
fascia	378	lateral	505
Crescentic lobes of cerebellum	444	musculo	514
Crest, ethmoidal	22	middle	509
frontal	17	perforating	515
iliac	60	perineal	515
of ilium	60	Cuticle of skin	361
incisor	32	Cutis vera.....	361
of lacrimal bone	25	Cystic duct	298
nasal	31		
occipital, external.....	13	D	
internal	13	Dartos of scrotum	378
of pubis	60	Darwin, tubercle of	348
spheroidal	22	Deciduous teeth	260
of tibia.....	78	Decussation of pyramids of medulla	
turbinated	26	oblongata	452
of urethra	370	Deglutition muscles of :	124
Cribriform fascia	164	Deiters cells	359
plate of ethmoid	24	Deltoid, impression.....	66
Cricoarytenoid muscles	126	ligament	108
Cricoid cartilage	245	muscle	155
Crista galli.....	24	tubercle	62-66
vestibuli	354	Depression—	
Crucial anastomosis	216	Pacchionian	16-408
groove	439	rhomboid	62
ligaments	107	Depressor alae nasi muscle	117
ridge	14	anguli oris muscle	118
Crura, cerebri.....	437	labii inferioris muscle.....	118
of diaphragm.....	140	Derma	361
of fornix	431	Descendens hypoglossi nerve	489
of penis	376	Descent of testes	378
Crural—		Diameters of pelvis	57
canal	166	Diaphragm	139
nerve	508	crura of	140
ring	166	ligaments of.....	140
sheath	166	openings of.....	140
Crureus muscle.....	167	urogenital	150
Crus, clitoris	386	Diaphragma sellae	408
inferior and superior.....	145	Diaphysis of bone	4
Crusta, of midbrain	438	Diarthroses	87
petrosa	262	Diencephalon	434
Crypts, of Lieberkuhn.....	284	Digastric, fossa	35
of tonsils	259	groove	19
Crystalline lens	342	muscle	122
Cuboid bone	83	nerve from facial	483
Cul-de-sacs	286-462	Digital arteries, of foot.....	212
Cuneate tubercle.....	453	Digital arteries, of hand	200
Cuneiform bones—		Dilator, naris muscles	117
of foot	83	pupillae	339
of hand	72	Diploe, veins of.....	218
cartilage	246	Discus proligerus	395
Cupola	356	Diverticulum, Meckel's	285
Curves of vertebral column	44	Dorsal, artery of penis.....	207
Cardiac valves	180	interossei muscles.....	163-178
Cutaneous nerve—		Dorsal interosseous artery, foot.....	178
femoral	508	hand	163
from external popliteal	514	Dorsales pollicis arteries	200
musculo spiral	499	Dorsalis, hallucis artery	210
gluteal	515	indicis artery.....	200

INDEX

	Page		Page
Dorsalis (Continued)—		Ear (Continued)—	
linguae artery	192	semicirc. canals of, memb.	358
pedis artery.....	210	tympanum	349
Douglas, pouch of	276-386	utricle of	357
Drum of ear	349	vestibule of	354-357
Duct or ducts—		Ejaculatory ducts	383
of Bartholin.....	266	Elbow	70
bile	296	articulation of	100
biliary	296	bones of.....	70
of cochlea.....	357	bursae of.....	101
cystic.....	298	Eminence—	
ejaculatory	383	frontal	17
Gartner's	392	hypothenar	162
hepatic	296	iliopectineal	57
interlobular	295	olivary	21
lactiferous	398	parietal	16
lacrimal	346	thenar	162
lymphatic, right.....	239	Eminentia cinerea	455
nasal	347	collateralis	429
pancreatic	300	teres	455
parotid	263	Emissary veins.....	218
of Rivinus	266	Enamel of teeth.....	262
of Santorini	300	Enarthrosis	87
seminal	382	Encephalon	415
Stenson's	265	End-bulbs	362
of sublingual gland	266	Endocardium	184
of submaxillary gland.....	266	Enlargement of cord	461
thoracic	238	Endolymph	357
Wharton's	266	Endomysium	112
Ductless glands.....	304	Endoneurium	406
Ductus, arteriosus.....	213	Endoskeleton	1
cochlearis	358	Endosteum of bone.....	2
communis choledochus.....	296	Ensiform appendix.....	39
ductus sacculi.....	357	Ependyma	455
utriculi	357	cells	462
endolymphaticus	357	Epicardium	184
venosus	213	Epicondyle—	
Duodenal, fossae	276	of femur.....	77
impression of liver	292	humerus	68
Duodenum	283	Epicranial aponeurosis.....	114
Dura, of brain	407	Epidermis	361
of spinal cord	456	Epididymis.....	382
E		Epidural space	456
Ear	347-360	Epigastric artery, deep	208
auditory canal.....	349	superficial	208
meatus	349	superior	198
cochlea of	355	vein, deep.....	229
drum of.....	349	Epiglottis	246
external	347	Epimysium	112
internal	354	Epineurium	407
labyrinth	354	Epiphyseal cartilage.....	4
membrane tympani.....	349	Epiphysis of bone	4
middle	349	Epiphysis cerebri	309
modiolus	355	Episternal notch.....	39
nerves	349-353-359	Epistropheus (the axis)	49
ossicles of.....	350	Equilibration	360-449
pinna of.....	347	Equilibrium	360-449
point of.....	348	Erector, clitoridis muscle	152
sacculi of.....	357	penis muscle.....	152
semicircular canals of, bony.....	354	spinae muscle.....	135
		Esophagus	268
		Ethmoid bone	23

INDEX

	Page		Page
Eustachian—		Fascia or Fasciae (Continued)—	
tube	353	intercostal	137
valve	186-230	ischio-rectal	150
Exoskelton	1	late	164
Extensor muscles (see Muscles).		of leg	172
Extraspinal veins	227	lumbar	130
Extrinsic ligaments of larynx	243	masseteric	120
muscles of tongue	329	obturator	150
Eye	331	of neck	127
appendages of	343	nuchal	127
aqueous humor of	341	palmar	159
choroid	336	parotid	128
ciliary body	337	pectoral	154
cornea of	334	pelvic	149
crystalline lens of	342	of pelvic outlet	149
iris	338	perineal	150
refracting media of	341	plantar	176
retina of	339	pretracheal	128
sclera of	333	prevertebral	128
suspensory ligament of	333	quadratus lumborum	149
tunics of	333	rectovesical	150
vitreous body of	341	of Scarpa	144
Eyeball	331	of shoulder	154
Eyebrows	343	spermatic	378
Eyelashes	345	of thigh	164
Eyelids	344	of thoracic region	154
		of thorax	154
F		transversalis	147
Face, bones of	25	triangular	146
muscles of	117-118	of upper extremity	154
Facial artery	192	Fasciculus—	
nerve	483-484	Bechterew	441
suture, transverse	8	longitudinal	438-442
vein	222	perpendicular	442
Falciform ligament	95-294	Meynert's	438
Fallopian tube	392	uncinate	442
ampulla of	392	Fauces, isthmus of	258
isthmus of	392	pillars of	258
Falx cerebelli	408	Female—	
cerebri	408	reproductive organs	366
Fascia or Fasciae—		urethra	371
of abdomen	142-144	Femoral—	
of arm	156	artery	208
axilla	154	canal	166
of back	127	nerves	507
brachial	154	region, muscles of	164
buccopharyngeal	128	ring	166
of Camper	144	sheath	166
carotid	128	trigone	168
cervical	128	Femur	75
clavipectoral	154	Fenestra ovalis	354
of Colles	146	vestibuli	354
covering quadratus lumborum	149	Fetal circulation	212
cremasteric	147-378	Ferments	300
cribriform	164	Fibres, arcuate	453
deep perineal	150	of brain	453
of foot	176	of Bechterew	441
of forearm	158	of medulla oblongata	452-453
iliac	163	association	442
infundibuliform	147-378	of cerebellum	448
intercolumnar	146	commissural	426-442
		cortico-pontine	439

INDEX

	Page		Page
Fibres (Continued)—		Fissure or Fissures (Continued)—	
fronto-pontine	439	transverse	294
intercolumnar, of the abdominal		tri-radiate	420
ring	145	Flat bones.....	4
longitudinal	442	Flexor muscles (see Muscles).	
peduncular	442-448	Flexures—	
projecting	428-442	of colon	289
pyramidal	439	hepatic	289
tangential	441	splenic	289
temporo-pontine	439	sigmoid	289
transverse	428	Floating ribs.....	42
Fibrocartilages	3	Flocculus of cerebellum.....	446
articular	3	Flood's ligament.....	99
circumferential	3	Foetal circulation.....	212
intervertebral	90	Folia of cerebellum	444
Fibula	82	Follicles—	
Fibular artery.....	210	Graafian	394
Fillets	438	solitary	284
Filum terminale.....	459	Fontana, spaces of.....	335
Fimbria of Fallopian tube.....	392	Fontanelles	11
hippocampi	429	Foot, bones of.....	83
Fissure or Fissures—		Foramen or Foramina—	
calloso-marginal	426	carotid	19-183
calcarine	426	caecum	17-286
central lobe.....	424	condyloid	14
of cerebellum	444	ethmoidal	23
cerebral	425	infraorbital	29
infraorbital	29	interventricular	434
circular	426	intervertebral	517
collateral	426	jugular	14
dentate	425	of Key and Retzius	455
of frontal lobe.....	419	lacerum, anterius	22
Glasserian	352	posterius	14
horizontal	443	magnum	14
hippocampal	425	of Majendie	454
intercerebral	413	malar	32
intraparietal	421	mental	35
limbic lobe	424	of Monro	434
longitudinal	413	nasal	25
limiting	426	obturator	61
of liver.....	294	olfactory	24-329
of lungs	253	optic	21
of medulla oblongata.....	451	ovale	22-213
occipital	423	patellaris	341
occipito-temporal	426	rotundum	22
orbital	420	sacrosciatic	97
palpebral	344	great	97
parieto-occipital	425	lesser	97
parietal	420	of Scarpa	31
of parietal lobe	420	spinal	47
portal	294	spinosum	22
postcentral	444	of Stenson	31
postclival	444	supraorbital	17
post pyramidal	446	Thebesii	182
post nodular	447	Versalii	22
pre-pyramidal	446	of Winslow	272
pre-central	444	Forearm, bones of.....	70
pre-clival	444	fascia of.....	156
of Rolando	425	muscles of	156
of spinal cord	461	Forebrain	410-428
Sylvius	425	Foregut	256
of temporal lobe.....	422	Foreskin	376

INDEX

	Page		Page
Formatio reticularis	451	Frontal (Continued)—	
Fornix	431	sinus	17
Fossa—		suture	16
antecubital	158	vein	222
canine	29	Fundus glands	278
coronoid	68	Funiculus cuneatus	452
cubital	158	gracilis	452
digastric	35	Rolando	142
duodenal	276		
glenoid	19	G	
iliac	60	Galen, vein of	220
incisive	29	Gall-bladder	296
infraspinous	63	duct of	298
intersigmoid	276	structure of	296
jugular	14-19	Gangliated cord	516
myrtiform	29	Ganglion—	
nasal	10-326	of Andersch	486
navicularis	371-385	Arnold's	482
occipital	14	of Bochdalek	479
olecranon	68	carotid	486
orbital	8	cervical	518
ovalis	213	ciliary	478
pericecal	276	coccygeal	517
popliteal	77-174	of Corti	359
radial	68	dorsal	518
recto-vaginal	276	Gasserian	477
retroperitoneal	276	geniculate	483
scaphoid	348	habenulae	437
of skull	10	jugular	486
sphenomaxillary	10	lenticular	478
sublingual	35	Meckel's	479
submaxillary	35	ophthalmic	478
subscapular	63	otic	482
supraspinous	63	petrous	486
temporal	10	phrenic	519
triangular	348	semilunar	477
trochlear	68	sphenopalatine	479
vesico-pubic	276	spiral	359
uterine	276	of Corti	359
zygomatic	10	submaxillary	482
Fourchette	385	of Valentin	479
Fovea, centralis	341	vestibular	485
dentalis	48	Gasserian ganglion	477
elliptica	354	Gastric artery	204
hemispherica	354	glands	278
hemielliptica	354	impression of liver	292
inferior	455	nerve	488-507
superior	455	plexus of nerves	519
spherica	354	vein	231
Frenulum—		Gastrocnemius muscle	175
of clitoris	385	Gastrocolic omentum	275
lips	257	Gastroduodenal artery	204
of penis	376	Gastroepiploic arteries	205
tongue	256	Gastrohepatic omentum	275
Fraenum linguae	256-330	Gastrosplenic omentum	275
preputii	376	Gemellus, inferior muscle	171
Frontal, artery	193	superior muscle	171
bone	16	Generative organs	366
eminence	16	Genesisiology	366
lobe	420	Geniculate body, external	436
nerve	477	internal	436

INDEX

	Page		Page
Geniohyoglossus muscle	122	Glands (Continued)—	
Geniohyoid muscle	122	tonsils	258
Genitals	366	thymus	308
Genu of corpus callosum	427	thyroid	306
Gerlach, valve of	287	of trachea	248
tonsil	353	Glans clitoridis	386
Germinal—		penis	378
spot	395	Glasserian fissure	352
vesicle	395	Glenoid, cavity	65
Gimbernat's ligament	145	fossa	19
Giraldes, organ of	384	ligament	99
Gladiolus	39	Glia cells	406
Glands	304	Glisson's coat	294
adrenals	305	Globus, major	382
axillary	235	minor	382
of Bartholin	386	pallidus	433
of Bowman	329	Glossopharyngeal nerve	485
bulbo-urethral	376	Glottis	247
Brunner's	284	Gluteal, aponeurosis	170
buccal	257	region, muscles of	170
cardiac	278	Gluteus, maximus muscle	170
carotid	310	medius muscle	170
ceruminous	349	minimus muscle	170
coccygeal	310	Goll, column of	463
Cowper's	376	Gomphosis	87
ductless	304	Goose-flesh or skin	364
esophageal	268	Gowers, tract of	463
fundus	278	Graafian follicles	394
gastric	278	vesicles	394
intestinal	284	Gracilis muscle	167
labial	257	Gray commissure of spinal cord	461
lacrimal	345	matter of cerebellum	451
of Lieberkuhn	284-290	substance of brain	441
of Littre	371	Grooves—	
lymphatic (see lymph nodes)		basilar	14
mammary	397	bicipital	68
Meibomian	345	digastric	19
molar	262	intertubercular	68
of Montgomery	398	lacrimal	10-26
Pacchionian	310	musculospiral	66
palatine	258	occipital	19
parasympathetic	310	optic	21
parathyroid	308	subclavian	62
parotid	263	transverse	15
peptic	278	Gums	260
Peyers	284	Gustatory—	
pineal	309	cells	331
pituitary	310	hair	331
prostate	372	Gyrus or gyri	421
pyloric	278	angular	421
renal	305	annectant	420-423
salivary	262	breves	424
sebaceous	364	callosal	424
serous	316	central lobe	423
solitary	284	cerebral	413
sublingual	266	cinguli	424
submaxillary	266	dentate	425
subrethral	386	fornicatus	424
sudoriferous	364	of frontal lobe	419
suprarenal	305	geniculate	428
sweat	364	hippocampal	424
tarsal	345	infracalcarine	423

INDEX

	Page		Page
Gyrus or Gyri (Continued)—		Highmore, antrum of	29
lingual	422-423	Hilum of kidneys	312
limbic lobe	424	lymph glands	232
marginal	419	suprarenal glands	305
occipital	423	Hindbrain	443
orbital	420	Hindgut	256
paracentral	419	Hip-bone	57
parietal	421	articulations of	105
precentral	419	bursae of	105
rectus	420	muscles of	163
subcalcarine	422	Hippocampus	424
subcollateral	422	Hippocampi	424
supra-callosal	428	Hirci	363
supra-marginal	421	Homer's muscle	116
Gyri, temporal	421	Horns of spinal cord	465
H		Horny layer of skin	361
Hairs	363	Humerus	66
auditory	359	ligaments of	98
cells	359	muscles of	154
follicle	363	Hunter's canal	170
gustatory	331	Hyaloid, canal	341
olfactory	329	membrane	341
taste	331	Hydatids of Morgagni	392
Hairlets	359	Hymen	386
Hamstring muscles	171	Hyoglossus muscle	122
Hamular process	356	Hyoid bone	37
Hamulus	356	Hypogastric, arteries	213
Hard palate	258	plexus of nerves	519
Hasner, valve of	347	vein	229
Haversian canal	2	Hypoglossal nerve	488
lamellae of bone	2	Hypophysis cerebri	310
system	2	Hypothenar eminence	162
Head, arteries of	191	Hyrtl, muscle of	153
bones of	12	I	
Heart	180	Ileocecal valve	289
Helicis major muscle	114	Ileum	283
minor muscle	114	Iliac, arteries, common	206
Helicotrema	356	external	208
Helix of ear	348	internal	206
Hemispheres, cerebral	419	fascia	163
Hemolymph nodes	234	region, muscles of	163
Hemorrhoidal, artery	206-207	veins	229
nerve, inferior	515	Iliacus muscle	163
plexus of nerves	519	Iliofemoral ligament	105
veins	229	Iliolumbar, artery	207
Henle—		ligament	94
ligament of	147	Iliopectineal line	57
loop of	314	Iliotibial band	164
triangle	401	Ilium	58
Hepatic, artery	204-296	Impression, deltoid	66
duct	296	Incisura cerebelli	443
flexure of colon	289	intertragica	348
plexus of nerves	519	marsupialis	443
veins	230-296	Incus	350
Hernia	399	Inferior vena cava	230
Hesselbach, ligament of	147	Infundibula of lungs	251
triangle of	401	Infundibuliform fascia	147-378
Hiatus, sacral	53	Infundibulum	416

INDEX

	Page		Page
Infundibulum (Continued)—		Jugular (Continued)—	
of cochlea	355	sinus	224
of Fallopian tube	392	veins	224
nose	328		
Inguinal canal	147	K	
Innominate, artery	190	Kerkring, valves of	284
bones	57	Key, foramina of	455
veins	225	Kidneys	310
Insula	423	arteries of	206-314
Integument of scrotum	378	columns of	312
Interbrain	434	fixation of	311
Interclavicular, ligament	97	function	314
notch	39	glomeruli of	313
Intercolumnar, fascia	146	hilum of	312
fibres of external abdominal ring	145	lymphatic vessels of	238
Intercostal, arteries	198-202	nerves of	314
ligaments	93	pelvis	314
muscles	137	structure of	310
nerves	505	tubules of	314
space	39	variations of	311
veins	225-228	veins of	230-314
Interlobular ducts	295	Knee-joint	105
Internal abdominal ring	147	end-bulbs of	362
Interossei muscles, foot	178	ligaments of	105
hand	163	nerves of	508
Interosseous arteries, foot	210	synovial membrane of	108
hand	202		
Interosseous veins	226	L	
Interpeduncular space	435	Labia, majora	384
Interpleural space	240	minora	384
Intersigmoid fossa	276	Labial artery	192
Intertransverse ligaments	90	glands	257
Intestinal glands	284	nerves	479
plexus of nerves	519	Labyrinth of ear	354
Intestines	281-286	membranous	354
large	286	osseous	354
small	281	of ethmoid	23
Intracranial spinal cord	450	Lachrymal (see Lacrimal).	
Intrinsic ligaments of larynx	243	Lacrimal, apparatus	345
Iris	338	artery	193
Irregular bones	4	bone	25
Ischiocavernosus muscle	152	canal	346
Ischiorectal fascia	150	crest of	26
region, muscles of	152	gland	345
Ischium	60	groove	26
Islands of Langerhans	300	papilla	344
of Reil	423	process	28
Isthmus cerebri	437	sac	346
of Eustachian tube	353	sulcus	26
of Fallopian tube	392	Lacteals	232
of fauces	258	Lactiferous duct	398
		Lacunae of Morgagni	371
J		Lacus lacrimalis	345
Jacobson, cartilage of	326	Lambda	8
Jaw	34	Lambdoid suture	7
Jejunum	283	Lamina, chorio-capillaris	336
Joints	86	cinerea	415
Jugular, foramen	14-20	cribrosa	335
fossa	14-20	medullary	433
ganglion	486	reticularis	359
process	14		

INDEX

	Page		Page
Lamina (Continued)—		Ligaments (Continued)—	
spiralis	356	costovertebral	93
suprachoroidea	336	cotyloid	105
vasculosa	336	crucial	107
Langerhans—		cruciform	90
cells of.....	300	deltoid	108
islands of.....	300	dentate	458
Lanugo	363	of diaphragm	140
Laryngeal, artery.....	192-248	falciform	95-294
nerve	248-485	Flood's	99
sacculæ	248	of foot.....	110
veins	248	Gimbernat's	145
Larynx	241	glenoid	99
arteries of	192	of Henle.....	147
cartilages	243	of Hesselbach.....	147
interior of	247	of hip-joint	105
ligaments of	243	ilio-femoral	105
movements of.....	242	ilio-lumbar	95
mucous membrane of.....	243	inguinal	145
muscles of	126	knee-joint	106
nerves of.....	487	lacunæ	145
sac, or sacculi	248	larynx	243
veins of	248	lateral, of liver.....	294
Latissimus dorsi muscle	134	of uterus	389
Leg, bones of.....	77	lumbo sacral	94
fasciæ of.....	172	nuchæ	90
muscles of	172	odontoid	92
Lemnisci	438	orbicular	101
Lens, crystalline.....	342	of ossicles.....	352
ligament of, suspensory.....	342	palmar	104
Lenticular ganglion.....	474	patellar	106
nucleus	432	peritoneal	275
Lesser—		pleural	251
internal cutaneous nerve	499	Poupart's	145
omentum	272	of radius	101
Levator muscles (see muscles).		recto-uterine	389
Lieberkuhn, crypts of	284	rhomboid	97
Ligamenta subflava	90	round, of hip-joint	105
Ligaments	86	of liver.....	294
acromioclavicular	97	of uterus	389
alaria	92-108	sacro-uterine	389
ankle-joint	108	of scapula	98
annular	101-159	Schlem's	99
arcuate	140	sciatic, greater and lesser.....	97
atlanto-axial	90	stellate	93
of bladder.....	368	supraclavicular	98
broad	294-389	teres of liver	294
capsular (see Capsular).		of hip-joint.....	105
check	92-333	of uterus	389
chondrosternal	94	tibio-fibular	108
chondroxiphoid	94	tibio-tarsal	108
colles	146	transverse, of acetabulum	105
common, anterior.....	90	of atlas	90
posterior	90	hip-joint	105
conoid	98	humeral	99
coracoacromial	98	of knee-joint.....	108
coraco-clavicular	98	of scapula.....	98
coracohumeral	98	trapezoid	98
coronary, of knee joint	108	triangular, in female	151
of liver	294	in male	150
costoclavicular	97	umbilical	368
costotransverse	93	of uterus	389

INDEX

	Page		Page
Ligaments (Continued)—		Lobe or Lobes (Continued)—	
vertebral	90	of cerebellum	443
vesico-uterine	389	cerebral	419
of Winslow	106	clival	445
of wrist	159	crescentic	444
of wrist-joint	103	culmen	445-446
Y	105	of ear	348
of Zinn	116	flocculus	446
Ligamentum arcuata	140	frontal	419
annular, radii	101	gracile	447
arteriosus	214	limbic	424
denticulatum	458	liver	292
laciniatum	177	of lungs	253
lacunae	145	nodular	447
arteriosum	214	occipital	423
nuchae	90	olfactory	417
patellae	106	parietal	420
pectinatum iridis	339	post-central	424
reflexum	146	pre-central	424
suspensorium	93	pyramidal	447
teres (see Ligament).		quadrate, or quadratus	294
transversum cruciatum	177	semilunar	447
venosum of liver	214	slender	447
Light spot	350	Spigelii	294
Limbic lobe	424	temporal	421
Line, iliopectineal	57	tonsil	446
intertrochanteric	76	tuber	447
nuchal	13	uvular	447
Ligula	455	Lobules, cuneate	423
Linea, alba	145	of liver	294
aspera	76	lungs	255
quadrata	76	mammary gland	398
semilunaris	148	pancreas	298
splendens	458	paracentral	419
transverse	148	precuneus	421
Lingual arteries	192	Locus perforatus anticus	417
bone	37	posticus	417
muscles	122	caeruleus	455
nerves	482	Long bones	4
veins	224	Longissimus dorsi muscle	135
Lingula	36-445	Longus capitis muscle	126
Lips	256	Longus colli muscle	126
Liver	292	Lower extremity, arteries of	208
arteries of	201-292	articulations	105
colic impression of	292	bones of	75
ducts of	295	fasciae of	164
duodenal impression of	292	muscles of	163
fissures of	294	veins of	228
function	296	Lucidum, septum	431
gastric impression of	292	Lumbar aponeurosis	130
ligaments of	294	arteries	206
ligamentum venosum	214	enlargement of spinal cord	461
lobes of	292	fascia	130
lobules of	294	nerves	506-507
nerves of	296	plexus of nerves	506-507
parenchyma of	294	veins	230
veins of	230-296	vertebrae	52
vessels of	294	Lumbosacral, ligament	94
Lobe or Lobes, biventral	447	plexus of nerves	507
cacuminal	445	Lumbricales muscle, foot	177
caudate or caudatus	294	hand	163
central	423-446	Lungs	251

INDEX

	Page		Page
Lungs (Continued)—		Lymphatic Glands or	
arteries of	202-255	Nodes (Continued)—	
color of	252	spaces	232
fetal	213-253	Lymphatic or Lymphatics	232
fissures of	253	duct, left	232-238
infundibula of	251	duct, right	232-239
lobes of	253	glands	232
lobules of	255	Lymphatic vessels of abdomen	236
nerves of	255	of abdominal viscera	236
parenchyma of	255	of bladder	236
root of	255	of brain	234
structure of	255	of diaphragm	238
substances of	251	of ear	234
surfaces of	253	of face	234
veins of	255	of head	234
Lunula	362	of intestine	238
Lunette	362	of liver	236
Lymph	239-319	of lower extremity	236
Lymphatic Glands or Nodes—		of lungs	238
abdomen	236	of mammary gland	238
aortic	236	of mouth	234
auricular, posterior	234	of neck	234
axillary	235	of pelvic viscera	236
brachial	235	of pinna	234
bronchiomediastinal	238	of rectum	236
buccal	234	of scalp	234
cardiac	238	of spleen	236
cervical	234	of stomach	236
coeliac	236	temporal	234
definition of	232	of thoracic viscera	238
of face	234	of thorax	238
gastric	236	of tongue	234
of head	234	of upper extremity	232
hepatic	236	Lyra	432
iliac	236		
inguinal	236	M	
intercostal	238	Macula acustica saccularis	358
lingual	234	lutea	340
of lower extremity	236	utricularis	357
lumbar	236	Majendie, foramen of	454
mandibular	234	Malar, bone	32
maxillary	234	foramina	32
mesenteric	238	nerve	485
occipital	234	Male, breast	398
para-uterine	238	reproductive organs	372
parotid	234	urethra	369
pectoral	235	Malleolar arteries	210
pelvis	236	Malleolus, external	83
pericardial	236	internal	79
preaortic	236	Malleus	350
pyloric	236	Malpighian body	302-312
rectal	236	Mammae	397
retroaortic	236	Mammary artery	198-398
retropharyngeal	234	Mammary gland	397
sacral	236	vessels of	398
splenic	236	nerves of	398
submaxillary	234	structure of	397
subpyloric	236	variations in	398
subscapular	235	veins of	225-398
of thorax	238	Mandible	34
of upper extremity	234	Mandibular nerve	481
vesical	236	region, muscles of	117-118

INDEX

	Page		Page
Manubrium of sternum.....	39	Membrane (Continued)—	
Marrow, bone	3	tectoria	359
Masseter, muscle of.....	118	tympanic	349
Mastoid air cells	353	vitelline	395
antrum	353	Membranous, canal of cochlea	358
bone	18	labyrinth of ear	356
process of temporal bone	18	semicircular canals	358
Masto-occipital suture.....	8	Meningeal, artery	193
Masto-parietal suture.....	8	veins	218
Matrix of nails	362	Meninges of brain.....	407
Maxillae	29	of cord	456
Maxillary, artery	192	Meningorachidian veins	227
bone, superior	29	Mere	503
inferior	34	Mesencephalon	411-437
nerve, inferior.....	481-485	Mesenteric artery	205
superior	478	plexus of nerves.....	519
sinus	29	veins	231
vein	222	Mesentery	275
Meatus, auditory.....	19	Mesoappendix	275
external	19	Mesocolon	275
internal	19	Meso-rectum	275
of nose.....	10-327	Mesosigmoid	275
urinarius	369-371	Metacarpal bones.....	72
Meckel's diverticulum.....	285	Metacarpophalangeal articulat's	105
ganglion	479	Metacarpus	72
Median nerves	501	Metatarsal bones.....	83
veins	226	Metatarsophalangeal articulat's	111
Mediastinum	241	Metencephalon	443
testis	379	Metopic suture.....	7
Medulla, of oblongata.....	450	Meynert, fasciculus	438
fissures of.....	451	Midbrain	410-437
function of.....	453	Midgut	256-281
funiculus of	451	Milk teeth	260
nuclei	453	Mitral valve	182
olive of	452	Modiolus	355
pyramids of.....	452	Molar teeth.....	260
structure of	451	Monro, foramen of.....	434
Meibomian glands.....	345	Mons Veneris.....	384
Membrana, arachnoid.....	408-456	Montgomery, glands of.....	398
basilaris	358	Monticulus cerebelli	444
granulosa	394	Morgagni, columns of.....	290
nictitans	345	hydatids of	392
pupillaris	339	lacunae of.....	371
tectoria	359	sinus of	248
tympani	349	Mouth	256
secundaria tympani	356	cavity of.....	256
Membrane, basilar.....	358	Mucous membranes	316
of Bowman.....	335	of bladder	369
of brain.....	407	of cheeks	257
cornea	334	of colon	289
of Corti.....	359	of larynx	243
of Demours	335	of nasal fossae	328
of Descemet	335	of nose	328
hyaloid	341	of small intestines.....	284
mucous	316	of soft palate.....	258
pituitary	328	of stomach.....	278
of Reissner	358	of tongue	330
Schneiderian	328	of trachea.....	248
serous	316	of tympanum	349
of spinal cord	456	of uterus	389
synovial	86	of vagina	386
		Multifidus spinae muscle.....	136

INDEX

	Page		Page
Muscle or Muscles	112	Muscle or Muscles (Continued)—	
of abdomen	142	depressor alae nasi	117
abductor digiti quinti	162	anguli oris	118
hallucis	177	labii inferioris	118
minimi digiti, foot	177	of diaphragm	139
hand	161	digastric	122
pollicis, longus	161	dilator naris	117
accelerator urinae	152	dilator pupillae	339
adductor, brevis	168	of ear	114
longus	168	epicranius	114
magnus	168	epiglottis	126
obliquus hallucis	177	erector, clitoridis	152
pollicis	162	penis	152
transversus hallucis	177	spinae	135
pollicis	162	extensor brevis digitorum	177
anal	153	digiti quinti	160
anconeus	160	pollicis	161
antitragicus	115	carpi radialis, brevis	160
of arm	156	longus	160
arrectores pilorum	364	ulnaris	160
articularis genu	167	coccygis	136
aryteno-epiglottic	127	communis digitorum	160
arytenoideus	127	indicis	161
attachment to spine	130	longus digitorum	175
attolens aurem	114	hallucis	174
atrahens aurem	114	pollicis	161
of auricular region or ear	114	minimi digiti	160
azygos uvulae	124	ossis metacarpi pollicis	161
of back	130	primi internodii pollicis	161
biceps brachii	156	secundi internodii pollicis	161
femoris	171	of femoral region	164
flexor cubiti	156	flexor accessorius	177
biventer cervicis	135	perforatus	159
brachialis anticus	156	brevis, digitorum	162
brachioradialis	160	digiti quinti brevis	162
of buccal region	118	hallucis	175-177
buccinator	118	minimi digiti, foot	177
bulbocavernosus	152	hand	162
cervicalis ascendens	135	pollicis	162
chondroglossus	123	carpi radialis	159
ciliary	337	ulnaris	159
coccygeus	153	digiti quinti brevis	162
complexus	135	longus digitorum	175
compressors	154	pollicis	161
compressor nasi	117	profundus digitorum	160
narium minor	117	sublimis digitorum	159
urethrae	152	of foot	176
constrictor, inferior of pharynx	124	of forearm	158
middle	124	tarsi tibialis	174
superior	123	gastrocnemius	175
constrictors	124	gemellus, super and infer	171
coracobrachialis	156	geniohyoglossus	122
corrugators	153	geniohyoid	122
corrugator cutis ani	153	of gluteal region	170
supercillii	116	gluteus maximus	170
of cranium	114	medius	170
cremaster	147	minimus	170
cricoarytenoid	126	gracilis	167
lateralis	126	hamstring	171
cricothyroid	126	of hand	161
crureus	167	of head	114
deltoid	155	helicis, major	114

INDEX

	Page		Page
Muscle or Muscles (Continued)—		Muscle or Muscles (Continued)—	
helicis, minor	114	orbicularis, oris.....	118
of hip.....	171	palpebrarum	116
Homer's	116	orbital	116
hyoglossus	122	origin of, definition of.....	112
ilacus	163	of palatal region.....	124
iliocostalis	135	palatoglossus	123
infracostales	139	palatopharyngeus	124
infraspinatus	155	of palmar region	162
intercostal	137	palmaris brevis	162
interossei, foot.....	178	longus	159
of hand.....	163	of palpebral region	116
interspinales	136	pectineus	168
intertransversales	136	pectoralis, major.....	155
ischiocavernosus	152	minor	155
of ischiorectal region.....	152	of pelvic outlet.....	149-152
kerato-cricoideus	127	of perineum in female.....	152
of larynx.....	126	in male	152
latissimus dorsi	134	peroneus, brevis.....	176
laxator tympani	115	longus	176
of leg.....	174	tertius	174
levator anguli, oris	117	of pharyngeal region	123
scapulae	124	of pinna of ear	114
ani	153	plantaris	175
labii inferioris	118	platysma	120
labii superioris alaeque nasi.....	117	popliteus	175
menti	118	pronator quadratus.....	161
palati	124	teres	159
palpebrae	116	psoas magnus	163
levator costarum	139	parvus	163
lingual region	122	pterygoid	118
lingualis	123	pyramidalis adboiminis	149
longissimus dorsi	135	nasi	117
longus capitis	125	pyriformis	171
longus colli.....	126	quadratus femoris.....	171
of lower extremity	163	lumborum	149
lumbricales, foot	177	menti	118
hand	163	plantae	177
masseter	118	quadriceps extensor.....	167
of maxillary region.....	117	recti of eyeball	116
multifidus spinae.....	136	rectus abdominis	148
musculo-accessorius	135	capitis anticus	125-126
mylohyoid	122	lateralis	126
of nasal region.....	117	posticus, major & minor.....	136
of neck	119	femoris	167
of nose.....	117	respiration	142
oblique, ascending	146	retrahens aurem	114
descending	144	rhomboideus	134
external, abdominal	144	risorius	118
internal, abdominal.....	146	rotatores spinae.....	136
obliquus auriculae	115	salpingopharyngeus	124
inferior of eyeball	116-136	sartorius	166
superior of eyeball	116-136	scalenus anticus	126
of muscles of the back	136	medius	126
obturator externus	171	posticus	126
internus	171	semispinalis colli.....	135
occipitofrontalis	114	dorsi	135
omohyoid	122	semimembranosus	172
opponens digiti quinti	162	semitendinosus	172
hand	162	serratus anticus.....	155
pollicis	162	magnus	155
orbicularis oculi	116	posticus	135

INDEX

	Page		Page
Muscle or Muscles (Continued)—		Muscle or Muscles (Continued)—	
of shoulder	154	of tympanum	115
of soft palate	124	of ulnar region	158
soleus	175	of upper extremity	154
sphincters	153	vastus externus	167
spinalis colli	135	internus	167
dorsi	135	intermedius	167
splenius capitis	135	lateralis	167
colli	135	medialis	167
stapedius	115	of vertebral region	125-130
sternohyoid	122	zygomaticus major	117
sternomastoid	121	minor	117
sternothyroid	122	Musculi papillares	184
striated	112	pectinati	180
striped	112	Musculocutaneous nerve	499
stylohyoid	122	Musculophrenic artery	198
stylopharyngeus	124	Musculospiral, groove	66
styloglossus	123	nerve	503
subanconeus	158	Myelencephalon	411-443
subclavius	155	Mylohyoid muscle	122
subcostals	139	Myocardium	184
subcrureus	167	Myology	112
subscapularis	155		
of superficial cervical region	119	N	
supinator brevis	161	Nails	362
longus	160	lunula of	362
of suprahyoid region	122	matrix	362
supraspinales	136	Nares, anterior	328
supraspinatus	155	posterior	328
temporal	118	Nasal—	
of temporomandibular region	118	bones	25
tensors	154	duct	347
tensor fasciae femoris	166	fossae	10-326
palati	124	meatus	327
tarsi	116	nerve	478
tensor tympani	116	region, muscles of	117
teres, major and minor	156	Nates	439
of thigh	164	Navicular bone, foot	83
of thoracic region	137	hand	72
of thorax	137	Neck—	
thyroepiglottideus	127	arteries of	191
thyrohyoid	122	fascia of	127
tibialis anticus	174	muscles of	119
posticus	176	triangles of	120-194
of tongue	122	veins of	224
trachelomastoid	135	Nerve or Nerves	405-465
tragicus	115	abducent	482
transversalis	146	acoustic	359-485
abdominis	146	acromial	494
cervicis	135	afferent	406-467
colli	135	ampullar	485
transverse perineal	152	of ankle-joint	512
transversus, auriculae	115	anococcygeal	515
perinei	152	articular, from extern popliteal	512
transversus thoracis	139	from great sciatic	512
trapezius	134	from internal popliteal	512
triangularis, menti	118	from posterior tibial	512
sterni	139	from ulnar	501
triceps, brachii	156	of articulations, of elbow-joint	501
extensor cubiti	156	of shoulder joint	498-499-505
triticeo-glossus	127	of auditory canal	359
of trunk	127		

INDEX

	Page		Page
Nerve or Nerves (Continued)—		Nerve or Nerves (Continued)—	
auditory	359-485	of ear	349-354-359-504
auricular, anterior	481	efferent	406-467
great	494	eighth	485
posterior	483	eleventh	488
from vagus	486	external pterygoid	481
auriculotemporal	481	of esophagus	270-488
axones	406	of eye	335-339-347-504
beginnings, peripheral	405	of eyelids	347-504
of bile ducts and liver	296-505	facial	483-484
of bladder	369-510	femoral	508
of bone	4	fibres	405
of brain	504	arcuate	453
buccal	481	association	413-442
calcaneal	512	of cerebral cortex	441
calorific	467	commissural	413-426-442
cardiac, cervical	487	glia	406
thoracic	488	projection	413-428-442
of cardiac muscle	505	radiating	448
of cells	405	of spinal cord	462
of centres	407-522	sympathetic	516
of cerebral cortex	441	vasomotor	438
cerebellar nuclei	448	fifth	475
cervical	494	first	471
cervicofacial	485	fourth	475
chorda tympani	483	frontal	477
of choroid	339	function of	467-470
ciliary	478	of gall bladder	296
circumflex	499	ganglion (see Ganglion).	
clavicular	494	gastric	280
of clitoris	515	genitocrural	507-508
coccygeal	490	glossopharyngeal	485
cochlear	485	gluteal	510-515
communicantes hypoglossi	495	of heart	505
of conjunctiva	347	hemorrhoidal	515
of cornea	335	inferior	515
cranial	470	of hip-joint	507-510
crural anterior	507	hypogastric	507
cutaneous, of abdomen	505	hypoglossal	488
external	507-508	iliac	507
femoral	508-515	iliohypogastric	507
from external popliteal	514	ilioinguinal	507
from musculospiral	503	infraclavicular	496-498
gluteal	515	infraorbital	485
internal	499	infratrochlear	477
lesser	499	intercostal	504-505
lateral	505	internal pterygoid	481
middle	508	interosseous anterior	501
palmar	501	of intestines	285-291-505
perforating	515	of iris	339
peroneal	514	of kidneys	314
dental	479-481-482	of knee-joint	508
descenders hypoglossi	489	of labia majora	387
digastric, from facial	483	labial	479
dorsal	504	lacrimal	347-477
dorsal, of clitoris	515	of Lancisci	428
of penis	515	of large intestines	291-510
of duodenum	285-505	laryngeal	488
of dura of brain	489-504	inferior recurrent	487
aural, of spinal cord	456	of larynx	248
from hypoglossal	489	lingual	481-482
from vagus	486	from glossopharyngeal	486

INDEX

	Page	Nerve or Nerves (Continued)—	Page
Nerve or Nerves (Continued)—		petrosal, deep	483
of liver.....	296-505	superficial	483
lumbar	507-510	pharyngeal	486-487
of lungs	255-505	of pharynx	268-505
malar	485	phrenic	495
of superior maxillary.....	478	of pia of brain.....	504
of mammary gland.....	398	of pituitary body.....	310
mandibular	481	of pleura	255-505
from facial (inframaxillary).....	485	plantar	512-514
masseteric	481	plexus (see Plexus).	
maxillary, inferior	481	pneumogastric	486
superior	478	popliteal	512-514
median	501	of prostate gland.....	375-510
of membrane tympani.....	353	pterygoid	481
meningeal, from hypoglossal	489	pudendal	515
from superior maxillary	478	pudic	505-515
from vagus	487	pulmonary	488
motor oculi	474	pyriformis	510
muscular, of brachial plexus	496	radial	503
from glossopharyngeal	486	respiratory, of Bell.....	495-496
from great sciatic	512	sacral	510-514
from hypoglossal	489	saphenous	509-512
from internal plantar.....	512	sciatic	512-514
popliteal	514	second	472
from median	501	seventh	483
from posterior tibial.....	514	sixth	482
from ulnar.....	501	of skin	362
musculocutaneous	499	of small intestines.....	285-510
musculospiral	503	of Soemmering	515
mylohyoid	482	spinal	490
nasal	329-478-479	accessory	488
fossae	329	splanchnic	517
nasopalatine	481	of spleen	304-505
nasopharyngeal	479	sternal	494
neuroglia	405	of stomach.....	280-505
ninth	485	stylohyoid	483
of nose.....	329	of sublingual gland.....	266
obturator	507	subscapular	499
accessory of.....	507	supraclavicular	496
occipital, great.....	492	supraorbital	477
small	494	of suprarenals.....	306
third	492	suprascapular	496
oculomotor	474	supratrochlear	477
of esophagus	270-505	sural	512
olfactory	471	system	405
ophthalmic	477	central	405
optic	472	development of	409
orbital	478	structure of.....	405
origin of	458-465	sympathetic	517
of ovaries	397	tarsal	347
palatine	479	of taste.....	331-485
palpebral	477-479	of teeth	262-504
of pancreas	300-505	temporal, from facial	485
of parathyroid glands	308	from internal maxillary	481
parotid	481	from superior maxillary.....	478
of parotid glands	266	temporofacial	485
patellar	508	temporomalar	479
of penis	515	tenth	486
perforating cutaneous.....	515	of testes	383
perineal	515	third	474
peroneal	514	thoracic	504-505
petrosal	483		

INDEX

	Page		Page
Nerve or Nerves (Continued)—		Nymphæ	385
anterior	498	O	
long, or posterior	496	Obex	455
of thymus gland	309	Occipital, artery	192
thyrohyoid	489	articulation with atlas and axis	91
of thyroid gland.....	307	bone	13
tibial	512	fossa	14
anterior	514	lobe	423
posterior	512	nerves	492
of tongue.....	331	plane	13
of tonsil.....	260	protuberance, external	13
tonsillar	486	internal	15
of trachea	250	sinus	219
bifacial	475	veins	222
trigeminal	475	Occipitofrontalis muscle.....	114
trochlear	475	Oculomotor nerve.....	474
twelfth	488	Odontoid ligaments.....	92-93
tympanic, from facial.....	483	Oesophageal, opening diaphragm....	140
from glossopharyngeal	486	plexus of nerves.....	488
of tympanum.....	353	Oesophagus	268
ulnar	501	Olecranon fossa	68
of ureters	315-510	Olfactory—	
of uterus	391-510	bulb	417
utricular	485	cells	329
of vagina	387-510	foramina	24
vagus	486	hairs	329
vestibular	485	lobe	417
vidian	479-482	mucous membrane	329
of voluntary muscles.....	112	nerve	329-471
of Wrisberg	499	tract	417
Nervi nervorum	407	trigone	417
Neural groove.....	410	Olivary, body	452
Neuroglia	405	process	21
Neurolemma	406	Olive of medulla oblongata.....	452
Neurones	406	Omentum or omenta	272
Nucleolus of nerve cell.....	405	Omohyoid muscle.....	122
Nidus avis.....	447	Openings (see ring or foramen).	
Nipple	397	Opercula insulae	424
Nodes of Ranvier.....	406	Operculum	424
Nodule	447	Ophthalmic, artery.....	193
Nose	324	ganglion	477
Notch cerebellar	443	nerve	477
cotyloid	105	Opponens minimi digiti muscle.....	162
episternal	39	Optic commissure.....	415
interclavicular	39	chiasma	415
jugular	39	chiasm	415
sacrosciatic	60	disk	341
sigmoid	36	entrance	341
supraorbital	17	foramen	22
suprascapular	63	groove	21
Nuchal lines.....	13	nerves	472
plane	13	papilla	341
Nuclei of cerebellum	448	tract	418
Nucleus, amygdaloid.....	429-433	Orbital cavities.....	8
caudate	433	Organ or Organs—	
cuneatus	453	Corti	359
emboliformis	448	digestion	256
fastigii	448	Giraldes	384
globosus	448	female.....	384
lenticular	433		
red	438		
ruber	438		

INDEX

	Page		Page
Organ or Organs (Continued)—		Palpebral (Continued)—	
of Jacobson	326	region, muscles of	116
male	372	Pampiniform plexus of veins	230
olfactorum	324	Pancreas	298
respiratory	240	accessory	300
Rosenmuller	392	arteries of	300
special sense	324	ferments of	300
voice	240	nerves of	300
Orbicularis ciliaris	338	veins of	300
Orbicularis oculi	116	Pancreatic, duct	300
oris	118	juice	300
palpebrarum	116	Pancreaticoduodenal arteries	205
Ora serrata	339	veins	231
Orientation	360	Papilla, spiralis	358-359
Osteology, division of	1	Papillae of tongue	330
Os externum	388	Papillary layer of skin	362
internum	388	Paradidymis	384
plenum	23	Parasympathetic bodies	310
uteri	153	Parathyroid glands	308
Ossa coxae	57	Parietal—	
Ossa innominata	57	bone	16
Ossa triquetra	5	eminence	16
Ossicles of ear	350	lobe	420
Otoliths	357	peritoneum	272
Otic ganglion	482	Parotid—	
Ova	394	fascia	128
Ovarian plexus of nerves	519	glands	263
Ovaries	392	arteries of	266
arteries of	397	duct of	265
at different ages	396	nerves of	266
nerves of	397-510	structure of	263
structure of	392	veins of	266
veins of	397	nerves	266
Oviduct	392	Parovarium	392
Ovicapsule	394	Pars ciliaris retinae	339
Ovisacs	394	iridica retinae	338
P		Patella	77
Pacchionian bodies of brain	310-408	Pathways of cord	462
depressions	16	Pectineus muscle	168
Pacinian corpuscles	362	Pectoral fascia	154
Palate	257	Pectoralis major muscle	155
arteries of	192	minor muscles	155
bone	26	Peculiar ribs	42
cleft	258	thoracic vertebrae	51
Palatine artery	192	Peduncle of cerebellum	448
canal	10	cerebral	437
glands	258	of corpus callosum	426
Palatoglossus muscle	123	of pineal body	437
Pallium	424	Pelvic, colon	289
Palmar, arch, deep	202	curve of vertebral column	44
superficial	202	fascia	149
cutaneous nerve	501	outlet, fasciae of	149
fascia	159	muscles of	152
interossei muscles	163	plexuses of nerves	519
veins	226	Pelvis	57-366
Palmaris brevis muscles	162	brim of	57
longus muscle	159	cavity of	58
Palpebral arteries	193	axis of	58
fissure	344	circumference of	58
portion of conjunctiva	345	diameters of	58
		Pelvis, difference between male and female	57

INDEX

	Page		Page
Penis	376	Placenta	212
Pericardium	184	Plantar, arch.....	212
Pericecal fossa	276	arteries	212
Perichondrium	3	ligaments	110
Perilymph	357	nerves	512
Perimetrium	388	region, fascia of	176
Perineal, arteries	207	muscles of	178
body	151	Plantaris muscles	178
muscle	152	Plate, cribriform, of ethmoid.....	25
nerves	515	horizontal, of bone.....	23
Perineum	149-290	perpendicular, of ethmoid bone.....	24
central tendinous point of	149	vertical, of ethmoid	24
Perineurium	407	of palate bone.....	27
Periosteum of bone.....	2	Platysma myoides muscle.....	120
Perirenal fat	311	Pleurae	251
Peritoneal cavity.....	272	arteries of.....	251
fossa of.....	276	cavity of.....	251
parietal	272	cervical	251
recto-vesical fold of	276	costal	251
recto-vaginal	276	capula	251
sacs	276	diaphragmatic	251
vesico-uterine	276	ligaments of.....	251
visceral	272	mediastinal	251
Peroneal, arteries	210	nerves of.....	251
bone	82	reflections of.....	251
nerve	514	structure of	251
Peroneus brevis muscle	176	veins of.....	251
longus muscle	176	Plexus—	
tertius muscle.....	174	brachial	496-497
Pes accessorius.....	429	cardiac	488-519
hippocampi	429	carotid	518
of midbrain	438	cervical	494-518
Petit, triangle of.....	146	choroid, of fourth ventricle.....	454
Petrosphenoidal suture	8	of lateral ventricles	432
Petrous, ganglion.....	486	of third ventricle	435
portion of temporal bone.....	18	of nerves.....	407-494-521
Peyer's patches	284	coeliac	519
Phalanges of foot.....	6-84	coronary	519
of hand.....	6-75	epigastric	519
Pharyngeal aponeurosis.....	268	gastric	519
artery	192	hemorrhoidal	519
nerve	486-487	hepatic	487-519
plexus of nerves	487	hypogastric	519
region, muscles of	123	infraorbital	479
spine	15	lumbar	507-508
tonsil	260	lumbosacral	510
veins	224	mesenteric	519
Pharynx	266	oesophageal	488
Phrenic, arteries.....	204	ovarian	519
ganglion	519	pampiniform	230
nerve	495	pelvic	519
veins	231	pharyngeal	486
Pia of brain.....	409	phrenic	519
of spinal cord	458	prostatic	519
Pillars of, external abdominal ring	145	pudendal	514-515
fornix	431	pulmonary	519
fauces	258	renal	519
Pineal body.....	309	sacral	494-507-510-514
Pinna of ear	347	solar	519
Pisiform bone	72	spermatic	519
Pituitary body.....	310	splenic	519

INDEX

	Page		Page
Plexus (Continued)—		Process or Processes (Continued)—	
suprarenal	519	unciform	23
tonsillar	486	vaginal	20
uterine	519	zygomatic, of malar.....	31
vaginal	519	of maxillae	29
Plica semilunaris	344	of temporal bone	19
Pneumogastric nerve	486	Proencephalon	410
Polygon of Willis.....	194	Profunda arteries—(See arteries).	
Pomum Adami	243	Pronator quadratus muscle.....	161
Pons—		teres	159
hepaticus	294	Prostate gland	372
Tarini	417	arteries of.....	375
Varolii	449	function of.....	373
Popliteal, artery	210	nerves of.....	375
space	77-174	structure of	372
vein	229	veins of.....	375
Popliteus muscle.....	175	Prostatic ducts.....	370-373
Portal system	231	orifice of.....	369
vein	231	Protuberance, mental	35
Postcava	230	occipital	13-15
Pouches	276	Psoas magnus muscles.....	163
Poupart's ligament.....	145	Pubic—	
Precava	225	artery	208
Pregnancy—		bones	58
adjustments during.....	391	ligaments	97
changes, in uterus	390	vein	229
Process or processes, acromion	63	Pubes	58
alveolar, of maxillae.....	31-35	Pudendal plexus.....	514
angular, of frontal bone.....	17	Pudic artery.....	207
articular, of spine	47	vein	229
axis-cylinder	406	Pulmonary, artery.....	188
basilar	14	circulation	187
ciliary	337	valve	185
clinoid	21	veins	188
condyloid, of mandible	36	Pulvinar	436
coracoid	65	Punctum lacrimale.....	344
coronoid, of mandible	36	Pupil of eye	338
of ulna.....	70	Purkinjean cells	449
ethmoidal	29	Putamen	433
falciform	97	Pyloric—	
hamular	22	orifice	277
jugular	14	sphincter	277
lacrima.....	28	valve	277
malar	31	Pyramid of medulla oblongata.....	452
mamillary	52	Pyramidalis, muscle.....	148
mastoid	18	nasi muscle.....	117
maxillary	27	Pyriformis muscle.....	171
mental	35		
nasal, of maxillae	29	Q	
odontoid	49	Quadratus femoris muscle	171
olecranon	70	lumborum muscle.....	149
orbital, of malar.....	32	fascia covering	149
of palate bone	27	menti muscle	118
palatal, of maxillae.....	30	Quadriceps extensor muscle	167
pterygoid, of sphenoid bone.....	22	Quadrigeminal bodies.....	439
of palate	27		
spheroidal, of palate.....	27	R	
styloid, of fibula.....	82	Radial, artery	200
of radius.....	70	nerve	503
of temporal	18	recurrent artery	200
of ulna.....	72		
spinous	47-52		

INDEX

	Page		Page
Radial (Continued)—		Ribs (Continued)—	
region, muscles of	158	vertebral	42
veins	226	Ridge, crucial.....	15
Radius	70	temporal	18
Ranine artery	192	Rima glottidis	247
vein	224	Ring or Rings—	
Ranvier, constrictions of	406	aortic	145-271
nodes of.....	406	crural	166
Receptaculum chyli	239	deep abdominal	147
Recessus, ellipticus.....	354	esophageal	140-271
cochlearis	354	external abdominal	145
sphericus	354	femoral	166-272
Rectal valves	290	internal abdominal	147-271
Rectovaginal fold	276	rectal	272
pouch	276	subcutaneous	145
Rectovesical fold	276	superficial abdominal	145
fossa	276	urethral	272
Rectum	290	umbilical	270
ampulla of	290	vaginal	272
Rectus, abdominis muscle	148	venae caval	140-271
femoris muscle.....	167	Risorius muscle	118
lateralis muscle	126	Rivinus, duct of	266
Reflexes	522	Rods of Corti	359
Reflex actions.....	522	Rolando, fissure of.....	425
Refracting media	341	Rosenmuller	392
Regions of, skull.....	7	Rostrum of corpus callosum	427
abdomen	270	Rotatores spinae muscle	136
asterion	8	Ruyschiana tunic	336
bregma	7		
lambda	8	S	
obelion	8	Sac, lacrimal	346
pterion	8	recto-vaginal	276-386
Renal, arteries.....	206-314	of Douglas.....	276-386
Renal, columns.....	312	Saccule	357
fascia	311	Sacculation	289
papillae	312	laryngeal	248
sinus	311-312	Sacral, arteries	206-207
veins	230-314	canal	53
Reproductive organs, female	384	cornua	55
male	372	plexus of nerves.....	510
Reservoir of Pacquet	239	Sacroiliac articulation	95
Respiratory organs.....	240	ligaments	95
Restiform body.....	453	Sacrum	53
Rete mucosum	361	ala of.....	55
testis	380	female	56
Reticular layer of skin	362	promontory of.....	53
Retina	339	Salivary glands	262
yellow spot of.....	340	Santorini, cartilage of	247
Retrahens aurem muscle.....	114	duct of	300
Retro-peritoneal fossa.....	276	Saphenous, nerves	508-512
Retzius, foramina of	455	opening	164
Rhodopsin	340	veins	228
Rhombencephalon	443	Sarcolemma	112
Rhomboideus muscle	134	Sartorius muscle	166
Ribs	39	Scala, media.....	358
cervical	44	tympani	356
common characters of.....	39	vestibuli	356
false	39	Scalenus anticus muscle	126
floating	39-42	medius muscle.....	126
peculiar	42	posticus muscle	126
true	39		
typical	40		

INDEX

	Page		Page
Scaphoid—		Sinus or Sinuses (Continued)—	
bone of foot.....	83	cavernous	220
of hand	72	circular	219
fossa	348	confluence of.....	15-219
Scapula.....	63	coronary	182
ligaments of	98	frontal air.....	17
Scarpa, fascia of	144	jugular	224
foramina of.....	31	lateral	219
triangle of	168	longitudinal	218
Schlemm, canal of	335	maxillary	29
ligament	99	of Morgagni.....	248
Schwann, sheaths of	406	occipital	219
Sciatic, artery.....	207	petrosal	219-220
nerves	512-514	pocularis	370
notches	60	sagittal	219
veins	229	spheno-parietal	220
Sclera	334	rectal	290
Sclerotic coat.....	334	renal	311
Scrotum	378	straight	219
dartos of	378	transverse	220
integument of.....	378	of Valsalva	186
septum of	378	venous	218
Sebaceous glands.....	364	venosus sclera.....	335
Sella turcica.....	21	Skin	360
Semen	381	appendages of	362
Semicircular canals	354	color	361
membranous	358	corium of	361
Semilunar bone.....	72	cuticle of.....	361
ganglion	477	glands of.....	364
Semimembranosus muscle	172	nerves of.....	362
Seminal duct.....	382	true	361
vesicles	383	Skull, region of	7
Semispinalis colli muscle	135	bones of.....	5
dorsi muscle	135	difference in, due to age	12
Semitendinosus muscle	172	Small cardiac vein	218
Sense organs.....	324	intestine	281
Sense, organs of.....	324	Solar plexus of nerves.....	519
Sense of smell	324	Soleus muscle	175
Septum lucidum	431	Solitary glands	284
pellucidum	431	Space, axillary	154
posticum	458	cubital	158
Serous circulation.....	317	epidural	408-456
Serum	316	of Fontana	335
Serous membranes.....	316	intercostal	40
Serratus magnus muscle	155	interpeduncular	416-435
posticus muscles	135	interpleural	240
Sesamoid bones	5	perforated, poster & anter.....	417
Short bones.....	4	popliteal	77-174
Shoulder, blade.....	63	quadrilateral	120
fascia of.....	156	retropharyngeal	130
girdle	61	subarachnoid	409-457
joint, articulations of.....	98	subdural	408-457
bursae of	99	Tenon's	332
muscles of	155-156	Special sense organs	324
Sigmoid—		Spermatic, arteries	206
cavity of radius	70	canal	147
of ulna.....	71	cord	382
flexure	289	fascia	147-378
fossa	276	nerve	519
mesocolon	289	plexus of nerves.....	519
Sinus or Sinuses	218	veins	230
basilar	220	Spermatozoa	381

INDEX

	Page		Page
Sphenoid bone	20	Stomach (Continued)—	
Sphincter Muscles.....	153	arteries of.....	280
ani	153	curvatures of.....	277
Hyrtil	153	mucous membrane of	278
pyloric	277	openings of.....	277
pupillae	153-339	structure of	276
rectum	153-290	Stratum cinereum	439
tertius	153	granulosum	361
urethral	152	mucosum	361
uterus	153	lucidum	361
vagina	152	germinativum	361
vesicae	153	lemnisci	439
Spigelian lobe of liver.....	294	Stratum opticum	439
Spinal, accessory nerve.....	488	zonale	439
canal	47	Structure of an organ	240
column	44	Styloid Process—	
cord	458	of fibula.....	82
columns of	463	of radius	70
curves of.....	44	temporal	18
Spinal cord, columns of	463	of ulna	72
commissure of gray	461	Stylopharyngeus muscle	124
cornua of.....	465	Subarachnoid cisterna	400
dura of	456	Subclavian artery	196
enlargements of	461	Subclavius muscle	155
filum	459	Sublingual, duct.....	266
horns of.....	465	fossa	35
membranes of	456	gland	266
pia of	458	Submaxillary, artery.....	192
roots of	492	fossa	35
tracts of	462	gland	266
ventricle of.....	462	ganglion	482
Spinalis colli muscle.....	135	Substantia nigra	439
dorsi muscle.....	135	ferruginea	455
Spine	44	gelatinosa	465
ethmoidal	20	Submaxillary gland.....	266
mandibular	36	triangle	195
nasal	17	Succus entericus	292
pharyngeal	15	Sudoriferous glands	364
of scapula	63	Sulcus, or Sulci.....	415-419
Splanchnic nerves	517	central	424-425
Splanchnology, definition of.....	1-256	circular	424
Spleen	300	frontal lobe	419
arteries of	205-304	intra-parietal	421
function of	302	lacrimal	26
nerves of	304	lateral	438
Splenium of corpus callosum.....	427	limbic	424
Splenius capitis muscle.....	135	limiting	424
colli muscle.....	135	occipital lobe	423
Squamoparietal suture.....	8	orbital	420
Squamous portion of temporal bone	18	post central	421
Stapes	352	precentral	419
Stapedius	351	temporal	421
Stenson, duct of	265	tri-radiate	420
foramina of.....	31	valleculae	447
Sternohyoid muscle.....	122	Supercilia	343-363
Sternum	39	Supinator (brevis) muscle	161
ensiform appendix of.....	39	longus muscle	160
gladiolus of	39	Suprarenal artery.....	206
manubrium of	39	Suprarenal glands	305
xiphoid appendix of.....	39	hilum	305
Stomach	276	Surae, triceps	174
alterations in position of	276	Sustentaculum tali	83

INDEX

	Page		Page
Sutura, of skull	87	Temporal, bone	18
Sutures	8	Temporomandibular articulation	88
basilar	8	muscles of	118
coronal	7	Tendons	112
frontal	7	conjoined	146
interfrontal	16	cordiform	139
internasal	25	of diaphragm	139
lambdoid	7	of quadriceps extensor muscle.....	167
masto-occipital	8	trefoil	140
metopic	7	Tenon's capsule	332
sagittal	7	Tentorium cerebelli.....	408
sides of skull	8	Testes (See also Testicle).....	378
transverse	8	Testicle	378
Sweat glands.....	364	blood supply.....	382
Sylvian aqueduct	440	coverings of.....	378
fissure	425	ducts of.....	380
Sympathetic nerve system	516	nerves	504
Symphysis—		parenchyma	379
of mandible	35	Thalamencephalon	434
of pubis	60	Thalami	435
Synarthroses	87	Thebesius, valve of	182
Syndesmology, definition of.....	86	Thenar eminence.....	162
Syndesmosis	87	Thigh, fascia of	164
Synovia	86	Thoracic, aorta.....	202
membrane	86	duct	238
bursal	86	nerves	504
of hip-joint.....	105	Thorax	37-240
of knee-joint	106	fasciae of	137
shoulder, joint.....	99	muscles of	137
vaginal	86	Thymus gland	308
Systemic circulation	179	Thyroid artery	192-196
heart	179	axis	196
portal	231	body	306
veins	179-217	cartilage	244
		gland	306
		notch	245
		Thyroidea ima artery.....	190
		Tibia	77
		Tibial artery, anterior	210
		posterior	210
		Tibialis anticus muscle	174
		Tongue	260-329
		Tongue, arteries of.....	331
		mucous membrane of	330
		muscle of	122
		nerves of	331
		papillae of.....	330
		structure of	260-329
		Tonsils	258
		Gerlach's	353
		pharyngeal	260
		submerged	260
		Torcular Herophili	15-219
		Touch corpuscles	362
		Trachea	248
		cartilages of.....	248
		glands of.....	248
		mucous membrane of	248
		Tract—	
		Burdach	463
		cerebellar	463
		comma	464

INDEX

	Page		Page
Tract (Continued)—		Tubercle (Continued)—	
Goll	463	of Darwin	348
Gower's	463	deltoid	62-66
ground bundle	464	hyoid	37
olfactory	417	infra-glenoid	64
optic	418	tibia	78
pyramidal	463	Tuberosity, bicipital.....	70
of spinal cord	462	of humerus.....	68
Tractus ilio-tibialis	164	of ischium.....	60
Tragi	363	of tibia.....	78
Tragus of ear.....	348	Tubuli seminiferi	380
Transversalis—		Tunica albuginea	379
fascia	147	intima	187
muscle	146	serosa	272-312
Transverse aorta	190	vaginalis	378
colon	289	Tunics of arteries and veins	187
Trapezius muscle.....	134	eye	333
Trapezium	72	of testicle.....	378
Trapezoid	72	Turbinated bone.....	28
Triangle, carotid.....	121-194	Tympanum	349
digastric	121-195		
Hesselbach's	148	U	
muscular	121-194	Ulna	70
neck	120-194	Ulnar artery.....	200
occipital	121-196	Umbilical arteries	213
Petit's	146	Unciform bone.....	72
Scarpa's	168	Uncus	425
subclavian	121-196	Ungual wall.....	362
submaxillary	121-195	Upper extremity, arteries of.....	191
supra-clavicular	121	muscles of	154
Triangular—		Urachus	368
fascia	145	Ureters	314
ligament, in female.....	150	nerves	315
in male.....	150	pelvis of	314
Triangularis (stern) muscle	139	structure of	314
Triceps brachii muscles.....	156	Urethra	369
surae	174	female	371
Tricuspid orifice.....	182	male	369
Trifacial nerve	475	Urethral bulb.....	371
Trigeminal nerve	475	Urinary bladder.....	366
Trigone, of bladder.....	369	Uriniferous tubules, structure of.....	313
of femoral.....	168	Urinogenital organs	366
of olfactory.....	417	Uro-genital diaphragm.....	150
of vesicae	369	Uterus	388
Trigonum—		appendages	392
acustici	456	blood supply.....	391
habenula	437	changes in at different ages	390
hypoglossi	456	masculine	370
lumbale	146	nerves of.....	391
vagi	456	Utricle	357
Trochanter	75	Uvea	338
Trochlea of brachium	68	Uvula	258-369
of femur	77		
Trochlear nerve.....	475	V	
Tube, Eustachian	353	Vagina	386
Tuber cinereum	415	Vaginal plexus of nerves.....	519
Tuber valvulae.....	447	Vagus nerve	486
vermis	447	Vallecula cerebelli	443
Tubercle, carotid.....	51	Sylvii	425
Chassaignac's	51	Valves	179
conoid	62		
cuneate	453		

INDEX

	Page		Page
Valve, aortic	186	Vein or Veins (Continued)—	
Valve, of Bauhin	289	femoral	229
bicuspid	182	frontal	222
coronary	182-186	of Galen	220
Eustachian	186	gastric	231
of Gerlach	287	gluteal	229
of heart, action of	182	of head	218-222
of Hasner	347	of heart	218
of Heister	298	hemorrhoidal	229
ileocecal	289	hemiazygos	228
of Kerkring	284	hepatic	230
mitral	182	hypogastric	229
pulmonary	183-185	iliac, common	229
pyloric	277	external	229
rectal	290	internal	229
spiral	298	innominate	225
of Thebesius	182-186	intercostal	225-228
semilunar	183	interosseous	226-228
tricuspid	182	intraspinal	227
of Vieussens	454	jugular	224
Valvulae conniventes	284	of kidneys	230
ureteris	315-369	of large intestines	231
Vas deferens	382	lingual	224
Vas spirale	359	of liver	230-231
Vasa vasorum	187	of lower extremity	228
Vastus externus muscle	167	lumbar	230
internus muscle	167	mammary	225
Vein or veins	186-217	maxillary	222
of abdomen	230	median	226
angular	222	medulla	222-227
auricular	222	meningeal	218-227
axillary	227-228	mesenteric	231
azygos	227	of neck	218-222
basilar	221	obturator	229
basilic	226	occipital	222
of bladder	369	ovarian	230
of bodies of vertebrae	227	palmar	226
brachial	226	pericardial	228
brachio-cephalic	225	pharyngeal	224
of brain	220	phrenic	231
bronchial	228	plantar	229
cardiac	218	popliteal	229
cephalic	220-226	portal	231-296
cerebellar	220	postcava	230
cerebral	220	precava	225
cervical	227	prostatic	229
circumflex iliac	229	pudic	229
clitoris	229	pulmonary	188-217
cochlear	224	radial	226
coronary	218	renal	230
cystic	231	ranine	224
deep	217	saphenous	228
definition of	186-217	sciatic	229
digital	226-228	of small intestines	231
of diploe	218	spermatic	230
dorsal, of penis	229	spinal	227
emissary	218	splenic	231
epigastric	229	subclavian	227
esophageal	228	subcutaneous	217
extraspinal	227	superficial	217
of face	222	supra-orbital	222
facial	222-224		

INDEX

Vein or Veins (Continued)—		Vertebral aponeurosis	130
renal	230	bodies	46
temporal	222	canal	47
temporo-maxillary	222	column	44
of stomach	231	region, muscles of	130
of Thebesius	218	ribs	42
of thorax	227-228	Vertemere	503
thyroid	224-225	Vesical arteries	207
tibial	229	sphincter	153
of tongue	224	Vicq d' Azyr, bundle of	431
of tonsil	224	Vidian artery	193
upper extremity	226	Villi of small intestines	284
umbilical	212	Vitelline membrane	395
ulnar	226	yolk	395
uterine	229	Vitreous body	341
vaginal	229	humor	341
vertebral	225-227	Vocal cords	247
vesical	229	Voice	248
Velum interpositum	434	Voice, organs of	240
pendulum palati	258	Vomer	33
Vena or Venae basis vertebrarum	227	Vomerine cartilage	326
cava, inferior	217-230	Vulva	384
superior	217-225		
cerebri magna, Galeni	220	W	
comites	217	Wharton's duct	266
Ventricle—		Windpipe	248
of cord	462	Womb	388
of choroid plexus	432-454	Worm of cerebellum	443
fourth	454	Wormian bones	4
fifth	431	Wrisberg, cartilage of	246
of heart	180	nerve of	499
lateral	428	Wrist-joint, ligaments of	103
third	434		
Venules	187	X	
Vermis	443	Xiphoid appendix	39
Vermiform appendix	287		
process	443	Y	
Verumontanum	370	Y-ligament	105
Vertebra	44	Yellow spot of retina	340
cervical	44-47-51		
atlas of	47	Z	
Vertebra, cervical—		Zinn, ligament of	116
seventh	50	zonule of	341
axis of	49	Zona arcuata	358
Vertebra, cervical, seventh	50	pectinata	358
coccygeal	53	Zonula ciliaris	341
dorsal	52	of Zinn	341
lumbar	52	Zygoma	19-32
peculiar	47	Zygapophysis	47
prominens	50		
thoracic	51		
typical	46		