

COLUMBIA LIBRARIES OFFSITE  
HEALTH SCIENCES STANDARD



HX64061477

QM25 M61 Q An atlas of anatomy


**RECAP**

**Columbia University**  
in the City of New York

**College of Physicians and Surgeons**

**Library**





Digitized by the Internet Archive  
in 2010 with funding from  
Open Knowledge Commons







AN  
ATLAS OF ANATOMY

OR  
PICTURES OF THE HUMAN BODY

IN TWENTY-FOUR QUARTO COLOURED PLATES

COMPRISING ONE HUNDRED SEPARATE FIGURES

WITH DESCRIPTIVE LETTERPRESS

BY

MRS. FENWICK MILLER

MEMBER OF THE LONDON SCHOOL BOARD; OF THE LADIES' MEDICAL COLLEGE, WITH HIGHEST CLASS HONOURS; AUTHOR OF THE  
PHYSIOLOGICAL SECTIONS OF 'SIMPLE LESSONS FOR HOME USE,' AND OF 'THE HOUSE OF LIFE,' ETC.;  
AND LATE LECTURER ON PHYSIOLOGY TO THE WORKING WOMEN'S COLLEGE  
AND THE NATIONAL HEALTH SOCIETY

LONDON  
EDWARD STANFORD, 55 CHARING CROSS, S.W.

1879

QM 25

M 61

Q


Garway  
35 2567



OCT 12 346

35-2567

# P R E F A C E.



It is hoped that this work, being issued at a comparatively low price, may be found useful both to science teachers and to students of all kinds. To the private student, whose access to anatomical preparations and physiological laboratories is limited, such a book is indispensable. Students of medicine, although they have seen with their own eyes, yet know the use of Pictures and Diagrams, both for accurate comprehension of Text-books, and for aid to the memory in its heavy task ; for example, they will find the three drawings of the brain, two being sections such as would frequently not be made by the student himself, valuable to them in assisting both understanding and recollection of Anatomy. Again, children, with their keen interest in the facts of Nature, and with their fresh undistracted minds full of curiosity about what is around them, are almost always found to take a deep interest in the wonderful structure and functions of their own bodies. The subject has been introduced into many of the London Board Schools, and has been found to be surprisingly popular among the children themselves ; one of our Inspectors records that he has often been much struck with the alacrity with which boys rush to their seats for an oral examination in Physiology, even at the very end of a long and tiring day of inspection. Thus, this volume would generally be found an acceptable gift to an intelligent youth of twelve or fourteen, and would afford him useful instruction for his adult life in any case, but most of all where it was designed that medicine should hereafter be studied as a profession.

As I have not, of course, either drawn or lithographed the Plates, I may be allowed to say that many of them are quite admirably executed. Nearly all of them are new drawings, never before published in any form in England. Some of them are taken from the recent famous *Anatomischer Atlas* of Dr. Heitzmann ; others are newly drawn from preparations in the Vienna Museum of Anatomy, and other places. Most of them are, therefore, quite modern, and some obtain special value from that fact as embodying the latest results of anatomical research. In this connection attention may be specially drawn to the Structure of the Ear, Plate XXII.

In writing the Letterpress I have had mainly in view the requirements of young and individual students, and have not assumed that my readers would possess any knowledge of the subject. At the same time, in order to avoid undue length, I have made the Index to the Plates as fully explanatory in itself as possible. For this reason I would advise beginners of the study to first carefully look out on each Plate the parts referred to by each number in the Index, and afterwards to turn to the Letterpress about the Plate, and in reading it not to spare continual reference from the text to the picture.

FLORENCE FENWICK MILLER.

LONDON, *March* 1879.



# AN ATLAS OF ANATOMY.

## Preliminary Observations.

THE human body is exceedingly complex in structure, and marvellous in function; and yet, like a beautiful picture, it is composed of comparatively few materials. It contains fourteen of the sixty-six "chemical elements" into which all matter in nature can be separated, and those fourteen elements in combination form all the tissues of the body, and build up the numerous organs by which the vital processes are carried on.

The knowledge of the structure and positions of those tissues and organs forms the science of *Anatomy*; the facts of the vital processes performed by those tissues and organs make up *Physiology*.

The sister sciences of *Anatomy* and *Physiology* are as closely connected as the Siamese twins. They are almost one; there is an indivisible connection between them, but, at the same time, they are distinct subjects for study.

A knowledge of *Anatomy* is an absolutely essential preliminary to the study of *Physiology*. For many hundreds of years this truth was not recognised, and the ancient physiologists tried vaguely to guess at the functions of the various organs, without the aid of the clue which they might have found in even a rough examination of the structure of the parts. It must be acknowledged, however, that small progress could ever have been made in anatomical research before the discovery of the microscope. Throughout the plates of this volume, the work of the microscope is discernible, and those young students who are not accustomed to the use of that instrument must be careful not to get their ideas confounded as to the relative size of the objects represented, by neglecting to note whether they are magnified or not, and where they are so, to what extent they are enlarged.

In writing a description of the plates in this book, my subject is necessarily *Anatomy*; but I shall not, therefore, consider myself excluded from briefly describing also, wherever possible, the work of the various structures. On the contrary, I shall endeavour to include in these pages a brief sketch of the physical life of man; so that the young student, by reading attentively, and constantly referring to the plates, may gain a general knowledge of the living human body.

The **Chemical Elements** which are normally found in the structure of the body are the following:—Oxygen, Hydrogen, Nitrogen, Carbon, Sulphur, Phosphorus, Sodium, Potassium, Lime, Chlorine, Magnesium, Iron, Silicon, and Fluorine. No one of these is found by itself, as an element; but, mixed one with another, they form every particle of the body.

The most important of these fourteen elements are the four first named. The physiological chemist in his laboratory finds that he can analyse nearly every part and tissue of the body into these four elements—Oxygen, Hydrogen, Nitrogen, and Carbon—with a mere infinitesimal portion of some of the other substances named. Suppose he thus analyses the entire body of a man weighing eleven stone (154 pounds), only about one stone (14 pounds) would be found to consist of the last ten elements named above;

and of even that one stone, by far the greater portion would consist of the ashes of the bones; so that the softer parts of the body contain only a very small proportion of the other elements, besides the combinations of Oxygen, Hydrogen, Carbon, and Nitrogen of which they are mainly formed.

Everywhere in the living body there is found a remarkable substance which is composed of those four principal elements, together with a very little of some few others. This is called *Protoplasm*, from Greek words meaning the *first formative material*, because it is the earliest condition of living matter; and it has very remarkable vital properties.

The word "vital" is derived from the Latin for life, and "vital force" simply means, therefore, the force of life. Living matter, in whatever form, from the lowest up to the highest organism, has certain powers inherent in itself as vital properties; the product of some force peculiar to it, which therefore receives the name of vital force. We cannot produce vital force apart from living matter; that is, probably, impossible for ever. The chemist can put together the elements of protoplasm, but he cannot thereby produce the force of life. To talk about vital power is thus only one way of concealing our practical ignorance of nature's secrets.

But if we cannot produce the force, we can study it; and this can be done quite as effectually by considering the tiniest individual particle of living protoplasm, as by the largest mass of it. As Tennyson says, apostrophising a tiny flower—

"If I could understand  
What you are, root and all, and all in all,  
I should know what God and man is."

The lower animal organisms, such as the jelly-fish, for instance, which may sometimes be seen on the sea-shore (where I remember when I was a very little girl I found one, and an impertinent boy tried to persuade me it was the moon fallen down) are little more than lumps of simple protoplasm. There are tiny microscopic animal forms even simpler than the jelly-fish. Now, when one of these is inspected and watched, it is found that the minute speck of matter is endowed with certain powers, produced by an inherent vital force which is practically and essentially the same as that which is observed in all living creatures. If a chemist could (but he cannot, as we all know) make in his laboratory one of those tiny specks of living protoplasm, his making any other animal would be possible, for the principle of life exists equally in that speck and in a man.

These vital powers consist, to speak broadly, of the power of movement; of the power of receiving from the outside matter which serves it as food, and of converting that food into its own substance; and of the power of increasing in size, or reproducing itself, in consequence of its conversion of food into living protoplasm.

The protoplasmic speck can move about in the fluid in which it is found by means of a shifting of its substance; the whole mass of protoplasm is moved by the movement of first one atom and then another atom of it. When a particle of food comes against it, the protoplasm flows round the food, so to speak, takes it in, and by vital action upon

it, turns as much as possible of it into new protoplasm. By and by the one speck becomes two, either by breaking in halves, or by a new speck growing out at the side, which presently becomes a new individual.

Such a minute portion of protoplasm is called a *Cell*. Generally, a darker and even more minute speck can be detected somewhere in the substance of the cell, which is called its nucleus. The ordinary way of growth and reproduction of cells is for the nucleus to divide into two parts, each part gathering around it an equal quantity of cell-substance; and then each newly-separated nucleus and its surrounding protoplasm absorbs nourishment, and increases in size, until the two cells are each as large as the one original cell; and then each repeats the same process.

It may be useful that I should mention that the simplest animal form to which the description given above applies, is a microscopic organism found in stagnant water. There, each individual cell leads its individual life, absorbing nourishment, showing the power of vital movement in its substance, growing, and reproducing itself; and yet being, so far as can be discovered, a simple speck of protoplasm. This minute living unit has been called the *ameba*; and consequently, the vital properties of a cell, as described above, are often spoken of as *ameboid*.

Now, it is not possible to watch the growth of the tissues in a higher animal, in the same way in which the whole growth and vital manifestations of these very low animal existences may be watched. But there is every reason to believe that the tissues of man grow and are reproduced, in a broad sense, exactly like the whole bodies of these lower forms of animal life.

The simpler tissues are distinctly found to be formed of cells, which obtain their nourishment from the blood, and which, doubtless, grow and develop like cells outside the body. When these ultimate tissues are examined under the microscope, the cell-nuclei can be discovered in them. Each cell—or probably it is more exact to say each nucleus—has the power of drawing from the blood, by which nutriment is carried to the whole body, exactly the elements required to make its own particular tissue, and none other. Thus, one fat-cell will draw from the blood the elements necessary to increase fat, and enable the one cell to multiply itself; one of the cells of the skin will draw out of the blood the special matter for its growth and reproduction; and so on, in accordance with the mysterious vital laws of their being.

The *Elementary Tissues* are those which cannot be divided without destroying their construction; they are the first results of the grouping together of cells, and their subsequent development. The following is an enumeration of them; they will be frequently referred to hereafter:—

1. **Epithelium** (Plate XVIII, F, G) consists of simple cells, placed side by side, and generally so united as to form a continuous layer, termed a *Membrane* (skin). These cells are reproduced in the manner above described; besides separating from the blood matter for its own sustenance, each cell generally secretes a little spare fluid. The membrane (called *mucous*) which covers the inside of the lips, and which is continued all through the alimentary canal and other spaces opening outside the body, is only slightly modified epithelium; so is the membrane (*serous*), which forms shut bags within which various organs are inclosed, as will be described in speaking of the heart; and so, indeed, is the external skin which covers the outside of the body. This consists essentially of cells, which are soft and plump in the lower layer, where they are produced from the blood, and being gradually pushed upwards by constant growth below become flatter and harder as they approach the surface, and having reached it are gradually rubbed away in the form of an impalpable dust.

2. **Cartilage**, commonly known as gristle. This is

seen, under the microscope, to consist of cells imbedded in a hard substance, which is called the *matrix*.

3. **Adipose or Fatty Tissue**.—The fatty tissue consists of a collection of cells, each containing a nucleus and a quantity of fatty matter.

4. **Connective Tissue** (sometimes called *fibrous tissue*), which is so named because this tissue passes through all parts of the body connecting the one with another. In it cells seem to stretch out into long fibres, of which the tissue is made up.

5. **Pigment-cells**, in which the cell contains a quantity of colouring matter. Such cells are found in the eye, and, as will be mentioned again hereafter, in a layer of the skin.

The structure of nervous tissue and muscular tissue will be spoken of farther on.

And finally, among these elementary tissues, is

6. **Bone**, a figure of the microscopic structure of which is found on Plate III, Fig. E. This beautiful figure represents a slice taken across one of the long bones, such as that of the upper arm, and magnified about 150 times.

The space in the middle of each of the rings in which the bone is seen to be arranged, is a tiny canal about  $\frac{3}{16}$  of an inch in diameter, which runs through the bone in a longitudinal direction. These *Haversian canals* do not run straight on, however, the whole length of the bone, but diverge in various directions and join into one another, and can always finally be traced to the outside of the bone, where blood-vessels enter them. They are really canals for the blood-vessels to run through; an artery or vein is found in each shaft.

The large black spaces surrounding the Haversian canals are called *lacunae*. In a fresh bone, a nucleus with a little protoplasm around it occupies each of those many spaces.

The very fine hair-like lines which are seen running in every direction, from one lacuna to another, are exceedingly minute tubes excavated in the bone, and are called *canaliculi*.

By means of this marvellously beautiful and delicate arrangement, the whole of the hard tissue of bone is kept bathed by the blood. The vital fluid runs through the Haversian canals, and the nutriment is drawn from thence through the minute canals to the living cells in the lacunae.

Besides these minute cavities, which are only distinctly seen under the microscope, long bones have a canal running straight through their centres, filled with that soft fatty substance called marrow. This is very plentifully supplied with blood (or, as it is called in technical language, is *highly vascular*), by means of an artery which passes into it through the bone; and some of the blood which nourishes the substance of the bone is supplied from the marrow-artery.

We may now proceed to consider

## The Skeleton.

Plates I. to VI.—Bones are divided into four classes: *long*, *short*, *flat*, and *irregular*. The human skeleton consists of about 200 distinct bones.

In making this calculation, of course each bone is counted regardless of how firmly it may be jointed to a neighbour. Thus, the spine consists of 26 separate bones, which can be seen best in Plates I. and II. Fig. B. There the 24 vertebrae, numbered 6, 7, and 8, can be counted, and the sacrum (9) and its tail-piece the coccyx (10) are seen to form the twenty-fifth and twenty-sixth of the number.

Each *vertebra* consists of two chief parts. First, a hard solid portion called its *body*, which is turned inwards, and is seen in Fig. A. of the plate, with the numbers 16, 17, and 18 placed upon the respective *bodies* of three vertebrae. These, being placed on top of one another, and



jointed firmly together by the plates of cartilage which are seen in the picture as dark rings between them, form a strong column which gives support to the trunk. Second, each vertebra has a ring of bone, called its *arch*, running round behind the body, so that when the vertebræ are in their natural position, their arches, or rings, form a continuous bony canal, which contains the spinal cord. It is the arches that are shown in the back view of the spine in Fig. B.

The first and second vertebræ are different from all the rest, and they are therefore specially figured on Plate III. (Figs. F and G). The first one, Fig. F, is called the *atlas*. The ancients had a fable that the globe was supported on the shoulders of a mighty man named Atlas; and the first cervical vertebra is called after him because it supports the globe of the head. In the figure just above (B) No. 15 shows the surfaces of the occipital bone of the skull which come against the depressions made to receive them (5, Fig. F) on the top of the atlas. G. shows the second cervical vertebra, which is called the *axis*. The point projecting upwards of this bone is called the *odontoid process*; the figure 2 points out the spot of that process which comes against the spot marked 4 in F. For the odontoid process projects up through the middle of the atlas, and is held there by a ligament that runs across from the projecting point against which the figure 4 stands to the similar point opposite to it. By this means the head is able to turn a little from side to side, and to nod backwards and forwards, without the whole of the spine moving. The atlas really moves upon the pivot provided by the odontoid process of the axis.

I have made the Index to the Plates as complete as possible, so as to avoid useless repetition here. The majority of the bones in the complete skeleton can be studied by aid of the index alone.

## The Skull.

“ You are bones ! and what of that ?  
Every face, however full,  
Padded round with flesh and fat,  
Is but modelled on a skull.”

The skull, even more than the whole of the strange relic of departed existence which a skeleton is, affords a suggestive theme to poets and text to moralists. For the muscles that covered these bones made the face, so full of life and expression; within the gaping cavity of the jaw-bones moved the tongue, perchance potent to influence, or strong to command, or tender to soothe and cheer; in that socket flashed or melted the eye; and protected in the midst of the casket of strong hard bones lay the jewel of the body, the busy wonderful brain, which thought and felt and willed.

“ Once of the ethereal spirit full,  
This narrow cell was life's retreat,  
This space was thought's mysterious seat.  
What beauteous visions filled this spot !  
What dreams of pleasure, long forgot !  
Nor hope, nor love, nor joy, nor fear,  
Hath left one trace of record here.”

In the whole skull, including both face and head, there are twenty-two distinct bones; in the head alone there are eight. Fig. C. of Plate V. shows the bones of the skull of an embryo—a child at a very early period of existence. In connection with this Plate, a few words may be said on the growth of the bones. The figures 3 and 4 are placed in the figure on the membranes which, in this incomplete state of development, intervene between the several bones of the skull. The anterior and posterior fontanelles can both be felt through the skin in the head of a child up to four or six months old; and the anterior one often remains

membranous until the child is from one to two years of age. This arrangement enables the head to grow. The membrane gradually becomes turned into bone, by the earthy salts being passed into it out of the blood; and as this goes on, the size of the head gradually increases, until at last the whole membrane is ossified (made into bone, that is), and the development of the cranium is completed. The various bones as they grow present an appearance along their edges like the teeth of a saw; and the projections of one edge fit into the depressions of its neighbour, and *vice versa*, so that a very firm joint is secured.

All the bones in the body are developed in practically the same way, only most bones are first modelled in cartilage, not in membrane. Chemically, bone consists of an animal base—gelatine, and of certain earthy salts, mostly lime, deposited in the gelatine, and making it hard. The bone exists first, in the very young (embryo) child, as mere cartilage, and a portion of each bone remains cartilaginous until the full growth is attained. The earthy matter is not drawn out of the blood into all parts of the bone at once, but only at certain points, which are called the *centres of ossification*. The lime begins to appear at these points, and from thence continues to spread. Meantime, the cartilage grows in length, and the lime does not overtake the growing cartilage (so to speak) until such time as the full size of the bone is attained. Then the cartilage ceases to grow, and the bony salts are deposited throughout it.

In the long bones, such as the arm and the leg and the finger bones, there are usually at least three centres of ossification; that is to say, three places where growing cartilage is to be found. These are at each end of the bone, and in its centre. The end ossifying cartilages are called the *epiphyses*, and these remain separated from the shaft of the bone (which ossifies from the middle “centre”) by a portion of unossified and growing cartilage, until quite adult age; varying in the different bones from the sixteenth to the twenty-fifth year of life.

## Joints and Ligaments.

**Plate VI.** The various bones are fastened to one another, and these *joinings* of the bones are called *joints*, or *articulations*. The bones are held together by plates of cartilage; and generally bands of the same tough material, which are called ligaments, pass from one bone of an articulation to the other, helping to keep them connected.

Joints are divided by anatomists into two great classes: *Imperfect* or *Immovable* joints, and *Perfect* or *Movable* ones.

The vertebral column is an instance of the first kind; a plate of cartilage intervening between the vertebræ, and only allowing as much movement as the spring of that cartilage permits. The sutures of the head also form joints of this class.

The second class may be subdivided into three kinds—viz. *Pivot* joints, such as the atlas and axis already described; *Hinge* joints, such as the elbow and the ankle, which are articulated on the same plan as a door is hung on its hinges; and *Ball-and-socket* joints, such as the hip and the shoulder.

It is obvious in a moment that the purpose for which the bones are thus jointed is that they may move upon one another. The power by which such movement takes place must next be briefly studied.

## The Muscles.

If the outer skin were removed from a man's body, the wonderful and beautiful arrangement shown in Fig. A of Plates VII. VIII. would be seen. There are a multitude of

muscles of all shapes and of all sizes, and running in the most various directions; but when we come to study those muscles in action, we find that every single one, from the tiniest one in the face to the greatest one in the thigh, is just the shape and the strength that it ought to be for its own special work. Every one has its office to perform, and is precisely suited to perform it.

Nor are the muscles seen in this figure all that the body possesses. This is only the superficial layer, and in many parts (as Fig. B serves to illustrate) the external layer must be quite removed to show the equally powerful and equally needful second or third layers beneath.

The muscles are fastened on to the bones in the elaborate and wonderful manner shown in C, D, E, F of this Plate, as well as in A. The ends of the muscles pass almost imperceptibly into tough, white cords, called *tendons*, which are attached to the bones. In cases where several muscles are fastened close beside each other, or where they are intermingled one with another (as in the hand, where many muscles are needed to supply the power for the infinite variety of movements of which that member is capable), the various tendons and sheaths which bind them into place are so complicated, and yet so perfect, that they arouse our wonder and admiration.

Thus, in the hand and foot, which may be studied carefully in the Plate before us, the tendons are very numerous and carefully arranged. The muscles which bend (or flex) and open (or extend) the fingers, are situated in the lower arm—the extensor muscles at the back, and the flexors at the front. In the same situation are also the muscles which move the whole of the lower arm in certain directions, and those which flex and extend the wrist. Now the tendons of the muscles which move the fingers have a long distance to run (see Fig. A, 23, 24, 25), so that if they were not carefully bound down, they would start out in every direction when the muscles acted, in the most extraordinary manner. The fingers are flexed by two distinct muscles, which lie on the front of the forearm (as the arm below the elbow is called), one below the other. In the right forearm of Fig. A the second or under layer of muscle is shown; and the large muscle marked 23, which is seen to divide into four tendons, is the deep flexor of the fingers. Anatomists always use Latin or Greek terms; and as any one who means to study Anatomy in detail must learn the Latin names, the muscles are described in that language in the Index to the Plates. The name which I have just given to this muscle is merely a literal translation of the name that will be found there. The deep flexor of the fingers has the end of its tendons attached to the tip of the fingers in front, as shown in Fig. A. The upper flexor of the fingers has its tendons attached to the second finger-joint (Fig. C, 6).

Now these tendons are seen to be held down first of all at the wrist, by the *anterior* and *posterior annular ligaments*, which pass around the wrist like a broad bracelet. In the palm of the hand is another portion of fibrous tissue, which equally firmly holds the tendons down beneath it, and which is removed in the picture to show the tendons. Finally, the complex bandage of ligaments around the tendons on the fingers themselves can be studied in Fig. C, where the sheath investing the tendons is left entire on the little and the third fingers, but removed from the first and second fingers, to show the attachment of the tendons of the upper flexor (*sublimis digitorum*).

It is not possible, in the brief space at my disposal, to thus describe in detail the arrangements of other muscles. But the reader will understand that this is merely an instance of the very elaborate way in which the muscles are arranged and suited to their use in every part of the body. A careful study of the several figures on Plates VII. VIII. will show many other obvious instances.

## Work of Bones and Muscles.

The offices of bones and muscles are, broadly, two in number—viz. to *protect the delicate vital organs*, and to *produce motion and locomotion*.

That they perform the office first mentioned, is seen at a glance. The brain rests fully enclosed in the bones of the skull, and further protected by muscles. The ribs enclose the heart and lungs; the rectus, the obliquus, and other muscles, close in the cavity of the abdomen, and protect the important organs that lie there (see Plates XIV. XV.), and the pelvis shares in the same service. But to understand how the muscles and bones produce motion and locomotion, we must study the functions of muscular tissue.

**Plate IX.** Fig. D represents a muscular fibre, treated with an acid which has caused its minute structure to become visible, and immensely magnified; and Fig. E shows a muscular fibre of quite a different kind. You will notice at a glance that D is marked with stripes both longitudinally and running round, the latter being rather the more distinctly seen, while E is perfectly smooth, and contains a nucleated cell in its midst.

Physiological research has shown that the *striated* (*i.e.* striped) muscular fibre composes all the muscles that are under the control of the will, which includes, of course, all the muscles of the limbs; we move our limbs by our volition. The *unstriated* fibres are found in the gullet, in the coats of the blood-vessels, and in other situations where muscular action takes place without the order of the will. Striped muscular tissue is therefore often called *voluntary*, and unstriated *involuntary* muscle.

Fig. D, 1, shows at the torn end of the fibre that the fibre really consists of a great number of smaller fibrils; while at 5 it is seen that the fibre readily splits up into discs, which are composed of numerous little rounded particles. Each *fibre* is about  $\frac{1}{1000}$  of an inch in breadth; each of its *fibrils* is only about  $\frac{1}{10000}$  to  $\frac{1}{15000}$  of an inch across—a smallness quite unimaginable to anybody not accustomed to microscopic work. The *fibrils* are found to be fastened together to form a *fibre* by a fine membrane (not seen in the figure), called the *sarcolemma*. Then a number of *fibres* are in like manner bound together by a fine membrane into bundles, and a number of these bundles are again fastened up with each other to form a muscle. To carefully dissect an orange will give one some idea of this repeated binding up of bundles to form one whole.

The muscles are plentifully supplied with blood-vessels, which run all through amongst the *fibres*, forming a network around them, but never penetrating through the *sarcolemma* which binds together the *fibrils*.

Nerves also enter the muscles, but they are so exceedingly delicate that it is still far from certain how they end. Fig. C shows what is believed to be the method of the termination of nerve in a voluntary muscular fibre.

This same figure, C of Plate IX., also introduces us to the *action* of the muscles whose structure we have now fully studied.

The special power peculiar to muscular tissue is that of *contraction*. When a muscle contracts, it becomes *shorter* and *thicker*. If you lay one hand upon the *biceps* muscle (Plate VII. Fig. A, 1) of the opposite arm, and then draw up the lower part of the arm towards the shoulder, you distinctly feel the *biceps* grow thicker and shorter under your hand. And by looking at it in the Plate just named, you can see at once that, since one end of the muscle is fixed to the shoulder, and the other end to the forearm just below the elbow-joint, the effect of its growing thicker and shorter must needs be to draw up the forearm.

The entire muscle contracts by the contraction of each of its fibres. Most probably, every one of the tiny particles into which the fibre can divide transversely (Pl. IX. Fig. D, 5)



becomes closer and wider ; so that the whole fibre is made shorter, and correspondingly wider or thicker ; and by the simultaneous action of all its fibres the entire muscle is thus altered in shape for as long as the state of contraction is kept up. This is very well represented (diagrammatically) in Fig. C, Plate IX., where 1 shows the muscle at rest, and 2 in a state of contraction.

The bones are jointed together on definite mechanical principles, so that they form a system of levers ; and the muscles, by their contractions, furnish the moving power to act upon the bones, and to produce motion and locomotion.

## The Heart.

This organ, as is seen at once by a glance at Fig. B of Plate IX., is made of muscle. Now, the heart is an *involuntary* muscle, and in connection with it, the necessity for the muscles of organic life being removed from the control of the will becomes at once most strongly apparent. For what a terrible thing it would be if the will were in any degree required to maintain the increasing muscular contractions, the stoppage of which, for a few instants, means death, and the irregularity of which is painful disease.

“ No rest that throbbing slave may ask,  
For ever quivering o'er his task.”

But it has to be particularly noted that the heart is made of *striated* muscular fibres. The stripes are less distinct, and the fibres are shorter, than in voluntary muscles ; but nevertheless it is a curious fact that the heart is the solitary instance in the body of striped muscle being outside the control of the will.

All involuntary muscles are excited to act, through the agency of the nervous system, by some cause, differing for each muscle, which is called the *stimulus*. Thus, the stimulus to the gullet is food coming into it ; the stimulus to the heart is the filling of its cavities with blood.

To study the internal arrangement of the heart we must turn to the next plate (Plate X. Figs. B, C, D).

The heart is divided inside into four distinct cavities. It is divided first longitudinally (from *base* to *apex*: the broad end being the former, and the point the latter) by a thick muscular wall, or *septum*. Fig. C is the representation of the heart cut across, at about the part where the figure 1 is placed in B of Plate IX. This is the portion of the heart which comes below that figure, and we are supposed to be looking down into it. The septum is marked 3, and you will observe that it is very thick and strong. It runs the whole length of the heart, and it has no orifice in it anywhere ; so that the heart is completely divided into two halves—a right and a left half. (See diagram of this division in Plates XII. XIII. Fig. A, where the left half is coloured red, and the right half blue.) Then each half is again divided into two parts—an upper and a lower—by means of a strong fibrous membrane. The two top parts thus formed are called the *auricles*, and the two bottom parts the *ventricles*—one of each *right* and one *left*. The auricles are much smaller than the ventricles. In Plate IX. Fig. B, the whole of the part coloured red is composed of the ventricles ; the paler portion above indicates the size of the auricles. The left ventricle is thicker and longer than the right, and by projecting a little below the latter it forms the apex, or point, of the heart, as shown in Plate X. B, where the whole of the right half of the organ, together with the septum, is cut away, and yet the extreme tip of the heart is seen.

The septum completely divides the right auricle and ventricle from the left auricle and ventricle ; not a drop of fluid can possibly pass through from the one side of the heart to the other. But the partition between each auricle

and its corresponding ventricle is not complete ; fluid does pass from the auricle into the ventricle. The fibrous membrane which forms the fixed partition is arranged as a ring round the interior wall of the heart at the point where the auricle ceases and the ventricle begins ; and the centre of this ring is a hole about large enough to admit the tips of three fingers. That hole is called the *auriculo-ventricular aperture*. It may be compared to a doorway between the auricle and ventricle ; and it has doors which are alternately open and shut. These doors, which can completely close the aperture, are called the *valves of the heart*.

The heart is covered outside and inside alike with a tough shining membrane. That outside is called the *pericardium* ; that inside, the *endocardium*.

The doors which fill up the two auriculo-ventricular apertures are simply flaps of the endocardium, attached by one end to the fibrous rings surrounding the apertures, but free at their tips, so that they hang loosely down in the ventricle when the heart is empty, as after death.

On the right side of the heart there are three flaps, so shaped that when they are lifted up they completely close the aperture, their points and sides coming together. This is the *tricuspid* (i.e. three-pointed) *valve*.

On the left side there are only two flaps, which, however, just as effectually as the three close the aperture. As its shape somewhat resembles that of a bishop's mitre, this valve is called the *mitral valve*.

The free sides and tips of each of these flaps have fine tendinous cords fastened to them ; and those *chordæ tendinæ* are affixed at the other end to small muscular projections, which stand out on the inside of the ventricle, and which are called the *papillary muscles*. The cords are just long enough to keep the sides and tips of the flaps in juxtaposition when they are raised up to close the apertures. But for this the flaps might be pushed right up through the apertures into the auricles, and so become useless as doors. The arrangement is, in short, like that of the swing doors often seen in banks, which would go right in and right out of the doorway, were it not for the leathern band which prevents them from opening in the direction opposed to it, while allowing them to come freely towards the wall where it is attached. This arrangement will be presently further explained.

Large pipes are found to lead out of both the auricles and both the ventricles (Plate IX. Fig. B, 7, 8, 10 ; also Plate X. Fig. B, 5). These pipes are

## The Blood-vessels.

Blood-vessels are found in every part of the body ; they are pipes which contain the fluid called blood.

Three kinds of blood-vessels are found in the body, viz. *Arteries, Capillaries, and Veins*. The arteries and veins are all good-sized tubes, though some of them are much larger than others ; but the capillaries are generally microscopic, and cannot be seen at all with the naked eye.

Now what are the distinctions between arteries and veins ?

In the first place, there are differences of structure. The arteries are stronger and thicker tubes than the veins, having more elastic tissue in their coats ; on the other hand, the veins have valves in them, while the arteries have not.

Fig. E, Plate X., shows the valves of veins to be merely pouches of membrane, with all their mouths turned in one direction—viz. open towards the heart. Obviously, fluid would flow along those pipes *over the back* of the valve pouches (that is, *towards* the heart) without finding any obstruction from them ; but if the fluid attempted to run back in the opposite direction, it would catch in the pouches, and swell them out so that they would fill up the tube. They thus effectually prevent the flow of the

blood in a backward direction, and compel it to pass always on one way.

Now, wherever you may commence in a body to trace out the course of either an artery or a vein, you inevitably discover one thing—that is, that you come to the heart at last. Starting with the finest twig, either arterial or venous, that can be seen in any part of the body, and tracing its course, you would soon find that it joined with a second twig, that the two made a somewhat larger stem, and that this in its turn soon joined into another and thus formed a yet larger branch, and so on. (See Plate X. Fig. A, and trace one of the small venous twigs at the top of the head until it is seen to communicate with the large vein marked 18.) And at last, following the joinings of the vessels into one another on and on, and noting how a larger tube results from each junction, we finally come to the largest veins and the largest artery of the body, and find that these lead straight into the heart. (Plates XII. XIII., 4, 5, largest veins; 12, largest artery.)

The best way to completely study the “distribution,” as the arrangement and division of the blood-vessels is anatomically called, is, therefore, to begin at the heart.

The largest artery of the body, the *Aorta*, rises out of the **left ventricle**. Fig. D, Plate X. diagrammatically represents the ventricle cut across so that the valve which guards the mouth of the aorta is shown (5, which is intended to indicate the three half-moon-shaped flaps of membrane, nearly closed, but still allowing a glimpse of the red interior of the heart between their edges); and there it is seen that the great blood-vessel goes out from the very top of the cavity, close up beside the mitral valve. The aorta first rises upwards towards the neck, immediately behind the breast-bone; but when it has ascended to opposite the second rib cartilage, it arches over towards the back, and then runs downwards close against the spine. Several smaller arteries arise out of the aorta all down its course (see, for instance, Plate XII. 14, 15, 16), these going to the head, the upper extremities, the liver, stomach, etc. Opposite the fourth lumbar vertebra, the aorta itself divides into two branches, called the *common iliac arteries*, which run towards the legs. Presently, each of these divides into two others; and each of those again subdivides, and so on, in the same manner as the external carotid artery may be traced in doing in A, Fig. X. 1. And with every division, the tubes become less in circumference, and also their coats become less thick and strong.

Calling in the aid of the microscope, the anatomist sees that the smallest arteries pass into—or, in fact, make by yet further subdivision of themselves—excessively fine tubes, which are much smaller than the hairs of the head, and which are arranged in a network, running into one another (Plate XII. Fig. C). These are the *Capillaries*, so called because of their extreme fineness (Latin, *capillus*, a hair). The capillary network is found in every organ and nearly every tissue of the body. Its meshes are in some parts even closer than the size of the capillaries themselves. In the skin, the interspaces of the network are from three to four times as large as the capillaries of which the network is made; and yet we can scarcely put the point of the finest needle through the skin without breaking open a capillary and letting the blood flow out of it. The average diameter of a capillary vessel is  $\frac{1}{50000}$  of an inch.

Tracing along the capillary network, the anatomist discovers that these minute vessels are connected at their other end with the veins; or, to put it in another way, after a time two capillaries of the network join together and make one tube, somewhat larger than the two individually were, and this larger one joins with another similarly made by two capillaries to form a yet larger tube, and so on, over and over again, till at last this process

ends in the two great veins of the body—the *venæ cavae*, which open into the **right auricle** (Plate XII. A, 4, 5).

Rising out of the **right ventricle**, another great tube is discovered. This is easily traced away from the heart into the lungs (Plate XII. A, 8), and is therefore called the *Pulmonary* (i.e. *lung*) *artery*. It divides (not shown in this diagram) into a branch for each lung immediately it leaves the heart, and within the lung each branch divides and subdivides into capillaries, which are especially small and close meshed.

The lung capillaries join to make veins, just as these tiny vessels do elsewhere; and finally four great veins come out of the lungs (two from each), and enter into the **left auricle** (Plate X. Fig. B, 5). These are the *Pulmonary veins*.

Thus there is a complete round of pipes in the body, with the heart as a centre. *Circulation* literally means *going round*; and the blood passes round the body to get from the *left* ventricle (where the *aorta* rises) to the *right* side of the heart; and passes round through the lungs to get from the *right* ventricle (where the *pulmonary artery* rises) to the *left* side of the heart, from whence it starts off through the aorta again. The going round the whole body is called the *systemic* or *greater* circulation; that through the lungs is the *pulmonary* or *lesser* circulation.

It will have been noticed that the vessels which take the blood *away* from the heart are called *arteries*, while those which *bring back* the blood to the heart are called *veins*. This is the proper distinction between arteries and veins: all tubes which carry blood away from the heart are arteries, all which bring blood to it are veins.

Besides these differences in the structure of the tubes and in their office in relation to the heart, there is also a difference in the blood which they carry. One point of this difference is visible at a glance. When blood is shed from an artery, anywhere in the system, it is found to be of a bright scarlet tint, while that which is drawn from a vein is a very dark crimson. This change of hue is, however, only an outward and visible sign of important chemical changes which closer examination discovers to have taken place.

Now, since the blood goes always round in the circle of arteries, capillaries, and veins, with the heart as a centre, it is clear that the alteration in the blood which causes it to be darker in the veins than in the arteries of the system, must take place as it passes through the capillaries of the system; and, on the other hand, since the blood returns to the right side of the heart through the *venæ cavae* of a dark tint, and leaves the left side of the heart again through the aorta of a bright tint, it is equally clear that the blood is changed from the venous to the arterial condition in passing through the lungs. The full explanation of this cannot be given until we have studied the lungs. But, meanwhile, it must be noted here that in consequence of the venous blood being carried away from the heart to be changed in the lungs to arterial, the pulmonary artery, with its branches within the lung, is the only artery in the body which carries dark blood, and conversely the pulmonary veins are the only veins which carry bright blood (Plate XII. A, 8, 9). In Plate X. Fig. B, the pulmonary veins are shown injected with a blue preparation.

And now, having studied both the heart and the blood-vessels of which it forms the centre, we may proceed to briefly review the mechanism of

## The Circulation of the Blood.

Let us begin at the left auricle, at the instant when the heart is taking its momentary rest after its contraction—i.e. between two beats. In this brief pause, the blood pours out of the four pulmonary veins into the left auricle.



The stimulus to the muscular contraction of each part of the heart is its becoming filled with blood; as soon, therefore, as the auricle is filled from the pulmonary veins, it suddenly and sharply contracts. That is to say, all its sides become thicker and shorter. Now a moment's thought shows us that the result of this must be that the size of the cavity is greatly reduced; the sides of the auricle must draw nearly close together. The blood which filled the space while the muscle was uncontracted must, therefore, be pushed out when it contracts. There are two directions in which it is possible for it to run—there are the mouths of the veins by which it came in, and there is the auriculo-ventricular aperture. But, of course, it goes where there is least resistance, and that is through the aperture; for the ventricle is empty, waiting to receive it, while the pulmonary veins are still full of blood pressing on to enter the auricle. The contraction of the auricle, therefore, drives the blood down into the ventricle.

As the ventricle fills, the fluid gets behind the flaps of the valves and floats them up, so that when the ventricle is filled they just meet in the centre of the auriculo-ventricular aperture and close it up. Thus, when the ventricle contracts, as it does the moment it is full, the valve closes the aperture, and the blood cannot run back into the auricle.

The flaps of the valve, you remember, are fastened to muscular projections on the walls of the heart by tendinous cords, which are just long enough to hold the valve in place when the ventricle is quiescent. But when it contracts, and the sides draw so near together as almost to touch each other, it is clear that the tendinous cords would naturally become slack, and permit the valve to be pushed by the squeezing blood right through into the auricle. To prevent this is why the tendinous cords are fastened to the projecting fleshy pillars; these latter contract at the same time as the sides of the ventricle, and thus draw down the ends of the tendinous cords affixed to them, just so far as is necessary to keep them "taut," and to hold the edges of the valve firmly against the pressure of the blood till the contraction ceases.

The blood being thus prevented from returning into the auricle, is compelled to enter the aorta. The aorta is, of course, already full of blood; but the contraction of the left ventricle is so strong, and the fresh portion of blood is pumped out with such vigour by it, that the shock thrusts the additional quantity of blood into the aorta, and so throws along the whole of the blood in all the vessels. The elastic coats of the arteries are distended by this sudden push of the blood inside them; and that distension makes what we call the pulse.

So the impulse of the throw of the blood out of the left ventricle into the aorta passes over all the arteries, and the blood is thus driven along through them all, and into the capillaries; the blood already in the capillaries is pushed onward into the veins, and so up through the veins the blood presses toward the other side of the heart.

But the impulse given to the blood by the stroke of the left ventricle becomes weakened before it reaches the veins, by being diffused all over the multitude of capillaries. This is the main reason why the veins are provided with valves, while the arteries are not; the valves being so placed as to allow of movement of the blood toward the heart, but to obstruct its running the other way.

There is enough force left, however, to push the blood along the whole of the veins, and to thus drive a portion of that which was in the *vena cava* into the right auricle. This at once contracts, and the portion of blood passes on into the right ventricle, and so into the pulmonary artery, and thus through the lung capillaries, and round into the pulmonary veins to the left side of the heart once more. And so the circulation continues unceasingly while life lasts.

About a wine-glassful of blood is sent along by each contraction of the heart.

The two auricles contract at one instant, and the two ventricles likewise together immediately after. On an average, the whole process described above is gone through 70 to 80 times in each minute. The whole of the blood in the body is thus passed through the heart in about the course of each minute.

## The Blood.

The fluid which is thus pumped into every tissue and every corner of the organism is much more complex than appears at first sight. The clotting of blood shows that it consists of a fluid called *plasma*, and of a great number of little bodies which float in the plasma, and are called the *corpuscles*. The plasma may again be separated into two parts—a fibrous material which forms itself into strings and is called *fibrin*, and a clear liquid called *blood serum*. The corpuscles are of two kinds—the *red* and the *white*.

The white ones are the larger and the more numerous, and they are remarkable because, in living blood, they are in a continual state of internal amoeba-like vital movement. They are, in fact, tiny masses of living protoplasm. Each colourless corpuscle contains a nucleus, and it is believed by anatomists, though it is not yet certain, that the red corpuscles are simply the nuclei of the white ones enlarged and more fully developed. The white corpuscles themselves are probably to a large extent the immediate products of the digestion of food.

The red corpuscles are shown in Fig. F of Plate X. Seen singly, they are of a pale yellow colour, but it is to the presence of a vast number of them that the blood owes its hue. The darker colour in the middle is simply the effect of an optical peculiarity, which cannot be avoided in looking through a microscope at so minute an object. The corpuscle really is alike throughout every part of its substance. Each is about one three-thousandth of an inch in diameter.

The plasma and the corpuscles together contain all the elements of the body. The blood is like a carrier, bearing to each organ of the body the supply of nutrition which it needs, and bringing away from each organ the waste matter that it requires to get rid of. Each tissue is bathed by the blood as the blood passes through the exceedingly thin-walled capillary vessels; and each tissue then draws out of the blood exactly what is required for its own life and growth, and returns certain waste substances which the blood carries away.

The difference in colour between the blood in the arteries and that in the veins of the system is thus accounted for. The arterial blood is going to supply the tissues with nourishment; the venous blood is bringing away their waste.

Part of that waste is passed out of the body through the lungs, and so the blood is made bright and arterial once more.

## The Lungs.

The exterior of the lungs is shown in Plate XI. Fig. A. They are seen to lie one on either side of the heart, the right lung being marked off into *three* lobes, the left into only *two*. They are covered with fine serous membranes, the *pleura*; and each pleura turns backwards at either of its ends, so as to form a closed bag, the outer half of which adheres to the wall of the chest, while the lung is wrapped up in the inner half, and a little fluid is secreted in the bag, just enough to keep it moist and allow of easy movement.

For the internal structure of the lung we must turn to the next plate (Plates XII. XIII.) Each lung is composed mainly of three things—

1. Blood-vessels.
2. Air-vessels.
3. Elastic fibrous tissue, binding the others together.

In Fig. A the left lung is dissected so as to show the pulmonary arteries and veins, the capillaries connecting them being, of course, too small for the naked eye to see; and the right lung is dissected so as to show the air-tubes as far as possible. Like the blood-vessels, however, the air-pipes continue dividing until their smallest twigs are too minute to be examined with the naked eye.

The **Windpipe** or **Trachea** (2) is the stem from which all the air-pipes branch out. The trachea divides into two branches in the chest, and one of these goes into each lung, and there divides and subdivides exactly as the arteries do. The two first branches of the windpipe are called the **bronchi**, and their subdivisions are the **bronchial tubes**.

The bronchial tubes all end as shown in Fig. B. The smallest tubes are very minute, and each one at its very end spreads out into a small dilatation, not quite round, but generally rather funnel-shaped. This dilatation is not perfectly smooth, but, on the contrary, its walls everywhere pouch out, so as to show a great number of tiny projections when the bronchial tube is viewed from the outside, as it is in Plates XII. XIII. Fig. B; or of caverns when it is cut open and viewed from the inside. These little recesses are the *air-cells*. Of course all the air-cells of one group communicate with the one central passage from which they pouch out. Their walls are of exceedingly thin skin. Each group of air-cells averages only  $\frac{1}{10}$  of an inch in diameter.

Figs. C and D of this Plate show the close relation between the capillaries and the air-cells. Each cell is covered with a very close network of capillaries, which completely surrounds it; and generally, where the capillaries dip down between two air-cells, there is only one set of the blood-vessels, so that they have air-cells on either side of them. The coats of the pulmonary capillaries are exceptionally fine and delicate.

## Respiration.

The air-cells just described are always full of air. The act of **respiration** or breathing consists of a continual drawing into the lungs of the air which surrounds us (*i.e.* *inspiration*) and expelling it again (*expiration*). But every breath only passes in and out of a certain portion of the bronchial tubes; the smaller tubes with the air-cells can never be emptied by the most complete expiration. The air which they contain in them is constantly renewed, however, because with every breath some portion of the fresh air remains in the lungs to mix by degrees with the whole of the air that it finds there, while an equivalent quantity of the stale air comes out at the expiration.

Thus the blood in the capillaries of the lungs is constantly in contact with air in the air-cells, the blood and the air being only kept apart by the two very thin skins of which the vessels and cells are made; and the air is constantly renewed by the act of breathing.

Now it is proved by direct experiment outside the body that gases are not prevented from uniting with one another by being enclosed in a thin moist skin.

Fresh air is composed mainly of three gases—Oxygen, Nitrogen, and a very little Carbonic Acid. Thus there are gases in the air-cells. There are likewise gases in the blood. Gases can be united with fluids. Liquid ammonia, for instance, is merely ammonia gas in water; and the blood in the body carries about gases mixed with it.

You will remember that it is in the lungs that the blood becomes changed from dark venous to bright arterial red.

That change in colour is merely a sign that the blood has parted with some portion of one gas that it had in it, and has taken up an equal quantity of another gas.

Various experiments, which I have not space now to detail, show that the gas taken up by the blood out of the air in the air-cells is **Oxygen**; and the gas which the blood passes out into the air-cells in exchange is **Carbonic Acid Gas**. These gases are held in the red corpuscles, and the effect upon them of being charged with oxygen is to cause them to become lighter in tint, while the effect upon them of being full of carbonic acid is to deepen their colour.

The carbonic acid passed out of the blood into the air-cells mixes with the stationary air in the bronchial tubes, in like manner that the oxygen does in the opposite direction; and so the waste gas presently gets into the larger bronchial tubes, and through the windpipe out of the mouth.

This is the explanation of the change from venous into arterial blood in the lungs; and as there will not be another opportunity, I will here briefly refer to the opposite change in the blood which takes place as it passes through the capillaries of the system.

Oxygen is carried away from the lungs in the arterial blood. The element Carbon is a part of every living tissue of the body (see p. 1). As the great stream of the blood flows through the systemic capillaries, the oxygen passes out through the thin coats of the minute vessels, and acts upon the carbon of the tissues, combining with it: and the product of the combination of carbon and oxygen is Carbonic Acid Gas. This is waste, like the ashes from a fire, and has to be got rid of; and, therefore, the blood flows on to the lungs, to pass away that gas, and take in fresh oxygen.

Why does this combination take place? will be the immediate question of every thoughtful reader.

In the first place, the *Force* of the human body is produced by the combining of the oxygen, which is taken from the blood as it passes through the capillaries, with the substance of the tissues; the chemical change which then takes place making itself visible as force, and the products of the change being waste matter. Part of this waste is carbonic acid, produced by the oxidising of carbon.

Secondly, our *Animal Heat* is produced by the uniting of oxygen with carbon and hydrogen. Such uniting is the essence of combustion. When a candle or any other substance burns outside the body, it does so because the carbon and hydrogen which it contains unite with the oxygen of the air. This can be very easily proved by completely shutting off a small piece of lighted candle from the air by turning a tumbler down over it; the oxygen in the small portion of air confined under the tumbler will soon be used up, and then the candle will go out. Now, as burning outside the body produces heat, so it does inside; and the respiratory process in the body is chemically identical with burning. But in the body, the burning is very slow, and is also damp; and thus, as with a smouldering fire, we do not have any flame, though we have heat from the combustion.

## The Mechanism of Breathing.

Respiration is accomplished mainly by three several powers, viz.—

- a. The Diaphragm.
- b. The Muscles of the Ribs.
- c. The Elasticity of the Lung Tissue.



The **Diaphragm** is a great muscle which separates the chest from the abdomen. The heart and lungs lie above it, and all the other organs of the trunk beneath it; the great blood-vessels and the gullet pierce through its substance. It is in the shape of an arch, with the convexity turned upwards towards the chest, and the concavity towards the abdomen. Its situation can be pretty accurately judged from the outside by the ribs; it arches up just beneath the lowest true ribs (see Plates XII. XIII. Fig. A, and Plates XIV. XV. Fig. A, 1).

The pleure, the covering membranes of the lungs, are affixed at their ends to the diaphragm. That great muscle contracts continuously and regularly, as the breath is drawn. It necessarily draws down in the centre when it contracts—its arch becomes less—and the pleure being fastened to it, it drags them, and consequently the lungs, down with it. A space is thus made in the bronchial tubes, which the air rushes in to fill. Then the muscle ceases contracting, and as it rises up to its former arched shape, the lungs return to their unstretched condition and the breath is pushed out.

The **External Intercostal Muscles**, which run across from each rib to the one next to it, act by lifting the ribs, and the breastbone to which they are fastened, outwards. This increases the capacity of the chest from before to behind; and as the pleure are fastened to the chest wall, the bronchial tubes are stretched open by this action, and the air enters the space. The **internal intercostals** run across in the reverse direction from that taken by the external ones, and perform a directly opposite action, so that they aid expiration.

The **Elastic Tissue** of the lungs, which binds together the blood-vessels and air-cells, always assists expiration, by its constant tendency to spring together again, after it has been forcibly expanded by the action of the diaphragm and the external intercostals. Thus it presses on the bronchial tubes, and assists the internal intercostals, the rising diaphragm, and the abdominal muscles, in pushing air out of the lungs.

Now listen, as a conclusion to this part of the subject, to the poet-anatomist's recapitulation of it.

“The smooth, soft air, with pulse-like waves,  
Flows murmuring through the hidden caves,  
Whose streams of brightening purple rush  
Fired with a new and livelier blush,  
While all their burden of decay  
The ebbing current steals away,  
And red with Nature's flame they start  
From the warm fountains of the heart.

“No rest that throbbing slave may ask,  
For ever quivering o'er his task,  
While far and wide a crimson jet  
Leaps forth to fill the woven net,  
Which in unnumbered crossing tides  
The flood of burning life divides,  
Then kindling each decaying part  
Creeps back to find the throbbing heart.”  
(DR. OLIVER WENDELL HOLMES: “*The Living Temple*.”)

## Digestion.

Since the heat of the human body, and the force by which it performs all its functions (both vital and volitional) are produced by the using up of the tissues, it is clear that those tissues must be continually reproduced; else the body would shortly be entirely burnt away, like a fire when it is not replenished.

The fuel of the body is Food. The substances which we use as food, whether animal or vegetable, are made of the same elements as our own bodies are. Those substances can, therefore, supply the needs of every tissue. To enable

them to reach the whole of the organism, food-substances have first to be reduced into such a condition that they can be taken up by the blood, and carried by it into every part of the system. The preparation of food for its entry into the blood is *Digestion*.

Plates XIV. XV. and XVI. show the principal organs of digestion, which are—the *Stomach*, the *Liver*, the *Pancreas*, and the *Intestines*.

The process of resolving the food into such a condition that it can be taken into the blood really begins, however, in the mouth. The **Teeth**, which are figured among the bones of the body (Plate III. C), are the first in order of action of the digestive organs. They receive the food between them, and tear and crush it into small particles. People who have lost their teeth nearly always suffer from indigestion, because the preparation of the food in the mouth is insufficient, and the labour which ought to have been performed by the teeth is thrown on the stomach.

While the teeth—acted upon by the powerful muscles of the jaws—are crushing the food up, the **Salivary Glands** are busily employed in pouring out upon it the fluid which they separate from the blood—the *Saliva*. These little bodies are six in number, and are arranged in pairs, three on either side of the face. The *Parotid* pair lie just under and in front of the ears (Plate XVII. E). The other two pairs are smaller; they are figured in connection with the under side of the tongue on Plate XXI. (B). The *Sub-maxillary Glands* lie just underneath the lower jawbone; the *Sub-lingual Glands* are under the tongue. The saliva not only moistens the food, and enables the tongue to form it into a compact bolus, but, in addition, has an important chemical action, turning what starch there may be in the food into sugar; sugar being very readily absorbed into the blood, while starch cannot be taken up into it at all.

The tongue pushes the mass of food backwards, and it passes between the tonsils (Plate XVIII. A, 30) under the soft palate with its central flap the *Uvula* (22), which protects the back openings of the nose. The food then passes over a gristly lid, called the *epiglottis*, which guards the top of the trachea by bending down so as to cover that opening during the instant that the food is being passed into the gullet, the opening of which lies immediately behind that of the wind-pipe (33, 34, 40).

The **Esophagus**, or gullet, is a tube made of involuntary muscular fibres. The stimulus to their action is the coming against them of the small bolus of food. The ring of muscle which the mouthful touches at once contracts above it, and so pushes it down into the next portion, which similarly contracts and sends it lower down, and so on. This is called *vermicular* (i.e. worm-like) action, because a worm moves by consecutive contractions of its whole length in this manner.

Now we return to Plates XIV. XV., where the *oesophagus* is seen to pierce through the diaphragm and enter or merge into the stomach.

The **Stomach** is a muscular bag, covered outside by the *peritoneum* (a membrane which invests all the abdominal organs), and lined within by mucous membrane. In Fig. A of this Plate (XIV. XV.), the stomach is shown in the position which it occupies in the body; the liver, however, which is here turned back upon itself to show how the small intestine is joined to the stomach, is in its natural position laid upon the stomach at that end. In Fig. B the muscular coat of the stomach is shown; and in Fig. C the organ is laid open, and the mucous membrane is seen. The *Omentum* shown in connection with this figure are simply folds of the peritoneum by which the stomach is held in position.

The *Mucous Membrane of the stomach* demands our attention. It is seen in this figure to be laid in folds; but when

the stomach is distended with food the folds disappear, stretching out to accommodate the demand for space.

All over the mucous membrane are seen the openings of the *Gastric Glands*. These glands are tubes of membrane, lined with epithelium, and covered outside by a fine capillary network (Plate XVI. A 5). Sometimes they contain a mass of nucleated cells in their lower part (4), and sometimes they are branched into two or more ends, with one common opening (3).

When food enters the stomach, two immediate effects are produced.

In the first place, the stomach at once receives an increased blood-supply, so that the mucous membrane becomes of a deep red colour; and the glands above described having drawn from the blood which is circulating actively through the capillaries around them a peculiar fluid, called the *gastric juice*, pour it out, drop after drop, upon the food.

Secondly, the muscular fibres of the stomach are stimulated to contract; and they do so in a manner which keeps up a constant movement of the food along the organ, backwards and forwards, by which the gastric juice is enabled to mix more thoroughly with the food, and also the digested portions are brought against the orifice through which they are to pass.

That orifice is at the opposite end of the stomach from the opening of the œsophagus (see Plates XIV. XV. C, 2). At that place muscular fibres pass circularly, so as to form a ring around the orifice. The touch of a portion of undigested food causes this ring to contract so tightly that nothing can pass through it; and, for this reason, the ring is called the *pylorus* (i.e. doorkeeper), and the opening which it guards is named the *pyloric orifice*.

The *Gastric Juice* is the agent by which that dissolving of the food which commenced in the mouth is continued in the stomach. The gastric juice is a watery fluid, white and thin, and acid to the taste. Chemical analysis shows its two principal ingredients to be *hydrochloric acid*, and a peculiar substance, not found elsewhere, to which the name of *pepsin* has been given. This latter is probably the principal agent in the digestive process. The effect which the gastric juice has upon the food is to dissolve it, and to so far change the nature of some portions of it that they become "diffusible;" that is, they will pass through fine membranes. The portions of the food thus completely digested are, probably, at once taken up into the blood, passing through the coat of the stomach into the veins. The remainder of the food is merely dissolved into smaller particles, so that it forms a thick liquid; and this, which is called *Chyme*, passes out through the pylorus. If an undissolved lump approaches the orifice, the pyloric ring contracts and retains that in the stomach for further digestion; but no obstacle is offered to the passage through the pylorus of the chyme.

When the food has passed through the pyloric orifice, it is in the small intestine (Plates XIV. XV. A, c and 4). The *Intestines* form one long tube, about 30 feet in length in an adult person. The part nearest to the stomach is much narrower than the opposite end; hence, the first portion is called the *small intestine*, the latter the *large intestine*. The small intestine is doubled backwards and forwards many times, to get it into the space allotted to it, which is that enclosed by the large intestine (Fig. A). In this figure it is shown drawn out, to exhibit its length; the large intestine, however, is in its natural position.

For convenience of description, the small intestine has been marked off into three divisions, viz.—the *duodenum* (d), the *jejunum* (e), and the *ileum* (f), but there are not any important anatomical differences between the three portions. In like manner, the large intestine is divided into the *cæcum* (g), the *colon* (i, k, l), and the *rectum* (n).

The internal structure of the small intestine is very note-

worthy. The first point that strikes the naked eye (Plate XIV. XV. C, 8) is, that a short distance below the pylorus the internal membrane of the duodenum is doubled up into innumerable folds. These are most numerous and largest in the part of the intestine here shown, just below the common entrance of the bile and pancreatic ducts (9 and 10). They are called the *valvule conniventes*, and their purpose appears to be to cause the food to move more slowly.

Noting, before we pass on, the spot at which those tubes enter through which the bile and the secretion of the pancreas are passed on to the food, and leaving further mention of the organs which secrete those fluids till by and by, let us turn to the next plate. Fig. D, Plate XVI., gives a diagrammatic view of the peculiar structures of the small intestines. This is a fine picture, and merits looking at carefully, with the aid of the index. The little depressions of the mucous membrane named *Lieberkuhn's crypts* secrete a thin fluid called the *intestinal juice*, the action of which is not yet fully understood. The *Solitary Glands* (13) are the same bodies as when gathered in groups form what are called *Peyer's Patches* (C, 2). The exact use of these glands is not yet made out clearly. It is thought that they exercise some influence upon the action of the lymphatic vessels, and that they are similar in structure to the lymphatic glands of the rest of the body, of which I shall presently proceed to speak.

But most interesting and important of all these details of the minute structure of the small intestine are the *Villi* (C, 1; and D, 7). The interior of the small intestine presents an appearance resembling the pile of velvet, so closely are these little bags, or projections, set over it. In the whole course of the intestine there are calculated to be about four millions of them. Each villus contains inside it an artery and a vein (D, 8), with their connecting capillary network; and also, enclosed by the blood-vessels, the blind end or ends of a *lymphatic vessel* (10). It will be understood that each villus contains all three, although in this diagram, for clearness' sake, they are severally shown.

Now, what is a *lymphatic vessel*?

In almost every part of the body, and entering into nearly every tissue, are found small and delicate tubes, which contain an almost colourless fluid. These tiny vessels begin blindly in the tissues, so far as is at present made out. They join into one another frequently (or *anastomose*, as the anatomists call it), but they do not by this means form large trunks. Every here and there the tubes enter small round bodies, which lie in their course, and which are called the *lymphatic glands*. In those glands the vessels divide and subdivide, and then appear as one or two tubes again on the opposite side of the gland. Finally, all the lymphatic vessels end in two tubes, the *thoracic duct*, which opens into the left subclavian vein (as shown at Plate XI. A, 21, 23), and the *lymphatic duct*, which enters the corresponding vein on the right side. These two veins immediately pour their contents into the superior vena cava, and so the fluid which enters them from the lymphatics is at once thrown into the heart, and so into the general current of the blood.

The lymphatic vessels, taking the body as a whole, have the office to perform of gathering up the excess, so to speak, of the blood which the various tissues have drawn out of the capillaries for their use. There is no doubt whatever that the fluid portion of the blood passes out through the capillaries to bathe the tissues, and it is possible that the same happens to some extent with the corpuscles themselves. Whatever cannot be used by the tissues is gathered up by the lymphatics, and restored through them to the general course of the circulation.

But those particular lymphatics which we have seen beginning in the villi of the intestine do more than gather



up the overflow. Through them the new matter of the digested food chiefly passes, to reach the blood, by which it is carried around to form part of the tissues.

The lymphatics arising in the small intestine are called *Lacteals*, which means milky, because of the milky appearance of the fluid which they contain immediately after a meal; but they do not differ in any other respect from the other lymphatics. They pass away from the intestine, and enter numerous lymphatic glands that lie in the midst of a broad fold of the peritoneum which holds the small intestines up to the back wall of the abdomen, and which is called the *Mesentery*. After ramifying here, the lacteals finally enter the thoracic duct at its lower part, and so their contents pass through that duct to the heart.

The contents of the lacteals are the final products of the digestion of the food. As the chyme passes over the common orifice of the bile and pancreatic ducts, it excites a gush of fluid, which mixes with it, and continues the digestive process upon it. The food is now called *Chyle*, and is passed along the length of the intestine by movements similar to those of the oesophagus, already described. As it is thus pushed along, the lymphatics of the villi draw it through the membrane into themselves, and carry it away to the thoracic duct. No doubt the capillaries which surround the lacteals carry away some of the food; but the fatty matters especially are passed through into the lymphatic roots themselves.

But all food has certain husks and fibres which cannot be so dissolved, and which are useless as food; and by the time the chyle has passed through the length of the small intestine, these waste matters alone, or almost alone, remain, the whole of the good and useful parts of the chyle having been absorbed by the lacteals.

Where the ileum joins into the cæcum (Plates XIV. XV. D) there is a valve which prevents the mass that has once passed it from retrograding into the small intestine. Attached to the cæcum is a curious pipe-like appendix, which is of no use in man, and seems to be only a relic of the long cæcum which is found in other mammals.

As the mass of digested food passes along the large intestine, in which there are no villi, the veins in its coats doubtless suck up any portions of useful matter that may remain, and finally the waste remainder is expelled from the body.

We must now return to the two organs which we have already seen are part of the digestive apparatus, though not in the course of the alimentary canal—viz. the *Pancreas* and the *Liver*.

### The Pancreas.

Plates XIV. XV. A, 9, show this viscus in its natural position, with its duct joining with the *common bile duct*, and immediately entering the duodenum. Sometimes, however, the pancreatic duct and the bile duct are found to open into the duodenum separately, and this peculiarity is shown in the figure of the pancreas laid open, on Plate XVI. E. The fluid which the pancreas draws out of the capillaries, and passes through its duct into the intestine, is very similar to saliva. It appears to act mainly upon the fats of the food.

### The Liver

has a very complicated structure, and performs a very important work. It is the largest organ in the body, weighing about four pounds (50 to 60 ounces). It lies immediately below the diaphragm, partly covering the stomach. In Plates XIV. XV. it is shown partly turned up, so that its under surface is seen. The liver is divided by five fissures upon its under surface into as many portions of unequal sizes, which are called its *lobes*. The smallest sub-

divisions of the liver are called *lobules*, and each of these is a many-sided body about the size of a mustard-seed.

Fig. B is a greatly magnified and diagrammatic section of a portion of a lobule. The final branches of the *portal vein* (D) and of the *hepatic artery* (E) are seen to run round the margin of the lobule, and to break up within it into a multitude of capillaries, which themselves are seen in the opposite corner of the picture (which would be really the centre of the entire lobule) to unite into a central *hepatic* or *intra-lobular vein* (F). The little bodies which crowd the meshes of the capillaries are the *liver-cells* (H), and the *bile-duct* (A), partly injected with a yellow preparation, is shown mingling with the capillaries and surrounding the cells.

Now let us examine these various structures, which all together make up the lobule—viz. Portal vein, Hepatic vein, Hepatic duct, Hepatic artery, and Liver-cells.

Three of the four tubes just named enter the liver side by side at a spot on its under surface called the *porta*, or gate, of the liver. Hence the name given to one of the three vessels, the *portal vein*. The portal vein is, as its being called a *vein* implies, formed by the joining together of capillaries. The blood which is in it is that which has circulated in the capillaries of the stomach, the spleen, and the intestines. The other two vessels which enter the liver at the same place as the portal vein are the *hepatic artery*, which brings blood from the aorta to nourish the substance of the liver, and the *hepatic duct*, which comes from the gall-bladder (Plates XIV. XV. A, w).

These three tubes enter the liver side by side, and keep together throughout their course. The portal vein, though a true vein in that it is made by the joining together of capillaries, and is conveying blood towards the heart, yet behaves like an artery; it divides and subdivides into capillaries again. The hepatic artery of course divides also, and the hepatic duct does the same, the three vessels always accompanying one another, and dividing and subdividing in the substance of the liver in canals made for the purpose. Finally, a network of small portal veins (Plates XVI. Figs. B, D) is made, which surrounds and marks off each lobule from the rest, and these veins are called the *inter-lobular veins* (i.e. between the lobules). From that surrounding network small veins enter *within* the lobule, and immediately break up into capillaries. The hepatic artery sends a branch into the lobule with each of these veins, and the capillaries of the artery and those of the vein inside the lobule join together, so that the blood in the lobular capillaries is a mixture of that brought in by both portal vein and hepatic artery. The meshes of that network inside the lobule are filled with the minute cells called *hepatic cells* (Plate XVI. Fig. B, H). Thus the blood is in very close relation with the cells, only the fine skin of the capillaries keeping them apart; and while the blood is slowly passing along the capillaries, the cells draw out of it the peculiar constituents of the *Bile*.

Now, does the hepatic duct, which certainly accompanies the portal vein and the artery so far as to the outside of the lobules, also enter into the lobules with them? Upon this point there is some difference of belief. It must be remembered how very small the lobules each are (about the size of a mustard-seed), and then the difficulty of deciding the point with absolute certitude will be understood. It is most probable, and is now generally held, that what is shown in Fig. B of Plate XVI. is what really happens to it, viz. that it enters the lobule with the blood-vessels, and there breaks up into a network much finer even than the capillary one, generally enclosing only one or two cells in each mesh. Thus the cells can readily discharge the bile which they secrete, so that it passes through into these tiny tubes.

Whether this is the exact method of their termination or no, certainly the bile finds its way into the hepatic duct

at the exterior of the lobule, and passes along that tube until it comes to the outside of the liver, where it goes down and enters the common bile duct (Plate XIV. A, w), and either at once passes into the intestine or goes up to the gall-bladder to be stored till required. The secretion of bile is continuous, but its discharge into the intestine only takes place while digestion proceeds.

Now we must return to Plate XVI. Fig. B, to see what becomes of the blood that is poured into the capillaries within the lobule. In the very centre of each lobule is a small vein (F), which is called the *intra-lobular vein*, and which is really the smallest branch of the venous system that gathers up the liver capillaries. The tiny vessels in the lobule all ramify towards this central vein, and pour their contents into it. This veinlet passes out of the middle of the lobule into a somewhat larger *hepatic vein*; and several of those join to make yet larger tubes, and so on over and over again, as veins always do, until at last all the blood is carried to four great hepatic veins, which open into the *vena cava inferior*, and so convey the blood to the heart.

Besides secreting bile, the liver-cells act upon certain constituents of the blood, and turn them into sugar, but this process is very complicated, and not yet fully understood.

### The Excretory Organs.

Throughout the last few pages the term "*Secretion*" has been repeatedly used, and it would be gathered by the reader that the meaning of this word was the separating of some substance from the blood. *Excretion* is an analogous process, with the difference that an excretion is cast out of the body as waste, while a secretion is used again for some physiological purpose. Thus, bile and pancreatic juice are *secretions*, while perspiration and carbonic acid gas are *excretions*.

All organs which either secrete or excrete receive the generic name of **Glands**; and all glands have one fundamental structure. They consist essentially of a simple membrane with epithelial cells on one side of it and blood-vessels on the other. The epithelial cells are the active agents in the work; they draw the peculiar secretion out of the capillaries, which are on the opposite side of the basement membrane which they cover. *How* they do this in any given case is a vital mystery: the cells are to all appearance identical in every situation, yet the cells of a sweat gland never produce saliva, the cells of the salivary glands never secrete bile, etc., but everywhere the cells produce the proper secretion of the gland in which they are found.

We have already seen that glands vary greatly in form and in respect of the complexity of their structure, from the simple depressions of the membrane in the intestine to the elaborate arrangement of the liver-cells in their lobules. But however wide the apparent differences, careful examination shows the elementary structure just described to be always present.

The **Excretions** of the body are those waste matters which are produced by the chemical changes of the tissues. They are finally, when they leave the body, reduced to three principal forms, viz. *Water, Carbonic Acid, and Urea*. The first-named is the product of mixing together oxygen and hydrogen, the second of oxygen and carbon, and the third of oxygen and nitrogen; so that the principal elements of the tissues, which are also necessarily the principal elements of our foods, after producing force and heat by their chemical change within our bodies, are thus cast out in those changed forms, and are thrown away like the soot and the ashes of a fire. Minute quantities of the other elements of the body are also passed away as excretions, but of course the quantity of these in the sweat and in the urine is proportionately small compared to the matters

above named, just as is their quantity in the body compared to that of the oxygen, nitrogen, carbon, and hydrogen.

The **Excretory Organs** are the *Lungs*, which we have already studied, and which we know to pass away much carbonic acid with a little water; the *Kidneys*, which pass away most urea, with a good deal of water; and the *Skin*, which gets rid of a considerable quantity of all three waste products.

### The Kidneys.

Plate XVII. is entirely devoted to showing the structure of the kidney, with the exception of one figure of the parotid gland (E). In Fig. A the kidney is drawn in its natural position, with its external capsule partly turned back to show how the blood-vessels enter. The blood is seen to go into the kidney direct from the aorta. In Fig. B a section through the midst of the organ is shown.

At a glance, it is seen that the interior of the kidney may be divided into two parts, one much firmer in texture than the other. The external hard portion is called the *cortex* (bark), and the internal softer portion the *medulla* (marrow) of the kidney. The microscope shows the reason for this difference in the naked-eye appearance: the cortex contains in its substance a great number of tiny round bodies, the medulla consists almost wholly of a multitude of fine tubes, which run (14) towards the concave part of the kidney, gathering into bundles as they approach there in such a fashion as to form *pyramids*. The pyramids end by a small nipple-like projection into the central open space of the kidney, each projection being called a *papilla* (13), and each one of them having the orifices of about a thousand tubes upon its summit.

The tubes which open upon the papillæ are the true secreting apparatus of the kidney: they are called the *uriniferous tubules*, and are lined throughout (D, 2, 4) with secreting epithelial cells. Fig. C traces diagrammatically the course of a single tubule backwards from the spot where it (7) opens on the papilla. The tubule is seen to branch out, and to become continuous with a number of interlooped and convoluted smaller tubules, which in their turn finally end in (4) somewhat enlarged tubes in the cortical part of the kidney. At the end of each of these larger tubes there is a dilatation (see D, 2) of the tube into a round body, called the Malpighian capsule, shown in Fig. C, 2. Into that capsule an artery penetrates. This arrangement will be better understood by turning to Fig. D, which is a very greatly enlarged representation of the terminal tubules and the blood-vessels within them. The convoluted tubule is seen to become wider, and to spread out into the Malpighian capsule, into which enters a branch of (1) the *renal artery* (the artery which we saw in A, 7, entering the kidney), and immediately within the capsule divides and subdivides into a multitude of capillaries, forming a tuft which is called a *glomerulus*. The blood passing through these is in immediate relationship with the cells, and here a portion of the excretion which the kidneys separate, the *urine*, is drawn out. But as though this could not do the whole work, a very peculiar arrangement of the blood-vessels and tubules is made, so that *after* the blood has passed through the glomeruli it is *again* submitted in capillaries to the action of cells. The capillaries in the Malpighian capsule join together and make a small vein, which issues from the capsule near where the artery enters; but instead of joining with other similar vessels to make one larger tube, as veins commonly do, this little vein again breaks up into a number of capillaries which completely surround the uriniferous tubules in the cortex (C, 2). and only after thus a second time passing through capillaries can the blood reach the small renal vein (C, 3) by the joinings and communications of which it is carried out, through the principal *renal vein* (A, 10) and into the *vena cava inferior*



(A, 9). There is no doubt that the secretion of the urine takes place from the second set of capillaries, and by the tubules, as well as from the glomeruli.

The fluid thus secreted consists mainly of water and urea, the waste product of the using up of nitrogen in the tissues. It contains, also, small quantities of several salts, which, like the urea, are dissolved in the water.

The fluid passes down the minute uriniferous tubes by which it is secreted from the blood, and out at the openings of the pyramids on the papillæ. The papillæ project into a space of considerable size, called the *pelvis*, or basin of the kidney (B, 17), which is divided into parts called *calices*, for the reception of the tips of the pyramids (B, 12). The *pelvis* is continuous in each kidney with a tube, the *ureter* (A, 5, B, 5), which runs down and opens into a bag of muscle and skin that lies in the bony pelvis, just above the *os pubis*, and serves as a receptacle for the urine. This is the *urinary bladder*; and from it the excretion of the kidneys is passed out of the body through the *urethra*. Thus the uriniferous tubules are indirectly in communication with the outside of the body.

### Ductless Glands.

One of the ductless glands being shown in Fig. A, this appears the best place for saying a few words about those bodies. The ductless glands comprise the **Spleen** (Plates XIV, XV, Fig. A, 7), the **Thymus** and the **Thyroid glands** (Plate XI, A, 3 and 5), and the **Supra-renal Capsules** (Plate XVII, A, 4). These bodies are all alike in one respect, viz. that they receive a full blood-supply, and yet have no ducts through which any secretion is passed out of them. Whatever change they work in the blood, therefore, they return at once to the blood itself. It is thought that they are probably manufactories, so to speak, of the blood-corpuscles; and this theory is strengthened by the fact that the thymus gland is active and large during childhood while the body is growing, but wastes away and becomes quiescent when the body is fully developed. No certainty has yet been reached upon this point, however.

### The Skin

performs two functions; it is both the seat of the organ of touch and a part of the excretory apparatus. It is figured among the organs of sense, but it will be more convenient to briefly consider it now.

Plate XXI, Fig. E, is a diagram to show the various structures which are to be found in the skin. These are not, of course, found consecutively in every part of the skin; it is a *diagram*, not a section from one particular place.

The skin can be divided, anatomically, into two layers: the *dermis*, or true skin, beneath; the *epidermis*, or cuticle, externally. Each of these, again, is readily divisible into two portions. The epidermis consists of a lower layer of soft cells (2) somewhat rounded in form, which have just been born from the blood, as cells are reproduced (see p. 2); and an upper layer, consisting of similar but older cells, which have been pushed upwards by the constant growth beneath of the new cells, and have become harder and flatter as they neared the surface (1). The dermis consists of a narrow upper layer of fibres in which the nerves of the skin are distributed, and a lower layer of fibrous tissue fibres, not well seen in the diagram, which intertwine so as to make a sort of a network.

The uppermost layer of the dermis (3) is called the *papillary layer*, because it is elevated into minute cone-shaped eminences, the *papillæ*, which contain the ends of nerve-fibres, and also one or more capillary loops. Where the sense of touch is weak, the papillæ are small, and comparatively few in number; where the sense is very acute,

they are both numerous and large, and in addition contain within them curious bodies, shaped something like a fir-cone, upon which the nerves end, in the manner shown in Fig. F of Plate XXI. These are the *tactile corpuscles*. This layer of the dermis, therefore, is the one which contains the *sense of touch*. The whole epidermic layer appears devoted merely to preserving the more sensitive parts beneath it from pain and injury; and the *secreting apparatus* must be looked for in the lower part of the dermis.

There we note first the **sebaceous, or oil glands** (8), which are found very sparingly in most parts of the skin, and are usually connected with the hair-ducts, or placed around the joints. Lower down, embedded in fat, are seen the coils of fine membrane which constitute the **sweat glands** (6), with their ducts running up to the surface of the skin, and opening upon the exterior (7). The membrane which is thus coiled round to form the gland is a true secreting membrane, being lined inside by cells; and each coil is surrounded by a network of capillaries, not shown in the diagram, from the blood within which the cells draw the secretion—the *sweat* or *perspiration*. There are calculated to be about three million sweat glands in the body. In the palm of the hand there have been ascertained to be as many as three thousand of these openings on a square inch of skin.

Sweat is constantly secreted by the glands, and evaporates from the skin insensibly; it is only when the quantity is increased beyond the ordinary amount that it forms drops, and that we become sensible of it. Perspiration, like the kidney and the lung excretions, contains, and passes out of the body, water, carbonic acid, and urea, and small quantities of various waste salts.

### The Nervous System.

We have already seen that various muscular movements of the body are executed at the command of the will; and we have just noted that the skin contains a provision for sensation. We are now naturally led to enquire into the mechanism of will and of sensation.

The **Nervous System** is composed of a multitude of fine cords, found in every part of the body—the **Nerves**; and of central parts to which those cords lead. The central portions are two—the **Cerebro-Spinal Nervous Centre**, which consists of the *brain* and the *spinal cord*; and the **Sympathetic Nervous Centre**, which is composed of two rows of lumps (called *ganglia*) of nervous matter, joined into chains by cords which run from one to another, and lying along each side of the backbone.

**Nerve-Matter**, of which both nerves and nerve-centres are composed, is a delicate soft tissue, of which there are two kinds—*grey* and *white*. The distinction in the office of these is not clearly made out; but the grey appears to be the more highly organised, inasmuch as in the brains of the most intellectual persons there appears to be a greater quantity of it than in those of less gifted ones; and, moreover, the grey is found only in the nerve-centres, while the white alone makes the nerves, and mingles with the grey in the centres.

Close microscopic examination shows that the grey matter is chiefly made up of *cells*, while the white matter is formed of *fibres*. The nerve cells have various shapes; very frequently they are star-shaped, sometimes they are oval. They always contain a nucleus. The nerve-fibres, the constituents of the white matter, separate soon after death into two parts; a white substance, supposed to be a fluid fatty matter, surrounding and protecting a delicate firm interior, which is believed to be the essential part of the nerve. This latter is called the *axis-cylinder*; and the fatty protection is the *white substance of Schwann*. The two parts are enclosed within a fine membrane, called the *tubular*

*sheath.* These three parts make up a nerve-fibre. Of course the nerves generally, like muscles, are composed of bundles of these primitive fibres. Fig. D, 2, of Plates XIX. XX. represents an appearance often seen in nerve-fibres, from the tendency of the white substance on the least pressure to run together, while the delicate tubular sheath sinks in.

The chemical analysis of nerve-matter shows that it is composed of water (85 parts in a hundred), albumen, fat, and salts. Phosphorus is the salt which is present in the largest quantity, there being about one part of it in a hundred parts of nerve-matter. Indeed, phosphorus appears to be distinctly connected with nervous action, since increased exercise of the brain adds to the quantity of waste phosphorus passed away by the kidneys.

The Sympathetic nervous system is of less importance than the cerebro-spinal. It must not be supposed that there is a complete distinction between the sympathetic and cerebro-spinal systems; on the contrary, some of the fibres which take their rise in the sympathetic ganglia running down on either side of the spine, pass into the spinal nerves, and are distributed with them; while, on the other hand, the sympathetic nerves generally contain some fibres supplied by the cerebro-spinal system. Notwithstanding this, however, the sympathetic nerves are broadly distinct from the others, and have their special office to perform. They control or influence the functions of the vital organs. These organs, as we have already seen, are quite outside the control of the will, and yet are governed by the nervous system; for they act when a certain stimulus is applied to them, and are quiescent when the stimulus is absent. This unconscious watchfulness is the work of the ganglionic centres. That they are to a considerable extent independent of the cerebro-spinal centre is shown by the fact that the organs supplied by them will continue their normal motion for some time after being severed from the body. The sympathetic nerves also send filaments to the coats of the blood-vessels, regulating the degree of their contraction, and so determining the blood-supply of any part.

The Cerebro-spinal System is by far the more important. It is composed of the Brain, which is the seat of Consciousness,—thought, emotion, sensation, and will; of the spinal cord, which controls and directs many of those motions which seem to be voluntary, but are half automatic; and of the nerves of sensation and of motion, which go to and from the various organs of the senses, the muscles, and the skin. We will briefly view the cerebro-spinal system in each of these parts.

## The Brain,

“The cloven sphere that holds  
All thought in its mysterious folds,  
That feels sensation's faintest thrill  
And flashes forth the sovereign will,”

is enclosed within the cavity of the skull. Plate XVIII. Fig. A, shows the brain in its natural position, but cut longitudinally, exactly through its centre. The great top mass (1, 2, 3) is the principal part of the brain, the *Cerebrum*. In the cerebrum the grey matter is external to the white, and is doubled up into a great number of folds, or *convolutions*, which are seen better in the next Plates, XIX. XX. Fig. A. The effect of this is to increase the surface of grey matter; and it is a noteworthy fact that as animals descend in the scale of intelligence their brains contain fewer and fewer convolutions, while men of exceptional ability have been found, by *post-mortem* examination, to possess brains remarkable for the numerous convolutions, and for the depth of the intervals between the folds, the *sulci*. The cerebrum is divided nearly into two halves by

a central longitudinal fissure; in Plate XVIII. A, the cut has been made through the direct centre, so that the knife has passed down the fissure without cutting into the convolutions. They can be seen cut through on Plate XXII. Fig. A. The bridge of white matter at the bottom of the fissure by which the two halves of the cerebrum are joined together is seen cut through (4, *corpus callosum*). Each half of the cerebrum is further marked off into three lobes, by fissures extending some distance down into its centre.

Beneath the cerebral lobes and the corpus callosum are various layers and masses of nerve substance, to each of which a distinct name has been given. The student who wishes to master these minute details must do so by referring from one to another of the following figures:—Plate XVIII. A; Plates XIX. XX. A; Plate XXII. A. In one of these figures the structures are shown in a longitudinal section, in another in a transverse and vertical section, and in the other the brain is exhibited as removed from the skull and turned upside down, without any dissecting away. By careful study, with the aid of the index, these three plates will serve to make the relationship of the parts quite clear.

The spinal cord is seen to run up into the brain, widening out at its upper end into (Plates XVIII. and XIX. XX. 12) a broad portion of nervous matter called the *medulla oblongata*. The medulla is about an inch and a quarter long. It contains a central cavity—it is hollow, to put the matter more simply—and that cavity is called the *fourth ventricle* of the brain. The medulla is divided by central grooves into two halves, and each half is again marked off into four columns; the one nearest the front being called the *anterior pyramid*, the next the *olive body*, the next the *retiform body*, and the one next to the back groove the *posterior pyramid* (Plates XIX. XX. A, 21).

Immediately above the medulla is the *pons Varolii*, or bridge of Varolius (11), so called because it connects together the medulla, the cerebellum, and the cerebrum. It contains both transverse and longitudinal fibres. The transverse fibres enter the pons from the cerebellum, from either side of which they sweep across the top of the medulla (XIX. XX. 11), and so form a bridge from the one to the other half of the cerebellum. The longitudinal fibres enter into the substance of the pons from the medulla itself; and from the pons those fibres go on their way to the cerebral hemispheres.

In front of and above the pons again appear two thick bundles of nervous fibres, the *crura cerebri*, which on close examination are seen to be the longitudinal fibres that have passed through the pons. These bundles spread out as they pass forwards (Plates XIX. XX., the dark diverging portion between the III. and IV. nerves), and then enter into the under part of the cerebral hemispheres, some distance below (as Plate XVIII. 10, shows) the level of the corpus callosum. The fibres pass through what are sometimes called the ganglia of the brain—two large masses of grey matter named respectively the *optic thalami* and the *corpora striata*.

The figure 9 in the plate just referred to is intended to indicate the narrow passage close to the left of which it is placed. That passage, the *aqueduct of Sylvius*, runs from the fourth ventricle in the medulla up to the much larger *third ventricle* in which the figure 5 is placed. This figure stands on one of the two masses of nervous matter into which the fibres from the crura cerebri first pass, and which are named the *optic thalami*. Of course the other optic thalamus has been cut off with the half of the brain which is entirely removed in this figure. When they are both in their natural position, however, there is a space between these two thalami, and that space is called the third ventricle. (Consult Plate XXII. A, 11.)

The plaited appearance just above the figure 5 is the



*choroid plexus*; while just beneath and in front of it is the *corpus striatum*, and below the curious little projection called the *pituitary body* (7).

The *fornice* (6) is a longitudinal portion of white matter, which forms the foundation, as it were, for the *corpus callosum*, and also, in part, serves as a floor for the largest of the ventricles of the brain—the *lateral ventricles*.

These spaces (the lateral ventricles) extend right into the cerebral hemispheres. A portion of one is seen in the figure before us—the triangular opening beneath the *corpus callosum*, and close beside the figure 6. The third ventricle opens by a narrow aperture at either end of its anterior bounding membrane into the lateral ventricles. Thus we see that all these spaces communicate with one another, just as, by the passing of fibres from one part to another, the whole brain substance communicates. In fact, no portion of the entire nervous system, of whatever structure or office, stands by itself; all the parts are joined into one great whole. The importance of this is seen at once when the office of the nervous system is understood.

Twelve pairs of nerves arise out of the brain at its base, and, passing out of the skull through foramina (windows) provided for the purpose (XIX. XX. C), go to various parts of the body. Their names and functions I have given in the index, and they need not all be repeated here. One or two points only must be remarked upon.

It will be seen that the nerves of smell (I) are the most intimately connected with the cerebral hemispheres. The next pair of nerves, the optic, arise back in the optic thalami, and pass forward in the direction shown in Plates XIX. XX. (being so far called the optic tract), until at (10) the fibres from each side meet and cross over. This junction is the *optic chiasma* or *commissure*. This remarkable crossing of the nerve fibres, doubtless, has something to do with our seeing only *one* object, though we look at a thing with *two* eyes. All the other nerves except these two arise, directly or indirectly, out of the medulla. The *spinal accessory* is the only one needing a word of special notice; it arises in a very remarkable manner (XI.) Its roots originate in the spinal cord, at the side of the spinal nerves, even as low down as the sixth cervical nerve (I<sub>1</sub>, II<sub>2</sub>, III<sub>3</sub>.) Passing upwards and joining, the fibres enter the skull, and emerge from it again by the same foramen as the pneumogastric (XIX. XX. C, X. XI.)

### The Cerebellum,

or little brain, lies at the back of the skull, completely overlung by the posterior lobes of the cerebrum, and itself partly overhanging the medulla, but extending also quite into the back of the skull behind the medulla. It, like the cerebrum, is divided by a deep fissure into two hemispheres. It is not convoluted, but is marked by numerous curved lines upon its outer surface. The grey matter is external to the white, as in the cerebrum; and the white is so curiously arranged within the grey as to give an appearance like a branching tree when the cerebellum is cut through (XVIII. 13). This arrangement is hence called the *arbor vitæ* (tree of life).

### The Spinal Cord,

which runs down from the brain through the centre of the vertebral column, contains both grey and white matter, but arranged in precisely the opposite manner from that of the cerebrum and cerebellum. In the cord the white matter is external, and the grey is inside arranged like two half-moons with their backs turned toward each other. A narrow canal, called the *central canal*, runs right through the centre of the cord, and is continuous with the fourth ventricle.

Thirty-one pairs of **Spinal Nerves** arise from the spinal cord (XIX. XX.—I. to XXXI.) by a number of delicate filaments down each half of the cord. These roots join into bundles, which coalesce into the trunk of a nerve. The nerve passes out of the backbone through a space left for it between the vertebræ (the intervertebral foramen), and passing onwards in its proper direction divides and subdivides into a multitude of fine filaments, which supply the skin and the muscles of every part of the body except those supplied by the cranial nerves.

**Protecting Membranes** cover both brain and spinal cord. The external one is close to the bone, and is called the *dura mater* (Plates XIX. XX. A, 15). The next beneath is a fine membrane, which is reflected on itself like the pleura and the pericardium; this is the arachnoid (16). Finally, a delicate membrane called the *pia mater* envelops the brain and cord closely (17).

### Functions of the Nervous System.

When the trunk of a nerve is cut or otherwise injured immediately after its issue from the spinal column, two results invariably are found to follow. The part to which the filaments of that nerve go, becomes *incapable of feeling, and cannot be moved by the will*. From this fact we learn that the nerves are simply like telegraph wires; they convey messages to and from the nervous centres, but they themselves, by themselves, have no more sensation or will than any other structure has. The nerves which convey the message of sensation from their terminations to the nerve centres, can be distinguished from those which carry the message of command for movement back to the place where the terminations are. The former are called *sensory*, the latter *motor* nerves.

Consciousness—under which general name we include sensation, will, emotion, and thought—resides in the cerebral hemispheres. This we know, firstly, because any injury which crushes the spine so as to disorganise it places all those parts which are supplied by nerves from below the seat of the injury outside the control of the will, and deprives them of sensation. Thus when the lower part of the spine is so injured that messages cannot pass along it from the nerves supplying the lower limbs, not only is the patient unable to move his legs and feet by his will, but also he does not feel if they are cut or burnt. Moreover, when the cerebral hemispheres are themselves injured, intelligence and volition are lessened or altogether lost.

The *cerebellum* appears to order the combined movements which we often perform, not quite automatically but also hardly consciously. Its functions, however, as well as those of the neighbouring parts of the brain, are very imperfectly understood at present.

**Nervous Force**, by which messages pass along the nerves, is, like most other similar existing facts of nature, ultimately a mystery. It is very likely somewhat related to electricity, but it is not the same thing, and rapidly though messages appear to fly from the peripheral terminations of the nerves to the centres and back again, yet nerve-force is found to be considerably less rapid in its movement than electricity.

### The Organs of Sense.

All the nerves, both cranial and spinal, terminate in innumerable spread-out fibres, which form what are termed the *peripheral extremities* of the nerves. The sensory nerves generally are so arranged that they receive impressions from the outer world, and the peculiar structures in which their peripheral extremities are found are called the *organs*

of the senses. Each sense has its own special organ. No differences, or at most very slight ones, can be discovered in the nerves of the various sense-organs; but the arrangements in the midst of which their terminations are placed are different in each organ, and no one sense-organ ever did the work proper and peculiar to another.

We will proceed briefly to study the sense-organs in the order in which they are figured upon the plates; by so doing we consider first the simpler structures of the nose, the tongue, and the skin, and reserve the very elaborate and interesting details of the ear and the eye for our final subject.

### The Organ of Smell.

The *ethmoid bone*, which is situated at the top of the nose between the two eyes, has its lower surface next to the nose perforated with a number of holes like a sieve. The bulbs of the olfactory nerve run on to the *cribriform plate*, as this piece of bone is called, and then divide up into tiny filaments, which penetrate through the holes into the nose (Plates XIX. XX. Fig. E, 7, 8). The filaments then spread out in a certain part of the mucous membrane which covers the internal cavities of the nose. In this mucous membrane also a German observer has lately discovered the peculiar rod-shaped filaments attached to cells which are figured below (Fig. J). The filaments of the olfactory nerve do not, however, extend through the whole of the mucous membrane. The fifth nerve also enters the nose (E. 9 and 15), and its filaments are distributed to the lower part of the nasal cavities.

The septum, which divides the nostrils below, is continuous through the nose up to its root at the brow. But, beside the two cavities thus made, the peculiar shape of the bones which form the sides of the nose (within the cheek, as it were) separates it into somewhat elaborate passages. These may be studied in section in Fig. H. The olfactory nerve, as Fig. E shows, only descends upon the uppermost two of the three *turbinated* scroll-shaped bones. The olfactory nerve distributes fibres also on each side of the septum.

Odoriferous particles float into the nasal chambers with the air, and, striking upon the termination of the olfactory nerve, excite it, and the excitement passing on through the olfactory lobes to the brain, there becomes recognised by consciousness as a sensation.

The shape of the nasal passages shows why a person sniffs up the air when he wishes to detect a faint odour. The back openings of the nose (posterior nares) have already been seen on Plate XVIII. A.—that large space between the Fig. 22 and the bone above, in which the No. 32 is placed. While the breath is drawn quietly it passes straight through the lower part of the nose, not much of it ascending to the upper cavity where the olfactory nerve is spread out. But a sniff is really a sudden inspiration through the nostrils: and when this inspiratory effort is made air is drawn out of the upper cavities into the lungs, and the fresh air from outside, laden with the odour, rushes in and fills the space thus left, as well as agitating the whole of the air there, and setting up a current like a wind on a small scale.

What is commonly meant by "the nose," that portion of it which is seen on the face, is shown in Figs. F and G to be composed of two small bones and of cartilage.

### The Organ of Taste.

The *Tongue* (like the skin) serves two purposes. Not only is the tongue the seat of the peripheral terminations of the nerves of taste, but it is also the principal organ of speech. It will be necessary to briefly consider it in each capacity.

Two nerves supply filaments to the tongue—the glosso-pharyngeal (9th), and a branch of the trigeminus (5th) named the *lingual* or *gustatory*. These nerves end in little eminences called papillæ, which are scattered over the surface of the tongue (Plate XXI. Fig. A). The papillæ are of three kinds. Fig. C shows diagrammatically each of these, with the nerve filaments entering and ending in them. The filiform papillæ (2) are most numerous at the tip of the tongue; farther back, the fungiform (1) and filiform are mingled; and the circumvallate (3), few in number, are arranged in the form of the letter V at the root of the tongue (A, 6).

A perfectly dry substance has no flavour at all; and since it is necessary for taste that a substance should be dissolved, it is found very difficult practically to experiment so as to discover in which part of the tongue the sensation resides, or which papillæ possess the most acute nerves. German physiologists have lately assigned the principal power to curious little bodies called *taste-goblets* or *gustatory bulbs* (Fig. D). These are found in the hollow around the V formed by the circumvallate papillæ, on those papillæ themselves, and also on the upper surface of the fungiform papillæ. It appears certain that they must perform some office in connection with the sense of taste. An eminent English physiologist (M. Foster) has, however, denied that they are the "specific organs of taste," and so the exact nature of their function must be considered as still uncertain.

*Speech* is articulate sound, and must not be confounded with *voice*. The organ by which voice is produced is figured on Plate XVIII. B, C, D, and E. It consists of a cartilaginous box, called the larynx, which is seated on the top of the windpipe, having the epiglottis above it. Across it, from back to front, run two fleshy bands, the *vocal cords*; they are affixed to the centre of the *thyroid cartilage* in front, and to the corners of the *arytenoid cartilages* behind. While the muscles connected with them (C) are quiescent, the two corners of the arytenoid cartilages are some little distance apart, and the vocal cords are necessarily also kept away from one another by this means. But by the contraction of various muscles, the tips of the arytenoid cartilages are brought together, so that the vocal cords lie straight beside each other, and are made tense. In this condition, the air breathed out over them causes them to vibrate, and give forth a sound, which varies in pitch according to the degree of their tension. This sound is *voice*.

Voice is made into speech by the conjoint action of the tongue and the lips, with the aid of the teeth and the hard palate. The tongue has much to do with this forming articulate sounds, but it is not absolutely essential to the production of many sounds, and persons whose tongues have been removed have been found to be able to make their speech understood.

The *Sense of Touch* has already been spoken of (p. 13) at sufficient length, and we may now proceed to the more complex

### Organ of Hearing.

Plate XXII. A, somewhat diagrammatic, shows the ear in its natural position: for the organ of hearing does not consist only, or even essentially, of that outside portion of it which is commonly called the ear. The essential parts of the organ, indeed, are set deep in the head, place for them being excavated in the petrous portion of the temporal bone, near the base of the skull.

The ear is divided into three parts: the *external ear*, the *middle ear* or *tympnum*, and the *internal ear* or *labyrinth*.

The external ear consists of the outside cartilage, which



serves merely as a sort of natural ear-trumpet, collecting sounds and aiding them to enter the ear; and of the passage which leads from the exterior to the membrane of the drum of the ear. In the *external auditory meatus* (14, 15) are several small glands which secrete the ear-wax.

At the bottom of the meatus a membrane (the *membrana tympani*, 16) is stretched tightly across, and encloses a cavity full of air (18) like a drum. The tympanic cavity is not wholly closed on the opposite side from the *membrana tympani*; a small passage, the *Eustachian tube*, runs up from the pharynx, and opens into the tympanic cavity, and through this air can enter.

Running across the cavity of the drum (as best seen on the left side in this figure) are three small bones, united together into a chain. They are shown about the natural size in the natural situation; but below (Fig. B) they are somewhat enlarged, and separated, in order that the curious shape of each may be seen. The first one (Fig. B, *a*) is attached to the middle of the *membrana tympani*; its shape is something like that of a hammer (*malleus*), after which it is therefore named. The next one (*incus*) is called the *anvil*. It has a depression at the top, into which the head of the hammer is inserted. The third little bone is exactly like a stirrup, and is thence named the *stapes*. Its top fits into one of the feet of the *anvil*, and its lower part, answering to the foot-plate of the stirrup, is fixed into a membrane which closes up an aperture in the opposite wall of the cavity (A, 20). Thus the tympanic cavity is completely bridged across by these tiny ossicles.

In the opposite wall from the membrane of the drum are two openings, each filled in with membrane, like a window with glass. One has already been mentioned as having the stirrup fastened to it: that is the oval window, or *fenestra ovalis*. The other is lower down (shown just to the right of the figure 19), and is round in shape; it is called the *fenestra rotunda*, or round window.

Past those windows, on the other side of the bone in which they are, is the *internal ear*, or *labyrinth*. The latter name has been given to it from the exceeding complexity of its detailed structure.

It is partly made of bone and partly of membrane; or, as it might be put, there are certain excavations made in the bone of the head, and membranous structures are found within those bony passages.

Fig. C shows the labyrinth laid open. It is divisible into three parts: on the one side the *semicircular canals* (9, 10, 11); on the other the *cochlea* (2, 3, 4); and a central part with which both the others communicate, the *vestibule* (5, 6, 7).

The *semicircular canals*, three in number, open into the vestibule by only five ends, two of them joining together, and so having one common aperture. Within them, in the natural state, lie *membranous* *semicircular canals*, which open into a membranous vestibule enclosed in the bony one. These membranous structures form closed bags. They are considerably smaller than the bone in which they lie, and are separated from it by a surrounding fluid (the *perilymph*), in which they float. The membranous canals and vestibule also contain a fluid inside them (the *endolymph*), in which are found minute particles of stone. The membranous canals, like the bony ones (Fig. C), widen out a little near their ends where they enter the vestibule; those expansions are called the *ampullæ*, and inside them are found cells, which have attached to their ends little stiff hair-like projections that stand out into the cavity of the ampullæ. A part of the nerve of hearing is spread out in a network in the midst of the cells of the ampullæ.

The *Cochlea* also consists of a bony portion and a membranous portion, but these are more intricate in arrangement. The cochlea receives its name from its general resemblance to a snail's shell. It consists, in the first place,

of a roundabout passage, excavated out of the hard bone of the head so as to turn upon itself (as a spiral staircase does) two and a half times (A, 19; C, 2, 3, 4). The exact middle of this excavated coil is occupied by a straight pillar of bone, which stops a little short of the very top of the coil, so as to leave above it a dome called the *cupola* (D, 8). The pillar itself is called the *modiolus*. It is not perfectly solid, but is channelled by numerous small passages through which the auditory nerve fibres pass (D, 7).

A thin plate of bone, the *lamina spiralis ossea*, twines around the modiolus, its twists corresponding to those of the sides of the cochlea. It is clear that if this bony spiral went right across from the modiolus in the centre to the side, each twist of the cochlea would be divided into two halves—one above and one below the *lamina spiralis*. But it does not go more than half-way across; then the bone ends, and two delicate membranes start from it, and continue across to the sides. These membranes diverge as they go, and are affixed to the outer bone at some distance (microscopically, of course) from one another, so that another passage is enclosed between them. Each turn of the cochlea is thus divided into three passages—one above the *lamina spiralis*, one beneath it, and the third enclosed within the membranes which arise from the edge of it. (Consult carefully D, 1, 2, 3.)

The space contained between the two membranes, being the centre one, is called the *scala media*. The passage beneath this communicates with the cavity of the drum by means of the round window (C, 1), and is therefore called the *scala tympani*. The passage above the *scala media* opens into the vestibule, and is therefore named the *scala vestibuli*.

In Fig. E we have a diagrammatic representation of a transverse section of the cochlea, and this merits careful study. 1 is the *scala tympani*, and above it, 5, is the *basilar membrane*, by which it is separated from 2, the *scala media*. 6 is the other of the two membranes which take their rise from 4, the *lamina spiralis*. It is named the *membrane of Reissner*, and it separates the *scala vestibuli*, 3, from the *scala media*.

The *lamina spiralis* is here (4) seen to be composed of two thin plates of bone, between which the auditory nerve's branches run to be finally distributed on the basilar membrane, and in close connection with those remarkable structures which are figured lying upon the basilar membrane. These elaborate and curious structures form *Corti's organ*. They are, of course, excessively minute; so minute, indeed, that their anatomy and physiology are still somewhat uncertain. The organ of Corti is bounded above by a delicate membrane (9), between which and the basilar membrane (5) are seen spherical cells (10, 13, 17); cells which bear along their tops a number of fine hair-like processes, and which are therefore called the *hair-cells* (15); and finally the curious rod-like bodies called the *fibres* or *rods of Corti*. These latter are club-shaped bodies, set up on end so as to lean against one another and leave a triangular space beneath them (11, 12). It is believed that filaments of the nerve project into the triangular space. The latest investigations, indeed, lead to the belief that the nerve ends in the hair-cells. In any case the terminal fibres of the nerve are certainly in close relation with the rods of Corti. There are an immense number of Corti's rods set all along the basilar membrane, from top to bottom of the length of the spiral coil, giving it an appearance like the key-board of a piano.

Such, leaving aside a few exceedingly minute details, is the structure of the organ of hearing. A few words will explain as much of the physiology of the sense as is at present clearly known.

**Sound** is the result of vibrations of the atmosphere striking upon the terminations of the auditory nerve in their

functional relationship with the special structure of the organ of hearing. Any body which gives forth a sound, does so by throwing the air which surrounds it into waves. Those waves are continued through the atmosphere, and for some distance remain strong enough to set the *membrana tympani* also in a state of vibration when they strike upon it. The vibration is continued across the tympanic cavity, partly through the air which it contains, and partly by means of the chain of little bones. The sound-wave is thus caused to strike upon both the round window and the oval window; through one of which it agitates the fluid in the semicircular canals, and so affects the nerve-fibres there distributed; through the other it reaches the *scala tympani*, and so directly strikes against the basilar membrane and throws the organ of Corti into vibrations, which affect the nerve-fibres that end there. The agitation is carried on through the nerve into the brain, and consciousness of the sound is produced.

The organ of Corti has been known for only a very few years. In an edition of one of the finest English works on Anatomy published only ten years ago, the membrane of Reissner and the basilar membrane are described as only one membrane, the *scala media* being unknown; and that single membrane which the author said extended from the edge of the *lamina spiralis* to the side of the cochlea was, he informed the reader, stated by one authority to be a muscle, and by another to be connective tissue! I mention this chiefly to try to convey some idea to the reader's mind of how very minute and delicate the wonderful structure of the organ of Corti is. This fact may explain how it is that we still do not know with any certainty what office its various structures perform. We know that we are capable of distinguishing an immense variety of notes and sounds. Even those of us most destitute of "a musical ear," as the power of recognising shades of tone is commonly called, yet know our friends by their voices, and are conscious of innumerable variations of sound. When we survey the structure of the organ of Corti, with its hundreds or even thousands of fibres set so regularly side by side, and gradually shortening from one end to the other, we are irresistibly compelled to infer that this must be the mechanism by which the waves of sound are made to vibrate into the brain as so many musical notes. But we do not really *know* at present that this is the case.

## The Organ of Sight.

The Eye, if not quite so complex in arrangement as the ear, is certainly equally wonderful. In it, again, we find an exceedingly thin and delicate membrane, proving under the microscope to contain elaborate structures, which are provided for the special excitement of the end fibres of the nerve; and we find also external to that, careful arrangements for bringing outside impressions against the structures just mentioned.

The eyeball is protected by being placed in the bony cavity of the skull called the *orbit*. The entire eyeball moves in the orbit, in all directions; and so many and delicate are the variations required in its movements, that six separate muscles are employed in the work (Plate XXIII. A, 2-7). The orbit is padded with fat; and the bone is pierced with several openings through which pass the nerves and blood-vessels.

Fig. B, the diagrammatic section of an eyeball, gives a general view of its structure on the one side, and shows the remarkable capillary plexus of the middle coat of the eyeball on the other side.

The external coat of the eyeball is a tough fibrous membrane behind, with a transparent glittering portion in front. The former (B, 1) is called the *sclerotic coat*. The

latter is the part which is seen in front of the eye, and is called commonly "the white of the eye;" its technical name is the *cornea* (B, 2). It will be noticed that the cornea is more convex than it would be if the eye were a perfect globe; it projects out as a watch-glass does from its case. The cornea is covered outside by a delicate membrane (17) called the *conjunctiva*, which is reflected over the *cycliids* and lines them internally.

Behind the cornea is a space called the *anterior chamber*, (6) which contains a white watery fluid called the *aqueous humour*.

The second coat of the eye comprises several important structures. Over the posterior four-fifths of the eyeball, this second coat, just under the sclerotic, consists of a membrane called the *choroid coat* (3), which contains a very great many blood-vessels (20), and is lined inside by a layer of dark pigment-cells. At the front of the eye, the choroid ends in the remarkable manner shown at 11 in this figure, and more enlarged and exact on the next plate, Fig. B. Near the point where the sclerotic merges in the cornea, the choroid coat ends by doubling up into a number of folds or plaits, which receive the name of the *ciliary processes*. The pigment-cells which cover these are continuous with those dark pigment-cells which cover the back of the *iris*, or coloured part of the eye (XXIV. B, 11). The *iris* (rainbow) is a muscular curtain with a hole, the *pupil*, in its centre; and being affixed to the front ends of the choroid, it may be described as the front part of the second coat of the eye. It is, however, also connected with the sclerotic and cornea by a band of muscular fibres (6), which runs right round the *iris*, arising, as shown, from the point of junction of the sclerotic and cornea, and passing backwards over the ciliary processes (to which it is affixed), and finally being fastened behind on the outer surface of the choroid coat. It is clear that when this *ciliary muscle* contracts, it will pull the choroid coat and ciliary processes forward towards the point of junction of the cornea and sclerotic. This would be the natural result of the shortening of the ciliary muscle, inasmuch as this would be more easily accomplished than would the dragging downwards of the cornea to which the other end of the muscle is fixed. The reason for this muscle's existence and action we will see presently.

The *posterior chamber* (7) is a small space, filled with the same aqueous fluid as the anterior chamber, and intervening between the back of the *iris* and the *crystalline lens*. The anterior and posterior chambers communicate through the *pupil*.

The *crystalline lens* (XXIII. B, 9) is a beautifully clear, transparent, hard body, like crystal. It is placed behind the *iris*, and is covered at its edges by the ciliary processes. The lens is doubly convex—*i.e.* is bowed outwards both before and behind. It is enclosed in an elastic and transparent membrane called the *capsule of the lens*, and is held in its place by a thin membrane called the *suspensory ligament*, which passes from the capsule to the inner side of the choroid, on to which it is affixed. It passes underneath the ciliary processes, and just as the ciliary muscle fits into their folds above, so the suspensory ligament fits into their folds below, the ligament having projections where the processes are depressed, and *vice versa*.

Now let us see what happens to all these structures when the ciliary muscle contracts. The lens is held constantly in a flatter state than its shape would be, by the tightness of its suspensory ligament. When the ciliary muscle contracts, it necessarily drags forward the edge of the choroid and the ciliary processes to which it is affixed. The suspensory ligament is also affixed to the same structures, and thus must be pulled forward by them; and its tension is necessarily slackened by this means. Immediately, the elasticity of the lens comes into play, and it bows more

outwards (becomes more convex). When the contraction of the ciliary muscle ceases, the suspensory ligament is carried back to its former position, and so again exercises pressure upon the lens and lessens its convexity.

This proceeding is the mechanism by which the eye accommodates itself to distances. It is known to be necessary, by the laws of optics, to have a more convex lens to throw the image of a *near* object upon the back of the eye, than is required to throw the image of a *distant* object upon the same spot. Thus, the nearer the object at which we wish to look, the more we contract the ciliary muscle; and conversely, the farther off the object is, the less the muscle needs to act.

Behind the lens is a great cavity, filled with a clear jelly-like matter, which is called the *vitreous humour* (10). It is enclosed in a very delicate membrane called the *hyaloid* membrane, represented here by the narrow yellow line against which the figure 14 is placed.

The vitreous humour supports and holds out the innermost coat of the eye, and the really essential part of the organ—the *retina*. To the naked eye, the retina is a thin delicate silvery membrane; and it is wonderful to learn from the microscope how elaborately constructed this fragile and thin membrane is.

The retina extends over the back and sides of the interior cavity of the eyeball, and ends, not far behind the ciliary muscle, by a jagged edge, having gradually diminished in thickness from behind to this point. Exactly at the back of the eye a slight depression is noticed in the retina (XXIII. A, 14). This is called the *macula lutea*, or *yellow spot*. A little more to the nasal side of the eyeball is the point at which the *optic nerve* pierces the external coats of the eye, and spreads out in fibres which form the internal layer of the retina.

Fig. C on Plate XXIII. shows the structure of the retina and the entrance of the optic nerve. The nerve is seen to enter (all the other structures of the retina disappearing at that exact spot) and immediately to spread out on either side to form a layer (*a*) of (7) the retina, and a very thick layer in comparison with all the others (*b* to *g*). The minute structure of the retina is best seen on the next Plate, XXIV. Fig. A. The various delicate structures which are seen to lie between the fibres of the optic nerve and the outermost layer (9) of the retina, are partly connective and partly nervous. The connective elements begin at 1, the anterior limiting membrane, and end at 8, the posterior limiting membrane; and they pass under and amidst the granular layers (4, 6), and the ganglionic corpuscles (3), supporting and bearing up these nervous structures. The outermost layer of the retina—that is to say the layer nearest the choroid—is seen to be outside these connective elements. This important and remarkable layer is, however, embedded at its tips in the pigment-cells already described as lining the choroid; and indeed it has

lately been claimed by some anatomists that the pigment-cells ought really to be described as belonging to the retina, because they are thus closely connected with it. The layer which meets the pigment cells (9, 10) is called the *layer of rods and cones*. It consists, as seen, of a number of rod-like and sugar-loaf-shaped bodies, from the ends of which nervous filaments pass forward into the outer layer of granules. The rods and cones are thicker and longer over the yellow spot than they are elsewhere; while, on the other hand, all the other layers of the retina become exceedingly thin there, and the fibres of the optic nerve do not pass over it at all. At the point of entrance of the optic nerve, on the contrary, as we have already seen, only the fibres of the nerve are to be found, all the other layers being absent. From this anatomical arrangement, we learn the remarkable physiological fact that the fibres of the optic nerve are absolutely blind, and that the rods and cones are the essential intermediaries between the impulse which can arouse the sense, and the nerve by which the sense is carried to the brain. To put it in another way—light cannot excite the optic nerve itself; but light excites the rods and cones, and they excite the end fibres of the nerve. We know this to be the case because when the reflection of an object falls into the eye so that, on optical principles, it falls on the yellow spot, vision is most perfect; while when the image is so thrown as to fall on the point of entrance of the nerve, no sensation of seeing is aroused in the brain.

The **Appendages of the Eye** are the eyebrows and lids, and the lachrymal apparatus. The eyelids are chiefly composed of cartilage, covered externally with skin and internally with the mucous membrane called the *conjunctiva*, before mentioned as being reflected from over the surface of the cornea. Along each eyelid runs a row of small glands, the *Meibomian glands* (Plate XXIV. D, 2; E, 3), which secrete a little fluid that prevents the adhesion of the lids to each other.

The *lachrymal glands* are lodged in depressions in the bone of the orbit, at the top of the eyeballs (Fig. D, 3). Each eye has one gland, which opens by six or seven little ducts on the interior of the upper eyelid. The tears are secreted by the lachrymal gland, and are generally only sufficient in quantity to moisten the conjunctiva, and enable the lids to move without pain or difficulty; after which the excess is passed through the canals (6, 7) into the lachrymal duct (9), down which it passes into the nose. Painful emotion has the very curious effect of so increasing the secretion of the lachrymal glands that it can no longer be all passed away through the duct, but overflows the eyelids in the drops called tears.

The upper eyelid is raised by the action of a special small muscle, the *levator palpebræ superioris*. The eyelids are closed by the action of a muscle called the *orbicularis*, the fibres of which pass circularly within the eyelid.





# INDEX TO THE PLATES.

## Plates I. and II.

### A. SKELETON—FRONT VIEW.

1. Frontal bone.
2. Parietal bone.
3. Temporal bone.
4. Superior maxillary.
5. Inferior maxillary.
6. Cervical vertebrae.
7. Humerus.
8. Radius.
9. Ulna.
10. Bones of the hand.
11. Clavicle.
12. Sternum, or breast bone.
13. Ensiform process; cartilaginous end of the breast-bone.
14. True ribs (which are fastened immediately on to the sternum).
15. False ribs (so called because attached only to a piece of cartilage, and by its means to the sternum).
16. Thoracic vertebrae.
17. Lumbar vertebrae.
18. Sacrum.
19. Ilium (part of the innominate bone).
- 19a. Ischium.
- 19b. Os pubis.
20. Femur.
21. Patella.

22. Tibia.
23. Fibula.
24. Bones of the foot.

### B. SKELETON, SEEN FROM BEHIND.

1. Occipital bone.
2. Parietal bones.
3. Temporal bone.
4. Malar bone.
5. Inferior maxillary.
6. Cervical vertebrae.
7. Thoracic vertebrae.
8. Lumbar vertebrae.
9. Sacrum.
10. Coccyx.
11. Clavicle.
12. Scapula.
13. True ribs.
14. False ribs.
15. Innominate bone.
16. Ischium.
17. Humerus.
18. Radius.
19. Ulna.
20. Bones of the hand.
21. Femur.
22. Tibia.
23. Fibula.
24. Bones of the foot.

## Plate III.

### A. SKULL, FROM IN FRONT.

1. Frontal bone.
2. Parietal bones.
3. Sphenoid bones.
4. Temporal bones.
5. Malar bones.
6. Nasal bones.
7. Nasal septum.
8. Superior maxillary, facial part.
9. Inferior maxillary.

### B. SKULL, FROM BELOW.

1. Superior maxillary, palatine, and alveolar processes.
2. Superior maxillary, facial surface.
3. Palate bones.
4. Sphenoid.
5. Vomer.
6. Temporal bones.
7. Temporal bone, petrous portion.
8. Occipital bone, basilar process.
9. Occipital bone, occipital part.
10. Foramen magnum, through which the spinal cord passes into the brain.
11. Posterior nares.
12. Temporal bone, styloid process.
13. Malar or cheek bones.
14. Parietal bones.
15. Condyles of occipital bone; for articulation with first cervical vertebra.

### C. THE TEETH.

- 1, 2. Incisors.
3. Canine.
- 4, 5. Bicuspid.
- 6, 7. Molars.

### 8. Wisdom tooth.

- a. Crown.
- b. Neck.
- c. Fang.

### D. SECTION THROUGH A TOOTH.

1. Dentine.
2. Enamel.
3. Pulp cavity with canal.
4. Cement.
5. Nerves and blood-vessels entering.
6. Jawbone.
7. Gum.

### E. SECTION OF BONE.

1. Haversian canals.
2. Lamellae, showing lacunae and canaliculi.

### F. FIRST CERVICAL VERTEBRA (ATLAS), FROM ABOVE AND BEHIND.

1. Anterior arch.
2. Posterior arch.
3. Transverse processes.
4. Articulating surfaces for odontoid process.
5. Articulating surfaces for occipital condyles.
6. Spinal canal.

### G. SECOND CERVICAL (AXIS), FROM IN FRONT.

1. Odontoid process.
2. Its articulating surface.
- 3, 4. Superior and inferior articulating surfaces.
5. Transverse process.

## Plate IV.

### A. MONGOLIAN SKULL, LATERAL ASPECT.

### C. NEGRO SKULL, LATERAL ASPECT.

### B. MONGOLIAN SKULL, ANTERIOR ASPECT.

### D. NEGRO SKULL, ANTERIOR ASPECT.

### E. PREHISTORIC CRANIUM FROM A BELGIAN CAVE.

## Plate V.

### A. HYOID BONE.

1. Body.
2. Greater cornua.
3. Lesser cornua.

### C. SKULL OF A VERY YOUNG CHILD.

1. Anterior fontanelle.
2. Posterior fontanelle.
3. Anterior lateral fontanelle.
4. Posterior lateral fontanelle.

### B. ATTACHMENTS OF MUSCLES AND CARTILAGES TO THE HYOID BONE.

1. Body of the hyoid bone.
2. Greater cornua, left.
3. Larynx.
4. Two sterno-hyoid muscles.
5. Thyro-hyoid muscles.
6. Hyo-glossus muscles.
7. Stylo-hyoid muscle.
8. Sterno-mastoid.

### D. SKULL OF A CHILD WITH THE MILK TEETH AND THE GERMS OF THE PERMANENT ONES.

1. Milk teeth, lower jaw.
2. Milk teeth, upper jaw.
3. Germs of permanent teeth.

### E. SKELETON OF GORILLA, TO COMPARE WITH THAT OF MAN.

## Plate VI.

### A. SKELETON OF RIGHT HAND—DORSAL SURFACE.

1. First row of phalanges.
2. Second row of phalanges.
3. Third row of phalanges.
4. Metacarpal bones.

#### CARPAL BONES—

5. Trapezium.
6. Trapezoid.
7. Os magnum.
8. Unciform.
9. Scaphoid.
10. Semilunar.
11. Cuneiform.
12. Pisiform.
13. Radius } Bones of the forearm.
14. Ulna }

### B. LIGAMENTS AND JOINTS OF THE 4TH AND 5TH FINGERS OF THE RIGHT HAND—PALMAR SURFACE.

1. First phalanx.
2. Second phalanx.
3. Third phalanx.
4. Metacarpal bones.
5. External lateral ligament.
6. Internal lateral ligament.
7. Capsular ligament.
8. Transverse metacarpal ligament.

### C. SKELETON OF RIGHT FOOT—PLANTAR SURFACE.

1. First phalanx.
2. Second phalanx.
3. Third phalanx.
4. Metatarsal bones.

#### TARSAL BONES—

5. Internal cuneiform.
6. Middle cuneiform.
7. External cuneiform.
8. Cuboid.
9. Scaphoid.
10. Astragalus.
11. Os calcis.

12. Sesamoid bones, external and internal.

### D. LIGAMENTS AND JOINTS OF THE 4TH AND 5TH TOES OF THE RIGHT FOOT—PLANTAR SURFACE.

1. First phalanx.
2. Second phalanx.
3. Third phalanx.
4. Metatarsal bones.
5. External lateral ligament.
6. Internal lateral ligament.
7. Transverse metatarsal ligament.

### E. PATELLA—POSTERIOR VIEW.

1. Apex.
2. Articular surfaces for the condyles of the femur.

### F. LIGAMENTS OF THE KNEE JOINT.

1. External condyle of the femur.
2. Internal condyle of the femur.
3. Tibia.
4. Patella, thrown downwards.
5. Insertion of the quadriceps extensor muscle (forming part of capsule of joint).
6. Ligaments, crucial and alar.
7. Lateral ligaments.

## Plates VII. and VIII.

## A. THE MUSCLES.

1. Facial muscles.
2. Sterno-cleido mastoid.
3. Trapezius.
4. Deltoid.
5. Pectoralis major.
6. Serratus magnus.
7. Latissimus dorsi.
8. Rectus abdominis.
9. Obliquus externus.
10. Gluteus maximus.
11. Rectus femoris.
12. Sartorius.
13. Vastus externus.
14. Tibialis anticus.
15. Extensor longus digitorum.
16. Soleus.
17. Gastrocnemius.
18. Flexor longus digitorum.
19. Muscles of the foot.
20. Triceps.
21. Biceps.
22. Brachialis anticus
23. Flexor digitorum profundus
24. Flexor pollicis longus
25. Extensor communis digitorum.
26. Extensors of the thumb.
27. Supinator longus.
28. Muscles of the back of the hand.

B\*. MUSCLES OF THE BACK.  
a-g—CERVICAL VERTEBRÆ.  
1-XII—DORSAL VERTEBRÆ.

1. Sterno-mastoid.
2. Splenius capitis.
3. Trapezius.
4. Levator anguli scapulae.
5. Latissimus dorsi.
6. Deltoid.
7. Rhomboideus major.
8. Infraspinatus.
9. Teres major.
10. Rhomboideus minor.
11. External intercostals.
12. Serratus posticus inferior.
13. Sacrolumbalis.
14. Longissimus dorsi.
15. Spinalis dorsi.
16. Supraspinatus.

\* To the right hand of the student the superficial layer of muscles is shown; to the left, some of the muscles of the lower layers are displayed by the laying back of part of the superficial layer.

## C. MUSCLES AND LIGAMENTS OF THE HAND—PALMAR SURFACE.

1. Oblique ligaments.
2. Cruciate ligaments.

3. Annular ligaments.
4. Anterior annular ligament of the wrist joint.
5. Flexor brevis minimi digiti.
6. Tendons of flexor sublimis digitorum.
7. Lumbricales.
8. Palmaris brevis.
9. Adductor pollicis.
10. Flexor brevis pollicis.
11. Opponens pollicis.
12. Abductor pollicis.
13. Flexor sublimis digitorum.
14. Pisiform bone.
15. Tendon of flexor longus pollicis.

## D. MUSCLES AND LIGAMENTS OF HAND—DORSAL SURFACE.

1. Extensor proprius minimi digiti.
2. Extensor communis digitorum.
3. Transverse ligament.
4. Interossei.
5. Abductor minimi digiti.
6. Extensor primi internodii pollicis.
7. Extensor secundi internodii pollicis.
8. Abductor pollicis.
9. Posterior annular ligament of wrist joint.
10. Radius.
11. Ulna.

## E. MUSCLES AND LIGAMENTS OF FOOT—DORSAL SURFACE.

1. Extensor longus digitorum.
2. Extensor brevis digitorum.
3. Extensor proprius pollicis.
4. Tibialis anticus.
5. Interossei.
6. Abductor pollicis.
7. Abductor minimi digiti.
8. Anterior annular ligament of ankle joint.

## F. MUSCLES AND LIGAMENTS OF FOOT—PLANTAR SURFACE.

1. Flexor brevis digitorum.
2. Flexor longus digitorum.
3. Flexor longus pollicis.
4. Abductor pollicis.
5. Abductor minimi digiti.
6. Interossei.
7. Lumbricales.
8. Tendon.
9. Os calcis.

## Plate IX.

## A. EXTERNAL MUSCLES OF THE HEAD.

1. Tendon of occipito-frontalis.
2. Frontal portion of occipito-frontalis.
3. Temporal.
4. Orbicularis palpebrarum.
5. Zygomaticus major.
6. Zygomaticus minor.
7. Levator labii superioris et alae nasi.
8. Compressor narium.
9. Buccinator.
10. Orbicularis oris.
11. Masseter.
12. Sterno-cleido-mastoid.
13. Trapezius.
14. Splenius capitis.
15. Levator labii superioris proprius.
16. Levator anguli oris.
17. Musculus risorius Santorini.
18. Depressor alae nasi.
19. Depressor anguli oris.
20. Depressor labii inferioris.
21. Levator menti.
22. Pyramidialis nasi.
23. { Fibres of orbicularis palpebræ covering upper and lower eyelids (Ciliaris Kiolani).
25. Attollens aurem.
26. Attrahens aurem.
27. Retrahens aurem.
28. Occipital portion of the occipito-frontalis.

## B. EXTERNAL MUSCLES OF THE HEART, FROM IN FRONT.

1. Muscle of right ventricle.
2. Muscle of left ventricle.

3. Muscle of right auricle.
4. Muscle of left auricle.
5. Common muscles of the two auricles.
6. Left auricular appendix.
7. Pulmonary veins.
8. Superior vena cava.
9. Inferior vena cava.
10. Pulmonary artery with conus arteriosus.

## C. STRIPED MUSCULAR FIBRES, WITH NERVES ENTERING. DIAGRAMMATIC.

1. Muscular fibre at rest.
2. Muscular striæ at moment of contraction.
3. Motor nerve.
4. Terminal plate of nerve.

5. Nerve nuclei.
6. Muscle nuclei.

## D. STRIPED MUSCULAR FIBRES, TREATED WITH WEAK ACIDS. MUCH ENLARGED.

1. Primitive fibrils.
2. Transverse striæ.
3. Longitudinal striæ.
4. Cell-nuclei.
5. Decomposition of muscular fibres into discs.

## E. SMOOTH MUSCULAR FIBRE. MUCH ENLARGED.

1. Incompletely formed.
2. Completely developed.

## Plate X.

## A. BLOOD-VESSELS OF FACE AND SCALP.

1. External carotid.
2. Internal carotid.
3. Posterior auricular.
4. Occipital artery.
5. Superficial temporal.
6. Anterior branch of same.
7. Posterior branch of same.
8. Internal maxillary.
9. Facial.
10. Submental.
11. Coronary arteries.
12. Angular artery.
13. Supra-orbital.
14. Facial vein.
15. Superficial temporal veins.
16. Superficial temporal.
17. Deep temporal.
18. External jugular.
19. Internal jugular.
20. Occipital vein.
21. Posterior external jugular.

## B. LONGITUDINAL SECTION OF HEART.

1. Left ventricle, with columnæ carneæ.
2. Mitral valve.
3. Left auricle.
4. Auricular appendix.
5. Pulmonary veins, injected with a blue preparation.

## C. TRANSVERSE SECTION THROUGH HEART.

1. Left ventricle.
2. Right ventricle.
3. Septum ventriculorum.

4. Wall of right ventricle.
5. Wall of left ventricle.
6. Coronary vessels and fat in anterior inter-ventricular grooves.
7. The same in posterior furrow.

## D. VALVE OF THE AORTA, WITH THE MITRAL VALVE OF THE LEFT VENTRICLE.

1. Septum between left auricle and ventricle, with the mitral valve.
2. Left ventricle.
3. Aorta.
4. Coronary artery.
5. Semilunar valves of aorta, consisting of three folds, each with a small nodule in centre of free edge.

## E. INTERNAL ASPECT OF A VEIN.

1. Direction of blood current.
2. Pouch-like valves to prevent regurgitation of blood.

## F. BLOOD-CORPUSCLES. MAGNIFIED.

1. Corpuscles, treated with water, perfectly circular.
2. Disc-shaped corpuscles.
3. Side view of the same.
4. Ordinary shape of the corpuscles.
5. Fibrin.
6. Dried blood-corpuscles.
7. Blood discs running together like rolls of coins.

## Plate XI.

## A. THORACIC VISCERA OF A CHILD.

1. Thyroid cartilage.
2. Cricoid cartilage.
3. Thyroid gland.
4. Trachea.
5. Thymus (well developed only up to second year of childhood, after that only a mere rudiment).
6. Bronchi.
7. Superior lobe of right lung.
8. Middle lobe of right lung.
9. Inferior lobe of right lung.
10. Superior lobe of left lung.
11. Inferior lobe of left lung.
12. Right ventricle.
13. Left ventricle.
14. Left auricle.
15. Left atricle.
16. Vena cava superior.
17. Vena cava inferior.
18. Pulmonary artery.
19. Pulmonary veins.
20. Aorta.

21. Branches of superior cava.
22. Diaphragm.
23. Thoracic duct.
24. Lymphatic vessels.

## B. TRANSVERSE AND DIAGONAL SECTION THROUGH THORAX, JUST ABOVE THE DIAPHRAGM.

1. Right lung.
2. Left lung.
3. Diaphragm.
4. Apex of heart (this peculiar arrangement of muscular fibres is called the *vortex*).
5. Pericardium.
6. Inferior vena cava.
7. Aorta.
8. Oesophagus.
9. Pneumogastric nerves or vagi.
10. Thoracic duct.
11. Sympathetic nerve.
12. Ninth thoracic vertebra with its ribs.



13. Eighth rib (*a*) and spine of eighth vertebra (*b*).
14. Seventh rib.
15. Sixth rib.
16. Fifth rib.
17. Latissimus dorsi.
18. Serratus magnus.
19. Trapezius.
20. Pectoralis major.

**C. TRANSVERSE SECTION THROUGH ABDOMEN, JUST BELOW THE DIAPHRAGM.**

1. Liver.
2. Vena portæ.
3. Inferior vena cava.
4. Aorta.

**Plates XII. and XIII.**

**A. TRACHEA, BRONCHI, AND BLOOD-VESSELS OF THE LUNGS. DIAGRAMMATIC.**

1. Larynx.
2. Trachea.
3. Bronchial branches in the right lung.
4. Superior vena cava.
5. Inferior vena cava.
6. Right auricle.
7. Right ventricle.
8. Left pulmonary artery.
9. Left pulmonary veins.
10. Left auricular appendix.
11. Left ventricle.
12. Aorta.

13. Right subclavian
  14. Right carotid.
- } arising from aorta by one trunk—the innominate.

15. Left carotid.
16. Left subclavian.
17. Liver.
18. Stomach.
19. Peritoneum.
20. Diaphragm.
- 21-27. True ribs.
- 28-29. Two false ribs.
30. Cartilage of true ribs.
31. Cartilage of false ribs.
32. Part of pleura.

**Plates XIV. and XV.**

**A. ABDOMINAL VISCERA.**

1. Diaphragm.
2. Œsophagus.
3. Stomach.
  - a.* cardiac orifice.
  - b.* fundus.
  - c.* pylorus.
4. Duodenum.
  - d.* entrance of common bile and pancreatic duct.
5. Remainder of small intestine drawn out.
  - e.* jejunum.
  - f.* ileum.
6. Large intestine in its natural position.
  - g.* cæcum.
  - h.* vermiform appendix.
  - i.* ascending colon.
  - k.* transverse colon.
  - l.* descending colon.
  - m.* sigmoid flexure.
  - n.* rectum.
7. Spleen.
8. Liver.
8. Liver (turned back).
  - o.* right lobe.
  - p.* quadrate lobe.
  - q.* left lobe.
  - r.* spigelian lobe.
  - s.* superior or anterior surface.
  - t.* ligaments.
  - v.* gall-bladder.
  - w.* ductus choledochus or bile-duct.
9. Pancreas.
10. Right kidney.
11. Left kidney.

5. Thoracic duct.
6. Stomach.
7. Spleen.
8. Suprarenal body.
9. Sympathetic nerve.
10. Diaphragm.
11. Eleventh thoracic vertebra and its rib.
12. Tenth rib (*a*) and spine of tenth vertebra (*b*).
13. Ninth rib.
14. Eighth rib.
15. Seventh rib.
16. Sixth rib.
17. Serratus muscle.
18. Latissimus dorsi.
19. Abdominal muscle.

**B. TERMINAL BRANCHES OF THE AIR PASSAGES WITH THE PULMONARY VESICLES. VERY GREATLY ENLARGED.**

1. Branches of the bronchi.
2. Pulmonary vesicles, or air-cells.

**C. TRANSVERSE SECTION OF PULMONARY VESICLES WITH VASCULAR NETWORK. DIAGRAMMATIC.**

1. Blood-vessel.
2. Its branches.
3. Vesicles cut across.

**D. PULMONARY VESICLE WITH ITS VASCULAR NETWORK. VERY MUCH ENLARGED.**

1. Septum between vesicles.
2. Looping capillaries.
3. Capillaries in which proceeds the exchange of carbonic acid for oxygen.
4. Cell-nuclei of matrix.

**B. MUSCULAR BANDS OF STOMACH—SEEN FROM THE EXTERIOR.**

1. Œsophagus.
2. Cardiac orifice.
3. Central part.
4. Cardiac end.
5. Lesser curvature.
6. Greater curvature.
7. Pylorus.
8. Duodenum.

**C. STOMACH AND DUODENUM, DIVIDED IN THE MIDDLE LINE.**

1. Cardiac orifice.
2. Pylorus.
3. Folds of mucous membrane.
4. Gastrophrenic omentum.
5. Gastrosplenic omentum.
6. Great omentum.
7. Small omentum.
8. Duodenum with folds.
9. Common bile duct. (Cut.)
10. Pancreatic duct. (Cut.)

**D. COMMUNICATION OF SMALL INTESTINE WITH THE LARGE ONE (VALVULA BAUHNI, OR ILEO-CÆCAL VALVE).**

1. Small intestine (ileum).
2. Cæcum.
3. Vermiform appendix.
4. Ascending colon.

**Plate XVI.**

**A. SECTION OF STOMACH-WALL. 3/4°.**

1. Longitudinal muscular fibres with cells.
2. Mucous-muscular layer.
3. Secreting glands (empty) cut across.
4. The same, full of secreting cells.
5. Secreting glands, surface of.
6. Orifices of glands on the inner surface of stomach, deprived of its mucous layer.

3. External circular layer.
4. Internal longitudinal layer.
5. Internal circular layer.
6. Mucous membrane.
7. Villi, covered with epithelium.
8. Blood-vessels branching in villi.
9. Lymph network of the mucous membrane.
10. Lymph vessels of villi.
11. Nerves.
12. Lieberkuhn's crypts.
13. A follicle or solitary gland.
14. Lymphatic vessel.

**B. DIAGRAM OF PART OF A LOBULE OF THE LIVER.**

- A. Hepatic duct, injected with yellow.
- B. Hepatic duct, not injected.
- C. Hepatic artery, cut.
- D. Portal vein.
- E. Interlobular branch of portal vein.
- F. Intra-lobular veinlet.
- H. Hepatic cells.

**E. DUODENUM AND PANCREAS.**

1. Apex of pancreas.
2. Head of pancreas.
3. Duct of pancreas.
4. Santorini's duct (seldom present).
5. Orifice of this duct.
6. Orifice of bile duct.

*Note.*—The pancreatic duct commonly joins with the bile duct just before opening into the intestine, and the two fluids enter the duodenum by the common tube.

**C. INNER SURFACE OF SMALL INTESTINE. 1/2°.**

1. Villi.
2. Elevations of the glands of Peyer (when standing singly = solitary glands; when in groups = Peyer's patches).
3. Lieberkuhn's crypts.

7. Longitudinal folds of duodenum.
8. Transverse folds.

**D. DIAGRAMMATIC SECTION THROUGH SMALL INTESTINE.**

1. Peritoneal covering.
2. External longitudinal layer.

**F. SHOWS THE TWO KINDS OF CAPILLARY VESSELS IN THE LIVER.**

1. Branches of portal vein.
2. Branches of hepatic vein.

**Plate XVII.**

**A. RIGHT KIDNEY AND SUPRA-RENAL BODY.**

**XII. Twelfth thoracic vertebra and last rib.**

**I. II. III. Lumbar vertebrae.**

1. Kidney, external edge.
2. Capsule.
3. Surrounding adipose tissue.
4. Supra-renal body.
5. Ureter.
6. Abdominal aorta.
7. Renal arteries.
8. Supra-renal arteries.
9. Vena cava inferior.
10. Renal veins.
11. Supra-renal veins.

4. Urniferous tubules, with dilated ends forming the capsules of the glomeruli.
5. Looped tubules (of Henle) running down in pyramids.
6. Contorted portion of tubules.
7. Straight tubules running down to form the pyramids and open on their apices.
8. Capsule.

**D. URINARY TUBULES, CONSIDERABLY ENLARGED.**

1. Renal arteriole.
2. Urinary tubule, surrounding a bundle of capillaries (a glomerulus), and showing renal venule leaving the capsule.
4. Commencement of a tubule, covered like the glomeruli with cells.

**B. LEFT KIDNEY, LONGITUDINAL SECTION.**

12. Calices.
13. Papillæ with openings of ducts.
14. Medulla; pyramids formed of the tubules.
15. Boundary of cortical and medullary portions.
16. Cortex with Malpighian bodies and commencement of urinary tubules.
17. Pelvis.

**C. STRUCTURE OF KIDNEY, SOMEWHAT DIAGRAMMATIC AND SIMPLIFIED.**

1. Branches of renal artery.
2. The glomeruli (Malpighian bodies).
3. Branches of renal vein.

**E. PAROTID GLAND, DISSECTED OUT, AND THE VESICLES SOMEWHAT MAGNIFIED.**

1. Parotid gland.
2. Accessory parotid, rarely present.
3. Steno's duct.
4. Its orifice in the mouth on the inner side of the buccinator muscle.
5. Gland vesicles.
6. Masseter muscle.
7. Buccinator muscle.
8. Sterno-mastoid muscle.
9. Trapezius muscle.
10. Facial nerve (VII.)

## Plate XVIII.

## A. LONGITUDINAL SECTION THROUGH MIDDLE OF HEAD AND NECK.

a.g. Cervical vertebrae.

I. II. III. Dorsal vertebrae.

## BRAIN.

1. Frontal lobe } of the
2. Parietal lobe } cerebrum.
3. Occipital lobe }
4. Corpus callosum.
5. Placed on one of the optic thalami which form the lateral boundaries of the third ventricle.
6. Fornix (which consists of white nerve matter).
7. Pituitary body.
8. Corpora albicantia.
9. Aqueduct of Sylvius.
10. Cerebral peduncles, or crura cerebri.
11. Pons varolii.
12. Medulla oblongata.
13. Arbor vitae.
14. Cerebellum.
15. Canal of spinal cord.
16. Openings for spinal nerves.

## NASAL CAVITY.

17. Nasal bone.
18. Superior turbinate bone.
19. Middle turbinate bone.
20. Inferior turbinate bone.

## ORAL CAVITY.

21. Hard palate.
22. Soft palate and uvula.
23. Inferior maxillary bone.
24. Median septum of tongue.
25. Lingualis muscle.
26. Genio-hyo-glossus muscle.
27. Genio-hyoid muscle.
28. Hyoid bone.
29. Frenum linguae.
30. Tonsil.

## PHARYNX AND LARYNX.

31. Back opening of nose.
32. Eustachian tube.
33. Epiglottis.
34. Rima glottidis.
35. Thyroid cartilage.
36. Arytenoid cartilage.
37. Cricoid cartilage.
38. Trachea.
39. Thyroid gland.
40. Pharynx.
41. Oesophagus.
42. Sternum.

## B. LARYNX—FROM IN FRONT.

1. Body of hyoid bone.
2. Greater cornua of hyoid bone.
3. Lesser cornua of hyoid bone.
4. Epiglottis.
5. Thyroid cartilage.
  - a. Superior cornu.
  - b. Inferior cornu.
6. Cricoid cartilage.
7. Tracheal rings.

## C. LARYNX—FROM ONE SIDE.

1. Left ala of thyroid.
  - a. Cornu.
  - b. Anterior edge with section of the right ala (removed).
2. Cricoid.
3. Right arytenoid.
4. Right cuneiform cartilage.
5. Right Santorini's cartilage.
6. Articulating surface of lower cornu of the right ala.
7. Tracheal cartilages.
8. Crico-thyroid muscle tensor of vocal cords (cut).
9. Thyro-epiglottic muscle (not usually described).
10. Ary-epiglottic.
11. Transverse and oblique arytenoid muscles, which approximate the vocal cords.
12. Posterior crico-arytenoid, and
13. Thyro-arytenoid do the same.
14. Lateral crico-arytenoid—opens the glottis by rotating the arytenoid cartilages.
15. Membrane of trachea.
16. Oesophagus.
17. Epiglottis.

## D. INTERNAL VIEW OF ANTERIOR HALF OF LARYNX—SEEN FROM BEHIND.

1. Root of tongue.
2. Epiglottis.
3. Prominence of thyroid.
4. False vocal cords.
5. True vocal cords.
6. Lower part of larynx.
7. Thyroid cartilage.
  - a. Right ala.
  - b. Left ala.
8. Cricoid cartilage.
9. Tracheal cartilage.
10. Ary-epiglottic muscle.
11. Thyro-arytenoid do.
12. Hyoid bone.

## E. LARYNX—FROM ABOVE.

1. Posterior wall of pharynx.
2. Pharyngeal cavity.
3. Ary-epiglottic fold, with
4. Santorini's (or cuneiform) and
5. Wrisberg's (or criciform) and
6. Rima glottidis.
7. False vocal cords.
8. True vocal cords.
9. Prominence of epiglottis.
10. Epiglottis.
11. Middle glosso-epiglottic ligament.
12. Root of tongue.

## F. SECTION THROUGH THE MUCOUS MEMBRANE OF A VOCAL CORD.

1. Surface of flat epithelium.
2. Fibrous framework.

## G. SECTION THROUGH MUCOUS MEMBRANE OF A FALSE VOCAL CORD.

1. Surface of ciliated epithelium.
2. Fibrous framework.

## Plates XIX. and XX.

## A. BRAIN.

## B. SPINAL CORD.

1. Right frontal lobe.
2. Left frontal lobe.
3. Right temporal lobe.
4. Left temporal lobe.
5. Right half of cerebellum.
6. Left half of cerebellum.
7. Pituitary body.
8. Tuber cinereum.
9. Corpora albicantia.

10. Optic chiasma (close by the entrance of internal carotid).
11. Pons Varolii. (Between III. and IV. are the crura cerebri.)
12. Medulla oblongata.
  - a. Pyramids.
  - b. Olivary bodies.
13. Vertebral arteries, entering the foramen of the sixth cervical vertebra, and uniting to form one trunk at the edge of the pons Varolii.

14. Spinal cord.
15. Dura mater, laid open at 15b.
16. Arachnoid.
17. Pia mater.
18. Caula equina.
19. Brachial plexus.
20. Sciatic and lumbar plexus.
21. Section of medulla at (a, b) (References as to 12.)
22. Section of cord between the fifth and sixth cervical vertebrae.
23. Section of cord between fifth and sixth dorsal vertebrae.
24. Section of cord between third and fourth lumbar vertebrae.
25. Section of the nerves.

## CRANIAL NERVES.

- I. Olfactory nerve and bulb.
  - II. Optic.
  - III. Oculo-motor (moving the eye).
  - IV. Trochlear (goes to the superior oblique muscle of the eye).
  - V. Trigeminal (so called because it arises by three roots; it supplies gustatory nerves to the tongue).
  - VI. Abducens (goes to the external rectus muscle of the eye).
  - VII. Facial.
  - VIII. Auditory.
  - IX. Glosso-pharyngeal (nerve of the tongue; also supplies the pharynx with motor fibres).
  - X. Vagus, or pneumogastric, sends filaments to heart, lungs, liver, and stomach.
  - XI. Spinal accessory; motor nerve of muscles of neck.
  - XII. Hypoglossal, motor nerves of the tongue.
- SPINAL NERVES.
- I.-VIII. Cervical nerves.
  - IX.-XX. Dorsal nerves.
  - XXI.-XXV. Lumbar nerves.
  - XXVI.-XXXI. Sacral nerves.

## C. BASE OF SKULL, WITH THE NERVES LEAVING IT, AND VENOUS SINUSES.

1. Anterior cerebral fossa, for frontal lobes.
2. Middle, fortemporo-sphenoidal.
3. Posterior, for cerebellum.
4. Venous sinuses.
5. Internal carotid.
  - I. Olfactory nerve.
  - II. Optic.
  - III. Oculo-motor.
  - IV. Trochlear.
  - V. Trigeminal.
  - VI. Abducens.
  - VII. Facial.
  - VIII. Auditory.
  - IX. Glosso-pharyngeal.
  - X. Vagus.
  - XI. Spinal accessory.
  - XII. Hypoglossal.
  - XIII. Spinal cord.

## D. NERVE FIBRES, MAGNIFIED.

## A. TONGUE—UPPER SURFACE.

1. Greater cornua of hyoid bone.
2. Epiglottis.
3. Root of tongue.
4. Mucous glands.
5. Foramen cecum.
6. Papillae circumvallatae.
7. Papillae filiformes.

## E. RIGHT NASAL CAVITY, WITH SEPTUM REMOVED. EXPANSION OF NASAL NERVE ON THE WALL OF THE RIGHT NOSTRIL.

1. Superior meatus, between the superior and middle turbinate bones.
2. Middle, between middle and inferior.
3. Inferior, between inferior and floor.
4. Orifice of antrum of Highmore.
5. Frontal lobes of brain.
6. Corpus callosum.
7. Olfactory bulb, spreading into filaments which pass through the ethmoid bone into the nasal cavities.
8. Branches of olfactory nerve in the mucous membrane.
9. Meckel's ganglion—connected by filaments with the second division of the trigemini (XXIV. C. II. 14) and the sympathetic.
10. Nerve for mucous membrane of pharynx.
11. For that of nose.
12. Posterior palatine.
13. Anterior palatine.
14. Nerve for incisor teeth.
15. Nasal branch of ophthalmic nerve, which is a part of the fifth cranial nerve (Plate XXIV. C. I. 4, 5).
16. Frontal sinuses.
17. Sphenoidal sinuses.

## F. CARTILAGES OF NOSE—SEEN FROM RIGHT SIDE.

1. Nasal bone.
2. Frontal bone.
3. Cartilaginous septum.
4. Triangular cartilages.
5. Alar cartilages.
6. Sesamoid cartilages.
7. Integument.
8. Naso-lachrymal duct (Plate XXIV. D. 9).

## G. CARTILAGES OF NOSE—SEEN FROM IN FRONT.

1. Nasal bone.
2. Frontal bone.
3. Cartilaginous septum.
4. Triangular cartilages.
5. Alar cartilages.
6. Sesamoid cartilages.
7. Superior maxillary.

## H. NASAL CAVITIES—IN SECTION.

1. Superior turbinate bone.
2. Middle turbinate bone.
3. Inferior turbinate bone.
4. Ethmoid cells.
5. Antrum of Highmore.
6. Superior } meatus.
7. Middle }
8. Inferior }
9. Septum.
10. Ethmoid bone, with apertures for olfactory nerve fibres.
11. Hard palate.
12. Soft palate.

## J. OLFACTORY CELLS.

## Plate XXI.

8. Papillae fungiformes.
9. Palato-glossus muscle.
10. Glosso-pharyngeal nerve.

## B. TONGUE—LOWER SURFACE.

1. Hyoid bone.
2. Hyoglossus muscle (depressor of tongue).

3. Genio-hyo-glossus, depressing and protruding.
4. Stylo-glossus, withdrawing the tongue.
5. Thyro-hyoid muscle.
6. Submaxillary gland.
7. Sublingual gland.
8. Wharton's duct.
9. Sublingual fossa.
10. Kuhn's gland.
11. Ranine artery.
12. Hypoglossal nerve.
13. Gustatory nerve (from the third branch of trigeminus (XXIV. C, III. 16)).
14. Glosso-pharyngeal nerve, Sensory, IXth cranial.
15. Frenum lingue, with a fold of mucous membrane on each side.

**C. VERTICAL LONGITUDINAL SECTION THROUGH THE END-ORGANS OF TASTE. DIAGRAMMATIC.**

1. Fungiform papilla.
2. Filiform papilla.
3. A circumvallate papilla.
4. Simple papilla (similar to those of the organ of touch).
5. Glands.
6. Gustatory bulbs, or taste goblets.
7. Glosso-pharyngeal nerve filaments.
8. Filaments of lingual or gustatory nerve (a branch originating in the fifth nerve).

**D. TASTE GOBLET WITH THE CELLS HIGHLY MAGNIFIED.**

1. Taste goblet in the wall of a circumvallate papilla, closed at top.
2. The same, open, with taste cells (nervous).
- 3-9. Various forms of taste cells.

**E. DIAGRAMMATIC SECTION OF HUMAN SKIN.**

1. Epidermis.
2. Rete Malpighi.
3. Papillæ with capillary loops.
4. Tactile corpuscles.
5. Nerve threads.

**Plate XXII.**

- A. DIAGRAMMATIC TRANSVERSE VERTICAL SECTION THROUGH THE HEAD.**
- |                          |             |                     |
|--------------------------|-------------|---------------------|
| 19. Cochlea.             | } labyrinth |                     |
| 20. Vestibule.           |             | } or inter-nal ear. |
| 21. Semicircular canals. |             |                     |
| 22. Auditory nerve.      |             |                     |
| 23. Eustachian tube.     |             |                     |

**a. THROUGH THE BRAIN between the anterior and middle thirds of the Corpus Callosum.**

1. Parietal lobes.
2. Temporal lobes.
3. Corpus callosum.
4. Fornix.
5. Corpus striatum.
6. Thalamus opticus.
7. Lenticular nuclei.
8. Claustrum.
9. Sylvian fissure, which separates the anterior and middle lobes of the cerebrum.
10. Lateral ventricle.
11. Third ventricle.
12. Pituitary body.

**ò. EAR.**

13. Pinna or outer ear.
14. External auditory meatus with hairs and ceruminous glands.
15. Osseous portion of same.
16. Membrana tympani.
17. Auditory ossicles, malleus, incus, and stapes.
18. Middle ear or tympanic cavity.

**c. ORAL CAVITY.**

24. Soft palate.
25. Uvula.
26. Arches enclosing entrance.
27. Tonsils.
28. Section of tongue.
29. Parotid gland.
30. Submaxillary gland.
31. Sublingual gland.

**B. AUDITORY OSSICLES—MAGNIFIED.**

- a. MALLEUS.**
1. Head.
  2. Neck.
  3. Handle.
  4. Long process.
  5. Short process.

**ò. INCUS.**

1. Short process.
2. Long process.
3. Body.
4. Orbicular bone.

- c. STAPES.**
1. Head.
  2. Legs.
  3. Footplate.

**C. LABYRINTH—OPENED. ½°.**

1. Fenestra rotunda.
2. Scala tympani.
3. Scala vestibuli (the figure is placed on the lamina spiralis).
4. Cupola.
5. Vestibule.
6. Fovea hemi-spherica.
7. Fovea hemi-elliptica.
9. Superior semicircular canal.
10. Inferior semicircular canal.
11. Exterior semicircular canal.

**D. COCHLEA—OPENED. ¼°.**

1. Scala tympani.
2. Scala media.
3. Scala vestibuli.

4. Lamina spiralis ossea.
5. Membrana basilaris.
6. Reissner's membrane.
7. Nerve of the cochlea.
8. Cupola.

**E. CORTI'S ORGAN. DIAGRAMMATIC.**

1. Scala tympani.
2. Scala media.
3. Scala vestibuli.
4. Lamina spiralis ossea.
5. Basilar membrane.
6. Reissner's membrane.
7. Cochlear nerve.
8. Zona denticulata.
9. Corti's membrane.
10. Spherical cells.
11. Inner row of Corti's rods.
12. External row of Corti's rods.
13. Interanglion cells—hair cells.
14. Membrana reticulata.
15. Corti's hair cells.
16. Deiter's supporting cells.
17. Cells of Claudius.
18. Ligamentum spirale.

**Plate XXIII.**

**A. THE TWO EYES FROM ABOVE, WITH THEIR VESSELS AND MUSCLES.**

1. Optic chiasma.
2. Rectus superior muscle.
3. Rectus inferior muscle.
4. Rectus externus muscle.
5. Rectus internus muscle.
6. Superior oblique muscle.
7. Inferior oblique muscle.
8. Lachrymal gland.
9. Section of eyelid.
10. Internal view of eyelid.
11. Ophthalmic artery.
12. Lachrymal artery.
13. Arteria centralis retinae.
14. Ciliary arteries.
15. Supra-orbital arteries.
16. Frontal arteries.
17. Ethmoidal arteries—anterior and posterior.

8. Pupil.
9. Crystalline lens.
10. Vitreous body.
11. Ciliary muscle.
12. Canal of Petit.
13. Optic nerve.
14. Macula lutea.
15. Internal and external sheaths of optic nerve.
16. Tenon's fascia.
17. Conjunctiva.
18. Descemet's membrane.
19. Canal of Schlemm.
20. Tonica Ruysschiana (or middle vascular layer of the choroid).
21. External rectus.

**C. SECTION THROUGH THE ENTRANCE OF THE OPTIC NERVE. ¼°.**

1. Optic nerve.
2. Arteria centralis retinae.
3. Edges of the optic disc.
4. Sheath.
5. Sclerotic.
6. Choroid.
7. Retina.

**B. TRANSVERSE SECTION OF AN EYE. LEFT SIDE SHOWING VESSELS; RIGHT, RELATIVE THICKNESS OF THE LAYERS. DIAGRAMMATIC.**

1. Sclerotic.
2. Cornea.
3. Choroid.
4. Iris.
5. Retina.
6. Anterior chamber.
7. Posterior chamber.

- a. Nerve fibre layer.
- b. Ganglionic layer.
- c. Internal granular layer.
- d. Internal nuclear layer.
- e. External granular layer.
- f. External nuclear layer.
- g. Layer of rods and cones.

**Plate XXIV.**

**A. LAYERS OF THE RETINA—VERY GREATLY ENLARGED.**

1. Internal limiting membrane.
2. Nerve fibre layer.
3. Ganglion cell layer.
4. Internal granular layer.
5. Internal nuclear layer.
6. External granular layer.
7. External nuclear layer.
8. External limiting membrane.
9. Rods and cones.
10. Pigment layer (generally described as the internal layer of the choroid coat).

4. Vitreous body.
5. Corpus ciliare.
6. Ciliary muscle.
7. Fontana's spaces.
8. Schlemm's canal.
9. Sclerotic.
10. Cornea.
11. Iris.
12. Conjunctiva.
13. Epithelium.

**C. NERVUS TRIGEMINUS AND ITS MOST IMPORTANT BRANCHES.**

- I. FIRST BRANCH (Sensory).**
1. Frontal.
  2. Supra-orbital.
  3. Lachrymal.
  4. Infraorbicular.
  5. Nasal.

**B. SECTION THROUGH THE JUNCTION OF THE CORNEA AND SCLEROTIC. 45°.**

1. Anterior chamber.
2. Posterior chamber.
3. Lens.



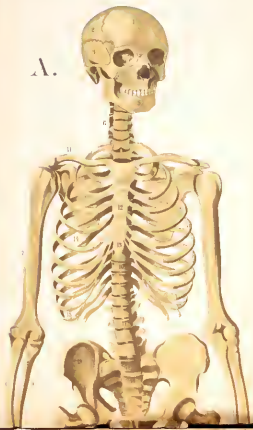- II. SECOND BRANCH (Sensory).  
 6. Temporo-malar.  
 7. Buccal.  
 8. Infraorbital.  
 9. Nasal, and to upper lip.  
 10. Superior anterior dental.  
 11. Reichdaleh's ganglion.  
 12. Posterior dental.  
 13. Nerve to wisdom tooth.  
 14. Meckel's ganglion.
111. Chiefly MOTOR NERVES for Muscles of Mastication and
- for the Articulation of the lower Jaw. The following are mainly sensory:—  
 16. Lingual or gustatory.  
 17. Submaxillary ganglion.  
 18. Nerves for teeth of lower jaw.  
 19. Inferior mental.  
 20. Labial.  
 21. Nerve for the external rectus muscle (IV. cranial).  
 22. Ciliary ganglion.  
 23. Optic nerve (II. cranial).
- D. PROTECTIVE STRUCTURES OF THE EYE AND THE LACRYMAL APPARATUS SOMEWHAT ENLARGED.  
 1. Upper eyelid, with eyelashes.  
 2. Lower eyelid (skin and muscle removed to show the Meibomian glands and their openings on the edge of the lids).  
 3. Lachrymal glands with their ducts.  
 4. Plica semilunaris.  
 5. Caruncula lachrymalis.  
 6, 7. Canaliculi with the puncta lachrymalia.
8. Lachrymal sac.  
 9. Lachrymal duct.
- E. VERTICAL SECTION THROUGH THE UPPER EYE-LID—ENLARGED.  
 1. Levator palpebre superioris muscle.  
 2. Fat tissue, with smooth muscular fibres.  
 3. Meibomian glands.  
 4. Conjunctiva.  
 5. Sudoriparous glands of the corium (external skin).  
 6. Hairs of the corium.  
 7. Sebaceous glands of the corium.

## INDEX TO THE LETTERPRESS.

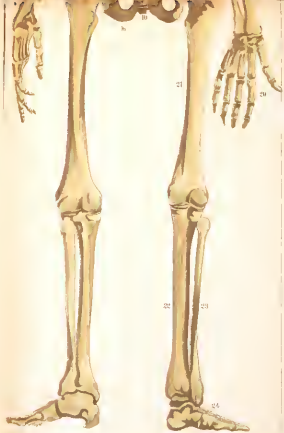
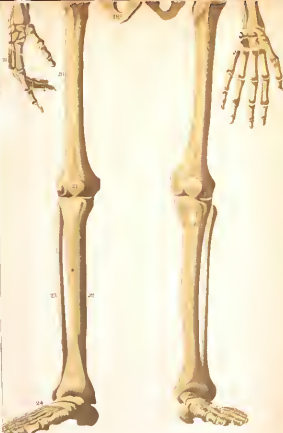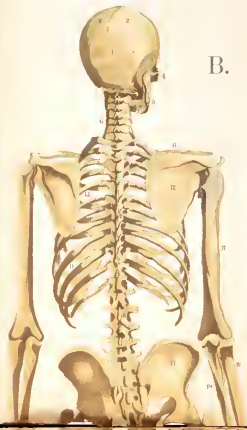- ADIPOSE TISSUE, 1.  
 Amoeba, 2.  
 Anatomy, 3.  
 Aorta, 6, 12.  
 Arteries, 5, 6, 12, 17.  
 Auricles, 5, 7.  
 Axis and atlas, 3.  
 Axis-cylinder, 13.
- BASILAR MEMBRANE, 17.  
 Bile, 11.  
 Blood, 7.  
 circulation of, 6.  
 vessels, 5.  
 Bones, 2-3, 16, 17.  
 Brain, 13-14.  
 Breathing, 8.  
 Bronchial tubes, 3.
- CANALICULI, 2.  
 Capillaries, 6.  
 Carbon, 1, 8.  
 Carbonic acid gas, 8.  
 Cartilage, 2, 3.  
 Centres of ossification, 3.  
 Cells, 2, 11, 13.  
 Cerebrum, 14.  
 Cerebellum, 15.  
 Chordæ tendinæ, 5.  
 Ciliary processes, 18.  
 Cochlea, 17.  
 Connective tissue, 2.  
 Conjunctiva, 18, 19.  
 Colon, 10.  
 Cecum, 10.  
 Cornea, 18.  
 Corpuscles, blood, 7.  
 nerve, 13.  
 Crystalline lens, 18.
- DIAPHRAGM, 8.  
 Digestion, 9.  
 Diostlenum, 10.
- EAR, 16-18.  
 Elastic tissue, 9.
- Endocardium, 5.  
 Epiphyses, 3.  
 Epithelium, 2, 12.  
 Eustachian tube, 16.  
 Excretion, 11.  
 Expiration, 8.  
 Eye, 18.
- FENESTRE OF EAR, 17, 18.  
 Fibres, muscle, 4.  
 nerve, 13.  
 Fibrin, 7.  
 Fontanelles, 3.  
 Force, vital, 1, 8.  
 Fornix, 14.
- GANGLIA, 13.  
 Gastric juice, 10.  
 Gelatine, 3.  
 Glands, 9, 10, 12, 13, 19.  
 Gustatory bulbs, 16.
- HAVERSIAN CANALS, 2.  
 Heart, 5.  
 Heart, animal, 8.  
 Hepatic duct, etc., 11.  
 Hydrochloric acid, 10.  
 Hydrogen, 1, 8.
- ILEUM, 10.  
 Intestines, 10.  
 Inspiration, 8.  
 Iris, 18.
- JEJUNUM, 10.  
 Joints, 3.
- KIDNEYS, 12.
- LACRYMAL GLANDS, 19.  
 Lacteals, 10.  
 Lacunæ, 2.  
 Ligaments, 3.
- Liver, 11.  
 Lungs, 7.  
 Lymphatics, 10.
- MEDULLA OBLONGATA, 14.  
 Membrane, 2, 7, 9.  
 Mesentery, 11.  
 Microscope, 1.  
 Muscles, 3-4, 9, 19.
- NERVOUS SYSTEM, 13-15.  
 force, 15.  
 Nerve-matter, 13.  
 Nerves, cranial, 15, 16, 17, 19.  
 spinal, 15.  
 sympathetic, 14.  
 Nucleus, 2.  
 Nitrogen, 1, 9.  
 Nose, 16.
- ODONTOID PROCESS, 3.  
 (Esophagus, 9.  
 Omenta, 9.  
 Optic thalami, 14.  
 chiasma, 15.  
 Oxygen, 1, 8.
- PANCREAS, 11.  
 Papillæ of skin, 13.  
 tongue, 16.
- Pelvis, 13.  
 Pepsin, 10.  
 Pericardium, 5.  
 Peritoneum, 9.  
 Peripheries of nerves, 15.  
 Perspiration, 13.  
 Peyer's patches, 10.  
 Physiology, 1.  
 Plasma, 7.  
 Pleuræ, 7.  
 Protoplasm, 1.  
 Pylorus, 10.
- RECTUM, 10.  
 Reissner's membrane, 17, 18.
- Respiration, 8.  
 Retina, 19.  
 Rods and cones, 19.
- SCALE OF COCHLEA, 17.  
 Sclerotic, 18.  
 Semicircular canals, 17.  
 Skeleton, 2.  
 Skin, 13.  
 Skull, 3.  
 Smell (sense of), 16.  
 Sound, 17.  
 Spleen, 13.  
 Spine, 2, 3.  
 Spinal cord, 13, 15.  
 Stimulus, 5.  
 Stomach, 9.  
 Sympathetic nerves, 14.
- TASTE (sense of), 16.  
 Teeth, 9.  
 Tendons, 4.  
 Tissues (elementary), 2.  
 Trachea, 8.  
 Thoracic duct, 10.  
 Thymus, 13.  
 Thyroid gland, 13.  
 cartilage, 16.
- UREA, 12.  
 Ureters, 13.
- VALVES OF HEART, 5, 7.  
 veins, 5.  
 Vascularity, 2.  
 Veins, 6, 11, 12.  
 Ventricles, 5, 7.  
 Vertebrae, 2, 15.  
 Villi, 10.  
 Vital force, 1.  
 Vitreous humour, 18.  
 Voice, 16.
- WINDPIPE, 8.



A.

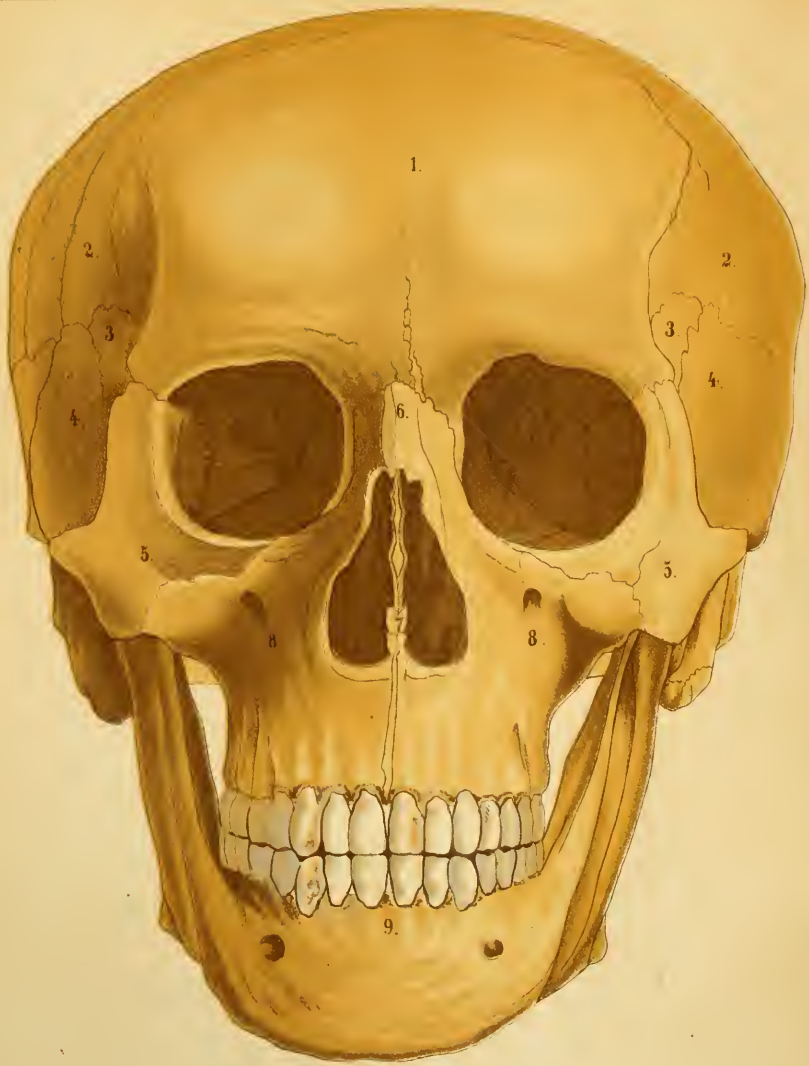

B.

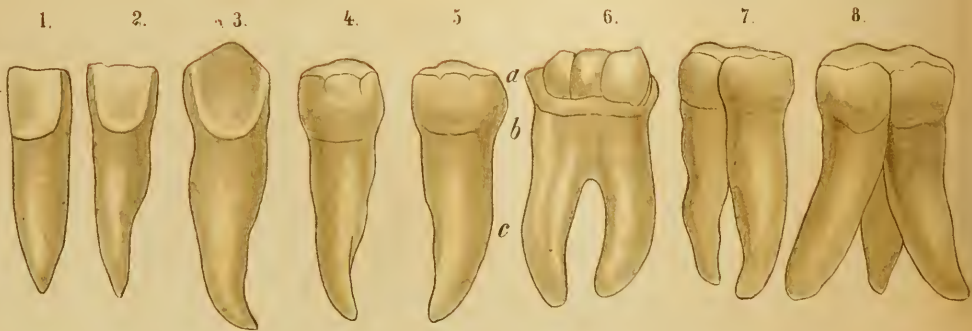




A.

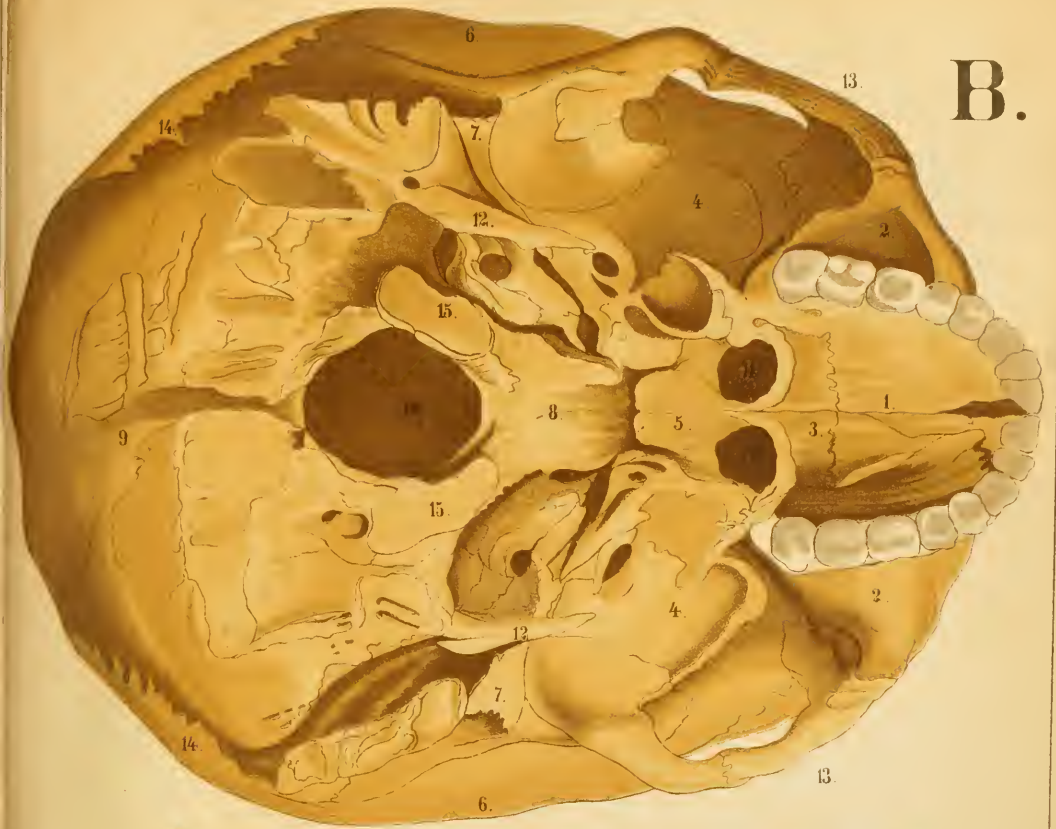

C.

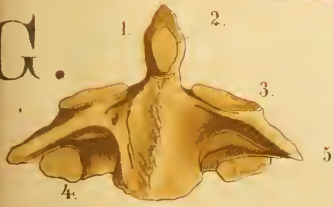




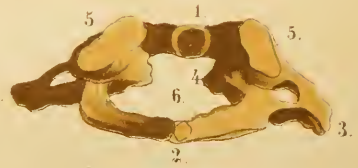B.



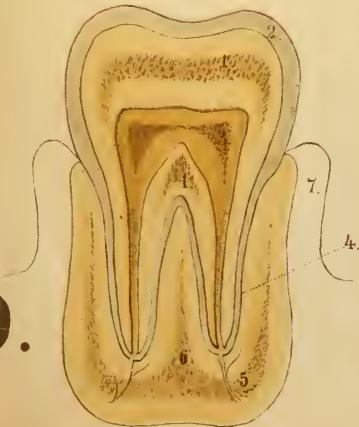
G.



F.



D.



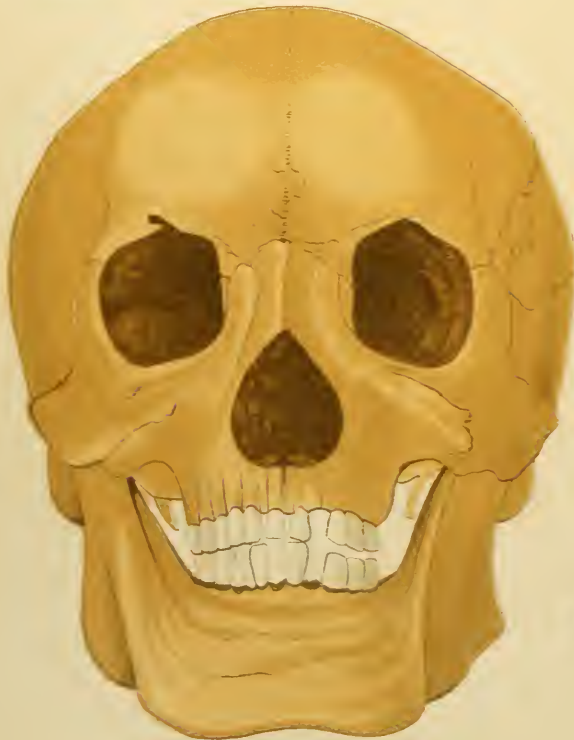
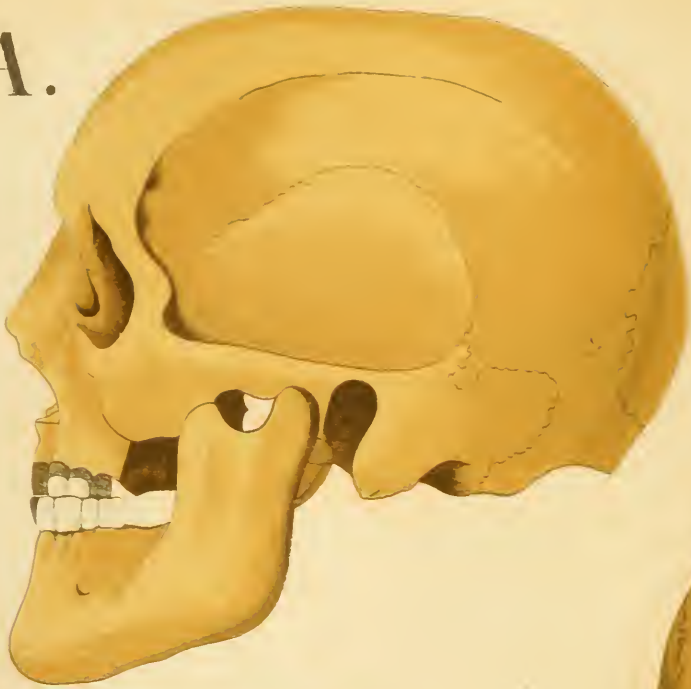
E.





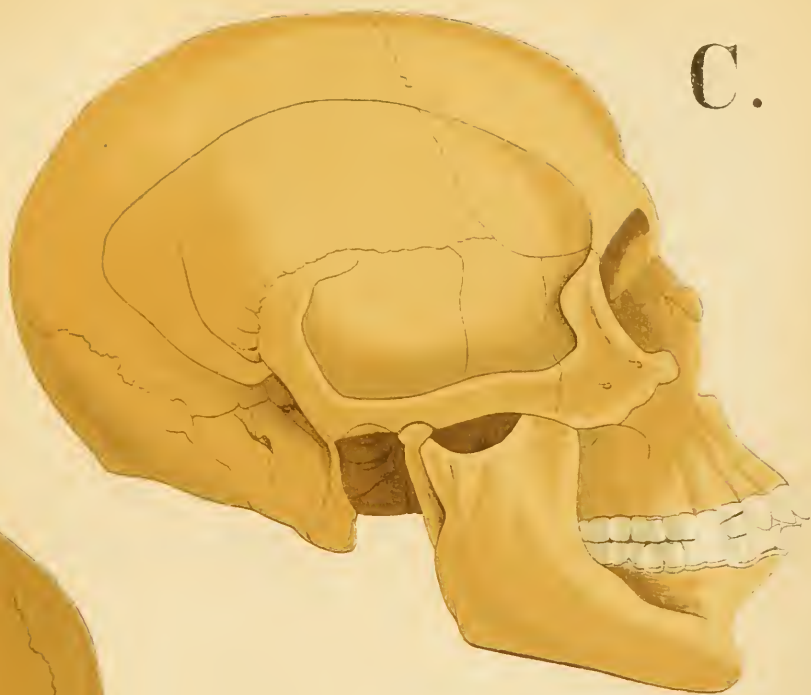


A.

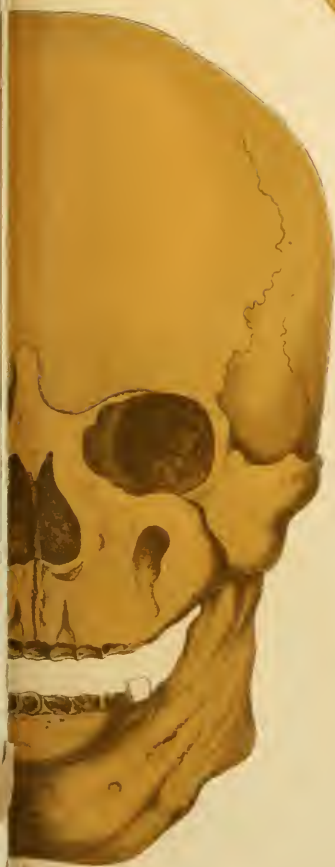

B.

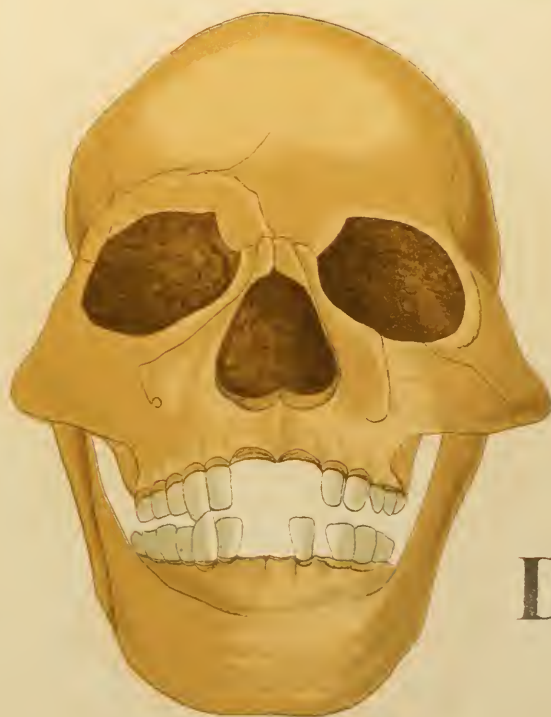C.



E.



D.

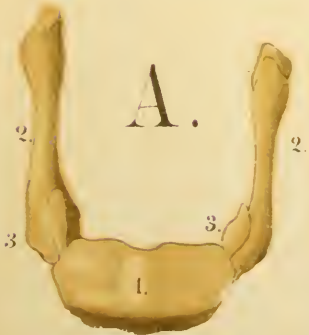
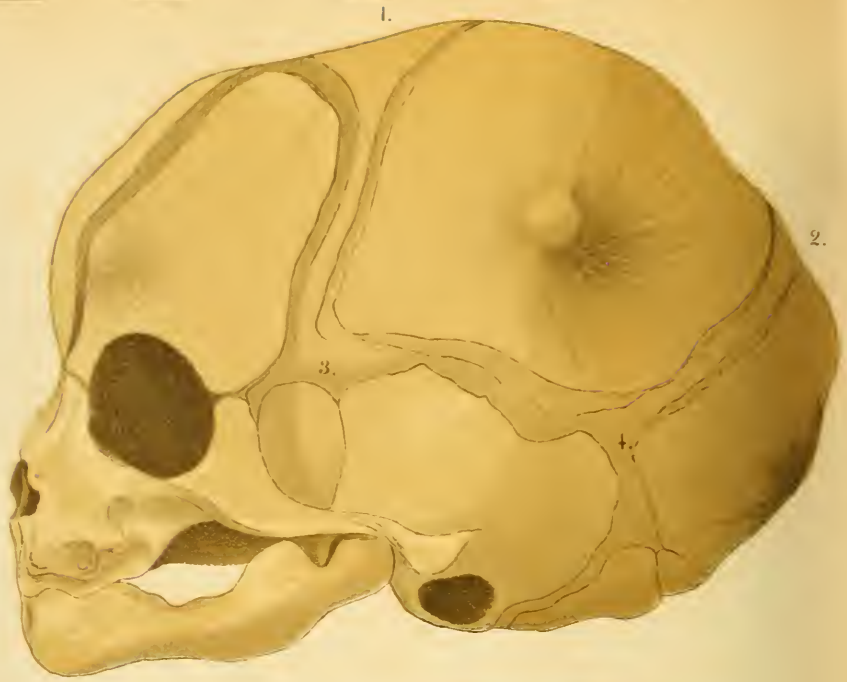





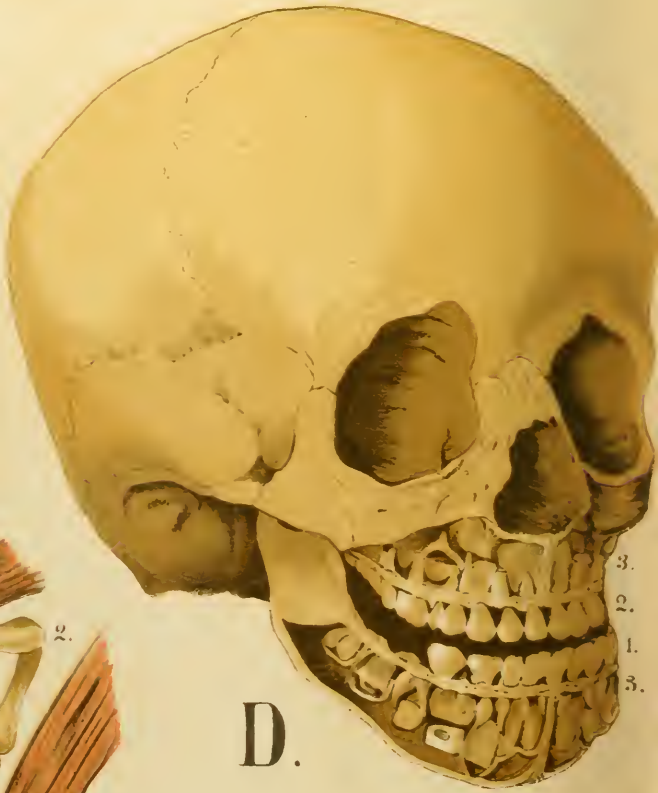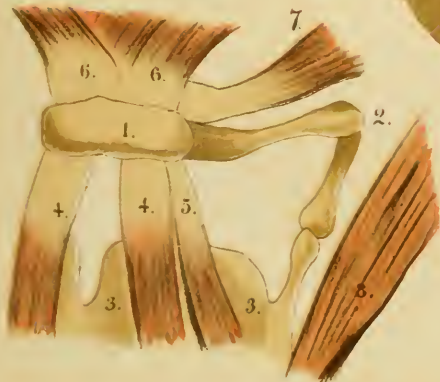


C.



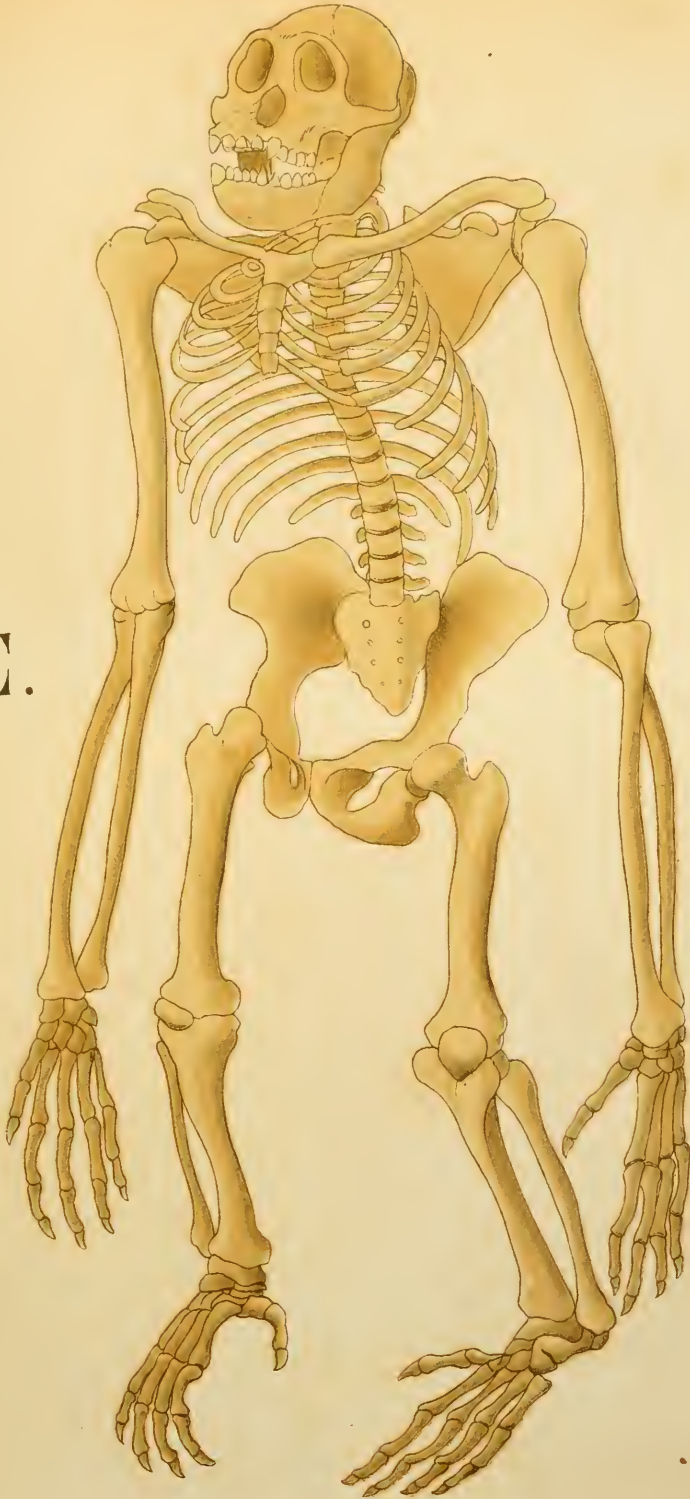
A.

B.



D.

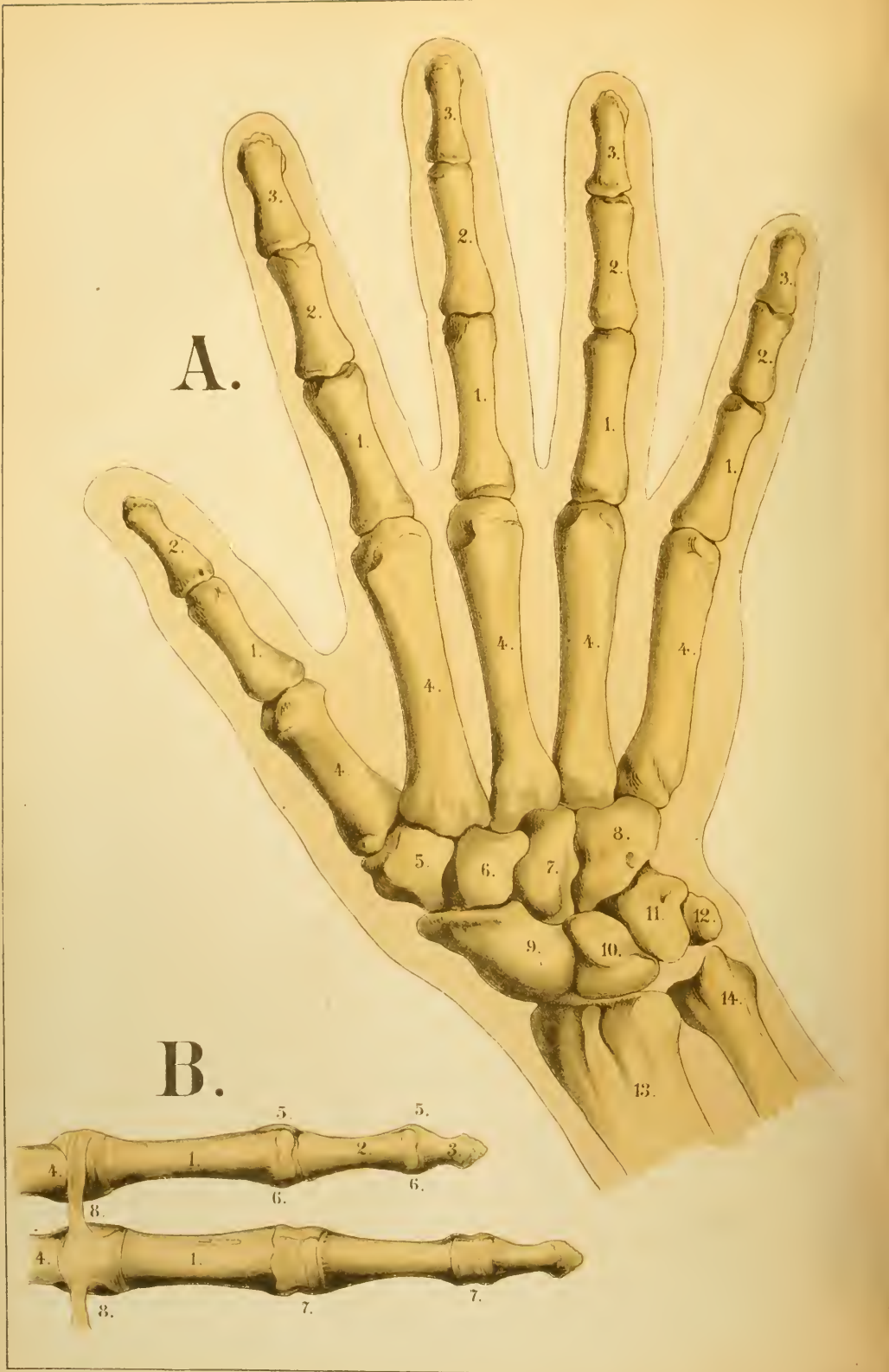E.

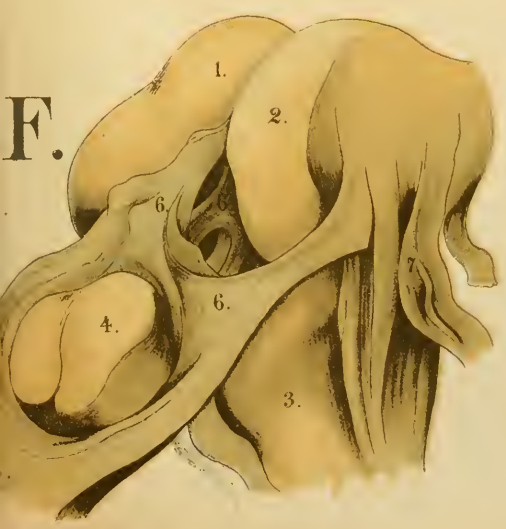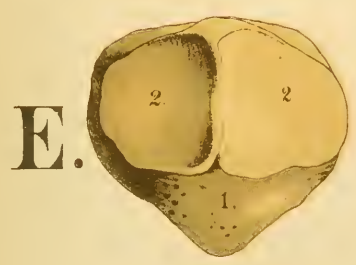
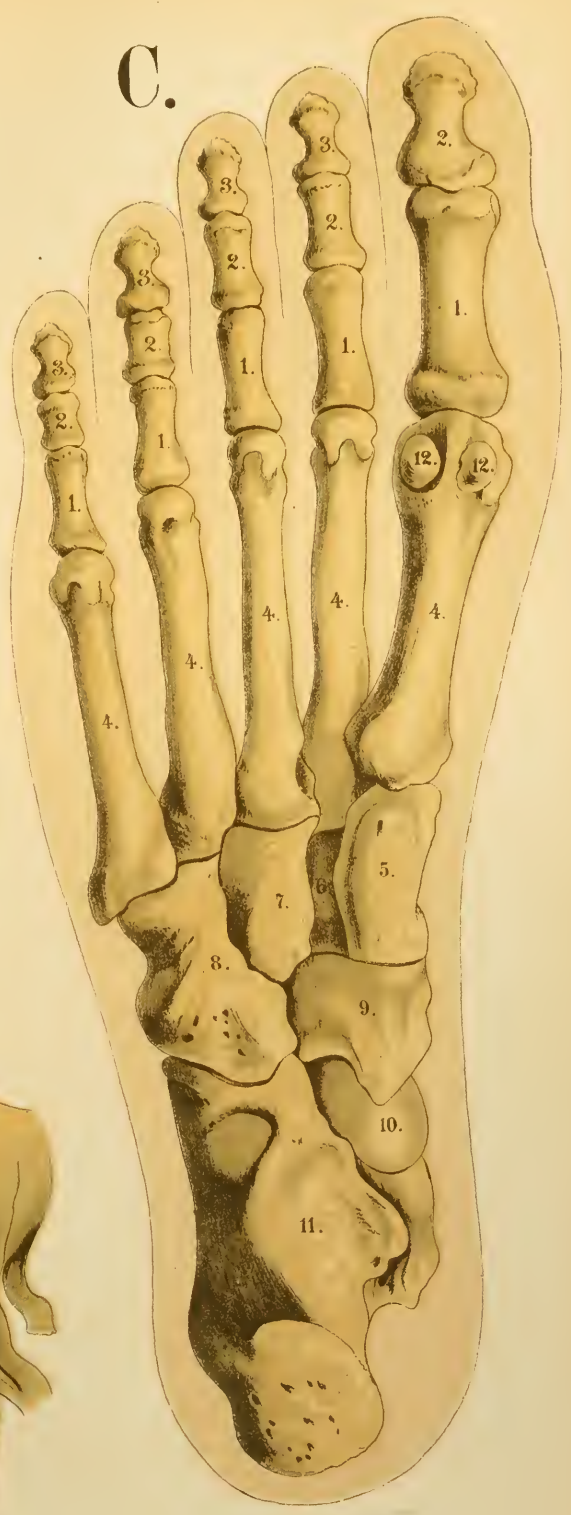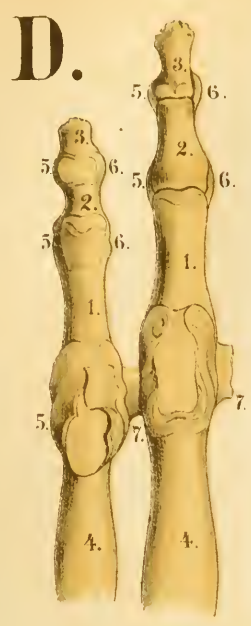








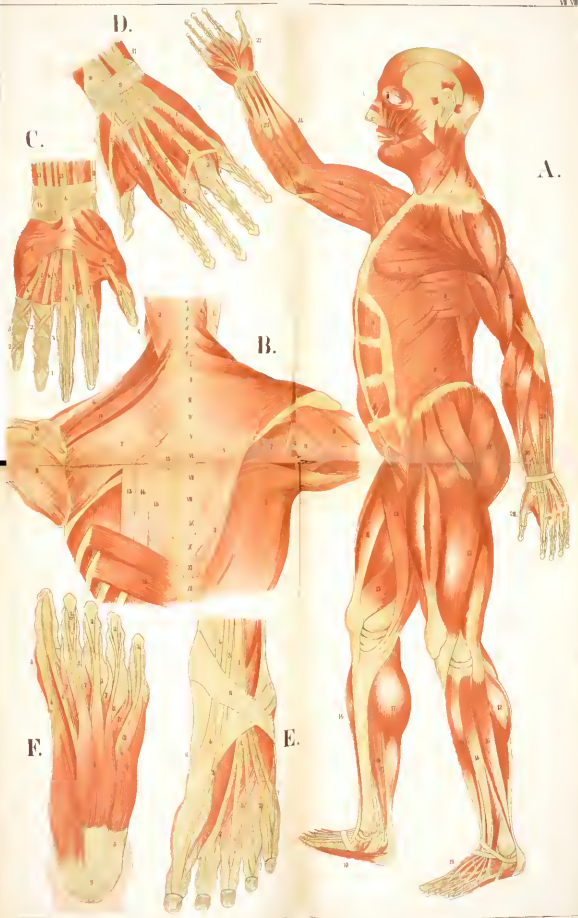












D.

C.

A.

B.

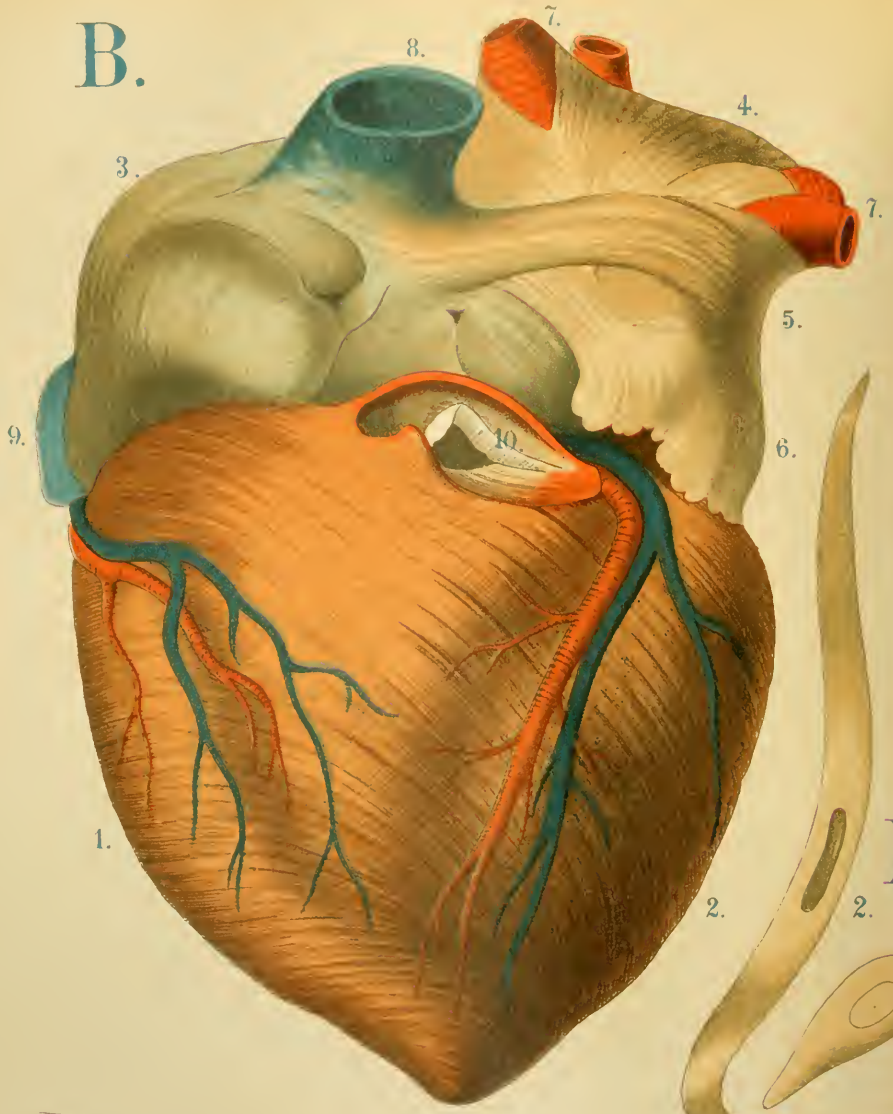
F.

E.





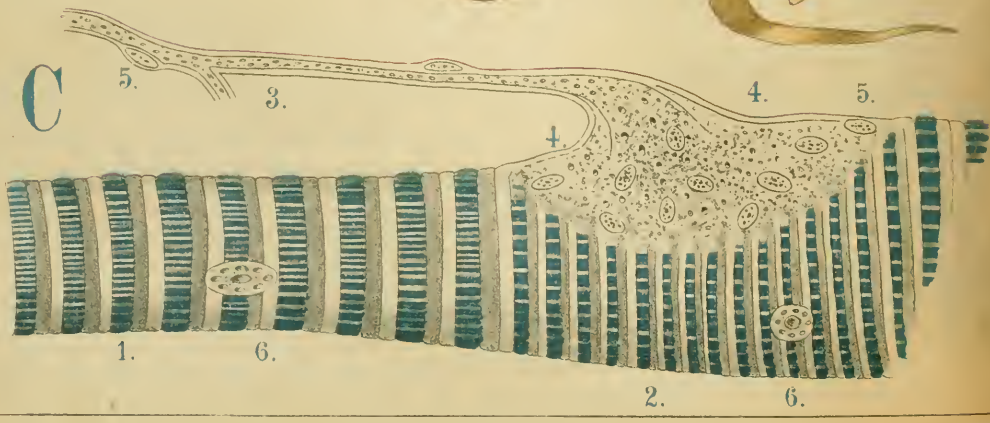
B.



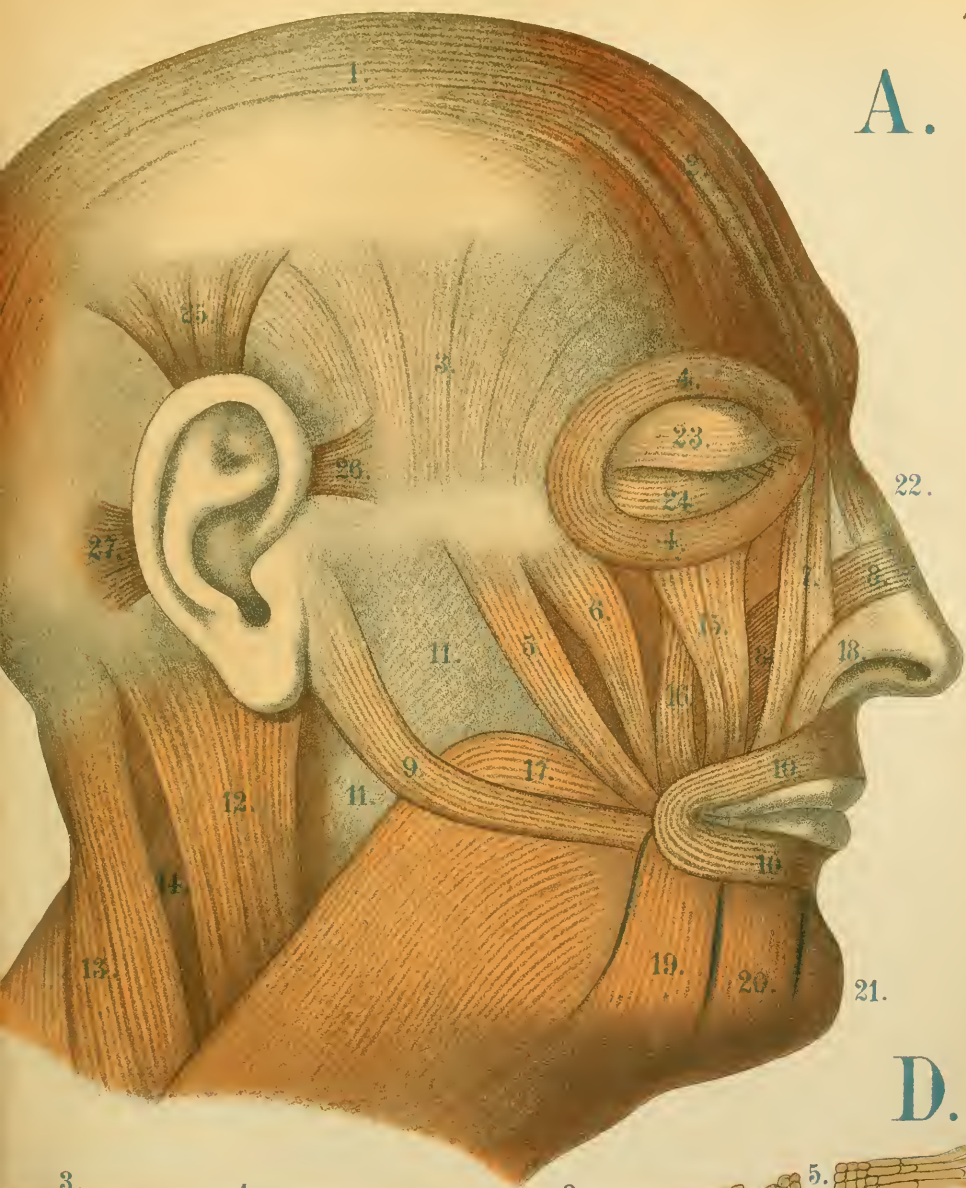
E.



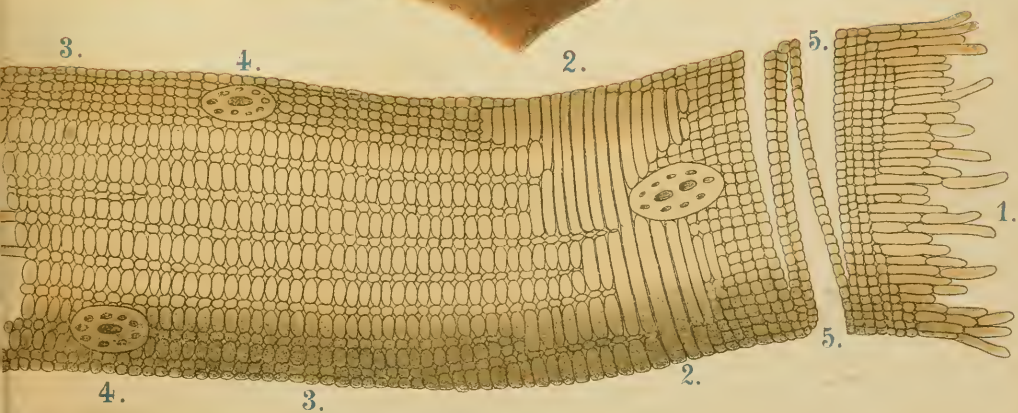
C



A.



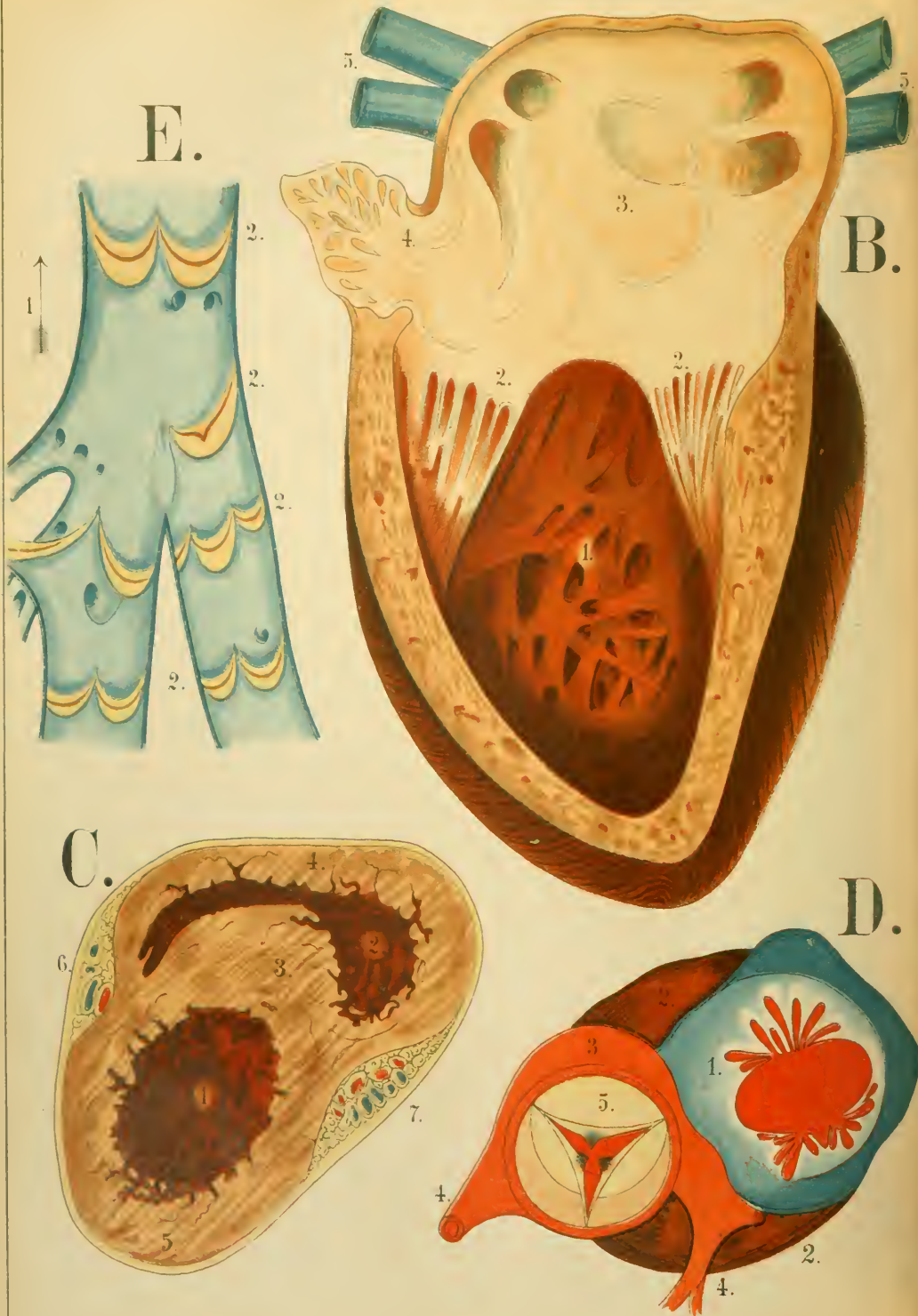
D.

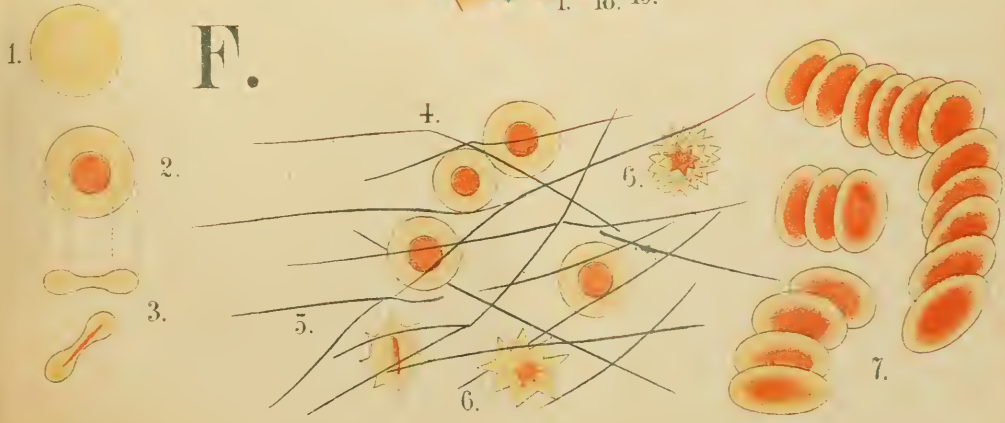
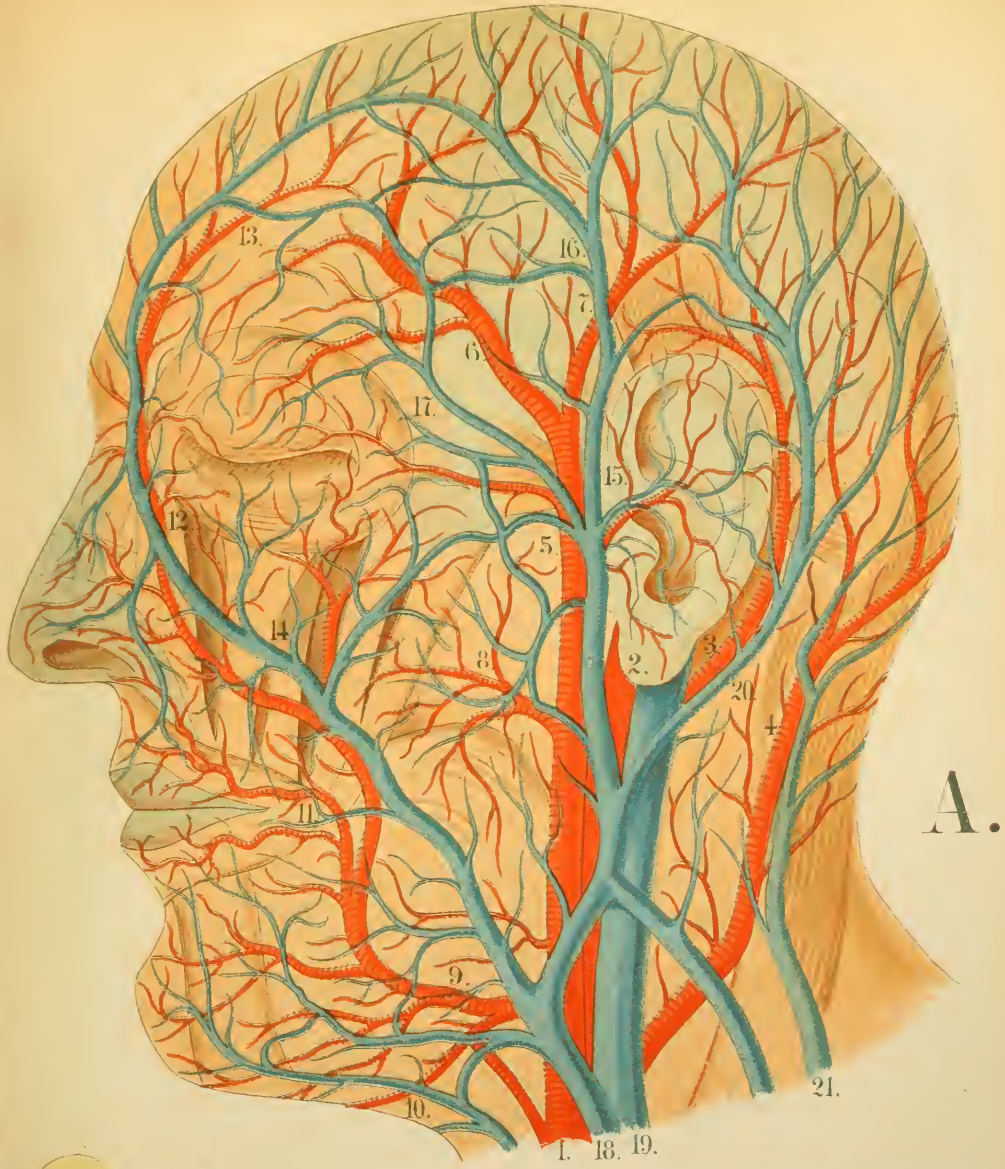












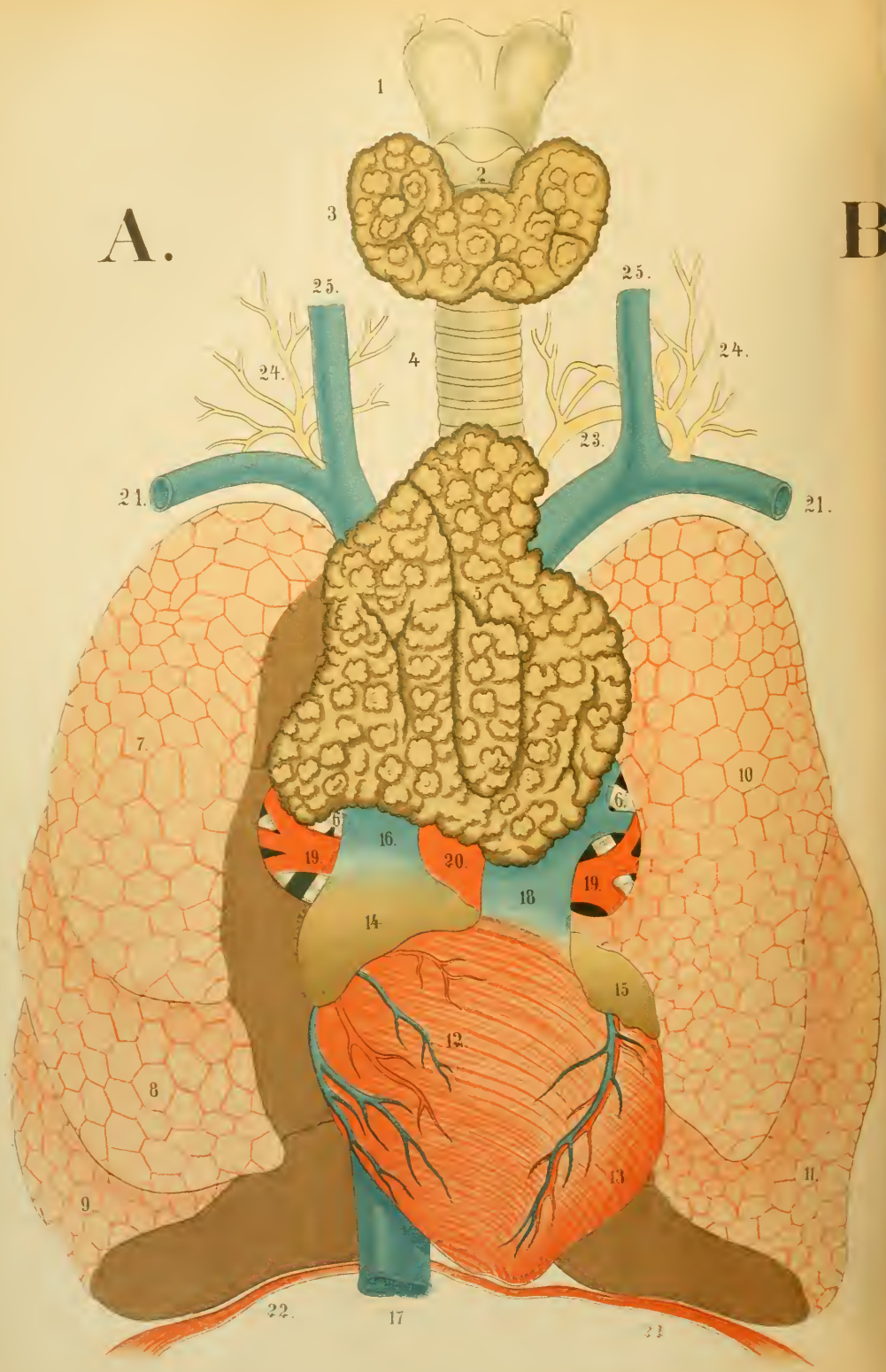

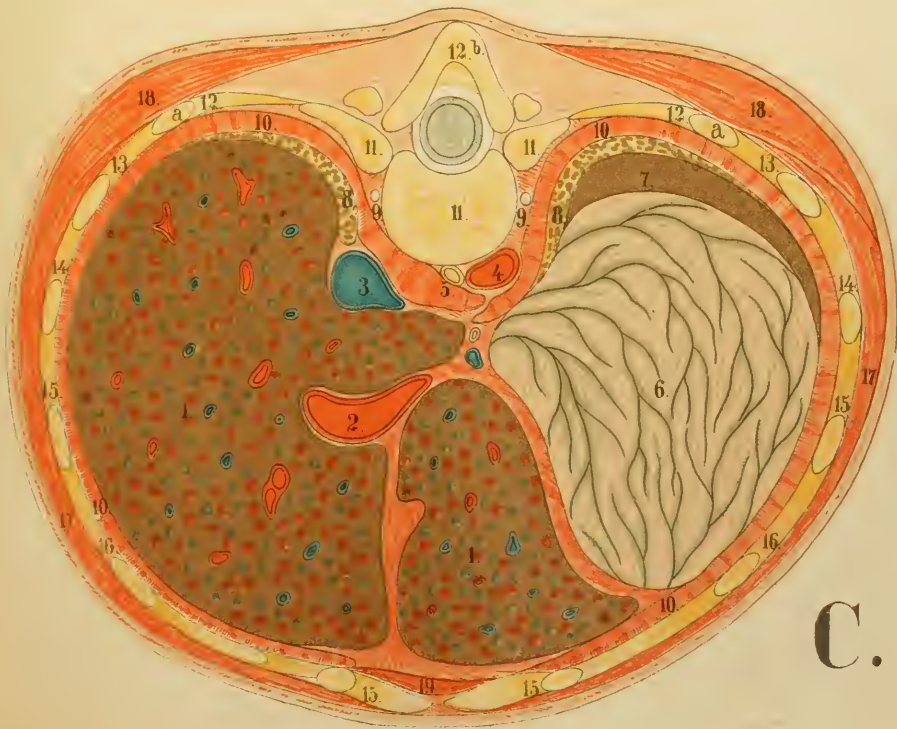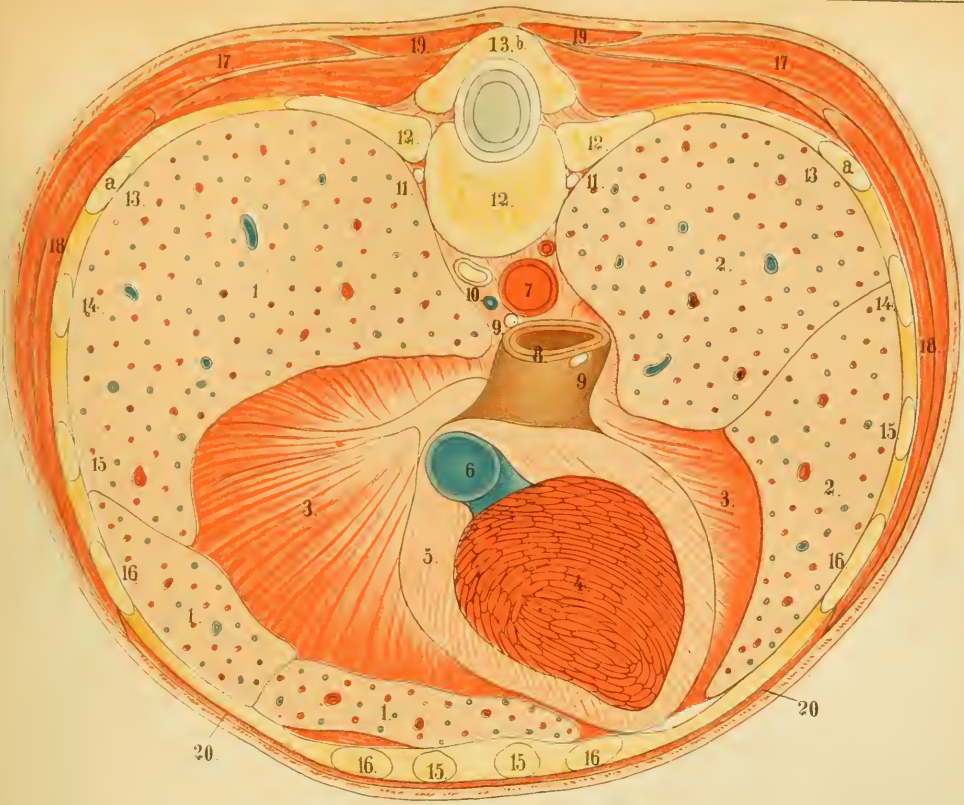




A.

B





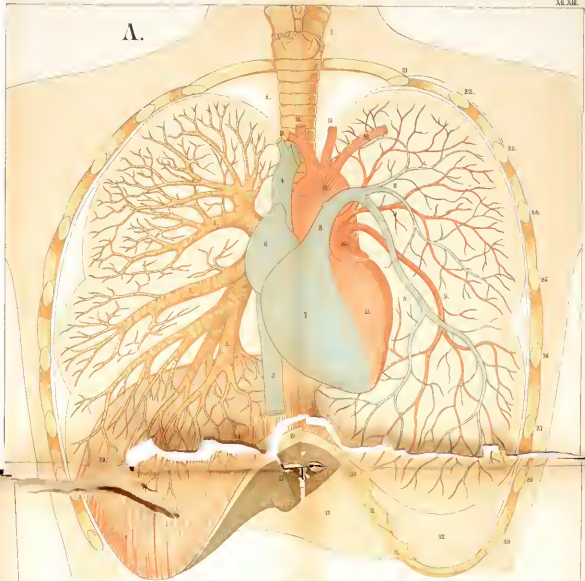
C.



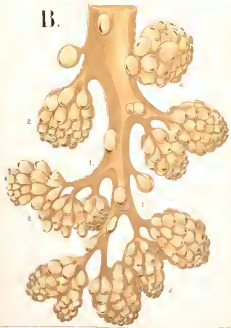




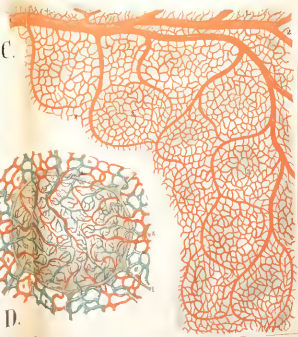
A.



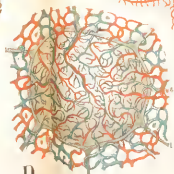
B.



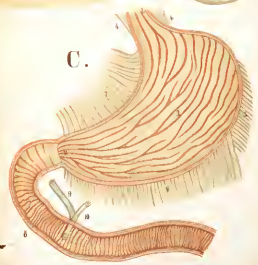
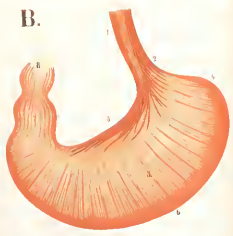
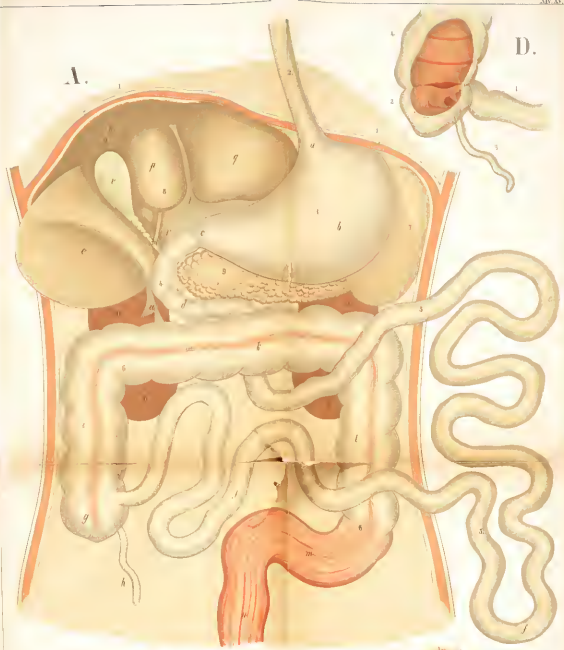
C.



D.

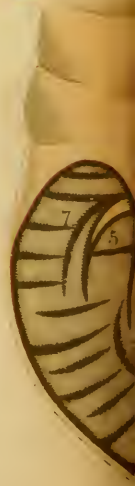
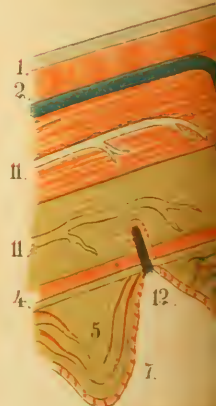
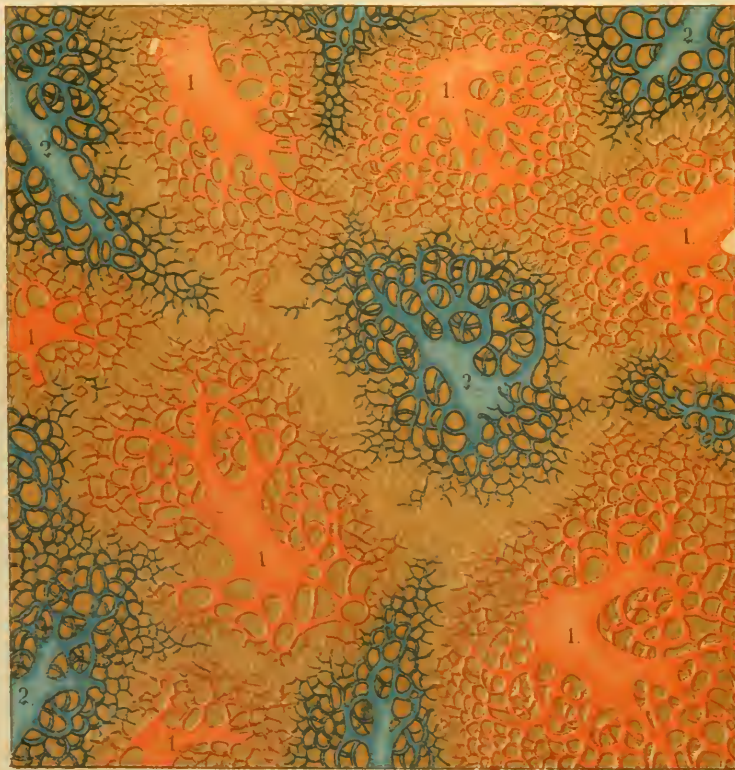
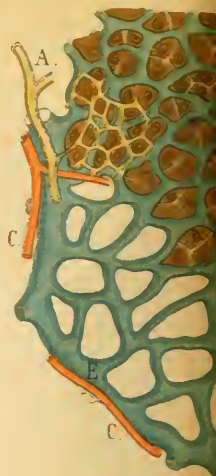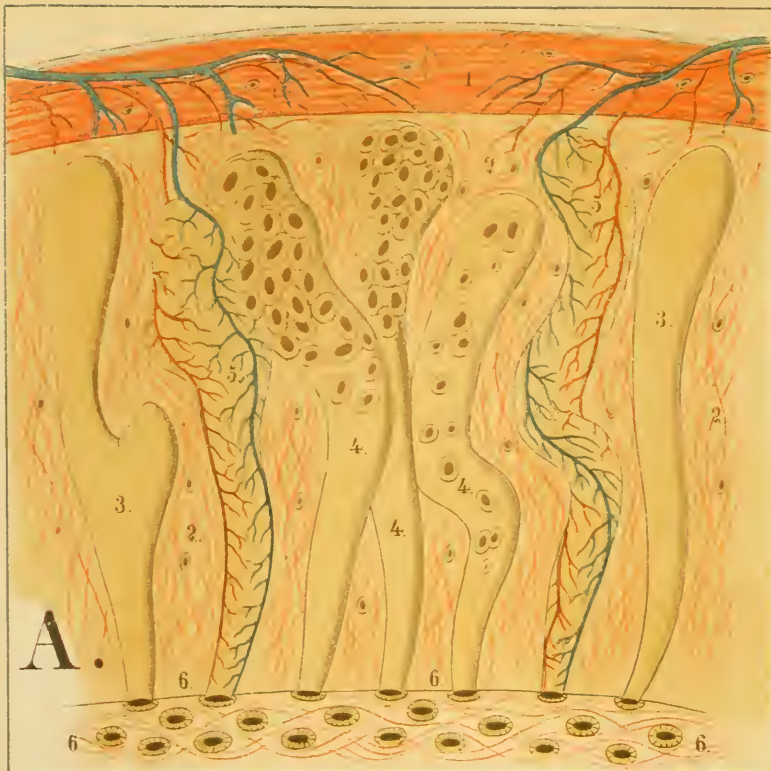




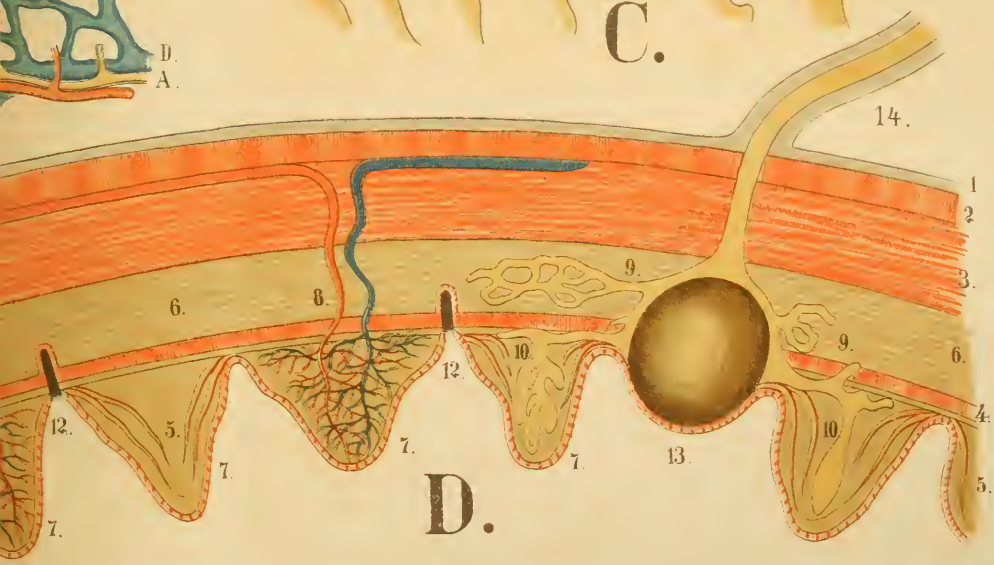
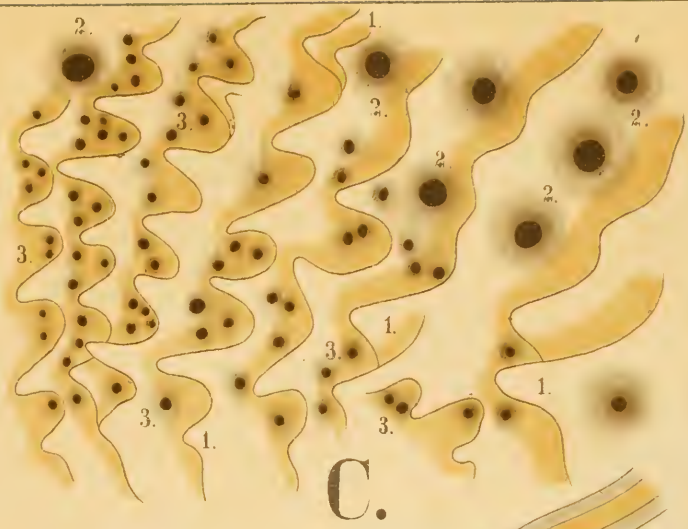
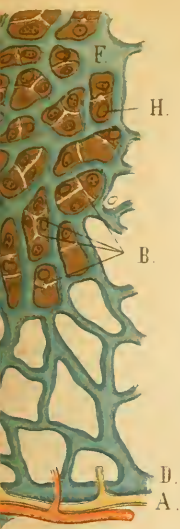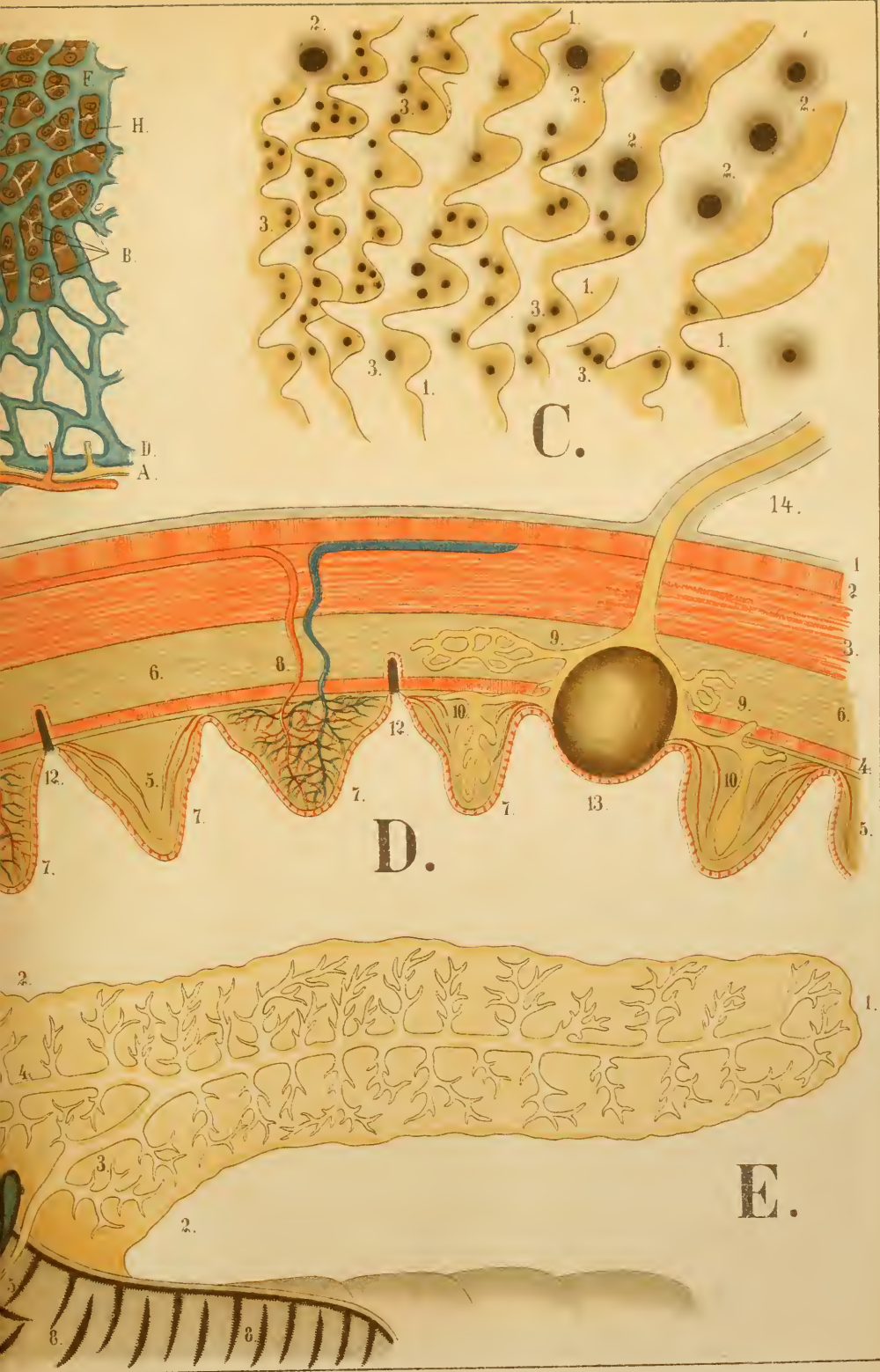








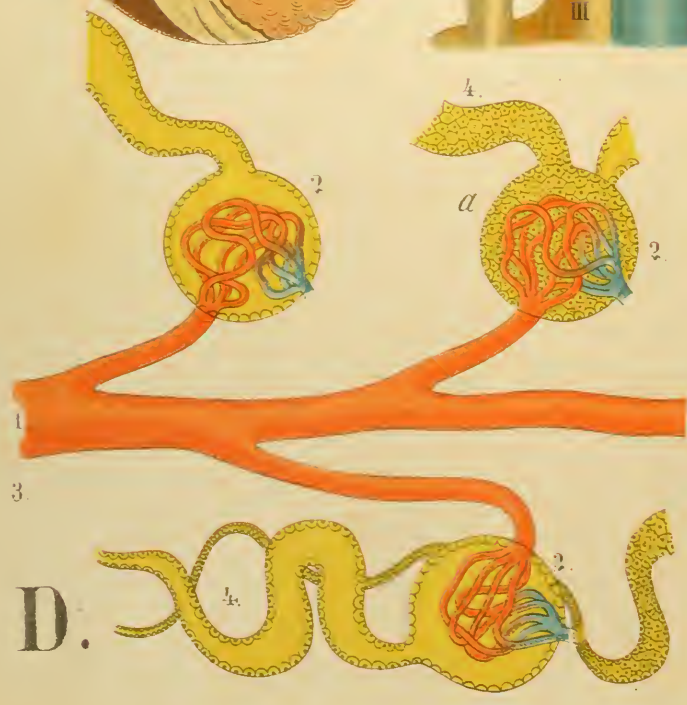
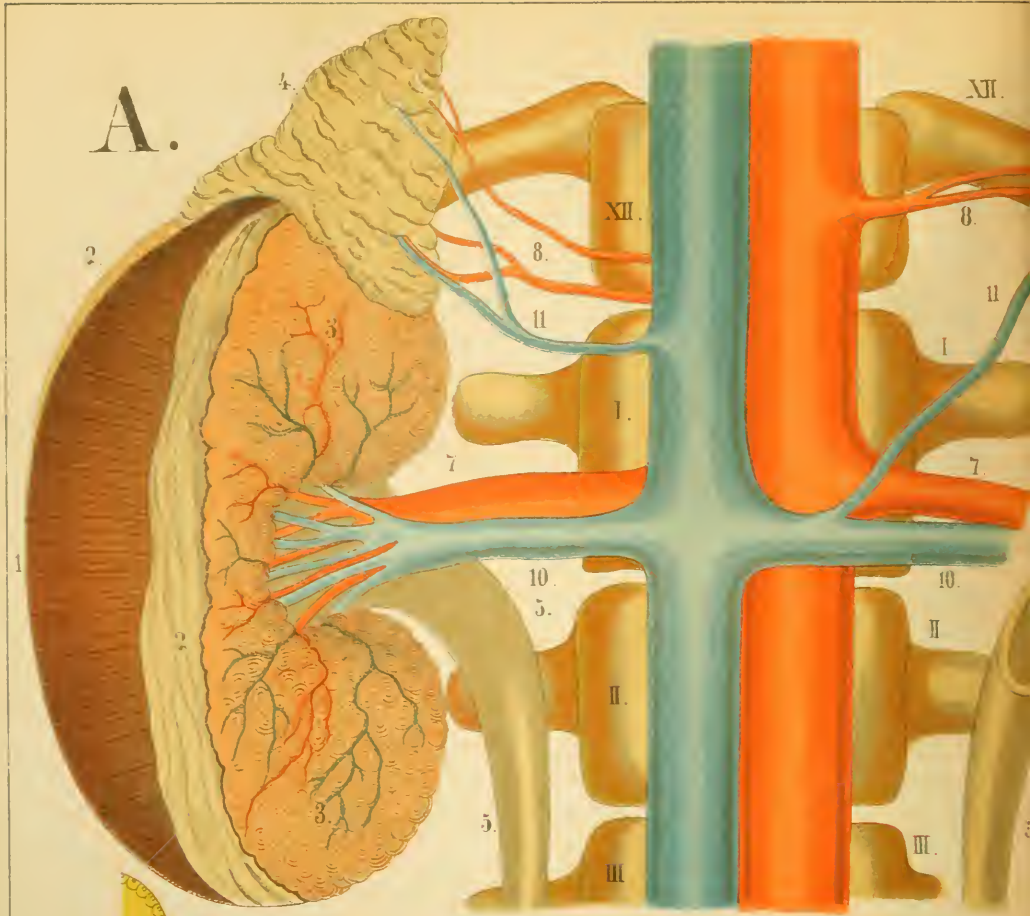
**F.**



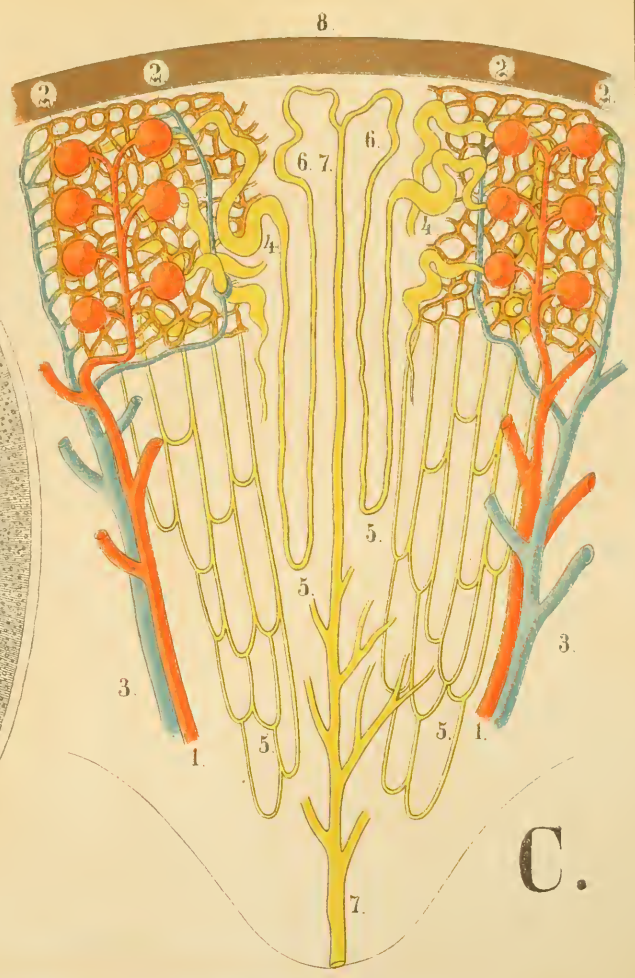
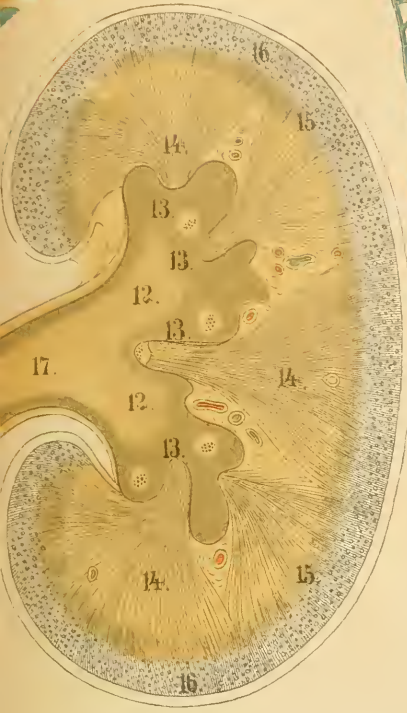


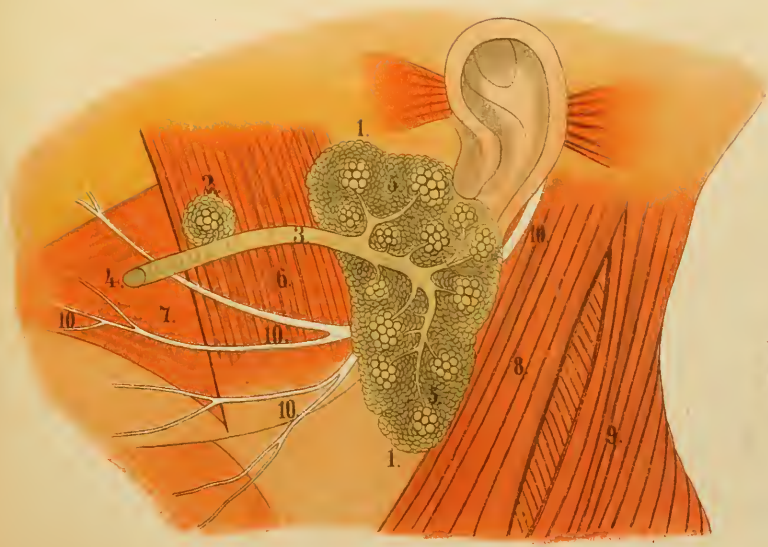




B.



C.

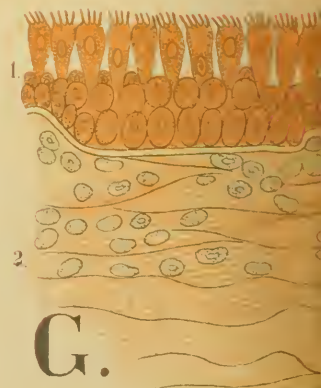
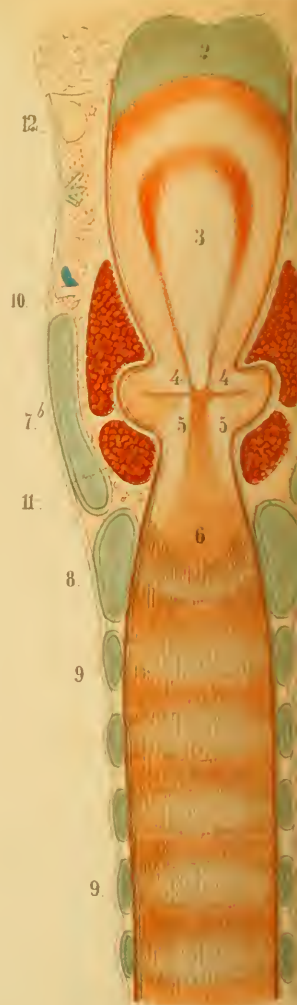
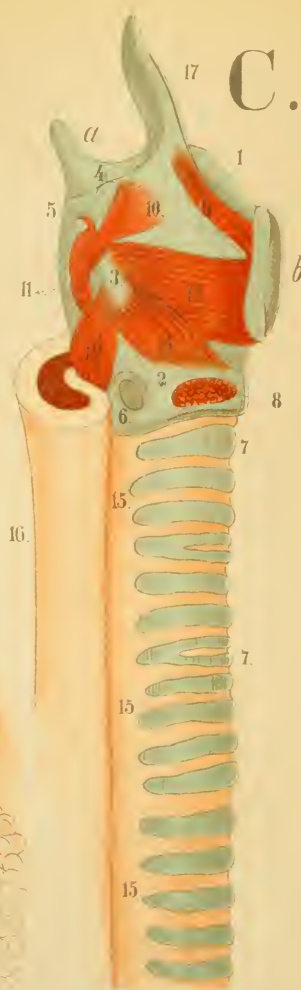


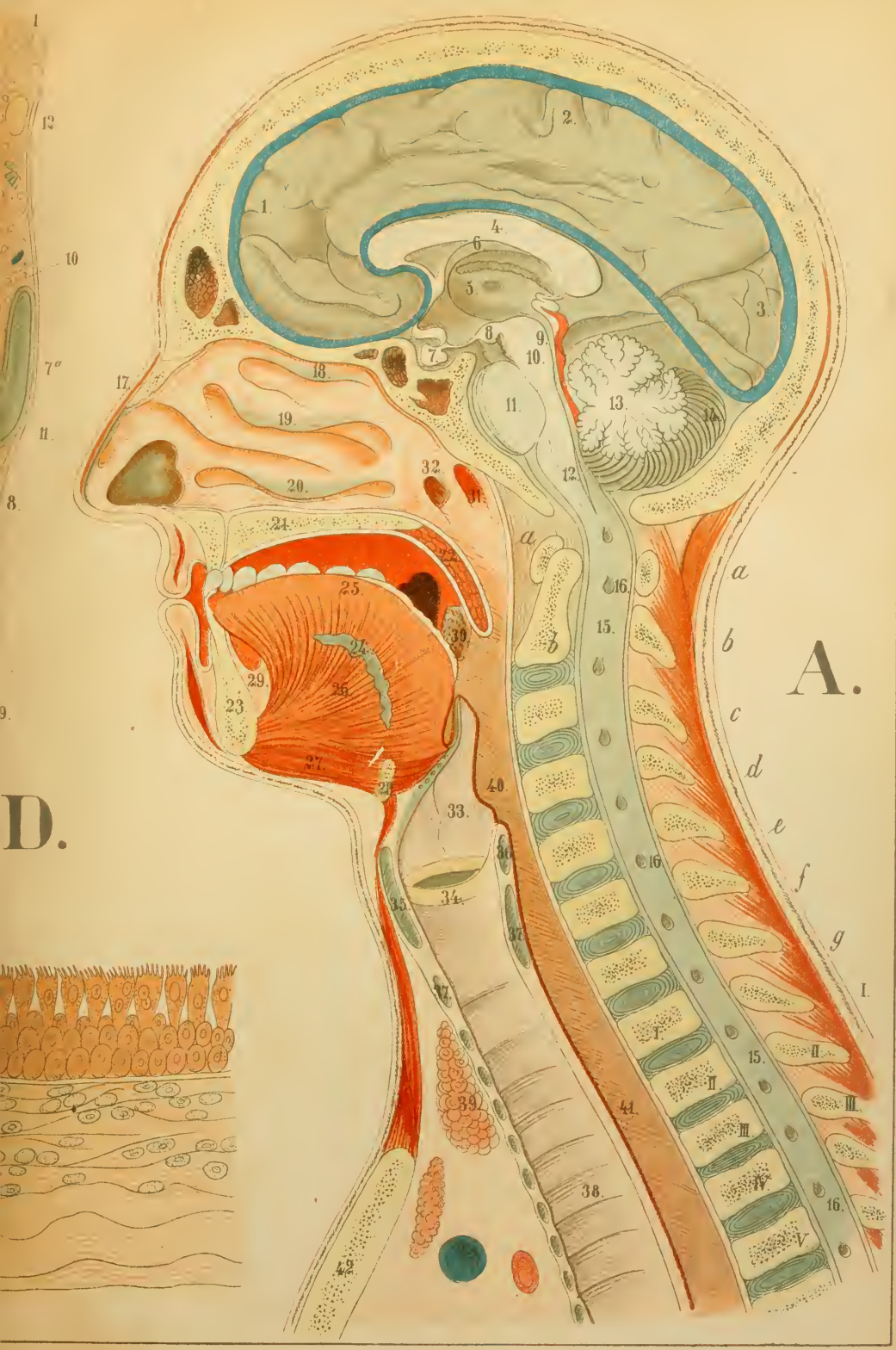E.









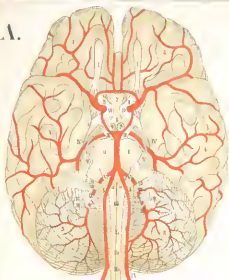



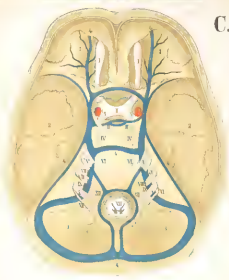




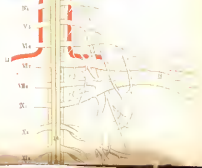
A.



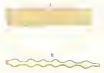
C.



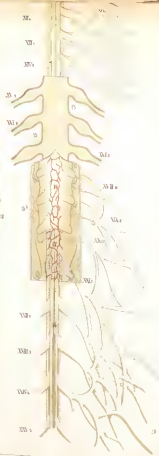
B.



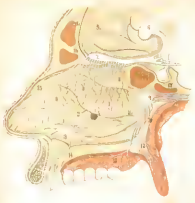
D.



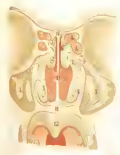21



E.



H.



F.




G.



J.

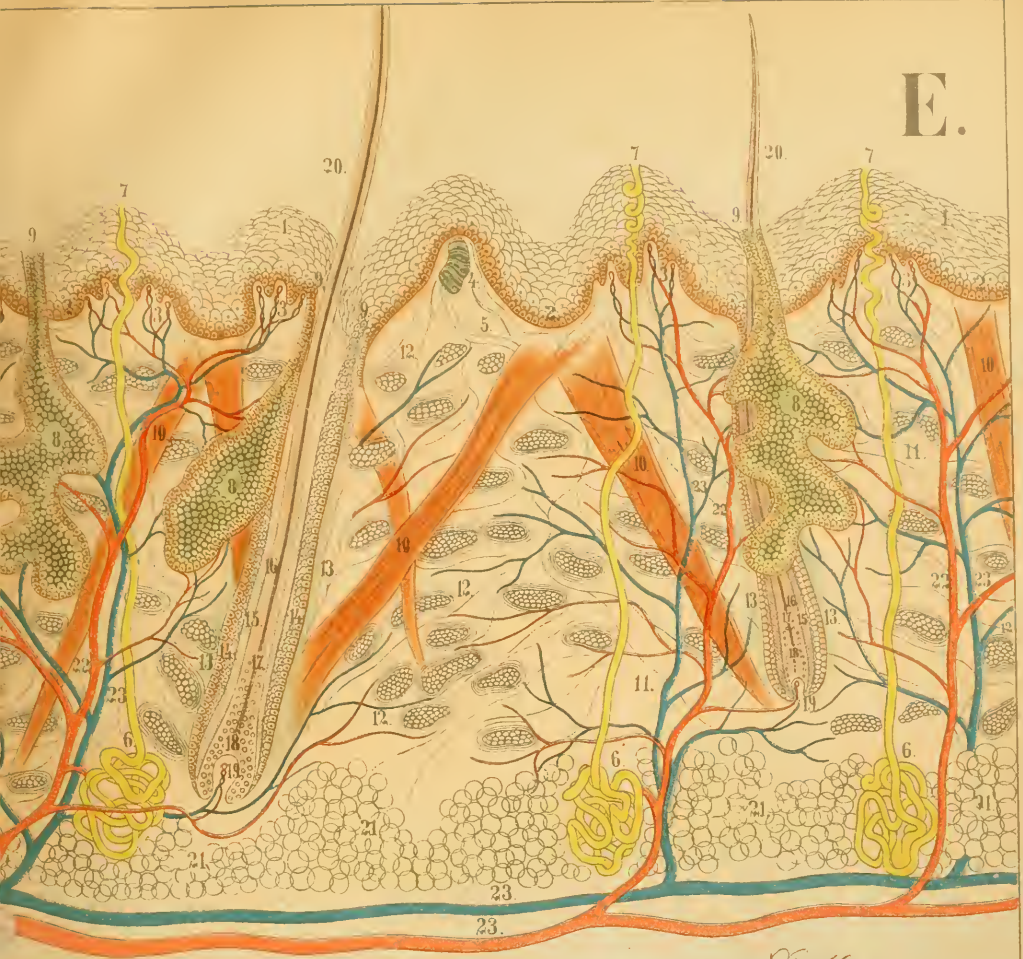




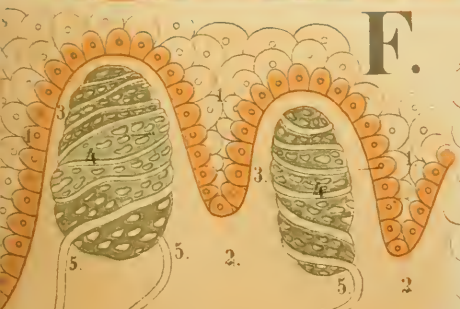


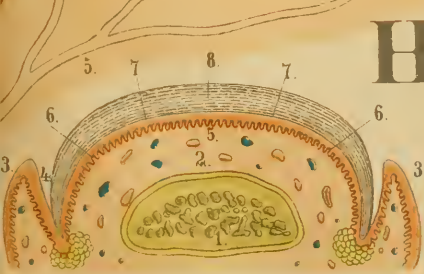
# E.



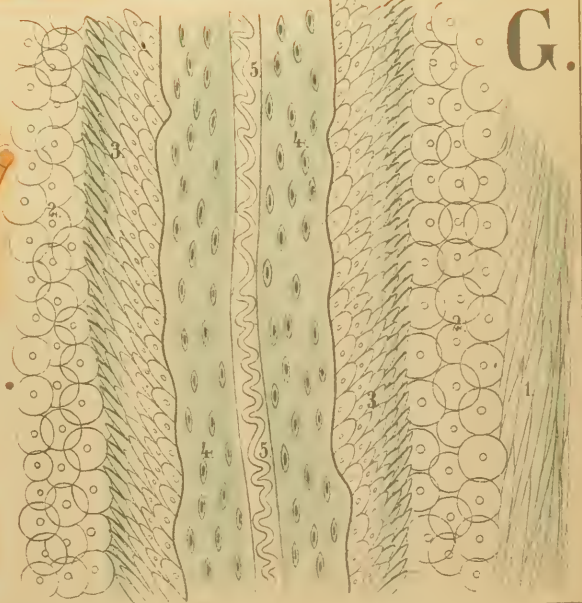
# F.



# H.



# G.







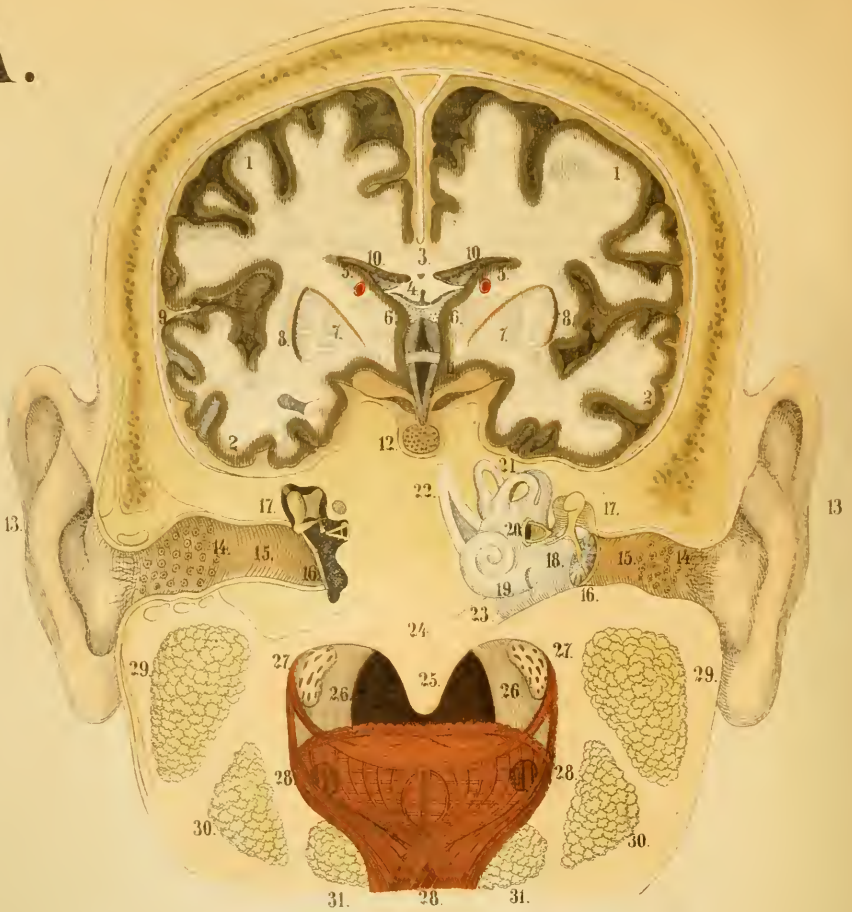


A.

a.

b.

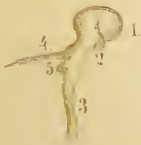c.



a.

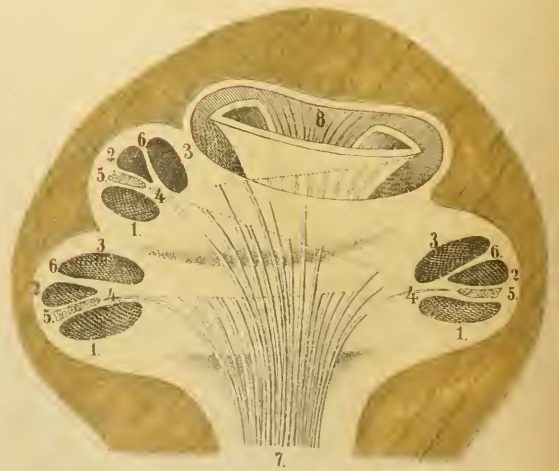b.

c.

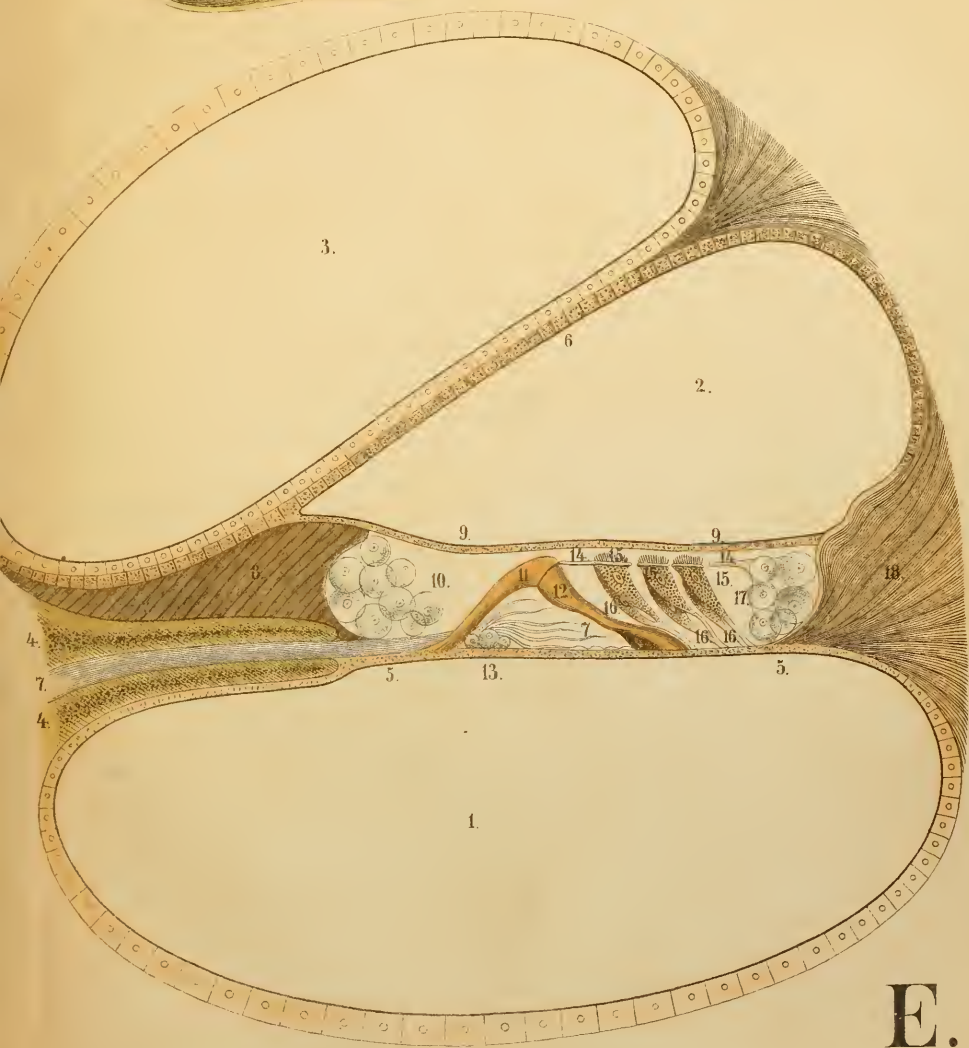
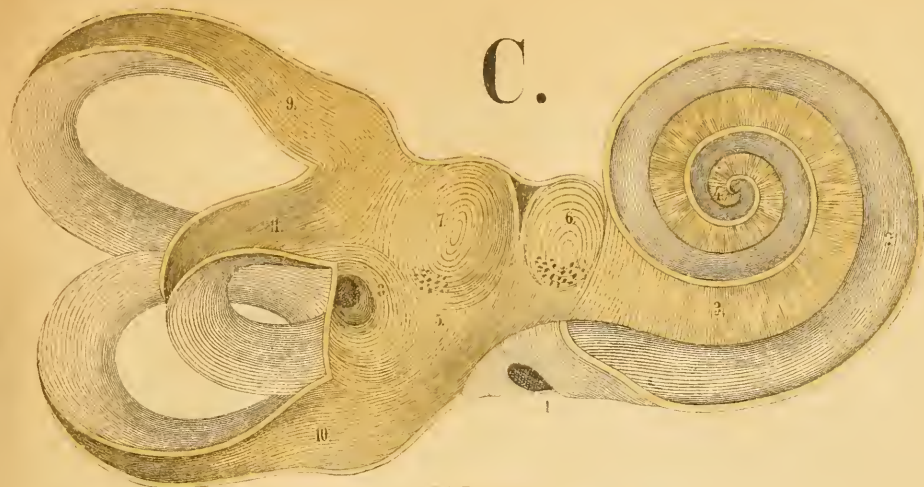


B.

D.



C.

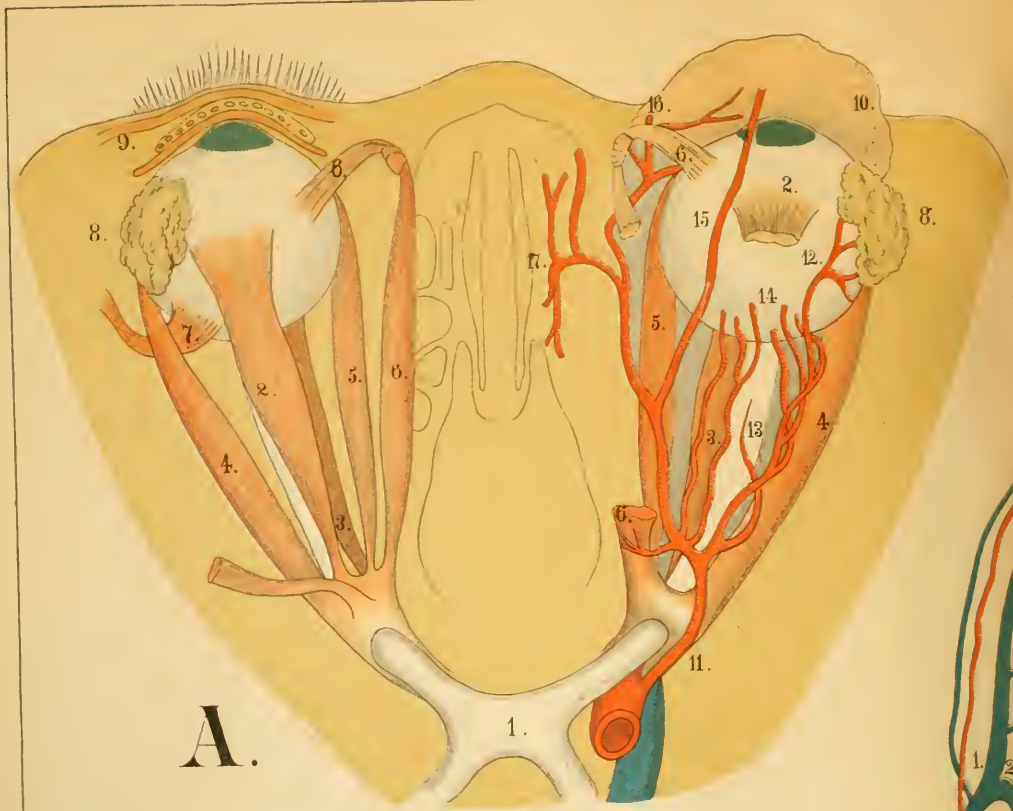


E.

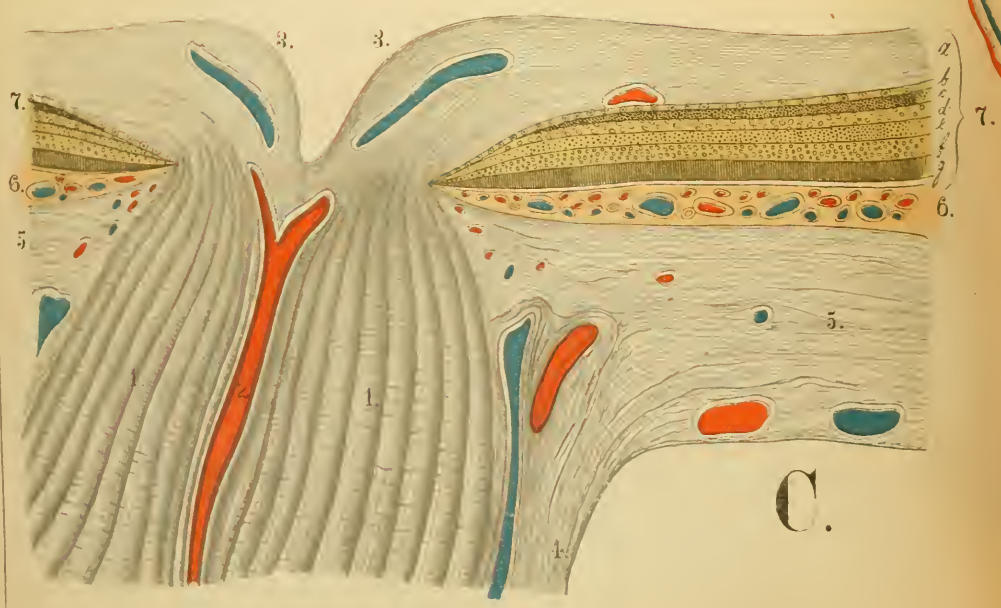







A.



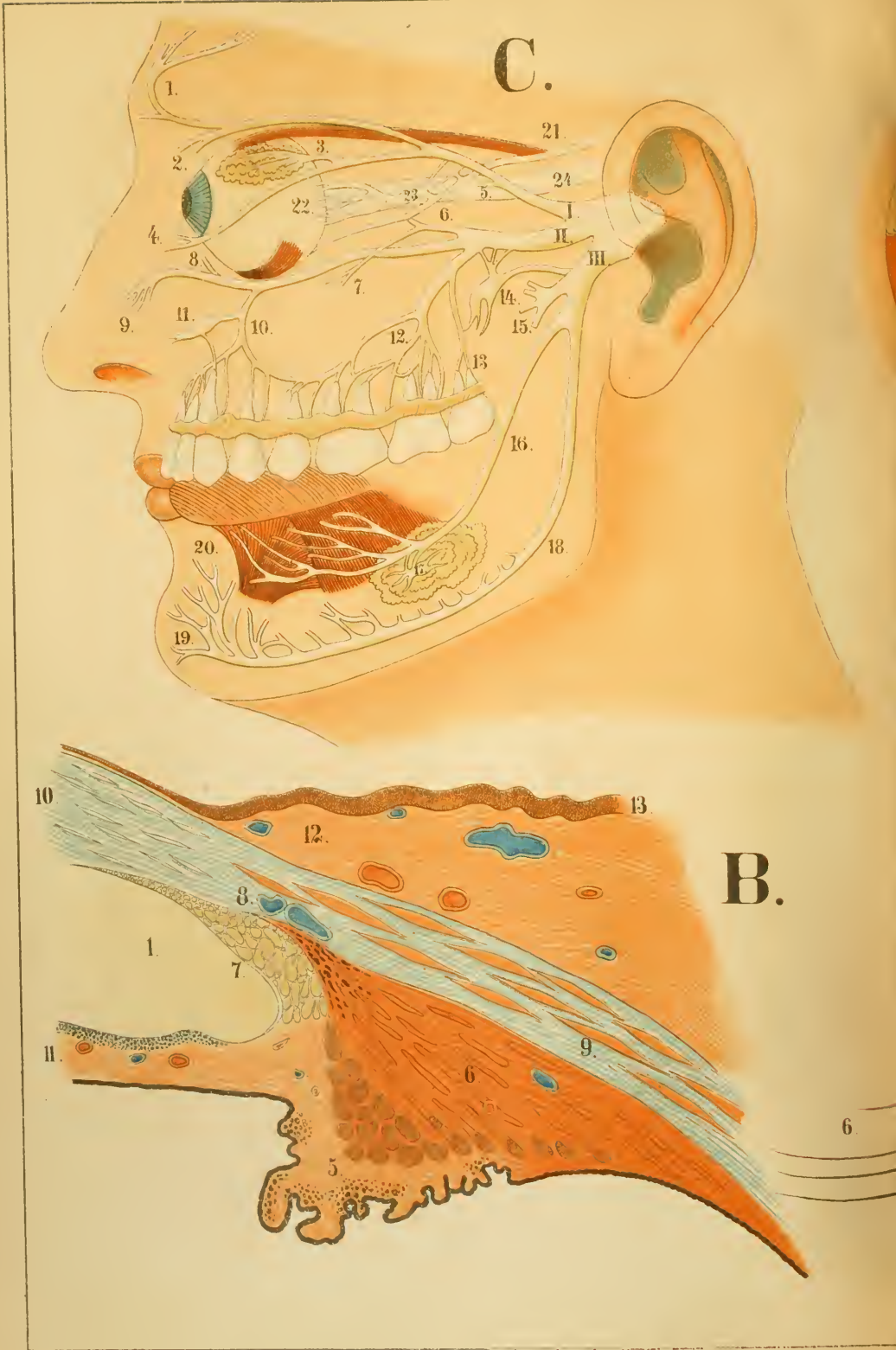
C.

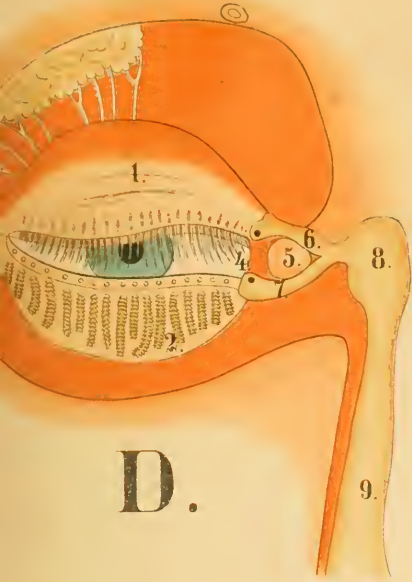




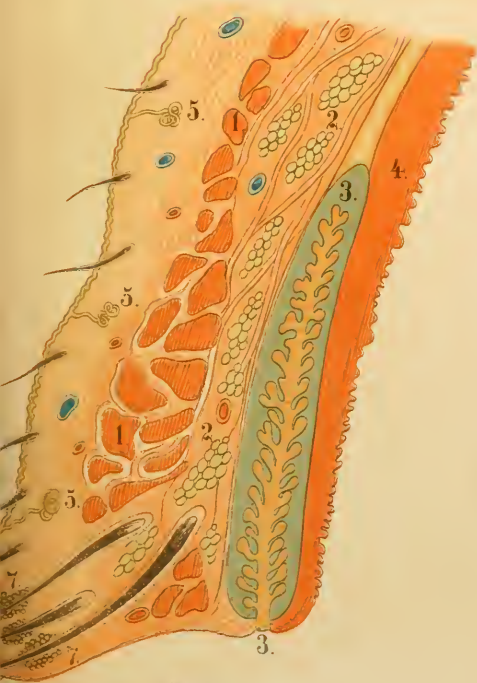



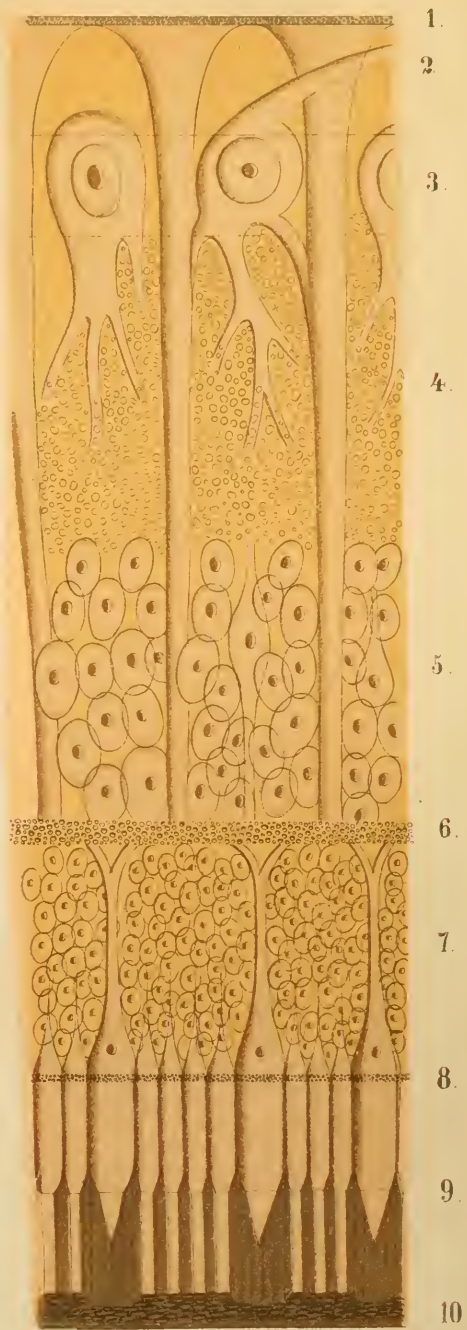




D.



E.



A.















COLUMBIA UNIVERSITY LIBRARY  
QM 25 M61 Q C. 1  
An atlas of anatomy  
  
2002193051

QM25 M61  
Miller Q

QM25 M61  
Q

