
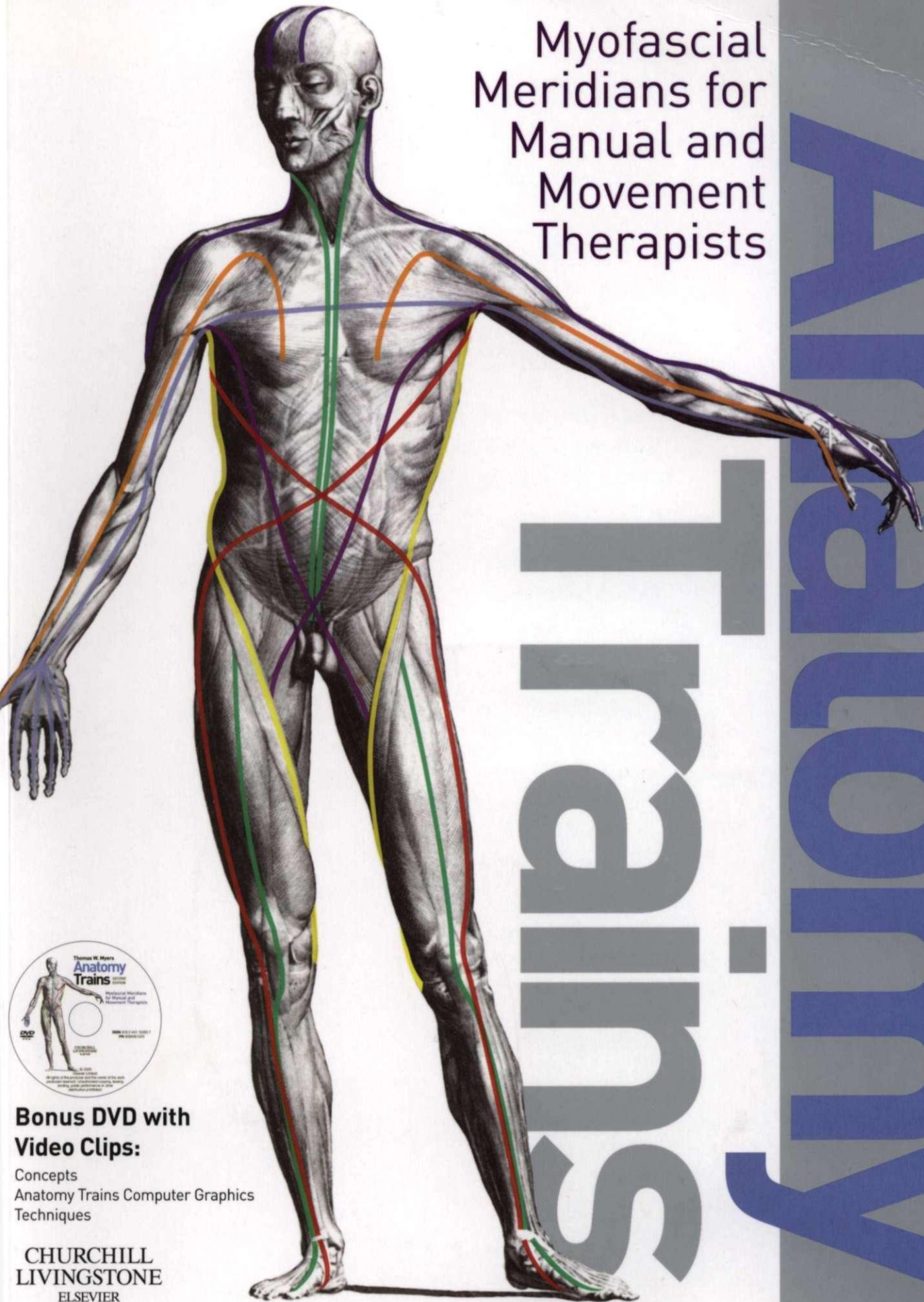


Myofascial
Meridians for
Manual and
Movement
Therapists

SECOND EDITION

Anatomy Trains

Thomas W. Myers



**Bonus DVD with
Video Clips:**

Concepts
Anatomy Trains Computer Graphics
Techniques

CHURCHILL
LIVINGSTONE
ELSEVIER

About the book


Understanding the role of fascia in healthy movement and postural distortion is of vital importance to all somatic practitioners. *Anatomy Trains: Myofascial Meridians for Manual and Movement Therapists* presents a 'whole systems' view of myofascial/locomotor anatomy, especially the body-wide connections among the muscles within the fascial net. This accessible book details how patterns of strain communicate through the myofascial 'webbing', contributing to both movement stability and postural compensation.

Key features:

- Full-color illustrations of 12 myofascial meridians and the rules for constructing other meridians
- Numerous color charts and drawings to detail the muscular and fascial structures involved in the meridians
- Presents information on assessment of structural and movement patterns and gives related application to manual therapy and movement education
- Provides a selection of techniques from the library of structural integration
- Includes an introduction to the fascial system as a whole, with new points of view and recent research findings on the fascial system's responses
- References to supporting material by means of websites, video programs, and further reading

Anatomy Trains is suitable for all levels – from the student, athlete or client, to the most experienced therapist. Professional groups that will find the book useful and relevant to their practice include all manual and movement therapists:

- massage therapists
- structural integration practitioners
- craniosacral therapists
- yoga teachers and therapists
- osteopaths
- physical therapists
- athletic trainers
- dance and movement teachers
- chiropractors
- acupuncturists



Bonus DVD with video clips:

Concepts
Anatomy Trains Computer Graphics
Techniques

Also available are the new **Anatomy Trains Posters:**
Myofascial Meridians for Manual and Movement Therapists.
Second Edition.

Thomas W. Myers

Churchill Livingstone: ISBN 978 0 443 10293 6

CHURCHILL
LIVINGSTONE
ELSEVIER

www.elsevierhealth.com

Fascial networks ... can point to practical therapeutic options ... and different clinical choices. Quite simply, this book is revolutionary.

Leon Chaitow ND DO, Honorary Fellow, University of Westminster, Editor-in-Chief, *Journal of Bodywork & Movement Therapies*.

Clinicians, researchers and educators alike will find this an invaluable text.

Thomas Findley MD PhD, Professor of Physical Medicine and Rehabilitation, University of Medicine and Dentistry of New Jersey, Editor-in-Chief, *International Journal of Therapeutic Massage and Bodywork: Research, Education and Practice*.

For everyone interested in integrative medicine and functional anatomy, this artistic book is recommended. It even makes studying functional anatomy enjoyable.

Andry Vleeming PhD, Professor of Clinical Anatomy and editor of *Movement, Stability & Lumbopelvic Pain*.

An essential guide ... All aboard, everyone!

Diane Lee BSR, MCPA, FLAMT, physiotherapist and author of *The Pelvic Girdle*.

An anatomical playwright, Tom's latest offering captures our curiosity with incomparable biomechanical prose ... and breathtaking graphic designs.

Erik Dalton, PhD Author of *Myoskeletal Alignment Techniques®*.

There is no doubt that this beautiful and inspiring book will contribute many important insights to the scientific understanding of musculoskeletal function.

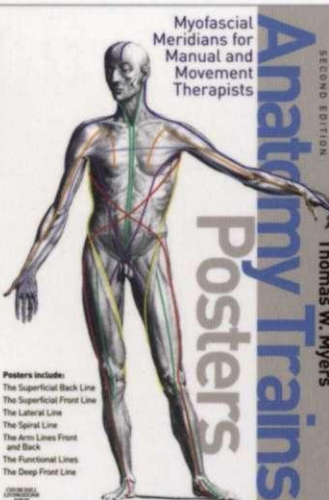
Helene M. Langevin MD, University of Vermont.

Invaluable and vivid insight ... **the** manual for any serious teacher or student of movement.

Marie-Jose Blom Lawrence, Master Teacher of Pilates; Director, Long Beach Dance Conditioning; Creator of Smart Spine Back Support System.

This book is a must-own, must-read.

Deane Juhan is a long time teacher of Trager and the author of *Job's Body: A Handbook for Bodywork* and *Touched by the Goddess: The Physical, Psychological and Spiritual Powers of Bodywork*.



Posters include:
The Superficial Back Line
The Superficial Front Line
The Lateral Line
The Spiral Line
The Arm Lines Front and Back
The Functional Lines
The Deep Front Line

ISBN 978-0-443-10283-7



9780443102837

Anatomy Trains

SECOND EDITION

Dedication

To Edward, for the gift of language.

To Julia, for the tenacity to see it through.

'Every act of the body is an act of the soul.'

(William Alfred')

'I don't know anything, but I do know that everything is interesting
if you go into it deeply enough.'

(Richard Feynman²)

For Elsevier:

Publisher: *Sarcna Wotfaard*

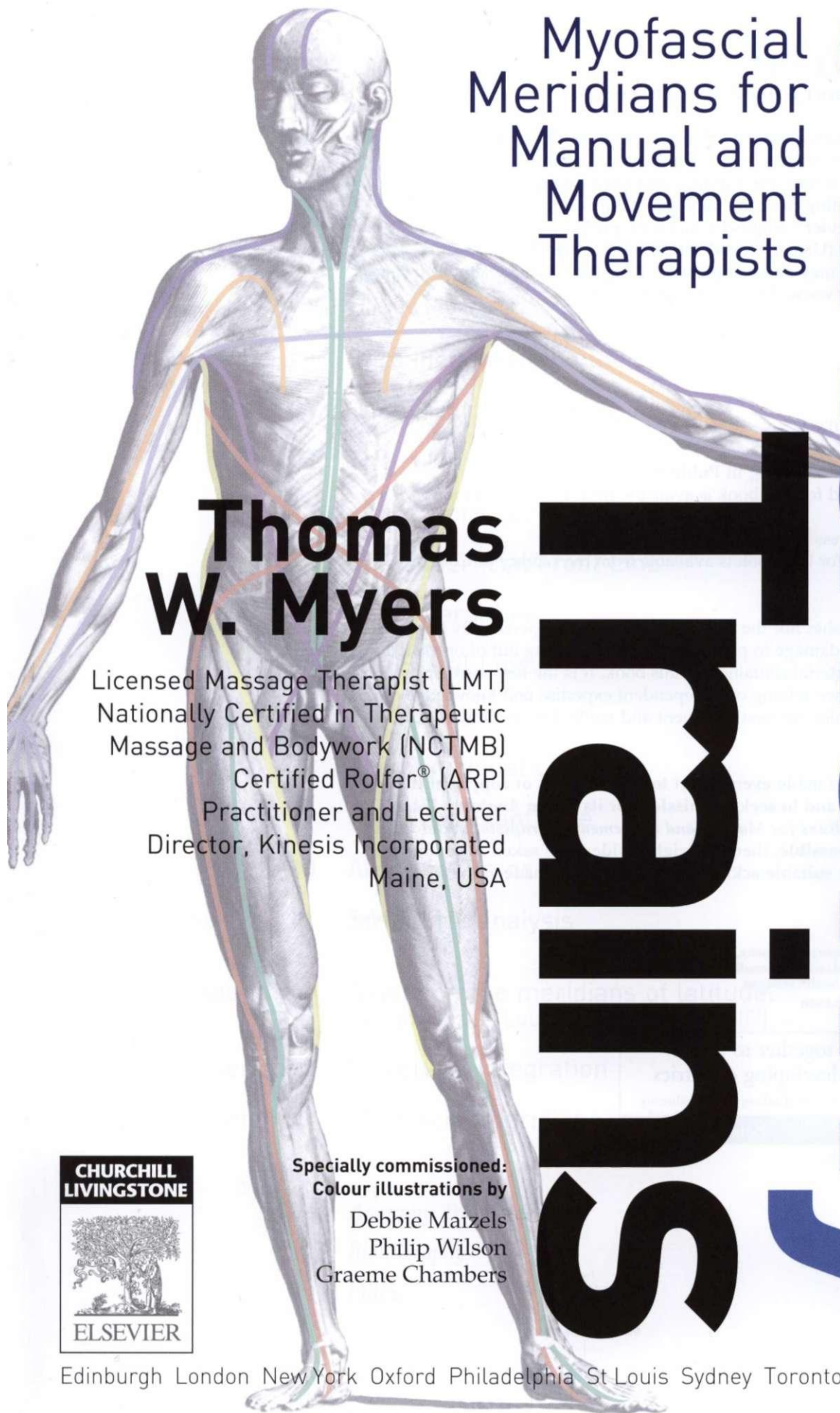
Development Editor: *Slieila Black*

Project Manager: *foannalt Duncan*

Designer: *Steioart Larking*

1. Alfred W. *The Curse of an Aching Heart. Out of print.*

2. Feynman R. *Six Easy Pieces. Neil' York: Addison Wesley: 1995.*




Myofascial
Meridians for
Manual and
Movement
Therapists

SECOND EDITION

**Thomas
W. Myers**

Licensed Massage Therapist (LMT)
Nationally Certified in Therapeutic
Massage and Bodywork (NCTMB)
Certified Rolfer® (ARP)
Practitioner and Lecturer
Director, Kinesis Incorporated
Maine, USA

Anatomy Trains



Specially commissioned:
Colour illustrations by
Debbie Maizels
Philip Wilson
Graeme Chambers

Edinburgh London New York Oxford Philadelphia St Louis Sydney Toronto 2009

CHURCHILL
LIVINGSTONE
ELSEVIER

© 2001, 2009, Elsevier Limited. All rights reserved.

No part of this publication may be reproduced or transmitted in any form or by any means, electronic or mechanical, including photocopying, recording, or any information storage and retrieval system, without permission in writing from the publisher. Permissions may be sought directly from Elsevier's Rights Department: phone: (+1) 215 239 3804 (US) or (+44) 1865 843830 (UK); fax: (+44) 1865 853333; e-mail: healthpermissions@elsevier.com. You may also complete your request on-line via the Elsevier website at <http://www.elsevier.com/permissions>.

First edition 2001
Second edition 2009
Reprinted 2009

ISBN: 978-0-443-10283-7

British Library Cataloguing in Publication Data
A catalogue record for this book is available from the British Library

Library of Congress Cataloging in Publication Data
A catalog record for this book is available from the Library of Congress

Notice

Neither the Publisher nor the Author assumes any responsibility for any loss or injury and/or damage to persons or property arising out of or related to any use of the material contained in this book. It is the responsibility of the treating practitioner, relying on independent expertise and knowledge of the patient, to determine the best treatment and method of application for the patient.

The Publisher has made every effort to trace holders of copyright in original material and to seek permission for its use in *Anatomy Trains: Myofascial Meridians for Manual and Movement Therapists*. Should this have proved impossible, then copyright holders are asked to contact the Publisher so that suitable acknowledgment can be made at the first opportunity.

The Publisher

ELSEVIER your source for books,
journals and multimedia
in the health sciences
www.elsevierhealth.com

Working together to grow
libraries in developing countries
www.elsevier.com | www.bookaid.org | www.sabre.org
ELSEVIER **BOOK AID** **Sabre Foundation**
International

The
publisher's
policy is to use
paper manufactured
from sustainable forests

Printed in China

Contents

<i>Elsevier DVD-ROM Licence Agreement</i>	<i>vi</i>
<i>Preface</i>	<i>vii</i>
<i>Preface to the 1st edition</i>	<i>viii</i>
<i>Acknowledgments</i>	<i>ix</i>
<i>How to use this book</i>	<i>xi</i>
Introduction: laying the railbed	1
1 The world according to fascia	13
2 The rules of the game	65
3 The Superficial Back Line	73
U The Superficial Front Line	97
5 The Lateral Line	115
6 The Spiral Line	131
7 The Arm Lines	U9
8 The Functional Lines	171
9 The Deep Front Line	179
10 Anatomy Trains in motion	203
11 Structural analysis	229
Appendix 1 A note on the meridians of latitude: the work of Dr Louis Schultz (1927-2007)	255
Appendix 2 Structural Integration	259
Appendix 3 Myofascial meridians and oriental medicine	273
<i>Anatomy Trains terms</i>	283
<i>Bibliography</i>	285
<i>Index</i>	289



ELSEVIER DVD-ROM LICENCE AGREEMENT

PLEASE READ THE FOLLOWING AGREEMENT CAREFULLY BEFORE USING THIS PRODUCT. THIS PRODUCT IS LICENSED UNDER THE TERMS CONTAINED IN THIS LICENCE AGREEMENT ("Agreement"). BY USING THIS PRODUCT, YOU, AN INDIVIDUAL OR ENTITY INCLUDING EMPLOYEES, AGENTS AND REPRESENTATIVES ("You" or "Your"), ACKNOWLEDGE THAT YOU HAVE READ THIS AGREEMENT, THAT YOU UNDERSTAND IT, AND THAT YOU AGREE TO BE BOUND BY THE TERMS AND CONDITIONS OF THIS AGREEMENT. ELSEVIER LIMITED ("Elsevier") EXPRESSLY DOES NOT AGREE TO LICENSE THIS PRODUCT TO YOU UNLESS YOU ASSENT TO THIS AGREEMENT. IF YOU DO NOT AGREE WITH ANY OF THE FOLLOWING TERMS, YOU MAY, WITHIN THIRTY (30) DAYS AFTER YOUR RECEIPT OF THIS PRODUCT RETURN THE UNUSED PRODUCT AND ALL ACCOMPANYING DOCUMENTATION TO ELSEVIER FOR A FULL REFUND.

DEFINITIONS As used in this Agreement, these terms shall have the following meanings:

"Proprietary Material" means the valuable and proprietary information content of this Product including without limitation all indexes and graphic materials and software used to access, index, search and retrieve the information content from this Product developed or licensed by Elsevier and/or its affiliates, suppliers and licensors.

"Product" means the copy of the Proprietary Material and any other material delivered on DVD-ROM and any other human readable or machine-readable materials enclosed with this Agreement, including without limitation documentation relating to the same.

OWNERSHIP This Product has been supplied by and is proprietary to Elsevier and/or its affiliates, suppliers and licensors. The copyright in the Product belongs to Elsevier and/or its affiliates, suppliers and licensors and is protected by the copyright, trademark, trade secret and other intellectual property laws of the United Kingdom and international treaty provisions, including without limitation the Universal Copyright Convention and the Berne Copyright Convention. You have no ownership rights in this Product. Except as expressly set forth herein, no part of this Product, including without limitation the Proprietary Material, may be modified, copied or distributed in hardcopy or machine-readable form without prior written consent from Elsevier. All rights not expressly granted to You herein are expressly reserved. Any other use of this Product by any person or entity is strictly prohibited and a violation of this Agreement.

SCOPE OF RIGHTS LICENSED (PERMITTED USES) Elsevier is granting to You a limited, non-exclusive, non-transferable licence to use this Product in accordance with the terms of this Agreement. You may use or provide access to this Product on a single computer or terminal physically located at Your premises and in a secure network or move this Product to and use it on another single computer or terminal at the same location for personal use only, but under no circumstances may You use or provide access to any part or parts of this Product on more than one computer or terminal simultaneously.

You shall not (a) copy, download, or otherwise reproduce the Product or any part(s) thereof in any medium, including, without limitation, online transmissions, local area networks, wide area networks, intranets, extranets and the Internet, or in any way, in whole or in part, except for printing out or downloading a non-substantial portion of the text and images in the Product for Your own personal use; (b) alter, modify, or adapt the Product or any part(s) thereof, including but not limited to decompiling, disassembling, reverse engineering, or creating derivative works, without the prior written approval of Elsevier; (c) sell, license or otherwise distribute to third parties the Product or any part(s) thereof; or (d) alter, remove, obscure or obstruct the display of any copyright, trademark or other proprietary notice on or in the Product or on any printout or download of portions of the Proprietary Materials.

RESTRICTIONS ON TRANSFER This Licence is personal to You, and neither Your rights hereunder nor the tangible embodiments of this Product, including without limitation the Proprietary Material, may be sold, assigned, transferred or sublicensed to any other person, including without limitation by operation of law, without the prior written consent of Elsevier. Any purported sale, assignment, transfer or sublicense without the prior written consent of Elsevier will be void and will automatically terminate the Licence granted hereunder.

TERM This Agreement will remain in effect until terminated pursuant to the terms of this Agreement. You may terminate this Agreement at any time

by removing from Your system and destroying the Product and any copies of the Proprietary Material. Unauthorized copying of the Product, including without limitation, the Proprietary Material and documentation, or otherwise failing to comply with the terms and conditions of this Agreement shall result in automatic termination of this licence and will make available to Elsevier legal remedies. Upon termination of this Agreement, the licence granted herein will terminate and You must immediately destroy the Product and all copies of the Product and of the Proprietary Material, together with any and all accompanying documentation. All provisions relating to proprietary rights shall survive termination of this Agreement.

LIMITED WARRANTY AND LIMITATION OF LIABILITY Elsevier warrants that the software embodied in this Product will perform in substantial compliance with the documentation supplied in this Product, unless the performance problems are the result of hardware failure or improper use. If You report a significant defect in performance in writing to Elsevier within ninety (90) calendar days of your having purchased the Product, and Elsevier is not able to correct same within sixty (60) days after its receipt of Your notification, You may return this Product, including all copies and documentation, to Elsevier and Elsevier will refund Your money. In order to apply for a refund on your purchased Product, please contact the return address on the invoice to obtain the refund request form ("Refund Request Form"), and either fax or mail your signed request and your proof of purchase to the address indicated on the Refund Request Form. Incomplete forms will not be processed. Defined terms in the Refund Request Form shall have the same meaning as in this Agreement.

YOU UNDERSTAND THAT, EXCEPT FOR THE LIMITED WARRANTY RECITED ABOVE, ELSEVIER, ITS AFFILIATES, LICENSORS, THIRD PARTY SUPPLIERS AND AGENTS (TOGETHER "THE SUPPLIERS") MAKE NO REPRESENTATIONS OR WARRANTIES, WITH RESPECT TO THE PRODUCT, INCLUDING, WITHOUT LIMITATION THE PROPRIETARY MATERIAL. ALL OTHER REPRESENTATIONS, WARRANTIES, CONDITIONS OR OTHER TERMS, WHETHER EXPRESS OR IMPLIED BY STATUTE OR COMMON LAW, ARE HEREBY EXCLUDED TO THE FULLEST EXTENT PERMITTED BY LAW.

IN PARTICULAR BUT WITHOUT LIMITATION TO THE FOREGOING NONE OF THE SUPPLIERS MAKE ANY REPRESENTATIONS OR WARRANTIES (WHETHER EXPRESS OR IMPLIED) REGARDING THE PERFORMANCE OF YOUR PAD, NETWORK OR COMPUTER SYSTEM WHEN USED IN CONJUNCTION WITH THE PRODUCT, NOR THAT THE PRODUCT WILL MEET YOUR REQUIREMENTS OR THAT ITS OPERATION WILL BE UNINTERRUPTED OR ERROR-FREE.

EXCEPT IN RESPECT OF DEATH OR PERSONAL INJURY CAUSED BY THE SUPPLIERS' NEGLIGENCE AND TO THE FULLEST EXTENT PERMITTED BY LAW, IN NO EVENT (AND REGARDLESS OF WHETHER SUCH DAMAGES ARE FORESEEABLE AND OF WHETHER SUCH LIABILITY IS BASED IN TORT, CONTRACT OR OTHERWISE) WILL ANY OF THE SUPPLIERS BE LIABLE TO YOU FOR ANY DAMAGES (INCLUDING, WITHOUT LIMITATION, ANY LOST PROFITS, LOST SAVINGS OR OTHER SPECIAL, INDIRECT, INCIDENTAL OR CONSEQUENTIAL DAMAGES ARISING OUT OF OR RESULTING FROM: (I) YOUR USE OF, OR INABILITY TO USE, THE PRODUCT; (II) DATA LOSS OR CORRUPTION; AND/OR (III) ERRORS OR OMISSIONS IN THE PROPRIETARY MATERIAL.

IF THE FOREGOING LIMITATION IS HELD TO BE UNENFORCEABLE, OUR MAXIMUM LIABILITY TO YOU IN RESPECT THEREOF SHALL NOT EXCEED THE AMOUNT OF THE LICENCE FEE PAID BY YOU FOR THE PRODUCT. THE REMEDIES AVAILABLE TO YOU AGAINST ELSEVIER AND THE LICENSORS OF MATERIALS INCLUDED IN THE PRODUCT ARE EXCLUSIVE.

If the information provided in the Product contains medical or health sciences information, it is intended for professional use within the medical field. Information about medical treatment or drug dosages is intended strictly for professional use, and because of rapid advances in the medical sciences, independent verification of diagnosis and drug dosages should be made. The provisions of this Agreement shall be severable, and in the event that any provision of this Agreement is found to be legally unenforceable, such unenforceability shall not prevent the enforcement or any other provision of this Agreement.

GOVERNING LAW This Agreement shall be governed by the laws of England and Wales. In any dispute arising out of this Agreement, you and Elsevier each consent to the exclusive personal jurisdiction and venue in the courts of England and Wales.

Preface

Since initial publication in 2001, the reach and application of the ideas in this book have far outstripped this author's expectations. We have been invited to present these ideas and their application on every continent save Antarctica to a wide variety of professionals, including rehabilitation doctors, physiotherapists, chiropractors, osteopaths, psychologists, athletic trainers, yoga teachers, martial artists, performance coaches, massage therapists, and somatic therapists of all stripes. A simple Google® search of *Anatomy Trains* now yields nearly 200000 hits, as therapists and educators find useful applications far beyond our original conception.

This 2nd edition includes many small updates and corrections that arose out of our continuing teaching and practice, as well as preliminary findings from the dissections we have initiated since the 1st edition with Todd Garcia and the Laboratories of Anatomical Enlightenment. We have been able to include some recent discoveries made in the fascial and myofascial world since initial publication (much of it summarized in the Fascial Research Conference of October 2007 - www.Tascia.2007.com), as well as to fill in areas where our initial ignorance of the wider world has been rectified.

This edition benefits from completely new artwork by Debbie Maizels and Philip Wilson, as well as color updating of the artwork provided by Graeme Cham-

bers. New client assessment photos have been produced by Michael Frenchman and Videograf. The new full color design allows color-coded access to the information, allowing for a quick gathering of the relevant concepts for a hurried reader, or a detailed analysis for the curious.

Like most textbooks these days, this edition makes increasing use of electronic media. The text is studded with website addresses for further study, and our own website, www.anatomytrains.com, is being constantly updated. There are also consistent references to the set of a dozen or more DVDs we have produced to support professional application of the Anatomy Trains concepts. The DVD accompanying this book provides other goodies not otherwise available in a book format, including clips from this DVD series, computer graphic representations of the Anatomy Trains, further dissection photographs and video clips, and some extra client photos for visual assessment practice.

Both the understanding of the role of fascia and the implications and applications of Anatomy Trains are developing rapidly. This new edition and its connections to the web ensure an up-to-date point-of-view on fascia, a largely missing element in movement study.

*Thomas W. Myers
Maine 2008*

Preface to the 1st edition

I stand in absolute awe of the miracle of life. My wonder and curiosity have only increased during the more than three decades of immersion in the study of human movement. Whether our ever-evolving body was fashioned by an all-knowing if mischievous Creator, or by a purely selfish gene struggling blindly up Mount Improbable,¹ the ingenious variety and flexibility shown in somatic design and development leaves the observer shaking his head with a rueful grin of astonishment.

One looks in vain inside the fertilized ovum for the trillion-cell fetus that it will become. Even the most cursory examination of the complexities of embryology leaves us amazed that it works as often as it does to produce a healthy infant. Hold a helpless, squalling baby, and it seems almost unbelievable that so many escape all the possible debilitating pitfalls on the road to a healthy and productive adulthood.

Despite its biological success, the human experiment as a whole is showing some signs of strain. When I read the news, I confess to having feelings of ambivalence as to whether humankind can or even should continue on this planet, given our cumulative effect on its surface flora and fauna and our treatment of each other. When I hold that baby, however, my commitment to human potential is once again confirmed.

This book (and the seminars and training courses from which it developed) is devoted to the slim chance that we as a species can move beyond our current dedication to collective greed - and the technocracy and alienation that proceed from it - into a more cooperative and humane relationship with ourselves, each other and our environs. One hopes the development of a 'holistic' view of anatomy such as the one outlined herein will be useful to the manual and movement therapists in relieving pain and resolving difficulties in the clients who seek their help. The deeper premise underlying the book, however, is that a more thorough and sensitive contact with our 'felt sense' - that is, our kinesthetic, proprioceptive, spatial sense of orientation and movement - is a vitally important front on which to fight the battle for a more human use of human beings, and a better integration with the world around us. The progressive deadening of this 'felt sense' in our children, whether through simple ignorance or by deliberate schooling, lends itself to a collective dissociation, which leads in turn to environmental and social decline. We have long been familiar with mental intelligence (IQ) and more recently have recognized emotional intelligence (EQ). Only by re-contacting the full reach and educational potential of our kinesthetic intelligence (KQ) will we have any hope of finding a balanced relationship with the larger systems of the world around us, to fulfill what Thomas Berry called 'the Dream of the Earth'.^{4,5}

The traditional mechanistic view of anatomy, as useful as it has been, has objectified rather than humanized our relationship to our insides. It is hoped that the

relational view ventured in this book will go some little way toward connecting Descartes' view of the body as a 'soft machine' with the living experience of being in a body which grows, learns, matures and ultimately dies. Although the Anatomy Trains ideas form only one small detail of a larger picture of human development through movement, an appreciation of the fascial web and balance in the myofascial meridians can definitely contribute to our inner sense of ourselves as integrated beings. This, coupled with other concepts to be presented in future works, leads toward a physical education more appropriate to the needs of the 21st century.^{6,9}

As such, Anatomy Trains is a work of art in a scientific metaphor. This book leaps ahead of the science to propose a point of view, one that is still being literally fleshed out and refined. I have frequently been taken to task by my wife, my students, and my colleagues for stating my hypotheses baldly, with few of the qualifying adjectives which, though necessary to scientific accuracy, dampen the visceral force of an argument. As Evelyn Waugh wrote: 'Humility is not a virtue propitious to the artist. It is often pride, emulation, avarice, malice - all the odious qualities - which drive a man to complete, elaborate, refine, destroy, and renew his work until he has made something that gratifies his pride and envy and greed. And in so doing he enriches the world more than the generous and the good. That is the paradox of artistic achievement.'¹⁰

Being neither a scholar nor a researcher, I can only hope that this work of 'artifice' is useful in providing some new ideas for the good people who are.

Finally, I hope that I have honored Vesalius and all the other explorers before me by getting the anatomy about right.

Maine 2001 Thomas W. Myers

References

1. Dawkins R. The selfish gene. Oxford: Oxford University Press; 1990.
2. Dawkins R. The blind watchmaker. New York: WB Norton; 1996.
3. Dawkins R. Climbing Mount Improbable. New York: WB Norton; 1997.
4. Csikzentimihalyi M. Flow. New York: Harper & Row; 1990.
5. Berry T. The dream of the earth. San Francisco: Sierra Club; 1990.
6. Myers T. Kinesthetic dystonia. Journal of Bodywork and Movement Therapies 1998; 2(2):101-114.
7. Myers T. Kinesthetic dystonia. Journal of Bodywork and Movement Therapies 1998; 2(4):231-247.
8. Myers T. Kinesthetic dystonia. Journal of Bodywork and Movement Therapies 1999; 3(1):36-43.
9. Myers T. Kinesthetic dystonia. Journal of Bodywork and Movement Therapies 1999; 3(2):107-116.
10. Waugh E. Private letter, quoted in the New Yorker, 4 Oct 1999.

Acknowledgments

I would like to express my profound gratitude to a number of people who have guided my way and helped lead to the 'myofascial meridians' concept. To Buckminster Fuller, whose systems approach to design and wide appreciation for the way the world works have informed my work from the very beginning, who urged me not to reform people but to reform the environment around them.¹ To Dr Ida Rolf and Dr Moshe Feldenkrais, both of whom pointed the way to practical and literal ways of reforming the most immediate environment people have, their body and their perception of it;^{2,3} I owe these pioneers a deep debt of gratitude for the gift of worthwhile work.

To Dr James Oschman and Raymond Dart, for giving me the original inspiration on fascially connected kinetic chains.⁴ To the late Dr Louis Schultz, the original Chair of the Rolf Institute's Anatomy Faculty, whose ideas are much in evidence in this book.⁵ Dr Schultz gave me the broadest of conceptual fields in which to play as he started me on my path of learning fascial anatomy. To my colleagues on the Rolf Institute's Life Sciences faculty, specifically Paul Gordon, Michael Murphy, and particularly Robert Schleip, who offered warm but firm critical feedback to these ideas and thus improved them.⁶ To Deane Juhan, whose comprehensive view of human function, so elegantly put forth in *Job's Body*, has been an inspiration to me as to so many.⁷ To Michael Frenchman, my old friend, who demonstrated early faith in our ideas by putting in many hours realizing them in video form. To the innovative Gil Hedley of Somanautics and Todd Garcia of the Laboratories of Anatomical Enlightenment, whose skills in dissection are on view in this book, through the medium of Averill Lehan's camera and Eric Root's microscope. I honor their dedication to exposing the actual experience of the human form for testing new ideas such as those in this book. We honor the donors whose generosity makes these advances in knowledge possible.

Many other movement teachers, at slightly greater distance, also deserve credit for inspiring this work: the yoga of Iyengar as I learned it from his able students such as Arthur Kilmurray, Patricia Walden, and Francois Raoult; the highly original work in human movement of Judith Aston through Aston Patterning, the contributions of Emilie Conrad and Susan Harper with their Continuum work, and Bonnie Bainbridge-Cohen and her Body-Mind Centering school.^{8,9,11} I owe a debt to Caryn McHose and Deborah Raoult for bringing some of this work close enough to grasp, and also to Frank Hatch and Lenny Maietta for their developmental movement synthesis expressed in their unique Touch-in-Parenting program.^{12,13}

From all these people and many more I have learned a great deal, although the more I learn, the farther the horizon of my ignorance extends. They say that stealing ideas from one person is plagiarism, from ten is scholarship, and from one hundred is original research. Thus,

there is nothing completely original in this bit of grand larceny. Nevertheless, while these people are responsible for instilling exciting ideas, no one but myself is responsible for any errors, which I look forward to correcting in future iterations of this work.


To my many eager students, whose questions have goaded more learning than I would ever have undertaken on my own. To Annie Wyman, for early support and maritime contributions to my sanity. To my teachers in the Kinesis school, especially the early support of Lou Benson, Jo Avison, David Lesondak, and Michael Morrison, whose tenacity in dealing with both my eccentricities and my poetic treatment of fact (as well as my electronic challenges) has contributed signally to this artefact. Current teachers, including (alphabetically) Lauren Christman, James Earls, Peter Ehlers, Mark Finch, Ron Floyd, Yaron Gal, Carrie Gaynor, Michael Janssen, Simone Lindner, Lawrence Phipps, and Eli Thompson, have also contributed to the accuracy and scope of this edition.

To Dr Leon Chaitow and the editorial staff at Elsevier, including Mary Law and the patient Mairi McCubbin, who initially shepherded this project to market. To Sarena Wolfaard, Claire Wilson, Sheila Black, Charlotte Murray, Stewart Larking, and Joannah Duncan, who measurably improved upon the 1st edition with this larger and more complex version. To Debbie Maizels, Philip Wilson, and Graeme Chambers, who so meticulously and artistically brought the concept to life via the illustrations. To my proofreaders Felicity Myers and Edward Myers, whose timely and tireless work has improved the sense and sensibility of this book.

To my daughter Mistral and her mother Giselle, who enthusiastically and good-naturedly tolerated my fascination with the world of human movement, which often led me far from home, and took up a great deal of time which might otherwise have been theirs. And finally to Quan, my friend, 'mostly companion', and my muse, who has contributed the silent but potent currents of love, depth, and a connection to a greater reality that run below the surface of this and all my work.

References

1. Fuller B. Utopia or oblivion. New York: Bantam Books; 1969. (Further information and publications can be obtained from the Buckminster Fuller Institute, www.bfi.com)
2. Rolf I. Rolfing. Rochester VT: Healing Arts Press; 1977.
3. Feldenkrais M. The case of Nora. New York: Harper and Row; 1977.
4. Oschman J. Energy medicine. Edinburgh: Churchill Livingstone; 2000.
5. Schultz L, Feitis R. The endless web. Berkeley: North Atlantic Books; 1996.
6. Schleip R. Talking to fascia, changing the brain. Boulder, CO: Rolf Institute; 1992.
7. Juhan D. Job's body. Tarrytown, NY: Station Hill Press; 1987.
8. Iyengar BKS. Light on yoga. New York: Schocken Books; 1995.

- 
- Silva M, Mehta S. Yoga the Iyengar way. New York: Alfred Knopf; 1990.
- Cohen B. Sensing, feeling, and action. Northampton, MA: Contact Editions; 1993.
- Aston J. Aston postural assessment workbook. San Antonio, TX: Therapy Skill Builders; 1998.
12. McHose C, Frank K. How life moves. Berkeley: North Atlantic Books; 2006.
13. Hatch F, Maietta L. Role of kinesthesia in pre- and perinatal bonding. *Pre- and Perinatal Psychology* 1991; 5(3). (*Further information can be obtained from: Touch in Parenting, Rt 9, Box 86HM, Santa Fe, NM 87505*)

How to use this book

Anatomy Trains is designed to allow the therapist or general reader to gather the general idea quickly or to allow a more detailed reading in any given area. The book includes forays into several related areas, designated in the margins next to the headings by icons:



Manual techniques or notes for the manual therapist



Movement techniques or notes for the movement therapist



Visual assessment tools



Ideas and concepts related to kinesthetic education



Video material on the DVD accompanying this book. Numbering relates to relevant entries on DVD



Video material on educational DVDs available from www.anatomytrains.com



Return to main text

The chapters are color-coded for easy location with a thumb. The first two chapters examine fascia, the myofascial meridians concept, and explain the 'Anatomy Trains' approach to the body's anatomical structures. Chapters 3-9 elaborate on each of the 12 main 'lines' of the body commonly seen in postural and movement patterns.

Each of the 'lines' chapters opens with summary illustrations, descriptions, diagrams and tables for the reader who wants to grasp the scope of the concept quickly. The final two chapters apply the 'Anatomy Trains' concept to some common types of movement and provide a method of analyzing posture.

Because individual muscles and other structures can make an appearance in different lines, the index can be used to find all mentions of any particular structure. A Glossary of 'Anatomy Trains' terms is also included.

Three Appendices appear at the end. These include a discussion of the latitudinal meridians of Dr Louis Schultz, a new explanation of how the Anatomy Trains schema can be applied to Ida Rolf's Structural Integration protocol, and a correlation between the meridians of acupuncture and these myofascial meridians.

The accompanying DVD also includes several videos useful to the interested reader, teacher, or presenter.

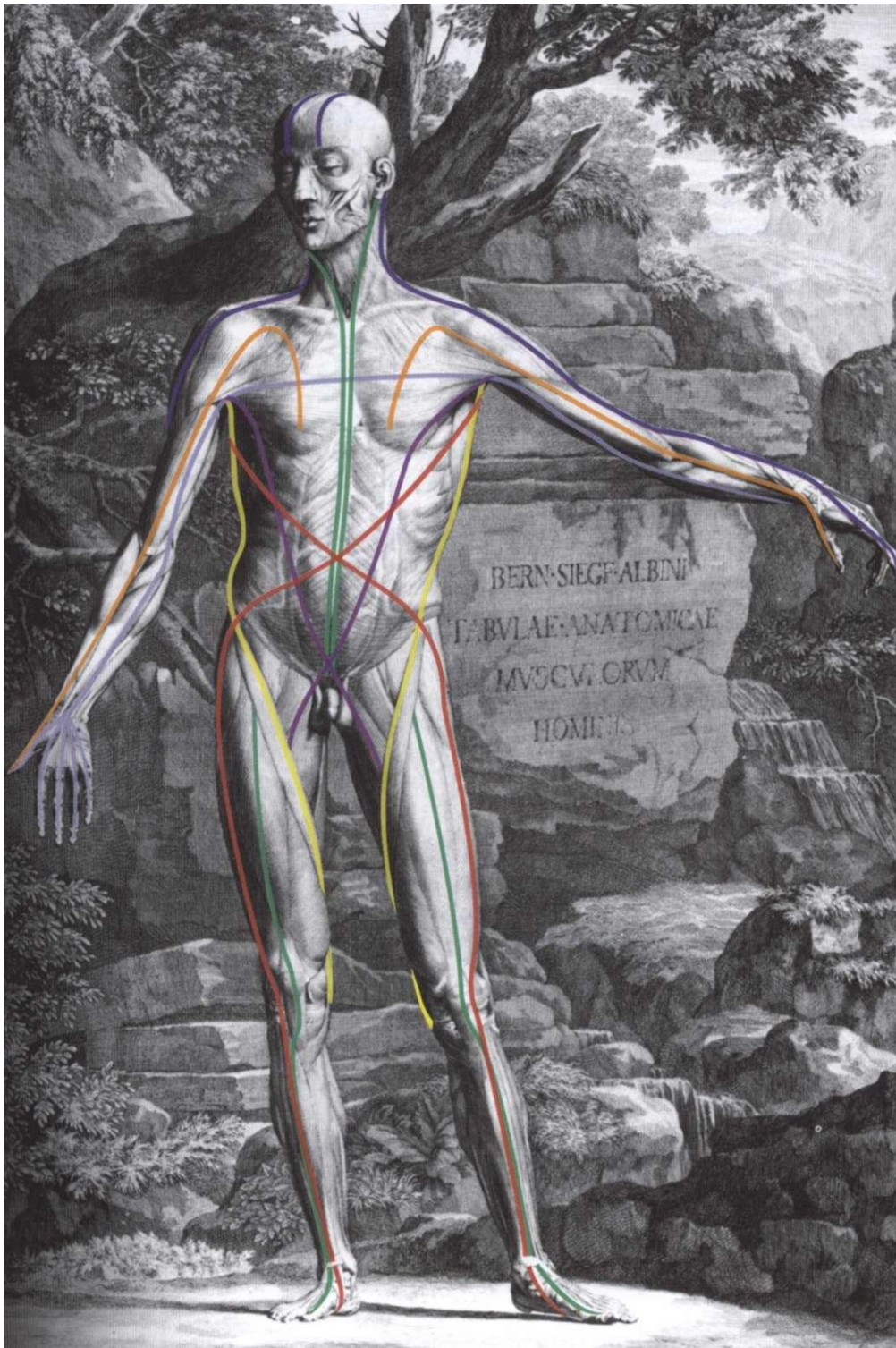



Fig. In. 1 A general Anatomy Trains 'route map' laid out on the surface of a familiar figure from Albinus. (Saunders JB, O'Malley C. The illustrations from the works of Andreas Vesalius of Brussels. Dover Publications; 1973.)

Introduction: laying the railbed



The hypothesis

The basis for this book is simple: whatever else they may be doing individually, muscles also influence functionally integrated body-wide continuities within the fascial webbing. These sheets and lines follow the warp and weft of the body's connective tissue fabric, forming traceable 'meridians' of myofascia (**Fig. In. 1**). Stability, strain, tension, fixation, resilience, and - most pertinent to this text - postural compensation, are all distributed via these lines. (No claim is made, however, for the exclusivity of these lines. The functional connections such as those described at the end of this introduction, the ligamentous bed described as the 'inner bag' in Chapter 1, and the latitudinal shouldering of strain detailed in the work of Huijing, also in Chapter 1, are all alternate avenues for the distribution of strain and compensation.)

Essentially, the Anatomy Trains map provides a 'longitudinal anatomy' - a sketch of the long tensile straps and slings within the musculature as a whole. It is a systemic point of view offered as a supplement (and in some instances as an alternative) to the standard analysis of muscular action.

This standard analysis could be termed the 'isolated muscle theory'. Almost every text presents muscle function by isolating an individual muscle on the skeleton, divided from its connections above and below, shorn of its neurological and vascular connections, and divorced from the regionally adjacent structures.¹¹⁰ This ubiquitous presentation defines a muscle's function solely by what happens in approximating the proximal and distal attachment points (**Fig. In. 2**). The overwhelmingly accepted view is that muscles attach from bone to bone, and that their sole function is to approximate the two ends together, or to resist their being stretched apart. Occasionally the role of myofascia relative to its neighbors is detailed (as in the role that the vastus lateralis takes in pushing out against and thus pre-tensing the iliotibial tract). Almost never are the longitudinal con-

nections between muscles and fasciae listed or their function discussed (as in, for instance, the large attachment between the iliacus muscle and the medial intermuscular septum of the thigh and vastus medialis - **Fig. In. 3**).

The absolute dominance of the isolated muscle presentation as the first and last word in muscular anatomy (along with the naïve and reductionistic conviction that the complexity of human movement and stability can be derived by summing up the action of these individual muscles) leaves the current generation of therapists unlikely to think in any other way.

This form of seeing and defining muscles, however, is simply an artifact of our method of dissection - with a knife in hand, the individual muscles are easy to separate from surrounding fascial planes. This does not mean, however, that this is how the body 'thinks' or is biologically assembled. One may question whether a 'muscle' is even a useful division to the body's own kinesiology.

If the elimination of the muscle as a physiological unit is too radical a notion for most of us to accept, we can tone it down in this way: In order to progress, contemporary therapists need to think 'outside the box' of this isolated muscle concept. Research supporting this kind of systemic thinking will be cited along the way as we work our way through the implications of moving beyond the 'isolated muscle' to see systemic effects. This book is an attempt to move ahead - not to negate, but to complement the standard view - by assembling linked myofascial structures in this image of the 'myofascial meridians'. We should be clear that 'Anatomy Trains' is not established science - this book leaps ahead of the research - but at the same time, we have been pleased with how well the concepts play out in clinical practice.

Once the particular patterns of these myofascial meridians are recognized and the connections grasped, they can be easily applied in assessment and treatment across a variety of therapeutic and educational

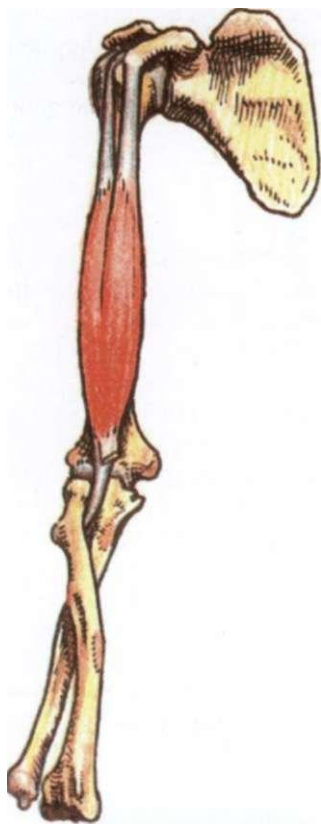
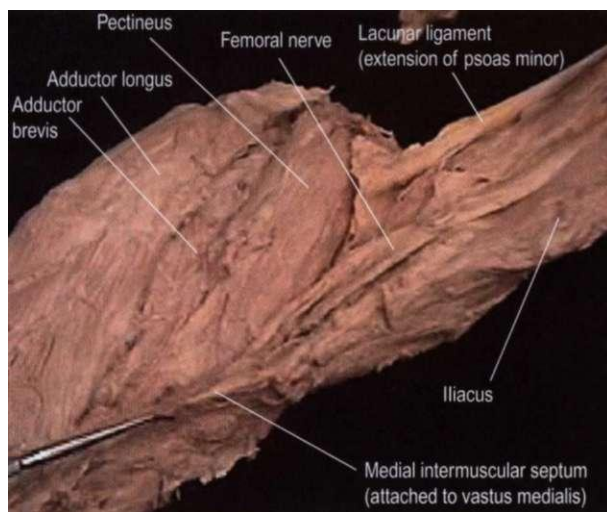


Fig. In. 2 The common method of defining muscle action consists of isolating a single muscle on the skeleton, and determining what would happen if the two ends are approximated, as in this depiction of the biceps. This is a highly useful exercise, but hardly definitive, as it leaves out the effect the muscle could have on its neighbors by tightening their fascia and pushing against them. It also, by cutting the fascia at either end, discounts any effect of its pull on proximal or distal structures beyond. These latter connections are the subject of this book. (Reproduced with kind permission from Grundy 1982.)



approaches to movement facilitation. The concepts can be presented in any of several ways; this text attempts to strike a balance that meets the needs of the informed therapist, while still staying within the reach of the interested athlete, client, or student.

Aesthetically, a grasp of the Anatomy Trains scheme will lead to a more three-dimensional feel for musculo-skeletal anatomy and an appreciation of whole-body patterns distributing compensation in daily and performance functioning. Clinically, it leads to a directly applicable understanding of how painful problems in one area of the body can be linked to a totally 'silent' area at some remove from the problem. Unexpected new strategies for treatment arise from applying this 'connected anatomy' point of view to the practical daily challenges of manual and movement therapy.

Though some preliminary dissective evidence is presented in this edition, it is too early in the research process to claim an objective reality for these lines. More examination of the probable mechanisms of communication along these fascial meridians would be especially welcome. As of this writing, the Anatomy Trains concept is presented merely as a potentially useful alternative map, a systems view of the longitudinal connections in the parietal myofascia.

The philosophy

The heart of healing lies in our ability to listen, to perceive, more than in our application of technique. That, at least, is the premise of this book.

It is not our job to promote one technique over another, nor even to posit a mechanism for how any technique works. All therapeutic interventions, of whatever sort, are a conversation between two intelligent systems. It matters not a whit to the myofascial meridians argument whether the mechanism of myofascial change is due to simple muscle relaxation, release of a trigger point, a change in the sol/gel chemistry of ground substance, viscoelasticity among collagen fibers, resetting of the muscle spindles or Golgi tendon organs, a shift in energy, or a change in attitude. Use the Anatomy Trains scheme to comprehend the larger pattern of your client's structural relationships, then apply whatever techniques you have at your disposal toward resolving that pattern.

These days, in addition to the traditional fields of physiotherapy, psychiatry, and orthopedics, there is a wide variety of soft tissue and movement methods on offer, and a wider circle of osteopathic, chiropractic, and energetic techniques, as well as somatically based psychotherapeutic interventions. New brand names sprout daily in the field, though in truth there is very little that is actually new under the sun of manipulation. We have seen that any number of angles of approach can be effective, regardless of whether the explanation offered for its efficacy ultimately prevails.

The current requirement is less for new technique, but rather for new premises that lead to new strategies for application, and useful new premises are a lot harder to come by than seemingly new techniques. Thus, significant developments are often opened by the point of view assumed, the lens through which the body is seen. The Anatomy Trains is one such lens - a global way of looking at musculoskeletal patterns that leads to new educational and treatment strategies.

Much of the manipulative work of the last 100 years, like most of our thinking in the West for at least half a millennium, has been based on a mechanistic and reductionistic model - the microscopic lens (**Fig. In. 4**). We keep examining things by breaking them down into smaller and smaller parts, to examine each part's role. Introduced by Aristotle, but epitomized by Isaac Newton and Rene Descartes, this mechanical type of approach has led, in the physical medicine field, to books filled with goniometric angles and force vectors based on drawing each individual muscle's insertion closer to the origin (**Fig. In. 5**). We have many researchers to thank for brilliant analysis and consequent work on specific muscles, individual joints, and particular impingements.¹¹⁻¹³

If you kick a ball, about the most interesting way you can analyze the result is in terms of the mechanical laws of force and motion. The coefficients of inertia, gravity, and friction are sufficient to determine its reaction to your kick and the ball's final resting place, even if you can 'bend it like Beckham'. But if you kick a large dog, such a mechanical analysis of vectors and resultant forces may not prove as salient as the reaction of the dog as a whole. Analyzing individual muscles biomechanically likewise yields an incomplete picture of human movement experience.

Early in the 20th century by means of Einstein, Bohr, and others, physics moved into a relativistic universe, a language of relationship rather than linear cause and effect, which Jung in turn applied to psychology, and many others applied to diverse areas. However, it took that entire century for this point of view to spread out

and reach physical medicine. This book is one modest step in this direction - general systems thinking applied to postural and movement analysis.

What can we learn from looking at synergetic relationships - stringing our parts together rather than dissecting them further?

It is not very useful merely to say 'everything is connected to everything else', and leave it at that. Even though it is ultimately true, such a premise leaves the practitioner in a nebulous, even vacuous, world with nothing to guide him but pure 'intuition'. Einstein's special theory of relativity did not negate Newton's laws of motion; rather it subsumed them in a larger scheme. Likewise, myofascial meridian theory does not eliminate the value of the many individual muscle-based techniques and analyses, but simply sets them in the context of the system as a whole. This scheme is generally a supplement to, not a replacement for, existing knowledge about muscles. In other words, the splenius capitis still rotates the head and extends the neck, *and* it operates, as we shall see, as part of spiral and lateral myofascial chains.

The myofascial meridians approach recognizes a pattern extant in the musculoskeletal system as a whole

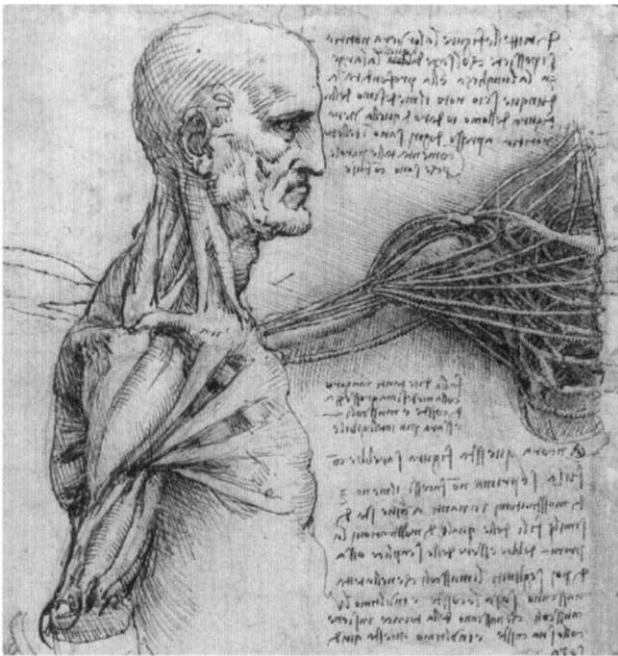


Fig. In. 4 Leonardo da Vinci, drawing without the pervasive prejudice of the mechanistic muscle-bone viewpoint, drew some remarkably 'Anatomy Train'-like figures in his anatomical notebooks.

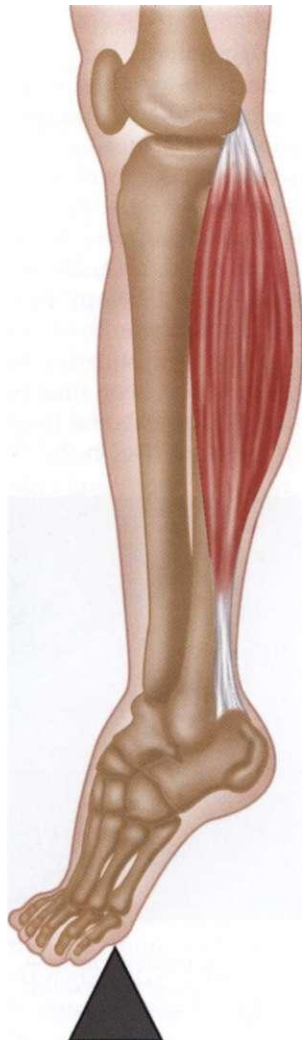

Fig. In. 5 The concepts of mechanics, applied to human anatomy, have given us much information about the actions of individual muscles in terms of levers, angles, and forces. But how much more insight will this isolating approach yield? (Reproduced with kind permission from Jarney 2004.f)

- one small aspect of this one system among the myriad rhythmic and harmonic patterns at play in the living body. As such, it is a small part of a larger re-vision of ourselves, not as Descartes' 'soft machines' but as integrated informational systems, what the non-linear dynamics mathematicians call autopoietic (self-forming) systems.¹⁴⁻¹⁸

Although attempts to shift our conceptual framework in a relational direction may sound fuzzy at first, compared to the crisp 'if... then...' statements of the mechanists, ultimately this new view leads to powerful integrative therapeutic strategies. These new strategies not only include the mechanics but also go beyond to say something useful about the systemic behavior of the whole unpredicted by summing up the behaviors of each individual part.

Anatomy Trains and myofascial meridians: what's in a name?

'Anatomy Trains' is a descriptive term for the whole schema. It is also a way of having a bit of fun with a fairly dense subject by providing a useful metaphor for the collection of continuities described in this book. The image of tracks, stations, switches and so on, is used throughout the text. A single Anatomy Train is an equivalent term for a myofascial meridian.

The word 'myofascia' connotes the bundled together, inseparable nature of muscle tissue (myo-) and its accompanying web of connective tissue (fascia), which comes up for a fuller discussion in Chapter 1 (**Fig. In. 6**).

Manual therapy of the myofasciae has spread quite widely among massage therapists, osteopaths, and physiotherapists from several modern roots. These include the work of my own primary teacher, Dr Ida Rolf,¹⁹ a UK version of NeuroMuscular Therapy promulgated by Dr Leon Chaitow,²⁰ and others, many of whom make various claims to originality, but who, in fact, are part of an unbroken chain of hands-on healers running back to Asklepios (*Lat*: Aesculapius), and from early Greece into the mists of pre-history (**Fig. In. 7**).^{21,22}

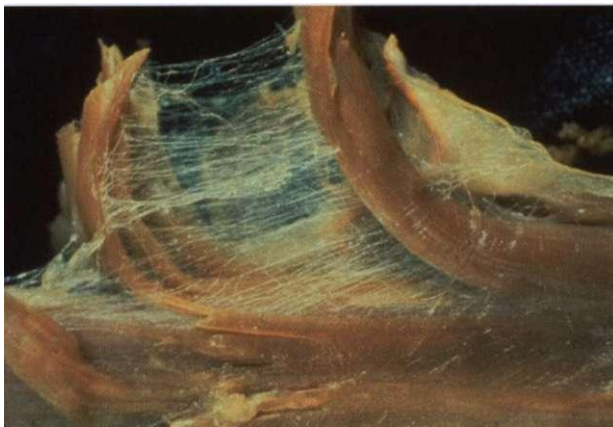

Fig. In. 6 A magnification of the myofascia: the 'cotton candy' is endomyesial collagen fibers enwrapping and thoroughly enmeshed with the fleshy (and teased up) muscle fibers. (Reproduced with kind permission from Ronald Thompson.)

While the term 'myofascial' has steadily gained currency over the last couple of decades, replacing 'muscle' in some texts, minds, and brand names, it is still widely misunderstood. In many applications of 'myofascial' therapies, the techniques taught are actually focused on individual muscles (or myofascial units, if we are to be precise), and fail to address specifically the communicating aspect of the myofasciae across extended lines and broad planes within the body.²³⁻²⁴ The Anatomy Trains approach, as we have noted, does not displace these techniques but simply adds a dimension of connectivity to our visual, palpatory, and movement considerations in assessment and treatment (**Fig. In. 8**). Anatomy Trains fills a current need for a global view of human structure and movement.

In any case, the word 'myofascial' is a terminological innovation only, since it has always been impossible, under whatever name, to contact muscle tissue at any time or place without also contacting and affecting the accompanying connective or fascial tissues. Even that inclusion is incomplete, since almost all of our interventions will also necessarily contact and affect neural, vascular, and epithelial cells and tissues as well. Nevertheless, the approach detailed in this book largely ignores these other tissue effects to concentrate on one aspect of the patterns of arrangement - the design, if you will - of the 'fibrous body' in the upright adult human. This fibrous body consists of the entire collagenous net, which includes all the tissues investing and attaching the organs as well as the collagen in bones, cartilage, tendons, ligaments, and the myofasciae. 'Myofasciae' specifically narrows our view to the muscle fibers embedded in their associated fasciae (as in **Fig. In. 6**). In order to simplify, and to emphasize a central tenet of this book - the unitary nature of the fascial web - this tissue will henceforth be referred to in its singular form: myofascia. There is really no need for a plural, because it arises from and remains all one structure. For the myofascia, only a knife creates the plural.

The term 'myofascial continuity' describes the connection between two longitudinally adjacent and aligned structures within the structural webbing. There is a



Fig. In. 7 Dr Ida P. Rolf (1896-1979), originator of the Structural Integration form of myofascial manipulation. (Reproduced with kind permission from Ronald Thompson.)

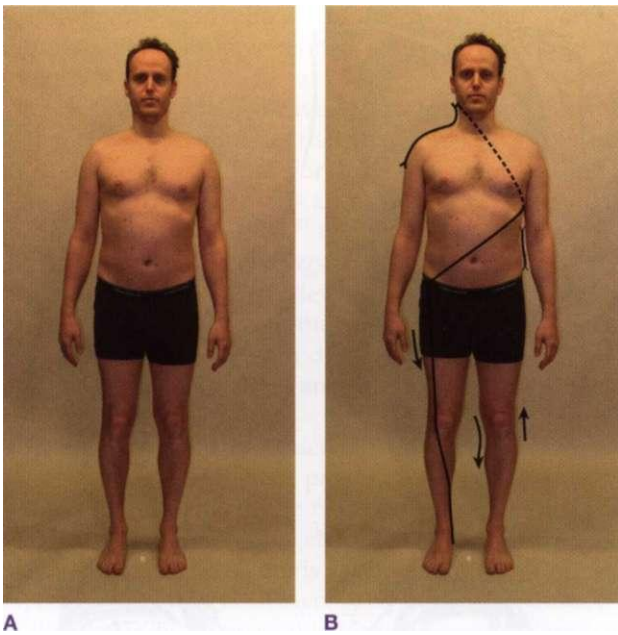


Fig. In. 8 Shortness within or displacement of the myofascial meridians can be observed in standing posture or in motion. These assessments lead to globally based treatment strategies. Can you look at A and see the shortnesses and shifts noted in B? (Photo courtesy of the author; for an explanation of the lines, see Ch. 11.) (DVD ref: BodyReading 101)

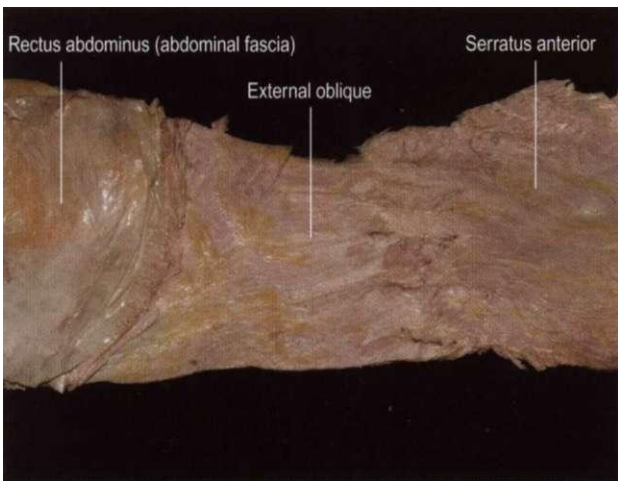


Fig. In. 9 Early dissective evidence seems to indicate a structural reality for these longitudinal meridians. Here we see how strong the fabric connection is between the serratus anterior muscle and the external oblique muscle, independent of the bones to which they attach. These 'interfascial' connections are rarely listed in anatomy texts. (Photo courtesy of the author; dissection by Laboratories of Anatomical Enlightenment.)

'myofascial continuity' between the serratus anterior muscle and the external oblique muscle (**Fig. In. 9**). 'Myofascial meridian' describes an interlinked series of these connected tracts of sinew and muscle. A myofascial continuity, in other words, is a local part of a myofascial meridian. The serratus anterior and external oblique are both part of the larger overall sling of the upper Spiral Line that wraps around the torso (**Fig. In. 10**).

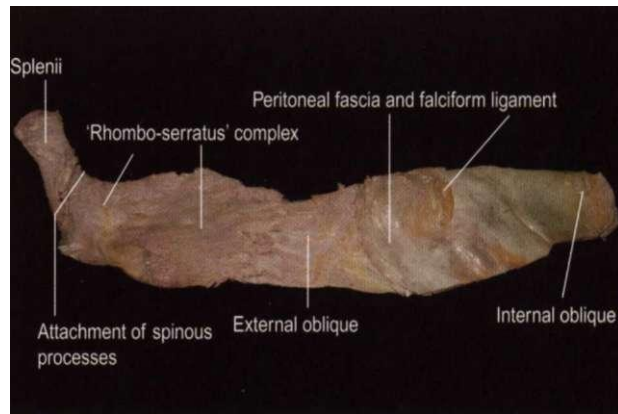


Fig. In. 10 The myofascial continuity seen in **Figure In. 9** is actually part of the larger 'meridian' shown here: The splenii in the neck are connected across the spinous processes to the contralateral rhomboids, which are in turn strongly connected to the serratus, and on around through the abdominal fasciae to the ipsilateral hip. This set of myofascial connections, which are of course repeated on the opposite side, become a focus for the mammalian ability to rotate the trunk, and are detailed in Chapter 6 on the Spiral Line. See **Figures 6.8** and **6.21** for comparison. (Photo courtesy of the author; dissection by Laboratories of Anatomical Enlightenment.) (DVD ref: Early Dissective Evidence)

The word 'meridian' is usually used in the context of the energetic lines of transmission in the domain of acupuncture.^{25,27} Let there be no confusion: the myofascial meridian lines are not acupuncture meridians, but lines of pull, based on standard Western anatomy, lines which transmit strain and movement through the body's myofascia around the skeleton. They clearly have some overlap with the meridians of acupuncture, but the two are not equivalent (see Appendix 3, p. 273). The use of the word 'meridians' has more to do, in the author's mind, with the meridians of latitude and longitude that girdle the earth (**Fig. In. 11**). In the same way, these meridians girdle the body, defining geography and geometry within the myofascia, the geodesies of the body's mobile tensegrity.

This book considers how these lines of pull affect the structure and function of the body in question. While many lines of pull may be defined, and individuals may set up unique strains and connections through injury, adhesion, or attitude, this book outlines twelve myofascial continuities commonly employed around the human frame. The 'rules' for constructing a myofascial meridian are included so that the experienced reader can construct other lines which may be useful in certain cases. The body's fascia is versatile enough to resist other lines of strain besides the ones listed herein as created by odd or unusual movements, readily seen in any roughhousing child. We are reasonably sure that a fairly complete therapeutic approach can be assembled from the lines we have included, though we are open to new ideas that further exploration and more in-depth research will bring to light (see Appendix 2, p. 259).

After considering human structure and movement from the point of view of the entire fascial web in Chapter

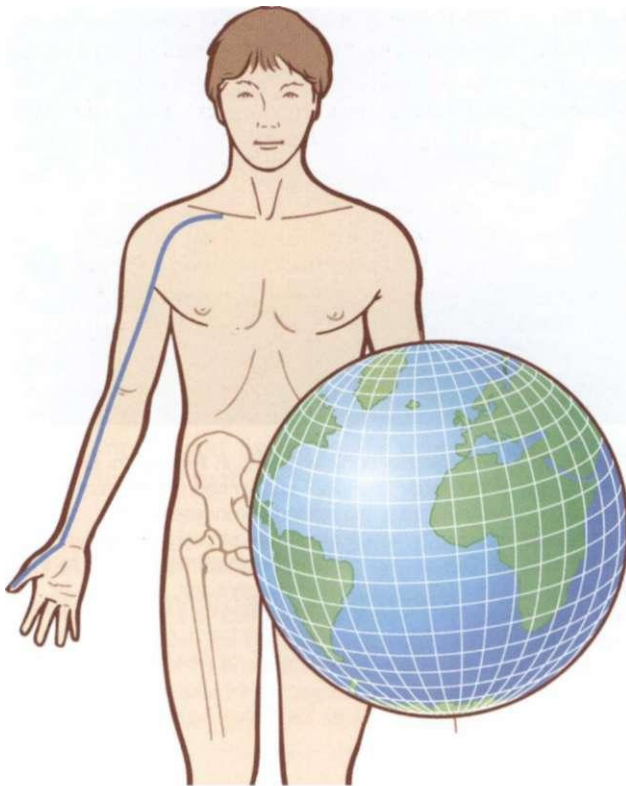


Fig. In. 11 Although the myofascial meridians have some overlap with oriental meridian lines, they are not equivalent. Think of these meridians as defining a 'geography' within the myofascial system. Compare the Lung meridian shown here to **Figures In. 1** and **7.1** - the Deep Front Arm Line. See also Appendix 3.

1, Chapter 2 sets up the rules and the scope for the Anatomy Trains concept. Chapters 3-9 present the myofascial meridian lines, and consider some of the therapeutic and movement-oriented implications of each line. Please note that in Chapter 3, the 'Superficial Back Line' is presented in excruciating detail in order to clarify the Anatomy Trains concepts. Subsequent chapters on the other myofascial meridians are laid out using the terminology and format developed in this chapter. Whichever line you are interested in exploring, it may help to read Chapter 3 first. The remainder of the book deals with global assessment and treatment considerations, which will be helpful in applying the Anatomy Trains concept, regardless of treatment method.

History

The Anatomy Trains concept arose from the experience of teaching myofascial anatomy to diverse groups of 'alternative' therapists, including Structural Integration practitioners at the Rolf Institute, massage therapists, osteopaths, midwives, dancers, yoga teachers, physiotherapists, and athletic trainers, principally in the USA, the UK, and Europe. What began literally as a game, an aide-memoire for my students, slowly coalesced into a system worthy of sharing. Urged to write by Dr Leon Chaitow, these ideas first saw light in the *Journal of Bodywork and Movement Therapies* in 1997.

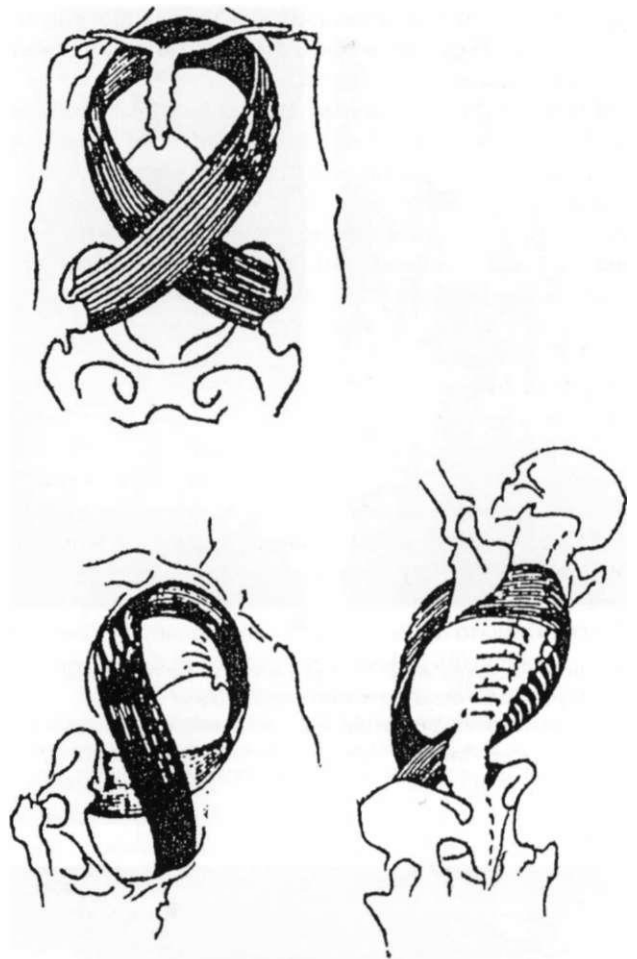


Fig. In. 12 Although Dart's original article contained no illustrations, this illustration from Manaka shows the same pattern Dart discussed, part of what we call the Spiral Line. (Reproduced from Manaka et al. Paradigm Publishers; 1995.)

Moving out from anatomical and osteopathic circles, the concept that the fascia connects the whole body in an 'endless web'²⁸ has steadily gained ground. Given that generalization, however, the student can be justifiably confused as to whether one should set about fixing a stubborn frozen shoulder by working on the ribs or the hip or the neck. The next logical questions, 'how, exactly, are these things connected?', or 'are some parts more connected than others?', had no specific answers. This book is the beginning of an answer to these questions from my students.

In 1986, Dr James Oschman,^{29,30} a Woods Hole biologist who has done a thorough literature search in fields related to healing, handed me an article by the South African anthropologist Raymond Dart on the double-spiral relationship of muscles in the trunk.³¹ Dart had unearthed the concept not from the soil of the australopithecine plains of South Africa, but out of his experience as a student of the Alexander Technique.³² The arrangement of interlinked muscles Dart described is included in this book as part of what I have termed the 'Spiral Line', and his article started a journey of discovery which extended into the myofascial continuities presented here (**Fig. In. 12**). Dissection studies, clinical

application, endless hours of teaching, and poring through old books have refined the original concept to its current state.

Over this decade, we have looked for effective ways to depict these continuities that would make them easier to understand and see. For instance, the connection between the biceps femoris and the sacrotuberous ligament is well documented,³³ while the fascial interlocking between the hamstrings and gastrocnemii at the lower end of **Figure In. 13** is less often shown. These form part of a head-to-toe continuity termed the Superficial Back Line, which has been dissected out intact in both preserved (see **Figs In. 3 and In. 10**) and fresh-tissue cadavers (**Fig. In. 14**).

The simplest way of depicting these connections is as a geometric line of pull passing from one 'station' (muscle attachment) to the next. This one-dimensional view is included with each chapter (**Fig. In. 15**). Another way to consider these lines is as part of a plane of fascia, especially the superficial layers and the fascial 'unitard' of the profundis layer, so this two-dimensional 'area of influence' is also included for some lines (**Fig. In. 16**). Principally, these lines are collections of muscles and their accompanying fascia, a three-dimensional volume - and this volumetric view is featured in three views at the beginning of each chapter (**Fig. In. 17**).

Additional views of the Anatomy Trains in motion have been developed for our video series (**Fig. In. 18**),

and for a Primal Pictures DVD-ROM product (**Fig. In. 19**). Stills from these sources have been used here when they shed additional light. As well, we have used still photos of action and standing posture with the lines superimposed to give some sense of the lines *in vivo* (**Figs In. 20 and In. 21**).

Although I have not seen the myofascial continuities completely described elsewhere, I was both chagrined (to find out that my ideas were not totally original) and relieved (to realize that I was not totally off-track) to discover, after I had published an early version of these ideas,^{33,34} that similar work had been done by some German anatomists, such as Hoepke, in the 1930s (**Fig. In. 22**).³⁵ There are also similarities with the *chaines musculaires* of Francoise Meziere^{36,37} (developed by Leopold Busquet), to which I was introduced prior to completing this book. These *chaines musculaires* are based on *functional* connections - passing, for instance, from the quadriceps through the knee to the gastrocnemii and soleus - whereas the Anatomy Trains are based on direct *fascial* connections (**Fig. In. 23**). The more recent diagrams

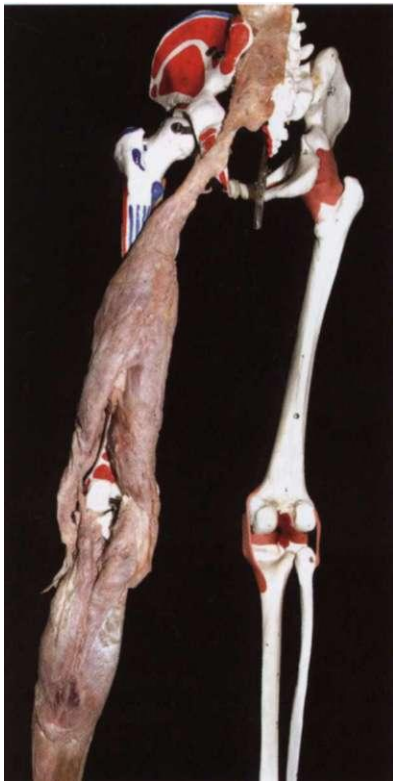


Fig. In. 13 The hamstrings have a clear fibrous fascial continuity with the sacrotuberous ligament fibers. There is also a fascial continuity between the distal hamstring tendons and the heads of the gastrocnemii, but this connection is often cut and seldom depicted. (Photo courtesy of the author; dissection by Laboratories of Anatomical Enlightenment.)

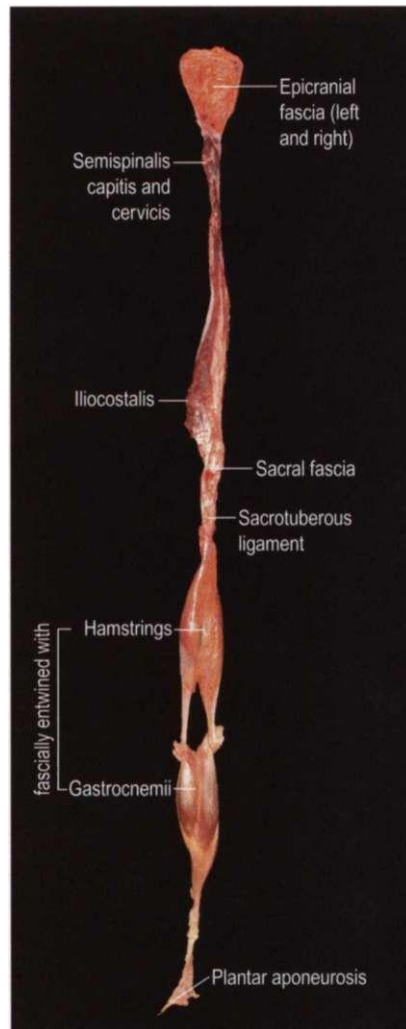


Fig. In. 14 A similar Superficial Back Line dissected intact from a fresh-tissue cadaver. (Photo courtesy of the author; dissection by Laboratories of Anatomical Enlightenment.) (DVD: A video of this specimen is on the DVD accompanying this book)



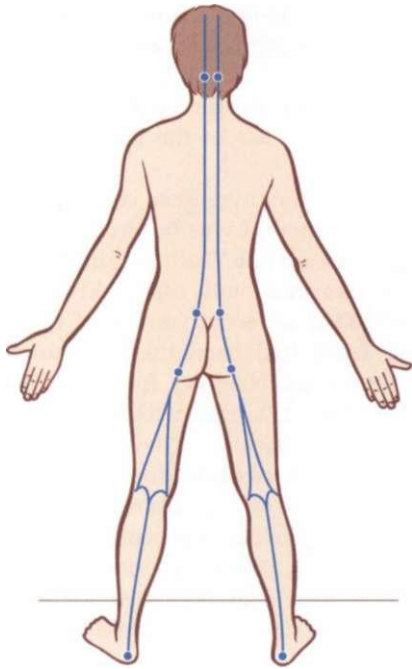


Fig. In. 15 The Superficial Back Line shown as a one-dimensional line - the strict line of pull.

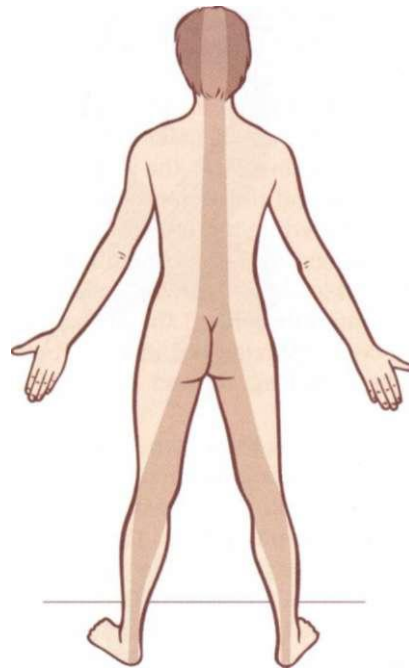


Fig. In. 16 The Superficial Back Line shown as a two-dimensional plane - the area of influence.

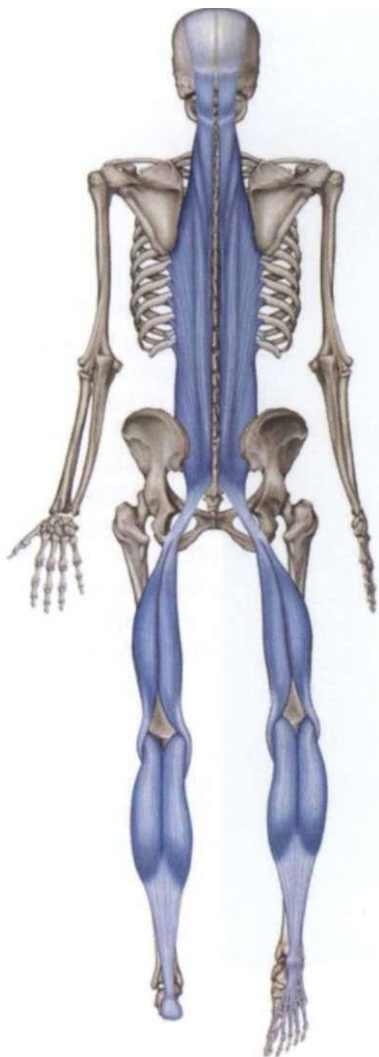

Fig. In. 17 The Superficial Back Line shown as a three-dimensional volume - the muscles and fasciae involved.

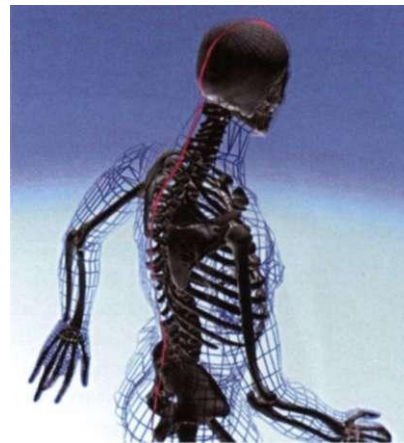


Fig. In. 18 A still from the computer graphic video of the Superficial Back Line. (Graphic courtesy of the author and Videograf, NYC.) (DVD: A computer graphic video of this and the other lines are on the DVD accompanying this book)

of the German anatomist Tittel are likewise based on functional, rather than fascial, linkages, passing through bones with gay abandon (**Fig. In. 24**).³⁹ All of these 'maps' have some overlap with the Anatomy Trains, and their pioneering work is acknowledged with gratitude.

Since publication of the 1st edition, I have also become aware of the work of Andry Vleeming and associates on 'myofascial slings' in relation to force closure of the sacroiliac joint,^{39,40} especially as applied clinically by the incomparable Diane Lee⁴¹ (**Fig. In. 25**). Vleeming's

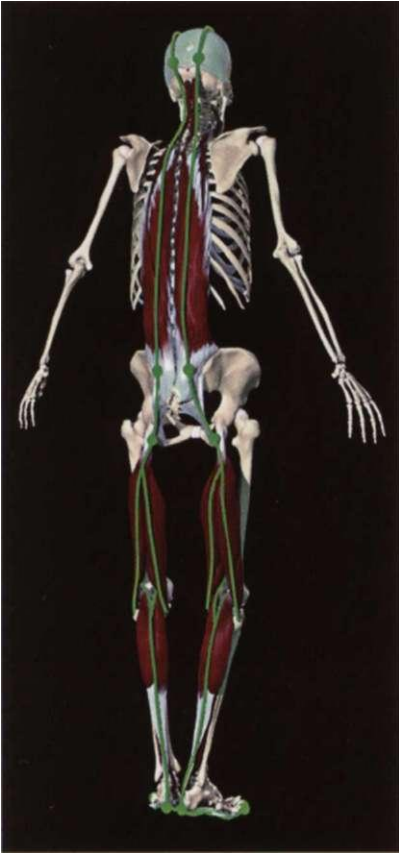

Fig. In. 19 A still from the Primal Pictures DVD-ROM program on the Anatomy Trains. (Image provided courtesy of Primal Pictures, www.primalpictures.com.) (DVD ref: Primal Pictures Anatomy Trains)




Fig. In. 20 The lines in action in sport - see Chapter 10. In this photo, the Superficial Front Line is lengthened and stretched, the Superficial Back Arm Line on the right side sustains the arm in the air, and the Superficial Front Arm Line on the left side is stretched from chest to thumb. The Lateral Line on the left side is compressed in the trunk, and its complement is conversely open. The right Spiral Line (not shown) is more shortened than its left counterpart.

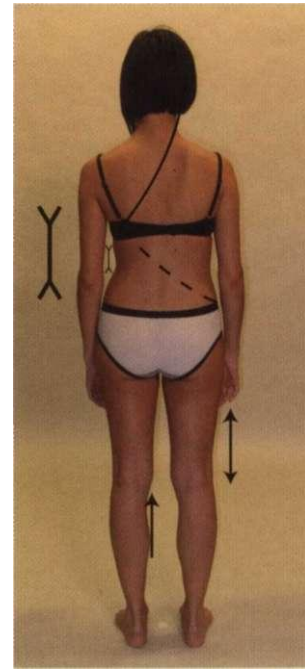


Fig. In. 21 The lines showing postural compensations - see Chapter 11. (Photo courtesy of the author.)

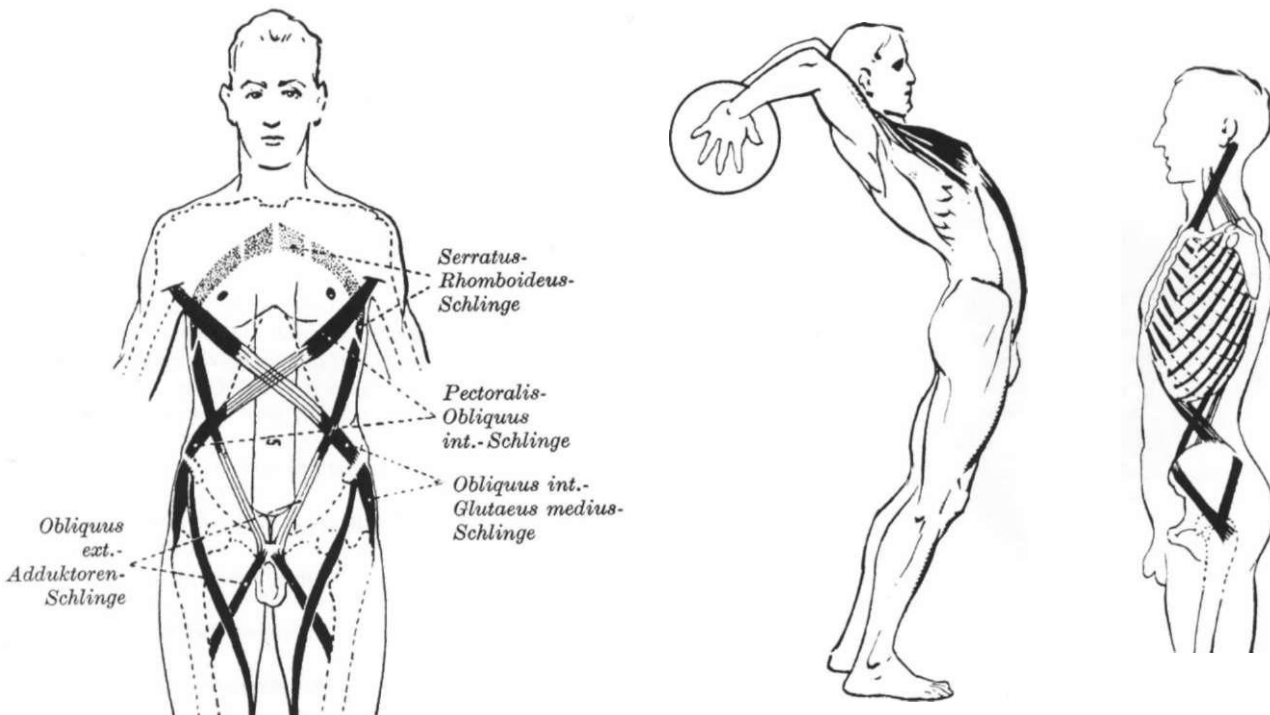


Fig. In. 22 The German anatomist Hoepke detailed some 'myofascial meridians' in his 1936 book, which translates into English as 'Muscle-play'. Less exact but similar ideas can be found in Mollier's *Plastische Anatomie* (Mollier 1938). (Reproduced with kind permission from Hoepke H, *Das Muskelspiel des Menschen*, G Fischer Verlag, Stuttgart 1936 with kind permission from Elsevier.)

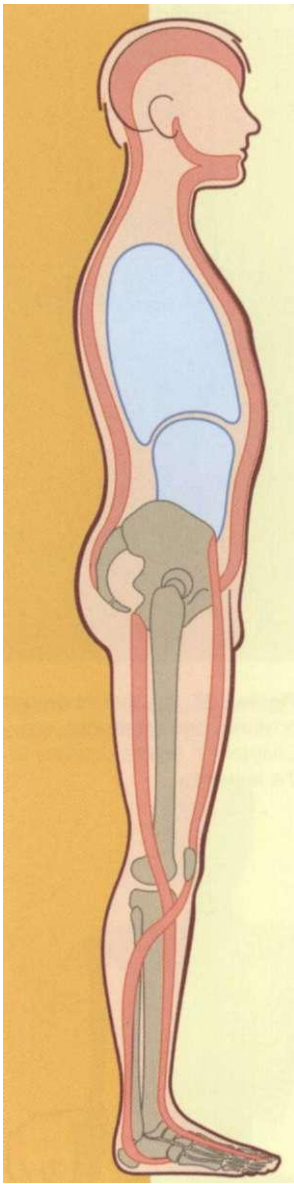
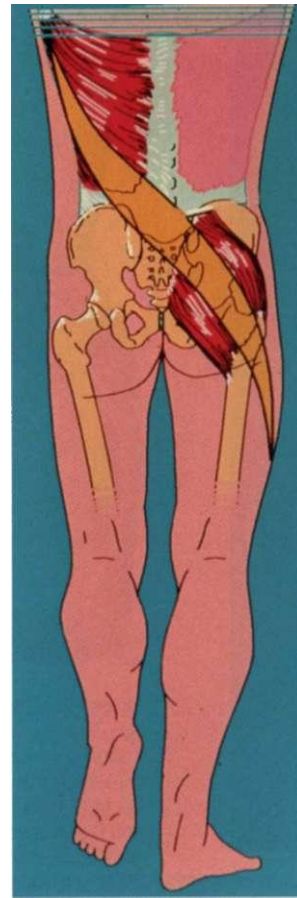
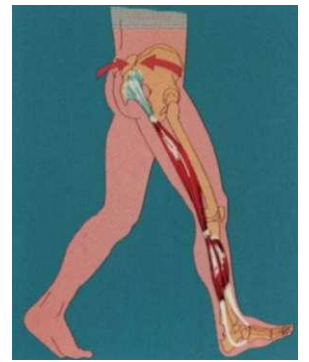


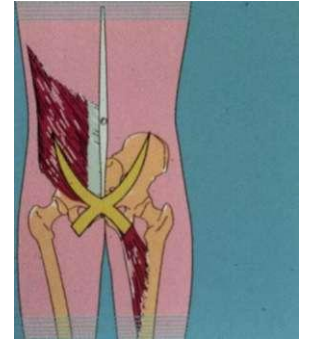
Fig. In. 23 The French physiotherapist Leopold Busquet, following Frangoise Meziere, termed his muscle linkages '*chaines musculaires*', but his concept of the linkages is functional, whereas the Anatomy Trains linkage is fascial. Notice, for instance, how the lines cross from front to back at the knee. Such connections are not 'allowed' in myofascial meridians theory. (Diagram reproduced from Busquet 1992 (see also www.chainesmusculaire.com.)



A



B



C

Fig In. 25 Andry Vleeming and Diane Lee described the Anterior and Posterior oblique slings, very similar to the Front and Back Functional Lines described in this book (and very similar to the *ligne de fermeture* and *ligne d'ouverture* described by Meziere). Vleeming's Posterior longitudinal sling is contained within the Superficial Back Line in this text. (A. Modified from Vleeming et al 1995⁴² with kind permission; B. reproduced from Vleeming & Stoekhart 2007⁴³ with kind permission; C. reproduced from Lee 2004 with kind permission.)



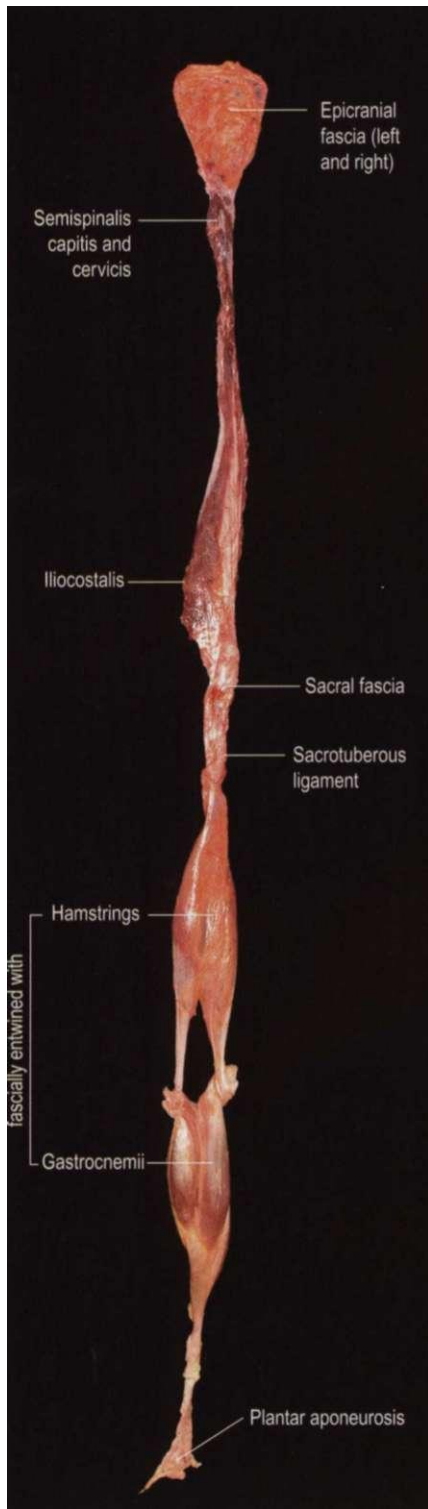
Fig. In. 24 The German anatomist Tittel also drew some marvelously athletic bodies overlaid with functional muscular connections. Once again, the difference is between these muscular functional connections, which are movement-specific and momentary, and the Anatomy Trains fascial 'fabric' connections, which are more permanent and postural. (Reproduced with kind permission from Tittel: *Beschreibende und funktionelle Anatomie des Menschen*, 14th edition © Elsevier GmbH, Urban & Fischer Verlag Munich).

Anterior Oblique sling and Posterior Oblique sling coincide generally with the Functional Lines to be found in Chapter 8 of this book, while his Posterior Longitudinal sling forms part of what is described in this book as the much longer Superficial Back Line (Ch. 3). As stated previously, the presumptuous book you hold in your hand reaches ahead of the research to present a point of view that seems to work well in practice but is yet to be validated in evidence-based publications.

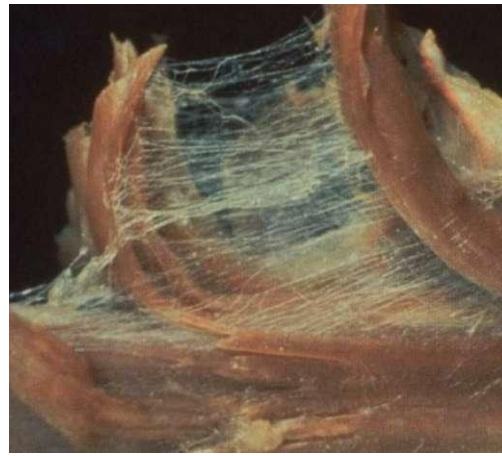
With the renewed confidence that comes from such confirmation accompanied by the caution that should pertain to anyone on such thin scientific ice, my colleagues and I have been testing and teaching a system of Structural Integration (Kinesis Myofascial Integration - www.anatomytrains.com, and see Appendix 2, p. 259) based on these Anatomy Trains myofascial meridians. Practitioners coming from these classes report significant improvement in their ability to tackle complex structural problems with increasing success rates. This book is designed to make the concept available to a wider audience. Since the publication of the 1st edition in 2001, this intent has been realized: the Anatomy Trains material is in use around the world in a broad variety of professions.

References

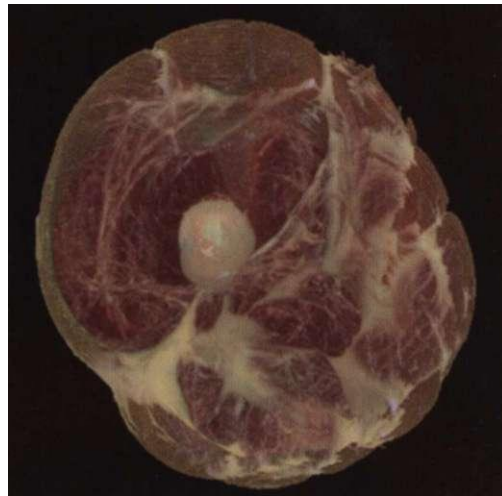
- Biel A. Trail guide to the body. 3rd edn. Boulder, CO: Discovery Books; 2005.
- Chaitow L, DeLany J. Clinical applications of neuromuscular techniques. Vols 1,2. Edinburgh: Churchill Livingstone; 2000.
- Jarmey C. The atlas of musculoskeletal anatomy. Berkeley: North Atlantic Books; 2004.
- Kapandji I. Physiology of the joints. Vols 1-3. Edinburgh: Churchill Livingstone; 1982.
- Muscolino J. The muscular system manual. Hartford, CT: JEM Publications; 2002.
- Platzer W. Locomotor system. Stuttgart: Thieme Verlag; 1986.
- Simons D, Travell J, Simons L. Myofascial pain and dysfunction: the trigger point manual. Vol. 1. Baltimore: Williams and Wilkins; 1998.
- Schuenke M, Schulte E, Schumaker U. Thieme atlas of anatomy. Stuttgart: Thieme Verlag; 2006.
- Luttgens K, Deutsch H, Hamilton N. Kinesiology. 8th edn. Dubuque, IA: WC Brown; 1992.
- Kendall F, McCreary E. Muscles, testing and function. 3rd edn. Baltimore: Williams and Wilkins; 1983.
- Fox E, Mathews D. The physiological basis of physical education. 3rd edn. New York: Saunders College Publications; 1981.
- Alexander RM. The human machine. New York: Columbia University Press; 1992.
- Hildebrand M. Analysis of vertebrate structure. New York: John Wiley; 1974.
- Prigogine I. Order out of chaos. New York: Bantam Books; 1984.
- Damasio A. Descartes mistake. New York: GP Putnam; 1994.
- Gleick J. Chaos. New York: Penguin; 1987.
- Briggs J. Fractals. New York: Simon and Schuster; 1992.
- Sole R, Goodwin B. Signs of life: How complexity pervades biology. New York: Basic Books; 2002.
- Rolf I. Rolfing. Rochester, VT: Healing Arts Press; 1977. *Further information and publications concerning Dr Rolf and her methods are available from the Rolf Institute, 295 Canyon Blvd, Boulder, CO 80302, USA.*
- Chaitow L. Soft-tissue manipulation. Rochester, VT: Thorson; 1980.
- Sutcliffe J, Duin N. A history of medicine. New York: Barnes and Noble; 1992.
- Singer C. A short history of anatomy and physiology from the Greeks to Harvey. New York: Dover; 1957.
- Barnes J. Myofascial release. Paoli, PA: Myofascial Release Seminars; 1990.
- Simons D, Travell J, Simons L. Myofascial pain and dysfunction: the trigger point manual. Vol. 1. Baltimore: Williams and Wilkins; 1998.
- Mann F. Acupuncture. New York: Random House; 1973.
- Ellis A, Wiseman N, Boss K. Fundamentals of Chinese acupuncture. Brookline, MA: Paradigm; 1991.
- Hopkins Technology LLC. Complete acupuncture. CD-ROM. Hopkins, MN: Johns Hopkins University.
- Schultz L, Feitis R. The endless web. Berkeley: North Atlantic Books; 1996.
- Oschman J. Readings on the scientific basis of bodywork. Dover, NH: NORA; 1997.
- Oschman J. Energy medicine. Edinburgh: Churchill Livingstone; 2000.
- Dart R. Voluntary musculature in the human body: the double-spiral arrangement. British Journal of Physical Medicine 1950; 13(12NS):265-268.
- Barlow W. The Alexander technique. New York: Alfred A Knopf; 1973.
- Myers T. The anatomy trains. Journal of Bodywork and Movement Therapies 1997; 1(2):91-101.
- Myers T. The anatomy trains. Journal of Bodywork and Movement Therapies 1997; 1(3):134-145.
- Hoepke H. Das Muskelspiel des Menschen. Stuttgart: Gustav Fischer Verlag; 1936.
- Godelieve D-S. Le manuel du mezieriste. Paris: Editions Frison-Roche; 1995.
- Busquet L. Les chaines musculaires. Vols 1-4. Freres, Mairlot; 1992. Maitres et Clefs de la Posture.
- Tittel K. Beschreibende und Funktionelle Anatomie des Menschen 14th edition. Munich: Urban & Fischer; 2003.
- Vleeming A, Stoeckart R, Volkens ACW et al. Relation between form and function in the sacroiliac joint. Part 1: Clinical anatomical concepts. Spine 1990; 15(2):130-132.
- Vleeming A, Volkens ACW, Snijders CA et al. Relation between form and function in the sacroiliac joint. Part 2: Biomechanical concepts. Spine 1990; 15(2):133-136.
- Lee DG. The pelvic girdle. 3rd edn. Edinburgh: Elsevier; 2004.
- Vleeming A, Pool-Goudzwaard AL, Stoeckart R, van Wingerden JP, Snijders CJ. The posterior layer of the thoracolumbar fascia: its function in load transfer from spine to legs. Spine 1995; 20:753.
- Vleeming A, Stoeckart R. The role of the pelvic girdle in coupling the spine and the legs: a clinical-anatomical perspective on pelvic stability. Ch. 8 In: Movement, stability & lumbopelvic pain, integration of research and therapy. Eds. Vleeming A, Mooney V, Stoeckart R. Edinburgh: Elsevier; 2007.



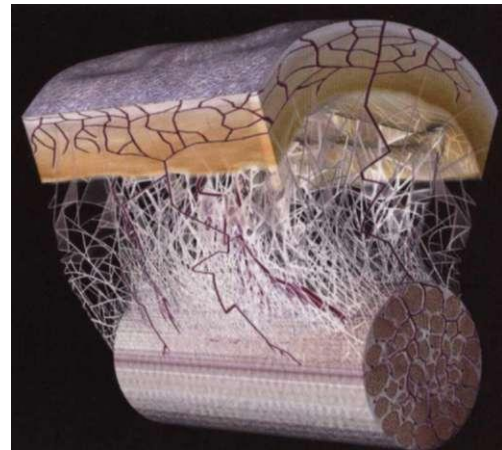
A



B



C



D

Fig. 1.1 (A) A fresh-tissue specimen of the myofascial meridian known as the Superficial Back Line, dissected intact by Todd Garcia from the Laboratories of Anatomical Enlightenment. (Photo courtesy of the author.) (DVD ref: This specimen is explained on video on the accompanying DVD) (B) A dissection of teased muscle fibers, showing surrounding and investing endomysial fascia. (Reproduced with kind permission from Ronald Thompson.) (DVD ref: This and other graphics are available and explained in **Fascial Tensegrity**, available from www.anatomytrains.com) (C) A section of the thigh, derived from the National Library of Medicine's Visible Human Project, using National Institute of Health software, by structural practitioner Jeffrey Linn. This gives us the first glimpse into what the fascial system would look like if that system alone were abstracted from the body as a whole. Once this process is complete for an entire body, a laborious process now underway, we will have a powerful new anatomical rendering of the responsive system that handles, resists and distributes mechanical forces in the body. (Reproduced from US National Library of Medicine's Visible Human Data® Project, with kind permission.) (DVD ref: This and other graphics are available and explained in **Fascial Tensegrity**, available from www.anatomytrains.com) (D) A diagram of the fascial microvacuole sliding system between the skin and the underlying tendons as described by Dr J. C. Guimberteau. (Diagram courtesy of Dr J. C. Guimberteau.) (DVD ref: **Strolling Under the Skin**, available from www.anatomytrains.com)

The world according to fascia



1

While everyone learns something about bones and muscles, the origin and disposition of the fascinating fascial net that unites them is less widely understood (**Fig. 1.1**). Although this situation is changing rapidly as increased research broadens our knowledge,¹ the vast majority of the public - and even most therapists and athletes - still base their thinking about their own structure and movement on the limited idea that there are individual muscles that attach to bones that move us around via mechanical leverage. As Schultz and Feitis put it:

The muscle-bone concept presented in standard anatomical description gives a purely mechanical model of movement. It separates movement into discrete functions, failing to give a picture of the seamless integration seen in a living body. When one part moves, the body as a whole responds. Functionally, the only tissue that can mediate such responsiveness is the connective tissue.²

In this chapter, we set a context for the Anatomy Trains by making a run at a holistic understanding of the mechanical role of fascia or connective tissue as an entirety (including, in this second edition, more recent research on its responsiveness and ability to remodel in the face of injury or new challenges) and interactions between the fascia and the cells of the other body systems.

DVD ref: The arguments made in this chapter are summarized in less detail on: Fascia! Tensegrity, available from www.anatomytrains.com.

Please note that this chapter presents a point of view, a particular set of arguments that build toward the Anatomy Trains concept, and is by no means the complete story on the roles or significance of fascia. Here, we go long on geometry, mechanics, and spatial arrangement, and drastically short on chemistry. We concern ourselves with the healthy supporting role of fascia in posture and movement, totally avoiding any discussion of pathology. Other more diverse and excellent descriptions are referenced here for the interested reader; the

more clinically minded may wish to skip this antipasti and go straight on to the main course which begins in Chapter 3.

'Blessed be the ties that bind': fascia holds our cells together

Life on this planet builds itself around a basic unit - the cell. Although we can easily imagine great globs of undifferentiated but still highly organized protoplasm, they do not exist, except in certain obscure tree molds or the minds of science fiction writers. For about one-half of the 4 billion years or so that life has existed on this planet, all organisms were single-celled - first as simple prokaryotic Protista, which apparently combined symbiotically to produce the familiar eukaryotic cell.³ All of the so-called 'higher' animals - including the humans who are the focus of this book - are coordinated aggregates of these tiny droplet complexes of integrated biochemistry contained within an ever-flowing fluid medium (we are still about two-thirds water), surrounded by constantly shifting membranes, all managed by stable self-replicating proteins in the nucleus. In our case, on the order of 10^{13} or 10^{14} (10-100 trillion) of these buzzing little cells somehow work together (with a vastly greater number of enteric bacteria) to produce the event we know as ourselves. We can recognize bundles of these cells even after years of not seeing them or from several blocks away by observing their characteristic manner of movement. What holds all our ever-changing soup of cells in such a consistent physical shape?

As in human society, cells within a multicellular organism combine individual autonomy with social interaction. In our own tissues, we can identify four basic classes of cells: neural, muscular, epithelial, and connective tissue cells (each with multiple subtypes) (**Fig. 1.2**). We could oversimplify the situation only a little by saying that each of these has emphasized one of the functions

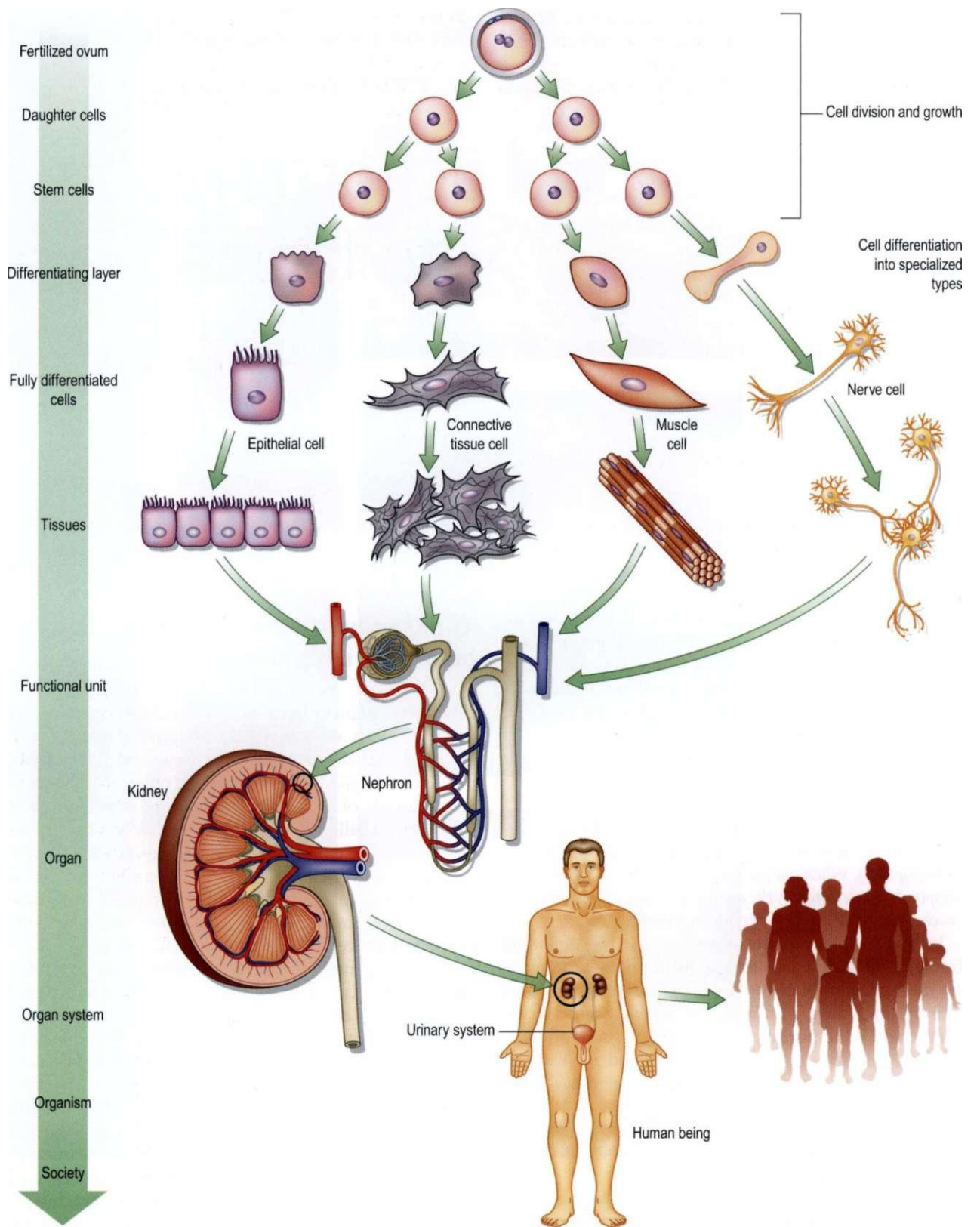


Fig. 1.2 Each of the body's major cell types specializes in one of the functions shared by the original ovum and the stem cells, e.g. secretion, conduction, contraction, or support. The specialized cells combine into tissues, organs, organisms, and societies.

shared by all cells in general (and the fertilized ovum and stem cells in particular). For instance, all cells conduct along their membranes, but nerve cells have become excellent at it (at a cost, incidentally, to their ability to contract or reproduce well). All cells contain at least some actin, and are thus capable of contraction, but muscle cells have become masters of the art. Epithelial cells also contract, but very feebly, while they specialize in lining surfaces and in the secretion of chemical products such as hormones, enzymes, and other messenger molecules.

Connective tissue cells are generally less effective at contraction (with one major exception explained later in this chapter) and only so-so as conductors, but they secrete an amazing variety of products into the intercellular space that combine to form our bones, cartilage, ligaments, tendons, and fascial sheets. In other words, it is these cells that create the structural substrate for all the others, building the strong, pliable 'stuff' which holds us together, forming the shared and communicative environment for all our cells - what Varela⁴ termed a form of 'exo-symbiosis' - shaping us and allowing us directed movement. (As an aside, we cannot let the word 'environment' enter our discussion without quoting from the master of the term, Marshall McLuhan:⁵ 'Environments are not passive wrappings, but are, rather, active processes which are invisible. The ground-rules, pervasive structure, and overall patterns of environments elude easy perception.' This may go some way toward explaining why the cellular environment of the extracellular matrix has remained essentially 'unseen' for some centuries of research.)

According to *Gray's Anatomy*:⁶

*Connective tissues play several essential roles in the body, both **structural**, since many of the extracellular elements possess special mechanical properties, and **defensive**, a role which has a cellular basis. They also often possess important trophic and morphogenetic roles in organizing and influencing the growth and differentiation of the surrounding tissues.*

We will leave the discussion of the defensive support offered by the connective tissue cells to the immunologists. We will touch on the trophic and morphogenetic role of connective tissues when we take up embryology and tensegrity later in this chapter.^{7,8} For now, we concern ourselves with the mechanical support role the connective tissue cell products offer the body in general and the locomotor system in particular.

The extracellular matrix

The connective tissue cells introduce a wide variety of structurally active substances into the intercellular space, including collagen, elastin, and reticulin fibers, and the gluey interfibrillar proteins commonly known as 'ground substance' or more recently as glycosaminoglycans or proteoglycans. Gray calls this proteinous mucopolysaccharide complex the extracellular matrix:

The term extracellular matrix (ECM) is applied to the sum total of extracellular substance within the connective tissue. Essentially it consists of a system of insoluble

protein fibrils and soluble complexes composed of carbohydrate polymers linked to protein molecules (i.e. they are proteoglycans) which bind water. Mechanically, the ECM has evolved to distribute the stresses of movement and gravity while at the same time maintaining the shape of the different components of the body. It also provides the physico-chemical environment of the cells imbedded in it, forming a framework to which they adhere and on which they can move, maintaining an appropriate porous, hydrated, ionic milieu, through which metabolites and nutrients can diffuse freely.⁹

This statement is rich, if a little dense; the rest of this chapter is an expansion on these few sentences, pictured in **Figure 1.3**.

Dr James Oschman refers to the ECM as the living matrix, pointing out that 'the living matrix is a continuous and dynamic "supermolecular" webwork extending into every nook and cranny of the body: a nuclear matrix within a cellular matrix within a connective tissue matrix. In essence, when you touch a human body, you are touching an intimately connected system composed of virtually all the molecules within the body linked together.'¹¹

Taken altogether, the connective tissue cells and their products act as a continuum, as our 'organ of form'.¹² Our science has spent more time on the molecular interactions that comprise our function while being less thorough on how we shape ourselves, move through environments, and absorb and distribute impact in all its forms - endogenous and exogenous. Our shape is said to be adequately described by anatomy, but how we think about shape results partly from the tools available to us. For the early anatomists, this was principally the knife. 'Anatomy' is, after all, separating the parts with a blade. From Galen through Vesalius and beyond, it was the tools of hunting and butchery which were applied to the body, and presented to us the fundamental distinctions we now take for granted (**Fig. 1.4**). These knives (later scalpels, and then lasers) quite naturally cut along the often bilaminar connective tissue barriers between different tissues, emphasizing the logical distinctions within the extracellular matrix, but obscuring the role of the connective tissue syncytium considered as a whole (**Figs 1.5, 7.15 and 7.29**).

If we imagine that instead of using a sharp edge we immersed an animal or a cadaver in some form of detergent or solvent which would wash away all the cellular material and leave only the connective tissue fabric (ECM), we would see the entire continuum, from the basal layer of the skin, through the fibrous cloth surrounding and investing the muscles and organs, and the leathery scaffolding for cartilage and bones (**Fig. 1.6A and B**). This would be very valuable in showing us this fascial organ as a continuum, emphasizing its uniting, shaping nature rather than simply seeing it as the line where separations are made (**Fig. 1.7**). This book proceeds from this idea and this chapter attempts to fill in such a picture.

We are going to refer, a bit improperly, to this body-wide complex as the fascia, or the fascial net. In medicine, the word 'fascia' is usually applied more narrowly

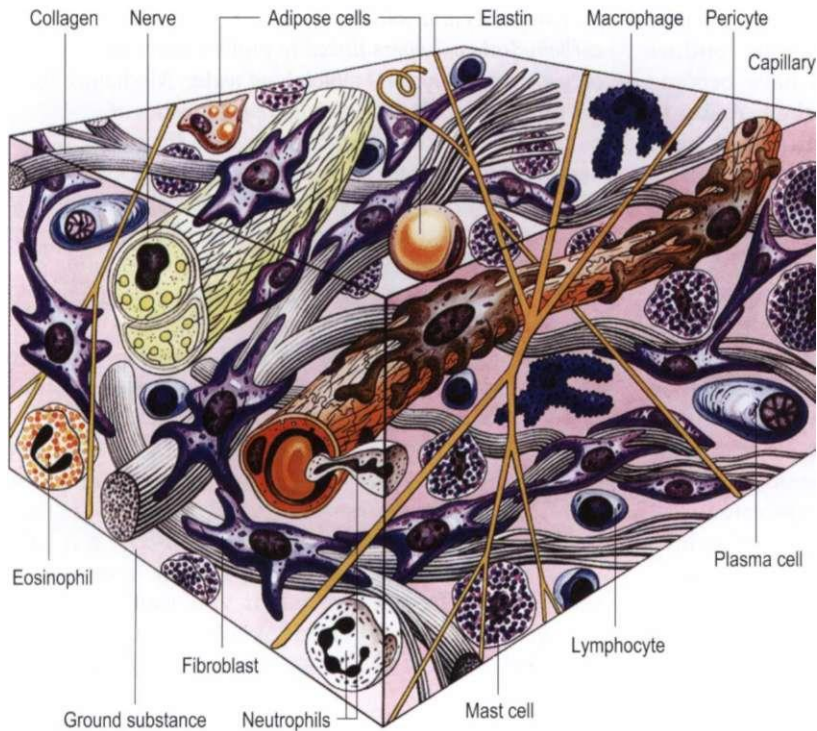


Fig. 1.3 All the connective tissues involve varying concentrations of cells, fibers, and interfibrillar ground substance (proteoglycans). (Reproduced with kind permission from Williams 1995.)

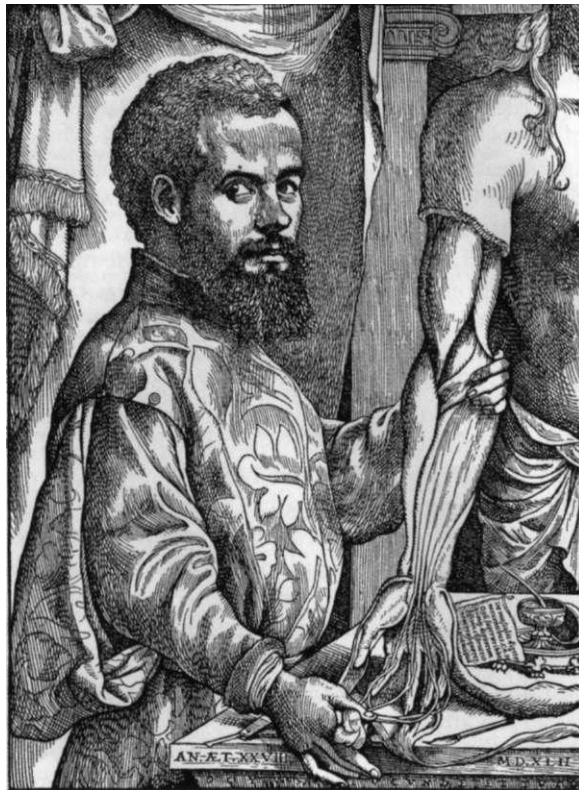


Fig. 1.4 Vesalius, like other early anatomists given the opportunity to study the human body, exposed the structures with a knife. This legacy of thinking into the body with a blade is with us still, affecting our thinking about what happens inside ourselves. 'A muscle' is a concept that proceeds from the scalpel approach to the body. (Reproduced with permission from Saunders JB, O'Malley C. Dover Publications: 1973.)

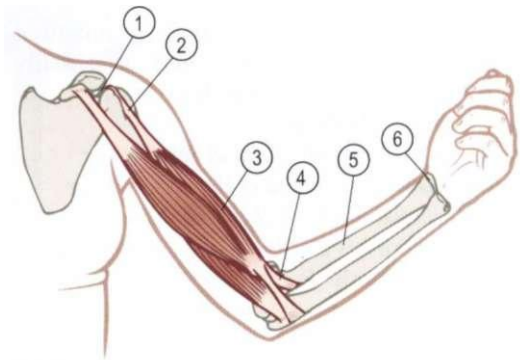
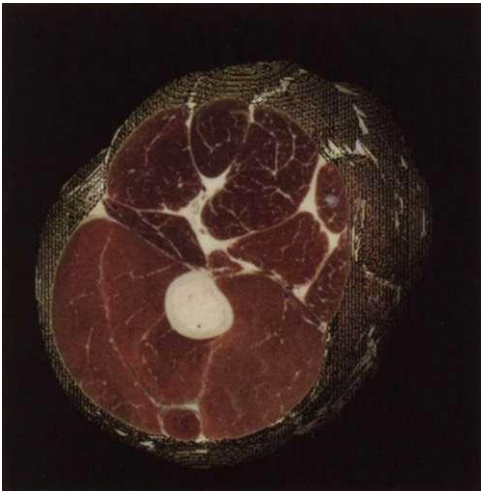

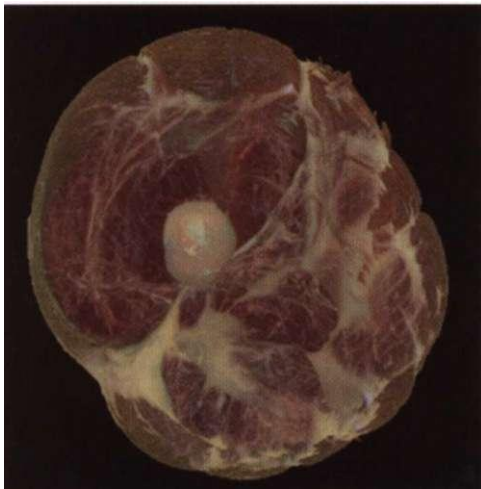
Fig. 1.5 The tensile part of mechanical forces is transmitted by the connective tissues, which are all connected to each other. The joint capsule (1) is continuous with the muscle attachment (2) is continuous with the epimysial fascia (3) is continuous with the tendon (4) is continuous with the periosteum (5) is continuous with the joint capsule (6), etc. For dissections of such continuities in the arm, see **Figures 7.7** and **7.29**.

to the large sheets and woven fabric that invest or surround individual muscles, but we choose to apply it more generally. All naming of parts of the body imposes an artificial, human-perceived distinction on an event that is unitary. Since we are at pains in this book to keep our vision on the whole, undivided, ubiquitous nature of this net, we choose to call it the fascial net. (If you wish, substitute 'collagenous network' or 'connective tissue webbing' or Gray's 'extracellular matrix'; here we will go with the simple 'fascia'.)

Connective tissue is very aptly named. Although its walls of fabric do act to direct fluids, and create discrete pockets and tubes, its uniting functions far outweigh its



A



B

Fig. 1.6 A section of the thigh, derived from the National Library of Medicine's Visible Human Project by Jeffrey Linn. The more familiar view in (A) includes muscle and epimysial fascia (but not the fat and areolar layers shown in Fig. 1.24). The view in (B) gives us the first glimpse into what the fascial system would look like if that system alone were abstracted from the body as a whole. (Reproduced from US National Library of Medicine's Visible Human Data® Project, with kind permission.)

separating ones. It binds every cell in the body to its neighbors and even connects, as we shall see, the inner network of each cell to the mechanical state of the entire body. Physiologically, according to Snyder,¹³ it also 'connects the numerous branches of medicine'.

Part of its connecting nature may lie in its ability to store and communicate information across the entire body. Each change in pressure (and accompanying tension) on the ECM causes the liquid crystal semiconducting lattice of the wet collagen and other proteins to generate bioelectric signals that precisely mirror the original mechanical information.¹⁴ The perineural system, according to Becker, is an ancient and important parallel to the more modern conduction along nerve membranes.¹⁵

Although there are a number of different cells within the connective tissue system - red blood cells, white blood cells, fibroblasts, mast cells, glial cells, pigment

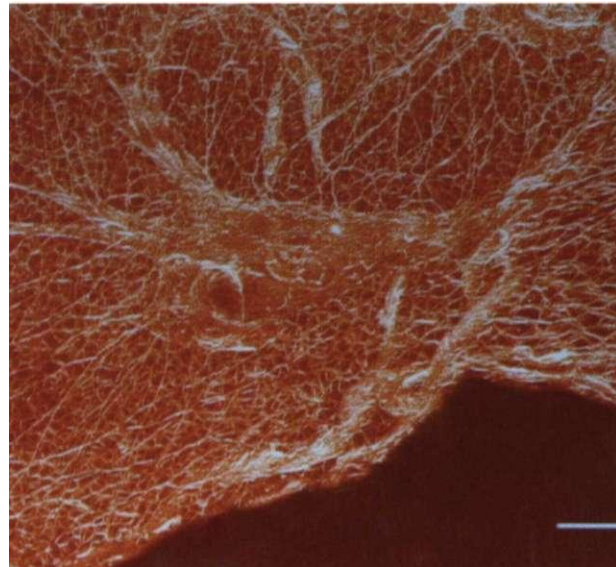


Fig. 1.7 The fascial matrix of the lower leg (of a rat), showing the histological continuity among synergistic and even antagonistic muscles. This 3-D reconstruction, using three frozen sections of the anterior and lateral crural compartments, enhances the connective tissue structures within each section. The smallest divisions are the endomysial fibers which surround each muscle fiber. The 'divisions' between these muscles - so sharp in our anatomy texts - are only barely discernable. (Used with kind permission from Prof. Peter Huijing, Ph.D., Faculteit Bewegingswetenschappen, Vrije Universiteit Amsterdam.)

cells, fat cells, and osteocytes among others - it is the fibroblasts and their close relatives that produce most of the fibrous and interfibrillar elements of such startling and utilitarian variety. It is to the nature of these intercellular elements that we now turn our attention.

The dramatis personae of the connective tissue elements is a short list, given that we are not going to explore the chemistry of its many minor variations. There are three basic types of fibers: collagen, elastin, and reticulin (Fig. 1.8). Reticulin is a very fine fiber, a kind of immature collagen that predominates in the embryo but is largely replaced by collagen in the adult. Elastin, as its name implies, is employed in areas such as the ear, skin, or particular ligaments where elasticity is required. Collagen, by far the most common protein in the body, predominates in the fascial net, and is readily seen - indeed, unavoidable - in any dissection or even any cut of meat. There are around 20 types of collagen fiber, but the distinctions need not concern us here, and Type 1 is by far the most ubiquitous in the structures under discussion. These fibers are composed of amino acids that are assembled like Lego® in the endoplasmic reticulum and Golgi complex of the fibroblast and then extruded into the intercellular space, where they form spontaneously (under conditions described below) into a variety of arrays. That the transparent cornea of the eye, the strong tendons of the foot, the spongy tissue of the lung, and the delicate membranes surrounding the brain are all made out of collagen tells us something about its utilitarian variety.

The ground substance is a watery gel composed of mucopolysaccharides or glycosaminoglycans such as hyaluronic acid, chondroitin sulfate, keratin sulfate, and heparin sulfate. These fern-like colloids, which are part of the environment of nearly every living cell, bind water in such a way as to allow the easy distribution of metabolites (at least, when the colloids are sufficiently hydrated), and form part of the immune system barrier, being very resistant to the spread of bacteria. Produced by the fibroblasts and mast cells, this proteoglycan forms a continuous but highly variable 'glue' to help the trillions of tiny droplets of cells both hold together and yet be free to exchange the myriad substances necessary for living. In an active area of the body, the ground substance changes its state constantly to meet local needs; in a 'held' or 'still' area of the body, it tends to dehydrate to become more viscous, more gel-like, and to become a repository for metabolites and toxins. The synovial

fluid in the joints and the aqueous humor of the eye are examples where ground substance can be seen in large quantities, but smaller amounts of it are distributed through every soft tissue.

How to build a body

To stand and walk, a human requires diverse and complex building materials. As a thought experiment, imagine that we were going to build a body out of things that could be bought in a local hardware store or builder's supply. We will imagine that we have already engaged Apple® (of course) to build the computer to run it, and that we have already obtained little servo-motors for the muscles, but what would we need to buy to build an actual working model of the body's structure? Put less archly, what kind of structural materials can connective tissue cells fashion?

You might suggest wood, PVC pipe, or ceramic for the bones, silicon or plastic of some sort for the cartilage, string, rope, and wire of all kinds, hinges, rubber tubing, cotton wool to pack the empty places, cling-wrap and plastic bags to seal things off, oil and grease to lubricate moving surfaces, glass for the lens of the eye, cloth and plastic sacks, filters and sponges of various kinds. And where would we be without Velcro® and duct tape?

The list could go on, but the point is made: connective tissue cells make biological correlates of all these materials and more, by playing creatively with cell function and the two elements of the ECM - the tough fiber matrix and the viscous ground substance. The fibers and ground substance, as we shall see, actually form a continuous spectrum of building materials, but the distinction between the two (non-water-soluble collagen fiber and hydrophilic proteoglycans) is commonly used. The ECM, as we will learn in the section on tensegrity, is actually continuous with the intracellular matrix as well, but for now, once again the distinction between what is outside the cell and what is inside is useful.¹⁶

Table 1.1 summarizes the way in which the cells alter the fibers and the interfibrillar elements of connective

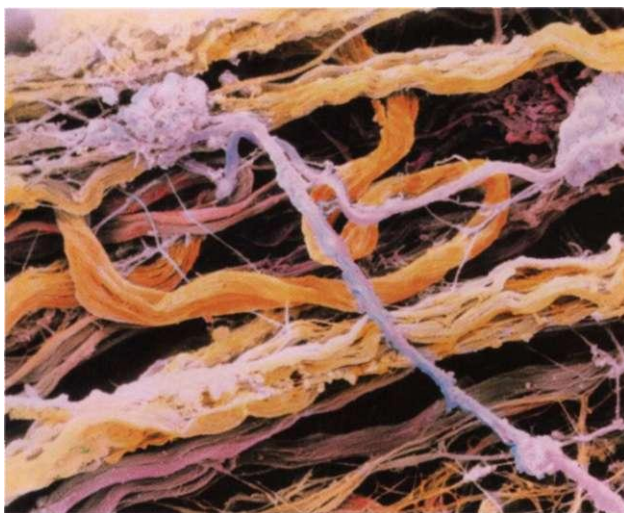

Fig. 1.8 This photomicrograph shows very clearly the fibroblasts extruding tropocollagen, which combines into the three-strand collagen molecule along the bottom. There are also bendy yellow elastin fibers, and the much smaller reticulin fibers (© Prof. P. Motta/Science Photo Library. Reproduced with kind permission.)

Table 1.1 Building materials

Tissue type	Cell	Fiber types (insoluble fiber proteins)	Interfibrillar elements, ground substance, water-binding proteins
Bone	Osteocyte, osteoblast, osteoclast	Collagen	Replaced by mineral salts, calcium carbonate, calcium phosphate
Cartilage	Chondrocyte	Collagen and elastin	Chondroitin sulfate
Ligament	Fibroblast	Collagen (and elastin)	Minimal proteoglycans between fibers
Tendon	Fibroblast	Collagen	Minimal proteoglycans between fibers
Aponeurosis	Fibroblast	Collagen mat	Some proteoglycans
Fat	Adipose	Collagen	More proteoglycans
Loose areolar	Fibroblasts, white blood cells, adipose, mast	Collagen and elastin	Significant proteoglycans
Blood	Red and white blood cells	Fibrinogen	Plasma

Connective tissue cells create a stunning variety of building materials by altering a limited variety of fibers and interfibrillar elements. The table shows only the major types of structural connective tissues, from the most solid to the most fluid.

tissue to form all the building materials necessary to our structure and movement.

Let us take a common example to help us understand the table: the bones you have found in the woods or seen in your biology classroom (presuming you are old enough to have handled real, as opposed to plastic, skeletons) are really only half a bone. The hard, brittle object we commonly call a bone is in fact only part of the material of the original bone - the calcium salts part, the interfibrillar part in the table. The fibrillar part, the collagen, had been dried or baked out of the bone at the time of its preparation; otherwise it would decay and stink.

Perhaps your science teacher helped you understand this by taking a fresh chicken bone and soaking it in vinegar instead of baking it. By doing this for a couple of days (and changing the vinegar once or twice), you can feel a different kind of bone. The acid vinegar dissolves the calcium salts and you are left with the fibrillar element of the bone, a gray collagen network the exact shape of the original bone, but much like leather. You can tie a knot in this bone. Living bone, of course, includes both elements, and thus combines the collagen's resistance to tensile and shearing forces with the mineral salt's reluctance to succumb to compressive forces.

To make the situation more complex (as it always is), the ratio between the fibrous element and the calcium salts changes over the course of your life. In a child, the proportion of collagen is higher, so that long bones will break less frequently, having more tensile resilience.¹⁷ When they do break, they will often break like a green twig in spring (**Fig. 1.9A**), fracturing on the side that is put into tension, and rucking up like a carpet on the side that goes into compression. Young bones are difficult to break, but also hard to set back together properly, though

they often mend quickly enough due to the responsiveness of the young system and the prevalence of collagen to reknit.

In an older person, by contrast, where the collagen is frayed and deteriorated, and thus the proportion of mineral salts is higher, the bone is likely to break like an old twig at the bottom of a pine tree (**Fig. 1.9B**), straight through the bone in a clean fracture. Easily put back in place but hard to heal, precisely because it is the network of collagen that must cross the break and reknit to itself first, to provide a fibrous scaffolding for the calcium salts to bridge the gap and recreate solid compressional support. For this reason, bone breaks in older people are often pinned, to provide solid contact between the surfaces for the extra time required for the remaining collagenous net to link up across the fracture.

Likewise, the various types of cartilage merely reflect different proportions of the elements within it. Hyaline cartilage - as in your nose - represents the standard distribution between collagen and the silicon-like chondroitin sulfate. Elastic cartilage - as in your ear - contains more of the yellowish elastin fibers within the chondroitin. Fibrocartilage - as in the pubic symphysis or intervertebral discs - has a higher proportion of tough fibrous collagen compared to the amount of silicon-like chondroitin.¹⁸ In this way, we can see that bone and cartilage are really dense forms of fascial tissue - a difference in degree, rather than a true difference in type.

In regard to fat, the experienced hands-on practitioner will recognize that some fat allows the intervening hand in easily, enabling the therapist to reach layers below the fat layer, while other fat is less malleable, seeming to repel the practitioner's hand and to resist attempts to feel through it. (No prejudice implied here, but certain former rugby players of the author's acquaintance come to mind.) The difference here is not so much in the chemistry of the fat itself, but in the proportion and density of the collagenous honeycomb of fascia that surrounds and holds the fat cells.

In summary, the connective tissue cells meet the combined need of flexibility and stability in animal structures by mixing a small variety of fibers - dense or loose, regularly or irregularly arranged - within a matrix that varies from quite fluid, to gluey, to plastic, and finally to crystalline solid.

Connective tissue plasticity

While the building metaphor goes some distance toward showing the variety of materials connective tissue has at its disposal, it falls short of the mark in portraying the versatility and responsiveness of the matrix even after it has been made and extruded into the intercellular space. Not only do connective tissue cells make all these materials, these elements also rearrange themselves and their properties - within limits, of course - in response to the various demands placed on them by individual activity and injury. How could supposedly 'inert' intercellular elements change in response to demand?

The mechanism of connective tissue response and remodeling is important to understand if we intend to

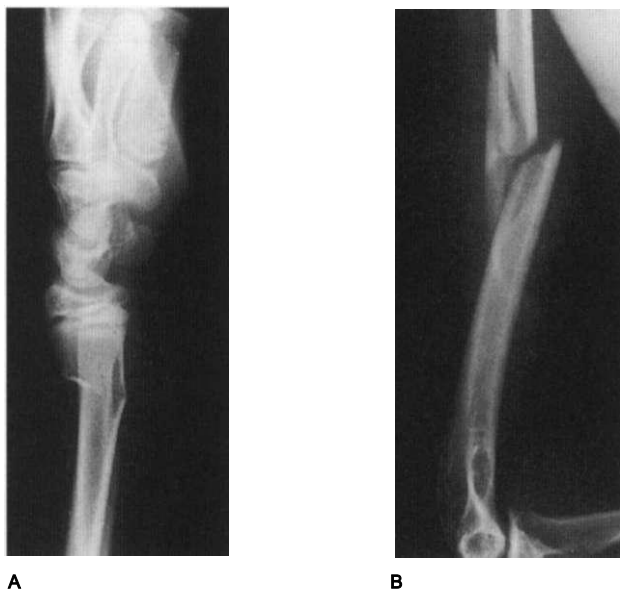

Fig. 1.9 (A) Young bone, with a higher fiber content, breaks like green wood. (B) Old bone, with a proportionally higher calcium apatite content, breaks like dry wood. (Reproduced with kind permission from Dandy 1998.)

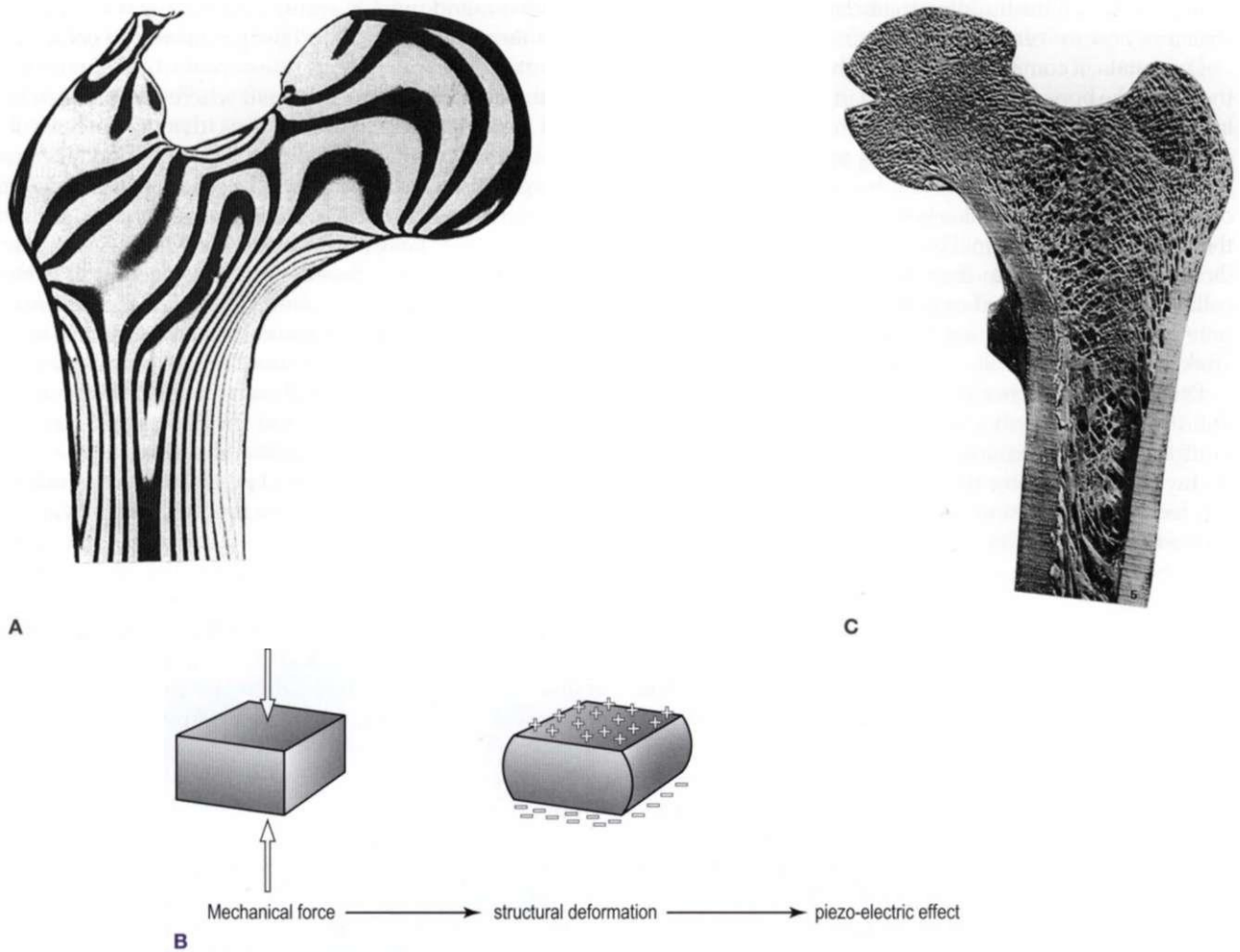


Fig. 1.10 'Virtually all the tissues of the body generate electrical fields when they are compressed or stretched [which are] representative of the forces acting on the tissues involved . . . containing information on the precise nature of the movements taking place. . . . One of the roles of this information is in the control of form' (Oschman 2000, p. 52). **(A)** Stress lines in a loaded plastic model of the femur. (Reproduced with kind permission from Williams 1995.) **(B)** Any mechanical force which creates structural deformation creates such a piezo-electric effect, which then distributes itself around the connective tissue system. (Reproduced with kind permission from Oschman 2000.) **(C)** The trabeculae of bone which form in response to individualized stresses. (Reproduced with kind permission from Williams 1995.)

intervene in human structure and movement. To continue the metaphor for a moment, the human body is a talented 'building' that is readily moveable, self-repairs if it is damaged, and actually reconstructs itself over both the short and medium term to respond to different 'weather conditions' such as a prevailing wind, a typhoon, or an extended drought.

Stress passing through a material deforms the material, even if only slightly, thereby 'stretching' the bonds between the molecules. In biological materials, among others, this creates a slight electric flow through the material known as a piezo- (pressure) electric charge (**Fig. 1.10A and B**).¹⁴ This charge can be 'read' by the cells in the vicinity of the charge, and the connective tissue cells are capable of responding by augmenting, reducing, or changing the intercellular elements in the area.

As an example, the head of most everyone's femur is made of cancellous, spongy bone. An analysis of the trabeculae within the bone shows that they are brilliantly constructed, to an engineer's eye, to resist the forces being transmitted from the pelvis to the shaft of

the femur. Such an arrangement provides the lightest bones within the parameters of safety, and could easily be explained by the action of natural selection. But the situation is more complex than that; the internal bone is shaped to reflect not only species' needs but also individual form and activity. If we were to section the femur of someone with one posture and someone else with a quite different posture and usage, we would see that each femoral head has slightly different trabeculae, precisely designed to best resist the forces which that particular person characteristically creates (**Fig. 1.10C**). In this way, the connective tissue responds to demand. Whatever demand you put on the body - continuous exertion or dedicated couch potato, running 50 miles a week or squatting 50 hours a week in the rice paddies - the extracellular elements are altered along the path of the stress to meet the demand within the limits imposed by nutrition, age, and protein synthesis.

With the concept of piezo-electric currents, this seeming miracle of preferential remodeling within the intercellular elements becomes easier to understand.

Inside and around the bone is a sparse but active community of two types of osteocytes: the osteoblasts and the osteoclasts. Each are sent forth with simple commandments: osteoblasts lay down new bone; osteoclasts clean up old bone. Osteoblasts are allowed to lay down new bone anywhere they like - as long as it is within the periosteum. The osteoclasts may eat of any bone, except those parts that are piezo-electrically charged (mechanically stressed).²⁰ Allow the cells to operate freely under these rules over time, and a femoral head is produced that is both specifically designed to resist individual forces coming through it, but also capable of changing (given some reaction time) to meet new forces when they are consistently applied.

This mechanism explains how dancers' feet get tougher bones during a summer dance camp: the increased dancing creates increased forces which create increased piezo-electric charges which reduce the ability of the osteoclasts to remove bone while the osteoblasts carry on laying it down - and the result is denser bone. This is also part of the explanation for why exercise is helpful to those with incipient osteoporosis: the forces created by the increased stress on the tissues serve to discourage the osteoclastic uptake. The reverse process operates in the astronauts and cosmonauts deprived of the force of gravity to create the pressure charge through the bones: the osteoclasts have a field day and the returning heroes must be helped off their ship in wheelchairs until their bones become less porous.

This extraordinary ability to respond to demand accounts for the wide variety in joint shapes across the human spectrum, despite the consistent pictures aver-

aged into most anatomy textbooks. A recent study detailed distinct differences in the structure of the subtalar joint.²¹ Smaller differences can be observed over the entire body. In **Figure 1.11 A** we see a 'normal' thoracic vertebra. However, in **Figure 1.11B**, we can see the body distorted as pressure creates a demand for remodeling under Wolff's Law,²² and hypertrophic spurs forming as the periosteum is pulled away by excess strains from the surrounding connective tissues and muscles (see also Ch. 3 on heel spurs). A non-union fracture can often be reversed by creating a current flow across the break, reproducing the normal piezo-electric flow, through which the collagen orients itself and begins the process of bridging the gap, to be followed by the calcium salts and full healing.²³⁻²⁴

This same process of response occurs across the entire extracellular fibrous network, not just inside the bones. We can imagine a person who develops, for whatever reason (e.g. shortsightedness, depression, imitation, or injury) a common 'slump': the head goes forward, the chest falls, the back rounds (**Fig. 1.12**). The head, a minimum of one-seventh of the body weight in most adults, must be restrained from falling further forward by some muscles in the back. These muscles must remain in isometric/eccentric contraction (eccentric loading) for every one of this person's waking hours.

Muscles are designed to contract and relax in succession, but these particular muscles are now under a constant strain, a strain that robs them of their full ability, and facilitates the development of trigger points. The strain also creates a piezo-electric charge that runs through the fascia within and around the muscle (and often beyond in both directions along the myofascial

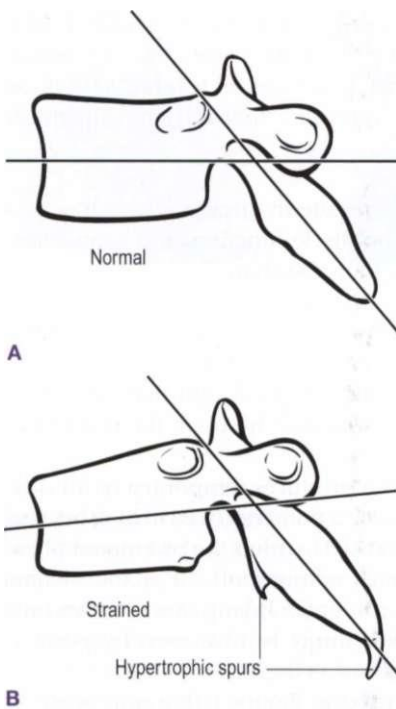


Fig. 1.11 Even bones will alter their shape within certain limits, adding and subtracting bone mass, in response to the mechanical forces around them. (Reproduced with kind permission from Oschman 2000.)

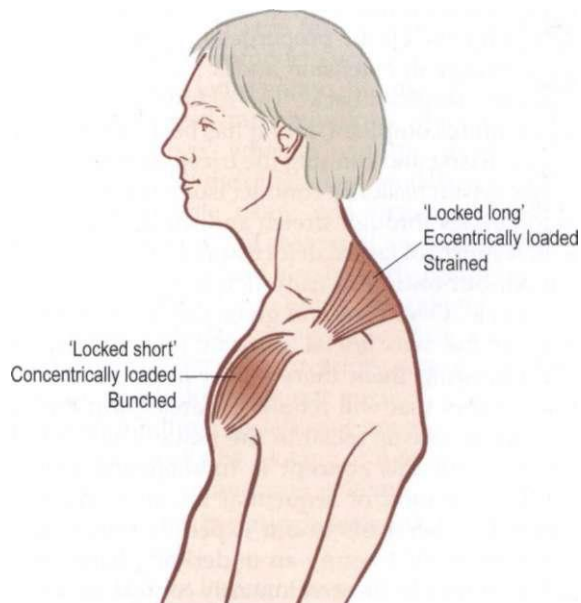


Fig. 1.12 When body segments are pulled out of place and muscles are required to maintain static positions - either stretched/contracted ('locked long') or shortened/contracted ('locked short') - then we see increased fascial bonding and thixotropy of the surrounding intercellular matrix (ECM),

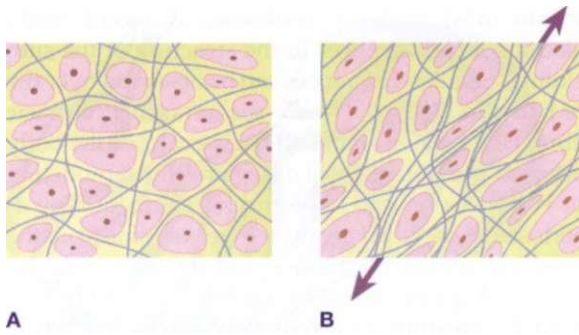


Fig. 1.13 (A) The ECM is designed to allow the relatively free flow of metabolites from blood to cell and back again in the flow of interstitial fluid and lymph. **(B)** Chronic mechanical stress through an area results in increased laying down of collagen fiber and decreased hydration of the ECM's ground substance, both of which result in decreased nourishment to certain cells in the 'back-eddies' caused by the increased matrix.

meridians). Essentially, these muscles or parts of muscles are being asked to act like straps (**Fig. 1.13A and B**).

Stretched, a muscle will attempt to recoil back to its resting length before giving up and adding more cells and sarcomeres to bridge the gap.²⁵ Stretch fascia quickly and it will tear (the most frequent form of connective tissue injury). If the stretch is applied slowly enough, it will deform plastically: it will change its length and retain that change. Slowly stretch a plastic carrier bag to see this kind of plasticity modeled: the bag will stretch, and when you let go, the stretched area will remain, it will not recoil.

In short, muscle is elastic, fascia is plastic.^{26,27} While this is a clinically useful generalization for the manual therapist, it is not strictly true. Certain fascial tissues - the ear, for instance - have higher proportions of elastin that render the non-muscular tissue quite deformably elastic. Beyond that, however, certain arrangements of pure collagen have elastic properties that allow for the storage of energy in extension and a recoil shortening as that energy is 'given back'. The Achilles tendon, for instance, is quite compliant, and it has been shown that in human walking and running the triceps surae (soleus and gastrocnemii) basically contract isometrically while the tendon cycles through stretch and shortening.^{28,30a,b}

The mechanism of fascial deformation is incompletely understood, but once it is truly deformed, fascia does not 'snap back'. Over time and given the opportunity - i.e. bringing the two fascial surfaces into apposition again and keeping them there - it will, however, lay down new fibers that will rebind the area.³¹ But this is not the same as elastic recoil in the tissue itself. A full understanding of this concept is fundamental to the successful application of sequential fascial manipulation. Practicing therapists in our experience make frequent statements that betray an underlying belief that the fascia is either elastic or voluntarily contractile, even though they 'know' it is not. The plasticity of fascia is its essential nature - its gift to the body and the key to unraveling its long-term patterns. We will return to fascial contractility and elasticity at the cellular level in the section on 'tensegrity' below.

Back to our slump: eventually, fibroblasts in the area (and additional mesenchymal stem cells or fibroblasts that may migrate there) secrete more collagen in and around the muscle to create a better strap. The long collagen molecules, secreted into the intercellular space by the fibroblasts, are polarized and orient themselves like compass needles along the line of piezo-electric charge, in other words, along the lines of tension (**Fig. 1.14**). They bind with each other with numerous hydrogen bonds via the interfibrillar glue (proteoglycans or ground substance), forming an inelastic strap-like matrix around the muscle.

Figure 1.15 illustrates this phenomenon very well. It shows a dissection of some of the fascial fibers running over the sternum between the two pectoral muscles. If we compare the fibers running from upper right to lower left, we can see that they are denser and stronger than those running from the upper left to the lower right. This means that more strain was habitually present in that one direction, perhaps from being left-handed, or (entirely speculatively) from being a big city bus driver who used his left hand predominantly to drive. This strain caused lines of piezo-electricity, and the fibroblasts responded by laying down new collagen, which oriented along the lines of strain to create more resistance.

Meanwhile, the muscle, overworked and undernourished, may show up with reduced function, trigger-point pain, and weakness, along with increased thixotropy in the surrounding ground substance, and increased metabolite toxicity. Fortunately - and this is the tune sung by Structural Integration, yoga, and other myofascial therapies - this process works pretty well in reverse: strain can be reduced through manipulation or training, the fascia reabsorbed, and the muscle restored to full function. Two elements, however, are necessary to successful resolution of these situations, whether achieved through movement or manipulation:

1. a reopening of the tissue in question, to help restore fluid flow, muscle function, and connection with the sensory-motor system,
- and
2. an easing of the biomechanical pull that caused the increased stress on that tissue in the first place.

Either of these alone produces temporary or unsatisfactory results. The second point urges us to look beyond 'chasing the pain' and calls to mind the prominent physiotherapist Diane Lee's admonition: 'It is the victims who cry out, not the criminals.' Taking care of the victims and collaring the local thugs is addressed by point 1, going after the 'big shots' is the job of point 2.

In the slump pictured in **Figure 1.12** (reminiscent of Vladimir Janda's upper crossed syndrome³²), the muscles in the back of the neck and top of the shoulders will have become tense, fibrotic, and strained, and will require some work. But the concentric pull in the front,

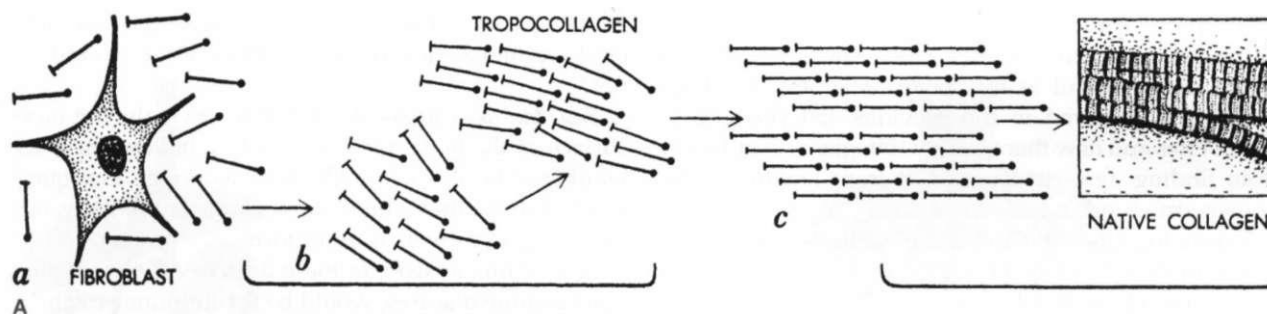


Fig. 1.14 (A) The collagen molecules, manufactured in the fibroblast and secreted into the intercellular space, are polarized so that they orient themselves along the line of tension and create a strap to resist that tension. In a tendon, almost all fibers line up in rows like soldiers. (Reproduced with kind permission from Juhan 1987.) **(B)** If there is no 'prevailing' tension, the fibers orient willy-nilly, as in felt. (Reproduced from Kessel RG, Kardon RH. WH Freeman & Co. Ltd; 1979.)




Fig. 1.15 A dissection of the superficial pectoral fascia in the sternal area. Notice how one leg of the evident 'X' across the sternum, from upper right to lower left in the picture, is more prevalent than the other, almost certainly as a result of use patterns. (Reproduced with kind permission from Ronald Thompson.)

be it from the chest, belly, hips, or elsewhere, will need lengthening first, and the structures beneath it rearranged to support the body in its 'new' (or more often 'original', natural) position.

In other words, we must look globally, act locally, and then act globally to integrate our local remedies into the whole person's structure. In strategizing our therapy in this global-local-global way, we are acting exactly as the ECM itself does, as we will explore below in the section on tensegrity. Connective tissue cells produce ECM in response to local conditions, which in turn affect global

conditions that re-impinge on local conditions in an unending recursive process.³³ Understanding of the myofascial meridians assists in organizing the search for both the silent culprit and the necessary global compensations - reversing the downward spiral of increasing immobility.

More serious deformations of the fascial net may require more time, remedial exercise, peri-articular manipulation (such as is found in osteopathy and chiropractic), outside support such as orthotics or braces, or even surgical intervention, but the process described above is continual and ubiquitous. Much restoration of postural balance, whether via the Anatomy Trains scheme or any of the other good models currently available, is attainable using non-invasive techniques. A preventive program of structural awareness (call it 'kinesthetic literacy') could also be fairly easily and productively incorporated into public education.³⁴⁻³⁷

In order to build a new picture of the ECM acting as a whole, and with these prefatory concepts in place, we are now ready to frame our particular introduction to fascia within three specific but interconnected ideas:

- physiologically by looking at it as one of the 'holistic communicating systems';
- embryologically through seeing its 'double bag' arrangement;
- geometrically through comparing it to a 'tensegrity' structure.

These metaphors are presented in general terms - in other words, the skeleton is there, but there is no space to flesh them out fully and still attend to our primary purpose. For the more scientifically minded, we note

that aspects of these metaphors run ahead of the supporting research. Nevertheless, some speculative exploration seems useful at this point. Anatomy has been thoroughly explored in the previous 450 years. New discoveries and new therapeutic strategies will not come from finding new structures, but from looking at the known structures in new ways.

Taken together, the following sections expand the notion of the role of the fascial net as a whole, and form a supporting framework for the Anatomy Trains concept explained in Chapter 2. Following these ideas, we draw this chapter together with a new image of how the fascial system actually puts all these concepts to work together *in vivo*.

The three holistic networks

Let us begin with a thought experiment, fueled by this question: Which physiologic systems of the body, if we could magically extract them intact, would show us the precise shape of the body, inside and out? In other words, which are the truly holistic systems?

Imagine that we could magically make every part of the body invisible except for one single anatomic system, so that we could see that system standing in space and moving as in life. Which systems would show us the exact and complete shape of the body in question?

The Vesalius rendering of a contemplative skeleton is a familiar attempt (and among the first) to isolate a system and present it as if *in vivo* (Fig. 1.16). Imagine the same for a room full of people, a party for instance: we would see a group of skeletons engaged in talking, eating, and dancing. We would certainly see the general shape of each body, and something of their attitude perhaps, as Vesalius beautifully shows us, but much detail would necessarily be lost. We would have very little idea of changing facial expression beyond an open or closed mouth. We might be able to distinguish male from female pelvises, although the fact that there is overlap between the two would make even gender identification difficult. We might recognize pearl divers or opera singers by their large rib cages, or chronic depressives and asthma sufferers by their characteristic rib cage shapes. But unless we were forensic experts allowed a close examination, we would certainly not know who is fat or thin, muscular or sedentary. We might be able to make some guesses as to who was who, but dental records would be necessary for positive identification. So, the skeletal system is *not* a good candidate for being a 'holistic' system as we have defined it.

Likewise, if we could suddenly isolate the digestive system, magically 'disappearing' everything but the digestive tract and its associated organs, we would not see the body as a whole (Fig. 1.17). We might, with a little practice, be able to read a great deal about the emotional state of the person from peristaltic rhythms and other state changes, but this part of our body, be it ever so ancient, reveals only part of the picture, confined as it is to the ventral cavity.

What about the skin, our largest single organ? If everything were eliminated from view except the skin,

we would, in fact, see the exact shape of the body and easily recognize our friends and their smiles, would we not?

But the skin alone would show us only the *outer* surface of the body, providing only a hollow shell; we would not be able to see the inner workings. Our quest is for systems that would show us the entire body, our inner shapes as well as outer form.

A tempting answer, in these days of AIDS and other autoimmune diseases, would be the immune system. If the immune system were a physical system, this would certainly be a good answer, but examination shows that there is no anatomical artifact we can identify as the immune system as such. Rather, an immune *function* pervades every system, residing in no particular tissues or area, but involving the entire cellular and intercellular matrix.

It turns out that there are three, and only three, positive answers to our question in palpable, anatomical

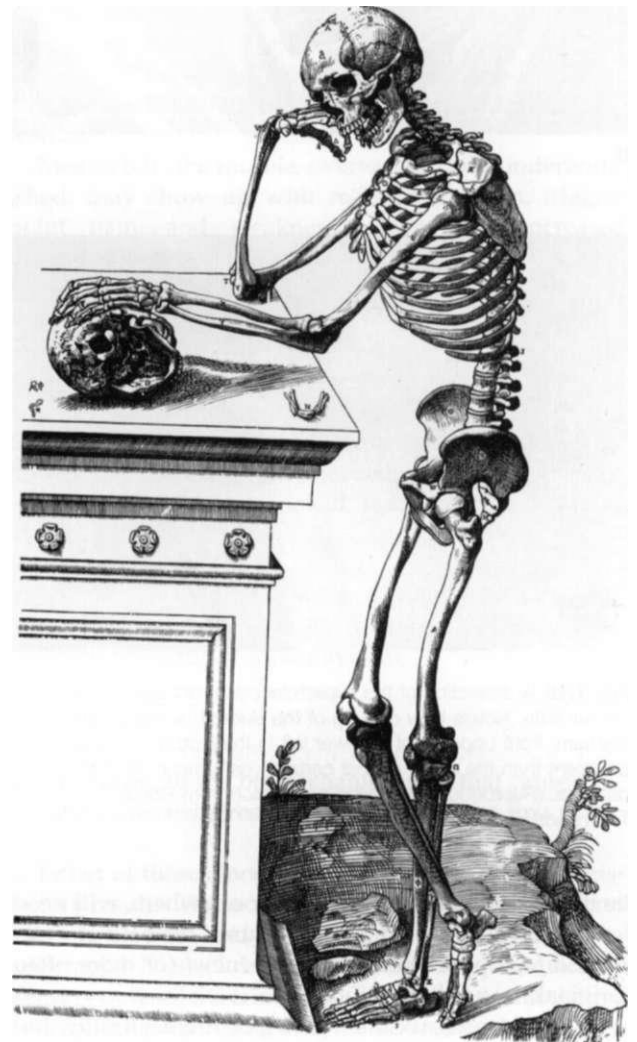

Fig. 1.16 A familiar figure: an abstraction of the skeletal system rendered as in life by Vesalius. This picture was as radical and 'mind-blowing' for its day, when the body was simply not depicted this way, as a picture of the earth as seen from the moon has been for ours. (Reproduced with permission from Saunders JB, O'Malley C. Dover Publications; 1973.)

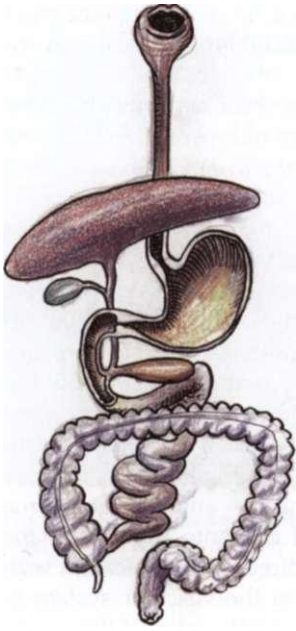

Fig. 1.17 Abstracting the digestive system, the ancient gut around which we are built, creates an interesting shape, but does not show us the shape of the entire body. (Reproduced with kind permission from Grundy 1982.)

terms: the nervous system, the circulatory system, and the fibrous (fascial) system - an idea, we must admit, so unoriginal that Vesalius, publishing in 1548, rendered versions of each of them. We will examine each of these in turn (in full knowledge that they are all fluid systems that are incompletely separate and never function without each other), before going on to look at their similarities and specialties, and speculate on their place in the somatic experience of consciousness.

The neural net

If we could make everything invisible around it and leave the nervous system standing as if in life (a tall order even for magic, considering the nervous system's fragility), we would see the exact shape of the body, entirely and with all the individual variations (**Fig. 1.18**). We would see the brain, of course, which Vesalius unaccountably omitted, and the spinal cord, which he left encased in the vertebrae. All the main trunks of the spinal and cranial nerves would branch out into smaller and smaller twigs until we reached the tiny tendrils which insinuate themselves into every part of the skin, locomotor system, and organs. Vesalius presents only the major trunks of nerves, the smaller ones being too delicate for his methods. A more modern and detailed version, albeit still with only the major nerve trunks represented, can be seen in the Sacred Mirrors artwork at www.alexgrey.com.

We would clearly see each organ of the ventral cavity in the filmy autonomic system reaching out from the sympathetic and parasympathetic trunks. The digestive system is surrounded by the submucosal plexus, which has as many neurons spread along the nine yards of the digestive system as are in the brain.³⁸ The heart would be particularly vivid with the bundles of nerves that keep it tuned.

Of course, this system is not equally distributed throughout; the tongue and lips are more densely inner-

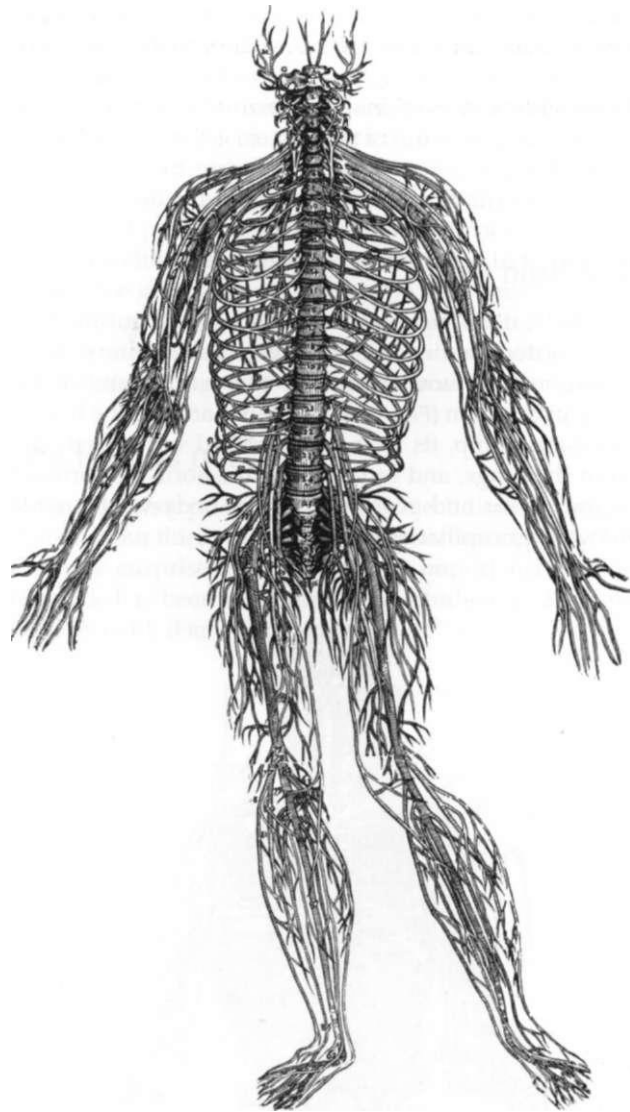


Fig. 1.18 It is amazing, given the methods available at the time, that Vesalius could make such an accurate version of the delicate nervous system. A modern and strictly accurate version of just this system would not include the spine, as Vesalius did, and would, of course, additionally include the brain, the autonomic nerves, and the many finer fibers he was unable to dissect out. (Reproduced with permission from Saunders JB, O'Malley C. Dover Publications; 1973.)

ated than the back of the leg by a factor of 10 or more. The more sensitive parts (e.g. the hands, the face, the genitals, the eye and neck muscles) would show up with greater density in our filmy 'neural person', while the otherwise dense tissues of bones and cartilage would be more sparsely represented. No part of the body, however, except the open lumens of the circulatory, respiratory, and digestive tubes, would be left out.

If your nervous system is working properly, there is no part of you that you cannot feel (consciously or unconsciously), so the whole body is represented in this network. If we are going to coordinate the actions of trillions of quasi-independent entities, we need this informational system that 'listens' to what is taking place all over the organism, weighs the totality of the many separate impressions, and produces speedy coor-

minated chemical and mechanical responses to both external and internal conditions. Therefore, every part of the body needs to be in close contact with the rapid-fire tentacles of the nervous system.

The functional unit of this system is the single neuron, and its physiological center is clearly the largest and densest plexus of neurons within it - the brain.

The fluid net

Similarly, if we made everything invisible but the vascular system, we would once again have a filmy representation that would show us the exact shape of the body in question (**Fig. 1.19**). Centered around the heart's incessant pump, its major arteries and veins go to and from the lungs, and out through the aorta and arteries to the organs and every part of the body via the wide network of capillaries.

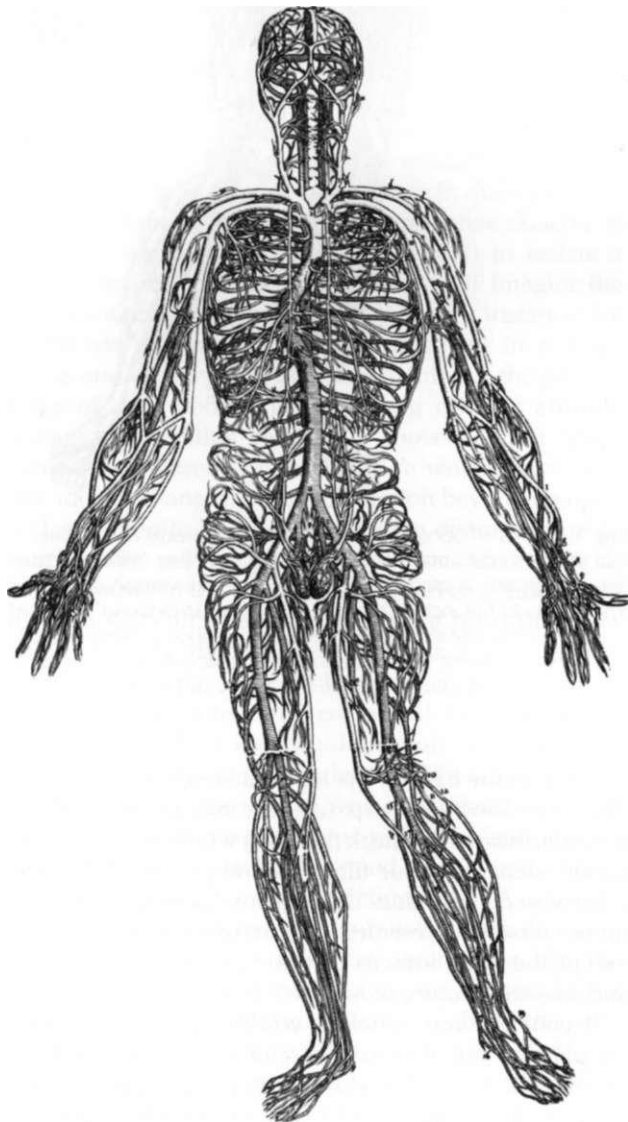


Fig. 1.19 Vesalius, in 1548, also created a picture of our second whole-body system, the circulatory system. (Reproduced with permission from Saunders JB, O'Malley C. Dover Publications; 1973.)

Although the concept can clearly be seen in the early attempt by Vesalius, notice that in his conception the veins and arteries do not join with each other - it would take another two centuries for William Harvey to discover capillaries and the closed nature of the circulatory net. A full accounting would show tens of thousands of miles (about 100000 km) of capillary nets, giving us another filmy 'vascular body' that would be complete down to the finest detail (**Figs 1.20-1.22** or see the complete system modeled at www.bodyworlds.com). If we included the lymphatic and the cerebrospinal fluid circulation in our consideration of the vascular system, our 'fluid human' would be even more complete, down to the finest nuances of everything except hair and some gaps created by the avascular parts of cartilage and dense bone.

In any multicellular organism - and especially true for those who have crawled out onto dry land - the inner cells, which are not in direct communication with the outside world, depend on the vascular system to bring nourishing chemistry from the edge of the organ-

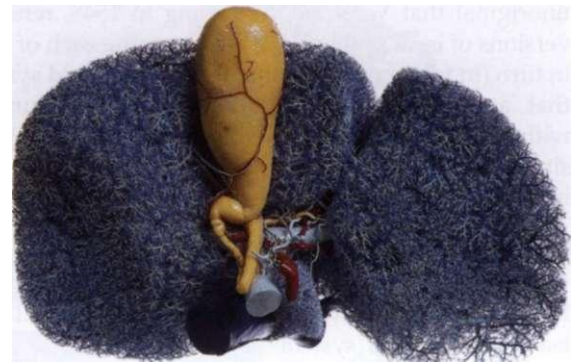


Fig. 1.20 A cast of the venous system inside the liver from below. The sac in the center is the gall bladder. (© Ralph T Hutchings. Reproduced from Abrahams et al 1998.)

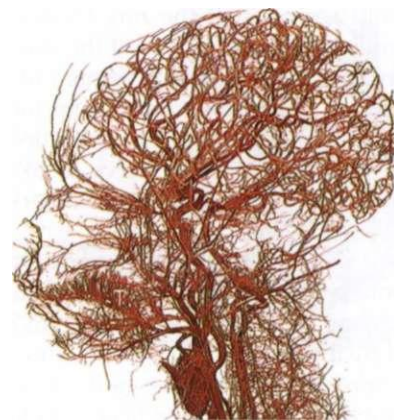

Fig. 1.21 Even with just these few large arteries represented, we can see something about this person. You might guess a Nilo-Hamitic person, for instance, but it is, in fact, an infant. (© Ralph T Hutchings. Reproduced from Abrahams et al 1998.)

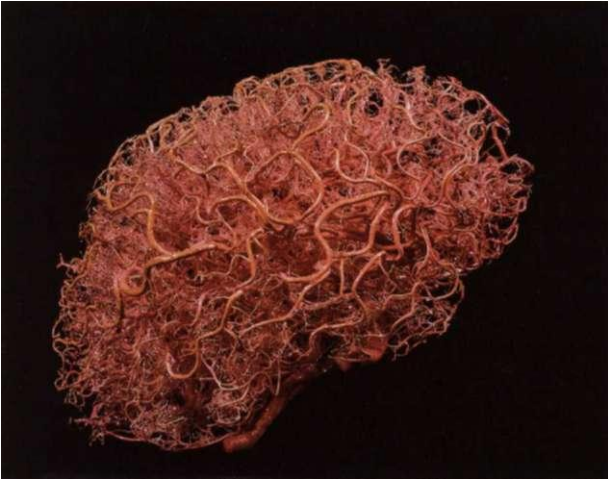

Fig. 1.22 Even the brain itself is full of blood vessels (and the heart is full of nerves). Is it only the neurons of the brain that 'think'? (© Ralph T Hutchings. Reproduced from Abrahams et al 1998.)

ism to the middle, and to take otherwise toxic chemistry from the middle to the edge where it can be dispersed. The organs of the ventral cavity - the lungs, the heart, the digestive system, and the kidneys - are designed to provide this service for the inner cells of the body. To provide a comprehensive 'inner sea' complete with nourishing and cleansing currents, the network of capillaries must penetrate into the immediate neighborhood of most individual cells of whatever type to be able to deliver the goods via diffusion from the capillary walls. Cartilage and ligament injuries take longer to heal because their cells are so far from the shores of this inner sea that they must rely on seepage from farther away.

The fibrous net

It can be no surprise, given our subject, that the fascial system is our third whole-body communicating network; the only surprise is how little the importance of this network has been recognized and studied as a whole until recently (**Fig. 1.23**).

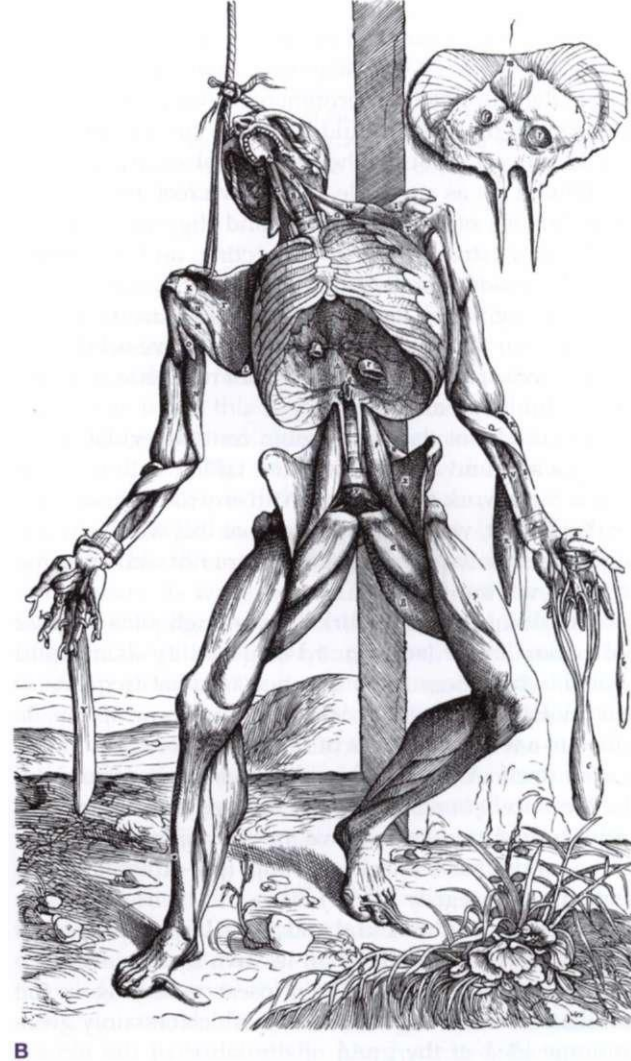


Fig. 1.23 (A) Vesalius shows the fibrous net in the familiar way - as a layer of muscles - but the overlying layers of fascial fabric have been removed. (B) The second view shows a deeper layer of musculature; fascial septa would fill in all the gaps and lines among the muscles. In (B), notice the black line extending from the bottom of the diaphragm to the inside arch of the foot, and compare it to the Deep Front Line (see Ch. 9). (Reproduced with permission from Saunders JB, O'Malley C. Dover Publications; 1973.)

If we were to render all tissues invisible in the human body except the fibrillar elements of the connective tissue - principally collagen, but with some added elastin and reticulin - we would see the entire body, inside and out, in a fashion similar to the neural and vascular nets, though the areas of density would once again differ. The bones, cartilage, tendons, and ligaments would be thick with leathery fiber, so that the area around each joint would be especially well represented. Each muscle would be sheathed with it, and infused with a cotton-candy net surrounding each muscle cell and bundle of cells (see Fig. 1.1 B). The face would be less dense, as would the more spongy organs like the spleen or pancreas, though even these would be surrounded by one or two denser, tough bags. Although it arranges itself in multiple folded planes, we emphasize once again that no part of this net would be distinct or separated from the net as a whole; each of these bags, strings, sheets, and leathery networks is linked to each other, top to toe. The center of this network would be our mechanical center of gravity, located in the middle of the lower belly in the standing body, known in martial arts as the 'hara'.

The bald statement is that, like the neural and vascular webs, the fascial web so permeates the body as to be part of the immediate environment of every cell. Without its support, the brain would be runny custard, the liver would spread through the abdominal cavity, and we would end up as a puddle at our own feet. Only in the open lumens of the respiratory and digestive tracts is the binding, strengthening, connecting, and separating web of fascia absent. Even in the circulatory tubes, filled with flowing blood, itself a connective tissue, the potential exists for fiber to form at any moment we need a clot (and in some places where we do not need one, as when plaque builds in an artery).

We could not extract a cubic centimeter, let alone Shylock's pound of flesh, without taking with us some of this meshwork of collagen. With any touch more than feathery light, we contact the tone of this web, registering it whether we are conscious of it or not, and affecting it, whatever our intention.

This ubiquitous network has enough of a regular molecular lattice (see Fig. 1.14) to qualify as a liquid crystal, which begs us to question to what frequencies this biological 'antenna' is tuned, and how it can be tuned to a wider spectrum of frequencies or harmonized within itself. Although this idea may seem farfetched, the electrical properties of fascia have been noted but little studied to date, and we are now glimpsing some of the mechanisms of such 'tuning' (pre-stress - see the section on tensegrity below).^{39^2}

In contrast to the neural and vascular net, the fascial net has yet to be depicted on its own by any artist we have seen to date. Vesalius' closest rendering is the familiar ecorche view of the body, which certainly gives us some idea of the grain of the fabric of the fibrous body, but really renders the myofascia - muscle and fascia together, with a heavy emphasis on the muscle. This is a prejudgment that has been continued in many anatomies, including those in wide use today: the fascia

is largely removed and discarded to give visual access to the muscles and other underlying tissues.^{43^5}

These common pictures have also removed and discarded two important superficial fascial layers: the epidermis that provides a carpet backing for the skin, and the fatty areolar layer with its well-funded store of white blood cells (Fig. 1.24). If we left these hefty layers in the full picture, we would see the animal equivalent of a citrus 'rind' beneath the very thin skin. This has helped to contribute to a general attitude of viewing the fascial net as a 'dead' scaffolding around the cells, to be parted

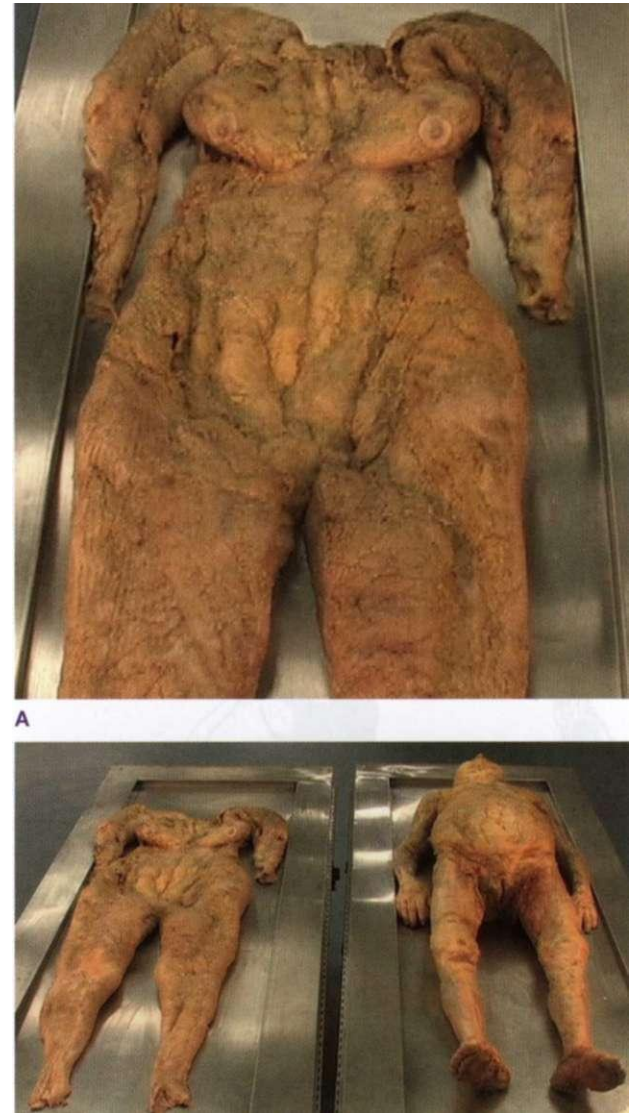


Fig. 1.24 (A) An extraordinary one-piece dissection of the areolar/adipose layer of superficial fascia fills in the picture not covered by **Figure 1.23** (or **Fig. 1.6**). This picture does not include the dermis layer of the skin, but does include the fat, the collagen matrix around the fat, and of course the many leucocytes at the histological level. **(B)** Here we see the specimen in full along with the donor who provided it. The concept of this fascial layer as a nearly autonomous organ, somewhat akin to the rind of the grapefruit pictured in **Figure 1.25**, is given a concrete reality through this feat of dissection. (© Gil Hedley 2005. www.gilhedley.com. Used with kind permission.)

and discarded on the way to the 'good stuff. Now, however, we are at pains to reverse this trend to create a picture of the fascial net with *everything else*, including the muscle fibers, removed.

New methods of depicting anatomy have brought us very close to this picture. Structural Integration practitioner Jeffrey Linn,⁴⁶ using the Visible Human Project data set, created **Figure 1.1 C** by mathematically eliminating everything that was not fascia in a section of the thigh; he gives us the closest approximation of a 'fascial human' we yet have - though this view also omits the superficial fascial layers.

If we can imagine extending this method to the entire body, we would see an entirely new anatomical view. We would see the fascial sheets organizing the body's fluids into areas of flow. We would recognize the intermuscular septa for the supporting guy-wires and sail-like membranes they really are. The densely represented joints would be revealed as the connective tissue's organ system of movement.

It will be some time before such methods can be used to show the entire fascial system, for it would include (as **Fig. 1.1C** does not, but **Fig. 1.1B** does) the cotton wool infusing each and every muscle, as well as the perineural system of oligodendrocytes, Schwann cells, and glial cells and attendant fats which permeate the nervous system, as well as the complex of bags, ligaments, and spider webs that contain, fix, and organize the ventral organ systems.

If we could then take such a rendition into motion, we would see the forces of tension and compression shifting across these sheets and planes, being met and accommodated in all normal movements.

A grapefruit provides a good metaphor for what we are trying to envision (**Fig. 1.25**). Imagine that you could somehow magically extract all the juice out of a grapefruit without disturbing the structure within. You would still have the shape of the grapefruit intact with the rind of the dermis and areolar layers, and you would see all the supporting walls of the sections (which, if dissected would turn out to be double-walled membranes, one half going with each section - just like our intermuscular septa). Plus we would see all the little filmy walls that separated the single cells of juice within each section. The fascial net provides the same service in us, except it is constructed out of pliable collagen instead of the more rigid cellulose. The fascial bags organize our 'juice' into discrete bundles, resisting the call of gravity to pool at the bottom. This role of directing and organizing fluids within the body is primary to an understanding of how manual or kinetic therapy of this matrix can affect health.

When you roll the grapefruit under your hand prior to juicing it, you are breaking up these walls and making it easier to juice. Fascial work (more judiciously applied of course) does much the same in a human, leaving our 'juices' more free to flow to otherwise 'drier' areas of our anatomy.

If we were to add the interfibrillar or ground-substance elements to our fascial human, that picture would fill in substantially, making the bones opaque with

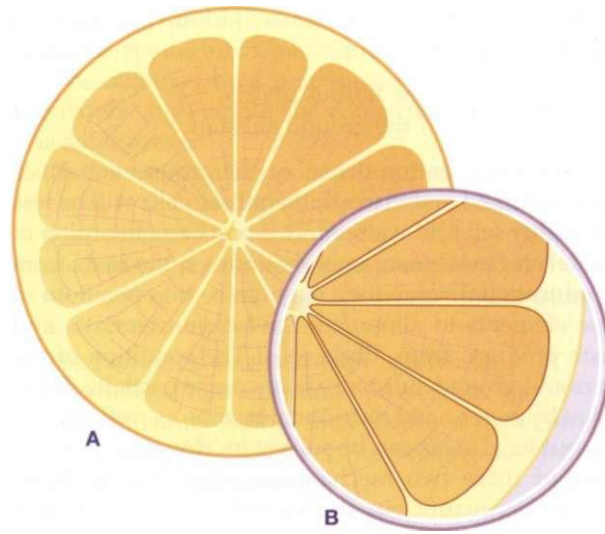


Fig. 1.25 A person is not unlike a grapefruit in construction. The skin is much like our own skin - designed to deal with the outside world. The rind is akin to the 'fat suit' we all wear, seen in **Figure 1.24**. Each segment is separated from the next by a wall we see when we cut the grapefruit through the equator for breakfast. But when we peel it and separate the sections as we might with an orange, we realize that the seeming one wall is actually two walls - one half goes with each section. The intermuscular septa are the same way. We often separate them with a knife, so we think of them as simply the epimysium of each muscle. But just as the walls are left after we eat a grapefruit, the walls are what is left in **Figure 1.1C**, and we can see what strong structures they are, worthy of separate consideration.

calcium salts, the cartilage translucent with chondroitin, and the entire 'sea' of intercellular space gummy with acidic glycosaminoglycans.

It is worth our while to focus our microscope in for a moment, to see this sugary glue in action.

In **Figure 1.13**, we imagine ourselves at the cellular level (similar to **Fig. 1.3**). The cells are deliberately left blank and undefined; they could be any cells - liver cells, brain cells, muscle cells. Nearby is a capillary; when the blood is pushed into the capillary by systole of the heart, its walls expand and some of the blood is forced - the plasma part, for the red blood cells are too stiff to make it through - into the interstitial space. This fluid carries with it the oxygen, nutrients, and chemical messengers carried by the blood, all intended for these cells. In between lies the stuff that occupies the intercellular realm: the fibers of the connective tissue, the interfibrillar mucousy ground substance, and the interstitial fluid itself, which is very similar (indeed, readily interchangeable) to the blood's plasma and lymph. The plasma, termed interstitial fluid when it is pushed through the capillary walls, must run the gauntlet of the connective tissue matrix - both fibrous and interfibrillar (ground substance) - to get the nourishment and other messenger molecules into the target cells. The denser the mesh of fiber and the less hydrated the ground substance, the more difficult that job becomes. Cells lost in the 'back-eddies' of fluid circulation will not function optimally. (See **Fig. 1.3** and the accompanying discussion.)

How easily the nutrients make it to the target cells is determined by:

1. the density of the fibrous matrix;
2. the viscosity of the ground substance.

If the fibers are too dense, or the ground substance too dehydrated and viscous, then these cells will be less thoroughly fed and watered. It is one basic intention of manual and movement interventions - quite aside from the educational value they may have - to open both of these elements to allow free flow of nutrients to, and waste products from, these cells. The condition of the fibers and ground substance is of course partially determined by genetic and nutritional factors, as well as exercise, but local areas can be subject to 'clogging' through either of these two mechanisms when excess strain, trauma, or insufficient movement has allowed such clogging to occur. Once the clog is dispersed, by whatever means, the free flow of chemistry to and from the cells allows the cell to stop functioning on metabolism-only 'survival' mode to resume its specialized 'social' function, be that contraction, secretion, or conduction. 'There is but one disease,' says Paracelsus,⁴⁷ 'and its name is congestion.'

Back at the macro level, we need one final note on the distribution of the net in general: it is worthwhile making a separation, for clinical analysis only, among the fibrous elements inhabiting the two major body cavities - dorsal and ventral (**Fig. 1.26**).

The dura mater, arachnoid layer, and pia mater are connective tissue sacs that surround and protect the brain, and are in turn surrounded by and awash in the cerebrospinal fluid (CSF). These membranes arise from the neural crest, a special area at the junction between the mesoderm and ectoderm in the developing embryo.⁴⁸ They interact with the central nervous system and the CSF to produce a series of palpable pulses within the dorsal cavity, and by extension, to the fascial net as a whole.^{49ab,5c} These pulses are well known to the cranial osteopaths and others who use them therapeutically, though the mechanism is not yet well understood, and even the existence of these wave motions is still denied by some.⁵¹⁻⁵²

Besides the billions of neurons that make up the brain and spinal cord, there are, within the dorsal cavity, additional connective tissue cells: the support cells which surround and infuse the entire nervous system, called the perineural network. These astrocytes, oligodendrocytes, Schwann cells, and other neuroglia are 'greater in number [than the neurons] but have received less attention because they were not thought to be directly involved in neural transmission', according to Charles Leonard.⁵³ Now they are: 'beginning to cast a shadow over the performing brilliance of the neurons'. During development, support cells guide the neurons to their final destination, provide nutrients to neurons, create protective barriers, secrete neuroprotective chemicals, and literally provide the glue and skeleton to hold the nervous system together. Recent research has pointed to the participation of the neuroglia in brain function, particularly in the area of emotional feelings.⁵⁴

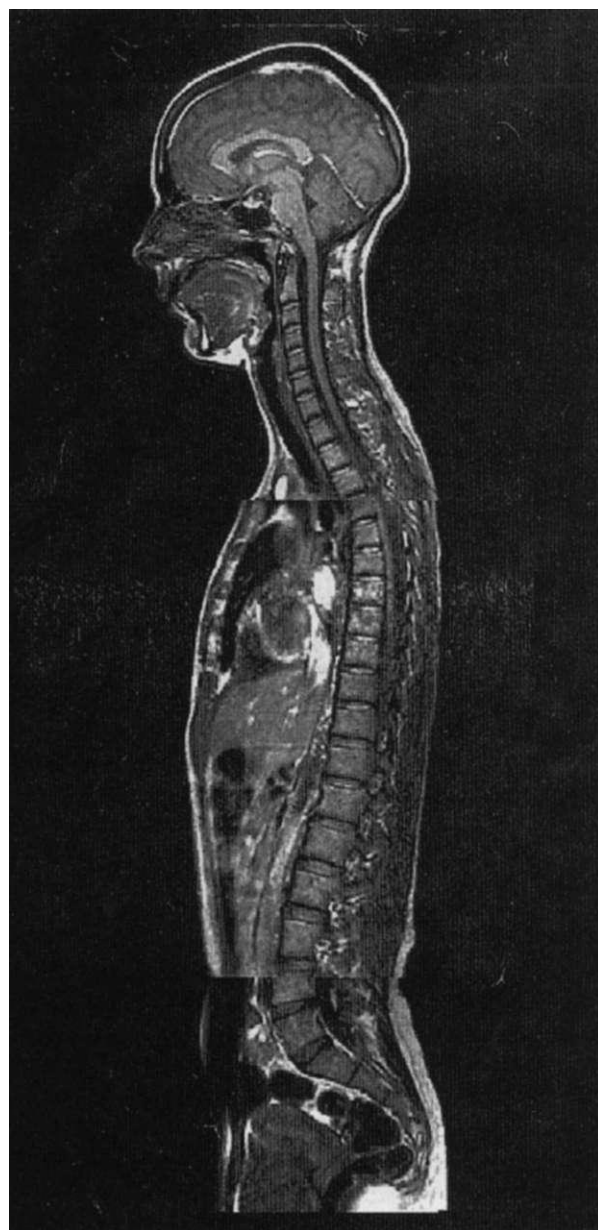

Fig. 1.26 The subject of this book is the myofascia in the body's locomotor chassis. But the connective tissue net extends into the dorsal and ventral cavities as well, to surround and invest the organs. (Reproduced with kind permission from Williams 1995.)

If we could lift the perineural system intact from the body, it would show the exact outline of the nervous system, as every nerve, both central and peripheral, is covered or surrounded by this system of the perineurium. These coatings speed neural signal transmission (myelinated fibers transmit faster than unmyelinated fibers). Many so-called 'neurological' diseases such as Parkinsonism, polio, diabetic neuropathy, or multiple sclerosis are in fact problems of the neuroglia which then interrupt the easy working of the nerves themselves.

The perineural cells also have a signal transmission system of their own, perhaps a more ancient precursor to the highly specific digital capabilities of the neuronal

transmission. In normal functioning and in wound healing, the slow waves of DC current that run along the perineural network help to organize generation and regeneration, and may act as a kind of integrating 'pace-maker' for the organism.^{55,57}

In embryological development, the perineural cells take on a morphogenetic role. For example, the cells of the neocortex develop deep in the brain on the shores of the ventricles. Yet they must locate themselves incredibly precisely in a layer exactly six cells thick, on the very surface of the brain. These developing neurons use long extensions of neighboring neuroglia, gliding up the extension like the reverse of a fireman on a pole, ushered to their precise final position on the brain's surface by the supporting connective tissue network.⁵⁸

The temptation to jump the gun and give this perineural network a role in consciousness is barely resistable.^{59,60}

In the ventral cavity, the fibrous net organizes organic tissues, providing some of the trophic and morphogenetic support referred to in the beginning of this chapter in the quote from Gray's, and to which we will return shortly. The bags that envelop the heart, lungs, and abdominal organs develop from the linings of the coelom during embryonic development. The result is a series of differently thickened organ 'puddings' in cloth bags, tied loosely or tightly to the spine and each other, and moved about within a limited range by the continual waves of the muscular diaphragm in the middle, and to a lesser degree by other bodily movements as well as exogenous forces such as gravity.

The French physiotherapist and osteopath Jean-Pierre Barral has made an interesting observation that these interfacing surfaces of serous membranes moving on each other could be thought of as a series of inter-organ 'joints'.⁶¹ He has made a fascinating study of the normal excursion of the organs within their fascial bags during breathing, as well as their inherent motility (a motion similar to the craniosacral pulse). According to Barral, the ligaments that attach these organs to surrounding structures determine their normal axes of movement. Any additional minor adhesions that restrict or skew these motions (which are, after all, repeated more than 20 000 times each day) can adversely affect not only organ function over time, but also expand into the surrounding myofascial superstructure.

If the dorsal cavity contains one section of the fibrous net, and the ventral cavity another, the domain of the book in your hand is the third segment of the fascial net: the myofascia of the locomotor system that surrounds both of these cavities. It is interesting that a therapeutic approach has been derived for each of these sections of the fascial net. Practitioners of both visceral and cranial manipulation posit that effects from twists and restrictions in their respective systems are reflected in the musculoskeletal structure. That is an assertion we have no desire to refute, though we assume that such effects are carried both ways. To be clear, however, our domain for the rest of this book is (arbitrarily) confined to that portion of the entire fascial net that comprises the 'voluntary' myofascial system around the skeleton.

This suggests that a complete approach to the 'fibrous body' - a 'spatial medicine' approach, if you will - would best be obtained by a practitioner having skill in four ultimately and intimately connected but still distinguishable areas:

- The meninges and perineurium that surround and pervade the predominantly ectodermal tissues of the dorsal cavity, currently dealt with by the methods of cranial osteopathy, craniosacral therapy, methods of dealing with adverse neural tension, and sacro-occipital technique;
- The peritoneal sacs and their ligamentous attachments that surround and pervade the predominantly endodermal tissues of the ventral cavity are addressed by the techniques and insights of visceral manipulation;
- The 'outer bag' (see the following section on embryology for an explanation of these terms) of myofascia, which contains all of the myofascial meridians described herein and yields to the many forms of soft-tissue bodywork such as strain-counterstrain, trigger-point therapy, myofascial release, and structural integration, and finally
- The 'inner bag' of periosteal, joint capsules, thickened ligaments, cartilage, and bones that comprise the skeletal system, responsive to the joint mobilization and thrust techniques common to chiropractic and osteopathy, as well as deep soft-tissue release techniques found in structural integration.

A fifth skill set that encompasses all four of these areas is to set them all in motion, implying the host of skills in movement addressed by physiatry rehabilitation medicine, physiotherapy, yoga, Pilates, the Alexander Technique, and a host of personal and postural training programs.

It would be an interesting experiment to create an educational program where practitioners would be conversant with all these five sets of skills. Many schools pay lip service to inclusion, but few practitioners can navigate the entire fibrous body with ease and set it into balanced motion as well.^{62,63}

Three holistic networks: a summary

Before going on to the embryological origin of this fascial net, it is useful to compare these three holistic networks for similarities and differences.

All three are networks

At the outset, we have noted that they are all complex networks, with a fundamental genetically determined core form, though they seem to be distributed chaotically (in its mathematical sense) in their outer reaches. This fractal nature suggests that they would be fairly labile in their smaller scale structures, but quite stable in their larger structures. *In vivo*, they are also, of course, utterly intermeshed with each other both anatomically and functionally, and this entire separation exercise is simply a useful fantasy (**Table 1.2**).

Table 1.2 Summary of the holistic communicating nets

Variable	Neural	Fluid <i>All networks</i> <i>All tubular</i>	Fibrous
Tube type	Unicellular (neuron)	Multicellular (capillary)	Cell products (fibril)
Information	Digitally coded/binary	Chemical	Mechanical (tension/compression)
Function	Environment simulator	Milieu (inner sea) balance	Spatial organization
Cell metaphor	Meta-nucleus	Meta-cytoplasm	Metamembrane
Speed of transmission	Seconds	Minutes-hours	1. Speed of sound (force transmission) 2. Days-years (adjustment/compensation)
Element	Time	Matter	Space
Consciousness	Temporal memory	Emotional memory	Belief systems

The table summarizes the information carried on the three holistic communicating nets. Exceptions and caveats can be found to these generalizations, but the overall idea stands. The bottom line (what kind of consciousness is held in each system) is pure speculation on the part of the author, based on empirical observation and experience. It represents a plea to expand consciousness from being solely the domain of the brain to include the accumulated wisdom of the rest of the nervous system, the chemical wisdom of the fluid system, and the spatial wisdom found in the semiconducting fluid crystal of the connective tissue web.

All three are made from tubes

We can also note that the units for these networks are all tubular. The cylindrical tube is a fundamental biological shape - all the early multi-celled organisms had a basically tubular shape, which still lies at the very core of all the higher animals.⁶⁴ Each of these communicating systems is also built around tubular units (Fig. 1.27). (These tubes do not exhaust the use of the tubes in the body, of course: the digestive system is a tube, the spinal cord is a tube, as well as the bronchioles, the nephrons of the kidney, the common bile duct and other glandular ducts - they are literally everywhere.)

The neuron is a one-celled tube, holding an imbalance of sodium ions on the outside of the tube and potassium ions inside until a pore in the membrane opens via an action potential. The capillary is a tube containing blood with walls of epithelial cells, confining the flow path of red blood cells while allowing the diffusion of plasma and white blood cells. The basic unit of the fascial web is a collagen fibril, which is not cellular at all, but rather a cell product. The molecular shape, however, is also tubular, a triple helix (like three-stranded rope). Some have suggested that this tube also has a hollow center, though whether this is true or whether anything flows through this tiny tube is still open to investigation.⁶⁵ So, while all the networks are tubular, the construction of the tubes is not the same.

Neither is the scale. The axons of the nerve 'tubes' range from about 1 μm to 20 μm in diameter,⁶⁶ while capillaries vary from 2 μm to 7 μm .⁶⁷ The collagen 'tube' is much smaller, each fiber being only 0.5-1.0 μm in diameter, but very long and cable-like.⁶⁸ If an old three-strand rope - a triple helix like the collagen fiber - were 1 cm thick, it would have to be more than a meter long to match the proportions of a collagen molecule.

All three convey information

Although each of these networks communicates, the information carried by these networks differs. The neural net carries encoded information, usually in a

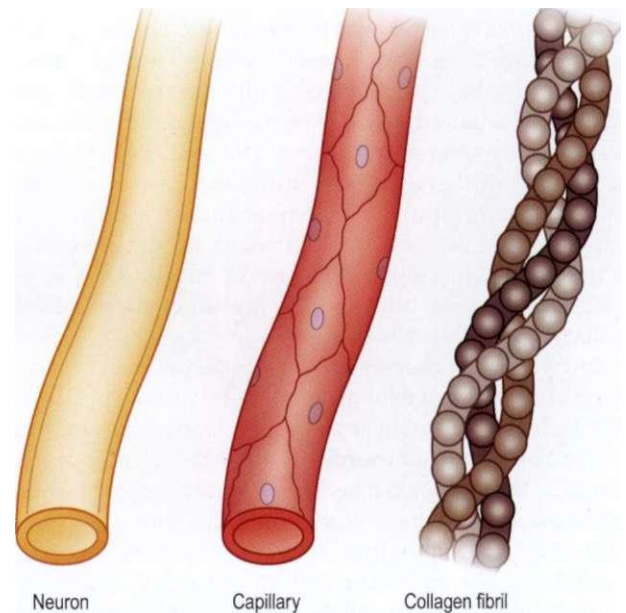


Fig. 1.27 Each of the major body communicating networks is made up of tubular subunits. The nerves are unicellular tubes, the capillaries are multicellular tubes, and the tubes of the collagen fibers are cell products, woven by the fibroblasts.

binary form: on or off. Starling's law dictates that either the stimuli to a nerve achieve a threshold allowing the nerve to fire, or they do not and it remains quiet.⁶⁹ The nervous system, in other words, works on frequency modulation (FM) not amplitude modulation (AM). A loud noise does not make bigger spikes up cranial nerve VIII, it simply makes more of them - interpreted by the temporal lobe as a louder noise. But whatever information is sent, it is encoded as 'dots and dashes' and must be decoded properly.

As an example of the limitation of this coding, press the heel of your hand on the orb of your closed eye until you 'see' light. Was there any light? No, the pressure merely stimulated the optic nerve. The optic nerve goes to a part of the brain that can only interpret incoming signals as light. Therefore, the signal 'pressure' was

erroneously decoded as 'light'. The famed neurologist Oliver Sacks has produced a compendium of books detailing many stories of conditions where the neurological system 'fools' its owner into seeing, feeling, or believing that the world is something other than it appears to the rest of us, including his personal experience of sensorimotor amnesia so relevant to the manual or movement therapist, *A Leg to Stand On*.⁷⁰

The circulatory net carries chemical information around the body in a fluid medium. The myriad exchanges of actual physical substance (as opposed to the encoded information carried by the nervous system) take place through this most ancient of conduits.

Though we must be clear that these two systems work seamlessly in the living body, the difference between these two types of information conveyed is easily explained. If I wish to lift a glass to my mouth, I can conceive of this idea in my brain (perhaps stimulated by thirst, perhaps by my discomfort on a first date, it matters not), turn it into a code of dots and dashes, send this code down through the spine, out through the brachial plexus, and down to my arm. If some security agency intercepted this message halfway in between the two, the actual signal would be meaningless - just a series of on-off switches. At the neuromuscular junction, the message is decoded into meaning - and the relevant muscles contract according to the coded sequence.

Suppose, however, that in order to carry out the nervous system's command, that muscle requires more oxygen. It is simply not possible for me, even if I could conceive that idea in my brain, to encode some signal that could be decoded somewhere down the nervous system as an oxygen molecule. It is instead necessary that the actual oxygen molecule be captured from the air by the surfactant bordering the epithelium of the alveolus, cross through this surface layer, over the interstitial space and connective tissue layer, pass through the alveolar capillary wall, 'swim' through the plasma until it finds a red blood cell, pass through the membrane of the red blood cell and hook itself on to a bushy hemoglobin molecule, ride with the red blood cell out to the arm, detach itself from the hemoglobin, escape from the red blood cell through its double-layered membrane, pass with the plasma through the capillary wall, pass between the fibers and the ground substance in the interstitial space and squiggle through the membrane of the cell in question, finally to enter the Krebs cycle in the service of raising my arm. As complex as this series of events may seem, it is happening millions and millions of times every minute in your body.

These systems have social correlates, which may also serve to illustrate the differing functions of the neural and circulatory nets. It is increasingly common for us as a society to encode data into unrecognizable form and have it decoded at the other end. Although this book would be a primitive form of such encoding, phone calls, DVDs, and the internet provide a better example. My daughter lives far from me; when I write 'I love you' on e-mail, it is turned into a pattern of electrons which bears no resemblance to the message itself, and would carry no meaning for anyone else who might intercept it along

the way. At the other end, though, is a machine that decodes the electrons and turns it back into a message with meaning that I hope brings a smile. This is quite similar to how the neural net coordinates both sensory perception and motor reaction.

If, on the other hand, an e-mail or phone call will simply not do, and she needs a genuine hug, I must get into my little 'blood cell' of an automobile, and travel the 'capillaries' of the roadways and 'arteries' of the airways until I reach the physical proximity that allows a genuine, non-virtual hug. That is the way the circulatory fluid net works to provide direct chemical exchange.

The third system, the fascial system, conveys mechanical information - the interplay of tension and compression - along the fibrous net, the gluey proteoglycans, and even through the cells themselves. Please note that we are *not* talking here of the muscle spindles, Golgi tendon organs, and other stretch receptors. These proprioceptive sense organs are how the nervous system informs itself, in its usual encoded way, about what is going on in the myofascial net. The fibrous system has a far more ancient way of 'talking' to itself: simple pulls and pushes, communicating along the grain of the fascia and ground substance, from fiber to fiber and cell to cell, directly (Fig. 1.28).⁷¹

This kind of mechanical communication has been studied less than the neural or circulatory communication, but it is clearly present. We will return to its particulars below in the section on tensegrity. For now, we note that the Anatomy Trains myofascial meridians are simply some common pathways for this kind of tensile communication.

A tug in the fascial net is communicated across the entire system like a snag in a sweater, or a pull in the corner of an empty woven hammock. This communication happens below our level of awareness for the most part, but through it we create a shape for ourselves, registered in the liquid crystal of the connective tissue, a recognizable pattern of posture and 'acture' (defined as 'posture in action' - our characteristic patterns of doing - by Feldenkrais⁷²), which we tend to keep unless altered for better or worse.

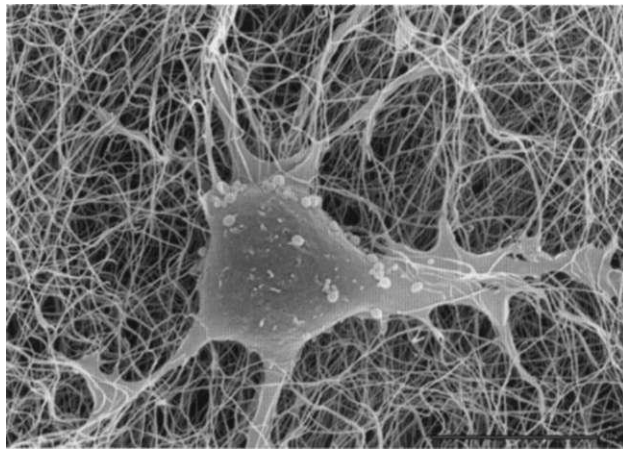


Fig. 1.28 The connective tissue forms a syncytium - a continuity of cells and the intercellular fibers - in which the cells can exert tension through the entire network of the ECM. (Reproduced from Jiang H, Grinnell F. *American Society for Cell Biology*; 2005.)

As well as the type of information carried, the timing of the communication within these systems differs as well. The nervous system is widely regarded as the fastest, working in milliseconds to seconds at speeds of 7-170 miles per hour (10-270 km/h) - not like e-mail at the speed of light.²³ The slowest neural message, throbbing pain, runs along tiny nerves at about one meter per second, and thus might take about two seconds to get from the stubbed toe of a tall man to his brain. Other messages pass more quickly but still on the same order - the reaction time of a trained martial artist is $\frac{1}{5}$ of a second from the reception of a stimulus to the beginning of a response in movement. This approaches the reaction time for a simple reflex arc like the knee-jerk response.

The circulatory system works on a slower time scale. The standard is that most red blood cells return through the heart every 1.5 minutes. Despite the recurring movie motif of the instant drug knockout, even injected drugs will take a few minutes to make it to the brain. Many chemical levels in the blood (e.g. salt and sugar levels) fluctuate on several-hour cycles, so we can set this system's average responsive rhythm as minutes to hours. Of course, many fluid rhythms work at slower scales - from the slow pulse of the 'long tide' in the cranial system through the 28-day cycle of the menstrual system.

The nervous system and fluid systems developed in tandem, both in the individual and in our species, so the division between them is purely an analytical exercise. Still, the distinction is useful.

Some years ago I revisited England after several years Stateside. I was driving several children out to the country. While daydreaming along one of those narrow Devon hedgerowed byways, I was suddenly confronted by an oncoming car. My American driving habits took over and I pulled to the right, while the other driver responded to his English instincts and pulled to the left. We missed each other by millimeters and I fetched up in a boggy ditch, shaking and white.

This shakiness and blood redistribution was produced by the sympathetic branch of my autonomic nervous system, suddenly alerting my entire somatic nervous system that immediate action was required. My immediate action, stupid though it was, did not result in disaster. We all got out, cheerfully cursed the bloody Yank, reassured each other that we were all right, pushed my car back onto solid footing, and said goodbye.

But when I got back in the car to drive on, I found that I was again shaking, that I was white and faint, and needed a few additional moments to gather myself before driving on. Among the many messages the sympathetic nervous system sent out in the initial instant of alarm was one to the adrenal glands that was decoded into the squeeze of a gland's worth of adrenaline - the bearer of a similar action-oriented 'fight-or-flight' message - into the bloodstream. This method of alerting the body is slower and more ancient than the nervous system's, but helps to sustain the response, when necessary, over a longer period of time, as in a sporting event. This hormone took a few minutes to circulate and to

have its way with my body. By this time, the emergency was over and I was getting ready to drive again, but the adrenaline was just getting down to business. After a few minutes of no further emergency, my system calmed down and I drove on, now chemically and consciously very alert to where I was; no coffee needed for the remainder of the drive.

The timing of the fascial system is interesting in that it has two rhythms; at least, two that have interest to us. On the one hand, the play of tension and compression communicates around the body as a mechanical 'vibration' traveling at the speed of sound. This is roughly equivalent to 720 mph (1100 kph), which is more than three times faster than the nervous system. So, contrary to conventional wisdom, the fibrous net communicates more quickly than the nervous system. One can feel this if one steps from one room to another in which there is an unexpected drop of an inch or more. The nervous system, setting the springs of responsive muscles to the expected level of floor, is unprepared for the sharp shock that does come, which is thus absorbed instead almost entirely by the fascial system over a fraction of a second. We will take up the mechanism of this immediate communication in the tensegrity section below; for now we note that every nuance of changing mechanical forces is 'noticed' and communicated along the fabric of the fibrous net.

On the other hand, the speed at which this system communicates compensation around the structural body is much slower. Structural bodyworkers commonly find that this year's neck pain was built on last year's mid-back pain, which derived in turn from a sacroiliac problem three years earlier, which in fact rests on a lifelong tendency to sprain that left ankle. A careful history-taking is always necessary in working with the fibrous system because even small incidents can have repercussions removed at some space and time from the initial incident.

These patterns of compensation, often with a fixation in the myofascia well away from the site of pain, are daily bread for Structural Integration practitioners. 'If your symptoms get better,' said Dr Ida Rolf, 'that's your tough luck.' Her interest was in resolving patterns of compensation, not merely eradicating symptoms, which would then tend to pop up some months or even years later in another form.

For example, a middle-aged woman came to my practice a while ago, complaining of pains in the right side of her neck. An office worker, she was sure that the pain was related to her computer workstation and 'repetitive strain' from keyboard entry and mouse use. She had run the gamut of healing, having seen a chiropractor, physiotherapist, and a massage therapist. Each of these methods offered temporary relief, but 'as soon as I start working again, it comes back.'

When presented with a situation like this, there are two possible 'causes': the one offered, that work really is producing the problem, or, conversely, that some other area of the client's pattern is not supporting the new position demanded by her workstation. By examining this woman (using the method of seeing outlined in

Ch. 11), we found that the rib cage had shifted to the left, dropping the support out from under the right shoulder (a similar pattern can be seen in **Fig. In. 8**, p. 5). The rib cage had moved to the left to take weight off the right foot. The right foot had not taken its share of the weight since a mild skiing injury to the medial side of the knee three years earlier. The whole pattern was now set into the neuromyofascial webbing.

By working manually with the (by now long-healed but not yet resolved) tissues of the knee and lower leg, then with the quadratus lumborum, iliocostalis, and other determinants of rib cage position, we were able to support the right shoulder from below, so that it no longer 'hung' from the neck. The woman was able to point and click to her heart's content without any recurrence of her 'work-related' problem.

In summary, we may view the connective tissue as a living, responsive, semiconducting crystal lattice matrix, storing and distributing mechanical information. As one of the three anatomic networks that govern and coordinate the entire body, the ECM can be seen as a kind of *metamembrane*, according to Deane Juhan.⁷⁴ Just as the membrane is now seen to envelop the inside as well as the surface of a cell, our fibrous metamembrane surrounds and invests all our cells, our tissues, our organs, and ourselves. We develop this idea further in the section on embryology below.

All systems intertwine

Of course, examining these holistic networks apart from each other has been just another reductionist analytical trick - they always are interacting, and always have within the individual and the species, time out of mind

(**Fig. 1.29**). We could as easily speak of a single 'neuromyofascial' web that would encompass all three of these networks acting singly to respond to the changes in the environment.⁷⁵ We cannot entirely divorce the mechanical communication of the fibrous net from the neurological communication that would occur nearly simultaneously. Likewise, neither of these networks can be considered separately from the fluid chemistry that brings the nourishment that allows each of them to work in the first place. In fact, each and every biological system is fundamentally a fluid chemical system dependent on flow.

Persisting, then, in this metaphor for one more image, each system has a set of 'ambassadors' that run in both directions, with the ability to alter the state of the other systems and keep them inter-informed (**Fig. 1.30**). The hormones and neurotransmitters inform the circulatory net what the neural net is 'thinking'; neuropeptides and other hormone-like chemicals keep the nervous system up to date in what the circulatory system is 'feeling'. The circulatory net feeds proteins to the fibrous net and maintains turgor within the pressure-system bags within the body; the fibrous net guides the flow of fluids, allowing and restricting for better or worse as we have described above. It also affects the tonus of the myofibroblasts through fluid chemistry, as we shall describe below in the tensegrity section.

The nervous system feeds into the fibrous system by means of the motor nerves that change the tonus of muscles. Perhaps the most interesting leg of this three-legged stool for the clinician is the set of mechanoreceptors that feed information from the fascial net back to the nervous system. This fascial network is the largest 'sense organ' in the body, dwarfing even the eyes or ears

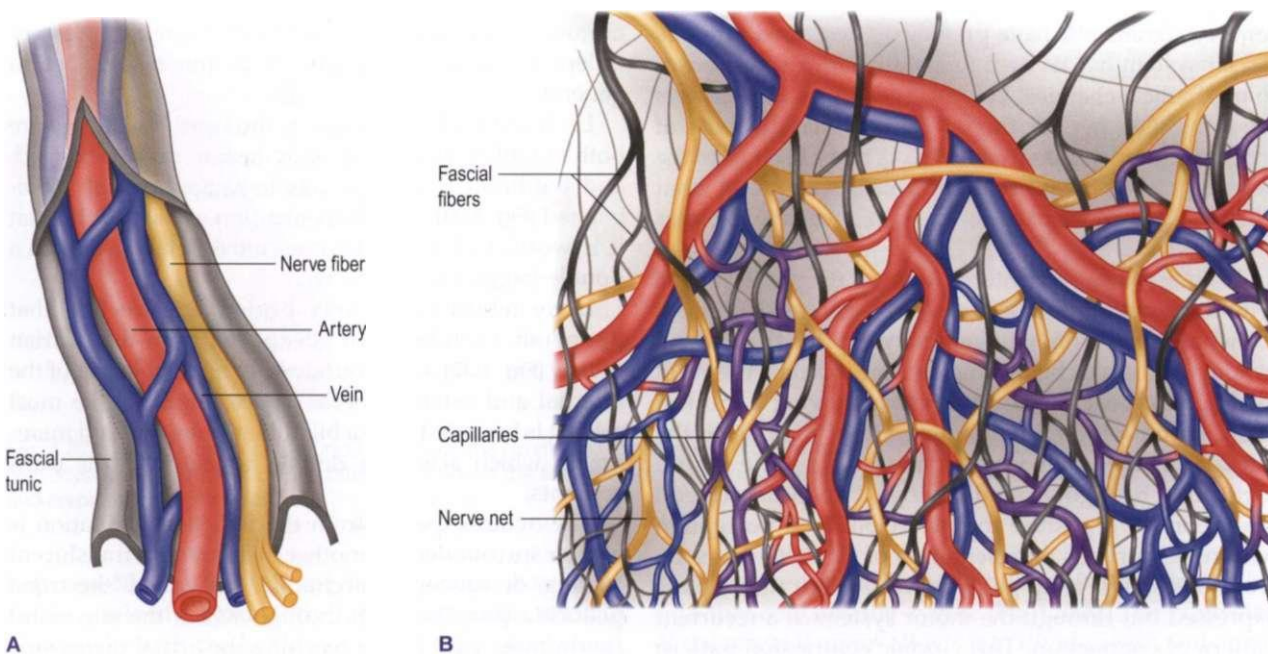


Fig. 1.29 The neural, vascular, and fascial systems run parallel in the neurovascular bundles (**A**) that extend the viscera out into the limbs and farther recesses of the body, with the connective and neural tissues forging the way. When they reach their destination, however, they spread into three enmeshed networks all occupying the same space (**B**).

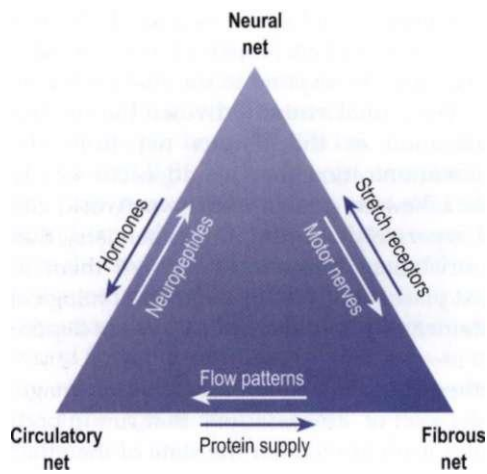


Fig. 1.30 Relationships among these holistic nets are complex. Each of the nets has 'ambassadors' to the other nets to alter their state and to keep the systems inter-informed and regulated.

in its rich diversity and proliferation of primarily stretch receptors.⁷⁶ These sensory nerves frequently outnumber their motor compatriots in any given peripheral nerve by nearly 3:1.

There are a number of different types of receptors within the interstitial substrate of the ECM, including Golgi receptors, Pacini corpuscles, Ruffini endings, and ubiquitous free nerve endings.⁷⁷ These specialized endings pick up and pass along information concerning changes in stretch, load, pressure, vibration, and tangential (shear) force. The free nerve endings are especially interesting, in that they are the most abundant (they are even found within bone), they are connected to autonomic functions such as vasodilation, and they can function as mechanoreceptors or as nociceptors (pain).⁷⁸

Obviously, the nervous system is responsive, and can change muscle tone in response to signals from these sensory signals. We have previously described how the fascial system has its own (generally slower) responses to mechanical changes. Woven together, as they always are in a living person, they point to a rich diversity of modes of intervention to the fibrous body itself or to the neurological web within it. The jury is still out on what exactly causes both pain and its cure, but new avenues are promising.

To demonstrate this interweaving of the three systems with an example: the person who becomes depressed, for whatever reason, will generally express that feeling in somatic form as being stuck on the exhale - they will generally appear to the observer as having a sunken chest, without full excursion upward of the ribs on the inhale. Put the other way around, few people with a high, full chest go around saying, 'I'm so depressed.' The depressive posture may start out as a perception within the nervous representation of the self versus the world involving guilt, pain, or anxiety, but that soon is expressed out through the motor system as a recurrent pattern of contraction. This chronic contraction pattern is accommodated after a time by the fascial system, often reaching out over the whole body - the pattern in the chest requires compensation in the legs, neck, and

shoulders as well as the ribs. The diminution of the breathing in turn creates a different balance of chemistry in the blood and body fluids, lowering oxygen and raising Cortisol levels. Changing this whole pattern may not be possible simply by changing the rate of serotonin reuptake with antidepressant drugs, or even by changing the internal perception of self-worth, because the pattern is written into a habit of movement, a set of fascial fibers, as well as a set of chemical pathways in the fluids.

In modern medicine, the neural and chemical aspects of such patterns are often considered, while the 'Spatial Medicine' aspect of these patterns is too often ignored. Effective treatment considers all three, but individual treatment methods tend to favor one over any other. The old saying goes: 'If your hand is a hammer, everything looks like a nail.' Whatever tool we are using to intervene, we do well to remember all three of these holistic communicating systems.

The double-bag theory

When the BBC asked the great British naturalist J. B. S. Haldane if his lifelong study had taught him anything about the mind of the Creator, he replied, 'Why, yes, He shows an inordinate fondness for beetles.' (Haldane was so fond of this answer that he arranged to be asked the same question a number of times, so that he could delight himself and others with minor variations of the same reply.)

The modern anatomist, given the same question, can only answer, 'an inordinate fondness for double-bagging'. Two-layered sacs show up so often in connective tissue anatomy, often derived from embryology that it is worth a brief separate exploration, before returning to its relevance to the Anatomy Trains theory per se. We also take the opportunity, while rummaging around in embryology, to point out a few of the larger mileposts in the development of the fascial net in general.

Each cell is double-bagged, the heart and lungs are both double-bagged, the abdomen is double-bagged, and the brain is at least double-bagged, if not triple-bagged (**Fig. 1.31**). It is the contention of this section that it is worth looking at the musculoskeletal system as a double-bagged system as well.

If we return to the very beginnings, we find that the ovum, even before it is expelled from the ovarian follicle (**Fig. 1.32**), is surrounded by the double bag of the internal and external theca.⁷⁹ Once released, like most cells, it is bounded with a bilaminar phospholipid membrane, which acts as a double bag around the cell's contents.

The ovum expelled from the follicle at ovulation is further surrounded by another membrane, a translucent coating of mucopolysaccharide gel called the zona pellucida (**see Fig. 1.32**), through which the successful sperm must pass before reaching the actual membrane of the egg. While we commonly retain a Darwinian picture of fertilization, with victory going to the fastest-swimming and most aggressive sperm, the fact is that

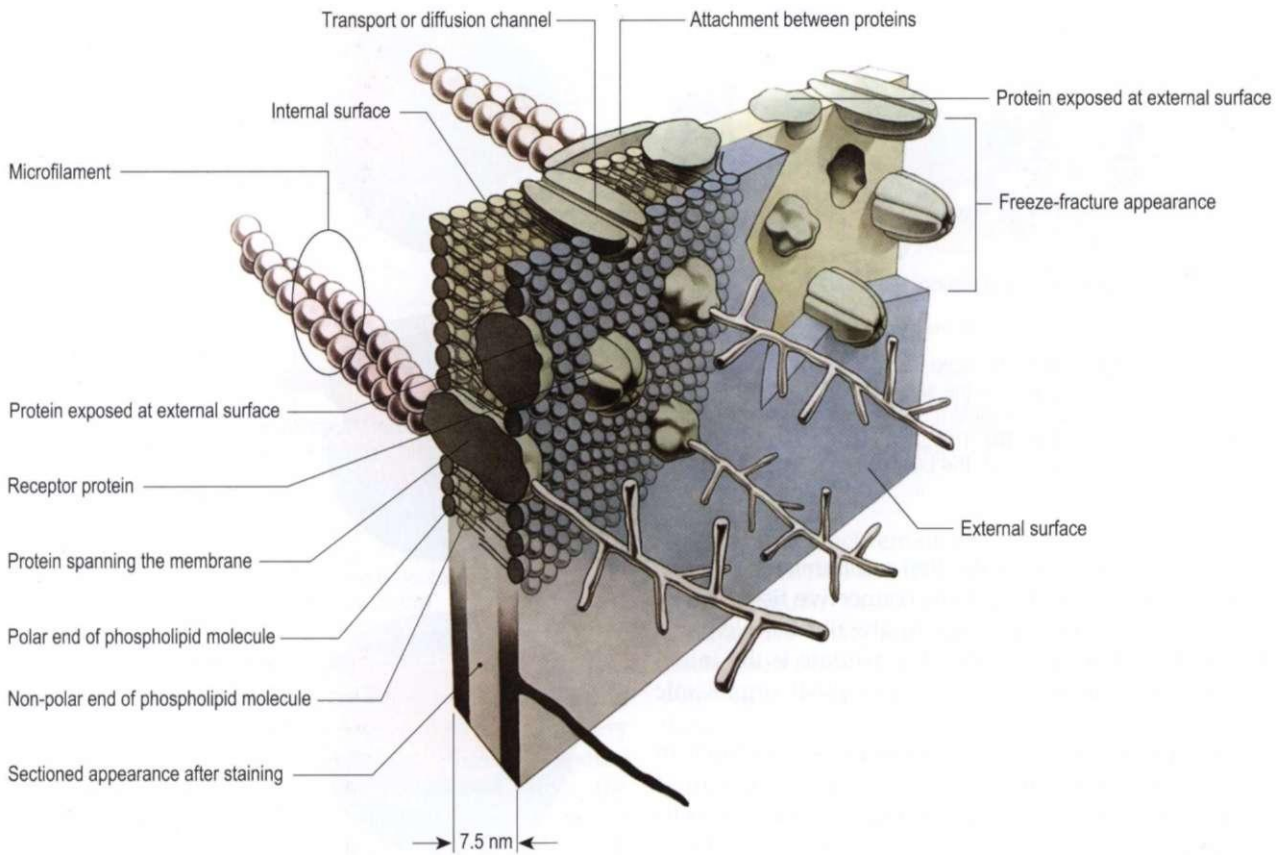


Fig. 1.31 The bilaminar membrane of the cell forms the original pattern for the double-bag image, which is repeated over and over again in macro-anatomy. (Reproduced with kind permission from Williams 1995.)

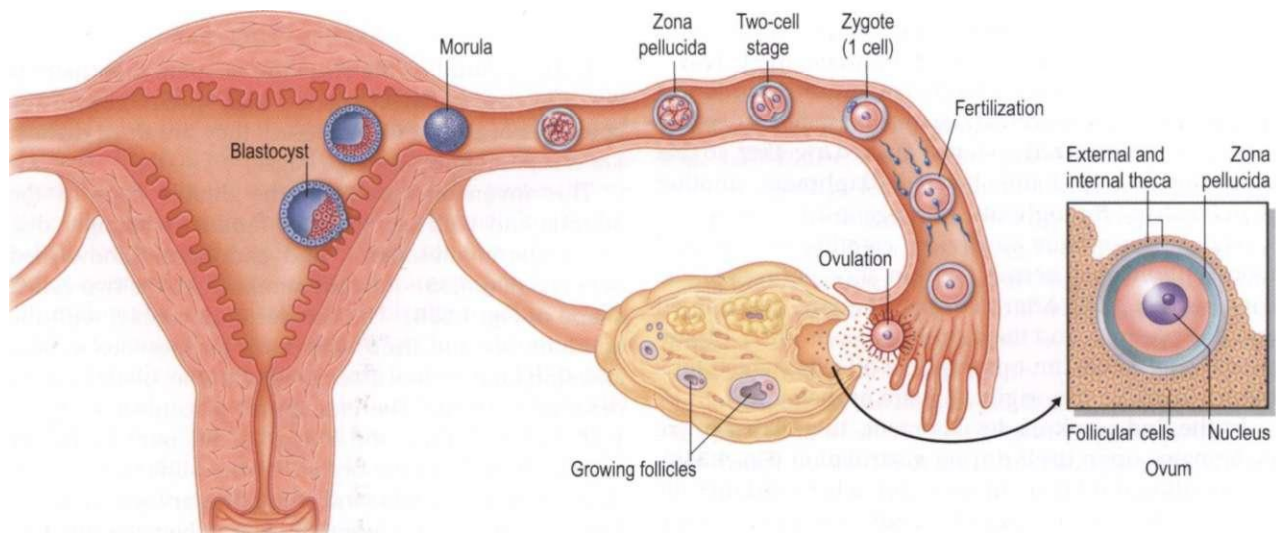


Fig. 1.32 The mucousy zona pellucida surrounds the ovum, and continues as an organismic membrane around the morula and blastocyst until it thins and disintegrates at the end of the first week of embryonic development as the blastocyst expands, differentiates, and prepares for implantation.

between 50 and 1000 of the fastest sperm beat their heads uselessly against the zona pellucida, making pockmarks with the hyaluronidase in their heads (and dying) until some lucky slowpoke comes along and comes in contact with the cell membrane itself and does the actual fertilization.

When the fertilized egg divides, it is this zona pellucida that contains the zygote (Fig 1.33A). The huge size of the original ovum allows it to divide again and again within the zona pellucida, and each successive set of cells takes up nearly the same amount of space as the original large cell. Thus this 'ground substance' shell



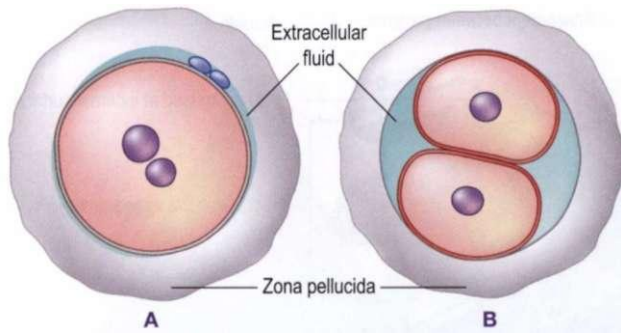


Fig. 1.33 When the ovum is fertilized, its membrane and the gummy zona pellucida surround the same space (A). With the first cell division, the two-celled organism is held in place by the *metamembrane* of the zona (B). The zona persists as the organismic limit right up through the blastocyst stage.

around the zygote forms the first *metamembrane* for the organism. This is the first of the connective tissue products to do so, later to be joined by the fibrillar elements of reticulin and collagen. But this exudate is the initial organismic environment, and the original organismic membrane.

With the first division, a small amount of cytoplasm escapes the two daughter cells, forming a thin film of fluid surrounding the two cells, and between the cells and the zona pellucida (Fig. 1.33B).¹ This is the first hint of the fluid matrix, the lymphatic or interstitial fluid that will be the main means of exchange among the community of cells within the organism.

We can also note that while the single cell is organized around a point, the two-celled organism is organized around a line drawn between the two centers of the cells. The early zygote will alternate between these two - organization around a point, then organization around a line. Further, the two-celled organism resembles two balloons (two pressurized systems) pushed together, so that their border is a double-layered diaphragm, another popular shape throughout embryogenesis.

The cells continue to divide, creating a 50-60-cell morula (bunch of berries) within the confines of the zona (see Fig. 1.32). After five days, the zona has thinned and disappeared, and the morula expands into a blastosphere (Fig. 1.34A), an open sphere of cells (which thus echoes in shape the original sphere of the ovum).

In the 2nd week of development, this blastosphere invaginates upon itself during gastrulation (Fig. 1.34B). Gastrulation is a fascinating process where certain cells in one 'corner' of the sphere send out pseudopods which attach to other cells, and then, by reeling in the extensions, create first a dimple, then a crater, and finally a tunnel that creates an inner and an outer layer of cells (Fig. 1.34C).¹ This is the basic double-bag shape, a sock turned halfway inside-out or a two-layered cup. Notice that this ancient tunicate-like shape creates three potential spaces:

1. the space within the inner bag;
2. the space between the inner and the outer bag;
3. the environment beyond the outer bag.

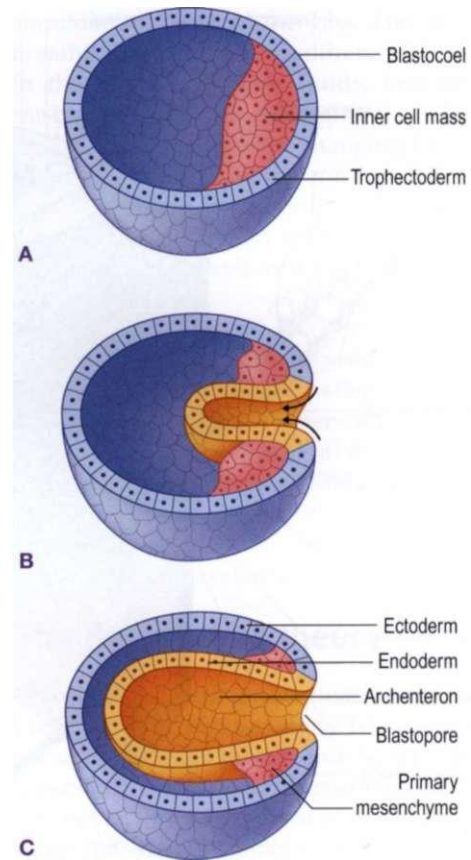


Fig. 1.34 The first definitive autonomous motion of the embryo is to fold the blastosphere in upon itself to form a double bag, which connects the epiblast and hypoblast into the bilaminar membrane. This motion forms the first double bag.

If the 'mouth' of the structure is open, then there is no difference between space 1 and space 3, but if the sphincter of the mouth is closed, they are three distinct areas separated by the two bags.

This inversion results in the double bags of the amnion and yolk sac, with the familiar trilaminar disc of ectoderm, mesoderm, and endoderm sandwiched between (Fig. 1.35 - note the similarity to the two-celled shape in Fig. 1.33B). The ectoderm, in contact with the amniotic sac and fluid, will form the nervous system and skin (and is thus associated with the 'neural net' as described above). The endoderm, in contact with the yolk sac, will form the linings of all our circulatory tubing, as well as the organs of the alimentary canal, along with the glands (and is the primary source of the fluid vascular net). The mesoderm in between the two will form all the muscles and connective tissues (and is thus the precursor of the fibrous net), as well as the blood, lymph, kidneys, most of the genital organs, and the adrenal cortex glands.

The formation of the fascial net

If we may digress from double-bagging for a moment to follow the development of the fibrous net within the embryo: this initial cellular specialization within the embryo, which occurs at about two weeks' develop-

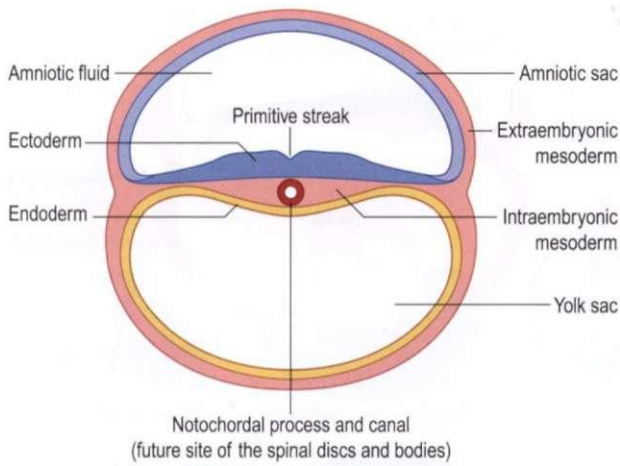


Fig. 1.35 Gastrulation, a turning inside-out motion of the embryonic sock, forms the trilaminar disc (ecto-, meso-, and endoderm) between the two large sacs of the amnion and yolk (transverse section). This action turns the double bag into a tube. Notice the similarity in shape to **Figure 1.33B**.

ment, is a very important moment. Up until this point, most cells have been carbon copies of each other; very little differentiation has taken place. Therefore, spatial arrangement is not crucial. During this time, the mucousy 'glue' among the cells and their intermembranous gap junctions have sufficed to keep the tiny embryo intact. Now, however, as increasing specialization takes place, it is imperative that concrete spatial arrangements be maintained while still allowing movement, as the embryo begins to increase exponentially in size and complexity.

If we look more closely at this middle layer, the mesoderm, we see a thickening in the middle below the primitive streak, called the notochord, which will ultimately form the spinal column - vertebral bodies and discs. Just lateral to this, in the paraxial mesoderm, is a special section of the mesoderm called the mesenchyme (literally, the mess in the middle).³² Mesenchymal cells, which are the embryonic stem cells for fibroblasts and other connective tissue cells, migrate among the cells throughout the organism, to inhabit all three layers (**Fig. 1.36**). There they secrete reticulin (an immature form of collagen with very fine fibers) into the interstitial space.³³ These reticulin fibers bind with each other, chemically and like Velcro®, to form a body-wide net - even though the entire body is only about 1 mm long at this point.

As an aside, some of these pluripotential mesenchymal cells are retained in the tissues of the body, ready to convert themselves into whatever connective tissue function is most called upon. If we eat too much, they can convert to fat cells to handle the excess; if we are injured, they can become fibroblasts and help heal the wound; or if we are subject to a bacterial infection, they can convert to white blood cells and go forward to fight the infection.³² They are a perfect example of the supreme adaptability and responsiveness of this fibrous/connective tissue system to our changing needs.

The reticular fibers these mesenchymal cells generate will gradually be replaced, one by one, by collagen

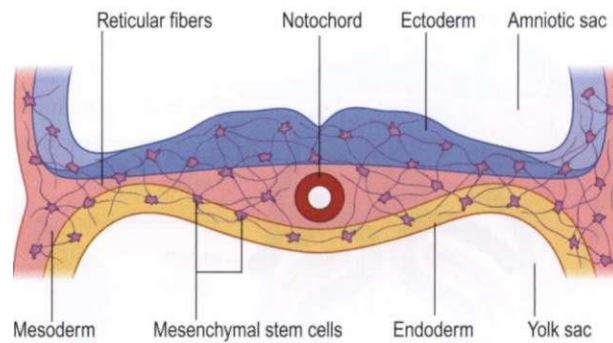


Fig. 1.36 Mesenchymal cells from the paraxial mesoderm disperse through all three layers of the embryo to form the reticular net, the precursor and foundation for the fascial net, in order to maintain spatial relationships among the rapidly differentiating cells.

fibers, but the fact remains: this is the source of our singular fibrous net, and the reasoning behind our favoring of the singular 'fascia' over the plural 'fasciae'. While we may, for analytical purposes, speak of the plantar fascia, the falciform ligament, the central tendon of the diaphragm, lumbosacral fascia, or dura mater, each of these is a man-made distinction imposed on a net that is in truth *unitary* from top to toe and from birth to death. Only with a knife can these or any other individual parts be separated from the whole. This fibrous net can fray with age, be torn asunder by injury, or be divided with a scalpel, but the fundamental reality is the unity of the entire collagenous network. The naming of parts has been one of our favorite human activities since Genesis, and indeed a very useful one, as long as we do not lose sight of the fundamental wholeness.

Once the three layers and the binding net of fascia are established, the embryo performs a magnificent feat of auto-origami, folding and refolding itself to form a human being from this simple trilaminar arrangement (**Fig. 1.37A**). The mesoderm reaches around the front from the middle, forming the ribs, abdominal muscles, and pelvis, creating and supporting the endodermal alimentary canal within (**Fig. 1.37B**). It also reaches around to the back, forming the neural arch of the spinal column and the cranial vault of the skull, which surrounds and protects the central nervous system (the fasciae within these cavities were briefly described at the end of the section on the fibrous net earlier in this chapter - **Fig. 1.37C**). One of the last bits of origami is the fold that brings the two halves of the palate together. Since it is one of the last bricks in the wall of developmental stages, if any brick below it is missing it could result in a cleft palate, which explains why this is such a common birth defect (**Fig. 1.38**).³⁴

Just lateral to the mesenchyme, near the edge of the embryo, lie the tubes of the intraembryonic coelom.³⁵ This tube runs up each side of the embryo, joining in front of the head. These tubes will form the fascial bags of the thorax and abdomen. The very top part of the coelomic tube will fold under the face and surround the developing heart with the double bag of the endocardium and pericardium (**Fig. 1.39**) as well as the central part of the diaphragm. The upper part on either side

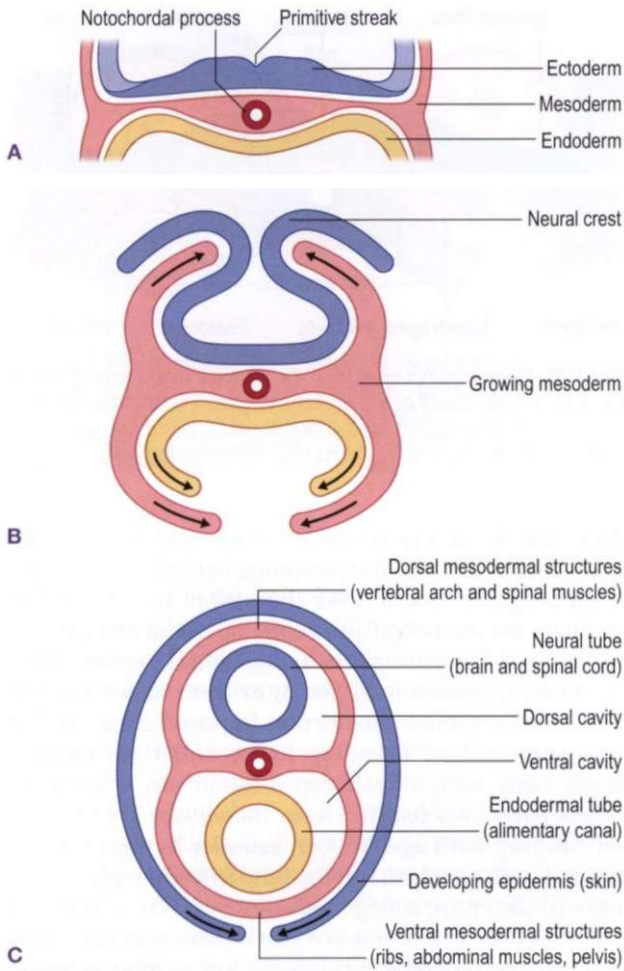


Fig. 1.37 The middle layer of the trilaminar disc, here seen (as in Figs 1.35 and 1.36) in transverse section, grows so fast that the cells boil out around the other two layers to form two tubes - digestive and neural - and to surround them in two protective cavities - the dorsal and ventral cavities. Part of the ectoderm 'escapes' to form the skin - another tube outside all the others.

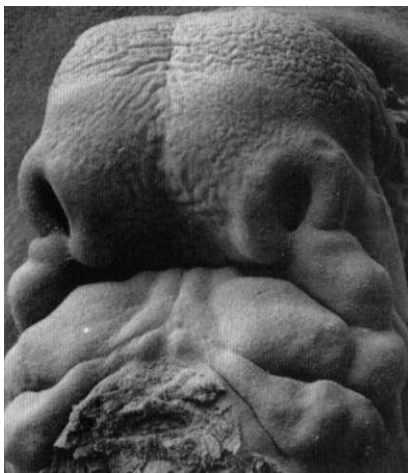


Fig. 1.38 In the complex origami of embryological development, the formation of the face and upper neck is especially intricate. One of the last folds is to bring the two halves of the palate together, and thus this is a common area for congenital defects. (Reproduced from Wolpert L. Oxford University Press; 1991.)

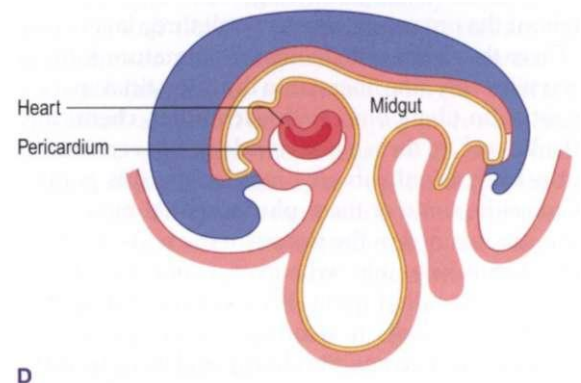
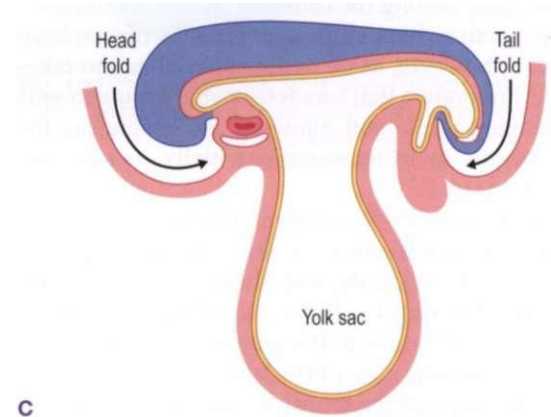
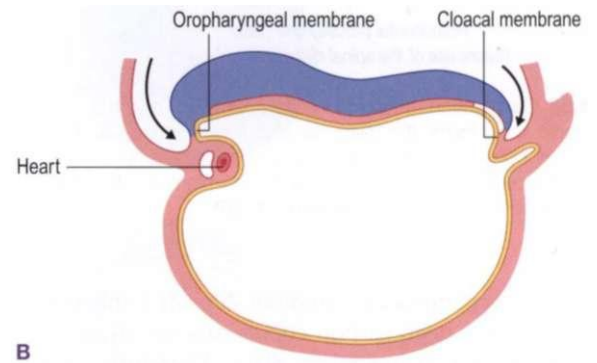
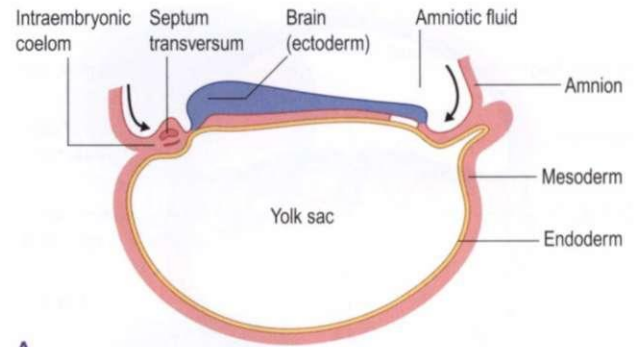


Fig. 1.39 A sagittal section of the embryo through the 4th week. The tube of intra-embryonic coelom which runs through the embryo is divided into separate sections which 'double bag' the heart as it folds into the chest from the transverse septum 'above' the head. A similar process happens from the side with the lungs in the thorax and intestines in the abdominopelvic cavity. (Adapted from Moore and Persaud 1999.)

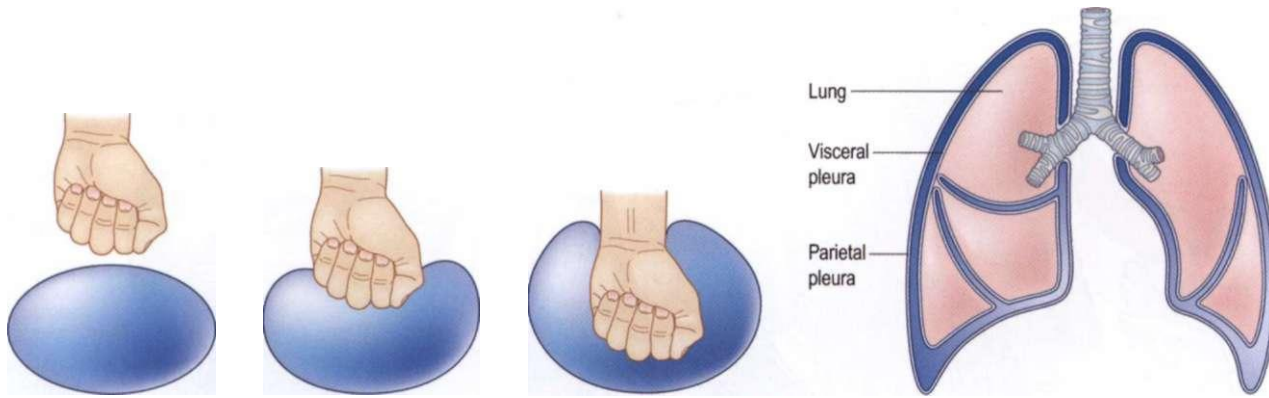


Fig. 1.40 Although they differ in form when they reach mature stages, the fundamental structure of the balloon pushed in to form a double bag by the tissue of the organ is found around nearly every organ system, in this case with the double-layered pleura around the lung.

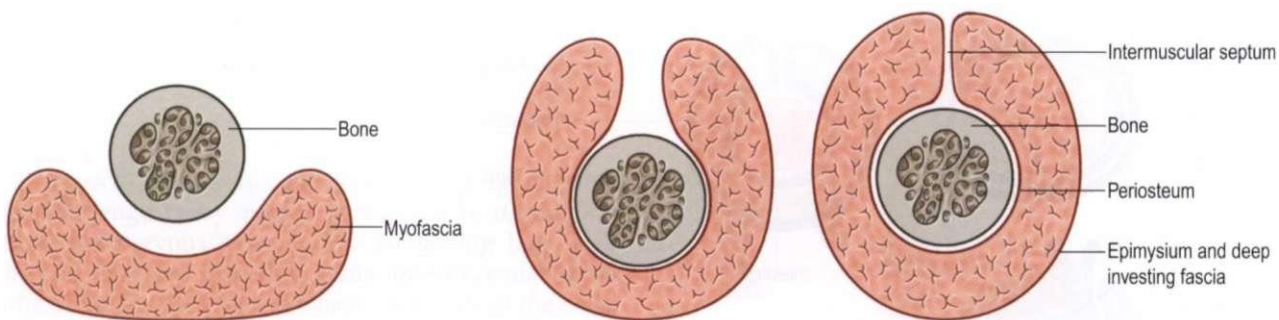


Fig. 1.41 We can imagine, whether it is embryologically correct or not, that the bones and muscles share a similar double-bag pattern.

will fold in to surround the lungs with the double bag of the visceral and parietal pleura (**Fig. 1.40**). The upper and lower parts will be separated by the invasion of the two domes of the diaphragm. The lower outside part of each tube will fold in to form the double bag of the peritoneum and mesentery.

The double- and triple-bagging around the brain and spinal cord is more complex, developing from the neural crest, the area where the mesoderm 'pinches' off the ectoderm (with the skin on the outside and the central nervous system on the inside), so that the meninges (the dura and pia mater) form from a combination of these two germ layers.⁸⁶

Double-bagging the muscles

We have given short shrift to this fascinating area of morphogenesis, but we must return to the subject at hand - the myofascial meridians in the musculoskeletal system.

With such an 'inordinate fondness' for double-bagging, might we not look for something similar in the musculoskeletal system? Yes, in fact: the fibrous bag around the bones and muscles can be viewed as having much the same pattern as we see in the way the fascial bag surrounds the organs (**Fig. 1.41**). The inner bag sur-

rounds the bones and the outer bag surrounds the muscles.

To create a simple model for this idea, imagine that we have an ordinary plastic carrier bag lying on the counter with its open end toward us (**Fig 1.42**). Now lay some wooden thread spools on top of the bag in a row down the middle. Insert your hands into the bag on either side of the spools, and bring your hands together above the spools. Now we have:

1. spools
2. an inner layer of plastic fabric
3. hands
4. another outer layer of plastic fabric.

Substitute 'bones' for 'spools', 'muscles' for 'hands', and 'fascial' for 'plastic' and we are home free.

The human locomotor system is, like nearly every other fascial structure in the body, constructed in double-bag fashion - although this is speculative (**Fig. 1.43**). The content of the inner bag includes very hard tissues - bone and cartilage - alternating with almost totally fluid tissue - synovial fluid; the spools and spaces between them in our simple model. The inner fibrous bag that encases these materials is called *periosteum* when it is the cling-wrap sleeve around the bones,

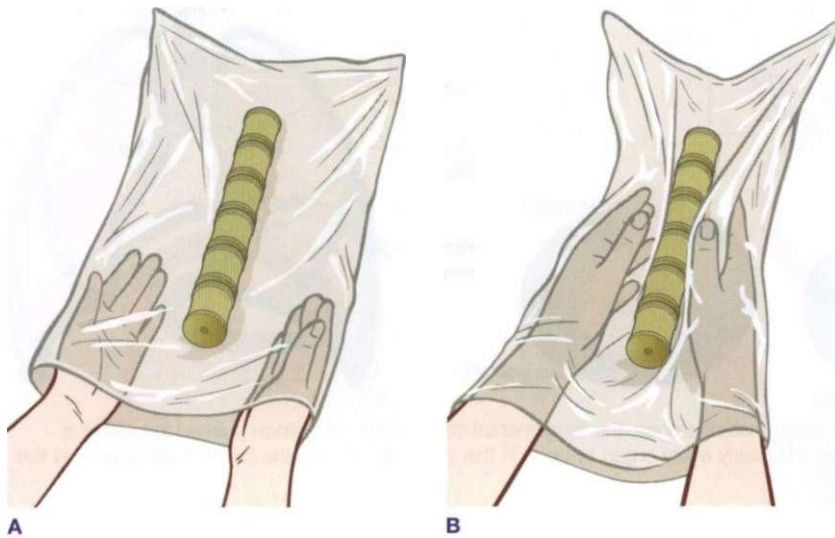

Fig. 1.42 Perform this little demonstration yourself with a common carrier bag and some spoons or similar cylindrical objects to see how the bones and muscle tissue interact in a continuous 'double bag' of fascial planes.

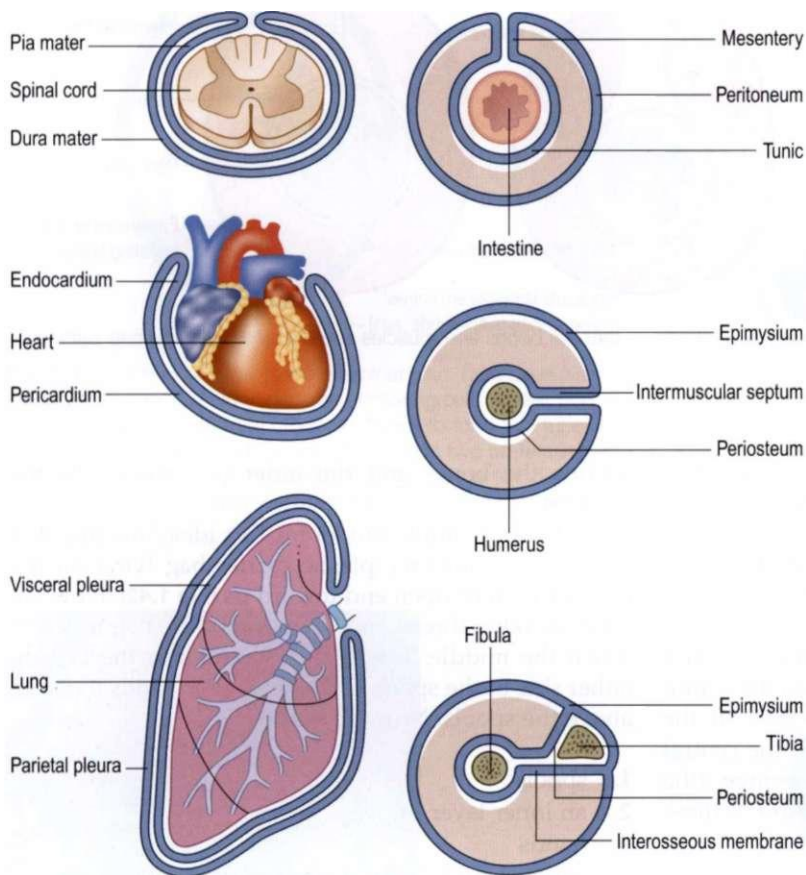


Fig. 1.43 Examining the fascia of the upper arm and lower leg reveals a suspiciously similar 'echo' in the pattern of disposition by other organic 'double-bagged' fascial layers.

and *joint capsule* when it is the ligamentous sleeve around the joints. These connective tissue elements are continuous with each other, and have always been united within the fascial net, but, once separated for analysis, tend to stay separate in our conception. This is strongly reinforced for every student by ubiquitous anatomical drawings in which all the other fabric around a ligament is carefully scraped away to expose the ligament as if it were a separate structure, rather than just

a thickening within this continuous inner bag of the net (**Fig. 1.44**). Taken altogether, the ligaments and periosteum do not form separate structures, but rather a continuous inner bag around the bone-joint tissues. Even the cruciate ligaments of the knee - often shown as if they were independent structures - are part of this continual inner bag.

The content of the outer bag - where our hands were in the model - is a chemically sensitive fibrous jelly we

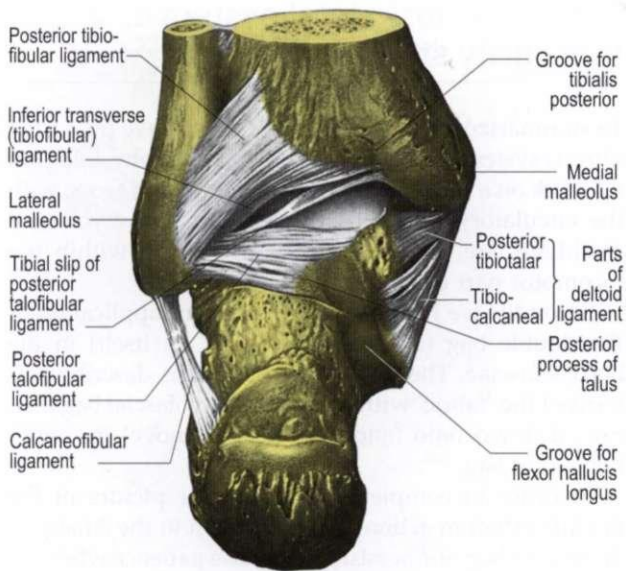


Fig. 1.44 The ligaments we see separated and detailed in the anatomy books are really just thickenings in the continuous encircling 'bone bag' part of the musculoskeletal double-bagging system. (Reproduced with kind permission from Williams 1995.)

call muscle, which is capable of changing its state (and its length) very quickly in response to stimulation from the nervous system. The containing bag itself we call the deep investing fascia, intermuscular septa (the double-walled part between our hands at the end), and myofascia. Within this conception, the individual muscles are simply pockets within the outer bag, which is 'tacked down' to the inner bag in places we call 'muscle attachments' or 'insertions' (Fig. 1.45). The lines of pull created by growth and movement within these bags create a 'grain' - a warp and weft - to both muscle and fascia.

We need to remind ourselves once again at this point that muscle never attaches to bone. Muscle cells are caught within the fascial net like fish within a net. Their movement pulls on the fascia, the fascia is attached to the periosteum, the periosteum pulls on the bone.

There really is only one muscle; it just hangs around in 600 or more fascial pockets. We have to know the pockets and understand the grain and thickenings in the fascia around the muscle - in other words, we still need to know the muscles and their attachments. All too easily, however, we are seduced into the convenient mechanical picture that a muscle 'begins' here and 'ends' there, and therefore its function is to approximate these two points, as if the muscle really operated in such a vacuum. Useful, yes. Definitive, no.

Muscles are almost universally studied as isolated motor units, as in Figure 1.46. Such study ignores the longitudinal effects through this outer bag that are the focus of this book, as well as latitudinal (regional) effects now being exposed by research.⁸⁷ It is now clear that fascia distributes strain laterally to neighboring myofascial structures; so that the pull on the tendon at one end is not necessarily entirely taken by the insertion at the other end of the muscle (see Fig. 1.7). The focus on isolat-

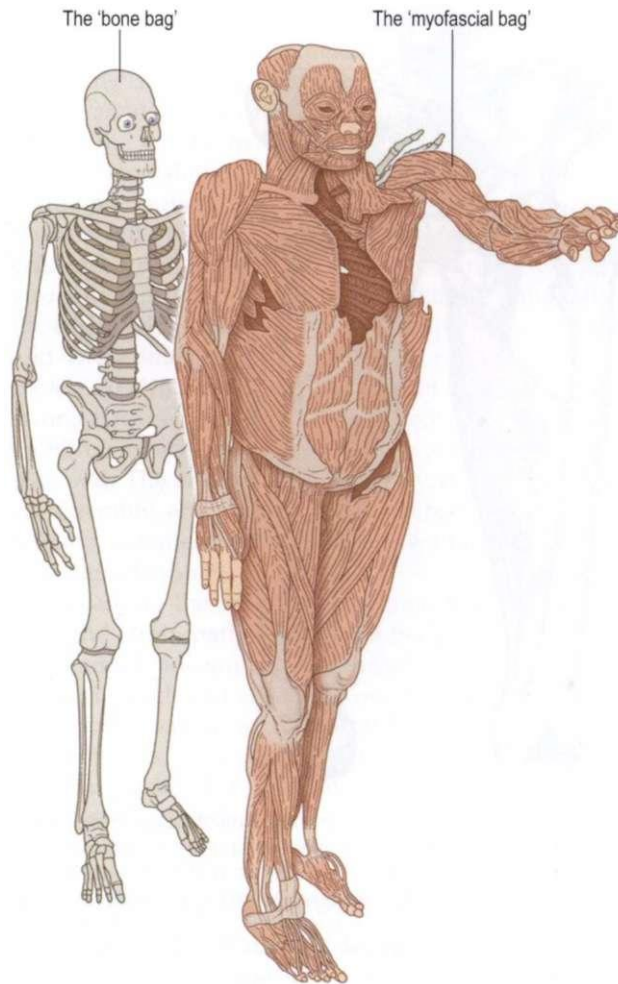


Fig. 1.45 This image, redrawn after a photo of the plastinated bodies in the *Körperwelten* project of Dr Gunter van Hagens, shows more clearly than any other the connected nature of the myofascia and the fallacy (or limitation, at least) of the 'individual muscle connecting two bones' image we have all learned. To connect this image to this chapter, the 'inner bag' would be the ligamentous bed surrounding the skeleton on the left, and the 'outer bag' would be surrounding (and investing) the figure on the right. To prepare this specimen, Dr van Hagens removed the entire myofascial bag in large pieces and reassembled them into one whole. The actual effect is quite poignant; the skeleton is reaching out to touch the 'muscle man' on the shoulder, as if to say, 'Don't leave me, I can't move without you'. (The original plastinated anatomical preparation is part of the artistic/scientific exhibition and collection entitled *Körperwelten* (BodyWorlds). The author recommends this exhibition without reservation for its sheer wonder as well as the potency of its many ideas. Some taste of it can be obtained through visiting the website (www.bodyworlds.com) and purchasing the catalog or the video.) The Anatomy Trains tracks are some of the common continuous lines of pull within this 'muscle bag', and the 'stations' are where the outer bag tacks down onto the inner bag of joint and periosteal tissue around the bones.

ing muscles has blinded us to this phenomenon, which in retrospect we can see would be an inefficient way to design a system subject to varying stresses. Likewise, we have focused on individual muscles to the detriment of seeing the synergetic effects along these fascial meridians and slings.

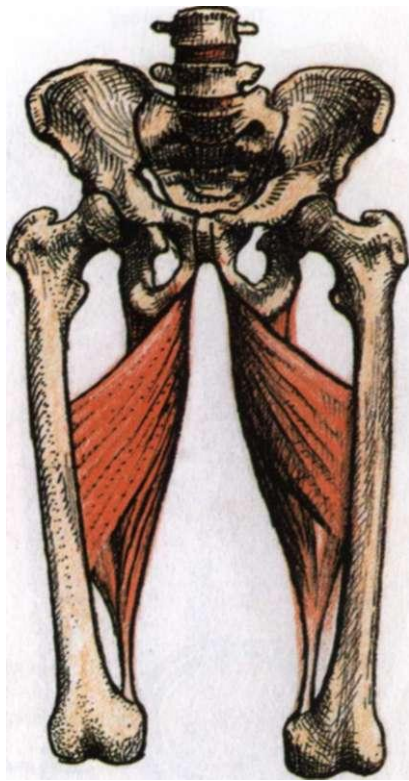


Fig. 1.46 Contrast the living reality of the myofascial continuity in **Figure 1.45** and **1.49A** with the isolated single muscle pictured here. No matter how much we can learn from this excellent and unique depiction of the strange adductor magnus, the common practice of isolating muscles in anatomies results in 'particulate' thinking that leads us away from the synthetic integration that characterizes animal movement. (Reproduced with kind permission from Grundy 1982.)

Applying the Anatomy Trains scheme within this vision, the myofascial meridians can now be seen as the long lines of pull through the outer bag - the myofascial bag - which both form, deform, reform, stabilize, and move the joints and skeleton - the inner bag. The lines of continuous myofascia within the outer bag we will call the 'tracks', and the places where the outer bag tacks down onto the inner bag we will call 'stations' - not end points, but merely stops along the way. Some of the intermuscular septa - the ones that run superficial to profound like the walls of the grapefruit sections - join the outer to the inner bag into the single fascial balloon our body really is (compare **Fig. 1.25** with **Fig. 1.43**, and **Fig. 1.41** with **Fig. 1.42** and see the net result in **Fig. 1.1C**).

This book defines the layout of lines of pull in the outer bag, and begins the discussion of how to work with them. Work with the inner bag - manipulation of peri-articular tissues as practiced by chiropractors, osteopaths, and others - as well as the inner double-bags of the meninges and coelomic peritonea and pleura, are likewise very useful, but are not within the scope of this book. Given the unified nature of the fascial net, we may assume that work in any given arena within the net might propagate signaling waves or lines of pull that would affect one or more of the others.

The musculoskeletal system as a tensegrity structure

To summarize our arguments so far, we have posed the fibrous system as a body-wide responsive physiological network on a par in terms of importance and scope with the circulatory and nervous systems. The myofascial meridians are useful patterns discernible within the locomotor part of that system.

Secondly, we have noted the frequent application of the double bag (a sphere turned in on itself) in the body's fasciae. The myofascial meridians describe patterns of the 'fabric' within the outer myofascial bag connected down onto (and thus able to move) the inner bone-joint bag.

In order to complete our particular picture of the fascial system in action and its relation to the Anatomy Trains, we beg our persistent reader's patience while we place one final piece of the puzzle: to view the body's architecture in the light of 'tensegrity' geometry.

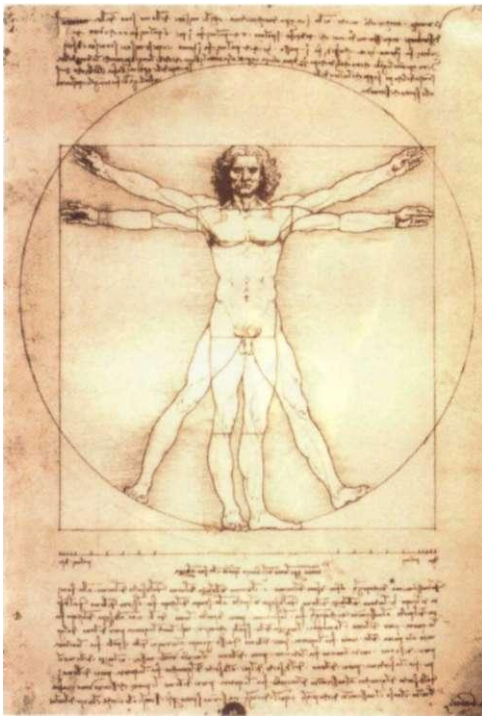
Taking on 'geometry' first, we quote cell biologist Donald Ingber quoting everybody else: 'As suggested by the early 20th century Scottish zoologist D'Arcy W. Thompson, who quoted Galileo, who in turn cited Plato: the book of Nature may indeed be written in the characters of geometry.'⁸⁸

While we have successfully applied geometry to galaxies and atoms, the geometry we have applied to ourselves has been generally limited to levers, angles, and inclined planes, based on the 'isolated muscle' theory we outlined in our introduction. Though we have learned much from the Newtonian force mechanics that underlie our current understanding of kinesiology, this line of inquiry has still not produced convincing models of movements as fundamental as human walking.

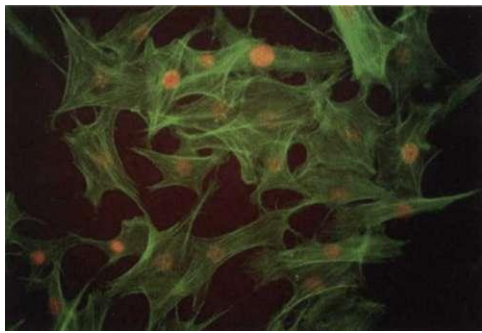
A new understanding of the mechanics of cell biology, however, is about to expand the current kinesiological thinking, as well as give new relevance to the search of the ancients and Renaissance artists for the divine geometry and ideal proportion in the human body. Though still in its infancy, the recent research summarized in this section promises a fruitful new way to apply this ancient science of geometry in the service of modern healing - in other words, the development of a new spatial medicine (**Fig. 1.47A and B**).

In this section we briefly examine this way of thinking about body structure at two levels - first at the macroscopic level of the body architecture as a whole, and then at the microscopic level of the connection between cell structure and the extracellular matrix. As with the hydrophilic and hydrophobic building blocks of connective tissue, these two levels actually form part of a seamless whole, but for discussion the macro- / micro- distinction is useful.⁸⁹ Both levels contain implications for the entire spectrum of manual and movement work.

'Tensegrity' was coined from the phrase 'tension integrity' by the designer R. Buckminster Fuller (working from original structures developed by artist Kenneth



A



B

Fig. 1.47 The ancients and Renaissance artists sought a geometrical ideal for the human form (A), but the modern equivalent is arising from a consideration of the spatial needs of the individual cells (B), which could determine a geometric 'ideal' for each body. (A: public domain; B: photo courtesy of Donald Ingber.)

Snelson - **Fig. 1.48A and B**). It refers to structures that maintain their integrity due primarily to a balance of woven tensile forces continual through the structure as opposed to leaning on continuous compressive forces like a stone wall. 'Tensegrity describes a structural relationship principle in which structural shape is guaranteed by the finitely closed, comprehensively continuous, tensional behaviors of the system and not by the discontinuous and exclusively local compressional member behaviors.'⁹⁰

Notice that spiderwebs, trampolines, and cranes, as wonderful as they are, are anchored to the outside and are thus not 'finitely closed'. Every moving animal structure, including our own, must be 'finitely closed', i.e. independent, and able to hang together whether standing on your feet, standing on your head, or flying through the air in a swan dive. Also, although every

structure is ultimately held together by a balance between tension and compression, tensegrity structures, according to Fuller, are characterized by *continuous tension around localized compression*. Does this sound like any 'body' you know?

'An astonishingly wide variety of natural systems, including carbon atoms, water molecules, proteins, viruses, cells, tissues, and even humans and other living creatures, are constructed using ... tensegrity.'⁹¹ All structures are compromises between stability and mobility, with savings banks and forts strongly at the stability end while kites and octopi occupy the mobility end. Biological structures lie in the middle of this spectrum, strung between widely varying needs for rigidity and mobility, which can change from second to second (**Fig 1.49**). The efficiency, adaptability, ease of hierarchical assembly, and sheer beauty of tensegrity structures would recommend them to anyone wanting to construct a biological system.

Explaining the motion, interconnection, responsiveness and strain patterning of the body without tensegrity is simply incomplete and therefore frustrating. With tensegrity included as part of our thinking and modeling, its compelling architectural logic is leading us to re-examine our entire approach to how bodies initiate movement, develop, grow, move, stabilize, respond to stress, and repair damage.


Macrotensegrity: how the body manages the balance between tension and compression

There are but two ways to support something in this physical universe - via tension or compression; brace it up or hang it up. No structure is utterly based on one or the other; all structures mix and match these two forces in varying ways at different times. Tension varies with compression always at 90°: tense a rope, and its girth goes into compression; load a column and its girth tries to spread in tension. Blend these two fundamental centripetal and centrifugal forces to create complex bending, shearing, and torsion patterns. A brick wall or a table on the floor provides an example of those structures that lean to the compressional side of support (**Fig. 1.50A**). Only if you lean into the side of the wall will the underlying tensional forces be evident. Tensional support can be seen in a hanging lamp, a bicycle wheel, or in the moon's suspended orbit (**Fig. 1.50B**). Only in the tides on earth can the 90° compressional side of that invisible tensional gravity wire between the earth and the moon be observed.

Our own case is simultaneously a little simpler and more complex: our myofasciae provide a continuous network of restricting but adjustable tension around the individual bones and cartilage as well as the incompressible fluid balloons of organs and muscles, which push out against this restricting tensile membrane. Ultimately, the harder tissues and pressurized bags can be seen to 'float' within this tensile network, leading us to the strategy of adjusting the tensional members in order

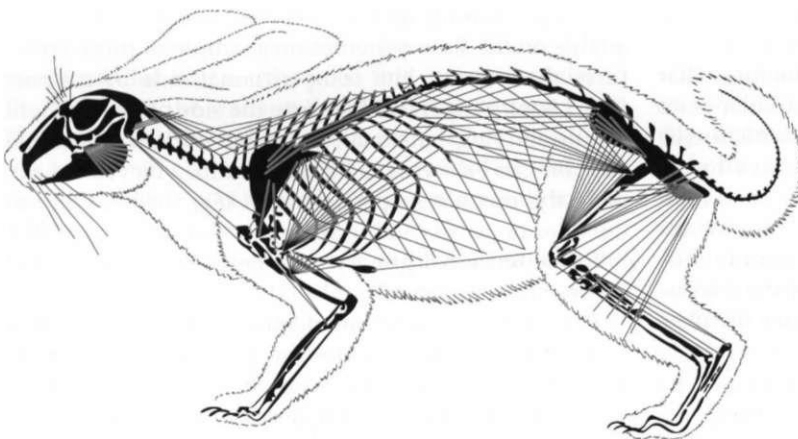


A

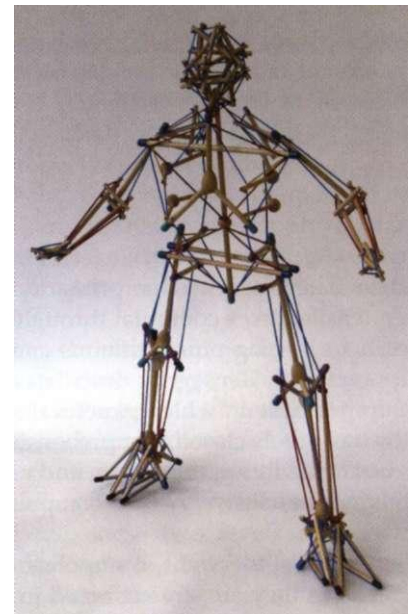


B

Fig. 1.48 (A) More complex tensegrity structures like this mast begin to echo the spine or rib cage. **(B)** Designer R. Buckminster Fuller with a geometric model. (Reproduced with kind permission from the Buckminster Fuller Institute.)



A



B

Fig. 1.49 (A) A tensegrity-like rendition of a rabbit. This was created by drawing a straight line from origins to insertions for the rabbit's muscles. (Reproduced with kind permission from Young 1981.) (Compare to **Fig. In. 4.**) **(B)** An attempt to 'reverse engineer' a human in tensegrity form, a fascinating line of inquiry by inventor Tom Flemons (© 2008 T. E. Flemons, www.intensiondesigns.com.)

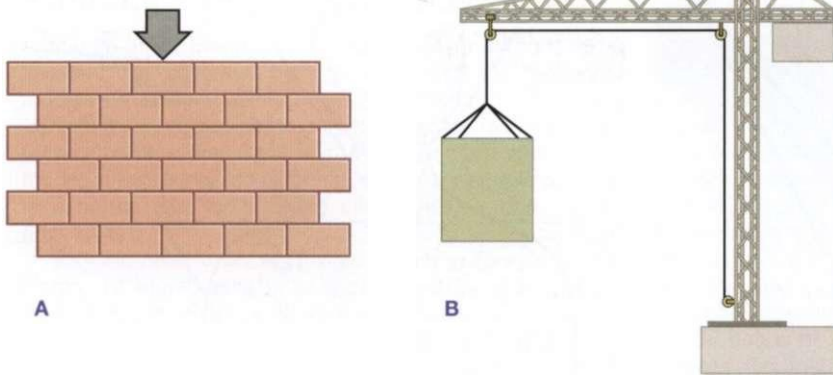


Fig. 1.50 There are two ways to support objects in our universe: tension or compression, hanging or bracing. Walls brace up one brick on top of another to create a continuous compression structure. A crane suspends objects via the tension in the cable. Notice that tension and compression are always at 90° to each other: the wall goes into tension horizontally as the pressure falls vertically, while the cable goes into compression horizontally as the tension pulls vertically.

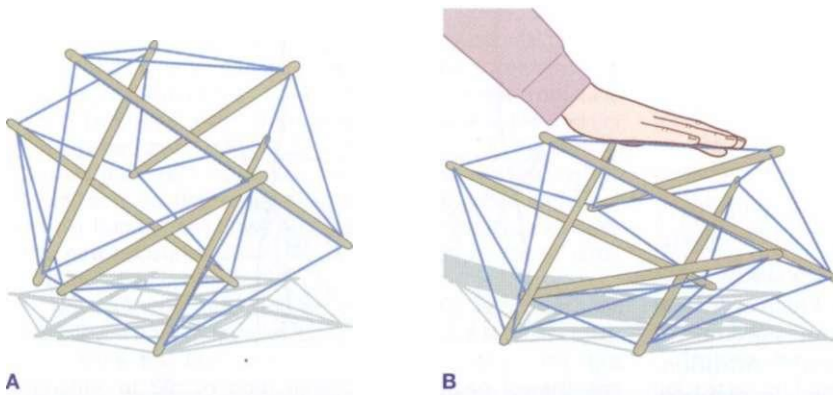
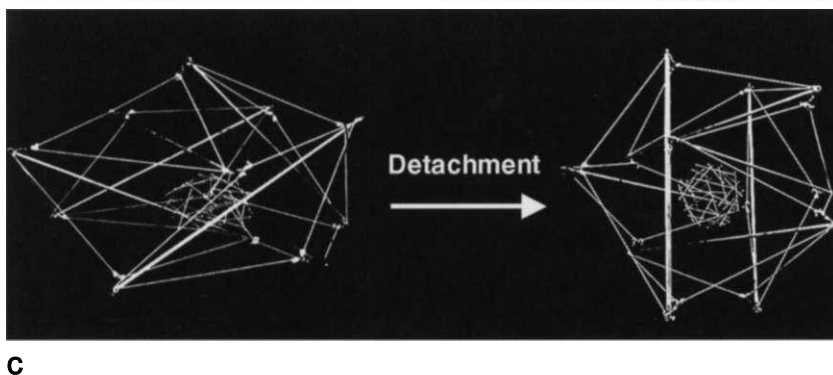


Fig. 1.51 (A) In the class of structures known as 'tensegrity', the compression members (dowels) 'float' without touching each other in a continuous 'sea' of balanced tension members (elastics). When deformed by attachments to an outside medium or via outside forces, the strain is distributed over the whole structure, not localized in the area being deformed. **(B)** That strain can be transferred to structures on a higher or lower level of a tensegrity hierarchy. **(C)** Here we see a model within a model, roughly representing the nucleus within a cell structure, and we can see how both can be de- or re-formed by applying or releasing forces from outside the 'cell'. (Photo courtesy of Donald Ingber).



to reliably change any malalignment of the bones (**Fig. 1.51**).

Tensegrity structures are maximally efficient

The brick wall in **Figure 1.50** (or almost any city building) provides a good example of the contrasting common class of structures based on continuous compression. The top brick rests on the second brick, the first and second brick rest on the third, the top three rest on the fourth, etc., all the way down to the bottom brick, which must support the weight of all the bricks above it and transmit that weight to the earth. A tall building, like the wall above, can also be subject to tensile forces as well - as when the wind tries to blow it sideways - so that most compressive-resistant 'bricks' are reinforced with

tensile-resistant steel rods. These forces are minimal, though, compared to the compressive forces offered by gravity operating on the heavy building. Buildings, however, are seldom measured in terms of design efficiencies such as performance-per-pound. Who among us knows how much our home weighs?

Biological structures, on the other hand, have been subjected to the rigorous design parameters of natural selection. That mandate for material and energetic efficiency has led to the widespread employment of tensegrity principles:

All matter is subject to the same spatial constraints, regardless of scale or position.... If is possible that fully triangulated tensegrity structures may have been selected through evolution because of their structural efficiency - their high mechanical strength using a minimum of materials.⁹¹




Fig. 1.52 A complex model shows how the pelvis, for instance, could be made up of smaller pre-stressed tensegrity units. (Photo and concept courtesy of Tom Flemons, www.intensiondesigns.com.)

Tensional forces naturally transmit themselves over the shortest distance between two points, so the elastic members of tensegrity structures are precisely positioned to best withstand applied stress. For this reason tensegrity structures offer a maximum amount of strength for any given amount of material.⁹⁰ Additionally, either the compression units or the tensile members in tensegrity structures can themselves be constructed in a tensegrity manner, further increasing the efficiency and 'performance/kilo' ratio (**Fig. 1.52**). These nested hierarchies can be seen from the smallest to the largest structures in our universe.^{92,93}

Now, our commonly held and widely taught impression is that the skeleton is a continuous compression structure, like the brick wall: that the weight of the head rests on the 7th cervical, the head and thorax rest on the 5th lumbar, and so on down to the feet, which must bear the whole weight of the body and transmit that weight to the earth (**Fig. 1.53**). This concept is reinforced in the classroom skeleton, even though such a representation must be reinforced with rigid hardware and hung from an accompanying stand. According to the common concept, the muscles (read: myofascia) hang from this structurally stable skeleton and move it around, the way the cables move a crane (**Fig. 1.54**, compare to **Fig. 1.50B**). This mechanical model lends itself to the traditional picture of the actions of individual muscles on the bones: the muscle draws the two insertions closer to each other and thus affects the skeletal superstructure, depending on the physics.

In this traditional mechanical model, forces are localized. If a tree falls on one corner of your average rectangular building, that corner will collapse, perhaps without damaging the rest of the structure. Most modern manipulative therapy works out from this idea: if a part is injured, it is because localized forces have overcome local tissues, and local relief and repair are necessary.

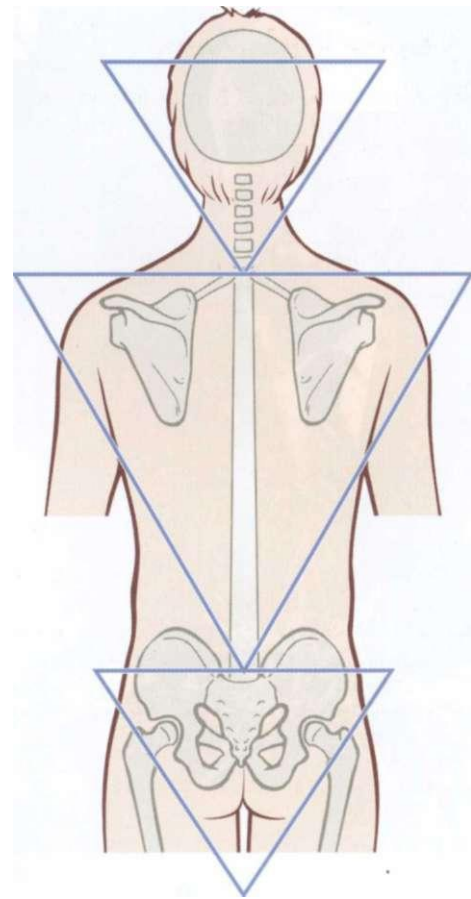


Fig. 1.53 Given the ease of building and simplicity of continuous compression structures, and given how many of them we make to live and work in, it is not surprising that the principles of tensegrity remained obscured for so long. This figure shows a familiar continuous compression model of the body - the head resting on C7, the upper body resting on L5, and the entire body resting like a stack of bricks on the feet. (Redrawn from Cailliet R. FA Davis; 1997.)

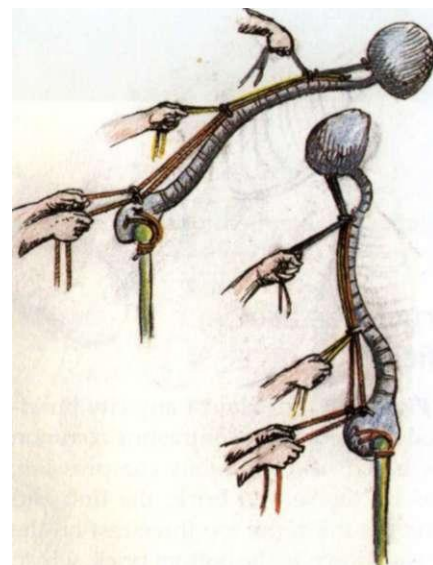


Fig. 1.54 The erector spinae muscles can be seen as working like a crane, holding the head aloft and pulling the spine into its primary and secondary curves. The actual biomechanics seem to be more synergetic, less isolated, requiring a more complex model than the traditional kinesiological analysis. (Reproduced with kind permission from Grundy 1982.)

Building a tensegrity model

Although a clothesline, a balloon, Denver airport, or a 'Skwish!' toy (invented by the designer of the tensegrity models on display in this book, Tom Flemons, www.intensiondesigns.com) are commonly seen structures employing tensegrity principles, you can build a more 'pelvis-like' model, a tensegrity icosahedron, on a very simple scale. It is a potent tool for showing clients how a body works (Fig. 1.55).

You will need 6 equal dowels, ideally a foot or less in length, 12 thumbtacks or pushpins, and 24 equally-sized rubber bands. Push a thumbtack into each end of all the dowels, leaving a little of the shaft showing so that four rubber bands can be slipped under the head of each tack.

You may need a friend to help hold dowels for this project, especially your first time out and especially in the latter stages of building.

Take two dowels and hold them vertically parallel to each other, and place another dowel horizontally between them at the top, to form a letter T. Connect rubber bands from each of the two upper ends of the verticals to each of the ends of the one horizontal dowel - four bands in all. Turn the vertical dowels over 180° so that the horizontal dowel lies on the table, and do the same operation at the other end: four rubber bands from these ends of the uprights to both ends of a new horizontal dowel. You will now have a capital letter T (Fig. 1.56A).

Now turn the structure 90° so that the two horizontal dowels are upright, turning it into an 'H' with a double cross-bar. Place the fifth dowel horizontally between the two uprights, at 90° to both other sets, pointing toward and away from you, and again connect the two uprights to the two ends of the new horizontal dowel. This is where it gets difficult to do with only two hands, because as you place these bands, the lower ends of the uprights want to spread into a letter 'A', and in early attempts the structure may spring apart. Persevere! Turn the structure over and repeat the same operation with the sixth and last dowel (Fig. 1.56B).

To finish the structure, add the remaining rubber bands in the same pattern, connecting each dowel end to all the four adjacent ends *except* the obvious one - the ends of each

dowel's parallel 'brother'. In the end, the structure should stand alone, balanced and symmetrical, with three sets of parallel pairs of dowels. Each dowel end should have four rubber bands going out to all the ends near it, save that of its parallel partner. You can take extra turns around the tacks with some of the rubber bands to even out the tension and thus the position of the dowels.

The sturdiness of your structure will depend on the relative length of the dowels and rubber bands. If the bands are too long, the structure will have 'lax ligaments' and may collapse under its own weight. If the bands are too tight, the structure will bounce well but will not demonstrate a lot of responsiveness in the following experiments. So add rubber bands or take more turns around the ends until you achieve the middle ground in which these moves make sense:

Try pushing a dowel out of place, and see the whole structure respond to the deformation. Try tightening one rubber band, and see how this tightness can produce a change in the shape of the 'bones' at some distance from where you are putting the strain. Push two parallel dowels together and watch the whole structure (counter-intuitively) compress together. Pull two parallel dowels apart (gently) and see the structure expand in every direction.

Push on any side to see the structure bend to accommodate the strain. Where will it break? At its weakest point, since no matter where the strain is introduced, it is transferred to the structure as a whole. All these attributes are properties that your little tensegrity structure shares with human bodies.

Notice how the rubber bands form a continuous outer net - you can travel anywhere around the whole structure on the rubber bands, but each dowel is isolated. Continuous tension, discontinuous compression. In this model, the Anatomy Trains are commonly used pathways for distributing strain, via the groups of rubber bands that run more or less in straight lines.

Bodies are strain distributors, not strain focusers, whenever they can be. A whiplash, for example, is a problem of the neck for only a few weeks before it becomes more distributed throughout the spine. Through this phenomenon of tensegrity, within a few months this is a 'whole-body' pattern, not just a localized injury.

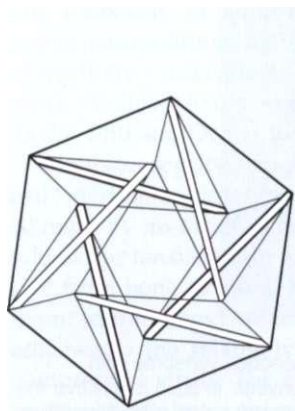


Fig. 1.55 A simple tensegrity tetrahedron gets not-so-simple when you try to make one. (Reproduced with kind permission from Oschman 2000.)

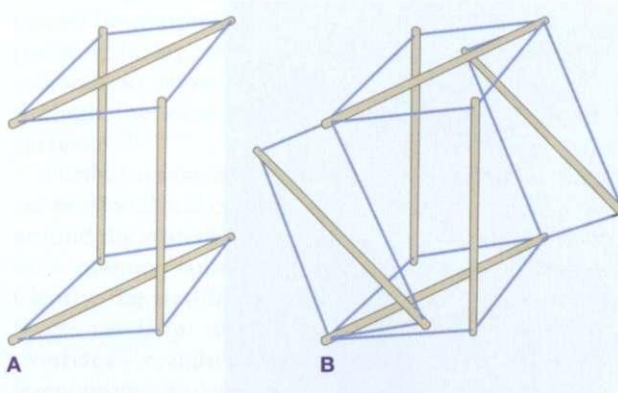


Fig. 1.56 Assemble the model through these stages to make it easier. In the end, each dowel end will be connected to all the other four nearest dowel ends - excepting its parallel brother.

Tensegrity structures are strain distributors

A tensegrity model of the body paints an altogether different picture - forces are distributed, rather than localized (see Fig. 1.51). An actual tensegrity structure is difficult to describe - we offer several pictures here, though building and handling one gives an immediate felt sense of the properties and differences from traditional views of structure (see p. 49) - but the principles are simple. A tensegrity structure, like any other, combines tension and compression members, but here the compression members are islands, floating in a sea of continuous tension. The compression members push outwards against the tension members that pull inwards. As long as the two sets of forces are balanced, the structure is stable. Of course, in a body, these tensile members often express themselves as fascial membranes, not just as tendinous or ligamentous strings (Fig. 1.57).

The stability of a tensegrity structure is, however, generally less stiff but more resilient than the continuous compression structure. Load one 'corner' of a tensegrity structure and the whole structure - the strings and the dowels both - will give a little to accommodate (Fig. 1.58). Load it too much and the structure will ultimately break - but not necessarily anywhere near where the load was placed. Because the structure distributes strain throughout the structure along the lines of tension, the tensegrity structure may 'give' at some weak point at some remove from the area of applied strain, or it may simply break down or collapse.

In a similar analysis, a bodily injury at any given site can be set in motion by such (often) long-term strains in other parts of the body. The injury happens where it does because of inherent weakness or previous injury, not purely and always because of local strain. Discovering these pathways and easing chronic strain at some remove from the painful portion then becomes a natural part of restoring systemic ease and order, as well as preventing future injuries.




Fig. 1.57 While most tensegrity sculptures are made with cable-like tension members, in this model (and in the body) the tension members are more membranous, as in the skin of a balloon. (Photo and concept courtesy of Tom Flemons, www.intensiondesigns.com.)

Thus we can see the bones as the primary compression members (though the bones can carry tension as well) and the myofascia as the surrounding tension members (though big balloons, such as the abdominopelvic cavity and smaller balloons such as cells and vacuoles (see last section of this chapter) can also carry compression forces). The skeleton is only apparently a continuous compression structure: eliminate the soft tissues and watch the bones clatter to the floor, as they are not locked together but perched on slippery cartilage surfaces. It is evident that soft-tissue balance is the essential element that holds our skeleton upright - especially those of us who walk precariously on two small bases of support while lifting the center of gravity high above them.




Fig. 1.58 The spine is modeled in wooden vertebrae with processes supported by elastic 'ligaments' in such a way that the wooden compression segments do not touch each other. Such a structure responds to even small changes in tension through the elastics with a deformation through the entire structure. It is arguable whether this simple model really reproduces the mechanics of the spine, but can the spine be said to operate in a tensegrity-like manner? (Photo and concept courtesy of Tom Flemons, www.intensiondesigns.com.)




Fig. 1.59 The rest of the body in a simple tensegrity rendition. This structure is resilient and responsive, like a real human, but is of course static compared to our coordinated myofascial responses. The position of the wooden struts (bones) is dependent on the balance of the elastics (myofasciae) and the surrounding superficial fascial 'membrane'. The feet, knees, and pelvis of this model have very lifelike responses to pressure. If we could integrate the spine pictured in **Figure 1.58** and a more complex cranial structure, we would be approaching human structure. (Photo and concept courtesy of Tom Flemons, www.intensiondesigns.com.)

In this concept, the bones are seen as 'spacers' pushing out into the soft tissue, and the tone of the tensile myofascia becomes the determinant of balanced structure (**Fig. 1.59**). Compression members keep a structure from collapsing in on itself; tensional members keep the compression struts relating to each other in specific ways. In other words, if you wish to change the relationships among the bones, change the tensional balance through the soft tissue, and the bones will rearrange themselves. This metaphor speaks to the strength of sequentially applied soft-tissue manipulation, and implies an inherent weakness of short-term repetitive high-velocity thrust manipulations aimed at bones. A tensegrity model of the body - unavailable at the time of their pioneering work - is closer to the original vision of both Dr Andrew Taylor Still and Dr Ida Rolf.^{94,95}

In this tensegrity vision, the Anatomy Trains myofascial meridians described in this book are frequent (though by no means exclusive) continual bands along which this tensile strain runs through the outer myofasciae from bone to bone. Muscle attachments ('stations' in our terminology) are where the continuous tensile net attaches to the relatively isolated, outwardly-pushing compressive struts. The continuous meridians one sees in dissection photos throughout this book result, essentially, from turning the scalpel on its side to separate these stations from the bone underneath, while retaining the connection through the fabric from one 'muscle' to another. Our work seeks balanced tone along these tensile lines and sheets so that the bones and muscles



Fig. 1.60 Who more than Fred Astaire embodies the lightness and easy response suggested by the tensegrity model of human functioning? While the rest of us slog around as best we can trying to keep our spines from compressing like stacks of bricks, his bones eternally float with a poise rarely seen elsewhere.

will float within the fascia in resilient equipoise, such as is seen at nearly all times in the incomparable Fred Astaire (**Fig. 1.60**).

A spectrum of tension-dependent structures

Some writers do not agree with this macrotensegrity idea at all, seeing it as a spurious modeling of human structure and movement.⁹⁶ Others, notably orthopedist Stephen Levin, MD, who has pioneered the idea of 'biotensegrity' for over 30 years (www.biotensegrity.com), see the body as entirely constructed via different scale levels of tensegrity systems hierarchically nested within each other.^{97,99} Levin asserts that bony surfaces within a joint cannot be completely pushed together, even with active pushing during arthroscopic surgery, though others cite research to show that the weight is indeed passed through the knee via the harder tissues of bone and cartilage.^{100,101}

Further research is required to quantify the constituent tensional and compressional forces around a joint or around the system as a whole, to see if it can be analyzed in a manner consistent with tensegrity engineering. Clearly, the traditional notions of inclined planes and levers needs, at minimum, an update - if not a total overhaul - in light of the increasing evidence for 'floating compression' as a universal construction principle.

In our view, allowances must be made in this vision of tensegrity for the reality of the body in motion. The body runs the gamut, in different individuals, in different parts of the body, and in different movements in various situations, from the security of a continuous compression structure to the sensitive poise of pure,

self-contained tensegrity. We term this point of view 'tension-dependent spectrum' - the body operating through different mechanical systems in different situations and in different parts of the body.

A herniated disc is surely the result of trying to use the spine as a continuous compression structure, contrary to its design. On the other hand, a long jumper landing at the far end of his leap relies momentarily but definitively on the compressive resistance of all the leg bones and cartilages taken together. (Though even in this case, where the bones of the leg could be thought of as a 'stack of bricks', the compressive force is distributed through the collagen network of the bones, and out into the soft tissues of the entire body in 'tensegrity' fashion.) In daily activities, the body employs a spectrum of structural models from tensegrity to more compression-based modeling.¹⁰²

Looking at some models that fill in the range from the pure compression of a stack of blocks to the self-contained tensegrity of **Figure 1.59**, a sailboat provides one of several 'middle ground' structures (**Fig. 1.61**). At anchor, the mast will stand on its own, but when you 'see the sails conceive, and grow big-bellied with the wanton wind', the fully loaded mast must be further supported by the tensional shrouds and stays or it will snap. By means of the tensile wires, forces are distributed around the boat, and the mast can be thinner and lighter than it otherwise would be. Our spine is similarly constructed to depend on the balance of tension member 'stays' (the erector spinae, longissimus specifically) around it to reduce the necessity for extra size and weight in the spinal structure, especially in the lumbar (**Fig. 1.62**).

The structures of Frei Otto, beautiful membranous biomimetic architecture that relies on tensional principles but is not pure autonomous tensegrity (because it is anchored to and relies on its connections to the ground), can be seen in Denver's new airport, or at www.freiotto.com (**Fig. 1.63**). Here we can see, especially with the cable and membrane structures that characterize the Munich Olympiazentrum, a further exploration of a tension-compression balance which leans strongly toward reli-




Fig. 1.61 A sailboat is not strictly a tensegrity structure, but the structural integrity still depends somewhat on the tension members - the shrouds, stays, halyards, and sheets that take some of the excess strain so that the mast can be smaller than it otherwise would have to be.

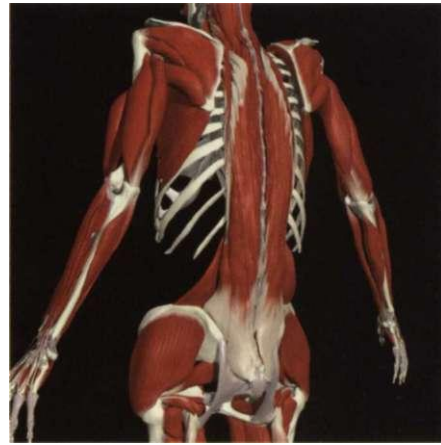

Fig. 1.62 In a similar way, the erectors, specifically the longissimus, act as our 'stays' in the spine, allowing the spine to be smaller than it would otherwise have to be if it were a continuous compression structure. The iliocostalis is constructed and acts like the mast below (Image provided courtesy of Primal Pictures, www.primalpictures.com.)

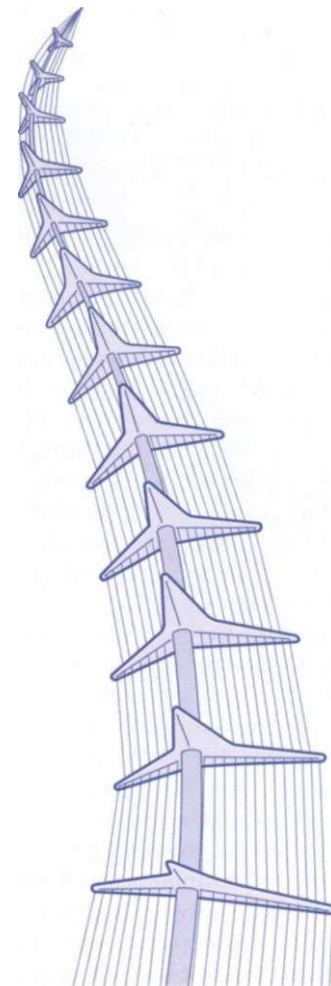


Fig. 1.63 This mast of Frei Otto relies even more heavily on tension for its integrity. The core is flexible, and would fall over without the cables to hold it up. By adjusting the cables and then securing them, this mast can be made a solid support in any number of different positions.

ance on the tensional side of the spectrum. The flexible core is held aloft by a balance of the cords attached to its 'processes'. With the cords in place, pulling on them can put the mast anywhere within the hemisphere defined by its radius. Cut the cords, and the flexible core would fall to the ground, unable to support anything. This arrangement parallels the iliocostalis muscles, seen on the outer edge of the erectors in **Figure 1.62**.

While we are convinced that the body's overall architecture will ultimately be fully described by tensegrity mathematics, perhaps the safer statement at this point is that it potentially can be so employed, but frequently and sadly is used less efficiently, as described above. While this is a subject for further research and discussion, what is clear is that the body's tensile fascial network is continuous and retracts against the bones, which push out against the netting. What is clear is that a body distributes strain - especially sustained long-term strain - within itself in an attempt to equalize forces on the tissues. It is clinically clear that release in one part of the body can produce changes at some distance from the intervention, though the mechanism is not always evident. This all points toward tensegrity as an idea at least worthy of consideration, if not the primary geometry for constructing a human. The models of inventor Tom Flemons (www.intensiondesigns.com and **Figs 1.49B, 1.52 and 1.57-1.59**) are wonderfully evocative. These early 'force diagrams' of human standing approach, but do not yet replicate in their resilience and behavior, a human architectural model. They are brilliantly suspended in homeostasis, but are of course not self-motivating (tropic) as with a biological creature.

Pre-stress

Once we take these models into motion and differing load situations, we need more adjustability. Loose tensegrity structures are 'viscous' - they exhibit easy deformation and fluid shape change. Tighten the tensile membranes or strings - especially if this is done evenly across the board - and the structure becomes increasingly resilient, approaching rigid, columnar-like resistance until they reach their breaking point.

As Ingber¹⁰³ puts it: 'An increase in tension of one of the members results in increased tension in members throughout the structure, even ones on the opposite side.' In fact, even more specifically, all the interconnected structural elements of a tensegrity model rearrange themselves in response to a local stress. And as the applied stress increases, more of the members come

to lie in the direction of the tensional part of the applied stress, resulting in a linear stiffening of the material (though distributed in a non-linear manner).

This is certainly reminiscent of the reaction of the fibrous system to mechanical stresses that we described in the beginning of this chapter in response to piezoelectric charges, as well as simple pull - take a wad of loose cotton wool and gently pull on the ends to see the multidirectional fibers suddenly line up with your fingers in a similar way until the stretching comes to a sudden stop as the fibers line up and bind. Our fibrous body reacts similarly when confronted with extra strain, just like a tensegrity structure or a Chinese finger puzzle (**Fig. 1.64**).

In other words, tensegrity structures show resiliency, getting more stiff and rigid (hypertonic) the more they are loaded. If a tensegrity structure is loaded beforehand, especially by tightening the tension members ('pre-stress'), the structure is able to bear more of a load without deforming. Being adjustable in terms of 'pre-stress' allows the biological tensegrity-based structure to quickly and easily stiffen in order to take greater loads of stress or impact without deforming, and just as quickly unload the stress so that the structure as a whole is far more mobile and responsive to smaller loads.

We have described two ways in which the myofascial system can remodel in response to stress or the anticipation of stress: (1) the obvious one - muscle tissue can contract very quickly at the nervous system's whim within the fascial webbing to pre-stress an area or line of fascia, and (2) long-term stresses can be accommodated by the remodeling of the ECM around piezoelectric charge patterns, adding matrix where more is demanded. Recently a third way to pre-stress the fascial sheets has emerged (the research was begun some time ago, but the story has only recently made it to bodywork and osteopathic circles), so we include a brief report on this new class of fascial response - the active contraction of a certain class of fibroblasts on the ECM itself.

The reader may well ask: If fascial cells display active contractility within the matrix, why has it taken us this long into the chapter to say so? All our previous discussion has centered on the passive response of the cells and the matrix itself to outside forces coming through the matrix. Might not an element this important have come up earlier in the discussion of the fascial net?

The reason for our placement of this new research is that the unique role of the myofibroblasts provides a perfect transition between the tissue-and-bone world of macro-tensegrity to the cytoskeletal world of micro-




Fig. 1.64 By 'pre-stressing' a tensegrity structure, that is, putting a particular strain on it beforehand, we notice that (1) many of the members, both compressional and tensional, tend to align along the lines of the strain, and (2) the structure gets 'firmer' - prepared to handle more loading without changing shape as much. (Photo courtesy of Donald Ingber.)

tensegrity which will occupy us for the rest of the chapter. Aside from that, the exact therapeutic implications of this discovery are as yet unclear.

Suffice it to say that fascia has long been thought to be plastic or viscoelastic, but otherwise inelastic and non-contractile. Both these shibboleths are being revised in light of new research. According to Schleip, 'It is generally assumed that fascia is solely a *passive* contributor to biomechanical behavior, by transmitting tension which is created by muscles or other forces ... [but] there are recent hints which indicate that fascia may be able to contract autonomously and thereby play a more active role.'¹⁰⁴

Myofibroblasts

In fact, fascia can now be said to be contractile. But the circumstances under which such a contraction is exerted are limited and therefore quite interesting. We now know that there is a class of cells in fascia that are capable of exerting clinically significant contractile force in particular circumstances - enough, for instance, to influence low-back stability.¹⁰⁵ This class of cell has been termed myofibroblasts (MFBs - see **Fig. 1.47B**). MFBs represent a middle ground between a smooth muscle cell (commonly found in viscera at the end of an autonomic motor nerve) and the traditional fibroblast (the cell that primarily builds and maintains the collagenous matrix). Since both smooth muscle cells and fibroblasts develop from the same mesodermal primordium, it comes as little surprise (in retrospect, as usual) that the body might find some use for the transitional cell between the two, but some surprising characteristics of these cells kept them from being recognized earlier. Apparently, evolution found variable uses for such a cell, as MFBs have several major phenotypes from slightly modified fibroblasts to nearly typical smooth muscle cells.¹⁰⁶

Chronic contraction of MFBs plays a role in chronic contractures such as Dupuytren's contracture of the palmar fascia or adhesive capsulitis in the shoulder.¹⁰⁴ MFBs are clearly very active during wound healing and scar formation, helping to draw together the gap in the metamembrane and build new tissue.¹⁰⁷ To be brief, we will let the reader follow the references for these possibly intriguing roles in body pathology so that we can hew closely our stated goal of describing how fascia works normally.

It is now clear that MFBs occur in healthy fascia, and in fascial sheets in particular, such as the lumbar fascia, fascia lata, crural fascia, and plantar fascia. They have also been found in ligaments, the menisci, tendons, and organ capsules. The density of these cells may vary positively with physical activity and exercise, but in any case, the density is highly variable in different parts of the body and among people.

One very surprising aspect of these cells is that - unlike every other muscle cell in the body, smooth or striated - they are *not* stimulated to contract via the usual neural synapse. Therefore, they are beyond the reach of conscious control, or even unconscious control

as we would normally understand it. The factors that induce the long-duration, low-energy contraction of these cells are: (1) mechanical tension going through the tissues in question, and (2) specific cytokines and other pharmacological agents such as nitric oxide (which relaxes MFBs) and histamine, mepyramine, and oxytocin (which stimulate contraction). Unexpectedly, neither norepinephrine or acetylcholine (neurotransmitters commonly used to contract muscle), nor angiotensin or caffeine (calcium channel blockers) has any effect on these MFBs. Many MFBs are located near capillary vessels, the better to be in contact with these chemical agents.¹⁰⁸

The contraction, when it occurs, comes on very slowly compared to any muscle contraction, building over 20-30 minutes and sustaining for more than an hour before slowly subsiding. Based on the *in vitro* studies to date, this is not a quick-reaction system, but rather one built for more sustained loads, acting as slowly as it does under fluid chemical stimulation rather than neural. One aspect of the fluid environment is of course its pH, and a lower, acidic pH in the matrix tends to increase the contractility of these MFBs.^{109,110} Therefore, activities that produce pH changes in the internal milieu, such as breathing pattern disorder, emotional distress, or acid-producing foods, could induce a general stiffening in the fascial body. Here ends this brief foray into chemistry, which is so well-covered elsewhere.¹¹⁰

MFBs also induce contraction through the matrix in response to mechanical loading, as would be expected. With the slow response of these cells, it takes 15-30 minutes or more before the fascia in question gets more tense and stiff. This stiffness is a result of the MFBs pulling on the collagen matrix and 'crimping' it (**Fig. 1.65**).

The manner in which the MFB contracts and tenses the fiber matrix of the ECM is instructive, and will lead us into the wonderful world of tensegrity on a cellular level.

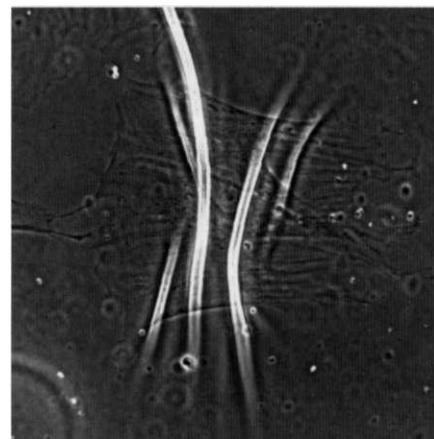


Fig. 1.65 A contracting myofibroblast (MFB) can produce visible 'crimping' on the *in vitro* substrate, demonstrating the ability of the motive power of the MFB to affect the surrounding matrix. (Photo provided by Dr Boris Hinz, Laboratory of Cell Biophysics, Ecole Polytechnique Federate de Lausanne, Lausanne, Switzerland.)

Regular fibroblast cells contain actin, as do most cells, but they are incapable of mounting the degree of tension or forming the kinds of intracellular and extracellular bonds necessary to pull significantly on the ECM (**Fig. 1.66A**). Under mechanical stress, however, the fibroblast will differentiate into a proto-MFB, which builds more actin fibers and connects them to the focal adhesion molecules near the cell surface (**Fig. 1.66B**). Further mechanical and chemical stimulation can result in full differentiation of the MFB, characterized by a complete set of connections among the fibers and glycoproteins of the ECM through the MFB membrane into the actin fibers connected with the cytoskeleton (**Fig 1.66C**).

The contraction produced by these cells - which often arrange themselves in linear syncytia as muscle cells also do, like boxcars on a train - can generate stiffening or shortening of large areas in the sheets of fascia where they often reside (**Fig. 1.67**).

This discovery, though still in its early stages in terms of research, promises myriad implications concerning the body's ability to adjust the fascial webbing. This form of 'pre-stress' - a middle ground between the immediate contraction of pure muscle and the fiber-creation remodeling shown by the pure fibroblast - can prepare the body for greater loads or facilitate transfer of loads from one fascia to another. In terms of the responsiveness of fascia, we see a spectrum of contractile ability from the instant and linear pull of the skeletal muscle through the more generalized spiral contraction of the smooth muscle cell on into the varying degrees of MFB expression to the more passive but still responsive fibroblast at the other end of the connective tissue spectrum.

Given how these MFBs can be stimulated by mechanical (fibrous) loading or by fluid chemical agents, we can also discern in this system the dance among the neural,

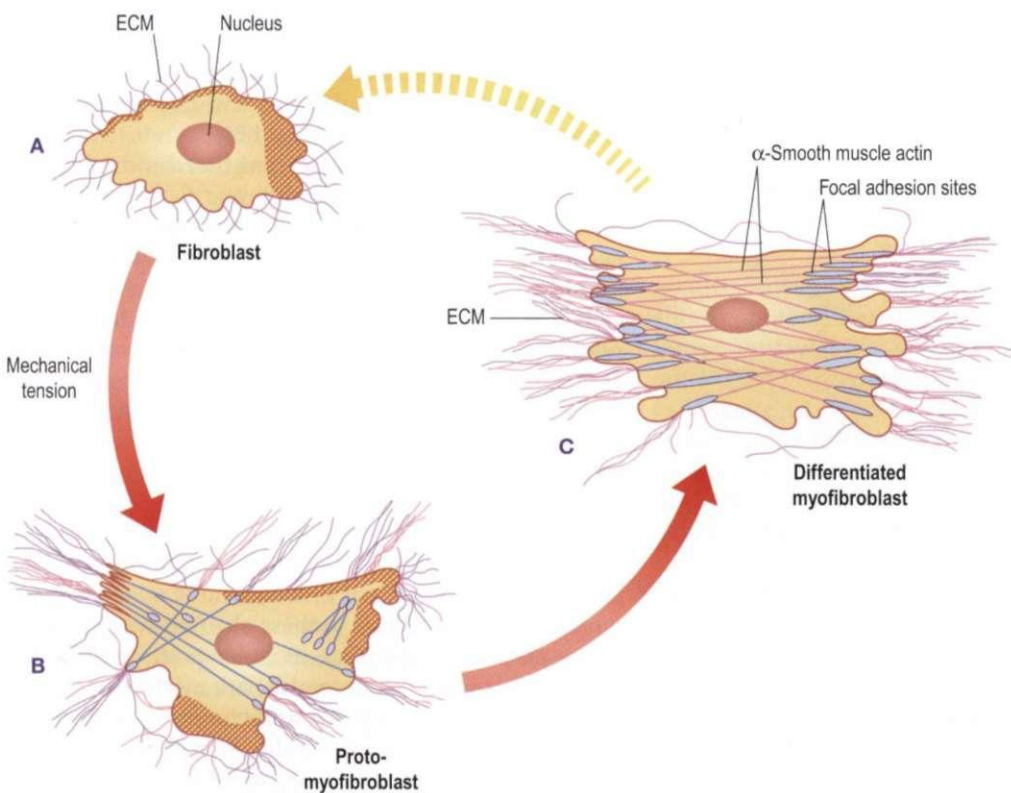


Fig. 1.66 MFBs are thought to differentiate in two stages. Though normal fibroblasts have actin in their cytoplasm and integrins connecting them to the matrix, they do not form adhesion complexes or show stress fibers (**A**). In the proto-MFB stage, they do form stress fibers and adhesion complexes through the cell's membrane (**B**). Mature MFBs show more permanent stress fibers formed by the α -smooth muscle actin, as well as extensive focal adhesions that allow the pull from the actin through the membrane into the ECM (**C**). (Redrawn from Tomasek J et al. Nature Reviews. Molecular Cell Biology; 2002.)

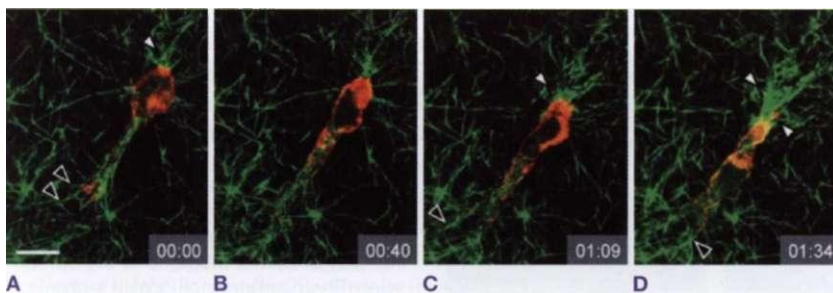


Fig 1.67 Stills from a video of a melanoma cell migrating through a 3-D collagen latticework over an hour's time. Notice how the (green) collagen is remodeled by the passage of the cell, through an interaction with the integrins on the cell's surface. (From Friedl 2004, with kind permission from Springer-Science+ Business Media.)

vascular, and fibrous web that goes into making what we have here termed 'Spatial Medicine': how the body senses and adapts to changes of shape caused by internal or external forces.

Returning to our discussion of tensegrity, we introduced the MFBs at this point because they show how the body can alter the 'pre-stress' of the body's tensegrity to stiffen it for greater loading. Because of the time involved, there has to be an anticipation of further stress and loading to put the contraction in place. Thus one is tempted to question whether emotional stress can induce similar loading and MFB response, creating a generally 'stiffer' (literally), less sensitive (interstitial sensory nerve endings would be rendered inert), and less adaptable person biochemically.

Moving to the other end of the scale, this discussion also leads us to how microtensegrity works to connect the entire inner cell workings to the ECM of the fascial net. It is not only MFBs that are capable of hooking up to the ECM. On this microscopic level, the tensegrity applications are more unambiguous, and have every promise of revolutionizing our approach to medicine by bringing to the fore the spatial and mechanical aspect as a complement to the predominant biochemical view.

Microtensegrity: how the cells balance tension and compression

Up to this point, we have been discussing tensegrity on the macroscopic level, as it relates to our Anatomy Trains model. In discussing the MFBs, we saw how the internal cell structure could hook to the macrostructure of the ECM. This end of the tensegrity geometry argument has recently been boosted with extensive research, now more familiar under the name mechanobiology, with relevance to myofascial work and manual intervention of all types. Before we leave tensegrity for the main body of the book, we repair once again to the microscope. Here we find a new set of connections with an unexpected glimpse into the possible effect of manual work on cellular function, even including genetic expression.

On the basis of this book, one could be forgiven, saving the last few paragraphs about MFBs, for thinking that the cells 'float' independently within the ECM we have been describing, and indeed that is how I myself taught it for years. 'Medicine has done great things', I would pontificate, 'by concentrating on the biochemis-

try within the cells, while manual and movement therapists concentrate on what goes on between the cells.' The cell has been viewed as 'a balloon filled with Jello®', in which the organelles float, in the same way the cell floats in the medium of the ECM.

This new research - and here we rely heavily on the work of Dr Donald Ingber and his faculty at Children's Hospital in Boston - has knocked any such separation into a cocked hat. It has been definitively shown that there is a very structured and active 'musculo-skeletal system' within the cell, called the cytoskeleton, to which each organelle is attached, and along which they move.¹¹¹ The cytoskeleton is slightly misnamed in that it also contains actomyosin molecules that can contract to exert force within the cell, on the cell membrane, or - as we saw with the MFBs - through the membrane to the matrix beyond, so it is really the cell's musculo-skeletal or myofascial system. These mechanically active connections - compressional microtubules, tensile microfilaments, and interfibrillar elements - run between the inner workings of nearly every cell and the ECM, a mutually active relationship that forever puts to rest the idea that independent cells float within a sea of 'dead' connective tissue products (Fig. 1.68).

It has been known for some time that the 'double bag' of the phospholipid cell membrane is studded with globular proteins that offer receptor sites both within and without the cell, to which many but highly particular chemicals could bind, changing the activity of the cell in various ways (see Fig. 1.31). Candace Pert's research summarized in the *Molecules of Emotion*, making endorphins a household word, is one example of the kinds of links in which the chemistry beyond the cell, binding to these cross-membrane receptors, affects the physiological workings within the cell.¹¹²

Integrins

The newer discovery, and one even more relevant to our work, is that in addition to these chemoreceptors, some of the membrane-spanning globular proteins (a family of chemicals known as integrins) are mechanoreceptors which communicate tension and compression from the cell's surroundings - specifically from the fiber matrix - into the cell's interior, even down into the nucleus (Fig. 1.69). So, in addition to chemoregulation, we may now add the idea of mechanoregulation.

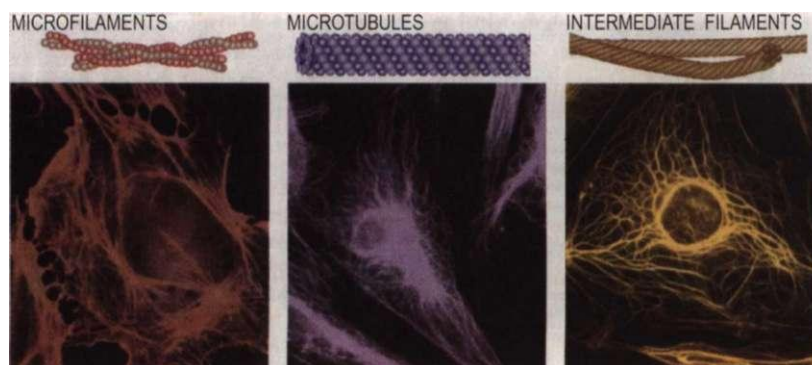


Fig. 1.68 Cytoskeletal fibers - like the microfilaments, dynamic microtubules, and smaller interfibrillar elements - connect the nuclear center of each cell to the ECM outside its borders, and constitute the interplay of Spatial Medicine at the cellular level. (Photo courtesy of Donald Ingber.)

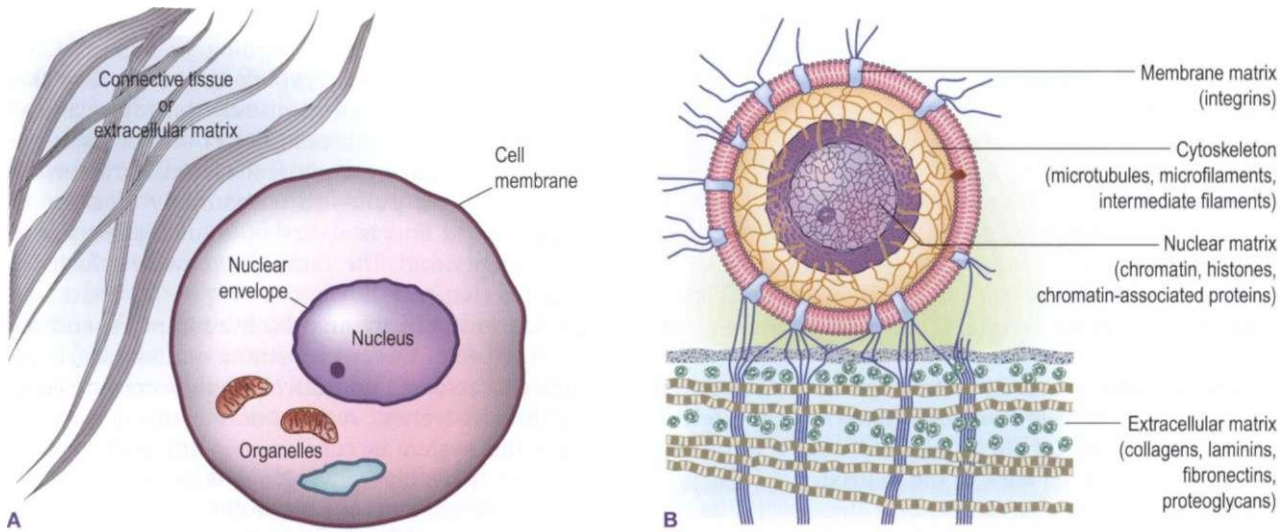


Fig. 1.69 Two views of the relationship between the cell and the surrounding ECM. **(A)** The traditional view, in which each element has its autonomy. **(B)** The more current view, in which the nuclear material, nuclear membrane, and cytoskeleton are all mechanically linked via the integrins and laminar proteins to the surrounding ECM. (Reproduced with kind permission from Oschman 2000.)

By the early 1980s, it was understood in scientific circles that the ground substance and adhesive matrix proteins were linked into the system of the intracellular cytoskeleton." It is that linkage - from the nucleus to the cytoskeleton to the focal adhesion molecules inside the membrane, through the membrane with the integrins, and then via the proteoglycans such as fibronectin to the collagen network itself (**Fig. 1.70**) - which is extraordinarily strong in the MFBs, working generally from the cell out onto the matrix, but the same kind of mechanoregulatory process extends to every cell, often working from the outside in: movements in the mechanical environment of the ECM can affect, for better or worse, how the cell functions.

While it is obvious that some kind of cell adhesion is necessary to hold the body together, the extent and importance of this mechanical signaling, now called mechanotransduction, is being seen to have a role in a wide variety of diseases, including asthma, osteoporosis, heart failure, atherosclerosis, and stroke, as well as the more obvious mechanical problems such as low back and joint pain.¹¹³ 'Less obviously, it helps to direct both embryonic development and an array of processes in the fully formed organism, including blood clotting, wound healing, and the eradication of infection.'^{114,115}

For instance:

A dramatic example of the importance of adhesion to proper cell function comes from studies of the interaction between matrix components and mammary epithelial cells. Epithelial cells in general form the skin and lining of most body cavities; they are usually arranged in a single layer on a specialized matrix called the basal lamina. The particular epithelial cells that line the mammary glands produce milk in response to hormonal stimulation. If mammary epithelial cells are removed from mice and cultured in laboratory dishes, they quickly lose their regular, cuboidal shape and the ability to make milk proteins. If, however, they are grown in the presence of laminin (the basic adhesive protein in the basal

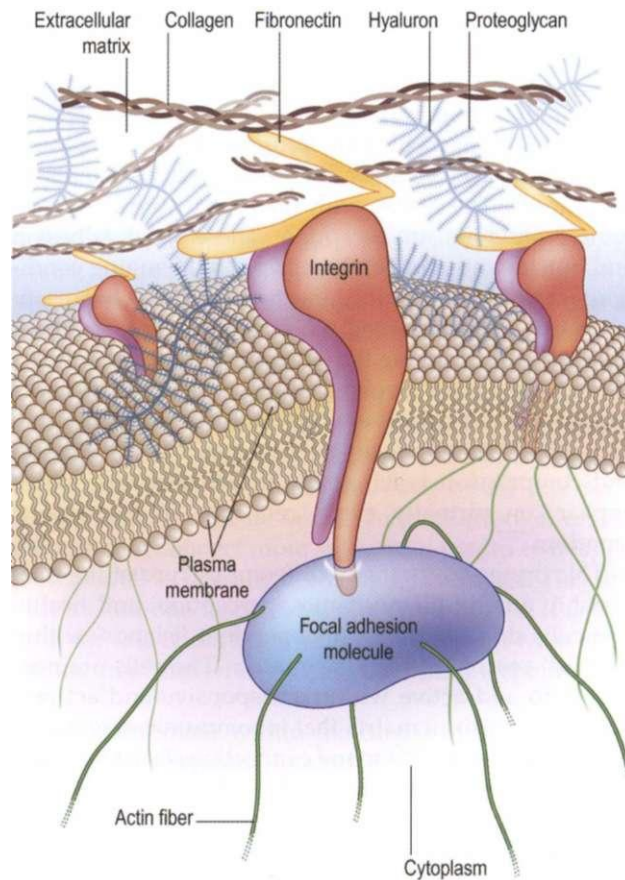


Fig. 1.70 The integrins - 'floating' in the phospholipid membrane - make Velcro®-like connections between the cellular elements shown in **Figure 1.68** and the extracellular elements of the ECM.

lamina) they regain their usual form, organize a basal lamina, and assemble into gland-like structures capable once again of producing milk components.¹¹⁶

In other words, the mechanical receptors and the proteins of the ECM are linked into the cell in a communi-

eating system via the integrins on the cell's surface. These connections act to alter the shape of the cells and their nuclei (see Fig. 1.51), and with that, their physiological properties. How do cells respond to changes in the mechanics of their surroundings?

The response of the cells depends on the type of cells involved, their state at the moment, and the specific makeup of the matrix. Sometimes the cells respond by changing shape. Other times they migrate, proliferate, differentiate, or revise their activities more subtly. Often, the various changes issue from the alterations in the activity of genes.¹⁷

Information conveyed on these spring-like 'mechanical molecules' travels from the matrix into the cell to alter genetic or metabolic expression, and, if appropriate, out from the cell back to the matrix:

We found that when we increased the stress applied to the integrins (molecules that go through the cell's membrane and link the extracellular matrix to the internal cytoskeleton), the cells responded by becoming stiffer and stiffer, just as whole tissues do. Furthermore, living cells could be made stiff or flexible by varying the prestress in the cytoskeleton by changing, for example, the tension in contractile microfilaments?¹⁷

The actual mechanics of the connections between the extracellular matrix and the intracellular matrix is generally achieved by numerous weak bonds - a kind of Velcro® effect - rather than a few strong points of attachment. The MFBs, with their very strong connections, would be an exception. These focal adhesion and outside integrin bonds respond to changing conditions, connecting and unconnecting rapidly at the receptor sites when the cell is migrating, for instance. Mechanically stressing the chemoreceptors on the cell's surface - the ones involved in metabolism, as in Pert's work - did not effectively convey force inside the cell. This job of communicating the picture of local tension and compression is left solely to the integrins, which appear 'on virtually every cell type in the animal kingdom'.¹⁷

This brings us to a very different picture of the relationship among biomechanics, perception, and health. The cells do not float as independent 'islands' within a 'dead' sea of intercellular matrix. The cells are connected to and active within a responsive and actively changing matrix, a matrix that is communicating meaningfully to the cell, via many connections (see Figs 1.69B and 1.70). The connections are linked through a tensegrity geometry of the entire body, and are constantly changing in response to the cell's activity, the body's activity (as communicated mechanically along the trails of the fiber matrix), and the condition of the matrix itself.¹⁸

Microtensegrity and optimal biomechanical health

It appears that cells assemble and stabilize themselves via tensional signaling, that they communicate with and move through the local surroundings via integrins, and

that the musculo-fascial-skeletal system as a whole functions as a tensegrity. According to Ingber: 'Only tensegrity, for example, can explain how every time that you move your arm, your skin stretches, your extracellular matrix extends, your cells distort, and the interconnected molecules that constitute the internal framework of the cell feel the pull - all without any breakage or discontinuity.'¹⁷ This is a very up-to-date statement of the sentiment from *The Endless Web* with which we started this chapter.

The sum total of the matrix, the receptors, and the inner structure of the cell constitute our 'spatial' body. Though this research definitively demonstrates its biological responsiveness, a question remains concerning whether this system is 'conscious' in any real sense, or whether we perceive its workings only via the neural stretch receptors and muscle spindles arrayed throughout the muscle and fascia of the fibrous body.

Structural intervention - of whatever sort - works through this system as a whole, changing the mechanical relations among a countless number of individual tensegrity-linked parts, and linking our perception of our kinesthetic self to the dynamic interaction between cells and matrix.

Research into integrins has just begun to show us the beginnings of 'spatial medicine' - and the importance of spatial health:

To investigate the possibility further [researchers in my group] developed a method to engineer cell shapes and function. They forced living cells to take on different shapes - spherical or flattened, round or square - by placing them on tiny adhesive 'islands' composed of extra-cellular matrix. Each adhesive island was surrounded by a Teflon-like surface to which cells could not adhere.¹⁶

By simply modifying the shape of the cell, they could switch cells among different genetic programs. Cells that were stretched and spread flat became more likely to divide, whereas rounded cells that were prevented from spreading activated a death program known as apoptosis. When cells are neither too expanded nor too hemmed in, they spend their energy neither in dividing nor in dying. Instead they differentiated themselves in a tissue-specific manner; capillary cells formed hollow capillary tubes, liver cells secreted proteins that the liver normally supplies to the blood, and so on.

Thus, mechanical information apparently combines with chemical signals to tell the cell and cytoskeleton what to do. Very flat cells, with their cytoskeletons stretched, sense that more cells are needed to cover the surrounding substrate - as in wound repair - and that cell division is necessary. Rounding and pressure indicates that too many cells are competing for space on the matrix and that cells are proliferating too much; some must die to prevent tumor formation. In between those two extremes, normal tissue function is established and maintained. Understanding how this switching occurs could lead to new approaches in cancer therapy and tissue repair and perhaps even to the creation of artificial-tissue replacements.¹⁸

The new proportion

This research points the way toward a holistic role for the mechanical distribution of stress and strain in the body that goes far beyond merely dealing with localized tissue pain.¹¹⁸ If every cell has an ideal mechanical environment, then there is an ideal 'posture' - likely slightly different for each individual, based on genetic, epigenetic, and personal use factors - in which each cell of the body is in its appropriate mechanical balance for optimal function. This could lead to a new and scientifically based formulation of the old search for the 'ideal' human proportion - an ideal not built on the geometry of proportion or on musical harmonics, but on each cell's ideal mechanical 'home'.

Thus, creating an even tone across the myofascial meridians, and further across the entire fascial net, could have profound implications for health, both cellular and general. 'Very simply, transmission of tension through a tensegrity array provides a means to distribute forces to all interconnected elements, and, at the same time to couple or 'tune' the whole system mechanically as one.'¹¹⁸

For manual and movement therapists, this role of tuning the entire fascial system could have long-term effects in immunological health, prevention of future breakdown, as well as in the sense of self and personal integrity. It is this greater purpose, along with coordinating movement, augmenting range, and relieving pain, that is undertaken when we seek to even out the tension to produce an equal tonus - like the lyre's string or the sailboat's rigging - across the Anatomy Trains myofascial meridians (see Fig. 10.1).

In fact, however, every cell is involved in what we could term a 'tensile field' (see also Appendix 3 on acupuncture meridians for more in this vein). When the cell's need for space is disturbed, there are a number of compensatory moves, but if the proper spatial arrangement is not restored by the compensations, the cell function is compromised - that is what this research makes clear.¹¹⁹ The experienced therapist's hand or eye can track disturbances and excesses in the tensile field, although an objective way to measure these fields would be welcome. Once discovered, a variety of treatment methods can be weighed and tried to relieve the mechanical stress.

The microvacuole theory

The body has to relieve and distribute such stress continually, sometimes without benefit of manual therapy. The mechanism for doing so - a fascinating fractal adapting system in the connective tissues - has recently been uncovered and documented. We cannot leave the world of fascia without sharing some of the insights and beautiful images that have come from the work of the French plastic and hand surgeon Dr Jean-Claude Guimberteau.¹²⁰ These images show the interface between microtensegrity and macrotensegrity (an artificial distinction in the first place) in action in the living body (Fig. 1.71).



Fig. 1.71 Actual *in vivo* photos of the connective tissue network by Dr J. C. Guimberteau show the varying polygonal shapes of the microvacuolar sliding system - in this picture resembling the trabeculae of the bones. One can see here how the capillaries are held within the extensible connective tissue network. (Photo courtesy of Dr Guimberteau.) (DVD ref: These illustrations are taken from 'Strolling Under the Skin', a video available at www.anatomytrains.com)

So many of the images, both verbal and visual, that we present here are taken from *in vitro* experiments or from cadaverous tissue. The microvacuolar photos in this section were photographed *in vivo* during hand surgery, with permission. How well they demonstrate the healthy functioning of normal fascia, revealing a surprising new discovery of how fascial layers slide on each other.

Fascial layers in the hand, specifically in the carpal tunnel, must slide on each other more than any other apposite surfaces, so it is understandable that a hand surgeon would seek more precision on this question. Every fascial plane, however, has to slide on every other if movement is not to be unnecessarily restricted. Yet, when doing dissection in either fresh-frozen or preserved cadavers, one does not see fascial planes sliding freely on each other; one sees instead either a delicate fascial 'fuzz' or stronger cross-linkages that connect more superficial planes to deeper ones, as well as laterally between the epimysia. This fits with the 'all-one fascia' image of continuity that is the motif for this book, but it calls into question what constitutes 'free' movement within the fascial webbing (Fig. 1.72).

Such movement within the carpal tunnel and with the lower leg tendons around the malleoli is usually depicted in the anatomies as having tenosynovial sheaths, or specialized bursae for the tendons to run in - often rendered in blue in anatomy atlases such as Netter's¹²¹ or Gray's.¹²² Dr Guimberteau has poked his camera inside these supposed bursae of the 'sliding system' and come up with a startling revelation that applies not only to his specialized area of the hand, but to many of the loose interstitial areas of the body: there is no discontinuity between the tendon and its surroundings. The necessary war between the need for movement and the need for maintaining connection is solved by a constantly changing fractally divided set of polyhedral bubbles which he terms the 'multimicrovacuolar collagenic absorbing system'.





Fig. 1.72 'The fibrils, made of collagen and elastin, delimit the microvacuoles where they cross each other. These microvacuoles are filled with hydrophilic jelly made of proteoaminoglycans.' What a still photo cannot convey is the fractal and frothy way these microvacuolar structures roll over each other, elasticize, reform, blend, and separate. (Photos (and quote) courtesy of Dr Guimberteau from *Promenades Sous La Peau*. Paris: Elsevier; 2004.)



Fig. 1.73 The microvacuolar system of Guimberteau synthesizes the predictions made by tensegrity geometry with the pressure system concepts from visceral manipulation proffered by another Frenchman Jean-Pierre Barral. This picture demonstrates how this system can respond to all the forces under the skin - tensegrity and optimal use of space/closest packing, osmotic pressure, surface tension, cellular adhesions, and gravity. (Photo courtesy of Dr Guimberteau.)

Pictured here (**Fig. 1.73**), the skin of these bubbles is formed from elastin and collagen Types I, II, IV and VI. The bubbles are filled with 80% water, 5% fat, and 15% hydrophilic proteoglycoaminoglycans. The fern-like molecules of the sugar-protein mix spread out through the space, turning the contents of the microvacuole into a slightly viscous jelly. When movement occurs between the two more organized layers on either side (the tendon, say, and the flexor retinaculum), these bubbles roll and slide around each other, joining and dividing as soap bubbles do, in apparently incoherent chaos. 'Chaos', understood mathematically, actually conceals an implicate order. This underlying order allows all the tissues within this complex network to be vascularized (and therefore nourished and repaired), no matter which direction it is stretched, and without the logistical difficulties that present themselves whenever we picture the sliding systems the way we have traditionally done (**Fig. 1.74**).

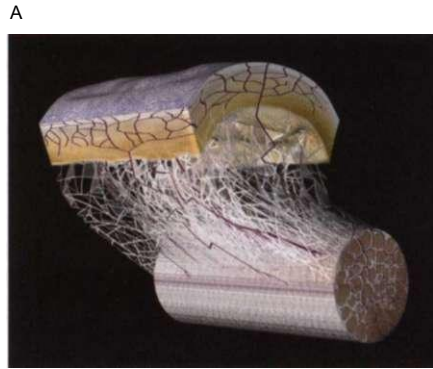
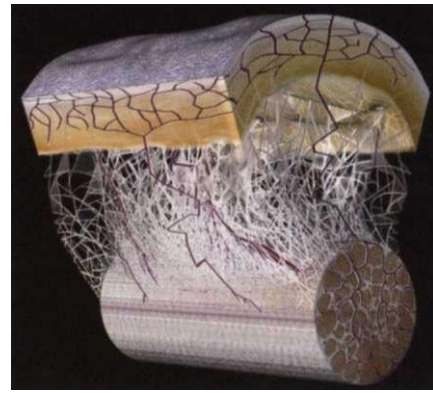


Fig. 1.74 The 'microvacuolar collagenic absorbing system' diagrammed from skin to tendon, showing how there is no discontinuity among fascial planes, just a frothy relationship of polygons that supports the vascular supply to the tendon while still allowing sliding in multiple directions. (Photo courtesy of Dr Guimberteau.)

This kind of tissue arrangement occurs all over the body, not just in the hand. Whenever fascial surfaces are required to slide over each other in the absence of an actual serous membrane, the proteoglycans cum collagen gel bubbles ease the small but necessary movements between the skin and the underlying tissue, between muscles, between vessels and nerves and all adjacent structures. This arrangement is almost literally everywhere in our bodies; tensegrity at work on a second-by-second basis.

There is little to add to these images; they speak for themselves. To see this system in motion, Dr Guimberteau's video is available from www.anatomytrains.com. The photo here shows the complexity, but not the diversity in how the microvacuoles and microtrabeculae rearrange themselves to accommodate the forces exerted by internal or external movement. The trabecular 'struts' (actually parts of the borders between vacuoles) shown in **Figure 1.75**, which combine collagen fibers with the gluey mucopolysaccharides, spontaneously change nodal points, break and reform, or elasticize back into the original form. Also not visible in the still pictures is how each of these sticky guy-wires is hollow, with fluid moving through the middle of these bamboo-like struts.

Guimberteau's work brings together the tensegrity concepts on both a macroscopic and microscopic level.

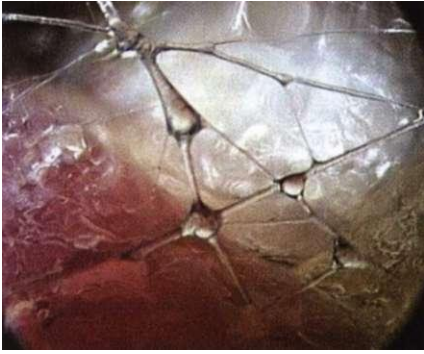


Fig. 1.75 The gluey, elastic, hollow fibrils in ever-responsive interplay with the vacuoles create an array of rigging and sails that changes with every traction or movement from the outside. Again, a still photo fails to convey the dynamism and ability to instantly remodel that characterizes this ubiquitous tissue. This gluey areolar network could be said to form a body-wide adaptive system allowing the myriad small movements which underlie or larger voluntary efforts. (Photo courtesy of Dr Guimberteau.)

It shows how the entire organismic system is built around the pressure balloons common to both cranial osteopathy and visceral manipulation. It suggests a mechanism whereby even light touch on the skin could reach deeply into the body's structure. It demonstrates how economical use of materials can result in a dynamically adjusting system.

One last personal note, however familiar it is, on the scientific method: it is not simply observing, but observing with understanding that makes the difference. I and many other somanauts have observed these microvacuoles as we dissected tissue. Each year at a class in the Alps we dissect the Paschal lamb just after slaughtering and before it becomes dinner. For years I observed these bubbles between the skin and the fascia profundis and in other areolar tissue, but dismissed them as artifacts of either the dying process or being exposed to the air. **Figure 1.76A** is a microscopic photo we took at a fresh-tissue dissection 6 months before I was exposed to Dr Guimberteau's work. This photograph is part of a short video (which is on the accompanying DVD) in which we were watching the behavior of the fascial fibers and ground substance, but completely ignored the role of the microvacuoles in the tissue samples, again dismissing them as an unimportant artifact.

To look at what everyone has looked at, and see what no one else has seen - this is the essence of all the new discoveries detailed in this chapter. Like any writer, I live in hope that the Anatomy Trains idea that we will now unfold has some element of this kind of discovery in it, although the introduction makes it quite clear that this idea lies in a continuum that builds on previous ideas of kinetic chains, fascial continuities, and systems theory in general.

Let us go then, you and I, and leave the larger picture and the long words behind to expose the specifics of how this fascinating fascial web is arranged around the muscles and the skeleton.



A



B

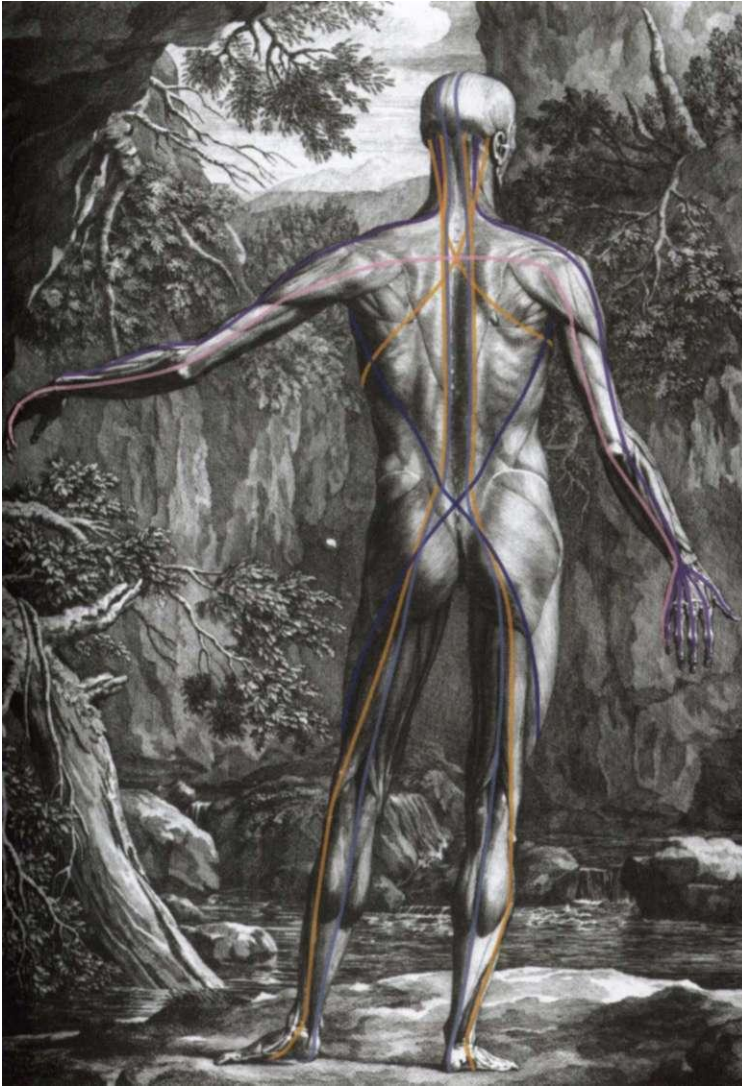
Fig. 1.76 (A) Microvacuoles embedded in the gluey proteoaminoglycans with capillaries running through. This photo was taken of fresh human tissue through a microscope at a dissection conducted by the author some months before his acquaintance with the work of Dr Guimberteau. At the time, we did not know what we were looking at; in retrospect, its importance is obvious. (Photo courtesy of Eric Root.) **(B)** Similar bubbles are visible to the unaided eye in fresh animal dissection or occasionally, as here, in embalmed cadavers. Again, before being exposed to the work of Guimberteau, we took this as an artifact of death or tissue exposure during the dissection, and therefore did not realize the significance of what we were seeing. (Photo courtesy of the author and Laboratories for Anatomical Enlightenment.)

References

1. www.fascia2007.com. Follow recent developments in fascial research on this website.
2. Schultz L, Feitis R. The endless web. Berkeley: North Atlantic Books; 1996:vii.
3. Margulis L, Sagan D. What is life? New York: Simon and Schuster; 1995:90-117.
4. Varela F, Frenk S. The organ of form. Journal of Social Biological Structure 1987; 10:73-83.
5. McLuhan M, Gordon T. Understanding media. Corte Madera, CA: Gingko Press; 2005.
6. Williams PL. Gray's anatomy, 38th edn. Edinburgh: Churchill Livingstone; 1995:75.
7. Becker RO, Selden G. The body electric. New York: Quill; 1985.
8. Sheldrake R. The presence of the past. London: Collins; 1988.
9. Kunzig R. Climbing through the brain. Discover Magazine 1998; August:61-69.
10. Williams PL. Gray's anatomy, 38th edn. Edinburgh: Churchill Livingstone; 1995:80.
11. Oschman J. Energy medicine. Edinburgh: Churchill Livingstone; 2000:48.
12. Varela F, Frenk S. The organ of form. Journal of Social Biological Structure 1987; 10:73-83.
13. Snyder G. Fasciae: applied anatomy and physiology. Kirksville, MO: Kirksville College of Osteopathy; 1975.

14. Ho M. The rainbow and the worm. 2nd edn. Singapore: World Scientific Publishing; 1998.
15. Becker RO, Selden G. The body electric. New York: Quill; 1985.
16. Oschman J. Energy medicine. Edinburgh: Churchill Livingstone; 2000:45-16.
17. Williams PL. Gray's anatomy, 38th edn. Edinburgh: Churchill Livingstone; 1995:475-477.
18. Williams PL. Gray's anatomy, 38th edn. Edinburgh: Churchill Livingstone; 1995:448-452.
19. Williams PL. Gray's anatomy, 38th edn. Edinburgh: Churchill Livingstone; 1995:415.
20. Williams PL. Gray's anatomy, 38th edn. Edinburgh: Churchill Livingstone; 1995:472-473.
21. Hively W. Bruckner's anatomy. Discover Magazine 1998; (11):111-114.
22. Schoenau E. From mechanostat theory to development of the 'functional muscle-bone-unit'. Journal of Musculoskeletal and Neuronal Interactions 2005; 5(3):232-238.
23. Bassett CAL, Mitchell SM, Norton L et al. Repair of non-unions by pulsing electromagnetic fields. Acta Orthopædica Belgica 1978; 44:706-724.
24. Becker RO, Selden G. The body electric. New York: Quill; 1985.
25. Williams P, Goldsmith G. Changes in sarcomere length and physiologic properties in immobilized muscle. Journal of Anatomy 1978; 127:459.
26. Rolf I. The body is a plastic medium. Boulder, CO: Rolf Institute; 1959.
27. Currier D, Nelson R, eds. Dynamics of human biologic tissues. Philadelphia: FA Davis; 1992.
28. Bobbert M, Huijing P, van Ingen Schenau G. A model of the human triceps surae muscle-tendon complex applied to jumping. Journal of Biomechanics 1986; 19:887-898.
29. Muramatsu T, Kawakami Y, Fukunaga T. Mechanical properties of tendon and aponeurosis of human gastrocnemius muscle in vivo. Journal of Applied Physiology 2001; 90:1671-1678.
- 30a. Fukunaga T, Kawakami Y, Kubo K et al. Muscle and tendon interaction during human movements. Exercise and Sport Sciences Reviews 2002; 30:106-110.
- 30b. Alexander RM. Tendon elasticity and muscle function. School of Biology, University of Leeds, Leeds; 2002.
31. Williams PL. Gray's anatomy, 38th edn. Edinburgh: Churchill Livingstone; 1995:413.
32. Janda V. Muscles and cervicogenic pain syndromes. In: Grand R, ed. Physical therapy of the cervical and thoracic spine. New York: Churchill Livingstone; 1988.
33. Varela F, Frenk S. The organ of form. Journal of Social Biological Structure 1987; 10:73-83.
34. Myers T. Kinesthetic dystonia. Journal of Bodywork and Movement Therapies 1998; 2(2):101-114.
35. Myers T. Kinesthetic dystonia. Journal of Bodywork and Movement Therapies 1998; 2(4):231-247.
36. Myers T. Kinesthetic dystonia. Journal of Bodywork and Movement Therapies 1999; 3(1):36-43.
37. Myers T. Kinesthetic dystonia. Journal of Bodywork and Movement Therapies 1999; 3(2):107-116.
38. Gershon M. The second brain. New York: Harper Collins; 1998.
39. Oschman J. Energy medicine. Edinburgh: Churchill Livingstone; 2000.
40. Ho M. The rainbow and the worm. 2nd edn. Singapore: World Scientific Publishing; 1998.
41. Sultan J. Lines of transmission. In: Notes on structural integration. December 1988, Rolf Institute.
42. Keleman S. Emotional anatomy. Berkeley: Center Press; 1985.
43. Netter F. Atlas of human anatomy. 2nd edn. East Hanover, NJ: Novartis; 1997.
44. Clemente C. Anatomy: a regional atlas. 4th edn. Philadelphia: Lea and Febiger; 1995.
45. Rohen J, Yoguchi C. Color atlas of anatomy. 3rd edn. Tokyo: Igaku-Shoin; 1983.
46. Access to a movie version of this image plus many other fascinating views can be obtained via members.aol.com/crsbouquet/intro.html
47. Read J. Through alchemy to chemistry, London: Bell and Sons; 1961.
48. Moore K, Persaud T. The developing human. 6th edn. London: WB Saunders; 1999.
- 49a. Magoun H. Osteopathy in the cranial field. 3rd edn. Kirksville, MO: Journal Printing Company; 1976.
- 49b. Upledger J, Vredevoogd J. Craniosacral therapy. Chicago: Eastland Press; 1983.
50. Milne H. The heart of listening. Berkeley: North Atlantic Books; 1995.
51. Ferguson A, McPartland J, Upledger J et al. Craniosacral therapy. Journal of Bodywork and Movement Therapies 1998; 2(1):28-37.
52. Chaitow L. Craniosacral therapy. Edinburgh: Churchill Livingstone; 1998.
53. Leonard CT. The neuroscience of human movement. St Louis: Mosby; 1998.
54. Fields RD. The other half of the brain. Scientific American 2004; 290(4):54-61.
55. Becker RO, Selden G. The body electric. New York: Quill; 1985.
56. Becker R. A technique for producing regenerative healing in humans. Frontier Perspectives 1990; 1:1-2.
57. Oschman J. Energy medicine. Edinburgh: Churchill Livingstone; 2000:224.
58. Kunzig R. Climbing up the brain. Discover Magazine 1998; 8:61-69.
59. Oschman J. Energy medicine. Edinburgh: Churchill Livingstone; 2000:Ch 15.
60. Becker R. Evidence for a primitive DC analog system controlling brain function. Subtle Energies 1991; 2:71-88.
61. Barral J-P, Mercier P. Visceral manipulation. Seattle: Eastland Press; 1988.
62. Schwind P. Fascial and membrane technique. Edinburgh: Churchill Livingstone/Elsevier; 2003 (German), 2006 (English).
63. Paoletti S. The fasciae. Seattle: Eastland Press; 2006 (English).
64. Wainwright S. Axis and circumference. Cambridge, MA: Harvard University Press; 1988.
65. Erlingheuser RF. The circulation of cerebrospinal fluid through the connective tissue system. Academy of Applied Osteopathy Yearbook; 1959.
66. Fawcett D. Textbook of histology. 12th edn. New York: Chapman and Hall; 1994:276.
67. Rhodin J. Histology. New York: Oxford University Press; 1974:353.
68. Rhodin J. Histology. New York: Oxford University Press; 1974:135.
69. Williams PL. Gray's anatomy, 38th edn. Edinburgh: Churchill Livingstone; 1995:75.906.
70. Sacks O. A leg to stand on. New York: Summit Books; 1984.
71. Grinnell F. Fibroblast-collagen-matrix contraction: growth-factor signalling and mechanical loading. Trends in Cell Biology 2002; 10:362-365.
72. Feldenkrais M. The potent self. San Francisco: Harper Collins; 1992.
73. Williams PL. Gray's anatomy, 38th edn. Edinburgh: Churchill Livingstone; 1995:75.906.

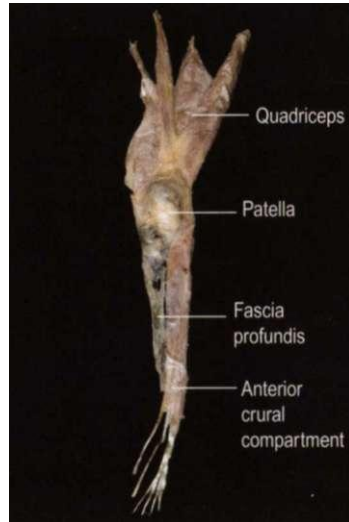
74. Juhan D. Job's body. Tarrytown, NY: Station Hill Press; 1987:61.
75. Schleip R. Explorations in the neuromyofascial web. Rolf Lines. Boulder, CO: Rolf Institute; 1991 (Apr/May).
76. Schleip R. Fascial plasticity. Journal of Bodywork and Movement Therapies 2003; 7(1):11-19.
77. Stecco L. Fascial manipulation for musculo-skeletal pain. Padua: PICCIN; 2004.
78. Schleip R. Active fascial contractility. In: Imbery E, ed. Proceedings of the 1st International Congress of Osteopathic Medicine, Freiburg, Germany. Munich: Elsevier; 2006:35-36.
79. Moore K, Persaud T. The developing human. 6th edn. London: WB Saunders; 1999:23.
80. Moore K, Persaud T. The developing human. 6th edn. London: WB Saunders; 1999:30.
81. Moore K, Persaud T. The developing human. 6th edn. London: WB Saunders; 1999:53-56.
82. Snyder G. Fasciae: applied anatomy and physiology. Kirksville, MO: Kirksville College of Osteopathy; 1975.
83. Schultz L, Feitis R. The endless web. Berkeley: North Atlantic Books; 1996:8-10.
84. Moore K, Persaud T. The developing human. 6th edn. London: WB Saunders; 1999:216-221.
85. Moore K, Persaud T. The developing human. 6th edn. London: WB Saunders; 1999:60-71.
86. Moore K, Persaud T. The developing human. 6th edn. London: WB Saunders; 1999:61-63.
87. Huijing, PA, Baan GC, Rebel GT. Non-mytotendinous force transmission in rat extensor digitorum longus muscle. Journal of Experimental Biology 1998; 201:682-691.
88. Ingber D. The architecture of life. Scientific American 1998; January:48-57.
89. Ingber D. The origin of cellular life. BioEssays 2000; 22:1160-1170.
90. Fuller B. Synergetics. New York: Macmillan; 1975:Ch 7.
91. Ingber D. The architecture of life. Scientific American 1998; January:48-57.
92. Lakes R. Materials with structural hierarchy. Nature 1993; 361:511-515.
93. Ball P. The self-made tapestry; pattern formation in nature. New York: Oxford University Press; 1999.
94. Still AT. Osteopathy research and practice. Kirksville, MO: Journal Printing Company; 1910.
95. Rolf L. Rolfing. Rochester, VT: Healing Arts Press; 1977.
96. Simon H. The organization of complex systems. In: Pattee H, ed. Hierarchy theory. New York: Brazillier; 1973.
97. Levin S. The scapula is a sesamoid bone. Journal of Biomechanics 2005; 38(8):1733-1734.
98. Levin S. The importance of soft tissues for structural support of the body. Spine: State of the Art Reviews 1995; 9(2).
99. Levin S. A suspensory system for the sacrum in pelvic mechanics: biotensegrity. In: Vleeming A, ed. Movement, stability, and lumbopelvic pain. 2nd edn. Edinburgh: Elsevier; 2007.
100. Tyler T. http://hexdome.com/essays/floating_bones/index.php.
101. Ghosh P. The knee joint meniscus, a fibrocartilage of some distinction. Clinical Orthopaedics and Related Research 1987; 224:52-63.
102. Myers T. Tensegrity continuum. Massage 1999; 5/99:92-108. *This provides a more complete discussion of this concept, plus an expansion of the various models between the two extremes.*
103. Ingber D. The architecture of life. Scientific American 1998; January: 48-57.
104. Schleip R. Active fascial contractility, fn: Imbery E, ed. Proceedings of the 1st International Congress of Osteopathic Medicine, Freiburg, Germany. Munich: Elsevier; 2006:35-36.
105. Tomasek J, Gabbiani G, Hinz B et al. Myofibroblasts and mechanoregulation of connective tissue modeling. Nature Reviews. Molecular Cell Biology 2002; 3:349-363.
- 106a. Schleip R, Klinger W, Lehmann-Horn F. Fascia is able to contract in a smooth muscle-like manner and thereby influence musculoskeletal mechanics. In: Leipsch D. Proceedings of the 5th World Congress of Biomechanics. Munich: Medimand S.r.l.; 2006:51-54.
- 106b. Langevin H, Cornbrooks CJ, Taatjes DJ. Fibroblasts form a bodywide cellular network, Histochemistry and Cell Biology 2004; 122:7-15.
107. Gabbiani G, Hirschel B, Ryan G et al. Granulation tissue as a contractile organ, a study of structure and function. Journal of Experimental Medicine 1972; 135:719-734.
108. Schleip R, Klinger W, Lehmann-Horn F. Fascia is able to contract in a smooth muscle-like manner and thereby influence musculoskeletal mechanics. In: Leipsch D. Proceedings of the 5th World Congress of Biomechanics. Munich: Medimand S.r.l.; 2006.
109. Papelzadeh M, Naylor I. The in vitro enhancement of rat myofibroblast contractility by alterations to the pH of the physiological solution. European Journal of Pharmacology 1998; 357(2-3):257-259.
110. Chaitow L, Bradley D, Gilbert C. Multidisciplinary approaches to breathing pattern disorders. Edinburgh: Elsevier; 2002.
111. Ingber DE. Cellular tensegrity revisited I. Cell structure and hierarchical systems biology. Journal of Cell Science 2003; 116:1157-1173.
112. Pert C. Molecules of emotion. New York: Scribner; 1997.
113. Ingber D. Mechanobiology and the diseases of mechanotransduction. Annals of Medicine 2003; 35:564-577.
114. Ingber D. The architecture of life. Scientific American 1998; January: 48-57.
115. Ingber D. Mechanical control of tissue morphogenesis during embryological development. International Journal of Developmental Biology 2006; 50:255-266.
116. Horwitz A. Integrins and health. Scientific American 1997; May:68-75.
117. Ingber D. The architecture of life. Scientific American 1998; January: 48-57.
118. Ingber DE. Cellular mechanotransduction: putting all the pieces together again. FASEB Journal 2006; 20:811-827.
119. Tomasek J, Gabbiani G, Hinz B et al. Myofibroblasts and mechanoregulation of connective tissue modeling. Nature Reviews. Molecular Cell Biology 2002; 3:349-363.
120. Guimberteau J. Strolling under the skin. Paris: Elsevier; 2004.
121. Netter F. Atlas of human anatomy. 2nd edn. East Hanover, NJ: Novartis; 1997.
122. Williams PL. Gray's anatomy, 38th edn. Edinburgh: Churchill Livingstone; 1995.



A



B



C

Fig. 2.1 (A) A back view summary of the Anatomy Trains myofascial meridians described in this book, laid over a figure from Albinus. (Reproduced with kind permission from Dover Publications, NY - see also **Fig. In. 1**) (B) A dissection of an Anatomy Trains 'station'. Notice how the serrated attachments fan out to connect to the periosteum of the ribs, but some of the fascia travels on to the next 'track'. Notice also how the arterioles use the fascia as scaffolding. (Reproduced with kind permission from Ronald Thompson.) (C) The lower section of the Superficial Front Line, showing a dissection of the continuous biological fabric which joins the anterior compartment of the lower leg - toe extensors and tibialis anterior - through the bridle around the patella and into the quadriceps, spread here for easy viewing. Notice the inclusion of the fascia profunda (crural fascia) layer over the tibia. This is explained more fully in Chapter 4, but serves here to demonstrate the concept of the myofascial 'track'. (Photo courtesy of the author and Laboratories for Anatomical Enlightenment.) (DVD ref: Video and audio available: Early Dissective Evidence)

The rules of the game

2

Although the myofascial meridians are intended as a practical aid to working clinicians, finding an 'Anatomy Train' is most easily described as a game within this railway metaphor. There are a few simple rules, designed to direct our attention, among the galaxy of possible myofascial connections, toward those with common clinical significance. Since the myofascial continuities described here are not exhaustive by any means, the reader can use the rules given below to construct additional trains not explored in the body of this book.

In summary: to be active, myofascial meridians must proceed in a consistent direction and depth, via fascial or mechanical connections (through a bone). It is also clinically useful to note where the fascial trains attach, divide, or display alternative routes (**Fig. 2.1**).

From time to time, we will find places where we have to bend or break these rules. These breaks in the rules are given the name 'derailments', and the reasons for persisting in spite of the break are given.

1. Tracks proceed in a consistent direction without interruption

To look for an Anatomy Train, we look for 'tracks' made from myofascial or connective tissue units (which are human distinctions, not divine, evolutionary, or even anatomically discrete entities). These structures must show a continuity of fascial fibers, so that like a real train track, these lines of pull or line of transmission through the myofascia must go fairly straight or change directions only gradually. Some myofascial connections are only pulled straight in a certain position or by specific activities.

Likewise, since the body's fascia is arranged in planes, jumping from one depth to another among the planes amounts to jumping the tracks. Radical changes of direction or depth are thus not allowed (unless it can be demonstrated that the fascia itself actually acts across such a change), nor are 'jumps' across joints or through sheets of fibers that run counter to the tracks. Any of these would nullify the ability of the tensile fascia to transmit strain from one link of the chain to the next.

A. Direction

As an example, the pectoralis minor and the coracobrachialis are clearly connected fascially at the coracoid process (**Fig. 2.2A**, and see Ch. 7). This, however, cannot function as a myofascial continuity when the arm is relaxed by one's side, because there is a radical change of direction between the two myofascial structures. (We will abandon this awkward term in favor of the less awkward 'muscles' if the reader will kindly remember that muscles are mere ground beef without their surrounding, investing, and attaching fasciae.) When the arm is aloft, flexed as in a tennis serve or when hanging from a chinning bar or a branch like the simian in **Figure 2.2B**, these two line up with each other and *do* act in a chain that connects the ribs to the elbow (and beyond in both directions - the Deep Front Arm Line to the Superficial Front Line or Functional Line).

The usefulness of the theory comes with the realization that problems with the tennis serve or the chin-up may show up in the function of either of these two muscles or at their connecting point, and yet have their source in structures farther up or down the tracks. Knowing the trains allows the practitioner to make reasoned but holistic decisions in treatment strategy, regardless of the method employed.

On the other hand, fascial structures themselves can in certain cases carry a pulling force around corners. The peroneus brevis takes a sharp curve around the lateral malleolus, but no one would doubt that the myofascial continuity of action is maintained (**Fig. 2.3**). Such pulleys, when the fascia makes use of them, are certainly permitted by our rules.

B. Depth

Like abrupt changes of direction, abrupt changes of depth are also frowned upon. For example, when we look at the torso from the front, the logical connection in terms of direction from the rectus abdominis and the sternal fascia up the front of the ribs would clearly be the infrahyoid muscles running up the front of the throat (**Fig. 2.4A**). The error of making this 'train' becomes clear when we realize that the infrahyoid muscles attach to the

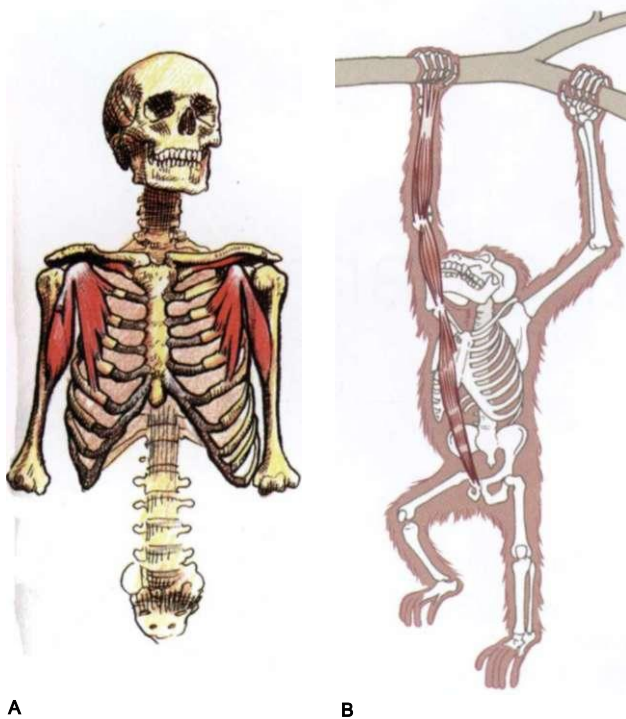


Fig. 2.2 While the fascia connecting the muscles that attach to the coracoid process is always present (A), the connection only functions in our game of mechanical tensile linkage when the arm is above the horizontal (B). (A is reproduced with kind permission from Grundy 1982.)

back of the sternum, thus connecting them to a deeper ventral fascial plane within the rib cage (part of the Deep Front Line), not the superficial plane (Fig. 2.4B).

C. Direct vs mechanical connections

A direct connection is purely fascial, while a mechanical connection passes through intervening bone. The external and internal obliques thus have a clear direct connection across the abdominal aponeurosis and the linea alba. The iliotibial tract likewise ties directly into the

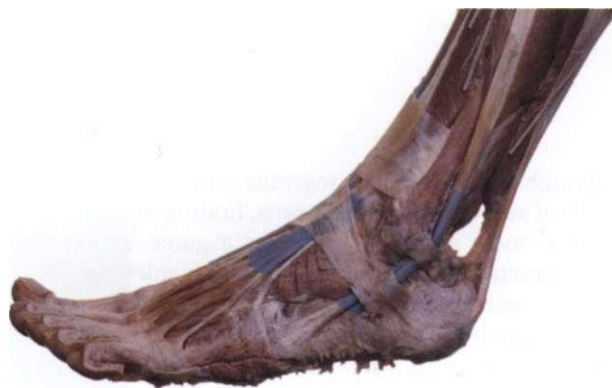

Fig. 2.3 Tendons acting around corners like pulleys are an acceptable exception to the 'no sharp turns' rule. (© Ralph T Hutchings. Reproduced from Abrahams et al 1998.)

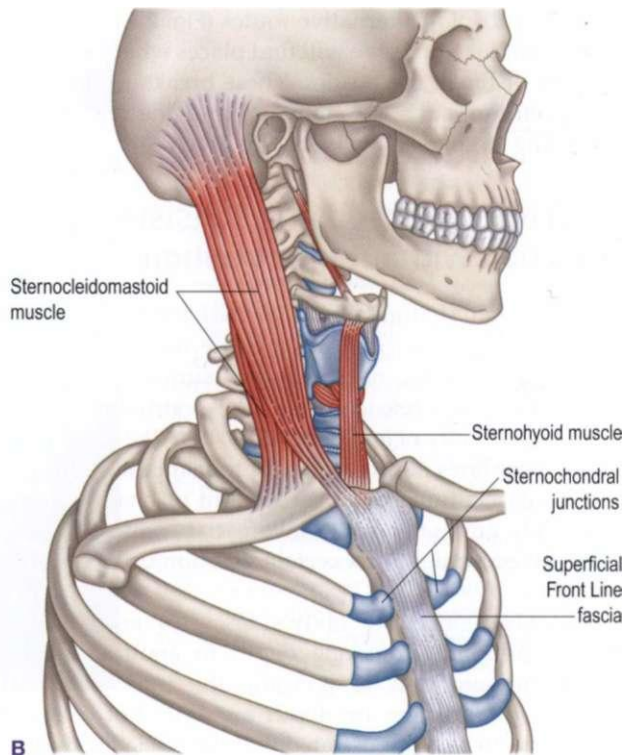
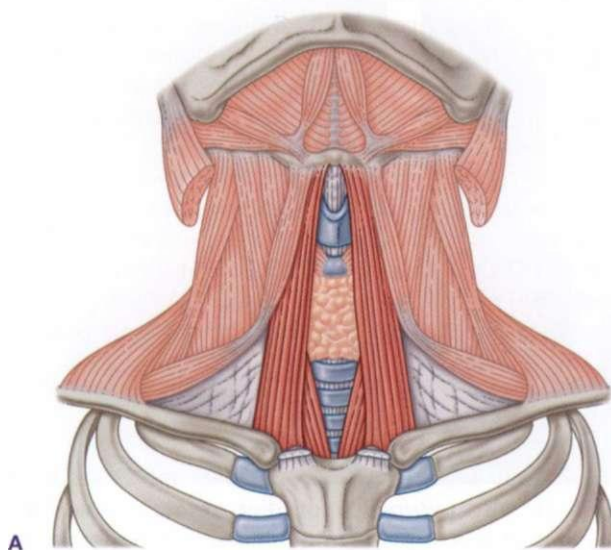


Fig. 2.4 Although a mechanical connection can be felt from chest to throat when the entire upper spine is hyperextended, there is no direct connection between the superficial chest fascia and the infrahyoid muscles because of the difference in depth of their respective fascial planes. The infrahyoids pass deep to the sternum, connecting them to the inner lining of the ribs and the intrathoracic fascia (A). The more superficial fascial planes connect the sternocleidomastoid to the fascia coming up the superficial side of the sternum and sternochondral junctions (B).

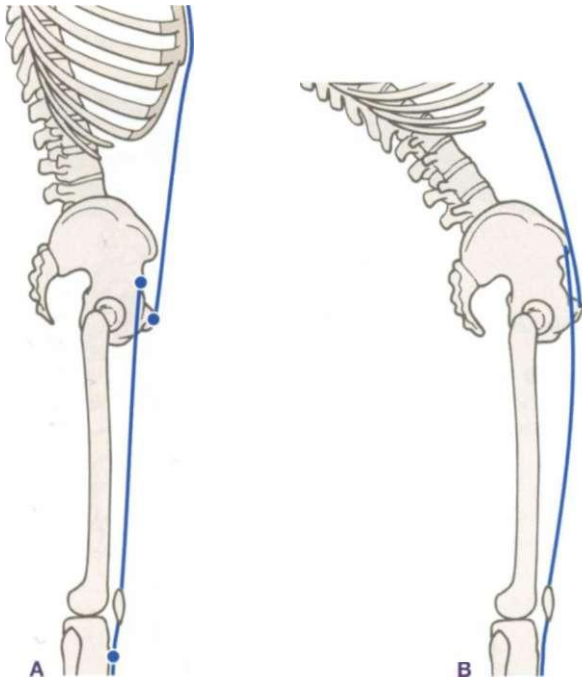


Fig. 2.5 The rectus femoris and the rectus abdominis have a mechanical (via a bone) vs a direct (via fascial fabric only) connection through the hip bone.

tibialis anterior muscle (see Ch. 6 for both of these examples). The rectus abdominis and the rectus femoris, however, have scant direct fascial connection without turning sharp corners, but have an indirect mechanical connection through the pelvic bone in sagittal (flexion-extension) motions, such as anterior and posterior tilt of the pelvis (**Fig. 2.5** and see Ch. 4).

D. Intervening planes

Resist all temptation to carry an Anatomy Train through an intervening plane of fascia that goes in another direction, for how could the tensile pull be communicated through such a wall? As an example, the adductor longus comes down to the linea aspera of the femur, and the short head of the biceps goes on from the linea aspera in the same direction. Surely that constitutes a myofascial continuity? In fact it does not, for there is the intervening plane of the adductor magnus, which would cut off any direct tensile communication between longus and biceps (**Fig. 2.6**). Again, there may be some mechanical connection between these two, as in the example given in C above, but a direct fascial communication is negated by the fascial wall between.

2. These tracks are tacked down at bony stations' or attachments

In the Anatomy Trains concept, muscle attachments ('stations') are seen as places where some underlying fibers of the muscle's epimysium or tendon are enmeshed or continuous with the periosteum of the accompanying bone, or, less often, with the collagen matrix of the bone itself. In the terms we set out in Chapter 1 (section on

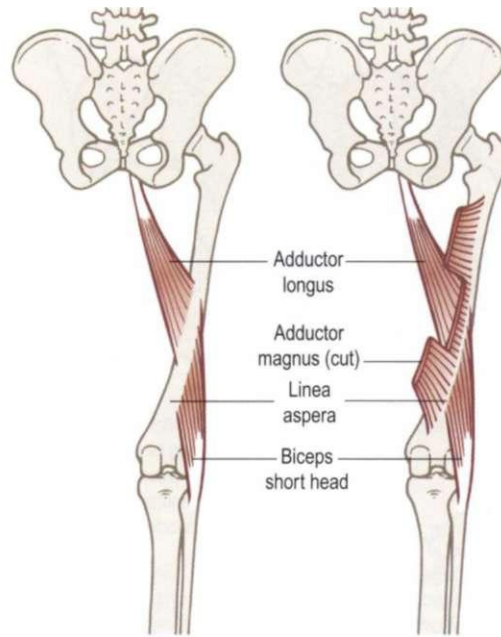


Fig. 2.6 If we just look at adductor longus and the short head of the biceps femoris (as on left), they appear to fulfill the requirements for a myofascial continuity. But when we see that the plane of adductor magnus intercedes between the two (as on right) to attach to the linea aspera, we realize that such a connection breaks the rules.

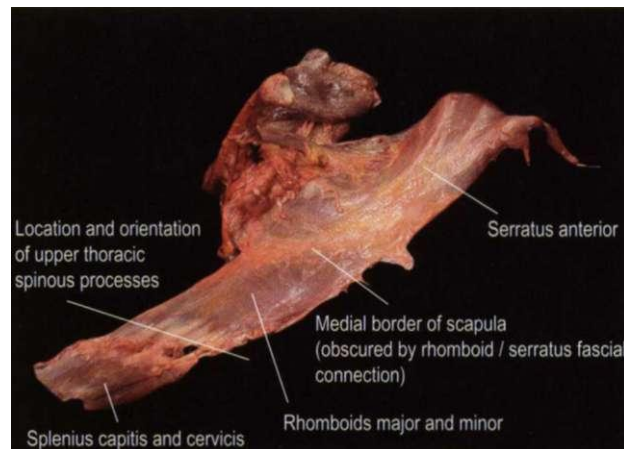


Fig. 2.7 In this photo of a recent dissection, a series of muscles were detached from their attachments to show the continuity of fascial fabric from muscle to muscle independent of the skeleton. (Photo courtesy of the author and Laboratories for Anatomical Enlightenment.)

double-bag theory), a station is where the outer myofascial bag attaches itself onto the inner 'osteoarticular' bag.

The more superficial fibers of the myofascial unit, however, can demonstrably be seen to run on, and thus communicate, to the next piece of the myofascial track. For instance, in **Figure 2.1 B** we can see that some of the fibers at the end of the myofascia on the right are clearly tied to the ribs, while some fibers continue on into the next 'track' of myofascia. In **Figure 2.7**, we can clearly see that when the rhomboids, serratus anterior and the

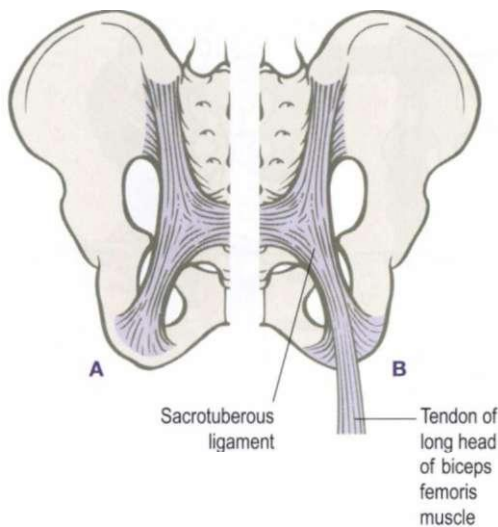


Fig. 2.8 A traditional view of the sacrotuberous ligament (A) shows it linking the ischial tuberosity to the sacrum. A more inclusive view (B) shows the hamstring tendons - especially that of the biceps femoris - being continuous with the surface of the sacrotuberous ligament and then on up into the sacral fascia.

external oblique are removed from their bony attachments, there remains a strong and substantial sheet of biological fabric connecting all three. In fact, one can argue that separating them into separate muscles is a convenient fiction.

Thus, for example, the hamstrings clearly attach on the posterior side of the ischial tuberosities. Just as clearly, some fibers of the hamstring myofascia continue on over and into the sacrotuberous ligament and up onto the sacrum (Fig. 2.8). These ongoing connections have been de-emphasized in contemporary texts that tend to treat muscles or fascial structures singularly in terms of their actions from origin to insertion, and contemporary musculoskeletal illustrations tend to reinforce this impression.

Most stations have more communication with the next myofascial linkage in the superficial rather than the deeper fibers, and the sacrotuberous ligament is a convenient example. The deeper layers clearly join bone to bone and have very limited movement or communication beyond that connection. The more superficial we go, the more communication through to the other myofascial 'tracks' there is (Fig. 2.9). Too much communication in the deeper layers approximates the term 'lax ligaments'; too little approximates 'stiffness' or 'immobility'.

3. Tracks join and diverge in 'switches' and the occasional 'roundhouse'

Fascial planes frequently interweave, joining with each other and splitting from each other, which we will call 'switches' (UK: points) in keeping with our train metaphor. The laminae of the abdominal muscles, for example, arise together from the lumbar transverse pro-

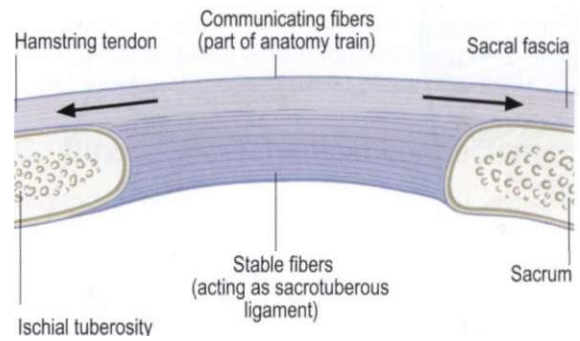


Fig. 2.9 The deeper fibers of a station 'communicate' less along the tracks, while the superficial fibers - the ones we can more easily reach manually - communicate more.

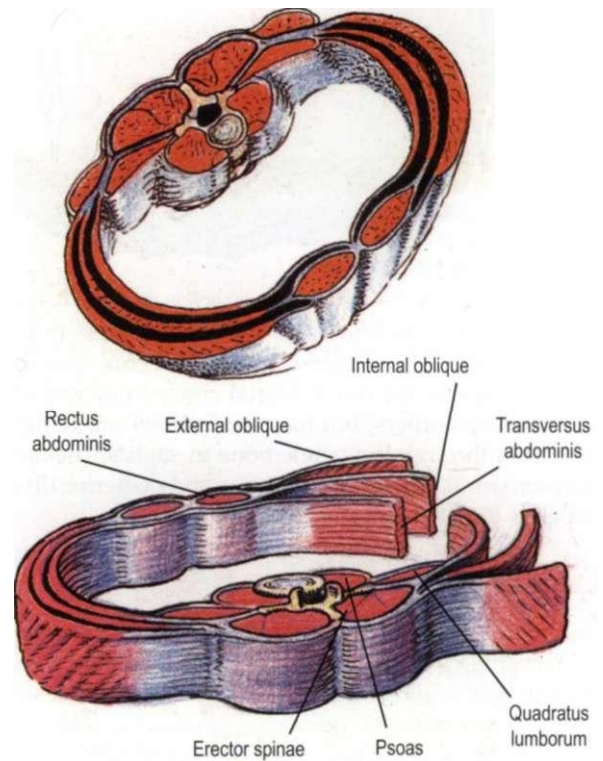


Fig. 2.10 The layers of abdominal fascia converge and diverge in a complex functional pattern. (Reproduced with kind permission from Grundy 1982.)

cesses, divide into the three differently grained layers of the obliques and transversus muscles at the lateral raphe, only to split uniquely around the rectus abdominis, join into one at the linea alba, and repeat the whole process in reverse on the opposite side (Fig. 2.10). As another example, many laminae of fascia intermingle in the thoracolumbar and sacral area, where they blend into stronger sheets, often inseparable in dissection.

Switches present the body - and sometimes the therapist - with choices. The rhomboids span from the spinous processes to the medial scapular border. At the scapula, there is a clear fascial connection to both the serratus anterior (especially from the fascia on the profound side of the rhomboids), which carries on around

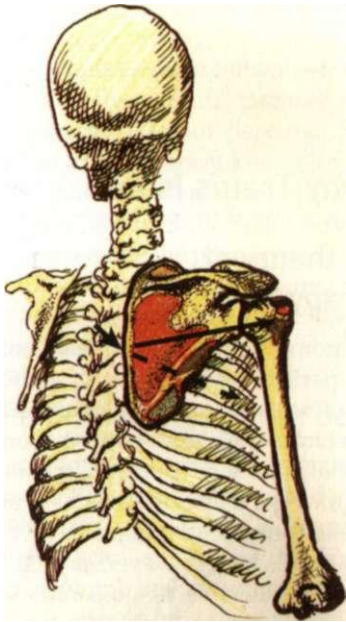


Fig. 2.11 From the rhomboids (arrow on left) we could switch onto either the serratus anterior with one track around the trunk (dotted arrow under scapula - part of the Spiral Line, Ch. 6), or the infraspinatus with another track out the arm (solid arrow on right - part of the Deep Back Arm Line, Ch. 7).

under the scapula to the rib cage, but also (from the fascial layer on the superficial side of the rhomboids) to the infraspinatus, which carries on out the arm (**Fig. 2.11**). We will often see fascial and myofascial planes divide or blend, and we will see the strain or force or posture emphasize one track or another depending on body position and outside forces. Which Anatomy Train to use in any given posture or activity is not a matter for voluntary choice, though individual patterns of muscle contraction will be a factor, and adjustments - say in a yoga pose - will change the exact route of force transmission. By and large, however, the amount of force down any given track is determined by the physics of the situation.

A 'roundhouse' is where many myofascial vectors meet and/or cross, the pubic bone or the anterior superior iliac spine being prime examples (**Fig. 2.12**). Because of the competing tugs on these areas, noting their position is crucial to an Anatomy Trains analysis of structure.

4. 'Expresses' and 'locals'

Polyarticular muscles (crossing more than one joint) abound on the body's surface. These muscles often overlie a series of monarticular (single-joint) muscles, each of which duplicates some single part of the overall function of the polyarticular muscle. When this situation occurs within an Anatomy Train, we will call the multi-joint muscles 'expresses' and the underlying single-joint muscles 'locals'.

As an example, the long head of biceps femoris runs from 'above' the hip joint to below the knee, hence it is

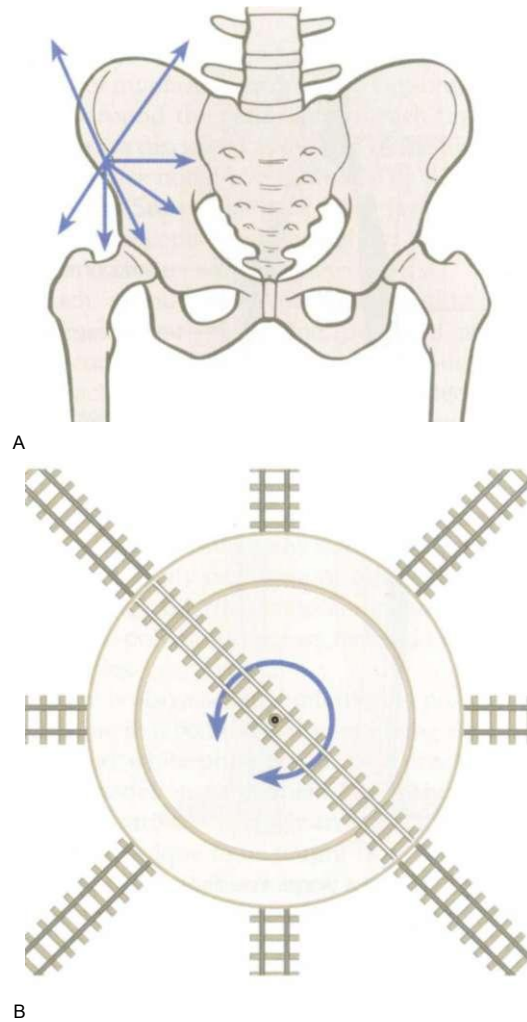


Fig. 2.12 Many competing vectors of myofascial force proceed out in all directions from the 'roundhouse' of the anterior superior iliac spine.

an express affecting both joints. Deep to it lie two locals: the adductor magnus - a one-joint local crossing the hip and extending as well as adducting it - and the short head of the biceps - a one-joint muscle crossing and flexing only the knee (**Fig. 2.13**).

The significance of this phenomenon is that it is our contention that general postural 'set' is determined less by the superficial expresses than by the deeper locals, which are too often ignored because they are 'out of sight, out of mind'. This would suggest, for instance, that an anterior tilt of the pelvis (postural hip flexion) would yield more to release in the pectineus and iliacus (single-joint hip flexors) than to release in the rectus femoris or sartorius, or that chronic flexion of the elbow would best be treated by release of the brachialis rather than concentrating all our attention in the more obvious and available biceps brachii.

Summary of rules and guidelines

While we have attempted to be fairly thorough in presenting what we have found to be the principal large myofascial meridians at work in the human body (**Fig.**

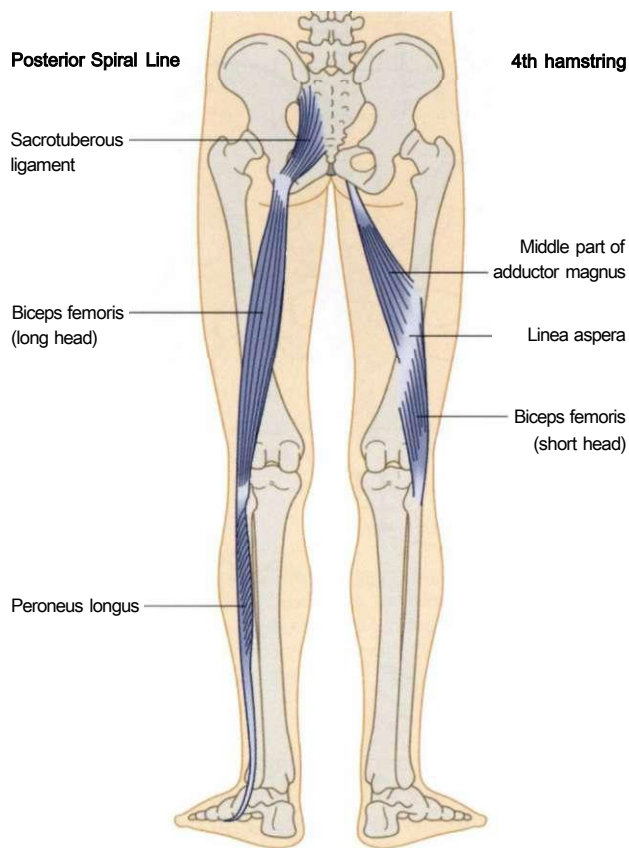


Fig. 2.13 The long head of the biceps femoris is a two-joint 'express', part of the Spiral Line (left). Beneath it lie the one-joint 'locals' of the short head of the biceps connecting across the linea aspera to the middle of the adductor magnus muscle (right). The two locals closely mirror individually the collective action of the express.

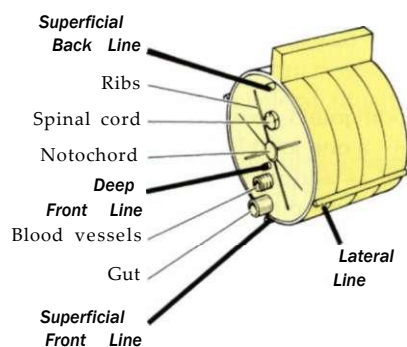


Fig. 2.14 The five lines that run more or less straight longitudinally (the four cardinal, counting the left and right Lateral Lines as two, and the Deep Front Line) identified on a cross-section of the basic vertebrate body plan (as if you are looking at a section cut from a fish). Note the relationship among the lines themselves, as well as to major organic structures.

2.14), readers can find and construct their own by following these rules:

- Follow the grain of the connective tissue, maintaining a fairly steady direction without jumping joints or levels or crossing through intervening planes of fascia.
- Note the stations where these myofascial tracks tie down to the underlying tissues.

- Note any other tracks which diverge or converge with the line.
- Look for underlying single-joint muscles that may affect the working of the line.

What the Anatomy Trains is not

A comprehensive theory of manipulative therapy

This book and the Anatomy Trains theory deals only with the 'outer bag' of parietal myofascia as described in Chapter 1. The whole area of joint manipulation is left to the osteopathic and chiropractic texts, and is beyond the scope of the myofascial meridians concept. Certainly, we have found that balancing the lines eases joint strain and thus perhaps extends joint life. Attention to the 'inner bag' of peri-articular tissues, however, as well as dorsal and ventral cavity connective tissue complexes (cranial and visceral manipulation), is essential, advisable, and simply not covered by this book.

A comprehensive theory of muscle action

Firstly, Anatomy Trains theory is not designed to replace other findings of muscle function, but to add to them. The infraspinatus is still seen to be active in laterally rotating the humerus and in preventing excessive medial rotation, and in stabilizing the shoulder joint. We are simply adding the idea that it *also* operates as part of the Deep Back Arm Line, a functionally connected meridian of myofascia that runs from the little finger to the thoracic and cervical spine.

Secondly, while this book includes most of the body's named muscles within the lines, certain muscles are not easily placed within this metaphor. The deep lateral rotators of the hip, for example, could be construed fascially to be part of the Deep Front Line or perhaps a putative Deep Back Line. They do not really lend themselves, however, to being part of any long line of fascial transmission. These muscles are most easily seen as combining with others around the hip to present a series of three interlinked fans.¹

Those muscles not named as part of the Anatomy Trains map are obviously still active in a coordinated fashion with others in the body, but may not be operating along these articulated chains of myofascia.

A comprehensive theory of movement

While some movement definitely takes place along the meridian lines, anything more complex than the simplest reflex or gesture defies description in terms of the action of a single line. The actions involved in fixation, stabilization, and stretch are more amenable to Anatomy Trains analysis and readily conform to the meridians. Thus the system lends itself to postural analysis, which depends primarily upon fixation.

Each meridian describes one very precise line of pull through the body, and most complex movements, of

course, sweep across the body, changing their angles of pull second by second (for example, the footballer kicking or the discus thrower). Although an Anatomy Trains analysis could probably be made of complex movements, it is not clear that this would add a great deal to contemporary kinesiological discussion. On the other hand, an analysis of which lines restrict the response of the body to the primary movement or stabilize to enable the primary movement - in other words, which lines of stabilization are overly tight or necessarily held - is very useful and leads to new strategies of structural unfolding.

The only way to parse body structure

Many forms of structural analysis are abroad in the world.^{2^A*} The method described in Chapter 11 has shown itself to be useful in practice, and has the advantage of being psychologically neutral. Some approaches overlay a grid, plumb line, or some form of platonic 'normal' on the varieties of human physique. We prefer to keep the frame of reference to relationships within the individual only.

A complete anatomy text

Although the subject of this book is musculoskeletal relationships, it is not designed as a comprehensive anatomy text. Anatomy Trains could be described as a 'longitudinal anatomy'. The use of any good regionally organized anatomy atlas as a supplement to the text and illustrations included here is recommended.⁵⁻⁹ (DVD ref: Myofascial Meridians)

A scientifically supported theory

The concepts in this book are backed by the anecdotal evidence of years in practice, and are successfully being applied by therapists in a number of different disciplines. The dissective evidence included in this edition is an early indication that supports the ideas, which have not yet been confirmed by detailed dissection or other scientifically reliable evaluation. Caveat emptor - Anatomy Trains is a work in progress.

How we present the lines

Presentation of three-dimensional, living and moving anatomy on the quiet two-dimensional page has plagued anatomy teachers since Renaissance times when Jan Stefan van Kalker started drawing for Andreas Vesalius. The myofascial meridians can be described in a variety of ways: as a strict one-dimensional line, as an articular chain of myofascia, as representing a broader fascial plane, or as a volumetric space (see Figs In. 15-17). We have attempted to blend all four of these in this book, in hopes of catching the reader's imagination with one or more of them. The medium of the map is, as always, inadequate to the territory, but nevertheless can be helpful.

The strict lines with their tracks and stations are shown at the beginning of each chapter. The articular chains of myofascia are described at some length. Larger issues around the penumbra of each line or section of the line are discussed at the end of the line's description or otherwise noted in a sidebar. The first line described (Ch. 3, the Superficial Back Line) lays out the terminology and concepts used throughout the rest of the chapters, and is thus worth reviewing first.

Each chapter also contains a guide to palpation and movement of the line, designed as a guide for both consumer and practitioner. While some clinical approaches are discussed, individual techniques, many of which come from the library of Structural Integration,² are presented sparsely, for several reasons.

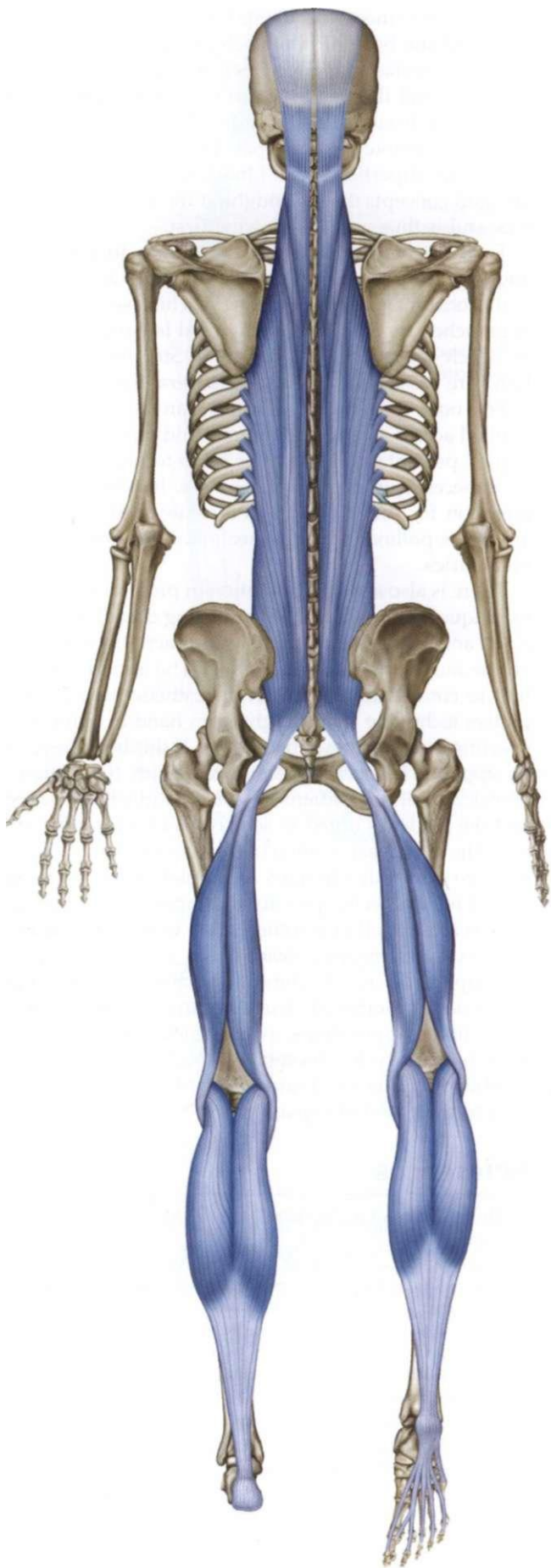
For one, the Anatomy Trains can be successfully applied across a variety of manual and movement techniques; presentation of any one set of techniques would be unnecessarily exclusive of others. It is the author's intention for this theory to contribute to the dialogue and cross-pollination across technical and professional boundaries.

There is also a severe limitation in presenting a living technique in a book, usually involving dreadful, posed, black and white photographs of a practitioner's hands on the model on a treatment table. The author is reluctant to contribute to such an unaesthetic process, and prefers technique to be taught from hand to hand with a feeling unattainable in book form. If this book inspires an appetite for techniques to deal with the patterns revealed by the meridians analysis, so much the better, and the reader is urged to seek out a class or a mentor or at the very least a video of instruction, rather than a book, to satisfy that hunger. A complete set of videos of fascial release techniques to accompany this book, as well as a list of other recommended videos, is available from www.anatomytrains.com.

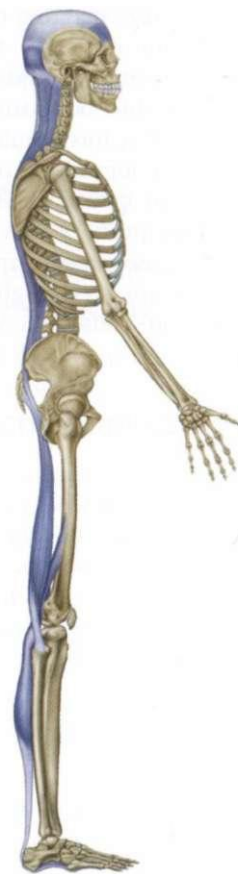Chapters 10 and 11 present specific applications of the system in terms of structural analysis and, briefly, some other applications, with which the author has some familiarity. It is fervently hoped that practitioners in other disciplines will carry forward this type of analysis into their field of expertise.

References

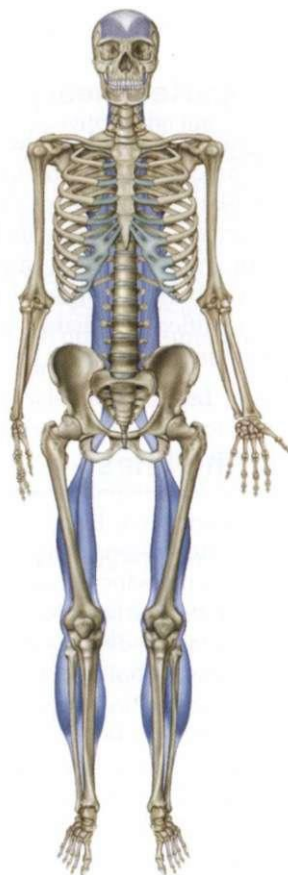1. Myers T. Fans of the hip joint. *Massage Magazine* No. 75 January 1998.
2. Rolf I. *Rolfing*. Rochester, VT: Healing Arts Press; 1977.
3. Aston J. *Aston postural assessment workbook*. San Antonio, TX: Therapy Skill Builders; 1998.
4. Keleman S. *Emotional anatomy*. Berkeley, CA: Center Press; 1985.
5. Netter F. *Atlas of human anatomy*. 2nd edn. East Hanover, NJ: Novartis; 1997.
6. Clemente C. *Anatomy: a regional atlas*. 4th edn. Philadelphia: Lea and Febiger; 1995.
7. Biel A. *Trail guide to the body*. Boulder, CO: Discovery Books; 1997.
8. Ross L, Lamperti E. *Atlas of anatomy*. New York: Thieme; 2006.
9. Gorman D. *The body moveable*. Cuelph, Ontario: Ampersand Press; 1981.



A



B



C

Fig. 3.1 The Superficial Back Line.

The Superficial Back Line

3

This first line, the Superficial Back Line (SBL) (**Fig. 3.1**), is presented in considerable detail, in order to clarify some of the general and specific Anatomy Trains concepts. Subsequent chapters employ the terminology and format developed in this chapter. Whichever line interests you, it may help to read this chapter first.

Overview

The Superficial Back Line (SBL) connects and protects the entire posterior surface of the body like a carapace from the bottom of the foot to the top of the head in two pieces - toes to knees, and knees to brow (Fig. 3.2/Table 3.1). When the knees are extended, as in standing, the SBL functions as one continuous line of integrated myofascia. The SBL can be dissected as a unity, seen here both on its own and laid over a plastic classroom skeleton (Figs 3.3 and 3.4).

Postural function

The overall postural function of the SBL is to support the body in full upright extension, to prevent the tendency to curl over into flexion exemplified by the fetal position. This all-day postural function requires a higher proportion of slow-twitch, endurance muscle fibers in the muscular portions of this myofascial band. The constant postural demand also requires extra-heavy sheets and bands in the fascial portion, as in the Achilles tendon, hamstrings, sacrotuberous ligament, thoracolumbar fascia, the 'cables' of the erector spinae, and at the occipital ridge.

The exception to the extension function comes at the knees, which, unlike other joints, are flexed to the rear by the muscles of the SBL. In standing, the interlocked tendons of the SBL assist the cruciate ligaments in maintaining the postural alignment between the tibia and the femur.

Movement function

With the exception of flexion from the knees on down, the overall movement function of the SBL is to create extension and hyperextension. In human development, the muscles of the SBL lift the baby's head from embryological flexion, with progressive engagement and 'reaching out' through the eyes, supported by the SBL down through the rest of the body to the ground - belly, seat, knees, feet - as the child achieves stability in each of the developmental stages leading to upright standing about one year after birth (**Fig. 3.5**).

Because we are born in a flexed position, with our focus very much inward, the development of strength, competence, and balance in the SBL is intimately linked with the slow wave of maturity, as we move from this primary flexion into a full and easily maintained extension. The author of Psalm 121, who wrote 'I will lift up mine eyes unto the hills, from whence cometh my help', is enabled to do so by the Superficial Back Line.

The Superficial Back Line in detail

NOTE: We begin most of the major 'cardinal' lines (those lines on the front, back, and sides) at their distal or caudal end. This is merely a convention; we could have as easily worked our way down from the head. The body will frequently create a tension either way, or a bind in the middle that works its way out toward both ends. No causation is implied in our choice of where to start.

General considerations

The most general statement that can be made about any of these Anatomy Trains lines is that strain, tension (good and bad), trauma, and movement tend to be passed through the structure along these fascial lines of transmission.



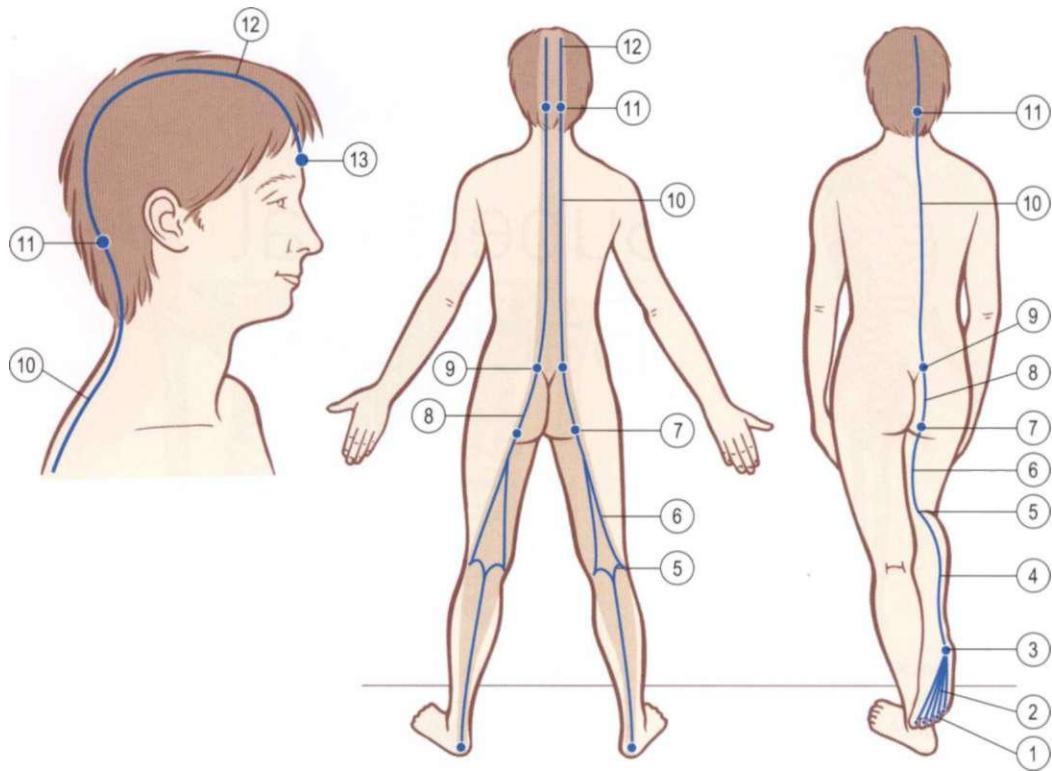


Fig. 3.2 Superficial Back Line tracks and stations. The shaded area shows where it affects and is affected by the more superficial fasciae (dermis, adipose, and the deeper fascia profundis).

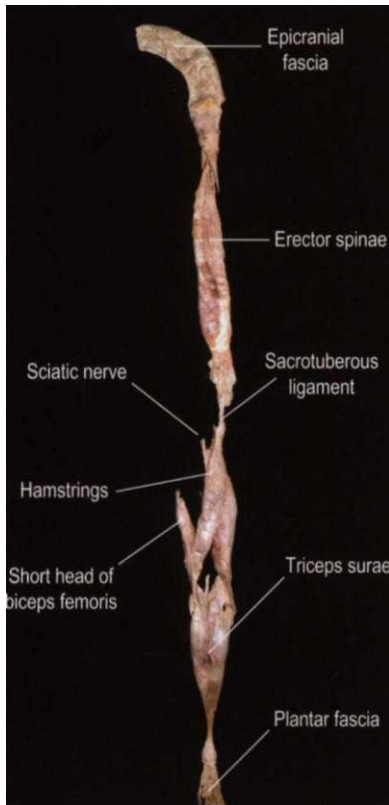


Fig. 3.3 The Superficial Back Line dissected away from the body and laid out as a whole. The different sections are labeled, but the dissection indicates the limitation of thinking solely in anatomical 'parts' in favor of seeing these meridians as functional 'wholes'.

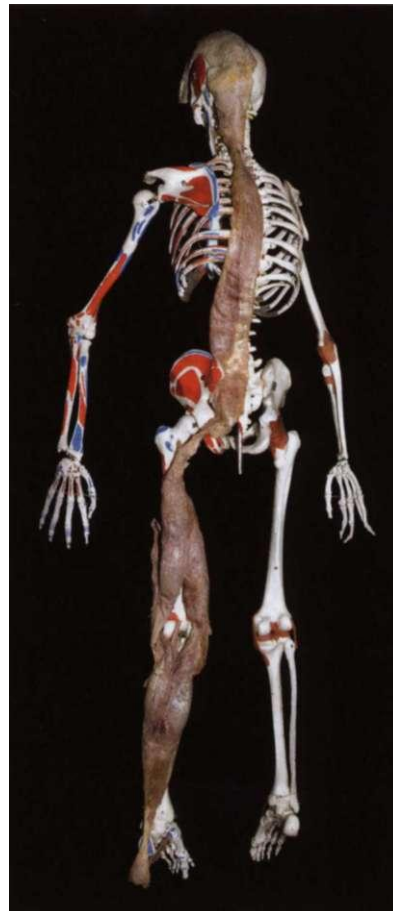

Fig. 3.4 The same specimen laid out on a classroom skeleton to show how the whole is arrayed. The cadaver was a good deal taller than the skeleton.

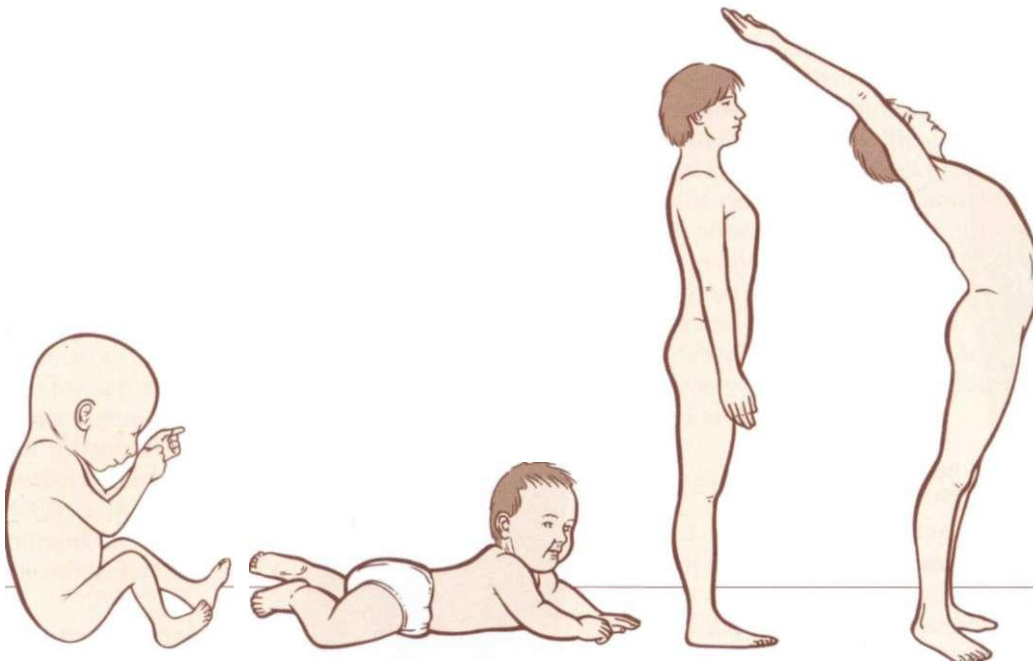


Fig. 3.5 In development, the SBL shortens to move us from a fetal curve of primary flexion toward the counterbalancing curves of upright posture. Further shortening of the muscles of the SBL produces hyperextension.

Table 3.1 Superficial Back Line: myofascial 'tracks' and bony 'stations' (Fig. 3.2)

Bony stations	Myofascial tracks
Frontal bone, supraorbital ridge 13	12 Galea aponeurotica/epicranial fascia
Occipital ridge 11	10 Sacrolumbar fascia/erector spinae
Sacrum 9	8 Sacrotuberous ligament
Ischial tuberosity 7	6 Hamstrings
Condyles of femur 5	4 Gastrocnemius/Achilles tendon
Calcaneus 3	2 Plantar fascia and short toe flexors
Plantar surface of toe 1 phalanges	

deep lateral rotators), anterior pelvic shift, sacral nutation, extensor widening in thoracic flexion, suboccipital limitation leading to upper cervical hyperextension, anterior shift or rotation of the occiput on the atlas, and eye-spine movement disconnection.

From toes to heel

Our originating 'station' on this long line of myofascia is the underside of the distal phalanges of the toes. The first 'track' runs along the under surface of the foot. It includes the plantar fascia and the tendons and muscles of the short toe flexors originating in the foot.

These five bands blend into one aponeurosis that runs into the front of the heel bone (the antero-inferior aspect of the calcaneus). The plantar fascia picks up an additional and important 6th strand from the 5th metatarsal base, the lateral band, which blends into the SBL on the outside edge of the heel bone (**Figs 3.6 and 3.7**).

These fasciae, and their associated muscles that pull across the bottom of the foot, form an adjustable 'bowstring' to the longitudinal foot arches; this bowstring helps to approximate the two ends, thus maintaining the heel and the 1st and 5th metatarsal heads in a proper relationship (**Fig. 3.8**). The plantar aponeurosis constitutes only one of these bowstrings - the long plantar ligament and spring ligament also provide shorter and stronger bowstrings deeper (more cephalad) into the tarsum of the foot (visible below the subtalar joint in **Fig. 3.8**).

The plantar fascia

The plantar surface of the foot is often a source of trouble that communicates up through the rest of the line. Limitation here often correlates with tight hamstrings,

The SBL is a cardinal line that primarily mediates posture and movement in the sagittal plane, either limiting forward movement (flexion) or, when it malfunctions, exaggerating or maintaining excessive backward movement (extension).

Although we speak of the SBL in the singular, there are, of course, two SBLs, one on the right and one on the left, and imbalances between the two SBLs should be observed and corrected along with addressing bilateral patterns of restriction in this line.

Common postural compensation patterns associated with the SBL include: ankle dorsiflexion limitation, knee hyperextension, hamstring shortness (substitution for



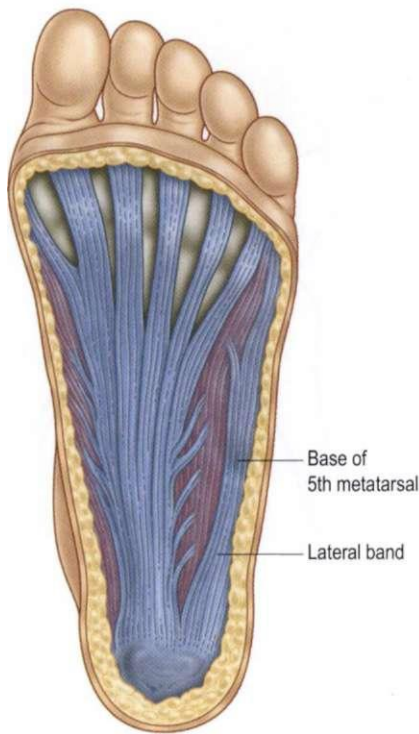


Fig. 3.6 The plantar fascia, the first track of the SBL, including the lateral band.



Fig. 3.7 A dissection of the plantar fascia. Notice the lateral band (A) comprising a somewhat separate but related track. (© Ralph T Hutchings. Reproduced from McMinn et al 1993.)

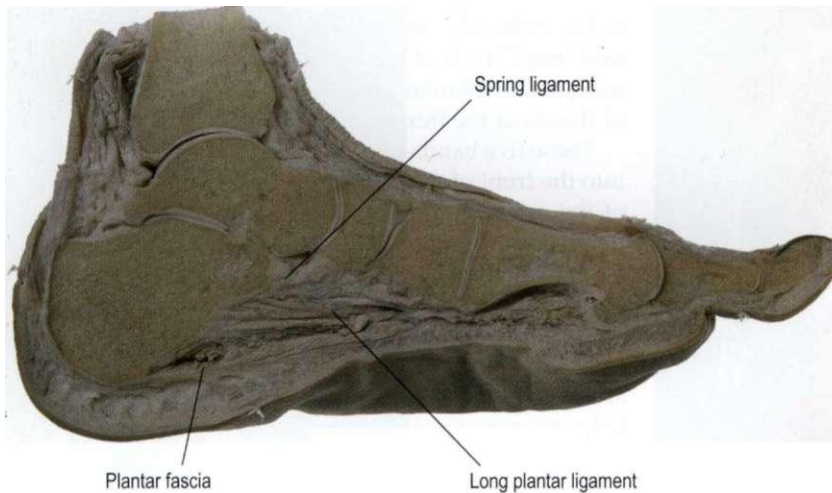


Fig. 3.8 A sagittal section of the medial longitudinal arch, showing how the plantar fascia and other tissues deep to it form a series of 'bowstrings' which help to hold up and act as springs for the medial arch. (© Ralph T Hutchings. Reproduced from Abrahams et al 1998.)

lumbar lordosis, and resistant hyperextension in the upper cervicals. Although structural work with the plantar surface often involves a lot of knuckles and fairly hefty stretching of this dense fascia, any method that aids in releasing it will communicate to the tissues above (**DVD ref: Superficial Back Line, 10:57-16:34**). If your hands are not up to the task, consider using the 'ball under the foot' technique described below in 'A simple test'.

Compare the inner and outer aspect of your client's foot. While the outer part of the foot (base of little toe to heel) is always shorter than the inner aspect (from base of big toe to heel), there is a common balanced proportion. If the inner aspect of the foot is proportionally short, the foot will often be slightly lifted off the medial surface (as if supinated or inverted) and seemingly curved toward the big toe in a 'cupped hand' pattern, as if a slightly cupped hand were placed palm



down on the table. In these cases, it is the medial edge of the plantar fascia that needs lengthening.

If the outer aspect of the foot is short - if the little toe is retracted or the 5th metatarsal base is pulled toward the heel, or if the outer aspect of the heel seems pulled forward - then the outer edge of the plantar fascia, especially its lateral band, needs to be lengthened (DVD ref: **Superficial Back Line**, 20:29-22:25). This pattern often accompanies a weak inner arch and the dumping of the weight onto the inner part of the foot, but can occur without the fallen arch.

Even in the relatively balanced foot, the plantar surface can usually benefit from enlivening work to make it more supple and communicative, especially in our urbanized culture where the feet stay locked up in leather coffins all day. A default approach to the plantar tissues is to lengthen between each of the points that support the arches: the heel, the 1st metatarsal head, and the 5th metatarsal head (**Fig. 3.9**).

A simple test

For a sometimes dramatic and easily administered test of the relatedness of the entire SBL, have your client do a forward bend, as if to touch the toes with the knees straight (**Fig. 3.10**). Note the bilateral contour of the back and the resting position of the hands. Draw your client's attention to how it feels along the back of the body on each side.

Have your client return to standing and roll a tennis ball (or a golf ball for the hardy) deeply into the plantar fascia on one foot only, being slow and thorough rather than fast and vigorous. Keep it up for at least a couple of minutes, making sure the whole territory is covered

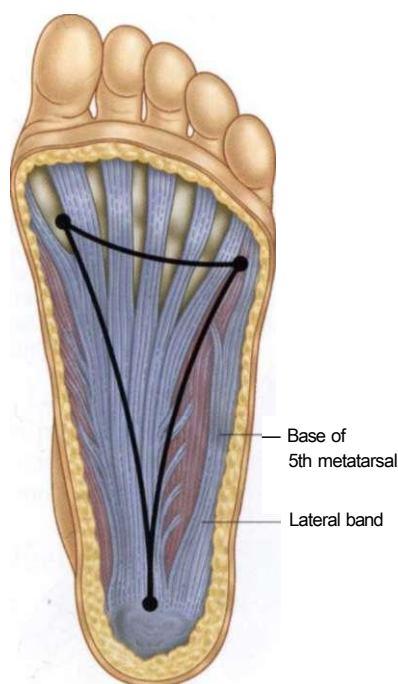


Fig. 3.9 The plantar aponeurosis forms a 'trampoline' under the arches - one springy arch between each point of contact: the 5th metatarsal head, the 1st metatarsal head, and the heel.

from the ball of all five toes back to the front edge of the heel, the whole triangle shown in **Figure 3.9**.

Now have the client do the forward bend again and note the bilateral differences in back contour and hand position (and draw the client's attention to the difference in feeling). In most people this will produce a dramatic demonstration of how working in one small part can affect the functioning of the whole. This will work for many people, but not all: for the most easily assessable results, avoid those with a strong scoliosis or other bilateral asymmetries.

Since this also functions as a treatment, do not forget to carry out the same procedure on the other side after you assess the difference.

Heel spurs

It is 'common knowledge' that the muscles attach to bones - but this commonsense view is simply not the case for most myofasciae. The plantar fascia is a good case in point. People who run on the balls of their feet, for instance, or others who for some reason put repetitive strain on the plantar fascia, tug constantly on the calcaneal attachment of the plantar fascia. Since this fascia is not really attached to the calcaneus but rather blends into its periosteal 'plastic wrap' covering, it is possible in some cases for the periosteum to be progressively tugged away from the calcaneus, creating a space, a kind of 'tent', between this fabric and the bone (**Fig. 3.11**).

Between most periosteal and their associated bones lie many osteoblasts - bone-building cells. These cells are constantly cleaning and rebuilding the outer surface of the bone. In both the original creation and the continuing maintenance of their associated bone, the osteoblasts are programmed to fill in the bag of the periosteum. Clients who create repetitive strain in the plantar fascia are likely to create plantar fasciitis anywhere along the

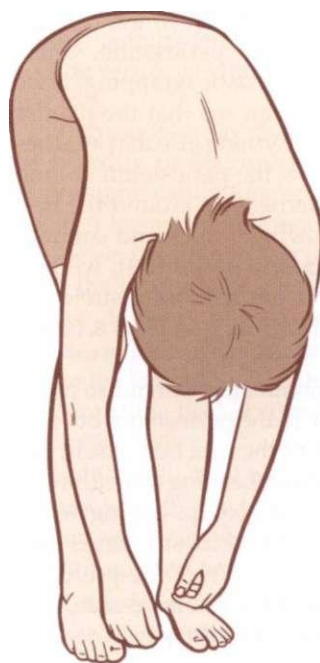

Fig. 3.10 A forward bend with the knees straight links and challenges all the tracks and stations of the Superficial Back Line. Work in one area, as in this move for the plantar fascia, can affect motion and length anywhere and everywhere along the line. After work on the right plantar surface, the right arm hangs lower.



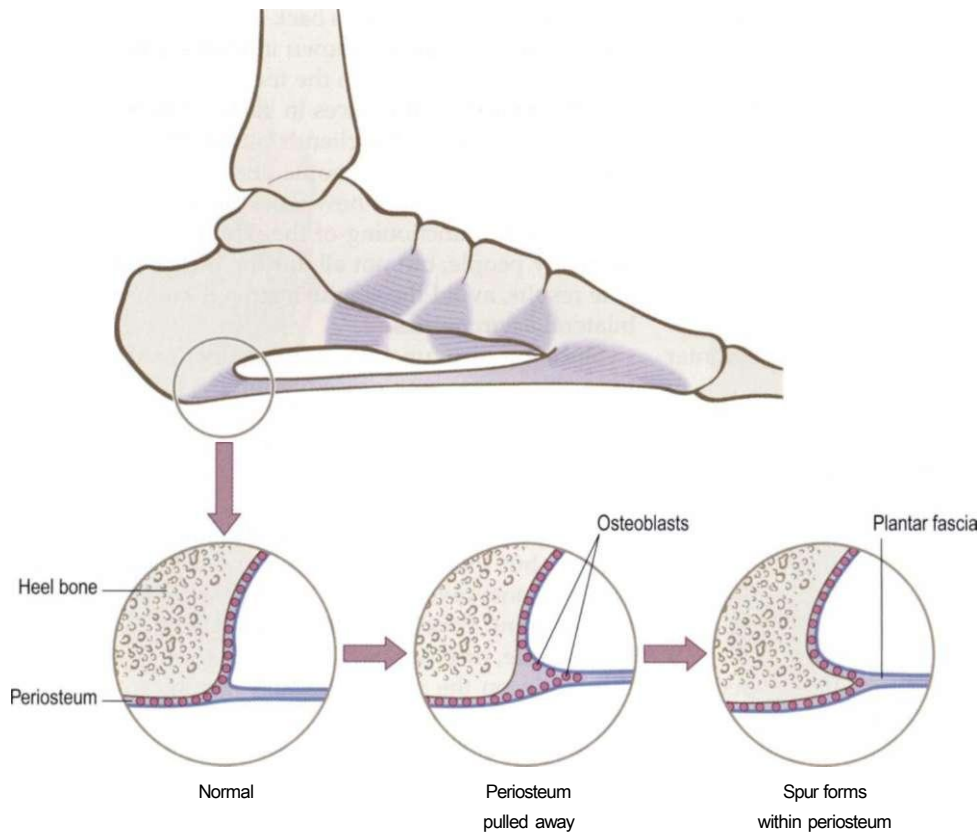


Fig. 3.11 The formation of a heel spur by the osteoblasts which fill in under a pulled-away periosteum illustrates both the adaptability of the connective tissue system and one limitation of the simplistic 'muscles attach to bones' concept.

plantar surface where it tears and inflames. If instead the periosteum of the calcaneus gives way and comes away from the bone, then the osteoblasts will fill in the 'tent' under the periosteum, creating a bone spur.

From heel to knee

As discussed in Chapter 2, the fasciae do not just attach to the heel bone and stop (as is implied, for instance, in **Figs 3.6** and **3.11**). They actually attach to the collagenous covering of the calcaneus, the periosteum, which surrounds the bone like a tough plastic wrapping. If we begin to think in this way, we can see that the plantar fascia is thus continuous with anything else that attaches to that periosteum. If we follow the periosteum around the calcaneus, especially underneath it around the heel to the posterior surface (following a thick and continuous band of fascia - see **Figs 3.12** and **3.15B**), we find ourselves at the beginning of the next long stretch of track that starts with the Achilles tendon (**Figs 3.12** and **3.13**).

Because the Achilles tendon must withstand so much tension, it is attached not only to the periosteum but also into the collagenous network of the heel bone itself, just as a tree is rooted into the ground. Leaving the calcaneus and its periosteum, our train passes up, getting wider and flatter as it goes. Three myofascial structures feed into the Achilles tendon: the soleus from the profound side, the gastrocnemius from the superficial side, and the little plantaris in the middle (**Fig. 3.12**).

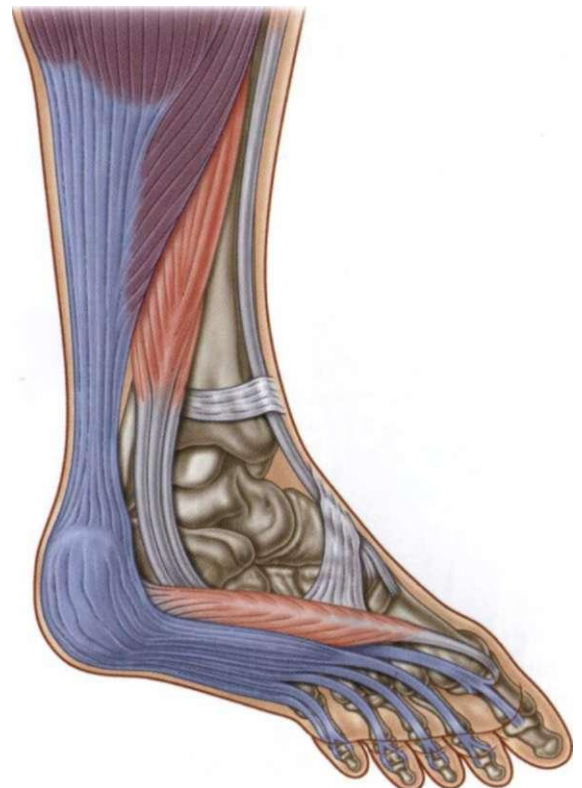

Fig. 3.12 Around the heel, there is a strong and dissectable fascial continuity between the plantar fascia and the Achilles tendon and its associated muscles.

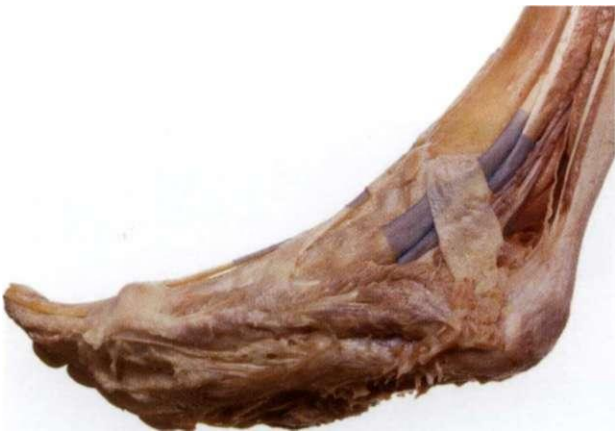
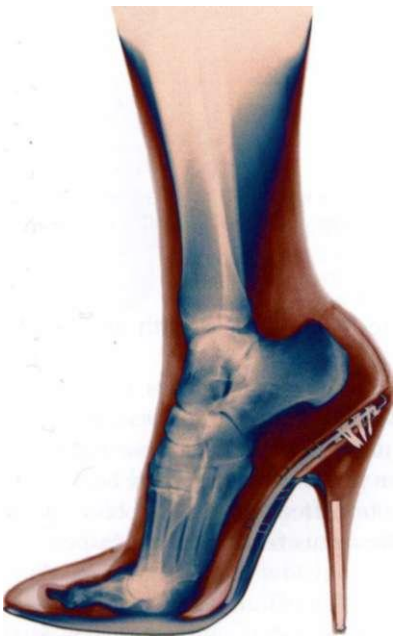
Fig. 3.13 A dissection of the heel area demonstrates the continuity from plantar tissues to the muscles in the superficial posterior compartment of the leg. (© Ralph T Hutchings. Reproduced from Abrahams et al 1998.)



Let us take this first connection we have made - from the plantar fascia around the heel to the Achilles tendon - as an example of the unique clinical implications that come out of the myofascial continuities point-of-view.

Heel as arrow

In simple terms, the heel is the patella of the ankle, as we can see in the X-ray of a foot (**Fig. 3.14**). From a 'tensegrity' point of view, the calcaneus is a compression strut that pushes the tensile tissues of the SBL out away from the ankle and creates proper tone around the back of the tibio-talar fulcrum, with the soft tissue spanning

from knee to toes. (Contrast this leverage with the proximity of the joint-stabilizing muscles: the fibularii (peroneals) of the Lateral Line that snake right around the lateral malleolus and the deep toe flexors of the Deep Front Line that pass close behind the medial malleolus.)

To see the clinical problem this patterning can create, imagine this lower section of this Superficial Back fascial line - the plantar fascia and Achilles-associated fascia - as a bowstring, with the heel as an arrow. As the SBL chronically over-tightens (common in those with the ubiquitous postural fault of a forward lean of the legs (an anterior shift of the pelvis), it is capable of pushing the heel forward into the subtalar joint; or, in another common pattern, such extra tension can bring the tibia-fibula complex posteriorly on the talus, which amounts to the same pattern. (**Fig. 3.15**).

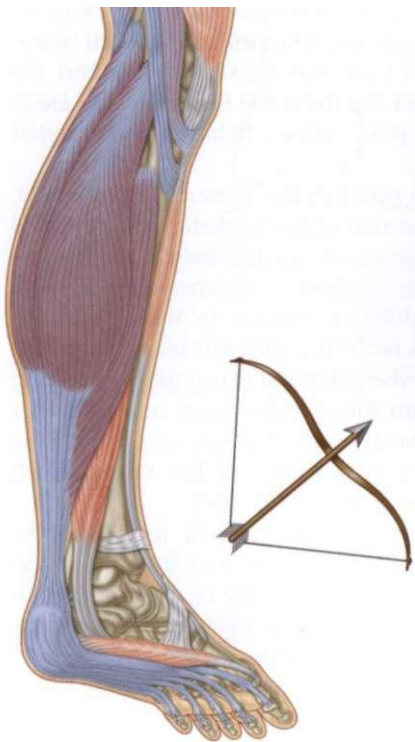
To assess this, look at your client's foot from the lateral aspect as they stand, and drop an imaginary vertical line down from the lower edge of the lateral malleolus (or, if you prefer, place your index finger vertically down from the tip of the malleolus to the floor). See how much of the foot lies in front of this line and how much behind. Anatomy dictates that there will be more foot in front of the line, but, with a little practice, you will be able to recognize when there is comparatively little heel behind this line (**Fig. 3.16A and B**).

Measure forward from the spot below the lateral malleolus to the 5th metatarsal head (toes are quite variable, so do not include them). Measure back from the spot to the place where the heel leaves the floor (and thus offers no support). On a purely empirical clinical basis, this author finds that a proportion of 1:3 or 1:4 between the hindfoot and the forefoot offers effective support. A ratio of 1:5 or more indicates minimal support for the back of the body. This pattern cannot only be the result of tightness in the SBL but also the cause of more tightness as well, as it is often accompanied by a forward shift at the knees or pelvis to place more weight on the forefoot, which only tightens the SBL further. As long as this pattern remains, it will prevent the client from feeling secure as you attempt to rebalance the hips over the feet.

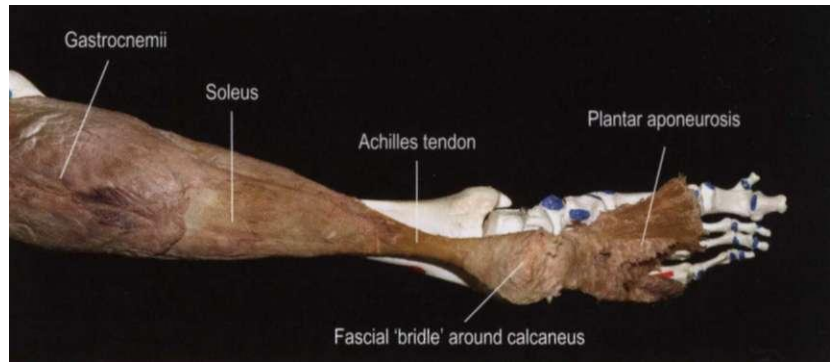
To those who say that this proportion is determined by heredity, or that it is impossible for the calcaneus to move significantly forward or backward in the joint, we suggest trying the following:

- release the plantar fascia, including the lateral band, in the direction of the heel (DVD ref: **Superficial Back Line, 10:57-16:34, 20:29-22:25**)
- release the superficial posterior compartment of the leg (soleus and gastrocnemius) down toward the heel (DVD ref: **Superficial Back Line, 22:27-24:30**)
- mobilize the heel by stabilizing the front of the tarsum with one hand while working the heel through its inversion and eversion movements in your cupped hand.

In more recalcitrant cases, it may be necessary to further release the ligaments of the ankle by working

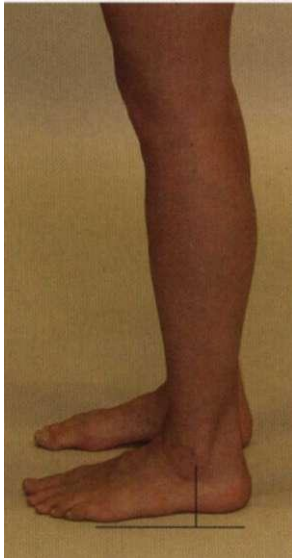

A

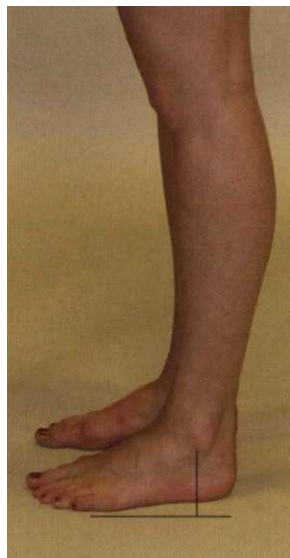

B

Fig. 3.15 When the myofascial continuity comprising the lower part of the SBL tightens, the calcaneus is pushed into the ankle, as an arrow is pushed by the tautened bowstring (A). Notice how the fascia around the heel acts as a 'bridle' or a 'cup' to embrace and control the heel bone (B).



A



B

Fig. 3.16 The amount of the foot in front of the ankle joint should be balanced by about 1/3 to 1/4 behind the ankle joint. Without this support for the back body, the upper body will lean forward to place the weight in front.

deeply but slowly from the corner of each malleolus (avoiding the nerves) diagonally to the corner of the heel bone. The result will be a small but visible change in the amount of foot behind the malleolar line, and a very palpable change in support for the back of the body in the client. Therefore, strategically, this work should

precede any work designed to help with an anterior pelvic shift.

Please note that the mark of success is a visibly increased amount of heel when you reassess using the malleolus as your guide. Repetition may be called for until the forward lean in the client's posture is resolved by your other efforts (e.g. freeing the distal ends of the hamstrings, lifting the rectus femoris of the Superficial Front Line, etc.).

'Expresses' and 'locals'

Two large muscles attach to the Achilles band: the soleus from the deep side, and the gastrocnemius from the superficial side. The connection of the SBL is with the superficial muscle, the gastrocnemius. First, however, we have an early opportunity to demonstrate another Anatomy Trains concept, namely 'locals' and 'expresses'.

The importance of differentiating expresses and locals is that postural position is most often held in the underlying locals, not in the more superficial expresses. Express trains of myofascia cross more than one joint; locals cross, and therefore act on, only one joint. With some exceptions in the forearms and lower leg, the locals are usually deeper in the body - more profound - than the expresses. (See Ch. 2 for a full definition and examples.)

This superficial posterior compartment of the lower leg is not, however, one of these exceptions: the two heads of the gastrocnemius cross both ankle and knee joints, and can act on both (Fig. 3.17). The deeper soleus





Fig. 3.17 The Achilles tendon and the gastrocnemius muscle form the superficial express muscle that crosses both knee and ankle.

crosses only the ankle joint - passing from the heel to the posterior aspects of the tibia, interosseous membrane, and fibula - and acts only on this joint. (The so-called ankle joint is really two joints, consisting of the tibio-talar joint, which acts in plantar- and dorsiflexion, and the subtalar joint, which acts in what we will call inversion and eversion. Though the triceps surae - plantaris, gastrocnemius and soleus together - does have some effect on the subtalar joint, we will ignore that effect for now, designating the soleus a one-joint muscle for the purposes of this example.)

If we took the soleus local, we could keep going on the same fascial plane and come onto the fascia on the back of the popliteus, which crosses the knee and flexes it (and also rotates the tibia medially on the femur when the knee is flexed, though that is outside our current discussion). The gastrocnemius express can thus participate in both plantarflexion and knee flexion, while each of the two locals provides one action only. We will see this phenomenon repeated throughout the myofascial meridians.

Derailment

Following the SBL via the gastrocnemius, we come to the first of many bends in the Anatomy Trains rules, which we will term 'derailments'. Derailments are exceptions to the Anatomy Trains rules, which can be

explained in terms useful for soft-tissue and movement work. In a derailment, the Anatomy Trains still work, but only under particular conditions.

In order to understand this first important exception, we need to look more closely at the interface between the two heads of the gastrocnemius and the tendons of the three hamstrings (**Fig. 3.18**).

It is easy to see from comparing **Figure 3.3** with **Figure 3.18** that the gastrocnemius and hamstrings are both separate and connected. In dissection, the fascia clearly links from near the distal ends of the hamstrings to near the proximal ends of the gastrocnemii heads. In practice, a slight flexion of the knees delinks the one from the other. While by strict Anatomy Trains rules they are a myofascial continuity, they do function as one only when the knee is extended. The gastrocnemii heads reach up and around the hamstring tendons to insert onto the upper portions of the femoral condyles. The hamstrings reach down and around the gastrocnemii to attach to the tibia and fibula. As long as the knee is bent, these two myofascial units go their own ways, neighboring but loosely connected (**Fig. 3.19A**). As the knee joint goes into extension, however, the femoral condyles come back into both these myofasciae, tightening the complex, engaging these elements with each other, and making them function together almost as if they were two pairs of hands gripped at the wrists (**Fig. 3.19B-D**). This configuration also bears a strong resemblance to a square knot, loosened when the knee is bent, tightened as the knee straightens.

This provides a long-winded but accurate explanation of why it is less of a stretch to pick up your dropped keys from the floor by flexing your knees rather than keeping



Fig. 3.18 The relationship between the heads of the gastrocnemii and the tendons of the hamstrings in the popliteal space behind the knee. (© Ralph T Hutchings. Reproduced from Abrahams et al 1998.) See also **Figure 3.3**.

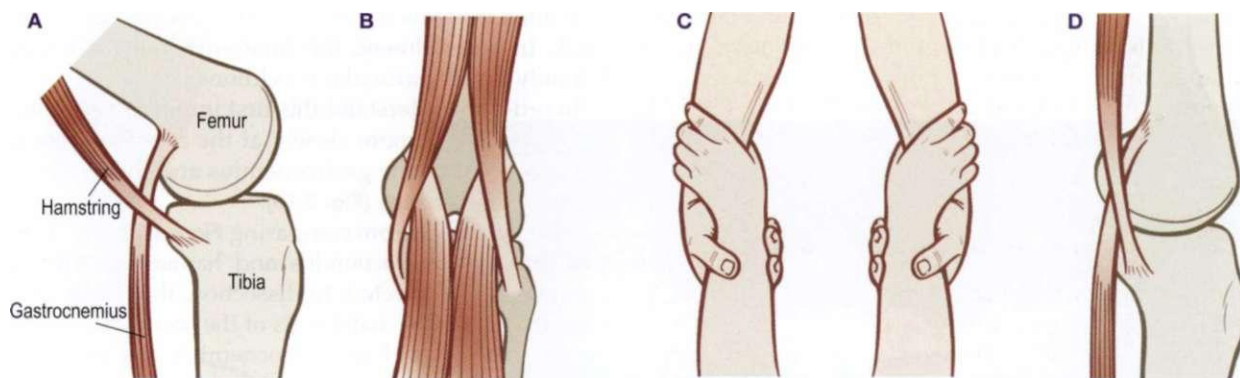


Fig. 3.19 When the knee is flexed, the myofascia of the thigh and the myofascia of the lower leg function separately (A). When the knee is extended, these myofasciae link into one connected functioning unit (B), like the interlocked hands of a pair of trapeze artists (C - compare to Fig. 3.18). The configuration is reminiscent of a reef or square knot; able to form a tight knot, yet readily loosened as well (A versus D).

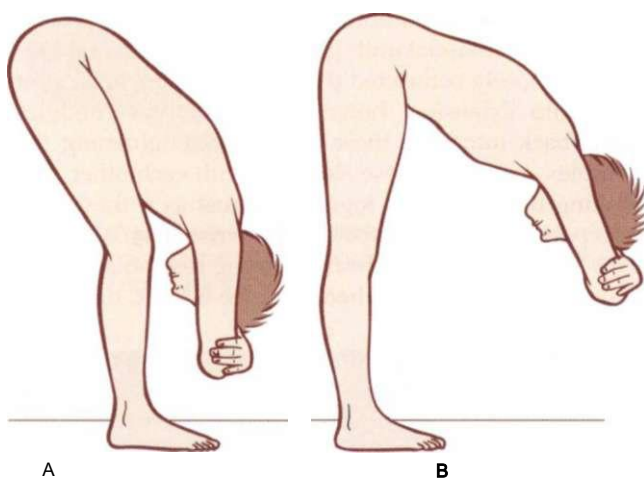


Fig. 3.20 When the knees are bent (A), the upper and lower parts of the SBL are relatively separate, and it is easier to fold at the hips. With the knees extended (B), the SBL is linked into one unit, and a forward bend may not be as easy.

them extended (Fig. 3.20). A very slight flexion of the knees is sufficient to allow significantly more forward bend in the spine and hips. The traditional explanation is that the hamstrings are shortened by the knee flexion, thus freeing the hips to flex more. In fact, bending the knees only a tiny amount, e.g. moving the knees forward a mere inch or a few centimeters, does not shorten the distance from the ischial tuberosity to the lower leg appreciably, and yet it frees the hip flexion considerably. Our explanation would be that even a slight flexion loosens the square knot, unlinking the lower part of the SBL from the upper. The linked SBL is harder to stretch into a forward fold; the unlinked SBL is easier.

The entire SBL is a continuity in a regular standing posture. In yoga, for instance, postures (asanas) which utilize a forward bend with straightened legs (as in the Downward-Facing Dog, Plow, Forward Bend, or any simple hamstring stretch) will engage the SBL as a whole, whereas forward bends with the knees bent (e.g. Child's pose) will engage only the upper myofascia of the line, except in those with very short SBLs, for whom

even flexing the knees is not enough to allow a full forward bend.

The distal hamstrings

The interface between the heads of the gastrocnemii and the 'feet' of the hamstrings can get tied up; the result is usually not a flexed knee but a tibia that seems to sit behind the femur when viewed from the side.

This technique requires some finger strength, but tenacity will be rewarded. It also requires precise finger placement to avoid pain for the client. Have your client lie prone, with one knee bent to near 90°. Support this foot with your sternum or shoulder, so that the hamstring can temporarily relax. Hook your fingers, palms facing laterally, inside the hamstrings at the back of the knee, 'swimming' in between these tendons (two on the inside and one on the lateral side) to rest on the heads of the gastrocnemii (Fig. 3.18). Be sure to take a little skin with you and keep your fingers moving out against the hamstring tendons to avoid pressuring the endangerment site in the middle of the popliteal space. This technique should not produce any nerve pain or radiating sensations. Have your client retake control over her leg, then remove your support. The hamstring tendons will pop out as they tense, so keep your fingers in position.

Have your client slowly lower her foot to the table as you move slowly up the inside of the hamstring tendons (but mostly simply maintaining your position, while the client does the work). The client will be lengthening both the hamstrings and gastrocnemii in eccentric contraction, freeing their distal ends from each other. When effectively done, this will result in the tibia moving forward under the femur (DVD ref: **Superficial Back Line 25:56-28:45**).

From knee to hip

Assuming, then, that the legs are straight and the knees extended, we continue up the myofascial continuity provided by the hamstrings, which takes us to the posterior side of the ischial tuberosities (Fig. 3.21). The dual

medial hamstrings, the semimembranosus and semitendinosus, are complemented by the single lateral hamstring, the biceps femoris (although the outer leg is also supported by two 'hamstrings' - see Ch. 6, p. 139). All three of the hamstrings are 'expresses', affecting both knee and hip.

Separating the hamstrings

Much has been written about the hamstrings, but very little about the separate functions of the hamstrings. The medial hamstrings (semitendinosus and semimembranosus) create medial tibial rotation when the knee is flexed. The lateral hamstring (biceps femoris) creates lateral rotation of the lower leg on the femur in the same situation. To perform these separate functions, the two sets of muscles must be able to work separately. This differential movement between inner and outer hamstrings is especially important in sports or activities where the hips move side-to-side while there is pressure on the knee, as in jazz dance, skiing, football, or rugby. In running - pure flexion and extension - this separation is not required as the inner and outer hamstrings always work in tandem.

To feel how far the inner and outer hamstring function is separated, have your client lie prone, preferably with the knee flexed for easier access, and begin to feel your way up the space between the two sets of hamstrings, just above the endangerment area in the popliteal space (Figs 3.18 and 3.21). Here it will be easy to feel the separation, for they are quite tendinous, and at least an inch or two (3-5 cm) apart. Now move up toward the ischial tuberosity, being careful to stay in the 'valley' between the two sets of muscles. How far up can you feel a palpable valley? For some people, the entire group of three muscles will be bound together a few inches up from the popliteal space; for others a division will be palpable halfway or more to the ischial tuberosity. In dissection the potential separation can go up to within a few inches, or 10 cm, of the ischial tuberosity.

To test this functionally, have your client bend the knee you are assessing to a right angle, and then twist that foot medially and laterally, while you rest a hand across the muscles and palpate to feel if they are working separately.

To treat bound hamstrings, insert (or wiggle or 'swim') your fingers in between the muscles at the lowest level of binding as your client continues to slowly rotate the lower leg medially and laterally with the knee bent. The binding fascia will gradually release, allowing your fingers to sink toward the femur. Continue working upward a few inches at a time until you reach the limit of that technique (DVD ref: **Superficial Back Line**, 31:08-33:57).

Rotation at the knee

Although functional rotation of the knee is only possible when the knee is flexed, postural rotation of the tibia on the femur, medial or lateral, is quite common. Although several factors, including strain in peri-articular tissues

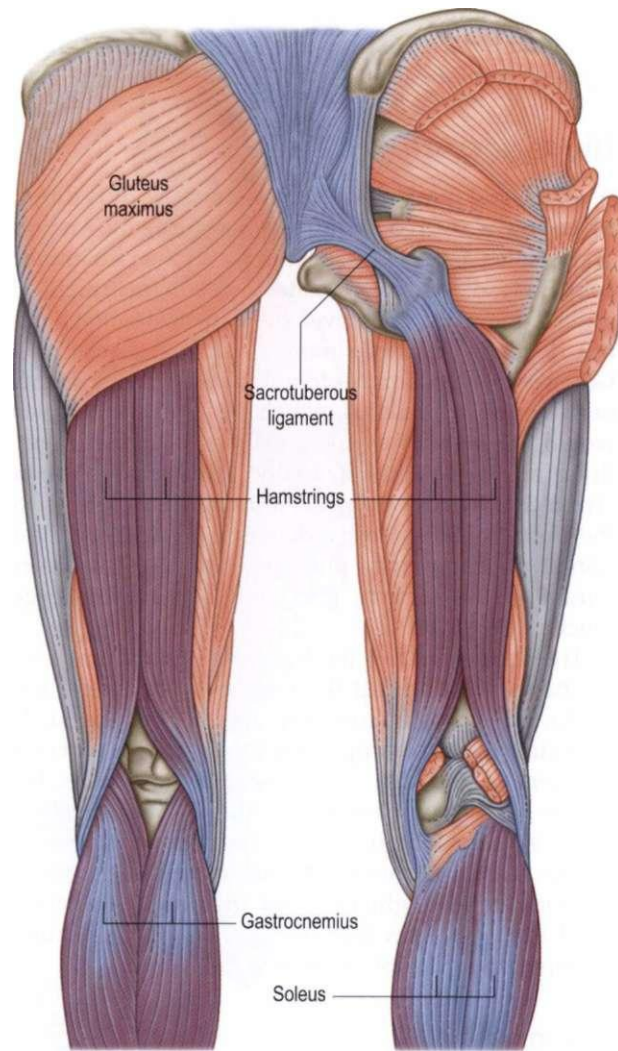


Fig. 3.21 A superficial view (left) shows the hamstrings disappearing under the gluteus maximus, but despite the gluteus being a superficial muscle on the back, it is not part of the SBL. It is disqualified by involving both a change in direction, and a change of level. Remove the gluteus (which will show up later as part of other lines) to see the clear connection from the hamstrings to the sacrotuberous ligament.

and strains coming up from the foot, can contribute to this pattern, working differentially on the two sets of hamstrings can be very helpful in releasing the leg back into alignment.

If the tibia is medially rotated (as measured by the direction in which the tibial tuberosity faces relative to the patella - the outside edges of the patella and tibial tuberosity should form an isosceles triangle), then manual or stretching work on the medial set of hamstrings (semitendinosus and semimembranosus) is required. If the tibia is turned laterally, work on the biceps femoris (both heads) is necessary. The tissues should be worked toward the knee. Begin with whatever general stretching or work with the hamstrings you had planned, then do additional work on the relevant hamstring to reduce the rotation, using the client's slow eccentric lengthening of the tissues occasioned by bringing the knee from flexion to extension. The tissues that maintain these rotations are located deep within the hamstring



Hip to sacrum

If we are still thinking in terms of muscles, it is difficult to see how we can continue from here using the Anatomy Trains rules, for no muscle attaches to the ischial tuberosity in a direction opposite to the hamstrings. The gluteus maximus goes over the hamstring attachment, but it clearly runs in a more superficial fascial plane. Going onto the quadratus femoris, the adductor magnus, or the inferior gemellus, which are on a similar plane, would all involve a rule-breaking radical change of direction. If we think fascially, however, we are not stymied at all: the sacrotuberous ligament arises from the back of the tuberosity, demonstrably as a continuation of the hamstrings, and passes across to the lateral border of the sacrum, just above the sacrococcygeal junction (**Fig. 3.21**).

The inferior end of the ligament is continuous with the hamstrings. In fact the tendon of the lateral hamstring, the biceps femoris, can actually be separated in dissection and traced up to the sacrum. (This part of the ligament is probably a degenerated muscle; we have only to look at our close mammalian relative, the horse, to see a biceps femoris muscle that runs all the way up to the sacrum. A horse sacrum, of course, bears less proportionate weight than our own and is allowed a good deal more freedom of movement than a human sacrum could possibly enjoy.)

3



Stations

Let us be clear about fascial communication at the 'stations', or attachments. Here we pause again for a fuller explanation, as this is a good example of the general functioning of an Anatomy Trains 'station'. We are not saying that the entire sacrotuberous ligament is an extension of the hamstrings. The very strong, almost bone-like tensile connection between the sacrum and the ischial tuberosity is absolutely necessary to upright human posture and pelvic integrity. Without it, our 'tail' would pop up into the air, painfully and irretrievably, every time we bent over. The ligament is absolutely tacked down to the bones and cannot slide significantly as a whole toward the hamstrings or the sacral fascia.

What we *are* saying is that the more superficial layers of fascia are continuous with the myofascia on either side, and are, or should be, able to communicate both movement and strain across the fascial fibers adjacent to the surface of the ligament (**see Fig. 2.9**). How many layers are able to communicate and how many are stuck down varies from person to person and depends on the person-specific mechanical needs of the area. In extremely stuck cases, the dermis of the skin will be tied down to other layers (sometimes creating a dimple), a sure indication of a station that is not communicating. In extremely loose cases, usually after some trauma, but

sometimes due to overstretching or overmanipulating, layers that should be intrinsic to the local stations become too communicative, requiring extra myofascial tightening elsewhere to maintain some form of integrity at the sacroiliac joint.

The superior end of the ligament is likewise firmly joined to the sacrum, but has more superficial connections to the other fasciae in the area, specifically down to the coccyx and up onto the posterior spine of the ilium. In dissection, it is possible to lift the superficial communicating fibers of the sacrotuberous ligament off the body maintaining their strong connection with the hamstrings and erector spinae fascia (as in **Fig. 3.3**).

The sacrotuberous ligament

The following, then, does not address the sacrotuberous ligament *per se*, but rather the tissue of the SBL that passes over the sacrotuberous ligament on its way from the hamstrings to the sacral fascia. Because the medial edge of the gluteus maximus attaches over the tissue we want to access, enter from the medial side of the heavy ligamentous line from the lower lateral aspect of the sacrum down, drawing the tissue down and laterally to the ischial tuberosity, or vice versa, depending on the pattern.

This tissue should generally be carried in a downward direction for those with an anterior tilt to the pelvis, and carried upward in those with a flat lumbar spine or a posterior tilt to the sacrum (DVD ref: Superficial Back Line 35:03-36:35). Use a deep, firm, and consistent pressure, without chopping or digging.

From sacrum to occiput

From the superior end of the sacrotuberous ligament, our rules require that we keep going in roughly the same direction, and we have no trouble doing that: the erector spinae arise from the layers of sacral fascia continuous with the sacrotuberous ligament (**Fig. 3.22**) (DVD ref: Superficial Back Line, 1:04:24-1:06:52). The erector spinae span the spine from sacrum to occiput, with the expresses of the longissimus and iliocostalis complex overlying the ever deeper and shorter locals of the spinalis, semispinalis, and multifidus (**Fig. 3.23**). The deepest layer, the transversospinalis group, provides the shortest one-joint locals, which reveal the three basic patterns followed by all the erector muscles (**Fig. 3.24**). The functional anatomical details of all these muscle complexes have been ably covered elsewhere.¹⁻³

The most superficial 'express' layers of fascia in this complex tie sacrum to occiput. We should note that even though the erectors are part of what is termed the Superficial Back Line, several layers of even more superficial myofascia overlie the line here in the form of the serratus posterior muscles, the splenii, the rhomboids, the levator scapulae, and the superficial shoulder musculature of the trapezius and latissimus dorsi. These muscles form parts of the Spiral, Arm, and Functional Lines, and are addressed in Chapters 6, 7, and 8 respectively.

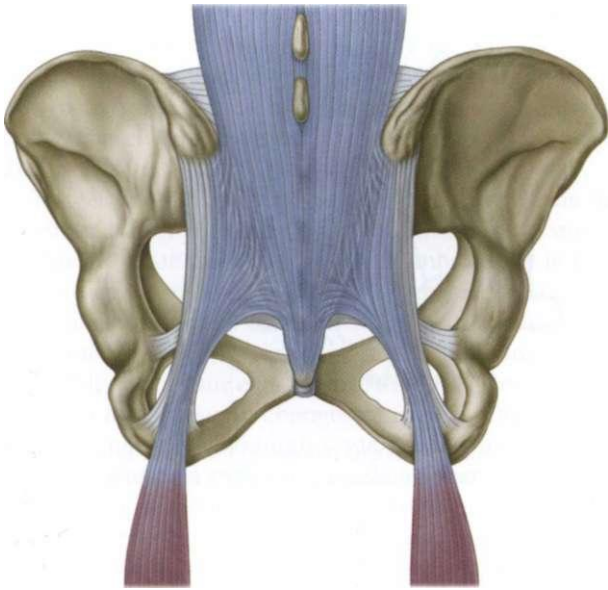


Fig. 3.22 With a knife, it is possible to isolate the sacrotuberous ligament as a separate structure. In life, though, it (at least superficially) connects both up to the sacral fascia and the erector spinae and down to the biceps femoris.

Erector spinae fascia

The methods for treating the back muscles are so myriad and diverse that many books would be required to detail all of them. We include a few global considerations and techniques.

Since the erector spinae cover the posterior side of the spinal curves, they co-create the depth of these curves, along with the muscles that attach to the front of the spine in the neck and the lumbar (see Ch. 9 on the Deep Front Line). With that in mind, our first consideration is the depth of the curves in the spine: is there a lumbar or cervical lordosis, or a thoracic kyphosis? Observe: do the spinous processes protrude like bumps or a ridge beyond the surrounding tissue (are they 'mountains?'); or do they sink below the surrounding myofascial tissue in a groove (do they form 'valleys'?).

The general rule is counter-intuitive: pile up on the mountains, and dig out the valleys. Myofascial tissue has spread away from the spinous processes that protrude (as in a kyphosis), widening and sticking to surrounding layers. These tissues need to be moved medially, toward the spinous processes, not only to free the tissues for movement, but also to give some forward impetus to those vertebrae that are too far back. Conversely, when the vertebrae are buried deep (as in a lordosis), contiguous myofascial tissues migrate medially and tighten, forming the 'bowstring' to the spinal bow. These tissues must be moved laterally and lengthened progressively from superficial to deep. This will allow the buried vertebrae some room to move back.

To assess the ability to lengthen at various levels of the spine, seat your client on a stool (or on the edge of a treatment table, provided it is low enough for the client's feet to be comfortably on the floor). Help your

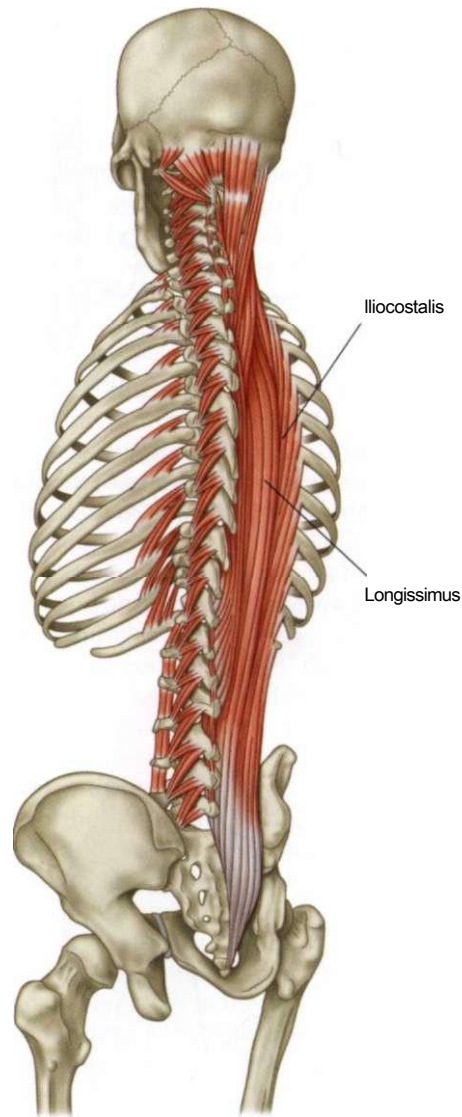


Fig. 3.23 The erector spinae form the next track of the SBL. The muscles run from the sacrum to the occiput; the fascia runs from the sacrotuberous ligament to the scalp fascia. On the left are some of the underlying 'locals' of the transversospinalis - intertransversarii, rotators, and levatores costarum.

client assume an upright posture, with the weight on the ischial tuberosities and the head lengthened away from the floor but still horizontal (looking straight ahead). Instruct your client to drop his chin toward his chest until he feels a comfortable stretch in the back of the neck. Let the weight of his forehead begin to carry him forward, 'one vertebra at a time', while you stand beside him and watch. Look for places where the individual spinous processes do not move away from each other like a train pulling out of the station one car at a time. In all but the healthiest of spines, you will find places where a couple or even a whole clump of vertebrae move together, without any differentiation. Really bound clients may move the spine as a whole, getting most of their forward motion through flexion at the hips, rather than by curling or flexing the spine itself (**Fig. 3.25**).

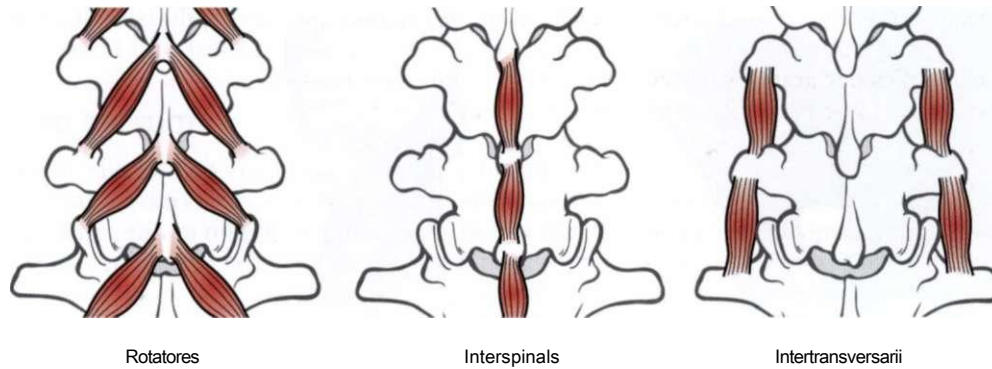


Fig. 3.24 The deepest level of the spinal musculature demonstrates three primary patterns: spinous process to transverse process, spinous process to spinous process, and transverse process to transverse process. The more superficial muscles can be analyzed as ever-longer express versions of these primary locals.

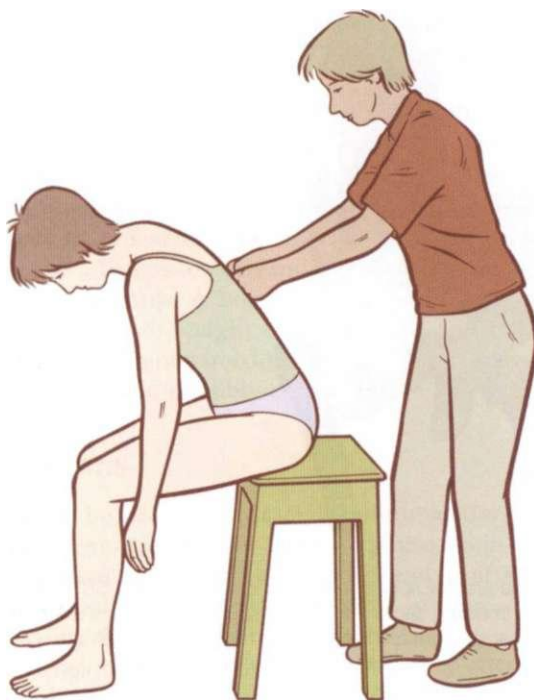

Fig. 3.25 Working the erector spinae and associated fascia in eccentric contraction from a bench is a very effective way of creating change in the myofascial function around the spine.

The assessment can turn into treatment very easily by putting your hand gently on a stiff area and encouraging your client to find the bend or movement in that part of the spine. More assertive manual treatment can also follow. Stand behind the bench, and as the client begins to roll forward with the chin slightly tucked, place the dorsal surface of all the proximal phalanges (in English: an open, soft fist) on both sides of the spine at the level of the cervicothoracic junction. Move down as the client curls forward, keeping pace with him, moving tissue down and out or down and in (depending on the 'mountains' and 'valleys') as you go. You should reach the sacral fascia at about the same time he is fully forward,

chest to thigh (DVD ref: **Superficial Back Line, 36:44-57:04**).

It is very important that the client stay grounded in his feet, pushing back against your pressure from his feet, but not from the back or neck. This technique should be totally comfortable for the client; desist immediately if it is painful. Your pressure should be more down the back than forward.

For more specific work, a knuckle may be used as an applicator, and a 'seeing' elbow is also good for getting heavier work done.

There is a variation that can be good in the case of a kyphotic spine, but may only be applied to those with a strong lower back. Lower back pain during this technique contraindicates the treatment. Have your client begin the spinal flexion movement as detailed above. When your applicator (fist, elbow, knuckle) is at the most posterior part of the thoracic curve (which is likely to be the tightest, most frozen area as well), instruct your client to 'curve in the opposite direction; bring your sternum to the wall in front of you'. Maintain your position in the back as he opens into hyperextension with flexed hips (somewhat like a figurehead on the old ships). This can produce dramatic opening in the chest and thoracic spine.

These techniques can be repeated a number of times, within a session or in successive sessions, without negative effect - as long as it remains pleasurable, not painful, for the client.

The suboccipitals

Many techniques for general traction and stretching of neck tissues, as well as muscle-specific techniques for cervical musculature, have been well documented elsewhere, and these can be effectively used in terms of the SBL (DVD ref: **Superficial Back Line, 1:00:00-1:02:20**). The deepest layers of muscles (the suboccipital 'star') are crucial to opening up the entire SBL; indeed, the rectus capitis posterior and obliquus capitis muscles can be considered the functional centerpieces of the SBL (**Fig. 3.26**). The high number of stretch receptors in these

tissues, and their essential link from the eye movements to coordination of the rest of the back musculature, ensure their central role. These muscles have been shown to have 36 muscle spindles per gram of muscle tissue; the gluteus maximus, by contrast, has 0.7 spindles per gram.⁴

To feel this linkage for yourself, put your hands up on either side of your head with your thumbs just under the back of your skull. Work your thumbs gently in past the superficial muscles so that you can feel the really deep ones under the occipital ridge. Close your eyes. Now, move your eyes right and left, while your hands, essentially over your ears, ensure that your head is still. Can you feel the small changes of muscle tonus under your thumbs? Even though your head is not moving, these ancient and primary muscles are responding to your eye movements. Look up and down and you will feel other muscles within this set engage in a similar way. Try to move your eyes without these muscles moving and you will find that it is nearly impossible. They are so fundamentally connected - and have been for nearly our entire vertebral history - that any eye movement will produce a change in tonus in these suboccipitals. Altering this deep neural 'programming' is difficult, but is sometimes necessary for vision or reading disorders, and certain problems of the neck. The rest of the spinal muscles 'listen' to these suboccipitals and tend to organize by following their lead.

The adage 'A cat always lands on its feet' is also an illustration of this concept. When a cat finds itself in the air, it uses its eyes and inner ear to orient its head horizontally. This puts certain tensions into these suboccipital muscles, which the brain reads from the myriad stretch receptors, and then reflexively orders the rest of the spinal muscles to organize the entire spine from the neck down, so that the cat's feet are under it before it ever hits the carpet. Though we are upright, our head-neck-upper back relationship functions in much the same way. Thus, how you use your eyes, and more particularly, how you use your neck, determines the tonus pattern for the rest of your back musculature. This plays into a number of postural patterns we see every day in our practice: loosening the neck is often key to intransigent problems between the shoulder blades, in the lower back, and even in the hips.

Retracting the neck and head is also a fundamental part of the fear response. Most animals respond to fear with a retraction of the head, and humans are no exception. Since most of us do not get out of childhood without some unresolved fear, this retraction, either as a habit before we begin a movement or as a permanent postural state, becomes built into our movement as a socially acceptable, unobserved, but ever-so-damaging state of being. Being so deep and of such long standing, such a habit is not easy to root out - teachers of the Alexander Technique spend years at it - but the effort is worthwhile for the psychological and physical feeling of freedom it gives.

The four suboccipital muscles which are a part of the SBL are the rectus capitis posterior minor (RCPM), the rectus capitis posterior major (RCPMaj), the obliquus

capitis superior (OCS), and the obliquus capitis inferior (OCI). They run among the occiput, the atlas (CI), and the axis (C2). The transverse processes (TPs) of CI are quite large, while the spinous process (SP) is quite small. To feel the relative position of the CI TPs, have your client lie supine, and sit at the head end of the table with your hands around the skull such that the *intermediate* phalanx of both your index fingers lies against the mastoid processes, leaving the distal bone free. Your wrists should be close to or on the table, so that your index finger follows roughly the direction of the sternocleidomastoid (SCM). Now gently flex the distal part of your index fingers into the flesh just inferior to the mastoid. If your wrists are too far off the table and your fingers are pointing down, you will miss the atlas. If your wrists are too low or your index finger is in front of the mastoid, you will go into the space between the jaw and the mastoid, which is definitely not recommended. Sometimes you can feel the TPs directly, just inferior and anterior to the mastoid; sometimes, because so many muscles are competing for attachment space on the TP, you can only feel them by implication. If, however, you keep the middle phalanx in contact with the mastoid process, with a little practice you will be able to feel accurately whether one TP is more prominent than the other (indicating a lateral translation or shift to the prominent side); or forward of the other (indicating a rotation of the atlanto-occipital (O-A) joint), or closer to the skull than the other (indicating a lateral flexion or tilt between the two).

The OCI is badly named, since it does not attach directly to the head, but runs from the large SP of the axis to the large TPs of the atlas, somewhat like the reins on a horse (Fig. 3.27). This muscle parallels the splenius capitis and provides the deepest and smallest muscle of ipsilateral rotation, creating that 'no' motion, the rotation of the atlas and occiput together on the axis. You can find this muscle by locating the TPs of the atlas and the SP of the axis, positioning your index fingertips right between the two (in most clients there is an indicative 'divot' there between the trapezius and SCM), fixing the skull with your thumbs, and calling for head rotation against the resistance.

The other three suboccipital muscles run down from deep underneath the occipital shelf. Going from medial to lateral, the RCPM runs from the occiput to the spinous process of the atlas, crossing only the O-A joint. But we have already said that the atlas does not have much of a spinous process, so what few anatomy books seem to show clearly is that this muscle runs interiorly *and very much forward* to do this (Fig. 3.28).

The next muscle laterally, the RCPMaj, runs down to the SP of the axis, but since that bone has such a huge spinous process, this muscle runs pretty much straight up and down. This points to a difference in function between these two muscles: the RCPM, among its other functions, tends to pull the occiput *forward* on the atlas (occipital protraction, or an anterior shift of the occiput on the atlas, sometimes called axial flexion), while the RCPMaj creates pure hyperextension in both the A-A (atlanto-axial) and the O-A joints. (The RCPM cannot

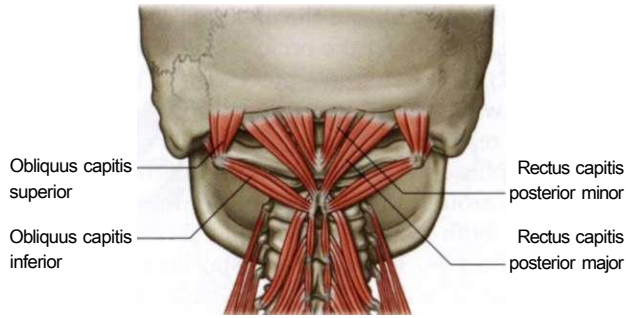


Fig. 3.26 The small but central suboccipital set of muscles is the functional centerpiece of the SBL.

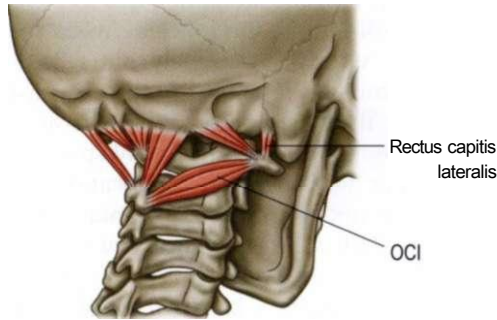


Fig. 3.27 An oblique view of the suboccipitals gives a much better sense of how the muscles relate to each other and to head movement. The OCI, running between the SP of C2 and TPs of C1, is a fundamental modulator of rotation in the spine.

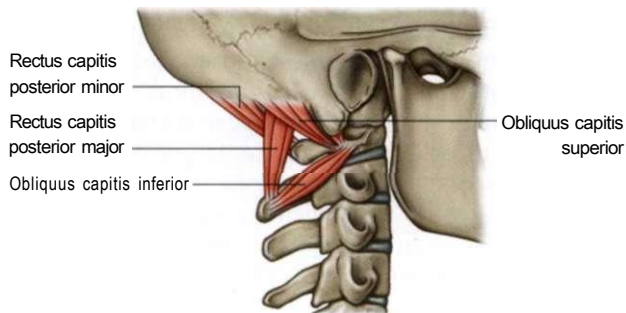


Fig. 3.28 A lateral view of the suboccipitals shows us how the RCPM and OCS pull the skull down and forward, whereas the RCPMaj tends to pull the skull down and just a little back. In extreme cases, they all work together, but in 'fine tuning' a head-neck relationship, differentiating among them is essential to the best work.

pull the atlas posteriorly because the dens of C2 prevents this motion.)

The most lateral of these three, the obliquus capitis superior (OCS), runs down and forward again from the posterolateral part of the occiput, this time to the large TPs of the atlas. This muscle, which runs on a parallel course to the RCPM, will have the same effect - pulling the occiput forward on the atlas (as well as helping to create a postural rotation in the O-A joint if it is tighter on one side than the other).

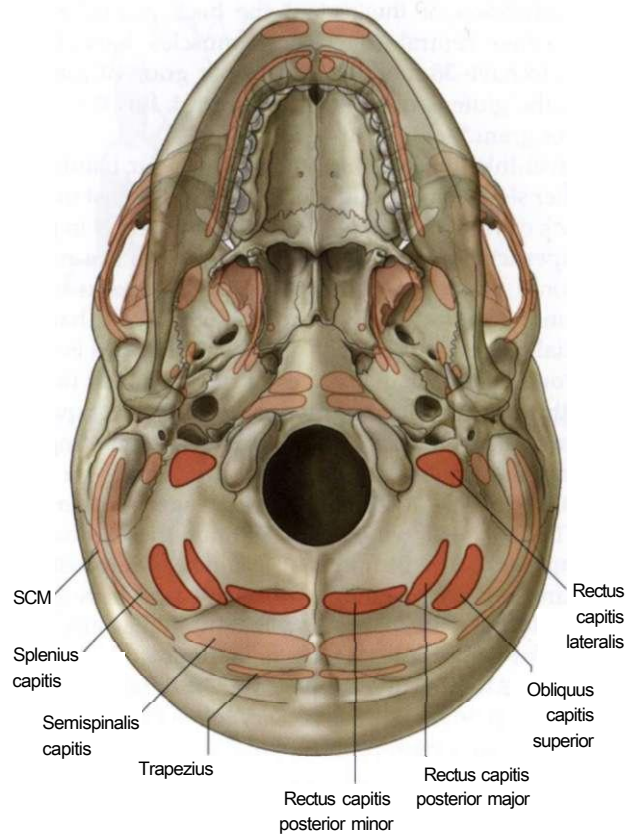


Fig. 3.29 A view looking up at the skull from below. The three middle fingers of each hand usually correspond 'handily' to the origins of the three suboccipital muscles at the deepest level of the upper spine.

Though treatment of these muscles can be a complex process of unwinding, for the reasons given above, we can facilitate palpation. Once again, your supine client's head rests in your hands, but this time the occiput is cradled in your palms, so your fingers are fully free. Curl your fingers fully up under the occiput (so that they point toward you, not toward the ceiling), and 'swimming' in past the trapezius and semispinalis to these deep little muscles. Leave the little fingers on the table, and let your ring fingers touch at the client's nuchal midline, so that six fingertips are arrayed along the bottom of the occiput (**Fig. 3.29**). With adjustments for differently sized hands and heads, your ring fingers will be in contact with the RCPM, your middle fingers on the RCPMaj, and your index fingers on the OCS. Strumming back and forth with the middle finger will often (but not always) reveal the more prominent band of the RCPMaj, and the two other fingers can be placed evenly on either side of it (**DVD ref: Superficial Back Line, 1:02:20-1:04:22**).

To reverse the common postural problem of the occiput being held forward on the atlas (occipital protraction or axial flexion), you need to create length and release in the muscles under your index and ring fingers. To combat postural hyperextension of the neck, you need to release the slightly more prominent RCPMaj

under your middle fingers (while getting your client to engage the longus muscles in the front of the neck). While these two patterns often accompany each other in the extreme head forward posture, they also occur separately, so that this distinction becomes useful.



From occiput to supraorbital ridge

From the occipital ridge the SBL continues up and over the occiput as these layers blend into the galea aponeurotica, or scalp fascia, which includes the small slips of the occipitalis and frontalis muscles, all clearly oriented in the same direction as the SBL. It finally comes to rest in a strong attachment at the brow or supraorbital ridge, on the frontal bone just above the eye socket (**Fig. 3.30**).



The scalp

Though the scalp may seem plastered down to the skull and largely amuscular, it is still an active area within the SBL and other lines, where much relief can be obtained. The scalp is the end of several of the longitudinal lines, so tugging and releasing here can be like playing with the strings of a marionette. Larger areas of stringy tension can be 'scraped' caudally with the fingertips working in extension. In those with a head forward posture, the fascial attachments of the erectors 'creep' up the back of the occiput, seeking higher leverage on the skull, just as a quadruped's erectors do - thus explaining why your cat or dog loves to be scratched behind the ears. Part of the solution, besides easing pulls from the Superficial and Deep Front Lines and correcting faulty breathing, is to release these extra fascial attachments to allow the head to rise (**Fig. 3.31**).

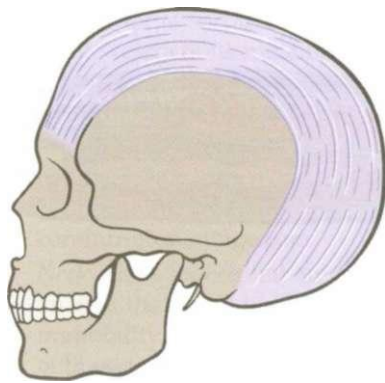


Fig. 3.31 The scalp is a rich area for releasing the head from its accustomed posture, but also for releasing the very tops of the Anatomy Trains myofascial meridians.

A detailed examination of the scalp from the occipital ridge to the brow ridge will also reveal little spindle-shaped fascicles that, though sometimes difficult to find because they are so small, are often extraordinarily tight and painful to the touch. They can be released through steady finger (or even fingernail) pressure, applied to the very center of the knot (use client feedback to locate yourself) for around a minute or until the knot or trigger point is entirely melted. Effectively applied, this can often occasion blessed relaxation through the entire affected line.

Care must be taken to notice the orientation of the spindles, since several lines melt into the scalp fascia, and the spindle will line up like a compass needle along the direction of pull. Pulls from any of the cardinal lines - Front, Back, or Lateral - plus the Spiral Line or the Superficial Back Arm Line, can all show up here.

A generally over-tight scalp can be released more gently by applying the fingerpads slowly in a circular motion, moving the skin on the bone until you feel the scalp melt itself free from the skull beneath. This method can be particularly effective if you stay with the pads, not the fingertips, and stay with melting, not forcing (**DVD ref: Superficial Back Line, 57:05-59:59**).

The neurocranium and the SBL

Although there are further fascial connections from the brow down onto the face, they are very superficial and loose, and do not constitute a line of structural pull. The facial muscles are loosely set into the superficial fascia, readily palpable as you move the tissue of the face around (compare to the minimal movement available in the fascia under the skin in the forehead). The brow ridge is the effective end of the SBL.

It also makes sense for the SBL to end above the eye socket when we consider its evolutionary origins. In the earliest vertebrates, the agnathous (jawless) fishes, the skull ended just above the eyes. The underside of the eyes and the mouth were all defined by soft tissue alone. It was some millions of years later that the bony structure of the gill arches 'migrated' up into the face to form the zygomatic, maxillary, and mandibular arches

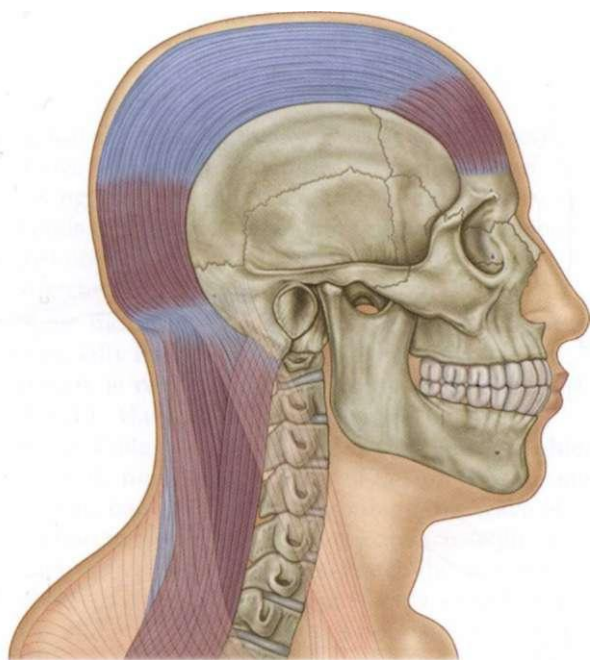


Fig. 3.30 From the erector fascia the SBL travels over the top of the skull on the galea aponeurotica, or scalp fascia, to attach firmly onto the frontal brow ridge.



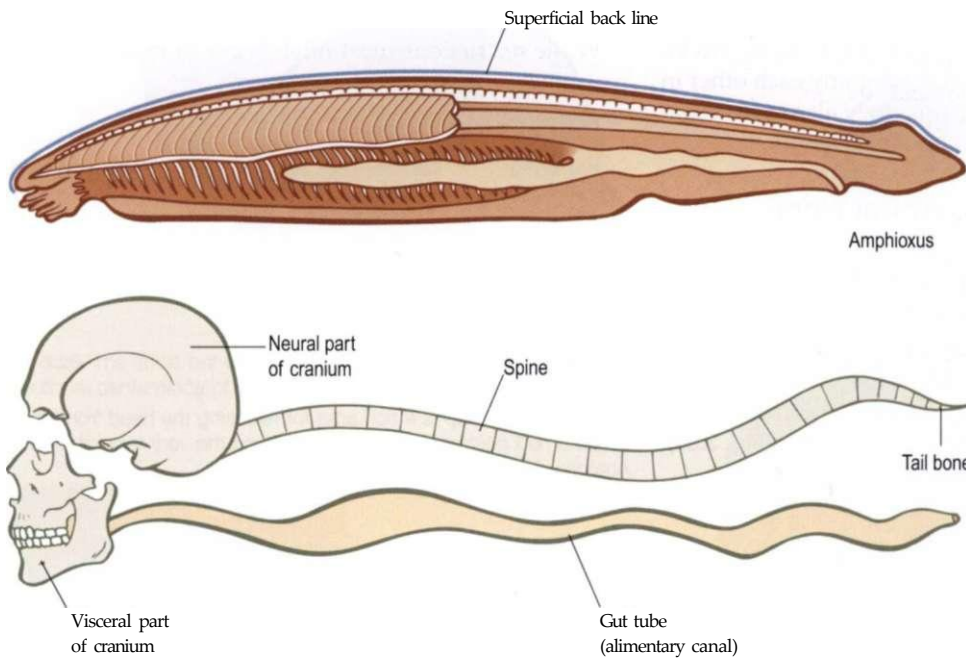


Fig. 3.32 Our seemingly solid, one-piece skull is actually formed from two different embryological sources. Looking at the skull of primitive chordates and early fish, we see that these animals had a cranium but no facial bones. The neurocranial part of our skull is an extension of the spine, while the viscerocranial facial structures develop from our branchial apparatus. The SBL stops near the forward end of the neurocranium.

that now join with the more ancient neurocranium to form our familiar skull (Fig. 3.32).



General movement treatment considerations



A generally mobile and motile SBL allows trunk and hip flexion with the knees extended, and creates trunk hyperextension, knee flexion, and plantar flexion. Thus, the various types of forward bends are all good ways to stretch the line as a whole or to isolate parts, while postural hyperextension is a mark of hypertonus or shortening of the SBL myofascia. Extension exercises would engage the SBL and tonify it where necessary.

Overall stretches

NOTE: These stretches, mostly drawn from yoga asanas, are included for clarity and inspiration. Attempting them yourself or putting clients into the stretches without proper preparation and training can cause an injury or negative result. Use caution, get trained, or refer.

Overall stretches (in an ascending scale of difficulty) include a Seated Forward Bend (Fig. 3.33A), Standing Forward Bend (Fig. 3.33B), the Downward-Facing Dog (Fig. 3.33C), and the Plow position (Fig. 3.33D).

The child's pose can be used to stretch the fascia of the erectors and scalp. The shoulder stand is specific to the upper back and neck part of the SBL. A forward bend leaning onto a table will isolate the leg portion of the SBL.

For those with access, rolling prone over a large physio-ball provides a good way to relax the SBL as a whole.

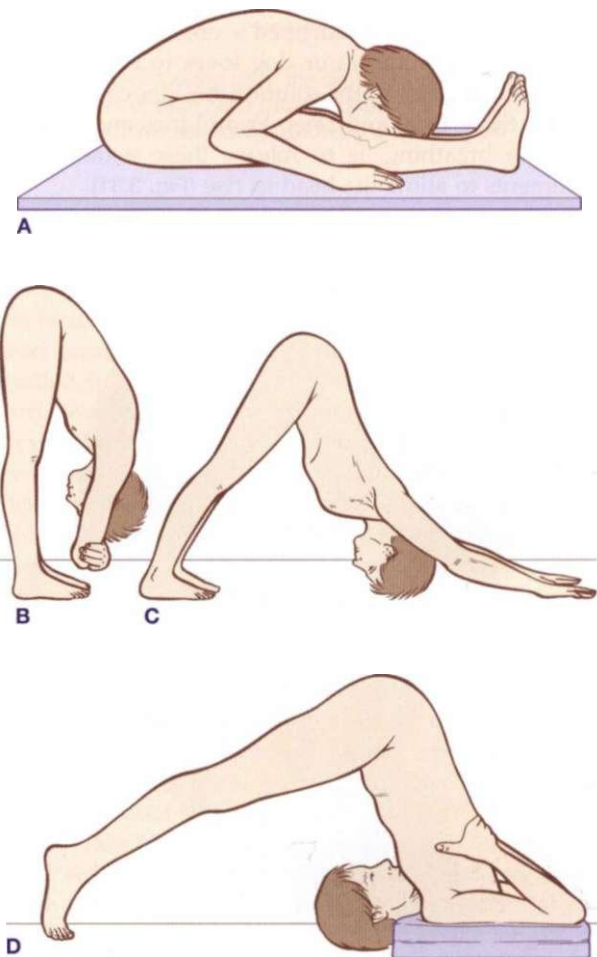


Fig. 3.33 There are many different stretches, easy and difficult, for the parts and the whole of the SBL.

Specific areas

- *Plantar*: Taking the SBL from the bottom, tense plantar fascia will limit foot and toe mobility as well as limit movement in the SBL as a whole. A simple but effective technique calls for having your client stand barefoot and do a forward bend with straight knees, just to see how it feels. Then have the client (standing again) place a tennis ball under her foot. Now have her give weight into various parts of the plantar surface from the front of the heel out to the ball of the foot, looking for places that hurt or feel tight. She should give enough weight to reach that point between pleasure and pain, and should sustain the pressure on each point for at least 20 seconds. The whole exercise should take a few minutes.

Remove the ball and have her lean forward again, and call her attention to the difference in feeling between the two sides of the SBL. Often the comparison is quite dramatic. Have her do the other foot, of course, and check if the forward bend is once again even, though more mobile. A more advanced, limber, or masochistic client can graduate to a golf ball.

Any movement that requires dorsiflexion will stretch the plantar-calf section of the SBL. A simple but effective stretch for the plantar fascia and its connection around to the Achilles is to kneel with the feet dorsiflexed and the toes hyperextended under you, and then sit on (or toward, for the stiffer among us) your heels. For the more limber, 'walk' the knees back toward the toes to increase the stretch.

- *Calf*: Leaning forward and resting your forearms on a wall, the lower leg section of the SBL can be stretched by putting one foot back and resting into the heel. If the heel reaches the floor easily, flex the knee forward toward the wall to increase the stretch on the soleus.
- *Hamstrings*: Any of the forward bends described above will help lengthen the hamstring group. Swing the upper body left and right during these bends to ensure that the entire muscle group, not just one line through it, gets activated and stretched.
- *Spine*: Inducing wave motions throughout the SBL, especially in the erector spinae and surrounding tissues, is very good for loosening and waking up the SBL. Have your client lie prone, or in any comfortable lying position. Ask the client to tighten the belly muscles, so a wave of flexion goes through the low back and pelvis. Encourage this wave of motion to spread progressively out across the entire back or even down the legs. Watch the motion, and observe where there are 'dead' spots - places where the motion is stifled and does not pass through. Place your hand on the dead spot and encourage the client to bring motion to that area. Clients will frequently try ever-larger efforts to force the motion through the dead spot, but smaller motions, with

pauses for absorption, are often more effective. While restrictions most often occur in the flexion-extension pattern, waves involving lateral flexion or rotation can be helpful also*.

This simple movement has been beautifully elaborated by Continuum, which can be explored via www.continuummovement.com, or www.continuummontage.com.

- *Neck*: The suboccipital area at the top of the neck is an area that often holds excess tension and immobility. The importance of the rectus and obliquus capitis muscles, which mediate between eye movements and spinal movements, to the general mobility of the SBL can hardly be overstated. These muscles create the beginnings of hyperextension and rotation, and occipital protraction (an anterior shift of the head on the neck). They are stretched by upper cervical flexion, rotation, and sliding the occiput posterior on the condyles of the atlas.

To induce movement in this area requires some concentration to focus the movement at the top of the neck, since similar movements can be produced in the lower cervicals by the expresses that overlie these essential, ancient, and tiny locals. Lying supine, and keeping attention at the top of the cervicals under the skull, slide the back of your head up away from the body, but without lifting it off the surface you are lying on. Maintaining this position of upper cervical flexion and length, move slowly into rotation, again focusing on the upper cervicals.

The 'Awareness Through Movement' lessons of Moshe Feldenkrais, which separate eye movements from neck and body movements, are unequaled in their ability to clarify and differentiate these muscles and this area.⁵

Palpation guide for the SBL

Beginning again from the distal end of the SBL, the first station is at the underside of the tips of the toes, which we cannot feel very well through the pads, but we can find the tendons of the short toe flexors under the thinner-skinned proximal part of the toes. The plantar fascia really begins at the ball of the foot station, narrowing as it passes back toward the front of the heel, where it is less than an inch (2 cm) wide. Pulling the toes up into extension brings the plantar fascia into sharp relief, where its edges can be easily felt. The lateral band is hard to feel directly through the thick overlying padding, but can be inferred by putting your finger or knuckle into the line that runs between the outer edge of the heel to the 5th metatarsal base, a clearly palpable knob of bone halfway between the heel and the little toe (**Figs 3.6 and 3.7**, p. 76). The lateral band, and the accompanying abductor digiti minimi can be found between the base of the 5th metatarsal and the outer edge of the calcaneus.

The track runs around and through the heel, which is hard to feel through the tough padding on the bottom,



but can be felt on the back of the heel bone. Put your fingers on the heel bone while you flex and extend the toes to feel the effect on the fascia around the heel (**Fig. 3.12**, p. 78). The Achilles tendon is easily felt and familiar to most, but follow it up the calf as it widens and thins. If your model is standing on the balls of her feet, the lower edges of the gastrocnemii heads are easily palpable where they attach to this aponeurosis. Relax the ankle, and the large soleus is easily felt deep to this fascial sheet.

The next station, the heads of the gastrocnemii, lies between the strong tendons of the hamstrings behind and above the knee at the back of the femoral condyles (**Fig. 3.18**, p. 81). The hamstrings reach down with their tendons below the knee: the two semis (semimembranosus and semitendinosus) to the medial part of the tibia, the singular biceps femoris to the fibular head on the lateral part of the lower leg. Follow the hamstrings up to the posterior aspect of the ischial tuberosity (**Fig. 3.21**, p. 83).

If you reach under the medial edge of the gluteus maximus just above the tuberosity, you can find the almost bone-like sacrotuberous ligament - the shortest, most dense track of this line. Reach in along its medial side, following it up to the lower, outer edge of the sacrum (**Fig. 3.22**, p. 85).

From this station of the sacrum, between the two posterior superior iliac spines, the erector spinae and the underlying transversospinalis traverse the entire spinal column in a long track up to the occipital ridge. The innermost of the erector spinae, the spinalis muscle, less than a half inch wide in most cases, can be felt right up against the spinous processes, most easily at the mid-thoracic, 'bra line', level (**Fig. 3.23**, p. 85).

The middle of the erector spinae group, the longissimus, is easily felt as a series of strong cables just lateral to the spinalis. The most lateral of the muscles, the iliocostalis, can be felt between the cables of the longissimus and the angle of the ribs. The slips of this muscle often feel like the raised ridges of corduroy as you strum them horizontally at this level. Any of these muscles can then be traced up or down from where you locate them.

At the top of the neck, the semispinalis muscle is easily palpable under the trapezius (especially when your model pushes the head back against resistance) as two vertical cables narrowing down from the occiput.

From the station at the occipital ridge, the epicranial fascia, or galea aponeurotica, runs up over the occipital bone (containing, in most people, slips of the occipitalis muscle), over the top of the head and down the forehead (enveloping the frontalis muscle) to attach to its final station, the brow ridge (**Fig. 3.30**, p. 89).

ditional anatomical thinking recognizes the thoracic and sacrococcygeal curves of the spine, which are concave to the front of the body, as primary curves, that is, curves that still reflect the flexed position of fetal development.

During late pregnancy and in the first year of life, the secondary curves form in sections within the baby's primary flexion curve. Activating the neck muscles (to lift the head) and later the lower back muscles (to sit and crawl) changes the shape of the intervertebral discs to reverse the convexity of the cervical and lumbar curves respectively (see **Figs 10.28-10.34**, p. 219-20). In the standing posture, however, we can expand our view of the spinal undulation to the whole body, seeing the cranial curve as a primary curve, the cervical as secondary, the thoracic as primary, the lumbar as secondary, and the sacrococcygeal as primary.

Extending this point of view down the legs, the slight flex of the knees can be seen as secondary, the curve of the heel as primary, and the arch of the foot as secondary, and the ball of the foot as primary. The knee 'curve' forms in the process of learning to stand, and the final secondary curve to form, the foot arches, takes final shape as the child strengthens the deep calf muscles in walking.

While these curves are not all developmentally equivalent, this concept is quite practical, and admits wide application in the field of manual and movement therapy. All the primary curves are more or less maintained by the shape of the surrounding bones. The cranium is interlocked to itself, the thoracic curve is maintained by the ribs and sternum complex, the sacrococcygeal curve by the hip bones and pelvic ligaments, and the heel by the shape of the foot bones (**Fig. 3.34**).

All the secondary curves, however, are more dependent on the balance of muscles, first to create and then to maintain their position: thus the cervicals and lumbar, being the free-standing sections of the spine, depend more heavily on the guy-wires of the surrounding myofascia for their stability and positioning. The bones and ligaments leave the knee free to run from full flexion to hyperextension; muscle balance determines where the knees habitually rest. The arches of the foot are likewise pulled into final position as the child stands and walks, and their maintenance depends as much on the successful balance of soft tissues in the leg and foot as on any actual arch in the bones. (The muscles that reach down from the calf to pull up on the various arches will turn up later as the lower ends of other major train lines - see Chs 5, 6, and 9 on the Lateral, Spiral, and Deep Front Lines.)

In functional posture and movement, all of these secondary curves are also related to each other. Lack of balance in one often asserts a compensatory pattern into other nearby secondary curves. The illustrated relation between the knees and lower back is readily seen in day-to-day observation (**Fig. 3.35**). Proper balance among all the primary and secondary curves, accompanied by an evenness of tone in the SBL tissues, can be seen as a balanced unfolding into 'maturity' from the embryonic fetal curve. Postural flexion or hyperextension patterns can be related to areas where full maturation was not complete. Chronic flexion of the hips is often occasioned by the failure of the hips to fully extend as the child grows; this lack of extension will require indicative, 'readable' compensation in the SBL. A person who is completely 'evolved' (in its literal sense of 'unfolded') displays a 'tensegrity' balance of the body's alternating sagittal waves.

The SBL links the posterior aspect of all these curves together, from top to bottom. The general tenet of the myofascial meridians approach is that strain travels up or down along these lines. Thus, problems in any of these curves may create strain up or down the line. The converse also works: stubborn pain problems may best be served by extending our assessment and treatment to other parts of the line, often quite distant from the site of pain. This book is an extended plea to create time and space in which to consider such an

Discussion 1

The SBL and the waves of the spine

The SBL provides a functional link across the waves that constitute the primary and secondary curves of the spine and legs. In the plantigrade human posture, the body arranges itself in an alternating series of counterbalancing curves. Tra-



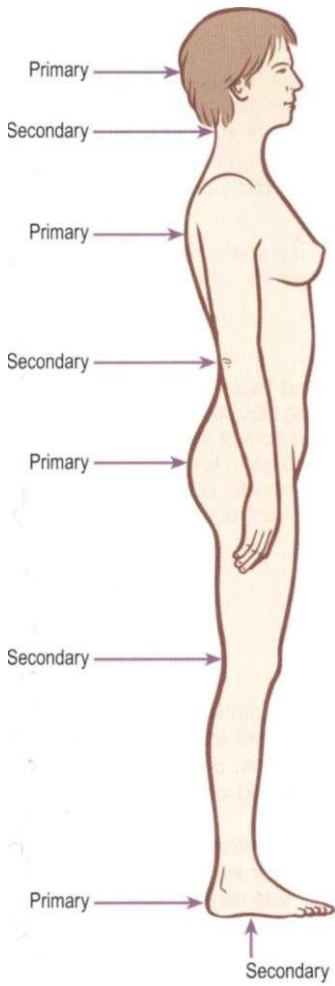


Fig. 3.34 The alternation of primary and secondary curves in the spine can be seen as extending across the whole back of the body. The SBL extends behind all these curves, and the tone of its tissues is instrumental in maintaining an easy balance among them.

overall systemic view of the interaction along an entire myofascial meridian, or, as we proceed, among the meridians, instead of focusing solely on single muscles or individual fascial structures as culprits.

Discussion 2

Is there a Deep Back Line?

According to standard anatomical nomenclature, if there is a Superficial Back Line, there should be a Deep Back Line. Besides, if there is clearly a Deep Front Line as well as a Superficial Front Line, does symmetry not require that there be a Deep Back Line? In fact, whether symmetry requires it or not, anatomically, there is no Deep Back Line. Though there are isolated areas along the SBL where there are deeper layers of myofascia, there is no consistent and connected layer deeper than the one already discussed.

Taking a brief look at these areas is instructive. In the plantar surface of the foot, for instance, many layers lie superior (profound) to the plantar fascia. These layers contain the short flexors and the ab- and adductors of the toes and their associated fascia, as well as the long plantar and spring ligaments that underlie the tarsal arches. The plantar fascia was described above as the bowstring of the arches' bow, but of

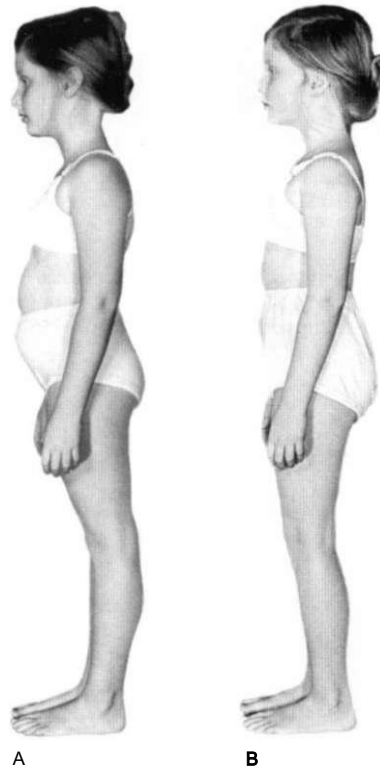


Fig. 3.35 The hyperextended knees can be viewed, in Anatomy Trains terms, as a secondary curve problem. **(A)** Before treatment, this secondary curve has been reversed to a primary curve, exporting extra strain to the other secondary curves - in this case the lumbar and cervical areas. **(B)** After Structural Integration processing, the knee curve has normalized, and so have the rest of the secondary curves. (Reproduced with kind permission from Toporek 1981⁺.)

course the bow is not static, given the many possible motions of the foot in daily and sporting life. In motion, all of these successively deeper layers of myofascia and ligament are active in sustaining the arches (**Fig. 3.36** and see **Fig. 3.8**).

These constitute layers that are deeper than the SBL, but when we come to their proximal or distal ends, we cannot point to a fascial continuity with any other sections of the body, beyond the 'everything-is-connected-to-everything-else-in-the-fascial-net' generalization.

In the lower leg, there is the deeper set of locals (soleus and popliteus) that underlie the gastrocnemii, but they are still part of the SBL, being attached simply to the underside of the Achilles fascia (and we will include little plantaris in this group also).

There is a group of muscles deep to the soleus, between it and the back surface of the interosseous membrane - the deep posterior compartment - consisting of the long toe flexors and the tibialis posterior (**Fig. 3.37**). These muscles, however, will be very clearly shown to be part of the Deep Front Line (see Ch. 9), despite their posterior position in this segment of the body, and thus do not qualify as a Deep Back Line. The peroneal muscles, in the lateral compartment, will be clearly shown to be part of the Lateral Line (see Ch. 5).

In the thigh, the hamstrings overlie the short head of the biceps and the adductor magnus, which constitute a local under the express of the long head of the biceps (see the section on the 4th hamstring in Ch. 6). So all of these muscles, right down to the bone, can be thought of as part of the SBL.

There is another story in the back of the hip. Although they do not directly underlie the structures of the SBL, the deep lateral rotators nevertheless act like a Deep Back Line in this

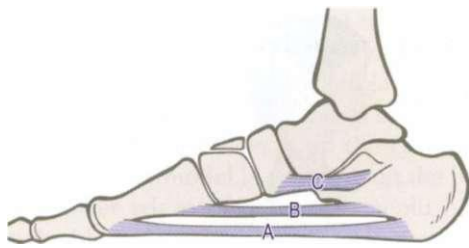


Fig. 3.36 The plantar fascia is, in fact, only the most superficial of several layers of myofascia, including the long plantar ligament and the spring ligament, that act to support the arches (Compare to Fig. 3.8)

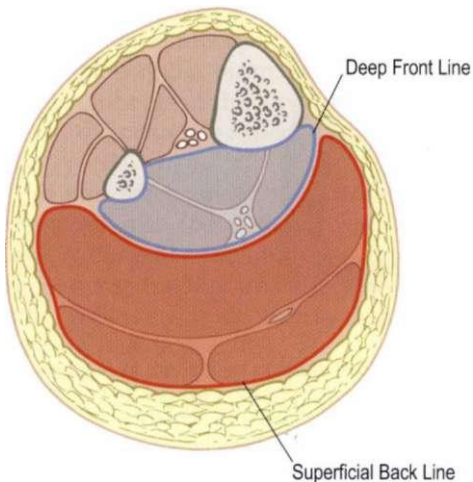


Fig. 3.37 The SBL occupies the entire superficial posterior compartment of the lower leg. The deep posterior compartment belongs not to a 'Deep Back Line' but, paradoxically, to the Deep Front Line.

area, limiting hip flexion along with the hamstrings, as well as helping to keep the spine aloft and in balance. In this light, this group might better have been named *extensor coxae brevis*, the short extensors of the hip. These muscles, from piriformis down through the obturators and the gemelli to the quadratus femoris, have a continuity of function with each other, but no linear fascial continuity with other local myofascial structures. These deep lateral rotators are best thought of as a branch of the Deep Front Line in the myofascial meridians theory (see Ch. 9), though their lack of linear longitudinal connections makes them difficult to place in the Anatomy Trains metaphor. They are best considered in light of another concept, the fans of the hip joint.

In the spinal area, it could be argued that the muscles we have included as part of the SBL fall into two major fascial planes, the more superficial erector spinae (*spinalis*, *longissimus*, and *iliocostalis*) and the deeper *transversospinalis* (*semispinalis*, *multifidus*, *rotatores*, *interspinous*, and *intertransversarii*). While it is true that there is a fascial plane between these two groups, it is argued here quite firmly that this is simply a massively complicated set of locals and expresses, with the tiny monarticular locals forming three distinct patterns over the 26 bones between sacrum and occiput (see Figs 3.23 and 3.24, pp. 85 and 86). These patterns - spinous process to spinous process, transverse process to transverse process, and spinous process to transverse process - are repeated with ever-greater polyarticular intervals by the overlying muscles.

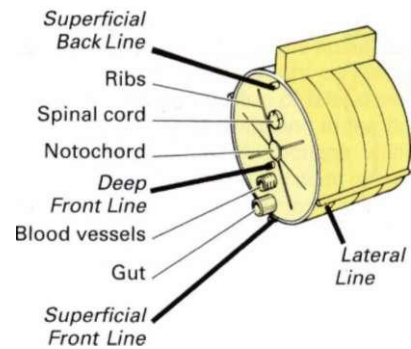


Fig. 3.38 The location of the cardinal lines on a generalized vertebrate body plan. Notice that the SBL lies behind the spine, while the Deep Front Line lies just in front of the spine, and the Superficial Front Line in front of the organs. From the beginning of vertebrate evolution, the left-right symmetry of the musculoskeletal system has not been matched by a front-back symmetry.

In the last part of the SBL, the scalp fascia, there is clearly only one thick layer of fascia between the periosteum of the skull and the dermal layer of the skin, and several lines and levels of myofascia, as we mentioned earlier, blend into this layer.

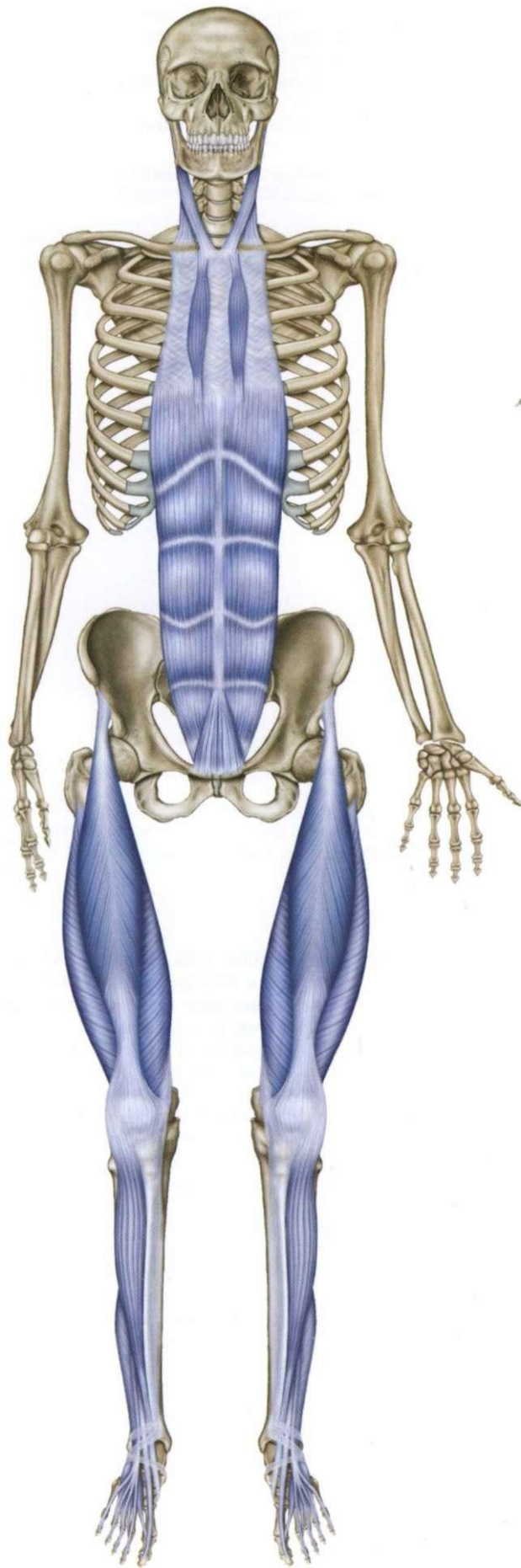
The answer to our question, therefore, is that there is no myofascial Deep Back Line, whether symmetry requires it or not. The argument for symmetry falls away in any case as we examine our evolutionary history and realize that the Deep Front Line began as the original back line of our tunicate 'gut body' self (Fig. 3.38). (See also the general discussion of the Deep Front Line in Ch. 9.)

An argument can be made for a 'Deep Back Line' that would consist of the connective tissue that surrounds the central nervous system, the dura, and its extension into the neural and neurovascular bundles that snake through the limbs. This has an attraction in that the Deep Front Line surrounds the ventral organs, and its projections into the arms (via the Deep Front Arm Line) and legs, can be seen as the extension of these organs into the arms and legs. Likewise, the dura surrounds the organs of the dorsal cavity, and thus its extensions into the limbs could be termed the Deep Back Line, especially the sciatic nerve. As more work is done with the connections of dural and nerve sheath anatomy, we may find this argument has merit, but given that (1) this fascial configuration would be associated with no muscles except perhaps the piriformis, and (2) the fascial extensions of the dura follow the nerves everywhere in the body (front, back and sides, not just the inner back of the leg), we choose to stay with the idea that there is simply no coherent myofascial continuity that could be termed the Deep Back Line.

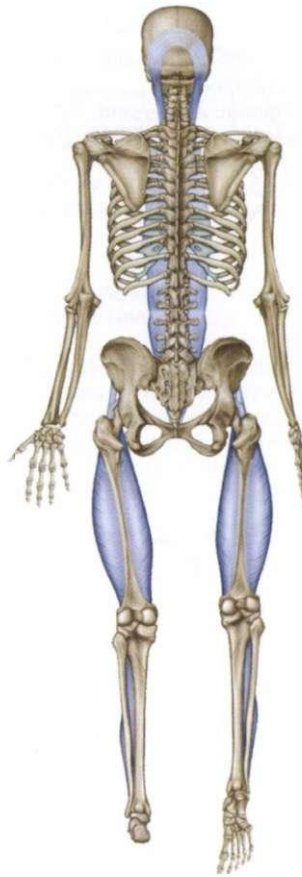There are, as we have seen, several places on the SBL where important locals underlie the multi-joint expresses. Because the skeleton underlying the SBL undulates with primary and secondary curves, we can note that these locals tend to congregate around the secondary, posteriorly convex curves - under the foot arches, around the knee, and in the lumbar and cervicals. The exception here is of course the thoracic area, where just as many locals underlie the expresses around a primary curve. This provides the opportunity for local strain, and thus for many tenacious trigger points which, paradoxically, are often best addressed posturally from the front (see the section on the interaction between the SBL and the Superficial Front Line in Ch. 4, p. 111).

References

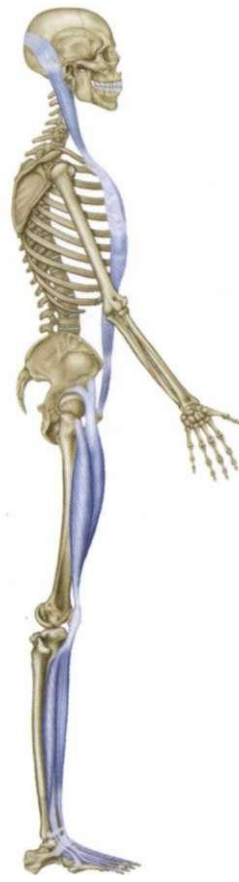1. Bogduk N. Clinical anatomy of the lumbar spine and sacrum. 3rd edn. Edinburgh: Churchill Livingstone; 1997.
2. Gorman D. The body moveable. Ontario: Ampersand; 1978.
3. Kapandji I. The physiology of the joints. Vol. 3. Edinburgh: Churchill Livingstone; 1974.
4. Peck D, Buxton D, Nitz A. A comparison of spindle concentrations of large and small muscles. *Journal of Morphology* 1984; 180:245-252.
5. Feldenkrais M. Awareness through movement. New York: Penguin; 1977.
6. Toporek R. The promise of Roling children. Transformation News Network; 1981.
7. Myers T. Fans of the hip joint. *Massage Magazine* No. 75, January 1998.



A



B



C

Fig. 4.1 The Superficial Front Line.

The Superficial Front Line

4

Overview

The Superficial Front Line (SFL) (Fig. 4.1) connects the entire anterior surface of the body from the top of the feet to the side of the skull in two pieces - toes to pelvis and pelvis to head (Fig. 4.2/Table 4.1) - which, when the hip is extended as in standing, function as one continuous line of integrated myofascia.

Postural function

The overall postural function of the SFL is to balance the Superficial Back Line (SBL), and to provide tensile support from the top to lift those parts of the skeleton which extend forward of the gravity line - the pubis, rib cage, and face. Myofascia of the SFL also maintain the postural extension of the knee. The muscles of the SFL stand ready to defend the soft and sensitive parts that adorn the front surface of the human body, and protect the viscera of the ventral cavity (Fig. 4.3)

The SFL begins on the tops of the toes. By the 'everything-connects-to-everything-else' fascial principle, the SFL technically joins with the SBL through the periosteum around the tip of the toe phalanges, but there is no discernible 'play' across this connection. Functionally these two Anatomy Trains lines oppose each other, the SBL being responsible for flexing the toes, and the SFL taking on the job of extending them, and so on up the body. More practically, in postural terms, the dorsiflexors act to restrain the tibia-fibula complex from moving too far back, and the plantarflexors prevent it from leaning too far forward.

Sagittal postural balance (A-P balance) is primarily maintained throughout the body by either an easy or a tense relationship between these two lines (Fig. 4.4). In the trunk and neck, however, the Deep Front Line must be included to complete and complicate the equation (see Fig. 3.38 and Ch. 9).

When the lines are considered as parts of fascial planes, rather than as chains of contractile muscles, it is worth noting that in by far the majority of cases, the SFL

tends to shift down, and the SBL tends to shift up in response (Fig. 4.5).

Movement function

The overall movement function of the SFL is to create flexion of the trunk and hips, extension at the knee, and dorsiflexion of the foot (Fig. 4.6). The SFL performs a complex set of actions at the neck level, which comes up for discussion below. The need to create sudden and strong flexion movements at the various joints requires that the muscular portion of the SFL contain a higher proportion of fast-twitch muscle fibers. The interplay between the predominantly endurance-oriented SBL and the quickly reactive SFL can be seen in the need for contraction in one line when the other is stretched (Fig. 4.7).

The Superficial Front Line in detail

The tendons that originate on the top of the toes form the beginning of the SFL. Moving up the foot, the SFL picks up two additional tendons (Fig. 4.8). On the lateral side, we get the peroneus tertius (if there is one) originating from the 5th metatarsal. From the medial side, we find the tendon of the tibialis anterior from the 1st metatarsal on the medial side of the foot. The SFL thus includes both the short extensor muscles on the dorsum of the foot and the long tendons from the lower leg.

General manual therapy considerations

As with the SBL, there are actually two SFLs, one just to the right and one just to the left of the midline. Viewing the client from the front will help assess differences between the right and left sides of this line, though a good first course of action in the majority of cases is to resolve any general shortness in the SFL. Viewing the client from the side reveals the state of balance between the SFL and SBL, and gives a good indication of where to open and lengthen the line in general.

The SFL, along with the SBL, mediates movement in the sagittal plane. When it malfunctions it acts to create



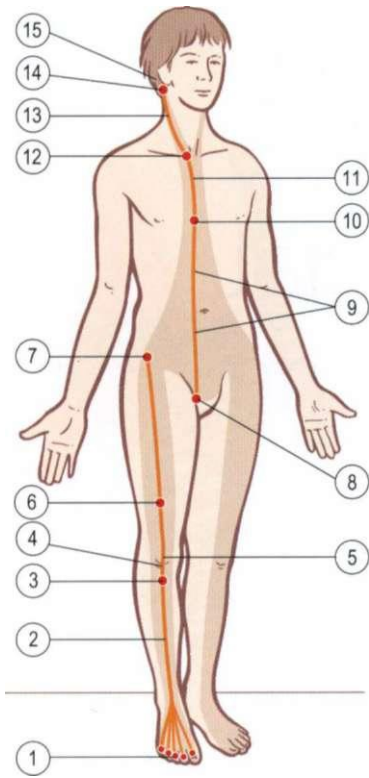


Fig. 4.2 Superficial Front Line tracks and stations. The shaded area shows the area of superficial fascial influence.

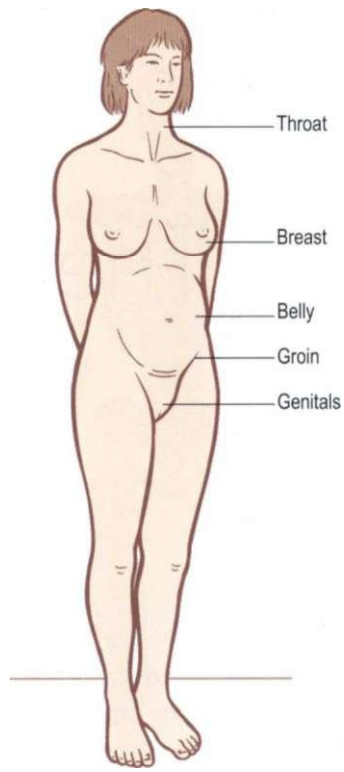


Fig. 4.3 Human beings have developed a unique way of standing which presents all their most sensitive and vulnerable areas to the oncoming world, all arrayed along the SFL. Compare this to quadrupeds, who protect most or all of these vulnerable areas (see Fig. 4.31).

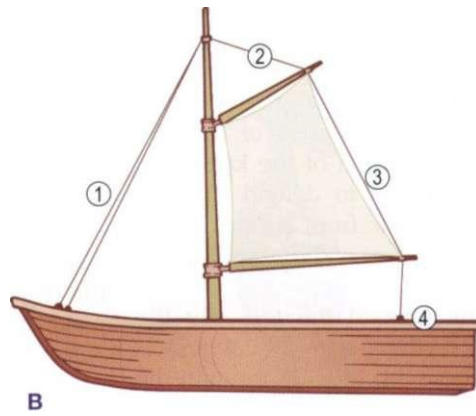
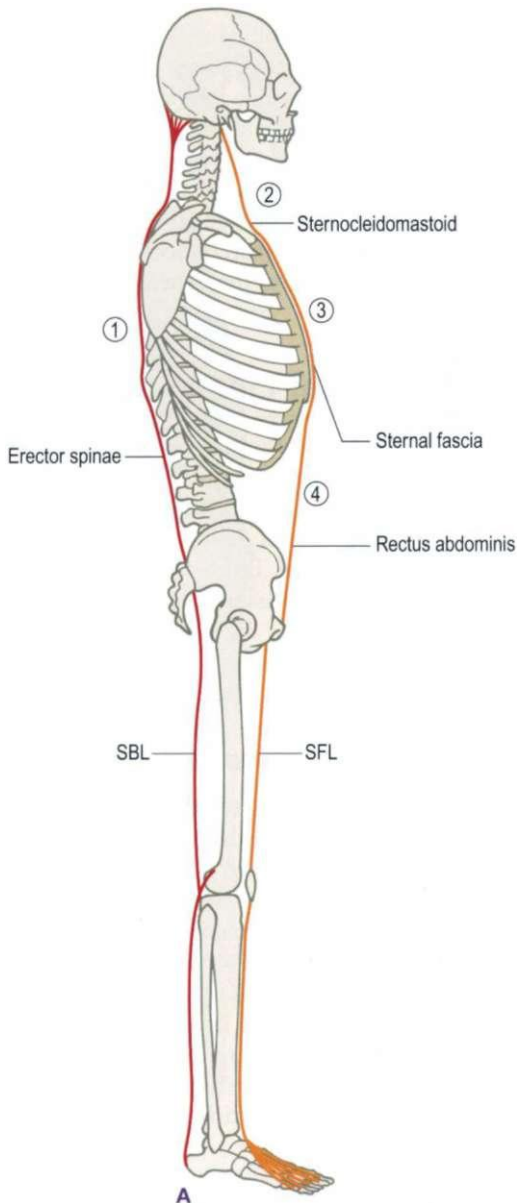


Fig. 4.4 The SBL and the SFL have a reciprocal relationship, not unlike the rigging of a sailboat. The SBL is designed to pull down the back from the bottom to the top, and the SFL is designed to pull up the front from neck to pelvis. (Based on Mollier.)

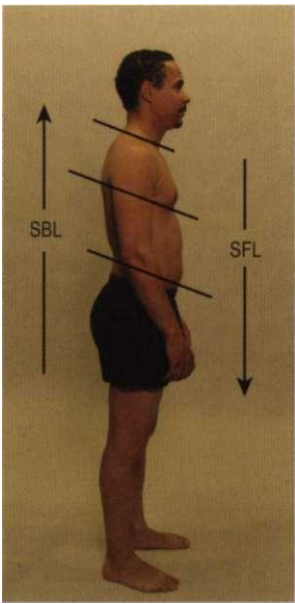


Fig. 4.5 It is a very common pattern for the SFL to be pulled down the front while the SBL hikes up the back (vertical lines). This creates a disparity between the corresponding structures in the front and the back of the body (horizontal lines). This is the foundation for a host of future problems for the neck, the arms, breathing, or the lower back.

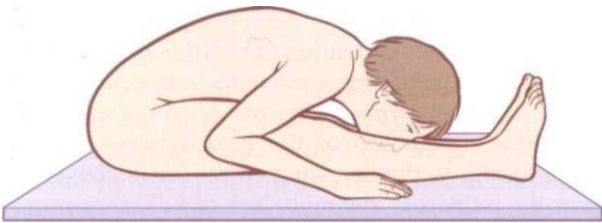

Fig. 4.6 Contraction of the SFL extends the toes, dorsiflexes the ankles, extends the knees, and flexes the hips and trunk.

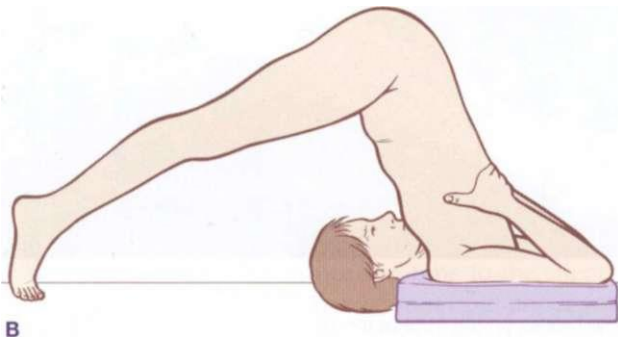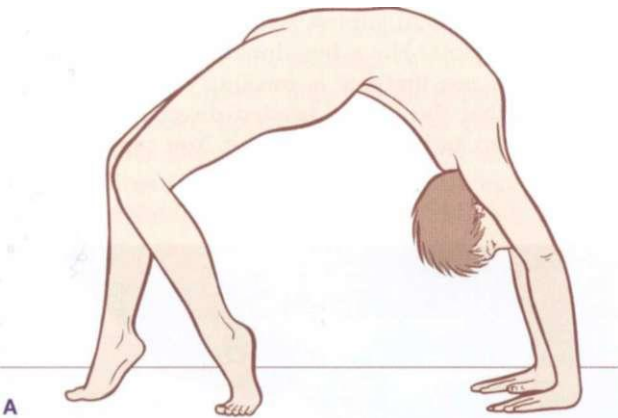


Fig. 4.7 The reciprocal relationship between the SBL and SFL can be seen in these two poses. In (A), the SBL is contracted and the SFL stretched, vice versa in (B).

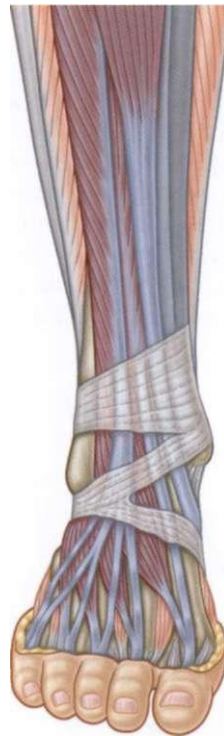

Fig. 4.8 The initial track of the SFL consists of seven tendons running under the even more superficial retacula to combine into the anterior compartment of the leg.

Table 4.1 Superficial Front Line: myofascial 'tracks' and bony 'stations' (Fig. 4.2)

Bony stations	Myofascial tracks
	15 Scalp fascia
Mastoid process	14
	13 Sternocleidomastoid
Sternal manubrium	12
	11 Sternalis/sternochondral fascia
5th rib	10
	9 Rectus abdominis
Pubic tubercle	8
Anterior inferior iliac spine	7
	6 Rectus femoris/quadriceps
Patella	5
	4 Subpatellar tendon
Tibial tuberosity	3
	2 Short and long toe extensors, tibialis anterior, anterior crural compartment
Dorsal surface of toe	1
phalanges	

forward movement (flexion) or to restrict backward movement (extension). Trouble abounds when the SFL myofascia start to pull inferiorly on the skeleton from a lower stable station, rather than pulling superiorly from an upper stable station, i.e. the belly muscles start acting to pull the ribs toward the pubic bone, instead of bringing the pubic bone up toward the ribs.

Common postural compensation patterns associated with the SFL include: ankle plantarflexion limitation, knee hyperextension, anterior pelvic tilt, anterior pelvic shift, anterior rib and breathing restriction, forward head posture.



The shin

The fascial plane of the SFL passes up into the anterior compartment of the lower leg, but on its way it passes under the extensor retinaculum. The retinaculum is essentially a thickening of an even more superficial fascial plane, the deep investing fascia called the crural fascia in the lower leg. This retinacular thickening is necessary to hold the tendons down (otherwise the skin would pop out between the toes and the middle of the shin every time the muscles contracted - **Fig. 4.9**).

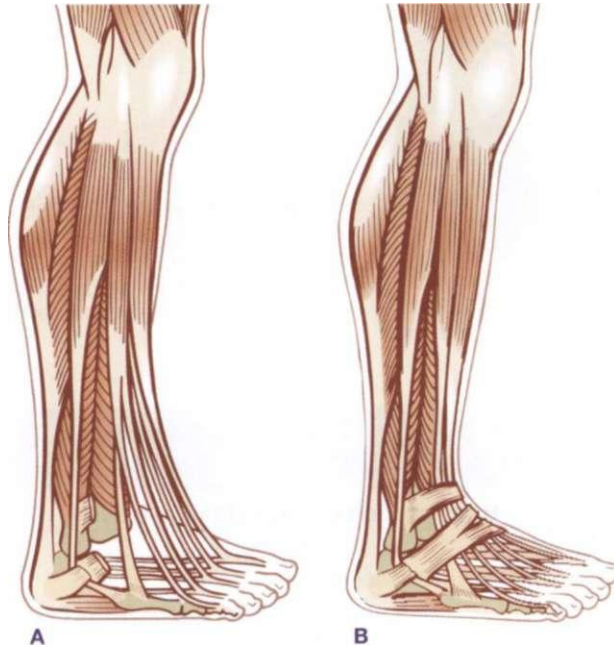

Fig. 4.9 The retinacula, which are thickenings in the deep investing fascial layer called the crural fascia, provide a pulley to hold in the tendons of the SFL and direct their force from the shin muscle to the toes.

Because the tendons run around a corner (allowed by our rules in this case because of the clear fascial and mechanical continuity), lubricating sheaths wrap around the tendons to ease their movement under the retinacular strap (another example of the double-bag theory at work - see Ch. 1 and **Fig. 2.3**).

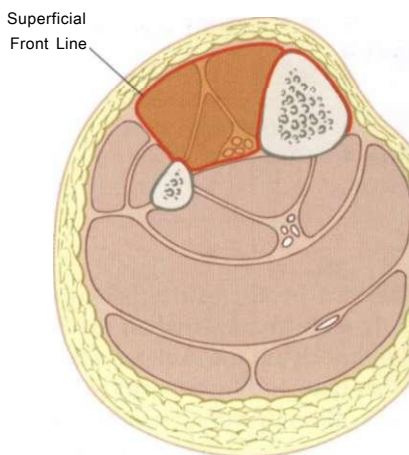
Above the retinaculum, the SFL passes up the front of the lower leg. On the lateral side, it contains the muscles of the anterior compartment - the tibialis anterior and the extensor digitorum and hallucis longus - in the scooped-out shape anterior to the interosseous membrane. On the medial side, we have found that, for best effect, the tissue that overlies the tibia and its periosteum must also be included (compare **Fig. 4.10** to **Fig. 2.1C**, p. 64).

The anterior crural compartment

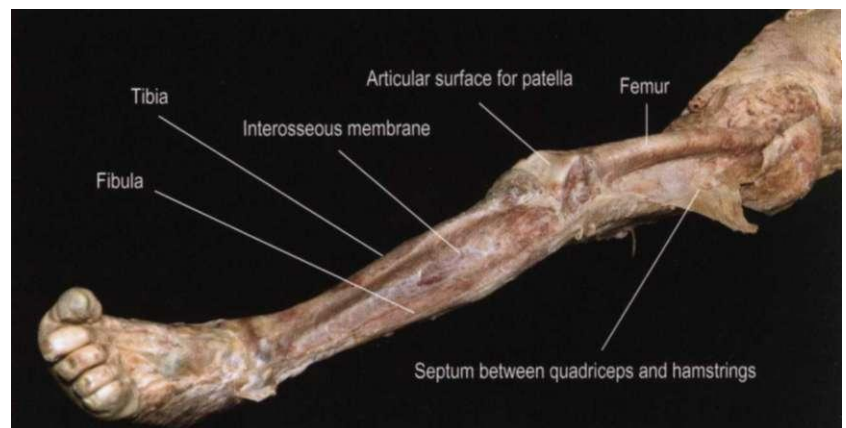
The tibialis anterior is generally the strongest muscle of the anterior compartment, but the compartment as a whole produces dorsiflexion and resists plantarflexion. Here we deal with the two most common pattern problems in this compartment.

When the series of tendons from this compartment pass under the restricting strap of the retinaculum, they can get 'stuck' in terms of free movement. Presumably the lubricating tunnels of the tendosynovial sheaths adhere locally to the investing crural fascia above and below the retinacula, owing to lack of full-range movement use and being 'set' at a constant tension. Whatever the cause, the solution is fairly simple and straightforward, and often produces surprised pleasure on the part of the client due to increased ease of movement after just a few passes.

Have your client supine, with the heels just off the end of the table. Have her dorsiflex and plantarflex, checking to see that she is tracking straight with the ankle, so that the foot is headed directly toward the knee, not up and in or up and out. You can add more



A



B

Fig. 4.10 The SFL occupies the anterior compartment of the leg, and the tissues on the front of the tibia (shinbone) as well. In **(B)**, we see how little of the leg is left when the SFL is removed. See also **Figure 1.1C**, where both these parts of the crural fascia have been dissected as one piece - the anterior compartment and the surface fascia coating the tibia. Where holes appear in this fascia are probably places where the person suffered trauma to the shin (as in falling upstairs), resulting in the crural fascia adhering to the periosteum underneath. (DVD ref: **Early** Dissective Evidence).

muscular differentiation by adding toe flexion and extension to the ankle movement.

Apply a broad surface of a loose fist to the dorsum of your client's foot distal to the retinacula, while the other hand guides the client's dorsi- and plantarflexion. Have your client pass slowly through the sequence of motion as you move slowly up the foot and ankle, passing through the retinaculum and up onto the shin beyond. If the retinacula are too tight, or if the tendons are stuck, you will feel 'slowed' in your progress up the shin. Using the client's movement, repeat the pass (perhaps using a bit more pressure) until the feeling of restriction is gone, both from **your** sensing hand and from the client's feeling within the movement (DVD ref: **Superficial Front Line, 11.16-19:24**).

Where you stop above the retinacula varies from client to client. In some people you run out of 'juice' just above the ankle; in others you feel as if you are 'skating' over the surface of the shin. Stop at this point. For some, the feeling of connecting and freeing extends well up the shin toward the knee, and you may continue on up as far as you still feel work is being done.

When **your** work does extend above the ankle, pay attention to which side of the shin is more restricted, the medial or the lateral. Since you began on the tendons, the natural progression is up onto the muscles of the anterior compartment, on the lateral side of the anterior shin. The SFL, however, also includes the periosteum and superficial fascial layers that pass over the tibia on the anteromedial side (see Figs 1.1C, 4.10A and 4.11).

We have arrived at the second common pattern problem in this area, so let us define the problem before we finish with the technique. In any kind of forward lean of the legs, where the knee rests posturally on a line anterior to the ankle, the posterior calf muscles tighten (eccentrically, or locked long), and the anterior muscles and tissue move down (and tighten concentrically, locked short). One of the best remedies for this is to move the tissue of the anterior surface up again (while the corresponding tissues of the SBL are moved down).

So, above the ankle, superior to the retinacula, you can work both the muscle surface and the shinbone surface. Since they are at angles with each other, they can be worked sequentially, or both at once with two hands. The two-handed technique involves putting both hands into a loose fist, with the proximal phalanges against the surface, one hand conforming to the front of the anterior compartment of muscles, the other to the anterior surface of the tibia above (DVD ref: **Superficial Front Line, 19:24-25:53**). In this position, your right and left sets of knuckles rest near or against each other. Sink into the tissue enough to engage, but not with digging pressure that would cause pain to the tibial periosteum.

Let your hands work upward in time to the client's movement, pausing as she stretches out from under you in plantarflexion, carrying the tissue cephalad as she dorsiflexes, until you run out of effectiveness or reach the top of the muscle compartment, whichever comes first.

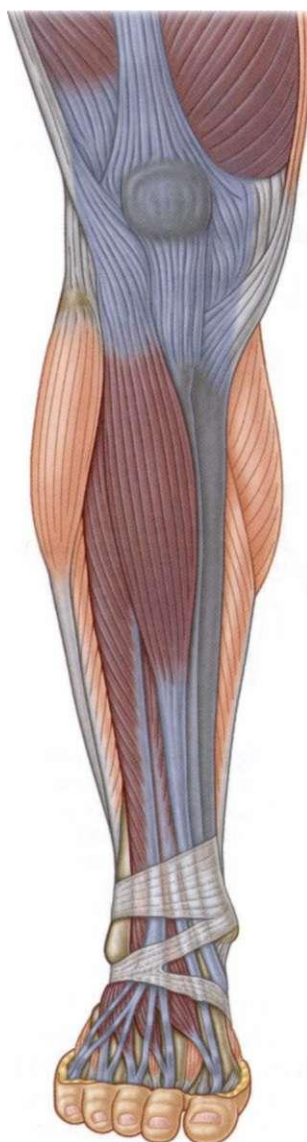


Fig. 4.11 The top of the anterior compartment leads past the tibial tuberosity onto the subpatellar tendon and the quadriceps complex.

Do not fail to have your client dorsi- and plantarflex after you have finished the treatment, since you will often be rewarded by the exclamation of increased freedom.

The thigh

Although the muscles themselves have attachments within the anterior compartment to the tibia, fibula, and interosseous membrane, the next station for the SFL is at the top of both the medial and lateral side of this track, the tibial tuberosity (**Fig. 4.11**).

Continuing in a straight line upward is no problem: the quadriceps begin their upward sweep here with the subpatellar tendon. The SFL includes the patella, the large sesamoid bone designed to hold the SFL away from the knee joint fulcrum so that the tissues of the quadriceps have more leverage for extending the knee. The patella rests in a channel in the femur, which also assures that the quadriceps, with its several different directions of pull, still tracks directly in front of the hinge of the knee joint.



Fig. 4.12 The penumbra of the SFL could be said to include the entire quadriceps group, but a stricter interpretation sticks with the rectus femoris part of this group, passing up onto the anterior inferior iliac spine.

The three vastii of the quadriceps all grab onto various parts of the femoral shaft, but the fourth head, the rectus femoris, continues bravely upward, carrying the SFL to the pelvis (**Fig. 4.12**). Although the rectus occupies the anterior surface of the thigh, its proximal attachment is not so superficial. Its upper end dives beneath the tensor fasciae latae and the sartorius to attach to the anterior inferior iliac spine (AIIS), a little bit below and medial to the anterior superior iliac spine (ASIS). There is a small but important head of the rectus that wraps around the top of the hip joint. Palpation and experience with dissection reveals that in some undetermined percentage of the population there is an additional fascial attachment of this muscle to the ASIS.



The quadriceps

The strictest interpretation of the SFL would include only the rectus femoris, not the entire quadriceps, but for the freedom of this line, we must ensure that the rectus, being a two-joint muscle, is free to do its job at both hip and knee. Repetitive motion patterns, especially in athletics, can result in the rectus being stuck down to the underlying vastii.

The following technique requires a careful set-up of client movement. What we are after here is the client's use of his ankle movement to flex the knee and the hip. Your client lies supine with his heels on the table. Place a finger or hand against the bottom of the client's heel,

to keep the heel from moving downward. Have your client dorsiflex; the heel will press down against your restraining hand, and the client's femur will be pressed into his hip. Have him dorsiflex again, adding just a minimal lifting/flexing of the knee. This time, your hand acts as an anchor (you can add the suggestion, 'Imagine the back of your heel is glued to the table while you flex your ankle'), and the knee and the hip will flex as the ankle 'pumps' the knee up.

Watch the hip. If the client's ASIS moves toward the knee (lumbar hyperextension) as the knee rises, have him be as passive as possible in the hip. The hip should remain neutral or even fall back as the foot is dorsiflexed and the knee flexes. If the hip is actively flexing, work with the client's movement until it is minimally disturbing to the knee and hip, and most of the work is taking place at the ankle.

Place whatever applicator **you** wish to use just above the patella (feel free to use everything from fingertips to elbows depending on the body type and muscular development of the client). Work slowly cephalad up the rectus femoris, while the client repeats the dorsiflexing movement, keeping the heel 'glued' to the table. Pay particular attention to the receptor-rich area between the patella and the belly of the muscle. You can follow it, especially in those with an anterior pelvis, all the way to the AIIS (remember to track the muscle into its attachment, deeper and lower than the ASIS). Your goal is to free the two-joint rectus from its monarticular knee extensors below; the client's movement will help **you** accomplish this (**DVD ref: Superficial Front Line, 25:44-33:12**).

Branch lines

Returning to the upper part of the shin, there are alternative routes or switches here (**Fig. 4.13**). Instead of going straight up with rectus femoris, we could choose to follow the anterior edge of the iliotibial tract (ITT) from the tibialis anterior muscle (as we will in Ch. 6 with the Spiral Line), which would carry us laterally up the thigh to the ASIS. This could be seen to mechanically link to the internal oblique.

On the medial side of the knee, we could follow the sartorius from its distal attachment on the periosteum of the tibia around the medial thigh, again arriving at the ASIS, though this time the 'follow through' north of the ASIS would be the external oblique (see the new Ipsilateral Functional Line in Ch. 8). These various branch lines of pull coming off the 'roundhouse' of the ASIS would allow us to travel in various ways up the abdomen to the ribs (**Fig. 4.14**). While these trains are obviously in use in daily movement, we are choosing to emphasize, in this chapter, the direct and vertical link up the front of the body.

Derailment

At the upper station of the rectus femoris, our Anatomy Train seems to come to a halt. No muscle or fascial structure takes off from here in a generally superior direction; the abdominal obliques take off at angles (**Fig.**

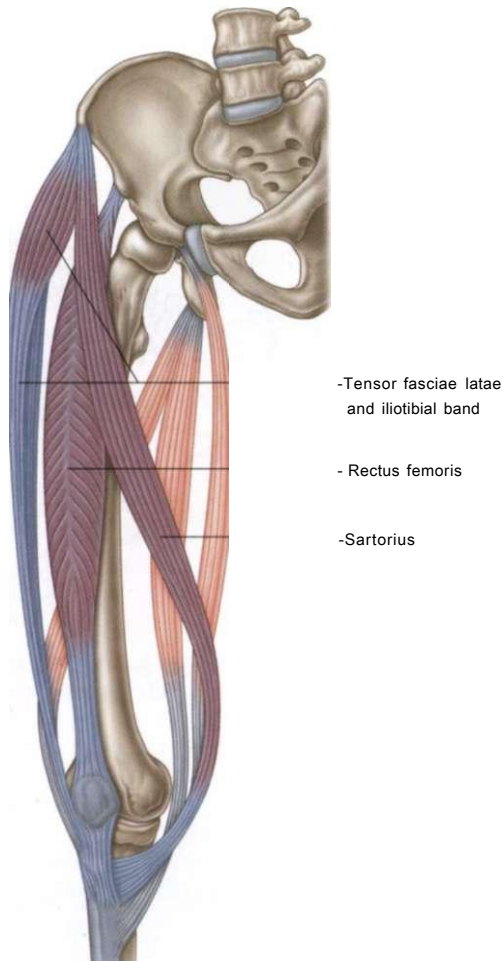
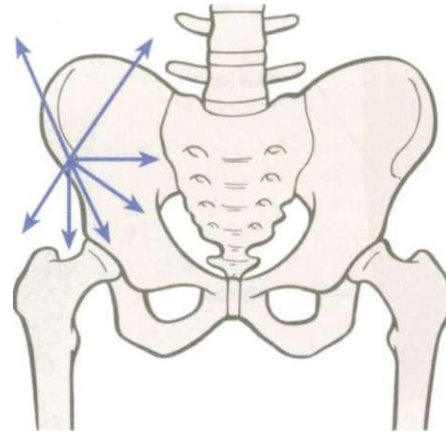
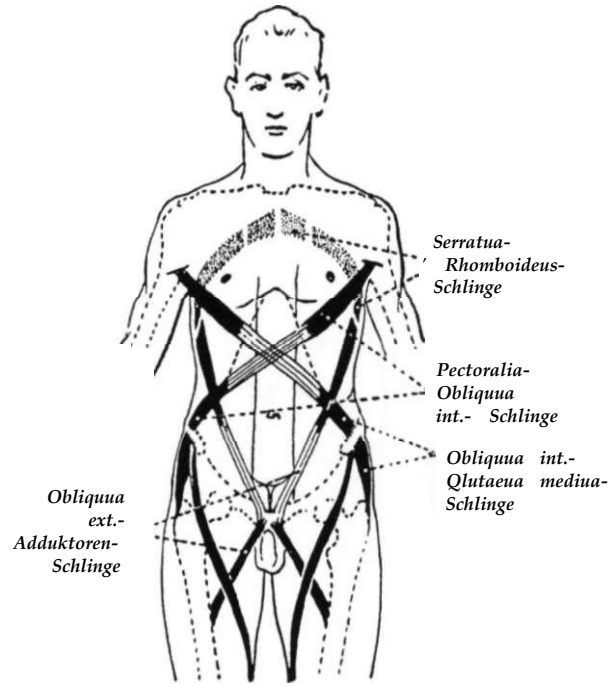


Fig. 4.13 There are two branch lines or alternative routes to the rectus femoris from the knee to the hip. The sartorius curves up from the inside to the anterior superior iliac spine, and the anterior edge of the iliotibial tract does the same on the outside of the leg.



B

Fig. 4.14 (A) The extensions of the branch lines in **Figure 4.13** would start to form spirals around the trunk, lines we will take up in the following chapters. (Reproduced with kind permission from Hoepke et al 1936.) **(B)** Each of the muscles contributes to the 'roundhouse' of attachments to the ASIS.

4.14A). The muscle contiguous to the rectus femoris on the medial side is the iliacus, so an argument could be made for some kind of linkage between the two structures, but the iliacus is part of a deeper plane, the Deep Front Line; for the SFL, we are looking for the surface continuity up the front (**Fig. 4.15**). The rectus-iliacus connection is a special case that we will consider when we consider the interactions between the SFL and the Deep Front Line in Chapter 9.

The myofascia that clearly continues the run up the front line of the body is the rectus abdominis, so we will simply have to break the Anatomy Trains rules to make a logical jump over to the pubis. The rationale for this jump is as follows: the AIIS and the pubis are part of the same bone (at least in anyone over one year in age) (**Fig. 4.16A**). So, for every millimeter the pubis is pulled up by the rectus abdominis, the rectus femoris must lengthen by a millimeter to allow it to happen. If both contract, the front of the rib cage and the knee will approximate (**Fig. 4.16B**). If the body is arched into hyperextension, both must stretch reciprocally. If one cannot elongate, the other must make up for it or pass the strain up or down the train (**Fig. 4.16C and D**).

Thus, even though there is not a myofascial continuity, there is a mechanical continuity through the hip bone. This Anatomy Train works as a single track *as long as we limit our discussion to movement in or near the sagittal plane*. The SFL will *not* work as a continuous band in movements that involve hip or trunk rotations, but *does* act as a continuity in postural issues, and in sagittal stretches and movements (**Fig. 4.17**).

The abdomen

Having now reseeded ourselves on the top of the pubis, we can ride up on the abdominal fascia, including the muscular elements of the pyramidalis and rectus abdominis, and the fascial layers that surround the rectus from the obliques and transversus (**Fig. 4.18**).



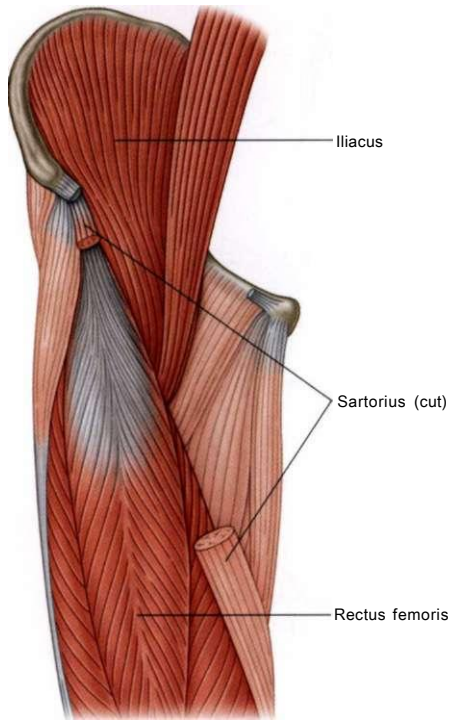


Fig. 4.15 Once you travel up the rectus femoris, what train can you take from there? No muscle goes directly in a cranial direction (see also **Fig. 4.14B**). The iliacus continues this direction, but there are two problems with this track: (1) the rectus femoris and the iliacus, though nearly contiguous, do not connect fascially, and (2) this portion of the iliacus is a temporary surfacing of a deeper track, the Deep Front Line (see Ch. 9).

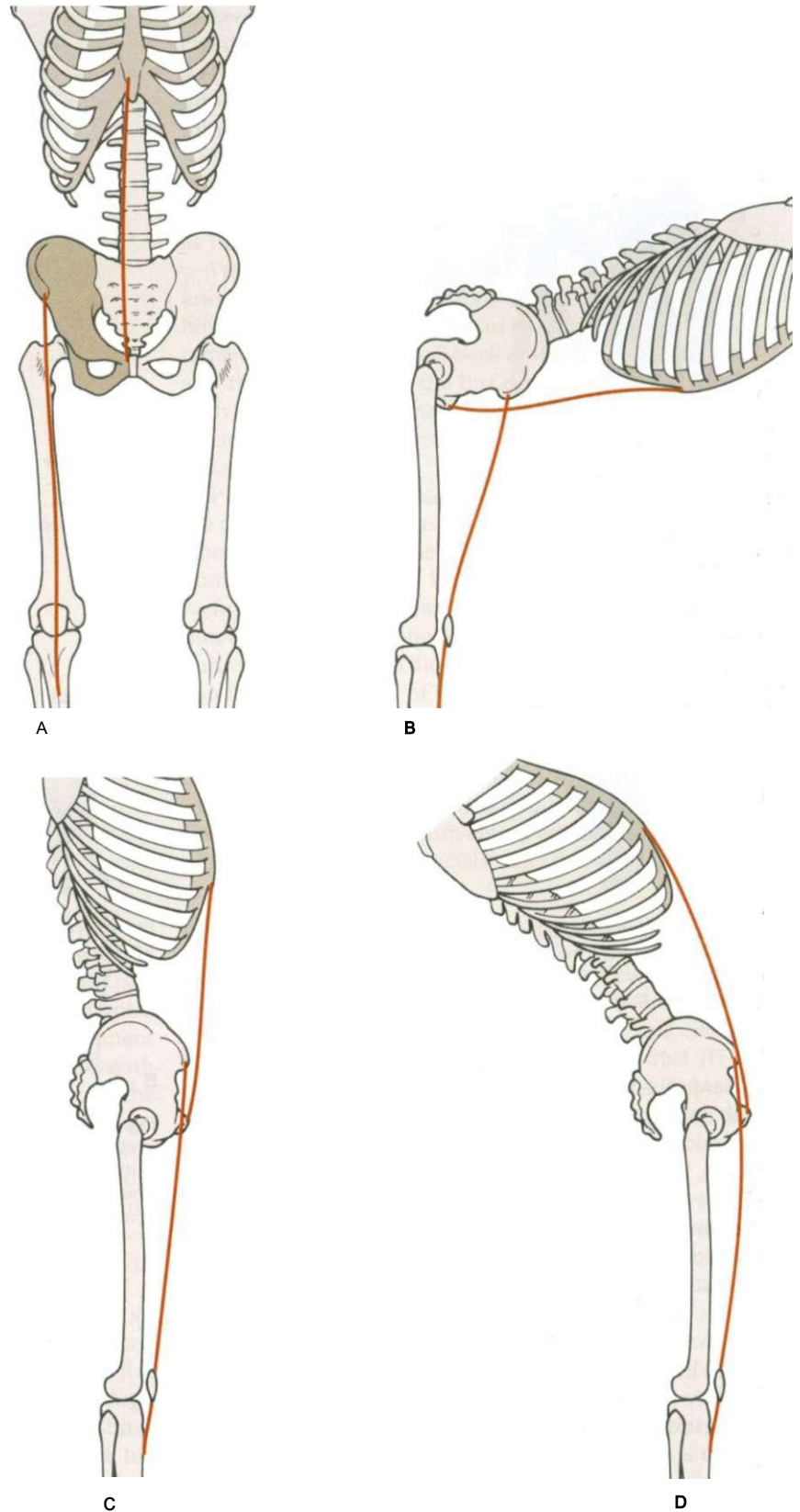


Fig. 4.16 (A) The rectus femoris and rectus abdominis are connected mechanically through each hip bone. (B) If both contract, the hip and trunk flex to approximate the rib cage and the knee. (C) In standing, relative tonus will help determine pelvic tilt. (D) In hyperextension, both are stretched away from each other - if one part is inelastic, the other must make up for it or pass the strain along the SFL.

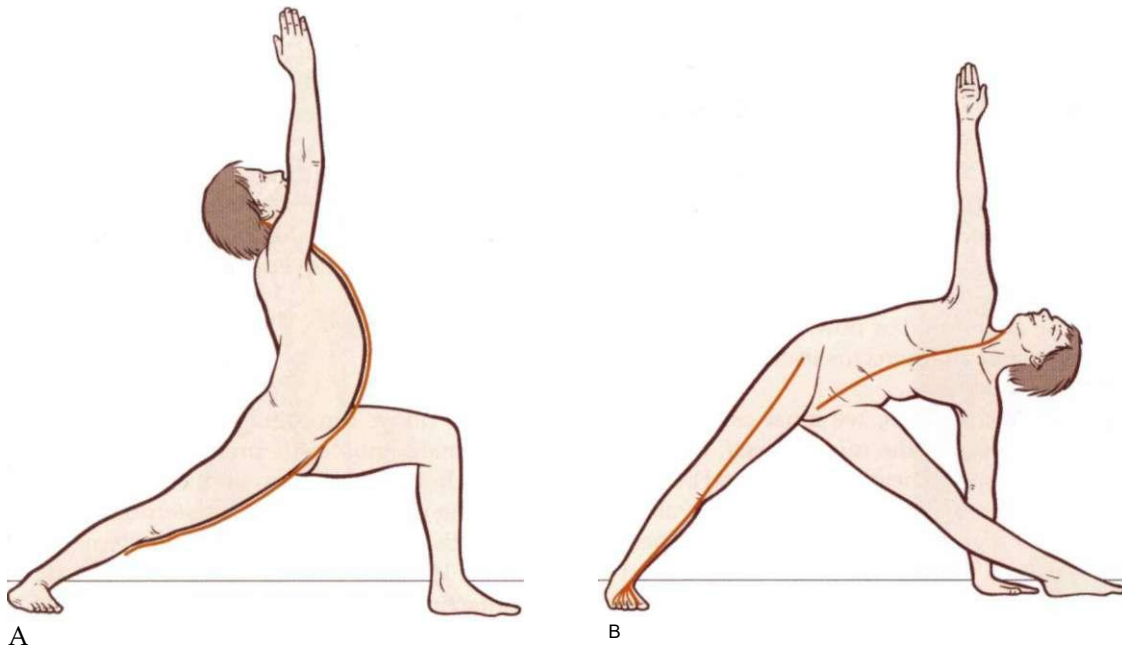


Fig. 4.17 (A) Purely sagittal (flexion-extension) movements will engage the SFL as a whole. **(B)** Rotational movements through the hips or trunk disengage the upper portion of the SFL from the lower.

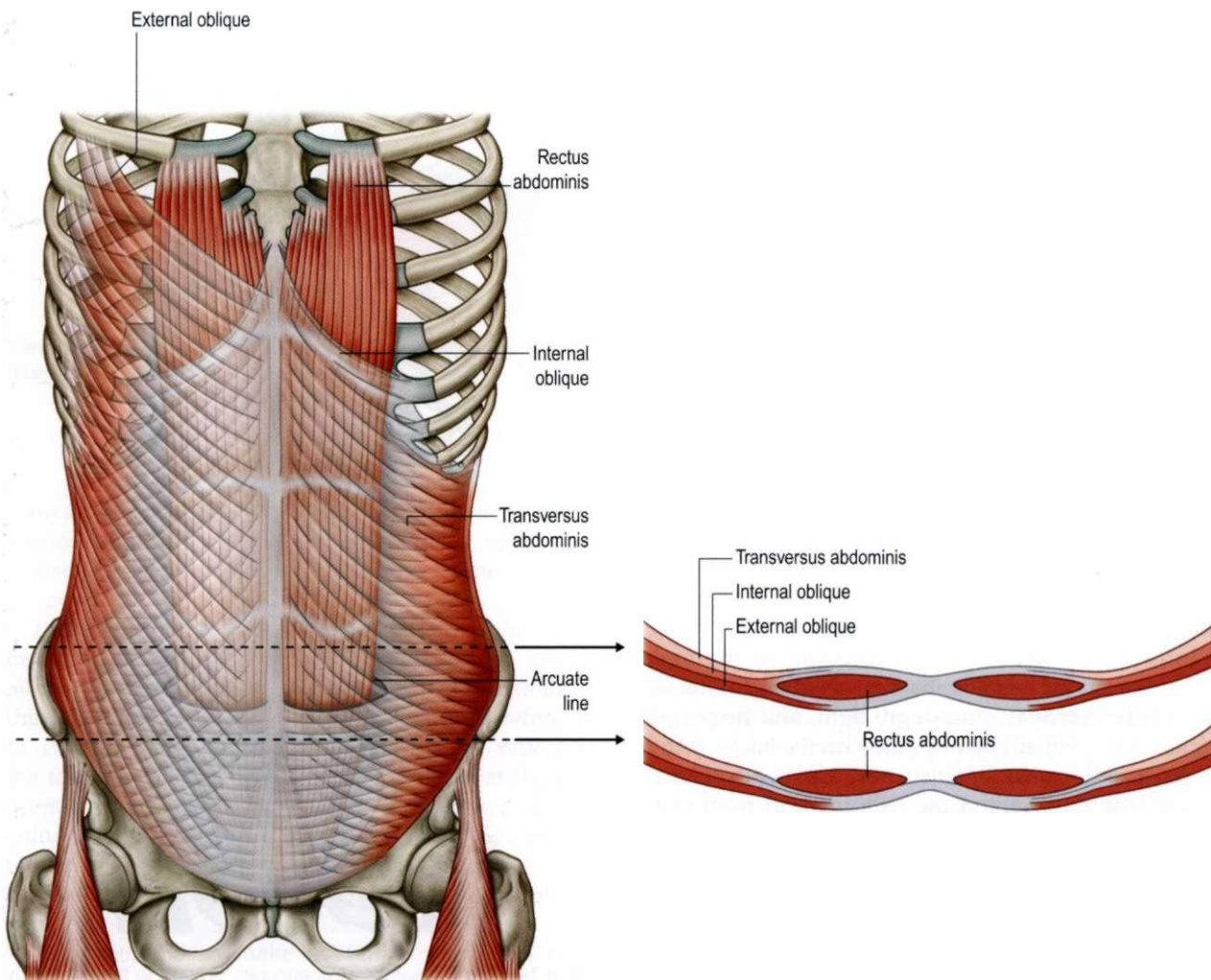


Fig. 4.18 The rectus abdominis is the most superficial *muscle* of the abdomen all the way from the chest to the pubic bone. In terms of *fascial* layering, however, the rectus begins as superficial at the 5th rib, but shortly dives under the external oblique fascia within a few inches. Two inches (5 cm) lower than that, the internal oblique fascia splits to surround the rectus. Below the navel, the rectus slides through behind the transversus abdominis at a hole at the arcuate line to become, by the time it reaches the pubic bone, the deepest muscle of the abdomen. Such an understanding of fascial, as opposed to simply muscular, anatomy leads to different strategies for 'Spatial Medicine'.



The rectus abdominis

The poor rectus abdominis: over-exercised by the 'go for the burn' crowd, and under-treated by the manual therapist. It is important to understand that the SFL involves at least three layers at this level: the fascial aponeurosis that runs in front of the rectus, the muscle itself, and the fascial sheet that runs behind it (**Fig. 4.18**). These aponeuroses are shared with the other abdominal muscles, and will come up for consideration with other lines (see Chs 5, 6, 8, and 9). For now, we will concern ourselves with the span of the rectus itself between the pubis and the 5th rib.

As we view the rectus, then, we must assess three separate parts: the tonus of the muscle itself, and the tonus of the two enveloping sheaths, in front and behind the muscle. If the rectus is flat - a set of 'six-pack' abs - then we can suspect high tonus in the superficial sheet and in the muscle itself. If the rectus bulges out, we must assess the tonus of the muscle, but we can be fairly sure that the deeper sheet, behind the muscle, is shortened (DVD ref: Superficial Front Line, **33:15-35:05**).

To free the front sheet and the muscle, have your client lie supine with his knees up, feet on the table. Facing cephalad, hook the tips of flexed fingers into the lower part of the muscle and move tissue upward, toward the ribs, taking a new purchase each time you reach one of the tendinous inscriptions in the rectus. You can repeat this move as necessary to continue the process of freeing the superficial aspect of the rectus up to the 5th rib.

To reach the back of the rectus requires a more invasive but very effective technique. First, we must assess the nature of the shortness. If the lumbar is hyperextended into a lordosis, or the pelvis is held into an anterior tilt, the lumbar may simply be pushing the abdominal contents forward into the restraining rectus. In that case, it is necessary to free the SBL in the lumbar to give the abdomen more room to drop back (see Ch. 3).

If this is not the case, the bulging abdomen can also be due to enlargement of the abdominal contents caused by overeating or bloating, which must be solved by dietary means. Or, of course, there can be excess fat, either subcutaneously or, especially in men, in the omentum underlying the peritoneum.

In any case, even if the belly sticks out and the muscle tonus seems low, it is possible that the tonus of the wall behind the rectus is quite high, tight, and responsible for restricting breathing or pulling on the back. With no bones near to work against, how can we isolate the sheath that runs behind the rectus but in front of the peritoneum? Since the back of the rectus sheath is part of the Deep Front Line, see Chapter 9 for the answer (or DVD ref: Deep Front Line, Part **2**).

The various tracks which crisscross the abdomen will be discussed in Chapters 6 and 8; for the moment we are moving due north on the rectus and its accompanying fascia. Of course, these abdominal lines all interact, but the SFL runs a straight (though widening) track up to its next station at the 5th rib. The rectus must reach

as high as the 5th rib to achieve sufficient stability for all the strong actions it must perform. The lower 'abdominal' ribs, with their long cartilaginous attachments to the sternum, would be too mobile to provide a stable attachment for the SFL, especially considering their large excursion during breathing.

Mobilization and freeing extra adhesions where the rectus abdominis attaches is frequently rewarded with expanded breathing movement (DVD ref: **Superficial Front Line, 40:38-45:26**).

The chest

From the 5th rib we can continue in the same direction via the sternalis muscle (if present) or its associated fascia (which almost always is), including the sternal fascia passing up the surface of the sternum, along with the pectoralis fascia out as wide the sternochondral joints at the lateral edge of the sternum (**Fig. 4.19**). (The rectus attachment at the 5th rib will make another appearance when we consider, in Chapter 7, the anterior Arm Lines, which both start from the 5th rib attachment of the pectoralis minor and major. The rectus fascia thus

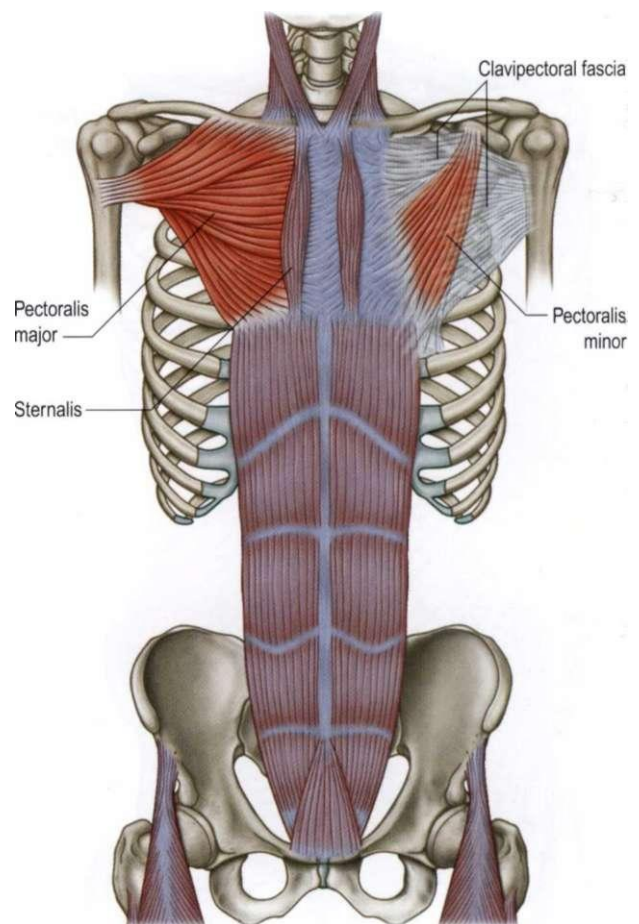


Fig. 4.19 The rectus abdominis attaches strongly to the 5th rib, but the fascia continues up the sternalis myofascia and the fascia running along the sternochondral joints. The rectus also links fascially into the pectoralis major and minor, connecting the SBL to both the Front Arm Lines (see Ch. 7).

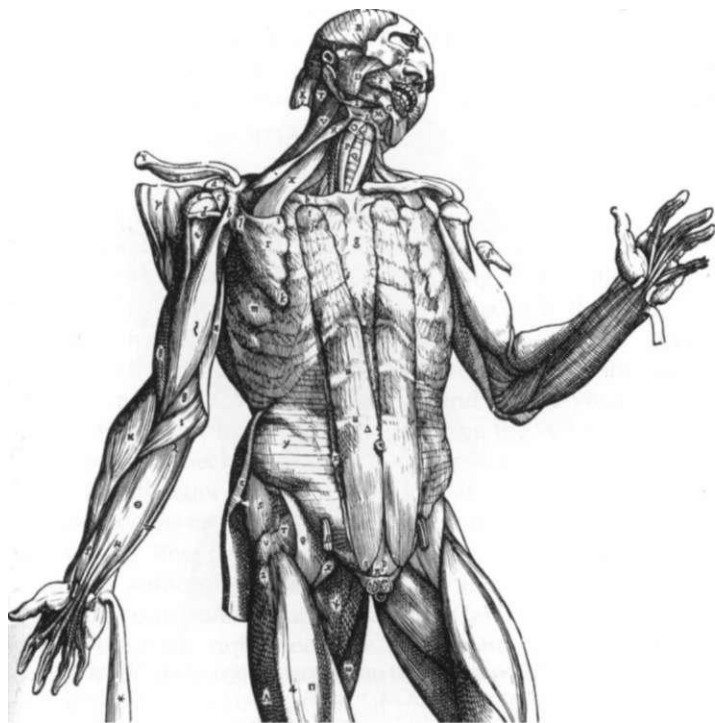


Fig. 4.20 Vesalius, in an early precursor of the myofascial meridians theory, shows the rectus abdominis fascia going up the rib cage nearly to the collarbone. Why? (Reproduced with permission from Saunders JB, O'Malley C. Dover Publications; 1973.)

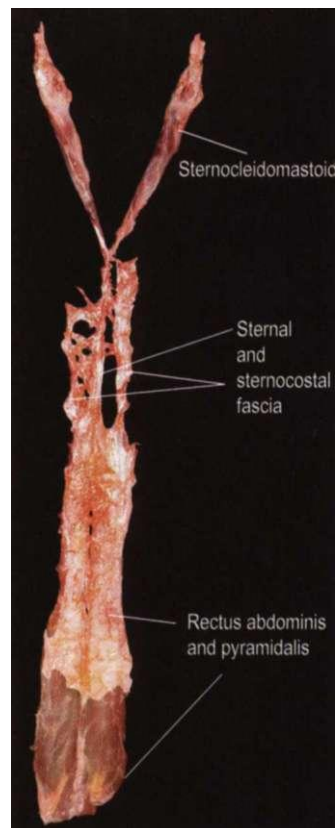


Fig. 4.21 Our attempt to reproduce what Vesalius indicates as a connection from the rectus on up the chest yielded a disappointing lacework, at least on the part lateral to the sternum over the chondral portion of the ribs. Given the palpable layer of tissue that can be felt in this area, future dissections using fresh-tissue cadavers for comparison will include investigation of the pectoral fascia itself.

shows a 'switch' here, a choice point, where strain or tension could follow either line, depending on the circumstances of movement, posture, and the necessity of physics.)

It is interesting to note that Vesalius shows the rectus fascia proceeding under the pectoralis major almost all the way to the clavicle (**Fig. 4.20**). Modern anatomists think he may have been making a deliberate reference to canine anatomy, but perhaps he was reflecting the fascial reality of his time. Could it be that the predominant activities at that period - chopping and agricultural work in general; in other words, active flexion movements - resulted in the laying down of increased sagittally oriented fascia traversing the front of the trunk?

Our attempts to make a similar dissection have fallen short of Vesalius's picture (**Fig. 4.21**). On the basis of only a few attempts at dissection, we have been able to follow the fascia up the sternum, but not any wider on the cartilaginous 'breastplate' to either side of the

sternum, where our results could best be described as 'lacey'.

The sternalis is an anomalous, capricious and surface muscle, though it is often expressed fascially even when it is not expressed muscularly. Whether or not the sternalis muscle or fascia can be detected, the SFL continues up from the rectus by means of fascial layers, which are readily palpable, over the sternum, the sternochondral joints, and the costal cartilages, up to the origin of the sternocleidomastoid. We suspect that stronger forces are transmitted mechanically through the sternum, as well as fascially via these layers and the pectoral fasciae as well.

The sternal area

Above the costal arch, the rectus may be lifted headward from the front with extending fingertips or the heel of the hand. Although the rectus formally stops at





the 5th rib, the SFL does not, and you can continue up the sternal area, including the tissues superficial to the sternum itself, but also the tissue overlying the sternochondral joints between the sternum and the medial edge of the pectoralis major. Generally, this tissue wants to be moved cephalad, but sometimes, as in the case of a pinched or narrow chest, requires a lateral vector also (DVD ref: **Superficial Front Line, 33:05-40:38**).



The SFL in the neck

Following the SFL upward on these tissues between and beneath the two medial edges of the pectoralis major muscles, we come to the top of the front of the sternum. A superficial glance at standard anatomy plates seems to indicate that the logical direction from here is to keep going straight, right up the front of the throat to the lower part of the jaw using the infrahyoid muscles (**see Fig. 2.4A**). These muscles would connect through the hyoid to the mandible, and from the mandible via the jaw muscles onto the lower part of the cranium, temptingly close to the upper end of the SBL on the brow ridge.

But this beautiful theory is about to be destroyed by an ugly fact: the error of following this path for the SFL is evident as soon as we look at the lower attachments of these hyoid muscles. They do not attach to the front of the sternum, but tuck instead behind it into the posterior aspect of the sternal manubrium, and thus they are not on the same fascial plane as the SFL myofasciae (**see Fig. 2.4B**, p. 66). In fact the hyoid grouping is part of the visceral cylinder of the neck, joined to the thoracic viscera through the thoracic inlet, and will be seen again as one route in the Deep Front Line (see Ch. 9).

The mechanical connection from the front of the chest to these muscles can nevertheless be felt by hyperextending the neck and pointing the chin up into the air. The discerning will notice, however, that most of that pull extends down the inside of the rib cage, not down the superficial surface with the SFL.

To continue up the SFL, we must look at what attaches to the outside of the top of the sternum. What does attach here, of course, is our familiar friend and member of the superficial cylinder of the neck (fascia colli superficialis), the sternocleidomastoid (SCM). The sternal head, in particular, of the SCM myofascia attaches firmly to the top and front of the sternum, interfacing with the sternal layer that comes up under the pectoralis fascia. This important track leads up laterally and posteriorly to the mastoid process of the temporal bone, and onto the lateral and posterior parts of the galea aponeurotica (**Fig. 4.22**).

The fact that the myofascial pull running up the sensitive front of the body makes a sudden jump via the SCM for the back of the skull produces a very interesting counter-intuitive situation. Tightening the SFL causes flexion of the trunk, either in motion or in posture, but produces hyperextension at the top of the neck (**see Fig. 4.23**). (The SCM produces neck flexion in the supine position, as in a sit-up, when it is lifting the head against

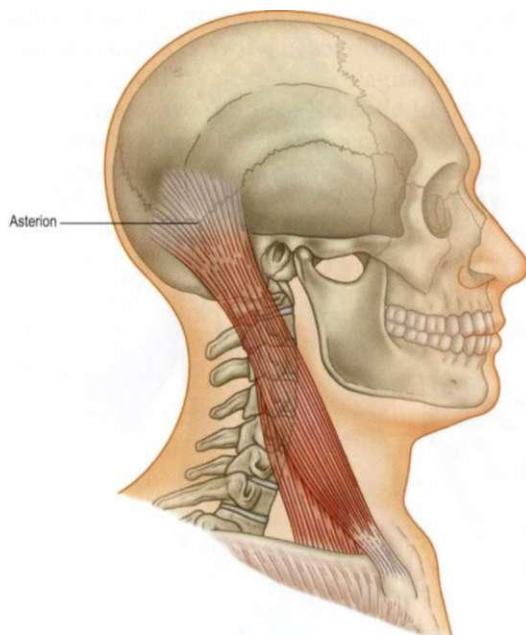


Fig. 4.22 The fourth and uppermost portion of the SFL is the sternocleidomastoid (SCM) muscle, which tracks back along the neck onto the posterior portion of the temporal bone and the asterion - the sutural junction among the temporal, parietal, and occipital bones, and a major attachment of the tentorium cerebelli on its medial side.

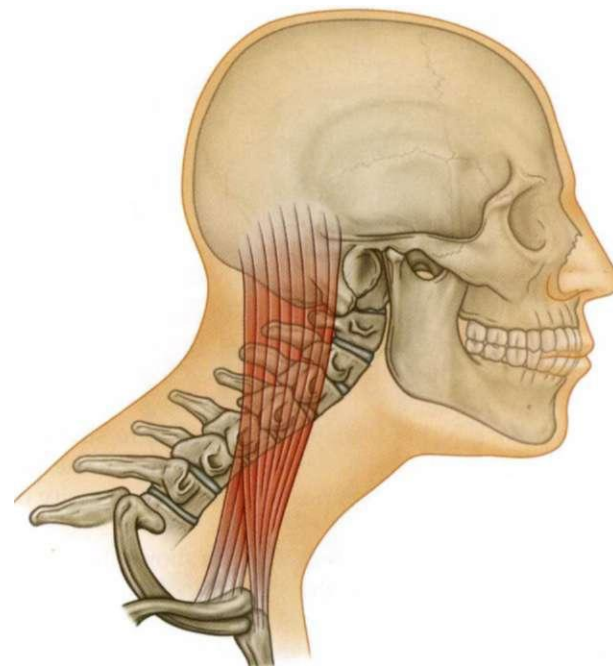

Fig. 4.23 The SCM is uniquely positioned, in standing posture, to create lower cervical flexion at the same time that it creates upper cervical hyperextension. The exact cervical level where this switch is made varies with posture, but is usually between C2 and C3.

the force of gravity Even in standing, put your hand against your forehead and push forward with your head, and you will feel the SCM contract. In standing posture, however, because it attaches to the mastoid process, it runs posterior to the hinge of the atlanto-



occipital and atlanto-axial joints, thus it works with gravity to help produce lower neck flexion and upper neck hyperextension.)

The sternocleidomastoid

The sternocleidomastoid (SCM) is a difficult muscle to stretch, the more so because often the underlying scalenes and suboccipitals are so limited in their movement that they may reach their limitation long before the superficial SCM is brought into a stretch (see Ch. 9 for a discussion of these underlying muscles).

To stretch and open the superficial fascial cylinder in general, and the SCM in particular, stand beside your supine client and place your open fist along the SCM on one side of her neck, with your fingers pointing posteriorly. The direction of your pressure is crucial here: *do not push into the neck*. The direction of your stretch is to follow your fingers back, around the neck along the 'equator', without significant pressure into the neck. The design is to pull the superficial fascia (and the SCM) toward the back, not to occlude the carotid artery or jugular vein. Any significant change of color in the client's face or report of intracranial pressure should cue you to desist.

As you begin your move, have your client assist by rotating her head away from you, taking the tissue out from under your hand as you move along the neck toward the back. Make sure your client is rotating around the axis of the neck, not simply rolling her head away from you on the table. You can use your other hand to guide her head, and you can also cue her: if she is really rotating her head, she will be able to hear her hair on the table. Just rolling the head on the table will not create the same noise to the client's ear (DVD ref: Superficial Front Line, 46:58-52:45).

The scalp

The line of pull from the SFL up onto the skull overlies and particularly affects movements at the asterion, the juncture among the occiput, parietal, and temporal bones. Consider the line of pull of both SFLs, especially if they are tight (as in extreme forward head posture) - they can form a functional loop up and over the occiput at or about the lambdoidal suture (Fig. 4.24). This loop can be palpated and released (DVD ref: Superficial Back Line, 57:03-59:55). Otherwise, the fascia of the SFL blends with that of the SBL through the posterior part of the scalp fascia.

Where the fascia of the SCM and the superficial cylinder of the neck join the galea aponeurotica of the scalp, the same considerations and techniques as were already discussed in terms of the SBL (Ch. 3, p. 89) apply equally to the SFL: look for spindles of extra-tight fascia aligned along the direction of the SCM above the mastoid process near the asterion.

General movement treatment considerations

The muscles of the SFL create dorsiflexion at the ankle, extension at the knee, and flexion of the hip and trunk. In the neck, the action of the SFL depends on one's position relative to gravity; although in standing, the SCM creates lower cervical flexion and upper cervical hyperextension (see Discussion 2 below, p. 112). At the same time, the SFL should stretch to allow for full extension and hyperextension of the trunk and flexion at the knee. Various degrees of backbends and front of the leg stretches can thus be used to mobilize the SFL. Postural flexion of the trunk, forward head posture, or

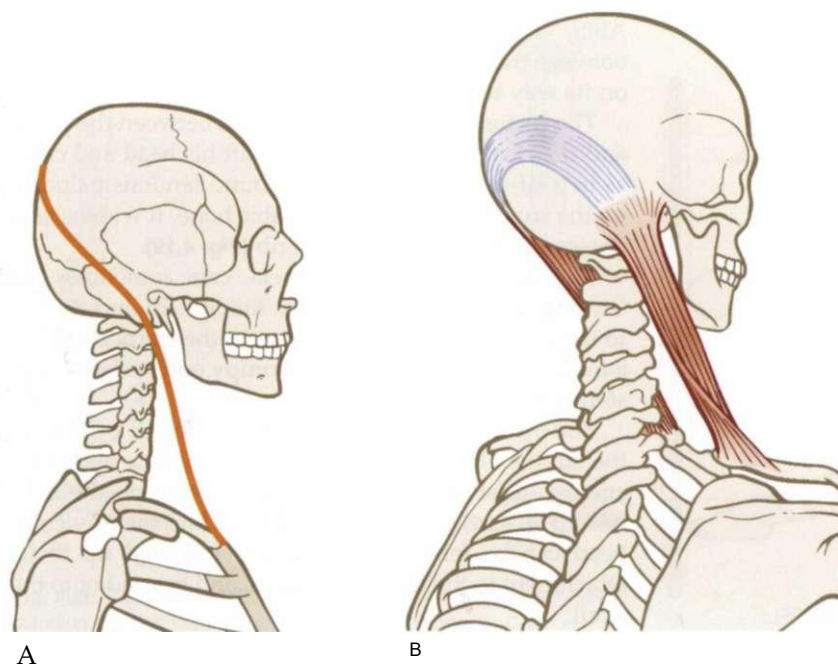


Fig. 4.24 The SCM muscle stops on the mastoid process, but the line of pull continues over the head, roughly along the line of the lambdoidal suture, connecting with the other SCM to form a scarf-like loop.

locked knees are all signs of excessive tension in the SFL.

NOTE: Once again, as with the stretches offered in Chapter 3, caution is urged in assigning or attempting these stretches (see note on p. 90).

- Kneeling on the toes in plantarflexion and sitting into the heels is an easy way to test the ability of the lowest part of the SFL to stretch.
- The 'cobra' stretch is an easy way to extend the stretch into the belly from the toes (**Fig. 4.25A**). Be aware of the head: if there is too much hyperextension in the neck, the stretch in the belly will be counteracted by the shortening of the SCM. Keep the chin tucked in a little, and the head high.
- Leaning back into hip extension (fully supported for most beginners; meaning enough support to completely avoid lumbar strain or pain) extends the stretch of the SFL above the knee to the hip (**Fig. 4.25B**).
- The 'bridge' provides another intermediate stretch for the upper part of the SFL (**Fig. 4.25C**). Keep the neck flat to extend the mastoid process away from the sternal notch. Keep the toes pointed in plantarflexion to include the legs.
- The backbend is the most complete stretch for the SFL, for those with the strength and flexibility to sustain it. It is not recommended for the beginner, though a physioball is a great support to give the beginner a feeling for what a full opening of the SFL would involve (**see Fig. 4.7A**).

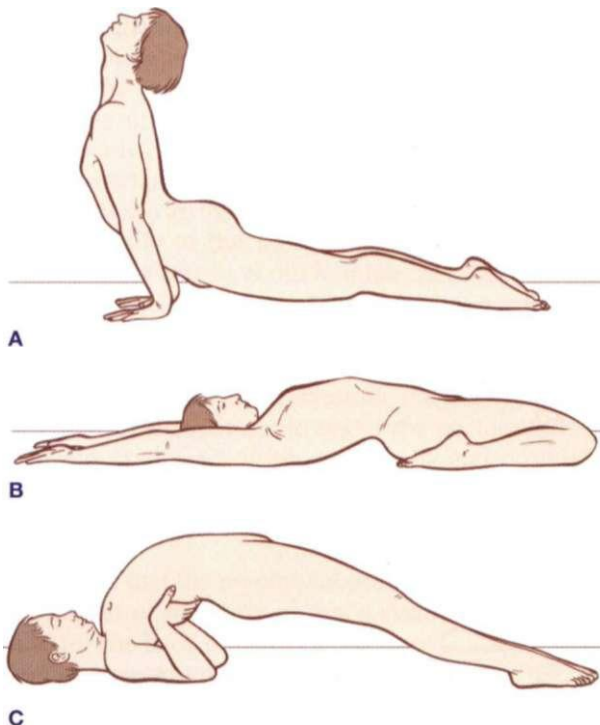


Fig. 4.25 Common stretches for parts or all of the SFL.

Palpating the Superficial Front Line

The departing station of the SFL is clearly palpable on the tops of the five toes, with the first track running back with the tendons onto the dorsum of the foot. The short extensor muscles of the toes can be felt on the lateral side of the upper foot, while the long tendons stay the course under the retinaculum and on up into the leg. The tibialis anterior tendon can be clearly seen and felt when the foot is dorsiflexed and inverted. If you dorsiflex and evert the foot, you may find the peroneus tertius tendon (if you or your model has one), just lateral to the little toe tendon, going down to the middle of the 5th metatarsal (**Fig. 4.11**).

All of these tendons run under the retinacula to gather into the anterior compartment of the leg. The thickened areas of the retinacula can sometimes be felt when the foot is strongly dorsiflexed, just to either side of these tendons, running to both malleoli.

In the leg, the individual toe extensor muscles disappear under the tibialis anterior, which can be followed right up to the bump of the tibial tuberosity below the knee. The lateral edge of the anterior compartment is marked by the anterior intermuscular septum, which can be traced by walking your finger up from the lateral malleolus while dorsiflexing and plantarflexing the foot. The tibialis - anterior to the malleolus - will be active on dorsiflexion, while the neighboring peroneals, in the compartment posterior to and superior to the malleolus, will be active on plantarflexion. The septum is the wall between the two. If you follow it accurately, you will reach the top of the septum just in front of the fibular head.

The subpatellar tendon can be easily palpated between the tibial tuberosity and the patella. With an extended knee, the tendon of the rectus femoris is also easily palpable, as is the muscle, which can usually be 'strummed' horizontally most of the way up to the AIIS. As you approach the top of the thigh, the sartorius and tensor fasciae latae can be felt converging toward the ASIS, while the rectus, in most cases, dives down between these two, creating a small but palpable 'pocket' on its way to the AIIS (**Fig. 4.12**).

The rectus abdominis is easily felt between the pubis and the ribs by having the client lift his head and chest as in a sit-up. It begins as two round tendons palpable on the superior aspect of the pubic bone. It widens as it passes up the body to the 5th rib (**Fig. 4.19**).

The sternalis and its fascia can sometimes be 'strummed' horizontally above the 5th rib and medial to the pectoralis, but the fascia over the sternochondral joints can be readily felt at the bumpy outer edges of the sternum.

The SCM can also be easily distinguished by having the supine client rotate the head to one side and lift it against resistance, such as a hand resting on the forehead (**Fig. 4.22**). Both the sternal head and the clavicular head can be felt, and the muscle followed up to its attachment to the mastoid process, and beyond onto the skull.



Discussion 1

Balance between the Superficial Front and the Superficial Back Lines

The first aspect of the SFL to note is its disjointed, disparate nature compared to the long conjoined flow of the SBL. In contrast, the SFL shows more discrete functioning of its constituent parts: the anterior crural compartment, the quadriceps, the rectus abdominis, and the SCM. Though they often work together to create consistent pulls along the SFL, they tend to conjoin truly into a single band only in relatively extreme hyperextended postures such as a backbend (Fig. 4.26 or Fig. 4.7A), or in extreme contraction (Fig. 4.30).

This brings us to the obvious, but complex, relationship between the SFL and the SBL, the two lines that traverse the front and back aspects of the body. In the example of the 'military' or 'compensated oral' postural preference, the SBL (or some portion of it) is 'locked short' like a bowstring (Fig. 4.27). In the same example, the SFL (or some portion of it) will be 'locked long' - i.e. strained, stretched, or pulled on, with the visceral contents of the ventral cavity pushed forward against its restraining tension. If the SBL is acting like a bowstring, the SFL starts to act like the wood on the front of the drawn bow.

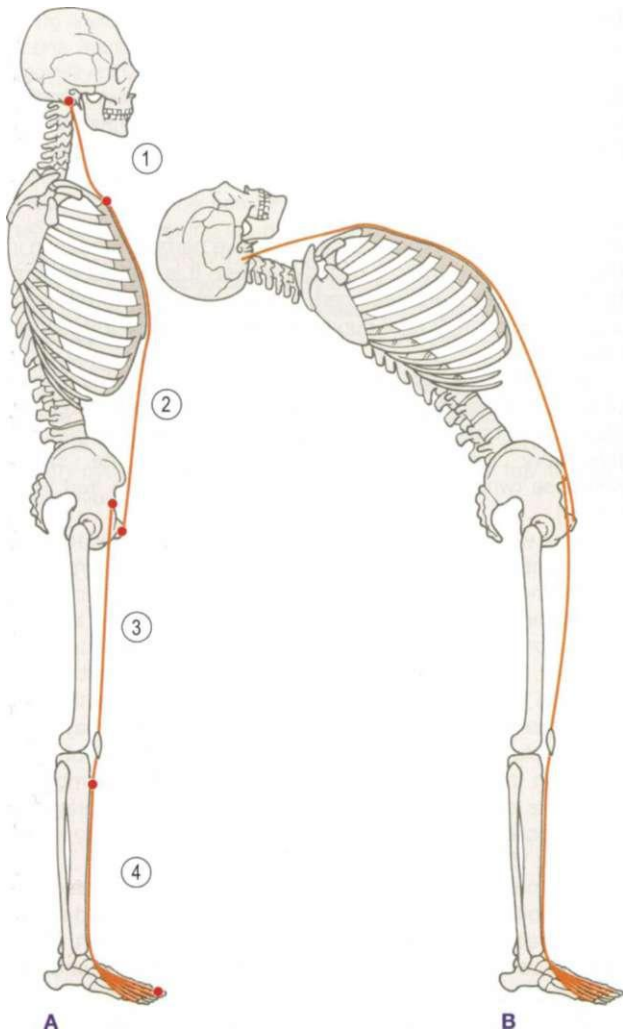


Fig. 4.26 The four tracks of the SFL are able to work separately in standing, but will conjoin in trunk hyperextension.

Perhaps a better image would be of a strip of wood with a string stretched on either side (Fig. 4.28A). As the string on one side was shortened, the wood would bend, stretching, perforce, the string on the other side (Fig. 4.28B).

A commonly observed pattern shows the hamstrings and the muscles surrounding the sacrum becoming shortened and bunched, pushing the pelvis and hip forward. The muscles on the front of the hip then become tight as they are stretched and strain to contain the forward push from the back. It is very important clinically to distinguish between the muscle that is tense because it is shortened, and the muscle that is tense because it is strained, as treatment of the two conditions will differ (Fig. 4.29).

Just as often, however, we see the opposite pattern between the SFL and the SBL: the front is locked short, rounding the thoracic spine or flattening the lumbar curve, creating

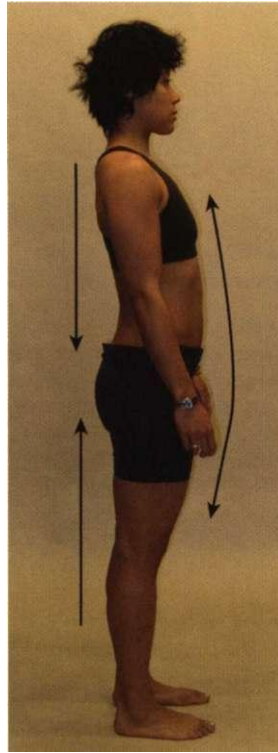


Fig. 4.27 The 'military' style of posture involves shortening and tightening the SBL, especially the middle part, while the SFL must lengthen in some other part to accommodate it.

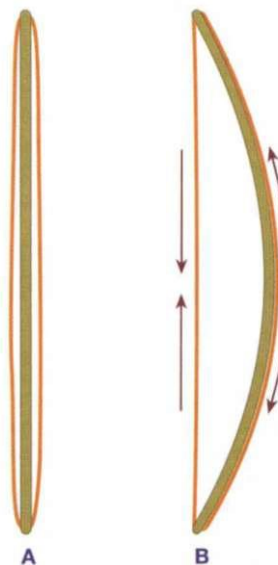


Fig. 4.28 (A) Myofascial units are often arranged in antagonistic pairs on either side of the skeletal armature. (B) When one side is held chronically short, either muscularly or fascially ('locked short'), the other side is stretched tight ('locked long').

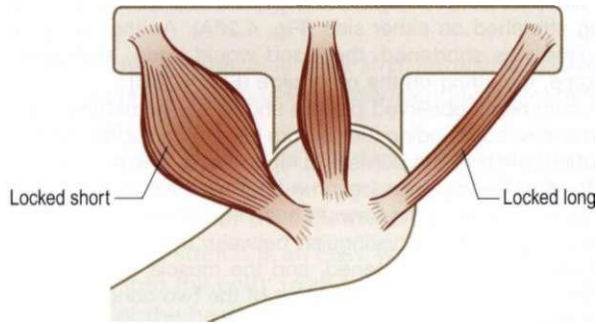


Fig. 4.29 The locked long muscles are often the noisy ones in terms of pain, but the locked short muscles, often silent, are the ones that need to be opened and stretched for permanent resolution of the pattern.

a collapsed or 'overburdened' posture. In considering a fully lengthened, easily maintained posture, it is hard to escape the idea that the muscles of the SFL are designed to pull 'up'. Now muscles, as far as is known, show no propensity or even possibility for determining their direction of pull. They simply pull on the surrounding fascial net, and physics determines whether the result pulls origin toward insertion, insertion toward origin, or neither, as in an isometric or eccentric contraction.

Nevertheless, if we consider the SFL from the top down, we could see that the SCM portion originating from the mastoid process would be the origin of movement, helping to pull up on the top of the rib cage via the sternum (see Fig. 4.4). In turn, the rectus abdominis could pull up on the pubic bone, helping to prevent an anterior tilt of the pelvis. Too often, however, the very opposite occurs, and the rectus pulls down on the rib cage, depressing the ribs and restricting breathing. This pull is conveyed through the sternalis and sternum to the SCM, which pulls down, in its turn, on the head, bringing it forward (see Fig. 4.5).

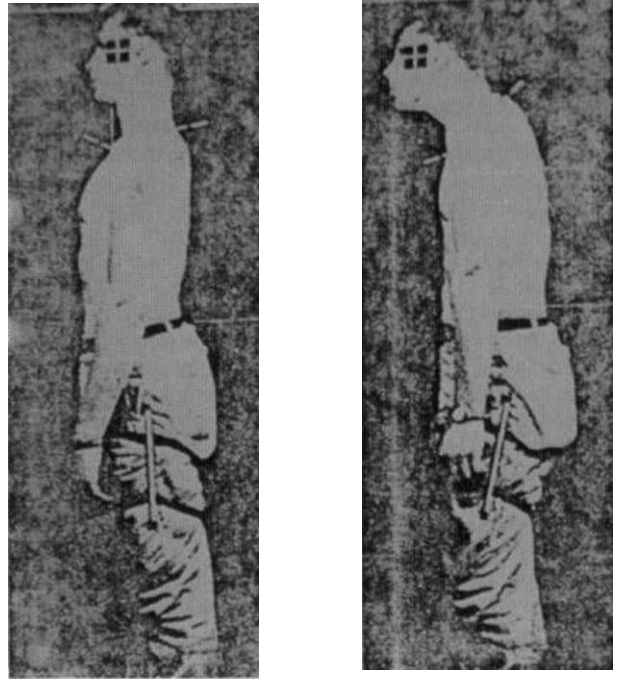
When this occurs, an extra burden is shifted onto the SBL: in addition to supporting the back of the body in extension, it must now counteract the downward pull of the SFL. This often leads to super-tight muscles and to extra fibrotic and stuck-down fascia along the back line of the body, tissue which aches and cries out to be worked on. The practitioner viewing this pattern will, however, be well advised to work up the front of the body, freeing the SFL so that the SBL can return to its proper job. Working only the SBL and back in cases like these will result in only temporary relief and, over time, a worse posture. How many bodywork clients say, 'Just work my back and shoulders today, please, that's what's really aching'? The knowledgeable practitioner turns his or her attention to other places along the front line, or to postural re-education.

Discussion 2

The SFL, the neck, and the startle response

'All negative emotion', says Feldenkrais, 'is expressed as flexion.'¹ The general truth of this simple statement is brought home to any observer of human behavior every day. We see the hunch of anger, the slump of depression, or the cringe of fear many times and in many different forms.

Only humans, as we have noted, rear up on their hind legs, which takes all their most vulnerable parts and puts them literally 'up front' for all to see (or bite) (see Fig. 4.3). Subtly or



A

B

Fig. 4.30 A subject (A) just before and (B) just after a blank gun was fired behind him. The startle response is cross-cultural, and can be viewed as a sudden contraction of the SFL, which serves to protect the spine as well as all the sensitive parts on the front of the body shown in Figure 4.3. (Reproduced with kind permission from Frank Jones.)

obviously, people protect those sensitive parts: a retraction in the groin, a tight belly, a pulled-in chest. It is natural enough that when they feel threatened, humans should return toward a younger (primary fetal curve) or more protected (quadrupedal) posture.

There is, however, one notable exception to Feldenkrais's observation: negative emotion regularly produces hyperextension of the upper neck, not flexion (Fig. 4.30). We can see this very clearly in the reaction called the startle response (what Thomas Hanna referred to as the 'red light' reflex).

What we can see very clearly is that the startle response is not, strictly speaking, a total flexion response, but rather a shortening and tightening along the SFL. The clear indication of this general response is that the mastoid process is brought closer to the pubic bone. It acts to protect the organs along the front, but to retract the neck into hyperextension, bringing the head forward and down. There have been several theories put forward as to why this pattern of contraction may have been evolutionarily advantageous. The most tellingly obvious is that in the quadruped, where the SFL shows up more or less in its current form, contracting the SFL would bring the head closer to the ground without sacrificing the ability to see and hear (Fig. 4.31).

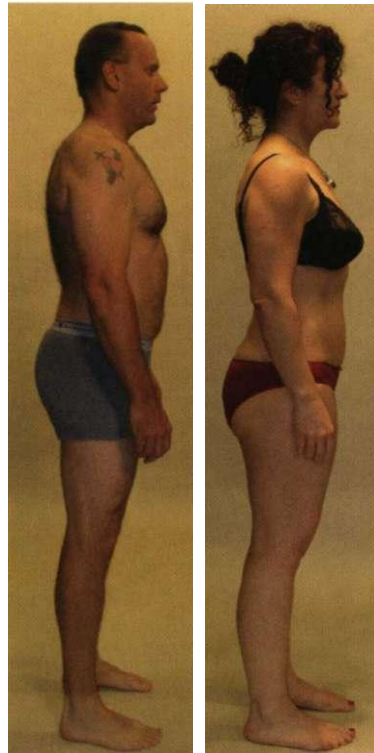The muscles of the Superficial Front Arm Line also frequently join in this response, bringing elbow flexion and shoulder protraction into this picture. The total posture, then, of the startled person involves rigidity in the legs, plus trunk and arm flexion, coupled with upper neck hyperextension.

The problem comes when the startled posture is maintained, which humans are perfectly and repeatedly capable of doing over an extended period (Fig. 4.32). This posture and its variants can affect nearly every human function negatively,





Fig. 4.31 In a quadruped, the SFL runs along the underside of the body, but passes up behind the head. When it contracts, the back arches in flexion, but the face and eyes stay in contact with the outside world.



A

B

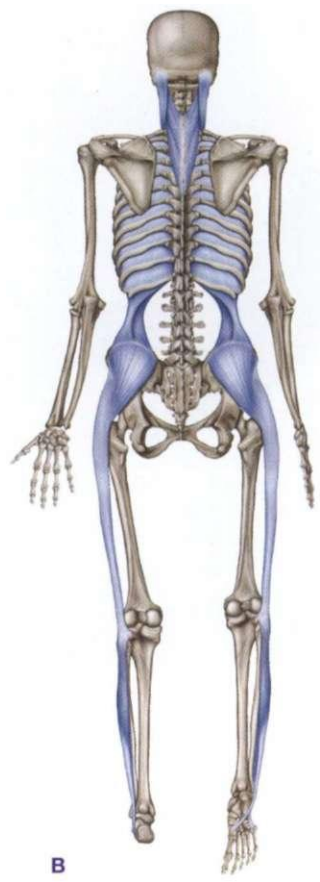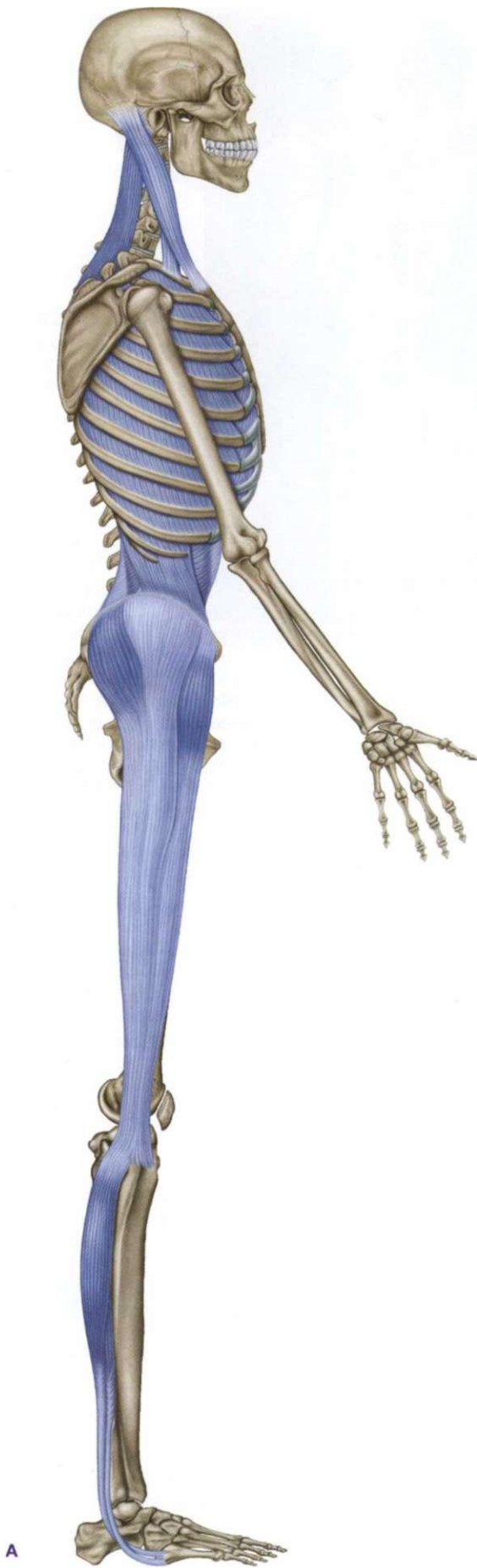Fig. 4.32 Humans can manage to maintain a postural version of the startle response, along with its underlying psycho-emotional state, for many years, until structural or psychological intervention (**A**). In some cases, a shortened portion of the SFL is compensated by a shortening in the SBL (**see Fig. 4.27**). We are looking for balanced tone between the tissues of the SFL and SBL as is approximated in (B), without regard, for the time being, to whether that tone is high or low. Get balance first, then go for proper tone. (DVD ref: Body Reading 101)

though breathing, in particular, is restricted by shortening of the SFL. Easy breathing depends on upward and outward movement of the ribs, as well as a reciprocal relationship between the pelvic and respiratory diaphragms. The shortened SFL pulls the head forward and down, requiring compensatory tightening in both the back and the front that restricts rib movement. Shortening in the groin, if the protective tightness proceeds beyond the rectus abdominis into the legs, throws off the balance between the respiratory and pelvic diaphragms, resulting in over-reliance on the front of the diaphragm for breathing.

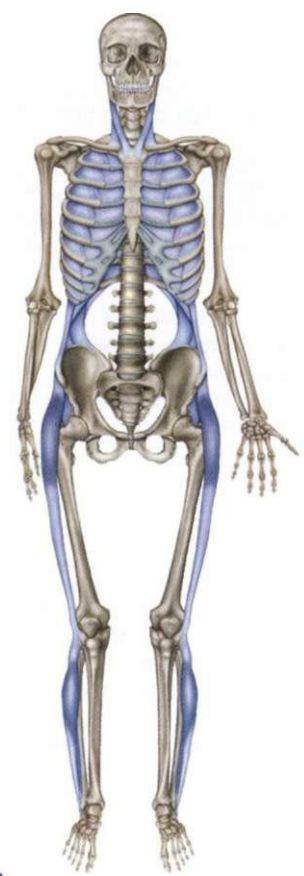The real, original startle response involves an explosive exhale; the maintained startle response shows a marked postural tendency to be stuck on the exhale side of the breath cycle, which in turn can accompany a trip through depression.

References

1. Feldenkrais M. *Body and mature behavior*. New York: International Universities Press; 1949.
2. Hanna T. *Somatics*. Novato, CA: Somatics Press; 1968.



B



C

Fig. 5.1 The Lateral Line.

The Lateral Line

5

Overview

The Lateral Line (LL) (Fig. 5.1) brackets each side of the body from the medial and lateral mid-point of the foot around the outside of the ankle and up the lateral aspect of the leg and thigh, passing along the trunk in a 'basket weave' or shoelace pattern under the shoulder to the skull in the region of the ear (Fig. 5.2 A,B/Table 5.1).

Postural function

The LL functions posturally to balance front and back, and bilaterally to balance left and right (Fig. 5.3). The LL also mediates forces among the other superficial lines - the Superficial Front Line, the Superficial Back Line, all the Arm Lines, and the Spiral Line. The LL fixes the trunk and legs in a coordinated manner to prevent buckling of the structure during any activity with the arms.

Movement function

The LL participates in creating a lateral bend in the body - lateral flexion of the trunk, abduction at the hip, and eversion at the foot - but also functions as an adjustable 'brake' for lateral and rotational movements of the trunk (Fig. 5.4).

The Lateral Line in detail

The LL manages to connect both the medial and the lateral side of the foot to the lateral side of the body. We begin - at the bottom again, simply as a convenience - with the joint between the 1st metatarsal and 1st cuneiform, about halfway down the foot on its medial side, with the insertion of the tendon of peroneus longus (Fig. 5.5). Following it, we travel laterally under the foot, and, via a channel in the cuboid bone, turn up toward the lateral aspect of the ankle. (The peroneal muscles were recently renamed as the 'fibularis' muscles. Here we use both terms interchangeably.)

The LL picks up another connection, the peroneus brevis, about halfway down the lateral side of the foot. From its insertion at the base of the 5th metatarsal, the peroneus brevis tendon passes up and back to the posterior side of the fibular malleolus, where the two peroneal muscles comprise the sole muscular components of the lateral compartment of the lower leg (see Fig. 2.3, p. 66). Thus both sides of the metatarsal complex are strongly tied to the fibula, providing support for the lateral longitudinal arch along the way (Fig. 5.6).

General manual therapy considerations

Although both of the other 'cardinal' lines have both a right and a left side, the two Lateral Line myofascial meridians are sufficiently far from each other and from the midline to exert substantially more side-to-side leverage on the skeleton than either the SFL or the SBL, into both of which the Lateral Line blends at its edges (Fig. 5.2A). The LL is usually essential in mediating left side-right side imbalances, and these should be assessed and addressed early in a global treatment plan.

Common postural compensation patterns associated with the LL include: ankle pronation or supination, ankle dorsiflexion limitation, genu varus or valgus, adduction restriction/chronic abductor contraction, lumbar side-bend or lumbar compression (bilateral LL contraction), rib cage shift on pelvis, shortening of depth between sternum and sacrum, shoulder restriction due to over-involvement with head stability.

The lateral arch

The lateral band of the plantar fascia was included in the Superficial Back Line (p. 76). Although it is technically not part of the LL per se, it merits a mention as a factor in lateral balance. If the peroneal compartment is so short as to evert the foot, or the foot is pronated in any case, the lateral band of the plantar fascia, running from the outer lower edge of the calcaneus straight forward to the 5th metatarsal base, will commend itself to work in the side-lying position, spreading the tissue between the two attachments (DVD ref: Lateral Line, 10:27-13:00).



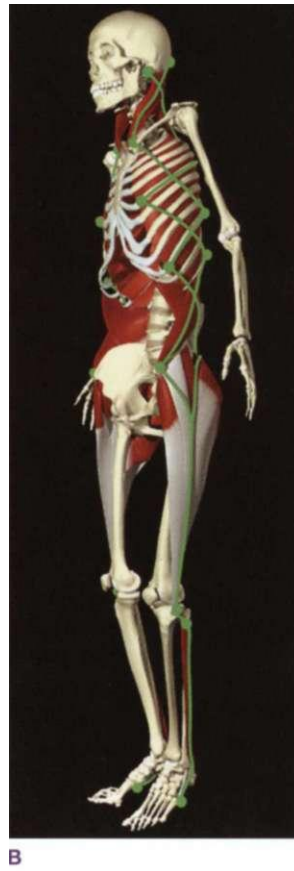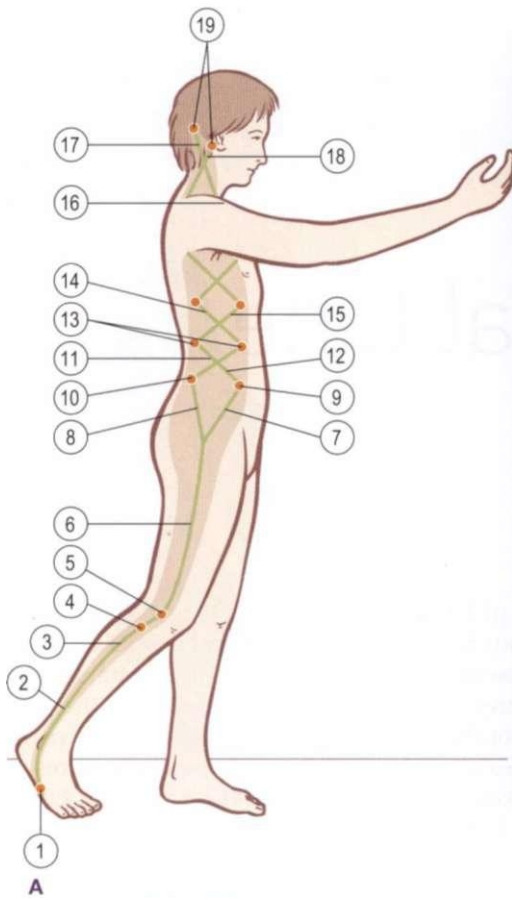


Fig. 5.2 (A) Lateral Line tracks and stations. The shaded area shows the area of superficial fascial influence. **(B)** Lateral Line tracks and stations using the Primal Pictures Anatomy Trains DVD-ROM, available from www.anatomytrains.com. (Image provided courtesy of Primal Pictures, www.primalpictures.com.)

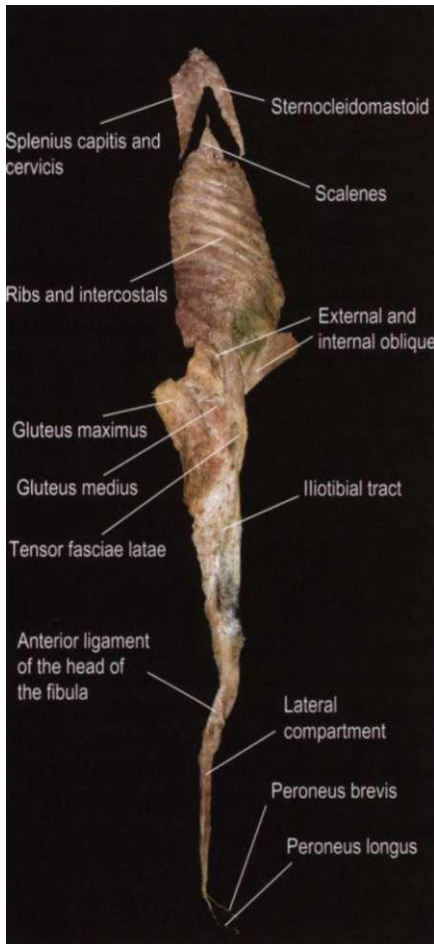


Fig. 5.3 Here we see a dissection, taken from an embalmed cadaver, of the Lateral Line, including the peroneals (fibularii), connecting tissues at the lateral knee, the iliotibial tract and abductors, which are fascially continuous with the lateral abdominal obliques. The ribs from the sternochondral junction in the front to the angle of the ribs posteriorly are included with their corresponding intercostal layers. The scalenes, attached to the upper two ribs, are included, but the quadratus lumborum is not. The upper two muscles, the sternocleidomastoid and splenii looking like a chevron, do not attach to the rest of the specimen because they both attach inferiorly near or at the midline, and the specimen takes only about 30° each side from the coronal midline. (DVD ref: **Early Dissective Evidence**)

Table 5.1 Lateral Line: myofascial 'tracks' and bony 'stations' (Fig. 5.2)

<u>Bony stations</u>	<u>Myofascial tracks</u>
Occipital ridge/mastoid process	17, 18 Splenius capitis/ sternocleidomastoid
1st and 2nd ribs	14, 15 External and internal intercostals
Ribs	11, 12 Lateral abdominal obliques
Iliac crest, ASIS, PSIS	8 Gluteus maximus
	7 Tensor fasciae latae
	6 Iliotibial tract/abductor muscles
Lateral tibial condyle	5 Anterior ligament of head of fibula
Fibular head	4 Peroneal muscles, lateral crural compartment
1 st and 5th metatarsal bases	

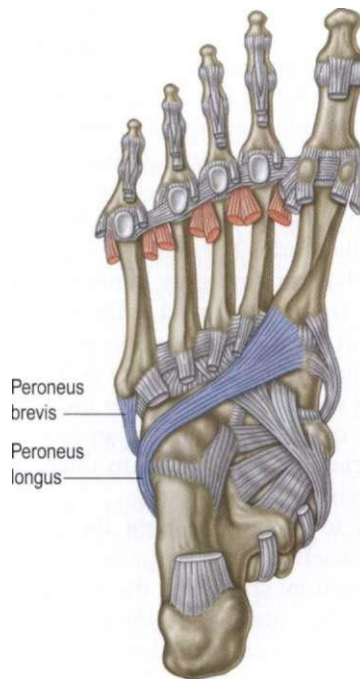


Fig. 5.5 The Lateral Line begins in the middle of the medial and lateral arches of the foot, at the bases of the 1 st and 5th metatarsals.

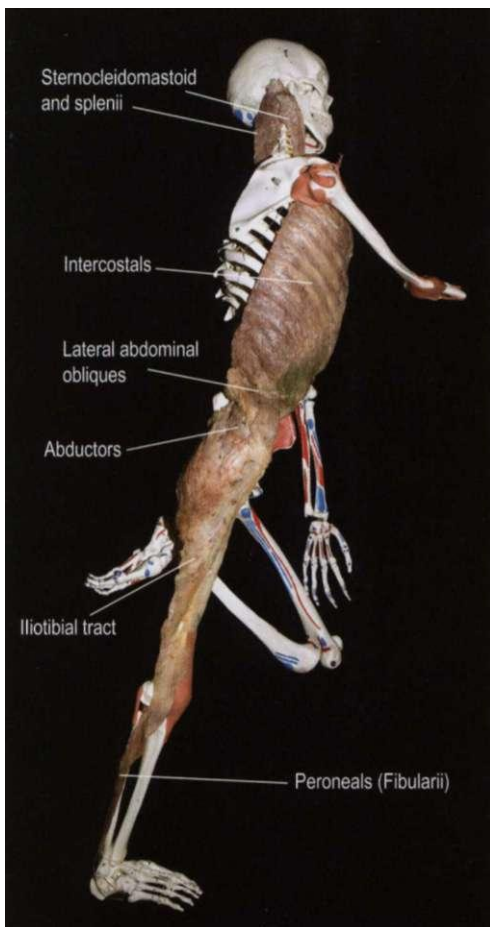


Fig. 5.4 Here we see the same specimen laid into a classroom skeleton. The position is not quite accurate because the scapula was fixed and could not be moved or removed, but this photo nevertheless gives a sense of how the Lateral Line is used to stabilize the body given our predominantly sagittal motivation.

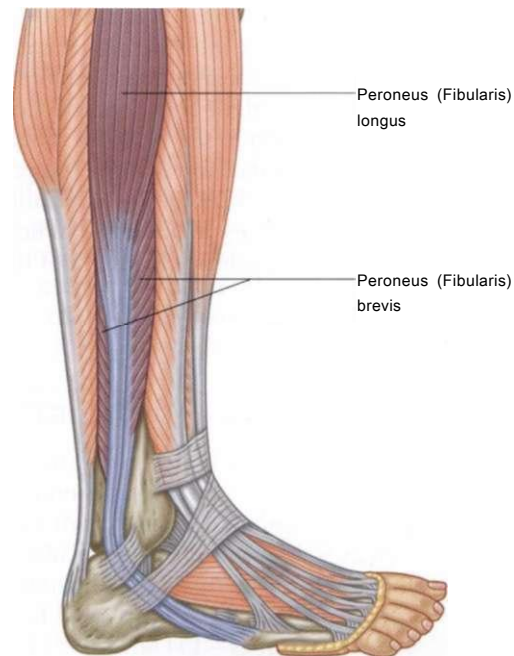


Fig. 5.6 The first track of the Lateral Line joins the metatarsal complex to the lateral side of the fibula, supporting the lateral longitudinal arch along the way.



The peroneals (fibulari)

The depth of the peroneus longus tendon on the underside of the foot and the brevity of the peroneus brevis make it impossible to accomplish anything useful with the LL below the malleolus, so we begin with the lateral crural compartment (Fig. 5.7). Peroneus longus and brevis blend together in this compartment, which is bounded by septa on either side. The anterior septum can be found on a line that runs roughly between the lateral malleolus and the front of the head of the fibula. The posterior septum, between the peroneals and the soleus, can be traced from just in front of the Achilles tendon up to just behind the fibular head. (See the palpation section below for more detail.) These septa and the overlying crural fascia are good places to open to relieve all forms of compartment syndrome.

As well as direct work to open these septa, the peroneal myofascial units themselves can be lengthened and softened by cross-fiber friction: spreading the tissue of this compartment both to the anterior and the posterior of the lateral line with fingertips or knuckles, while the client moves through the dorsiflexion-plantarflexion range (DVD ref: Lateral Line, 12:51-19:12).

The peroneals are often used posturally to prevent dorsiflexion, as in standing, and can create excessive eversion when they are too short.



The thigh

Although the peroneus brevis originates on the lower half of the fibula, the longus (and thus the fascial compartment) and this train of the LL continue on up to the fibular head. The obvious, straight-ahead connection from this point is to continue on to the biceps femoris, and this myofascial meridian will be explored in the chapter on the Spiral Line (Ch. 6). The continuation of the LL, however, involves a different switch, going slightly anterior onto the anterior ligament of the



5

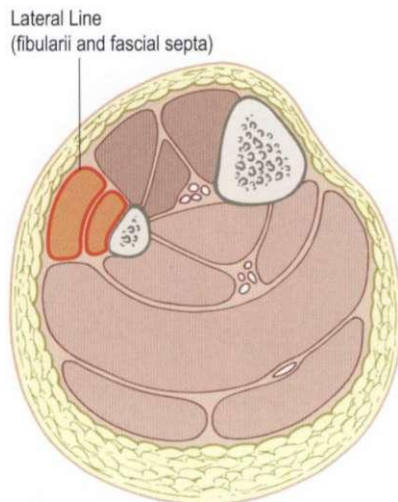
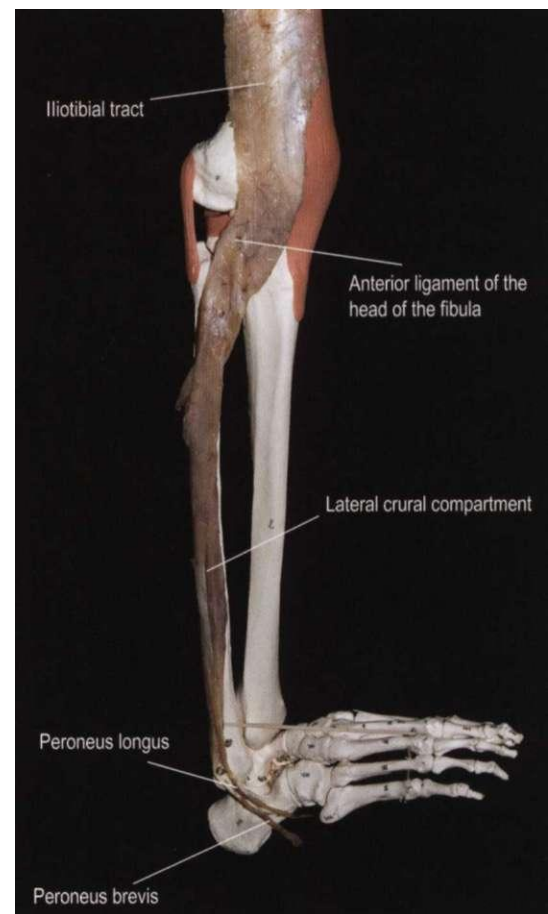
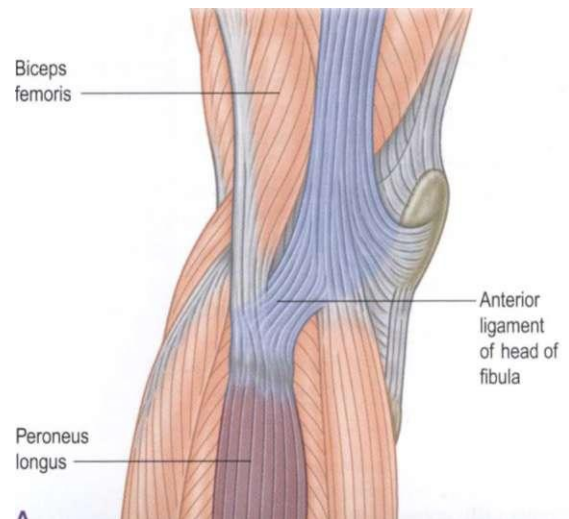


Fig. 5.7 The lateral compartment consists of the deeper fibularis brevis and the overlying fibularis longus. This compartment is bound by septa on both anterior and posterior aspects, separating it from the anterior compartment (SFL) and the superficial posterior compartment (SBL) respectively.

head of the fibula onto the tibial condyle and blending into the broad sweep of the inferior fibers of the iliotibial tract (ITT) (Fig. 5.8A and B).

The ITT begins its upward journey here, starting from the lateral tibial condyle as a narrow, thick, and strong



B

Fig. 5.8 (A) The Lateral Line goes from the lateral compartment via the anterior ligament of the head of the fibula to the bottom of the iliotibial tract. **(B)** In fact, however, the tissues of the lower end of the iliotibial tract spread to join to the tibia, the fibula, and the fascia of the lateral crural compartment.

band that can be clearly felt on the lateral aspect of the lower thigh. Like the Achilles tendon, the ITT widens and thins as it passes superiorly. By the time it reaches the hip, it is wide enough to hold the greater trochanter of the femur in a fascial cup or sling (**Fig. 5.9**). The tension on the ITT sheet, which is maintained and augmented by the abductors from above and the vastus lateralis from beneath, helps keep the ball of the hip in its socket when weight is placed on one leg. This arrangement also acts as a simple tensegrity structure to take some of the direct compressive stress of our body weight off the femoral neck.

The LL continues to widen above the trochanter, to include three muscular components: the tensor fasciae latae along the anterior edge, the superior fibers of the gluteus maximus along the posterior edge, and the gluteus medius, which attaches to the underside, the profound side, of the ITT's fascial sheet (**see Figs 5.3 and 5.4**).

All these myofasciae attach to the outer rim of the iliac crest, stretching from the ASIS to the PSIS. This entire complex is used in the weighted leg in every step to keep the trunk from leaning toward the unweighted leg. In other words, the abductors are less often used to create abduction, but are used in every step to prevent hip adduction. This involves a stabilizing tension along the whole lower LL.

The iliotibial tract

In terms of its role in the LL, the ITT can be considered to begin at a point at the bottom (the tibial condyle, but really the whole outside of the knee), spreading upward to three points at the top (the ASIS, PSIS, and the strong fascial attachment at the middle of the iliac crest).

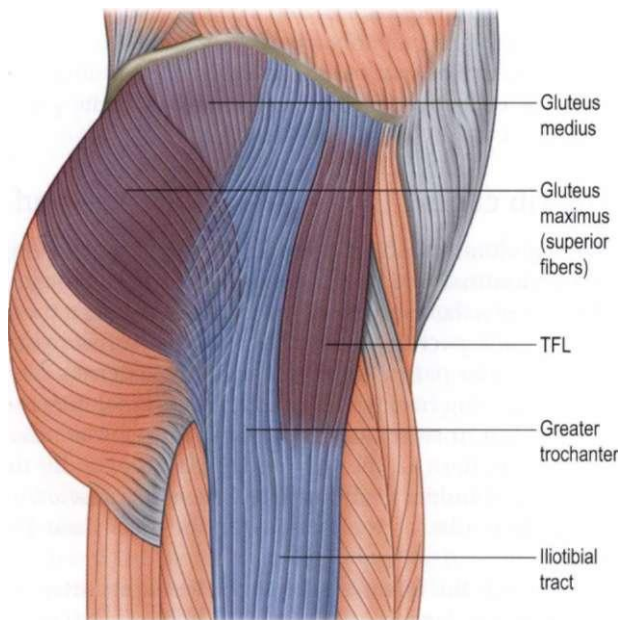


Fig. 5.9 The second major track of the Lateral Line consists of the iliotibial tract and the associated abductor muscles, the tensor fasciae latae, the gluteus medius, and the superior fibers of the gluteus maximus.

Depending on the postural angle of the pelvis, it may be advisable to work the leading or following edge of the ITT more strongly. Left-right imbalances in ITT tone will be present in lateral tilts of the pelvis. Imbalance between the ITT and adductor muscles will be present in *genu varum* and *valgum* (laterally or medially shifted knees).

The ITT can be worked in a manner similar to the peroneals: with the client side-lying and the knee supported, the practitioner can work either up or down the ITT and associated abductors, spreading laterally from the lateral midline with knuckles or loose fists. Since fibers of the ITT are meshed with the circumferential fibers of the fascia lata, it can also be useful to work the side of the leg vertically. Use the flat of the ulna, placing one just under the iliac crest, the other just above the greater trochanter. Slowly but deliberately bring the lower elbow toward the knee, stretching the ITT. The client can help by bringing the knee forward and back (**DVD ref: Lateral Line, 19:13-25:51**).

Searching fingers can assess: Is the anterior edge of the ITT thicker, more fixed, or tighter than the posterior edge? If so, then the angle of the forearm on the leg can be adjusted, like changing the angle of a violin bow to sound another string, to emphasize either the anterior portion or the posterior portion.

The abductor muscles and the greater trochanter

The abductor muscles themselves, tensor fasciae latae and the three superficial gluteal muscles, can be worked generally by working with the point of the elbow or well-placed knuckles to move the tissue in a radiating pattern away from the greater trochanter toward and up to the iliac crest. You may wish to work these tissues differentially in the case of anteriorly tilted pelvis, say, where the anterior tissues, acting as flexors, will be very much shorter and denser. Do not neglect the 'facets' of the greater trochanter itself, which can be very productive of new and freer movement (**DVD ref: Deep Front Line, Part 1: 25:52—30:57**).

Derailment

As we move from the appendicular portion to the axial portion of the LL, we face another derailment - a break with the general Anatomy Trains rules. To carry on, we would need to find sheets or lines of myofasciae that continued to fan outward and upward from these points, or at least from the front and back extremes (the ASIS and PSIS). The ITT - in fact, the whole lower LL - looks a bit like the letter 'Y' (**Fig. 5.9**); to continue we would have to keep going up and out on the upper prongs of the 'Y' (as in **Fig. 5.1 OA**). We will find these continuations in the Spiral and Functional Lines (Chs 6 and 8). If, however, we look at how the myofasciae arranges itself along the lateral aspect of the trunk from here on up, we find that the fascial planes cross back and forth in a 'basket weave' arrangement (**Figs 5.2 and 5.1 OB**).

Although these sharp changes in direction break the letter of the Anatomy Trains rules, the overall effect of



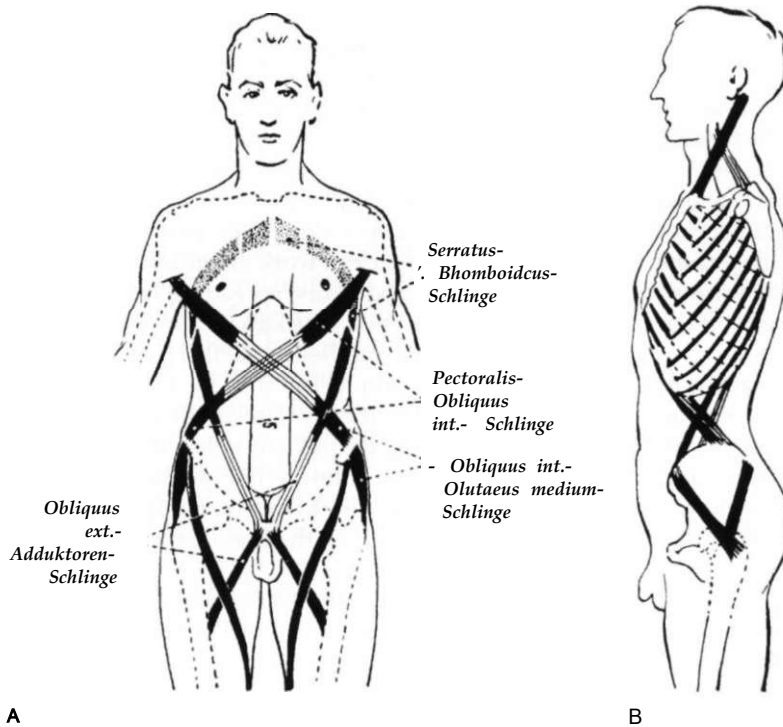


Fig. 5.10 Anatomy Trains rules would require that the 'Y' of the iliotal tract continue out and around the body in spirals as in (A), but the actuality of the Lateral Line is that it starts a series of crisscrossing 'X's up the lateral aspect of the trunk, essentially like shoelaces sewing the front and back together via the sides (B). (Reproduced with kind permission from Benninghoff and Goertler 1975.)

these series of 'X's (or diamonds, if you prefer) is to create a mesh or net which contains each side of the body as a whole - a bit like the old Chinese finger traps. The resultant structure is a wide net of a line that contains the lateral trunk from hip to ear (**see Fig. 5.2**).

The iliac crest and waist

The upper edge of the iliac crest provides attachments for the latissimus dorsi and the three layers of the abdominal muscles. The outer two of these, the obliques, form part of the LL, and are fascially continuous with the ITT over the edge of the iliac crest (**see Fig. 5.3**). The external oblique attaches to the outside edge of the iliac crest, the internal oblique to the top of the iliac crest, and the transversus abdominis (which is part of the Deep Front Line) to the inside edge. Practitioners can affect different layers by adjusting their pressure, angle, and intent accordingly.

In terms of the LL, the iliac crest is a frequent site of connective tissue accumulation, and 'cleaning' these layers off the bone can be helpful in coaxing length from the LL (**DVD ref: Lateral Line, 30:50-35:38**). Direction matters here: in cases where the pelvis is in anterior tilt, the tissue needs to be moved posteriorly; in cases of posterior tilt, the inverse is true. In cases with neutral pelvic tilt, tissue can be spread in either direction from the midline (**DVD ref: Lateral Line, 35:39-37:23**).

When the rib cage is shifted posteriorly relative to the pelvis, the lower lateral ribs move closer to the posterior aspect of the iliac crest. In these cases, it is necessary to focus more on the internal oblique part of this local 'X', to lift the ribs superior and anterior. In the far rarer case where these lower ribs move down and forward toward the pelvis, the external oblique would need to be lengthened.

Instead of following the same direction, then, let us turn a sharp switchback from the PSIS on the most posterior fibers of the internal oblique, which head upward and forward to the lower ribs. Laid over this is the more superficial track from the ASIS, consisting of the posterior fibers of the external oblique, which go upward and backward. The fibers of both these muscles are nearly vertical along the lateral aspect of the trunk, but still take an oblique direction so that they form an 'X' (**Fig. 5.11**). If you pinch your waist at the side, the fibers of the external oblique, running up and back from the ASIS, will be more superficial. Deep to this will be the internal oblique, palpably running up and forward. This myofascia can be worked individually in rotational patterns, or collectively just to lift the ribs off the pelvis (**DVD ref: Lateral Line: 37:24-*1:00**).

The rib cage

These abdominal obliques attach to the lower floating and abdominal ribs. We can move up from here using both the ribs themselves and the muscles between them. The lateral aspect of the rib cage is likewise crisscrossed with a similar pattern of myofasciae: the external intercostals running backward and up, the internal intercostals running forward and up. These muscles continue the same pattern all the way up the rib cage, under the overlying shoulder girdle and its associated muscles, up to the first ribs at the bottom of the neck (**see Fig. 5.10B**).

Although the intercostals follow the same pattern as the obliques, they are much shorter, being interspersed with ribs, so they do not respond in the same manner. The fascia over the ribs can be stretched or moved with broad sweeps. The intercostals can be affected somewhat by a fingertip inserted between the ribs from the



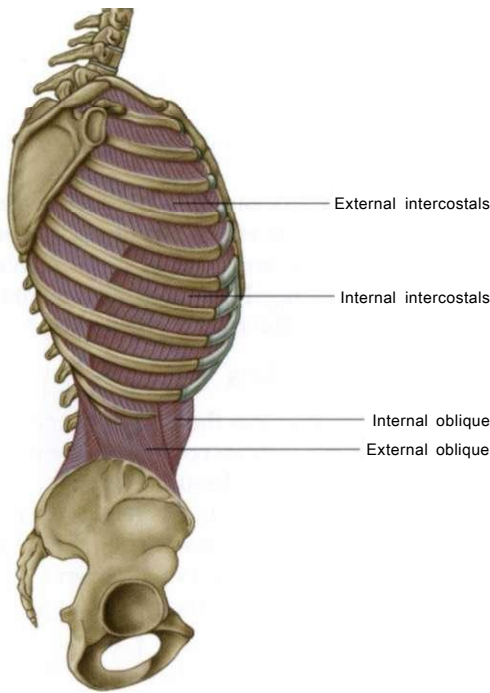


Fig. 5.11 The abdominals form a large 'X' on the side of the abdomen, and the intercostals.

outside, but the amount of change is limited (DVD ref: Lateral Line, 41:00-43:42).

A hand from the outside can be a cue for clients to help themselves by breathing the ribs open from the inside. Do not neglect the lateral aspect of the upper ribs, which can be reached by putting the flat of the hand on the ribs with the fingertips into the armpit between the pectoralis and latissimus muscles. By sliding the hand gently into the armpit, you can reach the side of the 2nd and 3rd ribs, either for direct manual work or to bring awareness there for increased movement in breathing (DVD ref: Deep Front Line, 42:45-44:27).

The neck

In the neck, from the ribs to the skull, the 'X' pattern repeats itself, and once again the forward and up portion lies deep to the backward and up portion (**Fig. 5.12**). The splenius capitis, which originates on the spinous processes of the lower cervicals and upper thoracics and ends on the lateral border of the occiput and posterior portion of the temporal bone, forms the back leg of the 'X'.

We have already addressed the sternocleidomastoid (see Ch. 4 or DVD ref: Superficial Front Line, 46:58-52:45), which can also be worked side-lying. We have noted that this myofascial unit participates in the SFL as well, emphasizing the role of the LL in mediating between the SFL and SBL and the connections among the lines: if the SFL is pulled downward, the LL will be adversely affected.

The counterpart to the SCM in the LL is the splenius capitis, which is more difficult to affect in this position.

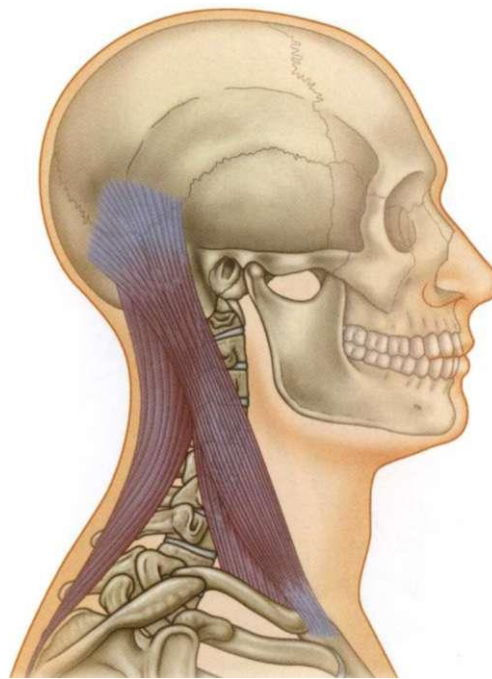


Fig. 5.12 In the neck, the final 'X' of the Lateral Line consists of the sternocleidomastoid muscle (especially the clavicular head) on the outside with the splenius capitis muscle forming the other leg underneath.

To lengthen the splenius, have your client supine. Support the occiput in one hand, and reach under the occiput with the other hand to the side you wish to affect. Grip your fingers against the bone just where the mastoid process joins the occipital ridge, so that one fingertip is just above the ridge, one just below. Slowly but firmly bring the tissue back toward the midline, as the client turns his head in time with you toward the side you are working (DVD ref: Lateral Line, 57:55-59:06).

The Lateral Line and the shoulder

Clearly, the LL and the arms are related: the arms hang off the side of the body, covering the lateral ribs and the myofascia of the LL. Please note, though, that the LL itself does not involve the shoulder girdle directly; in the trunk it is a line of the axial skeleton. This is a conceptual separation only - the tissues of the arm lines of course blend right in to the tissues of the Lateral Line.

This conceptual separation has an important practical aspect, however, because it is our contention that support of the head is more properly accomplished as an entirely axial event, so that the shoulders are absolutely free of any role in supporting the head. The tensional balance between the SCM and splenii is sufficient to accomplish outer lateral support of the head, if the underlying structure of the ribs is in place.

There are a couple of Arm Line myofasciae, however, that can get inadvertently caught up in what should be the Lateral Line's job - balancing support of the head. One of these is the levator scapulae, which con-



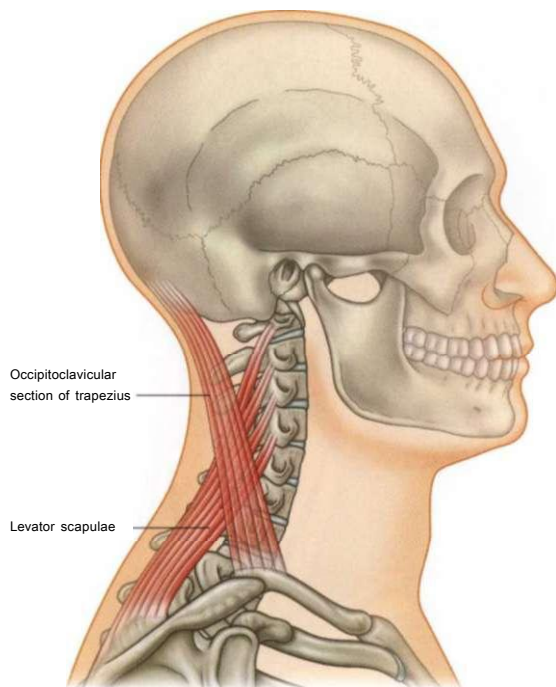


Fig. 5.13 The levator scapulae would seem to fulfill the same requirements as the splenius as part of the Lateral Line, but this is a common 'mistake' that the body sometimes makes, involving the shoulder in the stability of the trunk. A similar 'mistake' is made in substituting the anterior edge of the trapezius for the sternocleidomastoid.

nects the transverse processes of the cervicals with the apex of the scapula. This muscle parallels the splenius and is well situated to counterbalance any anterior pull on the cervicals or head (**Fig. 5.13**). The problem is that the scapula is not a firm base of support, and the result of reversing the origin and insertion to use levator scapulae as 'cervicus-preventus-going-forwardus' is often that the scapula begins to be pulled up toward the back of the neck. Clients will often report pain and trigger points at the lower attachment of the levator, ascribing it to 'stress', when the actual cause is their reaction to the ubiquitous 'head forward' posture (**Fig. 5.14**).

The leading edge of the trapezius, attached to the outer edge of the clavicle, can similarly substitute for the more stable and axial sternocleidomastoid, again drawing the shoulder assembly into the support of the head. This pattern can now be understood as a misuse of the LL, which should underlie and be relatively independent of the shoulder assembly. It is when the dynamic balance of the 'X's of the LL get disturbed that the levator or trapezius try to take over the job. (See also the discussion of the levator and trapezius in their proper role, as part of the Arm Lines, in Ch. 7, p. 158.)



General movement treatment considerations

Almost any kind of lateral flexion of the trunk and abduction of the leg will engage the LL, stretching it on one side and contracting it on the other.

Since the muscles of the LL create lateral flexion, restrictions in the myofascia or excess muscle tensions will show up in postures involving lateral flexion or in restrictions to free movement on the opposite side, i.e. restriction of lateral flexion to the right usually resides in the left Lateral Line.

Since the LL from the trochanter to the ear is a series of switchbacks, the involvement of this line with spiral and rotational movement is worth noting, as we have in the section below on walking. Rotational movement will be taken up more fully in the next chapter.

Assessment and stretches

- A quite simple way to assess the LL is to stand in a doorway (or anywhere where you or the client can get a firm grip on a bar or something steady overhead) and hang from the hands (**Fig. 5.15**). For self-observation, you can feel where the tissues of the LL resist the call of gravity. When observing a client, look for asymmetries in the two sides as the person hangs from the arms.
- In terms of overall stretches, the half-moon stretch, a simple lean to one side with the arms overhead, is the most obvious overall stretch for the LL (see also **Fig. 10.37**, p. 222). The LL links into the Arm Lines seamlessly, but for now it is not important to our purposes that the arm be stretched. It is, however, very necessary to be aware of whether the upper body leans forward or backward from the hip (in other words, a rotation of the trunk), as the best assessment depends on achieving pure lateral flexion, without sagittal flexion or extension. The head moves away from the neck, the neck from the rib cage, and the ribs should fan away from each other. As the waist opens, the ribs move away from the hip, the iliac crest moves away from the trochanter.
- The Triangle pose and its variants (see **Fig. 4.17B** and Ch. 10) are a good stretch for the lower part of the LL; the inversion at the ankle ensures a stretch in the peroneals as the subtalar joint is passively

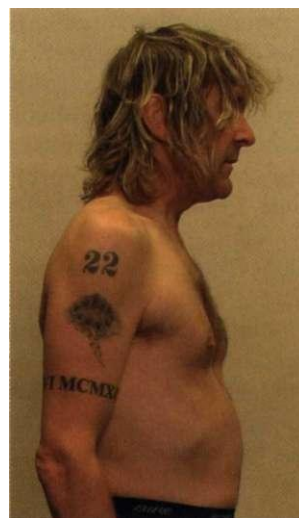

Fig. 5.14 The 'head forward' posture necessitates the involvement of the shoulder girdle with the stability of the head on the trunk, a common but inefficient compensatory pattern.

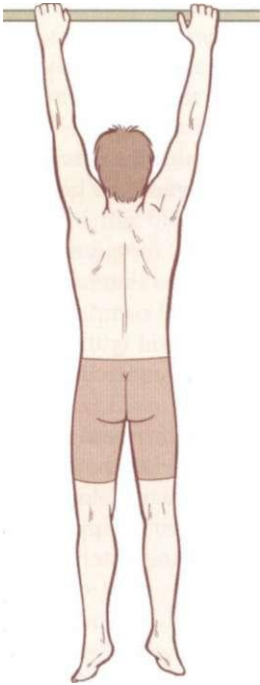

Fig. 5.15 Aside from simply viewing the body from the front or back, having your client hanging from a chinning bar allows you to see underlying patterns of imbalance in the two Lateral Lines.

inverted. In other words, the distance between the outside of the foot and the iliac crest is maximized. In general, inversion and dorsiflexion of the foot done at the same time will stretch the peroneals, while eversion and plantarflexion is created by their contraction.

- An interesting stretch for the ITT-abductor portion of the line is to stand with one foot placed in front of and outside the other. Do a forward bend, and the ITT of the posterior leg will be stretched.
- The lateral portion of the trunk and neck may be stretched through a variety of common stretches, such as *Parighasana* or the Gate pose in yoga.

In movement terms, the lateral flexion movement through the spine is a primary foundation stone for walking. Lying prone on the floor and developing an even eel-like 'wiggle' contributes to integration through this line. In a therapeutic setting, the practitioner can observe this side-to-side movement and either use it as an assessment for where to work, or use a hand to bring the client's attention to where movement is not happening.

Discussion 1

The Deep Lateral Line

There are two sets of myofascia that need to be considered for a complete view of the lateral line, even though they clearly belong to (and will be further discussed with) the Deep Front Line (Ch. 9). Together, these two muscle sets - actually lateral elements of the Deep Front Line - comprise a 'Deep Lateral Line', which is included here because working with these structures will frequently improve your results with LL issues, including breathing and bilateral asymmetries. (DVD ref: Lateral Line 52:57-58.10)

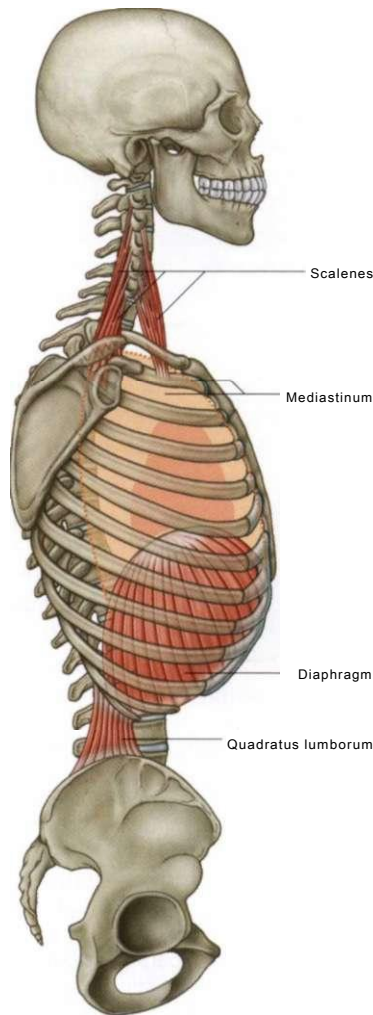


Fig. 5.16 Two deeper concomitants of the Lateral Line, although both structures are technically part of the Deep Front Line, are the scalenes and the quadratus lumborum, which suspend the rib cage between them.

The quadratus lumborum (QL) is part of a layer deep to the transversus abdominis and thus not fascially connected to the superficial abdominal muscles of the LL. We cannot, however, ignore its congenial relationship with the LL. Running essentially from the iliac crest up to the 12th rib, it is the real paraspinous muscle in the lumbar. The erectors (SBL), though they (iliocostalis especially) can be involved in lateral flexion, are more often employed to create extension and hyperextension. The rectus abdominis (SFL) creates primarily trunk flexion. The psoas (the medial portion of the Deep Front Line in this area, see Ch. 9) can create a complex of moves, including flexion, hyperextension, lateral flexion, and rotation in the lumbar. The QL, however, is uniquely placed to mediate a fairly pure lateral flexion. Therefore any work with the LL should also include some attention to the tone and fascia of the QL, even though it is not, by Anatomy Trains rules, directly part of the LL.

At the other end of the rib cage, we have a deep layer in the neck, the scalenes and associated fascia. The scalenes form a kind of skirt around the cervical vertebrae, acting to create or stabilize lateral flexion of the head and neck, in a similar fashion to the QL. We can imagine the rib cage (and indeed the lungs) as being suspended between the QL pulling from one end and the scalenes pulling from the other (Fig. 5.16).

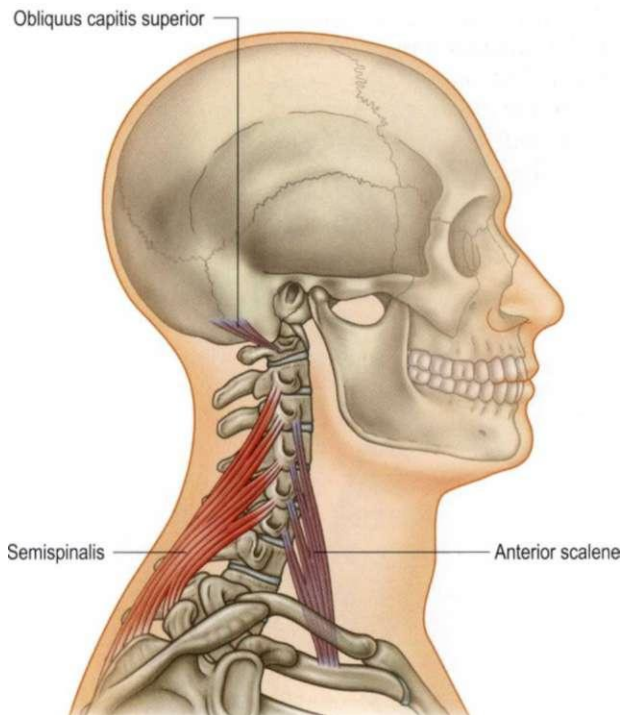


Fig. 5.17 Another inner leg of lateral stability consists of the anterior scalene linked to deeper structures of the back of the neck, such as the upper part of semispinalis and (pictured here) obliquus capitis superior. The lower part of semispinalis (pictured) acts as an antagonist to the anterior scalene.

We can also see another leg of an 'X', parallel to but deeper than the SCM. This innermost layer consists of the anterior scalene muscle, running up and back from the 1st rib to the transverse processes of the middle cervicals. The pull of this muscle forms a functional connection, if not a fascial continuity, with the suboccipital muscles, most particularly the obliquus capitis superior or upper semispinalis capitis (**Fig. 5.17**). These muscles take the occiput into protraction or anterior translation, and the upper cervical joints into hyperextension, while the anterior scalene pulls the lower cervicals into flexion. The combination helps to contribute to a familiar form of the 'head forward' posture.



Palpating the Lateral Line

You can find the originating points of the LL on both the medial and lateral sides of the foot (**Fig. 5.5**). On the medial side, we are looking for the distal insertion of peroneus (fibularis) longus. Although it is hard to touch directly, we can locate it by starting with the big toe and walking our fingers up its metatarsal extension until we come to a bump on the top inside of the foot about two inches in front of the ankle. From here, walk your fingers down the inside of the foot toward the underside, keeping in contact with the little valley that represents the joint between the 1st metatarsal and 1st cuneiform. As you pass to the underside of the foot, you will encounter the overlying tissues which make the deep peroneal tendon hard to palpate, but the end point of this muscle, and thus the beginning of the

LL, lies just on the inferior and lateral part of this joint.

The other origination of the LL is easily felt: run your fingers up along the lateral edge of the foot from the little toe. You will encounter the clearly palpable knob of the 5th metatarsal base, and it is from here that the peroneus brevis makes its way up toward the back of the fibular malleolus.

By everting and plantarflexing the foot, you can feel these two tendons just below the lateral malleolus, passing behind it to fill the lateral compartment of the leg (**Fig. 5.6**). Of the two, the brevis is the more prominent, the longus disappears rapidly into the flesh below the malleolus.

To find the septa that border this compartment is very simple: for the anterior septum, start with the fibular malleolus, and walk your fingers upward along the bone (**Fig. 5.6 and 5.7**). As the bone begins disappearing into the flesh, look for a valley between the anterior and lateral compartments. It may feel like a valley, or alternatively, in the very tight or very toxic, like a string of small beads or pearls. These 'pearls' (principally calcium lactate and other metabolites) have no value, and can be worked out with vigorous manual therapy, resulting in increased freedom of movement for the recipient (with the occasional post-session feeling of slight nausea for the client). Movement can be very helpful to your search if the valley (the compartmental division) is difficult to feel. Plantarflexion will engage the peroneals, while stretching the anterior compartment muscles; dorsiflexion and toe extension will engage the muscles of the anterior compartment and stretch those in the lateral compartment. By placing your fingerpads on the outside of the leg where you think the valley is, you will be able clearly to distinguish the area where these two opposing movements meet. That place is the septum between the two compartments.

Obviously, this anterior crural septum will end just in front of the fibular head. If you draw a mental line between the lateral malleolus and just in front of the fibular head, the septum will lie close to this line.

Many people confuse the soleus with the peroneals, because in plantarflexion the squeezed soleus often bulges out on the lateral side of the leg, looking for all the world like the peroneals. To avoid this error, start in the clear division between the fibular malleolus and the Achilles tendon. Work upward, staying in the valley between them. The lateral compartment is very small at the inferior end, so use eversion to pop those tendons so that you can stay clearly behind the lateral compartment. This septum should end just behind the fibular head. Here, the lateral compartment (and thus the peroneals) attaches to the lateral aspect of the head of the fibula, whereas the soleus attaches to the posterior aspect of the fibula (**Fig. 5.8**).

By alternately pressing the toes into the floor and lifting them while your hands explore the area of the head of the fibula, you will be able clearly to distinguish the tibialis anterior (anterior compartment, SFL) and the soleus (superficial posterior compartment, SBL), and by

default, the top of the peroneus longus in-between (lateral compartment, LL).

While the tendon of the lateral hamstring is the most prominent structure attaching to the head of the fibula, the LL continues by way of the anterior ligament of the head of the fibula (**Fig. 5.8A**). This fascial link can be felt coming into tension just anterior and superior to the head of the fibula when the leg is actively abducted while lying on the side, or supine, when the leg is medially rotated and the foot is lifted from the ground (**Fig. 5.8B**). It forms a clearly palpable connection between the head of the fibula running slightly anterior toward the lateral tibial condyle and on into the ITT.

The ITT, the next fascial element of the LL, is clearly palpable on the lateral aspect of the thigh at or just above the femoral condyle, as a strong superficial band. Follow it upward to feel it widen and thin out along the thigh superficial to the muscular feel of the vastus lateralis, which can be contracted by extending the knee.

Above the level of the greater trochanter, the LL includes more muscular elements: the tensor fasciae latae can be easily felt by placing your fingers just under the lateral lip of the ASIS, and then medially rotating the hip (turning the knee in) (**Fig. 5.9**). The upper fibers of the gluteus can be similarly felt by placing your fingers under the lateral aspect of the PSIS and then laterally rotating and abducting the hip.

Between these two, the strong central part of the ITT can usually be felt passing up to the middle of the iliac crest, with the gluteus medius muscle lining it on the inside. This muscle can be clearly felt in abduction.

To feel the parts of the abdominal obliques involved in the LL, pinch the waist along the lateral aspect (**Fig. 5.11**). Providing that muscle can be felt, the more superficial external oblique will have a 'grain' that runs down and forward toward the hip. A deeper pinch contacts the internal oblique whose 'grain' runs the other way: down and back from the ribs to the hip. Performing small trunk rotations is helpful in differentiating these two layers. Both muscles are closer to vertical out here on the side than they are in the anterior abdominal region, but the differences in direction can still be clearly felt.

The external intercostals can be felt between the ribs, especially just superior to the attachments of these abdominals, before the ribs are covered over by various layers of shoulder musculature. The internal intercostals are difficult to feel through the externals, but can be felt by implication in forced expiration or in rotation of the rib cage to the same side as the palpation.

The three layers of myofasciae in the neck are all accessible to palpation. The SCM, clearly palpable on the surface, has already been covered in our discussion of the SFL (**Fig. 5.12**). The splenius capitis is most easily palpated by putting your hands on your client's head so that the palpating fingers are just under and slightly posterior to the mastoid processes, but with your hand arranged so that your thumbs can offer some resistance to head rotation (**DVD ref: Lateral Line, 58:00-**

59:05). Have your client rotate his head, and you will feel the splenius contract on the same side he is turning toward, just under the superficial (and usually quite thin) trapezius muscle. You can also do this palpation on yourself.

The deepest layers of neck myofasciae involved in the LL require precision and confidence to palpate. To find the anterior scalene, have your client lie supine, and gently lift the SCM forward with the fingernail side of your fingers, and press in gently with your fingertips to feel the solidity of the motor cylinder (the scalenes and the other muscles surrounding the cervical vertebrae) (**Fig. 5.16**). The most lateral of these muscles is the middle scalene (**DVD ref: Lateral Line, 1:00:25-1:01:47**). Slide the pads of your fingers along the front of the motor cylinder, not pressing into it, not shying away from it, with your ring finger just above the collar bone. (The client will feel pain or tingling in his fingers or a drawing pain in the scapula if you are pressing on the brachial plexus; if so, move.) The half-inch band under your fingertips is the anterior scalene. Have the client breathe deeply; the anterior scalene should engage during, and for many especially at the top of, the inhalation (**DVD ref: Lateral Line,**

The other end of this line, the obliquus capitis superior, can be felt by bringing your hands around to cup the occiput in your palms, so that your fingers are free and under the back of the neck. Curl your fingers under the occiput and insinuate your fingertips under the occipital shelf, mindful that you must feel through the trapezius and the underlying semispinalis muscles. Come to rest with fingertips under the occiput, with three fingertips in a row, preferably the ring, middle, and index fingers, with the ring fingers almost touching at the midline, and the index fingers medial to where the occiput starts to curve around toward the mastoid process. Sizes of hands and skulls vary, but for most the six fingertips will be comfortably together on either side of the midline. The occipital attachment of the obliquus capitis is just under your index finger, and can be tractioned by pinning the index finger and pulling posteriorly and superiorly with a gentle hand.

The other end of the 'Deep Lateral Line', the quadratus lumborum (QL), can be palpated in the side-lying client by hooking one's fingertips over the superior edge of the iliac crest near the ASIS and walking the fingers back toward the PSIS. At or behind the midline, you will encounter the leading edge of the QL fascia, often very tough, which leads the fingers away from the crest toward the lateral end of the 12th rib - a clear indication that you have accurately found the QL. This will not work if your fingers are walking back in the top or outside of the iliac crest; because of the depth of the QL, your fingertips must be on the inner rim of the iliac crest to reach this fascial layer.

To work the QL toward greater length and responsiveness, work along this outer edge, freeing it from the iliac crest toward the 12th rib (**DVD ref: Lateral Line, 52:58-57:09**).

Discussion 2

The Lateral Line and fish: vibration, swimming, and the development of walking

Sensing vibration

The top of the LL embraces the ear, located in the temporal bone on the side of the head; indeed, the ideal of Lateral Line posture is always described as passing through the ear. The entire ear, of course, contains structures sensitive to vibratory frequencies from about 20 to 20000 Hz, to gravitational pull, and to acceleration of motion. The ear is a sophisticated rendering of vibratory sensors that are set along the entire lateral line of many ancient and some modern fish, such as sharks, who 'hear' the thrashing of their prey from these lines (**Fig. 5.18**). Later vertebrates seem to have concentrated most of their vibratory sensitivity at the leading end of the organism. Some connection seems to remain, however, in the way that left/right differences can reflect balance problems more than front/back differences.

Swimming

Almost all fish swim with a side-to-side motion. This obviously involves the contraction of the two lateral muscle bands in

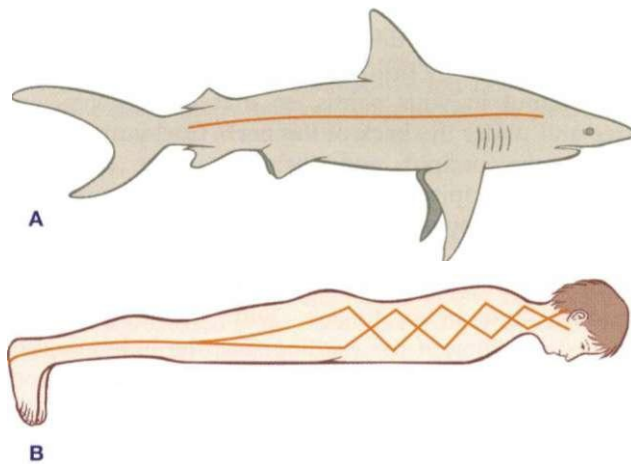


Fig. 5.18 Some fish such as sharks have a line of vibratory sensors running down their lateral line. Humans seem to have concentrated most of that vibratory sensitivity in the ear at the top of the line.

succession. Perhaps the original creator for this movement (and thus the deepest expression of the lateral line) is found in the tiny intertransversarii muscles that run from transverse process to transverse process in the spine. When one side contracts, it stretches the corresponding muscle on the other side (**Fig. 5.19**). The spinal stretch reflex, an ancient spinal cord movement mediator, causes the stretched muscle to contract, thus stretching the first muscle on the opposite side, which contracts in its turn, and so on. In this way, a coordinated swimming movement (in other words, coordinated waves running down the lateral musculature) can occur with minimal involvement by the brain. A lamprey eel, a modern equivalent to ancient fish, can be decerebrated, and when it is placed in flowing water, it will still swim upstream in a blind, slow, but coordinated fashion, working only through spinal mechanisms - the stimulation from the vibratory sensors on the lateral skin linking to the stretch reflex.

Of course, corresponding movements remain in humans. There are many movements such as walking that work through reciprocal stretch reflexes. The side-to-side motion itself is not so visible in regular adult walking, but its underlying primacy is indicated in the infant at about three to six months, when the side-to-side movement of creeping begins. This movement will later be replaced by more sophisticated crawling movement, which combines flexion/extension and rotation along with the lateral flexion.

Walking

When we assess adult walking, excessive side-to-side motion is seen as an aberration. We expect to see the head and even the thorax moving along fairly straight ahead, with most of the side-to-side accommodation handled at the waist and below. From the point of view of myofascial meridians, the entire LL is involved in such adjustments, and should be considered in correcting deviations of too much or too little lateral flexion in the underlying pattern of walking.

For our primary forward motivating force we humans use flexion/extension, sagittal motion (as the dolphins and whales do as well), not side-to-side motion as the fish do. Our walking involves a little side-to-side accommodation, as we have noted, but the contralateral motion of human walking involves a lot of rotation, especially through the waist and lower rib cage, which mediate between opposed oscillations of the pelvic girdle and the shoulder girdle.

The series of 'X's or the 'basket weave' that characterizes the LL in the trunk and neck are perfectly situated to modulate and 'brake' these rotatory movements. Therefore, the woven structure of the LL in the trunk can be seen as partial arcs of spirals that are used like springs and shock absorbers to

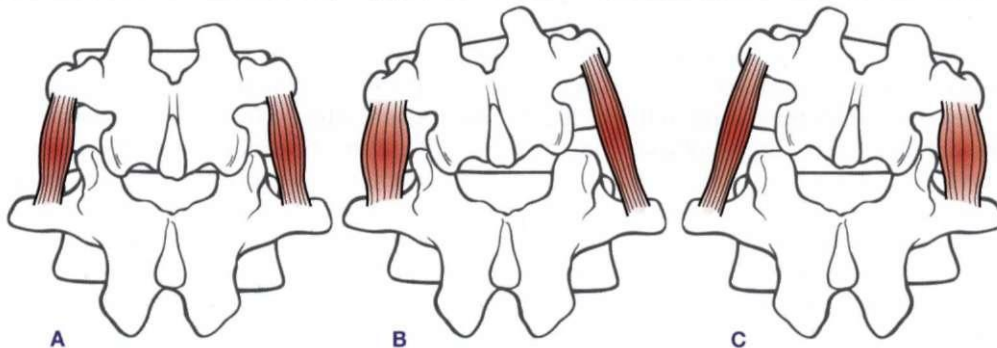


Fig. 5.19 Lateral movement, the kind involved in the swimming motions of a fish or forward motion of an eel or snake, consists of reciprocal reflexes flowing down the musculature in waves. When one side is contracted, the other side is stretched, inducing a contraction in it, which stretches the first side, so it contracts, and so on and on upstream.



Fig. 5.20 The intercostals can be seen as operating like a watch spring, winding and unwinding the rib cage reciprocally with each step. As you take a step forward with the right foot and the rib cage rotates to the left, the external intercostals on the right are being contracted, while the internal intercostals on the left are contracting to create the movement. Their complements are being stretched, preparing to take the rib cage back the other way. (DVD ref: body Heading 101)

smooth out the complexities of walking. In this way, we can see the slanted direction of the intercostals as acting almost like a watch spring, storing up potential energy when the rib cage is twisted one way, releasing it into kinetic energy as the rib cage rotates in the other direction (Fig. 5.20). I have found interesting results considering the intercostals primarily as muscles of walking rather than as muscles of breathing (an idea first given to me by Jon Zahourek of Zoologik Systems).

Lateral vs sagittal movement

In the early 1980s, in a suburb near London, I was just beginning a Saturday seminar to a group of aerobic instructors when the cheerful cacophony of a school band drowned me out. I went over to the window to see, and called my students over to witness a simple but telling phenomenon. We were looking down from the 6th floor at a Remembrance Day parade. From above, we could see the parade starting out, with the heads of the World War II veterans clearly moving from side to side, while the heads of the teenage band members were clearly bobbing up and down (Fig. 5.21).

The message was clear: the older veterans had diminished accommodation in the lateral lines around the waist (and perhaps some degenerative arthritis in their hips as well). They were thus compelled, as they

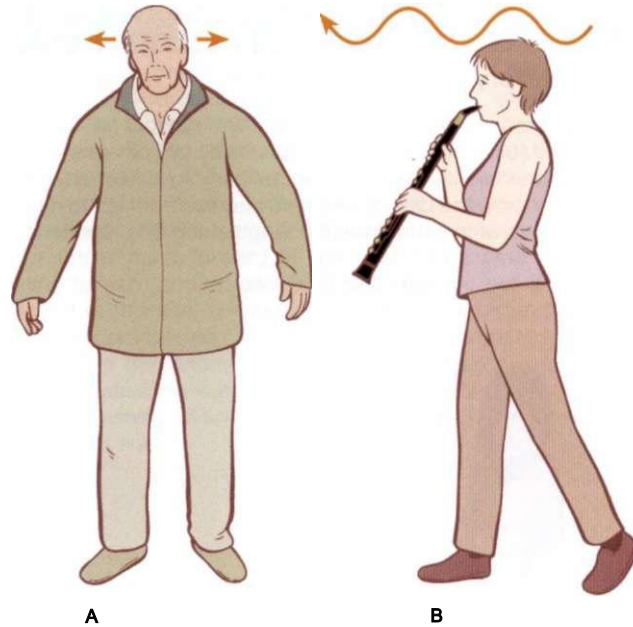


Fig. 5.21 Older people tend to walk with a greater side-to-side movement of the head due to the decreasing ability of the hips and waist to accommodate shifting weight. Teenagers tend to walk with the head steady in the right-left dimension, but not infrequently their heads will shift up and down as they walk, due to chronic tension in the flexors of the hips.

'marched', to shift their weight from one foot entirely onto the other, causing their heads to move from side to side. The teenagers carrying the instruments were doing just fine on the side-to-side accommodation, but (we surmise) the collision between increased hormone levels and Britain's general reticence about sex had possibly caused a little tension in the hip flexors at the front of the pelvis, so that all the up and down motion in the feet was being transferred right through the hip up to the spine and head.

Whatever the cause, the veterans were exhibiting LL problems as a group, and the teenagers were showing SBL and SFL restrictions.

Discussion 3

The Lateral Line and seduction

If presenting the SFL, in all its sensitivity and erogenous zones (see Ch. 4, Discussion 2, p. 112) is essentially a statement of trust, or a 'Yes', and presenting the SBL, the carapace ('turning your back') is essentially an expression of protection, or 'No', what is the meaning of the presentation of the side, or Lateral Line? The answer is 'Maybe'. Therefore, presentation of the Lateral Line can be associated with the complex reeling in known as seduction. This ties into issues that link safety to sensuality and sexuality. Any perusal of the ads or fashion shoots in *Vogue* or the *Sunday Fashion Supplements* will reveal how often presentation of the body's side is used to sell clothes, perfume, jewelry, make-up, or the other accoutrements of the play of seduction (Fig. 5.22). (This psychobiological idea comes courtesy of Anatomy Trains instructor James Earls.)

Discussion A

The summary lateral 'X'

Since we are more or less bilaterally symmetrical (at least in the musculoskeletal system), it is a fairly simple matter to examine our clients from the front or back to detect any differences in how the Lateral Lines are handled from left to right, and correct any imbalance by lengthening the shortened

tissues. Looking at the 'basket weave' of the LL from the side is a bit more complex, but just as useful. We can assess the individual 'X's as they run along the trunk, or we can take an overview and assess the trunk as a whole.

To do this: look at your client from the side (or yourself in a mirror or photo). Imagine that one leg of the 'X' runs from the spinous process of the 7th cervical vertebra to the pubic bone, while the other runs from the sternal notch to the apex of the sacrum (Fig. 5.23). Is one of these legs significantly



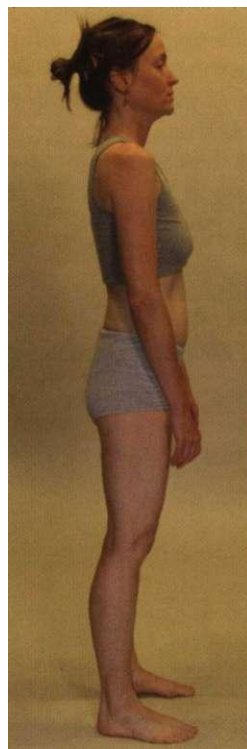
Fig. 5.22 A full frontal view of the body says 'yes', while a body turned away says 'no'. A body halfway in between says 'maybe', and therefore the Lateral Line is often presented in advertisements that want to portray the attitude of seduction. (© iStockphoto.com, reproduced with permission. Photograph by Chris Scredon.)

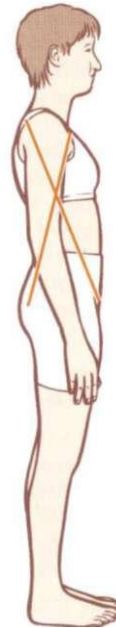
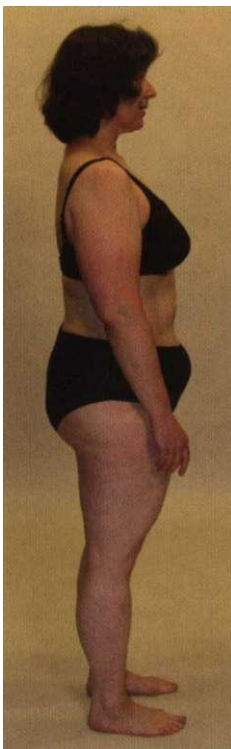
Fig. 5.23 An imaginary 'X', one leg drawn from the spinous process of C7 to the pubic bone and the other drawn from the sternal notch to the top of the sacrum, is a simple way to assess the summary of 'X's across the trunk.



A



B



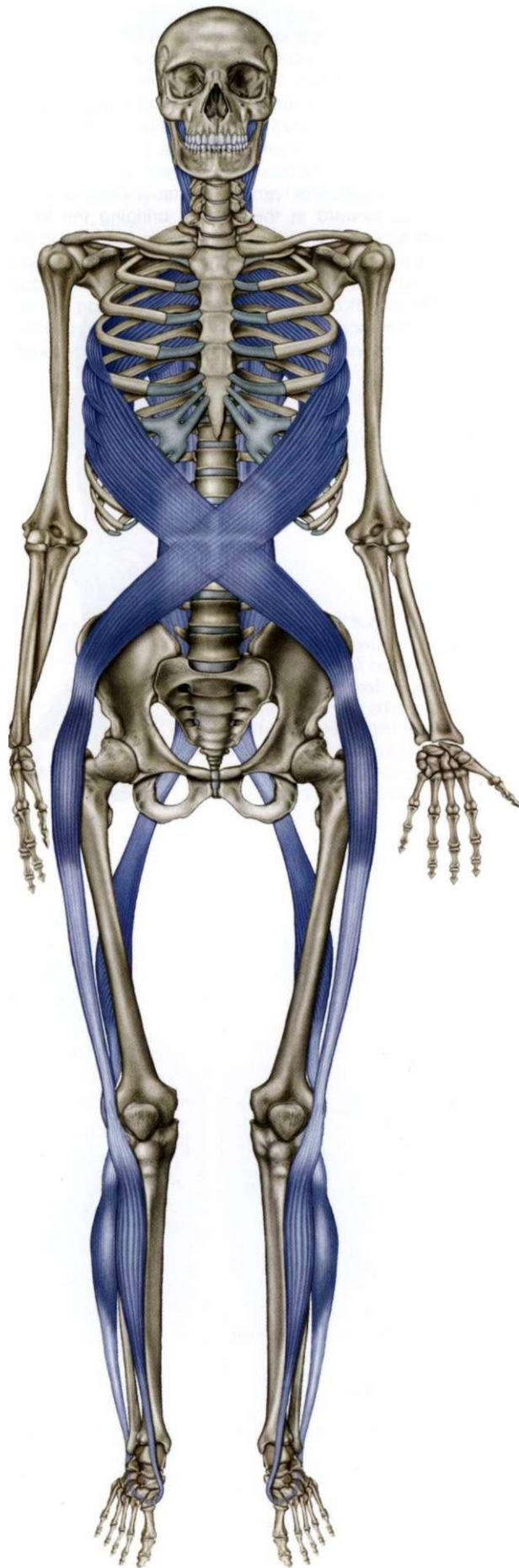C

Fig. 5.24 A balanced structure shows an even balance of all the 'X's in the trunk (A). Having the sternum fall close to the sacrum is a very common Western pattern (B). Pulling the sacrum forward and sticking the chest out, as in a military posture, simply changes the compensatory pattern, but not the underlying structure (C). Much rarer is the pattern where the rib cage collapses forward on the pelvis, bringing C7 closer to the pubic bone.

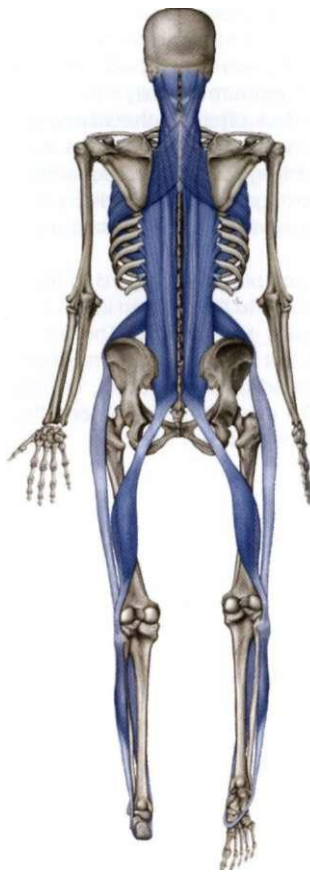longer than the other? Nearly all of those with a depressed or 'burdened' body type will display a sternum-to-sacrum line that is visibly shorter than the 7th cervical-to-pubis line (**Fig. 5.24B**). The 'military' type of posture usually throws the sternum well up and forward, but often at the expense of bringing the sacrum up and forward also, so that the line is not lengthened, merely moved (**Fig. 5.24C**). Infrequently (at least in Western cultures) the rib cage will be shifted down and forward compared to the pelvis, and the sternum-sacrum line will be the longer of the two.

Even though the more common pattern in regard to this 'X' is that the leg from the sternal notch to the sacrum is too short, it is difficult to reach the tissues responsible. The internal oblique is one possible avenue, but often this pattern is buried in the root of the diaphragm, quadratus lumborum, or mediastinal structures (see Ch. 9). An approach through breathing awareness is often more effective and less invasive.

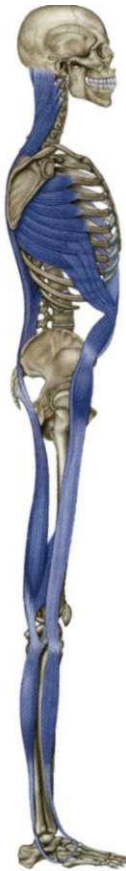With your client standing sideways in front of you, place your hands on the manubrium of the sternum and on the low back at the sacrolumbar junction. Follow your client's breathing for a few cycles, noticing whether and how your hands are moved on the inhale. Then encourage your client to move your two hands apart from each other on the inhale, and allow them to fall back on the exhale. Some clients, by increasing the inhale, will increase the excursion between your hands, others will work hard but only succeed in bringing the upper hand forward at the cost of bringing the lower hand forward and up as well, resulting in no net gain in the length of this line. By moving your hands a bit and by your encouragement, you can help the client induce an actual change in the length of the line, the sternum going up and forward while the sacrum drops. Ask your client to repeat the move a number of times between sessions to reinforce length along this line.



A



B



C

Fig. 6.1 The Spiral Line.

The Spiral Line

6

Overview

The Spiral Line (SPL) (Fig. 6.1) loops around the body in a double helix, joining each side of the skull across the upper back to the opposite shoulder, and then around the ribs to cross in the front at the level of the navel to the same hip. From the hip, the Spiral Line passes like a 'jump rope' along the anterolateral thigh and shin to the medial longitudinal arch, passing under the foot and running up the back and outside of the leg to the ischium and into the erector myofascia to end very close to where it started on the skull.

Postural function

The SPL functions posturally to wrap the body in a double spiral that helps to maintain balance across all planes (Fig. 6.2A-C/Table 6.1). The SPL connects the foot arches with the pelvic angle, and helps to determine efficient knee-tracking in walking. In imbalance, the SPL participates in creating, compensating for, and maintaining twists, rotations, and lateral shifts in the body. Depending on the posture and movement pattern, especially relative to the weighted and unweighted leg, forces from the legs can travel up the same side or cross to the opposite side of the body at the sacrum. Much of the myofascia in the SPL also participates in the other cardinal meridians (SBL, SFL, LL) as well as the Deep Back Arm Line (see Ch. 7). This insures the involvement of the SPL in a multiplicity of functions, and that dysfunction in the Spiral Line will affect the easy functioning of these other lines.

Movement function

The overall movement function of the SPL is to create and mediate spirals and rotations in the body, and, in eccentric and isometric contraction, to steady the

trunk and leg to keep it from folding into rotational collapse.

The Spiral Line in detail

For convenience, we will change tactics to begin detailing the SPL from the top, keeping in mind that *in vivo* any of these lines can, and do, pull from either end (or outward or inward) from nearly any place along their length.

The SPL begins on the side of the skull, at or above the lateral part of the nuchal line, at the junction between the occiput and temporal bone, sweeping down and in on the splenius capitis muscle. On its way, it picks up the splenius cervicis, meeting the spinous processes from C6 to T5 (Fig. 6.3A).

Crossing over the tips of the spinous processes with a continuous fascial sheet, we pick up the rhomboids major and minor on the other side as part of the same fabric (see Figs In. 10 and 2.7, pp 5 and 67). (We could also imagine a mechanical link from the splenius to the smaller serratus posterior superior which underlies the rhomboids and attaches to the ribs just lateral to the erectors - Fig. 6.3B). The rhomboids carry us along the same line of pull over to the medial border of the scapula, thus connecting the left side of the skull to the right scapula and vice versa (Fig. 6.4).

From the medial border of the scapula, there is a direct fascial connection to the infraspinatus and subscapularis, which we will explore with the Arm Lines in the next chapter. The SPL, however, continues on a less obvious but nevertheless very strong fascial connection with the serratus anterior, deep to the scapula (Fig. 6.5). In dissections we have done, it seems that the connection of the rhomboids to the serratus anterior is stronger and more 'meaty' than the connection of either muscle to the scapula itself.

The rhomboids connect to a goodly portion of the serratus, which is a complex muscle with many internal



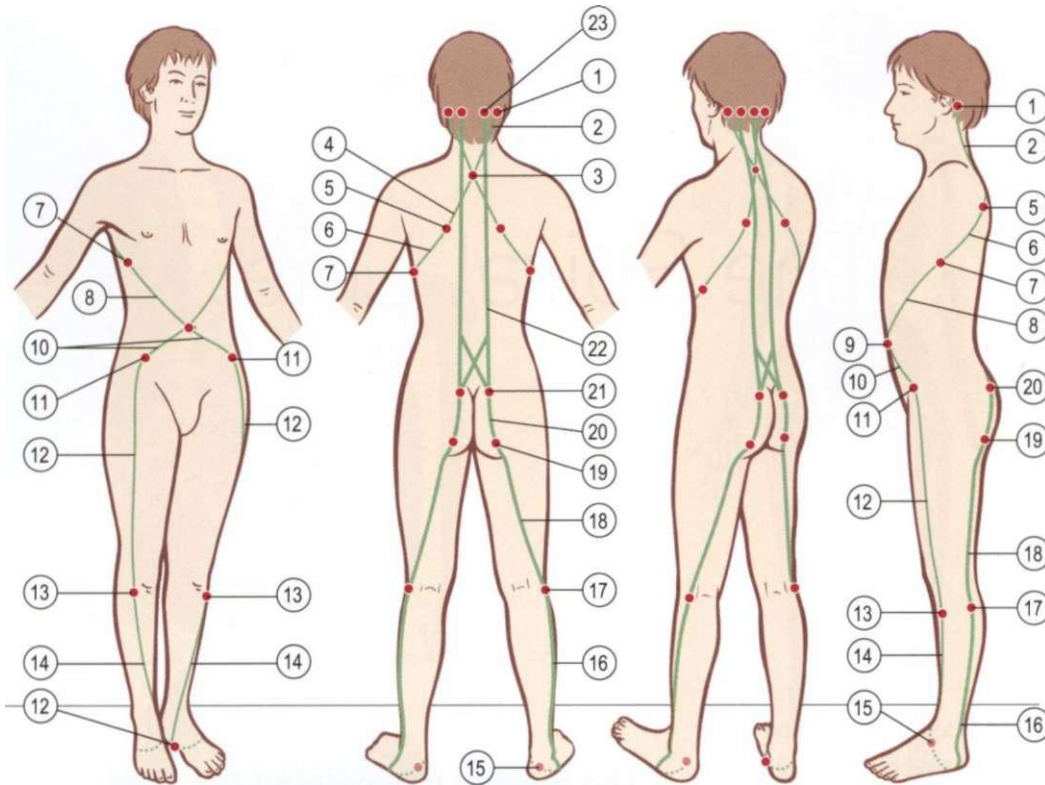
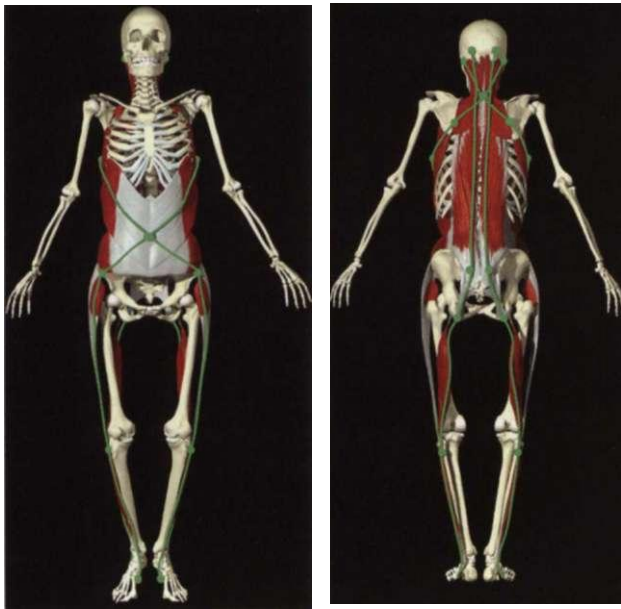


Table 6.1 Spiral Line: myofascial 'tracks' and bony 'stations' (Fig. 6.2)

Bony stations	Myofascial tracks
Occipital ridge/mastoid process atlas/axis TPs	1
	2 Splenius capitis and cervicis
Lower cervical/upper thoracic SPs	3
	4 Rhomboids major and minor
Medial border of scapula	5
	6 Serratus anterior
Lateral ribs	7
	8 External oblique
	9 Abdominal aponeurosis, linea alba
	10 Internal oblique
Iliac crest/ASIS	11
	12 Tensor fasciae latae, iliotibial tract
Lateral tibial condyle	13
	14 Tibialis anterior
1st metatarsal base	15
	16 Peroneus longus
Fibular head	17
	18 Biceps femoris
Ischial tuberosity	19
	20 Sacrotuberous ligament
Sacrum	21
	22 Sacrolumbar fascia, erector spinae
Occipital ridge	23



B **C**

Fig. 6.2 (A) Spiral Line tracks and stations. (B) and (C) Spiral Line tracks and stations as seen by Primal Pictures. (B and C images provided courtesy of Primal Pictures, www.primalpictures.com.) (DVD ref: Primal Pictures Anatomy Trains)

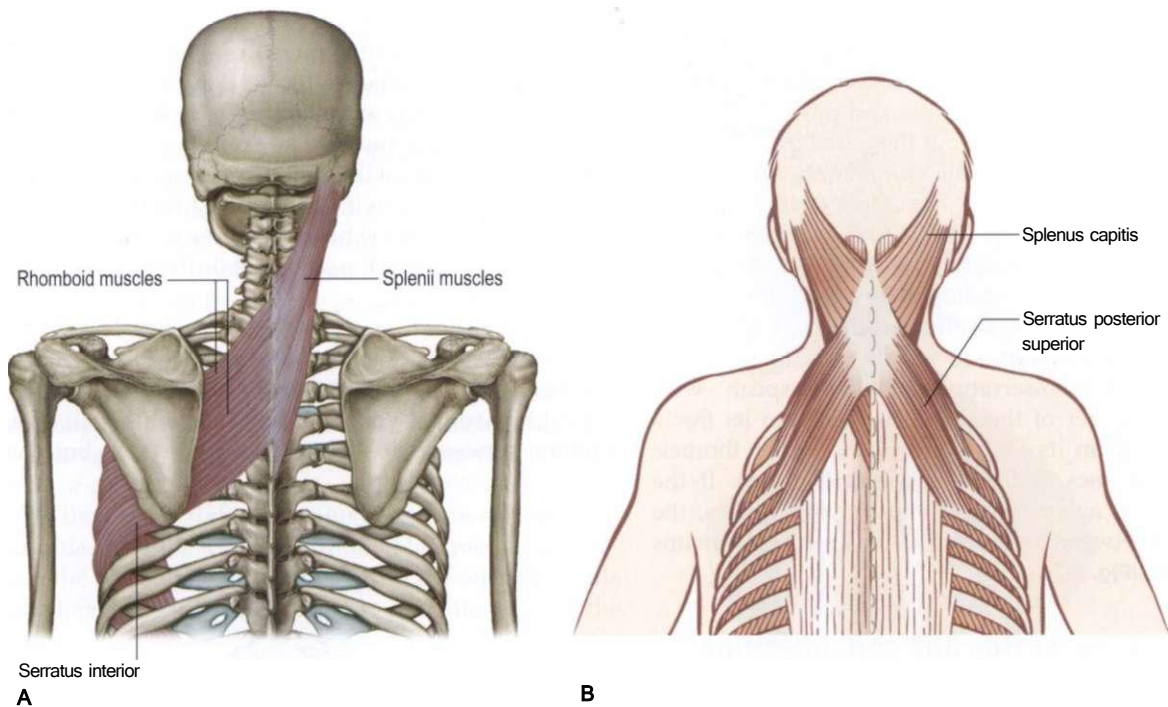


Fig. 6.3 The opening myofascial continuity of the Spiral Line is a fascial connection over the spinous processes (A) to the rhomboids that go to the scapula. A branch line connection could also be made (B) to the serratus posterior superior muscle, which goes underneath the rhomboids but over the erector fascia to attach to the ribs.

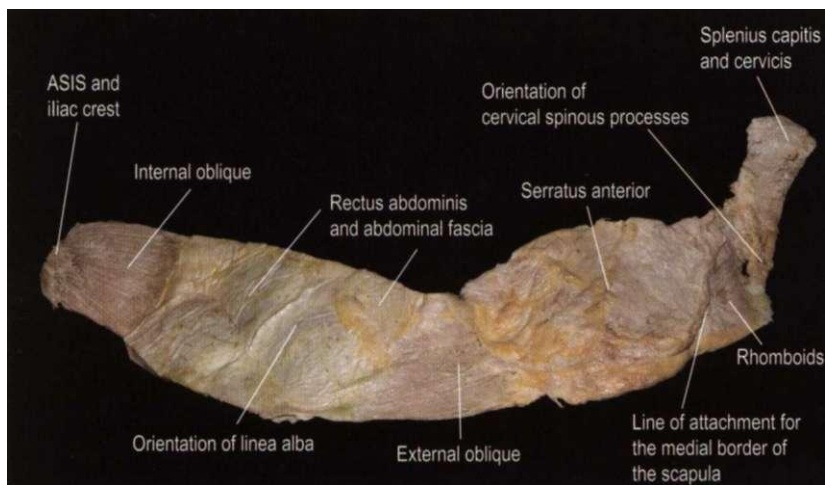


Fig. 6.4 A dissection of the upper Spiral Line, showing the clear fascial continuities from the skull to the hip, by way of the splenii, rhomboids, serratus anterior, and abdominal fasciae containing the oblique muscles. The scapula has been removed from this specimen, leaving a visible line, but no break in the rhombo-serratus part of the sheet. (DVD ref: **Early Dissective Evidence**)

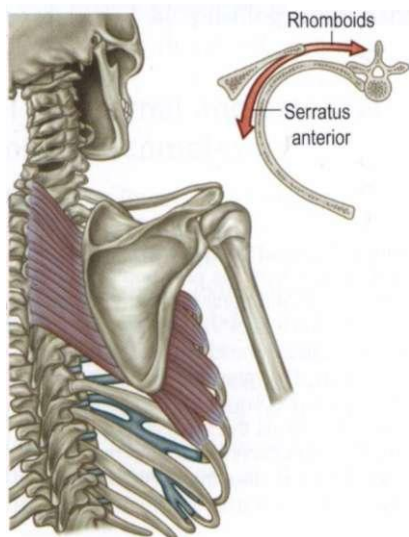


Fig. 6.5 Taken together, the rhomboids and serratus anterior, the next continuity in the Spiral Line, form a myofascial sling for the scapula. Thus the scapula is suspended between them, and its position will depend on the relative myofascial tone of these two. (Adapted from Calais-Germain 1993.)



fiber directions. The SPL track as described above passes primarily through the lower part of the serratus anterior muscle. The serratus originates on the profound side of the medial border of the scapula and passes to attachments on the first nine ribs, but the part that attaches to ribs 5 through 9 provides the spiral continuity we are following (see Discussion 2, the Upper Spiral Line and Forward Head Posture, p. 144, to follow another of the directions within the serratus). In dissection, the fascial continuity with the rhomboids is very clear. If we could fold the glenoid section of the scapula back to expose the serratus, we would see clearly that there is one muscle - the rhombo-serratus muscle, so to speak - with the medial border of the scapula glued into its fascia about halfway in its journey from the upper thoracic spinous processes to the lateral ribs (Fig. 6.6). If the scapula is cut away from the underlying tissues, the connection between the rhomboids and serratus remains very strong (Fig. 6.7).



General manual therapy considerations

The SPL cuts across many of the other lines as a 'parasite', meaning that most of the structures involved in the SPL also take part in other lines as well. Techniques for the splenius capitis, tensor fasciae latae, and fibularii (peroneals) can be found in Chapter 5 (or the Lateral Line DVD). There is more on the rhomboids with the Deep Back Arm Line in Chapter 7, on the biceps femoris and erector spinae in Chapter 3 (or the Superficial Back Line), and on the tibialis anterior and abdominal muscles in Chapter 4 (or the Superficial Front Line DVD). Here in this chapter we focus on additional techniques aimed at areas exclusive to the Spiral Line.

Common postural compensation patterns associated with the SPL include: ankle pronation/supination, knee rotation, pelvic rotation on feet, rib rotation on pelvis, one shoulder lifted or anteriorly shifted, and head tilt, shift, or rotation.

side imbalance that can be corrected manually. Taking the medial to lateral differences first: a common pattern is that the rhomboids are locked long (overstretched, eccentrically loaded) with the serrati locked short (concentrically loaded), pulling the scapula away from the spine. This pattern will show up commonly in body-builders, and those with a tendency to the kyphotic spine (anterior thoracic bend). In these cases, the therapist wants to lengthen the serrati while the client engages the rhomboids.

Seat your client on a low table or a bench with his feet on the floor and the knees lower than the hips. Have him bend slightly forward at the mid-chest. Move in behind him so that your chest is close to his back. (Use a pillow between you if this is uncomfortable, but you

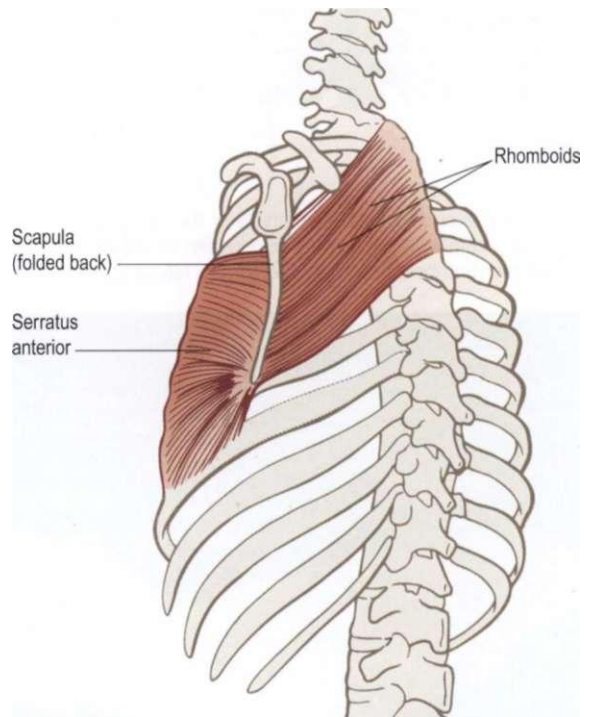


Fig. 6.6 If we fold the scapula back, we can see how there is really a 'rhombo-serratus' muscle with the medial border of the scapula essentially 'glued' into the middle of this myofascial sheet.



The rhombo-serratus muscle

The rhombo-serratus muscle (the rhomboid-serratus anterior sling) often shows medial to lateral or side-to-

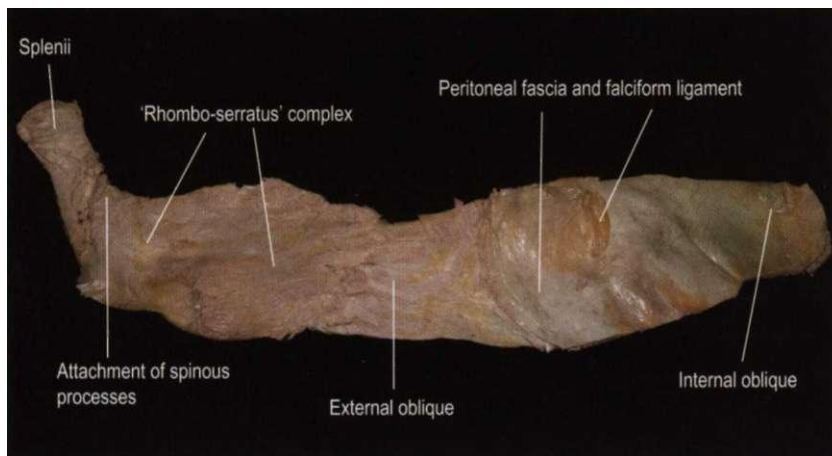


Fig. 6.7 The same specimen as Figure 6.4, viewed from the profound side. The peritoneum and transversalis fascia, as well as the remnants of the falciform ligament, can be seen in the lower part of the specimen. The attachments of the serratus and external obliques to the ribs can be seen, as well as the stark fact of the stronger attachment that both muscles have for each other than either has for the ribs.

must be close for this technique to be supportable for the practitioner and to work for the client.) Put your open fists out on the lateral rib cage, just outside of or just on the lateral border of the scapula and the lateral edge of the latissimus dorsi. Your proximal phalanges are resting on, and parallel to, the client's ribs, and your elbows are as wide and forward as you can comfortably position them. Peel the tissue around the rib cage toward your chest and his back, bringing the latissimus and scapula with you toward the posterior midline. Do not dig into the rib cage, but rather bring the entire shoulder structure around the ribs. At the same time have the client lift his chest in front with a big, proud inhale. This will stretch the myofasciae of the serratus anterior, and encourage the rhomboids to assume proper tone, with a bit of practice (DVD ref: **Spiral Line, 16:00-20:28**).

If there is a right-left difference between the two scapulae, use the same positioning, but merely emphasize the pressure to create change on the one side while stabilizing both the client and the practitioner with the other.

The converse pattern is less common, but still encountered frequently, where the rhomboids are locked short and the serrati locked long. In these patterns, the scapulae tend to be held high and close to the spinous processes, a pattern which often accompanies a flat (extended) thoracic spine.

To address this pattern in the SPL, have your seated client bend forward a little (not so far that he can rest his elbows on his knees) to expose the area between the thoracic spine and the vertebral border of the scapula. Standing behind, work out from the center line toward the scapula using your knuckles or elbows, lengthening in both directions away from the spine. The client can help in two ways: by pushing up from the feet into your pressure, the client will help keep the back sturdy and create more of a roundness (flexion). To get extra stretch out of the rhomboids, have the client reach out in front and bring the arms across each other as if giving someone a big hug (DVD ref: **Spiral Line, 20:28-25:53**).

To emphasize one side more than the other, merely increase the pressure on the shorter side. Alternatively, cross your hands over each other, with one against several thoracic SPs, and the other against the vertebral border, and by pushing your hands apart, induce a stretch in the rhomboids and trapezius.

The internal and external oblique complex

From the lower attachments of the serratus, our way forward is clear: the serratus anterior has strong fascial continuity with the external oblique (Figs 6.7 and 6.8). The fibers of the external oblique blend into the lamina of the superficial abdominal aponeurosis, which carries over to the linea alba, where they mesh with the opposing fibers of the internal oblique on the opposite side (Fig. 6.7). This carries us to our next station, the ASIS (anterior superior iliac spine) and an opportunity for a brief sidetrack, or, in this case, a roundhouse (see 'Roundhouse: the anterior superior iliac spine' below).

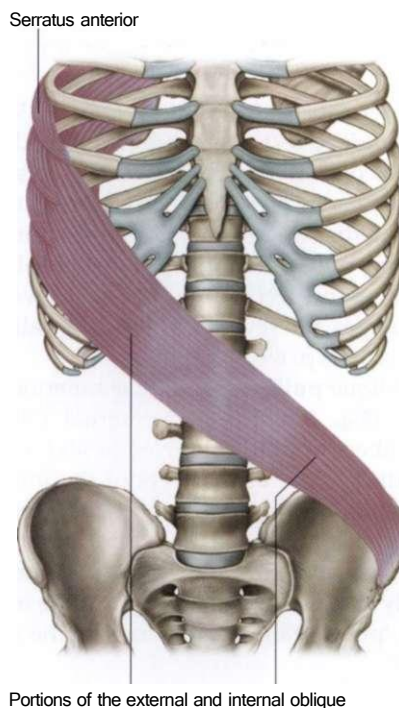


Fig. 6.8 The next set of continuities in the Spiral Line carries it from the serratus anterior onto the external oblique, on through the linea alba, and over to the anterior superior iliac spine via the internal oblique.




Fig. 6.9 The Spiral Line connections in the abdomen in action. Note that it is the left Spiral Line (running from the fellow's right ribs to left pelvis) that is being contracted, while the other side is being stretched. Consistent postural positioning of one set of ribs closer to the opposite hip is a red flag for Spiral Line treatment. (Reproduced with kind permission from Hoepke 1936.)

In the abdomen, one set of external/internal oblique (abdominal ribs to opposite pelvis) complex may be visibly shorter than the other (Fig. 6.9). Position the fingertips into the superficial layers of abdominal fascia and lift them diagonally and superiorly toward the opposite ribs (DVD ref: **Spiral Line, 12:28-16:00**). This will usually serve to correct this imbalance, although more complex counterbalancing patterns often involve the psoas as well (see Ch. 9).



Roundhouse: the anterior superior iliac spine

The SPL passes over the anterior superior iliac spine (ASIS), touching there as a station before passing down the leg. The ASIS is of such central importance to structural analysis in general, and myofascial continuity theory in particular, that we must pause here to note the various mechanical pulls from this point. It could be compared to a clock or a compass, but since we are mired in train images for this book, we will call it a roundhouse (**Fig. 2.12B**, p. 69).

The internal oblique pulls the ASIS in a superior and medial direction (**Fig. 2.12A**). Other internal oblique fibers, as well as fibers from the transversus abdominis, pull directly medially. Still other fibers of the internal oblique fan, plus the restraining cord of the inguinal ligament, pull medial and inferior. The sartorius, attaching to the ASIS on its way to the inner knee, pulls mostly down and slightly in. The iliacus, clinging to the inside edge of the ASIS, pulls straight down toward the inner part of the femur.

The rectus femoris, as we noted in discussing the Superficial Front Line, does not attach to the ASIS in most people; nevertheless it exerts a downward pull on the front of the hip from its attachment a bit lower on the AIIS. The tensor fasciae latae pulls down and out on its way to the outer aspect of the knee. The gluteus medius pulls down and back toward the greater trochanter, the transversus abdominis pulls back nearly horizontally along the iliac crest, and the external oblique pulls up and back toward the lower edge of the rib cage.

Getting all these forces to balance around the front of the hip in both standing and gait involves an attentive eye, progressive work, and more than a little patience. This balance involves at least three of the Anatomy Trains lines - this Spiral Line, the Lateral Line, the Deep Front Line, and, by mechanical connection, the Superficial Front Line. Proper assessment involves weighing an ever-shifting dance of pulls created by a host of myofascial units across each semi-independent side of the pelvis.

Because of the many pulls and tracks competing to set the position of the ASIS, the SPL does not always win out in communicating between its upper track (the skull

to ribs to hip portion we have just covered) and its lower track (the 'jump rope' around the arches we are about to cover). Therefore, we often assess and consider these two halves of the line separately.

The lower Spiral Line

The lower SPL is a complex sling from hip to arch and back to the hip again.

Continuing on from the ASIS, we must keep going in the same direction to obey our rules. Rather than sharply switching our course onto any of these other lines of pull, we pass directly across, mechanically connecting from the internal oblique fibers to the tensor fasciae latae (TFL) from the underside of the ASIS and lip of the iliac crest. **Figure 6.10** shows how the TFL blends with the anterior edge of the iliotibial tract (ITT), which, as we noted when discussing the Lateral Line, passes down to the lateral condyle of the tibia (**Fig. 6.11**).

This time, however, instead of jogging over to the peroneals, as we did with the Lateral Line, we will keep going straight, with a more obvious fascial connection, especially for the anterior edge of the ITT, onto the tibialis anterior (**Fig. 6.12**). This connection is easily dissected (**Fig. 6.13**).

The 'violin' of the iliotibial tract

In the legs, lengthening this section of the SPL from the ASIS to the outer knee can be accomplished through a stroke, either up or down, designed to free and lengthen the anterior edge only of the ITT. Usually the flat of the ulna is used, with the client side-lying. In this position, the ITT curves over the surface of the thigh like the strings of a violin. Your ulna then acts like a bow: by altering the angle of your arm, you can emphasize the connection from the gluteus maximus to the posterior part of the ITT, or (as suggested here for the SPL) concentrate on the anterior portion from the TFL to the tibialis anterior just below the knee. Near the knee, the anterior edge of the ITT is easy to feel; nearer the hip, stay on a line from the ASIS to the middle of the lateral part of the knee (DVD ref: Spiral Line, 25:53-29:32).

Since this area can be quite painful when first approached, several repetitions in a more gentle fashion will often answer well.

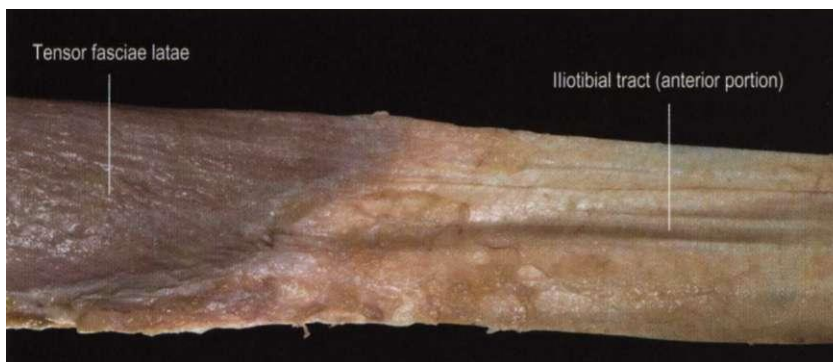

Fig. 6.10 The myofascial blend we call the tensor fasciae latae muscle becomes the iliotibial tract as the muscle attenuates to nothing - but it is all one fascial sheet. (DVD ref: **Early Dissective Evidence**)

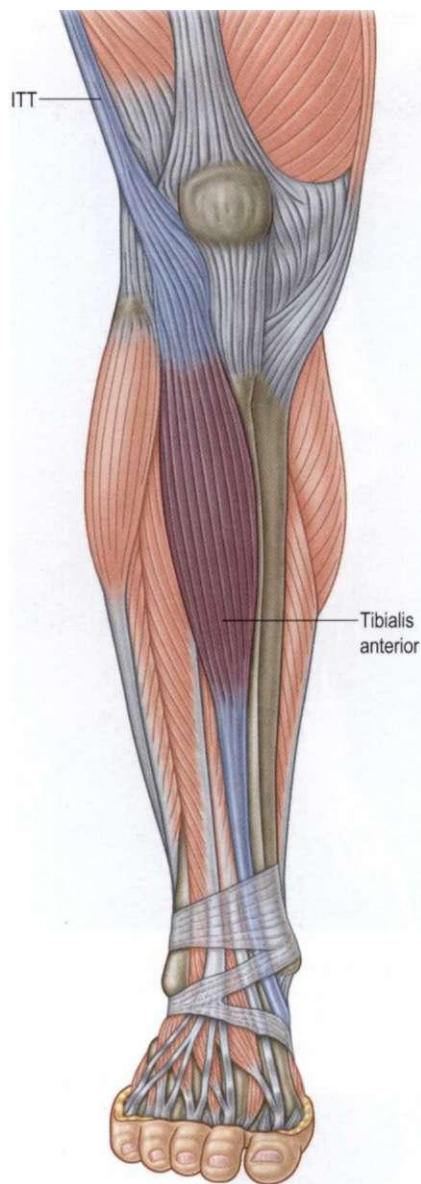
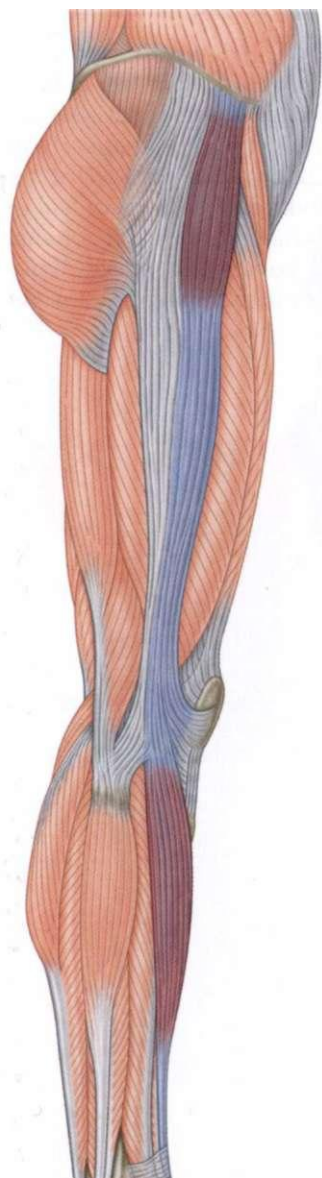


Fig. 6.11 From the ASIS, the Spiral Line passes down the anterior edge of the iliotibial tract and directly onto the tibialis anterior.

Fig. 6.12 The tibialis anterior continues the spiral from the outside of the knee across the shinbone to the inside of the ankle.

➤ The lower leg

➤ The tibialis anterior passes down and in, crossing the lower shinbone to attach to the joint capsule between the 1st cuneiform and 1st metatarsal. In standard anatomy, this would seem to be the end point of the SPL until we look around to the other side of that joint capsule to find a direct fascial connection with the peroneus longus, likewise with a bifurcated tendon into those same bones and joint capsule (**Fig. 6.14**). In other words, there is both a fascial and mechanical continuity between the tibialis anterior and the peroneus longus. Again, this can be easily dissected to maintain the fascial continuity of this 'sling' (**Fig. 6.15**). This connection has been noted before,¹ but can now be understood as part of a larger picture (see below on the SPL and foot arches).

The arches and the stirrup'

The stirrup under the arch is fairly inaccessible in the foot itself, and can best be worked from the lower leg. Oddly, the two ends of this sling, the tibialis anterior and the fibularis (peroneus) longus, lie next to each other on the anterolateral aspect of the lower leg (**Fig. 6.16** or see **Fig. 5.8**, p.118). As we noted in looking at the Lateral Line (Ch. 5), there is a fascial intermuscular septum between the two muscles (**see Fig. 5.7**).

In the case of a pronated foot, you will often find that the tibialis anterior is locked long, and the peroneus locked short. Therefore, in these cases, the fascia of the tibialis anterior needs to be lifted and that of the peroneus lengthened interiorly, and the tibialis often needs additional strengthening work. In a supinated foot, the reverse treatment applies (**DVD ref: Spiral Line, 33:5046:44**).



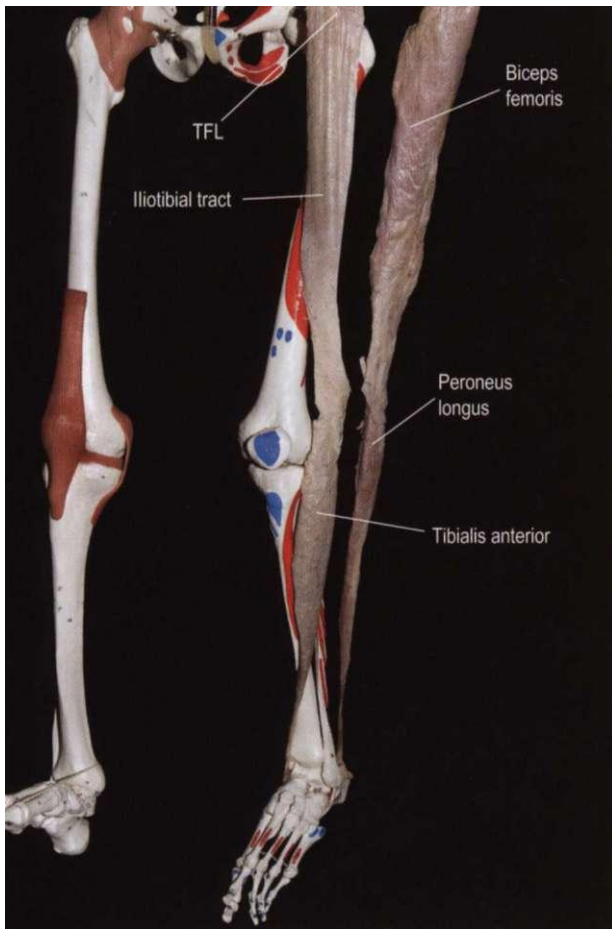


Fig. 6.13 The fascial continuity between the ITT and tibialis anterior is very strong and easily dissected.

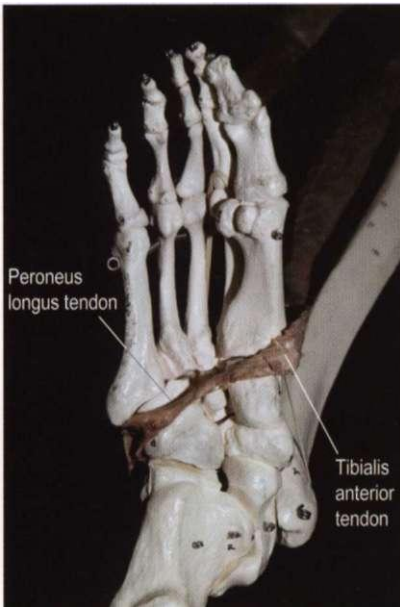


Fig. 6.15 The connection between the tibialis anterior and fibularis longus tendons can be dissected. They each attach to the periosteum of the 1st metatarsal and 1st cuneiform, but they also attach to each other. This connection is seldom displayed in contemporary anatomy books or dissections.

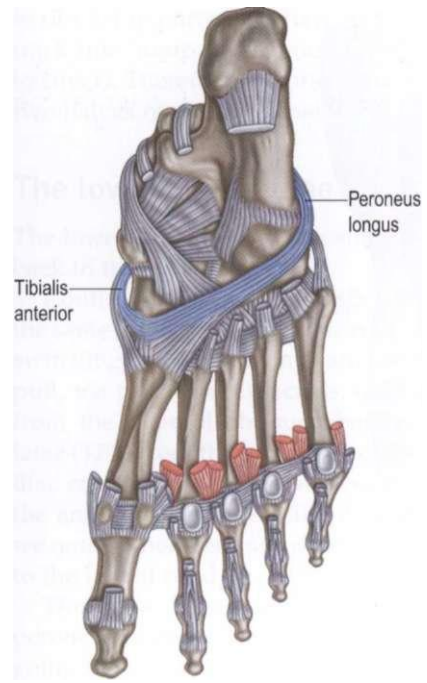


Fig. 6.14 The sole of the foot, showing the traditional view of the biomechanical connection between tibialis anterior and the peroneus longus at the 1st cuneiform / 1st metatarsal joint.

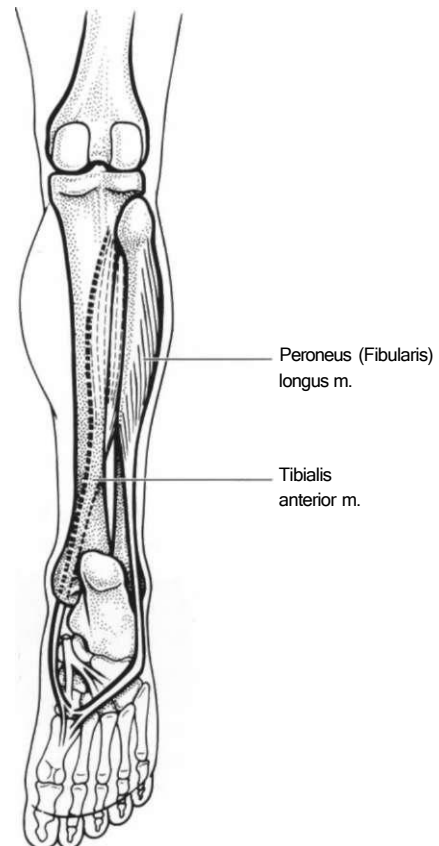


Fig. 6.16 The sling (or stirrup, as it is sometimes called) of the tibialis anterior and the fibularis longus connects the medial longitudinal arch to the upper calf.

The back of the leg

Once onto the fibularis, we pass easily along it to the head of the fibula, as we did with the LL, but this time we take the more obvious route from the head of the fibula onto the biceps femoris, the lateral hamstring (Fig. 6.17). The long head of the biceps carries us up to the ischial tuberosity. This whole complex - TFL to ITT to anterior tibialis to fibularis longus to biceps femoris - can be seen as a conjoined 'jump rope' that travels from hip to arch down the anterolateral portion of the leg,

and then arch to hip up the posterolateral aspect of the leg (Figs 6.13, 6.18 and 6.19).

The 4th hamstring

Deep to the biceps femoris long head, which is an express crossing both hip and knee, lies an important and not so obvious set of locals. This underlying connection can sometimes provide the answer to recalcitrant hamstring shortness and limitations to hip flexion and hip-knee integration. The first of these two locals is the short head of the biceps, which starts from the same tendinous attachment at the head of the fibula as the long head and passes to the linea aspera about one-third of the way up the femur (Figs 6.19 and 6.20). Here there is a fascial continuity with the middle section of the adductor magnus, which passes up beneath the rest of the biceps femoris to attach to the inferior aspect of the ischial ramus, just anterior to the hamstring attachments.

The short head of the biceps component may be over-active in chronically flexed knees or with a laterally rotated tibia, while the adductor magnus component may contribute to a posteriorly tilted pelvis, or the inability of the hip joints to flex properly.

Reaching this '4th hamstring' requires precision in getting under the superficial hamstrings. Find the singular biceps femoris tendon outside the knee, coming up from the fibular head. The short head of the biceps can be found by reaching around this tendon on both its medial and lateral sides. With your client lying prone with the knee flexed, pin the muscle against the back of the femur, which will be stretched and lengthened as your client slowly lowers the leg and foot to full knee extension. The short head can also be reached side-lying, still using the knee extension to stretch it (Line, 29:33-33:49).

The adductor magnus (which makes another appearance as part of the Deep Front Line in Ch. 9) can most easily be reached by having your client side-lying with the upper knee and hip flexed (and the thigh resting on a pillow) so that the medial aspect of the leg is open for work (DVD ref: Deep Front Line - Part 1, 37.32-11:59).

Find the hamstring attachments on the posterior aspect of the ischial tuberosity, and palpate along the bottom edge of the ischial tuberosity anterior about an inch to find the strong adductor magnus attachment. Instructing the client to lift the knee toward the ceiling will isolate this tendon from the hamstrings. Once found, work the adductor magnus down from its attachment toward the middle of the femur, remembering that this is a substantial piece of myofascia and several passes may be necessary to achieve the necessary depth.

Movement teachers can isolate this part of the adductor magnus by having their students stretch into hip flexion while keeping the knees slightly flexed. The stretch will be felt to run a bit deeper in the back of the thigh than the usual straight-legged forward bend.

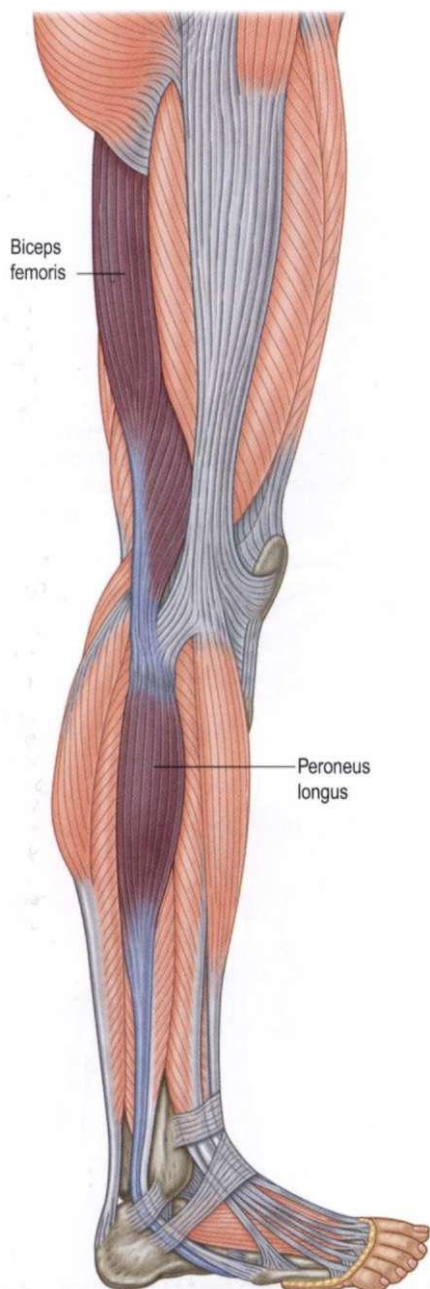


Fig. 6.17 There is a clear and direct fascial connection at the head of the fibula between the fibularis longus and the biceps femoris muscle.



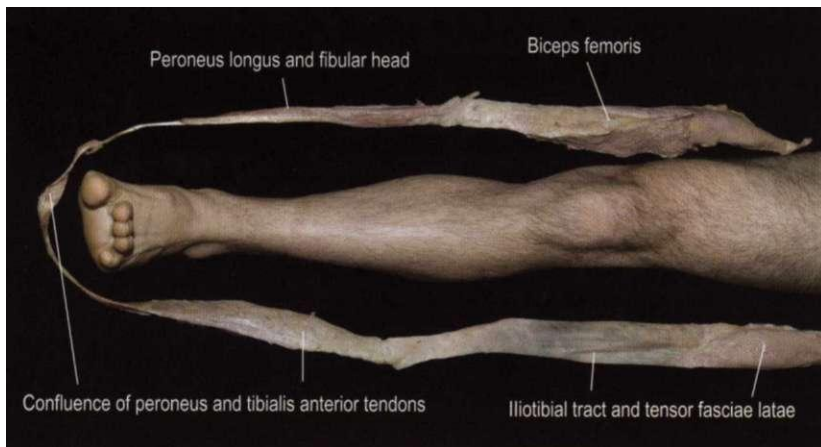


Fig. 6.18 In this dissection laid around a living leg, we see how the arch stirrup has connection right up the leg to the pelvis. (DVD ref: **Early Dissective Evidence**)

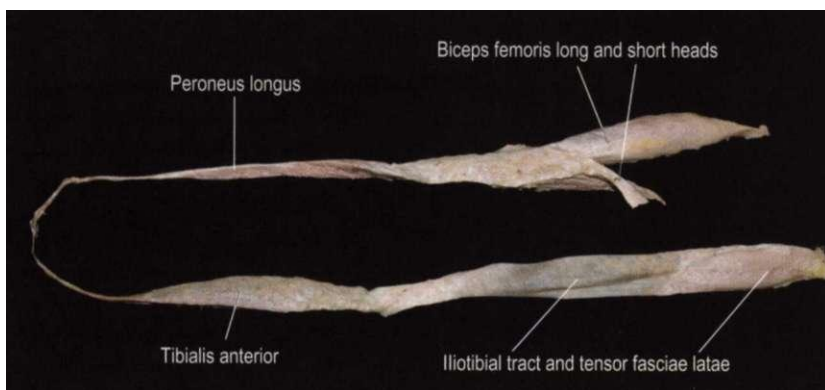


Fig. 6.19 The 'jump rope' of the lower Spiral Line, on its own, with the short head of the biceps femoris reflected back.

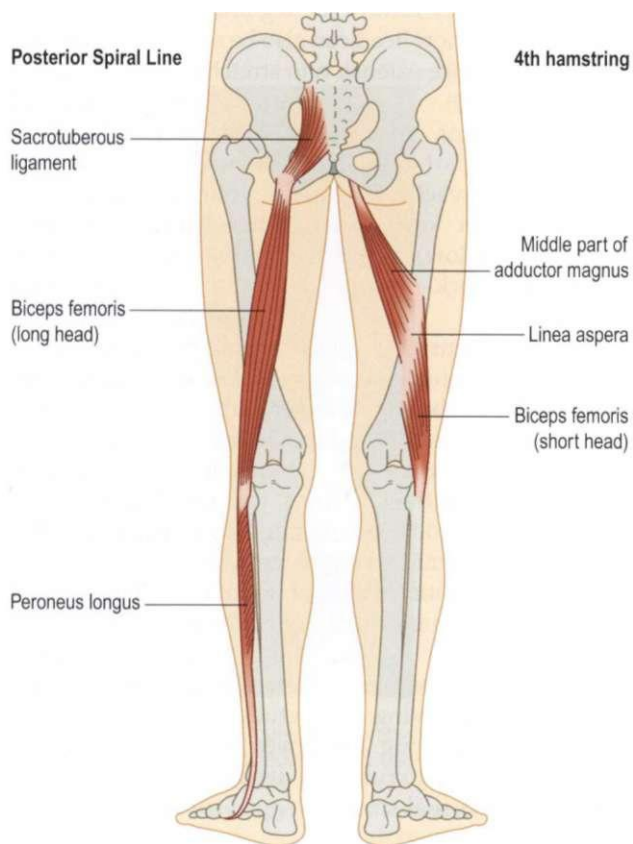


Fig. 6.20 Beneath the express of the long head of the biceps femoris lies a set of two locals termed the '4th hamstring'. It consists of the short head of the biceps running from the fibula up the linea aspera of the femur, and the middle section of the adductor magnus running from the same place on the femur up to the ischial ramus just in front of the hamstrings.

The posterior Spiral Line

From the lateral hamstring, we can follow the trail already blazed by the Superficial Back Line (Ch. 3, pp 85 and 86) onto the sacrotuberous ligament, the sacral fascia, and on up the erector spinae (**DVD ref: Superficial Back Line, 36:44-57:04 and 1:04:24-1:06:52**). Depending on the pattern, however, the SPL (as opposed to the SBL) is capable of transferring tension across the sacral fascia to the contralateral spinal muscles (**Fig. 6.2A**). These patterns have to do with differential leg length, lateral pelvic tilt, and which leg is more heavily weighted.

This final track of the erectors thus passes beneath the very beginning of this Spiral Line, the splenius capitis and cervicis, to attach to the occiput (**Fig. 6.21**). Thus the SPL comes to rest on the back of the occiput, quite close

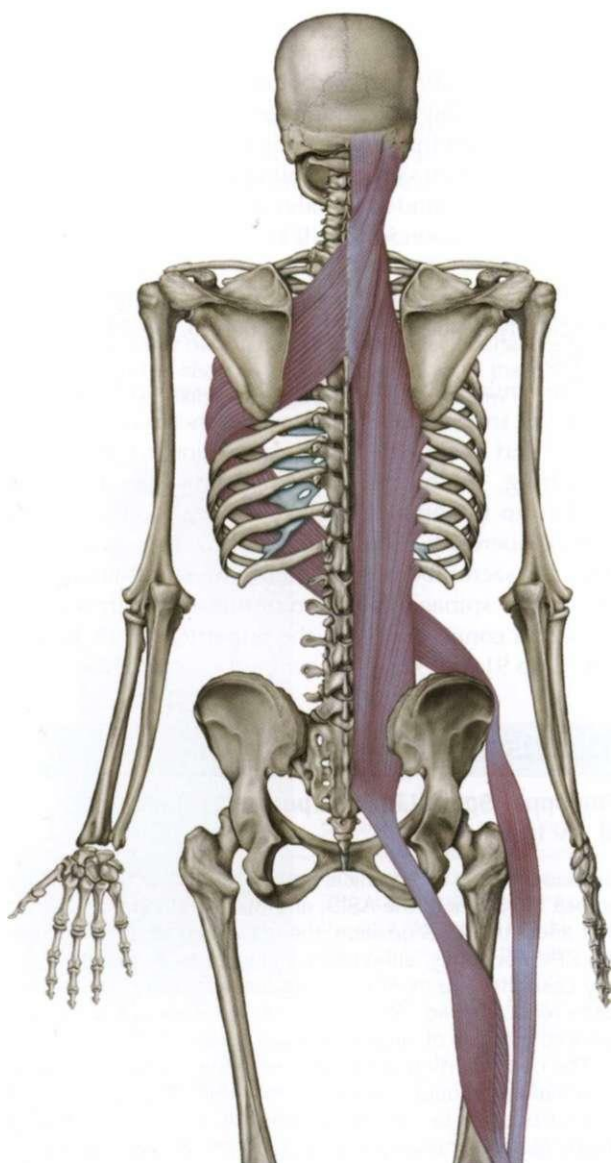


Fig. 6.21 From the lateral hamstring, the Spiral Line connections parallel the Superficial Back Line connections onto the sacrotuberous ligament, and on up the erector spinae to the back of the skull, just next to where it began.

to where we began many pages and several meters of fascia ago.

This line - which is of course expressed on both sides - joins each side of the skull across the back of the neck to its opposite shoulder, continuing around the belly in front to the hip on the same side as it started. From here the line drops down the outside of the thigh and knee, but crosses over the front of the shin to form a sling under the inner arch, which rises up the back of the body to rejoin the skull just medial to where it started.

The helical routes around the body are not by any means limited to the Spiral Line described here. See the discussion at the end of Chapter 8 (Functional Lines) and in Chapter 10 for a more expanded view.

General movement considerations: reciprocity

Obviously, the SPL will be both stretched and engaged by rotational and twisting movements. The currently popular 'crunch' (upper body sit-up) with a twist, where one elbow heads for the opposite knee, engages the upper part of the SPL. Yoga 'twists' will stretch the upper SPL, and the Triangle pose in particular is designed to engage the entire line (**Fig. 6.22**). There is a clear reciprocal relationship between the two sides of the line; sitting (to fix the pelvis) and twisting the entire upper body to look over the right shoulder will stretch the upper left SPL while it employs the upper right SPL in concentric contraction.

Palpating the Spiral Line

Though the SPL begins with the fascia on the posterolateral aspect of the skull, its first real station is at the occipital ridge extending onto the mastoid process, and the first track is the splenius capitis and cervicis, which we first encountered as part of the Lateral Line (**Fig. 6.3A**). It can be clearly felt below the occipital ridge, slanting in from the side toward the cervical spinous processes below the superficial trapezius. It will pop into your fingers when the head is turned to the same side against resistance. To feel the splenii, have your client lie supine, with the head resting in your hands. Sink your fingers gently into the soft tissue below the occiput, a bit away from the midline. Have your thumbs alongside the client's head. As the client turns into the resistance of your thumbs, the splenii, with their fibers slanting down and in toward the upper thoracic spine, will be clearly felt on the same side just deep to the thin trapezius.

The rhomboids, the next track on this line, can be more easily seen and felt on someone else, since they occupy that space on your back that is so difficult to scratch when it itches. Have your model bring the shoulder blades up and together, and on most people you will see the shape of the rhomboids pushing out against the overlying trapezius.

If you can insinuate your fingers under the vertebral border of your model's scapula, you can feel where the



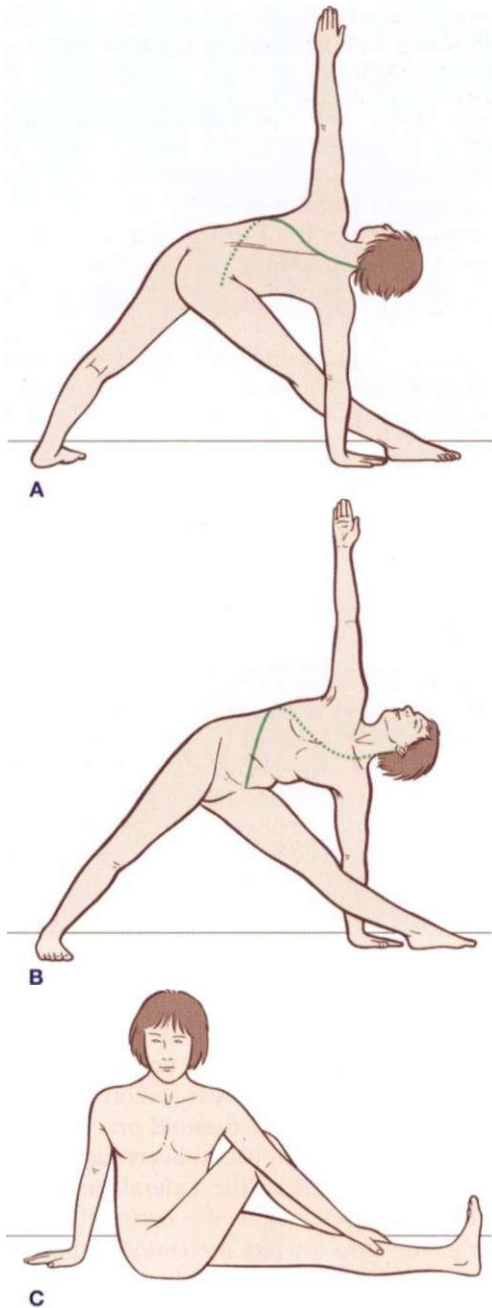


Fig. 6.22 Spinal twist poses such as the Triangle pose or Seated Twist are custom-made to stretch the upper portion of the Spiral Line on one side, while engaging it on the other.

rhomboids continue on into the serratus anterior. Most of that large sheet of muscle, however, is invisible under the scapula. In thin individuals, the lower four or five slips (which are the part under discussion here) can be seen outside the edge of the latissimus when the model contracts the muscle (e.g. in a push-up) (**Fig. 6.8**).

The link from the anterior part of the lower serratus onto the external oblique, across the linea alba into the internal oblique on the opposite side, is well known and can be easily palpated or observed, as in **Figure 6.9**. This brings us to the connection of the internal oblique onto the anterior iliac crest and ASIS.

To continue down from here, place your fingers under the edge of the anterior iliac crest, then abduct and medially rotate the hip joint (**Fig. 6.11**). The tensor fasciae latae (TFL) muscle will pop your fingers out. From here, the iliotibial tract (ITT) can be felt, dimly at the top of the thigh but more distinctly as you pass down toward the knee. With the hip abducted and the foot off the ground, the connection from the ITT across the knee joint to the tibialis anterior can be clearly felt (**Figs 6.12 and 6.13**).

Follow the tibialis anterior down the front of the shin next to the tibia and find its strong tendon emerging from under the retinacula on the medial side of the front of the ankle. Strongly dorsiflex and invert the foot to feel the tendon as far down as you can toward its station between the 1st metatarsal and 1st cuneiform (**Fig. 6.14**).

The fibularis longus starts just on the other side of this attachment, with a fascial continuity through the fascia of the joint capsule, but this is very difficult to feel, except by implication, owing to the overlying myofascia and fascial padding on the bottom of the foot (**Fig. 6.15**). The fibularis longus tendon passes under the foot deep to almost everything else, running through a canal in the cuboid (again very difficult to feel) and emerging to our fingers just under the lateral malleolus of the ankle (**Fig. 6.17**). Two tendons will be palpable here, but the fibularis brevis tendon (which is part of the LL but not the SPL) will be superior to our fibularis longus tendon and clearly headed for, and attached to, the 5th metatarsal base.

The fibularis longus myofascia passes up the outside of the leg to the fibular head, where there is a clear, palpable, and easily dissected connection to the lateral hamstring, the biceps femoris. Follow the hamstring tendon up the outside back of the leg to arrive at the ischial tuberosity. From here the SPL connection passes onto the sacrotuberous ligament, the sacral fascia, and the erector spinae. (Palpation of these structures is discussed in connection with the Superficial Back Line in Ch. 3, pp 91 and 92, so we will not repeat it here.)

Discussion 1

The upper Spiral Line and postural rotations of the trunk

Because of the mechanical rather than direct connection across the pelvis at the ASIS, and the roundhouse of vectors that affect the ASIS position, the upper and lower portions of the SPL frequently, although not always, work separately; in any case they are most easily discussed separately. The two parts remain linked, of course, and can work in concert, but are also capable of singing different tunes.

The upper portion of the SPL, from the occiput around the contralateral shoulder girdle to the ASIS (**Fig. 6.7**), is in a perfect position to mediate rotations in the upper body (**Fig. 6.23**). 'Mediate' because clinical experience suggests that the Spiral Line is only sometimes the *cause* of such postural rotations or twists, but is often involved in compensating for deeper spinal twists which may come from any of a number of structural or functional sources (see also Ch. 9 on the Deep Front Line).



Thus the SPL complex of myofascia can be used to create twists in daily movements or specific exercises, or it can be used as a superficial postural bandage over a deeper scoliosis or other axial rotation. Any core rotation will affect the superficial lines, and none more than the SPL, which is often locked in a compensatory pattern. If the core pattern in the spine is a right rotation, the sleeve pattern in the SPL usually involves a counterbalancing shortness in the left SPL. This has the effect of making the body look straight in the end, but in fact the body will be both restricted and short. (Take a towel and twist it, and notice it shorten in length - any fabric that is twisted will become shorter.)

Once this pattern is recognized, it is important to release the sleeve first, before attempting to release the core muscles of the spine. This is the intent of the work on the SPL in these patterns. Please note well: when one releases such a compensatory pattern in the sleeve-like SPL, the core rotation will usually become more apparent, so that the client may report feeling or looking more twisted at this juncture in their work with you. It is important to educate them as to what is unfolding - because only when the sleeve rotation in the SPL is removed can one effectively step in to work with the core rotation in the Deep Front Line or deep spinal muscles.

Because of the interplay between deeper and superficial patterns, the number of specific modifications and individual ways of using the SPL in rotation are legion. Postural shortening directly up the line from the ASIS to the skull produces a characteristic posture, which any practitioner will recognize from **Figure 6.23**.

As the line pulls through the abdominal fascia via the internal and external obliques from the hip onto the opposite serratus, it protracts the rib cage on that side, with the shoulder usually coming along for the ride. This usually pulls the upper back and/or lower neck toward that shoulder, so that the head shifts toward the shoulder, sometimes tilting to the opposite side - all of this visible in **Figure 6.23**. The pattern is discern-

ible in the absence of, or sometimes in competition with, other forces. An individually tight muscle (e.g. infraspinatus) or a competing pull from another line (e.g. a short Lateral Line on the same side as the SPL in question) will modify and perhaps obscure, but not obliterate, the pattern created by shortness in the upper SPL.

The SPL frequently works from the ASIS up. Owing to the weight of and competing forces in the pelvis, the SPL rarely pulls the ASIS out of place from above, from the shoulder or ribs. It is, however, quite common to have parts of this line tighten without transferring the tension throughout the line. Thus, one section of the SPL may shorten without the shortness being passed to succeeding sections. In some cases, the section from the skull to the serratus tightens without the involvement of the belly, or the belly can pull through to the neck without the shoulder being protracted in the process.

Practice is necessary to discern the specific modifications in the pattern, but there are four 'red flags' that should alert the practitioner to possible or probable imbalance in the SPL: (1) shifts or tilts in the head position relative to the rib cage, (2) one shoulder more forward than the other, (3) lateral rib cage shifts relative to the pelvis, or (4) differences in the direction of the sternum and pubis, which usually can also be read as marked differences in the measurement from one costal arch (where the outside edge of the rectus abdominis crosses the costal cartilages) to the opposite ASIS. In **Figure 6.9**, for example, the measurement from his left ribs to right hip is clearly longer than the corresponding measurement from the right ribs to the left hip. In **Figure 6.23**, it is shorter from the left ribs to right hip than its converse, but this is not so easily detected in a small photo. Purchase of a micrometer is not necessary; if it is not easy to tell which of these lines is shorter, then there is probably not a significant SPL issue at this level.

Figure 6.24 shows examples of other patterns of imbalance, mostly in the right Spiral Line.

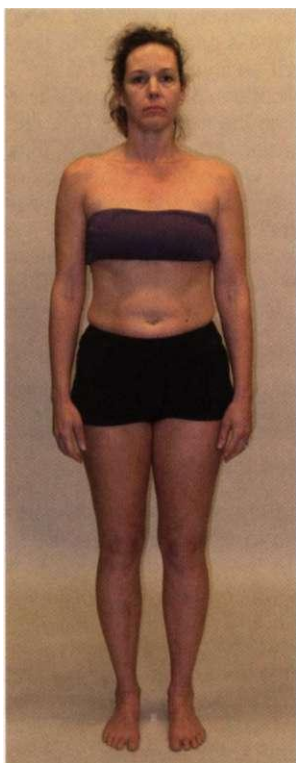

Fig. 6.23 A common postural pattern involving a shortening of one side of the upper Spiral Line - in this case, the right SPL is consistently short from the right side of the head to the right hip by way of the left shoulder and ribs. A head shifted and/or tilted to one side, differences in the scapular positions, and a shift or twist in the rib cage - all of which are present in this model - any of these should alert the practitioner to a possibility of Spiral Line involvement in the pattern.

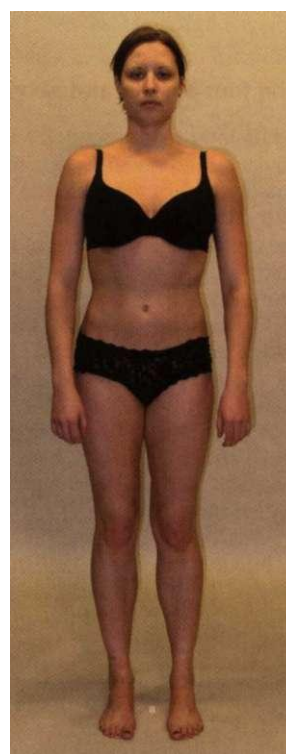
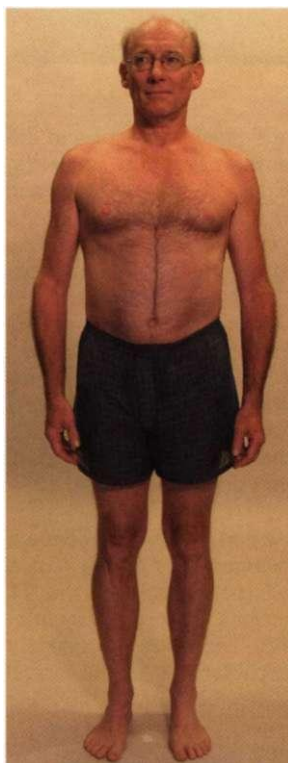


Fig. 6.24 More common Spiral Line patterns, as seen in standing posture.



Discussion 2

The SPL and forward head posture

The serratus anterior, as we noted above, is a complex muscle, a broad combination of a quadrate and triangular muscle that both stabilizes and controls the shoulder. Earlier in our phylogenetic history, the serratus was primarily responsible for creating a sling to support the rib cage within the uprights of the scapulae (see Ch. 7 or DVD ref: Shoulder and Arm Lines, 3:22-5:07).

The lower slips of serratus definitely belong to the SPL, but the middle slips form a connection with each other across the bottom of the sternum, under the pectoralis major, at the level of the 'bra line'. (See also Appendix 1 - this corresponds to Schultz's chest band, p. 255) This creates a 'branch line' for the SPL of interest where you see the ubiquitous forward head posture.

If we follow this line from the midline just above the xiphoid process, around the middle slips of the serratus to the middle of the rhomboid and across to the splenius capitis on the opposite side, we end up on the skull. To see or feel this for yourself - and it is worthwhile to understand this pattern - take a six- to eight-foot strip of fabric like a yoga belt or a length of gauze, stand behind your model, place the middle of the strip above the xiphoid and bring the two ends behind the model, crossing them up between the shoulder blades to 'attach' them to the skull by holding them there with your hands. (It is possible to do this on yourself, but difficult to avoid getting tangled up.)

Now have the model jut their head forward of the rest of the body. Feel the strip tighten and pull back on the sternum. So many of those with forward head posture also have the tight chest band, and this is a major avenue for the transmission of the strain. If you wish to see the chest band loosen its hold on your model's breathing, get the head back up on top of the body. That will ease this line and help restore the full excursion of the chest in breathing.

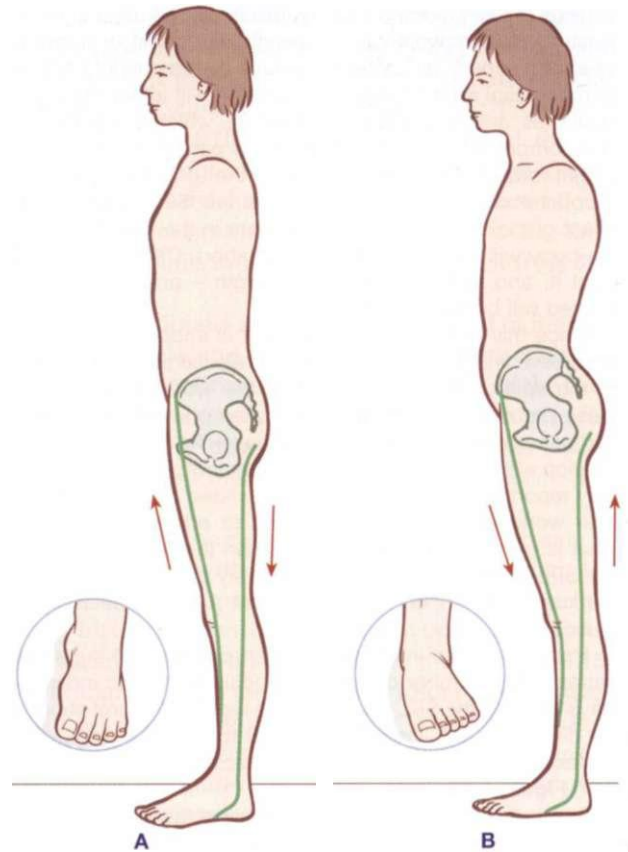


Fig. 6.25 The pattern of the sling under the foot can be extended, via the Spiral Line, to connect with the angle of pelvic tilt.

from the tibialis, creating a tendency (but not a certainty) toward a fallen medial arch (B). Conversely, a posterior pelvic tilt would tend to pull up on the tibialis and slacken the fibularis, creating the tendency toward an inverted foot (A).

Take note of the further implication: a very tight SPL on the back of the leg could overcome the front of the SPL and produce both a posterior pelvis *and* an everted foot (Fig. 6.26A). When we view this pattern, we know that the back of the lower SPL must have some significant shortening somewhere along these tracks. In the reverse pattern (B), an inverted foot with an anterior tilt pelvis points to shortness along the front of the lower SPL (tibialis anterior - anterior ITT), though this pattern can also be linked to a short Deep Front Line (see Ch. 9).

Discussion A

The lower Spiral Line and knee tracking

The SPL can affect knee tracking (the ability of the knee to track straight forward and back in walking, keeping more or less the same directional vector as the hip and ankle).

To assess knee tracking, you can watch your client walk straight at you or straight away and see how the knees travel during the different phases of gait. An alternative assessment has your client stand in front of you with her feet parallel (meaning the 2nd metatarsals are parallel). Have her bring both knees forward, with her feet on the floor and while maintaining the upper body erect - neither sticking her bum back behind her nor seriously tucking it under to cause a backward lean in the rib cage - and see how the two knees track (Fig. 6.27). If one or both knees are heading



Discussion 3

The foot arches and pelvic tilt

It has long been recognized that the tibialis anterior and the fibularis (peroneus) longus together form a 'stirrup' under the arch system of the foot. The tibialis pulls up on a weak section of the medial longitudinal arch, the fibularis tendon supports the cuboid, the keystone of the lateral arch, and together they help to prevent the proximal part of the transverse arch from dropping (see Fig. 6.15).

Furthermore, there is a reciprocal relationship between the two: a lax (or 'locked long') tibialis coupled with a contracted (or 'locked short') fibularis will contribute to an everted (pronated) foot, with the tendency toward a drop in the medial arch (see Fig. 6.16). The opposite pattern, a shortened tibialis and a strained fibularis, tends to create an inverted (supinated) foot with an apparently high arch and the weight shifted laterally on the foot.

With our new view of the SPL, we can expand this concept to include the entire leg: the tibialis connects to the rectus femoris (SFL), the sartorius (SFL alternate route) and the ITT and TFL (SPL). All of these connections go to the very front of the hip bone: the ASIS or AHS. The fibularis connects through the long head of the biceps femoris to the ischial tuberosity, or in other words to the very back of the hip bone (Fig. 6.19).

Thus, the stirrup or 'sling' created by the tibialis and fibularis extends up the leg to the pelvis and relates to pelvic position (Fig. 6.25): an anterior pelvic tilt would bring the ASIS closer to the foot, and thus remove upper tensional support

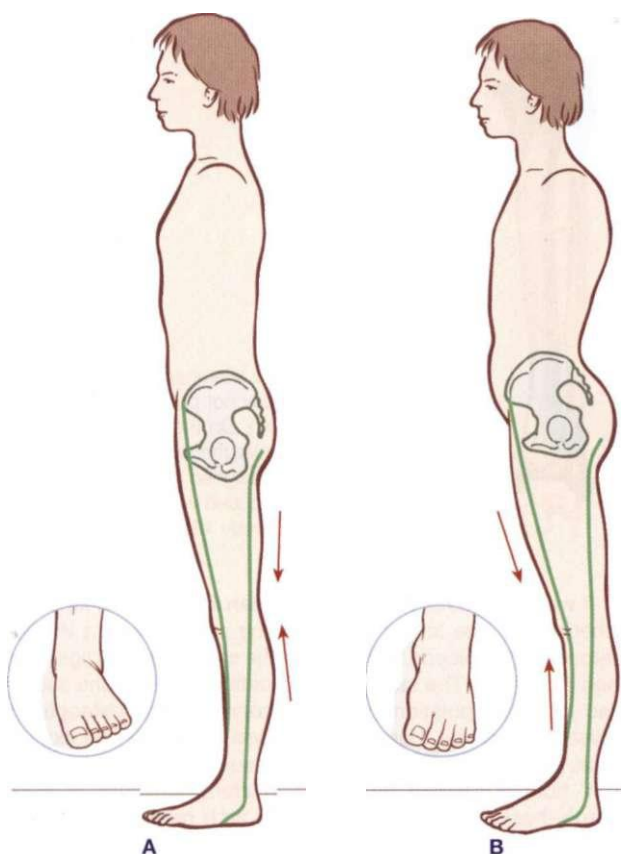


Fig. 6.26 Shortness in part of the lower SPL can create the complementary patterns to those in **Figure 6.23**

inward, toward the other, as she brings them forward, the entire lower SPL sling may be tight on that side.

When we note how the SPL runs from the ASIS in the front of the pelvis to the outside of the knee and then down to the inside of the ankle, we can clearly see how tightening it can affect knee direction, by pulling the outside of the knee toward a line running straight from the ASIS to the medial ankle (**Fig. 6.28**). Loosening this line from above or below prior to local soft-tissue work, or prior to assigning remedial exercise to restore proper knee tracking, will greatly increase the efficacy of the treatment (**DVD ref: Spiral Line, 46:45-51:37**)

Discussion 5

The 'heel foot' and the sacroiliac joint

It has long been noted that the bones of the foot divide fairly neatly down a longitudinal axis into the bones that comprise the medial arch and those that comprise the lateral arch (**Fig. 6.29**)

Borrowing terms from dance, these could be referred to as the 'heel foot' and the 'toe foot'. The 'toe foot' is clearly designed to take the primary weight: if you stand and let your weight swing onto your toes, you will feel the pressure in the first three metatarsal heads on up to the talus. Seeing how the talus lines up with the main weight-bearing bone of the shin, the tibia, only reinforces our conviction. Swinging forward and keeping your weight on the two outside toes, unless you are quite accustomed to it, is quite difficult to do, and nearly impossible to maintain.

The heel, of course, does take weight in standing and walking, but the outer two toes and the associated bones (4th and 5th metatarsals and the cuboid) are really designed more as balancers, outriggers for the foot's canoe (**Fig. 6.30**)

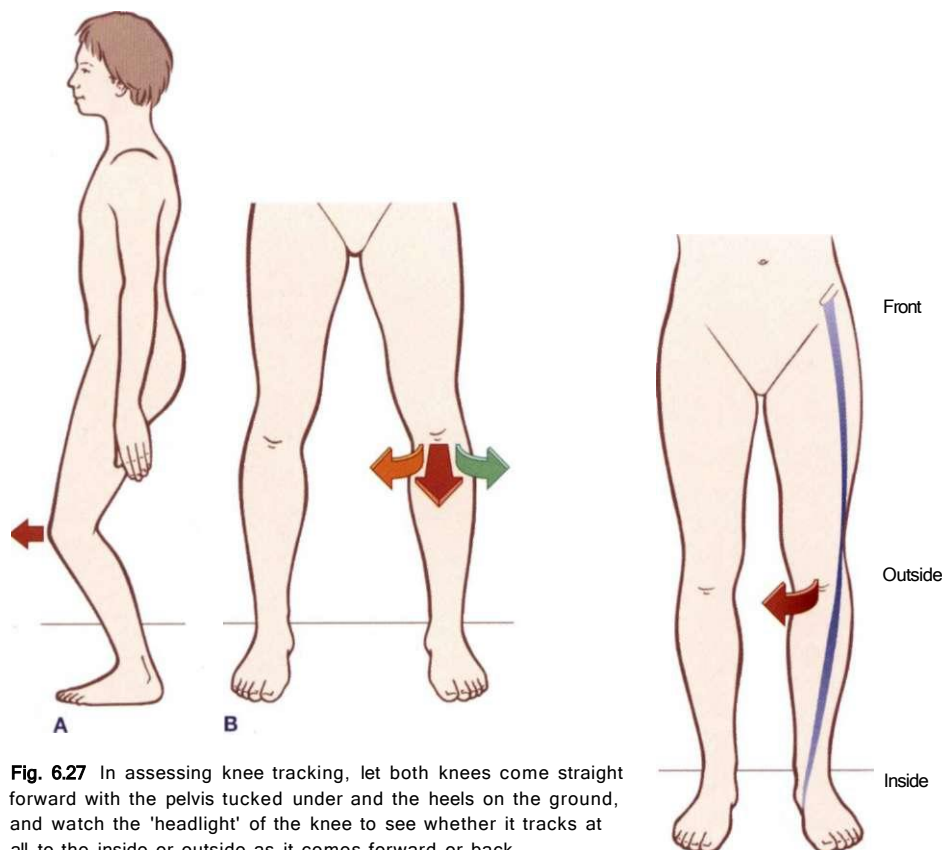


Fig. 6.27 In assessing knee tracking, let both knees come straight forward with the pelvis tucked under and the heels on the ground, and watch the 'headlight' of the knee to see whether it tracks at all to the inside or outside as it comes forward or back.

Fig. 6.28 Because the Spiral Line passes from the front of the hip to the outside of the knee to the inside of the ankle, tightening this line can tend to induce medial rotation at the knee.

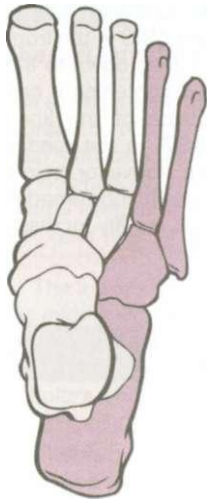


Fig. 6.29 The foot parses fairly neatly into the bones of the medial arch and those of the lateral arch. Some dancers call this the 'toe foot' and the 'heel foot' respectively.

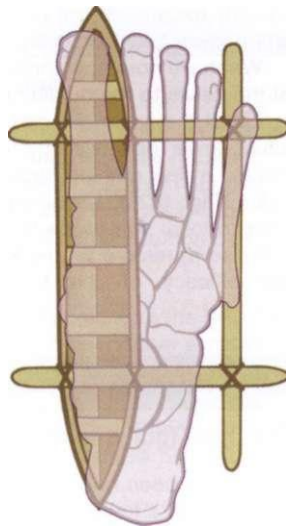


Fig. 6.30 In terms of function, the medial arch bones can be seen to be the major weight-bearing 'canoe', while the outer arch bones act like an 'outrigger', balancing and stabilizing but not bearing so much weight.



Fig. 6.31 Above the lateral arch bones is the fibula, which is clearly not positioned to transfer weight down. On the contrary, its position, tucked under the condyle of the tibia, suggests that it is designed instead to resist upward pull. (Reproduced with kind permission from Grundy 1982.)

Looking above the 'heel foot', we find the fibula, uniquely placed in being tucked under the tibial condyle (**Fig. 6.31**). It is very badly positioned to bear weight, and in fact looks better placed to resist being pulled up, rather than pulled down. Although eight muscles pull down on the fibula from the foot, one very large one, the biceps femoris, pulls directly up and in on it.

If we trace this entire linkage, we can link the 'heel foot' - in other words, the lateral arch - to the sacroiliac joint via the peroneals, the biceps femoris, and the sacrotuberous ligament (**see Fig. 6.20**). The success and holding power of the sacroiliac joint manipulations of our chiropractic and osteopathic colleagues can be markedly increased, in our clinical experience, through creating more soft-tissue balance of the 'heel foot', fibularii, head of the fibula, and lateral hamstring. In other words, heel position and the lateral arch relate to sacroiliac joint stability via the lower posterior SPL.

Reference

1. Clemente C. Anatomy, a regional atlas of the human body. 3rd edn. Philadelphia: Lea and Febiger; 1987: Fig. 506.

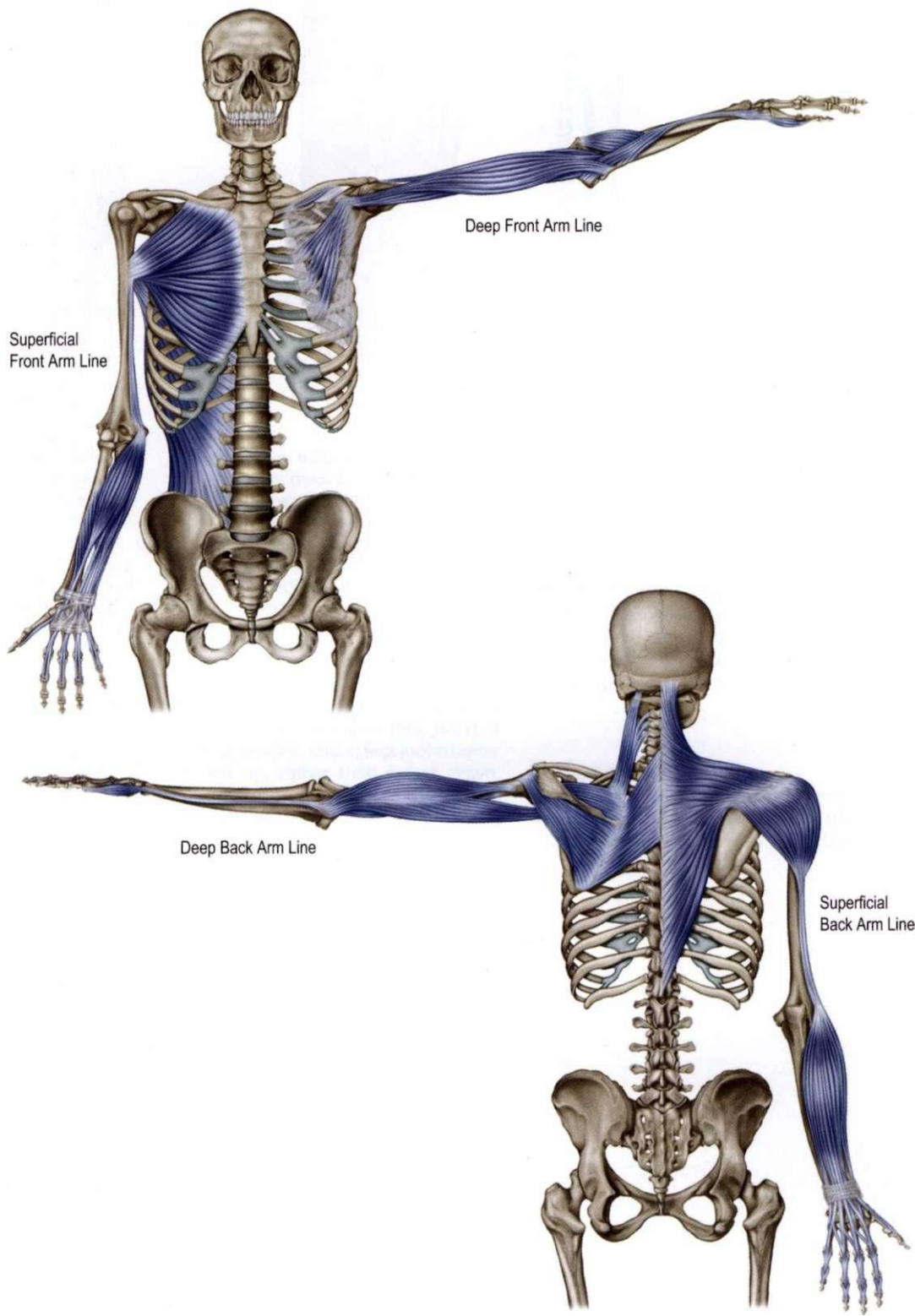


Fig. 7.1 The Arm Lines.

The Arm Lines

7

Overview

In this chapter we identify four distinct myofascial meridians that run from the axial skeleton to the four quadrants of the arm and four 'sides' of the hand, namely the thumb, little finger, palm, and back of the hand (DVD ref: **Shoulders and Arm Lines** 13:05-14:35). Despite this apparently neat symmetry, the Arm Lines (Fig. 7.1) display more 'crossover' myofascial linkages among these longitudinal continuities than do the corresponding lines in the legs. Because human shoulders and arms are specialized for mobility (compared to our more stable legs), these multiple degrees of freedom require more variable lines of control and stabilization and thus more inter-line links. Nevertheless, the arms are quite logically arranged with a deep and superficial line along the front of the arm, and a deep and superficial line along the back of the arm (Fig. 7.2/Table 7.1). The lines in the arm are named for their placement as they cross the shoulder (Fig. 7.3). (In Ch. 8 we look at the extensions of these lines that connect from the shoulder contralateral^A to the opposite pelvic girdle.)

Postural function

Since the arms hang from the upper skeleton in our upright posture, they are not part of the structural 'column' as such. Thus we have included the appendicular legs in our discussion of the cardinal and spiral lines, but left the arms for separate consideration. Given their weight, however, and their multiple links to our activities of daily driving and computer life, the Arm Lines do have a postural function: strain from the elbow affects the mid-back, and shoulder malposition can create significant drag on the ribs, neck, breathing function, and beyond. This chapter details the lines of pull on the axial skeleton from the arms when relaxed, as well as the tensile lines that come into play when using the arms in work or sport, supporting the body as in a

push-up or yoga inversions, or in hanging from the arms, as in a chin-up or tree play (DVD Ref: **Shoulders and Arm Lines**, 03:01-09:33).

Movement function

In myriad daily manual activities of examining, manipulating, responding to, and moving through the environment, our arms and hands, in close connection with our eyes, perform through these tensile continuities. The Arm Lines act across the 10 or so levels of joints in the arm to bring things toward us, push them away, pull, push or stabilize our own body, or simply hold some part of the world still for our perusal and modification. These lines connect seamlessly into the other lines, particularly the helical lines - the Lateral, Spiral and Functional Lines (Chs 5, 6, and 8 respectively).

The Arm Lines in detail

Common postural compensation patterns associated with the Arm Lines lead to all kinds of shoulder problems, as well as arm and hand problems, usually involving the shoulders being protracted, retracted, lifted, or rounded. These compensations are often founded in the lack of support from the rib cage, which leads us to look to the cardinal lines as well as the Spiral and Deep Front Lines for a solution. Carpal tunnel, elbow and shoulder impingements, and chronic shoulder muscle or trigger-point pain emerge over time from these postural and support faults.

The Arm Lines are presented from the axial skeleton out to the hand. The order in which they are presented carries no particular significance.

Orientation to the Arm Lines

The Arm Line anatomy presented in **Table 7.1** is sufficiently complex to merit a simple way to orient to these lines and organize them in the reader's mind before setting off on this intricate journey. You can see the following for yourself in a mirror, or by observing a model (DVD ref: **Shoulders and Arm Lines** 16:01-17:19).



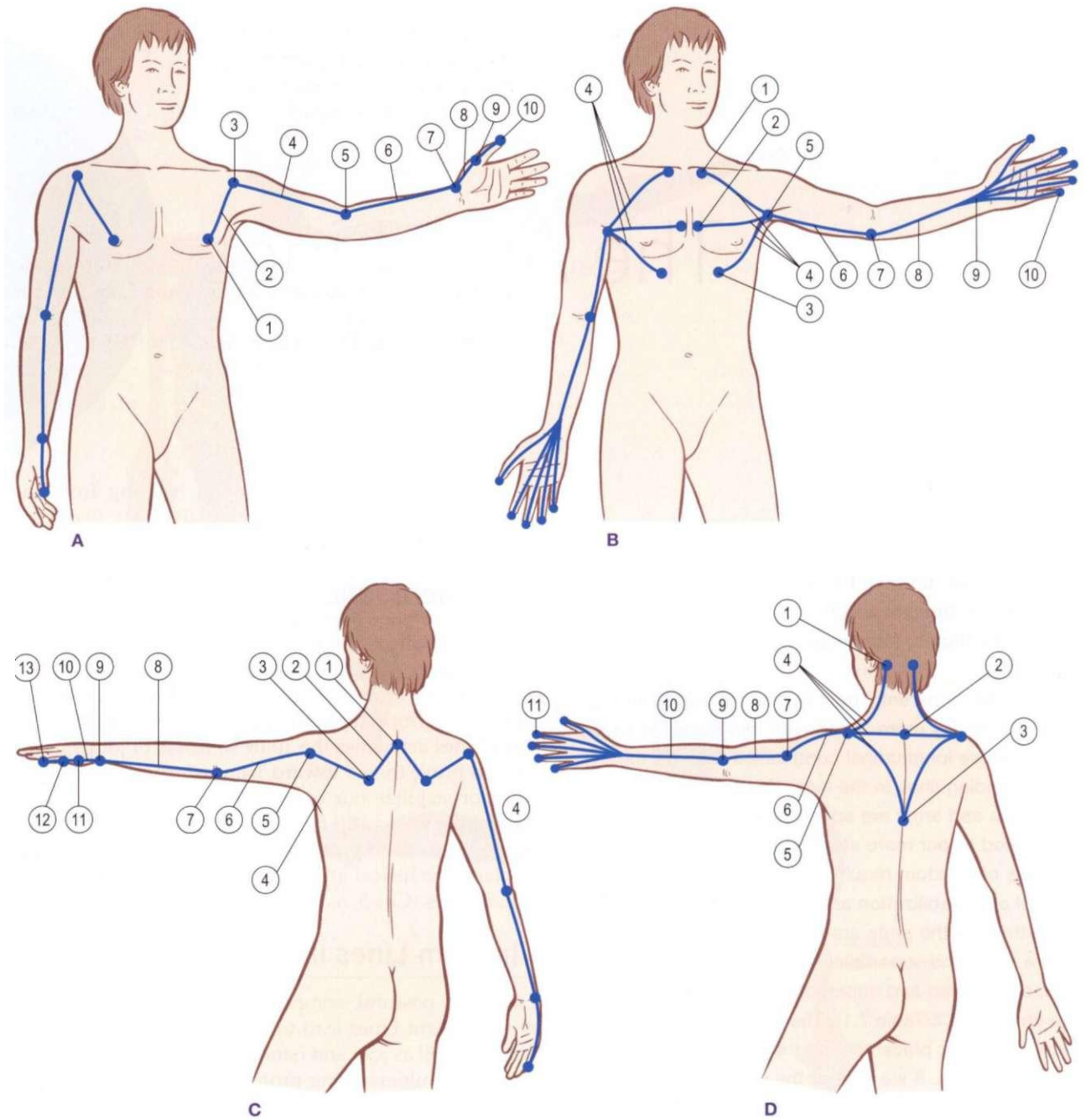


Fig. 7.2 Arm Lines tracks and stations.

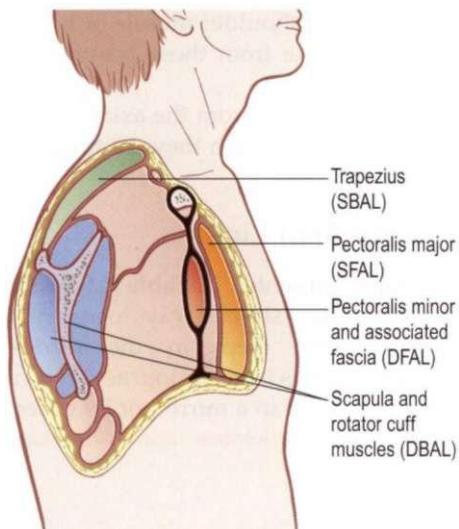


Fig. 7.3 The Arm Lines are named for their relative positions at the level of the shoulder. The four parallel planes that start the arm lines are clearly visible and divisible.

Table 7.1 Arm Lines: myofascial 'tracks' and bony 'stations' (Fig. 7.2)

Bony stations	Myofascial tracks
A. Deep Front Arm Line	
3rd, 4th and 5th ribs	1
	2
Coracoid process	3
	4
Radial tuberosity	5
	6
Styloid process of radius	7
	8
Scaphoid, trapezium	9
Outside of thumb	10
B. Superficial Front Arm Line	
Medial third of clavicle, costal cartilages, thoracolumbar fascia, iliac crest	1
	2
Medial humeral line	3
	4
Medial humeral epicondyle,	5
	6
Palmar surface of fingers	7
	8
C. Deep Back Arm Line	
Spinous process of lower cervicals and upper thoracic, C1-4 TPs	1
	2
Medial border of scapula	3
	4
Head of humerus	5
	6
Olecranon of ulna	7
	8
Styloid process of ulna	9
	10
Triquetrum, hamate	11
	12
Outside of little finger	13
D. Superficial Back Arm Line	
Occipital ridge, nuchal ligament, thoracic spinous processes	1, 2, 3
	4
Spine of scapula, acromion, lateral third of clavicle	5
	6
Deltoid tubercle of humerus	7
	8
Lateral epicondyle of humerus	9
	10
Dorsal surface of fingers	11

Position the arm out to the side, as in **Figure 7.2A**, and arrange it so that the palm faces forward and the olecranon of the elbow points down to the floor. The Superficial Front Arm Line (SFAL - **Fig. 7.2B**) is now arrayed along the front of your arm - palmar muscles, lower arm flexors, intermuscular septum, and pectoralis major. The Superficial Back Arm Line (SBAL - **Fig. 7.2D**) is arrayed along the back side of the arm - trapezius, deltoid, lateral intermuscular septum, extensors.

Rotate your arm medially at the shoulder (no pronation allowed), so that the palm faces the floor and the olecranon of the elbow points back, as in **Figure 7.2C**. In this position, the Deep Front Arm Line (DFAL - **Fig. 7.2A**) is arrayed along the front - thenar muscles, radius, biceps, and (under the major) pectoralis minor. The Deep Back Arm Line (DBAL - **Fig. 7.2C**) is arrayed along the back side of the arm - the hypothenar muscles, the ulna, the triceps, the rotator cuff, and (under the trapezius) the rhomboids and levator scapulae.

Keeping these 'sight lines' in mind when analyzing movement, especially movements where the arm plays a supporting role, will help distinguish which lines are being employed - and perhaps over-employed - in a movement. Overuse of a particular line 'downstream' (distally) will often precede strain injuries 'upstream' (proximally) in the given line.

The Deep Front Arm Line

The DFAL (**Fig. 7.4**) begins muscularly on anterior aspects of the 3rd, 4th and 5th ribs with the pectoralis minor muscle (**Fig. 7.5**). This muscle is actually embedded in the clavipectoral fascia (**Fig. 7.6A**) that runs underneath the pectoralis major from clavicle to armpit, and includes both the pectoralis minor and the subclavius muscles, with connections to the neurovascular bundle and lymphatic tissues in this area (**Fig. 7.6B** and **DVD ref: Shoulders and Arm Lines, 29:56-32:28**). The entire clavipectoral fascia, nearly as large as the pectoralis major, constitutes the initial track of this line; the pectoralis minor, however, provides the chief contractile structural support to the scapula from this complex, while the smaller subclavius tethers the clavicle.¹

The distal station for the pectoralis minor muscle is the coracoid process, a nub of the scapula which projects forward under the clavicle like a thumb or a 'crow's beak' (from whence it gets its name). Two other muscles proceed out to the arm from here, the short head of the biceps brachii and the coracobrachialis (**Fig. 7.5**). There is clearly a myofascial continuity between the pectoralis minor and both these more distal muscles (**Fig. 7.7**), but by our Anatomy Trains rules, this connection would seem to be out of the running, at least in a relaxed standing posture, due to the radical change of direction from the pectoralis minor in this position. When the arms are outstretched, however, at the horizontal or anywhere above (as in a tennis forehand), and especially in any hanging position (as in a swinging monkey or in a chin-up), these myofascial units link into a connected line (see **Fig. 2.2**, p. 66).



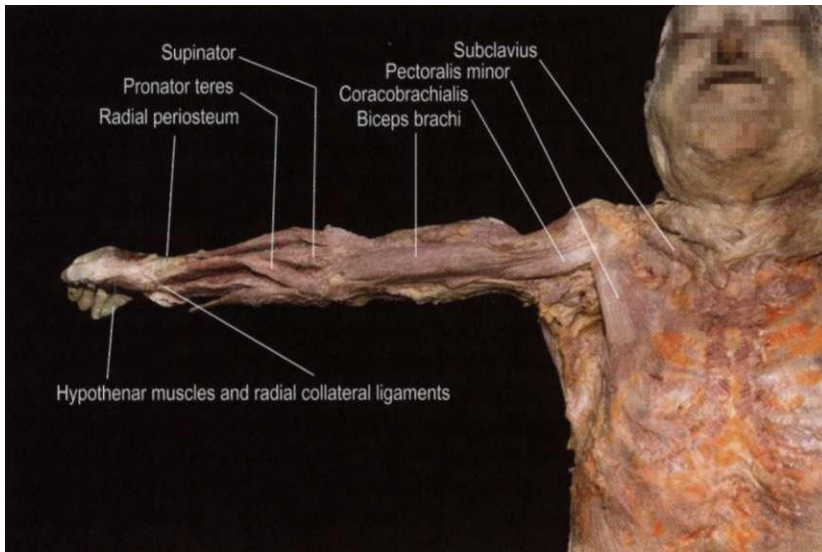


Fig. 7.4 The Deep Front Arm Line in dissection, *in situ*. The pectoralis major has been removed to show the connections between the pectoralis minor and the thumb.

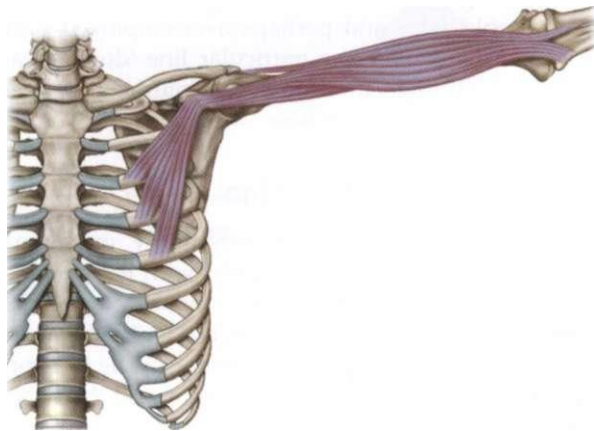
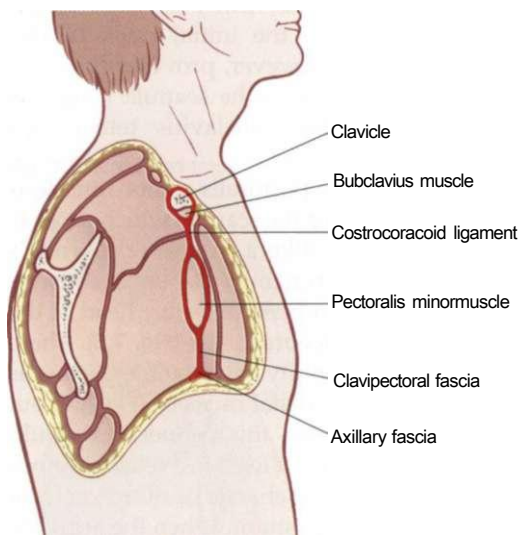
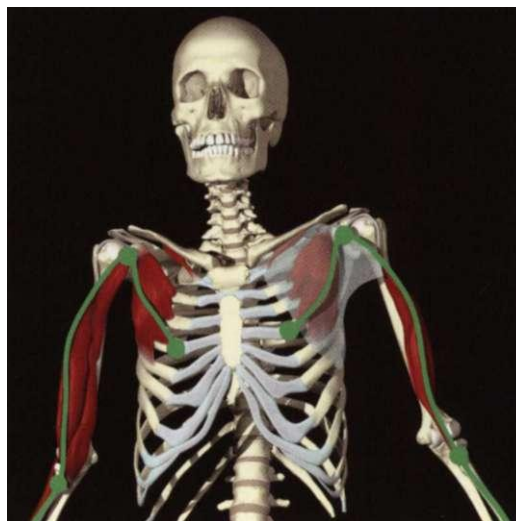

Fig. 7.5 The pectoralis minor clearly connects fascially to the short head of the biceps and coracobrachialis at the coracoid process, but they only function in an Anatomy Train fashion when the arm is nearly horizontal or above.



A



B

Fig. 7.6 (A) The beginnings of the Deep Front Arm Line include not only the pectoralis minor muscle, but also other structures in the same fascial plane from the clavicle down to the lower edge of the armpit. (B) This clavipectoral fascia which forms the proximal section of the DFAL, seen here in the computer imagery of Primal Pictures, is nearly as large as the overlying pectoralis major. (Image provided courtesy of Primal Pictures, www.primalpictures.com.)

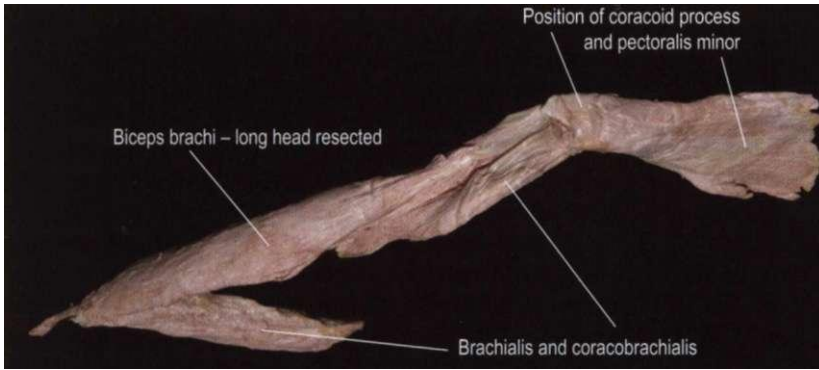


Fig. 7.7 The fascial 'fabric' connection between the pectoralis minor and the biceps is clear, even when the coracoid process is removed from underneath.

The DFAL is primarily a stabilizing line (comparable to the Deep Front Line in the leg), from the thumb to the front of the chest. In the quadruped, and in a rugby scrum or a yoga 'plank', this line would manage (restricting or allowing) side-to-side movement of the upper body. In the free arm, the DFAL controls the angle of the hand, principally via the thumb, and also the thumb's grip.

The pectoralis minor

The pectoralis minor and the clavipectoral fascia are difficult to find and stretch in isolation from the overlying pectoralis major. Excessive shortness in this myofascia can negatively affect breathing, neck and head posture, and, of course, the easy functioning of the shoulder and arm, especially in reaching upward. Hanging from a branch, or even putting the arm into hyperflexion (as in a deep 'Downward Dog' posture or kneeling before a wall and sliding the hands as far as possible up the surface), may result in creating a stretch in these tissues, but it is difficult for the practitioner to tell from the outside, as lifting the upper ribs by tilting the rib cage (and thus avoiding the pectoralis minor stretch) is a common compensation. Here is a reliable way to manually contact this vital and often restricted structure at the proximal end of the DFAL.

Three indications for functional shortness in the pectoralis minor and clavipectoral fascia include: (1) restriction in upper rib movement in inspiration, such that the shoulders and ribs move in strict concert, (2) if the client has trouble flexing the arm and lifting the shoulder to reach the top shelf in the cupboard, and (3) if the scapula is anteriorly tilted or the shoulders 'rounded'. To determine this last, view the client from the side: the medial border of the scapula should hang vertically, like a cliff. If it is sitting at an angle, like a roof, then a shortened pectoralis minor is likely pulling inferiorly on the coracoid process, tilting the scapula. The longer, outer slips of the pectoralis minor - to the 4th and 5th ribs - will be implicated in this pattern. If the shoulders are 'rounded' (medial rotation or strong protraction of the scapula - often seen when the client is supine and the tips of the shoulders are well off the table), the inner shorter slips to the 2nd (sometimes named as the costocoracoid ligament) and 3rd ribs are the ones that require lengthening.

Although a muscular pectoralis minor, especially the outer more vertical slips, may be felt through the overlying and more horizontal pectoralis major, approaching from the axilla is to be preferred over treating the minor through the major. Position your client supine with her arm up, elbow bent, so that the back of her hand is resting on the table near her ear. If this is difficult, support the arm on pillows, or alternatively bring the arm down by the client's side so that it rests on your wrist.

Put your fingertips on her ribs in the armpit between the pectoralis and latissimus tendons. Kneeling beside the table facilitates the proper angle of entry. Slide up slowly under the pectoralis major in the direction of the sternoclavicular joint, keeping your finger pads in contact with the front of the rib cage. It is vitally important to slide along the ribs, not into them or away from them. Pushing into the tissues overlying the ribs is a common error when first attempting this approach; since the rib periosteum are highly innervated, this pressure creates strong and useless pain. With the open client, the correct angle, and soft fingers, however, it is possible to go quite far underneath the pectoralis major, so a little practice is required to figure out how much skin to take with you - skin stretch is not the object (DVD ref: Shoulders and Arm Lines, 30:12-36:00).

Draw an imaginary line down and slightly medial from the coracoid process to the outer and upper attachment of the rectus abdominis. You must go far enough under the pectoralis major to meet this line before you would have any expectation of encountering the outer edge of the pectoralis minor. When you do, it varies from a few skinny slips of muscle plastered to the wall of the ribs to a full, free, distinctly palpable muscle (the desired condition - though even in this condition it can be muscularly or fascially short). In most cases no harm will come (and much benefit to shoulder mobility will arise) from going under the leading edge of the pectoralis minor, lifting the muscle away from the rib cage and stretching it toward its insertion at the coracoid. The client can help with a long slow inhale, or by lifting his arm toward the top of his head (**Fig. 7.8**). Be sure the arm is supported, not hanging free in the air.

Since the pectoralis minor muscle is embedded in the clavipectoral fascia, there is benefit in stretching the tissue under the pectoralis major muscle even if the

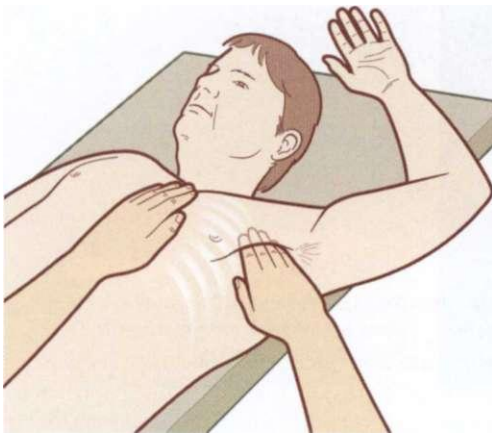

Fig. 7.8 The hand approaches the pectoralis minor from the axilla, under the pectoralis major, with the fingers heading in the direction of the sternoclavicular joint.

specific slips of the pectoralis minor are not felt. When the muscle can specifically be felt, be aware that the first slip you encounter is attached to the 5th rib. When this is freed or 'melted', the next slip further in will be attached to the 4th rib. In very open bodies, you can sometimes feel the slip attached to the 3rd rib (and most people will have an additional slip of fascia, some with muscle in it, on the 2nd rib as well).

This is frequently a little-used area in our culture, so stay within the limits of your client's tolerance for sensation; return at another time if necessary. When working with women, be aware that lymphoid tissue connects the breast around the edge of the pectoralis to the armpit. By 'swimming' your fingers gently under the pectoralis major along the ribs you can avoid any problem with overstretching this tissue. It is also possible to contact this area with the client side-lying, so that gravity takes the breast away from you, although the instability of the shoulder in this position as well as the resulting malposition of the opposite shoulder can present a disadvantage in some clients (**DVD ref: Shoulder and Arm Lines, 36:07-38:16**).

In a few cases - especially those with breast surgery of any kind, or radiation treatment - the pectoralis minor can be fastened fascially to the posterior surface of the pectoralis major. If the minor cannot be found by the methods above, supinate your hand so that the fingerpads face upward, and carefully strum along the posterior surface of the major. The minor presents itself as a series of fibers oblique to the direction of the pectoralis major fibers. When this condition is encountered, the minor can sometimes be teased away from the major by crooking your fingers and working slowly and carefully to make the separation between the fascial planes.

For movement therapists, you can contact these tissues by having your client kneel before a wall and having him slide his hands as far up the wall as possible while maintaining a straight back, or keeping the manubrium (not the xiphoid) of the sternum close to the wall. Kneel behind the client and slip your hands around the ribs under the pectoralis minor to find the same slips

referenced above. Have the client allow his hands to slide down the wall while you find shortened tissues, and slide his hands back up the wall to assist and control the stretch.

In terms of movement homework, the client can link his fingers behind his lower back and stretch them down toward his legs, so that the scapulae drop down the rib cage in back and somewhat together toward the spine (**Fig. 7.9**). This will stretch the pectoralis minor and surrounding tissues (and strengthen the antagonistic lower trapezius), but the client should beware of arching his low back as he does it, as this will change the angle of the rib cage and negate the stretch (see discussion of scapular position at the end of this chapter, p. 164).

The biceps express

The short head of the biceps runs down from the coracoid to the radial tuberosity, thus affecting three joints: the gleno-humeral joint, the humero-ulnar joint, and the radio-ulnar joint (the shoulder, elbow, and the spin of the lower arm) (**Fig. 7.10** and **DVD ref: Shoulders and Arm Lines, 42:25-43:47**). Contracting it can thus have the effect of supinating the forearm, flexing the elbow, and diagonally flexing the upper arm (any or all of these movements, depending on the physics of the situation and the contraction of surrounding, assisting, or antagonistic muscles).

This biceps 'express' (see Ch. 2, p. 69, for a definition) has a series of 'locals' beneath it to help sort out its multiple functions. The coracobrachialis runs under the biceps from the coracoid process to the humerus, thus adducting the humerus (**DVD ref: Shoulders and Arm Lines, 38:17-42:25**). The brachialis runs from the humerus, next to the coracobrachialis attachment, down to the ulna, clearly flexing the elbow (**DVD ref: Shoulders and Arm Lines, 43:48-45:47**). Finally, the supinator runs from ulna to radius, supinating the forearm.

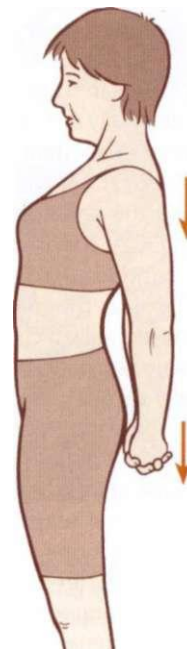


Fig. 7.9 Dropping the shoulder blades down the back and bringing them together while keeping the lumbar back will stretch and open the pectoralis minor and surrounding tissues.

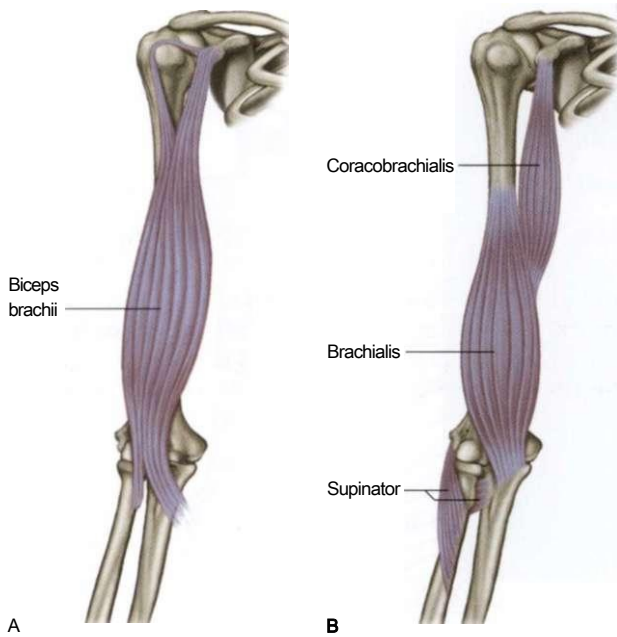


Fig. 7.10 The biceps brachii forms an express muscle (A), which covers three joints. Deep to the biceps lie three local muscles (B), each of which duplicates the biceps action on the individual joints. (Compare to the 4th hamstring, Fig. 6.20.)

This provides a very clear example of an organizing express arrayed over a series of differentiated locals. All of these muscles are part of the DFAL.

The practical point of this distinction is that postural 'set' is often more determined by the underlying locals than it is by the overlying express. Thus, while in extreme cases the biceps might have a role in chronic humeral adduction or elbow flexion, the therapist is far more likely to get results from addressing the underlying locals than from work on the biceps itself.

The long head of the biceps, as well as its other 'foot', the tendon of Lacertus or bicipital aponeurosis, are examples of 'crossovers', and are dealt with in that discussion at the end of this chapter.

The lower arm

Both the short head of the biceps and the supinator attach to the radius. In the lower arm, we are inclined to include the pronator teres in this line because with the supinator it clearly controls the degree of rotation of the radius, and thus the thumb (see Fig. 7.4 or 7.11 - pronator and supinator form a 'V' converging on the radius), even though strictly speaking pronator teres is a crossover from the Superficial Back Arm Line. From all these radial attachments, we pass along the periosteum of the radius to its styloid process at the distal end on the inside of the wrist (DVD ref: Shoulders and Arm Lines, 45:48-47:34). The fascial fabric below the distal ends of the two rotators is adherent to the periosteum of the radius, which is very reluctant to separate from the bone in dissection (see Fig. 7.4 distal to the 'V') - This long 'station' violates the spirit of the Anatomy Trains idea of longitudinal fascial continuities separable from their underlying bones (see the discussion of the 'inner



Fig. 7.11 The DFAL runs down the periosteum of the radius and crosses over the inside of the wrist to join the thumb and its associated intrinsic thenar muscles.

and outer bags' in Ch. 1). Spirit or not, such a fastening is a practical necessity when we consider the stabilizing function of this line and its corresponding Deep Back Arm Line. The periosteum of the radius and ulna is of course continuous with the interosseous membrane spanning between them. The bones are nevertheless capable of sliding on one another (to reassure yourself of this, put the thumb and forefinger of your left hand on the radial and ulnar styloid processes at the wrist of your right hand. Ad- and abduct the wrist (radially and ulnarly deviate if you prefer) to feel the limited slide of the radius on the ulna. In order to stabilize this movement, both of these lines must fasten to the periosteum of these bones and (by implication) to the interosseous membrane.

From the wrist, we traverse the radial collateral ligament over the thumb-side carpals, the scaphoid, and the trapezium, to the thumb itself (Fig. 7.11). Although the extensor pollicis brevis and abductor pollicis longus tendons accompany these tissues, these muscles arise from the ulna as part of the Deep Back Arm Line - one of the many examples of crossover between the lines discussed at the end of this chapter. The thenar muscles are included as part of the DFAL (DVD ref: Shoulders and Arm Lines, 47:35-49:16).

The 'thumb line'

Practitioners of Shiatsu or any other technique employing pressure through the thumb need to stay aware of the DFAL, which ends at the thumb. Good body mechanics for a long-term practice require that the DFAL stay open and lengthened, with the arms in a rounded position (elbows bent) while putting the pressure on the thumb (see Fig. 10.43, p. 225). Those practitioners who report pain as a result of this kind of pressure in the thumb itself or the saddle joint at its base will almost invariably show a collapsed DFAL, frequently at the area of the upper arm-coracoid or coracoid-ribs connections and frequently accompanied by extended elbows. (See the section on the pectoralis minor above.)

The Superficial Front Arm Line

The Superficial Front Arm Line (SFAL) overlies the DFAL in the shoulder, beginning with a broad sweep of attachments, which in this line includes several muscles. The pectoralis major, which has a broad set of attachments from the clavicle down onto the middle ribs, begins this line in the front (Fig. 7.12 and DVD ref: Shoulders and Arm Lines, 18:25-25:03). The latissimus dorsi (which begins its embryological life as 'latissimus

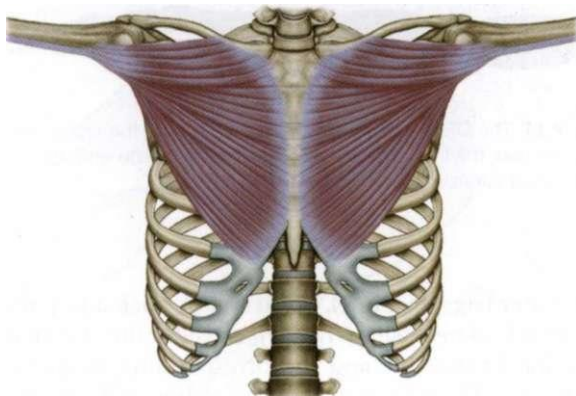


Fig. 7.12 The pectoralis major is a principal player in the start of the Superficial Front Arm Line.

ventri', a muscle on the front with a firm attachment to the anterior surface of the humerus, next to pectoralis, thus staking its tenuous claim to being part of the SFAL) sweeps up from the spinous processes of the lower thoracics, the lumbosacral fascia, the iliac crest, and lower lateral ribs (**DVD ref: Lateral Line, 43:58-48:40**). Between the pectoralis major and the latissimus, the SFAL has nearly an entire circle of attachments, reflecting the wide degree of control the SFAL exerts on movement of the arm in front of and to the side of the body (**Fig. 7.13**).

The latissimus picks up the teres major (another crossover muscle - see discussion) from the lateral border of the scapula, and all three of these muscles twist and focus into bands of tendon which attach alongside each other to the underside of the anterior humerus (**Fig. 7.14**). These bands surround and connect into the beginning of the medial intermuscular septum, a fascial wall between the flexor and extensor group in the upper arm, which carries us down to the next bony station, the medial humeral epicondyle (**Fig. 7.15** and **DVD ref: Shoulders and Arm Lines, 25:04-25:56**).

The track of the common flexor tendon continues down from the epicondyle, joining with the many-layered longitudinal muscles on the underside of the forearm (**Fig. 7.16A** and **DVD ref: Shoulders and Arm Lines: 25:56-27:40**). The shorter of these muscles go to the carpal bones; the flexor superficialis muscles go to the middle of the fingers, and the profundus muscles reach to the tips of the fingers. This breaks, we should note, the usual pattern of having the deeper muscles be the shorter (**Fig. 7.16B**). These muscles to the fingers run through the carpal tunnel under the flexor retinaculum, to spread out to the ventral carpal and the palm sides of the fingers (**Fig. 7.17** and **DVD ref: Shoulders and Arm Lines: 27:41-29:55**).

As implied in our first paragraph, the SFAL controls the positioning of the arm in its wide range of motions in front of and beside us. The large muscles of the pectoralis and latissimus provide the motive force for the large movements of adduction and extension, such as a swimming stroke or a tennis smash or a cricket bowl. By controlling the wrist and fingers, the SFAL participates with the DFAL in the grip. Although the author is

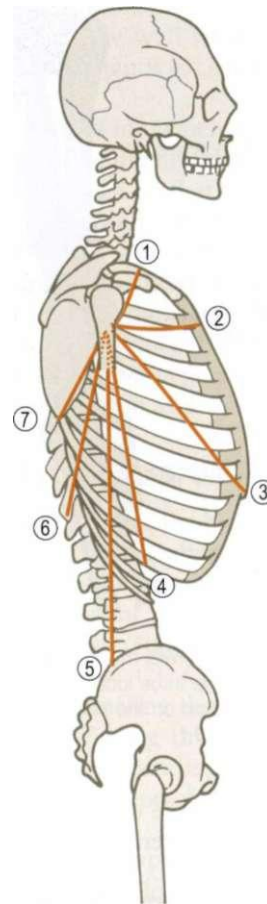


Fig. 7.13 Between the two triangular muscles - the pectoralis major and latissimus dorsi - the SFAL has a broad origin around the trunk from the clavicle (1) around the ribs to the pelvis (5) and the thoracic spine (7).

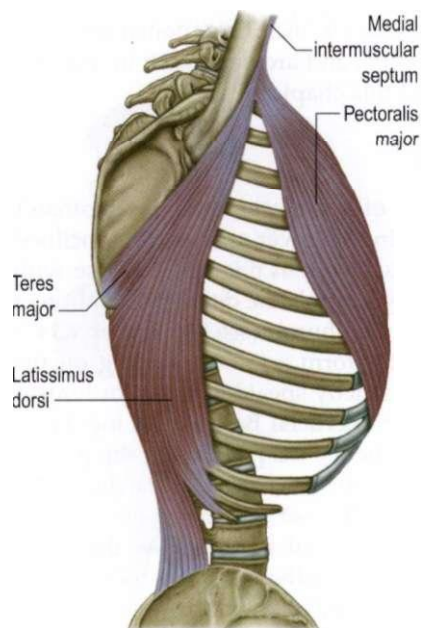


Fig. 7.14 The latissimus dorsi and teres major, even though they come from the back, are clearly connected into the same functional myofascial plane as the pectoralis major.

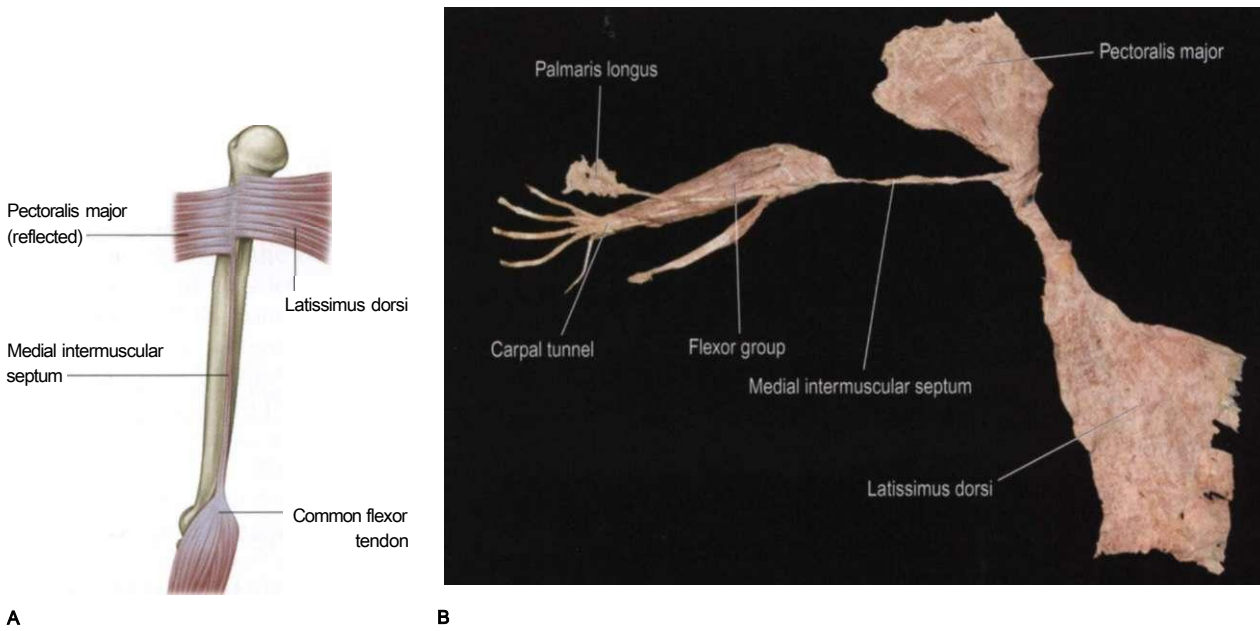


Fig. 7.15 (A) The SFAL connects from the medial humerus down the medial intermuscular septum to the medial humeral epicondyle on the inner side of the elbow. (B) A dissection of the entire SFAL intact as one myofascial meridian.

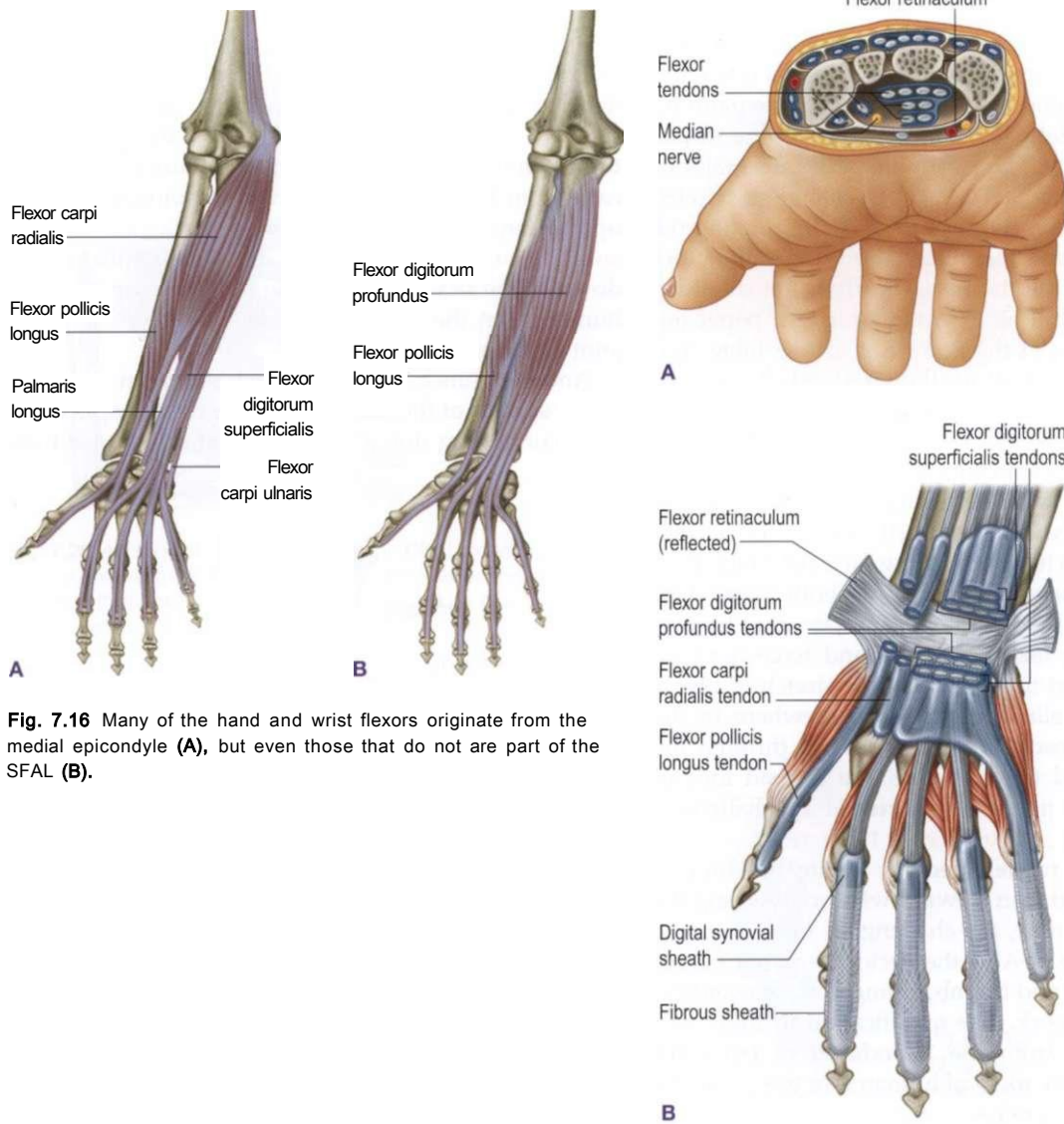


Fig. 7.16 Many of the hand and wrist flexors originate from the medial epicondyle (A), but even those that do not are part of the SFAL (B).

Fig. 7.17 The SFAL passes through the carpal tunnel and out onto the palmar surface of the hand and fingers.

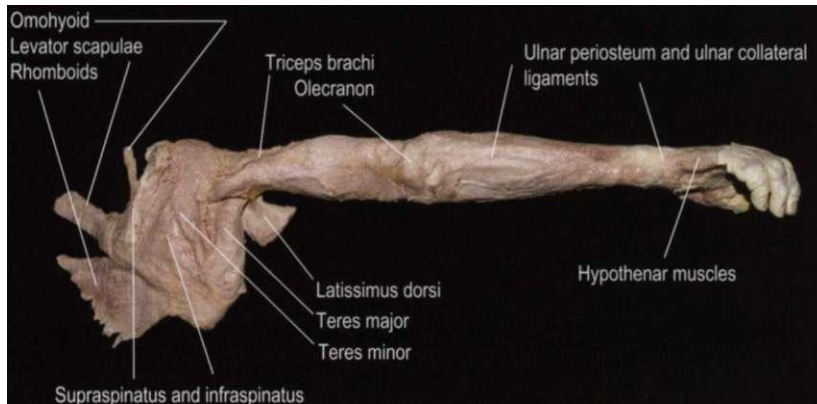


Fig. 7.18 The Deep Back Arm Line in dissection *in situ*, showing the connections from the rhomboids and scapula down to the little finger.

unfamiliar with avian anatomy in detail, in most birds the SFAL provides both the motive power of the wing beat, and the control of the 'ailerons' - the outer feathers. In a quadruped, the SFAL provides the forward motive power for the foreleg.



Stretch assessment for the Superficial and Deep Front Arm Lines

To feel the difference between the Superficial and Deep Front Arm Lines, lie supine near the edge of a treatment table or hard bed, and drop the arm, with the palm up and the shoulder abducted, off the edge. This is a stretch for the SFAL, and will be felt in the pectoralis major or somewhere along the SFAL track. To change the stretch to the DFAL, turn the thumb up (medially rotating the shoulder to do it) and then reach it out along the other fingers, stretching the thumb away from the shoulder, as if reaching the thumb to grasp a piece of paper out behind you as you let the arm drop off the table. You will feel the stretch track up the DFAL, all the way to the pectoralis minor.

Alternately, stand behind a model holding her wrists. Allow the model to lean forward from the ankles like the beginning of a swan dive, with you counterbalancing the weight - assuring yourself and the model that you can easily hold her from falling forward. She is now both hanging from and leaning into both Front Arm Lines. Have the model laterally rotate the humeri (thumbs up), then take her wrists and have her lean forward, and report to you where the stretch is. She is likely to report feelings of stretch somewhere in the SFAL - from the pectoralis major on out through the hand flexors - and this can give you a good idea of where the tissues might be shortened or challenged (DVD ref: **Shoulders and Arm Lines: 17:20-17:52**).

Then have the model medially rotate her humeri (thumbs down) and lean forward with you holding the wrists again. This time, the challenge is likely to come in some part of the DFAL - the pectoralis minor on out through the biceps and thumb, giving you some indication of where to work. The qualification in these two statements comes from the abundance of crossover muscles that, in the variety of human arm usages, make blanket statements unwise.

The Deep Back Arm Line

The Deep Back Arm Line (DBAL) begins at the spinous processes of the upper thoracic and 7th cervical vertebrae, passing down and out with the rhomboid muscles to the vertebral border of the scapula (Fig. 7.18 and DVD ref: **Shoulders and Arm Lines, 52:03-52:18**). The rhomboids are thus part of both the Spiral Line (Ch. 6) and the DBAL (Fig. 7.19 and DVD ref: **Shoulders and Arm Lines, 53:18-1:01:57**). The fascial track splits here with a switch at the vertebral border: the Spiral Line continues deep to the scapula with the serratus anterior muscle (DVD ref: **Spiral Line, 16:00-20:28**), while this DBAL continues around the scapula with the rotator cuff, specifically from the rhomboids to the infraspinatus, picking up the teres minor along the way (DVD ref: **Shoulders and Arm Lines, 1:04.21-1:08:10**). These two muscles tack down to the next station on the posterior aspect of the humerus, on the greater tubercle, contiguous with the joint capsule.

Another branch line of the DBAL begins on the lateral lower surface of the occiput with the rectus capitis lateralis, continuing down with the levator scapulae from

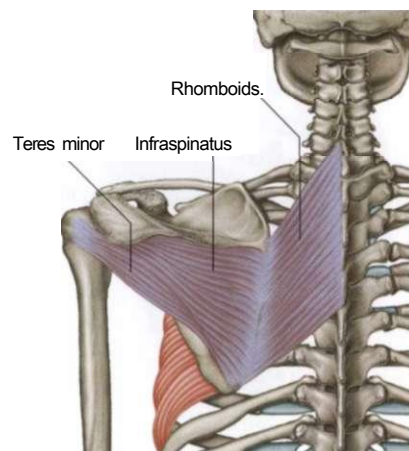


Fig. 7.19 The Deep Back Arm Line opens with the rhomboids, whose superficial layers of fascia pass across to the infraspinatus. This represents a switch, as we saw the rhomboids also connecting under the scapula to the serratus anterior in the Spiral Line (see Fig. 6.4, p. 133).

the posterior tubercles of the transverse processes of the first four cervical vertebrae (**Fig. 7.20**). The distal station of this line is the superior angle of the scapula, just above where the rhomboids join, but these fascial fibers link to the supraspinatus, which runs along the top of the scapula in the supraspinous fossa to the top of the ball of the humerus (**DVD ref: Shoulders and Arm Lines, 1:02:00-1:04:20**). Thus the DBAL includes at least three of the rotator cuff muscles.

The fourth of the rotator cuff set, the subscapularis, which covers the anterior surface of the scapula and goes to the anterior aspect of the head of the humerus, is certainly linked into this line, though it is a little difficult to justify this as a direct connection in terms of Anatomy Trains rules (**Fig. 7.21**). The rhomboid myofasciae certainly pull on the scapula, which is intimately connected with the subscapularis, though we would be hard pressed to connect rhomboideus in a direct fascial manner with subscapularis. We can say that the whole complex is joined mechanically through the bone of the scapula. Whatever our justification, the subscapularis clearly plays a crucial role in the balance of the shoulder, and should be considered, rules or not, as part of the

DBAL complex (DVD ref: Shoulders and Arm Lines, 1:08:11-1:09:57).

These four muscles of the rotator cuff control the rounded head of the humerus in much the same way as the ocular muscles control the orbit of the eye (**Fig. 7.22**). According to Frank Wilson, author of the delightful *The Hand*:

The brain points the arm and finger as accurately as it points the eye. In the orbit and at the shoulder, the eye and the humerus are free to rotate (or swing) in front-to-

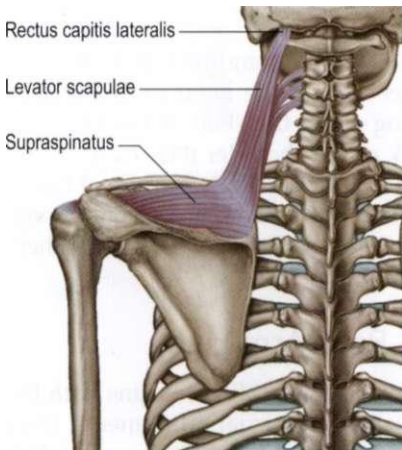
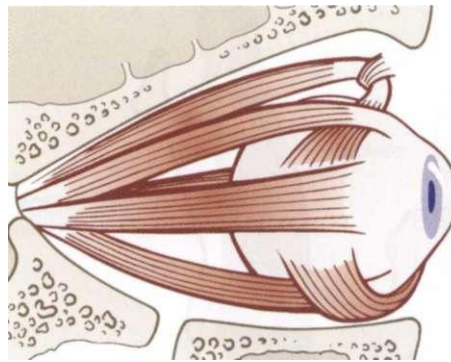
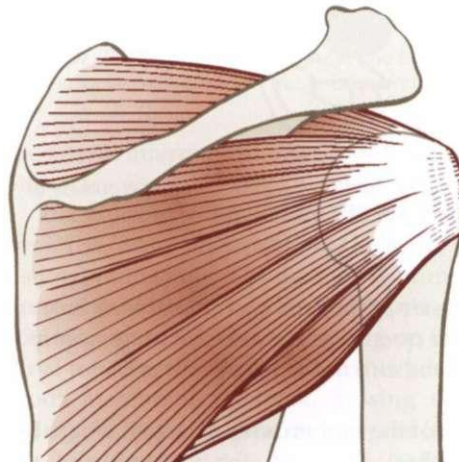


Fig. 7.20 An alternative branch line for the DBAL consists of the rectus capitis lateralis leading down onto the levator scapulae. Together, these two connect the head and neck to the supraspinatus over the apex of the scapula.



A



B

Fig. 7.22 There is an interesting muscular parallel between the control of the orb of the eye and the control of the rounded head of the humerus.

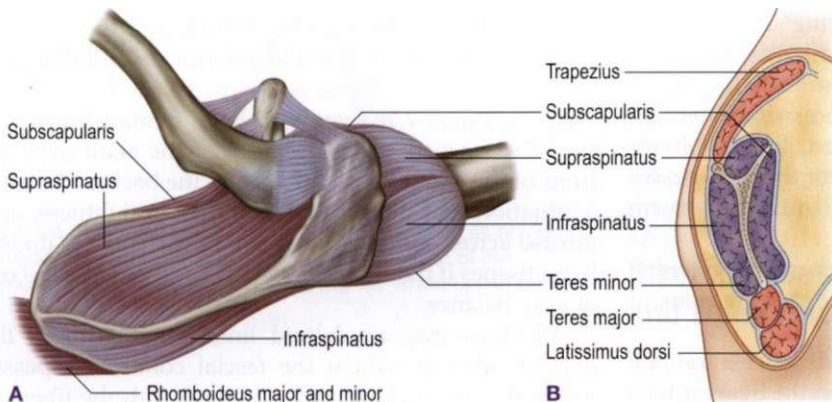


Fig. 7.21 The second track of the DBAL is the entire rotator cuff complex that sandwiches the scapula, including the subscapularis.

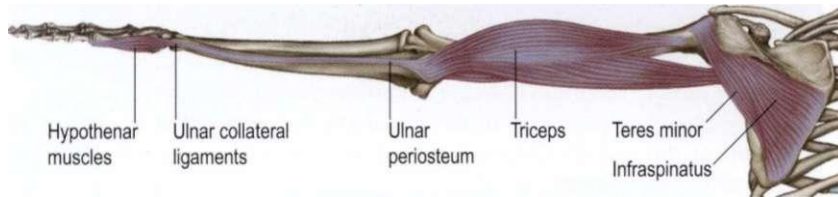


Fig. 7.23 The rotator cuff track of the DBAL connects to the triceps, with the proviso that the arm needs to be up at near horizontal or above for this connection to be active. The DBAL runs from the triceps attachment at the olecranon of the elbow down the periosteum of the ulna, across the outer edge of the wrist to the hypothenar muscles and the little finger. Compare to Fig. 7.18.

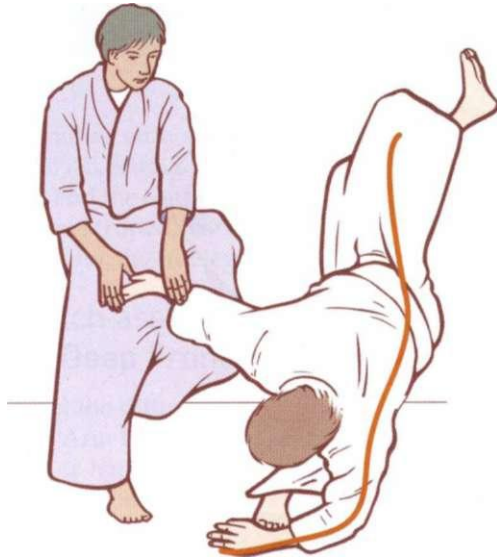

Fig. 7.24 A judo roll runs right up the DBAL, from the outside of the little finger to the rotator cuff, before continuing on the Back Functional Line (see Ch. 8).

back and side-to-side planes, and also around their long axes. And in both cases there is a precise arrangement of muscles aligned and attached to power each of these movements.

From the shaft of the humerus near the ball where the rotator cuff attaches, and from the underside of the glenium near the teres minor insertion, come the three heads of the triceps brachii, the next track of this line (Fig. 7.23). In the hanging arm, with a similar pattern to the Deep Front Arm Line, the step from the rotator cuff to the triceps involves a radical change of direction, but with the shoulder abducted, as in a tennis backhand, these two are fascially and mechanically linked. The triceps carries us down (including the anconeus along the way) to the tip of the elbow, the olecranon of the ulna (DVD ref: Shoulders and Arm Lines, 1:09:58-1:11:16). To keep going straight from here, we are stymied if we look for a muscular connection, but not if we look for a fascial one: the periosteum of the ulna passes down the entire length of the outside of the lower arm (DVD ref: Shoulders and Arm Lines, 1:11:17-1:13:04). As with the DFAL, the DBAL is firmly fastened to the ulna for the distal half of the ulna, for the same reasons of stability.

When we reach the ulnar styloid process on the outside of the wrist, we can continue on the ligamentous

capsule of the wrist, specifically the ulnar collateral ligament, outside the triquetral and hamate carpal bones and onto the periosteum and ligaments that run up the little-finger side of the hand (Fig. 7.23). The hypothenar muscles are part in this line (DVD ref: Shoulders and Arm

The DBAL, roughly equivalent to the Lateral Line in the leg, works with the DFAL to adjust the angle of the elbow, to limit or allow side-to-side movement of the upper body when in a crawl position, and to provide stability from the outside of the hand to the back of the shoulder.

A judo roll

An aikido or judo roll traces along the DBAL. It starts when the little-finger side of the hand makes contact with the mat, passing along the shaft of the ulna, the triceps, and the back of the shoulder (Fig. 7.24). (A full roll will then continue along the Back Functional Line - see Chs 8 and 10.) It is important to keep this line strong, full, and round for a successful roll. Collapse anywhere along the line can lead to injury.

The Superficial Back Arm Line

The Superficial Back Arm Line (SBAL) begins with the wide sweep of the trapezius's axial attachments, from the occipital ridge through the spinous process of T12. These fibers converge toward the spine of the scapula, the acromion of the scapula, and the lateral third of the clavicle (Fig. 7.25 and DVD ref: Shoulders and Arm Lines, 49:25-53:25).

In fact, the specific connections here are interesting: the thoracic fibers of the trapezius link roughly with the posterior fibers of the deltoid; the cervical fibers of trapezius link with the middle deltoid; and the occipital fibers of trapezius link to the anterior deltoid (Fig. 7.26 and DVD ref: Shoulders and Arm Lines, 53:27-54:55). Draping Figure 7.26 over a skeleton demonstrates that the SBAL sweeps from the back of the skull over the front of the shoulder and thence to the back of the arm, a situation that often causes confusion, tightness, and misuse across the anterior deltoid area and the underlying tissues if the shoulder is - and it frequently is - out of easy balance.

All these trapezio-deltoid lines converge onto the deltoid tubercle, where the fascial connection passes under the brachialis muscle to blend with the fibers of

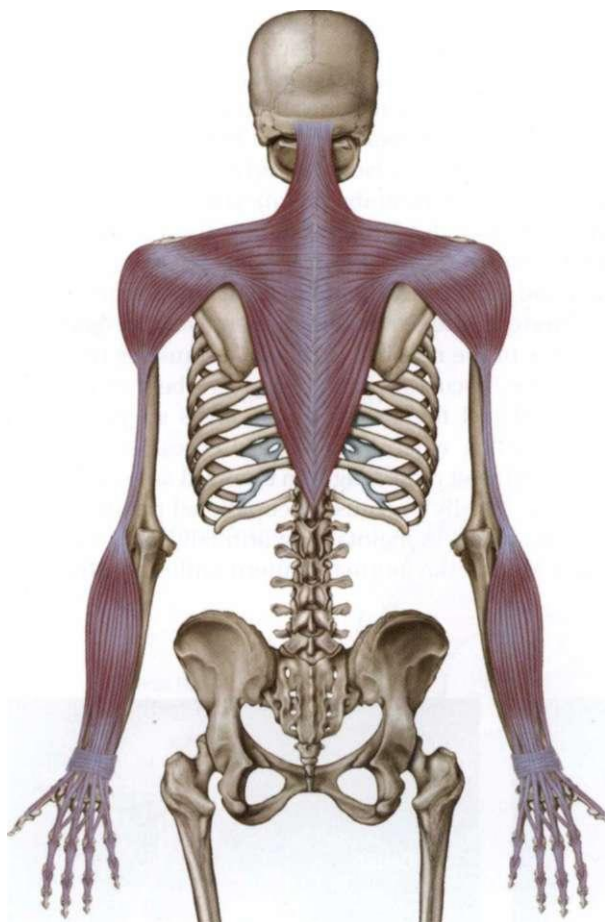


Fig. 7.25 The Superficial Back Arm Line starts with the trapezio-deltoid complex.

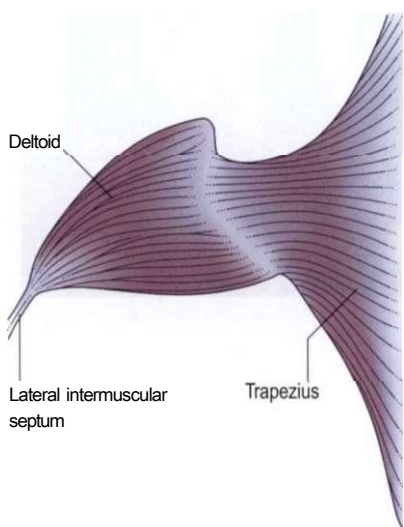


Fig. 7.26 The trapezio-deltoid complex can be seen as one large triangular muscle that focuses down on the outside of the humerus from a broad attachment along the whole upper spine.

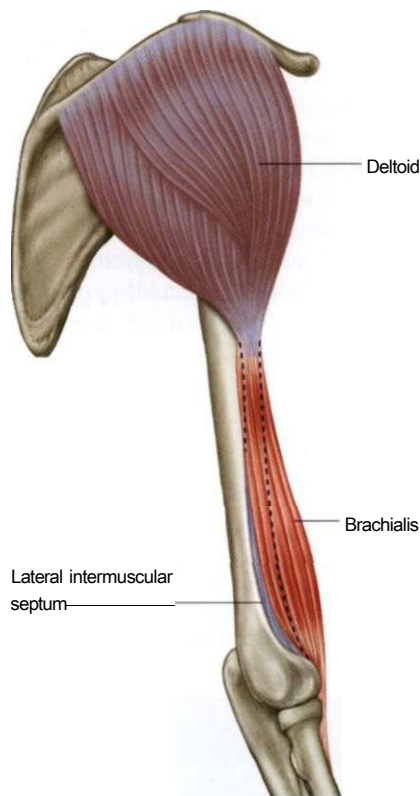


Fig. 7.27 The deltoid connects under the brachialis to the lateral intermuscular septum down to the lateral humeral epicondyle.

the lateral intermuscular septum (**Fig. 7.27** and **iTV** **Shoulders and Arm Lines, 54:56-55:53**).

The septum, which divides the flexors from the extensors (the 'front' and 'back' of the arm), passes down to its lower attachment at the lateral humeral epicondyle. From this station, the line continues directly onto the common extensor tendon, picking up the many longitudinal muscles that lie dorsal to the radius-ulna-interosseous membrane complex, passing under the dorsal retinacula to the carpals and fingers (**Fig. 7.28** and **DVD ref: Shoulders and Arm Lines, 55:53-57:33**). Similarly to the SFAL, the muscles show a reversal to the usual arrangement, with the superficial muscles controlling the carpals at the wrist, while the deep muscles reach all the way to the fingertips.

The SBAL is a single fascial unity from the spine to the backs of the fingertips (**Fig. 7.29A.B** and **DVD ref: Shoulders and Arm Lines, 57:35-59:00**). This line controls the arm for the limited amount of moving we do behind our lateral midlines, like a backhand tennis shot, but acts mostly to limit and contain the work of the SFAL. The SBAL also controls the lifting (abduction) of the shoulder and arm, so it tends to get overworked if the rib cage or spine collapses or slumps out from under the shoulder girdle.

Stretch assessment for the Superficial and Deep Back Arm Lines

Face your client, take hold of her wrists, and have her lean back from the ankles into the 'sling' of her arms,



7

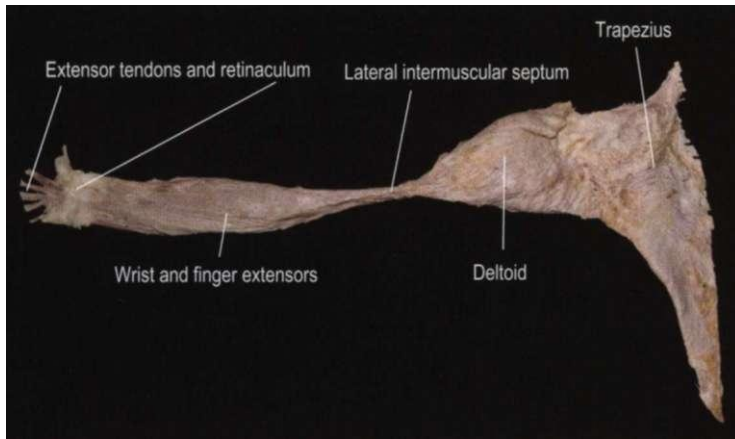




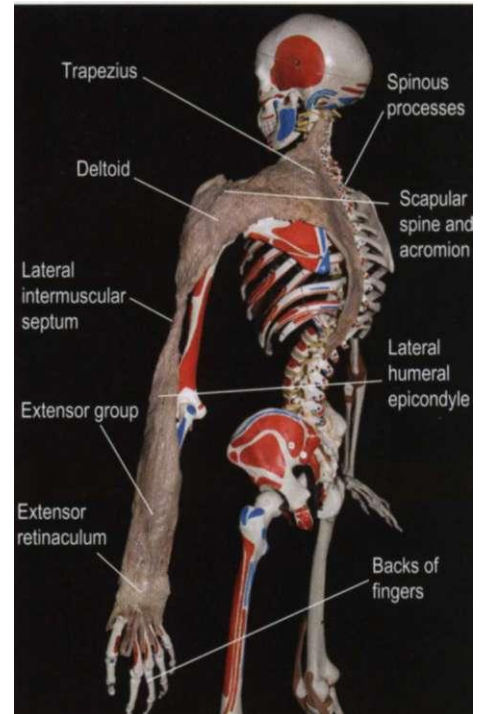
Fig. 7.28 From the lateral epicondyle, the common extensor tendon, along with the other deeper extensors, brings the SBAL down to the back of the hand.

while you support her weight. She is now hanging off and leaning into her two Back Arm Lines. If you turn her wrists and arms in a lateral rotation (palms up), your client will generally feel the stretch (or restriction) in the SBAL, from the trapezius on out through the extensors. If you hold her wrists and arm in a moderately strong medial rotation (thumbs down), she will generally feel the stretch in the DBAL, through the rhomboids and rotator cuff and on out that line (DVD ref: **Shoulders and Arm Lines**, 17:53-18:27).

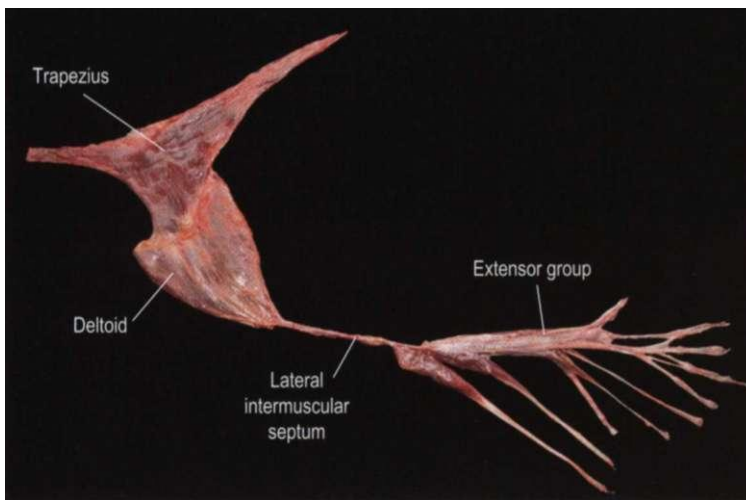
This exercise is full of 'generally' and 'probably' because of the number of crossover muscles within the arms (see Discussion 2, on crossovers, below). If a client does not feel the stretch in the areas suggested, it is worth noting where they do feel excessive stretch, as working to get more length in reported areas will - once again 'generally', because occupational patterns can be very powerful in maintaining arm tensions - move the client toward the 'normal' pattern outlined above.



A



B



C

Fig 7.29 The SBAL in dissection. In **(A)**, the trapezius has been detached from the spinous processes and an unusually small attachment to the occiput. The fascial fabric connection over the scapular spine has been retained, as has the strong fascial connection from the deltoid to the lateral intermuscular septum, and finally the connection over the surface of the lateral epicondyle into the extensor group. The extensor retinaculum can be seen still covering these extensor tendons, which were cut shy of the fingers. In **(B)**, this specimen has been laid over a classroom skeleton. **(C)** A fresh-tissue dissection of the SBAL, showing the same clear connections, but with the forearm muscles separated out for clarity. (Photos and dissection courtesy of the Laboratories of Anatomical Enlightenment.) (DVD ref: **Early Dissective Evidence**)



Summary overview - fascia/muscle alternation

Thus are the four arm lines arranged along the various aspects of the arm. In the shoulder, the lines are clearly arranged superficial and deep on the front and back of the rib cage, and it is from this cross-section that they derive their names (**see Fig. 7.3**).

In the upper arm, the four lines surround the humerus in a quadrant, the two superficial lines are represented

fascially, and the two deep lines more muscularly (**Fig. 7.30**).

In the lower arm and hand, the arrangement is still quadrate, but the expression is reversed: the two superficial lines include many muscles, the two deep lines are almost purely fascial (**Fig. 7.31**). In the hand, the muscles of the two superficial lines become tendinous (although some intrinsic muscles of the hand could be included in our thinking here). The two deep lines include the thenar and hypothenar muscles covering the flexor retinaculum as indicated.

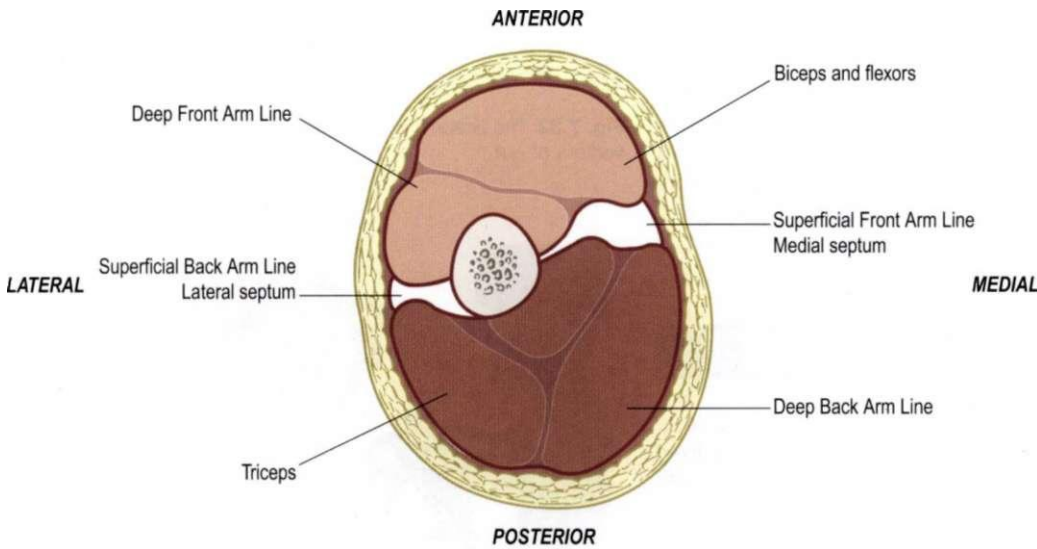


Fig. 7.30 In the upper arm, the two deep lines are muscular and the superficial lines are purely fascial.

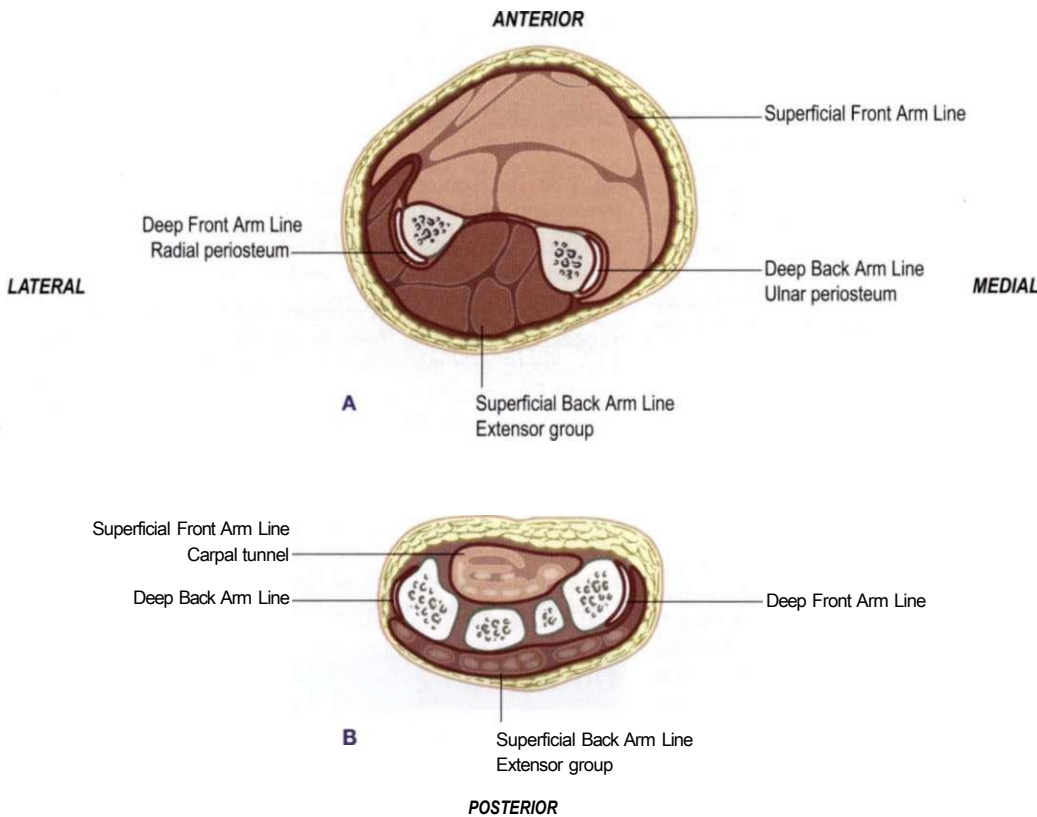


Fig. 7.31 In the lower arm, the two superficial lines are muscular, while the two deep lines are purely fascial.



This leads us to an image that cannot be pressed very hard without breaking, but is nonetheless useful to note. Both superficial lines, front and back, are muscular around the shoulder (traps, lats, pects and delts), fascial septa in the upper arm, muscular flexors and extensors in the lower arm, and fascial tendons in the wrist and hand (**DVD ref: Shoulders and Arm Lines, 14:35-15:17**).

Both Deep Arm Lines are more fascial than their superficial counterparts in the shoulder area (though with stabilizing muscles like the rotator cuff, levator scapulae, rhomboids, pectoralis minor and subclavius). In the upper arm, these deep lines are highly muscular with the triceps and biceps. In the lower arm, these deep lines retreat to fascial stability along the bones, but in the hand they blossom into muscularity with the thenar and hypothenar muscles at the base of the hand.

This alternation generally corresponds to the alternation of joints in the arm between those of multiple degrees of freedom, like the shoulder and radio-ulnar joints, versus those with more limited, hinge-like motion, e.g. the elbow and wrists. Again, the arm being designed for mobility over stability, this idea requires a host of qualifying adjectives and exceptions.

Discussion 1

Scapular position and postural balance

The mobility of the scapula (as compared with the more fixed hip bone) is crucial to the many services which our arms and hands provide. The clavicle has limited movement, and functions primarily to hold the arm away from the ribs in front (a uniquely primate need, since most quadrupeds prefer the shoulder joint close to the sternum under a proportionally narrower rib cage).

While our clavicle is a fairly stable strut, our humerus, with its rounded head, maintains the widest range of possibilities. It is the scapula that must move the glenoid socket to keep the peace between the two and manage the arm's shifting positions while retaining some stability on the axial skeleton. Finding the proper place for the scapula, a neutral position where it has the most possibility to move in response to our desires, is a worthy goal for manual and movement therapy.

Understanding the balance among the series of muscles that surround the roundhouse of the scapula will help us in this effort, especially concentrating on the scapular 'X'. Looking at the human scapula from behind, we see the array of vectors pulling it in nearly every direction (**Fig. 7.32** or for a more detailed explanation: **DVD ref: Shoulders and Arm Lines, 06:22-12:59**).

Of these, four stand out in providing scapular stability and determining postural scapular position, and these four form an 'X'. One leg of this 'X' is formed by the rhombo-serratus muscle, which we first saw in the Spiral Line (Ch. 5). While the rhomboids and the serratus anterior work together in the SPL, they work reciprocally as far as scapular position for the Arm Lines is concerned (**Fig. 7.33**). The serratus protracts the scapula anteriorly and laterally; the rhomboids retract it superiorly and medially. A chronically shortened ('locked short') serratus will pull the scapula wide on the posterior rib cage, causing the rhomboids to be strained ('locked long'). This pattern frequently accompanies a kyphotic thoracic spine. When the rhomboids are locked short, which frequently accompanies a shallow thoracic curve (flat back), the serratus will be locked long, and the scapula will rest closer to the spinous processes.

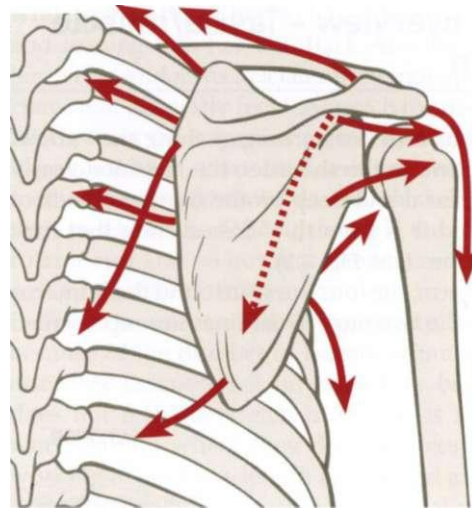


Fig. 7.32 The scapula is a roundhouse with many competing vectors of pull.

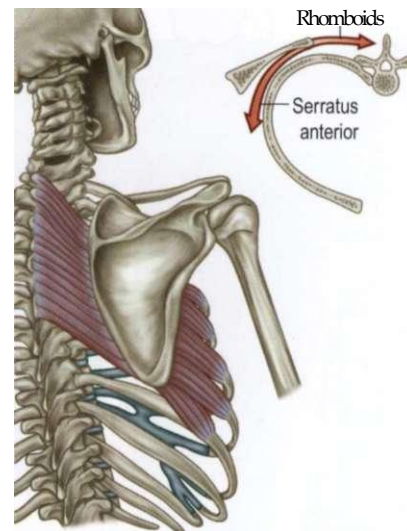


Fig. 7.33 The reciprocal arrangement between the serratus anterior and the rhomboids gives them a crucial role in setting the postural position of the scapula along one leg of the scapular 'X'.

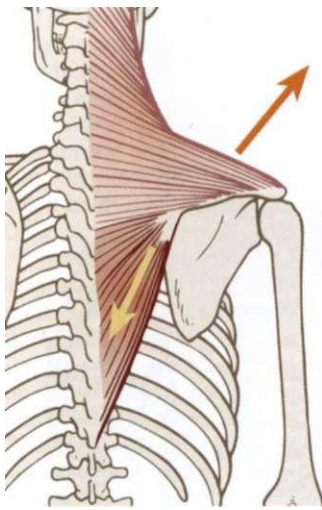
The other leg of the 'X' consists of the lower portion of the trapezius, which pulls medially and inferiorly on the spine of the scapula, and the pectoralis minor, which pulls down and in on the coracoid process, thereby pulling the scapula superiorly and laterally (**Fig. 7.34**). This antagonistic relationship most often appears with the pectoralis minor locked short and the lower trapezius locked long, resulting in an anterior tilt of the scapula on the ribs. Please note that this anterior tilt can often be disguised by a posterior tilt of the rib cage, leaving the appearance of a vertical scapula, but the underlying pattern remains the same, and lengthening work on the pectoralis minor is required for both (**Fig. 7.35**).

Discussion 2

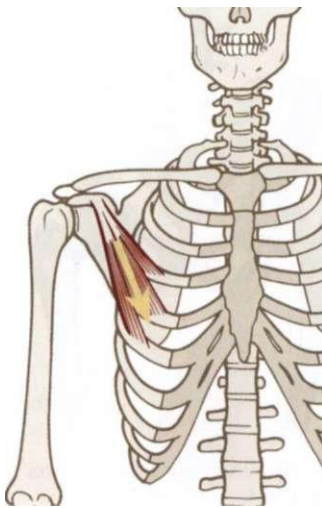
Crossovers

Though the lines we have described here are very logical, and certainly work usefully in practice, the amount of rotational



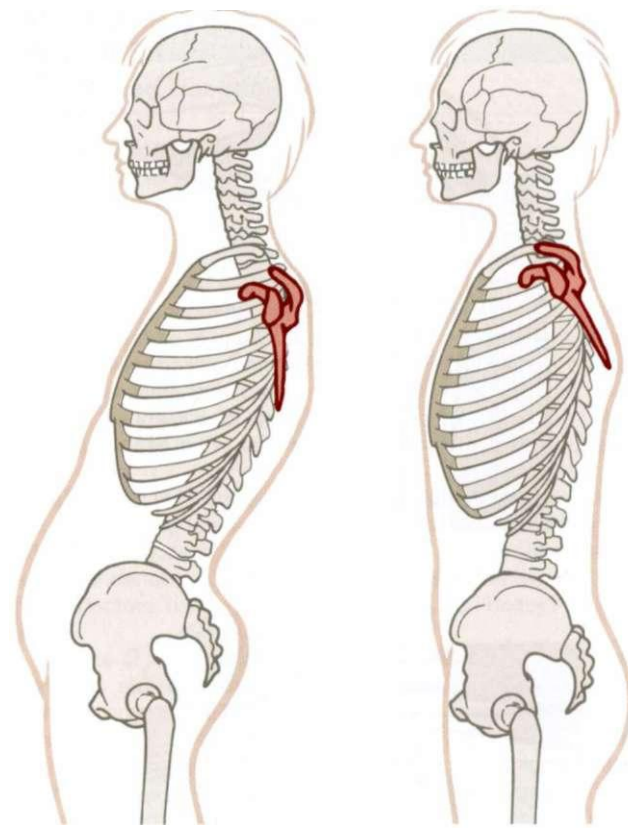


A



B

Fig. 7.34 The other leg of the scapular 'X' consists of a mechanical connection through the scapula between the lower part of the trapezius in the back and the pectoralis minor in the front.



A

B

Fig. 7.35 The relative tilt of the scapula must be measured against the rib cage. If the rib cage is posteriorly tilted (a common postural pattern in the Western world), the scapula may appear vertical to the floor but in fact be anteriorly tilted relative to the rib cage, involving a short pectoralis minor. Both (A) and (B) show an anteriorly tilted scapula relative to the rib cage; both need length in the pectoralis minor.

ability in the shoulder, lower arm, and hand requires a number of crossover 'switches' that muddle the neat precision of the Arm Lines, but provide additional possibilities for mobility and stability in movement (DVD ref: **Shoulders and Arm Lines, 15:18-15:38**).

The two heads of the biceps brachii gives us an instance of a crossover link between lines. So far, we have enunciated only the connection of the short head from the coracoid process to the radial tendon, which suited our purposes for the DFAL. The long head, however, passes through the intertubercular groove and onto the top of the glenum of the scapula, thus joining mechanically with the supraspinatus of the rotator cuff and on into the levator scapulae - or, in our language, connecting the DFAL to the DBAL (Fig. 7.36).

In addition to the two heads that give it its name, the biceps also has two 'feet', and this other foot provides another crossover. Aside from the radial tendon, the distal end of the biceps sports the odd bicipital aponeurosis weaving itself into the flexor group, thus linking the DFAL with the SFAL (Fig. 7.37). This structure, along with the oblique cord between the ulna and the radius, allows us to carry weight in the arms almost entirely through myofascial connection between the scapula and the fingers, without putting undue strain on the delicate elbow and radio-ulnar joints.

To expand this weight-carrying function, as it is yet another example of a crossover, when we carry an object like a suitcase by our sides, the weight is primarily carried by the fingers

curled and held by the flexors of the SFAL (reinforced by the thumb gripped with the DFAL). This tensile weight is not carried to the medial epicondyle and on up the rest of the SFAL, however; it is intercepted by the bicipital aponeurosis and transferred to the biceps muscle, thus diverting strain from the vulnerable elbow and crossing over into the DFAL. At the top of the short head of the biceps, the tension is transferred superiorly at the coracoid process to the coracoclavicular ligament and thus to the clavicle, where it is picked up by the clavicular portion of the trapezius (and thus transferred to the SBAL), which carries the tension to the occiput - a frequent site of headaches in those who venture out carrying a heavy object on one side (Fig. 7.38 and **Shoulders and Arm Lines, 15:39-16:05**). (The need to counterbalance this pull on the other side can also lead to strain and pain in the opposite side of the neck or low back as well, especially for the unpracticed. Experienced carriers of asymmetrical loads, like mailmen, will have distributed the load, more or less successfully, over the whole structure.)

Releasing the upper structures of the DFAL is thus part of a strategy of relieving forward head posture or hyperextended upper cervicals, especially in those accustomed to carrying significant loads.

The distal attachment of the deltoid is right up against the brachialis muscle. If we take this switch instead of the standard SBAL deltoid-lateral intermuscular septum connection, we have a link between the SBAL and the DFAL (Fig. 7.39).

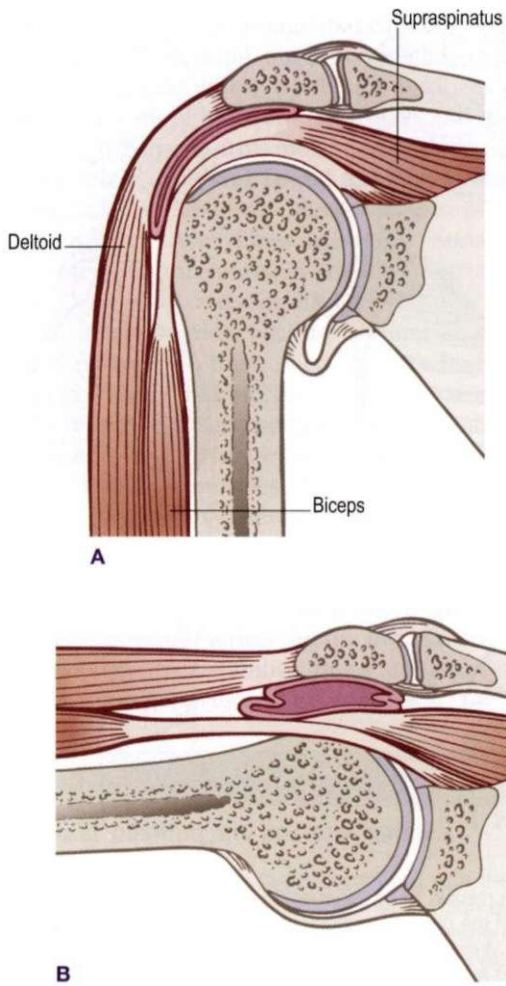


Fig. 7.36 There is a mechanical link between the supraspinatus and the long head of the biceps when the arm is abducted. This forges a crossover link from the DBAL and the DFAL.

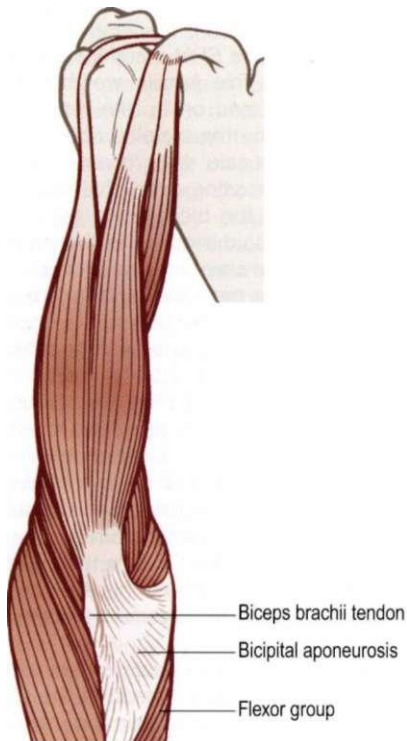


Fig. 7.37 The second tendon of the biceps brachii, which connects into the fascia of the forearm flexors, creates a link between the DFAL and the SFAL.

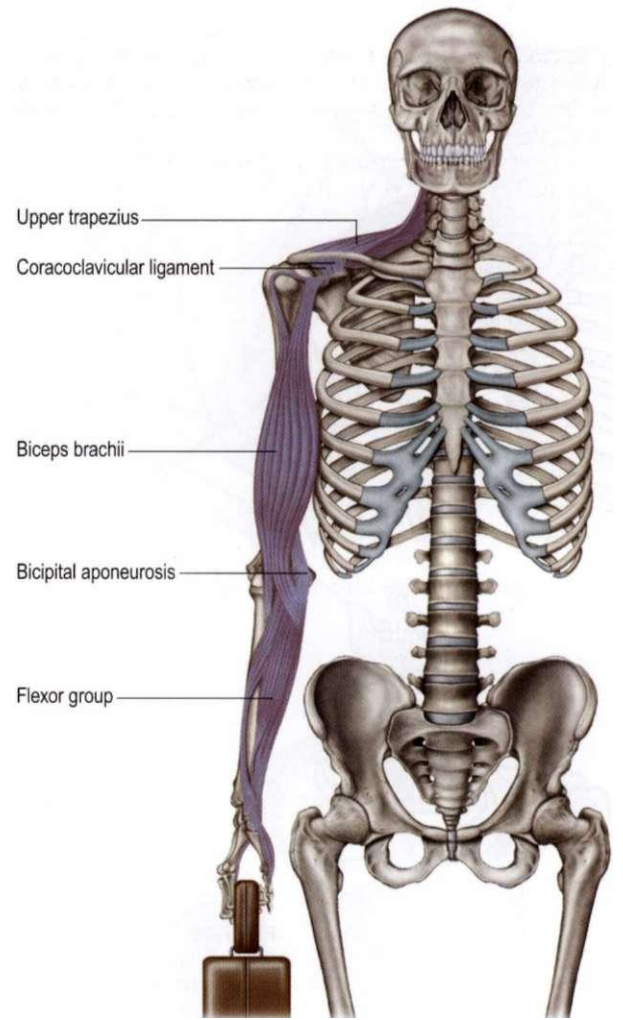


Fig 7.38 When the arm is hanging, the myofascial continuity travels up from the hand to the short head of the biceps to the coracoclavicular ligament to the trapezius, terminating at the occiput.

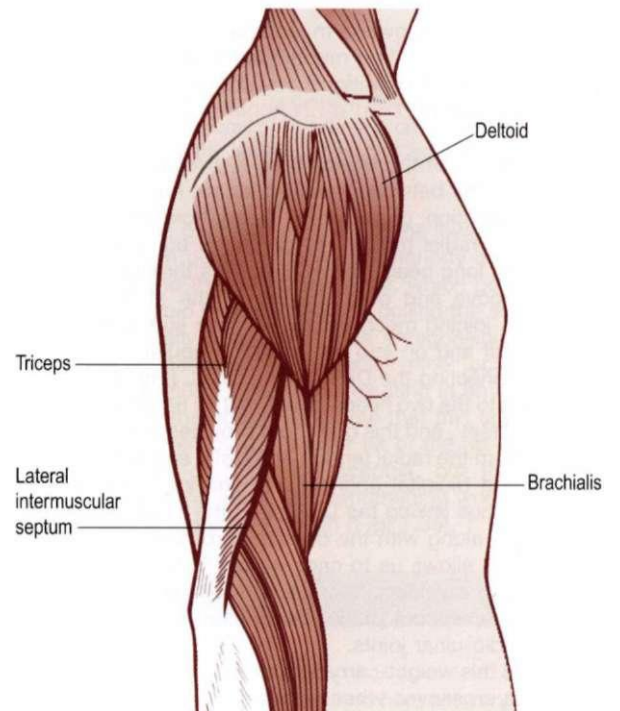


Fig. 7.39 The fascia of the deltoid is continuous with a portion of the brachialis, making a connection between the SBAL and the DFAL.

The teres major muscle, which we included with the latissimus in the SFAL, is actually a crossover from the scapula (and thus the DBAL) into the SFAL, with its distal attachment on the anterior surface of the humerus (Fig 7.14).

The brachioradialis arises from the lateral intermuscular septum and goes to the radius, thus making another connection from the SBAL to the DFAL (Fig. 7.40). The pronator teres could be said to make the same kind of connection from the DFAL to the SFAL.

Finally, the long pollicis muscles, abductor, and extensor longus and brevis, build from the periosteum of the ulna to the upper surface of the thumb, and could thus be said to connect the DBAL to the SBAL.

Other connections among the lines are made by the arms on a minute-by-minute basis to accommodate the varying movements and strains placed on the shoulder-arm complex. This does not, however, alter the basic value of the connections we have detailed in the four formal longitudinal myofascial meridians of the arms.

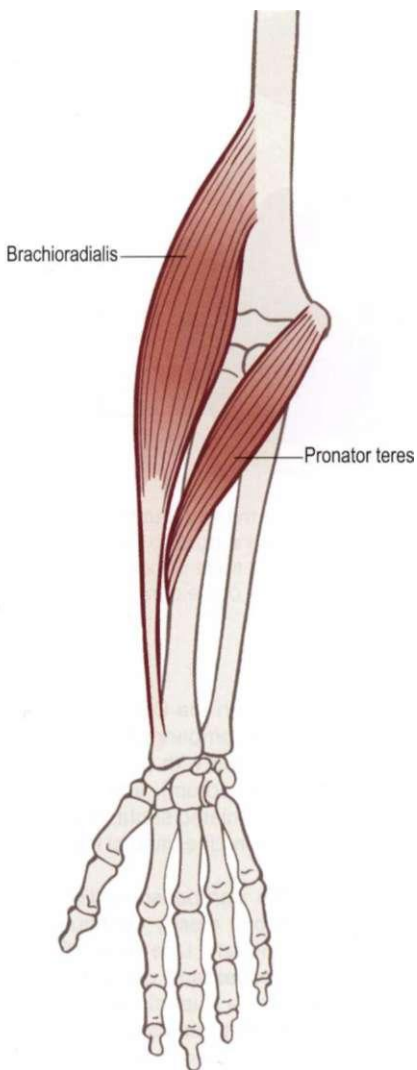


Fig. 7.40 The brachioradialis and pronator teres connect to the radial periosteum, creating crossover links from the SBAL and SFAL to the DBAL.

Discussion 3

Arm and Leg Line comparison

The alert reader will notice that the four arm lines bear some resemblance to four of the lines that course through the leg. (A clinically useful correlate to the Spiral Line in the arm has not been found.) Although the leg and the arm are functionally different, the structural similarities beg for a comparison, and the results are quite astonishing.

The correspondence between the arm and the leg in the skeletal structure is unmistakable: a girdle arrangement close to the axial frame (hip bone and scapula) is followed by a ball-and-socket joint, one bone in the upper limb, a hinge, two bones in the lower limb, three bones in the first tier of the outer limb, four bones in the second tier, and five digits with fourteen bones each.

Aside from the bony similarity (strange when one considers that the arm and leg evolved at somewhat different times for different purposes), the muscles also display interesting correspondences, e.g. the hamstrings parallel the biceps, and the abductors have often been termed the 'deltoid of the hip'.³

In spite of these obvious ties, the tracks of the myofascial meridians spectacularly fail to fall in line as direct parallels between arm and leg. On one level, the reason for this is developmental: all the limbs bud straight out from the side of the embryo, but in subsequent development, the legs rotate medially on the trunk, while the shoulder rotates laterally. Thus when we adopt the fetal position, the elbows and knees tend to meet. You can demonstrate this for yourself by getting on your hands and the balls of your feet, and then bending both elbows and knees. The knees will go forward - maybe a little out or in, depending on your patterns, but primarily toward your arms. The elbows will bend in the opposite direction, toward the legs - again, maybe more outward, depending on your habit, but primarily toward your legs. Keep your hands on the floor and try to turn your elbows around so they look like knees to feel the impossibility of having your arms approach a parallel position to the legs.

On another level, the lack of correspondence is testimony to the malleability and plasticity of the fascial connections in the body. The parallels in the bones remain; the parallels in the muscles remain, but the longitudinal connections through the fascia have changed with the times. The salamander's sideways extensions of the spine have a different set of myofascial meridians from the loping forepaw and hind leg of the dog or the bear, which is again different from the unique upper limb of *homo faber*.

Our own leg is quite similar to the quadruped hindlimb, with some allowances for the different attitude of the spine and hip, but the structure and function of mobility in the front and back lines, and stability in the inner and outer lines. The primate arm, however, went through some decisive changes, presumably during our ancestors' arboreal phase, which make its longitudinal connections unique. It is thus a useful exercise (though perhaps only to the anatomy nerds among us) to track the differences in each section of the two limbs.

Comparing the hand and foot first, we can see easy parallels side to side, but the front and back are reversed (Fig. 7.41A). The Deep Front Arm Line connects on the inside to the thumb, as the Deep Front Line of the leg (yet to come, in Ch. 9) connects to the inner arch and big toe. The Deep Back Arm Line connects to the little finger as the Lateral Line connects to the outer arch and 5th metatarsal.

The Superficial Front Line of the leg, which involves toe and ankle extensors, corresponds easily to the Superficial Back Arm Line, which contains finger and wrist extensors. The Superficial Back Line of the leg, flexing the toes and ankle,

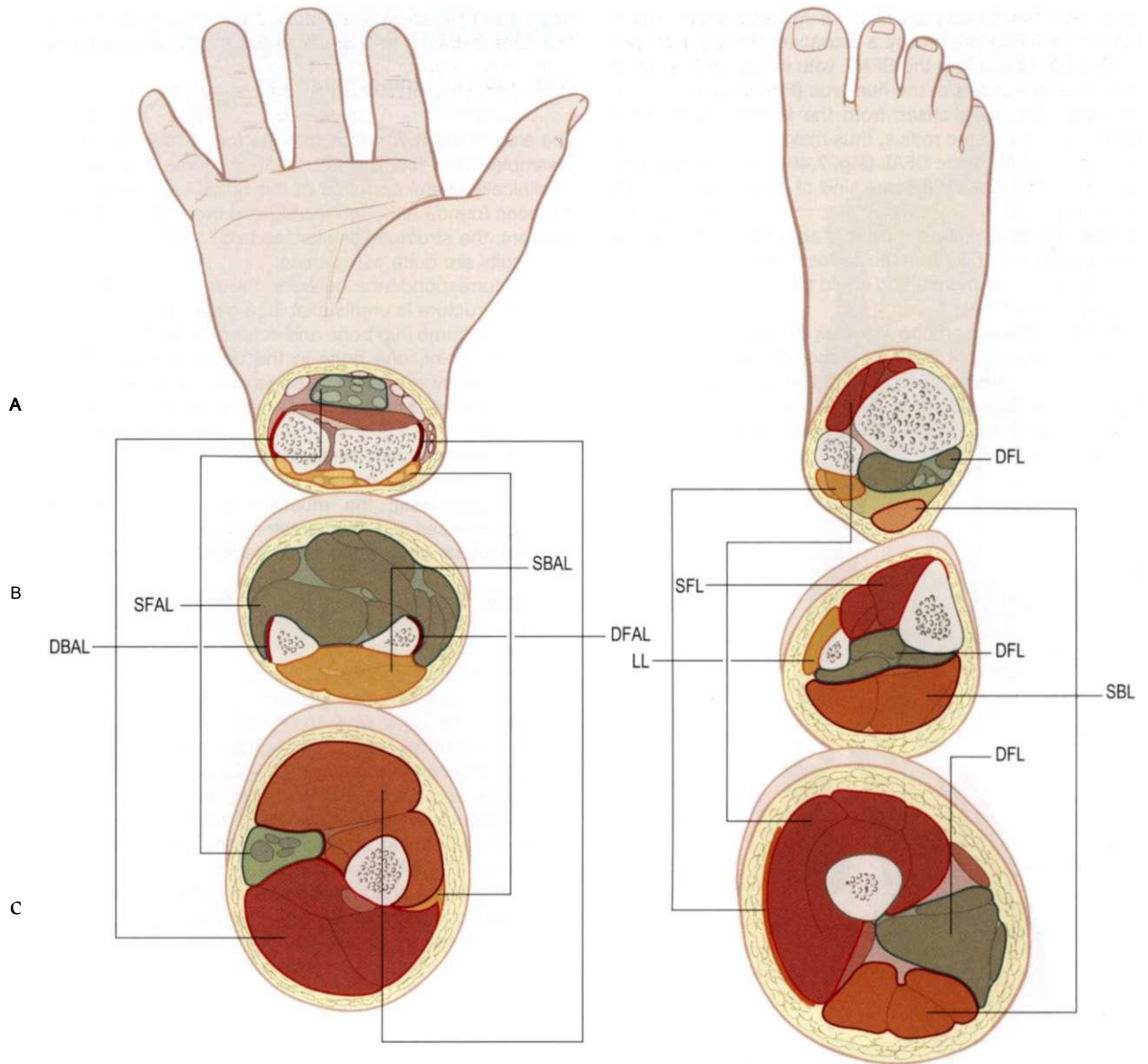


Fig. 7.41 (A) In the hand, the Deep Arm Lines correspond to the lateral and medial (Deep Front Line) lines of the foot, but the front and back lines are reversed. (B) In the lower arm, the reversal of the front and back lines continue, but the medial line goes to the 'fibula' of the arm, while the lateral line goes to the arm's 'tibia' - the ulna. (C) In the upper arm, the deep and superficial trade places - the quadriceps and hamstrings of the front and back lines of the leg (SFL and SBL) correspond to the deeper lines of the arm - the biceps of the DFAL and the triceps of the DBAL.

corresponds at this level to the Superficial Front Arm Line that curls the fingers.

In the lower arm, these parallels continue, with the exception that the Lateral Line connects via the peroneals to the fibula, while the Deep Back Arm Line connects to the tibia-equivalent ulna (**Fig. 7.41 B**). In the leg, the Deep Front Line connects to the weight-bearing tibia, while the Deep Front Arm Line is tied inextricably to the more mobile radius. We can also note that in the lower leg, only the gastrocnemius, popliteus, and plantaris cross the knee; the rest of the foot-moving muscles are confined to the lower leg, whereas many of the muscles of both the SFAL and SBAL cross the elbow, though they are not designed to affect it very much.

By the time we get to the upper arm and upper leg, most of the parallels are spiraling out of control (**Fig. 7.41 C**). We find that at this level, the Superficial Front Line of the leg (primarily the quadriceps) compares now with the Deep Back Arm Line (triceps). The Superficial Back Line (biceps femoris and

the other hamstrings) now equates with the Deep Front Arm Line (biceps brachii and its underlying compadres). The Lateral Line of the leg (iliotibial tract) compares with the Superficial Back Arm Line (lateral intermuscular septum), and the Deep Front Line (adductor muscles and associated septa) compares fairly easily to the Superficial Front Arm Line (medial intermuscular septum).

At the shoulder-to-hip level, the comparisons dim even more, but the Lateral Line (abductors) clearly continues the comparison to the Superficial Back Arm Line (deltoid). The Deep Front Line of the leg - the psoas and other flexors - might be compared with, strangely, the Superficial Front Arm Line, in that the pectoralis major and latissimus dorsi, like the psoas, both reach from the axial skeleton out across the ball and socket to the proximal limb bone, though under greater scrutiny the parallels begin to fade.

The Deep Back Arm Line (rhomboids to rotator cuff) can be usefully compared with the quadratus lumborum to iliacus

connection - the iliacus paralleling the subscapularis, leaving the gluteus minimus as the infraspinatus of the leg. However, another argument can be made that the rotator cuff is similar to the deep lateral rotators of the leg (technically part of the Deep Front Line, and practically part of a non-existent 'Deep Back Line').

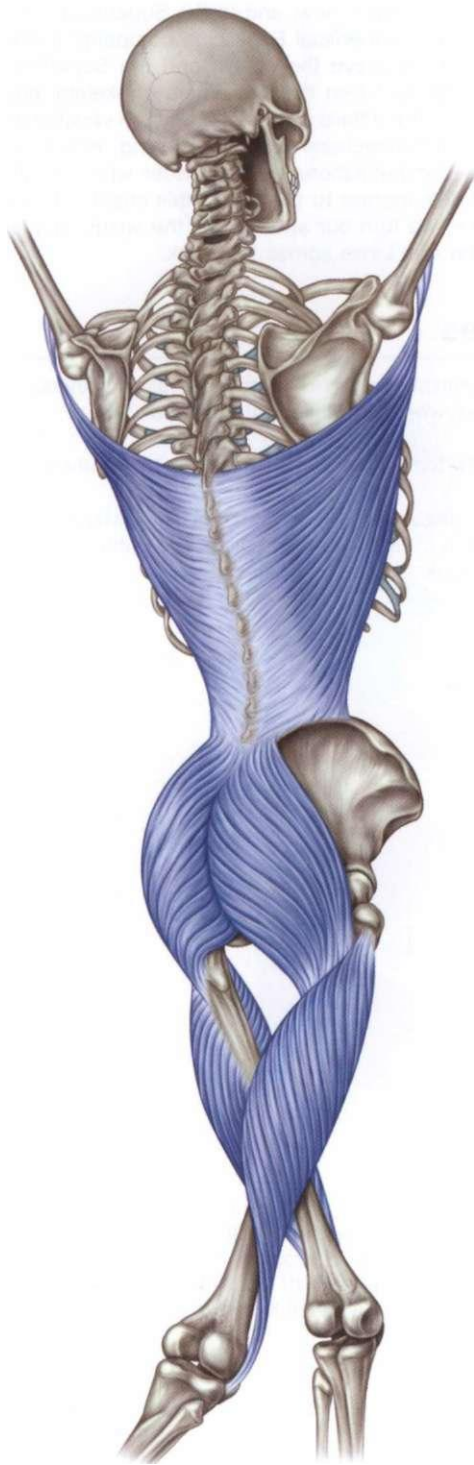
The Deep Front Arm Line (biceps-pectoralis minor) might bear comparison to the Superficial Back Line of the leg (biceps femoris-sacroterous ligament), though it also has elements of the Deep Front Line (proximity to the neurovascular bundle, and the clear parallel between adductor magnus and coracobrachialis).

The long and twisting road of evolution and the literal twisting of the arm and leg that takes place during fetal development have both served to blur any easy one-to-one comparisons among the arm and leg lines, as differing kinetic connections have been made in each. That said, the Lateral Line corresponds to the Superficial Back Arm Line above the elbow, and the Deep Back Arm Line below. The Deep Front Line compares to a combination of the Deep and Superficial Front Arm Lines above the elbow, and the Deep Front Arm Line below. The Superficial Front Line compares to the Deep

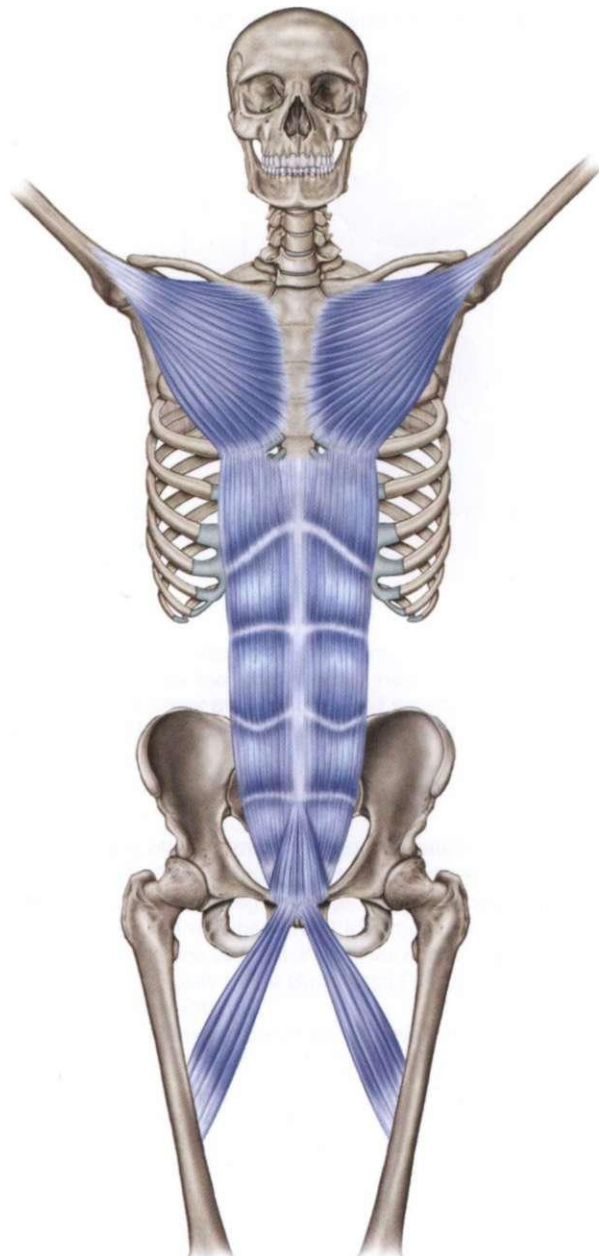
Back Arm Line above the elbow, and to the Superficial Back Arm Line below. The Superficial Back Line compares to the Deep Front Arm Line above the elbow, and the Superficial Front Arm Line below. Given the similarities of skeletal and muscular structure, the differences created by the variation in longitudinal fascial connections are quite striking. And strikingly complex - congratulations to any reader who actually made it through this morass to the end of this chapter. In the following chapter, we turn our attention to the vastly simpler extensions of the Arm Lines across the trunk.

References

1. Myers T. Treatment approaches for three shoulder 'tethers'. *Journal of Bodywork and Movement Therapies* 2007; 11(1):3-8.
2. Wilson FR. *The hand*. New York: Vintage Books/Pantheon Books; 1998.
3. Myers T. Hanging around the shoulder. *Massage Magazine* 2000 (April-May). Also available in *Body*, self-published in 2004 and available via www.anatomytrains.com.



A



B

Fig. 8.1 The Back and Front Functional Lines.

The Functional Lines

8

Overview

The Functional Lines (Fig. 8.1) extend the Arm Lines across the surface of the trunk to the contralateral pelvis and leg (or up from the leg to the pelvis across to the opposite rib cage, shoulder, and arm, since our meridians run in either direction). These lines are called the 'functional' lines because they are rarely employed, as the other lines are, in modulating standing posture. They come into play primarily during athletic or other activity where one appendicular complex is stabilized, counterbalanced, or powered by its contralateral complement (Fig. 8.2/Table 8.1). An example is in a javelin throw or a baseball pitch, where the player powers up through the left leg and hip to impart extra speed to an object thrown from the right hand (Fig. 8.3).

Postural function

As mentioned, these lines are less involved in standing posture than any of the others under discussion in this book. They involve superficial muscles, for the most part, that are so much in use during day-to-day activities that their opportunity to stiffen or fascially shorten to maintain posture is minimal. If they do distort posture as a whole, their action is to bring one shoulder closer to its opposite hip, either across the front or across the back. Although the pattern just described is certainly not uncommon - especially closing across the front - the source usually resides in the Spiral Line or in the deeper layers. Once these other myofascial structures have been balanced, these Functional Lines often fall into place without presenting significant further problems of their own.

These lines do, however, have strong postural stabilizing functions in positions outside the resting standing posture. In many yoga poses, or postures that require stabilizing the upper girdle to the trunk (as, for example,

when working above the head), these lines transmit the strain downward or provide the stability upward to fix the base of support for the upper limb. Less frequently, they can be used to provide stability or counterbalance for the work of the lower limb in a similar way, as in a football kick.

There is but one common postural compensation pattern associated with the Functional Lines and that is a preference rotation usually associated with handedness or a specific and oft-repeated activity such as a sport preference, bringing one shoulder closer to the opposite hip, although this affects all four Functional Lines, as well as having a Spiral or Lateral Line element to the pattern.

Movement function

These lines enable us to give extra power and precision to the movements of the limbs by lengthening their lever arm through linking them across the body to the opposite limb in the other girdle. Thus the weight of the arms can be employed in giving additional momentum to a kick, and the movement of the pelvis contributes to a tennis backhand. While the applications to sport spring to mind when considering these lines, the mundane but essential example is the contralateral counterbalance between shoulder and hip in every walking step.

The Functional Lines appear as spirals on the body, and always work in helical patterns. They could be considered as appendicular supplements to the Spiral Line, or, as stated above, the trunk extensions of the Arm Lines. In real-time activity, the lines of pull change constantly, and the precision of the lines detailed below is a summary of a central moment in the sweep of forces.

The Functional Lines in detail

The Back Functional Line

The Back Functional Line (BFL) begins (for analytic purposes; in practice it connects in with the Superficial

Table 8.1 Functional Lines: myofascial 'tracks' and bony 'stations' (Fig. 8.2)

Bony stations	Myofascial tracks
Back Functional Line	
Shaft of humerus 1	
2	Latissimus dorsi
3	Lumbodorsal fascia
4	Sacral fascia
Sacrum 5	
6	Gluteus maximus
Shaft of femur 7	
8	Vastus lateralis
Patella 9	
10	Subpatellar tendon
Tuberosity of tibia 11	
Front Functional Line	
Shaft of humerus 1	
2	Lower edge of pectoralis major
5th rib and 6th rib cartilage 3	
4	Lateral sheath of rectus abdominis
Pubic tubercle and symphysis 5	
6	Adductor longus
Linea aspera of femur 7	

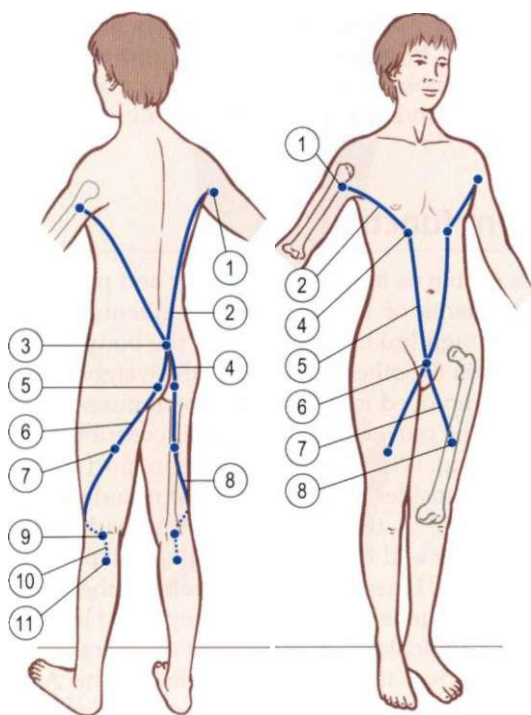
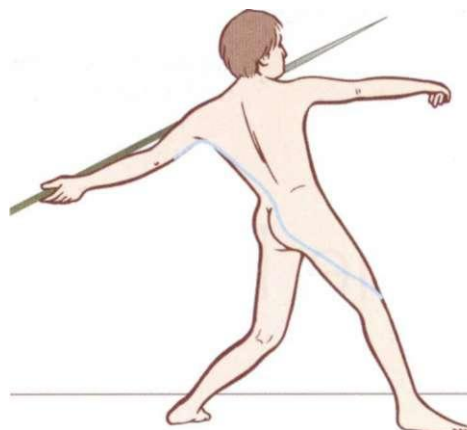
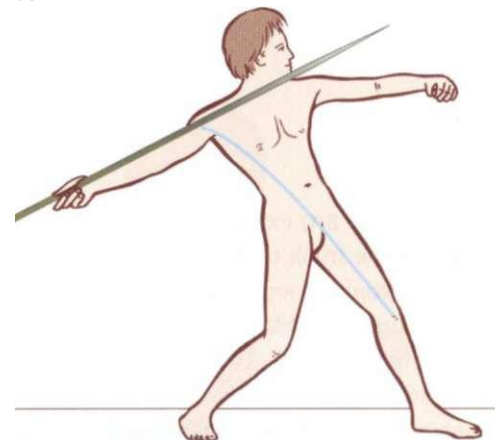


Fig. 8.2 Functional Lines tracks and stations.

Front or Deep Back Arm Lines, depending on the particular action) with the distal attachment of the latissimus dorsi (see Fig. 8.1A). It runs down a little lower than the approximate center of that muscle's spread, joining into the laminae of the sacrolumbar fascia.



A



B

Fig. 8.3 The Functional Lines add the impetus of the trunk momentum and musculature to the strength of the limbs, stabilized by the contralateral girdle. In this instance, as the arm is drawn back to throw the javelin, the right Back Functional Line is contracted, while the right Front Functional Line is stretched and readied for contraction. The left FFL is lightly shortened, and the left BFL lightly stretched during this maneuver. When the javelin is thrown, all these conditions reverse - the right FFL contracts, the right BFL is stretched, and their left-side complements exchange stabilizing roles.

The BFL crosses the midline approximately at the level of the sacrolumbar junction, passing through the sacral fascia to connect with the lower (sacral and sacrotuberal) fibers of the gluteus maximus on the opposite side.

The lower fibers of gluteus maximus pass under the posterior edge of the iliotibial tract (ITT), and thus under the Lateral Line, to attach to the posterolateral edge of the femur, about one-third of the way down the femoral shaft. If we continue on in the same direction, we find fascial fibers linking the gluteus and the vastus lateralis muscle, which in turn link us down through the quadriceps tendon to the patella, which is connected, via the subpatellar tendon, to the tibial tuberosity. We choose to end the line analysis here, though, having reached the tibial tuberosity, we could continue this line down to the medial arch by means of the tibialis anterior and the anterior crural fascia (as discussed in Ch. 4 on the SFL).

The Front Functional Line

The Front Functional Line (FFL) begins at about the same place as its complement, with the distal attachment of the pectoralis major on the humerus passing along the lowest fibers of that muscle to their origin on the 5th and 6th ribs (**Fig. 8.1 B**). Since the clavipectoral fascia containing the pectoralis minor also connects to the 5th rib, the FFL could be said to be an extension of both the Superficial and Deep Front Arm Lines.

These pectoral fibers form a fascial continuity with the abdominal aponeurosis that links the external oblique and rectus abdominis muscles, and the line passes essentially along the outer edge of the rectus or inner edge of the oblique fascia to the pubis. Passing through the pubic bone and fibrocartilage of the pubic symphysis, we emerge on the other side with the substantial tendon of the adductor longus, which passes down, out, and back to attach to the linea aspera on the posterior side of the femur.

From the linea aspera, we can imagine a link to the short head of the biceps, and thus to the lateral crural compartment and the peroneals/fibularii (Spiral Line, Ch. 6, p. 139). This, however, would involve passing through the intervening sheet of the adductor magnus, which is not allowed by the Anatomy Trains rules. We will therefore end the FFL at the end of the adductor longus on the linea aspera (**see Fig. 2.6**).

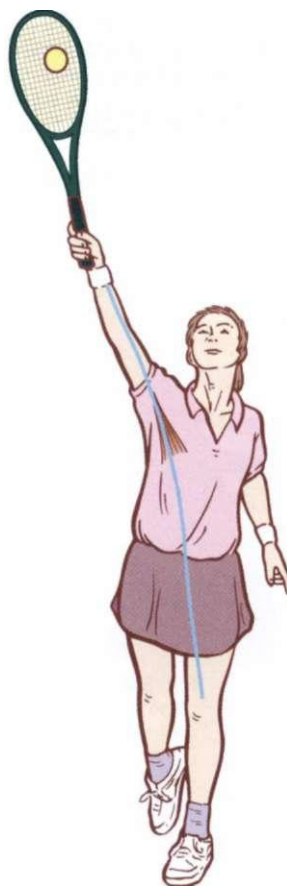

Fig. 8.4 The Front Functional Line in a tennis serve. The stronger and more vertical the serve, the more the Superficial Front Line will also participate in driving the ball.

Discussion 1

Shifting forces

Our description of these lines required several approximations, not only because of individual differences but also because movements along these lines often sweep across the fans of muscle and sheets of fascia. In other words, bringing back a javelin for a throw will pass through the precise BFL only for an instant as the force sweeps from the lateral outer edge of the latissimus around to its upper inner edge. Hurling the javelin a second later will likewise occasion a sweep of force across the fans of the FFL in the pectoralii, abdominal obliques, and inner thigh muscles (**see Fig. 8.3**).

Let us illustrate the versatility of these lines with a tennis volley. The serve involves a sharp pull directly along the FFL, involving principally the pectoralis major, but perhaps also the pectoralis minor in a connection to the abdominal muscles, whose sharp contraction adds to the force of the serve and the expulsion of air and sound that often accompanies the serve, and finally the adductor longus or its neighbors who act to keep the abdominals from pulling the pubic bone up (**Fig. 8.4**).

The return shot a moment later might be a straight forehand shot, with the arm out relatively horizontally from the shoulder. In this case the linkage would go up the Superficial Front Arm Line from the palm that holds the racquet, to pass from one pectoralis across the chest to the pectoralis and Superficial Front Arm Line on the opposite side (**Fig. 8.5**). This connection can be felt across the chest in such a shot, or observed in the movement of the opposite arm forward to help impart momentum to the ball.

The backhand required a moment later could pass across from one latissimus to the other along their upper edges (**Fig. 8.6**). A side-swiping forehand might be carried across the body, essentially on the Spiral Line, to the opposite anterior

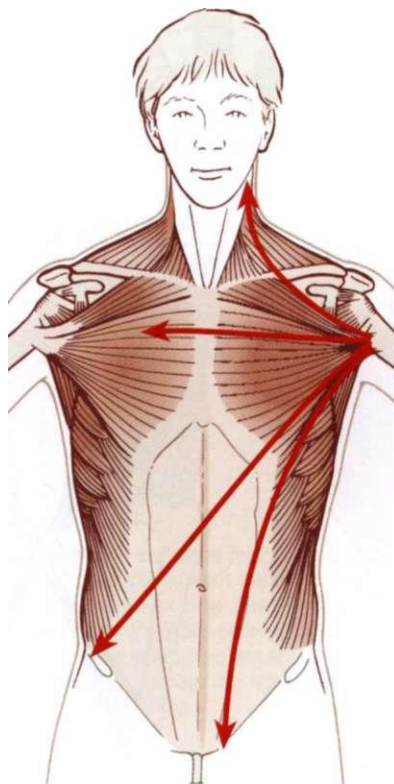


Fig. 8.5 A tennis forehand connects the Superficial Front Arm Line to its partner directly on the opposite side - one of several angles that the arms can transmit force to the front of the torso.

spine of the hip. Alternatively, **Figure 8.7.** shows another route crossing over from the Spiral Line to the FFL. A high backhand to return a lob might require the entire latissimus. The rest of the volley might go diagonally down and across as we have detailed with the BFL, or straight down the Superficial Front Line for a point-winning slam right at the net.

For another example, if we imagine a vaulter levering off the pole, we can see the force flicker across the entire tri-

angular field of the pectoralis or the latissimus, linking and anchoring to various tracks and stations from second to second. In this example, the stability-mobility equation is reversed, with the shoulder stabilizing the body on the pole, and the hips and legs imparting momentum over the bar. If we add the deltoid-trapezius connection from the Superficial Back Arm Line, we see an entire circle of stabilization around the shoulder joint, any piece or all of which may be called upon during the vault (**see Fig. 7.13**, p. 156).

The lower end of these Functional Lines works in the same way. In a hurdler, the forces approaching the roundhouse of the pubic bone from above sweep around the fan of abdominal muscle, and from below along the fan of adductors.'

Depending on his relation to the hurdles, and how much he abducts his leg to go over them, the line of pull from pubis to leg might travel on the pectineus, or any of the adductors, more than likely sweeping through all or most of them during each leap. In this case, the anteriority of the opposite shoulder works through this line to give added impetus to the leading leg (**Fig. 8.8**).

From this, we hope the reader grasps the idea that while the Functional Lines present the idealized line, the actuality of moment-to-moment movement flickers across the body on a multiplicity of connections combining the Functional, Spiral, and Lateral Lines.

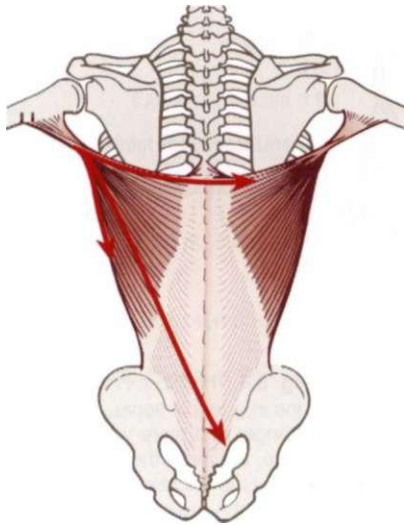


Fig. 8.6 A
backhand shot could similarly join the Superficial Back Arm Line to its opposite partner as well as down the torso to the pelvis and beyond.

Discussion 2

The Ipsilateral Functional Line

The following line is too small to merit its own chapter, but too functional to leave out entirely, so it is bundled here as a branch of the Functional Line.

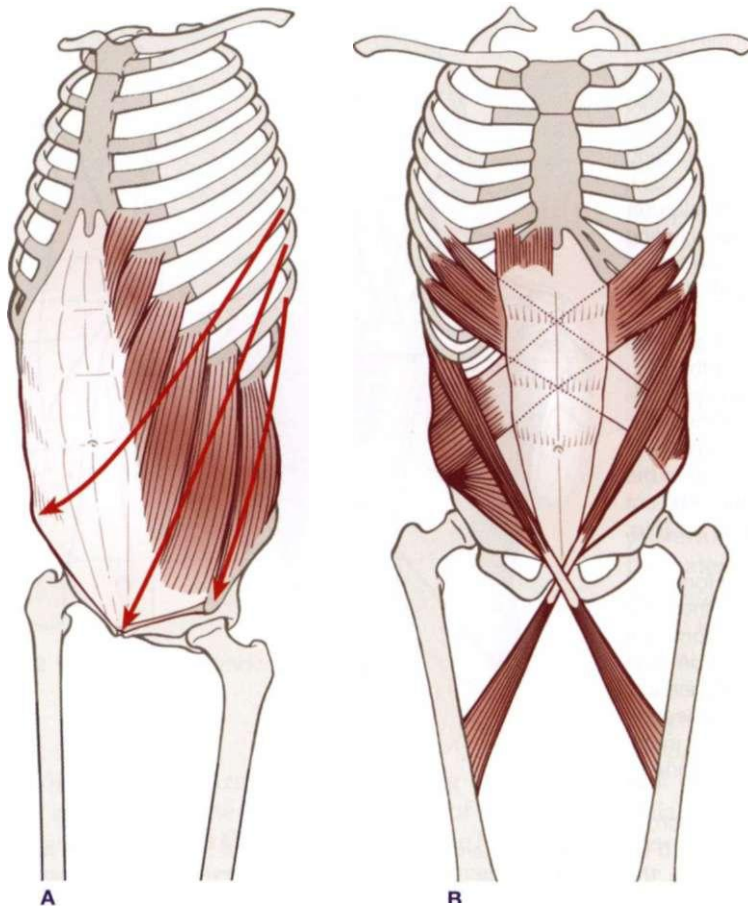


Fig. 8.7 As an example of the sweep of forces, consider the sheet of the external oblique (**A**), whose upper fibers all start from the ribs, but with various lower attachments. The lateral fibers go to the ipsilateral hip bone (part of the Lateral Line), the middle fibers go to the pubic bone (and on into the adductors on the opposite side), essentially a branch of the Functional Line shown in (**B**), while the upper fibers cross via the contralateral internal oblique to attach to the opposite hip bone (Spiral Line). Thus the torso portion of the Lateral Line, the Spiral Line, and the Functional Lines could be grouped as the 'helical' lines, as opposed to the Superficial Front and Back Lines, and the Lateral Line taken as a whole, which constitute the 'cardinal' lines.

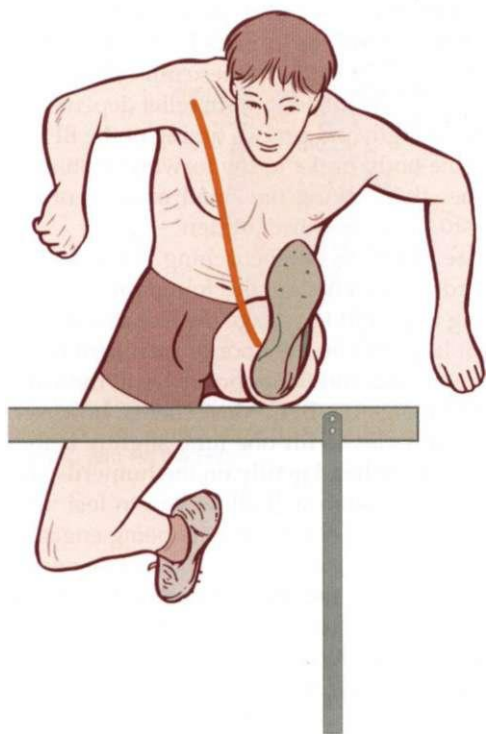


Fig. 8.8 The forces going through the hurdler's body cross the Front Functional Line only at one moment during the leap, but a connection between the forward leg and the opposite shoulder is maintained throughout the movement.

If we follow the most lateral fibers of the most lateral muscle, latissimus dorsi, we find them attaching to the outer portion of the lower three ribs (see Fig. 8.9), with a strong fascial fabric connection to the posterior fibers of the external oblique, employed in the Lateral Line in Chapter 5. If we follow those fibers of the external oblique, they arrive at the ASIS, where they connect fascially over the ASIS to the sartorius muscle (see Fig. In. 22A). The sartorius takes us down to the pes anserinus, on the medial epicondyle of the tibia.

This line can be felt when supporting the body on the latissimus, as when an athlete is on the rings, or on swimming when pulling the hand down through the water in a crawl stroke.

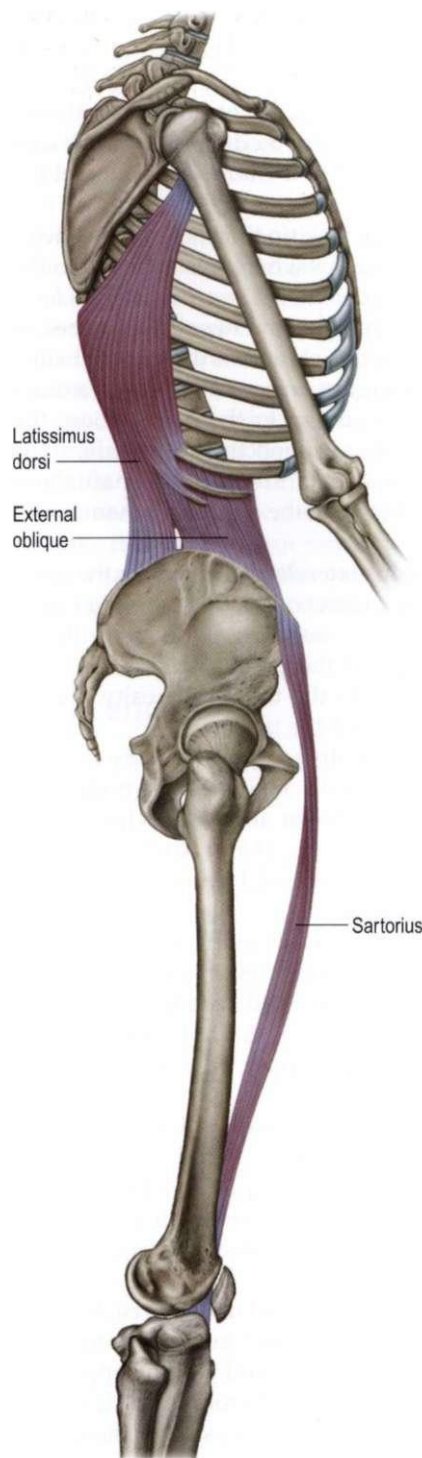


Fig. 8.9 The Ipsilateral Functional Line: we can find a Functional branch line, traced from the most lateral fibers of the latissimus dorsi to the lower outer ribs, thence onto the posterior external oblique over the ASIS onto the sartorius to the tibial condyle in the inside of the knee. This line is used in stabilizing an athlete on the rings, and to stabilize the torso during the pull down of the crawl stroke in swimming.

Palpating the Functional Lines

For both the front and Back Functional Lines, we begin in almost the same place: in the armpit, on the underside of the humerus, where the tendons of the pectoralis and the latissimus come together. Have your model stand with his arm straight out to the side and press down on your shoulder. It is easy for you to trace both these tendons from either side of the armpit up onto the antero-inferior aspect of the humerus.

Taking the BFL first, we can trace it from this attachment across the lower third of the latissimus directly to the midline at about the sacrolumbar junction. Have your model press an elbow down against resistance to feel this lateral part of the latissimus, though the line itself runs a bit medially from the lateral edge (DVD ref: **Functional Lines, 19:19-22:39**). The main sheet of the muscles runs around and down the back into the

lumbodorsal fascia (**DVD ref: Functional Lines, 22:40-26:03**). The sacral fascia comprises many layers; the BFL passes through the most superficial layers, which may not be separately discernible (**DVD ref: Functional Lines, 26:04-29:45**). If you stand behind your model with one hand on the sacrum while the model pushes back into your other hand with his lifted elbow, you will feel the sacral fascia tighten.

Across the sacrum, we pick up the line with the lower edge of the gluteus maximus where it is attached to the sacrum just above the tailbone (**DVD ref: Functional Lines, 29:45-35:18**). The BFL includes the lower two inches or so of this muscle. Track this section of the muscle below the gluteal fold (which is not muscular but lies in a more superficial fascial layer) down to the next station, the readily discernible lump of connective tissue where the gluteus attaches to the back of the femoral shaft about one-third of the way between the greater trochanter and the knee.

From here, the vastus lateralis can be felt as the muscular part of the lateral aspect of the thigh, diving under the iliotibial tract of the Lateral Line, joining with the rest of the quadriceps at the patella to link, through the subpatellar tendon, to the tibial tuberosity, clearly palpable at the front-top of the tibia.

The FFL is easier to palpate on oneself. Follow the lower edge of the pectoralis major, which forms the front wall of the armpit, down and in to where it ties into the ribs (**DVD ref: Functional Lines, 04:58-8:15**). The underlying pectoralis minor could be seen to connect into this line as well (**DVD ref: Functional Lines, 08:16-**

. The next track runs down along the edge of the rectus abdominis, which can be felt in most people by actively tightening the rectus and feeling for its edge (**DVD ref: Functional Lines, 12:25-15:50**). Follow it down as it narrows to the outer-upper edge of the pubic symphysis.

The tiny pyramidalis muscle runs obliquely up from the pubic bone and can thus be included as part of this line. The line crosses through the pubis (which may be a bit of a touchy palpation for some clients) but re-emerges in the tendon of the adductor longus on the opposite side (**DVD ref: Functional Lines, 15:51-18:58**). This tendon is readily palpable and usually visible when one sits cross-legged in a bathing suit or underwear. Follow this tendon into the thigh and you can approach, but usually not reach, the final station where it inserts into the linea aspera on the posterior side of the femur, about halfway down the thigh.

Engaging the lines

Pitching a baseball or bowling at cricket are perfect ways to engage these lines: the wind-up involves a shortening of the BFL and a stretching of the FFL, while the pitch itself reverses that process, shortening the FFL and stretching the BFL (**Fig. 8.10**) - and the same for the javelin thrower in **Fig. 8.3**. In the final act, the BFL acts as a brake to keep the strong contraction along the FFL and the momentum of the arm from going too far and damaging joints involved in the movement. Baseball

pitchers frequently turn up with damage to the rotator cuff tendons, particularly the supraspinatus and infraspinatus. While remedial work on these muscles or their antagonists may be helpful, long-term relief depends on reinforcing the strength and precise timing of the BFL in acting as a whole-body brake to the forward motion of throwing, rather than asking the small muscles of the shoulder joint to bear the entire burden.

While precise and individual coaching is required to effect this coordination change, the foundation can be laid by teaching the client to engage the line as a whole. Have the client lie prone on the floor or treatment table. Have them lift one arm and the opposite leg at the same time - this will engage the BFL. Most clients, however, will engage the muscles to lift **one** limb slightly before the other. Laying your hand gently on the humerus and opposite femur in question will allow you to feel with great precision which set of muscles are being engaged first (**DVD ref: Functional Lines, 35:20-40:09**). Use verbal or manual cues to elicit a coordinated contraction. Once the coordination is achieved, you can build strength by applying equal pressure to both your hands so that the client works against that resistance. Be sure to strengthen both the dominant and non-dominant side for best results.

The FFL can be similarly engaged as a whole by using your hands to help them coordinate the engagement of the contralateral girdles (**DVD ref: Functional Lines, 43:44-48:17**).

Both the Triangle and Reverse Triangle pose of yoga stretch the BFL on the side of the hand reaching for the



Fig. 8.10 The cricket bowler uses the Front Functional Line to add impetus to the power of the arm.

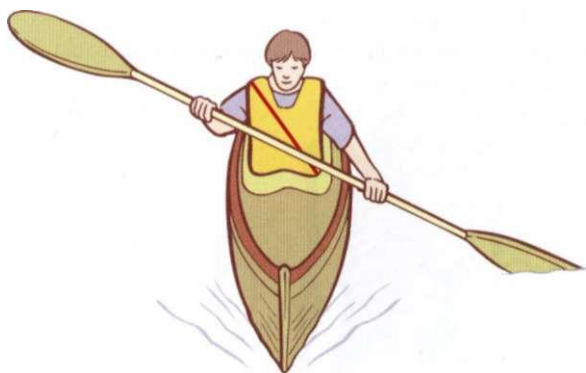

Fig. 8.11 The kayaker uses the opposite hip to stabilize his paddling - the lowered pulling arm via the BFL, and the lifted pushing arm via the FFL.

ground (see **Fig. 6.22**, p. 142 and DVD ref: Functional Lines, 40:10-43:41). The FFL can be easily stretched from a kneeling position by reaching up and back with a slight rotation toward the reaching arm (DVD ref: Functional Lines, 48:18-50:36).

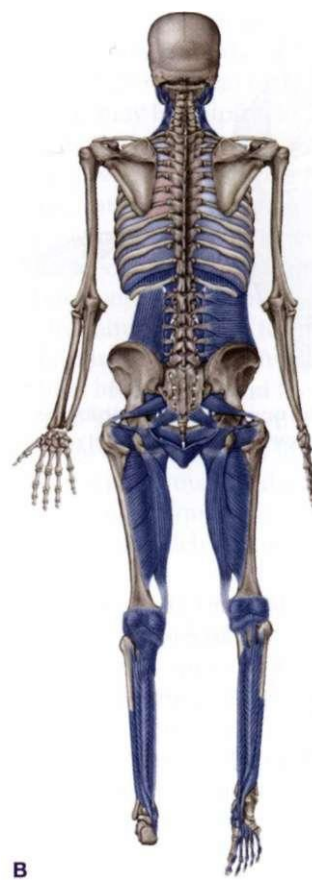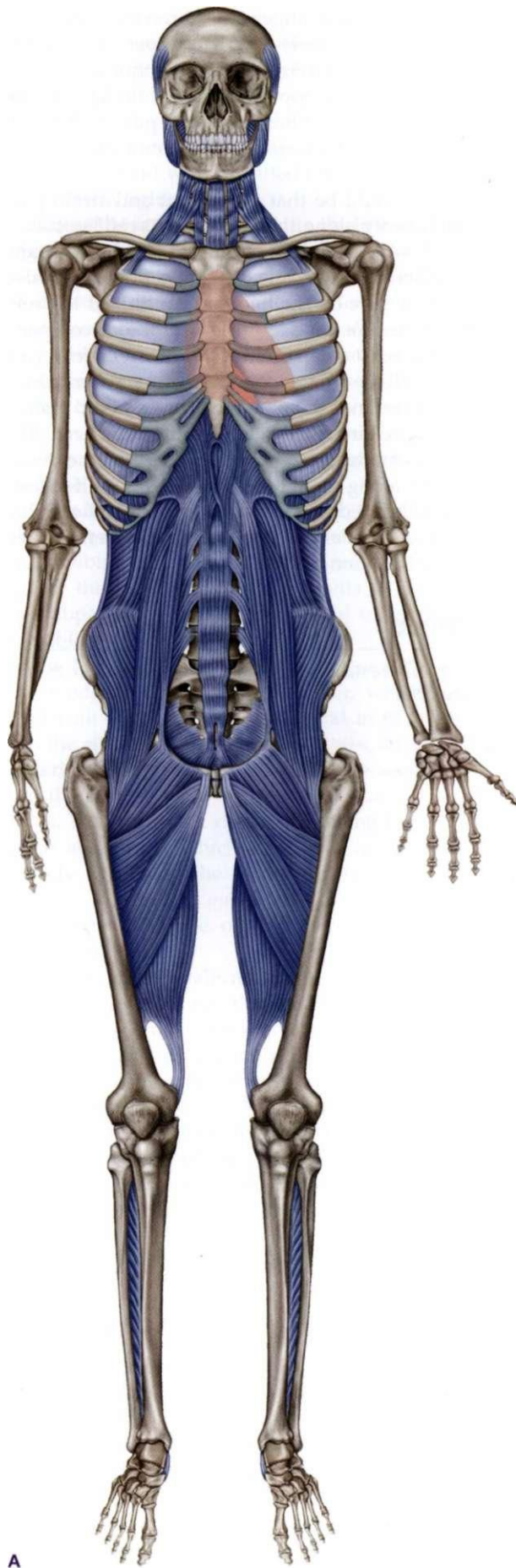
The act of paddling a kayak or canoe engages the stabilizing element of these two lines (**Fig. 8.11**). The paddling arm connects from the Deep Back Arm Line,

pulling from the little-finger side through to the BFL, stabilized to the opposite leg. The upper arm pushes through the Deep Front Arm Line to the thumb, stabilizing via the FFL to the opposite thigh. If the knee is not fixed against the side of the kayak, the push will be felt passing from foot to foot, almost in imitation of a walking movement.

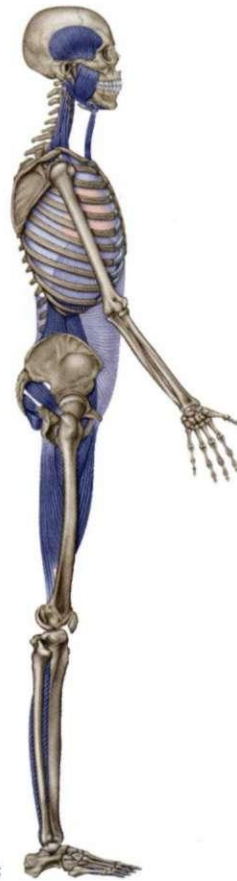The ideal would be that movement and strain pass easily and evenly along these lines (DVD ref: **Functional Lines**, 50:38-1:04:54). Excess strain or immobility at any track or station along the line could lead to a progressive 'pile-up' elsewhere on the line that could lead to problems over time. We have found it useful to accompany a sports enthusiast on an outing, whether it be for a run, a climb, a scull, or whatever, to determine where along these and other lines there may be some 'silent' restriction that is creating 'noisy' problems elsewhere. The client who is made aware of these lines and the desire for easy flow along them can sometimes do self-assessment when engaged in the sport. In practice, the limitations become especially evident when the client is tired or at the end of a long stint.

Reference

1. Myers T. Fans of the hip joint. *Massage Magazine* No. 75, January 1998.



B



C

Fig. 9.1 The Deep Front Line.

The Deep Front Line

9

Overview

Interposed between the left and right Lateral Lines in the coronal plane, sandwiched between the Superficial Front Line and Superficial Back Line in the sagittal plane, and surrounded by the helical Spiral and Functional Lines, the Deep Front Line (DFL) (Fig. 9.1) comprises the body's myofascial 'core'. Beginning from the bottom for convenience, the line starts deep in the underside of the foot, passing up just behind the bones of the lower leg and behind the knee to the inside of the thigh. From here the major track passes in front of the hip joint, pelvis, and lumbar spine, while an alternate track passes up the back of the thigh to the pelvic floor and rejoins the first at the lumbar spine. From the psoas-diaphragm interface, the DFL continues up through the rib cage along several alternate paths around and through the thoracic viscera, ending on the underside of both the neuro- and viscerocranium (Fig. 9.2/Table 9.1).

Compared to our other lines in previous chapters, this line demands definition as a three-dimensional space, rather than a line. Of course, all the other lines are volumetric as well, but are more easily seen as lines of pull. The DFL very clearly occupies space. Though fundamentally fascial in nature, in the leg the DFL includes many of the deeper and more obscure supporting muscles of our anatomy (Fig. 9.3). Through the pelvis, the DFL has an intimate relation with the hip joint, and relates the wave of breathing and the rhythm of walking to each other. In the trunk, the DFL is poised, along with the autonomic ganglia, between our neuromotor 'chassis' and the more ancient organs of cell support within our ventral cavity. In the neck, it provides the counterbalancing lift to the pull of both the SFL and SBL. A dimensional understanding of the

DFL is necessary for successful application of nearly any method of manual or movement therapy.

Postural function

The DFL plays a major role in the body's support:

- lifting the inner arch;
- stabilizing each segment of the legs;
- supporting the lumbar spine from the front;
- stabilizing the chest while allowing the expansion and relaxation of breathing;
- balancing the fragile neck and heavy head atop it all.

Lack of support, balance and proper tonus in the DFL (as in the common pattern where short DFL myofascia does not allow the hip joint to open fully into extension) will produce overall shortening in the body, encourage collapse in the pelvic and spinal core, and lay the groundwork for negative compensatory adjustments in all the other lines we have described.

Movement function

There is no movement that is strictly the province of the DFL, aside from hip adduction and the breathing wave of the diaphragm, yet neither is any movement outside its influence. The DFL is nearly everywhere surrounded or covered by other myofascia, which duplicate the roles performed by the muscles of the DFL. The myofascia of the DFL is infused with more slow-twitch, endurance muscle fibers, reflecting the role the DFL plays in providing stability and subtle positioning changes to the core structure to enable the more superficial structures and lines to work easily and efficiently with the skeleton. (This also applies to the DFL's first cousins, the Deep Arm Lines; see Ch. 7, pp. 151-155.)

Thus, failure of the DFL to work properly does not necessarily involve an immediate or obvious loss of function, especially to the untrained eye or to the less than exquisitely sensitive perceiver. Function can usually

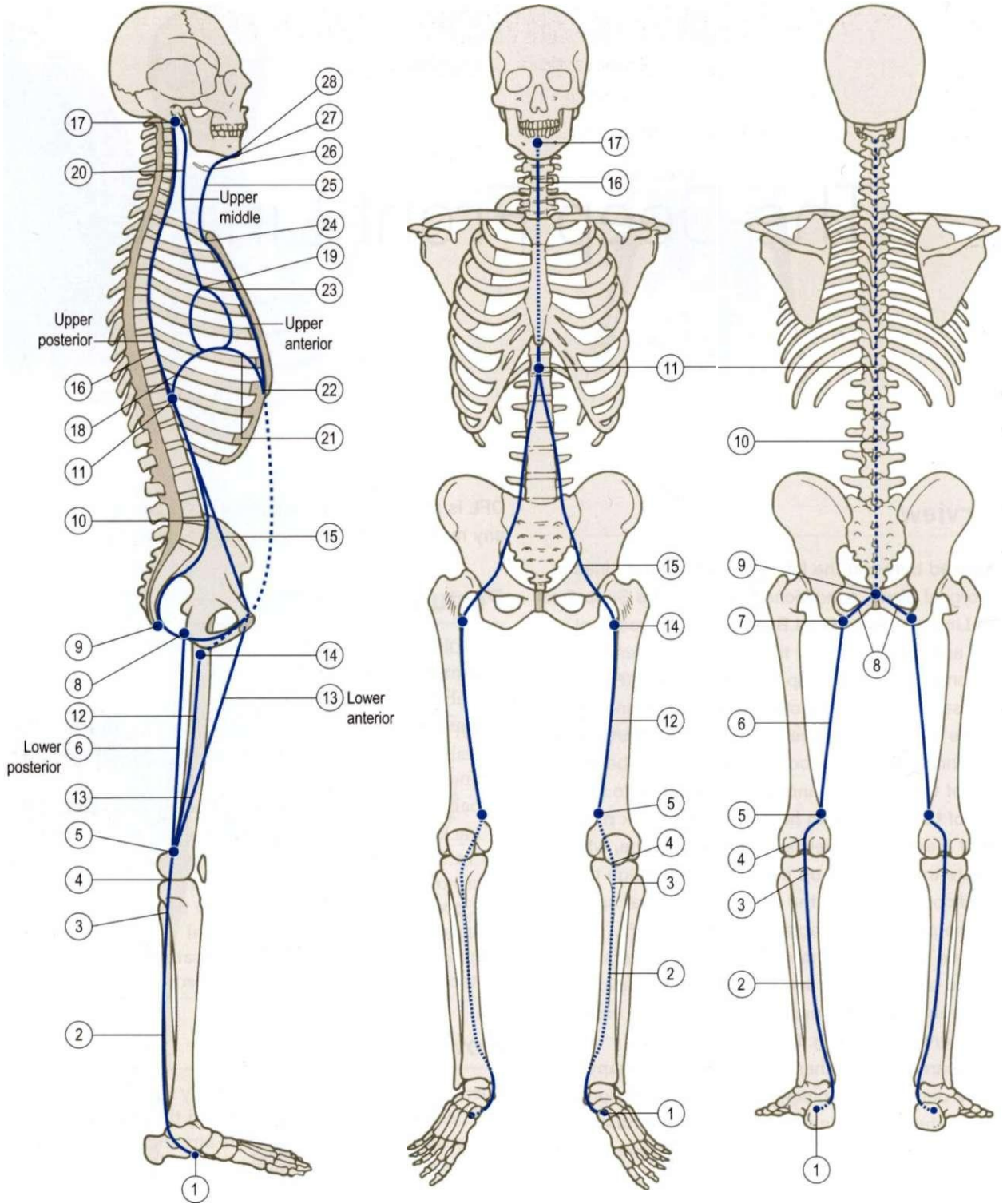


Fig. 9.2 Deep Front Line tracks and stations.

Table 9.1 Deep Front Line myofascial 'tracks' and bony 'stations' (Fig. 9.2)

Bony stations	Myofascial tracks
Lowest common	
Plantar tarsal bones, plantar surface of toes	1
	2 Tibialis posterior, long toe flexors
Superior/posterior tibia/fibula	3
	4 Fascia of popliteus, knee capsule
Medial femoral epicondyle	5
Lower posterior (see p. 186 for diagrams)	
Medial femoral epicondyle	5
	6 Posterior intermuscular septum, adductor magnus and minimus
Ischial ramus	7
	8 Pelvic floor fascia, levator ani, obturator internus fascia
Coccyx	9
	10 Anterior sacral fascia and anterior longitudinal ligament
Lumbar vertebral bodies	11
Lower anterior	
Medial femoral epicondyle	5
Linea aspera of femur	12
	13 Anterior intermuscular septum, adductor brevis, longus
Lesser trochanter of femur	14
	15 Psoas, iliacus, pectineus, femoral triangle
Lumbar vertebral bodies and TPs	11
Upper posterior	
Lumbar vertebral bodies	11
	16 Anterior longitudinal ligament, longus colli and capitis
Basilar portion of occiput	17
Upper middle	
Lumbar vertebral bodies	11
	18 Posterior diaphragm, crura of diaphragm, central tendon
	19 Pericardium, mediastinum, parietal pleura
	20 Fascia prevertebralis, pharyngeal raphe, scalene muscles, medial scalene fascia
Basilar portion of occiput, cervical TPs	17
Upper anterior	
Lumbar vertebral bodies	11
	18 Posterior diaphragm, crura of diaphragm, central tendon
	21 Anterior diaphragm
Posterior surface of subcostal, cartilages, xiphoid process	22
	23 Fascia endothoracica, transversus thoracis
Posterior manubrium	24
	25 Infrahyoid muscles, fascia pretrachialis
Hyoid bone	26
	27 Suprahyoid muscles
Mandible	28

be transferred to the outer lines of myofascia, but with slightly less elegance and grace, and slightly more strain to the joints and peri-articular tissues, which can set up the conditions over time for injury and degeneration. Thus, many injuries are often predisposed by a failure within the DFL some years before the incident that reveals them takes place.

'A Silken Tent'

The following sonnet by Robert Frost clearly and poetically summarizes the role of the Deep Front Line and its relationship to the rest of the Anatomy Trains, and the ideal of balance among the tensegrity system of the myofascial meridian lines:

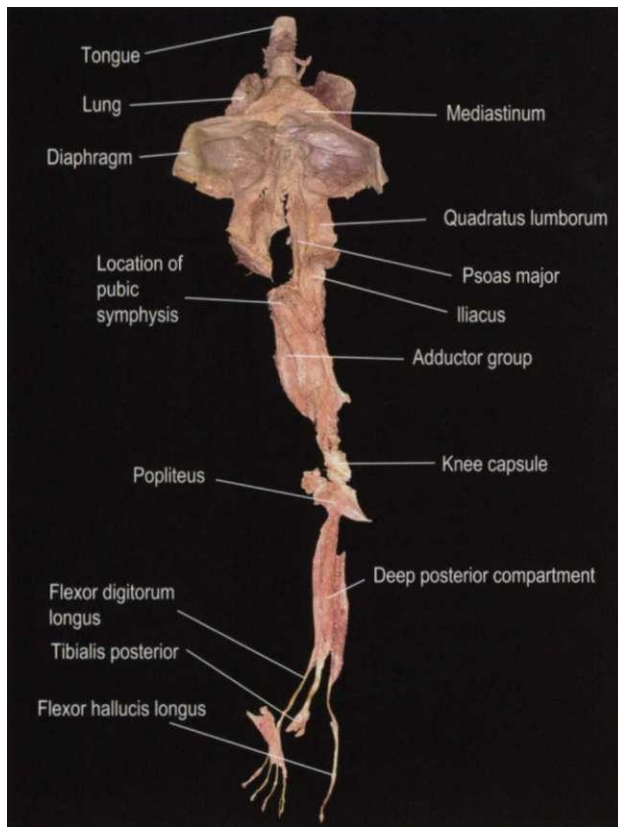


Fig. 9.3 An early attempt to dissect out the Deep Front Line shows a continual tissue connection from the toes via the psoas to the tongue.

*She is as in a field a silken tent
 At midday when a sunny summer breeze
 Has dried the dew and all its ropes relent,
 So that in guys it gently sways at ease,
 And its supporting central cedar pole,
 That is its pinnacle to heavenward
 And signifies the sureness of the soul,
 Seems to owe naught to any single cord,
 But strictly held by none, is loosely bound
 By countless silken ties of love and thought
 To everything on earth the compass round,
 And only by one's going slightly taut
 In the capriciousness of summer air
 Is of the slightest bondage made aware.*

(Reprinted from the Poetry of Robert Frost, Edward Connery Lathem, ed. Copyright 1942 by Robert Frost, Copyright 1970 by Lesley Frost Ballantine, by permission of Henry Holt & Co, LLC.)

The Deep Front Line in detail

The foot and leg

With a reminder that both function and dysfunction in any of these lines, but this one especially, can travel either up or down the tracks or out from the middle, we will begin once again at the bottom and work our way up.

The DFL begins deep in the sole of the foot with the distal attachments of the three muscles of the deep posterior compartment of the leg: the tibialis posterior and the two long flexors of the toes, the flexor hallucis and digitorum longus (**Fig. 9.4**).

The tissue between the metatarsals can also be included in this line - the dorsal interossei and accompanying fascia. This connection is a little hard to justify on a fascial level except via the link between the tibialis posterior tendon and the ligamentous bed of the foot. The lumbricals clearly link fascially and functionally with the SFL, but the interossei and the space between the metatarsals both feel and react therapeutically as part of the deep structure of the foot.

Depending on how you wield the scalpel, the tibialis posterior has multiple and variable tendinous attachments to nearly every bone in the tarsum of the foot except the talus, and to the middle three metatarsal bases besides (**Fig. 9.5**). This tendon resembles a hand with many fingers, reaching under the foot to support the arches and hold the tarsum of the foot together.

These three tendons pass up inside the ankle behind the medial malleolus (**see Fig. 3.13**). The tendon of the flexor hallucis (the tendon from the big toe) passes more posteriorly than the other two, beneath the sustentaculum tali of the calcaneus and behind the talus as well. This muscle-tendon complex thus provides additional support to the medial arch during the push-off phase of walking (**Fig. 9.6**). The tendons of the two toe flexors cross in the foot, helping to ensure that toe flexion is accompanied by prehensile adduction.

The three join in the deep posterior compartment of the lower leg, filling in the area between the fibula and tibia behind the interosseous membrane (**Fig. 9.7**).

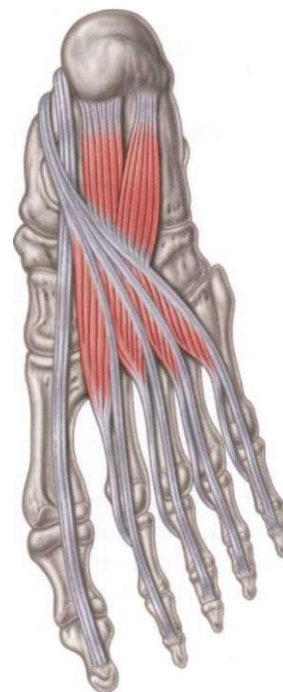

Fig. 9.4 The lower end of the DFL begins with the tendons of the flexor hallucis longus and flexor digitorum longus.



Fig. 9.5 Deep to the long toe flexors are the complex attachments of the tibialis posterior, also part of the DFL. (Reproduced with kind permission from Grundy 1982.)

This line employs the last available compartment in the lower leg (**Fig. 9.8**). The anterior compartment serves the Superficial Front Line (Ch. 4), and the lateral peroneal compartment forms part of the Lateral Line (Ch. 5). Just above the ankle, this deep posterior compartment is completely covered by the superficial posterior compartment with the soleus and gastrocnemii of the Superficial Back Line (Ch. 3) (**Fig. 9.9**). Access to this compartment for manual and movement therapy is discussed below.

General manual therapy considerations

Piecemeal experimentation with the myofascia of the Deep Front Line can produce mixed results. The myofascial structures of the DFL accompany the extensions of the viscera into the limbs - i.e. the neurovascular bundles - and are thus studded with endangerment sites and difficult points of entry. Practitioners familiar with working these structures will be able to make connections and apply their work in an integrated way. If these DFL structures are new to you, it is recommended that you absorb these methods from a class, where an instructor can assure your placement, engagement, and intent. With that in mind, we offer a palpation guide to structures in the DFL, but not to particular techniques in detail. References to the Anatomy Trains technique DVDs, where techniques are presented visually, are provided when appropriate.

Common postural compensation patterns associated with the DFL include chronic plantarflexion, high and fallen arch patterns, pronation and supination, genu valgus and varus, anterior pelvic tilt, pelvic floor insufficiency, lumbar malalignment, breathing restriction, flexed or hyperextended cervicals, temporomandibular

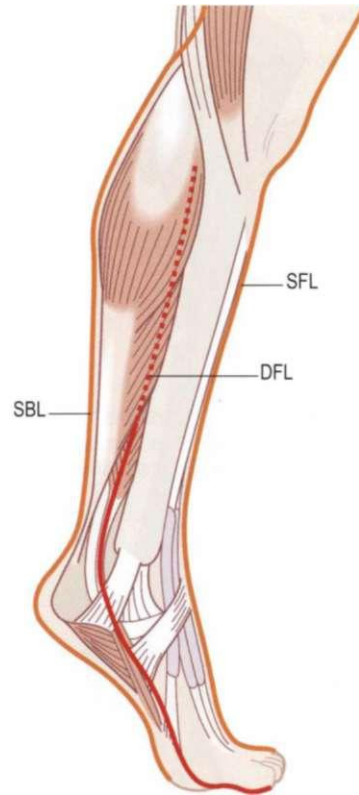

Fig. 9.6 The DFL passes between the SBL and SFL tracks, contracting during the push-off phase of walking to support the medial arch.

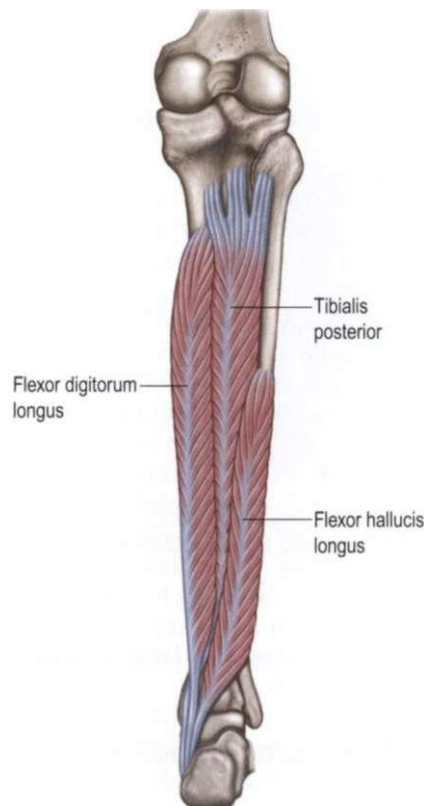


Fig. 9.7 The three muscles of the deep posterior compartment of the leg, deep to the soleus, comprise the DFL.

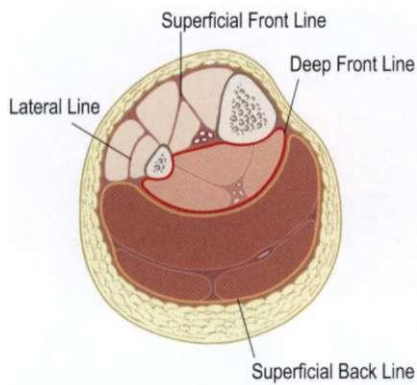


Fig. 9.8 The deep posterior compartment lies behind the interosseous membrane between the tibia and fibula. Notice that each of the fascial compartments of the lower leg ensheathes one of the Anatomy Trains lines.

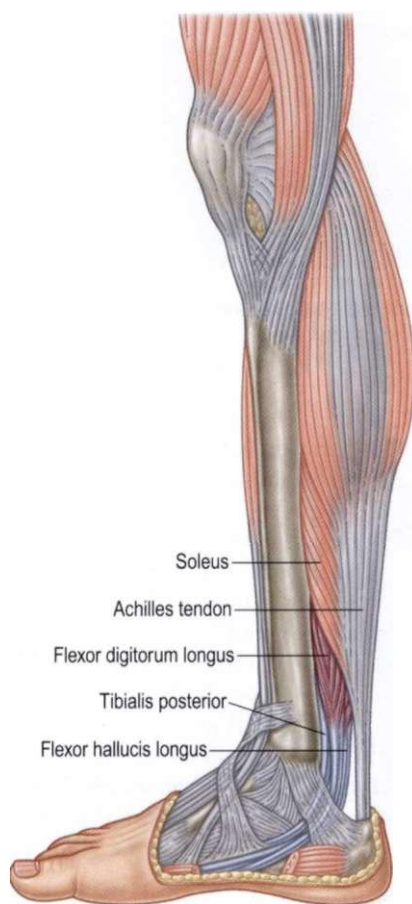


Fig. 9.9 A medial view of the lower leg, with the DFL structures highlighted. They can only be palpated directly just above the ankle.

joint (TMJ) syndrome, swallowing and language difficulties, and general core collapse.



Palpation guide 1: deep posterior compartment



Although it is next to impossible to feel the tendons of the flexor digitorum longus or the tibialis posterior on

the bottom of the foot, the flexor hallucis longus can be clearly felt. Extend (lift) your big toe to tighten the tendon, and it will be clearly palpable along the medial edge of the plantar fascia, under the medial arch (**Fig. 9.4** and **DVD ref: Deep Front Line, Part 1, 23:46-26:18**).

The tendons can be felt along the medial side of the foot and ankle, in roughly the same way the peroneal tendons run on the outside of the foot, and all three of them can be felt here. Place a finger directly under the medial malleolus, and invert and plantarflex the foot; the large tendon that pops under your finger is the tibialis posterior. The flexor digitorum runs about one finger width posterior to the tibialis posterior, and can be felt when the smaller toes are wiggled. The big toe flexor lies posterior and deep to these two: put a thumb or finger into the space in front of the Achilles tendon and press into the posteromedial aspect of your ankle, taking care not to press on the nerve bundle, and have your model flex and extend the big toe - the substantial tendon of flexor hallucis longus will slide under your finger (**DVD ref: Deep Front Line, Part 1, 08:05-09:18**).

These three muscles are covered completely by the soleus about three inches (7 cm) above the malleolus as they pass up into the deep posterior compartment (**Fig. 9.9**), just behind the interosseous membrane between the tibia and fibula (**Fig. 9.10**). Reaching this myofascial compartment manually is difficult. It is possible to stretch these muscles by putting the foot into strong dorsiflexion and eversion, as in the Downward-Facing Dog pose or by putting the ball of your foot on a stair and letting the heel drop. It is, however, often difficult for either practitioner or client to discern whether the soleus (SBL) or the deeper muscles (DFL) are being stretched.

It is possible to feel the state of the compartment in general by feeling through the soleus, but only if the soleus can be relaxed enough to make such palpation possible. In our experience, trying to work these muscles through the soleus is either an exercise in frustration or a way to damage the soleus by overworking it - almost literally poking holes in it - in the attempt to reach these muscles deep to it (**DVD ref: Deep Front Line, Part 1, 20:11-23:45**). An alternative way to reach this hidden layer is to insinuate your fingers close along the medial posterior edge of the tibia, separating the soleus from the tibia in order to get to the underlying (and often very tense and sore) muscles of the deep posterior compartment (**Fig. 9.11** and **DVD ref: Deep Front Line, Part 1, 09:20-15:03**).

Another hand can approach this from the outside by finding the posterior septum behind the peroneals, and 'swimming' your fingers into this 'valley' between the peroneals and the soleus on the lateral side. In this manner you have the fascial layer of the deep posterior compartment between the 'pincers' of your hands (**Fig. 9.10** and **DVD ref: Deep Front Line, Part 1, 15:03-20:10**). Couple this firmly held position with client movement, dorsi- and plantarflexion, and you can help bring mobility to these deeper tissues. Multiple repetitions may be necessary as the leg becomes progressively softer and more accessible, and movement more differentiated between the superficial and deep compartments.

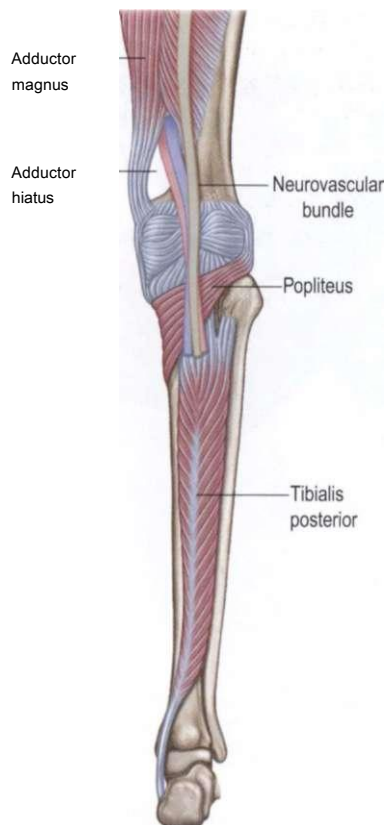


Fig. 9.10 The DFL passes behind the knee, in a deeper plane of fascia than the Superficial Back Line, with the popliteus, neurovascular bundle, and fascia on the back of the knee capsule.

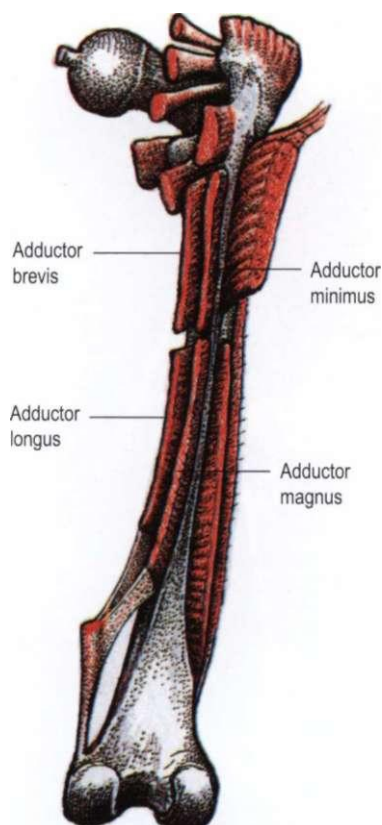


Fig. 9.12 From the medial epicondyle, two fascial planes emerge, one carrying up and forward with the adductor longus and brevis (the lower anterior track of the DFL), and another with the adductor magnus and minimus (the lower posterior track). Both ultimately surround the adductors, and both are connected to the linea aspera, but each leads to a different set of structures at the superior end.

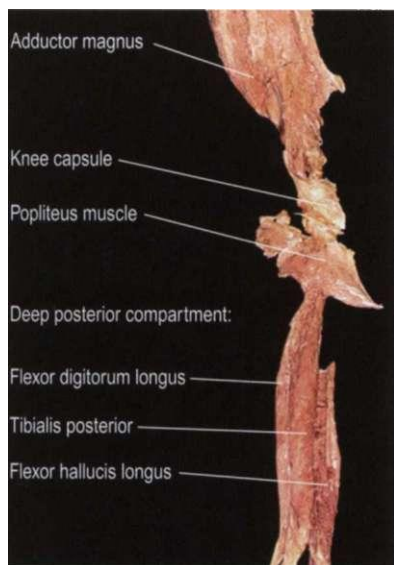


Fig. 9.11 The fascia surrounding the popliteus and the posterior surface of the ligamentous capsule of the knee links the tibialis posterior to the distal end of adductor magnus at the medial femoral epicondyle.

The thigh - lower posterior track

At the top of the deep posterior compartment, we pass over the back of the knee with the fascia which comprises the anterior lamina of the popliteus, the neurovascular bundle of the tibial nerve and popliteal artery, and the outer layers of the strong fascial capsule which surrounds the back of the knee joint (**Figs 9.10 and 9.11**). The next station of this line is at the medial side of the top of the knee joint, the adductor tubercle on the medial femoral epicondyle.

From this point, the fascia surrounding the adductors, although it is itself a unitary bag tying the adductors to the linea aspera of the femur, presents us with a switch, or choice point, as the heavy fascial walls on the front and back of the adductors head off in different directions, which will not rejoin again at the lumbar spine (**Fig. 9.12**). We will term these two fascial continuities the lower posterior and lower anterior tracks of the DFL.

The posterior track consists of the adductor magnus muscle and the accompanying fascia between the hamstrings and the adductor group (**Fig. 9.13**). If we run behind the adductor group from the epicondyle, we can follow this posterior intermuscular septum up the thigh to the posterior part of the ischial ramus near the ischial

These lower DFL tissues are very useful in easing stubborn arch patterns, both 'fallen' and 'high' arch patterns (DVD ref: **Deep Front Line, Part 1, 26:26-30:33**), as well as bunions (DVD ref: **Deep Front Line, Part 1, 30:33-32:26**).

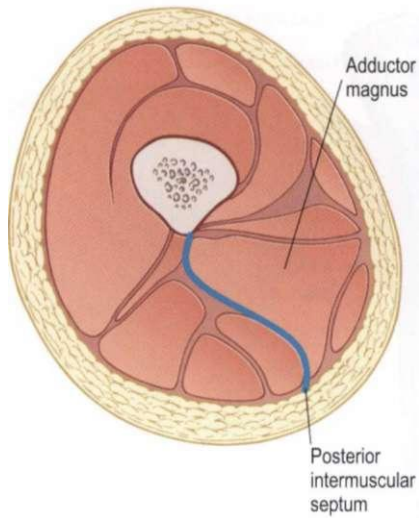


Fig. 9.13 The lower posterior track of the DFL follows the posterior intermuscular septum up the posterior aspect of the adductor magnus muscle.

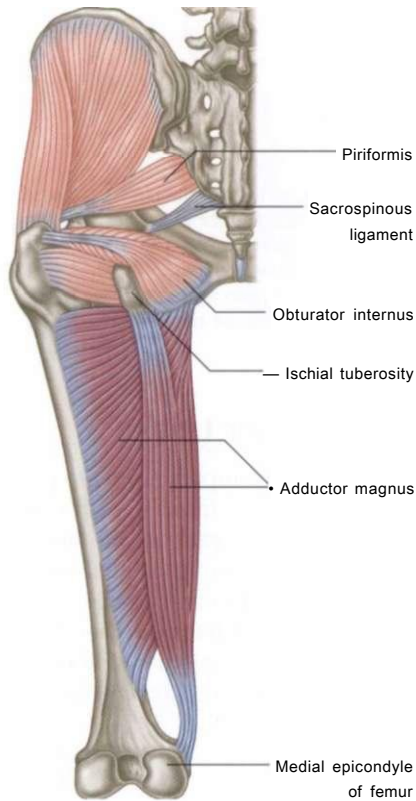


Fig. 9.14 The adductor group from behind, showing the lower posterior track of the DFL up to the ischial tuberosity. This lies in the same fascial plane as the deep lateral rotators, but the transverse direction of the muscular fibers prevents us from continuing up into the buttock with this line.

tuberosity (IT), which is the attachment point of the posterior 'head' of adductor magnus (Fig. 9.14).

From the ischium, there is a clear fascial continuity up the inner layer of the buttock and the group of muscles known as the deep lateral rotators (Fig. 9.15 and DVD ref: Deep Front Line, Part 1, 1:23:27-1:35:54). Thus if

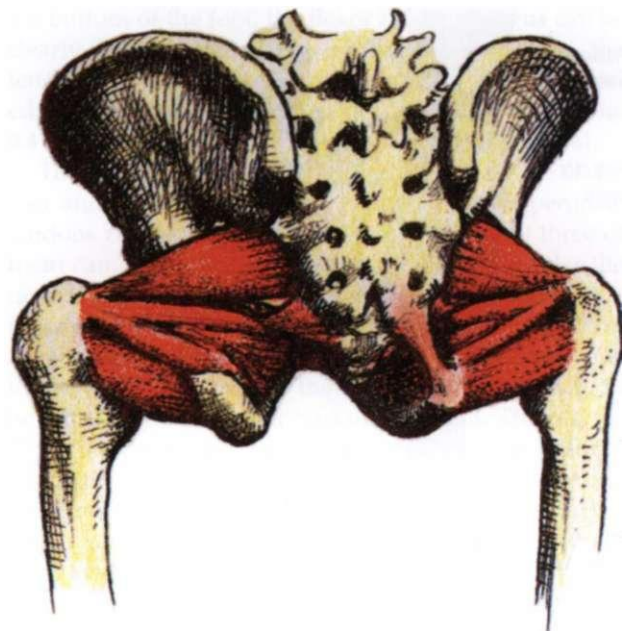


Fig. 9.15 The deep lateral rotators, although they are crucial to the understanding and optimization of human plantigrade posture, do not fit easily into the Anatomy Trains schema.

we were going to include the deep lateral rotators in the Anatomy Trains system, they would be, strangely, part of this lower posterior track of the DFL (see also the section on the 'Deep Back Line', p. 93). In fact, however, even though there is a fascial connection between the posterior adductors and the quadratus femoris and the rest of the lateral rotators, the muscle fiber direction of these muscles is nearly at right angles to the ones we have been following straight up the thigh. Thus, this connection cannot qualify as a myofascial meridian by our self-imposed rules. These important muscles are best seen as part of a series of muscular fans around the hip joint, as they simply do not fit into the longitudinal meridians we are describing here (see 'Fans of the Hip Joint' in *Body* published privately and available from www.anatomytrains.com).

We will have an easier time finding a myofascial track if we run inside the lower flange of the pelvis from the adductor magnus and its septum up onto the medial side of the IT-ischial ramus (Fig. 9.16). We can follow a strong fascial connection over the bone onto the strong outer covering of the obturator internus muscle, connecting with levator ani of the pelvic floor via the arcuate line (Fig. 9.17). This is an important line of stabilization from the trunk down the inner back of the leg.

The pelvic floor is a complex set of structures - a muscular funnel, surrounded by fascial sheets and visceral ligaments - worthy of several books of its own.² For our purposes, it forms the bottom of the trunk portion of the DFL, with multiple connections around the abdominopelvic cavity. We have been following the lower posterior track listed in Table 9.1. This track takes us from the coccygeus and iliococcygeus portions of the levator ani onto the coccyx, where we can continue north with the fascia on the front of the sacrum. This

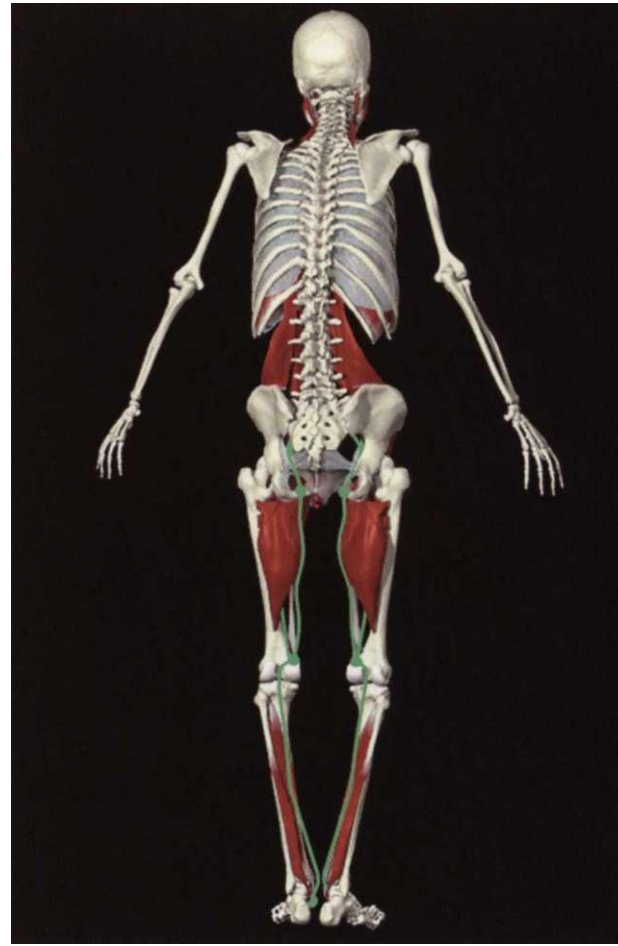
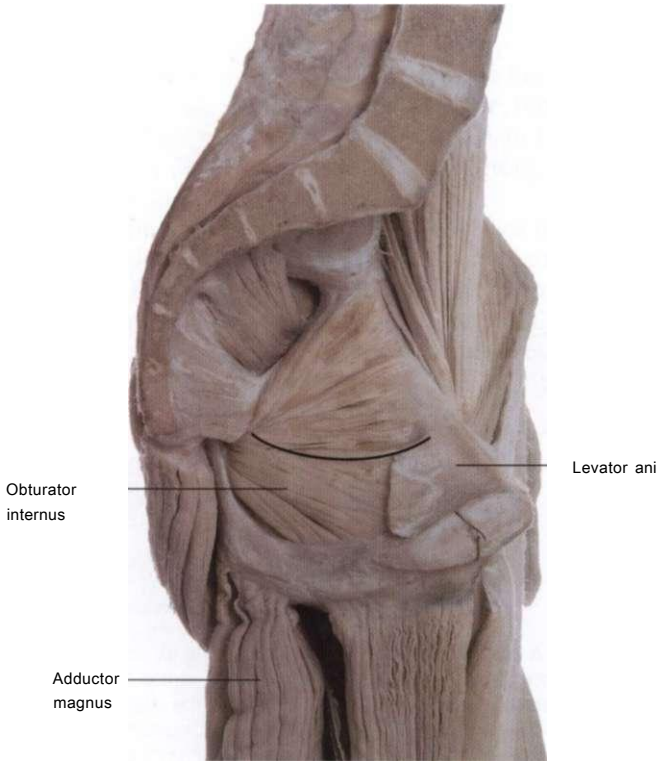


Fig. 9.18 Deep Front Line, lower posterior tracks and stations view as imaged by Primal Pictures. (Image provided courtesy of Primal Pictures, www.primalpictures.com.)

rectus abdominis reaching down from above (described later in this chapter - see **Fig. 9.31**).

Palpation guide 2: lower posterior track



The area of the DFL behind the knee is not easily amenable to palpation or manual intervention due to the passage of the neurovascular bundle and fat pad superficial to these tissues. The medial femoral epicondyle on the inside just above the knee is easily felt if you put your thumb along the medial side of your thigh and slide down with some pressure until you find the knob of the epicondyle a couple of inches above the knee.

This station marks the beginning of a division between the posterior septum that runs up the back of the adductors, separating them from the hamstrings, and the anterior (medial intermuscular) septum dividing the adductors from the quadriceps. Taking the posterior septum first, place your model on his side, and find the medial femoral epicondyle (**Fig. 9.14**). You will find a finger's width or more of space between this condyle and the prominent medial hamstring tendons coming from behind the knee.

Follow this valley upward as far as you can toward the IT. In some people, it will be easy to follow, and you

Fig. 9.16 Although the fascia has been removed in this dissection, there is a connection from the adductor magnus (and the posterior intermuscular septum represented by the dark space just behind it) across the ischial tuberosity and the lower obturator internus fascia to the arcuate line (horizontal line) where the levator ani joins the lateral wall of the true pelvis. (© Ralph T Hutchings. Reproduced from Abrahams et al 1998.)

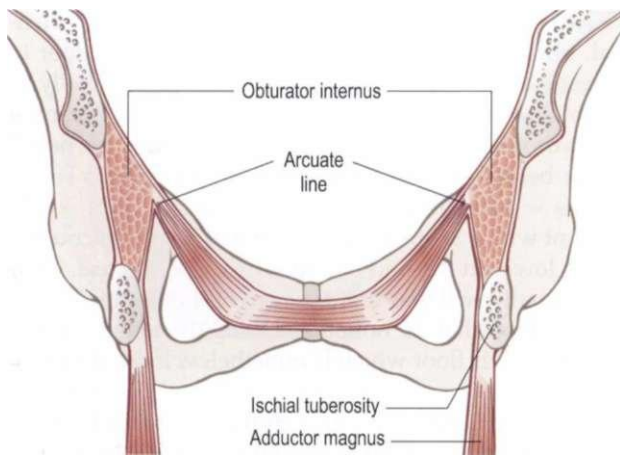


Fig. 9.17 From the posterior intermuscular septum and adductor magnus, the fascial track moves up inside the ischial tuberosity on the obturator internus fascia to contact the pelvic floor (levator ani).

fascia blends into the anterior longitudinal ligament running up the front of the spine, where it rejoins the lower anterior track at the junction between the psoas and diaphragmatic crura (**Fig. 9.18**).

The complex sets of connections here are difficult to box into a linear presentation. We can note, for instance, that the pelvic floor, in the form of the central pubococcygeus, also connects to the posterior lamina of the

can work your way more deeply into this septum in its 'S'-shaped course toward the linea aspera (see Fig. 9.13). In those where the adductor magnus is 'married' to the hamstrings, however, the septum and surrounding tissues may be too bound to follow the valley very far into the tissue; indeed, the septum may feel instead like a piece of strapping tape between the muscles. Having the space between these muscle groups open and free is the desired state, and fingers insinuated into this division accompanied by flexion and extension of the knee can lead to freer movement between the hamstrings and posterior adductors.

The upper end of this valley will emerge at the postero-inferior point of the ischial tuberosity. You can usually orient yourself at this point by placing your fingers in the lower posterior corner of the IT with your model side-lying, and having your model adduct (lift the whole leg toward the ceiling). Adductor magnus, attaching to the bottom of the IT, will 'pop' your fingers in this movement.

To isolate the hamstrings, alternate this movement with knee flexion (leg relaxed on the table while pressing the heel against some resistance you offer with your other hand or your outer thigh). The hamstrings attach to the posterior aspect of the IT; you will feel this attachment tighten in resisted knee flexion (Fig. 9.16). Place your fingers between these two structures and you will be on the upper end of the posterior adductor septum. The septum runs in a straight line between the femoral epicondyle and this upper end. In cases where the valley is impenetrable, work to spread the fascial tissues laterally and relax surrounding muscles will be rewarded with the valley appearing, and, more to the point, differentiated movement between pelvis and femur, and between hamstrings and adductor magnus (DVD ref: **Deep Front Line, Part 1, 43:25-44:59**).

The adductors themselves are amenable to general spreading work along their length (DVD ref: **Deep Front Line, Part 1, 36:20-42:00**), and to specific work up on the medial area of the hip joint near the ischial ramus, especially for correcting a functionally short leg (DVD ref: **Deep Front Line, Part 1, 45:00-52:20**).

From the adductor magnus, there is connecting fascia from the IT along its medial surface to the obturator internus fascia, and from this fascial sheet onto the pelvic floor sheets via the arcuate line (Fig. 9.18). Palpating in this direction is not for the faint of heart and should initially be practiced with a friend or tolerant colleague, but it is a rewarding and not very invasive way of affecting the pelvic floor, the site of so many insults to structure, especially for women. On your side-lying model, place your hand on the inside posterior edge of the IT. Keep your index finger in contact with the sacrotuberous ligament as a guide, rather than being any further anterior on the ischial ramus, and begin to slide upward and forward in the direction of the navel, keeping your fingerpads in gentle but direct contact with the bone. A little practice will teach you how much skin to take - stretching skin is not the object (Fig. 9.19).

Above the IT/ramus you will feel the slightly softer tissue of the obturator internus fascia under your fin-

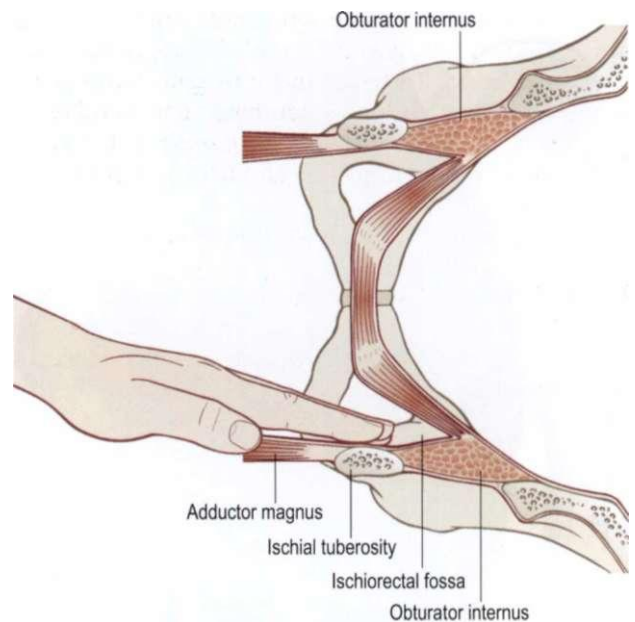


Fig. 9.19 A difficult but highly effective technique for contacting the posterior triangle of the pelvic floor involves sliding into the ischiorectal fossa along the ischial tuberosity in the direction of the navel until the pelvic floor is felt and assessed. Depending on its condition, manual therapy can be used to either lower both the tone and the position of the posterior pelvic floor, or encourage its increased tone.

gerpads. Care must be taken to stay away from the anal verge, and some verbal reassurance is often helpful. Continue upward along the obturator fascia until you encounter a wall ahead of your fingertips. This wall is the pelvic floor, the levator ani muscle.

Although no words will substitute for the experiential 'library' of assessing the state of the pelvic floor in a number of subjects, many pelvic floors, especially in the male of the species, will be high and tight, meaning that your fingers will have to run deep into the pelvic space before encountering a solid-feeling wall. Fewer clients - more female, and often post-partum - will present with a lax pelvic floor, which you will encounter much lower in the pelvis, and with a spongy feel. Only occasionally will you find the converse patterns - a low pelvic floor that is nonetheless highly toned, or the spongy pelvic floor which is nonetheless located high in the pelvis.

For those clients with the common pattern of a high, tightened levator ani, it is possible to hook your fingers into the obturator fascia just below the pelvic floor, and bring that fascia with you as you retreat toward the IT (Fig. 9.19). This will often relax and lower the pelvic floor. For those with a toneless or fallen pelvic floor, pushing the fingertips up against the pelvic floor while calling for the client to contract and relax the muscles will often help the client find and strengthen this vital area.

The thigh - lower anterior track

Returning to the inside of the thigh just above the knee, we can take the other track of the DFL in the thigh, the



lower anterior track, which is the more primary part of the DFL in our myofascial meridians approach. This fascial line penetrates the adductor magnus through the adductor hiatus with the neurovascular bundle, to emerge on the anterior side of this muscle, in the intermuscular septum between the adductor group and the quadriceps group (**Fig. 9.20**).

This septum lines the sulcus that underlies the sartorius muscle. Although we keep to our tradition in depicting this as a line, it is especially important here to expand one's vision to see this part of the DFL as a complex curvature in a three-dimensional fascial plane. It sweeps up in a sail shape: at the surface, its 'leech'

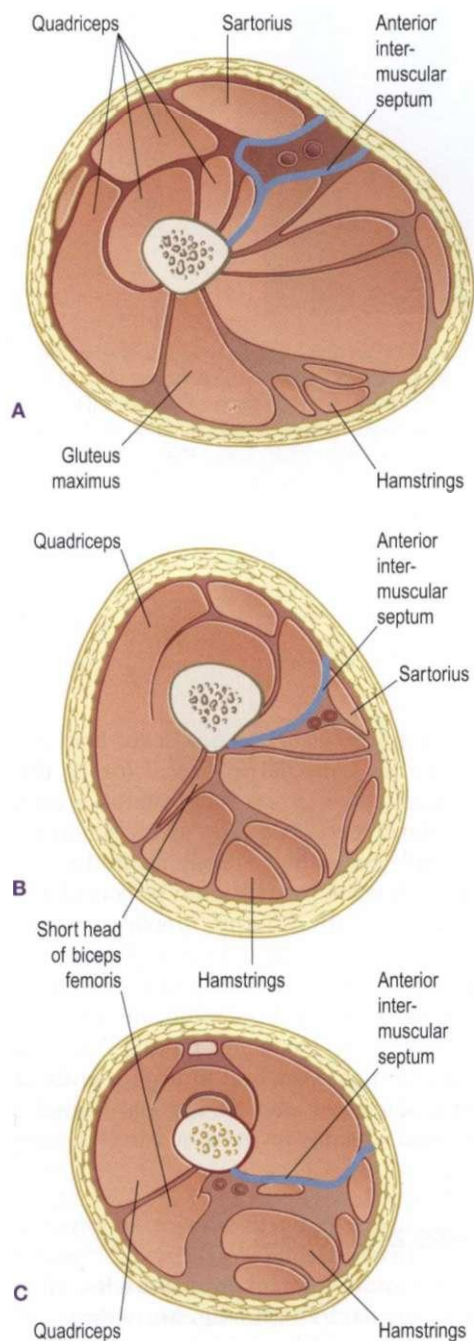


Fig. 9.20 The lower posterior track of the DFL follows the anterior intermuscular septum between the adductors and the hamstrings.

(outer edge) runs up under the sartorius from just above the inner part of the knee to the front of the hip and the femoral triangle (with the sartorius acting as a 'leech line' - adjustably tightening the edge of this fascia). The Tuff (inner edge) follows the linea aspera on the 'mast' of the femur from the medial posterior knee up the back of the femur to the lesser trochanter (**Fig. 9.21**).

From here the main track of the DFL continues up on the psoas muscle and associated fascia, which climb forward and up from the lesser trochanter. The psoas passes directly in front of the hip joint and rounds over the ilipectineal ridge, only to dive backward, behind the organs and their enfolded peritoneal bag, to join to the lumbar spine (**Fig. 9.22**). Its proximal attachments are to the bodies and transverse processes (TPs) of all the lumbar vertebrae, frequently including T12 as well. Each psoas fills in the gully between the bodies and TPs in the front of the spine, just as the transversospinalii fill in the laminar grooves between the TPs and spinous processes behind the spine (**Fig. 9.23**).

In the groin, the anterior intermuscular septum opens into the femoral triangle, or the 'Teg pit', bordered on the medial side by the adductor longus, on the lateral side by the sartorius, and superiorly by the inguinal ligament (**Fig. 9.24**). Within the femoral triangle we find the femoral neurovascular bundle, a set of lymph nodes, and the continuation of the DFL myofascia - the ilio-psoas on the lateral side and the pectineus on the medial side, both covering the front of the hip joint and head of the femur.

While the pectineus is confined to the femoral triangle, both the psoas and the iliacus extend above the

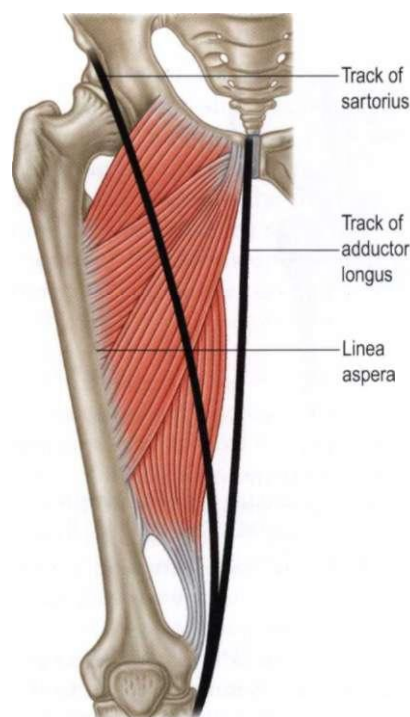


Fig. 9.21 The anterior septum of the thigh presents a complex curve not unlike a sail that sweeps from the linea aspera out to the sartorius.

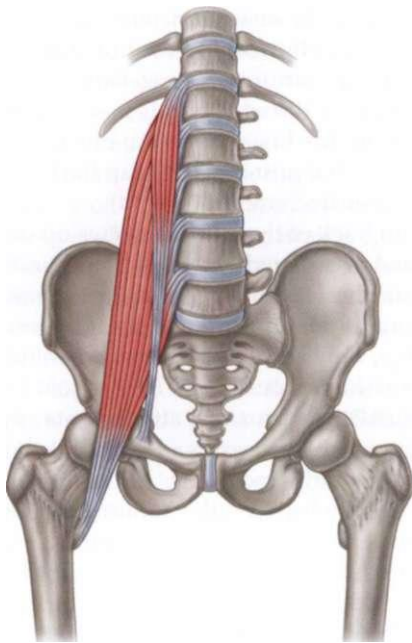


Fig. 9.22 The psoas major is the major supporting guy-wire between the spine and the leg, joining upper to lower, breathing to walking, and acting with other local muscles in complex ways for steadying various movements.

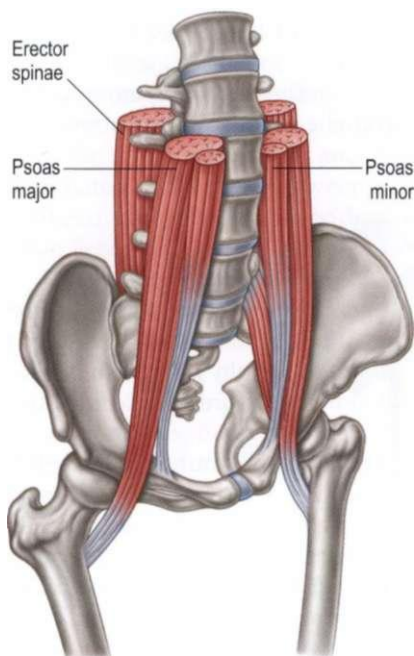


Fig. 9.23 There are four 'gullies' around the spine; the erector spinae muscles in the back and the psoas in the front fill in these gullies and support the lumbar vertebrae.

inguinal ligament into the trunk. The iliacus is a one-joint flexor of the hip, equivalent in some ways to the subscapularis in the shoulder. The iliacus is definitely and obviously a hip flexor, though there is some controversy over whether it is a medial or lateral rotator of the hip (see 'The Psoas Pseries'³).



Fig. 9.24 The femoral triangle, the leg's equivalent to the armpit, opens from the anterior septum between the sartorius (A) and the adductor longus (B). It passes, with the psoas (C), iliacus (D), pectineus (E), and neurovascular bundle (not pictured), under the inguinal ligament (F) into the abdominal cavity. The psoas, iliacus, and pectineus form a fan reaching up from the lesser trochanter to the hip bone and lumbar spine. Length and balanced tone in this complex is essential for structural health and freedom of movement. (© Ralph T Hutchings. Reproduced from Abrahams et al 1998.)

The psoas muscle, also clearly a hip flexor and also variously described as a medial or lateral (or, as this author has been persuaded, a non-) hip rotator, is even more mired in controversy in terms of its action on the spine (**Fig. 9.25**). This author is convinced, through clinical experience, that the psoas should be considered as a triangular muscle, with differing functions for the upper psoas, which can act as a lumbar flexor, and the lower psoas, which clearly acts as a lumbar extensor. If this differentiation of function is valid, the lumbar can be fully supported by balancing the various slips of the psoas with the post-vertebral multifidi, without reference to the tonus of the abdominal muscles (again, see 'The Psoas Pseries'³).

Psoas express and locals

We have said that multi-joint express muscles often overlie other monarticular locals. In the case of the psoas muscle, there are two sets of locals that serve the same area, but here they lie on either side of the express instead of underneath it (**Fig. 9.26**). While there is con-



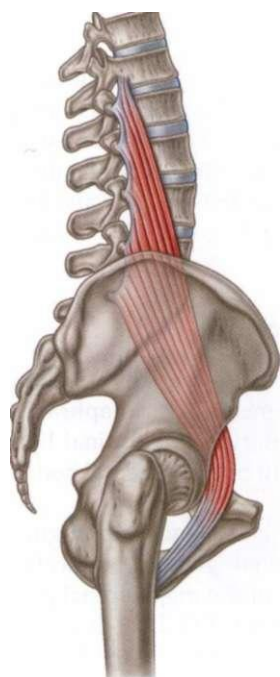


Fig. 9.25 The human psoas muscle makes a unique journey around the front of the pelvis - forward and up from the trochanter to the iliopectineal ridge, then back and up to the lumbar spine. No other animal makes use of such a course for the psoas; in most quadrupeds, the psoas does not even touch the pelvis unless the femur is extended to its limit.

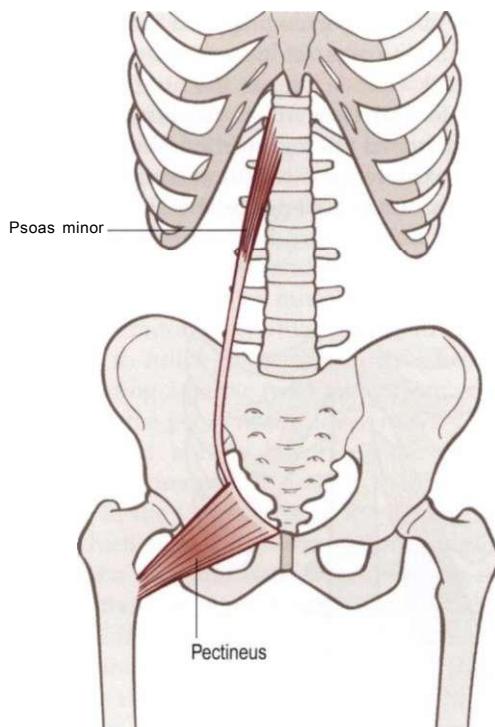


Fig. 9.27 The inner line of hip-spine locals comprises the pectineus, linking via the lacunar ligament with the psoas minor.

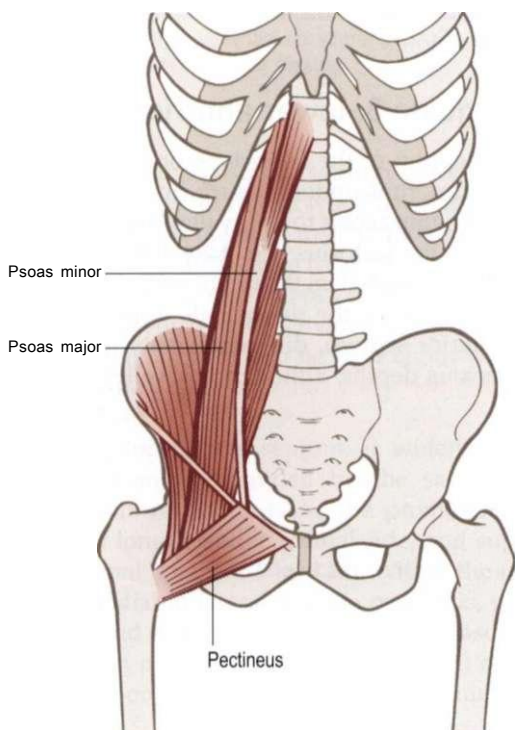


Fig. 9.26 The DFL attaches the inner femur to the core structures in front of the spine, including the diaphragm and mesentery (not pictured). In the center of these connections lies the psoas major express, flanked by two sets of locals.

trovsky as to exactly what functions the psoas performs,^{2,4-8} there is not about the territory it covers, which is from the lesser trochanter to the bodies and TPs of the 1st lumbar and often the 12th thoracic vertebrae.

We can cover the same territory in two other ways, one medial and the other lateral to the psoas major itself. On the medial side, we could follow the pectineus from

the lesser trochanter (and the linea aspera just below it) over to the iliopectineal ridge (**Fig. 9.27**). From here, with the connecting fascia of the lacunar ligament and only a slight change in direction, we can pick up the psoas minor (which is expressed as a muscle in about 51% of the population, but is expressed as a fascial band in nearly 100%).⁶ The psoas minor runs on top of the fascia of the psoas major to insert, or reach its upper station, at the 12th thoracic vertebra.

On the lateral side, we begin with the iliacus, widening up and laterally from the lesser trochanter to attach all along the upper portion of the iliac fossa (**Fig. 9.28**). The fascia covering the iliacus is continuous with the fascia on the anterior surface of the quadratus lumborum, which takes us up to the TPs of the lumbar vertebrae, just behind the psoas attachments, as well as to the 12th rib (DVD ref: Early Dissective Evidence: Deep Front Line).

Thus, when either the lower lumbar vertebrae or the thoracolumbar junction (TLJ) are being pulled down and forward toward the front of the pelvis, any or all three of these pathways could be involved, and all three should be investigated in dealing with a lower lumbar lordosis, compressed lumbar, an anteriorly tilted or even a posteriorly shifted pelvis.

In the misty past when this author began teaching manual therapy, few practitioners knew much about the psoas or how to find and treat it. In the past 20 years, its role has been more widely recognized, sometimes to the exclusion of these important more-or-less monarticular accompanying muscle groups, which, to be effective in changing patterns in the groin area, should draw practitioners' attention.

A lunge, or those asanas in yoga known as the 'warrior poses', are common ways to induce a stretch in the psoas, which work well as long as the lumbar bars are not allowed to fall too far forward in the lunge, and the pelvis is kept square to the leg in front (see Fig. 4.17A, p. 105). One can explore these two local complexes from this position (Fig. 9.29). To engage the outer iliacus-

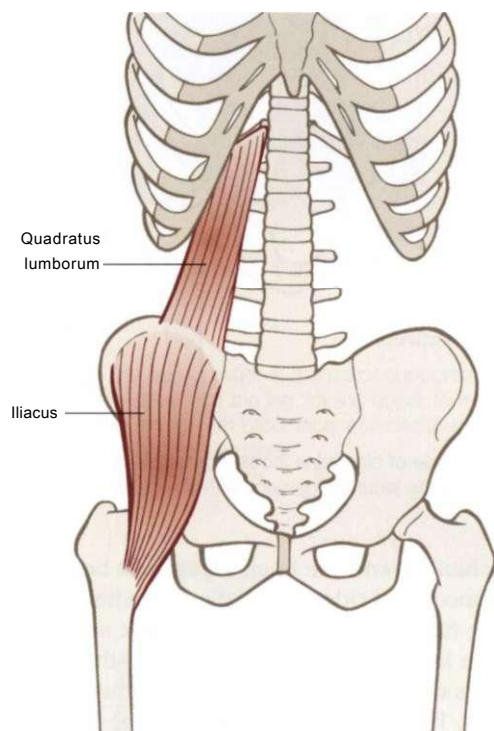


Fig. 9.28 The outer line of hip-spine locals comprises the iliacus, linking into the quadratus lumborum.

quadratus complex, let the knee of the extended leg turn medially toward the body, letting the heel fall out. Moving the ribs away from the hip on the same side will emphasize this stretch. To engage the inner pectineus-psoas minor complex, let the extended leg turn out, with the heel going in and the weight coming onto the inner big toe. Drop the hip toward the floor a little and this inner line through the groin will come into sharper relief.

The thoracolumbar junction (TLJ)

The upper end of the psoas blends fascially with the crura and other posterior attachments of the diaphragm, all of which blend with the anterior longitudinal ligament (ALL), running up the front of the vertebral bodies and discs.

The connection between the psoas and diaphragm - just behind the kidneys, adrenal glands, and celiac (solar) plexus, and just in front of the major spinal joint of the thoracolumbar junction (TLJ: T12-L1) - is a critical point of both support and function in the human body (Fig. 9.30). It joins the 'top' and 'bottom' of the body, it joins breathing to walking, assimilation to elimination, and is, of course, via the celiac plexus, a center for the 'gut reaction'.

Palpation guide 3: lower anterior track

The anterior septum of the adductors, or medial intermuscular septum, runs under the sartorius muscle, and you can usually gain access to this 'valley' by feeling for it just medial to the sartorius (Fig. 9.20). Like the sartorius, the septum is medial on the thigh on the lower end, but lies on the front of the thigh at its upper end. As with the posterior septum, different clients will allow you in to various depths, although this valley is more

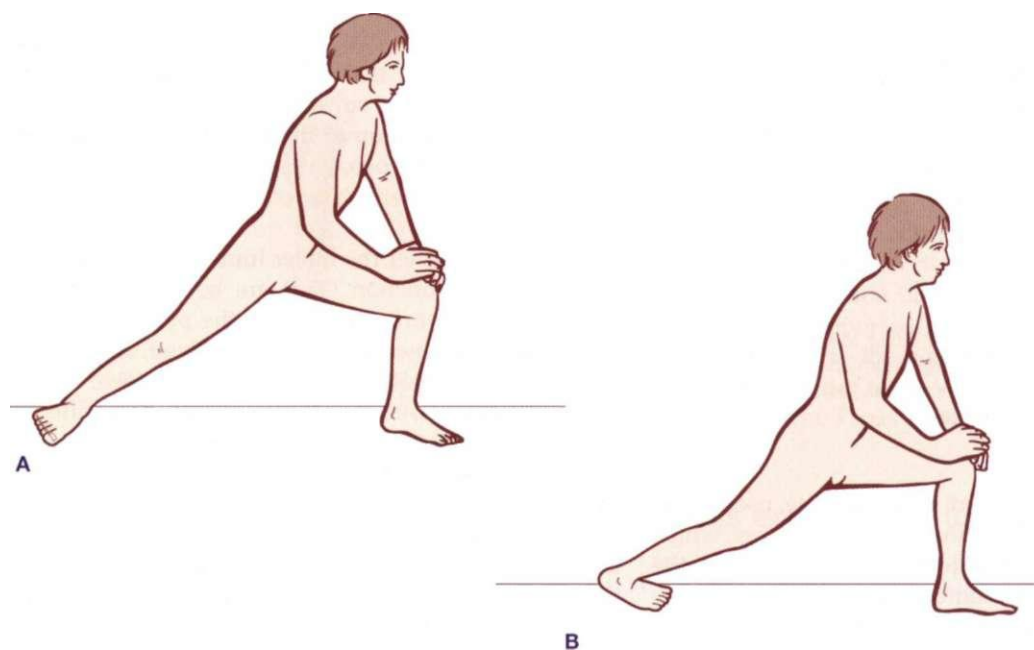


Fig. 9.29 Positions for emphasizing stretch in (A) the inner set of locals and (B) the outer set of locals.

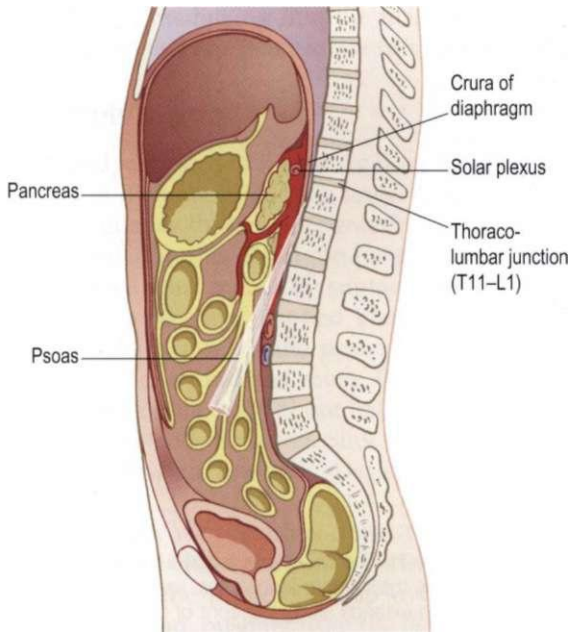


Fig. 9.30 The meeting place between the upper and lower tracks of the DFL is the front of the upper lumbar vertebrae, where the upper reaches of the psoas mingle with the lower crura of the diaphragm, where walking meets breathing. It corresponds closely to the location of an essential spinal transition (T12-L1), as well as the adrenal glands and solar plexus.

evident than the posterior septum in most people, and is evident in the thin client when he or she simply holds the entire leg off the table in a laterally rotated position. As you palpate the septum for depth and freedom, alternate the client's movements of adduction with knee extension (which will activate the quadriceps under your fingers) to help you be clear about where the line of separation lies (DVD ref: **Deep Front Line, Part 1, 42:00-43:24**).

At the top of this septum, it widens out into the femoral triangle, bounded by the sartorius running to the ASIS on the outside, the prominent tendon of adductor longus on the medial side, and superiorly by the inguinal ligament (**Fig. 9.24**). Within the femoral triangle, medial to lateral, are the pectineus, psoas major tendon, and iliacus. The femoral neurovascular bundle and lymph nodes live here also, so tread carefully, but do not ignore this area vital to full opening of the hip joint.

Have your model lie supine with her knees up. Sit on one side of the table facing her head, with one of her thighs against the side of your body. Reach over the knee, securing the leg between your arm and your body, and put your entire palmar surface onto the medial aspect of the thigh, fingers pointing down. Drop your fingers slowly and gently into the opening of this 'leg pit', with your ring or little finger resting against the adductor longus tendon as a guide, so that the rest of your fingers are just anterior and lateral to it. Watch out for stretching the skin as you go in; it sometimes helps to reach in with your outer hand to lift the skin of the inner thigh before placing your palpating inner hand in

the groin, so that you drop both the skin and your fingers into the femoral triangle at the same time (DVD ref: **Deep Front Line, Part 1, 52:22-54:40**).

Once into the space, if you extend your fingers, the fingernail side will contact the lateral side of the pubic bone. Ask your model to lift her knee toward the opposite shoulder (combining flexion and adduction) and, if you are properly placed, you will feel the pectineus pop into your fingers - a band an inch or more wide near the pubic ramus. The muscle can be best worked in eccentric contraction while the client either slides the heel out to full leg extension, or pushes down on her foot, creating a pelvic twist away from you.

To find the psoas at this level, move your fingers just anterior and a little lateral of the pectineus. Avoid putting any pressure or sideways stretch on the femoral artery. On the lateral side of the artery (usually; it can vary which side of the artery affords easier access) you will find a slick and hard structure lying in front of the ball of the hip joint. Have your model lift her foot straight off the table, and this psoas tendon should pop straight into your hands. There is little that can be done with it at this level in most people, as it is so tendinous, but this is the place where the psoas rests nearest the surface.

The iliacus is adjacent to the psoas, just lateral to it, and is chiefly and usually distinguished from the psoas by being a bit softer (because it is still more muscular as opposed to the tendinous psoas at this level). It can be followed (skipping over the inguinal ligament) up to its anterior attachment inside the lip of the anterior iliac crest.

The iliacus and psoas can both be reached above the inguinal ligament in the abdominal area as well. Standing beside your supine model, have her bend her knees until the feet are standing, heels close to the buttocks, and place your fingers in the superior edge of the ASIS (DVD ref: **Deep Front Line, Part 1, 59:15-1:02:03**). Sink down into the body, keeping your fingerpads in contact with the iliacus as you go. Keep the fingers soft, and desist if you create painful stretching in the model's peritoneal structures (anything gassy, heated, or sharp). The psoas should appear in front of the tips of your fingers at the bottom of the 'slope' of the iliacus (DVD ref: **Deep Front Line, Part 1, 1:02:05-1:12:30**). If the psoas remains elusive, have your model gently begin to lift her foot off the table, which should immediately tighten the psoas and make it more obvious to you. At this point, you are on the outside edge of the psoas, and these fibers come from the upper reaches of the psoas - the T12-L1 part.

Although you can follow these outside fibers up, it is not recommended that you work the psoas above the level of the navel without a detailed understanding of the kidney's attachments.

Having found this outside edge, keep a gentle contact with the 'sausage' of the psoas, staying at the level between a horizontal line drawn between the two ASISs and one drawn at the level of the umbilicus. Move up and across the top of the muscle until you feel yourself coming onto the inside slope. It is important not to lose

contact with the muscle as you do this (have your client lift the foot to flex the hip if you are in any doubt), and important not to press on anything that pulses. You are now on the inside edge of the psoas, in contact with the fibers which come from L4-L5 (and are thus more responsible, when short, for lumbar lordosis).

The psoas minor is only present as a muscle in about half the population, and, for this author, is often difficult to isolate from psoas major, except as a tight band across the anterior surface of the psoas major. With the client supine and the knees bent, you can sometimes feel the small band of the psoas minor tendon on the surface of the major by having the client do a very small and isolated movement of bringing the pubic bone up toward the chest. The problem is that this movement may produce contraction in the larger psoas, and may also produce contraction in the abdominals, which can be mistaken for contraction in the tiny psoas minor.

The final part of the psoas complex, the quadratus lumborum (QL), is best reached from a side-lying position. Walk your fingers on the inside of the iliac crest from the ASIS toward the back, and you will encounter a strong fascial line going up and back toward the end of the 12th rib. This is the outer edge of the QL fascia, and access to this outer edge, or the front surface just anterior to the edge, will allow you to lengthen this crucial structure. It is nearly impossible to affect this muscle approaching it posteriorly. The use of a deep breath to facilitate release can be very helpful. (DVD ref: Deep **Front Line**, Part 1, 1:12:31-1:18:26)

A branch line: the 'tail' of the Deep Front Line

From the medial arch to the psoas, the DFL follows the tradition of the other leg lines in having a right and left half, two separate but presumably equal (though due to injury, postural deviation, or at minimum handedness and 'footedness', they seldom are) lines proceeding from the inner foot to the lumbar spine. At the lumbar spine, the DFL more or less joins into a central line, which, as we move into the upper reaches of the DFL, we will parse as three separate lines from front to back, not right and left.

It is worth noting, however, that we have a possible third 'leg', or more properly 'tail' on the DFL, which we will describe here before proceeding upward. If we came down the DFL from the skull on the ALL, and instead of splitting right and left on the two psoases, we simply kept going on down (**Fig. 9.31**), we would pass down the lumbar, onto the sacral fascia and to the anterior surface of the coccyx.

From here, the fascia keeps going in the same direction by means of the pubococcygeus muscle that passes forward to the posterior superior surface of the pubic tubercle and pubic symphysis (**Fig 9.32**).

Since the rectus abdominis is the deepest of the abdominal muscles at this point, fascially speaking, the fascia from the pelvic floor runs up to the posterior lamina of the rectus abdominis fascia so that our 'tail' is carried right up the ribs. On its way, it includes the

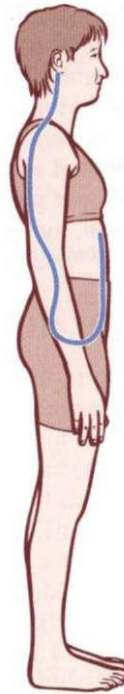

Fig. 9.31 The DFL passes down the mid-sagittal line as the anterior longitudinal ligament (ALL), which extends along the front of the sacrum and coccyx onto the pubococcygeus, the longitudinal muscle of the pelvic floor, a myofascial 'tail' on the spine.

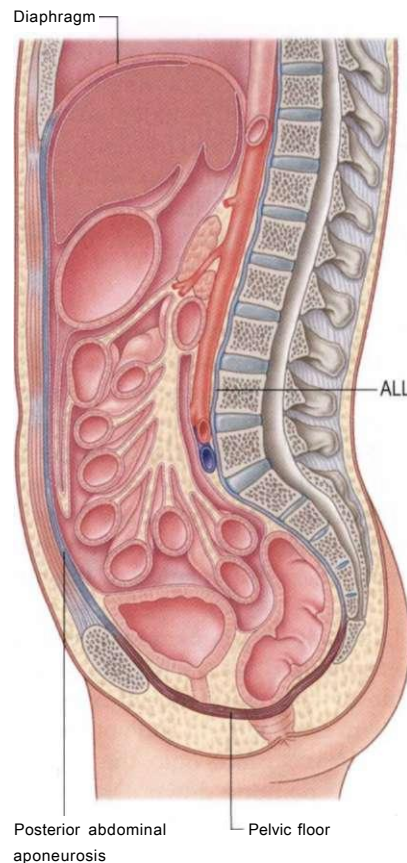


Fig. 9.32 If we follow the anterior longitudinal ligament down the midline to the tailbone we can continue onto the central raphe of the pelvic floor, across the levator ani to the back of the pubic bone and on up onto the posterior abdominal fascia behind the rectus.

umbilicus, thus linking into the many myofascial and visceral connections that radiate from there.

The pelvic floor

A second approach to the pelvic floor (the first appears above, in 'Palpation guide 2: lower posterior track', p. 187; techniques that involve entering body cavities are not included in this book) can be made from the pubic bone. Have your model lie supine with his knees up, and with a recently emptied bladder. This palpation requires that we reach the posterior side of the pubic bone, and by an indirect route. Place the fingertips of both hands on the belly about halfway between the top of the pubis and the navel. Sink gently down into the abdomen toward the back. Desist in the face of any pain.

Now curl your fingertips down toward the model's feet to come behind the pubic bone. Have your client gently bring the pubic bone up over your fingertips toward his head, pushing from the feet to avoid the use of the abdominal muscles (which, if used, will push you out). Then turn your fingertips up to come in contact with the back of the pubic bone (**Fig. 9.33**). Your fingers are now curled in a half circle, as if you are holding a suitcase handle. When you can find this spot properly, especially in someone whose body is open enough to allow you to get there easily, you can almost lift the 'suitcase' of the pelvis off the table by this 'handle'.

When you have contact with this aspect of the pubic bone, have your model squeeze the pelvic floor, and you and he both should be able to feel the contraction where the pelvic floor attaches to the posterior superior edge of the pubis. The connection between the pelvic floor and the rectus abdominis is also clear in this position. This access can be used to loosen the too tight anterior pelvic floor, or to encourage increased tone in those with a weak pelvic floor or urinary incontinence (**DVD ref: Deep Front Line, Part 2**).

To attain the proper placement, it is important to start high enough. The direct approach - starting at the pubic

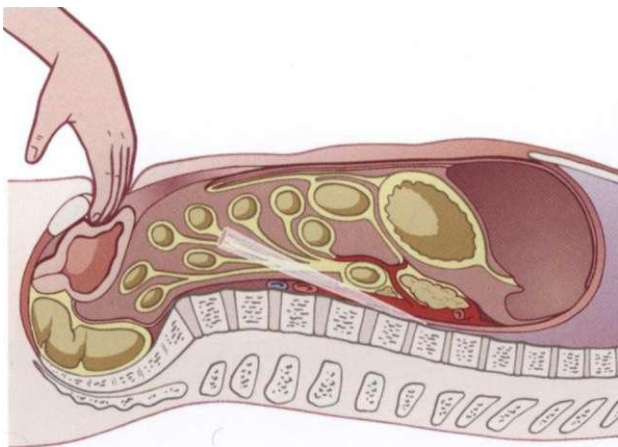


Fig. 9.33 The fascial connection between the abdominal fasciae and the pelvic floor behind the pubic bone is a potent spot for structural change, but must be approached with caution and sensitivity.

hair level and diving directly behind the bone - will not work. In clients with a tough layer of fat, overdeveloped abdominals, or in those not accustomed to intra-abdominal work, successive tries and reassuring words may help achieve this contact.

NOTE: Even this palpation (let alone work) is contraindicated in anyone with a bladder or any lower abdominal infection.

The umbilicus

The umbilicus is a rich source of emotional connections as well as fascial ones, being the source of all nourishment for the first nine months of life (**Fig. 9.34**). Although the umbilicus is easily reached on the front of the abdominal fascial planes, the holding is most often in the posterior laminae of the abdominal fascia, so we must find our way behind the rectus abdominis. This layer is in contact with the peritoneum, and therefore has many connections into the visceral space, including connections to the bladder and the falciform ligament dividing the liver.

To reach these layers, position your model supine with the knees up, and find the outer edge of the rectus. If it is hard to feel in a relaxed state, having your client lift the head and upper chest to look at your hands will bring the edge into relief. Position your hands with elbows wide, palms down, and the fingertips pointing toward each other under the edges of each rectus. Bring your fingers slowly together, being sure that the rectus muscle - not just fat tissue - is ceilingward of your fingers.

When you feel your fingertips in contact with each other, the tissues on the inner aspect of the umbilicus will be between your fingers. Gauge your pressure - even minimal pressure can be painful or emotionally challenging to some clients. Getting truly informed consent and staying engaged to the degree consistent

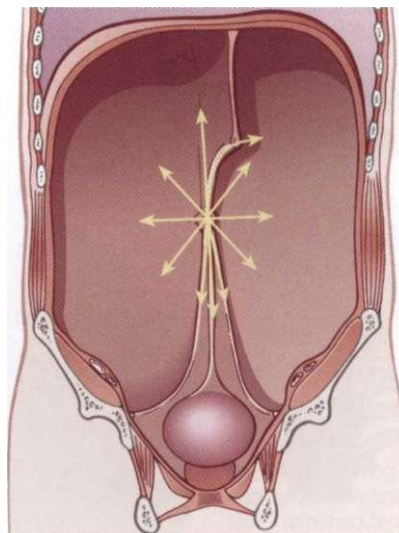


Fig. 9.34 A view looking forward at the posterior of the belly wall. The umbilicus, not surprisingly, since it is the fundamental source of nourishment for our first nine months of life, has numerous fascial connections in all directions.



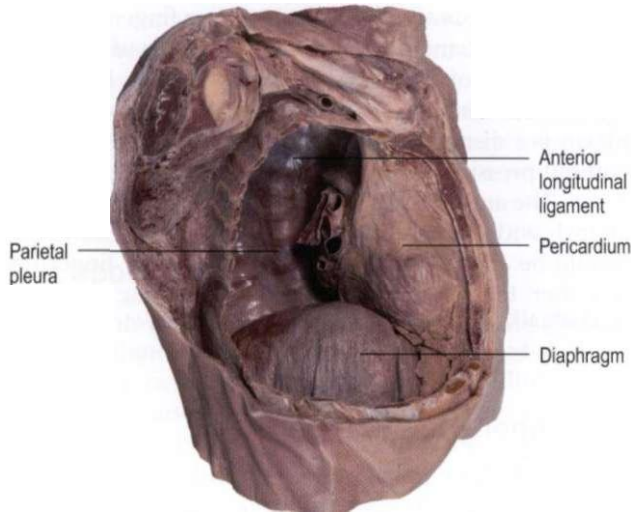


Fig. 9.38 From the central tendon of the diaphragm, the fascial continuity travels up the pericardium and parietal pleura of the lungs, forming sheaths and supporting webbing around all the nerves and tubes of the pulmonary and systemic circulation. (© Ralph T Hutchings. From Abrahams et al 1998.)

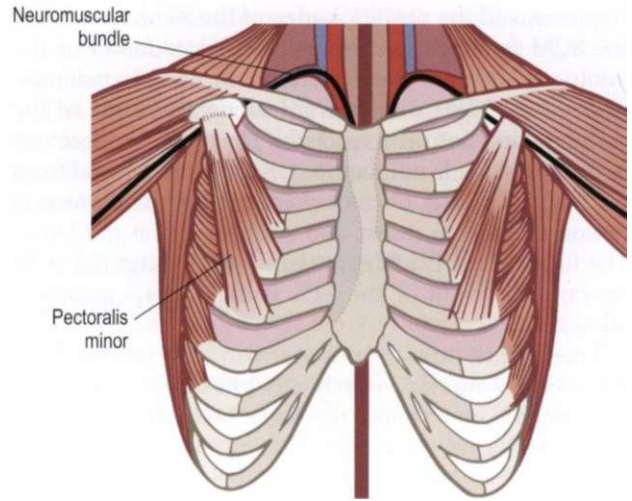


Fig. 9.40 The DFL connects to the myofascia of the Deep Front Arm Line, following the path of the neurovascular bundle.

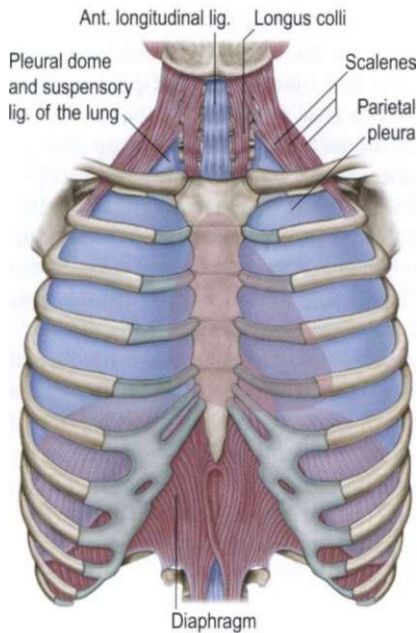


Fig. 9.39 Seen from the front, the mediastinum between the heart and lungs connects the diaphragm to the thoracic inlet.

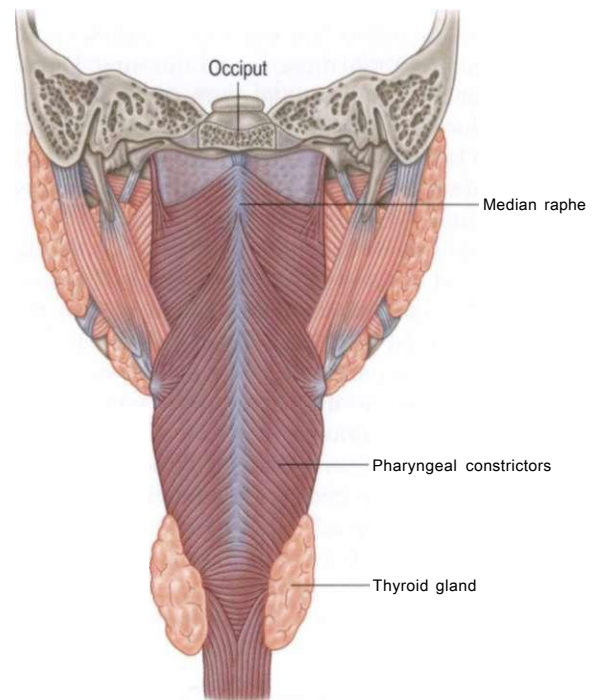


Fig. 9.41 A posterior view of the upper middle track of the DFL—the back of the throat, including the pharyngeal constrictors supported by the median raphe which hangs from the clivus of the occiput.

The major part of this middle line, however, passes up with the esophagus into the posterior side of the pharynx, including the pharyngeal constrictors, which can clearly be seen hanging from the median raphe of connective tissue in **Figure 9.41**. This line also joins the occiput (and the temporal via the styloid muscles, see below), slightly more anterior than the upper posterior track, attaching to a small protuberance known as the clivus of the occiput, or pharyngeal tubercle. The posterior fascia of this middle branch of the DFL (the buccopharyngeal or visceral fascia) is separated from the posterior line (the anterior longitudinal ligament and prevertebral layer of cervical fascia) at this point by a sheet called the alar fascia (**Fig. 9.42**).

The upper anterior track

The third and most anterior track of the DFL in the upper body follows the curve of the diaphragm all the way over to its anterior attachment at the xiphoid process at the bottom of the sternum (see **Fig. 9.2**, side view, upper anterior track, and DVD ref: Deep Front Line, Part 2: 32:29-38:37). This fascia connects to the fascia on the deep side of the sternum, although it requires a fairly sharp turn by Anatomy Trains standards from the nearly horizontal anteromedial portion of the diaphragm to the endothoracic fascia on the posterior aspect of the

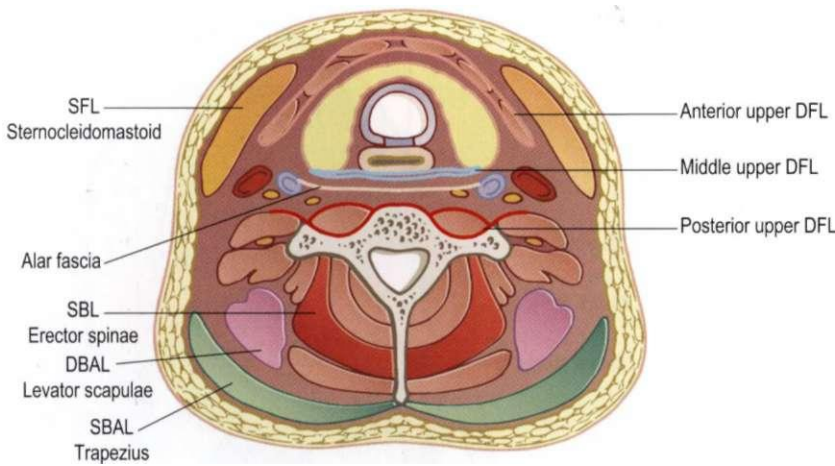


Fig. 9.42 A cross-section through the neck reveals the related but still distinct posterior, middle, and anterior tracks of the DFL.

sternum. We emphasize once again that all three of these tracks through the thorax are joined as one in the living body, and are being separated here for analysis only.

This fascia includes the serrated fan of the transversus thoracis muscle and by extension the entire plane of endothoracic fascia in front of the viscera but behind the costal cartilages (**Fig. 9.43**).

This line emerges from the rib cage just behind the manubrium of the sternum. This myofascial line clearly continues from this station with the infrahyoid muscles - the sternohyoid express covering the sternothyroid, thyrocricoid, and cricothyroid locals - up to the suspended hyoid bone itself (**Fig. 9.44**).

This group is joined by that odd leftover from the operculum, the omohyoid, which functions in speaking, swallowing, and also to form a protective tent around the jugular vein and carotid artery during strong contractions of the surrounding neck muscles.

From the hyoid, the stylohyoid connects back to the styloid process of the temporal bone. The digastric muscle manages to go both up and forward to the chin as well as up and back to the mastoid process. It even manages to avoid dirtying its hands by touching the hyoid at all - two slings of fascia reach up from the hyoid, allowing the digastric to pull straight up on the whole tracheal apparatus in swallowing. By these two muscles, this most anterior branch of the DFL is connected to the temporal bone of the neurocranium (**Fig. 9.45**).

Two muscles, the mylohyoid and geniohyoid, accompany the digastric in passing up and forward to the inside of the mandible, just behind the chin. These two form the floor of the mouth under the tongue. (It is interesting to note the parallel between the construction of the floor of the mouth and that of the floor of the pelvis, in which the geniohyoid equates with the pubococcygeus, and the mylohyoid equates with the iliococcygeus.)

From these hyoid muscles, we could claim a mechanical connection through the mandible (though a direct fascial connection is a little harder to justify) with the muscles which close the jaw (**Fig. 9.46**). The masseter, which lifts up from the zygomatic arch, and the medial pterygoid, which lifts up from the underside of the

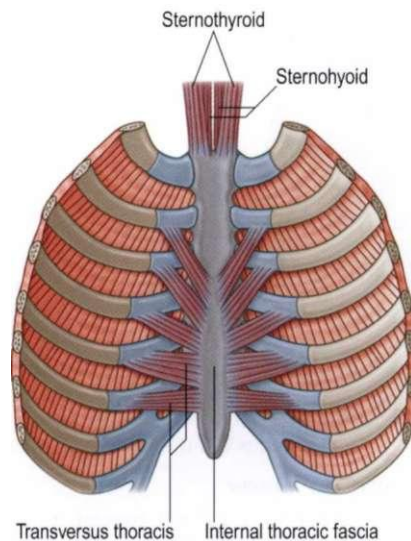


Fig. 9.43 This upper anterior track includes the transversus thoracis, that odd muscle on the inside of the front of the ribs which supports the costal cartilages and can contract the chest when we are cold.

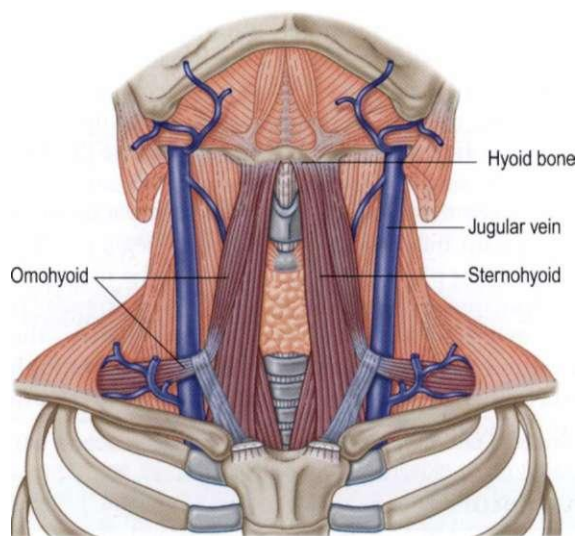


Fig. 9.44 The infrahyoid muscles emerge from behind the sternum, joining the inside of the ribs to the front of the throat and the hyoid bone.

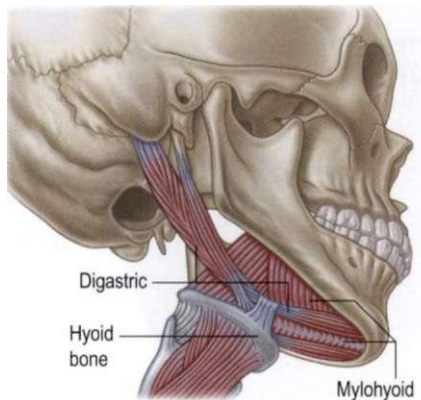


Fig. 9.45 From the hyoid bone, there are connections both forward to the jaw and back to the temporal bone of the cranium.

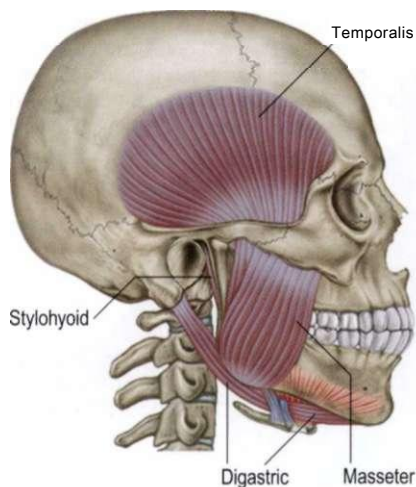


Fig. 9.46 Though the case for a direct connection from the delicate suprahyoid muscles to the strong jaw muscles is difficult to make, there is definitely a mechanical connection from the floor of the mouth to the jaw muscles to the facial and cranial bones. (DVD ref: Early Dissective Evidence: Deep Front Line.)



sphenoid, together form a sling for the angle of the jaw (Fig. 9.47). The temporalis pulls straight up on the coronoid process of the mandible from a broad attachment on the temporal bone, and its fascia runs across the skull coronally under the galea aponeurotica, the scalp fascia that was involved in the SFL, SBL, LL, and SPL (Fig. 9.48).

Thus we see the complex core of the body's myofascia, snaking up the 'hidden' places in the legs, passing through the 'leg pit' into the trunk to join the tissues in front of the spine. From here, we have seen it split (at least for analysis) into three major routes: behind the viscera directly in front of the spine, up through the viscera themselves, and up in front of the viscera to the throat and face.



Discussion 1

The Deep Front Line and stability in the legs

In the posture of the lower leg, the DFL structures tend to act as counterbalance to the Lateral Line structures (Fig. 9.49).

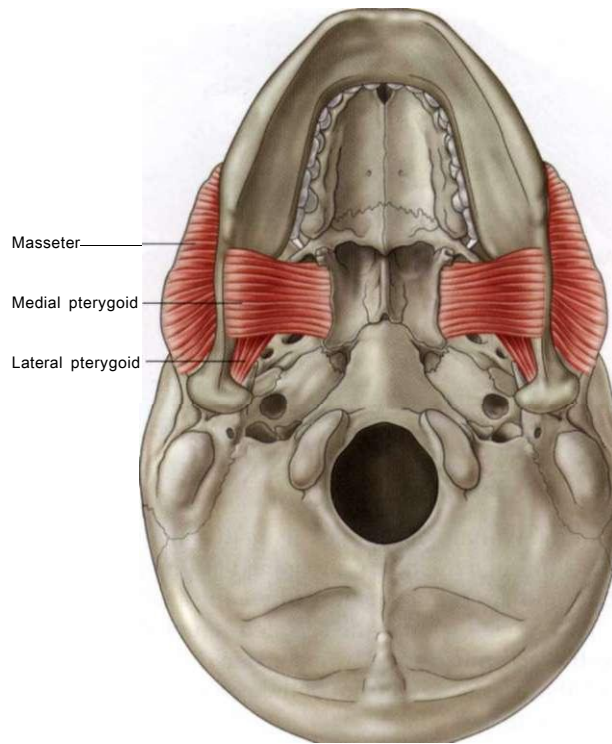


Fig. 9.47 Seen from below, the essential sling for the ramus of the mandible created by the two masters acting in concert with the two medial pterygoids is unmistakable.

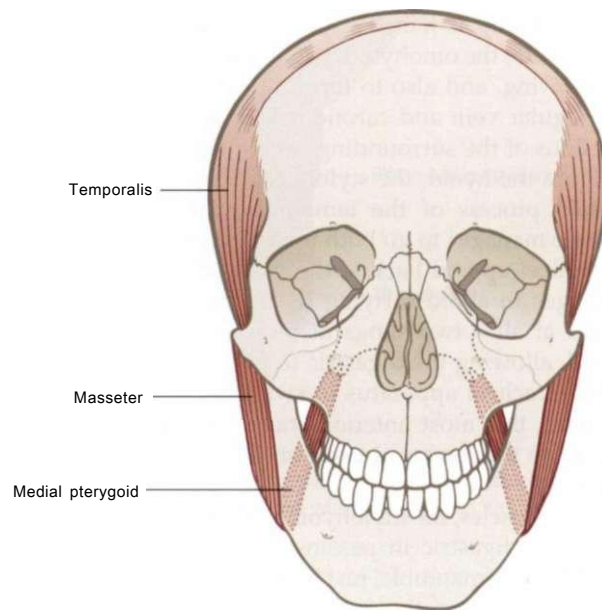


Fig. 9.48 The upper reaches of the DFL includes the sling created by the masseter on the outside and the medial pterygoid on the inside, and the fascia from the temporalis which loops up over the head beneath the SBL.

The peroneals (fibularii), when locked short, tend to create an everted, or pronated ankle, or a laterally rotated forefoot. While the tibialis anterior has been seen to counterbalance the peroneus longus, so does the tibialis posterior: if the muscles of the deep posterior compartment are over-shortened, they tend to create an inverted or supinated ankle, or a

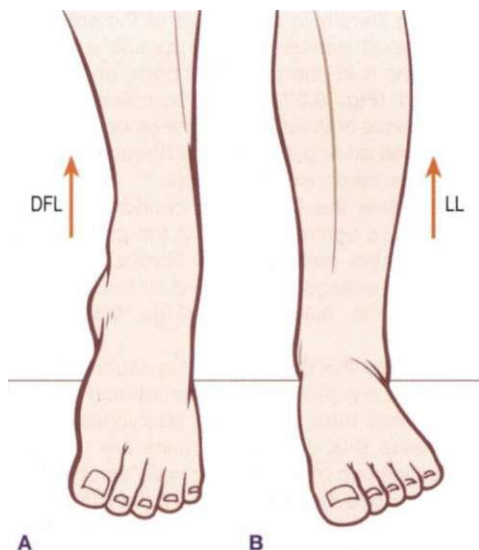

Fig. 9.49 In the lower legs, the Lateral Line and DFL are antagonists: when the DFL is too short, the feet tend toward supinated and inverted (**A**); when the Lateral Line becomes chronically short, the feet tend toward the pronated and everted (**B**).

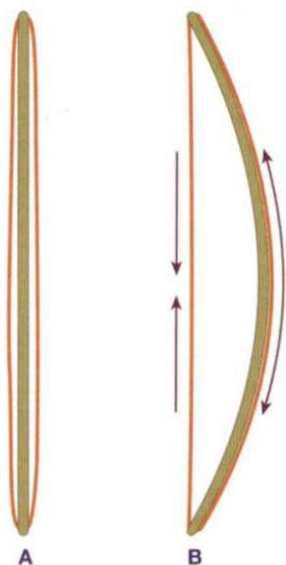


Fig. 9.50 When the tensile tissues on the inside or outside of the legs are tightened, the skeletal structure of the leg responds like the wooden bow, bending away from the contracture, and causing strain to the tissues on the convex side. The type of interaction between the DFL and the LL is active in knock-knees and bow legs (*genu varus* and *valgus*).

medially rotated forefoot. Together, these myofascia help to stabilize the tibia-fibula over the ankle, and maintain the inner arch.

At the knee, the DFL and LL counterbalance each other like bowstrings on either side of the leg (**Fig. 9.50**). When the legs are bowed ('O' legs, laterally shifted knees, *genu varus*), the DFL structures in the lower leg and thigh will be found to be short, and the LL structures, the iliotibial tract and peroneals, will be under strain. In the case of knock knees ('X' legs, medially shifted knees, *genu valgus*), the reverse will be true: the lateral structures will be locked short, and the DFL structures will be strained, or locked long. Pain will tend to occur on the strained side, but the side that needs work is that with the short bowstring.

In the thigh, the adductor muscles enclosed by the anterior and posterior septa also act to counterbalance the abductors of the LL, and any imbalance can often be seen by checking the relative position of tissues on the inside and outside of the knee, including the tissues of the thigh above the knee. With knock-knee patterns, the adductor fascia tends to be pulled

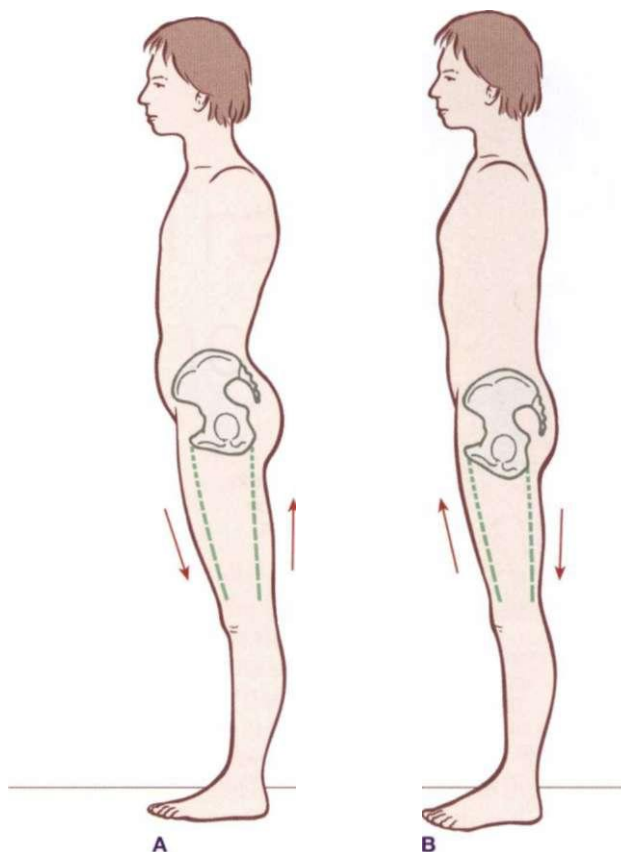


Fig. 9.51 In assessing the relative tilt of the pelvis, it is worthwhile considering the anterior (medial) and posterior intermuscular septa of the thigh as guy-wires that can exert a restriction on the flexion-extension excursion of the pelvis.

down toward the knee, and with bow-legged patterns, the DFL tends to be pulled up the inseam of the leg into the hip.

In regard to pelvic position, it is helpful to consider the septa themselves as structures worthy of consideration (**Fig. 9.51**). In an anteriorly tilted pelvis, the front septum is often short and glued down to both adjacent muscle groups, and requires lengthening along with adductor longus and brevis. In this case, the posterior septum is under strain and lifted, and its fascial plane should be induced to come caudally. In a posteriorly tilted pelvis, the reverse is true: the anterior plane often needs to be brought interiorly, and the posterior septum certainly needs to be free from the pelvic floor, the deep lateral rotators, and the adjacent muscle groups from each other. In this way, the anterior septum can be thought of as an extension of the psoas, and the posterior septum an extension of the deep lateral rotators, the piriformis specifically, and pelvic floor, associated with the adductor magnus muscle.

Discussion 2

The middle of the Deep Front Line and Visceral Manipulation

The endothoracic tissues of the DFL, from the diaphragmatic crura to the thoracic inlet, are not available to be reached by direct manipulative work. The entire rib cage forms a box in which there is always a negative pressure, pulling the tissues out against the ribs and attempting to pull the ribs in. These areas are amenable to indirect work, however, via the scalenes and neck fasciae from above, or via the peritoneum, the lower edge of the rib cage, or the psoas from below.



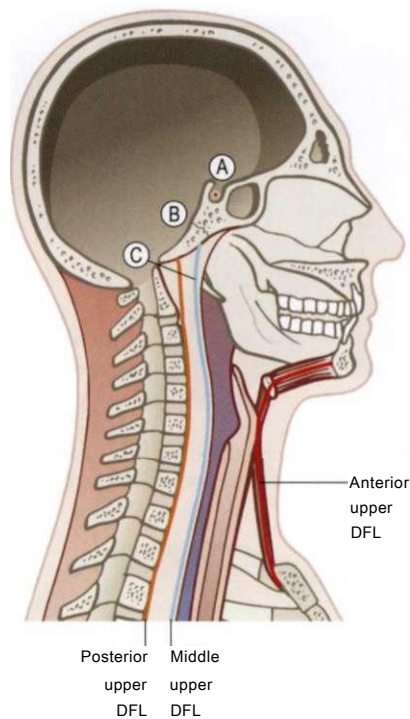


Fig. 9.52 At the upper pole of the DFL, we see a close approximation among important structures deriving from the three germ layers.

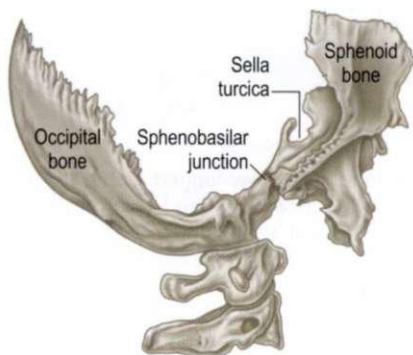


Fig. 9.53 The sphenobasilar junction (SBJ) is a crucial hinge of the cranosacral pulse, where the 'bodies' of the occipital and sphenoidal 'vertebrae' meet.

They may also be affected by the techniques of Visceral Manipulation. These techniques are ably set forth in several books by the developer of Visceral Manipulation, the French osteopath Jean-Pierre Barral.^{10,11}



Discussion 3

The upper pole of the DFL and the ecto-, meso-, endodermal connection

The very top of the DFL is a fascinating physiological crossroads. The posterior track of the anterior longitudinal ligament joins just anterior to the foramen magnum, the middle track of the pharynx joins just anterior to that, and the anterior track of the laryngo-hyoid complex joins, among other attachments, to the lower wings of the sphenoid.

It is tempting to note the proximity of these points to central structures deriving from the embryonic ectoderm, mesoderm,

and endoderm. Sitting literally in the saddle of the sphenoid (sella turcica), the hypothalamus-pituitary axis is a central junction box of both the fluid and the neural body, of primarily ectodermal derivation (**Fig. 9.52A**). This so-called 'master gland' sits below the circle of Willis, tasting the blood delivered fresh from the heart and adding its powerful hormonal spices and fundamental motor responses to the mix.

Just behind and below this lies the synchondrosis of the sphenobasilar junction, a central fulcrum of the cranosacral movement, itself a central feature of the fibrous body, the mesodermal body - the collagenous net and all the muscular pulses that produce the fluid waves (**Figs 9.52B and 9.53**).^{12,13}

Just behind and below this (but all within a couple of centimeters) lies the top of the pharynx, the central and original gullet of the endodermal tube, where the pharyngeal raphe joins the occipital base (**Fig. 9.52C**). Humans are uniquely situated so that the direction of the gut (basically vertical from mouth to anus) and the direction of movement (basically horizontally forward) are not the same. In our faces, 'bite' has been subordinated to 'sight', and the gut hangs from this crucial center at the bottom of the skull. Few other animals have so completely divorced the line of sight and motion from the line of direction of the spine and gut. This is at least possibly one source of our psychosomatic split from the rest of the animal world.¹⁴

One wonders about the communication among these anterior 'junction boxes'. Can pursing the lips for a kiss or receiving a strawberry, or the tensing of the tongue that accompanies 'disgust' be felt in the sphenobasilar junction, or perceived by the pituitary? One can at least imagine an inter-regulatory function among these three major systems proceeding from this point of proximity down the entire organism via the central nervous system, the submucosal plexus, the cranial pulse, or the long myofascial continuity from face and tongue to inner ankle we have traced here.

References

1. Myers T. Fans of the hip joint. *Massage Magazine* No. 75 January 1998.
2. Schleip R. Lecture notes on the adductors and psoas. Rolf Lines, Rolf Institute. 11/88 www.somatics.de
3. Myers T. The Psoas Pseries. *Massage and Bodywork* 1993; Mar-Nov. Also self-published in 2007 and available via www.anatomytmins.com.
4. Morrison M. Further thoughts on femur rotation and the psoas. Rolf Lines, Rolf Institute. M 4/01 www.anatomytrains.net
5. Bogduk N. *Clinical anatomy of the lumbar spine and sacrum*. 3rd edn. Edinburgh: Churchill Livingstone; 1997:102.
6. Rolf I. *Rolfing*. Rochester, VT: Healing Arts Press; 1989:170.
7. Murphy M. Notes for a workshop on the psoas. Unpublished: 1992.
8. Myers T. Poise: psoas-piriformis balance. *Massage Magazine* 1998; (Mar/Apr).
9. Simons D, Travell J, Simons L. *Myofascial pain and dysfunction: the trigger point manual, vol 1: upper half of body*. 2nd edn. Baltimore: William & Wilkins; 1998.
10. Barral JP, Mercier P. *Urogenital manipulation*. Seattle: Eastland Press; 1988.
11. Schwind P. *Fascial and membrane technique*. Edinburgh: Churchill Livingstone; 2006.
12. Upledger J, Vredevoogd J. *Craniosacral therapy*. Chicago: Eastland Press; 1983.
13. Milne H. *The heart of listening*. Berkeley: North Atlantic Books; 1995.
14. Kass L. *The hungry soul*. New York: MacMillan; 1994.

Anatomy Trains in motion

10

With the entire suite of 12 myofascial meridians delineated, let us proceed into some of the applications and implications of this Anatomy Trains scheme. Although such examples for both movement and manual therapy have been interspersed throughout the preceding chapters, the specific sequencing of soft-tissue releases or movement education strategies is left to subsequent publications or in-person training. This book is designed to aid the reader in observing these body-wide myofascial patterns, so that currently held skills and treatment protocols can be applied globally in novel ways.

These two final chapters expand on the variety of ways in which the Anatomy Trains concept can be applied as a whole. This chapter overviews application to some common domains of movement, while Chapter 11 lays out a method of standing postural analysis used in Structural Integration processing (see also Appendix 2). Neither of these forays is intended to be in any way exhaustive, but merely to guide the reader a little way down the road toward the variety of possible uses for the scheme, both as self-help and in the healing/performance/rehabilitation professions.

Although some movements are made with an entire myofascial meridian as a whole, we should note that Anatomy Trains is not primarily a theory of movement, but a map of how stability is maintained and strain distributed across the body during movement. For instance, put one foot on top of the other as you sit, and attempt to lift the lower foot against the upper by lifting the whole leg. Although the rectus femoris and psoas major may be the muscles primarily responsible for attempting to move the leg, the entire Superficial Front Line along the anterior surface will tense and 'pre-stress' from toes to hip and even can be felt into the belly and neck. This kind of stabilizing motion goes on mostly under the radar of our consciousness, but is vitally necessary for the effective 'anchoring' in one part that forms the basis of successful movement for another.

Similarly, place weight into your forward foot to feel both the Superficial Back Line and the Superficial Front Line of the leg stiffen fascially as a whole, no matter which muscles are actually involved in the movement.

Put your weight fully onto that single foot to feel the interplay between the Lateral Line and the Deep Front Line as they stabilize the inside-outside balance of the leg as the weight shifts second-by-second on the medial and lateral arches of the foot.

You can use your knowledge of the lines to see how compensations or inefficient postures are inhibiting integrated movement or effective strength in the moving body. The medium of a book limits us to still pictures; there is no substitute for the practice of seeing the lines in motion.

Applications

Let us begin with some fairly simple analyses of some classical sculpture, before moving on to some more functional applications:

Classical sculpture

KoillrOS (Fig. 10.1)

Aside from the modern and extraordinarily functional example of Fred Astaire, this pre-classical sculpture represents, to this author's eye, the most compelling example of poise and balance among the Anatomy Trains lines - better even than the Albinus figure that serves as a cover to this book. This Kouros (lad) - one of many such sculptures from the pre-classical period - presents a balanced tensegrity between the skeletal and myofascial structure rarely seen today; in fact rarely seen in art after this period. The muscles and bones are represented a bit massively for modern taste, but the whole neuromyofascial web 'hangs together' with a calm ease that nevertheless manages to convey a total readiness for action.

Notice the length and support through the core Deep Front Line that imparts support up the inner line of the leg and throughout the trunk. Notice the balance of soft-tissues between the inside and outside of the knee. See the ease with which the head sits on the neck, and the shoulders drape over the upright rib cage. There is distinct muscle definition, but the connection along the



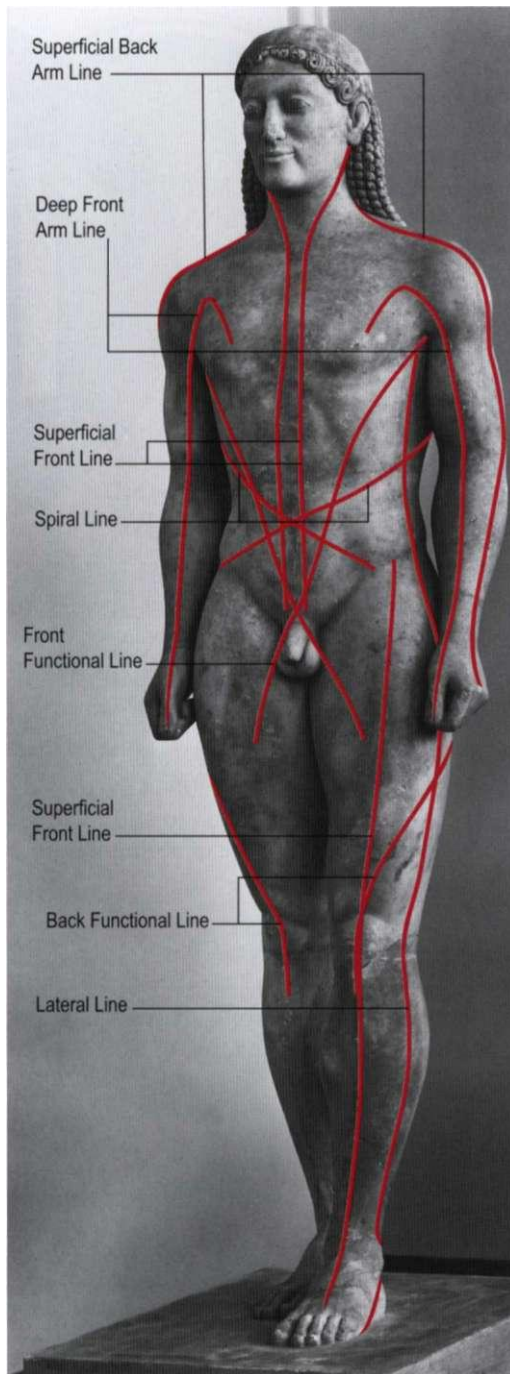


Fig. 10.1 Kouros. The pre-classical Kouros series of sculptures shows close to ideal 'coordinated fascial tensegrity' - balance and proper placement for the Anatomy Trains lines. (Reproduced with kind permission from Hirmer Fotoarkiv.)

lines is not lost or overcome. We could do worse, as a culture, than to work toward a physical education system which would generate bodies that approach this functional ideal.

Heracles (Fig. 10.2)

Here we see a weary Hercules, leaning on his club and resting from his labors, so it may be unfair to subject him to a critical lines analysis. This representation, however, is typical of classical art, and it provides a clear

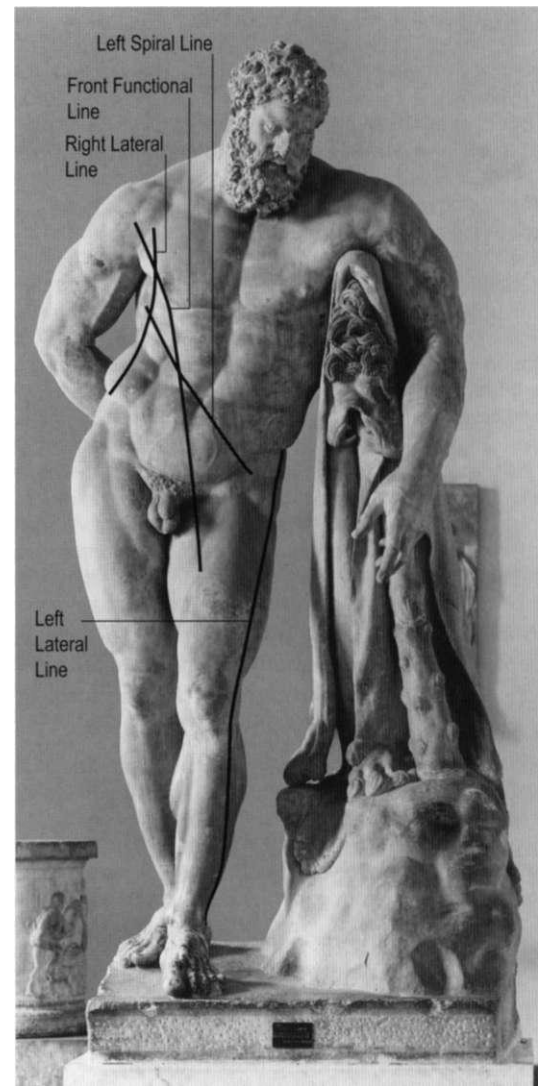


Fig. 10.2 Herakles (Heracles, Hercules). The classical Herakles shows a shortening of the core and asymmetrical imbalance among the lines. (Reproduced with kind permission from Hirmer Fotoarkiv.)

contrast with the pre-classical Kouros and the warrior Zeus (see Fig. 10.4).

Blessed with fabled strength though he may be, notice that Heracles' body shows the characteristic hip-hiked, off-center pose that can be found in most 'classical' art. This involves a commonly seen pattern: shortness in the lower left Lateral Line, and the upper right Lateral Line. This is accompanied by a retraction or collapse in the core or Deep Front Line, demonstrated in several ways. There is a twist in the core supporting the lower thoracic spine, i.e. in the psoas complex. The chest, though massive, seems slightly collapsed toward an exhalation pattern. The lack of inner length can also be seen in the 'girdle of Adonis' spilling over the edge of the pelvis (that is not fat, but rather a result of core shortening). It extends to the legs, where the shortness of the DFL in the adductor group and deep posterior compartment of the lower leg pulls up on the inner arch and helps to shift the weight onto the outside of the foot. The collapse can be read in the tissues of the knee, where the tissues

on the inner knee (DFL) are lower than the tissues on the outer knee (LL). Contrast this with the core support found in any of these examples, even the asymmetrical and unathletic Venus.

Aphrodite de Melos (Fig. 10.3)

We are, of course, unable to comment on Venus's Arm Lines, but the charm of her seductive pose is surely enhanced by a shortness in the left Spiral Line and the right Front Functional Line. Someone standing straight is not nearly as inviting (compare this pose to most of the statues of Athena - i.e. 'Justice' or the Statue of Liberty - who generally stands foursquare, inviting respect but not familiarity). The straight pose calls for maximum stability in the cardinal lines: front, back, sides, and core (Deep Front) lines. Any sinuous pose such as seen here or in the fashion magazines will involve the helical lines: the Lateral, Spiral, and Functional Lines.

Notice how the shortening of the left SPL shifts her head to the right, protracts the right shoulder, and gives




Fig. 10.3 Aphrodite de Melos (Venus de Milo). Any seductive pose will involve asymmetrical shortening of the helical lines (Reproduced with kind permission from Hirmer Fotoarkiv.)

a left rotation to the rib cage relative to the pelvis. The shortness in the right FFL further contributes to all of these and also to her modesty, as the adductor longus on the left side, the lower track of the right FFL, adducts the left hip across the body.

Additional shortening in the right Lateral Line is necessary to bring sufficient weight back onto the right leg. Even so, we are left with the impression of impending movement, in that she seems not quite securely balanced on her right leg. Some have surmised that in the original she was holding the baby Eros in her right arm, which would help counterbalance her weight, or perhaps she is about to take a step into the pool that will once again render her virginal.

Bronze Zeus (Fig. 10.4)

This sculpture shows the body beautifully poised for martial action. Though it is probably blasphemous to reduce Zeus to a lines analysis, we will risk the thunderbolt he looks ready to hurl to note how he stabilizes his body for maximum effect. The improbably long left arm is held out along the line of his sight, suspended by the Superficial Back Arm Line, counterbalancing the weight of the right arm. The right arm grips the bolt or spear with both thumb and fingers, engaging both the Superficial and Deep Front Arm Lines, thus linking into both the pectoralis major and minor across the front of

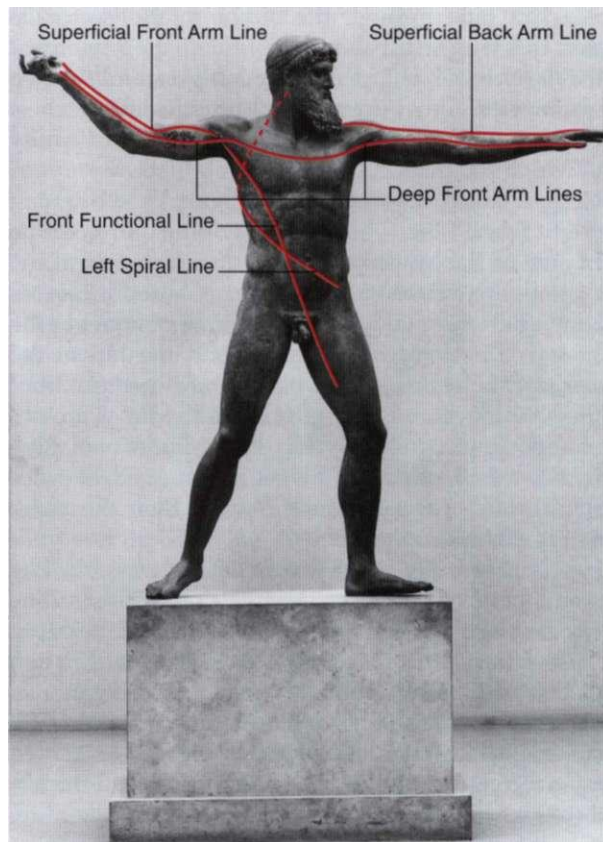


Fig. 10.4 Zeus. Most martial or sportive actions involve connecting the arm to the opposite leg to increase leverage. (Reproduced with kind permission from Hirmer Fotoarkiv.)

the chest to the opposite side. This connection allows the front of the outstretched arm to counterbalance and provide a base for the throw.

The right leg is contracting along the Superficial Back Line, pushing onto the ball of the foot and extending the hip to start the body on its forward path, pushing the weight onto the stable left leg. The left leg is planted firmly, though the knee is slightly bent, not locked, with stabilizing tension along all four leg lines, so that the left Spiral Line and right Front Functional Line, which are both anchored to the left leg, can assist the two front Arm Lines in imparting forward momentum to the right shoulder and arm.

Because the bolt is clearly to be thrown along the horizontal plane, the two Lateral Lines are quite balanced with each other. By this we can infer that it is being thrown for accuracy over a short distance (compare to the 'Hail Mary' throw in **Fig. 8.3** where the Arm Lines are also strongly assisted by the Spiral and Functional Lines). Were it to be thrown earthward from heaven, the left Lateral Line would necessarily shorten to angle the throw downward.

Discobolus (Fig. 10.5)

The discus thrower of Praxiteles is the consummate representation of the lines in service of an athletic skill. The trim young fellow holds the discus with the Superficial Front Arm Line of his right arm from the flexed fingers to the pectoralis major, stabilizing his hold with the pressure from his thumb, which connects up the Deep Front Arm Line through the biceps to the pectoralis minor. This tension is balanced by a similar engagement in the two front Arm Lines on the left side, and the two are connected across the pectoral muscles in the chest down the arm to his left hand, which is clearly fully involved in the throw.

He has 'coiled the spring' of his body by shortening the right Spiral Line, which is clearly pulled in from the right side of the head (the splenii muscles) around the left shoulder (rhomboid and serratus anterior) across the belly (left external and right internal oblique) to the right hip. This tension carries beyond the hip to the tensor fasciae latae, iliotibial band, and down the front of the shin via the tibialis anterior to the inner arch of his supporting right foot. The Front Functional Line from his left shoulder to his right femur is likewise short. The left Lateral Line is shorter than the right, which is extended.

He has been like this for over 2000 years, but any moment now he will 'rise and cast' the discus. The obvious power will come from the right SFAL bringing the discus forward across his body, but the coordination with the other lines will really make the difference in the distance the discus goes. Shortening the right SPL stretches and potentiates the left, which he will now shorten strongly, bringing his eyes and head to the left and the right shoulder forward working off the left hip. This will bring his weight as he turns onto the left leg and foot, which will become the fulcrum for the remainder of the movement. At the same time, he will shorten the Back Functional Line from the left shoulder to the

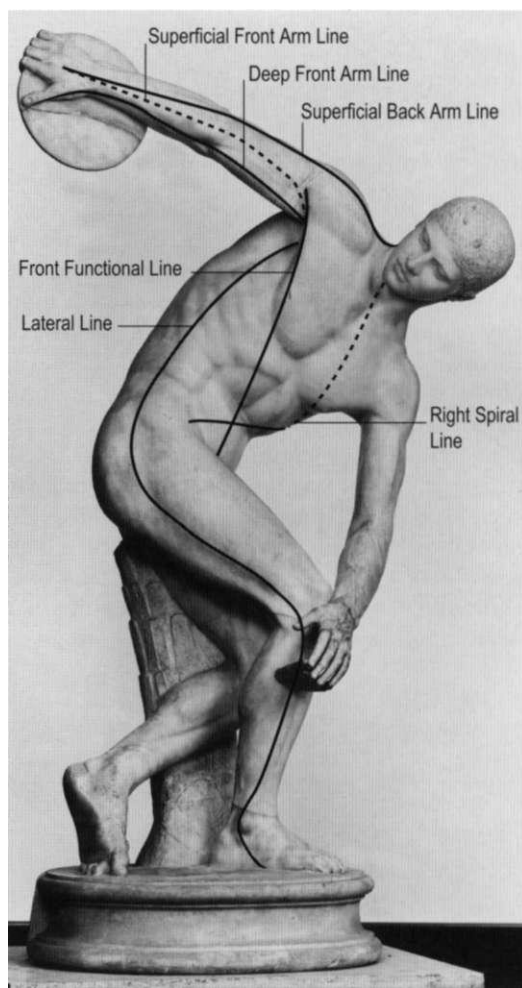


Fig. 10.5 Discobolus. The great athletes involve all the lines, distributing the strain evenly across the body. (Reproduced with kind permission from Hirmer Fotoarkiv.)

right femur, pulling the left shoulder back and rotating the whole trunk to the left. Shortening the right LL will help stabilize the platform of the shoulder and add a little more impetus to the throw. Finally, the erectors of the Superficial Back Line will straighten the flexion in his body, leaving his back extended and his head lifted to follow the flight of the discus. The right Back Functional Line, from right shoulder to left femur, will contract at the end of the movement to save his right rotator cuff from overstrain, allowing him to stay healthy for future contests.

Athletics

Tennis player (Fig. 10.6)

We can imagine our tennis server is short, so she leaps to get the highest advantage on the ball. The obvious lines for the power of the stroke are provided by both the Superficial and Deep Front Arm Lines that grip and power the racket, arrayed along the visible surface of the right arm in this picture. Notice how the left Front Arm Lines have contracted in against the body to provide more height and stretch to the right side.





Fig. 10.6 Tennis player. (© [iStockphoto.com](https://www.iStockphoto.com), reproduced with permission. Photograph by Michael Krinke.)




Fig. 10.7 Golfer at the end of a drive. (© [iStockphoto.com](https://www.iStockphoto.com), reproduced with permission. Photograph by Denise Kappa.)

In the torso, the power is passed to three lines in the trunk. First, the Front Functional Line continues the power in a straight line from the pectoralis major and the rectus abdominis through the pubic symphysis to the left adductor longus, which is pulling the left thigh a bit forward to counterbalance the right arm. Second, the right Spiral Line is shortened, turning the head to the right, pulling the left shoulder around the rib cage, and shortening the distance from the left ribs to the right hip. The left Spiral Line is conversely stretched or lengthened. Thirdly, these two are assisted by the Lateral Lines, where the left is shortened for stability, and the right is fully lengthened for reach. During the shot and follow through, the right Lateral Line and left Spiral Line will shorten along with the right Front Functional Line to provide more power.

When one is airborne, the only counterbalance to the weight of the racket and ball is the inertia of the body itself. We have seen how the weight of the arm is playing against the inertia of the left leg, but it is also working against the inertia of the core - the weight of the pelvis and upper legs themselves. This drawing on the stability of the core, represented in our scheme by the Deep Front Line, can be seen here in the supination of the feet and the pulling of the DFL structures up the inner line of the leg into the underside of the pelvis. This 'gathering' in the core is essential to the power and precision of the shot.

Golfer (Fig. 10.7)

This golfer, caught at the final moment of follow-through from a fairway shot, demonstrates a pleasing integra-

tion of the helical lines in motion. The entire upper part of the right Spiral Line, from the right side of the head around the left shoulder and ribs to the right hip and on down into the right arch, is clearly and evenly stretched - except for the head which must counter-rotate to follow the path of the ball. The left SPL is conversely contracted, right down to the supinating left foot. These lines were in opposite states of length at the beginning of the swing.

The only quarrel we might pick is with the height of the right shoulder, which is being restricted by the (out of sight) rotator cuff of the Deep Back Arm Line, causing the shoulder to lift slightly at this phase of the swing.

In terms of front-back balance, the Superficial Front Line is for the most part opened and stretched, especially on the right side, with the Superficial Back Line shortened, creating a bow to the body upon which the spirals are laid. Again, the swing starts with the SFL short and the SBL long, so this contraction lifts the head and rib cage during the latter part of the swing.

The weight on the legs has shifted to the inner part of the right foot (and right on past, at the moment of this picture) and onto the outside of the left foot. This involves a contraction of the Deep Front Line on the left leg (in addition to the contraction in the SPL already noted) and a stretch in the Lateral Line on the outside of the left leg. This balance between the Deep Front Line on the inner line of the leg and the Lateral Line on the outer aspect of the leg is crucial to remain centered on the legs while the Spiral Lines roll the weight through to the inside of the following foot and the outside of the leading foot. If these lines do not maintain a coordinated

tension through the myofascia, the upper lines cannot easily coordinate the precision swing.

The right Front Functional Line, from right shoulder to left hip, is fully contracted; its complement from right hip to left humerus is fully stretched. The left Back Functional Line is contracted, pulling the left shoulder back, and its complement, running from the right shoulder across the back and around the outside of the left thigh to the knee, is fully stretched. These have likewise traded roles from the moment of greatest backswing to this moment that the picture was taken.

Basketball (Fig. 10.8)

Again we are airborne, this time in the service of 'nothin' but net'. Working up from the bottom this time, obviously the Superficial Back and Front Lines have launched this muscular gentleman off his right foot, leaving the body in a bit of a bow that keeps his eyes on the ball. At the same time, notice how active the leading leg is - muscles bulging, foot dorsiflexed - the left leg is as important as the right arm in 'aiming' and guiding the body toward the hoop.

The right arm has fingers splayed, and the Superficial Front Arm Line from pectoral to palm is coming down, lifting the body and counterbalancing the throw with the left. The left Superficial Front Arm Line is providing the power, while the Deep Front Arm Line (see that thumb?) is doing the fine guiding of the ball for precision delivery.

In a similar manner to our previous two athletes, the left Front Functional Line is stretched prior to contracting for the dunk, while the right FFL stabilizes from the flexed left hip to outstretched right arm. The left Back




Fig. 10.8 Basketball player. (© [iStockphoto.com](https://www.iStockphoto.com), reproduced with permission. Photograph by Jelani Memory.)

Functional Line is contracted right now, but will have to relent in a second or two. The right BFL is stretched around the trunk from right shoulder to left hip. The left Spiral Line is more contracted, locating the head on the torso, and the right SPL is more stretched.

Finally, we note the difference between the left and right Deep Front Line in the legs, where the right DFL is fully stretched and open, but the definition in the adductors on the left side shows how essential this line is in providing core support for the balance of the trunk, even when the foot is not on the ground.

Football (Fig. 10.9)

Here we can comment on both number 23 and number 9, seemingly successful in stealing the ball from her competitor even as she falls. Our girl in blue shows a very even-toned stretch along the left Lateral Line coupled with a beautiful reciprocal motion: the closing twist from the right Spiral Line, and concomitant stretch of the left Spiral Line.

The Functional Lines, as above and as in most sportive moves, are likewise fully engaged, though in this case the movements of the arms are in the service of the coordination of the legs, not vice versa. The left Front Functional Line and right Back Functional Line are participating with the Spiral Line in generating the torso twist, while the two complementary lines are stretched into stabilizing straps. Notice how her arms attempt to stabilize the leg, with the left arm up and out in front, and the right arm in back, wrist and elbow flexed to connect the arm to the chest.

As in the basketball player, we can also see how the Deep Front Line is engaged on the inner line of the legs to give core support.

The defender has her (left) wrist extended, helping to tighten the back as her right leg works off her own body's inertia to hook the ball with her right foot, even in mid-fall. While we need not repeat the litany of helices in the Spiral and Functional Lines, we do note the interplay between the Lateral Lines and the Deep Front Lines in her legs: The LL on the outside of her right leg must



Fig. 10.9 Football players. (© [iStockphoto.com](https://www.iStockphoto.com), reproduced with permission. Photograph by Alberto Pomares.)




Fig. 10.10 Baseball outfielder.

relent and stretch to allow the DFL on the inside to pull the ball toward her. Conversely, the DFL on the left leg is lengthening, allowing the foot to stay on the ground until the last possible moment (any nano-second now). This interplay can be seen in skiing, skateboarding, or any sport such as football where side-to-side motion is part of the movement. It is then that these normally stabilizing lines become part of the movement and need to work reciprocally.

Baseball (Fig. 10.10)

Once more we go into the air, but with a difference. The left hand is making the catch, almost exclusively with the Superficial Front Arm Line. The Superficial Back Line has been shortened by the leap, with the head, spine, and right hip hyperextended. The Superficial Front Line is containing that hyperextension, keeping the ribs engaged with the pelvis. The right arm is not apparently bearing much weight, but notice how important this touch of the ground is to the orientation of the player to the ground, his body, and the ball.

Clearly the left Spiral Line has shortened to turn the ribs toward the ball, while its complement is lengthening as much as it can under the circumstances to allow the left arm to come up in the air. The right Front Functional Line assists the SFL in stabilizing the front, and the left FFL is stretching like the Spiral Line to allow the arm up. The left Back Functional Line is contracting to get that arm up there, working off the extended right

leg-



Musicians

Musicians the world over are among those who deal in intense concentration around an object which cannot change shape. The tendency for the body to shape itself around the solid instrument is very strong in all types of music. So strong in fact, that, during a time when I enjoyed a vogue with London's orchestral musicians in my practice, I could often accurately anticipate the player's instrument before being told, just on the basis of body posture. The accommodation to the flute, or violin (or guitar or saxophone) was so clear that the instru-

ment could almost be 'seen' still shaping the body, even when it was still in its case.

Through cross-fertilization from the world of dance concerning body use, and the proliferation of the Alexander Technique and other forms of re-patterning the use of the self, musicians and their teachers as a class have become more aware of postural and movement issues. Paying attention to self-use issues can certainly affect both the quality of playing and the longevity of the professional player.

Here are a few examples from the classical repertoire, though the same problems and the same principles would apply to rock, jazz, and traditional musicians. In the following examples, we presume right-handed players, as the pictures show. Many of the assessments would obviously switch sides with a left-handed player and instrument.

Cellist (Fig. 10.11)

Although this player demonstrates fairly good body use, we can see that the Superficial Front Line is significantly shortened, pulling the head down toward the pubic bone. This will negatively affect breathing during playing, as well as putting long-term strain into the lower back.

Secondly, the left Lateral Line is shortened, pulling the head to the left, and shortening the distance between the left armpit and the side of the left hip. This pattern is likely, over time, to pull on the core line, the Deep Front Line, and require compensations there that could have negative long-term structural and even physiological effects, as in a fascial shortening of the quadratus lumborum.

The sets of Arm Lines are used differently, of course, between fingering and bowing. In both cases, the arm is held abducted by the coordination of the Superficial and Deep Back Arm Line, and the playing depends on the opposition of the thumb and fingers - the Superficial and Deep Front Arm Lines. The fact that the bowing arm is held further away from the body, both to the front and out to the side, contributes toward the tendency to counterbalance by shortening the left LL. Slightly dropping the right elbow and lifting the left while playing can help to counterbalance this tendency. Pressing into the left foot a bit more than this fellow is could also help center his body relative to the cello.

Violist (Fig. 10.12)

The tendencies of the cellist are magnified in the violist or violinist, owing to the necessity to clamp the instrument between the left shoulder and the left side of the jaw. Although the photograph shows trained good use, the shortening of the left Lateral Line is still clear, and it extends into, and is often sharply present in, the neck. This chronic shortness can sometimes lead to impingement problems, either through soft-tissue tightening or actual stenosis, which can adversely affect the ability of the left hand to finger properly. This problem can be ameliorated, if not solved, by adding an extension to the




Fig. 10.11 A cellist. (From Kingsley and Ganeri 1996. © Phil Starling www.philstarling.co.uk. Reproduced with kind permission.)

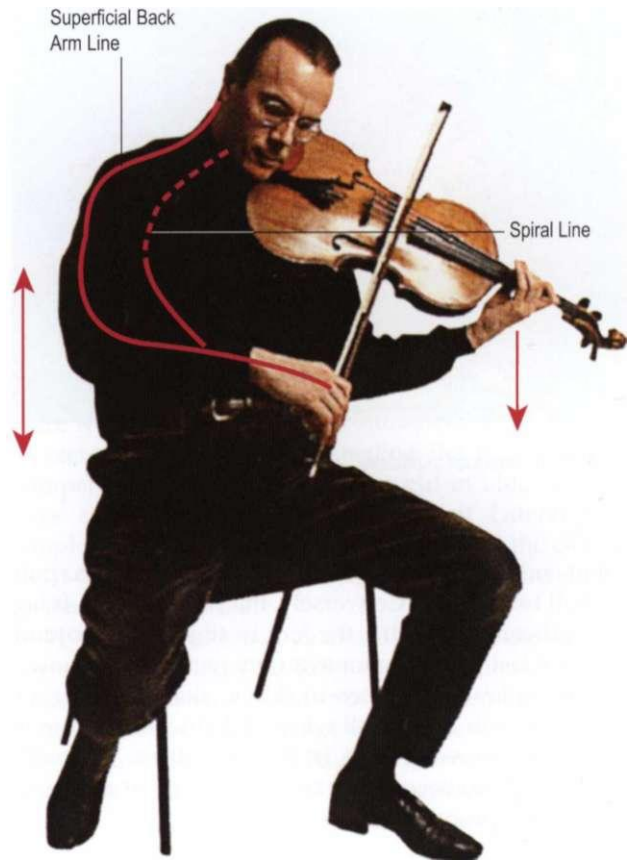


Fig. 10.12 A violist. (From Kingsley and Ganeri 1996. © Phil Starling www.philstarling.co.uk. Reproduced with kind permission.)

chin rest to make the two sides of the neck more equal in length.

In addition, the player of the smaller stringed instruments adds a rotational component, bringing the right shoulder across the body with the right Front Functional Line, while, counter-intuitively, the right Spiral Line brings the left shoulder and ribs closer to the right hip. This combination often leads to shortening of the Superficial Front Line along the front of the torso, and often a widening or weakening of the tissues of the Superficial Back Line.

The siren beauty of the violin's sound have lured many a musician to a host of structural problems because of the ability of the body to bend around the instrument, while the instrument is unable to return the favor. The shortness in this player's SFL causes his pelvis to be posteriorly tilted on the chair, putting the tailbone perilously near the seat. Note how this particular player has broadened his base of support by tucking his right foot back, thus ensuring more movement through his pelvis, despite its bad position. Good sitting will support both better playing and a longer career. Though it is hard to see with the bulky trousers, the anterior lower Spiral Line of the right leg will be strained in this posture, leading sometimes to medial collateral ligament problems for this tucked-back leg.

Flautist (Fig. 10.13)

The flute, like the violin family, requires serious asymmetrical accommodation, but to the opposite side. The right Lateral Line, the right Front Functional Line, and the left Spiral Line are all commonly shortened in flute playing. The Superficial Front Line also commonly shortens, but interestingly, because the head is turned to the left, the right Superficial Front Line, running from the pubic bone up through the sternocleidomastoid, is often more affected than the left part of that line.

The conflict between the lifted right arm (Superficial Back Arm Line) and the left rotated head can make for a confused area in the right shoulder and neck of many flute players, while the left arm, having to reach around the front of the body for the fingering, often puts eccentric strain on the upper left shoulder muscles - particularly the levator scapulae and supraspinatus of the Deep Back Arm Line.

The characteristic cock of the head, the shift of the rib cage toward the left, and the consequent right tilt of the shoulder girdle are dead giveaways of the flute player.

Trumpeter (Fig. 10.14)

Our previous examples all involve an asymmetrical relationship to the instrument; there is of course an

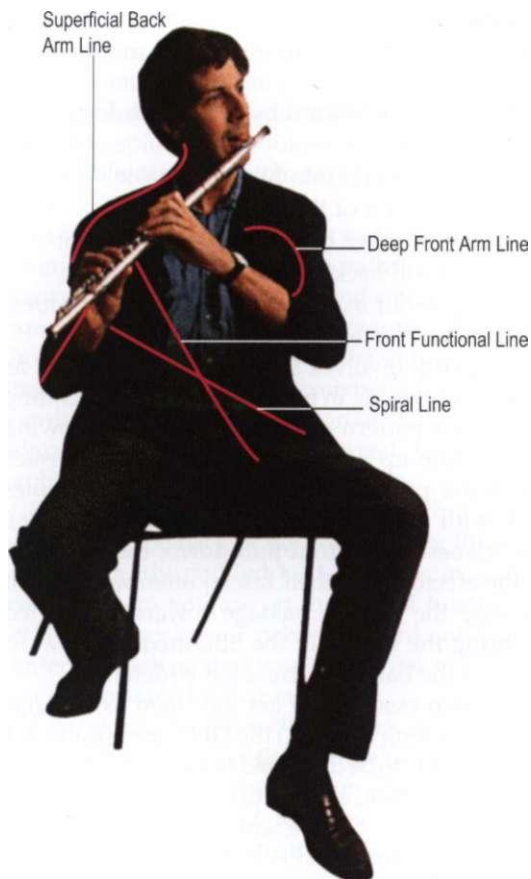

Fig. 10.13 A flautist. (From Kingsley and Ganeri 1996. © Phil Starling www.philstarling.co.uk. Reproduced with kind permission.)



Fig. 10.14 A trumpeter. (From Kingsley and Ganeri 1996. © Phil Starling www.philstarling.co.uk. Reproduced with kind permission.)

entire class of instruments held more or less symmetrically, such as the trumpet, the clarinet, oboe, and the like.

In these cases, any Spiral, Lateral, and Functional Line imbalances are less likely to be due to the instrument, but there is one imbalance common to these players. Since the arms and the instrument must be held in front of the body, the tissues of the Superficial Back Line tend to get short, especially the deep muscles of the spine. Given that the brass or woodwind player is more dependent than others on the breath, this shortness in the back forces the player to concentrate the breath in the front of the lungs and the front of the body. This trumpet player ably demonstrates the common result - the SBL is short, but the Superficial Front Line is long, so that the chest and belly are expended in front.

Despite ill-fitting jeans, this player has fairly good pelvic position but is still chronically extended in the lumbar. He could learn to counterbalance the weight of the trumpet and arms at less cost to his back.

Since approximately 60% of the lungs lie behind the mid-coronal line of the body, it is often beneficial to work with pelvic position for these players, to see whether a different positional support can result in release of some of the muscles of the back, so that more breath can reach the back part of the rib cage and the posterior diaphragm.

Sitting

Sitting, as common as it is in the Western world, is a fraught and dangerous activity (**Fig. 10.15**)! Sitting with the myofascial meridians in balance is a rare event (**Fig. 10.16**). The principles included here are applicable to driving, to basic office ergonomics, to authors at the end of a long season of book writing, and to anyone who must sit for significantly long periods.

Sitting more-or-less eliminates the legs from their support function, leaving the pelvis as the major base of support for the segmented tentpole of the human spine. In sitting, then, we can see the pure interplay among the myofascial meridians in the trunk. From front to back, we all must find balance among the Superficial Front Line, the Deep Front Line, and the Superficial Back Line. With asymmetrical sitting, we can involve the Lateral or Spiral Lines, and we will touch upon that before we leave the subject. Our main concern, however (because it is a ubiquitous postural problem), is with sagittal balance, flexion-extension balance, and thus with the three lines arrayed along the sagittal plane - the Superficial Front Line in front of the ribs, the Deep Front line in front of the spine, and the Superficial Back Line behind the spine.

The proper balance for the spine in sitting approximates the proper balance for standing: the spine in easy,





Fig. 10.15 Serious spinal damage at 0 miles per hour!
(© BackCare. Reproduced with kind permission, www.backcare.org.uk)

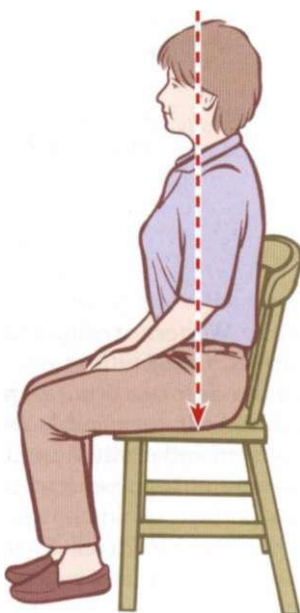


Fig. 10.16 Balanced upright sitting.

full extension, the major body weights of head, chest and pelvis poised one atop the other over the anterior ischial tuberosities, more or less on the same coronal plane as the top of the acetabulum. As we have noted in their previous respective chapters, the SFL generally creates trunk flexion (except at the upper neck), the SBL generally creates extension, and the DFL is capable of creating either at various levels of the spine. Easy alignment in sitting can be created by balancing these three lines, though at first attempt the balance may not seem so 'easy' because of the necessity of moving beyond the neuromuscular and connective tissue habitus.

It is extraordinarily easy, in fact, to fall into a habit of sitting that allows one or more of the following to happen:

1. the head to come forward by flexing the lower cervicals;
2. the upper neck to go into hyperextension;
3. the chest and front of the rib cage to fall;
4. the lumbar to move back and go into flexion;
5. the pelvis to roll back so that the weight goes onto the posterior aspect of the ischial tuberosities (i.e. the pelvis tips toward the tailbone).

This necessarily involves a shortening of the SFL, as well as likely shortening in parts of the DFL. Depending on the particular pattern of sitting displayed, allowing the body to come up may involve lengthening tissues along the trunk portion of the SFL (the fascial planes associated with the rectus abdominis, for example). When the tissues in the front pull down, the tissues of the SBL (the erectors and their fascia) often widen, so it will also ease the client's passage toward supported sitting to bring the tissues of the SBL medially, toward the midline of the back to correct the widening.

It is also often essential to get the client to 'engage' (create more standing tonus in) the DFL. Specifically, the psoas muscle needs to be deployed to steady the lumbar forward to lift the chest, and the deep longus capitis and longus colli muscles on the anterior of the cervical bodies must be employed to keep the cervicals back and counteract the tendency of both the SFL and SBL tissues to hyperextend the upper cervicals, pushing them forward.

The next section describes a spinal integration exercise for sitting that is helpful in bringing all these desirable ends to happen at once, but further work on individual components is often also required. Once balanced sitting is achieved, it needs to be practiced assiduously for some days or weeks until both the nervous system and its minions, the muscles, have adjusted to the change. After this initial period of conscious attention, this kind of sitting will be able to be nearly effortlessly maintained for hours without diminishing breathing or attention, nor creating structural pain.

Integrating the spine in sitting

(The author is grateful to Judith Aston (www.astonenterprises.com) for having conveyed the basis for this integration exercise, but notes that he learned the following sequence from her in 1975. By now it may not accurately represent her current approach, and, memory being what it is, additions or omissions have likely crept in - but she deserves credit for the original idea.)

Nearly everyone's schooling involved the postural adjustment to standard issue desks. The author's experience is echoed by many of his clients: curled into whatever desk fell to the alphabetical roll call, our thoracic spines bent over the desk, and when called upon, we raised only our heads, putting a hyperextended neck over the flexed spine, as in **Figure 10.15**. Desks that are adjustable to the children, like posturally efficient

orthopedic seats, would be wonderful, but are unlikely to arrive soon, given current school budgets. A brief lesson in adjusting yourself to the chair and desk - finding the comfortable seated posture, and using the spine as a whole in moving in a chair - is a cheaper alternative which might divert a lifetime of bad habit.

In such a sedentary culture, so married to its computers and its cars, the lack of generalized training in sitting lies somewhere between silly and sinful. The basis of the exercise is that postural adjustments in sitting are best thought of as adjustments of the entire spine, not any single body segment. The exercise is intended to evoke a spring-like, integrated motion of the spine for postural adjustments in sitting, to correct the 'school desk' problem.

Sit on a stool or forward on a chair, but do not touch or lean into the back of the chair during this exercise. A hard or lightly padded seat is better in order to feel exactly where you are on the ischial tuberosities (ITs). Sit tall, and rock your pelvis forward and back a bit to center yourself so that you are at your tallest, and there is a comfortable lumbar curve.

Very slowly let yourself roll back on your ITs, letting your body respond to the change in posture. Your tailbone comes slowly toward the chair and the lumbar curvature reduces and reverses. Keep the movement slow and small; stay sensitive to your response. If you let the rest of your body respond rather than holding a postural position, you will feel the chest begin to lower in the front as the pelvis tilts posteriorly.

Move back and forth, slowly and with small range of movement, between these two positions, and notice the relationship: rock the pelvis back, the chest falls or flexes a little; rock the pelvis forward, the chest is lifted again without effort.

Continue the movement, turning your attention to your neck: if you do not hold the head steady in relation to the room, but let it go with the rest of the spine, the head will start to incline forward as the neck naturally begins to flex, and the line of sight falls toward the floor. We are so inclined to separate the head from the rest of the body that this is the most difficult connection for most of us to get. We are accustomed to keeping our head oriented to our right-angled rooms, not letting it respond to the inner whispering of the rest of the spine. Persist and the feeling will arise.

Move from upright sitting to full flexion of the spine. At full flexion, the tailbone is close to the stool, your sternum is closer to your pubic bone, and you are looking into your lap (Fig. 10.17). Making sure you initiate from the pelvis, reverse the movement, letting the pelvis move the lumbar, which in turn move the thorax, which in turn extends the neck and lifts the head. Move through this sequence a few times until the spring of the spine feels easy with this movement.

It is important that you not let the chest fall behind the pelvis as you go into this movement (Fig. 10.18). The center of gravity of the chest and head taken together stay over the pelvis, even in full flexion. If, as you move into flexion, your breathing and organs feel cramped for

space, you are perhaps letting the weight of the upper body fall behind the pelvis. Check by doing the exercise beside a mirror.

Now, continue the movement from flexion to upright, and then through upright toward hyperextension, still initiating from the pelvis. Now the pubic bone moves toward the chair seat, the lumbar curve is exaggerated, and the sternum lifts. Be careful to let the angle of the head follow the dictates of the rest of the spine; do not let it lead the movement as usual (Fig. 10.19). If you let the head and neck coordinate with the rest of the spine, the neck will not reach full hyperextension in this movement; there will be some ability to hyperextend 'left over' (Fig. 10.20).

Let the body return to upright, passing through neutral toward flexion, and allow the spine to move through its entire range from flexion to hyperextension and back again, until the full movement is familiar. Initiate the movement at all times from the pelvis, feeling the slow shift of the weight from the back to the front of the ITs, stopping and moving more slowly if the head rebels and tries to take over the movement. Although children and impatient adults will want to run through the full range quickly, slower movement is better in getting the initial completeness into the spinal movement, and in integrating it into everyday activity.

Once the integrated movement is familiar, come from the hyperextended end of the movement with your eyes open, and stop when the eyes reach horizontal (see Fig. 10.16). Feel the position the rest of your body has taken. Feel the ease in your breathing. Perhaps you have found a new sitting position for yourself. Check it by moving on down into flexion, and then back up until your eyes are level, being careful to let the eyes be passive, while allowing the initiation to come from the pelvis. The more you practice this exercise, the easier it becomes to make this new position your own.

By these lights, we could hope that from here on in any change of head position involves a change of the whole integrated spring of the spine to support the head in the new position. To look down at your desk, or this book, or your knitting, let your pelvis roll back a bit to automatically and coherently carry your chest and eyes to the task. To look up, let the pelvis roll forward to biomechanically support the lifting of the body and the eyes up. To follow that bird above you, let the pelvis roll forward even more.

It is quite easy to add rotation to this pure flexion and extension by pushing on one foot and letting the body follow. To look up and to the left, let the pelvis roll forward as you increase the pressure on your right foot. To look down and left, roll your pelvis back while pressing more on the left foot (and letting the hips respond). Move in this way for a while and it will become reflexive, and you will engender a habit that will delight your spine for the rest of your life.

In this model, sitting up straight like a Victorian and dropping your head to read is just as silly as flexing your back and hyperextending your neck to look at the teacher. Both of these movements involve 'breaking' the

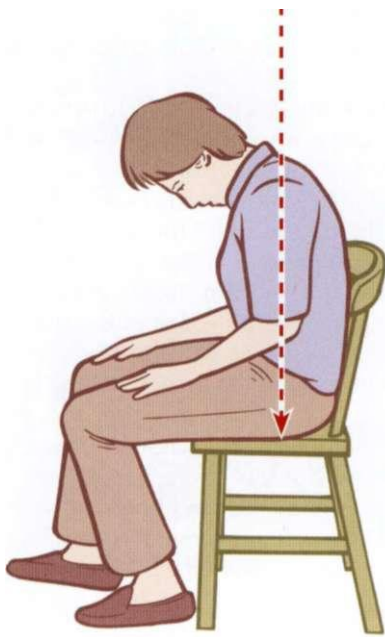

Fig. 10.17 Full-flexion phase.

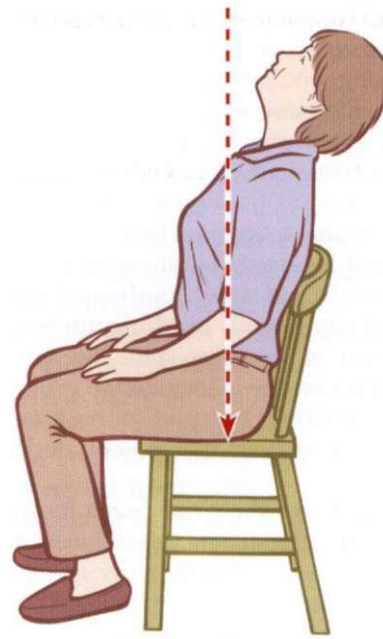


Fig. 10.19 Improper hyperextension phase with head hyperextended beyond the rest of the spine.

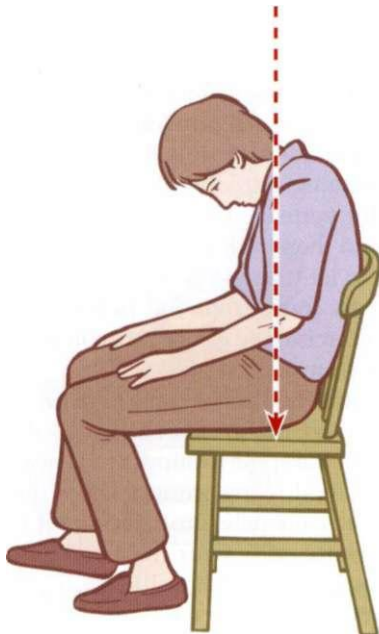

Fig. 10.18 Improper full flexion pose with chest falling behind pelvis.

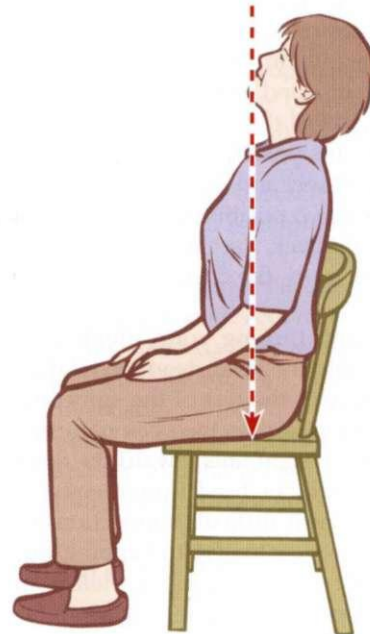

Fig. 10.20 Proper hyperextension phase.

integrity of the spine, which should act at all times like a unified spring, not like a Christmas 'slinky' in February.

Since sitting in this way projects a natural authority as well as ease, you may find that people in a group are naturally turning to you to see if you will speak. If this is uncomfortable, or not what you want to do, it is possible to let your back find the chair back while still maintaining the support from the pelvis, rather than

letting the chest fall off the pelvis, sitting on the tailbone, and assuming a subservient sitting posture.

If you guide clients into these movements, be sure they are initiating from the pelvis. A hand on their lower back will usually tell you where the movement is coming from. Sometimes another hand on the head is necessary to keep the head engaged with the rest of the spine. Be sure to let the client perform the full motion entirely solo several times before the session ends, and reinforce the

idea for several sessions running. An integrated spine is your (and their) reward.

Walking

As stated in Chapter 2, Anatomy Trains is not especially useful as a way to parse movement as a whole. Nevertheless, an analysis of simple walking may prove useful - although walking is of course not so simple.

Taking a step forward, although it may be initiated from the hip flexors of the DFL, such as the psoas and iliacus, or by release of the extensors, certainly involves the flexion at the hip, extension of the knee, and dorsiflexion at the ankle and metatarsophalangeal (ball of the foot) joints necessary to walking forward, all of which are created by the shortening of the myofascia of the SFL. The muscles may fire or engage in a sequence, but the leg portion of the SFL is also engaged as a fascial whole throughout the 'reaching forward', swing phase.

As the leg travels forward, its entire myofascia prepares to receive the weight of the body and the ground reaction. Muscles tense within the fascial web to handle the precise amount of force expected. One has only to step from one room into another in the dark with an unexpected drop or rise of no more than a couple of inches to realize how little is required to upset this preparation, and how much shock is sent through the unprepared musculoskeletal system when it is surprised in this way.

Once the heel strikes and the roll over the foot begins, the SBL myofascia takes over as the back of the leg engages into hip extension and plantarflexion. Again, no matter what the firing sequence of the muscles, the entire lower section of the SBL is engaged fascially from lower back to toes throughout this phase. During all these phases, movement should be tracking through the four 'hinges' of the leg in more or less a straightforward fashion. The hip, of course, does some rotation during walking, and the weight falls from lateral to medial across the metatarsophalangeal joint, but in general, differences in direction among these joints will result in joint wear, ligamentous overstrain, and myofascial imbalance (Fig. 10.21).

The Lateral Line's abductors, ITT, and lateral compartment of the lower leg provide stability that prevents the hip falling inward (adduction), while the adductor group and the other tissues of the DFL assist the flexion/extension motions and provide stability from the inner arch up the inside of the leg to the medial side of the hip joint, preventing excess or unwanted rotation of the hip.

It is important to understand that the pendulum of the leg starts at the 12th rib and 12th thoracic vertebra, with the upper reaches of the psoas and quadratus lumborum. With this concept, the movements of the innominate bones in walking become understandable, combining a simultaneous pelvic rotation around the vertical axis in the horizontal plane, a lifting (side shift or side bend) of each innominate in the coronal plane around the A-P axis, and a hemi-pelvic tilt in the sagittal

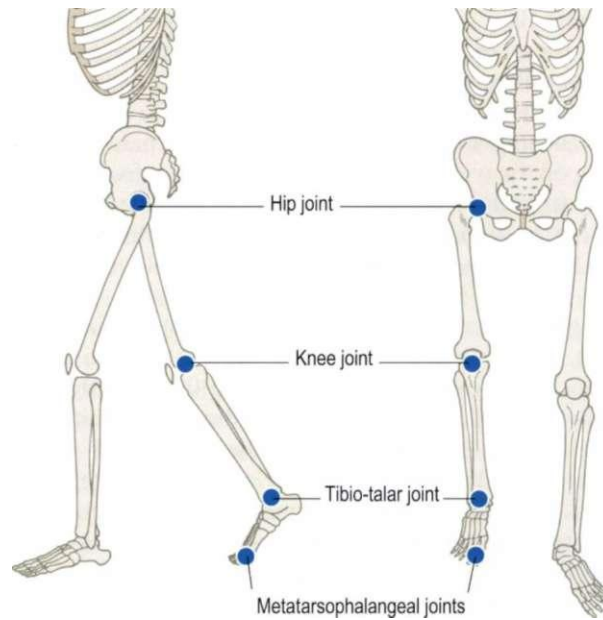


Fig. 10.21 Each step involves movement through four 'hinges' of the leg, around which the soft tissue must be balanced for joint longevity and efficient walking.

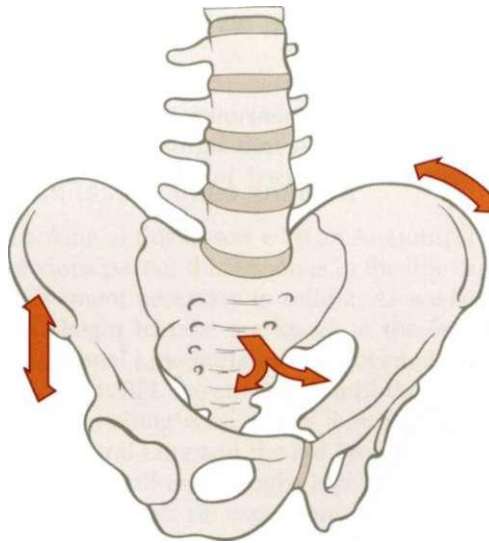


Fig. 10.22 The pelvis has movement in all three Euclidian planes in proper walking - side-to-side around the A-P axis, rotating around the vertical axis, and each innominate tilts sagittally around the left-right axis. Too little movement in one plane often results in excessive movement in another plane.

plane around the left-right axis in which the tilt of the innominate mirrors the tilt of the femur in walking (Fig. 10.22). With this in mind, one can see that for the pelvis, proper initiation of walking is a DFL coordination, whereas the line that has to move through the most range and provide the most adjustment and stability is the Lateral Line.

Different patterns of walking mix differing amounts of each of these three axial motions. Lack of one motion will usually require an increase in one or more of the



others in compensation. Learning how to read these motions in the walking pattern of your clients will make your work more efficient.

BodyReading 101J

In the upper body, the Lateral Lines alternate in shortening on the weighted side to keep the torso from falling away from the weighted leg. The common contralateral pattern of walking also involves the Functional Lines and Spiral Lines bringing the right shoulder and rib cage forward to counterbalance the left leg when it swings forward and vice versa (Fig. 10.23). Beneath this outer, appendicularly oriented movement, the torso winds like a watch spring, countering the twist that the metronome of the legs produces in the pelvis. This rotational energy, working through the intercostals in the ribs and the abdominal obliques, is created and released with each step. When this small inner movement is stopped for any reason, the movement is exported outward and can be seen in excessive motion of the arms in walking.

Lack of coordination or excessive myofascial binding in any of these tissues sets up characteristic patterns of walking, some of which are simply personal and idiosyncratic, while others are downright inefficient, and can lead to joint or myofascial stiffness problems.

An 'Awareness Through Movement' lesson



The short and simple movement exercise in the next section ('Rolling over') is inspired by the work of Dr Moshe Feldenkrais, who devised hundreds of move-

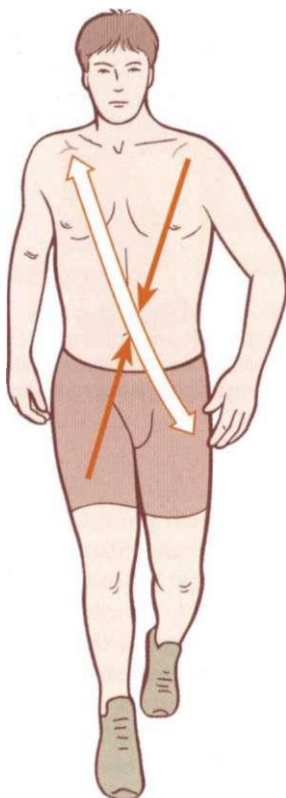

Fig. 10.23 The winding and unwinding of the torso in walking involves the Functional Lines (pictured) in alternating contraction, and the Spiral Lines and Lateral Lines as well.

ment explorations he termed 'Awareness Through Movement' (ATM) lessons. The specifics of the lesson and the analysis of the myofascial meridians related to the lesson are my own interpretation, but the general approach and the principles are definitely drawn from the Feldenkrais work.

This particular lesson was chosen for its simplicity and for its application to a number of common somatic restrictions. Even more importantly, it is an example of primal movement, representative of developmental movements (see next section) that are primary building blocks of our daily movement repertoire. It is the contention of many movement therapists that missing or eliding over any of the phases of developmental movement can predispose the subject to structural or movement difficulties. While such a claim is hard to prove, I have found that use of this and other primary developmental movements has been tremendously useful in discovering underlying dysfunctional patterns which lead to surface difficulty or tendency toward specific injury.

Rolling over

The following lesson is absolutely designed to be experienced; just reading it over will not convey its essence. You can read the lesson, then follow it on the floor, or have someone read it to you, or record the text and play it back to yourself as you move. Each suggested movement should be repeated again and again, gently and slowly, exploring the feelings they create in every part of the body. Many such lessons (and far more sophisticated ones) are available on tape and in print from a number of sources in the world of Feldenkrais ATM teachers (wivzo.feldenkraisresources.com, www.feldenkrais.com, www.feldenkraisinstitute.org).

Lie on your back with your knees up, so your feet are standing on the floor (Fig. 10.24). Begin by bringing both knees toward the floor to your right, and then come back to where you started. Do this a number of times, staying within the bounds of easy motion, not trying to stretch or strain. Let the knees slide past each other so that both feet stay on the floor, although eventually the left foot may leave the floor. You will feel the weight shifting over to the side of the right hip as you move, and coming back to center as you bring your knees back up.

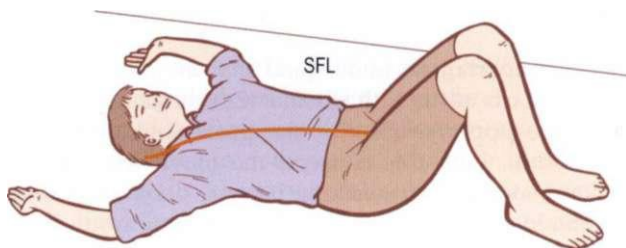


Fig. 10.24 Begin by lying comfortably on your back and letting your knees go to the right.

What is the response further up your body? Do you feel the ribs lifting off the floor on the left side, or feel some response in the shoulder girdle? Rest a moment.

Put your arms beside or above your head, palms up. Find the easiest comfortable place, again without stress or stretch. If this is too difficult or stressful, put your hands on your chest and adapt the next set of instructions to your comfort. Begin once more to let your knees fall to the right, but this time add another movement: each time you move your knees to the right, extend your right hand or elbow further up over your head. It does not have to go very far; the important part is to coordinate it with the knees, so that the arm is extended as the knees go right, and the arm comes back down as the knees return to upright.

As you repeat this motion, begin to extend it so that the ribs and your head follow the knees. Let the arm extend out more and you will find that you will eventually roll onto your side. Do this motion a number of times, moving from your back to your side and back again, coordinating the arm and the knees. If it is comfortable, let your head roll onto your right arm as you come to side-lying.

As you do this motion, you can let your left arm cross to the right, either across your chest or over your head. Let it arrive on the floor in front of your face. So now you are lying on your side, with your knees up (hips flexed) and your left arm in front of you (Fig. 10.25). Now begin to take your knees and elbows away from each other and then back toward each other. Most bodies will respond to this movement in such a way that as the knees and elbows move apart from each other, you will tend to go from your side to your belly. As the knees and elbows approach each other, you will tend to move toward lying once more on your side, and eventually your back. Experiment with this movement, especially with extending your limbs and trunk until you are lying on your belly (Fig. 10.26). Be aware of the tendency to fall toward the belly, and see if you can relax the muscles of your torso enough so that you can ease toward the floor without falling. Can you reverse the motion at any time, change your mind and go back to the side? Can you move from the back to the side to the belly by just moving your arms and knees?

Now that you are lying on your belly, turn your head so your face is to your right. Bring your feet up so that your knees are bent, and begin to take your feet over to

your left, as if to take the outside edge of your left foot to the ground. As before, let your legs slide on each other, so that your right knee comes off the ground only toward the end of the movement. Make sure the movement is comfortable, and repeat it several times until it is easy, even elegant.

As you do the movement, you may find that once again, your body is following the movement, that the right side of the ribs is beginning to lift up to follow the hips. Your head will probably be comfortable rolling onto your extended left arm. As you roll onto your left side, bring your knees and elbows together once again and you will find it easy to roll onto your back. Again, do this movement - from the belly over the left side to the back - several times until it feels easy and coordinated.

At this point you have completed a 360° roll of the body. If you have room, you can continue going in the direction you have started. If not, you can go back the way you came. Notice whether going one way is easier than the other. Practice rolling in both directions until it is easy and effortless. Do it more slowly rather than more quickly - doing it quickly is not an indication of movement mastery. If you can do it slowly, without falling or skipping over places, and without throwing yourself through the movement via momentum, then you can say you have mastered the movement.

As you do this movement in a coordinated way, you can feel the accordion-like folding and unfolding of the myofascial meridian lines.

ATM Lesson lines analysis

Looking at this lesson with an Anatomy Trains lens, the obvious part of this lesson is in the line doing the spiral movement necessary to rolling. As we lie on our backs and begin to take the knees to the left, the left Back Functional Line initiates the movement, and the left LL and right BFL are stretched until they begin to pull the body on along with it, like a string around a top. The right Spiral Line and the left Front Functional Line also begin to pull as the right hip bone turns to the right, pulling the left rib cage along with it, but the primary line of pull is through the BFL (Fig 10.27). The left FFL continues the pull from side to belly, and the right BFL completes the pull onto side and back, all coordinated with the two Spiral Lines.

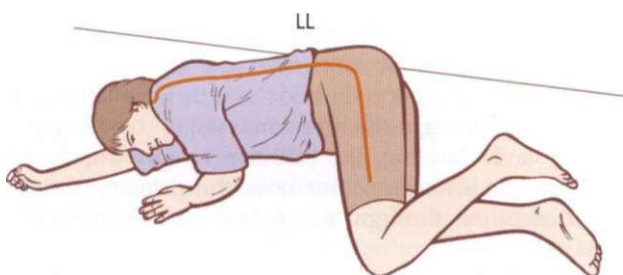


Fig. 10.25 When you reach side-lying, you can continue by taking your knees and elbows away from each other.

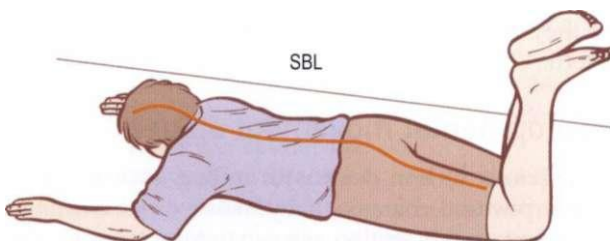


Fig. 10.26 After you reach the belly-lying position, you can continue on around the roll by taking your knees to the left and letting the rest of your body follow.

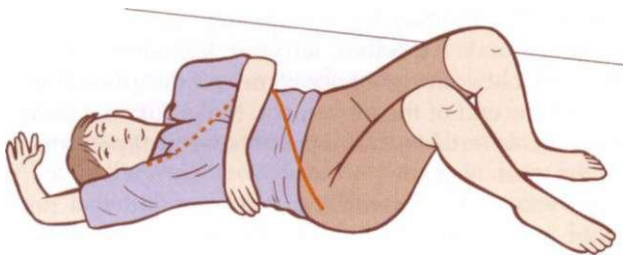


Fig. 10.27 The right Spiral Line is the primary rotator of the trunk, assisted in this movement by the left Front Functional Line bringing the left arm toward the right hip.

Looking into the lesson a little more subtly, we notice that in each phase of the movement, the cardinal lines open to the floor. When we are lying on the back, the Superficial Back Line opens and the Superficial Front Line subtly closes or shortens (see Fig. 10.24). We move to the right side by opening the right Lateral Line, whether we think of it that way or not. By the time we are lying on our right side, the right LL is more open overall, and the left LL more closed (not necessarily contracted, perhaps just passively short - see Fig. 10.25).

As we roll from the right side onto the front the SFL opens and the SBL closes (see Fig. 10.26). We see it in babies, rocking on their bellies to strengthen the SBL, and we can feel it in ourselves, even if it is not so marked in the adult body. To continue onto the left side, we must open the left LL and close the right. Once the movement is mastered and we are rolling freely, we can feel the lines opening to the floor as we approach them, and we can feel (as the student) or see (as the teacher or practitioner) where the body is holding or restricted in its ability to open, thus restricting other places in their ability to move. It is this opening to the floor that is really the key to an easy accomplishment of this primal movement, not the spiral pulls that initiate the movement (which can in any case vary widely in their point of initiation). Looking for where the opening of the cardinal lines is blocked and working with those restrictions will very often bring more ease into this sequence than working with the Functional or Spiral Lines, though such restrictions are of course possible also.

The take-away point here is that subtle and underlying neurologic accommodations in the meridians as a whole are keys to adaptive movement. These underlying adjustments to movement are fundamental, and established in our earliest, pre-verbal experiments with our bodies. They are harder to see than some of the obvious movements we looked at earlier in this chapter, but they are often key to unlocking and resolving a pattern.



Developmental movement stages

The previous section dealt with rolling over, which is the first postural change a baby makes on its own, but not the last. In this section, we expand our view to take in the whole progression from lying to standing that each of us must make if we are to successfully negotiate standing up and walking through this world. Running

yourself or your clients through this sequence is a marvelous self-help exercise that calms the mind and organizes the body through deep remembering of these primal and foundational movements (DVD ref: Functional Lines 50:40-1:05:27).

Almost all of us, even the most young or infirm, can easily lie on our backs, since the heavy body weights (head, chest, pelvis, and, if so desired, arms and legs, totaling seven) are all supported by the floor in this position (Fig. 10.28). As suggested in the last section, in this position, the SBL tends to relax into the floor, while the SFL tends to carry more tone.

Through experimentation (chiefly through trying to follow Mom with his eyes), a baby will eventually turn from back to side to belly, where the SBL gains more tone and the SFL snuggles to the floor (Fig. 10.29). In this position, the baby has supported one of the large weights - the head - up in the air, giving the eyes greater range and allowing greater freedom in creeping around. The muscles of the SBL strengthen in lifting up the head, and the cervical curve is strengthened and set into place.

By looking over his shoulder (on the side of the cocked leg - babies almost always have one leg flexed and the other extended) the baby employs the helical lines (Spiral, Functional, and Lateral) to twist around to sitting (Fig. 10.30). The weight must shift in the pelvis from the ASIS to the ischial tuberosity, which happens by the weight rolling out over the greater trochanter and onto the bottom of the pelvis. Sitting on the floor requires the same balance among the three sagittal lines as was described above in the section on sitting in a chair - the SBL, SFL, and DFL. In sitting, the child has managed to raise and support two of the body's heavy masses - the head and the chest - off the ground. The child's freedom of movement and reach of both hands and eyes are increased (and you are busy child-proofing the house).

The next developmental stage involves the baby reaching around and forward to pass onto hands and knees, into crawling (Fig. 10.31). Once this stage is reached, it requires yet more strength from the cardinal lines, and yet more coordination between the limbs via the Functional Lines. Greater strength in the SFL is also necessary to keep the trunk aloft and not allow the lumbar to fall into extreme lordosis. Notice that the baby has now managed to get three of the heavy weights into the air: head, chest, and pelvis. Now the question becomes - how do we get all this centered over the small base of support the feet provide?

The next stage, usually accomplished with the help of furniture or a parental leg, involves coming to kneeling, with one foot on the floor (Fig. 10.32). At this stage, all the leg lines must strengthen and develop in their coordination to support the body's entire weight through the hips. Through the previous stages of creeping, sitting, and crawling, the primary weight was borne through the shoulders, but now the primary weight must stabilize through the pelvis and through the hips.

When the legs are strong enough, the child spirals up from kneeling to precarious standing, which usually manifests as walking (Fig. 10.33). Although some parents

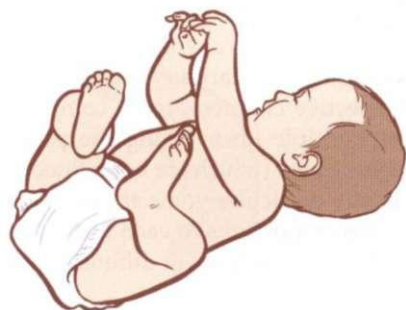

Fig. 10.28



Fig. 10.29

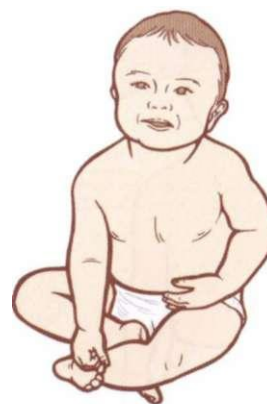

Fig. 10.30




Fig. 10.31

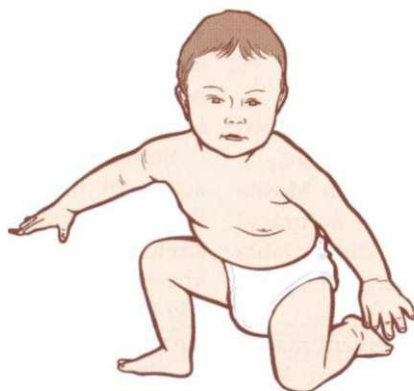


Fig. 10.32

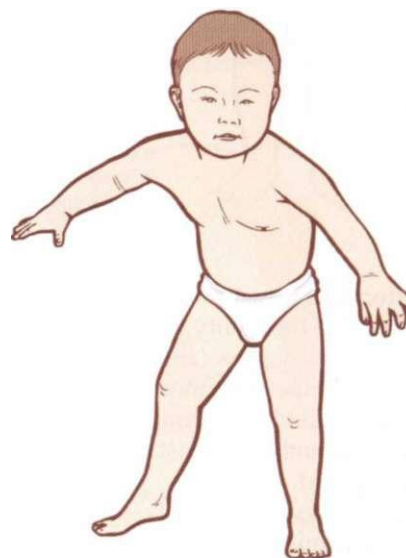

Fig. 10.33

Fig. 10.28 Lying on the back, a baby's first postural preference, supports all three axial weights - head, chest, and pelvis - and all four appendicular weights - arms and legs - when the baby relaxes them.

Fig. 10.29 Lying on the belly, a baby's first real postural change, achieves support for the head, allowing greater movement, and sets the stage for its first automotivation, creeping.

Fig. 10.30 Sitting supports two of the heavy axial weights above the pelvis, and allows the baby more manipulative freedom.

Fig. 10.31 Crawling liberates the last of the axial weights - the pelvis - from the floor, but involves support from all four, or at least three of the four, appendicular limbs.

Fig. 10.32 The increased precision in balance involved in kneeling can only be built on the skills in the previous stages.

Fig. 10.33 As the baby gets on top of the second foot, the seemingly precarious act of walking provides a momentum that makes this motion easier to maintain at first than the really precarious act of standing.

would disagree and development is malleable and differs among individuals, most children can walk before they can comfortably stand, as the momentum is easier to maintain than the stasis (as in riding a bike). In the walking or running position, the body is supported primarily on one foot, with a part of the other - the heel or the ball of the foot - providing some balance as the child moves.

True standing - and an approach to the balance of the lines approaching **Figure 10.1** - requires all this developmental movement, which has strengthened and aligned bones, developed joints, and brought fascial strength as well as muscular strength and coordination to these longitudinal lines of stability and support, all in the service of easy, balanced standing and marvelously efficient walking (**Fig. 10.34**).

All human activities rest in the cradle of this basic sequencing of perception and movement that leads the baby from a passive lying on the back to active participation in the world. Since you cannot talk a baby in and out of clothes, car seats, etc. during that first year, a great deal of what is communicated to the baby during this sequence is conveyed kinesthetically. This suggests that anyone who interacts with babies should be learning basic handling skills that could do a lot for alleviating movement problems in later life.

All parents and all therapists would benefit from being familiar with both this sequence, and with understanding the consequences when this sequence is interrupted or diverted. Children and this process are resilient, so even badly handled children arrive at standing and walking, but missing pieces can nevertheless

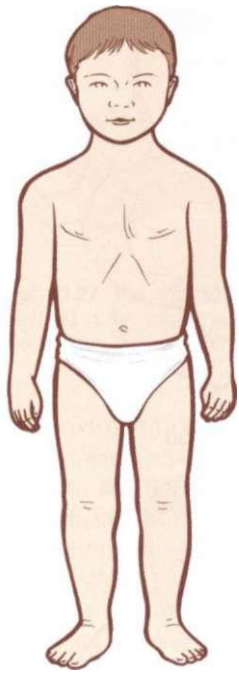


Fig. 10.34 The act of standing - human plantigrade posture - is the end-product of many stages of evolution, both phylogenetically and ontogenetically.

affect movement in profound ways, including perception, and the ability to respond to certain situations.

The story goes (and I got this verbally from Moshe Feldenkrais, so cannot otherwise attest to its accuracy) that Moshe Feldenkrais was sat down at a dinner table next to anthropologist extraordinaire Margaret Mead. Mead said:

'Oh, yes, Feldenkrais - you're the movement man. I have a question I've been meaning to ask you: Why can't the Balinese men learn to hop? They are good dancers, and otherwise coordinated, but I cannot teach them to hop from one leg to the other.'

'It sounds as if they are missing a stage of creeping', said Feldenkrais.

'Of course', said Mead, smacking her forehead, 'The Balinese don't let their babies touch the ground for the first "rice year" (seven months), so they never get to creep on their bellies.'

Watch a baby in the initial stages of motivating its belly across the floor at about six months or so, and you will see where the underlying movement for transferring the weight from foot to foot, and thus hopping, lies. The baby thrusts one foot as the other retracts, building the coordination that will later allow the transfer of the weight of the upper torso to each leg in turn - running, in Anatomy Trains terms, all the trunk lines into one set of leg lines, and then the other, alternating in turn. Without this stage grooved into their brains, the Balinese men could still walk, run, and dance, but not directly and specifically hop from one foot to the other.

The practiced eye can see into movement to determine which lines are underperforming, and which stages of development might have been missed or skewed. Easy familiarity with the patterns of changing posture in movement as outlined above are a prerequisite for this kind of seeing.

Some examples from Asian Somatics

Yoga asana

Although we have used several yoga poses to illustrate stretching or engaging the various individual lines in each of their respective chapters, more complex poses engage parts of multiple lines. Using the simple line drawings we include here (which are not refined enough to be accurate in any particular yogic approach), we can assign some asanas or postures to each individual line. These poses are named variously in different traditions; the names here are in common use.

Stretching of the Superficial Front Line (and consequent contraction along the Superficial Back Line) can be seen in the reach that begins the Sun Salutation pose (**Fig. 10.35A**), or the basic warrior poses such as the Crescent Moon (**Fig. 10.35B**). The Bridge pose is a basic regulated stretch for the SFL (**Fig. 10.35C**), as is the more advanced Bow pose (**Fig. 10.35D**). The Camel also provides a strong stretch for the entire SFL (**Fig. 10.35E**). The Wheel, or backbend, pictured on page 99 (**Fig. 4.7A**), is a strong stretch for the SFL. Many of these poses are nearly the same somatic configuration, simply with different orientations to gravity.

Stretching the Superficial Back Line is the primary action of the Downward Dog (**Fig. 10.36A**) and the Forward Bend poses (**Fig. 10.36B**). The Child's pose stretches the upper part of the SBL while allowing the knees to flex, which eases the stretch on the lower part (**Fig 10.36C**). The Shoulder Stand and Plow poses are also strong stretches for the SBL (**see Fig. 4.7B**, p. 99).

Although the Boat pose (**Fig. 10.36O**) is clearly a stretch to the SBL (as if the Downward Dog were turned upside down) and a muscle strength challenge for the SFL across the front of the legs and torso, this pose is actually a core strengthening pose which reaches into the psoas and other hip flexors of the Deep Front Line.

The Lateral Line is stretched by the Gate pose shown in **Figure 10.37A** - showing a stretch of the left side - as well as the Triangle pose (see **Fig. 4.17B**, p. 105 or **Fig. 10.41**). We can see how the Gate would also contact the lower SBL on the outstretched leg. The LL is also strengthened (a good thing for what is primarily a stabilizing line) by holding the body straight supported on one hand as in the Side Dog pose of **Figure 10.37B**, where the Lateral Line closest to the floor prevents the body from collapsing from ankle to ear. The Half Moon pose (not pictured) requires work from the Lateral Line closest to the ceiling.

The upper Spiral Line is stretched by the simple Sage pose and any of a number of complex twisting poses (**Fig 10.38A** and see also **Fig. 6.22**, p.142). Such poses strengthen one side of the Spiral Line while challenging its complement. Of course, such poses also offer challenges to the pelvic and spinal core, as well as the more superficial Spiral and Functional Lines. The Pigeon pose challenges the deep lateral rotators (a branch of the Deep Front Line) and the lower outer Spiral Line (biceps femoris and the peroneals - **Fig. 10.38B**). The anterior lower Spiral Line (tensor fasciae latae and tibialis anterior) can be stretched in the lunges and deep warrior

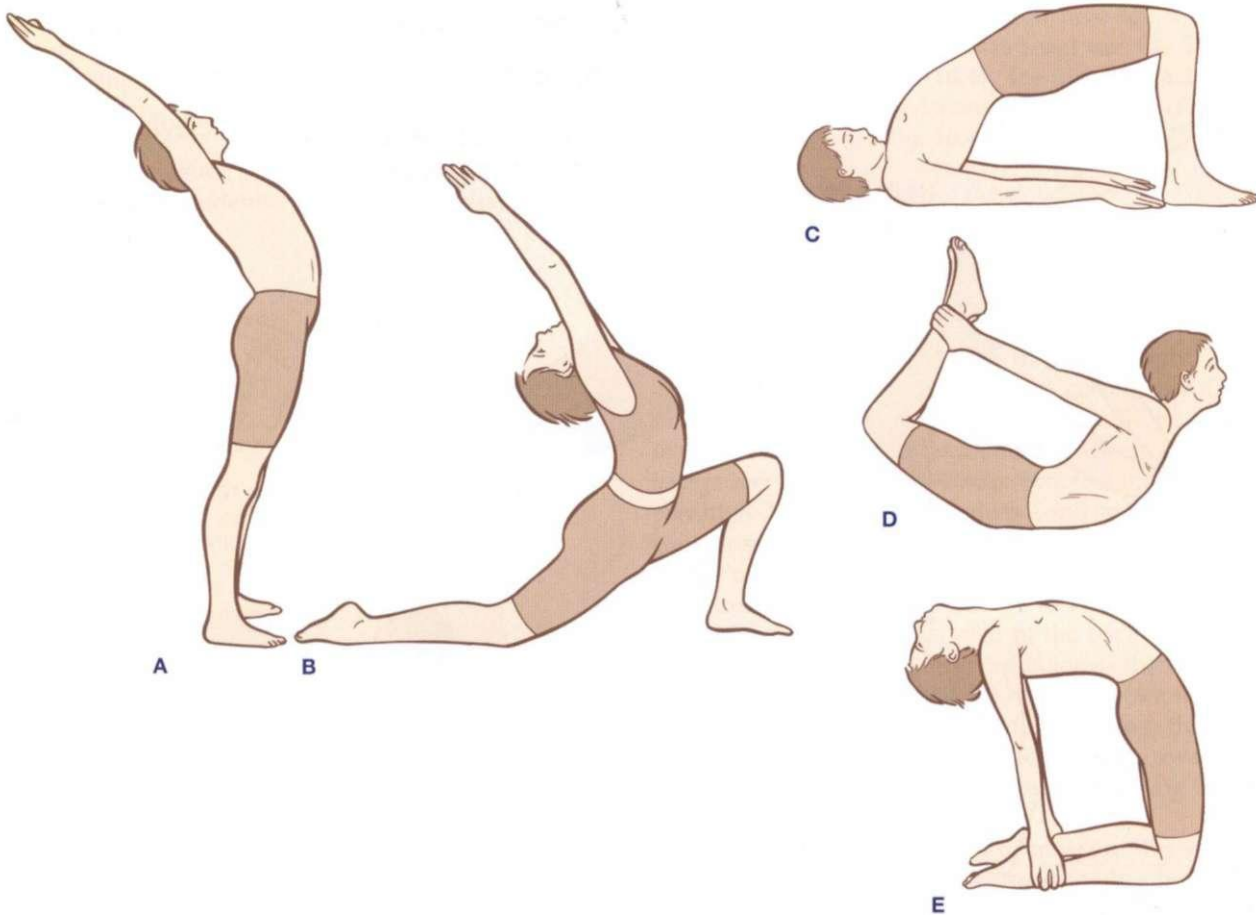


Fig. 10.35 Superficial Front Line stretches. In each of the following illustrations, each pose may stretch or challenge multiple muscles or lines, or have other intentions than mere stretch. We include these here for a simplified understanding of how the continual fascia within a line continuity may be stretched, as well as the individual structures.

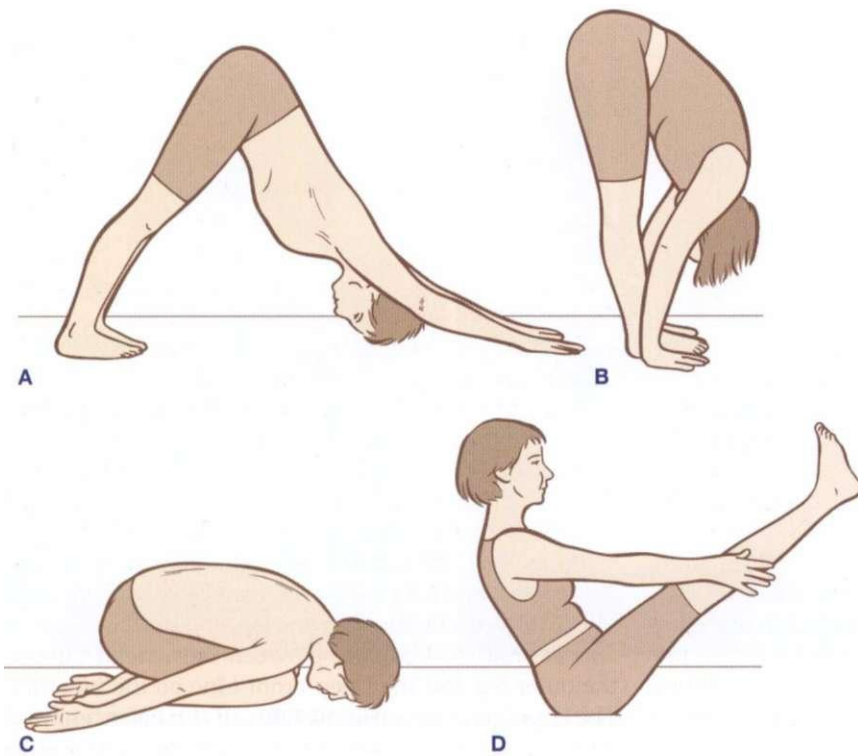


Fig. 10.36 Primary Superficial Back Line stretches.

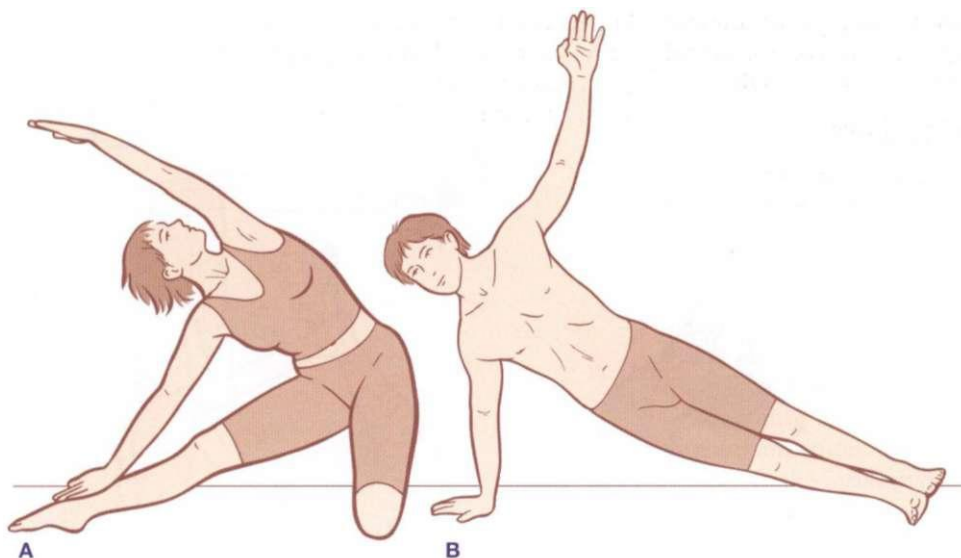


Fig. 10.37 A Lateral Line stretch, and a Lateral Line strengthening exercise.

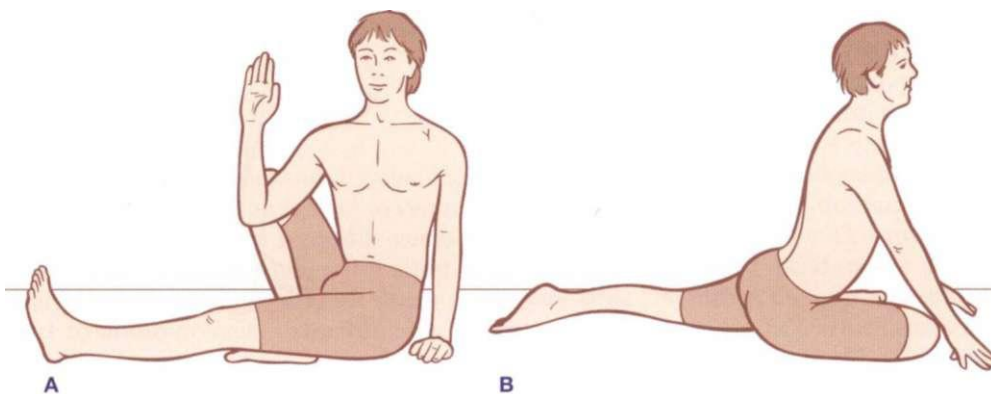


Fig. 10.38 Spiral Line stretches.

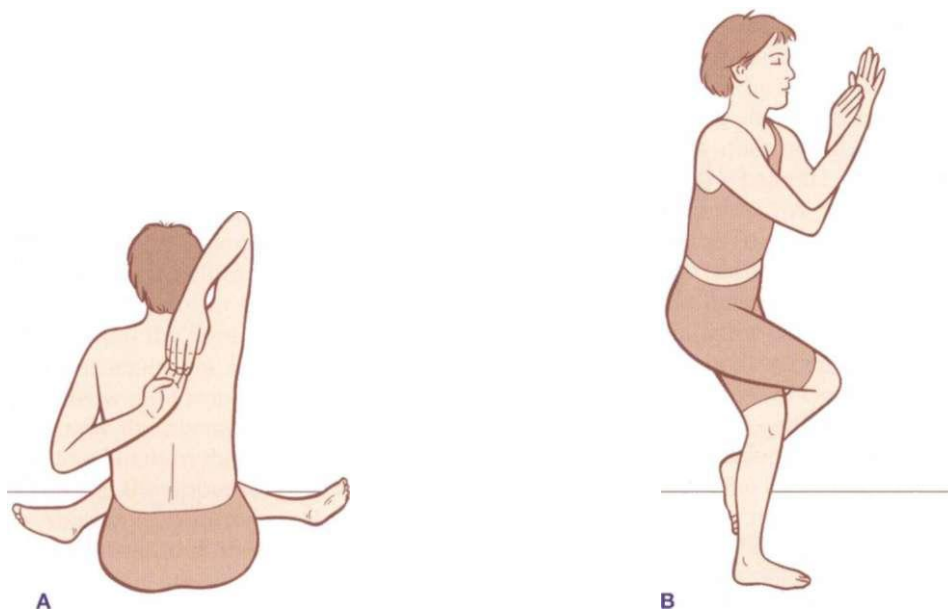


Fig. 10.39 Arm Line stretches.

poses by turning the stretched back foot out (laterally rotating the leg - see **Fig. 10.35B** and **Fig. 9.29**, p. 192).

All the Arm Lines are challenged by the shoulder-and-arm focused poses. The Cow pose challenges primarily the Superficial Front and Back Arm Lines, whereas the Eagle pose challenges primarily the Deep Front and Back Arm Lines (**Fig. 10.39A and B**).

Poses such as the Tree (**Fig. 10.40A**) are primarily balance-promoting poses, passing all the lines from the upper torso down through one leg, and promoting tonal and neurological balance between the Lateral Line on the outer leg and the Deep Front Line on the inner leg. The Headstand pose (**Fig. 10.40B**) calls for balance among all the torso lines - SBL, SFL, LLs, and SPLs, as well as

the DFL and Functional Lines, while using the arms and shoulders as temporary 'legs', i.e. as compressional support for much of the rest of the body's weight.

A Lines analysis for yoga teachers

A lines analysis such as yoga teachers might use in their assessments of students' progress and where the next

best challenge might be is offered here for two more complex poses. The two poses used are the Triangle pose (*Trikanasana* - Fig. 10.41, see also Fig. 6.22A and B, p. 142) and Revolved Lateral Angle pose (*Parsvavrikasana* - see Fig. 10.42).

Triangle pose (Fig. 10.41)

Compare the position in Figure 10.41 A to those in 10.41B and 10.41C. The woman in Figure 10.41 A is an experienced and certified teacher. The older gentleman in 10.41B has been practicing for some time. The fellow in 10.41C is a new student. Moving from left to right, we see a progressive inability to lengthen certain myofascial meridians. Although this progression could be defined in terms of individual muscles (and has been, www.bandhayoga.com or www.yogaanatomy.com), it is more usefully considered in terms of these lines - and such an analysis runs closer to the experience of the yoga practitioner.

The most obvious difference is in the extensibility of the models' left Lateral Line. In 10.41 A, the LL opens with ease from the lateral arch of the back foot up the outside of the leg to the iliac crest, across the waist and ribs to the neck. Looking at the other two (B and C), we see the tension along the outside of the leg, the reluctance of the abductors to let the pelvis move away from the femur and the resultant difficulty in getting the ribs to move away from the pelvis.

Although the obvious way to measure this is in the angle the trunk makes to the floor, another interesting way to look at this factor is from the opposite side. Look at the space between the *right* arm and the right hip in each photo. The contracture in the lower left LL in 10.41 B and C creates the need for contraction along the upper right LL. In A, the right LL of the trunk is allowed to

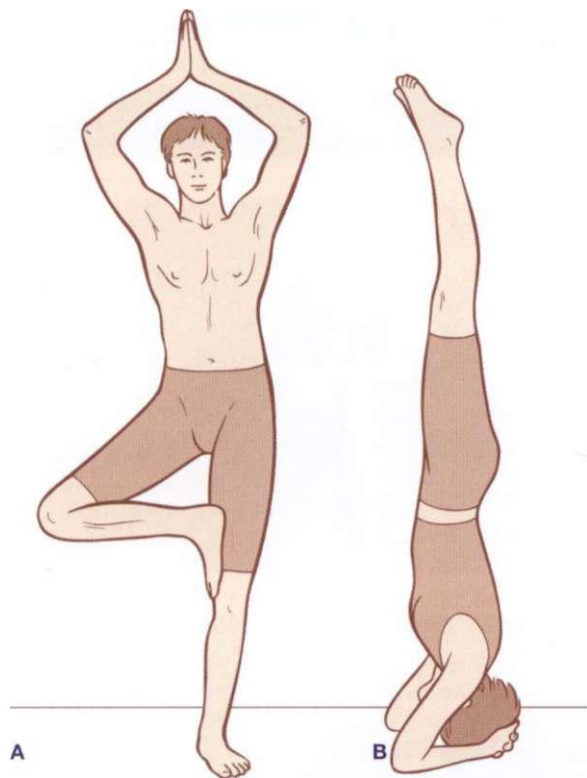


Fig. 10.40 Balancing poses.




Fig. 10.41 *Trikanasana* (Triangle pose) as performed by (A) an experienced teacher, (B) an experienced student, and (C) a neophyte student.

lengthen, until it is almost as long as the left. This would lead to the unexpected cue for the last two examples to 'lift the underside rib cage away from the hip' - lengthening the right upper LL to allow the body to go more deeply into the pose.

A deceptively important part of this pose lies in the forward leg. The obvious stretch is in the Superficial Back Line (hamstrings and gastroc/soleus complex). The twist in the hips, however, pulls the ischiopubic ramus away from the femur, resulting in a strong stretch of the Deep Front Line (specifically the adductor group and the associated fascia) of the medial leg. This pose calls for an ability to lengthen the adductor group, and the thigh's posterior intermuscular septum between the adductors and the hamstrings. In **10.41C**, the inability of the right inner thigh to lengthen results in strain and a slight medial rotation, as the fascia pulls at the inner right knee. (Teachers will commonly remind students in this pose to keep both knees laterally rotated to prevent collapse, strain to the medial collateral ligament, and eventual injury.) In **10.41B**, the back of the adductor group is more stretched out, allowing the ischial tuberosity to move away from the femur. The anterior (flexor) part of the adductor group, however, is keeping the pelvis from rotating away from the femur; consequently the pelvis in **10.41B** faces the floor more than that of **10.41A**, which is rotated left, more toward the viewer.

In the trunk, the right Spiral Line, from the right side of the head to right hip via the left shoulder, is being stretched, while its left complement is being contracted to create the pose. The ability to lengthen this line is expressed in the ability of the head to turn toward the ceiling (though it is possible that the models in **10.41B** and **C** simply forgot, in the heat of battle with the camera, to turn their heads ceilingward). A much more telling mark of the inability of the right SPL to lengthen is in the angle of the sternum. The rib cage in **10.41A** points directly at us. In **B**, and to a lesser extent in **C**, the sternum is still turned toward the floor a bit, consistent with the inability of the pelvis to rotate to the left away from the left thigh. We can also see the inability of the SPL to lengthen in the angle of the left shoulder and arm, which of course sits on the rib cage. It could be that the left Superficial Front Arm Line (pectoralis major to the palm) is short, but in **B** and **C**, the differences in the angle of the arm proceed from the inability of the right SPL (and/or deep spinal rotators) to allow the rib cage to rotate to the left.

In summary, **Figure 10.41 A** demonstrates an ease in extension of the lines, as well the strength necessary to sustain the body, which allows the pose to be entered completely and beautifully, with opposing lines balanced. Barring any genetic anomalies or limiting injuries, achieving such a balance for **10.41B** and **C** is simply a matter of practice.

Revolved lateral angle pose (Fig. 10.42)

The Revolved Lateral Angle pose presents some of the same challenges as the Triangle pose, but some different ones as well (**Fig. 10.42**). It is primarily a strong rotation - a left rotation in these photographs - of the thorax on the hips. Looking again at the progression from experi-

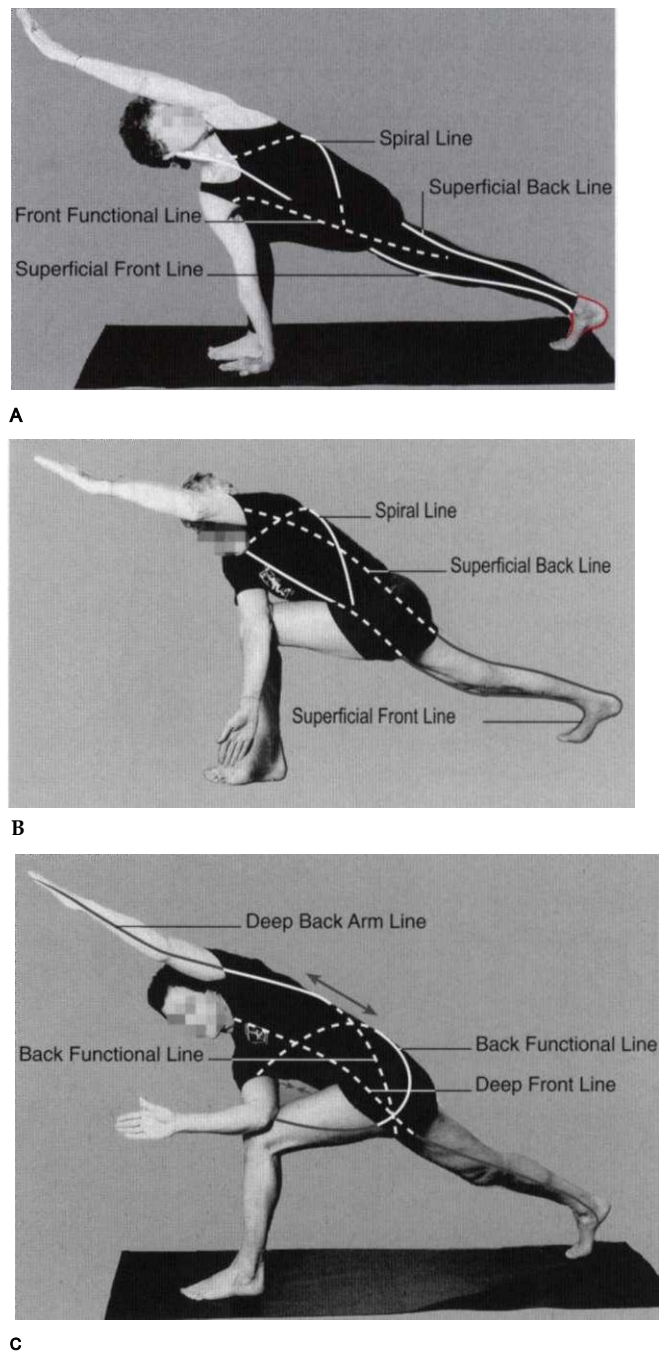


Fig. 10.42 *Parivrita Parsvakonasana* (Revolved Lateral Angle pose) as performed by **(A)** an experienced teacher, **(B)** an experienced student, and **(C)** a neophyte student.

enced teacher to neophyte student, we see a number of compensations in the lines involved.

The twist through the pelvis requires length through the Deep Front Line. This is available in **Figure 10.42A**, but in **10.42B** we see the inability of the right leg to fully extend due to shortness in the deep hip flexors. In **10.42C**, tightness in the deep lateral rotators and hamstrings prevents the left hip from flexing fully, leaving the lumbar in a posterior (flexed) position and the head turtled into the torso.

In **10.42A** we see the ability of the Superficial Front Line to lengthen evenly from the right mastoid process

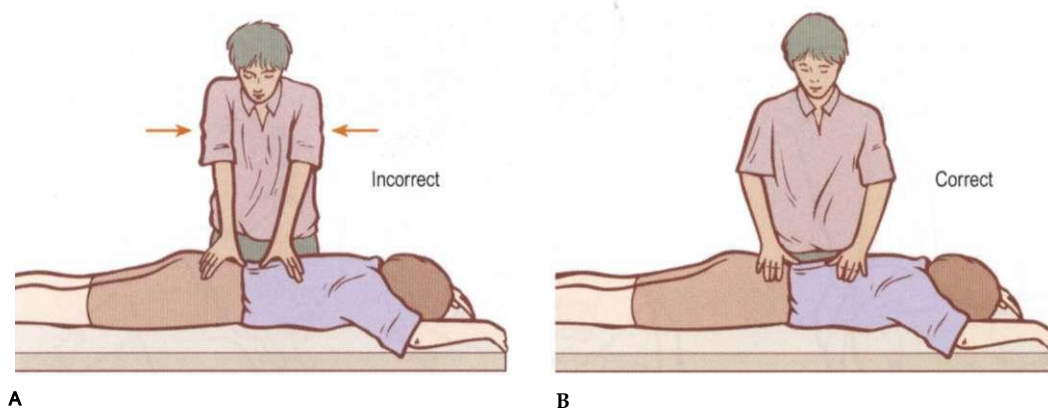


Fig. 10.43 Anyone relying on his thumbs to create pressure should take care to keep the Deep Front Arm Line open and round. Collapsing in the upper part of the DFAL is a reliable way to ensure subsequent hand, elbow, shoulder, or neck problems.

to the right shin, whereas **B** and **C** both show shortening along the front of the torso and misalignment between the thigh and lower leg. Once again, competence in the twist is demonstrated by the balance between the two Lateral Lines in the torso of **A**, whereas **B** shows some shortening and our new student shows significant shortening along the right side of the torso.

It is, of course, in the Spiral Lines that the differences are most evident. The reversal of the twist between the pelvis and shoulders emphasizes the need for length in the spirals. **A**'s ability to put her arm on the floor and to look at the ceiling is entirely dependent on her ability to stretch the right Spiral Line from the right hip around the left shoulder to the right side of the head. It also requires corresponding strength in the left Spiral Line. It is difficult for **B** to bring the left ribs away from the right hip, and thus the arm obscures the face. In **C** it is the hips that are reluctant to turn, perhaps because of tension in the deep lateral rotators, or the right Back Functional Line, as well as the SPL.

In the arms themselves, both the Superficial and the Deep Front Arm Lines, and the Deep Back Arm Line as well, must be able to lengthen in the outstretched left arm, out from their base in the Lateral and Functional Lines.

In summary, the straight lines through the skeleton we see in **Figure 10.42A** are allowed in this pose because of the availability of stretch and strength in the myofascial lines. Experience teaches that conscientious and well-tutored yoga practice turns the Bs and Cs into As.

Shiatsu, acupressure, or thumb work

The practice of Shiatsu, acupressure, and some other forms of pressure-point work such as finding and eradicating trigger points involve placing significant pressure through the thumbs. The thumb, we remember, is the end point of the Deep Front Arm Line. To 'give weight' and create sustained pressure through the thumb requires using many of the muscles of the arm - all four lines, in fact - as fixation muscles to steady the limb. We have noted that myofascial continuities can only pull, they cannot push. Given that the pressure is coming down through the thumb, one might expect that the DFAL was the least important of the lines, being in a

curved position and relatively relaxed for this motion compared to the other stabilizing lines of the arm. But because of the connection from the thumb to the ribs along the DFAL, it is very important.

Practitioners of these arts frequently present with problems in their shoulders or neck. Our experience is that when we have these practitioners mock up how they work, universally they are collapsing somewhere along the DFAL - in other words, along the myofascial meridian that runs from the ribs out the pectoralis minor and the inside curve of the arm to the thumb. When this line shortens, the rest of the lines, and most usually one of the back lines of the arm, must take up the flag and end up overworking (**Fig. 10.43A**). For the Shiatsu worker to stay healthy and pain-free in both joints and soft tissues, it is necessary to keep the DFAL open and lengthened, so that tension and pressure are distributed evenly around the tensegrity of the arm (**Fig. 10.43B**). In this way, the pressure is taken by the skeleton from the thumb to a balanced axial complex, not distributed sideways through the soft tissues of the Arm Lines.

Aikido or judo roll

Although the limbs are bony and angular, practitioners of martial arts can often make it look as if the body is made of India rubber as they roll effortlessly along legs, arms, and trunk. There are many rolls in Asian martial arts. Here we discuss a forward roll common to both aikido and judo, and probably several other arts. (Other rolls would of course exploit other lines in a different order.)

Looking at one of these forward rolls in terms of the Anatomy Trains, we can see that in a forward roll the little finger is the first edge of the body to make contact with the floor or mat, bringing our attention to the Deep Back Arm Line (**Fig. 10.44A**). The body supports or guides itself on this line (although in an actual roll, little weight is placed on the arm), moving up the surface of the ulna and onto the triceps.

As the roll reaches the back of the shoulder, the baton is passed from the triceps to the latissimus, or in Anatomy Trains terms, from the DBAL to its extension, the Back Functional Line. The body rolls on the diagonal of the BFL, by now supporting the weight of the entire

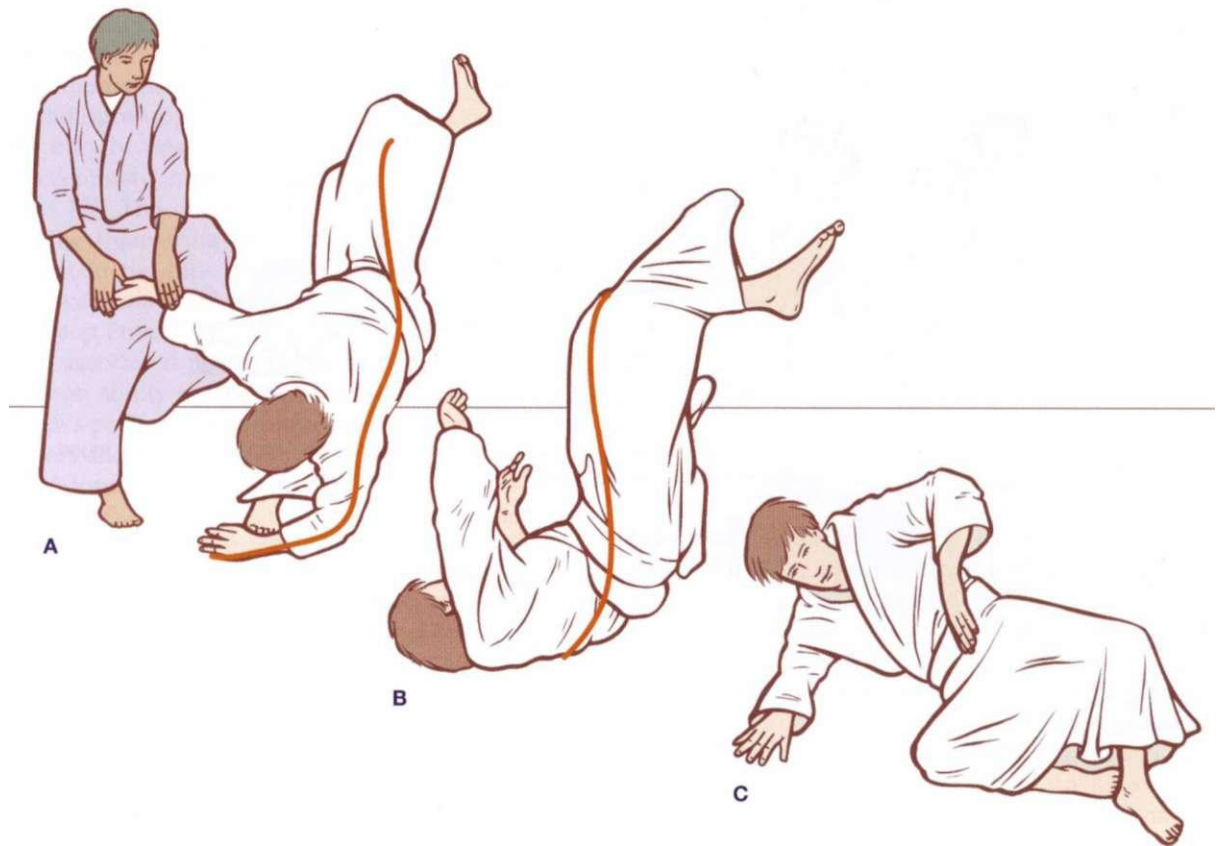


Fig. 10.44 An aikido forward roll travels along the Deep Back Arm Line, the Back Functional Line, and the Lateral Line.

body, crossing the midline of the back and onto the opposite hip (**Fig. 10.44B**). From here the body supports itself, if headed back for standing again, on the Lateral Line of the leg, passing down the iliotibial tract and the peroneals as the opposite foot hits the floor and begins the process of standing up again (**Fig. 10.44C**).

A roll also requires proper balance between the Superficial Front and Back Lines, as over-contraction of the SBL will interfere with obtaining a smoothly rounded shape for the back of the torso, and over-contraction of the SFL, which is very common in the early stages of learning, causes hyperextension of the upper cervicals, making it hard to tuck the head out of the way and coordinate the back muscles.

Staying strong, open, and aware of these lines as you pass through the roll will make it smoother and safer. Conversely, shortening, tightening, or retracting these lines when attempting a roll will result in a bumpy ride.

Karate kick

Figure 10.45A is a front snap kick taken from a photo of a teacher with a black belt. A karate kick to the front involves, fairly obviously, contraction of the Superficial Front Line to create the kick, and lengthening along the Superficial Back Line to allow the kick to happen. Restrictions in either of these lines could affect the ability of the student to perform this action.

Notice also how the arms counterbalance the flexed leg. The two front Arm Lines on the left flex the arm and

bring it across the chest, while the two Back Arm Lines abduct the right arm and extend the elbow. The left leg and right arm are stabilized across both front and back via the Functional Lines to provide a base for the action of the left arm and right leg, where the Front Functional Line adds to force of the kick, and the Back Functional Line must lengthen to allow it.

Less obviously, the Deep Front Line is involved in the ability to make this kick work for the whole body. The posterior adductors and posterior intermuscular septum must lengthen to allow the hip to flex fully without tilting the pelvis posteriorly. More to the point, the iliopsoas is active in flexing the hip and holding the femur in flexion. Either of these factors can create a downward pull on the DFL, which can result in compression along the front of the spine. In **Figure 10.45B**, a similar kick from the side likewise drawn from a photo, we can see this effect in action. The tissues of the SFL remain long, but the core is nevertheless pulled down. The front of the spine is clearly shortened from the anterior cervicals to the pelvic floor.

Some years ago it was my privilege to work with an Olympic contender on the British karate team. Long of limb (and very fast), this gentleman was set fair to bring home the gold, but for one problem - kicking caused an increasingly sharp and debilitating pain in his lower back. My first line of inquiry was up the SBL, reasoning that the tension of the hamstrings was being passed around through the sacrotuberous ligament to the sacrum and the sacrolumbar fascia, thus causing some kind of radicular compression. When this avenue proved

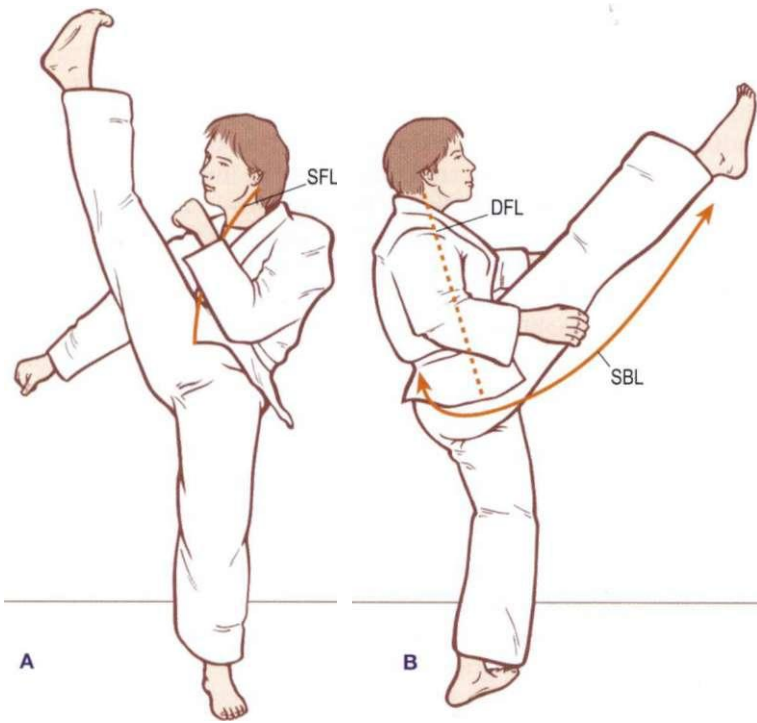


Fig. 10.45 Karate kicks to the front.

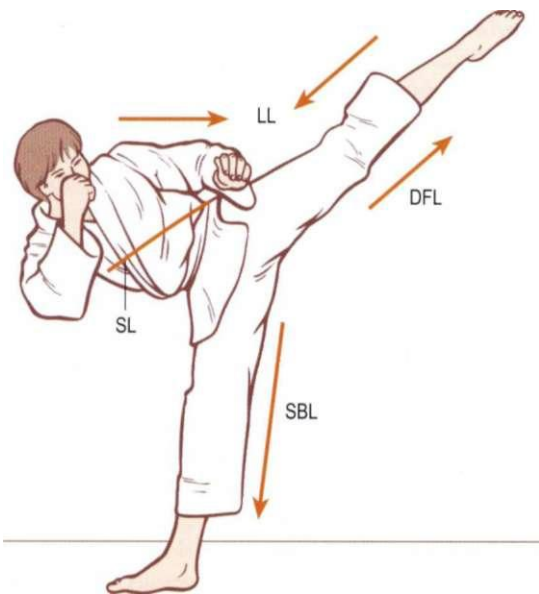


Fig. 10.46 A karate side kick.

fruitless, I watched him kicking once again and saw what I should have seen in the first place, what we see in **Figure 10.45B**, a slight shortening in the core of the trunk when he kicked. By examining the structures of the DFL, I determined that the upper-outer fibers of the psoas muscles were overworking, causing a compression of the lumbar spine (and thus some kind of impingement) when he kicked. By working to even out the load over the entire iliopsoas, we were able to reduce the compression and increase the springiness of the lumbar spine, and yes, he went on to capture a medal.

In **Figure 10.46**, we see another basic karate kick, the side kick. Here we can note the upper body leaning off the SBL of the grounded leg. The left Lateral Line is shortened all the way from the side of the head to the side of the foot to fix the body in a 'Y' shape. The height of the kick thus depends on the ability of the SBL to lengthen in the standing leg, the strength of the LL and its abduction ability, and the ability of the inner arch of the kicking leg to stretch away from the ischiopubic ramus and lumbar spine - in other words, the extensibility of the DFL, particularly in the adductors. This particular kicker seems also to be supporting the torso with the upper left Spiral Line, looping under the right ribs from the left side of the head to the left hip. Notice that very little kicking power is provided by the LL, which is primarily a line of stabilization; the power in the kick, as with a horse, comes from the combination of the sagittal lines - the extensors of SBL and SFL.

Summary

Movement education, functional rehabilitation, and performance enhancement are all pressing needs where improvement is both vitally important and easily possible, given the poor state of movement education in contemporary Western society. A few dollars per child given toward better physical education could yield a large benefit in terms of reduced medical costs and higher levels of health and performance. A few dollars per patient could improve rehabilitation and prevent relapses for all manner of physical injury or post-surgical recovery. Where the dollars are being spent - in athletics - insights are being gained that could be applied more widely in education and rehabilitation if there were the means to disseminate



nate these new insights more widely (though this process is underway).

Assessing movements by means of still photographs is a frustrating way to go about it, but is necessitated by the form of a book. Assessing clients in standing is explored more deeply in the next chapter, and in-person classes and **DVD** courses in motion assessment are available (zvivw.anatomytrains.com, ivmv.astonenterprises.com) (**DVD ref: BodyReading 101**).

These examples serve to show a few of the directions where the Anatomy Trains scheme can be applied in action. Obviously, applications into yoga, Pilates, personal training, and physical therapy rehabilitation can be expanded and given in more detail, but we have chosen to give a wider introduction in the available pages. The principles, however, are the same: look for the areas where fascial or muscle shortening are limiting motion, and then check out the full length of the lines in which these specific structures live and have their being. On the other side of the coin, areas that have laxity or too much movement / too little stability can be identified

and similarly strengthened. Strengthening through a line - so that the line as a whole responds rather than just a specific muscle - can improve functional stability.

When doing a functional assessment of a client or student, it is obviously useful to observe and assess which specific structures might be involved in an action or in its restriction. The examples in this chapter will perhaps have convinced the reader of the value in doing a more global myofascial meridian assessment as part of this process. View clients as they perform an action, preferably from a bit of a distance so that the entire body is within your foveal vision. Looking at clients slightly askance so that you assess their movement from your peripheral vision - originally developed to detect movement, after all - can also be helpful, and is sometimes more revealing than staring right at them, trying to deduce the fault in the movement. See whether one or more of these lines is not restricting the overall movement. Working with the entire line will often bring an increased freedom that working on only the obviously affected part will miss.

Reference

1. Kingsley B and Ganeri A. The young person's guide to the orchestra. San Diego: Harcourt Brace & Co.; 1996.

Structural analysis

11

Can we usefully compare postural and structural relationships in terms of these myofascial meridians? Can this information be developed into unambiguous treatment strategies for unwinding and resolving body-wide patterns of compensation? Attempts at objective and inter-operator reliable visual analysis of overall postural patterns are fraught with difficulty, with few norms having been established scientifically. Yet, useful clinical information can be gleaned from an analysis of the standing client. This chapter puts forward one method for obtaining such information and putting it to use. In this chapter, we refer only to still photos of standing posture; in practice, such information would and should be corroborated with a carefully taken history, palpation, and gait or other movement assessment.

The Anatomy Trains map was first developed as a visual assessment tool for Structural Integration clients (see Appendix 2 on our Structural Integration method). This chapter describes the language and method of 'bodyreading' that we employ in our training seminars, where we systematically expand this introductory overview to standing assessment. Although this process is most easily assimilated when taught in person, attentive readers will be able to utilize this tool with their own clients, patients, or students, to apply various therapeutic protocols in a global and progressive manner. A 'Visual Assessment' DVD course based on these same principles is also available (DVD ref: BodyReading 101).

This assessment tool rests on the concept of 'tensegrity' put forth in Chapter 1. Practitioners seeking biomechanical alignment and other forms of movement efficiency, as well as kinesthetic literacy (an accurate sensing of where our body is in space and how it moves), or even psychosomatic ease, will do well to consider the unique properties tensegrity geometry shares with the human body. These include tensegrity's unique ability to 'relax into length' as well as its distributive properties, accommodating local strain or trauma by dispersing it via small adjustments over the entire system (see Fig. 1.51, p. 47).

As clients resolve dysfunctional patterns, they more closely approach a 'coordinated fascial tensegrity'

balance among the lines, creating a resilient and stable 'neutral' around which movement occurs. When accumulated strain is unwound into the desired efficiency and ease, the struts of the bones seem literally to float within a balanced array of tensile collagenous tissues, including the more closely adherent ligamentous bed, as well as the parietal myofascial system arranged in the longitudinal meridians that are the subject of this book.

The process of modeling the human frame in this way is just getting underway, but already a certain sophistication is available in the tensegrity models of Tom Flemons (www.intensiondesigns.com - Fig. 11.1). The relationship between the bones, myofasciae, and ligaments is more closely approximated when the example in Figure 1.51A (p. 47) is modified to approach that of Figure 11.2, which is the same set of relationships, just shifted in their attachments, a process we can see happening to the connective tissue network *in vivo* in the films of Dr J-C. Guimberteau (Figs 1.71-1.75, pp. 59-61) (DVD ref:

Fascial tensegrity implies evenness of tone - with allowances for differences of muscle fiber type and density variations from superficial to deep - along each line and among the lines. Anecdote and informal clinical observation suggest that inducing this even tone produces increased length, ease, generosity of movement, and adaptability for the client in both somatic and psychosomatic terms. To gain these heights for ourselves and our subjects, we must first have an accurate reading of where the skeleton literally stands in terms of its sometimes very small but telling aberrations from vertical symmetrical balance. This will allow us to accurately map the meridians and soft-tissue components necessary to improve the state of balance and support.

The first section of this chapter sets out the procedure to assess any given posture using the myofascial meridians, with emphasis on the accurate description of skeletal position. The main body of the chapter analyzes the standing posture of several 'clients' using this procedure to generate a single- or multi-session strategy. The final part of this chapter sketches in some of the more subjective elements of the 'bodyreading' or body mapping process.




Fig. 11.1 The wonderful and varying models of Tom Flemons (www.intensiondesigns.com) demonstrate clear similarities to human postural response and compensation patterns. With each iteration, these models get more sophisticated; more complex models appear on the website as they are developed.

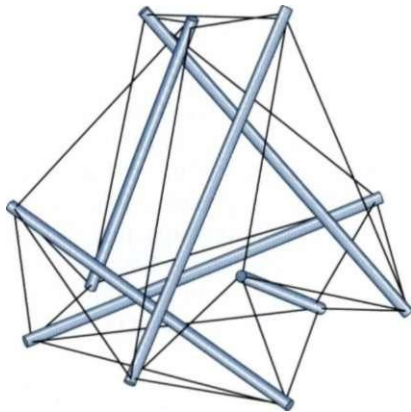


Fig. 11.2 The tensegrity icosahedron shown in **Figure 1.51A** (p. 47) is commonly used by advocates of tensegrity as a simple demonstration model. Especially in the limbs, our body works more like this still very simplified model. In fact, this model is the same as the one shown in **Figure 1.51A**, with the end points of the dowels slid closer to each other so that the same construction shifts into a more tetrahedral shape. This results in (1) a more stable, less deformable structure, (2) the long part of the elastics parallel the dowels, just as most of our myofasciae parallel the bones, and (3) the short elastics that are tying the end of the bones together resemble the joint ligaments. Jolt one of the bones, as in an accident, and the strain is transferred strongly to these ligaments.

Global postural assessment method

Many forms of structurally oriented manipulation use an analysis of standing posture as a guide in forming a treatment strategy. Osteopaths, chiropractors, physiotherapists, soft-tissue practitioners, and movement educators such as Alexander and yoga teachers have used

various grids, plumb lines, and charts to help assess the symmetry and alignment of the client. Our own approach and vocabulary emphasize the interrelationships within the person's body, rather than their relation to anyone else or to a Platonic ideal. For this reason, the photographs herein are devoid of such outside reference - except of course the line of gravity as represented in the orientation of the picture.

That there are benefits to an easy, upright alignment within the strong and shadowless gravitational field of the earth is a generally inescapable idea. The advisability, however, of in any way compelling left/right symmetry or even a 'straight' posture on a client is far more dubious. Alignment and balance are dynamic and neurologically adaptive, not static and biomechanically fixed. Postural reflexes, and the emotional connection to deeply held tension, lie fairly deep in the brain's movement structure. Efficient structural relationships must thus be exposed within the clients, not imposed upon them. The idea is to assist the client in the process of 'growing out of the pattern', not to box someone into a particular postural ideal. The former eases tension and leads to new discoveries; the latter piles more tension onto what is already there.

The goal of making such an analysis is to understand the pattern - the 'story', if you will - inherent in each person's musculoskeletal arrangement, insofar as such a task is possible using any analytical method. The use of such an analysis merely to identify postural 'faults' for correction will severely limit the practitioner's thinking and the client's empowerment.

Once the underlying pattern of relationships is grasped, any (or several) treatment methods may be employed to resolve the pattern. Applying the Anatomy Trains myofascial meridians to standing posture is obviously a vital step in this process of understanding structural patterns of collapse and shortness, but not the first step. The next section outlines a five-step method of structural analysis.

The steps are as follows:

1. Describe the **skeletal geometry** (where is the skeleton in space, and what are the intra-skeletal relationships?);
2. Assess the **soft-tissue pattern** creating or maintaining that position (individual muscles or myofascial meridians);
3. Synthesize an **integrating story** that accounts for as much of the overall pattern as possible;
4. Strategize a short- or long-term **strategy** to resolve the undesirable elements of the pattern;
5. **Evaluate and revise** the strategy in the light of observed results and palpatory findings.

Step 1: a positional vocabulary

Terminology

To describe the geometry of the skeleton - the position of the skeleton in space - we have developed a simple, intuitive but unambiguous language that can be used to describe any position in space, but which we use here

to describe interosseous relationships in standing posture. The vocabulary derives from Structural Integrationist Michael Morrison.⁵ This language has the dual advantage of making sense to (and thus empowering) clients, students, and patients, while also being capable of bearing the load of sufficient detail to satisfy the most exacting practitioner-to-practitioner or practitioner-to-mentor dialogue. It has the disadvantage of not conforming to standard medical terminology (e.g. 'varus' and 'valgus', or a 'pronated' foot). Because these terms are often used in contradictory or imprecise ways, this disadvantage may prove an advantage in the long run.

The four terms employed are: 'tilt', 'bend', 'rotate', and 'shift'. The terms describe the relationship of one bony portion of the body to another, or occasionally to the gravity line, horizontal, or some other outside reference. They are modified with the standard positional adjectives: 'anterior', 'posterior', 'left', 'right', 'superior', 'inferior', 'medial', and 'lateral'. These modifiers, whenever there is any ambiguity, refer to the top or the front of the named structure.

As examples, in a left lateral tilt of the head, the top of the head would lean to the left, and the left ear would approach the left shoulder. A posterior shift of the rib cage relative to the pelvis means that the center of gravity of the rib cage is located behind the center of gravity of the pelvis - a common posture for fashion models. In a left rotation of the rib cage relative to the pelvis, the sternum would face more left than the pubic symphysis (while the thoracic spinous processes might have moved to the right in back). Medial rotation of the

femur means the front of the femur is turned toward the midline. This use of modifiers is, of course, an arbitrary convention, but one that makes intuitive sense to most listeners (Fig. 11.3).

One strength of this terminology is that these terms can be applied in a quick overall sketch description of the posture's major features, or used very precisely to tease out complex intersegmental, intrapelvic, shoulder girdle, or intertarsal relationships.

Compared to what?

Because the terms are mostly employed without reference to an outside grid or ideal, it is very important to clarify exactly *which* two structures are being compared. To look at one common example that leads to much misunderstanding, what do we mean by 'anterior tilt of the pelvis' (sometimes termed an 'anterior rotation' of the pelvis, but in our terminology, it will be an 'anterior tilt')?

Imagining that we share a common understanding of what constitutes an anterior tilt pelvis, we are still open to confusion unless the question, 'Compared to what?' is answered. If we consistently compare the tilt of the pelvis to the horizontal line of the floor, for instance, this reading will not lead us to useful treatment protocols of femur-to-pelvis myofascia since these tissues relate the pelvis to the femur, not the pelvis-to-floor (compare Fig. 11.4A and B). Since the femur can also be commonly anteriorly tilted, the pelvis can easily be (and often enough is) anteriorly tilted compared to the ground while at the same time being posteriorly tilted corn-

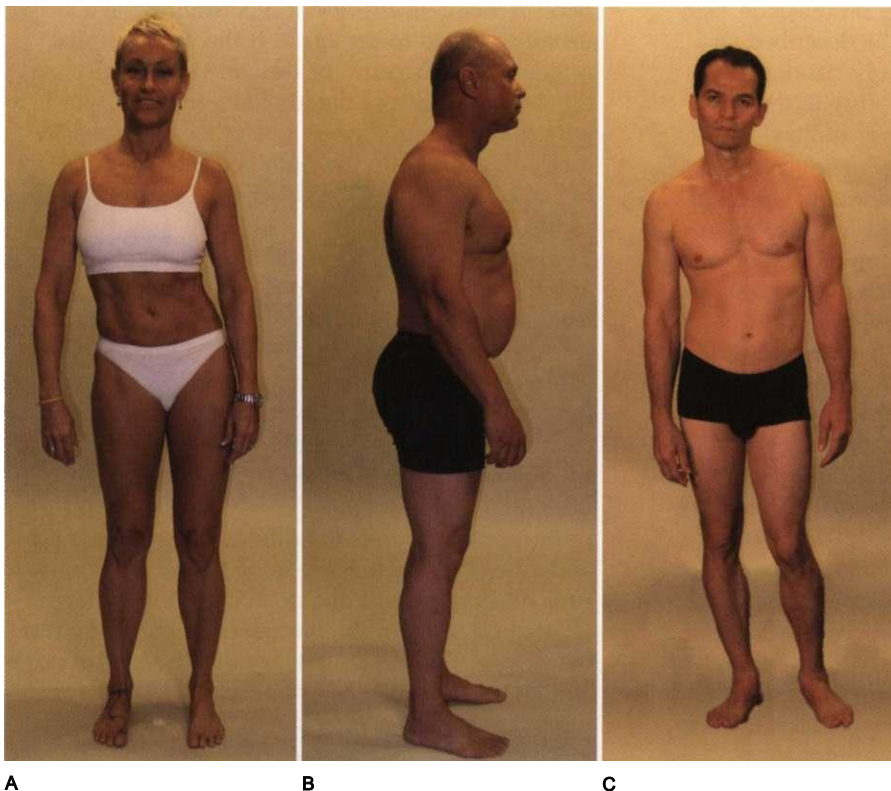


Fig. 11.3 These deliberately exaggerated postures show (A) a left shift of the pelvis relative to the feet, right shift of the ribs relative to the pelvis, and left shift of the head relative to the ribs. Notice that the head is not shifted relative to the pelvis. Although we cannot directly see them, we can presume multiple bends in the spine. The pelvis has a right tilt, and the head and shoulders have a left tilt. In (B), we see an anterior shift of the head relative to the ribs, and an anterior shift of the ribs relative to the pelvis. This involves posterior bends in both cervical and lumbar curves, as well as lateral rotations in all four limbs. The pelvis appears to have an anterior tilt, but neither the ribs nor the head are tilted relative to the ground. In (C), we can see a right tilt of the pelvis, a left tilt of the rib cage and shoulder girdle, and a right tilt of the head, with a concurrent right bend of the lumbar and left bend in the thoracics. The right femur shows a lateral rotation while the left demonstrates a medial rotation relative to the tibia.

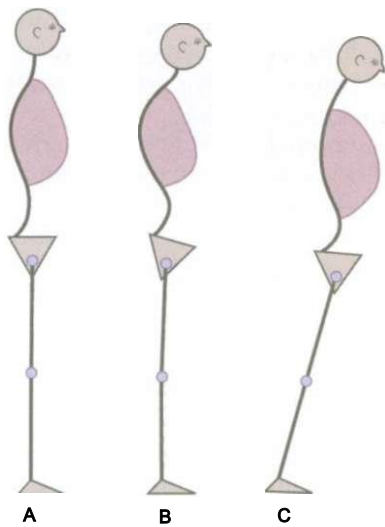


Fig. 11.4 In (A), 'neutral' posture, more or less, is depicted diagrammatically. If for a few pages we accept the convention of these diagrams, we can see that in (B), the pelvis is anteriorly tilted - the top of the pelvis tilts toward the front - relative to both the femur and the ground. In (C), we see the common but commonly mis-assessed situation of the pelvis being anteriorly tilted relative to the ground but *posteriorly* tilted relative to the femur. 'Compared to what?' is a meaningful question.

pared to the femur (Fig. 11.4C). Both descriptions are accurate as long as the point of reference is agreed.

Definitions: Tilt, Bend, Shift, and Rotation

- *Tilt*. 'Tilt' describes simple deviations from the vertical or horizontal, in other words, a body part or skeletal element that is higher on one side than on another. Although tilt could be described as a rotation of a body part around a horizontal axis (left-right or A-P), 'tilt' has a readily understood common meaning, as in the Tower of Pisa. 'Tilt' is modified by the direction to which the top of the structure is tilted. Thus, in a left side tilt of the pelvic girdle, the client's right hip bone would be higher than the left, and the top of the pelvis would lean toward the client's left (Fig. 11.5A). An anterior tilt of the pelvic girdle would involve the pubic bone going inferior relative to the posterior iliac spines, and a posterior tilt would imply the opposite (Fig. 11.5B). In a right side tilt of the head, the left ear would be higher than the right, and the planes of the face would tilt to the right (Fig. 11.5A). In a posterior tilt of the head, the eyes would look up, the back of the head approaches the spinous processes of the neck, and the top of the head moves posteriorly (Fig. 11.5B).

In Figure 11.4C, the leg as a whole is anteriorly tilted, and the pelvis is posteriorly tilted relative to it. The head in this diagram is anteriorly tilted - looking down - which is an equivalent position to the pelvis in Figure 11.4B. The terminology is applied consistently throughout the entire body.

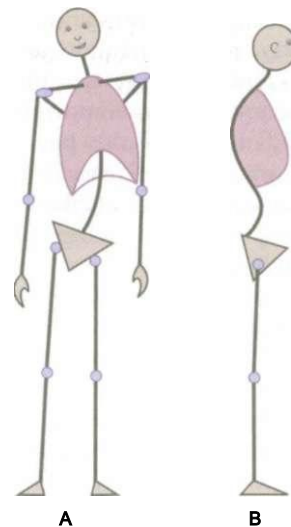


Fig. 11.5 In (A), the pelvis is tilted left, due to a short left leg. This has resulted in a compensatory right bend of the spine, right tilt of the shoulder girdle, and left shift of the rib cage relative to the pelvis. In (B), we see an anterior tilt of the pelvis, with a posterior bend of the lumbar spine and an anterior shift of the head due to an anterior bend in the upper thoracic spine. The neck is thus anteriorly tilted, and only by a sharp posterior bend in the upper cervicals can this fellow keep his eyes looking forward horizontally - compare to Figure 11.3B.

Tilt is commonly applied to the head, shoulder girdle, rib cage, pelvis, and tarsi of the feet. Tilt can be used broadly, such as 'a right side tilt of the torso relative to gravity', or very specifically, such as 'an anterior tilt of the left scapula relative to the right' or 'a posterior tilt of the right innominate bone relative to the sacrum' or 'a medial tilt of the navicular relative to the talus'. Once again, for clarity in communication and accuracy in translating this language into soft-tissue strategy, it is very important to understand to what the term being used is related: an 'anterior pelvic tilt relative to the femur' is a useful observation, a simple 'anterior pelvic tilt' opens the door to confusion. *Bend*. A 'bend' is a series of tilts resulting in a curve, usually applied to the spine. If the lumbar spine is side bent, this could be described as a series of tilts between each of the lumbar vertebrae, which we usually summarize as a bend - either side, forward, or back (in the right bend in Fig. 11.5A, the top of L1 faces more the client's right than the top of L5).

The normal lumbar curve thus has a back bend, and the normal thoracic spine a forward bend. A lordotic spine could be generally described as an 'excess posterior bend in the lower lumbar', or could be specified in more detail. A low but strong lumbar curvature might parse out on investigation as: 'the lumbar have a strong posterior bend from L5-S1 to about L3, but have an anterior bend from L3-T12.'

In the spine, the essential difference between a tilt and a bend is whether the deviation from 'normal' runs off in a straight line or a curve. If the rib cage is tilted off to the right, we can presume that either the pelvis is likewise right tilted so the lumbar run straight, or more likely, as in Figure 11.6A, the lumbar spine has a right side bend. Further, spinal mechanics dictates that the left bend in the lumbar very likely involves the tendency toward a right

rotation of some of those vertebrae. The spine can have one uncompensated bend, but commonly has two bends that compensate each other, and more complex spinal patterns, e.g. scoliosis, can have three or even four bends over the two dozen vertebral segments.

- **Rotation.** In standing posture, rotations usually occur around a vertical axis in the horizontal plane, and thus often apply to, for example, the femur, tibia, pelvis, spine, head, humerus, or rib cage. Rotations are named for the direction in which the front of the named structure is pointing. For instance, in a left rotation of the head (relative to the pelvis), the nose or chin would face to the left of the pubic bone (**Fig. 11.6A**). In **Figure 11.6A**, both the head and rib cage are right rotated relative to the pelvis. Relative to rotation, the head and the rib cage are neutral to each other. Making this observation is crucial to strategy: attempting to derotate the head of this person via the neck muscles would fail; it is the structures between the ribs and pelvis that govern this rotational pattern. Notice that, if the rib cage were left rotated relative to the pelvis, the head could be right rotated relative to the rib cage and still be neutral relative to the pelvis or feet (**Fig. 11.6B**). In this case, therapeutic strategy would need to consider the twist/rotational imbalance in both the cervical and lumbar tissues (as well as shoulder-to-axial structures) to resolve this more complex pattern. In paired structures, we use medial or lateral rotation (**Fig. 11.6C**). While this is in common use as regards femoral or humeral rotation, we extend this vocabulary to all structures. What is commonly

called a 'protracted' scapula would, in our vocabulary, be a 'medially rotated' scapula, since the anterior surface of the scapula turns to face the midline. A medially rotated calcaneus often accompanies what is commonly called a 'pronated' foot (which we would call, and not just to be confusing, a 'medially tilted' foot).

- **Shift.** 'Shift' is a more broad but still useful term for displacements of the center of gravity of a part (right-left, anterior-posterior, or superior-inferior). Balinese and Thai dance involves a lot of head shifting - side-to-side movement while the eyes stay horizontal. The rib cage likewise can shift to the back or side while still staying relatively vertical relative to the ground (**Fig. 11.7A and B**). Such shifts, of course, commonly involve tilts and bends, and often accompany rotations as well. We can use the terminology to specify these particular relationships when called for, but we have found that phrases such as 'left lateral shift of the rib cage' or 'the head is shifted to the right relative to the pelvis' are a useful shorthand when making an initial evaluation.

The mobile scapula is commonly shifted in any of the six modifying directions. The pelvis is commonly described as being anteriorly (as in **Fig. 11.7A**) or posteriorly shifted relative to the malleoli, with the understanding that some tilts must occur along the way in the upper or lower leg for that to happen. A protracted shoulder involves a lateral shift of the scapula on the ribs. A wide stance could be described as a lateral shift of the feet relative to the hips. Genu varus involves a lateral shift (and probably a medial rotation as well) of the knees.

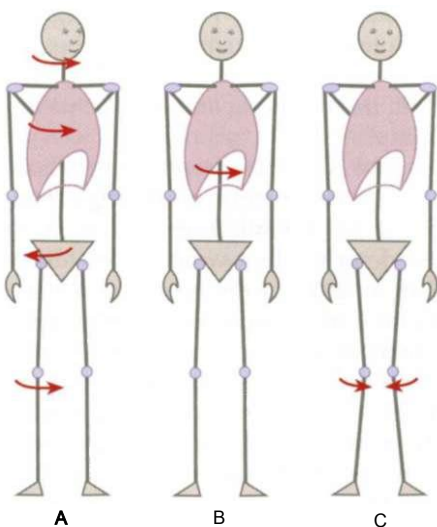


Fig. 11.6 Rotations all take place in the horizontal plane around a vertical axis, and are therefore modified only with left or right (for axial structures - **(A)**) or medial and lateral (for paired structures - **(C)**). Rotations frequently counter each other from the ground up **(A)**. One rotation in the middle, as in **(B)** (or mocked up in **Fig. 11.3A**), is not as simple as it looks to unwind.

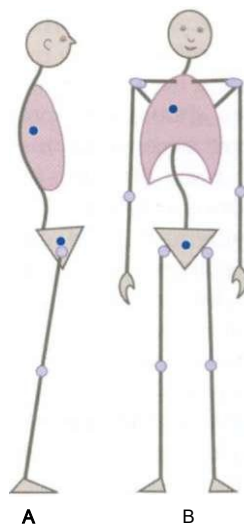


Fig. 11.7 In **(A)**, there is an anterior tilt of the legs that results in the pelvis being anteriorly shifted relative to the feet, but the pelvis has a posterior tilt relative to the femurs. The rib cage in this diagram is posteriorly shifted relative to the pelvis, and the head is anteriorly shifted relative to the rib cage, in a pattern that is sadly commonplace in the Westernized world. Notice that the ribs are fairly neutral relative to the feet, and the head is fairly neutral relative to the pelvis. Undoing this pattern involves soft-tissue release in nearly every segment of the body. In **(B)**, we see the pelvis neutral relative to the feet, but the ribs are right shifted relative to the pelvis, and the head left shifted relative to the ribs. The pelvis and head are thus relatively neutral, but as you begin to shift the rib cage on the pelvis via manipulation or training, the head will generally shift right relative to the pelvis, requiring work between the ribs and head.

None of these terms are mutually exclusive. A rib cage can have its center of gravity shifted relative to the pelvis, with or without a tilt, and additionally with or without a rotation. Identifying one event does not preclude the others.

Yet more detail

This simple yet comprehensive vocabulary allows for a quick sketch or can be used to describe a series of relationships in minute detail. What might initially present as the easily seen 'left tilted shoulder girdle' in our quick sketch (as in **Fig. 11.5A**) could parse out, with more detailed examination, as 'a left tilted shoulder girdle with an anterior tilt and a medial rotation in the right scapula, and a medially shifted left scapula'. This allows the practitioner to be as detailed or as general as necessary. The description can be noted down quickly, and accurately conveyed to another practitioner or mentor in a phone call or e-mail when seeking assistance or describing a successful strategy for others to follow.

In terms of this greater level of detail, it is worth focusing on the spine, shoulders, and feet to clarify how this vocabulary can be consistently applied. As noted, we could give a general description (e.g. 'the spine in the torso is generally right rotated'), or we could fill it in to whatever level of detail is necessary (e.g. 'the spine is left side tilted and right rotated from the sacrum through L3, right side tilted and left rotated from L3 through T10, and then right rotated from T10 through about T6, forward bent through the upper thoracics, and again left rotated in the cervicals to bring the head to face in the same direction as the pelvis'). The general sketch is quite helpful in getting a global handle on which myofascial meridians might be involved. The more detailed description aids in specific strategy for de-rotating vertebrae and getting specific to local muscle or even particular muscle slips in treatment plans.

Shoulders

Though in a general sketch, the shoulder girdle might be described as a whole - e.g. left or right tilt, or superior shift - closely reasoned strategy requires far more detailed description of each clavicle and scapula.

Scapulae are particularly interesting because of their great mobility. To simply describe a shoulder as 'protracted' or 'retracted' can easily, even necessarily, miss much of the detail that lies at the heart of soft-tissue specificity. Imagine a scapula described as follows: 'the right scapula is medially rotated, anteriorly tilted, and posteriorly shifted' (**Fig. 11.8**). The term 'protracted' might be applied to these scapulae, but would not distinguish the degree of medial rotation, or specify the anterior tilt, or how the shoulder was positioned in the A-P axis on the rib cage. All these characteristics, however, have significant implications for how the person's use pattern is understood and thus for our working strategy. A laterally shifted shoulder would lead us directly to the serratus anterior or the subscapularis

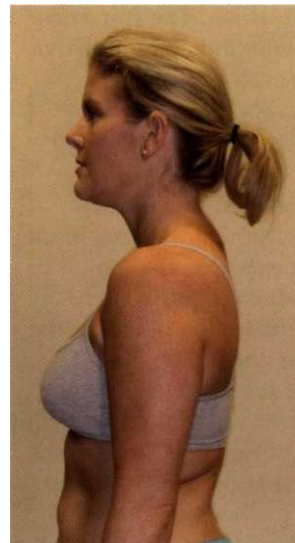

Fig. 11.8 Here we see shoulders that are posteriorly shifted - relative to the rib cage - but then medially rotated to bring the glenium anterior to the vertebral border, thus bringing the anterior face of the scapula to face the midline more; hence, a 'medial rotation' of the scapula is an essential part of protraction.

fascia or the upper slips of pectoralis minor. The anterior tilt element would send us to the lower pectoralis minor and the claviopectoral fascia. The posterior shift would lead us to strategize about the middle trapezius and to add work in the axilla. With this level of description, we approach our work with greatly increased precision. It also allows a discourse in the bodywork field where logical thinking can displace magical thinking.

Feet

The human plantigrade foot is complex enough to warrant special attention. When we use 'rotation' in describing the head or spine, we have a good intuitive sense of what is meant. The same is true for tilts of the pelvis and shoulder girdle, and rotations in the humerus and femur. When we get to the feet, however, the long axis of the metatarsals and of the foot itself is horizontal. Therefore, 'lateral rotation' of the foot will designate that the toes are pointing more lateral than the heels - but then we need to say, 'Relative to what?'. Does the rotation take place in the foot itself, at the ankle, within the knee, or at the hip?

If the top of the foot is farther lateral than the sole and the weight shifts to the outside (a supinated foot), we would say the foot is 'laterally tilted'. Conversely, falling onto the inside of the foot would be 'medially tilted' (see **Fig. 9.49**, p. 201). In the extremes of these patterns, one can also have a 'rotation' *within* the foot, meaning that the metatarsals are pointing more lateral or medial than the heel. The person with bunions could be pedantically described as having a 'laterally rotated hallux' or 'laterally rotated big toe' (in other words, use the midline of the body, rather than the midline of the foot, as the reference).

Since the calcaneus is often the key to support of the back body and sacroiliac joint, a few examples of calcaneal description are also offered. For the person who has the top of the calcaneus more toward the body midline than the bottom we would say, 'medially tilted calcaneus'. If a calcaneus has the lateral side farther forward

than the medial side, so that the front of the bone faces more medially, it would be termed - consistently but a bit counter-intuitively - a 'medially rotated calcaneus (relative to the tibia or the forefoot)'. Such medial rotation and/or medial tilt often accompany a so-called pronated foot, fallen arch pattern. Shifting the Superficial Back Line 'bridle' around the calcaneus is vital to arch restoration, as well as lengthening the *outside* of the foot, along the lateral band of the plantar fascia.

This language requires only a few hours of practice to manage, and only a couple of weeks of regular use of the notation for reasonable facility with the process. Of course, more usual language such as 'Tow arches' or 'pronated feet' can be used when it meets the needs of the moment, but reversion to our terminology can be used for argument, or for simplicity and accuracy in the resolution of ambiguity. It also has a pleasing neutrality: 'medially shifted knees with laterally rotated femurs' may be a mouthful, but for the client it is less demeaning than 'knock knees' and less distancing than '*genu valgus*' (see Fig. 11.6C).

Once the skeletal geometry of the client's standing resting posture has been described to the satisfaction of the practitioner, and noted down, either verbally or pictorially on such a form as can be found on the DVD for the reader's use, we proceed to the second stage.

Step 2: an assessment of the soft tissues

The second step is to apply a model to the soft tissues to see how the client's skeletal relationships, as described, might have been created or are maintained. The Anatomy Trains myofascial meridians is one such model, the one we will apply here, but single-muscle strategies or other available models could be employed as well.⁶⁻¹⁰

Step 2 begins with the question: 'What soft tissues could be responsible for pulling or maintaining the skeleton in the position we described in Step 1?' A second question, 'What myofascial meridians do these myofascial units belong to, and how are they involved in the pattern?' follows immediately.

For example, if it is determined that the pelvis has an anterior tilt (as in Fig. 11.4B), then we could look at the hip flexors for the soft-tissue holding - for example, the iliacus, pectineus, psoas, rectus femoris, or tensor fasciae latae myofasciae. Limitation in any of the first three would lead us toward the Deep Front Line; the rectus femoris might guide us to look at the Superficial Front Line; the sartorius (unlikely; it is too small and thin for postural maintenance) might lead us to the Ipsilateral Functional Line; and the tensor would suggest Spiral or Lateral Line involvement. Alternatively, the pelvis is being pulled up from behind by the erectors (Superficial Back Line) or the quadratus lumborum (Deep Front Line or Lateral Line).

If the shoulder on the right side lives farther away from the spinous processes than the one on the left, we could look to see whether the serratus anterior is locked short. If treatment of that single muscle results in a stable repositioning of the scapula, all well and good; but if not, we are guided toward assessment of the rest

of the left Spiral Line: Are the right ribs closer to the left ASIS than vice versa, as in Figure 11.6A? Perhaps lengthening of the left internal and right external obliques and their accompanying fascia will allow the work on the serratus to hold and integrate.

Perhaps, however, we find that the scapula is not being pulled into a lateral and inferior shift by a short serratus, but rather that the scapula is medially rotated (which often involves some lateral shift). In this case, we might suspect the pectoralis minor (which pulls down and in on the coracoid process to create a medial rotation or anterior tilt or both). If treatment of the pectoralis minor and associated fascia does not solve the problem, we might be drawn into working on either the Superficial Front Line, the Deep Front Arm Line, or the Front Functional Line to see if 'feeding' the pectoralis minor from its lower trunk connections might help the local work be successfully absorbed.

It is important to keep in mind that portions of lines may be involved without affecting the entire meridian. It is equally important to keep the broad meridian view, since, in our teaching experience, practitioners from almost all schools tend to fall into the mechanist's habit of trying to name the individual muscles responsible for any given position. This is, of course, not wrong, merely unnecessarily limited and ultimately frustrating, since it leaves out the fascia and effects over distance.

This 'bodyreading' process of Step 2 is modeled below using client photographs. Although many possible ways of analyzing soft-tissue distribution could be used at this point, we have an understandable prejudice toward employing the Anatomy Trains myofascial meridians schema here. This five-step process, however, can stand independently of any particular method.

By increasing familiarity with the system, it becomes a matter of a minute or two to analyze which lines might be involved in creating the pattern you have observed in Step 1. Trunk and leg rotations generally involve the Deep Front Line or Spiral Line, or both. Arm rotations involve either the Deep Front Arm Line or the Deep Back Arm Line. Side-to-side discrepancies often involve portions of the Lateral Line on the outside and Deep Front Line in the core. The balance between the Superficial Front and Back Line elements is always assessed and noted. If it appears that individual muscles are creating a pattern, we note in which lines this muscle is also involved. The relative positioning among the lines is also important (e.g. the SFL is inferior relative to the SBL, the DFL has fallen relative to the more superficial lines, etc.).

In summary, analysis of the soft-tissue patterning in Step 2 usually takes note of where tissues seem to be short or fixed, where tissues seem to be overlong, and where the biological fabric of the lines has lost its natural draping, i.e. the common pattern where the Superficial Back Line has migrated upward on the skeleton while the Superficial Front Line has migrated downward, independent of standing muscle tonus. These elements can also be noted on the bodyreading form in practice.

Step 3: the development of an integrating story

In the third stage we bring these skeletal and soft-tissue threads together to weave a 'story' - an inclusive view of the musculoskeletal and movement pattern, based on the client's history and all the factors we can see or ask about taken together. A simple (and single-pointed) version of this process might sound like this:

A client presents with shoulder pain in his dominant right side. In looking at the client's pattern, we observe shortness in the left Spiral Line, the right Front Functional Line, and the right Lateral Line, not unlike the exaggerated posture in **Figure 11.3C**. The client is an avid tennis player, and in watching him mock up how he plays tennis, we see all three of these lines are shortened to pull the shoulder down and forward off the rib cage. This short-term attempt to gain more power has long-term negative consequences in straining the trapezius, rhomboids, and/or levator scapulae, and throwing off the head-neck-shoulder balance.

Based on this, you construct a story that aggressive tennis playing has shortened the right side and pulled the shoulder off the torso. Lengthening these lines, while getting the weekend warrior to center his stroke in the middle of his body rather than out at the shoulder, will both improve his game (after a temporary disruption, of course, which some clients cannot endure) and his longevity with the game.

It could be, of course, that the shoulder being pulled off the axial torso and the shortening of the right side pre-dates the interest in tennis, so hold your story lightly and be ready to abandon it in the face of new information.

Include as much as you can in the story you construct, relating the various elements into a whole. In real life, the story can be much more complex, and may have a strong somato-emotional component. Your story may not account for all of the elements observed; after all, the client has had a long life, and not everything fits in neatly like a jigsaw puzzle. The attempt to relate a tilted pelvis (and accompanying sacroiliac pain) to the medially rotated knee and the medially tilted ankle on the opposite side is an instructive one. The story can help you know where to begin, even though it is some distance away from the site of pain, strain, or injury.

Perhaps you remember those clever Chinese wood puzzle boxes, where, in order to have the drawer open, several little pieces of wood would have to be slid past each other successively. As a child, you struggle to open the drawer, until some adult comes along to show you the sequence. Likewise in manual therapy, we struggle to fix some offending part. What the Anatomy Trains map, and this method of bodyreading in particular, does for us is to show where the other bits are - way on the other side of the 'box' - that need to move beforehand, so that when we return to the offending area, it just slips into place more easily.

Putting the observed skeletal misalignments and the soft-tissue pulls into a comprehensive and self-

convincing story is a subjective process, very much subject to revision in light of experience, but a valuable one nonetheless.

Step 4: the development of a strategy

Using the 'story' from Step 3, the fourth step is to formulate a strategy for the next move, a session, or a series of sessions, based on that global pattern view. Continuing this process for our tennis-playing client (again with the proviso that we are examining only one factor out of the multitude any given client would present), we decide to work up the right Lateral Line from hip to armpit, up the left Spiral Line from left hip to right scapula, and up the Front Functional Line toward the front of the right shoulder - all in an attempt to take away the postural elements that are pulling the shoulder off its supported position on the rib cage. We can then apply trigger point, positional release, cross-fiber friction therapy - whatever is appropriate to the specific injury - to the structure in trouble (perhaps the supraspinatus tendon, or the biceps tendon), secure in the knowledge that it has a far better chance of healing and staying healed if the shoulder is in a position where it can do its job properly without extra strain. Having lengthened the locked-short tissues, we can construct homework for the client to strengthen and tone the locked-long tissues.

In working more complex problems, the strategy may involve more than one session. The general strategy of Structural Integration (as we teach it - see Appendix 2) involves exploring and restoring each line over the course of a full session, resulting in a coherent series of sessions, each with a different strategy. With the role of each line in the 'story' noted down, it is quite possible to stay on a multiple session treatment strategy without addressing the injured part (except for palliation) until it is appropriate and fruitful.

If the strategy is less injury/pain oriented, and the work is being used for performance enhancement or as a 'tonic' for posture and movement, the story and strategy are still important to unwind the details of each person's unique and individual pattern.

Step 5: evaluation and revision of the strategy

Keep reassessing Steps 1 through 4 in light of results and new information. After completing the strategy from Step 4 on our putative client, we find that the shoulder is mostly repositioned, but now immobility is apparent between the scapula and the humerus in back, so we revise/renew our strategy to include the infraspinatus and teres minor tissues of the Deep Back Arm Line.

After completing any given treatment strategy, an honest assessment is required as to whether the strategy has worked or not, and what, precisely, the results are. We are required to make a fearless re-examination, i.e. go back to Step 1. If our strategy has worked, the skeletal relationships will have altered. We can note these, and go on to Step 2 to see what new set of soft tissues we

can address to move the pattern along toward increased balance and support. If there has been no change, then our strategy was wrong, and we go to Step 2 to develop another strategy, addressing a different set of soft tissues in hopes of freeing the skeleton to return to balance. If several successive strategies fail, it is time to refer to a mentor, refer the patient to another practitioner, or find some new, as yet untried, strategy.

Virtue

It is very important to note here that there is no virtue involved in having a symmetrical, balanced structure. Everyone has a story, and good stories always involve some imbalance. Without doubt the most interesting and accomplished people with whom we have had the pleasure and challenge to work have had strongly asymmetrical structures, and live far from their optimal posture. In contrast, some people with naturally balanced structures face few internal contradictions, and as a result can be bland and less involved. Assisting someone with a strongly challenged structure out of their pattern toward a more balanced pattern does not make them less interesting, though perhaps it will allow them to be more peaceful or less neurotic or to carry less pain. Just, at this juncture, let us be clear that we are not assigning any ultimate moral advantage to being straight and balanced. Each person's story, with so many factors involved, has to unfold and resolve, unfold and resolve,

again and again over the arc of a life. It is our privilege as structural therapists to be present for, and midwives to, the birth of additional meaning within the individual's story.

Postural analysis of five 'clients'

The following analyses of these clients are made solely on the basis of the photographs included herein. They were chosen to demonstrate particular patterns and because the compensations are easily seen in the small photos allowed in a book format. In person, much smaller (but still important) deviations can be observed, noted, and treated. A few other photos are included on the accompanying DVD; and many more photos are included in our Bodyreading DVD course (**DVD ref: BodyReading 101**).

Except for one set, we have no more history or access to their movement patterns than the reader does. Any photographic process necessarily involves some subjective elements - the happenstance of the clients positioning themselves, principally. Within those limitations, we will run through the steps of this process. In practice of course, the client's history, subjective reports, movement patterning in gait and other activities, and most importantly the repetition of the patterns observed would be part of our assessment. This section is designed simply to give the reader some practice with looking at postural compensation in this way.



Client 1 (Fig. 11.9A-E)

In taking an initial look at a prospective client from the front (**A**), we do well to tot up the advantages and strengths the client brings to the collaborative process before we detail any problems that concern her or ourselves. Here we see a strong young woman who seems securely planted, fairly well aligned, a long core, and with a gentle demeanor and a healthy glow. There is a slight 'down' feeling in the face and chest that goes against this basic vitality, with a deeper tension in what Phillip Latey would call 'the middle fist' or loss of heart energy, seen in the relative lack of depth in the rib cage.¹¹ The grounding and muscular responsiveness evident in this client are qualities that will help us in our journey if we call them forth.

Step 1

Having noted these general (and somewhat value-laden, so hold them lightly) considerations, we proceed to Step 1, describing as objectively as possible the relative skeletal position. Looking at lateral deviations from the front, this client presents with a slight left tilt to the pelvis, which causes a slight left shift of the rib cage (note the difference in the waist on the left and right to see this imbalance). This is combined with a right tilt of the ribs that brings the sternal notch back to the midline. The shoulders counterbalance this with a slight right tilt.

The back view (**B**) shows the same picture a little more clearly, and shows that the left leg is the more heavily weighted one. This makes some sense, because the rotation is in the right leg. As shown by the patella, the right femur seems to be medially rotated compared to the tibia-fibula, which seem laterally rotated. From the back, we can also see that the shoulders look medially shifted (retracted), laterally tilted (downward rotation), and superiorly shifted (lifted).

If we look at the side views (**C and D**), we see the head shifted forward (so we can presume an anterior bend in the upper thoracics, and a posterior bend (hyperextension) in the upper cervicals. Old Ida Rolf would have urged her to put her hair on top of her head so that it would not act as a counterweight for her head position. We can see that her shoulders, especially the right one, are superiorly shifted and posteriorly shifted relative to the rib cage, and the left one, though better situated in general on the ribs, has a slight anterior tilt. (Read this from the vertebral border of the scapula: the left is vertical like a cliff; the right is tilted a bit like a roof.)

The lumbar have a long curve, speaking to her long core structure, but what remains for the thoracic spine means a fairly sharp thoracic curve. The long lumbar curve relates to her knees, which are slightly posteriorly shifted (hyperextended). The pelvis, however, looks fairly neutral relative to both the femur in terms of tilt and the feet in terms of shift, though some would feel she has a slight anterior tilt.

Looking down from the top (**E**), and using the feet as a reference, we can see a slight left rotation of the pelvis

on the feet and a slight right rotation of the ribs on the pelvis (look at the bra line for this), whereas the shoulders are again left rotated on the ribs.

Step 2

Proceeding to Step 2, we make the following surmises based on our observations in Step 1. Looking from the side, we can see that the Superficial Front Line (SFL) is pulled down along most of its length. The shortness from the mastoid process to the pubic bone is readily visible, and the shortness along the front of the shin accompanies it.

The Superficial Back Line (SBL) is pulled up from the heels to the shoulders, and shortened through the neck and the back of her head.

The right Lateral Line (LL) is shorter than the left from ear to hip, while the left lower LL is shorter than the right on the outside of the leg.

We would expect to find the right upper Spiral Line (SPL) shorter than its left complement, as the right ribs are drawn toward the left hip, and the head is tilted slightly to the left. The anterior lower SPL (TFL, ITT, and tibialis anterior) is shortened on the right leg, where the left shows a more even-toned balance.

Pectoralis minor is pulling the right shoulder forward over the ribs and there is some adduction going on in both arms, probably due to the coracobrachialis or the myofascia of the back of the axilla. The humeri seem a little laterally rotated for her body (look at the cubital fossa) but not by much.

Step 3

Bringing all these observations into a coherent story would require weaving them in with a full history, but in general, we can say that most of this woman's pattern is built on:

1. The shortening and downward motion of the fascia in the front of the body, restricting the excursion of the ribs and the placement of the head, requiring compensation (lifting and hiking) in the shoulders and back.
2. She has a slightly longer right leg (probably functional, but we cannot tell from a simple photograph), which accounts for several things: the twist in the right leg is attempting to equalize the leg length, the tilt in the pelvis results from the length discrepancy, and the shift in the ribs away from the high hip is a common compensation. Additionally, the small twists in the torso and legs come from trying to accommodate the differences in what looks like a strong exercise regimen.

Step k

Based on this assessment, we can move toward Step 4, a general strategy leading to a specific treatment plan. The major elements of the overall plan for this client would include:

1. Lift the tissues of the entire SFL, especially in the areas of the shin, chest and subcostal angle, the neck fascia and sternocleidomastoid.

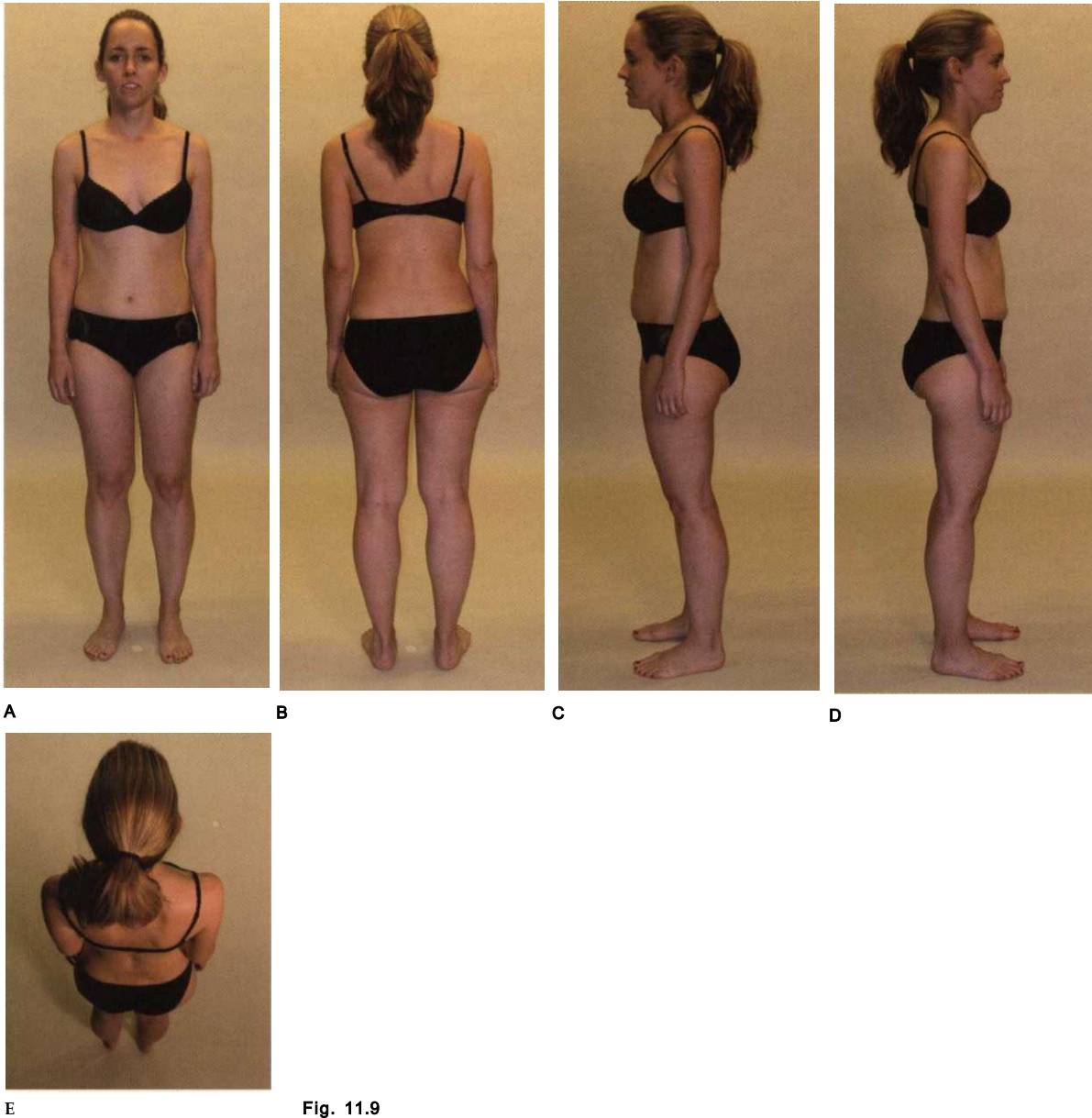


Fig. 11.9

2. Drop the tissues of the SBL from the shoulder to the heel.
3. Lengthen the tissue of the right LL between the hip and ear, especially in the lower ribs and lateral abdomen. Lengthen the tissues of the left LL along the outside of the left leg.
4. Lengthen the tissues of the upper right SPL from the left hip across the belly around the right shoulder and across again to the left occiput.
5. Ease and open the tissues of the right lower SPL and work around the knee to de-rotate the strain in the right knee.
6. Ease out the Deep Front Arm Line, especially the pectoralis minor/coracobrachialis complex on the right. Ease the Superficial and Deep Back Arm Lines to let the scapulae find their proper position farther away from the spine, and balance the rotator cuff.
7. Lift the tissues of the Deep Front Line along the medial side of both legs, and especially in the left groin leading to the left lumbar spine (psoas complex). Lengthen the tissues on the deep anterior of the neck that are anchoring the head into the chest and preventing chest excursion.

This outline covers at least several sessions, and would be sequenced according to the principles of Anatomy Trains treatment and myofascial release work (see Appendix 2). The treatment plan would always be subject to Step 5, reassessing in the light of new observations, the client reports, and palpatory experience.

Client 2 (Fig. -1-1-10A-E)

Here we see a middle-aged gentleman, clearly active and with his intelligence engaged with the world. He shows basic good balance from front to back, good muscle tone for his years, and solidly planted feet. Core support through the pelvis is fundamentally good, and the structure is basically open. That said, we have some significant compensations to usefully read from these photos.

Step 1

Looking from the front, the most prominent feature is the rib cage tilt to the right that helps create a right shift to the head. Bringing some detail into this picture, the right lower leg is laterally rotated and the right leg is shorter than the left (again, we do not know from a photo whether this is anatomical or functional). In either case, this creates a right tilt to the pelvis, and the whole structure of the body seems to 'fall' into the right groin, with the left hip being compressed.

Seeing this from the back, the medially tilting (pronating) right foot and the twist in the tissues of the right leg are prominent, the right tilt of the pelvis is again visible, along with the tilt and shift of the rib cage to the right. Coupled with this is the tilt of the shoulder girdle to the right, a tilt of the neck to the right, and a compensating tilt of the head back toward the left on the neck. We can imagine - but would have to do palpation tests to confirm - a slight left bend in the lumbar, a stronger right bend in the upper thoracics, and a left bend in the upper cervicals.

From the side, the head forward posture predominates, and we note the disparity between the shallower lumbar curve and the deep posterior bend of the mid- to upper cervicals. The shoulders are a bit posteriorly shifted, anteriorly tilted to counterbalance the head. Interestingly, the torso seems posteriorly shifted relative to the femur in the left-hand view, but more aligned over the femur in the right-hand view. This is countered by the view from above (E), where very little rotation is in evidence, even though we 'know' that the body cannot have the shifts and bends he shows without accompanying rotations.

Step 2

Based on this sketch of the prominent features, we observe that the SBL has been drawn up along its whole length, but especially from the sacrum up to the shoulders. The suboccipital muscles are also locked up. Correspondingly, the SFL is pulled down all along its length, somewhat similar to Client 1, though with a more male pattern.

On the left, the LL is pulled up from lateral arch to shoulder, and then pulled down from the ear to the shoulder. Work on this side should proceed out in both directions from the shoulder area. On the right, the LL is pulled down to just above the knee, and up from the arch to the knee, so work on this side should proceed out from mid-thigh in both directions.

The left upper SPL is clearly the shorter of the two SPLs, pulling the head into left lateral tilt, pulling the

right shoulder forward, and pulling the right costal arch over toward the left hip. In the legs, the left lower SPL is pulled up in its posterior aspect from lateral arch to hip, whereas the right lower SPL is shorter in the front, drawing the ASIS down toward the medially tilting inner arch.

The difference in the level of the hands is occasioned by the tilt of the shoulder girdle, which again rests on the tilt of the rib cage. Work with the rib cage position is probably the most effective way of getting the arms to even out, though some supplemental work with the Deep Front Arm Line on the right, and Deep Back Arm Line on the left will be helpful. The right Front Functional Line is clearly shorter than its complement.

In the Deep Front Line, we see a shortness in the right groin which is tied into the inner line of the right leg all the way down to the inner arch. This shortness is clearly pulling on the spine, creating compensatory tension in the opposite quadratus lumborum and other tissue of the left lower back. We can also imagine that the deep tissue on the left side of the neck - the middle and posterior scalenes in particular - is under eccentric strain (locked long).

Step 3

The story here focuses on the shortness in the right groin; much of the other patterning in the torso derives from compensations for this pulling down from the right leg in standing. Whether the fallen medial arch on the right foot pre-dates or post-dates the groin pulling, the arch seems mild in comparison to the hip. The rib and head shift, shoulder tilt, and torso rotation all proceed from this shortening.

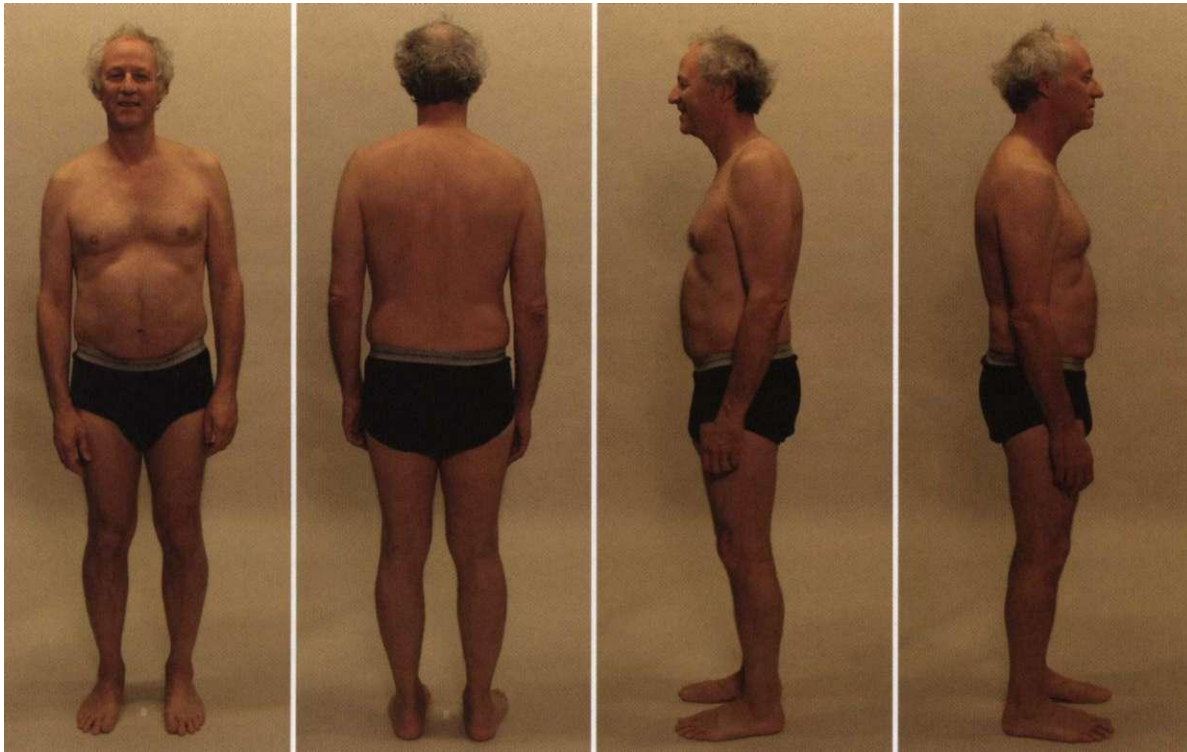This rotational pattern, coupled with the strong head forward posture, accounts for nearly all the compensatory patterning we see in this gentleman.

Step 4

The soft-tissue strategy would begin with lifting the SFL and dropping the SBL, paying particular attention to the tissues of the neck to free the suboccipitals (one suspects years of glasses or computer work). Letting go of the fascial lamina that runs behind the rectus abdominis would be important, and seeing the cervical curve reduce and the head go up on the body should begin with this SFL and SBL work.

The LL work has already been outlined above. On the left side, work the tissues of the LL up from the shoulder to the ear to lengthen the left side of the neck, but work down from the shoulder to the ankle to settle that side down. On the right side, the tissue needs to be lifted from above the knee to ear, and repositioned downward from mid-thigh to the lateral arch. We can surmise with some assurance that the abductors on the left side will be extra short and tight and require some opening work.

The left SPL will require lengthening from the left ASIS across the belly to the right ribs, and around the torso to the left side of the neck in back. The left upper SPL should require substantially more work and move-

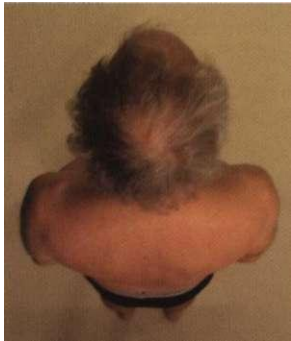

A

B

C

D



E

Fig. 11.10

ment than its counterpart on the right. In the legs, the posterior part of both SPLs could be dropped toward the outer arch, but in the right leg, the anterior lower SPL needs lifting from the arch to the ASIS. The fallen arch and the medial rotation of the knee relative to the tibia and foot are both indicators for this.

The shoulders and arms will require balancing work once the rib cage has taken a more relaxed and centered position.

The key to this overall pattern, however, lies in the Deep Front Line work, which has a chance, if the leg length difference is not anatomical, to open the right groin and allow the upper body to right itself. From the groin, the psoas complex reaches up to the lumbar spine, and freedom from the shortness in the right leg will make all the difference to the lumbar, the rib cage, and the neck.

Client 3 (Fig. H.HA-E)

In our third model we have a young woman who presents a structure which is superficially like that of Client 2, but with some fundamental differences. Here we see a strong and sturdy structure, well muscled and well founded, with a bright and attentive look from the eyes atop the structure. Nevertheless, this muscular strength is built around some skeletal aberrations that we would want to address before she did any more muscle-building work.

Step 1

The head shows a left tilt and right shift relative to the neck. The shoulder girdle is right tilted, as is the rib cage underneath it. The pelvis is also right tilted, but the alignment of the three major torso weight segments - head, ribs, and pelvis - shows that there must be a left bend in both the lumbar and the upper thoracic/lower cervical spine (both visible in the back view).

Although this woman looks somewhat pulled into the right groin - a milder version of what we saw in Client 2 - the cause is not the same. Here, the legs are the same length, and the pattern is almost entirely from a twist in the pelvis on top of the femurs, not a difference in the femurs making itself felt in the pelvis.

Below the pelvis, the knees have a lateral shift (*varus*), sitting on nice, wide, well-grounded feet. The difference in the arm length is once again due to the tilt on the rib cage, not an inherent difference between the arms.

Looking from above, and again remembering to use the feet as a reference, we can see the right rotation and right tilt of the pelvis relative to the feet, and the left rotation of the ribs relative to the pelvis.

These rotations go some way to explaining the difference we see between the left and right side views. Both show a slight anterior head posture, and both show an anterior shift of the pelvis over the feet, but these shifts on the right side are far more apparent than on the left. Both knees show a posterior shift (hyperextension locking).

Both sides show an anterior tilt of the pelvis relative to the femur, which leads to the long lumbar curve, which we would term a posterior bend of the lumbar. This posterior bend leaves the rib cage with a posterior tilt, which helps keep the head on top of the body. Lift her rib cage and hold it vertical to see the head go more out in front. Lengthening work with the anterior scalenes and sternocleidomastoid would be necessary to 'open the calipers' of the angle between the thoracic and cervical spine.

Step 2

We can see some pulling down in the upper SFL, though generally the shortness in the SBL is acting like a bowstring, and pushing the skeleton forward into the SFL. Thus, the SFL would assess as 'tight'; however, this would not be a call for loosening it, but rather the SBL between shoulders and heels. The hamstrings and lumbar erectors and multifidus cry out for work.

In terms of the LLs, both LLs in the thigh are in need of dropping, and the abductors will be short due to the postural abduction of the hip joints. In the upper body, the LL on the right needs lifting from waist to cervicals, and the left side needs dropping from ear to waist, though the deeper structures on that side, like the iliocostalis and quadratus lumborum, need serious lengthening.

As in Client 2, the left SPL is shorter than the right in the upper body, with the lower anterior SPL shorter on the right, and the lower posterior SPL shorter on the left.

The Back Arm Lines, both Deep and Superficial, need release in the proximal tissue to allow the shoulders to sit more comfortably down on the rib cage.

The Deep Front Line, the core, is again the key to opening this structure. The legs form a bow; therefore the inner line of the leg is the bowstring, short from ankle to ischial ramus. The shortening through the psoas complex on the right and the deep lateral rotators on the left will engage our attention to untwist the pelvis. Balancing around the lumbar spine would be our next job, in order to release the right side of the neck from the deep structures of the chest.

Step 3

We do not know whether the pelvis twist might not be occasioned by something internal, such as a rotated cervix, but this is certainly the centerpiece of this structure. It requires a tightening of the Deep Front Line below it, drawing the legs into a bow, and it is pulling down and twisting the torso above, despite her best efforts to stay balanced and symmetrical through her exercise. The key to unlocking this structure will be to free the pelvis from below, from the front, and from the back.

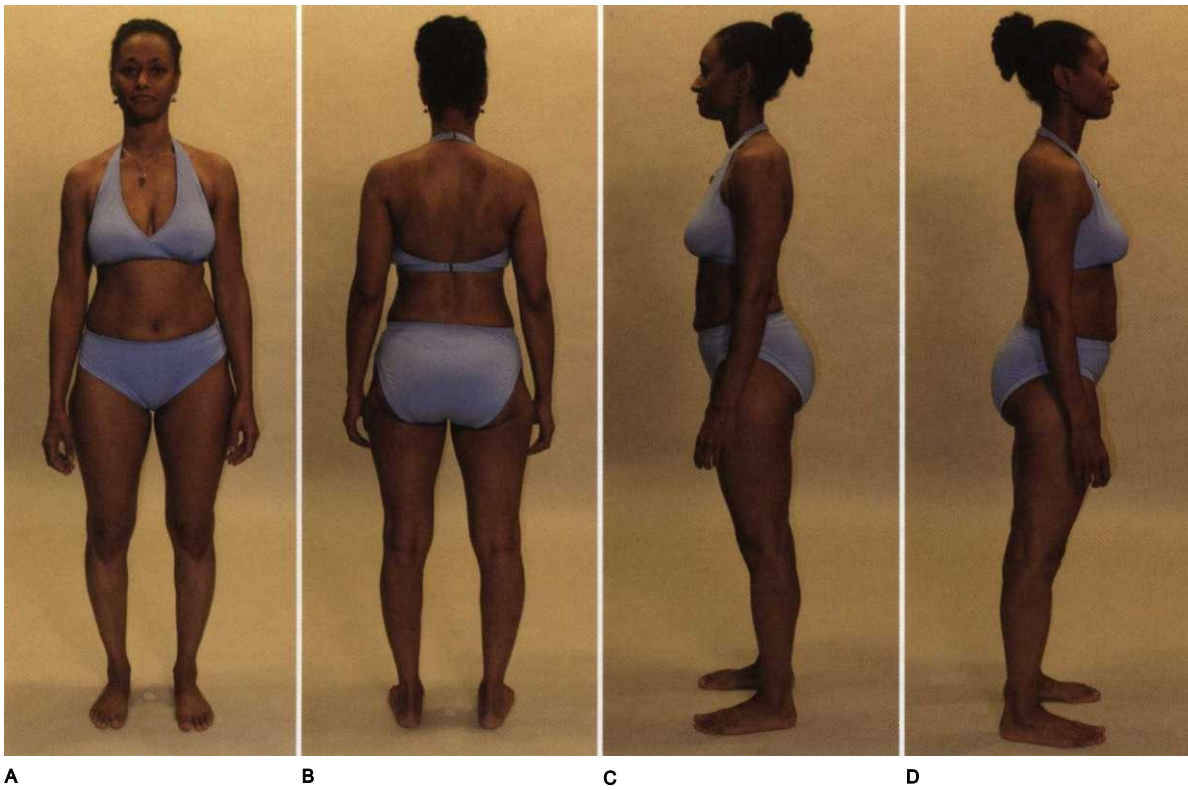
Step 4

This woman will not require so much work in the middle of the SFL, but will require work in the chest and neck to free the head from the ribs, and down in the shins to unlock the knees. The SBL, however, will require substantial work to undo the 'bow', and to loosen the tissue behind the cervical and lumbar curves.

The LLs mostly need spreading in either direction from the waist, but the right needs a lot of lifting in the upper quadrant, and more specific freeing in the lateral abdominals and quadratus lumborum on the left.

As stated, these would be preliminary moves to getting the pelvis to let go of the torque it is putting through the hips below and the spine above. This is primarily Deep Front Line work, letting go of the adductor fascia and the line of fascia down the inside of the tibia associated with the deep posterior compartment of the leg. The pectineus on both sides will need work to reduce the anterior tilt, but the apparent right rotation of the pelvis on the femur suggests that the right pectineus will engage more of our attention.

Freeing and balancing the pelvis will make for easier breathing (at present, she is tightening the upper abdominals to mediate between the pelvis and ribs, and this is

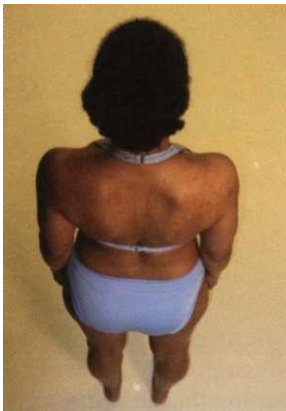

A

B

C

D



E

Fig. 11.11

restricting breathing, and as well with the posterior tilt of the ribs, the diaphragm is facing forward rather than facing down toward the pelvic floor).

When the pelvic rotation begins to free (no need to wait until it is perfect), the spinal muscles can be addressed to undo the rotation in the spine and ribs. This would also give us the opportunity to loosen the myofascia in the posterior shoulders, to let them sit down onto the 'new' rib cage and spine.

Client *k* (Fig. 11.12A-E)

This man with an ectomorphic tendency (big head, long thin bones and long thin muscles) is nevertheless relatively well muscled and presents with a gentle and light-hearted demeanor. What balance he has achieved could be augmented with some soft-tissue work.

Step 1

From the side, the relatively good alignment (compared to Client 3, for instance) nevertheless shows the same pattern of a bow from heel to shoulder, counterbalancing the head forward posture. Another way of putting this is that the head is over the pelvis and the shoulders are over the heels. The pelvis is a bit anteriorly shifted relative to the feet, and anteriorly tilted relative to the femur. The rib cage is posteriorly shifted relative to both head and pelvis, and a bit posteriorly tilted as well.

The scapulae both medially rotate strongly to bring the glenium around to the front. Without this move, the shoulders would be well behind the rest of the body.

Though there is relatively good right/left balance, we can see some underlying compensations. The head tilts to the right, while the neck tilts to the left. The shoulders seem slightly tilted to the right as seen from the back. The rib cage looks slightly tilted to the left, as does the pelvis. The weight is clearly falling more on the left leg.

The legs themselves seem well balanced medial to lateral, with a slight lateral shift in the knees, but not as prominent as Client 3. The right leg rotates laterally at the hip.

Seen from above, there appears to be a mild left rotation of the pelvis on the feet, and a corresponding mild right rotation of the ribs on the pelvis, with the shoulders going along for the ride. We can surmise, then, that there must be a slight left rotation of the cervicals to bring the eyes back into alignment with the pelvis and feet.

Step 2

The SFL is pulled down in a classic way all along its length, and the SBL correspondingly hiked up from heels to shoulders. The SFL needs special attention through the chest and neck areas, and in the SBL, the suboccipitals call out for opening and differentiating. (We know glasses are a factor here.)

The LLs are not much out of balance here, though the abductors look short on both sides, especially the left.

Likewise, the left side of the neck could use some more length.

In this case, the right SPL is shorter, pulling the head into a right tilt, and pulling the left shoulder and ribs around front toward the right hip.

The shoulders and arms will be helped by lifting the chest and bringing the ribs forward and up to support the shoulders, but the Front Arm Lines, Deep and Superficial, will aid in this shift as well.

Here, core length is countered with core rigidity, so opening the Deep Front Line from inner ankle to anterior neck will help to open up the movement, bring the pelvis back from its anterior tilt, and open the inner tissues of the rib cage.

Step 3

This structure shows remnants (and here we take a wild leap at conjecture) of having been the proverbial '90-pound weakling' when a child. Although now clearly adult in both form and function, these remnants can be seen in the arms, pelvis, and chest, and probably still 'run' this gentleman in subtle ways. The 'withdrawal' of the chest and the size and weight of the head are probably the most salient factors guiding this structure; get the chest up and forward in an integrated way and many of the rest of the factors will fall into place.

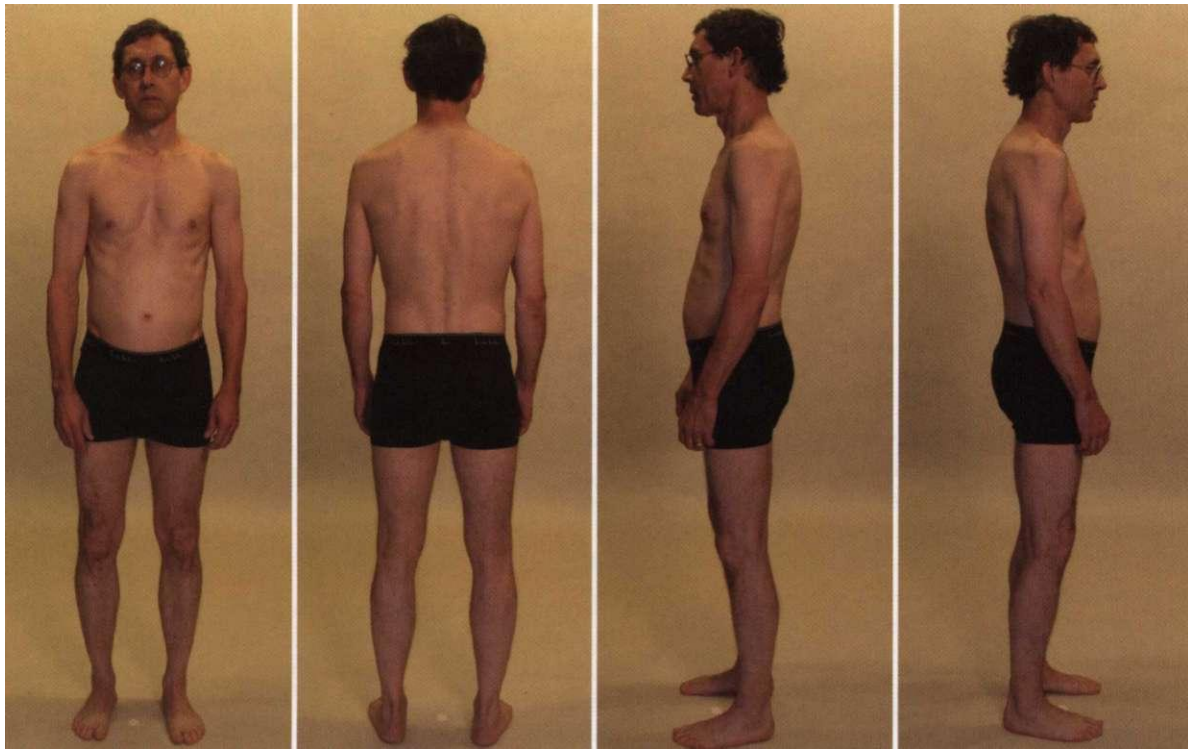
Step 4

The SFL must be lifted along its entire length, and the SBL dropped. Much attention will be needed for the chest, and under the costal arch, as well as the neck, to allow the front of the ribs to lift, and thus in turn lift the head.

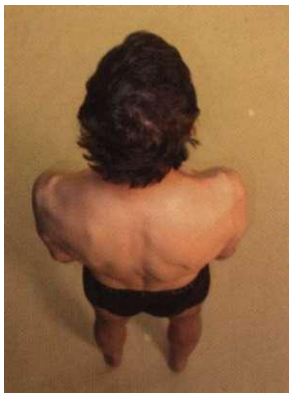The LLs could be worked out from the waist, but aside from making sure the abductors were a bit longer, these are not central to the cause. The right SPL, however, could use some attention to lengthen it away from the predominant rotation.

The upper reaches of the pectoralis minor (DFAL) and serratus anterior will need lengthening, as will the rotator cuff of the DBAL - loosening the cuff muscles so that the rhomboids and trapezius can tone up a bit to retract the scapulae.

Lengthening the Deep Front Line structures will take the remaining bow out of the legs, and help the pelvis come back from its anterior tilt. More extensive work (helped by a visceral approach) will allow the endothoracic mediastinal tissue to relent, allowing the ribs to come up and support the head.



A B C D



E

Fig. 11.12

Client 5 (Fig. 11.13A-E)

This very fit young woman arrives with basic good balance, a long core, and obviously well-trained muscle tone. Nevertheless, even this young woman shows tendencies which, if left unchecked, could lead to troubles in later life.

Step 1

Looking from the front, the most obvious feature is the left shift of the ribs relative to the pelvis. If we 'read' the waist, we can see that from the left waist, we only have to go out a little bit horizontally before we could drop vertically clear of the trochanter. If we do the same on the right, we see how much farther we must go horizontally before we could drop clear of the greater trochanter vertically. This is a good way to read the shift of the ribs on the pelvis; measuring the space between the arms and the body, although it works in this case, is not a good measurement tool.

The shift of the ribs is correlated with the right tilt of the rib cage, and the right tilt of the shoulder girdle follows along. The neck tries to tilt a bit to the left to counterbalance the right tilt of the ribs, but the head again tilts right.

A third and more subtle effect of the weight shift to the left can be seen in the left knee, where the strain on the medial side is clearly visible, and the rotation at the knee between the medially rotated femur on the laterally rotated tibia further increases the strain through this joint. At her age, she may feel none of this, but the stage is being set for medial collateral or anterior cruciate ligament problems some years down the road.

From the side, and working up from the bottom, we can see that her heels are anteriorly shifted - pushed into the foot, as it were - so that most of the body is located over the anterior foot (see p. 80 for further discussion). The knees tend toward hyperextension, and the pelvis is both anteriorly shifted relative to the feet, and anteriorly tilted relative to the femur.

There is a strong and sharpish posterior bend at the top of the lumbar, which sets the rib cage into a posterior tilt. The lower neck has an anterior tilt (again, if we held the rib cage vertical, the head would go further forward), and the occiput is anteriorly shifted on the atlas.

Shifts are most often accompanied by rotations, so in looking from above, we see a right rotation of the pelvis on the feet, a left rotation through the lumbar and lower thoracics, a right rotation in the upper thoracics (with which the shoulders go along), and therefore there must be a mild left rotation in the cervicals to bring the eyes to the front.

Finally, we note that the left calcaneus is medially tilted, whereas the forefoot on the right seems medially tilted.

Step 2

The obvious discrepancy front and back brings our attention to the relation between the SFL and the SBL. The SFL is 'up' in the chest mostly and in the neck as

well, but in the shins the SFL is pulling strongly down. In the SBL, the low back is an obvious place for lengthening, but the lower hamstrings beg for lengthening as well.

The left LL is short from hip to ankle, and the right LL needs lengthening from waist to ear. The shift in the ribs will require some complex unwinding in the lower back of both sides. The tissue is clearly pulled in overall on the left side, but the tissue running from the 12th rib to the lumbar is clearly shorter on the right. Once again, the left upper SPL will be shorter than its right-side counterpart.

The Deep Front Line is shorter up the inside of the left leg than the right, and is probably mediating the twist of the pelvis on the feet. Obviously the Deep Front Line is involved with the confusion in the lumbar area and the rib shift.

Step 3

We wonder whether something happened to the right leg that she shifted the weight off it onto the left, but in the absence of a history to refer to, or a living, speaking client, we can only surmise. In any case, almost everything in this structure is a result of that shift, right down to the feet, and up the head. There seems to be a slight maturity issue in the pelvis - it seems 'younger' than the rest of her - with the knees locked back, the pelvis in front of the feet, and the upper body leaning back.

Step k

A treatment strategy for this person would involve dealing with the front-back issues to some degree before tackling the main issue of the rib shift. The SBL would need to be dropped and opened in the lumbar, and an attempt made to get the lower leg under the upper leg. At the same time, the lower part of the SFL would need to be lifted, and the anterior track of the Deep Front Line opened to let the pelvis return toward a neutral tilt.

Once these tissues were somewhat resilient, the left-right issues could be addressed, releasing the LL on the left from hip to ankle and the LL on the right from hip to ear. The left SPL could be released, and then and only then would it be profitable to go into the psoas complex on the left, lifting the lumbar up and away from the left hip, and resettling the ribs in a more balanced place.

Getting more stability through the left heel and the right medial arch/forefoot would figure in our plans, as would balancing the head on the neck.

The adductors of the Deep Front Line on both sides, but perhaps more on the right, are involved with maintaining the twist between the pelvis and the feet. The psoas is clearly pulling the rib cage off to the left, but passive tension in the right psoas may be contributing to the left rotation in the lower thoracics. Getting these tissues balanced would be the main task of our interaction with this fit young woman. The strain in the knees should be relieved by these manipulations, but some attention to the knees themselves would be called for if they did not.

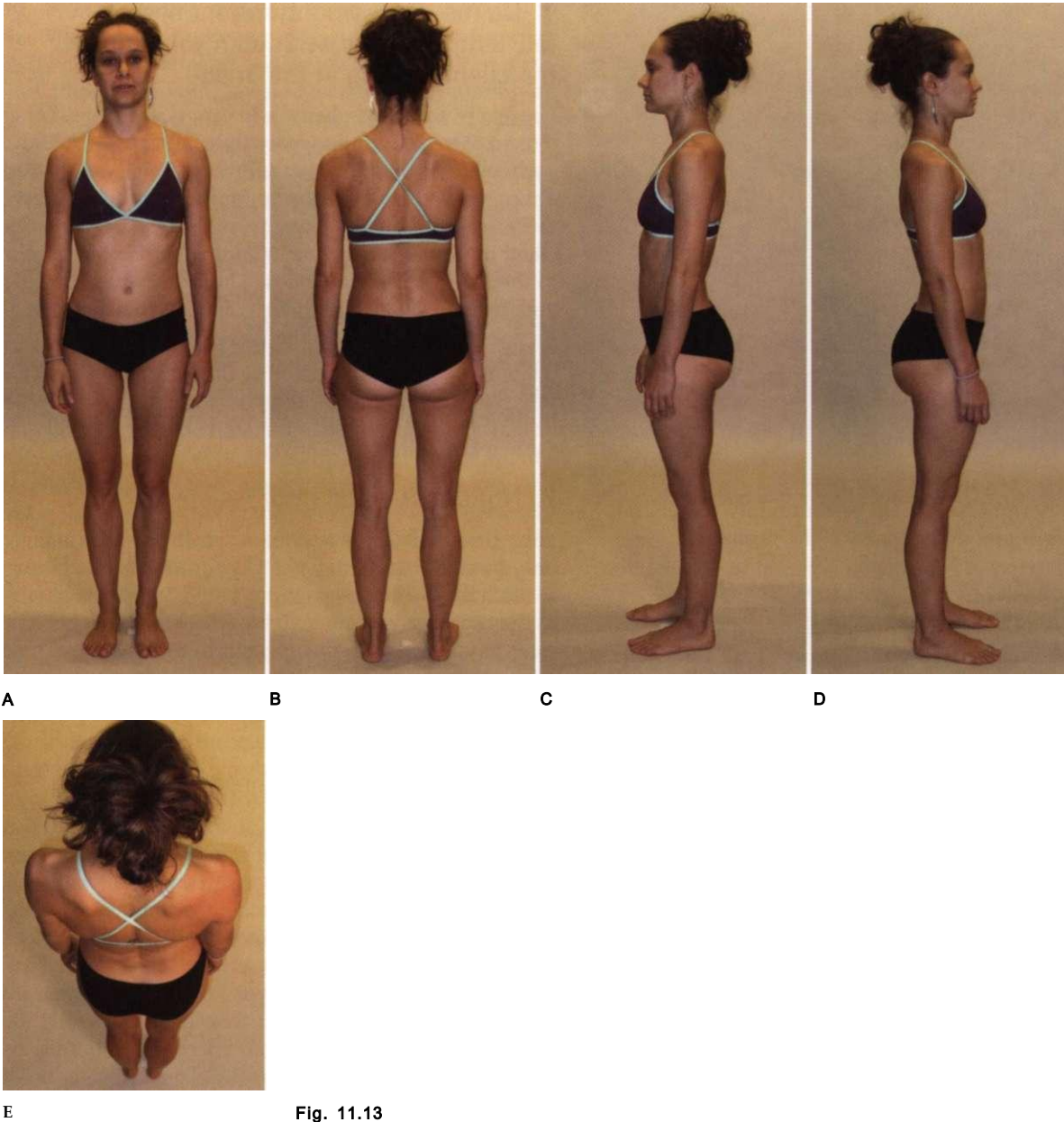


Fig. 11.13

Summary

We have deliberately presented these photos without recourse to the client histories or symptoms, so that we could see the structure/postural compensations objectively, without the filter of what we 'know' about them. In practice, of course, the two come together in the story-making part of the process. Even so, clients' reports of their own histories can be deceiving, giving added value to the objective analysis of clients or photos prior to getting their history, which can sometimes guide the practitioner down a primrose path.

As a simple example, a young man came for sessions whose lower right leg was clearly jutting laterally out from his knee more than the left. (In our language, his right lower leg was medially tilted, or if he stood with his feet close together and parallel, his right knee would

appear medially shifted.) When asked about this, he related that he had skied into a tree at age 22, badly fracturing his right lower leg. Thus reassured as to the source of the pattern, we went to work. Puzzled about the way the area was responding, I asked him to bring in photos of himself, preferably with fewer clothes, before the accident. Next session, he brought in a photo of himself aged 15, on a beach, catching a ball. The right leg was clearly manifesting the same pattern, so it obviously pre-dated the skiing accident. It turned out that the initial pattern began when his tricycle fell on his leg in a spill when he was but three years old. When he ran into the tree, we can surmise, he automatically protected those parts of his body that were clear in his body image, but this lower right leg had been partially out of his kinesthetic picture for a long time - what Hanna calls sensory-motor amnesia.¹² Thus it may not have received



the same amount of attention, or been able to react as quickly, so that, other things being equal, it was more prone to injury. In any case, it illustrates the need to watch the story within the body itself as well as the client's rendition, which must be listened to carefully yet taken with a pinch of salt.

This chapter introduced a method of postural analysis - or, more specifically, habitual patterns of overall compensation - which adds to the efficiency and efficacy of manual/movement therapies. A single chapter is necessarily introductory, and we offer an expanded presentation in DVD form (DVD ref: *BodyReading 101*). The great advantages of using the Anatomy Trains myofascial meridians approach in such an analysis are that:

- it encourages the development of a common terminology that could speak across multiple treatment methods;
- this description can also be commonly understood by clients and others outside the profession;
- the description is objective, internal to each person, and value-free;
- it leads to specific treatment plans which are testable hypotheses.

This is not intended to deny the value of other approaches; we have seen many times that almost any point of entry into viewing the human system can ultimately be followed to a useful description. This global pattern assessment myofascial meridians approach progresses from the skeletal geometry to a strategy for soft-tissue or movement work without resorting to such value-laden statements as "She's depressed", or "He doesn't breathe properly," or "She is not grounded because she hasn't worked out her 'father' issues." On the other hand, it does allow us to set a personal and inclusive context where the client is viewed not simply as 'a frozen shoulder' or 'an ACL tear' or a pair of flat feet.

It is the fond hope of the author, and of the many people who have contributed to the ideas herein, that this scheme or something like it can begin to bridge the gaps not only among modalities but also between the artist and the scientist who lives within each of us. The same two tendencies, of course, stretch within every one of the manual and movement therapy communities, as well as across the profession as a whole. This book is dedicated to the tireless work of these diverse people who, together, created the renaissance of hands-on and movement healing.

Subjective elements

In order to round out the 'artistic' side of bodyreading, we include some more subjective suggestions for using these ideas in practice.

While the method above is supremely useful in finding our way to work, the less objectifiable assessments nevertheless have significant value. The following four elements can be included, depending on the predilection of the practitioner or the client, into the process of visual assessment:

1. Do the assessment in front of a full-length mirror, with both you and the client looking at the image

Especially for those clients who are new to this, being looked at in your underwear while being assessed (and perhaps found wanting) can be too reminiscent of bad dating or medical experiences for many people. A lot of these feelings can be circumvented by standing your client in front of the mirror, standing behind and a little to the side (so that you can see both their back directly and their front in the mirror), and asking them what they see. Most people in the Western world have a long and detailed list about what is wrong with their body, and a short and vague list about what is right. But putting them in front of a mirror puts you both on the same team, rather than adversaries.

2. Notice your first impression

Your first impression carries a wealth of information, only some of which may rise to your awareness.¹³ Learn to catch the fleeting perceptions you have on first glance, as they so often contain insights which will only become clear to you later. Do not speak it to the client, but note it for yourself. It is surprising to us how often a student's initial and uneducated assessment turns out to be correct down the road.

3. Note a minimum of three positive aspects first

We noted some positive aspects in each of the analyses above. It is surprising how many practitioners only talk about the client's problems and shortcomings. Patients come to us with problems they want solved, so it is natural for both of us to tend to focus on the problems. At any given moment, however, far more is going right in the person in front of you than is going wrong. Be very careful not to reduce your client to a set of faults. Doing so can be damaging for the client - it is no boost to the self-esteem to be given a long list of areas in which your carriage or movement falls short of the ideal.

Focusing only on the problems can also be bad for the practitioner - you can miss the strengths that will help carry you and your client over the rough patches to whatever new territory you stake out. Good skin speaks to a responsive nervous system; stolidity can indicate good grounding; an eager smile denotes an enthusiasm of which you can make use - noting these things to yourself, or, better yet, aloud to the client, can ease the way toward a discussion of real goals, as well as showing you where the client's current physiology may be of real help.

h. Describe the issues you see in the objective language outlined above

The tilt-bend-shift-rotate language is less value-laden, and therefore less judgmental, than many other ways of stating the client's problems. These descriptions will lead you into Step 1 of the five-step process outlined above. The discipline of reducing each thing you see to

an objective finding makes it much easier to approach the whole client innocently and with humility. Jumping to conclusions can land you in the drink.

Additionally, you may find value in considering an assessment of some of the following more subjective parameters. (These are offered as extra, practically useful, and quick assessments, with references for further study when helpful. None of the following are essential to the Anatomy Trains process per se.)

A. Whole systems communicators

In Chapter 1, we noted that there are three whole-body networks, all of which communicate within themselves and with each other. It is a subjective but worthwhile exercise to call each of these to mind when looking at the client for the first time. What is the state of the neural network? (Are the eyes and skin clear? Are the client's responses timely and appropriate, or awkward and heavy-handed?) What is the state of the fluid network? (How is the skin color, and is it consistent across the body?) What is the state of the fibrous network? (Are they lax or tight? Toned or collapsed?) (See **Fig. 1.30**, p. 36 for more detail.)

B. Tissue dominance

Although it is less in vogue these days, noting where your client lies in the endo-, meso-, and ectomorphy scale is definitely worthwhile, as ectomorphs will respond quite differently to manual therapy than will endomorphs. You cannot approach Cassius (who has a 'lean and hungry look') in the same way you would approach Falstaff (who was born with 'something of a round belly', and whose voice was 'lost with hollering and the singing of anthems').²

Students of Aryurveda will note the similarity with the *doshas*.

C. Somato-emotional orientations

Since many of the patterns people present unconsciously express emotion (especially the unacknowledged ones), it is worth looking to see some of the more obvious telltale signs.

- An anterior pelvic tilt most often indicates a sympathetic, or ergotropic, orientation (a sanguine or choleric character), whereas the posterior pelvis more often accompanies a parasympathetically oriented, trophotropic character (phlegmatic or melancholic).¹⁴
- Breathing patterns often hover around one end or the other of the respiratory cycle. Those stuck on the exhale side of the pattern tend toward depression and introspection, relying too heavily on their own internal world, while those stuck around the inhale end of the cycle tend toward a false heartiness, relying too heavily on the impressions and responses of others for their sense of self (**Fig. 11.14A and B**).
- Various somatically oriented psychotherapists have coupled particular structural patterns with corresponding psychological tendencies and

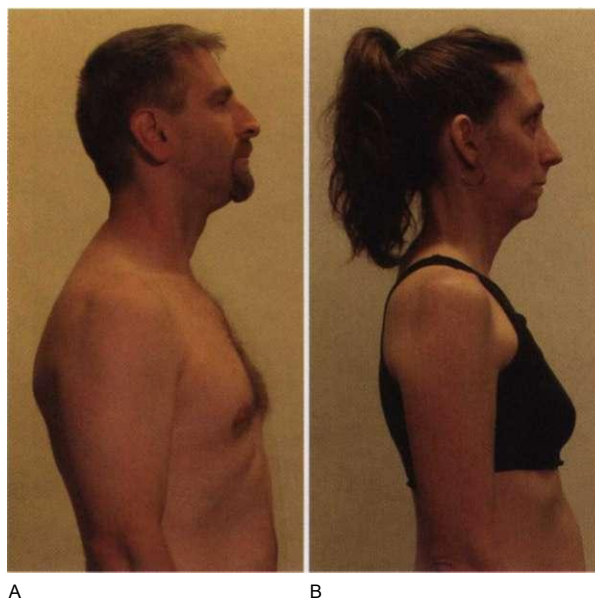

Fig. 11.14 Although we are of course looking at still photos, the man on the left shows signs of being 'stuck on the inhale' - with his breath pattern moving around the inhale end, whereas the woman on the right shows signs of being 'stuck on the exhale' - with her breath pattern oscillating around the exhale end of the spectrum.

common behavioral responses. Any of these typological systems can be helpful, though this author's experience has been that they are not totally reliable and can be tempting pigeon-holing traps.

D. Perceptual orientation

According to Godard, there are two primary orientations - one either grounds to reach out, or reaches out in order to ground.¹⁹ Here is a simple test for determining which is dominant: stand behind the client and have them jump lightly on the balls of their feet. It does not matter how high or well they do this. Make two tests, repeating each of these movements on successive jumps for a few seconds: (1) lift them slightly from the sides of their rib cage as they go up, or (2) press them lightly into the earth on their shoulders as they come down. Which movement produces the more organized result in the client - pressing down or lifting up? The ones for whom a slight pressing down results in a more organized spring up are oriented to the ground; those for whom even a few ounces of lift on your part produce a large result in terms of height and delight achieved, are oriented out into the environment around them.

E. Internal and external orientation/cylinders

Sultan, building on the flexion-extension preference models in Upledger's version of Craniosacral Therapy, has posited an Internal and External type, which has enjoyed currency at the Rolf Institute of Structural Integration (www.rolf.org).⁶⁻²⁰

A similar assessment can be made of each segment: It is easy to see that a human being is two cylinders side-by-side when looking at the legs, for that is essentially what we are, and each cylinder can medially or

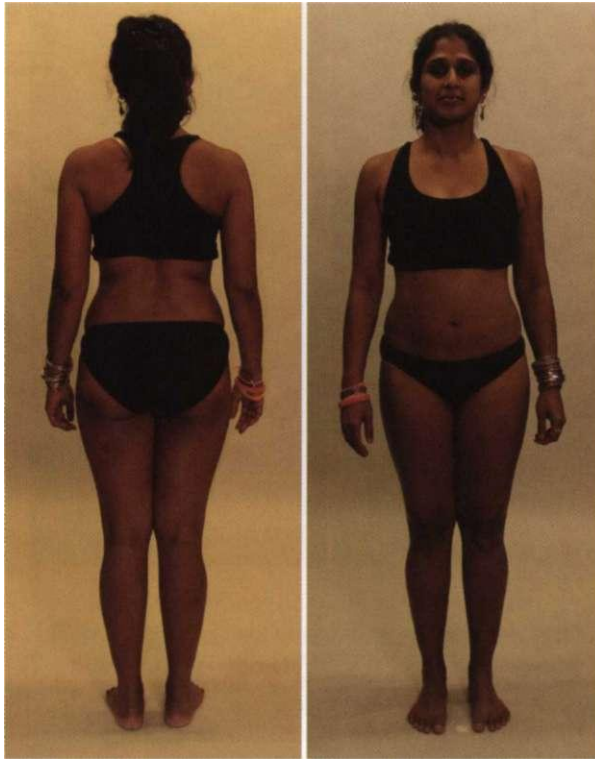


Fig. 11.15 In this model, we see a mild form of the alternation of 'cylinders'. In the torso area, the cylinders are turned outward, so that the front looks wider than the back. In the pelvis and legs, the 'cylinders' appear to be turned in, making the back appear wider than the corresponding area in front.

laterally (internally or externally) rotate. Imagine that these two cylinders extend into the trunk. In the pelvis, these two rotational preferences have a name - inflare and outflare - but the phenomenon extends to the belly, ribs, and shoulders. If the cylinders are rotated medially, that segment of the body looks wide in the back and narrow in the front. If the cylinders are rotated laterally, the segment looks wider in the front and narrower in the back. These patterns can sometimes alternate, with the lower back/belly segment in external rotation, counterbalanced by a chest segment in internal rotation (**Fig. 11.15**) In these cases, the narrow part of the segments needs repeated widening.

F. Primary rotation

Everyone I have worked on or observed over 30 years of practice has had a primary rotation to the spine. (Galaxies and DNA grow in spirals, why not us? Observe the photos of fetuses by Lennart Nilsson and others²¹ - each one can be seen to have a nascent spiral in the spine. Could this be a natural part of development, or must it be considered an aberration?) Observing the direction of that rotation, its degree, and the specific areas of counter-rotation that always accompany it are essential data for the most efficient unwinding of the entire pattern.

To observe spinal rotation quickly without benefit of an X-ray, stand behind the client. Place your thumbs on

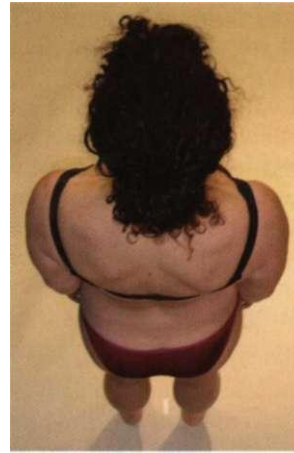

Fig. 11.16 A primary thoracolumbar rotation to the right.

the two posterior superior iliac spines (PSISs), with your fingers resting on and below the iliac crest. Adjust the client's pelvis so that the PSISs are equally lined up with the heels (thus temporarily and artificially eliminating any rotation in the legs, such as we saw in some of the clients above). Now peer down the client's back from above, as we have in all the 'E' pictures above (the short practitioner may need a stool to assess the tall client). By noting the tissues about an inch (2 cm) on either side of the spinous processes, one can see which side is more anterior or posterior (closer to you or further away). These differences are only rarely due to differential muscle development on either side of the spine. At any given level of the spine, the side closest to you indicates the direction of rotation of the spine as the transverse processes push the overlying myofascial tissue posteriorly.

In our experience, most clients will show a dominant rotation in the thoracolumbar area, which we term the 'primary' rotation (**Fig. 11.16**). Counter-rotations frequently occur in the legs or in the neck, but sometimes also within the thoracolumbar area itself. Infrequently, it can be difficult to tell which is the primary and which is the secondary rotation; in which case, further therapy may clear the picture, or the two rotations may indeed be nearly equal, and therefore the designation 'primary' has less meaning. With practice, one can gather quite detailed and specific information about the inherent spinal rotations using this method.

Another simple movement assessment can yield yet more information: Kneel behind the client, again with the hands steadying the pelvis and the thumbs on the PSISs. Give the client the instruction to 'look over your shoulder'. By not saying which shoulder, you allow them to choose, and they will almost always choose their preferential side - the side with the primary rotation. As they turn, encourage them to use the whole torso to turn, while you keep the pelvis steady relative to the feet with your hands. Observe where the spine rotates. Have them turn the opposite way, and observe the difference. Anyone with a significant primary rotation will have palpable or observable differences in where in the spine the rotation occurs on the two sides.

G. Pelvic position

The attention given to pelvic tilt and shift in our system yields four basic types based on pelvic position:

- Anterior tilt, anterior shift - this pattern produces a familiar swayback pattern;
- Anterior tilt, posterior shift - favored by toddlers just learning to stand;
- Posterior tilt, anterior shift - favored by suppressed neurotics everywhere;
- Posterior tilt, posterior shift - favored by plumbers and woodsmen (this position produces the 'vertical smile' at the top of the back of the jeans).

Soft-tissue strategies peculiar to each of these pelvic positional types can be found elsewhere.²² In our experience, it is necessary to make liberal allowances for individual patterns in any of these typologies.

H. Weight distribution in the feet

It is useful to assess where the weight comes down through the feet. By dropping a real or imaginary plumb line through the ankles in a side view, one can see if the weight is predominantly on the toes or heels, essentially a check on the balance between the Superficial Front and Back Line (**Fig. 11.17**).

A front view can be used to assess how much of the weight is being taken by the inner arch, and how much by the lateral arch. Wear on shoes can also be indicative in this regard. Generally, the more weight being taken

by the lateral arch, the more the Deep Front Line needs to be lengthened and lowered toward the medial arch. The more weight taken by the medial arch, the more the Lateral Line needs to be released and lowered, while the Deep Front Line and the anterior-inferior part of the Spiral Line need to be energized, toned, and lifted.

The front or back view will also show whether one leg is carrying significantly more weight than the other. (We all have some discrepancy in carrying weight, and we all have a relaxed 'waiting for the bus' posture where we transfer most of the weight to one leg.) The only way to measure this accurately, however, is to have the client step onto two scales, with one foot on each scale, and without looking at the readouts, attempt to stand evenly on both feet. The total of the two scale readouts, of course, will equal the total weight of the person, but the two scales will not necessarily be supporting equal weight. This test will often show that the client's reporting of 'balanced' is actually significantly more weighted on one foot or another. If you adjust the client so that the scales are reporting equal burdens, the client will insist that they are heavily weighted onto the leg that was taking less weight in the initial assessment. This is yet another example of how the client's reports are not always reliable and need to be leavened with the practitioner's acute observation.

I. Balancing halves

Although the following images need to be taken with some salt, since the realities are quite complex, these simplifications, however subjective, are still quite useful. A quick look at standing posture at the beginning can divide the body into three sets of 'halves': Which set has the largest discrepancies between one and the other? The answer is a good one to keep in mind as therapy proceeds in terms of treatment emphasis.

- A mid-sagittal line divides the body into right and left. Significant right and left differences often point to internal conflicts between the animus and anima (masculine and feminine tendencies). It is not as simple as right = male and left = female. But those with significant, complex, and intractable differences between the two sides, often involving the eyes and head shape as well as structural differences in the torso and legs, will reveal a significant battle, expressed in uniquely individual ways in work, relationships, artistic endeavor or sexuality, between the inner masculine and feminine aspects (**Fig. 11.18**).
- A mid-coronal line divides the body, front from back. Of course these two 'halves' are not symmetrical to begin with, but we can still observe the balance between the two. Strong imbalances in this dimension are often expressed as differences in how the person presents in public versus how they act or feel in private (**Fig. 11.19**).
- A line through the waist divides top from bottom (the exact line can vary individually from an 'empire' waist to just above the iliac crests). Obesity or muscle development can sometimes obscure the

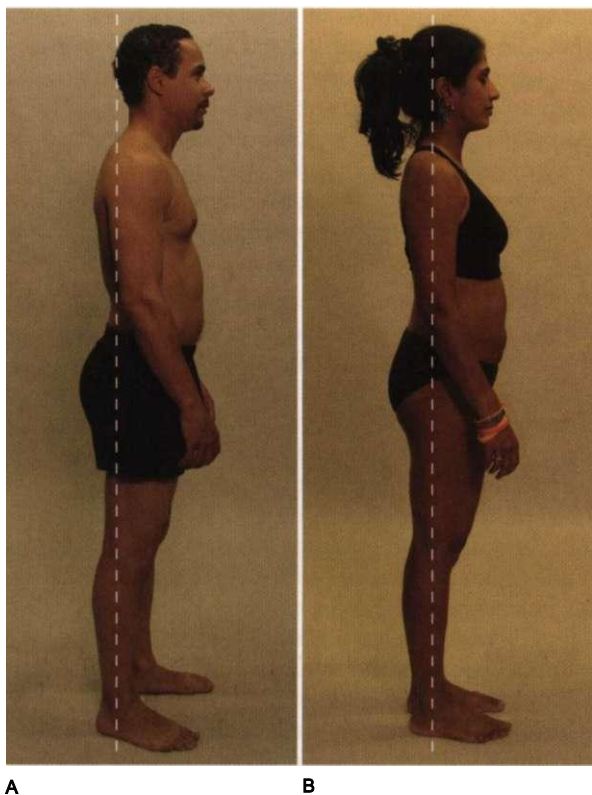
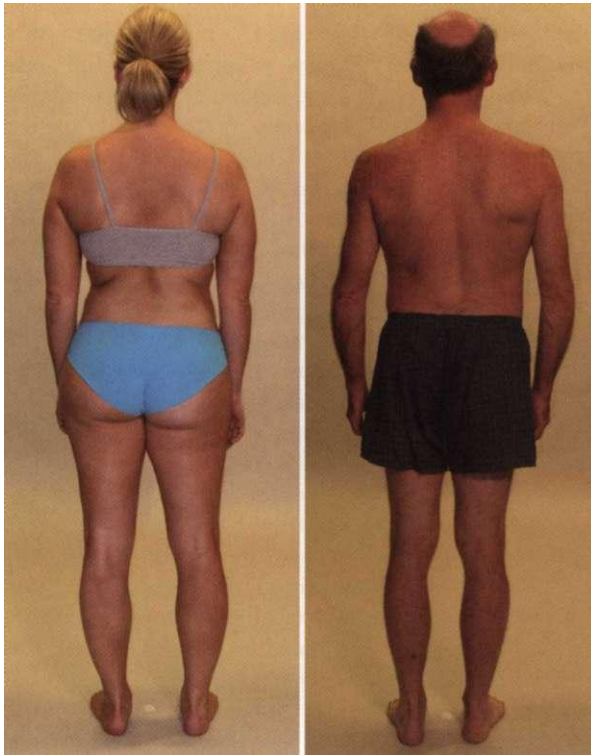

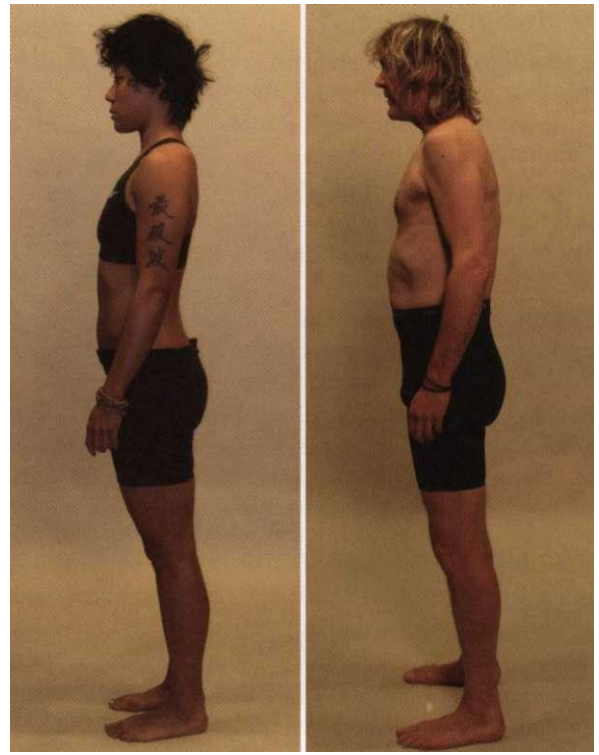
Fig. 11.17 Even if we put the vertical line just in front of the ankle, notice how much of the body rests into the front of the foot in these common postures.



A

B

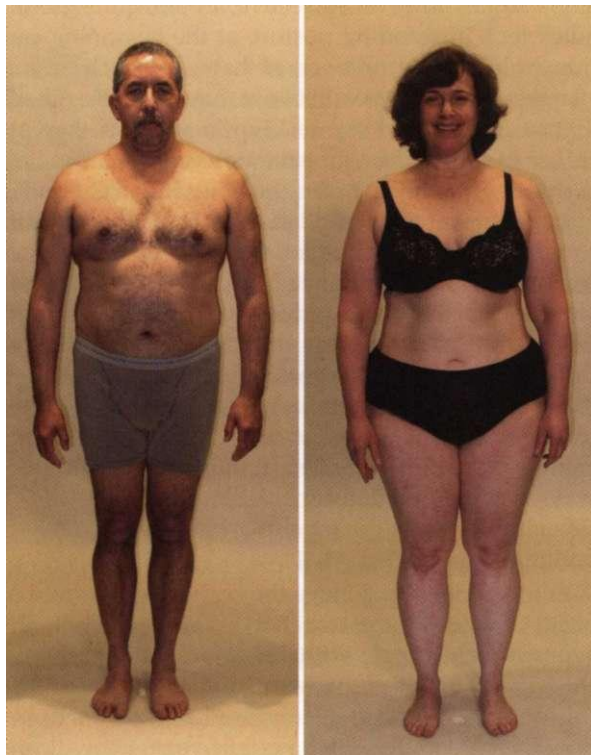Fig. 11.18 The back view is often the easiest - because we tend to make the front look good - to see strong right-left discrepancies, as in these two structures.



A

B

Fig. 11.19 The side view is the place to see front-back differences, where what you see in the front is not necessarily what you get in the back.



A

B

Fig. 11.20 Although a large shoulder girdle on top of a cinched in pelvic girdle is a quintessentially male pattern, and its opposite more often found in the female, as here, you will find the complementary patterns as well.

underlying bony structure, but what one is looking for here is an evenness of proportion between the shoulder and pelvic girdle, and between the torso and the legs, or the upper and lower body. Those with more weight and substance in the legs and pelvis versus the ribs and shoulders tend toward the introverted; those with a large torso and shoulders on top of smaller-built pelvis and legs will tend toward the extroverted (**Fig. 11.20**).

J. Somatic maturity

Grasping the kind of patterning in the skeletal geometry and myofascial meridians of tension can lead to a different level of seeing, and thus a deeper level of work. One of the most interesting contributions that can be made by quality manual and movement work is related to maturational development. As an example of what can be accomplished, look at Reginald from the side, (**A**) before Structural Integration, (**B**) just after the completion of a series of sessions (under the direction of Dr Ida Rolf) and (**C**) one year later, with no further work (**Fig. 11.21**). The pictures have been adjusted only to make them approximately the same size, since Reginald presumably grew over the year.

Before the work, Reginald shows a common randomized postural response: hyperextended knees, an anteriorly tilted pelvis, a posteriorly tilted rib cage, and an anteriorly tilted neck, among other things. His shoulders are integrated neither with the neck nor the rib cage, essentially hanging off the back of the body, putting

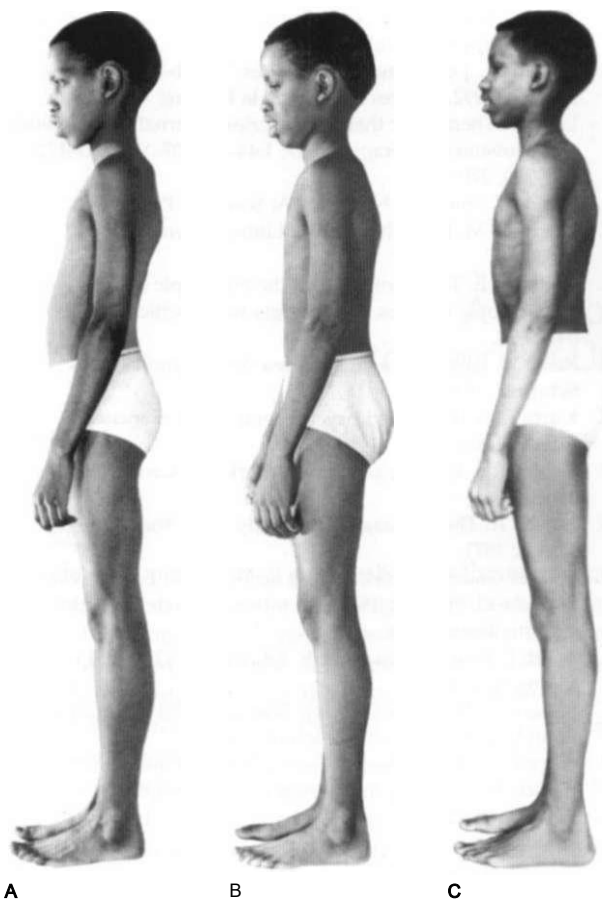


Fig. 11.21 Reginald before intervention (A), after (B), and one year later with no further work (C).

strain into the upper thoracics and both the superficial and deep pectoral muscles. In (B), the post-bodywork picture, he is demonstrably straighter, but not demonstrably better off. (One person, viewing only the first two pictures, accused us of 'somatic colonialism', saying, 'You took away his naturalness and gave him a weedy little white-boy posture! What good is that?')

Picture (C), with a year to let the work settle, tells a different story. With the knees resting more comfortably forward (although notice that Reginald has 'slipped back' somewhat in this regard over the year), the pelvis has assumed a more horizontal position relative to its former anterior tilt. (And notice that this parameter has improved since the end of the work.) With the pelvis horizontal, the rib cage can orient itself vertically, with a reduced lumbar curvature (see the section in Ch. 3 on primary and secondary curves, p. 92). With the yoke of the shoulder girdle now draped comfortably over the rib cage instead of hanging off behind it, the chest and chest muscles are more free to develop, so Reginald fills out, deepens, and looks a different boy. Our contention is that, left to himself, the boy on the left would not have developed into the boy on the right in a year, but the boy in the middle could (and did). After the initial work, 'compound essence of time' is the only medicine necessary to do the job.

Notice that the improvement is not unalloyed. The Reginald of C has reinstated the tension in the knees and

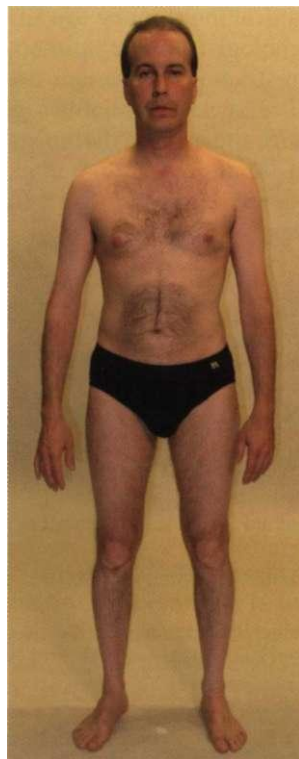

Fig 11.22 Even though this is a fully fledged adult male, can you see the childish remnants in his body structure? The head is the head of an adult; the body is that of a child aged three to six years. What does this mean? Can it be developed and matured at this point?




Fig. 11.23 While the rest of the structure has grown up, and everything has grown in size, the pelvis of this otherwise strong and balanced young woman nevertheless remains 'young' and immature relative to the rest of her. We see this happen with sexual trauma sometimes, but other factors as yet unmeasured may be in play as well.

ankles that was present in A but not in B. Not every element in a pattern responds to any given treatment.

Can you see the underlying very small boy within the postural pattern of the middle-aged man in **Figure 11.22**? Can you see that the pelvis of the young woman in **Figure 11.23** looks 'younger' than the rest of her structure? Are such observations clinically useful? In the latter part of this chapter we have stepped over the line

from remediation of biomechanical inefficiency toward the realm of the somatic psychologist. In our opinion, being able to recognize such restrictions, parse out the underlying patterns, and realize such potentialities is one of the more important jobs for the manual therapists of the coming century. The Anatomy Trains map, through not specifically developmental, is one way into seeing such underlying patterns.

References

1. Aston J. Aston postural assessment workbook. San Antonio, TX: Therapy Skill Builders; 1998.
2. Sheldon WH. The varieties of human physique. New York: Harper; 1940.
3. Keleman S. Emotional anatomy. Berkeley: Center Press; 1985.
4. Alexander RM. The human machine. New York: Columbia University Press; 1992.
5. Morrison M. A structural vocabulary. Boulder, CO: Rolf Institute; Rolf Lines: July 2001.
6. Sultan J. Toward a structural logic: the internal-external model. Notes on structural integration 1992; 86:12-18. Available from Dr Hans Flury, Badenerstr 21, 8004 Zurich, Switzerland.
7. Keleman S. Emotional anatomy. Berkeley: Center Press; 1985.
8. Pierrakos J. Core energetics. San Francisco: Liferhythms; 1990.
9. Aston J. Aston postural assessment workbook. San Antonio, TX: Therapy Skill Builders; 1998.
10. Busquet L. Les chames musculaires. Vols 1-4. Freres, Mairlot; 1992. Maitres et Clefs de la Posture.
11. Lately P. Themes for therapists (series). Journal of Bodywork and Movement Therapies 1997; 1:44-52, 107-116, 163-172, 222-230, 270-279.
12. Hanna T. Somatics. Novato, CA: Somatics Press; 1968.
13. Gladwell M. Blink. New York: Little, Brown & Co; 2005.
14. Gellhorn E. The emotions and the ergotropic and trophotropic systems. Psychologische Forschicht 1970; 34:48-94.
15. Reich W. Character analysis. New York: Simon and Schuster; 1949.
16. Kurtz R. Body centred psychotherapy. San Francisco: Liferhythms; 1990.
17. Keleman S. Emotional anatomy. Berkeley: Center Press; 1985.
18. Lowen A. The language of the body. New York: Hungry Minds; 1971.
19. Hubert Godard's work is most accessible in English via McHose C, Frank K. How life moves. Berkeley: North Atlantic Books; 2006.
20. Smith J. Structural bodywork. Edinburgh: Churchill Livingstone; 2005.
21. Nilsson L. The miracle of life. Boston: WGBH Educational Foundation; 1982. www.lennartnilsson.com
22. Gaggini L. The biomechanics of alignment. 6th edn. Boulder: Connective Tissue Seminars; 2005. www.connectivetissue.com

Appendix

A note on the meridians of latitude: the work of Dr Louis Schultz (1927-2007)



This book concerns itself primarily with the myofascial connections that run the full length of the body and limbs, the longitudinal meridians if you will. What we have described, of course, are only a few of the myriad fascial connections within the body. Another set, identified and written about by the late Dr Louis Schultz and Dr Rosemary Feitis, DO,¹ are local horizontal bands or straps within the body's myofascia, which act somewhat like retinacula. Like the retinacula at the ankle or wrist, they are thickenings in the deep investing layer of fascia and in the areolar layer of loose connective tissue (superficial to the myofascial layers we have been discussing; see also the discussion of Guimberteau's exploration of this layer at the end of Ch. 1) which restrain, for better or worse, the movement of the underlying tissues.

The Endless Web, written by Dr Schultz and Dr Feitis, discusses these body retinacula in detail. However, I learned these ideas from Dr Schultz, to whom I owe a deep debt of gratitude. Ideas in this book about fascial embryology and fascial connectivity were all inspired by his teaching, and the myofascial meridians described are extensions of his original concept.

These straps are not described in traditional anatomy texts, but are readily visible and often palpable in the more superficial layers of tissue. **Figure A1.1** shows seven bands commonly seen in the torso. The bands are variable in their exact positioning and in their degree of tension or binding.

The chest strap - roughly corresponding to the location of a bra strap - is visible on most people in the front, at or just above the level of the xiphoid. It is easy to see how excessive tightness or binding in this strap would restrict breathing, as well as the free movement of the SFL, FFL, and SPL in the superficial musculature under the strap. The other straps are more variable, but readily identifiable in many people. Since the bands lie superficially, they tend to restrict fat deposition; bands can often be identified in adipose tissue contours.

These straps can restrict or divert the pull through the superficial myofascial meridians, linking the lines together at a horizontal level, or restricting the free flow of movement through a meridian where it passes under the strap.

In structural or postural misalignment the binding nature of the straps is increased to try to stabilize an unstable structure. Interestingly the straps occur at the level of the spinal junctions (**Fig. A1.2**):

- the sphenobasilar junction connects with the eye band;
- the craniocervical junction connects with the chin band;
- the cervicothoracic junction connects with the collar band;
- the dorsal hinge (a functional mid-thoracic hinge, usually around the level of T6) connects with the chest band;
- the thoracolumbar junction connects with the umbilical band;
- the sacrolumbar junction connects with the inguinal band;
- the sacrococcygeal junction connects with the groin band.

The temptation to further link these levels with the autonomic plexi or endocrine gland is strong but resistible.

Schultz and Feitis offer some intriguing anecdotal correlates to emotional and developmental events in connection with these bands. Since our purpose here is less explanatory and more descriptive, we simply point out the empirical existence of these bands and refer the reader to *The Endless Web* for further development of these and other related ideas.

1. The lowest band in the torso (pubic band) extends from the pubic bone in front across the groin (which is thereby shortened), around the hip bones (the greater trochanter of the femur), and across the buttocks, including the junction of the sacrum and coccyx.
2. The band across the lower abdomen (inguinal band) is frequently more prominent in men. It connects the two projections of the pelvic bones in front (the anterior superior spines of the ilia). It usually dips slightly downward in front, like an inverted arch. Its lower margin tends to include the inguinal ligament, connecting the band

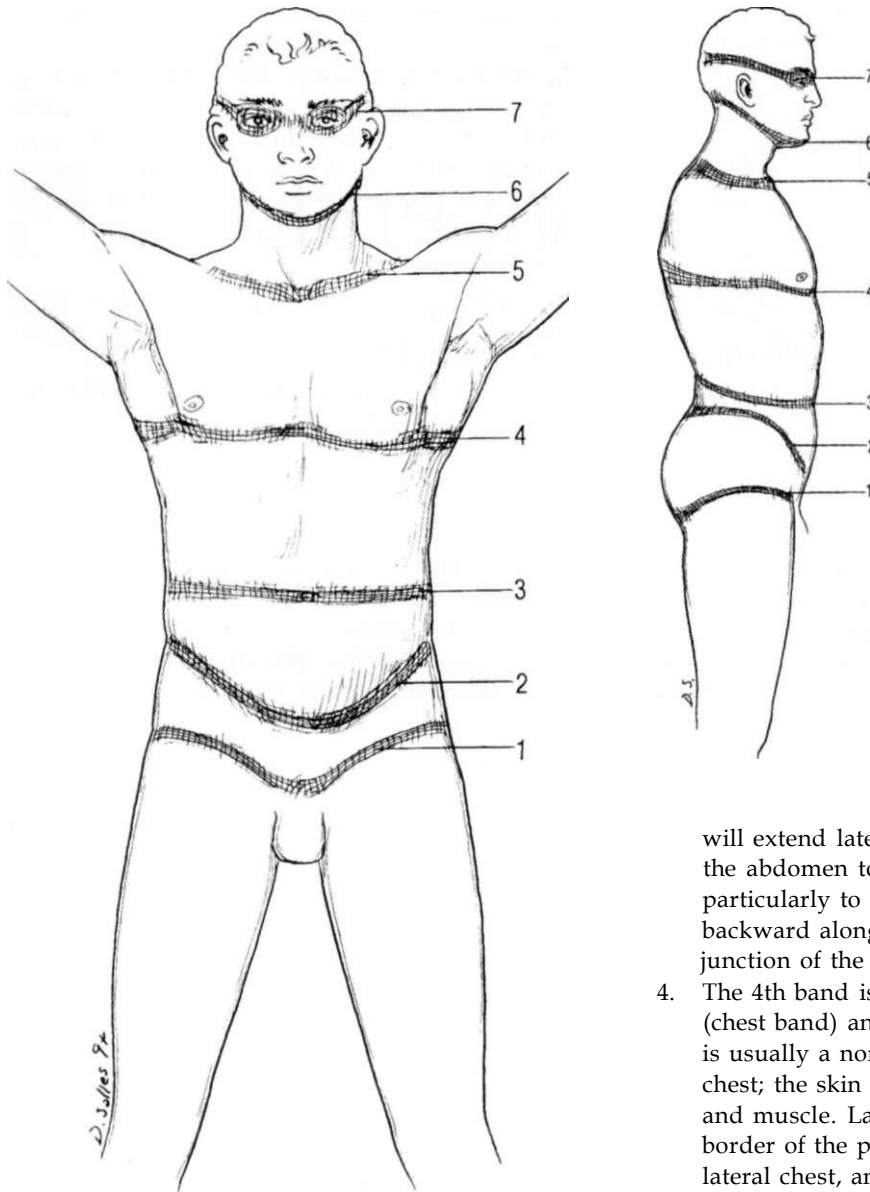


Fig. A1.1 Body retinacula: the seven body bands of the torso (see also Fig. A1.2). Dr Schultz has described another useful set of fascial meridians: the meridians of latitude. These bands lie in the more superficial layers of fascia for the most part, but may have connections into underlying layers and can thus affect the working transmission of the myofascial meridians described in this book. (Reproduced with kind permission from Schultz and Feitis 1996.)

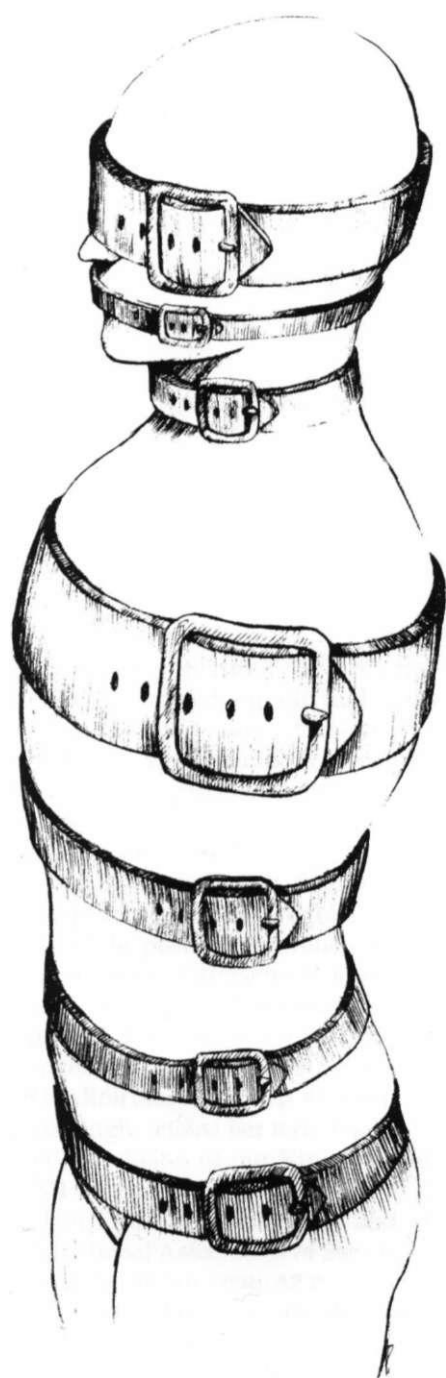
downward to the region of the pubic bone. This band extends laterally along the upper margin of the large wings of the pelvic bones (ilia), ending at the lumbosacral junction.

3. The 3rd band crosses the abdomen (belly/umbilical band) and is perhaps the most variable in location. It may cross at the umbilicus (sometimes creating a crease in the abdominal wall extending out on either side of the umbilicus), or it may lie midway between the umbilicus and the midcostal arch (tying together the two sides of the costal arch). In either case, it

Fig. A1.2 Body straps, side view. The meridians of latitude girdle the body at various levels (mostly, please note, at the levels of spinal transitions). (Reproduced with kind permission from Schultz and Feitis 1996.)

will extend laterally to form an arch across the abdomen to the lower ribs on each side - particularly to the free tip of the 11th rib. It travels backward along the lower ribs, ending at the junction of the thoracic and lumbar vertebrae.

4. The 4th band is in the area just below the nipples (chest band) and is visually the most apparent. It is usually a non-moving depressed area on the chest; the skin seems glued down onto the ribs and muscle. Laterally, it extends along the lower border of the pectoralis major, across the mid-lateral chest, and down the lateral margin of the latissimus dorsi where it begins to run parallel to the scapula toward the arm. The strap appears to tie the lower tip of the scapula to the back ribs and includes the dorsal hinge of the spine. When this strap is pronounced, there is not only a depressed mid-chest, but also an inability to expand the ribs sideways in breathing.
5. The 5th strap at the shoulders (collar band) involves the clavicle and is part of the tissue gluing the clavicle to the 1st and 2nd ribs in front. It can be felt as a pad of tissue just below and deep to the collar bone (clavicle). It extends laterally to the tip of the shoulder, with some fibers fanning down into the armpit. The strap continues toward the back on the inside and outside of the upper border of the shoulder blade (scapula), and ends at the junction of cervical and thoracic vertebrae.
6. The area below the chin (chin band) is an area of concentration of fibers and padding which includes the hyoid bone and the base of the jaw, passing just below the ear, and including the



base of the skull joins the first cervical vertebra (atlas).

7. The top band (eye band) is the most difficult to visualize. It originates on the bridge of the nose, travels across the eye sockets and above the ears, and includes the back of the skull just above the occipital crest (the bump at the back of the skull).

References

1. Schultz RL, Feitis R. *The Endless Web: Fascial Anatomy and Physical Reality*. North Atlantic Books, Berkely, 1996.
2. Keleman S. *Emotional anatomy*. Berkeley: Center Press; 1985.

Fig. A1.3 This somewhat more pessimistic view of the horizontal body straps, drawn from Keleman's brilliant *Emotional Anatomy*, nevertheless shows how these meridians of latitude act as controls on the pulsation, flow, pressure, and shape of the inner tubes and pouches of the organism. (Reproduced with kind permission from Keleman 1985.)

Appendix

Structural Integration

2

Since initial publication in 2001, the Anatomy Trains scheme has served a gratifyingly wide field of manual and movement workers, including orthopedists, physiatrists, physical therapists, osteopaths, chiropractors, massage therapists, yoga teachers, athletes and their conditioning coaches, martial artists, and personal trainers, even a few psychologists.

The Anatomy Trains map derived from our own attempt to organize a progressive series of sessions to unravel the postural and functional compensations discussed throughout the book and assessed in Chapter 11 (a sample chart for noting such assessments is shown in **Fig. A2.1**). This 'recipe' for working the lines in progression follows the same principles the author learned from Dr Ida Rolf (**see Fig. In. 7**, p. 4), and the resultant approach accordingly retains her term for it - 'Structural Integration'. Graduates of our Kinesis Myofascial Integration (KMI - www.anatomytrains.com/kmi) program are certified in Structural Integration and eligible to join the International Association of Structural Integrators (IASI - www.theIASI.org) (**Fig. A2.2**).

The idea in Structural Integration is to use connective tissue manipulation (myofascial work) and movement re-education to lengthen the body and organize it around its vertical axis. By 'redraping' the myofascial cape over the skeletal frame (or by achieving the 'floating bones' of coordinated fascial tensegrity, if you prefer), we see generally greater symmetry around the Euclidian planes. This restores the feeling of 'lift' as the person elongates from whatever random pattern they may have had toward the highest potential and kinetic energy of an easy upright alignment. In physical terms, this process seeks to lower the moment of inertia around the vertical axis, readying our bodies for all available movements without initial preparation (**Fig. A2.3**).

The KMI approach differs somewhat from other schools in this arena in that our series of 12 soft-tissue manipulation sessions is based around reading and treating the cohesive myofascial continuities of the

Anatomy Trains, rather than following any set formula. We include this brief guide to how our particular approach to this method unfolds, in hopes that this might be useful for others wishing to put the Anatomy Trains into practice. Of course, such an overview elides many complexities and the varying application to individual peculiarities. Some of the actual techniques that are employed in the training program appear in this book, others in our video presentations, and still others (for safety reasons) only in our training programs.

So, with the proviso that this appendix is not meant to limit experimentation and innovation we present an outline of how we currently apply the Anatomy Trains map in our training programs. This appendix will mean less to movement therapists, but more perhaps to manual therapists, especially those who employ 'direct' myofascial techniques.

The general order dictates that we begin with the more superficial myofascial tissues of the superficial lines - the Superficial Front Line, the Superficial Back Line, the Lateral Line, and finally the Spiral Line. This is followed by work with what is popularly called 'core', gathered in the Deep Front Line. The final stage of the process calls for integrating sessions that bring the core and the super-ficial 'sleeve' together in a coordinated symphony of movement with an 'easy' relaxed posture and 'acture' (**Fig. A2.4**).

Looking at the overall sequence before we outline each session, we note some elements that differ from other, similar approaches:

1. The Arm Lines come in for significant differentiating work for each of the first four sessions, since the myofascia of the arms is even more superficial than the Front, Back, and Lateral Lines. They have a session of their own at the end when the shoulder and arm assembly must be reintegrated into the new support from the decompensated trunk. The Functional Lines, joining the arms to the contralateral leg across

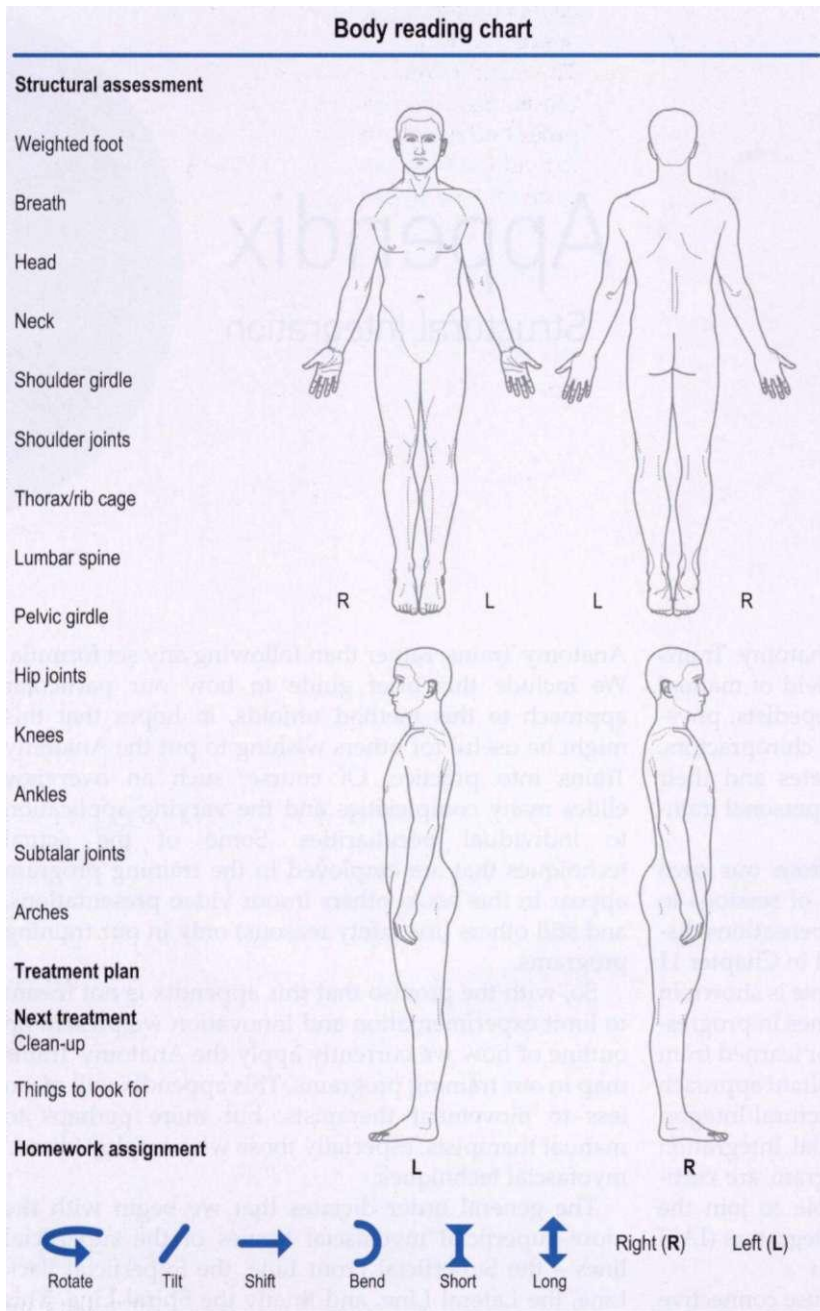


Fig. A2.1 Body reading chart for assessment purposes.



International Association of Structural Integrators

Fig. A2.2 The logo for Kinesis Myofascial Integration, a brand of Structural Integration based on the Anatomy Trains, and the logo for the International Association of Structural Integrators, the professional organization for all Structural Integration practitioners worldwide.

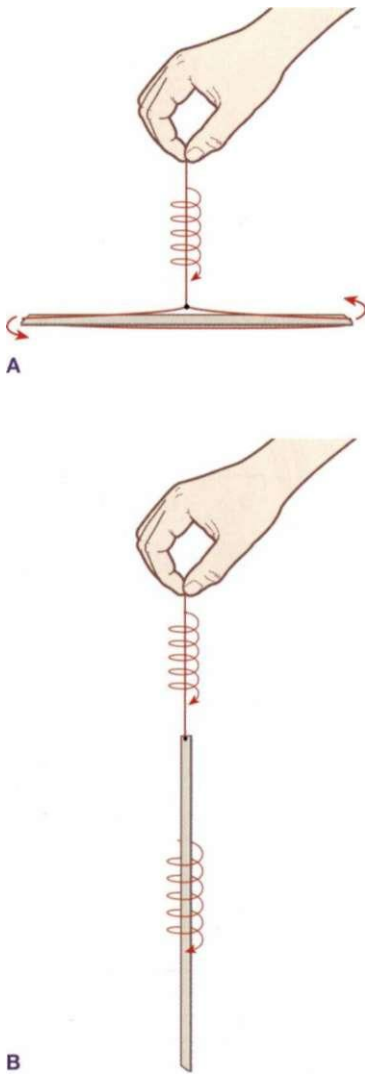


Fig. A2.3 Given that the stick on the top and the stick on the bottom have the same mass, the stick on the bottom has a lower 'moment of inertia'. Imagining that the stick is suspended from its middle, a large amount of turns in the string would be necessary to set the stick in motion. On the bottom, we can intuit that only a few turns of the string would set the stick in rapid motion. The mass is the same in both; the difference between the two is the distance from the axis of rotation of the mass. One sees the same effect in figure skating, where the skater starts to spin slowly with her arms out. When she brings her arms into her body, lowering her moment of inertia, the speed increases to a blur. Putting the arms back out allows her to slow again. Slouching, taking a wide stance, or any of the tilts and shifts described in Chapter 11 will increase our moment of inertia and make movement just that much harder, necessitating excess muscle tension and fascial binding that forces compression into the joints.

the front and back of the trunk, generally come in for consideration during these integrating sessions.

- Opening the lower leg, line by line, compartment by compartment, is spread over the first five sessions, giving plenty of time to open and balance the foundation of our structure. This area

comes up again for integration in the 9th and 12th session as well.

- The middle four sessions really explore and reorganize the core in a manner not attempted by other bodywork approaches. These sessions extend the connections of 'core' far beyond the usual meaning of the pelvic floor and inner abdominal muscles to a coherent fascial unity that runs from the bottom of the foot to the skull. The last of these, the 8th session (for the neck and head) is a fulcrum between the differentiation and integration - it both completes the first and begins the second.

With the proviso that each session differs in emphasis, method, and order depending on the client's individual pattern, the sessions unfold in the following manner (more detail can be found in the chapters regarding the details of addressing each line listed, as well as on the website www.anatomytrains.com):

The Anatomy Trains 'recipe'

Superficial sessions

Session 1

Open the Superficial Front Line, and differentiate Superficial and Deep Front Arm Lines from axial body (**Fig. A2.5**).

Goals:

- Introduce the client to deep, direct fascial work
- Open the breath in the front, disengage patterns of fear
- In general, lift the Superficial Front Line, and open the Front Arm Lines distally

Key structures:

- Ankle retinacula and crural fascia
- Subcostal arch and sternal fascia
- Sternocleidomastoid

Session 2

Open the Superficial Back Line, and differentiate the Superficial Back and Deep Back Arm Lines from axial body (**Fig. A2.6**).

Goals:

- Deepen the touch into the heavy fascia and endurance fibers of the back
- Improve grounding, bringing the client into their legs and feet
- Bring initial balance to the primary and secondary curves
- In general, drop the Superficial Back Line, and even the tonus of the Back Arm Lines

Key structures:

- Plantar aponeurosis
- Hamstring fascia
- Erector spinae
- Suboccipital muscles




Fig. A2.4 The Anatomy Trains recipe in diagrammatic summary.

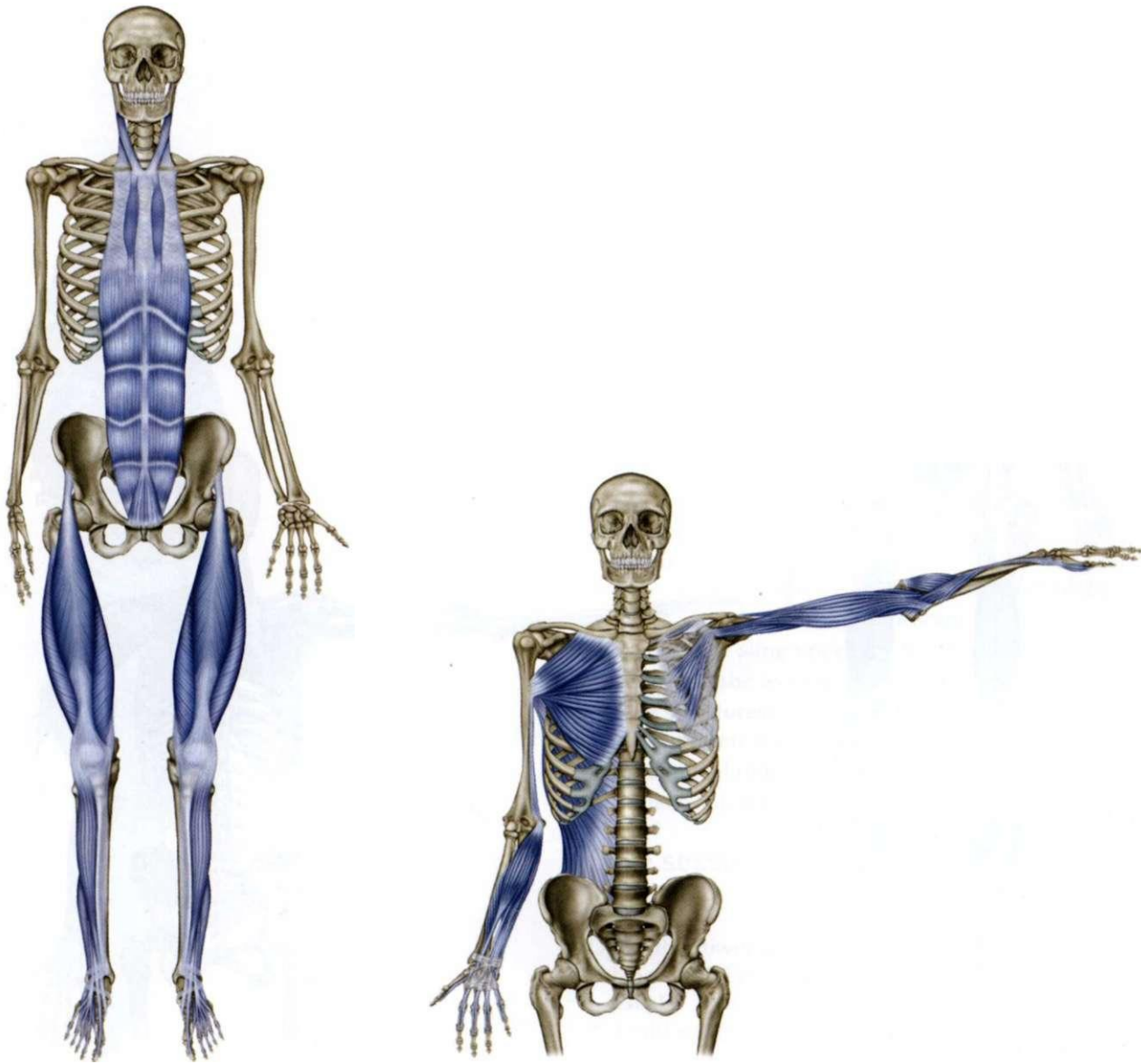


Fig. A2.5 The first session concentrates on lifting the Superficial Front Line and opening the two Front Arm Lines.

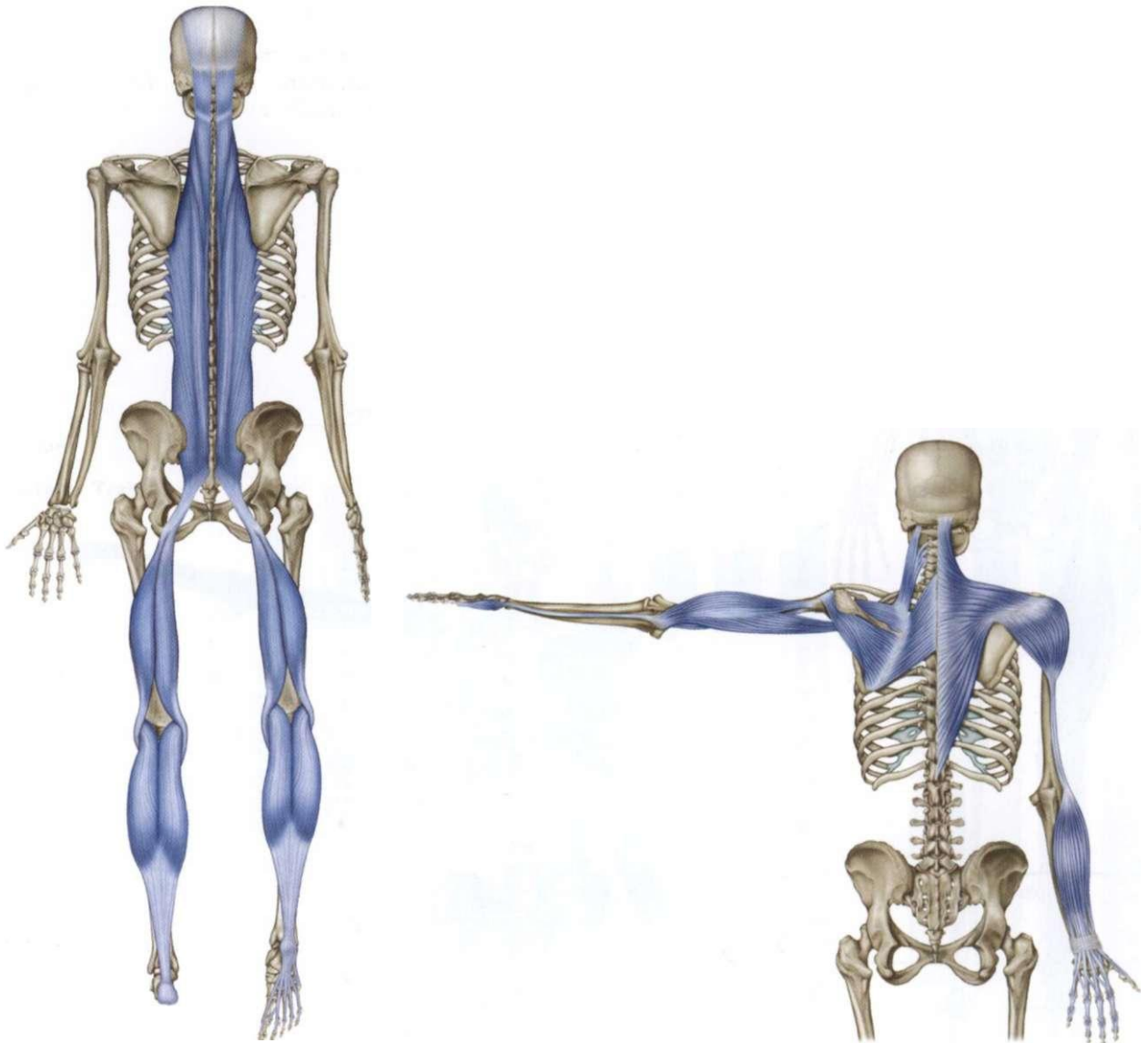
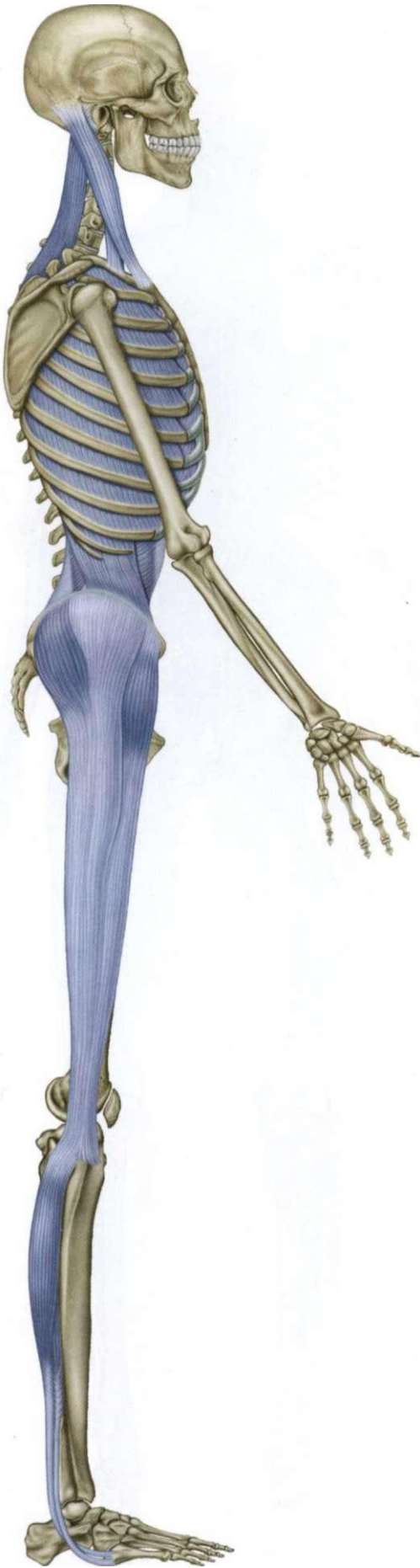


Fig. A2.6 The second session grounds the Superficial Back Line and opens the two Back Arm Lines.



Session 3

Open the Lateral Line, differentiate all four Arm Lines from below, and open lateral aspects of the Deep Front Line at either end of the rib cage (Fig. A2.7).

Goals:

- Open the body's sides, spread the 'wings' of the breath
- Contact and balance the body's stabilizing system
- Contact the body's 'lateral core'

Key structures:

- Peroneal fascia
- Iliotibial tract
- Quadratus lumborum and scalene myofascia

Session 4

Balance superficial myofasciae in terms of tonal balance of both right and left Spiral Line (Fig. A2.8).

Goals:

- Ease the restrictions in any superficial rotations
- Balance the sling around the scapula
- Balance the sling under the foot arches
- Complete the work on the superficial sleeve lines

Key structures:

- Rhombo-serratus complex
- Abdominal obliques
- Tibialis anterior-peroneus longus sling

Core sessions

Session 5

Open the lower portion of the Deep Front Line, and balance with Lateral Line (Fig. A2.9).

Goals:

- Build support through the inner leg
- Open and balance the adductor compartment
- Release the pelvis from below

Key structures:

- Deep posterior compartment of leg
- Adductor group
- Psoas complex attachments at lesser trochanter

Session 6

Open the trunk portion of the Deep Front Line, and revisit the Front Arm Lines, especially the Deep Front Arm Line (Fig. A2.5 & A2.9).

Goals:

- Find appropriate support and positioning for the lumbar
- Balance psoas and diaphragm to release the 'deeper breath'
- Find reciprocity between the pelvic floor and respiratory diaphragm

Key structures:

- Psoas
- Diaphragm
- Deep laminae of abdominal myofascia

Fig. A2.7 The third session focuses on the Lateral Line, and balancing the shoulders onto it.

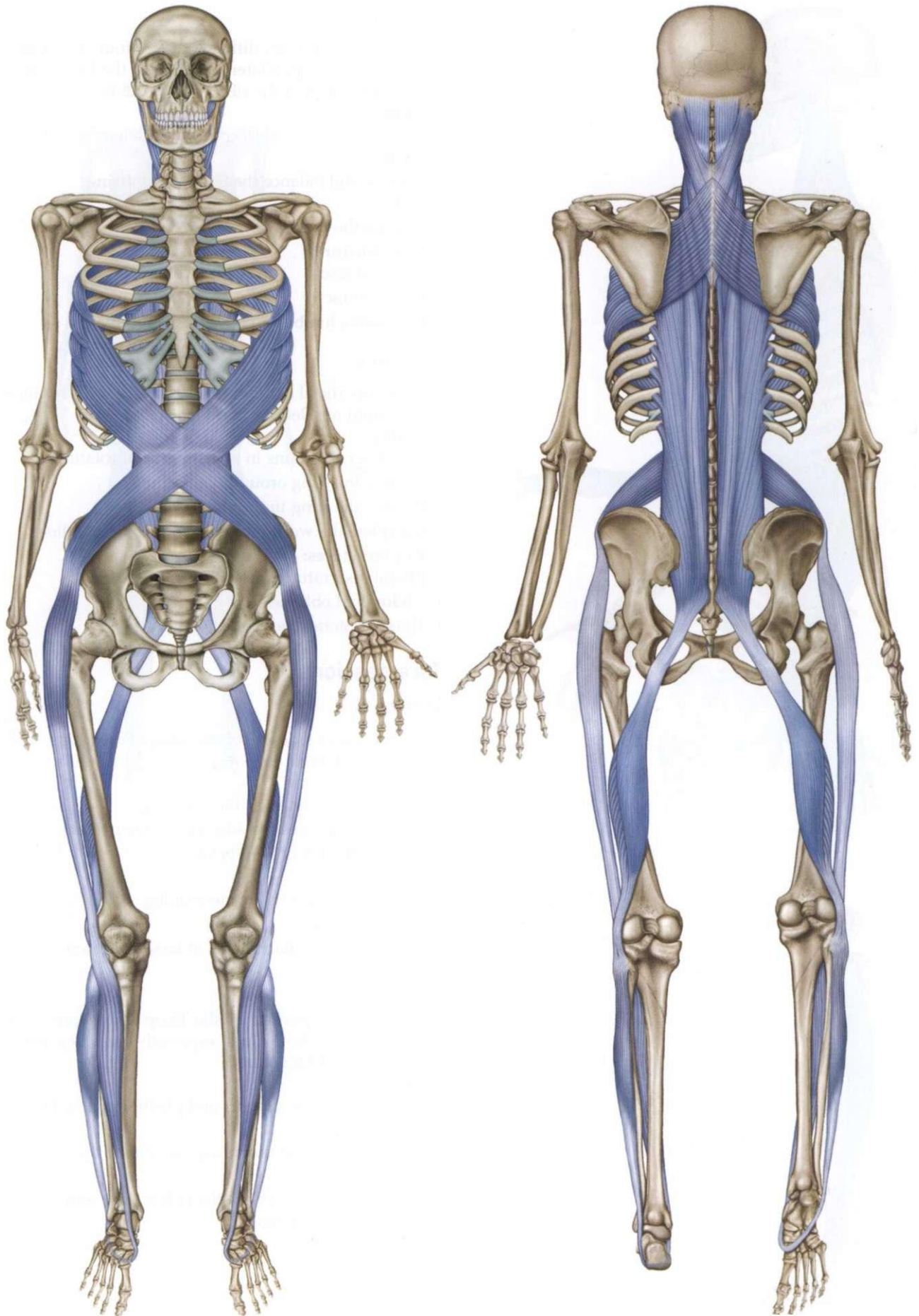

Fig. A2.8 The fourth session balances the double helix of the Spiral Lines, including the sling under the arch of the foot and the scapular position relative to the head and ribs.

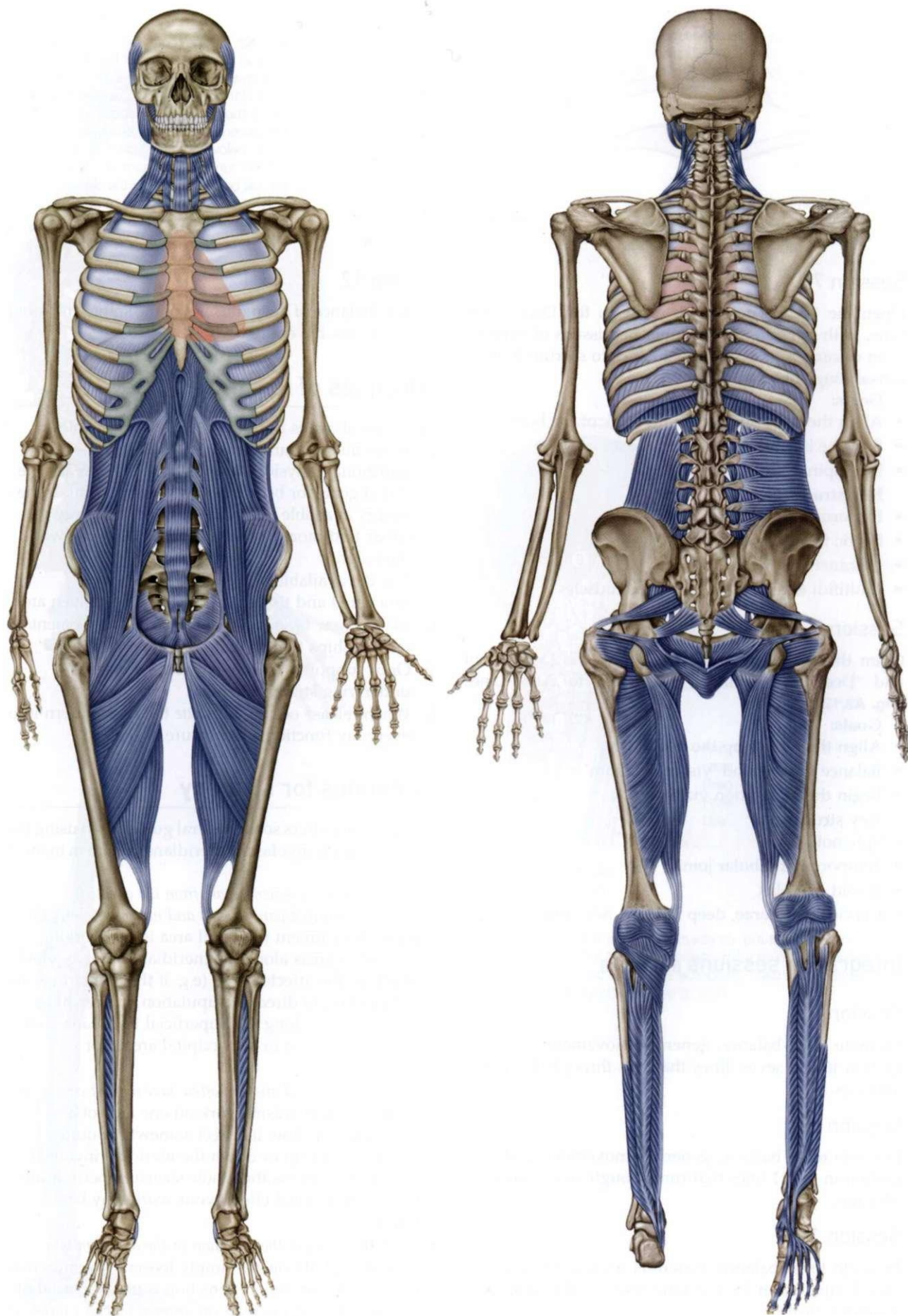

Fig. A2.9 The core sessions, beginning with session 5, concentrate on the Deep Front Line, which runs from the inner arch up through and around the pelvis and viscera to the jaw.

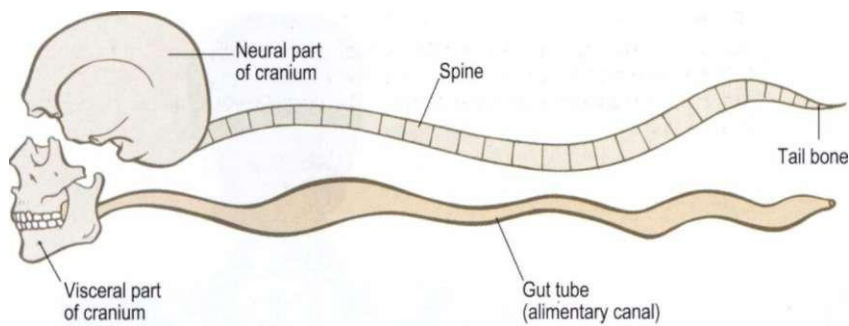


Fig. A2.10 The 'core sessions, especially session 6, make much of the separation and proper 'span' between the neuro-muscular body (what Maria Montessori called the 'white man', above) distinct from the visceral body (what she called the 'red man', below). The division is right at the anterior longitudinal ligament, running from the tail bone caudally to the separation between the viscerocranium and neurocranium at the top end.

Session 7

Open the 'Deep Back Line', relate to the Deep Front Line, with attention to the inner bag issues of support from calcaneus to ischial tuberosities to sacrum to mid-dorsal hinge of spine (**Fig. A2.11**).

Goals:

- Align the bony support in the back of the body
- Free the intrinsic motions of the sacrum
- Ease spinal bends and rotation

Key structures:

- Piriformis and deep lateral rotators
- Pelvic floor muscles
- Calcanei
- Multifidi and transversospinalis muscles

Session 8

Open the neck and head portions of the Deep Front and 'Deep Back' Lines, and relate to Arm Lines (**Fig. A2.12**).

Goals:

- Align the head atop the body
- Balance the jaw and 'viscerocranium'
- Begin the integration via the neck

Key structures:

- Sphenoid bone
- Temporomandibular joint
- Hyoid complex
- Cervical vertebrae, deep anterior neck muscles

Integration sessions (**Fig. A2.13**)

Session 9

Promote tonal balance, generous movement, and integration in the seven lines that run through the pelvis and legs.

Session 10

Promote tonal balance, generous movement, and integration in the 11 lines that run through and around the rib cage.

Session 11

Promote tonal balance, generous movement, and balanced integration in the four lines of the arms and shoulder girdle.

Session 12

Promote balance of deep muscles of the spine, and tonal balance across the entire body.

Principles of treatment

The recipe above is derived from these principles:

1. There must be sufficient *energy* available - nutritional, physical, hormonal, etc. - to reach the stated goals for both practitioner and client. If the energy available is insufficient, then you must either find more or persuade the client to lower their sights.
2. Use the available energy to seek increased functional and tissue *adaptability* in any given area.
3. Via the new tissue adaptability, change segmental relationships to gain increased *support*.
4. Once support is improved, seek *release* of underlying strain patterns.
5. When release occurs, *integrate* the new pattern into everyday function and posture.

Guidelines for strategy

The following offers some general guidance in using the Anatomy Trains myofascial meridians system in manual therapy:

- *In palpatory assessment, start from the affected/restricted/injured/painful area and move out along the trains.* If treatment to a local area is not working, seek other areas along the meridian that may yield results at the affected area (e.g. if the hamstrings are not yielding to direct manipulation or stretching, try elsewhere along the Superficial Back Line - on the plantar fascia or suboccipital areas, for example).
- *Work on the meridians can often have distant effects.* By whatever mechanism, work on one area of a meridian can show its effect somewhere quite distant, either up or down the meridian involved. Be sure to reassess the whole structure periodically to see what global effects your work may be having.
- *Work the tissue of the meridian in the direction you want it to go.* If you are simply loosening a muscular element of a meridian, direction is not as crucial. If you are shifting the relation among fascial planes, it

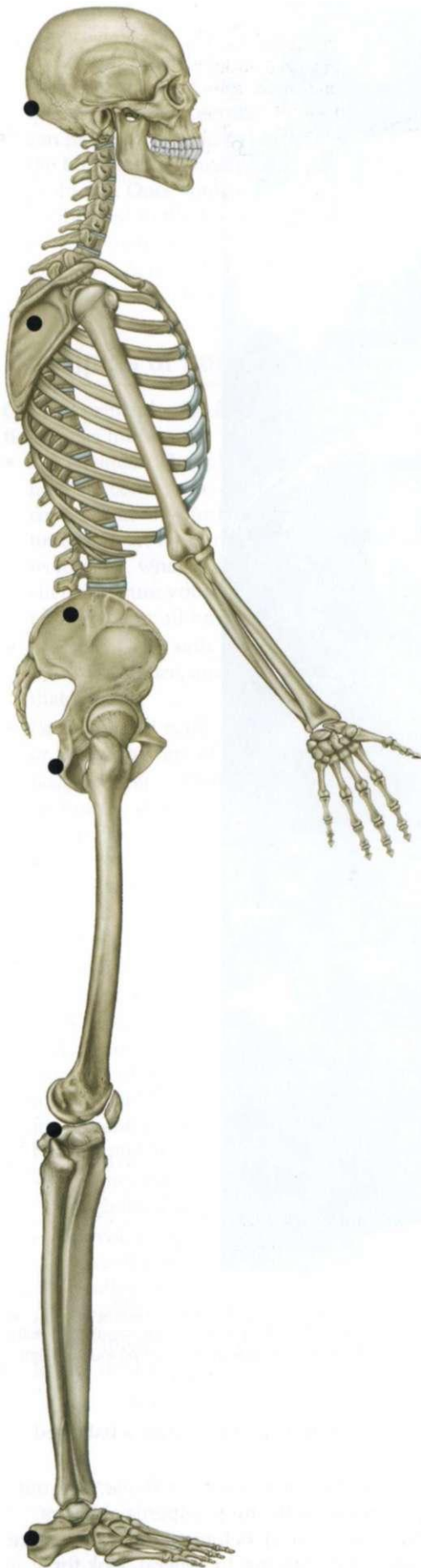


Fig. A2.11 Session 7 works with the deeper tissues on the back of the body to align the major bony landmarks - the heels, ischial tuberosities, sacroiliac joints, mid-dorsal hinge, and the occiput. The deep lateral rotators are key to this session.

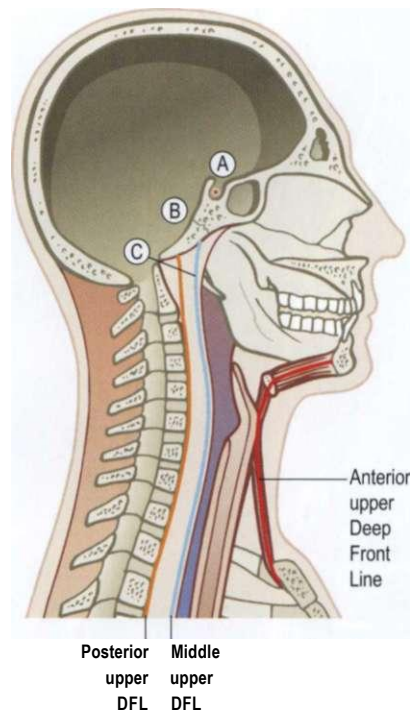


Fig. A2.12 Session 8 is an opportunity to 'put the head on'. At a deeper level, it is about bringing together the multiple physiologies of the neck and head, where the ectoderm, mesoderm, and endoderm meet very closely (see p. 202).

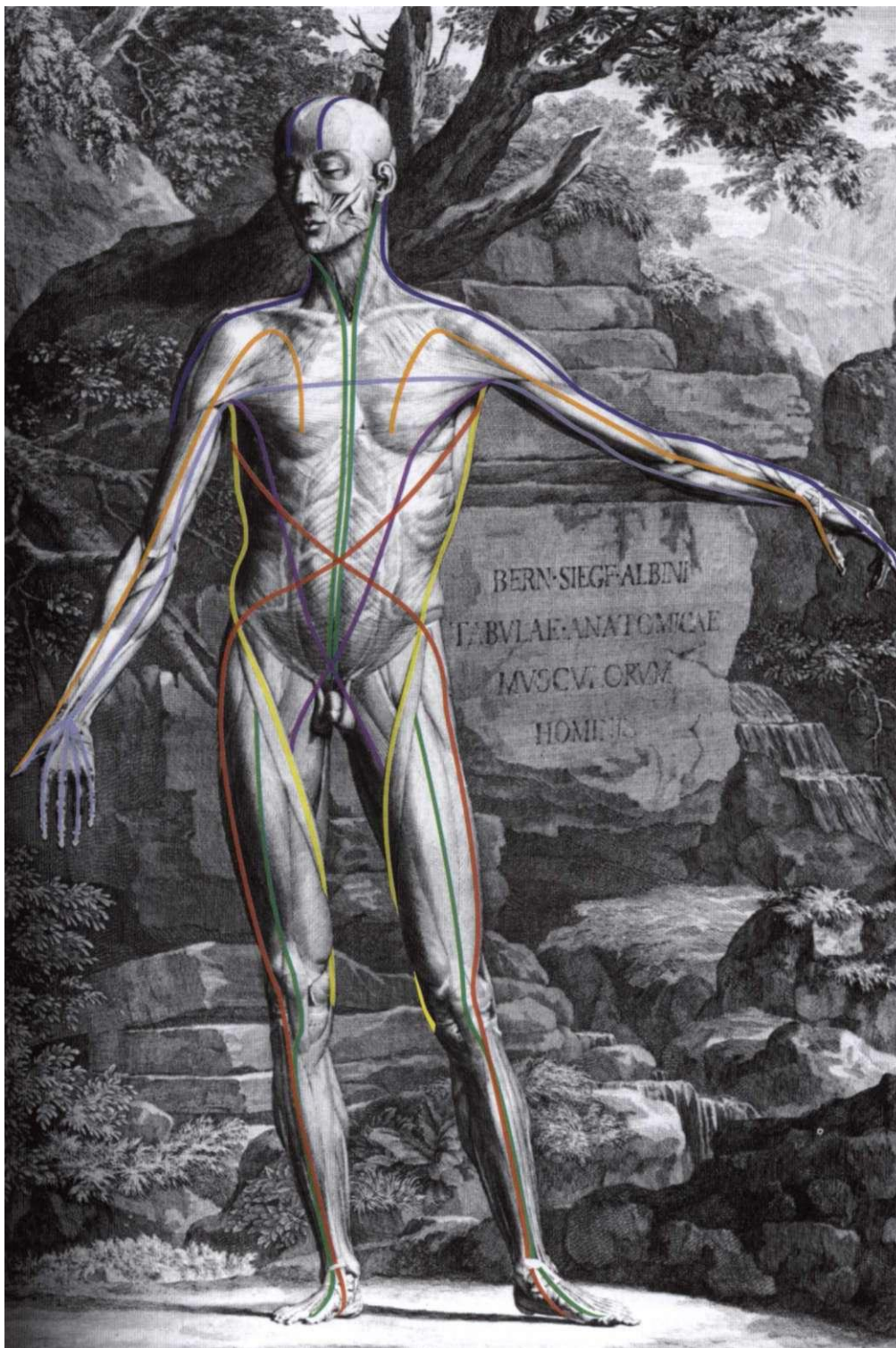


Fig. A2.13 The integrating sessions are a chance to bring harmony and coordination to the 12 myofascial meridians, moving progressively up the body. Session 9 deals with the pelvis and legs, session 10 with the torso and breath enhancement, session 11 with the shoulders and arms, and session 12 with the spine and neck relating out to the whole body (With thanks for use of Albinus' brilliant drawing, courtesy of Dover Publications.)

is. 'Put it where it belongs and call for movement', was Dr Ida Rolf's terse summary of her method. Frequently, for instance, the tissues of the Superficial Front Line need to move up in relation to the tissues of the Superficial Back Line, which need to move down to more effectively

'drape the toga' of the myofascia over a balanced skeleton.

- *Work from the outside in, and then inside out.* Sort out the compensations in the more superficial layers first, as far as is practical, before taking on the more deeply embedded patterns. In general, look for a

uniform resilience and adaptability in the Superficial Front and Back Lines, and the Lateral and Spiral Lines before attempting to unravel the Deep Front Line. Going for deep patterns too quickly, before loosening the overlying layers, can result in driving patterns deeper or reducing the body's coherence, rather than resolving problems. Once some resilience and balance is established in the Deep Front Line, return to the issues remaining in the more superficial lines, and drape the Arm and Functional Lines over the rebalanced structure.

Principles of body and hand use

General principles for fascial and myofascial manipulation are as follows:

- *Pay attention.* Though we tend to pay attention to how we contact the client or patient, i.e. what is coming out of your hands toward the client, less time is given in training to what the practitioner is feeling, i.e. what is coming up your arm from the client. Be sure you are attentive to what the tissue is telling you at all times.
- *Layering.* Go in only as far as the first layer that offers resistance, and then work within and along that layer.
- *Pacing.* Speed is the enemy of sensitivity; move at or below the rate of tissue melting.
- *Body mechanics.* Minimal effort and tension on the part of the practitioner leads to maximum sensitivity and conveyance of intent to the client. Using your weight and 'compound essence of time' is always better than using your strength to induce tissue change.

Principles of body mechanics are widely taught in training and widely ignored in practice.
- *Movement.* Client movement makes myofascial work more effective. With each move you make, seek a movement direction to give the client. Again, 'put it where it belongs and call for movement.' The client's movement, even a small movement, under your hands serves at minimum two purposes:
 - it allows the practitioner to feel with ease in which level of myofascia he is engaged
 - it involves the client actively in the process, increasing the proprioception from muscle spindles and stretch receptors.
- *Pain.* Pain is sensation accompanied by the client's 'motor intention to withdraw'. It is a reason to stop, let up, or slow down.

- *Trajectory.* Each move has a trajectory or an arc - a beginning, a middle, and an end. Each session has an arc, each series of sessions has an arc, and even each move has an arc. Know where you are in these overlapping arcs.

Goals

The goals of myofascial or movement work include the following:

- *Complete body image.* The client has access to the information coming from, and motor access to, the entire kinesthetic body, with minimal areas of stillness, holding, or 'sensory-motor amnesia'.
- *Skeletal alignment and support.* The bones are aligned in a way that allows minimum effort for standing and action.
- *Tensegrity/palintonicity.* The myofascial tissues are balanced around the skeletal structure such that there is a general evenness of tone, rather than islands of higher tension or slack tissues. The opposite of structural integration is structural isolation.
- *Length.* The body lives its full length in both the trunk and limbs, and in both the muscles and the joints, rather than moving in shortness and compression.
- *Resilience.* The ability to bear stress without breaking, and to resume a balanced existence when the stress is removed.
- *Ability to hold and release somato-emotional charge.* The ability to hold an emotional charge without acting it out, and to release it into action or simply into letting go when the time is appropriate.
- *Unity of intent with diffuse awareness.* Structural Integration implies the ability to focus on any given task or perception while maintaining a diffuse peripheral awareness of whatever is going on around this focused activity. Focus without contextual awareness breeds a fanatic; awareness without focus breeds a space cadet.
- *Reduced effort.* Reduced effort in standing and movement - less 'parasitic' tension or unnecessary compensatory movement involved in any given task.
- *Range of motion.* Generosity of movement, less restriction in any given activity, and that - within the limits of health, age, history, and genetic make-up - the full range of human movement is available.
- *Reduced pain.* Standing and activity be as free of structural pain as possible.

Appendix

Myofascial meridians and oriental medicine

3

The Anatomy Trains myofascial meridians evolved solely within the Western anatomical tradition. In the first edition, we deliberately omitted any comparison to the acupuncture and similar meridians used in traditional oriental medicine, in order to emphasize the anatomical basis of these continuities. The close relationship between the two, however, is inescapable, especially in light of recent research detailing the effects of acupuncture on and through the extracellular matrix. This edition includes a comparison of the acupuncture meridians, the Sen lines of Thai yoga massage, and the Anatomy Trains. Since we are all studying the same human body, it is unsurprising that we find overlap near the summit of two different routes of ascent.

Because this author is not knowledgeable in oriental medicine, he is grateful to Dr Peter Dorsher,¹ Dr C. Pierce Salguero,²⁴ Dr Helene Langevin,²² and Dr Phillip Beach DO²¹⁻²³ for help in accurately depicting these meridians and teasing out their details. There is variability among the many oriental medicine traditions in how the meridians are portrayed, so we have chosen the road more traveled and have not strayed into the underbrush of such variations.

As the accompanying illustrations from Dr Dorsher show, the Superficial Front Line (SFL), Superficial Back Line (SBL), and Lateral Line (LL) myofascial continuities show significant overlap with the energetic continuities of the Stomach meridian, Bladder meridian, and Gallbladder meridian respectively (**Fig. A3.1A-D**).

The four Arm Lines, from Superficial Front to Superficial Back, correspond quite closely to the Pericardium, Lung, Small Intestine, and Triple Heater meridians respectively (**Fig. A3.2A-D**).

The Deep Front Line, which is only occasionally accessible near the surface of the body, corresponds to the Liver meridian, which likewise travels through and around the ventral viscera, but in some areas to the Kidney meridian that traverses the inner line of the leg (**Fig. A3.3A and B**).

When it comes to the so-called helical lines - the Spiral Line and the Functional Lines - we find a problem in that they cross the body's front and back midline to join biomechanically with structures on the other side

of the body, whereas no acupuncture meridian crosses the midline. The Stomach meridian most closely approximates the anterior portion of the Spiral Line; when combined with the Bladder meridian, most of the Spiral Line is duplicated, but this correspondence is a bit contrived (**Fig. A3.4**).

If we switch our attention to the Sen lines used in traditional Thai massage, we find that while no meridians cross in the posterior aspect, many lines seem to meet and cross at the navel or *hara* in the front (**Fig. A3.5**).

Specifically, the Kalatharee line crosses in the front, joining (and mirroring the Anatomy Trains map) the front of the arm (Superficial Front Arm Line) across the body's midline to the contralateral femur (Front Functional Line), and connecting from the adductor longus down through the inner line of the leg to the inner arch via the Deep Front Line (**Fig. A3.6**).

Recent research highlights the link in both form and function between the workings of acupuncture and the fascial network in general. Findings by prominent acupuncture researcher and neuroscientist Dr Helene Langevin and others have shown that connective tissue - specifically the hydrophilic proteoglycans along with collagen fibers and fibroblasts - winds around the end of the acupuncture needle when it is rotated in place, creating detectable mechanical tissue effects (**Fig. A3.7**). These effects have been noted 4 cm away from the site of needle insertion (as this was the limit of the field of view; new experiments are underway to establish if the effect can be detected at a greater distance).

Additionally, Langevin postulated that oriental acupuncture meridians may follow intermuscular or intramuscular fascial planes. These findings, taken together, link the possible effects of acupuncture stimulation with the mechanical transduction within fascial planes of the extracellular matrix (ECM) detailed in the final pages of Chapter 1 (although of course other effects may be taking place with acupuncture as well). Langevin found an 80% correspondence in the arm between the sites of traditional acupuncture points and these fascial planes of division in the interstitial connective tissue.

This suggests that the clear 'signaling' and action at a distance which one associates with acupuncture is

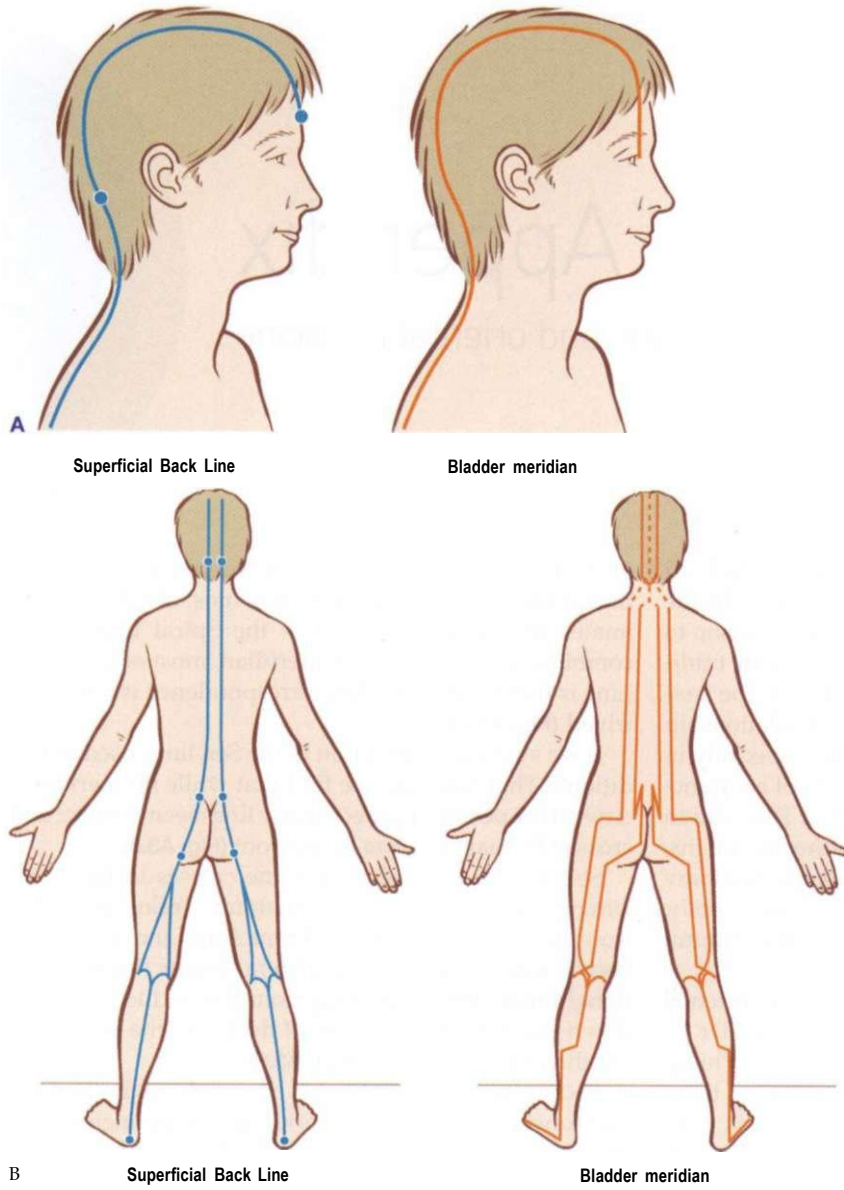
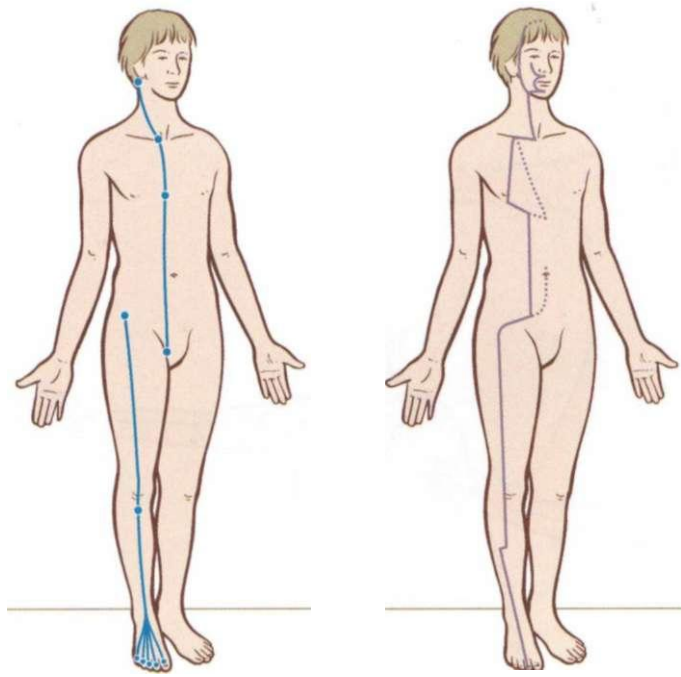
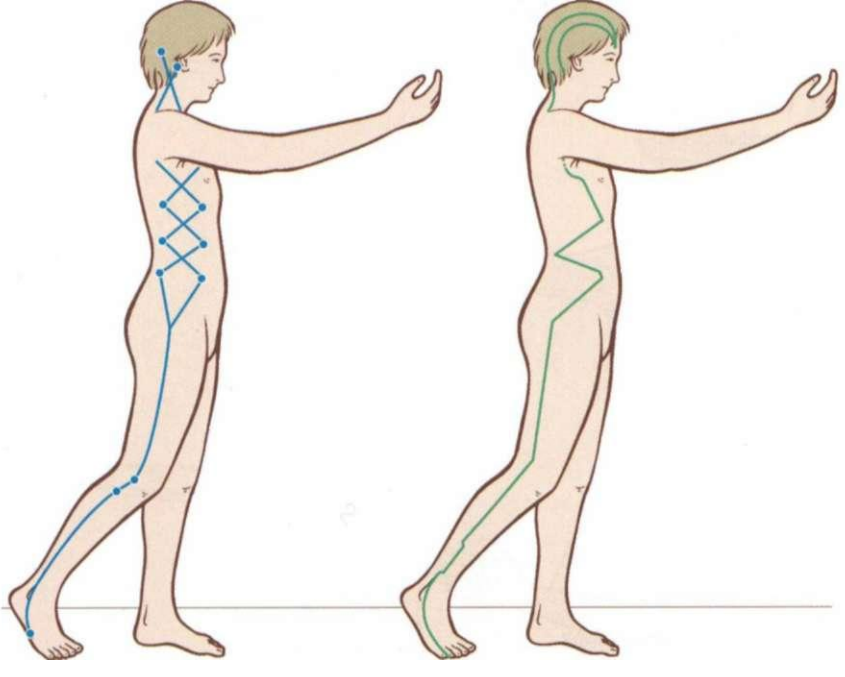


Fig. A3.1 There is a fairly close correspondence between the path of the Front, Back, and Lateral Lines and the Stomach, Bladder, and Gallbladder meridians respectively. (Used with the kind permission of Dr Peter Dorsher.)



C Superficial Front Line

Stomach meridian



D Lateral Line

Gallbladder meridian

Fig. A3.1 Continued

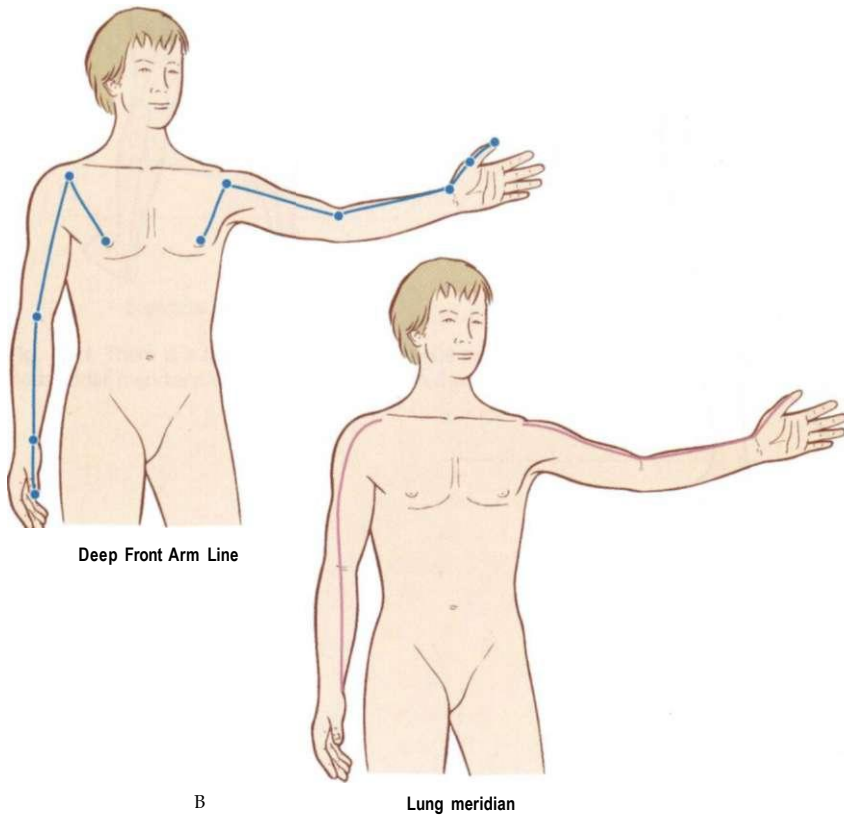
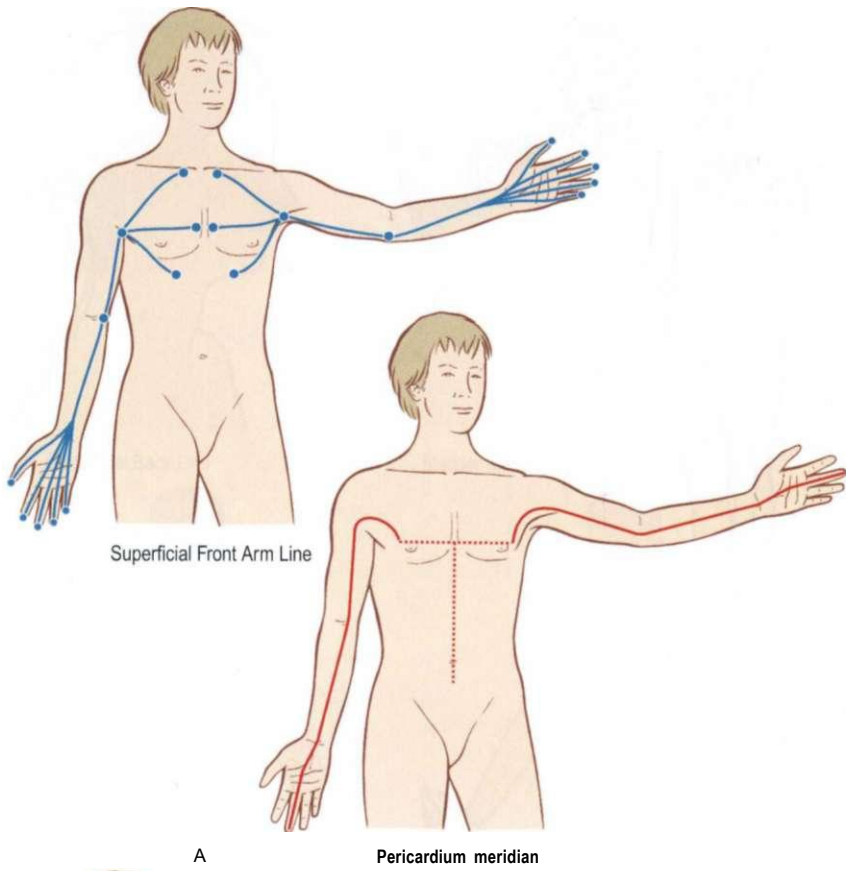
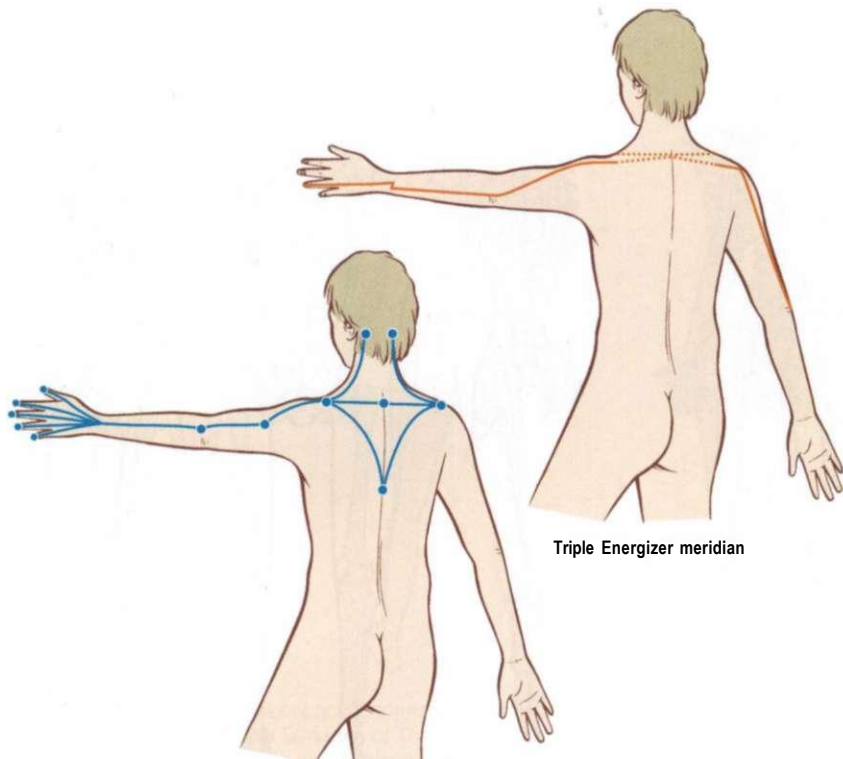
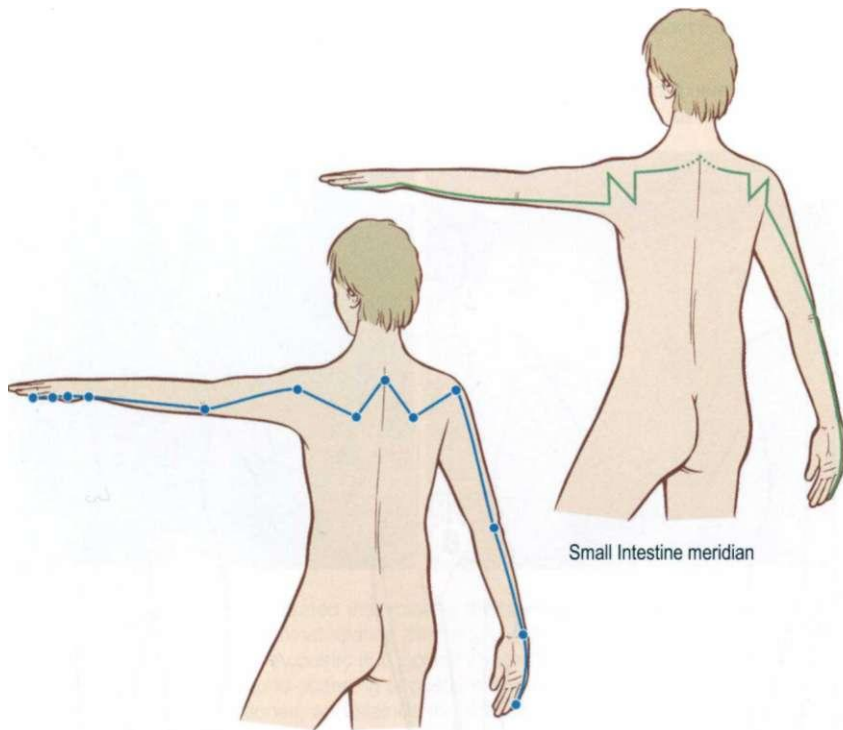


Fig. A3.2 There is a quite close correspondence between the paths of the four Arm Lines and the Pericardium, Lung, Triple Heater, and Small Intestine meridians. (Used with the kind permission of Dr Peter Dorsher.)



Triple Energizer meridian

C Superficial Back Arm Line



Small Intestine meridian

D Deep Back Arm Line

Fig. A3.2 Continued

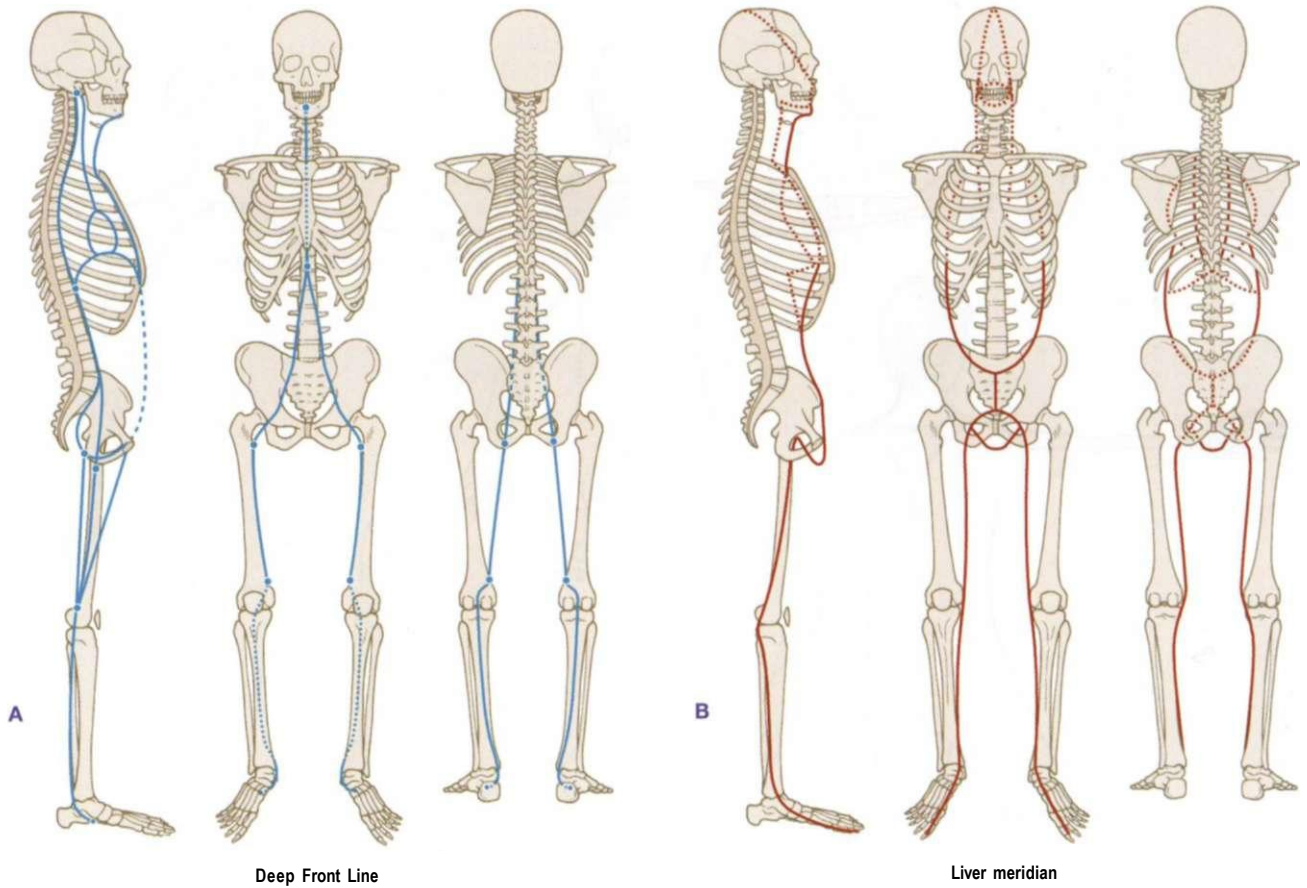


Fig. A3.3 The Deep Front Line corresponds with the Liver meridian, though the inner line of the leg seems to have a lot in common with the Kidney meridian as well, which terminates in the inner arch as the Deep Front Line also does. (Used with the kind permission of Dr Peter Dorsher.)

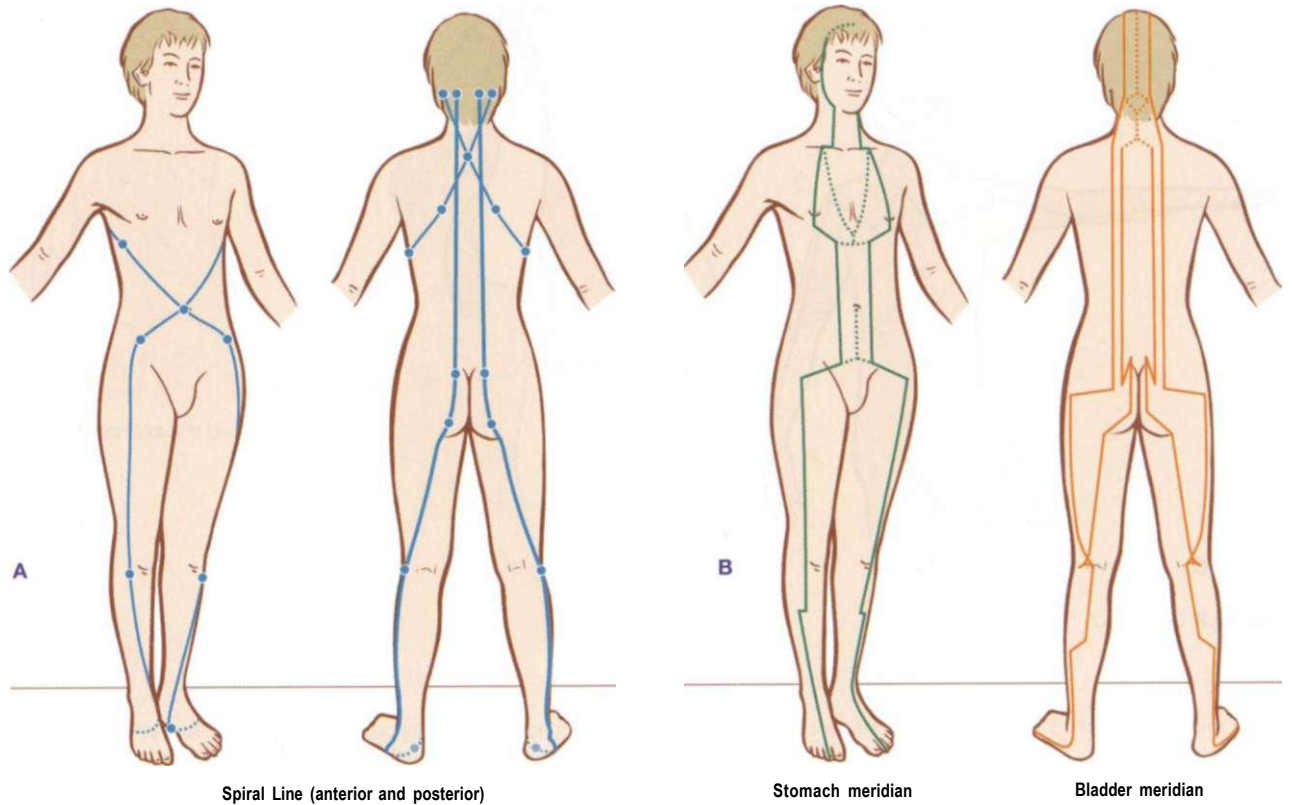


Fig. A3.4 The Spiral Line set of myofascial continuities can be approximated by combining the Stomach meridian and Bladder meridian, but the correspondence is a stretch. On the other hand, the Spiral Line does 'parasitize' the Front, Back, and Lateral Lines - sharing muscles and fascia with each of these lines - so perhaps it is not such a stretch that this meridian should also be derived from other meridians. (Used with the kind permission of Dr Peter Dorsher.)

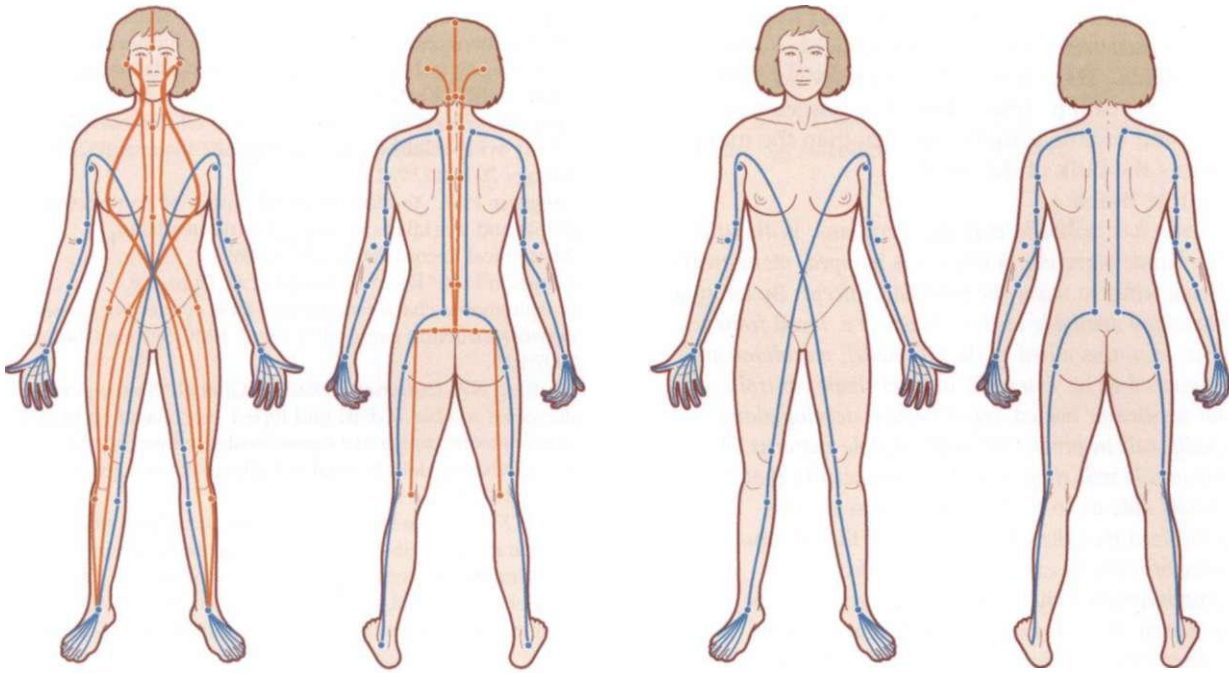


Fig. A3.5 Although no traditional acupuncture meridians cross the sagittal midline, the traditional Sen lines of Thai yoga massage cross the midline in front at the *hara*. (Adapted from Salguero CP. *Traditional Thai medicine: Buddhism, Animism, Ayurveda*. Prescott: Hohm Press, 2007, and used with the kind permission of C. Pierce Salguero, www.taomountain.org.)

Fig. A3.6 The Kalatharee line particularly echoes the Front Functional Line, connecting the Superficial Front Arm Line across the midline to the Deep Front Line in the leg of the opposite side. (Adapted from Salguero CP. *The encyclopedia of Thai massage*. Forres, Scotland: Findhorn Press, 2004, and used with the kind permission of C. Pierce Salguero, www.taomountain.org.)

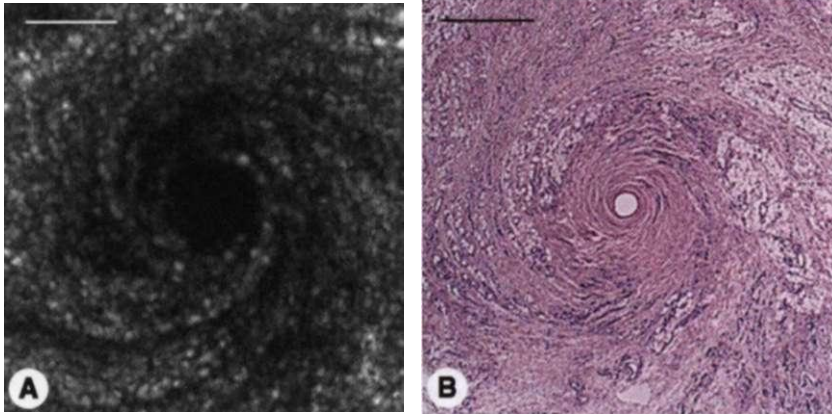


Fig. A3.7 It has been demonstrated that rotating the needles in acupuncture 'winds' the extracellular matrix around the shaft of the needle (in a mouse, at least). What relation this clearly visible interaction between the needle and the ECM has to therapeutic effects has not yet been elucidated. Acoustic and optical images of subcutaneous tissue with unidirectional needle rotation. **(A)** Fresh tissue sample imaged with ultrasound scanning acoustic microscopy; **(B)** the same tissue sample was formalin-fixed after ultrasound imaging, embedded in paraffin, sectioned, and stained for histology with hematoxylin/eosin. Scale bars: 1 mm. (Reproduced with kind permission from Langevin et al 2002.)

connected at the cellular and histological level with the new mechanotransduction communication channels being discovered among the connective tissue cells such as fibroblasts and leucocytes and the ECM complex surrounding them. Further research promises to be exciting for the field of acupuncture, movement rehabilitation and education, and therapeutic manipulation,

as these approaches draw together into a 'unified field' theory.

Finally, there is the real question as to whether both the Anatomy Trains system and the acupuncture map might not both arise from the same organismic responses to body development, movement, and protection. Australian osteopath Phillip Beach has developed the

concept of the 'contractile field' (CF), and hypothesized lateral, dorsal, ventral, helical, appendicular, radial and chiralic fields. The outer fields correspond with acupuncture meridian lines, but the association with muscles and organs is more complex than the mapping that forms the bulk of this book.

To quote Beach:

Bioscience has looked in vain for meridians. Without a modern understanding of what was mapped, mainstream medicine tends to reject the meridial concept. By using a methodology available to the Chinese, i.e. recoil from a noxious stimulus allied to the CF model, meridians are hypothesized to be 'emergent lines of shape control'. When needled or heated, recoil vectors develop along the body wall in predictable and sensible patterns. A blunt needle will elicit afield of contractility that the CF model aids us to understand. In essence it is hypothesized that the Chinese mapped the minimum number of lines, in exactly the right location, to accurately/predictably control subtle human shape in three dimensions. Shape and function are usually correlated. The correlation between the CF model and the deeply detailed and nuanced Chinese meridial map is uncanny. It was the meridial map that suggested to the author the association between the sense organs and the CFs, an association that was conceptually off the radar from a conventional musculoskeletal perspective.^{32,33}

'Shape control' might be the guiding principle that unites the signaling response through the connective tissue and the odd but intuitively apt course of the meridian lines across the body. Coupled with Becker's work, which suggests the connective tissue network could have had signaling and contraction functions that pre-date the organized muscle network, Anatomy Trains lines and/or the contractile fields could represent primitive lines of retraction away from noxious stimuli, or lines of reach toward favorable stimuli.^{32,33}

References

- Dorsher PT. Myofascial pain: rediscovery of a 2000-year-old tradition? *Medical Acupuncture* 85(9):e42. *Contact details for Peter T. Dorsher MS MD: Mayo Clinic, Jacksonville, FL; e-mail: dorsher.peter@mayo.edu.*
- Salguero CP. *A Thai herbal*. Forres, Scotland: Findhorn Press; 2003.
- Salguero CP. *The encyclopedia of Thai massage*. Forres, Scotland: Findhorn Press; 2004.
- Salguero CP. *The spiritual healing of traditional Thailand*. Forres, Scotland: Findhorn Press; 2006.
- Salguero CP. *Thai massage workbook: basic and advanced course*. Forres, Scotland: Findhorn Press; 2007.
- Salguero CP. *Traditional Thai medicine: Buddhism, Animism, Ayurveda*. Prescott: Hohm Press; 2007.
- Langevin HM,* Bouffard NA, Badger GJ et al. Subcutaneous tissue fibroblast cytoskeletal remodeling induced by acupuncture: evidence for a mechanotransduction-based mechanism. *Journal of Cellular Physiology* 2006; 207(3):767-774.
- Langevin HM,* Storch KS, Cipolla MJ et al. Fibroblast spreading induced by connective tissue stretch involves intracellular redistribution of a- and P-actin. *Histochemistry and Cell Biology* 2006; 14:1^9.
- Langevin HM,* Konofagou EE, Badger GJ et al. Tissue displacements during acupuncture using ultrasound elastography techniques. *Ultrasound in Medicine and Biology* 2004; 30:1173-1183.
- Langevin HM,* Cornbrooks CJ, Taatjes DJ. Fibroblasts form a body-wide cellular network. *Histochemistry and Cell Biology* 2004; 122:7-15.
- Langevin HM,* Yandow JA. Relationship of acupuncture points and meridians to connective tissue planes. *Anatomical Record* 2002; 269:257-265.
- Langevin HM,* Rizzo D, Fox JR et al. Dynamic morphometric characterization of local connective tissue network structure using ultrasound. *BMC Systems Biology* 2007;1:25.
- Bouffard NA, Cutroneo K, Badger GJ et al.* Tissue stretch decreases soluble TGF- β 1 and type-1 procollagen in mouse subcutaneous connective tissue: evidence from ex vivo and in vivo models. *Journal of Cellular Physiology* 2008; 214(2):389-395.
- Storch KN, Taatjes DJ, Bouffard NA et al.* Alpha smooth muscle actin distribution in cytoplasm and nuclear invaginations of connective tissue fibroblasts. *Histochemistry and Cell Biology* 2007; 127(5):523-530.
- Langevin HM,* Bouffard NA, Churchill DL et al. Connective tissue fibroblast response to acupuncture: dose-dependent effect of bi-directional needle rotation. *Journal of Alternative and Complementary Medicine* 2007; 13:355-360.
- Langevin HM,* Sherman KJ. Pathophysiological model for chronic low back pain integrating connective tissue and nervous system mechanisms. *Medical Hypotheses* 2007; 68:74-80.
- Langevin HM.* Connective tissue: a body-wide signaling network? *Medical Hypotheses* 2006; 66(6):1074-1077.
- Iatridis JC, Wu J, Yandow JA, Langevin HM.* Subcutaneous tissue mechanical behavior is linear and viscoelastic under uniaxial tension. *Connective Tissue Research* 2003; 44(5):208-217.
- Langevin HM,* Yandow JA. Relationship of acupuncture points and meridians to connective tissue planes. *Anatomical Record (Part B: New Anatomist)* 2002; 269:257-265.
- Langevin HM,* Churchill DL, Wu J et al. Evidence of connective tissue involvement in acupuncture. *FASEB Journal* 2002; 16:872-874.
- Langevin HM,* Churchill DL, Fox JR. Biomechanical response to acupuncture needling in humans. *Journal of Applied Physiology* 2001; 91:2471-2478.
- Langevin HM,* Churchill DL, Cipolla MJ. Mechanical signaling through connective tissue: a mechanism for the therapeutic effect of acupuncture. *FASEB Journal* 2001; 15:2275-2282.
- Beach P. What is the meridian system encoding? Part 1. *European Journal of Oriental Medicine* 1997; 2(3):21-28.
- Beach P. What is the meridian system encoding? Part 2. *European Journal of Oriental Medicine* 1997; 2(4):25-33.
- Beach P. What is the meridian system encoding? Part 3. *European Journal of Oriental Medicine* 1998; 2(5):42-47.
- Beach P. The manipulation of shape - muscles and meridians. *New Zealand Journal of (Medical) Acupuncture* 2004.
- Beach P. Meridians: emergent lines of shape control. *Medical Acupuncture* 2007; 19(2).
- Beach P. Meridians: emergent lines of shape control. *Australian Journal of Acupuncture and Chinese Medicine* 2007; 2(1):5-8.
- Beach P. The contractile field - a new model of human movement - Part 1. *Journal of Bodywork and Movement Therapies* 2007; 11:(4)308-317.

30. Beach P. The contractile field - a new model of human movement - Part 2. *Journal of Bodywork and Movement Therapies* 2008; 12(1):76-85.
 31. Beach P. The contractile field - a new model of human movement - Part 3. *Journal of Bodywork and Movement Therapy* 2008; 12(2):158-165.
 32. Becker RO, Selden G. *The body electric*. New York: Quill; 1985.
 33. Becker R. A technique for producing regenerative healing in humans. *Frontier Perspectives* 1990; 1:1-2.
- *Dr Langevin can be accessed at: <http://med.uvm.edu/neurology/WebBio.asp?SiteAreaID=71>*

Anatomy Trains terms

The following is a glossary of terms particular to this book. Standard anatomical terminology is for the most part not included, and can be found in any medical dictionary.

Anatomy trains The system of 12 myofascial meridians described in this book.

Branch line An alternative track to the primary myofascial meridian, often smaller and employed only under certain conditions.

Cardinal line A cardinal line runs the length of the body on one of the four major surfaces: the SBL on the back, the SFL on the front, and the LL on right and left sides.

Derailment A link within a myofascial meridian which only applies under certain conditions.

Express An express is a multi-joint muscle that thus enjoys multiple functions.

Helical lines Lines which traverse the body in a spiral, including the Functional Lines, the Spiral Lines, the Arm Lines (in practice), and portions of the Lateral Line.

Local A local is a single-joint muscle that duplicates one of the functions of a nearby or overlying express.

Locked long Used to designate a tense muscle held in a state longer than its usual efficient length, a muscle under strain, known in physiotherapy as 'eccentrically loaded'.

Locked short Used to designate a tense muscle held in a state shorter than its usual efficient length, a bunched or shortened muscle, known in physiotherapy as 'concentrically loaded'.

Mechanical connection A connection between two tracks across a station where the connection passes through an intervening bone.

Myofascial continuity Two or more adjacent and connected myofascial structures.

Myofascial meridian A connected string of myofascial or fascial structures, one Anatomy Train line.

Roundhouse An area where many myofascial continuities join, which is thus subject to a number of different

vectors; in simple language, a bony landmark where many muscles meet, such as the ASIS.

Station A place where the myofascial continuity or track in the 'outer' myofascial bag is 'tacked down' or attached to the fascial webbing of the 'inner' bone-ligament bag - in other words, a muscle attachment.

Switch An area where fascial planes either converge from two into one, or diverge from one into two.

Track A single myofascial or fascial element in a myofascial meridian.

Anatomy/physiology

Fascia For the purposes of this book, this term refers to the body-wide collagenous web or any section of it.

Ground substance Another name for the hydrophilic proteoglycans which constitute the various colloid inter-fibrillar elements of connective tissue.

Tensegrity Structures combining tension and compression where the tension members are determinant of the structure's integrity, where the compression members are isolated in a sea of continuous tension.

Thixotropy The tendency of colloids (such as ground substance) to become more fluid when stirred up by the addition of mechanical or thermal energy, and to become more solid or gelatinous when fluid or energy is extracted or when it sits undisturbed.

Abbreviations/acronyms

ALL Anterior longitudinal ligament

ASIS Anterior superior iliac spine

IT Ischial tuberosity

ITT Iliotibial tract

PSIS Posterior superior iliac spine

SCM Sternocleidomastoid

SP Spinous process (of vertebrae)

TFL Tensor fasciae latae

TLJ Thoracolumbar junction (T12-L1)

TP Transverse process (of vertebrae)

Lines

Cardinal

SFL Superficial Front Line. Runs from the top of the toes up the front of the leg and up the torso to the top of the sternum, and passes along the side of the neck to the back of the skull.

SBL Superficial Back Line. Runs from the underside of the foot up the back of the leg to the sacrum, and up the back to the skull, and over the skull to the forehead.

LL Lateral Line. Runs from the underside of the foot up the side of the leg and trunk, under the shoulder complex to the side of the neck and skull.

Helical

SL Spiral Line. Runs from the side of the skull across the neck to the opposite shoulder and ribs, and back across the belly to the front of the hip, the outside of the knee, the inside of the ankle, and under the arch of the foot and back up the leg and back to the skull.

FFL Front Functional Line. Runs from one shoulder across the front of the belly to the opposite leg.

BFL Back Functional Line. Runs from one shoulder across the back to the opposite leg.

Arms

SBAL Superficial Back Arm Line. Runs from the spinous processes over the shoulder and outside the arm to the back of the hand.

DBAL Deep Back Arm Line. Runs from the spinous processes through the scapula to the back of the arm and the little finger.

SFAL Superficial Front Arm Line. Runs from the sternum and ribs down the inside of the arm to the palm of the hand.

DFAL Deep Front Arm Line. Runs from the ribs down the front of the arm to the thumb.

Core

DFL Deep Front Line. A core line that begins deep on the sole of the foot and runs up the inside of the leg to the front of the hip joint and across the pelvis to the front of the spine and on up through the thoracic cavity to the jaw and the bottom of the skull.

Bibliography

- Abrahams PH, Hutchings RT, Marks Jr Sc. McMinn's colour atlas of human anatomy. 4th edn. London: Mosby; 1998.
- Acland R. Video atlas of human anatomy. Baltimore, MD: Williams and Wilkins; 1996 [and later editions].
- Agur A. Grant's atlas of anatomy. Baltimore, MD: Williams and Wilkins; 1991.
- Alexander C, Ishikawa S, Silverstein M. A pattern language. New York: Oxford University Press; 1977.
- Alexander FM. The use of the self. London: Gollancz; 1992.
- Alexander RM. The human machine. New York: Columbia University Press; 1992.
- Alfred W. The curse of an aching heart. 1972.
- Aposhyan S. Natural intelligence. Baltimore, MD: Williams and Wilkins; 1999.
- Aston J. Aston postural assessment workbook. San Antonio, TX: Therapy Skill Builders; 1998.
- Aston J. Moving beyond posture. Incline Village, CA: Aston Enterprises; 2007.
- Bainbridge-Cohen B. Sensing, feeling, and action. Northampton, MA: Contact Editions; 1993.
- Barlow W. The Alexander technique. New York: Alfred A Knopf; 1973.
- Barnes J. Myofascial release. Paoli, PA: Myofascial Release Seminars; 1990.
- Barral J-P. Manual thermal diagnosis. Seattle: Eastland Press; 1996.
- Barral J-P. Understanding the messages of your body. Berkeley: North Atlantic Books; 2007.
- Barral J-P, Crobier A. Manual therapy for the peripheral nerves. Edinburgh: Churchill Livingstone; 2007.
- Barral J-P, Mercier P. Visceral manipulation. Seattle: Eastland Press; 1988.
- Beck M. Milady's theory and practice of therapeutic massage. Albany, NY: Milady; 1994.
- Becker RO, Selden, G. The body electric. New York: Quill; 1985.
- Beach P. Meridians: emergent lines of shape control. Medical Acupuncture 2007; 19(2).
- Beach P. Meridians: emergent lines of shape control. Australian Journal of Acupuncture and Chinese Medicine 2007; 2(1):5-8.
- Beach P. The contractile field - a new model of human movement. Part 1. Journal of Bodywork and Movement Therapies 2007; 11(4):308-317.
- Beach P. The contractile field. Part 2. Journal of Bodywork and Movement Therapies 2008; 12(1):76-85.
- Beach P. The contractile field. Part 3. Journal of Bodywork and Movement Therapy 2008; 12(2):158-165.
- Benninghoff A, Goerttler K. Lehrbuch der Anatomie des Menschen. Munich: Urban and Schwarzenburg; 1975.
- Berman M. Coming to our senses. New York: Bantam Books; 1990.
- Berry T. The dream of the earth. San Francisco: Sierra Club; 1990.
- Berthoz A. The brain's sense of movement. Cambridge, MA: Harvard University Press; 2000.
- Biel A. Trail guide to the body. 3rd edn. Boulder, CO: Books of Discovery; 2005.
- Bion WR. Experiences in groups. New York: Routledge; 1994.
- Blechschildt E. The beginnings of human life. New York: Springer-Verlag; 1977.
- Blechschildt E. The ontogenetic basis of human anatomy. Berkeley: North Atlantic Books; 2004.
- Bogduk N. Clinical anatomy of the lumbar spine and pelvis. Edinburgh: Churchill Livingstone; 1998.
- Bond M. Balancing the body. Rochester, VT: Inner Traditions; 1993.
- Bond M, The new rules of posture. Rochester, VT: Inner Traditions; 2006.
- Bonner JT. On development. Cambridge, MA: Harvard University Press; 1974.
- Briggs J. Fractals. New York: Simon and Schuster; 1992.
- Busquet L. Les chaines musculaires. Vols 1-4. Freres, Mairlot; 1992. Maitres et Clefs de la Posture, www.chainesmusculaires.com
- Cailliet R. Soft tissue pain and disability. Philadelphia: FA Davis; 1977.
- Cairns-Smith AG. Seven clues to the origin of life. Cambridge, UK: Cambridge University Press; 1985.
- Calais-Germain B. Anatomy of movement. Seattle: Eastland Press; 1993.
- Calais-Germain B. The female pelvis. Seattle: Eastland Press; 2003.
- Cameron J, Skofronick J, Grant R. Physics of the body. Madison, WI: Medical Physics Publishing; 1992.
- Chaitow L. Soft tissue manipulation. Wellingborough, UK: Thorsons; 1980.
- Chaitow L. Palpatory skills. Edinburgh: Churchill Livingstone; 1996.
- Chaitow L. Clinical application of neuromuscular techniques. Vols 1,2. Edinburgh: Churchill Livingstone; 2000.
- Chaitow L. Palpation and assessment skills. 2nd edn. Edinburgh: Churchill Livingstone; 2003.
- Clemente C. Anatomy: a regional atlas of the human body. 3rd edn. Philadelphia: Lea and Febiger; 1987.
- Cottingham J. Healing through touch. Boulder, CO: Rolf Institute; 1985.
- Currier D, Nelson R. Dynamics of human biologic tissues. Philadelphia: FA Davis; 1992.

- Dalton E. Advanced myoskeletal techniques. Tulsa: Freedom From Pain Institute; 2006.
- Damasio A. Descartes' error. New York: GP Putnam; 1994.
- Dandy DJ, Edwards DJ. Essential orthopaedics and trauma. Edinburgh: Churchill Livingstone; 1998.
- Dart R. Voluntary musculature in the human body: the double-spiral arrangement. *British Journal of Physical Medicine* 1950; 13(12NS):265-268.
- Darwin C. The expression of the emotions in man and animals. Chicago: University of Chicago Press; 1965.
- Dawkins R. The selfish gene. Oxford: Oxford University Press; 1990.
- Dawkins R. The blind watchmaker. New York: WB Norton; 1996.
- Dawkins R. Climbing Mount Improbable. New York: WB Norton; 1997.
- Dobson J. Baby beautiful. Carson City, NV: Heirs Press; 1994.
- Ellenberger W, Dittrich H, Baum H. An atlas of animal anatomy. 2nd edn. New York: Dover; 1956.
- Ellis A, Wiseman N, Boss K. Fundamentals of Chinese acupuncture. Brookline, MA: Paradigm Publications; 1991.
- Ewing W. Inside information. New York: Simon and Schuster; 1996.
- Fast J. Body language. New York: MJF Books; 1970.
- Feitis R, ed. Ida Rolf talks about Rolling and physical reality. Boulder, CO: Rolf Institute; 1978.
- Feitis R, Schultz L, eds. Remembering Ida Rolf. Berkeley: North Atlantic Books; 1996.
- Feldenkrais M. Body and mature behavior. New York: International Universities Press; 1949.
- Feldenkrais M. The case of Nora. New York: Harper and Row; 1977.
- Feldenkrais M. Awareness through movement. New York: Penguin Books; 1977.
- Feynman R. Six easy pieces. New York: Addison Wesley; 1995.
- Foster M. Somatic patterning. Longmont, CO: EMS Press; 2004.
- Fox EL, Mathews D. The physiological basis of physical education. 3rd edn. New York: Saunders College; 1981.
- Frederick A, Frederick C. Stretch to win. Champaign, IL: Human Kinetics Publishers; 2006.
- Fritz S. Mosby's fundamentals of therapeutic massage. 2nd edn. New York: Mosby; 1999.
- Franklin E. Dynamic alignment through imagery. Champaign, IL: Human Kinetics Publishers; 1996.
- Franklin E. Pelvic power. Princeton: Princeton Book Company; 2003.
- Friedl P. Dynamic imaging of cellular interactions with extracellular matrix. *Histochemistry and Cell Biology* 2004; 122:183-190.
- Fuller B. Utopia or oblivion. New York: Bantam Books; 1969.
- Fuller B. Synergetics. New York: Macmillan; 1975.
- Fuller B, Marks R. The dymaxion world of Buckminster Fuller. New York: Anchor Books; 1973. *Further information and publications can be obtained from the Buckminster Fuller Institute, www.bfi.com.*
- Gehin A. Cranial osteopathic biomechanics, pathomechanics and diagnostics for practitioners. Edinburgh: Churchill Livingstone; 2007.
- Gellhorn E. The emotions and the ergotropic and trophotropic systems. *Psychologische Forschicht* 1970; 34:48-94.
- Gershon M. The second brain. New York: Harper Collins; 1998.
- Gintis B. Engaging the movement of life. Berkeley: North Atlantic Books; 2007.
- Gladwell B. Blink. New York: Little Brown & Co; 2005.
- Gleick J. Chaos. New York: Penguin Books; 1987.
- Godelieve D-S. Le manuel du mezieriste. Paris: Frison-Roche; 1995.
- Gorman D. The body moveable. Vols 1-3. Toronto: Ampersand; 1981.
- Grey A. Sacred mirrors. Rochester, VT: Inner Traditions; 1990.
- Grossinger R. Embryogenesis. Berkeley: North Atlantic Books; 1986.
- Grundy JH. Human structure and shape. Chilbolton, Hampshire: Noble Books; 1982.
- Guimberteau J-C. Strolling under the skin. Paris: Elsevier; 2004.
- Hale R, Coyle T. Albinus on anatomy. New York: Dover Publications; 1979.
- Hammer W. Functional soft tissue examination and treatment by manual methods. Gaithersburg, MD: Aspen Publishers; 1999.
- Hanna T. Somatics. Novato, CA: Somatics Press; 1968.
- Hanna T. The body of life. New York: Alfred A Knopf; 1980.
- Harrington A, Zajonc A, eds. The Dalai Lama at MIT. Cambridge, MA: Harvard University Press; 2003.
- Hatch F, Maietta L. Role of kinesthesia in pre- and perinatal bonding. *Pre- and Perinatal Psychology* 1991;5(3). *Information from: Touch in Parenting, Rt 9, Box 86HM, Santa Fe, NM 87505.*
- Hildebrand M. Analysis of vertebrate structure. New York: John Wiley; 1974.
- Hoepke H. Das Muskelspiel des Menschen. Stuttgart: G Fischer Verlag; 1936.
- Horwitz A. Integrins and health. *Scientific American* 1999; January:52-59.
- Ingber D. The architecture of life. *Scientific American* 1998; January:48-57.
- Iyengar BKS. Light on yoga. New York: Schocken Books; 1995.
- Jarmey C. The concise book of the moving body. Chichester: Lotus Publishing; 2006.
- Jiang H, Grinell F. Cell-matrix entanglement and mechanical anchorage of fibroblasts in three-dimensional collagen matrices. *Molecular Biology of the Cell* 2005; 16:5070-5076.
- Juhan D. Job's body. Barrytown, NY: Station Hill Press; 1987.
- Juhan D. Touched by the goddess. Barrytown, NY: Station Hill Press; 2002.
- Johnson D. The protean body. New York: Harper Colophon Books; 1977.
- Kapandji I. The physiology of joints. 5th edn. Vols 1-3. Edinburgh: Churchill Livingstone; 1982.
- Kass L. The hungry soul. New York: Macmillan; 1994.
- Keleman S. Emotional anatomy. Berkeley: Center Press; 1985.
- Kendall F, McCreary E. Muscles, testing and function. 3rd edn. Baltimore: Williams and Wilkins; 1983.
- Kessel R, Kardon R. Tissues and organs. San Francisco: WH Freeman; 1979.
- Ganeri A, Kingsley B. The young person's guide to the orchestra. San Diego, CA: Harcourt Brace; 1996.
- Kirtley C. Clinical gait analysis. Edinburgh: Churchill Livingstone; 2006.
- Konner MK. The tangled wing. New York: Henry Holt; 1982.
- Korperwelten [BodyWorld] www.bodyworlds.com
- Kurtz R. Body centered psychotherapy. Mendocino, CA: Liferhythms; 1997.
- Kurtzweil R. The age of spiritual machines. New York: Penguin Books; 2000.
- Langevin HM. Connective tissue: A body-wide signaling network? *Medical Hypotheses* 2006; 66(6):1074-1077.
- Langevin HM, Sherman KJ. Pathophysiological model for chronic low back pain integrating connective tissue and nervous system mechanisms. *Medical Hypothese* 2007; 68:74-80.
- Langevin HM, Yandow JA. Relationship of acupuncture points and meridians to connective tissue planes. *Anatomical Record (Part B: New anatomist)* 2002; 269:257-265.
- Langevin HM, Churchill DL, Cipolla MJ. Mechanical signaling through connective tissue: a mechanism for the therapeutic effect of acupuncture. *FASEB Journal* 2001; 15:2275-2282.
- Langevin HM, Churchill DL, Fox JR et al. Biomechanical response to acupuncture needling in humans. *Journal of Applied Physiology* 2001; 91:2471-2478.

- Langevin HM, Churchill DL, Wu J et al. Evidence of connective tissue involvement in acupuncture. *FASEB Journal* 2002; 16:872-874.
- Langevin HM, Cornbrooks CJ, Taatjes DJ. Fibroblasts form a body-wide cellular network. *Histochemistry and Cell Biology* 2004; 122:7-15.
- Langevin HM, Konofagou EE, Badger GJ et al. Tissue displacements during acupuncture using ultrasound elastography techniques. *Ultrasound in Medicine and Biology* 2004; 30:1173-1183.
- Langevin HM, Bouffard NA, Badger GJ et al. Subcutaneous tissue fibroblast cytoskeletal remodeling induced by acupuncture: evidence for a mechanotransduction-based mechanism. *Journal of Cellular Physiology* 2006; 207(3):767-774.
- Langevin HM, Storch KS, Cipolla MJ et al. Fibroblast spreading induced by connective tissue stretch involves intracellular redistribution of α - and β -actin. *Histochemistry and Cell Biology* 2006; 14:1-9.
- Langevin HM, Bouffard NA, Churchill DL et al. Connective tissue fibroblast response to acupuncture: dose-dependent effect of bi-directional needle rotation. *Journal of Alternative and Complementary Medicine* 2007; 13:355-360.
- Langevin HM, Rizzo D, Fox JR et al. Dynamic morphometric characterization of local connective tissue network structure using ultrasound. *BMC Systems Biology* 2007; 1:25.
- Latey P. *The muscular manifesto*. UK: self-published; 1979.
- Latey P. Themes for therapists (series). *Journal of Bodywork and Movement Therapies* 1997;1:44-52, 107-116,163-172, 222-230, 270-279.
- Lee D. *The pelvic girdle*. 2nd edn. Edinburgh: Churchill Livingstone; 1999.
- Lee D. *The thorax*. 2nd edn. White Rock, BC: Diane G Lee Physiotherapist Corporation; 2003.
- Lee J. *This magic body*. New York: Viking Press; 1946.
- Leonard CT. *The neuroscience of human movement*. St Louis, MO: Mosby; 1998.
- Levine P. *Waking the tiger*. Berkeley: North Atlantic Books; 1997.
- Lockhart R. *Living anatomy*. London: Faber and Faber; 1948.
- Long R. *Scientific keys*. Vol. 1: The key muscles of hatha yoga. 3rd edn. Plattsburgh, NY: Bandha Yoga; 2006.
- Luttgens K, Deutsch H, Hamilton N. *Kinesiology*. 8th edn. Dubuque, IA: Wm C Brown; 1992.
- McHose C, Frank K. *How life moves*. Berkeley: North Atlantic Press; 2006.
- McMinn R, Pegington J, Abrahams PH et al. *Color atlas of human anatomy*. 3rd edn. St Louis, MO: Mosby Year Book; 1993.
- Maitland J. *Spacious body*. Berkeley: North Atlantic Press; 1995.
- Maitland J. *Spinal manipulation made simple*. Berkeley: North Atlantic Books; 2001.
- Manaka Y, Itaya K, Birch S. *Chasing the dragon's tail*. Brookline, MA: Paradigm Publications; 1995.
- Mann F. *Acupuncture*. New York: Random House; 1973.
- Margules L, Sagan D. *What is life?* New York: Simon and Schuster; 1995.
- Masters R, Houston J. *Listening to the body*. New York: Delacorte Press; 1978.
- Maupin E. *A dynamic relation to gravity*. Vols 1,2. San Diego: Dawn Eve Press; 2005.
- Milne H. *The heart of listening*. Berkeley: North Atlantic Books; 1995.
- Mollier S. *Plastische Anatomie*. Munich: JF Bergman; 1938.
- Montagu A. *Touching*. 3rd edn. New York: Harper and Row; 1986.
- Moore K, Persaud T. *The developing human*. 5th edn. Philadelphia: WB Saunders; 1993.
- Morgan E. *The descent of the child*. New York: Oxford University Press; 1995.
- Morrison M. *Structural vocabulary*. Rolf Lines 7(1). Boulder, CO: Rolf Institute; 1999.
- Muscolino J. *The muscular system manual*. Redding, CT: JEM Publications; 2002.
- Myers T. *The anatomy trains*. *Journal of Bodywork and Movement Therapies* 1997; 1(2):91-101.
- Myers T. *The anatomy trains*. *Journal of Bodywork and Movement Therapies* 1997; 1(3):134-145.
- Myers T. *Kinesthetic dystonia*. *Journal of Bodywork and Movement Therapies* 1998; 2(2):101-114.
- Myers T. *Kinesthetic dystonia*. *Journal of Bodywork and Movement Therapies* 1998; 2(4):231-247.
- Myers T. *Kinesthetic dystonia*. *Journal of Bodywork and Movement Therapies* 1999; 3(1):36-43.
- Myers T. *Kinesthetic dystonia*. *Journal of Bodywork and Movement Therapies* 1999; 3(2):107-116.
- Netter F. *Atlas of human anatomy*. 2nd edn. New Jersey: Novartis; 1989.
- Noble E. *Primal connections*. New York: Simon and Schuster; 1993.
- Odent M. *Primal health*. London: Century Books; 1986.
- Odent M. *The scientification of love*. London: Free Association Books; 2001.
- Oschman J. *Energy medicine*. Edinburgh: Churchill Livingstone; 2000.
- Otto F, Rasch B. *Finding form*. Bayern Munich: Deutscher Werkbund; 1995.
- Penner C. *Behold your body*. Ramona, CA: Rosebud Publishing; 1996.
- Paoletti S. *The fasciae*. Seattle: Eastland Press; 2006.
- Pollan M. *The omnivore's dilemma*. New York: Penguin Books; 2007.
- Pert C. *Molecules of emotion*. New York: Scribner; 1997.
- Pischinger A. *The extracellular matrix*. Berkeley: North Atlantic Books; 2007.
- Platzer W. *Color atlas and textbook of human anatomy*. 3rd edn. Vol. 1. Stuttgart: Georg Thieme Verlag; 1986.
- Polhemus T, ed. *The body reader*. New York: Pantheon Books; 1978.
- Pollack G. *Cells, gels and the engines of life*. Seattle: Ebner & Sons; 2001.
- Prigogine I. *Order out of chaos*. New York: Bantam Books; 1984.
- Radinsky LB. *The evolution of vertebrate design*. Chicago: University of Chicago Press; 1987.
- Reich W. *Character analysis*. New York: Simon and Schuster; 1949.
- Roach M. *Stiff*. New York: WW Norton & Co; 2003.
- Rolf IP. *Rolfing*. Rochester, VT: Healing Arts Press; 1977.
- Rolf IP. *Ida Rolf talks*. Boulder, CO: Rolf Institute; 1978.
- Romer A. *The vertebrate body*. 6th edn. New York: Harcourt Brace; 1986.
- Ross L, Lamperti E. *Thieme atlas of anatomy*. Stuttgart: Thieme; 2006.
- Rywerant Y. *The Feldenkreis method*. San Francisco: Harper and Row; 1983.
- Safran M, Stone D, Zachazewski J. *Instructions for sports medicine patients*. Philadelphia: Saunders; 2003.
- Salguero C. *Encyclopedia of Thai massage*. Forres, Scotland: Findhorn Press; 2004.
- Saunders JB, O'Malley C. *The illustrations from the works of Andreas Vesalius of Brussels*. New York: Dover Publications; 1973.
- Schleip R. *Talking to fascia, changing the brain*. Boulder, CO: Rolf Institute; 1992.
- Schleip R, Klingler W, Lehmann-Horn F. Active fascial contractility: fascia may be able to contract in a smooth muscle-like manner and thereby influence musculoskeletal dynamics. *Medical Hypotheses* 2005; 65:273-277.
- Schultz L, Feitis R. *The endless web*. Berkeley: North Atlantic Books; 1996.
- Schwenk T. *Sensitive chaos*. London: Rudolf Steiner Press; 1965.

- Schwind P. Fascia and membrane technique. Edinburgh: Churchill Livingstone; 2006 (English translation).
- Sieg K, Adams S. Illustrated essentials of musculoskeletal anatomy. Gainesville, FL: Megabooks; 1985.
- Sheldon WH. The varieties of human physique. New York: Harper and Brothers; 1940.
- Sheldrake R. A new science of life. London: Paladin/Grafton Books; 1985.
- Sheldrake R. The rebirth of nature. Rochester, VT: Park Street Press; 1994.
- Shubin N. Your inner fish. New York: Pantheon Books; 2008.
- Silva M, Mehta S. Yoga the Iyengar way. New York: Alfred Knopf; 1990.
- Simeons A. Man's presumptuous brain. New York: EP Dutton; 1960.
- Simons D, Travell J, Simons L. Myofascial pain and dysfunction: the trigger point manual. Vol 1. Baltimore: William and Wilkins; 1998.
- Singer. A short history of anatomy and physiology from the Greeks to Harvey. New York: Dover; 1957.
- Smith F. Inner bridges. Atlanta, GA: Humanics New Age; 1986.
- Smith J. Shaping life. New Haven, CT: Yale University Press; 1998.
- Smith J. Structural bodywork. Edinburgh: Churchill Livingstone; 2005.
- Snyder G. Fasciae: applied anatomy and physiology. Kirksville, MO: Kirksville College of Osteopathy; 1975.
- Speece C, Crow W. Ligamentous articular strain. Seattle: Eastland Press, 2001.
- Still AT. Osteopathy research and practice. Kirksville, MO: Journal Printing Co.; 1910.
- Stirk J. Structural fitness. London: Elm Tree Books; 1988.
- Sultan J. Toward a structural logic: the internal-external model. Notes on structural integration 1986; 86:12-18. Available from Dr Hans Flury, Badenerstr 21, 8004 Zurich, Switzerland.
- Sutcliffe J, Duin N. A history of medicine. New York: Barnes and Noble; 1992.
- Sweigard L. Human ideokinetic function. New York: University Press of America; 1998.
- Swimme B, Berry T. The universe story. San Francisco: Harper Collins; 1992.
- Talbot M. The holographic universe. New York: Harper Collins; 1991.
- Thompson DW. On growth and form. Cambridge: Cambridge University Press; 1961.
- Todd M. The thinking body. Brooklyn, NY: Dance Horizons; 1937.
- Toporek R. The promise of Roling children. Transformation News Network; 1981.
- Upledger J, Vredevoogd J. Craniosacral therapy. Chicago: Eastland Press; 1983.
- Vander A, Sherman J, Luciano D. Human physiology. 5th edn. New York: McGraw-Hill; 1990.
- Varela F, Frenk S. The organ of shape. Journal of Social Biological Structure 1987; 10:73-83.
- Vleeming A, Mooney V, Stockhart R. Movement, stability, and lumbopelvic pain. 2nd edn. Edinburgh: Elsevier; 2007.
- Wainwright S. Axis and circumference. Cambridge, MA: Harvard University Press; 1988.
- Weintraub W. Tendon and ligament healing. Berkeley: North Atlantic Books; 1999.
- Werner W, Benjamin B. A massage therapist's guide to pathology. Baltimore: Williams and Wilkins; 1998.
- Whitfield P. From so simple a beginning. New York: Macmillan; 1993.
- Williams P. Gray's anatomy. 38th edn. Edinburgh: Churchill Livingstone; 1995.
- Wilson E. Sociobiology. Cambridge, MA: Harvard University Press; 1975.
- Wilson E. The future of life. New York: Alfred Knopf; 2002.
- Wilson F. The hand. New York: Vintage Books; 1998.
- Waugh A, Grant A. Ross and Wilson Anatomy and Physiology in Health and Illness. 10th edn. Edinburgh: Churchill Livingstone; 2006.
- Wolpert L. The triumph of the embryo. 3rd edn. Oxford, UK: Oxford University Press; 1991.
- Young JZ. The life of the vertebrates. 3rd edn. New York: Oxford University Press; 1981.

Index

Note: page numbers in *italics* refer to figures.

A.....

abdomen

- Deep Front Line, 194-196
- Functional Lines, 173, 174, 175, 176
- Lateral Line, 126, 227, 120, 221, 123, 125
- meridians of latitude, 255-256
- myofascial meridian rules, 68
- Spiral Line, 233, 234, 135, 136, 142, 143
- Superficial Front Line, 102-106
- see also specific muscles*

abductor pollicis longus, 155, 167

Achilles tendon, 78-79, 80-81, 91, 92, 93, 184

acupressure, 225

acupuncture meridians, 5, 273-280

adductor brevis, 185, 201

adductor longus

- Deep Front Line, 185, 189, 193, 201
- Front Functional Line, 173
- myofascial meridian rules, 67

adductor magnus

- Deep Front Line, 185-186, 187, 188, 189
- Front Functional Line, 173
- myofascial meridian rules, 67, 69, 70
- Spiral Line, 139, 240

adductor minimus, 185

adhesion molecules, 57

adipose layer dissection, 28-29

advertisements, 127, 128

aikido, 160, 225-226

ALL *see* anterior longitudinal ligament

Anatomy Trains history, 6-11

Anatomy Trains hypothesis, 1-2, 44, 70-71

Anatomy Trains myofascial meridians *see* myofascial meridians

Anatomy Trains philosophy, 2-3

Anatomy Trains terminology, 4-5

ankle

- Deep Front Line, 182, 184, 200-201
- leg-arm line comparison, 167-168
- Superficial Back Line, 79-81
- Superficial Front Line, 100-101, 102

'anterior', use of term, 231, 232

anterior crural compartment, 100-101, 110, 124

anterior inferior iliac spine (AIIS), 102, 103, 110, 144

anterior longitudinal ligament (ALL), 194, 196

anterior superior iliac spine (ASIS)

- Deep Front Line, 193
- Functional Lines, 175
- Lateral Line, 119, 120
- Spiral Line, 136, 142-143, 144, 145
- Superficial Front Line, 102, 203, 110

Aphrodite de Melos (Venus de Milo), 205

areolar layer dissection, 28-29

Arm Lines, 9, 148, 149-169, 284

acupuncture meridians compared, 273, 276-277

crossovers, 164-167

Deep Front Line and, 197, 198

expresses and locals, 154-155

extension across trunk surface *see*

Functional Lines

fascia/muscle alternation, 163-164

leg lines compared, 167-169

movement function, 149, 153

postural function, 149, 164

pressure-point workers, 225

stretch assessment, 158, 161-162

stretches, 153, 154, 158, 161-162, 222, 225

tracks and stations, 250, 151-161

see also movement assessments;

postural analysis; Structural Integration

arrow, heel as, 79-80

Asian somatics, 155, 160, 220-227

ASIS *see* anterior superior iliac spine

athletics, 173-174, 176, 206-209

atlanto-axial (A-A) joint, 87-89

atlanto-occipital (O-A) joint, 87-88

'Awareness Through Movement', 216, 217-218

B

Back Functional Line (BFL), 270

definition, 284

engagement, 176-177

palpation, 175-176

posterior oblique sling compared, 20

shifting forces, 173

tracks and stations, 171-172

see also movement assessments;

postural analysis; Structural Integration

backbends, 109, 110, 220

balancing body halves, 251-252

balancing poses, 222-223

Barral J.-P., 31, 202

baseball, 176, 209

basketball, 208

Beach P., 279-280

'bend', use of term, 231, 232-233

bends and stretches *see* stretches

BFL *see* Back Functional Line

biceps brachii, 253, 154-155, 263, 164, 165, 266

biceps femoris

- Lateral Line, 118
- myofascial meridian rules, 67, 69, 70
- Spiral Line, 139, 140, 142, 146
- Superficial Back Line, 83, 84, 92

biomechanical health, 58

see also tensegrity

Boat pose, 220, 221

body halves, balancing, 251-252

bodyreading *see* postural analysis; Structural Integration

bone

double-bag theory, 41-42, 43

as fascial tissue, 19

muscle attachments, 67-68

see also stations

plasticity, 20-21

tensegrity, 50-51

see also musculoskeletal system

Bow pose, 220, 222

bowlers, 176

brachialis, 253, 154, 255, 160-161, 165

brachioradialis, 167

brain development, 31, 41

brain membranes, 30

branch lines, 102, 203, 283

breast, Arm Lines and, 154

breathing

Deep Front Line, 179

Lateral Line, 121, 129

somato-emotional orientations, 249

Spiral Line, 144

startle response, 113

Bridge pose, 110, 220, 221

brow ridge, 89-90, 92

Busquet L., 7, 10

C

calcaneus

Deep Front Line, 182

postural analysis terminology, 234-235

Superficial Back Line, 75, 77-80, 91-92

calf stretches, 91

Camel pose, 220, 222

canoe paddling, 177

capillary network, 26-27, 32

cardinal lines, 283

see also Lateral Line; Superficial Back

Line; Superficial Front Line

carpal tunnel, 156, 257

cartilage, 19

cellists, 209, 210

cells, 13-15, 26, 29-31

double-bag theory, 36-38, 56

microtensegrity, 44, 47, 56-59

myofibroblasts, 53-56

tensile field, 59

see also fascia, mechanical role and

interactions

cerebrospinal fluid (CSF), 30

cervical hyperextension, 76, 196-197

cervical lordosis, 85, 197

chaines musculaires, 7, 10

chemoregulation

microtensegrity, 56

myofibroblast contractility, 54

- chest
 meridians of latitude, 256
 sitting, 213, 214
 Spiral Line, 144
 Superficial Front Line, 106-108, 110, 111, 113
 see also ribs/rib cage; thoracic cavity
- Child's pose, 220, 222
- circulatory system, 25, 26-27, 31-36
- classical sculpture, 203-206
- clavicle, 234
 see also clavipectoral fascia
- clavipectoral fascia
 Arm Lines, 151, 152, 153-154, 155
 Front Functional Line, 173
- cobra stretch, 110
- coccyx, 194
- collagen fibers, 17, 18
 building a body, 19
 embryological development, 39
 holistic communicating network, 28
 plasticity, 22, 23
 tubular structure, 32
- collagenous network/web see fascia
- compensation patterns see postural compensations
- compression-tension balance
 macrotensegrity, 45[^]18, 49, 50-53
 microtensegrity, 56-59
- connective tissue see fascia
- connective tissue cells, 13, 34, 15
 building a body, 18-19
 electric flow, 20
 extracellular matrix, 15
 formation, 39
 see also fibers
- contractile fields (CFs), 280
- contractility, myofibroblasts, 54-55, 56
- coracoclavicular ligament, 165, 266
- coracobrachialis, 253, 154, 255
 myofascial meridian rules, 65, 66
- coracoid process, 151, 252, 153, 154, 164, 165
- Core Lines, 284
 see also Deep Front Line
- costocoracoid ligament, 252, 153
- Cow pose, 222
- craniosacral pulse, 30
- cricket, 176
- crural fascia, 100
- curves, Superficial Back Line, 92-93, 94
- cylinders, 249-250
- cytoskeleton, 56, 57, 58
- D**
- Dart R., 6
- Deep Back Arm Line (DBAL), 248, 149-151, 161-162
 acupuncture meridians compared, 273, 277
 crossovers, 165, 166, 167
 definition, 284
 fascia/muscle alternation summary, 163-164
 leg lines compared, 167, 168-169
 stretch assessment, 161-162
 tracks and stations, 250, 252, 158-160
 see also movement assessments; postural analysis; Structural Integration
- Deep Back Line, 93-94
- Deep Front Arm Line (DFAL), 148, 149-151, 158
 acupuncture meridians compared, 273, 276
 crossovers, 165, 166, 167
 Deep Front Line and, 197, 198
 definition, 284
 expresses and locals, 154-155
 fascia/muscle alternation summary, 163-164
 leg lines compared, 167, 168, 169
 pressure-point workers, 225
 stretch assessment, 158
 tracks and stations, 150, 151-155
 see also movement assessments; postural analysis; Structural Integration
- Deep Front Line (DFL), 70, 178, 179-202
 acupuncture meridians compared, 273, 278
 arm lines compared, 167, 168, 169
 Deep Back Line and, 93, 94
 definition, 284
 ecto-/meso-/endodermal connection, 202
 expresses and locals, 190-192
 lateral elements, 123-124
 manual therapy considerations, 183-184
 movement function, 179-181
 palpation guide, 184-185, 187-188, 192-194, 195-196
 postural function, 179
 relation to other Anatomy Trains, 191-192
 stability in the legs, 200-201
 stretches, 192, 220, 224
 tracks and stations, 180-181
 foot and leg, 182-185
 head, 199-200
 neck, 196-197, 199
 pelvic floor, 195
 psoas, 189-194
 'tail', 194-195
 thigh, 185-190
 thoracic level, 196, 197-199
 umbilicus, 195-196
 Visceral Manipulation, 202
 see also movement assessments; postural analysis; Structural Integration
- Deep Lateral Line, 123-124
- deep lateral rotators, 186
- deep posterior compartment, 182, 183, 184-185, 200-201
- deltoid, 160-161, 162, 165, 366, 174
- depressive posture, 36
- derailments
 definition, 65, 283
 Lateral Line, 119-120
 Superficial Back Line, 81-82
 Superficial Front Line, 102-103, 104-105
- developmental movements, 216, 218-220
- DFAL see Deep Front Arm Line
- DFL see Deep Front Line
- diaphragm, 197, 198
- Discobolus, 206
- dorsal cavity, 30, 31, 39, 40
- double-bag theory, 36-44
- Downward Dog, 90, 220, 221
- E**
- Eagle pose, 222
- ear, vibration sensing, 126
- ectomorphs, 249
- elasticity, fascial, 22
- elastin fibers, 17, 18, 19, 28
- electric properties, fascia, 20-22, 28
- embryological development, 31, 36-41
 leg-arm line comparison, 167
 upper pole of the Deep Front Line, 202
 waves of the spine and legs, 92
- emotional orientations, 249
- The Endless Web*, 255
- endomorphs, 249
- endomysial fibers, 17
- epithelial cells, 13, 24, 15
- erector spinae, 84, 85-86, 91, 92, 94, 98, 141, 290
- evolutionary development, 89-90, 126, 167
- expresses, 80-81
 definition, 283
 rules of construction, 69, 70
 see also specific lines
- extensor pollicis brevis, 155, 167
- external-internal orientation, 249-250
- external oblique
 Functional Lines, 173, 274, 175
 Lateral Line and, 126, 120, 222, 125
 myofascial continuity, 5
 myofascial meridian rules, 68
 Spiral Line, 233, 234, 135, 136, 142, 143
 Superficial Front Line and, 105
- extracellular matrix (ECM), 15-18
 acupuncture, 273, 279
 see also fascia
- eye band, meridians of latitude, 257
- eye movements
 neck musculature and, 87, 91
 rotator cuff control and, 159-160
- F**
- facial muscles, 89
- fascia
 acupuncture, 273-279
 Anatomy Trains history, 6-11
 Anatomy Trains hypothesis, 1-2, 44, 70-71
 Anatomy Trains terminology, 4-5
 contractile fields, 280
 formation, 38-41
 mechanical role and interactions, 13-61
 basic cells, 13-15, 54
 building a body, 18-19
 see also tensegrity
 double-bag theory, 36-44
 electric properties, 20-22, 28
 extracellular matrix, 15-18
 plasticity, 19-24
 pre-stress, 53-54, 55, 56
 tensegrity, 44-61, 229, 230
 whole-body communicating network, 25, 27-36
 meridians see myofascial meridians
 meridians of latitude, 255-257
- fascial microvacuole sliding system, 22, 59-61
- fascial net see fascia
- fear response, 87
 see also startle response
- Feitis R., 255
- Feldenkrais M., 216, 220
- femoral triangle, 189, 290, 193
- femur
 Back Functional Line, 172

Deep Front Line, 286, 187, 188, 189, 190, 191
 Front Functional Line, 173, 176
 Lateral Line, 119, 125
 postural analysis terminology, 231-232, 233
 Spiral Line, 139
 Superficial Front Line, 101, 102
 FFL *see* Front Functional Line
 fibers, connective tissue, 17, 18-19, 22, 23
 formation, 39
 whole-body communicating network, 27-36
 fibroblasts, 17, 18, 22, 23, 39, 53-54, 55
see also myofibroblasts
 fibula
 Deep Front Line, 201
 Lateral Line, 118, 124-125
 Spiral Line, 139, 240, 146
 fibularii *see* peroneus brevis; peroneus longus
 fingers, 156, 257, 160, 161, 165
 fish, 89-90, 126-127
 flautists, 210, 221
 Flemons T., 46, 48, 50-51, 53, 229, 230
 flexor carpi radialis, 257
 flexor carpi ulnaris, 257
 flexor digitorum longus, 182, 183, 184
 flexor digitorum profundus, 257
 flexor digitorum superficialis, 257
 flexor hallucis longus, 182, 183, 184
 flexor pollicis longus, 257, 167
 fluid system, 25, 26-27, 31-36
 foot
 arm-leg lines compared, 167-168
 Deep Front Line, 179, 182-185, 200-201
 Lateral Line, 115, 117, 122-123, 124
 postural analysis terminology, 232, 233, 234-235
 Spiral Line, 137-139, 142, 144, 145-146
 Superficial Back Line, 75-80, 91-92, 93, 94
 Superficial Front Line, 97, 100-101, 102, 110
 weight distribution through, 251
 football, 208-209
 forward bends, 90, 91, 220, 222
 Front Functional Line (FFL), 270, 171, 272
 anterior oblique sling compared, 20
 definition, 284
 engagement, 176-177
 Kalatharee line and, 279
 palpation, 175, 176
 shifting forces, 173-174, 175
 tracks and stations, 272, 173
see also movement assessments; postural analysis; Structural Integration
 Frost R., 'A Silken Tent', 181-182
 Fuller R. B., 44-45, 46
 Functional Lines, 10, 270, 171-177
 acupuncture meridians compared, 273
 engagement, 176-177
 ipsilateral, 174-175
 Kalatharee line and, 279
 movement function, 171
 palpation, 175-176
 postural function, 171
 shifting forces, 173-174
 tracks and stations, 172-173
see also movement assessments; postural analysis

G

gastrocnemii, 7, 80-82, 83, 92
 gastrulation, 38, 39
 Gate pose, 220, 222
 geniohyoid, 199
 gleno-humeral joint, 154
 gluteus maximus, 83, 84
 Back Functional Line, 172, 176
 Lateral Line, 126, 119, 125
 gluteus medius, 116, 119, 125, 136
 golfers, 207-208
 grapefruit metaphor, fascial net
 construction, 29
 greater trochanter, 119, 125
 ground substance, 16, 18, 29-30, 283
 Guimberteau J.-C., 59-61

H

hamstrings
 Deep Front Line and, 187, 188
 Lateral Line, 118, 125
 myofascial meridian rules, 67, 68, 69, 70
 SBL-SFL balance, 111
 Spiral Line, 139, 240, 142, 146
 stretches, 91
 Superficial Back Line, 7, 75-76, 81-84, 91, 92, 93
 hand
 arm-leg line comparison, 167-168
 Deep Back Arm Line, 160
 Deep Front Arm Line, 252, 153, 155, 158
 fascia/muscle alternation, 163-164
 Superficial Back Arm Line, 161, 262
 Superficial Front Arm Line, 156, 257, 158
 head
 Deep Front Line, 179, 196, 199-200
 Lateral Line, 121-122, 124, 125
 postural analysis terminology, 231, 232, 233
 sitting, 213
 Spiral Line, 143, 144
 Superficial Back Line, 87-90, 91, 92, 94
 Superficial Front Line, 108, 109, 110
 Headstand pose, 222-223
 healing philosophy, 2-3
 heel
 as arrow, 79-80
 spurs, 77-78
 Superficial Back Line, 75-81, 91-92
 'heel foot', 145-146
 helical lines, 283
see also Back Functional Line; Front Functional Line; Spiral Line
 Hercules (Heracles), 204-205
 hip
 Deep Front Line, 179, 189-190, 193
 Functional Lines, 274
 Lateral Line, 119, 122, 125
 Spiral Line, 136, 139, 240, 142, 143, 144, 145
 Superficial Back Line, 82-84, 93-94
 Superficial Front Line, 97, 102, 103, 104, 110, 111
 walking, 215
 Hoepke H., 9
 holistic communicating networks, 24-36
 humero-ulnar joint, 154
 humerus
 Arm Lines, 159-160, 163, 164, 167

Functional Lines, 173, 175
 postural analysis terminology, 233
 hyaline cartilage, 19
 hydrophilic proteoglycans
 acupuncture, 273, 279
 interfibrillar *see* ground substance
 hyoid muscles
 Deep Front Line, 196, 199, 200
 myofascial meridian rules, 65-66
 Superficial Front Line and, 108

J

iliac crest, 120, 123, 125
 iliacus
 Anatomy Trains hypothesis, 1, 2
 Deep Front Line, 189-190, 191, 192, 193
 Superficial Front Line and, 103, 204
 iliocostalis, 84, 85, 92, 94
 iliotibial tract (ITT)
 Lateral Line, 226, 227, 118-119, 120, 123, 125
 Spiral Line, 136, 237, 238, 139, 240, 142, 144
 Superficial Front Line, 102, 103
 'inferior', use of term, 231
 infrahyoids
 Deep Front Line, 196, 199
 myofascial meridian rules, 65-66
 Superficial Front Line and, 108
 infraspinatus
 Arm Lines, 158, 259
 myofascial meridian rules, 68
 Spiral Line, 131
 Ingber D., 58
 inguinal ligament, 189, 193
 integrins, 56-58
 intercostals, 226, 227, 120-121, 125, 127
 interfibrillar connective tissue matrix *see* ground substance
 internal-external orientation, 249-250
 internal oblique
 Functional Lines, 274
 Lateral Line and, 226, 120, 222, 129
 Spiral Line, 233, 234, 135, 136, 142, 143
 Superficial Front Line and, 205
 interstitial fluid, 29, 38
 Ipsilateral Functional Line, 174-175
 ischial tuberosity (IT)
 Deep Front Line, 185-186, 187-188
 sitting, 213
 Spiral Line, 139, 142
 isolated muscle theory, 1, 2, 43, 44
 IT *see* ischial tuberosity
 ITT *see* iliotibial tract

J

joint capsule, double-bag theory, 42
 joint manipulation, 70
 judo, 160, 225-226

K

Kalatharee line, 273, 279
 karate kicks, 226-227
 kayak paddling, 177
 Kinesis Myofascial Integration (KMI), 11, 259-271

kinesthetic education
 Arm Lines, 155
 Deep Front Line, 194-196, 200-202
 Functional Lines, 174-175
 Lateral Line, 118-119, 121-122
 Spiral Line, 139, 141, 144
 Superficial Back Line, 77-78, 79-80, 81-82, 83-84, 86-89, 92-94
 Superficial Front Line, 102-103, 108-109, 111-113
see also Kinesis Myofascial Integration

knee
 Deep Front Line, 185, 187-188, 189, 201
 Lateral Line, 119
 postural analysis terminology, 233, 235
 Superficial Back Line, 78-84, 92, 93
 Superficial Front Line, 97, 101, 102, 110
 tracking, 144-145

knock knees, 201, 235

Kouros, 203-204

kyphosis, 85-86

L

Langevin H., 273

'lateral', use of term, 231, 233

lateral crural compartment, 118, 124

Lateral Line (LL), 70, 114, 115-129
 in action in sport, 9
 acupuncture meridians compared, 273, 275
 arm lines compared, 167, 168, 169
 Deep, 123-124
 Deep Front Line and, 200, 201
 definition, 284
 derailments, 119-120
 fish, 126-127
 movement function, 115
 movement treatment considerations, 122-123
 palpation guide, 124-125
 postural function, 115
 seduction, 127, 128
 stretches, 122-123, 220, 223-224
 tracks and stations, 116-117, 124-125
 iliac crest, 120, 125
 neck, 121, 125
 peroneals, 116, 117, 118, 124-125
 rib cage, 120-121, 125
 shoulder, 121-122
 thigh, 118-119, 125
 waist, 120, 125

'X' patterns, 128-129
see also movement assessments; postural analysis; Structural Integration

latissimus dorsi, 120, 155-156, 157, 158, 159
 Functional Lines, 173-174, 175-176
 Spiral Line, 135

latitude, meridians of, 255-257

Lee D., 8, 10

'left', use of term, 231, 232, 233

leg lines, 167-169
see also Deep Front Line; Lateral Line; Superficial Back Line; Superficial Front Line

levator ani, 186, 187, 188

levator scapulae, 121-122, 158-159, 164

Levin S., 51

ligaments, double-bag theory, 42, 43

LL *see* Lateral Line

locals, 80-81
 definition, 283
 rules of construction, 69
see also specific lines

locked long, definition, 283

locked short, definition, 283

longissimus, 84, 85, 92, 94

longus capitis, 196-197

longus colli, 196-197

lordosis, 76, 85-86, 191, 197

lumbar lordosis, 76, 85, 191

lumbar spine, bends, 232-233

M

macrotensegrity, 45-53

malleolus, 79, 80, 182

mandible, 199-200

manual techniques/notes
 Arm Lines, 153-155, 158, 161-162
 Deep Front Line, 183-185, 187-188, 192-194, 195-196, 200-202
 Lateral Line, 118, 119, 120-122, 124-125
 Spiral Line, 134-135, 136, 139, 141-144
 Superficial Back Line, 77-78, 79-81, 82, 83-84, 85-89, 90-92
 Superficial Front Line, 97-99, 100-101, 102, 106, 109, 110-112
see also movement assessments; palpation guide; Structural Integration

masseter, 199-200

maturity, somatic, 252-254

mechanical communication, fascial net, 33, 34-35, 36

mechanical connections, 283

mechanical model, musculoskeletal
 function, 3, 13, 43, 48

mechanobiology, 56

mechanoreceptors, 35-36, 56-58

mechanoregulation, microtensegrity, 56-59

mechano-transduction, 57, 58

'medial', use of term, 231, 233

meridians
 acupuncture, 5, 273-280
 of latitude, 255-257
 myofascial sec myofascial meridians
 use of term, 5

mesenchymal cells, 39

mesomorphs, 249

metatarsals, 182

Meziere E, 7, 10

microtensegrity, 53-61

microvacuole theory, 12, 59-61

mirrors, in postural analysis, 248

moral virtue, posture and, 237

movement assessments, 203-228
 Asian somatics, 220-227
 athletics, 206-209
 classical sculpture, 203-206
 developmental movements, 216, 218-220
 musicians, 209-211
 pressure-point workers, 224
 rolling over, 216-218, 225-226
 sitting, 211-215
 walking, 215-216, 218-220

movement function
 Arm Lines, 149, 153
 Deep Front Line, 179-181
 Functional Lines, 171
 Lateral Line, 115

Spiral Line, 131

Superficial Back Line, 73, 75

Superficial Front Line, 97, 99
see also movement assessments; movement techniques/notes

movement techniques/notes
 Arm Lines, 149-151, 153-154, 155, 158, 160, 161-162
 Deep Front Line, 184-185, 195, 200-201
 Functional Lines, 173-177
 Lateral Line, 118, 120-123
 Spiral Line, 134, 135, 139, 141-145
 Superficial Back Line, 77, 80-82, 83, 85-89, 90-91, 92-93
 Superficial Front Line, 97-99, 102-103, 109-110, 112-113
see also movement assessments; Structural Integration

movement theory, 70-71, 203

multifidus, 84, 94

muscle
 acupuncture meridians, 273-279
 Anatomy Trains history, 6-11
 Anatomy Trains hypothesis, 1-2, 44, 70-71
 Anatomy Trains philosophy, 2-4
 Anatomy Trains terminology, 4-5
 connective tissue plasticity, 21-22
 contractile fields, 280
 double-bag theory, 36, 41-44
 fascial net, 28
see also musculoskeletal system; myofascial meridians

muscle cells, 13, 34, 15, 54
see also myofibroblasts

musculoskeletal system
 leg-arm comparison, 167-169
 postural assessment *see* postural analysis

tensegrity, 44-61, 229, 230
see also muscle

musicians, 209-211

mylohyoid, 199, 200

'myofascia'
 tensegrity, 45-51, 53
 use of term, 4

myofascial continuity
 definition, 4-5
 gastrocnemius-hamstring, 7, 81
 history of Anatomy Trains concept, 6-7

myofascial meridians
 acupuncture meridians and, 5, 273-280
 applications
 movement assessments, 203-228
 postural analysis, 229-254
 Structural Integration, 259-271

Arm Lines, 9, 148-169, 284
 back view summary, 64
 Deep Front Line, 70, 178-202
 depiction, 7, 8, 71
 double-bag theory, 41-44
 Functional Lines, 20, 170-177
 history of concept, 6-11
 hypothesis, 1-2
 Lateral Line, 9, 70, 114-129
 movement theory and, 70-71
 philosophy, 3[^]1
 rules for construction, 65-71
 Spiral Line, 5, 6, 9, 70, 130-146
 Superficial Back Line, 7, 8, 12, 70, 72-94
 Superficial Front Line, 9, 64, 70, 96-113

tensegrity, 51, 59
 terminology, 4, 5
see also fascia, mechanical role and interactions
 myofascial slings, 8-11
 myofibroblasts (MFBs), 53-56

N

neck

Arm Lines, 165
 Deep Front Line, 179, 196-197, 199, 201
 integrating the spine in sitting, 213
 Lateral Line, 121, 123, 125
 meridians of latitude, 256-257
 Spiral Line, 143
 startle response, 112-113
 Superficial Back Line, 75, 85, 86-89, 91, 92
 Superficial Front Line, 108-109, 112-113
 nerve cells, 13, 24, 15, 30, 31, 32, 35-36, 56-58
 nervous system, 25-26, 30, 31-36
 neurocranium, 89-90
 neuroglia, 30-31
 neurons *see* nerve cells

O

obliquus capitis (OC) muscles, 85-88, 91, 124, 125
 obturator internus, 186, 187, 188
 occiput
 Arm Lines, 158-159, 165
 Deep Front Line, 196, 198
 Lateral Line, 121, 125
 Spiral Line, 131, 141, 142
 Superficial Back Line, 84-90, 91, 92
 omohyoid, 199
 Oriental medicine, 5, 273-280
 osteoblasts, 21, 77-78
 osteoclasts, 21
 osteoporosis, 21
 Otto R, 52-53

P

palmaris longus, 157
 palpation guide
 Deep Front Line, 184-185, 187-188, 192-194, 195-196
 Functional Lines, 175-176
 Lateral Line, 124-125
 Spiral Line, 141-142
 Superficial Back Line, 91-92
 Superficial Front Line, 110
see also manual techniques/notes
Pariivritta Parsvakonasana (Revolved Lateral Angle pose), 224-225
 patella, 79, 101, 110, 172
 pectineus, 190, 191, 192, 193
 pectoralis major, 107
 Arm Lines, 150, 151, 153, 154, 155-156, 157, 158
 Front Functional Line, 173, 176
 pectoralis minor
 Arm Lines, 150, 151, 252, 153-154, 158, 164, 265
 Front Functional Line, 173, 176
 myofascial meridian rules, 65, 66

pelvis
 basic position types, 251
 Deep Front Line, 179, 186-187, 188, 191, 194-195, 201
 Lateral Line, 119, 120, 128, 129
 postural analysis, 231-232, 233, 234, 235
 sitting, 213, 214
 somato-emotional orientations, 249
 Spiral Line, 144
 Superficial Back Line, 79-80, 84, 111, 112
 Superficial Front Line, 111, 112
 tensegrity, 48
 walking, 215
 perceptual orientations, 249
 perineural network, 30-31
 periosteum
 calcaneus, 77-78
 double-bag theory, 41-42, 43
 radius and ulna, 155, 160, 263, 267
 Superficial Front Line, 100
 peroneus brevis (fibularis brevis)
 Deep Front Line, 200-201
 Lateral Line, 115, 226, 227, 118, 122-123, 124
 myofascial meridian rules, 65
 peroneus longus (fibularis longus)
 Deep Front Line, 200-201
 Lateral Line, 115, 116, 227, 122-123, 124-125
 Spiral Line, 137-139, 140, 142, 144
 pharynx, 198, 202
 piezo-electric currents, 20-22
 Pigeon pose, 220, 222
 plantar fascia, 75-79, 91, 93, 94, 115
 plasticity, connective tissue, 19-24
 Plow pose, 90, 99, 220
 points *see* switches
 popliteus, 81, 93, 285
 'posterior', use of term, 231, 232
 posterior superior iliac spine (PSIS), 119, 120
 postural analysis, 229-254
 describing skeletal geometry, 230-235, 238, 240, 242, 244, 246
 assessing soft-tissue patterns, 235, 238, 240, 242, 244, 246
 developing an integrating story, 236, 238, 240, 242, 244, 246
 developing a strategy, 236, 238-239, 240-241, 242-243, 244, 246
 evaluating/revising the strategy, 236-237
 examples, 237, 238-248
 moral virtue, 237
 subjective elements, 248-254
 postural compensations
 analysis *see* postural analysis
 Arm Lines, 149
 Deep Front Line, 183-184
 fascial network communication speeds, 34-35
 Functional Lines, 171
 Lateral Line, 115
 lines showing, 9
 Spiral Line, 134
 Superficial Back Line, 75, 92-93
 Superficial Front Line, 99
 postural function
 Arm Lines, 149, 164
 Deep Front Line, 179
 Functional Lines, 171
 Lateral Line, 115
 Spiral Line, 131

Superficial Back Line, 73
 Superficial Front Line, 97
 postural version, startle response, 112-113
 pronator teres, 155, 167
 proteoglycans, hydrophilic interfibrillar
see ground substance
 'protracted', use of term, 234
 PSIS *see* posterior superior iliac spine
 psoas, 189-194
 pterygoid muscles, 199-200
 pubis
 Deep Front Line, 194, 195
 Functional Lines, 173, 174, 176
 Lateral Line, 228, 129
 meridians of latitude, 255
 Superficial Front Line, 103, 112
 pulleys, 65, 66
 pulse, craniosacral, 30

Q

quadratus lumborum (QL), 123, 125, 192, 194
 quadriceps, 101-102

R

radio-ulnar joint, 154, 165
 radius, Arm Lines, 155, 263, 165, 167
 rectus abdominis, 98
 Deep Front Line, 187, 194-195
 Front Functional Line, 173, 176
 myofascial meridian rules, 67
 Superficial Front Line, 103, 204, 205, 106-107, 110, 112
 rectus capitis lateralis, 158-159
 rectus capitis posterior (RCP) muscles, 86-89, 91
 rectus femoris
 myofascial meridian rules, 67
 Spiral Line, 136, 144
 Superficial Front Line, 102-103, 204, 110
 reticulin fibers, 17, 18, 28, 39
 retinacula, lower leg, 100-101, 110
 'retracted', use of term, 234
 Reverse Triangle pose, 176-177
 Revolved Lateral Angle pose, 224-225
 rhomboids
 Arm Lines, 158, 159, 162, 164
 myofascial meridian rules, 67-69
 Spiral Line, 131-135, 141-142
 rhombo-serratus muscle (rhomboid-serratus anterior sling), 134-135
 rhythms, fascial system communications, 34
 ribs/rib cage
 Arm Lines, 149, 153, 154, 155, 164, 265
 Deep Front Line, 179, 199, 201-202
 Functional Lines, 274, 175, 176
 Lateral Line, 120-121, 123, 125, 228, 129
 postural analysis terminology, 231, 232, 233, 234
 Spiral Line, 134, 135, 143
 Superficial Front Line, 106-108, 110, 112, 113
 'right', use of term, 231, 232, 233
 Rolf I. P., 4
 rolling over, 216-218, 225-226
 rotational movement, Lateral Line, 122, 126-127

- 'rotations'
 primary to the spine, 250
 use of term, 231, 233
- rotator cuff muscles
 Arm Lines, 150, 158-160, 162, 164
 Functional Lines, 176
- roundhouses
 anterior superior iliac spine, 103, 136, 142
 definition, 69, 283
 scapula, 164
- S**
- sacroiliac joint, 'heel foot' and, 145-146
- sacrospinous ligament, 83, 84, 85, 92
 myofascial meridian rules, 68
 Spiral Line, 140, 141, 146
- sacrum
 Deep Front Line, 186-187, 194
 Functional Lines, 172, 175-176
 Lateral Line and, 128, 129
 myofascial meridian rules, 68
 Spiral Line, 141
 Superficial Back Line, 84-89, 92, 111
- Sage pose, 220, 222
- sartorius, 102, 103, 144, 175, 189, 190, 192-193
- SBAL *see* Superficial Back Arm Line
- SBL *see* Superficial Back Line
- scalenes
 Deep Front Line, 196, 197, 201
 Lateral Line, 116, 123-124, 125
- scalp fascia, 89, 94, 109
- scapula, 122
 Arm Lines, 150, 151, 153, 154, 156, 158, 159, 160, 164, 165, 167
 myofascial meridian rules, 68-69, 151
 postural analysis
 soft tissue assessment, 235
 terminology, 233, 234
 Spiral Line, 131-135
- Schultz L., 255-257
- SCM *see* sternocleidomastoid
- sculpture, 203-206
- Seated Forward Bend, 90
- seduction, Lateral Line and, 127, 128
- seductive pose, Aphrodite de Melos, 205
- semimembranosus, 83, 92
- semispinalis, 84, 92, 94, 124
- semitendinosus, 83, 92
- Sen lines, 273, 279
- serratus anterior
 Arm Lines, 164
 myofascial continuity, 5
 myofascial meridian rules, 67-69
 Spiral Line, 131-135, 142, 144
- serratus posterior, 131
- SFAL *see* Superficial Front Arm Line
- SFL *see* Superficial Front Line
- Shiatsu, 155, 225
- 'shift', use of term, 231, 233
- shin, 100-101, 102, 110
- shoulder
 Arm Lines, 149, 150, 153, 155, 159-160, 161, 162, 163, 164
 Functional Lines, 174, 176
 Lateral Line and, 121-122
 meridians of latitude, 256
 postural analysis, 232, 234, 235
 Spiral Line, 143, 144
- Shoulder Stand, 99, 220
- Side Dog pose, 220, 222
- 'A Silken Tent', 181-182
- sitting, 211-215
- skeletal system *see* musculoskeletal system
- skin-tendon fascial microvacuole sliding system, 12, 59-61
- skull, 88, 89-90, 121, 131, 141, 200
- sliding system, microvacuole theory, 22, 59-61
- slump, 21-23
- soleus, 80-81, 83, 92, 93, 124-125, 184
- somatic maturity, 252-254
- somato-emotional orientations, 249
- sphenobasilar junction (SBJ), 202
- spinalis, 84, 92, 94
- spine
 bends, 232-233
 curves, 92-93, 232
 Deep Back Line, 94
 Deep Front Line, 179, 190-192, 194, 196-197
 integration in sitting, 212-215
 lateral flexion, 123
 movement treatment, 91
 postural analysis terminology, 232-233, 234
 primary rotation to, 250
 Spiral Line, 141
 stretch reflexes, 126
 Superficial Back Line, 84, 85-86, 87, 91, 92-93
 Superficial Front Line, 98
 swimming, 126
 as tensegrity structure, 50, 52
 waves of, 92-93
- Spiral Line (SPL), 230, 131-146
 in action in sport, 9
 acupuncture meridians compared, 273, 278
 definition, 284
 foot arches, 144
 forward head posture, 144
 'heel foot'-sacroiliac joint relation, 145-146
 history of Anatomy Trains concept, 6
 knee tracking, 144-145
 manual therapy considerations, 134
 movement function, 131
 myofascial continuity, 5
 myofascial meridian rules, 70
 palpation, 141-142
 pelvic tilt, 144
 posterior, 240, 141
 postural function, 131
 postural rotations of the trunk, 142-143
 reciprocity, 141
 stretches, 141, 142, 220-222, 224, 225
 tracks and stations, 232
 anterior superior iliac spine, 136
 erector spinae, 141
 hamstrings, 139
 iliolumbar tract, 136
 lower leg and foot, 137-139
 oblique muscle complex, 135
 rhombo-serratus muscle, 134-135
 sacral fascia, 141
 sacrotuberous ligament, 141
 tensor fasciae latae, 136
see also movement assessments; postural analysis; Structural Integration
- SPL *see* Spiral Line
- splenius capitis
 Lateral Line, 226, 227, 121, 125
- Spiral Line, 131, 133, 234, 141
- splenius cervicis
 Lateral Line, 116, 117
 Spiral Line, 131, 233, 234, 141
- standing
 developmental stages, 218-220
 posture analysis *see* postural analysis
- Standing Forward Bend, 90
- startle response, 112-113
- stations, 84
 definition, 44, 283
 dissection, 64
 rules of construction, 67-68
see also specific lines
- sternal fascia, 98, 106, 107-108, 110, 112
 Deep Front Line, 199
 Lateral Line, 128, 129
- sternalis, 107, 110, 112
- sternocleidomastoid (SCM)
 Deep Front Line, 196-197
 Lateral Line, 216, 121, 122
 Superficial Front Line, 98, 108-109, 110, 112
- sternohyoid, 199
- strain distribution, 49, 50-51, 53, 59
- stretch receptors, 86-87
- stretch reflexes, 126
- stretches, 220-225
 Arm Lines, 153, 154, 158, 161-162, 222, 225
 Deep Front Line, 192, 220, 224
 Lateral Line, 122-123, 220, 223-224
 Spiral Line, 141, 242, 220-222, 224, 225
 Superficial Back Line, 90-91, 220, 224
 Superficial Front Line, 109-110, 220, 221, 224-225
- Structural Integration, 11, 259-271
 body reading chart, 260
 goals, 271
 method, 261-268
 strategy guidelines, 268-271
 treatment principles, 268, 271
- stylohyoid, 199
- subclavius, 151, 252, 164
- suboccipitals, 86-89, 91, 124
- subscapularis, 131, 159
- Sun Salutation pose, 220, 221
- Superficial Back Arm Line (SBAL), 248, 149-151
 in action in sport, 9
 acupuncture meridians compared, 273, 277
 crossovers, 165, 266, 167
 definition, 284
 fascia/muscle alternation summary, 163-164
 leg lines compared, 167, 168, 169
 stretch assessment, 161-162
 tracks and stations, 250, 252, 160-161
see also movement assessments; postural analysis; Structural Integration
- Superficial Back Line (SBL), 70, 72, 73-94
 acupuncture meridians compared, 273, 274
 area of influence, 8
 arm lines compared, 167-168, 169
 curves, 92-93, 94
 Deep Back Line and, 93-94
 definition, 284
 depiction, 7, 8
 derailments, 81-82
 expresses, 80-81, 94
 history of Anatomy Trains concept, 7

- intact fresh-tissue dissections, 7, 12, 74
 line of pull, 8
 locals, 80-81, 94
 movement function, 73, 75
 movement treatment considerations, 90-91
 palpation guide, 91-92
 postural function, 73
 stretches, 90-91, 220, 224
 Superficial Front Line and, 97, 98, 99, 111-112, 123
 tracks and stations, 74, 75, 84, 91-92
 heel to knee, 78-81, 91-92
 hip to sacrum, 84, 92
 knee to hip, 82-84, 92
 occiput to supraorbital ridge, 89-90, 92
 sacrum to occiput, 84-89, 92
 toes to heel, 75-78, 91
 waves of the spine, 92-93
 see *also* movement assessments; postural analysis; Structural Integration
- Superficial Front Arm Line (SFAL), 148, 149-151
 in action in sport, 9
 acupuncture meridians compared, 273, 276
 crossovers, 165, 266, 167
 definition, 284
 fascia/muscle alternation summary, 163-164
 leg lines compared, 167-168, 169
 startle response, 112
 stretch assessment, 158
 tracks and stations, 150,151, 155-158
 see *also* movement assessments; postural analysis; Structural Integration
- Superficial Front Line (SFL), 64, 70, 96, 97-113
 in action in sport, 9
 acupuncture meridians compared, 273, 275
 arm lines compared, 167, 168, 169
 branch lines, 102,103
 definition, 284
 derailments, 102-103, 204-205
 movement function, 97, 99
 movement treatment considerations, 109-110
 palpation, 110
 postural function, 97
 startle response, 112-113
 stretches, 109-110, 220, 222, 224-225
 Superficial Back Line and, 97, 98, 99, 111-112, 223
 tracks and stations, 98, 99, 110
 abdomen, 103-106
 chest, 106-108, 110, 111, 113
 neck, 108-109,112-113
 scalp, 109
 shin, 100-101, 102, 110
 thigh, 101-103, 110
 see *also* movement assessments; postural analysis; Structural Integration
- 'superior', use of term, 231
 supinator, 154, 255
 supraorbital ridge, 89-90, 92
 supraspinatus, 258, 159, 166
- swimming, 126
 switches
 definition, 283
 rules of construction, 68-69
- T**
- temporalis, 200
 tendons
 microvacuole sliding system, 32, 59-61
 pulling force around corners, 65, 66
 tennis players, 173-174, 206-207, 236
 tensegrity, 44-61, 229, 230, 283
 tension-compression balance
 macrotensegrity, 45-48, 49, 50-53
 microtensegrity, 56-59
 tensor fasciae latae (TFL)
 Lateral Line, 336, 119, 125
 Spiral Line, 136, 139, 340, 142, 144
 teres major, 156, 358, 359, 167
 teres minor, 158, 259, 160
 TFL see tensor fasciae latae
 Thai medicine, 273, 279
 thigh
 Deep Front Line, 179,185-190, 201
 Lateral Line, 118-119, 125
 Superficial Front Line, 101-103, 110
 thixotropy, 283
 thoracic cavity, 196, 197-199, 201-202
 see *also* chest
 thoracic kyphosis, 85
 thoracolumbar junction (TLJ; T12-L1), 192
 thumb
 Arm Lines, 252, 153, 155, 257, 158,167, 225
 for pressure-point work, 225
- tibia
 Deep Front Line, 184, 200-201
 postural analysis terminology, 233
 Superficial Back Line, 82, 83-84, 92
 Superficial Front Line, 100, 101
 tibial tuberosity, 101, 110, 172
 tibialis anterior, 100, 102, 110, 124-125
 Spiral Line, 137-139, 240, 142,144
 tibialis posterior, 182, 183, 184, 200-201
 'tilt', use of term, 231, 232
- timescales
 fascial system communications, 34
 myofibroblast contraction, 54, 55, 56
- Tittel K., 8, 20
 TLJ see thoracolumbar junction
 'toe foot', 145, 246
- toes
 Deep Front Line, 182, 383, 184
 leg-arm line comparison, 167-168
 Superficial Back Line, 75-78, 91, 93
 Superficial Front Line, 97, 100, 110
- tracks
 definition, 44, 283
 dissection, 64
 rules of construction, 65-69, 70
 see *also* specific lines
- transversus abdominis
 Lateral Line and, 120
 Spiral Line, 136
 Superficial Front Line and, 305
- transversus thoracis, 199
- trapezius, 122
 Arm Lines, 350, 359, 160-161,162, 164, 165, 366
 Functional Lines, 174
 Tree pose, 222, 223
 Triangle pose (*Trikanasana*), 122-123, 141, 176-177, 220, 223-224
 triceps brachii, 358, 160, 263, 164, 166
 trumpeters, 210-211
 tubes
 embryological development, 39-41
 whole-body networks, 32
- U**
- ulna, 136, 155, 160, 263, 165
 umbilicus, 195-196
- vascular system, 25, 26-27, 31-36
 vastus lateralis, 172, 176
 ventral cavity, 30, 31, 39, 40
 Venus de Milo (*Aphrodite de fivlelos*), 205
 Vesalius, 26, 24, 25, 26, 107
 vibration sensing, 126
 violists, 209-210
 virtue, posture and, 237
 Visceral Manipulation, 202
 visual assessment tools
 Arm Lines, 149-151, 153-154
 Deep Front Line, 196-197, 200-202
 Spiral Line, 134,135,142-145
 Superficial Back Line, 79-81, 83-84, 85-93
 Superficial Front Line, 97-99, 100-101, 102, 106, 109-113
 see *also* movement assessments; postural analysis
- Vleeming A., 8-11
- W**
- waist, 120, 125
 walking
 Deep Front Line, 182, 283
 developmental stages, 218-220
 knee tracking, 144
 Lateral Line, 123, 126-127
 movement assessments, 215-216
- warrior poses, 192, 220, 221-222
 weight distribution, 251
 wrist, 155, 156, 157, 160, 161-162,163, 164
- Y**
- yoga massage, Thai, 273, 279
 yoga positions see stretches
- Z**
- Zeus, 205-206