Get Full Access and More at ExpertConsult.com

DIAGNOSTIC PATHOLOGY

Thoracic

SECOND EDITION

SUSTER | MORAN

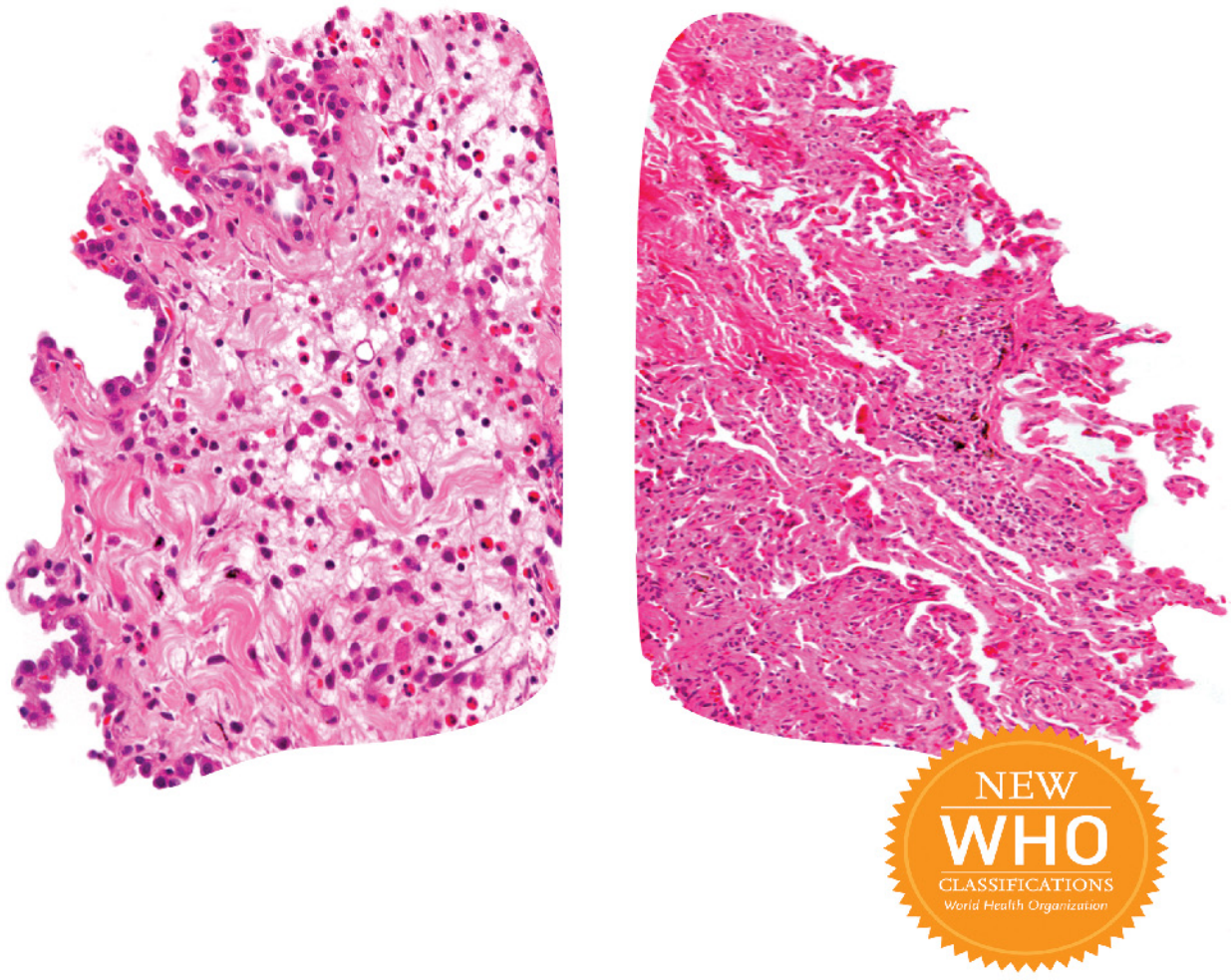

ELSEVIER

DIAGNOSTIC PATHOLOGY

Thoracic

SECOND EDITION

SUSTER | MORAN

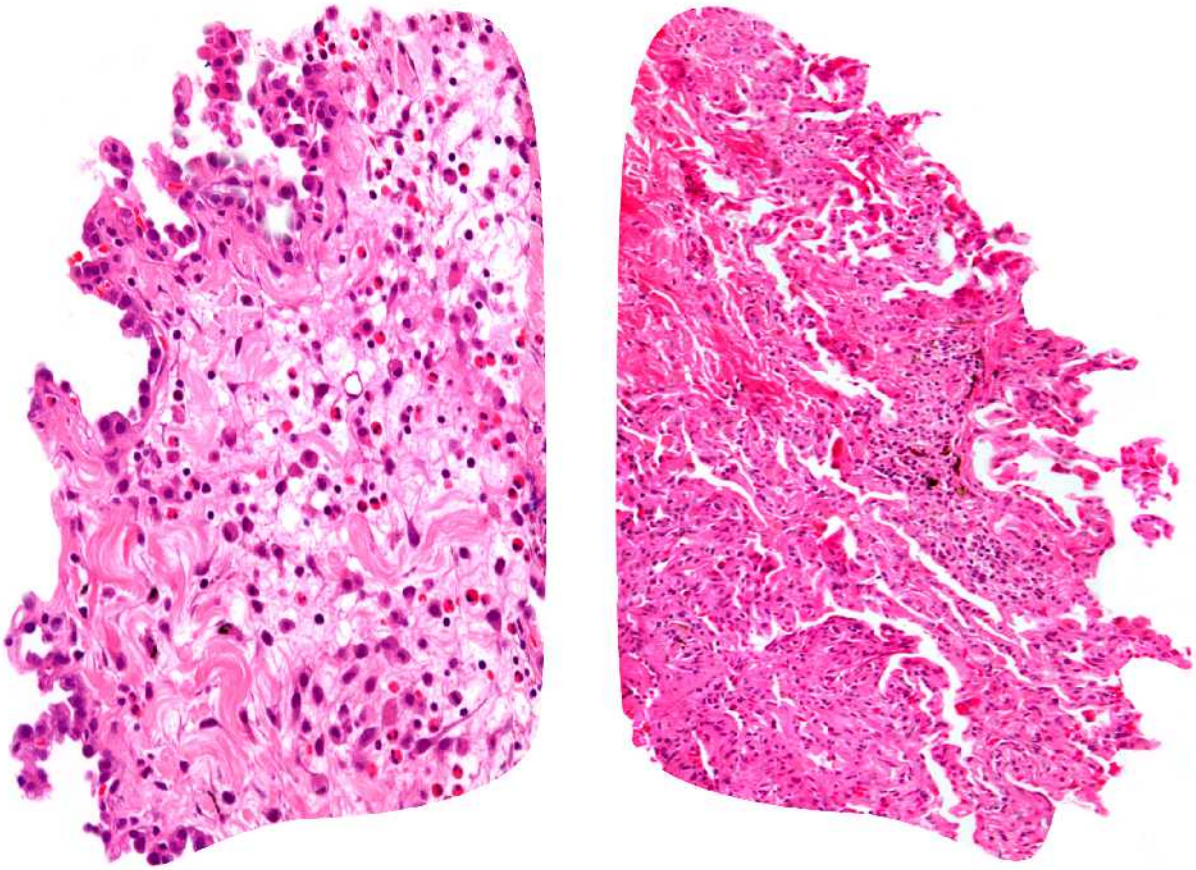

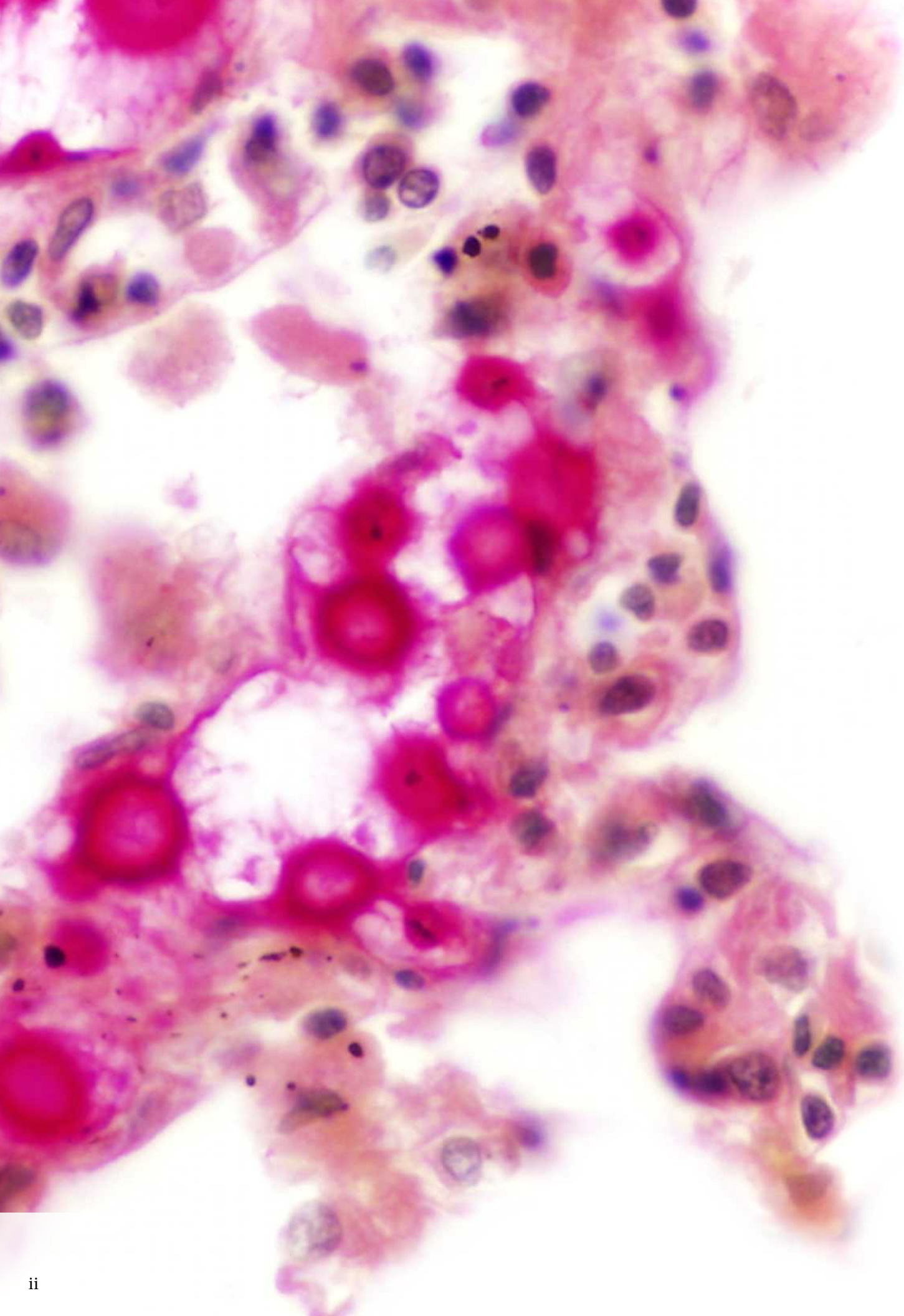

DIAGNOSTIC PATHOLOGY

Thoracic

SECOND EDITION

Saul Suster, MD

Professor and Chairman
Department of Pathology and Laboratory Medicine
Medical College of Wisconsin
Milwaukee, Wisconsin

Cesar A. Moran, MD

Professor and Deputy Chair
Chief, Thoracic Pathology
Department of Pathology
MD Anderson Cancer Center
Houston, Texas

ELSEVIER

1600 John F. Kennedy Blvd.
Ste 1800
Philadelphia, PA 19103-2899

DIAGNOSTIC PATHOLOGY: THORACIC, SECOND EDITION ISBN: 978-0-323-37715-7

Copyright © 2017 by Elsevier. All rights reserved.

No part of this publication may be reproduced or transmitted in any form or by any means, electronic or mechanical, including photocopying, recording, or any information storage and retrieval system, without permission in writing from the publisher. Details on how to seek permission, further information about the Publisher's permissions policies and our arrangements with organizations such as the Copyright Clearance Center and the Copyright Licensing Agency, can be found at our website: www.elsevier.com/permissions.

This book and the individual contributions contained in it are protected under copyright by the Publisher (other than as may be noted herein).

Notices

Knowledge and best practice in this field are constantly changing. As new research and experience broaden our understanding, changes in research methods, professional practices, or medical treatment may become necessary.

Practitioners and researchers must always rely on their own experience and knowledge in evaluating and using any information, methods, compounds, or experiments described herein. In using such information or methods they should be mindful of their own safety and the safety of others, including parties for whom they have a professional responsibility.

With respect to any drug or pharmaceutical products identified, readers are advised to check the most current information provided (i) on procedures featured or (ii) by the manufacturer of each product to be administered, to verify the recommended dose or formula, the method and duration of administration, and contraindications. It is the responsibility of practitioners, relying on their own experience and knowledge of their patients, to make diagnoses, to determine dosages and the best treatment for each individual patient, and to take all appropriate safety precautions.

To the fullest extent of the law, neither the Publisher nor the authors, contributors, or editors, assume any liability for any injury and/or damage to persons or property as a matter of products liability, negligence or otherwise, or from any use or operation of any methods, products, instructions, or ideas contained in the material herein.

Publisher Cataloging-in-Publication Data

Names: Suster, Saul. | Moran, Cesar.
Title: Diagnostic pathology. Thoracic / [edited by] Saul Suster and Cesar A. Moran.
Other titles: Thoracic.
Description: Second edition. | Salt Lake City, UT : Elsevier, Inc., [2017] | Includes bibliographical references and index.
Identifiers: ISBN 978-0-323-37715-7
Subjects: LCSH: Chest--Diseases--Handbooks, manuals, etc. | Respiratory organs--Diseases--Handbooks, manuals, etc. | MESH: Thoracic Diseases--pathology--Atlases. | Lung Diseases--pathology--Atlases. | Pleural Diseases--diagnosis--Atlases. | Diagnosis, Differential--Atlases.
Classification: LCC RC941.S92 2017 | NLM WF 17 | DDC 616.1--dc23

International Standard Book Number: 978-0-323-37715-7
Cover Designer: Tom M. Olson, BA

Printed in Canada by Friesens, Altona, Manitoba, Canada

Last digit is the print number: 9 8 7 6 5 4 3 2 1

Dedications

This book is dedicated to my wife, Jenny Suster, without whose support and companionship nothing would have been possible. And to our children, Dana Deborah and David Ilan, for having made the whole journey worthwhile.

SS

To my parents, Rigoberto Moran (RIP) and Leticia Moran. And to my wife, Susan, my daughters, Kate Leticia and Elisa Jean, and to my grandson, Robert Michael.

CAM

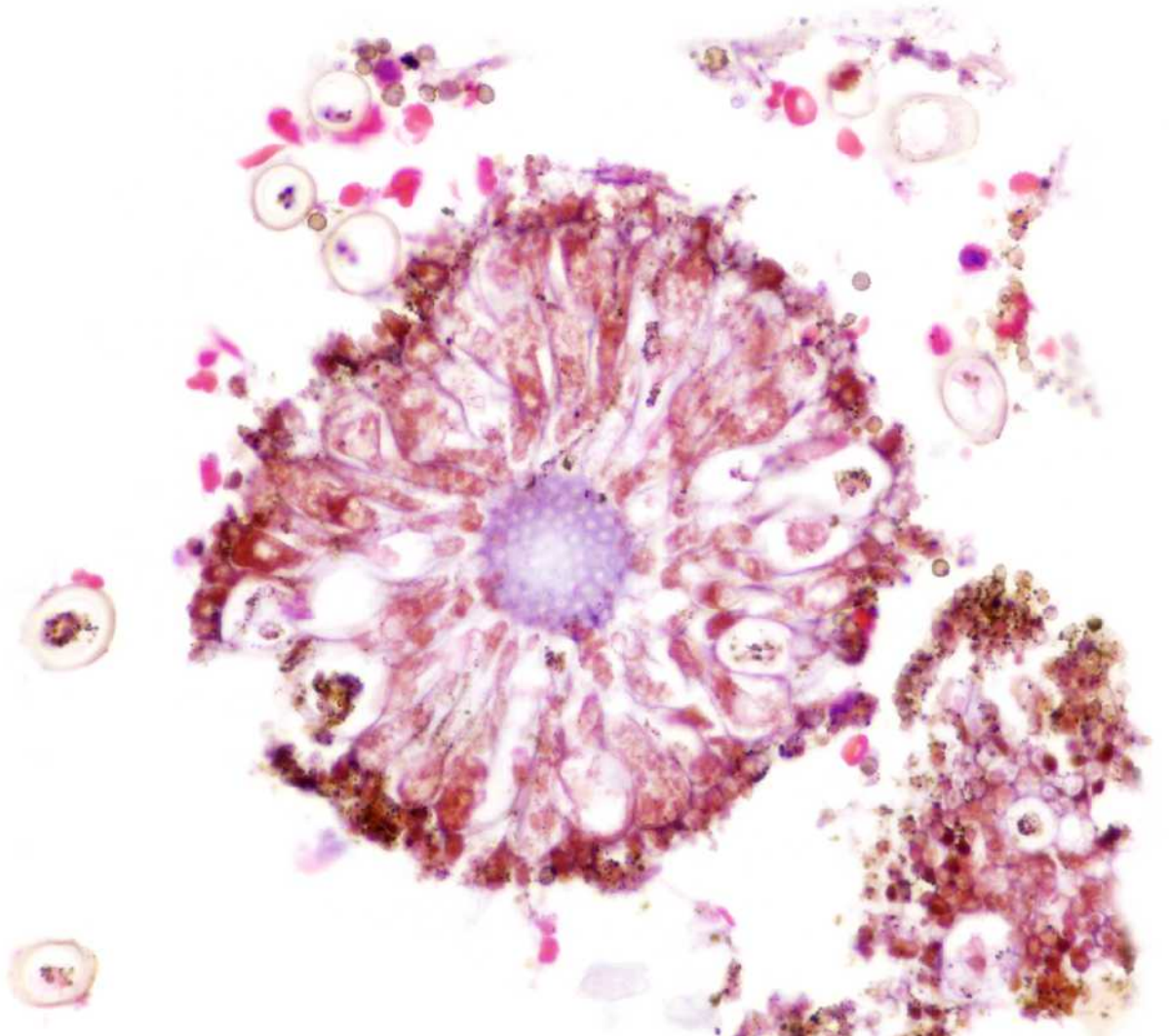

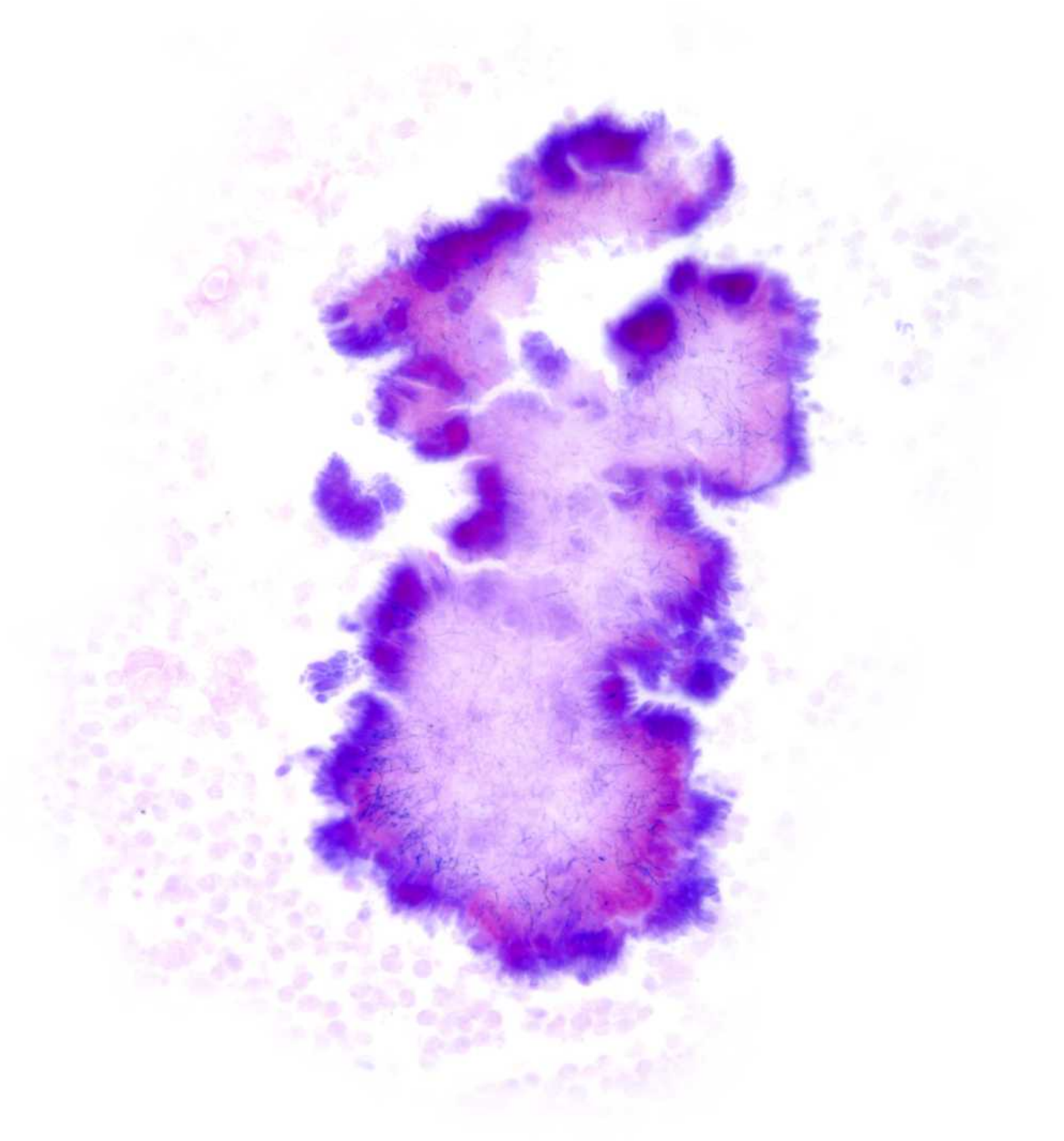

Preface

This second edition of *Diagnostic Pathology: Thoracic* will hopefully fulfill the need for a well-illustrated text on this topic that can help the busy practitioner and student of pathology obtain the most significant information on the various entities covered by this volume in a thorough and efficient manner. We were enormously gratified by the warm and favorable reception of the first edition and are hoping that this new edition will fulfill the expectations of our readers and maintain the high standards that we tried to attain in the first edition. A few minor changes have been introduced in the format of the book, including an increase in the number of overall illustrations per chapter. A few additional chapters dealing with newly described or emerging entities have also been added. All chapters have been updated to incorporate the advances that have taken place since the first edition of the book, as well as to provide updated references for the various topics.

As in the previous edition, we have endeavored to present a balanced perspective on the treatment of the various topics. As in all fields of scholarly inquiry, there may be areas in which opinions may differ among experts and for which concepts and the understanding of the lesions are still in evolution. An unintended bias is inevitable under such circumstances; we have attempted to be as balanced as possible in the presentation of the material and to consider all opinions and perspectives on controversial topics. In many areas, however, the opinions and statements contained herein reflect the opinions and the experience of the authors. We hope that the present volume will continue to assist practicing surgical pathologists, as well as pathology residents and fellows in training, to obtain the information that will help them resolve problems in thoracic pathology during their routine signout of cases.

Once again, we would like to thank the production team at Amirsys-Elsevier for their patience and support as well as Elizabeth Hammond, MD and Paula Woodward, MD for their support and for allowing us to work on this second edition.

Saul Suster, MD
Professor and Chairman
Department of Pathology and Laboratory Medicine
Medical College of Wisconsin
Milwaukee, Wisconsin

Cesar A. Moran, MD
Professor and Deputy Chair
Chief, Thoracic Pathology
Department of Pathology
MD Anderson Cancer Center
Houston, Texas

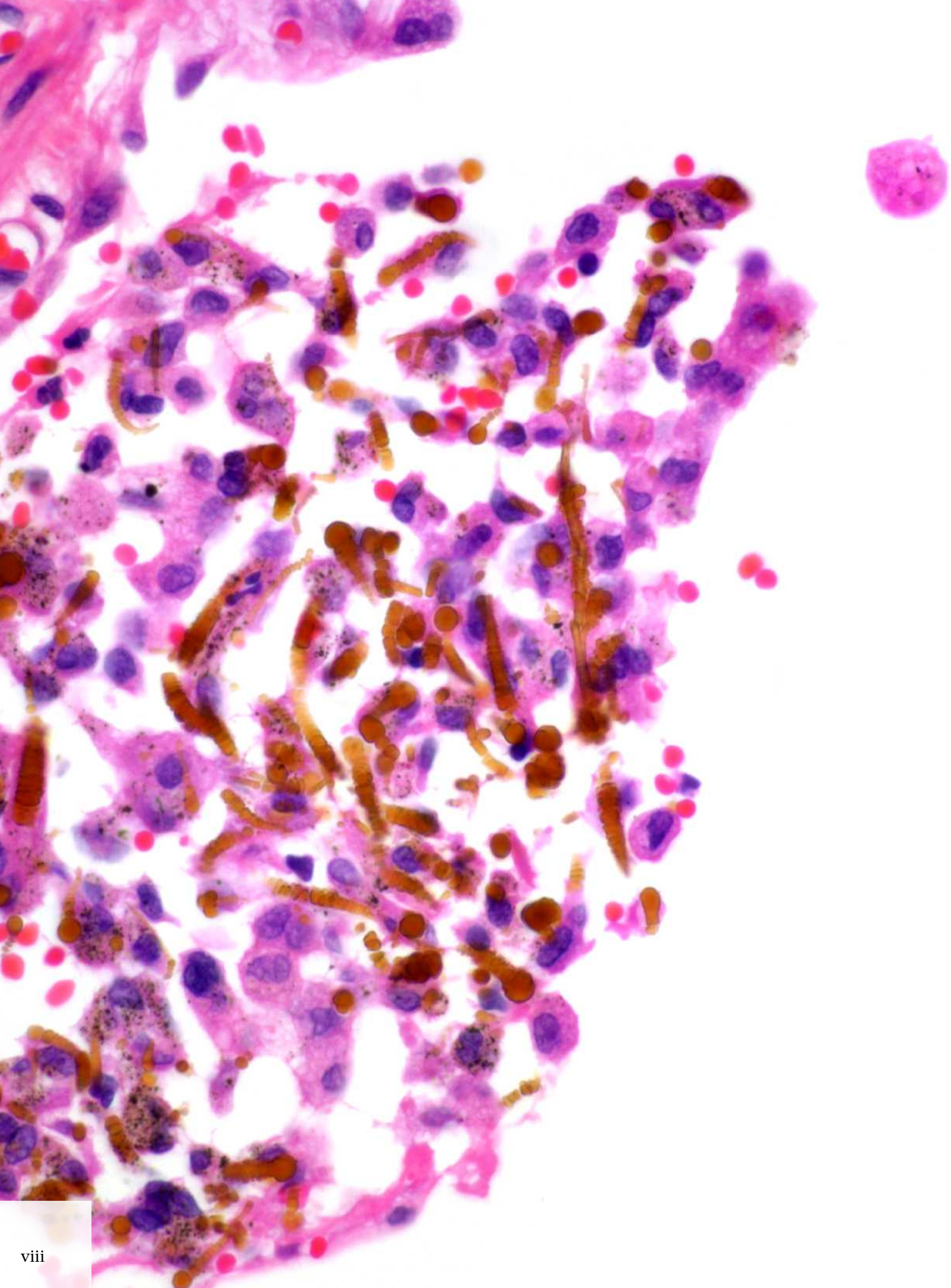

Acknowledgments

Text Editors

Nina I. Bennett, BA
Terry W. Ferrell, MS
Lisa A. Gervais, BS
Karen E. Concannon, MA, PhD
Matt W. Hoecherl, BS
Megg Morin, BA

Image Editors

Jeffrey J. Marmorstone, BS
Lisa A. M. Steadman, BS

Illustrations

Laura C. Sesto, MA
Lane R. Bennion, MS
Richard Coombs, MS

Art Direction and Design

Tom M. Olson, BA
Laura C. Sesto, MA

Lead Editor

Arthur G. Gelsinger, MA

Production Coordinators

Angela M. G. Terry, BA
Rebecca L. Bluth, BA
Emily Fassett, BA

ELSEVIER

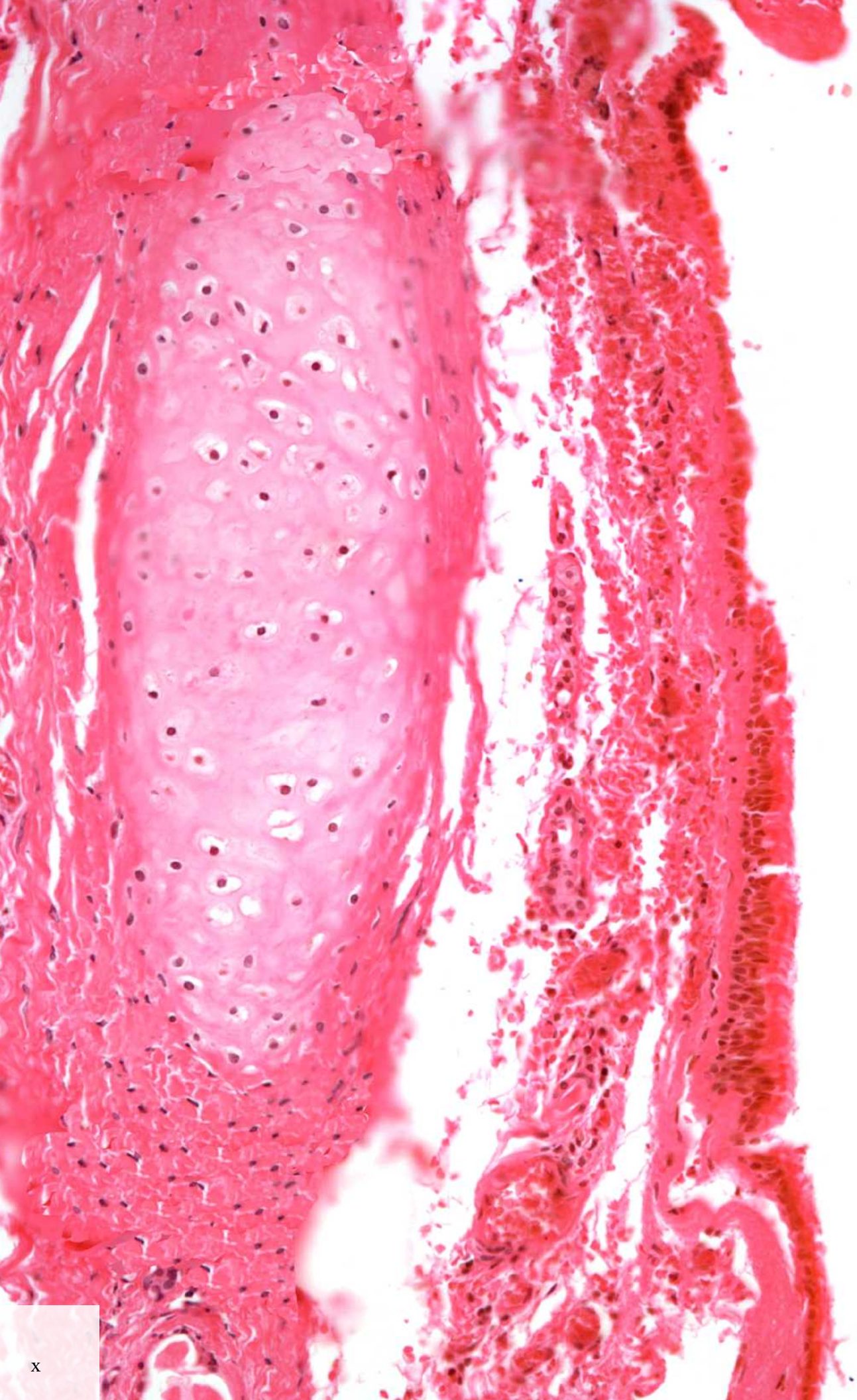

x

Sections

Part I: Lung

SECTION 1: Neoplasms, Benign
SECTION 2: Neoplasms, Malignant, Primary
SECTION 3: Neoplasms, Metastatic
SECTION 4: Nonneoplastic and Systemic Conditions
SECTION 5: Parasitic Disorders
SECTION 6: Infectious Diseases

Part II: Pleura

SECTION 1: Neoplasms, Benign
SECTION 2: Neoplasms, Malignant, Primary
SECTION 3: Other Lesions of Pleura

Part III: Mediastinum

SECTION 1: Neoplasms, Benign
SECTION 2: Neoplasms, Malignant, Primary
SECTION 3: Other Benign/Reactive Conditions

TABLE OF CONTENTS

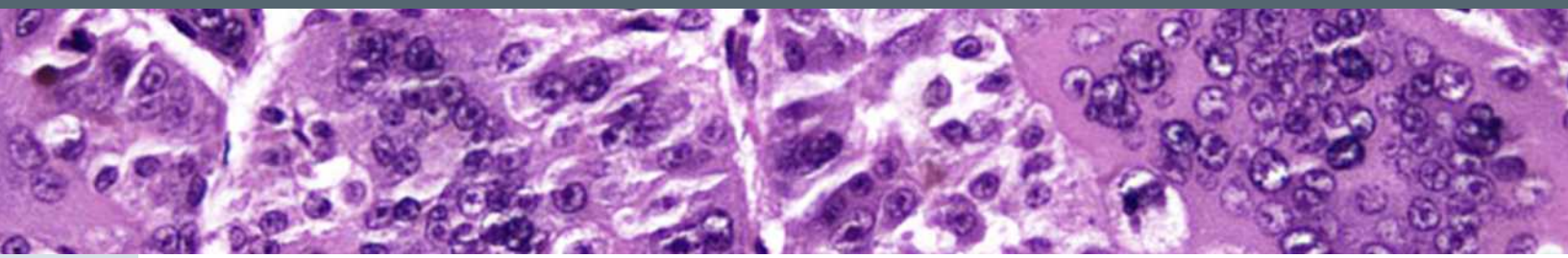

Part I: Lung

SECTION 1: NEOPLASMS, BENIGN

4 Cartilaginous Hamartoma
8 Alveolar Adenoma
12 Mucous Gland Adenoma
18 Endobronchial Lipoma
22 Pulmonary Adenofibroma/Adenomyoma
26 Intrapulmonary Solitary Fibrous Tumor
34 Glomus Tumor
38 Intrapulmonary Thymoma
42 Pulmonary Paraganglioma
46 Pulmonary Meningioma
52 Minute Pulmonary Meningothelial-Like Nodule
56 Granular Cell Tumor
60 Sclerosing Hemangioma (Pneumocytoma)
66 Clear Cell Sugar Tumor (PEComa)
70 Ciliated Muconodular Papillary Tumor

SECTION 2: NEOPLASMS, MALIGNANT, PRIMARY

EPITHELIAL NEOPLASMS

74 Overview of Malignant Epithelial Neoplasms of Lung
76 Adenocarcinoma
88 Bronchioloalveolar Carcinoma
94 Mucinous ("Colloid") Carcinoma
102 Signet Ring Cell Carcinoma
108 Endometrioid-Like Carcinoma
114 Squamous Cell Carcinoma
122 Spindle Cell (Sarcomatoid) Carcinoma
128 Lymphoepithelioma-Like Carcinoma
134 Poorly Differentiated Squamous Carcinoma, Small Cell Variant
140 Large Cell (Anaplastic) Carcinoma
148 Pleomorphic Carcinoma
154 Neuroendocrine Carcinoma (Including Small Cell Carcinoma)
166 Carcinosarcoma
172 Pulmonary Blastoma

SALIVARY GLAND-TYPE TUMORS

178 Adenoid Cystic Carcinoma
186 Mucoepidermoid Carcinoma
192 Epithelial-Myoepithelial Carcinoma
198 Acinic Cell Carcinoma
206 Mixed Tumor
212 Myoepithelial Carcinoma of Lung

MESENCHYMAL NEOPLASMS

216 Intrapulmonary Synovial Sarcoma
222 Leiomyosarcoma
228 Neurogenic Sarcoma (Malignant Peripheral Nerve Sheath Tumor)
232 Osteosarcoma
236 Chondrosarcoma
240 Epithelioid Hemangioendothelioma
246 Angiosarcoma
250 Kaposi Sarcoma
254 Pulmonary Artery Sarcoma

LYMPHOPROLIFERATIVE DISORDERS

258 Pulmonary BALT Hyperplasia
262 Pulmonary BALT Lymphoma
268 Diffuse Large Cell Lymphoma
276 Hodgkin Lymphoma
280 Plasmacytoma
284 Lymphomatoid Granulomatosis

OTHER RARE TUMORS AND BENIGN PSEUDOTUMORAL CONDITIONS

290 Ganglioneuroblastoma
294 Bronchial Malignant Melanoma
298 Inflammatory Pseudotumor
304 IgG4 Sclerosing Lung Disease
308 Juvenile Xanthogranuloma
312 Hyalinizing Granuloma
316 Amyloid Tumor
320 Metastatic/Dendriform Calcification
324 Lipoid Pneumonia (Paraffinoma)
328 Placental Transmogrification
332 Rosai-Dorfman Disease
336 Angiolymphoid Hyperplasia With Eosinophilia
340 Atypical Adenomatous Hyperplasia
342 Lymphangioleiomyomatosis
346 Capillary Hemangiomatosis

TABLE OF CONTENTS

SECTION 3: NEOPLASMS, METASTATIC

352 Benign Metastasizing Leiomyoma
356 Metastatic Carcinoma
366 Metastatic Sarcoma
376 Metastatic Malignant Melanoma

SECTION 4: NONNEOPLASTIC AND SYSTEMIC CONDITIONS

386 Diffuse Alveolar Damage
390 Bronchiolitis Obliterans With Organizing Pneumonia
394 Respiratory Bronchiolitis
398 Usual Interstitial Pneumonia
406 Desquamative Interstitial Pneumonia
410 Nonspecific Interstitial Pneumonia
414 Extrinsic Allergic Alveolitis
418 Allergic Angiitis and Granulomatosis (Churg-Strauss)
422 Bronchocentric Granulomatosis
426 Wegener Granulomatosis
430 Sarcoidosis
434 Hard Metal Pneumoconiosis Pneumonitis
438 Asbestos-Related Interstitial Fibrosis
442 Idiopathic Pulmonary Hemosiderosis
444 Alveolar Proteinosis
448 Pulmonary Amyloidosis
452 Eosinophilic Pneumonia
456 Langerhans Cell Histiocytosis
460 Erdheim-Chester Disease
464 Alveolar Microlithiasis

SECTION 5: PARASITIC DISORDERS

470 Strongyloidiasis
474 Dirofilariasis
478 Schistosomiasis
482 Echinococcosis (Hydatid Cyst)
486 Paragonimiasis

SECTION 6: INFECTIOUS DISEASES

492 Cryptococcosis
496 Coccidioidomycosis
500 Pneumocystosis
504 Blastomycosis
506 Histoplasmosis
510 Tuberculosis
514 Herpes Simplex Virus
518 Cytomegalovirus
522 Adenovirus
524 Measles Pneumonia
528 Sporotrichosis
530 *Klebsiella* Pneumonia
534 SARS Pneumonia
536 Nocardiosis
538 Actinomycosis
540 Aspergillosis
546 Botryomycosis
548 Malakoplakia

Part II: Pleura

SECTION 1: NEOPLASMS, BENIGN

554 Mesothelial Hyperplasia
558 Solitary Fibrous Tumor
568 Calcified Fibrous Pseudotumor

SECTION 2: NEOPLASMS, MALIGNANT, PRIMARY

EPITHELIAL NEOPLASMS

574 Overview of Malignant Pleural Neoplasms
576 Malignant Mesothelioma
584 Pseudomesotheliomatous Adenocarcinoma
590 Mucoepidermoid Carcinoma of Pleura
596 Angiosarcoma
602 Synovial Sarcoma
608 Malignant Solitary Fibrous Tumor (Fibrosarcoma)
614 Smooth Muscle Tumors of Pleura
620 Desmoplastic Small Round Cell Tumor

SECTION 3: OTHER LESIONS OF PLEURA

626 Pleural Endometriosis

Part III: Mediastinum

SECTION 1: NEOPLASMS, BENIGN

632 Lymphangioma
636 Hemangioma
640 Paraganglioma

SECTION 2: NEOPLASMS, MALIGNANT, PRIMARY

EPITHELIAL NEOPLASMS

648 Overview of Malignant Thymic Neoplasms
650 Thymoma
666 Atypical Thymoma
676 Thymic Carcinoma
690 Neuroendocrine Carcinomas of Thymus

GERM CELL TUMORS

696 Mediastinal Teratoma
702 Mediastinal Seminoma
708 Yolk Sac Tumor

TABLE OF CONTENTS

714 Choriocarcinoma
720 Embryonal Carcinoma

HEMATOPOIETIC MALIGNANCIES

726 Hodgkin Lymphoma of Mediastinum
734 Diffuse Large Cell Lymphoma of Mediastinum
748 Lymphoblastic Lymphoma
754 MALT Lymphoma of Thymus

MESENCHYMAL NEOPLASMS

758 Liposarcoma
768 Leiomyosarcoma
774 Synovial Sarcoma
786 Neurofibroma
790 Peripheral Nerve Sheath Tumor
796 Solitary Fibrous Tumor/Fibrosarcoma
806 Epithelioid Hemangioendothelioma
812 Mesenchymal Chondrosarcoma
816 Chordoma
822 Alveolar Soft Part Sarcoma
828 Rhabdomyosarcoma

SYMPATHETIC NERVOUS SYSTEM TUMORS

834 Ganglioneuroma
838 Neuroblastoma/Ganglioneuroblastoma
844 Ependymoma

OTHER TUMORS

848 Ectopic Parathyroid Tumor
854 Ectopic Thyroid Tumor

SECTION 3: OTHER BENIGN/REACTIVE CONDITIONS

860 Thymolipoma
864 Castleman Disease
870 Benign Mediastinal Foregut Cyst
876 Acquired Multilocular Thymic Cyst
884 Idiopathic Sclerosing Mediastinitis

This page intentionally left blank

This page intentionally left blank

DIAGNOSTIC PATHOLOGY

Thoracic

SECOND EDITION

SUSTER | MORAN

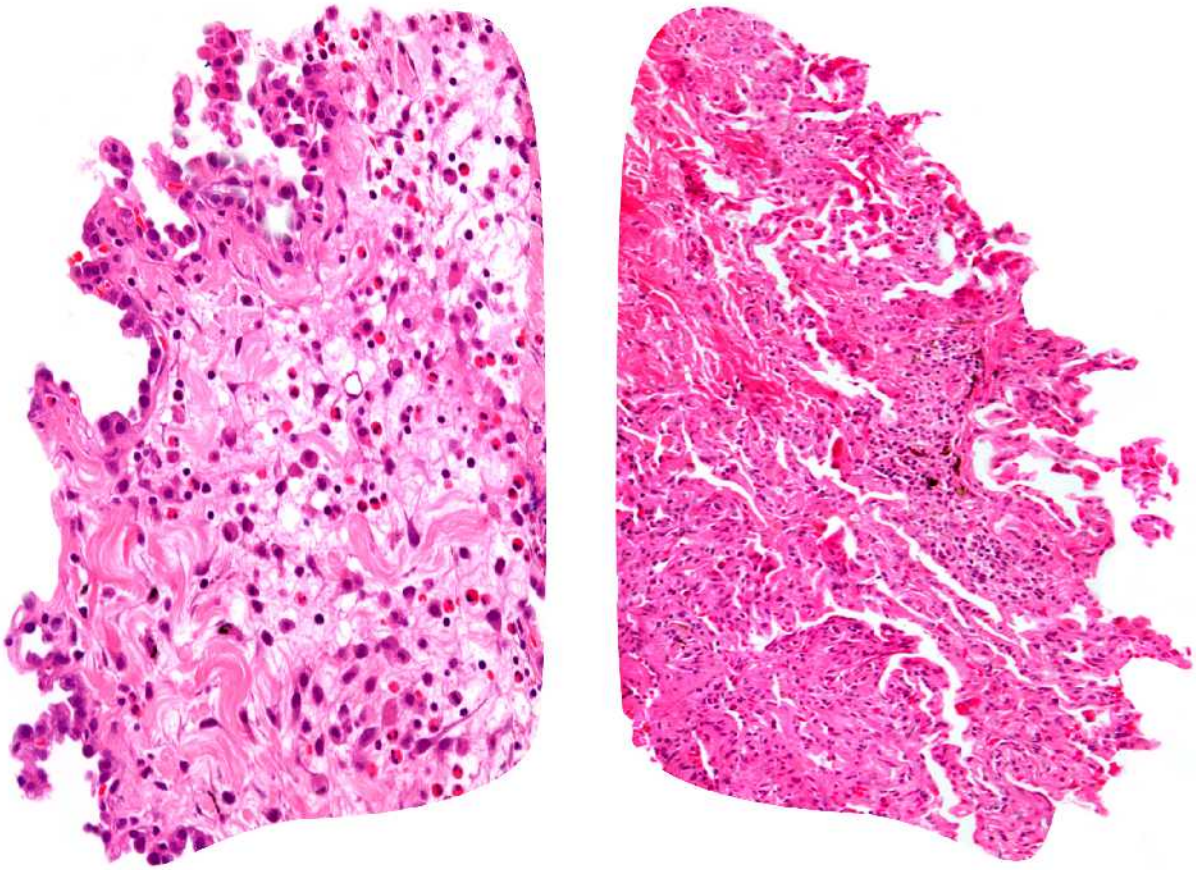

This page intentionally left blank

PART I
SECTION 1

Neoplasms, Benign

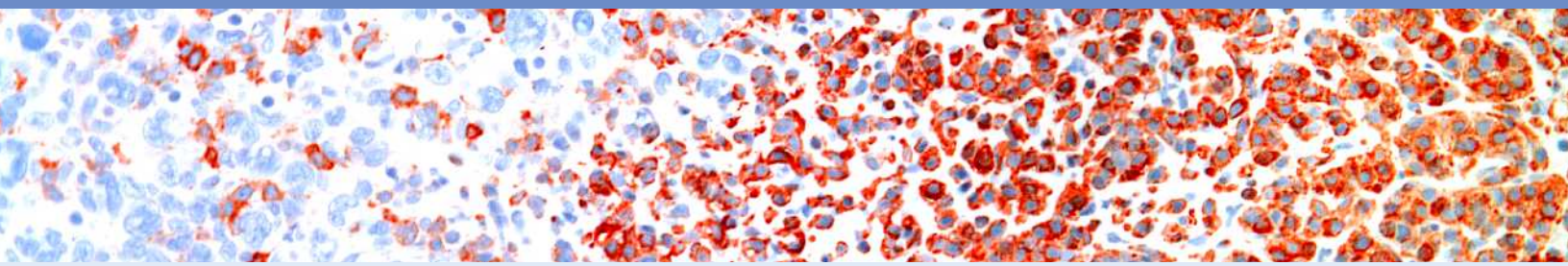

Cartilaginous Hamartoma	**4**
Alveolar Adenoma	**8**
Mucous Gland Adenoma	**12**
Endobronchial Lipoma	**18**
Pulmonary Adenofibroma/Adenomyoma	**22**
Intrapulmonary Solitary Fibrous Tumor	**26**
Glomus Tumor	**34**
Intrapulmonary Thymoma	**38**
Pulmonary Paraganglioma	**42**
Pulmonary Meningioma	**46**
Minute Pulmonary Meningothelial-Like Nodule	**52**
Granular Cell Tumor	**56**
Sclerosing Hemangioma (Pneumocytoma)	**60**
Clear Cell Sugar Tumor (PEComa)	**66**
Ciliated Muconodular Papillary Tumor	**70**

Cartilaginous Hamartoma

KEY FACTS

TERMINOLOGY

- Benign mesenchymoma

CLINICAL ISSUES

- Intrapulmonary coin lesion of variable size
- Central or peripheral tumor
- Complete surgical resection
- Excellent prognosis

MACROSCOPIC

- Well-circumscribed lesion
- Firm with mucoid and cartilaginous areas
- Usually single lesion
- Rarely hamartomas may present as multiple intrapulmonary lesions

MICROSCOPIC

- Mature cartilage (focal atypia may be present)
- Mature adipose tissue
- Invagination of respiratory epithelium

TOP DIFFERENTIAL DIAGNOSES

- Bronchial chondromas
  - Do not show invaginations of respiratory epithelium
  - May be associated with other conditions, such as gastric smooth muscle tumors
- Pleomorphic adenoma
  - Shows presence of epithelial component that immunophenotypically is myoepithelial
  - Pleomorphic adenoma in lung rarely will show mature cartilage
  - Also lacks presence of invaginations of respiratory epithelium
- Chondrosarcoma
  - Will display more cellular atypia
  - Does not have admixture of adipose tissue
  - Lacks presence of invaginations of respiratory epithelium

Macroscopic Features

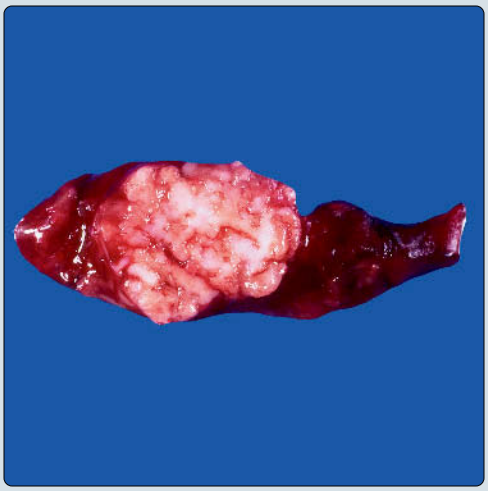

Cartilage and Adipose Tissue

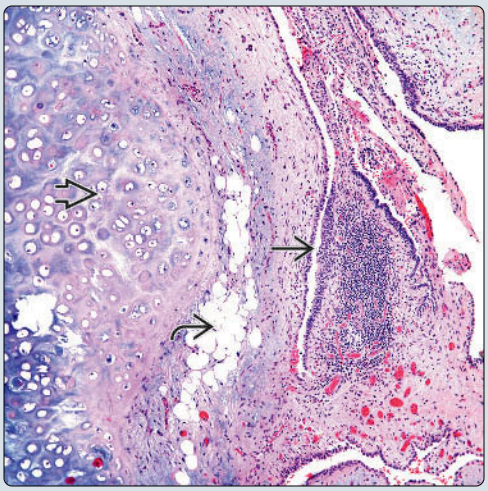

(Left) *Gross photograph shows a well-circumscribed intrapulmonary tumor, slightly lobulated with a cartilaginous appearance. These features are classic for cartilaginous hamartoma (CH).* **(Right)** *CH shows areas of well-formed cartilage ⇨, adipose tissue ⇨, and invaginated respiratory epithelium ⇨. These features are characteristic of hamartoma.*

Invagination of Epithelium

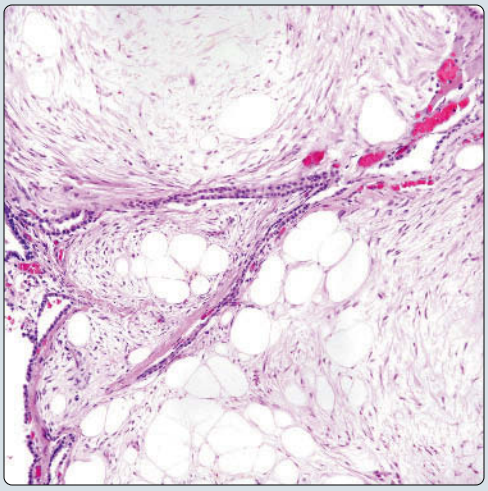

Focal Atypia

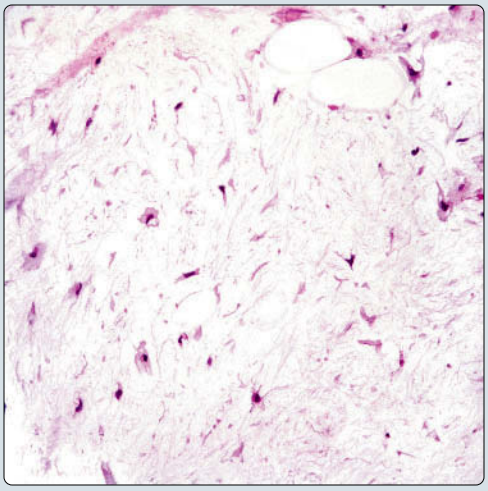

(Left) *Pulmonary hamartoma shows epithelial invagination, which is 1 of the most common features associated with hamartoma.* **(Right)** *High-power magnification of the chondroid component in a pulmonary hamartoma depicts areas of myxoid and hyaline change with some nuclear atypia.*

TERMINOLOGY

Abbreviations

- Cartilaginous hamartoma (CH)

Synonyms

- Benign mesenchymoma

Definitions

- Benign mesenchymal tumor of lung

ETIOLOGY/PATHOGENESIS

Pathogenesis

- It is not clear whether CH represents true tumor or hamartomatous lesion
  - Thus, both terms, benign mesenchymoma and hamartoma, have been used interchangeably

CLINICAL ISSUES

Presentation

- Intraparenchymal coin lesions of variable size
  - Represent ~ 90% of cases
- Central lesions
  - Represent ~ 10% of cases

Treatment

- Surgical approaches
  - Complete surgical resection

Prognosis

- Excellent prognosis; cured by simple excision

MACROSCOPIC

General Features

- Well-circumscribed lesion
- Firm with mucoid and cartilaginous areas
- Usually solitary
- Rarely hamartomas may present as multiple intrapulmonary lesions

MICROSCOPIC

Histologic Features

- Mature cartilage
- Adipose tissue
- Myxoid stroma
- Invaginations of respiratory epithelium

DIFFERENTIAL DIAGNOSIS

Bronchial Chondroma

- Does not show invaginations of respiratory epithelium
- Branchial chondroma rarely will show additional adipose tissue
- May be associated with other conditions, such as gastric smooth muscle tumors

Pleomorphic Adenoma

- Shows presence of epithelial component that immunophenotypically is myoepithelial
- Pleomorphic adenoma in lung rarely shows mature cartilage
- Also lacks presence of invaginations of respiratory epithelium

Chondrosarcoma, Primary or Metastatic

- Displays more cellular atypia
- Does not have admixture of adipose tissue
- Lacks presence of invaginations of respiratory epithelium
- Some cases of chondrosarcomas may arise from preexisting hamartomas
- In cases of metastatic disease, clinical history is most important feature

Bronchial Lipomas

- Almost exclusively composed of adipose tissue
- Lipomas do not display areas of cartilage
- Great majority of lipomas are in central location, whereas hamartomas are more common in periphery

DIAGNOSTIC CHECKLIST

Pathologic Interpretation Pearls

- Chondromyxoid tumor with invaginations of respiratory epithelium
- Mature cartilage
- Areas of ossification may be present
- Presence of adipose tissue
- Well-circumscribed tumor lesion

SELECTED REFERENCES

1. Lio E et al: Giant pulmonary chondroid hamartoma: imaging and pathology correlation of a rare tumor demonstrated with bone scintigraphy and 18F-FDG PET/CT. Clin Nucl Med. 40(1):79-81, 2015

Immunohistochemistry

Antibody	Reactivity	Staining Pattern	Comment
CK-PAN	Positive	Cytoplasmic	In invaginated respiratory epithelium
S100	Positive	Nuclear	Chondroid component
EMA	Positive	Cell membrane	Respiratory epithelium
SOX9	Positive	Nuclear	Cartilage
Desmin	Positive	Cytoplasmic	In muscle component
Vimentin	Positive	Cytoplasmic	
CD34	Positive	Cytoplasmic	In vessels and adipose tissue

Myxoid Changes

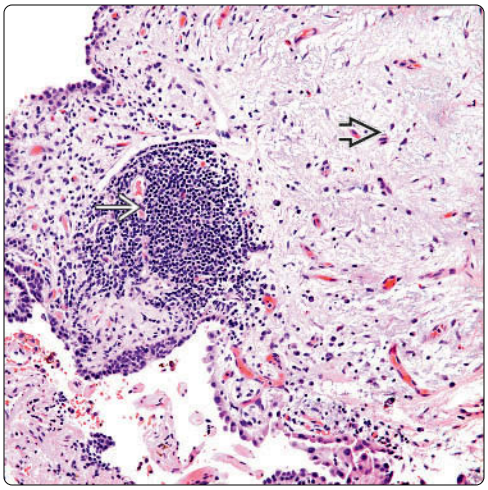

Invaginated Respiratory Epithelium

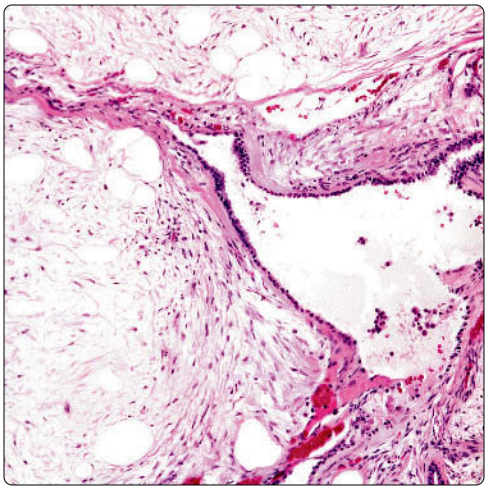

(Left) *Peripheral areas of a CH show extensive myxoid changes and inflammatory infiltrate. The sole presence of cartilage should raise the suspicion of pulmonary hamartoma.* **(Right)** *CH shows slight lobulation separated by invaginated respiratory epithelium. Note that there is not well-formed cartilage but rather myxoid change.*

Mature Cartilage and Adipose Tissue

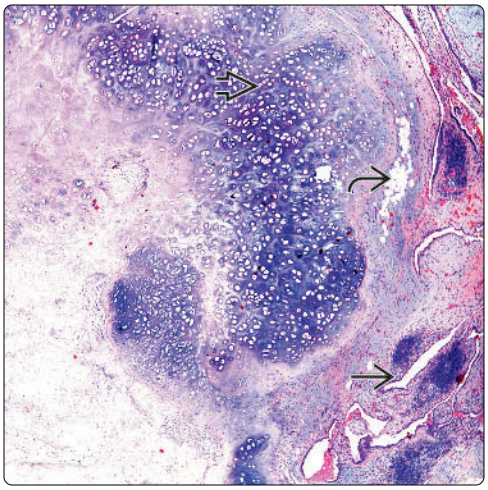

Spindle Cells

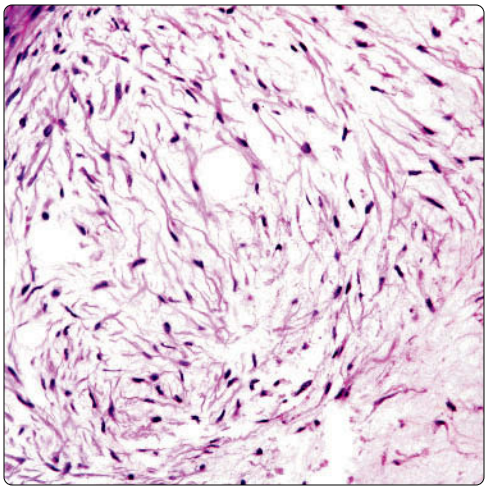

(Left) *CH is shown with different components in which the tumor shows predominantly mature cartilage, areas of adipose tissue, and entrapped epithelial elements. These are the classic features of a hamartoma.* **(Right)** *High-power magnification shows a myxoid area in a pulmonary hamartoma. Note the spindle cell proliferation in a myxoid background. Similar features may be seen in other mesenchymal tumors.*

Muscle Component

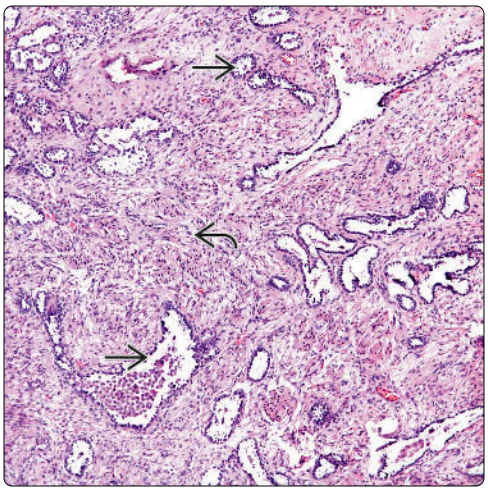

Mature Adipose Tissue

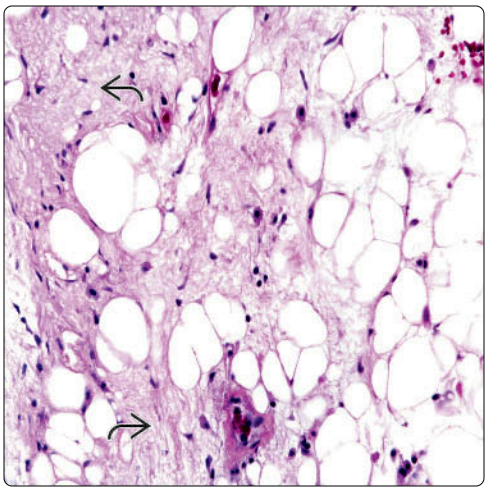

(Left) *Pulmonary hamartoma shows extensive areas of muscle differentiation with entrapped alveolar structures. In some unusual cases, the presence of muscle may be more extensive with only focal areas of cartilage.* **(Right)** *High-power view shows the adipose tissue component in a pulmonary hamartoma. Note the presence of mature adipose tissue with areas of myxoid change similar to that seen in true lipomatous tumors.*

Cartilage and Adipose Tissue

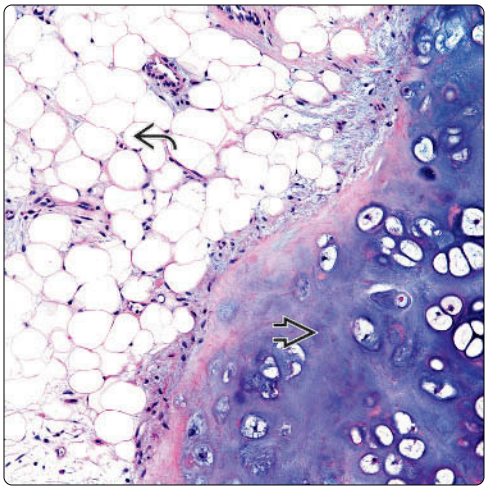

Extensive Epithelial Component

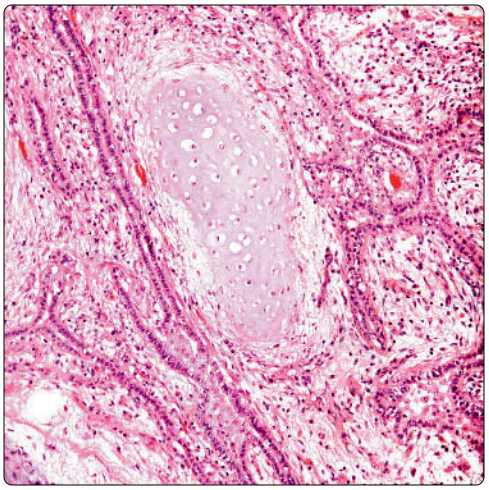

(Left) *Pulmonary hamartoma shows the typical features of mature cartilaginous and adipose tissue. These 2 components may be seen in different proportions.* **(Right)** *Mature cartilage and compressed lung parenchyma may also be present in CH. In this case, the cartilaginous component is rather minimal, while the lesion displays more prominent epithelial invaginations with associated myxoid change in the stroma.*

Cartilage With Mild Atypia

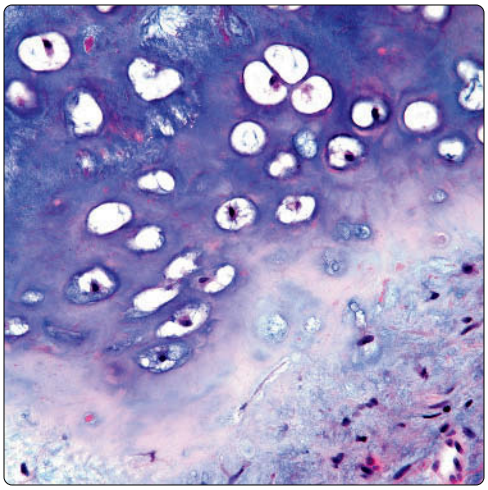

Inflammatory Changes

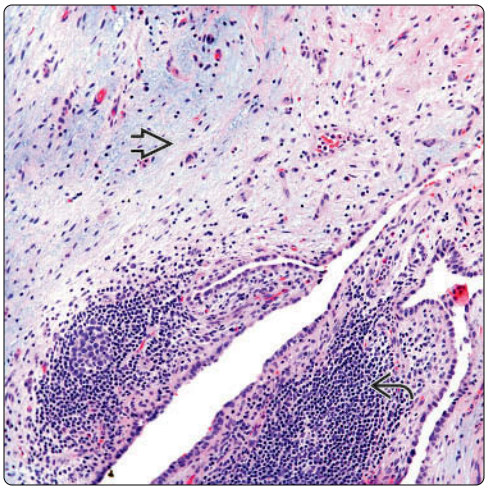

(Left) *High-power view shows the cartilaginous component in a pulmonary hamartoma. Note the absence of nuclear atypia or mitotic activity, which is useful in separating these lesions from other malignant cartilaginous tumors.* **(Right)** *CH shows areas in which the respiratory epithelium shows inflammatory changes and lymphoid hyperplasia. Note the presence of myxoid areas with an inflammatory reaction.*

Nuclear Atypia in Epithelium

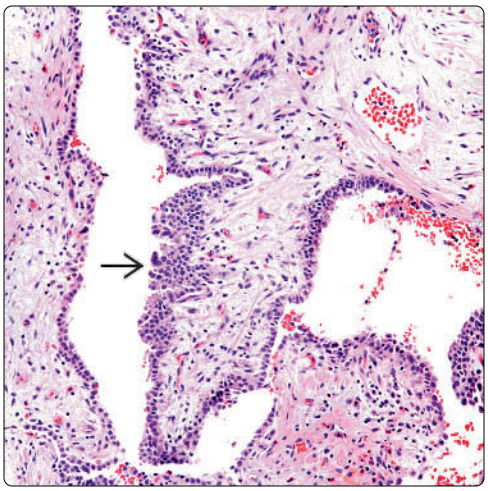

Entrapped Alveoli

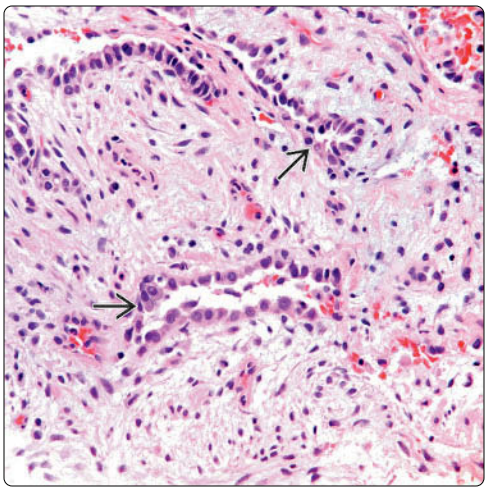

(Left) *Closer view shows the entrapped epithelial component of a CH with focal hyperplastic changes. The epithelial component associated with pulmonary hamartomas does not show any cellular atypia or dysplastic changes.* **(Right)** *Entrapped epithelial structures represent alveoli admixed with focal areas of myxoid change. These changes by themselves are not diagnostic of pulmonary hamartoma, as they may be seen in other conditions.*

Alveolar Adenoma

KEY FACTS

TERMINOLOGY

- Benign intraparenchymal lung tumor

ETIOLOGY/PATHOGENESIS

- Although etiology of this tumor is not completely understood, it may originate from pneumocytes

CLINICAL ISSUES

- General features
  - Unusual occurrence
  - Generally in adults
  - Solitary pulmonary lesion
  - Cough
  - Chest pain
  - No gender or ethnic predilection
- Treatment
  - Lobectomy
  - Wedge resection
- Prognosis
  - Excellent

IMAGING

- Solitary pulmonary mass (usually under 3 cm)

MICROSCOPIC

- Well circumscribed
- Generally cystic appearance
- Dilated spaces of different sizes
- Clear acellular material within cystic areas
- PAS-positive material

TOP DIFFERENTIAL DIAGNOSES

- Adenocarcinoma
- Bronchioloalveolar carcinoma
- Lymphangioma
- Glomus tumor

Dilated Alveolar Structures

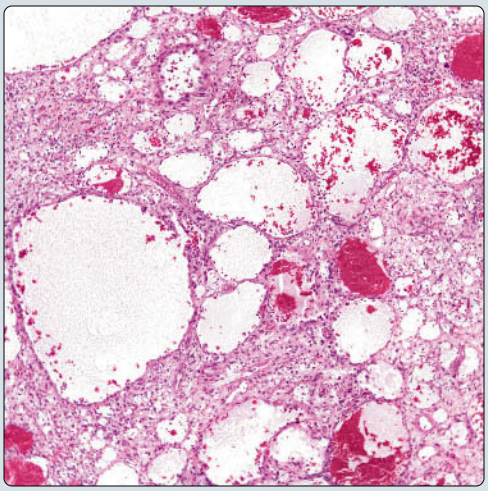

Vascular-Like Features

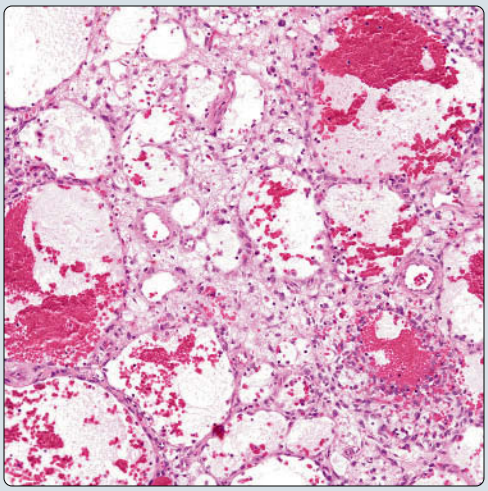

(Left) *Pulmonary alveolar adenoma shows characteristic cystic areas alternating with more solid areas. The low power mimics a vascular neoplasm.* **(Right)** *Cystically dilated areas of different sizes, some containing fresh blood, are shown. This feature can easily be confused with a hemangioma.*

Cystic and Solid Areas

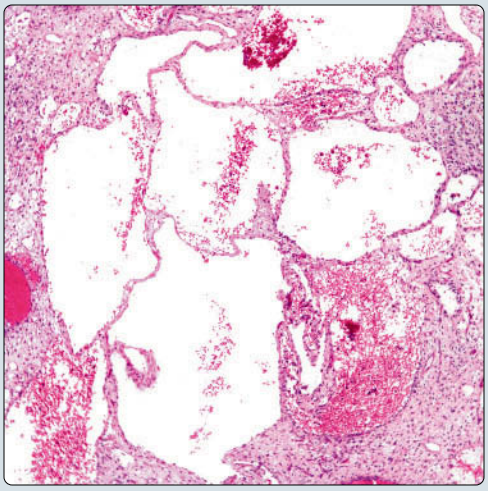

Solid Areas

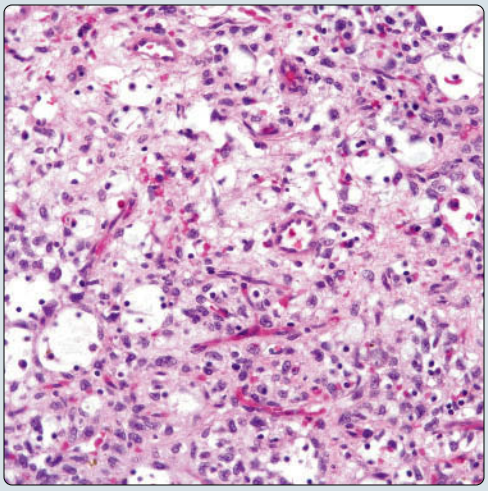

(Left) *In some areas, the cystic areas closely mimic a vascular neoplasm, and they can be confused for distended lymphatics or other vascular structures. Note that the cystic structures do not contain fluid.* **(Right)** *Alveolar adenoma shows a more solid proliferation in which the cells appear to have clear cytoplasm. Note the absence of cellular atypia or mitotic activity.*

TERMINOLOGY

Definitions

- Benign intraparenchymal lung tumor

ETIOLOGY/PATHOGENESIS

Etiology

- Although etiology of this tumor is not completely understood, it may originate from pneumocytes

CLINICAL ISSUES

Epidemiology

- Incidence
  - Rare tumor
- Age
  - Generally in adults
- Sex
  - No gender predilection
- Ethnicity
  - No ethnic predilection

Site

- Intrapulmonary mass

Presentation

- Cough
- Chest pain
- Asymptomatic

Treatment

- Surgical approaches
  - Lobectomy
  - Wedge resection

Prognosis

- Excellent

IMAGING

General Features

- Location
  - Solitary pulmonary mass

MACROSCOPIC

General Features

- Tumors may be cystic and hemorrhagic

Size

- Tumors may vary from 1-3 cm in diameter

MICROSCOPIC

Histologic Features

- Well circumscribed
- Generally cystic appearance
- Dilated spaces of different sizes
- Clear acellular material within cystic areas
- Dilated spaces lined by medium-sized cells with hobnail appearance
- Focal areas of glandular appearance
- Alternating solid areas

ANCILLARY TESTS

Histochemistry

- PAS-diastase
  - Reactivity: Positive

DIFFERENTIAL DIAGNOSIS

Lymphangioma

- Dilated lymphatic spaces
- It would be unusual for lymphangioma to show cystic and solid components
- May show positive staining for podoplanin (D2-40), whereas alveolar adenoma will be negative

Glomus Tumor

- Cystic and solid areas similar to alveolar adenoma
- Strong positive staining for actin

DIAGNOSTIC CHECKLIST

Clinically Relevant Pathologic Features

- Most patients are asymptomatic

Pathologic Interpretation Pearls

- Cystic and solid areas
- Acellular material within cystic spaces
- PAS-positive material in cystic spaces
- Absence of necrosis and mitotic activity

SELECTED REFERENCES

1. Hsieh MS et al: Cystic alveolar adenoma: an unusual clinical presentation of a rare lung neoplasm. Pathology. 47(1):78-80, 2015
2. Yousem SA et al: Alveolar adenoma. Hum Pathol. 17(10):1066-71, 1986

Immunohistochemistry

Antibody	Reactivity	Staining Pattern	Comment
CK-PAN	Positive	Cytoplasmic	Strong diffuse staining
EMA	Positive	Cell membrane	Strong and diffuse
Surfactant	Positive	Cytoplasmic	May be focal
TTF-1	Positive	Nuclear	May be focal in some cells lining cystic spaces and in some solid areas
CD34	Positive	Cytoplasmic	In stromal cells in some cases

Cystic Changes

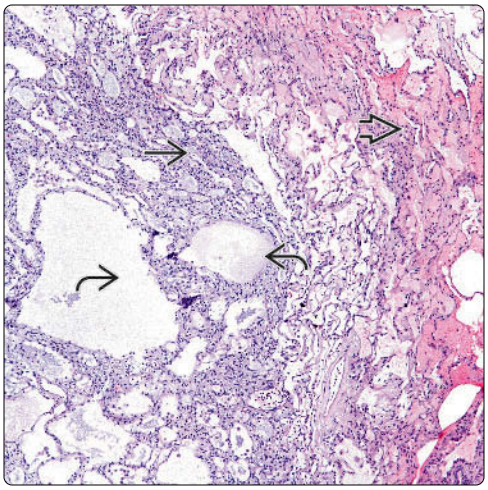

Intraalveolar Acellular Material

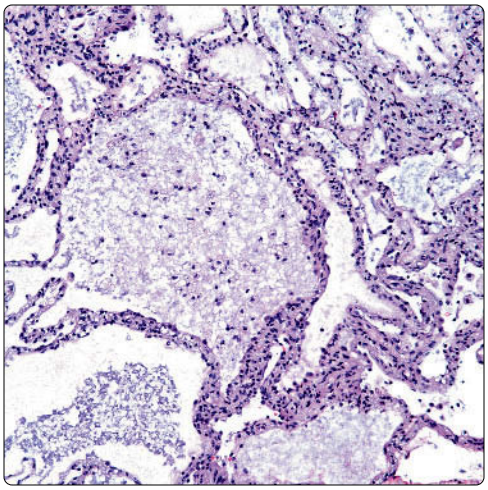

(Left) *Alveolar adenoma shows cystic areas admixed with solid areas. Note that the lesion is well circumscribed. Adjacent lung parenchyma appears to be congested.* **(Right)** *Cystically dilated areas in this alveolar adenoma contain clear fluid and scattered macrophages. The lining is flattened, and the appearance is that of a distended alveolar structure.*

Spindle Cell Proliferation

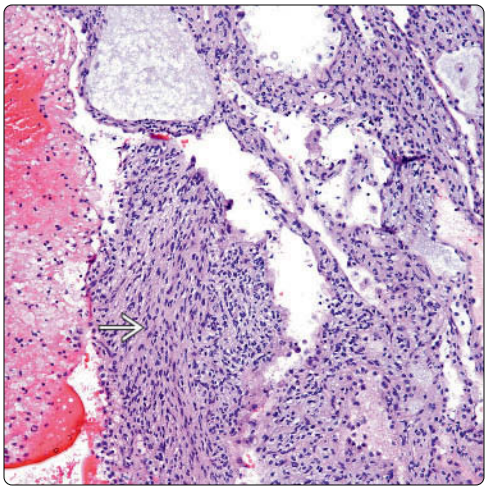

Solid and Cystic Areas

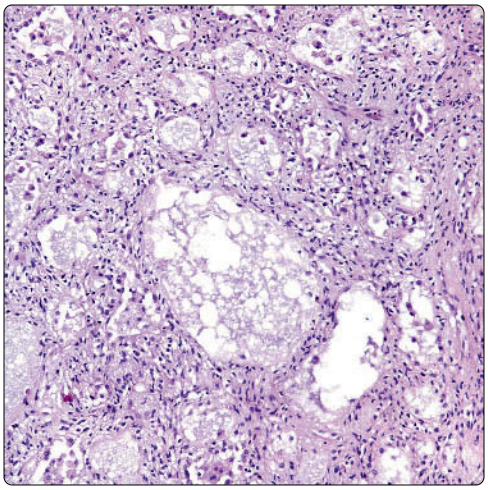

(Left) *In some focal areas, the solid component of an alveolar adenoma may take the form of a spindle cell proliferation. However, these areas lack nuclear atypia and mitotic activity.* **(Right)** *Alveolar adenoma shows alternating areas of cystic changes and solid cellular proliferation. Cellular atypia and mitotic activity are absent.*

Cellular Areas

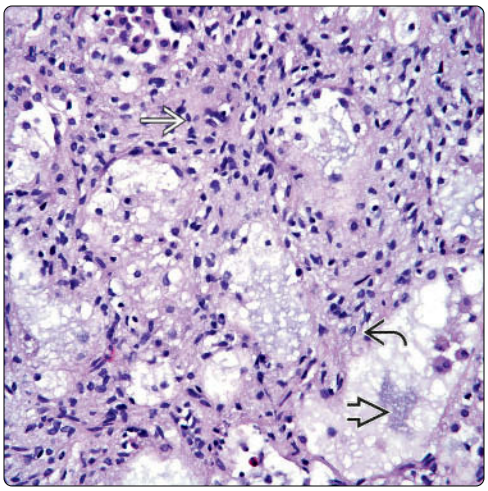

Absent Cellular Atypia

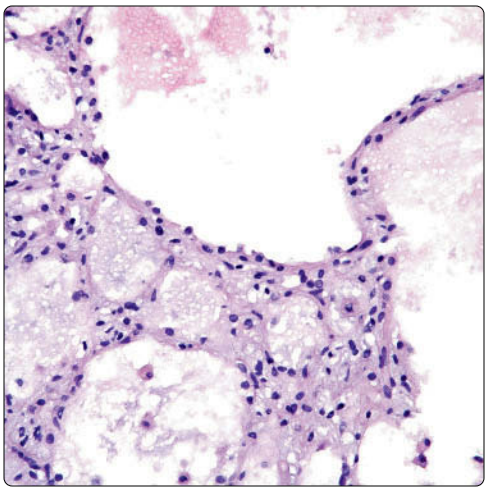

(Left) *Alveolar adenoma shows more cellular areas admixed with cystic areas. Interestingly, the material in the lumina of the cystic areas appears to be more chondroid-like.* **(Right)** *High-power magnification of an alveolar adenoma shows a cystic-like areas lined by flat epithelium likely representing pneumocytes. Note the absence of cellular atypia and mitotic activity.*

Solid and Cystic Areas

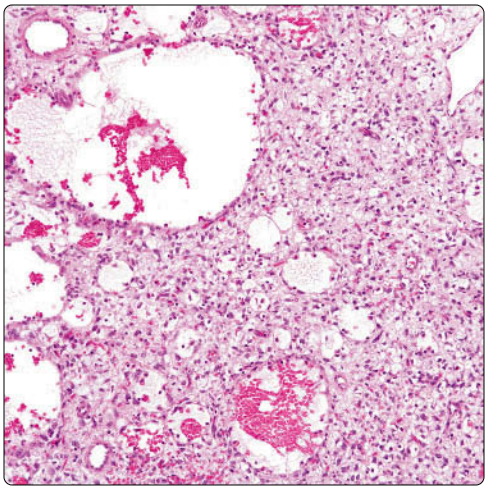

Subtle HPC Pattern

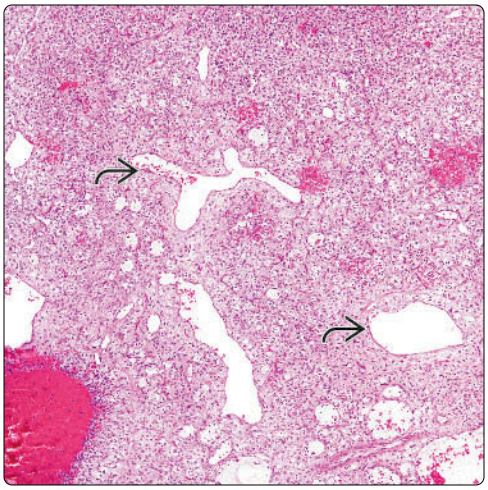

(Left) *Alveolar adenoma shows the more conventional histology consisting of cystic areas admixed with solid areas. The cystic areas contain fresh blood or clear acellular fluid.* **(Right)** *Low-power view shows an alveolar adenoma mimicking a hemangiopericytic growth pattern. The dilated spaces can be easily confused for vascular structures at this magnification.*

Pools of Blood

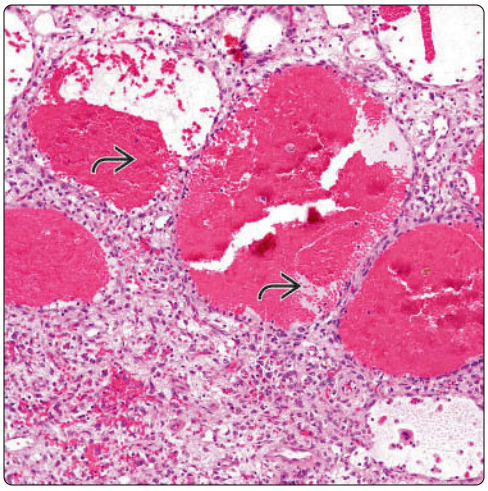

Ectatic Vessels

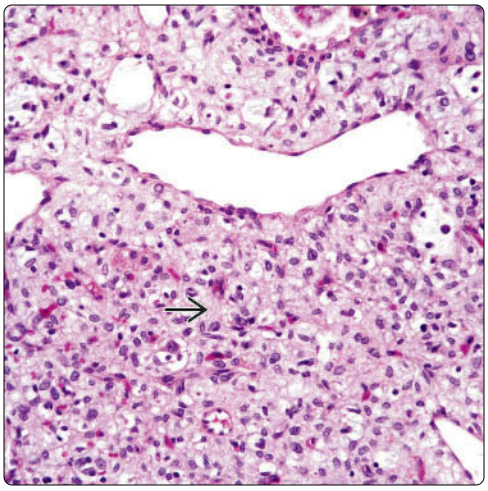

(Left) *Cystically dilated areas containing fresh blood admixed with more solid cellular proliferation are shown. However, the cystic structures are not lined by endothelial cells.* **(Right)** *Solid areas of an alveolar adenoma show a small cystically dilated area and a subtle hemangiopericytic appearance. In the solid component, the cells appear to have clear cell cytoplasm.*

Neural-Like Features

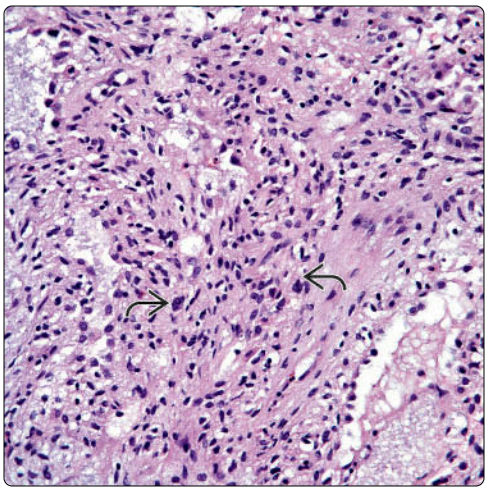

Clear Cells

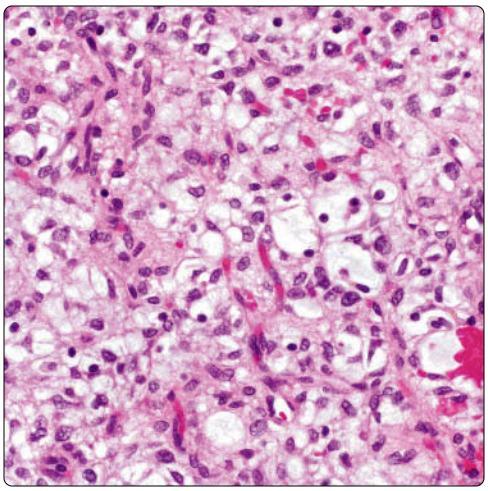

(Left) *Closer magnification of the solid spindle cell component, which closely mimics a neural tumor, is shown. Although there are some pyknotic nuclei, there is no mitotic activity.* **(Right)** *Solid areas in an alveolar adenoma with a clear cell appearance are shown. Note the absence of nuclear atypia and mitotic activity.*

Mucous Gland Adenoma

KEY FACTS

TERMINOLOGY

- Benign tumor characterized by exuberant enlargement of normal endobronchial glands filled with mucous content above cartilaginous plate

ETIOLOGY/PATHOGENESIS

- Exuberant dilatation and proliferation of normal endobronchial glands with mucoid material in lumina
- Enlargement of normal endobronchial glands

CLINICAL ISSUES

- Difficulty breathing
- Chest pain
- Cough
- Hemoptysis
- Asymptomatic
- Tumor is central in endobronchial location

MACROSCOPIC

- Exophytic endobronchial tumors
- Varying tumor size from 0.8-6.0 cm
- Well-circumscribed tumors
- Cystic, soft, contain jelly-like material

MICROSCOPIC

- Cystic
- Tubulopapillary
- Tubular cysts
- Epithelial, glandular
- Tumor does not extend beyond cartilaginous (bronchial) plate

TOP DIFFERENTIAL DIAGNOSES

- Mucoepidermoid carcinoma

Dilated Bronchial Glands

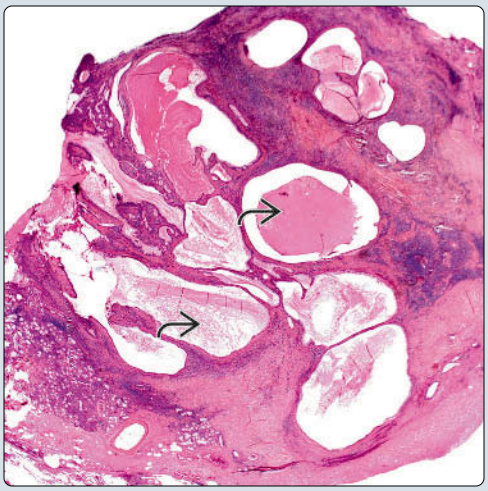

Exuberant Mucinous Glands

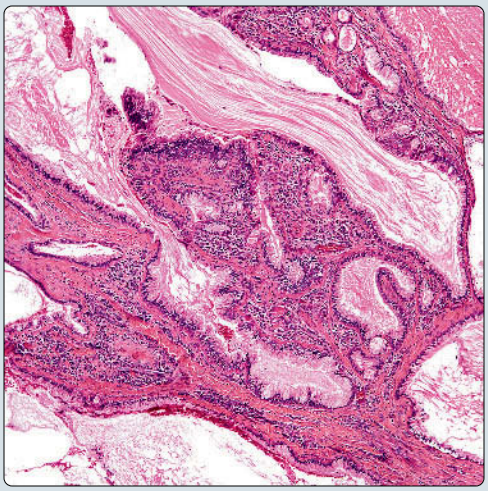

(Left) *Low-power view shows a mucous gland adenoma of the lung with abnormal dilatation of endobronchial glands.* **(Right)** *High-power view of a mucous gland adenoma shows dilated endobronchial glands displaying an absence of mitotic activity or nuclear atypia. Note the presence of mucous material in the lumen of the glands.*

Prominent Mucinous Epithelium

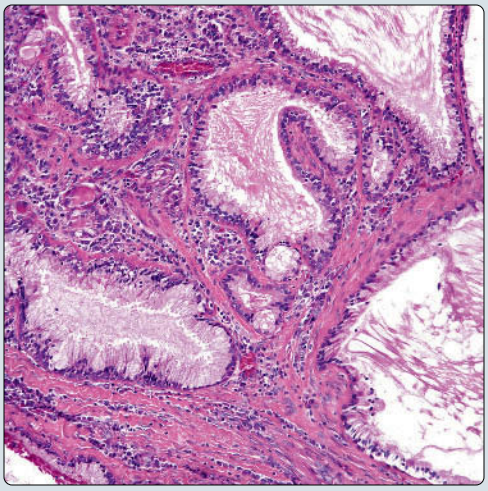

Cystic Changes

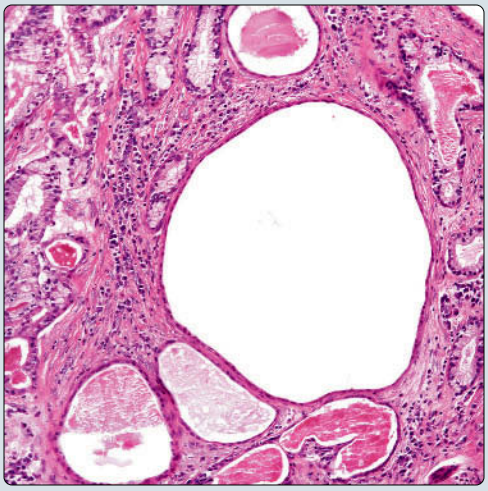

(Left) *Mucous gland adenoma shows hyperplastic changes of the mucinous epithelium lining normal endobronchial glands.* **(Right)** *Mucous gland adenoma shows cystic changes in which the cystic structures are lined by a flattened epithelium. Note the presence of of normal endobronchial gland around the cystic component.*

TERMINOLOGY

Synonyms

- Bronchial adenoma

Definitions

- Benign tumor characterized by exuberant enlargement of normal endobronchial glands filled with mucous content lying above cartilaginous plate

ETIOLOGY/PATHOGENESIS

Etiology

- Exuberant dilatation and proliferation of normal endobronchial glands with mucoid material in lumina
- Enlargement of normal endobronchial glands

CLINICAL ISSUES

Epidemiology

- Incidence
  - Rare tumors
- Age
  - May occur at any age
- Sex
  - No predilection

Site

- Tumor is central in endobronchial location

Presentation

- Cough
- Hemoptysis
- Chest pain
- Difficulty breathing
- Asymptomatic

Treatment

- Surgical approaches
  - Conservative surgical excision

Prognosis

- Excellent prognosis

IMAGING

General Features

- Usually centrally located neoplasm

MACROSCOPIC

General Features

- Exophytic endobronchial tumor
- Varying tumor size from 0.8-6.0 cm
- Well circumscribed
- Cystic, soft, contain jelly-like material

MICROSCOPIC

Histologic Features

- Tumor does not extend beyond cartilaginous (bronchial) plate
- Lining bronchial epithelium usually within normal limits
- Dilated normal glandular structures
- Hyperplasia of mucous glandular lining
- Inflammatory component
- Squamous metaplasia
- Focal areas of fibrosis with entrapped glandular structures may be seen
- Solid small glandular component
- Lack of mitotic activity
- Necrosis is unusual
- Lack of nuclear atypia
- Cystic changes in which cyst may be lined by
  - Flattened epithelium
  - Mucous epithelium

Predominant Pattern/Injury Type

- Cystic
- Tubulopapillary
- Tubular cysts
- Mucous cells
- Hyperplastic changes

Predominant Cell/Compartment Type

- Epithelial, glandular
- Mucinous

DIFFERENTIAL DIAGNOSIS

Mucoepidermoid Carcinoma

- Invades beyond cartilaginous (bronchial) plate into adjacent lung parenchyma
- May share some histopathological features with mucous gland adenomas
- Presence of glandular proliferation of different sizes is more in favor of mucus gland adenoma

Adenocarcinoma

- Nuclear pleomorphism, mitotic activity are features of adenocarcinoma
  - In bronchial adenomas, abnormal dilatation of normal endobronchial glands
  - Glandular proliferation is of different-sized glands
  - Mixture of seromucinous and dilated glandular structures is more in keeping with adenoma

Adenosquamous Carcinoma

- Unequivocal areas of adenocarcinoma must be present
- Unequivocal areas of squamous cell carcinoma must be present
- Lack of nuclear atypia &/or mitotic activity

Pleomorphic Adenoma (Mixed Tumor)

- Mixed tumor usually will show combination of other elements
  - Cartilage
  - Plasmacytoid cellular proliferation
  - Chondromyxoid matrix

Hyalinizing Clear Cell Carcinoma

- Hyalinizing clear cell carcinoma (HCCC) shows extensive areas of hyalinization
- Predominant feature in HCCC is presence of sheets of clear cells
- HCCC lack presence of mucous glands

Immunohistochemistry

Antibody	Reactivity	Staining Pattern	Comment
CK-PAN	Positive	Cytoplasmic	Diffuse
CK-LMW-NOS	Positive	Cytoplasmic	
EMA/MUC1	Positive	Cell membrane	Diffuse
CEA-M	Positive	Cytoplasmic	Diffuse
TTF-1	Positive	Nuclear	
NAPSIN-A	Positive	Cytoplasmic	In focal areas
p63	Positive	Nuclear	In squamous component
p40	Positive	Nuclear	In squamous component
CK5/6	Positive	Cytoplasmic	In squamous component
CK7	Positive	Cytoplasmic	
CDX-2	Negative		
CK20	Negative		
CD117	Negative		
DOG1	Negative		
Ki-67	Negative		

Histochemical Features of Mucous Gland Adenoma

Stain	Result	Location
Mucicarmine	Positive	In columnar cells
D-PAS	Positive	In columnar cells
PAS	Positive	In acinar cells

Molecular Features

FISH	Result
&5 7 & /0$/ translocation	Negative

Epithelial-Myoepithelial Carcinoma

- Epithelial-myoepithelial carcinoma (EMC) characteristically will show presence of 2 layers of cells, epithelial and myoepithelial
- EMC lacks presence of mucous glands
- EMC may show presence of sheets of clear cells

DIAGNOSTIC CHECKLIST

Clinically Relevant Pathologic Features

- Chest films should show well-demarcated centrally located tumor with no invasion into adjacent lung parenchyma
- Gross appearance

Pathologic Interpretation Pearls

- Tumor confined between bronchial epithelium and bronchial cartilage
- Proliferation of mucous glands
- Lack of mitotic activity
- May show combination of solid and cystic areas

SELECTED REFERENCES

1. Cho J et al: 18F-FDG PET/CT of bronchial mucous gland adenoma. Clin Nucl Med. 41(2):e118-9, 2016
2. Falk N et al: Primary pulmonary salivary gland-type tumors: a review and update. Adv Anat Pathol. 23(1):13-23, 2016
3. Fishbein GA et al: Primary salivary duct carcinoma of the lung, mucin-rich variant. Hum Pathol. 47(1):150-6, 2016
4. Huo Z et al: Primary pulmonary mucoepidermoid carcinoma: histopathological and molecular genetic studies of 26 cases. PLoS One. 10(11):e0143169, 2015
5. Karpathiou G et al: Pulmonary mucus gland adenomas: are they always of endobronchial localization? Case Rep Pathol. 2013:239173, 2013
6. Zhu F et al: Primary salivary gland-type lung cancer: clinicopathological analysis of 88 cases from China. J Thorac Oncol. 8(12):1578-84, 2013
7. Couraud S et al: Bronchial mucous gland adenoma revealed following acute pneumonia. Interact Cardiovasc Thorac Surg. 14(3):347-9, 2012
8. Milenković B et al: Mucous gland adenoma simulating bronchial asthma: case report and literature review. J Asthma. 44(9):789-93, 2007
9. Méjean-Lebreton F et al: [Benign salivary gland-type tumors of the bronchus: expression of high molecular weight cytokeratins.] Ann Pathol. 26(1):30-4, 2006
10. Morini F et al: Bronchial adenoma: an unusual cause of recurrent pneumonia in childhood. Ann Thorac Surg. 76(6):2085-7, 2003
11. Kwon JW et al: Mucous gland adenoma of the bronchus: CT findings in two patients. J Comput Assist Tomogr. 23(5):758-60, 1999
12. England DM et al: Truly benign "bronchial adenoma". Report of 10 cases of mucous gland adenoma with immunohistochemical and ultrastructural findings. Am J Surg Pathol. 19(8):887-99, 1995
13. Dickstein PJ et al: Bronchial mucous gland adenoma presenting as bronchogenic cyst. Pediatr Pulmonol. 16(6):370-4, 1993
14. Pass HI: Bronchial adenoma. Ann Thorac Surg. 52(5):1201-3, 1991

Tumor Does Not Extend Beyond Cartilage

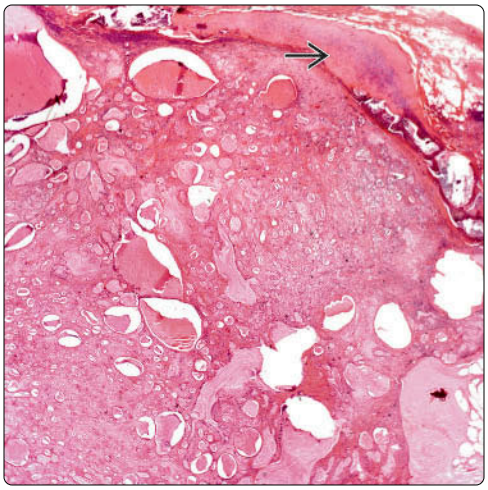

Proliferation of Endobronchial Glands

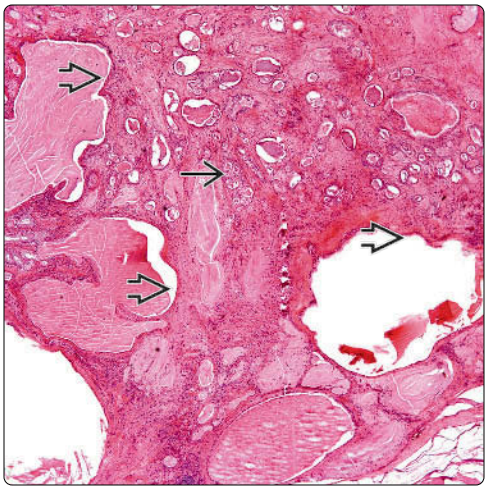

(Left) *Mucous gland adenoma shows a characteristic cystic growth pattern admixed with more solid areas. Note that the tumor does not penetrate beyond the cartilaginous (bronchial) plate.* **(Right)** *Mucous gland adenoma is shown with cystically dilated glands. The tumor also displays areas of solid proliferation adjacent to the dilated glands. All these changes represent enlargement of normal bronchial structures.*

Small Cysts

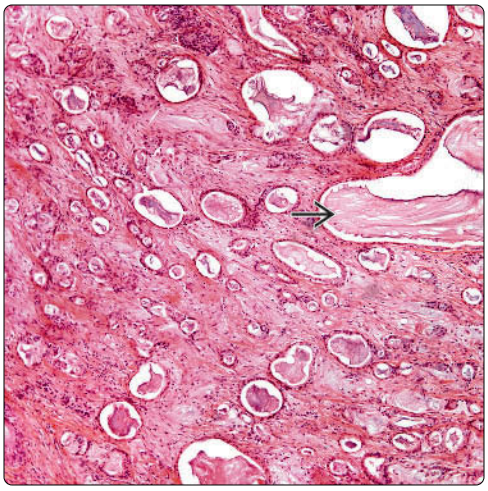

Flattened Epithelium

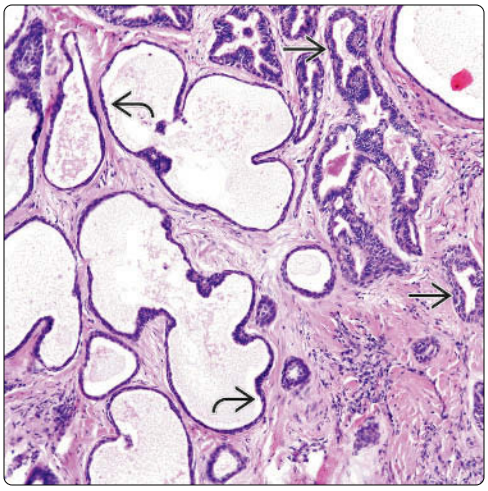

(Left) *Mucous gland adenoma is shown with small cystically dilated glands lined by squamous epithelium. More dilated glands are also present. This low-power view may also be seen in cases of low-grade bronchial mucoepidermoid carcinoma.* **(Right)** *Mucous gland adenoma shows a range of dilated glandular structures. Some glands are dilated with flattened epithelium, whereas other glands are compressed and appear to be within normal limits.*

Cellular Stroma

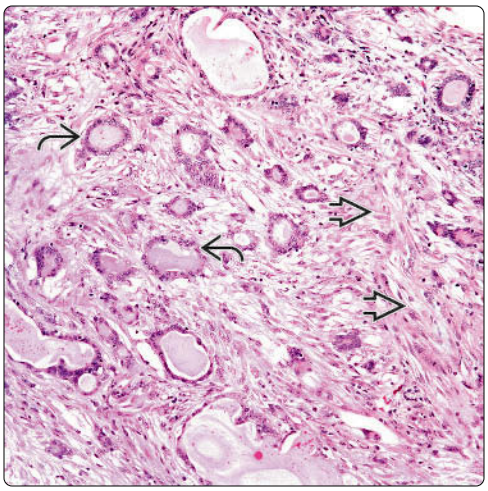

Prominent Cystic Structures

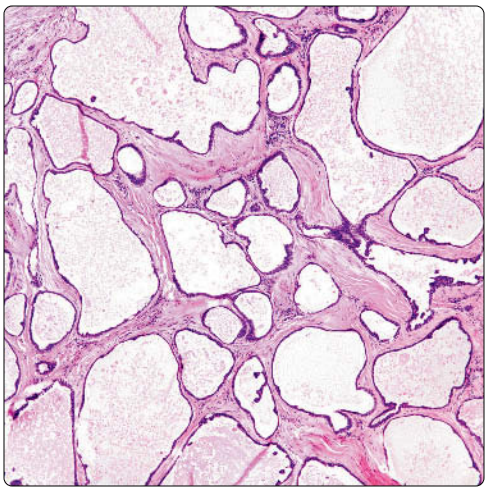

(Left) *Low-power view of a mucous gland adenoma shows a proliferation of glandular structures embedded in a spindle cell stroma. This particular pattern may also be seen in salivary gland-type tumors of the lung.* **(Right)** *Mucous gland adenoma is shown with dilated glands lined by flattened epithelium. Inside the glands, there is mucous secretion. The glands are separated by bands of collagenous tissue.*

Proliferation of Mucous Glands

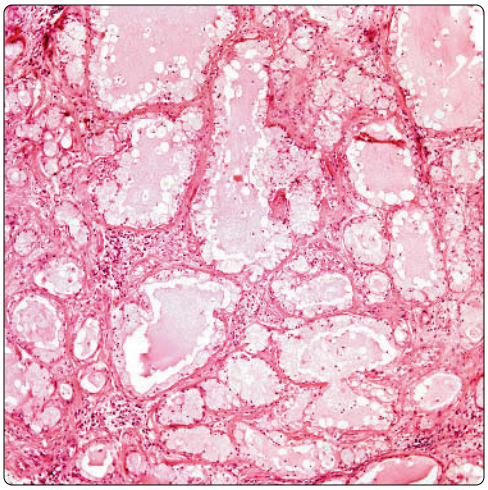

Seromucinous Component

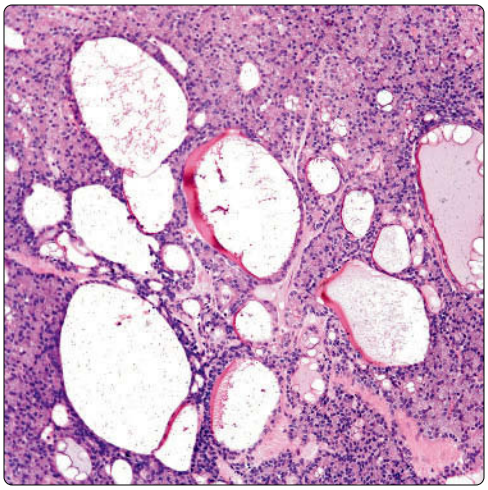

(Left) *Mucous gland adenoma shows dilated glands containing mucoid material in their lumina and lined by mucinous epithelium. This pattern may be confused with mucinous adenocarcinoma.* **(Right)** *Mucous gland adenoma shows dilated glands admixed with solid glandular proliferation. The solid glandular component represents an exuberant proliferation of serous endobronchial glands. No mitotic activity or nuclear atypia is present.*

Hyperplastic Mucinous Epithelium

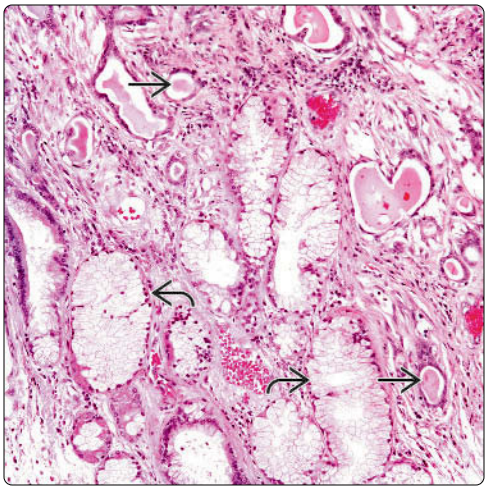

Prominent Mucous Gland Component

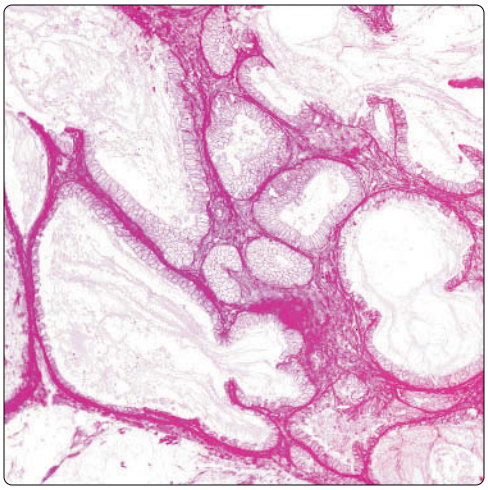

(Left) *Mucous gland adenoma shows dilated hyperplastic mucous glands adjacent to small glands. One of the characteristics of mucous gland adenoma is the presence of different-sized glandular structures.* **(Right)** *High-power view shows mucinous glandular proliferation in a mucous gland adenoma. Note the different sizes, absence of nuclear atypia, and mitotic activity. Similar features may be seen in mucinous adenocarcinomas.*

Dilated Mucinous Glands

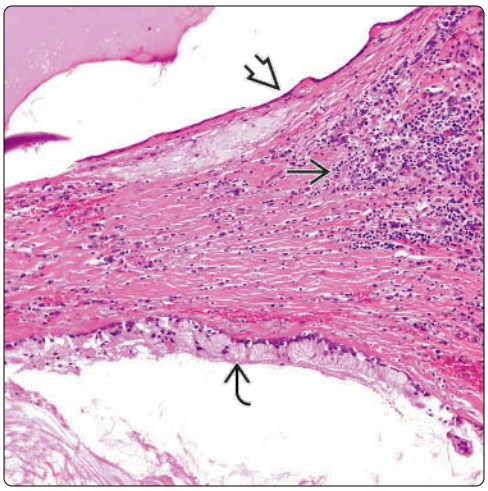

Small Glandular Proliferation

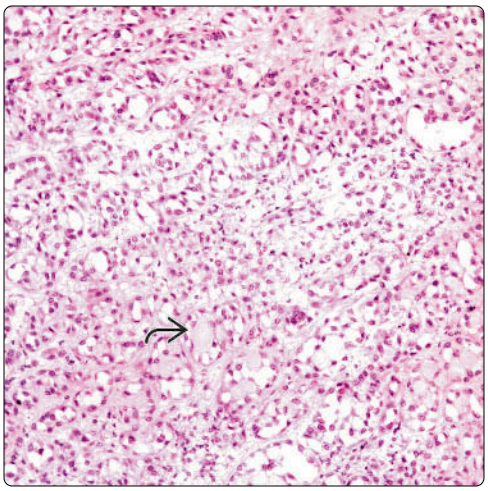

(Left) *Some mucous gland adenomas may show an extensive inflammatory reaction. Two types of glands are seen: 1 lined by flattened epithelium and the other by mucinous epithelium, separated by fibroconnective tissue with an inflammatory reaction.* **(Right)** *Mucous gland adenoma shows a solid growth pattern. This feature is unusual; however, one can still see the outline of some small glands that have coalesced to form this solid pattern.*

Centrally Located Tumor

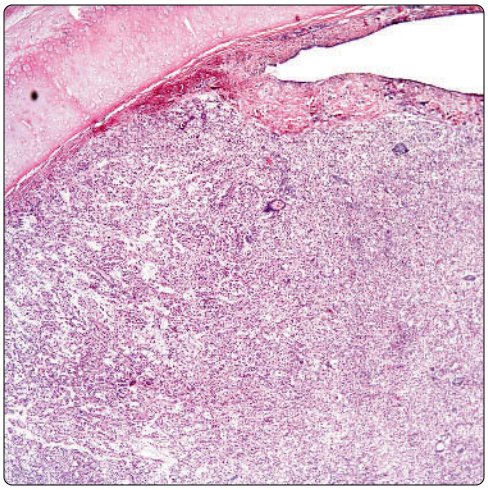

Small Glandular Component

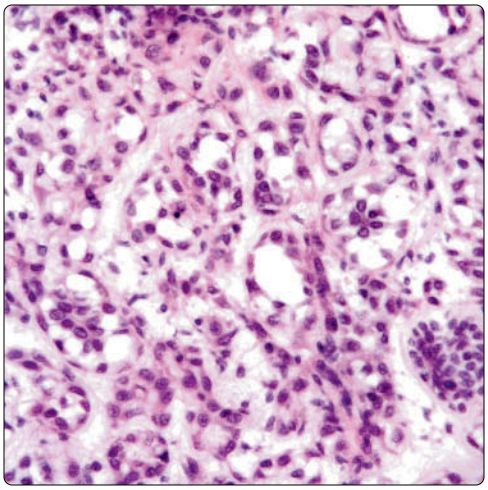

(Left) *Mucous gland adenoma shows a tumor that is limited between the bronchial epithelium and the cartilaginous plate. The tumor shows a solid component.* **(Right)** *Higher magnification of the "solid" component of a mucous gland adenoma shows a proliferation of small glands, some of them showing easily identifiable mucinous epithelium.*

Mucinous Glands

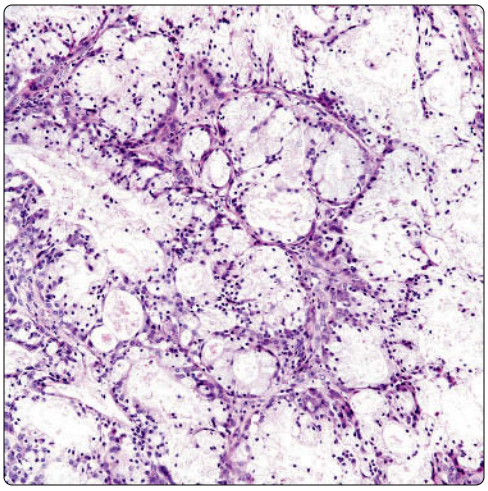

Prominent Inflammatory Reaction

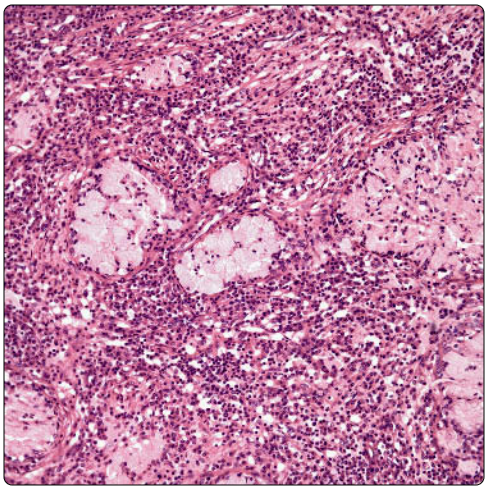

(Left) *Mucous gland adenoma is shown composed of prominent mucinous glands separated by thin fibrous strands and an inflammatory component.* **(Right)** *Mucous gland adenoma shows mucinous glands embedded in a prominent inflammatory background, predominantly composed of plasma cells.*

Glandular Proliferation

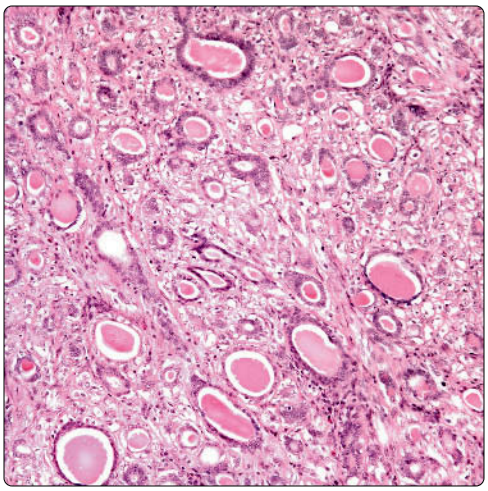

Flattened Epithelium

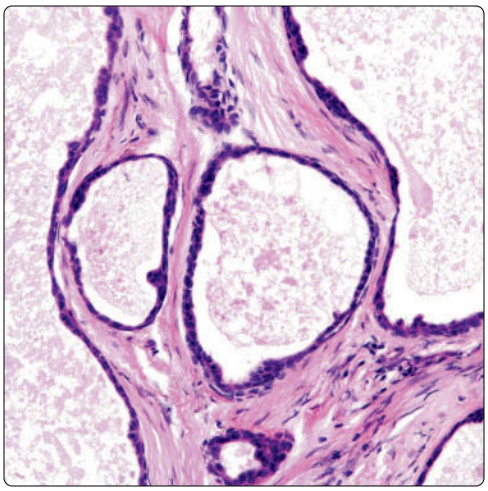

(Left) *The glandular proliferation in a mucous gland adenoma may show a more solid appearance with small glands lined by 1 layer of epithelial cells. Some of the glands contain an acellular material in the lumen.* **(Right)** *In other areas, the cystic changes may be more prominent and lined by a flattened epithelium and separated by a fibrous stromal tissue. Some of these structures still have an acellular material in their lumina.*

Endobronchial Lipoma

KEY FACTS

TERMINOLOGY

- Synonym: Lipomatous hamartoma
- Definition: Benign mesenchymal neoplasm composed exclusively of mature adipose tissue

CLINICAL ISSUES

- Cough
- Shortness of breath
- Obstructive pneumonia
- Lipomas are more commonly seen as bronchial tumors

MACROSCOPIC

- Well circumscribed
- Soft and yellowish
- Polypoid tumor obstructing bronchial lumen
- Variable size: 1-5 cm in diameter

MICROSCOPIC

- Mature adipose tissue
- Spindle cells
- Myxoid changes
- Absence of atypia or mitotic figures

TOP DIFFERENTIAL DIAGNOSES

- Hamartoma
  - Usually has presence of cartilage
  - Usually has invaginations of respiratory epithelium
- Mixed tumor (pleomorphic adenoma)
  - Usually has epithelial component
  - May also have chondromyxoid areas
- Angiomyolipoma
  - Commonly associated with tuberous sclerosis
  - Shows presence of vessels and smooth muscle proliferation
  - Immunohistochemical studies using HMB-45 and actin-sm will be useful

Macroscopic Features

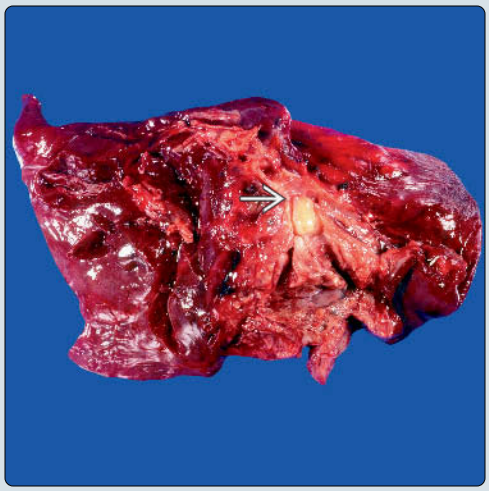

Endobronchial Tumor

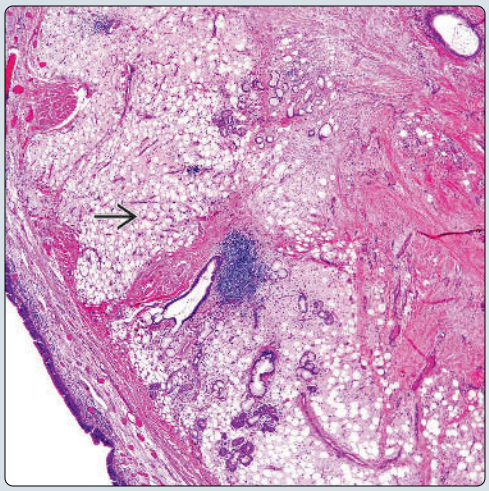

(Left) *Gross photograph shows an endobronchial lipoma ⇨. Note the presence of a yellow tumor mass obstructing the main pulmonary airway.* **(Right)** *Hematoxylin & eosin low-power view shows an endobronchial lipoma. Note the presence of extensive areas of mature adipose tissue ⇨.*

Adipose and Collagenous Tissue

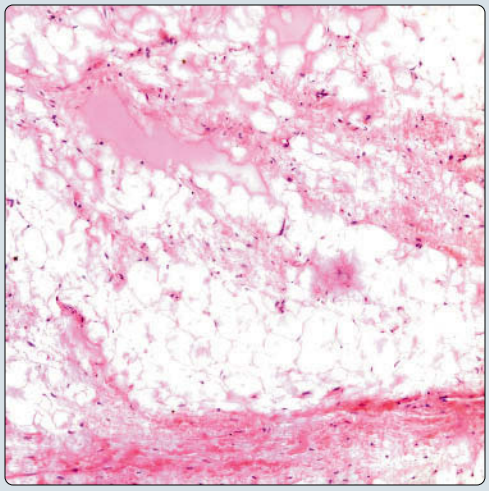

Mature Adipose Tissue

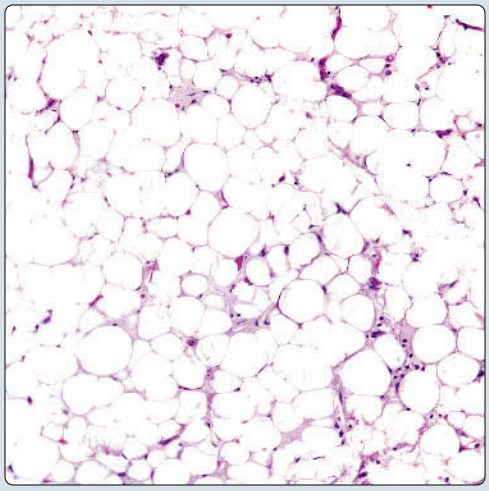

(Left) *Closer view at an endobronchial lipoma shows collagen deposition and mature adipose tissue. No cellular atypia or mitotic figures are present.* **(Right)** *Endobronchial lipoma shows mature adipose tissue without any atypical features. However, tumors with some atypia have also been described. The majority of cases show mature adipose tissue.*

TERMINOLOGY

Synonyms

- Lipomatous hamartoma, fibrolipoma

Definitions

- Benign mesenchymal neoplasm composed exclusively of mature adipose tissue

ETIOLOGY/PATHOGENESIS

Etiology

- These tumors are of unknown etiology
- Bronchial lipomas have been associated with obesity

CLINICAL ISSUES

Epidemiology

- Incidence
  - Bronchial lipomas are unusual tumors
- Age
  - Lipomas are more common in adults
- Sex
  - No sex predilection has been observed

Site

- Endobronchial location

Presentation

- Cough
- Shortness of breath
- Dyspnea
- Hemoptysis
- Obstructive pneumonia
- Asymptomatic

Treatment

- Surgical approaches
  - Lobectomy

Prognosis

- Excellent

MACROSCOPIC

General Features

- Well circumscribed
- Soft
- Yellowish
- Polypoid tumor obstructing bronchial lumen

Size

- Variable size between 1-5 cm in diameter

MICROSCOPIC

Histologic Features

- Mature adipose tissue
- Spindle cells
- Myxoid changes
- Absence of atypia or mitotic figures

Predominant Pattern/Injury Type

- Uniform

Predominant Cell/Compartment Type

- Adipose

DIFFERENTIAL DIAGNOSIS

Hamartoma

- Usually has presence of cartilage
- Usually has invaginations of respiratory epithelium

Mixed Tumor (Pleomorphic Adenoma)

- Usually has epithelial component
- May also have chondromyxoid areas
- Extensive areas of adipose tissue are not common in mixed tumors

Metastatic Liposarcoma

- Liposarcomas more commonly metastasize to lung parenchyma and not to endobronchial areas
- History of liposarcoma will aid in diagnosis
- Displays more cellular atypia

Angiomyolipoma

- Most angiomyolipomas in lung are not in endobronchial location
- Commonly associated with tuberous sclerosis
- Shows presence of vessels and smooth muscle proliferation
- Immunohistochemical studies using HMB-45 and actin-sm will be useful

DIAGNOSTIC CHECKLIST

Clinically Relevant Pathologic Features

- Gross appearance

Pathologic Interpretation Pearls

- Mature adipose tissue
- Lack of atypical features
- Absence of cartilaginous component

SELECTED REFERENCES

1. Nussbaumer-Ochsner Y et al: Endobronchial lipoma mimicking bronchial carcinoid tumour. Thorax. 70(8):809, 2015
2. Sarioglu N et al: An unexpected cause of hemoptysis: endobronchial lipomatous hamartoma. Med Arch. 68(1):65-6, 2014
3. Boland JM et al: Endobronchial lipomatous tumors: clinicopathologic analysis of 12 cases with molecular cytogenetic evidence supporting classification as "lipoma". Am J Surg Pathol. 37(11):1715-21, 2013
4. Oury Bah M et al: [Endobronchial lipoma: imaging findings. A case report.] Rev Pneumol Clin. 65(1):36-9, 2009
5. Pollefliet C et al: Endobronchial lipomas: rare benign lung tumors, two case reports. J Thorac Oncol. 4(5):658-60, 2009
6. Filosso PL et al: Hemoptysis caused by an endobronchial lipoma. J Thorac Cardiovasc Surg. 135(4):954-5, 2008
7. Basoglu A et al: Endobronchial lipoma: a rare cause of bronchial occlusion. Interact Cardiovasc Thorac Surg. 3(2):263-4, 2004
8. Muraoka M et al: Endobronchial lipoma: review of 64 cases reported in Japan. Chest. 123(1):293-6, 2003
9. De Abajo C et al: [Endobronchial lipomas. Apropos of 4 cases.] Rev Pneumol Clin. 52(6):373-7, 1996
10. Moran CA et al: Endobronchial lipomas: a clinicopathologic study of four cases. Mod Pathol. 7(2):212-4, 1994
11. Peng RL et al: Endobronchial lipoma associated with lipomatosis. AJR Am J Roentgenol. 158(1):210-1, 1992
12. Nataf P et al: [Endobronchial lipomas. Apropos of 16 cases.] Rev Pneumol Clin. 45(5):203-5, 1989
13. Schraufnagel DE et al: Endobronchial lipoma. Chest. 75(1):97-9, 1979

Preservation of Endobronchial Glands

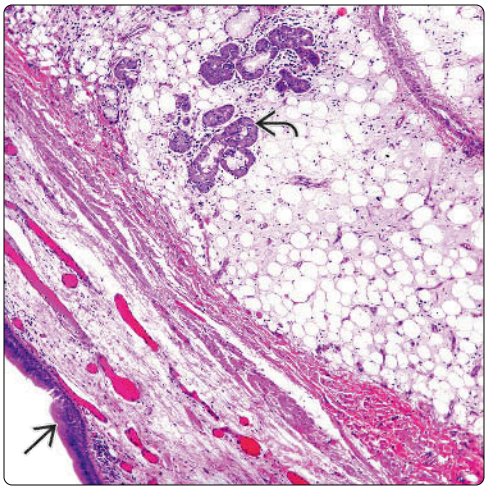

Inflammatory Changes

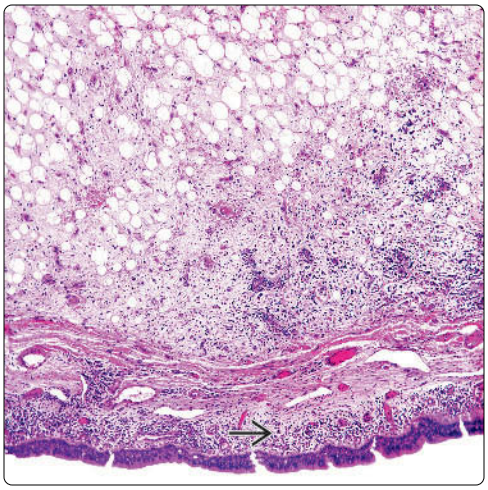

(Left) *Endobronchial lipoma shows mature adipose tissue and entrapped endobronchial glands. Note that the respiratory epithelium is within normal limits, and normal endobronchial glands are present.* **(Right)** *Endobronchial lipoma shows inflammatory changes underneath the respiratory epithelium. Essentially, there appears to be a cambium-like layer between normal structures and the tumor.*

Endobronchial Glands

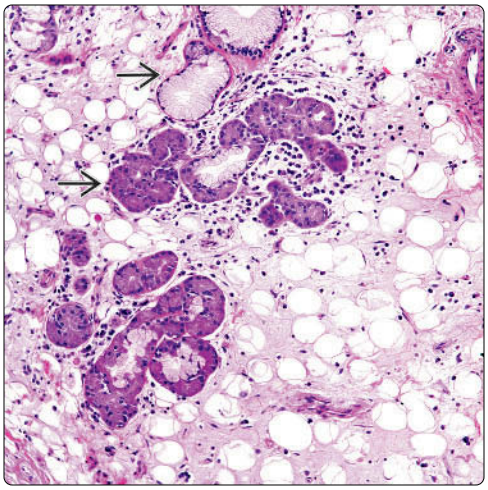

Inflammatory Reaction

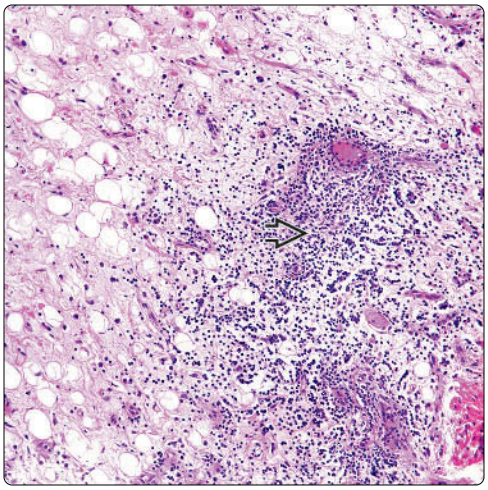

(Left) *High-power view shows an endobronchial lipoma with entrapped endobronchial glands. Some glands are serous and others are mucinous; however, the tumor does not involve or destroy normal endobronchial structures.* **(Right)** *Endobronchial lipoma shows areas of chronic inflammation admixed with the adipose tissue. Inflammatory changes in endobronchial lipomas are usually focal and not prominent.*

Areas of Hemorrhage

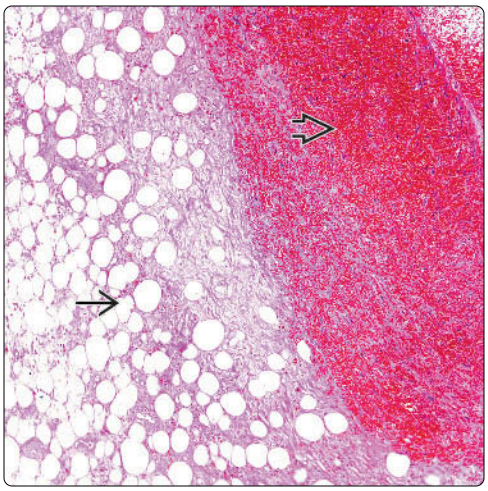

Myxoid Changes

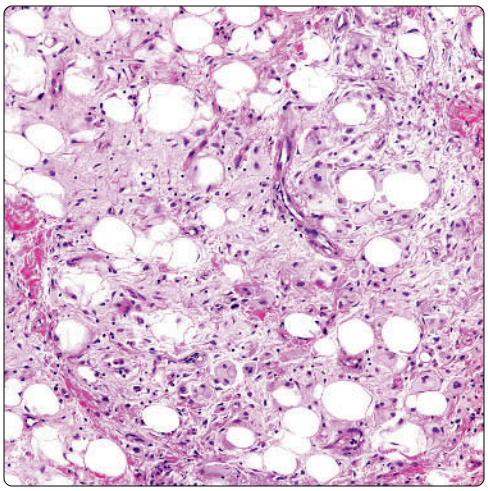

(Left) *Areas of hemorrhage, although unusual, can be seen in some cases of endobronchial lipomas. In this case, there is an extensive area of hemorrhage adjacent to more conventional lipomatous areas.* **(Right)** *Endobronchial lipoma shows adipose tissue with more myxoid changes and mild inflammation. The presence of myxoid changes should not be interpreted as atypical changes. Myxoid changes are invariably seen in these cases, at least focally.*

Ectatic Vessels

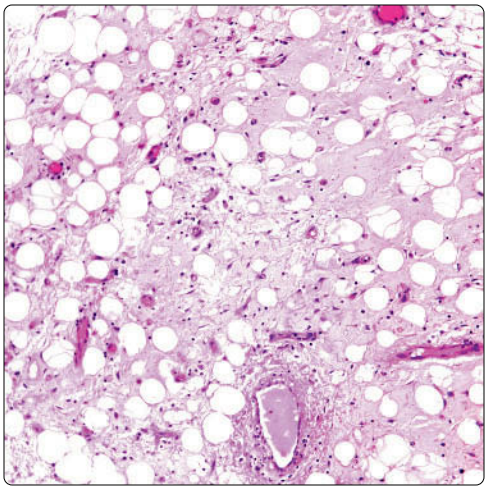

Myxoid Change

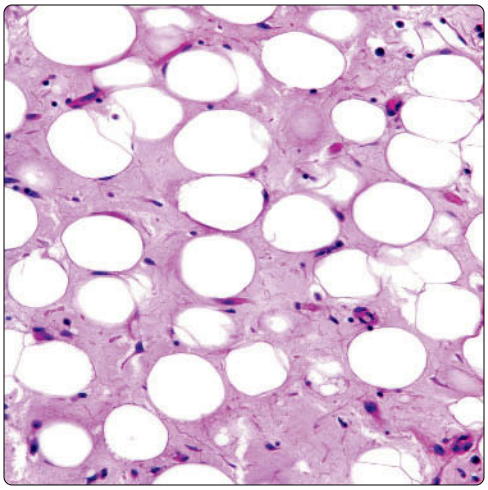

(Left) *Prominent myxoid changes and vascular proliferation are shown in an endobronchial lipoma. In this high-power view, the tumor does not display any cytological atypia.* **(Right)** *Higher power view shows an endobronchial lipoma with prominent myxoid changes. Pure myxoid endobronchial lipomas are rare; the majority of cases will display the presence of mature adipose tissue like that seen in lipomas of soft tissues.*

Fibrocollagenous Tissue

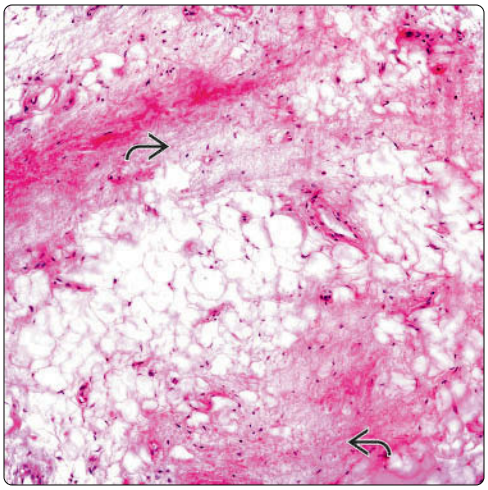

Mucinophages

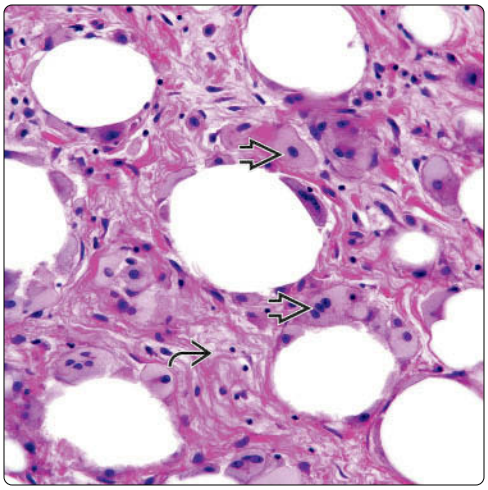

(Left) *In some cases of endobronchial lipoma, the fibrous component ⇨ may be more prominent. This feature has been used in the past as the basis for the term fibrolipoma.* **(Right)** *In some other cases, the lipomatous component is associated not only with the fibrous component ⇨ but also with numerous mucinophages ⇨.*

Atrophic Glands

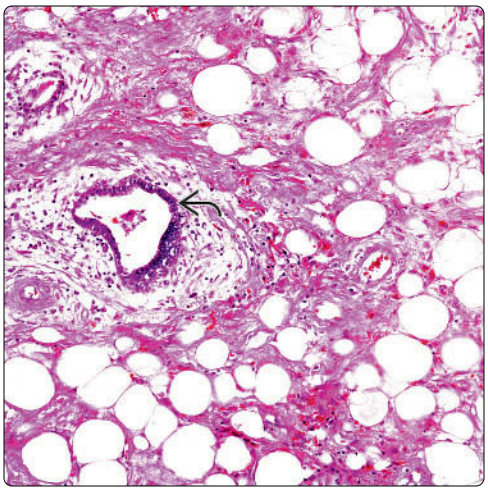

Spindle Cells

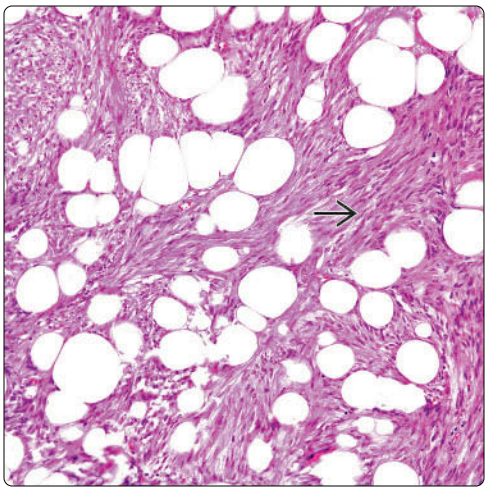

(Left) *Endobronchial fibrolipoma shows a focal area with a residual atrophic endobronchial gland ⇨. The adjacent areas show more conventional features of fibrolipoma.* **(Right)** *In some cases of endobronchial lipomas, the tumor may also show areas of spindle cellular proliferation ⇨ similar to that described in spindle cell lipomas of soft tissues.*

Pulmonary Adenofibroma/Adenomyoma

KEY FACTS

TERMINOLOGY

- Pulmonary fibroadenoma, adenofibromatous hamartoma, adenomyomatous hamartoma, fibroleiomyomatous hamartoma
- Benign, hamartomatous, intrapulmonary fibroblastic or myofibroblastic proliferation that entraps glands in its growth

CLINICAL ISSUES

- Intraparenchymatous, well-circumscribed nodule
- Solitary coin lesion
- Incidental finding on routine chest x-rays

MACROSCOPIC

- Well circumscribed but unencapsulated
- Usually small (1-2 cm in greatest diameter)

MICROSCOPIC

- Low-power view characterized by club-shaped papillary structures lined by layer of simple cuboidal epithelium
- Club-shaped papillae resemble papillary structures similar to those of müllerian adenofibromas of female genital tract
- Papillary structures contain spindle cells in stroma with bland cytologic appearance devoid of mitoses or nuclear pleomorphism
- Epithelium lining gland-like spaces and papillae is bland and devoid of cytologic atypia
- Spindle cell stromal component is made up of bland spindle cells with no mitotic activity or nuclear pleomorphism

ANCILLARY TESTS

- Epithelial cells lining papillae stain positive for cytokeratins and EMA
- Spindle cells stain positive for vimentin or may be positive for vimentin and SMA
- Spindle cells are negative for CD34 and Bcl-2
- Epithelial cells lining papillae show nuclear positivity for TTF-1

Pulmonary Adenofibroma

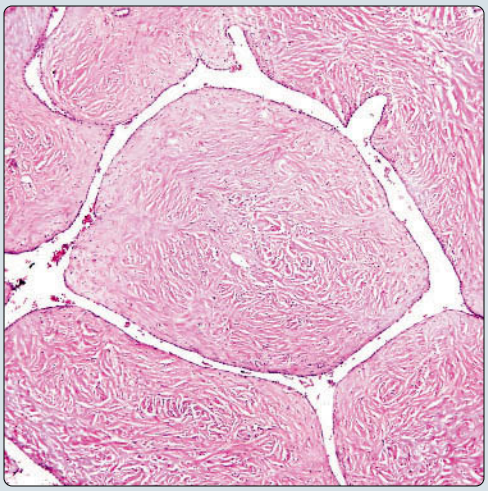

Club-Like Papilla

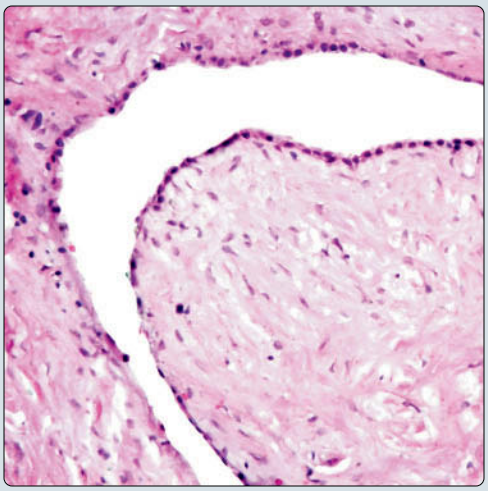

(Left) *Scanning magnification of pulmonary adenofibroma shows club-like papillae lined by a single layer of simple, cuboidal epithelium. The cores of the papillae contain a bland spindle cell population.* **(Right)** *High magnification of club-like papilla in pulmonary adenofibroma shows a single layer of cuboidal epithelial cells in the periphery and a bland spindle cell population in the cores embedded in collagenous stroma.*

Higher Magnification

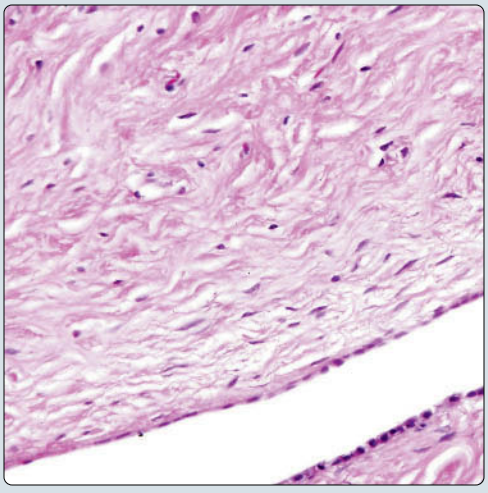

Vimentin Immunostaining

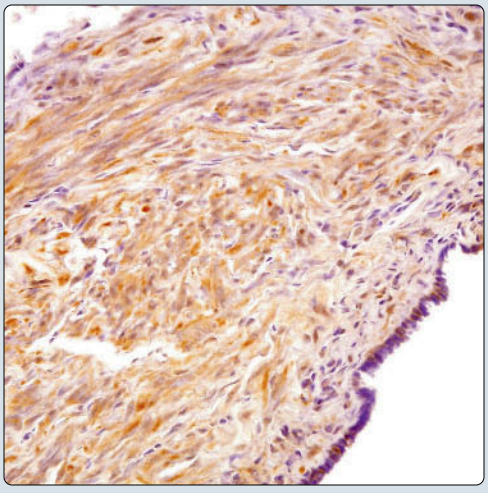

(Left) *Higher magnification of the papillary structures in pulmonary adenofibroma shows a sparse, bland-appearing population of fibroblastic spindle cells devoid of cytologic atypia.* **(Right)** *Most cases of pulmonary adenofibroma are vimentin-only tumors. The spindle cells in the stroma usually react only with vimentin antibodies and are negative for the majority of other markers, in particular SMA, CD34, and S100 protein.*

TERMINOLOGY

Synonyms

- Pulmonary fibroadenoma, adenofibromatous hamartoma, adenomyomatous hamartoma, fibroleiomyomatous hamartoma

Definitions

- Benign, hamartomatous, intrapulmonary fibroblastic or myofibroblastic proliferation that entraps glands in its growth

ETIOLOGY/PATHOGENESIS

Developmental Anomaly

- Hamartomatous origin most commonly postulated

Pathogenesis

- May also represent benign neoplastic stromal proliferation that entraps normal respiratory structures in its growth

CLINICAL ISSUES

Site

- Intraparenchymatous, well-circumscribed nodule

Presentation

- Solitary coin lesion
- Incidental finding on routine chest x-rays

Prognosis

- Benign tumor, cured by simple surgical excision

IMAGING

CT Findings

- Well-circumscribed small intraparenchymatous lesion

MACROSCOPIC

General Features

- Well-circumscribed but unencapsulated firm, rubbery tissue
- Homogeneous, tan-pink cut surface

Size

- Usually small (1-2 cm in greatest diameter)

MICROSCOPIC

Histologic Features

- Low-power view characterized by club-shaped papillary structures lined by layer of simple cuboidal epithelium
- Club-shaped papillae resemble papillary structures similar to those of müllerian adenofibromas of female genital tract
- Papillary structures contain spindle cells in stroma with bland, cytologic appearance devoid of mitoses or nuclear pleomorphism
- Lining of papillary structures can also be composed of tall columnar epithelium
- Occasional gland-like spaces can be seen scattered within lesion

Cytologic Features

- Epithelium lining gland-like spaces and papillae is bland and devoid of cytologic atypia
- Spindle cell stromal component is made up of bland spindle cells with no mitotic activity or nuclear pleomorphism
- Spindle stromal cells may show fascicular pattern of growth with areas of stromal hyalinization or myxoid change

ANCILLARY TESTS

Immunohistochemistry

- Epithelial cells lining papillae stain positive for cytokeratins and EMA
- Spindle cells stain positive for vimentin or may be positive for vimentin, SMA, and desmin
- Spindle cells are negative for S100, CD34, and Bcl-2

DIFFERENTIAL DIAGNOSIS

Cartilaginous Hamartoma

- Prominent mature cartilaginous component present
- Absence of significant spindle cell stromal component

Intrapulmonary Solitary Fibrous Tumor

- Intrapulmonary solitary fibrous tumor (SFT) may also contain entrapped gland-like spaces at periphery of lesion
- Formation of club-like papillary structures is not feature of SFT
- Tumor cells in SFT are positive for CD34 and Bcl-2

Biphasic Pulmonary Blastoma

- Glandular component displays more primitive appearance that resembles respiratory epithelium during weeks 8-10 of gestation
- Stromal spindle cell component is poorly differentiated and resembles sarcoma with high mitotic index
- May show areas of hemorrhage and necrosis

Pulmonary Carcinosarcoma

- Epithelial component in carcinosarcoma is frankly malignant (adenocarcinoma or squamous cell carcinoma)
- Stromal component in carcinosarcoma is frankly malignant with nuclear pleomorphism and high mitotic activity
- Stromal component may show smooth muscle, adipose, vascular, cartilaginous, osseous, or neural differentiation

Metastases of Sarcomas to Lung

- Metastatic sarcomas often entrap epithelial structures at their periphery, simulating adenofibroma
- Distribution of entrapped epithelial elements is at edges, not widespread and haphazard as in adenofibroma
- Spindle cell component in metastatic sarcoma is usually high grade and atypical
- Clinical history may be helpful by alerting pathologist to previous tumor at another location

SELECTED REFERENCES

1. Kumar R et al: Pulmonary adenofibroma: clinicopathological study of 3 cases of a rare benign lung lesion and review of the literature. Ann Diagn Pathol. 18(4):238-43, 2014
2. Suster S et al: Pulmonary adenofibroma: report of two cases of an unusual type of hamartomatous lesion of the lung. Histopathology. 23(6):547-51, 1993
3. Gorelkin L: Fibroleiomyomatous hamartoma: a rare benign pulmonary "coin lesion". South Med J. 71(1):88-9, 1978

Club-Like Papillae

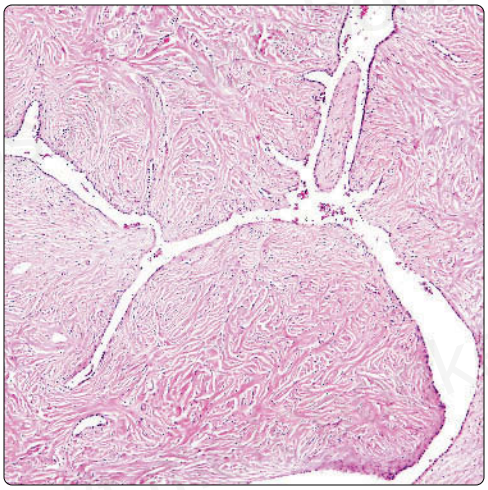

Club-Like Papilla: Higher Power

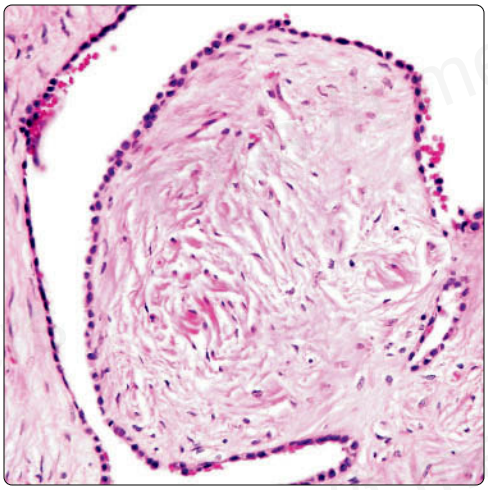

(Left) *Scanning magnification of pulmonary adenofibroma shows club-like papillae with sparse spindle cell population set against a collagenous stroma. The appearance is reminiscent of müllerian-derived adenofibromas of the ovaries.* **(Right)** *High magnification of pulmonary adenofibroma shows club-like papilla lined by a single layer of bland-appearing, cuboidal epithelial cells devoid of cytologic atypia. The central core of the papilla contains a sparse, bland-appearing spindle cell population.*

Entrapped Glandular Spaces

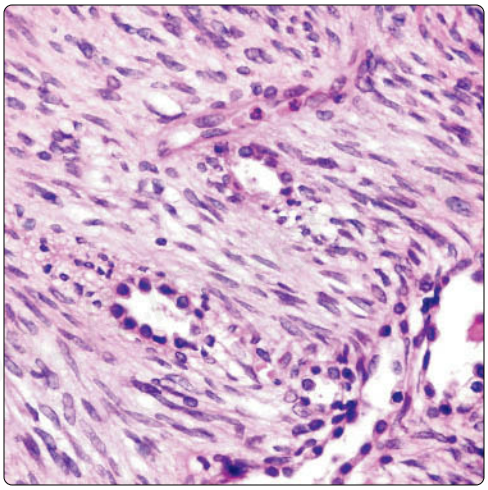

Stromal Hyalinization

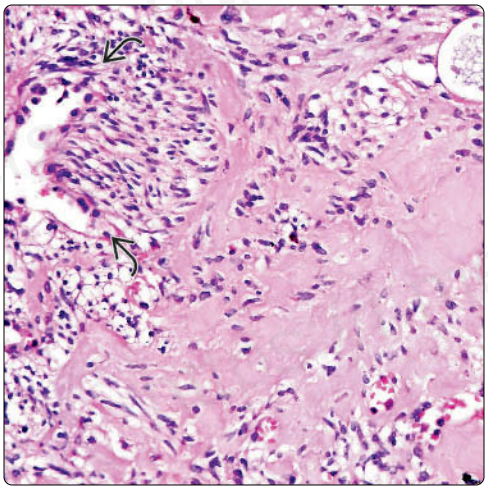

(Left) *Pulmonary adenofibroma shows small, entrapped, gland-like spaces embedded in the stroma deep within the tumor and surrounded by a bland-appearing fibroblastic spindle cell proliferation.* **(Right)** *High magnification of pulmonary adenofibroma shows a focal area of stromal hyalinization. Notice the branching glandular lumen ⇨ surrounded by a dense spindle cell population in the surrounding stroma. Cases like this can closely resemble solitary fibrous tumors of the lung.*

CK-PAN Immunostaining

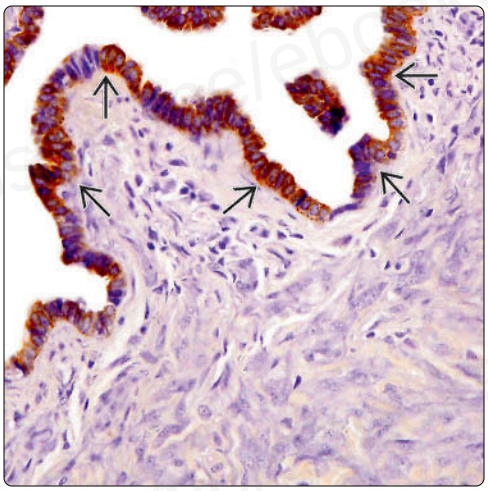

Vimentin Immunostaining

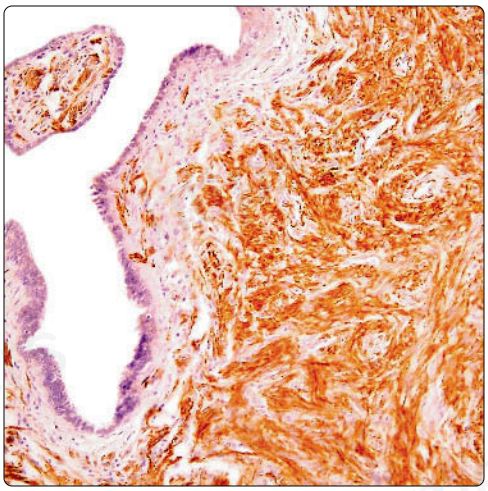

(Left) *CK-PAN in pulmonary adenofibroma decorates the tumor cells lining the abortive papilla ⇨. Notice the complete lack of reactivity of the bland spindle cells seen in the underlying stroma.* **(Right)** *Immunohistochemical staining for vimentin intermediate filaments in pulmonary adenofibroma shows strong positive staining of spindle cells in the stroma. Notice the negative staining of the epithelial cells lining the papillary structures.*

Papillary Architecture

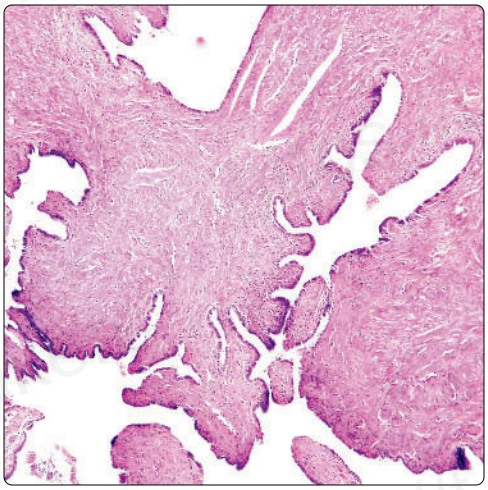

Short Club-Like Papillae

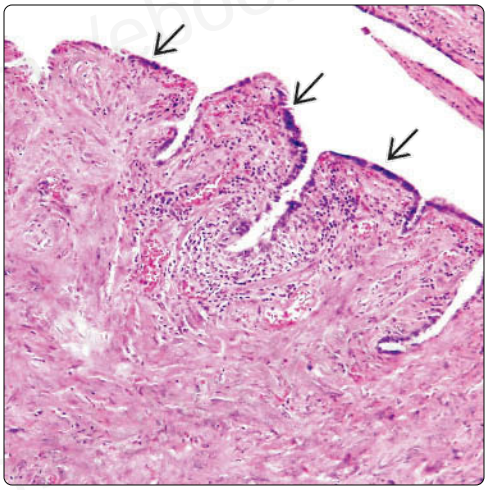

(Left) *Scanning magnification of pulmonary adenomyoma shows club-like papillary structures lined by a single layer of epithelial cells containing a cellular spindle stromal proliferation.* **(Right)** *High magnification of pulmonary adenomyoma shows small abortive papillae lined by a single layer of small, bland-appearing cuboidal epithelial cells ⇨. The underlying stroma contains a spindle cell proliferation characterized by spindle cells with oval nuclei and abundant eosinophilic cytoplasm.*

Pulmonary Adenomyoma

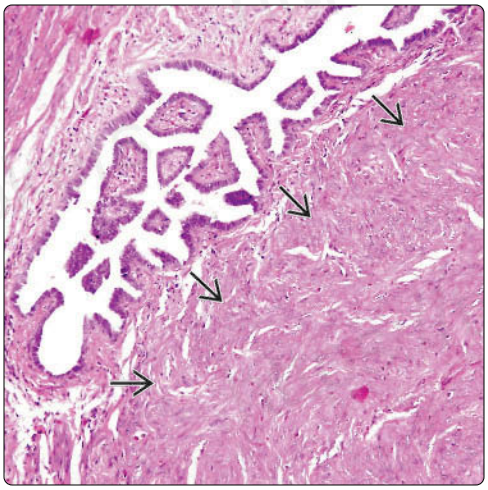

Dense Stromal Fibrosis

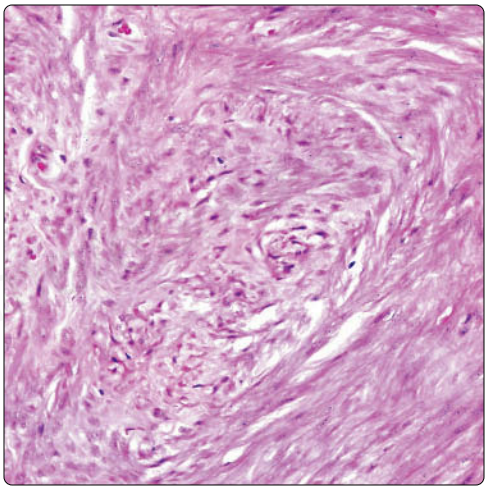

(Left) *Scanning magnification of pulmonary adenomyoma shows small, complex papillary projections into a lumen lined by a single layer of simple columnar epithelium. The stroma underneath this area shows a dense population of bland-appearing spindle cells with abundant eosinophilic cytoplasm ⇨.* **(Right)** *High magnification of stromal component in pulmonary adenomyoma shows fascicles of bland-appearing spindle cells with abundant eosinophilic cytoplasm devoid of mitotic activity.*

SMA Immunostaining

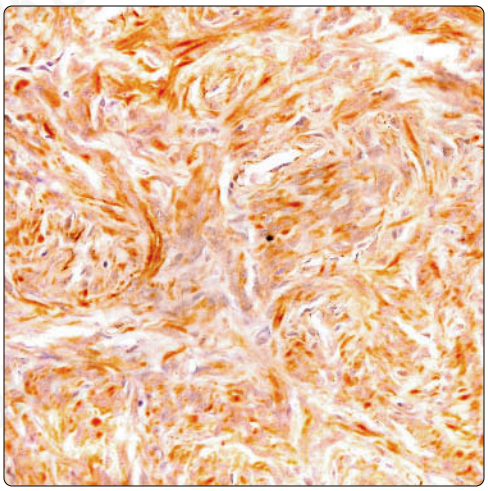

Desmin Immunostaining

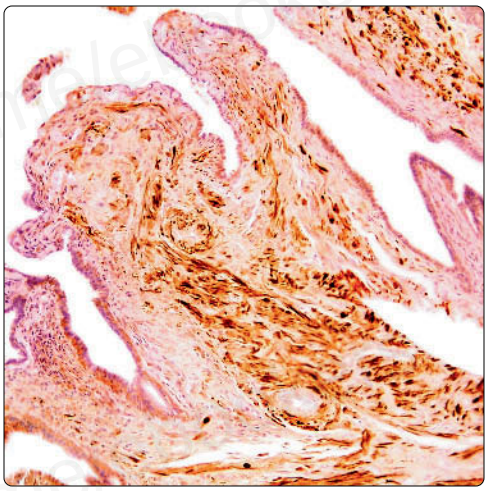

(Left) *Immunohistochemical staining of the stromal component of pulmonary adenomyoma for SMA shows diffuse positivity in the spindle cells.* **(Right)** *Immunohistochemical staining of pulmonary adenomyoma shows strong positivity of spindle cells in the stroma for desmin intermediate filaments. Notice the absence of immunohistochemical reactivity for this antibody in the thin layer of tall columnar epithelial cells lining the papillae.*

Intrapulmonary Solitary Fibrous Tumor

KEY FACTS

CLINICAL ISSUES

- Cough, chest pain, dyspnea, and clubbing of fingers
- Majority of tumors (90%) are benign and cured by complete excision
- ~ 10% behave aggressively [malignant solitary fibrous tumor (SFT)] and can lead to death of patient

MACROSCOPIC

- Generally well-circumscribed but unencapsulated intraparenchymatous masses
- Rubbery, whorled, tan-white cut surface

MICROSCOPIC

- Variation of growth patterns, including fascicular, storiform, hemangiopericytic, herringbone, wavy neural, and angiofibromatous
- Frequent admixture of cellular areas with hypocellular areas of stromal sclerosis
- Rope-like, linear pattern of stromal sclerosis is highly characteristic
- Tumors may often entrap benign bronchial structures and airspaces at lesion periphery, simulating biphasic neoplasm
- Marked increase in cellularity and nuclear pleomorphism in cases undergoing malignant transformation
- Increased mitotic activity (> 3 per 10 HPF) in malignant cases

ANCILLARY TESTS

- Spindle cells are positive for CD34, Bcl-2, CD99, and vimentin
- Negative for cytokeratins, EMA, S100 protein, muscle markers, and melanoma-associated markers
- Immunostaining for STAT6 is currently preferred method for establishing diagnosis, which recognizes 1$% -67$7 gene fusion that characterizes this tumor

Pulmonary Solitary Fibrous Tumor

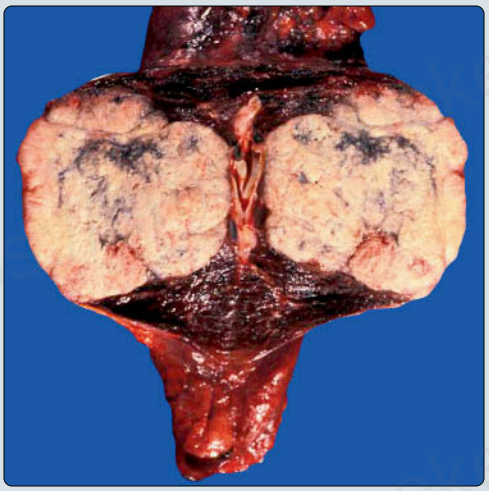

Rope-Like Pattern of Sclerosis

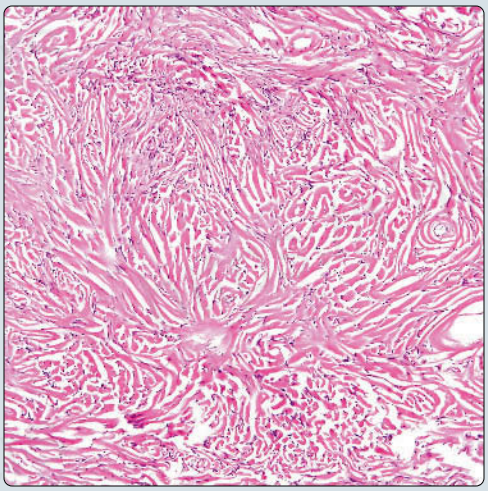

(Left) *Gross appearance of an intrapulmonary solitary fibrous tumor shows a large, fleshy, bosselated tumor mass located within lung parenchyma expanding the pleura.* **(Right)** *Characteristic histologic appearance of an intrapulmonary solitary fibrous tumor shows parallel arrays of rope-like collagen flanked by small, bland-appearing spindle cells.*

Spindle Cells: High Power

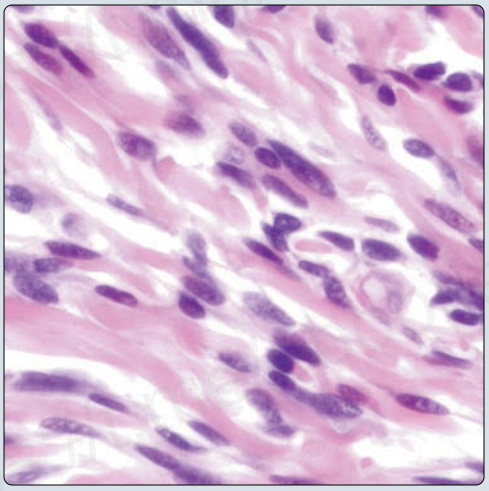

STAT6 Immunopositivity

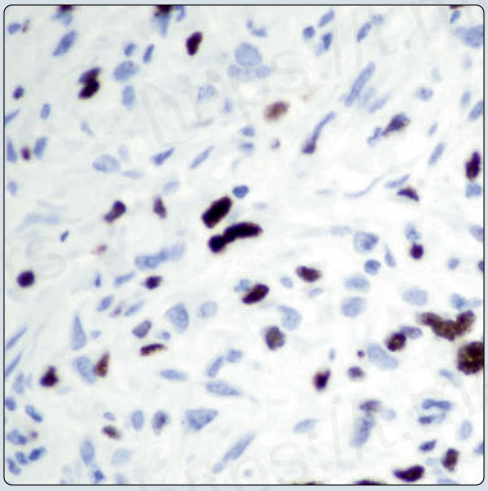

(Left) *Higher magnification in intrapulmonary solitary fibrous tumor shows a bland-appearing population of spindle cells with dense nuclear chromatin and absence of cytologic atypia.* **(Right)** *Immunohistochemical stain for STAT6 in intrapulmonary solitary fibrous tumor shows strong nuclear positivity in the spindle tumor cells.*

TERMINOLOGY

Abbreviations

- Solitary fibrous tumor (SFT)

Definitions

- Primary intrapulmonary neoplastic proliferation of dendritic fibroblasts

CLINICAL ISSUES

Presentation

- Cough, chest pain, dyspnea, and clubbing of fingers

Treatment

- Complete surgical excision (lobectomy) is favored approach

Prognosis

- Majority of tumors (90%) are benign and cured by complete excision
- ~ 10% behave aggressively (malignant SFT) and can lead to death of patient

MACROSCOPIC

General Features

- Generally well-circumscribed but unencapsulated intraparenchymatous masses
- Rubbery, whorled, tan-white cut surface

MICROSCOPIC

Histologic Features

- **Benign SFT**
  - Variegation of growth patterns, including fascicular, storiform, hemangiopericytic, herringbone, wavy neural, and angiofibromatous
  - Frequent admixture of cellular areas with hypocellular areas of stromal sclerosis
  - Rope-like linear pattern of stromal sclerosis is highly characteristic
  - Tumors may often entrap benign, bronchial structures and airspaces at lesion periphery, simulating biphasic neoplasm
- **Malignant SFT**
  - Poor circumscription and foci of infiltration of lung parenchyma and bronchial structures
  - Marked increase in cellularity and nuclear pleomorphism
  - Increased mitotic activity (> 3 per 10 HPF)
  - Presence of frequent atypical mitoses and multinucleated tumor cells
  - Foci of tumor cell necrosis and vascular invasion

Cytologic Features

- Composed of small spindle cells without cytologic atypia in majority of cases
- Spindle cells can show wavy nuclei simulating peripheral nerve sheath tumors
- Cases with prominent stromal sclerosis can show small, round hyperchromatic nuclei devoid of cytoplasmic rims
- Cases can be highly cellular with uniform cell population simulating growth pattern of synovial sarcoma
- Malignant cases show atypical cells with enlarged nuclei, prominent nucleoli, and increased mitotic activity
- Multinucleated cells of varying types may be observed in benign and malignant cases

ANCILLARY TESTS

Immunohistochemistry

- Spindle cells are positive for CD34, Bcl-2, CD99, and vimentin
- Negative for cytokeratins, EMA, S100 protein, muscle markers, and melanoma-associated markers
- Immunostaining for STAT6 is currently preferred method for establishing the diagnosis, which recognizes 1$%-67$7 gene fusion that characterizes this tumor

DIFFERENTIAL DIAGNOSIS

Synovial Sarcoma

- Spindle cells are atypical with variable mitotic activity and very uniform appearance
- Very scant vascularity and absence of stromal fibrosis
- Tumor cells are positive for cytokeratins and EMA and negative for CD34
- Characterized by distinctive cytogenetic translocation (X;18) in > 85% of cases

DIAGNOSTIC CHECKLIST

Clinically Relevant Pathologic Features

- Histologic findings do not always correlate with prognosis
  - Some cases can metastasize and behave aggressively despite benign-appearing histologic features
  - Some cases with atypical morphologic features may behave in indolent fashion

Pathologic Interpretation Pearls

- Variation of histologic growth patterns (e.g., fascicular, herringbone, storiform, hemangiopericytic, etc.) is frequently observed
- Alternating cellular and sclerotic areas are characteristic and often present
- High vascularity with prominent vessels with patent lumina is always seen
- Hemangiopericytic growth pattern is very common
- "Hemangiopericytoma of lung" is synonymous with intrapulmonary SFT
- Increased cellularity, atypia, necrosis, and high mitotic activity are associated with aggressive or malignant behavior

SELECTED REFERENCES

1. Guseva NV et al: The NAB2-STAT6 gene fusion in solitary fibrous tumor can be reliably detected by anchored multiplexed PCR for targeted next-generation sequencing. Cancer Genet. 209(7-8):303-12, 2016
2. Huang SC et al: The clinicopathological significance of NAB2-STAT6 gene fusions in 52 cases of intrathoracic solitary fibrous tumors. Cancer Med. 5(2):159-68, 2016
3. Rao N et al: Intrapulmonary solitary fibrous tumors: clinicopathologic and immunohistochemical study of 24 cases. Am J Surg Pathol. 37(2):155-66, 2013
4. Kouki HS et al: Solitary fibrous tumor of the lung. Gen Thorac Cardiovasc Surg. 56(5):249-51, 2008

Intrapulmonary Solitary Fibrous Tumor

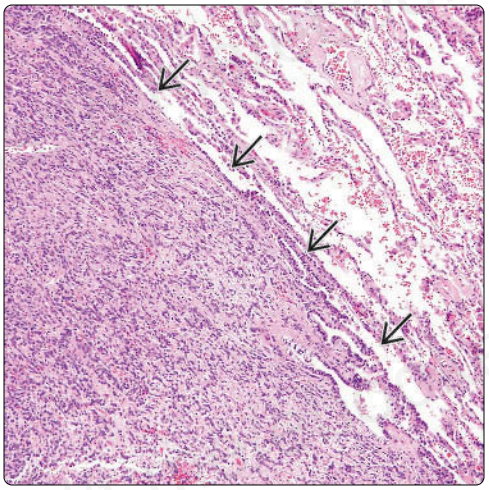

Short Storiform Pattern

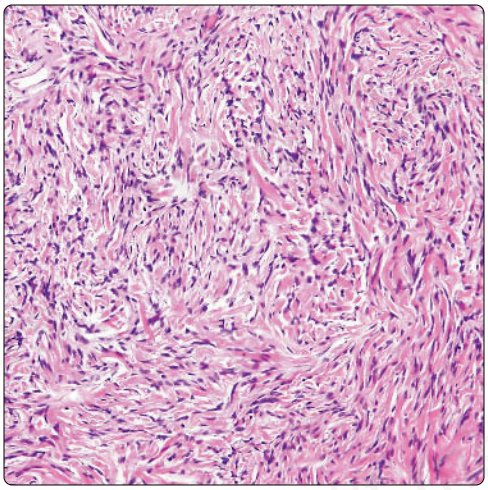

(Left) *Scanning magnification of an intrapulmonary solitary fibrous tumor shows a well-circumscribed but unencapsulated spindle cell proliferation ⇨ sharply separated from the surrounding lung parenchyma.* **(Right)** *Higher magnification of an intrapulmonary solitary fibrous tumor shows a bland spindle cell proliferation surrounded by abundant collagenous stroma. The spindle cells display a vague storiform pattern reminiscent of "fibrohistiocytic" tumors.*

Fascicular Pattern in Solitary Fibrous Tumor

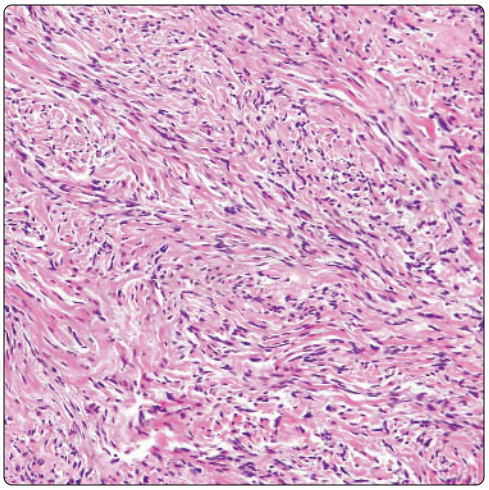

Bland-Appearing Spindle Cell Population

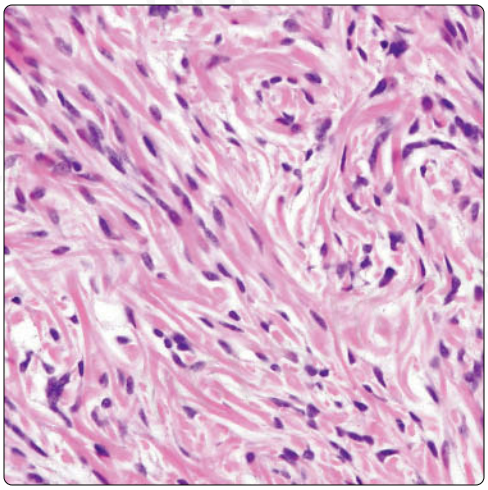

(Left) *A fascicular proliferation of spindle cells is seen in this intrapulmonary solitary fibrous tumor. The spindle cells are separated from one another by abundant collagenous matrix.* **(Right)** *Higher magnification of an intrapulmonary solitary fibrous tumor shows a bland-appearing population of cells lined by parallel linear strands of hyalinized, keloidal collagen adopting a rope-like configuration. This arrangement of interstitial collagen is highly distinctive for this tumor.*

Perivascular Hyalinization

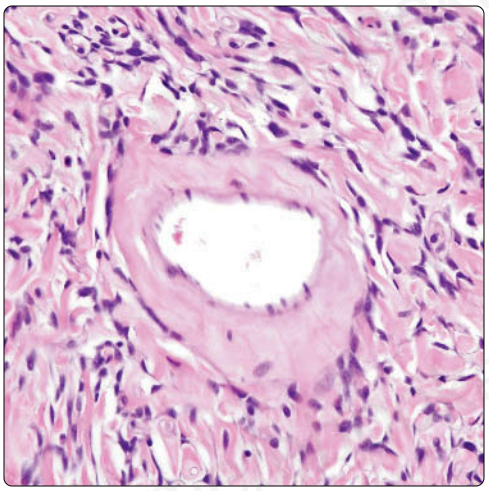

Spindle Cells in Solitary Fibrous Tumor

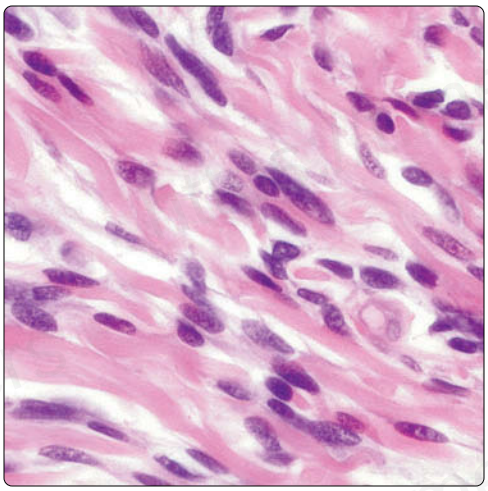

(Left) *Intrapulmonary solitary fibrous tumor shows a small-caliber vessel with prominent perivascular hyalinization. A dense vascular network with prominent perivascular hyalinization is a common feature seen in these tumors.* **(Right)** *High magnification of an intrapulmonary solitary fibrous tumor shows a bland-appearing population of spindle cells. The spindle cells display elongated nuclei with a dense chromatin pattern and scant rim of cytoplasm. No nucleoli or mitotic figures are seen.*

Entrapment of Airspaces in Solitary Fibrous Tumor

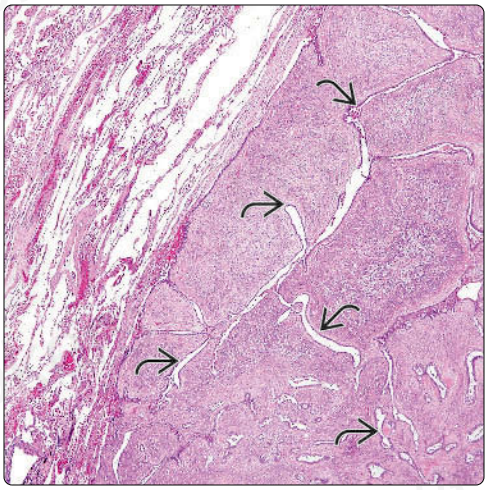

Hypercellular Area in Solitary Fibrous Tumor

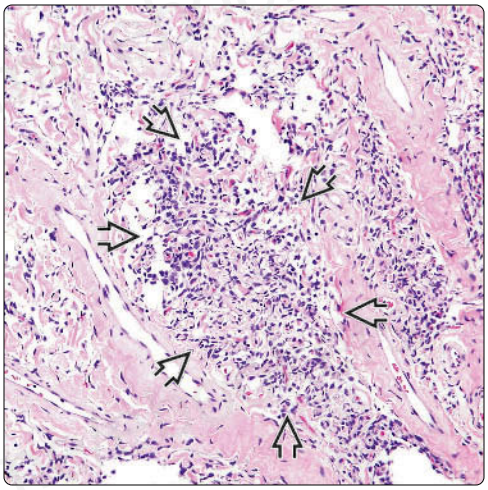

(Left) *Scanning magnification of an intrapulmonary solitary fibrous tumor shows entrapment of glandular structures and airspaces at the periphery of the tumor mass ⇨ resulting in an adenofibromatous appearance.* **(Right)** *Alternating hypercellular ⇨ and hypocellular areas are seen in this example of an intrapulmonary solitary fibrous tumor. Variegation in cellularity and in growth patterns is a hallmark of a solitary fibrous tumor and is often encountered in these neoplasms.*

Herringbone Pattern in Solitary Fibrous Tumor

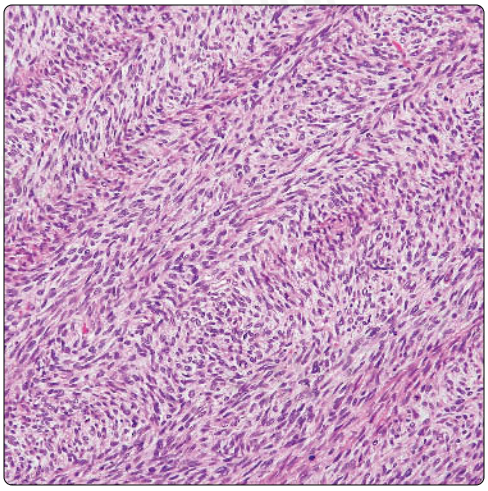

Hemangiopericytic Vascular Pattern

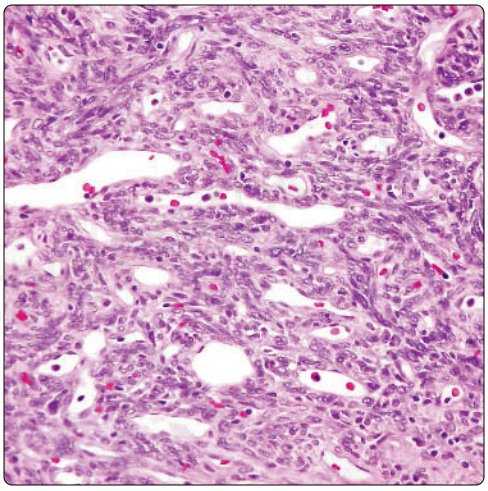

(Left) *Increased cellularity with a prominent herringbone pattern can often be seen in intrapulmonary solitary fibrous tumors and does not necessarily correlate with more aggressive behavior. Such tumors can be mistaken for synovial sarcoma and malignant peripheral nerve sheath tumors.* **(Right)** *Prominent hemangiopericytic growth pattern is seen in this intrapulmonary solitary fibrous tumor characterized by numerous small-caliber vessels with patent lumina.*

Neural-Like Pattern With Wavy Nuclei

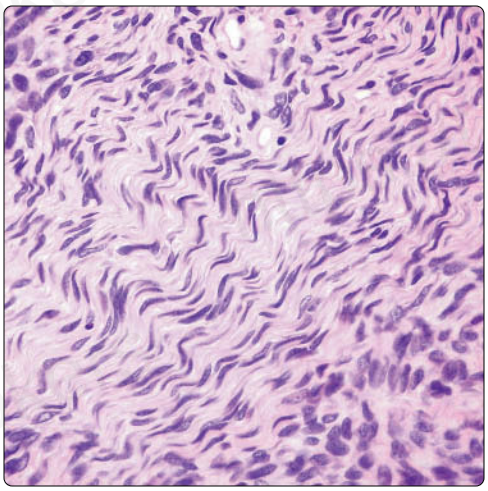

Stromal Collagenization

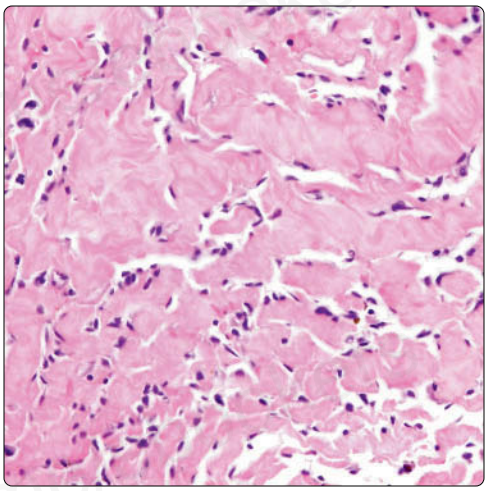

(Left) *Spindle cells with wavy nuclei closely reminiscent of schwannian neoplasms are seen in this example of an intrapulmonary solitary fibrous tumor. Application of immunohistochemical stains will be necessary in such cases to rule out a peripheral nerve sheath tumor.* **(Right)** *Extensive stromal collagenization is displayed by this intrapulmonary solitary fibrous tumor. The collagen bands are seen to compress and distort the nuclear morphology, producing small round dots.*

Stellate Cell in Solitary Fibrous Tumor

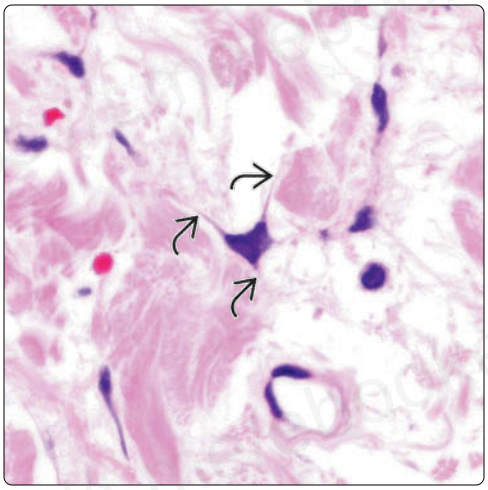

Multinucleated Cell in Solitary Fibrous Tumor

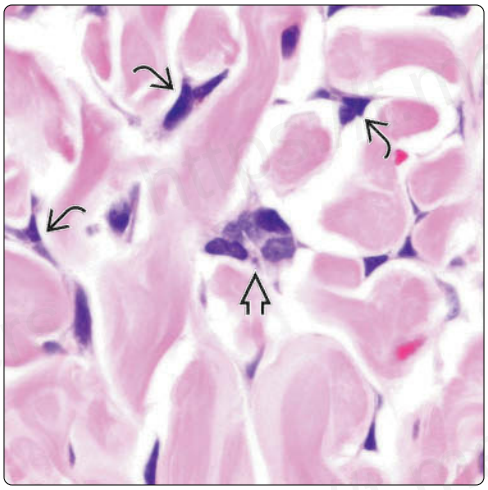

(Left) *High magnification of the sclerotic area in an intrapulmonary solitary fibrous tumor shows a stellate cell with a large, hyperchromatic nucleus and slender dendritic cytoplasmic prolongations that course along connective tissue planes and connect with neighboring cells.* **(Right)** *High magnification of the sclerotic area in an intrapulmonary solitary fibrous tumor shows multiple stellate dendritic cells and a multinucleated cell in the center of the field.*

STAT6 Immunostaining in Solitary Fibrous Tumor

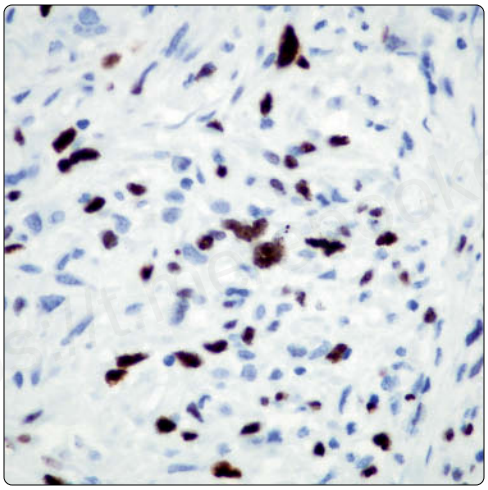

CD34 Immunoreactivity in Solitary Fibrous Tumor

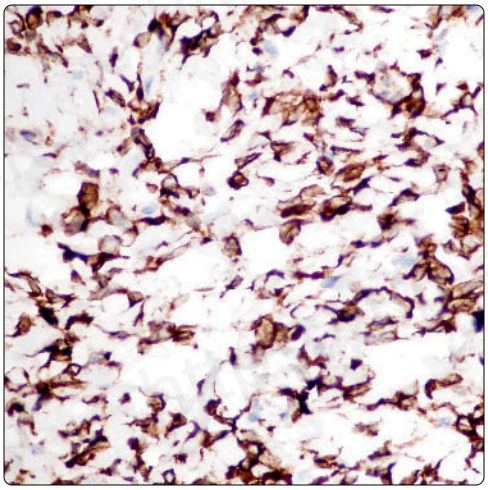

(Left) *Immunohistochemical staining of intrapulmonary solitary fibrous tumor with STAT6 shows numerous positive nuclei. This is currently the preferred antibody for establishing the diagnosis of solitary fibrous tumor.* **(Right)** *Immunohistochemical staining for CD34 antigen in an intrapulmonary solitary fibrous tumor shows strong positivity in the spindle cells. This marker can be positive in up to 75% of cases of benign solitary fibrous tumors.*

Bcl-2 Immunoreactivity in Solitary Fibrous Tumor

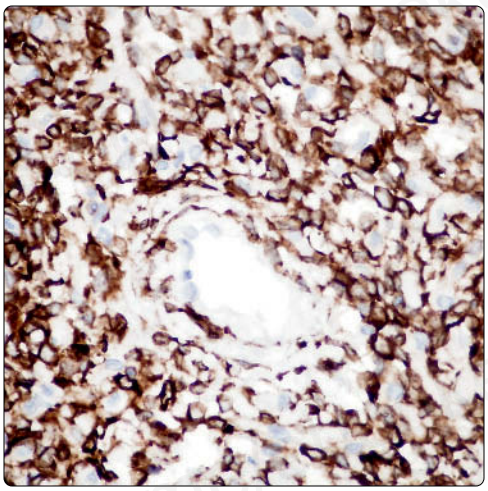

CD99 Immunoreactivity in Solitary Fibrous Tumor

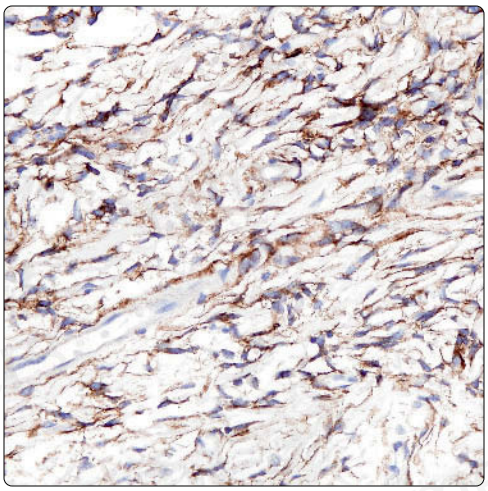

(Left) *Strong immunohistochemical staining of the spindle cells for Bcl-2 antibody is seen in this intrapulmonary solitary fibrous tumor. This marker is extremely sensitive (almost 100%) but nonspecific for these tumors.* **(Right)** *Immunohistochemical staining of spindle cells in an intrapulmonary solitary fibrous tumor for CD99 shows a positive reaction in the tumor cells. This is another helpful (although nonspecific) marker for the diagnosis of these tumors.*

Herringbone Pattern in Solitary Fibrous Tumor

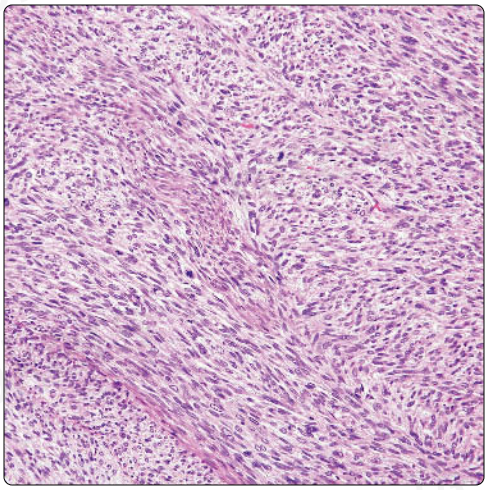

Tumor Cell Necrosis in Solitary Fibrous Tumor

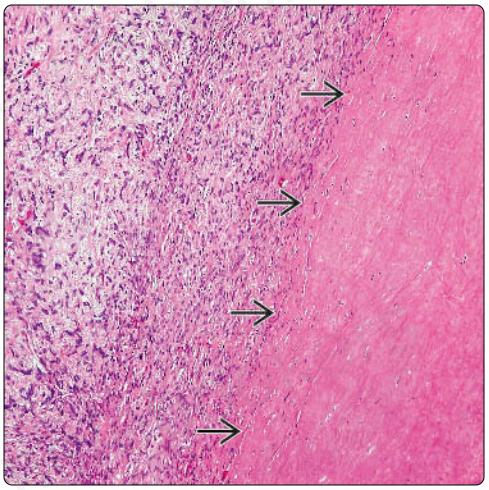

(Left) *Malignant intrapulmonary solitary fibrous tumor shows fascicles of spindle cells with a herringbone pattern and numerous (> 3 per 10 HPF) mitoses. Identification of other areas displaying the conventional features of solitary fibrous tumor are necessary for diagnosis.* **(Right)** *Extensive area of tumor cell necrosis is seen in this malignant intrapulmonary solitary fibrous tumor. Tumor cell necrosis correlates with aggressive behavior in these tumors.*

Alternating Hyper/Hypocellular Areas

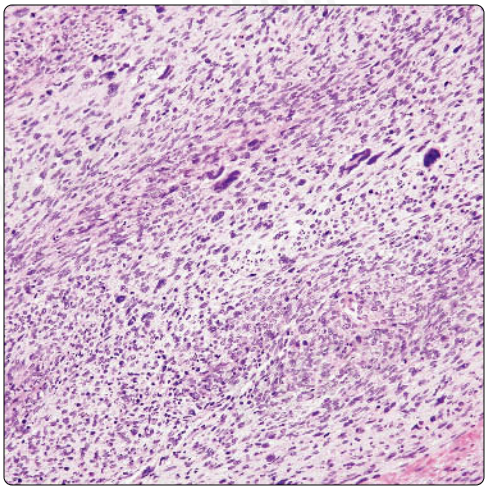

Abnormal Mitosis in Solitary Fibrous Tumor

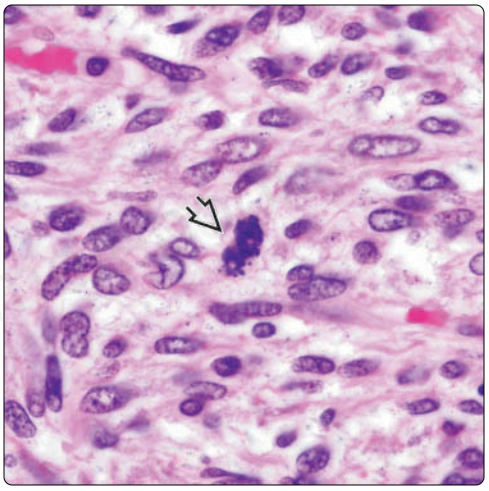

(Left) *Alternating areas of hyper- and hypocellularity are seen in this example of an intrapulmonary solitary fibrous tumor. Tumors with these features can appear indistinguishable from malignant peripheral nerve sheath tumors; electron microscopy and immunohistochemical stains will be of aid in arriving at a definitive diagnosis.* **(Right)** *Higher magnification from an intrapulmonary malignant solitary fibrous tumor shows an abnormal mitotic figure.*

Bizarre and Pleomorphic Tumor Cells

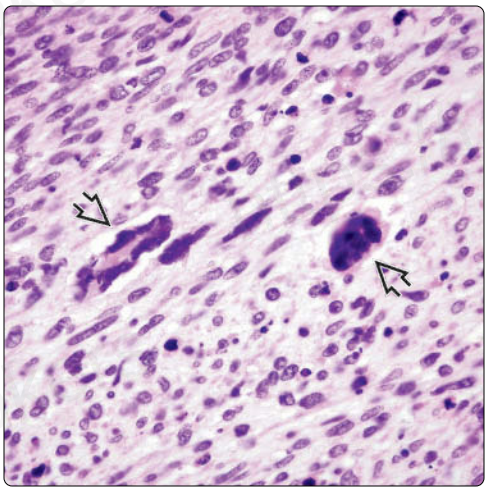

Wreath-Like Multinucleated Cell

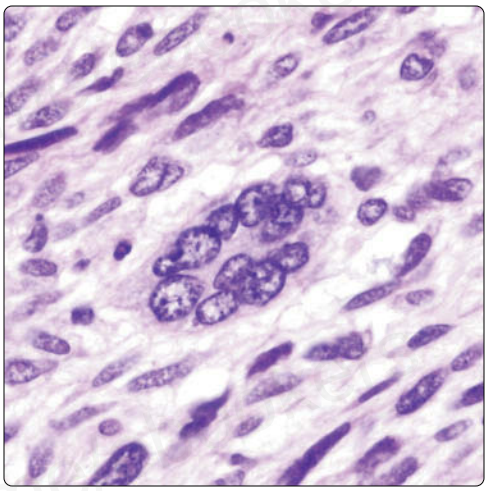

(Left) *High magnification of a metastasis of an intrapulmonary malignant solitary fibrous tumor shows bizarre and pleomorphic tumor cells. The original tumor in the lung did not display this degree of cytologic atypia; however, the tumor metastasized widely after 5 years leading to the death of the patient.* **(Right)** *A wreath-like multinucleated and atypical giant cell is seen in this example of malignant solitary fibrous tumor.*

Malignant Solitary Fibrous Tumor

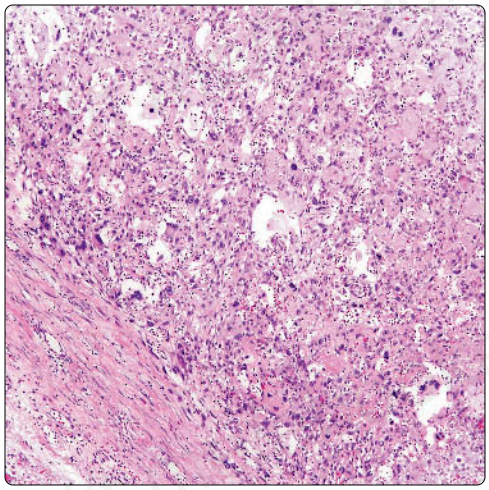

Nuclear Pleomorphism in Malignant Solitary Fibrous Tumor

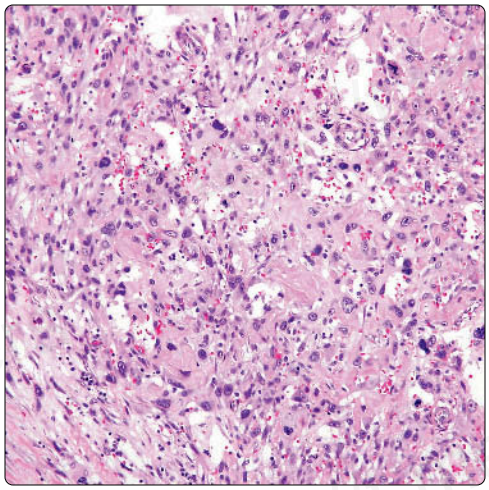

(Left) *Scanning magnification of an intrapulmonary malignant solitary fibrous tumor shows a dense population of large, pleomorphic tumor cells embedded in abundant connective tissue stroma. The histologic appearance of this tumor is indistinguishable from that of a pleomorphic high-grade sarcoma.* **(Right)** *Higher magnification of an intrapulmonary malignant solitary fibrous tumor shows sheets of large epithelioid cells embedded in abundant collagenous stroma.*

Pleomorphic Nuclei

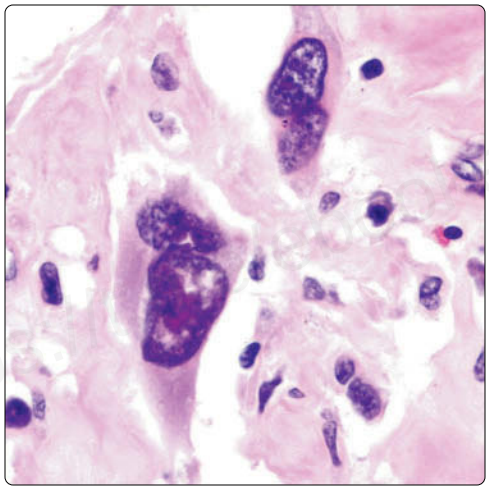

Abnormal Tripolar Mitosis

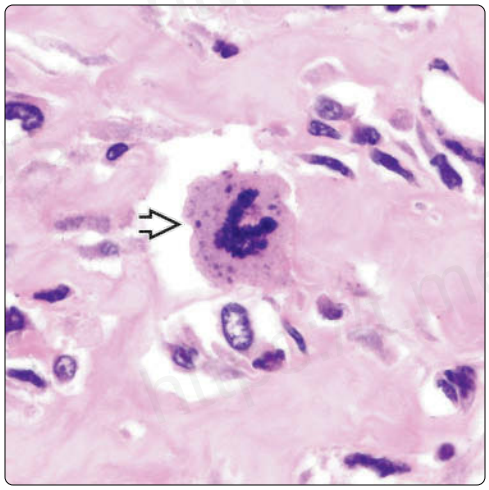

(Left) *Morphology of the tumor cells in an intrapulmonary malignant solitary fibrous tumor shows large multinucleated cells with bizarre nuclei, prominent and often multiple large, eosinophilic nucleoli, and an abundant rim of eosinophilic cytoplasm.* **(Right)** *High magnification of an intrapulmonary malignant solitary fibrous tumor shows an abnormal tripolar mitosis ⇨. Up to 3 normal mitoses can be seen in benign tumors, but abnormal mitoses should be worrisome for malignancy.*

Reed-Sternberg-Like Tumor Cell

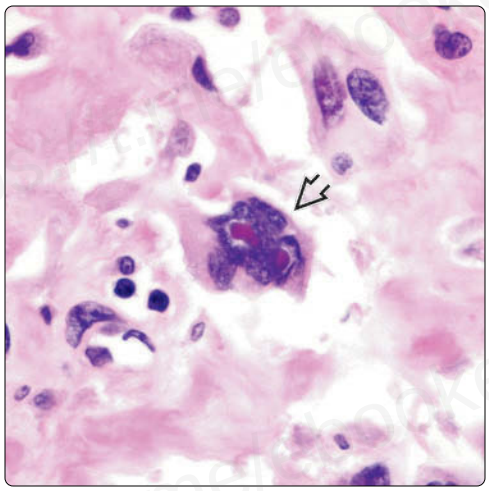

Marked Nuclear Pleomorphism

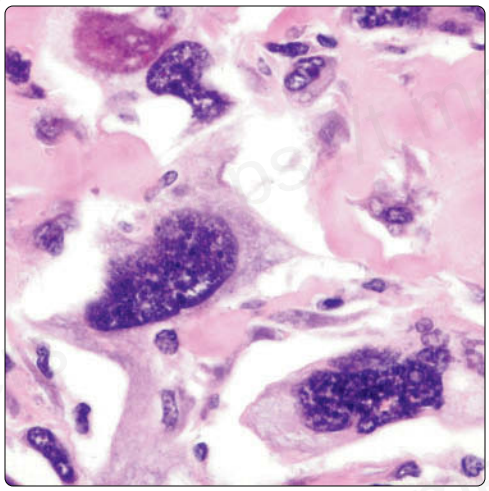

(Left) *Higher magnification of an intrapulmonary malignant solitary fibrous tumor shows a binucleated cell with prominent "owl-eyed" eosinophilic nucleoli resembling a Reed-Sternberg cell ⇨.* **(Right)** *Bizarre mononuclear cells with large, hyperchromatic nuclei are seen in this example of an intrapulmonary malignant solitary fibrous tumor. Tumors with these features will require extensive sampling to identify areas with more conventional features of solitary fibrous tumors.*

Fibrosarcomatous Appearance

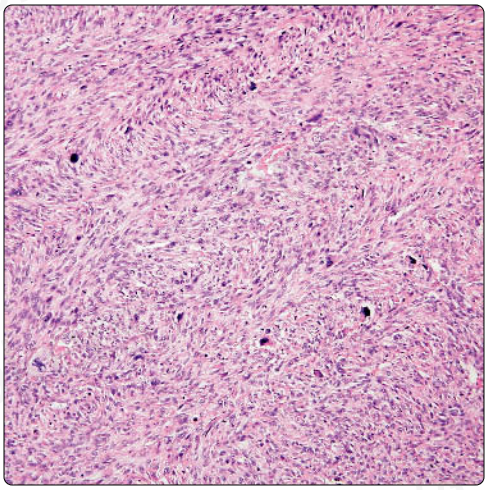

High-Grade Sarcomatous Appearance

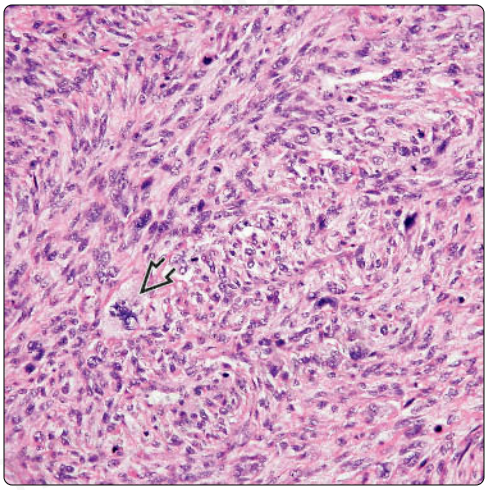

(Left) *Scanning magnification of an intrapulmonary malignant solitary fibrous tumor shows dense fascicles of atypical spindle cells containing multiple scattered pleomorphic and atypical nuclei. The histologic appearance of this tumor is essentially that of a high-grade fibrosarcoma.* **(Right)** *Higher magnification of an intrapulmonary malignant solitary fibrous tumor shows fascicles of atypical spindle cells with scattered mitoses. Notice the abnormal mitotic figure.*

Bizarre Nuclear Forms

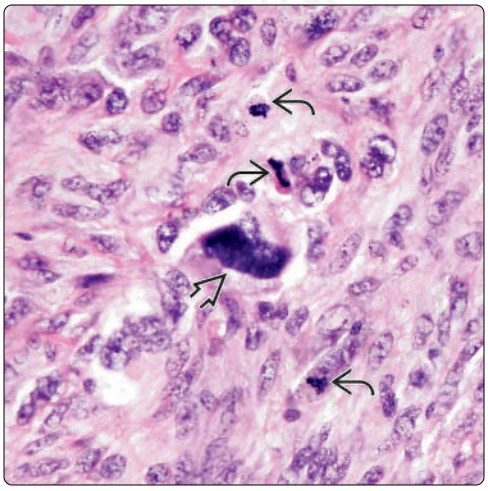

Perivascular Cuffing by Tumor Cells

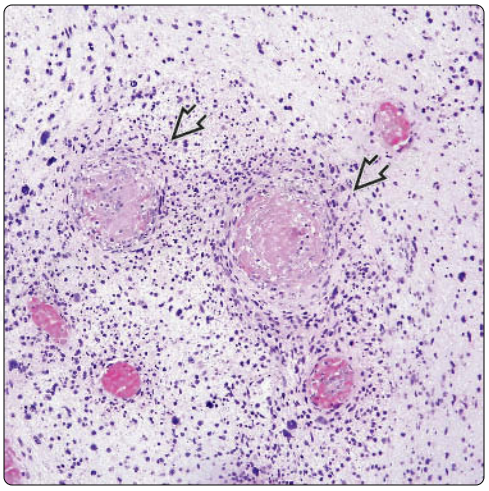

(Left) *Higher magnification of an intrapulmonary malignant solitary fibrous tumor shows atypical spindle cells with numerous mitoses (3 mitoses in this HPF). Also notice the bizarre nucleus in the large, atypical cell in the center of the field.* **(Right)** *Malignant intrapulmonary solitary fibrous tumor shows an atypical cell population containing scattered bizarre tumor cells with perivascular condensation embedded in an abundant myxoid matrix.*

Myxoid Stroma in Malignant Solitary Fibrous Tumor

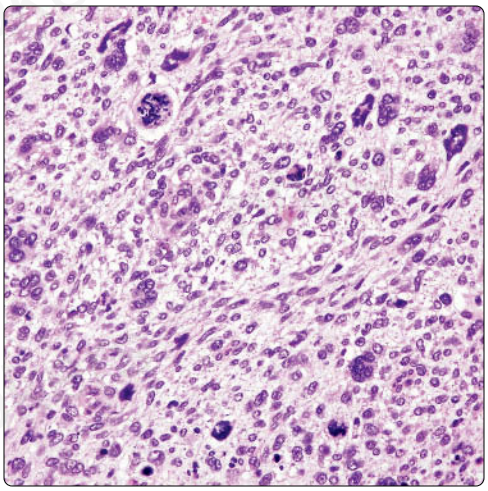

Abnormal Mitosis

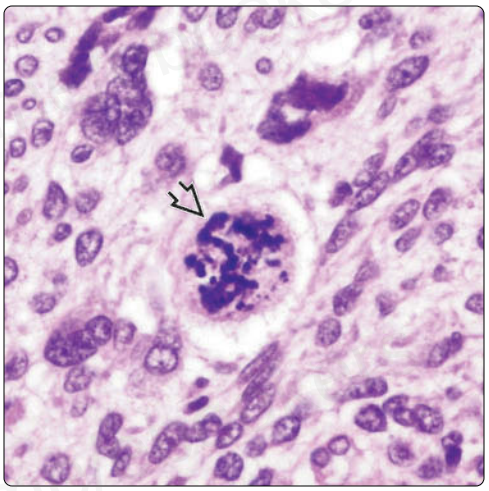

(Left) *Malignant intrapulmonary solitary fibrous tumor with prominent myxoid stroma shows a highly cellular area containing atypical spindle cells admixed with larger, bizarre cells with hyperchromatic nuclei and numerous mitoses.* **(Right)** *Higher magnification of a malignant intrapulmonary solitary fibrous tumor shows detail of the atypical cells. Notice that the large cell in the center has abnormal mitosis and a sunburst chromatin pattern.*

Glomus Tumor

KEY FACTS

TERMINOLOGY

- Synonyms: Glomangioma, glomic tumor

CLINICAL ISSUES

- Cough
- Shortness of breath
- Asymptomatic

IMAGING

- Coin lesion in intrapulmonary location
- Central tumor obstructing bronchial lumen

MICROSCOPIC

- Solid and homogeneous cellular proliferation
- Ectatic blood vessels
- Cellular proliferation with clear cytoplasm mimicking fried egg appearance
- Mitotic figures are absent
- Necrosis and hemorrhage are absent

ANCILLARY TESTS

- Immunohistochemical stain for actin is positive in these tumors

TOP DIFFERENTIAL DIAGNOSES

- Glomangiosarcoma
  - Mitotic figures and cellular pleomorphism are most important features to separate from glomangioma
- Leiomyoma
  - Rarely displays prominent ectatic blood vessels with edema of wall
  - Both tumors may show similar immunohistochemical profile
  - Tumor cells are mostly oval or spindled
- Carcinoma
  - Displays more cellular atypia and mitotic activity
  - Shows positive staining for epithelial markers

Well-Demarcated Tumor **Uninvolved Airway**

(Left) *Low-power view of a primary pulmonary glomus tumor shows a well-defined tumor mass replacing normal lung parenchyma.* **(Right)** *Glomus tumor is shown obliterating normal lung parenchyma; however, pulmonary airway is not involved by the tumor, which appears compressed by the tumor.*

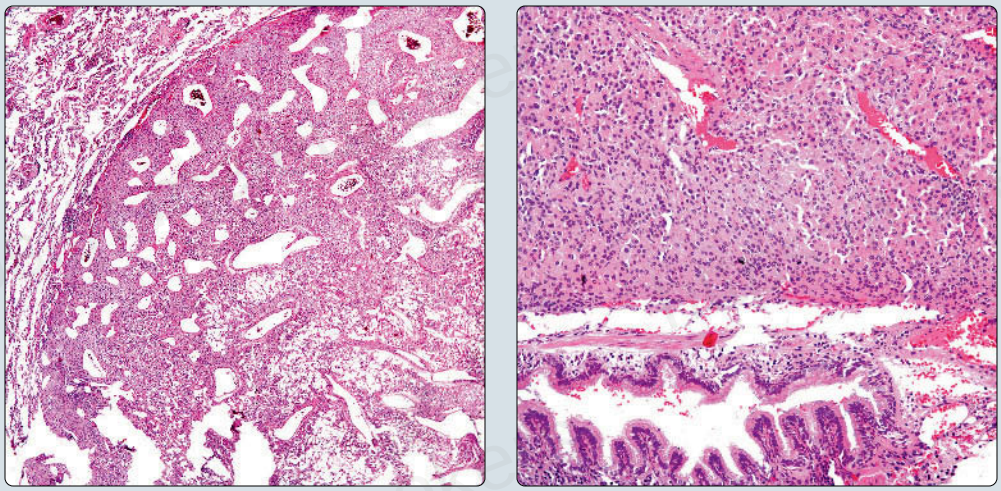

Clear Cell Change **Solid Proliferation**

(Left) *High-power view of a primary pulmonary glomus tumor shows ectatic blood vessels ⇨ and a cellular proliferation composed of medium-sized cells with clear and eosinophilic cytoplasm.* **(Right)** *Pulmonary glomus tumor shows a solid homogeneous proliferation composed of rather small cells with eosinophilic cytoplasm. Note the absence of mitotic activity.*

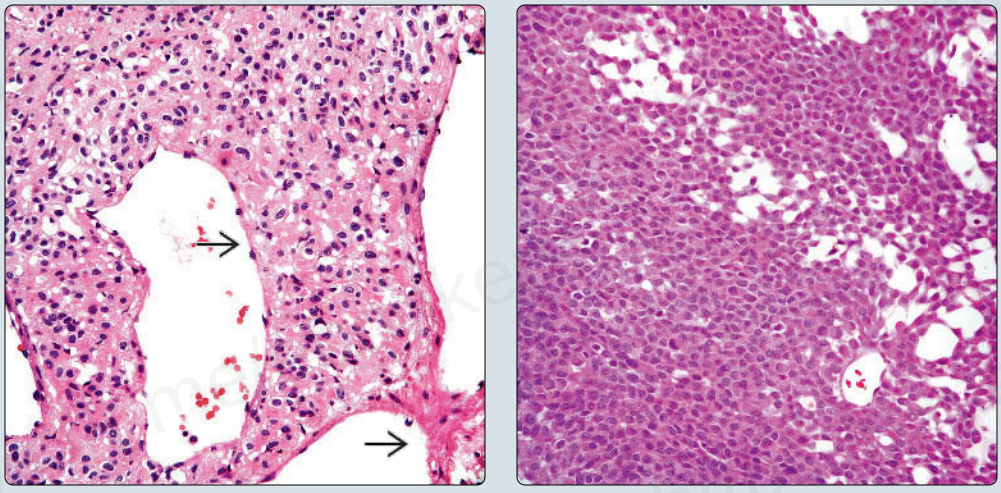

TERMINOLOGY

Synonyms

- Glomangioma, glomic tumor

Definitions

- Benign tumor with smooth muscle differentiation

ETIOLOGY/PATHOGENESIS

Etiology

- Glomus tumors are believed to originate from glomus body
- Debated whether it represents true tumor or hyperplasia

CLINICAL ISSUES

Epidemiology

- Incidence
  - Very rare tumor in lung
- Age
  - Cases reported have been in adults
- Sex
  - No sex predilection

Presentation

- Cough
- Shortness of breath
- Asymptomatic

Treatment

- Surgical approaches
  - Complete surgical resection

Prognosis

- Excellent

IMAGING

General Features

- Coin lesion in intrapulmonary location
- Central tumor obstructing bronchial lumen

MACROSCOPIC

General Features

- Well-circumscribed tumor embedded in lung parenchyma
- White to tan in color without hemorrhage &/or necrosis

Size

- May vary from 1-5 cm in diameter

MICROSCOPIC

Histologic Features

- Well-circumscribed tumor nodule
- Solid and homogeneous cellular proliferation
- Ectatic blood vessels
- Cellular proliferation with clear cytoplasm mimicking fried egg appearance
- Hemangiopericytic pattern
- Mucohyaline changes
- Mitotic figures are absent
- Necrosis and hemorrhage are absent

DIFFERENTIAL DIAGNOSIS

Glomangiosarcoma

- Mitotic figures and cellular pleomorphism are most important features to separate from glomangioma
- Areas of necrosis and sclerosis may be present
- In focal areas, more conventional areas of glomangioma are commonly seen

Leiomyoma

- Shows more spindle cellular proliferation
- Rarely displays prominent ectatic blood vessels
- Both tumors may show similar immunohistochemical phenotype
- Tumor cells are mostly oval or spindled

DIAGNOSTIC CHECKLIST

Pathologic Interpretation Pearls

- Cellular proliferation with clear cell changes admixed with ectatic blood vessels
- Monotonous appearance of tumor cells with fried egg appearance

SELECTED REFERENCES

1. Cunningham JD et al: Case report of malignant pulmonary parenchymal glomus tumor: imaging features and review of the literature. Clin Imaging. 40(1):144-7, 2016
2. Choi IH et al: Two cases of glomus tumor arising in large airway: well organized radiologic, macroscopic and microscopic findings. Tuberc Respir Dis (Seoul). 76(1):34-7, 2014
3. Koss MN et al: Primary pulmonary glomus tumor: a clinicopathologic and immunohistochemical study of two cases. Mod Pathol. 11(3):253-8, 1998

Immunohistochemistry

Antibody	Reactivity	Staining Pattern	Comment
Vimentin	Positive	Cytoplasmic	
Actin-sm	Positive	Cytoplasmic	
Desmin	Positive	Cytoplasmic	In some cases
NSE	Positive	Cytoplasmic	In some cases
LEU-7	Positive	Cytoplasmic	In some cases
CD34	Positive	Cytoplasmic	In some cases
CK-PAN	Negative		

Ectatic Vessels

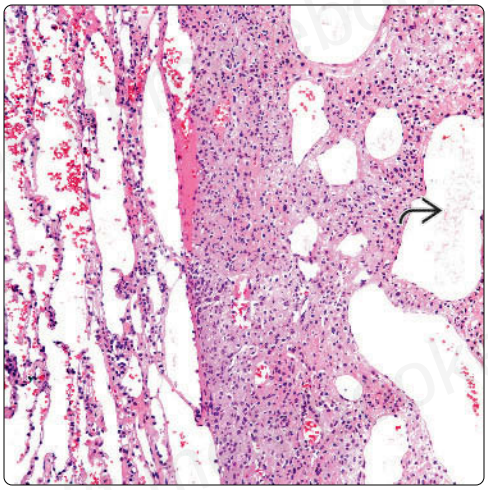

Subtle Hemangiopericytoma Pattern

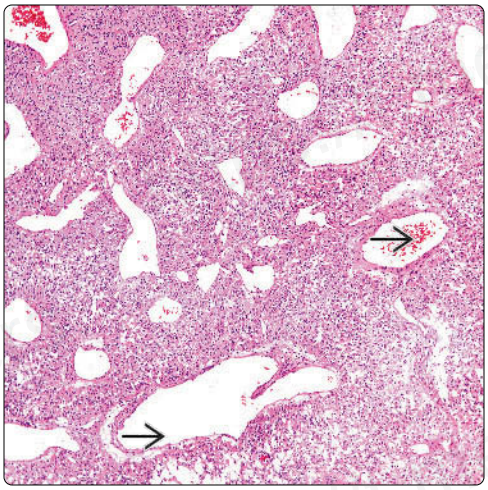

(Left) *Low-power view of a pulmonary glomus tumor shows the well-defined border of the tumor. Note that the tumor is not encapsulated, and, in addition, the tumor shows a rather homogeneous cellular proliferation with dilated spaces.* **(Right)** *Pulmonary glomus tumor shows classic appearance of a cellular proliferation alternating with numerous ectatic blood vessels, giving an appearance of a vascular neoplasm.*

Edematous Areas

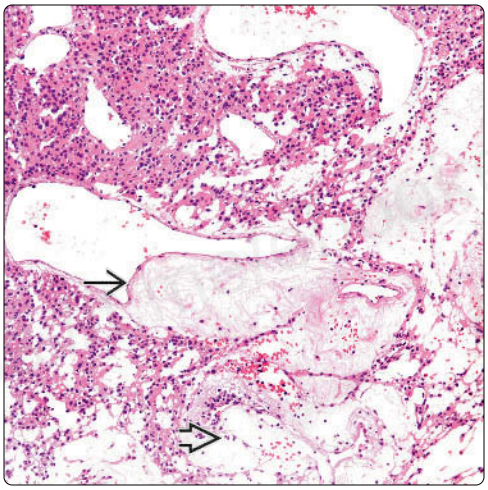

Absence of Mitosis

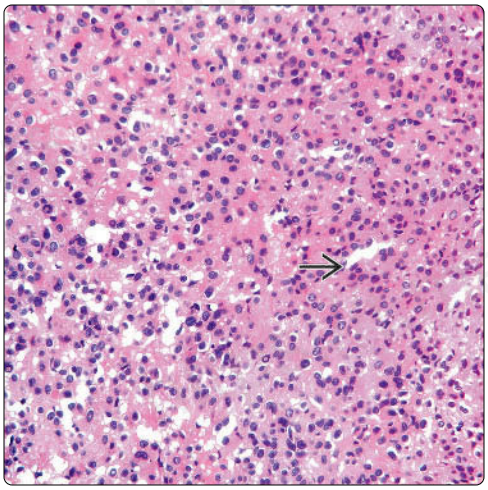

(Left) *The vessels in a pulmonary glomus tumor show prominent edematous changes in the walls. Some of the vessels are compressed and difficult to recognize as vascular structures.* **(Right)** *In other areas, a glomus tumor in the lung shows a predominantly solid growth pattern with inconspicuous blood vessels. The uniformity and bland cytologic appearance of the tumor cell population are clues for correct diagnosis.*

Extensive Acellular Areas

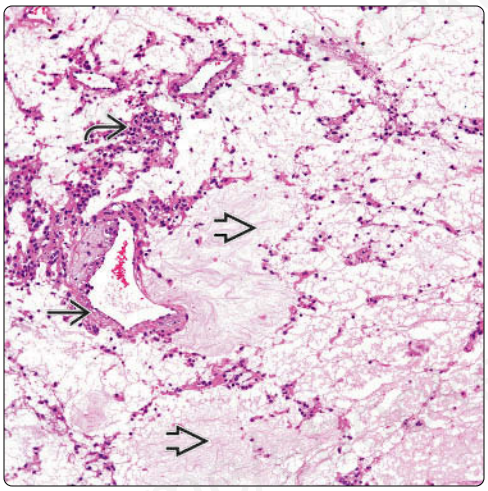

Edema-Like Changes

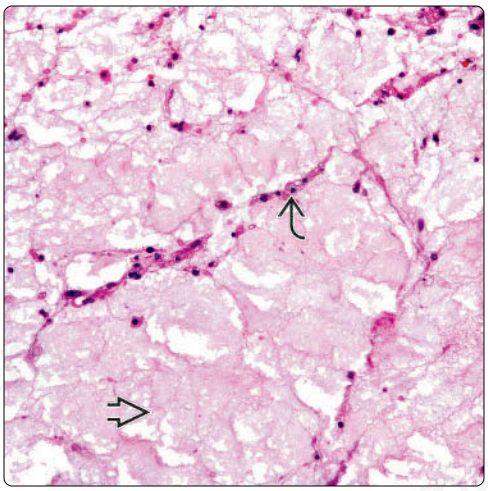

(Left) *Pulmonary glomus tumor with an extensive edematous component distends the alveolar spaces. Still, one is able to recognize a dilated vascular structure and cluster of tumor cells.* **(Right)** *High-power view shows the edematous component of a pulmonary glomus tumor. Although an unusual feature, extensive edematous areas may be seen in which the neoplastic cells can be easily missed.*

Prominent Clear Cells

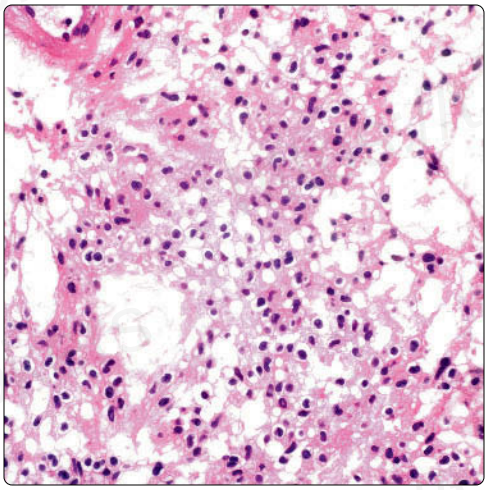

Mild Nuclear Atypia

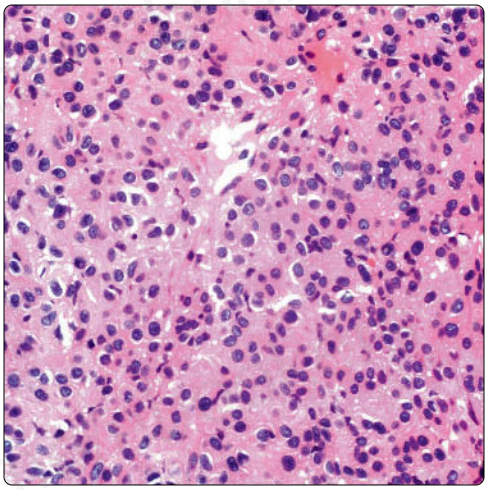

(Left) *High-power view of a pulmonary glomus tumor shows a cellular proliferation composed of medium-sized cells with clear cytoplasm and fried egg appearance. Note the absence of nuclear atypia or mitotic activity.* **(Right)** *High-power view of a more solid area of a glomus tumor shows medium-sized cells with eosinophilic cytoplasm. The round uniform cells with centrally placed dark nuclei are quite distinctive for this tumor.*

Glomangiosarcoma

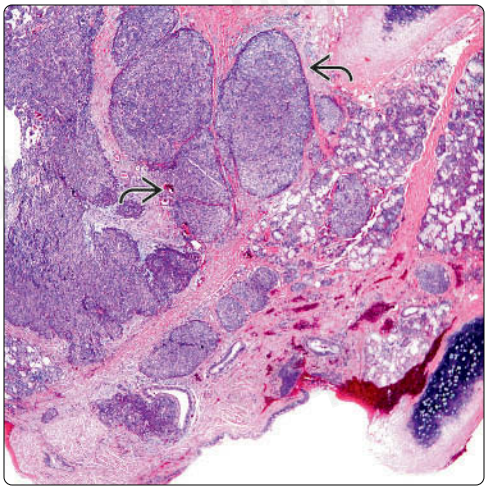

Nuclear Atypia

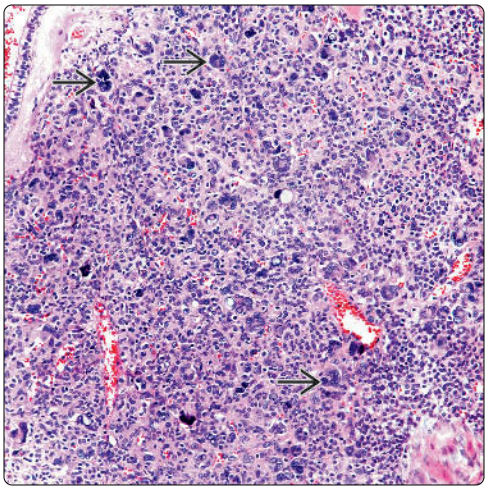

(Left) *Glomangiosarcoma shows a more haphazard growth pattern with infiltrative borders. In this case, the tumor is in a central location growing in lobules of different sizes adjacent to a bronchus.* **(Right)** *Pulmonary glomangiosarcoma shows prominent nuclear atypia and multinucleated cells. These cytologic features are not seen in the benign counterpart of a glomus tumor.*

Glomus: Glomangiosarcoma

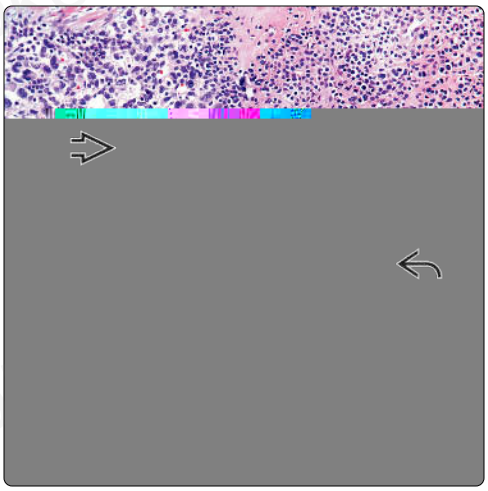

Smooth Muscle Actin

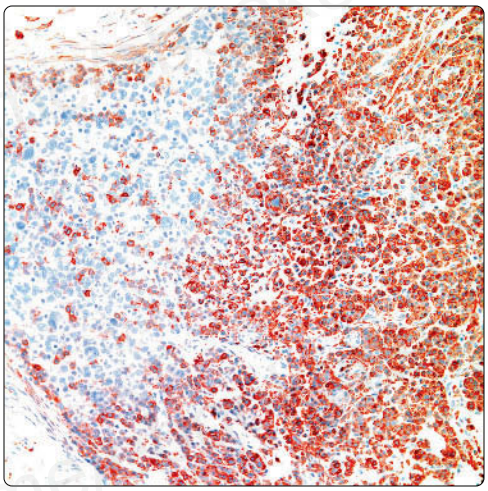

(Left) *Pulmonary glomangiosarcoma shows transitional areas with a benign glomus tumor developing into a malignant glomus tumor (glomangiosarcoma). This feature may be helpful in order to properly classify the tumor as glomangiosarcoma.* **(Right)** *Smooth muscle actin immunohistochemical stain shows a strong positive reaction in the glomus component and scattered positive cells in the glomangiosarcomatous component.*

Intrapulmonary Thymoma

KEY FACTS

TERMINOLOGY

- Primary thymic epithelial neoplasm arising from embryologically displaced elements within lung

CLINICAL ISSUES

- Intraparenchymatous location within lung parenchyma; central and peripheral
- Incidental finding on chest x-ray in 50% of patients

MACROSCOPIC

- Well-circumscribed tumor surrounded by normal lung parenchyma
- Gray-white, homogeneous cut surface
- May show areas of hemorrhage and cystic degeneration

MICROSCOPIC

- Well-circumscribed cellular proliferation showing various admixtures of epithelial cells and lymphocytes
  - Lymphocyte-rich thymoma (WHO types B1-B2)
  - Epithelial-rich thymoma (WHO type B3)
  - Spindle cell thymoma (WHO types A and AB)
- Epithelial cells in intrapulmonary thymomas are bland with minimal atypia
- Tumor cells are intimately admixed with small T lymphocytes in varying proportions

ANCILLARY TESTS

- Neoplastic epithelial cells show positive cytoplasmic staining for cytokeratins (AE1/AE3, CAM5.2, CK19)
- Neoplastic epithelial cells show strong nuclear positivity for p63
- Lymphocytes stain as immature T lymphoblasts (CD1a, CD3, TdT, and CD99 positive)
- Spindle cells are negative for mesenchymal markers of differentiation (S100 protein, SMA, desmin, CD34)
- Spindle cells may stain positive for calretinin and Bcl-2

Lymphocyte-Rich Intrapulmonary Thymoma

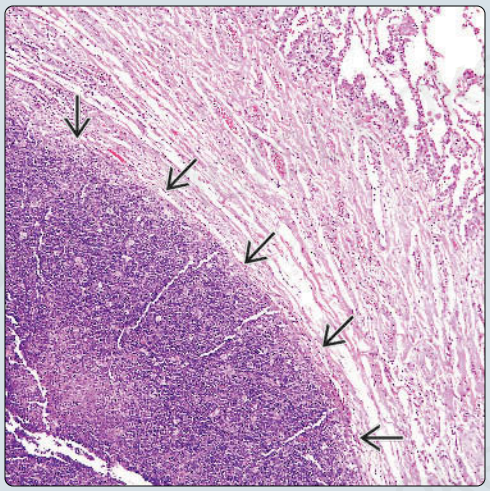

Intrapulmonary Thymoma: Higher Magnification

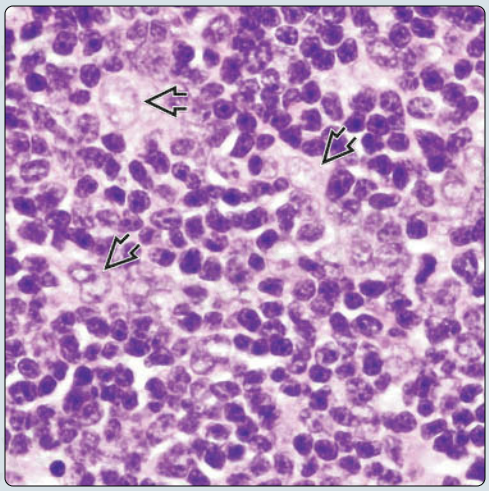

(Left) *Scanning magnification of an intrapulmonary thymoma shows a well-circumscribed nodule composed of densely packed small lymphocytes separated from the lung parenchyma by a band of connective tissue.* **(Right)** *Higher magnification of an intrapulmonary thymoma shows a characteristic biphasic population of cells with numerous small T lymphocytes and scattered larger epithelial cells with vesicular nuclei corresponding to a lymphocyte-rich (WHO B1) thymoma.*

Atypical Intrapulmonary Thymoma

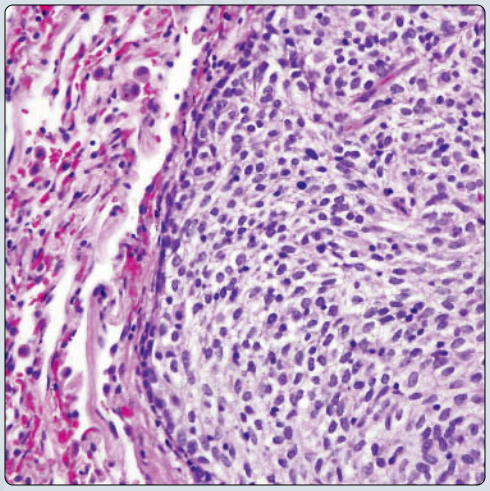

Atypical Thymoma: High Power

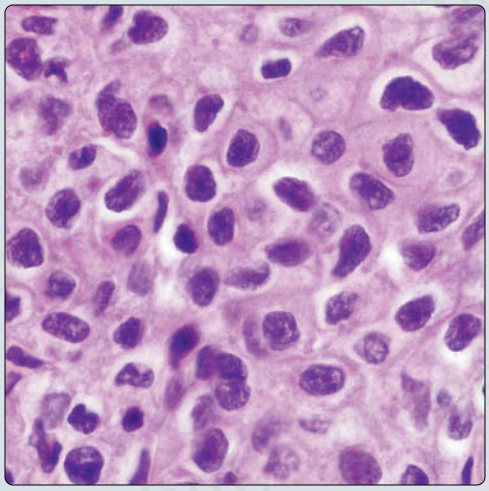

(Left) *This intrapulmonary nodule is composed of sheets of large epithelioid cells containing very few scattered small lymphocytes corresponding to an atypical (WHO B3) thymoma.* **(Right)** *Higher magnification from intrapulmonary atypical thymoma (WHO B3) shows a variable population of epithelial cells with enlarged, irregular nuclei with a dense chromatin pattern and scattered small lymphocytes.*

TERMINOLOGY

Definitions

- Primary thymic epithelial neoplasm arising from embryologically displaced elements within lung

CLINICAL ISSUES

Presentation

- Cough, chest pain
- Incidental finding on chest x-ray in 50% of patients

Prognosis

- Most cases cured with simple surgical excision

IMAGING

General Features

- Location
  - Well-circumscribed intraparenchymatous mass
- Size
  - 0.5-10.0 cm in greatest dimension

CT Findings

- Absence of mediastinal involvement on CT scans

MACROSCOPIC

General Features

- Well-circumscribed tumor surrounded by normal lung parenchyma

MICROSCOPIC

Histologic Features

- Well-circumscribed cellular proliferation showing variable admixture of epithelial cells and lymphocytes
- **Lymphocyte-rich thymoma (WHO types B1-B2)**
  - Sheets of small lymphocytes admixed with scattered, large, pale epithelial cells with large vesicular nuclei with prominent nucleoli
  - Areas of "medullary" differentiation (lighter areas within sheets of small lymphocytes)
  - Dilated perivascular spaces
  - Lobules separated by bands of fibrous tissue on scanning magnification
- **Epithelial-rich thymoma (WHO type B3)**
  - Sheets of large epithelioid cells with large nuclei showing prominent chromatin pattern and nucleoli
  - Sparse population of scattered small lymphocytes admixed with epithelial cells
  - Epithelial cells show sharp cell borders with areas of early or abortive squamous differentiation
  - Abundant perivascular spaces
- **Spindle cell thymoma (WHO types A and AB)**
  - Sheets of oval to spindle cells with minimal or no cytologic atypia or mitotic activity
  - Spindle cells may adopt fascicular, storiform, herringbone, or hemangiopericytic growth pattern
  - Sparse population of small lymphocytes admixed with spindle cells
  - Spindle cells may be seen surrounding occasional gland-like spaces

Cytologic Features

- Epithelial cells in most intrapulmonary thymomas are bland with minimal atypia
- Tumor cells are intimately admixed with small T lymphocytes in varying proportions

ANCILLARY TESTS

Immunohistochemistry

- Neoplastic epithelial cells show positive cytoplasmic staining for cytokeratins (AE1/AE3, CAM5.2, CK19)
- Neoplastic epithelial cells show strong nuclear positivity for p63
- Lymphocytes stain as immature T lymphoblasts (CD1a, TdT, and CD99 positive)
- Spindle cells are negative for mesenchymal markers of differentiation (S100 protein, SMA, desmin, CD34)

DIFFERENTIAL DIAGNOSIS

Lymphoblastic Lymphoma

- Sheets of lymphocytes with starry-sky appearance can be seen in both
- Positivity of small lymphocytes for TdT, CD3, and CD99 can be seen in both
- Lymphoma will be negative for cytokeratin stains
- Molecular studies will not show any gene rearrangements of T-cell receptors in thymoma

Well-Differentiated Squamous Cell Carcinoma

- Squamous cell carcinoma shows more prominent keratinization and cytologic atypia
- Lymphocytes in squamous cell carcinoma are of B-cell type rather than T lymphocytes
- Lobulation and perivascular spaces favor thymoma over squamous cell carcinoma

Sarcomatoid (Spindle Cell) Carcinoma

- Usually shows more pronounced cytologic atypia and mitotic activity than spindle cell thymoma
- Lacks immature T-lymphocytic component
- Negative for p63

Intrapulmonary Solitary Fibrous Tumor (Hemangiopericytoma)

- Prominent hemangiopericytic growth pattern can be seen in both
- Tumor cells are negative for cytokeratin stains and p63 and positive for CD34, Bcl-2 and STAT6

SELECTED REFERENCES

1. Ishibashi F et al: Differential diagnosis of primary intrapulmonary thymoma: a report of two cases. Surg Case Rep. 1(1):56, 2015
2. Myers PO et al: Primary intrapulmonary thymoma: a systematic review. Eur J Surg Oncol. 33(10):1137-41, 2007
3. Moran CA et al: Primary intrapulmonary thymoma. A clinicopathologic and immunohistochemical study of eight cases. Am J Surg Pathol. 19(3):304-12, 1995
4. James CL et al: Intrapulmonary thymoma. Histopathology. 21(2):175-7, 1992
5. Fukayama M et al: Pulmonary and pleural thymoma. Diagnostic application of lymphocyte markers to the thymoma of unusual site. Am J Clin Pathol. 89(5):617-21, 1988

Lymphocyte-Rich Intrapulmonary Thymoma

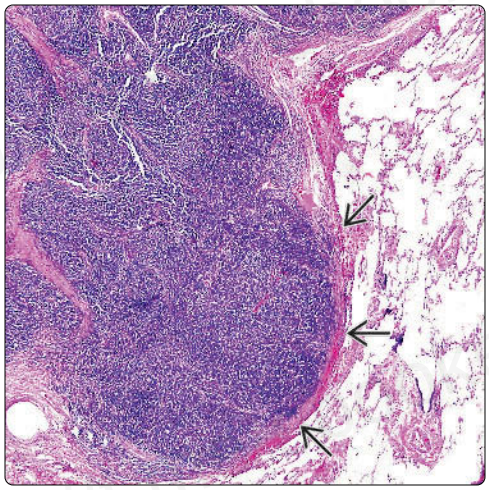

Thymic Epithelial Cells

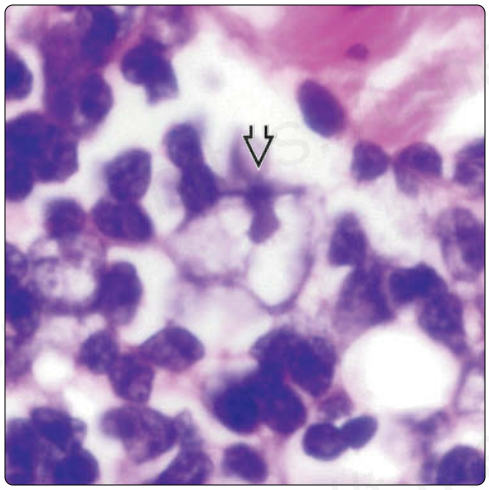

(Left) *Scanning magnification of intrapulmonary thymoma of lymphocyte-rich type (WHO B1) shows a dense population of small lymphoid cells sharply separated from the surrounding lung parenchyma by a thin fibrous capsule.* **(Right)** *Higher magnification of an intrapulmonary lymphocyte-rich thymoma shows a large cell with a vesicular nucleus and prominent eosinophilic nucleolus corresponding to a neoplastic thymic epithelial cell. Notice the large number of surrounding small lymphocytes.*

Mixed Lymphoepithelial Thymoma

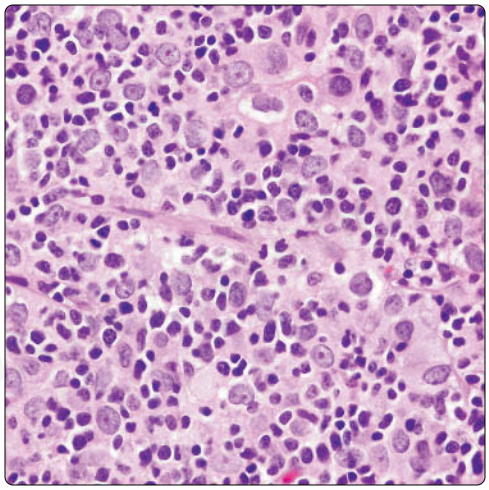

AE1/AE3 Cytokeratin Immunostaining

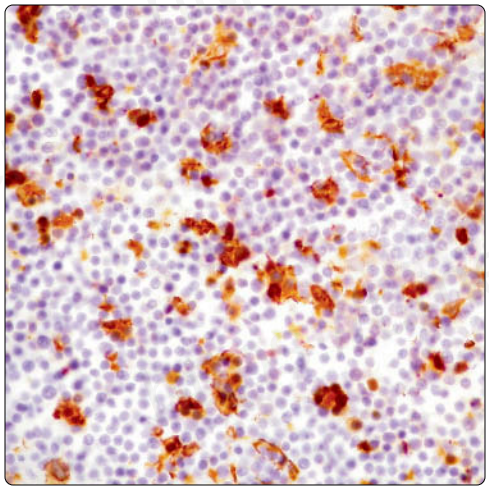

(Left) *Example of an intrapulmonary thymoma of lymphoepithelial type (WHO B2) shows an approximately even admixture of small lymphocytes and neoplastic thymic epithelial cells.* **(Right)** *Immunohistochemical staining of a lymphocyte-rich intrapulmonary thymoma for cytokeratin AE1/AE3 shows scattered keratin(+) (dark brown) cells corresponding to the neoplastic thymic epithelial cells. Notice the abundance of nonreactive small lymphocytes in the background.*

Intrapulmonary Spindle Cell Thymoma

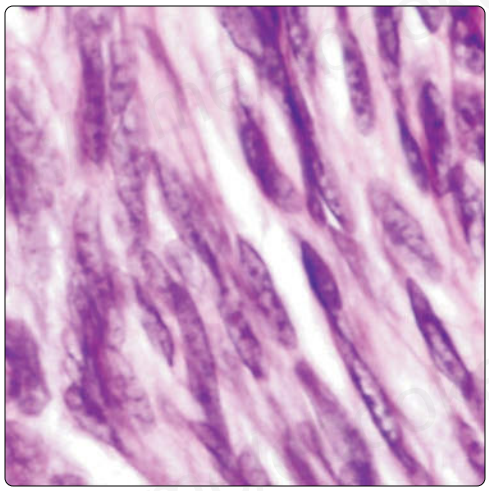

p63 Immunostaining

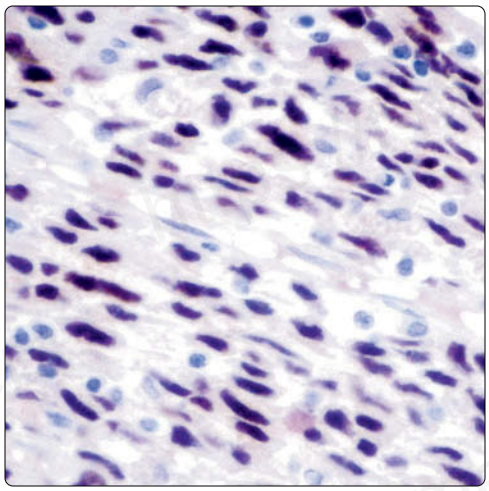

(Left) *Intrapulmonary spindle cell thymoma is composed of cells with slender nuclei with a scattered chromatin pattern and a scant rim of amphophilic cytoplasm. Notice the absence of small lymphocytes, cytologic atypia, or mitotic activity.* **(Right)** *Immunohistochemical staining of an intrapulmonary spindle cell thymoma for p63 antigen shows nuclear positivity in the spindle cells. p63 is a sensitive (although nonspecific) marker for thymic epithelial cells.*

Intrapulmonary Atypical Thymoma

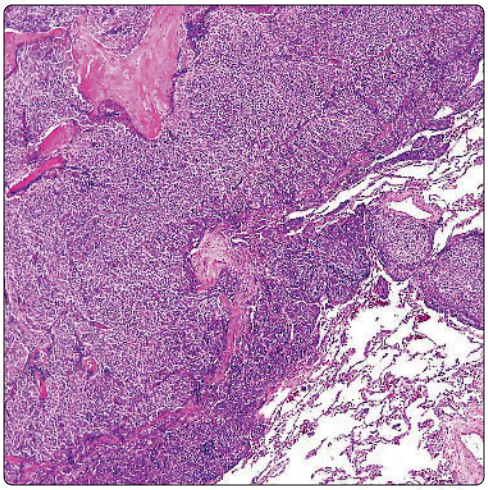

Lobulation in Atypical Thymoma

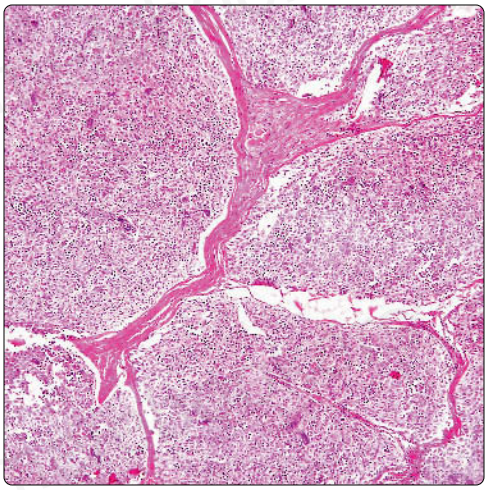

(Left) *Scanning magnification of an intrapulmonary atypical thymoma (WHO B3) shows sheets of large epithelioid cells separated from the surrounding lung parenchyma.* **(Right)** *Intrapulmonary atypical thymoma shows striking lobulation with large nodules of epithelial cells separated by broad bands of fibrous connective tissue. Preservation of the lobular architecture is one of the organotypical features of the thymus that distinguishes atypical thymoma (WHO B3).*

Atypical Thymoma: High Power

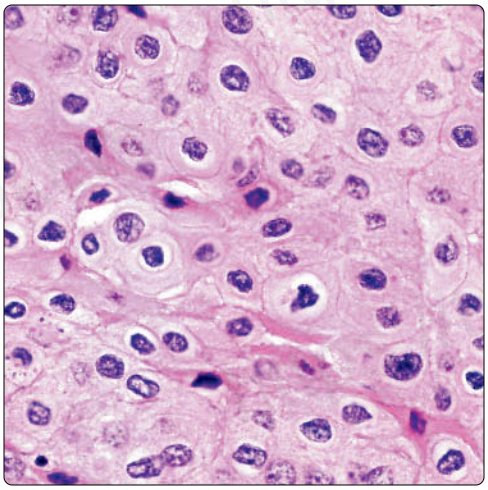

p63 Immunostaining

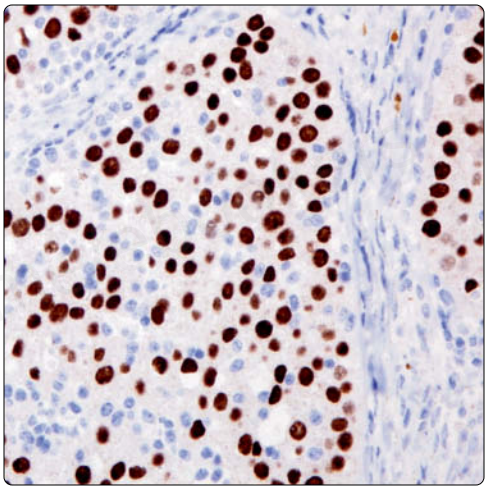

(Left) *High magnification of an intrapulmonary atypical thymoma shows sheets of round to polygonal epithelial cells with round to oval nuclei surrounded by an ample rim of eosinophilic cytoplasm with sharp cell borders. The sharp cell borders give the tumor a distinctive squamoid appearance.* **(Right)** *Immunohistochemical staining of intrapulmonary atypical thymoma with p63 antibody shows strong nuclear positivity of the tumor cells for this marker.*

Cytokeratin AE1/AE3 in Atypical Thymoma

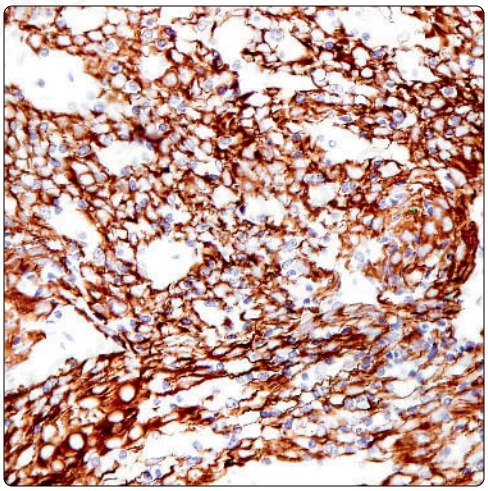

CD1a Immunostaining

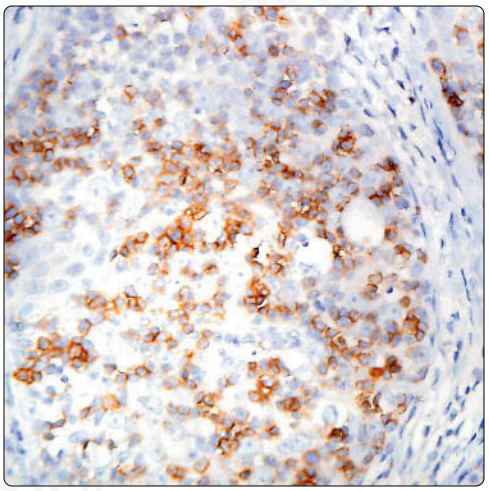

(Left) *Immunohistochemical staining of intrapulmonary atypical thymoma with broad-spectrum keratin (AE1/AE3) shows strong cytoplasmic positivity of the tumor cells.* **(Right)** *Immunohistochemical staining of intrapulmonary atypical thymoma with CD1a shows a few scattered positive small lymphocytes in the background. The demonstration of CD1a or TdT (+) immature T lymphoblasts admixed with the epithelial cells supports the thymic derivation of the tumor.*

Pulmonary Paraganglioma

KEY FACTS

TERMINOLOGY

- Primary neuroendocrine lung neoplasm derived from ectopic paraganglionic elements

CLINICAL ISSUES

- Extremely rare tumor in pulmonary location
- Solitary, peripheral coin lesion
- Central, endobronchial lesion
- Middle-aged adults (40-50 years)
- Endobronchial lesion may present with obstructive symptoms
- Majority of reported cases have been benign

MICROSCOPIC

- Principal feature is endocrine or organoid growth pattern
- Most common pattern of growth is discrete nests of tumor cells separated by fibrovascular septa (zellballen pattern)
- Large round or polygonal cells with abundant eosinophilic cytoplasm
- Large round cells with abundant clear cytoplasm
- Elongated cells with spindle nuclei and abundant cytoplasm
- Oncocytic cells with abundant granular eosinophilic cytoplasm
- Foci containing cells with macronuclei or bizarre nuclei but devoid of mitotic activity are common

ANCILLARY TESTS

- Strong positivity of tumor cells for neuroendocrine-associated markers, including chromogranin, synaptophysin, and CD56
- S100(+) sustentacular cells are seen surrounding tumor cell "nests"

DIAGNOSTIC CHECKLIST

- Histologic features are notoriously unreliable for predicting biologic behavior

Pulmonary Paraganglioma

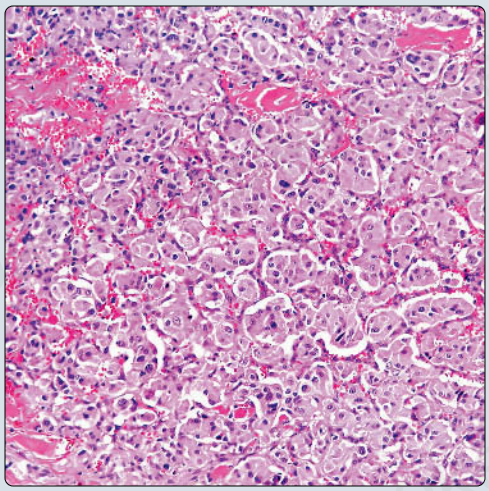

Zellballen Pattern

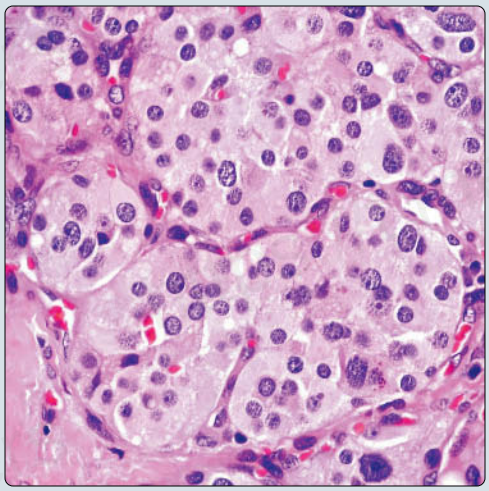

(Left) *Scanning magnification of pulmonary paraganglioma shows characteristic neuroendocrine architecture (zellballen pattern) of these tumors composed of discrete "nests" of epithelioid cells.* **(Right)** *Higher magnification of pulmonary paraganglioma shows a population of tumor cells with round nuclei and a stippled chromatin pattern that is surrounded by an ample rim of eosinophilic cytoplasm.*

Nucleomegaly

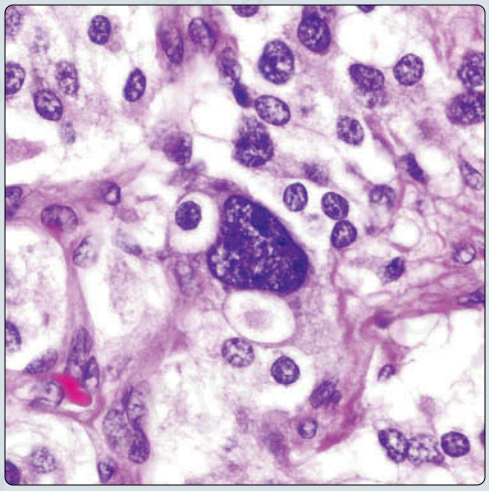

Chromogranin Immunostaining

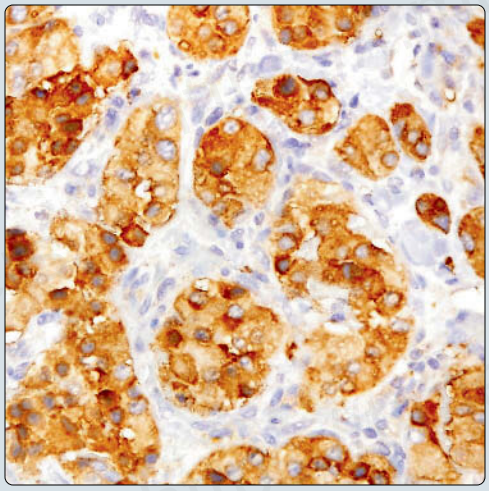

(Left) *Higher magnification of pulmonary paraganglioma shows one of the distinctive features of this tumor: Cells with enlarged, hyperchromatic nuclei with prominent nucleoli. In the absence of associated mitotic activity, this is regarded as an example of endocrine atypia.* **(Right)** *Immunohistochemical stain for chromogranin-A in pulmonary paraganglioma shows cytoplasmic positivity of the tumor cells.*

TERMINOLOGY

Synonyms

- Pulmonary chemodectoma, extraadrenal paraganglioma

Definitions

- Primary neuroendocrine lung neoplasm derived from ectopic paraganglionic elements

CLINICAL ISSUES

Epidemiology

- Incidence
  - Extremely rare tumor in pulmonary location
- Age
  - Middle-aged adults (40-50 years)
- Sex
  - Male predominance

Presentation

- Solitary, peripheral coin lesion
- Central, endobronchial lesion
- Endocrine symptoms (hypertension, increased serum norepinephrine, Cushing syndrome)
- Endobronchial lesion may present with obstructive symptoms (cough, wheezing, dyspnea)

Treatment

- Surgical excision

Prognosis

- Majority of reported cases have been benign

MACROSCOPIC

General Features

- Well-circumscribed intraparenchymatous nodule
- Smooth, well-circumscribed endobronchial lesion

MICROSCOPIC

Histologic Features

- Principal feature is endocrine or organoid growth pattern
- Most common pattern of growth is discrete nests of tumor cells separated by fibrovascular septa (zellballen pattern)
- Rare cases may show prominent stromal sclerosis
- Foci of necrosis or vascular invasion are only rarely encountered
- Stroma may be very vascularized with large, ectatic vessels
- Trabecular, microacinar, or ribbon-like growth patterns are distinctively rare in paraganglioma

Cytologic Features

- Large, round or polygonal cells with abundant eosinophilic cytoplasm
- Large, round cells with abundant clear cytoplasm
- Elongated cells with spindle nuclei and abundant cytoplasm
- Oncocytic cells with abundant granular eosinophilic cytoplasm
- Cell nuclei are generally small and contain inconspicuous nucleoli
- Foci containing cells with macronuclei or bizarre nuclei but devoid of mitotic activity are common
- Mitoses are rare and usually normal
- Intranuclear cytoplasmic inclusions ("pseudoinclusions") can be occasionally identified
- Large cells with abundant cytoplasm and large nuclei resembling ganglion cells can also be occasionally seen

ANCILLARY TESTS

Frozen Sections

- Immersion of fresh tissue in Bouin fixative or other picric acid-containing solution will characteristically turn specimen brown

Immunohistochemistry

- Strong positivity of tumor cells for neuroendocrine-associated markers, including chromogranin, synaptophysin, and CD56
- S100 protein-positive sustentacular cells are seen surrounding tumor cell nests
- Tumor cells contain neurofilament-type intermediate filaments, but these may be difficult to demonstrate by immunohistochemistry
- Other peptides that may be expressed by tumor cells include ACTH, VIP, leu- or met-enkephalins, and calcitonin

Electron Microscopy

- Large cells containing abundant cytoplasmic dense-core neurosecretory granules
  - Dense-core granules are characterized by eccentric halos imparting them with blister-like appearance

DIFFERENTIAL DIAGNOSIS

Well-Differentiated Neuroendocrine Carcinoma (Carcinoid Tumor)

- Tumor cells are universally positive for cytokeratins
- S100(+) sustentacular cells may also be present in carcinoid tumors
- Microacinar, trabecular, or ribbon-like growth patterns favor diagnosis of carcinoid tumor

Metastatic Paraganglioma to Lung

- Rare event; clinical history of previous tumor is only reliable means for making this diagnosis

DIAGNOSTIC CHECKLIST

Clinically Relevant Pathologic Features

- Histologic features are notoriously unreliable for predicting biologic behavior
- Diagnosis of malignancy is established based on documentation of metastases
- Most common differential diagnosis is with pulmonary "carcinoid" tumor

SELECTED REFERENCES

1. Huang X et al: Primary pulmonary paraganglioma: a case report and review of literature. Medicine (Baltimore). 94(31):e1271, 2015
2. Shibahara J et al: Primary pulmonary paraganglioma: report of a functioning case with immunohistochemical and ultrastructural study. Am J Surg Pathol. 28(6):825-9, 2004
3. Cerilli LA et al: Neuroendocrine neoplasms of the lung. Am J Clin Pathol. 116 Suppl:S65-96, 2001

Zellballen Growth Pattern

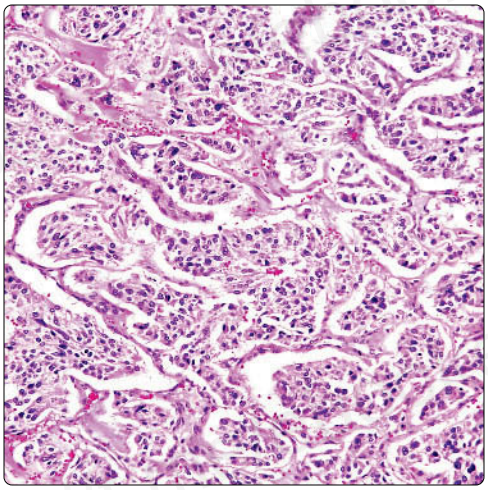

Sheet Like-Growth Pattern

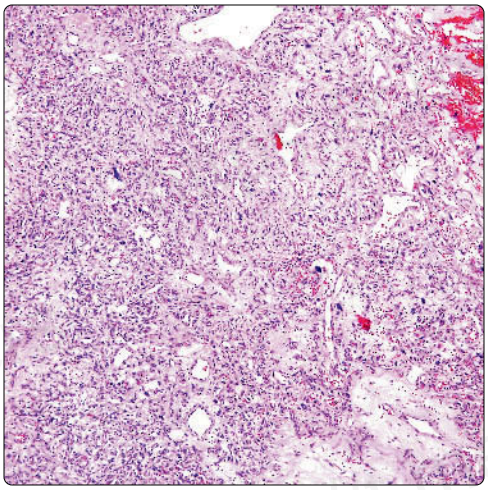

(Left) *Organoid growth pattern is the most typical appearance of a pulmonary paraganglioma and is characterized by well-defined nests of relatively uniform tumor cells surrounded by delicate fibrovascular septa (zellballen pattern).* **(Right)** *A more diffuse, sheet-like growth pattern can occasionally be observed in pulmonary paraganglioma and is caused by the confluence of the nests of tumor cells. Other areas in the same tumor, however, display the characteristic zellballen pattern.*

Stromal Sclerosis

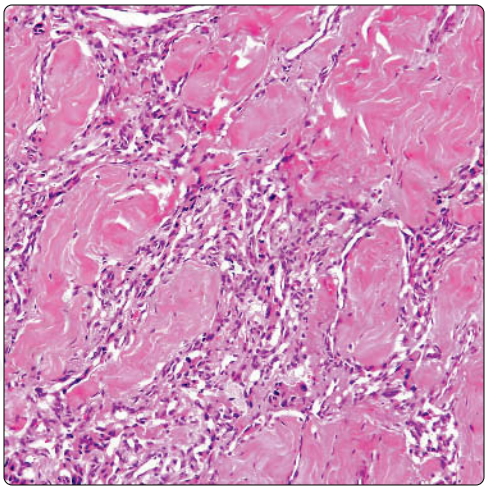

Compressed Tumor Cells

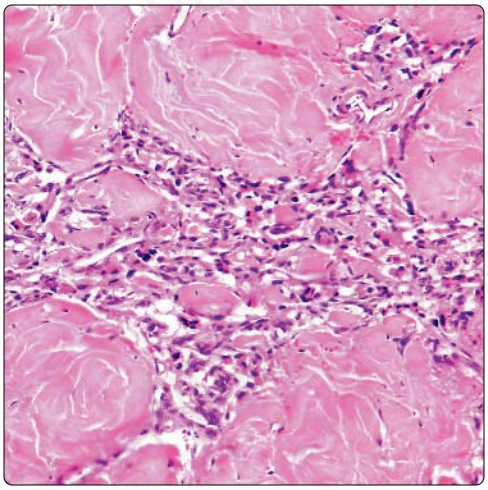

(Left) *Stromal sclerosis is another feature that may sometimes be observed in pulmonary paraganglioma. It is characterized by heavy deposits of dense collagen in the stroma surrounding the nests of tumor cells.* **(Right)** *Higher magnification of pulmonary paraganglioma with stromal sclerosis shows heavy deposits of hyalinized collagen circumscribing residual islands of tumor cells. The tumor cells in such cases tend to become distorted and often adopt an oval or spindled appearance.*

Perivascular Distribution

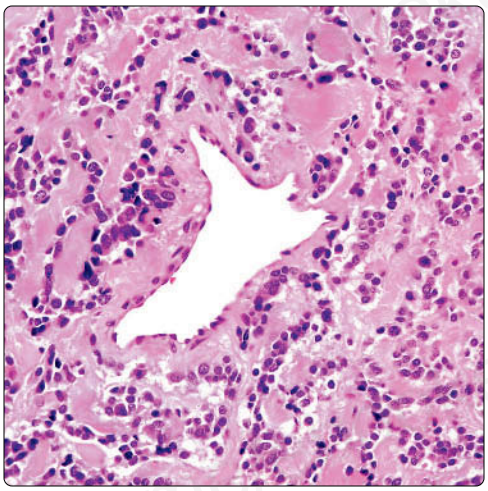

Perivascular Hyalinization

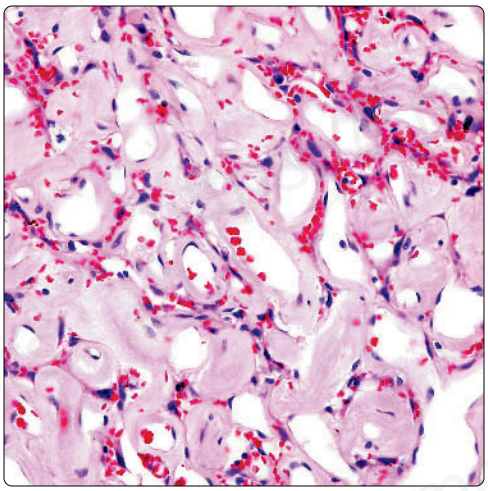

(Left) *Perivascular targetoid arrangement of tumor cells may be seen in pulmonary paraganglioma. The tumor cells tend to become arranged concentrically around the lumen of the vessel walls and to aggregate in small clusters that are separated by collagenized stroma.* **(Right)** *Perivascular hyalinization and stromal sclerosis are other features that can be observed focally in many paragangliomas as an expression of degenerative or involuting changes within the tumor.*

Neuroendocrine Appearance of Cells

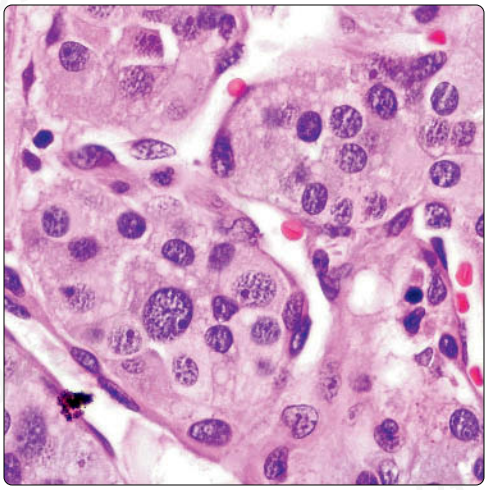

Nucleomegaly

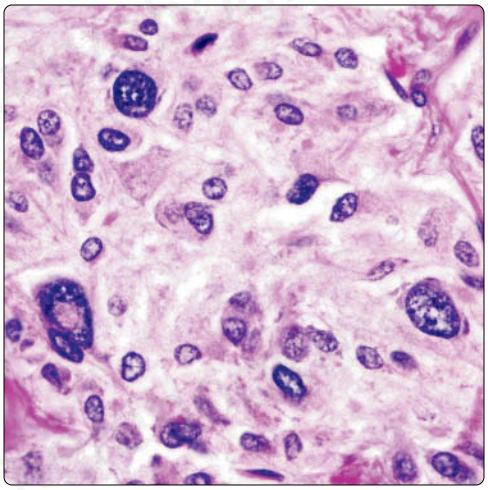

(Left) *Characteristic histology of pulmonary paraganglioma shows cells with round nuclei showing a dispersed chromatin pattern surrounded by an ample rim of granular, eosinophilic cytoplasm.* **(Right)** *High magnification of pulmonary paraganglioma shows nucleomegaly, with a few markedly enlarged, hyperchromatic nuclei. The presence of these atypical nuclei in the absence of significant or abnormal mitotic activity has no prognostic significance.*

Mitotic Figure

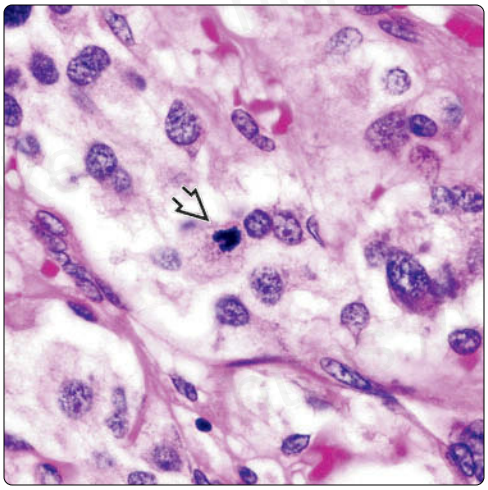

Chromogranin Immunoreactivity

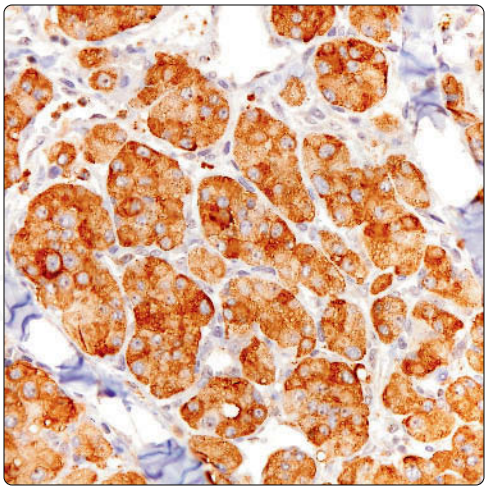

(Left) *An isolated mitotic figure is seen in the center of the field ⇨ in this pulmonary paraganglioma. Rare mitoses can be observed in otherwise benign paragangliomas, and this feature does not necessarily correlate with a more aggressive clinical behavior.* **(Right)** *Chromogranin stain in pulmonary paraganglioma shows diffuse cytoplasmic positivity. Unlike other "neuroendocrine" neoplasms, paragangliomas are almost always negative for cytokeratin stains.*

S100(+) Sustentacular Cells

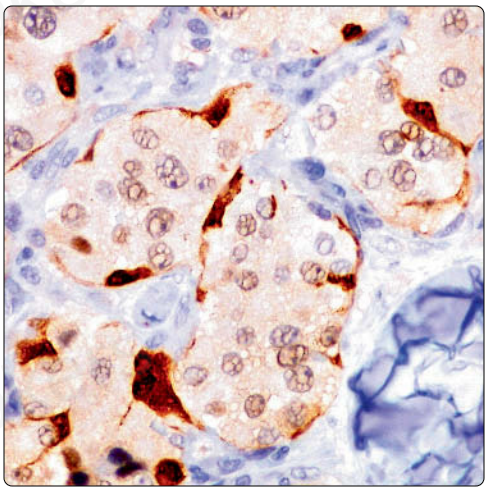

Dense Core Neurosecretory Granules



(Left) *Immunohistochemical staining of pulmonary paraganglioma for S100 protein shows a network of "sustentacular" S100(+) tumor cells surrounding the tumor cell "nests."* **(Right)** *Ultrastructural appearance of a tumor cell in pulmonary paraganglioma shows multiple membrane-bound, dense-core neurosecretory cytoplasmic granules. Notice the blister-like appearance of the granules caused by retraction of the membranes and eccentric location of the dense cores.*

Pulmonary Meningioma

KEY FACTS

TERMINOLOGY

- Primary intrapulmonary meningothelial neoplasm

CLINICAL ISSUES

- Cough
- Asymptomatic
- Lobectomy
- Wedge excision in small tumors
- Good prognosis in conventional cases
- Aggressive behavior in malignant tumors

MACROSCOPIC

- Varying tumor size: 1-6 cm
- Well circumscribed

MICROSCOPIC

- Spindle (fibrous meningioma)
- Meningothelial (transitional meningioma)
- Presence of psammoma bodies
- Whorled pattern
- Spindle cells arranged in subtle storiform pattern

ANCILLARY TESTS

- EMA
- Vimentin
- CK-PAN
- CD34
- TTF-1

TOP DIFFERENTIAL DIAGNOSES

- Well-differentiated neuroendocrine carcinoma (carcinoid)
- Malignant meningioma
- Meningothelial-like nodule
- Meningotheliomatosis
- Solitary fibrous tumor
- Spindle cell thymoma

Well-Circumscribed Tumor

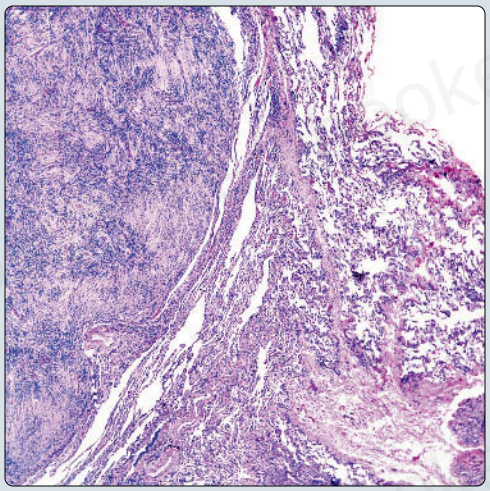

Mixed Component

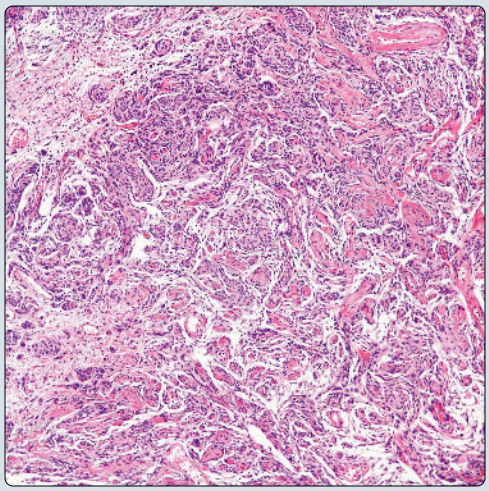

(Left) *Hematoxylin & eosin section shows a well-circumscribed intraparenchymal tumor replacing the normal lung parenchyma.* **(Right)** *Meningioma shows conventional transitional areas and spindle cell areas. Note the presence of dilated ectatic and sclerotic blood vessels.*

Spindle Cells

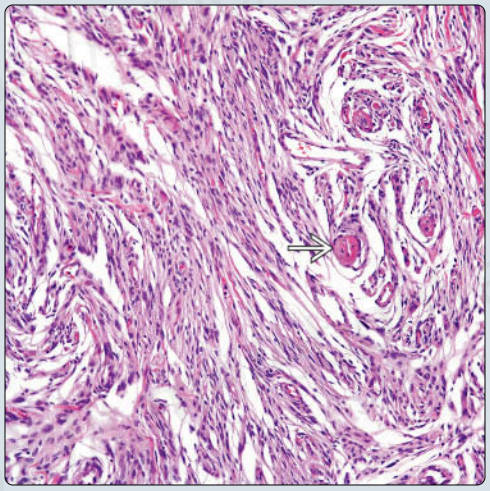

Spindle Cells

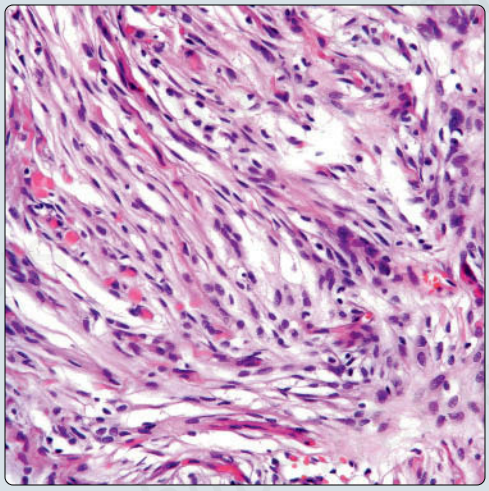

(Left) *Meningioma shows a spindle cell proliferation. Note the absence of nuclear atypia and mitotic activity. Several dilated sclerotic blood vessels are also present* ➡. **(Right)** *Predominantly spindle cell meningioma is shown with only focal areas of round (transitional) meningioma. The tumor lacks nuclear atypia and mitotic activity.*

TERMINOLOGY

Definitions

- Primary intrapulmonary meningothelial neoplasm

ETIOLOGY/PATHOGENESIS

Etiology

- Previous meningothelial-like nodules
- In cases where pulmonary meningioma is associated with other small lesions of same histology
- Pluripotential cells
- Cells capable of undergoing differentiation toward meningothelial cells
- Heterotopic embryonic rests
- Possible ectopic neuroectodermal tissue in lung

CLINICAL ISSUES

Epidemiology

- Incidence
  - Primary pulmonary meningiomas are exceedingly rare
  - Only few short series of cases have been reported
- Age
  - More common in adults
- Sex
  - No gender predilection for pulmonary meningiomas

Presentation

- Asymptomatic
- Cough
- Chest pain
- Shortness of breath

Treatment

- Surgical approaches
  - Lobectomy
  - Wedge excision in small tumors

Prognosis

- Generally excellent prognosis
- Aggressive behavior in malignant tumors

MACROSCOPIC

General Features

- Varying tumor size: 1-6 cm
- Well-circumscribed tumor
- Cut surface is white and homogeneous

MICROSCOPIC

Histologic Features

- Presence of psammoma bodies
- Whorled pattern of growth
- Spindle cells arranged in subtle storiform pattern
- Focal areas with presence of foamy macrophages
- Mixture of meningothelial "transitional" and spindle cells
- Absence of mitotic activity
- Necrosis in cases of malignant meningioma
- Increased mitotic activity in malignant meningioma
- Nuclear atypia and intranuclear inclusions in cases of malignant meningioma

Predominant Pattern/Injury Type

- Whorled
- Spindle cells

Predominant Cell/Compartment Type

- Meningothelial
- Spindle

DIFFERENTIAL DIAGNOSIS

Well-Differentiated Neuroendocrine Carcinoma (Carcinoid)

- Usually does not show characteristic whorled pattern
- Presence of psammoma bodies would be unusual for carcinoid tumors
- Presence of mixed histologies of spindle and transitional cells is not characteristic of carcinoid tumors
- Meningiomas are negative for neuroendocrine markers, whereas carcinoid tumors are positive

Malignant Meningioma

- Increased mitotic activity &/or presence of necrosis and hemorrhage
- Nuclear atypia and intranuclear inclusions are common
- Similar immunophenotype as conventional pulmonary meningioma

Meningothelial-Like Nodule

- Usually < 5 mm and may represent incidental finding
- Histology of both lesions is similar
- Similar immunophenotype as conventional pulmonary meningioma

Meningotheliomatosis

- Characterized by multiple small tumors
- Tumor nodules are < 5 cm in diameter
- Similar immunophenotype as conventional pulmonary meningioma

Solitary Fibrous Tumor

- Would not show strong positivity for EMA
- STAT6 and CD34 are commonly positive

Spindle Cell Thymoma

- Thymomas are usually positive for keratin
- Thymomas are usually negative for EMA
- Spindle cell thymomas may still show scattered lymphocytes

DIAGNOSTIC CHECKLIST

Pathologic Interpretation Pearls

- Whorled pattern
- Spindle cell pattern
- Mixed spindle and transitional pattern
- Psammoma bodies
- Lack of mitotic activity
- Lack of necrosis
- Usually tumor < 3 cm in diameter

Immunohistochemistry

Antibody	Reactivity	Staining Pattern	Comment
EMA/MUC1	Positive	Cell membrane	Diffuse
CK-PAN	Positive	Cytoplasmic	Focal in few cases
TTF-1	Positive	Nuclear	In some cases
ER	Positive	Nuclear	In some cases
PR	Negative		
Vimentin	Positive		
CK5/6	Negative		
STAT6	Negative		
p40	Negative		
p63	Negative		
S100	Negative		
CD31	Negative		
CD34	Negative		May show focal positive staining in fibrous meningiomas
β-catenin	Negative		
Bcl-2	Negative		
pax-8	Negative		
Ki-67	Positive	Nuclear	Varies from scattered positive cells to > 5% in cases of malignant meningioma

Histochemical Features

Stain	Result
PAS	Negative
PAS-D	Negative
Mucicarmine	Negative

Molecular Features

FISH	Result
1)	Positive in some cases

GRADING

Malignant Meningioma

- Presence of increased mitotic activity &/or necrosis and hemorrhage

SELECTED REFERENCES

1. Kim YY et al: Primary pulmonary meningioma: an unusual cause of a nodule with strong and homogeneous enhancement. Clin Imaging. 40(1):170-3, 2016
2. Caobelli F et al: A very unusual and aggressive form of a primary pulmonary meningioma seen with a ^{68}Ga-DOTATOC PET/CT image. Rev Esp Med Nucl Imagen Mol. 34(2):123-4, 2015
3. Chiarelli M et al: An incidental pulmonary meningioma revealing an intracranial meningioma: primary or secondary lesion? Ann Thorac Surg. 99(4):e83-4, 2015
4. Weissferdt A et al: Pleuropulmonary meningothelial proliferations: evidence for a common histogenesis. Am J Surg Pathol. 39(12):1673-8, 2015
5. Lepanto D et al: Atypical primary pulmonary meningioma: a report of a case suspected of being a lung metastasis. Ecancermedicalscience. 8:414, 2014
6. Ocque R et al: Cytopathology of extracranial ectopic and metastatic meningiomas. Acta Cytol. 58(1):1-8, 2014
7. Scognamiglio G et al: CD90 expression in atypical meningiomas and meningioma metastasis. Am J Clin Pathol. 141(6):841-9, 2014
8. Bernabeu Mora R et al: Diffuse pulmonary meningotheliomatosis diagnosed by transbronchial lung biopsy. Respiration. 86(2):145-8, 2013
9. Okiror L et al: Solitary lung meningioma with synchronous brain nodules: clinical and pathological features. Gen Thorac Cardiovasc Surg. 61(11):648-50, 2013
10. Weber C et al: Primary pulmonary malignant meningioma with lymph node and liver metastasis in a centenary woman, an autopsy case. Virchows Arch. 462(4):481-5, 2013
11. Masago K et al: Is primary pulmonary meningioma a giant form of a meningothelial-like nodule? A case report and review of the literature. Case Rep Oncol. 5(2):471-8, 2012
12. Incarbone M et al: Primary pulmonary meningioma: report of a case and review of the literature. Lung Cancer. 62(3):401-7, 2008
13. Meirelles GS et al: Primary pulmonary meningioma manifesting as a solitary pulmonary nodule with a false-positive PET scan. J Thorac Imaging. 21(3):225-7, 2006
14. van der Meij JJ et al: Primary pulmonary malignant meningioma. Ann Thorac Surg. 80(4):1523-5, 2005
15. Kros J et al: NF2 status of meningiomas is associated with tumour localization and histology. J Pathol. 194(3):367-72, 2001
16. Prayson RA et al: Primary pulmonary malignant meningioma. Am J Surg Pathol. 23(6):722-6, 1999
17. Moran CA et al: Primary intrapulmonary meningiomas. A clinicopathologic and immunohistochemical study of ten cases. Cancer. 78(11):2328-33, 1996

Transitional Meningioma

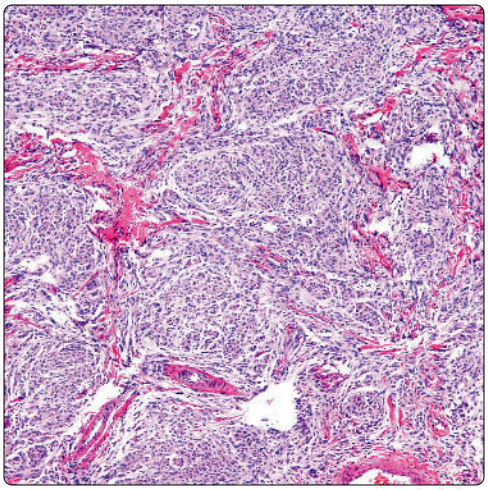

Whorling

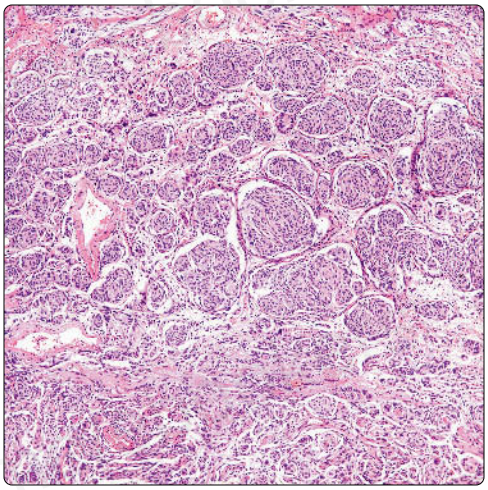

(Left) *Hematoxylin & eosin section shows a vague nested pattern separated in some areas by fibrocollagenous tissue. The tumor shows a homogeneous growth pattern without areas of necrosis or hemorrhage.* **(Right)** *Hematoxylin & eosin section shows a characteristic whorled pattern of growth. Tumor cells are separated in small nests by thin fibrocollagenous tissue. The cellular proliferation is fairly homogeneous. Areas of necrosis are absent.*

Presence of Collagen

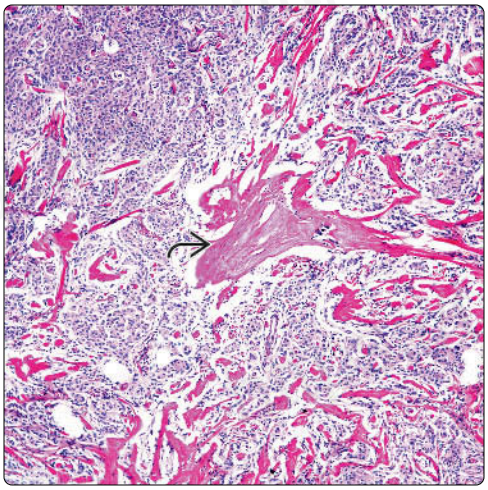

Small Vessel Proliferation

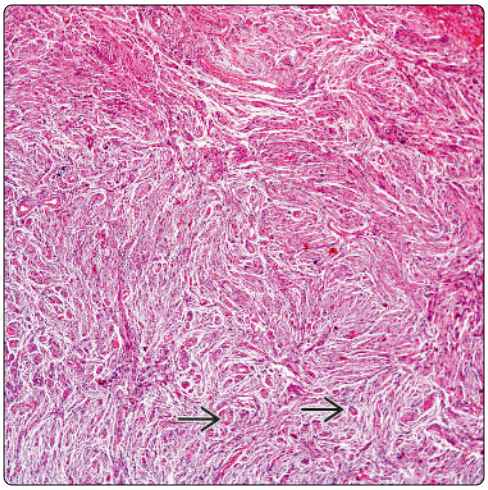

(Left) *This pulmonary meningioma shows extensive areas of collagenization ⇨, which can be misinterpreted as true mesenchymal neoplasms. Such areas are uncommon and are more often seen in fibrous meningiomas.* **(Right)** *Hematoxylin & eosin section shows a more prominent spindle cell component with a proliferation of small ectatic vessels ⇨. This growth pattern may suggest a true mesenchymal tumor. Still, nuclear atypia and mitotic activity are absent.*

Psammoma Bodies

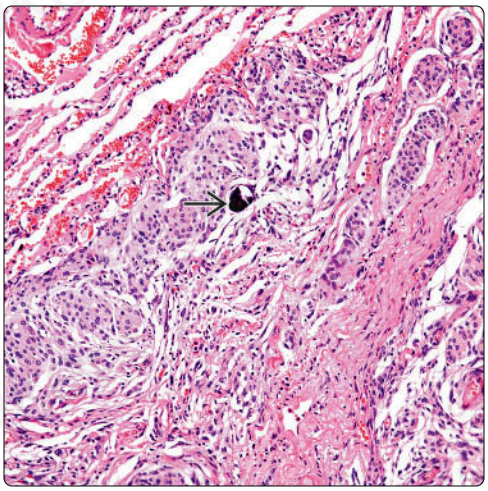

Bland Cytology

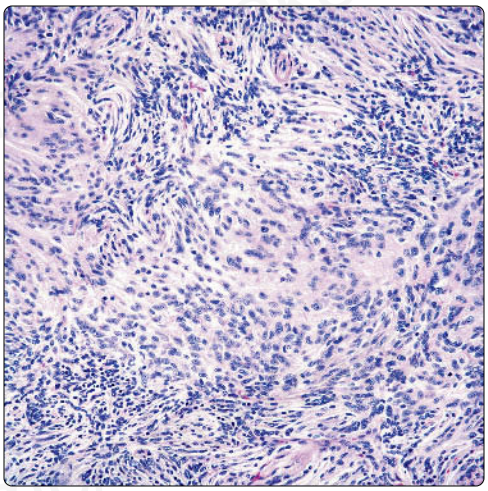

(Left) *Hematoxylin & eosin section shows a characteristic whorled pattern with the presence of psammoma bodies ⇨ toward the periphery of the tumor. In some cases, the presence of these calcifications may be focal or numerous.* **(Right)** *Hematoxylin & eosin section shows a high-power view of an intrapulmonary meningioma with a homogeneous growth pattern composed of rather small oval cells. Note the absence of mitotic activity or nuclear pleomorphism.*

Spindle and Round Cells

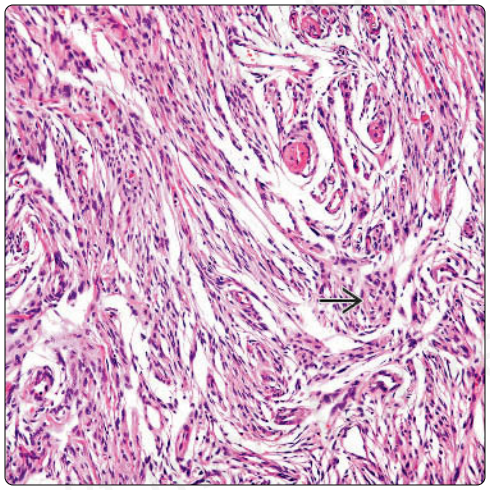

Mixed Histology

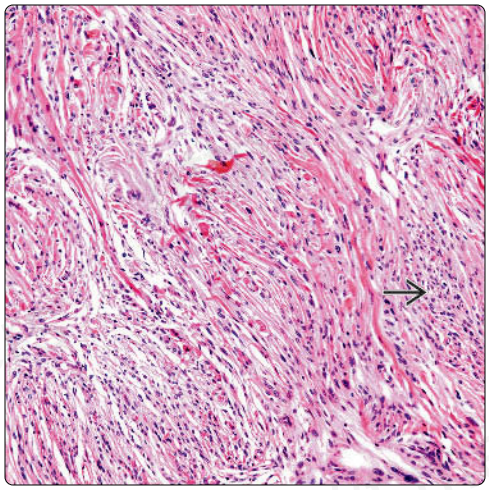

(Left) *Hematoxylin & eosin section shows a fibrous meningioma composed of spindle cells arranged in a vague storiform pattern. In some focal areas, it is still possible to identify transitional areas.* **(Right)** *Hematoxylin & eosin section shows a fibrous meningioma composed of spindle cells admixed with collagen fibers. Note the absence of nuclear atypia or mitotic activity. Still, in some areas, a hint of more conventional transitional areas is visible.*

Neural Pattern

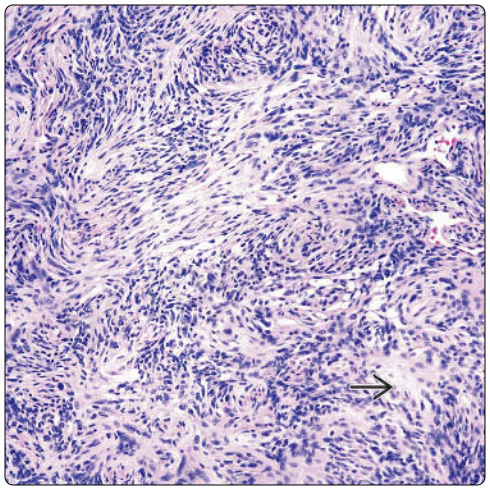

Neural Pattern

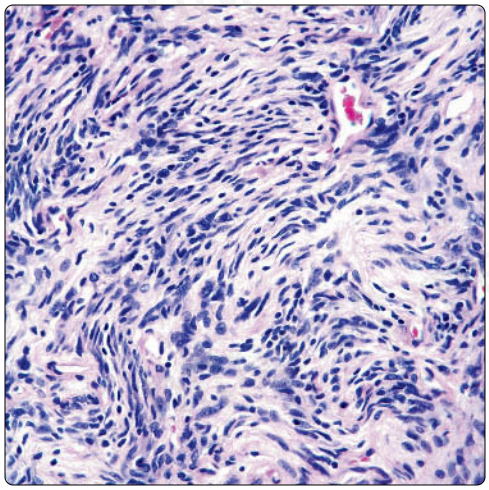

(Left) *Hematoxylin & eosin section shows a fibrous meningioma with focal areas of transitional meningioma and a characteristic whorled pattern. The pattern is reminiscent of a neural tumor.* **(Right)** *Hematoxylin & eosin section shows a high-power view of a fibrous meningioma displaying a pattern reminiscent of a neural tumor. The cellular proliferation is homogeneous and lacks mitotic activity and nuclear atypia.*

Inflammatory Reaction

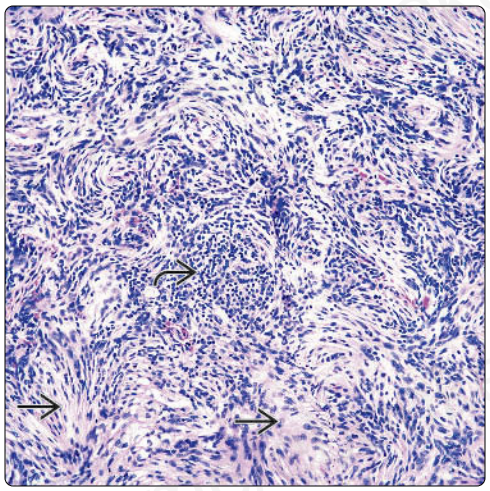

Psammoma Bodies

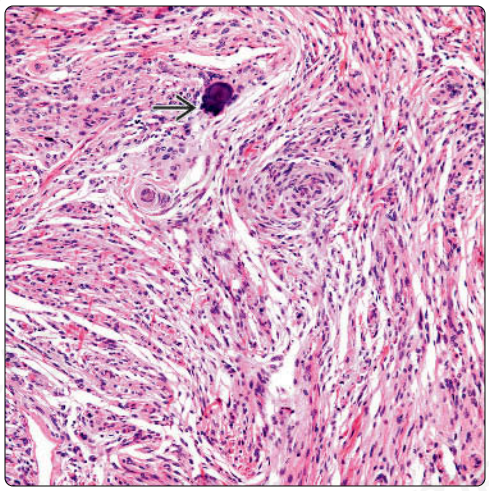

(Left) *Pulmonary meningioma with a spindle cell proliferation is admixed with inflammatory reaction composed mainly of lymphocytes. These features may be misleading for an inflammatory reaction; however, more conventional areas are also present.* **(Right)** *H&E toward the periphery of a fibrous meningioma shows more conventional areas of transitional meningioma with the presence of psammoma bodies. These areas are classic for the diagnosis of pulmonary meningioma.*

Malignant Meningioma

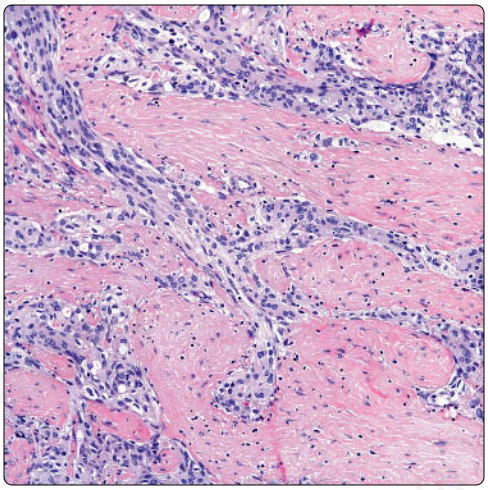

Clear Cells

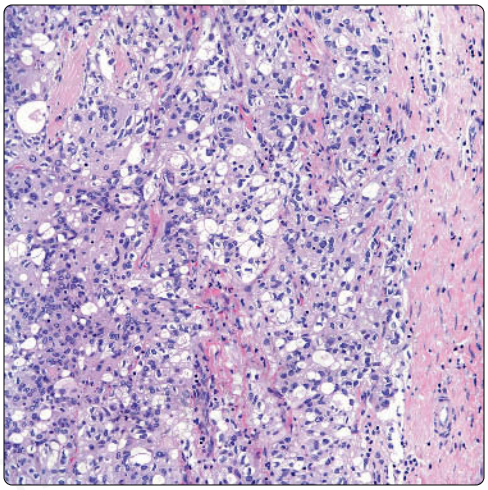

(Left) *Meningioma shows extensive areas of fibroconnective tissue. The tumor cells dissect the collagenous tissue. In this field, there is no nuclear atypia or mitotic activity.* **(Right)** *Malignant meningioma shows transitional meningioma areas admixed with areas of clear cell change. However, no mitotic activity or nuclear atypia is present.*

Mixed Areas

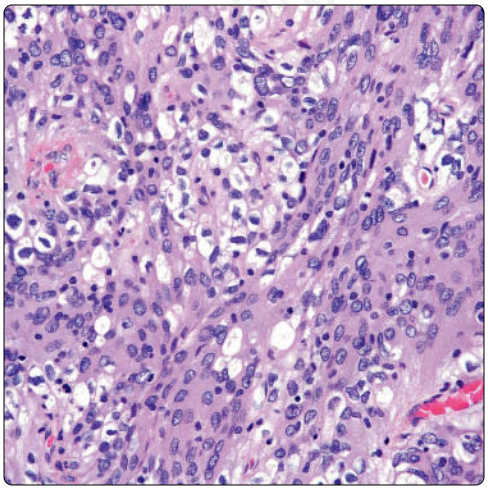

Clear Cells

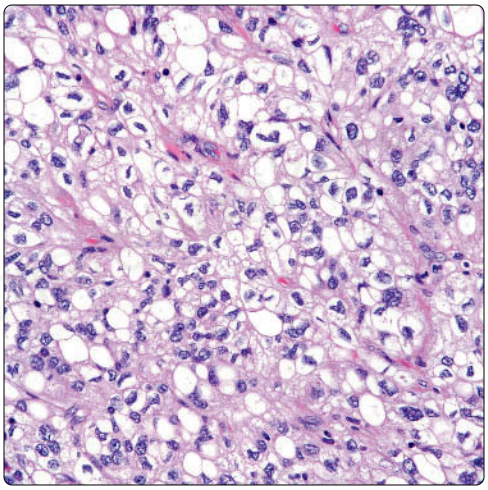

(Left) *Malignant meningioma shows mixed areas of transitional meningioma and a clear cell component. The clear cell component shows mild nuclear atypia. Mitosis is not present.* **(Right)** *Malignant meningioma shows prominent clear cell changes. There is mild to moderate nuclear atypia, but mitotic activity is not present.*

Neurophil-Like Areas

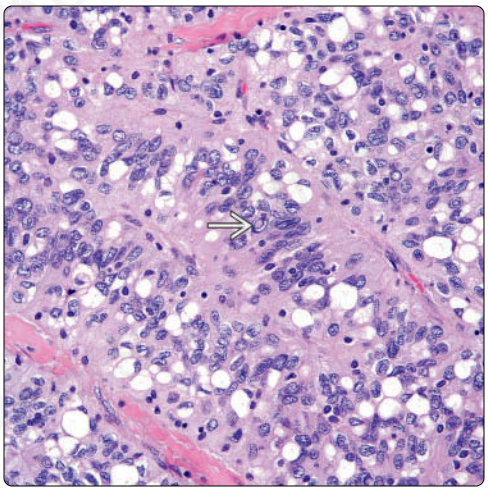

Mitotic Activity

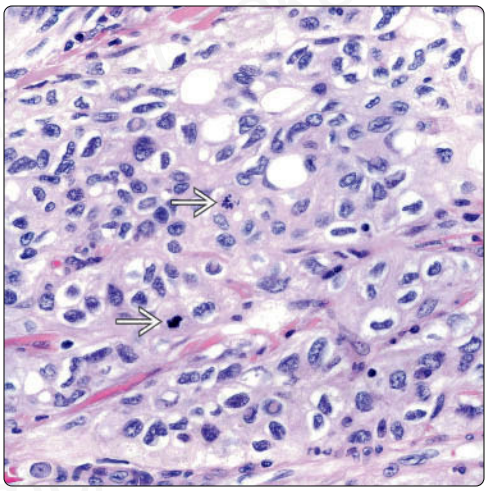

(Left) *Malignant meningioma shows areas of rosette-like formation and neurophil-like areas. Note some cells with intranuclear inclusions ➡ and mild nuclear atypia.* **(Right)** *Malignant meningioma shows a proliferation of cells with nuclear atypia, intranuclear inclusion, and mitotic activity ➡.*

Minute Pulmonary Meningothelial-Like Nodule

KEY FACTS

ETIOLOGY/PATHOGENESIS

- Believed to arise from rests displaced in lung during embryogenesis
- Distributed interstitially alongside small veins
- Often found in association with pulmonary thromboemboli

CLINICAL ISSUES

- Usually asymptomatic
- Can present with diffuse, symptomatic, bilateral interstitial lung infiltrates (diffuse pulmonary meningotheliomatosis)
- Lesions most often represent incidental finding of no clinical significance
- Found incidentally in lungs resected for other reasons, particularly lung adenocarcinoma

IMAGING

- Can present as randomly distributed micronodules on thin-section CT

MICROSCOPIC

- Ill-defined, focal accumulation of oval or epithelioid cells in pulmonary interstitium
- Oval or epithelioid cells tend to focally adopt whorled appearance
- Lesions may be microscopic (1-2 mm) or measure up to 1 cm in diameter
- Lesions may be seen in close proximity of vessels
- Cells are oval or epithelioid and surrounded by ample rim of eosinophilic cytoplasm with indistinct cell borders
- Cells contain small, centrally placed nuclei devoid of mitotic activity
- Nuclei may contain intranuclear cytoplasmic inclusions

ANCILLARY TESTS

- Tumor cells are positive for vimentin and EMA
- Cells contain long, branching, interdigitating cytoplasmic cell processes joined by numerous desmosomes

Spindle Cell Nodule

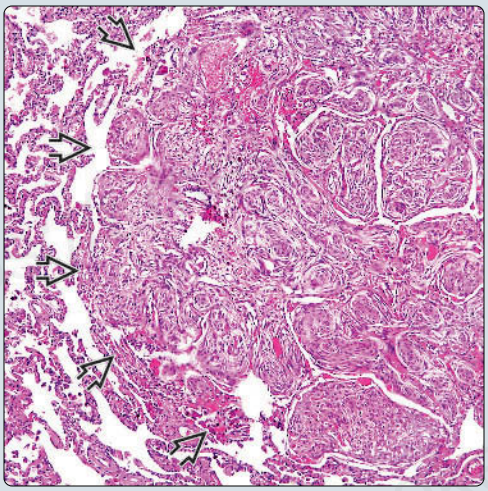

Meningothelial Whorls

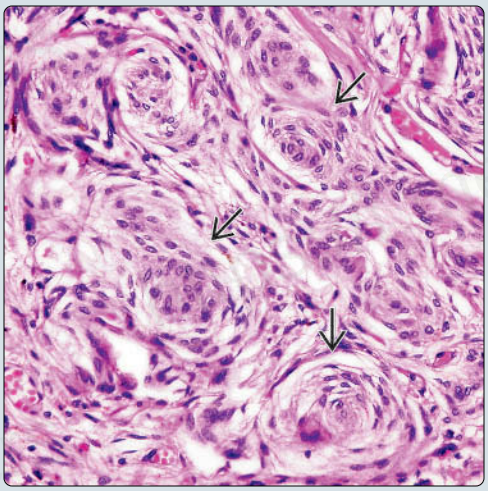

(Left) *Scanning magnification of a minute pulmonary meningothelial-like nodule shows well-circumscribed proliferation of epithelioid cells that are sharply separated from the surrounding lung parenchyma.* **(Right)** *High magnification of a minute pulmonary meningothelial-like nodule shows clusters and islands of round to oval cells with abundant eosinophilic cytoplasm displaying characteristic whorling effect.*

Meningothelial Whorl: High Power

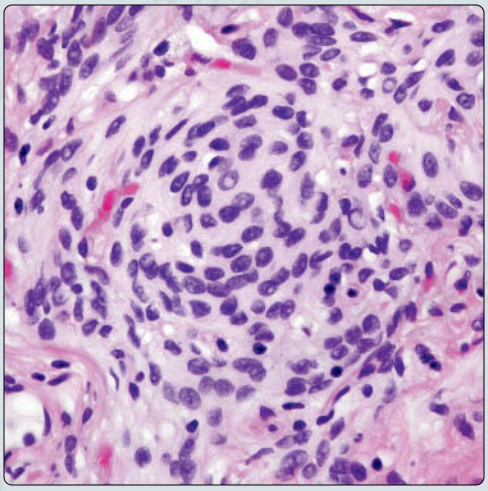

Meningothelial Cells

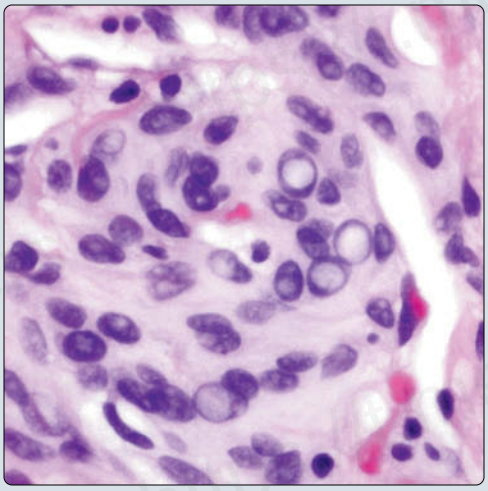

(Left) *Higher magnification of a minute pulmonary meningothelial-like nodule of the lung shows a solid cluster of cells with a concentric arrangement. The cells are devoid of cytologic atypia.* **(Right)** *Higher magnification of a minute pulmonary meningothelial-like nodule of the lung shows cells with round to oval nuclei with indistinct cytoplasm that contain numerous clear intranuclear cytoplasmic pseudoinclusions.*

TERMINOLOGY

Abbreviations

- Minute pulmonary meningothelial-like nodule (MMN)

Synonyms

- Minute pulmonary chemodectoma

Definitions

- Small, intrapulmonary nodules composed of cells bearing histologic, immunohistochemical, and ultrastructural features of meningothelial cells

ETIOLOGY/PATHOGENESIS

Developmental Anomaly

- Believed to arise from rests displaced in lung during embryogenesis
- Distributed interstitially alongside small veins
- Often found in association with pulmonary thromboemboli

Pathogenesis

- May result from clonal expansion as shown by amplification of X-linked human androgen receptor gene (HUMARA assay)

CLINICAL ISSUES

Presentation

- Usually asymptomatic
- Found incidentally in lungs resected for other reasons, particularly lung adenocarcinoma
- May present with progressive shortness of breath
- Can present with diffuse, symptomatic, bilateral interstitial lung infiltrates (diffuse pulmonary meningotheliomatosis)

IMAGING

CT Findings

- Can present as randomly distributed micronodules on thin-section CT

MACROSCOPIC

General Features

- Usually incidental microscopic finding

Size

- 1-3 mm
- In rare instances, may reach up to 1 cm in greatest diameter

MICROSCOPIC

Histologic Features

- Ill-defined, focal accumulation of oval or epithelioid cells in pulmonary interstitium
- Oval or epithelioid cells tend to focally adopt whorled appearance
- Lesions may be microscopic (1-3 mm) or measure up to 1 cm in diameter
- Lesions may be seen in close proximity of vessels

Cytologic Features

- Cells are oval or epithelioid and surrounded by ample rim of eosinophilic cytoplasm with indistinct cell borders
- Cells contain small, centrally placed nuclei devoid of mitotic activity
- Nuclei may contain intranuclear cytoplasmic inclusions

ANCILLARY TESTS

Immunohistochemistry

- Tumor cells are positive for vimentin and EMA
- Tumor cells may also react with antibodies to progesterone receptors
- Tumor cells are generally negative for neuroendocrine markers, S100 protein, cytokeratins, and other differentiation markers

Electron Microscopy

- Cells contain long, branching, interdigitating cytoplasmic cell processes joined by numerous desmosomes
- Cells contain no evidence of neurosecretory granules

Mutational Analysis

- Loss of heterozygosity affecting up to 3 genomic loci has been demonstrated in up to 25% of single case reports
- Loss of heterozygosity affecting multiple loci (> 7) has been demonstrated in cases with multiple disseminated lesions

DIFFERENTIAL DIAGNOSIS

Neuroendocrine Pulmonary "Tumorlet"

- Cells tend to be round with "salt and pepper" nuclear chromatin pattern
- Does not display whorling pattern of growth
- Cells positive for chromogranin and synaptophysin and negative for EMA

Lymphangioleiomyomatosis

- Spindle cells usually have rim of clear cytoplasm
- Spindle cells usually line walls of dilated cysts
- Spindle cells positive for HMB-45 and negative for EMA

Metastatic Carcinoma

- Usually shows striking lymphangitic rather than interstitial distribution
- Marked cytologic atypia, nuclear pleomorphism, and mitotic activity
- Strong cytokeratin positivity

SELECTED REFERENCES

1. Weissferdt A et al: Pleuropulmonary meningothelial proliferations: evidence for a common histogenesis. Am J Surg Pathol. 39(12):1673-8, 2015
2. Mizutani E et al: Minute pulmonary meningothelial-like nodules: clinicopathologic analysis of 121 patients. Hum Pathol. 40(5):678-82, 2009
3. Suster S et al: Diffuse pulmonary meningotheliomatosis. Am J Surg Pathol. 31(4):624-31, 2007
4. Ionescu DN et al: Pulmonary meningothelial-like nodules: a genotypic comparison with meningiomas. Am J Surg Pathol. 28(2):207-14, 2004
5. Kuroki M et al: Minute pulmonary meningothelial-like nodules: high-resolution computed tomography and pathologic correlations. J Thorac Imaging. 17(3):227-9, 2002
6. Sellami D et al: Minute pulmonary meningothelial-like nodules: thin-section CT appearance. J Comput Assist Tomogr. 25(2):311-3, 2001
7. Niho S et al: Immunohistochemical and clonal analysis of minute pulmonary meningothelial-like nodules. Hum Pathol. 30(4):425-9, 1999

Minute Meningothelial Nodule

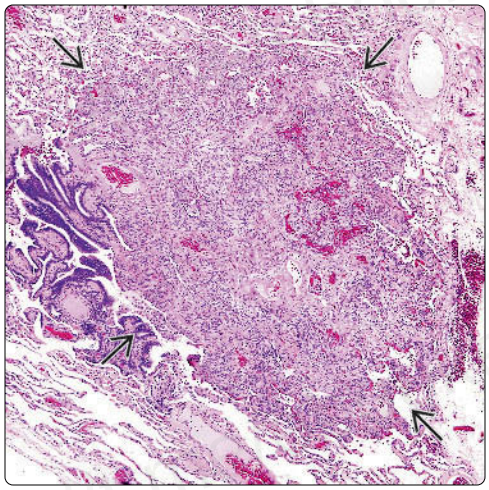

Epitheliod Cells: Higher Magnification

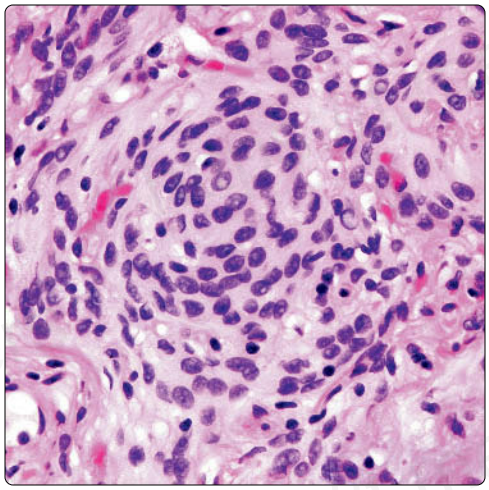

(Left) *Scanning magnification of a minute pulmonary meningothelial-like nodule shows a discrete, well-circumscribed area of consolidation adjacent to a small bronchiole that is sharply delineated from surrounding pulmonary parenchyma* ⇨. **(Right)** *Higher magnification of a minute pulmonary meningothelial-like nodule shows a cluster of oval epithelioid cells with an indistinct rim of eosinophilic cytoplasm adopting a concentric arrangement ("whorling") of the tumor cells.*

Thickening of Alveolar Septa

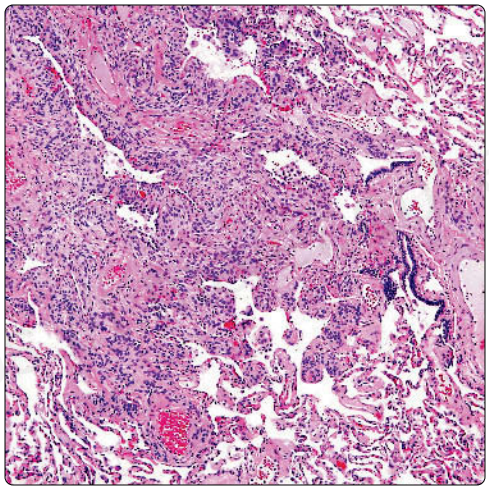

Multiple Small Cellular Clusters

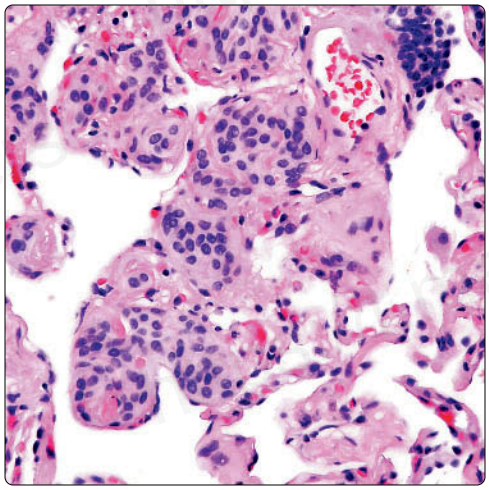

(Left) *Minute pulmonary meningothelial-like nodule shows thickening of alveolar septa by the proliferating meningothelial cells with compression of the airspaces and cuffing of small vessels by tumor cells.* **(Right)** *Higher magnification of a minute pulmonary meningothelial-like nodule shows small clusters of oval cells with abundant eosinophilic cytoplasm located in the interstitium of the alveolar septa. The cells closely resemble the pia-arachnoid cells in the brain.*

Perivascular Distribution

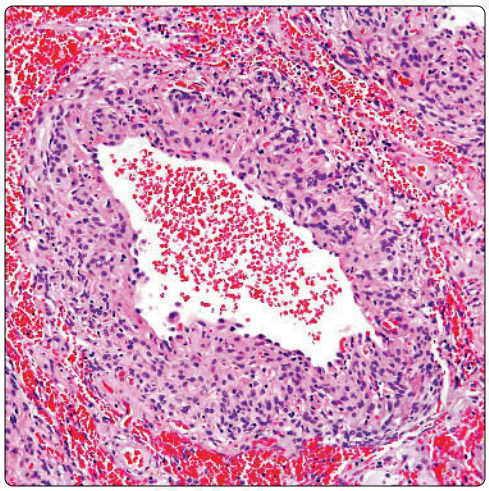

Multifocal Distribution

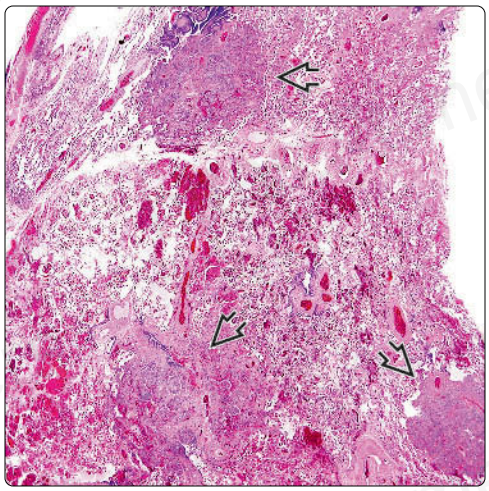

(Left) *Minute pulmonary meningothelial-like nodule shows distinct perivascular distribution with concentric arrangement of the meningothelial cells around the lumen of a dilated, medium-sized blood vessel.* **(Right)** *Diffuse pulmonary meningotheliomatosis shows multiple small, discrete nodules composed of clusters of meningothelial cells scattered throughout the lung parenchyma* ⇨. *The lesions in this condition are usually diffuse, bilateral, and symptomatic.*

Cluster of Meningothelial Nodules

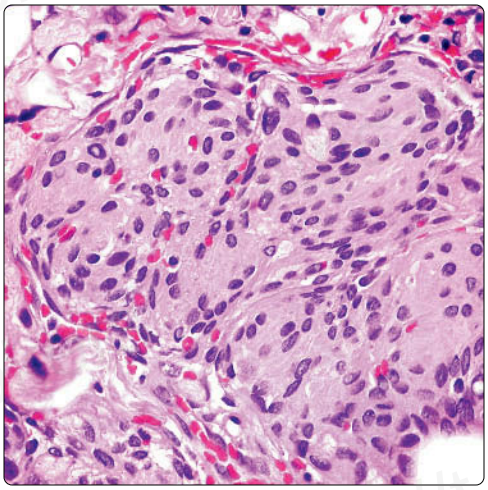

Intranuclear Cytoplasmic Inclusions

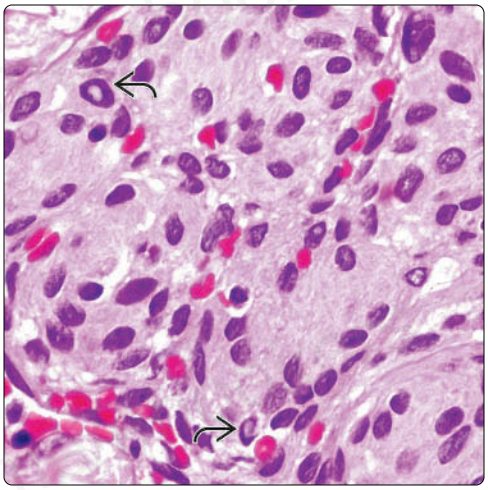

(Left) *Minute pulmonary meningothelial-like nodule shows small aggregates of uniform, oval to spindle cells. The cells in these nodules are indistinguishable from those seen in intracranial meningiomas.* **(Right)** *Higher magnification of a minute pulmonary meningothelial-like nodule shows cells with oval nuclei and a dense chromatin pattern surrounded by an indistinct rim of eosinophilic cytoplasm. Occasional intranuclear cytoplasmic inclusions are seen.*

Minute Focus

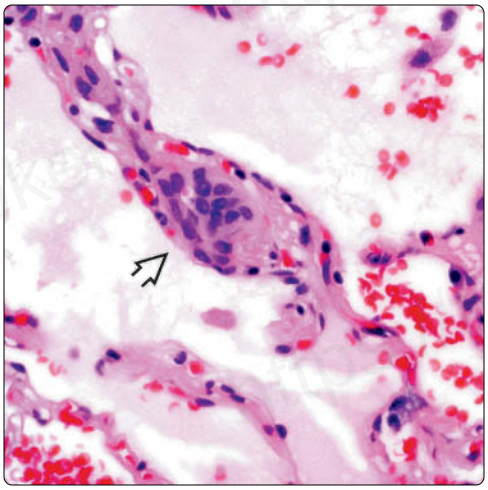

Cytokeratin AE1/AE3 Immunostaining

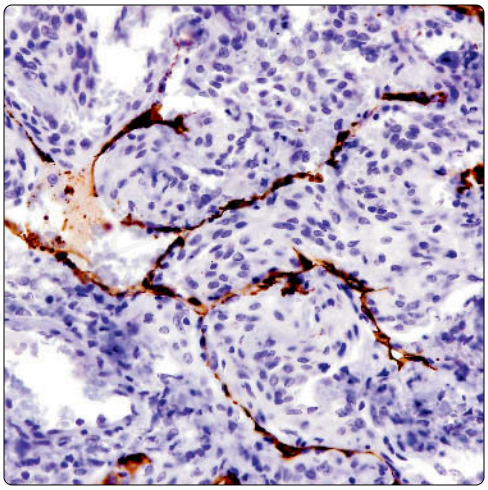

(Left) *High magnification shows an isolated focus of a minute pulmonary meningothelial-like lesion involving the alveolar wall. The cluster of meningothelial cells is minute and composed of about a dozen cells that form a tight cluster that expands and dilates the alveolar septum.* **(Right)** *Immunohistochemical staining of a minute pulmonary meningothelial-like nodule shows a continuous layer of cytokeratin-positive alveolar cells lining collapsed alveolar walls.*

EMA Immunostaining

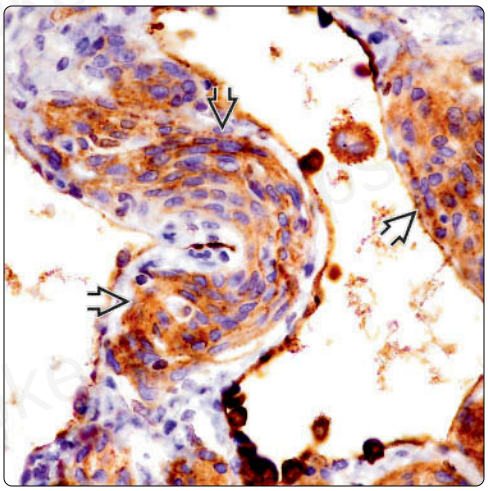

Vimentin Immunostaining

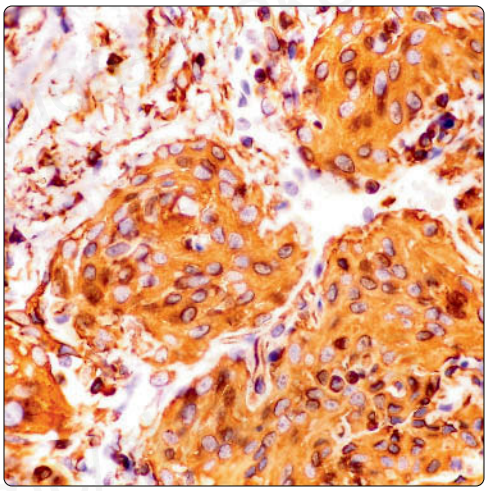

(Left) *Immunohistochemical staining of a minute pulmonary meningothelial-like nodule for EMA shows positive staining of alveolar cells lining the airspaces as well as strong positivity of the spindle and oval cells lying within the interstitium for this antibody.* **(Right)** *Immunohistochemical staining of a small pulmonary meningothelial-like nodule shows strong, positive cytoplasmic staining of the clusters of meningothelial cells with vimentin antibodies.*

Granular Cell Tumor

KEY FACTS

TERMINOLOGY

- Granular cell tumor (GCT)
  - Benign neoplasm composed of medium-sized cells with prominent granular cytoplasm
  - Malignant counterpart shows similar histology but with nuclear atypia and mitotic activity
- Synonym: Myoblastoma

ETIOLOGY/PATHOGENESIS

- More recently suggested as neural origin for these tumors
  - Still no universal agreement
- Uncertain histogenesis

CLINICAL ISSUES

- Complete surgical resection
- Excellent prognosis in benign cases
- Malignant GCT behaves aggressively
- Common symptoms include
  - Cough
  - Dyspnea
  - Hemoptysis
  - Wheezing
  - Patients may also be asymptomatic

MACROSCOPIC

- Central tumor, often endobronchial
- Size of tumors varies from 1-5 cm in diameter

TOP DIFFERENTIAL DIAGNOSES

- Melanoma
  - HMB-45 and Melan-A are negative in GCT
- Neurogenic sarcoma
- Carcinoma
  - Carcinomas generally show positive staining for epithelial markers (keratins, EMA), whereas GCTs are negative
- Neuroendocrine carcinoma (carcinoid tumor)

Bronchial Granular Cell Tumor

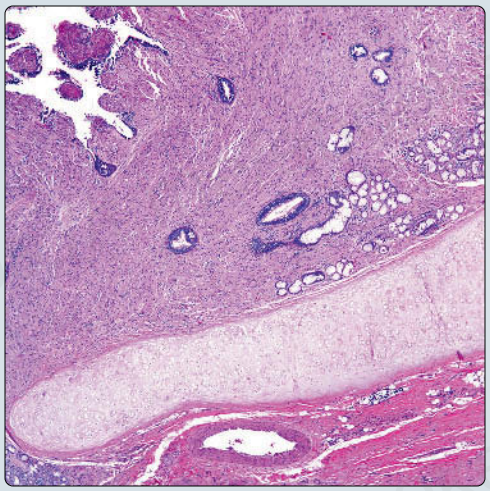

Residual Endobronchial Glands

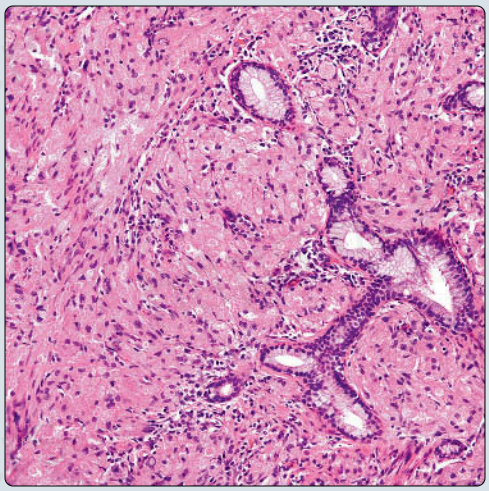

(Left) *Low-power view shows a granular cell tumor growing in an endobronchial location. Note the homogeneous pattern of growth.* **(Right)** *High-power view of a granular cell tumor shows the characteristic granular cytoplasm with a small round nucleus. No necrosis or mitotic activity is present.*

Tumor Merging With Lung Parenchyma

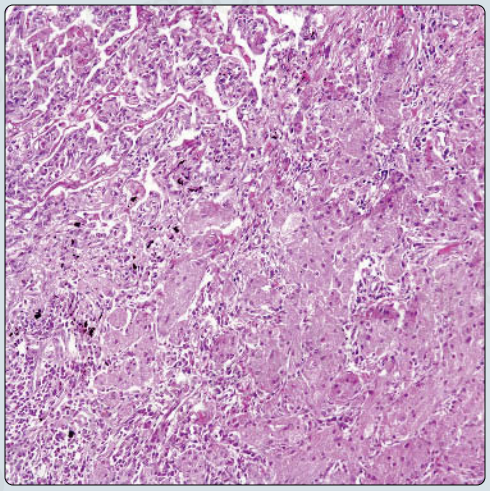

Absence of Mitotic Activity

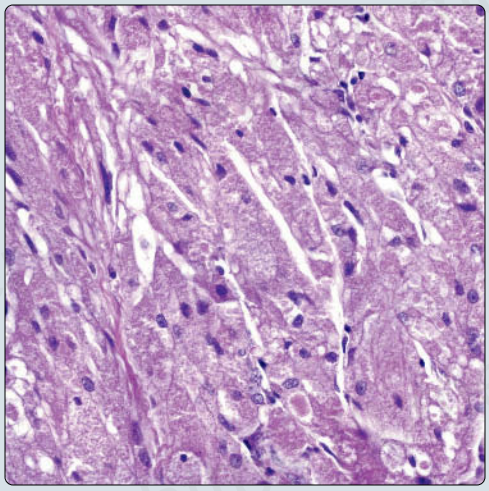

(Left) *Granular cell tumor of the lung shows areas in which the tumor cells (granular cells) appear to interface with normal lung parenchyma. Note that the tumor appears not well demarcated or encapsulated.* **(Right)** *High-power view of a granular cell tumor shows cells with prominent and ample granular nuclei. The tumor lacks mitotic activity or significant nuclear atypia.*

TERMINOLOGY

Abbreviations

- Granular cell tumor (GCT)

Synonyms

- Myoblastoma

Definitions

- Benign neoplasm composed of medium-sized cells with prominent granular cytoplasm
- Malignant counterpart shows similar histology but with nuclear atypia and mitotic activity

ETIOLOGY/PATHOGENESIS

Etiology

- Uncertain histogenesis
  - Recently, neural origin has been suggested

CLINICAL ISSUES

Presentation

- Cough
- Dyspnea
- Hemoptysis
- Wheezing
- Asymptomatic

MACROSCOPIC

General Features

- Central tumor, often endobronchial
- Tumors are firm and tan in color
- Size of tumors varies from 1-5 cm in diameter
- Polypoid tumor obstructing airway
- Coin lesion, less common
- Necrosis &/or hemorrhage are signs of aggressive behavior

MICROSCOPIC

Histologic Features

- In benign tumors
  - Medium-sized cells
  - Small nuclei with inconspicuous nucleoli
  - Absence of mitotic activity
  - Absence of hemorrhage or necrosis
  - Infiltration in peribronchial lymph nodes may be seen
- In malignant tumors
  - Necrosis and hemorrhage are commonly seen
  - Medium-sized cells with round nuclei and prominent nucleoli
  - Mitotic figures commonly encountered

DIFFERENTIAL DIAGNOSIS

Melanoma

- Cellular pleomorphism is more common in melanomas
- HMB-45 and Melan-A negative in GCT

Acinic Cell Carcinoma

- Acinic cell carcinoma (ACC) is positive for keratin
- PAS is strongly positive in ACC
- ACC shows negative staining for S100 protein

Bronchial Neuroendocrine Carcinoma (Carcinoid Tumor)

- Neuroendocrine (NE) neoplasms will show positive staining for NE markers
  - Chromogranin (+)
  - Synaptophysin (+)
  - CD56(+)
- GCT will show strong cytoplasmic staining for S100 protein

DIAGNOSTIC CHECKLIST

Clinically Relevant Pathologic Features

- Cytoplasmic features
- Mitotic rate

Pathologic Interpretation Pearls

- Granular cellular proliferation with absence of mitotic activity and nuclear atypia

SELECTED REFERENCES

1. Deavers M et al: Granular cell tumors of the lung. Clinicopathologic study of 20 cases. Am J Surg Pathol. 19(6):627-35, 1995

Immunohistochemistry

Antibody	Reactivity	Staining Pattern	Comment
S100	Positive	Cytoplasmic	Strong
NSE	Positive	Cytoplasmic	Although positive, it is not specific
Actin-sm	Positive	Cytoplasmic	May be positive, thus notion of muscle origin
LEU-7	Positive	Cytoplasmic	Variable intensity
Cathespin-B	Positive	Cytoplasmic	In some cases
Vimentin	Positive	Cytoplasmic	Although positive, it is not specific
Chymotrypsin	Positive	Cytoplasmic	In some cases with variable staining intensity
CD68	Positive	Cytoplasmic	Moderate staining in some cases
CK-PAN	Negative		
Desmin	Negative		

Small Granular Cell Tumor

Polypoid Granular Cell Tumor

(Left) *Granular cell tumor is seen with small clusters of tumor cells just beneath the respiratory epithelium. No epithelial component is present in the tumor.* **(Right)** *Granular cell tumor is growing focally in a polypoid fashion. Still, one can identify intact respiratory epithelium ⇨ and also some uninvolved bronchial glands ➡ scattered among the tumor.*

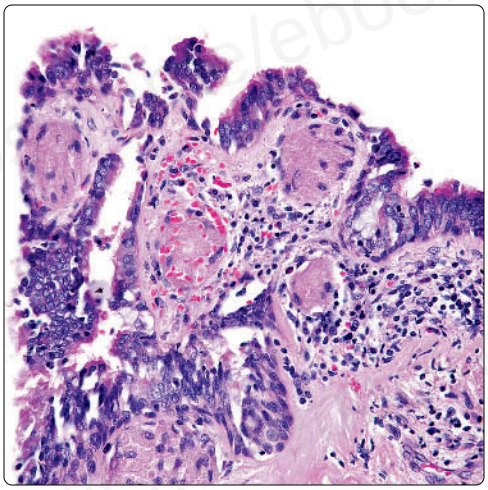

Granular Cell Tumor Sparing Normal Glands

Granular Cell Tumor With Areas of Hemorrhage

(Left) *Granular cell tumor of the lung shows a mixture of normal endobronchial glands ➡ and granular cells ⇨. It is important to note that the tumor does not destroy the normal endobronchial glands.* **(Right)** *Extensive areas of hemorrhage and islands of granular cell tumor are shown. The appearance is that of a neuroid neoplasm, and the cells have light eosinophilic to clear cytoplasm.*

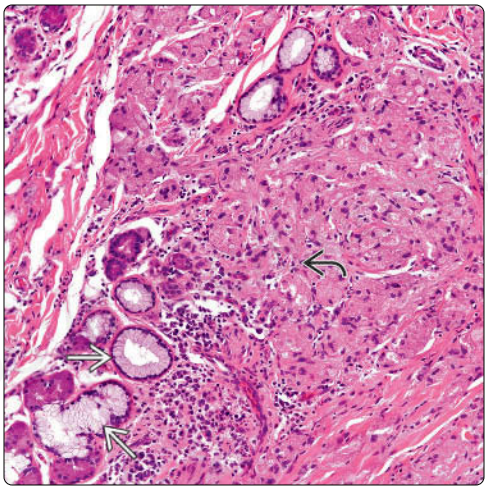

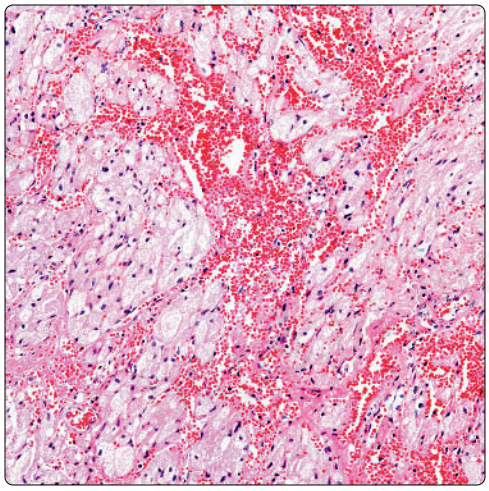

Granular Cell Tumor With Metaplastic Bone

Granular Cell Tumor With Neural Involvement

(Left) *Granular cell tumor is seen growing in cords dissecting strands of fibroconnective tissue. In addition, focal metaplastic bone formation is present ⇨.* **(Right)** *Granular cell tumor shows perineural involvement ⇨. This feature is unusual and should not be considered a feature of malignancy. Notice that the cellular proliferation does not show features of atypia.*

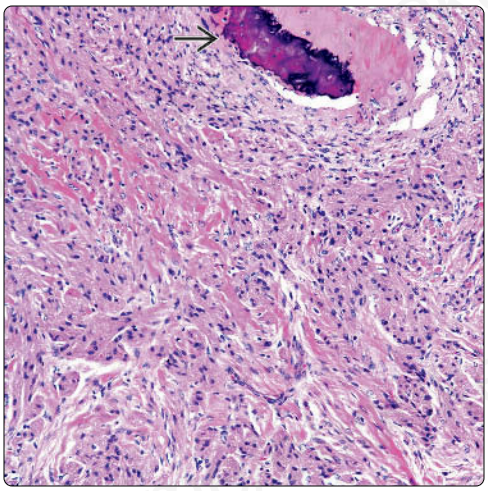

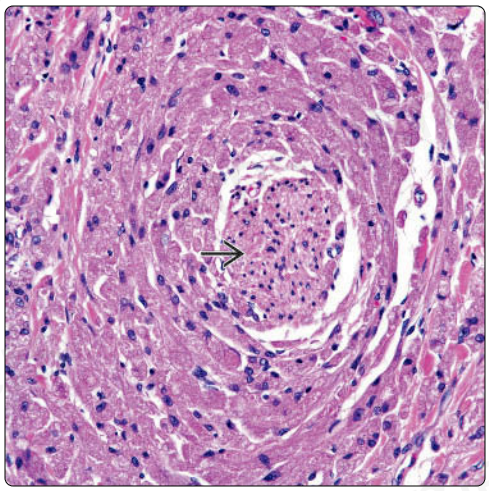

Granular Cell Tumor With Squamous Metaplasia

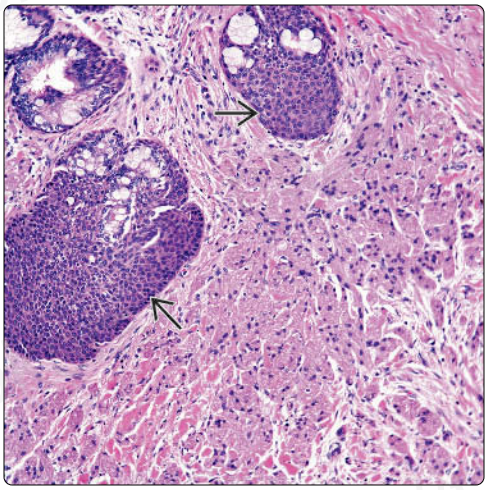

Granular Cell Tumor With Inflammatory Reaction

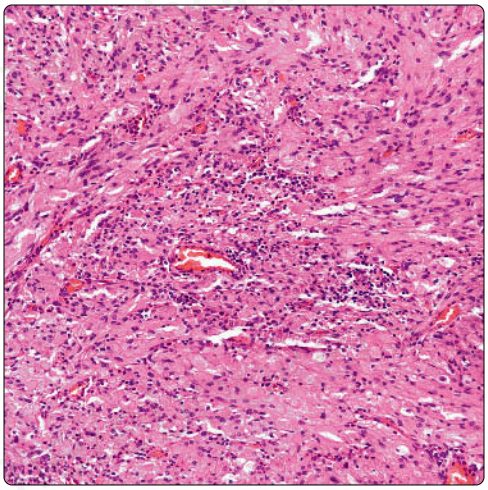

(Left) *Granular cell tumor is shown growing along bronchial glands with squamous metaplasia. One important feature of a granular cell tumor is the pattern of growth with sparing of the bronchial glands.* **(Right)** *Granular cell tumor shows focal inflammatory changes. In general, inflammatory changes are not common in granular cell tumors. Most granular cell tumors are fairly uniform tumors with a monotonous, homogeneous appearance.*

Granular Cell Tumor With Nodal Involvement

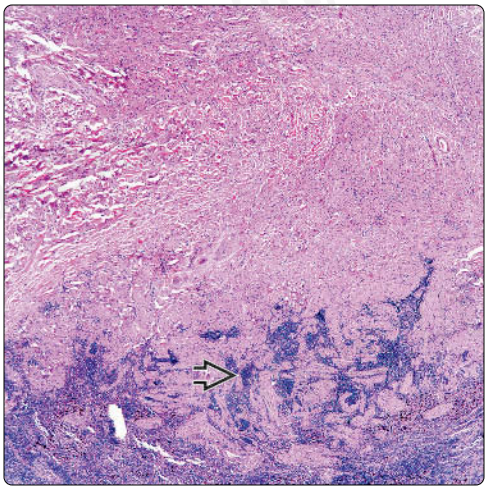

Granular Cell Tumor With Nodal Involvement

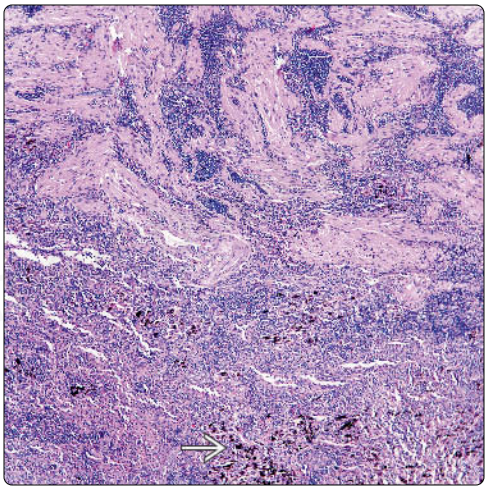

(Left) *Ill-defined granular cell tumor is shown growing adjacent to lymphoid tissue. Granular cell tumors characteristically are not encapsulated and many times have infiltrative borders.* **(Right)** *Closer view shows a granular cell tumor infiltrating a lymph node. This feature, although rare, occurs in some otherwise benign cases due to the ill-defined borders of the tumor. Note the presence of anthracotic pigment in the lymph node.*

Malignant Granular Cell Tumor

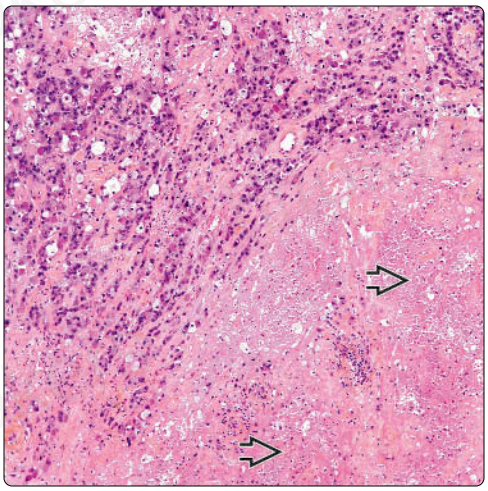

Mitosis in Malignant Granular Cell Tumor

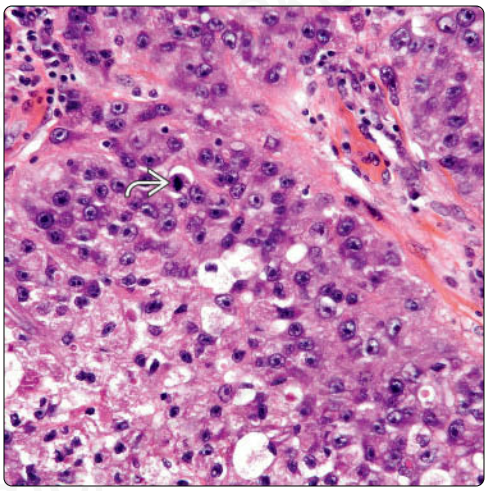

(Left) *Malignant granular cell tumor shows extensive areas of necrosis. The presence of necrosis is generally a sign of aggressiveness. In addition, such a feature should prompt a closer examination of the cellular proliferation.* **(Right)** *Hematoxylin & eosin staining shows a malignant granular cell tumor in which the cytologic atypia is marked. In addition, mitotic figures are easily identifiable. These features are the ones that separate benign from malignant tumors.*

Sclerosing Hemangioma (Pneumocytoma)

KEY FACTS

TERMINOLOGY

- Pneumocytoma

ETIOLOGY/PATHOGENESIS

- Tumor appears to have pneumocytic differentiation, yet histogenesis remains unclear

CLINICAL ISSUES

- Incidence
  - More common among women
  - Tumor is more common in 4th and 5th decades of life

MACROSCOPIC

- Well circumscribed but not encapsulated
  - More often peripheral tumor
  - Rarely central tumor

MICROSCOPIC

- Biphasic
- Solid
- Papillary
- Sclerotic
- Hemorrhagic
- Combination of patterns more often present in same tumor

TOP DIFFERENTIAL DIAGNOSES

- Papillary carcinoma
  - Sclerosing hemangioma (SH) lacks nuclear atypia &/or increased mitotic activity
  - Presence of biphasic cellular population characteristic of SH
- Mesothelioma
  - SH is positive for TTF-1, while mesotheliomas are negative
  - SH is generally intraparenchymal tumor rather than pleural based
  - Keratin 5/6 is generally negative in SH

Macroscopic Features

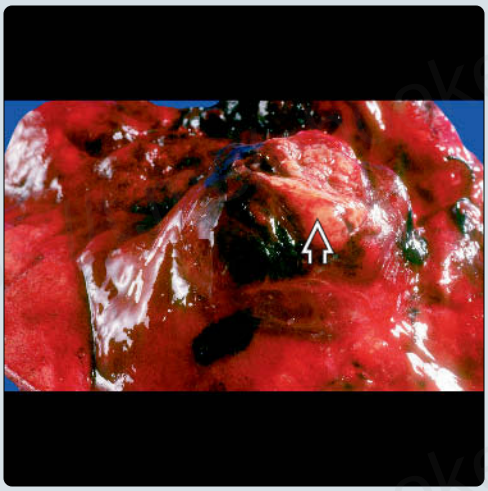

Hemorrhagic Areas

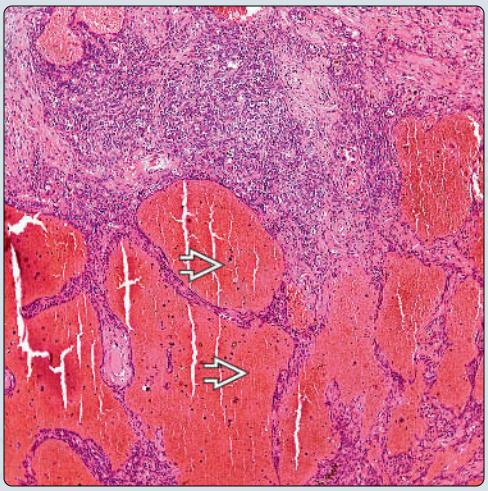

(Left) *Gross photograph of sclerosing hemangioma (SH) shows a well-circumscribed intrapulmonary tumor mass ⇨. The tumor has been bisected and shows a fleshy, focally hemorrhagic surface.* **(Right)** *SH shows dilated vascular spaces ⇨ filled with blood, giving the appearance of a true vascular tumor.*

Vascular-Like Neoplasm

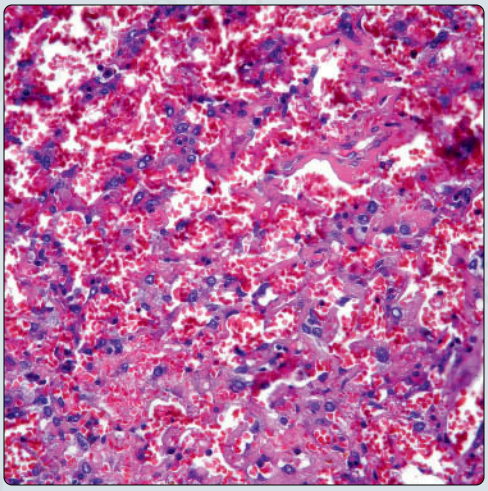

Papillary Areas

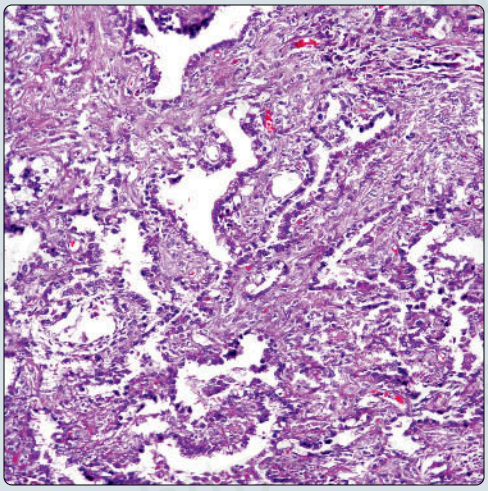

(Left) *SH (pneumocytoma) of the lung shows a pattern that can be easily confused for a vascular neoplasm of the lung. The fibrocollagen has split giving the impression of vascular channels.* **(Right)** *SH (pneumocytoma) shows more typical papillary areas with subtle sclerotic changes.*

TERMINOLOGY

Abbreviations

- Sclerosing hemangioma (SH)

Synonyms

- Pneumocytoma

Definitions

- Benign neoplasm of pneumocyte derivation

ETIOLOGY/PATHOGENESIS

Histogenesis

- Tumor appears to have pneumocytic differentiation, yet histogenesis remains unclear

CLINICAL ISSUES

Epidemiology

- Incidence
  - Tumor of rare occurrence
- Age
  - 4th or 5th decade of life
- Sex
  - More common among women

Presentation

- Asymptomatic
- Cough
- Chest pain
- Hemoptysis

Treatment

- Surgical approaches
  - Complete surgical resection

Prognosis

- Excellent
- In unusual cases, tumor metastasizes to lymph nodes

IMAGING

General Features

- Well-demarcated, single intrapulmonary mass
  - More common peripheral tumor
- Unusual cases may present with > 1 pulmonary mass

MACROSCOPIC

General Features

- Well circumscribed but not encapsulated
  - More often peripheral tumor; rarely central location
  - Tumors with > 1 single tumor mass have been described, but they are rare

Size

- 1-8 cm in diameter

MICROSCOPIC

Histologic Features

- Solid
- Papillary
- Sclerotic
- Hemorrhagic
- Calcifications
- Multinucleated giant cell may be present
- Mitotic activity is unusual
- Combination of patterns often present in same tumor

Cytologic Features

- Small cells with hobnail nuclei lining papillary structures
- Monotonous population of round/polygonal cells with clear cytoplasm in solid areas

DIFFERENTIAL DIAGNOSIS

Papillary Carcinoma

- Marked nuclear atypia &/or increased mitotic activity
- Presence of biphasic cellular population is characteristic of SH
- Carcinoma and SH show positive staining for similar markers, including keratin and TTF-1
- Increased proliferative activity (↑ Ki-67 stain)

Mesothelioma

- Would be unusual for mesothelioma to present with intrapulmonary mass
- Generally negative for TTF-1
- SH may show different growth patterns in same tumor
- Calretinin and CK5/6 are usually negative in SH and positive in mesotheliomas

Inflammatory Pseudotumor

- Usually shows presence of prominent inflammatory component based on plasma cells
- Generally negative for TTF-1
- Presence of dual cell population seen in SH is not present in inflammatory pseudotumor (IPT)
- ALK1 may be seen positive in IPT and negative in SH

Metastatic Papillary Carcinoma of Thyroid

- Both thyroid carcinoma and SH show positive staining for TTF-1
- SH is negative for thyroglobulin, while thyroid carcinoma is positive
- History of thyroid neoplasm or thyroid mass is very helpful

Adenocarcinoma

- SH and adenocarcinoma may show positive staining for TTF-1 and NAPSIN-A
- Adenocarcinoma will show more glandular pattern
- Adenocarcinoma may show more nuclear atypia and mitotic activity

DIAGNOSTIC CHECKLIST

Pathologic Interpretation Pearls

- Biphasic cellular proliferation composed of cuboidal cells and stromal (pale) cells

SELECTED REFERENCES

1. Kim MK et al: Bone metastasis in pulmonary sclerosing hemangioma. Korean J Intern Med. 30(6):928-30, 2015
2. Shin SY et al: Pulmonary sclerosing pneumocytoma of the lung: CT characteristics in a large series of a tertiary referral center. Medicine (Baltimore). 94(4):e498, 2015

Immunohistochemistry

Antibody	Reactivity	Staining Pattern	Comment
EMA/MUC1	Positive	Cytoplasmic	Stromal and cuboidal cells
TTF-1	Positive	Nuclear	Stromal and cuboidal cells
NAPSIN-A	Positive	Cytoplasmic	Stromal cells
β-catenin	Positive	Cell membrane and cytoplasm	Stromal and cuboidal
CK-PAN	Positive	Cytoplasmic	Weak and focal in stromal cells
CK-LMW-NOS	Positive	Cytoplasmic	Usually negative or weakly positive in stromal cells
CK7	Positive	Cytoplasmic	Usually negative in stromal cells
SURFACTANT	Positive	Cytoplasmic	Cuboidal cells
Clara cell antigen	Positive	Cytoplasmic	Cuboidal cells
S100	Positive	Cytoplasmic	In some cases
CEA-M	Positive	Cytoplasmic	In some cases
p40	Positive	Nuclear	In cuboidal cells in some cases
p63	Positive	Nuclear	In cuboidal cells in some cases
CD31	Negative		
CD34	Negative		
ERG	Negative		
Desmin	Negative		
Calretinin	Negative		May show focal staining in some cases
CK5/6	Negative		
Actin-sm	Negative		

Histochemical Features

Stain	Result
PAS	May show focal positivity
PAS-D	Negative
Mucicarmine	Negative

Ultrastructural Features

Papillary Areas	Stromal Areas
Pneumocytes type II	Microvillus process
Lamellated surfactant bodies	Numerous lysosomes
Microvilli	
Desmosomes	
Basal lamina	
Clara cell differentiation may be present	
Dense granules of lysosomal or lamellar appearance	

3. Xu HM et al: A rare case of pulmonary sclerosing hemagioma with lymph node metastasis and review of the literature. Int J Clin Exp Pathol. 8(7):8619-23, 2015
4. Lin XY et al: In pulmonary sclerosing hemangioma expression of β-catenin, Axin, and C-myc differs between the two cell types. Virchows Arch. 461(1):59-65, 2012
5. Kalhor N et al: So-called sclerosing hemangioma of lung: current concept. Ann Diagn Pathol. 14(1):60-7, 2010
6. Khoury JD et al: Cystic sclerosing haemangioma of the lung. Histopathology. 43(3):239-43, 2003
7. Devouassoux-Shisheboran M et al: A clinicopathologic study of 100 cases of pulmonary sclerosing hemangioma with immunohistochemical studies: TTF-1 is expressed in both round and surface cells, suggesting an origin from primitive respiratory epithelium. Am J Surg Pathol. 24(7):906-16, 2000
8. Moran CA et al: Sclerosing hemangioma of the lung. Granulomatous variant. Arch Pathol Lab Med. 118(10):1028-30, 1994
9. Katzenstein AL et al: Sclerosing hemangioma of the lung: a clinicopathologic study of 51 cases. Am J Surg Pathol. 4(4):343-56, 1980
10. Kennedy A: "Sclerosing haemangioma" of the lung: an alternative view of its development. J Clin Pathol. 26(10):792-9, 1973
11. Liebow AA et al: Sclerosing hemangioma (histiocytoma, xanthoma) of the lung. Cancer. 9(1):53-75, 1956

Papillary Growth Pattern

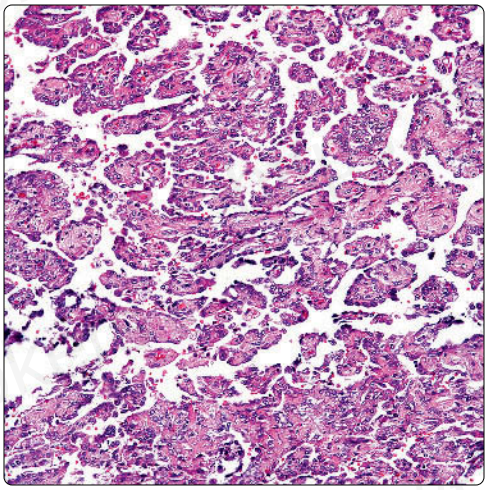

Solid Areas

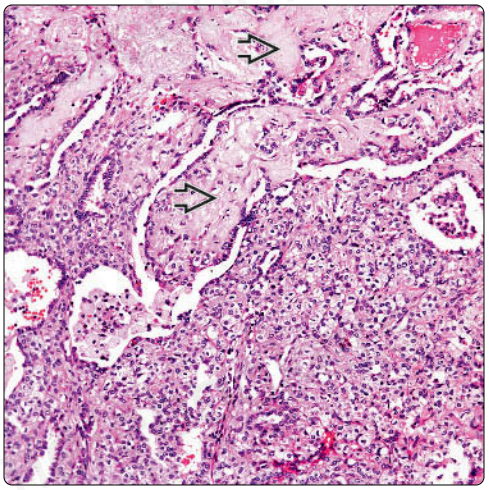

(Left) *SH shows a prominent papillary growth pattern, giving the appearance of a true papillary neoplasm. This feature may be extensive in some cases; however, it would be unusual for SH to exclusively have this pattern of growth.* **(Right)** *Solid cellular proliferation is shown with only focal ectatic vessels and areas of sclerosis. Most cases of SH will display a combination of different growth patterns.*

Sclerosis

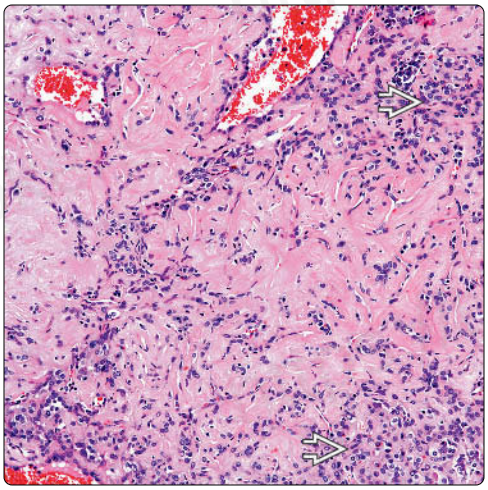

Vascular-Like Spaces

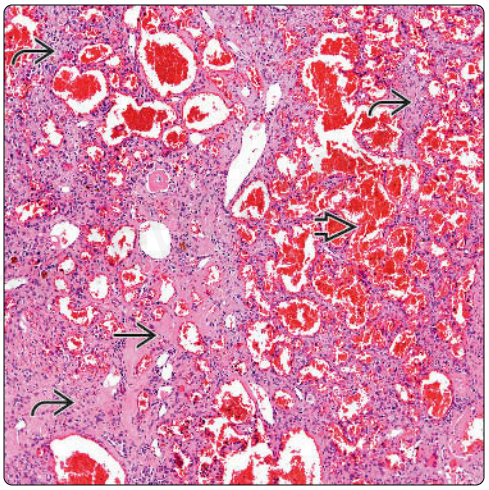

(Left) *SH shows prominent sclerotic changes with dilated vascular spaces. Note the presence of a more subtle cellular proliferation. This histological feature may make the diagnosis of SH more difficult.* **(Right)** *SH shows a combination of hemorrhagic areas mimicking a vascular tumor, focal sclerotic areas, and solid cellular proliferation.*

Solid Growth Pattern

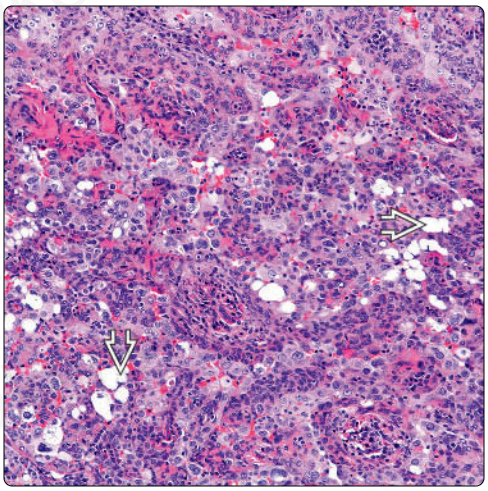

Cuboidal and Stromal Cells

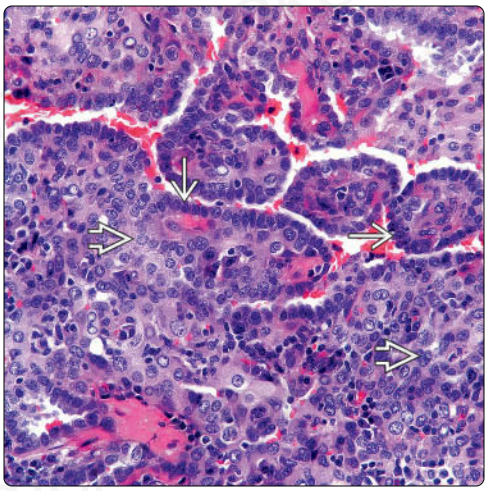

(Left) *SH shows a prominent solid cellular proliferation with focal entrapment of adipose tissue. There is no evidence of necrosis, nuclear atypia, &/or mitotic activity.* **(Right)** *SH shows the 2 classic types of cells: Low cuboidal in the surface and the so-called pale or stromal cells, which are round to oval.*

Psammoma Body

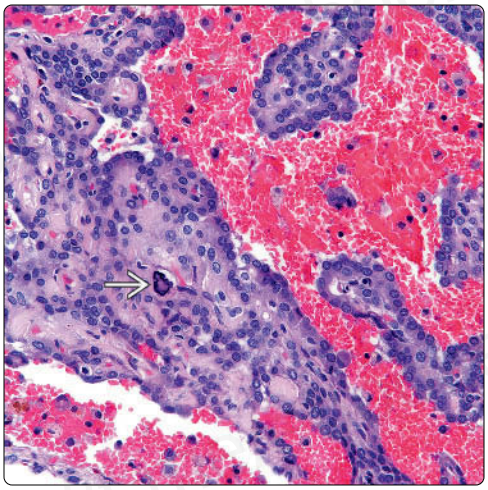

Solid Growth Pattern

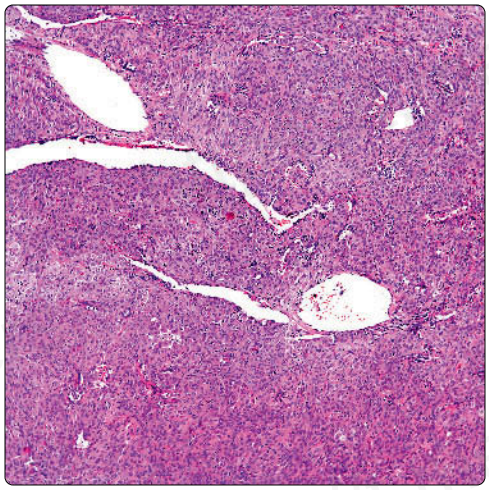

(Left) *SH shows a vague papillary growth pattern admixed with hemorrhagic areas. A single psammoma body is also present ⇨.* **(Right)** *SH shows a solid growth pattern with only focal dilated vascular spaces. Usually, SH will show a combination of at least 2 different growth patterns.*

Sclerotic Vessels

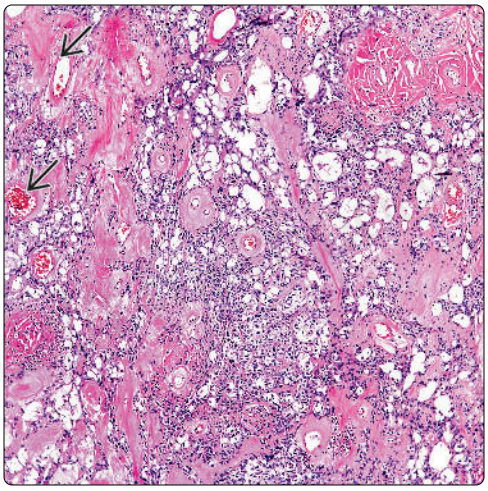

Cuboidal Cells

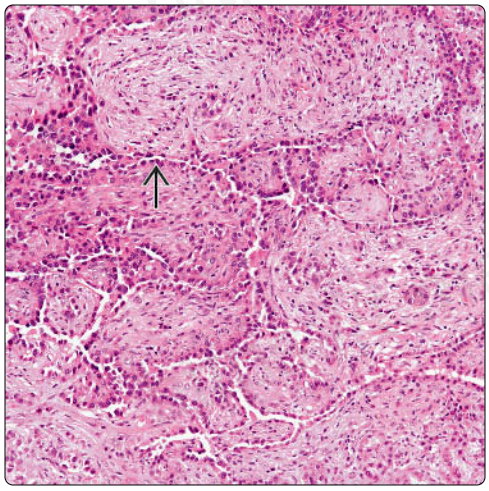

(Left) *SH shows extensive areas of sclerosis admixed with solid stromal cells. Note the presence of dilated, "true" vessels ⇨.* **(Right)** *In this SH, prominent surface low cuboidal cells lining the papillary infolding ⇨ are shown. The stromal or pale cells are not prominent and are embedded in the sclerotic areas.*

Giant Cells

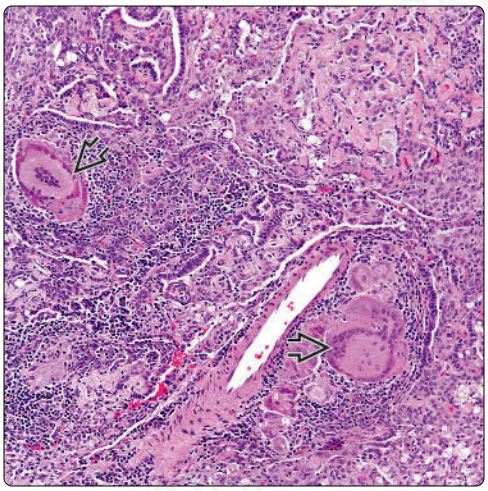

Sclerosing Hemangioma in Lymph Node

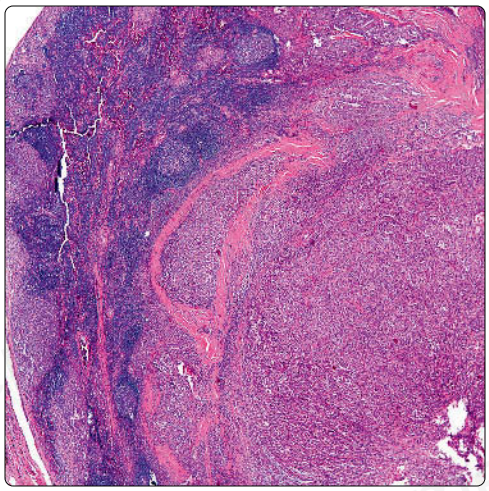

(Left) *SH shows prominent multinucleated giant cells ⇨ and adjacent inflammatory reaction, giving the appearance of a granulomatous process. These features are unusual in SH.* **(Right)** *A lymph node is shown with metastatic SH. Although this tumor is considered benign, some unusual cases will metastasize to hilar lymph nodes.*

Calcifications

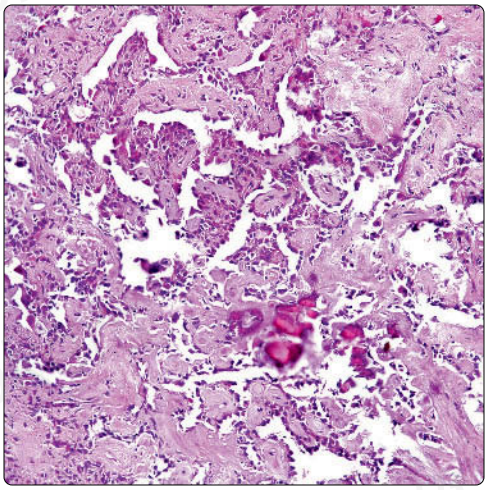

Subtle Spindle Cell Areas

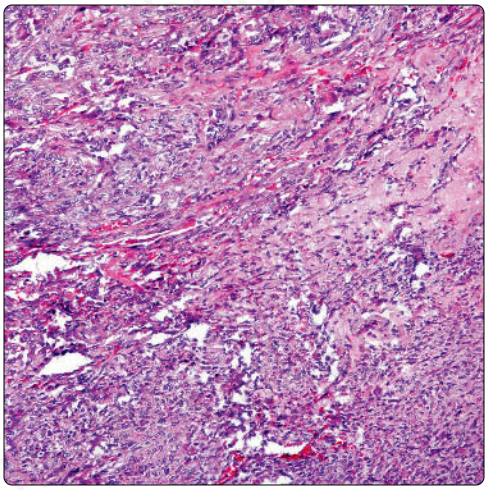

(Left) *SH (pneumocytoma) shows central calcification in a papillary area. Sclerotic areas are also present.* **(Right)** *SH (pneumocytoma) shows areas with some sclerosis in which the solid cellular proliferation has some spindle cells features.*

Solid Cellular and Sclerotic Areas

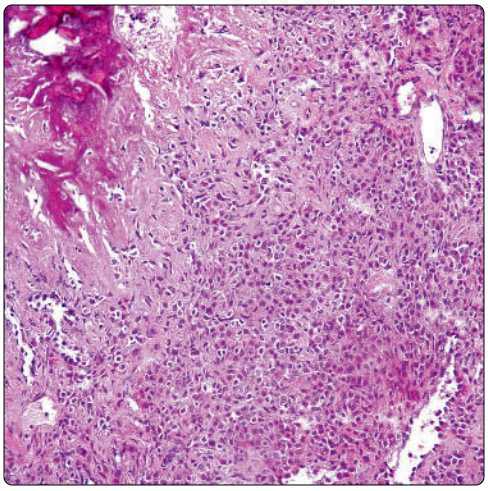

Dual Cellular Proliferation

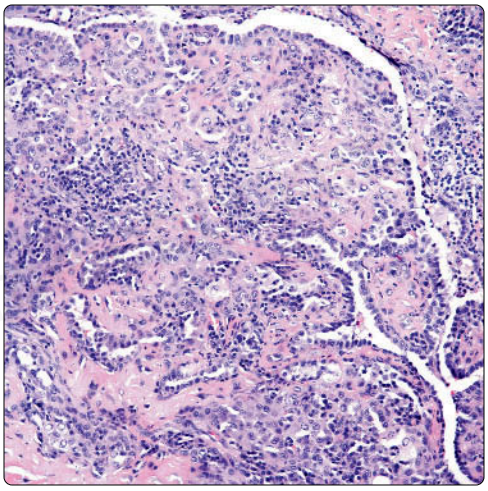

(Left) *SH (pneumocytoma) shows merging of prominent sclerotic areas with a more solid cellular component. The cellular proliferation is very homogeneous.* **(Right)** *SH (pneumocytoma) shows more classic areas of a dual population of cuboidal and stromal cells.*

Positive Staining for Pan Keratin

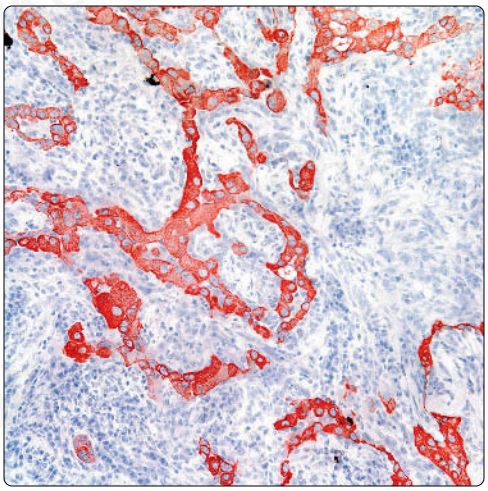

Positive Staining for TTF-1

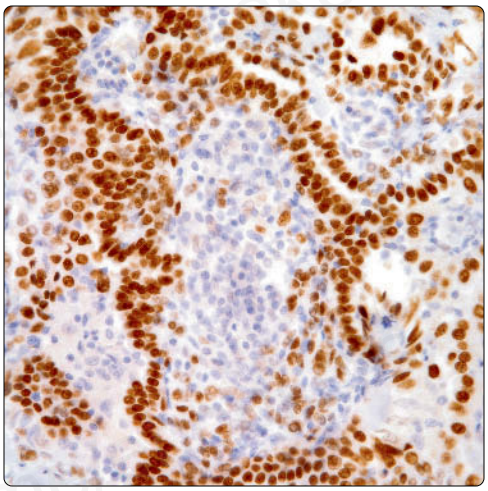

(Left) *Immunohistochemical stain for pan keratin outlines the epithelial component of the tumor.* **(Right)** *Immunohistochemical staining for TTF-1 shows strong nuclear staining in the epithelial component of the tumor, predominantly in the cuboidal cells.*

Clear Cell Sugar Tumor (PEComa)

KEY FACTS

TERMINOLOGY

- Benign intrapulmonary neoplasm with prominent clear cells

ETIOLOGY/PATHOGENESIS

- Myomelanocytic differentiation (PEComa)

CLINICAL ISSUES

- Although tumor is more common in adults, it has been reported in children
- No gender predilection
- Asymptomatic
- Complete surgical resection is treatment of choice

MACROSCOPIC

- Peripheral tumor
- 1-7 cm in diameter

MICROSCOPIC

- Sheets of clear cells with dilated vascular spaces
- Absence of mitotic activity
- Absence of necrosis

ANCILLARY TESTS

- Periodic acid-Schiff
  - Reactivity: Positive
- Positive immunohistochemical stains
  - HMB-45
  - CD34

TOP DIFFERENTIAL DIAGNOSES

- Clear cell carcinoma, primary or metastatic
  - Sugar tumor is negative for epithelial markers
  - Sugar tumor lacks nuclear atypia &/or mitotic activity

DIAGNOSTIC CHECKLIST

- Clear cells with abundant dilated vascular vessels mimicking hemangiopericytoma

Macroscopic Features

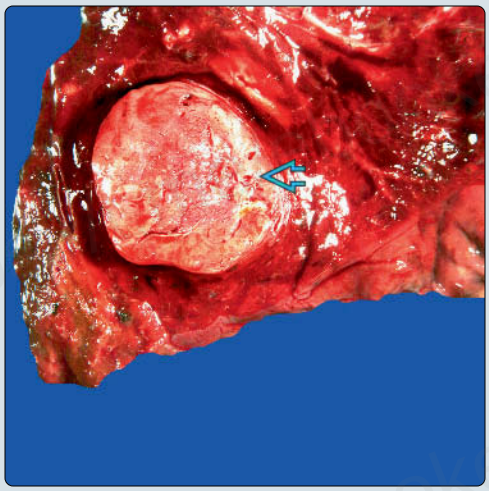

Uninvolved Airway

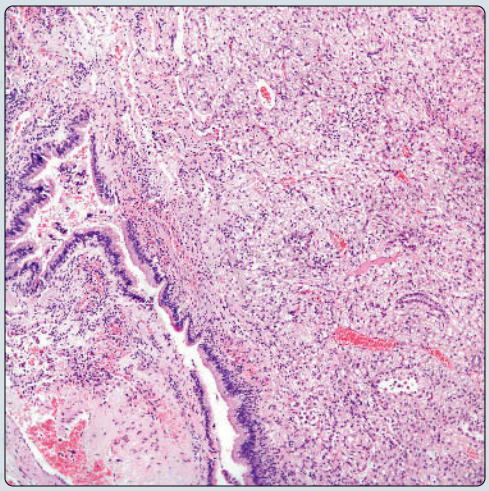

(Left) *Gross photograph shows a well-circumscribed intrapulmonary clear cell sugar tumor. The cut surface is homogeneous and light tan.* **(Right)** *Clear cell sugar tumor of the lung shows a clear cell proliferation replacing lung parenchyma. Note the adjacent airway is not involved by the neoplasm.*

Ectatic Vessels

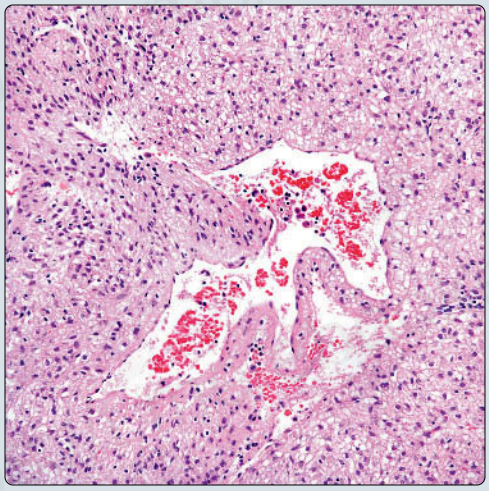

Lack of Mitotic Activity

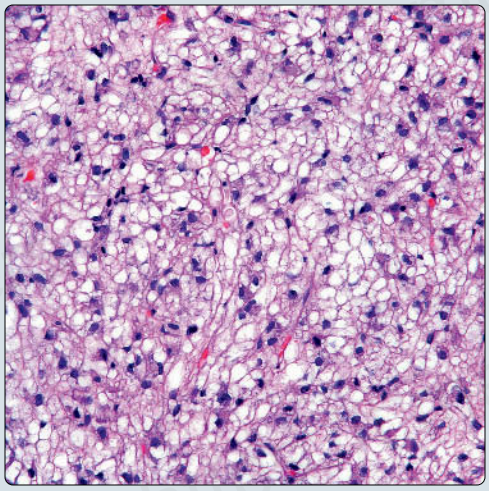

(Left) *Clear cell sugar tumor of the lung shows the characteristic dilated vascular structures, which impart a subtle hemangiopericytoma pattern to these tumors. Note the lack of cellular atypia and mitotic activity.* **(Right)** *Sugar tumor is seen with prominent clear cell proliferation. Note the absence of cellular atypia, necrosis, and mitotic activity.*

TERMINOLOGY

Synonyms

- Clear cell tumor

Definitions

- Benign intrapulmonary neoplasm with prominent clear cells
  - Isolated malignant cases have been reported

ETIOLOGY/PATHOGENESIS

Etiology

- Recently sugar tumor has been regarded as part of family of tumors designated as PEComas
- Myomelanocytic differentiation

CLINICAL ISSUES

Presentation

- Asymptomatic
- Fever
- Anemia
- Hemoptysis (rarely)
- History of tuberous sclerosis

Prognosis

- Excellent
  - Not enough experience with cases reported as malignant

MACROSCOPIC

General Features

- Peripheral tumor
- Well circumscribed, but not encapsulated
- Tan to pink in color
- 1-7 cm in diameter

MICROSCOPIC

Histologic Features

- Sheets of clear cells with dilated vascular spaces
- Absence of nuclear atypia
- Absence of necrosis &/or hemorrhage
- Absence of mitotic activity
- Occasionally cells may adopt spindle cell appearance

ANCILLARY TESTS

Histochemistry

- Periodic acid-Schiff
  - Reactivity: Positive
  - Staining pattern: Cytoplasmic

DIFFERENTIAL DIAGNOSIS

Clear Cell Carcinoma, Primary or Metastatic

- Renal cell carcinoma
  - History of, or presence of, renal tumor
  - Will display more cytologic atypia and mitotic figures
  - Will show positive staining for epithelial markers (keratin, EMA)

DIAGNOSTIC CHECKLIST

Pathologic Interpretation Pearls

- Clear cells with abundant dilated vascular vessels, mimicking hemangiopericytoma

SELECTED REFERENCES

1. Chen YB et al: Clear cell tumor of the lung: a retrospective analysis. Am J Med Sci. 347(1):50-3, 2014

Immunohistochemistry

Antibody	Reactivity	Staining Pattern	Comment
CD34	Positive	Cytoplasmic	It may be only focal
S100	Positive	Cytoplasmic	Some cases may be negative
CD1a	Positive	Cytoplasmic	Good number of cases are negative
HMB-45	Positive	Cytoplasmic	In cytoplasm of clear cells but may be negative in spindle cells
HMB-50	Positive	Cytoplasmic	Focal positivity in some cases
NSE	Positive	Cytoplasmic	Not specific for clear cell tumors
FXIIIA	Positive	Cytoplasmic	In some cases but not specific
cathepsin-B	Positive	Cytoplasmic	In some cases but not specific
CK-PAN	Negative		
EMA/MUC1	Negative		

Histochemical Features

Stain	Result	Comment
PAS	Positive	Glycogen content
PAS-D	Negative	Negative for intracellular mucin
Mucicarmine	Negative	Negative for intracellular mucin

Clear Cell Sugar Tumor (PEComa)

(Left) *Radiograph shows a well-defined intrapulmonary mass ⇒ (so-called coin lesion).* **(Right)** *Sugar tumor shows a homogeneous cellular proliferation composed of cells with light eosinophilic or clear cytoplasm. Note the absence of necrosis &/or hemorrhage. The tumor cell population is quite monotonous and grows forming solid sheets of cells.*

Chest Film

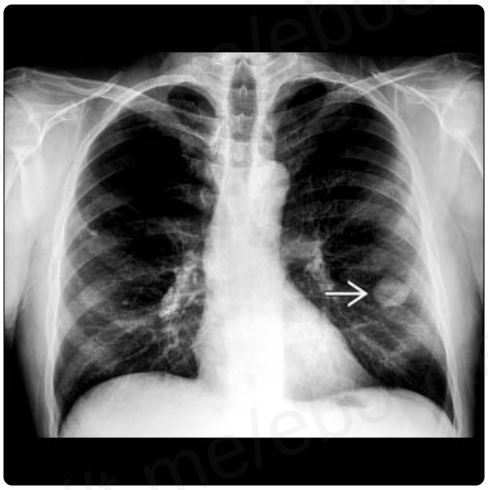

Solid Proliferation

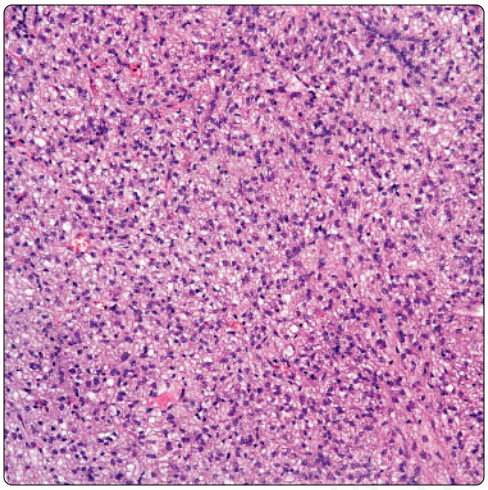

(Left) *Sugar tumor shows round cells with clear cytoplasm admixed with spindle cells with a vague storiform pattern ⇨. This pattern may be confused for a mesenchymal neoplasm.* **(Right)** *Hematoxylin and eosin shows a sugar tumor with focal areas of hemorrhage toward the periphery of the tumor. Uninvolved lung parenchyma is still present ⇨. These areas do not represent tumor hemorrhage, but rather ectatic vascular spaces with pools of red cells.*

Spindle Cell Component

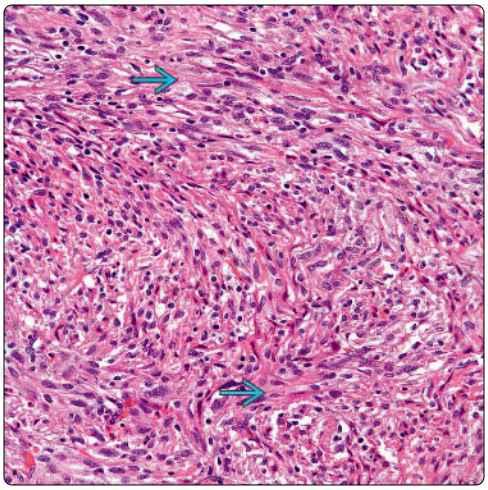

Prominent Vascular Spaces

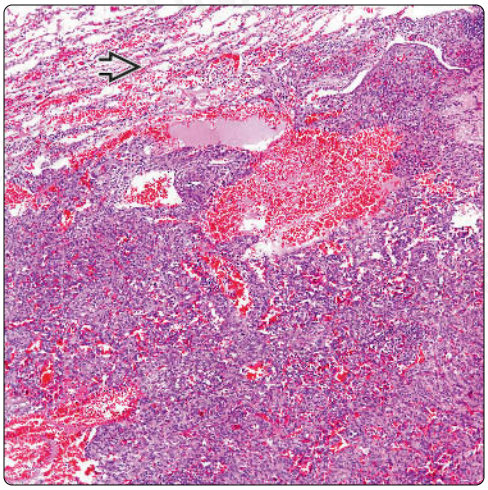

(Left) *Clear cell tumor is seen with prominent ectatic vessels, possibly mimicking a vascular tumor. However, even at this magnification, one can appreciate the presence of cells with clear cytoplasm.* **(Right)** *Hematoxylin and eosin shows a higher magnification of the clear cell proliferation around an ectatic blood vessel. The tumor does not show cellular atypia or mitotic activity. A discrete vascular network is present.*

Dilated Vessels

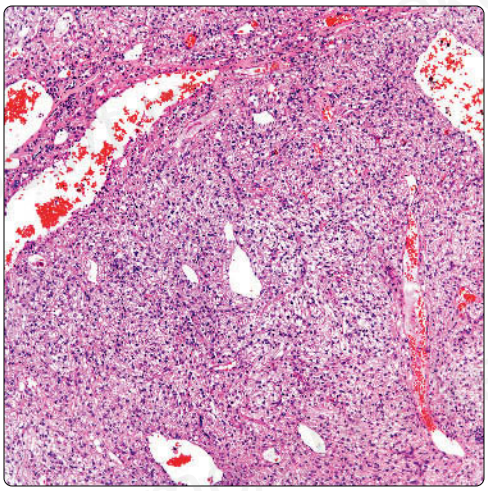

Absence of Nuclear Atypia

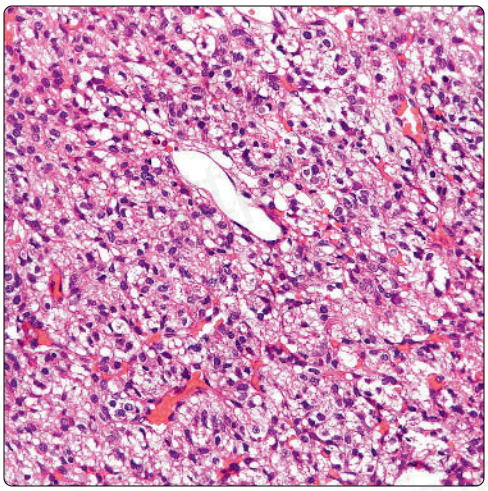

Ganglion-Like Cells

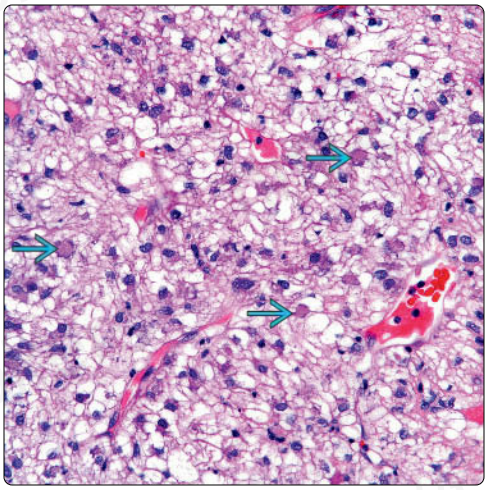

Neuroid Appearance

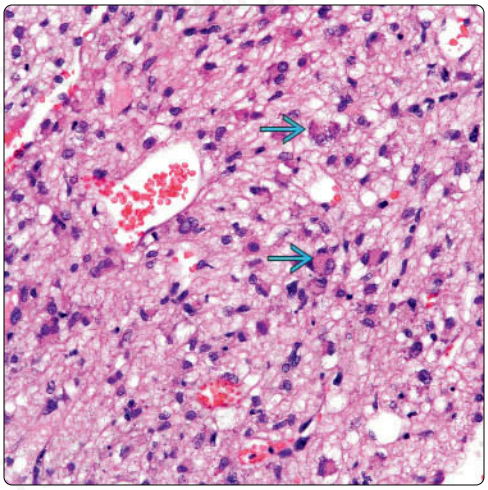

(Left) *Clear cell proliferation with ganglion-like cells gives the appearance of a neuroid neoplasm. These features, although not very conspicuous, are often seen in many cases.* **(Right)** *Hematoxylin and eosin shows numerous ganglion-like cells and fewer cells with clear cytoplasm and a fibrillary-like background. This appearance can be mistaken for a neural tumor.*

Rare Mitosis

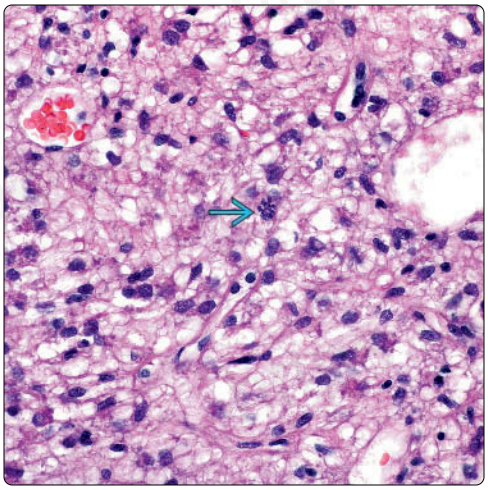

Calcifications

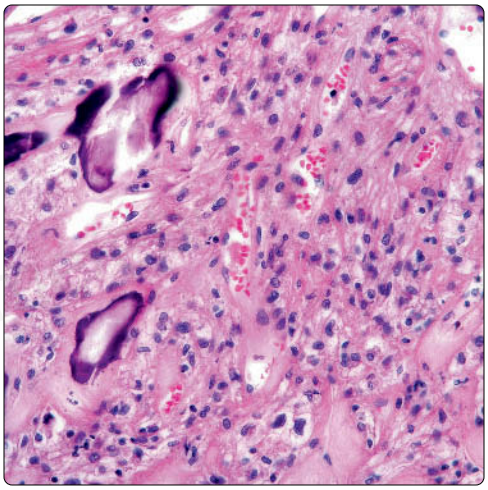

(Left) *Image shows a sugar tumor with clear cell proliferation. Note the presence of a mitotic figure . In a few cases, occasional mitotic figures may be observed; however, that is not a common feature.* **(Right)** *Hematoxylin and eosin shows a sugar tumor with focal areas of calcifications admixed with clear and spindle cells. This pattern can be easily confused for a true vascular tumor, such as a glomus tumor.*

Nested Pattern

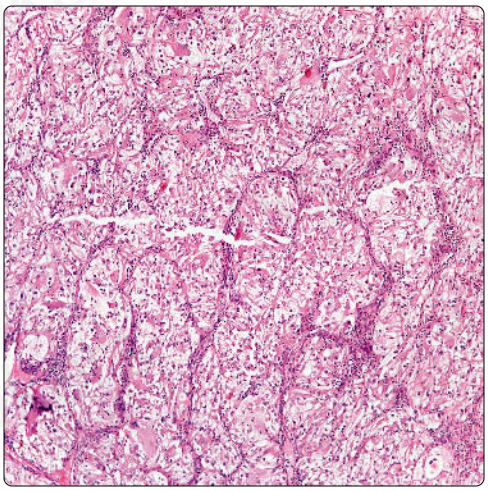

Oncocytic Appearance

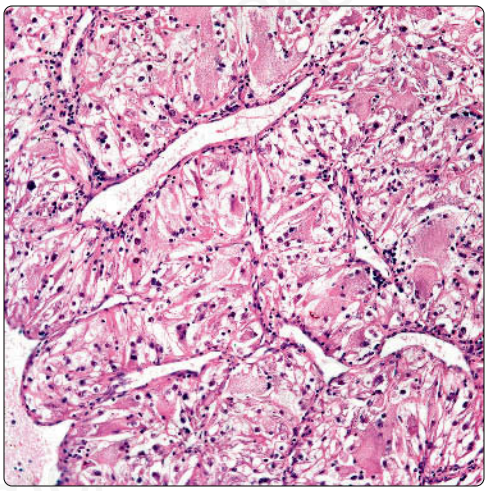

(Left) *Clear cell tumor is seen with a prominent nested pattern resembling a neuroendocrine neoplasm. In small biopsies, the use of immunohistochemistry to properly rule out a neuroendocrine tumor needs to be done.* **(Right)** *Clear cell tumor is seen with numerous so-called spider cells, which are another feature of sugar tumors. In addition, this pattern may be seen in paragangliomas, thus the need for a careful evaluation.*

Ciliated Muconodular Papillary Tumor

KEY FACTS

TERMINOLOGY

- Benign peripheral lung nodule composed of ciliated columnar cells, mucous cells, and basal cell proliferation

CLINICAL ISSUES

- Small, peripheral lung nodule 1 cm in average diameter
- Mostly asymptomatic; discovered on routine radiographs
- Mostly middle-aged and elderly patients
- Indolent behavior; excellent prognosis

IMAGING

- Small, peripheral, solid or partly solid nodules with irregular contours

MICROSCOPIC

- Glandular or papillary proliferation of epithelial cells showing admixture of ciliated columnar cell, mucous cells, and basal cells
- Periphery of lesions contains copious amounts of inspissated mucus filling alveoli
- Tumors penetrated by bronchovascular bundles or medium-sized muscular arteries
- Ciliated columnar cells line surface of glandular and papillary structures
- Continuous layer of basal cells present in outer layer of glands/papillae
- Mucous cells seen interspersed with other elements
- Relative amount or proportion of various cellular elements may vary from case to case
- Complete absence of cytologic atypia, nuclear pleomorphism, mitotic activity, or necrosis
- Mucin may occasional infiltrate adjacent parenchyma, suggesting invasive process

ANCILLARY TESTS

- p40/p63 highlights basal cell layer
- %5$) 9 (mutation
- $.7 mutation

Scanning Magnification

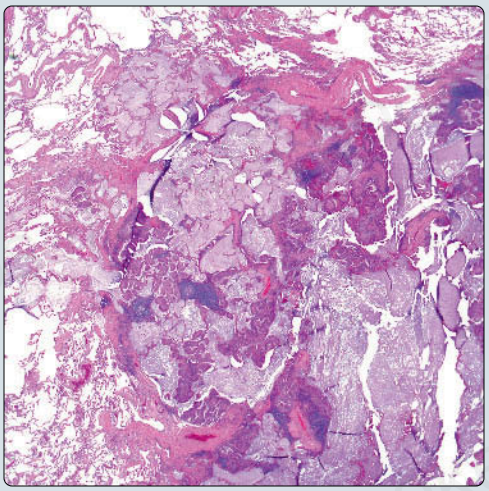

Papillary Architecture

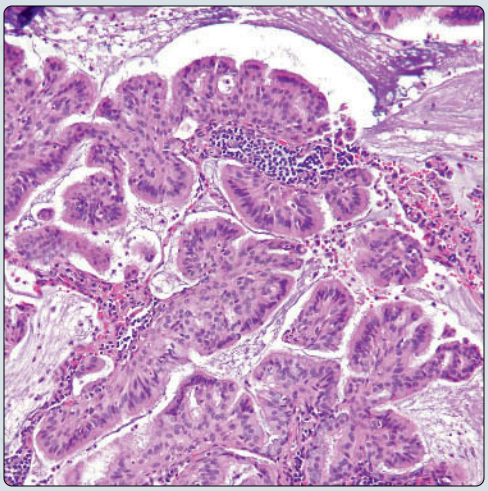

(Left) *Scanning magnification of ciliated muconodular papillary tumor of the lung shows a relatively well-circumscribed, but unencapsulated, cellular proliferation with focal papillary architecture and abundant mucin deposition.* **(Right)** *Higher magnification of ciliated muconodular papillary tumor of the lung shows well-developed papillary architecture surrounded by extracellular mucous pools.*

Higher Magnification

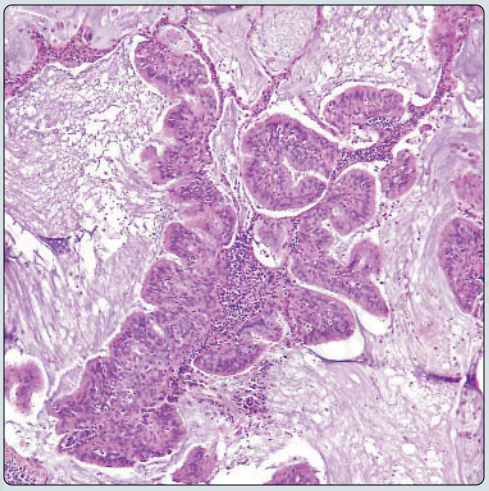

Ciliated Columnar Cells

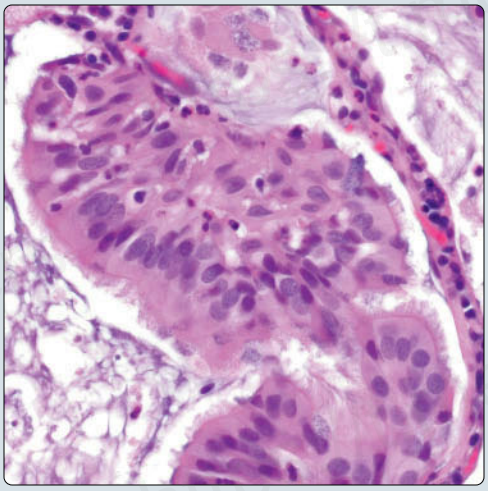

(Left) *Higher magnification of a papillary structure in ciliated muconodular papillary tumor of the lung shows a mixed cell composition, with mucinous cells, tall columnar cells lining the papilla, and a continuous layer of basaloid cells underlying the papillary structures.* **(Right)** *Higher magnification from a papilla in ciliated muconodular papillary tumor of the lung shows an outer layer of tall columnar cells with prominent cilia supported by a layer of basaloid cells.*

TERMINOLOGY

Definitions

- Benign peripheral lung nodule composed of ciliated columnar cells, mucous cells, and basal cell proliferation

ETIOLOGY/PATHOGENESIS

Probable Benign Neoplastic Proliferation

- %5$) 9 (driver mutation
- $.7 mutation

CLINICAL ISSUES

Presentation

- Small, peripheral lung nodule 1 cm in average diameter
- Mostly asymptomatic; discovered on routine radiographs
- Rarely may present with cough
- Mostly middle-aged and elderly patients

Treatment

- Surgical excision

Prognosis

- Indolent behavior; excellent prognosis

IMAGING

CT Findings

- Small, peripheral, solid or partly solid nodules with irregular contours
- Often misinterpreted as adenocarcinoma due to peripheral location and irregular contour

MACROSCOPIC

General Features

- Soft, well-circumscribed, gray-white nodule with mucinous or gelatinous cut surface

MICROSCOPIC

Histologic Features

- Glandular or papillary proliferation of epithelial cells showing admixture of ciliated columnar cell, mucous cells, and basal cells
- Periphery of lesions contains copious amounts of inspissated mucus filling alveoli
- Tumors are penetrated by bronchovascular bundles or medium-sized muscular arteries
- Mucin may occasional infiltrate adjacent parenchyma, suggesting invasive process

Cytologic Features

- Ciliated columnar cells line surface of glandular and papillary structures
- Continuous layer of basal cells present in outer layer of glands/papillae
- Mucous cells are seen interspersed with other elements
- Relative amount or proportion of various cellular elements may vary from case to case
- Complete absence of cytologic atypia, nuclear pleomorphism, mitotic activity, or necrosis

ANCILLARY TESTS

Immunohistochemistry

- p40/p63 highlights basal cell layer
- Ciliated cells focally positive for MUC5AC
- Rare chromogranin/synaptophysin positives cells present admixed with basal cells

Next Generation Sequencing

- %5$) 9 (mutation
- $.7 mutation

DIFFERENTIAL DIAGNOSIS

Mucinous Adenocarcinoma

- Lack ciliated cells and continuous basal cell layer
- Display more marked nuclear atypia and mitotic activity

Mucoepidermoid Carcinoma

- Contain intermediate (squamous) cells and lack basal cell layer or cilia
- Central location associated with bronchus rather than peripheral

Bronchiolar Metaplasia

- Does not cause major architectural distortion of lung parenchyma
- Incidental microscopic finding not visualized on CT scans
- Does not usually form discrete, macroscopically visible lesion

Colloid Carcinoma

- Lacks ciliated columnar cells and continuous basal cell layer
- Shows single cells or small clusters of neoplastic epithelial cells floating in mucin

DIAGNOSTIC CHECKLIST

Clinically Relevant Pathologic Features

- Admixture of 3 cell elements: Ciliated columnar cells, mucous cells, and basal cells

Pathologic Interpretation Pearls

- Identification of ciliated cells key to establishing benign nature and distinguishing from adenocarcinoma
- Identification of continuous basal cell layer with p40/p63 stains helpful for differential diagnosis

SELECTED REFERENCES

1. Ishikawa M et al: Ciliated muconodular papillary tumor of the lung: report of five cases. J Surg Case Rep. 2016(8), 2016
2. Liu L et al: Ciliated muconodular papillary tumors of the lung can occur in Western patients and show mutations in BRAF and AKT1. Am J Surg Pathol. ePub, 2016
3. Kamata T et al: Ciliated muconodular papillary tumors of the lung: a clinicopathologic analysis of 10 cases. Am J Surg Pathol. 39(6):753-60, 2015
4. Chuang HW et al: Ciliated muconodular papillary tumor of the lung: a newly defined peripheral pulmonary tumor with conspicuous mucin pool mimicking colloid adenocarcinoma: a case report and review of literature. Pathol Int. 64(7):352-7, 2014
5. Hata Y et al: Ciliated muconodular papillary tumor of the lung: a newly defined low-grade malignant tumor with CT findings reminiscent of adenocarcinoma. Jpn J Clin Oncol. 43(2):205-7, 2013

PART I
SECTION 2

Neoplasms, Malignant, Primary

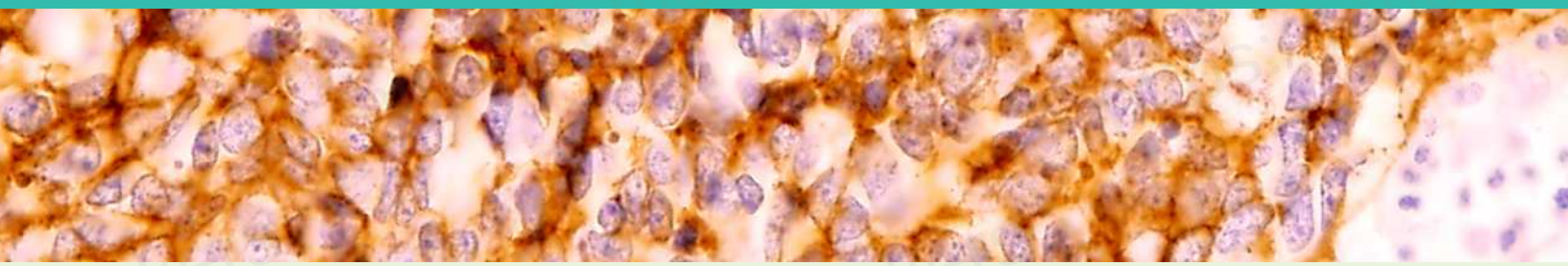

Epithelial Neoplasms

Overview of Malignant Epithelial Neoplasms of Lung 74
Adenocarcinoma 76
Bronchioloalveolar Carcinoma 88
Mucinous ("Colloid") Carcinoma 94
Signet Ring Cell Carcinoma 102
Endometrioid-Like Carcinoma 108
Squamous Cell Carcinoma 114
Spindle Cell (Sarcomatoid) Carcinoma 122
Lymphoepithelioma-Like Carcinoma 128
Poorly Differentiated Squamous Carcinoma, Small Cell Variant 134
Large Cell (Anaplastic) Carcinoma 140
Pleomorphic Carcinoma 148
Neuroendocrine Carcinoma (Including Small Cell Carcinoma) 154
Carcinosarcoma 166
Pulmonary Blastoma 172

Salivary Gland-Type Tumors

Adenoid Cystic Carcinoma 178
Mucoepidermoid Carcinoma 186
Epithelial-Myoepithelial Carcinoma 192
Acinic Cell Carcinoma 198
Mixed Tumor 206
Myoepithelial Carcinoma of Lung 212

Mesenchymal Neoplasms

Intrapulmonary Synovial Sarcoma 216
Leiomyosarcoma 222
Neurogenic Sarcoma (Malignant Peripheral Nerve Sheath Tumor) 228
Osteosarcoma 232
Chondrosarcoma 236
Epithelioid Hemangioendothelioma 240
Angiosarcoma 246
Kaposi Sarcoma 250
Pulmonary Artery Sarcoma 254

Lymphoproliferative Disorders

Pulmonary BALT Hyperplasia **258**
Pulmonary BALT Lymphoma **262**
Diffuse Large Cell Lymphoma **268**
Hodgkin Lymphoma **276**
Plasmacytoma **280**
Lymphomatoid Granulomatosis **284**

Other Rare Tumors and Benign Pseudotumoral Conditions

Ganglioneuroblastoma **290**
Bronchial Malignant Melanoma **294**
Inflammatory Pseudotumor **298**
IgG4 Sclerosing Lung Disease **304**
Juvenile Xanthogranuloma **308**
Hyalinizing Granuloma **312**
Amyloid Tumor **316**
Metastatic/Dendriform Calcification **320**
Lipoid Pneumonia (Paraffinoma) **324**
Placental Transmogrification **328**
Rosai-Dorfman Disease **332**
Angiolymphoid Hyperplasia With Eosinophilia **336**
Atypical Adenomatous Hyperplasia **340**
Lymphangioleiomyomatosis **342**
Capillary Hemangiomatosis **346**

https://t.me/ebookers

TERMINOLOGY

Definitions

- Neoplastic process showing histological, immunohistochemical, or ultrastructural evidence of epithelial differentiation

Principles of Classification

- Classification of lung carcinoma, which constitutes vast majority of primary lung cancers, based on clinical implications
  - Small cell carcinoma (SCC)
    - Rapidly growing tumors that have metastasized early and widely to distant organs at time of initial diagnosis
    - Respond well to chemo- and radiotherapy
    - Generally not considered good surgical candidates
  - Non-small cell lung carcinoma (NSCLC)
    - Tends to be slower growing and of lesser stage at time of diagnosis
    - When in lower stages (I-II), considered good surgical candidates
- Histopathologic classification of lung cancer according to lines of differentiation
  - Bronchogenic carcinoma
    - Squamous cell carcinoma
    - Adenocarcinoma
    - Large cell/anaplastic carcinoma
    - Neuroendocrine carcinoma (carcinoid, atypical carcinoid, and SCC)
  - Bronchial gland (salivary-type) tumors
    - Adenoid cystic carcinoma
    - Mucoepidermoid carcinoma
    - Epimyoepithelial carcinoma
  - Mixed epithelial-mesenchymal tumors
    - Carcinosarcoma
    - Pulmonary blastoma

EPIDEMIOLOGY

Age Range

- 40-70 years of age

Gender

- More common in men (M:F = 3:1)

Incidence

- Lung cancer is one of most common malignant neoplasms worldwide
- Lung cancer accounts for ~ 12% of all new cancers and 18% of all cancer deaths
- Areas of highest incidence and mortality include Europe, North America, Australia, and South America
- Certain populations are at increased risk (African Americans, Maoris in New Zealand)

ETIOLOGY/PATHOGENESIS

Pathogenesis

- Tobacco smoke is major predisposing factor for development of lung cancer
  - Smokers experience 8-15x increased risk for developing lung cancer than nonsmokers
  - Risk is directly proportional to number of cigarettes smoked per day and duration of smoking
- Occupational exposure is also strongly associated with development of lung cancer
  - Asbestos exposure is associated with increased risk for development of lung cancer
  - Ionizing radiation exposure is another factor involved in development of lung cancer
  - Urban air pollution is risk factor for lung cancer with excess risk in order of 50%

CLINICAL IMPLICATIONS

Clinical Presentation

- Progressive shortness of breath
- Cough
- Chest pain

Non-Small Cell Carcinoma of Lung

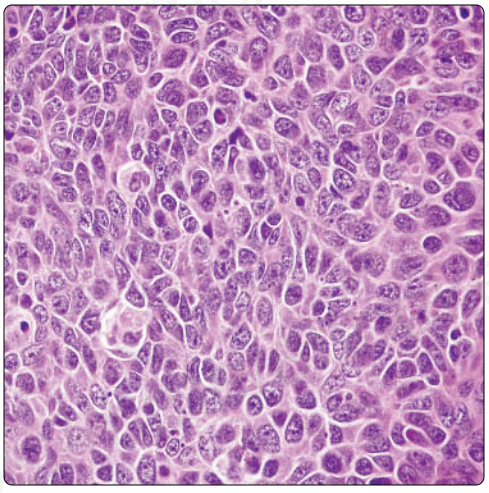

Cytokeratin AE1/AE3

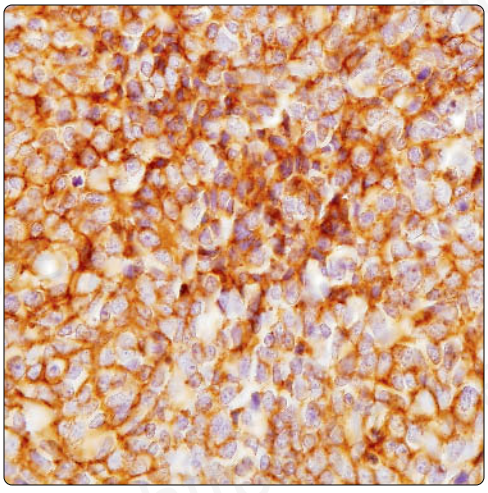

(Left) *Poorly differentiated non-small cell carcinoma of the lung shows sheets of large, atypical cells with large nuclei and prominent nucleoli and without evidence of glandular or squamous differentiation.* **(Right)** *Immunohistochemical staining for cytokeratin AE1/AE3 in poorly differentiated non-small cell carcinoma of the lung shows strong positivity of the tumor cells for this antibody.*

- Hemoptysis
- Pleural effusion
- Paraneoplastic symptoms
  - Ectopic secretion of peptide hormones: ACTH, ADH, etc.
  - Neurologic symptoms: Sensory abnormalities, autoimmune neuropathies, encephalomyelitis
  - Eaton-Lambert myasthenic syndrome
  - Hypercalcemia due to production of parathormone-like substance associated with squamous cell carcinoma
  - Clubbing of fingers (hypertrophic pulmonary osteoarthropathy)
  - Carcinoid syndrome due to serotonin production by neuroendocrine carcinomas

MICROSCOPIC

General Features

- Histologic examination remains mainstay of classification and diagnosis
- Bronchogenic carcinoma is characterized by recapitulating normal structures of tracheobronchial tree
  - Adenocarcinomas form glands and may be well, moderately, and poorly differentiated
    - Subtypes of adenocarcinoma include acinar, papillary, solid, signet ring, bronchoalveolar, mucinous, cribriform, fetal, and clear cell type
  - Squamous cell carcinoma recapitulates pavemented epithelium of squamous mucosa and may be well to poorly differentiated
    - Subtypes include keratinizing, papillary, small cell, lymphoepithelioma-like, basaloid, spindle (sarcomatoid), and clear cell
  - Large cell/anaplastic carcinomas are poorly differentiated tumors without evidence of squamous or glandular differentiation
    - Subtypes include pleomorphic, anaplastic, clear cell, giant cell, inflammatory, sarcomatoid, and rhabdoid
  - Neuroendocrine carcinomas show evidence of neuroendocrine differentiation by histology, immunohistochemistry, or ultrastructurally
    - Subtypes include well differentiated (carcinoid), moderately differentiated (atypical carcinoid), and poorly differentiated (SCC)

Immunohistochemical Features

- Markers associated with lung adenocarcinoma include TTF-1, napsin-A, CK7, CEA, and MOC-31
- Markers associated with squamous cell carcinoma include CK7, CK5/6, MOC-31, p40, and p63
- Markers associated with neuroendocrine carcinomas include CK7, chromogranin, synaptophysin, CD56, and CD57

Ultrastructural Features

- Organelles associated with adenocarcinomas include zymogen granules, microvilli, and intracellular lumina
- Organelles associated with squamous cell carcinomas include tonofilaments and well-developed desmosome-type intercellular junctions
- Organelles associated with neuroendocrine neoplasms include dense-core, membrane-bound neurosecretory intracytoplasmic granules

Genetic and Molecular Alterations

- Genetic changes frequent in all major histologic types
  - 7 3 mutations are detected in up to 50% of NSCLC and in over 70% of SCC
  - Inactivation of pathway encoding retinoblastoma gene, 5 % (13q11), leading to loss of Rb protein expression
  - Loss of heterozygosity (LOH) on chromosome 3p is detectable in up to 80% of NSCLC and SCC
  - Hypermethylation of cyclin-dependent kinase inhibitor p16 is seen in up to 50% of all lung cancers
  - LOH of fragile histidine triad ( ) + , 7) gene on chromosome 3p14.2 occurs in 40-70% of all lung cancers
- Genetic changes specific for some histologic types
  - . 5 $ 6 mutation (12p21) is found in 30-50% of all lung adenocarcinomas
  - Amplification of 0 < & (8q21-23) is common in small cell neuroendocrine carcinomas
  - (*) 5 mutations are present in NSCLC
    - 6 7 . (LKB1) mutations occur more commonly in lung adenocarcinoma and large cell carcinoma
  - $ / . gene rearrangements leading to (0 / $ / . fusion have been detected preferentially in adenocarcinomas

SELECTED REFERENCES

1. Sholl LM: The molecular pathology of lung cancer. Surg Pathol Clin. 9(3):353-78, 2016
2. Zhang N et al: The EGFR pathway is involved in the regulation of PD-L1 expression via the IL-6/JAK/STAT3 signaling pathway in EGFR-mutated non-small cell lung cancer. Int J Oncol. ePub, 2016
3. Lim EH et al: Using whole genome amplification (WGA) of low-volume biopsies to assess the prognostic role of EGFR, KRAS, p53, and CMET mutations in advanced-stage non-small cell lung cancer (NSCLC). J Thorac Oncol. 4(1):12-21, 2009
4. Alberg AJ et al: Epidemiology of lung cancer: ACCP evidence-based clinical practice guidelines (2nd edition). Chest. 132(3 Suppl):29S-55S, 2007
5. Jemal A et al: Cancer statistics, 2007. CA Cancer J Clin. 57(1):43-66, 2007
6. Pan H et al: Loss of heterozygosity patterns provide fingerprints for genetic heterogeneity in multistep cancer progression of tobacco smoke-induced non-small cell lung cancer. Cancer Res. 65(5):1664-9, 2005
7. Shigematsu H et al: Clinical and biological features associated with epidermal growth factor receptor gene mutations in lung cancers. J Natl Cancer Inst. 97(5):339-46, 2005
8. Sanchez-Cespedes M et al: Chromosomal alterations in lung adenocarcinoma from smokers and nonsmokers. Cancer Res. 61(4):1309-13, 2001
9. Gealy R et al: Comparison of mutations in the p53 and K-ras genes in lung carcinomas from smoking and nonsmoking women. Cancer Epidemiol Biomarkers Prev. 8(4 Pt 1):297-302, 1999

Adenocarcinoma

KEY FACTS

TERMINOLOGY

- Malignant epithelial neoplasm with glandular differentiation

ETIOLOGY/PATHOGENESIS

- Close association with tobacco smoking

CLINICAL ISSUES

- Cough
- Weight loss
- Chest pain
- Difficulty breathing

MACROSCOPIC

- Peripheral or central tumors
- Varying size from 0.6 cm to > 10 cm

MICROSCOPIC

- Acinar
- Solid
- Papillary

ANCILLARY TESTS

- Molecular analysis
  - (*) 5(exons 18, 19, 20, 21)
  - (0 / - $ / .fusion gene
  - . 5 $ 6
  - 5 2 6

TOP DIFFERENTIAL DIAGNOSES

- Adenocarcinoma from extrathoracic origin
- Atypical adenomatous hyperplasia
- Adenoid cystic carcinoma
- Fetal adenocarcinoma (monophasic pulmonary blastoma)
- Papillary carcinoma of thyroid origin

Intrapulmonary Adenocarcinoma

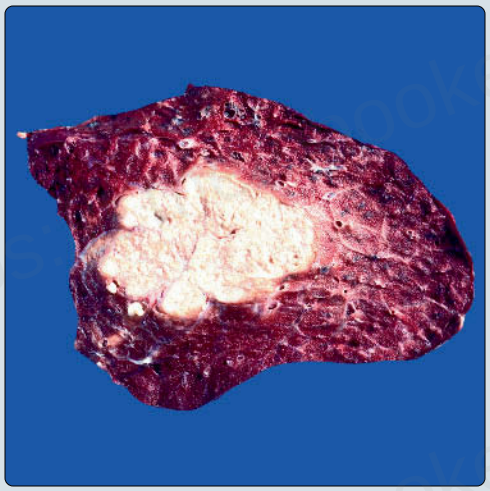

Adenocarcinoma

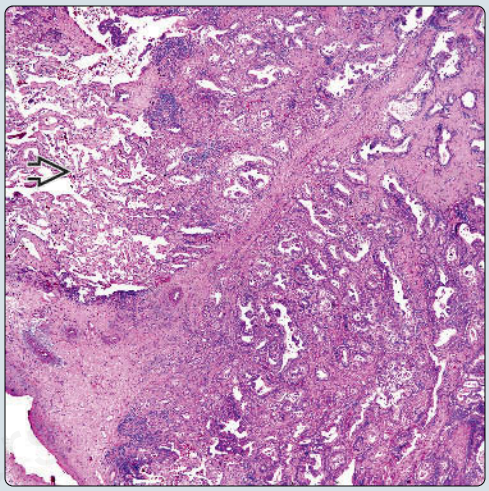

(Left) *Gross photograph shows a peripherally located lung adenocarcinoma. The mass is relatively well demarcated but not encapsulated. It is tan and nodular.* **(Right)** *Well-differentiated adenocarcinoma destroying normal lung parenchyma is shown. Note the contrast with normal lung parenchyma.*

Size Variability

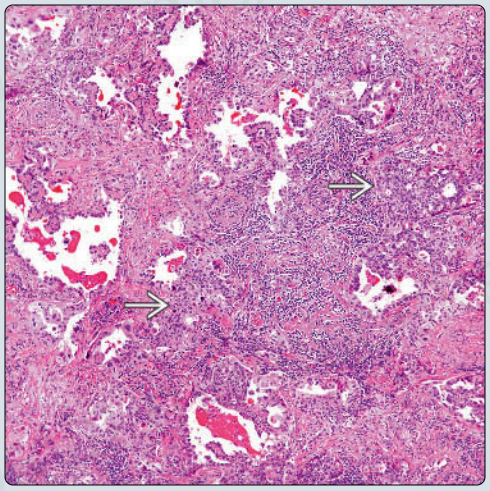

Glandular Component

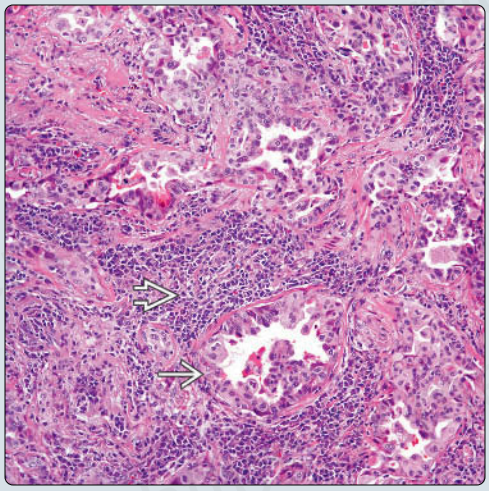

(Left) *Adenocarcinoma shows a glandular proliferation with glands of different sizes. In addition, the tumor displays compressed glandular component in some areas.* **(Right)** *Adenocarcinoma shows a typical glandular component. Note that the malignant glands are adjacent to inflammatory cells.*

TERMINOLOGY

Definitions

- Malignant epithelial neoplasm with glandular differentiation

ETIOLOGY/PATHOGENESIS

Environmental Exposure

- Close association with tobacco use
- Probably associated with some environmental hazards
- Probably some genetic predisposition

Etiology

- Tumor probably originates from endobronchial glands

CLINICAL ISSUES

Epidemiology

- Incidence
  - In last decade, adenocarcinomas have become more prevalent than any other nonsmall cell carcinoma
  - Currently is most common nonsmall cell carcinoma
- Age
  - More common in adults
  - Adenocarcinomas are more common in 6th and 7th decades of life
  - Some cases may occur in younger patients
  - Unusual cases may occur in children

Presentation

- Cough
- Weight loss
- Difficulty breathing
- Chest pain
- Cushing syndrome
- Superior vena cava syndrome
- Pancoast syndrome
- Hemoptysis
- Hoarseness
- Asymptomatic

Treatment

- Surgical approaches
  - Segmentectomy, lobectomy, pneumonectomy
    - Depending on the pathological stage
    - Depending on location of tumor
- Adjuvant therapy
  - Chemotherapy, radiation therapy, or both
    - Depending on pathological stage
    - Depending on performing status of patient
  - Depending on results of molecular analysis, chemotherapy will vary

Prognosis

- Depends on stage at time of diagnosis
- Patients with carcinomas positive for (*)5 mutation may have better prognosis
- It is also possible that tumors with better differentiated histology have more favorable outcome
- It may also be related to other pulmonary function factors as well as other medical conditions

MACROSCOPIC

General Features

- Peripheral or central tumors
  - Tumors may show necrosis &/or hemorrhage
  - Homogeneous tan surface
  - Well circumscribed but not encapsulated

Sections to Be Submitted

- Tumor in relation to pleural surface
  - Pleural involvement crucial for staging tumors < 3 cm in size
  - As many lymph nodes as possible
    - Location of lymph node is highly important and determines N1 and N2 disease
  - Bronchial margin, as needed
  - Parenchymal margin, as needed
  - Nonneoplastic lung parenchyma

Size

- Varying size from 0.6 cm to > 10 cm

MICROSCOPIC

Histologic Features

- Malignant glandular component

Predominant Pattern/Injury Type

- Acinar
- Solid
- Papillary
- Mixed
- Oncocytic

Predominant Cell/Compartment Type

- Epithelial

True Papillary Carcinoma

- Should be composed of at least 75% true papillae with fibrovascular cores
- This particular pattern is believed to be more aggressive
- Lymph node metastases in this pattern are commonly seen
- TTF-1(+) and thyroglobulin (-)

Papillary Carcinoma With Morular Component

- Similar criteria to true papillary carcinoma
- Presence of morular component in alveolar spaces
- "Morules" are of different sizes and always in intraalveolar location
- TTF-1(+) and thyroglobulin (-)

Micropapillary Carcinoma

- Composed of small micropapillae without fibrovascular cords
- This pattern is often seen in combination with true papillary carcinoma
- TTF-1(+) and thyroglobulin (-)

Hepatoid Adenocarcinoma

- Composed of cords of neoplastic cells resembling hepatic parenchyma
- This pattern is commonly placed among large cell carcinomas of lung

- TTF-1 may show focal positive staining

Warthin-Like Adenocarcinoma

- Prominent lymphoid component similar to tumors in salivary gland
- Some cases of mucoepidermoid carcinoma may also display similar features
- Glandular proliferation with cells producing mucin embedded in inflammatory background
- TTF-1 may show positive staining

Adenomatoid Tumor-Like Adenocarcinoma

- Bland appearance similar to true adenomatoid tumor
- In some cases, can be confused with so-called alveolar adenoma
- TTF-1 and CK7 (+)

ANCILLARY TESTS

Histochemistry

- Mucicarmine
  - Reactivity: Positive
  - Staining Pattern: Cytoplasmic
- PAS-diastase
  - Reactivity: Positive
  - Staining Pattern: Cytoplasmic

EGFR by Fluorescent In Situ Hybridization

- Analysis of exons 18, 19, 20, and 21
- Other molecular analysis
  - . 5 $ 6, $ / ., 5 2 6

DIFFERENTIAL DIAGNOSIS

Adenocarcinoma From Extrathoracic Origin

- Immunohistochemistry positive for TTF-1; CK7 would favor lung origin in vast majority of cases

Atypical Adenomatous Hyperplasia

- Lesion ≤ 0.5 cm in diameter
- Shares similar histological features with bronchoalveolar carcinoma

Adenoid Cystic Carcinoma

- Shows characteristic double layer-forming glands
- Immunohistochemical studies show myoepithelial differentiation

Fetal Adenocarcinoma (Monophasic Pulmonary Blastoma)

- Presence of morules and embryonic-type glandular structures
- Presence of cytoplasmic mucin content in favor of adenocarcinoma

Papillary Carcinoma of Thyroid Origin

- Histologically tumors with papillary pattern may show similar histological features
- Positive TTF-1 and negative staining for thyroglobulin favors primary lung cancer

Oncocytic Carcinoma of Extrathoracic Origin

- Use of full panel of immunohistochemical stains and appropriate clinical history are highly important

DIAGNOSTIC CHECKLIST

Pathologic Interpretation Pearls

- Size of lesion will separate carcinoma from atypical adenomatous hyperplasia
- Cases designated as AAH are under 5 mm in diameter

GRADING

Low Grade

- Well-differentiated adenocarcinoma composed of easily identifiable glandular structures and arranged in back-to-back arrangement
- Absence of necrosis, increased mitotic activity, and nuclear atypia
- Glandular tumoral structures may be separated by extensive areas of collagenization

Intermediate Grade

- Moderately differentiated adenocarcinoma composed of identifiable glands
- Tumor may show more nuclear atypia and mitotic activity
- Glandular structures may show more disarray

High Grade

- Poorly differentiated adenocarcinoma may show solid areas with ↑ mitotic activity and nuclear atypia
- Necrosis and hemorrhage may be present

SELECTED REFERENCES

1. Clavé S et al: ROS1 copy number alterations are frequent in non-small cell lung cancer. Oncotarget. 7(7):8019-28, 2016
2. Hong SY et al: Oncogenic activation of the PI3K/Akt pathway promotes cellular glucose uptake by downregulating the expression of thioredoxin-interacting protein. Cell Signal. 28(5):377-83, 2016
3. Kurebayashi Y et al: Comprehensive immune profiling of lung adenocarcinomas reveals four immunosubtypes with plasma cell subtype a negative indicator. Cancer Immunol Res. 4(3):234-47, 2016
4. Lu F et al: Identification of lung adenocarcinoma mutation status based on histologic subtype: Retrospective analysis of 269 patients. Thorac Cancer. 7(1):17-23, 2016
5. Schuler M et al: First-line afatinib versus chemotherapy in patients with non-small cell lung cancer and common epidermal growth factor receptor gene mutations and brain metastases. J Thorac Oncol. 11(3):380-90, 2016
6. Hu S et al: CDK2 inhibition causes anaphase catastrophe in lung cancer through the centrosomal protein CP110. Cancer Res. 75(10):2029-38, 2015
7. Park S et al: MET amplification, protein expression, and mutations in pulmonary adenocarcinoma. Lung Cancer. 90(3):381-7, 2015
8. Riquelme E et al: Modulation of EZH2 expression by MEK-ERK or PI3K-AKT signaling in lung cancer Is dictated by different KRAS oncogene Mmutations. Cancer Res. 76(3):675-85, 2015
9. VandenBussche CJ et al: Molecular alterations in non-small cell lung carcinomas of the young. Hum Pathol. 45(12):2379-87, 2014
10. Zhang J et al: Intratumor heterogeneity in localized lung adenocarcinomas delineated by multiregion sequencing. Science. 346(6206):256-9, 2014
11. Moran C: Importance of molecular features of non-small cell lung cancer for choice of treatment. Am J Pathol. 178(5):1940-8, 2011
12. Solis LM et al: Primary oncocytic adenocarcinomas of the lung: a clinicopathologic, immunohistochemical, and molecular biologic analysis of 16 cases. Am J Clin Pathol. 133(1):133-40, 2010
13. Wahbah M et al: Changing trends in the distribution of the histologic types of lung cancer: a review of 4,439 cases. Ann Diagn Pathol. 11(2):89-96, 2007
14. Moran CA: Pulmonary adenocarcinoma: the expanding spectrum of histologic variants. Arch Pathol Lab Med. 130(7):958-62, 2006
15. Prudkin L et al: Epidermal growth factor receptor abnormalities in lung cancer. Pathogenetic and clinical implications. Ann Diagn Pathol. 10(5):306-15, 2006
16. Moran CA et al: Papillary lung carcinoma with prominent "morular" component. Am J Clin Pathol. 122(1):106-9, 2004

Immunohistochemistry

Antibody	Reactivity	Staining Pattern	Comment
CEA-M	Positive	Cytoplasmic	
TTF-1	Positive	Nuclear	Often negative in mucinous tumors
CD15	Positive	Cytoplasmic	Often negative in poorly differentiated tumors
MOC-31	Positive	Cytoplasmic	Some mesotheliomas may show focal positive staining
TAG72	Positive	Cytoplasmic	
CK-PAN	Positive	Cytoplasmic	
CK7	Positive	Cytoplasmic	
CK20	Positive	Cytoplasmic	Positive in some pulmonary adenocarcinomas
SURFACTANT	Positive	Cytoplasmic	Negative in many cases of primary lung origin
EMA	Positive	Cell membrane	
CDX-2	Positive		Mainly in mucinous tumors
EpCAM/BER-EP4/CD326	Positive	Cell membrane	Some mesotheliomas are positive
D2-40	Negative		Positive in some cases
WT1	Positive	Nuclear	In ~ 30-40% of cases
Calretinin	Negative		Positive in some cases
p40	Negative		
p63	Positive	Nuclear	In ~ 25% of cases
CK5/6	Positive	Cytoplasmic	In ~ 5-10% of cases
NAPSIN-A	Positive	Cell membrane	Positive in most well-differentiated tumors
PRP	Negative		
Mammaglobin	Negative		
ERP	Negative		Some lung adenocarcinomas may be positive
met	Positive	Cell membrane	In some cases
PTEN	Positive	Cell membrane and cytoplasm	In some cases

Molecular Biology

FISH	
(*)5	Associated with ~ 25% of cases
.5$6	Associated with ~ 25% of cases
526	Associated with ~ 5% of cases
(0/-$./ fusion gene	Associated with ~ 5% of cases
3,. &$ (PI3K)	Associated with < 5% of cases

Histochemical Features

Stain	Result
PAS	May be focally positive
PAS-D	Positive in majority of cases
Mucicarmine	Positive in majority of cases

17. Amin MB et al: Micropapillary component in lung adenocarcinoma: a distinctive histologic feature with possible prognostic significance. Am J Surg Pathol. 26(3):358-64, 2002
18. Arnould L et al: Hepatoid adenocarcinoma of the lung: report of a case of an unusual alpha-fetoprotein-producing lung tumor. Am J Surg Pathol. 21(9):1113-8, 1997
19. Silver SA et al: True papillary carcinoma of the lung: a distinct clinicopathologic entity. Am J Surg Pathol. 21(1):43-51, 1997
20. Rosado-de-Christenson ML et al: Bronchogenic carcinoma: radiologic-pathologic correlation. Radiographics. 14(2):429-46; quiz 447-8, 1994
21. Haque AK: Pathology of carcinoma of lung: an update on current concepts. J Thorac Imaging. 7(1):9-20, 1991
22. Ishikura H et al: Hepatoid adenocarcinoma: a distinctive histological subtype of alpha-fetoprotein-producing lung carcinoma. Virchows Arch A Pathol Anat Histopathol. 417(1):73-80, 1990

Inflammatory Reaction

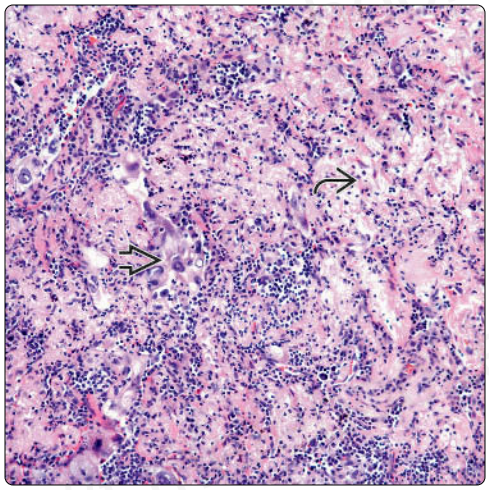

Necrosis

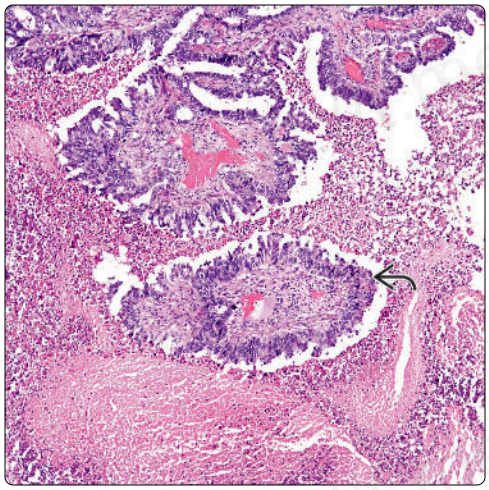

(Left) *Adenocarcinoma shows extensive areas of scarring and inflammatory reaction. Note the presence of a cluster of malignant cells embedded in extensive areas of collagenization.* **(Right)** *Adenocarcinoma is seen with malignant glands floating in areas of extensive necrosis. No residual lung parenchyma is present.*

Acinar Pattern

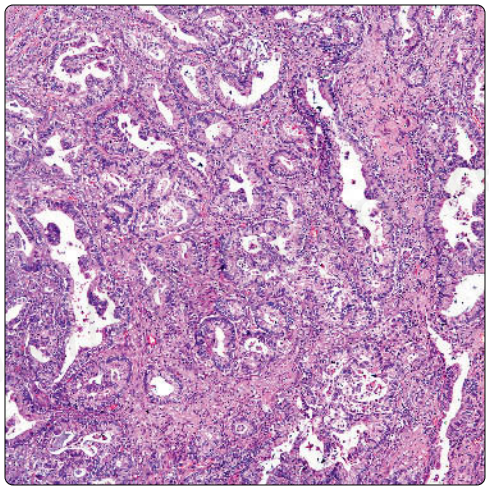

Mucinous and Nonmucinous Components

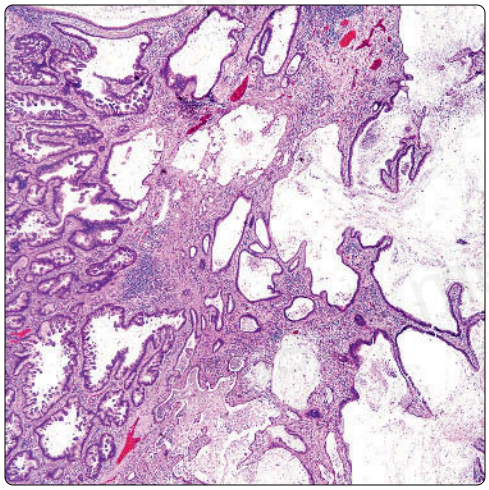

(Left) *Adenocarcinoma with an acinar pattern of growth is shown. The neoplastic glandular proliferation is composed of glands of different sizes in a back-to-back arrangement.* **(Right)** *Adenocarcinoma in which a nonmucinous component merges with a mucinous component shows cystic changes, while the nonmucinous component reveals a more acinar component.*

Glandular Component

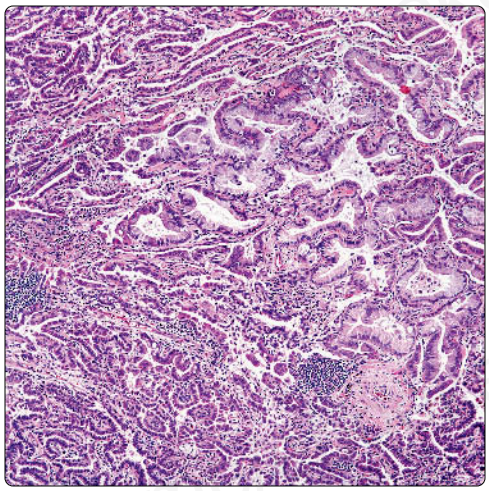

Cuboidal Epithelium

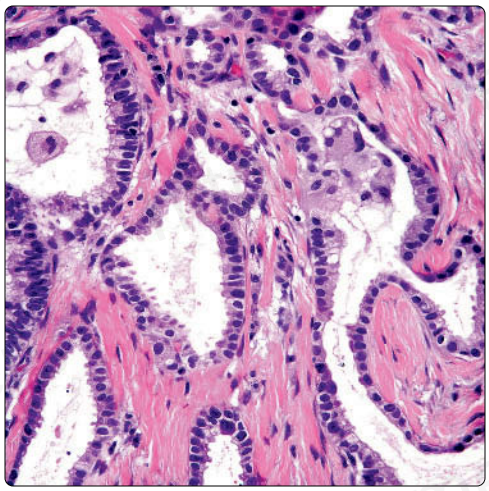

(Left) *Adenocarcinoma predominantly shows a nonmucinous type of glandular epithelium. In focal areas, a nonmucinous type of glandular proliferation merges with glands composed of a mucinous type of epithelium. This component may often be rather subtle.* **(Right)** *High-power view of a well-differentiated adenocarcinoma is composed of malignant glands with low cuboidal epithelium.*

Acinar Pattern

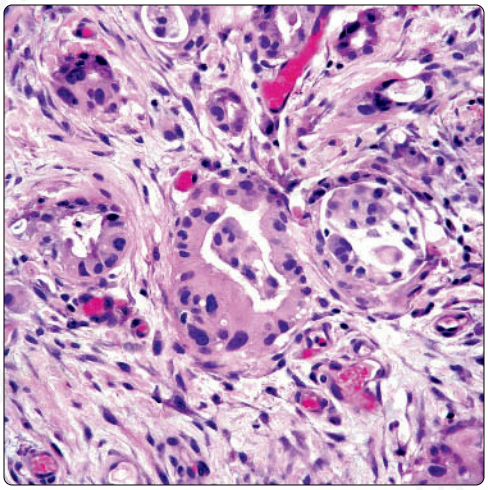

Necrosis and Incomplete Glands

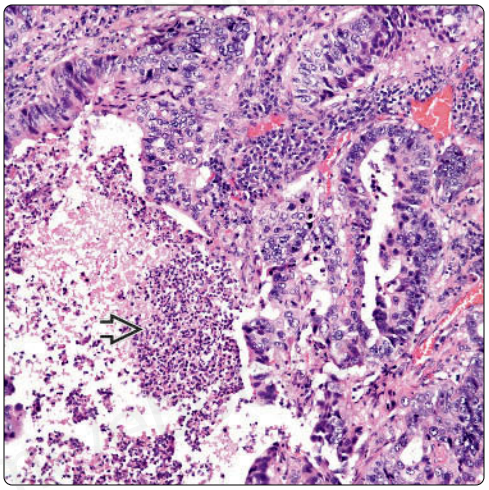

(Left) *High-power view shows a well-differentiated adenocarcinoma with an acinar growth pattern. The glands are irregular with nuclear atypia and scattered mitotic figures.* **(Right)** *Adenocarcinoma with prominent inflammatory changes ⇨ is shown. These changes may be very extensive or may form abscess areas within the tumor.*

Small Glands

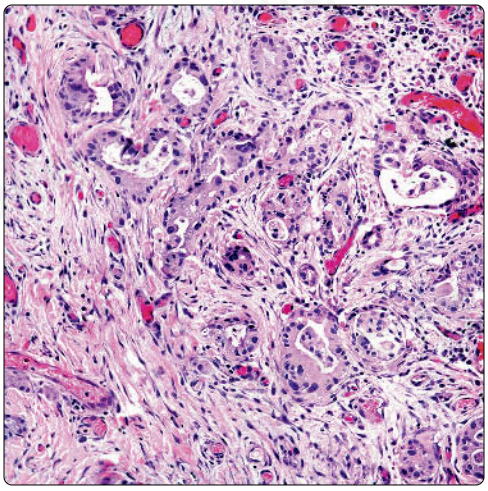

Nonmucinous Glands

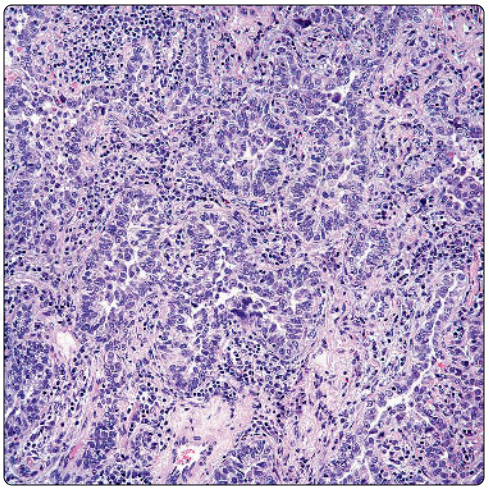

(Left) *Well-differentiated adenocarcinoma with an acinar growth pattern is composed of a small glandular proliferation of different sizes. The glands are arranged in a haphazard pattern with fibrotic and inflammatory reaction.* **(Right)** *Moderately differentiated adenocarcinoma displays easily recognizable glandular structures of different sizes. The glands are separated by an inflammatory reaction. Some of the glands are collapsed and show more nuclear atypia.*

Haphazard Distribution

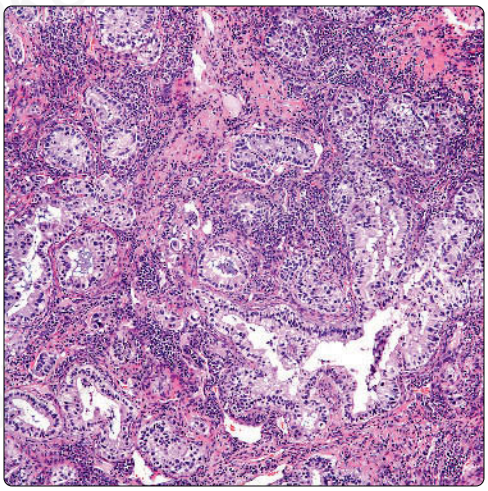

Nuclear Atypia and Mitosis

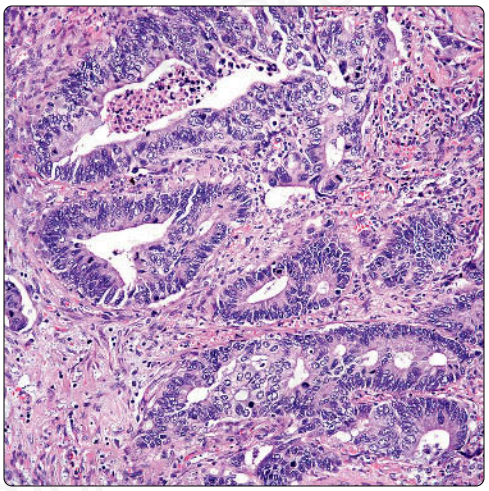

(Left) *Moderately differentiated adenocarcinoma shows the malignant glandular proliferation admixed with areas of fibrosis and inflammatory reaction.* **(Right)** *High-power view shows a moderately differentiated adenocarcinoma revealing glandular structures with more nuclear atypia and mitotic activity. The glands have a vague enteric type of differentiation, mimicking a metastasis from colonic origin.*

Comedo-Like Necrosis

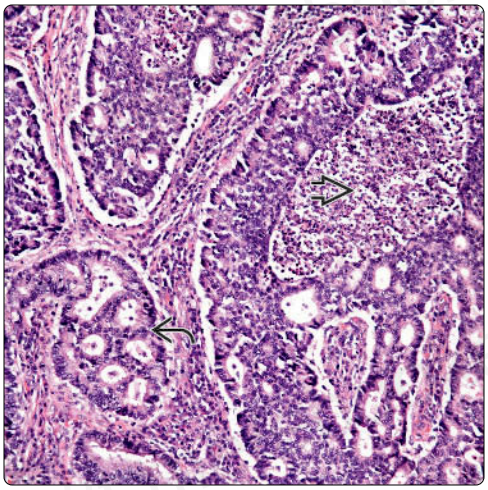

Subtle Glandular Component

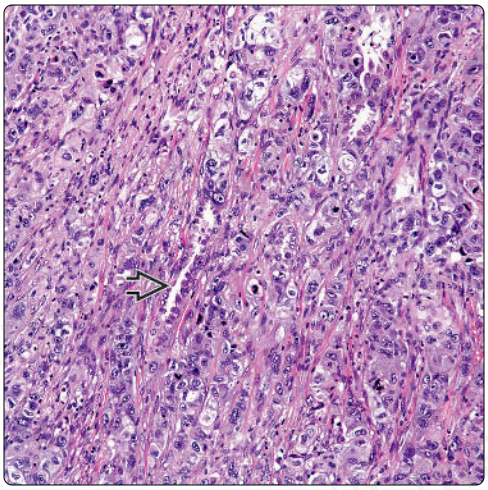

(Left) *Adenocarcinoma with comedo-like necrosis and acinar pattern is shown. The pattern has a vague neuroendocrine morphology, while in some areas, it shows conventional glandular differentiation.* **(Right)** *Intermediate-power view of a poorly differentiated adenocarcinoma with vague glandular formation is shown. The presence of glandular differentiation in some poorly differentiated adenocarcinomas may be focal.*

Solid and Glandular Component

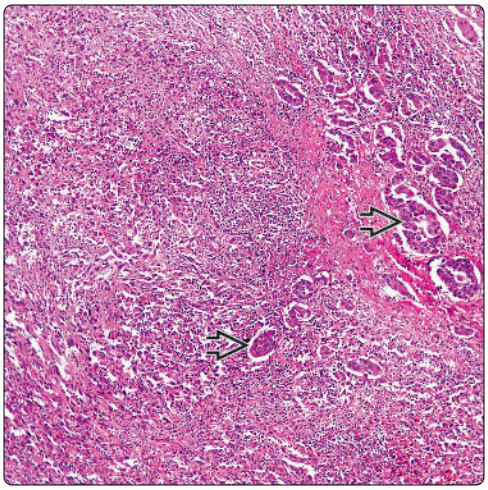

Marked Nuclear Atypia

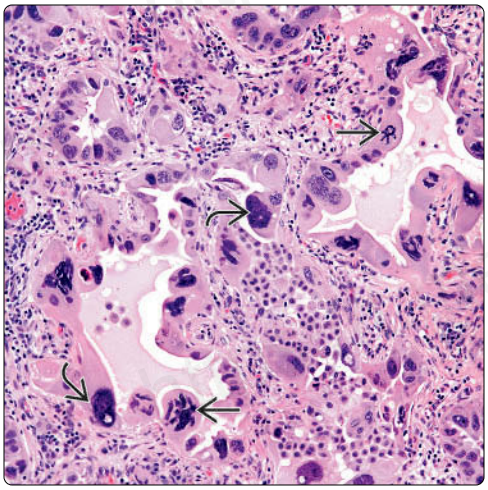

(Left) *Poorly differentiated adenocarcinoma with only focal glandular differentiation is shown. Most of the tumor has a predominantly solid growth pattern.* **(Right)** *Adenocarcinoma with the presence of numerous multinucleated giant cells is shown. Note the presence of atypical bizarre mitotic figures.*

Peripheral Adenocarcinoma

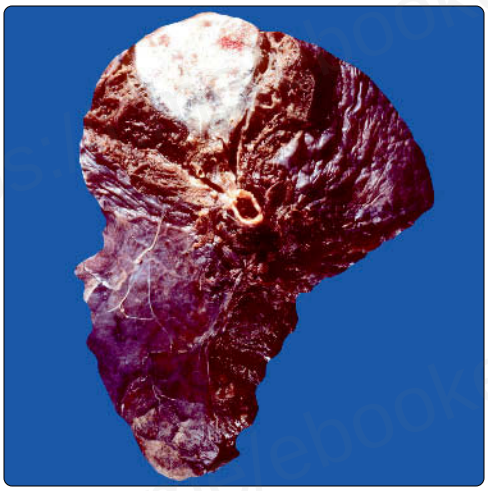

Pleural Involvement

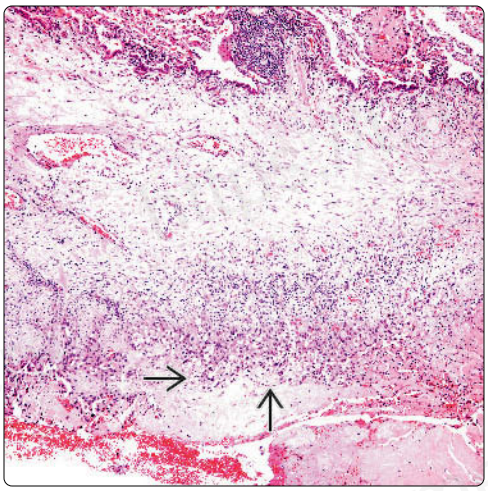

(Left) *Gross photograph shows an adenocarcinoma grossly involving the pleural surface. This feature is highly important in tumors < 3 cm in order to properly establish a pathological stage.* **(Right)** *Adenocarcinoma involving the pleural surface is shown. This particular feature is highly important in tumors < 3 cm in which pleural involvement will upgrade the pathologic staging of the tumor to a higher level (T2).*

Adenomatoid Pattern

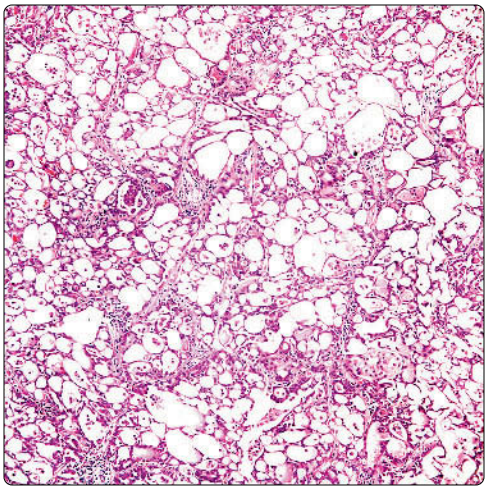

Adenomatoid Pattern

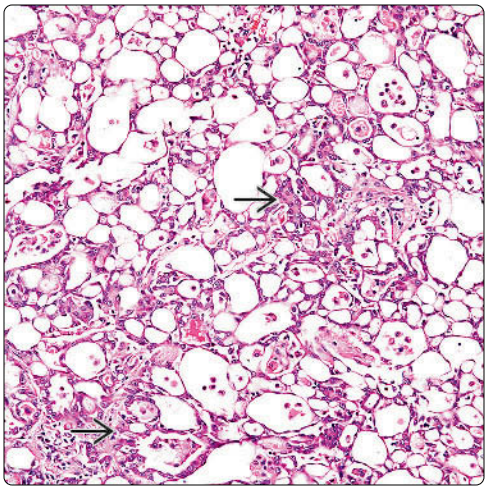

(Left) *An unusual pattern of growth in adenocarcinoma is shown. This pattern mimics an adenomatoid tumor due to the presence of bland, cystic-like areas admixed with cords of malignant cells.* **(Right)** *Adenomatoid-like adenocarcinoma of the lung is shown. Note the presence of cystic-like areas admixed with more solid groups of neoplastic cells.*

Absence of Marked Nuclear Atypia

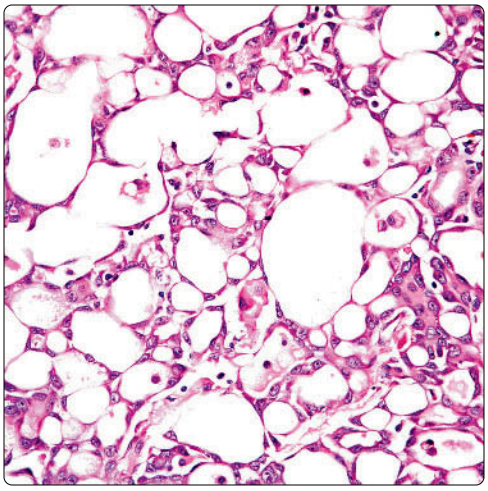

Rare Mitotic Activity

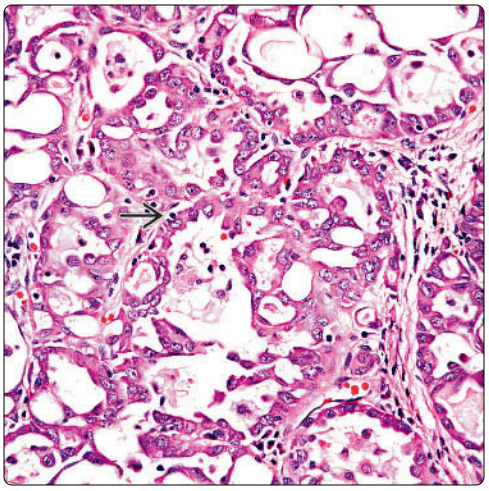

(Left) *High-power view shows an adenomatoid tumor-like adenocarcinoma. The cells have a bland appearance with absence of marked nuclear atypia and mitotic activity.* **(Right)** *High-power view shows an adenomatoid tumor-like adenocarcinoma. Note the presence of a more glandular component, nuclear atypia, and rare mitotic figures. These areas are more in keeping with a garden variety adenocarcinoma.*

Central Adenocarcinoma

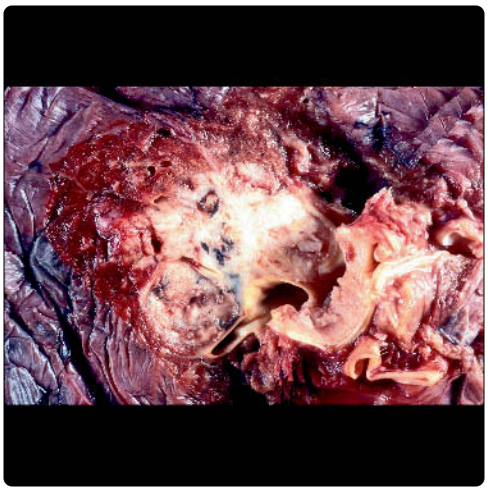

Papillary Adenocarcinoma

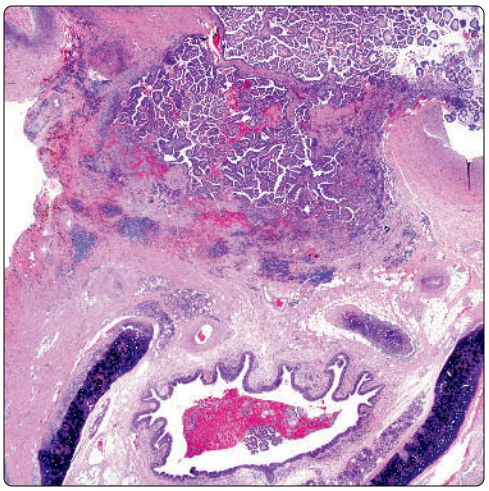

(Left) *Gross photograph shows centrally located pulmonary adenocarcinoma. The tumor is tan with irregular borders involving the airway.* **(Right)** *Low-power view shows a central adenocarcinoma with prominent papillary features. True papillary carcinoma of the lung should be composed of at least a 75% papillary component.*

Classic Papillary Adenocarcinoma

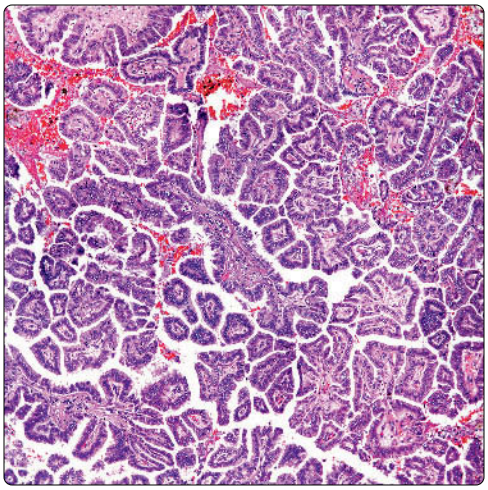

Optically Clear Nuclei

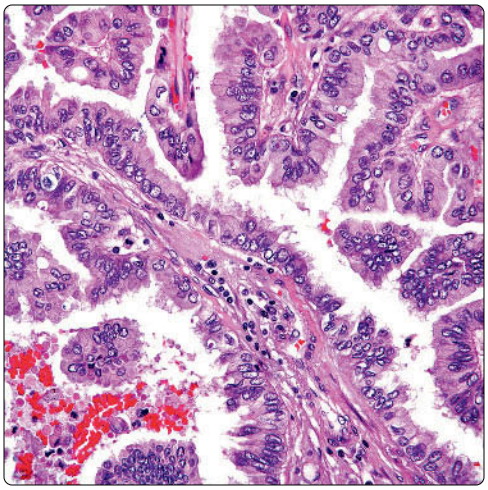

(Left) *True papillary carcinoma of the lung is shown. Note the predominant papillary pattern of growth of this neoplasm. In such a tumor, one may consider the possibility of metastatic papillary neoplasms of extrathoracic origin, such as thyroid carcinoma.* **(Right)** *High-power view shows a true papillary carcinoma of the lung; note the presence of true papillae. The nuclear characteristics of this tumor may mimic those seen in thyroid carcinomas.*

Psammoma Bodies

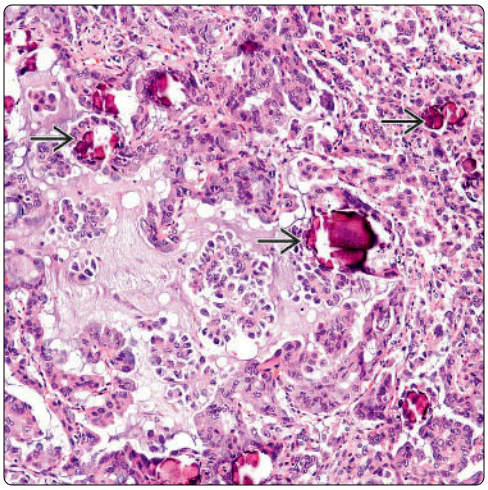

Micropapillary Pattern

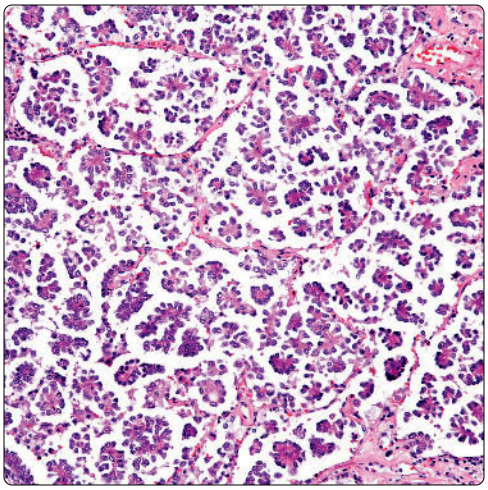

(Left) *High-power magnification shows a papillary carcinoma of the lung with numerous psammoma bodies ⇨ similar to those seen in papillary thyroid carcinomas.* **(Right)** *Micropapillary adenocarcinoma of the lung is shown. Note the presence of the micropapillae filling the alveolar spaces, most of them without any connection to the alveolar lining.*

Absence of Fibrovascular Cord

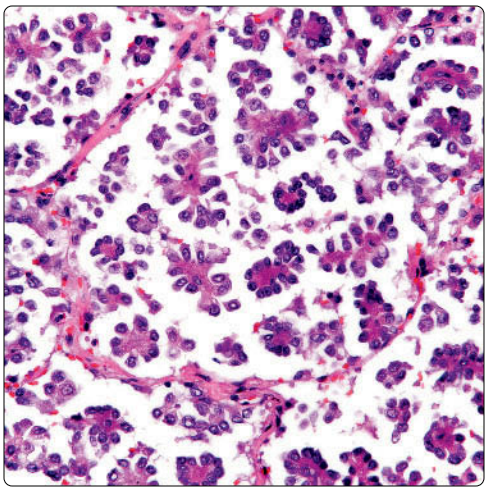

Morular Component

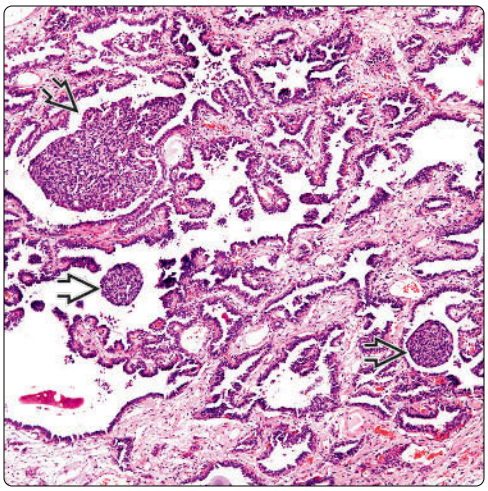

(Left) *High-power view shows a micropapillary adenocarcinoma of the lung. Note that the micropapillae filling the alveolar spaces are devoid of fibrovascular cord, contrary to true papillae.* **(Right)** *Pulmonary papillary adenocarcinoma shows the presence of a "morular" component floating in the alveolar spaces ⇨. This tumor has been designated as papillary adenocarcinoma with a morular component.*

Intraalveolar Morules

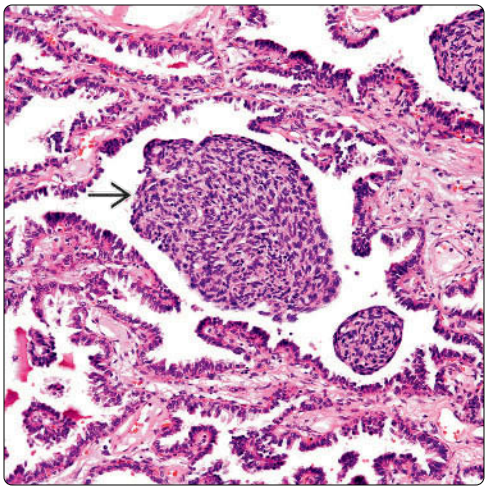

TTF-1 Immunostain

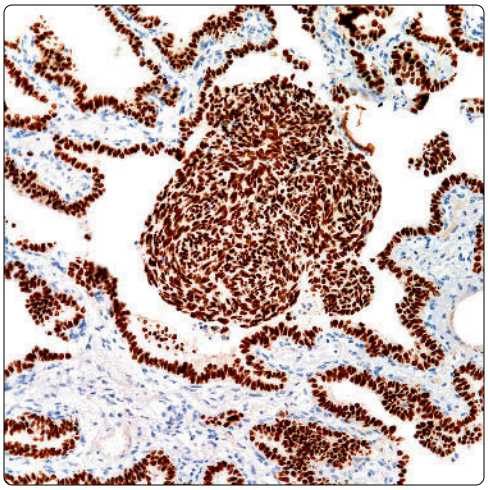

(Left) *High-magnification view shows a papillary adenocarcinoma with morular component. Note the presence of the "morules" within the alveolar spaces in contrast to those seen in monophasic blastomas, which are in the interstitium at the base of the glands.* **(Right)** *Immunohistochemical stain for TTF-1 with strong nuclear staining in the "morular" component of the tumor is shown. Note that adjacent neoplastic glands are also positive.*

Warthin-Like Pattern

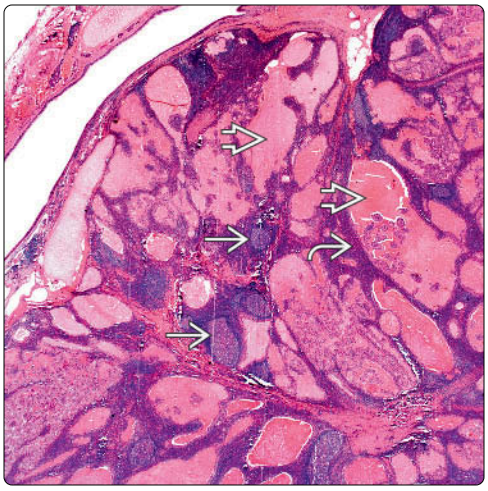

Warthin-Like Pattern

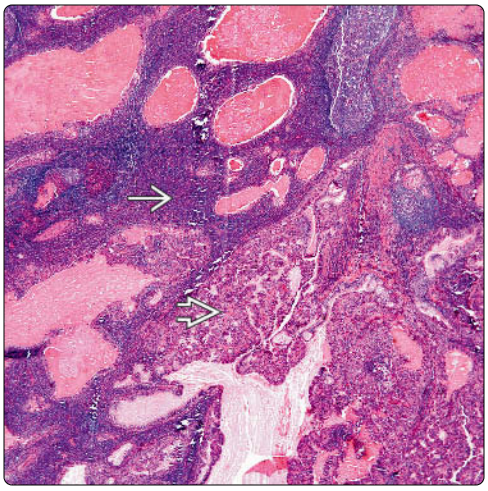

(Left) *Adenocarcinoma of the lung with a Warthin-like appearance is shown. The tumor is centrally located and exhibits the presence of a marked inflammatory reaction, intraluminal exudate, and germinal centers.* **(Right)** *Intermediate magnification shows the Warthin-like appearance of this pulmonary adenocarcinoma of the lung. Note the separation between the malignant component and the inflammatory reaction.*

Carcinoma and Dense Lymphoid Component

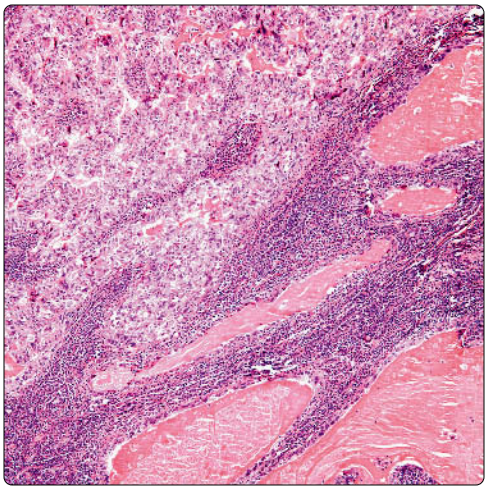

Plasma Cell Component

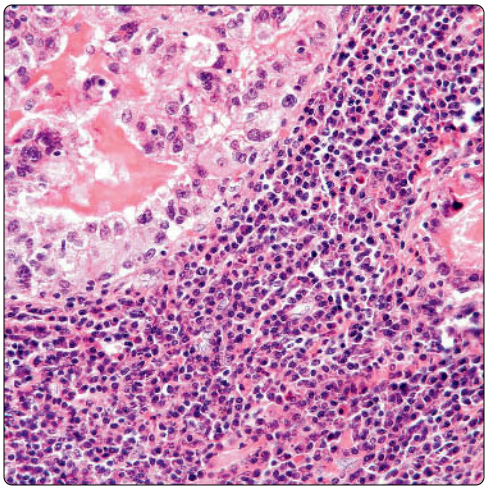

(Left) *High-power view shows a Warthin-like adenocarcinoma of the lung in which the epithelial malignant component exhibits features more in keeping with a conventional adenocarcinoma. Note that the adjacent areas have an inflammatory exudate.* **(Right)** *High-power view of the neoplastic glandular elements is composed of tall columnar epithelium and nuclei displaced toward the luminal surface. An adjacent inflammatory component is present.*

Hepatoid Pattern

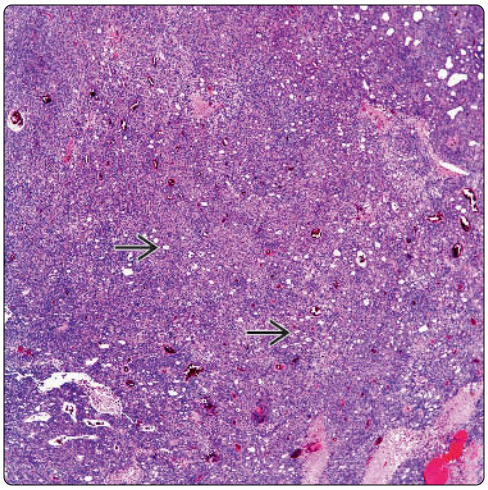

Fat Droplet-Like Areas

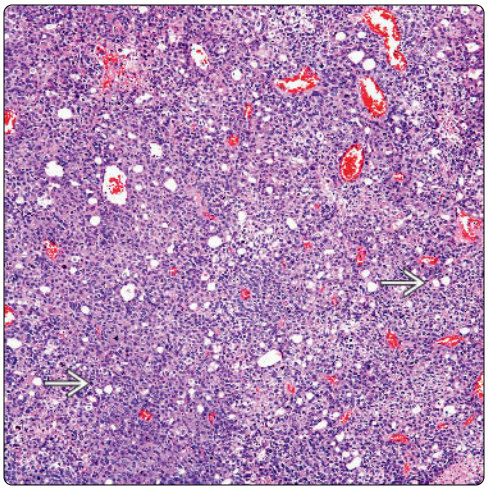

(Left) *Solid sheets of neoplastic cells of a hepatoid adenocarcinoma of the lung are shown. The tumor is essentially composed of neoplastic cells mimicking hepatic parenchyma. Note the presence of "empty spaces" mimicking fat droplets ⇨.* **(Right)** *Intermediate-power view shows a hepatoid adenocarcinoma of the lung. The sheets of neoplastic cells admixed with fat, droplet-like areas ➡ impart a hepatic-like look to this neoplasm.*

Hyaline Globules

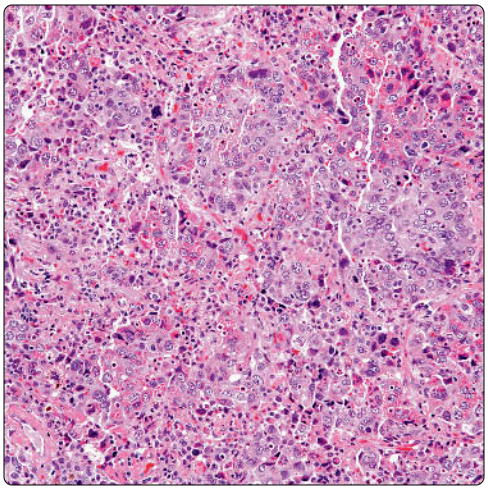

Intracellular Hyaline Globules

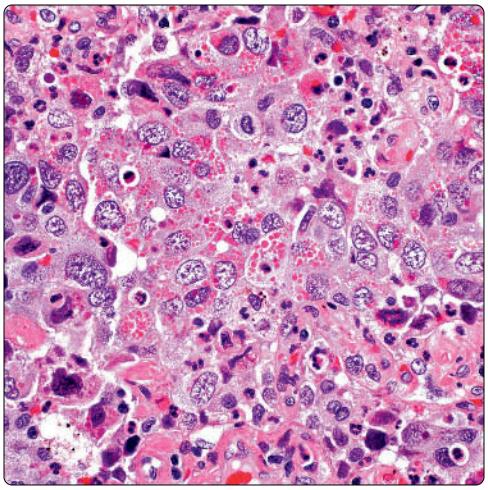

(Left) *Hepatoid adenocarcinoma of the lung with numerous intra- and extracellular hyaline globules is shown. Still, the tumor forms glandular structures.* **(Right)** *High-power view shows a hepatoid adenocarcinoma of the lung, revealing neoplastic cells with moderate amounts of eosinophilic cytoplasm, round nuclei, and some cells with prominent nucleoli. Also note the presence of hyaline globules.*

Adenocarcinoma

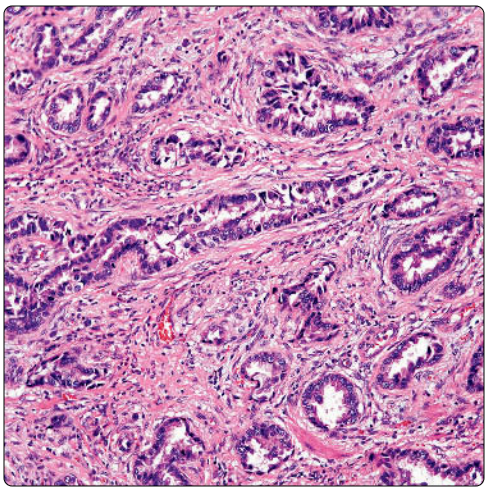

Fluorescent In Situ Hybridization Analysis

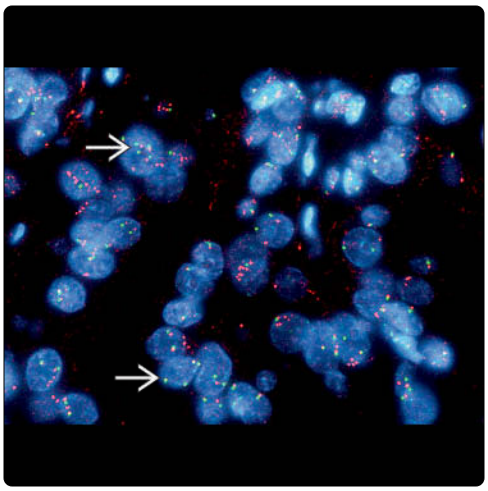

(Left) *Primary pulmonary adenocarcinoma in which FISH studies were available is shown. It is important to note that there is not a particular histopathologic growth pattern that can be correlated with mutational analysis.* **(Right)** *Fluorescent in situ hybridization shows gene amplification of the characteristic EGFR mutation in a pulmonary adenocarcinoma ➡.*

Necrotic Tumor

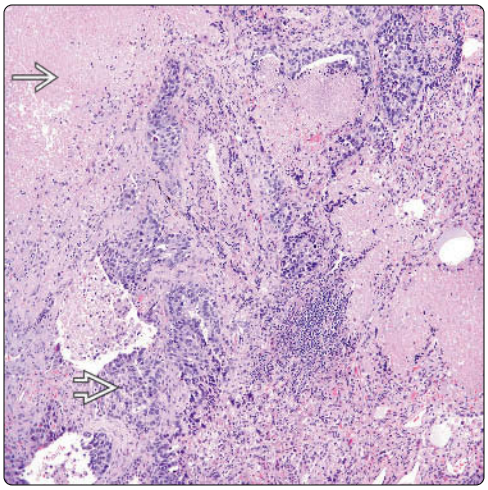

Extensive Necrosis

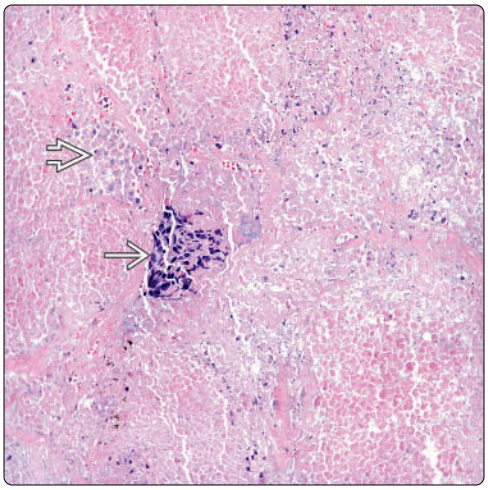

(Left) *Pulmonary adenocarcinoma shows areas of necrosis ➔ admixed with tumoral areas ➔. The tumor areas are easily identified, and the presence of necrosis does not pose a problem in the diagnosis.* **(Right)** *Pulmonary adenocarcinoma shows extensive and predominant areas of necrosis. Note 2 important features: Viable tumor ➔ and ghost tumoral areas ➔.*

Large Glands

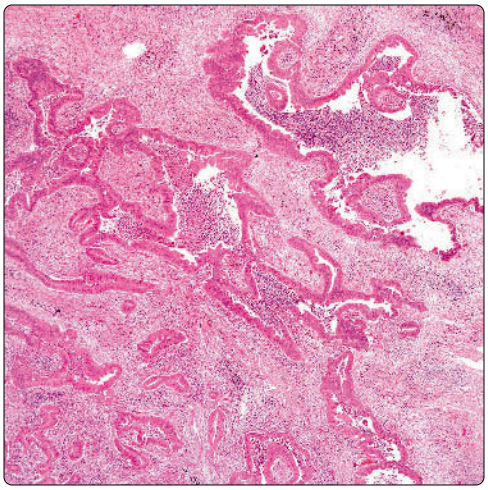

Intraluminal Necrotic Debris

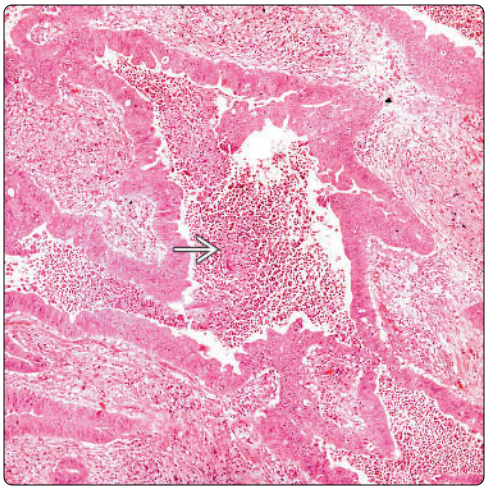

(Left) *Adenocarcinoma shows dilated malignant glandular structures in a fibrous collagenous stroma with inflammatory cells.* **(Right)** *Adenocarcinoma shows abundant necrotic debris within the glandular structures ➔, which may lead to consider the glands as reactive.*

Malignant Epithelium

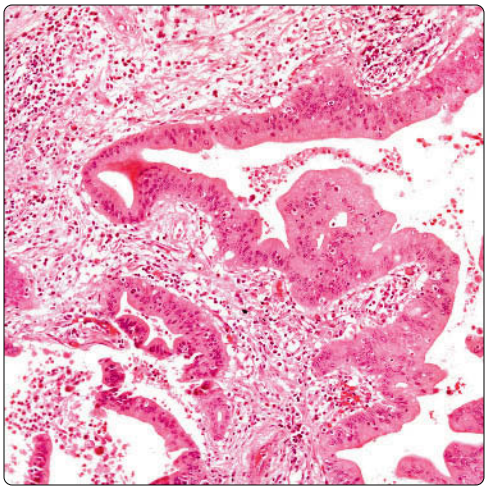

Ciliated Epithelium

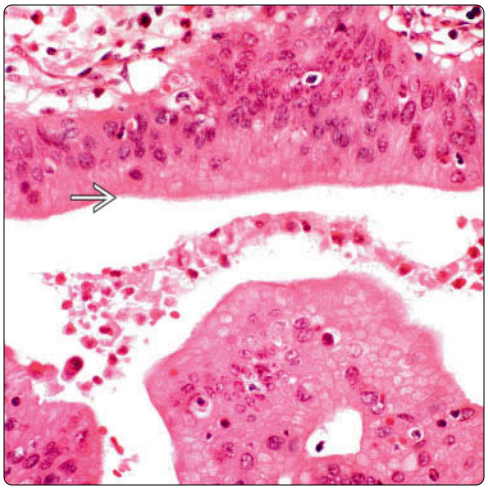

(Left) *Closer magnification at the glandular structures shows abnormal epithelium, incomplete glandular formation, and different sizes of glandular elements.* **(Right)** *Adenocarcinoma shows ciliated epithelium in the malignant gland ➔. This type of epithelium is rarely present in malignant glands in pulmonary adenocarcinomas.*

Bronchioloalveolar Carcinoma

KEY FACTS

TERMINOLOGY

- Bronchioloalveolar cell carcinoma (BAC)
  - Adenocarcinoma with BAC pattern and no evidence of stromal, vascular, or pleural invasion
  - Current definition is that of in situ adenocarcinoma
  - Definition of in situ adenocarcinoma has been questioned as it does not have meaningful statistical significance when compared to conventional adenocarcinomas T1N0M0
  - Overall survival of T1N0M0 adenocarcinomas appear to be similar regardless of growth pattern

ETIOLOGY/PATHOGENESIS

- BAC appears not to be associated with tobacco smoking

TOP DIFFERENTIAL DIAGNOSES

- Atypical adenomatous hyperplasia
  - Tumor nodule of < 0.5 cm in greatest dimension
- Metastatic adenocarcinoma
  - Good clinical history and physical examination
  - Immunohistochemical studies may be helpful in determining primary site
- Invasive adenocarcinoma
  - By definition, BAC is tumor with no lymphatic, pleural, or interstitial invasion
  - Complete examination of tumor required to rule out invasion
  - Presence of lymph node involvement rules out diagnosis of BAC
  - Presence of pleural invasion upgrades TNM status to T2
  - Role of multifocallity needs to be carefully considered
- Interpretation of cytology and biopsy specimens should be carefully evaluated
- Interpretation of intraoperative consultation should be carefully evaluated

Lack of Pleural Involvement

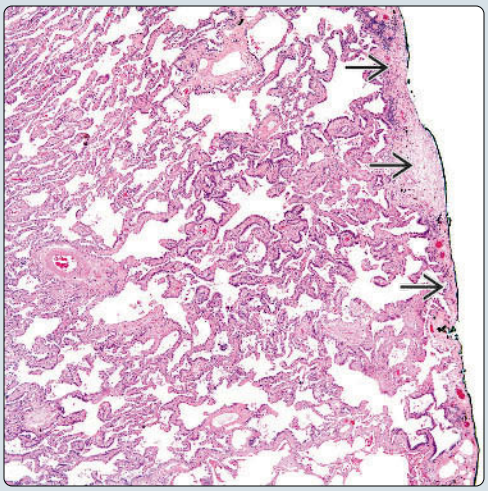

BAC/Lepidic Growth Pattern

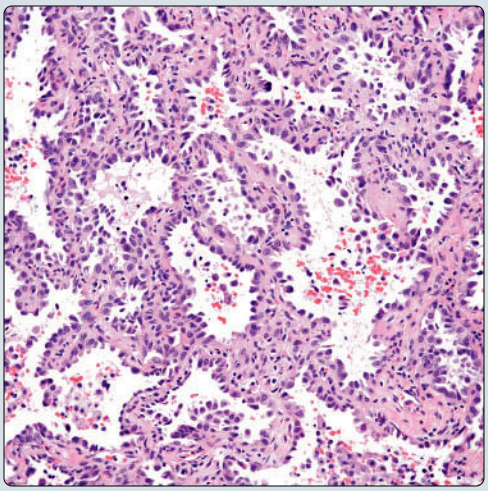

(Left) *Nodular (nonmucinous) pattern of bronchioloalveolar cell carcinoma (BAC) is shown. The tumor is in a subpleural location without pleural ⇨ or interstitial involvement.* **(Right)** *Adenocarcinoma is shown in which the alveolar walls are lined by cells displaying more nuclear atypia. However, the tumor cells do not show mitotic activity.*

Mild Nuclear Atypia

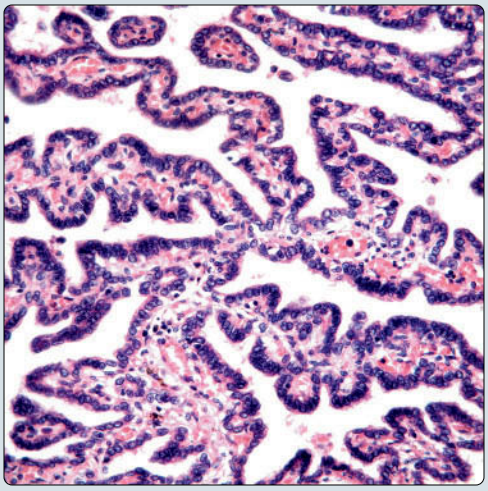

Lack of Interstitial Involvement

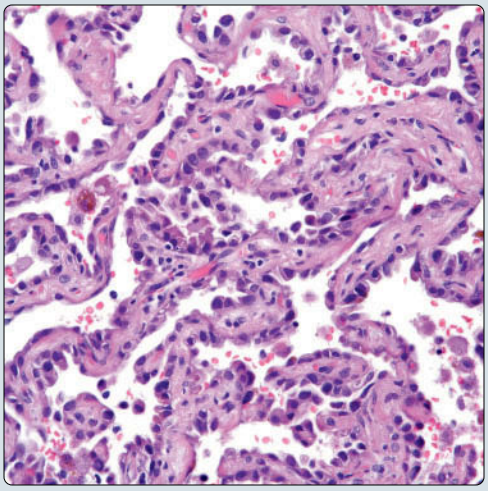

(Left) *Adenocarcinoma is seen composed of cellular proliferation lining the alveolar walls. The cells are low to flat cuboidal with pyknotic nuclei and an absence of mitotic activity or nuclear atypia. Note the lack of interstitial involvement.* **(Right)** *Carcinoma with mild nuclear atypia and no invasion into the interstitium is shown. The tumor cells lined the alveolar walls.*

TERMINOLOGY

Abbreviations

- Bronchioloalveolar cell carcinoma (BAC)

Synonyms

- In situ adenocarcinoma, well-differentiated adenocarcinoma, bronchioloalveolar carcinoma, adenocarcinoma with bronchioloalveolar pattern, adenocarcinoma with lepidic pattern

Definitions

- Well-differentiated adenocarcinoma
  - Lesion with relatively bland cytologic features that arises in periphery of lung and spreads along walls of distal air spaces
  - Subset of adenocarcinoma common and distinctive enough to warrant separation from other subtypes
- Adenocarcinoma with bronchioloalveolar pattern
  - No evidence of stromal, vascular, or pleural invasion
  - Essentially, current definition is similar to that of in situ adenocarcinoma
- More recent reports have questioned definition of in situ adenocarcinoma as prognosis of T1N0M0 appears to be similar to all adenocarcinomas without meaningful statistical significance among these tumors

ETIOLOGY/PATHOGENESIS

Environmental Exposure

- BAC appears not to be associated with tobacco use

CLINICAL ISSUES

Epidemiology

- Incidence
  - Incidence of true BAC is not high and may represent < 10% of all carcinomas of lung
- Age
  - Tumor can occur at any age

Presentation

- Cough
- Chest pain
- Shortness of breath
- Bronchorrhea

Treatment

- Surgical approaches
  - Wedge resection, lobectomy, or pneumonectomy
    - Should be based on clinical grounds rather than pathological growth pattern
    - Since initial approach is surgical biopsy, decision on final surgical approach is surgical/clinical decision

Prognosis

- As currently defined, BAC tumors ≤ 2 cm expected to do well
  - Recent reports state that staging at time of diagnosis plays more important role than growth pattern
  - Current management of T1N0M0 adenocarcinomas is surgical resection and staging regardless of growth pattern
  - Diagnosis of in situ adenocarcinoma should be seen with circumspection as may be misleading; does not have real value in diagnosis of these tumors
- In multifocal tumors, prognosis may not be as good
- More recent reports state that staging at time of diagnosis is more important than growth pattern

MACROSCOPIC

General Features

- Localized tumor mass: Usually < 3 cm in diameter
- Multinodular pattern: Extensive areas of lung parenchyma are involved in miliary fashion
  - Even though pattern is that of BAC, currently this neoplasm is considered adenocarcinoma
- Diffuse pattern: No distinct tumor mass or nodule is present
  - Lung parenchyma appears congested, mimicking lobar pneumonia
  - Size of tumor is crucial in assigning specific diagnostic category
  - Tumors > 3 cm are currently regarded as adenocarcinomas despite BAC growth pattern

MICROSCOPIC

Histologic Features

- Conventional type
  - Tumor cells are small and dark with hyperchromatic nuclei and scant cytoplasm
  - Tumor cells display prominent hobnail appearance and are devoid of nucleoli or mitotic figures
- Mucinous type
  - Tumor cells are tall, columnar, and contain abundant mucinous cytoplasm

Predominant Pattern/Injury Type

- Circumscribed
- Mucinous
- Diffuse

DIFFERENTIAL DIAGNOSIS

Atypical Adenomatous Hyperplasia

- Tumor nodule < 0.5 cm in greatest dimension
- Histology very similar to BAC

Pulmonary Invasive Adenocarcinoma

- BAC lacks presence of vascular, lymphatic, pleural, or interstitial involvement by tumor cells

Metastatic Adenocarcinoma

- History of previous adenocarcinoma is important
- Use of immunohistochemical stains plays important role in determining origin of carcinoma

DIAGNOSTIC CHECKLIST

Clinically Relevant Pathologic Features

- Noninvasive pattern
- Diagnosis of BAC cannot be achieved in biopsy specimens
- Histopathological examination of entire tumor is required for diagnosis of BAC

Immunohistochemistry

Antibody	Reactivity	Staining Pattern	Comment
KERATIN-LMW	Positive	Cytoplasmic	
CEA-M	Positive	Cytoplasmic	Helpful in both mucinous and nonmucinous tumors
CK7	Positive	Cytoplasmic	
TTF-1	Positive	Nuclear	In some mucinous cases, stain may be negative
NAPSIN-A	Positive	Cytoplasmic	
Surfactant	Positive	Cytoplasmic	
p63	Positive	Nuclear	Focal in rare cases
CK20	Negative		May show focal positive staining in tumor cells in some cases
CDX-2	Negative		May show focal positive staining in tumor cells in some mucinous tumors
GCDFP-15	Negative		
CK5/6	Negative		
p40	Negative		
Desmocollin-3	Negative		

Histochemical Features

Stain	Result
PAS	Focal positivity may be seen
PAS-D	Positive in mucinous tumors
Mucicarmine	Positive in mucinous tumors

Molecular Findings

FISH	Result
(*) 5	Positive in many cases
. 5 $ 6	Positive in some cases

- Lymph node sampling is required to properly rule out metastatic disease

Pathologic Interpretation Pearls

- Extensive pools of mucin
- Alveolar wall lined by neoplastic cells
- Absence of pleural invasion
- Absence of interstitial invasion

SELECTED REFERENCES

1. Kadota K et al: Prognostic significance of adenocarcinoma in situ, minimally invasive adenocarcinoma, and nonmucinous lepidic predominant invasive adenocarcinoma of the lung in patients with stage I disease. Am J Surg Pathol. 38(4):448-60, 2014
2. Weissferdt A et al: Reclassification of early stage pulmonary adenocarcinoma and its consequences. J Thorac Dis. 6(Suppl 5):S581-8, 2014
3. Weissferdt A et al: Pulmonary adenocarcinoma T1N0M0 and its classification. Semin Diagn Pathol. 31(4):260-4, 2014
4. Tsuta K et al: The utility of the proposed IASLC/ATS/ERS lung adenocarcinoma subtypes for disease prognosis and correlation of driver gene alterations. Lung Cancer. 81(3):371-6, 2013
5. Weissferdt A et al: Early-stage pulmonary adenocarcinoma (T1N0M0): a clinical, radiological, surgical, and pathological correlation of 104 cases. The MD Anderson Cancer Center Experience. Mod Pathol. 26(8):1065-75, 2013
6. Weissferdt A et al: Well-differentiated adenocarcinoma-bronchioloalveolar carcinoma-in situ adenocarcinoma: a conundrum. Adv Anat Pathol. 20(5):347-51, 2013
7. Travis WD et al: International association for the study of lung cancer/american thoracic society/european respiratory society international multidisciplinary classification of lung adenocarcinoma. J Thorac Oncol. 6(2):244-85, 2011
8. Birim O et al: Survival after pathological stage IA nonsmall cell lung cancer: tumor size matters. Ann Thorac Surg. 79(4):1137-41, 2005
9. Hajdu SI: The story of bronchioloalveolar carcinoma. Ann Clin Lab Sci. 35(3):336-8, 2005
10. Sidhu GS et al: The concept of bronchioloalveolar cell adenocarcinoma: redefinition, a critique of the 1999 WHO classification, and an ultrastructural analysis of 155 cases. Int J Surg Pathol. 11(2):89-99, 2003
11. Colby TV et al: Tumors of the lower respiratory tract. Atlas of Tumor Pathology: Armed Forces Institute of Pathology (AFIP). (13):203, 1995
12. Daly RC et al: Bronchoalveolar carcinoma: factors affecting survival. Ann Thorac Surg. 51(3):368-76; discussion 376-7, 1991
13. Manning JT Jr et al: Bronchioloalveolar carcinoma: The significance of two histopathologic types. Cancer. 54(3):525-34, 1984
14. Carter D et al: Tumors of the lower respiratory tract. Armed Forces Institute of Pathology (AFIP). (17):127, 1980
15. Liebow AA: Bronchiolo-alveolar carcinoma. Adv Intern Med. 10:329-58, 1960
16. Travis WD et al: WHO classification of tumours of the lung, pleura, thymus, and heart: World Health Organization (WHO). 4th Ed. Lyon: IARC Press, 2015

BAC/Lepidic Growth Pattern

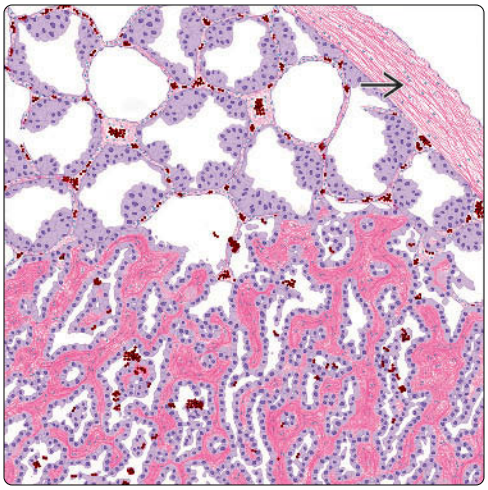

BAC/Lepidic Growth Pattern

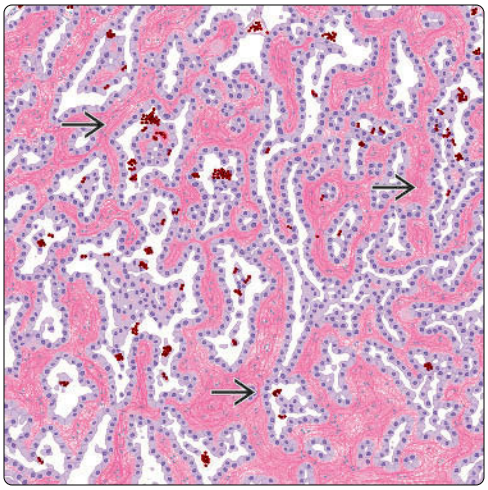

(Left) *BAC (in situ adenocarcinoma) highlights the absence of pleural involvement by the tumor ⇨. This is an important criterion for the diagnosis of BAC.* **(Right)** *BAC (in situ adenocarcinoma) demonstrates bronchioloalveolar proliferation with an absence of tumor cells in the interstitium ⇨.*

Breakdown of Alveolar Structures

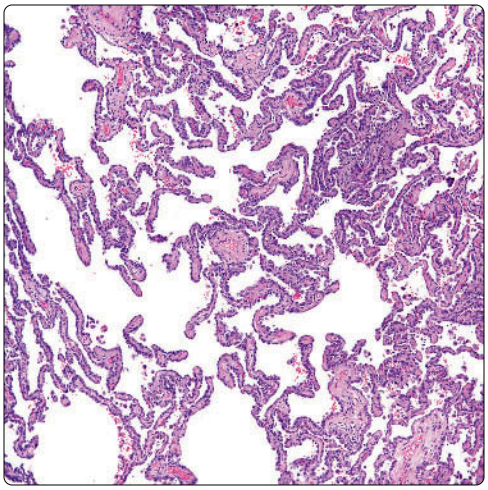

Large Vessel in Atypical BAC Proliferation

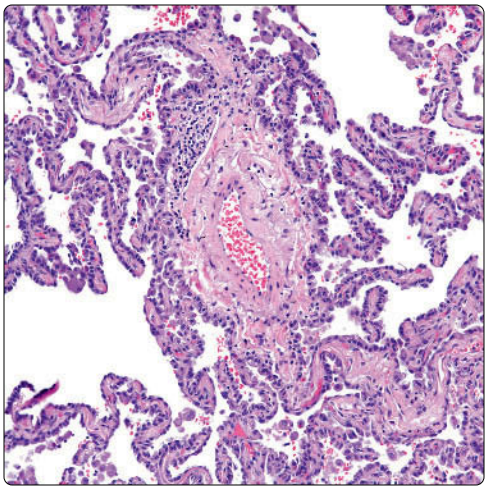

(Left) *Adenocarcinoma shows the typical low-power features of an adenocarcinoma growing along the alveolar walls. There is little interstitial tissue present.* **(Right)** *Adenocarcinoma is shown in which the malignant cells are lining the alveolar wall and separated by a large vessel. Note that there is no vascular invasion.*

Alveolar Macrophages

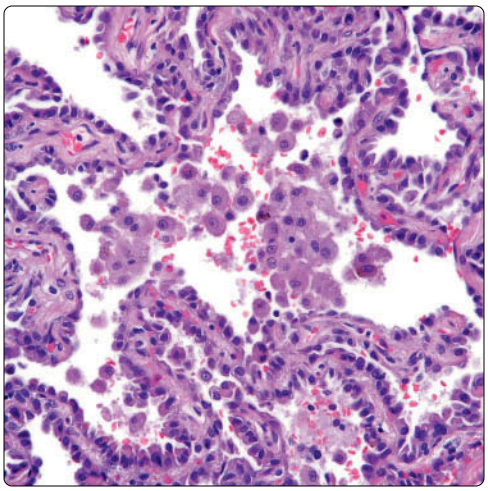

Transitional Areas

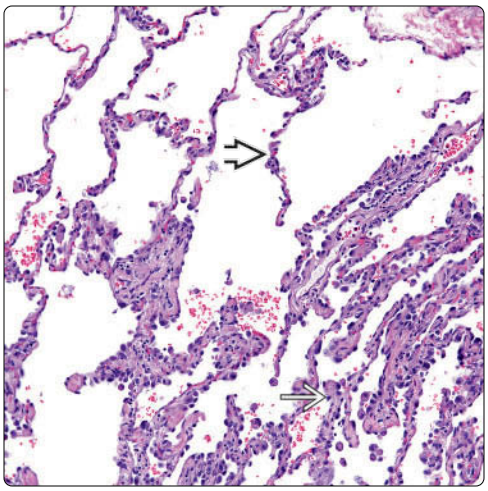

(Left) *Adenocarcinoma shows collections of alveolar macrophages within the lumen of the distended alveolar spaces lined by tumor cells.* **(Right)** *Adenocarcinoma with BAC/lepidic growth pattern ➡ shows transitional areas of tumor with benign alveolated lung parenchyma ⇨.*

Mucinous BAC/Lepidic Growth Pattern

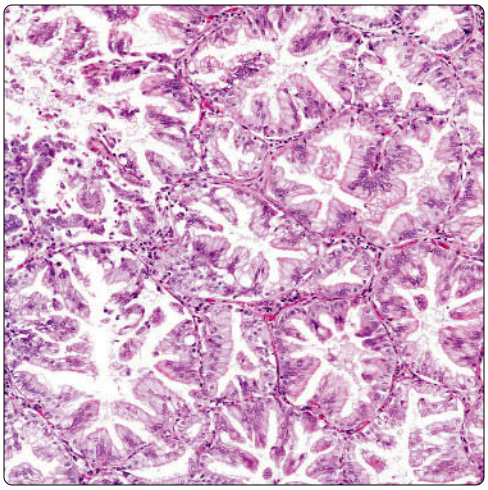

Mucinous BAC/Lepidic Growth Pattern

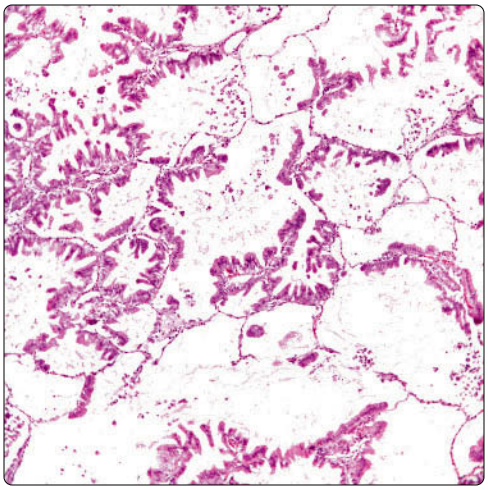

(Left) *Mucinous adenocarcinoma with BAC/lepidic growth pattern shows tightly packed nests of tumor cells separated by think interstitium.* **(Right)** *Mucinous adenocarcinoma with BAC/lepidic growth pattern shows malignant cells lining the alveolar lining. There is virtually no interstitium, and the neoplastic cells follow the normal architecture of the lung.*

Foamy Macrophages

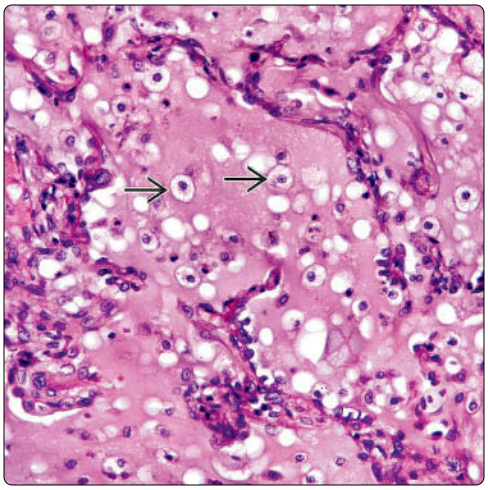

Pneumonic/Mucinous Type

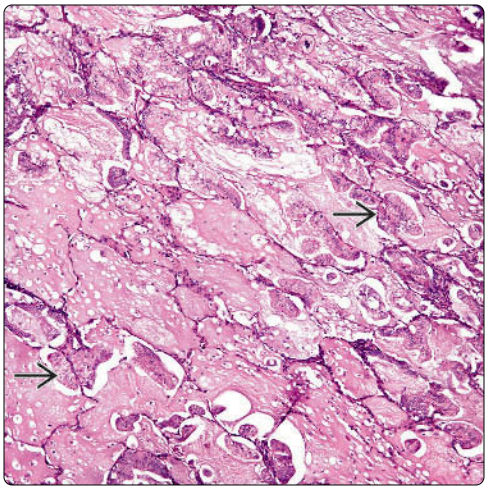

(Left) *Adjacent areas of normal lung parenchyma are shown in a mucinous adenocarcinoma with BAC/lepidic growth pattern. The alveoli are filled with fluid and numerous floating macrophages.* **(Right)** *Pneumonic pattern of BAC in which the alveoli are filled with edematous fluid is shown, with only focal areas of alveoli replaced by mucinous epithelium.*

Mucinous Type

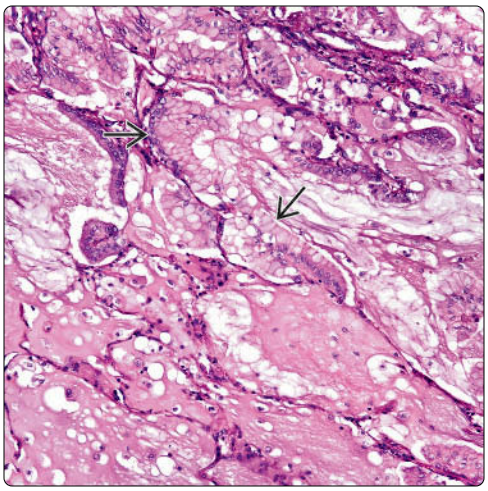

Mucinous Epithelium

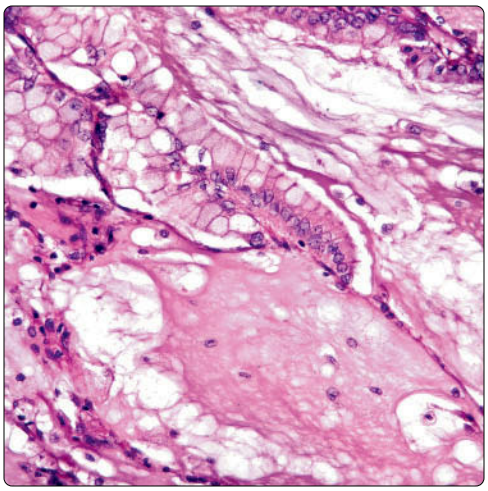

(Left) *Higher magnification shows the pneumonic variant of BAC. Note the presence of mucinous epithelium replacing the alveolar lining.* **(Right)** *Mucinous type of epithelium is shown replacing the alveolar lining. The mucinous epithelium is composed of columnar cells with nuclei displaced toward the base. No cellular atypia or mitotic activity is present.*

Mucinous Carcinoma

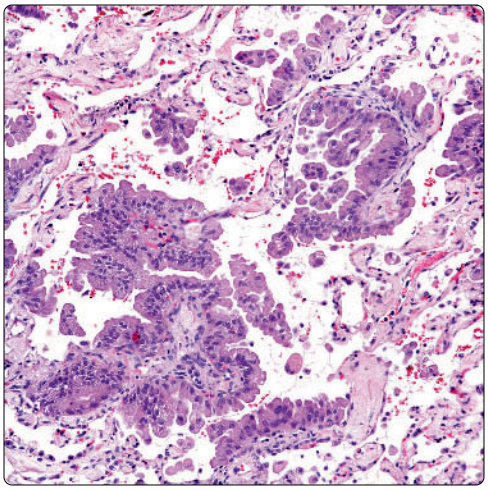

BAC/Lepidic Growth Pattern

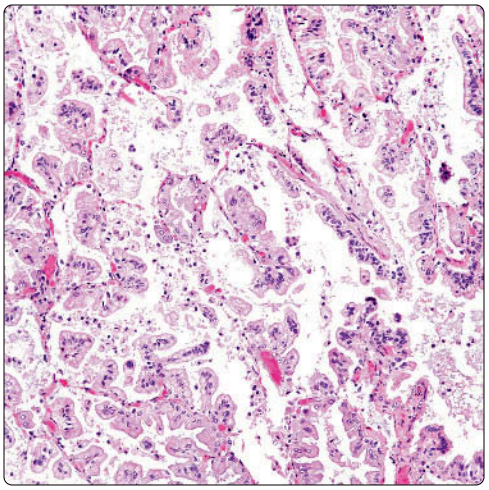

(Left) *Adenocarcinoma with BAC/lepidic growth pattern shows alveolar walls lined by columnar type of epithelium adjacent to areas of normal alveolar structures.* **(Right)** *BAC shows a lepidic growth pattern. Note the absence of tumor infiltrating the interstitium. However, absence of pleural invasion must also be excluded for this diagnosis.*

Classic Pattern of BAC/Lepidic Growth

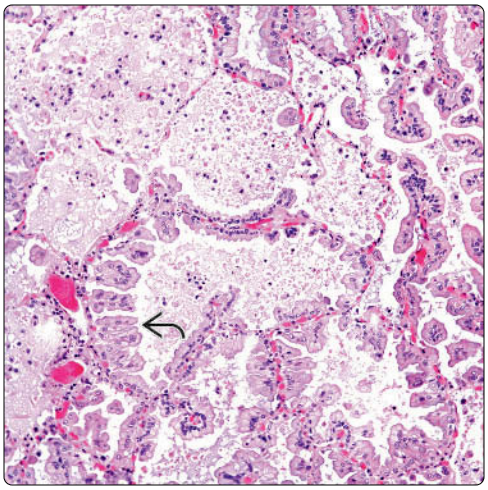

BAC/Lepidic Growth Pattern

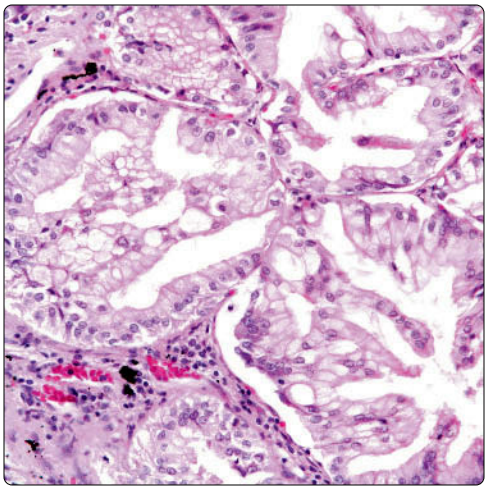

(Left) *Adenocarcinoma shows a classic pattern of BAC/lepidic growth. Note the presence of neoplastic cells lining the alveolar wall. Still, one is able to follow the "normal" architecture of the lung parenchyma.* **(Right)** *High-power view of a mucinous adenocarcinoma with BAC/lepidic growth pattern shows tumor composed of columnar epithelium and little intervening stroma.*

Minimal Nuclear Atypia

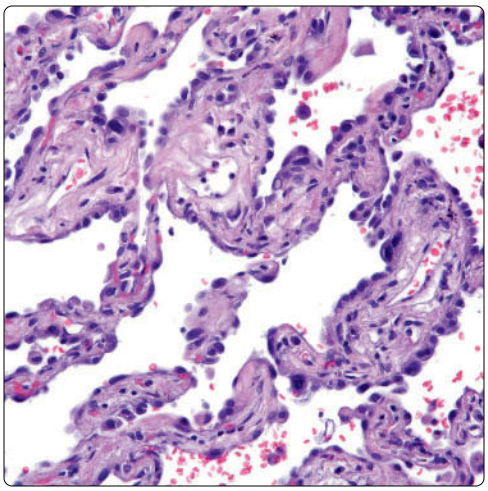

Mucinous Epithelium With Minimal Atypia

(Left) *Adenocarcinoma with BAC/lepidic growth pattern shows minimal nuclear atypia. The tumor generally does not show marked atypia or increased mitotic activity.* **(Right)** *Higher magnification of a mucinous adenocarcinoma with BAC/lepidic growth pattern shows mild nuclear atypia and absence of mitotic activity.*

TERMINOLOGY

Synonyms

- Mucinous cystadenoma, mucinous cystic tumor, multilocular cystic carcinoma, mucinous cystic tumor of borderline malignancy

Definitions

- Epithelial neoplasm with extensive mucin production

CLINICAL ISSUES

Epidemiology

- Incidence
  - Pure colloid carcinomas of lung are rare
- Age
  - Colloid carcinomas are more common in adult patients
- Sex
  - No predilection

Presentation

- Cough
- Chest pain
- Shortness of breath
- Asymptomatic

Treatment

- Surgical approaches
  - Lobectomy
  - Segmentectomy
  - Wedge resection

Prognosis

- Depends on staging at time of diagnosis
- Often tumor is T1, N0, M0
- Metastatic disease has been described
  - Brain, bone, lymph nodes

MACROSCOPIC

General Features

- Well-defined tumor mass
- Mucoid consistency
- Cystic changes may be present

Size

- Varies from 1 cm to > 10 cm

MICROSCOPIC

Histologic Features

- Extensive areas of mucin deposition
- Alveolar wall lined with mucinous epithelium
- Single cells or clusters of cells are seen floating in mucin
- Microscopic cystic changes
- Pools of mucin with focal cells present
- Absent inflammatory changes
- Subpleural location

Predominant Pattern/Injury Type

- Mucinous

Predominant Cell/Compartment Type

- Epithelial

DIFFERENTIAL DIAGNOSIS

Metastatic Mucinous Carcinoma of Extrathoracic Origin

- Clinical history of or clinical evaluation for colonic, ovarian, breast, or urachal carcinoma will be important
- Immunohistochemical studies important in determining primary site
- Some immunohistochemical features may be shared by some tumors

Bronchioloalveolar Carcinoma, Mucinous Variant

- In bronchioloalveolar carcinoma (BAC), lepidic growth pattern is characteristic feature in which alveolar lining is substituted by mucinous type of epithelium
- Tumor size will lead to specific subclassification when BAC is considered
- BAC commonly will diffusely involve entire lung or extensive areas of it
- Immunohistochemical features of BAC and colloid carcinoma may be similar

DIAGNOSTIC CHECKLIST

Clinically Relevant Pathologic Features

- Gross appearance

Pathologic Interpretation Pearls

- Extensive mucin
- Alveolar wall lined with mucinous epithelium

GRADING

Colloid Carcinoma

- Considered low-grade malignant neoplasm
- Behavior determined by pathological staging at time of diagnosis
- Often tumor is T1, N0, M0

SELECTED REFERENCES

1. Kamata T et al: Mucinous micropapillary pattern in lung adenocarcinomas: a unique histology with genetic correlates. Histopathology. 68(3):356-66, 2016
2. Qu Y et al: Prognostic analysis of primary mucin-producing adenocarcinoma of the lung: a comprehensive retrospective study. Tumour Biol. 37(1):887-96, 2016
3. Cruz-Rico G et al: Diagnosis of EML4-ALK translocation with FISH, immunohistochemistry, and real-time polymerase chain reaction in patients with non-small cell lung cancer. Am J Clin Oncol. ePub, 2015
4. Fu S et al: Detection of EML4-ALK fusion gene in Chinese non-small cell lung cancer by using a sensitive quantitative real-time reverse transcriptase PCR technique. Appl Immunohistochem Mol Morphol. 23(4):245-54, 2015
5. Geles A et al: Pulmonary mucinous adenocarcinomas: architectural patterns in correlation with genetic changes, prognosis and survival. Virchows Arch. 467(6):675-686, 2015
6. Shim HS et al: Unique genetic and survival characteristics of invasive mucinous adenocarcinoma of the ung. J Thorac Oncol. 10(8):1156-62, 2015
7. Truini A et al: Classification of different patterns of pulmonary adenocarcinomas. Expert Rev Respir Med. 9(5):571-86, 2015
8. Zenali MJ et al: An update on clinicopathological, immunohistochemical, and molecular profiles of colloid carcinoma of the lung. Hum Pathol. 46(6):836-42, 2015
9. Kalhor N: Colloid carcinoma of the lung: Current views. Semin Diagn Pathol. 31(4):265-70, 2014
10. Weissferdt A et al: Reclassification of early stage pulmonary adenocarcinoma and its consequences. J Thorac Dis. 6(Suppl 5):S581-8, 2014
11. Weissferdt A et al: Pulmonary adenocarcinoma T1N0M0 and its classification. Semin Diagn Pathol. 31(4):260-4, 2014

Immunohistochemistry

Antibody	Reactivity	Staining Pattern	Comment
TTF-1	Positive	Nuclear	May be negative in many cases
CK7	Positive	Cytoplasmic	Staining may be as strong as in solid adenocarcinomas
CEA-M	Positive	Cytoplasmic	
CK-PAN	Positive	Cytoplasmic	
CK20	Negative		May be positive in fair number of cases
CDX-2	Negative		May be positive in some colloid carcinomas
GCDFP-15	Negative		
PR	Negative		
ER	Negative		
pax-8	Negative		
GATA3	Negative		
GCDFP-15	Negative		
NAPSIN-A	Negative		
Chromogranin-A	Negative		
Synaptophysin	Negative		
CK5/6	Negative		
p40	Negative		
p63	Negative		
PTEN	Negative		
Surfactant-A	Negative		

Histochemical Features

Stain	Result	Comment
PAS	Negative	
PAS-D	Positive	Also in intracellular and extracellular areas
Mucicarmine	Strongly positive	In intracellular as well as extracellular areas

Molecular Features

FISH	Result
(*) 5	Usually negative
$ / .	Usually negative
5 2 6	Usually negative
. 5 $ 6	Usually negative
% 5 $)	Negative
0 (7	Negative

12. Weissferdt A et al: Well-differentiated adenocarcinoma-bronchioloalveolar carcinoma-in situ adenocarcinoma: a conundrum. Adv Anat Pathol. 20(5):347-51, 2013
13. Bacha D et al: A pulmonary mucinous cystic tumour of borderline malignancy. Pathologica. 100(3):189-91, 2008
14. Maeda R et al: Primary pulmonary mucinous (colloid) adenocarcinoma. Gen Thorac Cardiovasc Surg. 56(4):195-8, 2008
15. Moran CA: Pulmonary adenocarcinoma: the expanding spectrum of histologic variants. Arch Pathol Lab Med. 130(7):958-62, 2006
16. Türüt H et al: Primary pulmonary mucinous adenocarcinoma in a 15-year-old boy. Eur J Cardiothorac Surg. 29(5):851-3, 2006
17. Brownlee NA et al: Mucinous (colloid) adenocarcinoma of the lung. Arch Pathol Lab Med. 129(1):121-2, 2005
18. Okimasa S et al: Mucinous (colloid) adenocarcinoma. Jpn J Thorac Cardiovasc Surg. 53(6):305-8, 2005
19. Jayaram G et al: Mucinous carcinoma (colloid carcinoma) of the lung diagnosed by fine needle aspiration cytology: a case report. Malays J Pathol. 25(1):63-8, 2003
20. Moran CA: Mucin-rich tumors of the lung. Adv Anat Pathol. 2(5):299-305, 1995
21. Moran CA et al: Mucinous (so-called colloid) carcinomas of lung. Mod Pathol. 5(6):634-8, 1992
22. Graeme-Cook F et al: Pulmonary mucinous cystic tumors of borderline malignancy. Hum Pathol. 22(2):185-90, 1991

Cystic Areas

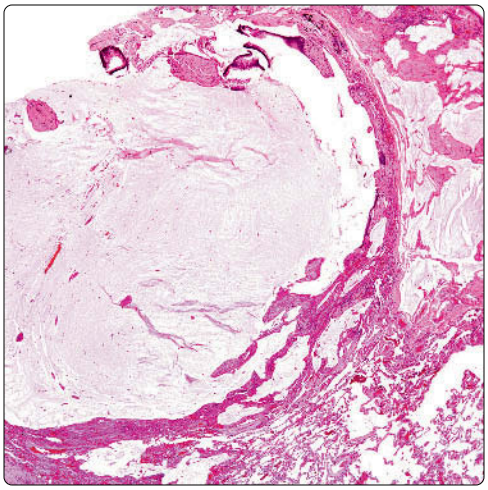

Breakdown of Alveolar Walls

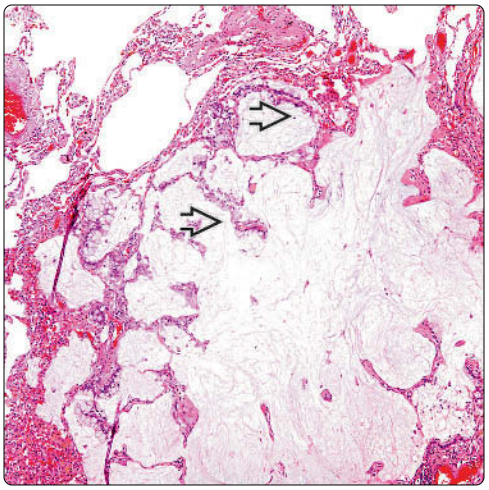

(Left) *In this lung parenchyma replaced by mucoid material, note the cyst-like appearance of the tumor destroying normal alveolar parenchyma. This feature can be incorrectly assumed to indicate a benign cystadenoma.* **(Right)** *Extensive mucoid material destroys normal alveolated parenchyma. Note that the alveolar wall is being replaced by mucinous epithelium ⇨.*

Mucinous Epithelium

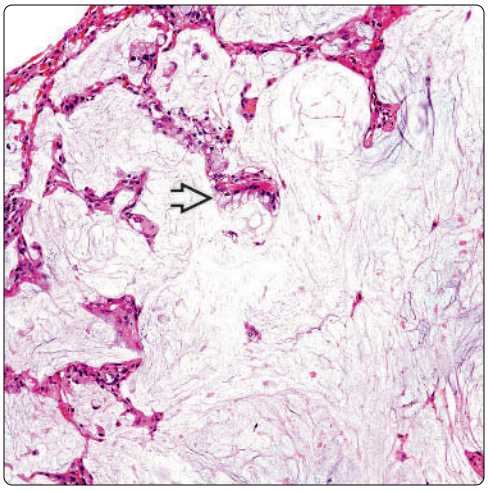

Mucin-Producing Epithelium

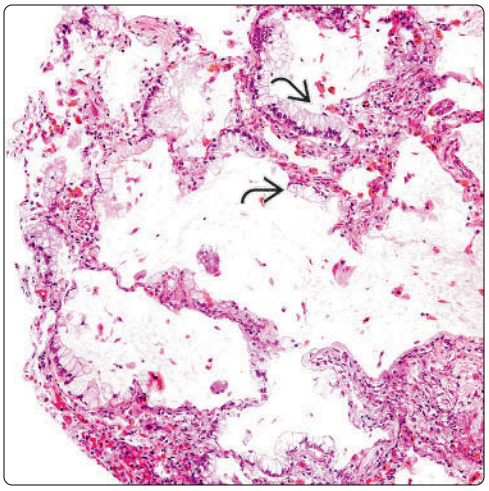

(Left) *Alveolated parenchyma is destroyed by large amounts of mucoid material. Note the focal areas in which the alveolar walls remain intact; they are lined by mucinous epithelium ⇨.* **(Right)** *Several areas in which the alveolar wall is being replaced by a mucinous type of epithelium ⇨ are shown. However, 1 important feature is the breakdown of alveolar walls with partial replacement by mucinous epithelium.*

Partial Lining of Cyst Wall

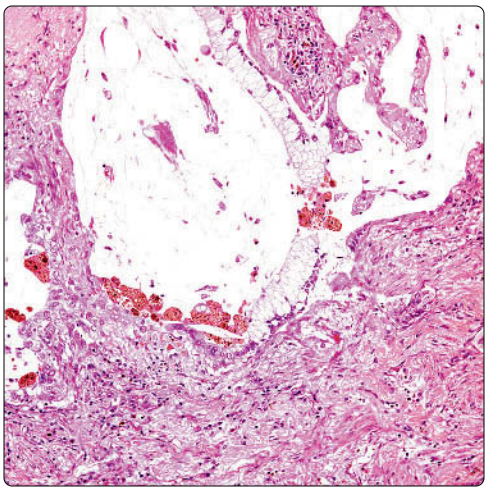

Malignant Mucinous Epithelium

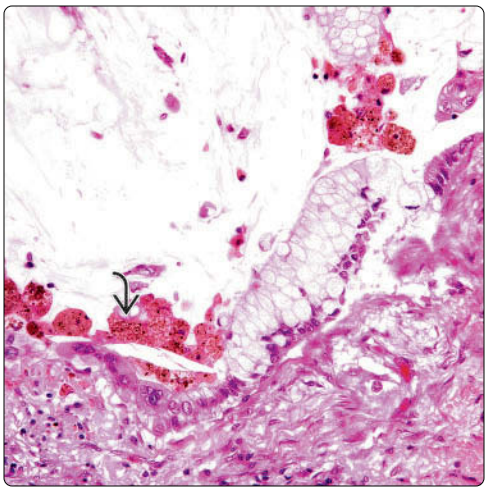

(Left) *Cystic areas are seen in which there is an obvious mucinous epithelial lining. In addition, there are adjacent areas of fibrosis with inflammatory changes.* **(Right)** *Closer view shows the mucinous type of epithelium of a cystic structure containing large amounts of mucinous material. In addition, there are many pigmented macrophages ⇨, whose appearance contrasts with that of the mucinous cells.*

Malignant Epithelium

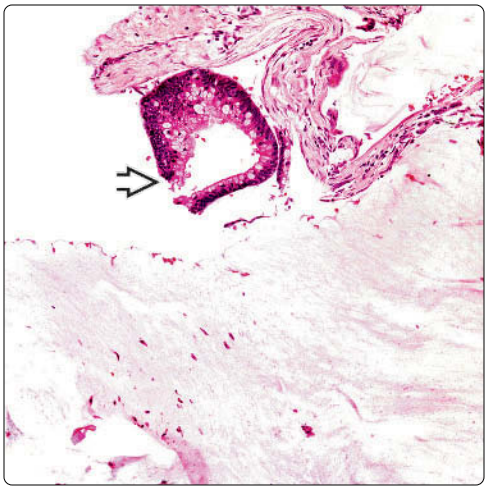

Large Cystic Areas

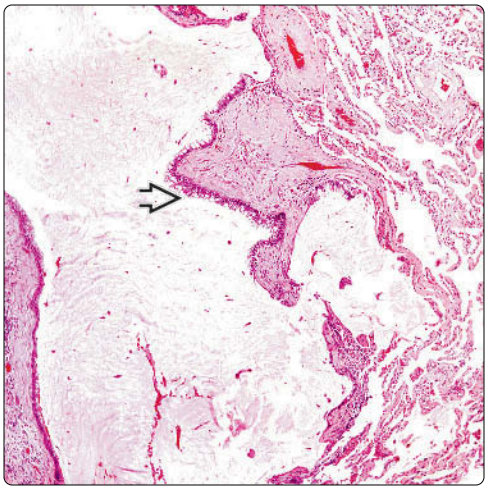

(Left) *Hematoxylin & eosin stain shows only a focus of mucinous type of epithelium ⇨. Extensive mucinous material is also present. The appearance may mimic a metastasis from gastrointestinal origin.* **(Right)** *Hematoxylin & eosin stain shows a cystic tumor with normal-appearing adjacent lung parenchyma. This appearance may give a false impression of bronchiectasis; however, note the presence of the mucinous type of epithelium ⇨.*

Focal Solid Proliferation

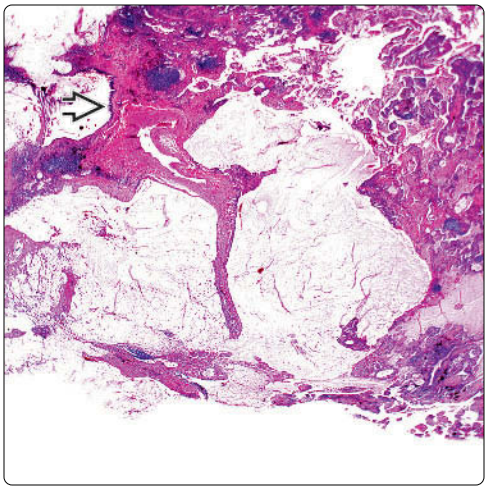

Mucinous Epithelium

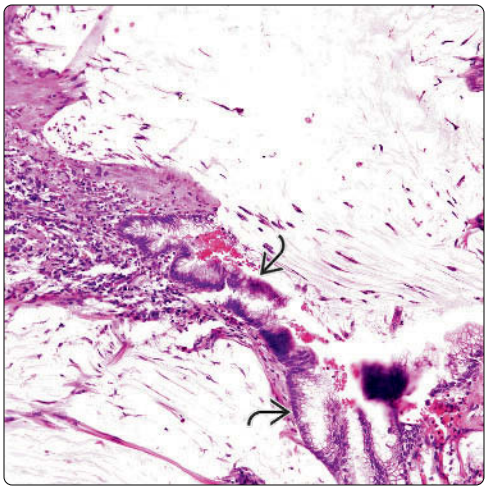

(Left) *Hematoxylin & eosin stain shows colloid carcinoma that is predominantly cystic, not the presence of cystic structures with extensive mucinous deposition. Note the presence of mucinous type of epithelium in 1 of the upper cysts ⇨.* **(Right)** *Hematoxylin & eosin stain shows extensive mucinous component with areas with prominent mucinous epithelium ⇨. This feature may be found only focally in these tumors.*

Single Malignant Cells

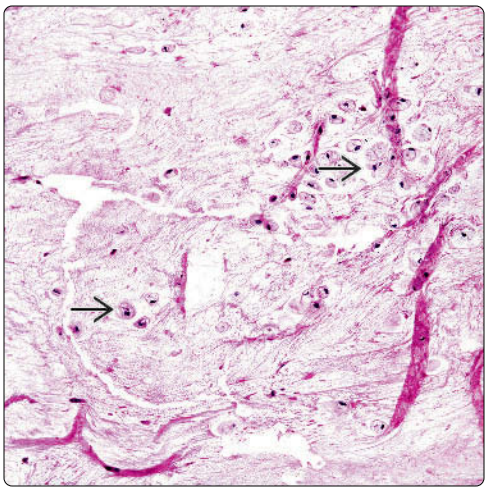

Signet Ring-Like Cells

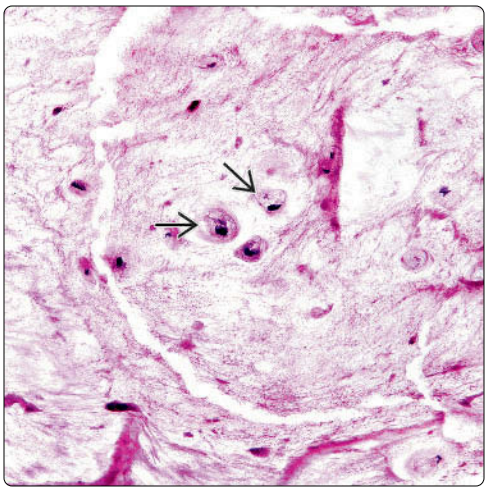

(Left) *Hematoxylin & eosin stain shows only extensive mucinous deposition. However, one can still see the presence of single neoplastic cells ⇨.* **(Right)** *Hematoxylin & eosin stain shows a closer view of single neoplastic cells floating in pools of mucin ⇨. This feature alone may also be seen in cases of signet ring cell carcinomas of the lung or in metastatic mucinous carcinomas from extrathoracic origin.*

Solid Areas

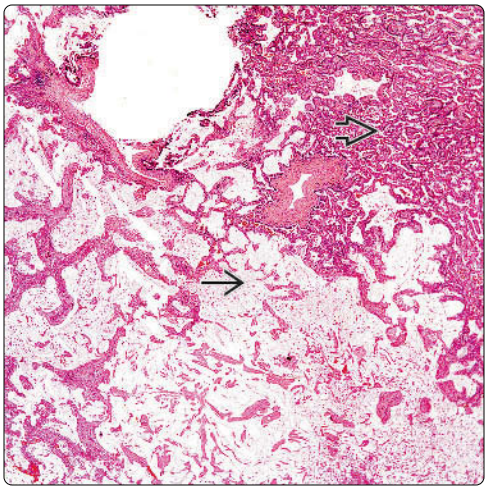

Mucinophages

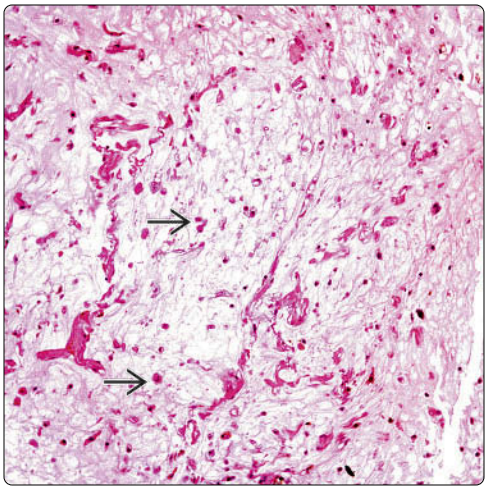

(Left) *Hematoxylin & eosin stain shows focal transitional areas of colloid carcinoma with more conventional areas of solid adenocarcinoma. This feature is seen in only a minority of cases of colloid carcinomas.* **(Right)** *Hematoxylin & eosin stain shows extensive areas of mucoid material with many mucinophages. No neoplastic cells are present in this area. This feature may be misinterpreted as a pneumonic process.*

Floating Malignant Cells

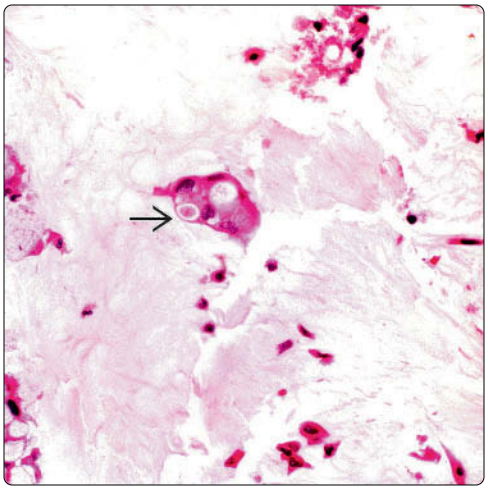

Malignant Cells and Mucinophages

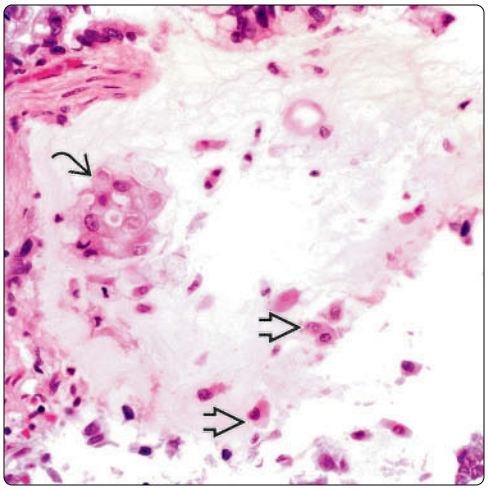

(Left) *Hematoxylin & eosin stain shows a single cluster of neoplastic cells floating in extensive areas of mucin. In some cases, this is a common occurrence.* **(Right)** *Hematoxylin & eosin stain shows a focus of neoplastic cells in association with many mucinophages. In cases in which one is not sure of the epithelial nature of the cellular proliferation, the use of immunohistochemical studies is helpful.*

Extensive Colloid Areas

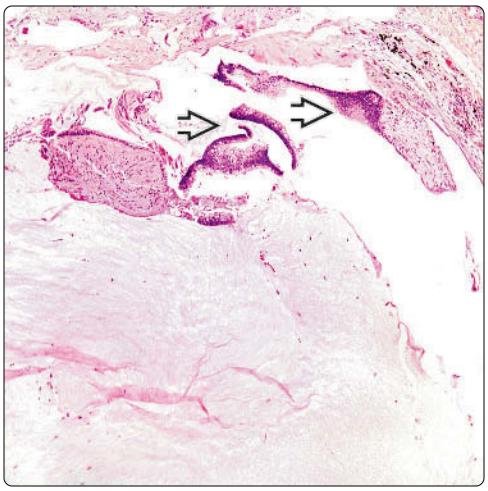

Cyst-Like Areas

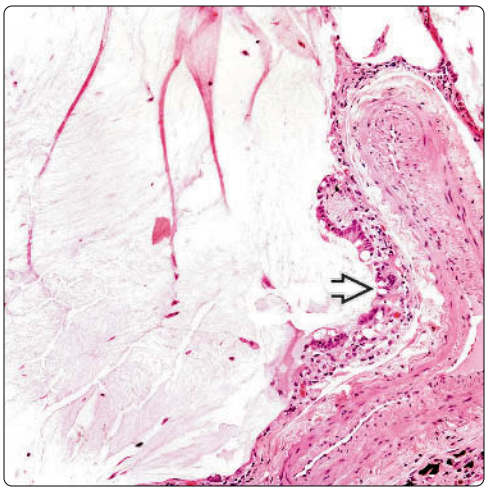

(Left) *Hematoxylin & eosin stain shows a predominantly cystic tumor with extensive areas of mucin and only a focal area of the mucinous type of epithelium. This feature has also been misinterpreted as a mucinous cystadenoma.* **(Right)** *Hematoxylin & eosin stain shows a predominantly cystic tumor in which only a focal area of a cystic wall is lined by mucinous type of epithelium. This feature is the one that has been used to also call these tumors "cystic mucinous tumors."*

Retention of Alveolar Walls

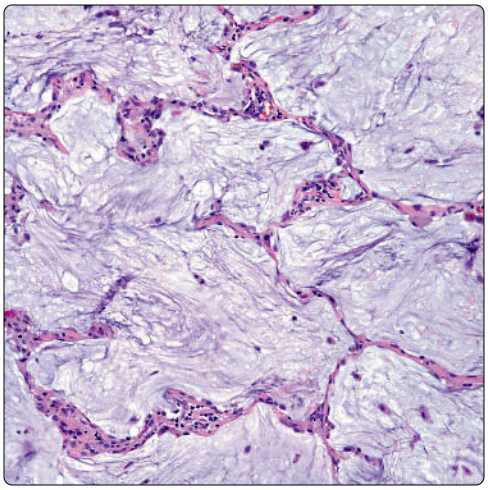

Cluster of Malignant Cells

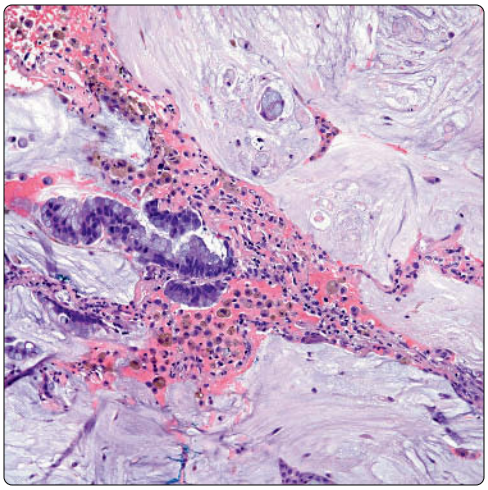

(Left) *Colloid carcinoma shows extensive colloid component filling alveolar spaces. However, in some areas, the alveolated structures are still preserved. No malignant epithelium is present here.* **(Right)** *Colloid carcinoma shows only focal areas of malignant epithelium embedded in pools of mucin. Adjacent pigmented alveolar macrophages are also present.*

Mucinous Epithelium

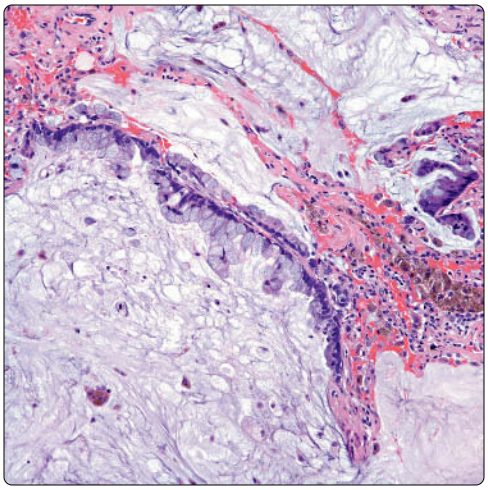

Keratin 7 Immunostain

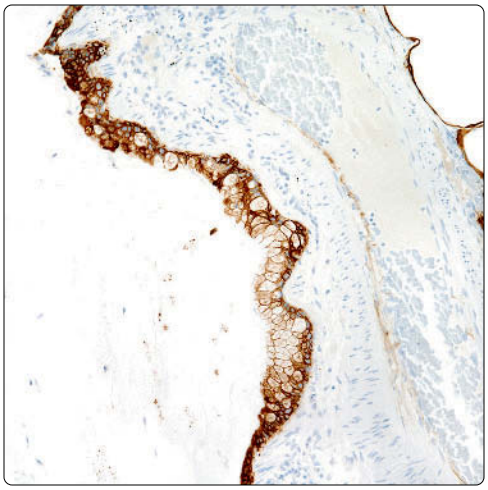

(Left) *Colloid carcinoma shows more obvious mucinous epithelium lining a cyst-like structure. The alveolar lung parenchyma is replaced by the mucin lakes.* **(Right)** *Colloid carcinoma shows a strong positive reaction in the mucinous epithelium for keratin 7.*

CDX-2 Immunostain

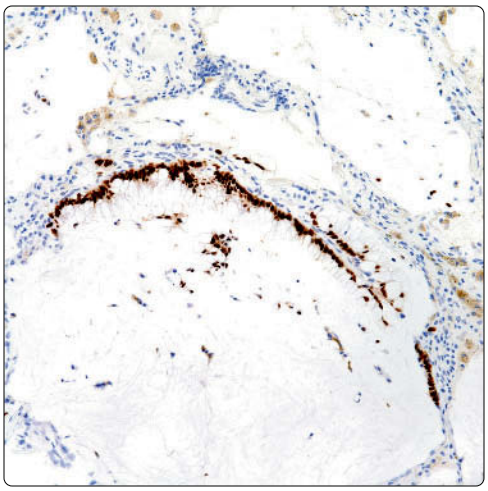

TTF-1 Immunostain

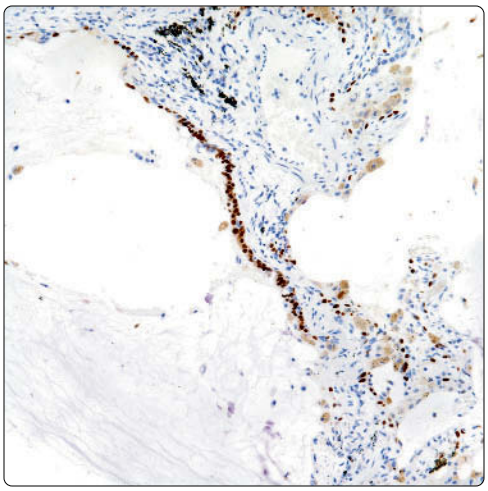

(Left) *Colloid carcinoma shows positive nuclear staining for CDX-2. This stain is commonly seen positive in this type of tumor.* **(Right)** *Colloid carcinoma shows positive nuclear staining for TTF-1. This positive stain may be only focal in these tumors.*

Signet Ring Cell Carcinoma

KEY FACTS

TERMINOLOGY

- Synonym: Adenocarcinoma with signet ring cells
- Definition
  - Non-small cell carcinoma with signet ring cells similar to those described in gastrointestinal tract

CLINICAL ISSUES

- Symptoms
  - Chest pain
  - Shortness of breath
  - Weight loss
  - Cough
  - Dyspnea
- Treatment
  - Lobectomy
  - Chemotherapy &/or radiation depending on clinical setting
  - Depends on molecular findings
- Prognosis
  - Aggressive behavior

MACROSCOPIC

- 1 to > 5 cm in greatest dimension
- May have central or peripheral location

MICROSCOPIC

- Tumor should be at least 75% signet cell component
- Predominant pattern/injury type
  - Acinar
  - Diffuse

TOP DIFFERENTIAL DIAGNOSES

- Metastatic signet ring cell carcinoma
  - Gastrointestinal, breast, and ovarian origin
- Colloid carcinoma of lung
  - Extensive mucinous "colloid" component
  - Only focal areas of signet ring cell component
  - May share similar immunohistochemical findings

Macroscopic Features

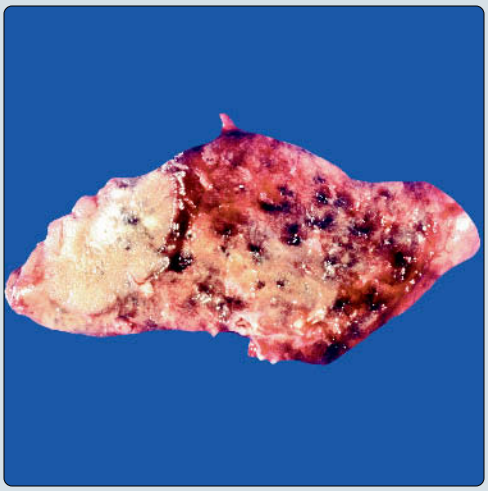

Acinar Pattern

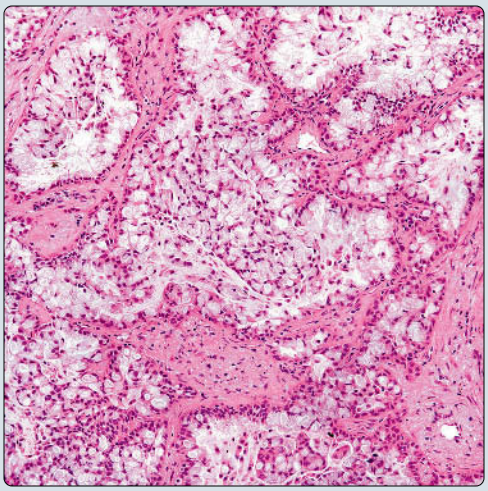

(Left) *Gross photograph shows a signet ring cell carcinoma. The mass is well defined but not encapsulated. The surface is tan and fairly homogeneous.* **(Right)** *Normal lung parenchyma is replaced by islands of tumor cells arranged in a glandular and acinar pattern. Note the cell composition made of cells with abundant clear cytoplasm.*

Signet Ring Cells

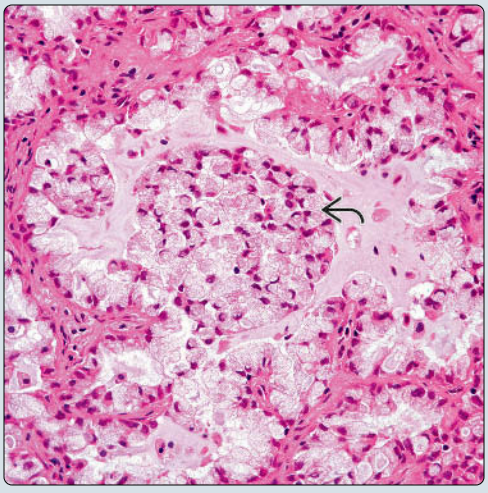

Signet Ring Cells

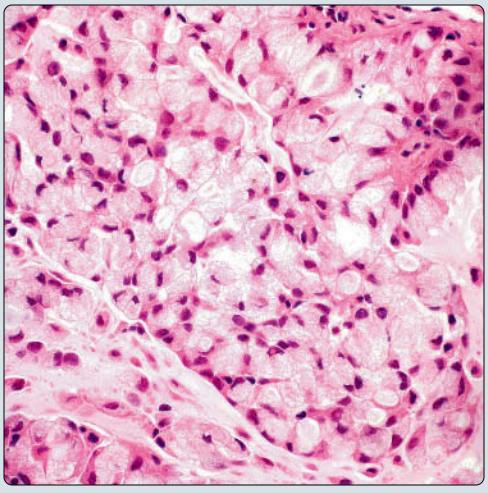

(Left) *Signet ring cell carcinoma of the lung shows a classic acinar growth pattern with numerous malignant cells floating in a mucoid material.* **(Right)** *Signet ring cell adenocarcinoma of the lung shows a cellular neoplastic proliferation composed of rather large cells with ample cytoplasm and nuclei displaced toward the periphery. Note the absence of mitotic activity.*

TERMINOLOGY

Synonyms

- Adenocarcinoma with signet ring cells

Definitions

- Non-small cell carcinoma (adenocarcinoma) with signet ring cells similar to those described in gastrointestinal tract
- Tumor is composed predominantly by signet ring cells, ~ 75% or more

ETIOLOGY/PATHOGENESIS

Etiology

- Signet ring cell carcinoma appears to be closely related to bronchial cell-type adenocarcinoma
- Bronchial glands may be site of origin for these tumors

CLINICAL ISSUES

Epidemiology

- Incidence
  - Primary signet ring cell carcinomas of lung are rare
  - No definitive data on epidemiology of this tumor
- Age
  - Individuals between 30-70 years old
  - Like conventional adenocarcinomas, signet ring cell carcinomas are more common in 6th and 7th decades of life
- Sex
  - No gender predilection

Site

- No apparent predilection for any side or any lung segment

Presentation

- Chest pain
- Shortness of breath
- Cough
- Weight loss
- Dyspnea
- Hoarseness
- General malaise

Treatment

- Surgical approaches
  - Lobectomy
- Adjuvant therapy
  - Chemotherapy and radiation therapy depending on clinical and pathological staging
  - May also depend on results of molecular studies

Prognosis

- Aggressive behavior

IMAGING

General Features

- Intrapulmonary mass of varying sizes

MACROSCOPIC

General Features

- 1 to > 5 cm in greatest dimension
- May have central or peripheral location
- Soft consistency, light tan, ± hemorrhage &/or necrosis

MICROSCOPIC

Histologic Features

- Tumor should be at least 75% signet cell component

Predominant Pattern/Injury Type

- Acinar
- Diffuse

Predominant Cell/Compartment Type

- Epithelial

DIFFERENTIAL DIAGNOSIS

Metastatic Signet Ring Cell Carcinoma

- Gastrointestinal, breast, and ovarian origin
  - Use of immunohistochemical stains is highly important in determining primary site
  - Current of previous clinical history is highly relevant

"Colloid" Carcinoma of Lung

- Presence of signet ring cells may be only focal
- Extensive areas of mucinous "colloid" component
- May share similar immunohistochemical features
- May share similar molecular findings

DIAGNOSTIC CHECKLIST

Pathologic Interpretation Pearls

- Signet ring cell component
- Presence of mucin
- Single cells or acinar arrangement

SELECTED REFERENCES

1. Alese OB et al: Anaplastic lymphoma kinase (ALK) gene alteration in signet ring cell carcinoma of the gastrointestinal tract. Ther Adv Med Oncol. 7(2):56-62, 2015
2. Choi IH et al: Analysis of histologic features suspecting anaplastic lymphoma kinase (ALK)-expressing pulmonary adenocarcinoma. J Pathol Transl Med. 49(4):310-7, 2015
3. Hao YQ et al: Primary signet-ring cell carcinoma of the lung treated with crizotinib: a case report. Oncol Lett. 9(5):2205-2207, 2015
4. Pareja F et al: Cytomorphological features of ALK-positive lung adenocarcinomas: psammoma bodies and signet ring cells. Cancer Cytopathol. 123(3):162-70, 2015
5. Qu Y et al: The clinicopathological significance of ALK rearrangements and KRAS and EGFR mutations in primary pulmonary mucinous adenocarcinoma. Tumour Biol. 36(8):6417-24, 2015
6. Boland JM et al: Pulmonary adenocarcinoma with signet ring cell features: a comprehensive study from 3 distinct patient cohorts. Am J Surg Pathol. 38(12):1681-8, 2014
7. Kocas O et al: Primary signet ring cell carcinoma of the lung with cerebellar metastasis showing full response to Cisplatin and docetaxel therapy. Case Rep Oncol Med. 2014:968723, 2014
8. Livieratos S et al: Primary signet ring cell carcinoma of the lung: a rare subtype. BMJ Case Rep. 2013, 2013
9. Moran CA: Pulmonary adenocarcinoma: the expanding spectrum of histologic variants. Arch Pathol Lab Med. 130(7):958-62, 2006
10. Castro CY et al: Primary signet ring cell adenocarcinomas of the lung: a clinicopathological study of 15 cases. Histopathology. 39(4):397-401, 2001

Immunohistochemistry

Antibody	Reactivity	Staining Pattern	Comment
CK8/18/CAM5.2	Positive	Cytoplasmic	Strong reaction in majority of cases
CK7	Positive	Cytoplasmic	Strong reaction in majority of cases
TTF-1	Positive	Nuclear	May be focal in some cases
NAPSIN-A	Positive	Cytoplasmic	Focally and weakly
TAG72	Positive	Cytoplasmic	
EpCAM/BER-EP4/CD326	Positive	Cell membrane and cytoplasm	
CEA-M	Positive	Cytoplasmic	Strong reaction in majority of cases
CD15	Positive	Cytoplasmic	May show only focal positivity
EMA	Positive	Cell membrane	May be weak positive reaction
CK20	Negative		Focal positive staining may be seen in some cases
CDX-2	Negative		
GCDFP-15	Negative		
ERP	Negative		
PRP	Negative		
Mammaglobin	Negative		
CK5/6	Negative		
p63	Negative		
p40	Negative		
Chromogranin-A	Negative		
Synaptophysin	Negative		
CD56	Negative		
Desmocollin-3	Negative		

Histochemical Features

Stain	Result
PAS	Focal areas containing intracellular glycogen
PAS-D	Positive reaction for intracellular mucin
Mucicarmine	Strong positive reaction for intracellular mucin

Molecular Features

FISH	Result
(*)5	May be positive in some cases
$/.	May be positive in some cases
.5$6	May be positive in some cases
526	May be positive in some cases
%5$)	May be positive in some cases
3,. &$	May be positive in some cases

Edema-Like Areas

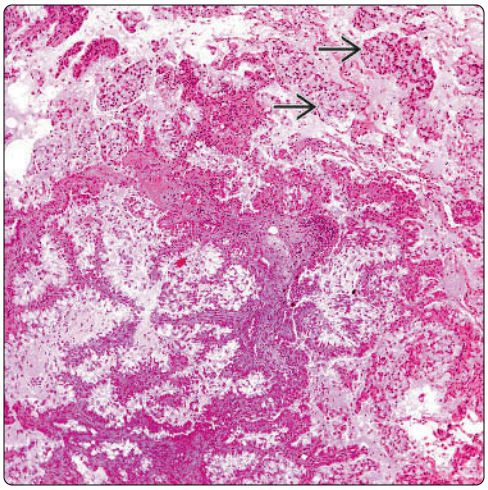

Fibrous Septa

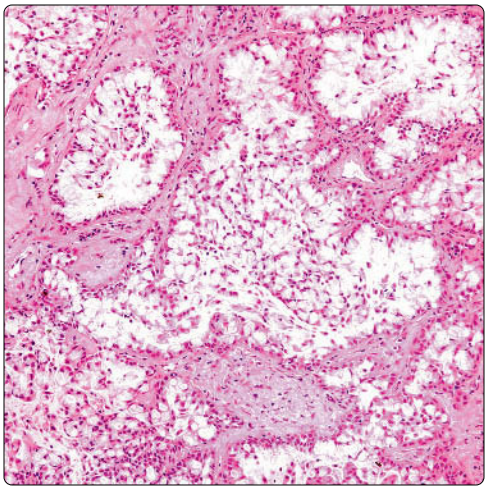

(Left) *Signet ring cell carcinoma destroys normal lung parenchyma with extensive areas of proteinaceous fluid filling some of the alveolar spaces. In addition, clusters of neoplastic cells are also present and fill alveolar spaces ⇨.* **(Right)** *Neoplastic cellular proliferation of round to oval cells is shown with clear cytoplasm and small nuclei in signet ring cell carcinoma of the lung. Fibrous collagen bands separate acini of neoplastic cells.*

Areas of Edema

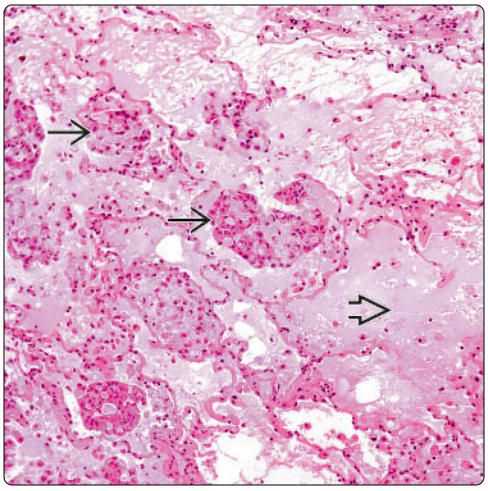

Diffuse Growth Pattern

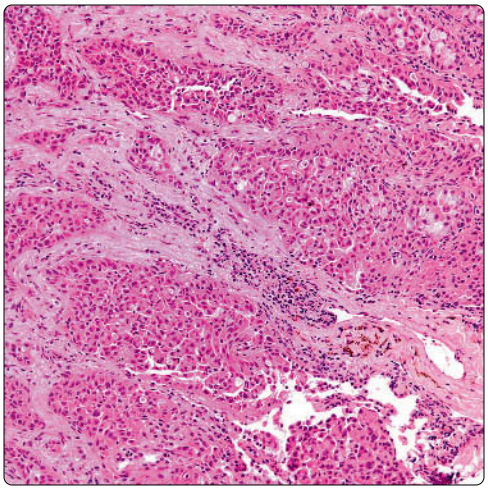

(Left) *Clusters of neoplastic cells fill alveolar spaces ⇨ in signet ring cell carcinoma of the lung. Note the presence of extensive areas of proteinaceous fluid filling the alveolar spaces ⇨.* **(Right)** *Signet ring cell carcinoma is shown with a predominantly solid growth pattern. However, even at this magnification, one can still identify signet ring cells.*

Signet Ring Cells

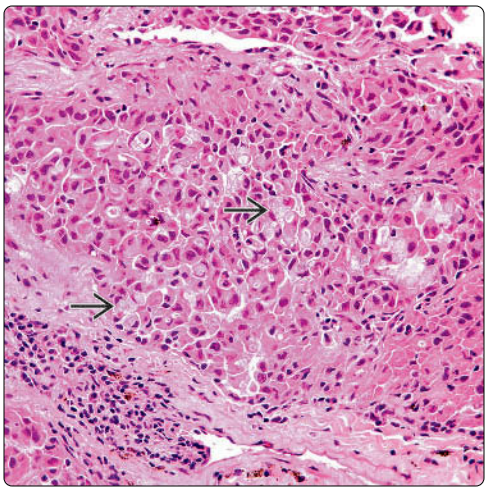

Signet Ring Cells

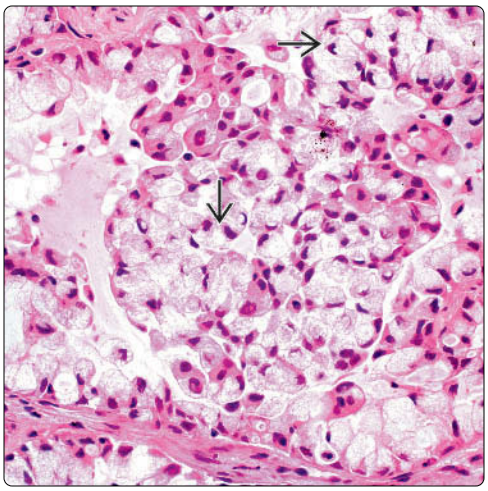

(Left) *High-power view shows a solid component of a signet ring cell carcinoma of the lung. Note the presence of numerous signet ring cells ⇨ admixed with more conventional neoplastic cells.* **(Right)** *High-power view of a signet ring cell carcinoma is shown. Note the presence of the classic morphological features of signet ring cells, essentially round to oval cells, clear cytoplasm, and nuclei displaced toward the periphery ⇨.*

Glandular and Acinar Pattern

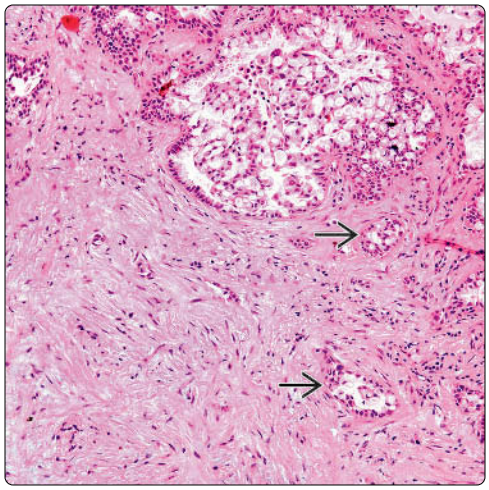

Nodular Pattern

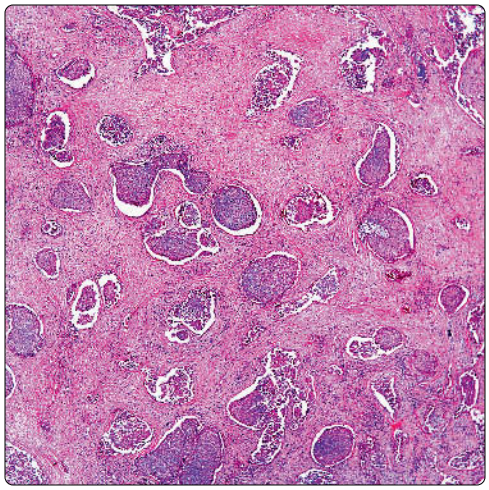

(Left) *Signet ring cell carcinoma is shown with acinar growth pattern and extensive areas of hyalinization. In some areas, neoplastic acini are dissecting the fibrocollagenous tissue.* **(Right)** *Signet ring cell carcinoma is shown with a nodular type of growth pattern. The nodules are separated by extensive areas of fibrocollagenous stroma, mimicking extensive lymphatic permeation.*

Tumor Nodules

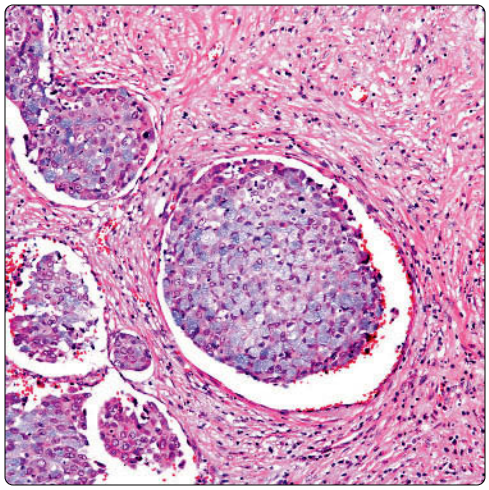

Adjacent Normal Glands

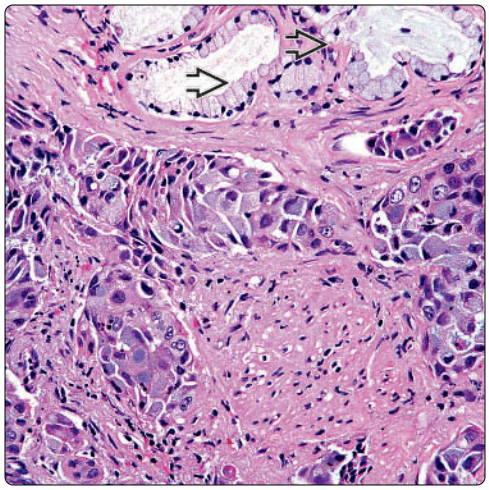

(Left) *High-power view shows a signet ring cell carcinoma with retraction artifact from areas of fibrocollagenous stroma. This type of extensive collagenization is rather unusual in signet ring cell carcinomas.* **(Right)** *Signet ring cell carcinoma with diffuse growth pattern is seen adjacent to normal submucosal glands.*

Metastatic Carcinoma

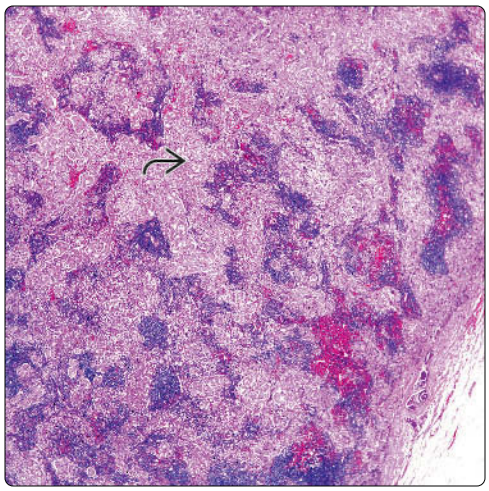

Metastatic Carcinoma

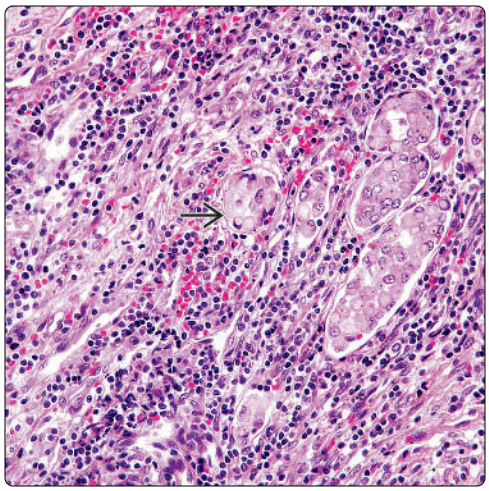

(Left) *Low-power magnification of lymph node is shown with metastatic signet ring cell carcinoma. The tumor is destroying extensive areas of nodal normal architecture.* **(Right)** *High-power view shows the neoplastic cells infiltrating nodal tissue. Note the presence of the preserved signet ring cell morphology at this metastatic site.*

Well-Circumscribed Tumor

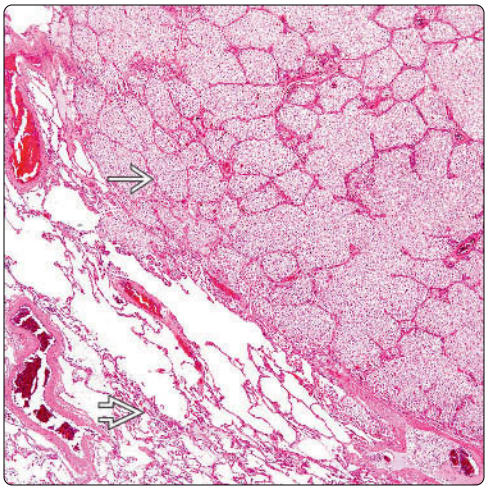

Pneumonic-Like Pattern

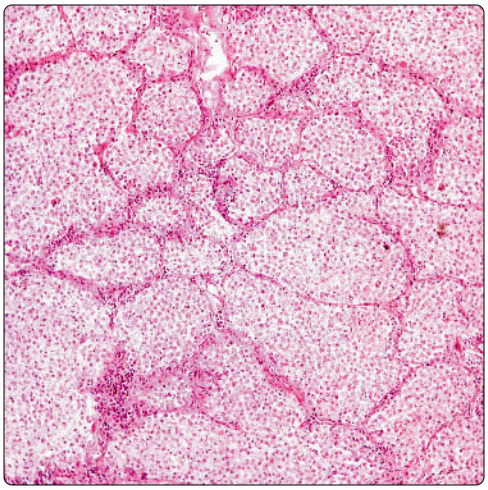

(Left) *Signet ring cell adenocarcinoma of the lung shows clear demarcation of tumor* ⇨ *and normal lung parenchyma* ⇨. *The tumor is not encapsulated but it is well demarcated.* **(Right)** *Signet ring cell adenocarcinoma shows extensive areas in which the neoplastic cellular proliferation is filling alveolar spaces in a manner similar to a pneumonic process.*

Tumor and Macrophages

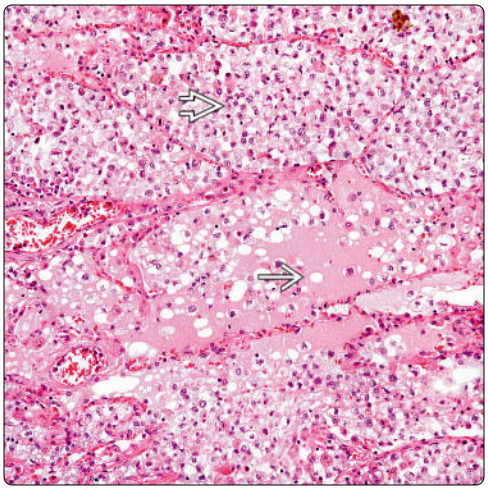

Neoplastic Cells

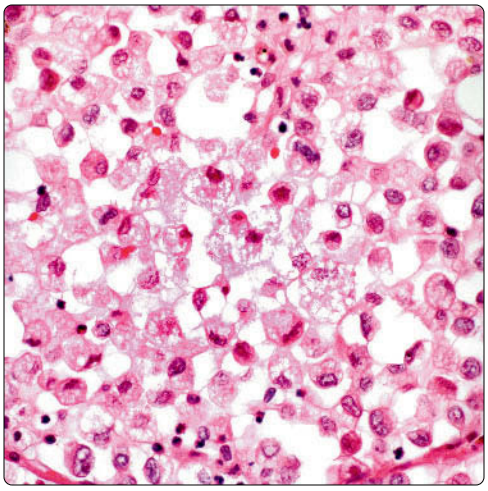

(Left) *In focal areas, the presence of edematous areas* ⇨ *admixed with macrophages could pose a problem with interpretation. However, note the presence of more atypical cells filling the alveolar spaces* ⇨. **(Right)** *Higher magnification shows the neoplastic cells filling the alveolar spaces. The cells are large with eccentric nuclei and ample cytoplasm; however, no mitotic activity is identifiable.*

Floating Intraalveolar Tumor

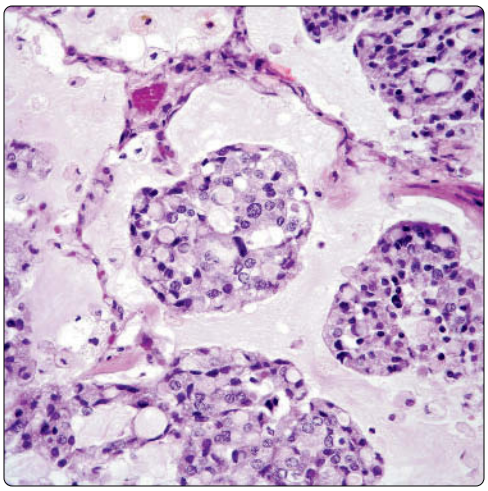

Intracellular Mucin

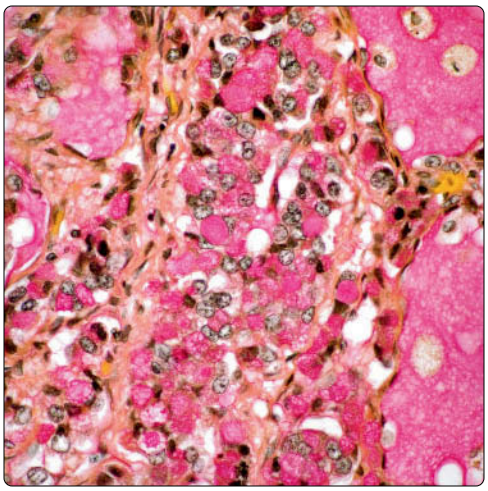

(Left) *A common occurrence in signet ring cell adenocarcinomas of the lung is to identify the presence of neoplastic cells floating in intraalveolar spaces. Note the presence of cellular atypia and signet ring cells.* **(Right)** *Mucicarmine stain shows strong presence of intracellular mucin. This is a common histochemical reaction that is easily identifiable in these tumors.*

Endometrioid-Like Carcinoma

KEY FACTS

TERMINOLOGY

- Malignant epithelial neoplasms with features mimicking secretory endometrium

CLINICAL ISSUES

- Symptoms
  - Cough
  - Dyspnea
  - Hemoptysis
  - Chest pain
- Prognosis
  - Depends on clinical and pathological stage
- Treatment options
  - Lobectomy or pneumonectomy
  - Radiation &/or chemotherapy depending on clinical stage

TOP DIFFERENTIAL DIAGNOSES

- Pulmonary blastoma: Endometrioid adenocarcinoma
  - Lacks morular component between glandular structures
  - Lacks primitive glands that recapitulate lung development of ~ weeks 11-16
  - Shows intracellular mucin, while blastoma lacks it
- Metastatic endometrioid adenocarcinoma from gynecologic primary
  - Differential diagnosis more important in female patients
  - Clinical history &/or complete physical examination → correct interpretation
  - Use of immunohistochemical stains may help in some cases
- Metastatic prostatic adenocarcinoma
  - Differential diagnosis more important in male patients
  - Clinical history &/or clinical evaluation of possible prostatic neoplasm is of utmost importance
  - Use of immunohistochemical stains will lead to proper interpretation

Macroscopic Features

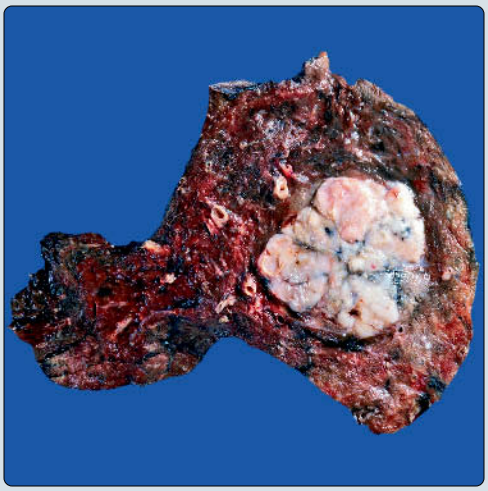

Well-Demarcated Tumor

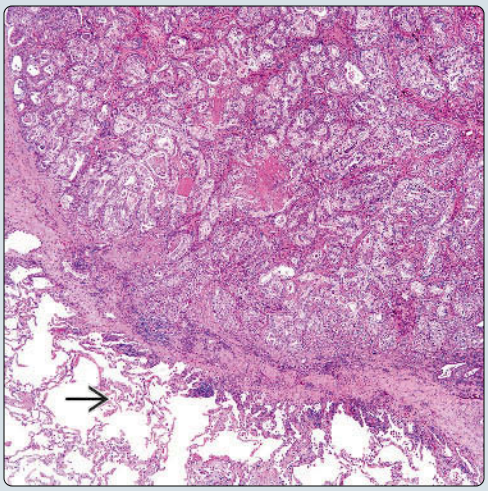

(Left) *Gross photograph of an endometrioid-like carcinoma of the lung shows a well-circumscribed but not encapsulated mass. The tumor is light tan and slightly lobulated.* **(Right)** *Endometrioid adenocarcinoma shows a malignant glandular proliferation destroying lung parenchyma. Note the tumor mass is well circumscribed and a rim of normal lung parenchyma is present ⇨.*

Back-to-Back Glands

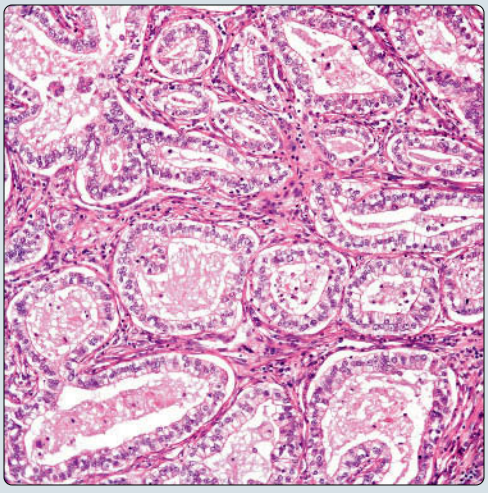

Mild Cellular Atypia

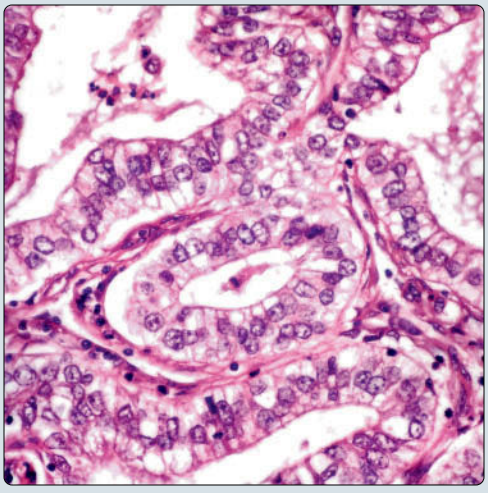

(Left) *Endometrioid adenocarcinoma of the lung shows a classic growth pattern of back-to-back glandular proliferation with very discrete fibroconnective tissue separating the malignant glands.* **(Right)** *Closer view of an endometrioid adenocarcinoma of the lung shows malignant glands composed of cells with clear cytoplasm, round nuclei with loss of polarity, and mild nuclear atypia.*

TERMINOLOGY

Synonyms

- Endometrioid adenocarcinoma

Definitions

- Malignant epithelial neoplasms that mimic secretory endometrium
- Non-small cell carcinoma
- Adenocarcinoma

CLINICAL ISSUES

Presentation

- Cough
- Hemoptysis
- Dyspnea
- Chest pain
- Hoarseness
- General malaise
- Weight loss

Treatment

- Surgical approaches
  - Lobectomy or pneumonectomy
- Adjuvant therapy
  - Radiation or chemotherapy depending on clinical stage
  - Depending on molecular findings

Prognosis

- Depends on clinical and pathological stage
- Depends on possible targeted therapy

IMAGING

General Features

- Intrapulmonary mass of variable size
- No specific lung or lung segment

MACROSCOPIC

General Features

- Tumor mass is light tan to brown
- From 1 cm to > 10 cm in greatest diameter
- Hemorrhage or necrosis may be seen
- Tumor may be central or peripheral

MICROSCOPIC

Histologic Features

- Glands composed of cells with clear cytoplasm mimicking secretory phase of endometrium
- Back-to-back glandular growth pattern
- Absence of morular component
- Neoplastic cells with intracellular mucin
- Intracellular mucin
- Necrosis and hemorrhage are common
- Low mitotic count

Predominant Pattern/Injury Type

- Glandular

Predominant Cell/Compartment Type

- Epithelial, glandular

DIFFERENTIAL DIAGNOSIS

Pulmonary Blastoma

- Endometrioid adenocarcinoma
  - Lacks morular component between glandular structures
  - Lacks primitive glands that recapitulate lung development of ~ weeks 11-16
  - Shows intracellular mucin, while blastoma lacks it

Metastatic Endometrioid Adenocarcinoma From Gynecologic Primary

- Differential diagnosis more important in female patients
- Clinical history &/or complete physical examination are of utmost importance
- Use of immunohistochemical stains may help in some cases
- TTF-1 may be positive in small number of primary endometrial adenocarcinomas

Metastatic Prostatic Adenocarcinoma

- Differential diagnosis more important in male patients
- Clinical history &/or clinical evaluation of possible prostatic tumor is of utmost importance
- Use of immunohistochemical stains will help in defining primary site
- TTF-1 is generally negative in prostatic adenocarcinomas

DIAGNOSTIC CHECKLIST

Clinically Relevant Pathologic Features

- Metastatic distribution

Pathologic Interpretation Pearls

- Malignant glands similar to those seen in menstrual phase of secretory endometrium
- Back-to-back glandular proliferation
- Presence of intracellular mucin
- Absence of morules

SELECTED REFERENCES

1. Er TK et al: Increase EGFR mutations detection rate in lung adenocarcinoma by real-time PCR screening followed by direct sequencing. Appl Immunohistochem Mol Morphol. 23(5):343-8, 2015
2. Renaud S et al: Prognostic value of the KRAS G12V mutation in 841 surgically resected Caucasian lung adenocarcinoma cases. Br J Cancer. 113(8):1206-15, 2015
3. Longo M et al: Fetal adenocarcinoma of the lung in a 25-year-old woman. J Thorac Oncol. 3(4):441-3, 2008
4. Siami K et al: Thyroid transcription factor-1 expression in endometrial and endocervical adenocarcinomas. Am J Surg Pathol. 31(11):1759-63, 2007
5. Adluri RK et al: Pulmonary blastoma--a rare tumor with variable presentation. Eur J Cardiothorac Surg. 29(2):236-9, 2006
6. Harada T et al: Pulmonary blastoma within bronchioloalveolar cell carcinoma. Respirology. 11(3):339-42, 2006
7. Steinhauer JR et al: 'Secretory endometrioid-like' adenocarcinoma of the lung. Histopathology. 47(2):219-20, 2005

Immunohistochemistry

Antibody	Reactivity	Staining Pattern	Comment
TTF-1	Positive	Nuclear	Some cases of uterine adenocarcinoma may also show positive nuclear staining
NAPSIN-A	Positive	Cytoplasmic	
KERATIN-LMW	Positive	Cytoplasmic	In glandular structures
CD15	Positive	Cytoplasmic	
MOC-31	Positive	Cytoplasmic	In glandular component
EpCAM/BER-EP4/CD326	Positive	Cell membrane	
CK7	Positive	Cytoplasmic	Strongly positive
CEA-M	Positive	Cytoplasmic	
TAG72	Positive	Cytoplasmic	May show weak positive reaction
CD10	Positive	Cytoplasmic	In some cases
WT1	Positive	Nuclear	May be positive or negative
CA125	Negative		May be positive in some lung adenocarcinomas
ER	Negative		Focal weak positive staining may be seen
GATA3	Negative		
β-catenin	Negative		
PTEN	Negative		
PR	Negative		
p63	Negative		May show focal positivity in some cases
p40	Negative		
Desmocollin-3	Negative		
Chromogranin-A	Negative		
Synaptophysin	Negative		
CD56	Negative		May show focal staining in some cases
CK20	Negative		
CDX-2	Negative		
p16	Negative		
pax-8	Negative		
PAP	Negative		
PSA	Negative		

Histochemical Features

Stain	Result	Comment
PAS	Positive	In cells containing glycogen
D-PAS	Positive	Intracellular mucin
Mucicarmine	Positive	Intracellular mucin

Molecular Features

FISH	Result
(*)5	Positive in some cases
.5$6	Positive in some cases
$/.	May be positive in some cases
526	May be positive in some cases
%5$)	May be positive in some cases
3,. &$	May be positive in some cases

Destruction of Lung Parenchyma

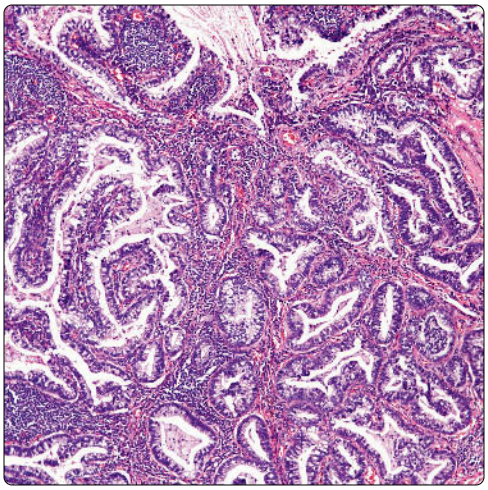

Intraluminal Mucoid Material

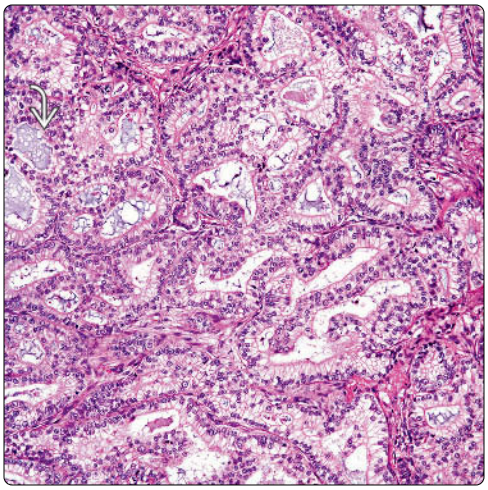

(Left) *Endometrioid adenocarcinoma of the lung shows a malignant glandular proliferation. Even at this magnification, it is possible to observe the clear cytoplasm.* **(Right)** *Closer view of the malignant glandular component shows focal areas in which the glands contain intraluminal mucinous material, while most of the glands have an empty lumen.*

Extensive Necrosis

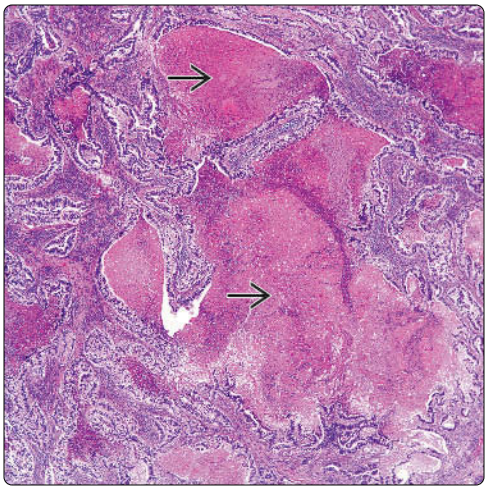

Intraglandular Macrophages

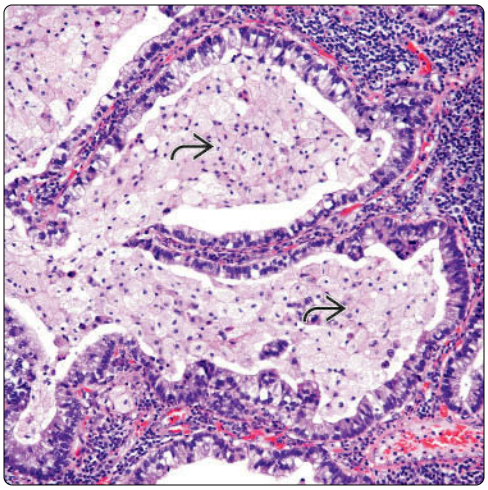

(Left) *Areas of necrosis are present in endometrioid adenocarcinoma; however, extensive areas of necrosis are not a common feature in this type of neoplasm.* **(Right)** *Malignant glands filled with foamy macrophages are probably due to obstruction. However, the basic histology of the endometrioid-like adenocarcinoma is still present.*

Focal Fibrotic Areas

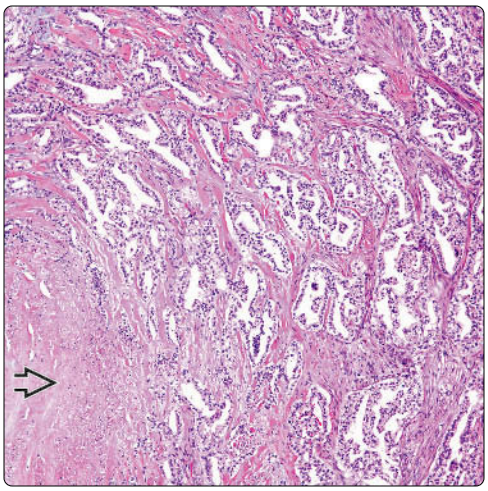

Glandular Proliferation

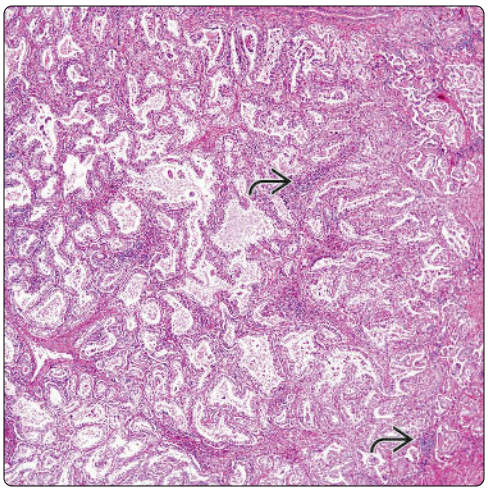

(Left) *Endometrioid adenocarcinoma shows a malignant glandular proliferation in which the malignant glands are separated by thin fibroconnective tissue. A focal area with more extensive fibrosis is also present.* **(Right)** *Endometrioid adenocarcinoma shows a malignant glandular proliferation separated by thin bands of fibroconnective tissue and focal inflammatory change.*

Clear Cytoplasm

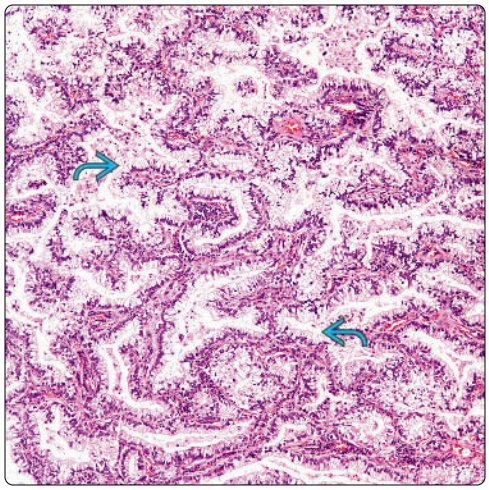

Different-Sized Glands

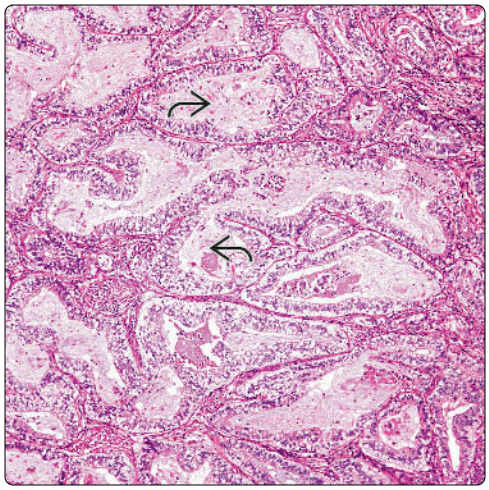

(Left) *Malignant glandular proliferation is shown in which the glands are composed of cells with prominent clear cytoplasm and basally located nuclei. Note the lack of cytologic atypia or increased mitotic activity.* **(Right)** *Endometrioid adenocarcinoma shows glands filled with acellular material. Note the presence of malignant glands of different sizes and tumor cells with clear cytoplasm.*

Secretory-Like Endometrial Pattern

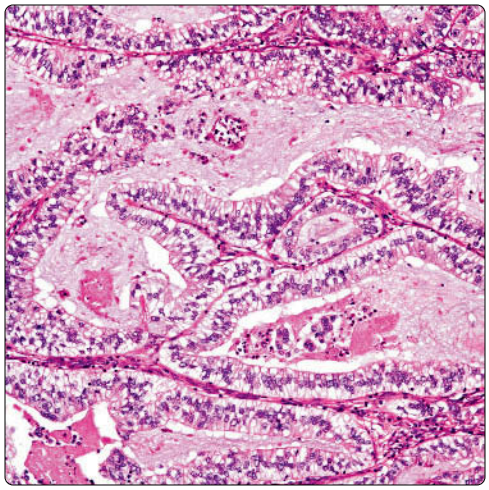

Malignant Glandular Proliferation

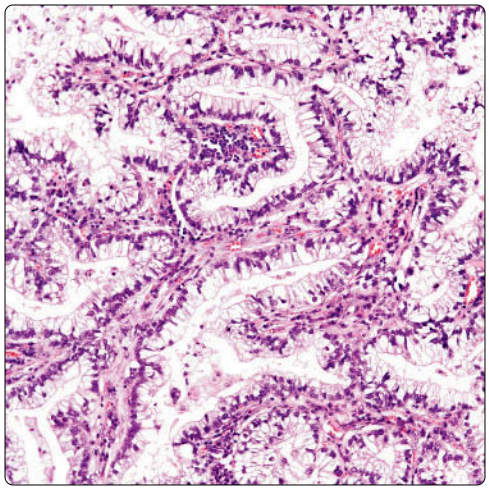

(Left) *Higher magnification view of the cellular component of endometrioid adenocarcinoma mimics the secretory phase of the menstrual endometrium.* **(Right)** *Closer view shows malignant glands with only moderate nuclear atypia and rare mitotic figures. Note the absence of a morular component.*

Low Mitotic Activity

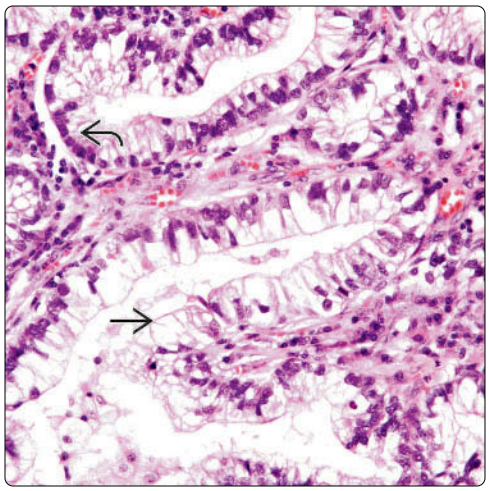

Loss of Polarization of Nuclei

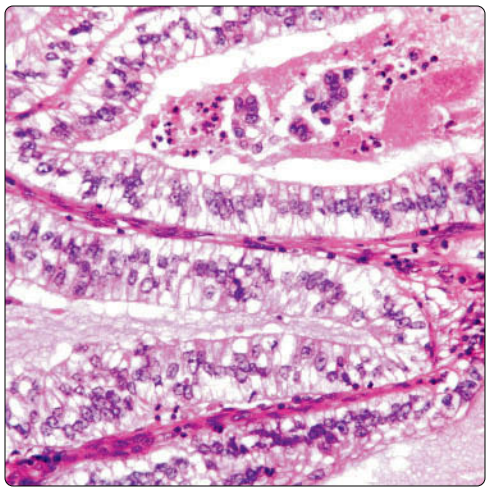

(Left) *Higher magnification of the glandular component shows basal location of the nucleus and clear cytoplasm. Mitotic figures are rare.* **(Right)** *Higher magnification of the cellular component shows the piano keys appearance, similar to that described in the secretory phase of the menstrual endometrium.*

Solid Areas

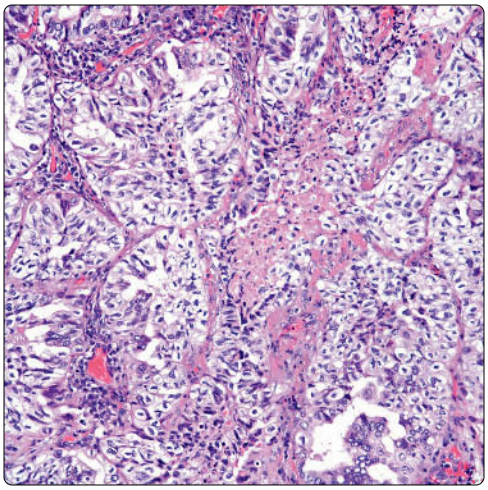

Fibrosis

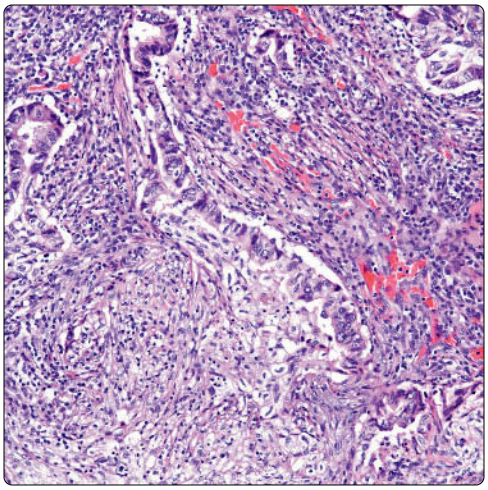

(Left) *Endometrioid adenocarcinoma shows focal solid areas. However, the neoplastic proliferation shows cells with clear cytoplasm and gland-like formation.* **(Right)** *Endometrioid adenocarcinoma shows incomplete gland formation and adjacent areas of fibrosis with inflammatory infiltrate.*

Glandular Formation

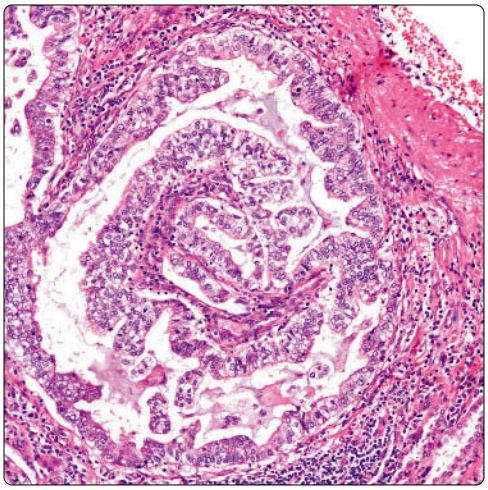

Back-to-Back Glands

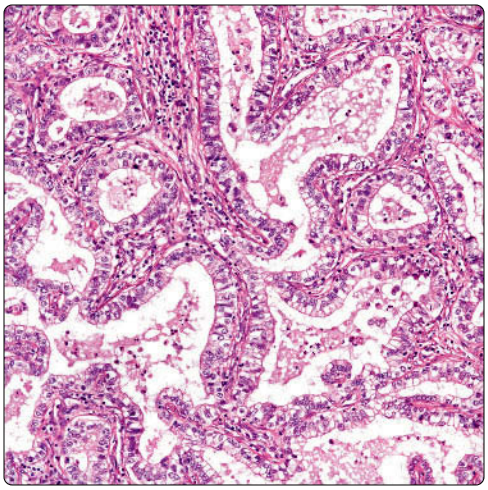

(Left) *Endometrioid adenocarcinoma shows a large glandular structure with involutional glandular changes as seen in intraglandular formation.* **(Right)** *Endometrioid adenocarcinoma shows a classic growth pattern of back-to-back glandular proliferation. Note the presence of the epithelium lining, the glands composed of cells mimicking those seen in secretory endometrium.*

Mitotic Activity

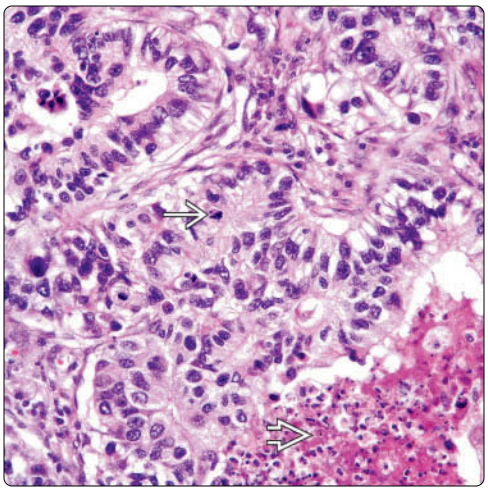

Inflammatory Reaction

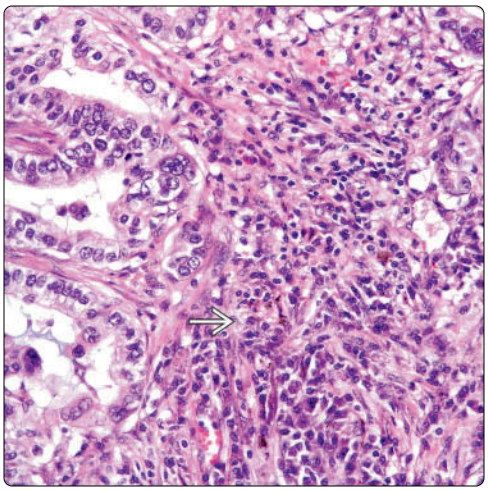

(Left) *Endometrioid adenocarcinoma shows mitotic activity* ➡ *and moderate nuclear atypia. Adjacent gland shows intraglandular necrosis* ➡. **(Right)** *Endometrioid adenocarcinoma shows the malignant glandular proliferation adjacent to areas of marked inflammatory reaction composed predominantly of plasma cells* ➡.

Squamous Cell Carcinoma

KEY FACTS

TERMINOLOGY

- Malignant epithelial neoplasm with squamous (epidermoid) differentiation

MACROSCOPIC

- Central or peripheral tumors
- White or light brown in color with homogeneous cut surface that may show areas of hemorrhage &/or necrosis
- Tumors may be predominantly cystic
- Tumor size may vary from 2 cm to > 10 cm in diameter

MICROSCOPIC

- Solid
- Cystic
- Spindled

TOP DIFFERENTIAL DIAGNOSES

- Small cell carcinoma
  - In cases of small cell variant of squamous cell carcinoma, may be able to identify in situ squamous component
  - Chromatin pattern of small cell carcinoma, salt and pepper, not present in small cell variant of squamous cell carcinoma
- Sarcoma
  - In spindle cell variant of squamous cell carcinoma, may identify residual focal areas of squamous differentiation
- Large cell neuroendocrine carcinoma
  - In cases of basaloid squamous cell carcinoma, large cell neuroendocrine carcinoma may enter differential diagnosis
- Mucoepidermoid carcinoma
  - Will show presence of mucous secreting cells
  - Likely will not show areas of keratinization
- Adenosquamous carcinoma
  - By definition, areas of adenocarcinoma must be present

Squamous Cell Carcinoma

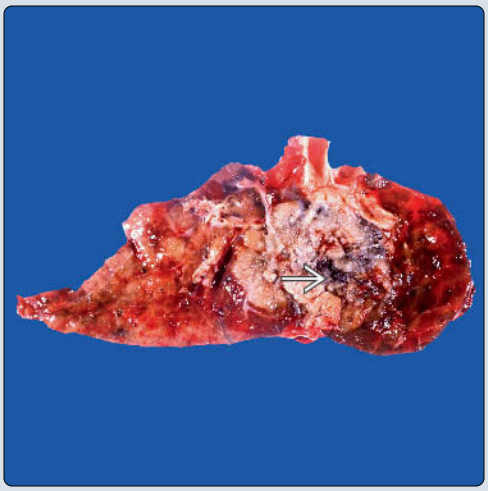

Well-Differentiated Squamous Cell Carcinoma

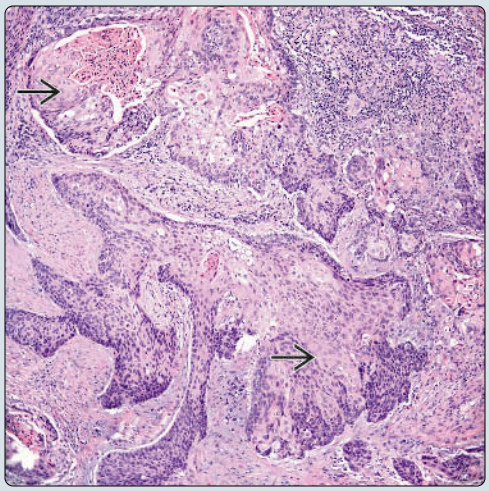

(Left) *Gross photograph of squamous cell carcinoma (SCC) of the lung shows a centrally located large neoplasm. The tumor has a soft consistency and focal areas of necrosis ⇒.* **(Right)** *Keratinizing well-differentiated SCC is shown. Note the presence of keratin formation ⇨, characteristic of well-differentiated tumors.*

Keratinization

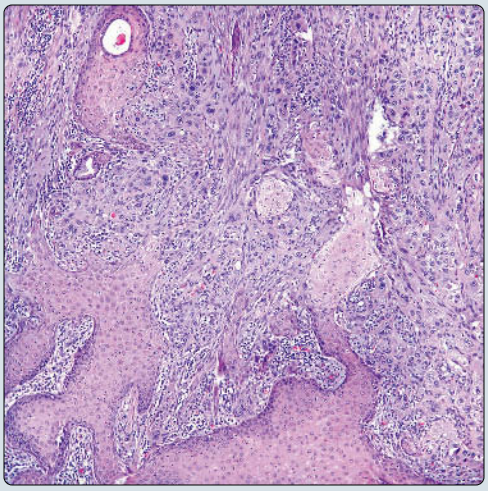

Atypia and Keratinization

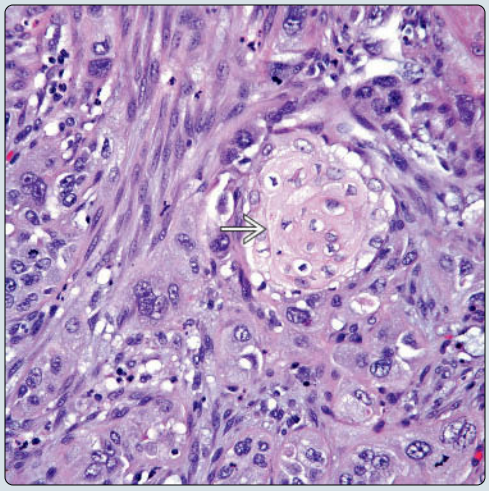

(Left) *Keratinizing SCC of the lung shows areas mimicking pseudoepitheliomatous hyperplasia. Note the infiltrative nature of the neoplasm.* **(Right)** *Higher magnification of a SCC shows an area of unequivocal keratinization ⇒. Adjacent tumor cells do not show obvious keratinization.*

TERMINOLOGY

Synonyms

- Epidermoid carcinoma

Definitions

- Malignant epithelial neoplasm with squamous (epidermoid) differentiation

ETIOLOGY/PATHOGENESIS

Environmental Exposure

- Associated with tobacco smoke
- Other environmental conditions may also play role

CLINICAL ISSUES

Presentation

- Cough
- Shortness of breath
- Hemoptysis
- Chest pain
- Wheezing
- Weight loss
- Hoarseness

Treatment

- Surgical approaches
  - Wedge resection
  - Lobectomy
  - Pneumonectomy
- Radiation
  - Chemotherapy or radiation therapy

Prognosis

- Depends on stage at time of diagnosis

IMAGING

General Features

- Central or peripheral intrapulmonary mass

MACROSCOPIC

General Features

- Central or peripheral tumors
- White or light brown in color with homogeneous cut surface
- Cut surface may show areas of hemorrhage &/or necrosis
- Tumors may be predominantly cystic
- Tumor size may vary from 2 cm to > 10 cm in diameter

MICROSCOPIC

Histologic Features

- Keratinization
- Keratin pearls
- Intercellular bridges

Predominant Pattern/Injury Type

- Solid
- Cystic
- Spindled

Predominant Cell/Compartment Type

- Epithelial, squamous

DIFFERENTIAL DIAGNOSIS

Small Cell Carcinoma

- In cases of small cell variant of squamous cell carcinoma, presence of in situ squamous component will be helpful for diagnosis
- Chromatin pattern of small cell carcinoma (salt and pepper) not present in small cell variant of squamous cell carcinoma
- May show positive staining for neuroendocrine markers and TTF-1

Sarcoma

- May identify residual focal areas of squamous differentiation in spindle cell variant of squamous cell carcinoma
- Immunohistochemical markers for mesenchymal origin may prove useful

Large Cell Neuroendocrine Carcinoma

- In cases of basaloid squamous cell carcinoma, large cell neuroendocrine carcinoma may enter differential diagnosis
- Basaloid squamous cell carcinoma is negative for neuroendocrine markers
- Immunomarkers for neuroendocrine origin will show positive staining

Mucoepidermoid Carcinoma

- Presence of myocytes is more in keeping with mucoepidermoid carcinoma (MEC)
- Lacks keratinization
- Low-grade MEC lacks marked nuclear atypia and high mitotic activity

Adenosquamous Carcinoma

- By definition, this tumor must have areas of conventional adenocarcinoma admixed with squamous cell carcinoma

DIAGNOSTIC CHECKLIST

Pathologic Interpretation Pearls

- Presence of keratinization, keratin pearls, &/or intercellular bridges

GRADING

Well-Differentiated Squamous Cell Carcinoma

- Tumor shows obvious keratinization, and at high-power view, intercellular bridges are apparent

Moderately Differentiated Squamous Cell Carcinoma

- Tumors show more cellular and nuclear atypia
  - Keratinization is not obvious

Poorly Differentiated Squamous Cell Carcinoma

- Sheets of tumor cells with only focal keratinization, high mitotic activity, and prominent cellular and nuclear atypia

In Situ Squamous Cell Carcinoma

- Tumor is limited to bronchial mucosa, full thickness

Immunohistochemistry

Antibody	Reactivity	Staining Pattern	Comment
CK5/6	Positive	Cytoplasmic	May also be positive in mesotheliomas
p63	Positive	Nuclear	May also be positive in other types of carcinomas
KERATIN-LMW	Positive	Cytoplasmic	Not specific for squamous cell carcinoma
CK-PAN	Positive	Cytoplasmic	
CK7	Positive	Cytoplasmic	~ 50% of cases
CK20	Negative		
NAPSIN-A	Negative		
Vimentin	Positive	Cytoplasmic	May also be positive in nonepithelial tumors
CD117	Positive	Cytoplasmic	In some cases
p40	Positive	Nuclear	
	Positive	Cytoplasmic	Desmocollin 3
met	Positive	Cell membrane	c-Met in some cases
PD-1	Positive	Cytoplasmic	~ 26% of cases; PD2 in ~ 23% of cases
TTF-1	Negative		In some cases, focal positive nuclear staining may be seen
Chromogranin-A	Negative		
Synaptophysin	Negative		In some cases, may show weak focal positive staining
CD56	Negative		In some cases, may show focal weak staining
	Positive	Cytoplasmic	MTSS1

Histochemical Features

Stain	Result
PAS	May show focal positive intracytoplasmic staining
PAS-D	Negative
Mucicarmine	Negative

Molecular Features

FISH/RT-qPCR	Result
1) mutation	In some cases
62; amplification	In some cases
)*)5 amplification	In some cases
.5$6 mutations	Likely negative
+0*$ expression	In some cases
0(7 amplification	Likely negative
(*)5	Likely negative
$/.	Likely negative

SELECTED REFERENCES

1. Eide HA et al: The MYCN-HMGA2-CDKN2A pathway in non-small cell lung carcinoma-differences in histological subtypes. BMC Cancer. 16(1):71, 2016
2. Fukazawa T et al: SOX2 suppresses CDKN1A to sustain growth of lung squamous cell carcinoma. Sci Rep. 6:20113, 2016
3. Redig AJ et al: Clinical and molecular characteristics of NF1 mutant lung cancer. Clin Cancer Res. ePub, 2016
4. Xie FJ et al: The clinical pathological characteristics and prognosis of FGFR1 gene amplification in non-small-cell lung cancer: a meta-analysis. Onco Targets Ther. 9:171-81, 2016
5. Kayser G et al: Downregulation of MTSS1 expression is an independent prognosticator in squamous cell carcinoma of the lung. Br J Cancer. 112(5):866-73, 2015
6. Kim MY et al: Clinicopathological analysis of PD-L1 and PD-L2 expression in pulmonary squamous cell carcinoma: Comparison with tumor-infiltrating T cells and the status of oncogenic drivers. Lung Cancer. 88(1):24-33, 2015
7. Steuer CE et al: Innovative clinical trials: The LUNG-MAP study. Clin Pharmacol Ther. 97(5):488-91, 2015
8. Weissferdt A et al: Microcystic squamous cell carcinoma of the lung: a clinicopathologic study of three cases. Am J Clin Pathol. 136(3):436-41, 2011
9. Pelosi G et al: CD117 immunoreactivity in stage I adenocarcinoma and squamous cell carcinoma of the lung: relevance to prognosis in a subset of adenocarcinoma patients. Mod Pathol. 17(6):711-21, 2004

In Situ Squamous Cell Carcinoma

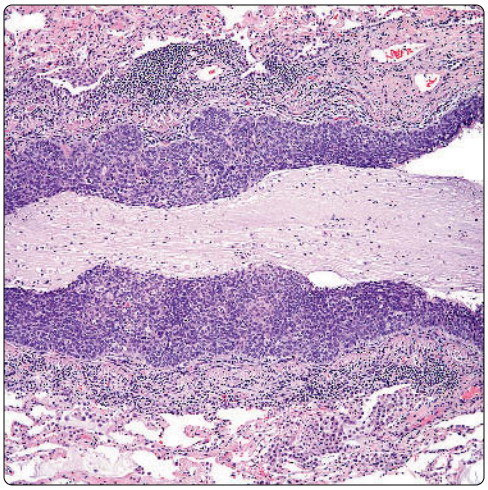

In Situ Squamous Cell Carcinoma

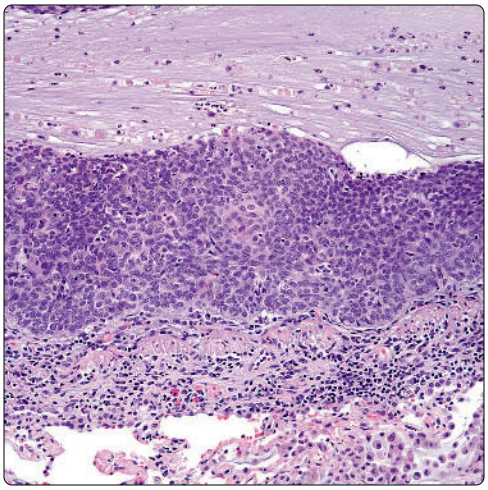

(Left) *In situ bronchial SCC shows bronchial mucosa completely replaced (full thickness) by neoplastic cells. Note the lack of invasion into adjacent lung parenchyma.* **(Right)** *Full thickness of the bronchial mucosa replaced by a neoplastic cellular proliferation characteristic of in situ SCC shows mild inflammatory reaction adjacent to the neoplastic cells.*

In Situ Squamous Cell Carcinoma

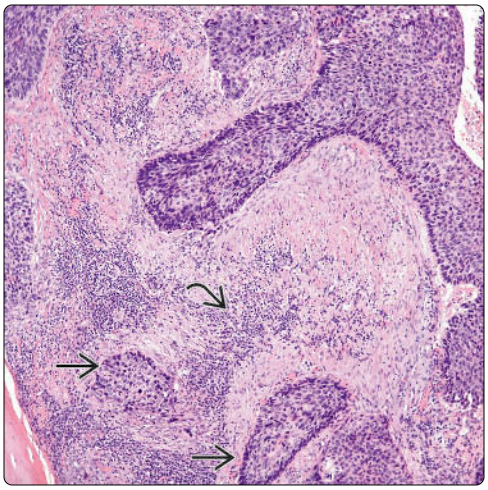

Invasive Squamous Cell Carcinoma

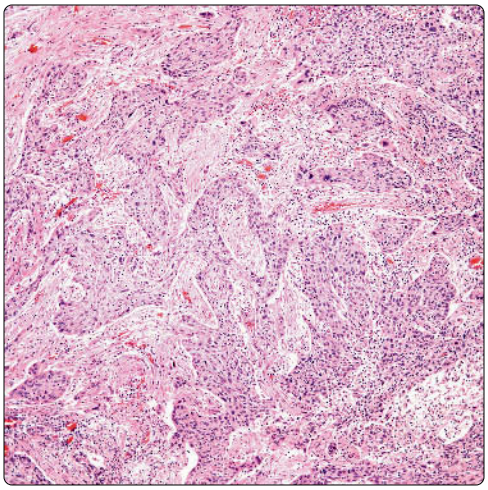

(Left) *Predominantly in situ SCC with focal areas of minimally invasive tumor is shown. Tumor islands of SCC ⇨ are admixed with an inflammatory reaction ⇨.* **(Right)** *Moderately differentiated SCC shows marked keratinization. This growth pattern is typical of SCC. Cellular and nuclear atypia are present.*

High-Grade Squamous Cell Carcinoma

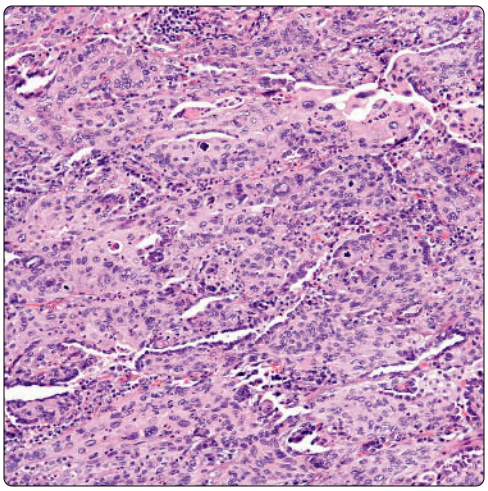

HIgh-Grade Squamous Cell Carcinoma

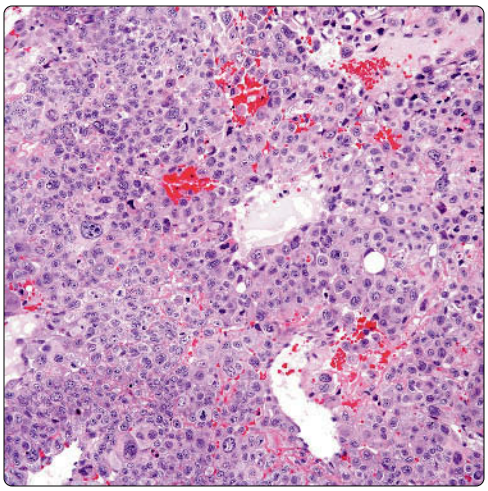

(Left) *Poorly differentiated SCC growing in cords of neoplastic cells is shown. Note the presence of marked cellular and nuclear atypia. Mitotic figures are present.* **(Right)** *Sheets of neoplastic cells with focal perivascular arrangement are seen in this example of poorly differentiated SCC. The tumor shows only focal single cell keratinization.*

Pseudoglandular Growth Pattern

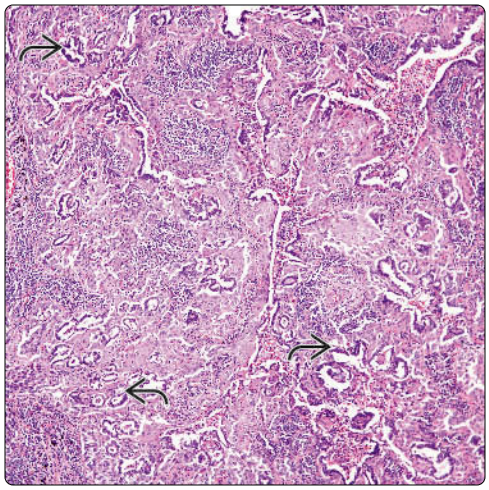

Pseudoglandular Growth Pattern

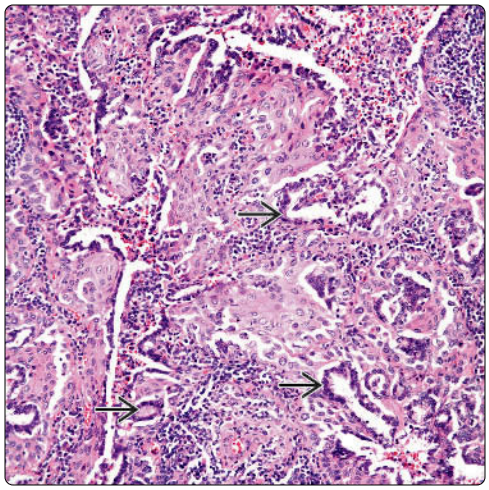

(Left) *Pseudoglandular appearance of a SCC, so-called adenoid-like SCC. Note the presence of glandular structures that can be confused for adenocarcinoma.* **(Right)** *SCC shows an adenoid-like growth pattern. Note the entrapped alveolar structures, which impart a pseudoglandular appearance.*

Cystic Squamous Cell Carcinoma

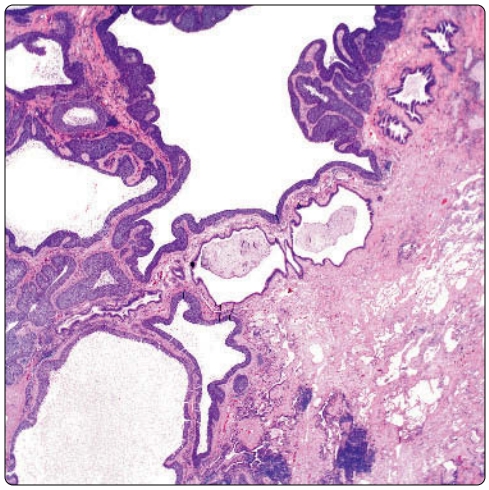

Cystic Squamous Cell Carcinoma

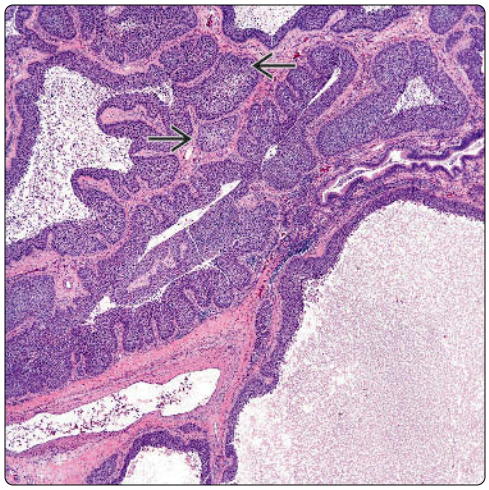

(Left) *SCC shows marked cystic changes. At this magnification, the tumor appears to be an in situ carcinoma due its cystic nature. This histological pattern is unusual and commonly associated with areas of necrosis.* **(Right)** *Cystic squamous cell carcinoma in which there are unequivocal areas of invasion is shown. This particular pattern is rather unusual in primary lung neoplasms.*

Ameloblastic-Like Growth Pattern

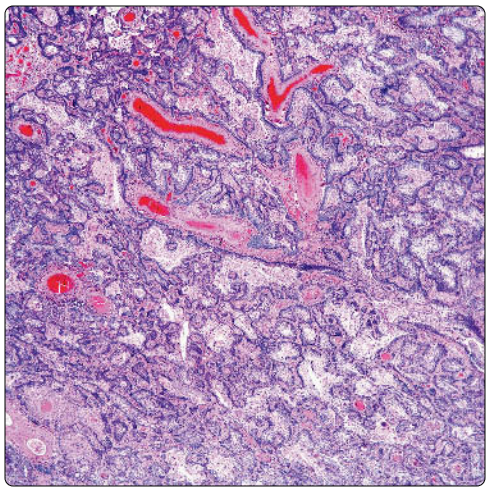

Ameloblastic-Like Growth Pattern

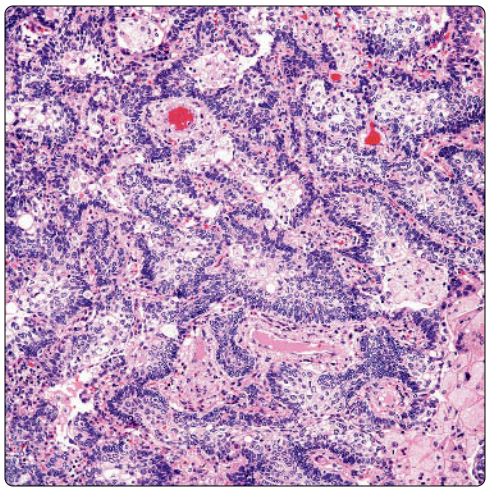

(Left) *SCC shows an extensive ameloblastoma-like pattern. The tumor grows in a manner similar to those tumors occurring in the jaw. Also note the presence of prominent clear cell changes.* **(Right)** *SCC shows ameloblastoma-like growth pattern displaying areas of keratinization and clear cells with squamous differentiation. Mild to moderate cellular and nuclear atypia are present.*

Granular Cell-Like Changes

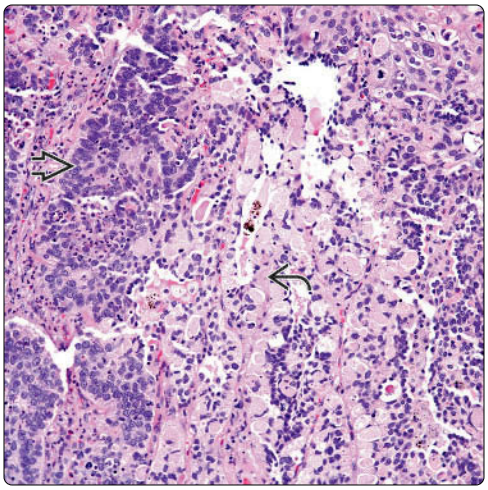

Granular Cell-Like Changes

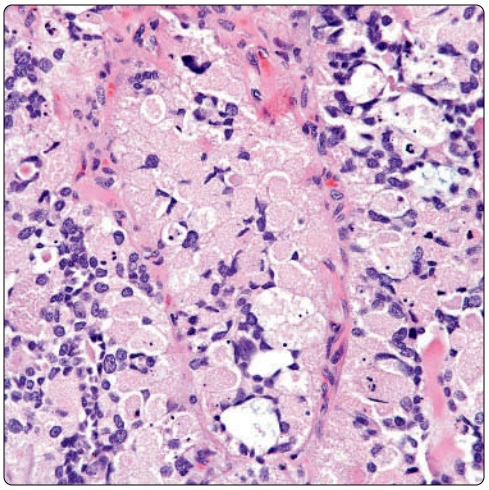

(Left) *SCC shows extensive areas of larger cells mimicking granular cells. Note the presence of conventional areas of SCC ⇨ transitioning into larger cells with granular-like changes ⇨.* **(Right)** *High magnification of SCC shows the large granular cell-like changes. The cells show prominent granular cytoplasm, similar to those in granular cell tumors. No mitotic activity or nuclear atypia are present.*

Necrosis in Squamous Cell Carcinoma

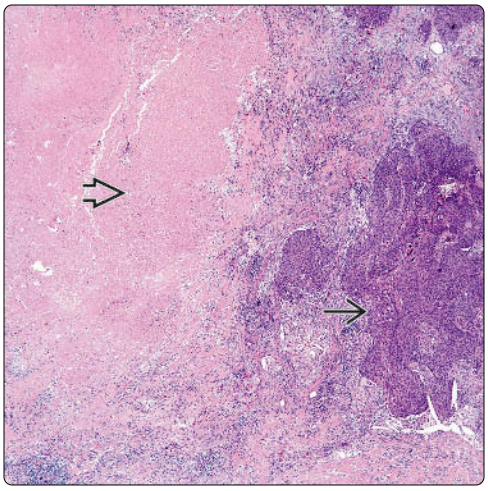

Syringomatous-Like Growth Pattern

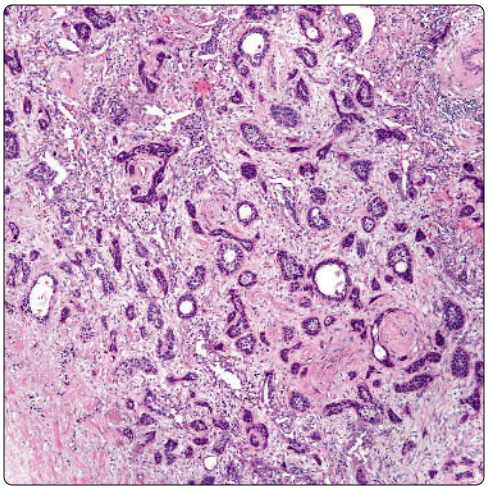

(Left) *Moderately differentiated SCC ⇨ shows extensive areas of necrosis ⇨ with no viable tumor. In some cases, the presence of viable tumor may be only focal.* **(Right)** *SCC shows a prominent syringomatous-like growth pattern. This growth pattern mimics that of adnexal skin tumors. This pattern is similar to the so-called microcystic SCC of the skin.*

Basaloid Squamous Cell Carcinoma

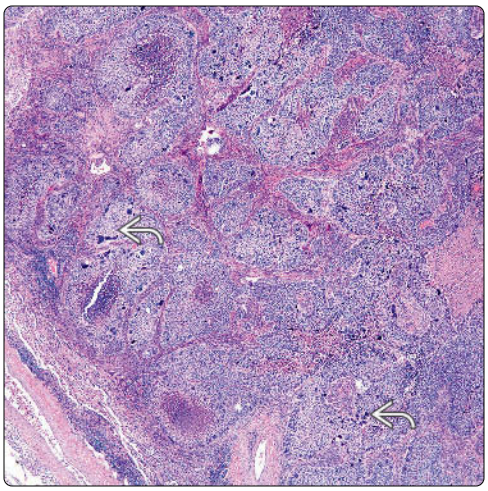

Basaloid Squamous Cell Carcinoma

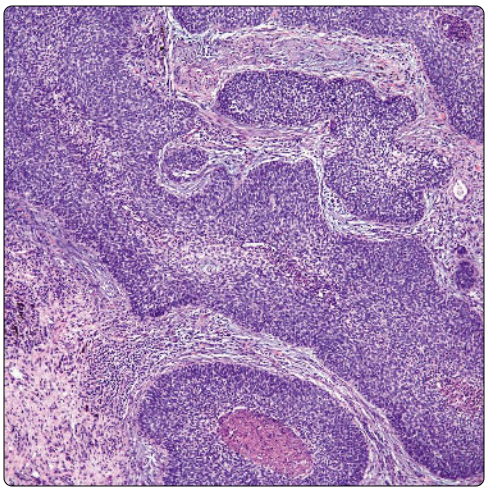

(Left) *SCC shows a prominent basaloid growth pattern. The tumor displays marked cellular atypia and areas of necrosis. Scattered large atypical cells ⇨ are seen admixed with the basaloid tumor cells.* **(Right)** *High-power view of a basaloid SCC shows that the tumor recapitulates the similar growth pattern of the adnexal basal cell carcinoma of the skin.*

Basaloid Squamous Cell Carcinoma

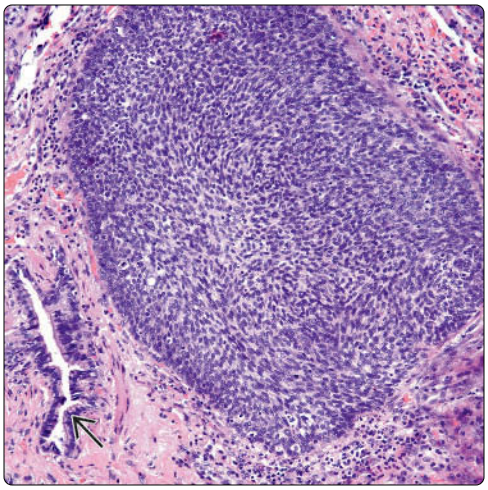

HIgh-Grade Squamous Cell Carcinoma

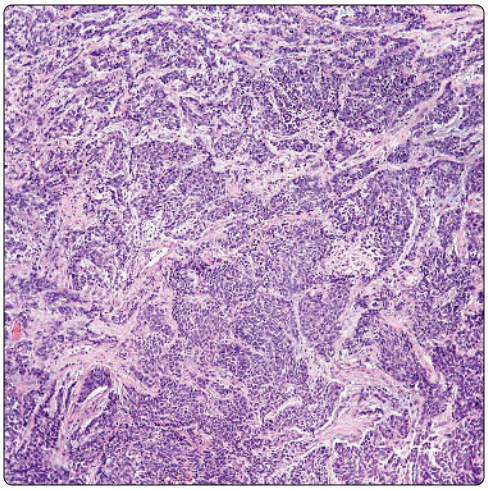

(Left) *Higher magnification of a basaloid SCC shows vague squamoid differentiation and prominent basaloid growth with palisading of the nuclei. Note the adjacent normal airway.* **(Right)** *Poorly differentiated SCC shows a neuroendocrine-like growth pattern. This tumor represents the so-called small cell variant of SCC.*

Small Cell Variant

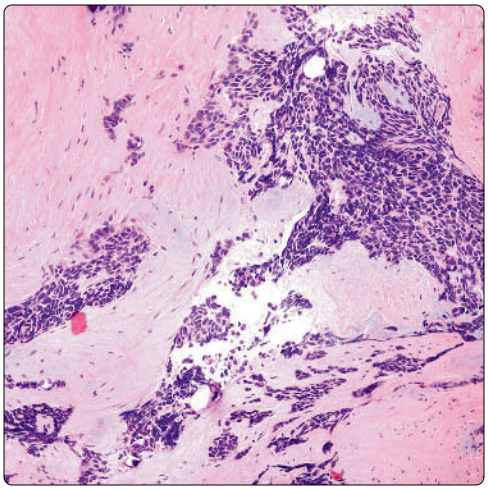

Small Cell Variant

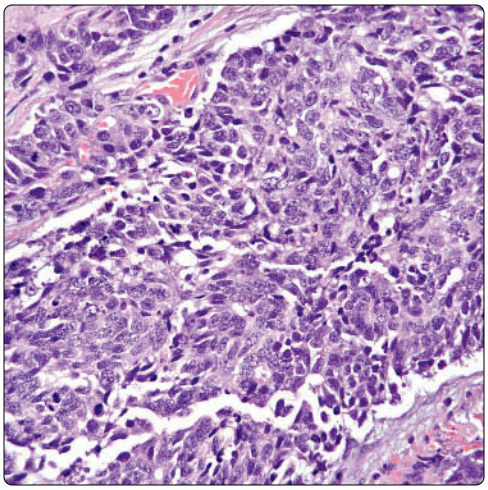

(Left) *SCC shows features of the so-called small cell variant of SCC. The tumor shows a neoplastic cellular proliferation composed of rather smaller cells in a pattern that mimics small cell carcinoma.* **(Right)** *Small cell variant of SCC shows features commonly associated with a non-small cell carcinoma. Note the presence of cells with scant cytoplasm; however, the presence of nucleoli is more in keeping with a non-small cell carcinoma.*

High-Grade Squamous Cell Carcinoma

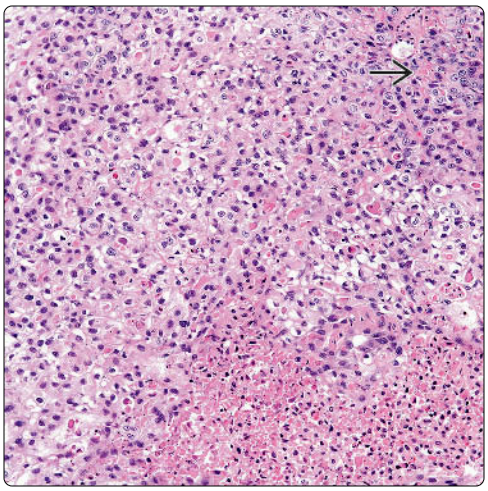

High-Grade Squamous Cell Carcinoma

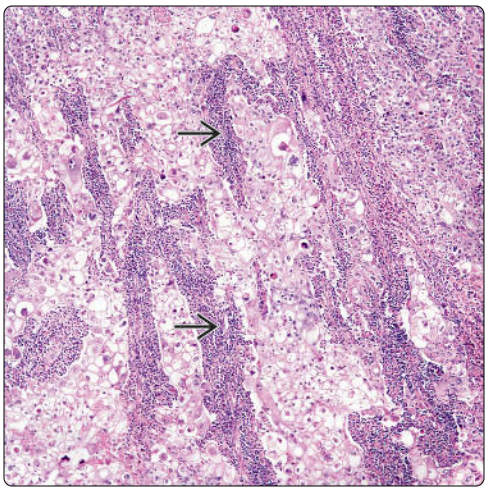

(Left) *Poorly differentiated SCC displays extensive areas of necrosis and clear cell features. Single-cell keratinization is present. Areas of clear cell changes are not pathognomonic of SCC.* **(Right)** *The clear cell component in SCC may be extensive in some cases. Note the presence of cellular and nuclear atypia and the presence of an admixed inflammatory response.*

Pseudoglandular Component

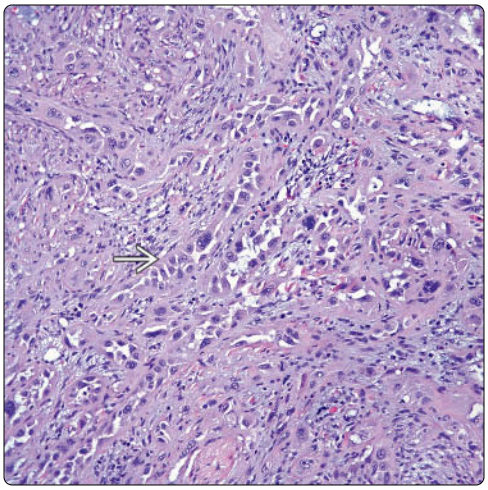

Spindle Cell Component

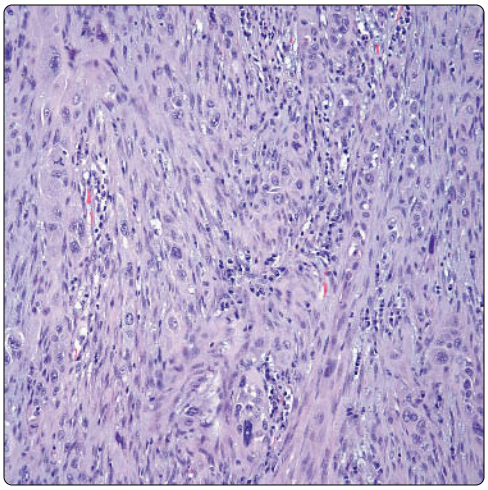

(Left) *SCC shows focal areas in which the tumor appear to be forming glands ⇨. This feature can easily be mistaken for adenosquamous carcinoma.* **(Right)** *SCC with prominent spindle cell component is shown. This feature may also be misinterpreted as sarcomatoid carcinoma.*

Solid Pattern

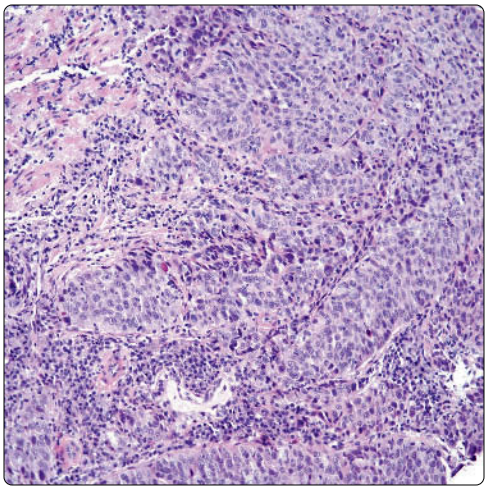

p40 Immunostain

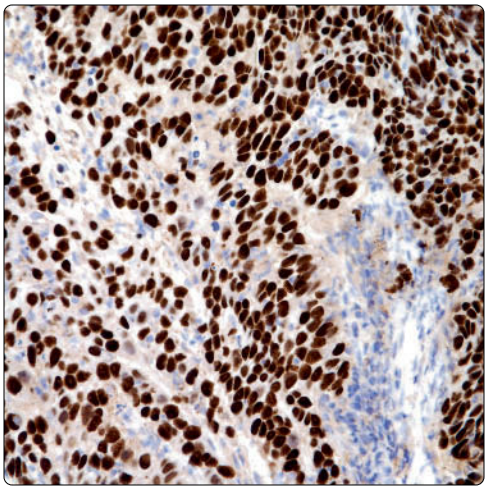

(Left) *Nonkeratinizing SCC shows solid areas of tumor with a subtle basaloid appearance.* **(Right)** *Immunohistochemical stain for p40 shows strong, positive nuclear staining in a SCC.*

p63 Immunostain

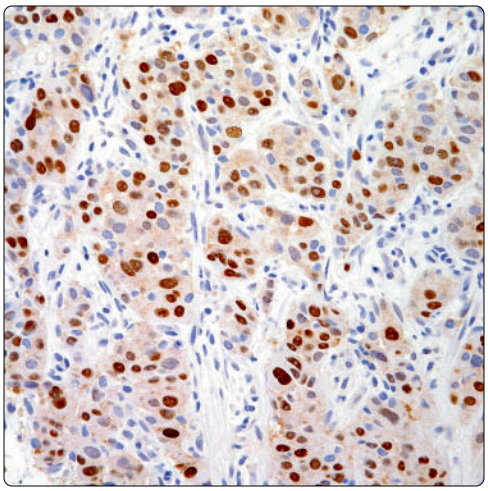

Keratin 5/6 Immunostain

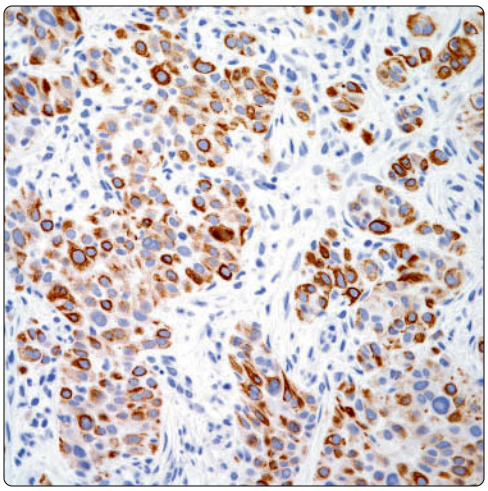

(Left) *SCC of the lung shows nuclear positive staining for p63. Although common in SCC, this stain may also show positive staining in other neoplasms.* **(Right)** *SCC of the lung shows cytoplasmic staining for keratin 5/6. Although this immunostain is commonly seen positive in SCC, it is also positive in other types of tumors (mesothelioma).*

Spindle Cell (Sarcomatoid) Carcinoma

KEY FACTS

TERMINOLOGY

- Carcinoma with pseudosarcomatous component, pseudosarcomatous carcinoma, spindle cell carcinoma

CLINICAL ISSUES

- Cough
- Chest pain
- Hemoptysis
- Dyspnea
- Hoarseness
- Weight loss

MACROSCOPIC

- Central or peripheral tumors
- 2 to > 10 cm in diameter
- Firm, light tan, and well circumscribed but not encapsulated
- Areas of necrosis may be seen

MICROSCOPIC

- Tumor composed exclusively of malignant spindle cells

ANCILLARY TESTS

- Keratin (+)
- Pneumocytic markers (-)
- Squamous cell markers (-)

TOP DIFFERENTIAL DIAGNOSES

- Pleomorphic carcinoma (PC)
  - In addition to spindle cell component, PC should have presence of multinucleated giant cells
- Leiomyosarcoma: Sarcomatoid carcinoma
  - Should have negative staining for desmin, caldesmon, or smooth muscle actin
- Malignant fibrous histiocytoma
  - Absence of immunoreactivity for epithelial markers

Macroscopic Features | **Central Tumor**

(Left) *Gross photograph shows an intrapulmonary large mass that is white, firm, and well circumscribed. The cut surface is smooth and homogeneous.* **(Right)** *Centrally located spindle cell (sarcomatoid) carcinoma shows a tumor with solid and diffuse malignant cellular proliferation.*

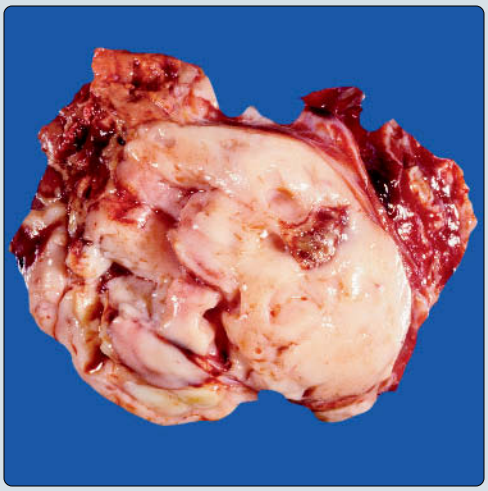

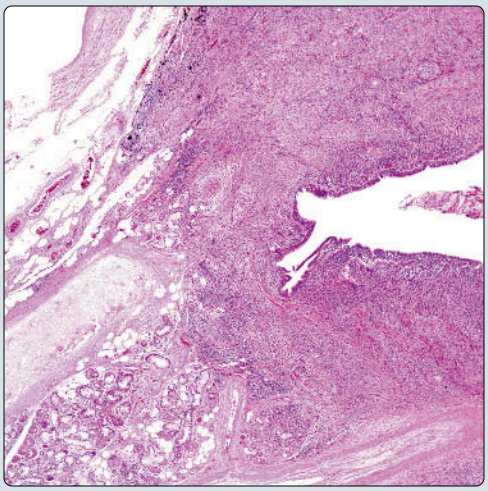

Spindle Cells | **Mitotic Activity**

(Left) *Sarcomatoid (spindle cell) carcinoma shows a growth pattern similar to that seen in spindle cell sarcomas.* **(Right)** *Sarcomatoid (spindle cell) carcinoma shows moderate nuclear atypia and mitotic activity ➡. These features are commonly seen in these tumors.*

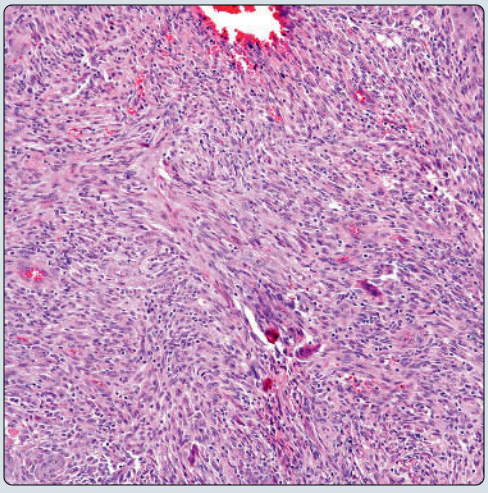

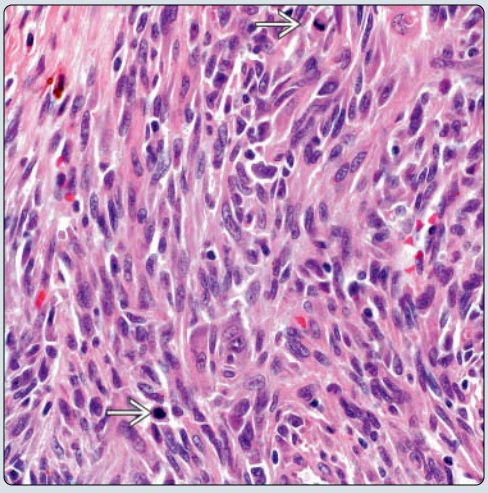

TERMINOLOGY

Synonyms

- Carcinoma with pseudosarcomatous component, pseudosarcomatous carcinoma, spindle cell carcinoma

Definitions

- Malignant epithelial neoplasm composed exclusively of spindle cells
- Term should be reserved for those tumors showing
  - No histological areas of squamous or adenocarcinoma
  - No pneumocytic or squamous differentiation by immunohistochemistry

ETIOLOGY/PATHOGENESIS

Etiology

- Sarcomatoid carcinomas may represent poorly differentiated squamous cell carcinomas
- In WHO 2015, grouped among "sarcomatoid" carcinomas of lung

CLINICAL ISSUES

Epidemiology

- Incidence
  - Sarcomatoid carcinomas account for small percentage of primary lung neoplasms
- Age
  - Similar to other non-small cell carcinomas
- Sex
  - No gender predilection

Presentation

- Cough
- Chest pain
- Hemoptysis
- Dyspnea
- Hoarseness
- Weight loss
- General malaise

Treatment

- Surgical approaches
  - Lobectomy or pneumonectomy
- Adjuvant therapy
  - Chemotherapy &/or radiation therapy

Prognosis

- Depends on stage at time of diagnosis
- Since most cases are in late stages, prognosis may not be good

IMAGING

Radiographic Findings

- Central or peripheral lung mass

MACROSCOPIC

General Features

- Central or peripheral tumors
- 2 to > 10 cm in diameter
- Firm, light tan, and well circumscribed but not encapsulated
- Areas of necrosis may be seen

MICROSCOPIC

Histologic Features

- Tumor composed exclusively of malignant spindle cells
- In some cases, focal areas of classic squamous cell carcinoma may be seen

Predominant Pattern/Injury Type

- Sarcomatoid

Predominant Cell/Compartment Type

- Epithelial

DIFFERENTIAL DIAGNOSIS

Pleomorphic Carcinoma

- In addition to spindle cell component, pleomorphic carcinoma (PC) should have presence of multinucleated giant cells
- PC and sarcomatoid carcinoma may share similar immunohistochemical profile

Leiomyosarcoma

- Sarcomatoid carcinomas
  - Negative staining for
    - Desmin
    - Caldesmon
    - Smooth muscle actin
    - Some cases of leiomyosarcomas may show focal positive staining for keratin

Malignant Fibrous Histiocytoma

- Absence of immunoreactivity for epithelial markers
- In some cases of malignant fibrous histiocytoma, keratin may show positive staining

DIAGNOSTIC CHECKLIST

Pathologic Interpretation Pearls

- Tumor composed exclusively of malignant spindle cells

SELECTED REFERENCES

1. Antoine M et al: [Pulmonary sarcomatoid carcinoma.] Ann Pathol. 36(1):44-54, 2016
2. Forest F et al: Histomolecular profiling of pleomorphic, spindle cell, and giant cell carcinoma of the lung for targeted therapies. Hum Pathol. 49:99-106, 2016
3. Pelosi G et al: Synergic activation upon MET and ALK co-amplification sustains targeted therapy in sarcomatoid carcinoma, a deadly subtype of lung cancer. J Thorac Oncol. ePub, 2016
4. Gu L et al: Clinical analysis of 95 cases of pulmonary sarcomatoid carcinoma. Biomed Pharmacother. 76:134-40, 2015
5. Lin Y et al: Characteristics and prognostic analysis of 69 patients with pulmonary sarcomatoid carcinoma. Am J Clin Oncol. ePub, 2014
6. Terra SB et al: Immunohistochemical study of 36 cases of pulmonary sarcomatoid carcinoma--sensitivity of TTF-1 is superior to napsin. Hum Pathol. 45(2):294-302, 2014
7. Vieira T et al: Blood vessel invasion is a major feature and a factor of poor prognosis in sarcomatoid carcinoma of the lung. Lung Cancer. 85(2):276-81, 2014
8. Avila Martínez RJ et al: Primary pulmonary sarcomatoid carcinomas. Arch Bronconeumol. 49(9):405-7, 2013
9. Huang SY et al: Pulmonary sarcomatoid carcinoma: a clinicopathologic study and prognostic analysis of 51 cases. World J Surg Oncol. 11:252, 2013

Immunohistochemistry

Antibody	Reactivity	Staining Pattern	Comment
KERATIN-LMW	Positive	Cytoplasmic	
CK-PAN	Positive	Cytoplasmic	
CK7	Positive	Cytoplasmic	Focally in some cases
EMA/MUC1	Positive	Cell membrane	
CK5/6	Negative	Not applicable	
D2-40	Positive	Cytoplasmic	Focally positive in some cases
WT1	Positive	Nuclear	Focally positive in some cases
Vimentin	Positive	Cytoplasmic	
CD15	Negative	Not applicable	Focally positive in some cases
NSE	Negative		
Actin-sm	Negative		May be focally positive in some cases
Desmin	Negative		
Caldesmon	Negative		
MYOD1	Negative		
CD31	Negative		
S100	Negative		
Calretinin	Negative		May be focally positive in some cases
CEA-M	Negative		
Chromogranin-A	Negative		
p63	Negative		Focally positive in some cases
TTF-1	Negative		May be focally positive in some cases
p40	Negative		
NAPSIN-A	Negative		
CK20	Negative		

Histochemical Features

Stain	Result
PAS	Negative
PAS-D	Negative
Mucicarmine	Negative

Molecular Features

FISH	Result
(*) 5	Likely negative
$ / . amplification	In some cases
. 5 $ 6 amplification	In some cases
5 2 6	Likely negative
3 , . & $	Likely negative
0 (7 amplification	In some cases

10. Chhatwani L et al: Adjuvant treatment of resected lung cancer. Proc Am Thorac Soc. 6(2):194-200, 2009
11. Rossi G et al: A reevaluation of the clinical significance of histological subtyping of non–small-cell lung carcinoma: diagnostic algorithms in the era of personalized treatments. Int J Surg Pathol. 17(3):206-18, 2009
12. Stinchcombe TE et al: Current treatments for advanced stage non-small cell lung cancer. Proc Am Thorac Soc. 6(2):233-41, 2009
13. Ro JY et al: Sarcomatoid carcinoma of the lung. Immunohistochemical and ultrastructural studies of 14 cases. Cancer. 69(2):376-86, 1992
14. Matsui K et al: Spindle cell carcinoma of the lung. A clinicopathologic study of three cases. Cancer. 67(9):2361-7, 1991
15. Humphrey PA et al: Pulmonary carcinomas with a sarcomatoid element: an immunocytochemical and ultrastructural analysis. Hum Pathol. 19(2):155-65, 1988
16. Suster S et al: Spindle cell squamous carcinoma of the lung. Immunocytochemical and ultrastructural study of a case. Histopathology. 11(8):871-8, 1987

Transition to Normal Lung

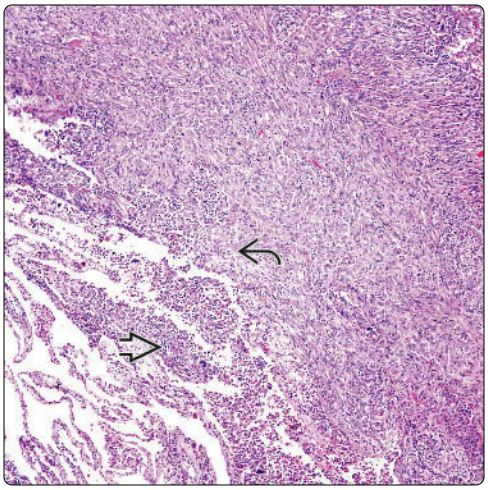

Residual Normal Glands

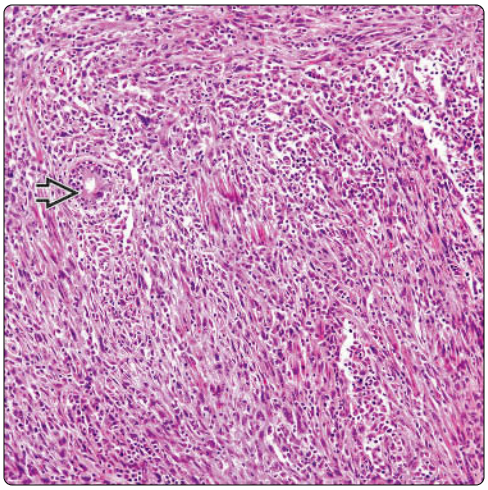

(Left) *Sarcomatoid carcinoma of the lung shows a tumor that is well circumscribed but not encapsulated. Note that toward the periphery there is the presence of normal lung parenchyma.* **(Right)** *Sarcomatoid squamous cell carcinoma shows malignant spindle cell proliferation composed of elongated cells with marked nuclear atypia. Note the presence of a residual normal endobronchial gland.*

Inflammatory Reaction

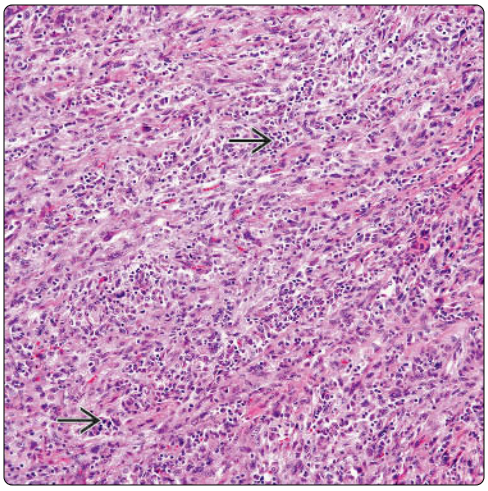

Entrapped Lung

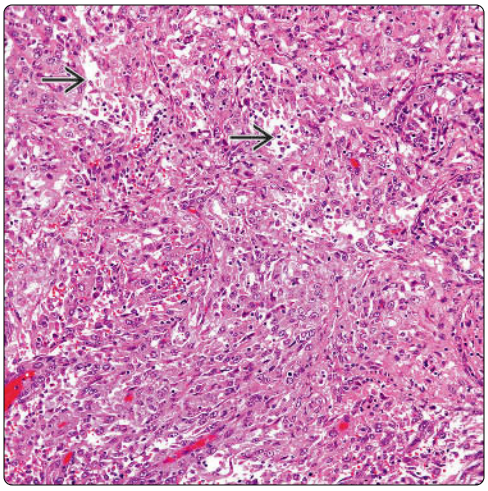

(Left) *Malignant spindle cell proliferation in a sarcomatoid squamous cell carcinoma of the lung is admixed with an inflammatory component composed of lymphocytes and plasma cells.* **(Right)** *Malignant spindle cell proliferation with residual dilated alveolar structures is shown. It is important to recognize these entrapped structures and not interpret them as part of the tumor, which may lead to the erroneous diagnosis of a biphasic neoplasm.*

Hemorrhagic Areas

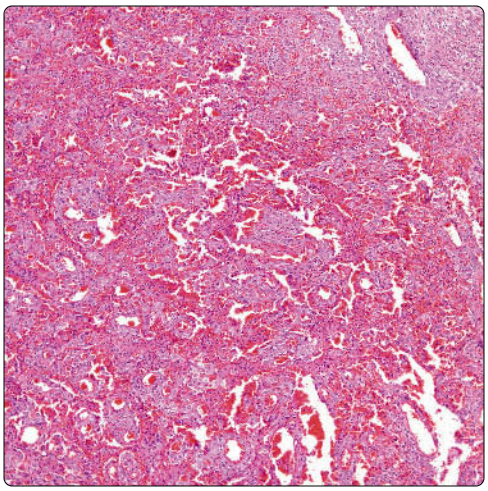

Marked Nuclear Atypia

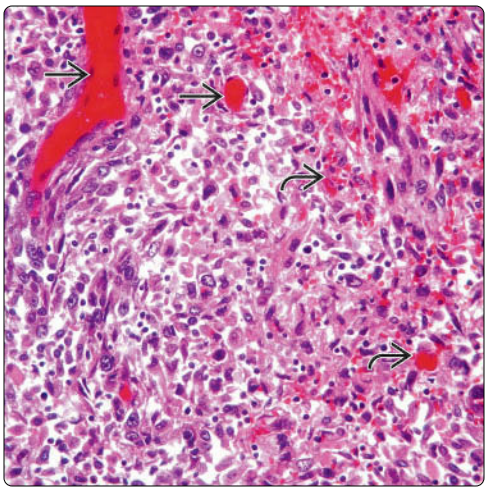

(Left) *Extensive presence of abundant red cells deposited in dilated spaces mimics a vascular neoplasm in sarcomatoid squamous cell carcinoma of the lung. Note the presence of a malignant spindle cell component admixed with the red cells.* **(Right)** *Malignant spindle cell proliferation composed of elongated cells with atypical nuclei and some cells with prominent nucleoli, admixed with red cells and dilated vascular spaces, mimics a vascular neoplasm.*

Extensive Necrosis

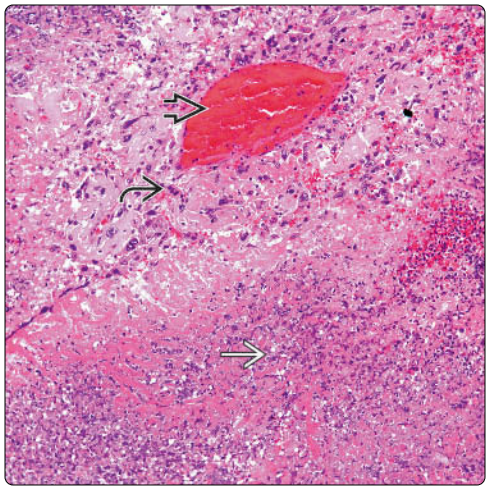

Focal Necrosis

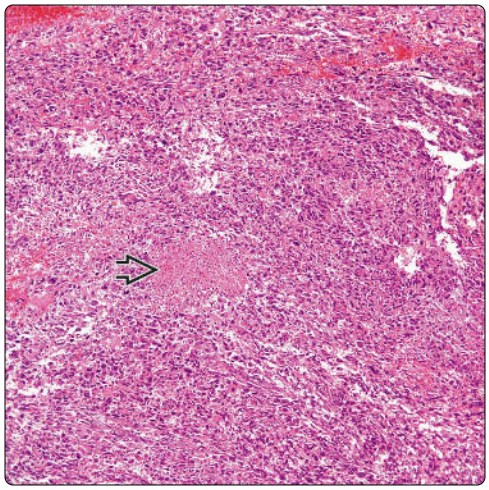

(Left) *Dilated vascular space surrounded by malignant spindle cells and extensive necrosis is seen in this sarcomatoid squamous cell carcinoma of the lung. This pattern can easily imitate a vascular neoplasm.* **(Right)** *Malignant spindle cell proliferation without any specific growth pattern and focal areas of necrosis is shown. A similar feature may be seen in other poorly differentiated carcinomas of the lung.*

Nonencapsulated Tumor

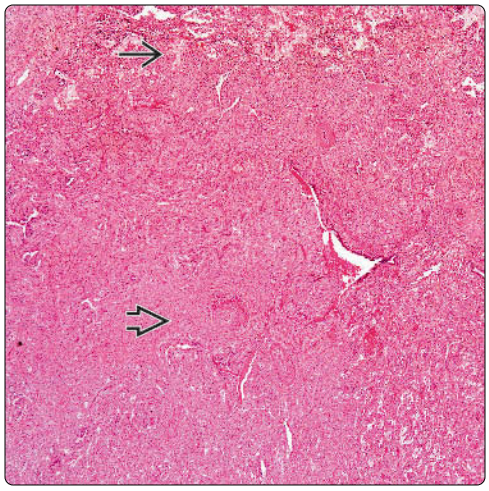

Spindle Cells

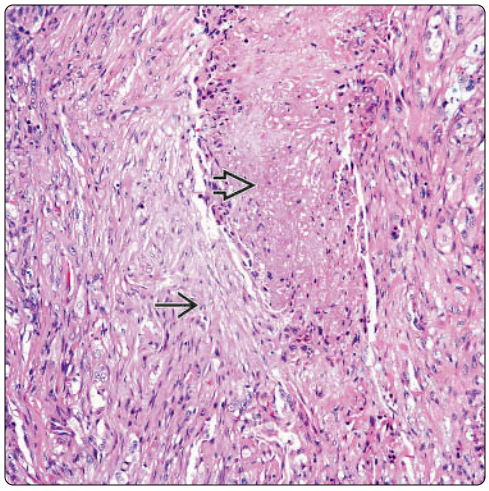

(Left) *Malignant spindle cell proliferation clearly delineated from normal lung parenchyma is seen in a sarcomatoid squamous cell carcinoma. However, at this power, this growth pattern can be confused with an organizing pneumonia.* **(Right)** *Sarcomatoid carcinoma shows a neoplastic proliferation of elongated cells admixed with areas of necrosis. The latter is a common feature in these tumors.*

Vascular Involvement

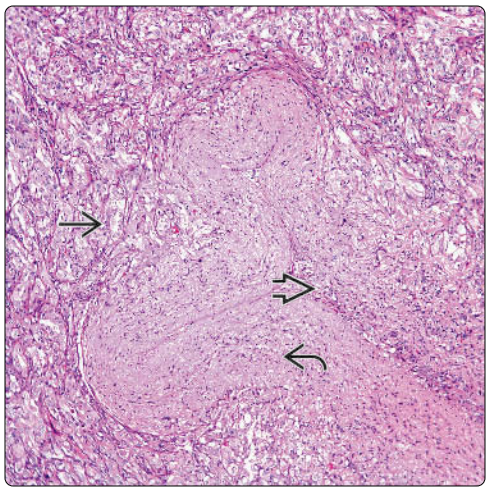

Nuclear Atypia

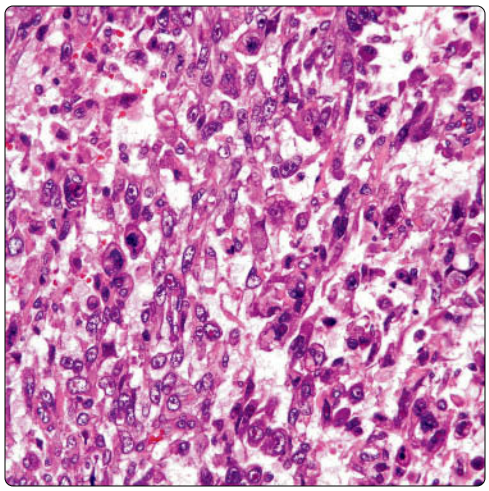

(Left) *Sarcomatoid carcinoma involving and compressing a large vessel is shown. There is vascular permeation of the tumor.* **(Right)** *Higher magnification of the spindle cell component in a sarcomatoid squamous cell carcinoma of the lung shows marked cellular and nuclear atypia.*

Inflammatory Component

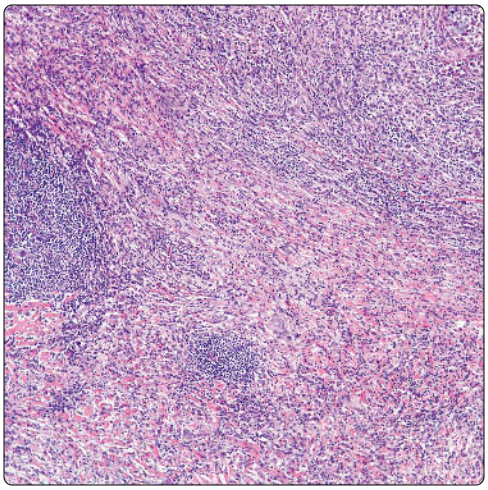

Extensive Hyalinization

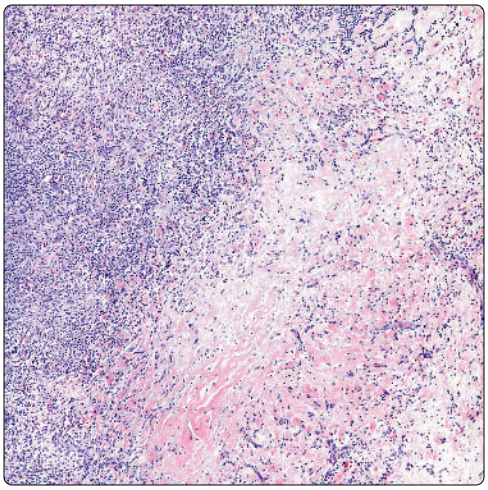

(Left) *Sarcomatoid (spindle cell) carcinoma shows areas of lymphocyte aggregates and mixed inflammatory component with tumor cells.* **(Right)** *Sarcomatoid (spindle cell) carcinoma shows extensive areas of hyalinization and inflammatory component, which obscures the malignant nature of the process.*

Marked Inflammatory Reaction

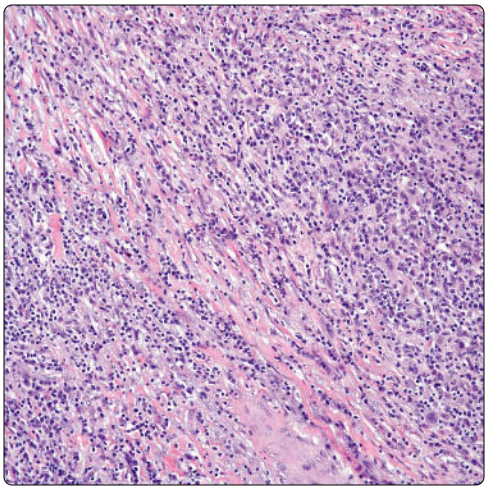

Nuclear Atypia

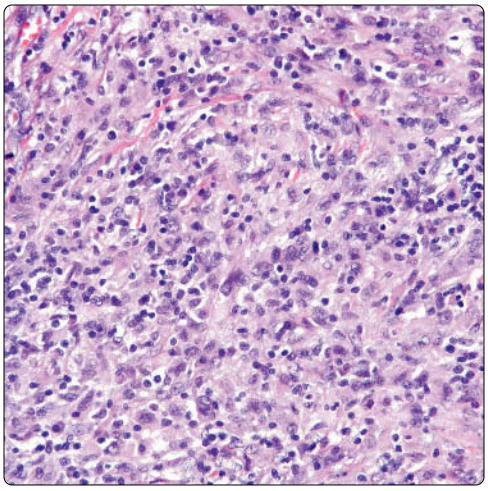

(Left) *The presence of an inflammatory reaction may be marked, which in turn may obscure the malignant component. Here the spindle cells are admixed with lymphocytes and plasma cells.* **(Right)** *Closer magnification clearly separates the malignant cells from the inflammatory cells. However, note that despite the presence of nuclear atypia, mitotic activity is absent.*

Mitotic Activity

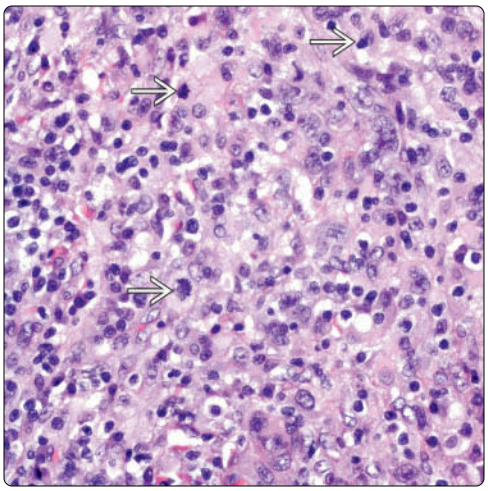

Pan Keratin Immunostain

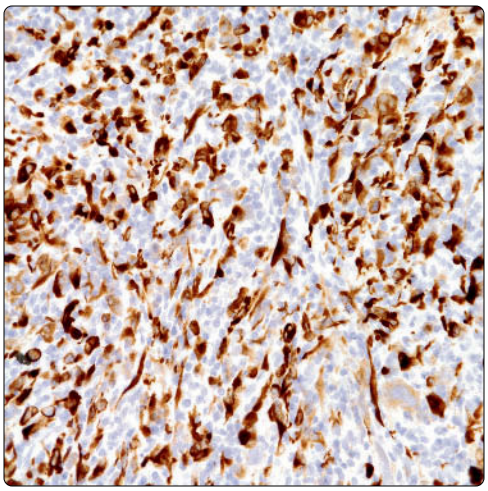

(Left) *Closer magnification shows a different area in which not only the tumor shows nuclear atypia but also mitotic figures are easily identified* ⇨. **(Right)** *Immunohistochemical stain for keratin shows strong positive staining in the spindle cells or a sarcomatoid (spindle cell) carcinoma of the lung.*

Lymphoepithelioma-Like Carcinoma

KEY FACTS

TERMINOLOGY

- Lymphoepithelioma-like carcinoma (LELC)
  - Malignant epithelial neoplasm with prominent inflammatory component

ETIOLOGY/PATHOGENESIS

- Appears not to be related to tobacco smoke
- Closely associated with Epstein-Barr virus infection
- More common in people of Asian background though also described in Caucasians

MICROSCOPIC

- Inflammatory
- Epithelial
- Malignant epithelial component embedded in inflammatory background composed predominantly of lymphocytes and plasma cells

TOP DIFFERENTIAL DIAGNOSES

- Metastatic nasopharyngeal carcinoma
  - Identical histological features as counterpart in head and neck
  - Clinical history &/or physical examination play important role in determining primary site
- Large cell carcinoma
  - Presence of prominent inflammatory component should raise suspicion of LELC
- Inflammatory myofibroblastic tumor (IMT)
  - IMT would show positive staining for ALK-1
- Anaplastic large cell lymphoma (ALCL)
  - ALCL will show positive staining for CD-30 and ALK-1
- Pleomorphic carcinoma (PC)
  - PC will show presence of giant and spindle cell component

DIAGNOSTIC CHECKLIST

- Histological features similar to nasopharyngeal carcinoma (Schmincke tumor)

Macroscopic Features

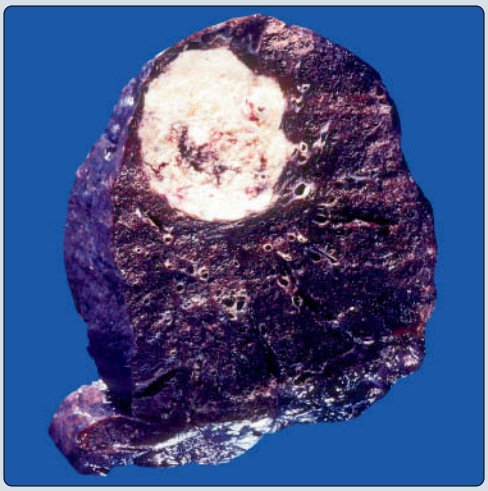

Nodular Pattern

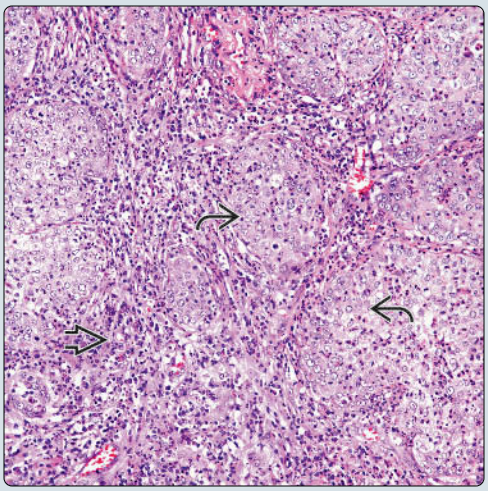

(Left) *Gross photograph of a lymphoepithelial-like carcinoma (LELC) shows a well-circumscribed intrapulmonary mass with focal central necrosis. The tumor has a peripheral subpleural location.* **(Right)** *LELC of the lung shows the classic appearance of clusters of neoplastic cells surrounded by a prominent inflammatory background.*

Fibrous Bands

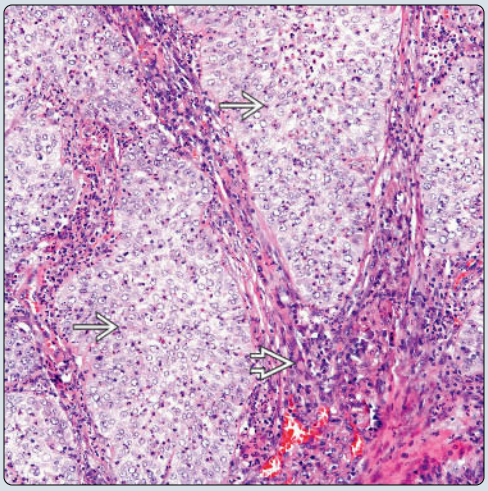

Cellular Atypia and Mitotic Activity

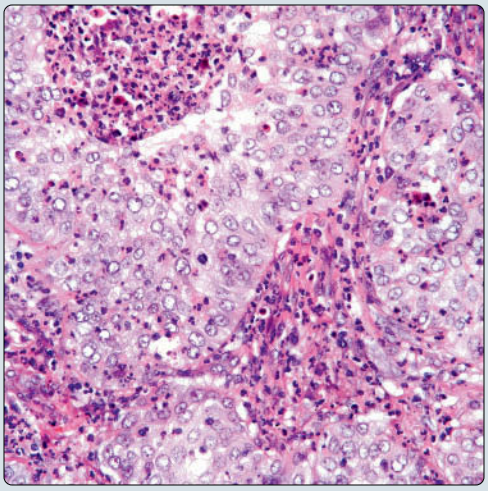

(Left) *LELC of the lung shows tumoral areas separated by fibrous bands containing an inflammatory infiltrate. The 2 components are easy to distinguish.* **(Right)** *LELC of the lung shows a marked inflammatory reaction composed of polymorphonuclear cells, lymphocytes, and plasma cells. The tumor areas show nuclear atypia and mitotic activity.*

TERMINOLOGY

Abbreviations

- Lymphoepithelioma-like carcinoma (LELC)

Definitions

- Malignant epithelial neoplasm with prominent inflammatory component

ETIOLOGY/PATHOGENESIS

Environmental Exposure

- Appears not to be related to tobacco smoke

Infectious Agents

- Closely associated with Epstein-Barr virus infection
- More common in people of Asian background though also described in Caucasians

CLINICAL ISSUES

Presentation

- Cough
- Hemoptysis
- Dyspnea
- Chest pain
- Weight loss
- Hoarseness

Treatment

- Surgical approaches
  - Lobectomy
- Adjuvant therapy
  - Chemotherapy or radiation therapy may be used depending on stage

Prognosis

- Depends on stage at time of diagnosis

IMAGING

General Features

- Intrapulmonary mass
- F-FDG-avid tumor

MACROSCOPIC

General Features

- Tumor may be in central or peripheral location
- Essentially indistinguishable from other nonsmall cell carcinomas
- Necrosis is common finding

Size

- Tumors may vary in size and may be > 10 cm

MICROSCOPIC

Histologic Features

- Large epithelial cells with scant cytoplasm and vesicular nuclei
- Lobulated pattern of growth
- Cells with round to oval nuclei and prominent nucleoli
- Nuclear atypia and increased mitotic activity
- Prominent inflammatory background
- Lymphocytes and plasma cells easily identified
- EBER studies are positive in tumor cells

Predominant Pattern/Injury Type

- Mixed
- Inflammatory

Predominant Cell/Compartment Type

- Epithelial

DIFFERENTIAL DIAGNOSIS

Metastatic Nasopharyngeal Carcinoma

- Identical histological features as counterpart in head and neck
- Clinical history &/or physical examination play important role in determining primary site
- Immunohistochemical features may be similar

Large Cell Carcinoma

- Presence of prominent inflammatory component should raise suspicion of LELC
- Will display sheets of large neoplastic cells with prominent nucleoli
- Extensive areas of necrosis &/or hemorrhage commonly seen

Inflammatory Myofibroblastic Tumor

- Inflammatory myofibroblastic tumor (IMT) usually is negative for epithelial markers
- IMT may show positive staining for ALK-1

Anaplastic Large Cell Lymphoma

- Anaplastic large cell lymphoma would show positive staining for CD-30 and ALK-1
- EMA may be expressed in both tumors

Pleomorphic Carcinoma

- Pleomorphic carcinoma (PC) will show characteristic presence of giant and spindle cells
- EBER will be negative in PC

DIAGNOSTIC CHECKLIST

Pathologic Interpretation Pearls

- Histological features similar to nasopharyngeal carcinoma (Schmincke tumor)
- Prominent inflammatory background
- Lymphocytes and plasma cells easily identified
- Histological features of large cell carcinoma
- EBER positive

SELECTED REFERENCES

1. Tong JH et al: MET amplification and exon 14 splice site mutation define unique molecular subgroups of non-small cell lung carcinoma with poor prognosis. Clin Cancer Res. 22(12):3048-56, 2016
2. Chang YL et al: PD-L1 is highly expressed in lung lymphoepithelioma-like carcinoma: A potential rationale for immunotherapy. Lung Cancer. 88(3):254-9, 2015
3. Fang W et al: PD-L1 is remarkably over-expressed in EBV-associated pulmonary lymphoepithelioma-like carcinoma and related to poor disease-free survival. Oncotarget. 6(32):33019-32, 2015
4. He J et al: Pulmonary lymphoepithelioma-like carcinoma: a surveillance, epidemiology, and end results database analysis. J Thorac Dis. 7(12):2330-8, 2015

Immunohistochemistry

Antibody	Reactivity	Staining Pattern	Comment
KERATIN-LMW	Positive	Cytoplasmic	
CK-LMW-NOS	Positive		
EMA/MUC1	Positive	Cell membrane	
Bcl-2	Positive	Cytoplasmic	Inflammatory component
CD45	Positive	Cytoplasmic	Inflammatory component
p53	Positive	Cytoplasmic	
CD15	Positive	Cytoplasmic	Inflammatory component
CK8/18/CAM5.2	Positive	Cytoplasmic	
CK7	Positive	Cytoplasmic	
TTF-1	Negative		Focal positive nuclear staining is found in some cases
NAPSIN-A	Negative		
p40	Positive	Nuclear	In some cases
p63	Positive	Nuclear	In some cases
pax-8	Negative		
CK20	Negative		
Desmocollin-3	Positive	Cytoplasmic	In some cases
PD-1	Positive	Nuclear & cytoplasmic	Overexpression

In Situ Hybridization

Probe	Type	Result	Interpretation	Comment
EBER	FISH	Positive	Cell membrane	In epithelial component as well as in inflammatory component

Histochemical Features

Stain	Result
PAS	Negative
PAS-D	Negative
Mucicarmine	Negative

Molecular Features

FISH	Result
(*) 5	Likely negative
$ / .	Likely negative
5 2 6	Likely negative
% 5 $)	Likely negative
0 (7 amplification	Likely negative

5. Wang L et al: Detection of rearrangement of anaplastic lymphoma kinase (ALK) and mutation of epidermal growth factor receptor (EGFR) in primary pulmonary lymphoepithelioma-like carcinoma. J Thorac Dis. 7(9):1556-62, 2015
6. Liu Q et al: Lack of epidermal growth factor receptor gene mutations in exons 19 and 21 in primary lymphoepithelioma-like carcinoma of the lung. Thorac Cancer. 5(1):63-7, 2014
7. Ho JC et al: Lymphoepithelioma-like carcinoma of the lung: experience with ten cases. Int J Tuberc Lung Dis. 8(7):890-5, 2004
8. Kobayashi M et al: Pulmonary lymphoepithelioma-like carcinoma: predominant infiltration of tumor-associated cytotoxic T lymphocytes might represent the enhanced tumor immunity. Intern Med. 43(4):323-6, 2004
9. Han AJ et al: Lymphoepithelioma-like carcinoma of the lung with a better prognosis. A clinicopathologic study of 32 cases. Am J Clin Pathol. 115(6):841-50, 2001
10. Chan JK et al: Primary lymphoepithelioma-like carcinoma of the lung. A clinicopathologic study of 11 cases. Cancer. 76(3):413-22, 1995
11. Gal AA et al: Detection of Epstein-Barr virus in lymphoepithelioma-like carcinoma of the lung. Mod Pathol. 4(2):264-8, 1991
12. Bégin LR et al: Epstein-Barr virus related lymphoepithelioma-like carcinoma of lung. J Surg Oncol. 36(4):280-3, 1987

Islands of Tumor and Inflammatory Reaction

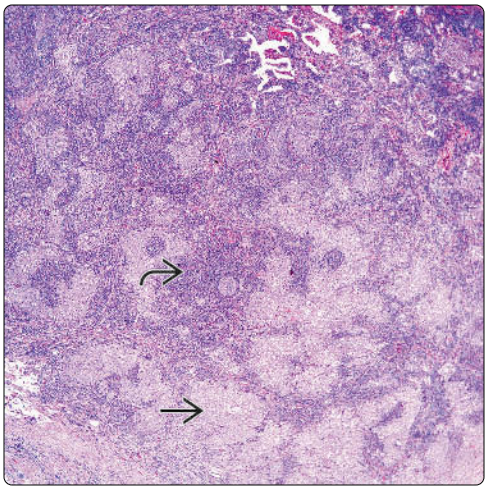

Subtle Acinar-Like Pattern

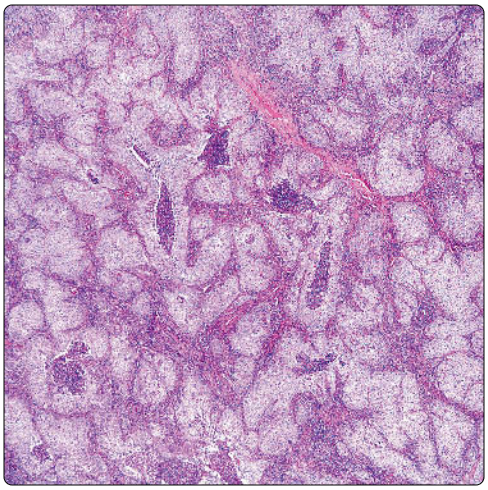

(Left) *Malignant epithelial cells ⇨ surrounded by a prominent inflammatory background ⇨ are shown. At this magnification, one can easily miss the malignant epithelial component as a reactive process.* **(Right)** *Malignant epithelial cells growing in a vague microacinar pattern are shown. At this higher magnification, the difference between the epithelial and the inflammatory component is easily demonstrated.*

Inflammatory Reaction

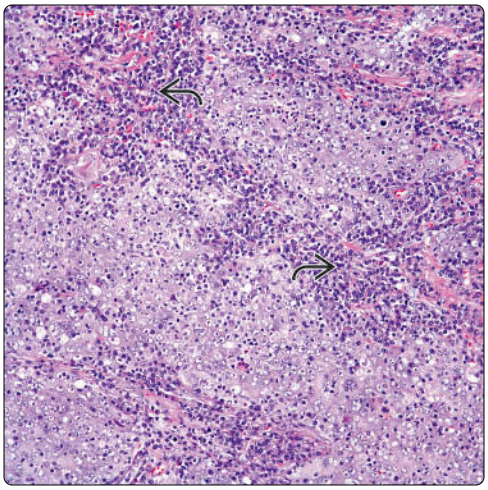

Pseudoglands

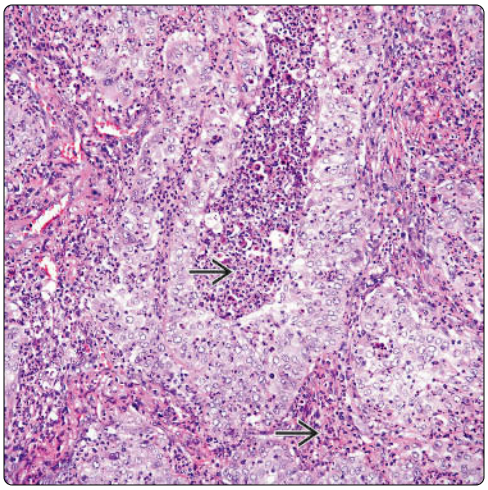

(Left) *LELC of the lung shows sheets of neoplastic cells growing in a rather nonspecific growth pattern. However, important to note is the presence of a marked inflammatory background ⇨.* **(Right)** *Malignant epithelial cells in a vague pseudoglandular arrangement are shown. Note the presence of inflammatory cells, predominantly lymphocytes ⇨, in the lumen of this pseudogland mimicking comedo-like necrosis.*

Nodular Pattern

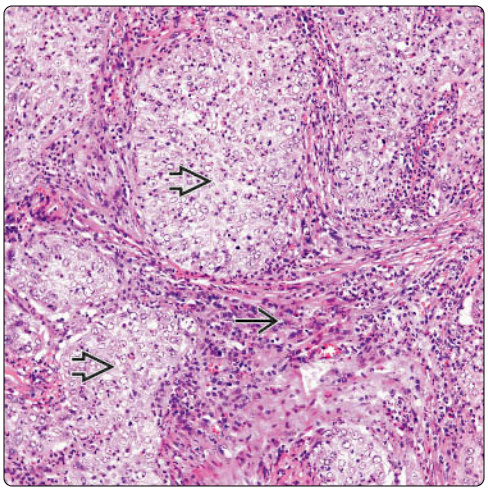

Extensive Necrosis

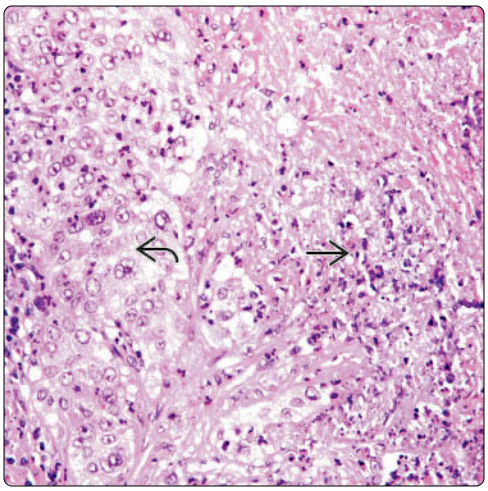

(Left) *Islands of malignant epithelial cells ⇨ of different sizes are separated by fibroconnective tissue with a prominent inflammatory background ⇨.* **(Right)** *Despite the presence of a prominent inflammatory background, extensive areas of necrosis are not that common in LELC. However, in some cases, focal areas of necrosis ⇨ may obscure the neoplastic process ⇨.*

Replacement of Lung Parenchyma

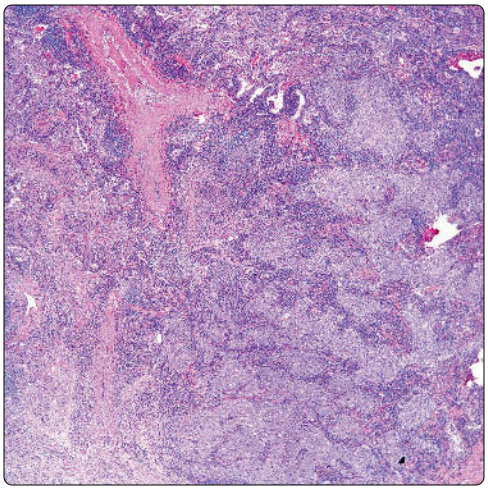

Giant Cells

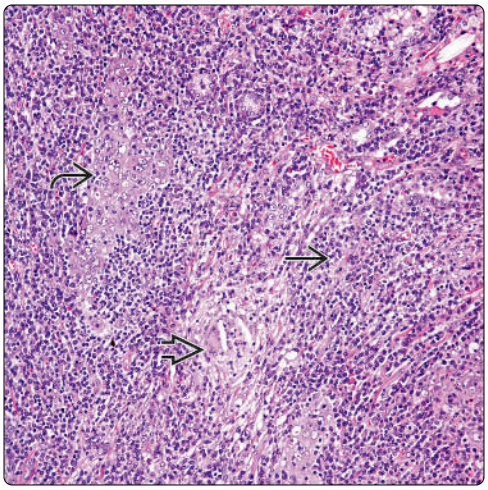

(Left) *Mixture of islands of malignant cells admixed with a prominent inflammatory background are seen, probably representing an organizing pneumonia associated with the tumor.* **(Right)** *A cluster of neoplastic cells is admixed with a marked inflammatory background. The inflammatory background is marked by the presence of giant cells.*

Haphazard Distribution

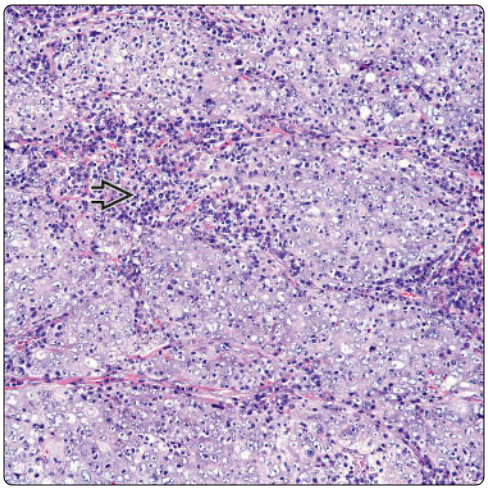

Marked Inflammatory Reaction

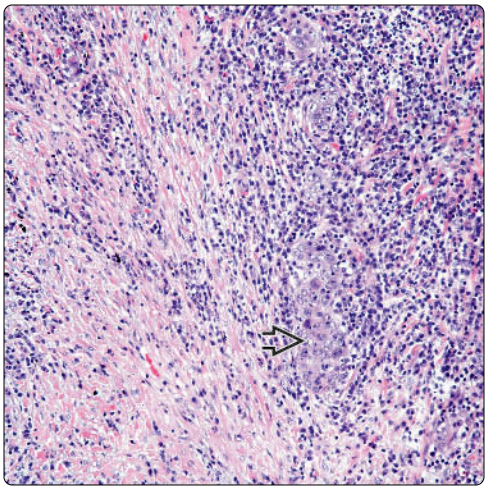

(Left) *Discrete inflammatory background in LELC is shown. The neoplastic component does not show any particular growth pattern.* **(Right)** *Predominantly inflammatory component is seen in this LELC. Note the presence of small islands of neoplastic cells. In some cases in which the inflammatory component is marked, the neoplastic process may be missed.*

Sheets of Neoplastic Cells

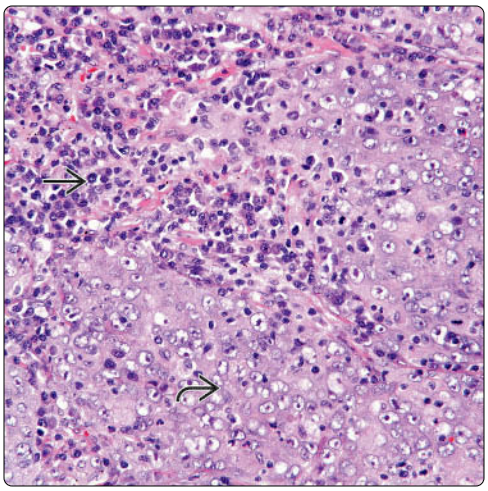

Nuclear Atypia

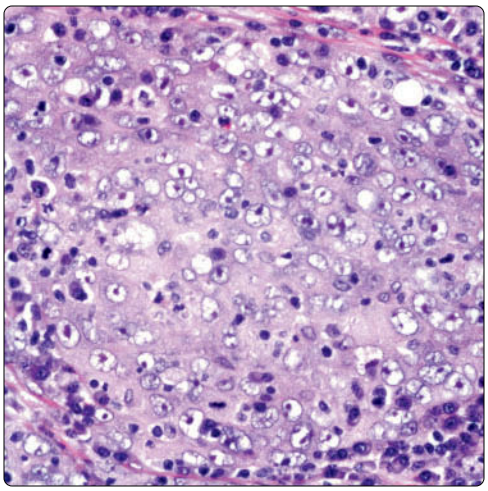

(Left) *Higher magnification of an LELC of the lung shows the 2 components in more detail, clearly highlighting the epithelial component from the inflammatory component.* **(Right)** *High-power view of the epithelial neoplastic component in LELC of the lung is shown. The cells are round to oval with indistinct cell membranes, ample cytoplasm, round to oval nuclei, and prominent nucleoli.*

Solid Pattern

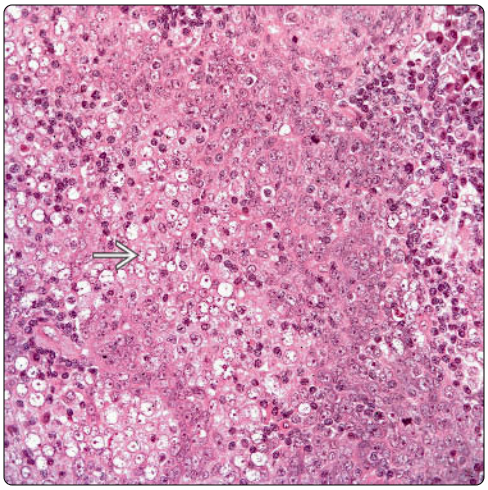

Mixed Neoplastic and Inflammation

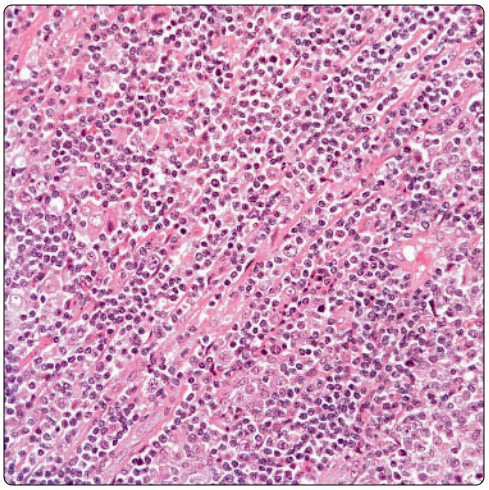

(Left) *LELC of lung shows a solid growth pattern. Note the presence of neoplastic cells with clearing of the nuclei* ➔ *opposite other more conventional neoplastic cells.* **(Right)** *LELC shows a marked inflammatory reaction with single cells distributed among the inflammatory cells. This feature may obscure the neoplastic nature of the process and can be easily overlooked.*

Acute Inflammation

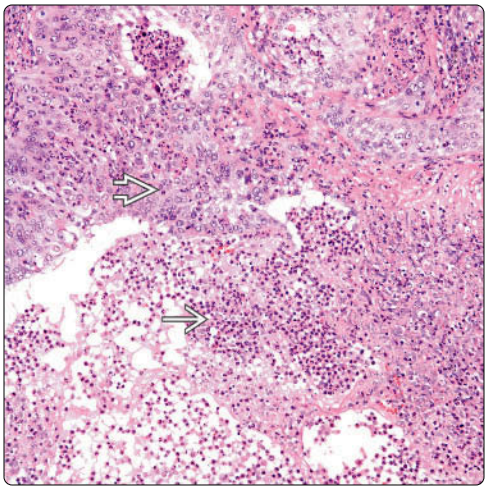

Plasma Cells

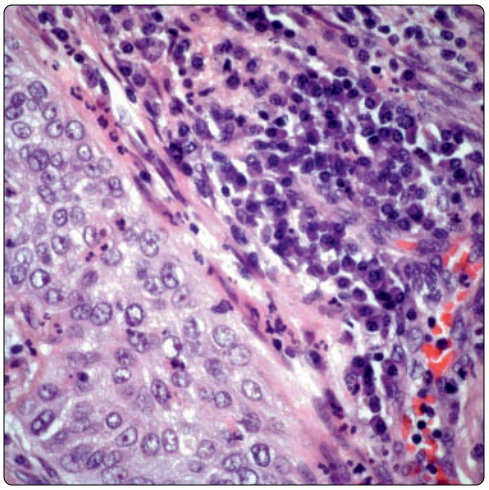

(Left) *LELC shows areas of microabscess formation* ➔*. Note the adjacent areas in which the neoplastic cells are easily identifiable* ➔*.* **(Right)** *LELC shows side-by-side areas of neoplastic cells and extensive presence of plasma cells. The 2 populations can be easily separated.*

Lymph Node

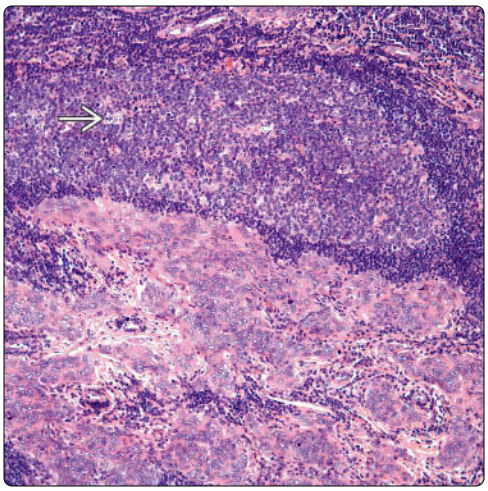

Metastatic Disease

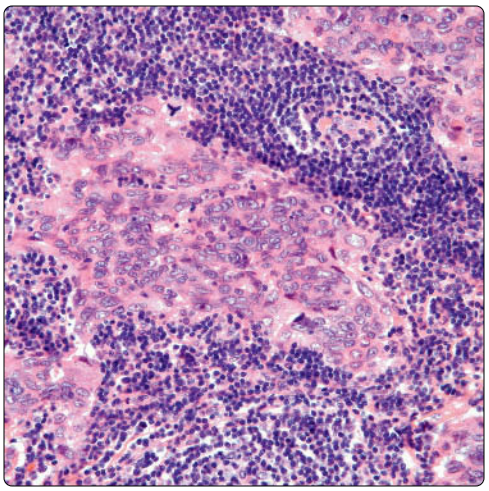

(Left) *Lymph node shows metastatic LELC. Note the presence of a germinal center* ➔*. The remainder of the tumor shows features similar to those seen in the original tumor.* **(Right)** *Lymph node shows metastatic LELC. Note the presence of islands of tumor cells replacing the normal architecture of the lymph node.*

Poorly Differentiated Squamous Carcinoma, Small Cell Variant

KEY FACTS

TERMINOLOGY

- Poorly differentiated squamous cell carcinoma exhibiting small cell morphology and lacking overt features of squamous differentiation
- This tumor essentially overlaps with so-called "basaloid" carcinoma of lung

MICROSCOPIC

- Islands, sheets, and cords of monotonous small, hyperchromatic tumor cells
- Tumor cell islands may display prominent basaloid peripheral palisading of nuclei
- Cells have large, hyperchromatic nuclei with dense chromatin pattern and prominent nucleoli
- Cells can be round, polygonal, or ovoid and display conspicuous rim of cytoplasm with distinct cell borders
- Tumor cells are positive for broad-spectrum cytokeratin and MOC-31
- Tumor cells are weakly and focally positive for CK7
- Tumor cells are uniformly negative for neuroendocrine markers, including chromogranin-A, synaptophysin, CD56, and NSE
- Tumor cells are negative for TTF-1, CK20, and CEA
- Tumor cell islands may show prominent central, comedo-like areas of necrosis
- Tumor cell cords and islands may be separated by prominent desmoplastic stroma with lymphoid cell infiltrates
- Tumor cell islands may be separated by geographic, irregular areas of necrosis
- Tumors can display high mitotic activity (> 10 mitoses per 10 HPF)

DIAGNOSTIC CHECKLIST

- Possibility of metastasis from basaloid squamous cell carcinoma of oral cavity or head and neck region should always be ruled out first

Basaloid Features

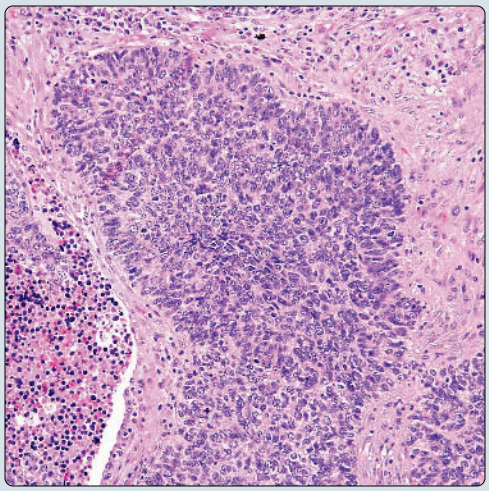

Nuclear Atypia and Mitosis

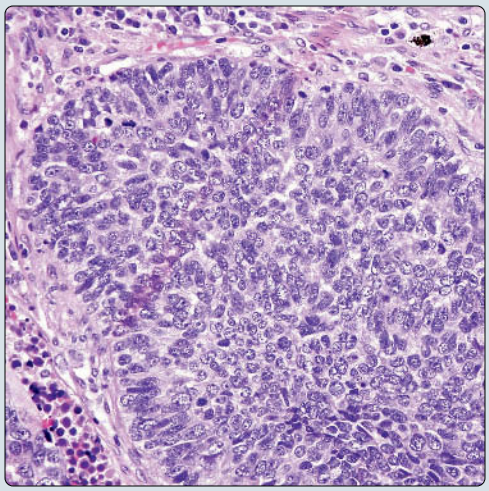

(Left) *Scanning magnification of small cell variant of poorly differentiated squamous cell carcinoma of the lung shows an island of small tumor cells with peripheral palisading of nuclei. This condition essentially overlaps with "basaloid" carcinoma of the lung.* **(Right)** *Non-small cell variant of poorly differentiated squamous cell carcinoma of the lung is characterized by a tightly packed small cell population with peripheral palisading of nuclei.*

Solid Nodule

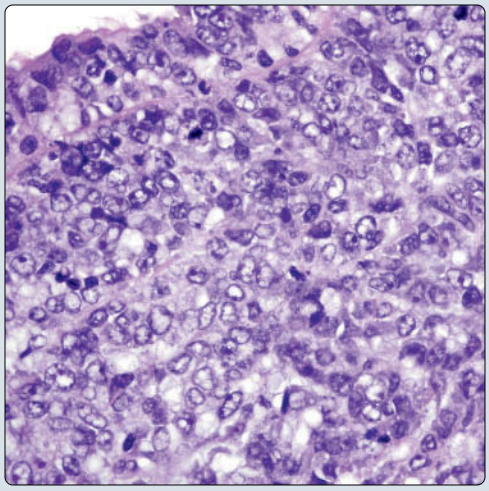

Neoplastic Cells With Finely Dispersed Chromatin

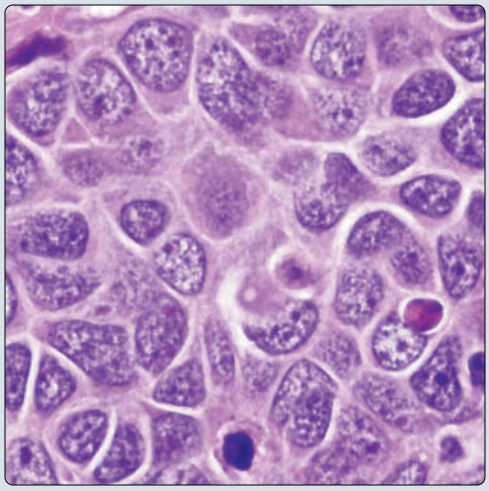

(Left) *Higher magnification of a solid nodule in small cell variant of poorly differentiated squamous cell carcinoma of the lung shows tightly packed sheets of small atypical cells with scattered mitoses.* **(Right)** *Higher magnification of small cell variant of poorly differentiated squamous cell carcinoma shows cells with large nuclei with dispersed chromatin pattern, absent or inconspicuous nucleoli, and molding of the cytoplasm. Notice the absence of intercellular bridges.*

TERMINOLOGY

Definitions

- Poorly differentiated squamous cell carcinoma exhibiting small cell morphology and lacking overt features of squamous differentiation

CLINICAL ISSUES

Presentation

- Cough, chest pain, weight loss, history of cigarette smoking

MACROSCOPIC

Sections to Be Submitted

- 1 section per cm of largest tumor diameter

MICROSCOPIC

Histologic Features

- Islands, sheets, and cords of monotonous small, hyperchromatic tumor cells
- Tumor cell islands may display prominent basaloid peripheral palisading of nuclei
- Tumor cell islands may show prominent central, comedo-like areas of necrosis
- Tumor cell cords and islands may be separated by prominent desmoplastic stroma with lymphoid cell infiltrates
- Tumor cell islands may be separated by geographic, irregular areas of necrosis
- Tumors can show evidence of vascular and perineural invasion

Cytologic Features

- Cells have large, hyperchromatic nuclei with dense chromatin pattern and prominent nucleoli
- Cells can be round, polygonal, or ovoid and display conspicuous rim of cytoplasm with distinct cell borders
- Tumors may show scattered single-cell keratinization or abortive foci of squamous differentiation
- Tumors can display high mitotic activity (> 10 mitoses per 10 HPF)

ANCILLARY TESTS

Immunohistochemistry

- Tumor cells
  - Positive for broad-spectrum cytokeratin and MOC-31
  - Weakly and focally positive for CK7
  - Uniformly negative for neuroendocrine markers, including chromogranin-A, synaptophysin, CD56, and NSE
  - Negative for TTF-1, CK20, and CEA
  - May display p63 nuclear staining, which is usually restricted to periphery of basaloid tumor islands

Electron Microscopy

- Tumor cells contain desmosomes and tonofilaments
- Tumor cells do not display cytoplasmic dense-core neurosecretory granules

DIFFERENTIAL DIAGNOSIS

Small Cell Neuroendocrine Carcinoma

- Nuclei show "smudged" nuclear chromatin pattern with little nuclear detail and small or inconspicuous nucleoli
- Only scant rim of cytoplasm surrounding nuclei
- Stains positive for neuroendocrine markers (chromogranin, synaptophysin, CD56, and NSE)
- Shows strong, dot-like paranuclear positivity for CK7

Moderately Differentiated Neuroendocrine Carcinoma ("Atypical Carcinoid")

- Morphologically, may be virtually indistinguishable from small cell variant of squamous cell carcinoma
- Strong positivity for neuroendocrine markers (chromogranin-A, synaptophysin, CD56, and NSE)

Large Cell Neuroendocrine Carcinoma

- Morphologically, large cell neuroendocrine carcinoma may be indistinguishable from small cell variant of squamous cell carcinoma
- Most important feature is positivity for neuroendocrine markers (chromogranin, synaptophysin, CD56, and NSE)

Combined Small Cell Carcinoma

- Shows admixture of small cell neuroendocrine carcinoma and squamous cell carcinoma
- Small cell component will express neuroendocrine markers by immunohistochemistry

Metastasis From Basaloid Squamous Cell Carcinoma of Head and Neck

- Morphologically may be indistinguishable from small cell variant of pulmonary squamous cell carcinoma
- Immunohistochemical features will be indistinguishable from small cell variant of pulmonary squamous cell carcinoma
- Obtaining clinical history of previous tumor in oral cavity or head and neck region is indispensable for diagnosis

DIAGNOSTIC CHECKLIST

Clinically Relevant Pathologic Features

- Tumors have similar biologic behavior as conventional squamous cell carcinoma and should not be mistaken for small cell neuroendocrine carcinoma
- Possibility of metastasis from basaloid squamous cell carcinoma of oral cavity or head and neck region should always be ruled out first

SELECTED REFERENCES

1. Vignaud JM: [Squamous cell carcinoma, basaloid squamous cell carcinoma and adenosquamous carcinoma in the lung.] Ann Pathol. 36(1):15-23, 2016
2. Hammar S: The use of electron microscopy and immunohistochemistry in the diagnosis and understanding of lung neoplasms. Clin Lab Med. 7(1):1-30, 1987
3. Churg A et al: Small cell squamous and mixed small cell squamous--small cell anaplastic carcinomas of the lung. Am J Surg Pathol. 4(3):255-63, 1980

Tumor Adjacent to Airway

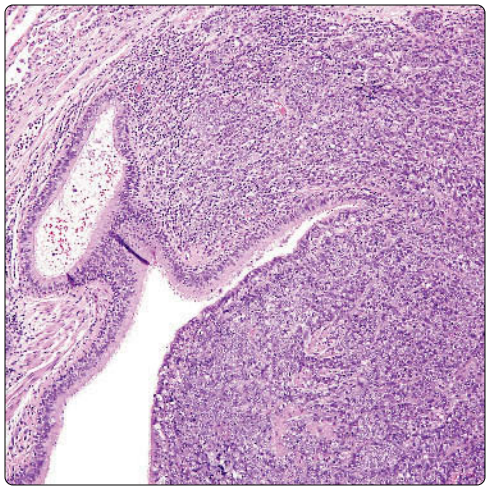

Mitotic Activity

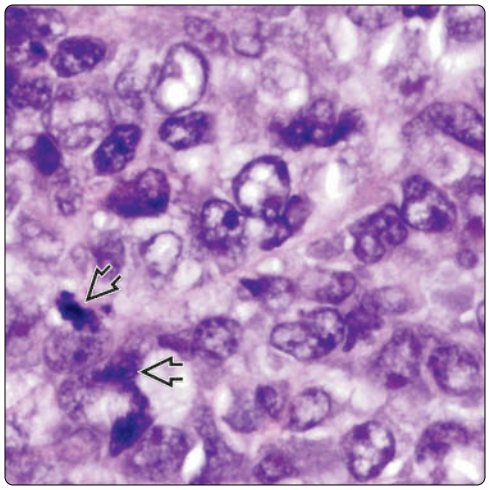

(Left) *Scanning magnification of small cell variant of poorly differentiated squamous cell carcinoma of the lung shows solid sheets of monotonous tumor cells arising from a subsegmental bronchus.* **(Right)** *High magnification of small cell variant of poorly differentiated squamous cell carcinoma of the lung shows sheets of tumor cells with round, often vesicular nuclei, prominent nucleoli, and a scant rim of amphophilic cytoplasm. The tumor shows scattered mitotic figures.*

Island of Atypical Cells

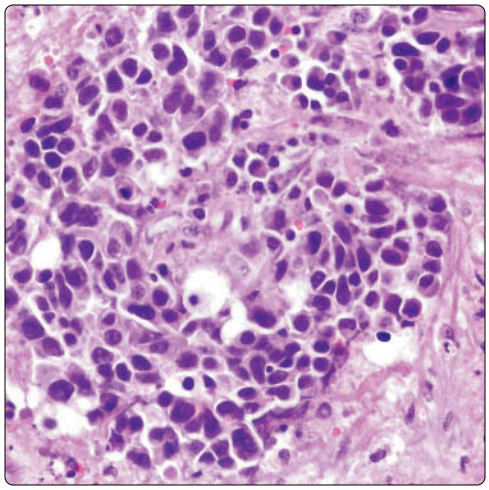

Nuclear Detail: High Power

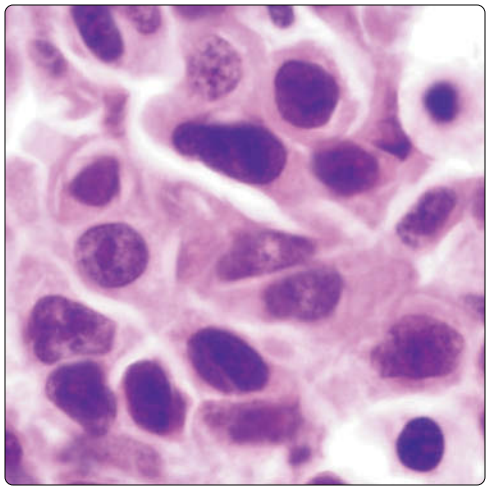

(Left) *High magnification of small cell variant of poorly differentiated squamous cell carcinoma of the lung shows an island of monotonous, relatively small tumor cells without obvious features of keratinization but with large, hyperchromatic nuclei showing abundant eosinophilic cytoplasm.* **(Right)** *Higher magnification of small cell variant of poorly differentiated squamous cell carcinoma shows round to oval nuclei with dense chromatin, occasional prominent nucleoli, and abundant cytoplasm.*

Necrosis

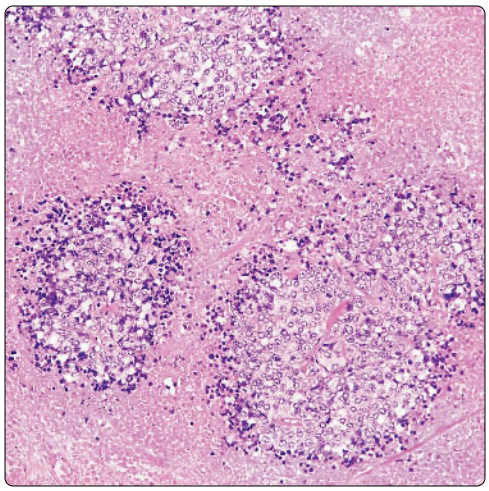

Focus of Squamous Differentiation

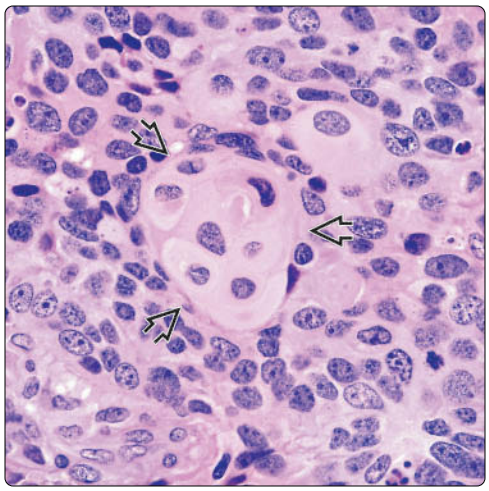

(Left) *Small cell variant of poorly differentiated squamous cell carcinoma of the lung shows perivascular tumor islands surrounded by irregular, geographic areas of necrosis.* **(Right)** *Small cell variant of poorly differentiated squamous cell carcinoma of the lung shows sheets of small tumor cells surrounding a central focus displaying features of abortive squamous differentiation, which contains larger cells with more abundant cytoplasm, sharp cell borders, and cell moulding.*

Desmoplastic Stroma

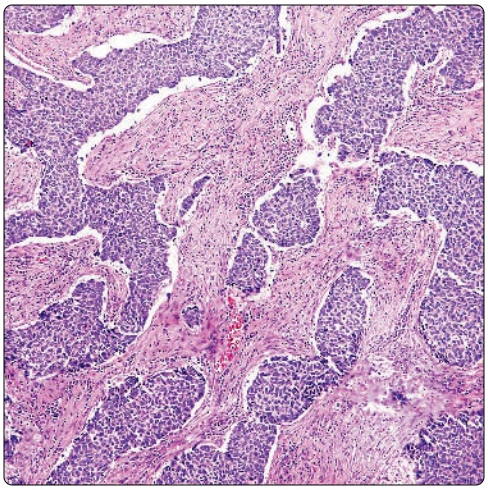

Retraction Artifact

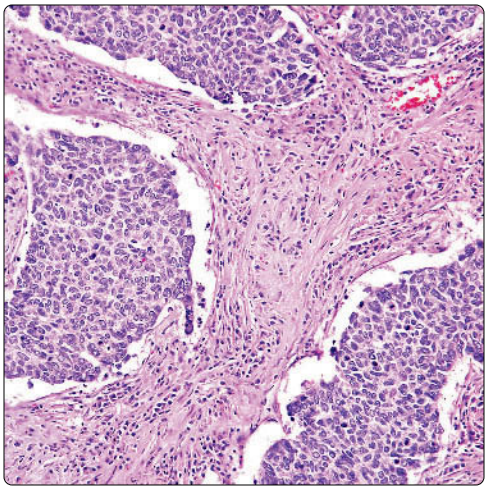

(Left) *Scanning magnification of small cell variant of poorly differentiated squamous cell carcinoma of the lung shows cords and islands of tumor cells separated by abundant desmoplastic stroma. Tumors with these features can be mistaken for large cell neuroendocrine carcinoma and atypical carcinoid.* **(Right)** *Higher magnification of small cell variant of poorly differentiated squamous cell carcinoma of the lung shows collagenized stroma with chronic inflammation. Notice the retraction artifact from the surrounding stroma.*

Peripheral Palisading of Nuclei

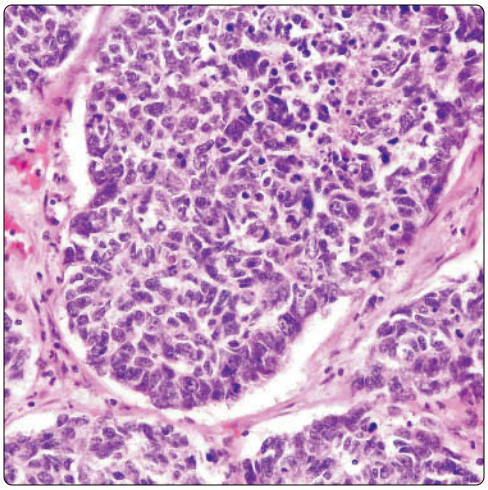

Tumor Island: Higher Power

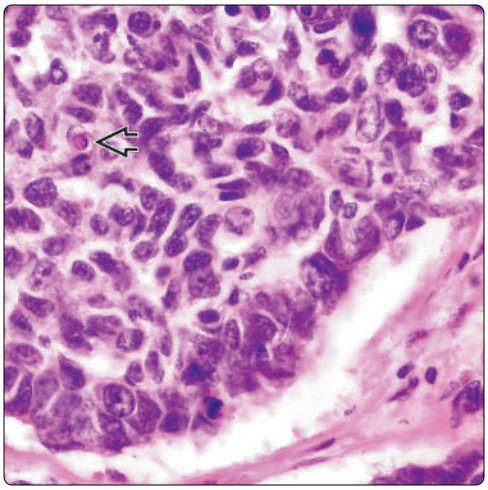

(Left) *Small cell variant of poorly differentiated squamous cell carcinoma of the lung shows a basaloid tumor cell island composed of monotonous proliferation of relatively small tumor cells with peripheral palisading of nuclei.* **(Right)** *Higher magnification of small cell variant of poorly differentiated squamous cell carcinoma of the lung highlights a primitive-appearing tumor cell population with scattered mitoses and occasional foci of single-cell keratinization ⇨.*

Small Tumor Island

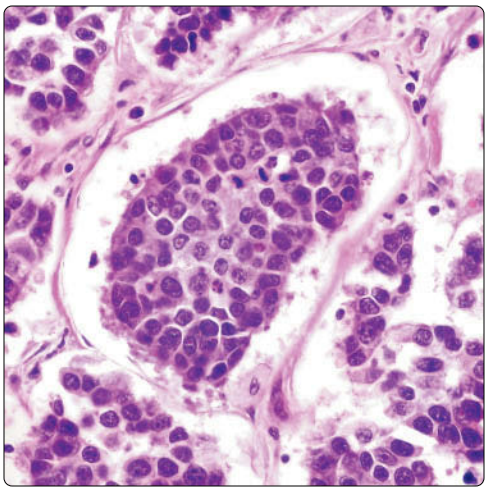

Mitotic Activity

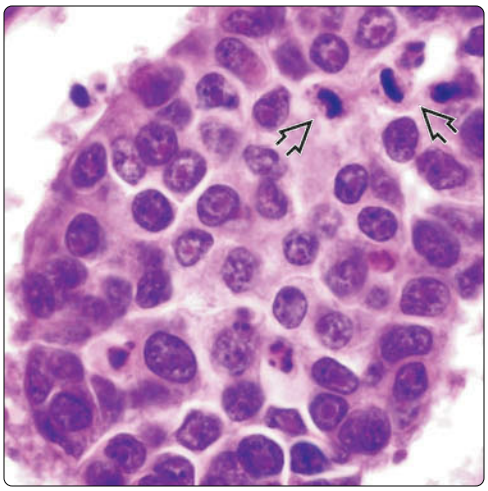

(Left) *Small islands of monotonous tumor cells are seen in small cell variant of poorly differentiated squamous cell carcinoma of the lung infiltrating into adjacent alveolar spaces at the edges of the tumor.* **(Right)** *Higher magnification of a tumor cell island in small cell variant of poorly differentiated squamous cell carcinoma of the lung shows cells with hyperchromatic nuclei, prominent nucleoli, and abundant cytoplasm. Notice the cell moulding and the scattered mitoses ⇨.*

Desmoplastic Stroma

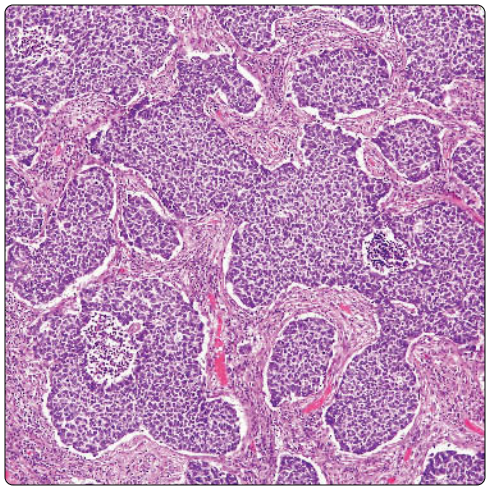

Comedo-Like Areas of Necrosis

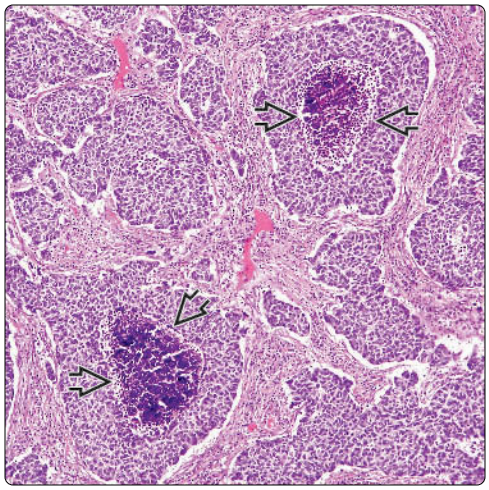

(Left) *Scanning magnification of small cell variant of poorly differentiated squamous cell carcinoma of the lung shows islands of small tumor cells separated by abundant desmoplastic stroma.* **(Right)** *Scanning magnification of small cell variant of poorly differentiated squamous cell carcinoma of the lung shows tumor cell islands separated by desmoplastic stroma. Notice the foci of comedo-like central necrosis displayed in 2 of the tumor cell islands.*

Focal Trabecular Arrangement

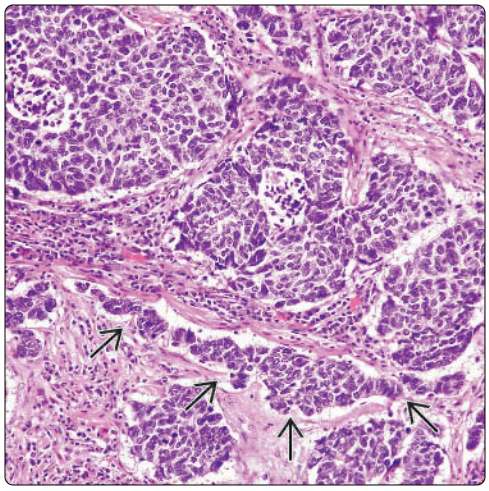

Cord-Like Pattern

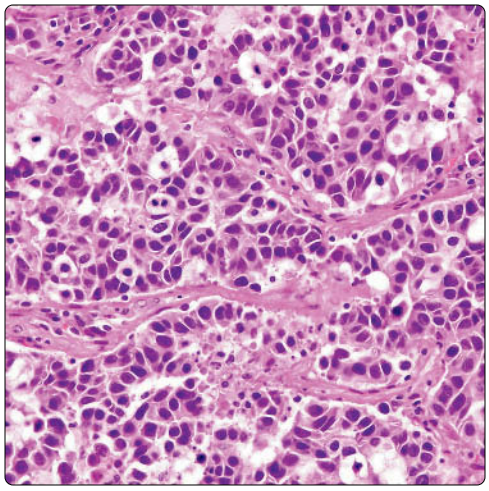

(Left) *Scanning magnification of small cell variant of poorly differentiated squamous cell carcinoma of the lung shows basaloid islands of monotonous tumor cells along with cord-like trabecular formation.* **(Right)** *Small cell variant of poorly differentiated squamous cell carcinoma of the lung shows a trabecular growth pattern with cord-like strands of monotonous small round tumor cells with hyperchromatic nuclei and abundant cytoplasm closely simulating a neuroendocrine carcinoma.*

Hyalinization of Stroma

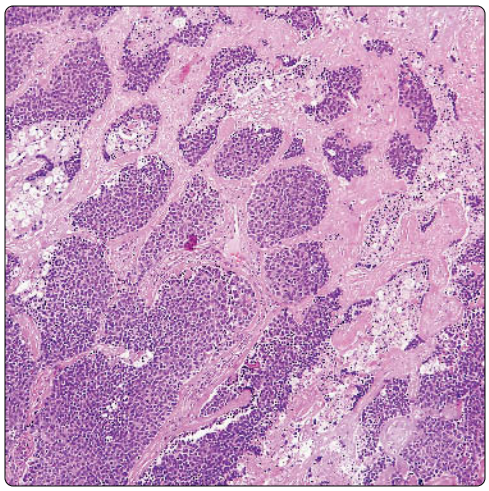

Uniform Small Tumor Cells

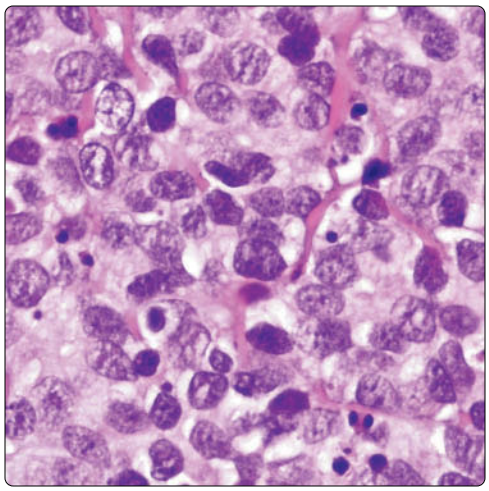

(Left) *Scanning magnification of small cell variant of poorly differentiated squamous cell carcinoma of the lung shows small islands of uniform tumor cells separated by hyalinized connective tissue stroma.* **(Right)** *Higher magnification from an island of tumor cells in small cell variant of poorly differentiated squamous cell carcinoma of the lung shows a primitive population of small tumor cells with hyperchromatic nuclei and a moderate rim of cytoplasm.*

Cytokeratin AE1/AE3 Immunostaining

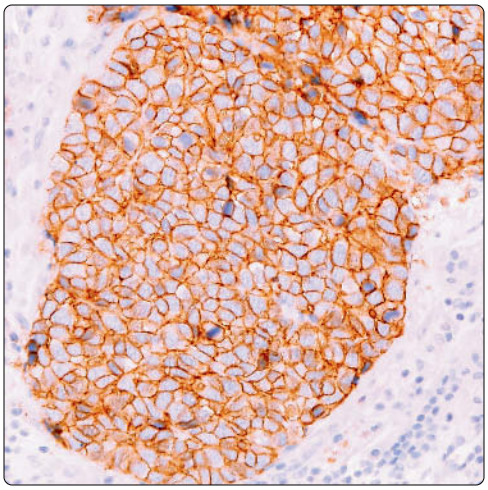

Chromogranin Immunostaining

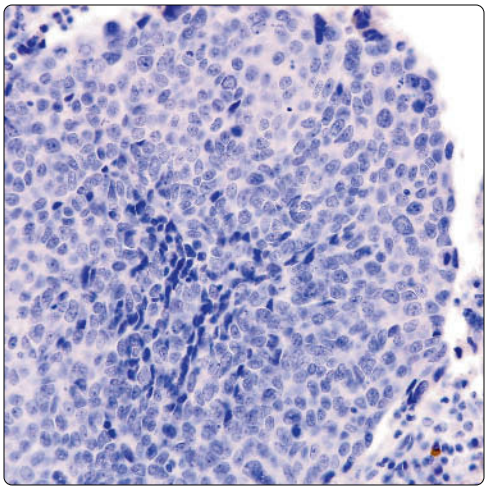

(Left) *Immunohistochemical staining for cytokeratin AE1/AE3 in small cell variant of poorly differentiated squamous cell carcinoma of the lung shows strong positivity of the tumor cells for this antigen.* **(Right)** *Immunohistochemical staining for chromogranin-A in small cell variant of poorly differentiated squamous cell carcinoma of the lung shows a negative reaction. Other neuroendocrine markers, such as synaptophysin, CD56, and NSE, are also negative.*

p63 Immunostaining

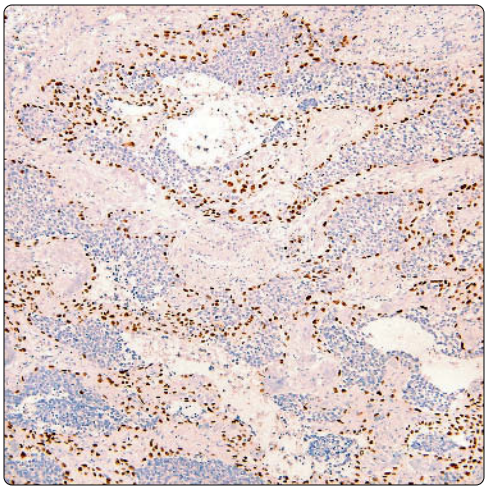

p63 Immunostaining

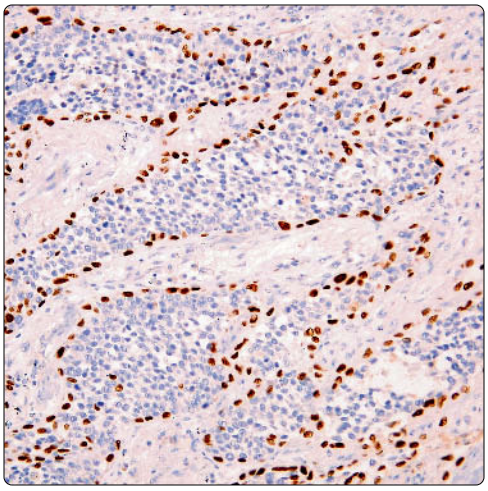

(Left) *Immunohistochemical staining for p63 in small cell variant of poorly differentiated squamous cell carcinoma of the lung with prominent basaloid features shows a distinctive pattern of staining restricted to the periphery of the basaloid islands.* **(Right)** *Higher magnification of immunohistochemical staining of small cell variant of poorly differentiated squamous cell carcinoma shows nuclear staining with p63 only in the periphery of the tumor cell islands.*

MOC-31 Immunostaining

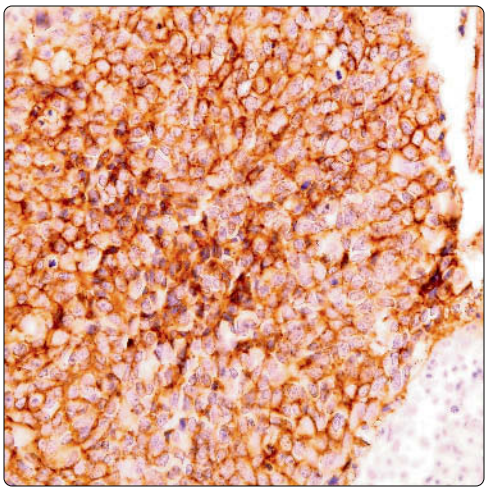

CK7 Immunostaining

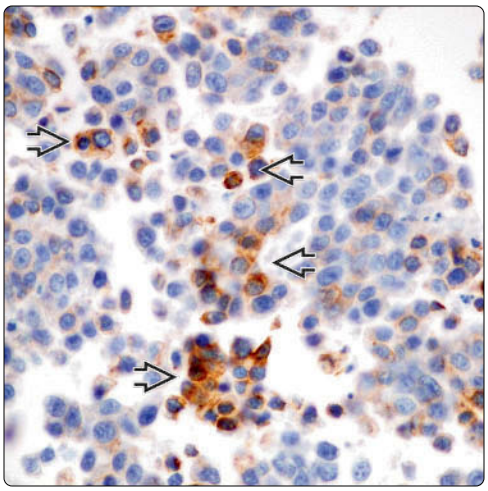

(Left) *Immunohistochemical staining of small cell variant of poorly differentiated squamous cell carcinoma of the lung for MOC-31 shows strong positivity of the tumor cells for this marker.* **(Right)** *Immunohistochemical staining of small cell variant of poorly differentiated squamous cell carcinoma of the lung for CK7 shows focal, weak positivity of the tumor cells for this antigen ⇨. Staining for CK7 is usually weak and focal in these tumors.*

Large Cell (Anaplastic) Carcinoma

KEY FACTS

CLINICAL ISSUES

- Cough
- Chest pain
- Dyspnea
- Generally poor prognosis with short survival
- Most commonly seen in smokers

IMAGING

- Periphery of lungs
- Generally large (> 5 cm in greatest diameter)

MICROSCOPIC

- Neoplastic population is composed of large tumor cells without histologic evidence of glandular or squamous differentiation
- Variegated histology with different growth patterns, including
  - Large cell carcinoma, not otherwise specified
  - Giant cell carcinoma
  - Clear cell carcinoma
  - Large cell carcinoma with rhabdoid features
- Tumor cells are usually very large and measure 3-4x size of normal histiocyte
- Nuclei are enlarged and may be multilobated or multinucleated
- Frequent mitotic figures with abnormal mitoses
- Lymphoid cell emperipolesis
- Syncytiotrophoblastic-like tumor cells

ANCILLARY TESTS

- Most cases are positive for broad-spectrum keratin and low-molecular weight cytokeratins (CAM5.2)
- Tumor cells are negative for neuroendocrine markers (chromogranin, synaptophysin, CD56)
- Pleomorphic tumor cells may be positive for β-HCG
- Tumors cells are largely negative for TTF-1 and NAPSIN-A antibodies

Large Cell Carcinoma of Lung

Large Tumor Cell Population

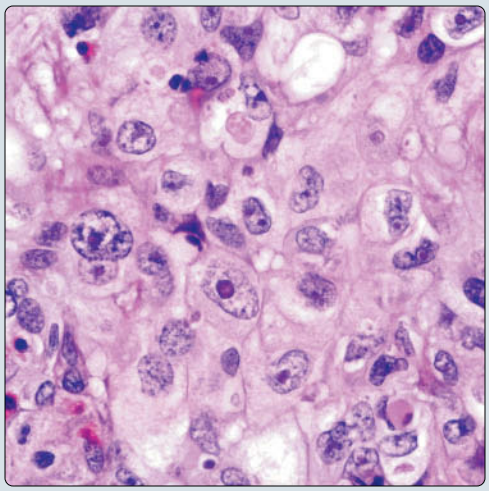

(Left) *Cut surface shows gross appearance of large cell (anaplastic) carcinoma of the lung characterized by a large, well-circumscribed, tan-cream tumor with foci of hemorrhage and necrosis.* **(Right)** *Histologic appearance of large cell (anaplastic) carcinoma of the lung shows sheets of large tumor cells without evidence of glandular or squamous differentiation.*

Inflammatory-Type Anaplastic Carcinoma

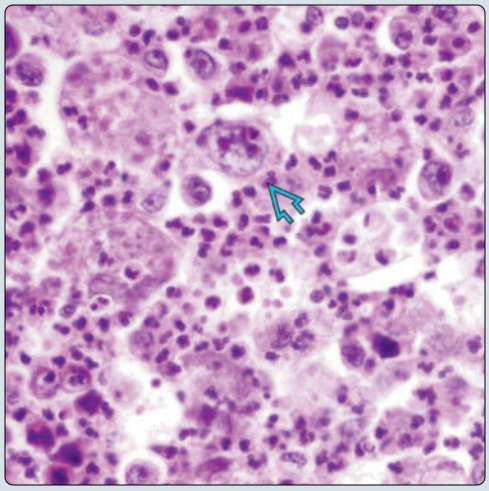

Cytokeratin Immunostaining

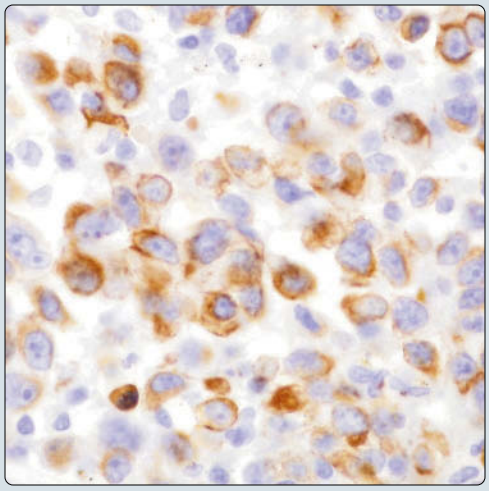

(Left) *Large cell carcinoma with anaplastic morphology can often contain a dense, acute inflammatory infiltrate composed of neutrophils, eosinophils, and scattered histiocytes that can mask the atypical cells.* **(Right)** *Cytokeratin immunostaining is often helpful for identifying the atypical epithelial cells in these tumors. This case shows focal cytoplasmic positivity for low-molecular weight cytokeratin (CAM5.2).*

TERMINOLOGY

Synonyms

- Pleomorphic carcinoma, giant cell carcinoma, rhabdoid carcinoma, large cell undifferentiated carcinoma

Definitions

- Malignant epithelial neoplasm of lung displaying large cell or anaplastic morphology with no specific histologic features of differentiation

CLINICAL ISSUES

Epidemiology

- Incidence
  - Accounts for ~ 8-10% of all lung cancers
  - Most commonly seen in smokers
- Age
  - Adults from 50-70 years (average: 60 years)
- Sex
  - Male predilection

Presentation

- Cough, chest pain, dyspnea

Prognosis

- Generally poor prognosis with short survival

MACROSCOPIC

General Features

- Large, well-circumscribed tumor mass with soft, tan-white tissue that bulges above cut surface
- Frequent areas of hemorrhage and necrosis

MICROSCOPIC

Histologic Features

- Neoplastic population is composed of large tumor cells without histologic evidence of glandular or squamous differentiation
  - Variegated histology with different growth patterns
- **Large cell carcinoma, not otherwise specified**
  - Sheets of large tumor cells with vesicular chromatin, prominent nucleoli, and abundant rim of cytoplasm
  - May display dyscohesive growth pattern that resembles sarcoma (e.g., undifferentiated sarcoma, pleomorphic subtype)
  - May be accompanied by abundant inflammatory cell infiltrate in stroma admixed with tumor cells ("inflammatory" subtype)
  - May display prominent engulfment of lymphoid cells (emperipolesis) by tumor cells
- **Giant cell carcinoma**
  - Sheets of large, pleomorphic tumor cells that are often multilobated and display prominent multinucleation
  - Tumor cells may resemble syncytiotrophoblastic tumor cells of choriocarcinoma
  - Pleomorphic tumor cells may secrete β-HCG
- **Clear cell carcinoma**
  - Tumor composed of sheets of large tumor cells with abundant clear cytoplasm
  - No histologic evidence of glandular or squamous differentiation
  - May show abortive features of glandular or squamous differentiation ultrastructurally
- **Large cell carcinoma with rhabdoid features**
  - Sheets of large, atypical tumor cells displaying large eosinophilic cytoplasmic inclusions
  - Eosinophilic inclusions may displace nucleus to periphery of cell
  - Eosinophilic inclusions contain admixture of cytokeratin and vimentin intermediate filaments

Cytologic Features

- Tumor cells are usually very large and measure 2-4x size of normal histiocyte
- Nuclei are enlarged and may be multilobated or multinucleated
- Frequent mitotic figures with abnormal mitoses
- Tumor cell emperipolesis
- Syncytiotrophoblastic-like tumor cells

ANCILLARY TESTS

Immunohistochemistry

- Most cases are positive for broad-spectrum keratin and low-molecular weight cytokeratins (CAM5.2)
- Tumor cells are negative for neuroendocrine markers (chromogranin, synaptophysin, CD56)
- Pleomorphic tumor cells may be positive for β-HCG
- Tumors cells are largely negative for TTF-1 and NAPSIN-A antibodies

DIFFERENTIAL DIAGNOSIS

Pleomorphic Undifferentiated Sarcoma

- Dyscohesive population of pleomorphic tumor cells
- Strong vimentin positivity; absence of reactivity for epithelial markers
  - Rare cases of pleomorphic undifferentiated sarcoma may show focally aberrant expression of cytokeratin

Metastasis of Anaplastic Carcinoma From Other Organs

- Anaplastic carcinoma of pancreas, thyroid, bladder, and stomach can metastasize to lungs
- Clinical history and imaging studies are indispensable to rule out metastasis

Metastasis of Choriocarcinoma From Genital Tract

- Mixture of cyto- and syncytiotrophoblastic cells set against heavily hemorrhagic background
- History of gonadal or retroperitoneal tumor is indispensable for diagnosis

SELECTED REFERENCES

1. Driver BR et al: Next-generation sequencing of a cohort of pulmonary large cell carcinomas reclassified by World Health Organization 2015 criteria. Arch Pathol Lab Med. 140(4):312-7, 2016
2. Micke P et al: The impact of the fourth edition of the WHO Classification of Lung Tumours on Histological Classification of Resected Pulmonary NSCCs. J Thorac Oncol. 11(6):862-72, 2016
3. Bahadur S et al: Large cell lung carcinoma with rhabdoid phenotype: Report of a rare entity presenting with chest wall involvement. J Cancer Res Ther. 11(3):657, 2015

Well-Circumscribed Tumor

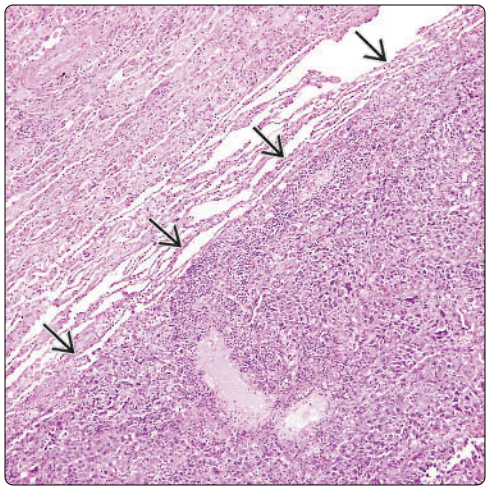

Sheets of Large Atypical Cells

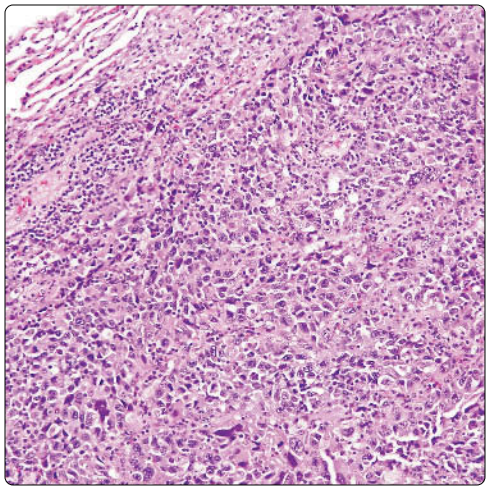

(Left) *Scanning magnification of large cell (anaplastic) carcinoma of the lung shows a well-circumscribed but unencapsulated tumor cell population sharply separated from the surrounding lung parenchyma.* **(Right)** *Large cell (anaplastic) carcinoma of the lung shows sheets of large, anaplastic tumor cells in a haphazard arrangement without any evidence of gland formation or squamous differentiation. Tumors like this may resemble malignant lymphoma or pleomorphic sarcoma.*

Higher Magnification

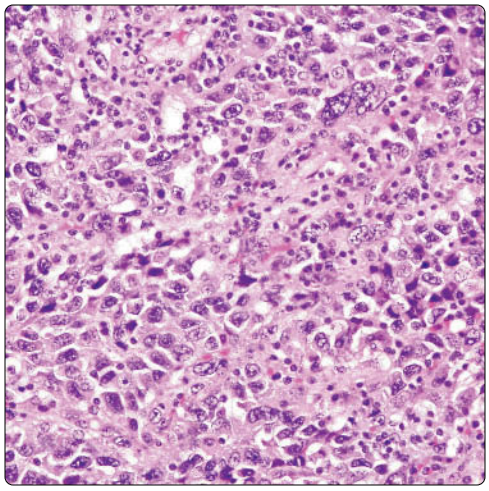

Large Cell Population

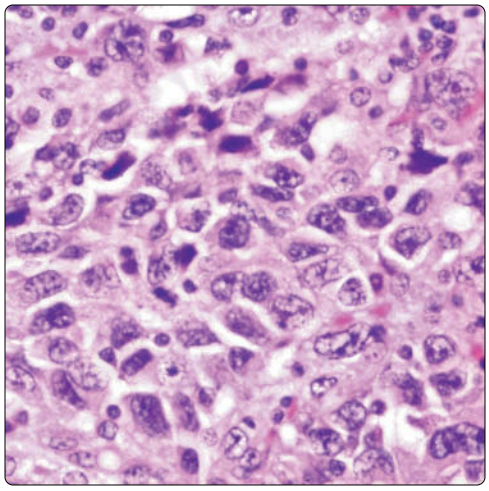

(Left) *Higher magnification of large cell (anaplastic) carcinoma of the lung shows sheets of large tumor cells without any supportive stroma. The dyscohesive appearance of the tumor cells can suggest a variety of alternate diagnoses due to the total absence of any distinctive features of differentiation.* **(Right)** *High magnification of large cell (anaplastic) carcinoma of the lung shows anaplastic tumor cells with enlarged, hyperchromatic nuclei and prominent nucleoli.*

Tumor Cell Necrosis

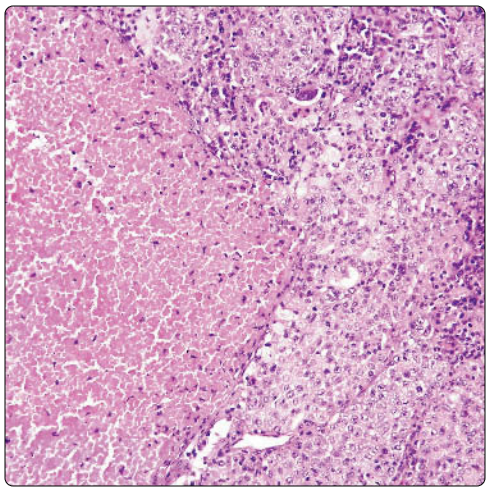

Sheet-Like Growth Pattern

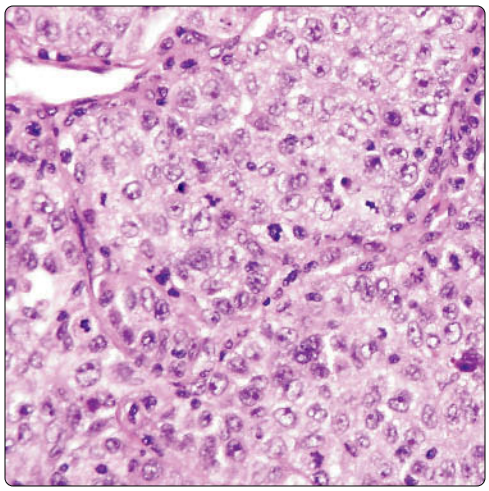

(Left) *Scanning magnification of large cell (anaplastic) carcinoma of the lung shows extensive areas of tumor necrosis (left) and sheets of large tumor cells without any apparent features of differentiation.* **(Right)** *High magnification of large cell (anaplastic) carcinoma of the lung shows sheets of large, atypical tumor cells with large vesicular nuclei, prominent nucleoli, and frequent mitotic figures. The sheet-like pattern of growth can simulate a diffuse large cell lymphoma.*

Bizarre Nuclear Morphology

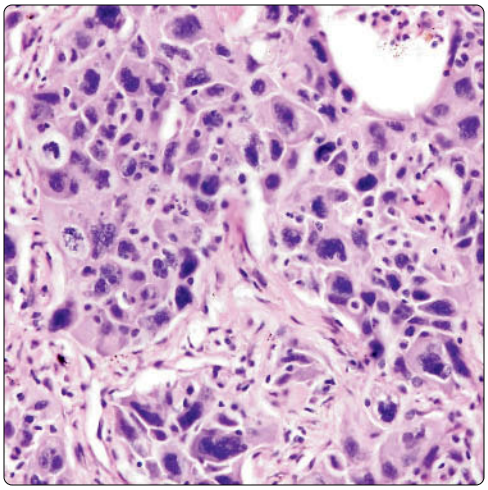

Abnormal Mitoses

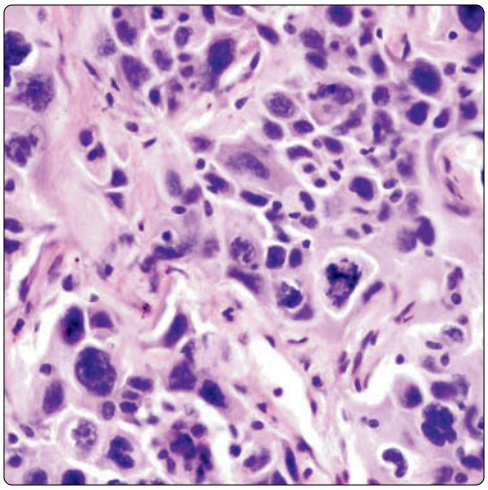

(Left) *Scanning magnification of large cell (anaplastic) carcinoma of the lung shows islands of large tumor cells with bizarre nuclei and numerous mitoses. The islands of tumor cells are separated by scant fibrovascular stroma.* **(Right)** *Higher magnification of large cell (anaplastic) carcinoma of the lung shows bizarre nuclear morphology with enlarged, hyperchromatic nuclei and occasional multinucleated tumor cells. Abnormal mitotic figures are noted.*

Mitotic Figure

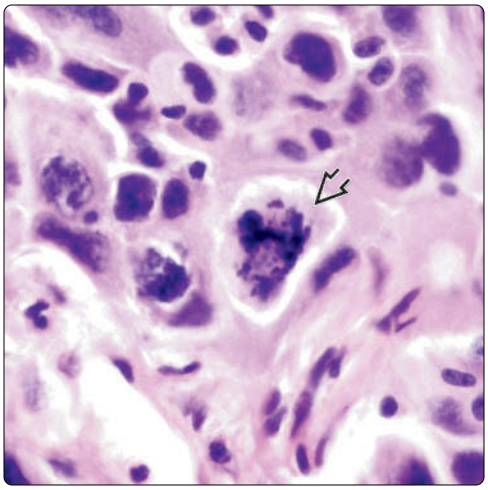

Hemorrhagic Stroma

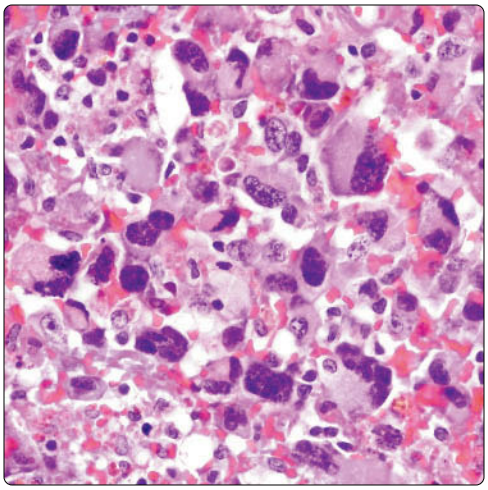

(Left) *High magnification in large cell (anaplastic) carcinoma of the lung shows bizarre tumor cells with enlarged, hyperchromatic nuclei and an indistinct rim of eosinophilic cytoplasm. Notice the abnormal mitotic figure in the center.* **(Right)** *Large cell (anaplastic) carcinoma of the lung shows a dyscohesive population of large, bizarre tumor cells devoid of any supporting stroma. Notice the abundance of red blood cells scattered in the background and a few scant small lymphocytes.*

Bizarre Nuclear Morphology

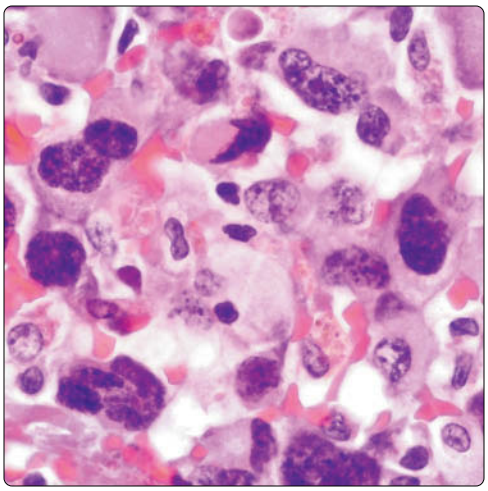

Cytokeratin AE1/AE3 Immunostaining

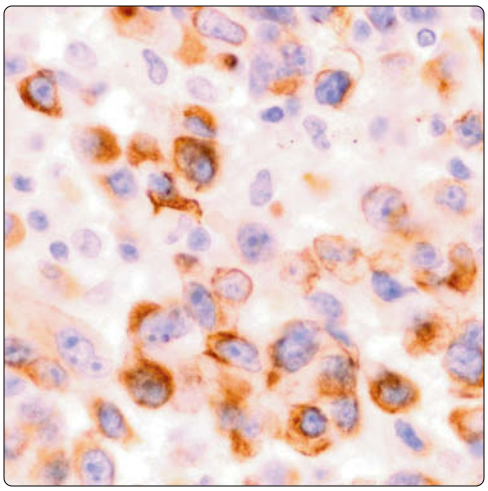

(Left) *Higher magnification of large cell (anaplastic) carcinoma of the lung shows large, bizarre tumor cells with abnormally shaped, hyperchromatic nuclei with large, often multiple eosinophilic nucleoli and a scant rim of eosinophilic cytoplasm.* **(Right)** *Immunohistochemical staining of large cell (anaplastic) carcinoma of the lung for cytokeratin AE1/AE3 (broad-spectrum keratin) shows strong cytoplasmic positivity in a large number of the tumor cells for this antibody.*

Syncytiotrophoblast-Like Cells

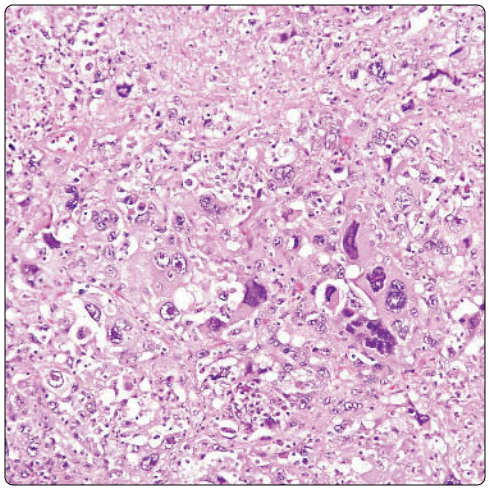

Bizarre Nuclear Forms

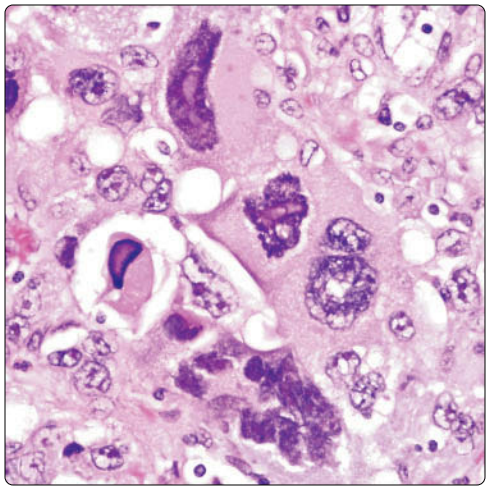

(Left) *Scanning magnification of large cell (anaplastic) carcinoma of the lung shows numerous bizarre tumor cells, somewhat reminiscent of syncytiotrophoblastic cells in choriocarcinoma.* **(Right)** *Choriocarcinoma-like appearance of large cell (anaplastic) carcinoma of the lung shows tumor cells with bizarre nuclei and multinucleated forms reminiscent of syncytiotrophoblastic tumor cells. These cells can stain positive with antibodies to β-HCG.*

Bizarre Nuclear Forms

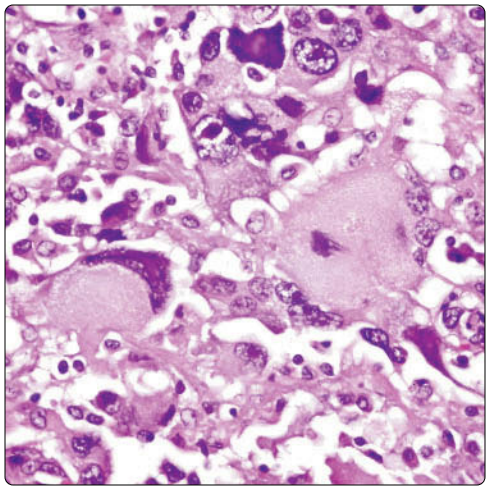

Hyaline Globules

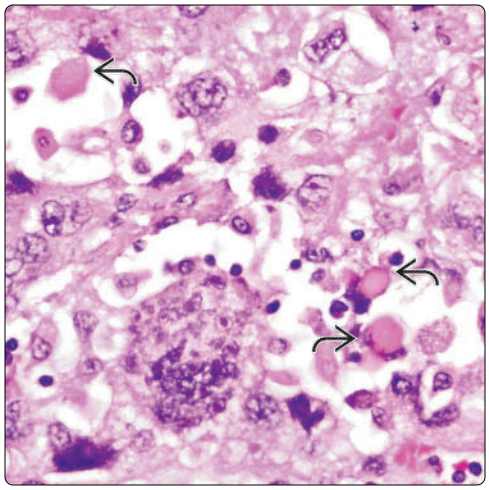

(Left) *Large cell (anaplastic) carcinoma of the lung shows bizarre tumor cells with abundant, finely granular and sometimes vacuolated cytoplasm reminiscent of tumor cells seen in "fibrohistiocytic" malignant neoplasms. Tumors with these features can be easily mistaken for malignant fibrous histiocytoma.* **(Right)** *Large cell (anaplastic) carcinoma of the lung shows dense, eosinophilic hyaline globules ⇨ scattered in between tumor cells in the interstitium.*

Reed-Sternberg-Like Cells

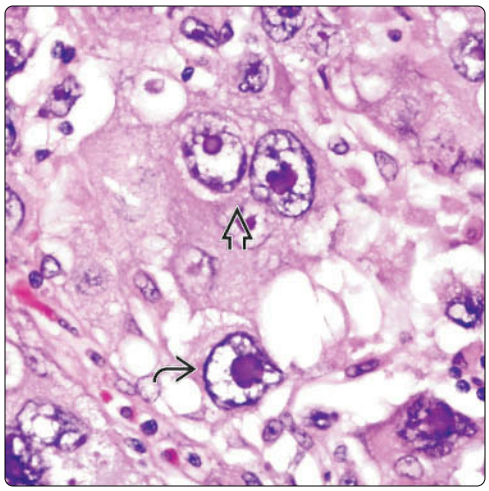

Anaplastic Tumor Cells

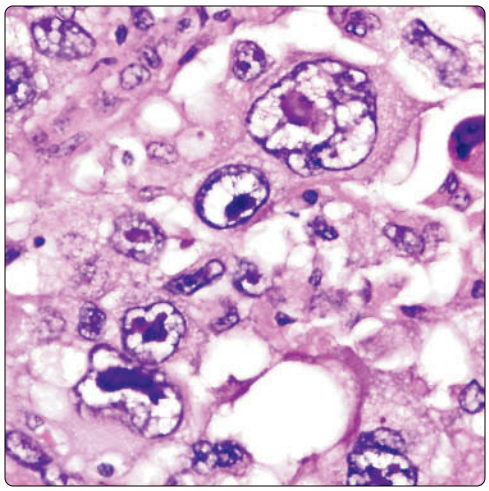

(Left) *High magnification of large cell (anaplastic) carcinoma of the lung shows Reed-Sternberg-like tumor cells. Notice the binucleated form at the top ⇨ displaying double nuclei with "owl-eyed" nucleoli and the mononuclear type ⇨ showing a single enlarged nucleus with a prominent eosinophilic nucleolus.* **(Right)** *Large cell (anaplastic) carcinoma of lung shows bizarre cells with deeply eosinophilic macronucleoli. Cases like this can be confused with Hodgkin disease.*

"Inflammatory-Type" Carcinoma

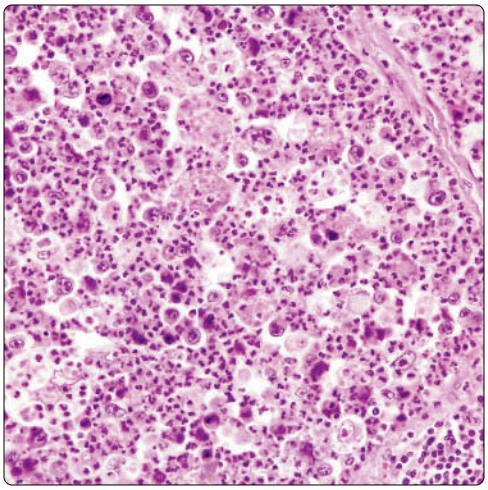

Anaplastic Tumor Cells

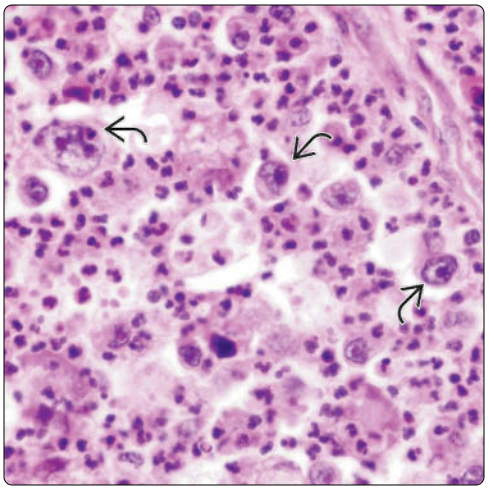

(Left) *Scanning magnification of large cell (anaplastic) carcinoma, "inflammatory variant," shows sheets of polymorphonuclear leukocytes admixed with scattered larger cells. The overall appearance on scanning magnification is that of an abscess.* **(Right)** *Higher magnification of "inflammatory variant" of large cell (anaplastic) carcinoma of the lung shows numerous polymorphonuclear leukocytes with only a few scattered larger, atypical cells in the background.*

Dense Inflammatory Infiltrates

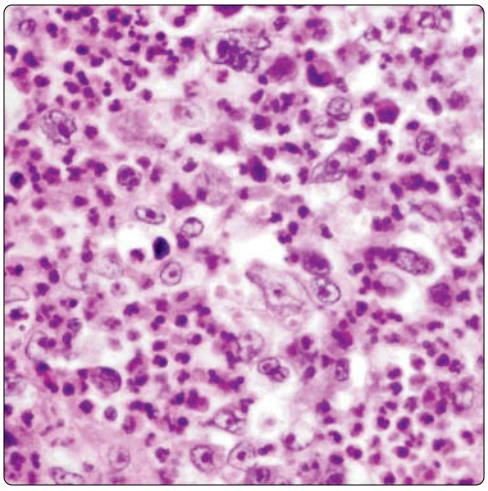

Anaplastic Tumor Cells

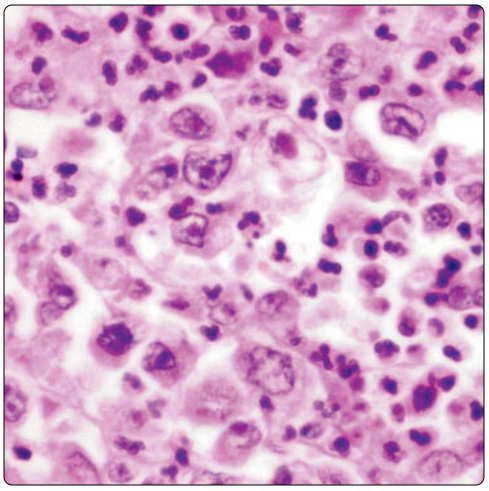

(Left) *Inflammatory type of large cell (anaplastic) carcinoma of the lung shows a dyscohesive population of atypical mononuclear cells surrounded by abundant polymorphonuclear leukocytes. Tumors with this appearance can be easily mistaken for inflammatory malignant fibrous histiocytoma.* **(Right)** *Higher magnification of "inflammatory-type" large cell (anaplastic) carcinoma of the lung shows atypical cells with vesicular nuclei and prominent nucleoli.*

Sheets of Anaplastic Tumor Cells

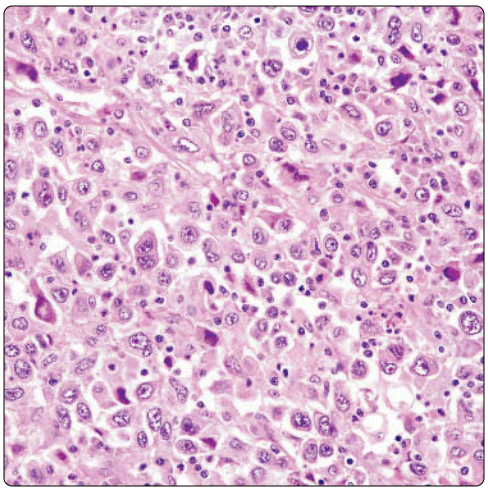

Atypical Tumor Cells

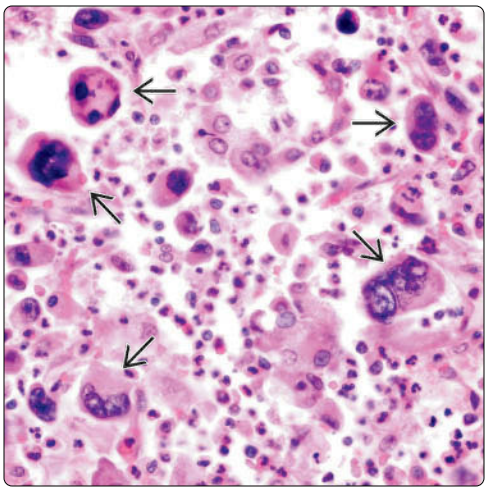

(Left) *Scanning magnification of "inflammatory-type" large cell (anaplastic) carcinoma of the lung shows sheets of large, atypical cells separated by inflammatory cells. The number of atypical cells is much larger and predominates over the inflammatory elements in this example.* **(Right)** *Higher magnification of large cell (anaplastic) carcinoma of the lung, "inflammatory type," shows an abundance of eosinophils and small lymphocytes scattered in between the large, atypical cells.*

Rhabdoid Morphology

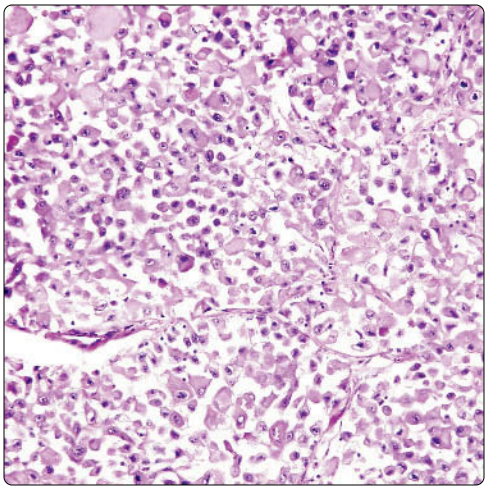

Rhabdoid Cells: Higher Power

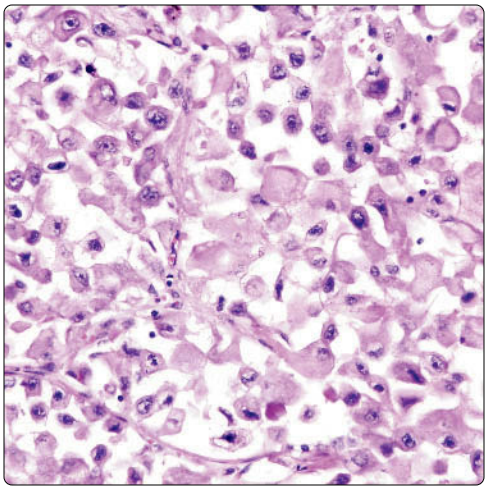

(Left) *Scanning magnification of large cell (anaplastic) carcinoma of the lung shows sheets of cells containing large, paranuclear, dense eosinophilic cytoplasmic inclusions simulating rhabdoid cells.* **(Right)** *Large cell (anaplastic) carcinoma of the lung shows cells with large, densely eosinophilic cytoplasmic inclusions. Tumors with these features can resemble the so-called rhabdoid tumors of the kidney and other organs, rhabdomyosarcoma, and metastatic malignant melanoma.*

Rhabdoid Cells

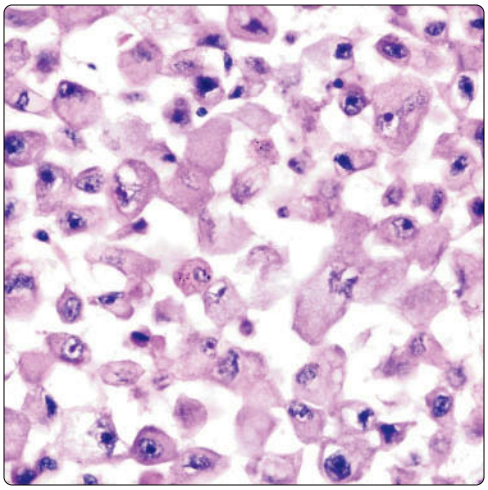

Rhabdoid Cells

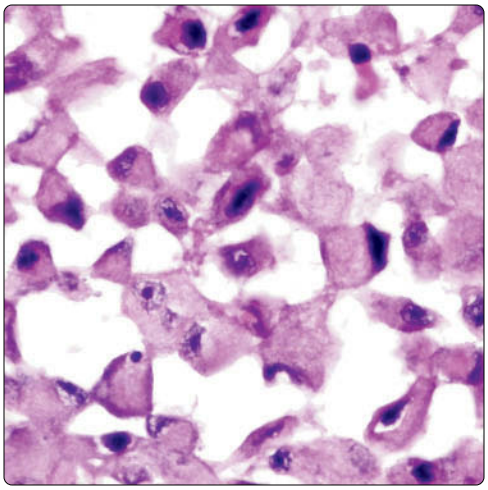

(Left) *Large cell (anaplastic) carcinoma of the lung composed of large, dyscohesive tumor cells with eccentric globular, eosinophilic cytoplasmic inclusions simulating rhabdoid cells is shown.* **(Right)** *Higher magnification of large cell (anaplastic) carcinoma of the lung with a rhabdoid appearance shows large cells with eccentric eosinophilic cytoplasmic inclusions. The dense cytoplasmic inclusions display abundant intermediate filaments by electron microscopy and are positive for cytokeratin.*

Rhabdoid Variant of Anaplastic Carcinoma

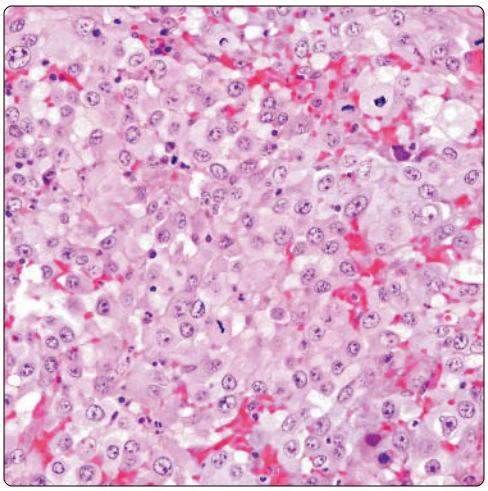

Rhabdoid Cells

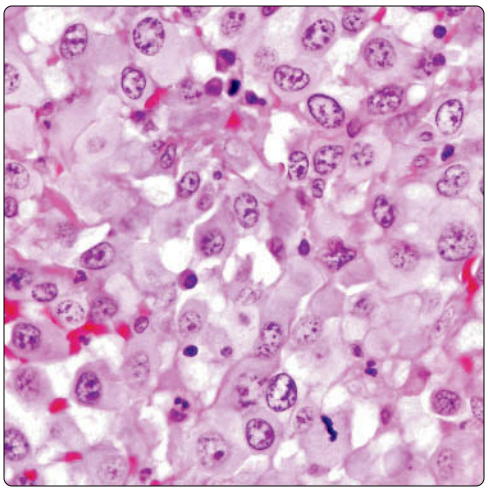

(Left) *Scanning magnification of large cell (anaplastic) carcinoma of the lung displays sheets of uniform tumor cells with dense eosinophilic cytoplasmic inclusions imparting them with a rhabdoid appearance.* **(Right)** *Higher magnification of large cell (anaplastic) carcinoma of the lung shows large, atypical cells containing dense, eosinophilic cytoplasmic inclusions. Use of immunohistochemical stains will be necessary in a case like this to distinguish the tumor from a metastasis.*

Focal Clear Cell Features

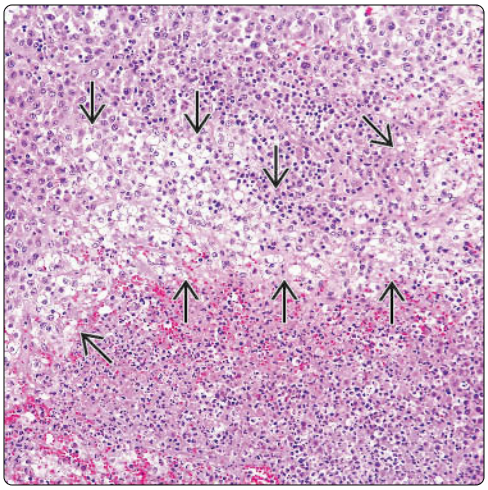

Clear Cell Variant of Anaplastic Carcinoma

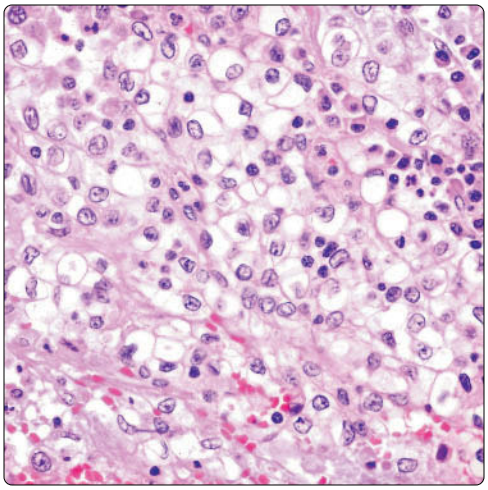

(Left) *Scanning magnification of large cell (anaplastic) carcinoma of the lung shows transition between cells with abundant eosinophilic cytoplasm (top) and cells with clear cytoplasm.* **(Right)** *Large cell (anaplastic) carcinoma of the lung shows sheets of large cells with abundant clear cytoplasm. Notice inflammatory cells admixed with the tumor cells. Tumors like this must be distinguished from metastases of clear cell carcinoma from other organs.*

Clear Cells in Anaplastic Carcinoma

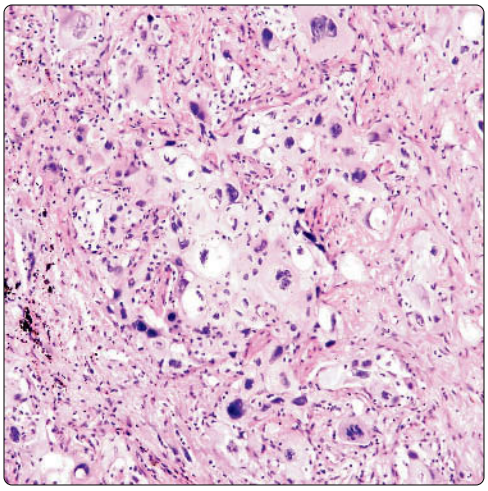

Clear Cells: Higher Magnification

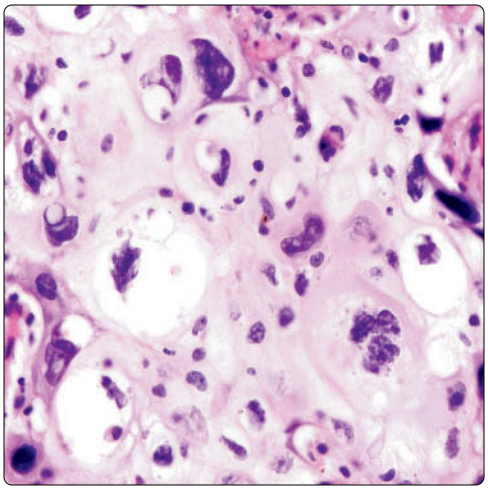

(Left) *Scanning magnification of large cell (anaplastic) carcinoma of the lung shows bizarre tumor cells with abundant clear cytoplasm. The islands of tumor cells are embedded in abundant fibrous stroma.* **(Right)** *Higher magnification of large cell (anaplastic) carcinoma of the lung, clear cell type, shows large, atypical tumor cells with bizarre nuclei surrounded by an ample rim of clear cytoplasm. The nuclear morphology in this example is quite pleomorphic and atypical.*

Clear Cell Variant of Anaplastic Carcinoma

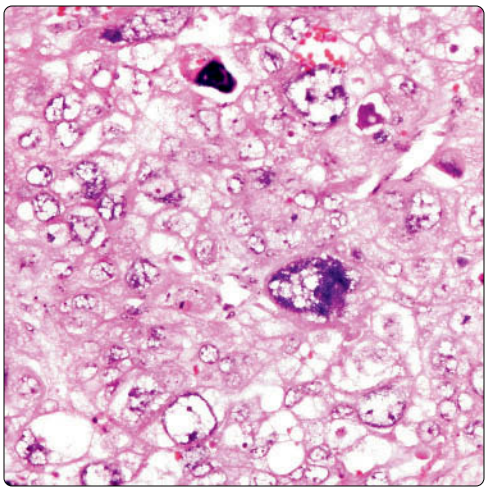

Bizarre Nuclei

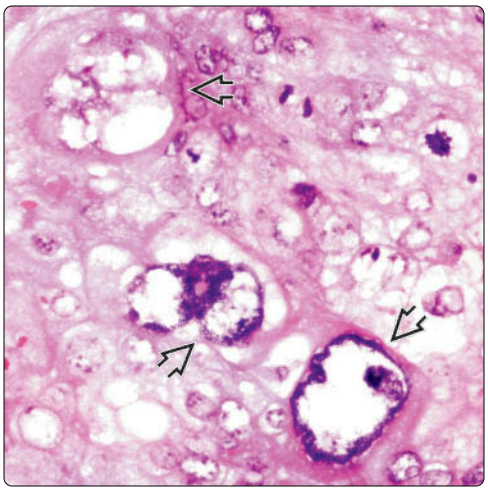

(Left) *Scanning magnification of large cell (anaplastic) carcinoma of the lung shows sheets of large, bizarre tumor cells with atypical nuclei with a vesicular chromatin pattern and abundant clear cytoplasm.* **(Right)** *Higher magnification of large cell (anaplastic) carcinoma of the lung shows bizarre, atypical cells with abundant clear or lightly eosinophilic cytoplasm. Notice the large, bizarre cells with vesicular nuclei and multinucleated forms.*

Pleomorphic Carcinoma

KEY FACTS

TERMINOLOGY

- Malignant epithelial neoplasm composed of spindle and multinucleated giant cells in different proportions

ETIOLOGY/PATHOGENESIS

- PC may represent genetically distinct type of malignancy separate from squamous and adenocarcinoma

CLINICAL ISSUES

- Symptoms
  - Chest pain
  - Hemoptysis
  - Cough
  - Weight loss
  - Hoarseness
- Prognosis
  - Majority of cases are in advanced clinical stages
  - Prognosis is poor
  - Molecular mutation analysis may be important to decide treatment
- Lobectomy or pneumonectomy
- Chemotherapy or radiation therapy depending on clinical setting

MICROSCOPIC

- Mixture of 2 distinct components, sarcomatoid and giant cells

ANCILLARY TESTS

- Keratin
- TTF-1
- p40

TOP DIFFERENTIAL DIAGNOSES

- Malignant fibrous histiocytoma
- Pulmonary leiomyosarcoma
- Sarcomatoid carcinoma
- Metastatic choriocarcinoma

Macroscopic Features

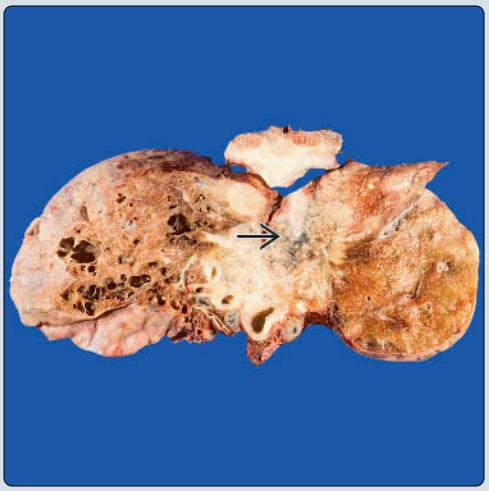

Marked Pleomorphism

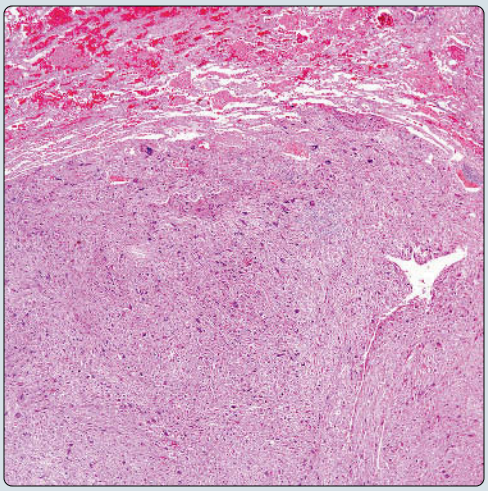

(Left) *Gross photograph of pleomorphic carcinoma of the lung shows a large, centrally located malignant neoplasm. The tumor shows a smooth cut surface and focal necrosis ⇨.* **(Right)** *Pleomorphic carcinoma of the lung shows a cellular proliferation composed of spindle and large, multinucleated giant cells. The tumor appears well circumscribed but not encapsulated.*

Giant Cells

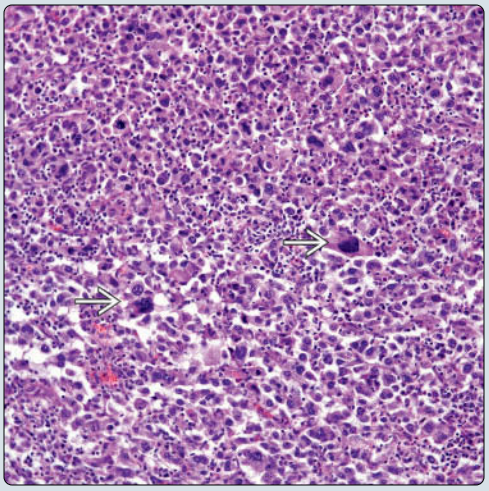

Marked Atypia

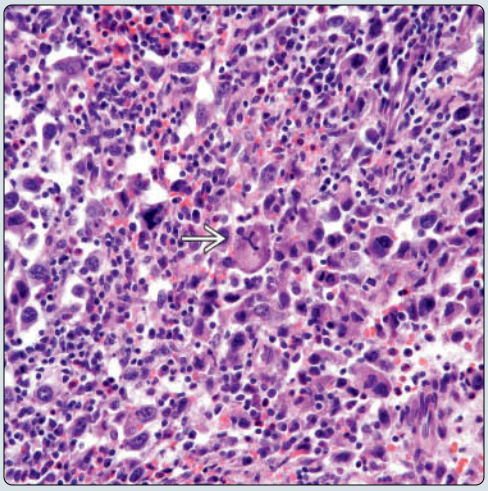

(Left) *Pleomorphic carcinoma shows undifferentiated areas composed of spindle and giant cells ⇨. The presence of giant cells here is only minimal.* **(Right)** *Pleomorphic carcinoma shows giant cells, some of them with mitotic activity ⇨. Pleomorphic carcinomas generally show marked cytologic atypia.*

TERMINOLOGY

Abbreviations

- Pleomorphic carcinoma (PC)

Synonyms

- Giant cell carcinoma, carcinoma with giant cells, carcinoma with pseudosarcomatous stroma, pseudosarcomatous carcinoma, metaplastic carcinoma

Definitions

- Malignant epithelial neoplasm composed of spindle and multinucleated giant cells in different proportions
- In latest WHO 2015, this tumor is grouped with "sarcomatoid" carcinomas of lung

ETIOLOGY/PATHOGENESIS

Etiology

- May represent genetically distinct type of malignancy separate from squamous cell carcinoma and adenocarcinoma
- May represent dedifferentiated neoplasm from conventional squamous or adenocarcinoma

CLINICAL ISSUES

Presentation

- Asymptomatic
- Chest pain
- Hemoptysis
- Cough
- Weight loss
- General malaise
- Hoarseness

Treatment

- Surgical approaches
  - Lobectomy or pneumonectomy
- Adjuvant therapy
  - Chemotherapy or radiation therapy depending on clinical setting
  - May also depend on molecular findings
    - Possible targeted therapy for those cases with specific mutations

Prognosis

- Depends on stage at diagnosis
- Tumor is usually diagnosed in late stages
- Depends on any possible mutations present in tumor
- Majority of cases are in advanced clinical stages
- Prognosis is poor

MACROSCOPIC

General Features

- Central or peripheral
- Varying size but generally large tumors
- Well circumscribed but not encapsulated
- Light tan with homogeneous cut surface
  - Areas of necrosis &/or hemorrhage may be seen

MICROSCOPIC

Histologic Features

- Mixture of 2 distinct components, spindle and giant cells

Predominant Pattern/Injury Type

- Sarcomatoid

Predominant Cell/Compartment Type

- Epithelial

DIFFERENTIAL DIAGNOSIS

Malignant Fibrous Histiocytoma

- Touton-type giant cells in malignant fibrous histiocytoma (MFH); multinucleated malignant cells in PC
- Areas of squamous cell carcinoma or adenocarcinoma in most cases of PC
- Studies using keratin antibodies helpful as sarcomatoid component may show keratin expression
  - MFH may also show focal positive staining for keratin

Pulmonary Leiomyosarcoma

- Immunohistochemistry studies for desmin, caldesmon, and SMA generally negative in PC cases while positive in leiomyosarcoma
- Presence of multinucleated giant cell component is not common feature, even in cases of high-grade leiomyosarcoma
- Most pulmonary leiomyosarcomas are confined to lung, while PC is commonly in advanced clinical stage

Sarcomatoid Carcinoma

- Though sarcomatoid carcinoma and PC are often coded under same category, PC has sarcomatoid component in association with multinucleated giant cells
- Sarcomatoid carcinoma shows only spindle cell component
- Both tumors share similar immunohistochemical profile

Metastatic Choriocarcinoma

- History of previous germ cell tumor is important
- Choriocarcinomas would show presence of cyto- and syncytiotrophoblastic components
- Areas of necrosis and hemorrhage admixed with tumor cells are more common in choriocarcinomas
- Immunohistochemical stains for hCG are more commonly and strongly positive in choriocarcinoma
- Some cases of PC may show positive staining for hCG

DIAGNOSTIC CHECKLIST

Pathologic Interpretation Pearls

- Mixture of malignant spindle cell components in association with malignant multinucleated giant cells

SELECTED REFERENCES

1. Forest F et al: Histomolecular profiling of pleomorphic, spindle cell, and giant cell carcinoma of the lung for targeted therapies. Hum Pathol. 49:99-106, 2016
2. Nishida A et al: Clinicoradiological outcomes of 33 cases of surgically resected pulmonary pleomorphic carcinoma: correlation with prognostic indicators. Eur Radiol. 26(1):25-31, 2016
3. Jia X et al: EGFR and KRAS mutations in pulmonary pleomorphic carcinoma and their correlation with clinicopathologic features. Contemp Oncol (Pozn). 19(1):22-7, 2015

Immunohistochemistry

Antibody	Reactivity	Staining Pattern	Comment
KERATIN-LMW	Positive	Cytoplasmic	May be only focally positive staining
CK7	Positive	Cytoplasmic	Focally positive in some cases
EMA/MUC1	Positive	Cell membrane	May be negative in many cases
Vimentin	Positive	Cytoplasmic	Nonspecific
Actin-HHF-35	Positive	Cytoplasmic	Focally positive in spindle cell component
CD68	Positive	Cytoplasmic	Focally positive in spindle cell component
TTF-1	Positive	Nuclear	In some cases
NAPSIN-A	Positive	Cytoplasmic	In some cases
p40	Positive	Nuclear	In some cases
CK5/6	Positive	Cytoplasmic	In some cases
p63	Positive	Nuclear	In some cases
CK20	Negative		
CDX-2	Negative		
Desmin	Negative		
MYOD1	Negative		
Myoglobin	Negative		
Caldesmon	Negative		
CD31	Negative		

Histochemical Features

Stain	Result
PAS	Focally positive in some cases
PAS-D	Positive if adenocarcinoma present
Mucicarmine	Positive if adenocarcinoma present

Molecular Features

FISH	Result
(*) 5	Mutation may be present if adenocarcinomatous component
$ / .	Mutation may be present if adenocarcinomatous component
. 5 $ 6	Mutation may be present if adenocarcinomatous component
3 , . & $	Mutation may be present if adenocarcinomatous component

4. Kamide Y et al: Anaplastic lymphoma kinase (ALK) rearrangement-positive lung cancer with transformation to pleomorphic carcinoma. Intern Med. 54(22):2905-9, 2015
5. Kato D et al: Successful treatment of two consecutive cases of pulmonary pleomorphic carcinoma with platinum chemotherapy. Oncol Lett. 10(5):3040-3042, 2015
6. Miyahara S et al: Clinicopathological analysis of pleomorphic carcinoma of the lung: diffuse ZEB1 expression predicts poor survival. Lung Cancer. 87(1):39-44, 2015
7. Oyaizu T et al: Tumor-related gene expression levels in pulmonary pleomorphic carcinoma. J Cardiothorac Surg. 10:79, 2015
8. Shiroyama T et al: A rare case of pleomorphic carcinoma of the lung harboring an anaplastic lymphoma kinase (ALK) rearrangement. Intern Med. 54(21):2741-3, 2015
9. Ji C et al: Surgical treatment for pulmonary pleomorphic carcinoma: A retrospective study of 60 patients. Thorac Cancer. 5(3):250-4, 2014
10. Chen F et al: Clinicopathological characteristics of surgically resected pulmonary pleomorphic carcinoma. Eur J Cardiothorac Surg. 41(5):1037-42, 2012
11. Toba H et al: [Surgically treated pleomorphic carcinoma of the lung.] Kyobu Geka. 62(3):202-6, 2009
12. Mochizuki T et al: Pleomorphic carcinoma of the lung: clinicopathologic characteristics of 70 cases. Am J Surg Pathol. 32(11):1727-35, 2008
13. Hirano H et al: Pulmonary pleomorphic carcinoma producing hCG. Pathol Int. 57(10):698-702, 2007
14. Yamamoto S et al: Clinicopathological investigation of pulmonary pleomorphic carcinoma. Eur J Cardiothorac Surg. 32(6):873-6, 2007
15. Yuki T et al: Pleomorphic carcinoma of the lung: a surgical outcome. J Thorac Cardiovasc Surg. 134(2):399-404, 2007
16. Przygodzki RM et al: Pleomorphic (giant and spindle cell) carcinoma is genetically distinct from adenocarcinoma and squamous cell carcinoma by K-ras-2 and p53 analysis. Am J Clin Pathol. 106(4):487-92, 1996
17. Fishback NF et al: Pleomorphic (spindle/giant cell) carcinoma of the lung. A clinicopathologic correlation of 78 cases. Cancer. 73(12):2936-45, 1994

Spindle and Giant Cells

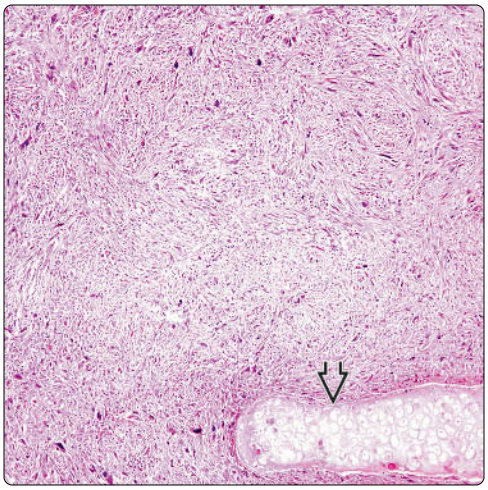

Residual Endobronchial Glands

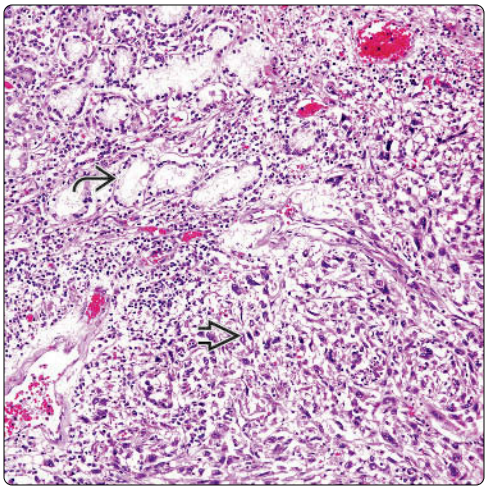

(Left) *Pleomorphic carcinoma demonstrates the classic histopathologic features of combined spindle and giant cell components arranged in a haphazard fashion. Note the presence of residual bronchial cartilage.* **(Right)** *Pleomorphic carcinoma shows conventional features of a mixture of giant and spindle cells. The tumor is sparing the normal endobronchial mucinous glands.*

Prominent Dilated Vasculature

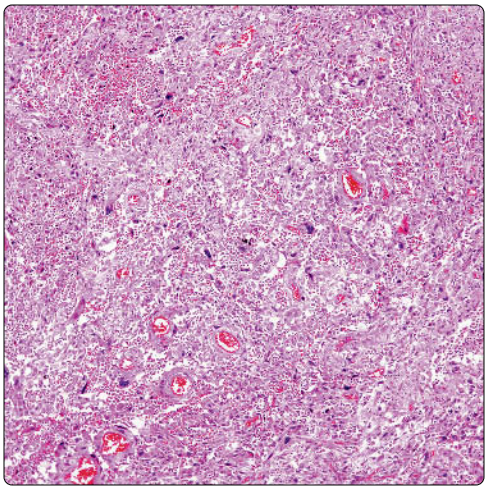

Extensive Necrosis

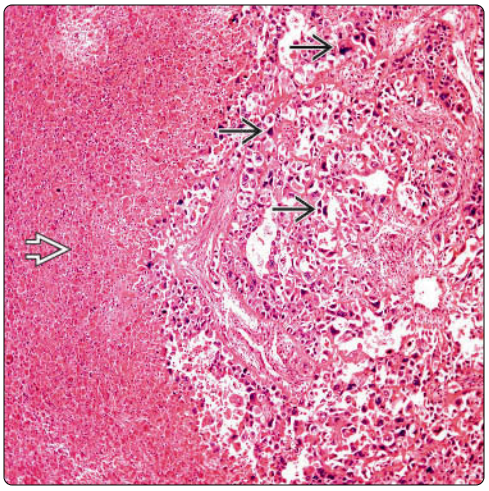

(Left) *Pleomorphic carcinoma demonstrates extensive areas of spindle and giant cell components admixed with dilated vascular spaces and mild inflammatory response.* **(Right)** *Pleomorphic carcinoma is shown with extensive areas of necrosis. Note that in this particular illustration, the epithelial component shows multinucleated giant cells but not the spindle cell component.*

Prominent Giant Cells

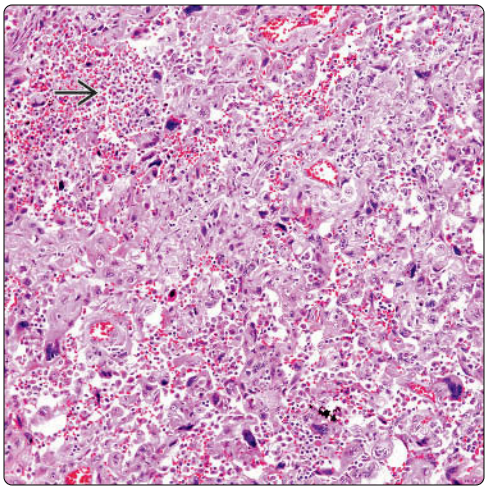

Multinucleated Giant Cells

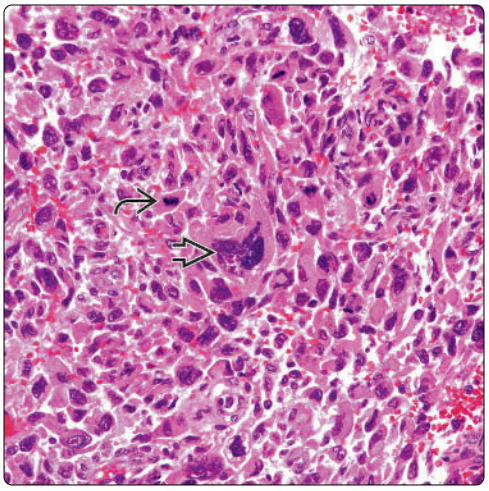

(Left) *Numerous malignant giant cells admixed with spindle cells and acute inflammation are present in this pleomorphic carcinoma. This growth pattern may be seen in pulmonary sarcomas.* **(Right)** *High-power view of a pleomorphic carcinoma shows large cells, some of them multinucleated with bizarre nuclei. Mitotic activity is present. These features are commonly seen in pulmonary pleomorphic carcinoma.*

Necrosis and Viable Tumor

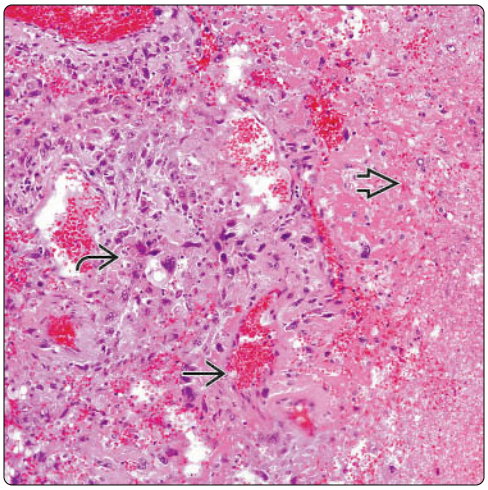

Inflammatory Reaction

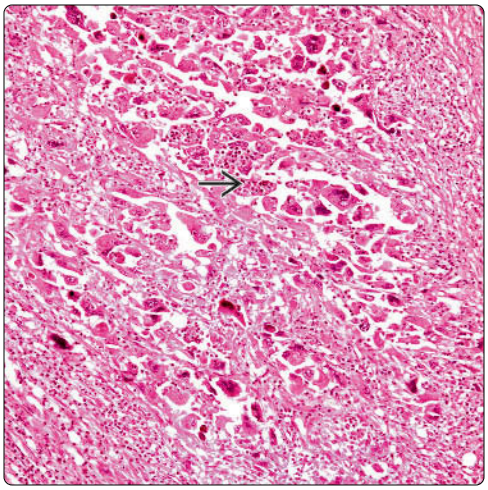

(Left) *Pulmonary pleomorphic carcinoma shows extensive necrosis and ectatic vessels, which could mimic a vascular neoplasm. However, the neoplastic cellular proliferation shows a mixture of multinucleated giant cells and spindle cells.* **(Right)** *Higher magnification shows a multinucleated malignant cell component admixed with an acute inflammatory component.*

Focal Hemorrhagic Changes

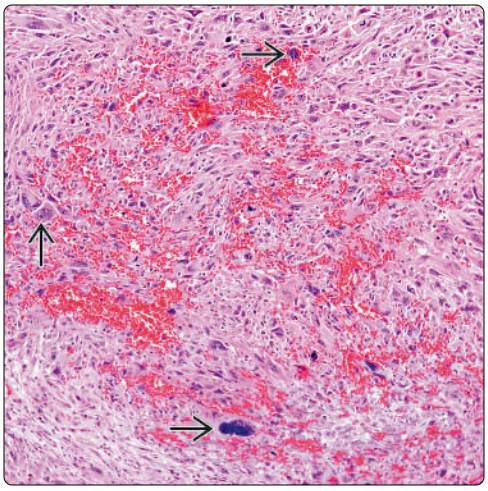

Sarcoma-Like Areas

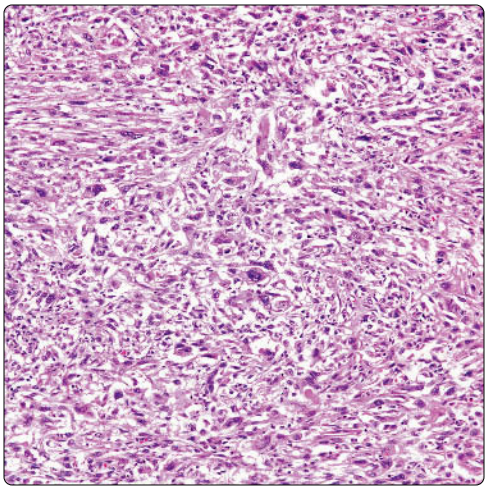

(Left) *H&E shows a pleomorphic carcinoma with a malignant spindle cell component admixed with numerous multinucleated giant cells and extensive areas of extravasated red cells, mimicking a vascular neoplasm.* **(Right)** *In some cases of pulmonary pleomorphic carcinoma, the spindle cell proliferation combined with giant cells closely mimics a true sarcoma, such as a malignant fibrous histiocytoma.*

Predominantly Spindle Cell Component

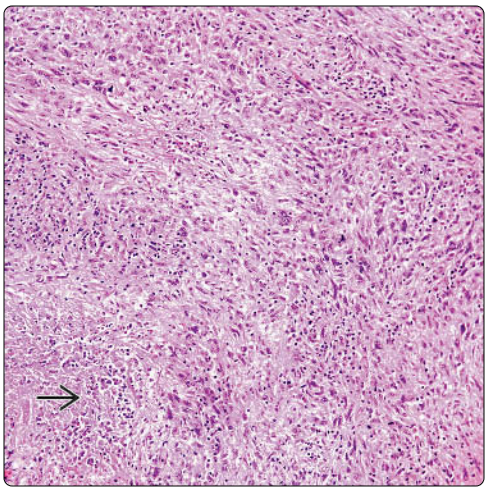

Giant Cells and Mitosis

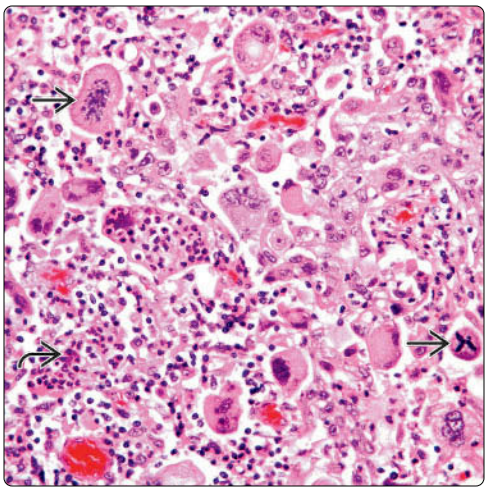

(Left) *Pleomorphic carcinoma is shown with a predominantly spindle cell component and an inconspicuous giant cell component. Areas of necrosis are present, while the spindle cell component mimics a sarcomatous growth pattern.* **(Right)** *Numerous malignant multinucleated giant cells in pleomorphic carcinoma are shown. Note the presence of atypical mitotic figures. An acute inflammatory component is also present.*

Osteoclast-Like Giant Cells

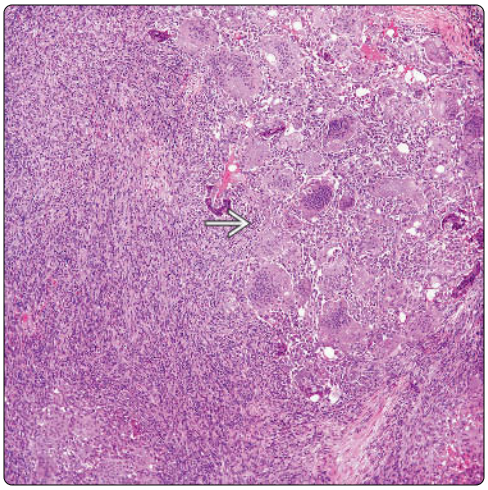

Spindle Cell Component

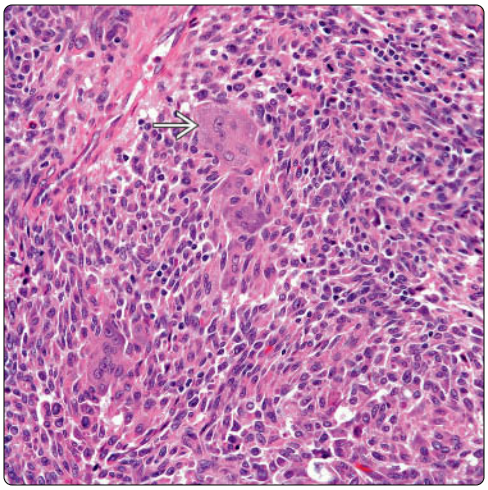

(Left) *Pleomorphic carcinoma in which the giant cells are composed of osteoclast-like giant cells ➡ is shown. Note the presence of the spindle cell component adjacent to the giant cells.* **(Right)** *Predominantly spindle cell component in a pleomorphic carcinoma in which the giant cells are only focally seen ➡ is shown.*

Osteoclast-Like Giant Cells

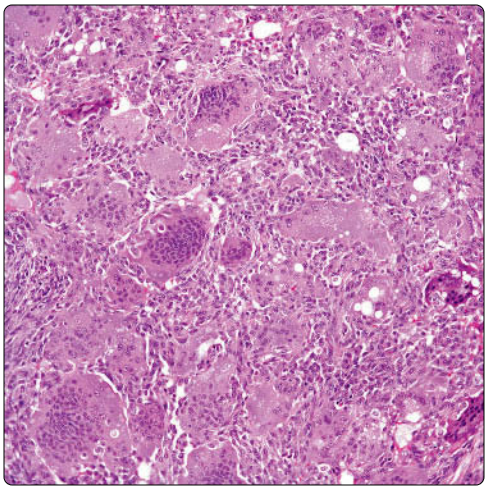

Focal Adenocarcinoma

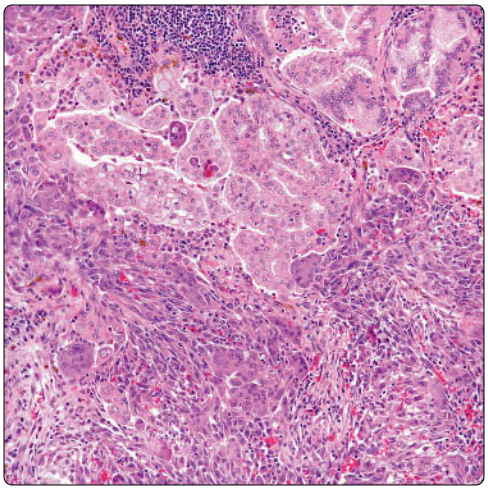

(Left) *Prominent osteoclast-like giant cells in a pleomorphic carcinoma are shown. Still one is able to identify areas of spindle cells surrounding the giant cell component.* **(Right)** *Pleomorphic carcinoma shows the merger of 3 different components: Spindle cells, giant cells, and adenocarcinoma. The association occurs in many cases of pleomorphic carcinoma.*

Keratin Stain

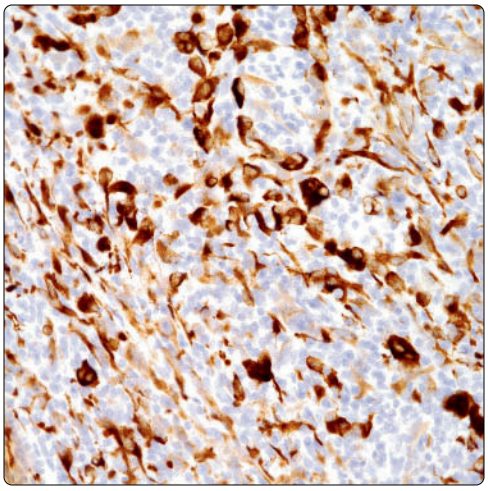

TTF-1 Stain

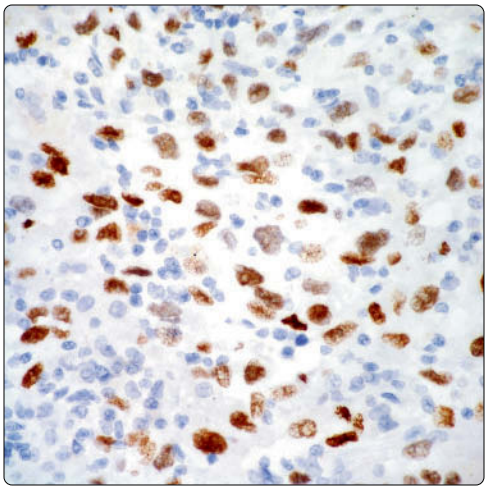

(Left) *Keratin stain shows strong positive reaction in tumor cells of the spindle cell component in a pleomorphic carcinoma.* **(Right)** *Immunohistochemical stain for TTF-1 in a pleomorphic carcinoma shows positive nuclear staining in the spindle cell component.*

Neuroendocrine Carcinoma (Including Small Cell Carcinoma)

KEY FACTS

TERMINOLOGY

- Spectrum of neoplasms ranging from low- to high-grade malignancy

CLINICAL ISSUES

- Paraneoplastic syndromes

MACROSCOPIC

- Endobronchial or intraparenchymal tumor
- 0.5 to > 10 cm in diameter

MICROSCOPIC

- Neuroendocrine pattern, mitotic activity, necrosis
- Low-grade tumors: Up to 3 mitotic figures per 10 HPF; absence of necrosis
- Intermediate-grade tumor: 4-10 mitotic figures per 10 HPF; comedo-like necrosis
- High-grade tumors: > 10 mitotic figures per 10 HPF; necrosis is present
- Large cell neuroendocrine carcinoma requires neuroendocrine pattern and positive staining with neuroendocrine markers (chromogranin-A, synaptophysin, CD56)
- In small cell carcinoma, mitotic count of > 10 per 10 HPF applies only to resected specimens, not biopsy material

ANCILLARY TESTS

- Chromogranin-A
- Synaptophysin
- CD56

DIAGNOSTIC CHECKLIST

- Mitotic rate

Neuroendocrine Carcinoma

Low-Grade NECa

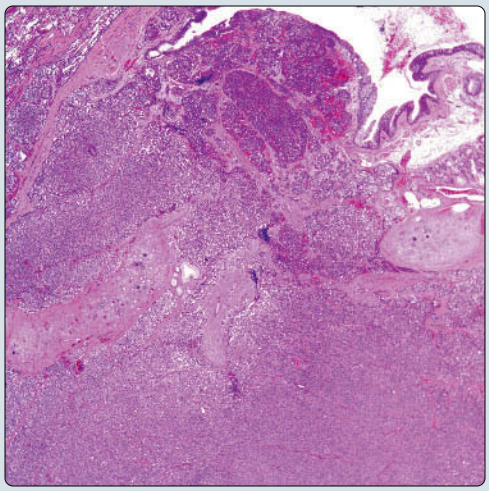

(Left) *Gross photograph of neuroendocrine carcinoma (NECa) shows an endobronchial tumor obstructing ~ 50% of the bronchial lumen.* **(Right)** *Low-power view of a low-grade endobronchial NECa (carcinoid tumor) is shown. Note the organized pattern of growth.*

Pseudoglandular Pattern

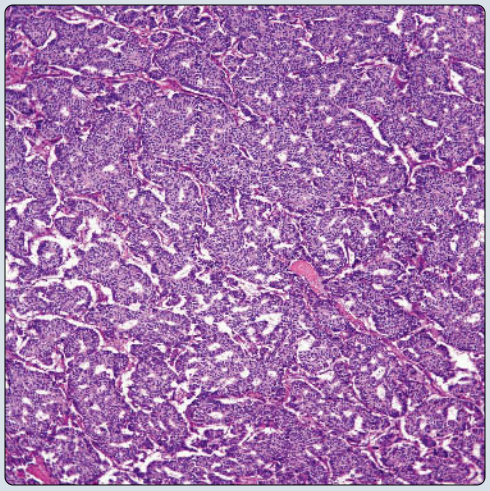

Mild Nuclear Atypia

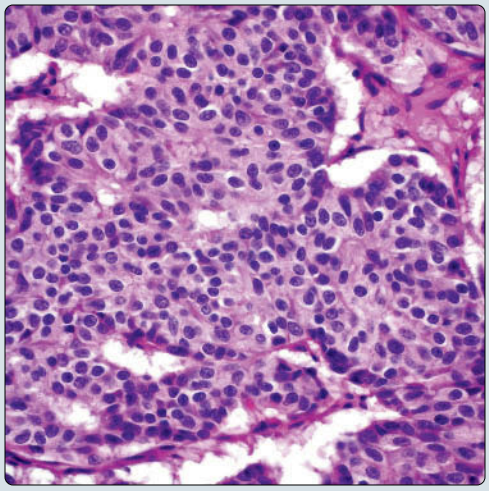

(Left) *Low-grade NECa shows a pseudoglandular growth pattern. However, note well-organized growth and the absence of necrosis.* **(Right)** *Low-grade NECa shows sheets of tumor cells with a homogeneous appearance, mild nuclear atypia, and absence of mitotic activity.*

TERMINOLOGY

Synonyms

- Carcinoid tumor, atypical carcinoid (AT), small cell carcinoma

Definitions

- Spectrum of neoplasms ranging from low- to high-grade malignancy showing neuroendocrine differentiation

ETIOLOGY/PATHOGENESIS

Etiology

- Tumor is thought to be derived from Kulchitsky cells

CLINICAL ISSUES

Presentation

- Cough
- Incidental finding
- Hemoptysis
- Paraneoplastic syndromes
- Chest pain
- Weight loss
- Dyspnea

Treatment

- Surgical approaches
  - Low- and intermediate-grade tumor
- Adjuvant therapy
  - High-grade tumors

Prognosis

- Low-grade neoplasms
  - Survival rate at 5 years: > 75%
- Intermediate-grade neoplasms
  - Survival rate at 5 years: ~ 50%
- High-grade neoplasms
  - Survival rate at 5 years: May be < 5%

MACROSCOPIC

General Features

- Endobronchial or intraparenchymal tumor
- High-grade tumor may show extensive areas of necrosis

Size

- 0.5 to > 10 cm in diameter

MICROSCOPIC

Histologic Features

- Low-grade tumors
  - Up to 3 mitotic figures per 10 HPF
  - Necrosis is absent
- Intermediate-grade tumors
  - 4-10 mitotic figures per 10 HPF
  - Comedo-like necrosis
- High-grade tumors
  - > 10 mitotic figures per 10 HPF
  - Necrosis is present
- Large cell neuroendocrine carcinoma (LCNEC) requires neuroendocrine pattern and positive staining with neuroendocrine markers (chromogranin-A, synaptophysin, CD56)
  - Cells with prominent nucleoli
  - Neuroendocrine markers must be positive
  - Electron microscopic studies show neurosecretory granules
  - Comedo-like necrosis
- Small cell carcinoma
  - Miotic figures > 10 per 10 HPF applies only to resected specimens
  - Neuroendocrine markers are not required for diagnosis

Predominant Pattern/Injury Type

- Nesting
- Diffuse
- Mucinous
- Glandular

Predominant Cell/Compartment Type

- Oncocytic
- Spindle
- Melanocytic
- Epithelial, neuroendocrine
- Clear

DIFFERENTIAL DIAGNOSIS

Low-Grade Neuroendocrine Carcinoma

- Up to 3 mitotic figures and absence of necrosis
- Well-organized growth pattern

Intermediate-Grade Neuroendocrine Carcinoma

- Mitotic activity from 4-10 per 10 HPF and necrosis
- Often combination of well-organized nested pattern and diffuse pattern of growth

High-Grade Neuroendocrine Carcinoma

- > 10 mitotic figures per 10 HPF, necrosis &/or hemorrhage (in resected specimens)
- Positive neuroendocrine markers (synaptophysin, chromogranin-B, &/or CD56) in cases of LCNEC
- In cases of small cell carcinoma, neuroendocrine markers may be negative

Carcinoid Tumorlet

- These tumors are usually < 5 mm in diameter
- Tumorlets and carcinoid tumors share same immunophenotype

Metastatic Neuroendocrine Carcinoma of Extrathoracic Origin

- Clinical history of previous tumor is of utmost importance
- Immunohistochemical study for TTF1 may be helpful

Pulmonary Paraganglioma

- Paragangliomas and neuroendocrine tumors show positive staining for neuroendocrine markers
- Paragangliomas are usually negative for keratin
- Paragangliomas generally do not show mitotic activity
- Paragangliomas usually show cells with macronuclei

Immunohistochemistry

Antibody	Reactivity	Staining Pattern	Comment
Chromogranin-A	Positive	Cytoplasmic	Strongly positive but not global
Synaptophysin	Positive	Cytoplasmic	Diffuse positive staining
CD56	Positive	Cytoplasmic	Diffuse staining
KERATIN-LMW	Positive	Cytoplasmic	Diffuse staining
TTF-1	Positive	Nuclear	In most cases
CD57	Positive	Cytoplasmic	In some cases
Bombesin	Positive	Cytoplasmic	In some cases
LEU-7	Positive	Cytoplasmic	In some cases
CK7	Positive	Cytoplasmic	Diffuse positive staining
CDX-2	Negative		
pax-8	Positive	Nuclear	Less than 10% of cases
Somatostatin	Positive	Cytoplasmic	
SOX10	Positive	Nuclear	In sustentacular cell of low-grade tumors

Molecular Features

Study	Result
11q deletion	Well-differentiated and moderately differentiated carcinomas
10q and 13q losses	Well-differentiated and moderately differentiated carcinomas
3q gain	Small cell carcinoma
10q-16q-17p deletions	High-grade neuroendocrine carcinomas
LOH at 3p14.2-p21.3	More common in moderately differentiated carcinomas
5 % gene	Well-differentiated and moderately differentiated carcinomas

Large Cell Carcinoma

- LCNEC must show neuroendocrine pattern and positive neuroendocrine markers

Large Cell Carcinoma With Neuroendocrine Differentiation

- Histology is that of conventional non-small cell carcinoma with positive neuroendocrine markers

Large Cell Carcinoma With Neuroendocrine Pattern

- Tumors show neuroendocrine histologic pattern but negative staining for neuroendocrine markers

DIAGNOSTIC CHECKLIST

Clinically Relevant Pathologic Features

- Mitotic rate

Pathologic Interpretation Pearls

- Neuroendocrine pattern
- Rosettes
- Necrosis
- Mitotic activity
- Positive neuroendocrine markers in LCNEC

GRADING

Low-Grade Neuroendocrine Carcinoma (Carcinoid Tumor)

- Tumors with up to 3 mitoses per 10 HPF and no necrosis

Intermediate-Grade Neuroendocrine Carcinoma (AT)

- Tumors with 4 to 10 mitoses per 10 HPF and necrosis

High-Grade Neuroendocrine Carcinoma

- Small cell carcinoma
- LCNEC
  - For LCNEC, neuroendocrine markers must be positive

SELECTED REFERENCES

1. Weissferdt A et al: Comparative immunohistochemical analysis of pulmonary and thymic neuroendocrine carcinomas using PAX8 and TTF-1. Mod Pathol. 26(12):1554-60, 2013
2. Tsuta K et al: Differential expression of somatostatin receptors 1-5 in neuroendocrine carcinoma of the lung. Pathol Res Pract. 208(8):470-4, 2012
3. Tsuta K et al: Oncocytic neuroendocrine tumors of the lung: histopathologic spectrum and immunohistochemical analysis of 15 cases. Hum Pathol. 42(4):578-85, 2011
4. Tsuta K et al: Histologic features of low- and intermediate-grade neuroendocrine carcinoma (typical and atypical carcinoid tumors) of the lung. Lung Cancer. 71(1):34-41, 2011
5. Moran CA et al: Neuroendocrine carcinomas of the lung: a critical analysis. Am J Clin Pathol. 131(2):206-21, 2009
6. Segawa Y et al: Immunohistochemical detection of neuroendocrine differentiation in non-small-cell lung cancer and its clinical implications. J Cancer Res Clin Oncol. 135(8):1055-9, 2009
7. Di Fabio R et al: Paraneoplastic neuromuscular disease in lung large cell neuroendocrine carcinoma. Can J Neurol Sci. 35(4):516-8, 2008
8. Dörffel Y et al: Neuroendocrine tumors: characterization with contrast-enhanced ultrasonography. Ultraschall Med. 29(5):506-14, 2008
9. García-Yuste M et al: Neuroendocrine tumors of the lung. Curr Opin Oncol. 20(2):148-54, 2008
10. Gustafsson BI et al: Bronchopulmonary neuroendocrine tumors. Cancer. 113(1):5-21, 2008

Nested Growth Pattern

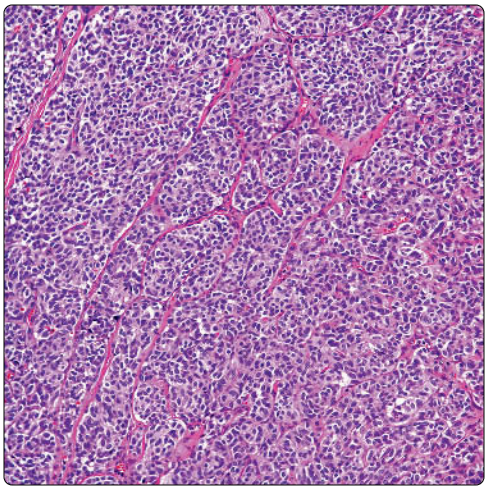

Absent Mitotic Activity

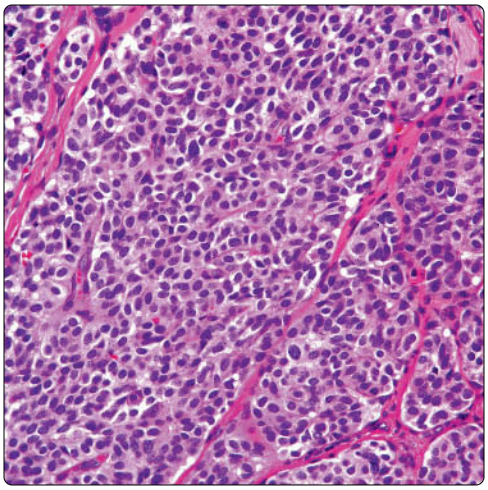

(Left) *Hematoxylin and eosin shows nesting pattern in a low-grade NECa. Note the well-organized growth and the delicate bands of fibroconnective tissue separating the nests of tumor cells.* **(Right)** *Homogeneous cellular proliferation without marked nuclear atypia, necrosis, or hemorrhage is shown. Notice the well-organized pattern of growth, which is one important parameter in low-grade neuroendocrine lung tumors.*

Glandular Pattern

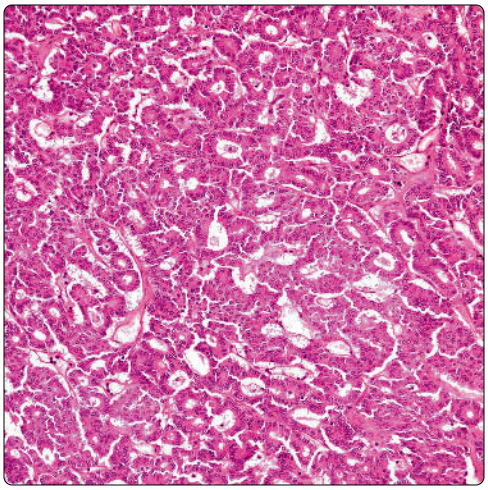

Conventional Nested Pattern

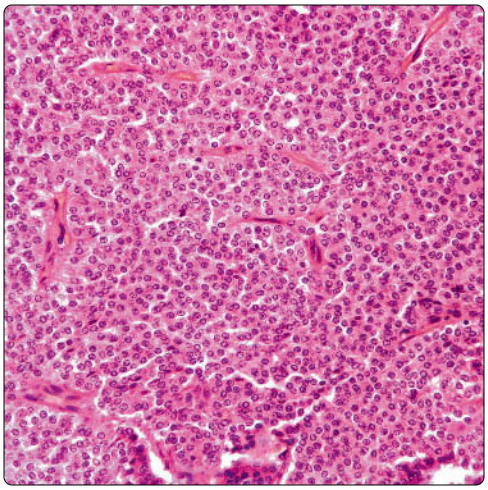

(Left) *Tubular (glandular) pattern of a low-grade NECa is shown. This glandular pattern at a low-power view may mimic adenocarcinoma.* **(Right)** *Sheets of cells with a homogeneous pattern in a low-grade NECa are shown. Note the absence of necrosis &/or hemorrhage. These features are highly important in low-grade tumors in helping to separate them from higher grade tumors.*

Rosette Formation

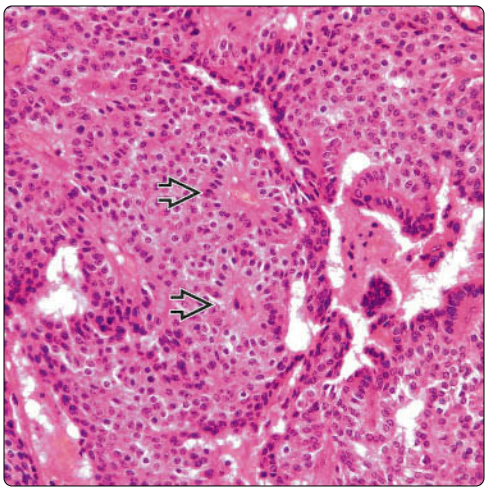

Spindle Cell Pattern

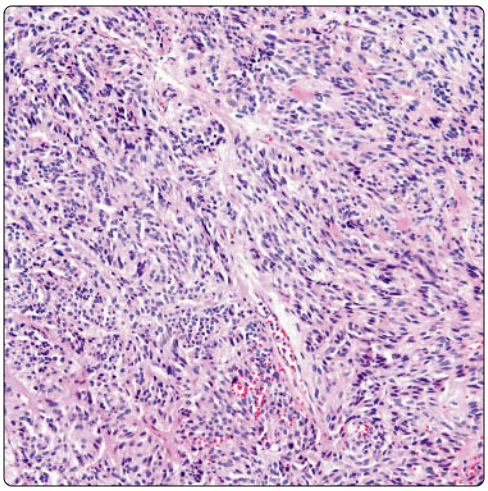

(Left) *Presence of rosettes ⇨ in a well-differentiated NECa is shown. Also important to note is the absence of mitotic activity &/or necrosis.* **(Right)** *Low-grade NECa with prominent spindle cell growth pattern is shown. The tumor does not show necrosis, hemorrhage, or mitotic activity, which are not features of low-grade tumors.*

HPC-Like Pattern

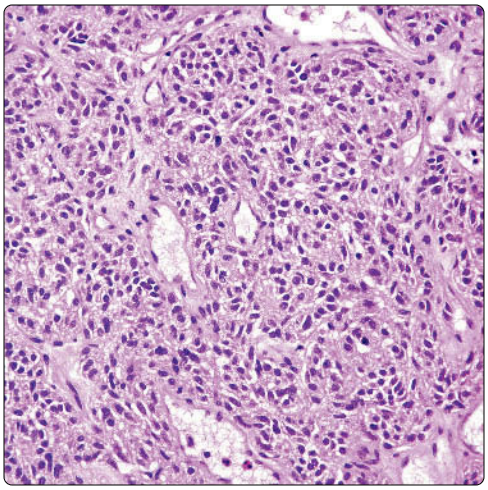

Spindle Cell Pattern

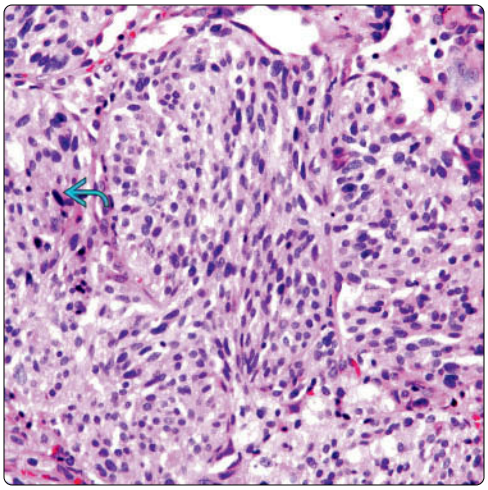

(Left) *Spindle cells around ectatic vessels in a manner mimicking hemangiopericytoma are shown.* **(Right)** *High-power magnification of a low-grade spindle cell NECa (carcinoid tumor) is shown. This growth pattern can be seen in some other mesenchymal or neuroectodermal tumors. Note the absence of mitotic activity or marked nuclear pleomorphism. Scattered apoptotic cells are present.*

Oncocytic Changes

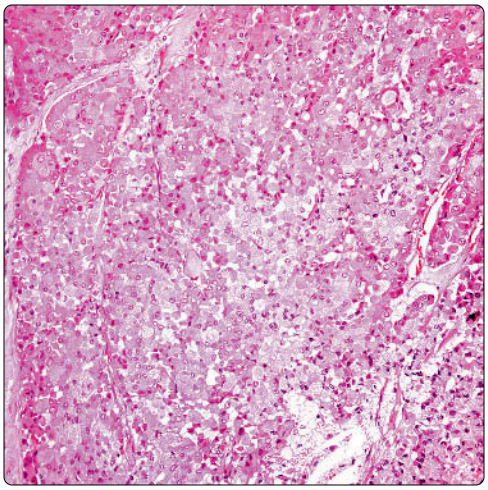

Oncocytic Changes

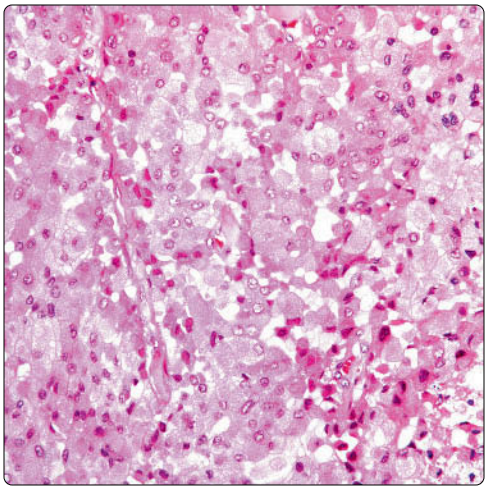

(Left) *Oncocytic variant of well-differentiated NECa of the lung on a hematoxylin and eosin shows sheets of oncocytic cells with a homogeneous appearance. Note the absence of nuclear atypia, necrosis, &/or mitotic activity.* **(Right)** *Hematoxylin and eosin shows oncocytic cells without mitotic activity. The cytoplasm of the cells is brightly eosinophilic, and the nuclei are homogeneous. In some cells, nucleoli are easily identifiable.*

Mucin and Oncocytic Changes

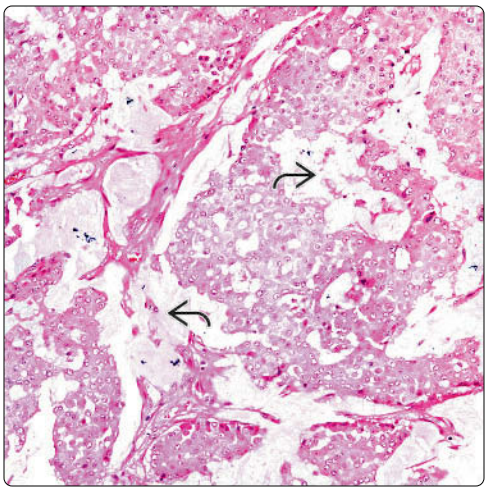

Extracellular Mucin

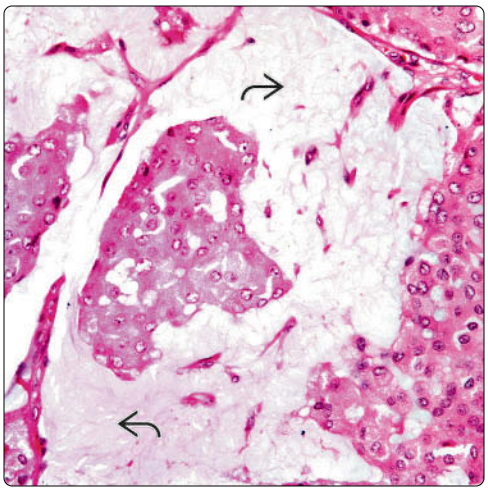

(Left) *Low-grade NECa is shown with presence of abundant mucoid material. In addition, the tumor shows oncocytic features. Mucinous NECas of the lung are rare.* **(Right)** *High-power magnification of a mucinous NECa is shown. Note that there is no mitotic activity or marked nuclear atypia. The presence of mucoid material is unusual and may be mistaken for a metastatic mucinous carcinoma.*

Glandular-Like Features

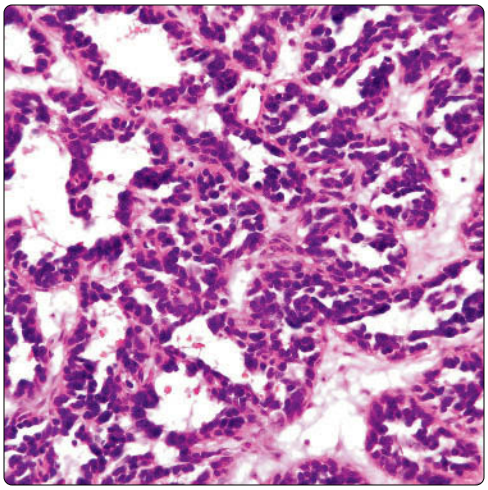

Prominent Glandular-Like Architecture

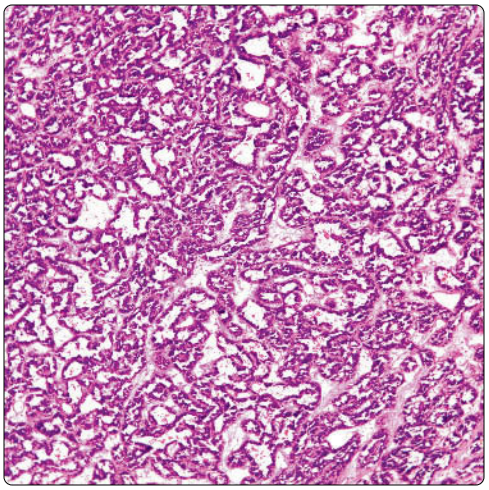

(Left) *Well-differentiated NECa shows glands composed of rather small cells without mitotic activity. This glandular architecture may be erroneously interpreted as adenocarcinoma. Thus, a careful cytological examination of the neoplastic cells is important.* **(Right)** *Glandular pattern of a low-grade NECa is shown. This complex architecture may mimic a well-differentiated adenocarcinoma.*

Spindle Cells With Lobular Architecture

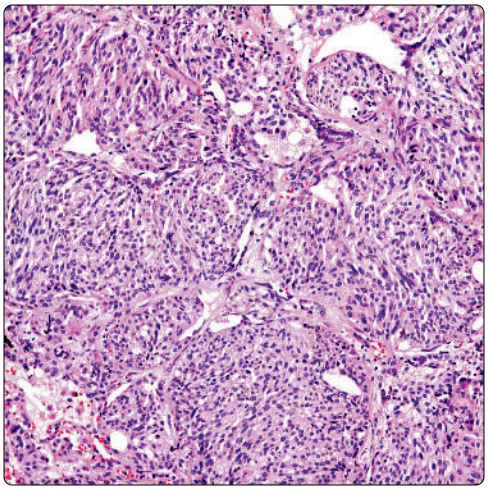

Spindle Cell With Neural Appearance

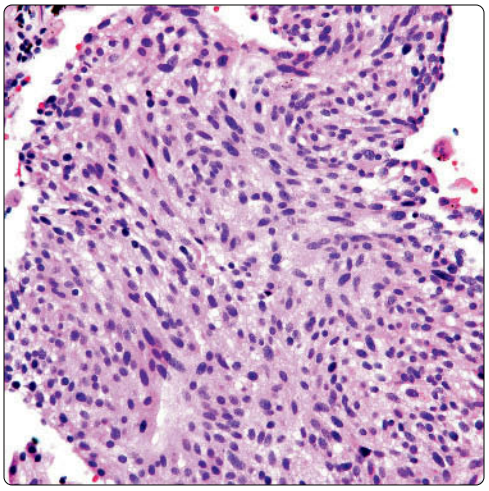

(Left) *Well-differentiated NECa shows a subtle nesting pattern with spindle cell proliferation. This architectural pattern may be misinterpreted as sarcoma or other neoplasms of neuroectodermal origin, such as melanomas.* **(Right)** *Spindle cells without nuclear atypia or mitotic activity are shown. The pattern of growth mimics a neural neoplasm. A spindle cell pattern may also be seen in higher grade tumors.*

Metaplastic Bone Formation

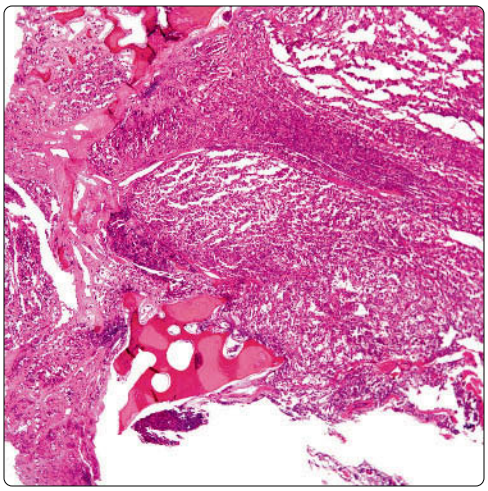

Metaplastic Bone

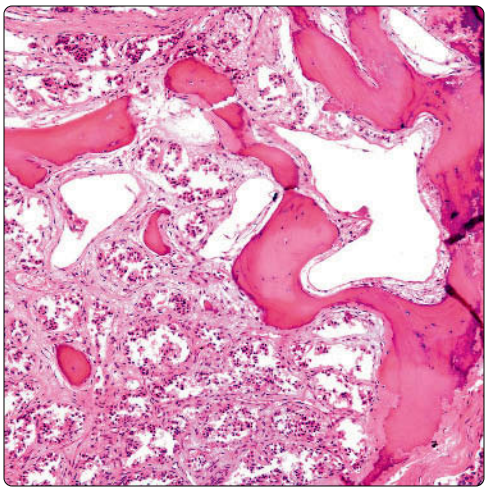

(Left) *Low-grade NECa is shown with areas of metaplastic bone formation. Bone formation in NECas is rare. This metaplastic change is rarely extensive.* **(Right)** *Closer view of the metaplastic bone formation in NECa is shown. Note the presence of a pseudoglandular arrangement of the neoplastic neuroendocrine cells.*

NECa With Focal Hemorrhage and Necrosis

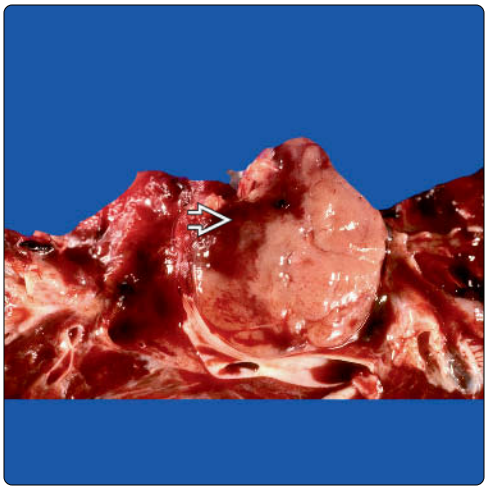

Diffuse Growth Pattern



(Left) *Gross pathology of bronchial NECa is shown. Note the presence of focal areas of hemorrhage and necrosis. Such features should raise the suspicion of a higher grade neoplasm and require extensive sampling.* **(Right)** *Intermediate-grade tumor with sheets of neoplastic cells without any particular architecture is shown. Note that the surface epithelium is intact and the tumor does not reach the respiratory epithelium.*

Extensive Comedo-Like Necrosis

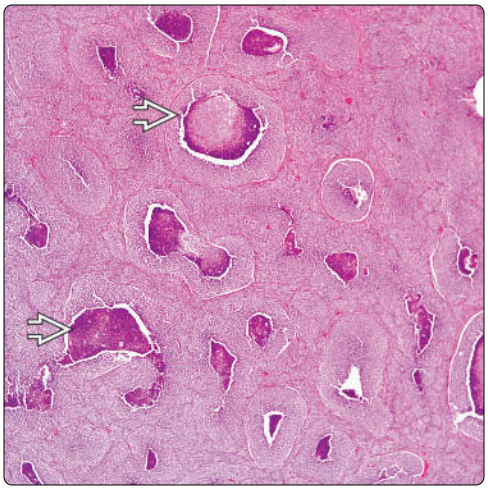

Comedo-Like Necrosis

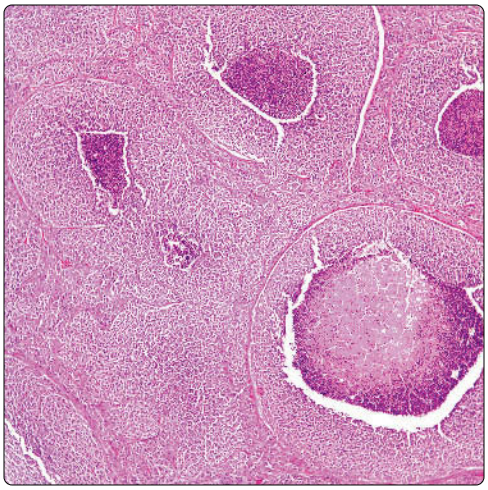

(Left) *Easily identifiable areas of comedo-like necrosis typical of intermediate-grade NECas are shown. Note the presence of nested and diffuse growth patterns, which are commonly seen in intermediate-grade tumors.* **(Right)** *Solid sheets and comedo-like necrotic areas characteristic of intermediate-grade NECs are shown. These features are very typical of intermediate-grade tumors.*

Intermediate-Grade NECa

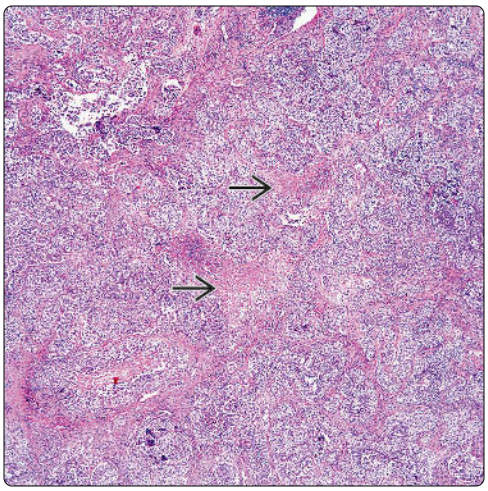

Areas of Necrosis

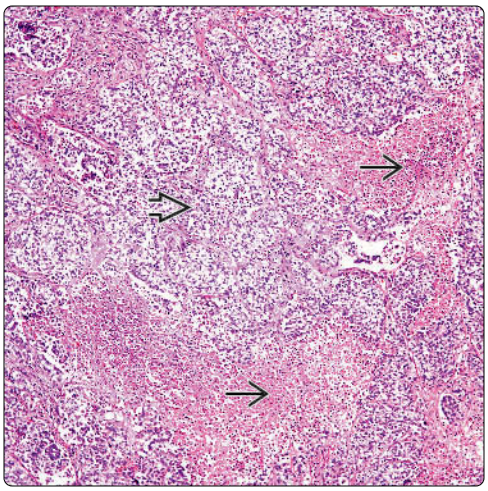

(Left) *Intermediate-grade NECa with a diffuse pattern of growth and discrete areas of necrosis is shown. The presence of areas of diffuse growth pattern should raise the suspicion of intermediate-grade tumors.* **(Right)** *Closer view of areas of necrosis in association with neoplastic neuroendocrine cells with vague nesting pattern are seen in this example of moderately differentiated NECa.*

Clear Cell Changes

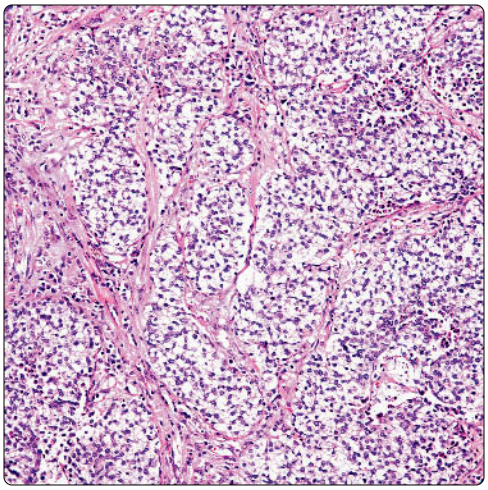

Clear Cells and Diffuse Growth Pattern

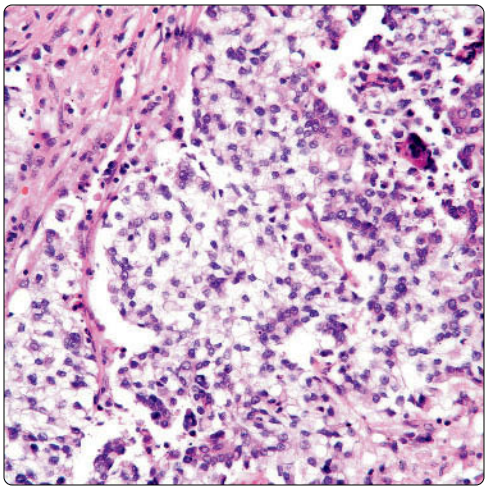

(Left) *H&E shows the characteristic nesting growth pattern of NECa; however, the neoplastic cellular proliferation is composed of clear cells. The presence of extensive areas of clear cell change in NECas is rare.* **(Right)** *A closer view shows neuroendocrine cellular proliferation composed predominantly of clear cells with small round and homogeneous nuclei. Nucleoli are inconspicuous.*

Intermediate-Grade Spindle Cell NECa

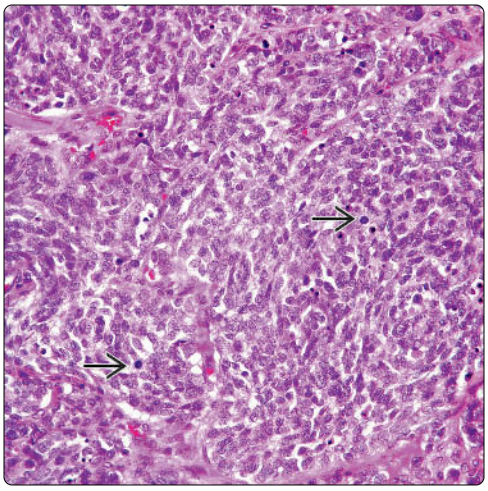

Intermediate-Grade NECa

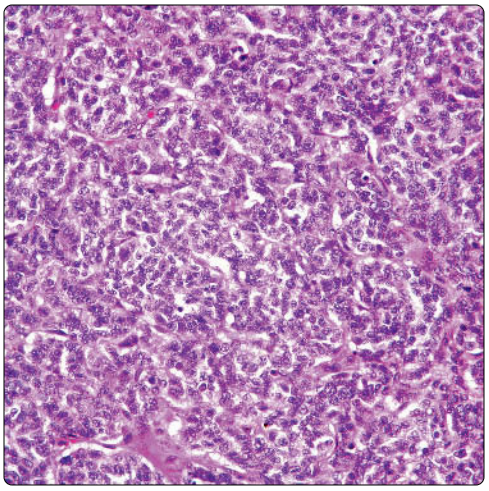

(Left) *Spindle cell NECa with easily identifiable mitotic figures ⇨ is shown. The mitotic count in NECa is the most important feature in the classification of these tumors.* **(Right)** *Sheets of neoplastic cells in a disorganized pattern of growth are shown. Nuclear atypia is evident and should prompt the search for mitotic activity.*

Extensive Areas of Necrosis

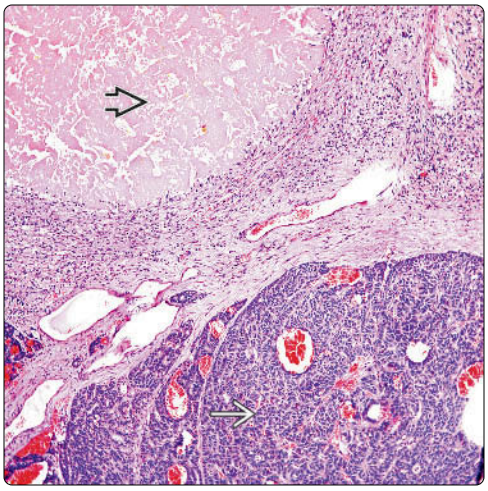

Easily Identifiable Mitotic Activity

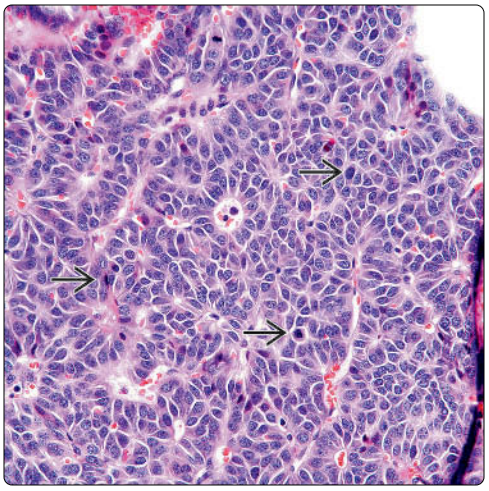

(Left) *Moderately differentiated NECa shows extensive areas of necrosis ⇨ with areas of viable tumor ➡. It is very important to separate tumor necrosis from other possible causes of necrosis, such as necrosis secondary to needle biopsy.* **(Right)** *Well-organized pattern with rosettes and easily identifiable mitotic figures ⇨ is shown. Although the pattern is fairly organized, the presence of mitotic figures is the most important criterion for grading these tumors.*

Small Cell Carcinoma Crush Artifact

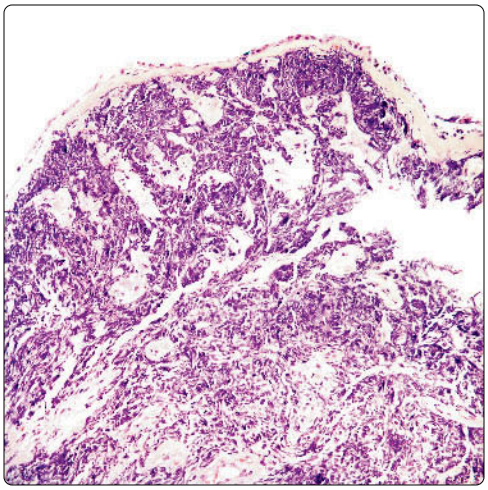

Core Biopsy of Small Cell Carcinoma

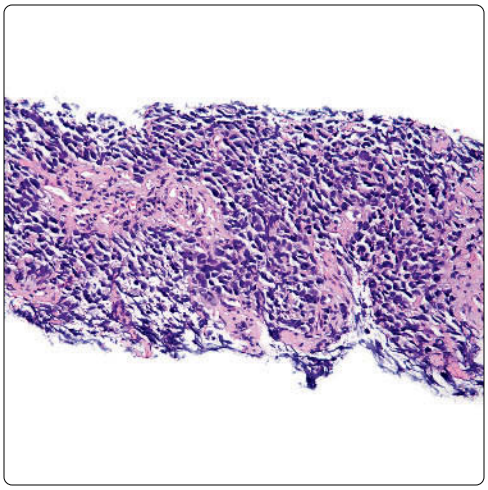

(Left) *Transbronchial biopsy specimen of small cell carcinoma with prominent crush artifact is shown. The presence of crush artifact appears to be more commonly seen in transbronchial biopsies than in core needle biopsies.* **(Right)** *Core biopsy specimen of a small cell carcinoma is shown. Note the preservation of tumor cells and the lack of crush artifact. The preservation of tumor cells is often better with this method.*

Viable Neoplastic Areas and Crush Artifact

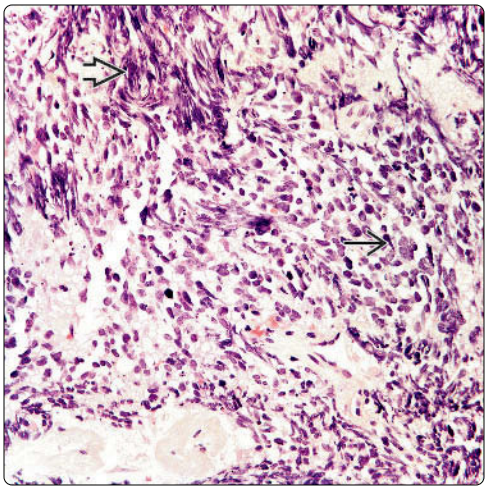

Intrapulmonary Well-Demarcated NECa

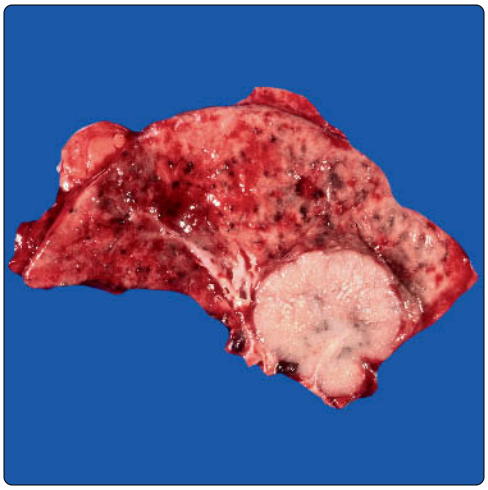

(Left) *Typical features of small cell carcinoma are shown. Note the viable areas of tumor cells ⇨ and the crush artifact ⇨. The mitotic count may not be high in a biopsy specimen, making precise categorization difficult in small samples.* **(Right)** *Gross photograph shows an intrapulmonary mass. The tumor is well circumscribed with a tan homogeneous cut surface. No areas of necrosis or hemorrhage are apparent.*

Lung Parenchyma Replaced by Tumor

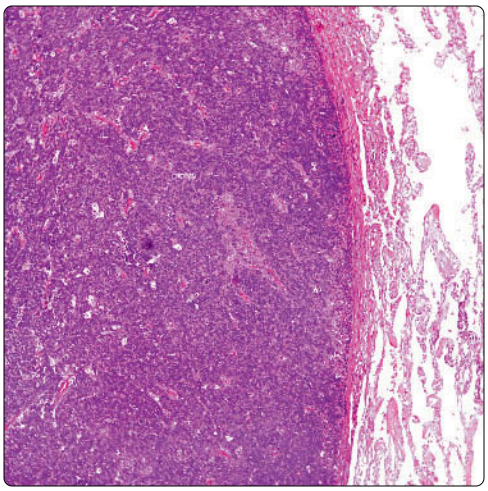

High-Grade Carcinoma

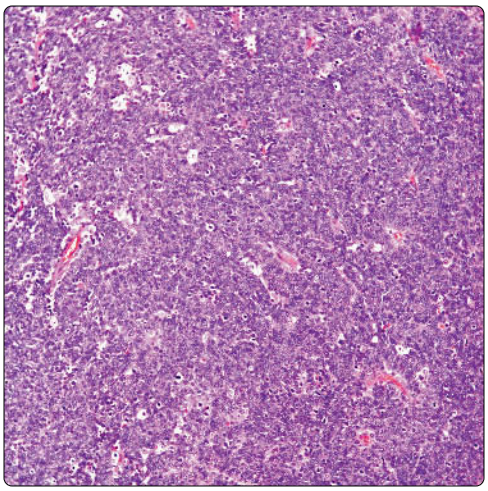

(Left) *Small cell carcinoma with diffuse sheets of tumor cells is shown. At this magnification, it is virtually impossible to unequivocally appreciate the small cell nature of the neoplasm.* **(Right)** *Sheets of neoplastic cells with obvious nuclear atypia, mitotic figures, and disorganized pattern of growth are seen in this high-grade NECa.*

Small Cell Carcinoma

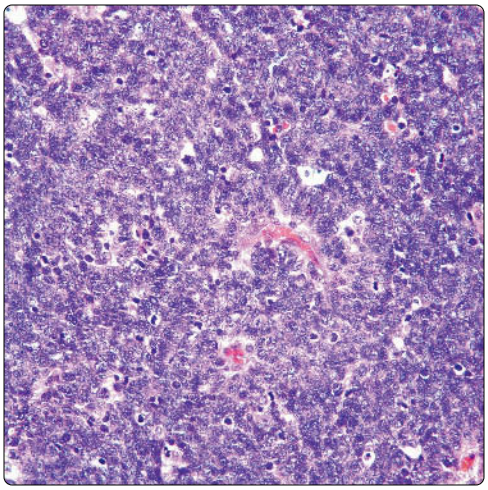

Small Cell Carcinoma and Adjacent Lymphocytes

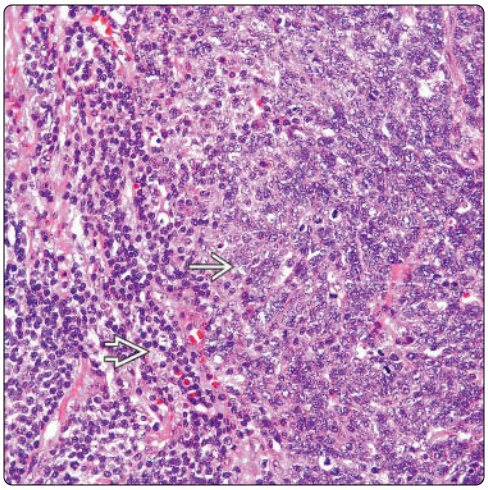

(Left) *Predominantly solid pattern of growth of neoplastic cells with high mitotic activity and prominent nuclear atypia is shown.* **(Right)** *Solid pattern of neoplastic cells admixed with numerous inflammatory cells, predominantly lymphocytes, are shown. In some cases, the inflammatory response may be very prominent. It is unusual to see this type of feature in small cell carcinomas.*

Extensive Geographic Necrosis

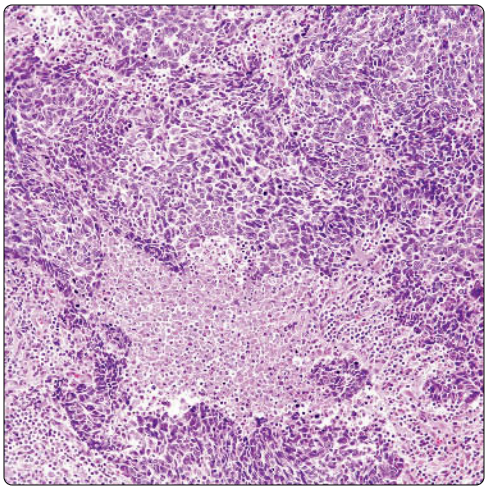

Absence of Nucleoli

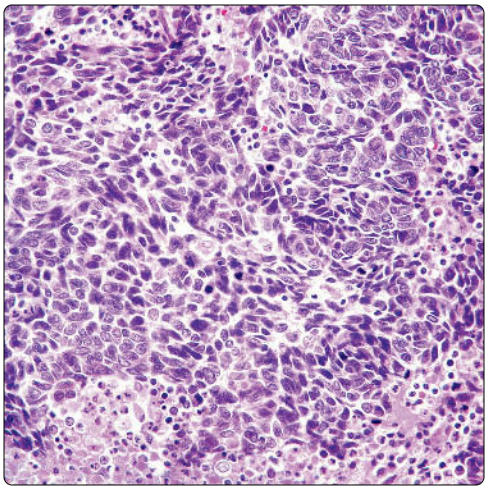

(Left) *High-grade NECa with extensive necrosis and sheets of neoplastic cells with a vague basaloid pattern is shown.* **(Right)** *Closer view of neoplastic cells in a high-grade NECa is shown. Note the absence of nucleoli, which is an important characteristic of these tumors. The features of small cell carcinomas in resected specimens may show better preservation than in biopsy specimens.*

Necrosis and Molding of Tumor Cells

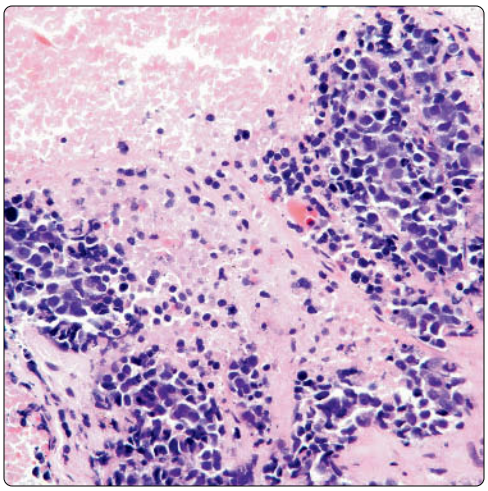

Viable Tumor in High-Grade NECa

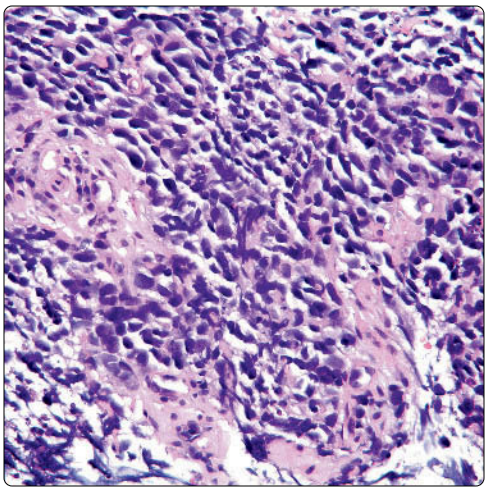

(Left) *Extensive necrosis and clusters of neoplastic cells are shown. The tumor cytology is that of small cells with scant cytoplasm and inconspicuous nucleoli. Often, the presence of extensive areas of necrosis is more commonly seen in high-grade tumors.* **(Right)** *Classic small cell morphology of small cells with nuclear molding and prominent atypia is shown. However, in this illustration, the presence of mitoses is not marked.*

Large Cell Neuroendocrine Carcinoma

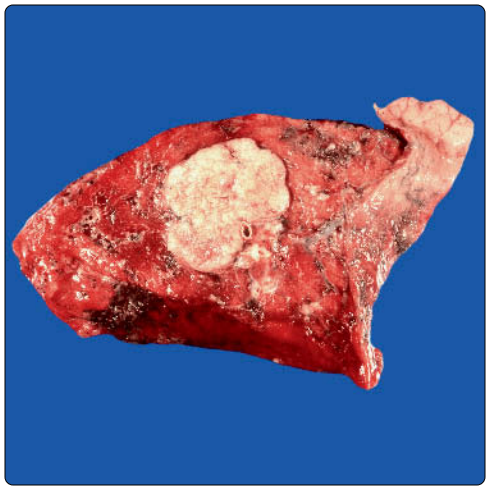

Nested Pattern



(Left) *Gross photograph shows a large intrapulmonary mass of irregular borders and focal areas of necrosis. The macroscopic characteristics of large cell NECa are not any different from other non-small cell carcinomas.* **(Right)** *Large cell NECa is shown. Note the well-circumscribed tumor mass destroying normal lung parenchyma. Even at this magnification, one can still see a nested pattern ⇨.*

Extensive Geographic Necrosis

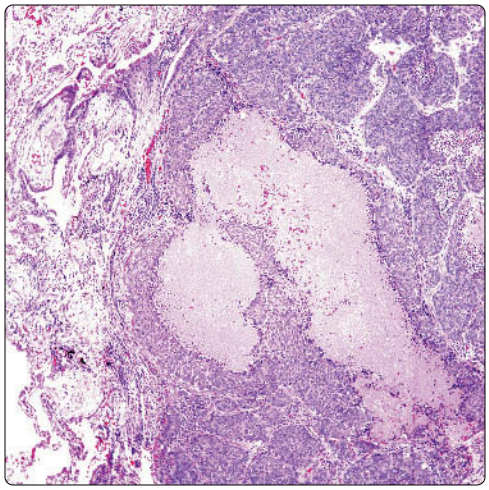

Ribbons and Nests of Neoplastic Cells

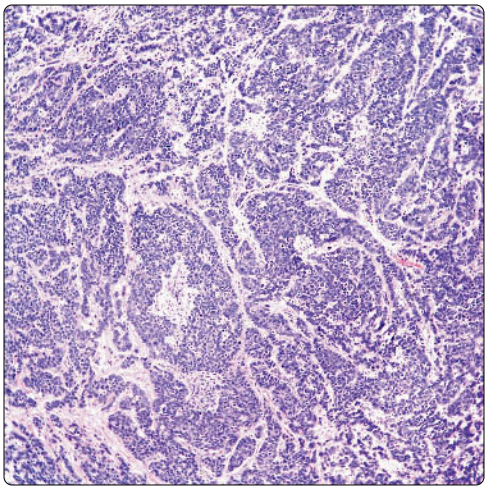

(Left) *Large cell NECa with areas of comedo-like necrosis is shown. The rest of the tumor shows a more basaloid growth pattern. This type of pattern is fairly common in large cell NECas.* **(Right)** *Large cell NECa with a subtle nested pattern is shown. Most of the tumor is arranged in ribbons or trabeculae of neoplastic cells.*

Prominent Basaloid Features

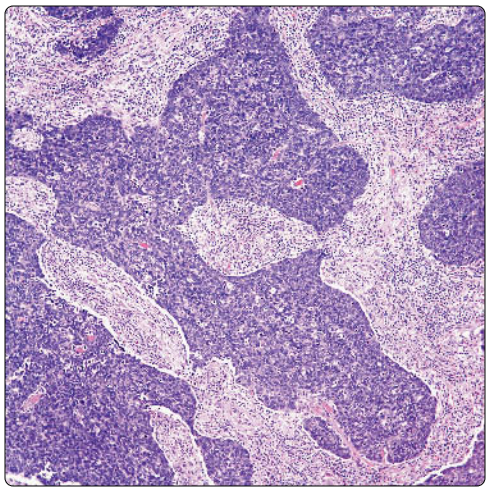

Oncocytic Features

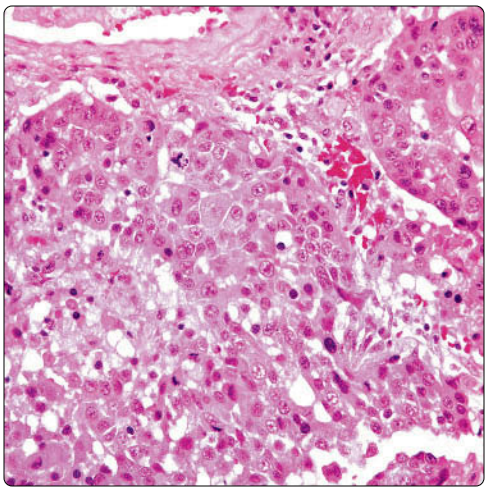

(Left) *Large cell NECa with basaloid features is shown. Note the nuclear palisading and the presence of an inflammatory component in the fibroconnective tissue.* **(Right)** *Closer view of the large cell NECa, displaying larger cells with round nuclei, light eosinophilic cytoplasm, and prominent nucleoli is shown. Essentially, the morphology is that of large cell carcinoma with positive neuroendocrine markers.*

Extensive Necrosis

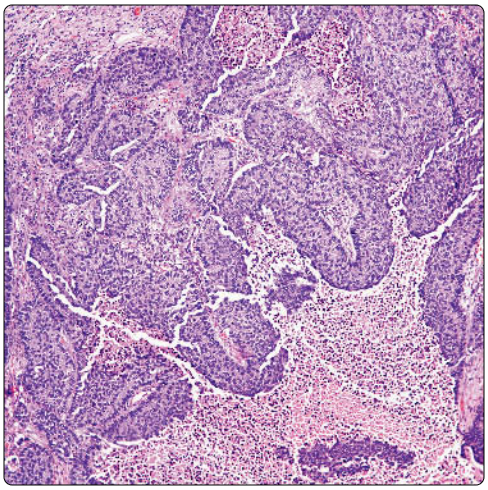

Presence of Nucleoli

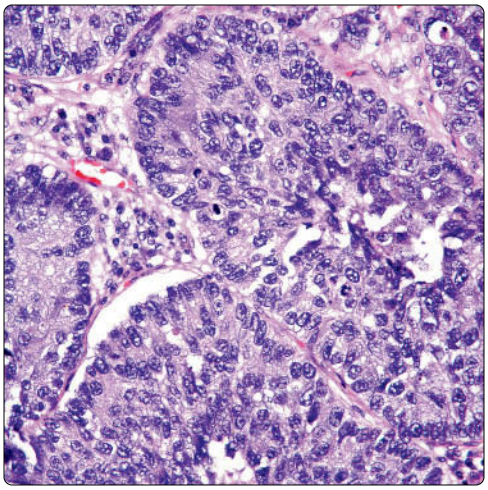

(Left) *Large cell NECa with necrosis and organoid pattern of growth is shown. This pattern, however, may be seen in tumors that do not show positive neuroendocrine markers.* **(Right)** *Closer view of neoplastic cells displaying nuclear atypia and prominent nucleoli are shown. However, it is the positive staining for neuroendocrine markers that confirms the diagnosis of large cell NECa.*

Large Cell Carcinoma

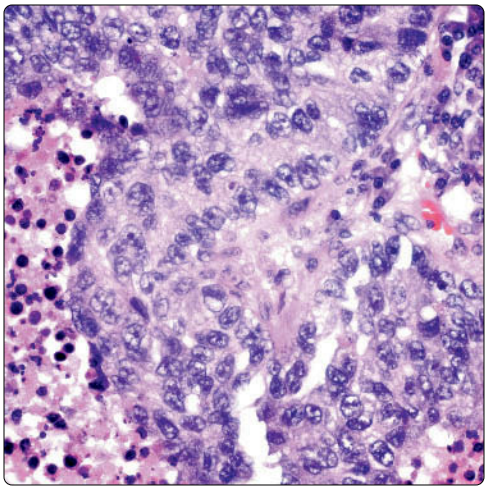

High-Grade NECa Mimicking Lower Grade

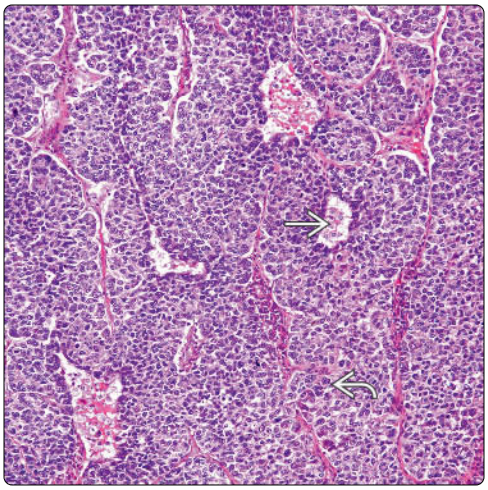

(Left) *High-power view of larger cells with ample cytoplasm, round nuclei, and prominent nucleoli is shown. These features are those of a non-small cell carcinoma.* **(Right)** *High-grade NECa with more conventional nesting pattern and absence of obvious necrosis is shown. In some focal areas, there is a hint of comedo-like necrosis ⇒ and the presence of larger pleomorphic cells ⇒.*

Well-Preserved Nested Growth Pattern

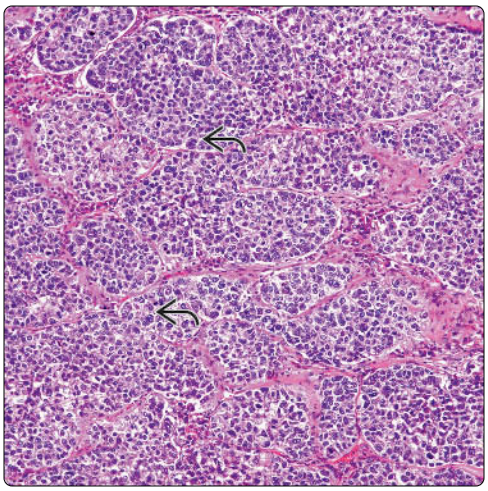

High-Grade NECa

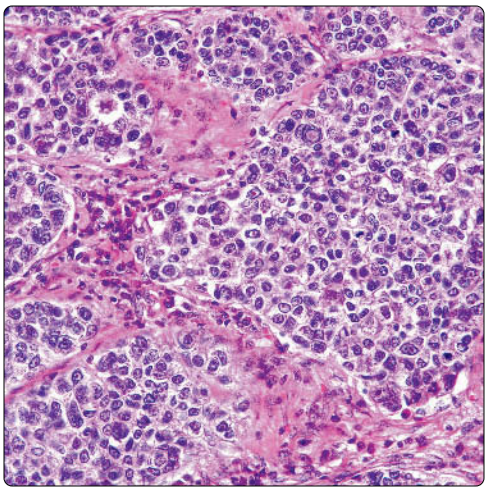

(Left) *High-grade NECa is shown with a very organized pattern of growth. Necrosis is absent; however, note the presence of marked nuclear atypia ⇒, which should raise the suspicion of a higher grade neoplasm.* **(Right)** *High-grade NECa shows the classic characteristics of prominent nuclear atypia and increased mitotic activity; however, necrosis is absent.*

Carcinosarcoma

KEY FACTS

TERMINOLOGY

- Malignant biphasic neoplasm composed of malignant epithelial and malignant mesenchymal components

ETIOLOGY/PATHOGENESIS

- Carcinosarcomas have been linked to tobacco use

CLINICAL ISSUES

- More common in men than women
- May be central or peripheral

MACROSCOPIC

- Central tumors may grow in polypoid fashion, obstructing airways
- Peripheral tumors may reach large size
- Areas of necrosis &/or hemorrhage are common
- 2 cm to > 10 cm in diameter

MICROSCOPIC

- Biphasic
- Presence of conventional carcinoma (any type) with sarcoma (any type)
- Squamous cell carcinoma is most common epithelial component
- Epithelial, biphasic, or mixed

TOP DIFFERENTIAL DIAGNOSES

- Carcinoma
  - In small biopsy specimen in which only epithelial component is present
    - Definitive diagnosis is rendered usually after complete resection of tumor
- Sarcoma
  - In small biopsy specimen in which only sarcomatous component is present
    - Definitive diagnosis is rendered usually after complete resection of tumor

Macroscopic Features

Biphasic Neoplasm

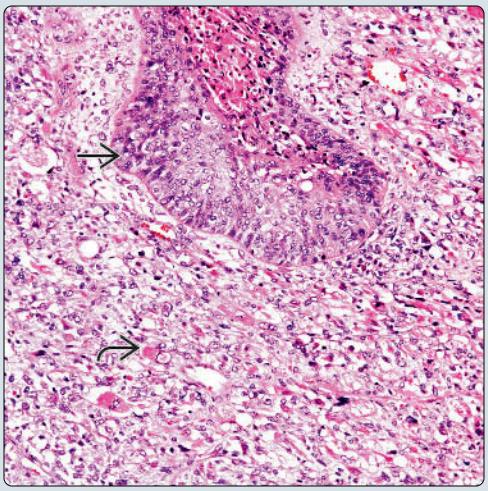

(Left) *Gross photograph of pulmonary carcinosarcoma shows a well-circumscribed, light tan, fleshy intrapulmonary mass. Note the absence of necrosis and hemorrhage.* **(Right)** *Primary carcinosarcoma of the lung shows classic features of squamous cell carcinoma and rhabdomyosarcoma.*

Carcinomatous Component

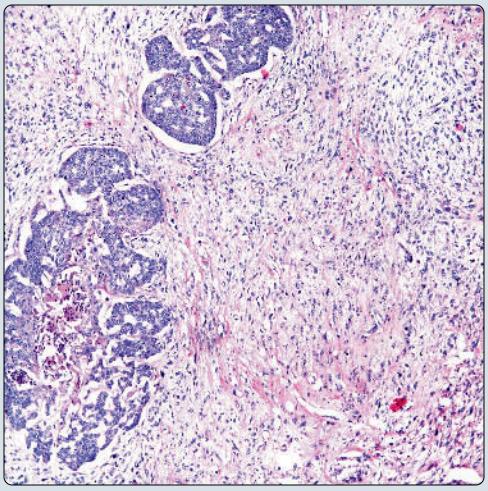

Sarcomatous Component

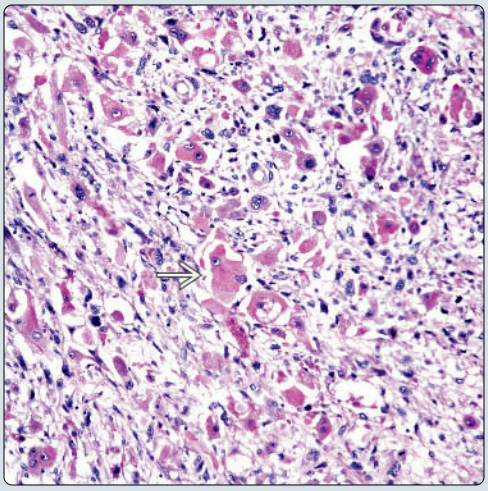

(Left) *Carcinosarcoma shows a solid epithelial component in the form of squamous cell carcinoma. The sarcomatous component is undifferentiated.* **(Right)** *Carcinosarcoma of the lung shows the sarcomatous component in the form of rhabdomyosarcoma. Note the presence of easily identifiable rhabdomyoblasts.*

Immunohistochemistry

Antibody	Reactivity	Staining Pattern	Comment
EMA/MUC1	Positive	Cell membrane	In epithelial component
CK5/6	Positive	Cytoplasmic	In epithelial component (squamous cell)
p40	Positive	Nuclear	In cases of squamous cell carcinoma component
p63	Positive	Nuclear	In cases of squamous cell carcinoma component
Chromogranin-A	Positive	Cytoplasmic	If small cell carcinoma is present
Synaptophysin	Positive	Cytoplasmic	If small cell carcinoma is present
CD56/NCAM/MOC1	Positive	Cytoplasmic	If small cell carcinoma is present
TTF-1	Positive	Nuclear	In cases of adenocarcinoma component
NAPSIN-A	Positive	Cytoplasmic	In cases of adenocarcinoma component
CK-PAN	Positive	Cytoplasmic	In epithelial component
CEA-M	Positive	Cytoplasmic	In epithelial component (adenocarcinoma)
Desmin	Positive	Cytoplasmic	In sarcomatous component (muscle differentiation)
MYOD1	Positive	Cytoplasmic	In sarcomatous component (muscle differentiation)
Caldesmon	Positive	Cytoplasmic	If muscle differentiation is present
MYOD1	Positive	Cytoplasmic	If muscle differentiation is present
CD31	Positive	Cytoplasmic	If vascular differentiation (angiosarcoma)
CD34	Positive	Cytoplasmic	If vascular differentiation (angiosarcoma)
ERG	Positive	Cytoplasmic	If vascular differentiation
S100	Positive	Cytoplasmic	Chondroid component
SOX2	Positive	Nuclear	Chondroid component
Myoglobin	Positive	Cytoplasmic	Muscle differentiation
STAT6	Negative		

Histochemical Features

Stain	Result
PAS	May show intracellular glycogen depending on epithelial component
PAS-D	May show intracellular mucin depending on epithelial component
Mucicarmine	May show intracellular mucin depending on epithelial component

Molecular Features

FISH	Result
( ) * 5	May be positive if adenocarcinoma is present

2. Noma D et al: A resected case of combined small cell lung carcinoma with carcinosarcoma. Pathol Int. 65(6):332-4, 2015
3. Braham E et al: Pulmonary carcinosarcoma with heterologous component: report of two cases with literature review. Ann Transl Med. 2(4):41, 2014
4. Sakakura N et al: Pulmonary carcinosarcoma successfully resected using the rib-cross thoracotomy approach: report of a case. Surg Today. 44(1):175-9, 2014
5. Kawachi K et al: Blastomatoid carcinosarcoma of the lung. Pathol Int. 63(7):377-9, 2013
6. Toyokawa G et al: The first case of lung carcinosarcoma harboring in-frame deletions at exon19 in the EGFR gene. Lung Cancer. 81(3):491-4, 2013
7. Carcano C et al: Bronchial carcinosarcoma. J Radiol Case Rep. 6(10):26-31, 2012
8. Chuang TL et al: Pulmonary carcinosarcoma: 18F-FDG PET/CT imaging. Clin Nucl Med. 37(11):1105-7, 2012
9. Pardo J et al: Primary mixed squamous carcinoma and osteosarcoma (carcinosarcomas) of the lung have a CGH mapping similar to primitive squamous carcinomas and osteosarcomas. Diagn Mol Pathol. 17(3):151-8, 2008
10. Mito A et al: [Case of pulmonary carcinosarcoma and a summary of 17 cases reported in Japan.] Nihon Kokyuki Gakkai Zasshi. 42(8):749-54, 2004
11. Aurello P et al: Squamocellular carcinoma and chondrosarcoma: a true pulmonary carcinosarcoma. Report of a case. Anticancer Res. 23(3C):3073-6, 2003
12. Petrov DB et al: Primary pulmonary sarcomas and carcinosarcomas--postoperative results and comparative survival analysis. Eur J Cardiothorac Surg. 23(4):461-6, 2003
13. Rossi G et al: Pulmonary carcinomas with pleomorphic, sarcomatoid, or sarcomatous elements: a clinicopathologic and immunohistochemical study of 75 cases. Am J Surg Pathol. 27(3):311-24, 2003
14. Koss MN et al: Carcinosarcomas of the lung: a clinicopathologic study of 66 patients. Am J Surg Pathol. 23(12):1514-26, 1999
15. Nappi O et al: Biphasic and monophasic sarcomatoid carcinomas of the lung. A reappraisal of 'carcinosarcomas' and 'spindle-cell carcinomas'. Am J Clin Pathol. 102(3):331-40, 1994
16. Davis MP et al: Carcinosarcoma of the lung: Mayo Clinic experience and response to chemotherapy. Mayo Clin Proc. 59(9):598-603, 1984

Biphasic Neoplasm

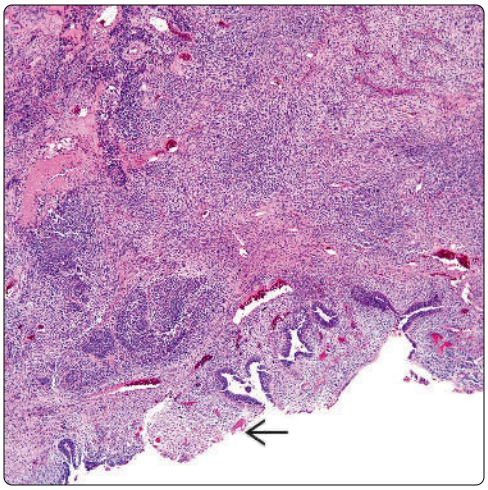

Mesenchymal Component

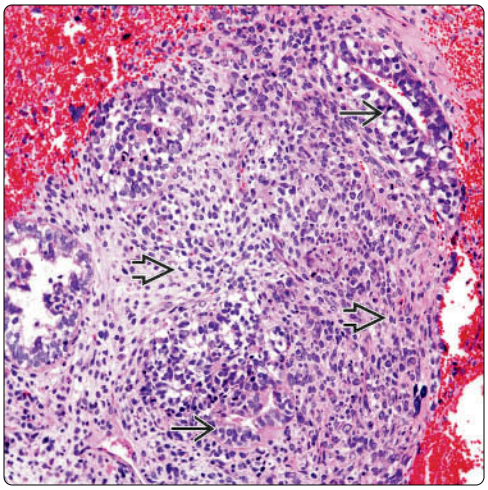

(Left) *This low-power view shows a mixed cellular composition. Note the presence of eroded superficial epithelium. This is a centrally located carcinosarcoma.* **(Right)** *Carcinosarcoma shows discrete merging between malignant epithelial and malignant mesenchymal components. In a cursory review, this tumor can be misdiagnosed as conventional carcinoma.*

Sarcomatous Component

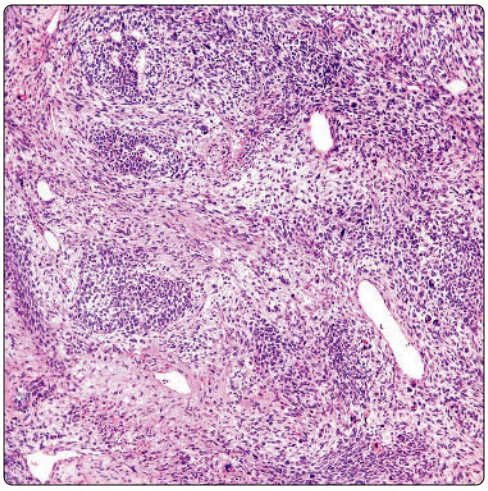

Rhabdomyosarcomatous Component

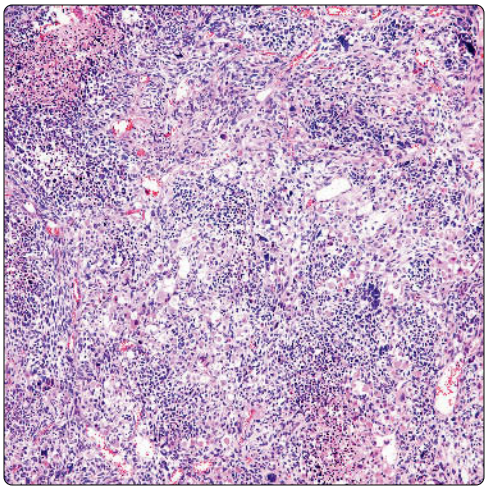

(Left) *Carcinosarcoma is shown with predominant sarcomatous elements. The sarcoma component of this tumor is of the high-grade type. In some cases, the use of immunohistochemistry may facilitate the identification of the specific sarcomatous component.* **(Right)** *Carcinosarcoma is shown in which there is myogenic differentiation in the form of rhabdomyosarcoma. In some cases, the merging of epithelial and mesenchymal components may not be so obvious.*

Epithelial Component

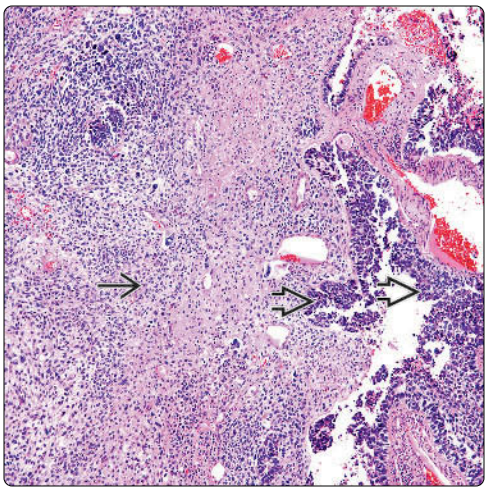

Squamous Cell Component

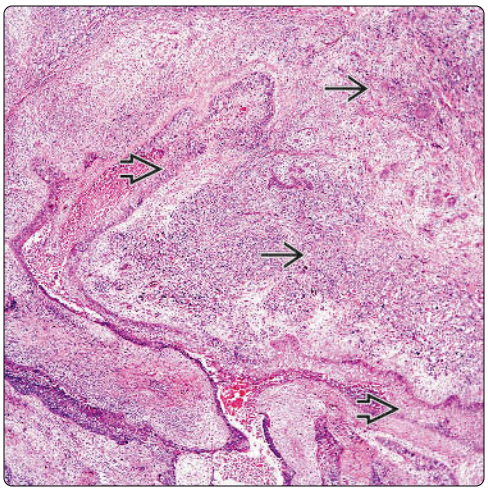

(Left) *Carcinosarcoma is shown in which the malignant component is of glandular type, whereas the sarcomatous component is rather undifferentiated.* **(Right)** *Carcinosarcoma is seen with an easily identifiable squamous cell carcinoma admixed with areas of a high-grade sarcomatous component. Squamous cell carcinoma is 1 of the most common components of carcinosarcoma.*

Chondrosarcomatous Component

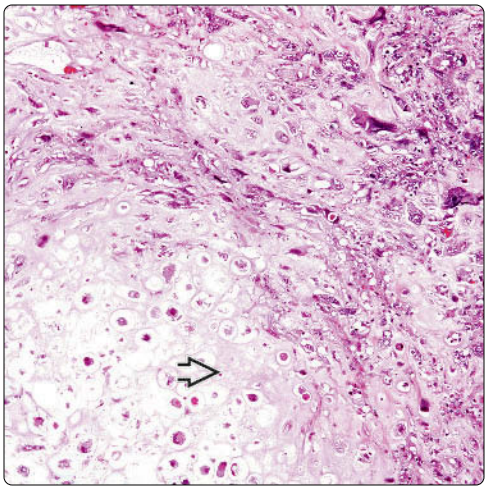

Strands of Squamous Cell Carcinoma

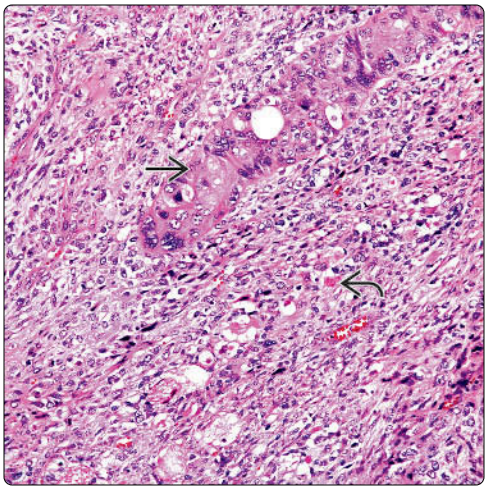

(Left) *Carcinosarcoma is shown with a high-grade chondrosarcoma as the mesenchymal component. In this image, the presence of an epithelial component is not obvious, and cases like this require extensive sampling to demonstrate its presence.* **(Right)** *In some cases of carcinosarcoma, the mesenchymal component may be more extensive than the epithelial component. In this illustration, the rhabdomyosarcoma is more prominent than the squamous cell carcinoma.*

Sarcomatous Component

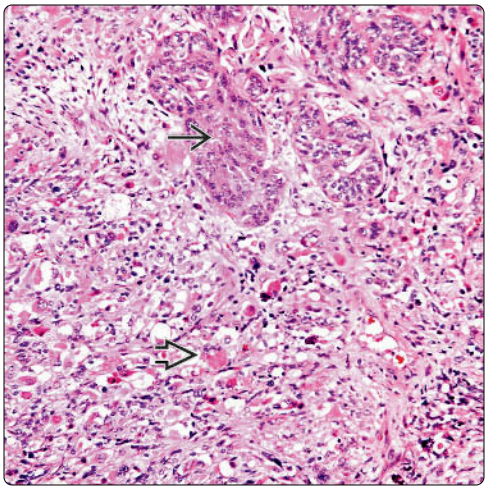

Osteosarcomatous Component

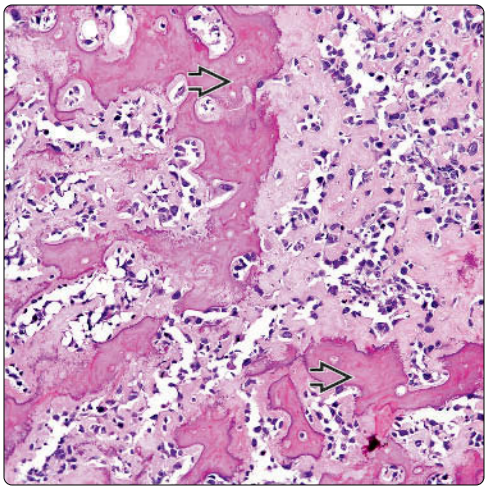

(Left) *Predominantly rhabdomyosarcomatous component is seen with only focal areas of a malignant epithelial component (squamous cell carcinoma). As seen here, the epithelial component may be a minor component in some cases.* **(Right)** *Carcinosarcoma is shown in which the mesenchymal component is composed of osteosarcoma. Note presence of bone formation. Essentially any sarcomatous component may be present in carcinosarcomas of the lung.*

Squamous Carcinoma and Sarcoma

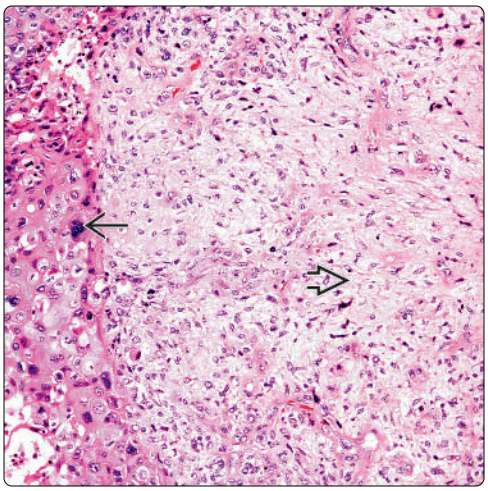

Rhabdomyosarcoma

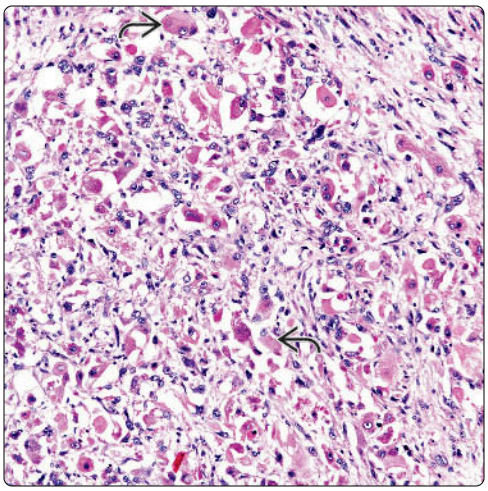

(Left) *Carcinosarcoma is shown with squamous cell carcinoma as well as a sarcomatous component with myxoid and vascular features. In some cases of carcinosarcoma, the light microscopy may not be helpful to differentiate the specific type of sarcoma.* **(Right)** *Classic rhabdomyosarcoma is shown with numerous rhabdomyoblasts as a component of a carcinosarcoma. In some tumors, the epithelial component may be minor.*

Biphasic Neoplasm

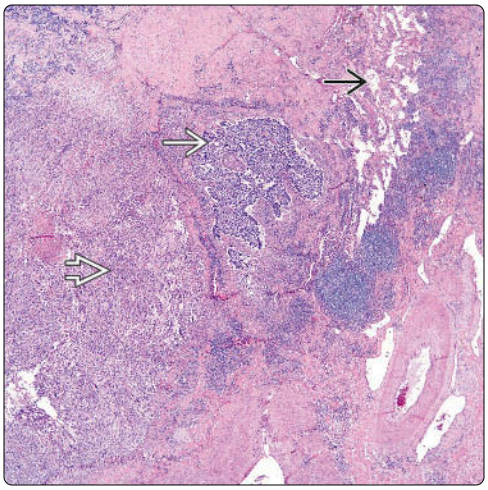

Biphasic Neoplasm

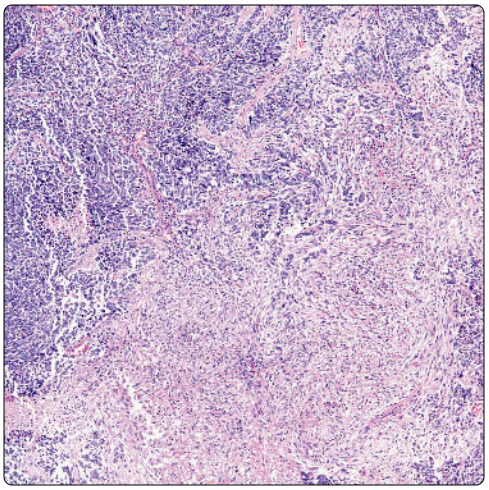

(Left) *Low-power view of a carcinosarcoma of the lung shows 2 different cell populations, one composed of round cells ⇨ and the other composed of spindle cells ⇨. Note the adjacent lung parenchyma ⇨.* **(Right)** *Carcinosarcoma shows 2 distinct cell populations, one clearly a carcinoma and the other a spindle cell sarcoma. Both of those components are easily identifiable on morphological grounds.*

Predominantly Sarcoma

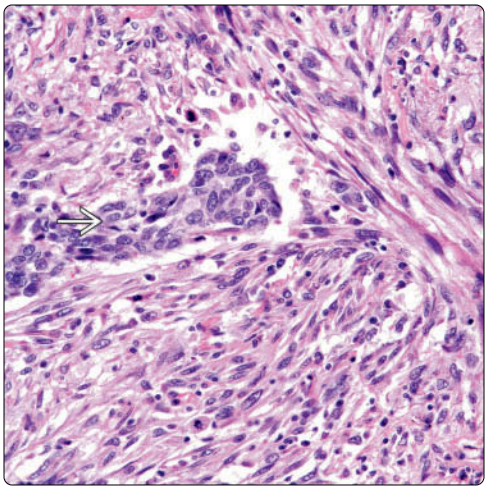

Predominantly Carcinoma

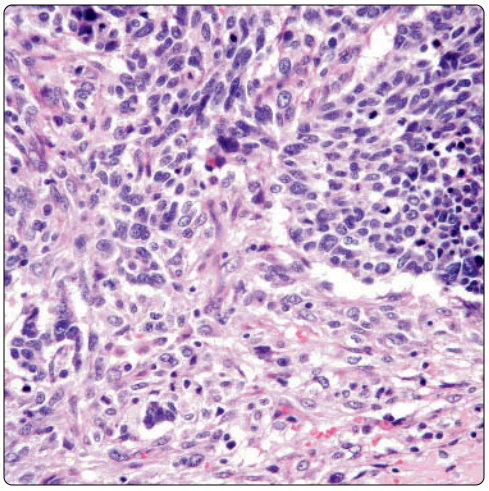

(Left) *Carcinosarcoma predominantly shows a spindle cell sarcoma with only islands of carcinomatous elements ⇨.* **(Right)** *In some areas, the predominant feature may be that of a carcinoma with only a subtle component of spindle cell sarcoma.*

Carcinoma

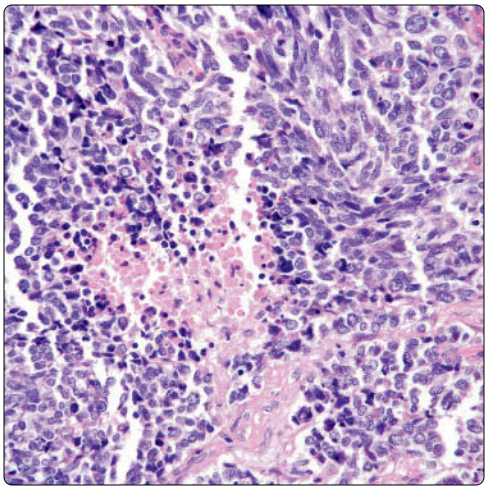

Sarcomatous Component

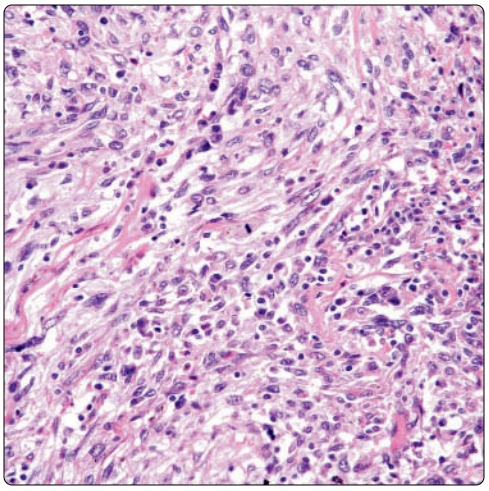

(Left) *Higher magnification of the carcinomatous component in a carcinosarcoma of the lung shows conventional small cell carcinoma. This type of carcinomatous component is unusual.* **(Right)** *Higher magnification of a carcinosarcoma of the lung shows the spindle cell sarcomatous component. In this case, it is represented by leiomyosarcoma.*

Pulmonary Blastoma

KEY FACTS

TERMINOLOGY

- Synonyms: Well-differentiated fetal adenocarcinoma, pulmonary embryoma
- Pulmonary blastoma (PB) monophasic type (well-differentiated fetal adenocarcinoma): Glandular component recapitulates embryonic development of lung
- PB biphasic type: Composed of epithelial glandular component and sarcomatous elements

CLINICAL ISSUES

- Monophasic PBs have better prognosis
- Biphasic PBs behave more aggressively
- Tumor size (> 5 cm) linked with poor prognosis

MICROSCOPIC

- Glandular component mimics embryologic development of lung between weeks 11-18
- Presence of morules

TOP DIFFERENTIAL DIAGNOSES

- Adenocarcinoma with morular component
  - Presence of intracellular mucin
  - Presence of morules is within glandular spaces
- Carcinosarcoma
  - Will show heterologous component in form of angiosarcoma, chondrosarcoma, rhabdomyosarcoma, or other form of sarcoma
  - Epithelial component is usually squamous cell carcinoma
- Pleuropulmonary blastoma
  - Epithelial component is benign
  - Tumor is pleural-based rather than intraparenchymatous
- Secretory endometrioid-like adenocarcinoma
  - Presence of intracellular mucin
  - Absence of morules

Pulmonary Blastoma

Monophasic

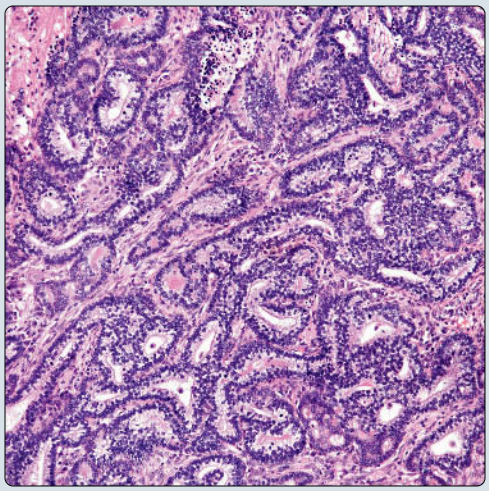

(Left) *Gross photograph of pulmonary blastoma (PB) shows an intrapulmonary mass with areas of hemorrhage and necrosis. The tumor in the more viable areas appears light tan in color ⇨.* **(Right)** *PB shows a complex glandular proliferation with a back-to-back arrangement with little intervening stromal tissue.*

Morules

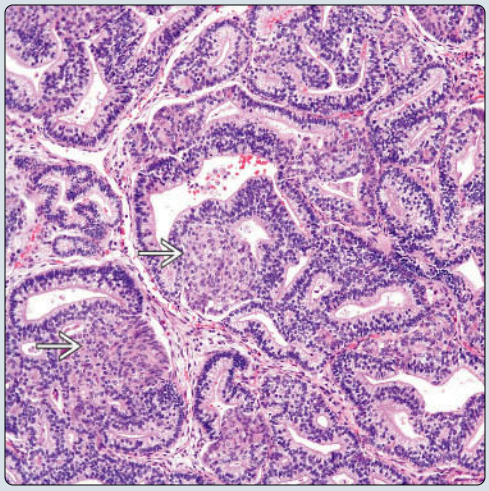

Vacuolization

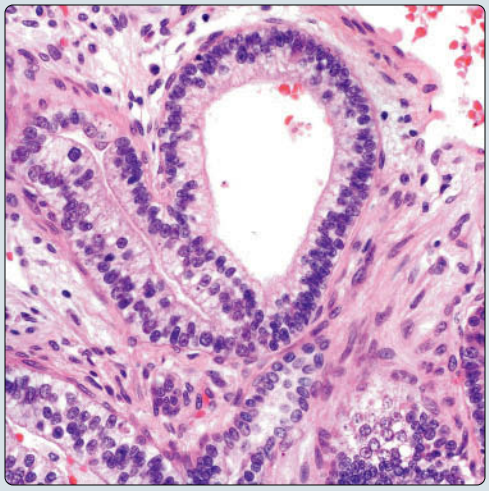

(Left) *PB shows the presence of morules ⇨, which represent a classic feature in the diagnosis of PB.* **(Right)** *PB shows back-to-back glands with the supranuclear vacuoles, which are characteristic of this neoplasm.*

TERMINOLOGY

Abbreviations

- Pulmonary blastoma (PB)

Synonyms

- Well-differentiated fetal adenocarcinoma
- Pulmonary embryoma

Definitions

- PB monophasic type (well-differentiated fetal adenocarcinoma)
  - Glandular component recapitulates embryonic development of lung
- PB biphasic type
  - Composed of epithelial glandular component and sarcomatous elements

CLINICAL ISSUES

Epidemiology

- Incidence
  - Rare; may account for < 1% of all pulmonary neoplasms
- Age
  - More common in adults
  - Unrelated to pleuropulmonary blastoma in children

Presentation

- Cough
- Hemoptysis
- Chest pain
- Hoarseness
- Weight loss
- General malaise
- Asymptomatic

Treatment

- Surgical approaches
  - Complete surgical resection
- Adjuvant therapy
  - No specific treatment
  - Chemotherapy may be used
  - Radiation may be used

Prognosis

- Monophasic PBs have better prognosis
- Biphasic PBs behave more aggressively
- Tumor size (> 5 cm) linked with poor prognosis

IMAGING

Radiographic Findings

- Intrapulmonary mass of varying size

MACROSCOPIC

General Features

- Central or peripheral tumor
- Well circumscribed but not encapsulated
- Homogeneous or slightly lobulated cut surface
- Tan in color ± areas of necrosis &/or hemorrhage
- 1-20 cm in diameter

MICROSCOPIC

Histologic Features

- Glandular component mimics embryologic development of lung between 11-18 weeks
- Back-to-back glandular proliferation
- Mild to moderate cellular atypia
- Mitotic count is not high
- Presence of morules (squamoid foci) more common in monophasic type
- Sarcomatous elements in biphasic type
- More cellular atypia and mitotic activity in biphasic type
- Differentiation into different tissues can occur
- Focal cartilaginous component may be seen in monophasic tumors

Predominant Pattern/Injury Type

- Glandular
- Biphasic

Predominant Cell/Compartment Type

- Epithelial, glandular
- Epithelial, biphasic, or mixed

DIFFERENTIAL DIAGNOSIS

Adenocarcinoma

- Glandular proliferation of PB recapitulates embryologic development of lung (weeks 11-18)
- Adenocarcinoma will lack presence of morules
- Absence of intracellular mucin in PB

Carcinosarcoma

- Most commonly has squamous cell carcinoma as epithelial component
- Glandular epithelial component will not show embryonic features of glandular component of PB
- Absence of morules

Pleuropulmonary Blastoma

- Tumor of children
- Epithelial component is benign
- Usually is cystic involving pleuropulmonary structures

Sarcoma

- If only spindle cell component is sampled
- Limited biopsy material

Metastatic Adenocarcinoma

- Pertinent clinical history will lead to correct interpretation
- Immunohistochemical stains for TTF-1 and B-catenin will be of of help

DIAGNOSTIC CHECKLIST

Clinically Relevant Pathologic Features

- Age distribution
- Predominantly in adult individuals
- Intrapulmonary mass

Pathologic Interpretation Pearls

- Glandular proliferation with morular component mimicking embryonic development of lung between weeks 11-18

Immunohistochemistry

Antibody	Reactivity	Staining Pattern	Comment
TTF-1	Positive	Nuclear	In glandular component in majority of cases
β-catenin	Positive	Cytoplasmic	In glandular component
KERATIN-LMW	Positive	Cytoplasmic	In glandular component
EMA/MUC1	Positive	Cell membrane	In glandular component
CEA-M	Positive	Cytoplasmic	In glandular component
Chromogranin-A	Positive	Cytoplasmic	Morules only
p53	Positive	Cytoplasmic	
Desmin	Positive	Cytoplasmic	In muscle component
SOX2	Positive	Nuclear	Chondroid component
Myoglobin	Positive	Cytoplasmic	Rhabdomyosarcomatous component
p40	Negative		
CK5/6	Negative		
p63	Negative		In some cases, may show focal positive staining
NAPSIN-A	Positive	Cytoplasmic	In some cases
Surfactant-A	Negative		
pax-8	Negative		
GATA3	Negative		
CDX-2	Negative		
CK20	Negative		

Histochemical Features

Stain	Result	Comment
PAS	Positive for intracellular glycogen	
PAS-D	Negative for intracellular mucin	
Mucicarmine	Negative for intracellular mucin	May show positive staining in intraluminal areas

Molecular Features

FISH	Result
(*) 5	May be positive in some cases
3 , . & $	May be positive in some cases
. 5 $ 6	May be positive in some cases
$ / .	Negative

- Glandular component lacks intracellular mucin
- Biphasic tumor

SELECTED REFERENCES

1. Suzuki M et al: High-grade fetal adenocarcinoma of the lung is a tumour with a fetal phenotype that shows diverse differentiation, including high-grade neuroendocrine carcinoma: a clinicopathological, immunohistochemical and mutational study of 20 cases. Histopathology. 67(6):806-16, 2015
2. Xiu Y et al: Classic biphasic pulmonary blastoma with brain and axillary metastases: a case report with molecular analysis and review of literature. Int J Clin Exp Pathol. 8(1):983-8, 2015
3. Kawasaki K et al: Surgery and radiation therapy for brain metastases from classic biphasic pulmonary blastoma. BMJ Case Rep. 2014, 2014
4. Lkhoyaali S et al: Neoadjuvant chemotherapy in well-differentiated fetal adenocarcinoma: a case report. BMC Res Notes. 7:283, 2014
5. Patnayak R et al: Well-differentiated fetal adenocarcinoma of the lung in an adult male: report of an unusual tumor with a brief review of literature. J Cancer Res Ther. 10(2):419-21, 2014
6. Nakayama T et al: Classic pulmonary blastoma: a subtype of biphasic pulmonary blastoma. Ann Thorac Cardiovasc Surg. 18(2):125-7, 2012
7. Van Loo S et al: Classic biphasic pulmonary blastoma: a case report and review of the literature. Lung Cancer. 73(2):127-32, 2011
8. Weissferdt A et al: Malignant biphasic tumors of the lungs. Adv Anat Pathol. 18(3):179-89, 2011
9. Berho M et al: Malignant mixed epithelial/mesenchymal neoplasms of the lung. Semin Diagn Pathol. 12(2):123-39, 1995
10. Koss MN et al: Pulmonary blastomas. Cancer. 67(9):2368-81, 1991
11. Nakatani Y et al: Pulmonary endodermal tumor resembling fetal lung: a clinicopathologic study of five cases with immunohistochemical and ultrastructural characterization. Hum Pathol. 21(11):1097-107, 1990
12. Kodama T et al: Six cases of well-differentiated adenocarcinoma simulating fetal lung tubules in pseudoglandular stage. Comparison with pulmonary blastoma. Am J Surg Pathol. 8(10):735-44, 1984

Normal Lung: Weeks 11-18

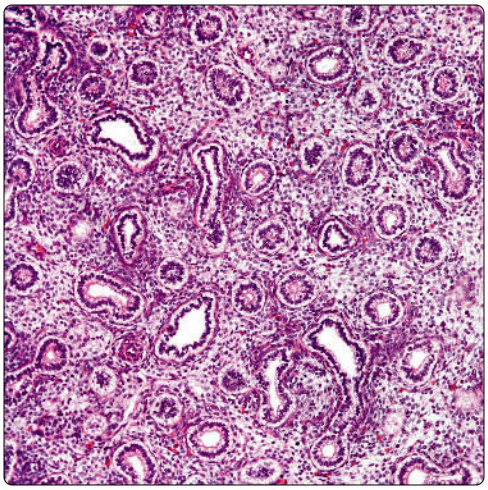

Monophasic

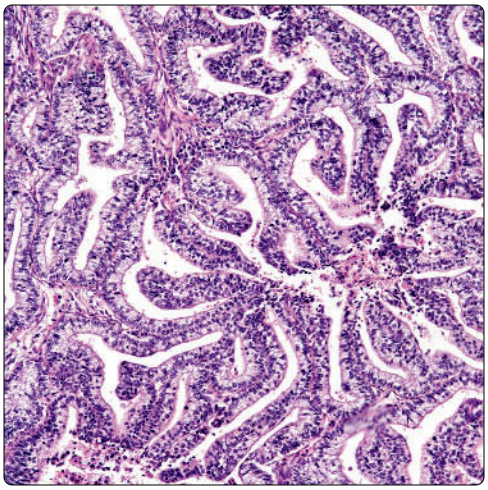

(Left) *Normal lung parenchyma of an embryo is shown between weeks 11-18. The resemblance to the monophasic pulmonary blastoma is marked, thus the designation of fetal-type adenocarcinoma.* **(Right)** *Monophasic PB is composed of anastomosing glands of different sizes with the classic supranuclear vacuole.*

Monophasic

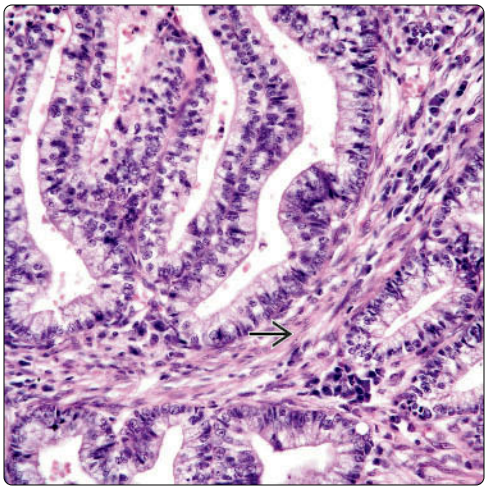

Morules

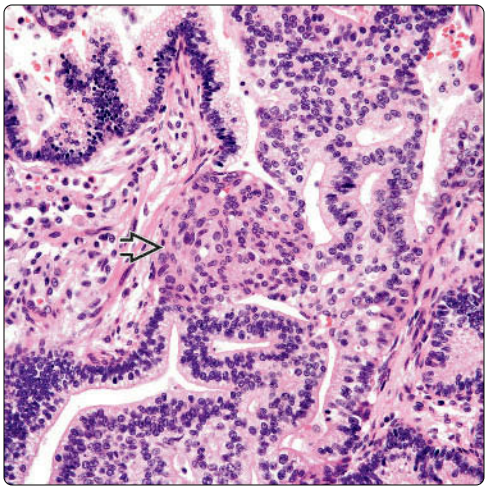

(Left) *Higher magnification shows a monophasic PB formed by glands with nuclei displaced toward the base and supranuclear vacuoles. This arrangement mimics endometrioid-like carcinomas. Also note the presence of the minimal stromal component* ⇨. **(Right)** *Monophasic PB is shown with the classic glandular arrangement and focal squamous morule formation* ⇨.

Necrosis

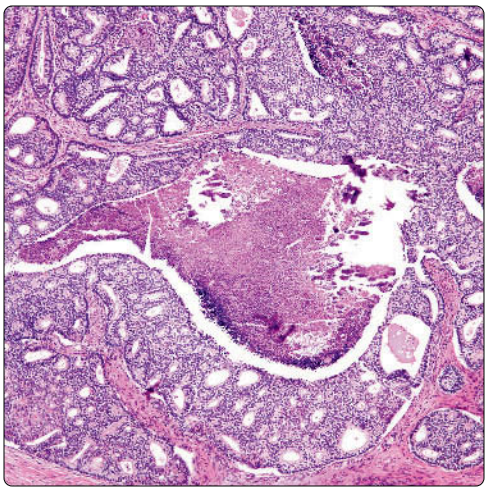

Monophasic

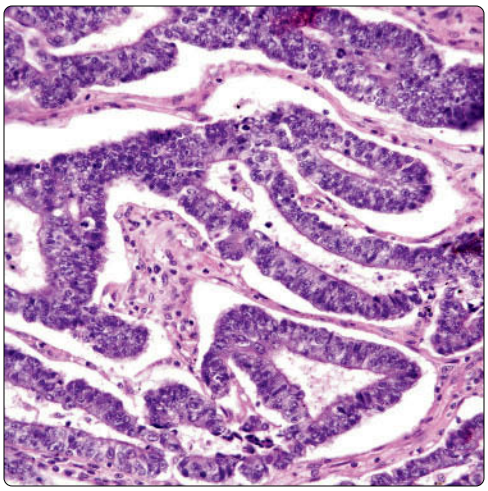

(Left) *Low-power view of a monophasic PB with comedo-like necrosis and a vague cribriform-like pattern is shown.* **(Right)** *Monophasic PB is shown in which the glandular proliferation is present within the alveolar spaces in an alveolar-like type of invasion. Note the presence of more nuclear atypia and mitotic activity.*

Cartilage

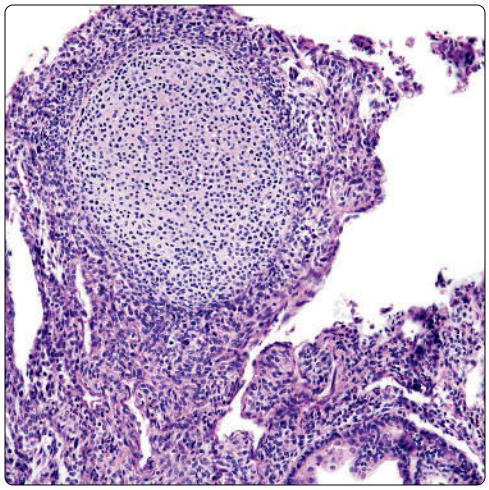

Biphasic

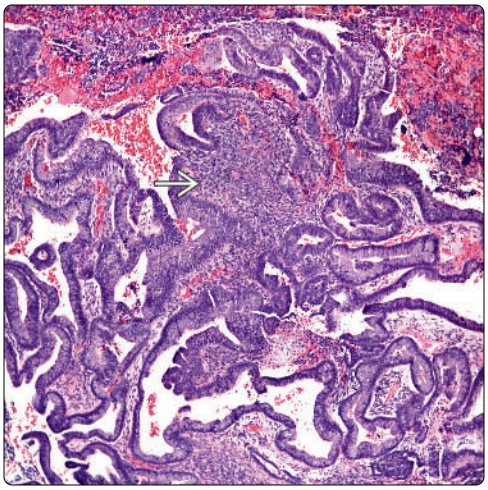

(Left) *Monophasic PB is shown with a focal area of cartilage. This feature may be confused for a carcinosarcoma or with a biphasic tumor. Although rare, this feature can occur in monophasic tumors.* **(Right)** *Biphasic PB shows a complex glandular arrangement with dilated glands. Within the glandular structures there is subtle spindle cell proliferation.*

Biphasic

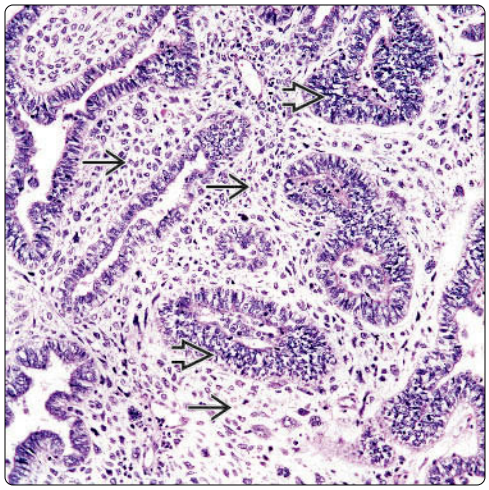

Biphasic

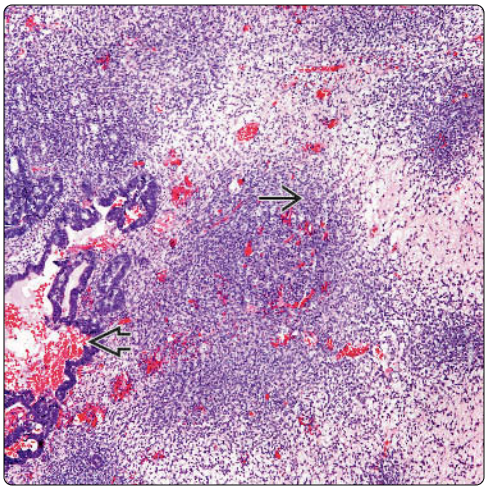

(Left) *Closer view shows a biphasic PB with 2 components: A glandular malignant epithelial component and a malignant mesenchymal component.* **(Right)** *Biphasic PB is shown with a prominent malignant mesenchymal component and only small areas of epithelial glandular elements.*

Biphasic

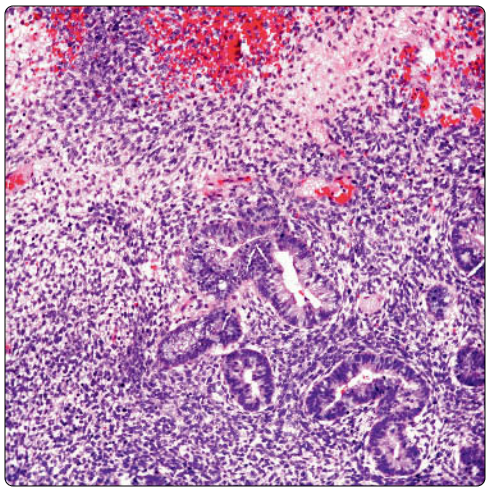

Hepatocellular Component

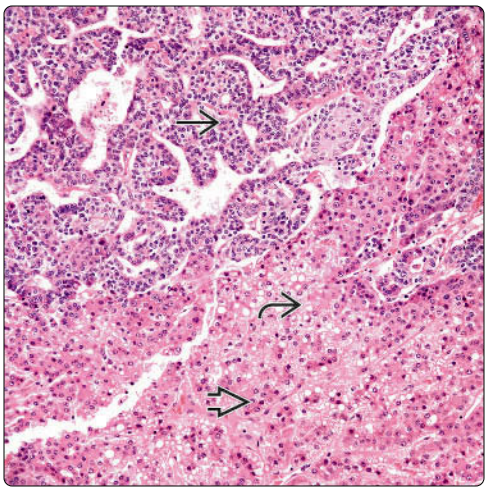

(Left) *Higher magnification of a biphasic PB with glandular and mesenchymal components is shown.* **(Right)** *PB is shown with a hepatocellular carcinomatous component. In the hepatocellular component, note the areas that can be construed as fat droplets. This is an unusual feature that only occasionally may be seen in these tumors.*

Glandular Proliferation

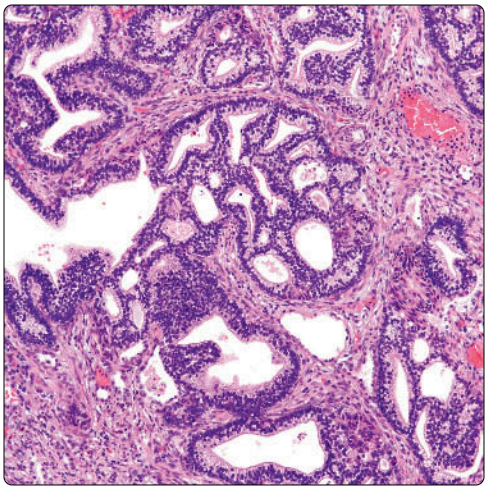

Rosette-Like Formation

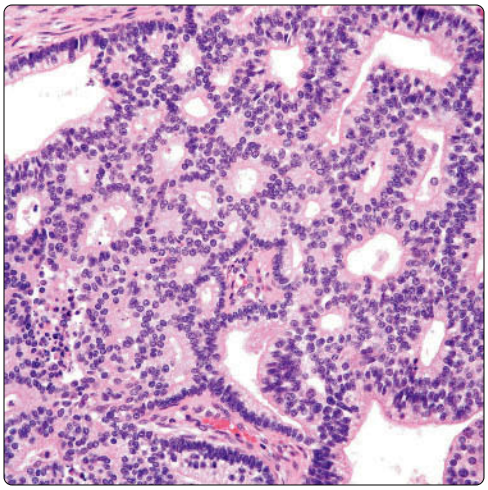

(Left) *Monophasic blastoma shows the typical glandular proliferation in a back-to-back pattern with distinct lumen formation.* **(Right)** *Monophasic blastoma shows solid areas in which the glands give the appearance of a rosette-like formation, similar to that seen in neuroendocrine carcinomas.*

Desmoplastic Stroma

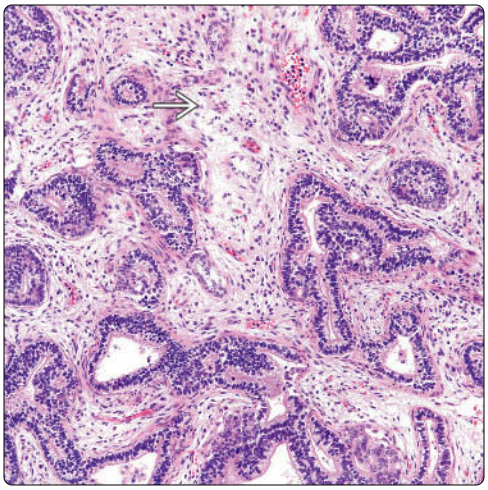

Incomplete Glands

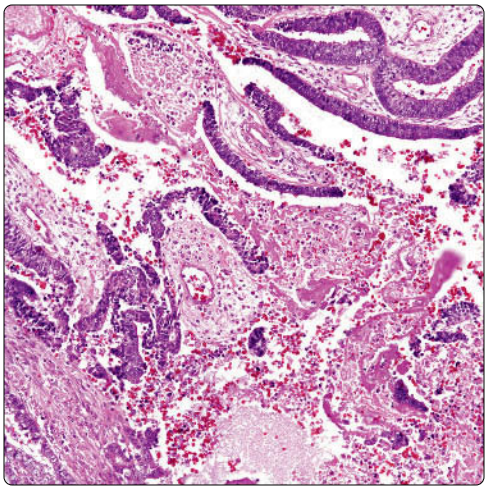

(Left) *Monophasic blastoma shows desmoplastic areas* ⇨*, which can be easily confused with sarcomatoid component in a biphasic neoplasm.* **(Right)** *Monophasic blastoma shows areas of fibrinoid necrosis with atypical epithelium and incomplete gland formation.*

β-Catenin Stain

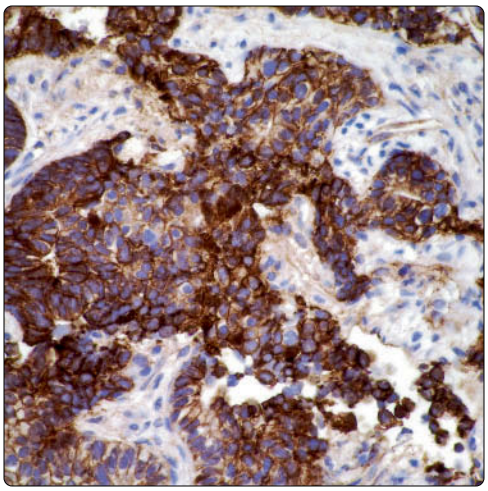

TTF-1 Immunostain

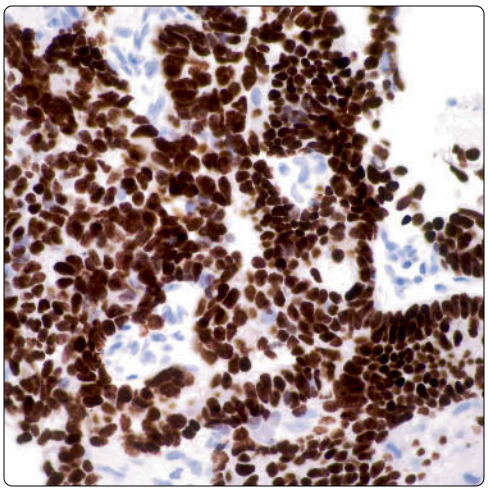

(Left) *Monophasic blastoma shows a strong β-catenin (+) reaction in tumor cells.* **(Right)** *Monophasic blastoma shows strong nuclear positivity for TTF-1.*

Adenoid Cystic Carcinoma

KEY FACTS

TERMINOLOGY

- Epithelial neoplasm similar to that occurring in salivary glands

CLINICAL ISSUES

- Presentation
  - Cough, hemoptysis, dyspnea, chest pain
- Treatment
  - Lobectomy or pneumonectomy
- Pathogenesis
  - May follow aggressive behavior with metastasis

MACROSCOPIC

- Endobronchial tumor
- Submucosal mass, which may penetrate bronchial wall

MICROSCOPIC

- Most common pattern cribriform with spaces within mass represent pseudocysts rather than glands
- Perineural invasion is common as in salivary gland tumor of same type

ANCILLARY TESTS

- Immunohistochemical stains confirm immunophenotype of myoepithelial cells: Positive with CK-PAN, actin-sm, and vimentin

TOP DIFFERENTIAL DIAGNOSES

- Adenocarcinoma

DIAGNOSTIC CHECKLIST

- Glands are composed of 2 rows of cells surrounding pseudocystic spaces

Bronchial Adenoid Cystic Carcinoma

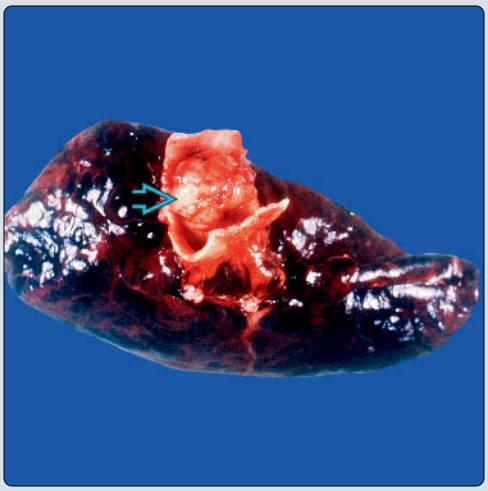

Cylindromatous Pattern

(Left) *Gross photograph of adenoid cystic carcinoma shows a polypoid endobronchial tumor mass obstructing most of the bronchial lumen.* **(Right)** *Adenoid cystic carcinoma shows a conventional cylindromatous growth pattern. Note the presence of bronchial cartilage and the tumor obliterating normal lung parenchyma.*

Mild Cellular Atypia

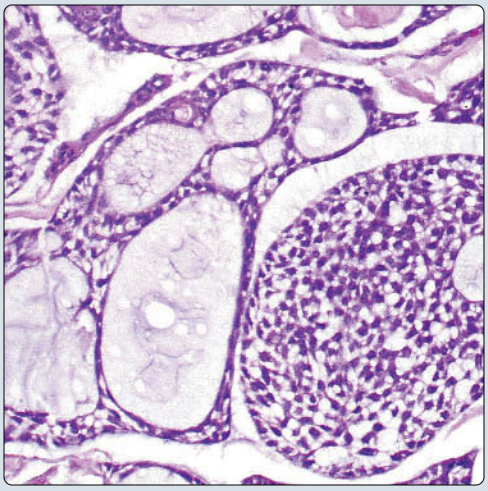

Actin Immunostain

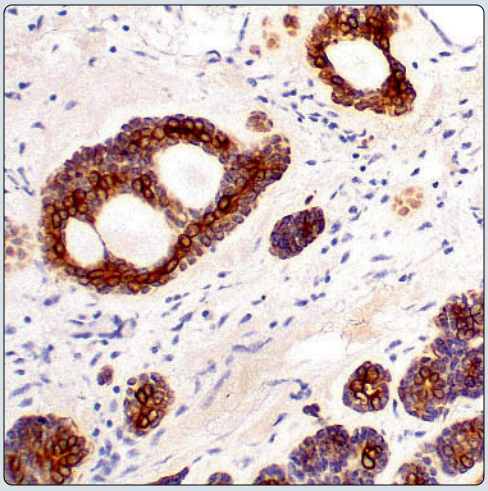

(Left) *Hematoxylin & eosin shows a classic cylindromatous pattern with the characteristic jigsaw puzzle appearance. This is the most common and the easier growth pattern to recognize in these tumors.* **(Right)** *Actin-sm shows positive staining in tumor cells. Basically, the presence of actin-sm and CK-PAN are important immunohistochemical features of adenoid cystic carcinoma.*

TERMINOLOGY

Synonyms

- Cylindroma
  - Old term for this tumor related to common cribriform growth pattern

Definitions

- Epithelial neoplasm similar to that occurring in salivary glands

ETIOLOGY/PATHOGENESIS

Etiology

- Tumor may originate from endobronchial glands
- Rare in parenchymal location

CLINICAL ISSUES

Epidemiology

- Incidence
  - 2nd most common salivary gland-type tumor of lung after mucoepidermoid carcinoma
- Age
  - Tumor appears to be more common in adults

Presentation

- Cough
- Hemoptysis
- Shortness of breath
- Chest pain

Treatment

- Surgical approaches
  - Lobectomy or pneumonectomy

Prognosis

- Slow-growth tumor
- May follow aggressive behavior with metastasis
  - Survival at 10 years varies from 40-45%
- Recurrences are common

MACROSCOPIC

General Features

- Endobronchial tumor
- Submucosal mass, which may penetrate bronchial wall

Size

- 1-3 cm in greatest dimension

MICROSCOPIC

Histologic Features

- Cylindromatous or cribriform growth pattern
- Spaces within mass represent pseudocysts rather than glands
- Spaces result from compression of cords of cell coursing through myxoid stroma
- Solid areas lack luminal structures and may show peripheral palisading
- True mucin-producing glands may be seen but are extremely rare
- Perineural invasion is common as in salivary gland tumor of same type

Predominant Pattern/Injury Type

- Cylindromatous
- Solid
- Tubular

Predominant Cell/Compartment Type

- Epithelial

ANCILLARY TESTS

Histochemistry

- PAS
  - Reactivity: Positive
  - Staining pattern: Stromal matrix
  - PAS will also stain mucinous material within gland lumina of true glands when they are seen
- Alcian blue
  - Reactivity: Positive
  - Staining pattern: Stromal matrix

DIFFERENTIAL DIAGNOSIS

Adenocarcinoma

- Presence of cylindromatous pattern and myoepithelial immunophenotype is more in keeping with adenoid cystic carcinoma
  - Adenocarcinomas do not show tumor cell staining with actin-sm or S100
- May have obvious mucin positivity and common true glands

Metastatic Adenoid Cystic Carcinoma

- Appearance is identical
- History of extrapulmonary adenoid cystic carcinoma

Mucoepidermoid Carcinoma

- Endobronchial mass
- Admixture of mucin-secreting cells, squamous cells, and intermediate cells in various proportions
- Solid areas of epidermoid component
- Immunophenotype is more of epithelial neoplasm rather than classic myoepithelial

Epithelial-Myoepithelial Carcinoma

- Epithelial-myoepithelial carcinoma (EMC) shows distinct proliferation of glandular component in which tumors sow layer of epithelial (outer layer) and myoepithelial layer (inner layer-clear cells)
- Both tumors may show perineural invasion
- Both tumors may show solid areas
- Both tumors may show focal squamous changes
- Both tumors may show similar immunophenotype (myoepithelial differentiation)
- Cylindromatous growth pattern would be unusual for EMC

DIAGNOSTIC CHECKLIST

Pathologic Interpretation Pearls

- Glands are composed of 2 rows of cells
- Cribriform pattern is most common
- Immunophenotype different from adenocarcinomas

Immunohistochemistry

Antibody	Reactivity	Staining Pattern	Comment
CK-PAN	Positive	Cytoplasmic	Tumor cells uniformly positive
CK-LMW-NOS	Positive	Cytoplasmic	
CK5/6	Negative		
Actin-sm	Positive	Cytoplasmic	Many, but not all, cells show staining, emphasizing dual nature of this tumor
S100	Positive	Nuclear	Usually only focal positive
Vimentin	Positive	Cytoplasmic	Uniform tumor cell staining
CD117	Positive	Cell membrane and cytoplasm	Does not correlate with C-kit-activating mutations
myb	Positive	Nuclear	
Collagenase IV	Positive		In basement membrane
Laminin	Positive		In basement membrane
DOG1	Positive	Cytoplasmic	In some cases in ductal and myoepithelial cells
p63	Positive	Nuclear	In some cases in myoepithelial cells

Histochemical Features

Stain	Result
PAS	Negative
PAS-D	Positive in intraluminal areas
Mucicarmine	Positive in intraluminal areas

Molecular Features

FISH	Result
0 < % gene rearrangements	In some cases
t(6:9)(q22-23;p23-24)	In some cases
(*) 5	No gene amplification and no mutation in exons 18-21
. 5 $ 6	Negative
$ / .	Negative
% 5 $)	Negative
3 , . & $	Negative
1 2 7 & +	Potential role in cell growth, invasion, and migration

  - Uniform staining of tumor cells with vimentin, actin-sm, and focal staining with S100
- Perineural invasion common

STAGING

Clinical Follow-Up

- Staging at time of diagnosis appears to be most important parameter in predicting prognosis

SELECTED REFERENCES

1. Brayer KJ et al: Recurrent fusions in MYB and MYBL1 define a common, transcription factor-driven oncogenic pathway in salivary gland adenoid cystic carcinoma. Cancer Discov. 6(2):176-87, 2016
2. Falk N et al: Primary pulmonary salivary gland-type tumors: a review and update. Adv Anat Pathol. 23(1):13-23, 2016
3. Mitani Y et al: Novel MYBL1 gene rearrangements with recurrent MYBL1-NFIB fusions in salivary adenoid cystic carcinomas lacking t(6;9) translocations. Clin Cancer Res. 22(3):725-33, 2016
4. Qu J et al: Notch2 signaling contributes to cell growth, invasion, and migration in salivary adenoid cystic carcinoma. Mol Cell Biochem. 411(1-2):135-41, 2016
5. Abd Raboh NM et al: Diagnostic role of DOG1 and p63 immunohistochemistry in salivary gland carcinomas. Int J Clin Exp Pathol. 8(8):9214-22, 2015
6. Hu MM et al: Primary adenoid cystic carcinoma of the lung: clinicopathological features, treatment and results. Oncol Lett. 9(3):1475-1481, 2015
7. Huo Z et al: Molecular genetic studies on EGFR, KRAS, BRAF, ALK, PIK3CA, PDGFRA, and DDR2 in primary pulmonary adenoid cystic carcinoma. Diagn Pathol. 10:161, 2015
8. Tian Z et al: Differences in MYB expression and gene abnormalities further confirm that salivary cribriform basal cell tumors and adenoid cystic carcinoma are two distinct tumor entities. J Oral Pathol Med. 2015
9. Zhu F et al: Primary salivary gland-type lung cancer: clinicopathological analysis of 88 cases from China. J Thorac Oncol. 8(12):1578-84, 2013
10. Aubry MC et al: Primary adenoid cystic carcinoma of the lung: absence of KIT mutations. Cancer. 110(11):2507-10, 2007
11. Moran CA: Primary salivary gland-type tumors of the lung. Semin Diagn Pathol. 12(2):106-22, 1995

Cylindromatous Pattern

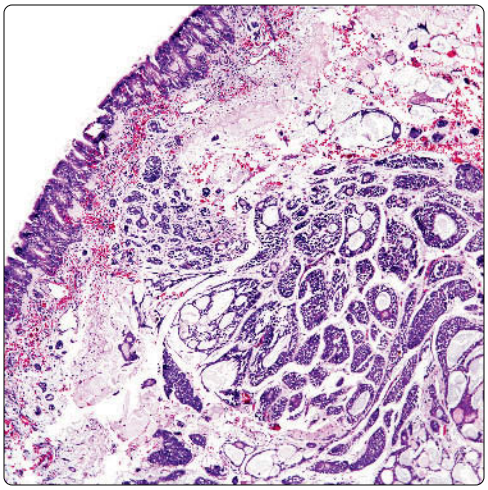

Cylindromatous Pattern

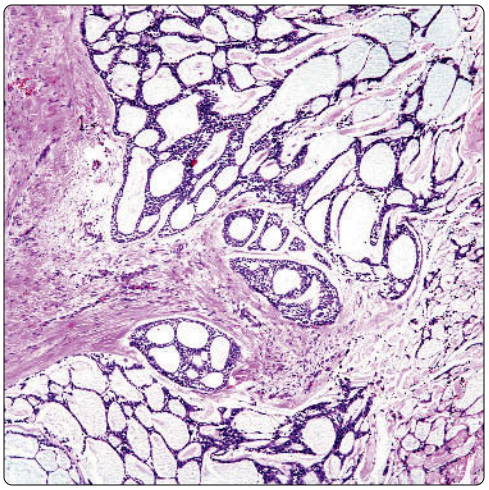

(Left) *Adenoid cystic carcinoma shows a conventional cylindromatous pattern. Note the presence of uninvolved respiratory epithelium, which appears to be within normal limits.* **(Right)** *The cylindromatous variant of adenoid cystic carcinoma is the most common. The tumor is composed of islands of tumor cells separated by fibroconnective tissue that show a striking cribriform architecture.*

Degenerative Changes

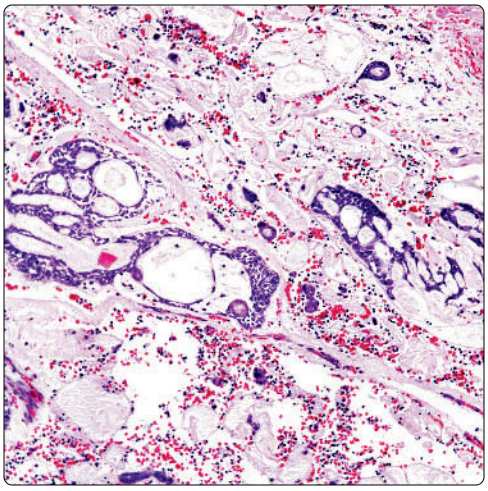

Cylindromatous Pattern

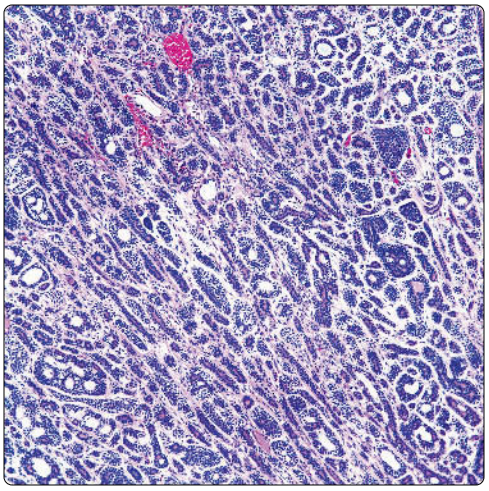

(Left) *In some areas, the islands of tumor cells are embedded in edematous stroma. However, the characteristic features are still preserved in the epithelial component.* **(Right)** *In other areas, the glandular proliferation may show prominent compression of the glandular structures, making it difficult to recognize the cylindromatous pattern of growth.*

Extensive Hyalinization

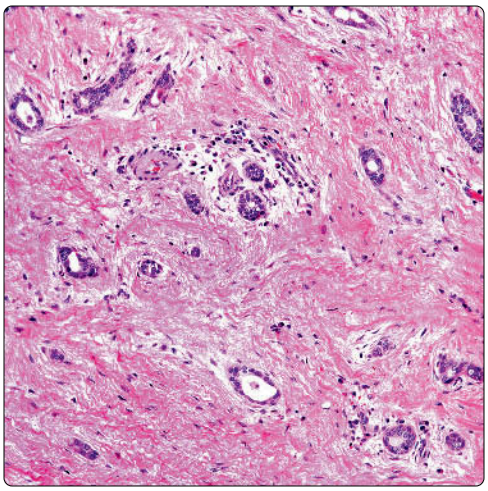

Perineural Invasion

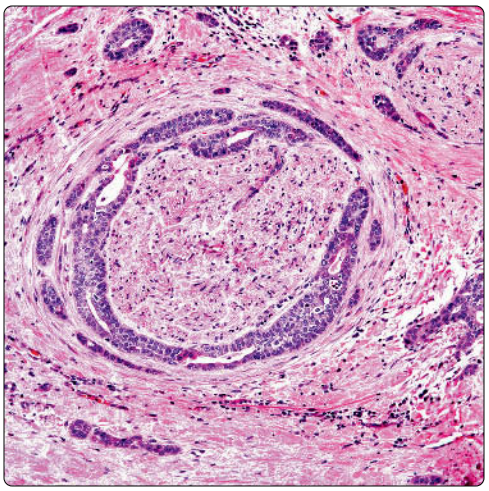

(Left) *Adenoid cystic carcinoma shows extensive areas of collagenization with only scattered areas of tumor cells. This type of pattern can also be seen in pleomorphic adenomas (mixed tumors).* **(Right)** *Prominent perineural invasion is present in these tumors and is an important feature that may aid in the diagnosis of adenoid cystic carcinoma.*

Solid and Cystic Changes

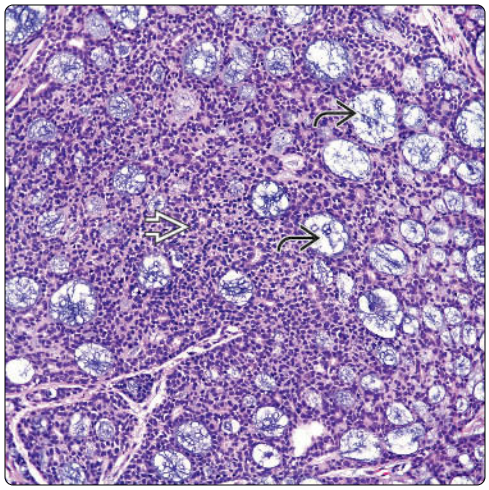

Clear Cell Component

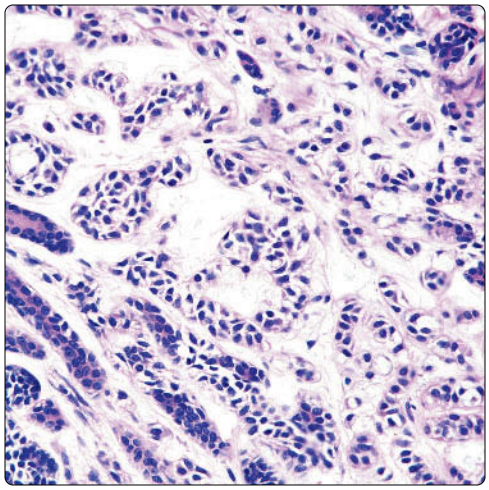

(Left) *Adenoid cystic carcinoma displays extensive areas of solid cellular proliferation. Note the cystic structures containing mucoid material. This feature is common in these tumors.* **(Right)** *Some cases of adenoid cystic carcinoma may show prominent clear cell changes. In some cases, the proliferation is similar to that seen in epithelial-myoepithelial carcinoma.*

Tubular Variant

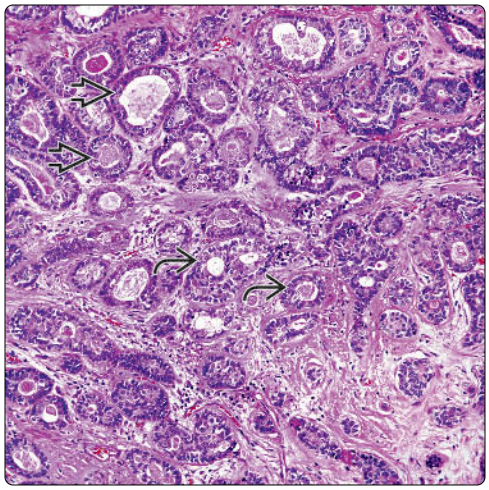

Tubular Variant

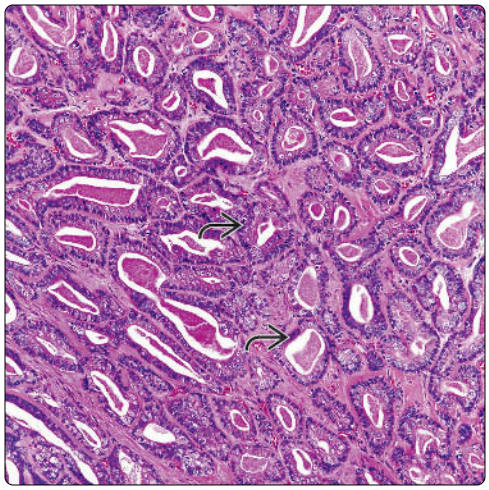

(Left) *Tubular variant of adenoid cystic carcinoma is seen merging with more conventional areas. It is common to see 2 growth patterns in the same tumor.* **(Right)** *Tubular growth pattern of adenoid cystic carcinoma shows a proliferation of glandular structures, which closely mimic a conventional adenocarcinoma.*

Tubular Pattern

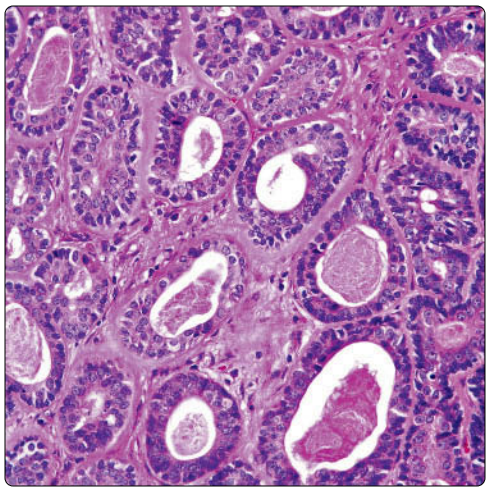

Cylindromatous Pattern

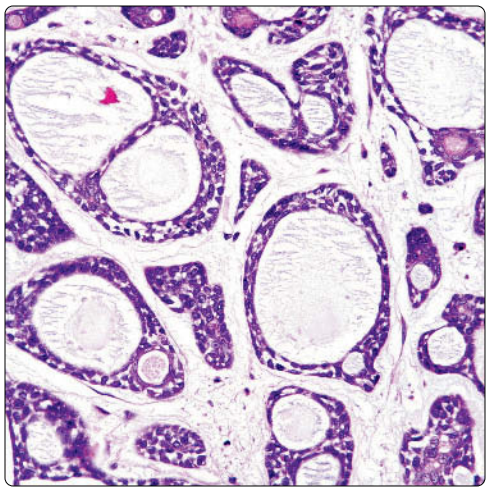

(Left) *Higher magnification of the neoplasm shows that these glandular structures are similar to the more conventional pattern of this tumor. The glands are composed of 2 rows of cells. Mitotic activity is not present.* **(Right)** *The cylindromatous variant of adenoid cystic carcinoma shows that the glands are also composed of 2 rows of cells and contain mucoid material. Mitotic activity is also absent.*

Necrosis and Degenerative Changes

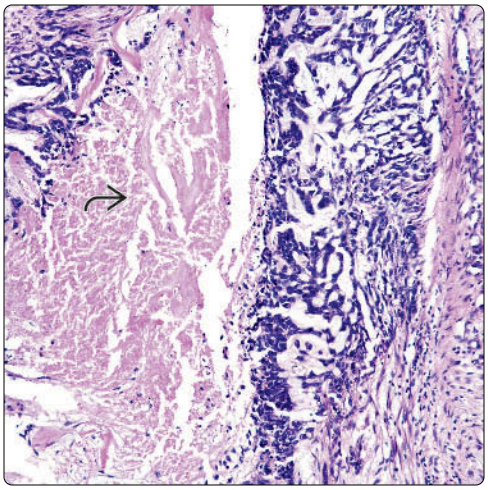

Trabecular Pattern

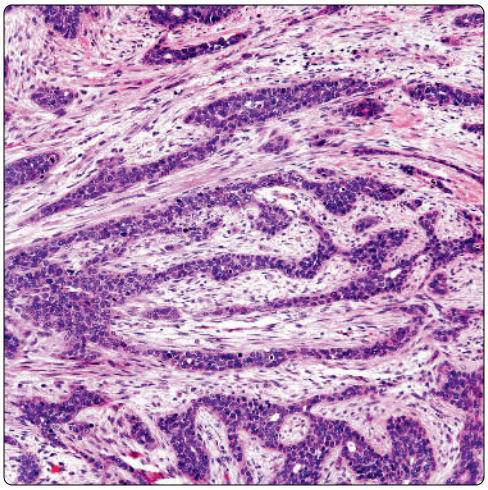

(Left) *Although not common, the presence of necrosis may be encountered focally in cases of adenoid cystic carcinoma. Extensive areas of necrosis are not common in these tumors.* **(Right)** *In some cases of adenoid cystic carcinoma, the tumor may display cords of neoplastic cells embedded in a fibroblastic stroma, giving the impression of a biphasic neoplasm.*

Sebaceous Differentiation

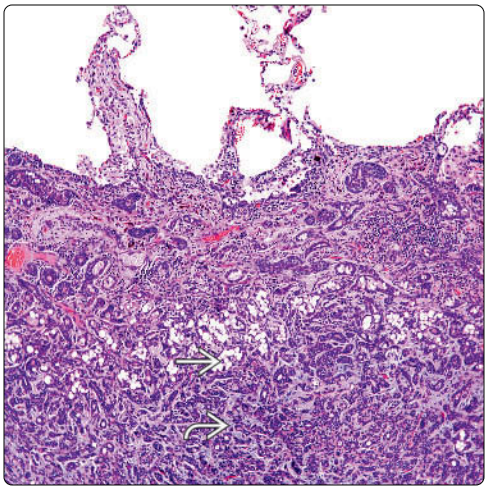

Sebaceous Differentiation

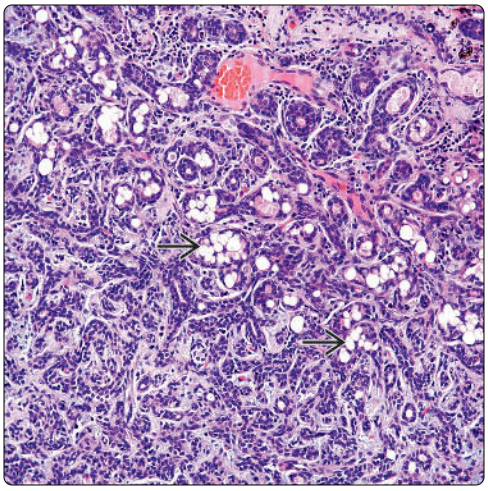

(Left) *Adenoid cystic carcinoma shows a prominent tubular component and clear cells. Also note the presence of a hyalinized stroma separating islands of tumor cells.* **(Right)** *Adenoid cystic carcinoma shows a classic histology with clusters of clear cells. The presence of clear cells suggests sebaceous differentiation. This feature is unusual in adenoid cystic carcinomas of the lung.*

Clear Cell Component

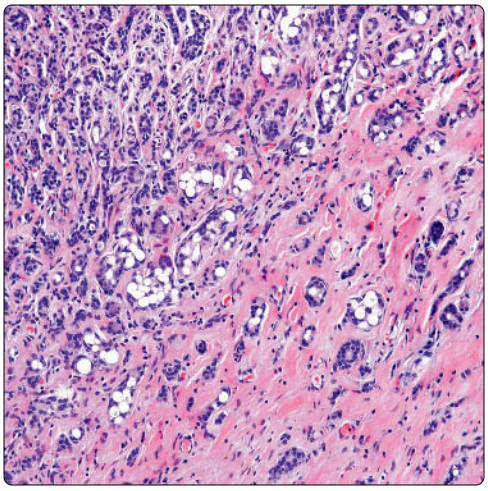

Sebaceous Differentiation

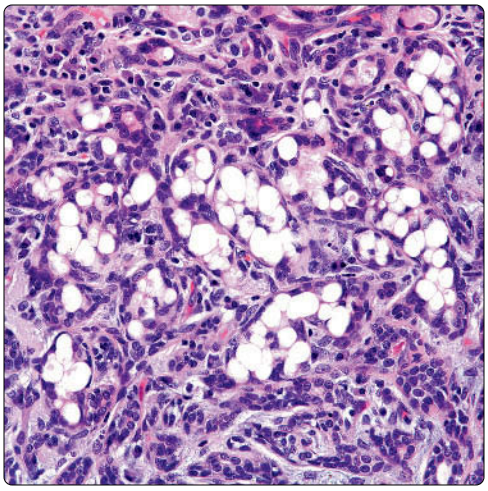

(Left) *Adenoid cystic carcinoma shows conventional growth pattern with a clear cell component dissecting fibrocollagenous stroma. This feature requires careful attention in determining the extent of invasion by the tumor.* **(Right)** *This is a closer look at the clear cells in adenoid cystic carcinoma, which represent sebaceous differentiation. The cytoplasm of the cells appears to contain lipid inclusions.*

Extensive Hyalinization

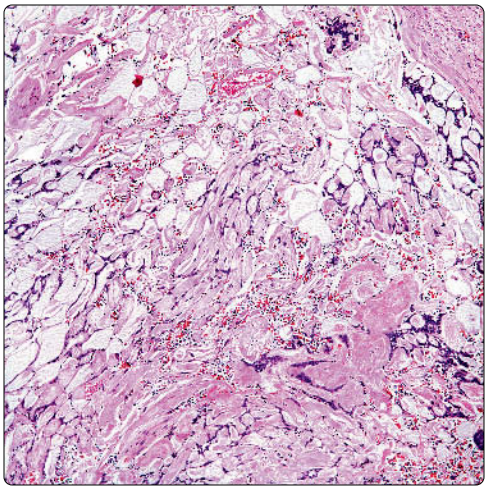

Cylindromatous Pattern

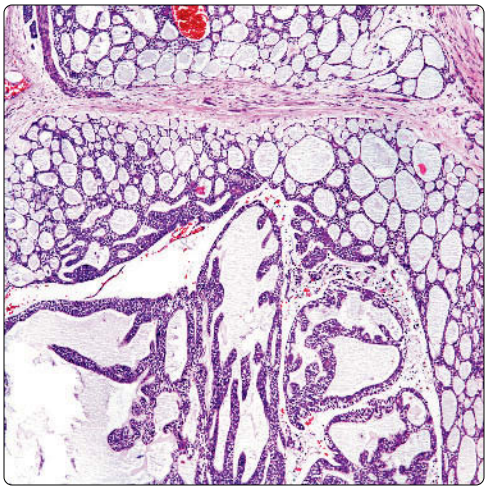

(Left) *Although unusual, extensive areas of hyalinization may be present in adenoid cystic carcinoma. This type of growth pattern is uncommon in the lung and can make the diagnosis difficult. Primary pleomorphic adenomas of the lung may show similar features.* **(Right)** *Adenoid cystic carcinoma is seen with focal presence of larger cysts and adjacent classic growth pattern. The presence of large cystic structures is uncommon and, when alone, can make the diagnosis difficult.*

Solid Variant

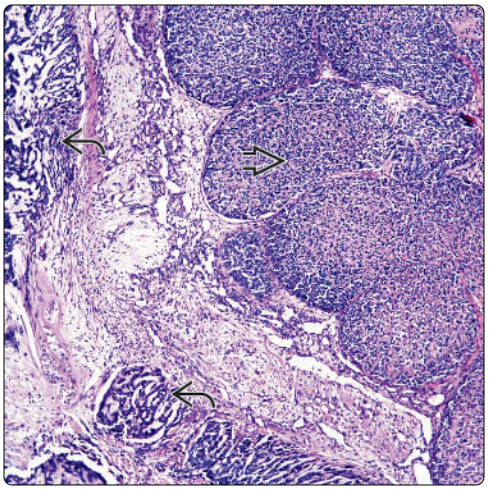

Solid Variant

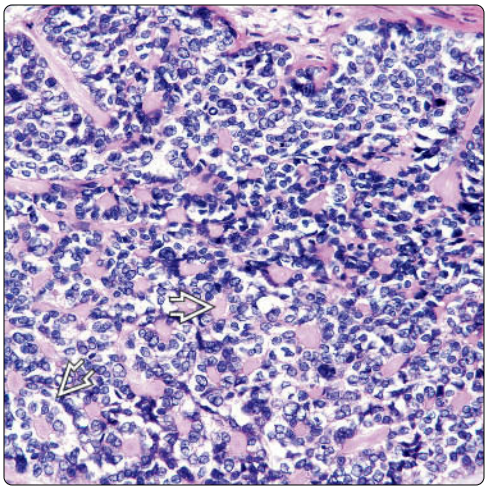

(Left) *Extensive areas of solid variant of adenoid cystic carcinoma ⇨ are separated by fibrocollagenous tissue from more conventional areas of this tumor ⇨.* **(Right)** *One can still identify a remnant of tubular structures ⇨ in this higher magnification of a solid area. These structures may also be confused for pseudorosettes and for a neuroendocrine tumor.*

Solid Variant

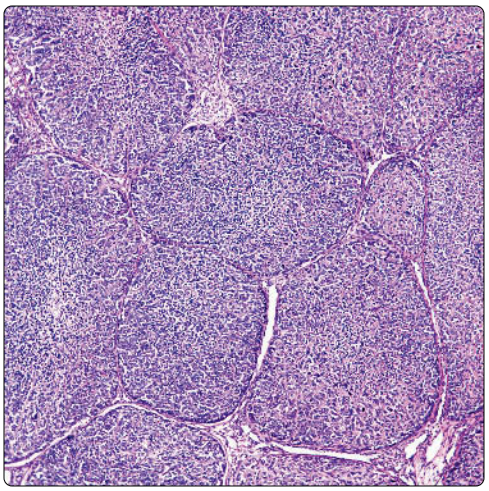

Solid Variant

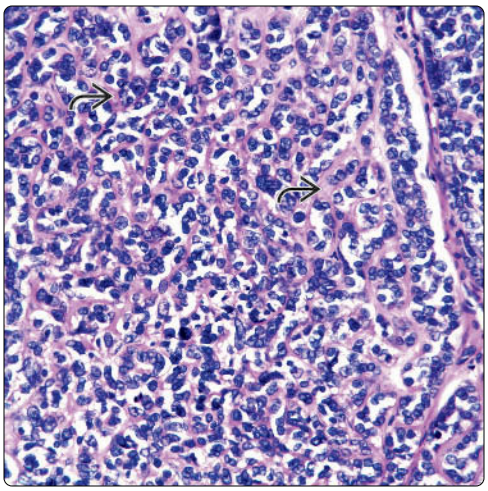

(Left) *Adenoid cystic carcinoma shows predominantly solid growth pattern with a subtle lobular appearance. Fortunately, even in cases with an extensive solid pattern, the tumor may also show focal areas of the conventional pattern.* **(Right)** *Higher magnification shows a cellular proliferation with moderate nuclear atypia and the presence of a basement membrane ⇨, which gives the appearance of amyloid deposition.*

Glandular Pattern

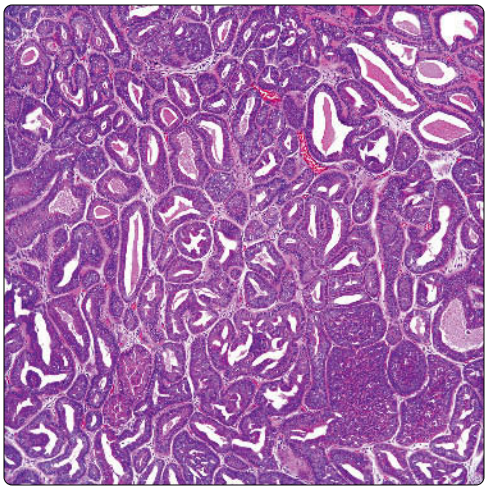

Neural Invasion

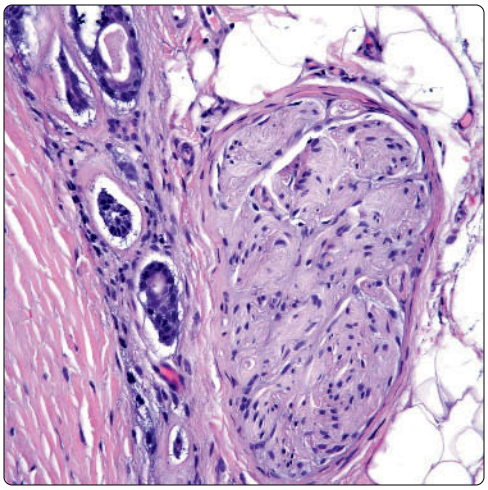

(Left) *Adenoid cystic carcinoma shows a biphasic growth pattern of solid areas admixed with more glandular component. This pattern can easily be misdiagnosed for a conventional adenocarcinoma.* **(Right)** *Adenoid cystic carcinoma shows focal tumoral areas wrapping a large nerve ending. Even though this features is common, it may not be a feature associated with recurrence of these types of tumors.*

Extensive Hyalinization

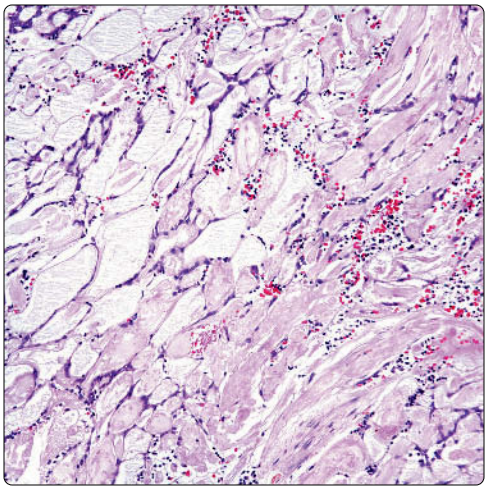

Cylindromatous Pattern

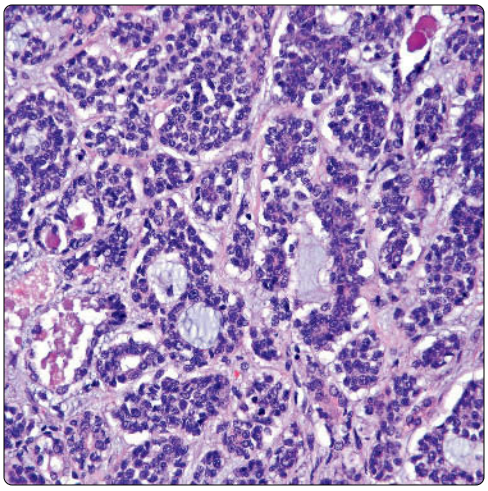

(Left) *Adenoid cystic carcinoma shows extensive hyalinization in which the tumor cells are arranged in strands without much growth pattern and only subtly arranged in an "alveolar" pattern.* **(Right)** *Adenoid cystic carcinoma shows focal areas of the most conventional features and predominantly nesting pattern. Note the presence of glands lined by 2 rows of cells.*

Myeloblastosis Immunostain

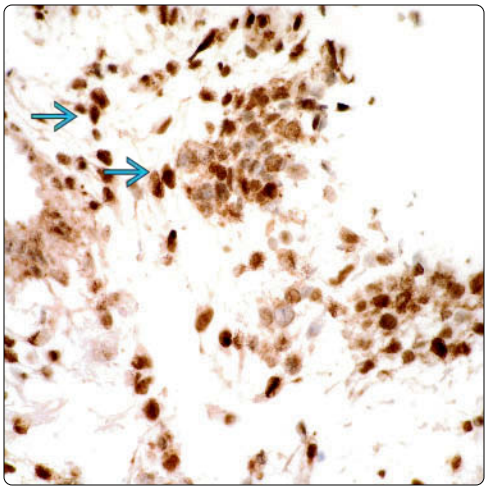

C-kit Immunostain

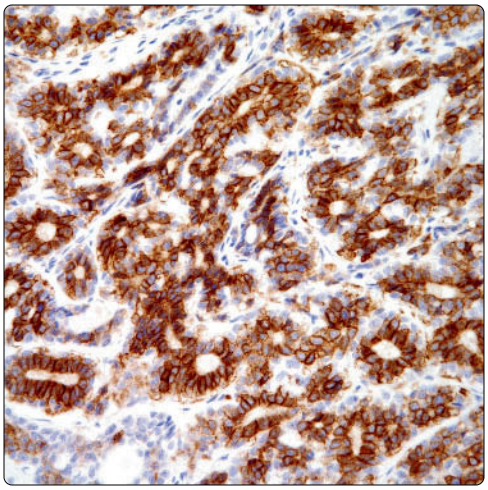

(Left) *Myeloblastosis immunohistochemical stain shows strong nuclear positive staining in a primary pulmonary adenoid cystic carcinoma.* **(Right)** *Immunohistochemical stain for CD117 (C-kit) shows a strong positive reaction in a primary pulmonary adenoid cystic carcinoma.*

Mucoepidermoid Carcinoma

KEY FACTS

TERMINOLOGY

- Mucoepidermoid carcinoma (MEC): Epithelial neoplasm composed of epidermoid and clear cells admixed with mucus-secreting cells (mucocytes)

CLINICAL ISSUES

- Prognosis
  - Depends on grading of tumor
  - For low-grade tumors, prognosis is very good
  - For high-grade tumors, additional medical treatment may be necessary
- Symptoms
  - Cough, shortness of breath, hemoptysis, chest pain, wheezing

MACROSCOPIC

- MEC usually endobronchial tumor
- Polypoid tumor obstructing bronchial lumen may also occur

MICROSCOPIC

- Epidermoid component without keratinization
- Clear cells (intermediate cells)
- Mucus-producing cells (mucocytes)
- Lack of nuclear atypia or high mitotic activity
- Oncocytic changes may also be seen

TOP DIFFERENTIAL DIAGNOSES

- Lymphoepithelioma-like carcinoma
- Adenosquamous carcinoma
- Squamous cell carcinoma
- Adenocarcinoma
- Metastatic MEC

DIAGNOSTIC CHECKLIST

- MEC generally does not show areas of keratinization
- Epidermoid cells admixed with mucous cells
- MEC may show positive 0 $ 0 /

Central MEC

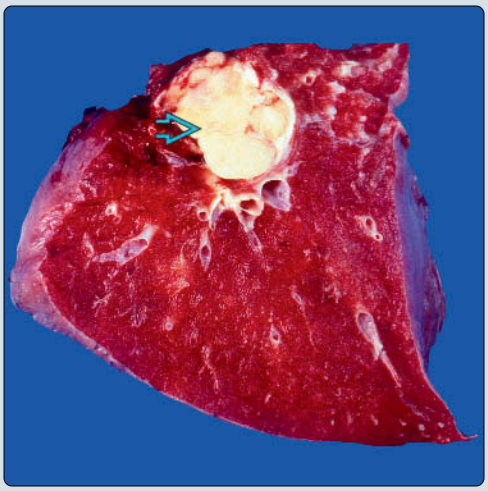

Low-Grade MEC

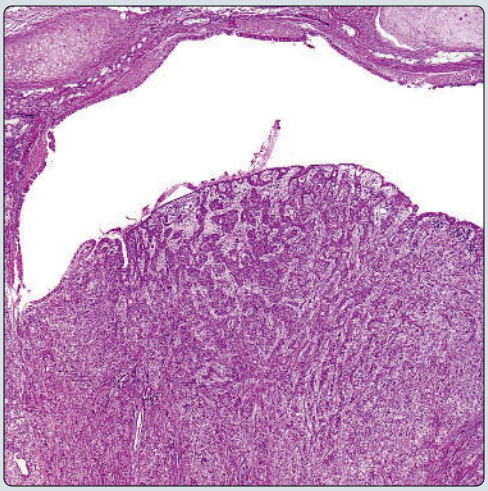

(Left) *Gross photograph shows a well-circumscribed, yellowish, central tumor mass. Usually, low-grade mucoepidermoid carcinomas (MEC) of the lung are central tumors.* **(Right)** *Panoramic view shows a low-grade MEC in an endobronchial location. The tumor is growing in a polypoid fashion, obstructing the bronchial lumen.*

Solid and Cystic Components

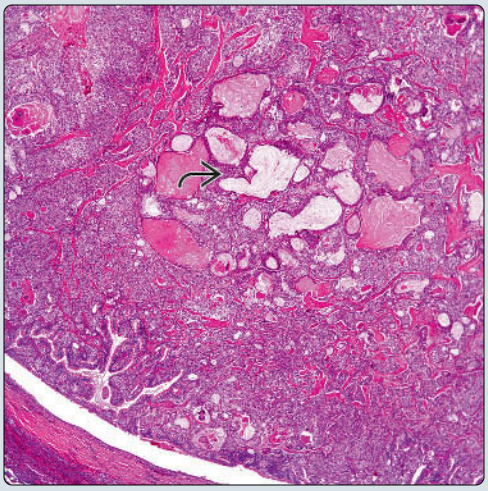

Mucocytes and Intraluminal Mucin

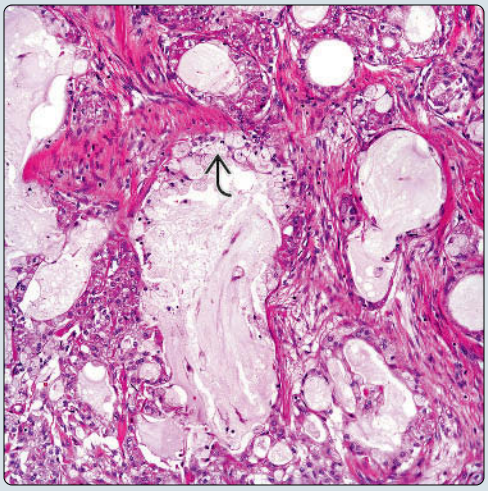

(Left) *Low-grade MEC shows extensive solid component and focal cystic structures. In cases in which the solid component is prominent, the diagnosis may pose more difficulties.* **(Right)** *Higher magnification shows mucin-producing cells lining cystic structures. Similar features may also be seen in cases of mucous gland adenomas of the bronchus.*

TERMINOLOGY

Abbreviations

- Mucoepidermoid carcinoma (MEC)

Synonyms

- Mucoepidermoid tumor

Definitions

- Epithelial neoplasm composed of epidermoid cells admixed with mucus-secreting cells (mucocytes)

ETIOLOGY/PATHOGENESIS

Incidence

- Tumor more common in adults but has been reported in children
  - Ages range from 3-78 years
  - Most common type is low-grade tumor

CLINICAL ISSUES

Presentation

- Cough
- Shortness of breath
- Hemoptysis
- Chest pain
- Wheezing

Treatment

- Surgical approaches
  - Complete surgical resection, usually lobectomy
    - Location of tumor may dictate surgical approach

Prognosis

- Prognosis depends on grading of neoplasm
  - Low-grade tumors, completely resected: Very good
  - High-grade tumors may require additional medical treatment in addition to surgical resection
    - Overall 3-year survival rate is ~ 94%
    - Overall 5-year survival rate is ~ 87%
      - Close follow-up is recommended in all cases

MACROSCOPIC

General Features

- Tumor more common in central location than in periphery of lung
  - MEC is usually endobronchial tumor
  - Polypoid tumor obstructing bronchial lumen may also be presentation

Size

- 1-5 cm in greatest dimension

MICROSCOPIC

Histologic Features

- Epidermoid component without keratinization
  - Clear cells (intermediate cells)
  - Mucus-producing cells (mucocytes)
  - Lack of nuclear atypia or high mitotic activity
    - Metastatic disease in lymph nodes may be present regardless of grading of tumor

Predominant Pattern/Injury Type

- Solid
- Cystic

Predominant Cell/Compartment Type

- Epithelial

DIFFERENTIAL DIAGNOSIS

Lymphoepithelioma-Like Carcinoma

- Usually shows increased mitotic activity and cellular atypia
- Characteristically has inflammatory stroma composed of lymphocytes and plasma cells
- Does not show presence of mucocytes or low-grade areas of MEC

Adenosquamous Carcinoma

- Shows conventional areas of adenocarcinoma and squamous cell carcinoma
- MEC shows only epidermoid component without keratinization

Squamous Cell Carcinoma

- In small biopsy, it may be difficult or impossible to separate both of these entities
  - Lack of keratinization and presence of mucocytes admixed with epidermoid cells will favor MEC
  - Presence of squamous cell carcinoma in situ would favor squamous cell carcinoma

Mucous Gland Adenoma

- Does not invade beyond cartilaginous bronchial tissue
  - Mucous gland adenoma represents overdistended normal glandular elements
  - Mucous gland adenoma does not show presence of solid epidermoid component admixed with mucocytes
  - Squamous metaplasia may be present

Adenocarcinoma

- Adenocarcinomas do not show presence of solid epidermoid component
  - Adenocarcinoma may show acinar, solid, or papillary growth pattern
  - Glandular proliferation with intra- or extracellular mucin
  - Adenocarcinomas are negative for p40 immunostain
  - Adenocarcinomas are commonly positive for TTF-1 and NAPSIN-A immunostains
  - p63 may be seen positive in adenocarcinoma, as well as in epidermoid component of MEC

Metastatic Mucoepidermoid Carcinoma

- Because these tumors are more common in salivary glands or trachea, it is important to obtain careful clinical history of previous head and neck surgery
- Histomorphology of primary and metastatic MEC is similar
- Metastatic tumors are more often seen in lung parenchyma, whereas primary tumors are centrally located
- Immunohistochemistry and molecular features are similar

DIAGNOSTIC CHECKLIST

Clinically Relevant Pathologic Features

- Gross appearance

Immunohistochemistry

Antibody	Reactivity	Staining Pattern	Comment
CK7	Positive	Cytoplasmic	Positive in epidermoid component of tumor
CK8/18/CAM5.2	Positive	Cytoplasmic	
AE1/AE3	Positive	Cytoplasmic	Positive in epidermoid component of tumor
CK5/6	Positive	Cytoplasmic	Positive in epidermoid component
CEA-M	Positive	Cytoplasmic	May be negative in some cases
p63	Positive	Nuclear	In epidermoid component
Vimentin	Negative		
CK20	Negative		
p40	Positive	Nuclear	In epidermoid component
TTF-1	Negative		
NAPSIN-A	Negative		
Desmocollin-3	Positive	Cytoplasmic	
D2-40	Negative		
WT1	Negative		
TAG72	Negative		

Histochemical Features

Stain	Result
PAS	Positive
PAS-D	Positive
Mucicarmine	Positive

Molecular Features

FISH	Result
- $ 0 / on chromosome 11q21	40-75% of cases
t(11;19)(21;p13) involving CREB-regulated transcription coactivator on chromosome 19p13	

- Central tumor obstructing bronchial lumen

Pathologic Interpretation Pearls

- MEC generally does not show areas of keratinization
  - Epidermoid cell admixed with mucous cells

GRADING

Low-Grade Mucoepidermoid Carcinoma

- Low-grade tumor characterized by epidermoid component with mucus-producing cells without increased mitotic activity, nuclear pleomorphism, necrosis, or hemorrhage

High-Grade Mucoepidermoid Carcinoma

- High-grade tumors characterized by epidermoid component with areas of nuclear pleomorphism, mitotic activity, necrosis, or hemorrhage

SELECTED REFERENCES

1. Falk N et al: Primary pulmonary salivary gland-type tumors: a review and update. Adv Anat Pathol. 23(1):13-23, 2016
2. Yamamoto T et al: Surgical treatment of mucoepidermoid carcinoma of the lung: 20 years' experience. Asian Cardiovasc Thorac Ann. 24(3):257-61, 2016
3. Huo Z et al: Primary pulmonary mucoepidermoid carcinoma: histopathological and molecular genetic studies of 26 cases. PLoS One. 10(11):e0143169, 2015
4. Komiya T et al: Primary lung mucoepidermoid carcinoma: analysis of prognostic factors using Surveillance, Epidemiology, and End Results Program (SEER). Clin Respir J. ePub, 2015
5. Wang YQ et al: Low-Grade and high-grade mucoepidermoid carcinoma of thelLung: CT findings and clinical features of 17 cases. AJR Am J Roentgenol. 205(6):1160-6, 2015
6. Roden AC et al: Histopathologic, immunophenotypic and cytogenetic features of pulmonary mucoepidermoid carcinoma. Mod Pathol. 27(11):1479-88, 2014
7. Shen C et al: Clinicopathological analysis of pulmonary mucoepidermoid carcinoma. World J Surg Oncol. 12:33, 2014
8. Vadasz P et al: Mucoepidermoid bronchial tumors: a review of 34 operated cases. Eur J Cardiothorac Surg. 17(5):566-9, 2000
9. Moran CA: Primary salivary gland-type tumors of the lung. Semin Diagn Pathol. 12(2):106-22, 1995
10. Yousem SA et al: Mucoepidermoid tumors of the lung. Cancer. 60(6):1346-52, 1987

Cystic Changes

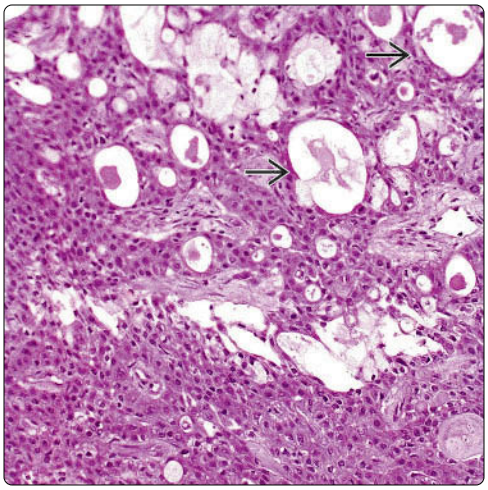

Nonkeratinizing Component

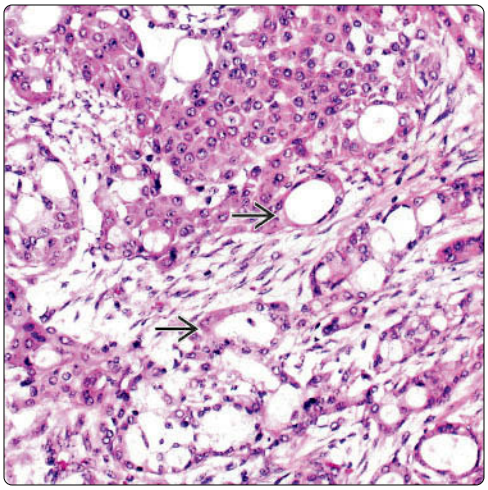

(Left) *Solid sheets of nonkeratinizing cells admixed with cystic spaces ⇨ contain acellular material in their lumina. The presence of solid and cystic areas is commonly seen in low-grade tumors.* **(Right)** *MEC shows a solid, epidermoid, nonkeratinizing cellular component and a pseudoglandular component ⇨. One important feature in these tumors is the lack of keratinization.*

Inflammatory Component

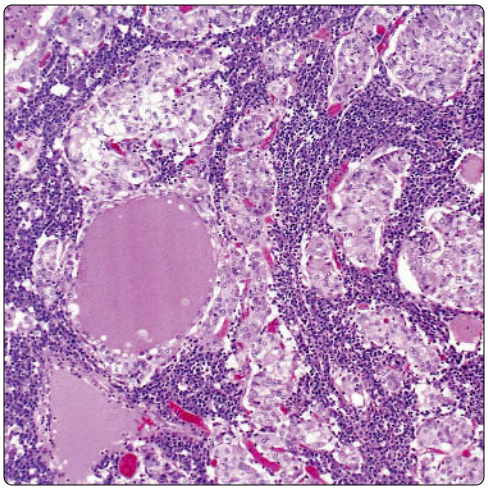

Inflammatory Component

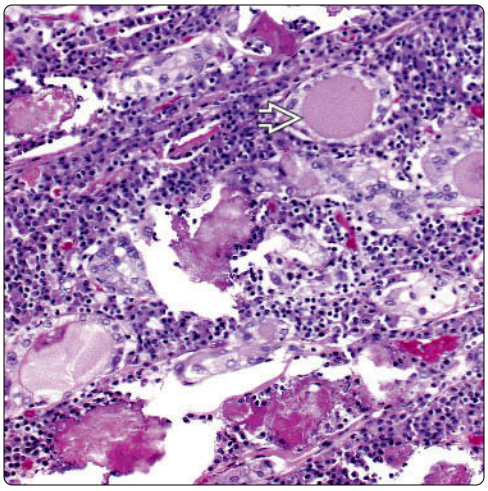

(Left) *MEC shows pseudoglandular structures with marked chronic inflammation, composed mainly of plasma cells. The presence of inflammatory changes in MEC is not common and may pose problems in the interpretation.* **(Right)** *MEC shows pseudoglandular pattern with acellular intraluminal material ⇨. Note the prominent inflammatory background. At this magnification, it is possible to distinguish both epithelial and inflammatory components.*

Calcifications

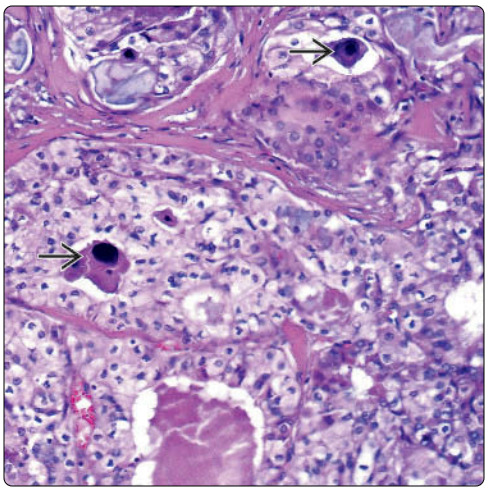

Intermediate Cells

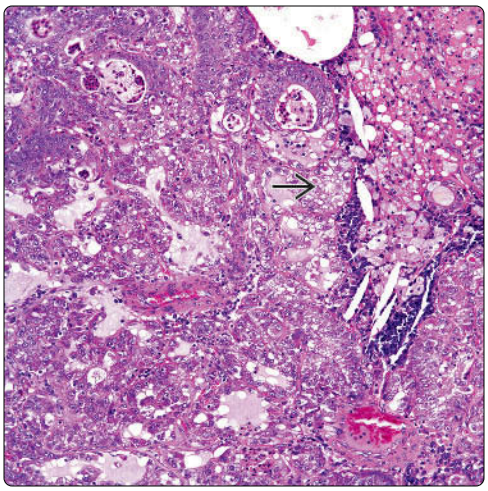

(Left) *MEC shows pseudoglandular epithelial component with numerous intraluminal calcifications ⇨. The presence of these calcifications is more commonly seen in tumors with inflammatory changes.* **(Right)** *MEC shows pseudoglandular proliferation with numerous clear (intermediate) cells ⇨. This may represent a pitfall in diagnosis, as similar features may be seen in non-small cell carcinomas with clear cell changes.*

Intermediate Cells

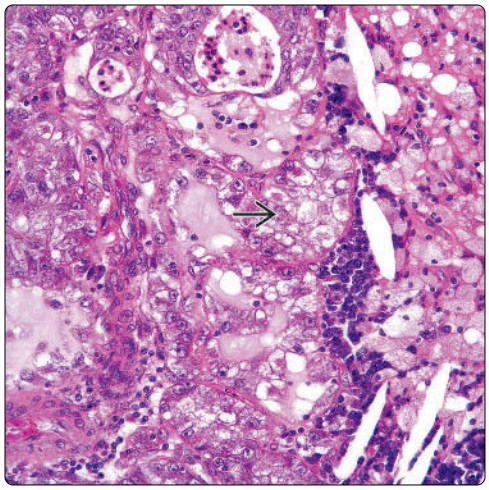

Nonkeratinizing Epidermoid Component

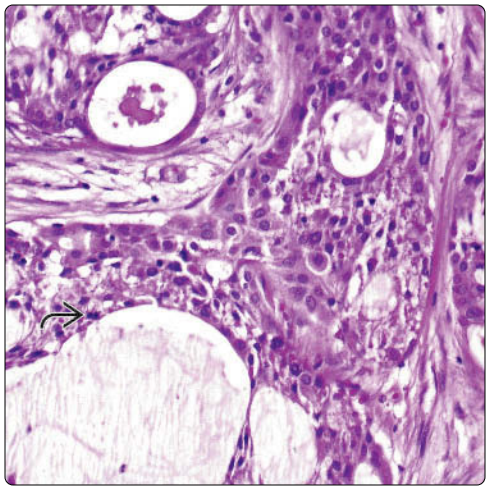

(Left) *MEC shows clear (intermediate) cells admixed with inflammatory cells. Note the absence of nuclear atypia and mitotic activity. More importantly, there is no keratinization or true glandular differentiation.* **(Right)** *MEC shows epidermoid component with cystic structures admixed with mucus-producing cells (mucocytes). This growth pattern is diagnostic of MEC.*

Mucus-Producing Cells (Mucocytes)

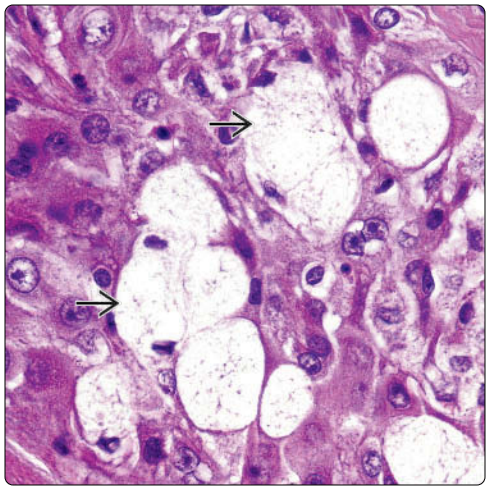

Mucocytes

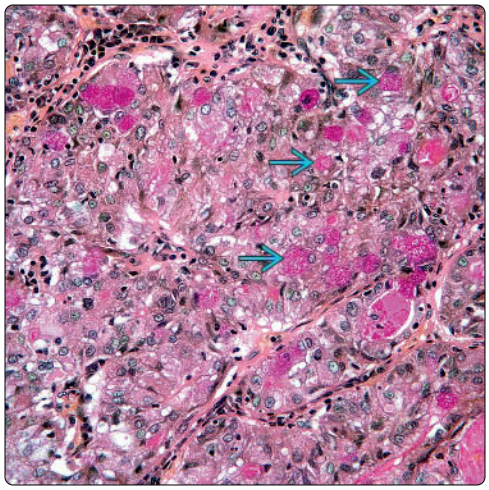

(Left) *MEC shows epidermoid nonkeratinizing cellular component admixed with mucocytes. The mucus-producing cells are bland and nonneoplastic, and their presence is essential for the diagnosis.* **(Right)** *Mucicarmine stain shows abundant mucin-producing cells (mucocytes). The use of histochemical stains to demonstrate the presence of mucin is helpful in these cases. In some cases, it may not be as florid as depicted here.*

Pseudoglandular Structures

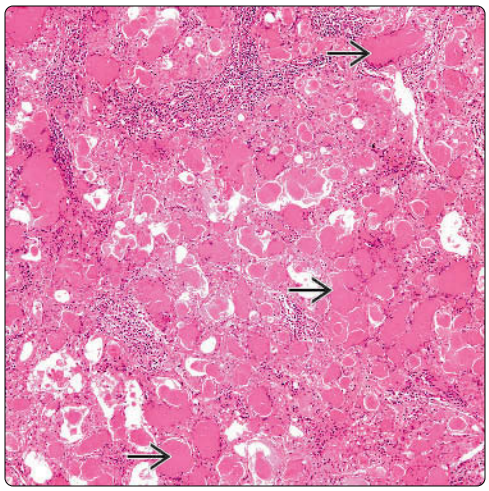

Solid Component

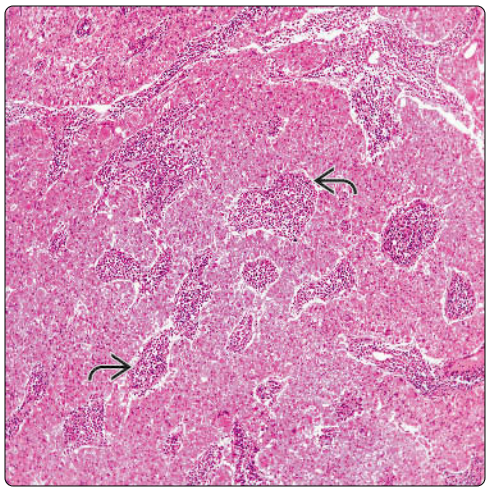

(Left) *Low-grade MEC is shown with prominent amorphous material in the lumina of the cystic structures.* **(Right)** *Low-grade MEC is shown with a more solid epithelial component arranged in trabeculae. Interestingly, the solid sheets of neoplastic cells have an oncocytic-like appearance. Note the discrete areas of inflammatory reaction. Oncocytic change is very rare in MEC of the lung.*

Clear Cell Component

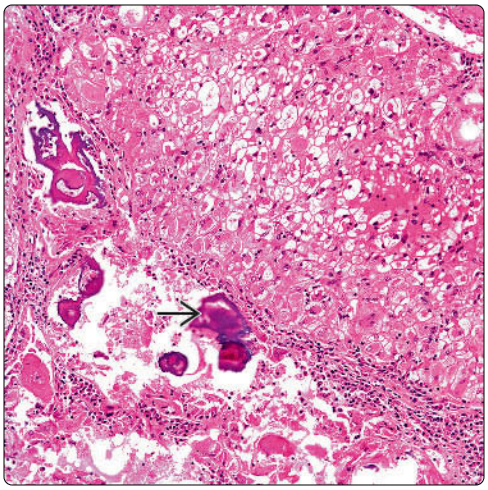

Clear Cell Component

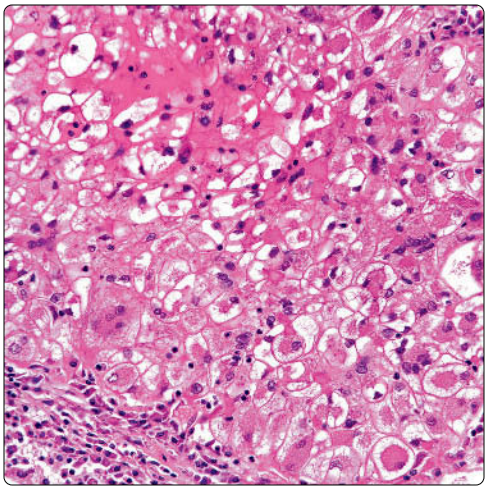

(Left) *Low-grade MEC shows prominent clear cells and adjacent calcifications. Similar features may also be seen in non-small cell carcinomas with clear cell features.* **(Right)** *Higher magnification of the clear cell component is shown in a low-grade MEC. Note the absence of nuclear atypia, mitotic activity, and keratinization. Some cells have an oncocytic appearance.*

Intraluminal Mucin

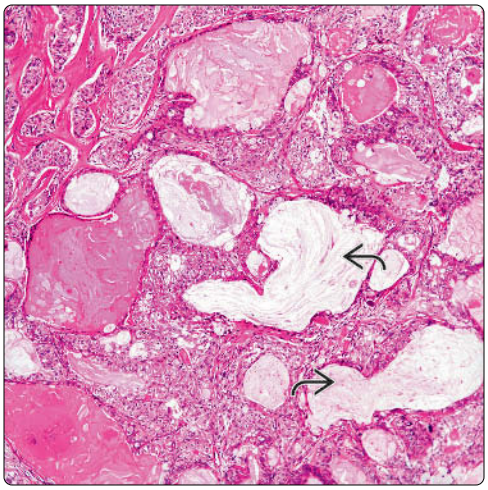

Osseous Metaplasia

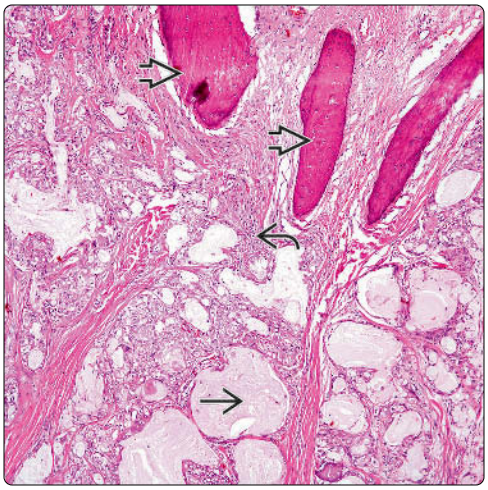

(Left) *Cystic structures in a low-grade MEC are shown with numerous mucocytes and the presence of intraluminal mucin. This high-power view shows the classic feature of these tumors.* **(Right)** *Low-grade MEC shows the classic admixture of mucous cells and intraluminal mucus alongside a solid cellular component and areas of ossification. Ossification is not a common feature of MEC.*

p40

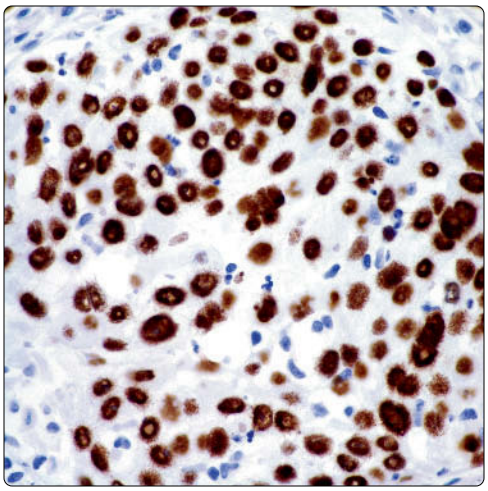

Keratin AE1/AE3

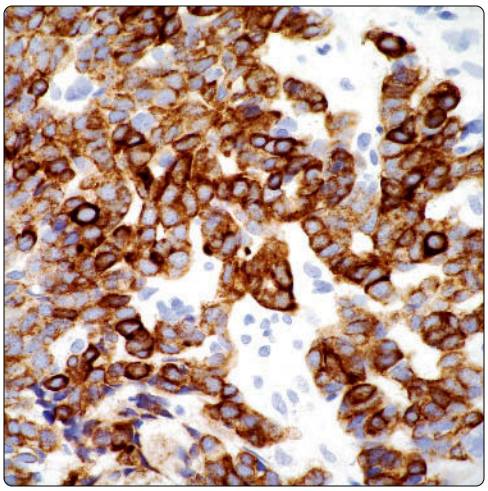

(Left) *Immunohistochemical stain for p40 shows strong nuclear staining in the epidermoid component of a MEC.* **(Right)** *The epidermoid component of a MEC is nicely decorated by keratin. Note the strong positive reaction in tumor cells.*

Epithelial-Myoepithelial Carcinoma

KEY FACTS

TERMINOLOGY

- Adenomyoepithelioma, epithelial-myoepithelial tumor, epithelial-myoepithelial tumor of unknown malignant potential, pneumocytic adenomyoepithelioma

CLINICAL ISSUES

- Cough
- Chest pain
- Hemoptysis

MACROSCOPIC

- Endobronchial tumor
- 2.5-5.0 cm in greatest dimension

MICROSCOPIC

- Tubular
- Epithelial, glandular
- Glandular with inner epithelial layer and outer myoepithelial layer
- Solid
- Focal squamous changes
- Low mitotic activity

ANCILLARY TESTS

- CK-PAN
- S100

TOP DIFFERENTIAL DIAGNOSES

- Adenoid cystic carcinoma
- Mixed tumor (pleomorphic adenoma)
- Adenocarcinoma

DIAGNOSTIC CHECKLIST

- Tubular structures with inner epithelial layer and outer layer of clear myoepithelial cells

Macroscopic Features

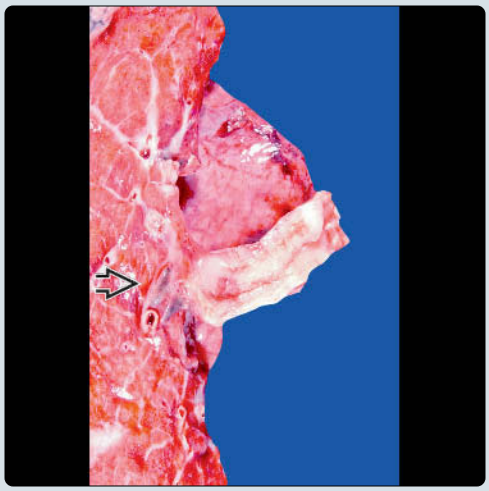

Panoramic View

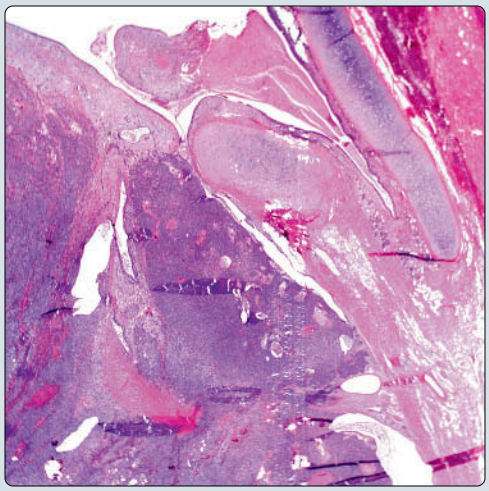

(Left) *Gross photograph of epithelial-myoepithelial carcinoma (EMC) shows an endobronchial tumor ⇨ obstructing most of the lumen. Note the infiltrative nature of the tumor.* **(Right)** *Panoramic view shows EMC with a solid and tubular pattern. This low-power view can be seen in other tumors of salivary gland origin.*

Dual Cell Population

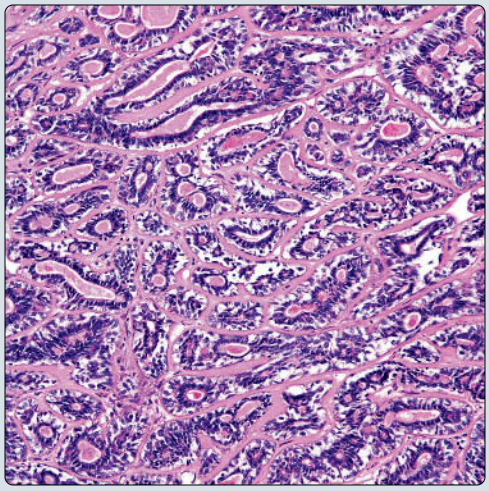

Glandular Appearance

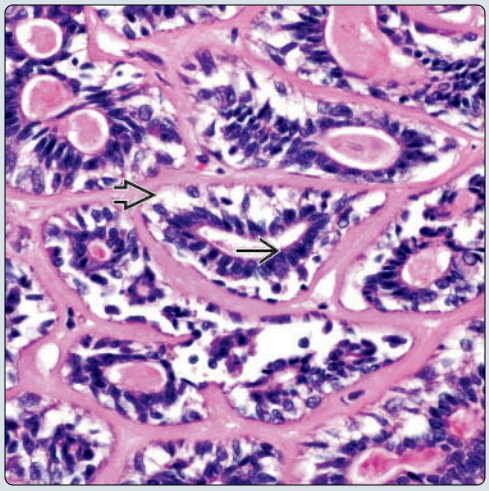

(Left) *Hematoxylin & eosin shows the characteristic growth pattern of EMC, tubular structures lined by a dual cell population. This is the classic histology of EMC.* **(Right)** *Higher magnification of the tubular structures shows an epithelial component ⇨ and a clear cell outer myoepithelial component ⇨ in this classic example of EMC of the lung.*

TERMINOLOGY

Abbreviations

- Epithelial-myoepithelial carcinoma (EMC)

Synonyms

- Adenomyoepithelioma
- Epithelial-myoepithelial tumor
- Epithelial-myoepithelial tumor of unknown malignant potential
- Pneumocytic adenomyoepithelioma

Definitions

- Salivary gland-type tumor with epithelial and myoepithelial component

ETIOLOGY/PATHOGENESIS

Etiology

- Origin of this tumor similar to other tumors of salivary gland type; may be from endobronchial glands

CLINICAL ISSUES

Epidemiology

- Incidence
  - Unusual occurrence as primary lung neoplasm
  - No more than 15-20 cases reported in literature

Site

- Invariably central tumor

Presentation

- Cough
- Shortness of breath
- Hemoptysis
- Fever

Treatment

- Surgical approaches
  - Lobectomy
  - Pneumonectomy

Prognosis

- Good
- Tumor has potential to metastasize

MACROSCOPIC

General Features

- Endobronchial tumor
- Rare tumor

Size

- 2.5-5.0 cm in greatest dimension

MICROSCOPIC

Histologic Features

- Glandular with inner epithelial layer and outer myoepithelial layer

Predominant Pattern/Injury Type

- Tubular
- Solid

Predominant Cell/Compartment Type

- Epithelial, glandular

ANCILLARY TESTS

Immunohistochemistry

- Can highlight inner epithelial and outer myoepithelial layers

DIFFERENTIAL DIAGNOSIS

Adenoid Cystic Carcinoma

- In small biopsies
  - Very difficult or impossible to differentiate
  - Both tumors show myoepithelial differentiation
  - Cylindromatous pattern is more common in adenoid cystic carcinoma
- In resected specimens
  - Presence of bilayer of cells forming glandular component is more common in adenoid cystic carcinoma
  - Areas of cylindromatous pattern is more common in adenoid cystic carcinoma
  - Presence of intraglandular mucoid material is more common in adenoid cystic carcinoma
  - Presence of glandular structures with internal layer (epithelial) and external layers of clear cells (myoepithelial cells) is classic for EMC

Mixed Tumor (Pleomorphic Adenoma)

- EMC lacks presence of mesenchymal components
  - Cartilage
  - Bone
  - Prominent chondromyxoid background
- Bilayer showing inner epithelial + outer clear cell layer of myoepithelial cells is characteristic of pulmonary EMC

Adenocarcinoma

- No bilayer of epithelial and myoepithelial cells
- Tumor cells may or may not be arranged in glands
- Tumor cells may have malignant cytological features

Hyalinizing Clear Cell Carcinoma

- Does not show 2 cell populations
- Has predominantly clear cell proliferation
- Lacks glandular appearance

DIAGNOSTIC CHECKLIST

Pathologic Interpretation Pearls

- Tubular structures with inner epithelial layer and outer layer of clear myoepithelial cells
- Solid cellular proliferation may predominate
- Focal squamous cell changes may occur
- Low mitotic activity
- Sebaceous differentiation may occur
- Oncocytic and apocrine changes may occur

GRADING

Low-Grade Carcinoma

- Tumor lacks marked nuclear atypia or increased mitotic activity
- Lymph node metastasis has been described

Immunohistochemistry

Antibody	Reactivity	Staining Pattern	Comment
CK-PAN	Positive	Cytoplasmic	
CK8/18/CAM5.2	Positive	Cytoplasmic	
S100	Positive	Nuclear & cytoplasmic	Focally and weakly
Actin-sm	Positive	Cytoplasmic	Stains only myoepithelial cells
TTF-1	Positive	Nuclear	In some cases
Vimentin	Positive	Cytoplasmic	
SOX10	Positive	Cytoplasmic	In some cases
Collagen IV	Positive	Not applicable	In some cases in basement membrane
p63	Negative		
p40	Negative		
NAPSIN-A	Negative		
EMA	Positive	Cell membrane	May be negative in some cases
DOG1	Negative		
CK5/6	Negative		
CD117	Negative		
pax-8	Negative		
myb	Negative		

Histochemical Features

Stain	Result
PAS	Negative
PAS-D	Negative
Mucicarmine	May show focal positive staining in intraluminal areas

Molecular Features

FISH	Result
0 < % protein expression	Negative
+ 5 $ 6 codon 61 mutations	May be present
. 5 $ 6 mutations	In few cases
1 5 $ 6 mutations	In few cases
% 5 $) mutations	Not present
3 , . & $ mutations	Not present

SELECTED REFERENCES

1. Falk N et al: Primary pulmonary salivary gland-type tumors: a review and update. Adv Anat Pathol. 23(1):13-23, 2016
2. Fonseca I et al: Global transcriptome and sequenome analysis of formalin-fixed salivary epithelial-myoepithelial carcinoma specimens. Genes Chromosomes Cancer. 54(4):249-59, 2015
3. Miettinen M et al: Sox10-a marker for not only schwannian and melanocytic neoplasms but also myoepithelial cell tumors of soft tissue: a systematic analysis of 5134 tumors. Am J Surg Pathol. 39(6):826-35, 2015
4. Tajima S et al: Primary epithelial-myoepithelial carcinoma of the lung: a case report demonstrating high-grade transformation-like changes. Oncol Lett. 10(1):175-181, 2015
5. Vázquez A et al: Epithelial-myoepithelial carcinoma of the salivary glands: an analysis of 246 cases. Otolaryngol Head Neck Surg. 153(4):569-74, 2015
6. Chiosea SI et al: HRAS mutations in epithelial-myoepithelial carcinoma. Head Neck Pathol. 8(2):146-50, 2014
7. Cho SH et al: Primary epithelial myoepithelial lung carcinoma. Korean J Thorac Cardiovasc Surg. 47(1):59-62, 2014
8. Rotellini M et al: Diagnostic utility of PLAG1 immunohistochemical determination in salivary gland tumors. Appl Immunohistochem Mol Morphol. 22(5):390-4, 2014
9. Stålhammar G et al: Sebaceous epithelial-myoepithelial carcinoma of the parotid gland: a case report of a new histologic variant. Ann Diagn Pathol. 18(4):248-52, 2014
10. Seethala RR: Oncocytic and apocrine epithelial myoepithelial carcinoma: novel variants of a challenging tumor. Head Neck Pathol. 7 Suppl 1:S77-84, 2013
11. Nguyen CV et al: Pulmonary epithelial-myoepithelial carcinoma: a clinicopathologic and immunohistochemical study of 5 cases. Hum Pathol. 40(3):366-73, 2009
12. Fulford LG et al: Epithelial-myoepithelial carcinomas of the bronchus. Am J Surg Pathol. 25(12):1508-14, 2001
13. Wilson RW et al: Epithelial-myoepithelial carcinoma of the lung: immunohistochemical and ultrastructural observations and review of the literature. Hum Pathol. 28(5):631-5, 1997

Solid and Glandular Appearance

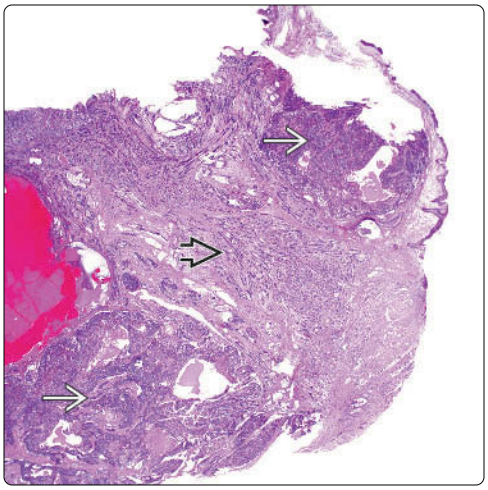

Tubular Component

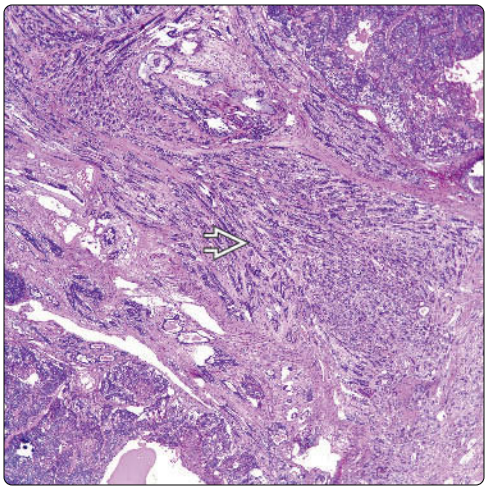

(Left) *EMC of lung shows solid areas ⇨ admixed with a glandular component ⇨ and focal areas of hemorrhage. This low-power view can be easily confused with conventional adenocarcinoma.* **(Right)** *Streaming of tubular structures ⇨ is shown. Adjacent tumor areas show a more glandular appearance. The presence of a bilayer glandular proliferation should suggest the differential diagnosis of EMC.*

Squamous Component

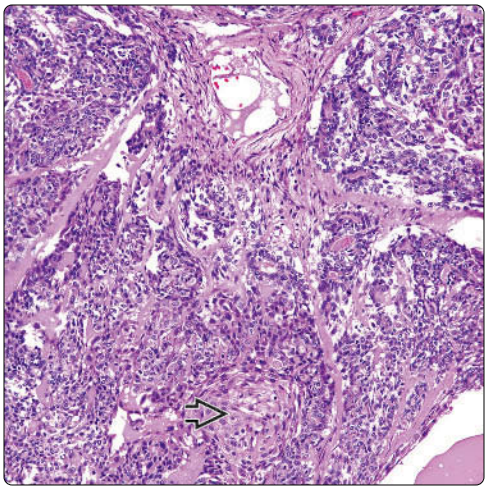

Clear Cell Component

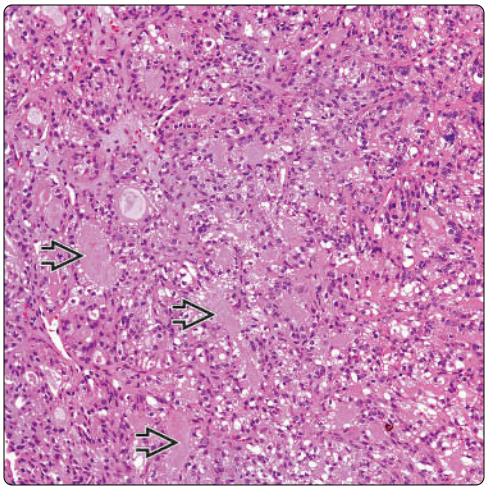

(Left) *EMC with a solid component and focal squamous morules ⇨ is shown. Although the presence of morules would suggest blastoma, the glandular component of EMC would be unusual in cases of pulmonary blastoma.* **(Right)** *Tubular structures are shown with amorphous acellular material in the lumen of glands ⇨. Even at this magnification, one can identify clear cells. This pattern may also be seen in cases of adenoid cystic carcinoma.*

Cords of Clear Cells

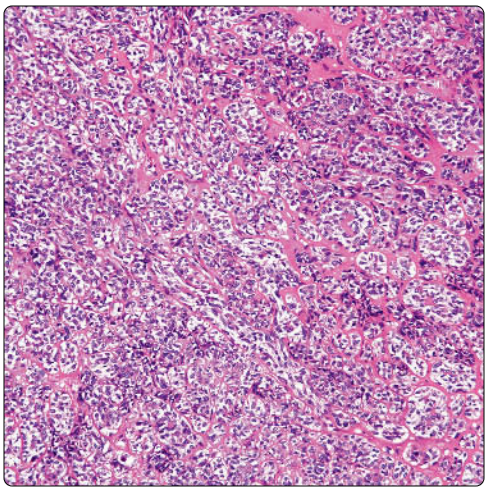

Compressed Glandular Component

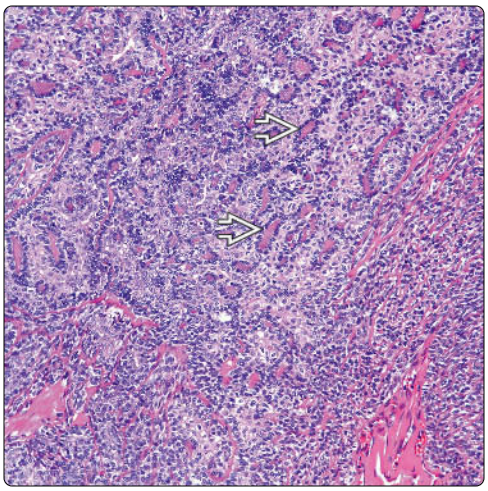

(Left) *A proliferation of clear myoepithelial cells separated by a thin fibrocollagenous material is shown. This pattern of predominant clear myoepithelial cells also suggests the possibility of pure EMC.* **(Right)** *Tubular structures with prominent epithelial component ⇨ are shown. Although the appearance is that of a glandular proliferation, the "glands" are composed of 2 cell populations.*

Tubules With Dual Cellular Component

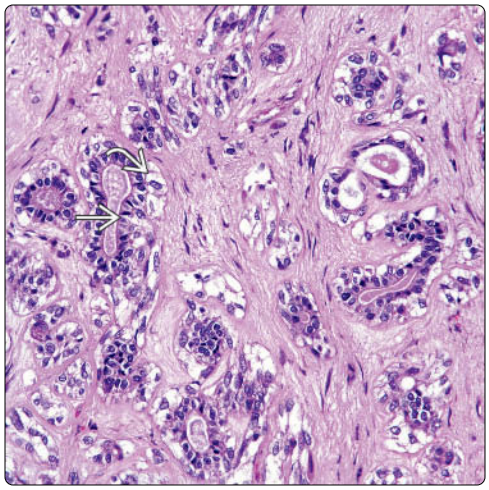

Metastasis in Lymph Node

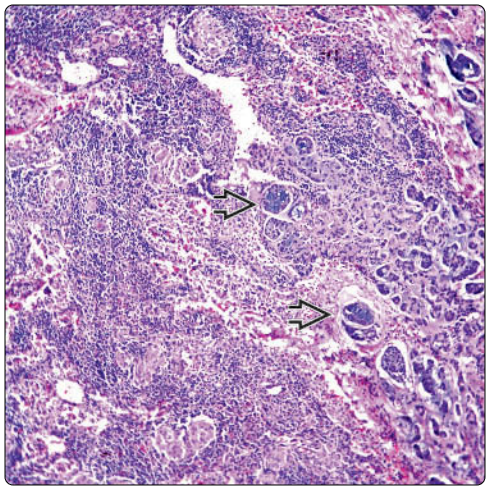

(Left) *EMC shows classic tubular structures with dual epithelial and clear cell myoepithelial components. This pattern is classic for the diagnosis of EMC.* **(Right)** *Metastatic EMC in a lymph node is shown. This feature is rarely seen in EMC and should be carefully evaluated in all those cases in which lymph nodes are available for histological examination.*

Keratin Immunostain

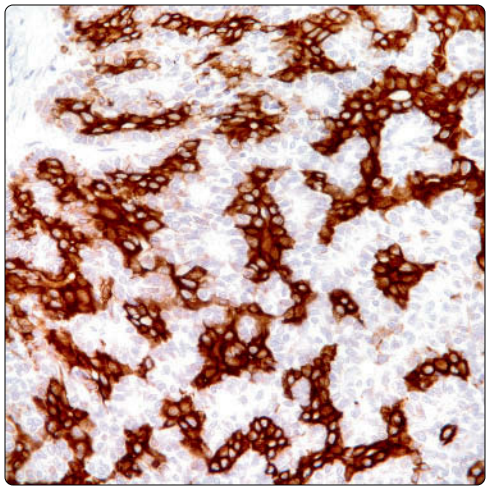

Actin Immunostain

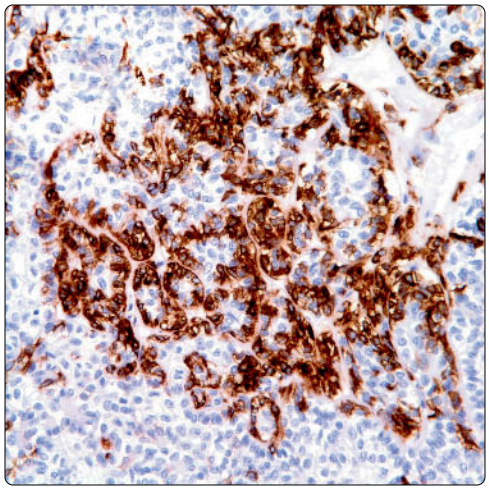

(Left) *CK-PAN shows a strong positive reaction in the epithelial component. It is important to recognize that this staining pattern is not necessarily pathognomonic of EMC.* **(Right)** *Actin-sm shows a strong positive reaction in the myoepithelial component. As with CK-PAN, this is not specific for EMC.*

Haphazard Growth Pattern

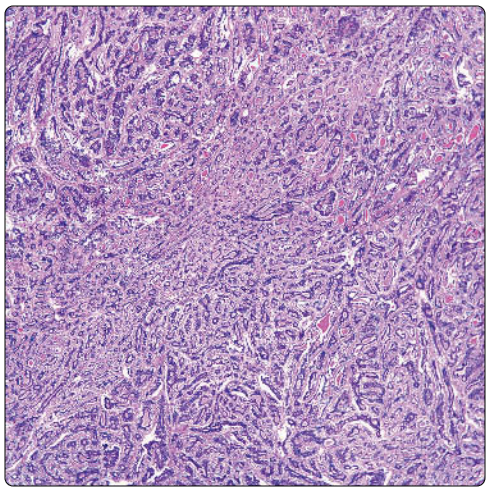

Solid Component

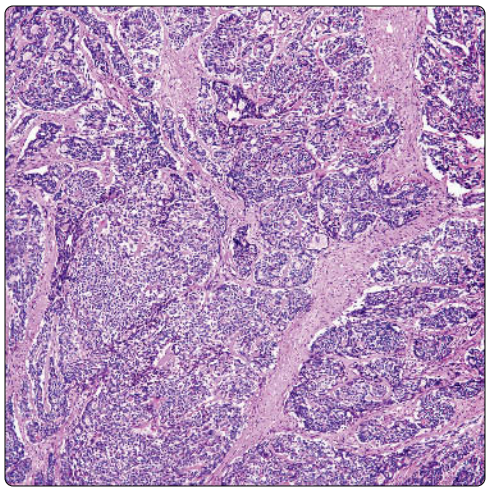

(Left) *EMC is shown growing in a more disorganized pattern of tubular structures of different sizes admixed with some solid components. A similar pattern may be seen in cases of adenoid cystic carcinoma.* **(Right)** *EMC with a more solid growth pattern and bands of fibroconnective tissue is shown. This image may also be seen in adenoid cystic carcinoma. Closer examination in these cases will show the typical features of EMC.*

Subtle Tubular Structures

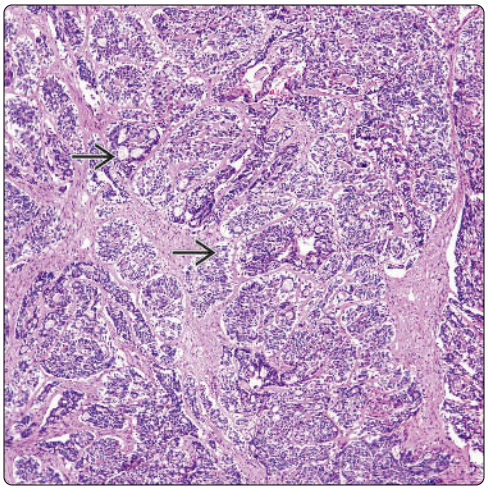

Dual Cell Component

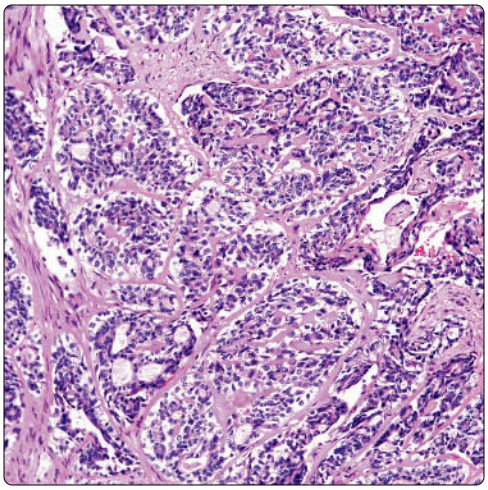

(Left) *Solid component in an EMC, in which one can still identify small tubular structures ⇨, is shown.* **(Right)** *Clusters of tubular structures are separated by thin fibroconnective tissue. In some tubular structures, one can identify a dual cellular proliferation. The identification of glands with a double layer of cells is important in establishing the diagnosis of EMC. Immunohistochemical stains will be of help in identifying the myoepithelial component.*

Squamous Component

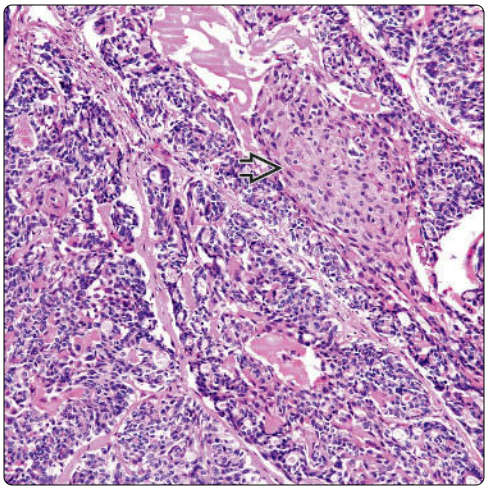

Hyalinization

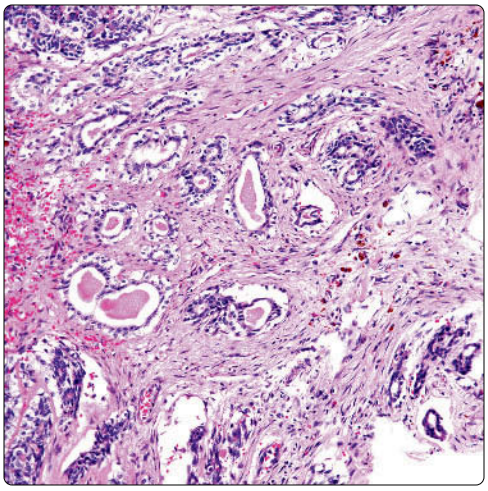

(Left) *EMC is shown with foci of squamous metaplasia. This histopathological finding may be more marked in some areas ⇨. However, this component is not extensive enough to suggest the possibility of a collision tumor.* **(Right)** *Marked hyalinization is shown with only a few groups of tubular structures in EMC. Still, the basic cellular component for the diagnosis of EMC is present.*

Fibrinoid Necrosis

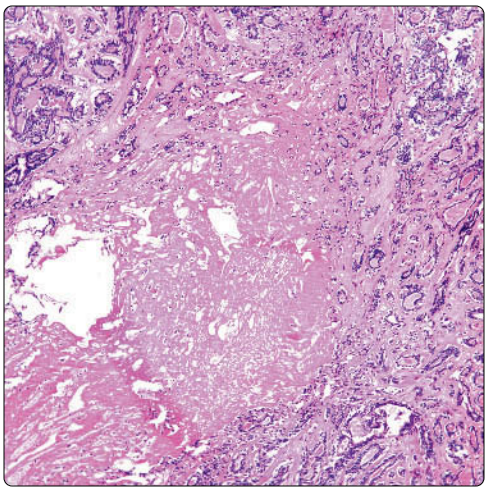

Absence of Mitotic Activity

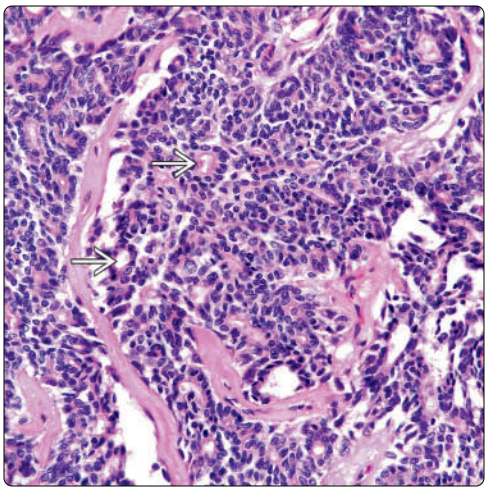

(Left) *Focal fibrinoid necrosis in EMC. Note the presence of the characteristic tubular structures around the fibrinoid areas of necrosis. This fibrinoid necrosis may be secondary to previous biopsy.* **(Right)** *Classic myoepithelial proliferation is composed of rather small cells with round to oval nuclei and absent nucleoli. Small residual tubular structures are still present ➡. Note the absence of increased mitotic activity.*

Acinic Cell Carcinoma

KEY FACTS

TERMINOLOGY

- Fechner tumor
- Epithelial neoplasm similar to that in salivary glands

CLINICAL ISSUES

- Cough
- Chest pain
- Asymptomatic

MACROSCOPIC

- Necrosis and hemorrhage are not common
- Tumor is well demarcated but not encapsulated
- Intraparenchymal mass
- Usually, tumors measure from 1-5 cm in greatest dimension

TOP DIFFERENTIAL DIAGNOSES

- Adenocarcinoma
  - Shows positive cytoplasmic staining for mucin content with D-PAS and mucicarmine
  - Shows more nuclear atypia and mitotic figures
- Oncocytic variant of neuroendocrine carcinoma
  - Acinic cell carcinoma negative for neuroendocrine markers
- Metastatic acinic cell carcinoma
  - Previous history of acinic cell carcinoma of head and neck region is crucial in establishing primary site

DIAGNOSTIC CHECKLIST

- Granular cytoplasm brightly positive for PAS
- EM: Electron-dense zymogen granules

Alveolar Distribution

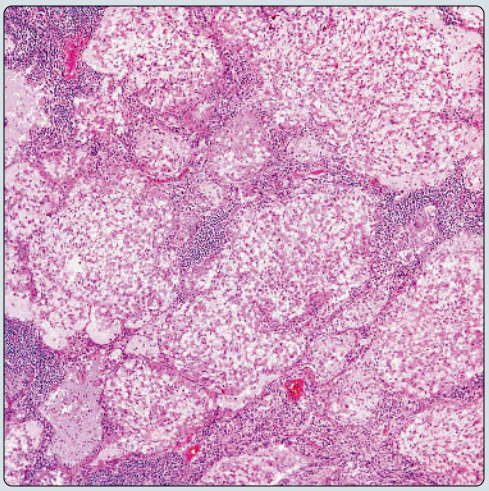

Solid and Glandular Components

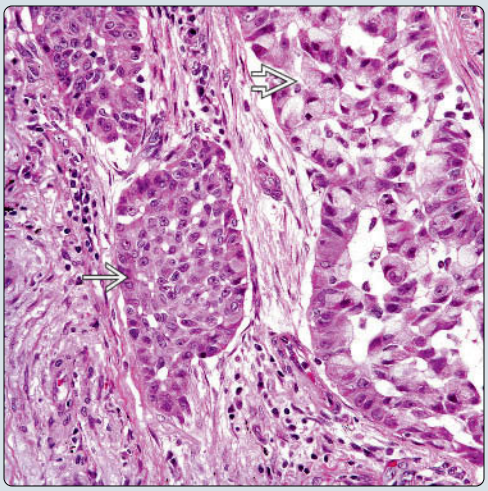

(Left) *Acinic cell carcinoma shows filling of the alveolar spaces. The tumor has a subtle nested and neuroendocrine growth pattern.* **(Right)** *Acinic cell carcinoma shows solid and glandular features. In the solid ⇨ component, the cells do not show ample cytoplasm, whereas, in the glandular component, the cells show more granular cytoplasm ⇨.*

Acinar Pattern

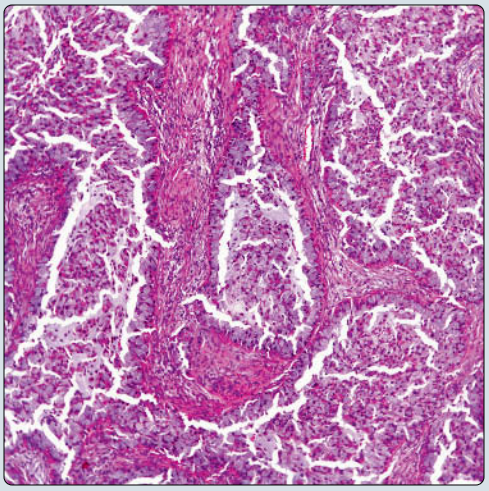

Granular Cytoplasm

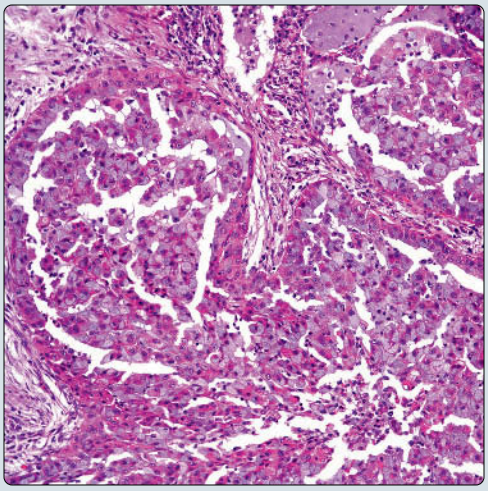

(Left) *Acinic cell carcinoma of the lung with acinar pattern is shown. Note the presence of bands of fibroconnective tissue giving the appearance of a lobulated neoplasm.* **(Right)** *Acinic cell carcinoma of the lung shows a vague glandular appearance and is composed of medium-sized cells with ample granular cytoplasm. Note the absence of nuclear atypia or mitotic activity.*

TERMINOLOGY

Synonyms

- Fechner tumor

Definitions

- Epithelial neoplasm similar to that in salivary glands

CLINICAL ISSUES

Presentation

- Chest pain
- Shortness of breath
- Cough
- Asymptomatic

Treatment

- Surgical approaches
  - Lobectomy

Prognosis

- Good in majority of cases
  - Tumor may follow aggressive behavior with metastasis

MACROSCOPIC

General Features

- Intraparenchymal mass
- Tumor is well demarcated but not encapsulated
- Necrosis and hemorrhage are not common

Size

- Usually, tumors measure 1-5 cm in greatest dimension

MICROSCOPIC

Histologic Features

- Large cells with abundant granular cytoplasm
- Signet ring-like cell appearance
- Low mitotic count to complete absence of mitotic activity
- Absence of nuclear atypia
- Absence of necrosis &/or hemorrhage

Predominant Pattern/Injury Type

- Acinar
- Cystic
- Organoid

Predominant Cell/Compartment Type

- Epithelial

DIFFERENTIAL DIAGNOSIS

Adenocarcinoma

- Will show more nuclear atypia and mitotic figures
- Will show positive cytoplasmic staining for mucin with D-PAS and mucicarmine
- Cells in acinic cell carcinoma are larger with abundant granular cytoplasm
- Acinic cell carcinoma will show by EM characteristic dark electron-dense zymogen granules
  - Shows strong positive cytoplasmic reaction with PAS

Oncocytic Variant of Neuroendocrine Carcinoma

- Acinic cell carcinoma negative for neuroendocrine markers
- By electron microscopy, neuroendocrine carcinoma will display neurosecretory granules
  - May show mitotic activity and necrosis

Metastatic Acinic Cell Carcinoma

- Previous history of acinic cell carcinoma of head and neck region is crucial in establishing primary site

Mammary Analog Secretory Carcinoma

- PAS does not show strong positive reaction
- Lack of electron-dense zymogen granules typical of acinic cell carcinoma
- ER and PR are usually positive in mammary analog secretory carcinoma

DIAGNOSTIC CHECKLIST

Clinically Relevant Pathologic Features

- EM: Electron-dense zymogen granules

Pathologic Interpretation Pearls

- Granular cytoplasm brightly positive for PAS
- Signet ring-like cells
- Low mitotic activity
- Oncocytic features
- Papillocystic features

SELECTED REFERENCES

1. Falk N et al: Primary pulmonary salivary gland-type tumors: a review and update. Adv Anat Pathol. 23(1):13-23, 2016
2. Abd Raboh NM et al: Diagnostic role of DOG1 and p63 immunohistochemistry in salivary gland carcinomas. Int J Clin Exp Pathol. 8(8):9214-22, 2015
3. Canberk S et al: Is DOG1 really useful in the diagnosis of salivary gland acinic cell carcinoma? - A DOG1 (clone K9) analysis in fine needle aspiration cell blocks and the review of the literature. Cytojournal. 12:18, 2015
4. Li X et al: Immunohistochemical expression of cytokeratins in human salivary gland acinic cell carcinomas. Oral Surg Oral Med Oral Pathol Oral Radiol. 120(2):248-57, 2015
5. Schmitt AC et al: Expression of SOX10 in salivary gland oncocytic neoplasms: a review and a comparative analysis with other immunohistochemical markers. Acta Cytol. 59(5):384-90, 2015
6. Bishop JA et al: Utility of mammaglobin immunohistochemistry as a proxy marker for the ETV6-NTRK3 translocation in the diagnosis of salivary mammary analogue secretory carcinoma. Hum Pathol. 44(10):1982-8, 2013
7. Elnayal A et al: Primary salivary gland-type lung cancer: imaging and clinical predictors of outcome. AJR Am J Roentgenol. 201(1):W57-63, 2013
8. Chuah KL et al: Recurrence of pulmonary acinic cell carcinoma. Arch Pathol Lab Med. 130(7):932-3, 2006
9. Sabaratnam RM et al: Acinic cell carcinoma: an unusual cause of bronchial obstruction in a child. Pediatr Dev Pathol. 7(5):521-6, 2004
10. Watanabe K et al: Fine-needle aspiration cytology of bronchial acinic cell carcinoma: a case report. Diagn Cytopathol. 30(5):359-61, 2004
11. Lee HY et al: Primary acinic cell carcinoma of the lung with lymph node metastasis. Arch Pathol Lab Med. 127(4):e216-9, 2003
12. Rodriguez J et al: Combined typical carcinoid and acinic cell tumor of the lung: a heretofore unreported occurrence. Hum Pathol. 34(10):1061-5, 2003
13. Ukoha OO et al: Acinic cell carcinoma of the lung with metastasis to lymph nodes. Chest. 115(2):591-5, 1999
14. Moran CA: Primary salivary gland-type tumors of the lung. Semin Diagn Pathol. 12(2):106-22, 1995
15. Moran CA et al: Acinic cell carcinoma of the lung ("Fechner tumor"). A clinicopathologic, immunohistochemical, and ultrastructural study of five cases. Am J Surg Pathol. 16(11):1039-50, 1992
16. Fechner RE et al: Acinic cell tumor of the lung. A histologic and ultrastructural study. Cancer. 29(2):501-8, 1972

Immunohistochemistry

Antibody	Reactivity	Staining Pattern	Comment
KERATIN-LMW	Positive	Cytoplasmic	In all cases
Amylase	Positive	Cytoplasmic	Only in some cases
Chymotrypsin	Positive	Cytoplasmic	Only in some cases
EMA	Positive	Cell membrane	
TTF-1	Positive	Nuclear	Not in all cases
NAPSIN-A	Positive	Cytoplasmic	In some cases
CK7	Positive	Cytoplasmic	
CK19	Positive	Cytoplasmic	
SOX10	Positive	Cytoplasmic	In some cases
DOG1	Positive	Cytoplasmic	
CK20	Negative		
p63	Negative		
CK5/6	Negative		
S100	Negative		
CDX-2	Negative		
Chromogranin-A	Negative		
Synaptophysin	Negative		
CD56	Negative		
CD117	Negative		
Mammaglobin	Negative		
PR	Negative		
ER	Negative		

Histochemical Features

Stain	Result	Comment
PAS	Strongly positive	
PAS-D	Negative	
Mucicarmine	Negative	Focal cytoplasmic mucin-positive cells may be seen

Ultrastructural Features

Electron Microscopy	Comment
Desmosomes and tonofilaments	
Electron-dense zymogen granules	Typical of acinic cell carcinoma

Molecular Analysis

FISH	Result
(79 175. gene fusion	Negative (positive in MASC)

0$6& PDPPDU\ DQDORJ VHFUHWRU\ FDUFLQRPD

Acinar Pattern

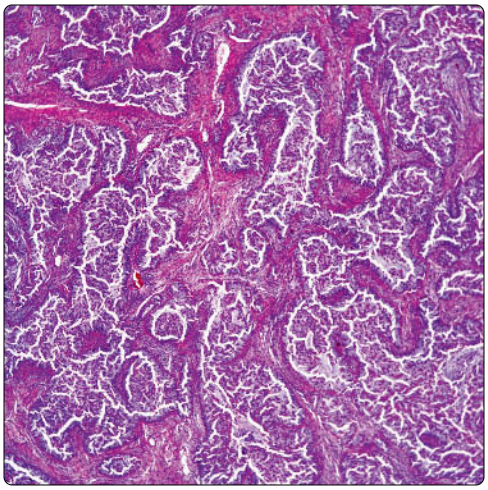

Absence of Nuclear Atypia

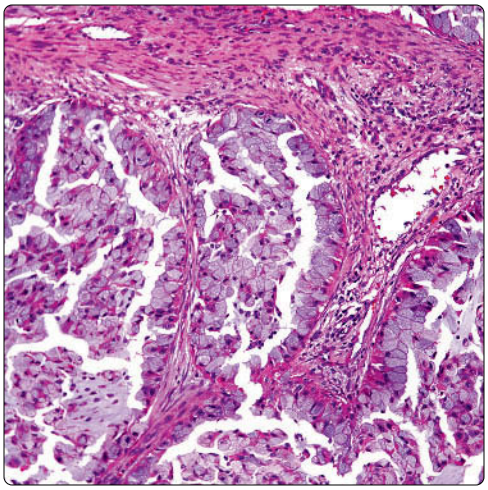

(Left) *Acinar pattern of acinic cell carcinoma of the lung shows tumor nests separated by thin bands of fibroconnective tissue.* **(Right)** *Acinar proliferation of large neoplastic cells with ample granular cytoplasm and small nuclei displaced toward the periphery of the cells is seen in acinic cell carcinoma of the lung. Note the absence of mitotic activity and nuclear atypia.*

Signet Ring Cell-Like Cells

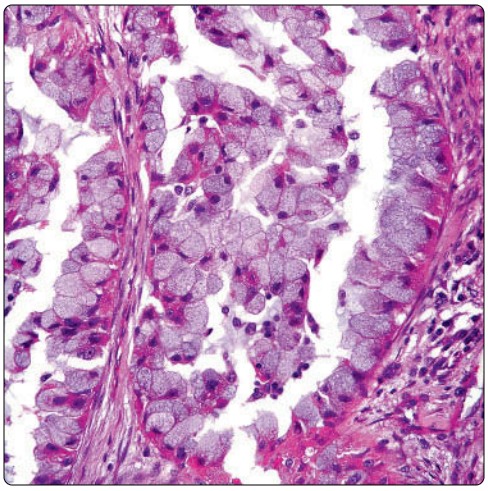

Alveolar Distribution

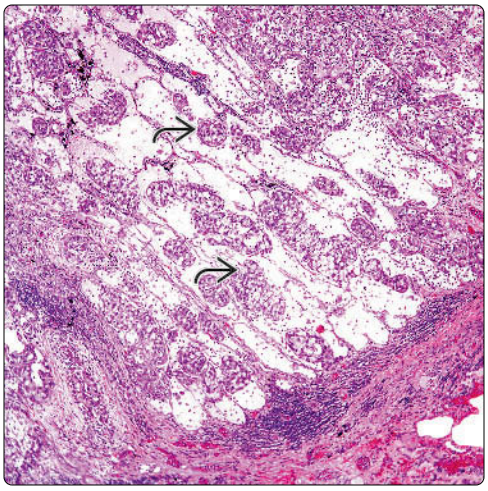

(Left) *High-power view of the cytologic features of acinic cell carcinoma shows large cells with eccentric nuclei, abundant cytoplasm, and inconspicuous nucleoli. Some of the cells may be confused with signet ring cells.* **(Right)** *Acinic cell carcinoma of the lung shows neoplastic cells floating in alveolar spaces giving the appearance of a pneumonic type of neoplasm.*

Solid Pattern

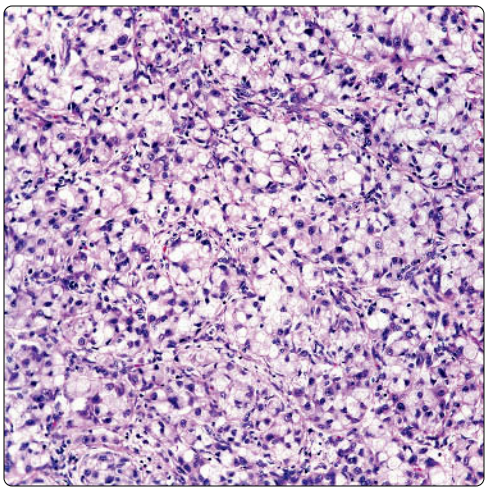

Infiltrative Pattern

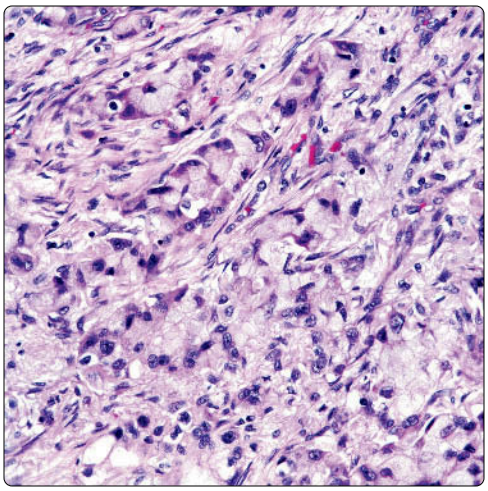

(Left) *High magnification of acinic cell carcinoma of the lung shows neoplastic cells with abundant clear cytoplasm and nuclei displaced toward the periphery of the cells. This appearance can be easily confused with a signet ring cell carcinoma of the lung.* **(Right)** *This acinic cell carcinoma is composed of cells with clear cytoplasm. The cells arranged in an acinar pattern appear to be dissecting fibroconnective tissue stroma.*

Microcystic Pattern

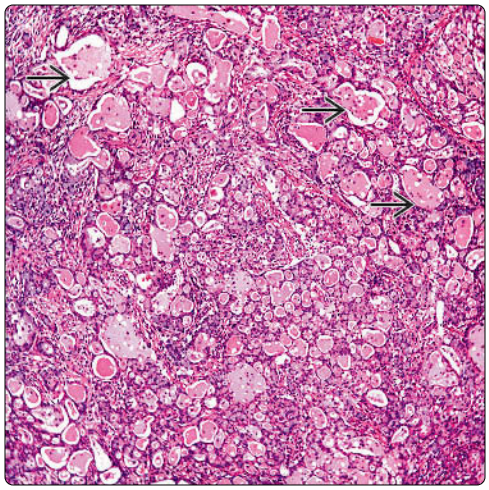

Cystic Pattern

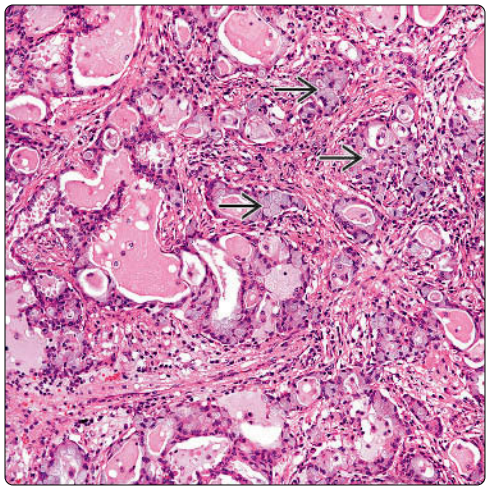

(Left) *Low-power view of acinic cell carcinoma shows a microcystic pattern ⇨ and focal solid acinar pattern. This low-power appearance can be seen in some other tumors of salivary gland type, such as mucoepidermoid carcinomas.* **(Right)** *Higher magnification shows cystic areas lined by neoplastic cells with abundant granular cytoplasm ⇨. Contrary to mucoepidermoid carcinomas that have mucin-producing epithelial cells, in acinic cell carcinoma, the cells contain glycogen.*

Clear Cells

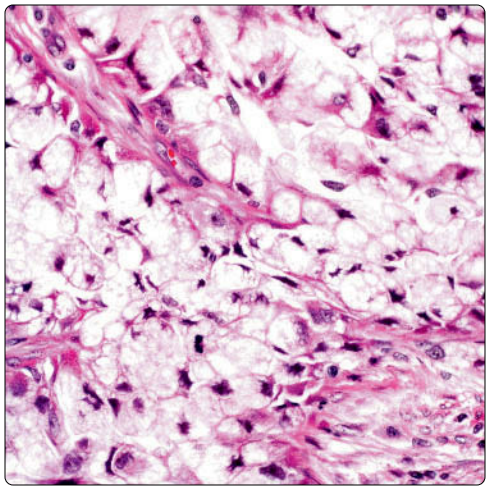

PAS Stain

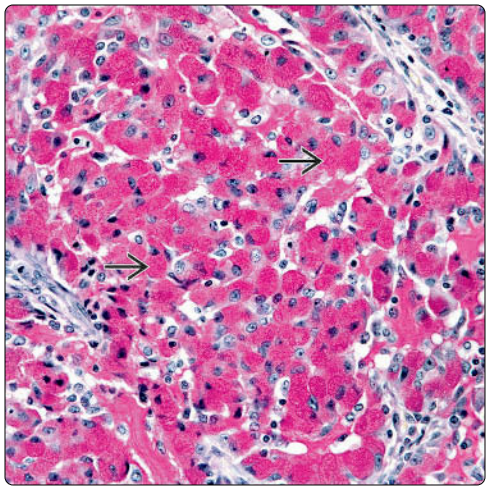

(Left) *Acinic cell carcinoma shows cells with clear cytoplasm and nuclei displaced toward the periphery. This appearance may mimic a signet ring cell carcinoma of either lung or gastrointestinal origin. Note the absence of marked nuclear atypia or mitotic activity.* **(Right)** *PAS stain before diastase digestion shows acinic cell carcinoma with strong positive cytoplasmic reaction ⇨. This is one of the most important features of acinic cell carcinoma.*

Prominent Acinar Component

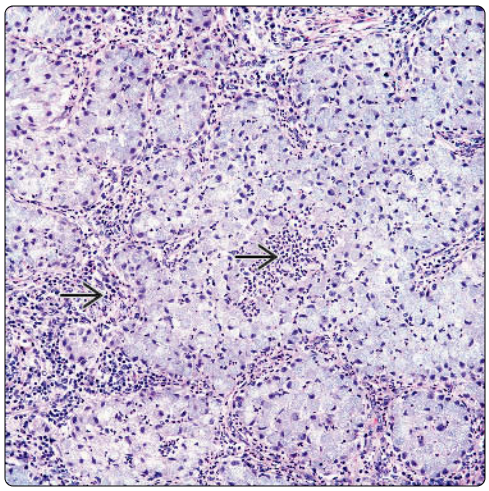

Signet Ring Cell Appearance

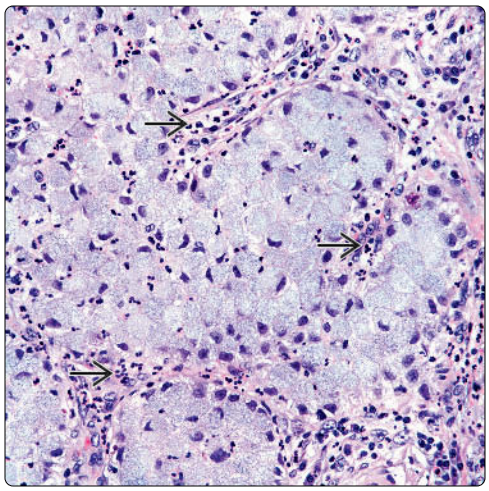

(Left) *Acinic cell carcinoma of the lung shows a classic acinar component. Note the presence of neoplastic cells admixed with an inflammatory component ⇨.* **(Right)** *Higher magnification shows a classic cellular component of acinic cell carcinoma admixed with an acute inflammatory infiltrate ⇨. Note the presence of tumor cells with granular cytoplasm and the absence of mitotic figures or nuclear atypia.*

Organoid Pattern

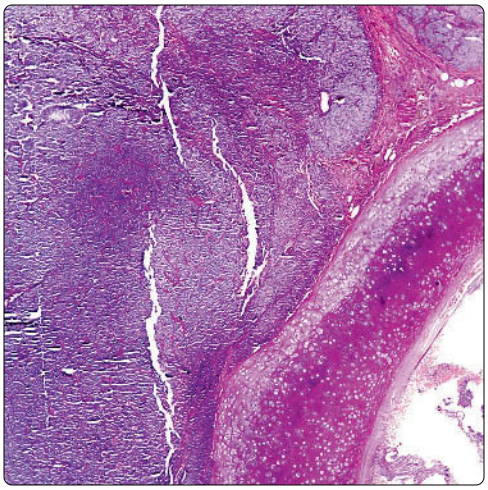

Small Nests

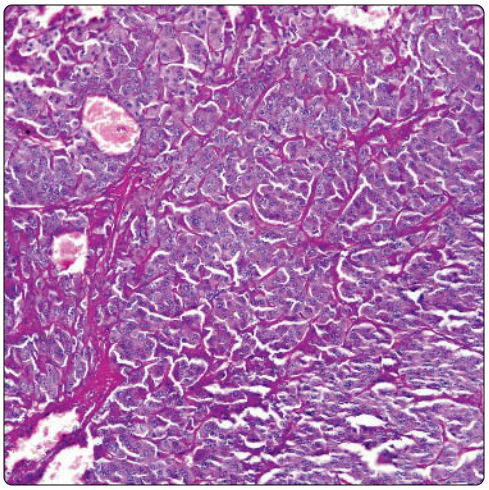

(Left) *Acinic cell carcinoma of the lung in a central location is seen. The tumor is in an endobronchial location but is not obstructing the bronchial lumen. In addition, note the prominent oncocytic changes and nested pattern.* **(Right)** *Acinic cell carcinoma is seen with a prominent nested pattern of growth with an oncocytic cellular proliferation. This appearance is similar to that of neuroendocrine carcinomas of the lung.*

Neuroendocrine-Like Pattern

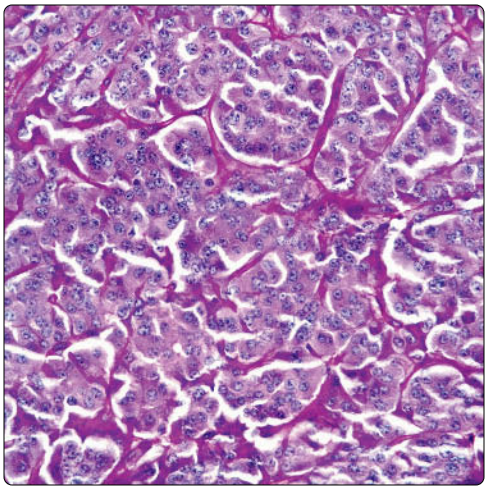

Electron Microscopy

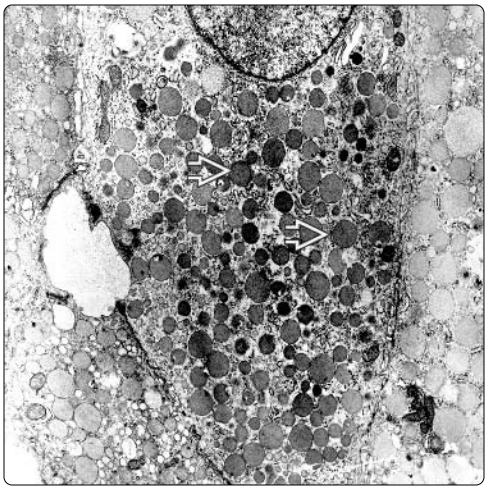

(Left) *High-power view shows a homogeneous cellular proliferation with round nuclei, oncocytic cytoplasm, and ample granular cytoplasm. Note the absence of necrosis and mitotic activity. Similar features may also be seen in conventional neuroendocrine carcinomas of the lung.* **(Right)** *TEM shows numerous electron-dense zymogen granules, a chief characteristic of acinic cell carcinoma ⇨. This feature alone is diagnostic of acinic cell carcinoma.*

Oncocytic Cells

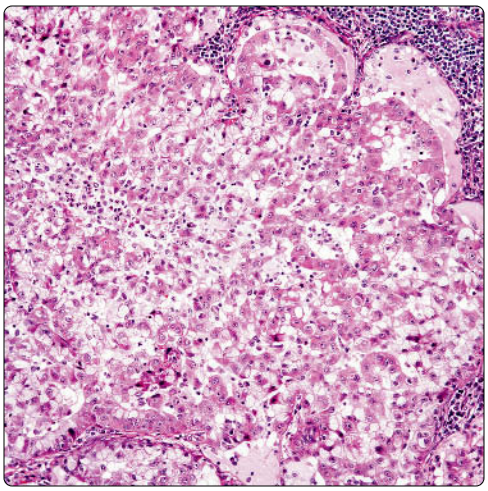

Absence of Mitotic Activity

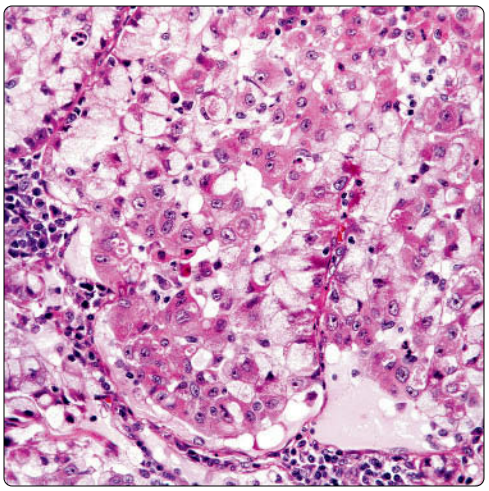

(Left) *Acinic cell carcinoma of the lung shows a more mixed type of histology. The neoplastic cellular proliferation is composed of clear and oncocytic cells. This pattern is not that common in these tumors.* **(Right)** *Higher magnification shows the admixture of clear and oncocytic cells in acinic cell carcinoma. Note the absence of nuclear atypia or mitotic activity. Still, the cytoplasm of the clear cells is granular, which raises the diagnosis of acinic cell carcinoma.*

Inflammatory Component

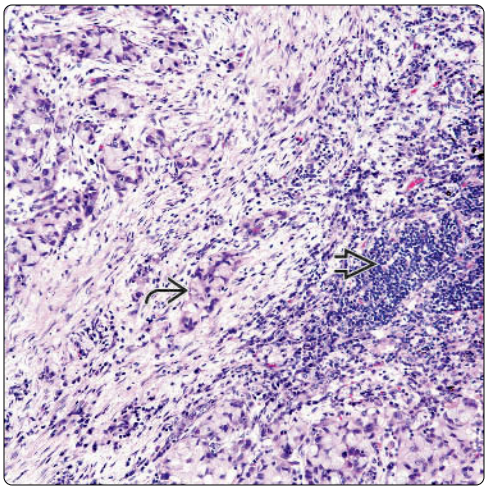

Solid Pattern

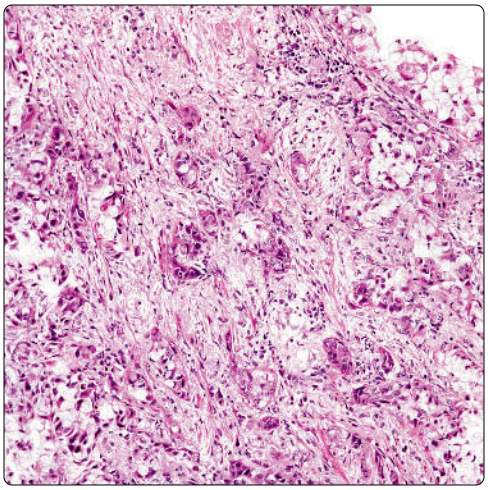

(Left) *Clusters of neoplastic cells dissect fibroconnective tissue. Adjacent tissue shows inflammatory changes, namely, the presence of lymphocytes.* **(Right)** *Acinic cell carcinoma of the lung shows a focal solid component admixed with more conventional features. A cursory review of similar areas may be mistaken for conventional adenocarcinoma.*

Extensive Fibrosis

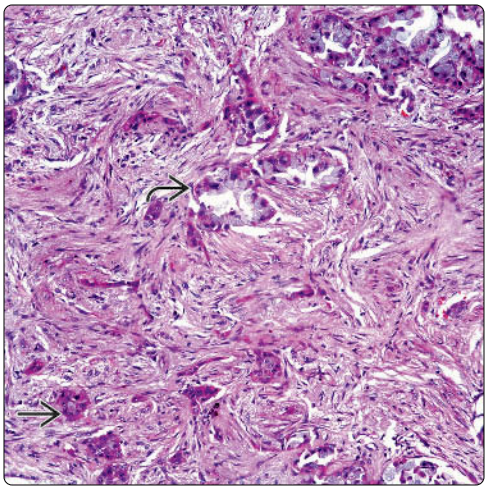

Contrast Between Inflammation and Tumor

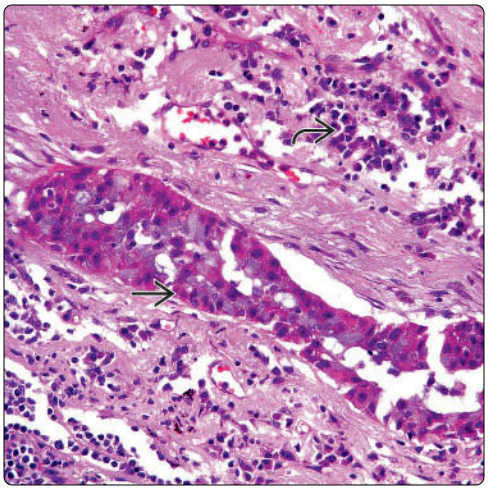

(Left) *In some cases of acinic cell carcinoma, there are areas of fibrosis in which one is able to identify glandular structures or small clusters of neoplastic cells.* **(Right)** *An isolated island of neoplastic cells is embedded in fibroconnective tissue. Adjacent tissue shows chronic inflammatory changes with presence of numerous plasma cells.*

Prominent Lymphoid Aggregates

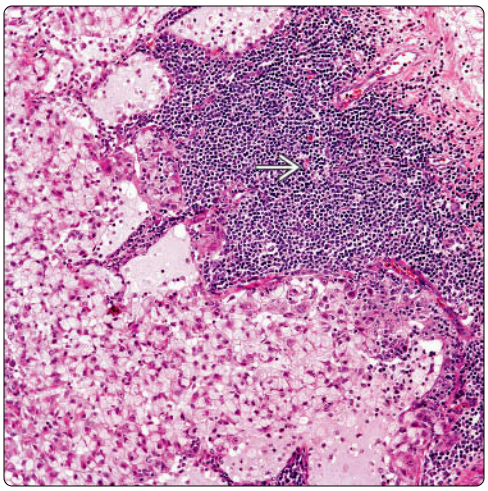

Obliteration of Normal Lung Parenchyma

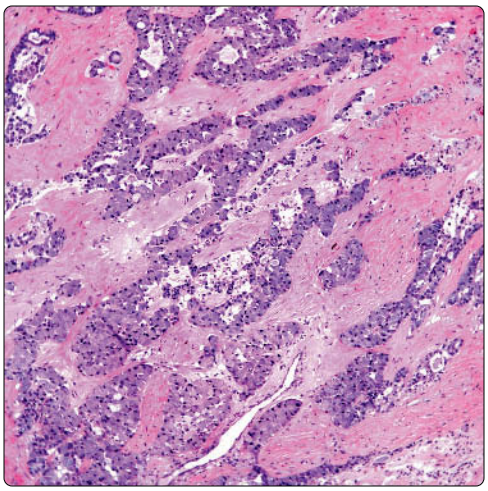

(Left) *In some cases of acinic cell carcinoma, the tumor may show lymphoid aggregates intermixed with the neoplastic cellular proliferation.* **(Right)** *Acinic cell carcinoma of the lung shows neoplastic cells arranged in cords and trabeculae dissecting areas of fibrocollagenous tissue. This pattern can also be seen in the conventional type of pulmonary adenocarcinoma.*

Hyperplasia of BALT and Tumor

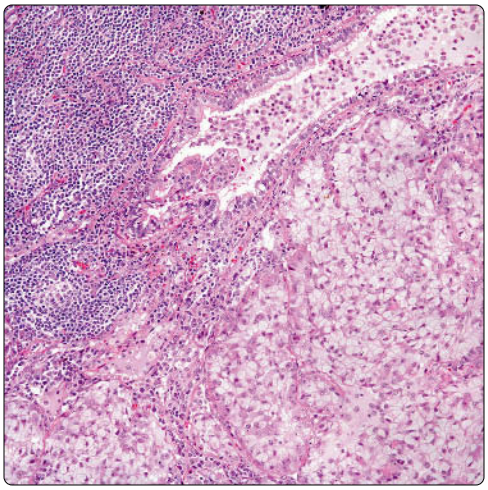

Alveolar Macrophages

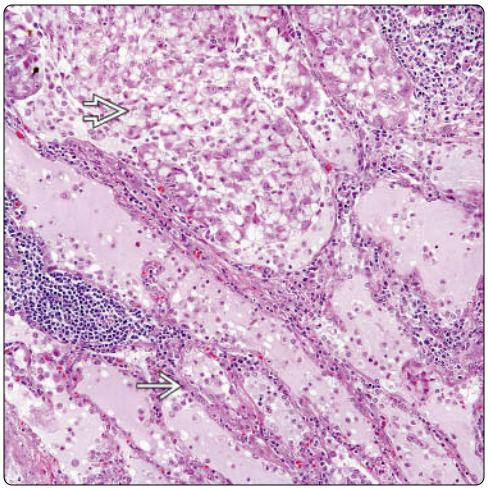

(Left) *Acinic cell carcinoma shows areas in which the airway has the presence of prominent lymphoid aggregates characteristic of hyperplasia of the bronchus-associated lymphoid tissue (BALT).* **(Right)** *Acinic cell carcinoma ⇨ replaces normal lung parenchyma and uninvolved lung parenchyma ⇨ in which the alveoli is filled with macrophages.*

Prominent Signet Ring Cell Features

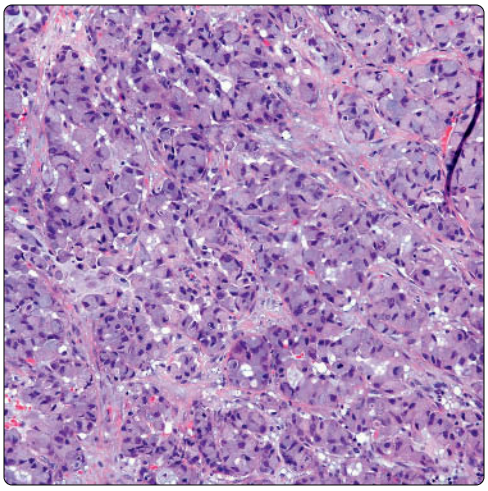

PAS-Positive Stain

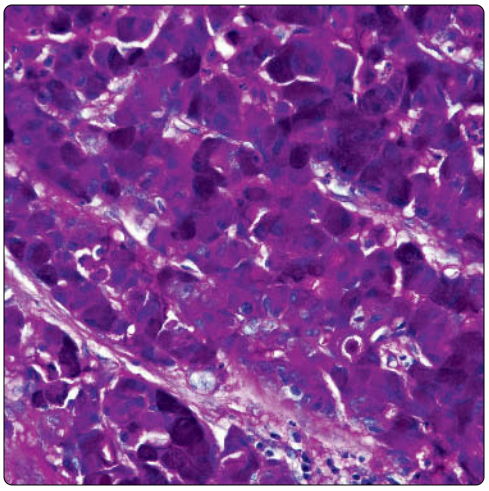

(Left) *Solid pattern of acinic cell carcinoma is seen in which the cells show a striking signet ring cell morphology.* **(Right)** *Histochemical stain for periodic acid-Schiff demonstrates the rich amount of glycogen in the malignant cells of acinic cell carcinoma.*

Amylase Positivity

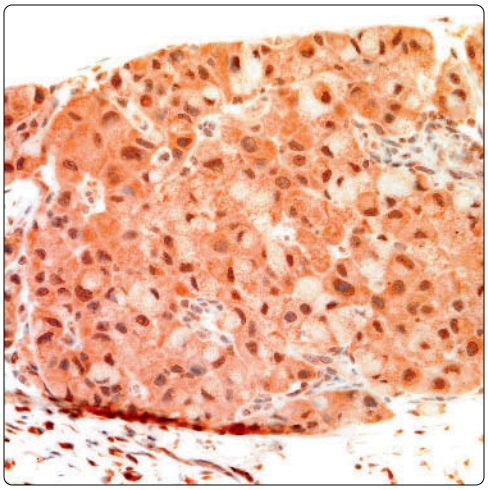

Strong α-1 ACT

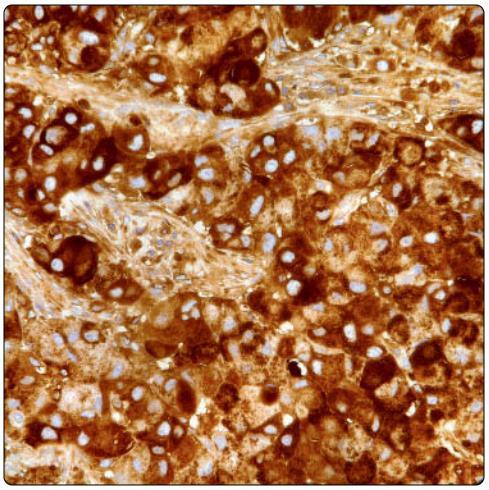

(Left) *Acinic cell carcinoma shows positive reaction in tumor cells for amylase. Even though the stain is not specific, it is often positive.* **(Right)** *Strong positive reaction is shown in tumor cells for α-1 antichymotrypsin (ACT) in acinic cell carcinoma. The stain is not specific for the diagnosis, but it is often positive.*

Mixed Tumor

KEY FACTS

TERMINOLOGY

- Synonym: Pleomorphic adenoma
- Biphasic neoplasm with epithelial/myoepithelial and mesenchymal differentiation

CLINICAL ISSUES

- Symptoms
  - Cough
  - Dyspnea
  - Chest pain
  - Hemoptysis
- Prognosis
  - Excellent for benign tumors
  - Malignant mixed tumors may need additional therapy

MACROSCOPIC

- Endobronchial tumor
- 1-5 cm in greatest dimension

MICROSCOPIC

- Chondromyxoid areas admixed with benign epithelial elements
- Plasmacytoid cellular proliferation
- Areas of keratinization

ANCILLARY TESTS

- GFAP
- CK-PAN
- S100
- Actin-sm

TOP DIFFERENTIAL DIAGNOSES

- Non-small cell carcinoma
- Epithelial/myoepithelial carcinoma
- Mucoepidermoid carcinoma
- Carcinosarcoma
- Pulmonary hamartoma

Centrally Located Tumor

Benign Epithelial Elements

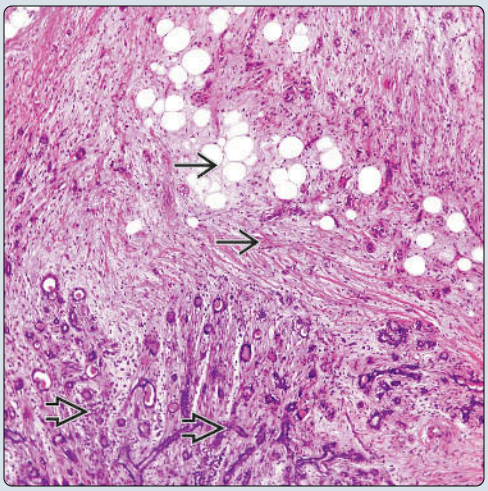

(Left) *Panoramic view shows a benign mixed tumor. Note the central location, as the tumor is growing just beneath the bronchial mucosa.* **(Right)** *Benign mixed tumor is seen with a mixture of epithelial elements and mesenchymal elements.*

Glandular Elements

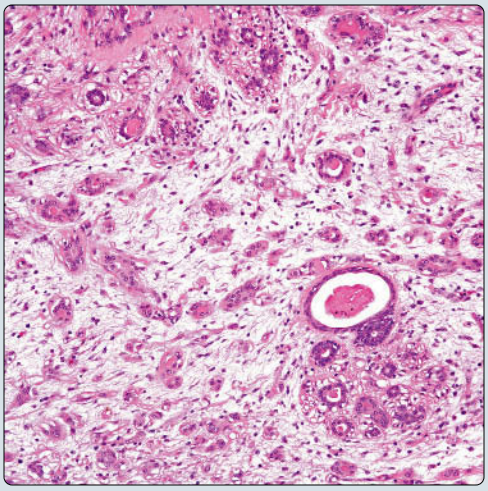

Chondromyxoid Component

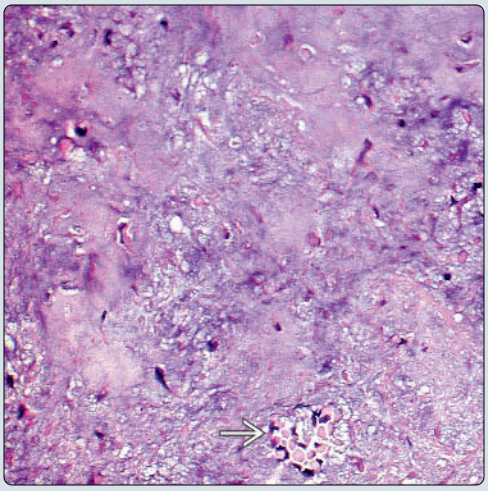

(Left) *Primary mixed tumor (pleomorphic adenoma) shows a proliferation of glandular structures embedded in loose fibroconnective tissue.* **(Right)** *Mixed tumor (pleomorphic adenoma) of the lung shows areas composed predominantly of chondromyxoid stroma with only focal cellular areas.*

TERMINOLOGY

Synonyms

- Pleomorphic adenoma

Definitions

- Biphasic neoplasm with epithelial/myoepithelial and mesenchymal differentiation

CLINICAL ISSUES

Presentation

- Cough
- Dyspnea
- Hemoptysis
- Chest pain
- Asymptomatic

Treatment

- Surgical approaches
  - Lobectomy

Prognosis

- Excellent for benign tumor
- Malignant mixed tumors may need additional therapy

IMAGING

General Features

- Single mass, often centrally located

MACROSCOPIC

General Features

- Endobronchial tumor

Size

- 1-5 cm in greatest dimension

MICROSCOPIC

Histologic Features

- Presence of chondromyxoid background with focal cartilage admixed with epithelial component
- Areas of keratinization
- Plasmacytoid cellular proliferation may be prominent
- Residual adnexal-like areas may be present
- Areas of solid cellular proliferation that could be spindle cell
- Well-formed mature cartilage is rare
- In cases of expleomorphic adenoma
  - Presence of malignant epithelial component
  - Presence of malignant mesenchymal component

Predominant Pattern/Injury Type

- Biphasic

Predominant Cell/Compartment Type

- Epithelial, biphasic, or mixed

DIFFERENTIAL DIAGNOSIS

Non-Small Cell Carcinoma

- In small biopsy with only well-differentiated epithelial component sampled
  - In resected specimens, diagnosis should not pose problem

Epimyoepithelial Carcinoma

- Both tumors show myoepithelial component
- Epithelial myoepithelial carcinoma does not show presence of cartilage or other heterologous elements
- Glandular component of inner layer of epithelial cells and outer layer of myoepithelial cells is characteristic of epithelial-myoepithelial carcinoma

Mucoepidermoid Carcinoma

- Issue in small biopsy with only epithelial component sampled
- In resected specimens, diagnosis is not problem
- Mucoepidermoid carcinomas show presence of mucus-producing and intermediate cells

Carcinosarcoma

- Carcinosarcomas will show presence of malignant mesenchymal and malignant epithelial components

Pulmonary Hamartoma

- Most hamartomas will show prominent cartilaginous component and invaginations of epithelium
- Hamartomas do not show presence of myoepithelial cellular proliferation

DIAGNOSTIC CHECKLIST

Clinically Relevant Pathologic Features

- Tissue distribution

Pathologic Interpretation Pearls

- Presence of epithelial/myoepithelial cells admixed with chondromyxoid or cartilaginous areas

GRADING

Benign Mixed Tumors

- Components are mature elements without atypical histological features

Malignant Mixed Tumor (Expleomorphic Adenoma)

- Malignant mixed tumors will display conventional malignant components either in epithelial or mesenchymal component

SELECTED REFERENCES

1. Falk N et al: Primary pulmonary salivary gland-type tumors: a review and update. Adv Anat Pathol. 23(1):13-23, 2016
2. Weissferdt A et al: Pulmonary salivary gland-type tumors with features of malignant mixed tumor (carcinoma ex pleomorphic adenoma): a clinicopathologic study of five cases. Am J Clin Pathol. 136(5):793-8, 2011
3. Moran CA: Primary salivary gland-type tumors of the lung. Semin Diagn Pathol. 12(2):106-22, 1995
4. Moran CA et al: Benign and malignant salivary gland-type mixed tumors of the lung. Clinicopathologic and immunohistochemical study of eight cases. Cancer. 73(10):2481-90, 1994

(Left) *Benign mixed tumor shows prominent chondromyxoid background and remnants of epithelial elements. The identification of embedded epithelial elements is an important feature in these tumors.* **(Right)** *Epithelial cells ⇨ are embedded in an acellular chondromyxoid background. Note the discrete vascular proliferation. The presence of mature cartilage in these tumors in the lung is rare.*

Myxoid Stroma

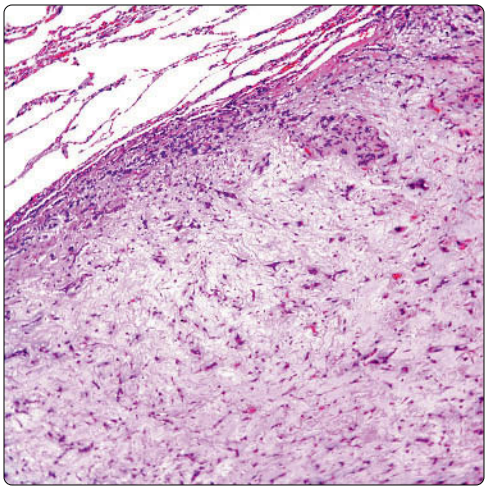

Clusters of Epithelial Cells

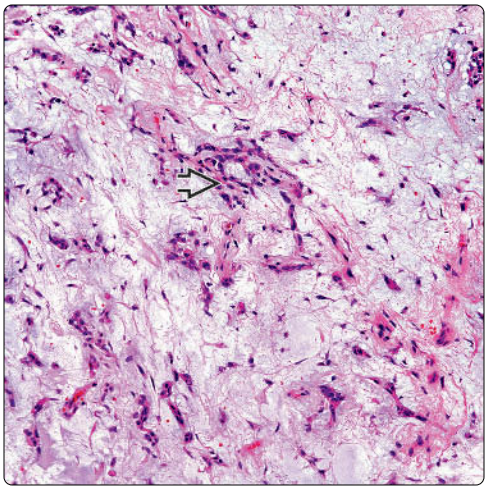

(Left) *Epithelial/myoepithelial proliferation is admixed with hypocellular areas ⇨. This growth pattern may mimic a benign vascular tumor due to the compressed appearance of the epithelial component.* **(Right)** *Disorganized epithelial/myoepithelial cellular proliferation is embedded in a myxoid matrix. In addition, there is a discrete vascular component.*

Hypo- and Hypercellular Areas

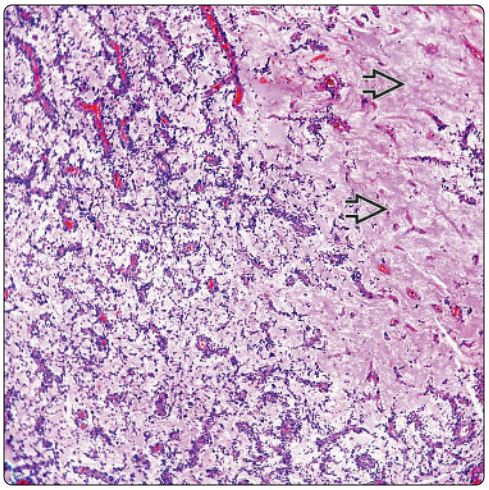

Myoepithelial Cells

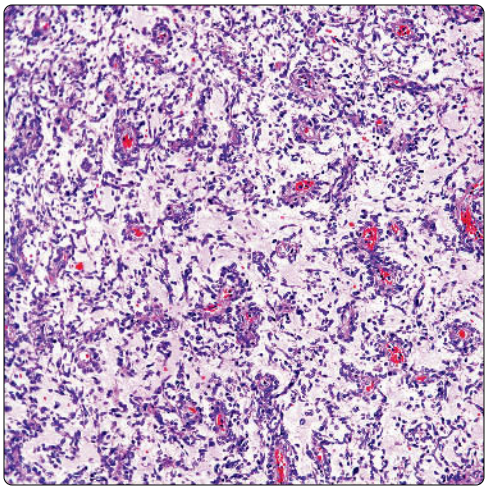

(Left) *Mixed tumor of the lung shows chondromyxoid background ⇨, epithelial proliferation ⇨, and squamous keratinization ⇨.* **(Right)** *Tubular structures ⇨ are seen embedded in a fibrocollagenous background. The tubular structures show dual cell layer; similar features may be seen in epithelial/myoepithelial carcinoma.*

Keratinization

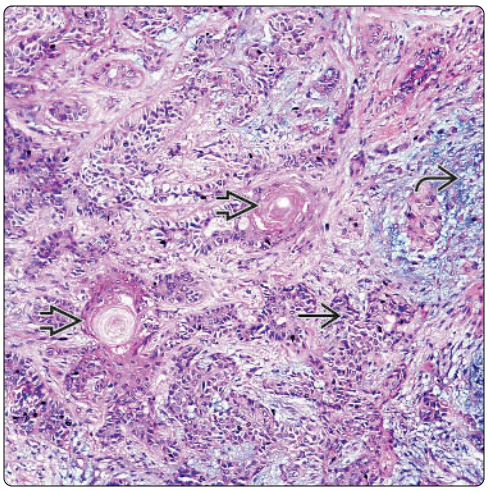

Tubular Proliferation

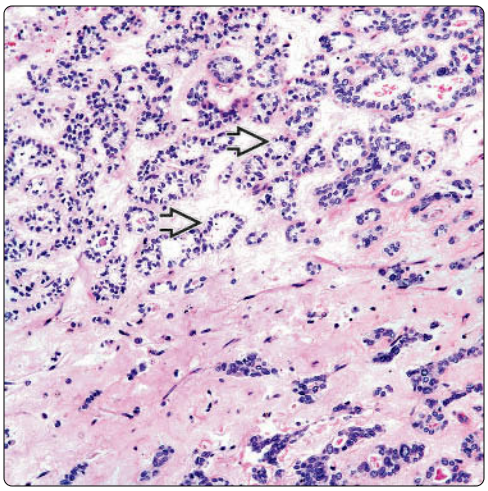

Solid Areas

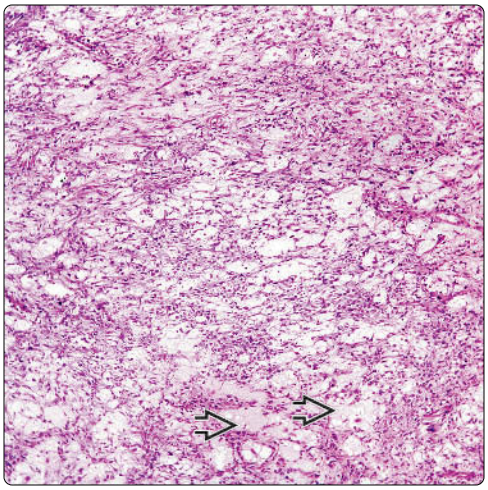

Lack of Mitotic Activity

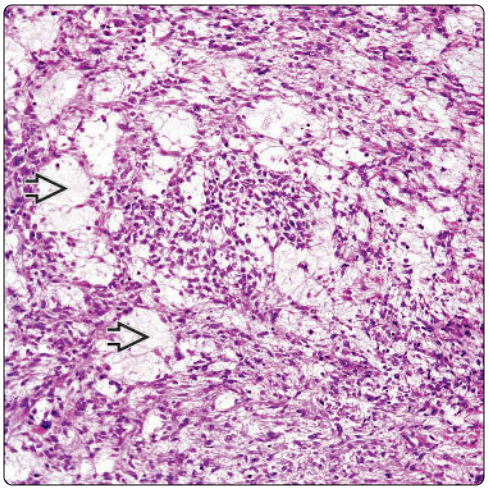

(Left) *Hypercellular myoepithelial areas show minimal myxoid component ⇨. The presence of solid areas in many cases raises the suspicion of malignant transformation.* **(Right)** *Closer view of myoepithelial cells and myxoid component ⇨ is shown. Note the absence of nuclear atypia, mitotic activity, necrosis, &/or hemorrhage.*

Prominent Cartilaginous Component

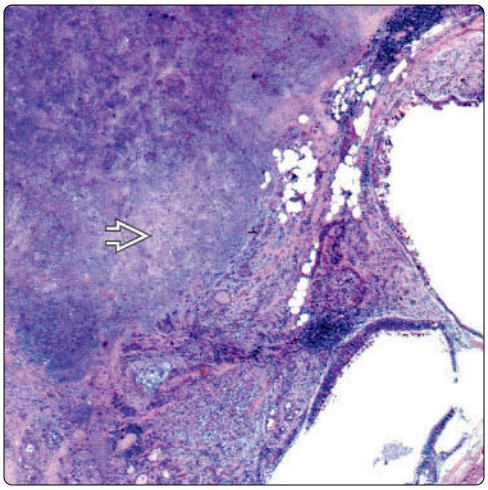

Chondromyxoid Areas

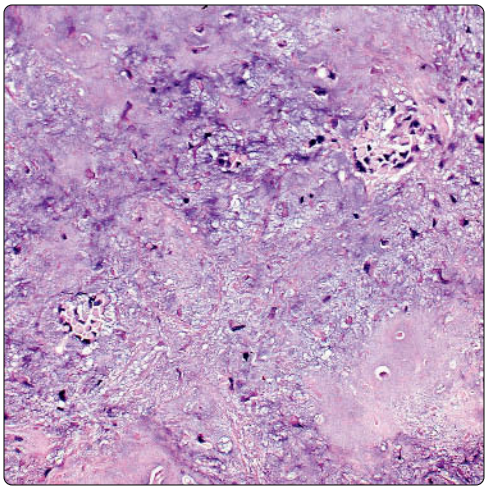

(Left) *Mixed tumor shows prominent cartilaginous component ⇨ and focal cystic changes. The presence of well-formed mature cartilage in mixed tumors of the lung is not common.* **(Right)** *Prominent chondromyxoid stroma shows low cellular epithelial component. Note the absence of nuclear atypia in both components. Such features are in keeping with a mixed (pleomorphic) adenoma.*

Plasmacytoid Cellular Component

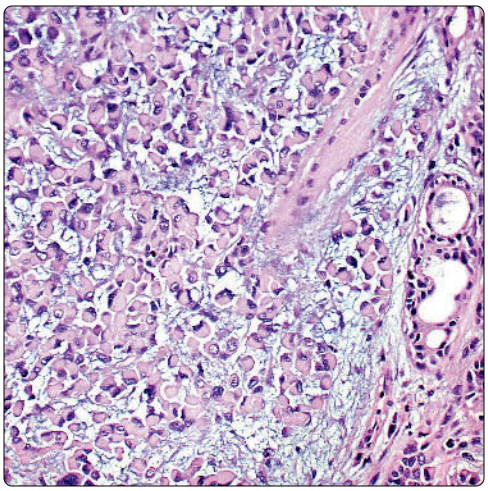

Squamous Metaplasia

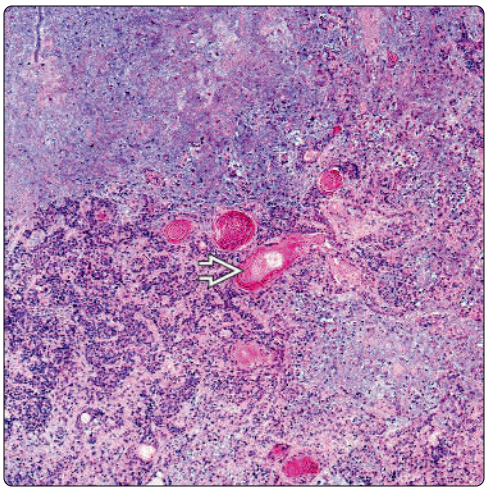

(Left) *Benign mixed tumor shows prominent plasmacytoid cellular component and myxoid background. This is another unusual feature for this tumor in the lung, and it can be confused for another type of neoplasm.* **(Right)** *Benign mixed tumor shows epithelial and chondromyxoid component and areas of squamous metaplasia ⇨. Although these features are commonly seen in salivary gland tumors, they are not common in the lung.*

Epithelial and Mesenchymal Components

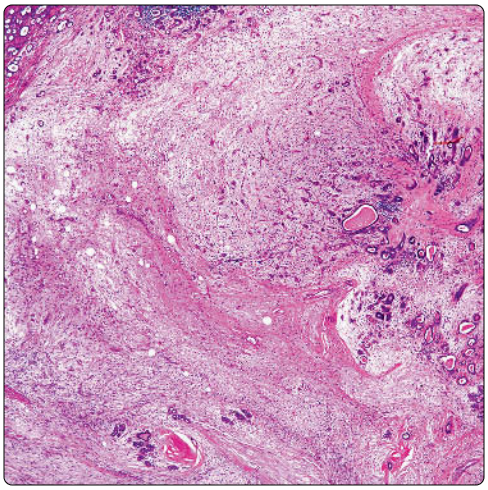

Adnexal-Like Structures

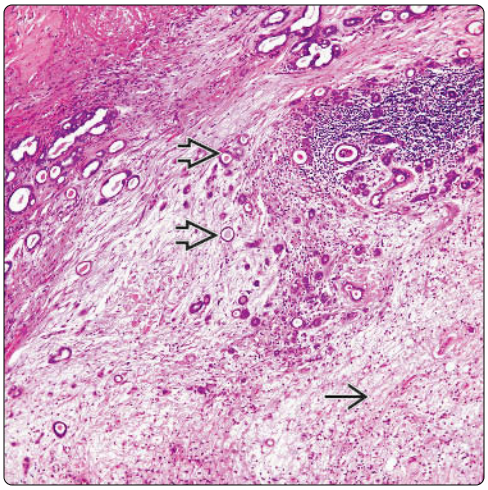

(Left) *Benign mixed tumor is shown with a mixture of different epithelial and mesenchymal elements. In this low-power view, the tumor can be easily interpreted as a hamartoma of the lung.* **(Right)** *Benign mixed tumor with epithelial component ⇨ resembles adnexal structures. Areas of hyalinized tissue are also present ⇨ admixed with some inflammatory reaction.*

Myxoid and Epithelial Components

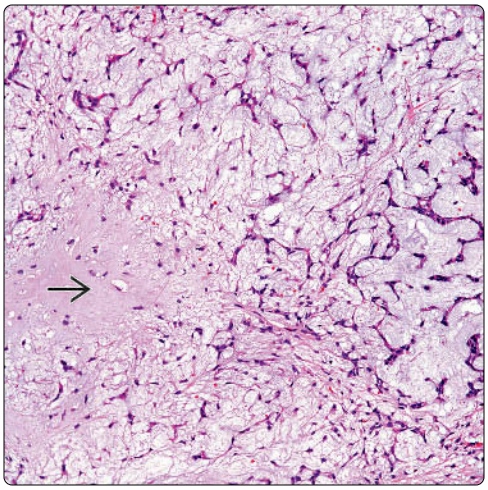

Focal Cellular Areas

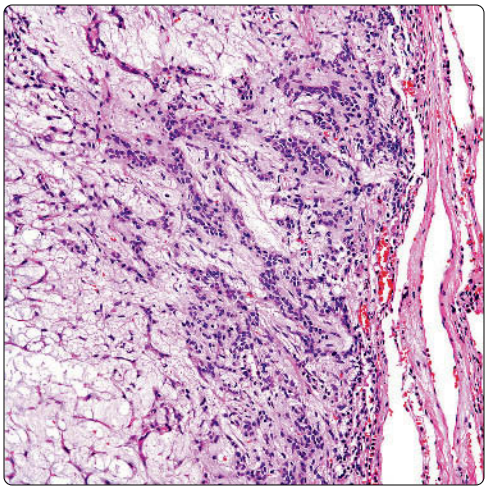

(Left) *Benign mixed tumor with a combination of myxoid, epithelial, and focal cartilaginous ⇨ elements is shown. These features should raise the suspicion of a primary mixed tumor of the lung.* **(Right)** *Benign mixed tumor shows a more epithelial component toward the periphery of the tumor, while, toward the center of the lesion, the tumor appears to be less cellular and more myxoid.*

Cystic Changes

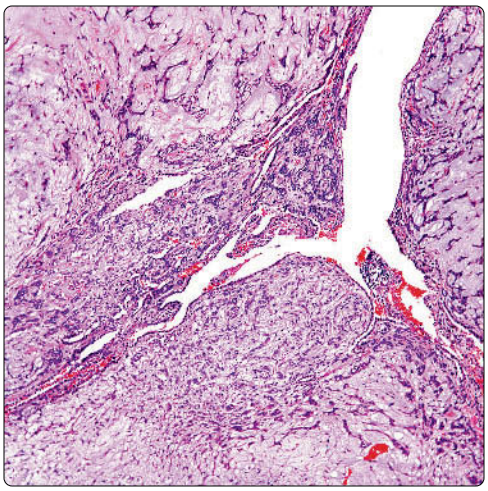

Myoepithelial Cellular Component

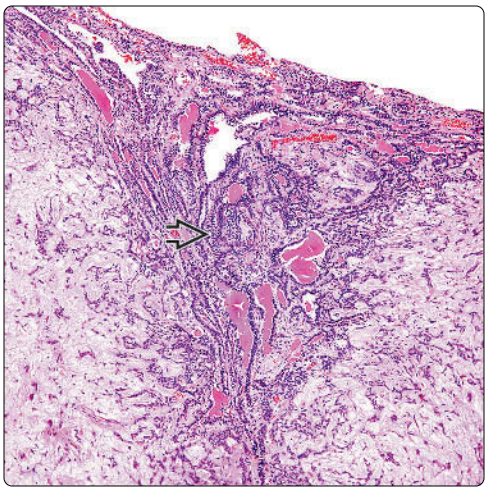

(Left) *Focal cystic areas are shown admixed with epithelial and myxoid elements in a benign mixed tumor. Such invaginations of epithelium are commonly seen in pulmonary hamartomas. However, in this case the cellular proliferation would be unusual for that lesion.* **(Right)** *Benign mixed tumor shows more characteristic epithelial component admixed with myxoid background. The epithelial component ⇨ is represented by the classic myoepithelial proliferation.*

Extensive Necrosis

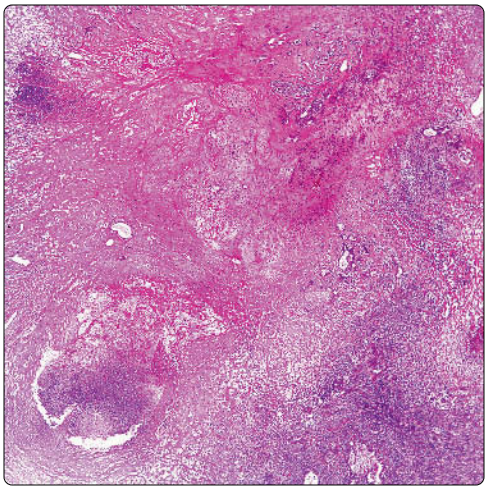

Necrosis and Hyalinization

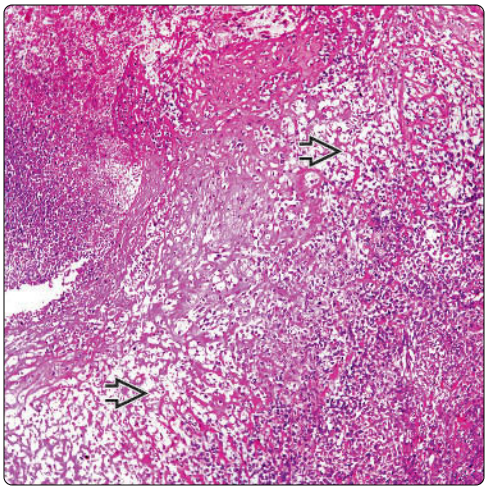

(Left) *Hypercellular areas are admixed with necrosis in malignant mixed tumor. The presence of necrosis should raise the suspicion of a malignant change, and careful review of the histology should be performed.* **(Right)** *Areas of necrosis and fibrinoid changes are admixed with clear myoepithelial cells ⇨ in a malignant mixed tumor. Note the disorganized growth of the tumor compared with the benign counterpart.*

Focal Cartilaginous Component

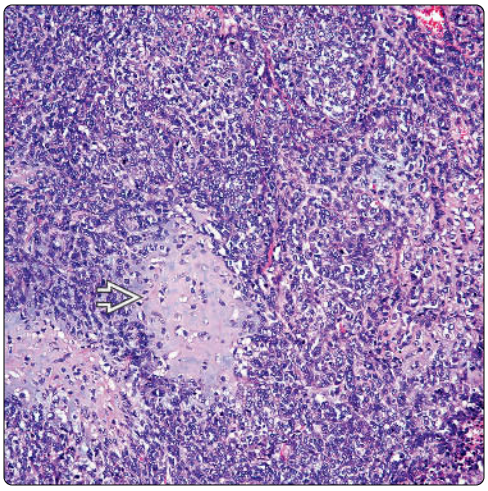

Mitotic Activity

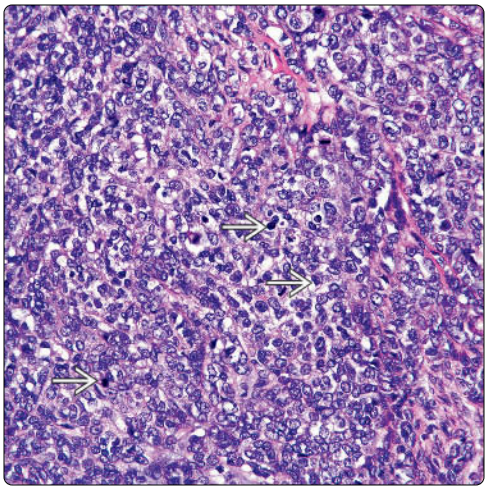

(Left) *Malignant mixed tumor is shown with a focal residual cartilaginous component ➡. The presence of cartilage and an undifferentiated epithelial malignant tumor raises the possibility of carcinosarcoma; however, the cartilage does not show malignant features.* **(Right)** *Malignant mixed tumor with hypercellular areas is shown. Note the presence of nuclear atypia and mitotic figures ➡. This feature by itself is not diagnostic of malignant mixed tumor.*

Cystic and Solid Areas

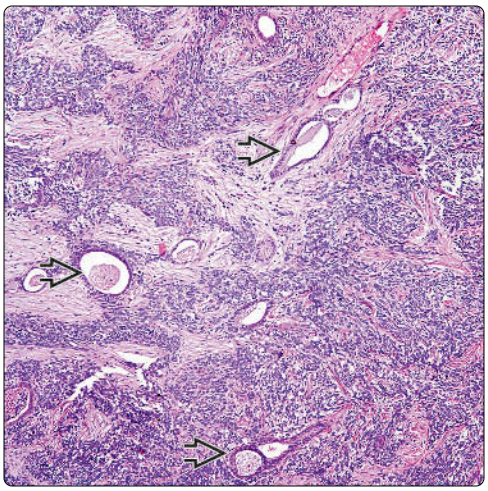

Benign Cystic Epithelial Structures

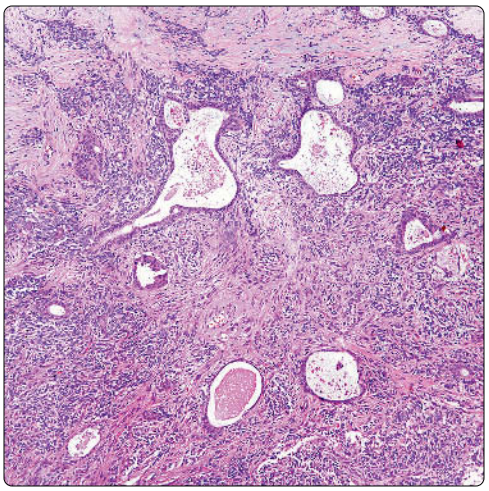

(Left) *Malignant mixed tumor shows areas resembling the benign counterpart, namely the presence of cystic epithelial elements ⇨. The presence of areas of benign mixed tumor is important in the diagnosis of malignant mixed tumors.* **(Right)** *Malignant mixed tumor shows cystic epithelial elements resembling benign mixed tumor. Note the adjacent atypical cellular proliferation in keeping with a malignant component.*

Myoepithelial Carcinoma of Lung

KEY FACTS

TERMINOLOGY

- Rare salivary gland-type primary lung tumor arising from bronchial submucosal glands and showing features of myoepithelial differentiation

CLINICAL ISSUES

- Patients 60-80 years of age
- Smoking history in > 70%
- Predilection for Asian patients
- Tumors are aggressive and often metastasize to brain, liver, lung, and soft tissue

MACROSCOPIC

- Central location; associated with bronchus
- Cut surface shows solid, tan-white, well-circumscribed, nodular mass
- 1-7 cm in greatest diameter

MICROSCOPIC

- Solid and nodular growth pattern
- Reticular growth pattern with fibroepitheliomatous cords of cells circumscribing hyaline or myxoid stroma
- Absence of ductular components
- Cells may be round/epithelioid, with clear cytoplasm, or spindled
- Focal squamoid and plasmacytoid cells may also be seen
- Minimal cytologic atypia and nuclear pleomorphism
- Mitotic activity can vary from scant (1 mitosis per 10 HPF) to abundant (> 10 mitoses per 10 HPF)

ANCILLARY TESTS

- Coexpression of epithelial and myoid markers is rule
- All cases show positivity for cytokeratins (AE1/AE3 most commonly reported)
- All cases must show positivity for at least 1 myoepithelial-cell related marker, such as SMA, MSA, calponin, S100, p63, or GFAP

Scanning Magnification

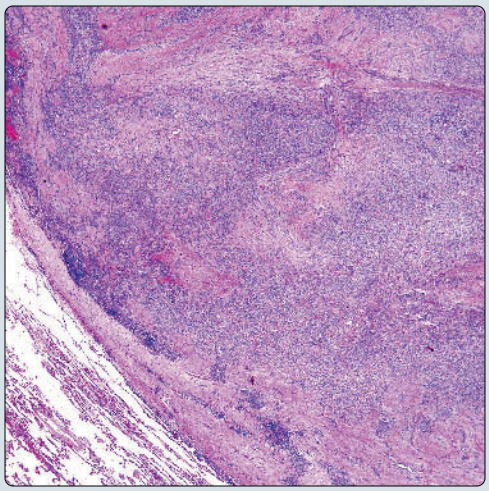

Lobular Pattern

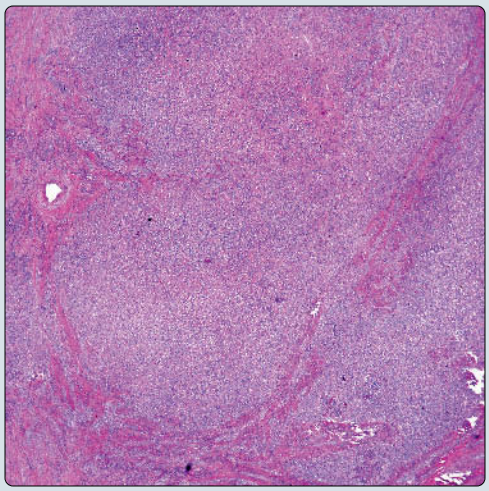

(Left) *Scanning magnification of pulmonary myoepithelial carcinoma shows a well-circumscribed cellular proliferation separated from the surrounding lung parenchyma by a thin, fibrous capsule.* **(Right)** *Higher magnification of myoepithelial carcinoma of the lung shows a lobular architecture composed of compact tumor cells separated by thin, fibrous tissue bands.*

Fibroepitheliomatous Appearance

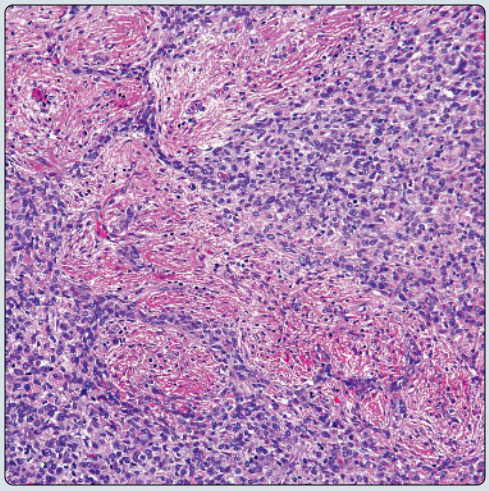

Spindle Cell Population

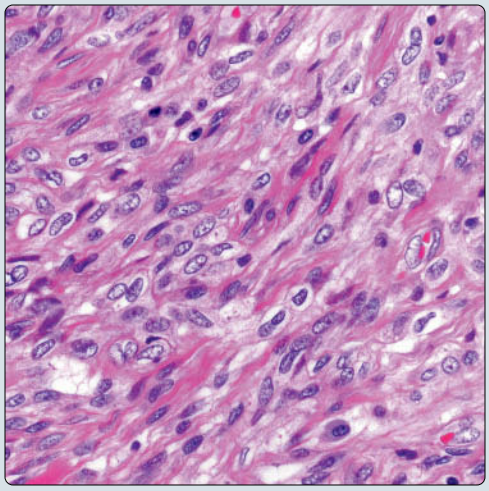

(Left) *Pulmonary myoepithelial carcinoma shows a focally fibroepitheliomatous appearance with thin strands and solid islands of monotonous tumor cells circumscribing a densely collagenized stroma.* **(Right)** *Higher magnification from a pulmonary myoepithelial carcinoma shows sheets of cells with oval to spindled nuclei and an inconspicuous rim of cytoplasm separated by thin strands of collagenized connective tissue.*

TERMINOLOGY

Definitions

- Rare, salivary gland-type primary lung tumor arising from bronchial submucosal glands and showing features of myoepithelial differentiation

CLINICAL ISSUES

Presentation

- Patients 60-80 years of age
- Smoking history in > 70%
- Slight male predilection
- Predilection for Asian patients

Treatment

- Surgical excision

Prognosis

- Tumors are aggressive and often metastasize to brain, liver, lung, and soft tissue
- High mitotic activity (> 10 mitoses per 10 HPF) correlates with more aggressive behavior

IMAGING

Radiographic Findings

- Discrete nodule or shadow

CT Findings

- Smoothly circumscribed, heterogenous mass
- Solid, spiculated mass
- Nodular shadow with irregular borders

PET Findings

- Hypermetabolic lesion

MACROSCOPIC

General Features

- Central location; associated with bronchus
- May also arise peripherally
- Cut surface shows solid, tan-white, well-circumscribed, nodular mass
- Usually noninvasive

Size

- 1-7 cm in greatest diameter

MICROSCOPIC

Histologic Features

- Solid and nodular growth pattern
- Reticular growth pattern with fibroepitheliomatous cords of cells circumscribing hyaline or myxoid stroma
- Peribronchial location with good circumscription
- May display thin, fibrous capsule
- May display focal hemorrhage and necrosis
- Absence of ductular components

Cytologic Features

- Uniform population of cells
- Cells may be round/epithelioid, with clear cytoplasm, or spindled
- Focal squamoid and plasmacytoid cells may also be seen
- Minimal cytologic atypia and nuclear pleomorphism
- Mitotic activity can vary from scant (1 mitosis per 10 HPF) to abundant (> 10 mitoses per 10 HPF)

ANCILLARY TESTS

Immunohistochemistry

- Coexpression of epithelial and myoid markers is rule
- All cases show positivity for cytokeratins (AE1/AE3 most commonly reported)
- All cases must show positivity for at least 1 myoepithelial cell-related marker, such as SMA, MSA, calponin, S100, p63, or GFAP
- Tumor cells negative for CD117, CEA, and CK7

DIFFERENTIAL DIAGNOSIS

Other Salivary Gland-Type Tumors of Lung

- Mixed tumor, adenoid cystic carcinoma, and epi-myoepithelial carcinoma can show similar features
- Myoepithelial carcinomas of lung lack ductal structures, which are present in all other types

Late Metastases From Salivary Gland Tumors From Other Organs

- Malignant salivary gland-type tumors may arise in other organs, including salivary glands, breast, skin, and soft tissue
- Salivary gland-type tumors may metastasize late (> 15 years following diagnosis)
- Detailed and complete clinical history is indispensable for correct diagnosis

DIAGNOSTIC CHECKLIST

Clinically Relevant Pathologic Features

- Good circumscription
- Peribronchial location
- Solid growth pattern without ductular differentiation
- Heterogeneous cell composition (i.e., round, spindled, plasmacytoid, clear cell)
- Immunohistochemical profile of myoepithelial cells (i.e., mixed epithelial + myoid phenotype)
- Mitotic activity most important feature that correlates with aggressive behavior

Pathologic Interpretation Pearls

- Tumor with nodular and reticular growth composed of monotonous, cytologically low-grade cell population
- Demonstration of combined epithelial and myoid phenotype by immunohistochemistry
- Myoid phenotype is very inconsistent and common markers such as SMA, MSA, and calponin may be absent or weak
- May need to rely on less specific, myoepithelial-associated markers such as S100 protein, GFAP, and p63

SELECTED REFERENCES

1. Rosen LE et al: Myoepithelial carcinoma of the lung: a review. Appl Immunohistochem Mol Morphol. 23(6):397-401, 2015
2. Wei J et al: Primary myoepithelial carcinoma of the lung: a case report and review of literature. Int J Clin Exp Pathol. 8(2):2111-6, 2015

Scanning Magnification

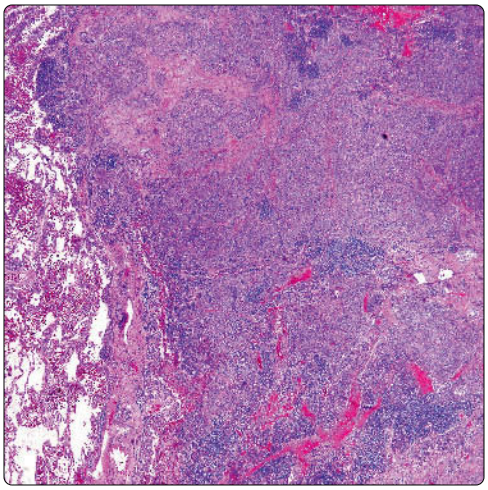

Solid Growth

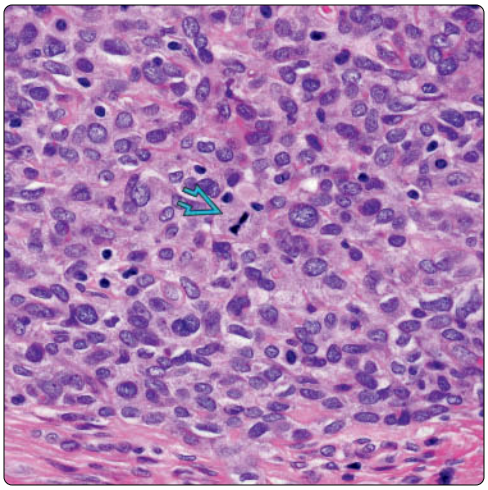

(Left) *Scanning magnification of myoepithelial carcinoma shows a well-circumscribed cellular proliferation with a vague nodular pattern but devoid of any other architectural arrangement, glandular or papillary structures, or any other evidence of differentiation.* **(Right)** *Higher magnification of pulmonary myoepithelial carcinoma shows solid sheets of monotonous cells with round to oval nuclei and a scant rim of amphophilic cytoplasm. Rare mitotic figures are seen scattered throughout* ⇨.

Stromal Sclerosis

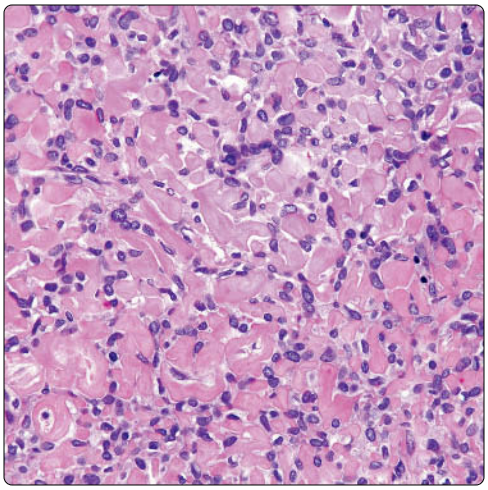

Reticular Growth Pattern

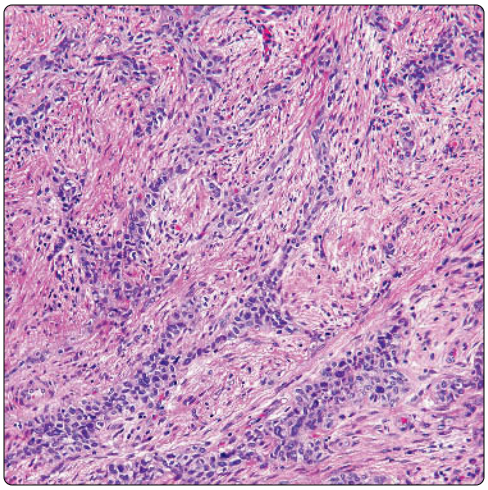

(Left) *Pulmonary myoepithelial carcinoma shows delicate pattern of densely eosinophilic intercellular sclerosis separating a bland population of round to oval tumor cells.* **(Right)** *Myoepithelial carcinoma of the lung focally shows a striking reticular growth pattern with elongated, fibroepitheliomatous strands of tumor cells separated by dense fibroconnective tissue stroma.*

Myxoid Stroma

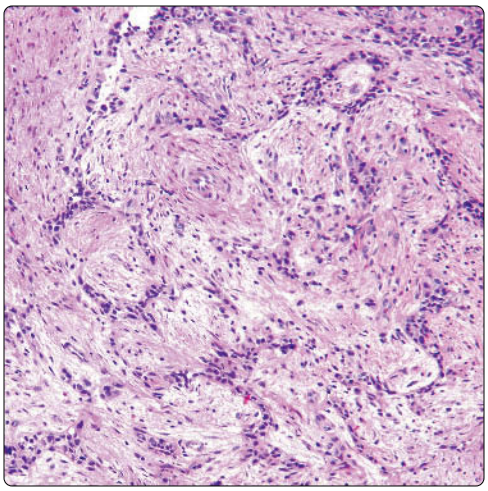

Peribronchial Distribution

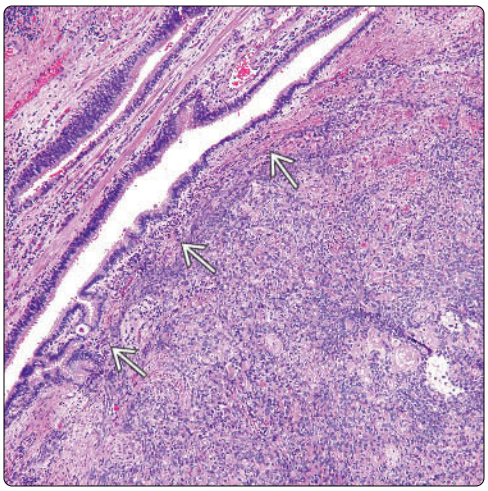

(Left) *Another example of the reticular, fibroepitheliomatous growth pattern in pulmonary myoepithelial carcinoma shows thin, anastomosing strands of epithelial cells circumscribing areas composed of dense collagenous stroma with myxoid changes.* **(Right)** *Myoepithelial carcinoma of the lung shows close relationship with a bronchus* ⇨. *Notice the dense peribronchial cell population showing discrete foci of stromal sclerosis adjacent to the bronchus.*

Round Cell Population With Sclerosis

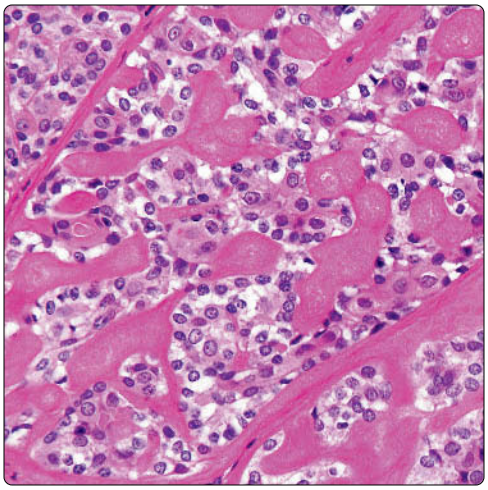

Clear Cell Morphology

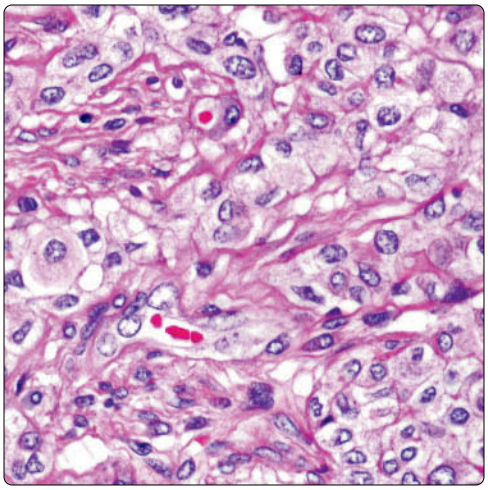

(Left) *Higher magnification of myoepithelial carcinoma of the lung shows small nests of monotonous round tumor cells surrounded by thick bands of acellular collagenous tissue.* **(Right)** *Myoepithelial carcinoma of the lung on higher magnification shows a monotonous population of cells with round to oval nuclei surrounded by an ample rim of clear cytoplasm.*

Cytokeratin AE1/AE3 Immunostaining

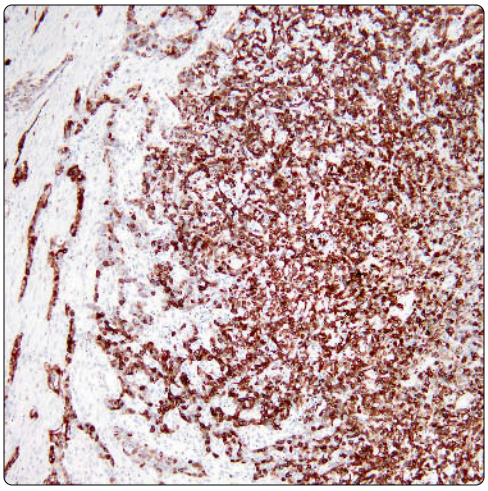

SMA Immunostaining

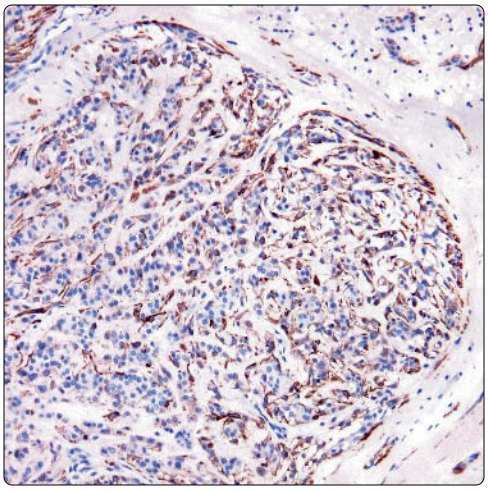

(Left) *Immunohistochemical staining for cytokeratin AE1/AE3 in myoepithelial carcinoma of the lung shows intense positivity of the tumor cells in the solid and trabecular areas.* **(Right)** *Immunohistochemical staining of myoepithelial carcinoma of the lung for smooth muscle actin (SMA) highlights the myoepithelial cell population in the tumor.*

S100 Immunostaining

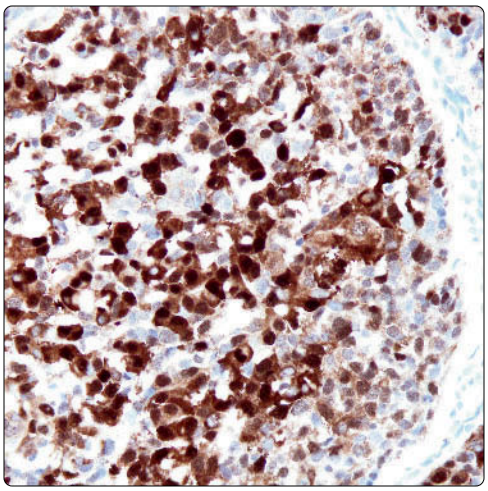

p63 Immunostaining

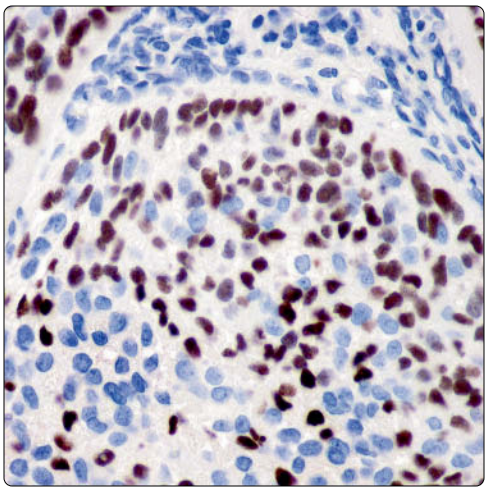

(Left) *Immunohistochemical stain for S100 in myoepithelial carcinoma of the lung shows strong nuclear and cytoplasmic staining of the tumor cells. S100 protein consistently stains myoepithelial carcinomas.* **(Right)** *Immunohistochemical stain for p63 in myoepithelial carcinoma of the lung shows strong nuclear positivity in many of the tumor cells, supporting the myoepithelial nature of the tumor.*

Intrapulmonary Synovial Sarcoma

KEY FACTS

CLINICAL ISSUES

- Chest pain
- Shortness of breath
- Cough
- Aggressive behavior with frequent recurrences and metastases
- Similar behavior as synovial sarcoma in peripheral soft tissue locations
- > 50% of patients die of tumor within 5-7 years after diagnosis
- May be asymptomatic and represent incidental finding on chest x-ray

MACROSCOPIC

- Well-circumscribed, unencapsulated, solitary mass within lung parenchyma
- Tan-white to gray, rubbery to gelatinous cut surface

MICROSCOPIC

- Fascicles of monotonous atypical spindle cells with variety of growth patterns
  - Herringbone pattern
  - Hemangiopericytic growth pattern
  - Storiform growth pattern
  - Neural-like, palisading growth pattern
- Tumor cells may display epithelioid morphology with round nuclei surrounded by scant eosinophilic cytoplasm

ANCILLARY TESTS

- Tumor cells show focal (spotty) cytoplasmic positivity for cytokeratins (AE1/AE3, CAM5.2, CK19)
- Tumor cells show focal (spotty) positivity for EMA
- Tumor cells consistently show diffuse and strong positivity for Bcl-2 oncogene
- Majority of cases (> 80%) show characteristic t(X;18) translocation
- Fusion products include 6<7 66; , 6<7 66; , and 6<7 66;

Synovial Sarcoma

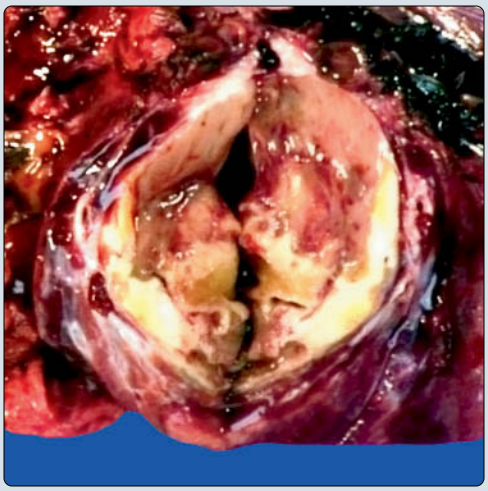

Intrapulmonary Synovial Sarcoma

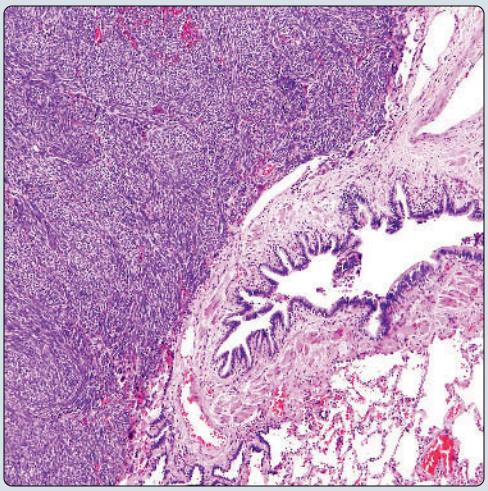

(Left) *Gross appearance of primary synovial sarcoma of the lung shows well-circumscribed, intraparenchymatous tumor mass with areas of necrosis and glistening homogeneous gray-white cut surface.* **(Right)** *Histologic appearance of synovial sarcoma of the lung on scanning magnification shows a solid tumor composed of sheets of spindle cells that is sharply circumscribed from the surrounding lung parenchyma.*

Herringbone Pattern

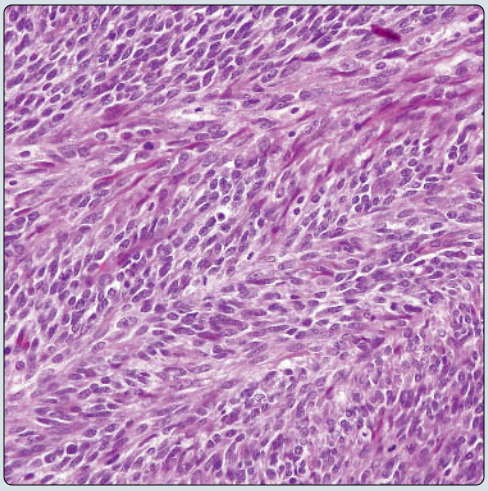

Monotonous Spindle Cell Population

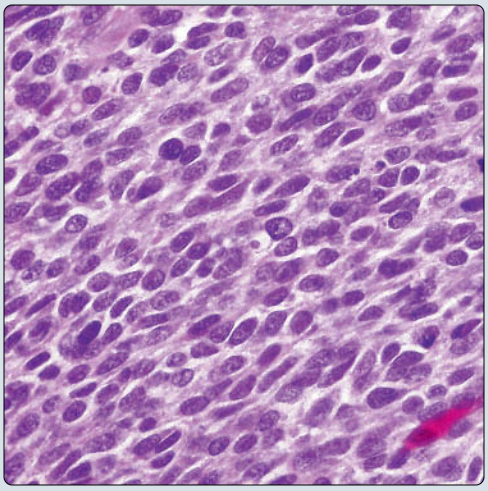

(Left) *A distinctive pattern of growth seen in synovial sarcoma is the herringbone pattern, characterized by short fascicles of spindle cells that appear to emanate from a central "spine."* **(Right)** *A distinctive feature of monophasic synovial sarcoma is a monotonous population of atypical spindle cells with dense nuclear chromatin and scant intercellular stroma.*

TERMINOLOGY

Definitions

- Primary pulmonary malignant neoplasm characterized by spindle cell morphology and displaying features of epithelial differentiation

CLINICAL ISSUES

Epidemiology

- Incidence
  - Rare (< 1% of all lung neoplasms)
- Age
  - Children to adults (mean age: 38 years)

Presentation

- Chest pain, dyspnea, cough, hemoptysis
- May be asymptomatic and represent incidental finding on chest x-ray

Prognosis

- Similar behavior as synovial sarcoma in peripheral soft tissue locations
- Aggressive behavior with frequent recurrences and metastases
- > 50% of patients die of tumor within 5-7 years after diagnosis

MACROSCOPIC

General Features

- Well-circumscribed, unencapsulated, solitary mass within lung parenchyma
- Tan-white to gray, rubbery to gelatinous cut surface
- May show prominent cystic changes, hemorrhage, and necrosis
- Most often found in periphery of lung
- Some tumors may be present endobronchially in central locations

Size

- 1-20 cm (median size: 4 cm)

MICROSCOPIC

Histologic Features

- Majority of tumors in lung are of monophasic spindle cell type
- Fascicles of monotonous atypical spindle cells with variety of growth patterns
  - Herringbone pattern
  - Hemangiopericytic growth pattern
  - Storiform growth pattern
  - Neural-like palisading growth pattern
- Some tumors may show prominent myxoid stromal changes
- Areas of hemorrhage and necrosis

Cytologic Features

- Monotonous population of atypical spindle cells with dense chromatin pattern and scant cytoplasm
- Striking absence of intervening stroma supporting tumor cells
- Tumor cells may display epithelioid morphology with round nuclei surrounded by scant eosinophilic cytoplasm
- Variable mitotic activity (range: 2-20 mitoses per 10 HPF)

ANCILLARY TESTS

Immunohistochemistry

- Tumor cells show
  - Focal (spotty) cytoplasmic positivity for cytokeratins (AE1/AE3, CAM5.2, CK19) and EMA
  - Diffuse and strong positivity for Bcl-2
  - Positivity for CD99 and TLE1
  - May be positive for S100 protein, calponin, calretinin, HBME-1, and CD117

Genetic Testing

- FISH and RT-PCR are useful for detecting fusion protein of translocation in formalin-fixed paraffin-embedded tissues
- Fusion products include 6<7 66; , 6<7 66; , and 6<7 66;
- Majority of cases (> 80%) show characteristic (X;18)(p11;q11) translocation

DIFFERENTIAL DIAGNOSIS

Intrapulmonary Solitary Fibrous Tumor

- Areas of stromal sclerosis and dense, linear, rope-like collagen deposition is common feature in solitary fibrous tumor (SFT)
- Tumors cells in SFT are generally positive for CD34 and negative for cytokeratins and EMA
- Show 1$% -67$7 gene fusion and are negative for X;18 translocation

Malignant Peripheral Nerve Sheath Tumor

- Pattern of expression of S100 protein may overlap with synovial sarcoma
- May also show focal expression of cytokeratins, EMA, and Bcl-2
- Generally negative for t(X;18)
- Distinctive, long, interdigitating cytoplasmic processes by electron microscopy

Metastasis of Synovial Sarcoma From Peripheral Soft Tissues

- Lung is 2nd most common site of metastasis from synovial sarcoma of soft tissue
- Existence of primary source outside lungs needs to always be ruled out clinically

SELECTED REFERENCES

1. Kim GH et al: Primary pulmonary synovial sarcoma in a tertiary referral center: clinical characteristics, CT, and 18F-FDG PET findings, with pathologic correlations. Medicine (Baltimore). 94(34):e1392, 2015
2. Lino-Silva LS et al: TLE1 is expressed in the majority of primary pleuropulmonary synovial sarcomas. Virchows Arch. 459(6):615-21, 2011
3. Hartel PH et al: Primary pulmonary and mediastinal synovial sarcoma: a clinicopathologic study of 60 cases and comparison with five prior series. Mod Pathol. 20(7):760-9, 2007
4. Suster S et al: Expression of bcl-2 oncoprotein in benign and malignant spindle cell tumors of soft tissue, skin, serosal surfaces, and gastrointestinal tract. Am J Surg Pathol. 22(7):863-72, 1998
5. Zeren H et al: Primary pulmonary sarcomas with features of monophasic synovial sarcoma: a clinicopathological, immunohistochemical, and ultrastructural study of 25 cases. Hum Pathol. 26(5):474-80, 1995

Intrapulmonary Synovial Sarcoma

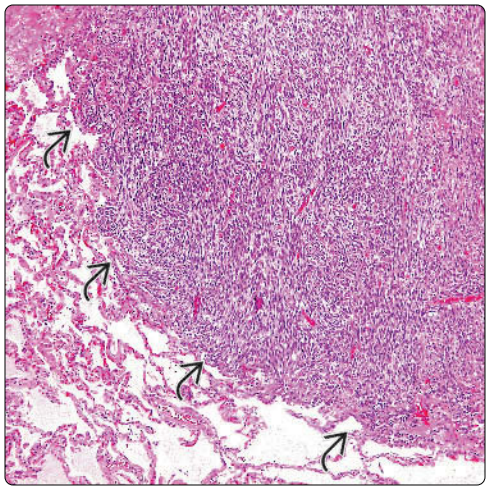

Monotonous Spindle Cell Population

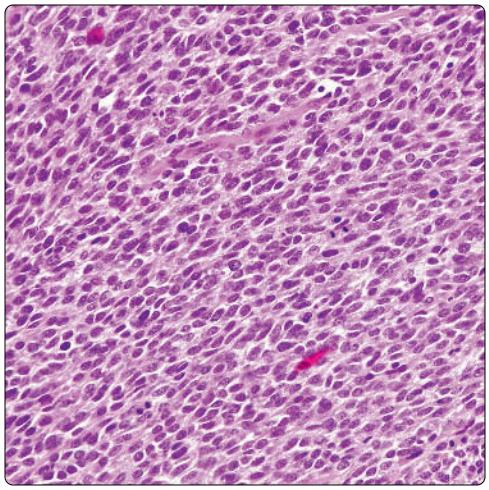

(Left) *Scanning magnification of a pulmonary synovial sarcoma shows a well-circumscribed tumor nodule composed of a uniform population of atypical spindle cells. Notice the absence of a capsule and sharp circumscription from the surrounding pulmonary parenchyma.* **(Right)** *Scanning magnification of intrapulmonary synovial sarcoma shows monotonous sheets of uniform, atypical spindle cells with very little intervening stroma. Hardly any vessels can be discerned in this field.*

Uniform Cell Population: Higher Power

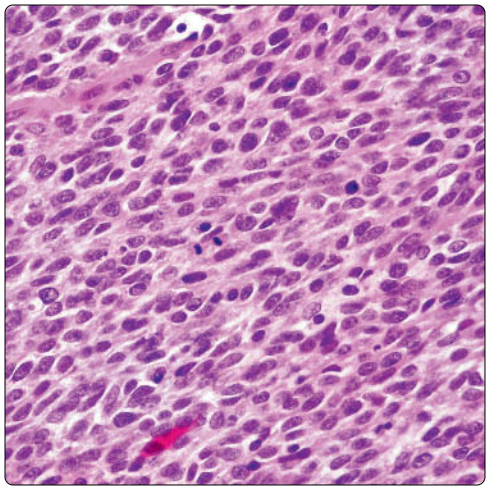

Mitotic Figure

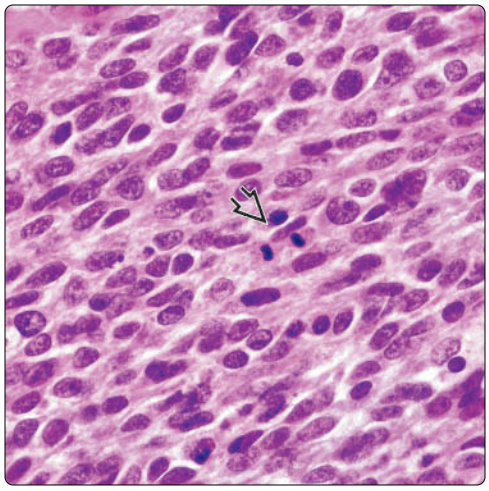

(Left) *Intrapulmonary synovial sarcoma shows sheets of monotonous tumor cells with oval nuclei and a dense chromatin pattern; there are also a few scattered mitotic figures. Mitotic activity can vary from very minimal (1-2 mitoses per 10 HPF) to high (> 10 mitoses per 10 HPF) in these tumors.* **(Right)** *Higher magnification of intrapulmonary synovial sarcoma shows a population of atypical spindle cells with hyperchromatic nuclei. Notice a mitotic figure in the center.*

Sharp Circumscription

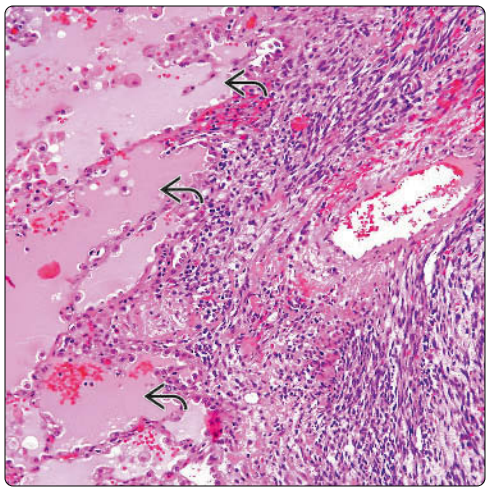

Cystic Changes

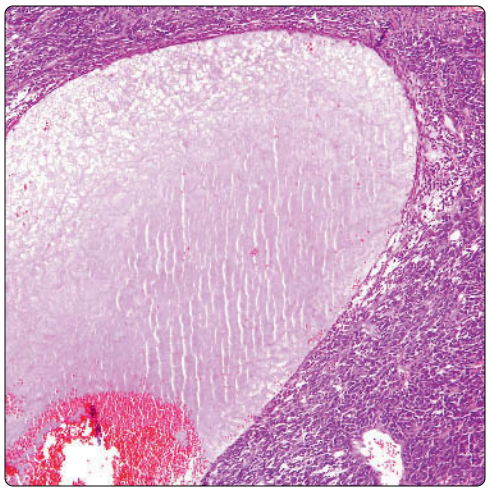

(Left) *Interphase between intrapulmonary synovial sarcoma (right) and adjacent lung parenchyma with pulmonary edema is shown. The neoplastic spindle cell population appears to end abruptly and does not infiltrate along the alveolar septa.* **(Right)** *Scanning magnification of an intrapulmonary synovial sarcoma shows prominent cystic changes involving the tumor. The cysts can coalesce and lead to extensive cystic degeneration that can be appreciated grossly as well as on imaging studies.*

Polypoid Endobronchial Growth

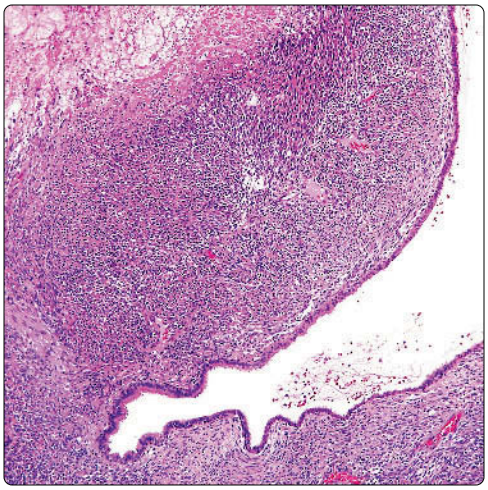

Entrapment of Airspaces

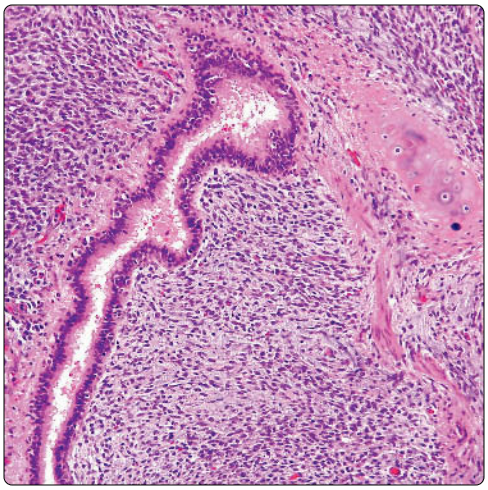

(Left) *Scanning magnification of intrapulmonary synovial sarcoma shows endobronchial growth with polypoid protrusion into the bronchial lumen. Such tumors can ulcerate and bleed, causing hemoptysis.* **(Right)** *Pulmonary synovial sarcoma shows entrapment and destruction of the wall of a bronchus. Areas displaying these features can be misinterpreted for a biphasic malignant neoplasm, such as carcinosarcoma. The entrapped glandular elements, however, are normal.*

Vascular Invasion

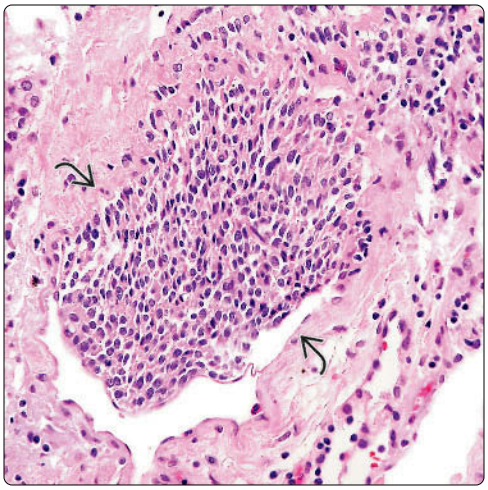

Coagulative Necrosis

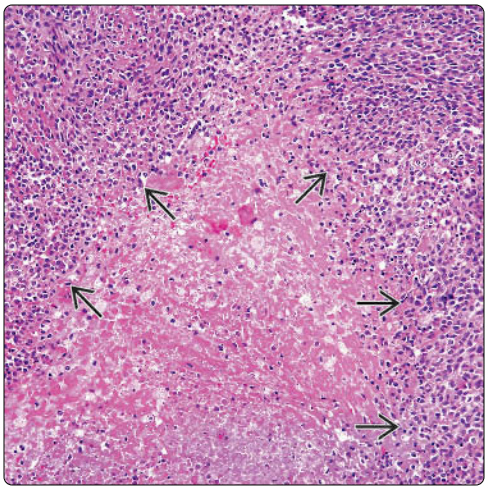

(Left) *Intrapulmonary synovial sarcoma shows a focus of vascular invasion in the lung parenchyma. Notice the tumor thrombus attached to the wall and protruding into and distorting the vessel lumen.* **(Right)** *Area of coagulative necrosis in pulmonary synovial sarcoma shows extensive necrotic debris (center) flanked by a residual viable tumor cell population. Intrapulmonary synovial sarcoma can often be accompanied by extensive intratumoral cell necrosis.*

Myxoid Stromal Changes

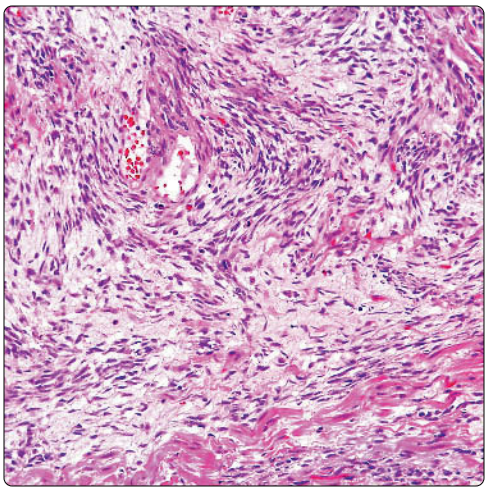

Myxoid Area: High Power

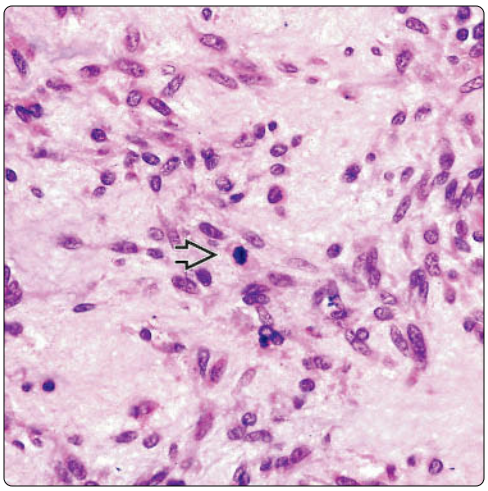

(Left) *Prominent myxoid stromal changes are seen in this intrapulmonary synovial sarcoma. Tumors with these features can be mistaken for nerve sheath neoplasms, metastases of myxofibrosarcoma, and other myxoid tumors.* **(Right)** *Higher magnification of pulmonary synovial sarcoma with myxoid changes shows spindle cell population embedded in abundant myxoid matrix. The spindle cells are monotonous and display similar features to other synovial sarcomas, including mitoses.*

Herringbone Pattern

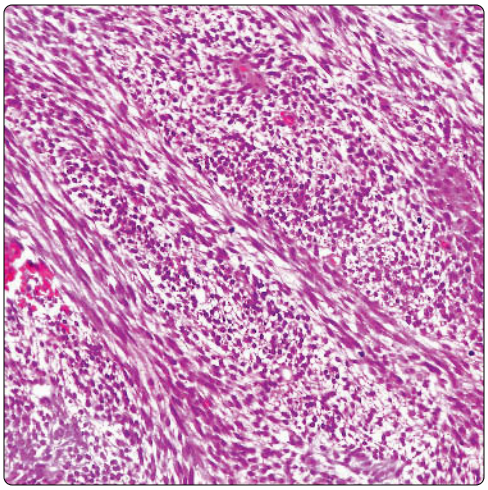

Storiform Pattern

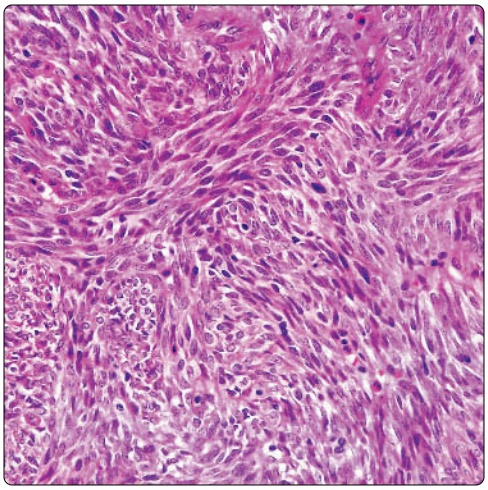

(Left) *Scanning magnification of pulmonary synovial sarcoma shows a herringbone growth pattern with fascicles of tumor cells intersecting at acute angles. This appearance can be indistinguishable from a malignant peripheral nerve sheath tumor.* **(Right)** *Intrapulmonary synovial sarcoma shows a storiform pattern of growth. Tumors displaying these features are commonly mistaken for "fibrohistiocytic" neoplasms, such as malignant fibrous histiocytoma.*

Storiform Pattern

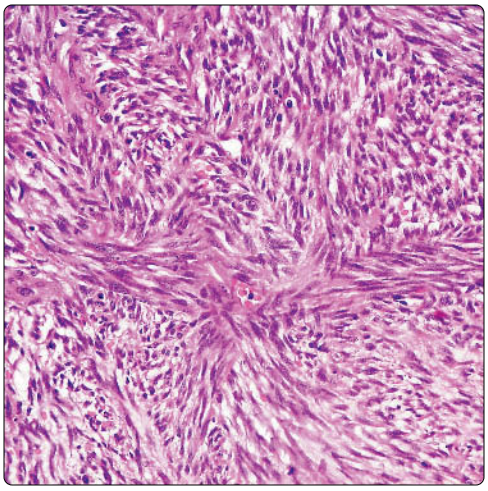

Mitotic Figure

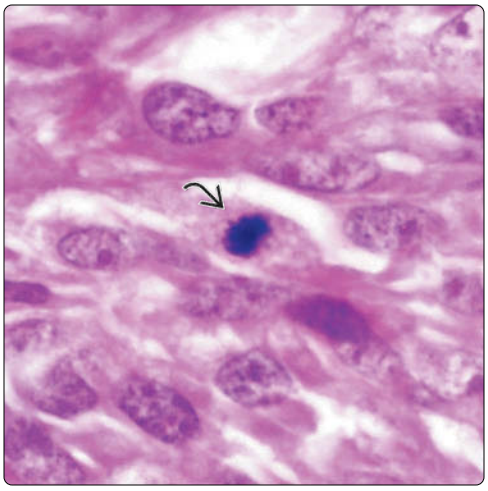

(Left) *Monophasic synovial sarcoma of the lung shows a striking storiform growth pattern reminiscent of malignant fibrous histiocytoma and other "fibrohistiocytic" tumors.* **(Right)** *Higher magnification of pulmonary synovial sarcoma with storiform pattern shows cells with uniform spindle-shaped nuclei with scant cytoplasm. The nuclei of the cells show vesicular chromatin with occasional small nucleoli. Notice the mitotic figure in the center.*

Epithelioid Appearance

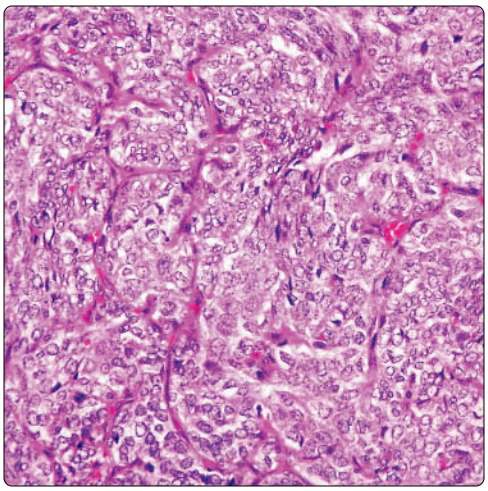

Poorly Differentiated Synovial Sarcoma

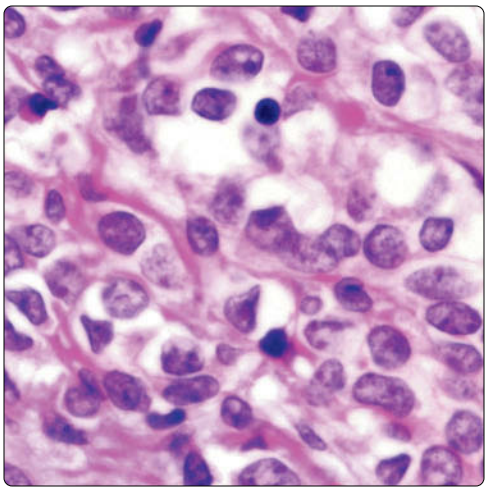

(Left) *Pulmonary synovial sarcoma shows a nested pattern of growth characterized by discrete round islands of tumor cells separated by thin fibrovascular septa. Tumors with these features can be easily mistaken for metastases of amelanotic malignant melanoma to the lung.* **(Right)** *Higher magnification of pulmonary synovial sarcoma shows uniform round nuclei with a scant rim of lightly eosinophilic to amphophilic cytoplasm. Tumors with these features are classed as "poorly differentiated."*

Hemangiopericytic Vascular Pattern

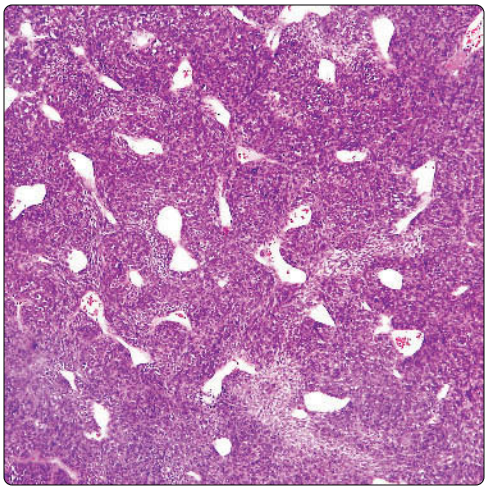

Hemangiopericytic Pattern: High Power

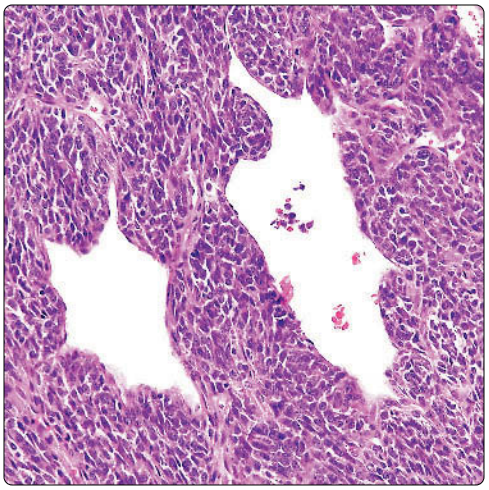

(Left) *Scanning magnification of intrapulmonary synovial sarcoma shows a striking hemangiopericytomatous growth pattern characterized by multiple small branching vessels with open lumina.* **(Right)** *Higher magnification of intrapulmonary synovial sarcoma with a hemangiopericytic growth pattern shows 2 small vessels with irregular contours and open lumina. Tumors with these features have been misdiagnosed in the past as pulmonary hemangiopericytoma.*

Perivascular Cuffing of Tumor Cells

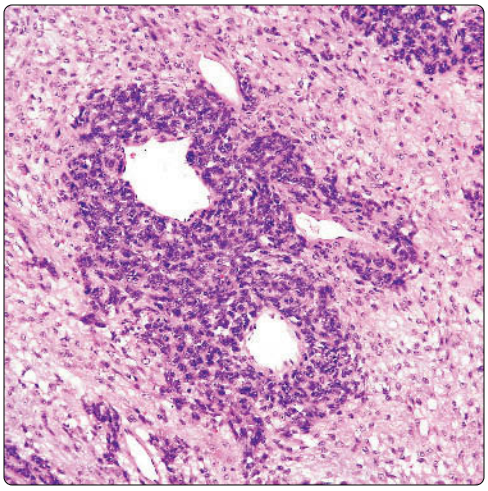

Cytokeratin Immunostaining Pattern

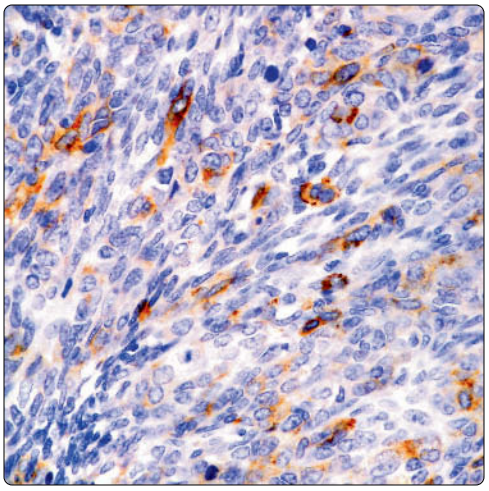

(Left) *Pulmonary synovial sarcoma shows perivascular cuffing of small vessels by tumor cells surrounded by abundant tumor cell necrosis.* **(Right)** *Characteristic pattern of staining in synovial sarcoma for cytokeratin broad-spectrum stain (cytokeratin AE1/AE3) shows spotty staining of isolated, scattered tumor cells with this antibody. Some cases may show complete absence of cytokeratin staining, and multiple tissue blocks may need to be evaluated to identify focal positivity.*

Bcl-2 Immunostaining Pattern

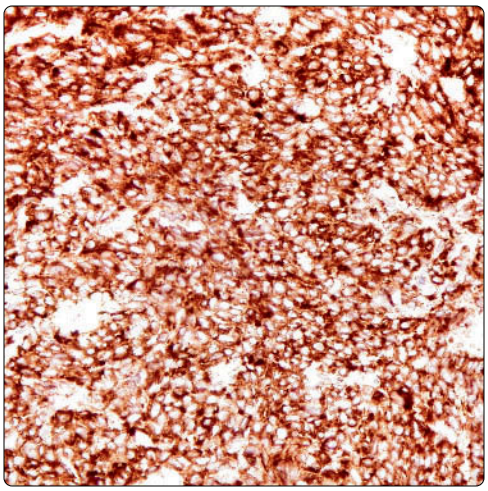

EMA Immunostain in Synovial Sarcoma

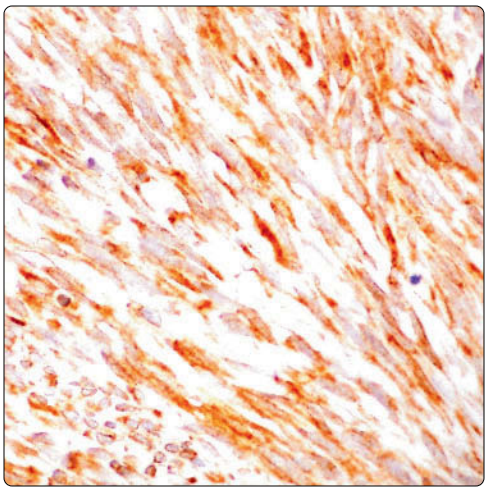

(Left) *Immunohistochemical staining of pulmonary synovial sarcoma for Bcl-2 oncogene shows a strong pattern of positivity. Virtually all the tumor cells show strong cytoplasmic positivity, a highly characteristic finding in synovial sarcoma.* **(Right)** *Immunohistochemical staining in pulmonary synovial sarcoma for EMA shows scattered positive cells. Positivity for this antigen can be just as spotty and weak as for cytokeratin.*

Leiomyosarcoma

KEY FACTS

CLINICAL ISSUES

- Incidence
  - Represents < 1% of all malignant neoplasms of lung
  - Described in any age group from newborns to adults
- Symptoms
  - Cough
  - Hemoptysis
  - Chest pain
  - Dyspnea
  - Weight loss
  - Asymptomatic

MACROSCOPIC

- Endobronchial or peripheral
- Areas of hemorrhage and necrosis may be present
- Tumors vary in size from 1 to > 10 cm in diameter

ANCILLARY TESTS

- Ultrastructural studies may show
  - Cytoplasmic myofilaments
  - Prominent rough endoplasmic reticulum
  - Abundant mitochondria

TOP DIFFERENTIAL DIAGNOSES

- Hemangiopericytoma
  - Usually does not display marked cellular pleomorphisms
  - Shows negative staining for muscle markers
- Monophasic synovial sarcoma
  - Usually shows more cohesive spindle cell proliferation
  - Generally shows negative results with muscle markers
  - Usually shows positive staining for keratin, EMA/MUC1, and Bcl-2
- Solitary fibrous tumor
  - Usually shows positive staining for CD34 and Bcl-2
  - Displays negative staining for muscle markers

Hemorrhagic Areas

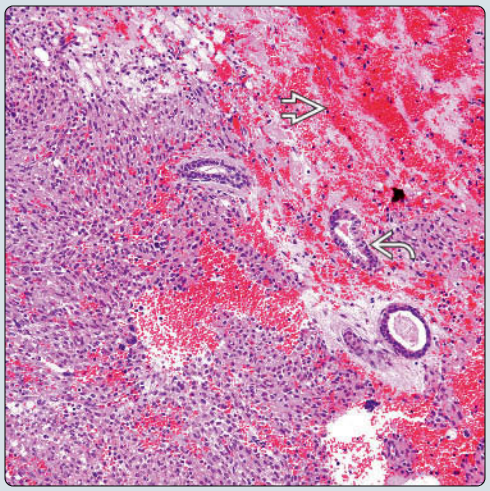

Solid Growth Pattern

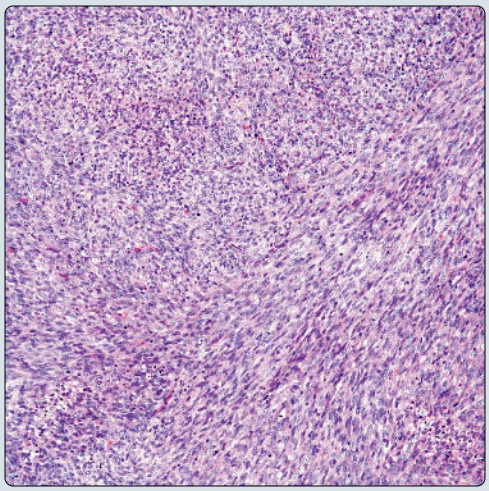

(Left) *Pulmonary leiomyosarcoma (LMS) shows a spindle cell proliferation composed of cells with eosinophilic cytoplasm. Areas of hemorrhage and entrapped epithelial structures are present.* **(Right)** *LMS shows a solid spindle cell proliferation arranged in subtle fascicles of tumor cells. Cellular atypia is noted at this magnification.*

Nuclear Atypia

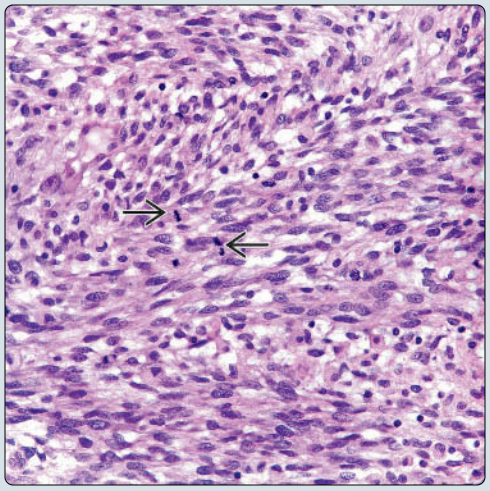

Mitotic Activity

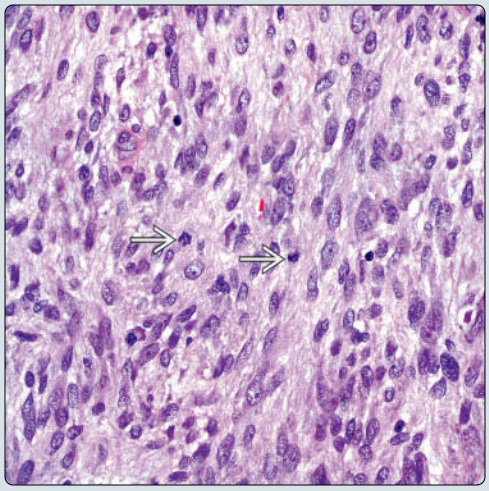

(Left) *Higher magnification of an LMS shows a distinct fascicular growth pattern with moderate nuclear atypia and numerous mitotic figures.* **(Right)** *LMS shows cellular and nuclear atypia with easily identifiable mitotic figures. These features are in keeping with a malignant smooth muscle neoplasm.*

TERMINOLOGY

Abbreviations

- Pulmonary leiomyosarcoma (LMS)

Definitions

- Malignant mesenchymal neoplasm of smooth muscle origin

CLINICAL ISSUES

Epidemiology

- Incidence
  - Represents < 1% of all malignant neoplasms of lung
- Age
  - Has been described in any age group from newborns to adult patients
- Sex
  - No predilection for any sex

Presentation

- Cough
- Hemoptysis
- Chest pain
- Shortness of breath
- Weight loss
- Asymptomatic

Treatment

- Surgical approaches
  - Lobectomy or pneumonectomy
- Adjuvant therapy
  - Chemoradiation may be used in some cases

Prognosis

- Depends on tumor differentiation and clinical staging
- Widespread metastatic disease can occur
- Some patients may follow aggressive course with death in < 24 months

IMAGING

General Features

- Intrapulmonary mass
- Tumor may vary in size
- Tumor may be centrally or peripherally located

MACROSCOPIC

General Features

- Well-circumscribed tumors
- Endobronchial or peripheral
- Cut surface is white and firm
- Areas of hemorrhage and necrosis may be present

Size

- Tumor varies in size from 1 cm to > 10 cm in diameter

MICROSCOPIC

Histologic Features

- Spindle cell proliferation of elongated cells with cigar-shaped nuclei
- Mitotic activity
- Necrosis &/or hemorrhage
- Infiltrative growth pattern
- Destruction of normal architecture

Predominant Pattern/Injury Type

- Sarcomatoid

Predominant Cell/Compartment Type

- Myoid

ANCILLARY TESTS

Electron Microscopy

- Some of ultrastructural features that may be associated include
  - Cytoplasmic myofilaments with focal densities
  - Prominent rough endoplasmic reticulum
  - Abundant mitochondria
  - Bundles of intermediate filaments

DIFFERENTIAL DIAGNOSIS

Hemangiopericytoma

- Does not usually display marked cellular pleomorphism
- Shows negative staining for muscle markers

Monophasic Synovial Sarcoma

- Usually shows more cohesive spindle cell proliferation
- Generally shows negative results with muscle markers
- Usually shows positive staining for keratin, EMA/MUC1, and Bcl-2

Solitary Fibrous Tumor

- Usually shows positive staining for CD34 and Bcl-2
- Displays negative staining for muscle markers
- Usually displays different growth pattern in same tumor

Sarcomatoid Carcinoma

- Sarcomatoid carcinoma (SC) may show positive staining for actin
- SC will also show positive staining for keratin
- SC may show positive staining for TTF-1 or p40

Carcinosarcoma

- Carcinosarcoma will show biphasic population epithelial/mesenchymal
- Squamous cell carcinoma is common feature in carcinosarcomas

Pleomorphic Carcinoma

- Pleomorphic carcinoma (PC) will show presence of spindle and giant cell component
- Large number of PC will also show areas of conventional adenocarcinoma or squamous cell carcinoma
- Keratin, p40, &/or TTF-1 may show positive staining in these components

DIAGNOSTIC CHECKLIST

Clinically Relevant Pathologic Features

- Mitotic rate

Pathologic Interpretation Pearls

- Spindle cell proliferation with variable mitotic activity and presence or absence of necrosis &/or hemorrhage

Immunohistochemistry

Antibody	Reactivity	Staining Pattern	Comment
Actin-HHF-35	Positive	Cytoplasmic	
Desmin	Positive	Cytoplasmic	May be negative in high-grade tumors
Caldesmon	Positive	Cytoplasmic	May be negative in high-grade tumors
Actin-sm	Positive	Cytoplasmic	
Vimentin	Positive	Cytoplasmic	
MYOD1	Positive	Cytoplasmic	
CK-PAN	Negative		May be focally positive in low-grade tumors
Myoglobin	Negative		
EMA	Negative		
CD34	Negative		
CD31	Negative		
CK5/6	Negative		
CK7	Negative		
CD99	Negative		
STAT6	Negative		
Bcl-2	Negative		
S100	Negative		
p40	Negative		
TTF-1	Negative		
NAPSIN-A	Negative		
D2-40	Negative		

Molecular Features

FISH/Cytogenetics	Result
Alternative lengthening of telomerase phenotype	May be associated with aggressive histology and poor outcome
MDM12 protein expression	May have oncogene role

GRADING

Low Grade

- Mild cytologic atypia
- Miotic figures: 1-3 per 10 HPF
- Necrosis and hemorrhage are absent
- Spindle fascicular growth pattern

Intermediate Grade

- Fascicular growth pattern
- Cytologic atypia is present but not marked
- Hypercellular areas
- Mitotic figures: 3-8 per 10 HPF
- Necrosis and hemorrhage are absent

High Grade

- Fascicular and solid growth patterns
  - Hemangiopericytic or storiform growth pattern may be present
- Necrosis &/or hemorrhage are present
- Cellular pleomorphism is obvious
- Mitotic figures: > 8 per 10 HPF
- Atypical mitotic figures may be seen

SELECTED REFERENCES

1. Unal OU et al: Clinicopathologic characteristics, treatment outcomes, and prognostic factors of primary thoracic soft tissue sarcoma: a multicenter study of the Anatolian Society of Medical Oncology (ASMO). Thorac Cancer. 6(1):85-90, 2015
2. Elouazzani H et al: Primary endobronchial leiomyosarcoma of the lung: clinical, gross and microscopic findings of two cases. J Clin Imaging Sci. 2:35, 2012
3. Anderson MF et al: Choroidal metastasis from primary pulmonary leiomyosarcoma. Clin Experiment Ophthalmol. 39(7):705-7, 2011
4. Arnold LM 3rd et al: Diagnosis and management of primary pulmonary leiomyosarcoma. J Am Osteopath Assoc. 110(4):244-6, 2010
5. Ketata W et al: [Primary pulmonary leiomyosarcoma revealed by spontaneous pneumothorax.] Rev Pneumol Clin. 65(5):309-12, 2009
6. Shoji F et al: Pulmonary leiomyosarcoma presenting as a pancoast tumor. Pathol Res Pract. 203(10):745-8, 2007
7. Moran CA et al: Primary leiomyosarcomas of the lung: a clinicopathologic and immunohistochemical study of 18 cases. Mod Pathol. 10(2):121-8, 1997
8. Jimenez JF et al: Primary bronchopulmonary leiomyosarcoma in childhood. Arch Pathol Lab Med. 110(4):348-51, 1986
9. Guccion JG et al: Bronchopulmonary leiomyosarcoma and fibrosarcoma. A study of 32 cases and review of the literature. Cancer. 30(3):836-47, 1972

Macroscopic Features

Solid Spindle Cell Proliferation

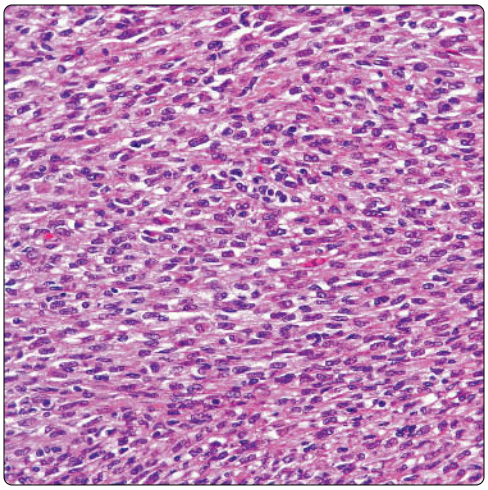

(Left) *Pulmonary LMS shows a large intraparenchymal tumor ⇨. The tumor is hemorrhagic, and, although close to the main airway, it does not appear to obstruct it.* **(Right)** *Pulmonary LMS is shown with its classic growth pattern composed of fascicles of cells with elongated nuclei. At this power, one cannot identify the presence of mitotic activity or necrosis.*

Extensive Necrosis

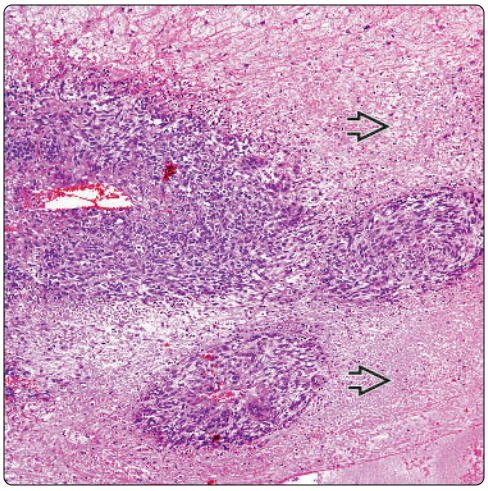

HPC-Like Pattern

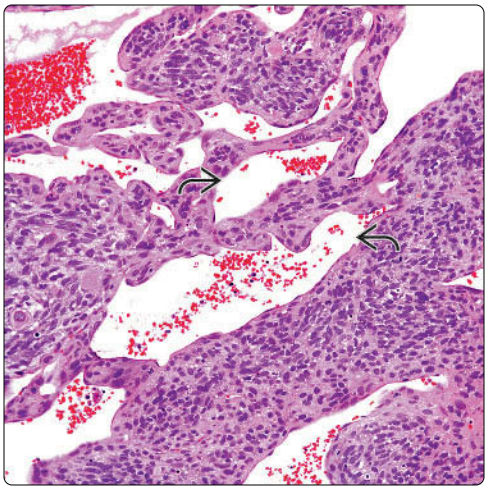

(Left) *LMS is shown with extensive areas of necrosis ⇨. The findings of necrosis and mitotic activity are features of high-grade sarcoma.* **(Right)** *LMS shows dilated vessels ⇨ reminiscent of hemangiopericytoma (HPC). HPC features may be commonly seen in LMS.*

Subtle Fascicular Pattern

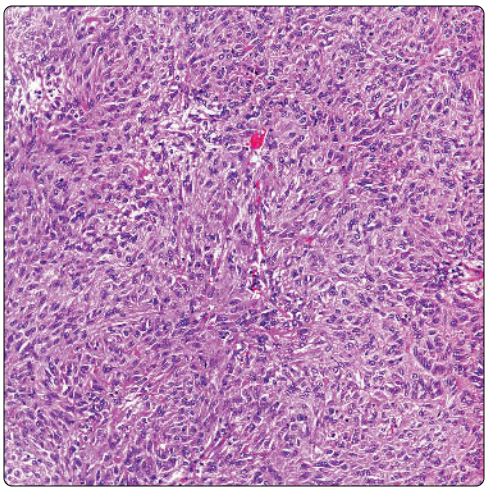

Collection of Foamy Macrophages

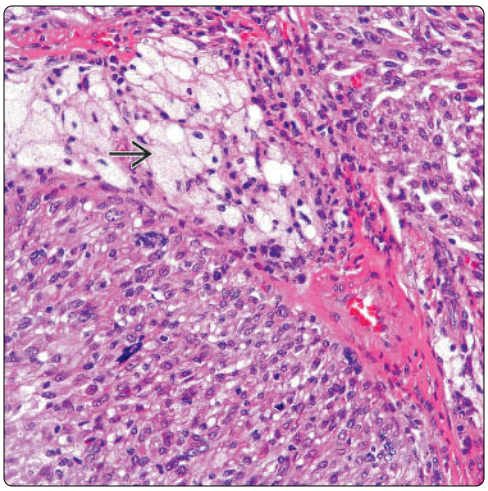

(Left) *Intermediate-grade pulmonary LMS shows a fascicular growth pattern with spindle cells with moderate amounts of eosinophilic cytoplasm and a more epithelioid appearance.* **(Right)** *Intermediate-grade pulmonary LMS shows an epithelioid appearance with collections of foamy macrophages ⇨ and a mild inflammatory reaction.*

Multinucleated Giant Cells

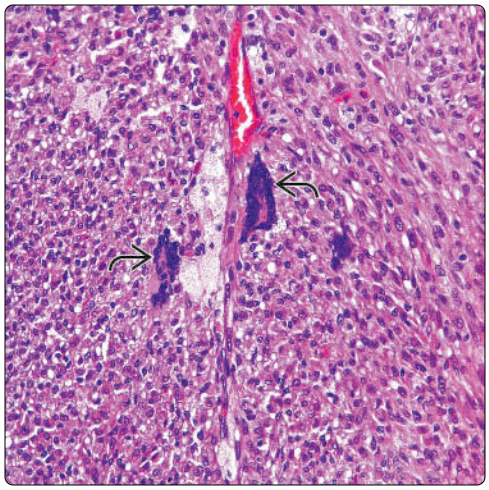

Macrophages and Spindle Cells

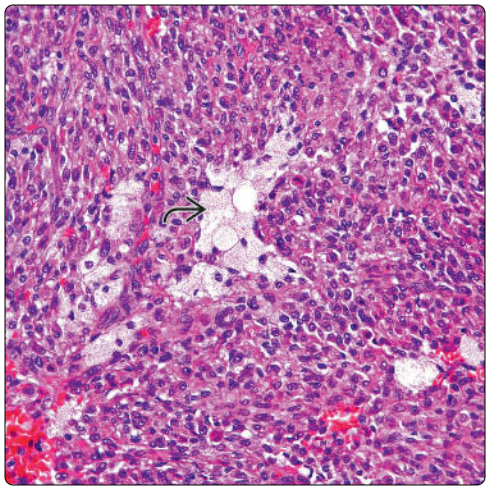

(Left) *Intermediate-grade pulmonary LMS is shown with a cluster of multinucleated giant cells. Note that the multinucleated giant cells do not show nuclear atypia or mitotic activity. This is an unusual feature in these tumors.* **(Right)** *LMS is shown with small collections of foamy macrophages. Such a finding may be seen, not only in smooth muscle tumors, but also in an inflammatory pseudotumor of lung.*

Spindle Cell Proliferation

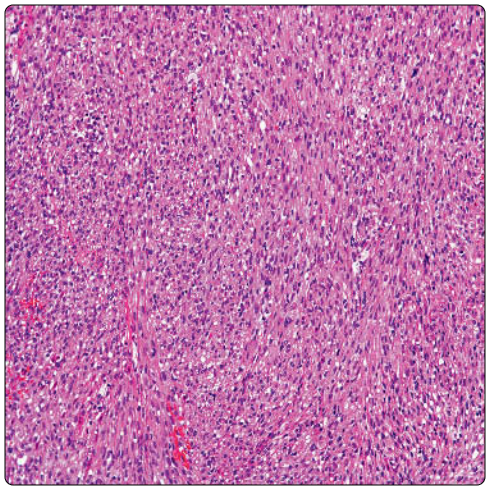

Epithelioid Appearance With Giant Cells

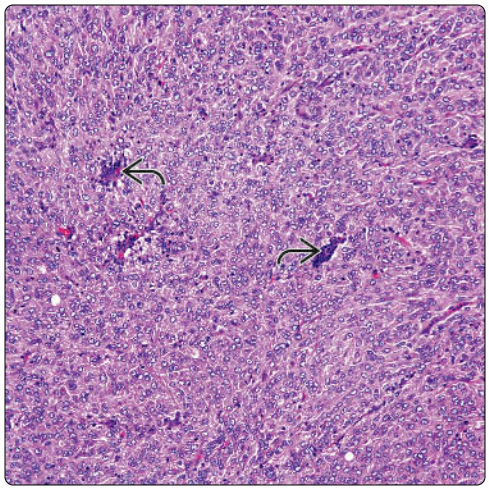

(Left) *LMS shows conventional features of a spindle cellular proliferation with cigar-shaped nuclei and mild nuclear atypia. The finding of mitotic activity is important for proper classification.* **(Right)** *LMS is shown with clusters of inflammatory cells. Note the epithelioid appearance of the tumor in contrast to the conventional spindle cellular proliferation.*

Extensive Necrosis

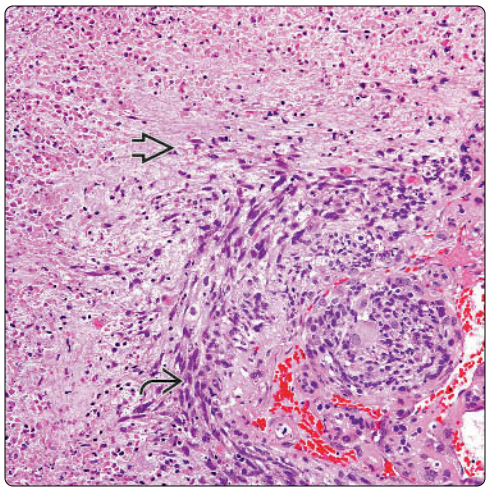

Mitotic Activity

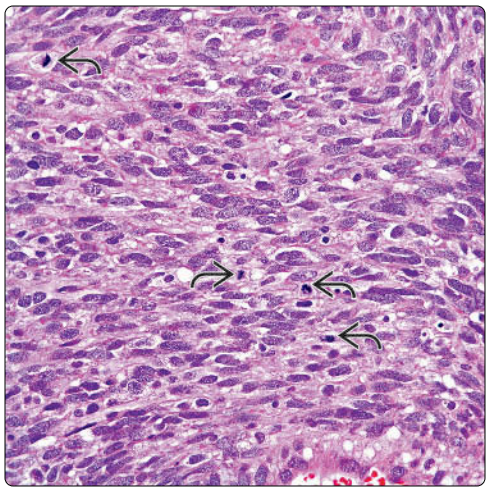

(Left) *High-grade LMS shows alternating areas of a pleomorphic spindle cell proliferation and areas of necrosis. These features are important for proper classification.* **(Right)** *High-grade LMS shows numerous mitotic figures. Usually, mitotic figures are easily identifiable in high-grade tumors.*

Epithelioid Appearance

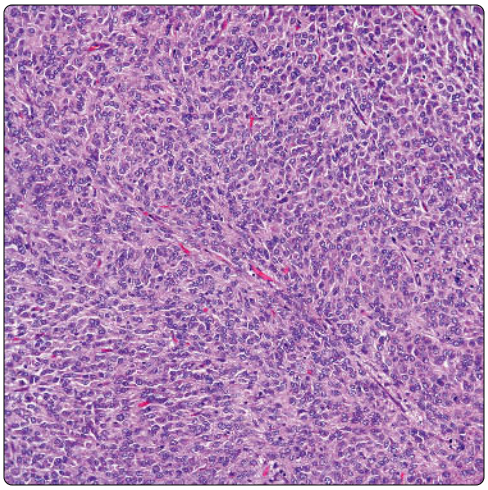

Epithelioid Appearance

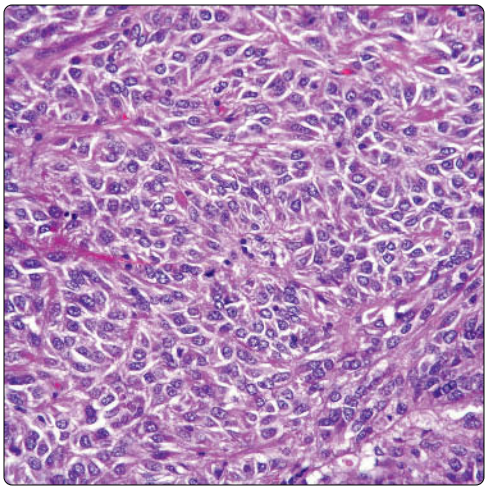

(Left) *Pulmonary LMS is shown with predominantly epithelioid appearance in which the tumor cells appear round with an oval nuclei.* **(Right)** *Higher magnification shows an epithelioid LMS composed of oval cells with ample eosinophilic cytoplasm. The nuclear atypia is moderate, and scattered mitotic figures are present.*

High-Grade Leiomyosarcoma

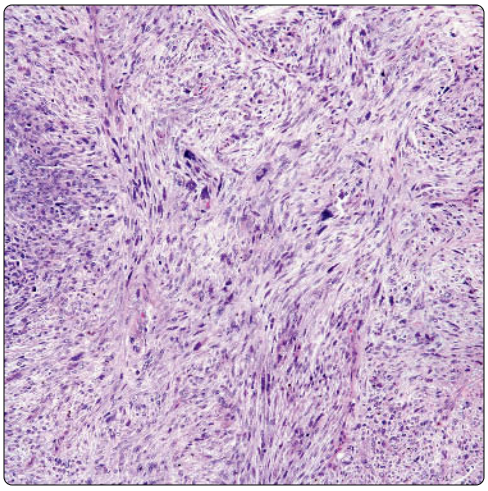

Nuclear Pleomorphism

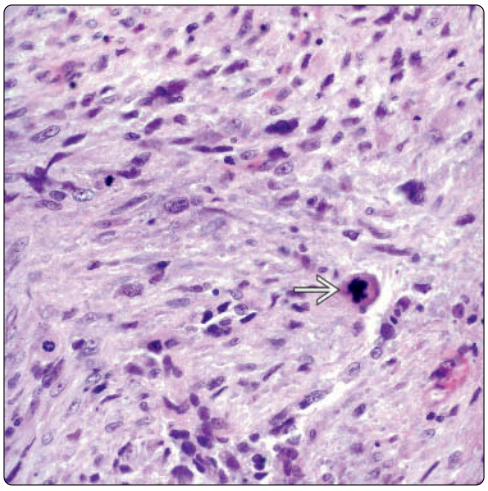

(Left) *Pulmonary LMS shows marked cellular pleomorphism. Note that the tumor still keeps fascicles of spindle cells. This feature is commonly seen in high-grade LMS.* **(Right)** *High-grade LMS shows marked nuclear pleomorphism with atypical mitotic figures* ⇨.

Positive Desmin

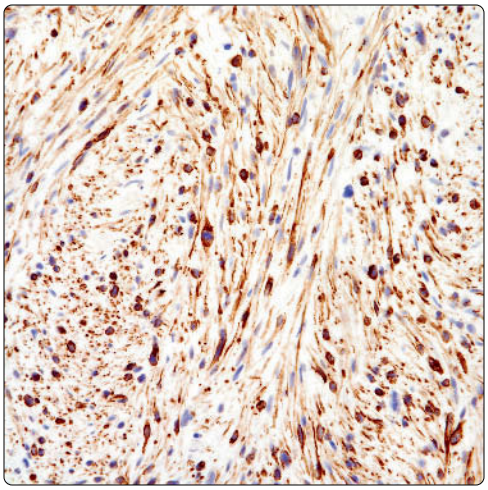

Positive Actin

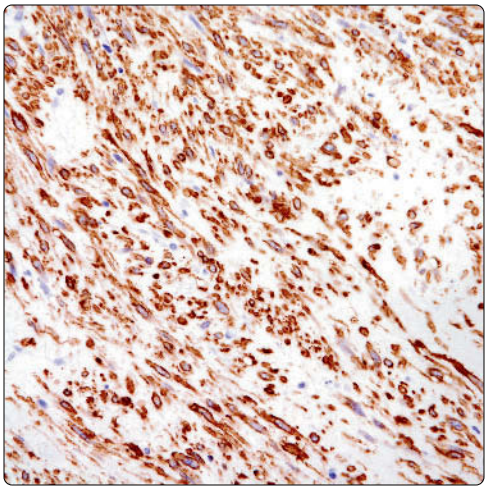

(Left) *Immunohistochemical stain for desmin shows positive staining in tumor cells in a pulmonary LMS.* **(Right)** *Immunohistochemical stain for actin shows positive staining in tumor cells of a pulmonary LMS.*

Neurogenic Sarcoma (Malignant Peripheral Nerve Sheath Tumor)

KEY FACTS

CLINICAL ISSUES

- Extremely rare tumor
- Often associated with neurofibromatosis
- Tumors may be central or peripheral
- Tumors may arise in endobronchial location
- Aggressive behavior with recurrences and metastases

MICROSCOPIC

- Fascicular atypical spindle cell proliferation
- Frequent herringbone pattern of growth
- Alternating hyper- and hypocellular areas
- Rhabdomyoblastic differentiation may be present (malignant triton tumor)
- Frequent areas of cystic degeneration, hemorrhage, and necrosis
- Prominent myxoid stromal changes

ANCILLARY TESTS

- S100 protein is of limited utility for diagnosis because expression is lost or only focal in malignant neural neoplasms
- Immunohistochemical staining has very low specificity for diagnosis of neurogenic sarcoma
- Shows complex interdigitating cytoplasmic processes covered by basal lamina material on EM

DIAGNOSTIC CHECKLIST

- Immunohistochemical staining may be of very limited value for diagnosis in neurogenic sarcoma
- 2 most reliable features for establishing diagnosis are history of neurofibromatosis and ultrastructural findings

Macroscopic Features

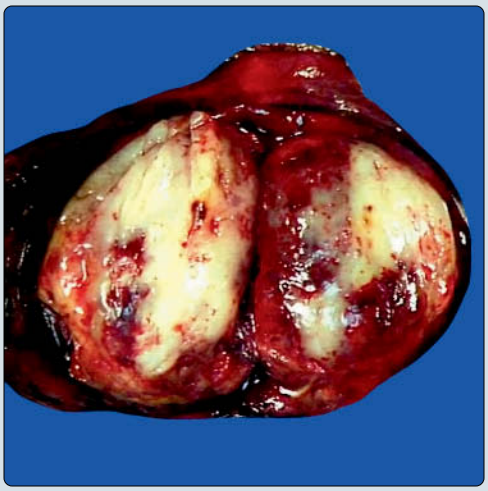

Intrapulmonary Neoplasm

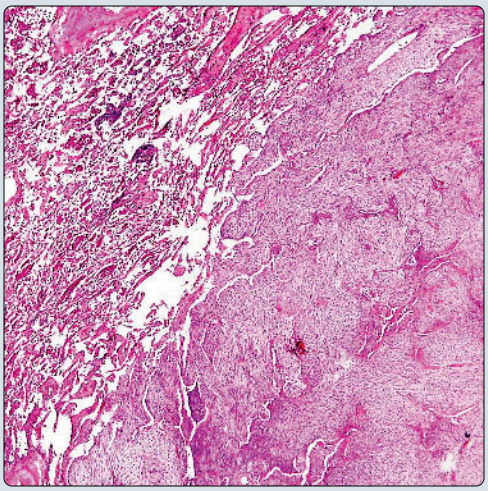

(Left) *Gross appearance of primary neurogenic sarcoma of the lung in a resected specimen shows a fleshy, well-circumscribed tumor mass with extensive areas of hemorrhage and a glistening cut surface.* **(Right)** *Neurogenic sarcoma of the lung shows well-circumscribed spindle cell tumor in lung parenchyma. Clinical history and special stains are required to separate this from other primary and metastatic tumors.*

Pseudonodular Pattern

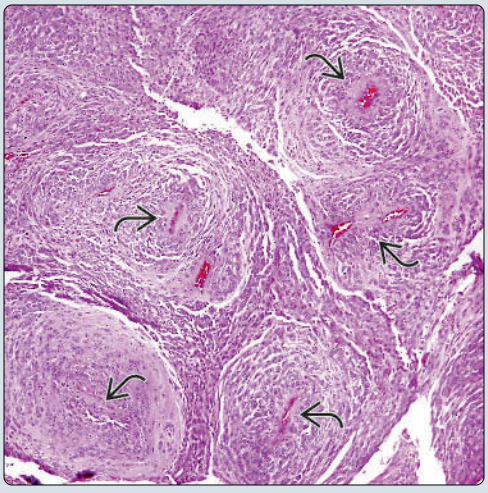

Mitotic Activity

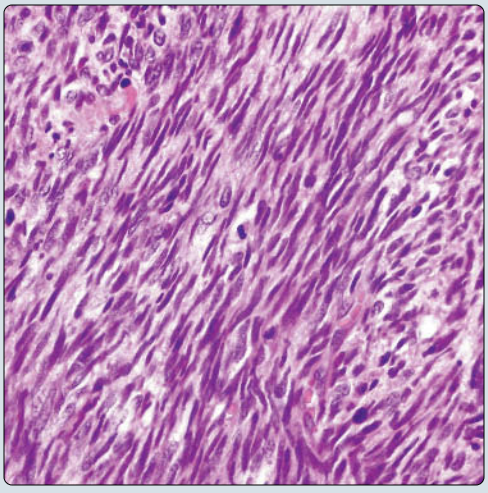

(Left) *Scanning magnification of neurogenic sarcoma of the lung shows pseudonodular growth pattern due to perivascular arrangement of tumor cells. This pattern of growth is more often encountered in the epithelioid variant of these tumors.* **(Right)** *High-power view of a neurogenic sarcoma shows a solid spindle cell proliferation composed of elongated cells with nuclear atypia and mitotic activity.*

TERMINOLOGY

Synonyms

- Malignant peripheral nerve sheath tumor
- Malignant schwannoma

Definitions

- Primary malignant lung neoplasm showing evidence of peripheral nerve sheath differentiation

CLINICAL ISSUES

Epidemiology

- Incidence
  - Extremely rare tumor
  - Often associated with neurofibromatosis
- Age
  - Affects all age groups
  - Most frequent in young adults and middle-aged patients (30-50 yr of age)

Presentation

- Large intraparenchymatous mass
  - Tumors may be central or peripheral
  - Tumors may arise in endobronchial location
- Shortness of breath
- Cough
- Chest pain
- Small peripheral tumors may be asymptomatic and discovered incidentally

Prognosis

- Aggressive behavior with recurrences and metastases
- Usually rapidly progressive course with fatal outcome

MACROSCOPIC

General Features

- Large, fleshy, gray-white, lobulated tumor
- May be partially encapsulated
- Frequent hemorrhage and necrosis

MICROSCOPIC

Histologic Features

- Fascicular atypical spindle cell proliferation
- Frequent herringbone pattern of growth
- Alternating hyper- and hypocellular areas
- Well-developed storiform pattern can be sometimes observed
- Perivascular pattern of growth with extensive intervening areas of necrosis
- Prominent myxoid stromal changes
- Frequent areas of cystic degeneration, hemorrhage, and necrosis
- Heterologous elements may be present including bone, cartilage, and benign glandular inclusions
- Rhabdomyoblastic differentiation may be present (malignant triton tumor)
- Tumor may entrap benign respiratory epithelium at periphery of lesion, simulating biphasic neoplasm

Cytologic Features

- Tumor cells may be spindle or epithelioid
- Spindle cells show enlarged, wavy nuclei with increased chromatin pattern and prominent nucleoli
- Mitotic activity can be pronounced (> 10 mitoses per 10 high-power fields)
- Epithelioid cells are large, round, or polygonal and contain hyperchromatic nuclei surrounded by abundant cytoplasm
- Malignant triton tumor contains foci of small, round, or spindle rhabdomyoblasts with hyperchromatic nuclei and eccentric pink cytoplasm

ANCILLARY TESTS

Immunohistochemistry

- S100 protein is of limited utility for diagnosis because expression is lost or only focal in malignant neural neoplasms
- Neurofilaments, nerve growth factor receptor (NGFR), CD57, and other neural-associated markers may be positive but are not distinctive
- In rare cases, focal positivity for keratin or EMA may be observed
- Rhabdomyoblastic elements in malignant triton tumors stain strongly with desmin, MYOD1, and myogenin

Genetic Testing

- No specific translocation or genetic profile has been demonstrated so far

DIFFERENTIAL DIAGNOSIS

Monophasic Synovial Sarcoma

- Also shows fascicular growth with prominent herringbone pattern
- Usually displays prominent hemangiopericytic growth pattern not seen in neurogenic sarcoma
- Can be positive for S100 protein in up to 30% of cases
- Focally positive for cytokeratin and EMA and strongly positive for Bcl-2 and CD99
- Does not display long, slender, and interdigitating cytoplasmic process by electron microscopy
- Associated in > 85% of cases with SYT cytogenetic translocation; t(X;18)

Solitary Fibrous Tumor

- Morphology may be indistinguishable from that of neurogenic sarcoma
- May also show fascicular growth with prominent herringbone pattern
- Shows immunohistochemical reactivity for CD34, Bcl-2, and CD99
- Does not display interdigitating cytoplasmic processes by electron microscopy

SELECTED REFERENCES

1. Fukaya K et al: [Primary malignant peripheral nerve sheath tumor of the lung; report of a case.] Kyobu Geka. 67(10):935-8, 2014
2. La Mantia E et al: Primary intrapulmonary malignant peripheral nerve sheath tumor mimicking lung cancer. J Thorac Dis. 5(4):E155-7, 2013
3. Cuneo KC et al: Pathologic complete response of a malignant peripheral nerve sheath tumor in the lung treated with neoadjuvant Ifosfamide and radiation therapy. J Clin Oncol. 30(28):e291-3, 2012

Unencapsulated Tumor

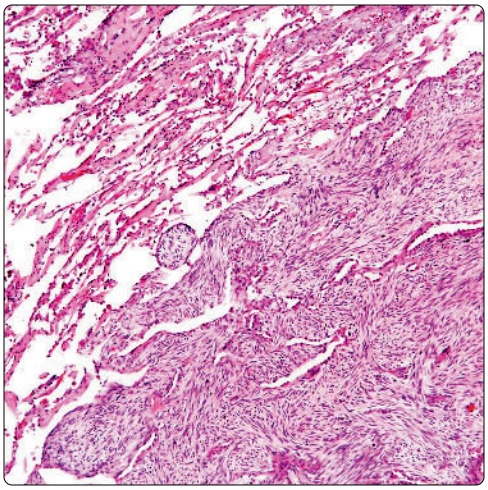

Fascicular Pattern

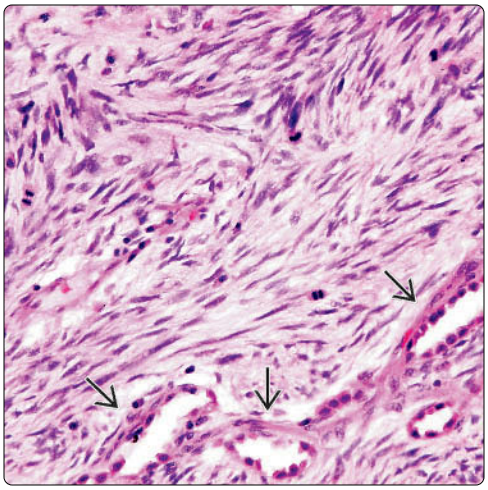

(Left) *Scanning magnification of malignant peripheral nerve sheath tumor of the lung (neurogenic sarcoma) shows a fascicular pattern of growth. Notice the sharp circumscription of the tumor from the surrounding lung parenchyma with absence of a capsule.* **(Right)** *High magnification of neurogenic sarcoma of the lung with fascicular growth pattern shows atypical spindle cells with scattered mitoses. Notice the entrapped gland-like airspaces at the periphery of the lesion simulating a biphasic neoplasm.*

Hypo-/Hypercellular areas

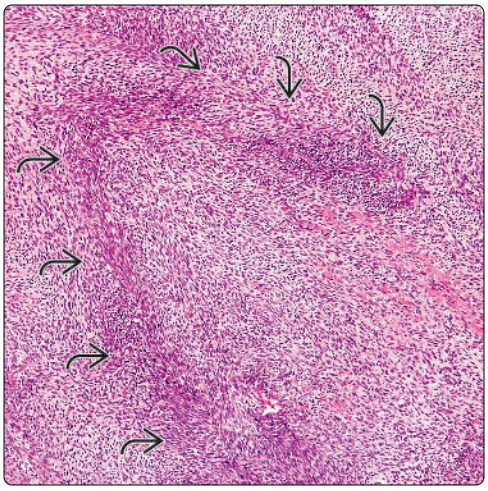

Palisading of Spindle Cells

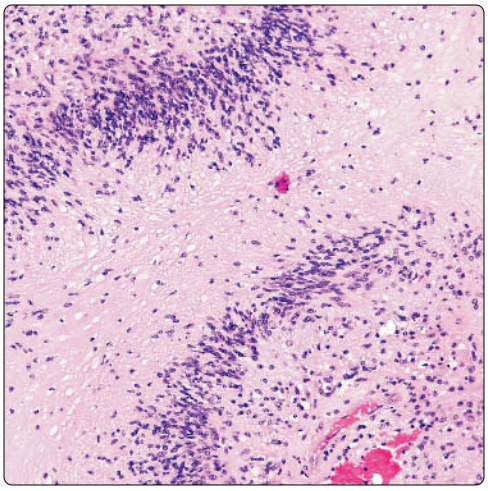

(Left) *Scanning magnification of neurogenic sarcoma of the lung shows a characteristic appearance with dark (hypercellular) zones alternating with lighter (hypocellular) areas.* **(Right)** *Neurogenic sarcoma of the lung shows palisading of spindle tumor cells reminiscent of Verocay bodies (Antoni type A pattern). This very unusual feature is rarely seen in these tumors. It is mostly observed only in the very well-differentiated examples of these lesions.*

Herringbone Pattern

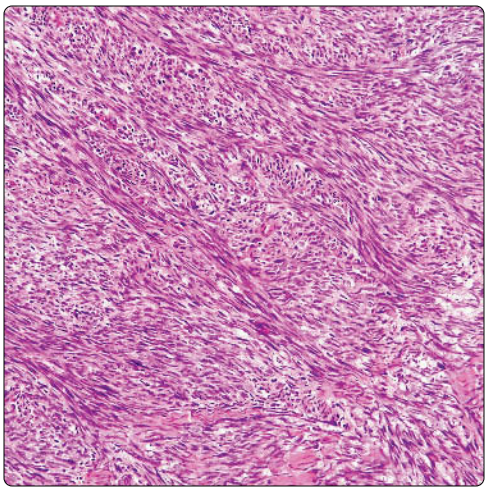

Peritheliomatous Pattern

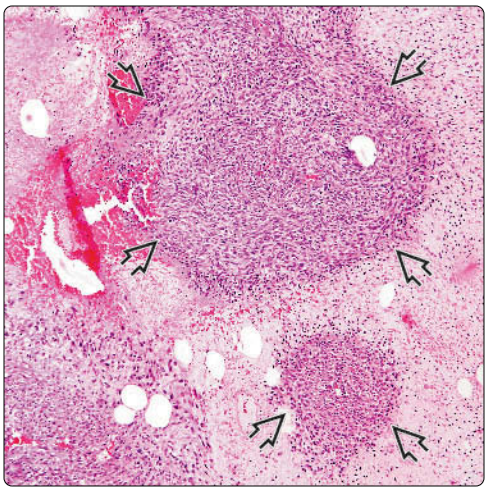

(Left) *Scanning magnification of a malignant peripheral nerve sheath tumor (neurogenic sarcoma) of the lung shows a striking herringbone pattern of growth that simulates a fibrosarcoma.* **(Right)** *Scanning magnification of neurogenic sarcoma of the lung shows a striking peritheliomatous growth pattern resulting in balls of tumor cells surrounding small vessels. The balls of tumor cells are characteristically surrounded by extensive intervening areas of necrosis.*

Mitotic Activity

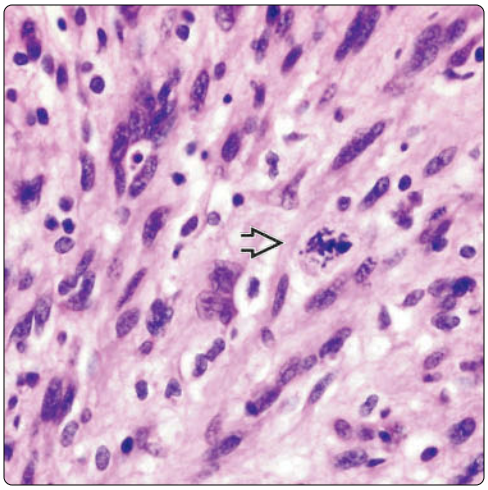

Nuclear Pleomorphism

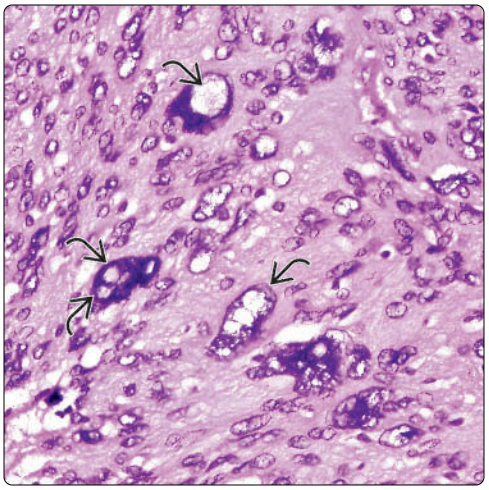

(Left) *High magnification of malignant peripheral nerve sheath tumor of the lung shows atypical spindle cell population with scattered abnormal mitoses ⇨. Notice the inflammatory cell infiltrate in the background stroma.* **(Right)** *Malignant peripheral nerve sheath tumor of the lung shows spindle cell population with marked nuclear pleomorphism. Notice large, hyperchromatic tumor cells displaying intranuclear cytoplasmic inclusions (nuclear pseudoinclusions) ⇨.*

Epithelioid Appearance

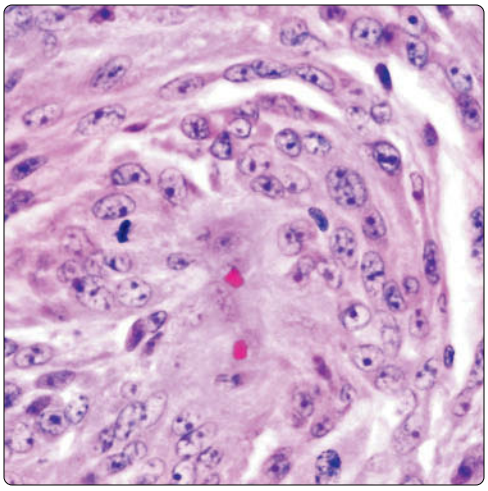

Rhabdomyoblastic Differentiation

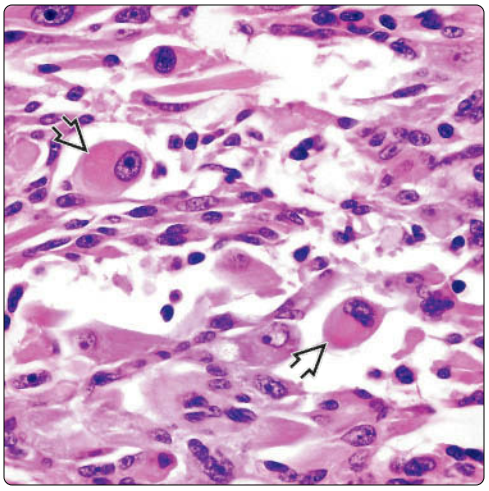

(Left) *Epithelioid variant of malignant peripheral nerve sheath tumor of the lung shows cells with round nuclei containing prominent eosinophilic nucleoli and surrounded by an abundant rim of eosinophilic cytoplasm.* **(Right)** *Malignant peripheral nerve sheath tumor of the lung with rhabdomyoblastic differentiation (malignant triton tumor) shows scattered large rhabdomyoblastic cells with eccentric nuclei and abundant pink cytoplasm ⇨.*

Atypical Spindle Cells

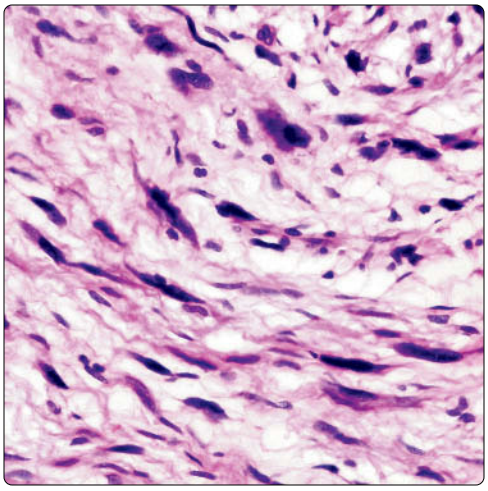

Ultrastructural Features

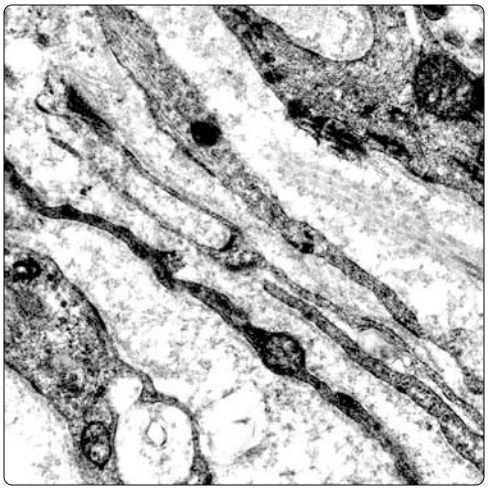

(Left) *Malignant peripheral nerve sheath tumor of lung shows atypical spindle cell population with wavy nuclei. Notice the abundant, lightly myxoid background matrix.* **(Right)** *Ultrastructural appearance of malignant peripheral nerve sheath tumor of the lung shows long, slender cytoplasmic prolongations that intertwine with one another and are partially covered by a thin layer of basal lamina material. This feature is distinctive for these tumors and a helpful adjunct for diagnosis.*

Osteosarcoma

KEY FACTS

TERMINOLOGY

- Malignant mesenchymal neoplasm with osseous differentiation

CLINICAL ISSUES

- Incidence
  - Osteosarcomas of lung are exceedingly rare with > 30 cases reported
  - Pulmonary osteosarcomas appear to be more common in 5th and 6th decades of life
- Symptoms
  - Cough
  - Dyspnea
  - Chest pain
  - Hemoptysis
  - Asymptomatic
- Laboratory findings
  - In most cases of pulmonary osteosarcoma, levels of alkaline phosphatase are normal
- Treatment and prognosis
  - No specific treatment
  - Poor survival
  - Death may occur within 12 months after initial diagnosis

MICROSCOPIC

- Spindle cell component
- Osteoid formation
- Osteoclast giant cells

TOP DIFFERENTIAL DIAGNOSES

- Bronchial chondroma
  - May show ossification in center of lesion
- Chondrosarcomas
  - Does not show osteoid formation
  - Does not display cellular atypia &/or mitotic activity
- Carcinosarcoma
  - Displays epithelial component

Intrapulmonary Tumor

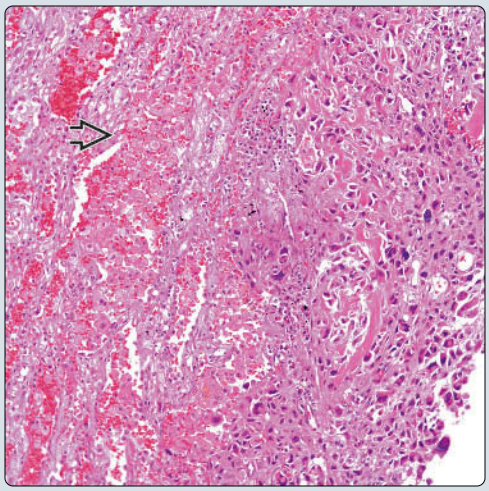

Osteoid Component

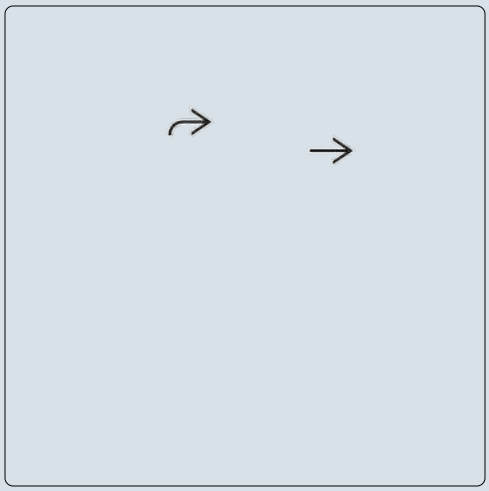

(Left) *Primary pulmonary osteosarcoma shows a pleomorphic cellular proliferation with numerous multinucleated giant cells of the osteoclast type. Note the presence of uninvolved lung parenchyma.* **(Right)** *High-power view of an osteosarcoma shows osteoid deposition and a rim of neoplastic cells.*

Spindle Cell Component

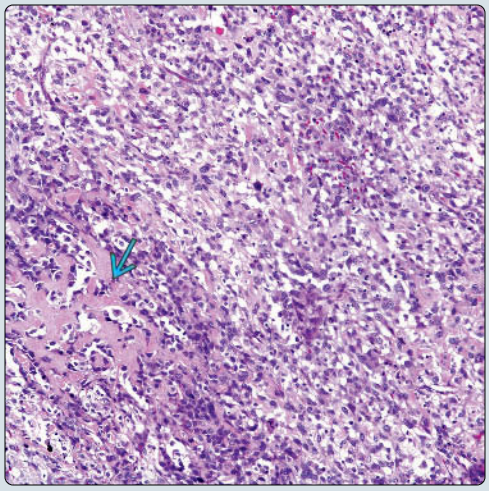

Mitotic Activity

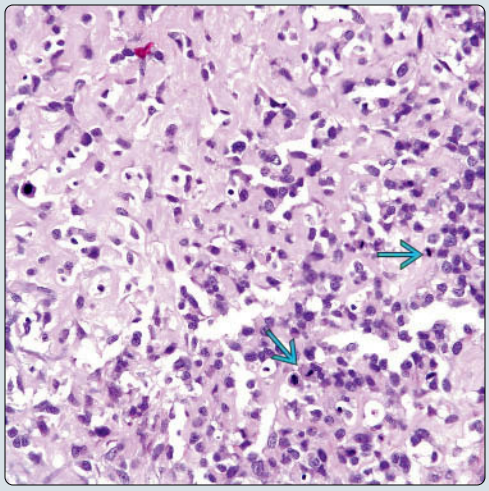

(Left) *Primary osteosarcoma of the lung shows a malignant spindle cell proliferation with only focal areas of osteoid deposition.* **(Right)** *Primary osteosarcoma of the lung shows more easily identifiable osteoid component associated with malignant cells with nuclear atypia and mitotic activity.*

TERMINOLOGY

Synonyms

- Osteogenic sarcoma

Definitions

- Malignant mesenchymal neoplasm with osseous differentiation

CLINICAL ISSUES

Epidemiology

- Incidence
  - Osteosarcomas of lung are exceedingly rare with < 30 cases reported in literature
- Age
  - Osteosarcomas of lung appear to be more common in 5th and 6th decades of life
- Sex
  - No gender predilection

Presentation

- Cough
- Shortness of breath
- Chest pain
- Hemoptysis
- Asymptomatic

Laboratory Tests

- In most cases of pulmonary osteosarcoma, levels of alkaline phosphatase are normal

Treatment

- Surgical approaches
  - Lobectomy or pneumonectomy
- Adjuvant therapy
  - Chemoradiation is questionable
- There is no specific treatment

Prognosis

- Poor survival
- Death may occur within 12 months after initial diagnosis

MACROSCOPIC

General Features

- Well-defined tumor
- Solid, "rock hard"

Size

- Varies from 4 to > 10 cm in diameter

MICROSCOPIC

Histologic Features

- Malignant spindle cell proliferation
- Osteoid formation
- Osteoclast giant cells
- Mitotic activity
- Cartilaginous component may be present

Predominant Pattern/Injury Type

- Ossification

Predominant Cell/Compartment Type

- Spindle

DIFFERENTIAL DIAGNOSIS

Bronchial Chondroma

- May show ossification in center of lesion
- Does not show osteoid formation
- Will not display cellular atypia &/or mitotic activity

Carcinosarcoma

- Displays epithelial component
- Adenocarcinoma, squamous cell carcinoma, or other malignant epithelial component must be present
- In majority of carcinosarcomas, osteoid component is only focal
- Immunohistochemical stains may be of aid

Chondrosarcoma

- Does not show osteoid formation
- Metaplastic bone may be seen in some cases

Hamartoma

- Displays more benign cartilaginous component
- Shows presence of invaginations of respiratory epithelium
- Lacks presence of osteoid

Poorly Differentiated Carcinomas (Non-Small Cell Type)

- In some carcinomas, presence of prominent basal lamina may be confused with osteoid
- Some pleomorphic carcinomas may show metaplastic bone
- Carcinomas will show positive staining for epithelial markers

DIAGNOSTIC CHECKLIST

Clinically Relevant Pathologic Features

- Gross appearance

Pathologic Interpretation Pearls

- Osteoid formation

SELECTED REFERENCES

1. Shenjere P et al: Primary pulmonary osteosarcoma: a report of 4 cases and a review of the literature. Int J Surg Pathol. 19(2):225-9, 2011
2. Karfis EA et al: Primary extraosseous osteosarcoma of the lung. Acta Oncol. 49(1):114-6, 2010
3. Niimi R et al: Primary osteosarcoma of the lung: a case report and review of the literature. Med Oncol. 25(2):251-5, 2008
4. Yamazaki K et al: Primary osteosarcoma of the lung: a case report. Ann Thorac Cardiovasc Surg. 12(2):126-8, 2006
5. Kadowaki T et al: Two cases of primary pulmonary osteosarcoma. Intern Med. 44(6):632-7, 2005
6. Chapman AD et al: Primary pulmonary osteosarcoma: case report and molecular analysis. Cancer. 91(4):779-84, 2001
7. Wagner MS et al: Primary chondroblastic osteosarcoma of the lung. Sarcoma. 3(3-4):193-5, 1999
8. Loose JH et al: Primary osteosarcoma of the lung. Report of two cases and review of the literature. J Thorac Cardiovasc Surg. 100(6):867-73, 1990
9. Colby TV et al: Primary osteosarcoma of the lung. A reappraisal following immunohistologic study. Arch Pathol Lab Med. 113(10):1147-50, 1989

Pleomorphic Neoplastic Cells

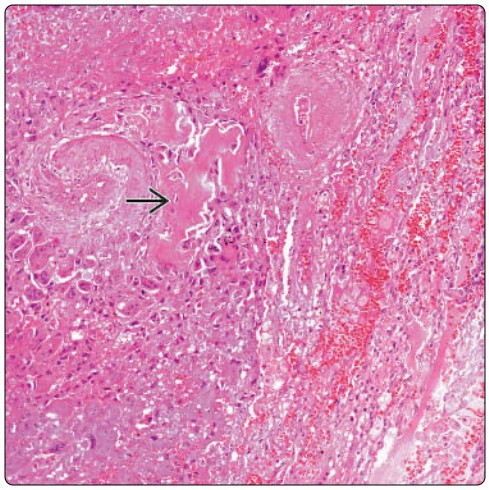

Osteoid Component

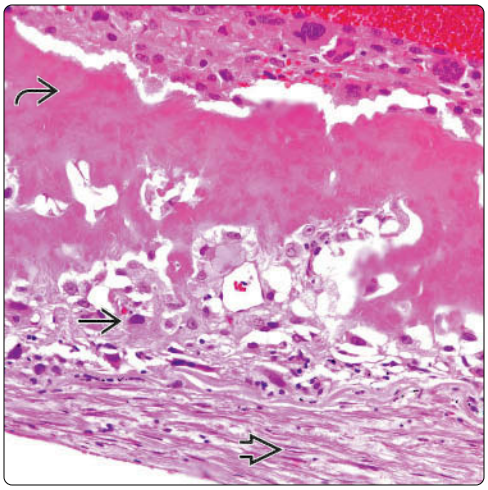

(Left) *In this pulmonary osteosarcoma with adjacent lung parenchyma, note that the tumor is not encapsulated but rather shows ill-defined borders. In addition, note the presence of osteoid formation ⇨ admixed with the neoplastic cellular proliferation.* **(Right)** *Osteosarcoma shows extensive osteoid deposition ⇨. The tumor is in a subpleural location ⇨. Numerous malignant cells are also present ⇨.*

Osteoclast Giant Cells

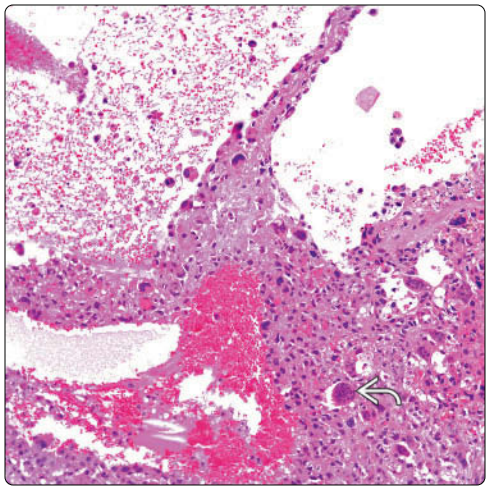

Mono- and Multinucleated Giant Cells



(Left) *Osteosarcoma shows cystic changes. Note the presence of numerous osteoclast-type giant cells ⇨ admixed with blood and other mononuclear cells.* **(Right)** *High-power view of the cellular composition of an osteosarcoma shows numerous osteoclast-type giant cells admixed with atypical mononuclear cells, some of them showing atypical mitotic figures ⇨.*

Minimal Osteoid Component

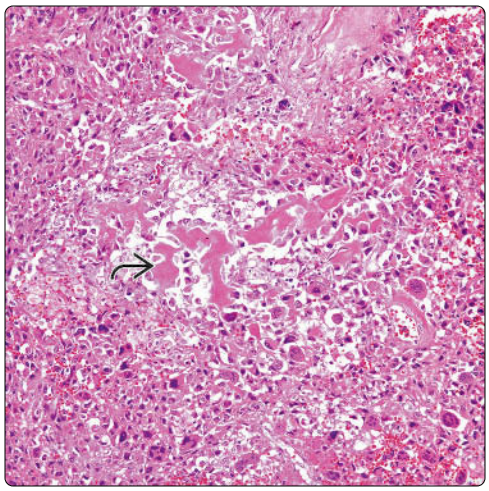

Mitotic Activity

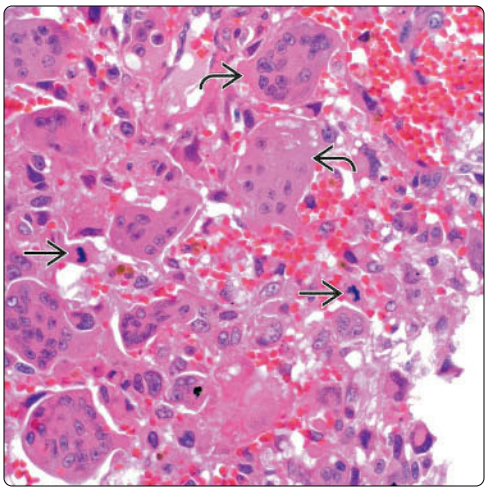

(Left) *In some cases of osteosarcoma, the presence of osteoid may be only minimal ⇨. The presence of osteoid is highly important to make the diagnosis of osteosarcoma.* **(Right)** *Higher magnification shows areas composed predominantly of multinucleated giant cells ⇨, which do not show mitotic activity. However, adjacent mononuclear cells show mitotic activity ⇨.*

Bronchial Epithelium

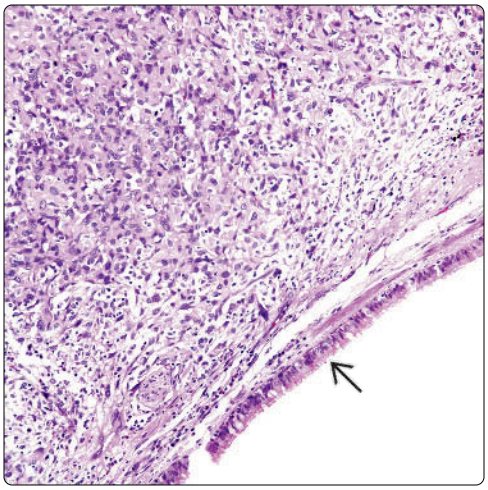

Ossification

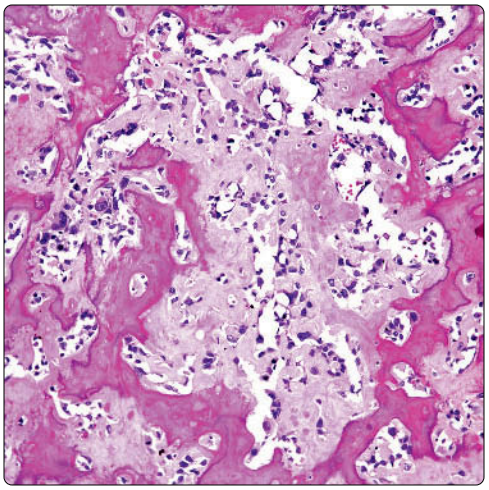

(Left) *Low-power view of an osteosarcoma of the lung shows a tumor growing beneath the bronchial epithelium. In this type of tumor, no in situ component is found.* **(Right)** *In some other cases of osteosarcoma, the presence of ossification is more apparent and easily identifiable. It is crucial to properly sample these tumors in order to rule out epithelial components.*

Neoplastic Cells and Osteoid

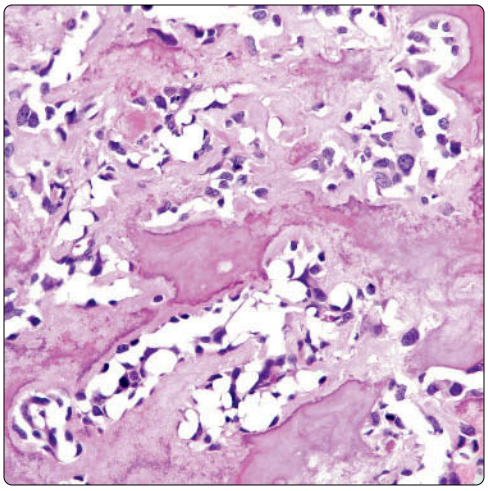

Subtle Nested Pattern

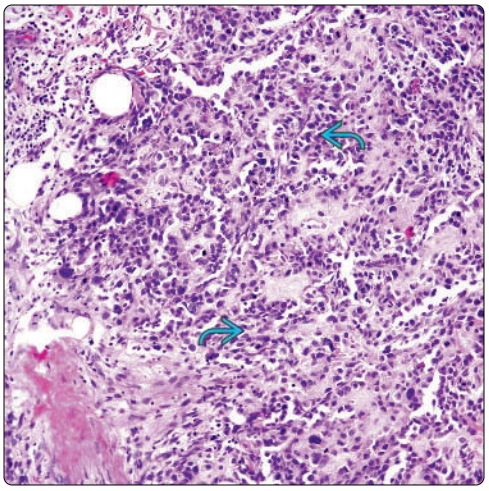

(Left) *Higher magnification shows a neoplastic cellular proliferation composed of rather small cells with indistinct cell borders, inconspicuous nucleoli, and an absence of mitotic activity. Note the presence of obvious osteoid formation.* **(Right)** *In cases in which osteoid is not easily identifiable, the tumor can be easily misdiagnosed for another sarcoma or epithelial malignancy. In this illustration, the tumor cells appear epithelial.*

Sheets of Neoplastic Cells

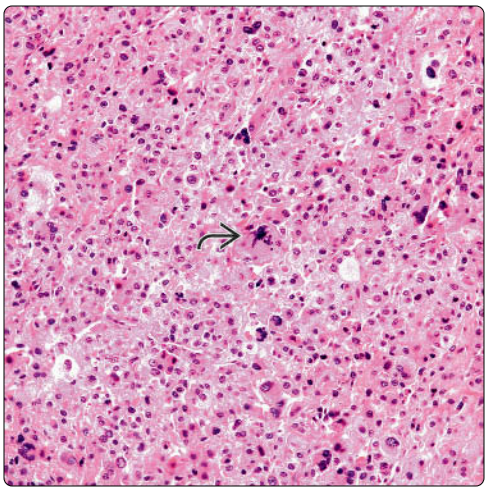

Prominent Spindle Cell Component

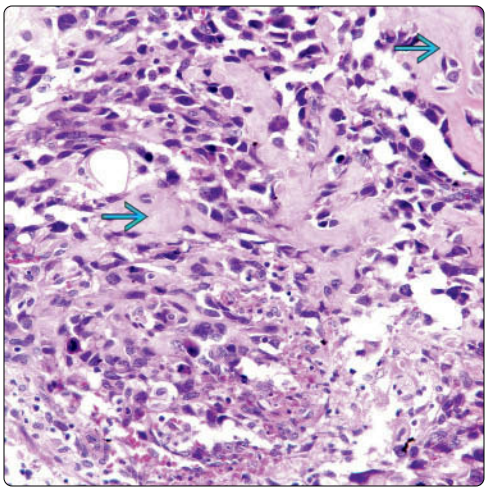

(Left) *This neoplastic cellular proliferation can be easily confused with an epithelial tumor. The cells show nuclear pleomorphism with atypical mitotic figures, but osteoid is not present.* **(Right)** *In some other cases, the neoplastic cellular proliferation shows spindle cell features mimicking some other type of spindle cell sarcoma. However, the presence of osteoid should raise the possibility of osteosarcoma.*

Chondrosarcoma

KEY FACTS

TERMINOLOGY

- Malignant mesenchymal neoplasm with cartilaginous differentiation

CLINICAL ISSUES

- Incidence
  - Primary chondrosarcomas of lung are exceedingly rare
  - More common in 6th and 7th decades of life
  - Can be either central or peripheral tumors
  - No gender predilection
- Symptoms
  - Dyspnea
  - Hemoptysis
  - Cough
  - Bronchial obstruction
  - Chest pain

MICROSCOPIC

- Atypical cartilage
- Chondromyxoid areas
- Myxoid change
- Atypical cellular proliferation embedded in myxoid stroma
- Mitotic activity

TOP DIFFERENTIAL DIAGNOSES

- Hamartoma shows invagination of respiratory epithelium
  - Shows mixed areas with adipose tissue
- Carcinoma is consideration in cases of mesenchymal chondrosarcoma
  - Shows positive staining with epithelial markers
- Mixed tumor may also show other types of tissues
- Carcinosarcoma should show evidence of epithelial component
- Metastatic chondrosarcoma
  - It would be unusual for metastasis to be centrally located

Central Cartilaginous Tumor

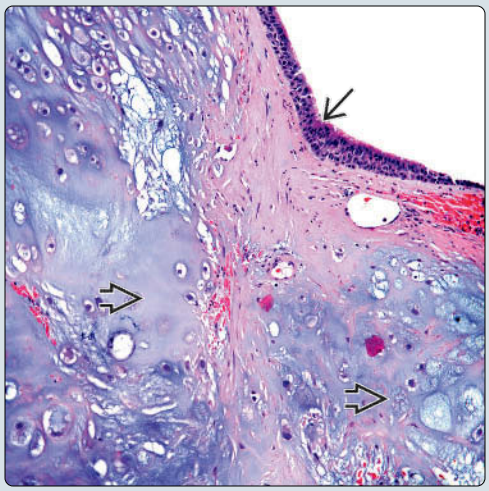

Lobulation

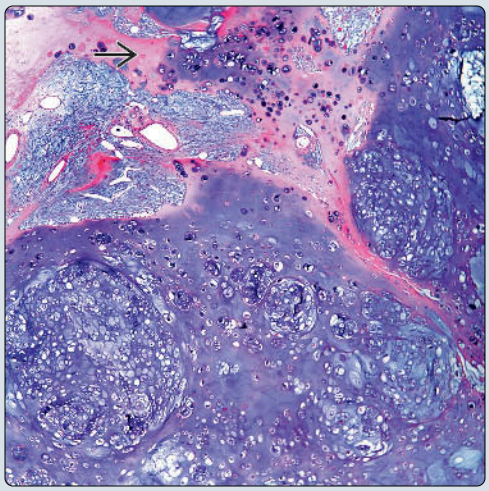

(Left) *Low-power view of a pulmonary chondrosarcoma shows the tumor ⇨ growing beneath the bronchial epithelium ⇨. The respiratory epithelium is not involved.* **(Right)** *Disorganized growth pattern with lobulation is seen at the center, with focal early ossification ⇨. The areas of ossification should not be interpreted as an osteosarcomatous component.*

Atypical Cartilage

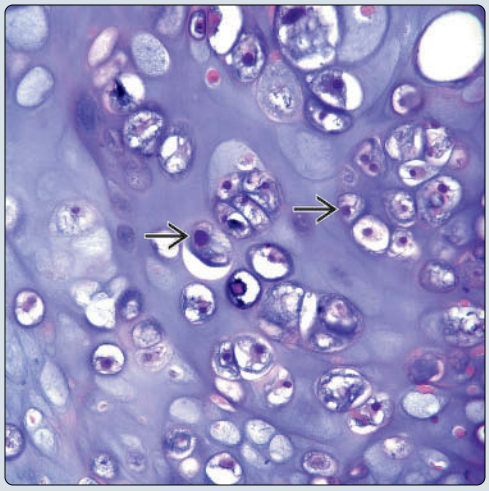

Atypical Cellular Proliferation

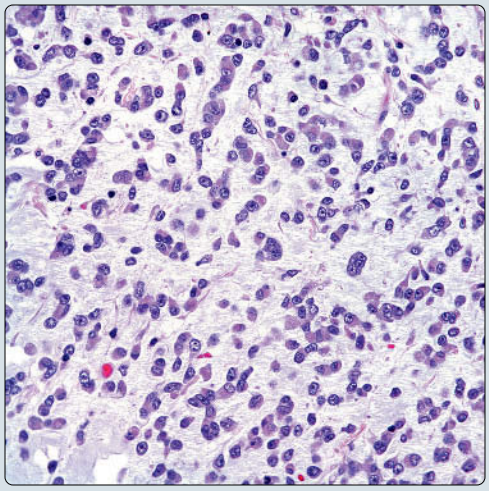

(Left) *High-power view of a low-grade pulmonary chondrosarcoma shows nuclear atypia ⇨. Mitotic figures are not present.* **(Right)** *Neoplastic cellular proliferation in primary chondrosarcoma of the lung shows the neoplastic cells embedded in a myxoid stroma. Even though the cells have prominent nucleoli, mitotic activity is absent.*

TERMINOLOGY

Definitions

- Malignant mesenchymal neoplasm with cartilaginous differentiation

CLINICAL ISSUES

Epidemiology

- Incidence
  - Primary chondrosarcomas of lung are exceedingly rare
- Age
  - Primary chondrosarcomas of lung are more common in 6th and 7th decades of life
- Sex
  - No gender predilection

Site

- Primary chondrosarcomas in lung can be either central or peripheral
- Tumor size varies

Presentation

- Dyspnea
- Chest pain
- Hemoptysis
- Cough
- Bronchial obstruction
- Asymptomatic

Treatment

- Surgical approaches
  - Lobectomy
  - Sleeve resection
  - Pneumonectomy
- Adjuvant therapy
  - Chemoradiation is questionable

Prognosis

- Central tumors may have less aggressive behavior
- Peripheral tumors may follow more aggressive behavior
- Survival is poor

IMAGING

General Features

- Central bronchial mass
- Peripheral tumor mass

MACROSCOPIC

General Features

- Tumor may obliterate bronchial lumen in central tumors
- Peripheral tumors are usually larger
- Well-delineated tumors
- White with slightly lobulated appearance
- Hard or mucoid consistency

Size

- Varies from 1-2 cm to > 10 cm in diameter

MICROSCOPIC

Histologic Features

- Atypical cartilage
- Chondromyxoid areas
- Myxoid areas
- Atypical cellular proliferation embedded in myxoid stroma
- Mitotic activity

Predominant Pattern/Injury Type

- Chondromyxoid

Predominant Cell/Compartment Type

- Cartilaginous

DIFFERENTIAL DIAGNOSIS

Hamartoma

- Shows invagination of respiratory epithelium
- Generally shows cartilage mixed with adipose tissue
- Would not show marked atypia &/or mitotic activity

Carcinoma

- Is consideration in cases of mesenchymal chondrosarcoma
- Shows positive staining with epithelial markers
- Generally would show more nuclear atypia and mitotic activity

Mixed Tumor (Pleomorphic Adenoma)

- Shows presence of associated epithelial component
- May also show other types of tissues
- Mixed tumors in lung usually do not show atypical cartilaginous component
- Mixed tumors would display myoepithelial differentiation

Carcinosarcoma

- Should show evidence of epithelial component
  - Squamous cell carcinoma
  - Adenocarcinoma
  - Large cell carcinoma

Metastatic Chondrosarcoma

- Clinical history is most important feature
- May show > 1 pulmonary lesion in lung
- May show bilateral distribution

DIAGNOSTIC CHECKLIST

Clinically Relevant Pathologic Features

- Gross appearance

Pathologic Interpretation Pearls

- Cartilaginous tumor with atypia

SELECTED REFERENCES

1. Kalhor N et al: Primary pulmonary chondrosarcomas: a clinicopathologic study of 4 cases. Hum Pathol. 42(11):1629-34, 2011
2. Steurer S et al: Dedifferentiated chondrosarcoma of the lung: case report and review of the literature. Clin Lung Cancer. 8(7):439-42, 2007
3. Huang HY et al: Primary mesenchymal chondrosarcoma of the lung. Ann Thorac Surg. 73(6):1960-2, 2002
4. Hayashi T et al: Primary chondrosarcoma of the lung. A clinicopathologic study. Cancer. 72(1):69-74, 1993

Atypical Cartilage

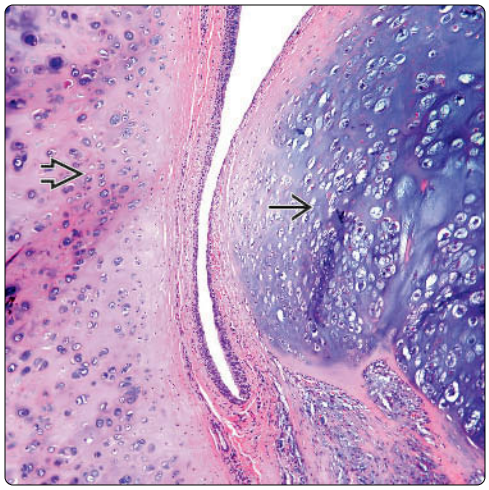

Osteoclast Giant Cells

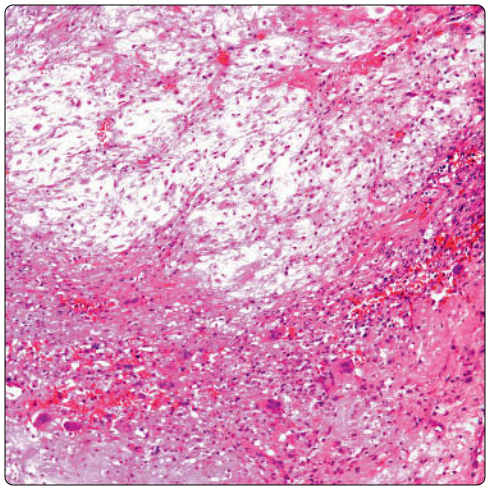

(Left) *Low-power view of a low-grade pulmonary chondrosarcoma shows a good comparison between neoplastic cartilage and normal bronchial cartilage. The tumor is obliterating the bronchial lumen.* **(Right)** *Primary chondrosarcoma of the lung is shown with myxoid features and the presence of osteoclast-like giant cells. This finding may also suggest the possibility of metastatic osteogenic sarcoma.*

Atypical Cell in Myxoid Stroma

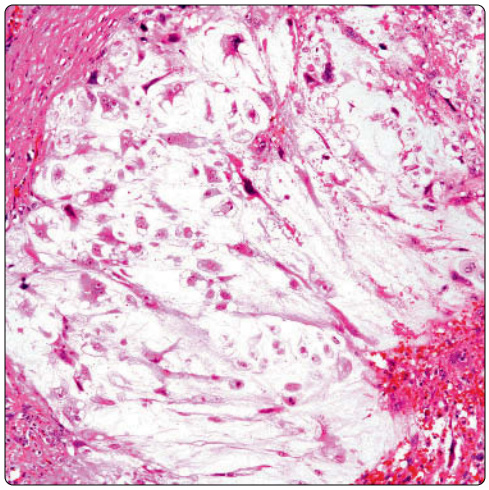

Nuclear Atypia

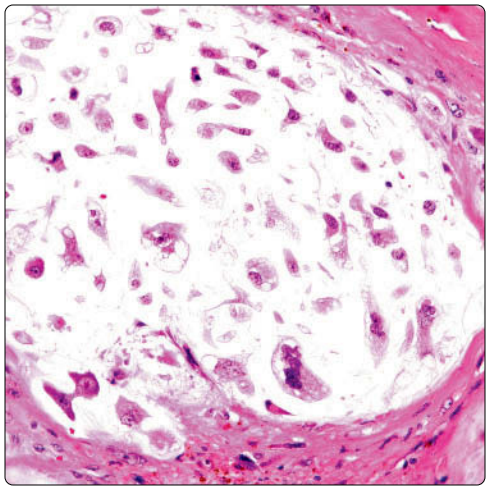

(Left) *Bronchial chondrosarcoma shows neoplastic cells embedded in a myxoid background. Even at this magnification, one can observe prominent nuclear atypia.* **(Right)** *High-power magnification shows prominent nuclear atypia and binucleated atypical cells.*

Solid Cellular Proliferation

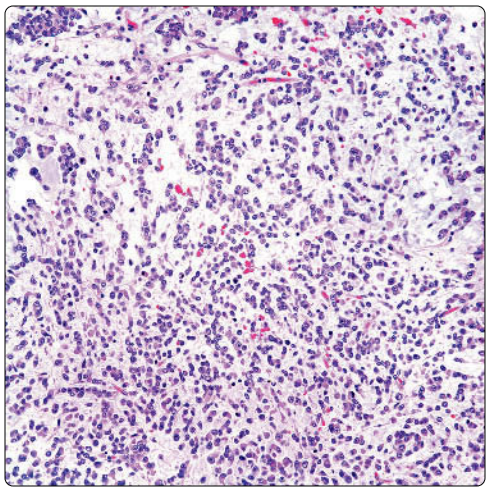

Scattered Mitosis

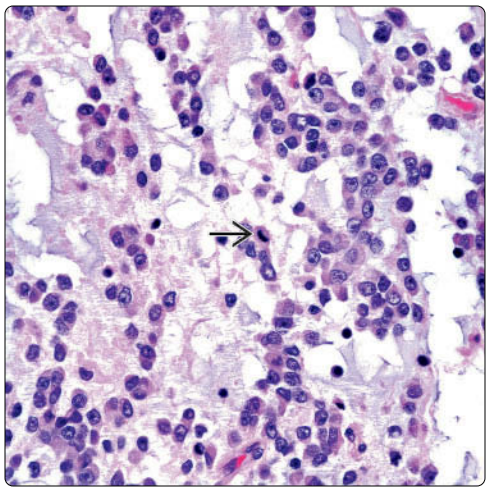

(Left) *Myxoid chondrosarcoma shows sheets of neoplastic cells without a particular growth pattern. This cellular proliferation can be easily confused for an epithelial neoplasm.* **(Right)** *High-power view of a primary myxoid chondrosarcoma of the lung shows a neoplastic cellular proliferation with more nuclear atypia and scattered mitotic figures.*

Focal Necrosis

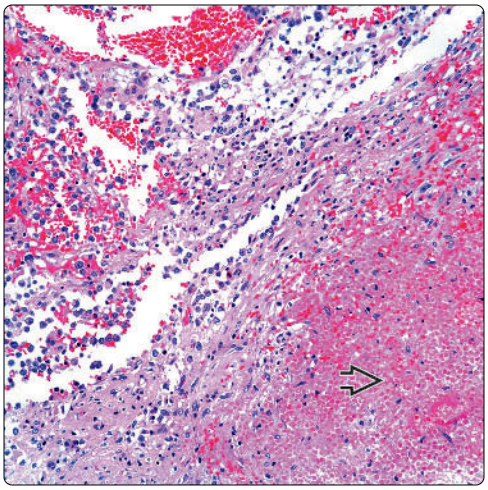

Bronchial Cartilage and Tumor

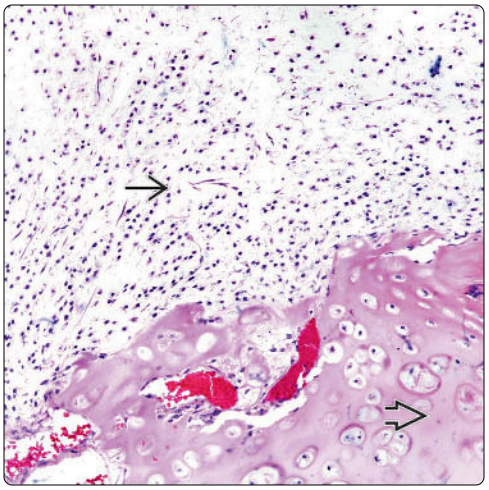

(Left) *Extensive areas of necrosis may be seen in unusual cases; however, necrosis is usually absent in low-grade tumors. Its presence usually indicates a high-grade tumor.* **(Right)** *Low-grade bronchial chondrosarcoma contrasts between the normal bronchial cartilage and the neoplastic cartilage.*

Prominent Nuclear Atypia

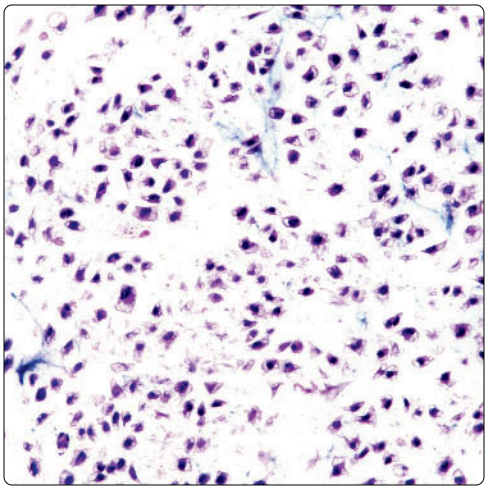

Solid Areas

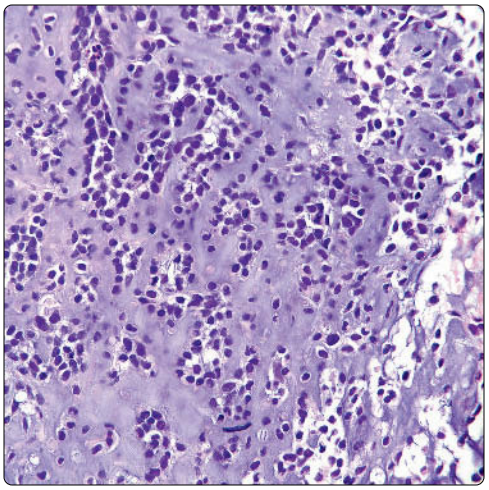

(Left) *High-power view of a low-grade chondrosarcoma shows an atypical cartilaginous proliferation; however, no mitotic activity is present.* **(Right)** *Low-power view of a primary pulmonary malignant neoplasm is composed of rather small cells embedded in a chondromyxoid background. These features are typical of mesenchymal chondrosarcoma. This pattern can be easily confused with a neuroendocrine carcinoma.*

Mitotic Activity

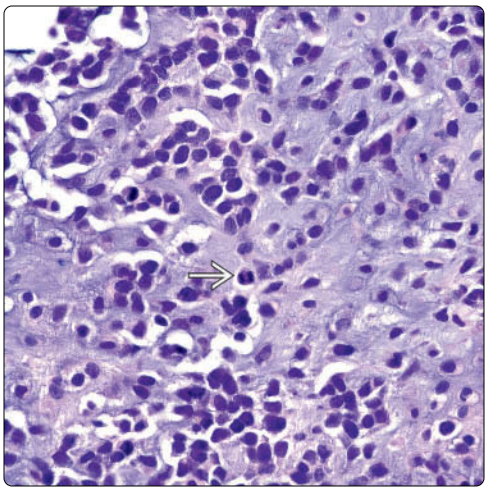

Positive Immunostain for SOX9

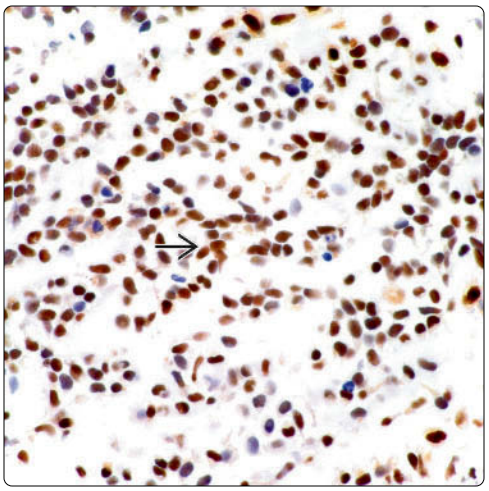

(Left) *High-power view of a primary mesenchymal chondrosarcoma of the lung shows a neoplastic cellular proliferation composed of small cells. Mitotic figures are easily identified.* **(Right)** *SOX9 immunostain in a mesenchymal chondrosarcoma of the lung shows strong nuclear staining in tumor cells. In cases with this type of morphology, the use of immunostains is important for proper classification of the tumor.*

Epithelioid Hemangioendothelioma

KEY FACTS

TERMINOLOGY

- Synonym: Intravascular bronchioloalveolar tumor

CLINICAL ISSUES

- Incidence
  - Unusual tumor in lung
  - Appears to be more common in young adults; age range: 7-72 years
  - More common in women
- Symptoms
  - Cough
  - Dyspnea
  - Pleuritic pain
  - Asymptomatic
- Presentation
  - Bilateral pulmonary infiltrates
- Treatment
  - There is no specific treatment

IMAGING

- Bilateral pulmonary nodules

ANCILLARY TESTS

- Presence of Weibel-Palade bodies by EM

TOP DIFFERENTIAL DIAGNOSES

- Angiosarcoma
  - Usually shows high mitotic count
  - May also show areas of necrosis
  - Shows more nuclear atypia
- Metastatic carcinoma
  - Shows positive staining for epithelial markers (keratins and EMA/MUC1)
  - Negative for vascular markers (FVIIIRAg, CD31, and CD34)
- Metastatic chordoma
  - Also negative for vascular markers (CD31, CD34)
  - Negative history of chordoma elsewhere

Panoramic View

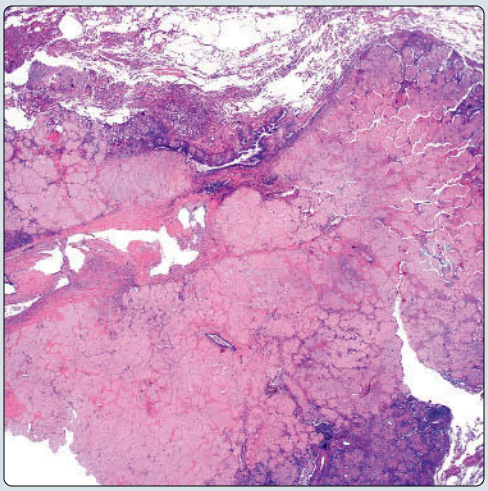

Myxohyaline Changes

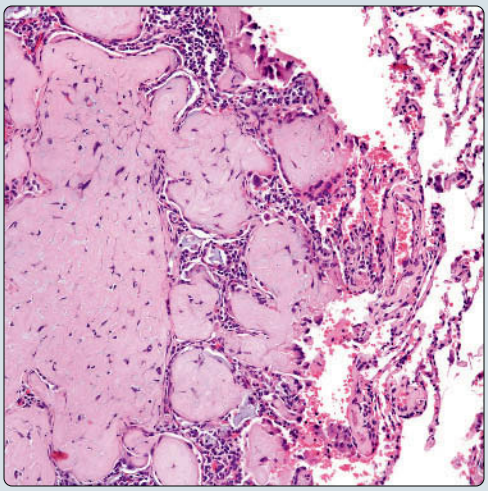

(Left) *Pulmonary epithelioid hemangioendothelioma (EH) shows an irregular tumor mass replacing normal lung parenchyma. Note the presence of extensive areas of hyalinization with more viable tumor cells in the periphery.* **(Right)** *Classic presentation of EH in the lung is shown. Note the presence of a nodule replacing the lung parenchyma and infiltrating the alveolar spaces.*

Myxohyaline Areas

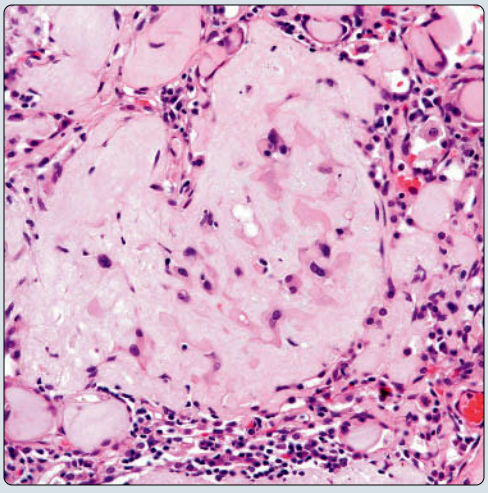

Viable Tumor Cells

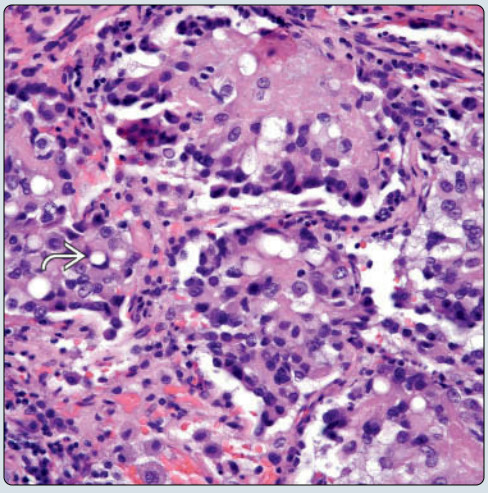

(Left) *High magnification of EH shows a chondromyxoid background with scattered epithelioid cells embedded in the stroma.* **(Right)** *Pulmonary EH shows a neoplastic cellular proliferation composed of medium-sized cells with round nuclei. Some cells have a subtle signet ring cell appearance.*

TERMINOLOGY

Synonyms

- Intravascular bronchioloalveolar tumor

Definitions

- Vascular neoplasm of low- to intermediate-grade malignancy

ETIOLOGY/PATHOGENESIS

Etiology

- Vascular origin from precursor mesenchymal cells

CLINICAL ISSUES

Epidemiology

- Incidence
  - Tumor is unusual in lung
- Age
  - Appears to be more common in young adults; however, age may range from 7-72 years
- Sex
  - F > M

Site

- Usually bilateral pulmonary infiltrates

Presentation

- Cough
- Shortness of breath
- Pleuritic pain
- Asymptomatic

Treatment

- There is no specific treatment
- Radiation and chemotherapy can be attempted
- Steroids have been tried

Prognosis

- Unpredictable
- Spontaneous regression can occur
- Protracted course may follow
- Aggressive course with fatal outcome may occur

IMAGING

General Features

- Bilateral pulmonary infiltrates

MACROSCOPIC

General Features

- Multiple nodules replacing normal lung parenchyma
- Nodules are soft or may be mucoid in consistency

Size

- Nodules may measure from few millimeters to 2-3 cm

MICROSCOPIC

Histologic Features

- Multiple pulmonary nodules
- Nodules in different phases of development
- Prominent chondromyxoid background
- Epithelioid cells embedded in chondromyxoid background
- Low mitotic count
- Signet ring cell-like cellular appearance
- Cluster of tumor cells in polypoid intraalveolar pattern
- Extravasated red cells

Predominant Pattern/Injury Type

- Chondromyxoid

Predominant Cell/Compartment Type

- Epithelioid

DIFFERENTIAL DIAGNOSIS

Angiosarcoma

- Usually shows high mitotic count
- May also show areas of necrosis
- Shows more nuclear atypia

Metastatic Carcinoma

- Shows positive staining for epithelial markers (keratins and EMA/MUC1)
- Negative for vascular markers (FVIIIRAg, CD31, and CD34)

Metastatic Chordoma

- Also negative for vascular markers (CD31, CD34)
- Negative history of chordoma elsewhere

DIAGNOSTIC CHECKLIST

Clinically Relevant Pathologic Features

- Gross appearance

Pathologic Interpretation Pearls

- Chondromyxoid background
- Multiple nodules
- Low mitotic count
- Positive staining for vascular markers

SELECTED REFERENCES

1. Lee SJ et al: Epithelioid hemangioendotheliomas with TFE3 gene translocations are compossible with CAMTA1 gene rearrangements. Oncotarget. 16;7(7):7480-8, 2016
2. Doyle LA et al: Nuclear expression of CAMTA1 distinguishes epithelioid hemangioendothelioma from histologic mimics. Am J Surg Pathol. 40(1):94-102, 2015
3. Puls F et al: YAP1-TFE3 epithelioid hemangioendothelioma: a case without vasoformation and a new transcript variant. Virchows Arch. 466(4):473-8, 2015
4. Shibuya R et al: CAMTA1 is a useful immunohistochemical marker for diagnosing epithelioid hemangioendothelioma. Histopathology. 67(6):827-35, 2015
5. Flucke U et al: Epithelioid hemangioendothelioma: clinicopathologic, immunhistochemical, and molecular genetic analysis of 39 cases. Diagn Pathol. 9:131, 2014
6. Sardaro A et al: Epithelioid hemangioendothelioma: an overview and update on a rare vascular tumor. Oncol Rev. 8(2):259, 2014
7. Białas M et al: Immunohistochemical investigation of selected endothelial markers in pulmonary epithelioid haemangioendothelioma. Pol J Pathol. 62(4):236-40, 2011
8. Weissferdt A et al: Primary vascular tumors of the lungs: a review. Ann Diagn Pathol. 14(4):296-308, 2010
9. Schwartz A et al: [Sclerosing intravascular bronchiolo-alveolar tumor.] Rev Mal Respir. 9(2):219-22, 1992
10. Yousem SA et al: Unusual thoracic manifestations of epithelioid hemangioendothelioma. Arch Pathol Lab Med. 111(5):459-63, 1987
11. Weiss SW et al: Epithelioid hemangioendothelioma and related lesions. Semin Diagn Pathol. 3(4):259-87, 1986

Immunohistochemistry

Antibody	Reactivity	Staining Pattern	Comment
CD31	Positive	Cytoplasmic	
CD34	Positive	Cytoplasmic	
FVIIIRAg	Positive	Cytoplasmic	
	Positive	Cytoplasmic	CD105
D2-40	Positive	Cytoplasmic	In some cases
ERG	Positive	Cytoplasmic	In some cases
Vimentin	Positive	Cytoplasmic	
FLI-1	Positive	Cytoplasmic	In some cases
TFE3	Positive	Cytoplasmic	In some cases
ERP	Positive	Nuclear	In some cases only
PRP	Positive	Nuclear	In some cases only
CK-PAN	Negative	Cytoplasmic	Can be positive in many cases
CK5/6	Negative		
EMA	Negative		May be focally positive in some cases
pax-8	Negative		
GATA3	Negative		
S100	Negative		
CD99	Negative		

Molecular Features

FISH/RT-PCR	Result
Reciprocal translocation t(1;3)(p36;q25)	Positive
::75 -&07 fusion gene	Positive
<$3 -7)(fusion gene	Positive

Ultrastructural Studies

Electron Microscopy	Results
Weibel-Palade bodies	Present

Histochemical Features

Stain	Result
PAS	Negative
PAS-D	Negative
Mucicarmine	Negative

12. Dail DH et al: Intravascular, bronchiolar, and alveolar tumor of the lung (IVBAT). An analysis of twenty cases of a peculiar sclerosing endothelial tumor. Cancer. 51(3):452-64, 1983
13. Bhagavan BS et al: Intravascular bronchiolo-alveolar tumor (IVBAT): a low-grade sclerosing epithelioid angiosarcoma of lung. Am J Surg Pathol. 6(1):41-52, 1982
14. Weiss SW et al: Epithelioid hemangioendothelioma: a vascular tumor often mistaken for a carcinoma. Cancer. 50(5):970-81, 1982
15. Weldon-Linne CM et al: Angiogenic nature of the "intravascular bronchioloalveolar tumor" of the lung: an electron microscopic study. Arch Pathol Lab Med. 105(4):174-9, 1981
16. Corrin B et al: Histogenesis of the so-called "intravascular bronchioloalveolar tumour". J Pathol. 128(3):163-7, 1979

Chondromyxoid and Cellular Component

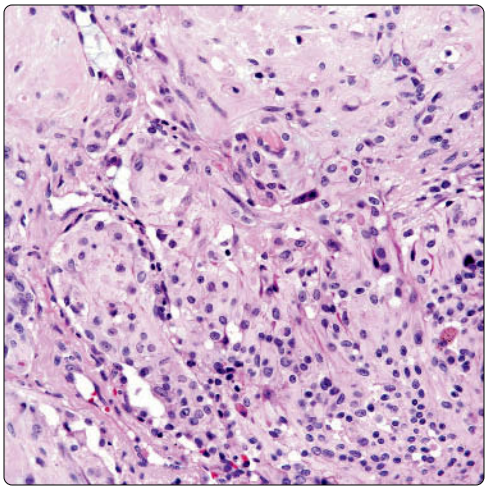

Nodules of Chondromyxoid Component

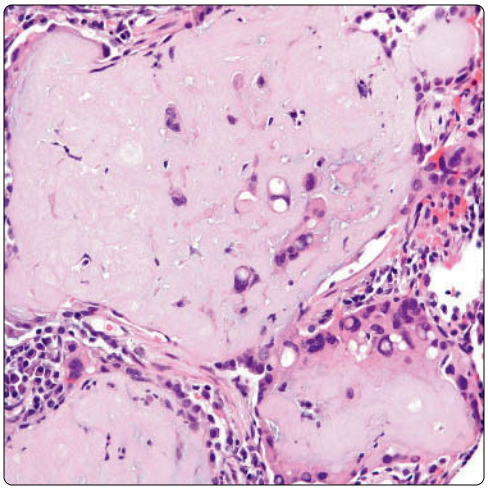

(Left) *This EH shows more cellular areas in which the chondromyxoid background is not that apparent. This growth pattern may be seen in other nonvascular tumors of the lung.* **(Right)** *High-power view of EH of the lung shows clusters of epithelioid cells embedded in a hyalinized acellular stroma. The epithelioid cells do not show nuclear atypia or mitotic activity.*

Intraalveolar Myxohyaline Nodule

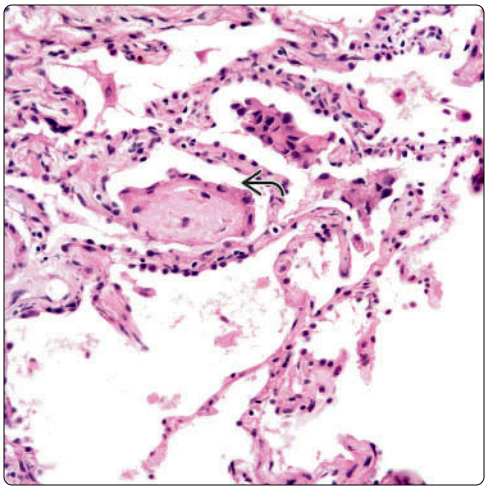

Entrapped Airway

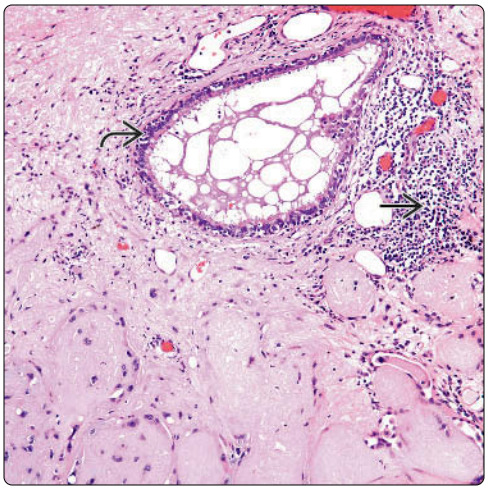

(Left) *EH of the lung shows a polypoid tumor nodule filling an alveolar space. This histological feature gave rise to the initial interpretation of EH as an intravascular bronchioloalveolar tumor.* **(Right)** *EH of the lung shows extensive hyalinized areas with low cellularity. In addition, there is an entrapped epithelial structure, which may suggest a biphasic neoplasm. Note the adjacent inflammatory infiltrate.*

Focal Papillary Structures

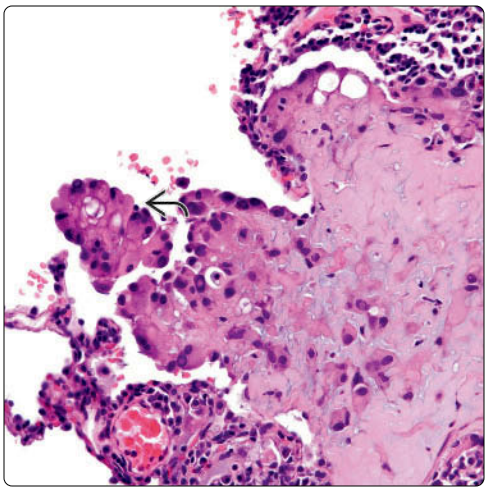

Cellular Atypia

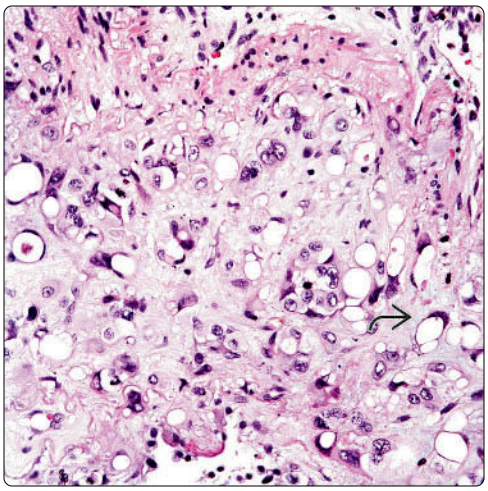

(Left) *In some areas, EH may appear as forming papillary structures as illustrated in this case. However, note the chondromyxoid background that is characteristic of EH.* **(Right)** *This EH shows more cellular areas, and some of the cells resemble signet ring cells. Thus, this tumor may easily be confused for a true epithelial malignancy.*

Rhabdoid Features

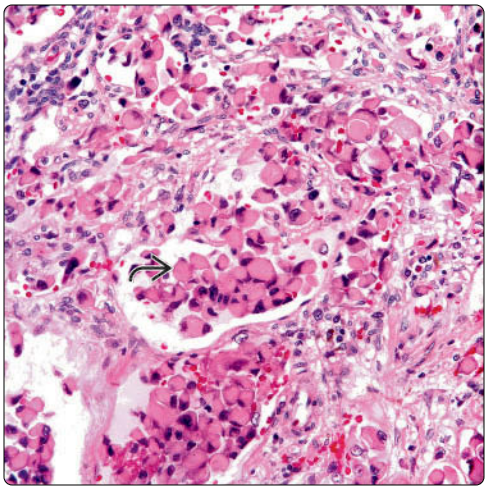

Extravasated Red Cells

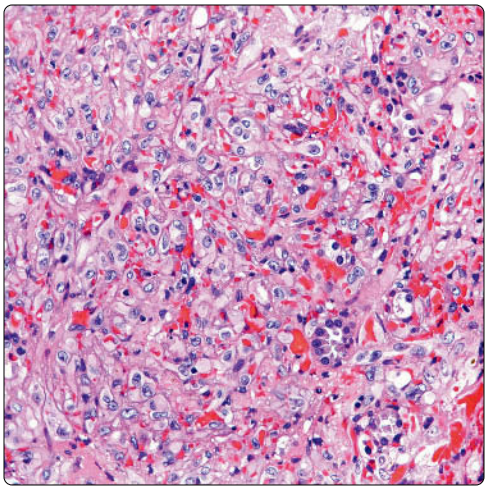

(Left) *EH of the lung shows cells with features of rhabdoid cells. This histologic feature may be easily confused for a metastatic sarcoma or carcinoma of the lung.* **(Right)** *EH of the lung is shown predominantly composed of spindle cells and extravasated red cells. Note the solid growth pattern and the absence of hyalinized areas.*

Inflammatory Areas

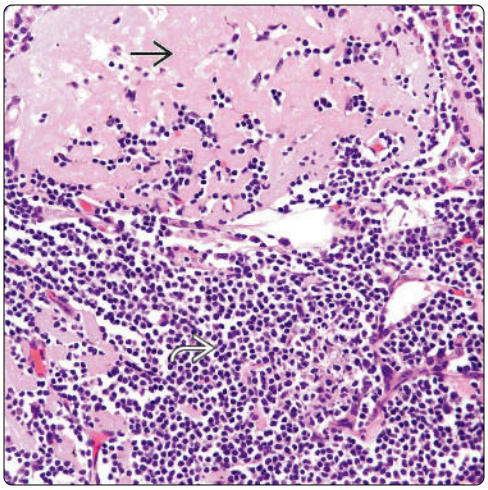

Plasma Cells and Acellular Material

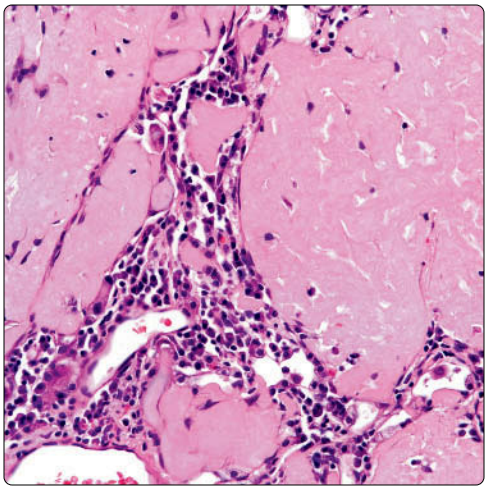

(Left) *High-power view shows a prominent hyalinized area in an EH of the lung. In addition, an inflammatory infiltrate is also present. This feature may also be confused with cases of amyloid deposition in the lung.* **(Right)** *High magnification shows the presence of plasma cells adjacent to areas of markedly amorphous material closely mimicking amyloid deposition.*

Cholesterol Cleft Granulomas

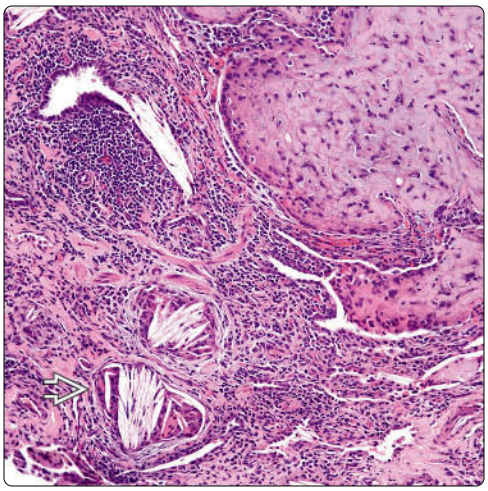

Pseudoglandular Structures

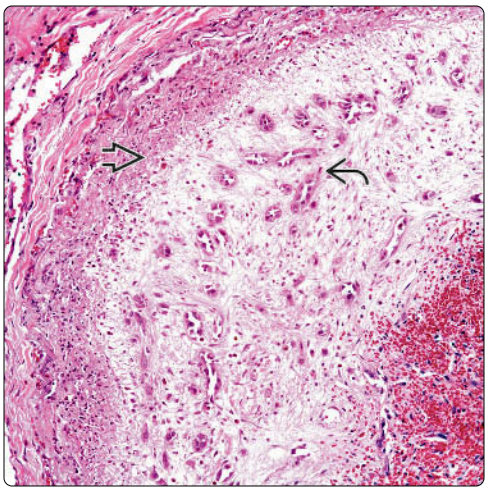

(Left) *The inflammatory changes present in EH of the lung may include cholesterol cleft granulomas and chronic inflammatory cells, namely plasma cells.* **(Right)** *In some unusual cases, EH may involve pulmonary vessels. The cellular proliferation is actually forming gland-like structures that may be confused with an adenocarcinoma.*

Multinodular Disease

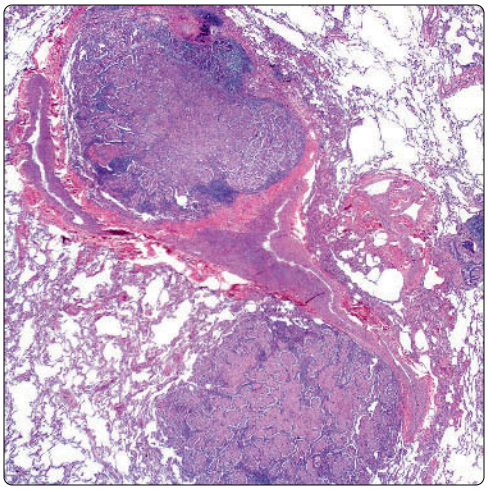

Inflammatory Reaction

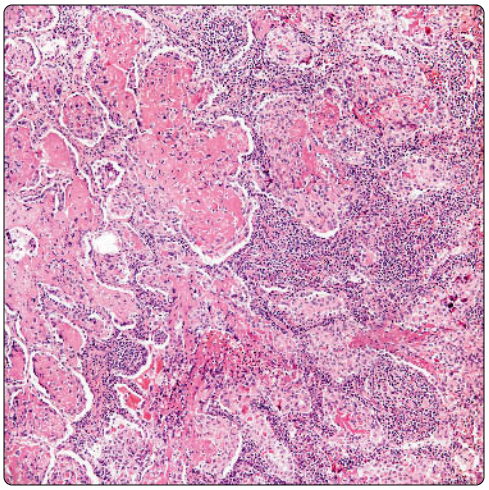

(Left) *Pulmonary EH shows 2 independent tumor nodules of almost similar size. EH in the lung commonly presents with multiple bilateral pulmonary nodules.* **(Right)** *Low-power view shows a pulmonary EH in which the tumor may be easily mistaken for an inflammatory reaction as the intraalveolar neoplasm can be misconstrued as fibrinous exudate. Note the presence of adjacent inflammatory reaction.*

Extensive Hyalinization

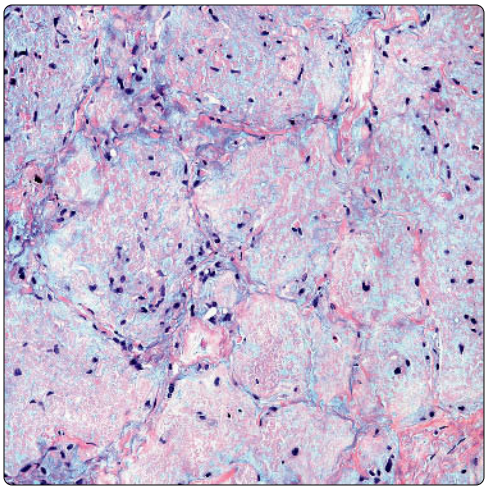

Calcification

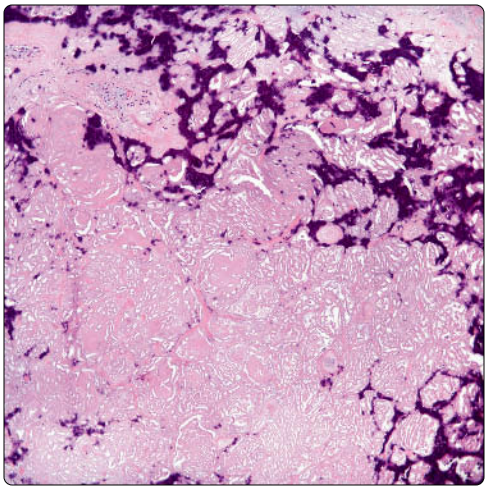

(Left) *Pulmonary EH shows extensive areas of hyalinization in which it is difficult to discriminate tumor cells. There are still a few neoplastic cells embedded in this stroma.* **(Right)** *In some cases of pulmonary EH, in addition to the areas of extensive hyalinization, the nodules may show fibrosis and calcification with little or negative presence of viable tumor cells.*

Immunostain for CD31

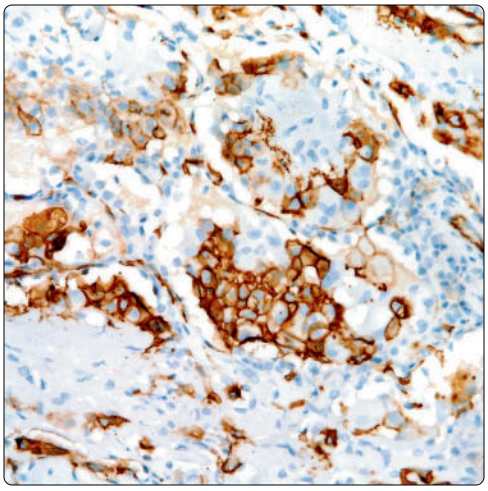

Immunostain for Keratin

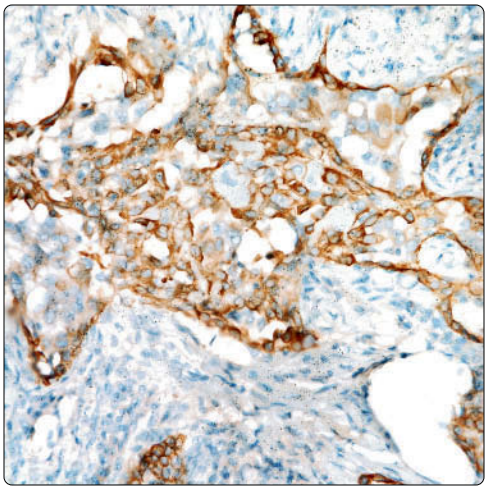

(Left) *Pulmonary EH shows positive staining for CD31. This immunostain is helpful in cases in which the histology may not be the classic one.* **(Right)** *In some cases of pulmonary EH, keratin staining may show a focal positive reaction in tumor cells. Thus, there is a need to be suspicious and add other vascular markers to the panel.*

Angiosarcoma

KEY FACTS

TERMINOLOGY

- Hemangiosarcoma

CLINICAL ISSUES

- Symptomatology
  - Shortness of breath
  - Hemoptysis
  - Frank pulmonary hemorrhage
- Epidemiology
  - Rare tumor
  - Accounts for < 1% of all primary tumors of lung

MACROSCOPIC

- Single or multiple pulmonary nodules
- Hemorrhagic nodule(s)

MICROSCOPIC

- Epithelioid malignant cells forming vascular channels
- Walls of vessels lined with hobnail-like cells
- Mitotic figures are common
- Areas of hemorrhage
- Areas of necrosis

TOP DIFFERENTIAL DIAGNOSES

- Epithelioid hemangioendothelioma
  - Lacks increased mitotic activity
  - Extensive areas of necrosis are not a feature
  - Characteristically shows chondromyxoid background
  - Shares similar immunophenotype with angiosarcoma
- Carcinoma
  - Will show negative staining with vascular markers and positive for epithelial markers
- Metastatic angiosarcoma
  - Clinical history is most important feature
  - Primary and metastatic angiosarcoma may share similar presentation

(Left) *Primary angiosarcoma of the lung shows a spindle cell proliferation ⇨ replacing lung parenchyma. One is still able to observe extravasated red cells.* **(Right)** *High-power view of a pulmonary angiosarcoma shows prominent nuclear atypia and increased mitotic activity ⇨.*

Spindle Cell Proliferation

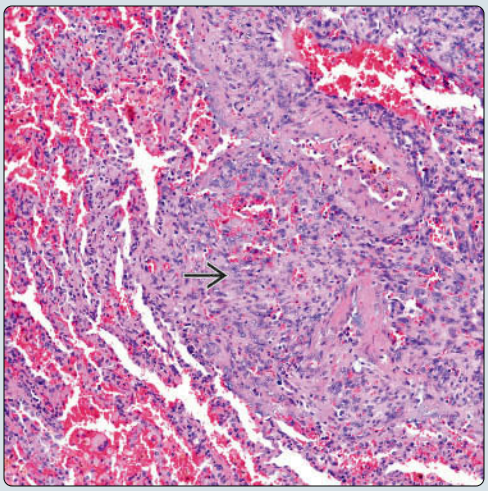

Mitotic Activity

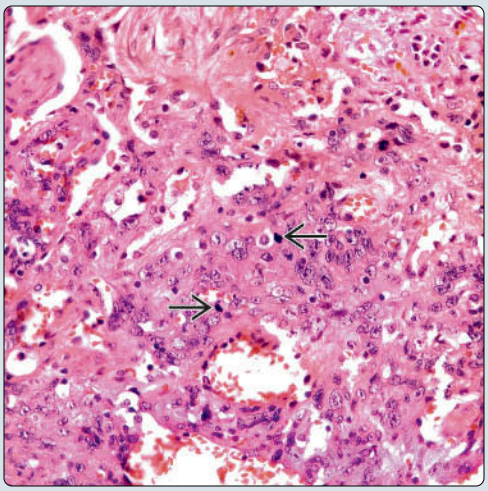

(Left) *Pulmonary angiosarcoma shows an epithelioid malignant cell proliferation around a vascular structure. Note the presence of an inflammatory response in addition to the presence of extravasated red cells.* **(Right)** *Pulmonary angiosarcoma shows mixed spindle and epithelioid cell proliferation accompanied by extravasated red cells.*

Inflammatory Response

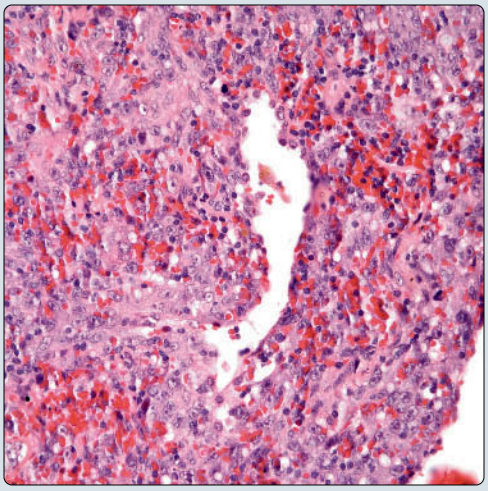

Extravasated Red Cells

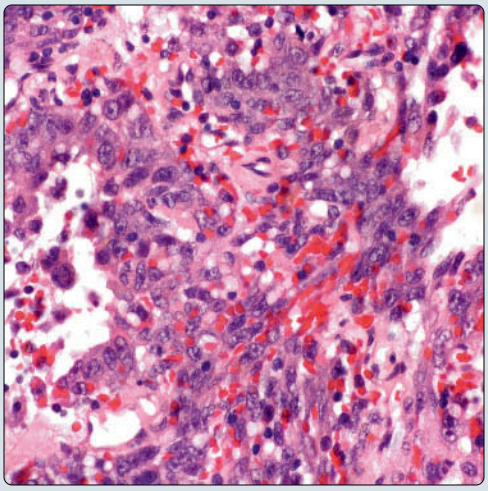

TERMINOLOGY

Synonyms

- Hemangiosarcoma

Definitions

- Malignant vascular neoplasm

ETIOLOGY/PATHOGENESIS

Environmental Exposure

- Some cases have been linked to radiation, others to farming

CLINICAL ISSUES

Epidemiology

- Incidence
  - Estimated to account < 1% of all lung tumors
- Age
  - All age groups
- Sex
  - No predilection

Presentation

- Shortness of breath
- Hemoptysis
- Pulmonary hemorrhage
- Chest pain

Treatment

- Surgical approaches
  - Lobectomy
  - Chemotherapy
  - Radiation

Prognosis

- Poor
- Widespread metastasis

MACROSCOPIC

General Features

- Single or multiple pulmonary nodules
- Ill-defined tumor nodule
- Hemorrhagic tumor nodule

Size

- Varies from 1 to > 5 cm in diameter

MICROSCOPIC

Histologic Features

- Epithelioid malignant cells forming vascular channels
- Walls of vessels lined with hobnail-like cells
- Mitotic figures are common
- Spindle cell component
- Areas of hemorrhage
- Areas of necrosis

Predominant Pattern/Injury Type

- Hemorrhagic

Predominant Cell/Compartment Type

- Epithelioid

DIFFERENTIAL DIAGNOSIS

Epithelioid Hemangioendothelioma

- Does not show increased mitotic activity
- Extensive areas of necrosis are not a component
- Characteristically shows chondromyxoid background
- Shares similar immunophenotype with angiosarcoma

Carcinoma

- Shows negative staining with vascular markers and positive staining for epithelial markers

Metastatic Angiosarcoma

- Clinical history is most important feature
- Primary and metastatic angiosarcoma may share similar presentation

DIAGNOSTIC CHECKLIST

Clinically Relevant Pathologic Features

- Gross appearance

Pathologic Interpretation Pearls

- Epithelioid or spindle cell neoplasm with vascular differentiation

SELECTED REFERENCES

1. Tanaka H et al: Primary pulmonary angiosarcoma: a case report. Pathol Int. 65(10):554-7, 2015
2. Wilson R et al: Complete radiographic response of primary pulmonary angiosarcomas following gemcitabine and taxotere. Lung Cancer. 61(1):131-6, 2008
3. Herrak L et al: [Primary pulmonary angiosarcoma.] Rev Mal Respir. 24(1):73-6, 2007
4. Saint-Blancard P et al: [Three-year survival after treatment of a primary pulmonary angiosarcoma.] Rev Pneumol Clin. 63(1):55-8, 2007

Immunohistochemistry

Antibody	Reactivity	Staining Pattern	Comment
CD31	Positive	Cytoplasmic	In vascular component
CD34	Positive	Cytoplasmic	In vascular component
ULEX-1	Positive	Cytoplasmic	In vascular component
FVIIIRAg	Positive	Cytoplasmic	
CK-PAN	Negative	Cytoplasmic	May be positive in rare cases

Papillary-Like Pattern

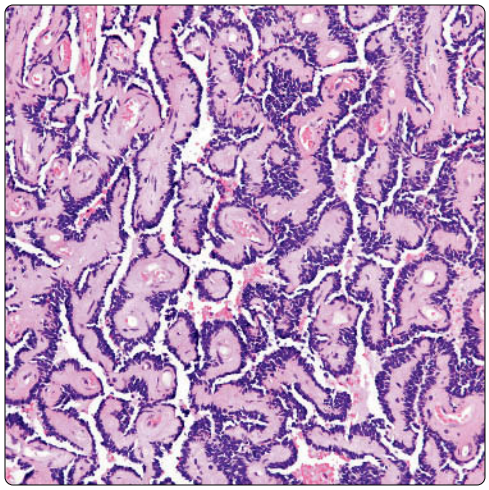

Hyalinized Papillary-Like Structures

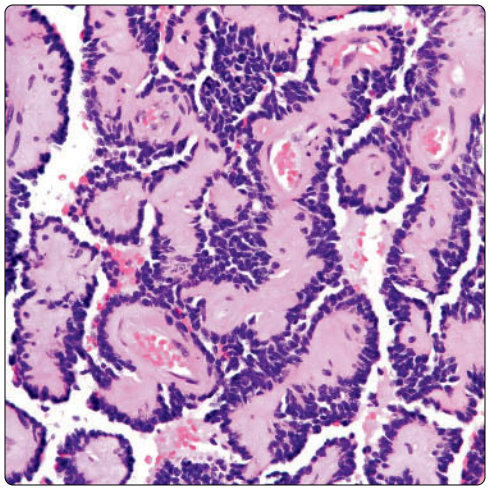

(Left) *Pulmonary angiosarcoma with prominent papillary-like architecture is an unusual feature and can be confused with other more common primary lung tumors.* **(Right)** *High magnification shows papillary-like structures lined by a neoplastic cellular proliferation composed of rather small cells. Mitotic activity is not prominent.*

Vascular Involvement

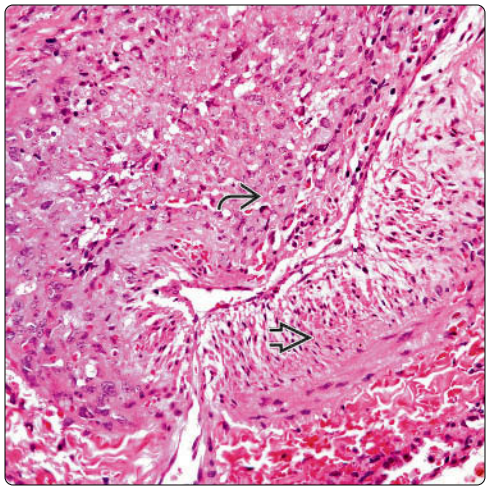

Dilated Vascular Spaces

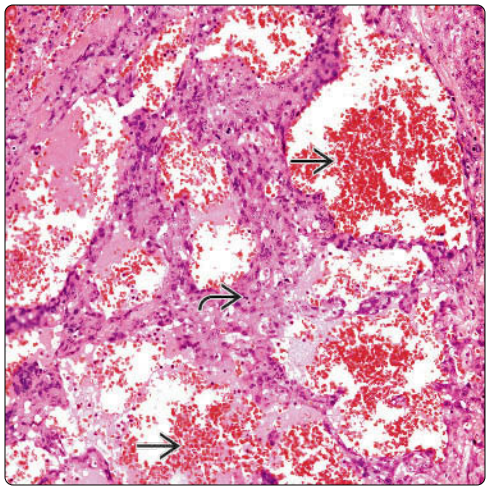

(Left) *Angiosarcoma is seen involving a large pulmonary vessel. Although unusual, such a feature may aid in the diagnosis of angiosarcoma.* **(Right)** *Low-power view of a pulmonary angiosarcoma shows the classic pattern of dilated vascular spaces replaced by tumoral cells mixed with fresh blood.*

Vascular Proliferation

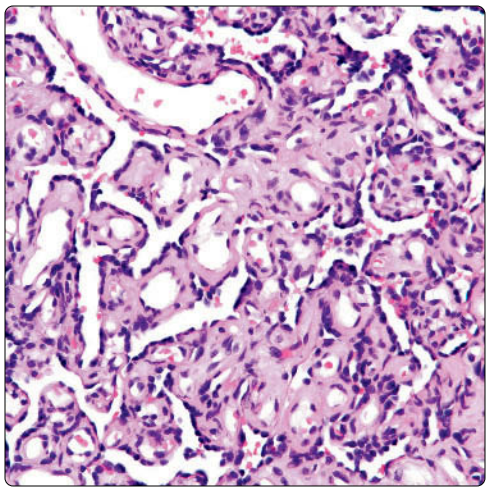

Solid Pattern

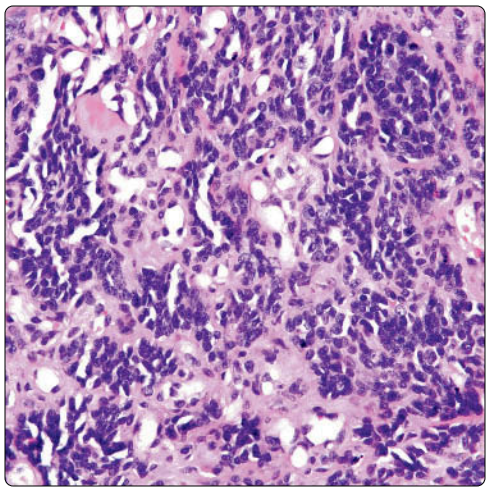

(Left) *More conventional areas of angiosarcoma show the typical vascular proliferation with flattened endothelial cells. Marked nuclear atypia and mitotic activity are not present.* **(Right)** *Angiosarcoma with solid areas is a histological feature that may be confused for an epithelial tumor, namely, a neuroendocrine carcinoma.*

Single-Cell Necrosis

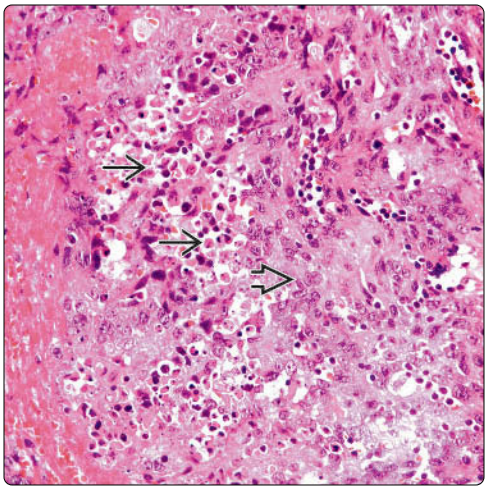

Vasoformative Areas

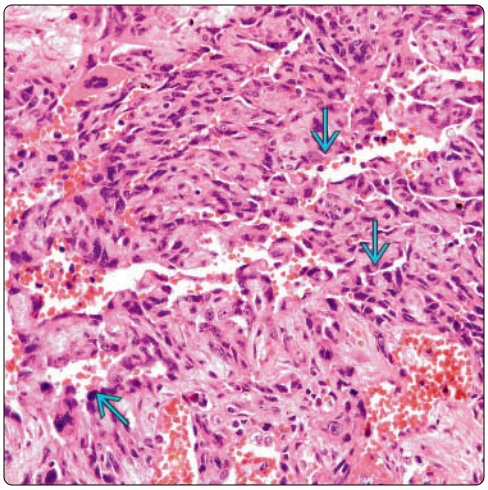

(Left) *Pulmonary angiosarcoma shows single-cell necrosis and solid areas composed of oval, medium-sized cells. Similar features may be seen in high-grade carcinomas of the lung. The vascular nature of the tumor is not apparent in this growth pattern.* **(Right)** *Pulmonary angiosarcoma shows vasoformative areas and prominent nuclear atypia. The presence of vasoformative areas should alert one to the possibility of angiosarcoma. Vascular markers should be helpful.*

Spindle Cell Features

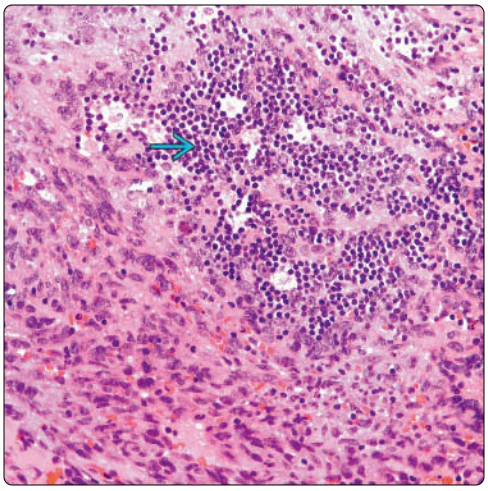

Focal Myxoid Change

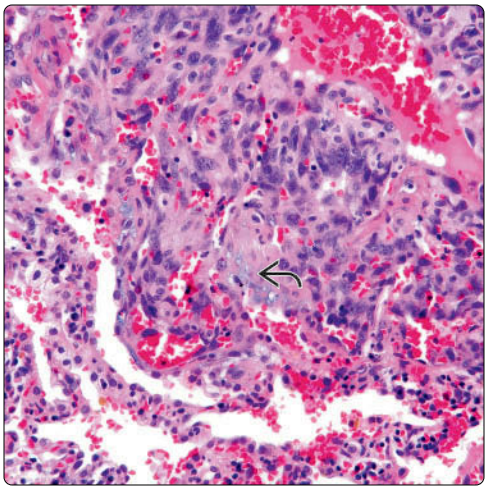

(Left) *H&E shows pulmonary angiosarcoma with prominent spindle cell features and focal areas of inflammatory infiltrate. The presence of inflammatory changes associated with angiosarcoma is not common, except in areas of necrosis.* **(Right)** *This angiosarcoma is composed of spindle cells with only focal areas that show some myxoid change, which may raise the possibility of hemangioendothelioma.*

Mitotic Activity

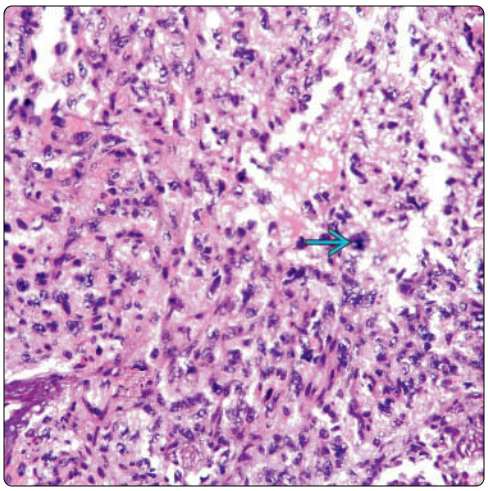

Positive Staining in Tumor Cells for CD31

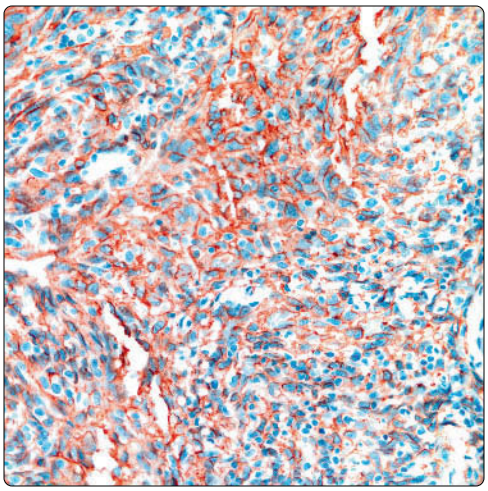

(Left) *High-power view of a pulmonary angiosarcoma shows prominent nuclear atypia and atypical mitotic figures. These features are more in keeping with a high-grade angiosarcoma.* **(Right)** *CD31 immunohistochemical stain shows positive staining in tumor cells in a pulmonary angiosarcoma. The use of immunohistochemical vascular markers is important in excluding other primary epithelial or mesenchymal tumors of the lung.*

Kaposi Sarcoma

KEY FACTS

ETIOLOGY/PATHOGENESIS

- Commonly associated with HIV infection in patients with AIDS
- Associated with human herpesvirus 8 (HHV-8) infection

CLINICAL ISSUES

- High incidence in homosexual men and intravenous drug abusers with AIDS
- May also affect immunosuppressed patients and transplant patients
- Cough, dyspnea, hemoptysis
- Poor prognosis; most patients die within 2 years of diagnosis

IMAGING

- Bilateral interstitial infiltrates with ill-defined nodularity
- Discrete, localized intraparenchymatous mass that may be associated with bronchus

MICROSCOPIC

- Monotonous spindle cell proliferation with fascicular growth pattern intersecting at right angles
- Frequent anastomosing and slit-like vascular spaces containing abundant extravasated red blood cells
- Spindle cells show mild to moderate cytologic atypia
- Cell nuclei are hyperchromatic and may show occasional small nucleoli
- Scattered mitoses are commonly present
- Dense extracellular hyaline globules may be seen scattered in interstitium
- Spindle cell population may be admixed with inflammatory cell elements, including small lymphocytes, plasma cells, and histiocytes

ANCILLARY TESTS

- Spindle tumor cells are positive for CD34 and CD31
- Tumor cells show strong nuclear positivity for HHV8

Kaposi Sarcoma of Lung

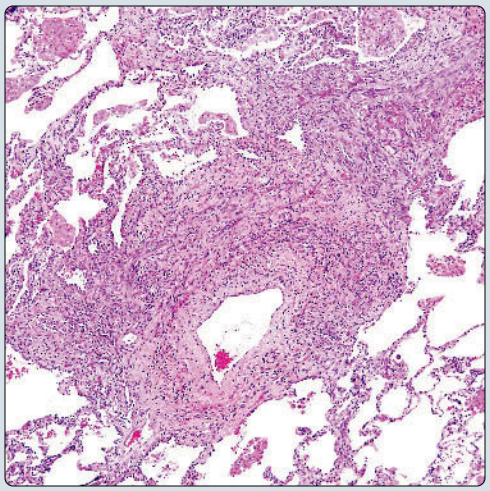

Peribronchial Distribution

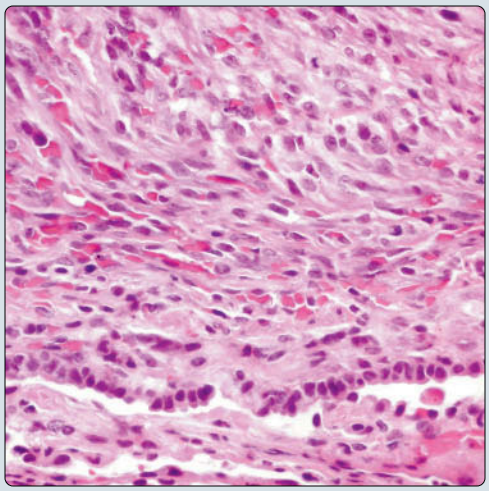

(Left) *Scanning magnification in pulmonary involvement by Kaposi sarcoma shows characteristic perivascular distribution of the atypical spindle cell proliferation extending into adjoining alveolar septa.* **(Right)** *Higher magnification in pulmonary involvement by Kaposi sarcoma shows the lumen of an airspace ➡ surrounded by a dense atypical spindle cell proliferation.*

Spindle Cell Proliferation

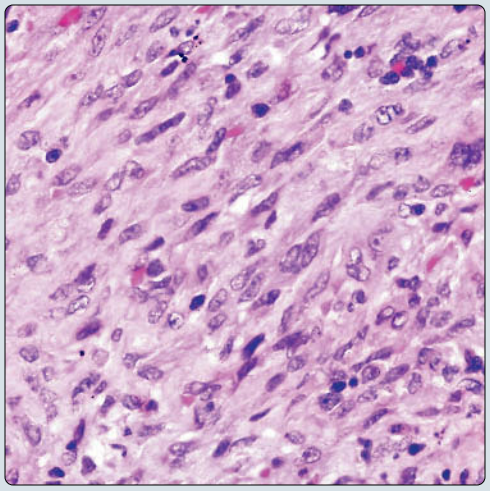

HHV8 Immunostaining

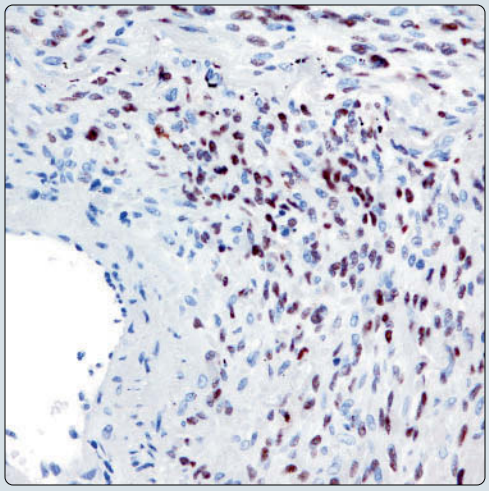

(Left) *Higher magnification of pulmonary Kaposi sarcoma shows dense, atypical spindle cell proliferation admixed with a few scattered inflammatory cells. Notice the scattered red blood cells in the interstitium.* **(Right)** *An immunohistochemical stain for HHV8 shows strong nuclear positivity of the tumor cells in pulmonary involvement by Kaposi sarcoma for this antigen.*

TERMINOLOGY

Definitions

- Low-grade spindle cell sarcoma derived from vascular endothelial cells

ETIOLOGY/PATHOGENESIS

Pathogenesis

- Commonly associated with HIV infection in patients with AIDS
- Associated with human herpesvirus 8 (HHV-8) infection

CLINICAL ISSUES

Epidemiology

- Incidence
  - High incidence in homosexual men and intravenous drug abusers with AIDS
  - May also affect immunosuppressed patients and transplant patients
- Age
  - 20-40 years of age

Presentation

- Cough, dyspnea, hemoptysis

Prognosis

- Poor prognosis; most patients die within 2 years of diagnosis
- Median survival is slightly better for responders to chemotherapy

IMAGING

General Features

- Bilateral interstitial infiltrates with ill-defined nodularity
- Discrete, localized intraparenchymatous mass that may be associated with bronchus
- Mediastinal lymphadenopathy

MICROSCOPIC

Histologic Features

- Lesions follow intrapulmonary fibrous septa with perivascular and peribronchial distribution
- Monotonous spindle cell proliferation with fascicular growth pattern intersecting at right angles
- Frequent slit-like vascular spaces containing abundant extravasated red blood cells

Cytologic Features

- Spindle cells show mild to moderate cytologic atypia
- Cell nuclei are hyperchromatic and may show occasional small nucleoli
- Scattered mitoses are commonly present
- Dense extracellular hyaline globules may be seen scattered in interstitium
- Spindle cell population may be admixed with inflammatory cell elements, including small lymphocytes, plasma cells, and histiocytes

ANCILLARY TESTS

Immunohistochemistry

- Spindle tumor cells are positive for CD34 and CD31
- Tumor cells show strong nuclear positivity for HHV8 antibody

DIFFERENTIAL DIAGNOSIS

Leiomyosarcoma

- Fascicular spindle cell proliferation of cells displaying blunt ends and intracytoplasmic vacuoles
- Commonly present as large intraparenchymatous tumors rather than as multiple small nodules
- Tumor cells are negative for vascular markers and show strong positivity for muscle markers (desmin, actin, h-caldesmon, calponin, etc.)
- Spindle cells contain abundant cytoplasmic microfilaments with focal densities on electron microscopy

Fibrosarcoma

- Fascicular spindle cell proliferation with prominent stromal sclerosis
- Commonly presents as large intraparenchymatous tumor rather than as multiple small nodules
- Tumor cells are negative for vascular markers (CD31, CD34) and only stain positive for vimentin

Synovial Sarcoma

- Fascicular spindle cell proliferation composed of monotonous atypical spindle cells with scant stroma
- May show prominent hemangiopericytic growth pattern but lacks abundance of anastomosing small vessels and extravasated red blood cells
- Commonly presents as large intraparenchymatous tumor rather than as multiple small nodules
- Tumor cells are positive for cytokeratin, EMA, Bcl-2, and CD99; negative for vascular markers (CD31, CD34)

DIAGNOSTIC CHECKLIST

Clinically Relevant Pathologic Features

- Multifocality and bilaterality of lesions with interstitial pattern of distribution in HIV(+) patients

Pathologic Interpretation Pearls

- Ill-defined nodular lesions composed of spindle cell fascicles with abundant extravasated red blood cells
- Presence of scattered hyalin globules admixed with spindle cells

SELECTED REFERENCES

1. Epelbaum O et al: Pulmonary Kaposi's sarcoma and its complications in the HAART era: a contemporary case-based review. Lung. 194(1):163-9, 2016
2. Sigel K et al: Lung malignancies in HIV infection. Semin Respir Crit Care Med. 37(2):267-76, 2016
3. Hoskote SS et al: Pulmonary Kaposi sarcoma in AIDS. Mayo Clin Proc. 87(10):e77, 2012
4. Weissferdt A et al: Primary vascular tumors of the lungs: a review. Ann Diagn Pathol. 14(4):296-308, 2010
5. Garay SM et al: Pulmonary manifestations of Kaposi's sarcoma. 1987. Chest. 136(5 Suppl):e30, 2009

Pulmonary Kaposi Sarcoma

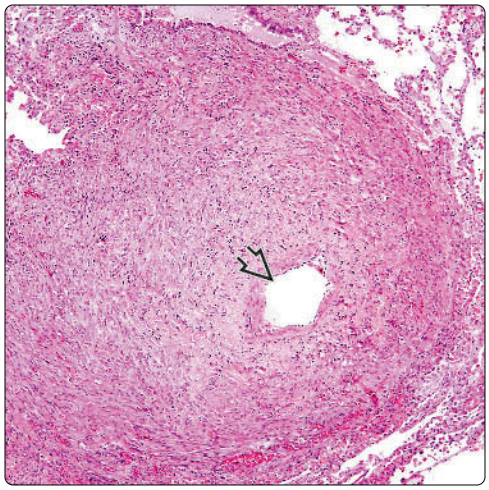

Perivascular Cuffing of Spindle Cells

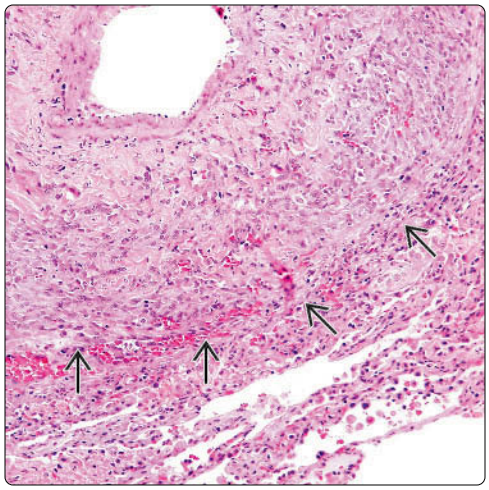

(Left) *Scanning magnification of a pulmonary lesion in Kaposi sarcoma shows perivascular distribution of the process. There is a dense spindle cell proliferation concentrically surrounding the entire wall of a small-caliber vessel.* **(Right)** *Higher magnification of a pulmonary lesion in Kaposi sarcoma shows dense perivascular spindle cell proliferation that is sharply circumscribed and separated from the surrounding uninvolved lung parenchyma.*

Solid Spindle Cell Proliferation

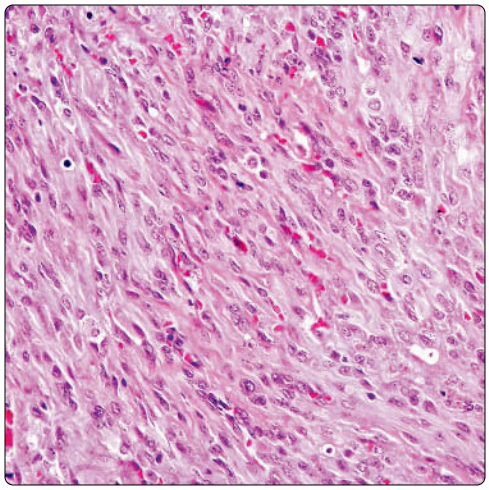

Peribronchial Distribution

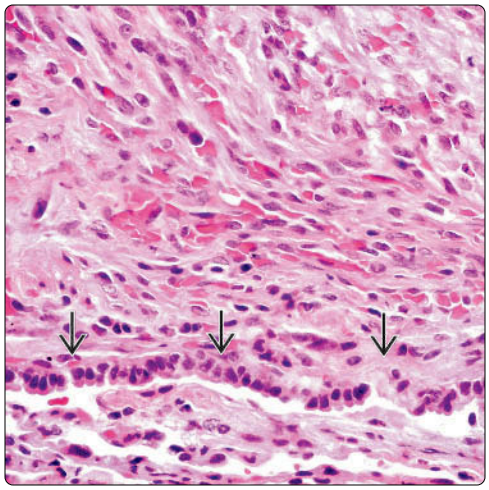

(Left) *Pulmonary lesion in Kaposi sarcoma shows fascicles of spindle cells containing a few scattered mitotic figures. There are numerous extravasated red blood cells scattered in the interstitium. The presence of these extravasated red blood cells should raise the possibility of Kaposi sarcoma in the differential diagnosis.* **(Right)** *Higher magnification of a pulmonary lesion in Kaposi sarcoma shows spindle cell proliferation abutting the wall of a bronchiole.*

Atypical Cells: High Power

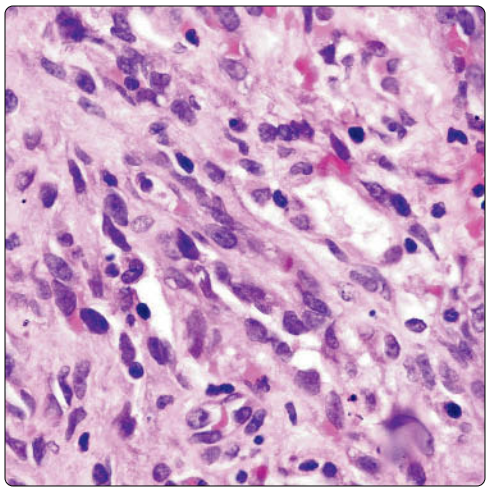

Mitotic Activity

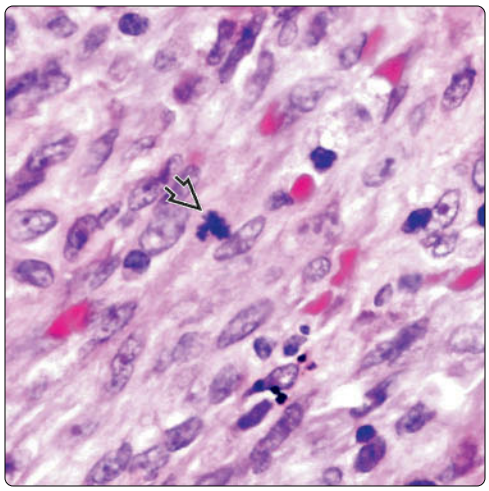

(Left) *High magnification of a pulmonary lesion in Kaposi sarcoma shows atypical spindle cell proliferation surrounding ectatic vascular spaces and vascular slits. The cells show scattered mitoses and occasional scattered extravasated red blood cells.* **(Right)** *High magnification in a pulmonary lesion of Kaposi sarcoma shows spindle cell proliferation displaying mild cytologic atypia with scattered nuclear chromatin and small eosinophilic nucleoli. Notice the single mitotic figure.*

Perivascular Distribution of Spindle Cells

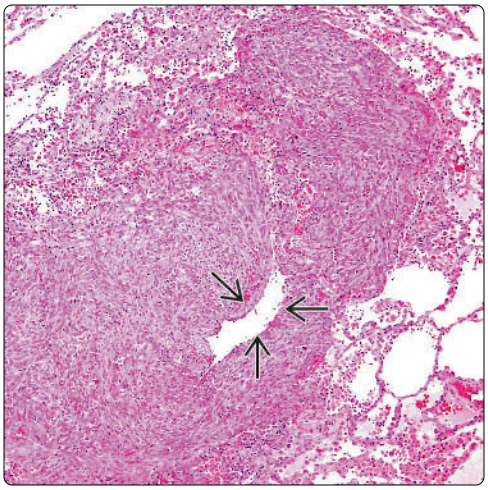

Pulmonary Lesion: Higher Magnification

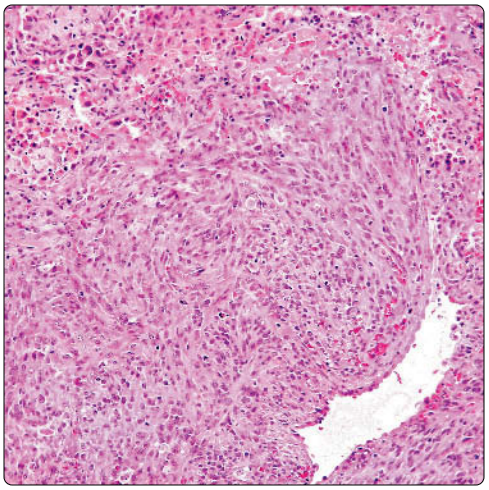

(Left) *Scanning magnification of a pulmonary lesion in Kaposi sarcoma shows perivascular proliferation forming a well-defined tumor nodule replacing the lung parenchyma. Notice the small dilated vessel ⇨ in the center of the nodule.* **(Right)** *Higher magnification of a pulmonary lesion in Kaposi sarcoma shows dense perivascular cellular proliferation composed of fascicles of spindle cells with minimal cytologic atypia that intersect at 90° angles.*

Dense Spindle Cell Population

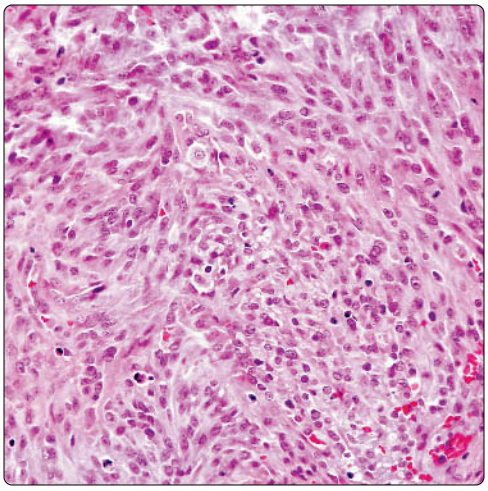

Peribronchial Spread

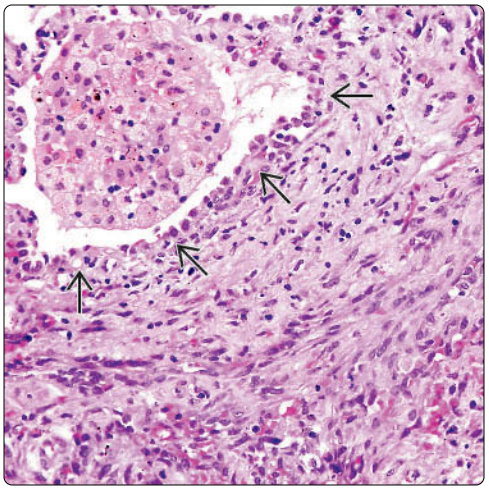

(Left) *High magnification of a pulmonary lesion in Kaposi sarcoma shows dense spindle cell proliferation forming fascicles that intersect at right angles. This histologic appearance can be mistaken for a benign or malignant smooth muscle proliferation (i.e., leiomyoma, low-grade leiomyosarcoma).* **(Right)** *High magnification of a pulmonary lesion in Kaposi sarcoma shows spindle cell proliferation with minimal atypia and extravasated red blood cells surrounding a dilated airspace ⇨.*

HHV8 Immunostaining

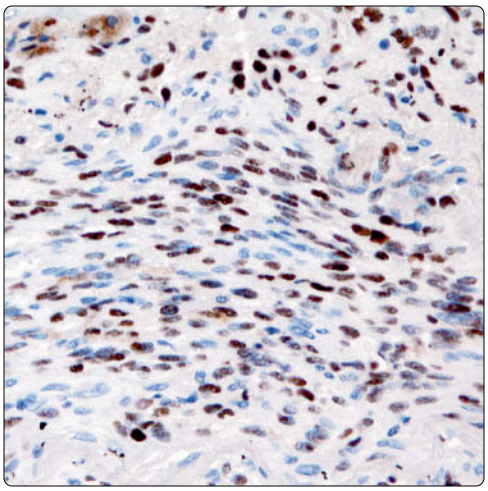

CD31 Immunostaining

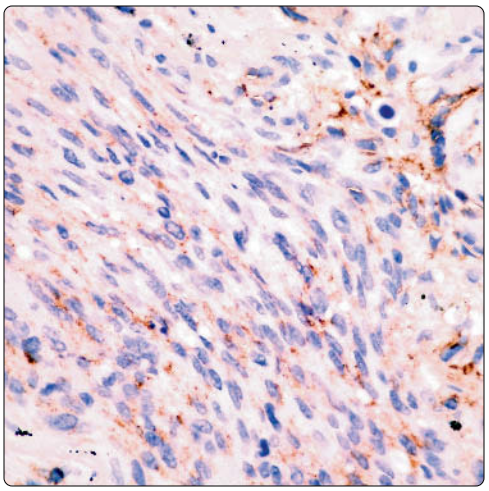

(Left) *An immunohistochemical stain for HHV8 antigen shows strong nuclear positivity in the spindle cells of intrapulmonary Kaposi sarcoma.* **(Right)** *Immunohistochemical staining of a pulmonary lesion of Kaposi sarcoma for the vascular endothelial-related marker, CD31, shows faint positivity in many of the proliferating spindle cells.*

Pulmonary Artery Sarcoma

KEY FACTS

TERMINOLOGY

- Synonym: Intimal sarcoma
- Malignant mesenchymal tumor originating from wall of pulmonary trunk

CLINICAL ISSUES

- Cough
- Chest pain
- Shortness of breath
- Fatigue
- Syncope

MACROSCOPIC

- Most important characteristic is that tumor must be attached to pulmonary artery

MICROSCOPIC

- Varied mesenchymal differentiation
- Angiosarcoma
- Rhabdomyosarcoma
- Chondrosarcoma
- Osteosarcoma
- Leiomyosarcoma

TOP DIFFERENTIAL DIAGNOSES

- Metastatic sarcoma
  - Clinical history of extrathoracic tumor should lead toward correct interpretation
- Primary intrapulmonary sarcoma
  - Identification of tumor into lumen of pulmonary artery is hallmark of this tumor

DIAGNOSTIC CHECKLIST

- Gross appearance
- Wide spectrum of sarcomatous differentiation

High-Grade Sarcoma

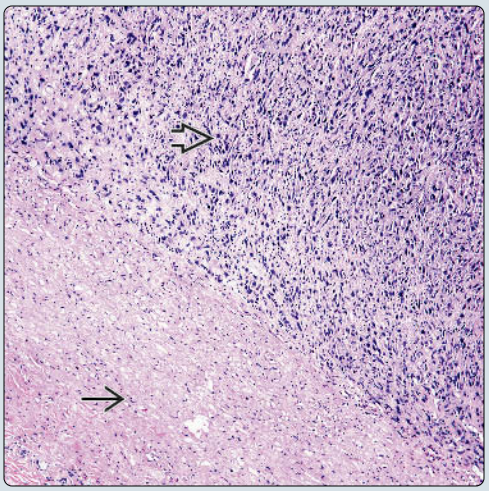

Pleomorphic Sarcoma



(Left) *Pulmonary artery sarcoma shows a high-grade sarcoma in close association with the wall of the pulmonary artery. Identification of the pulmonary vessel is essential for the diagnosis.* **(Right)** *High-grade sarcoma shows extensive areas of pleomorphic cells and atypical mitotic figures. In many cases, the type of sarcoma is unclassified.*

Undifferentiated Sarcoma

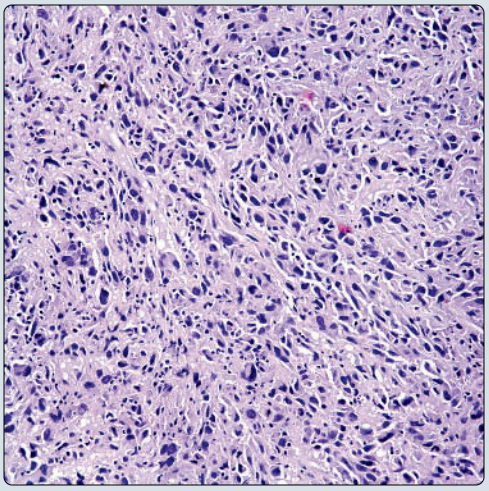

Spindle Cell Sarcoma

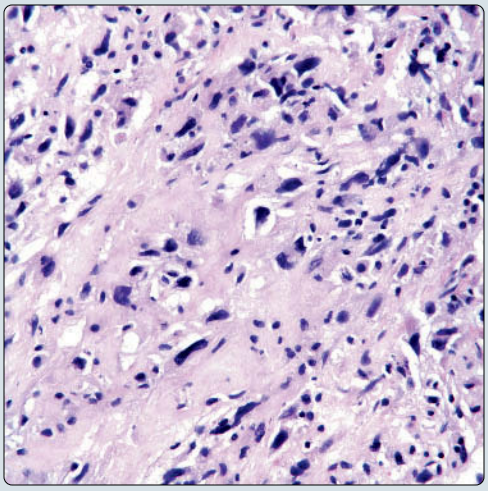

(Left) *Undifferentiated high-grade sarcoma shows numerous large and multinucleated cells. In some cases, even with the use of immunohistochemistry, no specific differentiation is encountered.* **(Right)** *Higher magnification shows the presence of spindle and multinucleated cells typical of high-grade sarcomas.*

TERMINOLOGY

Abbreviations

- Pulmonary artery sarcoma (PAS)

Synonyms

- Intimal sarcoma

Definitions

- Malignant mesenchymal tumor originating from wall of pulmonary trunk

CLINICAL ISSUES

Epidemiology

- Incidence
  - Rare tumors representing < 1% of all malignant mesenchymal tumors of lung
- Age
  - Usually occurs in adults

Presentation

- Cough
- Chest pain
- Shortness of breath
- Fatigue
- Syncope
- Often confused for other medical conditions, such as pulmonary hypertension, pneumonia, or asthma

Treatment

- Surgical approaches
  - Lobectomy or pneumonectomy
- Adjuvant therapy
  - Chemotherapy &/or radiation may be of use depending on type of sarcoma

Prognosis

- Intrathoracic metastasis may occur in 50% of patients
- Extrathoracic metastasis may occur in ~ 15% of patients
- Death may occur in period of 12 months after initial diagnosis

MACROSCOPIC

General Features

- Tumor obliterating lumen of artery
- Identification of pulmonary trunk
- Identification of pulmonary artery
- Polypoid tumor in intraluminal location

MICROSCOPIC

Histologic Features

- Varied mesenchymal differentiation
  - Angiosarcoma
  - Rhabdomyosarcoma
  - Chondrosarcoma
  - Osteosarcoma
  - Leiomyosarcoma

DIFFERENTIAL DIAGNOSIS

Metastatic Sarcoma

- Clinical history of extrathoracic tumor should lead to correct interpretation

Primary Intrapulmonary Sarcoma

- Identification of tumor growing into lumen of pulmonary artery is hallmark of this tumor

DIAGNOSTIC CHECKLIST

Clinically Relevant Pathologic Features

- Gross appearance

Pathologic Interpretation Pearls

- Tumor obliterating lumen of vessel
- Polypoid tumor protruding into arterial lumen
- Wide spectrum of sarcomatous differentiation

SELECTED REFERENCES

1. Nijjar PS et al: Primary pulmonary artery sarcoma masquerading as pulmonary embolism: role of cardiac MRI. Eur Heart J. ePub, 2016
2. Gadabanahalli K et al: Primary extraskeletal myxoid chondrosarcoma of pulmonary arteries: a rare mimic of acute pulmonary thromboembolism. Interact Cardiovasc Thorac Surg. 20(4):565-6, 2015
3. Huo L et al: Pulmonary artery sarcoma: a clinicopathologic and immunohistochemical study of 12 cases. Am J Clin Pathol. 125(3):419-24, 2006
4. Huo L et al: Pulmonary artery angiosarcoma: a clinicopathologic and radiological correlation. Ann Diagn Pathol. 9(4):209-14, 2005

Immunohistochemistry

Antibody	Reactivity	Staining Pattern	Comment
CD31	Positive	Cytoplasmic	If vascular differentiation
CD34	Positive	Cytoplasmic	If vascular differentiation
Myoglobin	Positive	Cytoplasmic	If rhabdomyosarcoma present
MYOD1	Positive	Cytoplasmic	If rhabdomyosarcoma present
Desmin	Positive	Cytoplasmic	If muscle differentiation
Muscle specific actin	Positive	Cytoplasmic	If muscle differentiation
S100	Positive	Nuclear	If chondroid differentiation
SOX9	Positive	Nuclear	If chondroid differentiation

Macroscopic Features

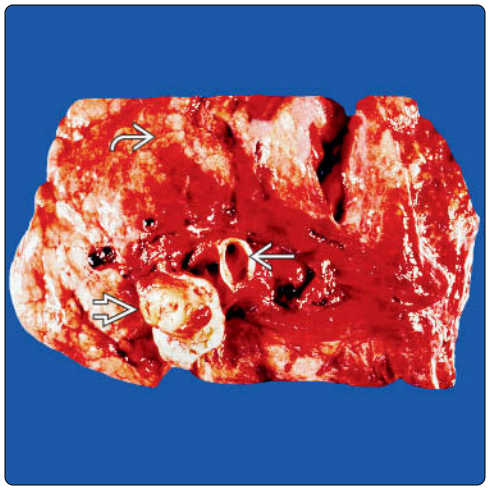

Elastic Stain Outlining Vessel

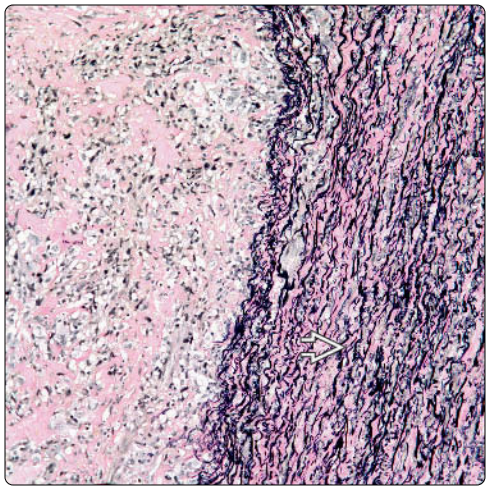

(Left) *Gross photograph shows a primary pulmonary artery sarcoma. It is important to properly identify the vessel with intraluminal tumor, the main airway should be patent and with no evidence of tumor. The remaining pulmonary parenchyma is congested but essentially within normal limits.* **(Right)** *In many cases of pulmonary artery sarcoma, special stains, such as elastic stains, may help in the identification of a pulmonary vessel.*

Wall of Vessel

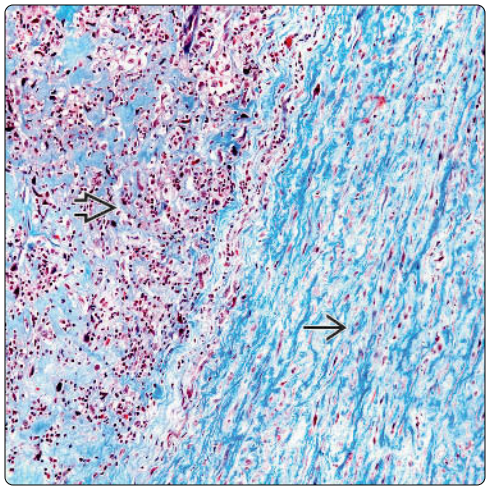

Extensive Necrosis

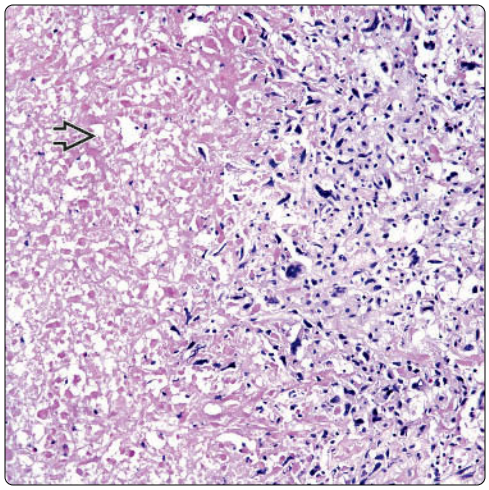

(Left) *Another histochemical stain that may help in separating a tumor from a pulmonary vessel is the Masson stain, which in this illustration clearly separates both components, tumor and vessel.* **(Right)** *One additional feature that is commonly encountered in cases of pulmonary artery sarcoma is the presence of necrosis. This feature is more common in high-grade sarcomas.*

Solid Spindle Cell Proliferation

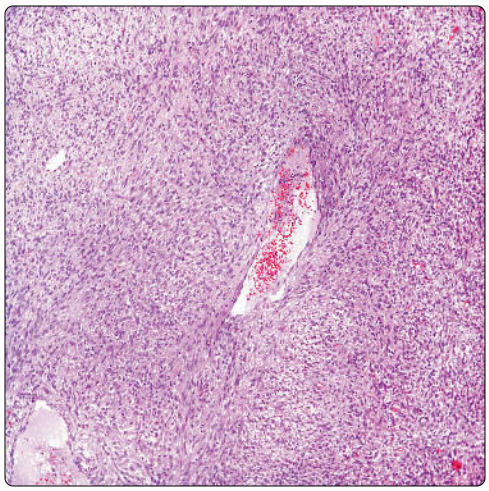

Mitotic Activity

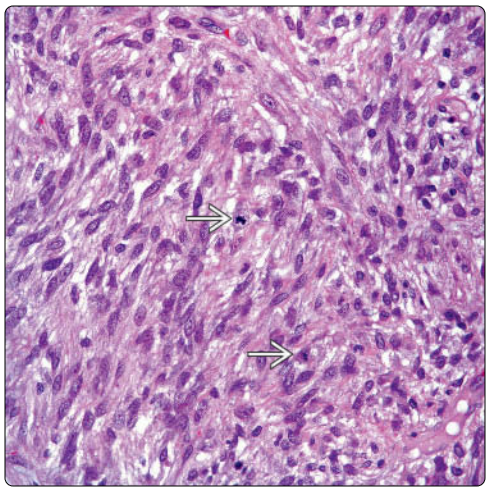

(Left) *Intimal sarcoma in which a solid spindle cell proliferation with presence of ectatic vessels is shown. This proliferation is much in keeping with leiomyosarcoma.* **(Right)** *Higher magnification of a leiomyosarcoma of the pulmonary artery is shown. The tumor shows the classic characteristics of leiomyosarcomas elsewhere. Note the presence of mitotic activity.*

Osteoid Formation

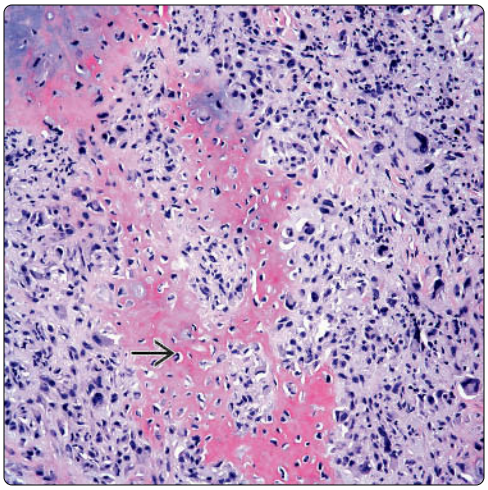

Multinucleated Giant Cells

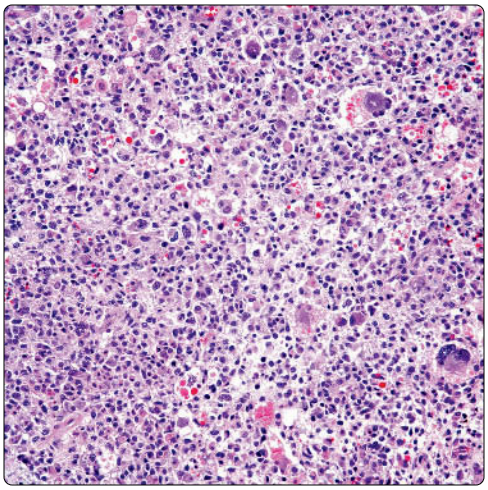

(Left) *High-grade pulmonary artery sarcoma shows osteosarcomatous differentiation. Note the presence of osteoid formation.* **(Right)** *High-grade pulmonary artery sarcoma shows a mixture of multinucleated giant cells and mononuclear malignant cells. This is a common feature of undifferentiated high-grade sarcomas.*

Rhabdomyosarcomatous Component

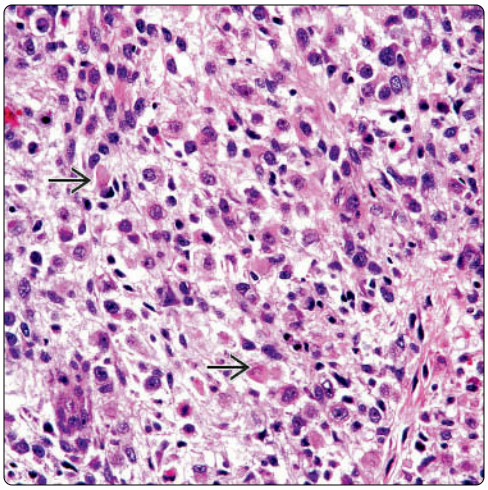

Presence of Rhabdomyoblasts

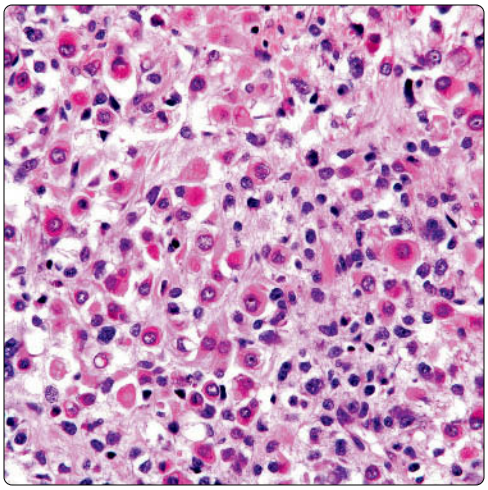

(Left) *Pulmonary artery sarcoma shows rhabdomyosarcomatous differentiation. The cells are oval, and numerous rhabdomyoblastic cells are also present.* **(Right)** *Closer view of a rhabdomyosarcoma arising in the pulmonary artery is shown. This differentiation is not uncommon among the different types of sarcomas that may arise from the pulmonary artery.*

Atypical Mitotic Activity

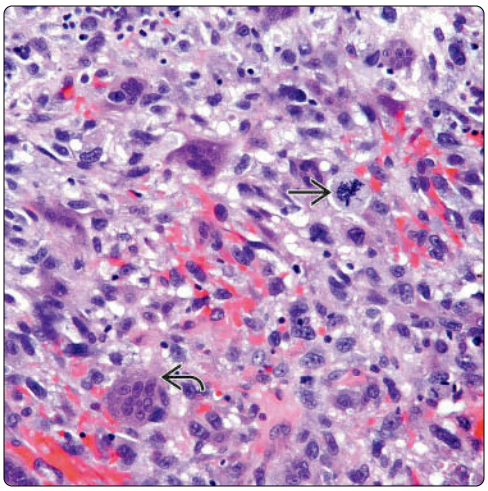

Spindle Cell Sarcoma

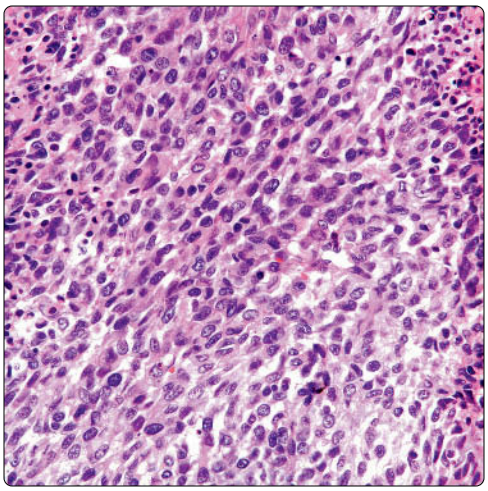

(Left) *High-power view of a pulmonary artery sarcoma is shown with a pleomorphic cellular proliferation. Note the presence of osteoclast-like multinucleated giant cells and atypical mitotic figures.* **(Right)** *High-power view of a pulmonary artery sarcoma displays a spindle cellular proliferation admixed with mitotic figures. The features highly suggest a neurogenic sarcoma.*

Pulmonary BALT Hyperplasia

KEY FACTS

TERMINOLOGY

- Polyclonal proliferation of small lymphocytes arising within lung parenchyma
- Pseudolymphoma, nodular lymphoid hyperplasia, lymphoid interstitial pneumonia

ETIOLOGY/PATHOGENESIS

- Commonly associated with underlying autoimmune disorders, such as Sjögren syndrome, rheumatoid arthritis, and collagen vascular diseases
- Associated with viral infection, including HIV and Epstein-Barr virus
- Associated with immunodeficiency, including common variable immunodeficiency, AIDS, and bone marrow transplants

CLINICAL ISSUES

- Mostly asymptomatic; discovered incidentally
- Adults 40-70 years (average: 50 years)
- Diffuse form of disease is more common in children
- Female predilection

MICROSCOPIC

- **Nodular lymphoid hyperplasia (nodular BALT hyperplasia)**
  - Multiple coalescent, enlarged follicles showing prominent germinal centers
  - Interfollicular lymphoplasmacytosis
- **Follicular bronchiolitis**
  - Discrete accumulations of small lymphoid aggregates in peribronchiolar location
  - Sparing of alveolar septa by lymphoid infiltrates
- **Diffuse lymphoid (BALT) hyperplasia (diffuse interstitial pneumonia)**
  - Predominantly interstitial proliferation of small lymphocytes distending alveolar septa
  - Process is generally bilateral and diffuse

Diffuse BALT Hyperplasia

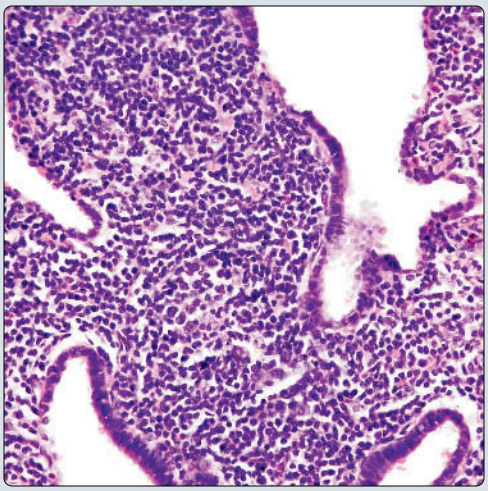

Higher Magnification

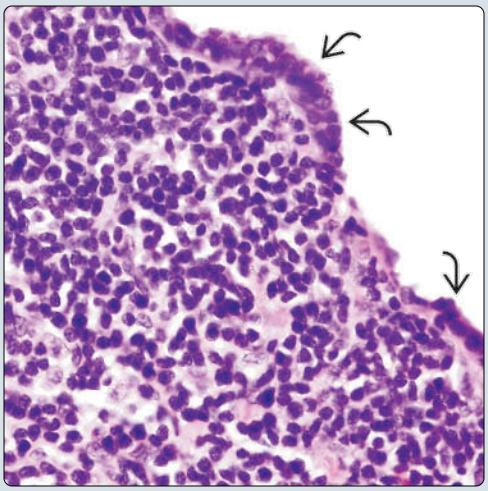

(Left) *Diffuse BALT hyperplasia of the lung shows massively distended alveolar septa occupied by a population of small lymphoid cells.* **(Right)** *Higher magnification of diffuse BALT hyperplasia shows a dense population of small lymphoid cells abutting the respiratory lining mucosa. The lymphoid cell infiltrate is composed of polyclonal small lymphocytes and plasma cells.*

Nodular BALT Hyperplasia

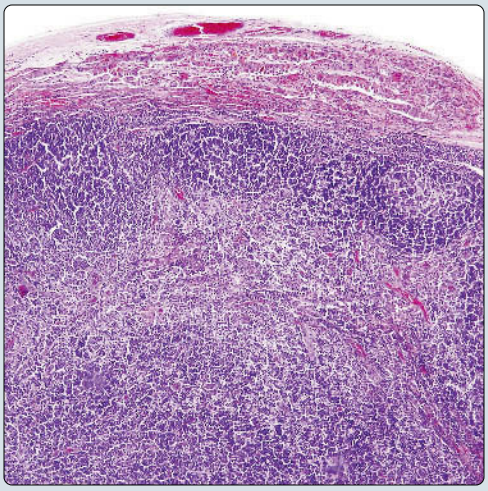

Hyperplastic Lymphoid Nodule

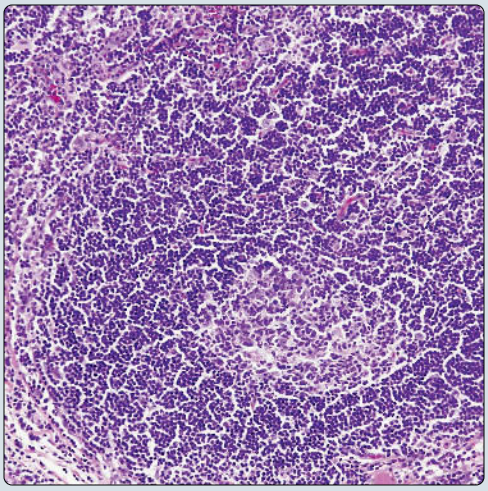

(Left) *Nodular BALT hyperplasia is characterized by a localized, expansile nodule within lung parenchyma that is composed of a dense lymphoid infiltrate with hyperplastic lymphoid follicles containing reactive germinal centers.* **(Right)** *Higher magnification from nodular BALT hyperplasia shows a hyperplastic follicle with reactive germinal center. The lymphoid cell population in nodular BALT hyperplasia is polyclonal.*

TERMINOLOGY

Synonyms

- Pseudolymphoma, nodular lymphoid hyperplasia, lymphoid interstitial pneumonia

Definitions

- Polyclonal proliferation of small lymphocytes arising within lung parenchyma

ETIOLOGY/PATHOGENESIS

Pathogenesis

- Commonly associated with underlying autoimmune disorders, such as Sjögren syndrome, rheumatoid arthritis, and collagen vascular diseases
- Associated with viral infection, including HIV and Epstein-Barr virus
- Associated with immunodeficiency, including common variable immunodeficiency, AIDS, and bone marrow transplants
- Idiopathic

CLINICAL ISSUES

Epidemiology

- Age
  - Adults 40-70 years (average: 50 years)
  - Diffuse form of disease is more common in children
- Sex
  - Female predilection

Presentation

- Cough, dyspnea; may be asymptomatic and discovered incidentally
- Asymptomatic; discovered incidentally

Treatment

- Surgical excision for localized lesions
- Steroid therapy for diffuse lesions

Prognosis

- Variable course depending on extent and progression of disease
- Complete resolution is most common outcome
- Diffuse cases may progress to end-stage pulmonary fibrosis with "honeycombing" of lung parenchyma
- Diffuse cases may progress to diffuse lymphocytic lymphoma (MALT lymphoma)
- Death may ensue due to comorbid conditions, superinfection, or renal failure

MICROSCOPIC

Histologic Features

- **Nodular lymphoid hyperplasia (nodular BALT hyperplasia)**
  - Multiple coalescent, enlarged follicles show prominent germinal centers
  - Interfollicular lymphoplasmacytosis
  - Hyperplastic follicles display prominent polarity
  - Well-demarcated follicle mantle zones contain cytologically bland, small lymphocytes
  - Lymphoid process does not extend along alveolar septa or into alveolar walls
- **Follicular bronchiolitis**
  - Discrete accumulations of small lymphoid aggregates in peribronchiolar location
  - Sparing of alveolar septa by lymphoid infiltrates
  - Considered small airway equivalent of nodular lymphoid hyperplasia
- **Diffuse lymphoid (BALT) hyperplasia (diffuse interstitial pneumonia)**
  - Predominantly interstitial proliferation of small lymphocytes distending alveolar walls
  - Occasional residual germinal centers may be seen
  - Process is generally bilateral and diffuse

Cytologic Features

- Lymphoid cell population in nodular lymphoid hyperplasia and follicular bronchiolitis consists of polyclonal B lymphocytes and plasma cells
- Lymphoid cell population in diffuse lymphoid hyperplasia is composed primarily of small T cells admixed with polyclonal B lymphocytes

ANCILLARY TESTS

Immunohistochemistry

- **Nodular lymphoid hyperplasia**
  - Polyclonal pattern of light chain expression in small lymphocytes and plasma cells
  - CD5(-), CD10(-), CD23(-)
  - CD21 highlights dendritic cell network in germinal centers
- **Diffuse lymphoid hyperplasia**
  - Polyclonal population of small B lymphocytes and plasma cells
  - Abundance of small T lymphocytes in interstitial infiltrates
  - Cases occurring in context of AIDS will show immunoreactivity for p21 protein of HIV

Genetic Testing

- Absence of clonality or gene rearrangements by molecular studies

DIFFERENTIAL DIAGNOSIS

MALT Lymphoma (Primary Pulmonary Marginal Zone Lymphoma)

- Diffuse proliferation of monoclonal small B lymphocytes showing kappa or lambda light chain restriction
- Colonization of germinal centers by marginal zone lymphocytes
- Formation of lymphoepithelial lesions
- Demonstration of t(11;18) (AP12/MALT1) translocation

SELECTED REFERENCES

1. Tashtoush B et al: Follicular bronchiolitis: a literature review. J Clin Diagn Res. 9(9):OE01-5, 2015
2. Bégueret H et al: Primary lung small B-cell lymphoma versus lymphoid hyperplasia: evaluation of diagnostic criteria in 26 cases. Am J Surg Pathol. 26(1):76-81, 2002
3. Abbondanzo SL et al: Nodular lymphoid hyperplasia of the lung: a clinicopathologic study of 14 cases. Am J Surg Pathol. 24(4):587-97, 2000

Nodular BALT Hyperplasia

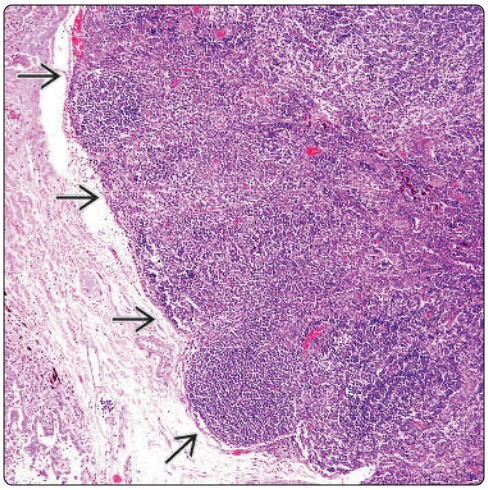

Nodular BALT Hyperplasia

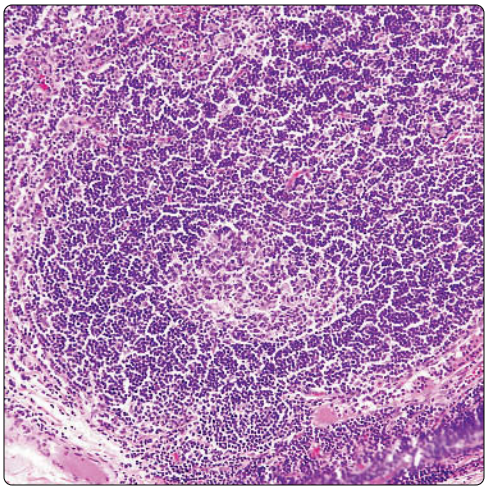

(Left) *Scanning magnification of nodular BALT hyperplasia of the lung shows a well-delineated area of consolidation separated from the surrounding lung parenchyma. The area of consolidation is composed of numerous small lymphoid cells with scattered reactive follicles.* **(Right)** *Higher magnification of nodular BALT hyperplasia shows an enlarged lymphoid follicle with a germinal center. The lymphoid cell population in this case was shown to be polyclonal.*

Enlarged Lymphoid Follicle

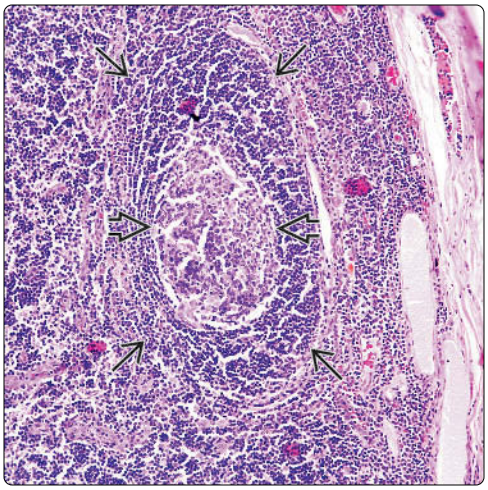

Reactive Germinal Center

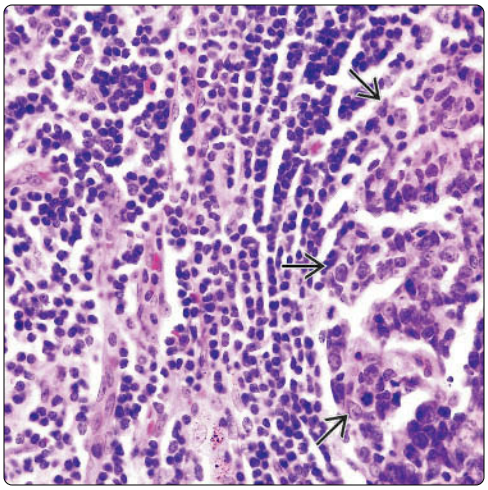

(Left) *Scanning magnification in nodular BALT hyperplasia shows a lymphoid follicle with a reactive germinal center. The lymphoid follicle shows good "polarization" (i.e., the mantle zone surrounding the germinal center is not uniformly enlarged).* **(Right)** *Higher magnification from nodular BALT hyperplasia shows a portion of a germinal center adjacent to an expanded interfollicular area that contains polyclonal small lymphocytes and plasma cells.*

Follicular Bronchiolitis

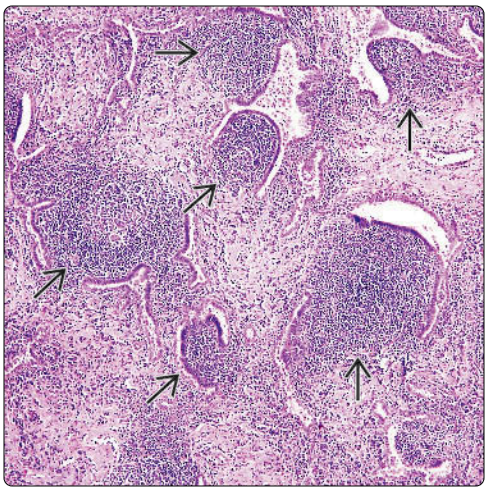

Bronchiole With Lymphoid Follicle

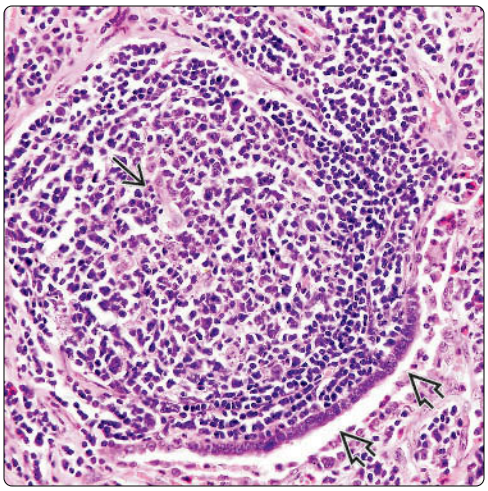

(Left) *Scanning magnification of follicular bronchiolitis shows the discrete accumulation of small lymphoid aggregates in a peribronchiolar location. Notice the sparing of the alveolar septa by the lymphoid infiltrates.* **(Right)** *Higher magnification of follicular bronchiolitis shows a well-formed lymphoid aggregate compressing the lumen of a small bronchiole. The follicle shows the presence of an immature germinal center in the center of the follicle.*

Diffuse BALT Hyperplasia

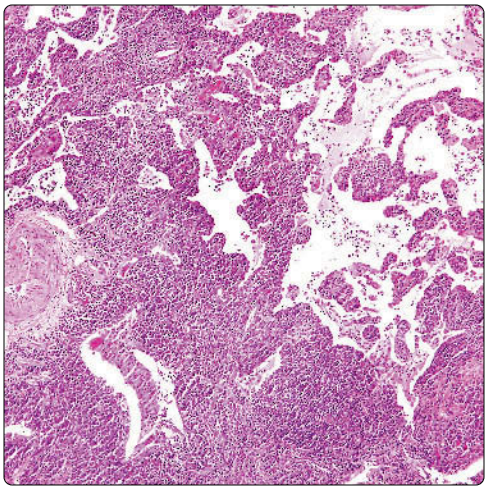

BALT Hyperplasia: Higher Magnification

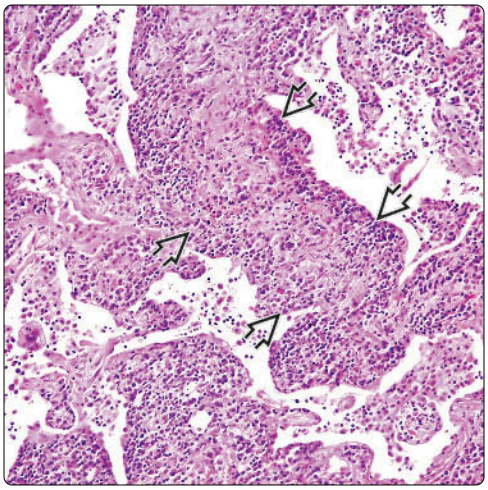

(Left) *Scanning magnification of diffuse BALT hyperplasia (lymphoid interstitial pneumonia) shows expansion of the alveolar septa by a diffuse infiltrate primarily composed of small lymphoid cells.* **(Right)** *Higher magnification of diffuse BALT hyperplasia of the lung (lymphoid interstitial pneumonia) shows widening of the alveolar septa ⇨ by a dense lymphoid cell population. The underlying epithelial lining of the alveolar wall remains preserved and intact.*

Mononuclear Cell Population

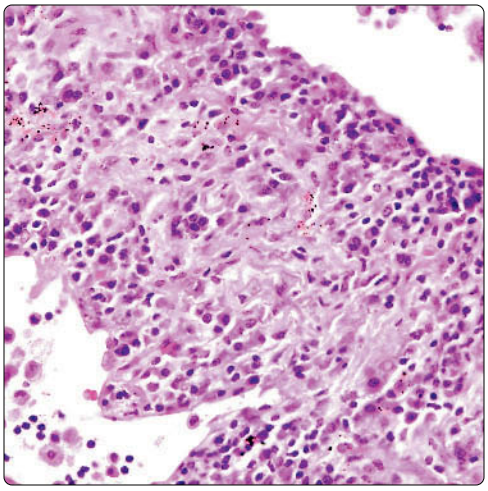

Plasmacytosis

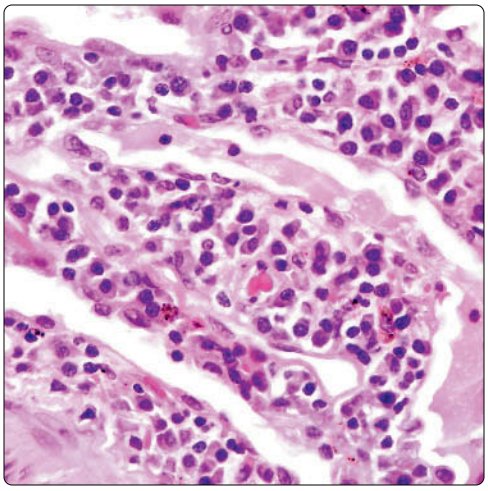

(Left) *Higher magnification of diffuse BALT hyperplasia of the lung (lymphoid interstitial pneumonia) shows expansion of the alveolar wall by a mononuclear population of lymphoid cells, including small lymphocytes, plasma cells, and histiocytes. No atypical cells are seen in the infiltrate.* **(Right)** *Higher magnification of diffuse BALT hyperplasia (lymphoid interstitial pneumonia) shows a dense polyclonal population of small lymphocytes admixed with plasma cells.*

Lymphoid Follicle in Alveolar Septum

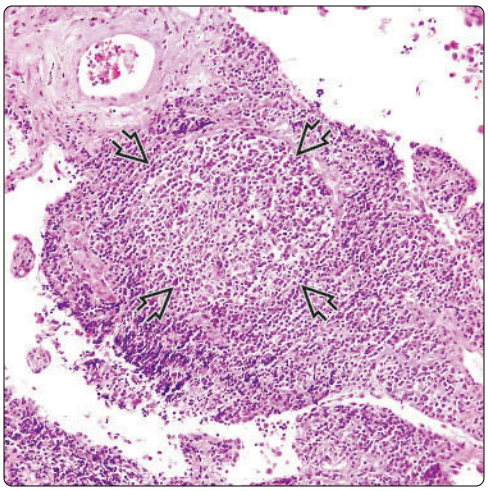

Abortive Residual Follicles

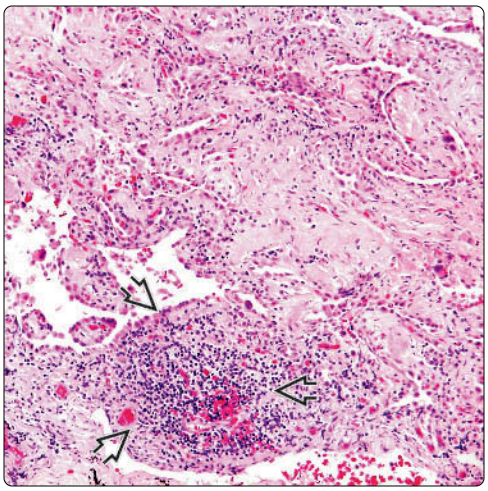

(Left) *Diffuse BALT hyperplasia (lymphoid interstitial pneumonia) of the lung shows widening of alveolar septa displaying a prominent lymphoid follicle ⇨. Cases showing these features can overlap with follicular bronchiolitis but are distinguished by the diffuse nature of the lymphoid infiltrates.* **(Right)** *Diffuse BALT hyperplasia (lymphoid interstitial pneumonia) in an advanced stage shows prominent interstitial fibrosis with only 1 small, abortive residual follicle present ⇨.*

Pulmonary BALT Lymphoma

KEY FACTS

TERMINOLOGY

- Monoclonal proliferation of small lymphocytes arising from marginal zone of B-cell follicles

CLINICAL ISSUES

- Most common presentation is solitary mass on routine imaging studies
- Most patients are asymptomatic
- Favorable prognosis; 5-year survival in ~ 85-95%
- May be localized or diffuse
- Small proportion of cases may progress to diffuse large B-cell lymphoma

IMAGING

- May present as single, solitary nodule or as diffuse bilateral disease mimicking diffuse interstitial pneumonia

MICROSCOPIC

- Diffuse lymphoid infiltrates composed of small lymphocytes admixed with reactive lymphoid follicles
- Reactive lymphoid follicles may show extensive infiltration by marginal zone lymphocytes (follicular colonization)
- Infiltration of underlying epithelial structures forming "lymphoepithelial" lesions is characteristic
- Cytomorphology of neoplastic small lymphocytes is variable and includes centrocytic cells, plasmacytoid cells, and monocytoid cells

ANCILLARY TESTS

- Neoplastic cells are CD19, CD20, CD79a, and Bcl-2 (+)
- Tumor cells are CD5, CD10, CD23, Bcl-1, and Bcl-6 (-)
- t(11;18)(q21;q21) is most common genetic abnormality (encountered in ~ 50% of cases)

BALT Gross Appearance

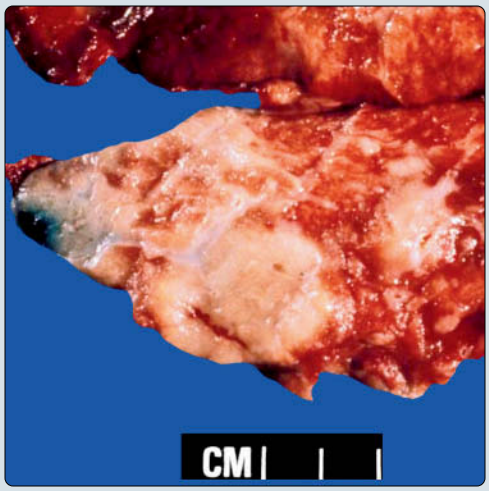

BALT of Lung: Low Power

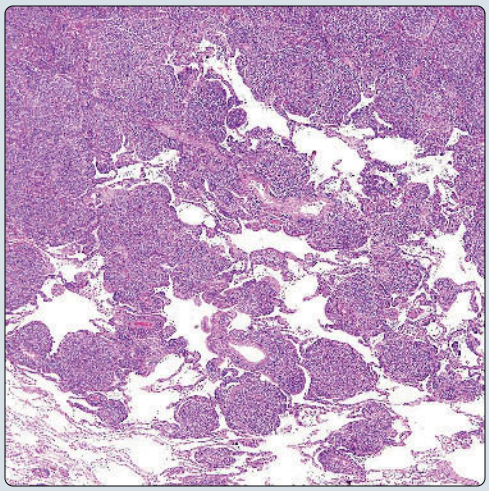

(Left) *Gross appearance of BALT lymphoma of the lung shows nodular, ill-defined, confluent areas of lung parenchyma replaced by tan-white, homogeneous, rubbery tissue.* **(Right)** *Characteristic histologic appearance of pulmonary BALT lymphoma shows expansion of alveolar septa by a monotonous population of small lymphoid cells with lymphangitic distribution.*

Lymphoid Hyperplasia

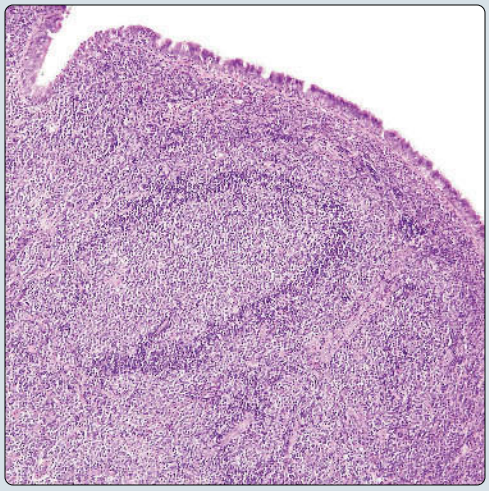

Sheets of Monocytoid Lymphocytes

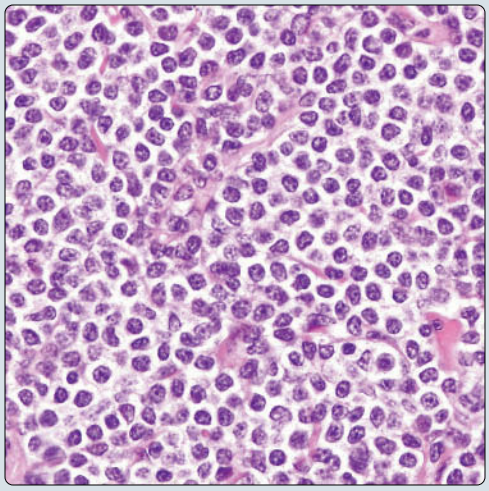

(Left) *Prominent lymphoid follicle is seen in the submucosa of the bronchial lining. The enlarged lymphoid follicles are surrounded by dense and monotonous sheets of mildly atypical lymphoid cells.* **(Right)** *The cell population in BALT lymphoma is comprised of sheets of small, monotonous lymphocytes with minimal nuclear irregularities and a clear perinuclear halo that imparts them with a monocytoid appearance.*

TERMINOLOGY

Synonyms

- Marginal zone B-cell lymphoma of mucosa-associated lymphoid tissue (MALT) type

Definitions

- Monoclonal proliferation of small lymphocytes arising from marginal zone of B-cell follicles

CLINICAL ISSUES

Epidemiology

- Incidence
  - Accounts for ~ 80% of primary lung lymphomas

Presentation

- Most common presentation is solitary mass on routine imaging studies; most patients are asymptomatic
- May be localized or diffuse
- Some patients may present with cough, dyspnea, and chest pain

Treatment

- Surgical approaches
  - Surgical excision achieves excellent results in localized, resectable tumors
- Adjuvant therapy
  - Indicated in patients with diffuse or bilateral involvement

Prognosis

- Favorable prognosis; 5-year survival in ~ 85-95%
- Small proportion of cases may progress to diffuse large B-cell lymphoma

MACROSCOPIC

Cut Surface

- Tan-white, fleshy, homogeneous rubbery tissue
- Involved area of lung parenchyma can be nodular and well circumscribed or diffuse

MICROSCOPIC

Histologic Features

- Diffuse lymphoid infiltrates composed of small lymphocytes admixed with reactive lymphoid follicles
- Reactive lymphoid follicles may show extensive infiltration by marginal zone lymphocytes (follicular colonization)
- Infiltration of underlying epithelial structures forming "lymphoepithelial" lesions is characteristic
- Scattered larger, immunoblastic cells may be seen admixed with small lymphoid cell infiltrate
- Lymphangitic distribution characteristically observed at edges of lesions
- Stromal hyalinization and fibrosis may be seen in advanced lesions

Cytologic Features

- Cytomorphology of neoplastic small lymphocytes is variable and includes
  - Small lymphocytes with minimal nuclear irregularities resembling germinal center centrocytes
  - Plasmacytoid small lymphocytes
  - "Monocytoid" B lymphocytes showing clear perinuclear halos and ample cytoplasm

ANCILLARY TESTS

Immunohistochemistry

- Neoplastic cells are CD19, CD20, CD79a, Bcl-2, and Bcl-10 (+)
- Tumor cells are CD5, CD10, CD23, Bcl-1, and Bcl-6 (-)
- Cytokeratin stains may be helpful to highlight lymphoepithelial lesions
- Light chain restriction for κ/λ can be demonstrated in paraffin sections only in minority of cases
- Stains for follicular dendritic cells, such as CD21, CD23, and CD35, can highlight reactive follicles disrupted by neoplastic cells

Genetic Testing

- t(11;18) translocation produces fusion protein involving % , 5 & (API2) and 0 $ / 7 genes and can be detected by expression of Bcl-10
- t(11;18)(q21;q21) is most common genetic abnormality (encountered in ~ 50% of cases)
- t(1;14) and (14;18) or trisomy 3 and 18 may also occur

PCR

- Clonal immunoglobulin heavy chain rearrangements are identified in majority of cases, even in absence of light chain restriction

DIFFERENTIAL DIAGNOSIS

Nodular Lymphoid Hyperplasia

- Composed of polyclonal population of lymphoid cells without lymphoepithelial lesions
- Lymphocytes do not show light chain restriction or heavy chain gene rearrangements by PCR

Diffuse Lymphoid Hyperplasia (Lymphocytic Interstitial Pneumonia)

- Interstitial lymphocytes in diffuse lymphoid hyperplasia stain as CD3(+) T cells
- B cells in diffuse lymphoid hyperplasia do not show light chain restriction or heavy chain gene rearrangements

SELECTED REFERENCES

1. Rubenstein JN et al: Extranodal marginal zone lymphoma of the lung: evolution from an underlying reactive lymphoproliferative disorder. J Clin Exp Pathol. 5(1), 2015
2. Ko HM et al: Cytomorphological and clinicopathological spectrum of pulmonary marginal zone lymphoma: the utility of immunophenotyping, PCR and FISH studies. Cytopathology. 25(4):250-8, 2014
3. Okabe M et al: API2-MALT1 fusion defines a distinctive clinicopathologic subtype in pulmonary extranodal marginal zone B-cell lymphoma of mucosa-associated lymphoid tissue. Am J Pathol. 162(4):1113-22, 2003
4. Kurtin PJ et al: Pathologic and clinical features of primary pulmonary extranodal marginal zone B-cell lymphoma of MALT type. Am J Surg Pathol. 25(8):997-1008, 2001

Expansion of Alveolar Septa

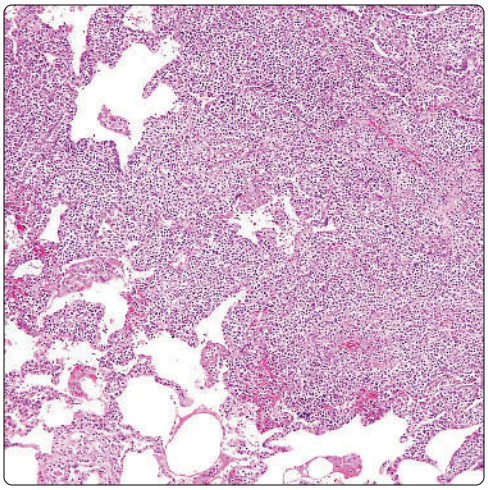

Lymphangitic Distribution

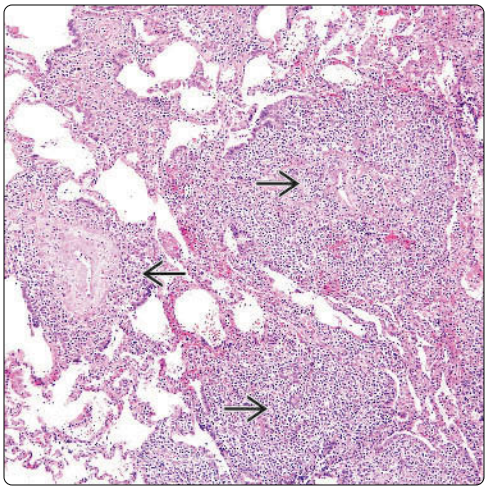

(Left) *Scanning magnification of BALT lymphoma of the lung (pulmonary marginal zone B-cell lymphoma) shows sheets of small lymphocytes expanding alveolar septa and forming a tumor nodule. The histologic appearance of this lesion can be indistinguishable from diffuse BALT hyperplasia.* **(Right)** *Scanning magnification of BALT lymphoma of the lung shows a lymphangitic type of distribution with small nodules ⇨ composed of lymphoid cells distributed along the course of the lymphatic vessels.*

Lymphoid Hyperplasia

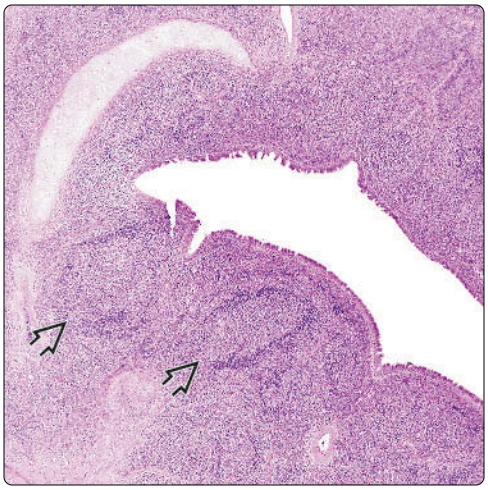

Reactive Germinal Center

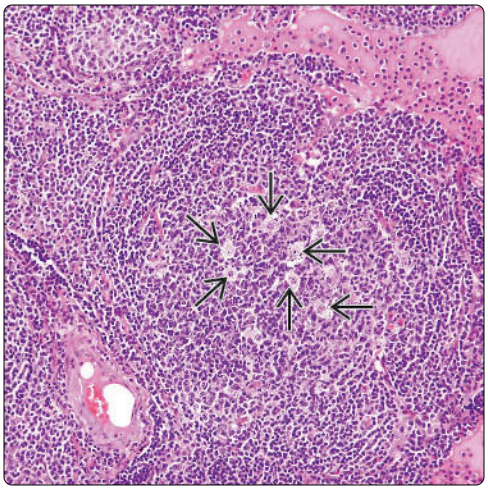

(Left) *Scanning magnification of BALT lymphoma of the lung (marginal zone B-cell lymphoma) shows involvement of a bronchus with destruction of the bronchial cartilage and a few residual hyperplastic lymphoid follicles ⇨.* **(Right)** *BALT lymphoma of the lung shows a residual hyperplastic lymphoid follicle with a reactive germinal center surrounded by monotonous interfollicular proliferation of small lymphocytes. Note abundant tingible body macrophages ⇨ within the germinal center.*

Sheets of Monocytoid Lymphocytes

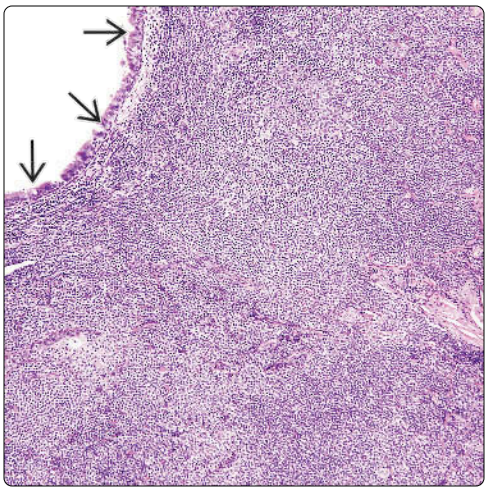

Burned-Out Lymphoid Follicle

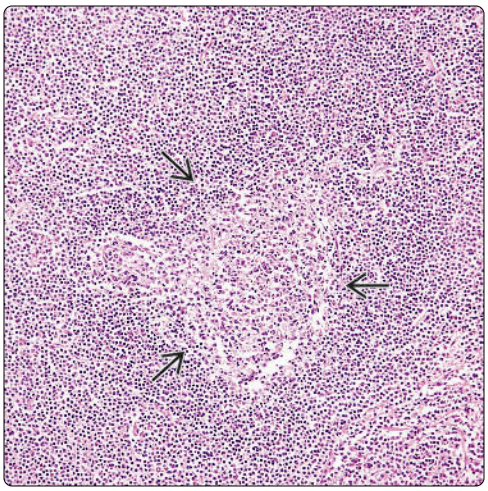

(Left) *Scanning magnification of diffuse BALT lymphoma of the lung shows a dense small lymphocytic proliferation distributed around a bronchial lumen ⇨ and displaying vague nodularity.* **(Right)** *Higher magnification of pulmonary BALT lymphoma (marginal zone B-cell lymphoma) shows a partially effaced lymphoid follicle with a burned-out, residual germinal center showing irregular infiltration by small marginal zone lymphocytes ⇨. This process is known as "colonization" of follicles.*

Compression of Airspaces

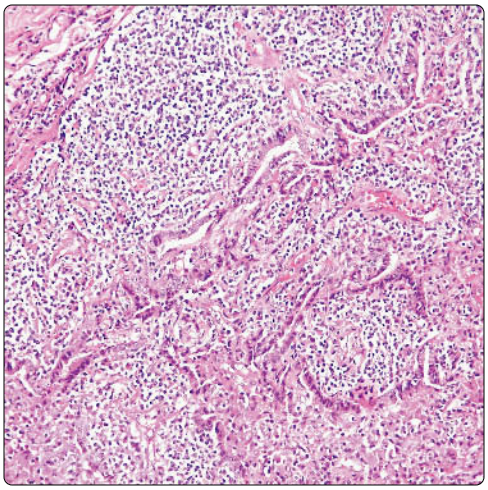

Lymphoepithelial Lesion

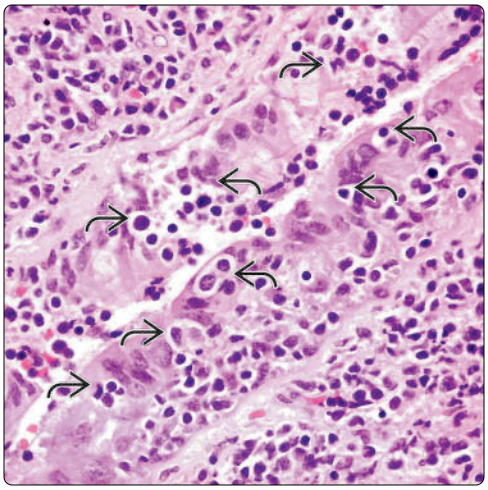

(Left) *Pulmonary BALT lymphoma (marginal zone B-cell lymphoma) shows multiple entrapped airspaces showing irregular infiltration of the mucosa by small lymphocytes.* **(Right)** *Higher magnification of pulmonary BALT lymphoma (marginal zone B-cell lymphoma) shows numerous lymphocytes expanding and replacing the epithelial lining in an airspace ⇨. The infiltrate is mononuclear as opposed to infiltration by neutrophils and eosinophils in acute bronchitis and bronchiolitis.*

Infiltration of Bronchiole

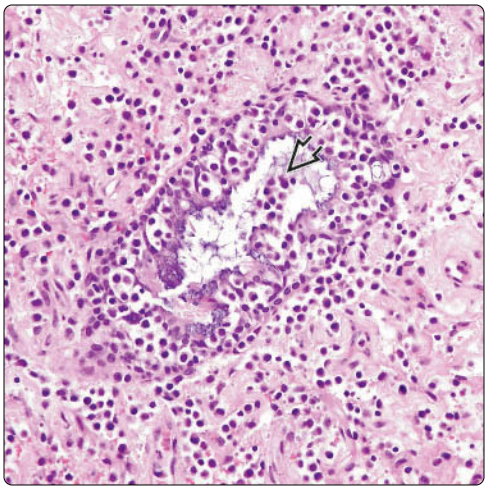

Lymphoepithelial Bronchiolar Lesion

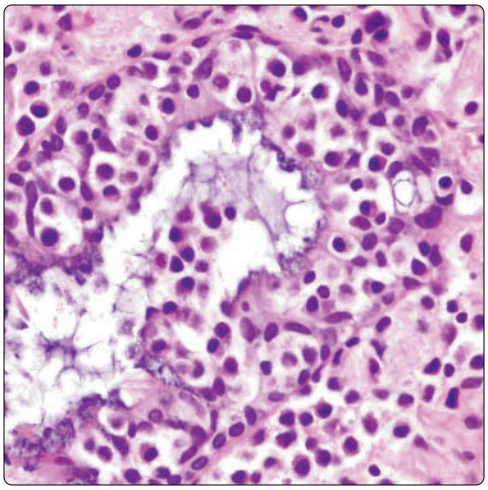

(Left) *Pulmonary BALT lymphoma (marginal zone B-cell lymphoma) shows a small airspace infiltrated by small lymphocytes. There is distortion of the bronchiolar lumen, and some of the small lymphocytes are seen to be spilling into the lumen ⇨.* **(Right)** *Higher magnification of a pulmonary BALT lymphoma shows a well-developed lymphoepithelial lesion. The wall of this bronchiole has been almost entirely replaced by the infiltrating small lymphocytes, some of which appear plasmacytoid.*

Infiltration of Bronchiole

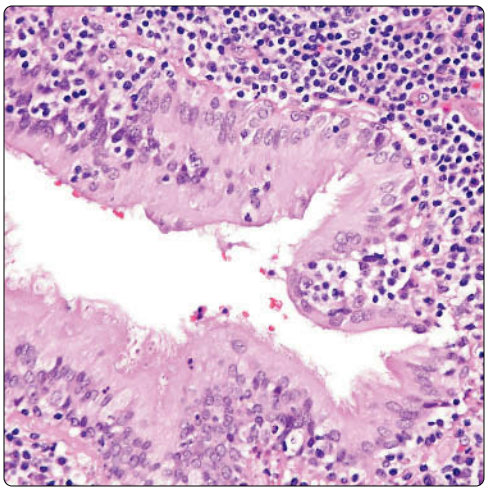

Lymphoepithelial Lesion

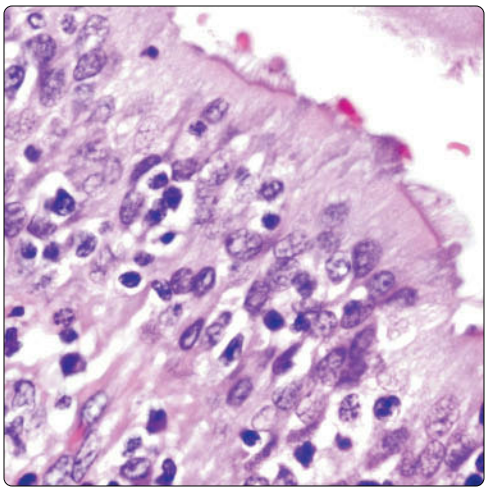

(Left) *Pulmonary BALT lymphoma shows a bronchiole with infiltration by small lymphocytes leading to the creation of a lymphoepithelial lesion. The respiratory mucosa displays a moth-eaten appearance resulting from the infiltrating lymphocytes.* **(Right)** *High magnification of a pulmonary BALT lymphoma (marginal zone B-cell lymphoma) shows close detail of a lymphoepithelial lesion with tall columnar respiratory mucosa harboring a mononuclear cell population.*

Sheets of Small Lymphocytes

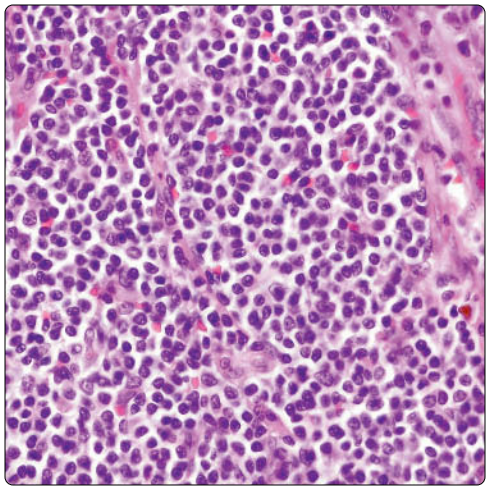

Monotonous Lymphoid Cells

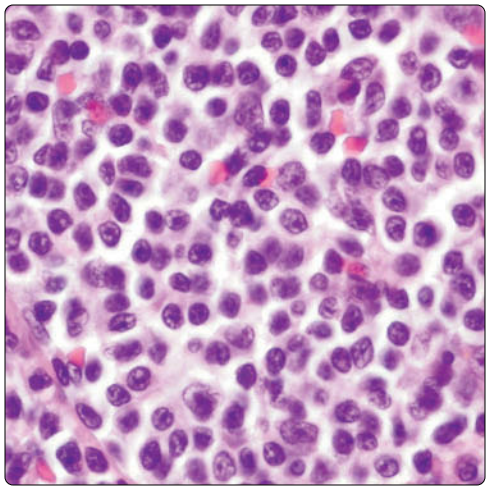

(Left) *Pulmonary BALT lymphoma (marginal zone B-cell lymphoma) shows a monotonous population of small B lymphocytes that resemble germinal center centrocytes. The infiltrate is very similar to that seen in small lymphocytic lymphoma/chronic lymphocytic leukemia (CLL), but the cells are CD5, CD10, and Bcl-6 (-).* **(Right)** *Higher magnification of pulmonary BALT lymphoma (marginal zone B-cell lymphoma) shows a monotonous population of small lymphocytes with minimal nuclear irregularities.*

Sheets of Monocytoid Cells

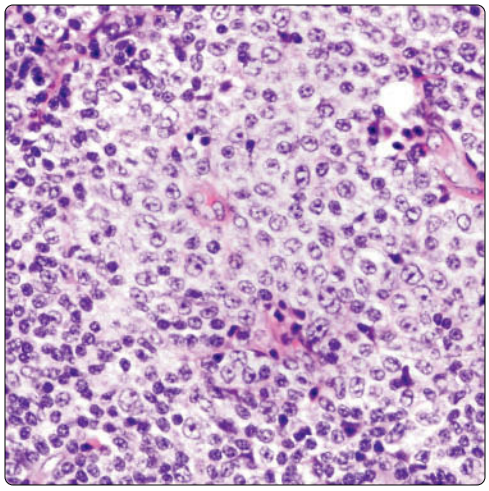

Monocytoid Cells With Perinuclear Halos

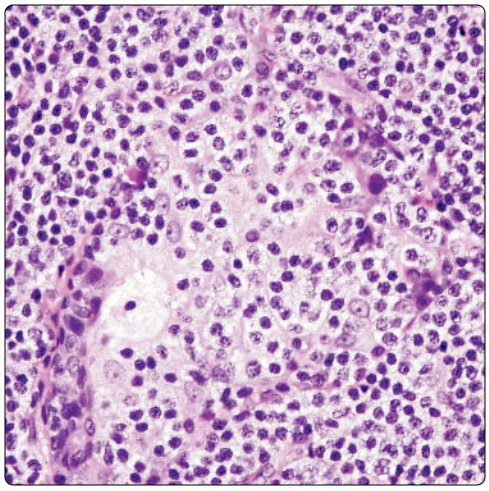

(Left) *Pulmonary BALT lymphoma shows a monotonous population of small lymphocytes with a striking monocytoid appearance. The cells appear less crowded than in conventional small lymphocytic lymphoma because of more abundant cytoplasm.* **(Right)** *Higher magnification of monocytoid marginal zone B cells in pulmonary BALT lymphoma shows clear perinuclear halos. These cells are positive for Bcl-2 in contrast to reactive monocytoid B cells, which are negative.*

Plasmacytoid Lymphocytes

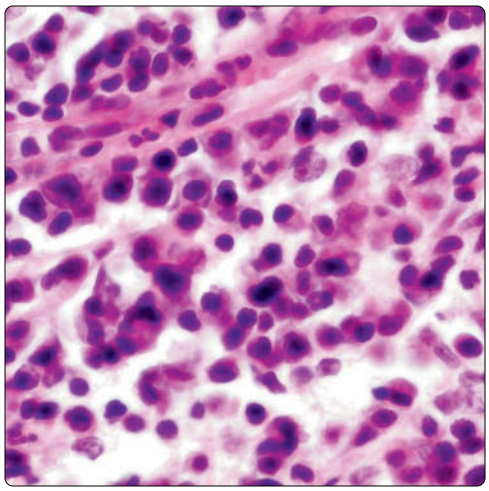

Stromal Sclerosis

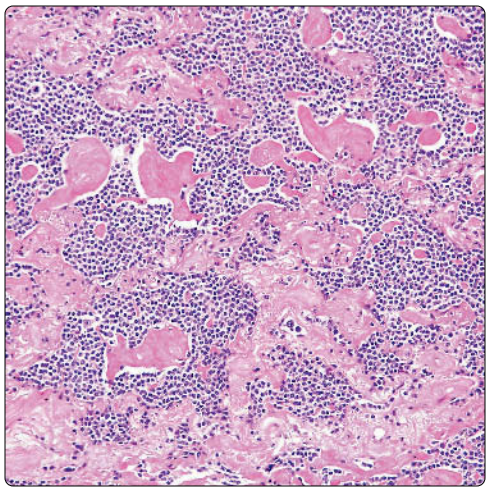

(Left) *Pulmonary BALT lymphoma (marginal zone B-cell lymphoma) shows a population of small lymphocytes with plasmacytoid features. Plasmacytic differentiation can be a prominent feature in these tumors that may lead to confusion with plasmacytoma.* **(Right)** *Pulmonary BALT lymphoma shows prominent stromal sclerosis. This phenomenon is often present in advanced and late lesions. Some tumors with plasmacytic differentiation can also display deposition of stromal amyloid.*

CD20 Immunostaining

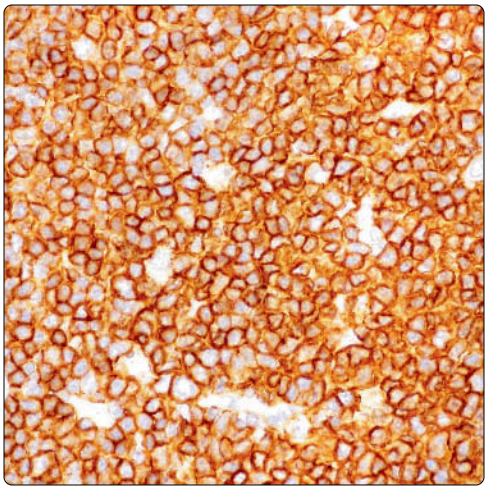

CD5 Immunostaining

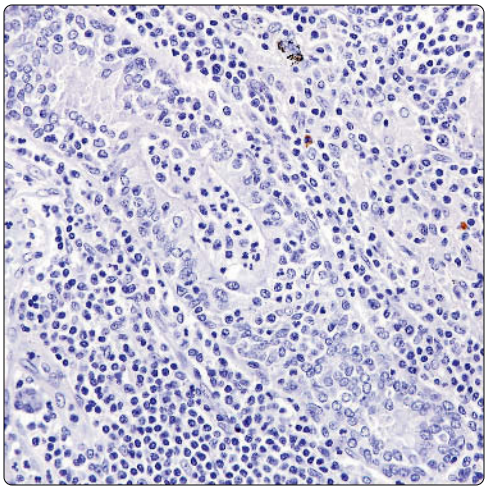

(Left) *Immunohistochemical staining of pulmonary BALT lymphoma (marginal zone B-cell lymphoma) for CD20 shows strong positivity of the tumor cells for this marker. The tumor cells in BALT lymphoma are also positive for the pan-B-cell marker, CD79-a.* **(Right)** *Immunohistochemical staining of a lymphoepithelial lesion in pulmonary BALT lymphoma for CD5 shows negative staining of the infiltrating lymphocytes, distinguishing it from small lymphocytic lymphoma/CLL.*

Bcl-2 Immunostaining

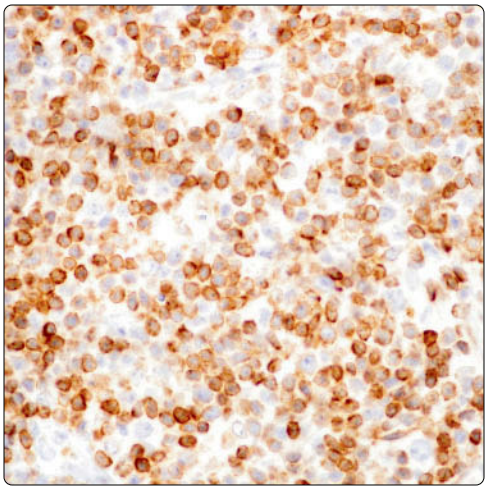

Bcl-2 Immunostaining

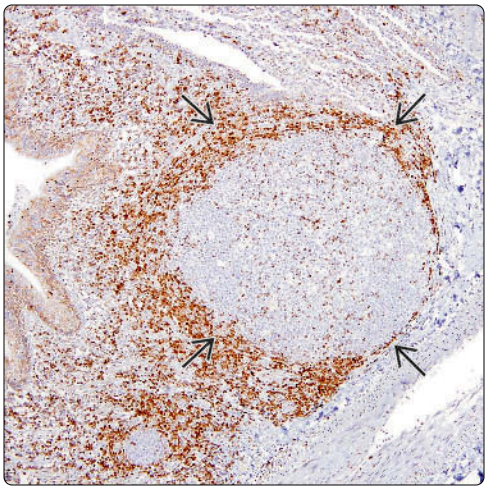

(Left) *Immunohistochemical staining of pulmonary BALT lymphoma (marginal zone B-cell lymphoma) for the Bcl-2 oncogene shows cytoplasmic positivity in the neoplastic lymphoid cells.* **(Right)** *Immunohistochemical staining of pulmonary BALT lymphoma (marginal zone B-cell lymphoma) for Bcl-2 shows a rim of positive small lymphocytes surrounding a lymphoid follicle ⇨ with a few scattered Bcl-2(+) lymphoid cells percolating into the follicle (follicular colonization).*

CD20 Immunostaining

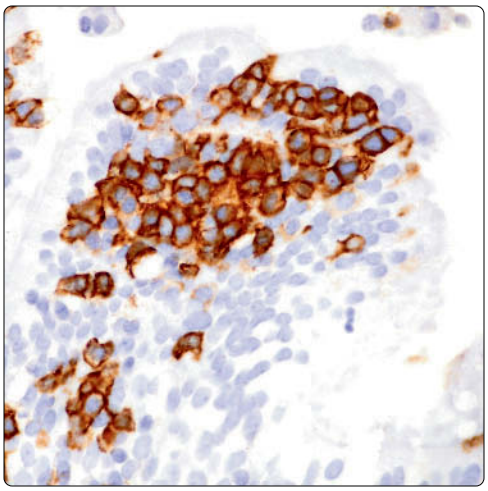

CD20 Immunostaining

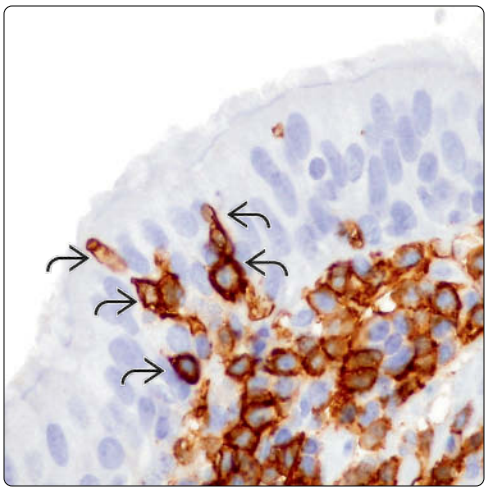

(Left) *Immunohistochemical staining of lymphoepithelial lesion in pulmonary BALT lymphoma (marginal zone B-cell lymphoma) shows numerous cells displaying strong positivity for CD20 percolating between the epithelial cells.* **(Right)** *Higher magnification of immunohistochemical staining with CD20 in lymphoepithelial lesion from a patient with pulmonary BALT lymphoma shows strongly positive small lymphocytes percolating in between the bronchial epithelial cells ⇨.*

Diffuse Large Cell Lymphoma

KEY FACTS

ETIOLOGY/PATHOGENESIS

- May arise from progressive transformation of preexisting low-grade MALT lymphoma

CLINICAL ISSUES

- Adults from 50-70 years of age
- Usually peripheral in location
- Cough, dyspnea, fever, and night sweats

MACROSCOPIC

- Well-circumscribed, tan-white tumor mass with rubbery cut surface

MICROSCOPIC

- Sheets of large lymphoid cells with irregularly shaped, vesicular nuclei and prominent nucleoli
- Areas of low-grade MALT-type lymphoma may be present focally
- Tumors show sharp interface with surrounding lung parenchyma
- Can show variable cytomorphology depending on cell type involved
  - Diffuse large B-cell lymphoma (DLBCL)
  - B-immunoblastic lymphoma (BIL)
  - Anaplastic large cell lymphoma (ALCL)
  - Peripheral T-cell lymphoma (PTCL)

ANCILLARY TESTS

- DLBCL and BIL
  - Positive for CD20, CD79-α, and kappa/lambda light chain restriction
- ALCL
  - Strong paranuclear and membrane staining with CD30 and pan-T-cell antigens
  - Positivity for ALK1 in subset of cases
- PTCL
  - Positive for pan-T-cell markers (CD3, CD45RO)

Diffuse Large Cell Lymphoma of Lung

Diffuse Large Cell Lymphoma

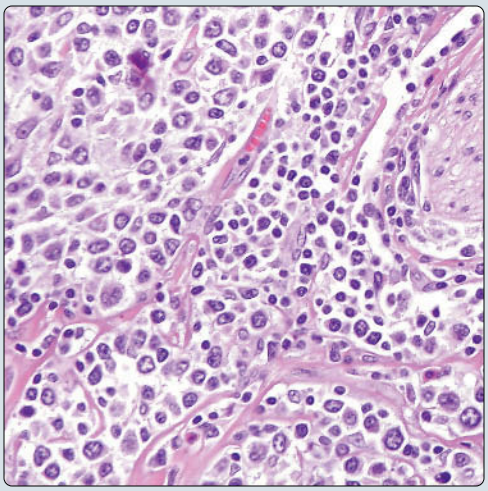

(Left) *Gross appearance of diffuse large B-cell lymphoma of the lung on cut section shows a well-circumscribed, tan-white nodule that is extensively replacing the lung parenchyma.* **(Right)** *Sheets of large, atypical lymphocytes are seen replacing lung parenchyma and alveolar spaces with a few remnants of alveolar walls and small vessels seen in the background.*

Diffuse Large Cell Lymphoma: High Magnification

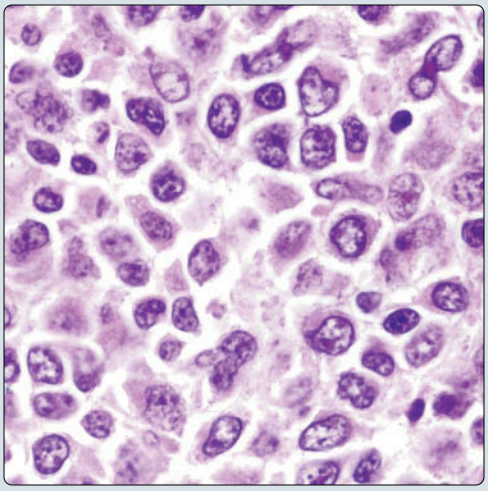

CD20 Immunostaining in Diffuse Large Cell Lymphoma

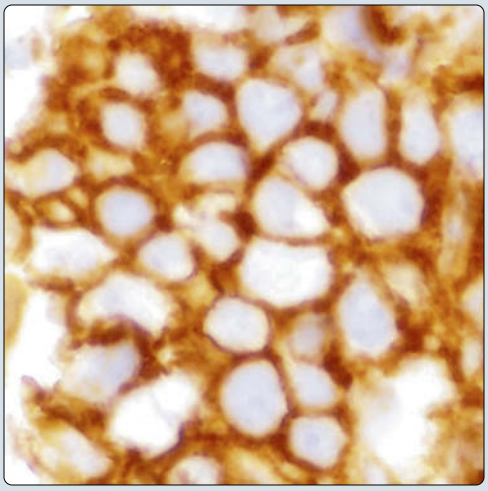

(Left) *Histological appearance of diffuse large B-cell lymphoma of the lung shows a population of large lymphoid cells that are at least the same size as or larger than histiocytes. The nuclei show dispersed chromatin with prominent nucleoli.* **(Right)** *Immunohistochemical staining for CD20 (B-cell marker) shows strong membrane positivity of the large cells in the infiltrate for this antigen.*

TERMINOLOGY

Abbreviations

- Diffuse large cell lymphoma (DLCL)

ETIOLOGY/PATHOGENESIS

Etiology

- Can occur as complication of immunosuppression
- May arise from progressive transformation of preexisting low-grade MALT lymphoma

CLINICAL ISSUES

Epidemiology

- Incidence
  - Represents 10-20% of all pulmonary lymphomas
- Age
  - Adults from 50-70 years of age

Presentation

- Cough, dyspnea, fever, and night sweats

IMAGING

Radiographic Findings

- Chest x-rays show multiple or single opacity

MACROSCOPIC

General Features

- Well-circumscribed, tan-white tumor mass with rubbery cut surface

MICROSCOPIC

Histologic Features

- Sheets of large lymphoid cells with irregularly shaped, vesicular nuclei with prominent nucleoli

Cytologic Features

- Can show variable cytomorphology depending on cell type involved
  - **Diffuse large B-cell lymphoma (DLBCL)**
    - Large cells with enlarged nuclei displaying coarse chromatin pattern and prominent single nucleoli
    - Some tumors may show polylobated nuclei and multinucleated cells
    - Frequent mitotic figures and areas of tumor necrosis
    - Destruction of underlying structures and lung parenchyma
  - **B-immunoblastic lymphoma (BIL)**
    - Large nuclei containing single, large eosinophilic nucleoli, thick cell membranes, and abundant rim of cytoplasm
    - Frequent areas of necrosis and high mitotic activity
  - **Anaplastic large cell lymphoma (ALCL)**
    - Most commonly of T-cell type [although subset of CD30(+) lymphomas may be of B-cell type]
    - Sheets of large, bizarre tumor cells with pleomorphic nuclei and abundant cytoplasm
    - Cells may resemble Reed-Sternberg cells or metastatic carcinoma cells
    - Horseshoe- or kidney-shaped nuclei are characteristic of ALCL
  - **Peripheral T-cell lymphoma (PTCL)**
    - Admixture of large and medium-sized atypical lymphocytes with prominent nuclear convolutions and nuclear hyperchromasia

ANCILLARY TESTS

Immunohistochemistry

- **DLBCL and BIL**
  - Tumor cells are positive for CD20 and CD79-α and show kappa/lambda light chain restriction
- **ALCL**
  - Strong paranuclear (Golgi zone) and membrane staining with CD30
  - Positivity of tumor cells for pan-T-cell antigens (CD3, CD45RO) and ALK1
- **PTCL**
  - Positive for pan-T-cell markers (CD3, CD45RO)

Genetic Testing

- Clonal gene rearrangements of immunoglobulin heavy chain can be demonstrated by PCR in DLBCL
- Demonstration of t(2;5) chromosomal translocation in ALCL
- Demonstration of clonal gene rearrangement of 7 & 5 (T-cell receptor) genes in PTCL

DIFFERENTIAL DIAGNOSIS

Primary or Metastatic Poorly Differentiated/Anaplastic Carcinoma

- Sheets of large, atypical cells with dyscohesive growth pattern that can mimic ALCL
- Positivity of tumor cells for epithelial markers (i.e., low molecular weight cytokeratins, EMA, MOC-31)

Metastatic Malignant Melanoma

- Sheets or nests of large, atypical tumor cells with prominent nucleoli and abundant cytoplasm
- Tumor cells are strongly positive for S100 protein and other melanoma-associated markers (HMB-45, Melan-A, tyrosinase)

Lymphoepithelioma-Like Carcinoma

- Sheets of large atypical cells with scant cytoplasm and prominent nucleoli that can resemble DLCL
- Syncytial growth pattern with dense stromal lymphoid cell infiltrates are characteristic
- Strong positivity for cytokeratins and negative staining for lymphoid markers

SELECTED REFERENCES

1. Maeshima AM et al: Clinicopathological features of histological transformation from extranodal marginal zone B-cell lymphoma of mucosa-associated lymphoid tissue to diffuse large B-cell lymphoma: an analysis of 467 patients. Br J Haematol. ePub, 2016
2. Piña-Oviedo S et al: Primary Pulmonary Lymphomas. Adv Anat Pathol. 22(6):355-75, 2015
3. Rush WL et al: Primary anaplastic large cell lymphoma of the lung: a clinicopathologic study of five patients. Mod Pathol. 13(12):1285-92, 2000
4. Koss MN: Pulmonary lymphoid disorders. Semin Diagn Pathol. 12(2):158-71, 1995

Sheets of Large Lymphoid Cells

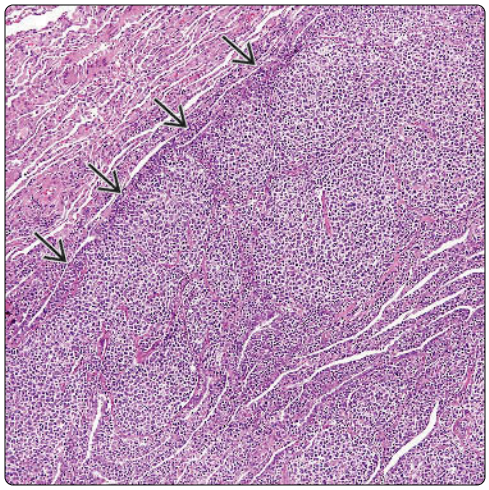

Atypical Lymphoid Infiltrate

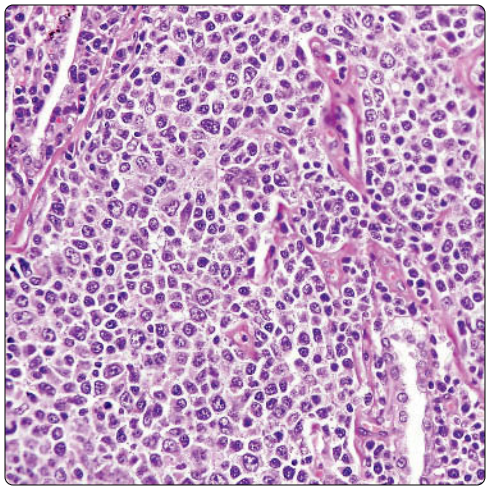

(Left) *Scanning magnification of diffuse large B-cell lymphoma of the lung shows a monotonous tumor cell population composed of sheets of large lymphoid cells that are sharply circumscribed from the surrounding uninvolved lung parenchyma* ⇨. **(Right)** *Diffuse large B-cell lymphoma of the lung shows sheets of large lymphoid cells growing with a dyscohesive growth pattern. The differential diagnosis in these cases includes anaplastic carcinoma and round cell sarcomas.*

Atypical Lymphocytes: Higher Magnification

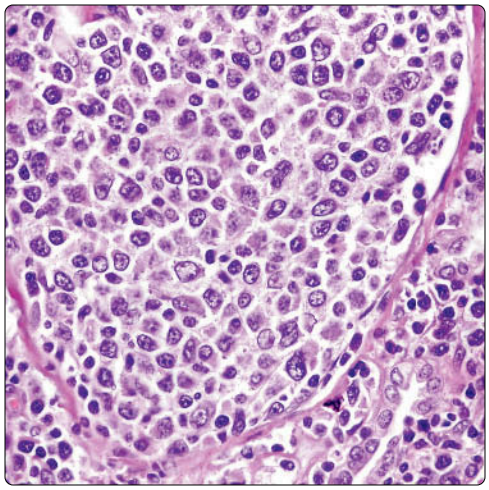

Entrapment of Airspaces

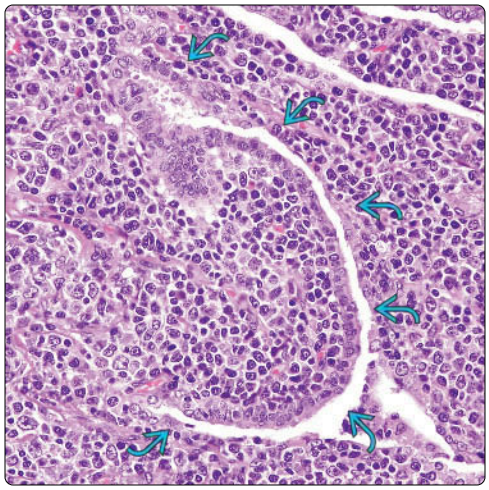

(Left) *Higher magnification of diffuse large B-cell lymphoma of the lung shows a monotonous population composed of sheets of dyscohesive large lymphoid cells with large nuclei and abundant cytoplasm.* **(Right)** *Diffuse large B-cell lymphoma of the lung shows entrapment of a small airspace* ⇨ *by the tumor. Notice that the atypical lymphoid cell population neither infiltrates the epithelial structures nor damages the epithelial lining of the entrapped airspace.*

Atypical Lymphoid Cells: High Power

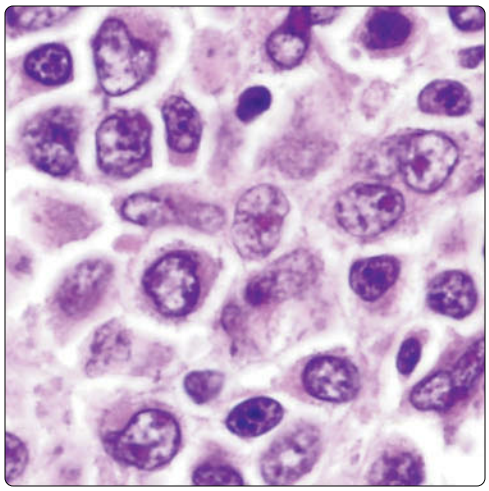

CD20 Positivity in Diffuse Large Cell Lymphoma

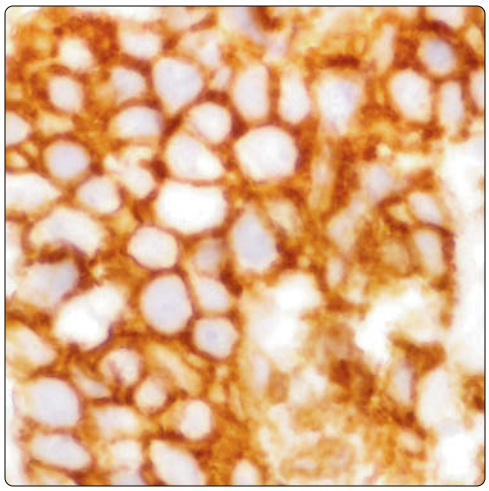

(Left) *Higher magnification of diffuse large B-cell lymphoma of the lung shows cells with enlarged nuclei that are at least the size of a normal macrophage with prominent eosinophilic nucleoli and a scant rim of amphophilic cytoplasm.* **(Right)** *Immunohistochemical staining of diffuse large B-cell lymphoma of the lung with the pan-B-cell marker CD20 shows strong positivity of the tumor cells for this antigen. The tumor cells will also react with antibodies to CD79-a and CD45.*

Entrapment of Bronchial Cartilage

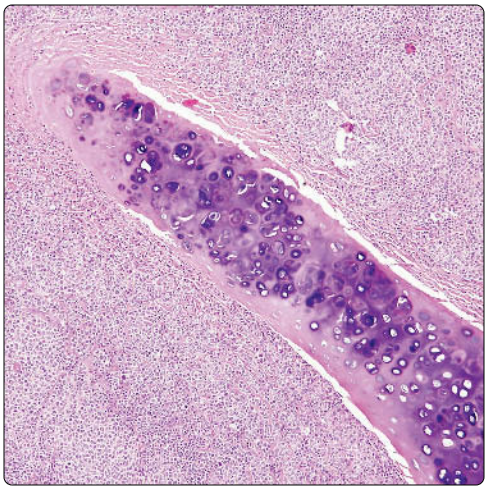

Entrapment of Bronchial Glands

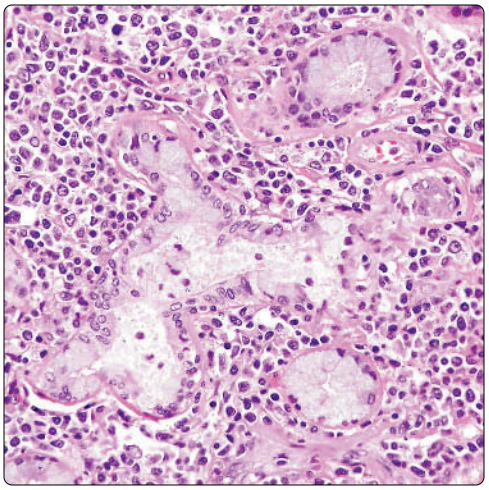

(Left) *Scanning magnification of diffuse large B-cell lymphoma of the lung shows infiltration and destruction of bronchial cartilage by the tumor. On rare occasions, the tumors can display an endobronchial location with prominent occlusion of the lumen.* **(Right)** *Diffuse large B-cell lymphoma of the lung shows entrapment of bronchial glands by the tumor. The tumor cells in this case were strongly positive for pan-B-cell markers, including CD20 and CD79-a.*

Perineurial Invasion

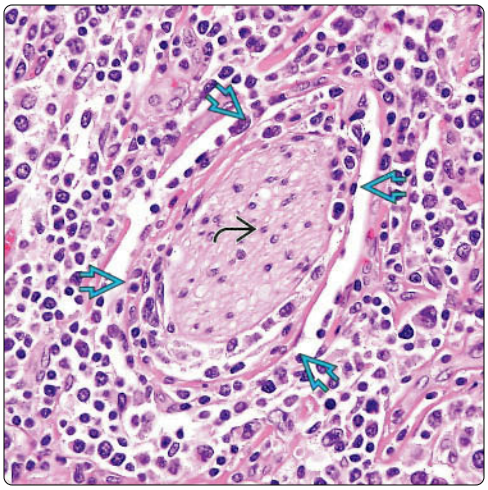

Perivascular Invasion by Lymphoma

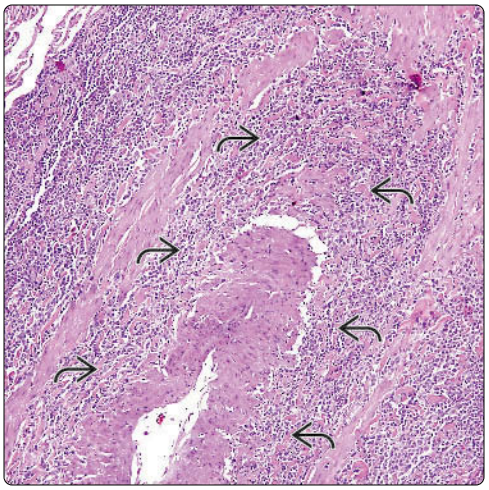

(Left) *Diffuse large B-cell lymphoma of the lung shows a focus of perineural invasion ⇨. The perineurial sheath of the small nerve ⇨ in the center is infiltrated by the large, atypical lymphocytes.* **(Right)** *Diffuse large B-cell lymphoma of the lung shows perivascular infiltration by the tumor. The tumor cells are seen to splay and replace the media in this large-caliber vessel ⇨. Cases like these need to be distinguished from lymphomatoid granulomatosis.*

Stromal Sclerosing

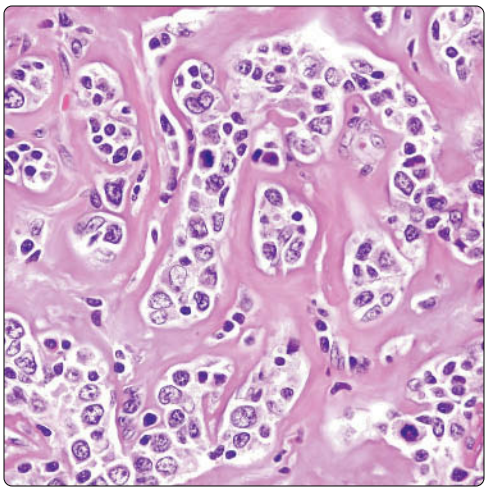

Submucosal Distribution

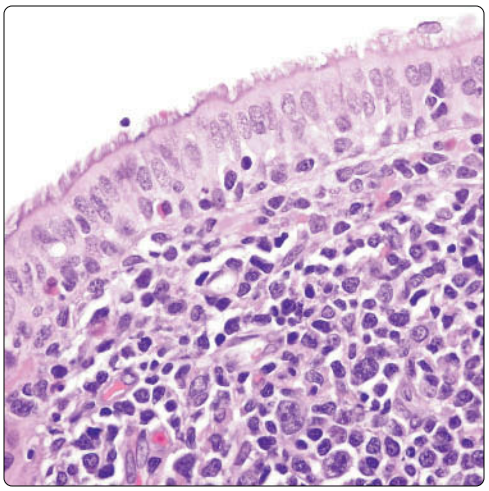

(Left) *Diffuse large B-cell lymphoma of the lung shows an unusual pattern of stromal hyalinization resulting in compartmentalization of tumor cells into small "nests" simulating carcinoma. This histologic appearance is very similar to that observed in primary diffuse large cell lymphomas of the mediastinum.* **(Right)** *Diffuse large B-cell lymphoma of the lung shows lymphoid cell infiltrate distributed underneath the bronchial mucosa, which does not infiltrate it.*

Peribronchial Distribution

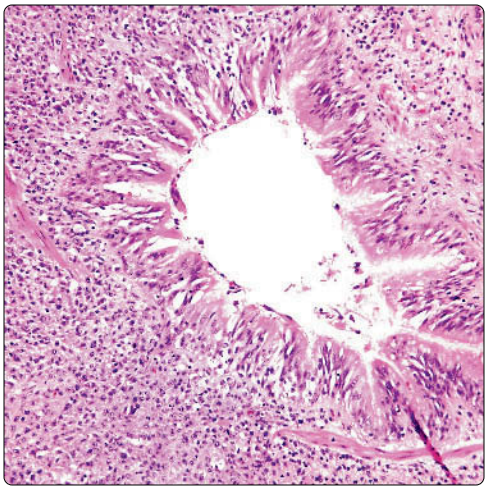

Immunoblastic Lymphoma of Lung

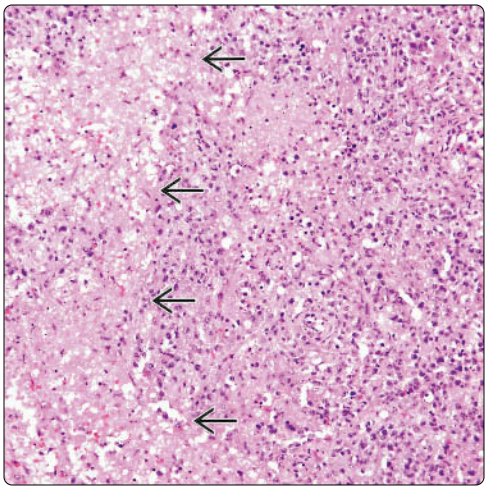

(Left) *Large cell immunoblastic lymphoma of the lung shows entrapment of an airspace by a dense, homogeneous population of large, atypical lymphoid cells.* **(Right)** *Immunoblastic large cell lymphoma involving the lung shows prominent areas of necrosis ⇨ surrounded by a diffuse atypical large lymphoid cell population. Immunoblastic lymphomas are high-grade malignancies that are often accompanied by extensive areas of tumor cell necrosis.*

Immunoblastic Lymphoma: High Power

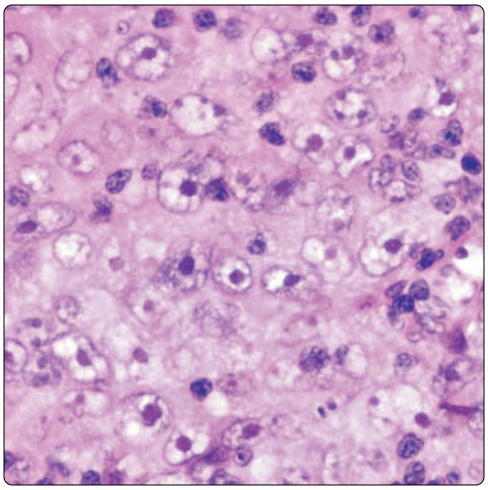

CD20 Positivity in Immunoblastic Lymphoma

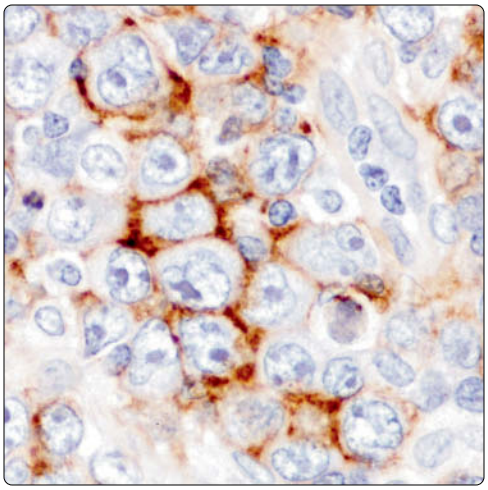

(Left) *Higher magnification of diffuse large B-cell lymphoma of the lung with immunoblastic features shows large tumor cells with large, vesicular nuclei and prominent eosinophilic nucleoli. The cells also contain abundant eosinophilic cytoplasm.* **(Right)** *Immunohistochemical staining of large immunoblastic lymphoma of the lung for CD20 shows positive staining in the large tumor cells. Stains for T-cell markers, CD30, and ALK1, were negative in this tumor.*

Immunoblastic Lymphoma of Lung

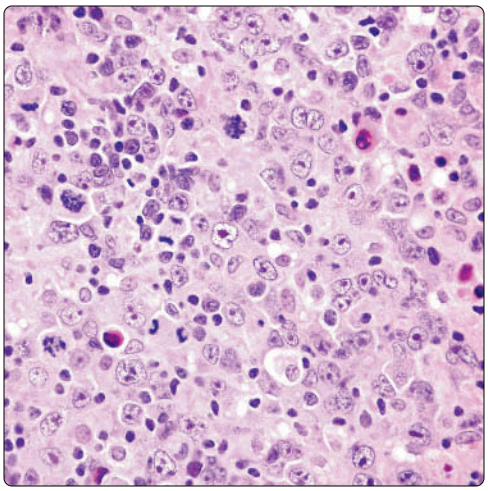

Immunoblastic Lymphoma: High Power

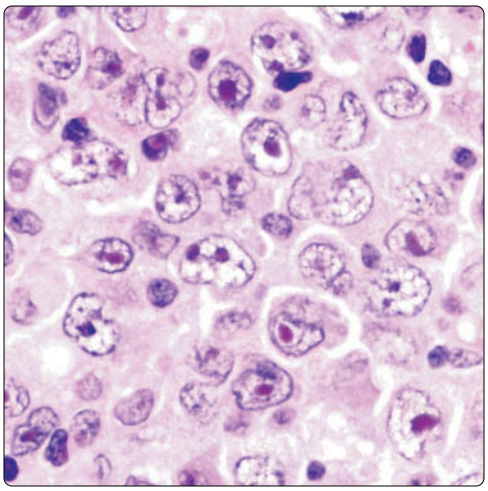

(Left) *Diffuse large B-cell lymphoma of the lung (immunoblastic type) shows sheets of large mononuclear cells with enlarged nuclei containing prominent nucleoli and surrounded by an abundant rim of cytoplasm.* **(Right)** *Higher magnification of immunoblastic large cell lymphoma of the lung shows large mononuclear cells with enlarged nuclei containing prominent eosinophilic nucleoli and abundant cytoplasm. These tumors are generally positive for CD20 and other pan-B-cell antigens.*

Anaplastic Large Cell Lymphoma of Lung

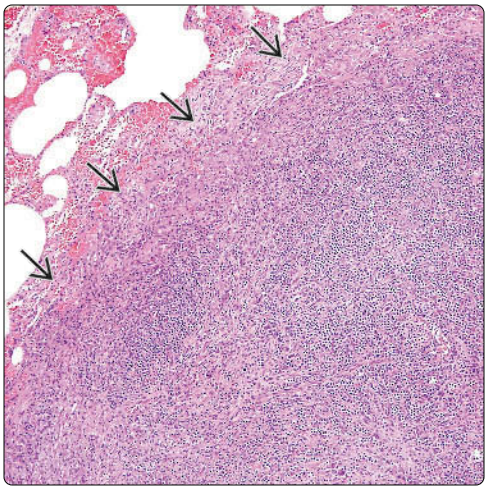

Entrapment of Airspaces in Anaplastic Large Cell Lymphoma

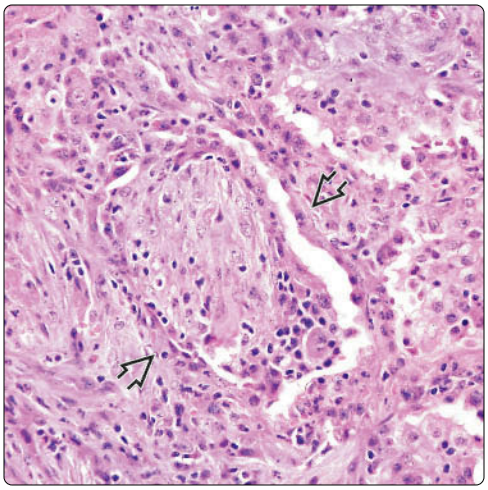

(Left) *Scanning magnification of anaplastic large cell lymphoma of the lung shows a well-circumscribed neoplastic population of cells composed of sheets of large, dyscohesive tumor cells. The tumor is sharply demarcated from the surrounding pulmonary parenchyma.* **(Right)** *Higher magnification of an anaplastic large cell lymphoma of the lung shows entrapment of airspaces within the tumor with plugging of alveolar spaces by large, atypical tumor cells.*

Anaplastic Large Cell Lymphoma: High Power

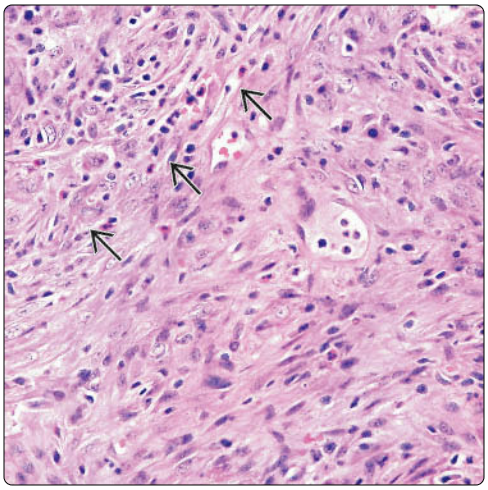

Anaplastic Large Cell Lymphoma: High Power

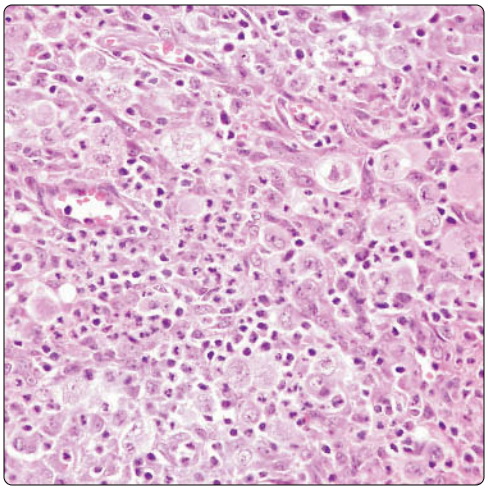

(Left) *Higher magnification of an anaplastic large cell lymphoma of the lung shows large atypical cells with abundant cytoplasm and epithelioid morphology blending with atypical spindle cell proliferation (lower right). Sarcomatoid appearance is an unusual feature of these tumors.* **(Right)** *Higher magnification of an anaplastic large cell lymphoma shows a mixed population composed of scattered small lymphocytes admixed with larger, round epithelioid cells.*

Anaplastic Large Cell Lymphoma: CD30 Immunostaining

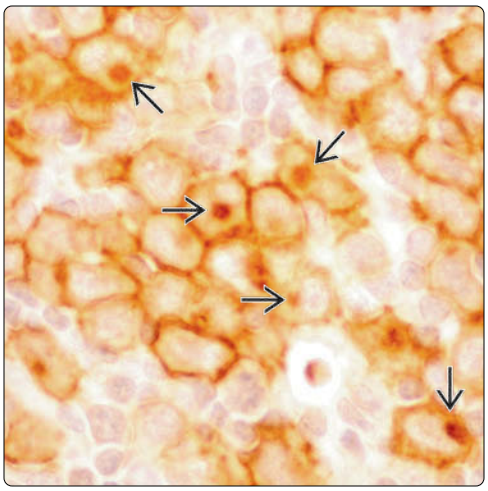

Anaplastic Large Cell Lymphoma: CD45 Immunostaining

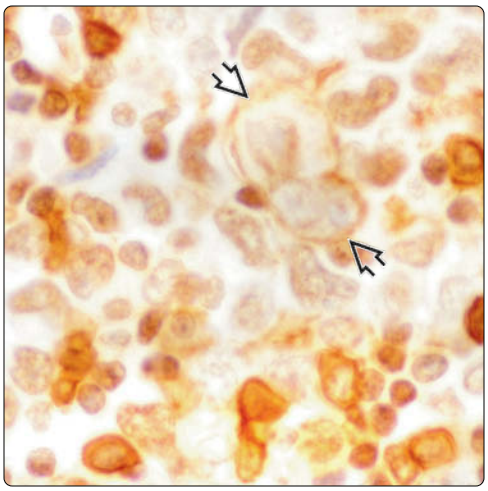

(Left) *Immunohistochemical staining of anaplastic large cell lymphoma of the lung with CD30 antibody shows strong membranous and paranuclear (Golgi zone, dot-like) staining in the large tumor cells.* **(Right)** *Immunohistochemical staining of an anaplastic large cell lymphoma of the lung with CD45RO (UCHL-1) pan-T-cell marker shows positivity of a few scattered small lymphocytes and also membrane positivity in the large, atypical lymphoid cells.*

Anaplastic Large Cell Lymphoma: Scanning Magnification

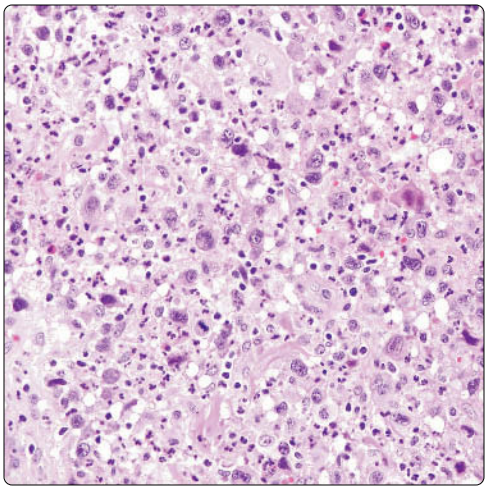

Anaplastic Large Cell Lymphoma: Hallmark Cells

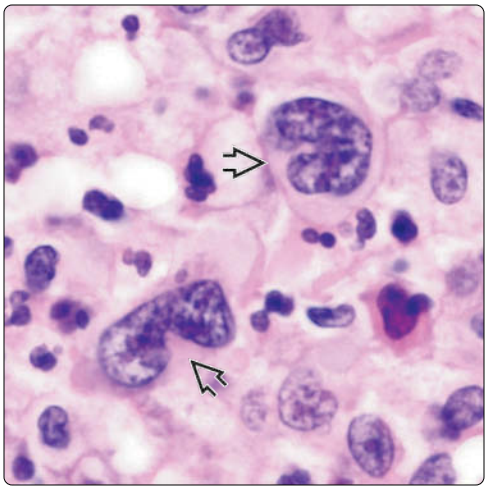

(Left) *Scanning magnification of an anaplastic large cell lymphoma of the lung shows a neoplastic population composed of sheets of large, atypical cells with bizarre nuclei admixed with scattered small lymphocytes.* **(Right)** *Characteristic histology of anaplastic large cell lymphoma of the lung shows large atypical cells with enlarged nuclei adopting a kidney-shaped or horseshoe configuration ⇨. This type of cell is highly distinctive (hallmark cell) for this tumor.*

Anaplastic Large Cell Lymphoma: Multinucleated Tumor Cells

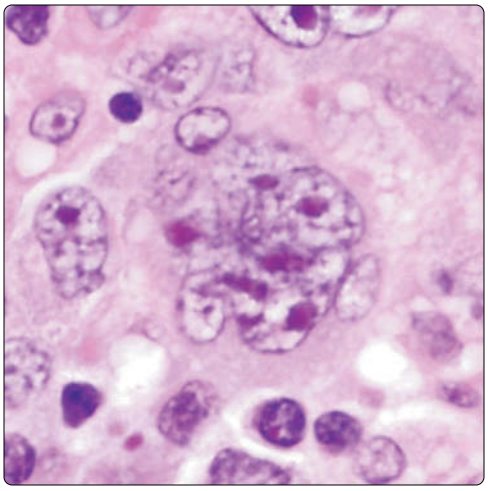

Anaplastic Large Cell Lymphoma: Reed-Sternberg-Like Cells

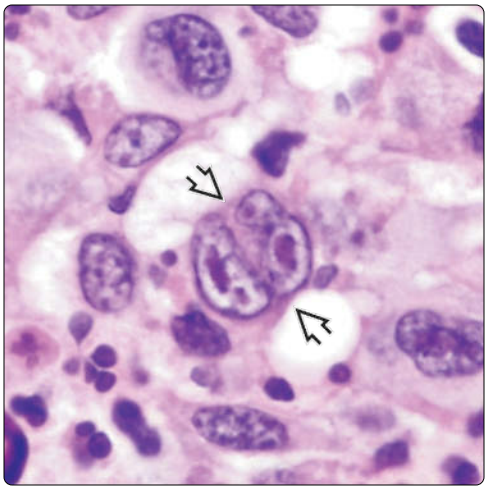

(Left) *Higher magnification of an anaplastic large cell lymphoma of the lung shows bizarre multinucleated tumor cells with multiple overlapping nuclei with prominent eosinophilic nucleoli resembling a Reed-Sternberg cell.* **(Right)** *Higher magnification in an anaplastic large cell lymphoma of the lung shows a Reed-Sternberg-like binucleated cell with prominent eosinophilic nucleoli ⇨. Cases like this can be difficult to distinguish from Hodgkin lymphoma.*

Anaplastic Large Cell Lymphoma: CD30 Immunostaining

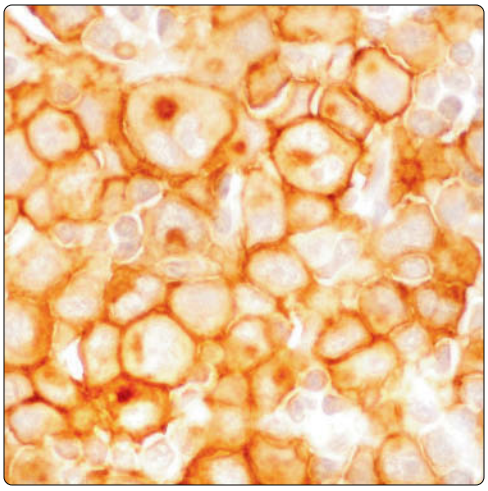

Anaplastic Large Cell Lymphoma: CD20 Immunostaining

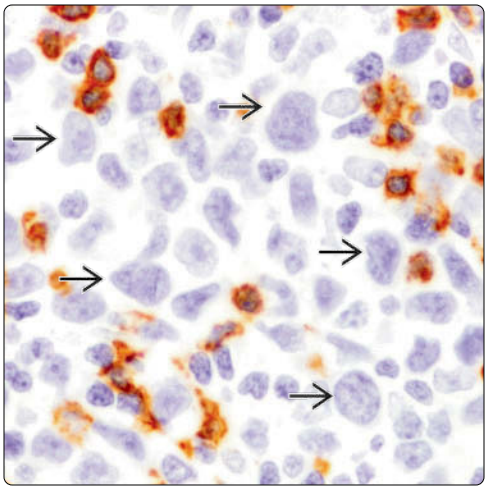

(Left) *Immunohistochemical staining of an anaplastic large cell lymphoma for CD30 antibody shows strong membranous and dot-like, paranuclear cytoplasmic staining in the large, atypical tumor cells.* **(Right)** *Immunohistochemical staining of an anaplastic large cell lymphoma for CD20 shows scattered positive small lymphocytes. Notice, however, that the large atypical cells in the background are negative ⇨. These tumors can stain positive for ALK1 and for pan-T-cell markers.*

Peripheral T-Cell Lymphoma of Lung

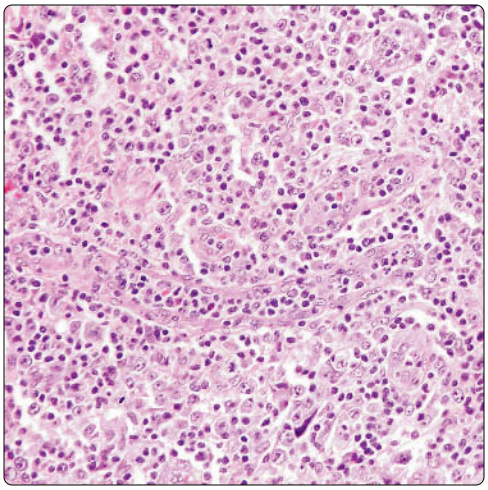

Pulmonary Peripheral T-Cell Lymphoma: Higher Magnification

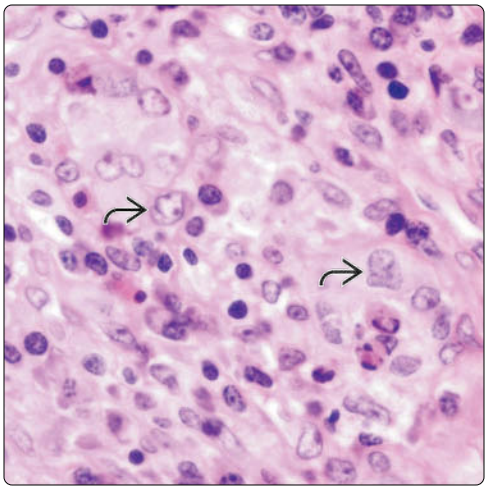

(Left) *Peripheral T-cell lymphoma of the lung shows sheets of lymphoid cells composed of a mixed population, including small lymphocytes, plasma cells, eosinophils, and scattered large, atypical lymphocytes. Notice the prominent stromal hypervascularity.* **(Right)** *Higher magnification of a pulmonary peripheral T-cell lymphoma shows a mixed population of cells, including small lymphocytes, plasma cells, eosinophils, and scattered, large, atypical lymphoid cells with convoluted nuclei.*

Pulmonary Peripheral T-Cell Lymphoma: Higher Magnification

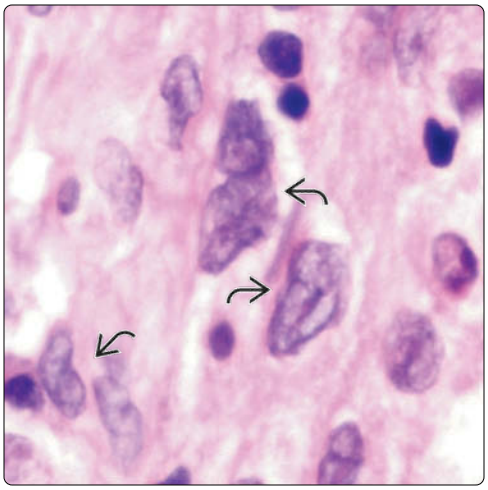

Pulmonary Peripheral T-Cell Lymphoma: CD45RO Immunostaining

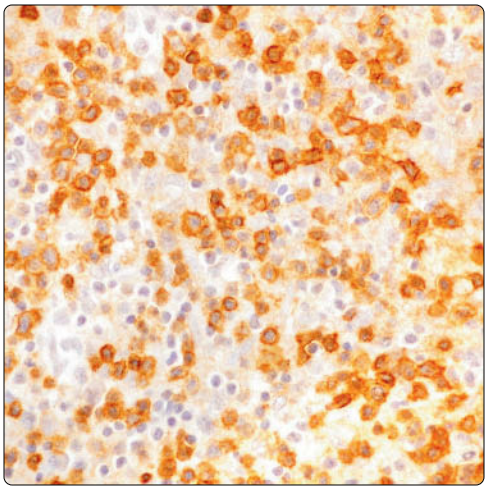

(Left) *Higher magnification of a pulmonary peripheral T-cell lymphoma shows atypical lymphoid cells with enlarged nuclei displaying irregular nuclear contours with a scant rim of amphophilic cytoplasm.* **(Right)** *Immunohistochemical staining of pulmonary peripheral T-cell lymphoma with a pan-T-cell marker [CD45RO (UCHL-1)] shows strong positive staining of the atypical T lymphocytes and negative staining in the smaller B cells scattered in the background.*

Pulmonary Peripheral T-Cell Lymphoma: CD3 Immunostaining

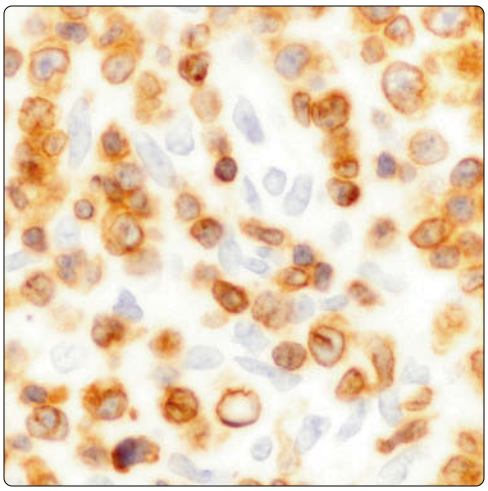

Pulmonary Peripheral T-Cell Lymphoma: CD20 Immunostaining

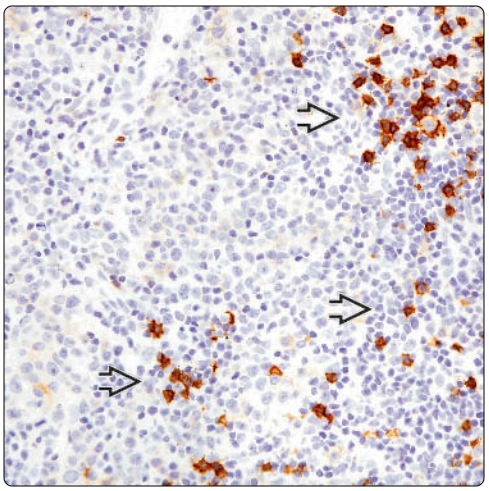

(Left) *Immunohistochemical staining of pulmonary peripheral T-cell lymphoma for CD3 antibody shows numerous positive cells with enlarged, irregular nuclei. Notice that the smaller, normal B lymphocytes in the background are negative.* **(Right)** *Immunohistochemical staining of pulmonary peripheral T-cell lymphoma with antibodies for the pan-B-cell marker (CD20) shows a few scattered positive cells. The larger, neoplastic T cells seen in the background are negative.*

Hodgkin Lymphoma

KEY FACTS

CLINICAL ISSUES

- Hodgkin lymphoma (HL) arising primarily in lungs is extremely rare
- Pulmonary involvement is most often seen in course of regional or systemic dissemination
- Mediastinal, cervical, or supraclavicular lymphadenopathy
- Primary extranodal pulmonary HL tends to follow more aggressive behavior than nodal-based HL

MICROSCOPIC

- Majority of cases are of nodular sclerosis subtype and rest are of mixed cellularity
- Nodules consist of varying numbers of lymphocytes, plasma cells, and eosinophils admixed with scattered Reed-Sternberg cells
- Neoplastic cells are represented by transformed atypical lymphocytes (Hodgkin cells and Reed-Sternberg cells)
- Hodgkin cells are large, mononuclear cells with large nucleus containing single prominent eosinophilic nucleolus
- Reed-Sternberg cells are bi- or multinucleated cells containing prominent eosinophilic nucleoli
- Neoplastic cells always represent minority of infiltrate (0.1-10% of cells in infiltrate)
- Background infiltrate is polymorphous and composed of small lymphocytes, plasma cells, eosinophils, and histiocytes

ANCILLARY TESTS

- Immunohistochemistry
  - Reed-Sternberg cells and their variants show strong membranous and paranuclear (Golgi zone) positivity for CD30 and CD15
  - Reed-Sternberg cells show weak positivity for pax-5 and can express EBV-encoded LMP-1
  - Reed-Sternberg cells are negative for CD45, CD79-a, and, in majority of cases, CD20

Pulmonary Hodgkin Lymphoma

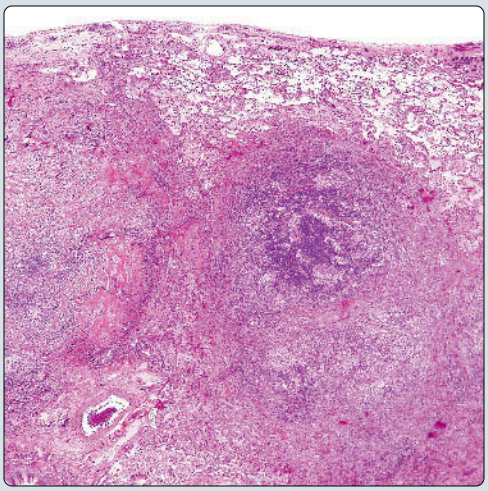

Dense Lymphoid Infiltrate

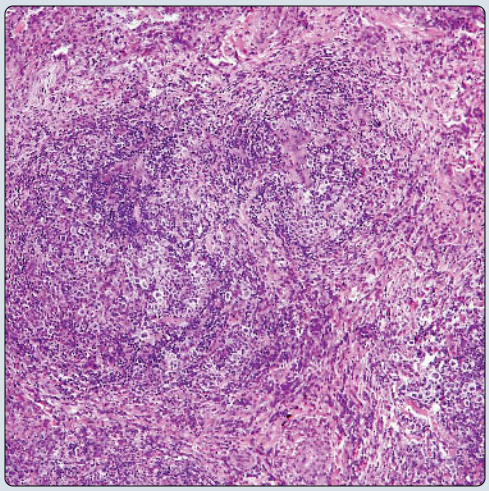

(Left) *Multiple tumor nodules are seen in this lung involved with Hodgkin lymphoma. The infiltrate is composed of a mixed population of lymphocytes, plasma cells, eosinophils, and scattered, large atypical cells. The tumor completely effaces the underlying pulmonary architecture.* **(Right)** *Higher magnification shows a mixed dense lymphoid infiltrate composed of lymphocytes, plasma cells, histiocytes, eosinophils, and scattered Reed-Sternberg cells and their variants.*

Reed-Sternberg Cell

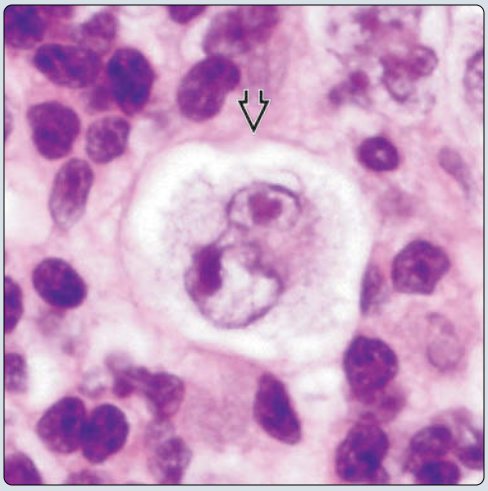

CD30 Positivity in Reed-Sternberg Cell

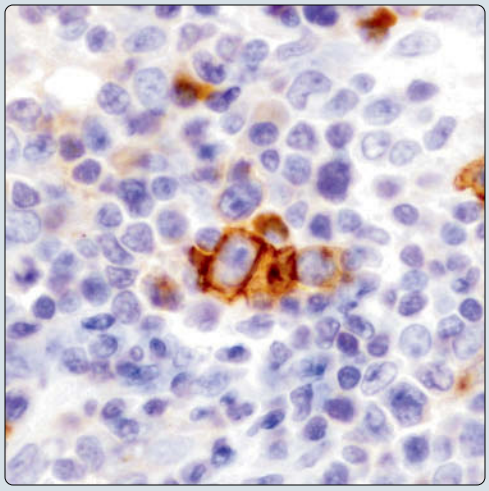

(Left) *High magnification of a pulmonary nodule in Hodgkin lymphoma shows a characteristic binucleated Reed-Sternberg cell with double nuclei and prominent "owl-eyed" eosinophilic nucleoli.* **(Right)** *Immunohistochemical staining with CD30 antibody shows membrane and dot-like paranuclear positivity of a Reed-Sternberg cell in the infiltrate.*

TERMINOLOGY

Abbreviations

- Hodgkin lymphoma (HL)

Definitions

- Lymphoid neoplasm composed of scattered mononuclear and multinucleated atypical lymphoid cells amid mixed lymphoreticular infiltrate

ETIOLOGY/PATHOGENESIS

Pathogenesis

- Epstein-Barr virus (EBV) has been claimed to play role in subset of cases
- EBV infection may be cofactor in genetic cascade of events leading to development of HL
- Neoplastic cells are derived from mature B cells at germinal center stage of differentiation in > 98% of cases

CLINICAL ISSUES

Epidemiology

- Incidence
  - HL arising primarily in lungs is extremely rare
  - Pulmonary involvement is most often seen in course of regional or systemic dissemination

Presentation

- Mediastinal, cervical, or supraclavicular lymphadenopathy

Treatment

- Adjuvant therapy
  - Combination chemotherapy

Prognosis

- Primary extranodal pulmonary HL tends to follow more aggressive behavior than nodal-based HL

IMAGING

General Features

- Morphology
  - Single or multiple nodules
  - Bilateral reticulonodular infiltrates are seen less frequently
  - Absence of associated lymphadenopathy in primary lung cases

MACROSCOPIC

General Features

- Well-circumscribed gray-white masses with areas of consolidation of lung parenchyma
- Nodules may be single or multiple and randomly distributed

MICROSCOPIC

Histologic Features

- Majority of cases are of nodular sclerosis subtype and rest are of mixed cellularity
- Nodules consist of varying numbers of lymphocytes, plasma cells, and eosinophils admixed with scattered Reed-Sternberg cells

Cytologic Features

- Neoplastic cells are represented by transformed atypical lymphocytes (Hodgkin cells and Reed-Sternberg cells)
- Hodgkin cells are large, mononuclear cells with large nuclei containing single prominent eosinophilic nucleoli
- Reed-Sternberg cells are bi- or multinucleated cells containing prominent eosinophilic nucleoli
- Cells with condensed cytoplasm and large pyknotic basophilic nuclei are known as "mummy" cells
- Neoplastic cells always represent minority of infiltrate (0.1-10% of cells in infiltrate)
- Background infiltrate is polymorphous and composed of small lymphocytes, plasma cells, eosinophils, and histiocytes

ANCILLARY TESTS

Immunohistochemistry

- Reed-Sternberg cells and their variants show strong membranous and paranuclear (Golgi zone) positivity for CD30 and CD15
- Reed-Sternberg cells are negative for CD45, CD79-a, and, in majority of cases, CD20
- Reed-Sternberg cells show weak positivity for pax-5 and can express EBV-encoded LMP1

In Situ Hybridization

- EBV-infected Reed-Sternberg cells show strong expression of EBER in their nuclei by in situ hybridization

Genetic Testing

- Reed-Sternberg cells contain clonal immunoglobulin (Ig) gene rearrangements in > 98% of cases
- Minority of cases (< 2%) may show T-cell receptor (TCR) gene rearrangements

DIFFERENTIAL DIAGNOSIS

Anaplastic Large Cell Lymphoma

- Sheets of anaplastic tumor cells resembling Reed-Sternberg cells in which anaplastic cells predominate
- Majority of anaplastic large cell lymphoma (ALCL) are of T-cell lineage and express ALK1 and T-cell markers
- ALK negative ALCL may be difficult to distinguish from HL, but it consistently demonstrates TCR gene rearrangements

Lymphomatoid Granulomatosis

- Lymphomatoid granulomatosis (LYG) may show similar histologic appearance to HL with scattered large atypical cells against mixed inflammatory background
- Atypical cells in LYG are CD20(+) and EBER(+) and do not stain for CD15 or CD30

SELECTED REFERENCES

1. Cooksley N et al: Primary pulmonary Hodgkin's lymphoma and a review of the literature since 2006. BMJ Case Rep. 2014
2. Rodriguez J et al: Hodgkin lymphoma presenting with exclusive or preponderant pulmonary involvement: a clinicopathologic study of 5 new cases. Ann Diagn Pathol. 10(2):83-8, 2006
3. Costa MB et al: Histologic patterns of lung infiltration of B-cell, T-cell, and Hodgkin lymphomas. Am J Clin Pathol. 121(5):718-26, 2004

Subpleural Nodule

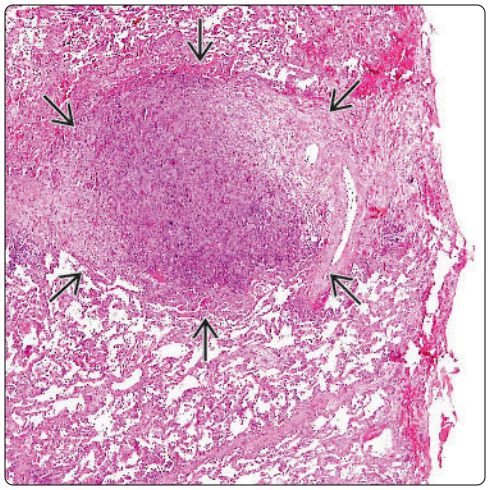

Polymorphous Lymphoid Infiltrate

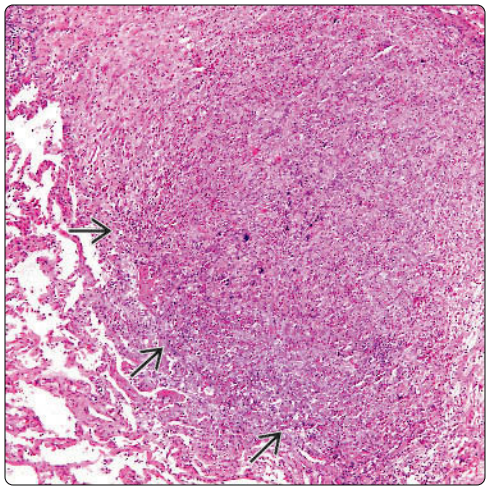

(Left) *Scanning magnification of Hodgkin lymphoma involving the lung shows a well-defined solid nodule in a subpleural location surrounded by normal-appearing pulmonary parenchyma.* **(Right)** *Lung involvement in Hodgkin lymphoma shows a well-defined area of condensation of pulmonary parenchyma. The differential diagnosis for lesions with this morphology incudes diffuse large cell lymphoma, anaplastic large cell lymphoma, and lymphomatoid granulomatosis.*

"Mummy" Cells

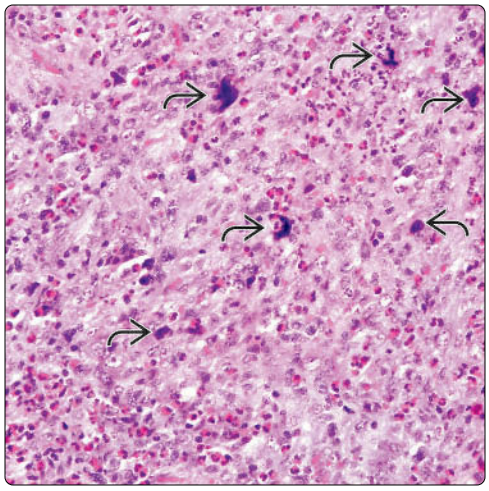

Mononuclear Hodgkin Cell

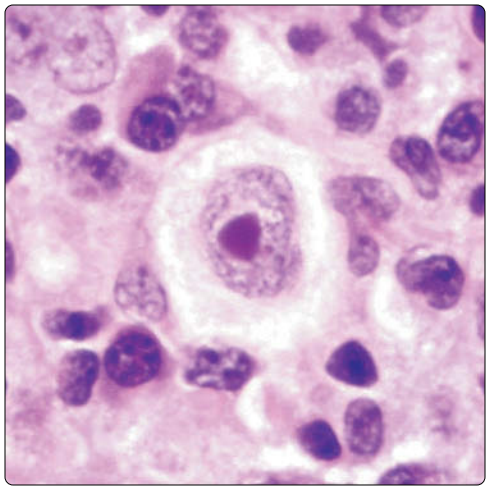

(Left) *Higher magnification of a pulmonary nodule in a patient with Hodgkin lymphoma shows a mixed cell population containing small lymphocytes, plasma cells, eosinophils, and histiocytes as well as scattered larger lymphoid cells. Some of the larger cells show pyknotic nuclei ("mummy" cells).* **(Right)** *Higher magnification of a lung nodule involved with Hodgkin lymphoma shows a large mononuclear cell with a prominent eosinophilic nucleolus (so-called Hodgkin cell).*

Binucleated Reed-Sternberg Cell

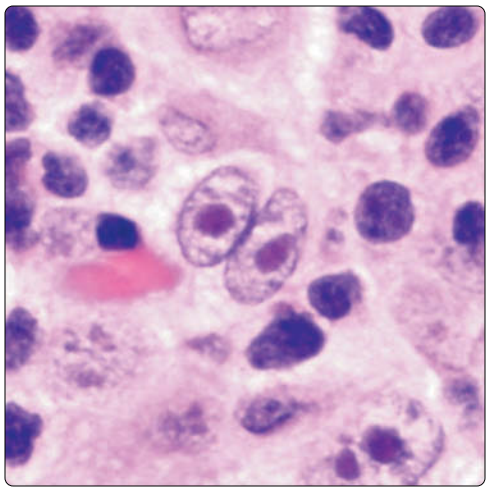

Multinucleated Reed-Sternberg Cell

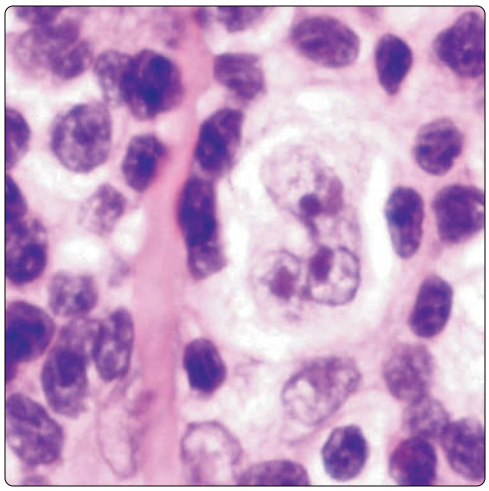

(Left) *Higher magnification of a lung nodule involved with Hodgkin lymphoma shows a classic binucleated Reed-Sternberg cell with the characteristic "owl-eyed" eosinophilic nucleoli. Mononuclear Hodgkin cells and bi- or multinucleated Reed-Sternberg cells are the neoplastic proliferating cells in Hodgkin lymphoma.* **(Right)** *High magnification of a lung nodule in Hodgkin lymphoma shows a multinucleated Reed-Sternberg cell with 3 nuclei containing prominent eosinophilic nucleoli.*

Focus of Pulmonary Hodgkin Lymphoma

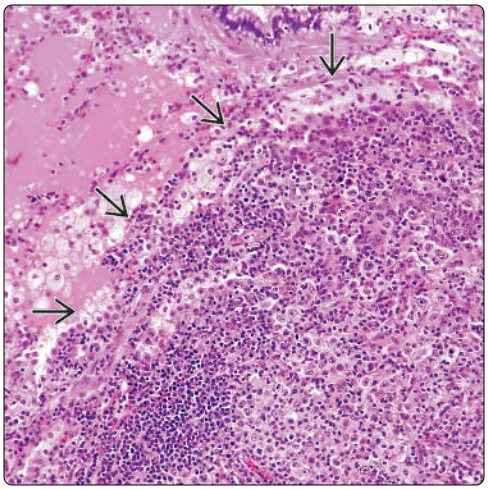

Polymorphous Lymphoid Infiltrate

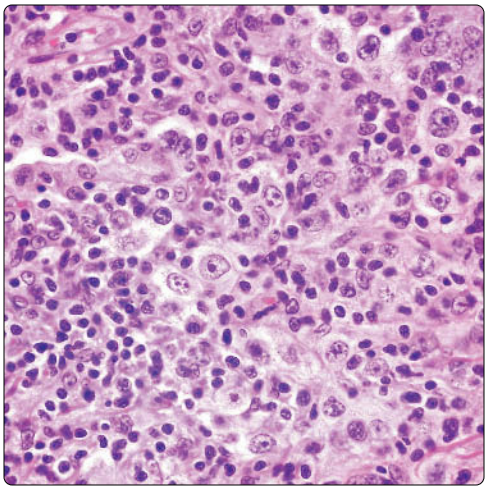

(Left) *Scanning magnification of a lung lesion in a patient with Hodgkin lymphoma shows a well-circumscribed area of parenchymal condensation ⇨ surrounded by normal lung parenchyma with intraalveolar edema fluid.* **(Right)** *Higher magnification from a lung nodule with Hodgkin lymphoma shows a mixed population of inflammatory cells including small lymphocytes, plasma cells, histiocytes, and eosinophils admixed with scattered larger lymphoid cells with prominent nucleoli (Hodgkin cells).*

Reed-Sternberg Cells

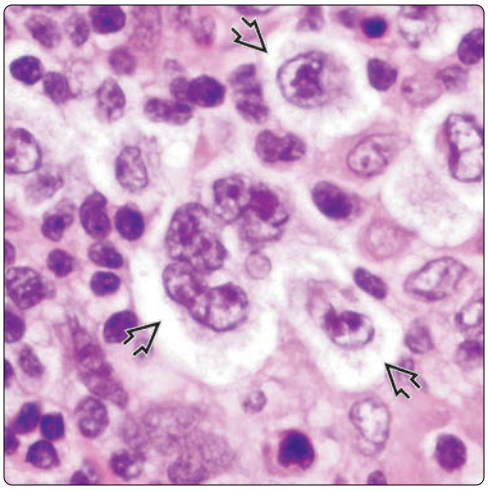

Mononuclear Hodgkin Cells

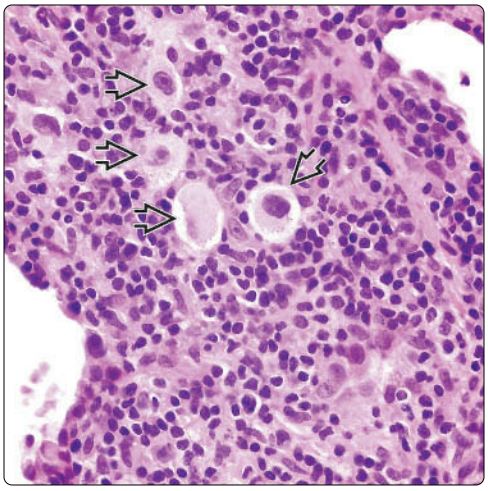

(Left) *Higher magnification of a lung nodule in a patient with Hodgkin lymphoma shows large, mononuclear and multinucleated atypical cells. Bi- and multinucleated Reed-Sternberg cells in the nodular sclerosis subtype are designated "lacunar" cells due to their clear perinuclear clearing ⇨.* **(Right)** *Hodgkin lymphoma involving the lung shows an interstitial pattern of spread with widening of the intraalveolar septa by a mixed population of lymphoid cells containing a few Hodgkin cells ⇨.*

CD30 Immunostaining

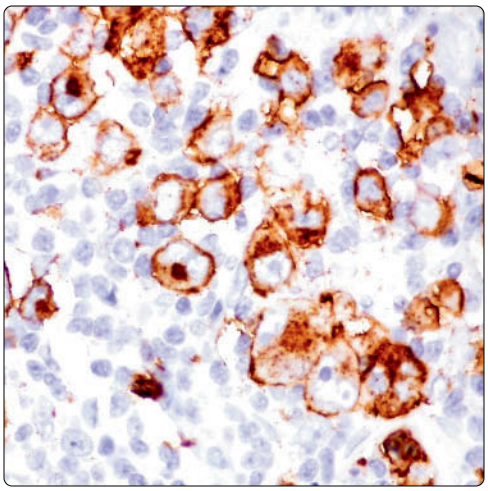

CD15 Immunostaining

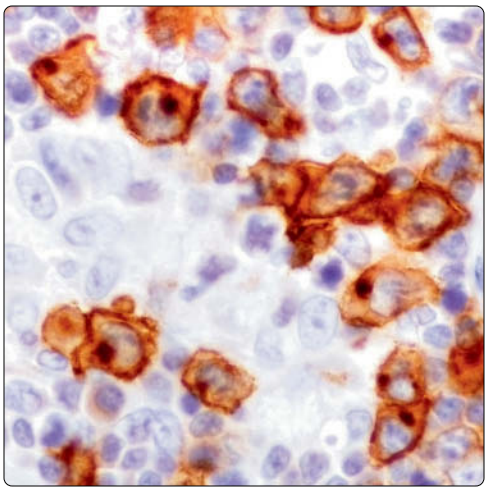

(Left) *Immunohistochemical staining of pulmonary Hodgkin lymphoma with CD30 shows membrane and paranuclear (Golgi zone) positivity in Reed-Sternberg cells. This antibody is expressed in 100% of cases in Hodgkin lymphoma.* **(Right)** *Immunohistochemical staining of pulmonary Hodgkin lymphoma for CD15 shows membrane and paranuclear (Golgi zone) positivity in the large atypical cells. CD15 stains these cells less frequently than CD30 (only in about 65% of cases).*

Plasmacytoma

KEY FACTS

CLINICAL ISSUES

- Incidence
  - Primary plasmacytomas of lung are rare
  - May represent ~ 5% of all extramedullary plasmacytomas
  - Tumor has been described essentially in adults
    - Patients 50-80 years old
- Symptoms
  - Cough
  - Hemoptysis
  - Dyspnea
  - Multiple myeloma
  - Asymptomatic
- Prognosis
  - 2-year survival rate: ~ 66%
  - 5-year survival rate: ~ 40%

MACROSCOPIC

- Hilar or parenchymal mass
- Tumors 2-8 cm in diameter
- Important to submit hilar lymph nodes, as they may also be involved

MICROSCOPIC

- Diffuse plasma cell proliferation
- Subtle nested pattern
- Focal angiectatic areas
- Monoclonal gammopathy
- Plasma cell with Dutcher bodies

TOP DIFFERENTIAL DIAGNOSES

- Inflammatory pseudotumor, plasma cell type
- Pneumonia
- Carcinoma
- Malignant lymphoma with plasmacytoid features

(Left) *Pulmonary plasmacytoma shows destruction of the lung parenchyma by a homogeneous neoplastic cellular proliferation. Note the bronchial cartilage that is without invasion.* **(Right)** *Closer view shows the neoplastic cellular proliferation composed exclusively of atypical plasma cells. There is no special growth pattern.*

Central Tumor

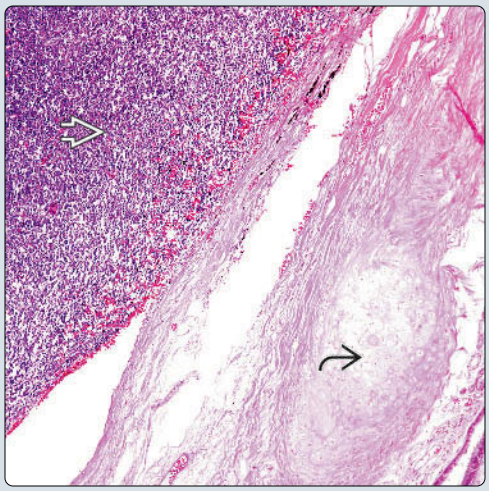

Diffuse Pattern

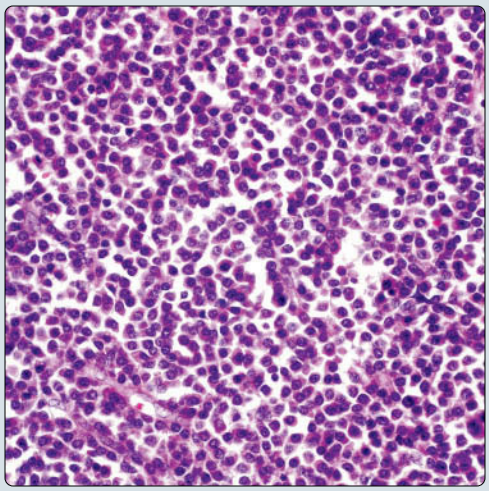

(Left) *Primary plasmacytoma of the lung shows a neoplastic cellular proliferation arranged in cords with a subtle nested pattern.* **(Right)** *Primary plasmacytoma of the lung shows a diffuse plasma cell proliferation composed of atypical plasma cells. Mitotic activity is present.*

Cords of Neoplastic Cells

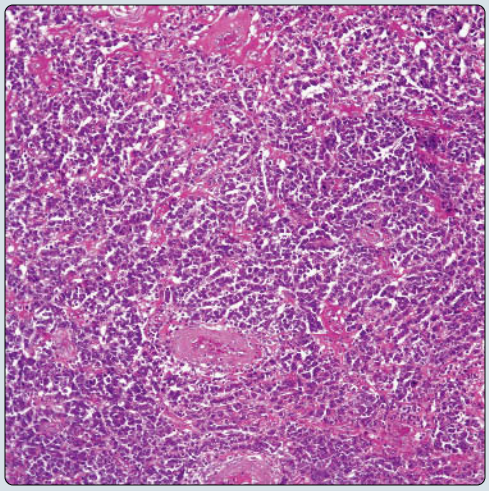

Atypical Plasma Cells

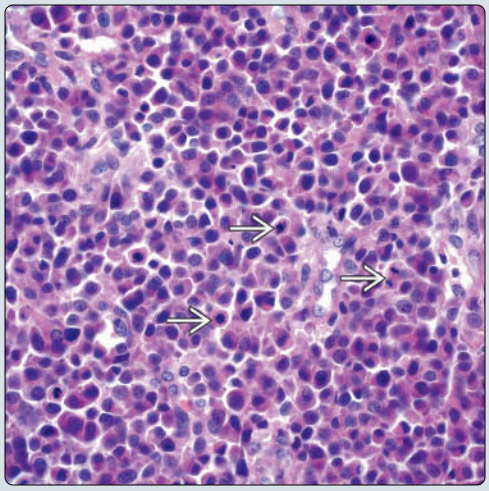

TERMINOLOGY

Definitions

- Malignant neoplasm composed of proliferation of monoclonal plasma cells

ETIOLOGY/PATHOGENESIS

Etiology

- Plasma cell dyscrasia

CLINICAL ISSUES

Epidemiology

- Incidence
  - Primary plasmacytomas in lung are rare
    - Represent ~ 5% of all extramedullary plasmacytomas
- Age
  - Described essentially in adults
    - Usually 50-80 years old

Presentation

- Cough
- Shortness of breath
- Hemoptysis
- Multiple myeloma
- Asymptomatic

Prognosis

- 2-year survival rate: ~ 66%
- 5-year survival rate: ~ 40%
- Good possibility for long-term survival

MACROSCOPIC

General Features

- Hilar or parenchymal mass
- Well circumscribed and firm
- Yellowish to gray in color

Sections to Be Submitted

- Important to submit hilar lymph nodes, as they may also be involved

Size

- Tumors 2-8 cm in diameter

MICROSCOPIC

Histologic Features

- Diffuse plasma cell proliferation
- Plasma cell with Dutcher bodies
- Subtle nested pattern
- Focal angiectatic areas
- Monoclonal gammopathy

DIFFERENTIAL DIAGNOSIS

Inflammatory Pseudotumor, Plasma Cell Type

- Plasma cell proliferation in plasmacytomas is monoclonal
- In inflammatory pseudotumor, plasma cells are usually admixed with spindle myofibroblastic cells

Pneumonia

- Infiltrate is mixture of plasma cells and polymorphonuclear leukocytes
- No monoclonality in pneumonia

Carcinoma

- Presence of plasma cell differentiation is important to establish proper diagnosis
- Use of immunohistochemical studies will lead to correct interpretation

Malignant Lymphoma With Plasmacytoid Features

- Plasmacytomas will have exclusive plasma cell proliferation
- Use of markers of plasma cells may be of help
- Possible association with multiple myeloma may be of help

DIAGNOSTIC CHECKLIST

Clinically Relevant Pathologic Features

- Age distribution

Pathologic Interpretation Pearls

- Plasma cell proliferation
- Monoclonal gammopathy

SELECTED REFERENCES

1. Zhang L et al: 18F-FDG PET/CT metabolic activity in a patient with solitary extramedullary plasmacytoma of the lung. Clin Nucl Med. 41(3):232-4, 2016
2. Agrawal SR et al: Pulmonary plasmacytoma with endobronchial extension: A rare presentation of solitary extramedullary plasmacytoma: A case report and brief review of literature. J Cancer Res Ther. 11(4):1026, 2015
3. Piña-Oviedo S et al: Primary pulmonary lymphomas. Adv Anat Pathol. 22(6):355-75, 2015
4. Huwer H et al: Solitary pulmonary plasmacytoma: report of two cases. Med Oncol. 27(1):59-61, 2010
5. Koss MN et al: Pulmonary plasmacytomas: a clinicopathologic and immunohistochemical study of five cases. Ann Diagn Pathol. 2(1):1-11, 1998

Immunohistochemistry

Antibody	Reactivity	Staining Pattern	Comment
CD138	Positive	Cytoplasmic	
CD20	Positive		May be positive in some cases
Kappa or Lambda	Positive	Cytoplasmic	Monoclonal gammopathy
EMA	Positive	Cell membrane	In some cases
CD45	Positive	Cytoplasmic	In some cases

Residual Endobronchial Glands

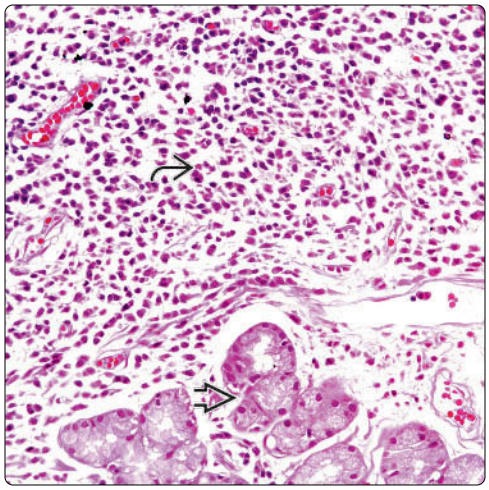

Nested Pattern

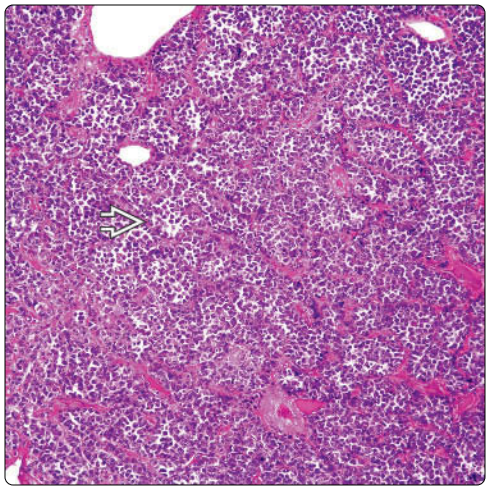

(Left) *Pulmonary plasmacytoma shows sheets of plasma cells. Endobronchial glands are present; however, these glands are not infiltrated by the plasmacytic proliferation.* **(Right)** *Pulmonary plasmacytoma shows a subtle nesting pattern that can be seen in other more common tumors of the lung, mainly neuroendocrine carcinomas. The tumor cells, however, are entirely composed of mature plasma cells.*

Ectatic Vessel With Acellular Material

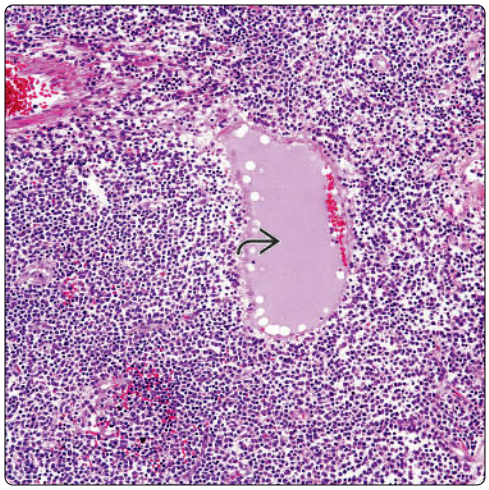

Vascular Involvement

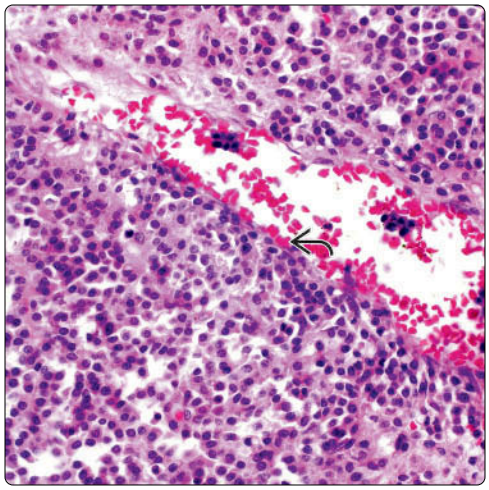

(Left) *Pulmonary plasmacytoma shows sheets of neoplastic cells around a pulmonary vessel containing edematous fluid in its lumen.* **(Right)** *In other areas, the pulmonary vessels can show extensive neoplastic cellular proliferation involving the endothelial cells and forming a neoplastic vasculitis.*

Diffuse Pattern

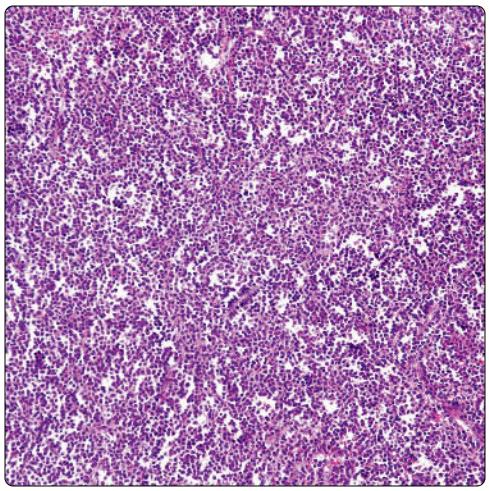

Focal Necrosis

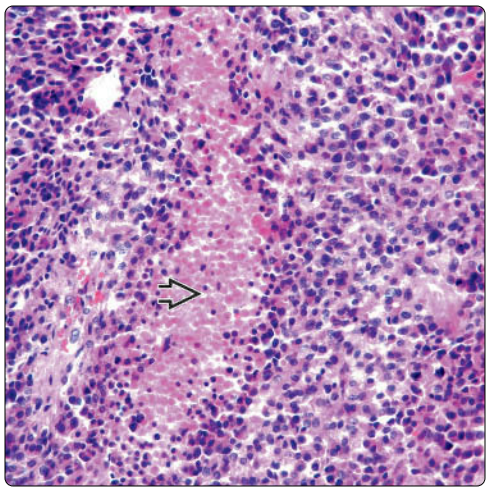

(Left) *The predominant feature of pulmonary plasmacytoma is a neoplastic homogeneous cellular proliferation growing in sheets. No definitive growth pattern is present in this case.* **(Right)** *In some cases of pulmonary plasmacytomas, there may be focal areas of necrosis. However, such a finding is not common in plasmacytomas of the lung.*

Atypical Mitosis

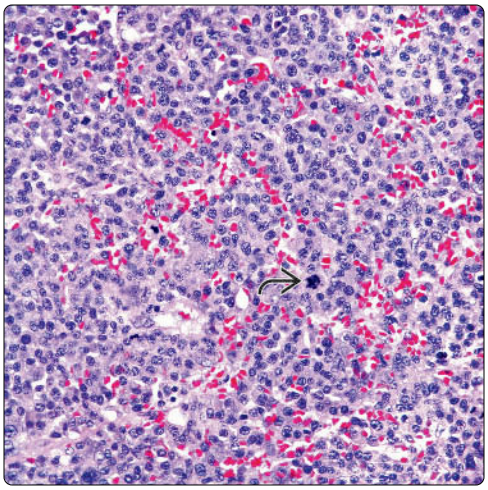

Nuclear Atypia

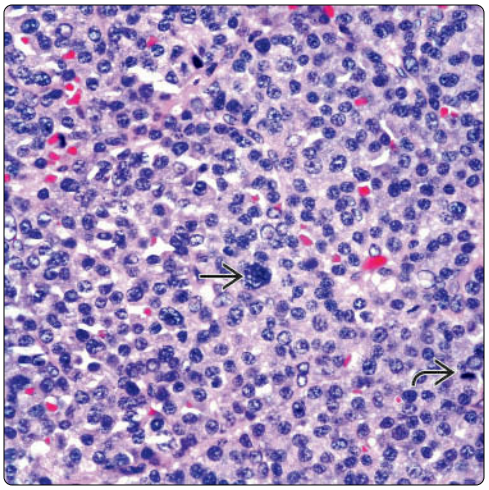

(Left) *High-power view of a less-differentiated plasmacytoma of the lung is shown. Note the presence of nuclear atypia and easily identifiable mitotic figures, some of them atypical.* **(Right)** *High-power view of a plasmacytoma of the lung is shown with a fairly homogeneous cellular proliferation and scattered multinucleated giant cells. Rare mitotic figures are also present.*

Dutcher Bodies

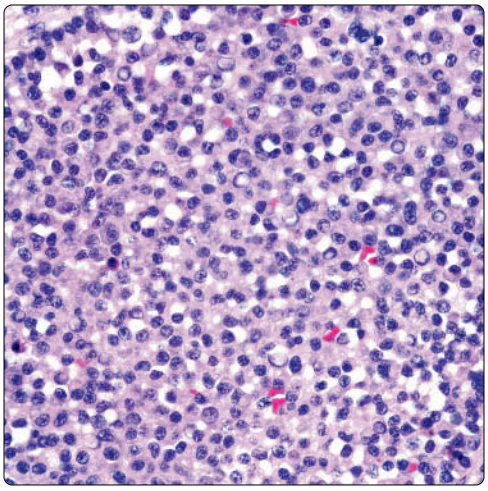

Hemorrhagic Areas

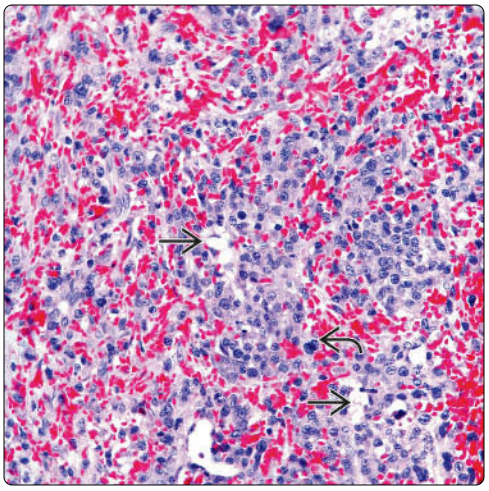

(Left) *High-power view shows the classic features of a pulmonary plasmacytoma with an atypical plasma cell proliferation, some of them containing Dutcher bodies.* **(Right)** *High-power view of a plasmacytoma of the lung is shown with unusual features of hemorrhage and pseudoglands. Note the presence of nuclear pleomorphism, even at this magnification.*

Extensive Collagen Deposition

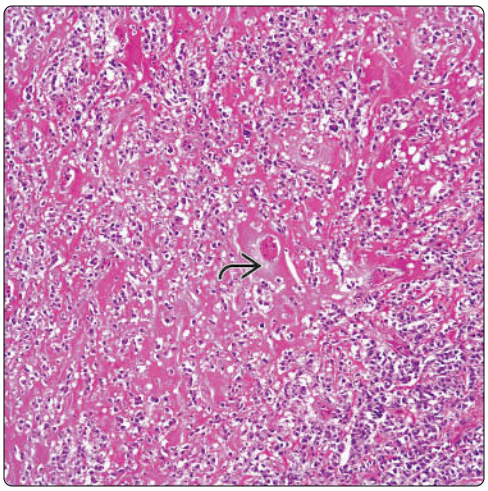

Prominent Hyalinization

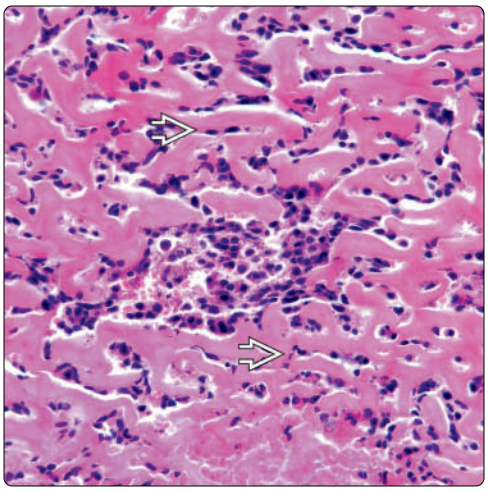

(Left) *Some cases of plasmacytoma may also show extensive areas of collagen deposition, which may be easily confused for amyloid.* **(Right)** *In some cases, the presence of marked collagen fibers can be so extensive that the tumor can be easily missed or misinterpreted as an inflammatory reaction.*

Lymphomatoid Granulomatosis

KEY FACTS

TERMINOLOGY

- Lymphomatoid granulomatosis (LYG): Angiocentric lymphoproliferative disorder composed of Epstein-Barr-infected B cells admixed with reactive T cells

CLINICAL ISSUES

- Cough
- Dyspnea
- Disease is most often confined to lung but can involve other organs, including skin, CNS, and kidney
- Some cases may progress to diffuse large B-cell lymphoma
- LYG associated with up to 70% mortality, but some cases may regress spontaneously

MICROSCOPIC

- Sheets of mixed, polymorphous atypical lymphoreticular infiltrates with destruction of lung parenchyma and extensive areas of necrosis
- Most salient feature is prominent angiocentricity of atypical lymphoid cells with concentric arrangement of lymphoid cells replacing intima and media
- Atypical lymphoid cells may be large and mononuclear or binucleated, resembling Reed-Sternberg cells
- LYG subdivided into 3 grades based on number of large, EBV(+) cells in infiltrate

ANCILLARY TESTS

- Bulk of infiltrate is composed of reactive small CD2(+), CD3(+), CD4(+) T-helper lymphocytes
- Larger, atypical cells are CD20 and CD79-α (+)
- Large, atypical cells are EBV-latent membrane protein (+)
- Large atypical cells react positively for EBV-encoded ribonucleotides (EBER) by in situ hybridization technique

Gross Appearance

Perivascular Lymphoid Infiltrates

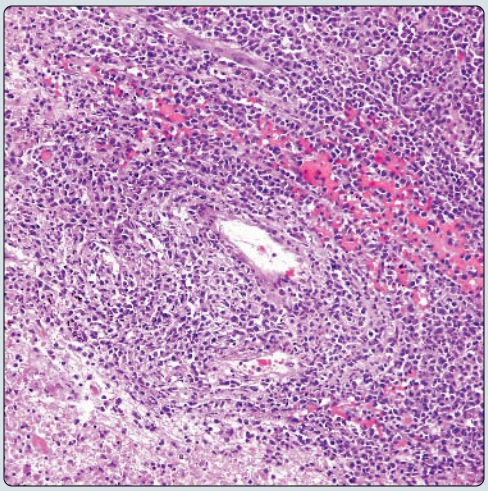

(Left) *Cut surface of the lung in a patient with lymphomatoid granulomatosis (LYG) shows a well-circumscribed, gray-white fleshy nodule with areas of necrosis.* **(Right)** *LYG of the lung shows characteristic concentric perivascular arrangement of atypical lymphoid cells. There is an area of necrosis present in the lower left corner.*

Atypical Lymphoid Cell Population

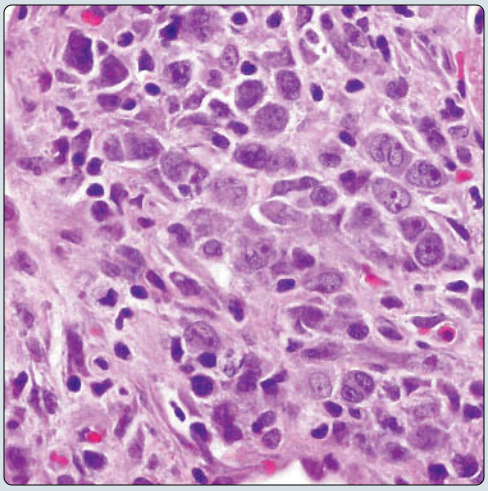

EBER DNA In Situ Hybridization

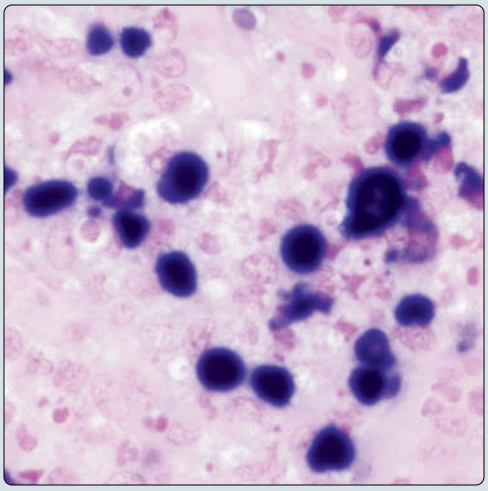

(Left) *LYG involving lung at high magnification shows sheets of large, atypical lymphocytes with nuclear irregularities and prominent eosinophilic nucleoli admixed with scattered, small lymphocytes in the background.* **(Right)** *DNA in situ hybridization test for Epstein-Barr virus (EBER) in a patient with LYG of the lung shows strong positive signal (dark blue dots) in the infected tumor cells. A positive EBER test is required for making this diagnosis.*

TERMINOLOGY

Abbreviations

- Lymphomatoid granulomatosis (LYG)

Synonyms

- Angiocentric immunoproliferative lesion

Definitions

- Angiocentric lymphoproliferative disorder composed of Epstein-Barr-infected B cells admixed with reactive T cells

ETIOLOGY/PATHOGENESIS

Pathogenesis

- Epstein-Barr-driven lymphoproliferative disorder arising in background of immune deficiency

CLINICAL ISSUES

Epidemiology

- Incidence
  - Rare disorder most commonly encountered in immunosuppressed patients
  - Seen in association with AIDS, transplants, or Wiskott-Aldrich syndrome
- Age
  - Most common in middle-aged adults; may also occur in children and young adults

Presentation

- Cough, dyspnea

Natural History

- Disease is most often confined to lung but can involve other organs, including skin, CNS and kidney
- Some cases may progress to diffuse large B-cell lymphoma
- LYG is associated with up to 70% mortality, but some cases may regress spontaneously

IMAGING

Radiographic Findings

- Multiple bilateral and peripheral nodular opacities ± cavitation
- May also present with diffuse reticulonodular infiltrates or with solitary mass

MACROSCOPIC

General Features

- Well-circumscribed tumor mass with homogeneous gray-white cut section
- Lesions frequently contain central areas of necrosis

MICROSCOPIC

Histologic Features

- Sheets of mixed, polymorphous atypical lymphoreticular infiltrates with destruction of lung parenchyma and extensive areas of necrosis
- Most salient feature is prominent angiocentricity of atypical lymphoid cells
  - Transmural infiltration of small and medium-sized vessels by atypical lymphocytes
  - Concentric arrangement of lymphoid cells replacing media and intima of vessels

Cytologic Features

- Infiltrate is polymorphous and contains abundant small lymphocytes, plasma cells, histiocytes, and scattered atypical lymphoid cells
- Atypical lymphoid cells may be large and mononuclear or binucleated, resembling Reed-Sternberg cells
- LYG is subdivided into 3 grades based on number of large, EBV(+) cells in infiltrate
  - Grade I: Small lymphocytes predominate, and large, EBV(+) B lymphocytes are scarce (< 5% of infiltrate)
  - Grade II: Large, EBV(+) B lymphocytes are increased and account for 5-20% of lymphoid infiltrate
  - Grade III: Large, EBV(+) B lymphocytes predominate, and lesion resembles diffuse large-cell lymphoma

ANCILLARY TESTS

Immunohistochemistry

- Bulk of infiltrate is composed of reactive small CD2(+), CD3(+), CD4(+) T-helper lymphocytes
- Larger, atypical cells are CD20 and CD79-α (+)
- Large, atypical cells are EBV-latent membrane protein (+)

In Situ Hybridization

- Large atypical cells react positively for EBV-encoded ribonucleotides (EBER) by in situ hybridization technique

DIFFERENTIAL DIAGNOSIS

Wegener Granulomatosis

- Lesions are characterized by neutrophil-rich areas of necrosis and true granulomas with multinucleated histiocytic giant cells
- Infiltrate is devoid of large, atypical CD20(+) B cells and EBER(+) lymphocytes

Hodgkin Lymphoma

- Hodgkin lymphoma lesions rarely display angiocentric distribution of lymphoid infiltrates
- Large atypical cells are CD30 and CD15 (+) and CD20 and CD79-α (-)

T-Cell-Rich B-Cell Lymphoma

- T-cell-rich B-cell lymphoma has similar cell population as LYG but without tumoral necrosis and angiocentricity
- Large atypical B cells are EBV(-)

DIAGNOSTIC CHECKLIST

Pathologic Interpretation Pearls

- Term granulomatosis is misnomer; granulomas and giant cells are not feature of process

SELECTED REFERENCES

1. Song JY et al: Lymphomatoid granulomatosis--a single institute experience: pathologic findings and clinical correlations. Am J Surg Pathol. 39(2):141-56, 2015
2. Tagliavini E et al: Lymphomatoid granulomatosis: a practical review for pathologists dealing with this rare pulmonary lymphoproliferative process. Pathologica. 105(4):111-6, 2013

Dense Lymphoid Cell Proliferation

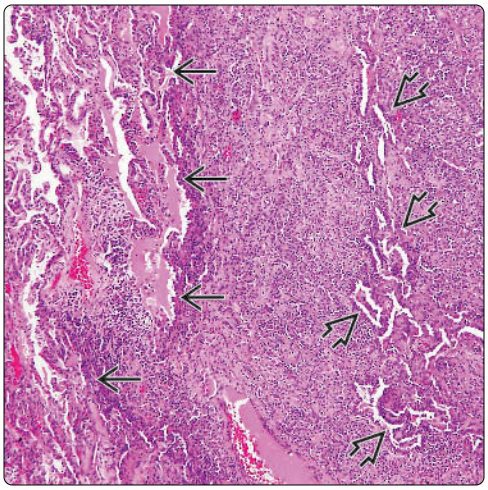

Entrapped Airspaces

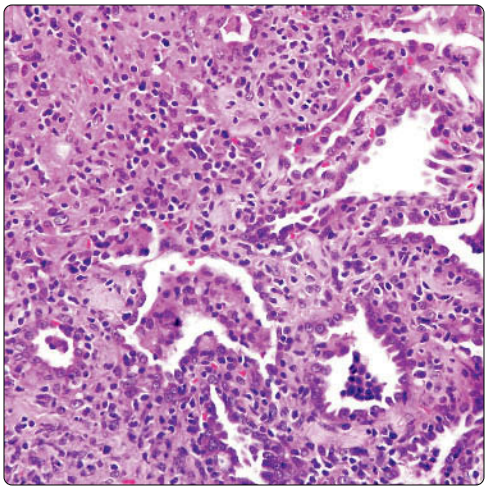

(Left) *Scanning magnification in a patient with pulmonary LYG shows that the dense, well-circumscribed proliferation of lymphoid cells is sharply separated from the surrounding lung parenchyma. Notice the entrapment of airspaces within the lesion.* **(Right)** *Higher magnification of a lung lesion in LYG shows entrapped normal airspaces surrounded by dense lymphoid cell infiltrate admixed with plasma cells and histiocytes.*

Tumor Cell Necrosis

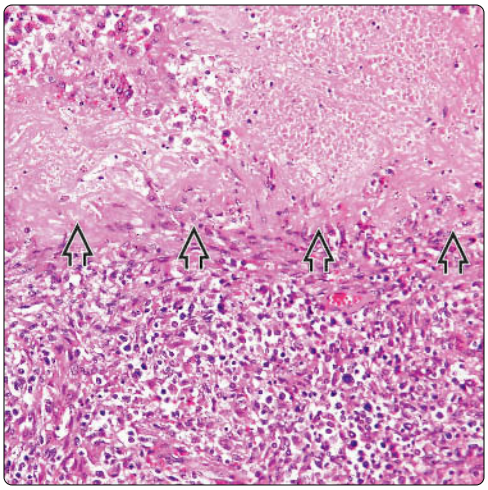

Concentric Infiltration of Vessel Wall

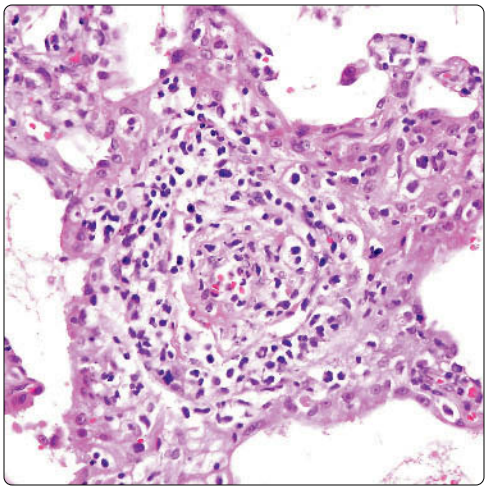

(Left) *Scanning magnification of a pulmonary lesion in LYG shows an extensive area of tumor cell necrosis. The bottom 1/2 of the field shows dense infiltration by a pleomorphic cell population containing large, atypical lymphocytes admixed with small lymphocytes.* **(Right)** *Higher magnification of a pulmonary lesion in LYG shows concentric infiltration of the wall of a small vessel within the lung parenchyma by atypical lymphocytes.*

Destruction of Vessel Wall

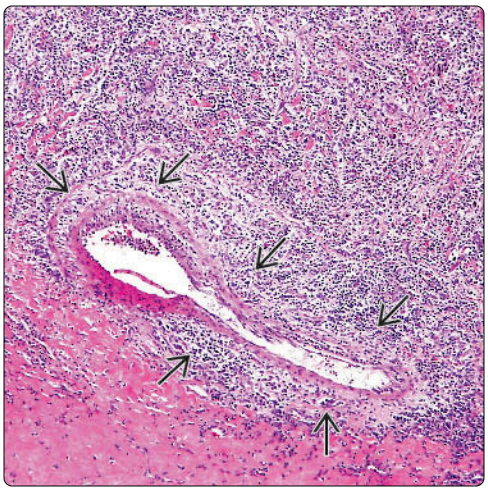

Transmural Infiltration of Vessel

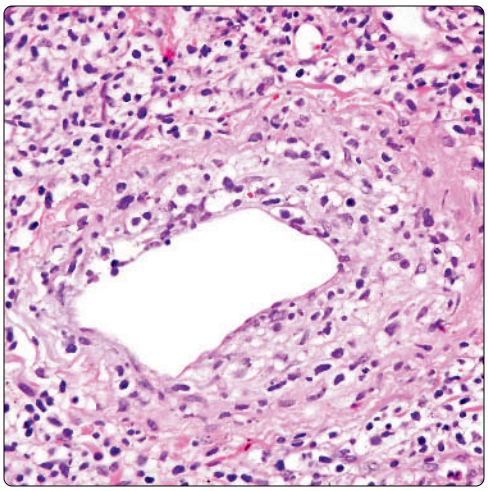

(Left) *Scanning magnification of a pulmonary lesion of LYG shows a large-caliber vessel with complete replacement and destruction of the adventitia and the media by a dense lymphoid cell population. The top portion of the field is also populated by a similar atypical lymphoid cell population.* **(Right)** *Pulmonary lesion in a patient with LYG shows transmural infiltration of a small-caliber vessel wall by the lymphoid cell population.*

Angiocentric Pattern

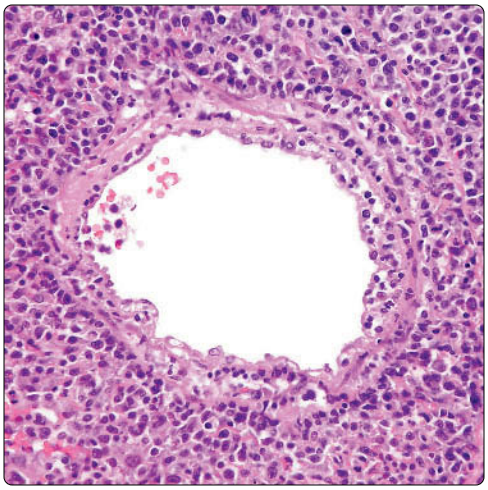

Concentric Arrangement of Tumor Cells

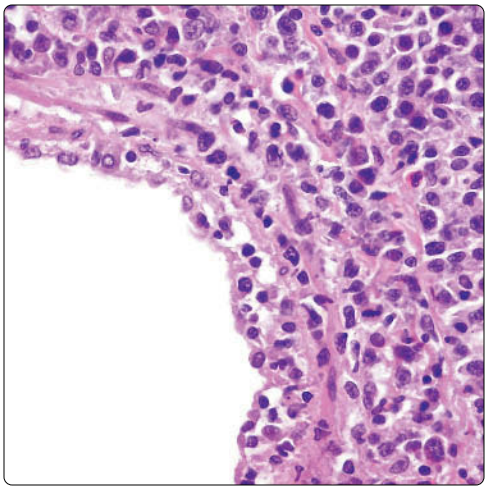

(Left) *Distinctive angiocentric pattern of infiltration of lymphoid cells in the wall of a small-caliber vessel in LYG shows a concentric linear arrangement of lymphocytes along the circumference of the vessel wall.* **(Right)** *Higher magnification of a small-caliber vessel in LYG shows a concentric, linear arrangement of the lymphocytes in the vessel wall with an "onion skin" distribution.*

Complete Infiltration of Vessel Wall

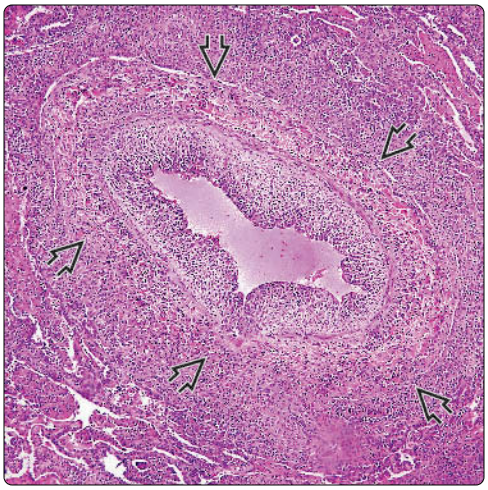

Lymphoid Infiltrate Replacing Intima

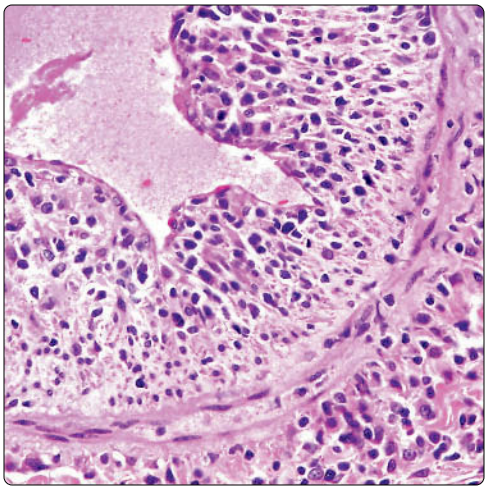

(Left) *Vessel wall in pulmonary LYG shows complete obliteration and replacement by sheets of lymphocytes invading the intima, media, and adventitia.* **(Right)** *Higher magnification of the wall of a middle-caliber vessel in a patient with pulmonary LYG shows complete replacement of the media and intima by dense lymphoid cell infiltrate. The lymphoid cell infiltrate is polymorphous and contains atypical lymphocytes.*

Complete Vascular Obliteration

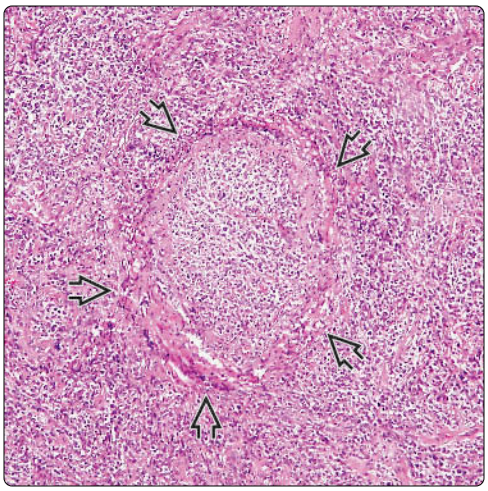

Vascular Obliteration: Higher Power

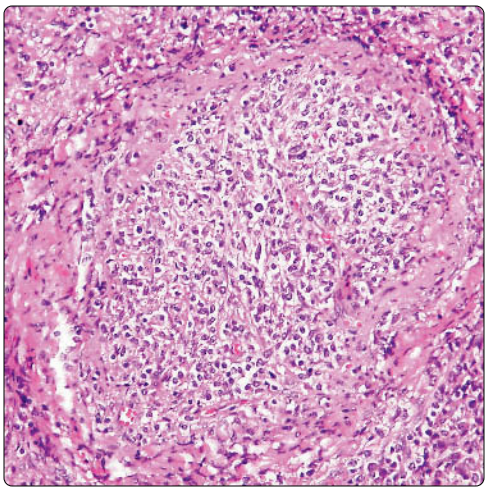

(Left) *Scanning magnification in LYG of the lung shows a discrete, well-circumscribed nodular area corresponding to a small vessel that has been completely replaced by dense atypical lymphoid cell infiltration.* **(Right)** *Higher magnification shows an area in pulmonary LYG containing a small blood vessel that has been completely replaced by the atypical lymphoid infiltrate. Notice that the lumen of the vessel has been completely obliterated.*

Grade I LYG

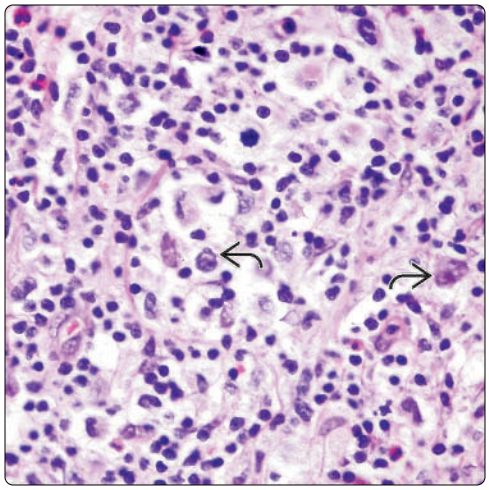

Grade I LYG: Higher Power

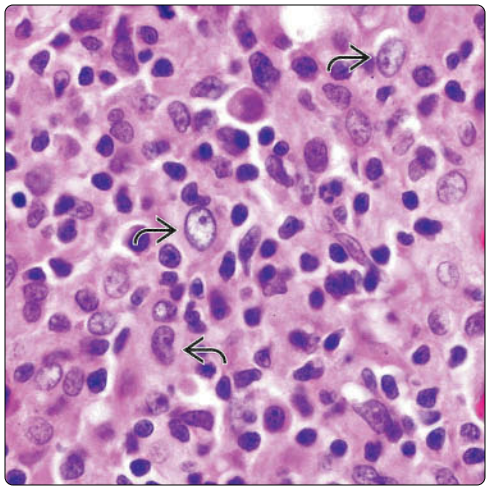

(Left) *Grade I lesion in LYG of the lung shows a polymorphous lymphoid cell population composed predominantly of small, round lymphocytes admixed with a few scattered, larger, atypical lymphoid cells.* **(Right)** *Higher magnification in a grade I LYG of the lung shows an abundance of normal-appearing small lymphocytes admixed with a few scattered larger, atypical lymphoid cells.*

Grade II LYG

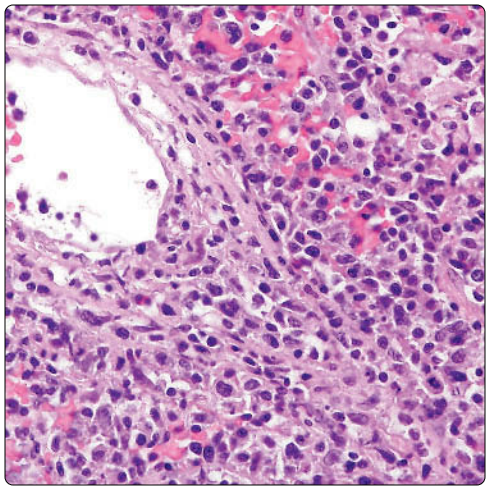

Grade II LYG: Higher Power

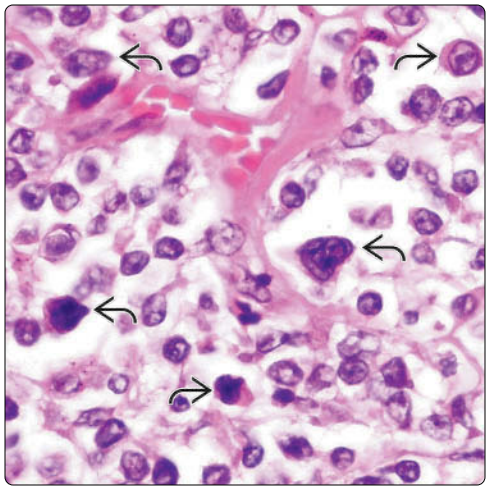

(Left) *Grade II lesion in LYG of the lung shows a dense lymphoid cell population with an increased number of large, atypical lymphoid cells admixed with numerous small, round, normal-appearing lymphocytes.* **(Right)** *Higher magnification of a grade II lesion in LYG of the lung shows large, atypical lymphoid cells admixed with small lymphocytes. The small lymphocytes correspond to helper T cells, and the larger lymphocytes are Epstein-Barr virus (EBV) (+).*

Grade III LYG

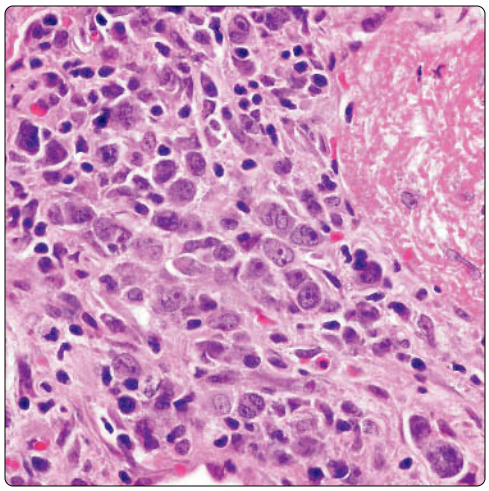

Grade III LYG: Higher Power

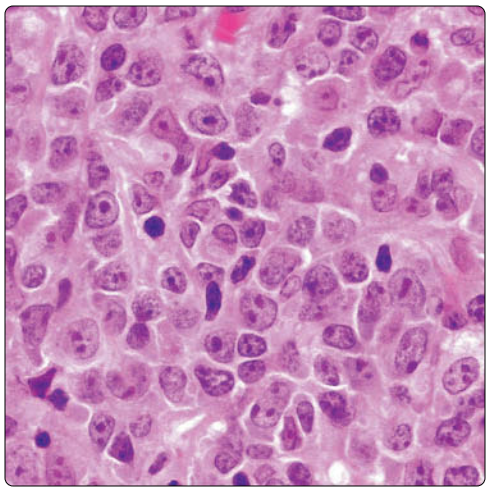

(Left) *Grade III lesion in LYG of the lung shows a dense population of atypical lymphoid cells with enlarged nuclei and prominent nucleoli admixed with a small number of small lymphocytes. The histologic appearance is indistinguishable from a diffuse large B-cell lymphoma.* **(Right)** *Higher magnification in a grade III lesion of LYG of the lung shows sheets of large, atypical lymphocytes with very few small lymphocytes.*

CD3 Immunostaining

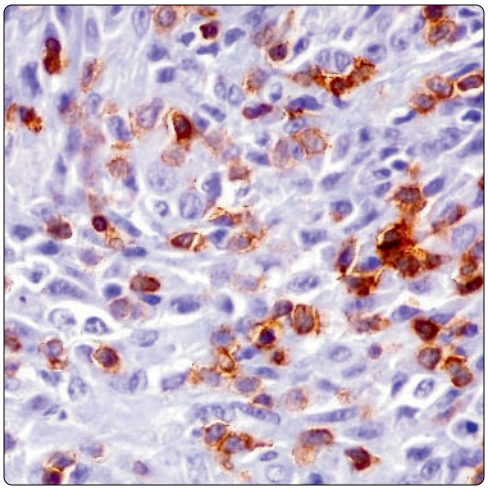

CD4 Immunostaining

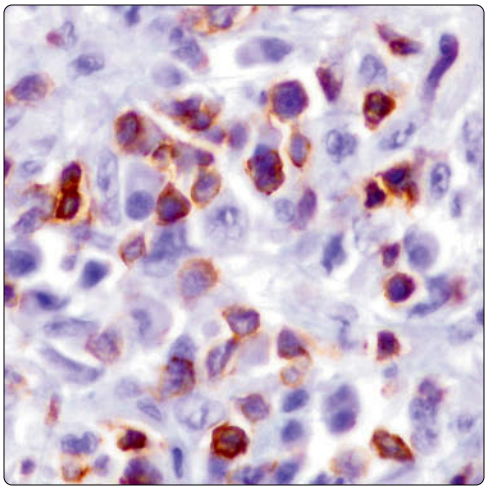

(Left) *Immunohistochemical staining for CD3 antigen in LYG of the lung shows numerous positive small lymphocytes admixed with larger atypical cells.* **(Right)** *Immunohistochemical staining of small lymphocytes in LYG of the lung for CD4 antigen identifies these cells as helper T cells. The neoplastic cells in this condition are actually the larger, atypical EBV(+), CD20(+) B lymphocytes.*

CD20 Immunostaining

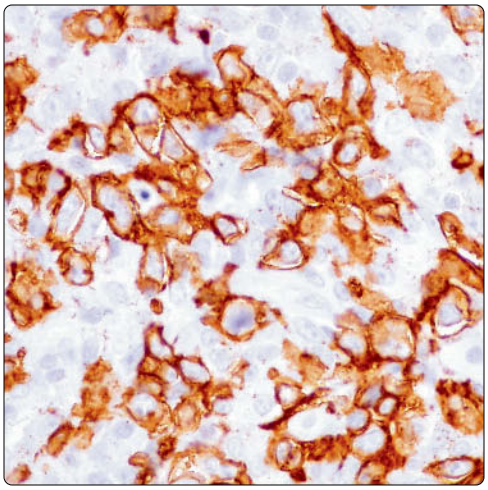

CD79-α Immunostaining

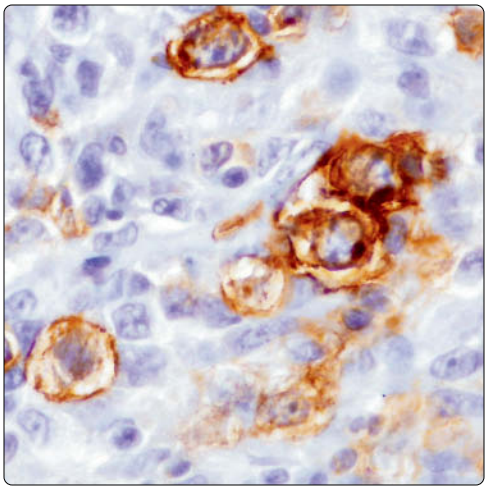

(Left) *Immunohistochemical staining for CD20 (pan-B-cell antigen) in LYG of the lung shows numerous large, atypical cells with cytoplasmic positivity. The smaller lymphocytes scattered in the background correspond to helper T lymphocytes.* **(Right)** *Immunohistochemical staining for the pan-B-cell marker, CD79-a, shows strong positivity in the large atypical cells and a negative reaction in the smaller T lymphocytes in the background.*

EBER DNA In Situ Hybridization

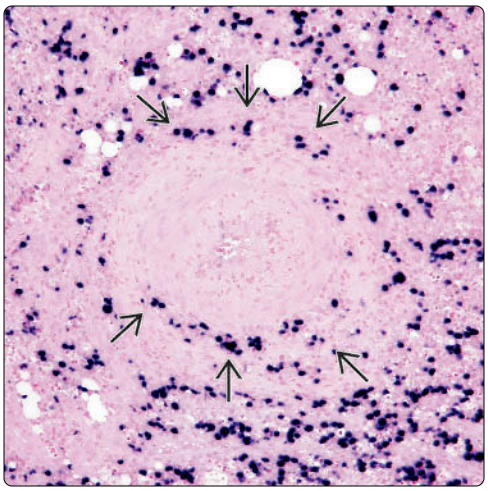

EBER(+) Cells

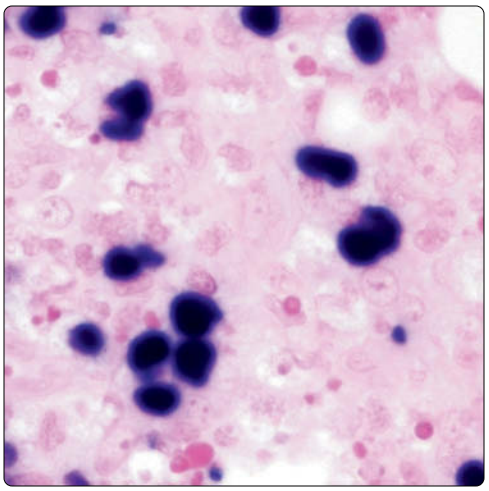

(Left) *In situ hybridization assay for the EBV-encoded RNA (EBER) shows scattered positive cells infiltrating a vessel wall ⇨ and the areas surrounding it. The number of EBER(+) cells (dark blue dots) in relation to the smaller, polymorphous lymphoid cells in the background form the basis for the histologic grading of these tumors.* **(Right)** *Higher magnification shows EBER(+) in situ hybridization in LYG of the lung.*

Ganglioneuroblastoma

KEY FACTS

TERMINOLOGY

- Pulmonary ganglioneuroblastoma (GNB)

CLINICAL ISSUES

- Incidence
  - GNBs are exceedingly rare tumors in lung
  - Cases described have been in adult patients
  - M = F
- Symptoms
  - Cough
  - Hypercalcemia
  - Gastric ulcers
  - Multiple endocrine neoplasia
  - Asymptomatic

MACROSCOPIC

- Intraparenchymal tumor
- Peribronchial tumor impinging into bronchial lumen

MICROSCOPIC

- Small cell proliferation
- Neuropil
- Larger cells with prominent nucleoli
- Necrosis &/or hemorrhage

TOP DIFFERENTIAL DIAGNOSES

- Small cell carcinoma
  - Carcinoma will display positive staining for keratin
- Neuroendocrine carcinoma (carcinoid tumor)
  - GNB is negative for neuroendocrine markers
- Rhabdomyosarcoma
  - GNB is negative for muscle markers
- Melanoma
  - GNB is negative for Mart-1 &/or HMB-45

(Left) *H&E shows pulmonary ganglioneuroblastoma (GNB) with a neoplastic cellular proliferation just underneath the bronchial cartilage* ⇨. **(Right)** *H&E shows pulmonary GNB with a rather small cellular proliferation admixed with areas of amorphous acellular material.*

Bronchial Tumor

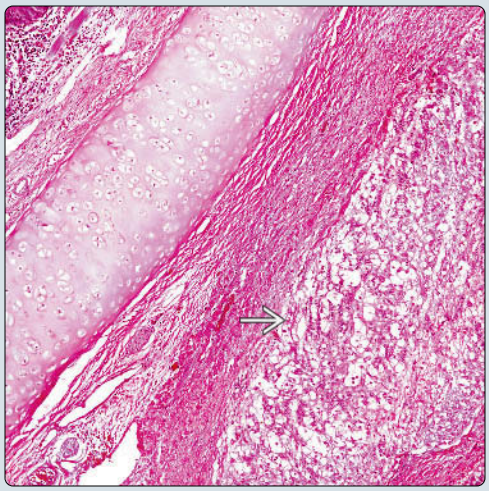

Small Cellular Proliferation

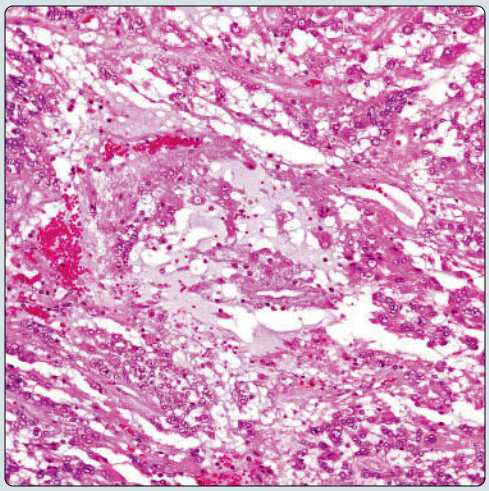

(Left) *Small cellular proliferation in a pulmonary GNB is shown. The arrangement of the cells is in cords but without any particular growth pattern.* **(Right)** *H&E shows pulmonary GNB with areas of neoplastic small cells admixed or embedded in an acellular stroma, which is fibrillary. This acellular material represents neuropil.*

Small Cellular Proliferation

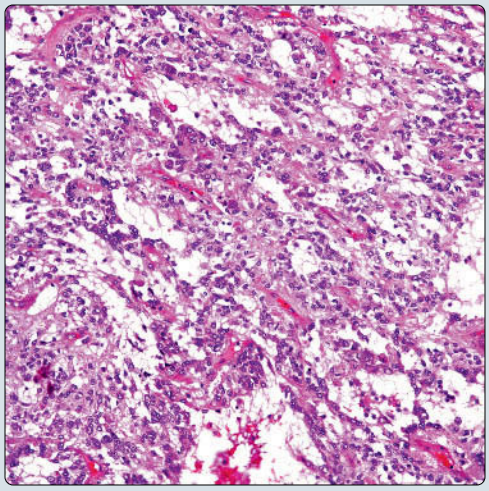

Areas of Neuropil

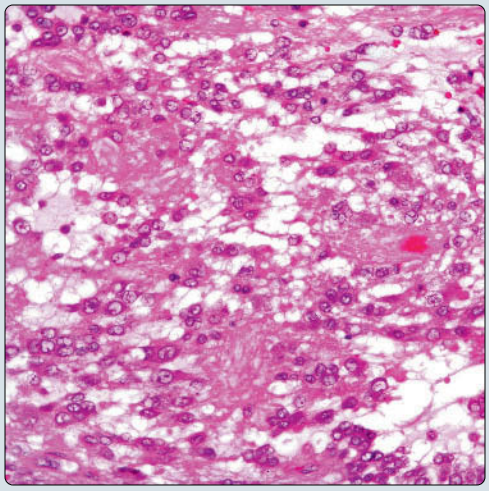

TERMINOLOGY

Abbreviations

- Pulmonary ganglioneuroblastoma (GNB)

Definitions

- Malignant neoplasm of neural origin

ETIOLOGY/PATHOGENESIS

Etiology

- Although etiology of these tumors is unknown, it is possible that they may arise from residual neural tissue in lung

CLINICAL ISSUES

Epidemiology

- Incidence
  - GNBs are exceedingly rare tumors in lung
- Age
  - Cases described have been in adults
- Sex
  - M = F

Presentation

- Cough
- Multiple endocrine neoplasia
- Gastric ulcers
- Hypercalcemia
- Asymptomatic

Treatment

- Surgical approaches
  - Lobectomy or pneumonectomy
- Adjuvant therapy
  - Questionable additional therapy

Prognosis

- Difficult to evaluate due to limited number of cases reported

MACROSCOPIC

General Features

- Well circumscribed
- Tan to white
- Homogeneous cut surface
- Intraparenchymal tumor
- Peribronchial tumor impinging into bronchial lumen

Size

- Variable size from 1-5 cm in diameter

MICROSCOPIC

Histologic Features

- Small cell proliferation
- Neuropil
- Nuclear atypia
- Mitotic activity
- Larger cells with prominent nucleoli
- Cystic changes
- Necrosis &/or hemorrhage

Predominant Pattern/Injury Type

- Diffuse

Predominant Cell/Compartment Type

- Nervous, neural

DIFFERENTIAL DIAGNOSIS

Small Cell Carcinoma

- Carcinoma will display positive staining for keratin
- Does not show presence of neuropil
- Ganglion differentiation is not present in small cell carcinomas

Neuroendocrine Carcinoma (Carcinoid Tumor)

- GNB is negative for neuroendocrine markers
- Nested or trabecular growth pattern and presence of rosettes are not features of GNB

Rhabdomyosarcoma

- GNB is negative for muscle markers
- May show more pleomorphic features with increased cellular atypia and mitotic activity
- Presence of rhabdomyoblast is not feature of GNB

Melanoma

- GNB is negative for Mart-1 &/or HMB-45
- Although melanoma may have wide range of different growth patterns, it would be unusual to show presence of neuropil

DIAGNOSTIC CHECKLIST

Clinically Relevant Pathologic Features

- Nuclear features

Pathologic Interpretation Pearls

- Proliferation of small cells embedded in neuropil
- Admixture of larger cells with prominent nucleoli

SELECTED REFERENCES

1. Adams K et al: Pleural-based neuroblastoma-like schwannoma: a case report with cytologic findings and review of literature. Diagn Cytopathol. 43(8):650-3, 2015
2. Weissferdt A et al: Ewing sarcoma with extensive neural differentiation: a clinicopathologic, immunohistochemical, and molecular analysis of three cases. Am J Clin Pathol. 143(5):659-64, 2015
3. Jrebi NY et al: Review of our experience with neuroblastoma and ganglioneuroblastoma in adults. World J Surg. 38(11):2871-4, 2014
4. Freeman JK et al: Combined carcinoid tumor and ganglioneuroblastoma of the lung: a case report. Int J Surg Pathol. 9(2):169-73, 2001
5. Hochholzer L et al: Primary pulmonary ganglioneuroblastoma: a clinicopathologic and immunohistochemical study of two cases. Ann Diagn Pathol. 2(3):154-8, 1998
6. Shields TW et al: Neurogenic tumors of the thorax. Surg Clin North Am. 68(3):645-68, 1988
7. Cooney TP: Primary pulmonary ganglioneuroblastoma in an adult: maturation, involution and the immune response. Histopathology. 5(4):451-63, 1981
8. Reed JC et al: Neural tumors of the thorax: subject review from the AFIP. Radiology. 126(1):9-17, 1978

Central Tumor

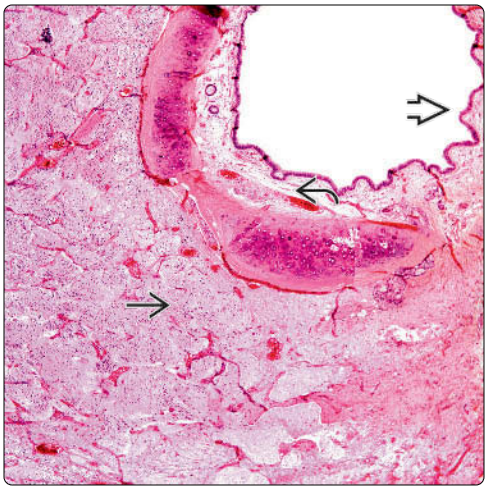

Rich Neuropil

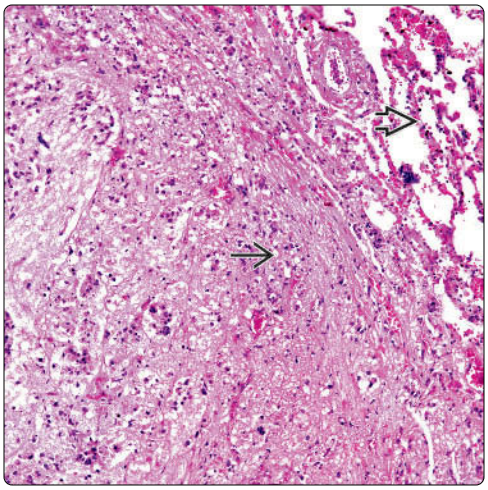

(Left) *Low-power view of a primary pulmonary GNB shows a neoplasm rich in neuropil. Note the demarcation of the tumor just beneath the bronchial cartilage. Also note that the bronchial lumen is not obstructed.* **(Right)** *Toward the periphery of a pulmonary GNB, one is able to identify lung parenchyma. Note that the tumor is not encapsulated.*

Calcifications

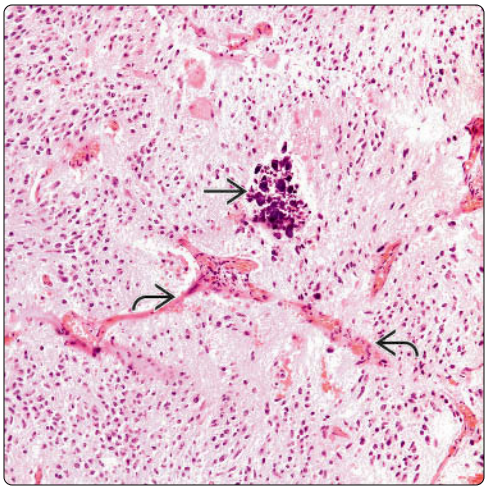

Rich Neuropil

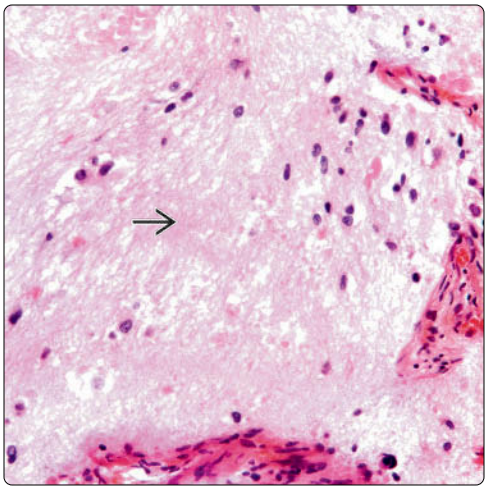

(Left) *Primary GNB of the lung shows classic features of a small cellular proliferation embedded in a background of eosinophilic acellular material (neuropil) and focal calcification. There are also dilated vascular spaces admixed with the tumor.* **(Right)** *In some cases of pulmonary GNB, the presence of neuropil can be extensive, making an unequivocal diagnosis of malignancy difficult. However, the presence of neutrophils should suggest a neural tumor.*

Classic Pattern

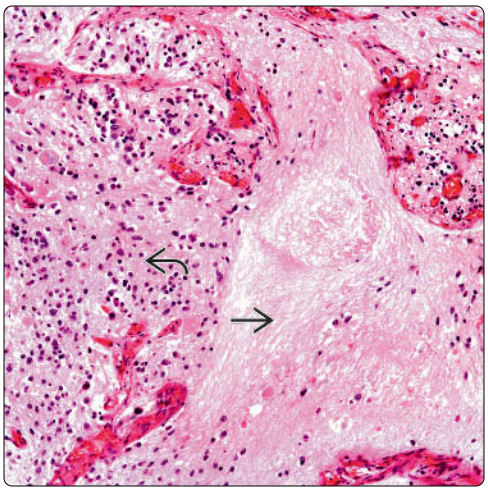

Small Cell Tumor

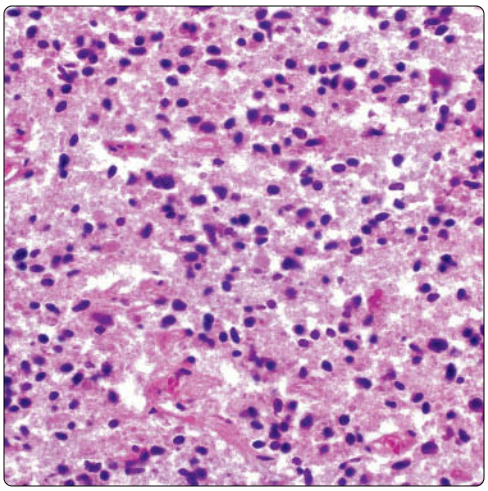

(Left) *Ganglioneuroblastoma shows alternating areas of hypo- and hypercellularity. These features are classic for this tumor.* **(Right)** *High-power view of a GNB shows small cells with scant cytoplasm, indistinct cell borders, and the absence of mitotic activity. The neoplastic cellular proliferation is embedded in neuropil.*

Perivascular Tumor

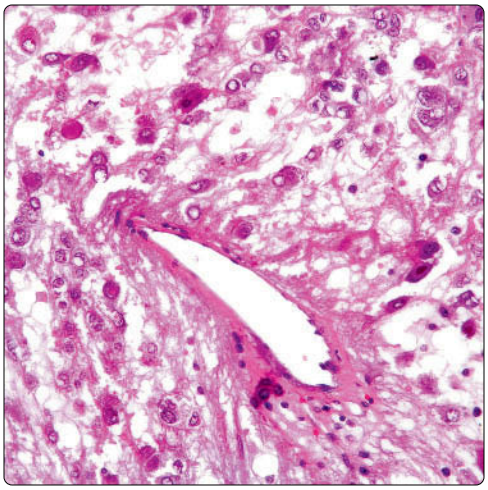

Malignant Cells With Neuropil

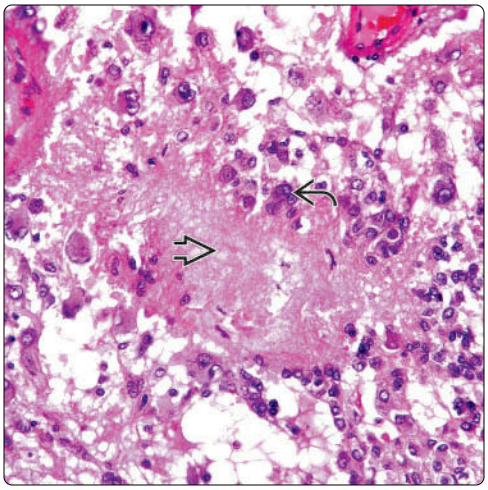

(Left) *In some cases, the neoplastic cells have a tendency to be around vessels; however, note that the intima of the vessel is not involved.* **(Right)** *In contrast to the previous image, the presence of neuropil is diagnostic of GNB. Note the presence of atypical cells around the neuropil.*

Subtle Nested Pattern

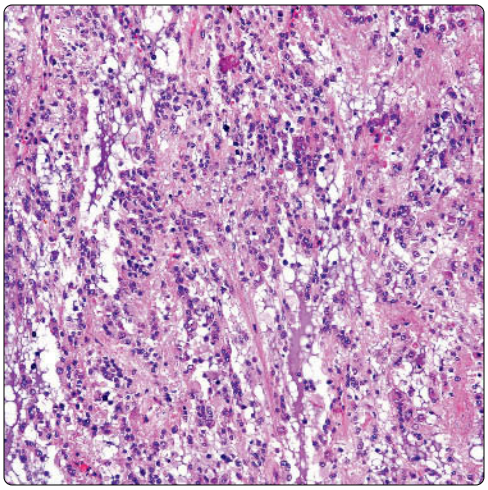

Small and Large Cells

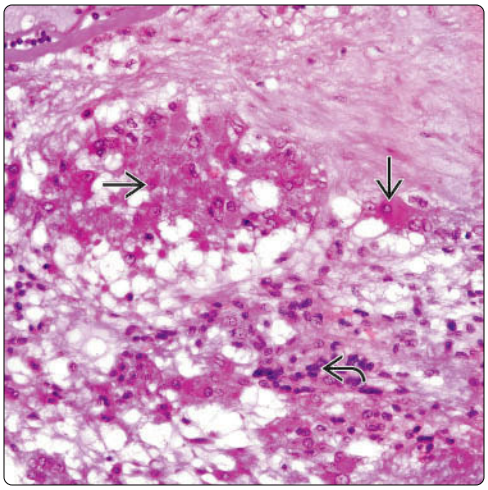

(Left) *Pulmonary GNB is shown in which the tumor cells are arranged in a small nest, giving a neuroendocrine growth pattern.* **(Right)** *Primary pulmonary GNB shows 2 populations of cells. One is composed of larger cells with prominent nucleoli and abundant eosinophilic cytoplasm, and the other is composed of smaller cells with indistinct cell borders.*

Positive Synaptophysin

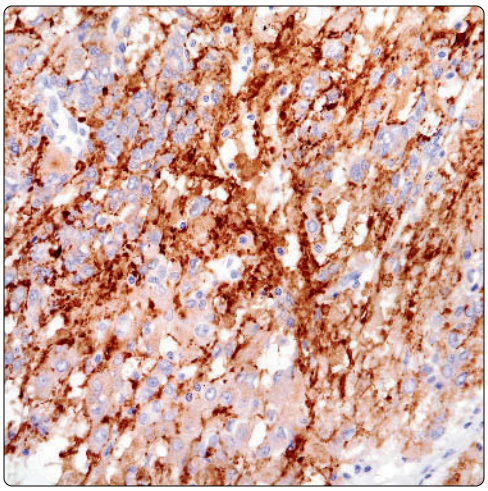

Positive PGP9.5

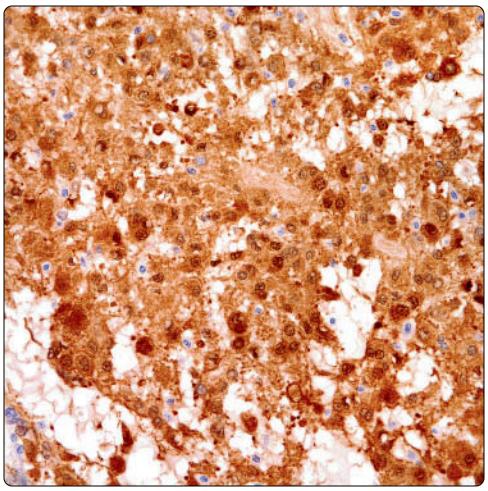

(Left) *Immunohistochemistry for synaptophysin shows positive staining in the neuropil component of a pulmonary GNB.* **(Right)** *Immunohistochemical stain for PGP9.5 shows positive staining (nuclear and cytoplasmic) in the tumor cells of a primary GNB of lung.*

Bronchial Malignant Melanoma

KEY FACTS

CLINICAL ISSUES

- Incidence
  - ~ 0.01% of all lung neoplasms
  - More common in adults in 6th decade of life
- Symptoms
  - Cough
  - Dyspnea
  - Chest pain hemoptysis
  - Fever
- Endoscopic findings
  - Possible pigmented lesion
- Clinical History
  - It is critical to obtain any previous history of pigmented lesion elsewhere
  - Sole presence of bronchial tumor does not necessarily rule out metastatic disease

MICROSCOPIC

- Nested pattern
- Spindle cell pattern
- Pigmented lesion
- Immunohistochemical support is highly important

TOP DIFFERENTIAL DIAGNOSES

- Carcinoma
  - Will show negative staining for S100 protein, HMB-45, &/or MART-1
- Neuroendocrine carcinoma
  - Melanomas are generally negative for neuroendocrine markers, i.e., chromogranin-A and synaptophysin
- Neurogenic sarcoma
  - S100 may show positive staining in both tumors
  - Negative for HMB-45 and MART-1
- Metastatic melanoma
  - Clinical history is most important and reliable way to determine primary site
  - Ocular evaluation is highly important

Bronchial Tumor

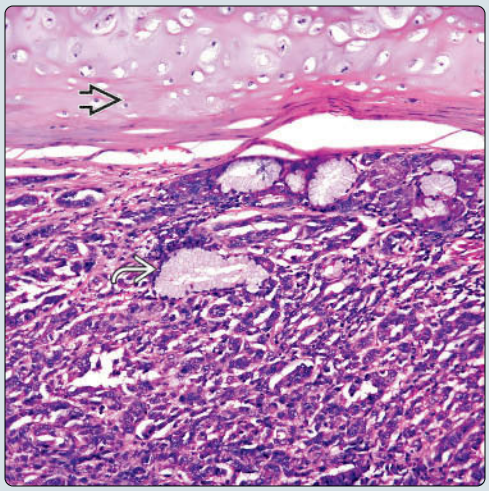

Marked Pleomorphism

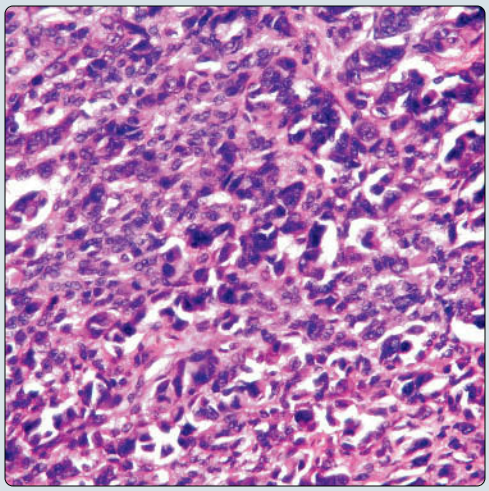

(Left) *Primary bronchial melanoma involving full thickness of the bronchial epithelium. Note the presence of residual endobronchial glandular structures as well as bronchial cartilage.* **(Right)** *High-power view of a bronchial malignant melanoma shows prominent nuclear atypia and mitotic activity. Cellular pleomorphism is a common feature of bronchial melanoma.*

Subtle Glandular-Like Appearance

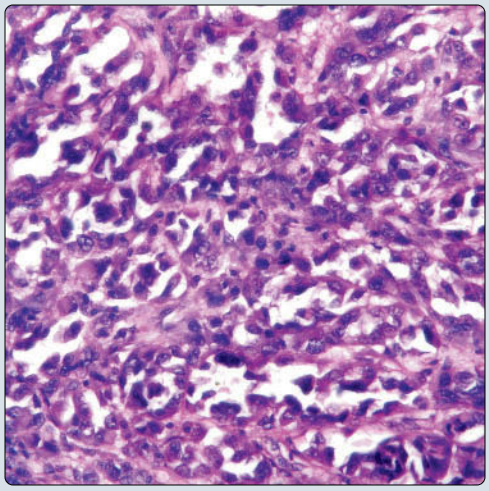

Sheets of Neoplastic Cells

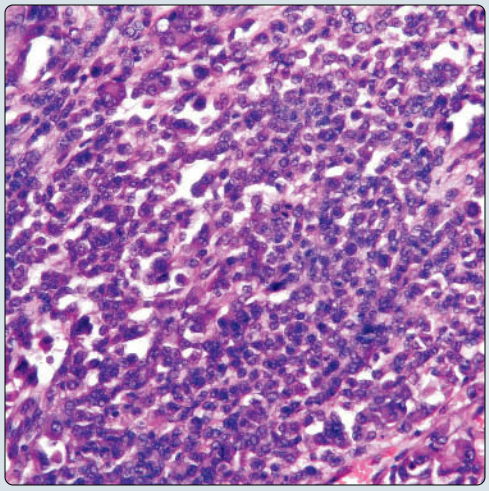

(Left) *Bronchial melanoma in which the tumor cells appear forming glandular-like structures, which can be easily misinterpreted as carcinoma, more specifically adenocarcinoma.* **(Right)** *Bronchial melanoma showing sheets of neoplastic cells in which the cellular proliferation does not have any specific pattern. Once again, this proliferation can be easily misinterpreted as carcinoma.*

TERMINOLOGY

Synonyms

- Pulmonary malignant melanoma

Definitions

- Malignant neoplasm of possible neural crest derivation

ETIOLOGY/PATHOGENESIS

Etiology

- No specific etiology for these tumors when they occur in lung

CLINICAL ISSUES

Epidemiology

- Incidence
  - Estimated that primary pulmonary melanomas represent ~ 0.01% of all lung neoplasms
- Age
  - More common in adults in 6th decade of life

Presentation

- Cough
- Shortness of breath
- Chest pain
- Hemoptysis
- Fever

Endoscopic Findings

- Possible pigmented lesion

Prognosis

- Variable
  - Death within 30 months after initial diagnosis
  - Possible survival at 5 years of 40%

MACROSCOPIC

General Features

- Well-defined tumor mass
- Pigment
- Homogeneous surface
- Areas of necrosis &/or hemorrhage may be seen
- Polypoid bronchial mass in some cases

MICROSCOPIC

Histologic Features

- Nested pattern
- Spindle cell pattern
- Pigmented lesion
- Cells with prominent nucleoli
- Pseudonuclear inclusion
- Mitotically active
- Hemorrhage &/or necrosis

Predominant Pattern/Injury Type

- Nesting

Predominant Cell/Compartment Type

- Epithelioid

DIFFERENTIAL DIAGNOSIS

Carcinoma

- Will show negative staining for S100 protein, HMB-45, &/or MART-1
- Melanomas and carcinomas may share positive staining for CEA-M

Neuroendocrine Carcinoma

- Melanomas are generally negative for neuroendocrine markers, i.e., chromogranin-A and synaptophysin
- Neuroendocrine carcinomas may show positive staining for S100 protein in sustentacular cells

Neurogenic Sarcoma

- S100 may show positive staining in both tumors
- Negative for HMB-45 and MART-1

DIAGNOSTIC CHECKLIST

Pathologic Interpretation Pearls

- Pigmented tumor composed of larger cells with prominent nucleoli or spindle cells

SELECTED REFERENCES

1. Watanabe M et al: Primary pulmonary melanoma: a report of two cases. World J Surg Oncol. 13:274, 2015
2. Wilson RW et al: Primary melanoma of the lung: a clinicopathologic and immunohistochemical study of eight cases. Am J Surg Pathol. 21(10):1196-202, 1997

Immunohistochemistry

Antibody	Reactivity	Staining Pattern	Comment
S100	Positive	Cytoplasmic	May be focal
HMB-45	Positive	Cytoplasmic	May not be positive in spindle cell tumors
Mart-1	Positive	Cytoplasmic	
Melan-A	Positive	Cytoplasmic	
SOX10	Positive	Nuclear	
CEA-M	Negative		May be positive in some cases
CK-PAN	Negative		

In Situ Change in Bronchial Epithelium

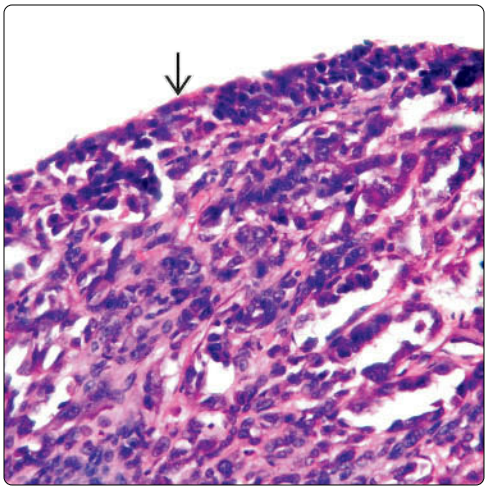

Residual Bronchial Glands

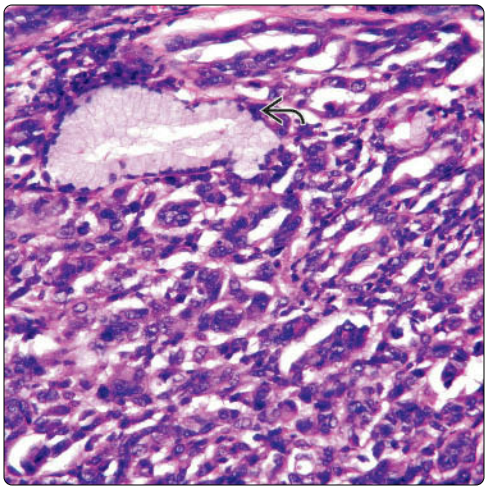

(Left) *Low-power view of a bronchial melanoma shows in situ changes in the surface epithelium. It is still possible to see some residual respiratory epithelium in the surface, which is helpful in cases of primary bronchial melanoma.* **(Right)** *Endobronchial glands are spared by a primary bronchial melanoma. This is an unusual feature as the tumor has a tendency to obliterate normal structures.*

Spindle Cell Pattern

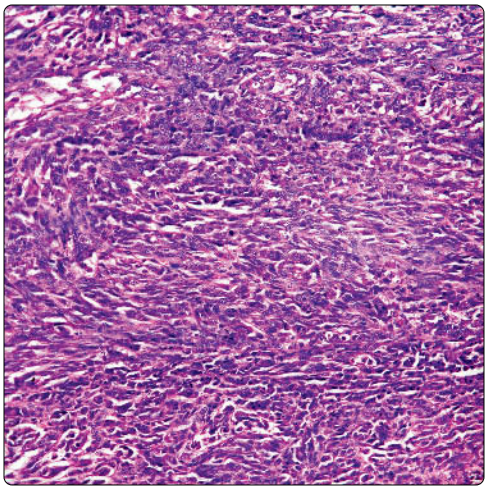

Extensive Necrosis

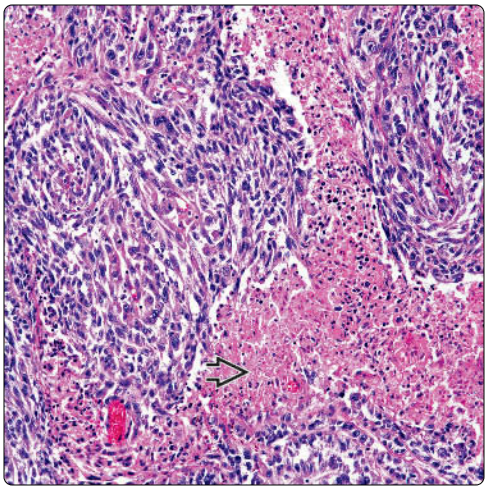

(Left) *Bronchial melanoma shows admixture of spindle and epithelioid cells. Both components show prominent nuclear atypia. This growth pattern may be seen in other primary malignant neoplasms of epithelial or mesenchymal origin.* **(Right)** *Spindle cell melanoma shows areas of necrosis. The presence of necrosis can be either focal or extensive.*

Nested Pattern

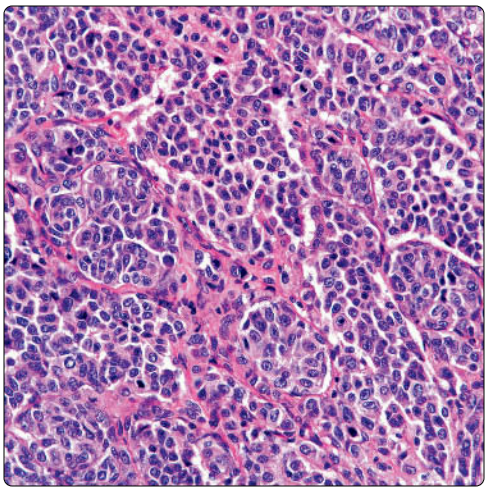

Rhabdoid Features

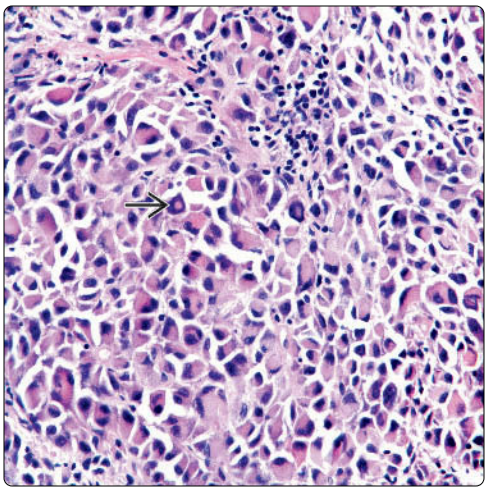

(Left) *Melanoma shows a nested pattern is composed of epithelioid cells closely mimicking a high-grade neuroendocrine carcinoma. Melanin pigment is absent.* **(Right)** *Higher magnification of the rhabdoid-like features of a bronchial melanoma shows displacement of the nuclei toward the periphery. Some of the cells show intranuclear inclusions. Similar features may be seen in rhabdoid carcinomas of the lung.*

Entrapped Mucous Glands

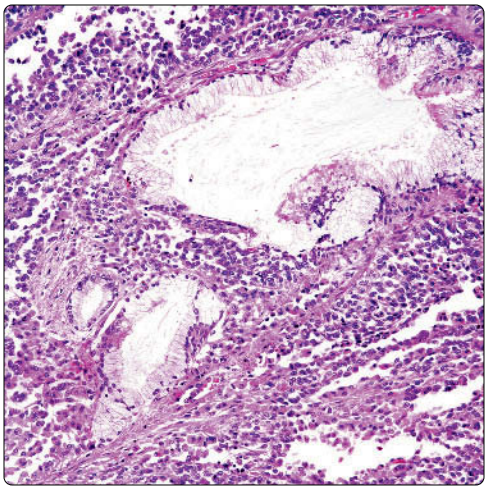

Neuroendocrine-Like Pattern

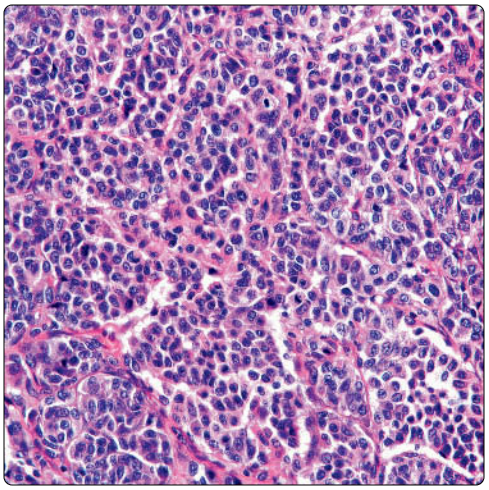

(Left) *Mucous endobronchial glands are dilated and surrounded by a rather small cellular proliferation, mimicking a neuroendocrine carcinoma.* **(Right)** *High-power view of a bronchial melanoma with cellular features is reminiscent of a neuroendocrine carcinoma. This growth pattern can be easily misdiagnosed for carcinoid tumor. However, the use of immunohistochemical studies may lead to the correct interpretation.*

Multinucleated Giant Cells

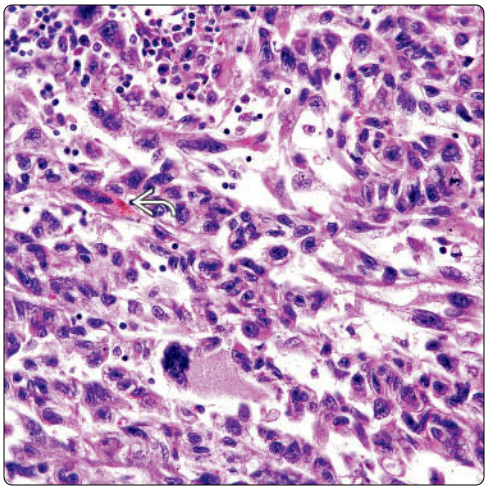

Papillary-Like Areas

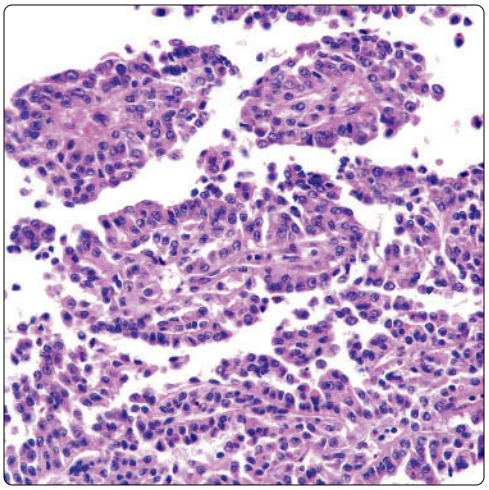

(Left) *Spindle cell melanoma with scattered multinucleated giant cells is shown. Note the subtle presence of intracellular melanin. In some tumors, melanin can be absent or only minimally present.* **(Right)** *High-power view shows the papillary-like structures of a bronchial malignant melanoma, which are composed of rather small cells with round nuclei and oncocytic cytoplasm. Similar features may be seen in primary lung carcinomas.*

Melanin Pigment

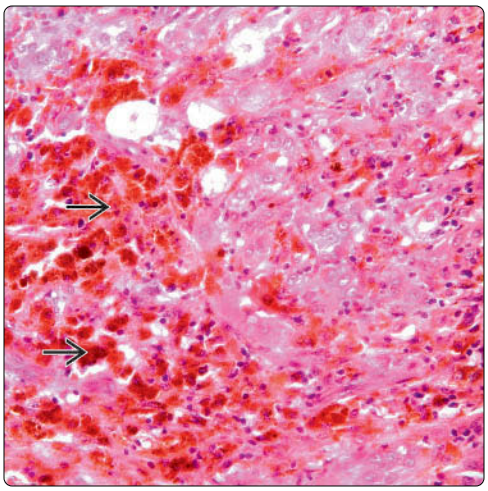

Giant Cells

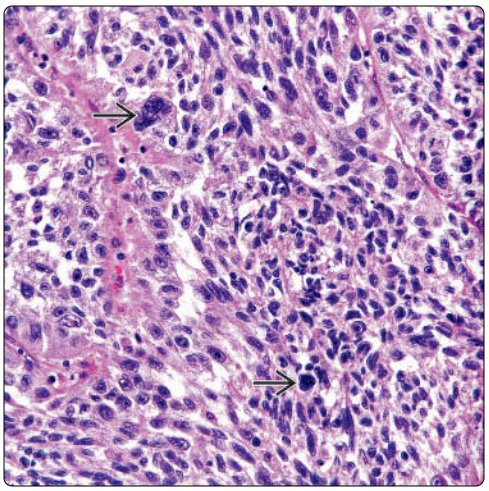

(Left) *Bronchial malignant melanoma shows epithelioid features and extensive areas of melanin pigment. The use of histochemical stains for melanin may be helpful to separate melanin from iron pigment.* **(Right)** *High-power view of a bronchial melanoma shows prominent spindle cell features and scattered multinucleated giant cells. Melanomas in the lung, like those in the skin, may show variability in their growth patterns.*

Inflammatory Pseudotumor

KEY FACTS

TERMINOLOGY

- Myofibroblastic tumor

ETIOLOGY/PATHOGENESIS

- Some cases linked to human herpesvirus-8
- Clonality demonstrated in some cases

CLINICAL ISSUES

- Tumor more common in young individuals < 40 years old
- Tumor can occur in pediatric age group
- Good prognosis if completely resected
- Recurrence if not completely resected

MACROSCOPIC

- Central tumor may grow in polypoid fashion, obstructing airway
- Peripheral tumors are larger with yellowish color
- Extrapulmonary involvement may be seen in some cases
- Tumors vary in size from 1-10 cm in diameter

MICROSCOPIC

- Plasma cell variant
- Fibrohistiocytic variant

TOP DIFFERENTIAL DIAGNOSES

- Plasmacytoma
- Sarcoma
- Sarcomatoid carcinoma of lung
- Intrapulmonary solitary fibrous tumor
- IgG4-related disease

DIAGNOSTIC CHECKLIST

- Plasma cell admixed with spindle fibroblastic proliferation
- Spindle cell fibrohistiocytic proliferation lacking nuclear atypia and increased mitotic activity

Inflammatory Pseudotumor | **Central Tumor**

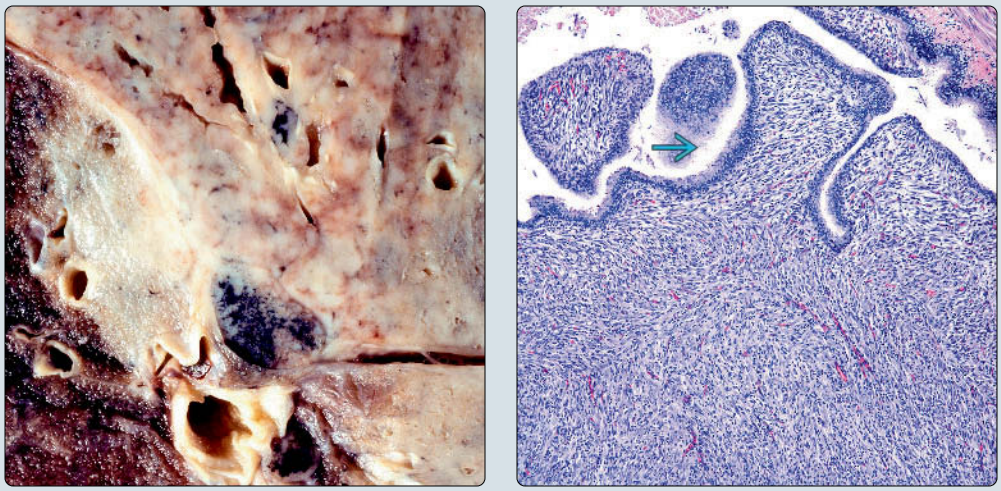

(Left) *Gross photograph shows an ill-defined tumor mass growing along vascular and bronchial structures. The tumor is grayish in color and does not show areas of necrosis &/or hemorrhage.* **(Right)** *Centrally located pseudotumor of the lung is shown. Note the presence of uninvolved respiratory epithelium ⇨. The bronchial wall has been replaced by a spindle cellular proliferation.*

Spindle Cell Component | **Spindle and Plasma Cells**

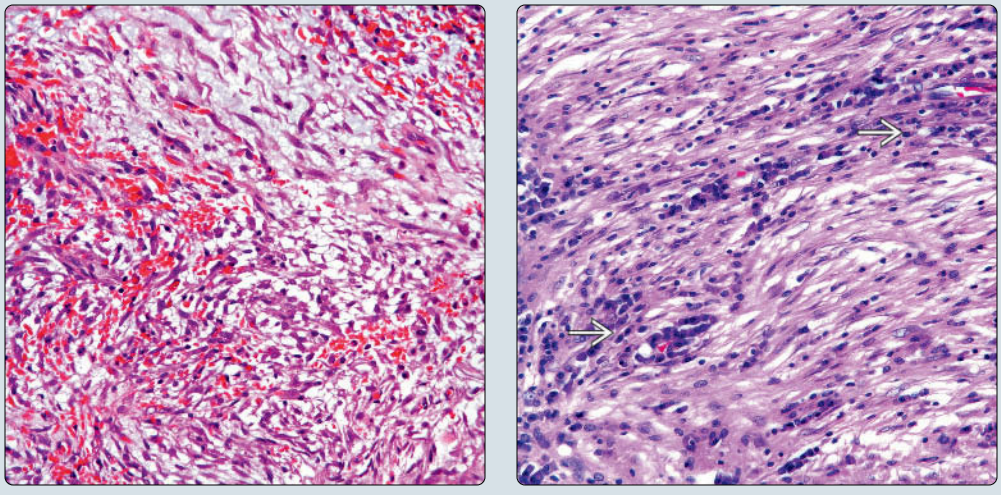

(Left) *Inflammatory pseudotumor shows a spindle cell proliferation composed of elongated cells in a loose edematous background. There is not mitotic activity and no defined specific growth pattern.* **(Right)** *Spindle cell proliferation is seen admixed with inflammatory cells ➡. Note that the spindle cells do not show mitotic activity or cellular pleomorphism.*

TERMINOLOGY

Abbreviations

- Inflammatory pseudotumor (IPT)

Synonyms

- Myofibroblastic tumor

Definitions

- Benign neoplasm of uncertain histogenesis

ETIOLOGY/PATHOGENESIS

Etiology

- Considerable debate whether IPT represents true tumor or inflammatory reaction
- Some cases may be associated to human herpesvirus-8
- Clonality has been demonstrated in some cases
- Uncertain histogenesis

CLINICAL ISSUES

Epidemiology

- Incidence
  - Tumor more common in individuals < 40 years old
  - Tumor can also occur in pediatric age group

Site

- Central tumor in endobronchial location
- Peripheral tumor
- Tumor may invade adjacent structures

Presentation

- Cough
- Fever
- Chest pain
- Dyspnea
- Hemoptysis
- General malaise
- Asymptomatic

Treatment

- Surgical approaches
  - Complete surgical resection
  - Spontaneous regression has been documented

Prognosis

- Good
- Recurrence if not completely resected
- Plasma cell variant appears to follow less aggressive course
- Fibrohistiocytic variant appears to be more aggressive

IMAGING

General Features

- Intrapulmonary mass
  - Central
  - Peripheral

MACROSCOPIC

General Features

- Central tumor may grow in polypoid fashion, obstructing airway
- Peripheral tumors are larger with yellowish color
- Extrapulmonary involvement may be seen in some cases

Size

- Tumors vary in size from 1-10 cm in diameter

MICROSCOPIC

Histologic Features

- Marked plasma cell component
- Presence of Russell bodies
- Plasma cell proliferation admixed with spindle myofibroblastic cells
- Predominant fibrohistiocytic spindle cell proliferation
- Mitotic activity rare but occasional mitoses may be seen

Predominant Pattern/Injury Type

- Mixed

Predominant Cell/Compartment Type

- Histiocyte/macrophage
- Plasma cell

DIFFERENTIAL DIAGNOSIS

Plasmacytoma

- Plasma cells in IPT are polyclonal
- Generally in plasmacytomas, plasma cell proliferation is not mixed with spindle myofibroblastic cells
- Dutcher bodies are common in plasmacytomas

Sarcoma

- IPT fibrohistiocytic variant does not show marked nuclear atypia or increased mitotic activity
- Immunohistochemical studies will be useful to determine cell type involved

Sarcomatoid Carcinoma of Lung

- Spindle cell (myofibroblastic) proliferation in IPT lacks marked nuclear atypia &/or increased mitotic activity
- Immunohistochemical studies for epithelial markers, such as keratins and EMA, may show strong positive reaction in sarcomatoid carcinoma
- Presence of inflammatory component composed mainly of plasma cells would be unusual for sarcomatoid carcinoma

Intrapulmonary Solitary Fibrous Tumor

- Solitary fibrous tumor (SFT) commonly show hyper and hypocellular areas
- Growth pattern of SFT shows more morphological variability
- Marked inflammatory reaction composed mainly of plasma cell would be unusual
- Immunostain for STAT6 is commonly positive in SFT
- ALK1 immunostain is generally negative in SFT

IgG4-Related Disease

- Similar features in term of extensive fibrosis and plasma cells
- IgG4-related disease will show increase IgG in serum
- IgG4 immunostain will show positive staining

Immunohistochemistry

Antibody	Reactivity	Staining Pattern	Comment
ALK1	Positive	Cytoplasmic	30-40% of cases
Actin-sm	Positive	Cytoplasmic	In spindle cells
Vimentin	Positive	Cytoplasmic	In spindle cells
CD68	Positive	Cytoplasmic	In some fibrohistiocytic tumors
κ light chain	Positive	Cytoplasmic	Polyclonal
Kappa or Lambda	Positive	Cytoplasmic	Polyclonal
CK-PAN	Positive	Cytoplasmic	Focal in some cases
p80	Positive	Cytoplasmic	In ~ 30%
p40	Negative		
STAT6	Negative		
Desmin	Negative		
TTF-1	Negative		
NAPSIN-A	Negative		
EMA	Positive	Cell membrane	Focally and weakly positive in some cases
CK5/6	Negative		
CD136	Positive	Cytoplasmic	In plasma cells
S100	Negative		
CD34	Negative		
CD15	Negative		

Molecular Findings

FISH	Result
Whole-genome and transcriptome sequencing	(79-175. fusion transcript
526	In few cases
3'*)5%	In few cases
5(7	Rearrangement

DIAGNOSTIC CHECKLIST

Pathologic Interpretation Pearls

- Plasma cell admixed with spindle fibroblastic proliferation
- Spindle cell fibrohistiocytic proliferation lack nuclear atypia and increased mitotic activity

SELECTED REFERENCES

1. Alassiri AH et al: ETV6-NTRK3 Is expressed in a subset of ALK-negative inflammatory myofibroblastic tumors. Am J Surg Pathol. 40(8):1051-61, 2016
2. Delteil C et al: [Immunoglobulin G4-related lung disease: case report and literature review.] Ann Pathol. 36(3):218-21, 2016
3. Giuseppucci C et al: Primary lung tumors in children: 24 years of experience at a referral center. Pediatr Surg Int. 32(5):451-7, 2016
4. Keenan JC et al: IgG4-related lung disease: a case series of 6 patients and review of the literature. Sarcoidosis Vasc Diffuse Lung Dis. 32(4):360-7, 2016
5. Surabhi VR et al: Inflammatory myofibroblastic tumors: current update. Radiol Clin North Am. 54(3):553-63, 2016
6. Antonescu CR et al: Molecular characterization of inflammatory myofibroblastic tumors with frequent ALK and ROS1 gene fusions and rare novel RET rearrangement. Am J Surg Pathol. ePub, 2015
7. Bhagat P et al: Pulmonary inflammatory myofibroblastic tumor and IgG4-related inflammatory pseudotumor: a diagnostic dilemma. Virchows Arch. 463(6):743-7, 2013
8. Sunbul M et al: A rare case of inflammatory pseudotumor with both involvement of lung and heart. Thorac Cardiovasc Surg. 61(7):646-8, 2013
9. Ezzine-Baccari S et al: Inflammatory myofibroblastic tumor of the lung: a benign lesion with aggressive behavior. Gen Thorac Cardiovasc Surg. 60(8):531-3, 2012
10. Siminovich M et al: Inflammatory myofibroblastic tumor of the lung in children: anaplastic lymphoma kinase (ALK) expression and clinico-pathological correlation. Pediatr Dev Pathol. 15(3):179-86, 2012
11. Takeda S et al: Clinical spectrum of pulmonary inflammatory myofibroblastic tumor. Interact Cardiovasc Thorac Surg. 7(4):629-33, 2008
12. Moran CA et al: Unusual non-neoplastic lesions of the lung. Semin Diagn Pathol. 24(3):199-208, 2007
13. Kobashi Y et al: Inflammatory pseudotumor of the lung: clinicopathological analysis in seven adult patients. Int J Clin Oncol. 11(6):461-6, 2006
14. Checrallah A et al: [Inflammatory pseudotumors of the lung with spontaneous regression.] J Med Liban. 53(4):229-33, 2005
15. Cerfolio RJ et al: Inflammatory pseudotumors of the lung. Ann Thorac Surg. 67(4):933-6, 1999
16. Su LD et al: Inflammatory myofibroblastic tumor: cytogenetic evidence supporting clonal origin. Mod Pathol. 11(4):364-8, 1998
17. Gal AA et al: Prognostic factors in pulmonary fibrohistiocytic lesions. Cancer. 73(7):1817-24, 1994
18. Spencer H: The pulmonary plasma cell/histiocytoma complex. Histopathology. 8(6):903-16, 1984
19. Bahadori M et al: Plasma cell granulomas of the lung. Cancer. 31(1):191-208, 1973

Obstruction of Bronchial Lumen

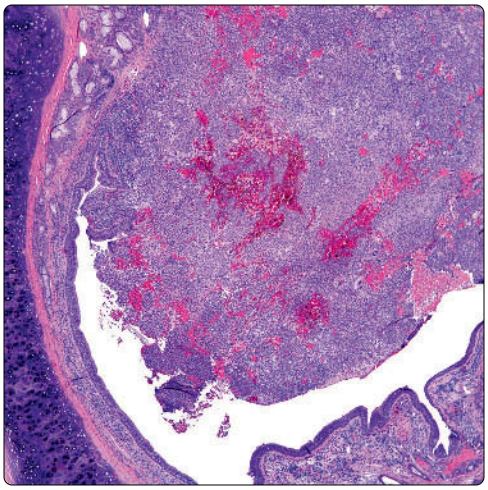

Residual Normal Bronchial Glands

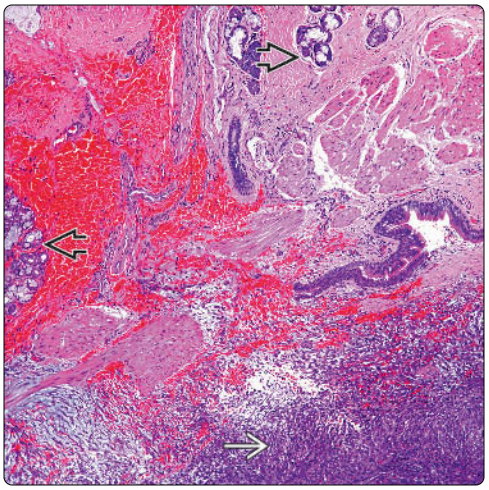

(Left) *Bronchial inflammatory pseudotumor is seen obliterating most of the bronchial lumen. This is a fairly common presentation of inflammatory pseudotumor.* **(Right)** *Inflammatory pseudotumor is shown in an endobronchial location. The epithelial surface is eroded, and there is a spindle cell proliferation admixed with areas of hemorrhage. Note the preservation of endobronchial glandular structures.*

Presence of Giant Cells

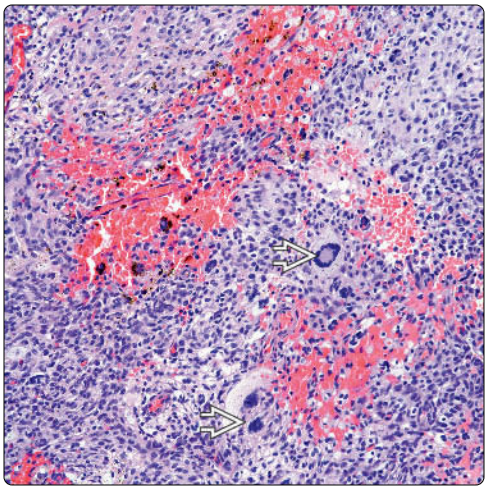

Collections of Foamy Macrophages

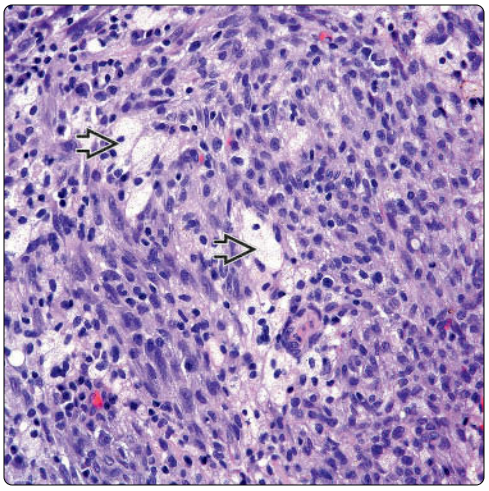

(Left) *Inflammatory pseudotumor of the fibrohistiocytic type with focal multinucleated giant cells (Touton type) is admixed with spindle cells. This feature, although helpful, is not commonly seen in these cases.* **(Right)** *Spindle fibrohistiocytic proliferation is admixed with large foamy macrophages. This is a helpful hint in the diagnosis of inflammatory pseudotumor. Note the absence of cellular atypia or mitotic activity.*

Giant Cells and Macrophages

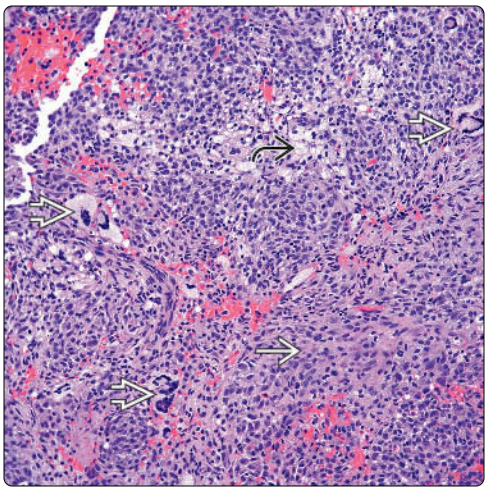

Spindle Cells With Macrophages

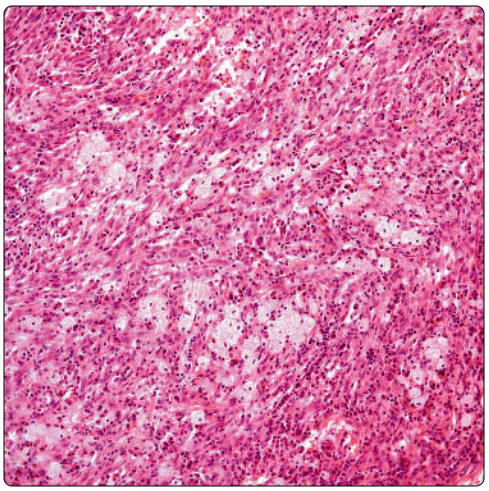

(Left) *Inflammatory pseudotumor of the fibrohistiocytic type is seen with numerous giant cells (Touton type), solid histiocytic proliferation, and foamy macrophages.* **(Right)** *Spindle cell proliferation is admixed with clusters of xanthomatous cells. This is a commonly seen feature in an inflammatory pseudotumor, and these features are seen invariably in the majority of cases.*

Residual Alveolar Component

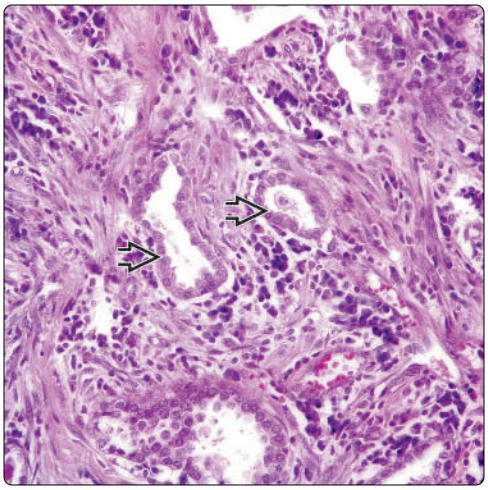

Extensive Hyalinization



(Left) *Hematoxylin and eosin shows an inflammatory pseudotumor, plasma cell type, with entrapped alveoli, fibrosis, and inflammation. These histological features are nondiagnostic of inflammatory pseudotumor but may be seen adjacent to the main tumoral lesion.* **(Right)** *Extensive areas of hyalinization and focal calcification are seen in an inflammatory pseudotumor, plasma cell type. This feature may make the diagnosis of inflammatory pseudotumor difficult to establish.*

Well-Circumscribed Tumor

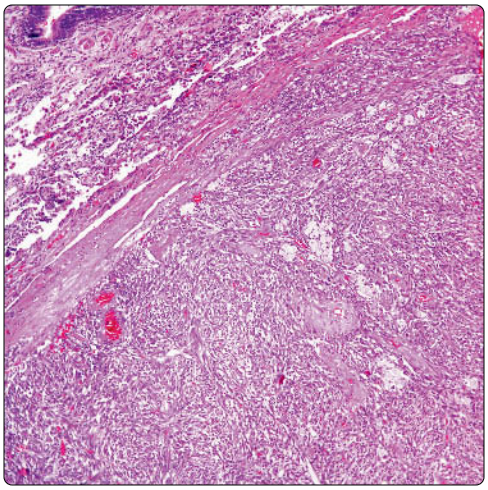

Subtle Storiform

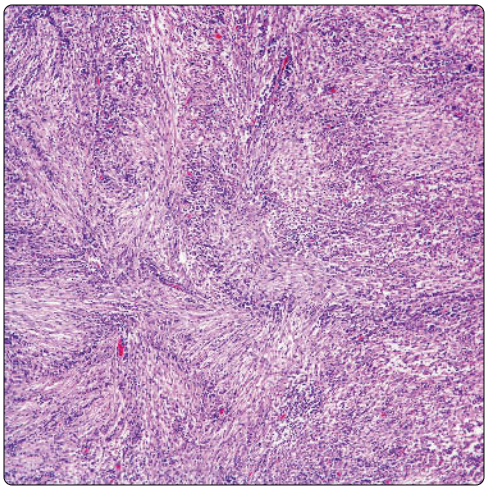

(Left) *A well-circumscribed but unencapsulated inflammatory pseudotumor is seen in the periphery of the lung parenchyma.* **(Right)** *Low-power view of an inflammatory pseudotumor shows a vague storiform pattern. The tumor is composed of a spindle cell fibroblastic proliferation admixed with inflammatory cells, namely plasma cells. This is a common occurrence in these tumors.*

Extravasated Blood

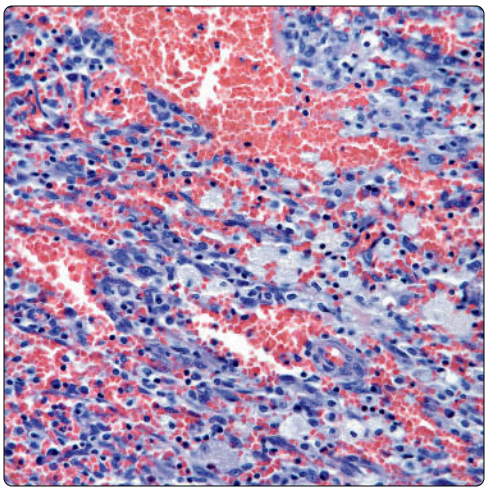

Solid Spindle Cellular Proliferation

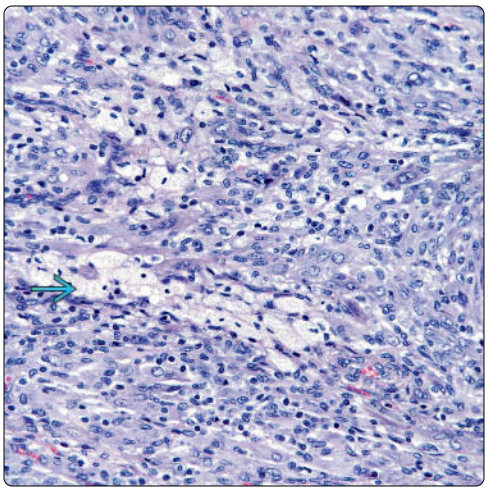

(Left) *Inflammatory pseudotumor shows areas of extravasated blood admixed with a spindle cellular proliferation and collections of macrophages. Areas like this one can be easily overlooked in small biopsies.* **(Right)** *Inflammatory pseudotumor shows a more solid spindle cellular proliferation interspersed with collections of foamy macrophages. These features are characteristics of this tumor.*

Lymphoma-Like Appearance

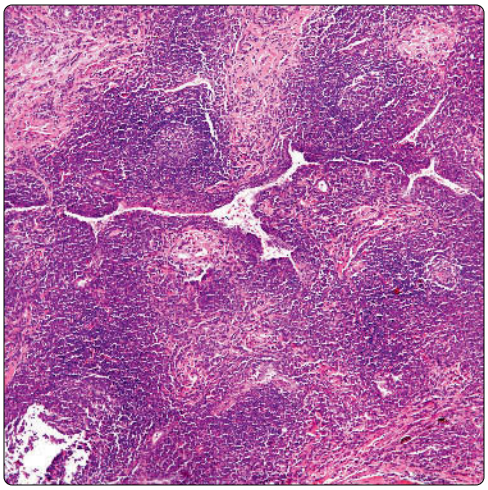

Plasma Cell Prolifera

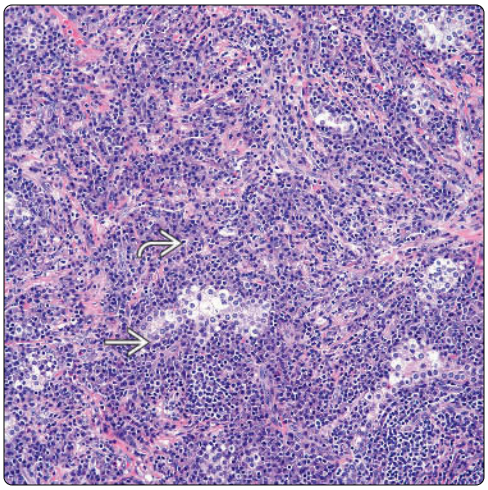

(Left) *Low-power view shows an inflammatory pseudotumor with prominent areas of plasma cell proliferation. These areas can appear worrisome and may prompt the investigation of lymphoproliferative disorder.* **(Right)** *Inflammatory pseudotumor, plasma cell type, shows increased plasma cells with scattered entrapped alveolar structures. This pattern may be easily confused for a pneumonic process.*

Plasma Cell With Scattered Spindle Cells

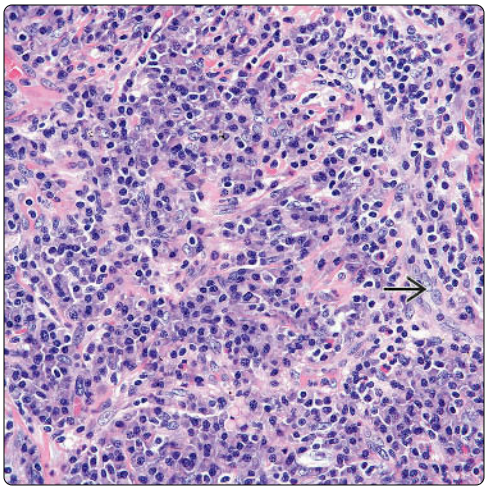

Mature Plasma Cells

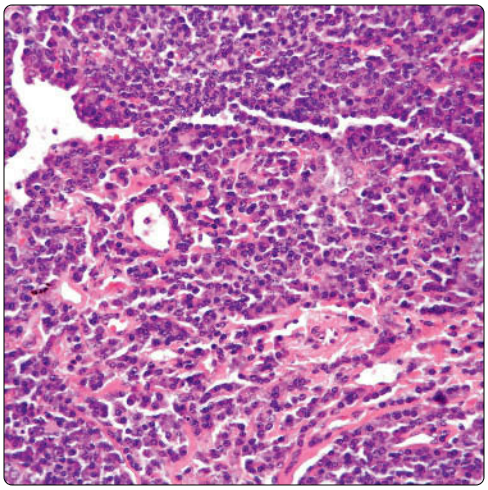

(Left) *Hematoxylin eosin shows marked presence of plasma cells with only scattered fibroblasts. This pattern would also suggest a plasma cell proliferation, thus the importance of using clonality studies to rule out the diagnosis of plasmacytoma.* **(Right)** *High-power view shows an inflammatory pseudotumor composed predominantly of mature plasma cells. There is a discrete deposition of collagen fibers, which have been dissected by plasma cells. Clonality studies are important in these cases.*

Combined Plasma and Spindle Cells

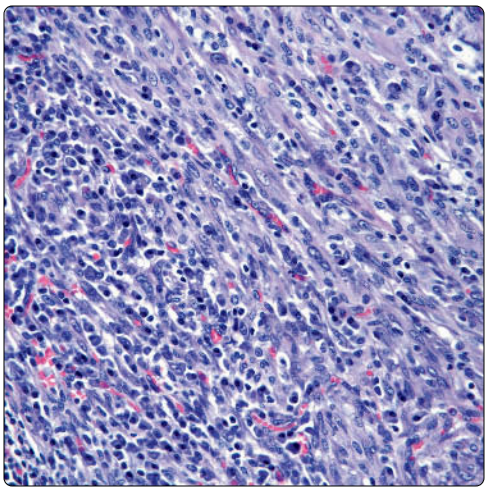

Scattered Giant Cells

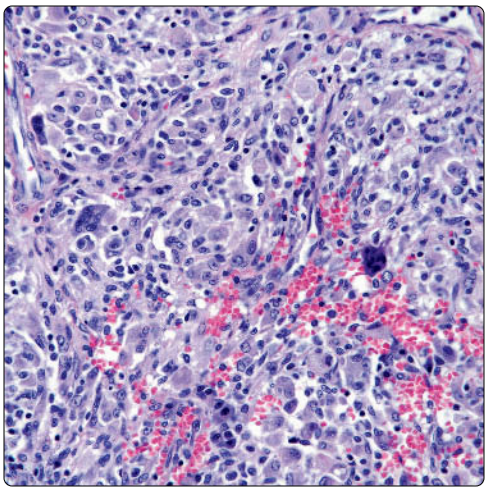

(Left) *Inflammatory pseudotumor of the lung shows a combined cellular proliferation of plasma cells and spindle myofibroblastic cells. This type of combination is more common in these tumors.* **(Right)** *Inflammatory pseudotumor shows a proliferation of spindle cells admixed with histiocytes and multinucleated giant cells. Note the absence of cellular atypia or mitotic activity.*

IgG4 Sclerosing Lung Disease

KEY FACTS

TERMINOLOGY

- Systemic disease of unknown etiology characterized by elevated production of IgG4(+) plasma cells and tissue stromal sclerosis

ETIOLOGY/PATHOGENESIS

- Unknown, but autoimmune mechanism or hypersensitivity reaction has been postulated
- Circulating autoantibodies are present in many patients
- May be associated with other autoimmune disorders, e.g., Sjögren syndrome

CLINICAL ISSUES

- Slowly progressive disease with involvement of multiple sites over period of years with elevation of serum titers of IgG4
- Most commonly involved sites include pancreas, hepatobiliary tract, salivary gland, orbit, and lymph nodes
- Middle-aged and elderly patients
- Male predominance

MICROSCOPIC

- 3 histologic patterns of involvement recognized in lung: Inflammatory pseudotumor-like, bronchovascular, and interstitial fibrosis-like
- Inflammatory infiltrate composed of small lymphocytes and mature plasma cells admixed with stromal fibrosis
- Eosinophils commonly present accompanying inflammatory infiltrates
- Lymphoid follicles may be present in 50% of cases
- Prominent vascular component characterized by endothelialitis of veins and arteries with narrowing and obliteration of vascular lumen

ANCILLARY TESTS

- Increased number of IgG4(+) plasma cells in tissue sections (> 50 per 10 HPF, with IgG4/IgG ratio of > 40%)
- Raised serum level of IgG4 (> 135 mg/dL) commonly seen but not essential for diagnosis

IgG4 Sclerosing Disease of Lung

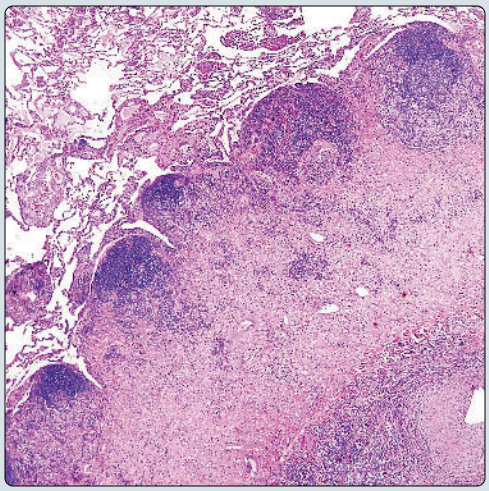

Stromal Sclerosis

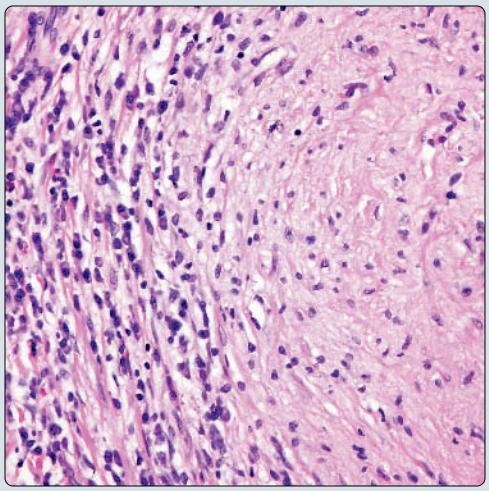

(Left) *IgG4 sclerosing lung disease shows a nodular, well-circumscribed area of lung parenchyma with prominent stromal sclerosis and reactive lymphoid follicles in the periphery.* **(Right)** *Higher magnification from an area of stromal sclerosis in IgG4 sclerosing disease of the lung shows dense infiltrate composed of plasma cells admixed with the sclerotic stroma.*

Plasma Cell Infiltrates

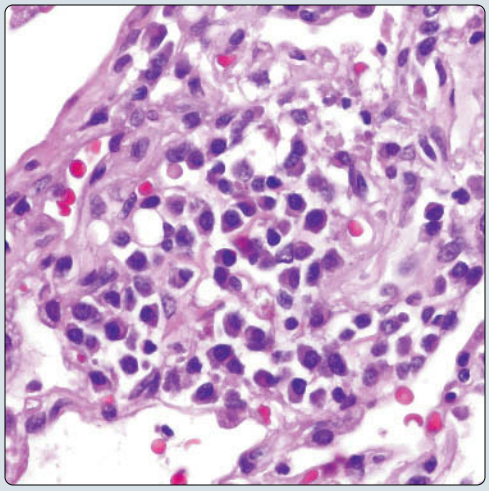

IgG4 Immunostain

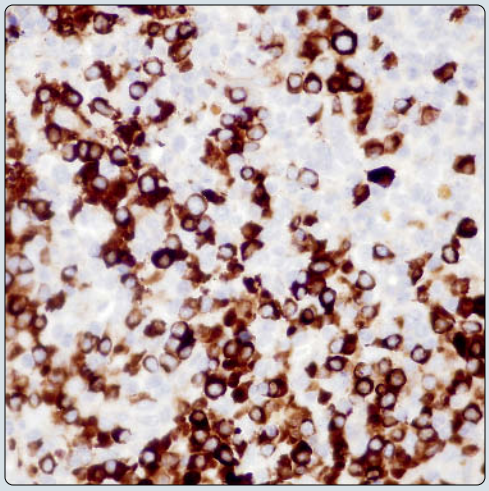

(Left) *Higher magnification from IgG4 sclerosing disease of the lung shows alveolar walls distended by a dense, mature plasma cell population.* **(Right)** *Immunohistochemical staining with antibodies against IgG4 shows numerous plasma cells with strong positivity for this antibody.*

TERMINOLOGY

Definitions

- Systemic disease of unknown etiology characterized by elevated production of IgG4(+) plasma cells and tissue stromal sclerosis

ETIOLOGY/PATHOGENESIS

Pathogenesis

- Unknown, but autoimmune mechanism or hypersensitivity reaction has been postulated
- Circulating autoantibodies present in many patients
- May be associated with other autoimmune disorders, e.g., Sjögren syndrome

CLINICAL ISSUES

Epidemiology

- Age
  - Middle-aged and elderly patients
- Sex
  - Male predominance

Presentation

- Asymptomatic incidental finding in chest x-ray
- Cough, hemoptysis, dyspnea, and pleural effusion

Natural History

- Slowly progressive disease with involvement of multiple sites over period of years with elevation of serum titers of IgG4
- Most commonly involved sites include pancreas, hepatobiliary tract, salivary gland, orbit, and lymph nodes
- Benign clinical course with good response to steroids
- Some cases may evolve to malignant lymphoma or may be associated with development of carcinoma

Prognosis

- Excellent response to steroid therapy

MICROSCOPIC

Histologic Features

- 3 histologic patterns of involvement recognized in lung
  - **Inflammatory pseudotumor-like**
    - Solid, nodular growth pattern characterized by well-circumscribed area of sclerosis admixed with lymphocytes and plasma cells
    - Lesions closely resemble inflammatory myofibroblastic tumor and inflammatory pseudotumor of lung
    - Fibrosis mostly paucicellular with few myofibroblasts
  - **Bronchovascular pattern of involvement**
    - Lymphoplasmacytic infiltration and fibrosis centered around bronchovascular bundles with lymphangitic distribution
    - Expansion along interlobular septa and pleura with paucicellular fibrosis
  - **Interstitial fibrosis-like**
    - Diffuse interstitial lymphoplasmacytic infiltrates and fibrosis involving alveolar septa
    - Pattern closely resembles lymphocytic interstitial pneumonia (LIP) or cellular nonspecific interstitial pneumonia (NSIP)
    - Fibrosis mostly paucicellular with few myofibroblasts
    - Prominent vascular involvement may closely resemble lymphomatoid granulomatosis, grade I

Cytologic Features

- Inflammatory infiltrate is composed of small lymphocytes and mature plasma cells admixed with stromal fibrosis
- Eosinophils are commonly present accompanying inflammatory infiltrates
- Lymphoid follicles may be present in 50% of cases
- Prominent vascular component characterized by endothelialitis of veins and arteries with narrowing and obliteration of vascular lumen
- Prominent histiocytes with emperipolesis reminiscent of Rosai-Dorfman disease may be seen

ANCILLARY TESTS

Immunohistochemistry

- Increased number of IgG4(+) plasma cells in tissue sections (> 50 per 10 HPF, with IgG4/IgG ratio of > 40%)

Serologic Testing

- Raised serum level of IgG4 (> 135 mg/dL) commonly seen but not essential for diagnosis

DIFFERENTIAL DIAGNOSIS

Inflammatory Pseudotumor/Inflammatory Myofibroblastic Tumor

- Prominent myofibroblastic component, which is usually not present in IgG4(+) sclerosing disease
- Inflammatory pseudotumor/myofibroblastic tumor is negative for IgG4(+) plasma cells

Rosai-Dorfman Disease

- Contains dense lymphoplasmacytic infiltrates admixed with prominent histiocytic proliferation with emperipolesis
- Rosai-Dorfman disease may contain numerous IgG4(+) plasma cells
- Histiocytes in Rosai-Dorfman disease are always S100(+), unlike those in IgG4(+) sclerosing disease, which are negative

Lymphomatoid Granulomatosis, Grade I

- Dense lymphoplasmacytic interstitial infiltrates with prominent vascular involvement
- Proliferating cells are strongly EBV(+) by EBER in situ hybridization, while plasma cells in IgG4(+) disease are negative for EBER

SELECTED REFERENCES

1. Fei Y et al: Intrathoracic involvements of immunoglobulin G4-related sclerosing disease. Medicine (Baltimore). 94(50):e2150, 2015
2. Shigemitsu H et al: IgG4-related interstitial lung disease: a new and evolving concept. Curr Opin Pulm Med. 15(5):513-6, 2009
3. Yamamoto H et al: Inflammatory myofibroblastic tumor versus IgG4-related sclerosing disease and inflammatory pseudotumor: a comparative clinicopathologic study. Am J Surg Pathol. 33(9):1330-40, 2009
4. Zen Y et al: IgG4-related lung and pleural disease: a clinicopathologic study of 21 cases. Am J Surg Pathol. 33(12):1886-93, 2009

IgG4 Sclerosing Lung Disease

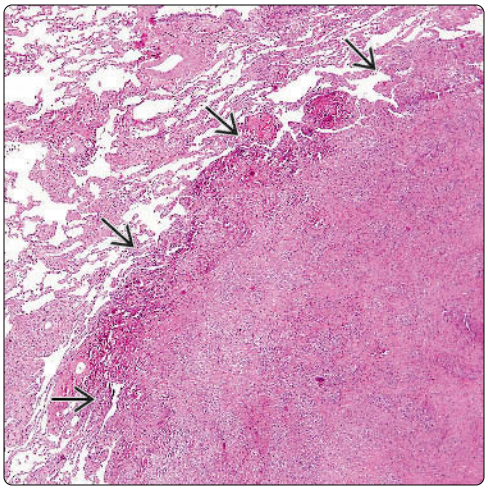

Area of Fibrosis

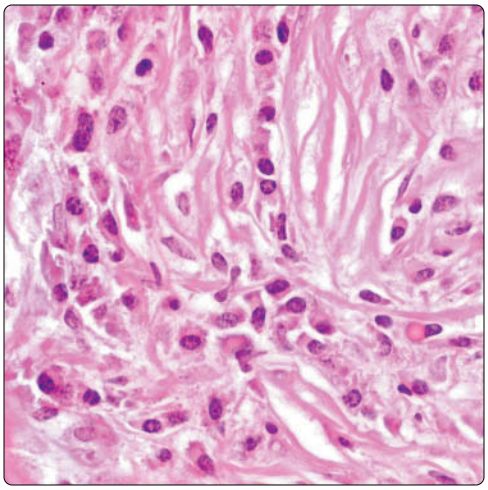

(Left) *Scanning magnification of inflammatory pseudotumor-like IgG4(+) sclerosing lung disease shows a well-circumscribed, intraparenchymatous lung nodule that is sharply separated from the surrounding lung parenchyma.* **(Right)** *Higher magnification from inflammatory pseudotumor-like IgG4(+) sclerosing lung disease shows a population of mature plasma cells set against a collagenous stroma. The fibrosis in these cases is paucicellular with scattered myofibroblasts.*

Bronchovascular Pattern of Fibrosis

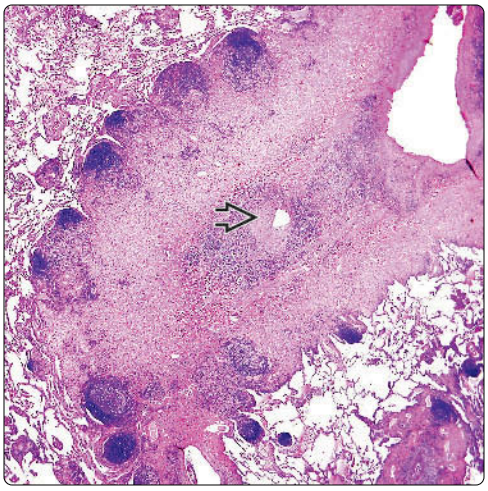

Mixed Infiltrate With Eosinophils

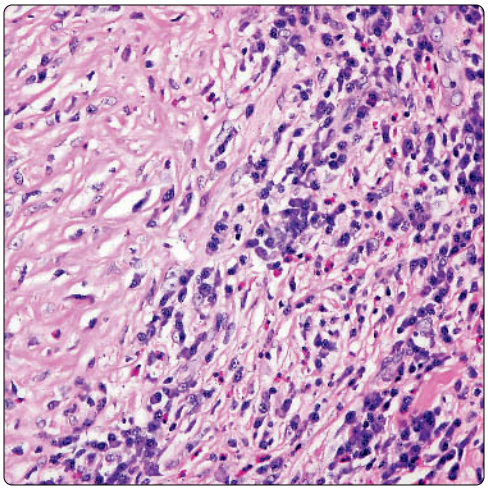

(Left) *Bronchovascular pattern of involvement of the lung in IgG4(+) sclerosing lung disease shows an area of fibrosis surrounded by multiple lymphoid follicles at the periphery and following the distribution of bronchovascular bundles. Note the sclerosed vessel in the center of the field.* **(Right)** *Higher magnification of bronchovascular pattern of involvement in IgG4(+) sclerosing lung disease shows dense lymphoplasmacytic infiltrates with scattered eosinophils surrounding an area of sclerosis.*

Interstitial Infiltration of Plasma Cells

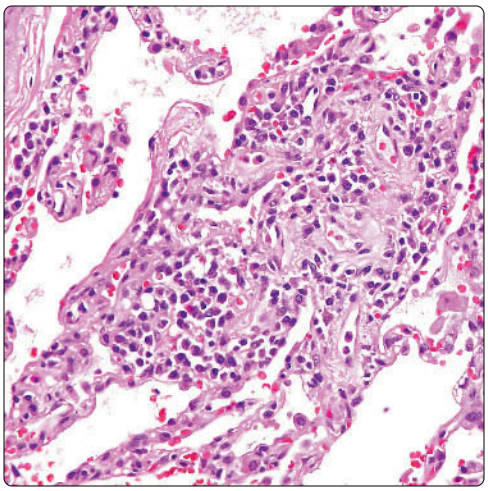

Dense Plasma Cell Infiltrate

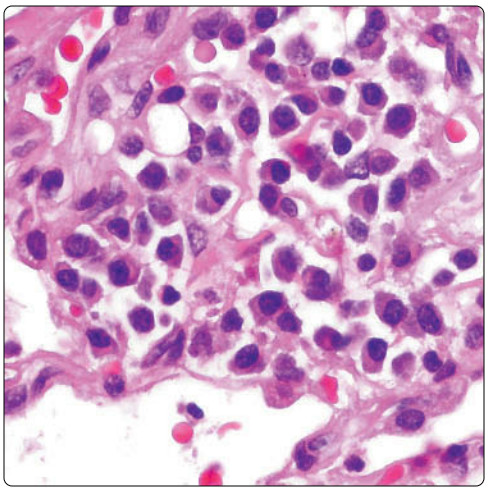

(Left) *Pattern of interstitial pneumonia in IgG4 sclerosing lung disease is characterized by expansion of alveolar septa by dense lymphoplasmacytic infiltrates with obliterative vascular changes. Lesions showing this growth pattern can be confused for the cellular form of NSIP, lymphoid interstitial pneumonia, or grade I lymphomatoid granulomatosis.* **(Right)** *Higher magnification of an interstitial pattern in IgG4 sclerosing lung disease shows dense plasmacytic infiltration of the alveolar wall.*

Plasma Cells and Eosinophils

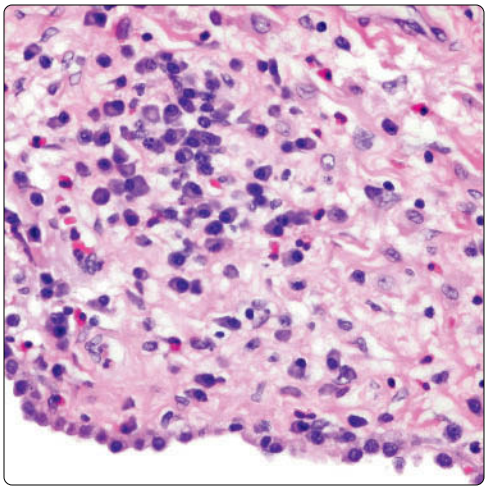

Reactive Lymphoid Follicle

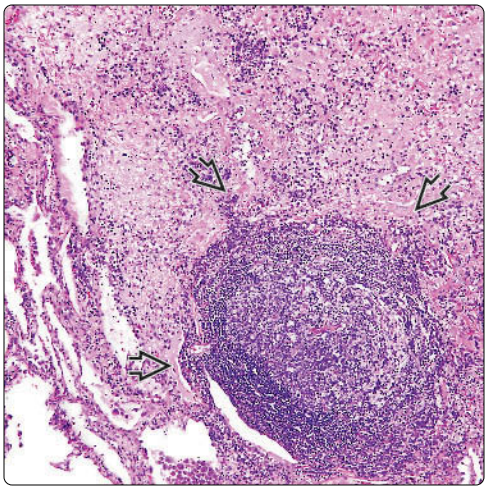

(Left) *Characteristic changes in IgG4 sclerosing lung disease include paucicellular stromal fibrosis and a lymphoplasmacellular inflammatory infiltrate that may harbor a prominent eosinophilic component.* **(Right)** *Reactive lymphoid follicles ⇨ are present in ~ 50% of IgG4(+) sclerosing lung disease cases. Lymphoid follicles may be abundant. In some instances, the follicles may display features of progressive transformation of germinal centers or Castleman disease.*

Vascular Obliteration

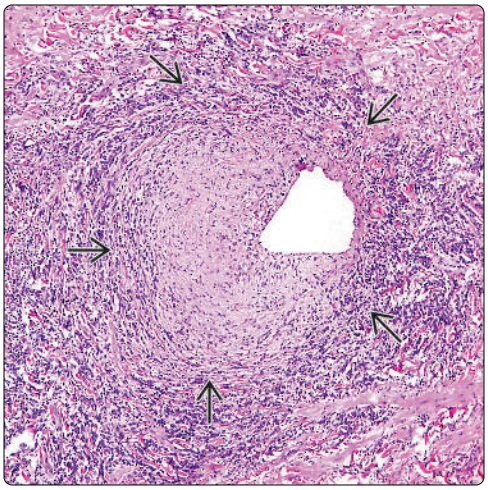

Venulitis in IgG4 Sclerosing Disease

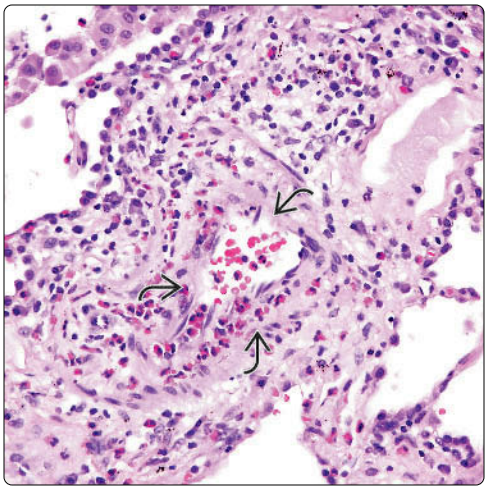

(Left) *Scanning magnification of lung in IgG4(+) sclerosing lung disease shows narrowing of the lumen of a midcaliber vessel by concentric sclerosis and inflammation ⇨. Obliterative vascular changes are a common finding in IgG4(+) sclerosing disease of the lung and tend to affect both the veins and arteries.* **(Right)** *Small vessel in the interstitium of the lung in a patient with IgG4(+) sclerosing lung disease shows prominent endothelialitis ⇨.*

Histiocytic Infiltrate

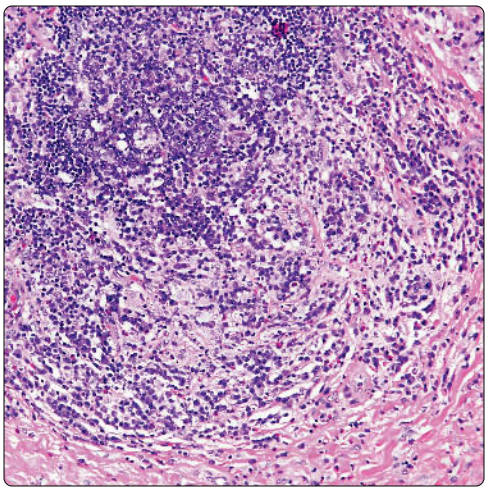

IgG4 Immunostaining

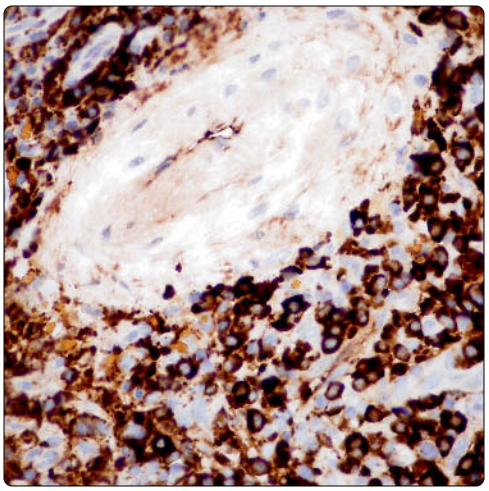

(Left) *IgG4(+) sclerosing lung disease shows an area with lymphoplasmacellular inflammatory infiltrates admixed with abundant histiocytes showing emperipolesis. Such areas can be closely reminiscent of Rosai-Dorfman disease.* **(Right)** *Immunohistochemical staining for IgG4 shows numerous plasma cells with strong cytoplasmic positivity in IgG4(+) sclerosing lung disease. There should be > 50 IgG4(+) plasma cells per 10 HPF, with an IgG4/IgG ratio of > 40%.*

Juvenile Xanthogranuloma

KEY FACTS

TERMINOLOGY

- Abbreviation
  - Pulmonary juvenile xanthogranuloma (JXG)
- Definition
  - Non-Langerhans histiocytic lesion

ETIOLOGY/PATHOGENESIS

- Contrary to other histiocytic lesions, cell of origin for JXG is unknown
  - Plasmacytoid monocyte has been speculated as possible origin for JXG

CLINICAL ISSUES

- Presentation
  - Bilateral or unilateral involvement of lung parenchyma
  - Multiple pulmonary lesions
  - Rarely, lesion will be single
  - Dermal involvement is common
  - Involvement of other organ systems may occur

MICROSCOPIC

- Cellular proliferation destroying lung parenchyma
- Histocytes admixed with inflammatory infiltrate composed of lymphocytes and plasma cells
- Multinucleated giant cells may be present but scattered
- Absence of nuclear atypia or mitotic activity

ANCILLARY TESTS

- This lesion may show positive staining for CD68, FXIIIA, and S100 protein while negative for CD1a

TOP DIFFERENTIAL DIAGNOSES

- Langerhans cell histiocytosis
- Rosai-Dorfman disease of lung
- Erdheim-Chester disease
- Pulmonary malacoplakia
- Mycobacterial infection

Replacement of Lung Parenchyma

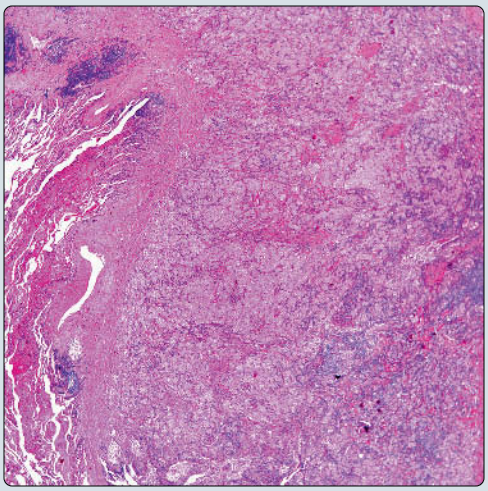

Airway Involvement

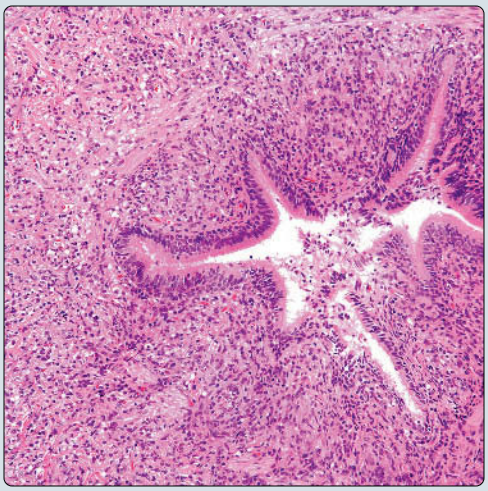

***(Left)** Low-power view of a juvenile xanthogranuloma (JXG) shows replacement of the lung parenchyma by a histiocytic proliferation admixed with inflammatory infiltrate. **(Right)** Pulmonary JXG shows a histiocytic proliferation, which is encircling the airway. However, the normal respiratory epithelium remains uninvolved by the process.*

Scattered Giant Cells

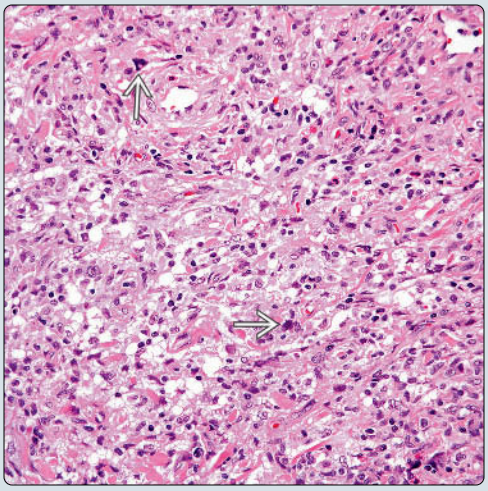

Prominent Histiocytic Component

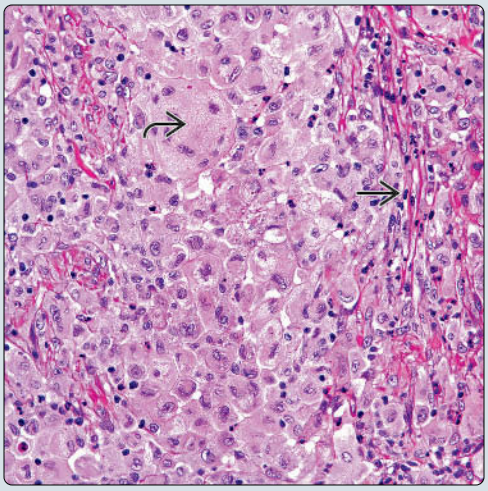

***(Left)** Diffuse histiocytic proliferation in this pulmonary JXG is shown. Note that the proliferation is also mixed with some inflammatory cells and scattered multinucleated giant cells. **(Right)** High-power view of the histiocytic proliferation shows large histiocytes with round nuclei and prominent nucleoli. A subtle inflammatory infiltrate is also present.*

TERMINOLOGY

Abbreviations

- Pulmonary juvenile xanthogranuloma (JXG)

Definitions

- Non-Langerhans histiocytic lesion

ETIOLOGY/PATHOGENESIS

Etiology

- Contrary to other histiocytic lesions, cell of origin for JXG is unknown
  - Plasmacytoid monocyte has been speculated as possible origin for JXG

CLINICAL ISSUES

Presentation

- Bilateral or unilateral involvement of lung parenchyma
- Multiple pulmonary lesions
- Rarely, lesion will be single
- Dermal involvement is common
- Involvement of other organ systems may occur

Prognosis

- Due to rarity of lesion in lung, it is difficult to unequivocally determine prognosis
- May be determined by extent of the process

MACROSCOPIC

General Features

- Tumor mass can range in size from 1-3 cm
- Well circumscribed but not encapsulated
- Soft and tan or yellowish in color

MICROSCOPIC

Histologic Features

- Cellular proliferation destroying lung parenchyma
- Histiocytic proliferation composed of small- to medium-sized histiocytes
- Histocytes admixed with inflammatory infiltrate composed of lymphocytes and plasma cells
- Multinucleated giant cells may be present but scattered
- Absence of nuclear atypia or mitotic activity

DIFFERENTIAL DIAGNOSIS

Langerhans Cell Histiocytosis

- Lesions in Langerhans cell histiocytosis (LCH) may vary from cellular to fibrotic
- Presence of large number of eosinophils is more common in LCH
- Histiocytes have characteristic grooving of nucleus
- LCH lesions have characteristic Medusa head, which is not present in JXG
- Usually associated with diffuse interstitial pneumonia-like reaction in adjacent lung parenchyma
- Positive for CD1a and S100

Rosai-Dorfman Disease of Lung

- Histiocytes in Rosai-Dorfman (R-D) disease are large with prominent nucleoli
- Enteropoiesis is characteristic of R-D disease
- Presence of prominent plasma cell component is more in favor of R-D disease
- Would be unusual for R-D disease to show presence of multinucleated giant cells
- S100 is strongly positive
- Usually single mass in lung

Erdheim-Chester Disease

- Histiocytic proliferation in Erdheim-Chester (E-C) disease characteristically follows septum and pleura
- Histiocytes in E-C disease are rather smaller
- Characteristically involves bones in symmetrical fashion
- S100 protein may show variable staining
- May share similar immunophenotype with JXG

SELECTED REFERENCES

1. Zaveri J et al: More than just Langerhans cell histiocytosis: a radiologic review of histiocytic disorders. Radiographics. 34(7):2008-24, 2014
2. Lin L et al: Solitary juvenile xanthogranuloma in the lung of a young adult. Pathology. 43(5):503-7, 2011
3. Bakir B et al: Atypical lung involvement in a patient with systemic juvenile xanthogranuloma. Pediatr Radiol. 37(3):325-7, 2007
4. Snijders D et al: Case for diagnosis: 4-month-old infant with increasing cough, hemoptysis, and anemia. Pediatr Pulmonol. 42(9):844-6, 2007
5. Cauro F et al: [Cerebellar, pulmonary and cutaneous localizations of juvenile xanthogranuloma.] Ann Dermatol Venereol. 129(3):307-10, 2002
6. Guthrie JA et al: Case report: juvenile xanthogranuloma with pulmonary, subcutaneous and hepatic involvement. Clin Radiol. 49(7):498-500, 1994
7. Gupta AK et al: Juvenile xanthogranuloma with pulmonary lesions. Pediatr Radiol. 18(1):70, 1988

Immunohistochemistry

Antibody	Reactivity	Staining Pattern	Comment
CD68	Positive	Cytoplasmic	Global and strong
FXIIIA	Positive	Cytoplasmic	May be focal
CD45	Positive	Cytoplasmic	In lymphocytic component
HLA-DR	Positive	Cytoplasmic	May be focal
S100	Positive	Cytoplasmic	May be focal
CD4	Positive	Cytoplasmic	May be focal
CD1a	Negative		

Uninvolved Airway

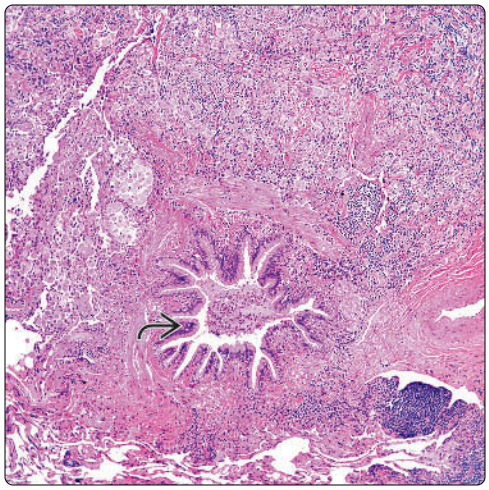

Partial Destruction of Airway

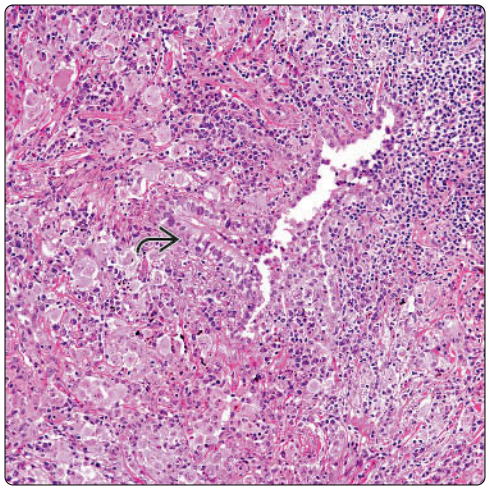

(Left) *Low-power view of a JXG shows an airway that is uninvolved by the histiocytic proliferation, even though some histiocytes are present within the lumen of the airway. Adjacent lung parenchyma shows inflammatory changes.* **(Right)** *In some cases of JXG, the histocytic proliferation destroys, not only lung parenchyma, but also airway structures. In this particular case, there is only residual bronchial epithelium.*

Unencapsulated Tumor Lesion

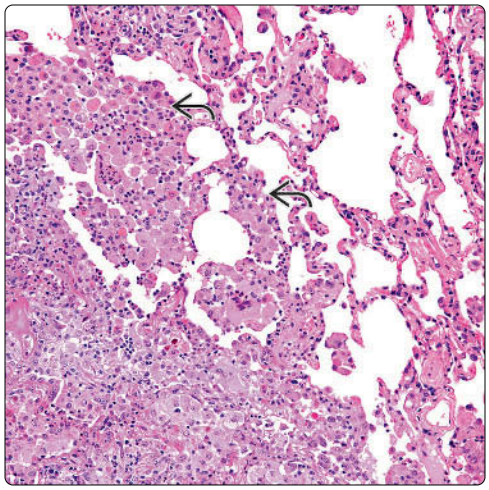

Well-Defined Tumor Lesion

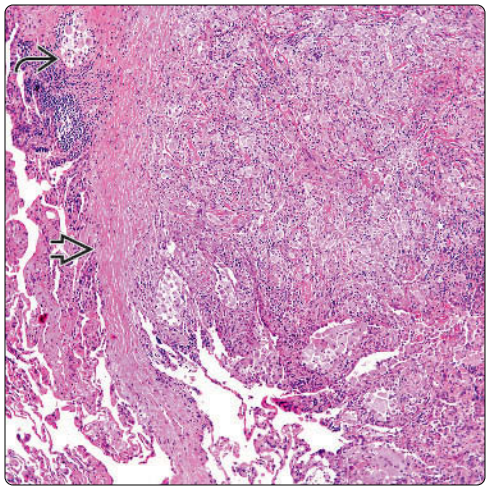

(Left) *Although the majority of cases of JXG consist of well-circumscribed lesions, they are not encapsulated. The histiocytic proliferation involves alveolar spaces, as can be seen in this case.* **(Right)** *In some other cases of JXG, the lesion appears to be well delimited by fibrocollagenous tissue. However, note that the histiocytic proliferation goes beyond that boundary into the lung parenchyma proper.*

Inflammatory Response

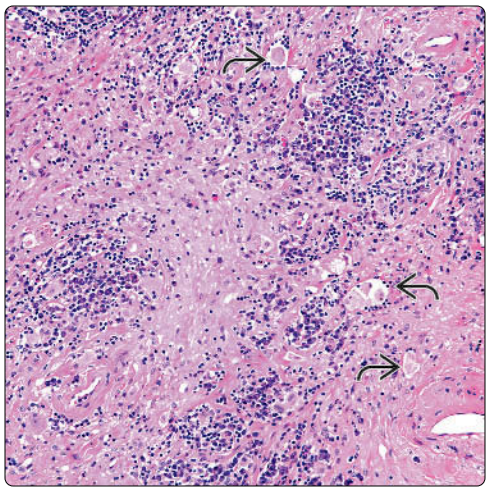

Multinucleated Giant Cells

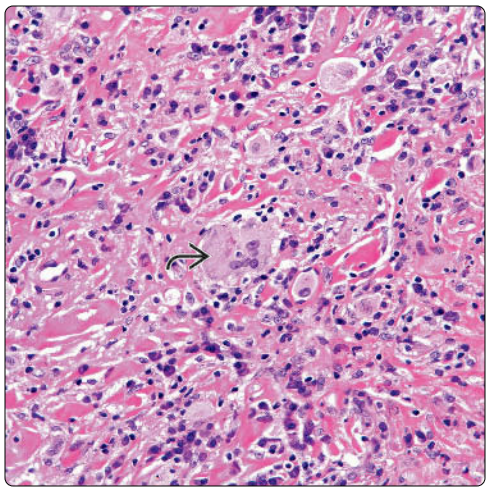

(Left) *Extensive areas of fibrosis with an inflammatory reaction composed of lymphocytes, plasma cells, and eosinophils are commonly seen in association with the histocytic proliferation, which can be scanty and subtle.* **(Right)** *Extensive areas of collagen deposition admixed with plasma cells, lymphocytes, and multinucleated histocytes are common features of JXG. However, similar features may also be seen in other types of histiocytosis.*

Giant Cells and Histiocytes

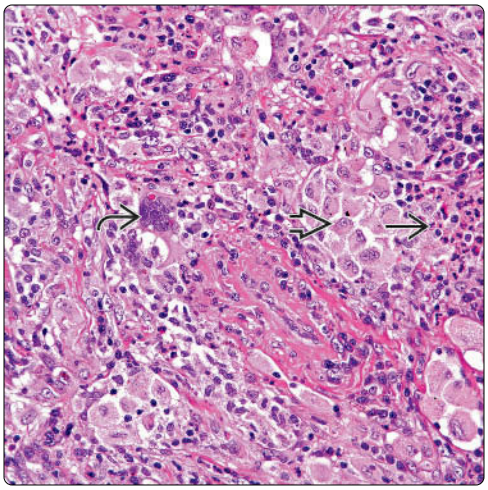

Marked Inflammatory Component

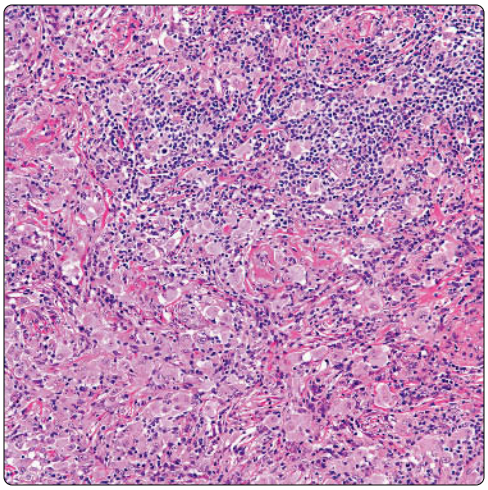

(Left) *Extensive histiocytic proliferation ⇨ with minimal inflammatory infiltrate ⇨ is shown. Note the presence of multinucleated giant cells ⇨ admixed with histiocytic proliferation.* **(Right)** *In other cases of JXG, the inflammatory infiltrate can be marked. The presence of this inflammatory infiltrate, composed mainly of plasma cells and lymphocytes, may also be observed in other types of histiocytosis.*

Solid Histiocytic Proliferation

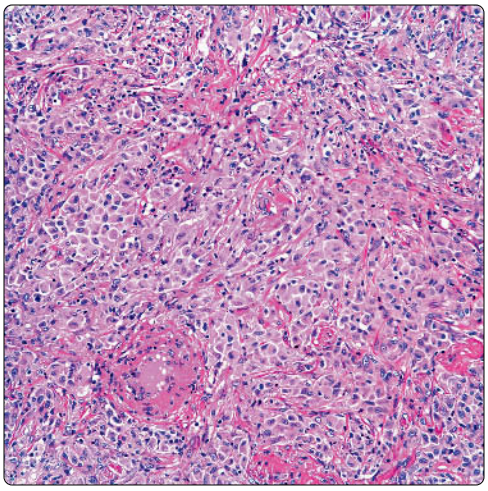

Large Histiocytes

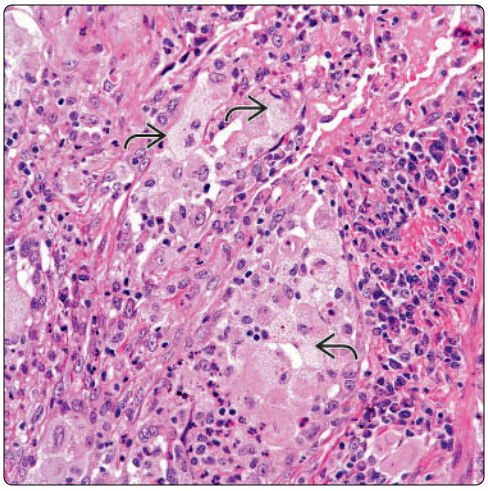

(Left) *JXG shows a more solid proliferation of histiocytes with only minimal inflammatory reaction. This type of proliferation can also be easily confused for a malignant neoplasm.* **(Right)** *High-power view of the histiocytic proliferation of JXG shows large histiocytes with round nuclei and prominent nucleoli. Note the ample cytoplasm of the histiocytes with more classic features of xanthomatous change ⇨.*

Subtle Nested Pattern

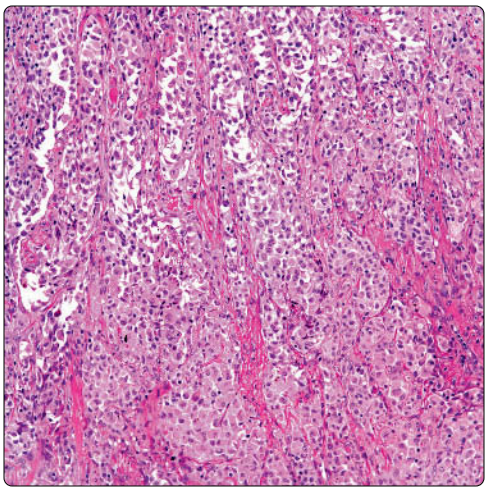

Lack of Mitotic Activity

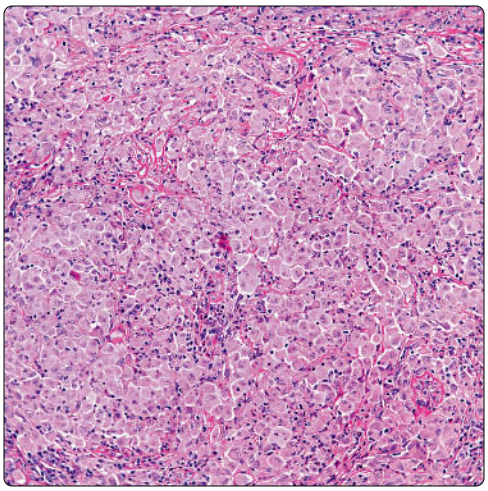

(Left) *In some cases of JXG, the histiocytic proliferation appears to actually show a subtle nested pattern. Similar features may be seen in some malignant neoplasms.* **(Right)** *In other cases of JXG, the histiocytic proliferation is rather solid and composed of large histiocytes but without evidence of mitotic activity &/or nuclear atypia. Note that, in this particular illustration, the inflammatory reaction is minimal.*

Hyalinizing Granuloma

KEY FACTS

ETIOLOGY/PATHOGENESIS

- Unusual condition of unknown origin
- May have autoimmune origin
- Pulmonary hyalinizing granuloma may be associated with conditions with similar histological features, including
  - Retroperitoneal fibrosis
  - Sclerosing mediastinitis

CLINICAL ISSUES

- Epidemiology
  - Rare occurrence
  - Any age group, but more common in middle-aged adults
- Symptoms
  - Cough
  - Dyspnea
  - Chest pain
  - Fever
- Laboratory findings
  - Antinuclear antibodies
  - Rheumatoid factor may be positive
  - Coombs-positive hemolithic anemia may be positive

IMAGING

- Single or multiple pulmonary nodules

MICROSCOPIC

- Prominent, dense, fibrocollagenous deposition
- Inflammatory reaction
- Dilatation of vascular spaces
- Focal calcification may be present

TOP DIFFERENTIAL DIAGNOSES

- Amyloid tumor
- Intrapulmonary solitary fibrous tumor
- Inflammatory pseudotumor, plasma cell type
- IgG4 disease
- Sclerosing mediastinitis

(Left) *Hyalinizing granuloma of the lung shows a centrally located tumor in which the tumor appears not to be involving the superficial respiratory epithelium. Also note that the bronchial cartilage is not involved.* **(Right)** *Low-power view of a hyalinizing granuloma of the lung is shown. Note the extensive fibrocollagenous tissue deposition ⇨ accompanied by an inflammatory reaction ⇨.*

Central Tumor

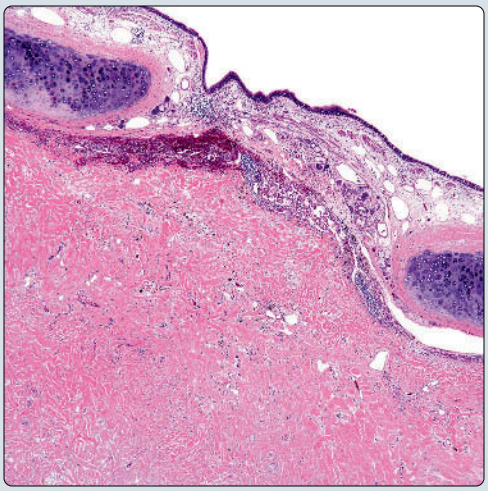

Replacement of Lung Parenchyma

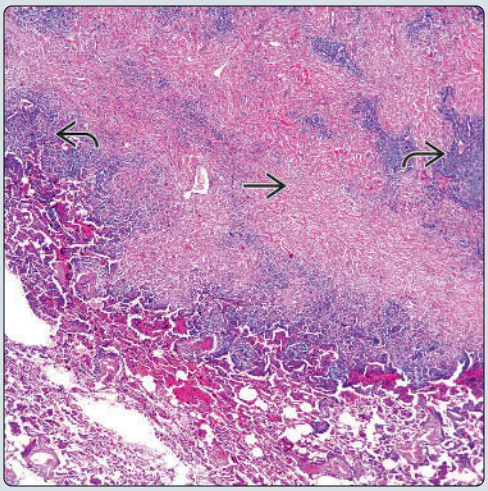

(Left) *High-power magnification shows dense fibrocollagenous tissue ⇨, rather acellular, accompanied by an inflammatory reaction ⇨.* **(Right)** *Hyalinizing granuloma of the lung shows prominent fibrocollagen and very little inflammatory reaction. Some of these features may be seen in other intrapulmonary tumors such as solitary fibrous tumor.*

Inflammatory Response

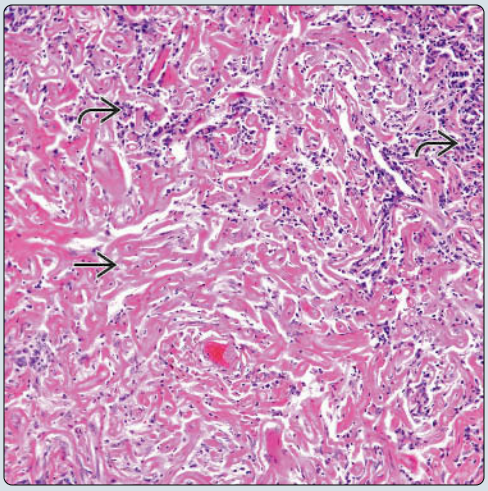

Prominent Collagen

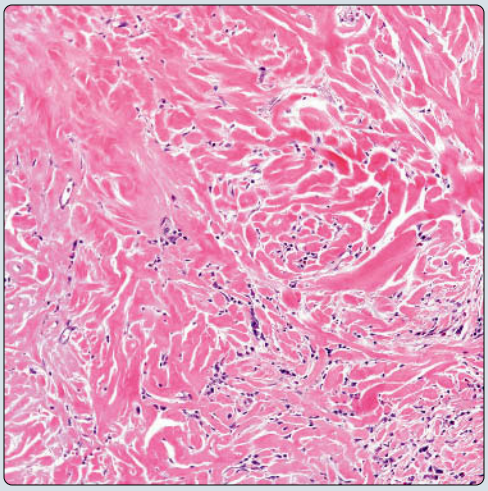

TERMINOLOGY

Abbreviations

- Pulmonary hyalinizing granuloma (PHG)

Definitions

- Benign reactive process, probably inflammatory or autoimmune

ETIOLOGY/PATHOGENESIS

Etiology

- Unusual condition of unknown etiology
- May have autoimmune origin

Associated Conditions

- PHG may be associated with conditions with similar histological features, including
  - Retroperitoneal fibrosis
  - Sclerosing mediastinitis

CLINICAL ISSUES

Epidemiology

- Incidence
  - Rare occurrence
- Age
  - Any age group, but more common in middle-aged adults
- Sex
  - No sex predilection

Presentation

- Cough
- Dyspnea
- Chest pain
- Fever
- Asymptomatic

Laboratory Tests

- Antinuclear antibodies may be positive
- Rheumatoid factor may be positive
- Coombs-positive hemolytic anemia may be positive

Treatment

- Surgical approaches
  - Complete surgical resection

Prognosis

- Good

IMAGING

General Features

- Single or multiple pulmonary nodules

MACROSCOPIC

General Features

- Nodules are firm and light tan in color

Size

- Vary from 1 cm to > 10 cm in diameter

MICROSCOPIC

Histologic Features

- Prominent, dense, fibrocollagenous deposition
- Replacement of normal lung parenchyma
- Inflammatory reaction, mainly lymphocytes and plasma cells
- Dilatation of vascular spaces
- Focal calcification may be present

DIFFERENTIAL DIAGNOSIS

Amyloid Tumor

- Usually shows presence of giant cells
- Congo red is generally positive
- Amorphous material is usually acellular with no inflammatory reaction

Intrapulmonary Solitary Fibrous Tumor

- Spindle cellular proliferation usually present
- Shows hemangiopericytic growth pattern
- Presence of an inflammatory reaction would be unusual
- Immunohistochemical studies for CD34, Bcl-2, and STAT6 are commonly positive

Inflammatory Pseudotumor, Plasma Cell Type

- Marked presence of plasma cells with collections of foamy macrophages
- Likely shows positive staining for smooth muscle actin &/or ALK

IgG4 Disease

- IgG4 disease is characterized by the presence of marked plasma cell component
- Positive staining by immunohistochemistry for IgG
- Usually increase of IgG in serum

Sclerosing Mediastinitis

- In unusual cases, it may involve lung parenchyma
- Generally it will present with anterior mediastinal mass
- Histologically, both conditions may share similar histopathology

DIAGNOSTIC CHECKLIST

Pathologic Interpretation Pearls

- Dense fibrocollagenous tissue
- Inflammatory reaction
- Ill-defined lesion replacing normal lung parenchyma

SELECTED REFERENCES

1. Keenan JC et al: IgG4-related lung disease: a case series of 6 patients and review of the literature. Sarcoidosis Vasc Diffuse Lung Dis. 32(4):360-7, 2016
2. Pfeifer K et al: Radiographic and pathologic manifestations of uncommon and rare pulmonary lesions. Can Assoc Radiol J. 67(2):179-89, 2016
3. Young AS et al: Pulmonary hyalinizing granuloma and retroperitoneal fibrosis in an adolescent. Pediatr Radiol. 37(1):91-5, 2007
4. Yousem SA et al: Pulmonary hyalinizing granuloma. Am J Clin Pathol. 87(1):1-6, 1987
5. Engleman P et al: Pulmonary hyalinizing granuloma. Am Rev Respir Dis. 115(6):997-1008, 1977

(Left) *Hyalinizing granuloma of the lung shows the classic histopathological features of dense fibrocollagenous tissue and inflammatory reaction. Note that the lesion is not encapsulated and appears to penetrate into alveolar tissue.* **(Right)** *Extensive hyalinization ⇄ with marked inflammatory reaction ⇒ is shown. At this power, the morphological features would suggest a granulomatous reaction; however, the presence of granulomas would be unusual for this condition.*

Ill-Defined Lesion

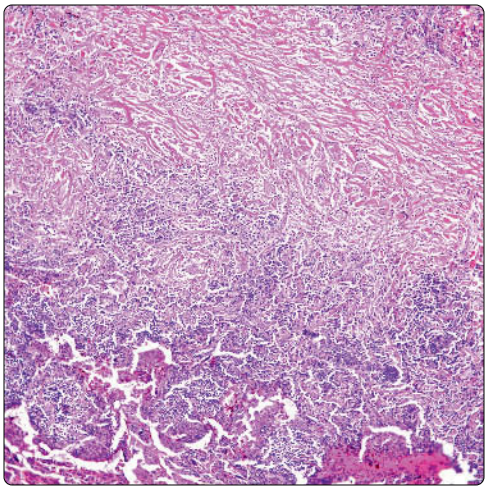

Inflammatory Reaction

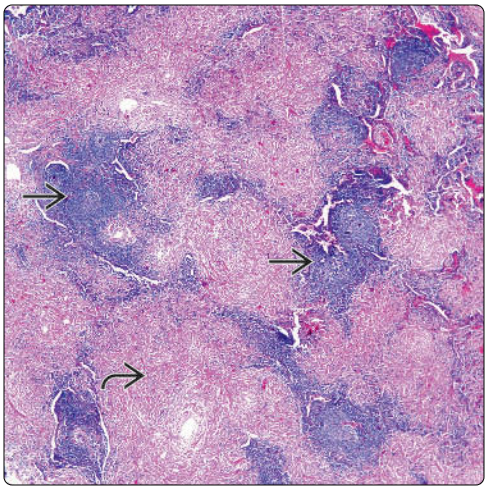

(Left) *In some areas of hyalinizing granuloma where there are marked inflammatory changes, there may be entrapped vessels ⇄, giving the appearance of vasculitis. Note also the presence of entrapped airway structures ⇒.* **(Right)** *Closer magnification demonstrates the presence of hyalinization represented by dense collagen fibers ⇒ and a marked inflammatory component composed mainly of lymphocytes ⇒. Note the entrapped airway structures ⇄.*

Ectatic Vascular Structures

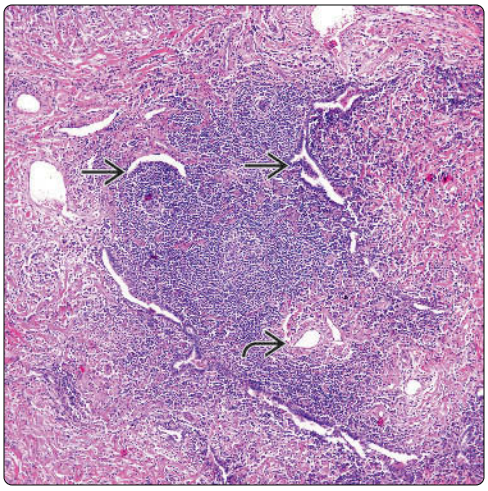

Entrapped Airway

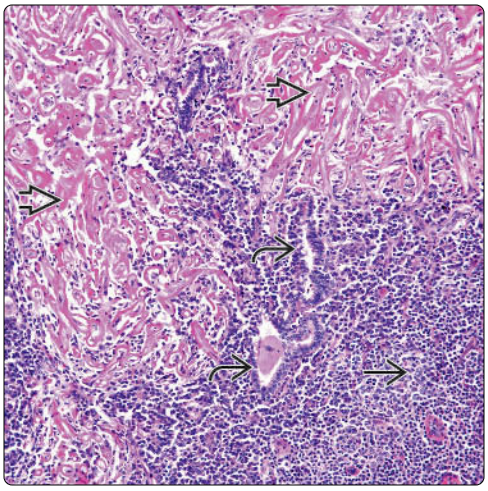

(Left) *Hyalinizing granuloma shows pushing borders ⇄ into the normal lung parenchyma, which shows thickening of the pulmonary septum ⇒. In addition, the inflammatory component is also present in focal areas in the pulmonary parenchyma ⇒.* **(Right)** *Higher magnification shows the acellular fibrocollagen admixed with inflammatory cells, mainly plasma cells. At this magnification, these features may also be shared by other tumoral conditions, including solitary fibrous tumor.*

Pushing Borders

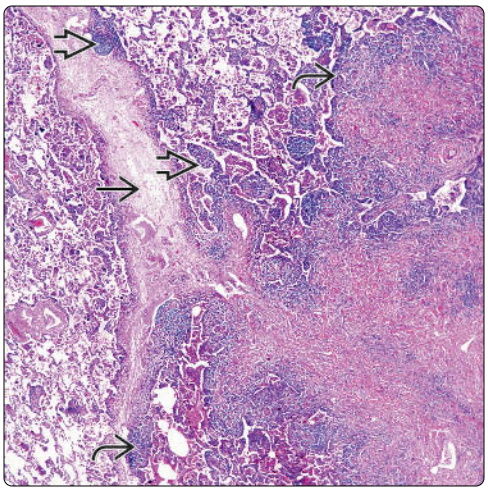

Mixed Inflammatory Reaction

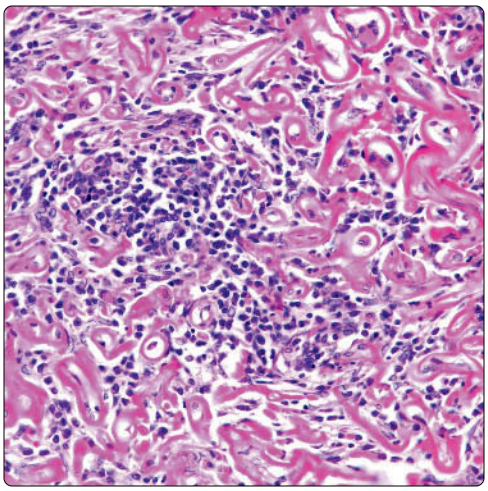

Subtle Presence of Fibrocollagen

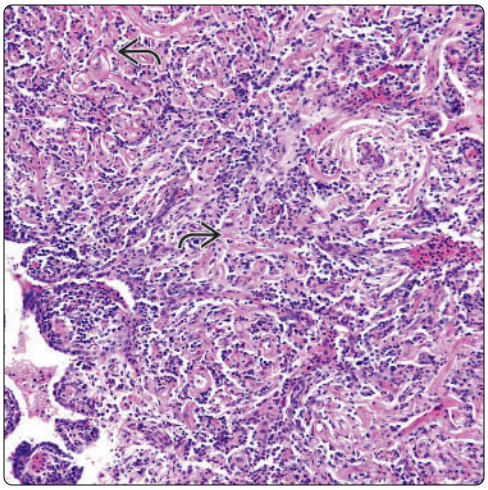

Partial Involvement of Airway

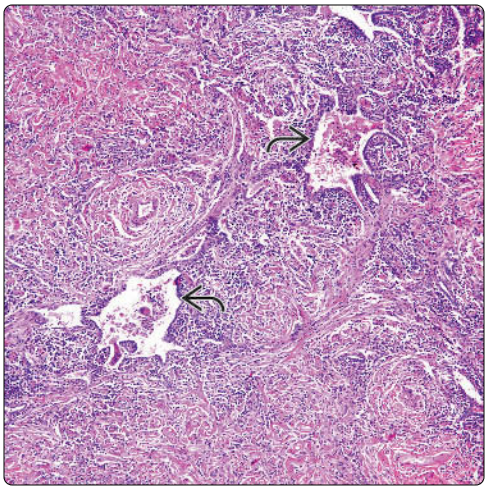

(Left) *In some areas of hyalinizing granuloma, the typical features may not be as easily identifiable. In this illustration, the presence of fibrocollagen is rather subtle and the inflammatory component is also marked.* **(Right)** *In some areas of hyalinizing granuloma, the process appears to be involving and destroying airway structures. The typical features of the process are apparent and should not be mistaken for a simple nonspecific inflammatory process.*

Plasma Cell Component

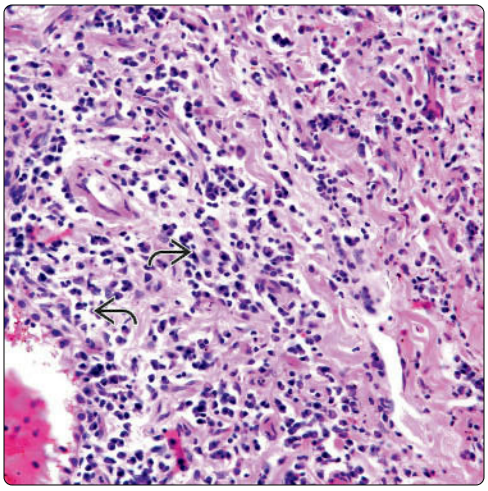

Prominent Vasculature

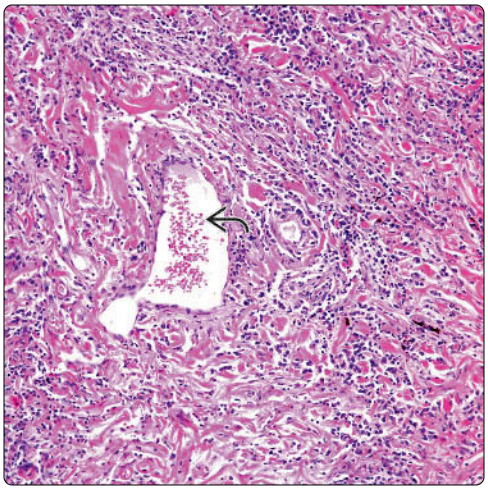

(Left) *Marked inflammatory reaction composed of mature plasma cells and lymphocytes dissecting fibrocollagen is shown. However, these changes are nonspecific and cannot be construed as diagnostic for hyalinizing granuloma.* **(Right)** *Extensive hyalinization with inflammatory reaction and an ectatic large vessel is shown. These changes can be easily associated with tumoral conditions such as solitary fibrous tumors or involvement of the lung by sclerosing mediastinitis.*

Prominent Fibrocollagen

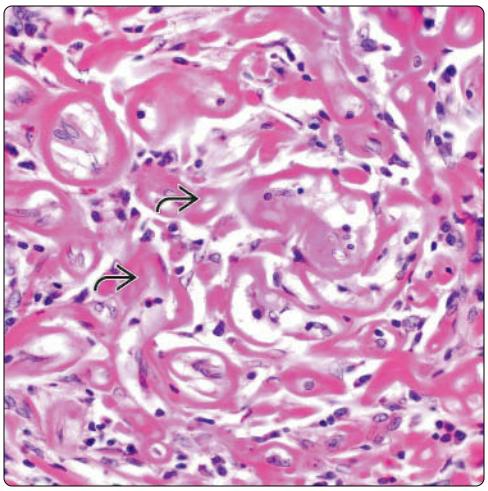

Intraalveolar Macrophages in Adjacent Lung

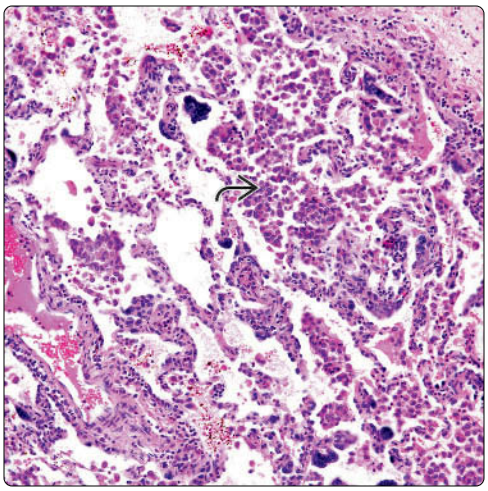

(Left) *Higher magnification of a hyalinizing granuloma of the lung shows the classic fibrocollagen that in some respects mimics the ropy collagen that is described in solitary fibrous tumor.* **(Right)** *Uninvolved section of the lung parenchyma shows collections of intraalveolar pigmented macrophages as well as inflammatory cells. These are common features observed in the adjacent lung parenchyma.*

Amyloid Tumor

KEY FACTS

TERMINOLOGY

- Synonym
  - Amyloidoma
- Definition
  - Pulmonary mass composed of amyloid without evidence of systemic disease

ETIOLOGY/PATHOGENESIS

- Specific cause to account for presence of amyloid in lung without systemic disease unknown; speculated to be related to
  - Light chain immunoglobulin
  - Plasma cells
- Associated conditions
  - Waldenström macroglobulinemia
  - Systemic amyloidosis
  - Multiple myeloma
  - Familial neuropathy
  - Niemann-Pick disease
  - Gaucher disease

CLINICAL ISSUES

- Rare occurrence
- Predominantly in adults
- Laboratory tests
  - Potassium permanganate oxidation technique appears to separate amyloid type AA from other types

MICROSCOPIC

- Amorphous acellular material replacing lung parenchyma
- It may be single mass or several nodules
- Multinucleated giant cells may be present
- Positive staining for Congo red

TOP DIFFERENTIAL DIAGNOSES

- Hyalinizing granuloma of lung
- Intrapulmonary solitary fibrous tumor

Replacement of Lung Parenchyma

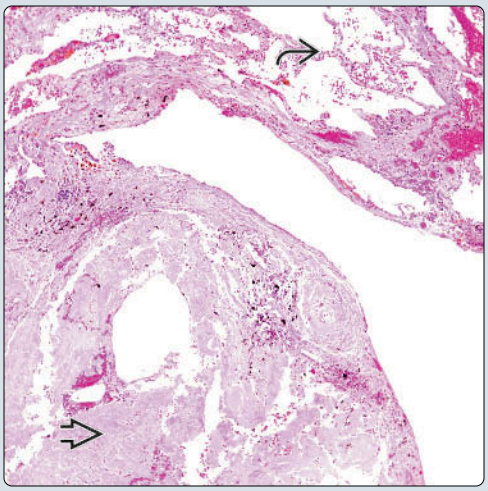

Focal Inflammatory Response

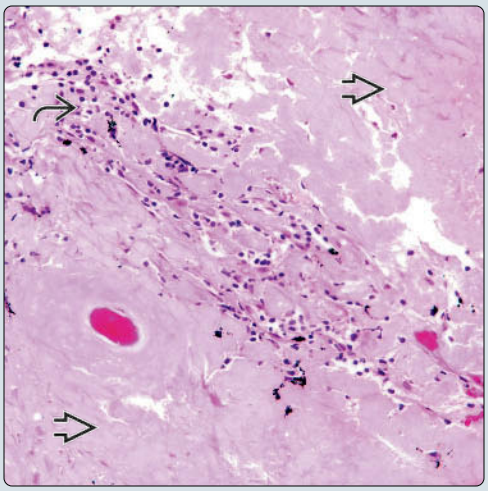

(Left) *Low-power view of a pulmonary amyloid tumor shows dense amorphous material replacing normal lung parenchyma. Adjacent lung parenchyma appears to be within normal limits.* **(Right)** *High-power view of a pulmonary amyloid tumor shows dense amorphous acellular material with only focal areas of inflammatory reaction. These features are classic for an amyloid tumor.*

Focal Cellularity

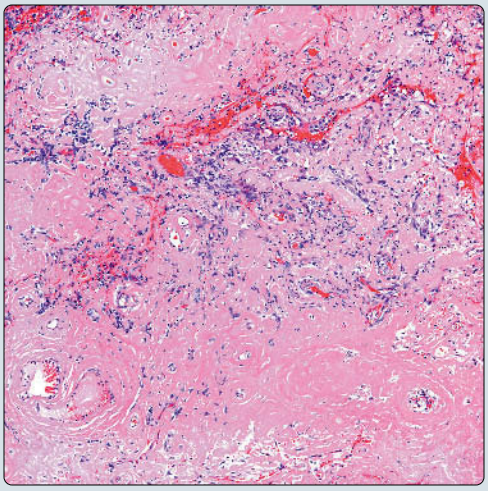

Entrapped Airway

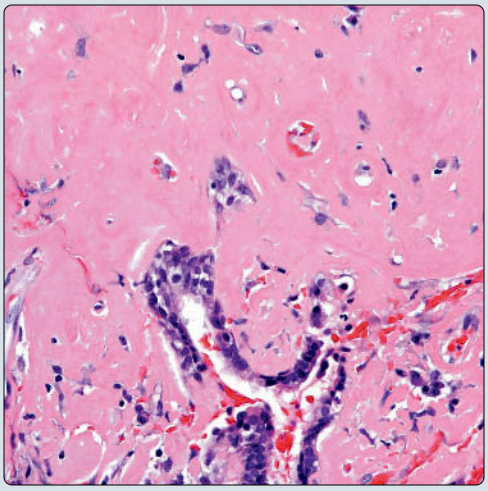

(Left) *Extensive areas of amyloid deposition replaces lung parenchyma with only focal areas of cellularity and vascular proliferation.* **(Right)** *Amyloidoma of the lung shows entrapment of airway structures. In the majority of cases, the amorphous material replaces normal lung parenchyma.*

TERMINOLOGY

Synonyms

- Amyloidoma

Definitions

- Pulmonary mass composed of amyloid without evidence of systemic disease

ETIOLOGY/PATHOGENESIS

Etiology

- Specific cause to account for presence of amyloid in lung without systemic disease is unknown
  - Speculated to be related to
    - Light chain immunoglobulin
    - Plasma cells

Associated Conditions

- Waldenström macroglobulinemia
- B-cell lymphoma
- Systemic amyloidosis
- Multiple myeloma
- Familial neuropathy
- Niemann-Pick disease
- Gaucher disease

CLINICAL ISSUES

Epidemiology

- Incidence
  - Rare occurrence
- Age
  - Predominantly in adults
- Sex
  - No gender predilection
- Ethnicity
  - No apparent ethnic predilection

Presentation

- Cough
- Chest pain
- Dyspnea
- Sjögren syndrome

Laboratory Tests

- Potassium permanganate oxidation technique appears to separate amyloid type AA from other forms of amyloid

Treatment

- Surgical approaches
  - Surgical resection of tumor mass by wedge resection or lobectomy

Prognosis

- It will depend on any possible associated condition

MACROSCOPIC

General Features

- Single or multiple pulmonary nodules
- Soft and well circumscribed
- Size can range from 1 cm to > 10 cm in diameter
- Light tan in color

MICROSCOPIC

Histologic Features

- There are essentially 2 patterns in which lung may be affected
  - Interstitial and diffuse pattern
  - Nodular
- Acellular amorphous eosinophilic material destroying lung parenchyma
- Subtle inflammatory infiltrate predominantly in periphery
- Numerous multinucleated giant cells
- Focal areas of ossification may be present

DIFFERENTIAL DIAGNOSIS

Pulmonary Scar

- Negative staining for Congo red amyloid stain
- Does not show subtle inflammatory reaction
- Multinucleated giant cells are generally absent in pulmonary scar

Hyalinizing Granuloma of Lung

- Negative for Congo red
- Dense ropy fibrocollagen
- Does not show presence of multinucleated giant cells

Pneumocystic Pneumonia

- Stains brightly with silver stains
- Negative for Congo red stain

Intrapulmonary Solitary Fibrous Tumor

- Negative staining for Congo red amyloid stain
- Likely shows hemangiopericytic pattern
- Multinucleated giant cells would be unusual feature for solitary fibrous tumor

DIAGNOSTIC CHECKLIST

Clinically Relevant Pathologic Features

- Some cases may be associated with MALT lymphoma of lung

Pathologic Interpretation Pearls

- Amorphous acellular material
- Subtle inflammatory infiltrate in periphery
- Presence of multinucleated giant cells

SELECTED REFERENCES

1. Barešić M et al: Solitary pulmonary amyloidoma mimicking lung cancer on 18F-FDG PET-CT scan in systemic lupus erythematosus patient. Lupus. 24(14):1546-51, 2015
2. Oezkan F et al: Hemoptysis in primary pulmonary amyloidoma treated with intrabronchial arterial coiling. Am J Respir Crit Care Med. 190(11):1311-4, 2014
3. Grogg KL et al: Nodular pulmonary amyloidosis is characterized by localized immunoglobulin deposition and is frequently associated with an indolent B-cell lymphoproliferative disorder. Am J Surg Pathol. 37(3):406-12, 2013
4. Calatayud J et al: Nodular pulmonary amyloidosis in a patient with rheumatoid arthritis. Clin Rheumatol. 26(10):1797-8, 2007
5. Mori S et al: Early rheumatoid arthritis in a patient with Sjögren's syndrome and pulmonary nodular amyloidosis: clinical implication of early limited use of infliximab. Mod Rheumatol. 17(6):500-6, 2007
6. Satani T et al: Amyloid deposition in primary pulmonary marginal zone B-cell lymphoma of mucosa-associated lymphoid tissue. Pathol Int. 57(11):746-50, 2007

Extensive Acellular Material

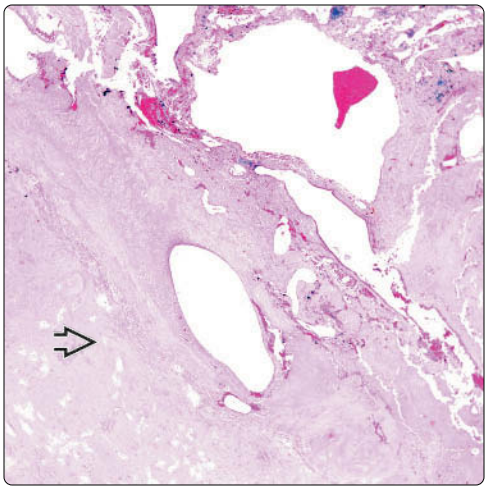

Accumulation of Macrophages

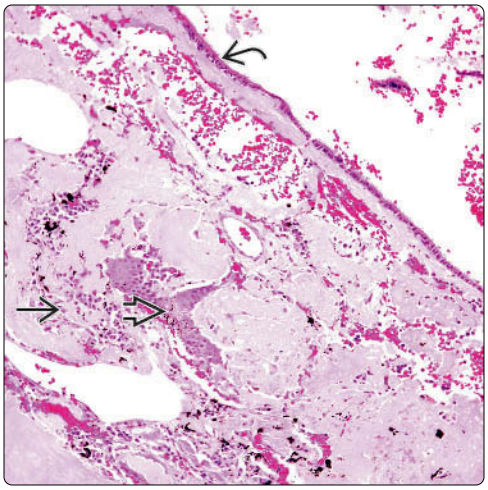

(Left) *Low-power view of a pulmonary amyloid tumor shows the classic features of amorphous acellular material replacing lung parenchyma. At this magnification, this can be easily mistaken for fibrinous material or scarring of the lung parenchyma.* **(Right)** *Pulmonary amyloid tumor shows conventional histological features. It is important to note the presence of a residual airway, an inflammatory reaction, and the accumulation of macrophages.*

Ectatic Vascular Structures

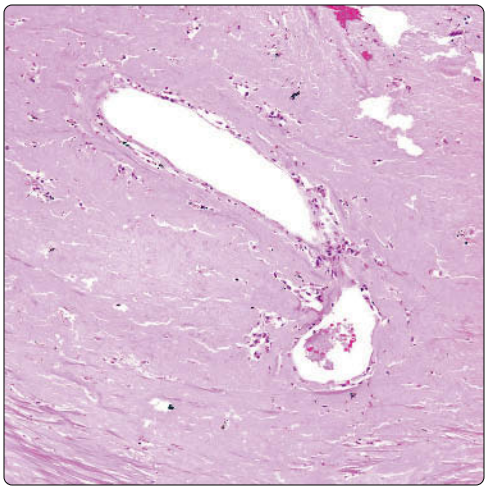

Amyloid and Collagen

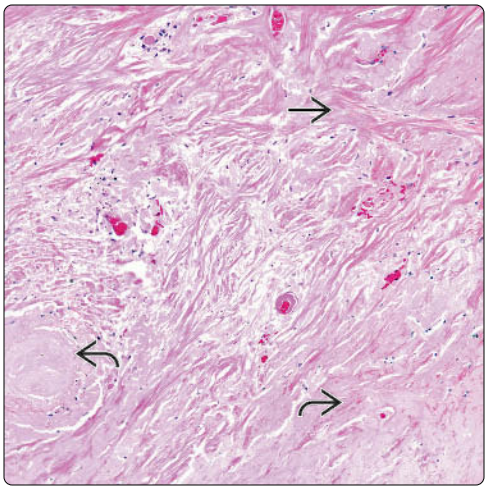

(Left) *Pulmonary amyloid tumor shows ectatic vessels and minimal inflammatory reaction. These features may be misleading for other conditions, including solitary fibrous tumor of hyalinizing granuloma of the lung.* **(Right)** *In some cases of amyloid tumor of the lung, the amorphous acellular material may be associated with areas of collagenization, which makes the distinction of the 2 very difficult. Amyloid and collagen are both depicted here.*

Mesothelial Lining

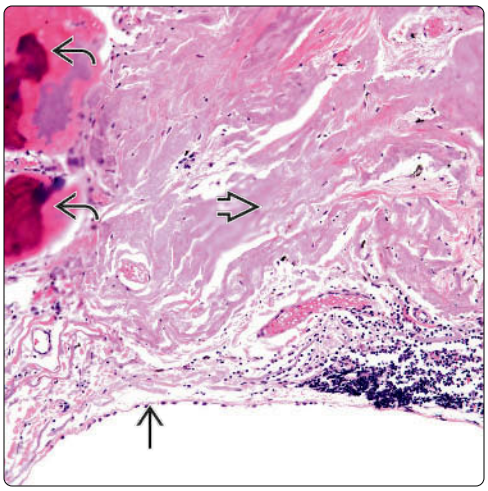

Residual Lung Parenchyma

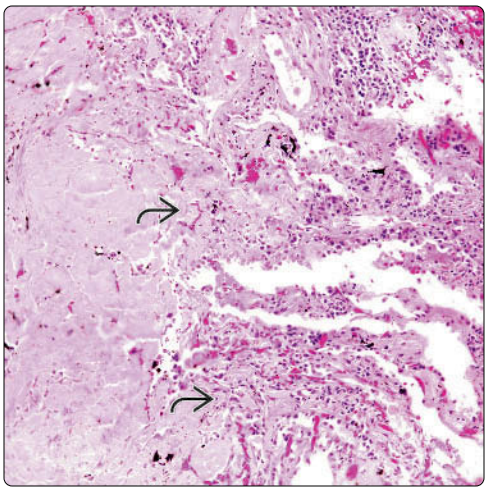

(Left) *In many cases of pulmonary amyloid tumor, the nodule is in a subpleural location; note the residual mesothelial lining. In addition, the amyloid looks denser with areas of ossification.* **(Right)** *Although most cases of pulmonary amyloid are characterized by the presence of well-demarcated nodules, in some cases, it is possible to identify areas in which such demarcation is not well defined and the amyloid transitions subtly into normal lung parenchyma.*

Multinucleated Giant Cells

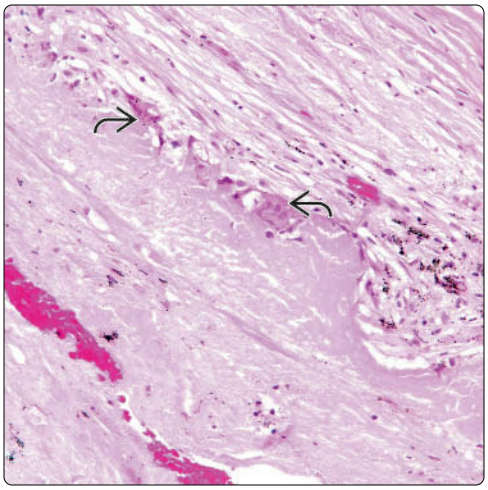

Calcifications

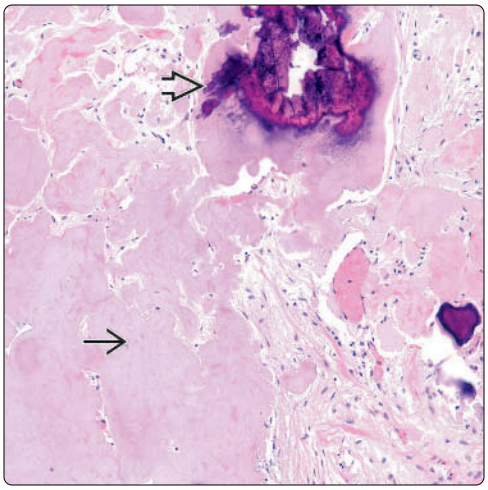

(Left) *The presence of multinucleated giant cells ⇨ at the periphery of the pulmonary nodule is a common feature of pulmonary amyloid tumor.* **(Right)** *In addition, a pulmonary amyloid tumor may also show areas of calcification ⇨ admixed with the dense amorphous acellular material ⇨.*

Ossification

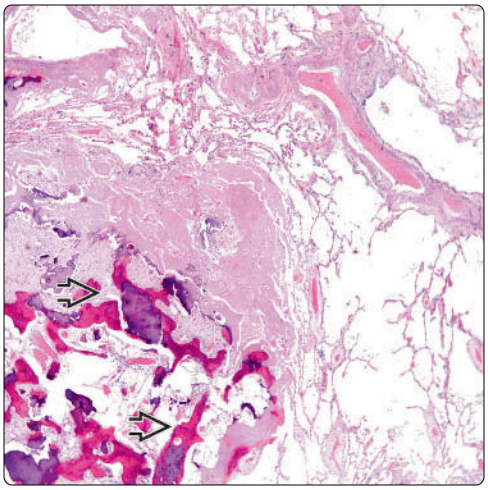

Inflammatory Response

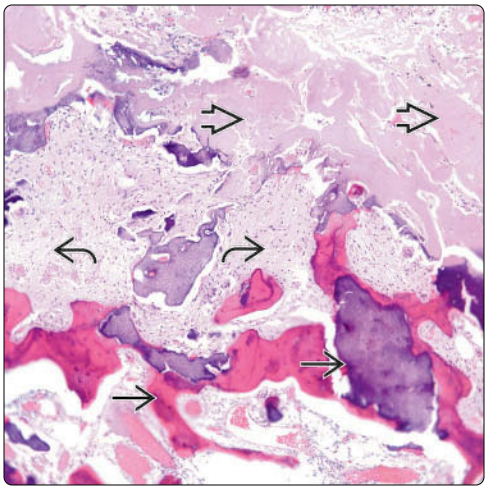

(Left) *In some cases, the presence of extensive areas of ossification ⇨ can make the diagnosis of pulmonary amyloid tumor more challenging as the ossification may interfere with the identification of amyloid.* **(Right)** *Higher magnification shows the presence of ossification ⇨ and calcification with reactive inflammatory changes ⇨. Adjacent to those changes, it is possible to identify the presence of amyloid ⇨.*

Ossification and Amyloid

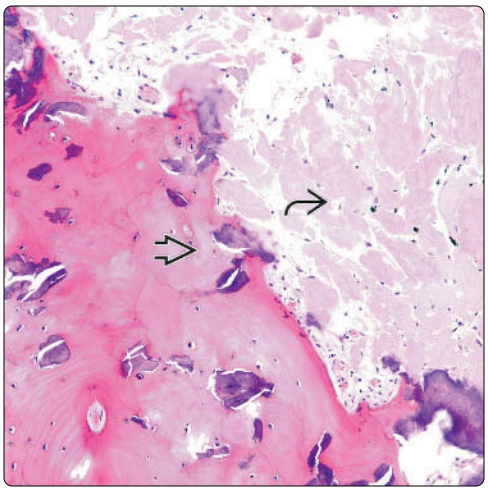

Intraalveolar Pigmented Macrophages

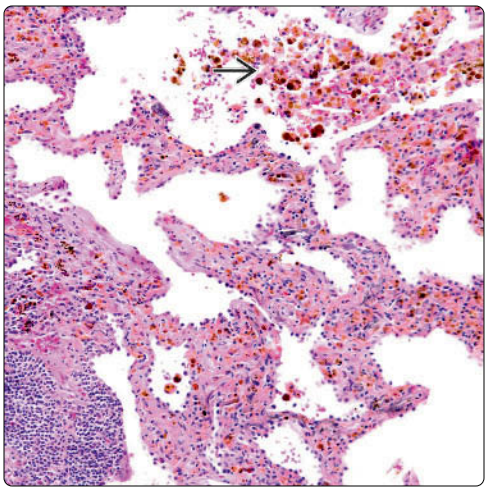

(Left) *High-power view shows transitional areas between ossification ⇨ and amyloid deposition ⇨. Although easily identifiable on conventional stains, the use of Congo red stain may facilitate the identification of amyloid in difficult cases.* **(Right)** *The changes observed in the adjacent lung parenchyma in cases of pulmonary amyloid tumor include the presence of a desquamative interstitial pneumonitis-like reaction. Note the presence of pigmented intraalveolar macrophages ⇨.*

Metastatic/Dendriform Calcification

KEY FACTS

TERMINOLOGY

- Nonneoplastic condition characterized by deposition of calcified material in lung parenchyma

ETIOLOGY/PATHOGENESIS

- This condition may appear in response to different clinical conditions that may include
  - Epithelial malignancies
  - Lymphoproliferative disorders
  - Post transplant
  - Renal failure
- Pathophysiology
  - Exact mechanism to account for occurrence of metastatic calcification is not known
  - Serum levels of calcium and phosphates may play role

CLINICAL ISSUES

- Prognosis
  - Depends on underlying condition
  - Depends on extent of process in lung
  - Process may not be limited to lung
- Serum level of calcium and phosphates may be altered

MICROSCOPIC

- Calcified material may follow some specific pattern of involvement of lung parenchyma
  - Interstitium
  - Around bronchial wall
  - Around airway
  - Usually follows alveolar outlines
  - More often bilateral
  - Unusual cases may be unilateral

DIAGNOSTIC CHECKLIST

- Pattern of distribution
- Clinical history of associated condition

Calcified Material in Lung Parenchyma | **Minimal Inflammatory Reaction**

(Left) *Low-power view of a section of lung shows extensive presence of calcified material in a haphazard pattern. The calcific material is deposited within the lung interstitium.* **(Right)** *High-power view of the presence of calcific material admixed with minimal inflammation and focal fibroblastic component is shown. Note the absence of cellular atypia.*

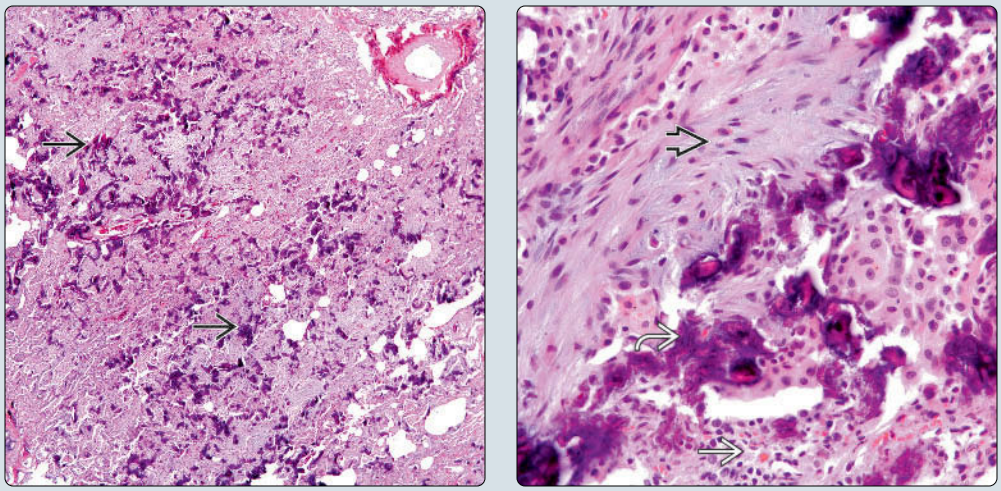

Uninvolved Airway | **Residual Alveoli**

(Left) *Most of the alveolated lung parenchyma has been replaced by calcified material. Note that the airway and large vessels are not involved by the process.* **(Right)** *Extensive areas of calcified material are deposited in the interstitium and alveolar walls. In some areas, remnants of alveoli are still recognizable containing macrophages.*

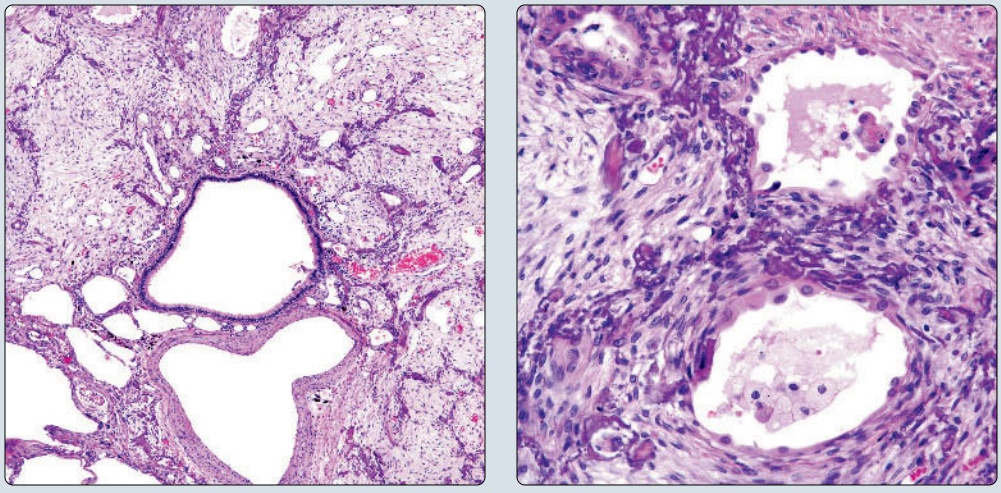

TERMINOLOGY

Synonyms

- Metastatic calcification, dendritic calcification

Definitions

- Nonneoplastic condition characterized by deposition of calcified material in lung parenchyma

ETIOLOGY/PATHOGENESIS

Etiology

- This condition may appear in response to different clinical conditions that may include
  - Epithelial malignancies
  - Lymphoproliferative disorders
  - Post transplant
  - Renal failure

Pathophysiology

- Exact mechanism to account for occurrence of this disorder is not known
- Serum level of calcium and phosphates may play role in its development

CLINICAL ISSUES

Epidemiology

- Incidence
  - Difficult to estimate since disorder is secondary to different clinical conditions
- Age
  - Can occur in any age group

Laboratory Tests

- Serum levels of calcium and phosphates may be altered

Natural History

- Develops as secondary process from diverse clinical conditions
- Process may not be limited to pulmonary system

Treatment

- Surgical approaches
  - Patients usually require surgical resection of portion of lung affected

Prognosis

- Depends on underlying condition
- From strict point of view of calcified deposits in lung parenchyma, prognosis depends on extent of process

IMAGING

General Features

- Bilateral
- Unusual cases may be unilateral
- Dense
- Asymmetrical

Other Studies

- Dual-energy digital radiography appears to be more sensitive modality

MACROSCOPIC

General Features

- Lung parenchyma appears congested and gritty
- Cut surface may be hard in consistency

MICROSCOPIC

Histologic Features

- Haphazard distribution of calcified material in lung parenchyma
- Calcified material may follow some specific pattern of involvement of lung parenchyma
  - Interstitial deposition
  - Around bronchial wall
  - Around airway
  - Calcified material usually follows outlines of alveoli
- No cytologic atypia or mitotic activity is present
- No osteoid material is present
- Fibroblast-like intraalveolar proliferation

DIFFERENTIAL DIAGNOSIS

Metastatic Osteogenic Sarcoma

- Clinical history of bone tumor is of utmost importance
- Shows presence of areas of osteoid
- Shows areas of cytologic atypia and mitotic activity
- Shows calcified material destroying lung parenchyma

Dystrophic Calcification

- Histological features may be very similar
- Does not require previous tissue injury
  - Dendriform calcification requires previous tissue injury

Pulmonary Chondroma

- Shows areas of cartilage
- Pattern of calcification outlining alveoli is not pattern of chondromas
- Chondromas are usually lung nodules or masses without diffuse distribution

Alveolar Microlithiasis

- Pattern of distribution is predominantly intraalveolar
- No preexisting condition accounts for process
- In general, microlithiasis is not associated with serum abnormalities of calcium or phosphates

DIAGNOSTIC CHECKLIST

Clinically Relevant Pathologic Features

- Pattern of distribution
- Clinical history of associated condition

Pathologic Interpretation Pearls

- Calcified material following alveolar outlines
- Absent cellular atypia or mitotic activity

SELECTED REFERENCES

1. Saraya T et al: Evidence of unilateral metastatic pulmonary calcification with a prolonged Fever and arthralgia caused by acute lymphoblastic leukemia in a chronic dialysis patient. Intern Med. 54(1):63-7, 2015

Partial Destruction of Lung Parenchyma

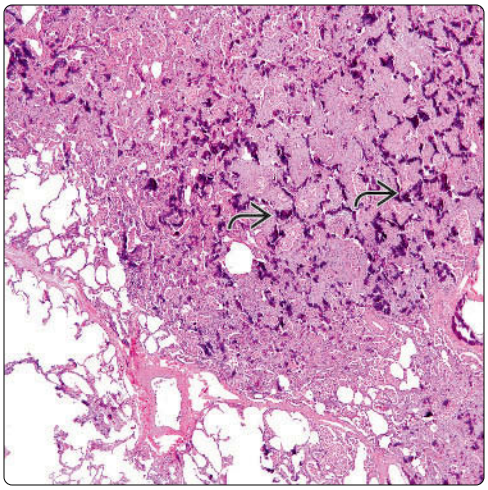

Subtle Nodular Pattern

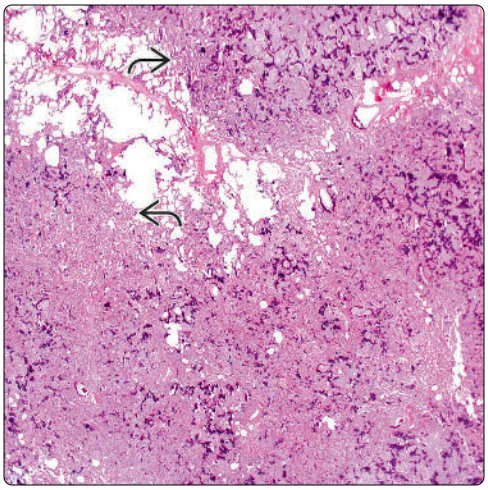

(Left) *Low-power view of a section of lung shows extensive deposition of calcified material in a manner mimicking a neoplastic process. Portions of the lung parenchyma are replaced by the presence of calcifications. (Right) In some cases, the pattern may appear to be forming tumor nodules with very little intervening normal lung parenchyma. The deposition of calcified material can be very extensive, replacing lung parenchyma and thus mimicking a malignant process.*

Scattered Calcifications

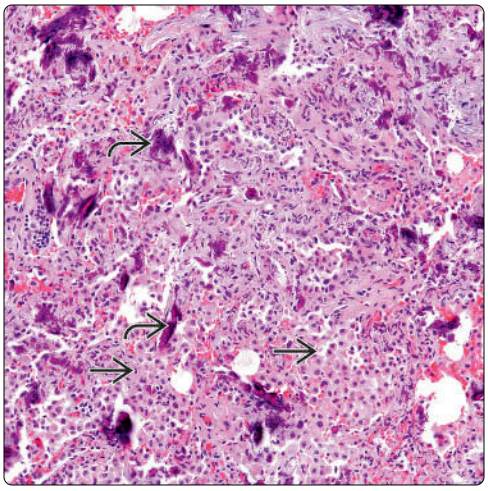

Interstitial Calcification

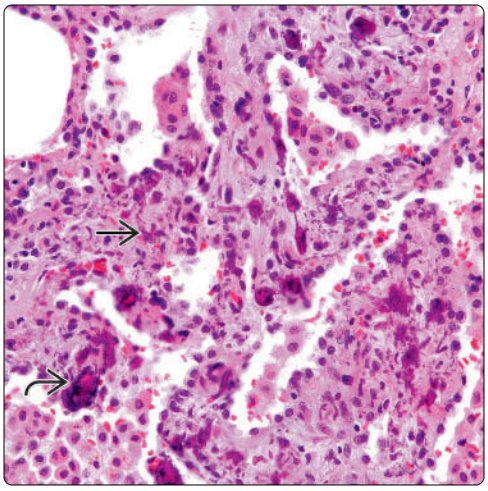

(Left) *In some cases, the presence of calcified material is more subtle and can be easily disregarded as simple calcification of the lung parenchyma. Note the presence of a more cellular component. (Right) High-power view shows calcified material predominantly deposited in the lung interstitium. In some areas, the calcified material is much more difficult to recognize, as it appears to be more dust-like.*

Extensive Calcification

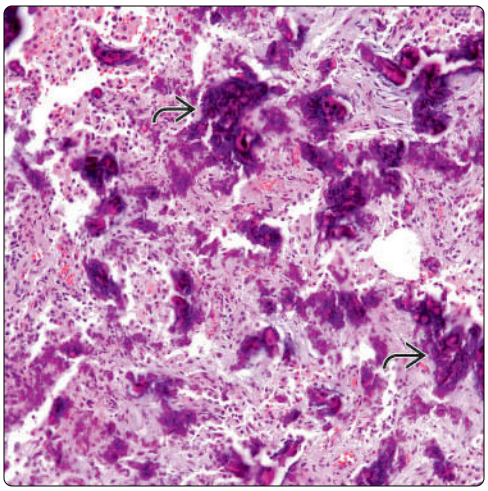

Focal Collection of Macrophages

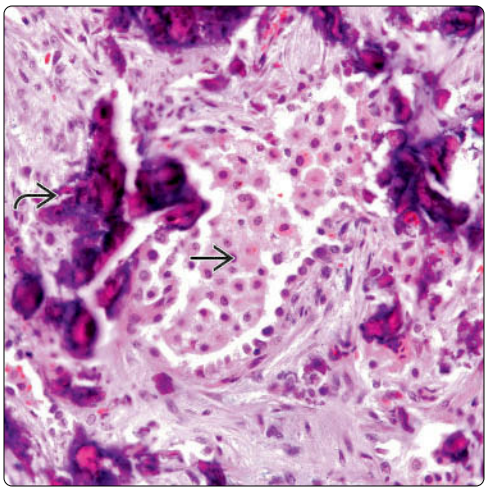

(Left) *The presence of calcified material is obvious in cases like this one. However, note that the calcifications are more in the interstitium than within alveolar spaces. It is also important to note the absence of cellular atypia. (Right) A close-up view shows the calcifications, which are admixed with collections of histiocytes and minimal or absent inflammatory response.*

Calcifications Outlining Alveolar Walls

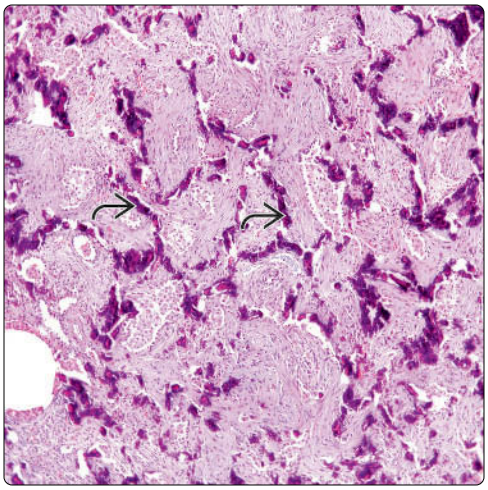

Fibroblastic Areas

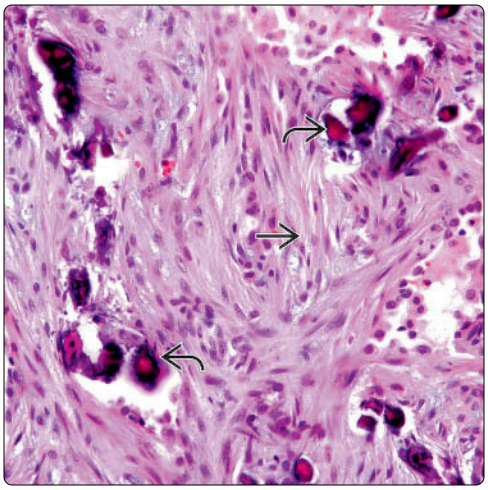

(Left) *Low-power view of a section of lung shows calcifications almost following the normal outlines of the alveolar architecture. This pattern is very common in this type of process and is an important feature for diagnosis.* **(Right)** *Higher magnification shows areas of calcification admixed with areas of a fibroblastic proliferation. This combination is rather common and should not be interpreted for a malignant process.*

Vascular Involvement

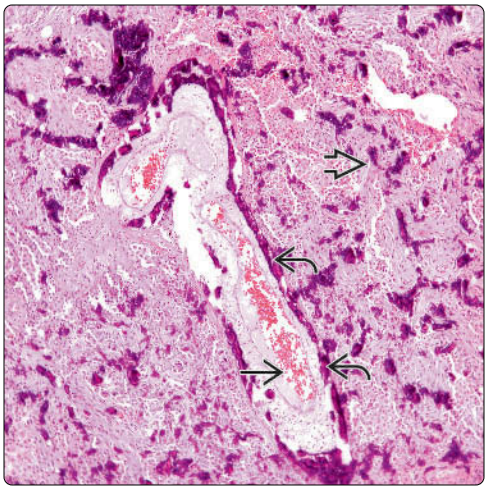

Calcification Around Wall of Vessel

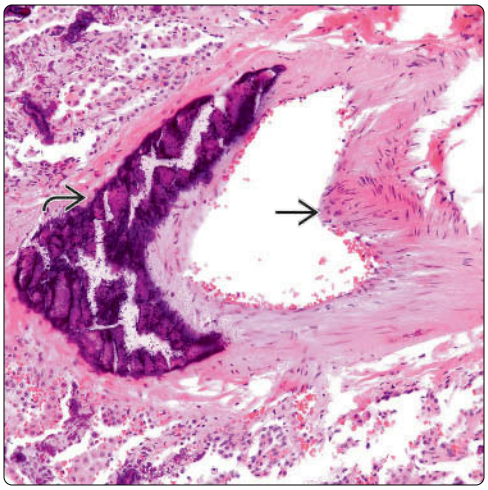

(Left) *Another important feature of dendriform calcification is the presence of calcific material around vascular structures. Also note that there are more calcifications involving the lung parenchyma.* **(Right)** *The presence of calcified material around vessels can be marked, resembling ossification. In this particular case, note the presence of a dilated vessel and the obvious calcification in its wall.*

Presence of Giant Cells

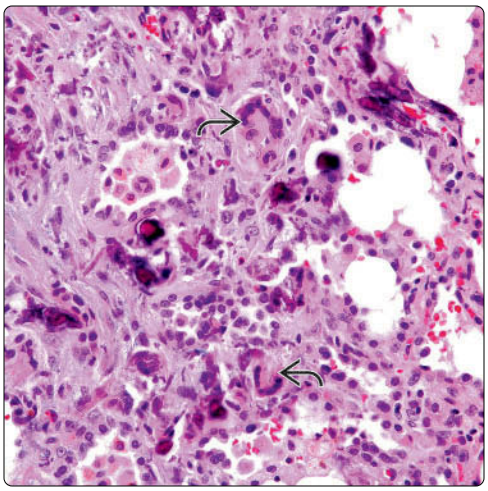

Inconspicuous Calcification

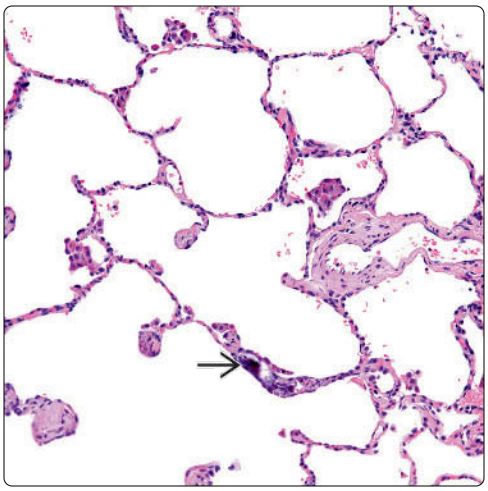

(Left) *In some unusual conditions, the calcified material may be admixed with an inflammatory reaction and also the presence of multinucleated giant cells. Such change may be secondary to the presence of the foreign material, which, in this case, is calcium.* **(Right)** *Even in areas of "normal" lung parenchyma, the presence of calcification may be very subtle, to the point of missing it. In this case, note the presence of calcified material within the interstitium.*

Lipoid Pneumonia (Paraffinoma)

KEY FACTS

TERMINOLOGY

- Synonyms
  - Cholesterol pneumonia, lipoid pneumonia, golden pneumonia
- Definition: Type of pneumonia that could be secondary to aspiration; can be classified as
  - Endogenous
  - Exogenous

ETIOLOGY/PATHOGENESIS

- Exogenous
  - Aspiration of oily substances
  - Mineral oil
  - Vegetable oil
  - Petroleum jelly
  - Oil mists
  - Some radiographic contrast media
- Endogenous
  - Result of pulmonary obstruction or gastroesophageal reflux
  - May result as breakdown of cell membrane or lipoprotein secretions

CLINICAL ISSUES

- Rare; may be seen in bedridden patients
- Can occur in any age group, children or elderly
- Prognosis depends on origin
  - In some cases it may follow fatal course

MICROSCOPIC

- Proliferation of foamy histiocytes
- Cholesterol cleft granulomas
- Foreign body giant cell reaction
- Fat droplets in interstitium
- Histochemical stain for oil red O is positive in fat droplets
- Inflammatory reaction may be minimal

Replacement of Normal Lung Parenchyma

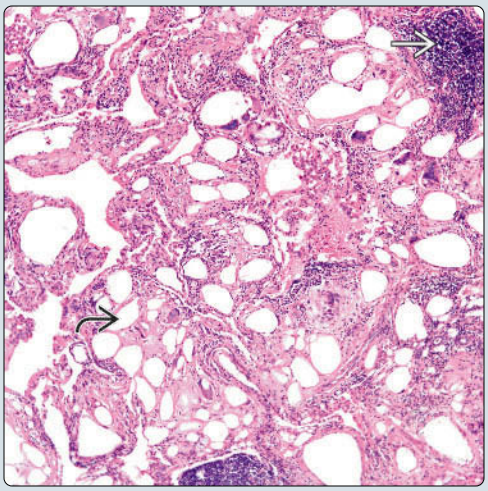

Presence of Giant Cells

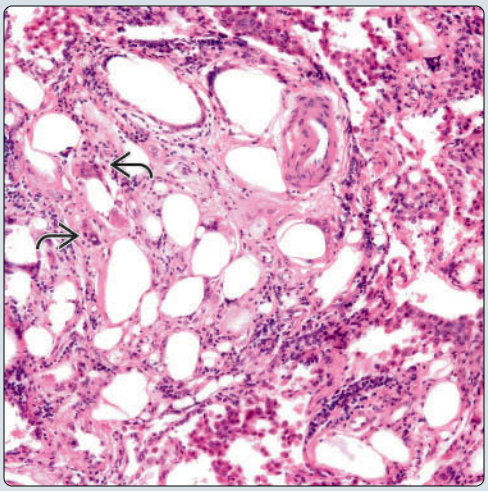

(Left) *Low-power view of lipoid pneumonia shows the characteristic Swiss cheese appearance. Note the number of cystic spaces and focal areas of inflammation.* **(Right)** *With this closer view of lipoid pneumonia, note the presence of several multinucleated giant cells. The normal lung architecture is lost, and the inflammatory reaction is minimal.*

Swiss Cheese Pattern

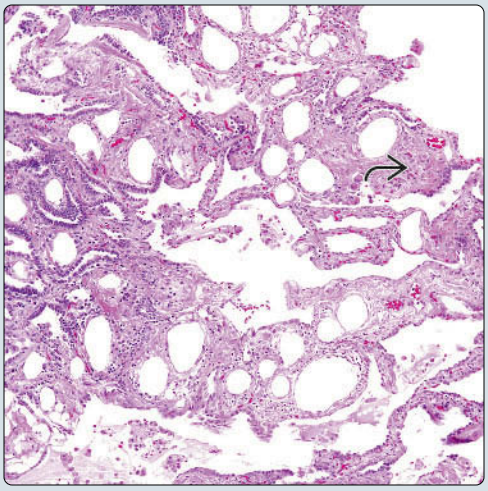

Fat Droplets

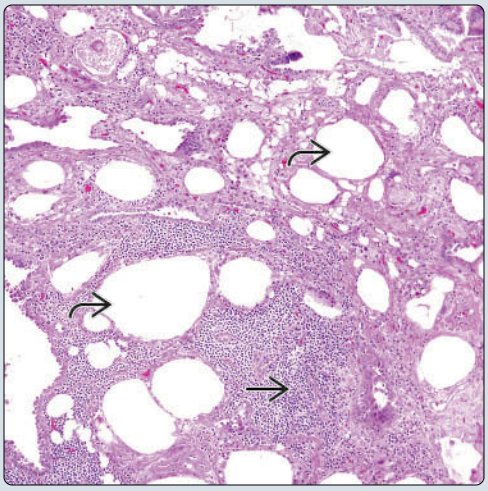

(Left) *Low-power view of a lipoid pneumonia shows the classic pattern of Swiss cheese-like appearance. Note the presence of areas of widening of the interstitium.* **(Right)** *Higher magnification of a lipoid pneumonia shows what appear to be fat droplets. In addition, there are focal areas of inflammatory reaction.*

TERMINOLOGY

Synonyms

- Cholesterol pneumonia, paraffinoma, golden pneumonia, exogenous/endogenous lipoid pneumonia

Definitions

- Type of pneumonia secondary to aspiration; can be classified as
  - Endogenous
  - Exogenous

ETIOLOGY/PATHOGENESIS

Etiology

- Exogenous
  - Aspiration of oily substances
    - Mineral oil
    - Vegetable oil
    - Petroleum jelly
    - Oil mists
    - Some radiographic contrast media
- Endogenous
  - Result of pulmonary obstruction or gastroesophageal reflux
  - May result from breakdown of cell membrane or lipoprotein secretions

CLINICAL ISSUES

Epidemiology

- Incidence
  - Rare; may be seen in bedridden patients
- Age
  - Can occur in any age group, children or elderly

Presentation

- Cough
- Chest pain
- Dyspnea
- Fever

Treatment

- In cases of endogenous lipoid pneumonia, dealing with cause of obstruction may be beneficial
- In cases of exogenous lipoid pneumonia, identification and stopping of probable cause is crucial
- Antibiotics may be necessary

MICROSCOPIC

Histologic Features

- Proliferation of foamy histiocytes
  - Intraalveolar
  - Interstitial
- Cholesterol cleft granulomas
- Foreign body giant cell reaction
  - Around fat droplets in exogenous pneumonia
  - May be absent in cases of endogenous pneumonia
- Fat droplets in interstitium
- Inflammatory reaction may be minimal

DIFFERENTIAL DIAGNOSIS

Mycobacterial Infection

- Shows organisms with acid-fast bacilli stain
- Unusual to have fat droplets

Rosai-Dorfman Disease

- Characteristically shows presence of emperipolesis
- Infiltrate is predominantly composed of histiocytes
- Does not show presence of fat droplets
- Shows negative staining for oil red O

Juvenile Xanthogranuloma

- Presents as pulmonary mass
- Histiocytic infiltrate destroys lung parenchyma
- Oil red O is negative
- Immunohistochemical studies for histiocytic markers show positive staining

Langerhans Cell Histiocytosis

- Characteristically shows positive staining for S100 protein and CD1a
- Characteristically presents as multiple pulmonary nodules
- Presence of eosinophils favors diagnosis of Langerhans cell histiocytosis

DIAGNOSTIC CHECKLIST

Pathologic Interpretation Pearls

- Fat droplets
- Positive staining for oil red O
- Giant cell reaction

SELECTED REFERENCES

1. Tavare AN et al: Exogenous lipoid pneumonia mimicking multifocal bronchogenic carcinoma. J Thorac Oncol. 10(12):1809-10, 2015

Histochemical Features

Stain	Result
PAS	Negative for intracellular glycogen
PAS-D	Negative for intracellular mucin
Mucicarmine	Negative for intracellular mucin
Oil red O	Positive in fat droplets

(Left) *Classic Swiss cheese-like appearance admixed with inflammatory reaction is shown. Note the presence of large ⇄ and small ⇉ empty spaces typical of this process. The interstitium shows only mild inflammatory changes.* **(Right)** *Different view of a lipoid pneumonia with widening of the interstitium ⇄ gives the appearance of a fibrinous component with focal inflammatory reaction ⇉. Still, large empty spaces ⇉ can be identified.*

Mild Inflammation

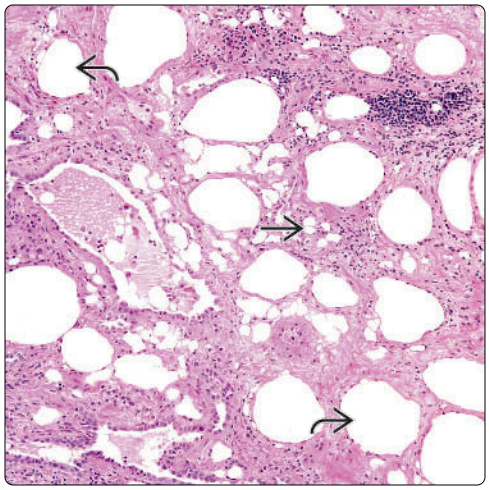

Cystic-Like Spaces

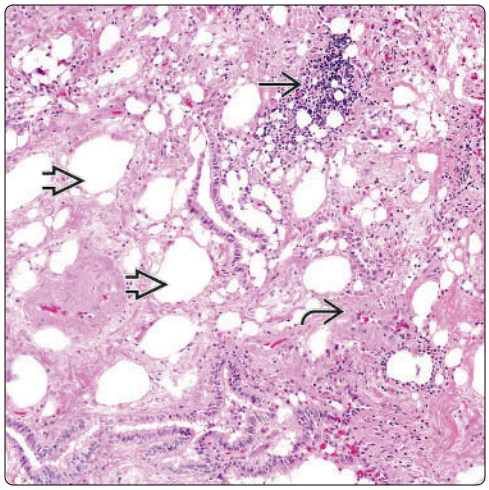

(Left) *Lipoid pneumonia shows some preservation of lung architecture in which the alveoli are filled with histiocytes ⇄ with focal areas of inflammatory reaction composed of lymphocytes ⇉. This pattern would suggest an infectious process.* **(Right)** *Higher magnification shows characteristic fat droplets ⇄ with focal inflammation ⇉ and the presence of multinucleated giant cells forming an ill-defined granuloma ⇉.*

Intraalveolar Macrophages

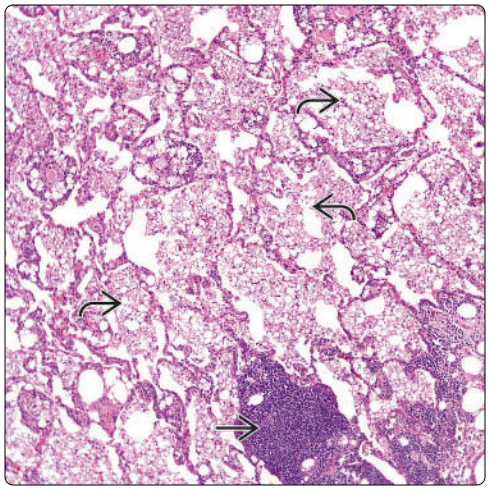

Ill-Defined Granuloma

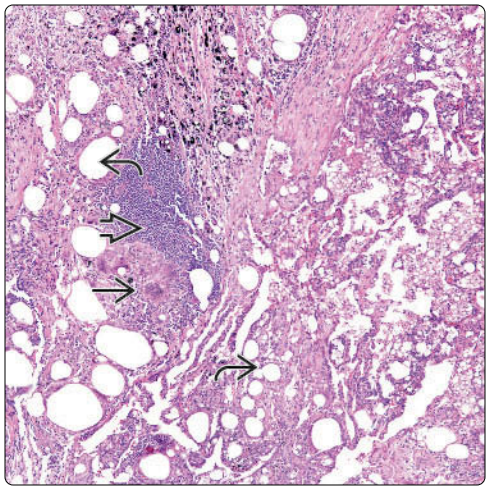

(Left) *Low-power view shows collections of intraalveolar foamy histiocytes ⇄ giving the appearance of an infectious process. In addition, there are focal areas of inflammatory reaction ⇉.* **(Right)** *Closer view of a lipoid pneumonia shows some inflammatory changes and destruction of the normal pulmonary architecture. Note the presence of fat droplets of different sizes ⇄.*

Intraalveolar Histiocytes

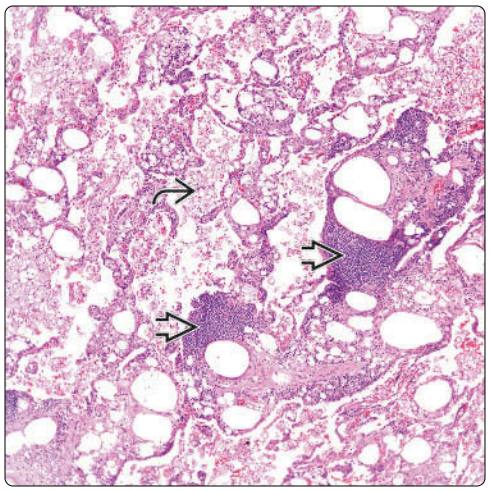

Fat Droplets

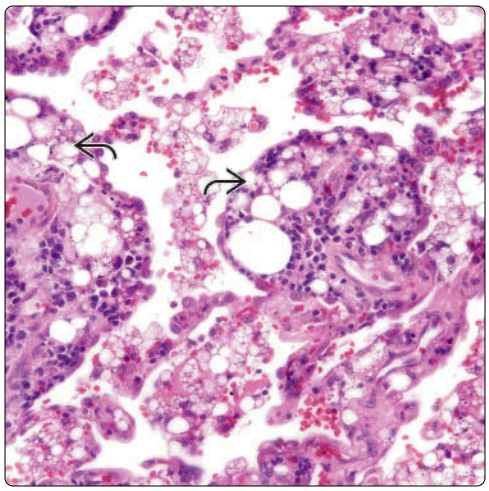

Distorted Lung Parenchyma

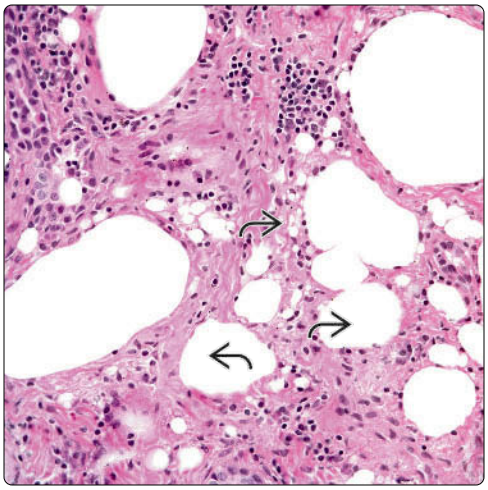

Giant Cells

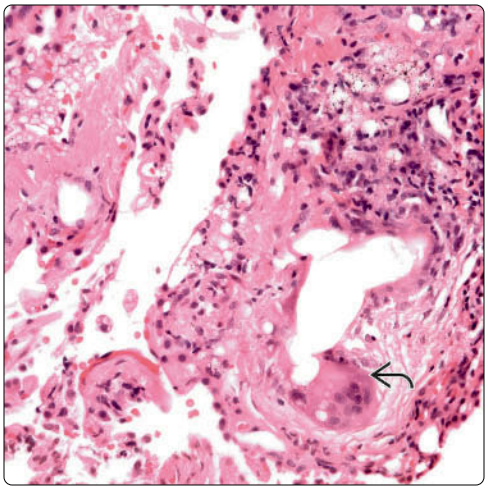

(Left) *Distorted pulmonary parenchyma shows the presence of fat droplets of different sizes. There is very little in terms of inflammatory reaction.* **(Right)** *Lipoid pneumonia shows a giant cell component around a pulmonary vessel. Such a finding is common, although, in some cases the giant cell reaction is not necessarily attached to a pulmonary vessel.*

Intraalveolar Macrophages

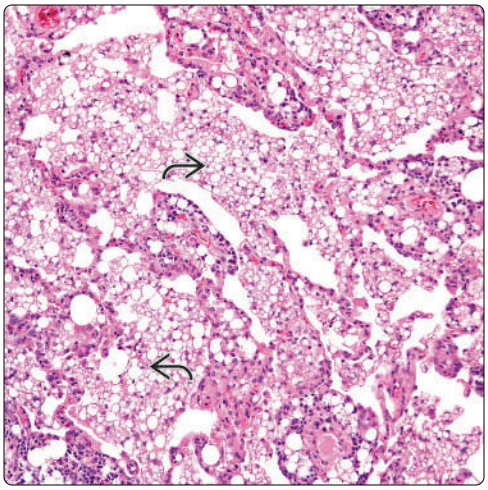

Minimal Inflammatory Reaction

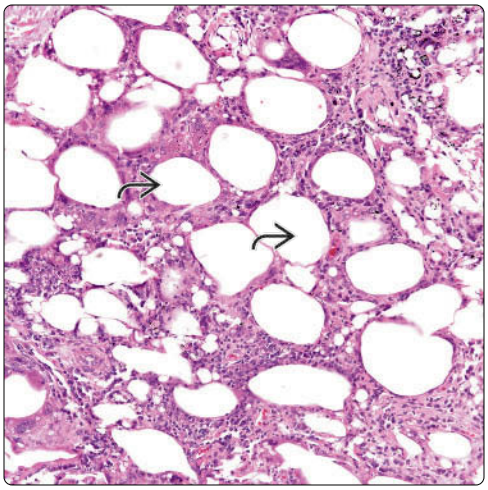

(Left) *Marked collection of intraalveolar macrophages admixed with more conventional areas of fat droplets is shown with destruction of the normal lung architecture. These findings are typical of this process.* **(Right)** *In some cases, the process appears to be more homogeneous with large fat droplets, which mimic alveolar structures. In addition, there is a subtle inflammatory reaction.*

Small Size Fat Droplets

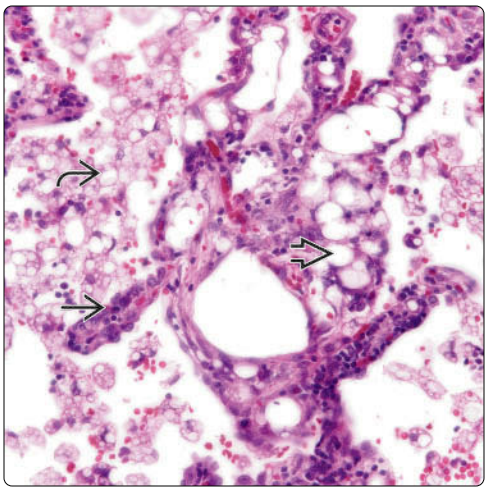

Extensive Presence of Fat

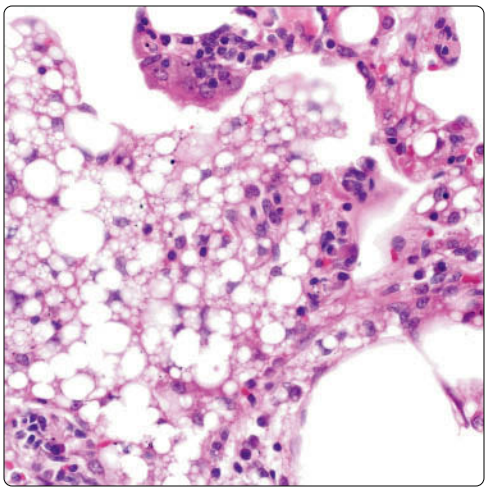

(Left) *Closer magnification reveals the presence of some intraalveolar macrophages. Note the presence of remnants of alveolar lining. In addition, numerous fat droplets are present, which are characteristic of lipoid pneumonia.* **(Right)** *Higher magnification shows foamy histiocytes admixed with fat droplets and some remaining alveolar lining. These features are typical of lipoid pneumonia.*

Placental Transmogrification

KEY FACTS

TERMINOLOGY

- Synonyms: Placentoid bullous lesion, giant bullous emphysema, pulmonary lipomatosis
- Benign, unusual condition characterized by bizarre changes in shape of normal lung parenchyma

ETIOLOGY/PATHOGENESIS

- Some cases have been associated with tobacco use, others with pneumonic process

CLINICAL ISSUES

- Process can be seen in elderly or young adults

MACROSCOPIC

- Ill-defined process with complete degeneration of normal lung parenchyma
- Cystic changes
- Grape-like structures
- Soft consistency and yellowish color
- Ill defined; may involve entire lobe or lobe segment

MICROSCOPIC

- Placental-like pattern
  - Lipomatous changes
  - Myxoid changes
  - Edematous changes

TOP DIFFERENTIAL DIAGNOSES

- Pneumonia
  - Shows areas of acute and chronic inflammatory cells, which are commonly absent in transmogrification
- Emphysema
  - There is very little residual alveoli in transmogrification
  - Extensive areas of papillary-like structures with adipose tissue
- Papillary carcinoma
  - Most likely would present as pulmonary mass

Macroscopic Features

Placentoid Structures

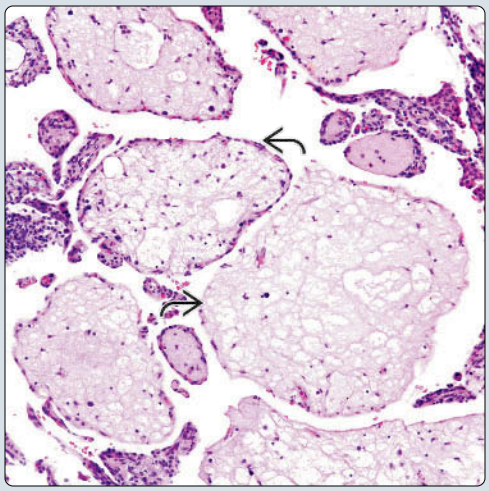

(Left) *This portion of the lung shows placental transmogrification. Note the grotesque appearance of the lung parenchyma.* **(Right)** *High-power view shows some of the placentoid structures ⇨ typical of placental transmogrification of the lung. Note the presence of the different sizes and the edematous internal composition.*

Papillary-Like Features

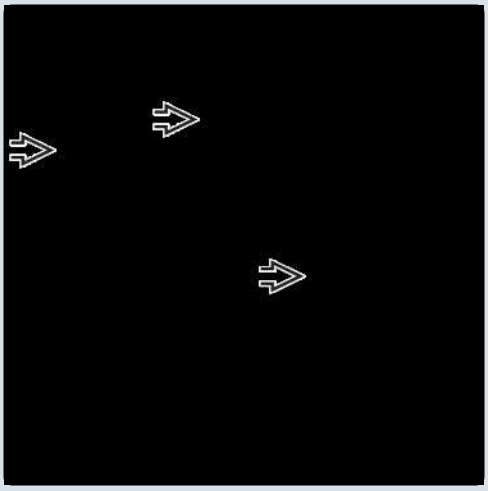

Calcifications

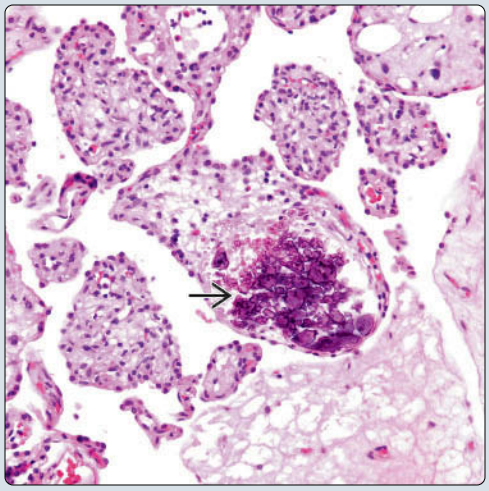

(Left) *Placental transmogrification of the lung shows papillary-like structures or placentoid structures ⇨ of different sizes with minimal inflammatory reaction.* **(Right)** *Placental transmogrification of the lung is shown with focal areas of calcifications ⇨. The presence of dystrophic calcifications may be seen sporadically in these cases.*

TERMINOLOGY

Synonyms

- Placentoid bullous lesion, giant bullous emphysema, pulmonary lipomatosis

Definitions

- Benign, unusual condition characterized by bizarre changes in shape of normal lung parenchyma

ETIOLOGY/PATHOGENESIS

Environmental Exposure

- Some cases have been associated with tobacco use

Infectious Agents

- Some cases have been associated with pneumonic process

CLINICAL ISSUES

Epidemiology

- Incidence
  - Can be seen in elderly or young adults

Presentation

- Cough
- Fever
- Pneumonia

Treatment

- Surgical approaches
  - Complete surgical resection

Prognosis

- Good

IMAGING

General Features

- Ill-defined pulmonary mass

MACROSCOPIC

General Features

- Ill-defined process with complete degeneration of normal lung parenchyma
  - Cystic changes
  - Grape-like structures
  - Soft consistency and yellowish color

Size

- Ill defined; may involve entire lobe or lobe segment

MICROSCOPIC

Histologic Features

- Papillary features without cellular atypia or mitotic activity
- Papillary component may show
  - Myxoid changes
  - Lipomatous changes
  - Edematous changes
  - Minimal inflammatory changes
- Placental-like pattern
- In focal areas, residual alveolated tissue may be present
- In focal areas, residual airway may be seen
- Lack of pulmonary fibrosis
- Focal calcifications may be seen

Predominant Pattern/Injury Type

- Ill defined

DIFFERENTIAL DIAGNOSIS

Pneumonia

- Show areas of acute and chronic inflammation that are usually absent in placental transmogrification
- Macroscopic features of pneumonia do not resemble bizarre features of transmogrification
- Highly unusual for pneumonic process to show presence of adipose tissue

Emphysema

- Presence of papillary structures with myxoid or lipomatous changes would be unusual for emphysema
- Entire lung parenchyma is destroyed in transmogrification
  - Leaves little residual alveoli

Papillary Carcinoma

- Lack of nuclear atypia or mitosis is feature of placental transmogrification
- Presence of myxoid or lipomatous changes would be unusual for carcinoma
- Macroscopic feature of transmogrification is diffuse
  - Carcinoma would be localized tumor mass

DIAGNOSTIC CHECKLIST

Clinically Relevant Pathologic Features

- Gross appearance: Destruction of normal appearance

Pathologic Interpretation Pearls

- Placentoid-like structures
- Lipomatous change
- Myxoid change
- Papillary-like structures

SELECTED REFERENCES

1. Hochhegger B et al: Placental transmogrification of the lung. Lung. 193(5):855-7, 2015
2. Moran CA et al: Unusual non-neoplastic lesions of the lung. Semin Diagn Pathol. 24(3):199-208, 2007
3. Vogel-Claussen J et al: Placental transmogrification of the lung. J Thorac Imaging. 20(3):233-5, 2005
4. Cavazza A et al: Placental transmogrification of the lung: clinicopathologic, immunohistochemical and molecular study of two cases, with particular emphasis on the interstitial clear cells. Hum Pathol. 35(4):517-21, 2004
5. Brevetti GR et al: Pulmonary placental transmogrification: diagnosis and treatment. J Thorac Cardiovasc Surg. 118(5):966-7, 1999
6. Hochholzer L et al: Pulmonary lipomatosis: a variant of placental transmogrification. Mod Pathol. 10(8):846-9, 1997
7. Horsley WS et al: Unilateral giant bullous emphysema with placental transmogrification of the lung. Ann Thorac Surg. 64(1):226-8, 1997
8. Fidler ME et al: Placental transmogrification of the lung, a histologic variant of giant bullous emphysema. Clinicopathological study of three further cases. Am J Surg Pathol. 19(5):563-70, 1995
9. Mark EJ et al: Placentoid bullous lesion of the lung. Hum Pathol. 26(1):74-9, 1995
10. McChesny T et al: Placental transmogrification of the lung: a unique case with remarkable histopathologic features. Lab Invest. 40:245-6, 1979

(Left) *Placental transmogrification shows the classic placentoid structures ⇨; however, normal alveolar structures are also present ⇨. Most of the time normal lung parenchyma is only focally present.* **(Right)** *Placental transmogrification of the lung shows large and small placentoid structures ⇨ destroying residual normal lung parenchyma ⇨. This growth pattern may be seen in some primary or metastatic carcinomas of the lung.*

Adjacent Normal Lung

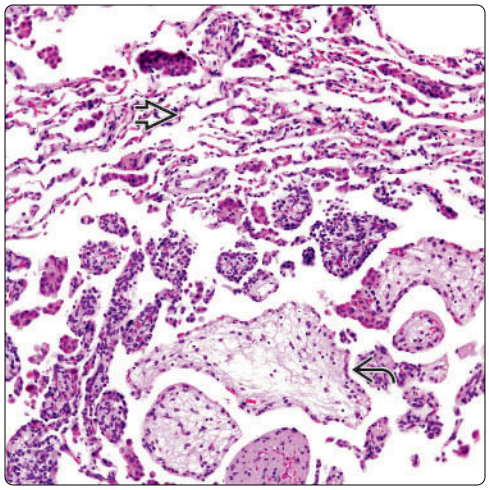

Replacement of Lung Parenchyma

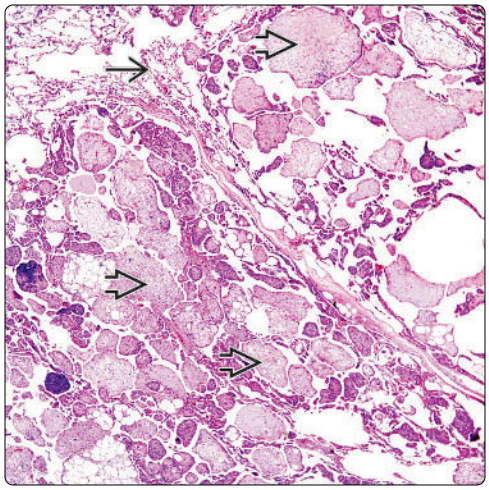

(Left) *Some of the placentoid structures composing placental transmogrification may show a more cellular component ⇨, while others remain more edematous ⇨. Focal residual macrophages are also seen ⇨.* **(Right)** *Although placental transmogrification destroys the normal lung parenchyma, one is still able to recognize focal areas in which there is residual airway ⇨. It is important to note that placental transmogrification does not involve the airway.*

Collection of Macrophages

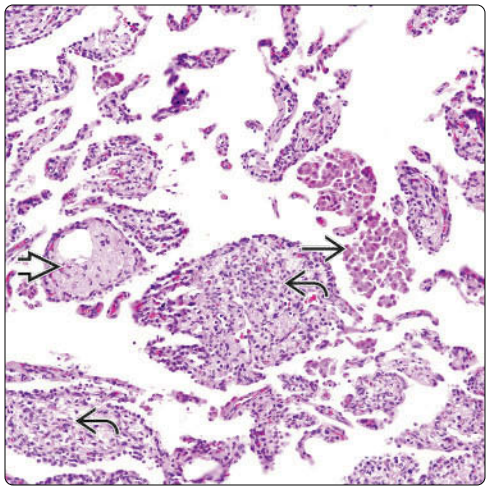

Residual Airway

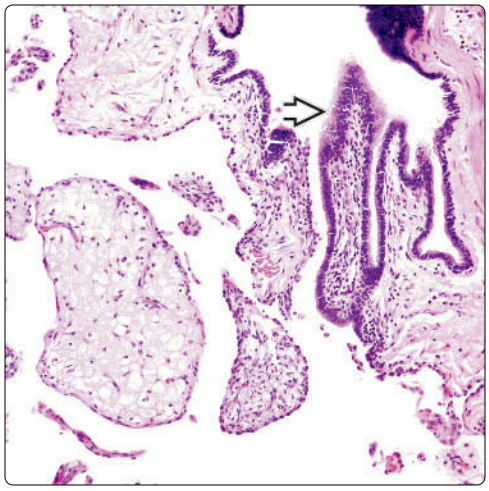

(Left) *Small, elongated, more cellular structures ⇨ are present mixed with relatively normal alveolar structures in placental transmogrification. These structures resemble morular structures present in some adenocarcinomas.* **(Right)** *Predominantly normal-appearing alveolar structures and a couple of classic structures of placental transmogrification of the lung ⇨ are present. The presence of these structures in small biopsies should raise the possibility of placental transmogrification.*

Morule-Like Structures

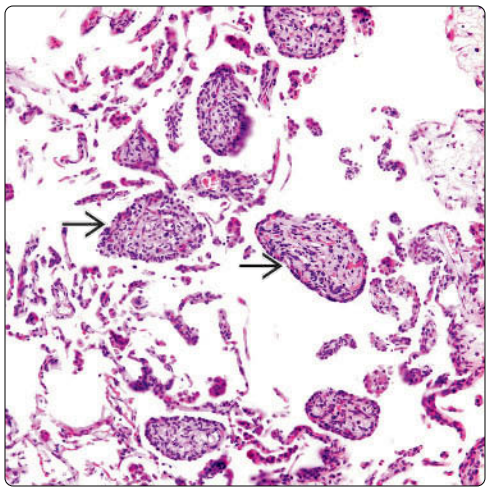

Alveolar Involvement

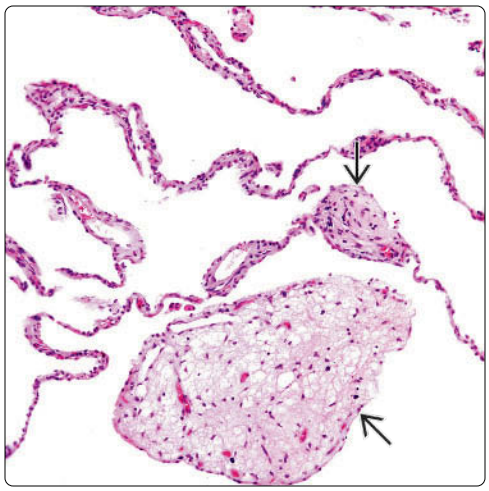

Calcifications

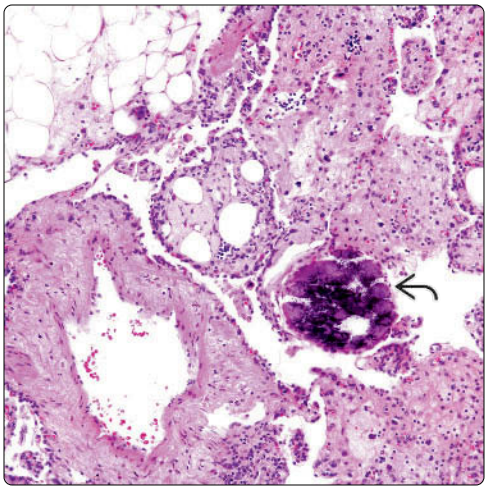

Inflammatory Reaction

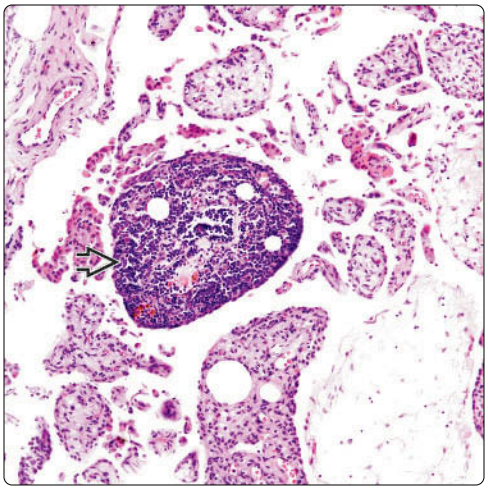

(Left) *Although an unusual feature, the presence of dystrophic calcifications may be seen in focal areas of placental transmogrification.* **(Right)** *Placental transmogrification of the lung shows one of the placentoid structures with marked inflammatory reaction. Inflammatory changes are also not a common feature of this process; most of these placentoid structures lack an inflammatory reaction.*

Adipose Tissue

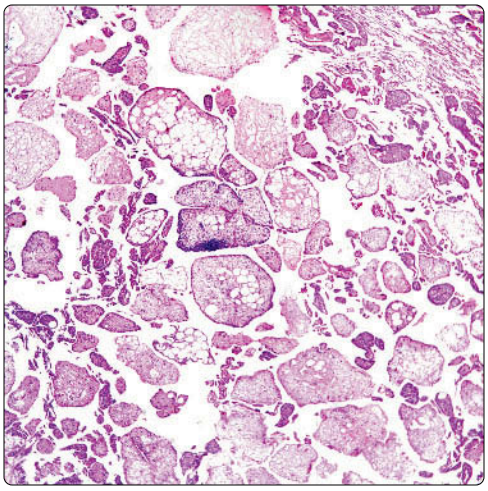

Myxoid and Edematous Changes

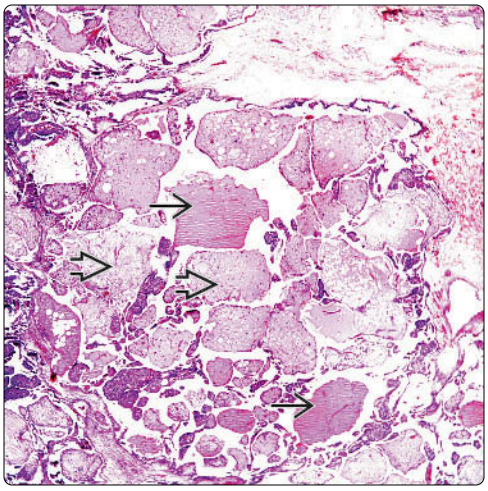

(Left) *Placental transmogrification of the lung shows structures of different sizes with almost total replacement of lung parenchyma. Note that in some of these placentoid structures, adipose tissue is present.* **(Right)** *Some of the placentoid structures show myxoid changes, while others show more edematous changes. These changes are commonly seen in these cases and may represent aging changes.*

Lipomatous Change

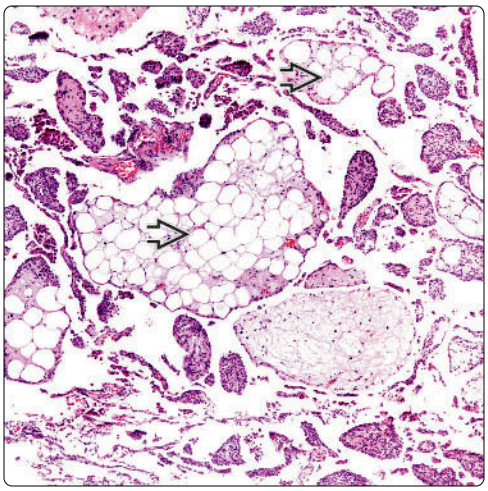

Mature Adipose Tissue

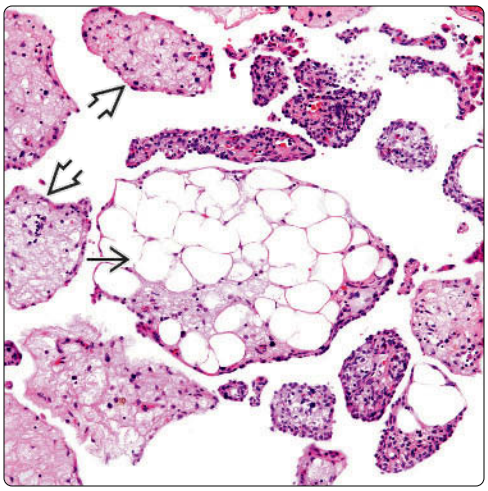

(Left) *Placentoid structures in placental transmogrification show prominent lipomatous changes. These histological features led some authors to coin the term lipomatosis.* **(Right)** *Higher magnification of placentoid structures in placental transmogrification of the lung shows prominent lipomatous changes. Note the adjacent structures with more myxoid change.*

Rosai-Dorfman Disease

KEY FACTS

TERMINOLOGY

- Rosai-Dorfman (R-D) disease
- Synonym: Sinus histiocytosis with massive lymphadenopathy (SHML)

ETIOLOGY/PATHOGENESIS

- Unknown
- Possible infectious origin
- Possible immunologic response

CLINICAL ISSUES

- R-D disease is unusual tumoral condition more commonly seen in lymph nodes
- May appear in extranodal sites in ~ 20% of cases
- Respiratory system most unusual site of occurrence
- Surgical resection is treatment of choice
- Chemotherapy can be used in more severe and extensive cases
  - However, has not shown meaningful results
- Prognosis
  - May follow nonaggressive course
  - In a few cases, fatal course may be observed, but that is unusual
  - Some patients may live with persistent disease
  - Number of cases involving lung too small to make definitive conclusions

MICROSCOPIC

- Large histiocytes engulfing lymphocytes (emperipolesis)
- Marked plasma cell component
- Positive staining for S100 protein in histiocytes

TOP DIFFERENTIAL DIAGNOSES

- Infectious process
  - Histochemical stains for fungi and acid-fast bacilli (-)
- Erdheim-Chester disease
- Langerhans cell histiocytosis
- Juvenile xanthogranuloma

Diffuse Histiocytic Proliferation

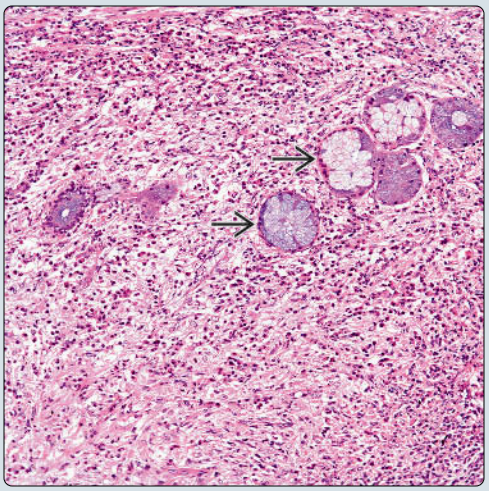

Histiocytes and Inflammatory Cells

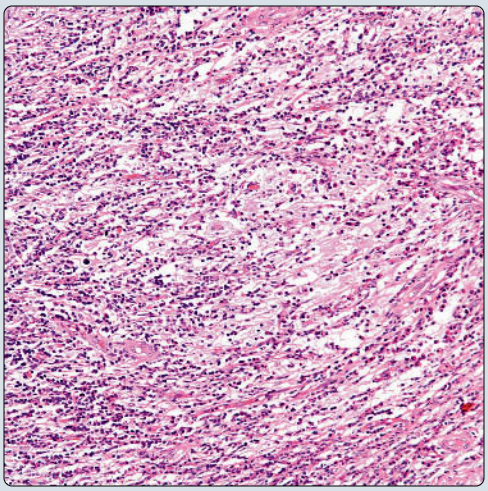

(Left) *Primary Rosai-Dorfman (R-D) disease of the lung shows residual endobronchial glands and prominent histiocytic proliferation admixed with inflammatory cells.* **(Right)** *Primary R-D disease of the lung shows prominent histiocytic proliferation admixed with inflammatory cells.*

Bronchial Cartilage Erosion

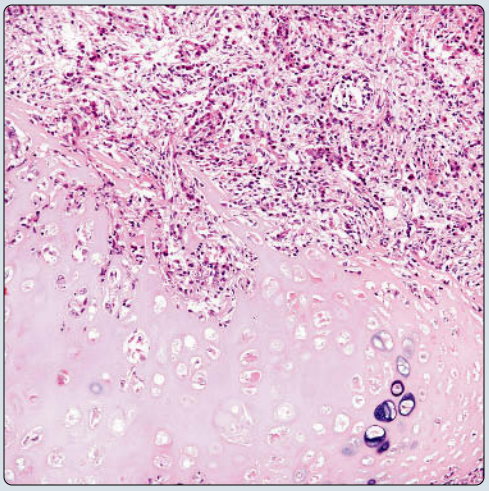

Large Histiocytes

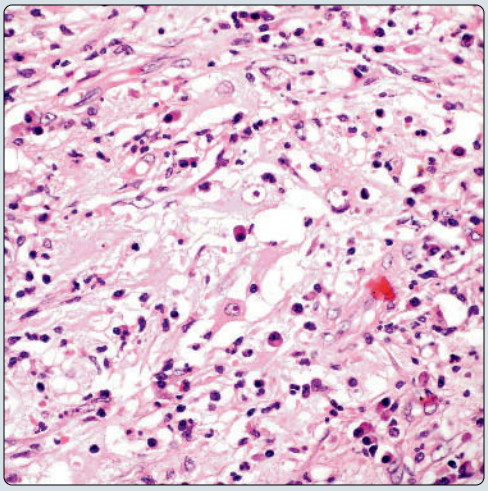

(Left) *Pulmonary R-D disease shows histiocytic proliferation superficially eroding the bronchial cartilage. Note the associated inflammatory component.* **(Right)** *R-D disease of the lung shows large histiocytes with round to oval nuclei and prominent nucleoli. In addition, there is an inflammatory component with numerous plasma cells.*

TERMINOLOGY

Abbreviations

- Rosai-Dorfman (R-D) disease

Synonyms

- Sinus histiocytosis with massive lymphadenopathy (SHML)

Definitions

- Histiocytic proliferation primarily affecting lymph nodes

ETIOLOGY/PATHOGENESIS

Etiology

- Unknown
- Possible infectious origin
- Possible immunologic response

CLINICAL ISSUES

Epidemiology

- Incidence
  - Unusual tumoral condition more commonly seen in lymph nodes
  - May appear in extranodal sites in ~ 20% of cases
  - Respiratory system most unusual site of occurrence
- Age
  - May occur at any age
    - Cases described in lung have been in adults

Presentation

- Cough
- Shortness of breath
- Chest pain

Treatment

- Surgical resection is treatment of choice
- Chemotherapy can be used in more severe and extensive cases
  - However, use has not shown meaningful results

Prognosis

- Generally good
- In a few cases, fatal course may be seen, but that is unusual
- Some patients may live with persistent disease

MICROSCOPIC

Histologic Features

- Diffuse proliferation of large histiocytes
- Presence of histiocytes engulfing lymphocytes (emperipolesis)
- Presence of inflammatory reaction, namely plasma cells
- When lung is affected, lymph nodes may also be involved

DIFFERENTIAL DIAGNOSIS

Erdheim-Chester Disease

- May show similar immunophenotype
- Shows histiocytes of normal size, while R-D disease shows large histiocytes
- Absence of emperipolesis
- Different growth pattern, namely in septum and pleura

Langerhans Cell Histiocytosis

- Shows positive staining for CD1a, while R-D disease is negative
- In lung, usually shows numerous nodules, while R-D presents as single mass
- Histiocytes rather small with grooves, whereas those in R-D are large without grooves
- Ultrastructural studies usually show classic Birbeck granules

Juvenile Xanthogranuloma

- Usually presents as multiple nodules in lung
- More common in young adults
- Usually also shows dermal involvement
- May share similar immunophenotype with R-D disease

DIAGNOSTIC CHECKLIST

Pathologic Interpretation Pearls

- Diffuse presence of large histiocytes
- Marked presence of plasma cells
- Histiocytes engulfing lymphocytes (emperipolesis)

SELECTED REFERENCES

1. Apperley ST et al: Intrathoracic Rosai Dorfman disease with focal aggregates of IgG4-bearing plasma cells: case report and literature review. Ann Am Thorac Soc. ePub, 2016

Immunohistochemistry

Antibody	Reactivity	Staining Pattern	Comment
S100	Positive	Cytoplasmic	In large histiocytes
CD68	Positive	Cytoplasmic	In histiocytes
CD163	Positive	Cytoplasmic	
CD15	Positive	Cytoplasmic	May stain other inflammatory cells
α-1-antichymotrypsin	Positive	Cytoplasmic	In histiocytes
CD1a	Negative		
FXIIIA	Negative		

Destruction of Lung Parenchyma

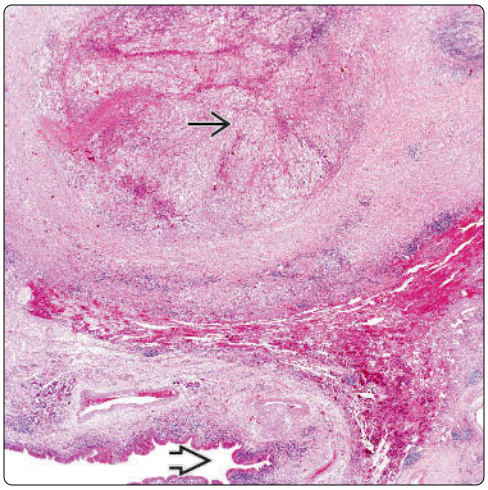

Residual Normal Lung

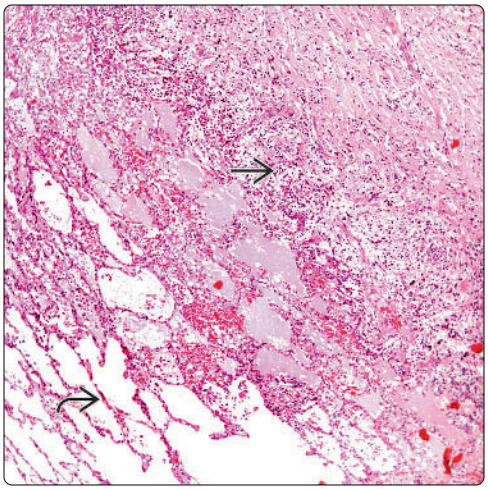

(Left) *Low-power view of R-D disease of the lung shows the presence of an airway that is not involved by the process. Adjacent lung parenchyma is obliterated by a histiocytic proliferation.* **(Right)** *R-D disease of the lung shows transitional areas between normal lung parenchyma and the histocytic process that is obliterating normal lung parenchyma.*

Uninvolved Bronchial Cartilage

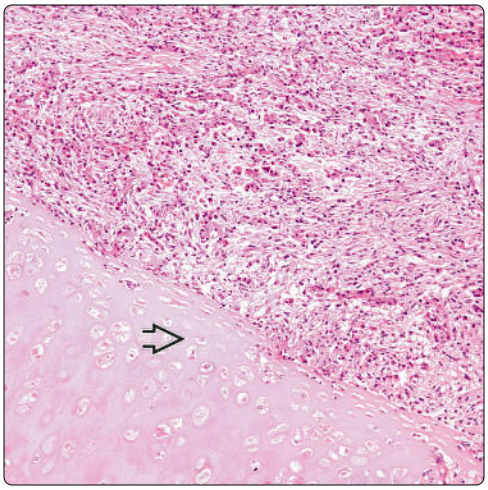

Residual Bronchial Glands

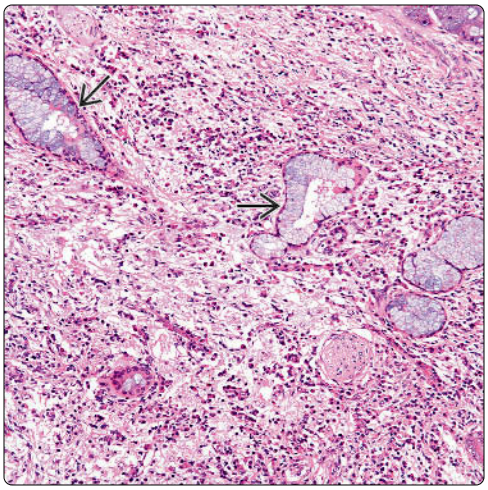

(Left) *R-D disease shows a prominent histiocytic cellular proliferation approaching the bronchial cartilage. Although the bronchial cartilage is not involved, the process lingers in the cartilaginous surface.* **(Right)** *R-D disease shows residual bronchial glands that are not involved by the process. R-D disease characteristically obliterates alveolated lung parenchyma.*

Hemorrhagic Areas

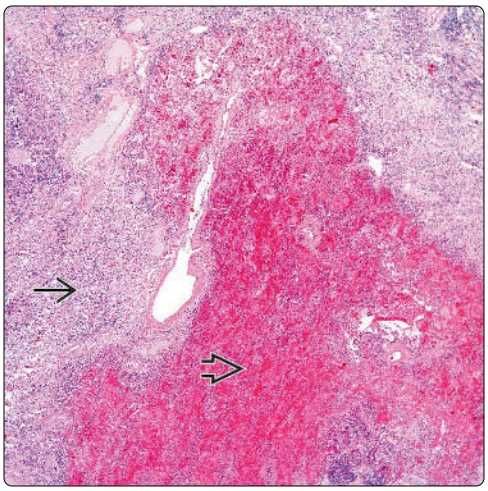

Histiocytic Proliferation

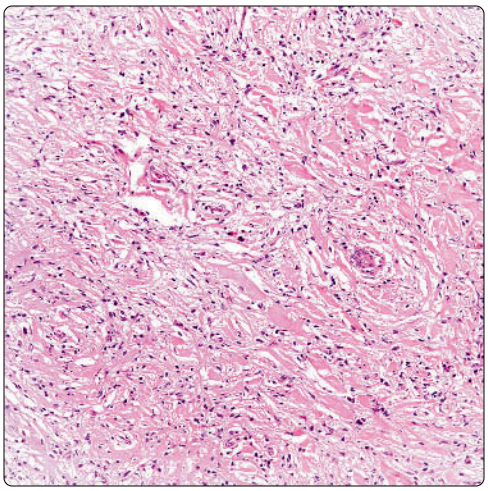

(Left) *Histiocytic proliferation is not easily identified in this case of R-D disease. The lung parenchyma appears to be congested by fresh blood, and the adjacent lung appears to be heavily inflamed.* **(Right)** *Histocytic proliferation is not easily identified in this case of R-D disease. The lung parenchyma has been replaced by dense collagen with only a discrete histiocytic infiltrate in between collagen fibers.*

Dense Collagenization

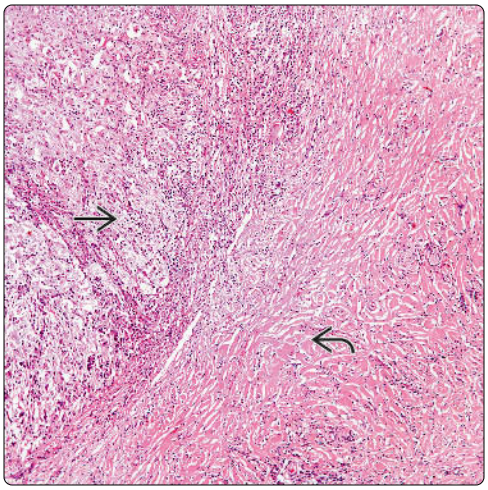

Uninvolved Vessels

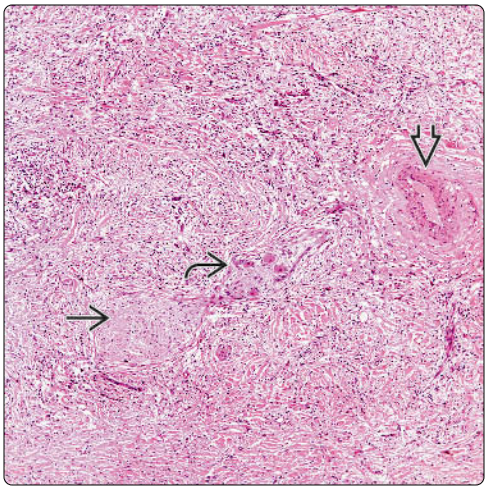

(Left) *R-D disease shows transitional areas between dense collagenization of the lung parenchyma and a more prominent histiocytic proliferation. The histological changes of R-D disease in the lung may vary in cellularity as is demonstrated in this image.* **(Right)** *R-D disease shows several normal structures entrapped by the histiocytic proliferation. A nerve, pulmonary vessel, and ganglion cells are shown.*

Large Histiocytes

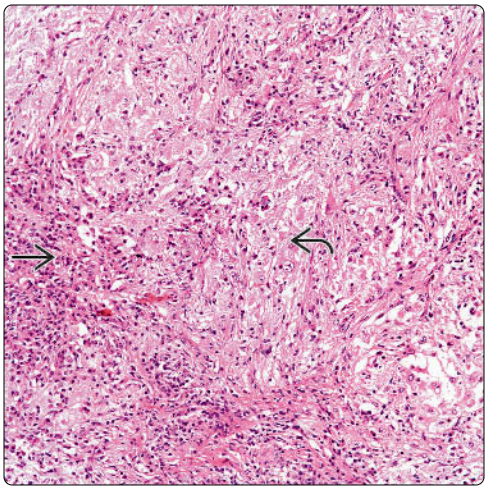

Marked Plasma Cell Component

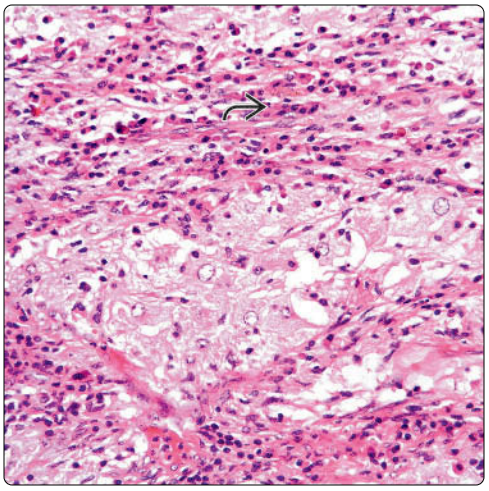

(Left) *R-D disease shows a prominent histiocytic proliferation composed of large histiocytes with abundant eosinophilic cytoplasm. In addition, note the presence of an inflammatory infiltrate composed almost exclusively of plasma cells. Plasma cells are invariably present in all cases of R-D disease.* **(Right)** *R-D disease shows large histiocytes with round to oval nuclei and abundant eosinophilic cytoplasm. Note the presence of plasma cells.*

Large Atypical Histiocytes

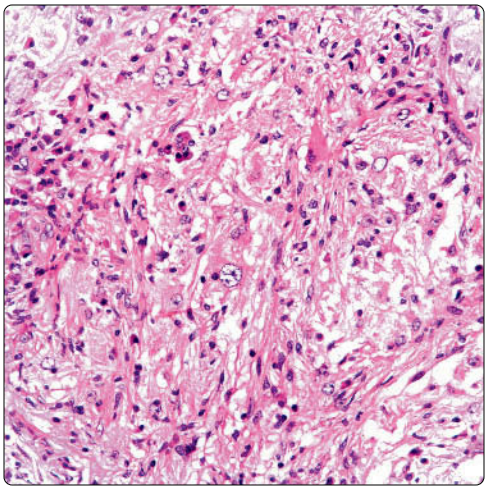

Emperipolesis

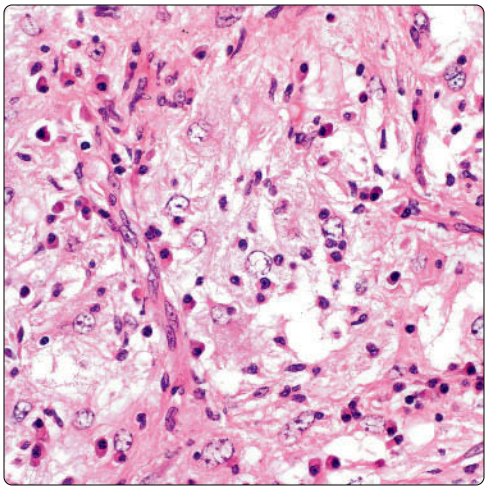

(Left) *R-D disease shows the characteristic histiocytic proliferation composed of large histiocytes. However, in some areas, the inflammatory response is minimal.* **(Right)** *R-D disease shows large histiocytes, some of them engulfing lymphocytes. Emperipolesis is one of the most important characteristics of R-D disease, even though in some cases it may be difficult to identify.*

Angiolymphoid Hyperplasia With Eosinophilia

KEY FACTS

TERMINOLOGY

- Angiolymphoid hyperplasia with eosinophilia (ALHE)
- Synonym: Epithelioid hemangioma

CLINICAL ISSUES

- Presentation
  - Cough
  - Dyspnea
  - Asthma
- Treatment of choice: Complete surgical resection
  - Lobectomy
  - Wedge resection
- Prognosis: Good

IMAGING

- Single pulmonary mass
- Ill-defined pulmonary mass

MICROSCOPIC

- Lymphoid hyperplasia
- Endothelial hyperplasia
- Inflammatory reaction
- Eosinophilia

TOP DIFFERENTIAL DIAGNOSES

- Hodgkin lymphoma
  - Absence of Reed-Sternberg cells in ALHE
  - Negative staining for Hodgkin lymphoma markers
- Eosinophilic pneumonia
  - ALHE characteristically shows presence of vascular proliferation and lymphoid hyperplasia
- Parasitic infection
  - ALHE does not show acute inflammation
  - Negative staining for infectious organisms

Unencapsulated Lesion

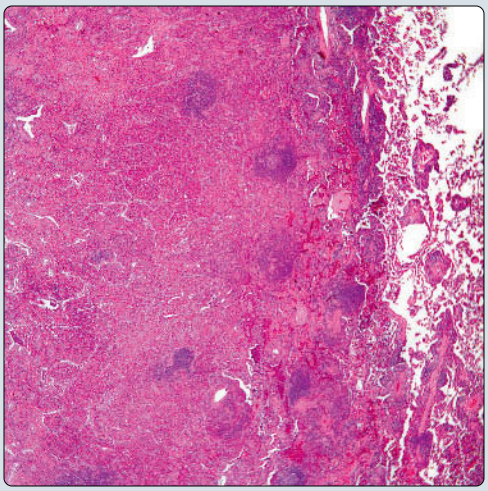

Vascular Proliferation

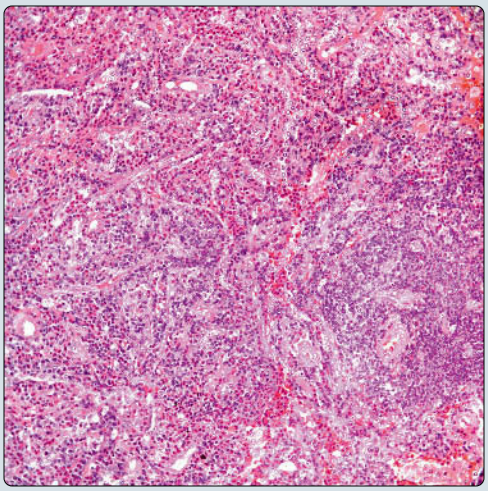

(Left) *Low-power view shows angiolymphoid hyperplasia with eosinophilia (ALHE) presenting as a pulmonary mass. The lesion is fairly well circumscribed.* **(Right)** *High-power view of ALHE shows the characteristic features of lymphoid aggregates, proliferation of small vessels, and prominent eosinophilic infiltrate.*

Lymphoid Hyperplasia

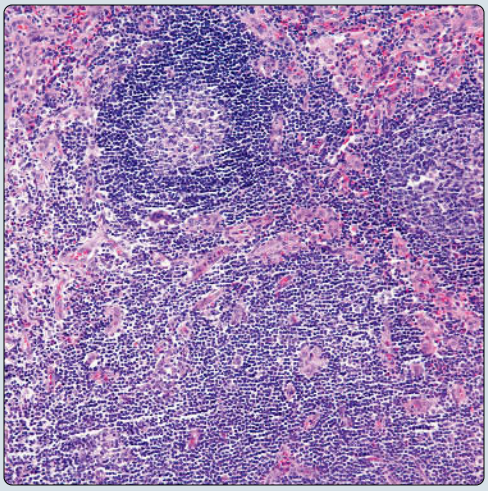

Tissue Eosinophilia

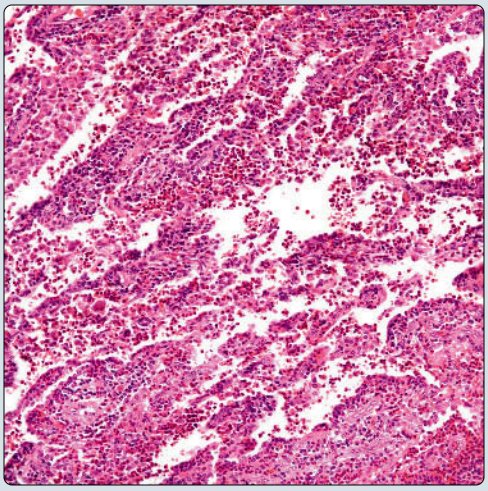

(Left) *ALHE of the lung shows areas of germinal centers and prominent lymphoid proliferation. Also note the presence of small vessels admixed with the lymphoid component.* **(Right)** *Adjacent areas of lung parenchyma near the main nodule of ALHE show prominent eosinophilic component in the interstitium and alveolar spaces.*

TERMINOLOGY

Abbreviations

- Angiolymphoid hyperplasia with eosinophilia (ALHE)

Synonyms

- Epithelioid hemangioma

Definitions

- Benign vascular tumor characterized by vascular proliferation, lymphoid hyperplasia, and eosinophilia

CLINICAL ISSUES

Presentation

- Cough
- Dyspnea
- Asthma

Treatment

- Surgical approaches
  - Complete surgical resection
    - Lobectomy
    - Wedge resection

Prognosis

- Good when lesions limited to lung

IMAGING

General Features

- Single pulmonary mass
- Ill-defined pulmonary mass

MACROSCOPIC

General Features

- Tumor nodule
  - Necrosis &/or hemorrhage are absent
  - Well circumscribed but not encapsulated

Size

- 2-3 cm in diameter

MICROSCOPIC

Histologic Features

- Eosinophilia and proliferation of epithelioid endothelial cells

Predominant Cell/Compartment Type

- Endothelial
- Lymphocyte

DIFFERENTIAL DIAGNOSIS

Hodgkin Lymphoma

- Absence of Reed-Sternberg cells in ALHE
- Negative staining for Hodgkin lymphoma (HL) markers
- Often HL presents in lung with multiple pulmonary nodules

Eosinophilic Pneumonia

- ALHE characteristically shows presence of vascular proliferation and lymphoid hyperplasia, which are not present in eosinophilic pneumonia
- Alveoli are filled with eosinophils
- Does not show endothelial or lymphoid hyperplasia

Parasitic Infection

- ALHE does not show acute inflammation
- Negative staining for infectious organisms
- No parasitic organisms are identified on conventional stains

Non-Hodgkin Lymphoma

- Presence of inflammatory infiltrate would be unusual for lymphoma
- Immunomarkers would show evidence of polyclonality in ALHE

DIAGNOSTIC CHECKLIST

Clinically Relevant Pathologic Features

- Tissue distribution

Pathologic Interpretation Pearls

- Endothelial and lymphoid hyperplasia are characteristic of ALHE
- Eosinophilia coupled with endothelial and lymphoid hyperplasia

SELECTED REFERENCES

1. Adler BL et al: Epidemiology and treatment of angiolymphoid hyperplasia with eosinophilia (ALHE): A systematic review. J Am Acad Dermatol. 74(3):506-512.e11, 2016
2. Rongioletti F et al: Successful management of refractory angiolymphoid hyperplasia with eosinophilia with thalidomide. J Eur Acad Dermatol Venereol. 30(3):527-9, 2016
3. Ye X et al: Pulmonary embolism as the initial clinical presentation of Kimura disease: case report and literature review. Blood Coagul Fibrinolysis. 26(4):414-8, 2015
4. Cham E et al: Epithelioid hemangioma (angiolymphoid hyperplasia with eosinophilia) arising on the extremities. J Cutan Pathol. 37(10):1045-52, 2010
5. Sotiriou E et al: Angiolymphoid hyperplasia with eosinophilia: good response to photodynamic therapy. Clin Exp Dermatol. 34(8):e629-31, 2009
6. Trindade F et al: Giant angiolymphoid hyperplasia with eosinophilia on the chest. J Cutan Pathol. 36(4):493-6, 2009
7. Koizumi H et al: Spontaneous regression of generalized angiolymphoid hyperplasia with eosinophilia in a 2-year-old boy. Acta Derm Venereol. 88(4):395-6, 2008
8. Thompson MJ et al: Angiolymphoid hyperplasia with eosinophilia affecting the eyelids. Arch Ophthalmol. 125(7):987, 2007
9. Macarenco RS et al: Angiolymphoid hyperplasia with eosinophilia showing prominent granulomatous and fibrotic reaction: a morphological and immunohistochemical study. Am J Dermatopathol. 28(6):514-7, 2006
10. Moran CA et al: Angiolymphoid hyperplasia with eosinophilia (epithelioid hemangioma) of the lung: a clinicopathologic and immunohistochemical study of two cases. Am J Clin Pathol. 123(5):762-5, 2005
11. Fetsch JF et al: Observations concerning the pathogenesis of epithelioid hemangioma (angiolymphoid hyperplasia). Mod Pathol. 4(4):449-55, 1991
12. Chan JK et al: Epithelioid haemangioma (angiolymphoid hyperplasia with eosinophilia) and Kimura's disease in Chinese. Histopathology. 15(6):557-74, 1989
13. Suster S: Nodal angiolymphoid hyperplasia with eosinophilia. Am J Clin Pathol. 88(2):236-9, 1987
14. Olsen TG et al: Angiolymphoid hyperplasia with eosinophilia. A clinicopathologic study of 116 patients. J Am Acad Dermatol. 12(5 Pt 1):781-96, 1985
15. Rosai J et al: The histiocytoid hemangiomas. A unifying concept embracing several previously described entities of skin, soft tissue, large vessels, bone, and heart. Hum Pathol. 10(6):707-30, 1979

Prominent Lymphoid Hyperplasia

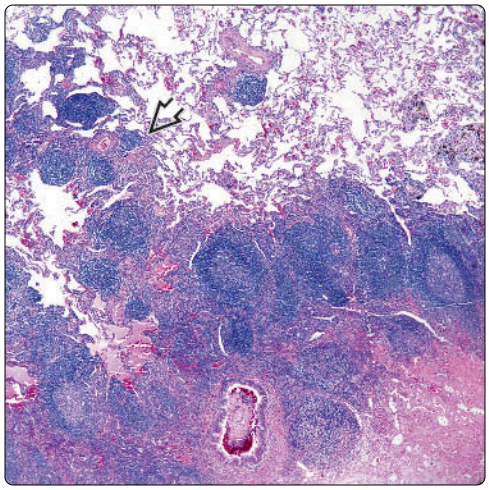

Small Vessel Proliferation

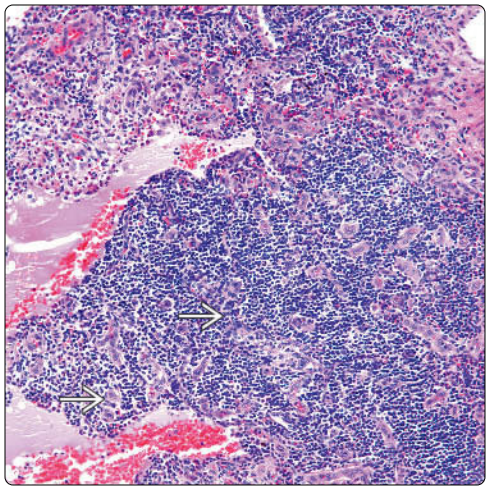

(Left) *Low-power view of ALHE shows a prominent lymphoid component with hyperplastic changes and an ill-defined tumor within the lung parenchyma. Note the spread of the tumor toward other areas of lung parenchyma.* **(Right)** *Prominent lymphoid component in ALHE of the lung obliterates numerous small blood vessels. The eosinophilic component is not marked.*

Presence of Germinal Centers

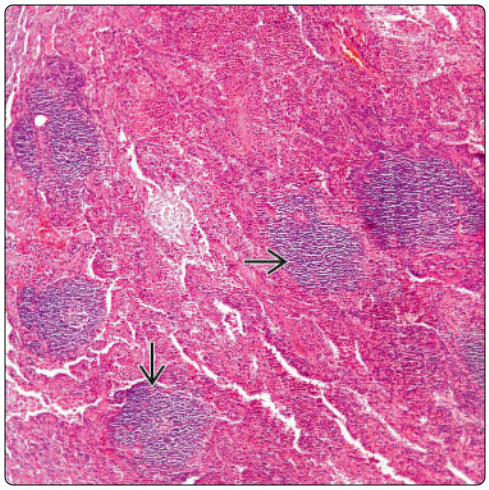

Dilated Vascular Structure With Eosinophils

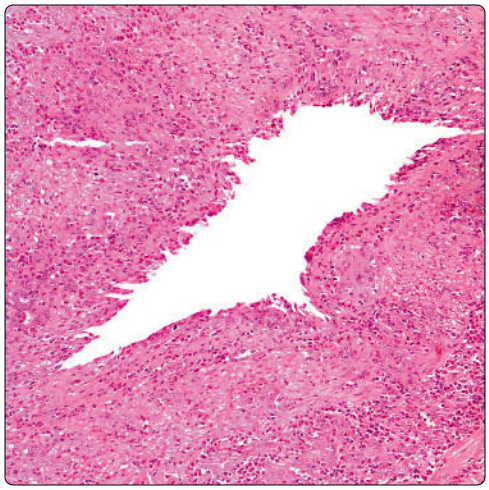

(Left) *ALHE shows more classic features with several germinal centers, blood vessel proliferation, and prominent infiltrate of eosinophils.* **(Right)** *ALHE in the lung shows a large pulmonary vessel with a prominent inflammatory infiltrate in the walls. The lumen is not obstructed; however, numerous eosinophils are easily identified in the walls of the vessels.*

Prominent Eosinophilic Component

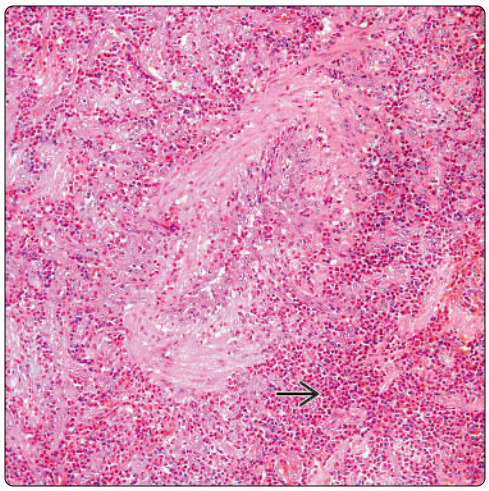

Airway Involvement

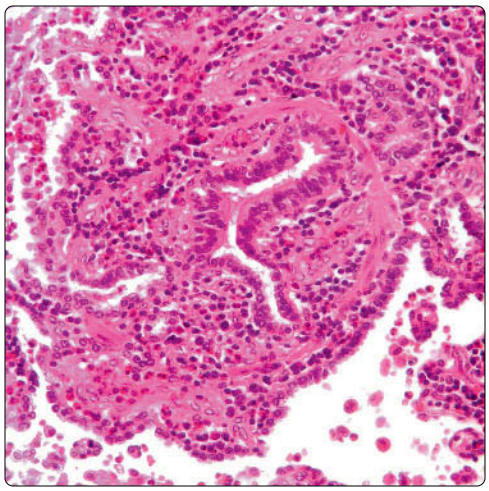

(Left) *Different view of a pulmonary vessel compressed by the inflammatory infiltrate is shown. Even in the compressed lumen, it is still possible to identify inflammatory cells (eosinophils). Note the prominent eosinophilic component in the adjacent lung parenchyma.* **(Right)** *ALHE in the lung involves the peribronchial soft tissue and adjacent alveolar structures. The presence of eosinophils is easily identified.*

Adjacent Vessels in Lung Parenchyma

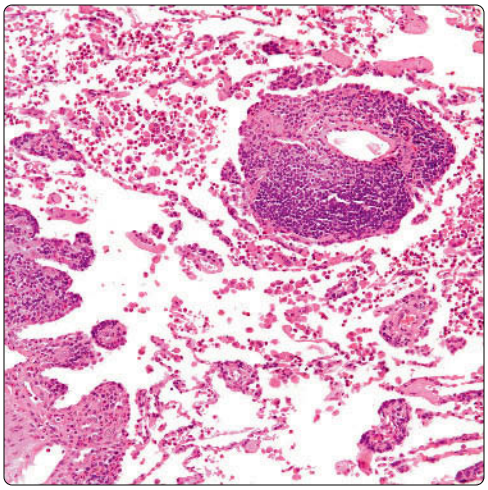

Areas of Fibrosis

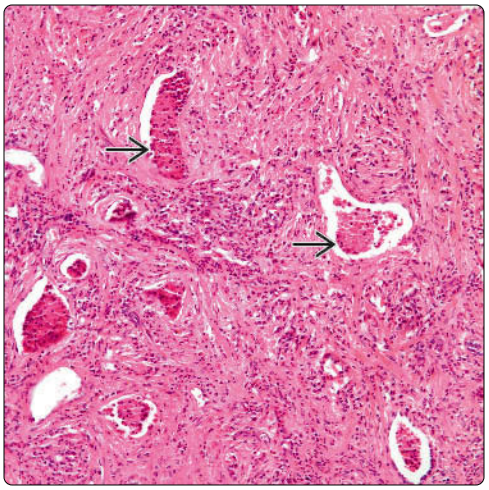

(Left) *Adjacent areas of lung parenchyma may also be affected by ALHE. In this case, small vessels away from the main tumor nodule show inflammatory changes with lymphoid aggregate.* **(Right)** *In other areas of the lung, ALHE demonstrates prominent eosinophilic infiltrate in areas of dense fibrosis. Note the dilated vascular structures ⇨ lined by hyperplastic endothelial cells with prominent epithelioid features.*

Eosinophilia and Vascular Proliferation

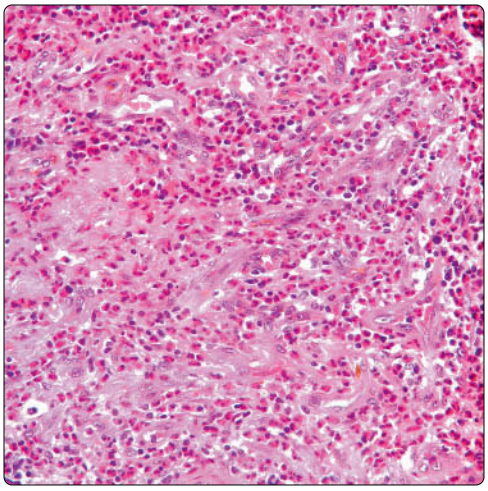

Lymphoid Hyperplasia and Eosinophilia

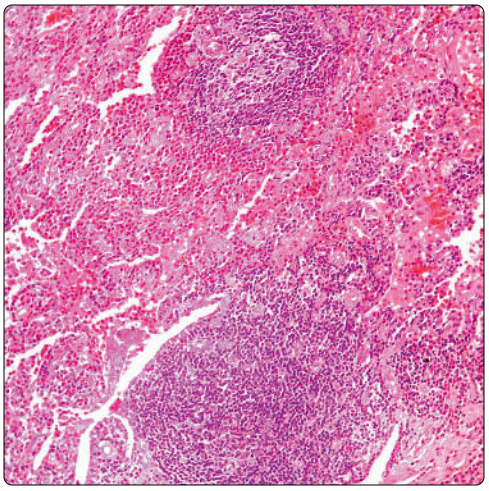

(Left) *High-power view of ALHE reveals numerous vascular channels showing hyperplastic changes. Also note the presence of marked eosinophilia.* **(Right)** *Different view of ALHE in the lung shows lymphoid hyperplasia, a proliferation of vessels, and prominent eosinophilic infiltrate. It is difficult to recognize normal lung parenchyma.*

Small and Large Vessels Involvement

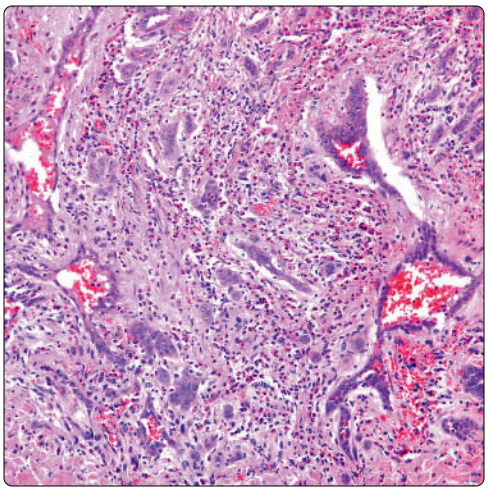

CD31 Highlights Vascular Structures

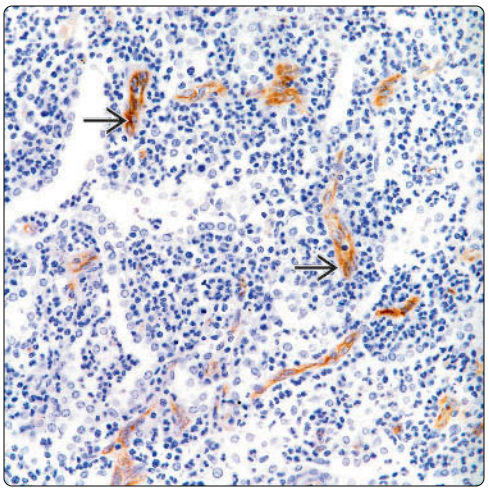

(Left) *ALHE in the lung shows a pattern in which the process is affecting predominantly small vessels, which appear compressed and surrounded by a prominent inflammatory infiltrate composed mainly of eosinophils.* **(Right)** *CD31 immunostain shows positive staining in the vascular structures ⇨ in ALHE of the lung. In some cases, immunostains are important to identify the vascular component.*

Atypical Adenomatous Hyperplasia

KEY FACTS

TERMINOLOGY

- Microscopic proliferation of atypical alveolar lining cells measuring < 5 mm in greatest diameter

CLINICAL ISSUES

- Incidental microscopic finding in lung tissues removed for other reasons

MICROSCOPIC

- Lining cells are round, cuboidal, or low columnar
- Hobnail cells or "peg" cells with apical snouts are often seen
- Nuclei are round and hyperchromatic with evenly dispersed chromatin
- Intranuclear inclusions may be present in some cells
- Lining cells are round, cuboidal, or low columnar
- Hobnail cells or "peg" cells with apical snouts are often seen
- Occasional short tufts of cells may protrude into lumen, but papillary structures are not seen
- Nuclei are round and hyperchromatic with evenly dispersed chromatin
- Occasional large, moderately atypical cells may be seen
- Intranuclear inclusions may be present in some cells
- Mitoses or areas of necrosis are rare
- Focal lesion composed of mildly to moderately atypical cells lining alveoli and, sometimes, respiratory bronchioles
- Absence of background fibrosis or inflammation
- Lesions stand out against background lung because of increased size and hyperchromatism of lining cells

ANCILLARY TESTS

- Atypical cells are strongly positive for TTF-1
- MIB-1/Ki-67 proliferation index is very low (< 1%)
- Atypical cells are strongly positive for TTF-1
- MIB-1/Ki-67 proliferation index is very low (< 1%)
- EGFR positive
- Ultrastructurally show admixtures of cells with features of Clara cells and of type II pneumocytes

(Left) *Scanning magnification of atypical adenomatous hyperplasia (AAH) of the lung shows a well-delineated area ⇨ of lung parenchyma that stands out from the surrounding tissue due to the larger size of the lining cells.* **(Right)** *Higher magnification of AAH shows alveolar septa lined by cells with enlarged, hyperchromatic nuclei with mild thickening of the intervening interstitium.*

AAH Scanning Magnification

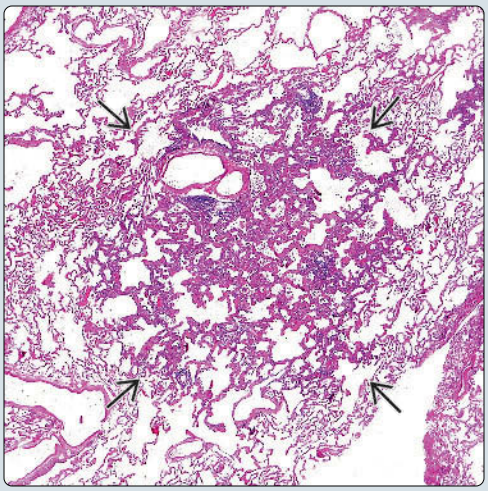

Alveolar Walls in AAH

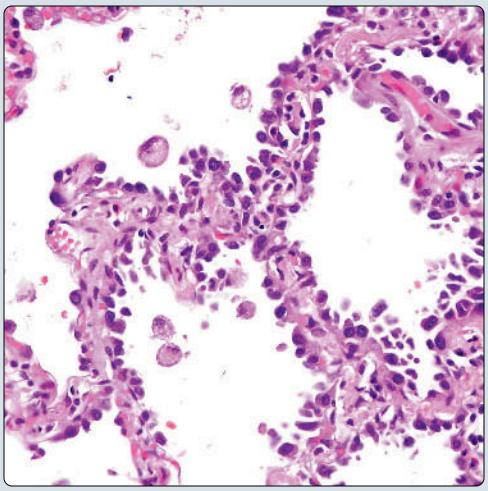

(Left) *Higher magnification of AAH shows large cells lining the walls of the alveoli. Many of the cells display a hobnail configuration with large, hyperchromatic and eccentric nuclei protruding into the alveolar lumen ⇨.* **(Right)** *Higher magnification of AAH shows atypical alveolar lining cells with enlarged, hyperchromatic nuclei displaying a hobnail configuration ⇨.*

AAH at Higher Magnification

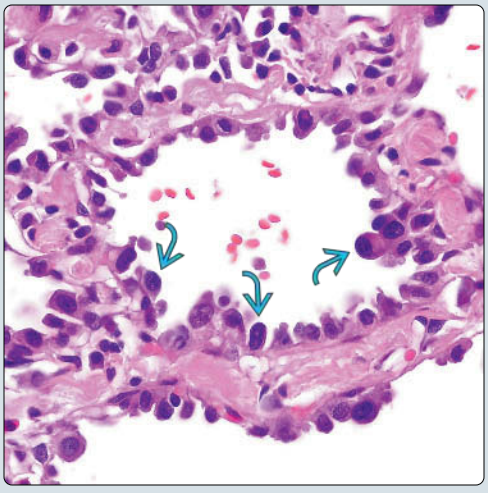

Cytology of AAH

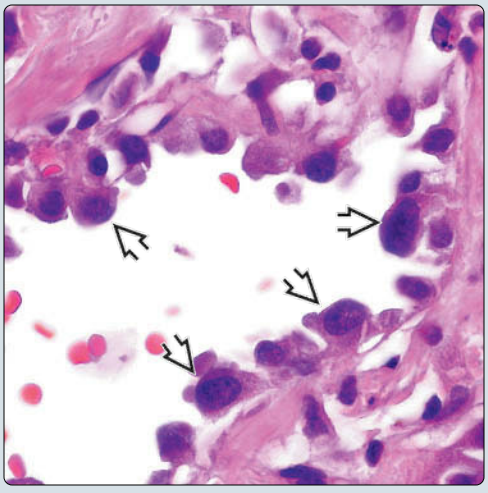

TERMINOLOGY

Abbreviations

- Atypical adenomatous hyperplasia (AAH)

Synonyms

- Bronchioloalveolar adenoma

Definitions

- Microscopic proliferation of atypical alveolar lining cells measuring < 5 mm in greatest diameter

ETIOLOGY/PATHOGENESIS

Pathogenesis

- Recent studies support that these lesions may be earliest precursors of peripheral lung adenocarcinoma
- Aberrant DNA methylation patterns and increased gene copy gains of (*)5 are implicated

CLINICAL ISSUES

Epidemiology

- Incidence
  - May be present in up to 50% of lung specimens surgically resected for lung adenocarcinoma
  - Most commonly associated with adenocarcinoma than with other histologic types of lung cancer
- Age
  - Adults and elderly patients
- Sex
  - Appears to be more common in female patients
- Ethnicity
  - Higher prevalence in Asians, where lepidic-type adenocarcinoma is most common type of lung cancer

Presentation

- Incidental finding in lung specimens resected for cancer or other conditions

Natural History

- Asymptomatic, incidental microscopic finding
- No known morbidity or mortality
- Lesions are believed to represent precursor lesions to well-differentiated adenocarcinoma
- No increased risk of subsequent development of cancer has been found in patients with these incidental lesions

Prognosis

- Benign lesion

IMAGING

General Features

- Morphology
  - Most lesions are completely invisible, even on high-resolution CT scans

MACROSCOPIC

General Features

- Lesions are grossly very difficult to visualize and most often pass unnoticed

Size

- < 5 mm in greatest diameter
- Lesions with similar features > 5 mm in diameter are generally considered as lepidic adenocarcinoma in situ

MICROSCOPIC

Histologic Features

- Focal lesion composed of mildly to moderately atypical cells lining alveoli and, sometimes, respiratory bronchioles
- Absence of background fibrosis or inflammation
- Lesions stand out against background lung because of increased size and hyperchromatism of lining cells

Cytologic Features

- Lining cells are round, cuboidal, or low columnar
- Hobnail cells or "peg" cells with apical snouts are often seen
- Occasional short tufts of cells may protrude into lumen, but papillary structures are not seen
- Nuclei are round and hyperchromatic with evenly dispersed chromatin
- Occasional large, moderately atypical cells may be seen
- Intranuclear inclusions may be present in some cells
- Mitoses or areas of necrosis are rare

ANCILLARY TESTS

Immunohistochemistry

- Atypical cells are strongly positive for TTF-1
- MIB-1/Ki-67 proliferation index is very low (< 1%)
- EGFR positive

DIFFERENTIAL DIAGNOSIS

Well-Differentiated Adenocarcinoma, Lepidic Type

- May be indistinguishable morphologically from AAH
- Arbitrary size criterion has been proposed of 0.5-cm diameter for separating lepidic well-differentiated adenocarcinoma from AAH
  - Size may not be reliable criterion for making this distinction
  - Most cases < 0.5 cm are regarded as AAH
  - Most cases > 0.5 cm in diameter are regarded as lepidic adenocarcinoma in-situ

Reactive Bronchioloalveolar Cell Hyperplasia

- Reactive bronchioloalveolar cell hyperplasia is generally observed against background of pneumonitis, whereas AAH is seen against background of normal lung

SELECTED REFERENCES

1. Selamat SA et al: DNA methylation changes in atypical adenomatous hyperplasia, adenocarcinoma in situ, and lung adenocarcinoma. PLoS One. 6(6):e21443, 2011
2. McIntire MG et al: Epidermal growth factor receptor gene amplification in atypical adenomatous hyperplasia of the lung. Am J Transl Res. 2(3):309-15, 2010
3. Seki M et al: Multiple lung adenocarcinomas and AAH treated by surgical resection. Lung Cancer. 55(2):237-40, 2007

Lymphangioleiomyomatosis

KEY FACTS

TERMINOLOGY

- Lymphangioleiomyomatosis (LAM)

ETIOLOGY/PATHOGENESIS

- Unknown etiology
- May share similar genetic relationship with tuberous sclerosis complex

CLINICAL ISSUES

- Incidence
  - More common in premenopausal women
  - Rarely described in children
- Symptoms
  - Cough
  - Shortness of breath
  - Chylous effusion
  - Pneumothorax
  - Hemoptysis

MICROSCOPIC

- Cystic changes
- Spindle cell proliferation lining cystic structures

ANCILLARY TESTS

- Important immunohistochemical stains include
  - HMB-45 and actin

TOP DIFFERENTIAL DIAGNOSES

- Leiomyoma
  - Usually forms tumor mass
  - Unusual for leiomyoma to present with prominent cystic changes
- Leiomyosarcoma
  - LAM lacks atypia or mitotic activity
- Tuberous sclerosis
  - Such distinction may not be possible on histologic grounds alone
  - It is important to obtain clinical history

Nodular Changes

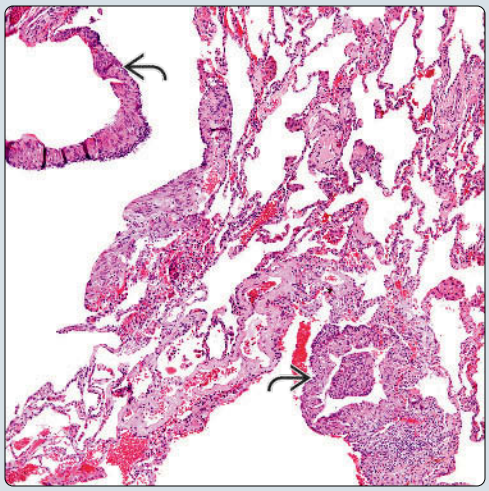

Smooth Muscle Nodule

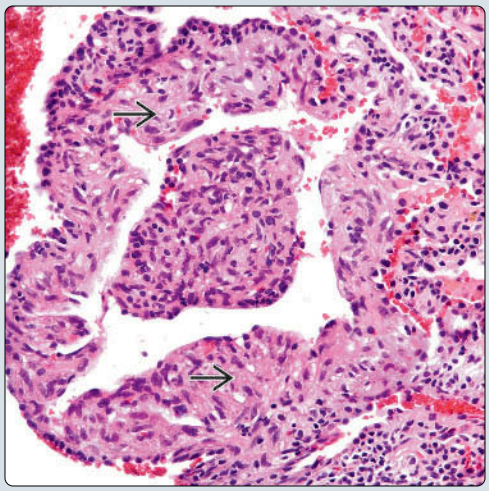

(Left) *Low-power view of lymphangioleiomyomatosis (LAM) shows 2 focal areas of muscle proliferation. Note that the rest of the pulmonary parenchyma appears to be within normal limits.* **(Right)** *High-power magnification of LAM shows the classic presence of smooth muscle proliferation. The muscle proliferation is obvious and has obliterated the normal alveolar lining.*

Hemorrhagic Areas

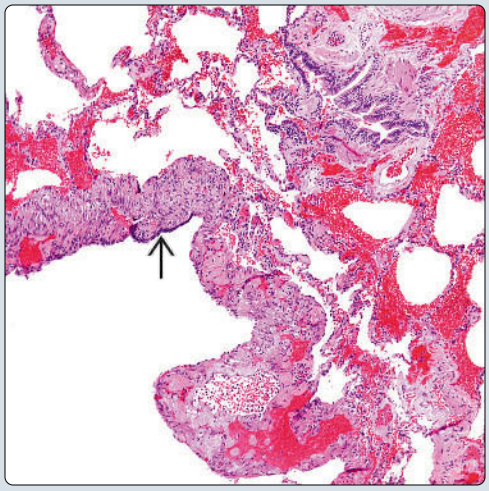

Polypoid Nodule of Smooth Muscle

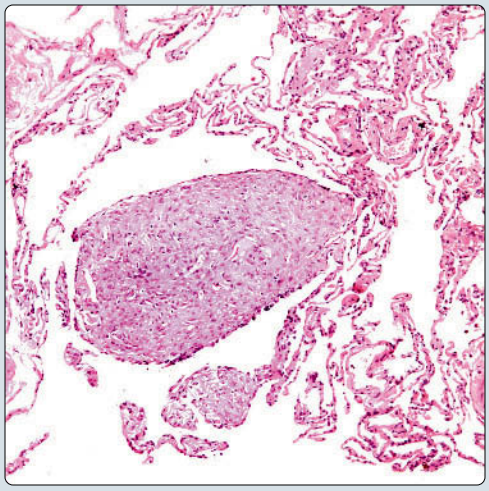

(Left) *In some cases of LAM, the presence of hemorrhage may obscure the presence of smooth muscle proliferation. However, closer attention should be directed to cystic structures.* **(Right)** *In some areas of LAM, the muscle proliferation appears as a polypoid lesion arising from the lining of the alveolar epithelium.*

TERMINOLOGY

Abbreviations

- Lymphangioleiomyomatosis (LAM)

Synonyms

- Lymphangiomyomatosis

Definitions

- Nonneoplastic lung condition characterized by presence of immature muscle proliferation

ETIOLOGY/PATHOGENESIS

Etiology

- Unknown
- May share similar genetic relationship with tuberous sclerosis complex

CLINICAL ISSUES

Epidemiology

- Incidence
  - LAM occurs in ~ 2 cases per million patients
  - May be underreported
- Age
  - More common in premenopausal women
  - Rarely described in children

Presentation

- Cough
- Shortness of breath
- Chylous effusion
- Pneumothorax
- Hemoptysis

Prognosis

- Predominantly cystic lesions may have poor prognosis
- 85% survival at 5 years
- 70% survival at 10 years

IMAGING

General Features

- Bilateral multiple nodular and cystic changes in lung parenchyma
- Unilateral involvement is also possible

MICROSCOPIC

Histologic Features

- Cystic changes
- Hemorrhage
- Spindle cell proliferation
  - In alveolar walls
  - Lining cystic structures
  - With focal clear cell change
  - Lacking atypia or mitotic activity

DIFFERENTIAL DIAGNOSIS

Leiomyoma

- Usually forms tumor mass
- Unusual for leiomyoma to present with prominent cystic changes

Leiomyosarcoma

- LAM lacks atypia or mitotic activity

Tuberous Sclerosis

- Such distinction may not be possible on histologic grounds alone
- It is important to obtain clinical history of tuberous sclerosis

DIAGNOSTIC CHECKLIST

Pathologic Interpretation Pearls

- Cystic changes with smooth muscle proliferation
- Spindle cells are positive for SMA and HMB-45
- Spindle cells are positive for ER/PR

SELECTED REFERENCES

1. Moir LM: Lymphangioleiomyomatosis: current understanding and potential treatments. Pharmacol Ther. 158:114-24, 2016

Immunohistochemistry

Antibody	Reactivity	Staining Pattern	Comment
Actin-sm	Positive	Cytoplasmic	In muscle component
Desmin	Positive	Cytoplasmic	In muscle component
HMB-45	Positive	Cytoplasmic	More often in clear cells
IGF-1	Positive	Cytoplasmic	
MMP-1	Positive	Cytoplasmic	
ER	Positive	Nuclear	May be focal
PR	Positive	Nuclear	May be focal

Molecular Biology

Exonic mutations of 7 6 & / 7 6 &	In some cases

Cystic Changes

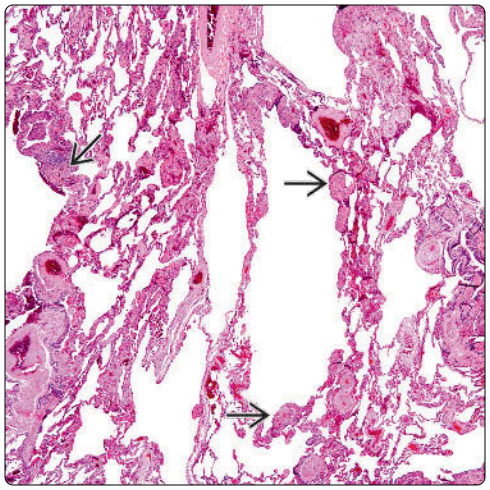

Cystic Changes

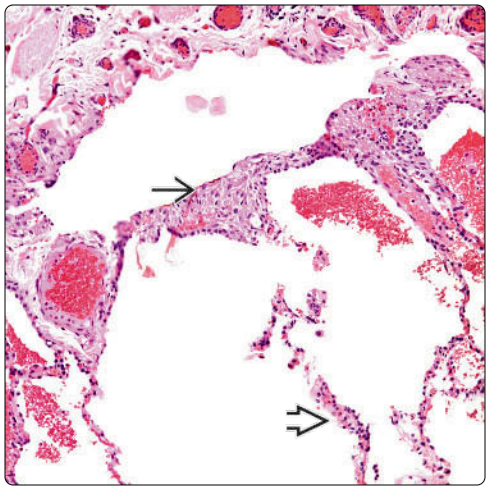

(Left) *Low-power view of lung parenchyma in LAM shows little change at this magnification. However, note the presence of cysts and the thickening of some cyst walls.* **(Right)** *Higher magnification shows alternating normal alveolar structures and other cystic structures lined by smooth muscle proliferation in pulmonary LAM.*

Vascular Proliferation

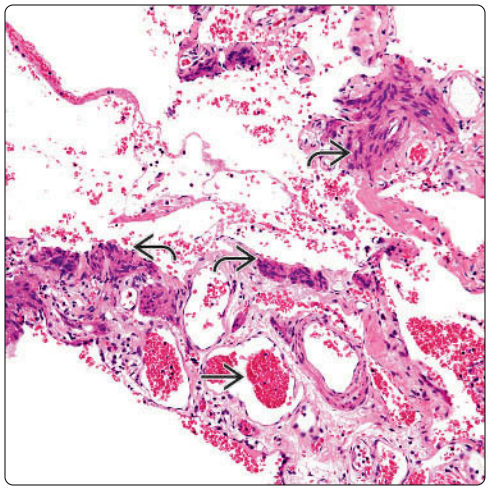

Small Nodule of Smooth Muscle

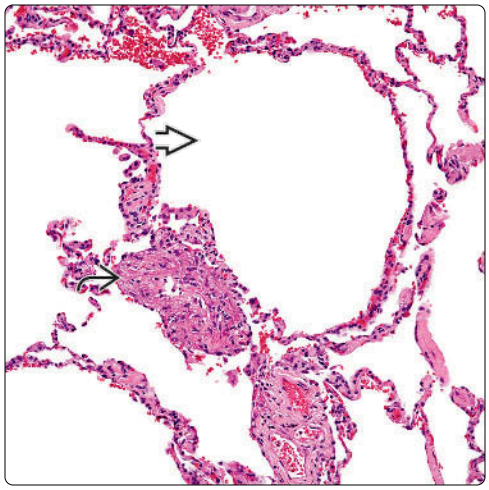

(Left) *LAM shows areas of nonneoplastic vascular proliferation; some of the vessels contain fresh blood. Note the presence of muscle proliferation adjacent to the dilated vascular structures.* **(Right)** *This LAM shows a very subtle area of muscle proliferation adjacent to an alveolar space. In some cases, the presence of muscle may be only focal and can easily be missed in a cursory review.*

Areas of Hemorrhage

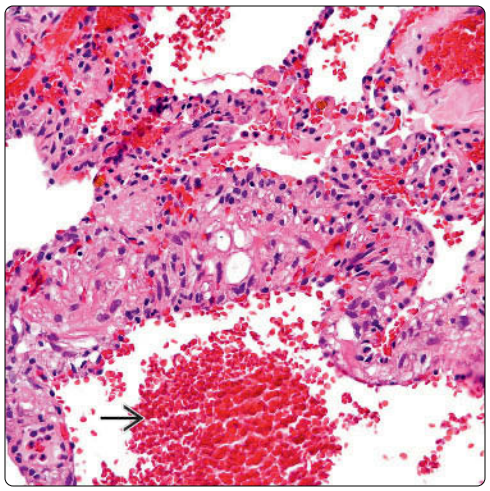

Clear Cells

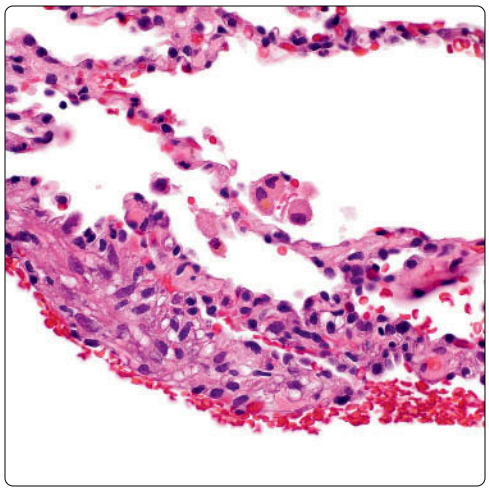

(Left) *This LAM shows areas of congestion and hemorrhage with the presence of fresh blood. However, note that the alveolar wall has been replaced by a muscle proliferation, which also shows some clear cell changes. Due to the areas of hemorrhage and congestion, these areas can be missed.* **(Right)** *High-power view of the smooth muscle proliferation in LAM is shown. Note that, in some areas, the cellular proliferation demonstrates focal clear cells.*

Smooth Muscle Component

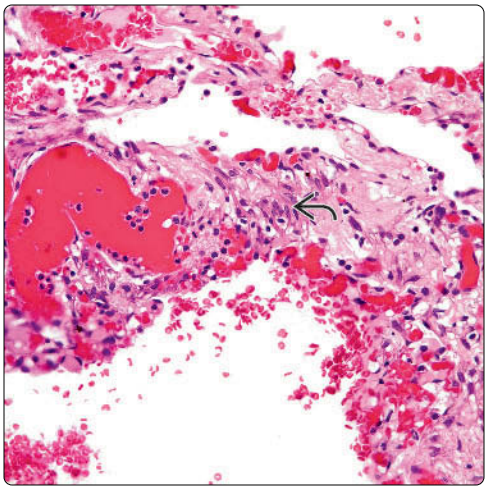

Two Distinct Muscle Components

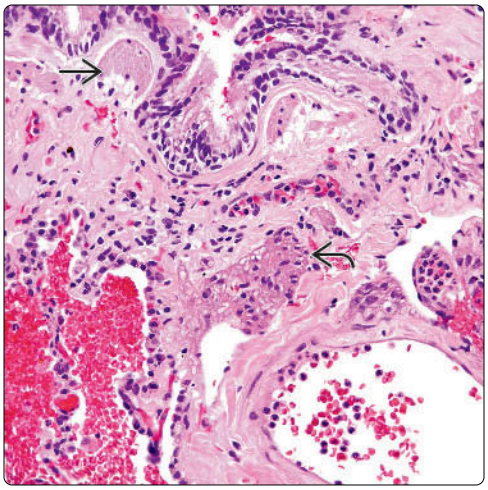

(Left) *The presence of hemorrhage and congestion in LAM can at times be very marked, and areas of muscle proliferation can be difficult to find. Note here, the muscle proliferation can be easily missed.* **(Right)** *The presence of muscle proliferation must be separated from the normal muscle layers that surround normal airway structures. Note the presence of the difference of the muscle of LAM in contrast to the normal muscular layer around the airway.*

Extensive Congestion

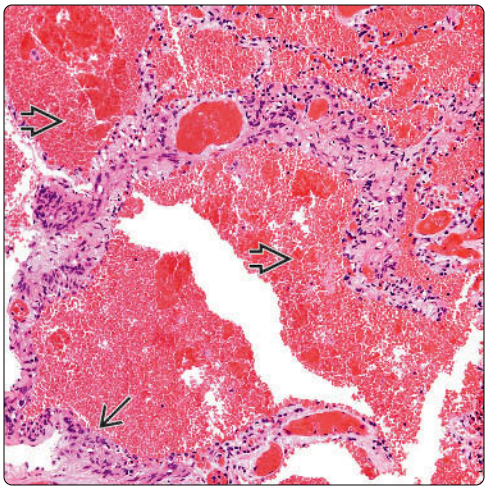

Extensive Muscle Component

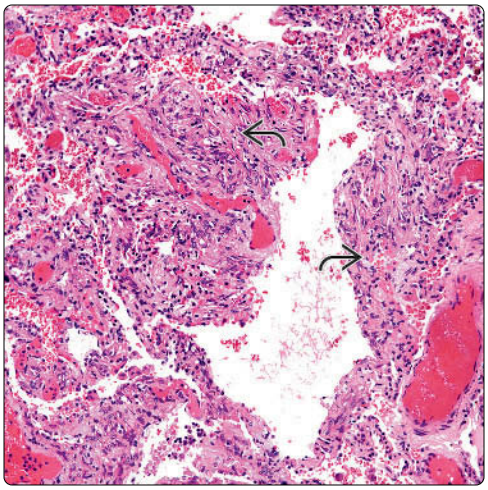

(Left) *Despite the presence of dilated alveolar spaces filled with fresh blood, one is still able to see smooth muscle proliferation.* **(Right)** *In some cases of LAM, the muscle proliferation can be marked and can actually mimic a smooth muscle tumor. The muscle proliferation in this case is extensive, destroying normal lung architecture.*

Pneumocyte Hyperplasia

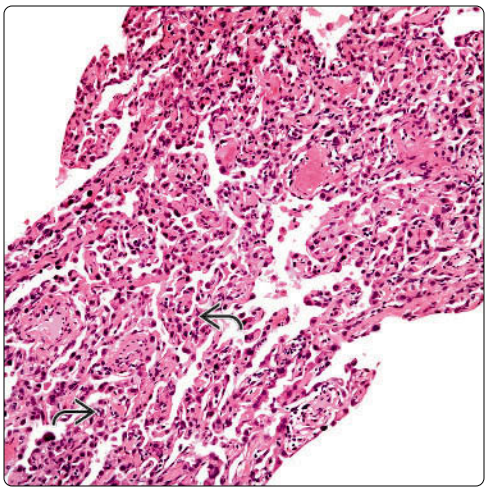

Pigmented Macrophages

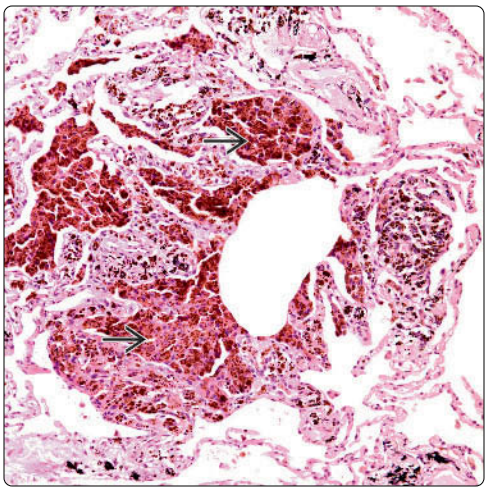

(Left) *An unusual feature that may be seen in some cases of LAM is the presence of pneumocyte hyperplasia. Such change may be in the form of small nodules that can raise the possibility of a malignant epithelial neoplasm.* **(Right)** *One additional feature that may be seen in most of the cases of LAM is the presence of hemosiderin-laden macrophages filling alveolar spaces, as shown here.*

Capillary Hemangiomatosis

KEY FACTS

TERMINOLOGY

- Benign condition characterized by proliferation of small capillaries in pulmonary interstitium

ETIOLOGY/PATHOGENESIS

- Possible autosomal recessive inheritance has been mentioned
- May also appear as incidental finding
- Mutations in eukaryotic translation initiation factor 2α kinase 4 ((,) $.) gene have been identified in familial and idiopathic capillary hemangiomatosis

CLINICAL ISSUES

- Unusual occurrence
- It may be familial or idiopathic
- It may occur in any age group
- Most cases appear to be more commonly diagnosed in 3rd or 4th decade of life
- Symptoms
  - Cough
  - Hemoptysis
  - Respiratory distress
  - Chest pain
  - Pulmonary hypertension
  - Interstitial lung disease
- Prognosis
  - Good if diagnosed early
  - Can be fatal in advanced stages

TOP DIFFERENTIAL DIAGNOSES

- Capillaritis
- Cavernous hemangioma
- Capillary hemangioma
- Pulmonary hemorrhage
- Angiosarcoma
- Normal lung parenchyma

Normal-Appearing Lung Parenchyma

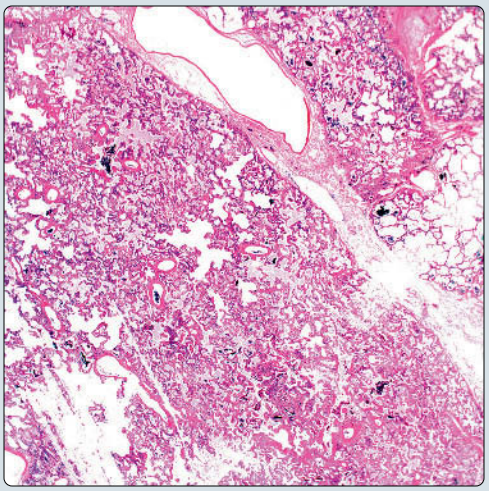

Widening of Interstitium

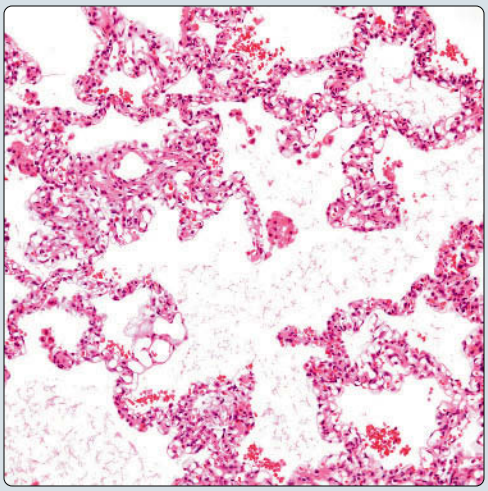

(Left) *Low-power view shows a lung section with capillary hemangiomatosis. At this power, the lung may look within normal limits, and in a cursory review, the pathological process can be easily missed.* **(Right)** *Capillary hemangiomatosis shows widening of the interstitium in which a proliferation of small vessels is easily identified.*

Normal-Appearing Lung

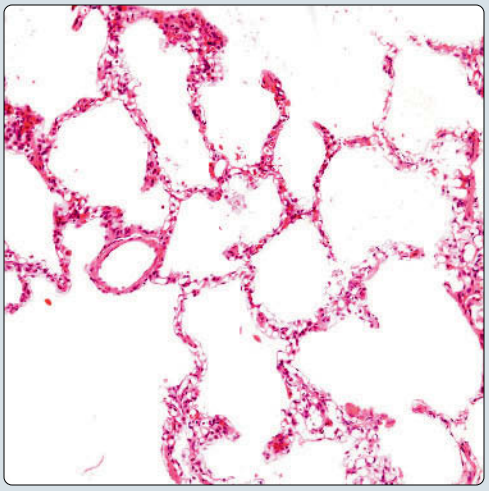

Capillary Proliferation

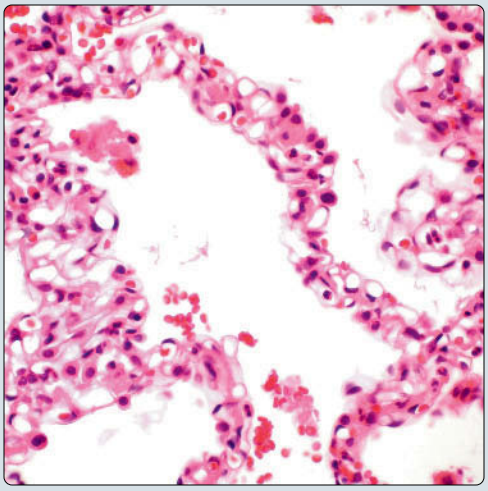

(Left) *In other areas of capillary hemangiomatosis, the basic normal architecture of the lung appears to be kept; however, the alveolar walls are lined by a proliferation of small capillaries.* **(Right)** *Closer view shows the proliferation of small capillaries lining the alveolar wall and occupying the interstitium.*

TERMINOLOGY

Abbreviations

- Capillary hemangiomatosis (CH)

Definitions

- Benign condition characterized by proliferation of small capillaries in pulmonary interstitium

ETIOLOGY/PATHOGENESIS

Etiology

- Possible autosomal recessive inheritance has been observed
- May also appear as incidental finding
- Mutations in eukaryotic translation initiation factor 2α kinase 4 ((,) $.) gene have been identified in familial and idiopathic CH

CLINICAL ISSUES

Epidemiology

- Incidence
  - Unusual occurrence
    - It may be familial
    - It may be idiopathic
- Age
  - It may occur in any age group
    - Most cases appear to be more commonly diagnosed in 3rd or 4th decade of life
- Sex
  - No gender predilection
- Ethnicity
  - No ethnic predilection

Site

- Pulmonary interstitium

Presentation

- Cough
- Hemoptysis
- Respiratory distress
- Chest pain
- Pulmonary hypertension
- Interstitial lung disease

Treatment

- Surgical approaches
  - Due to extensive nature of process, radical approach may be necessary
  - Lobectomy or pneumonectomy
- Drugs
  - Interferon α-2a

Prognosis

- Good if diagnosed early and if process is less diffuse
- Can be fatal due to pulmonary hemorrhage

MACROSCOPIC

General Features

- Congested lung parenchyma
- Sponge-like appearance
- Multicystic changes in lung parenchyma

MICROSCOPIC

Histologic Features

- Interstitial congestion
- Proliferation of small capillaries
- Capillaries may infiltrate into bronchi and larger vessels
- Presence of double capillaries
- Lack of cytologic atypia

DIFFERENTIAL DIAGNOSIS

Capillaritis

- In cases of capillaritis, there is usually inflammatory reaction associated with process
- May not be as diffuse as CH

Cavernous Hemangioma

- Shows more circumscription
- Vascular proliferation is more obvious with larger vessels

Capillary Hemangioma

- Vascular proliferation in capillary hemangioma is larger than in CH
- May be more circumscribed
- May present as pulmonary nodule or mass

Pulmonary Hemorrhage

- Blood lakes are formed in alveoli
- Does not show presence of capillary proliferation

Angiosarcoma

- Most likely will present as multiple pulmonary nodules rather than diffuse pattern
- Displays more cytologic atypia and mitotic activity

Normal Lung Parenchyma

- Does not show extensive capillary proliferation

DIAGNOSTIC CHECKLIST

Clinically Relevant Pathologic Features

- Diffuse capillary proliferation in pulmonary interstitium

Pathologic Interpretation Pearls

- Extensive capillary proliferation without atypia

SELECTED REFERENCES

1. Ma L et al: Pulmonary capillary hemangiomatosis: a focus on the EIF2AK4 mutation in onset and pathogenesis. Appl Clin Genet. 8:181-8, 2015
2. Odronic SI et al: Pulmonary capillary hemangiomatosis associated with connective tissue disease: a report of 4 cases and review of the literature. Ann Diagn Pathol. 19(3):149-53, 2015
3. McGuire F et al: Pulmonary capillary hemangiomatosis associated with CREST syndrome: a case report and review of the literature. Respiration. 80(5):435-8, 2010
4. Fugo K et al: Solitary capillary hemangioma of the lung: report of 2 resected cases detected by high-resolution CT. Am J Surg Pathol. 30(6):750-3, 2006
5. Lantuéjoul S et al: Pulmonary veno-occlusive disease and pulmonary capillary hemangiomatosis: a clinicopathologic study of 35 cases. Am J Surg Pathol. 30(7):850-7, 2006
6. Sullivan A et al: Pulmonary capillary hemangiomatosis: an immunohistochemical analysis of vascular remodeling. Eur J Med Res. 11(5):187-93, 2006
7. Sullivan A et al: Pulmonary capillary hemangiomatosis: an immunohistochemical analysis of vascular remodeling in a fatal case. Chest. 128(6 Suppl):576S, 2005

Dilated Vessel

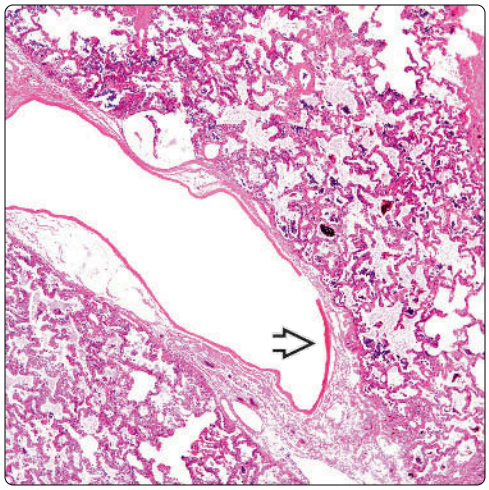

Widening of Interstitium

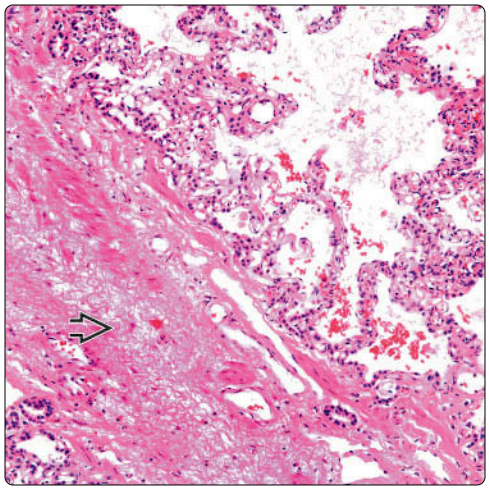

(Left) *Pulmonary capillary hemangiomatosis shows a dilated vascular structure in the septum of the lung. In either side of this dilated vascular structure, there is lung parenchyma, which at this power looks only congested.* **(Right)** *Areas of fibroconnective tissue deposition may be encountered. However, note that the alveolar spaces are rather dilated, and the interstitium is widened by a proliferation of capillaries.*

Collection of Macrophages

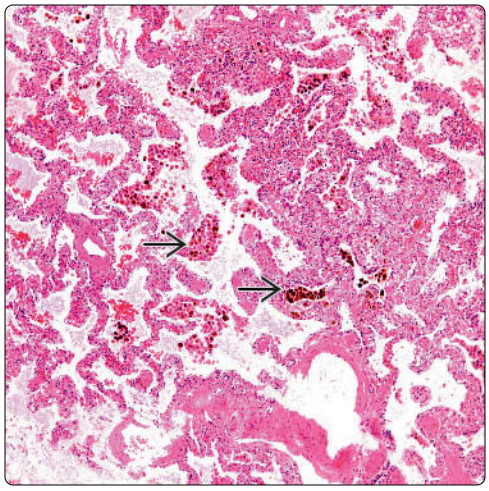

Pigmented Macrophages

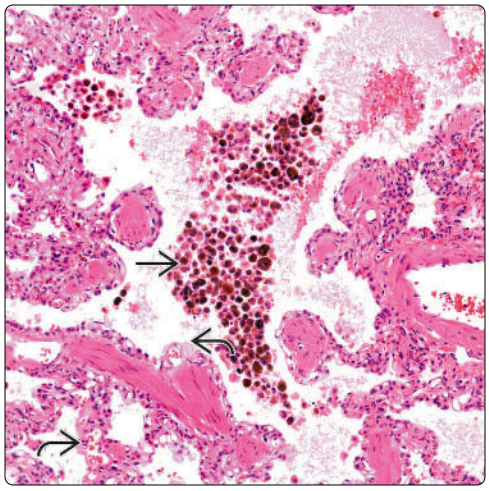

(Left) *In some areas, there may be pigmented macrophages within alveolar spaces. This feature may be secondary to hemorrhage as there may be a breakdown of capillaries within the pulmonary interstitium.* **(Right)** *High-power view shows a cluster of pigmented macrophages within what may have been an alveolar space. Also note that the adjacent pulmonary parenchyma is almost replaced by a capillary proliferation.*

Focal Intraalveolar Acellular Material

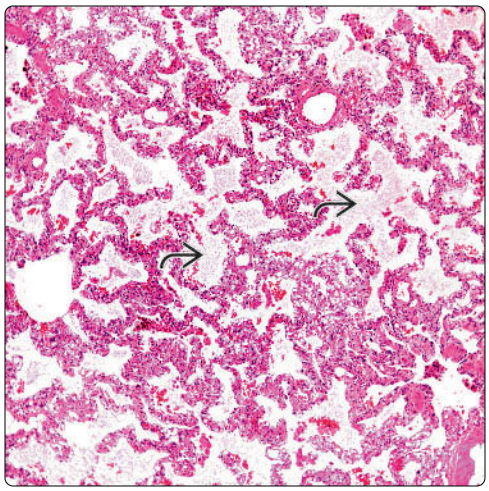

Proliferation of Small Capillaries

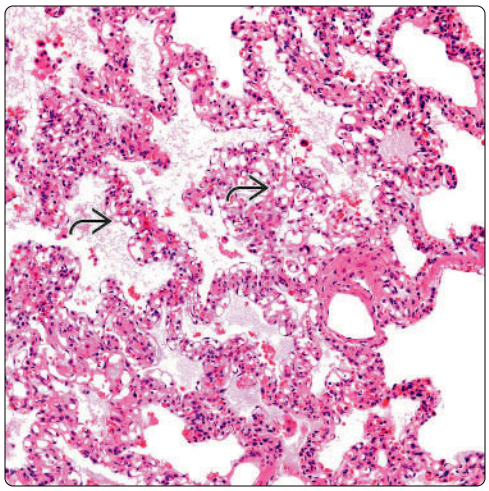

(Left) *Pulmonary capillary hemangiomatosis with areas of intraalveolar acellular edematous material gives a vague appearance of pulmonary edema.* **(Right)** *High-power view shows easily identifiable capillary proliferation lining not only the alveolar walls but also the interstitium. The edematous material within the alveolar spaces may be a secondary phenomenon that may be seen in some cases.*

Emphysema-Like Changes

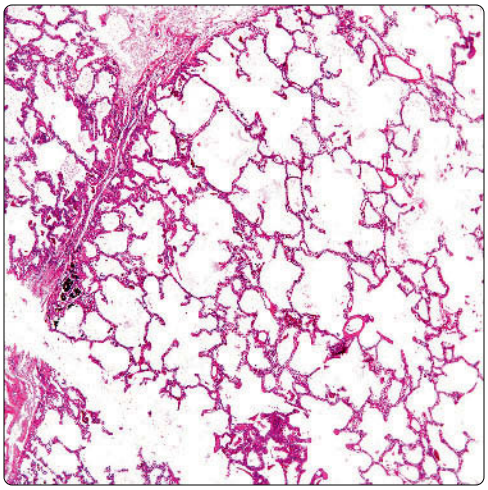

Rupture of Alveolar Walls

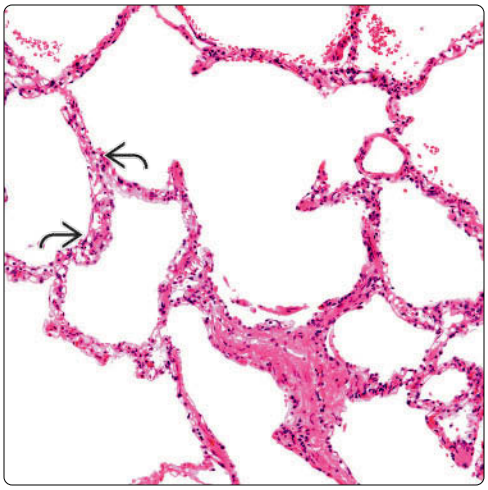

(Left) *Low-power view shows pulmonary hemangiomatosis with an appearance mimicking emphysematous changes. The true nature of this process may be easily missed if not properly examined at higher magnification.* **(Right)** *High-power view shows an emphysematous-like area in which there is some breakdown of alveolar walls. Note that the alveolar lining is being replaced by a capillary proliferation.*

Widening of Interstitium

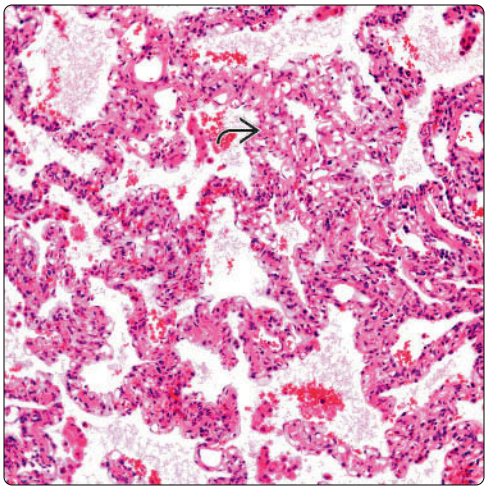

Extravasated Red Cells

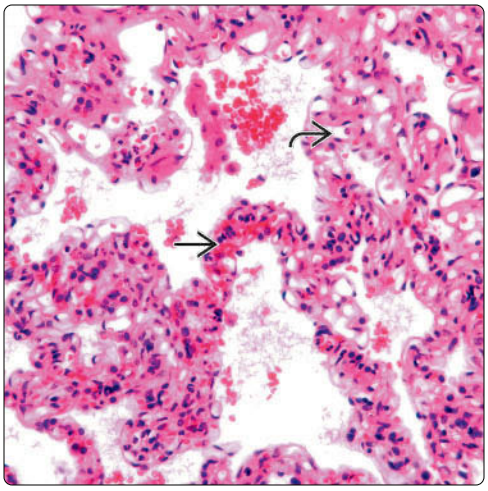

(Left) *Pulmonary capillary hemangiomatosis shows widening of the interstitium and easily identifiable capillary proliferation. The lung parenchyma may in some cases preserve some of the normal lung architecture.* **(Right)** *The capillary proliferation is composed of small capillaries with extravasated red cells. However, the capillary proliferation does not show any atypical features or mitotic activity.*

Prominent Small Vessel Proliferation

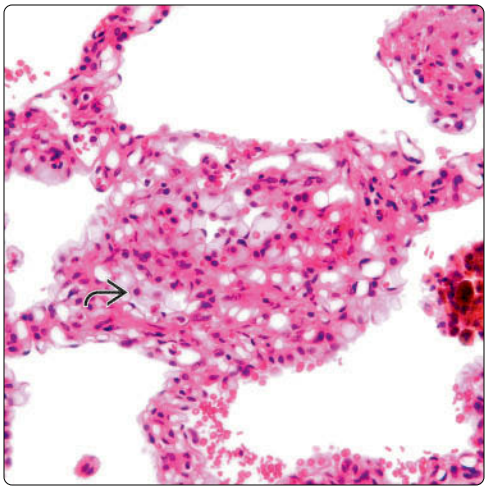

Uninvolved Pleura

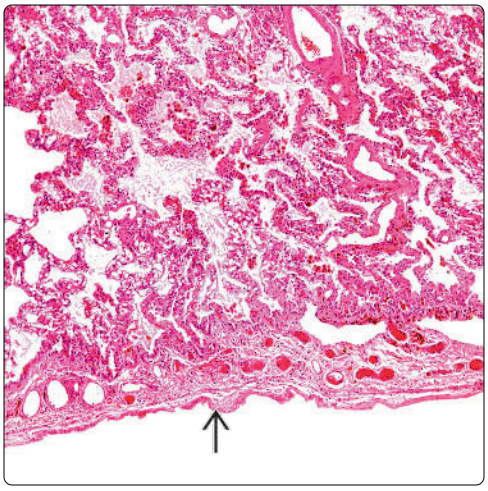

(Left) *Focal area of a more solid capillary proliferation in pulmonary hemangiomatosis is shown. These features are reminiscent of capillary hemangiomas of the subcutis.* **(Right)** *Although the process of capillary hemangiomatosis may be diffuse, involving extensive areas of the lung parenchyma, the process does not appear to involve the pleura, as is illustrated in this case with sparing of the pleural surface.*

This page intentionally left blank

PART I
SECTION 3

Neoplasms, Metastatic

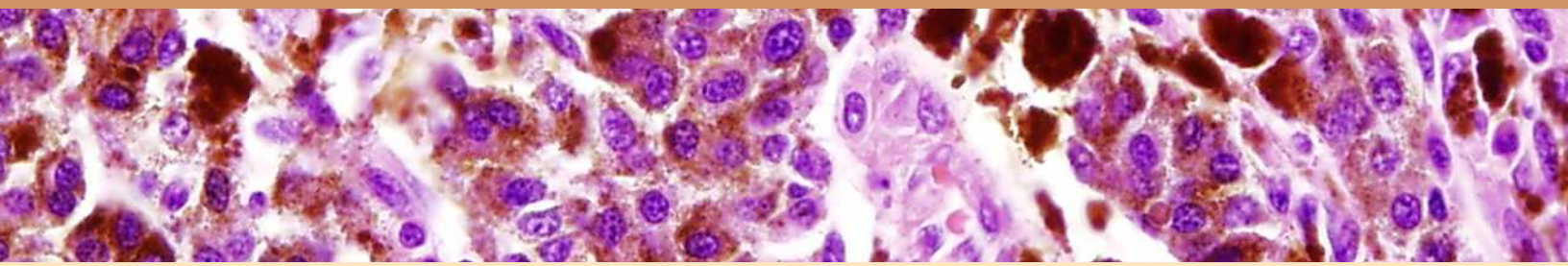

Benign Metastasizing Leiomyoma	**352**
Metastatic Carcinoma	**356**
Metastatic Sarcoma	**366**
Metastatic Malignant Melanoma	**376**

Benign Metastasizing Leiomyoma

KEY FACTS

ETIOLOGY/PATHOGENESIS

- Remote implantation of benign cells released into circulation during surgery
- True metastases from very low-grade, well-differentiated leiomyosarcomas
- Recent studies have demonstrated clonal origin by molecular-genetic analysis

CLINICAL ISSUES

- 30-50 years of age
- Exclusively observed in women
- Lesions are usually multiple and may be bilateral, suggesting metastatic disease

MICROSCOPIC

- Fascicles of monotonous, bland-appearing spindle cells that are sharply separated from surrounding lung parenchyma
- Lesions may entrap normal respiratory mucosa and airspaces in vicinity of lesions (adenomyomatous hamartoma)
- Spindle cells have blunt-ended nuclei showing dispersed chromatin pattern and small or inconspicuous nucleoli
- Spindle cells are surrounded by scant rim of fibrillary eosinophilic cytoplasm
- No evidence of nuclear pleomorphism, mitoses, or tumor cell necrosis

ANCILLARY TESTS

- Spindle cells are positive for smooth muscle actin (SMA), desmin, calponin, and H-caldesmon
  - Stain positive with Bcl-2 (feature shared with müllerian-derived smooth muscle)
  - May show expression of estrogen and progesterone receptors

Gross Appearance

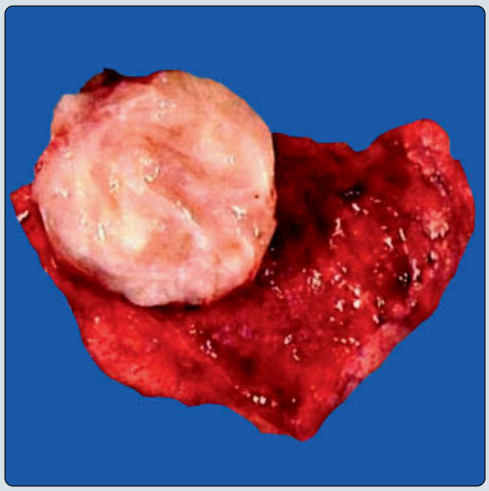

Scanning Magnification

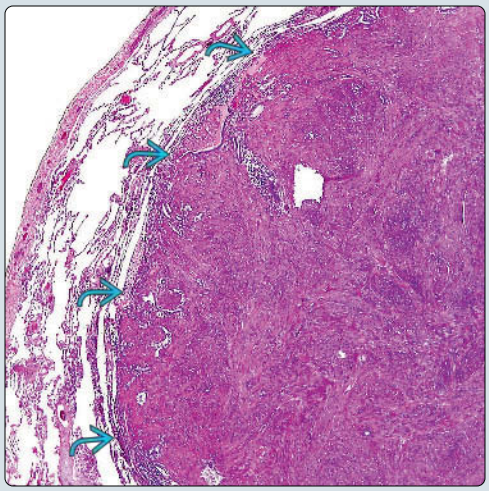

(Left) *Gross appearance of benign metastasizing leiomyoma of the lung in a 50-year-old woman shows a well-circumscribed, fleshy nodule that bulges above the cut surface.* **(Right)** *Scanning magnification of benign metastasizing leiomyoma shows a well-circumscribed nodule sharply separated from the surrounding pulmonary parenchyma.*

Higher Magnification

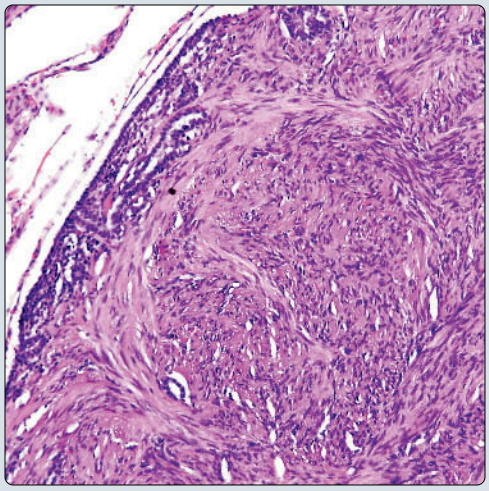

Higher Magnification

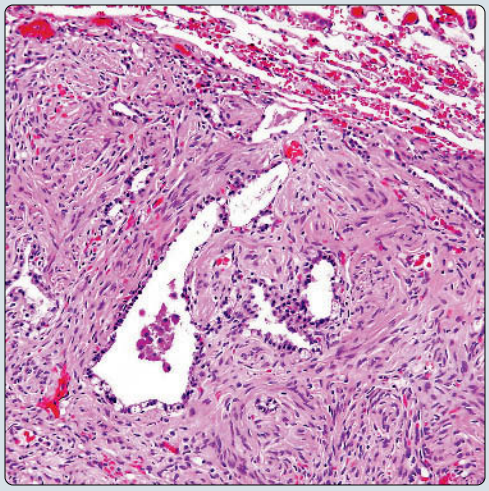

(Left) *Histologic appearance of benign metastasizing leiomyoma to the lung shows a well-circumscribed nodule composed of fascicles of bland-appearing smooth muscle cells.* **(Right)** *Higher magnification of benign metastasizing leiomyoma of the lung shows fascicles of spindle cells that are cut at right angles. Notice the bland appearance of the spindle cells, which are devoid of mitotic activity.*

TERMINOLOGY

Abbreviations

- Benign metastasizing leiomyoma (BML)

Definitions

- Benign smooth muscle proliferation of lung arising in women with history of previously resected uterine leiomyoma

ETIOLOGY/PATHOGENESIS

Pathogenesis

- Remote implantation of benign cells released into circulation during surgery
- True metastases from very low-grade, well-differentiated leiomyosarcomas
- Recent studies have demonstrated clonal origin by molecular-genetic analysis

CLINICAL ISSUES

Epidemiology

- Incidence
  - Very rare condition
- Age
  - 30-50 years of age
- Sex
  - Exclusively observed in women

Site

- No site predilection in lungs
- Lesions are usually multiple and may be bilateral, suggesting metastatic disease

Presentation

- Mostly asymptomatic and discovered incidentally on chest x-rays

Natural History

- Lesions may regress spontaneously or following hormonal manipulation
- Growth of nodules typically ceases with onset of menopause
- Nodules may be discovered after removal of uterine leiomyomas or concurrent with them

Treatment

- Surgical approaches
  - Nodulectomy or lobectomy, depending on size of lesion
- Hormonal therapy

Prognosis

- Excellent prognosis following surgery

MACROSCOPIC

General Features

- Well-circumscribed, tan-white nodule
- Whorled, homogeneous, rubbery tissue that bulges above cut surface
- No evidence of hemorrhage or necrosis

Size

- Nodules range from small (3 mm in diameter) to large (> 5 cm in greatest diameter)

MICROSCOPIC

Histologic Features

- Fascicles of monotonous, bland-appearing spindle cells
- Spindle cell fascicles may appear cut at right angles
- Lesions may entrap normal respiratory mucosa and airspaces at periphery of lesions (adenomyomatous hamartoma)

Cytologic Features

- Spindle cells have blunt-ended nuclei showing dispersed chromatin pattern and small or inconspicuous nucleoli
- No evidence of nuclear pleomorphism, mitoses, or tumor cell necrosis

ANCILLARY TESTS

Immunohistochemistry

- Spindle cells are positive for SMA, desmin, calponin, and H-caldesmon
  - Negative for other differentiation markers, including cytokeratins, EMA, and S100 protein
  - Positive for Bcl-2 (feature shared with müllerian-derived smooth muscle)
  - Expression of estrogen and progesterone receptors

DIFFERENTIAL DIAGNOSIS

Solitary Fibrous Tumor

- Bland spindle cell proliferation characterized by rope-like linear deposition of stromal collagen within tumor
- Prominent hemangiopericytic, herringbone, and storiform patterns
- Tumor cells are positive for CD34, CD99, and Bcl-2 and are negative for SMA, desmin, and calponin

Schwannoma

- Bland spindle cell proliferation with focal palisading of nuclei (Verocay bodies) and degenerative stromal changes
- Prominent perivascular hyalinization and cystic/myxoid changes
- Tumor cells are strongly positive for S100 protein and negative for smooth muscle markers

Metastatic Low-Grade Leiomyosarcoma

- Spindle cell proliferation with mild to moderate cytologic atypia and nuclear pleomorphism
- Mitotic activity
- History of leiomyosarcoma of soft tissue or other location

SELECTED REFERENCES

1. Miller J et al: Benign metastasizing leiomyomas to the lungs: an institutional case series and a review of the recent literature. Ann Thorac Surg. 101(1):253-8, 2016
2. Nuovo GJ et al: Benign metastasizing leiomyoma of the lung: clinicopathologic, immunohistochemical, and micro-RNA analyses. Diagn Mol Pathol. 17(3):145-50, 2008
3. Nucci MR et al: Distinctive cytogenetic profile in benign metastasizing leiomyoma: pathogenetic implications. Am J Surg Pathol. 31(5):737-43, 2007

Scanning Magnification

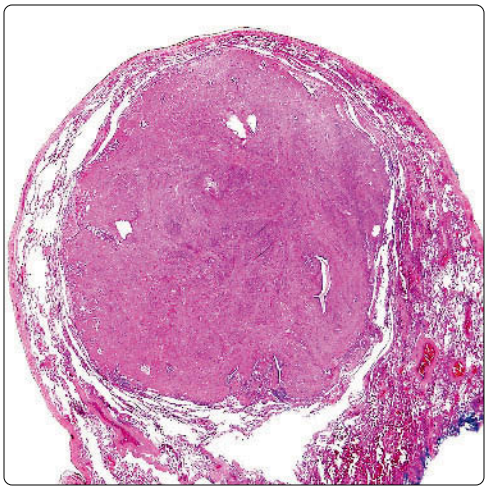

Unencapsulated Tumor Nodule

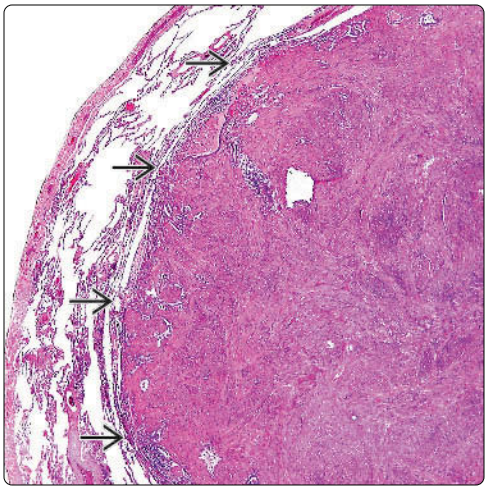

(Left) *Scanning magnification of a small lung nodule with benign metastasizing leiomyoma shows a well-circumscribed, intraparenchymatous nodule that is completely surrounded by normal pulmonary parenchyma.* **(Right)** *Higher magnification of benign metastasizing leiomyoma of the lung shows a well-circumscribed but unencapsulated tumor nodule ⇨ sharply demarcated from the surrounding lung parenchyma. No evidence of hemorrhage or necrosis is identified.*

Higher Magnification

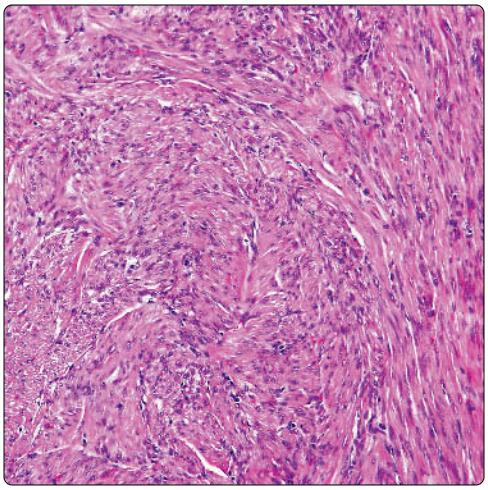

Stromal Hyalinization

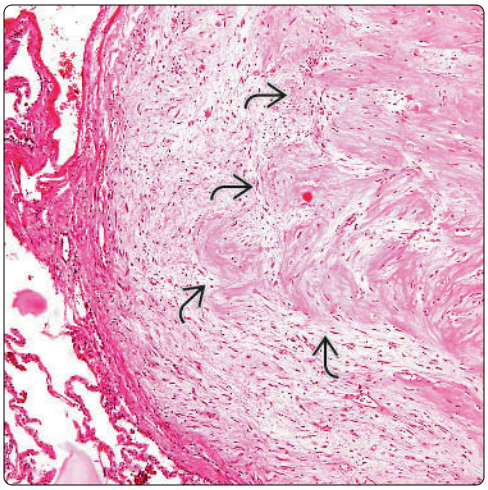

(Left) *Higher magnification of benign metastasizing leiomyoma of the lung shows a bland-appearing spindle cell proliferation displaying a fascicular architecture with fascicles that intersect at right angles.* **(Right)** *Benign metastasizing leiomyoma of the lung shows focal myxoid stromal changes and areas of stromal hyalinization ⇨. Occasional cases of benign metastasizing leiomyoma can display such changes, simulating a benign peripheral nerve sheath tumor.*

Entrapped Glands

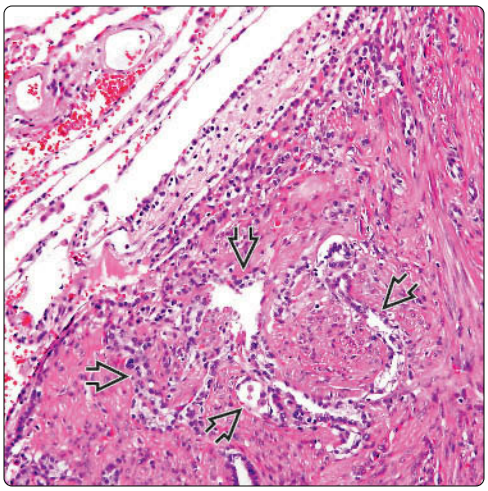

Entrapped Glands: High Power

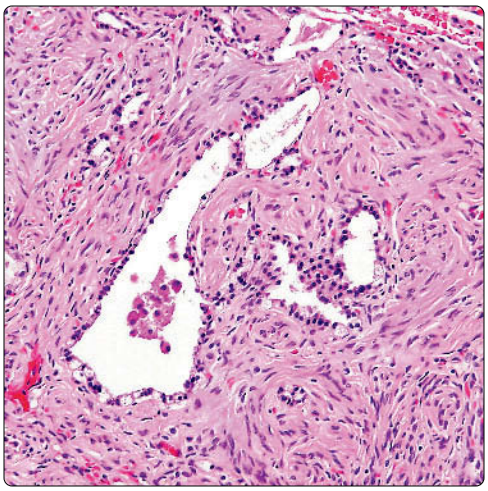

(Left) *Entrapment of glands ⇨ is seen at the periphery of this benign metastasizing leiomyoma to the lung. Cases showing these features have been designated as benign metastasizing adenomyoma or adenomyomatous hamartoma.* **(Right)** *Higher magnification from benign metastasizing adenomyoma shows entrapped glandular structures. The entrapped glandular epithelial structures are usually distributed along the periphery but may also be located deeper within the lesion.*

Smooth Muscle Nodule

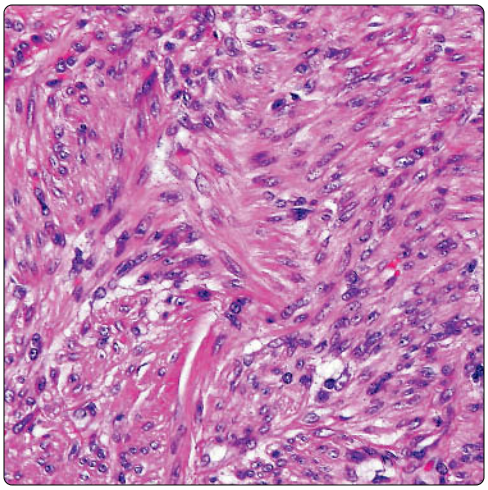

Higher Magnification

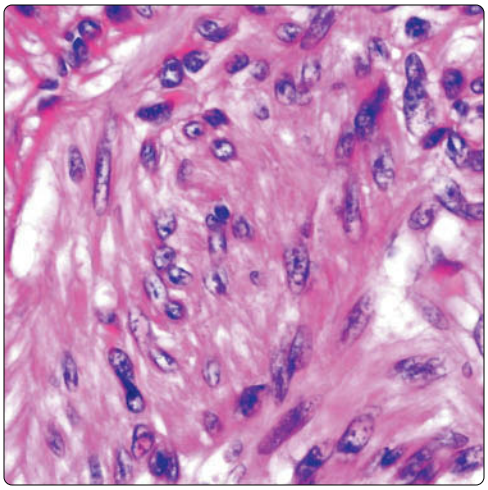

(Left) *Higher magnification of benign metastasizing leiomyoma of the lung shows a fascicular proliferation of bland-appearing spindle cells. The cells are devoid of nuclear pleomorphism, cytologic atypia, or mitotic activity. Presence of any of the above features should prompt consideration of a leiomyosarcoma.* **(Right)** *Higher magnification of a benign metastasizing leiomyoma to the lung shows bland-appearing spindle cells with oval to spindle nuclei and fibrillary cytoplasm.*

Smooth Muscle Actin

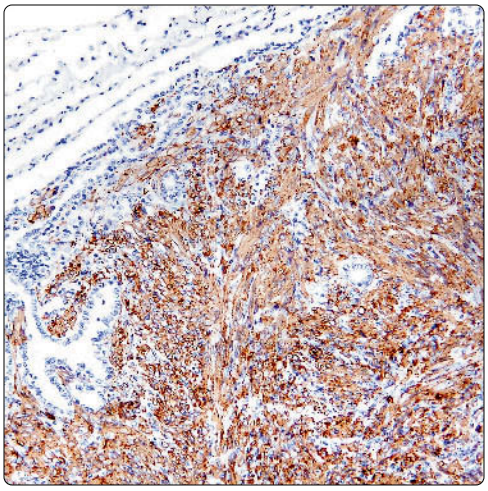

Progesterone Receptors

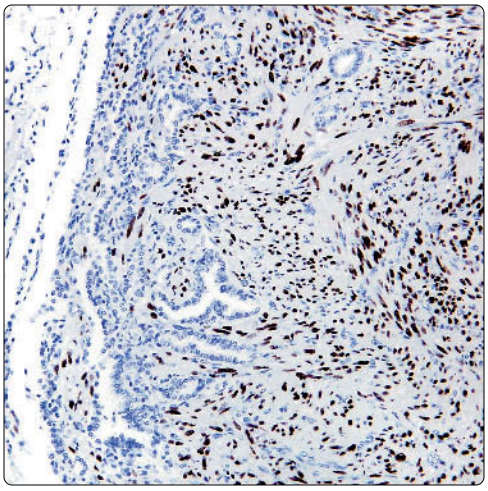

(Left) *Immunohistochemical staining for SMA shows strong positivity of the spindle tumor cells in this example of benign metastasizing leiomyoma to the lung.* **(Right)** *Immunohistochemical staining for PR in benign metastasizing leiomyoma of the lung shows strong nuclear positivity in the majority of spindle cells. Staining for estrogen and progesterone receptors is a characteristic feature of these tumors.*

Calponin Stain

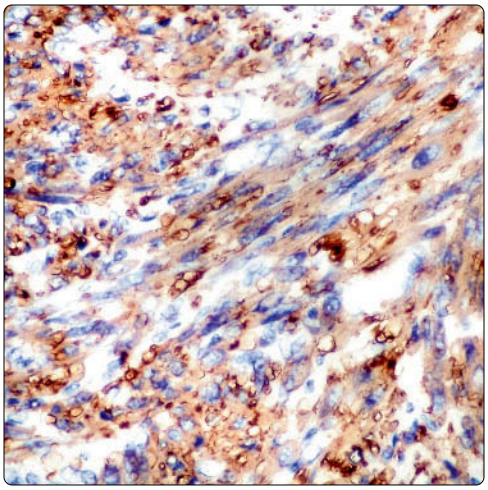

Bcl-2 Immunostaining

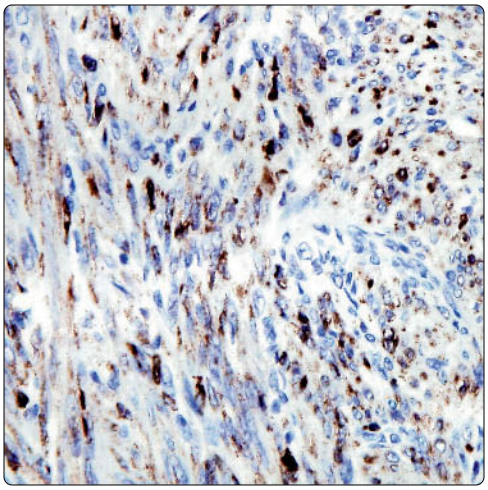

(Left) *Immunohistochemical staining for calponin shows strong cytoplasmic positivity for this antigen in benign metastasizing leiomyoma of the lung.* **(Right)** *Immunohistochemical staining for Bcl-2 oncogene shows positive staining for this antigen in many of the spindle tumor cells. Bcl-2 positivity is a feature of müllerian-derived (female genital) smooth muscle neoplasms that is not shared with other types of smooth muscle tumors in which Bcl-2 positivity is quite limited or absent.*

Metastatic Carcinoma

KEY FACTS

ETIOLOGY/PATHOGENESIS

- Majority of lung metastases occur via hematogenous route by spread through general circulation
- Malignant tumors may also reach lung through lymphatic dissemination

CLINICAL ISSUES

- Cough, chest pain, dyspnea, hemoptysis, and pleural effusion are most common presenting symptoms
- Most common primary sites: Genital, GI and GU tracts, pancreatohepatobiliary tract, head and neck

IMAGING

- Most common locations are lower lobes in subpleural distribution
- May vary from microscopic nodules to large nodules > 5 cm in diameter
- Lesions are most commonly multiple and of varying sizes
- Solitary coin lesion can be present in up to 9% of cases

MACROSCOPIC

- Multiple bilateral nodules most commonly in peripheral, subpleural areas of lower lobes

MICROSCOPIC

- Tumor nodule formation composed of glandular or papillary structures, squamous islands, or poorly differentiated sheets of cells
- Bronchioloalveolar (lepidic) pattern of growth with neoplastic cells lining alveolar spaces
- Endobronchial pattern of growth with polypoid tumor mass filling bronchial lumen
- Miliary pattern of growth with diffuse, small (< 0.5 cm) nodules diffusely studding lung parenchyma
- Lymphangitis carcinomatosa pattern characterized by plugging of peribronchial lymphatics by tumor cells

Schematic Representation

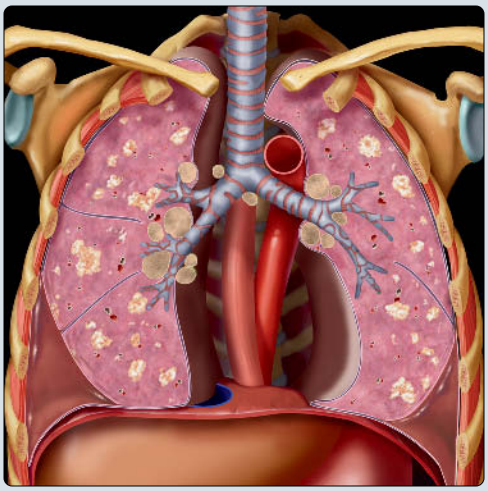

Metastases to Lung

(Left) *Graphic shows metastatic carcinoma in the lung. Note the higher density of metastases distributed in the subpleural areas of the lungs.* **(Right)** *Gross appearance of metastatic adenocarcinoma to the lung shows the pleural surface studded by multiple nodules of varying sizes. Notice central umbilication in some of the tumor nodules.*

Solid Nodule

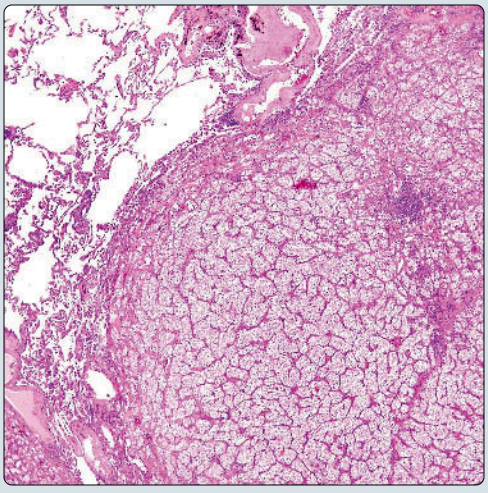

Lymphangitic Spread

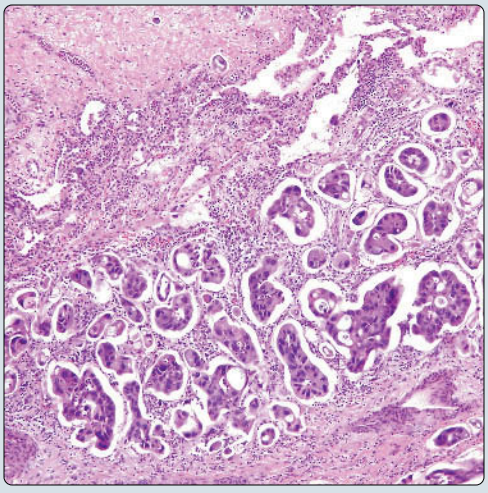

(Left) *Histologic appearance of a metastasis from clear cell renal cell carcinoma to the lung shows a well-demarcated solid nodule composed of nests of large cells with abundant clear cytoplasm.* **(Right)** *Prominent lymphangitic spread of metastatic carcinoma of the ovary to the lung is seen in this example in which peribronchial lymphatics are distended by multiple tumor emboli.*

TERMINOLOGY

Definitions

- Tumor nodules appearing in lung as result of spread from another primary site

ETIOLOGY/PATHOGENESIS

Metastatic Models

- Majority of lung metastases occur via hematogenous route by spread through general circulation
- Malignant tumors may also reach lung through lymphatic dissemination
- Less common mechanism of spread to lung involves large vessel tumor emboli, especially via pulmonary artery (liver and renal cancer)

CLINICAL ISSUES

Presentation

- Cough, chest pain, dyspnea, hemoptysis, pleural effusion
- Cor pulmonale and pulmonary hypertension
- Most common primary sites: Genital, GI and GU tracts, pancreatohepatobiliary tract, head and neck

Treatment

- Surgical approaches
  - Solitary metastatic nodules may respond well to excision
- Adjuvant therapy
  - Chemotherapy and radiation therapy are used for palliation of symptoms in advanced cases

Prognosis

- Generally poor but may vary based on type of tumor, grade, and presence of other metastatic lesions
- Patients with late metastases from low-grade indolent tumors (such as adenoid cystic carcinoma of salivary gland) may have good survival

IMAGING

General Features

- Location
  - Most common locations are lower lobes in subpleural distribution
- Size
  - May vary from microscopic nodules to large nodules > 5 cm in diameter
- Morphology
  - Lesions are most commonly multiple and of varying sizes
  - Solitary coin lesion can be present in up to 9% of cases
  - Rounded contour is most likely to be associated with metastasis as opposed to spiculated appearance of primary lung cancer

CT Findings

- CT is best imaging tool to characterize pattern and spread of disease

MACROSCOPIC

General Features

- Multiple bilateral nodules of various sizes, most commonly in peripheral, subpleural areas in lower lobes
- Endobronchial metastases may be polypoid and fill lumen of affected bronchus
- Miliary pattern of metastases may resemble miliary tuberculosis
- Pleural nodules show characteristic central umbilication

MICROSCOPIC

Histologic Features

- Histologic patterns of growth
  - Tumor nodule formation composed of glandular or papillary structures, squamous islands, or poorly differentiated sheets of cells
  - Bronchioloalveolar (lepidic) pattern of growth with neoplastic cells lining alveolar spaces
  - Endobronchial pattern of growth with polypoid tumor mass filling bronchial lumen
  - Miliary pattern of growth with diffuse, small (< 0.5 cm) nodules diffusely studding lung parenchyma
  - Lymphangitis carcinomatosa pattern characterized by microscopic plugging of peribronchial lymphatics by tumor cells

Cytologic Features

- May vary depending on type of tumor and degree of differentiation
  - Cells may be mucinous, clear, oncocytic, granular, signet ring, hobnailed, pleomorphic, or spindled

ANCILLARY TESTS

Immunohistochemistry

- Primary lung carcinomas are usually TTF-1 positive, CK7 positive, and CK20 negative
  - TTF-1 may be negative in up to 40% of pulmonary primary tumors
  - Other tumors can also express CK7, including GI primary tumors, renal cell carcinomas, gynecologic neoplasms, and bladder carcinoma
- Certain specific antibodies can be of value in identifying source of primary lesion, including
  - PSA and PSAP for prostate cancer
  - CDX-2 for GI tract primary cancers (colon, rectum, pancreas, biliary tract, etc.)
  - Hepar-1 for hepatocellular carcinoma
  - Thyroglobulin for thyroid carcinoma
  - RCC antigen for renal cell carcinoma
  - Villin surface protein for colorectal cancer
  - WT1 for serous papillary carcinoma of ovary
  - Mammaglobin, ER, and PR for breast cancer

DIFFERENTIAL DIAGNOSIS

Colorectal Carcinoma

- Immunohistochemistry for CDX-2 and CD20 are positive
- Dirty necrosis, mucinous features, and cribriform growth pattern are commonly seen
- Stains for TTF-1 are always negative

Renal Cell Carcinoma

- Sheets and islands of clear cells with abundant cytoplasm
- Blood lakes (pools of red blood cells) are commonly present in center of tumor cell islands

Immunohistochemistry

Antibody	Reactivity	Staining Pattern	Comment
Primary Lung Carcinoma			
TTF-1	Positive	Nuclear	Positive in > 75% of cases, mostly in adenocarcinoma
CK 7	Positive	Cytoplasmic	Positive in 97% of cases
P63	Positive	Nuclear	Positive in squamous cell carcinomas
CK20	Negative	Cytoplasmic	Positive in rare mucinous primaries only
Colorectal Carcinoma			
CK20	Positive	Cytoplasmic	Positive in 89% of cases
CDX-2	Positive	Nuclear	Positive in 91% of cases
TTF-1	Negative	Nuclear	May be positive in 2% of cases
CK 7	Negative	Cytoplasmic	May be positive in 13% of cases
Breast Carcinoma			
CK 7	Positive	Cytoplasmic	Positive in 93% of cases
TTF-1	Negative	Nuclear	Positive in no cases
ERP	Positive	Nuclear	Positive in 70% of cases; non-small cell lung cancer can be positive if 6F11 clone used
CK20	Negative	Cytoplasmic	May be positive in 4% of cases
Thyroid Carcinoma			
TTF-1	Positive	Nuclear	Positive in 98% of cases
CK 7	Positive	Cytoplasmic	Positive in 100% of cases
THYROGLOB	Positive	Cytoplasmic	Positive in 89% of cases
CK20	Negative	Cytoplasmic	Positive in no cases
Renal Cell Carcinoma			
RCC	Positive	Cytoplasmic	Positive in 78% of cases but very inconsistent antibody
TTF-1	Negative	Nuclear	Positive in no cases
CK 7	Negative	Cytoplasmic	May be positive in 15% of cases
CK20	Negative	Cytoplasmic	May be positive in 2% of cases
Prostatic Carcinoma			
PSA	Positive	Cytoplasmic	Positive in 89% of cases
TTF-1	Negative	Nuclear	May be positive in 16% of cases
CK 7	Negative	Cytoplasmic	Positive in no cases
CK20	Negative	Cytoplasmic	May be positive in 22% of cases

- Usually show low-grade nuclear features but may exhibit sarcomatoid features

Pancreatic or Biliary Adenocarcinoma

- Commonly associated with stromal desmoplasia and mucinous features
- Immunohistochemistry is helpful because tumors are negative for TTF-1 and positive for CDX-2

Endometrial Adenocarcinoma

- Subnuclear vacuolization, cribriform pattern, and squamoid morules are often present
- Tumor cells are positive for ER/PR and negative for TTF-1

DIAGNOSTIC CHECKLIST

Clinically Relevant Pathologic Features

- Clinical history of previous tumor elsewhere is indispensable for proper diagnosis
- Comparison of lung lesion with histology of previous tumors is also of critical importance for definitive diagnosis
- Correlation with endoscopic and imaging studies is critical to rule out occult malignancy

Pathologic Interpretation Pearls

- Multiple and bilateral nodules in lower lobes
- Immunohistochemistry is most useful ancillary technique
  - Clinicopathologic correlation should always be carried out regardless of results of immunohistochemical stains

SELECTED REFERENCES

1. Agolli L et al: Lung metastases treated with stereotactic ablative radiation therapy in oligometastatic colorectal cancer patients: outcomes and prognostic factors after long-term follow-up. Clin Colorectal Cancer. ePub, 2016
2. Jagirdar J: Application of immunohistochemistry to the diagnosis of primary and metastatic carcinoma to the lung. Arch Pathol Lab Med. 132(3):384-96, 2008

Metastasis of Breast Carcinoma

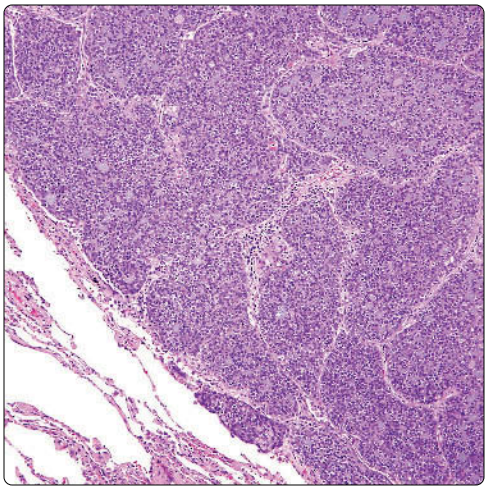

Metastasis of Ovarian Carcinoma

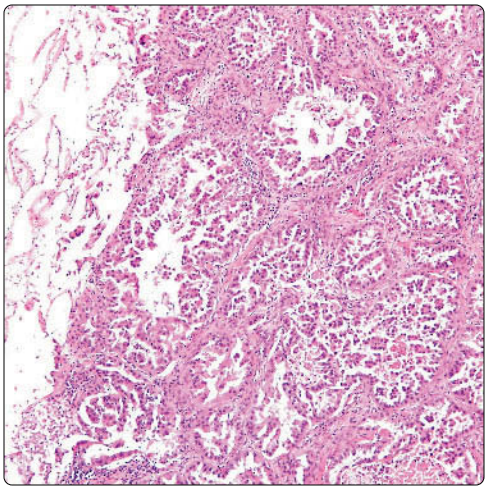

(Left) *Solid pattern of growth in a lung metastasis from a poorly differentiated carcinoma of the breast shows irregular islands composed of a compact population of poorly differentiated tumor cells without glandular or other type of differentiation.* **(Right)** *Solid pattern of metastasis to the lung from an adenocarcinoma of the ovary shows a papillary pattern of growth. The tumor is sharply demarcated from the surrounding lung parenchyma and contains numerous papillary and micropapillary structures.*

Metastasis With Lepidic Growth Pattern

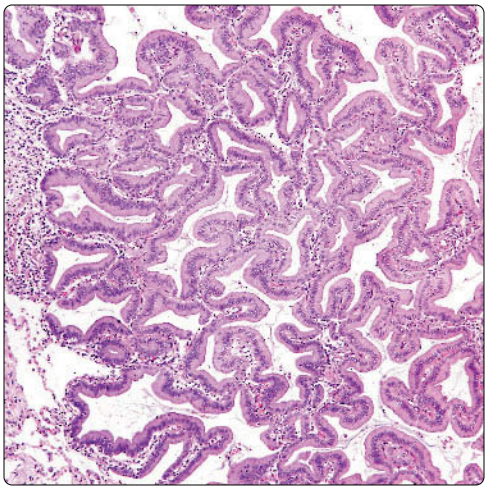

Miliary Pattern

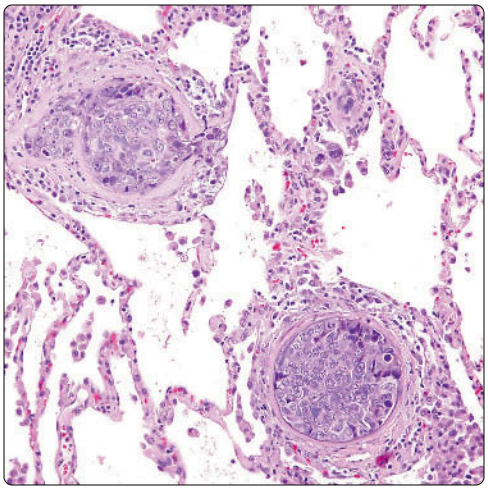

(Left) *Lepidic pattern of growth in metastatic carcinoma of the pancreas to the lung shows mucinous cells extending along the alveolar walls. Tumors with these features can be confused for the mucinous variant of bronchioloalveolar cell carcinoma.* **(Right)** *Metastatic carcinoma of the breast to the lung with miliary pattern shows microscopic tumor nests scattered throughout lung parenchyma. The clinical and radiologic presentation in these cases resembles that of interstitial lung disease.*

Lymphangitis Carcinomatosa

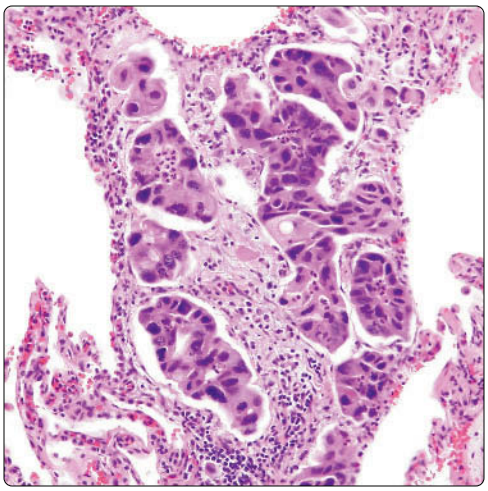

Lymphangitic Spread

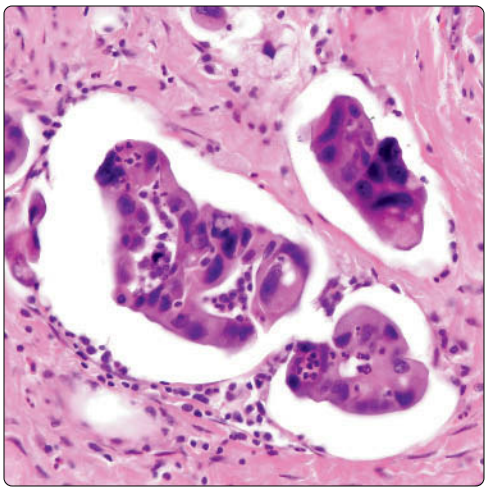

(Left) *Scanning magnification in lymphangitis carcinomatosa shows emboli of tumor cells from ovarian carcinoma distributed along lymphatic routes in the lung. The clinical and radiographic presentation in these cases simulate an interstitial lung process.* **(Right)** *High magnification of lymphangitic pattern of spread in metastatic ovarian carcinoma to the lung shows clusters of atypical tumor cells lying free within the lumen of dilated lymphatics.*

Metastatic Colonic Adenocarcinoma

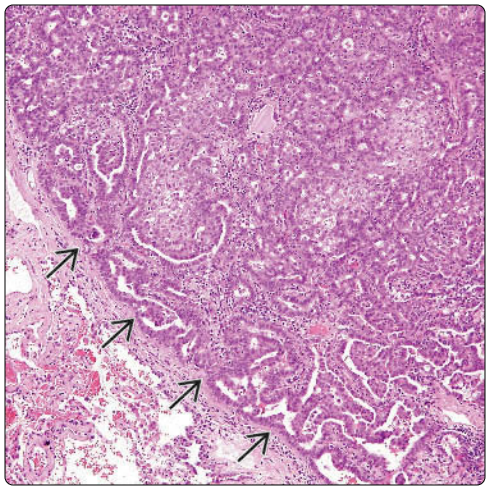

Cribriform Glandular Architecture

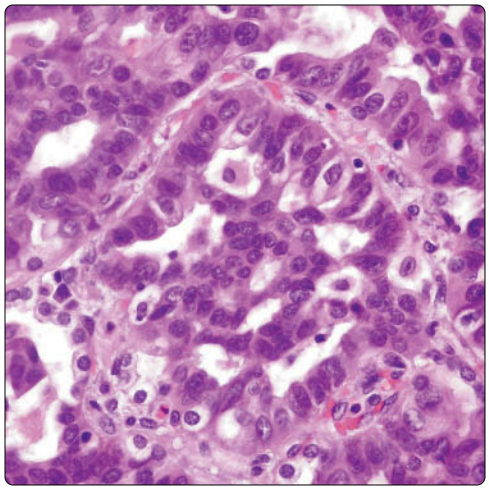

(Left) *Scanning magnification of a lung nodule in metastatic carcinoma of the colon shows a well-circumscribed tumor mass with glandular, solid, and cribriform areas. Notice the sharp circumscription from the surrounding lung parenchyma.* **(Right)** *Higher magnification of a lung metastasis from a colon adenocarcinoma shows prominent cribriform arrangement of glands, a feature that is often observed in carcinomas of colonic origin but is very unusual in primary lung cancer.*

Metastatic Colonic Adenocarcinoma

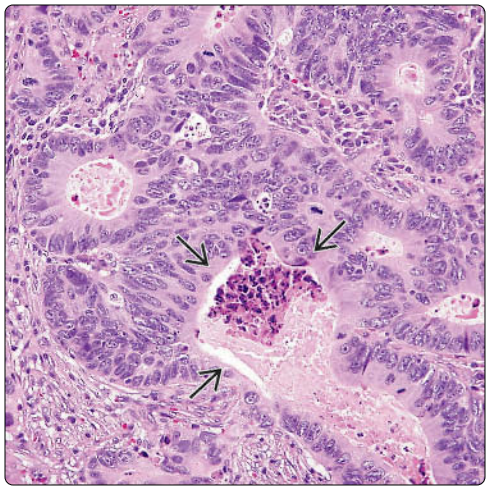

CDX-2 Immunostaining

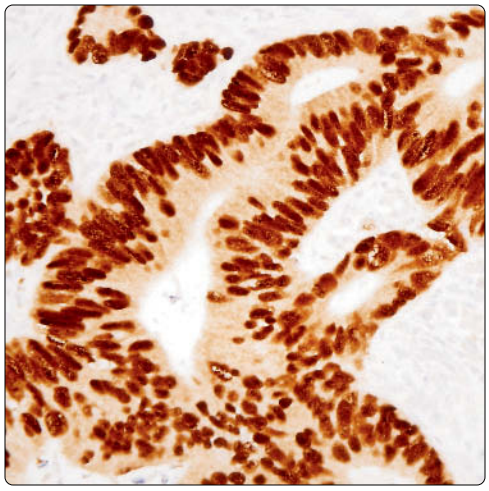

(Left) *Metastasis of colonic adenocarcinoma to the lung shows a focus of "dirty" necrosis in the center of a gland. The necrosis is composed of nuclear debris admixed with inflammatory cells and fibrinous exudate.* **(Right)** *Immunohistochemical staining for CDX-2 antibody in metastatic colonic adenocarcinoma shows strong nuclear staining of the tumor cells. CDX-2 is a transcription factor that is highly expressed in colon carcinoma but not in lung cancer.*

TTF-1 Immunostaining

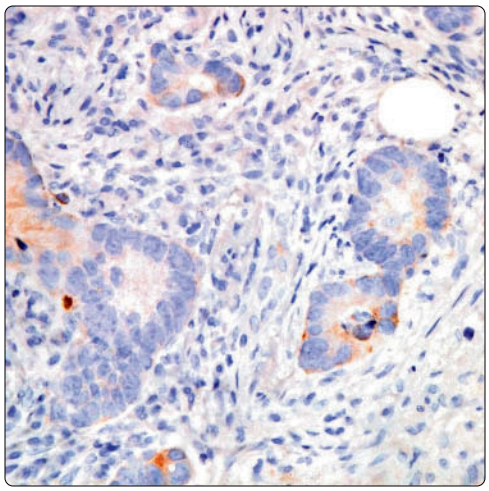

CK20 Immunostaining

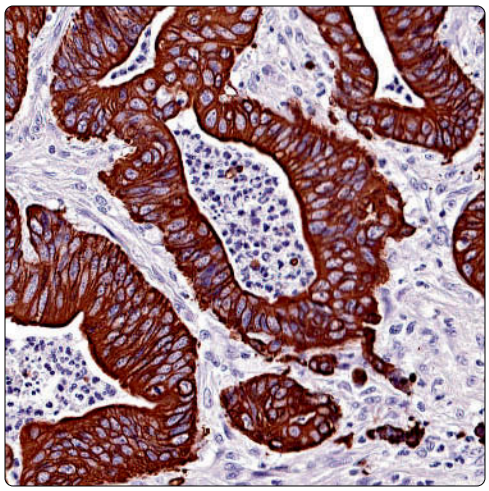

(Left) *Immunohistochemical staining of colon adenocarcinoma metastasis to the lung with TTF-1 antibody shows a negative reaction in the tumor cells. TTF-1 is highly specific and sensitive for primary lung adenocarcinoma.* **(Right)** *Immunohistochemical staining of metastatic adenocarcinoma of the colon to the lung with CK20 shows strong positivity in the tumor cells. CK20 is preferentially expressed in colonic adenocarcinoma. Stains for CK7 in the pictured tumor were negative.*

Metastatic Breast Carcinoma

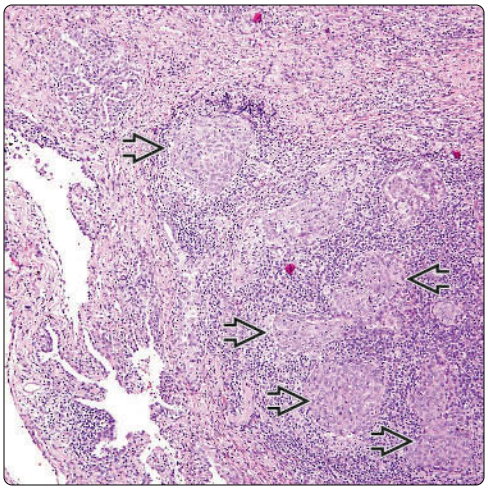

Metastatic Breast Carcinoma

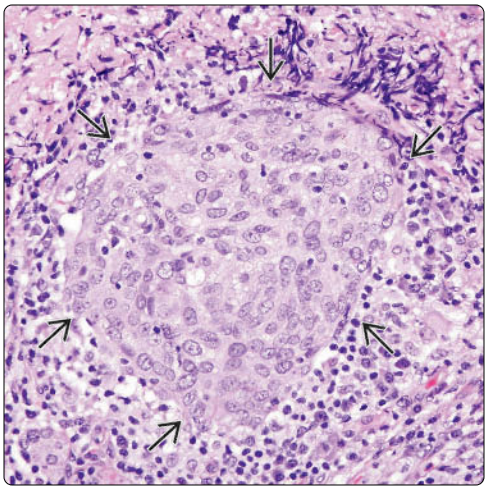

(Left) *Scanning magnification of a lung metastasis from a breast carcinoma shows ill-defined nodules ⇨ adjacent to dilated bronchial spaces that are surrounded by heavy lymphocytic infiltrates.* **(Right)** *Higher magnification of a small nodule of a metastatic breast carcinoma to the lung shows a compact population of epithelioid cells ⇨ surrounded by dense lymphoid stroma. Evaluation of such cases in the absence of a pertinent history can be extremely difficult.*

CK5/6 Immunostaining

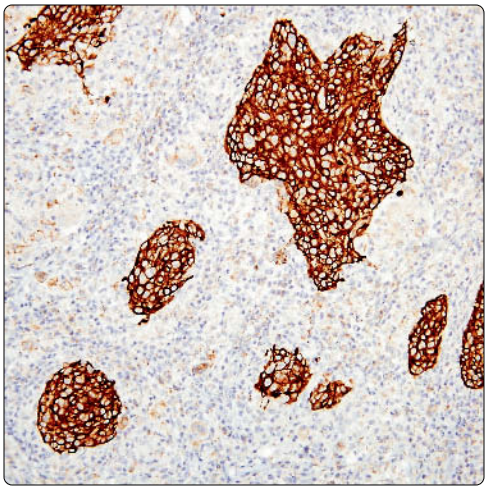

CK7 Immunostaining

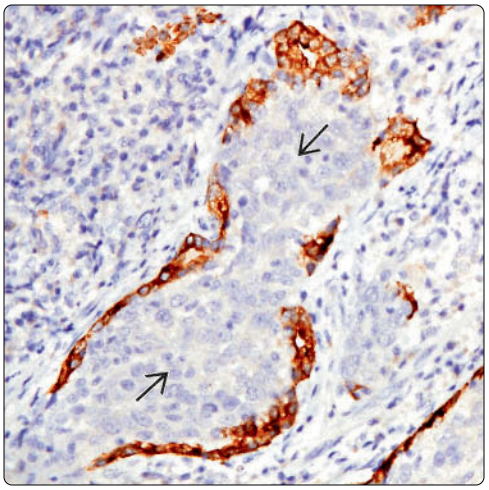

(Left) *Immunohistochemical staining of a metastatic carcinoma of the breast to the lungs with CK5/6 shows strong positivity in the islands of tumor cells. This marker is strongly positive in > 85% of breast cancers.* **(Right)** *Immunohistochemical staining for CK7 in a metastatic carcinoma of the breast to the lung shows strong positivity of residual entrapped respiratory epithelium surrounding the tumor cell island ⇨. CK20 was also negative in the tumor cells in this case.*

TTF-1 Immunostaining

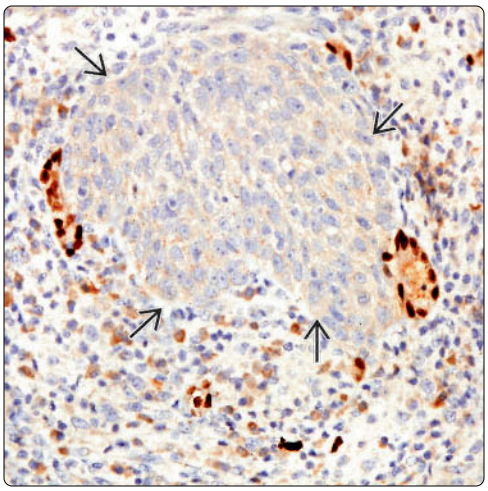

Estrogen Receptor Immunostaining

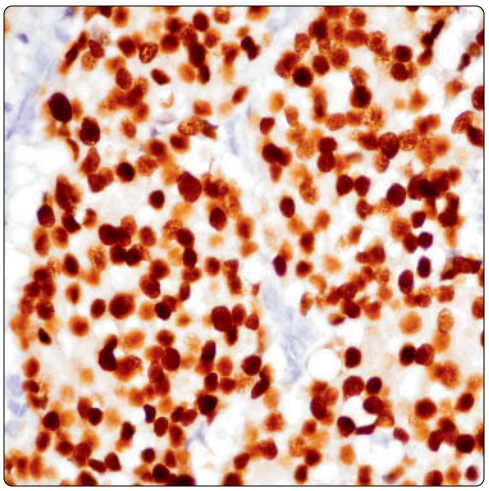

(Left) *Immunohistochemical staining for TTF-1 in metastatic breast cancer to the lung shows strong nuclear positivity in a few small residual airspaces entrapped at the periphery of a metastatic tumor cell island ⇨. TTF-1 is a transcription factor expressed in lung epithelial cells but not in breast cancer.* **(Right)** *Immunohistochemical staining of metastatic breast cancer to the lung for estrogen receptors shows strong nuclear positivity for this antibody. The primary tumor was also positive.*

Metastatic Renal Cell Carcinoma

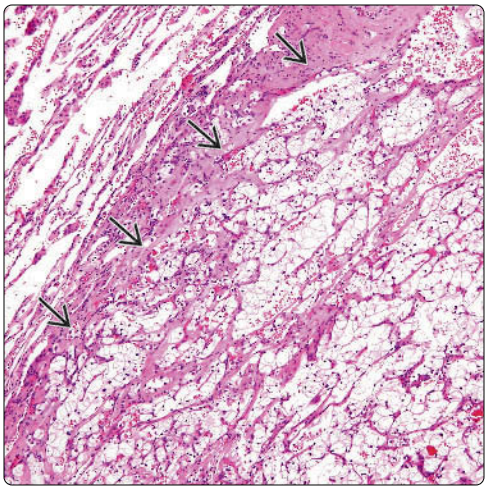

Renal Cell Carcinoma: High Power

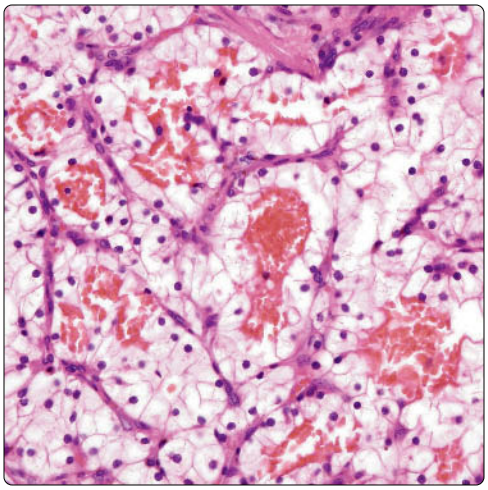

(Left) *Scanning magnification of a lung nodule due to metastatic clear cell renal cell carcinoma shows a sharply demarcated tumor composed of nests of cells with abundant clear cytoplasm.* **(Right)** *Higher magnification of metastatic renal cell carcinoma to the lung shows nests of large tumor cells with abundant clear cytoplasm and small hyperchromatic nuclei. Notice "pools" of blood in the center of the tumor cell nests. Intratumoral hemorrhage is a common feature of these tumors.*

AE1/AE3 Immunostaining

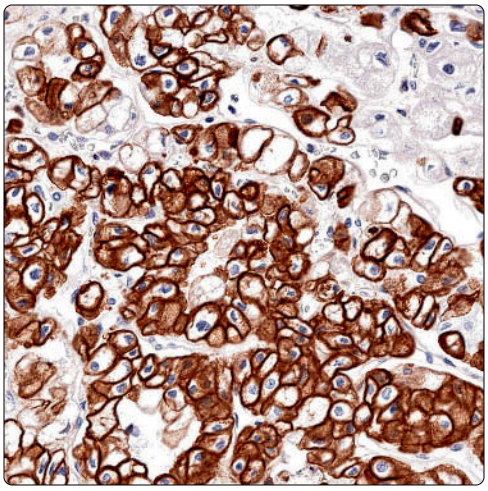

EMA Immunostaining

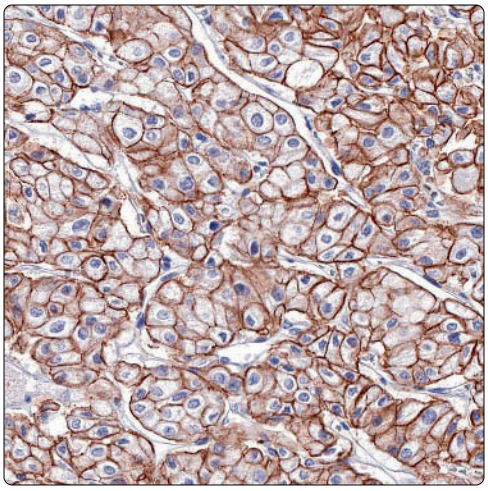

(Left) *Immunohistochemical staining of metastatic clear cell renal cell carcinoma to the lung shows strong cytoplasmic positivity for broad-spectrum cytokeratin AE1/AE3. These tumors react with low-molecular weight cytokeratins but are usually negative for CK7 and CK20.* **(Right)** *Lung metastasis of a renal cell carcinoma shows consistent positivity of the tumor cells for EMA. The tumors also react with vimentin, CD10, pax-2, and pax-8 antibodies.*

Sarcomatoid Renal Cell Carcinoma

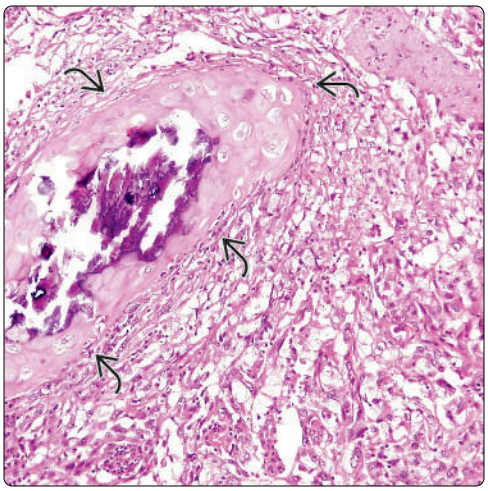

Sarcomatoid Renal Cell Carcinoma

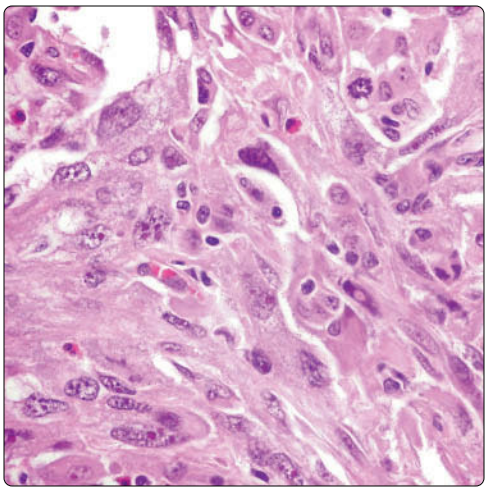

(Left) *Metastatic renal cell carcinoma to the lung with sarcomatoid features shows entrapment of residual bronchial cartilage by pleomorphic and spindle tumor cells. These tumors can be very difficult to distinguish from a spindle cell sarcoma. Identification of cytoplasmic positivity for cytokeratins and a history of previous kidney tumor are indispensable for diagnosis.* **(Right)** *Pleomorphic and spindle cells are seen in this lung metastasis of sarcomatoid renal cell carcinoma.*

Metastatic Papillary Thyroid Carcinoma

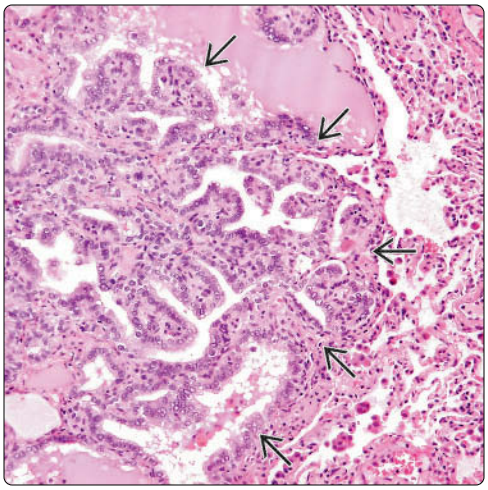

Clear Nuclear Features

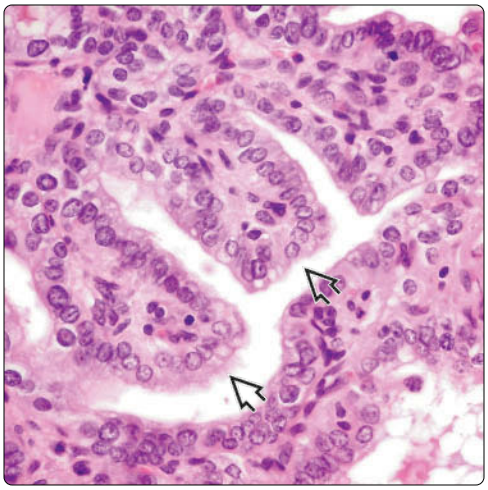

(Left) *Scanning magnification of metastatic papillary thyroid carcinoma to the lung shows proliferation of epithelial cells forming papillary structures ⇨ separated from the surrounding lung parenchyma.* **(Right)** *Higher magnification of a metastasis to the lung of a papillary thyroid carcinoma shows small finger-like papillary structures ⇨. The papillae are lined by a single layer of cells with oval to round nuclei with clearing of the nuclear chromatin.*

Longitudinal Grooves

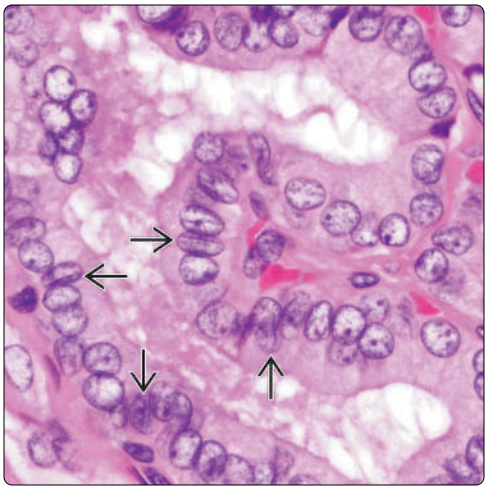

Lepidic Pattern of Metastasis

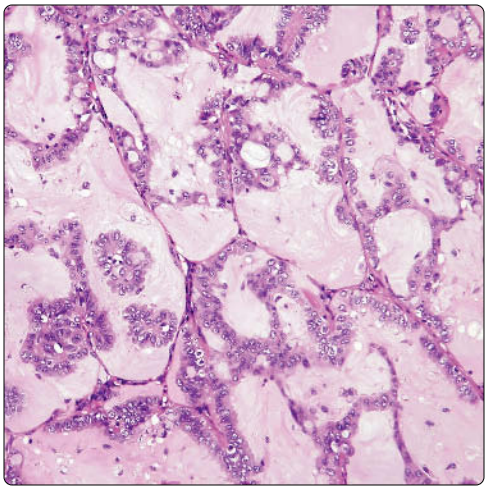

(Left) *Higher magnification of pulmonary metastasis from a papillary thyroid carcinoma shows characteristic nuclear features, including enlargement of nuclei, prominent clearing of the nuclear chromatin with margination to the periphery, and occasional longitudinal nuclear grooves ⇨.* **(Right)** *Striking lepidic pattern of growth is seen in this pulmonary metastasis of papillary thyroid carcinoma resembling a bronchioloalveolar cell carcinoma.*

TTF-1 Immunostaining

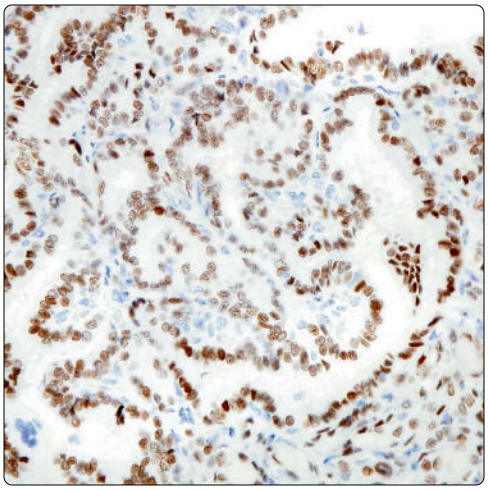

Thyroglobulin Immunostaining

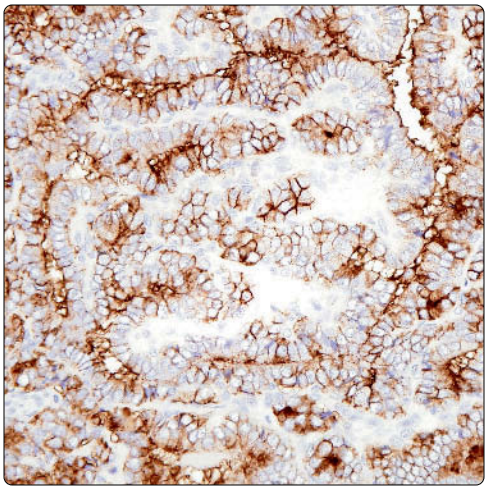

(Left) *Immunohistochemical staining for TTF-1 in a pulmonary metastasis of a papillary thyroid carcinoma shows strong nuclear positivity. This antibody needs to be used in conjunction with NAPSIN-A and thyroglobulin for definitive diagnosis.* **(Right)** *Immunohistochemical staining of metastatic papillary thyroid carcinoma to the lung with thyroglobulin antibodies shows cytoplasmic positivity in the tumor cells, supporting the diagnosis of papillary thyroid carcinoma.*

Metastatic Adenocarcinoma of Cervix

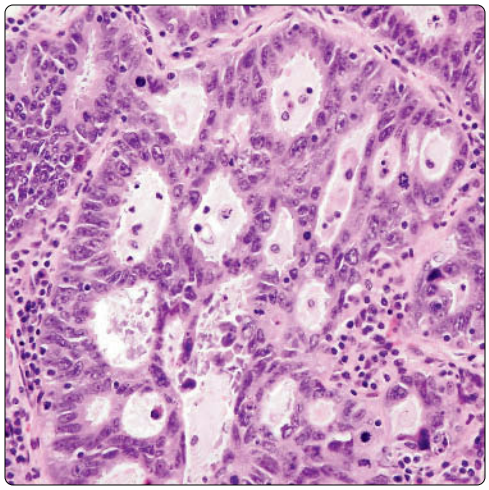

Metastatic Endometrial Adenocarcinoma

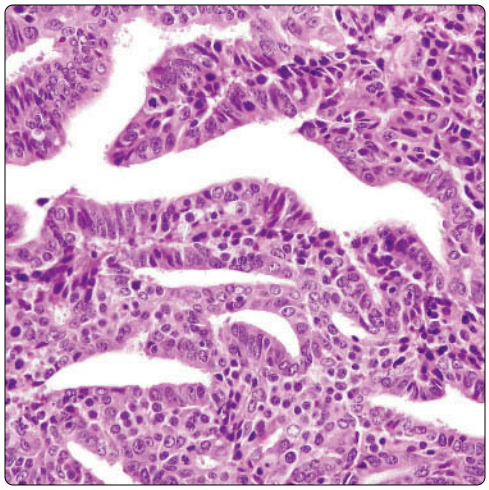

(Left) *Metastatic adenocarcinoma of the endocervix shows a cribriform pattern of growth. Tumors with these features can resemble primary lung adenocarcinoma; however, they are negative for TTF-1 and show strong nuclear positivity for p16 and monoclonal CEA.* **(Right)** *Metastasis of endometrial adenocarcinoma to the lung shows atypical glandular structures separated by inflammatory stroma. These tumors express CK7, ER/PR, and vimentin but are negative for TTF-1.*

Metastatic Serous Carcinoma of Ovary

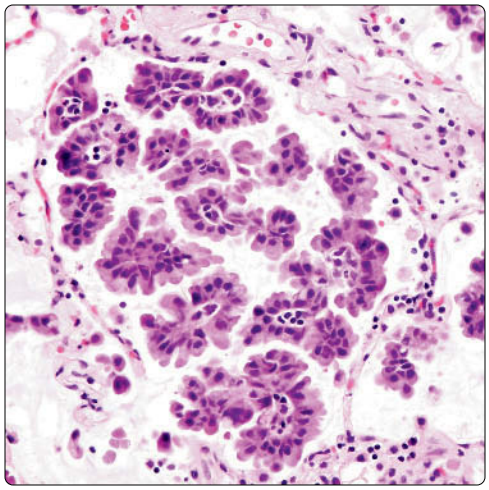

Psammoma Body

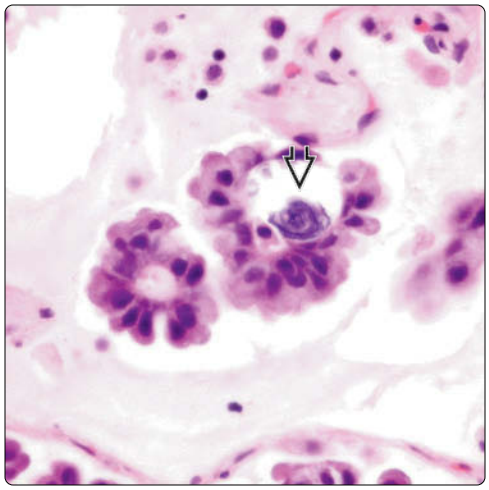

(Left) *Metastasis of serous papillary carcinoma of the ovary to the lung shows papillary structures lying within the lumen of a distended alveolus and lined by atypical cells with hyperchromatic nuclei. These tumors are usually strongly positive for WT1 and also stain for ER/PR antibodies.* **(Right)** *Higher magnification in a lung metastasis from a serous papillary carcinoma of the ovary shows micropapillary structures. Notice the psammoma body at the base of the papilla ⇨.*

Metastatic Urothelial Carcinoma

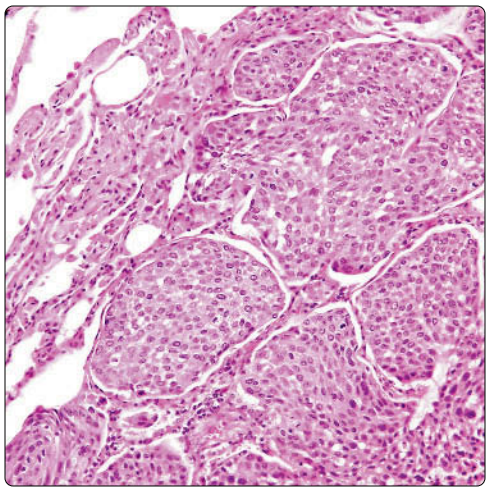

Metastatic Prostate Adenocarcinoma

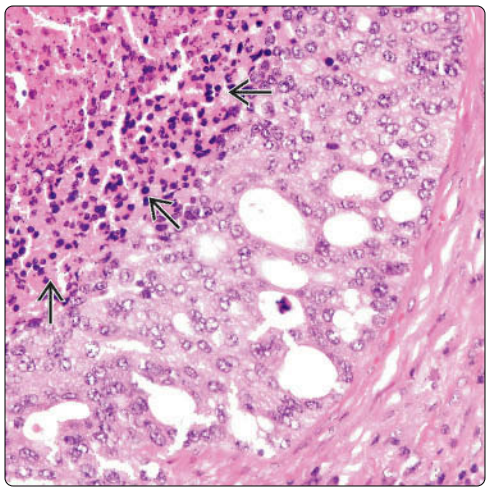

(Left) *Metastases to the lung from a transitional cell carcinoma of the urinary bladder show nests of uniform oval to spindle cells separated from the surrounding pulmonary parenchyma. Most cases of urothelial carcinoma are positive for both CK7 and CK20 and, in ~ 66% of cases, for uroplakin.* **(Right)** *Metastasis of prostate adenocarcinoma to the lung shows a cribriform pattern of growth and central necrosis ⇨. Prostate cancer reacts strongly with PSA, PSAP, and AMACR (P504S) antibodies.*

Metastatic Adenocarcinoma of Pancreas

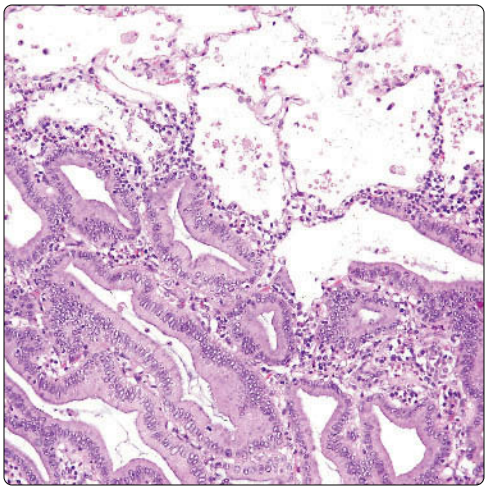

Mucin-Secreting Cells

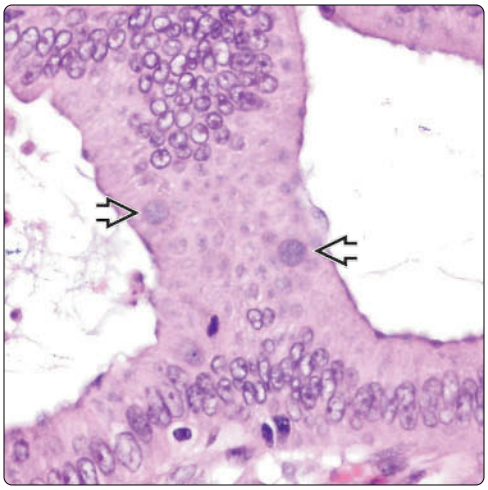

(Left) *Metastatic adenocarcinoma of the pancreas to the lung shows well-differentiated glandular proliferation with tall columnar cells that contain abundant cytoplasm. These tumors can closely resemble well-differentiated lung adenocarcinoma; they are strongly positive for CK7 but lack nuclear expression of TTF-1.* **(Right)** *Higher magnification of ductal adenocarcinoma of the pancreas metastatic to the lung shows mucin-secreting cells ⇨ scattered throughout.*

Metastatic Squamous Cell Carcinoma

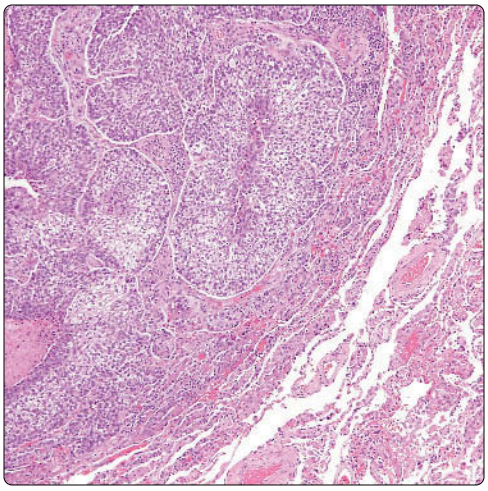

Metastatic Squamous Cell Carcinoma

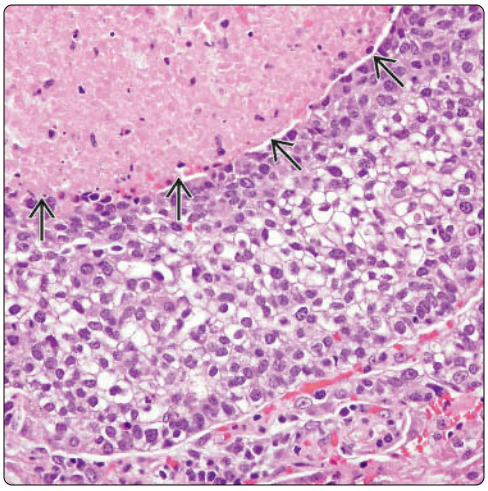

(Left) *Metastasis of squamous cell carcinoma of the larynx to the lung shows islands of large tumor cells with prominent clearing of the cytoplasm. In the absence of a clinical history, it may be impossible to distinguish a solitary metastasis from a primary squamous cell carcinoma of the lung.* **(Right)** *Higher magnification of a metastatic squamous cell carcinoma of the larynx to the lung shows poorly differentiated squamous cell islands circumscribing an area of necrosis ⇨.*

Metastatic Adenoid Cystic Carcinoma

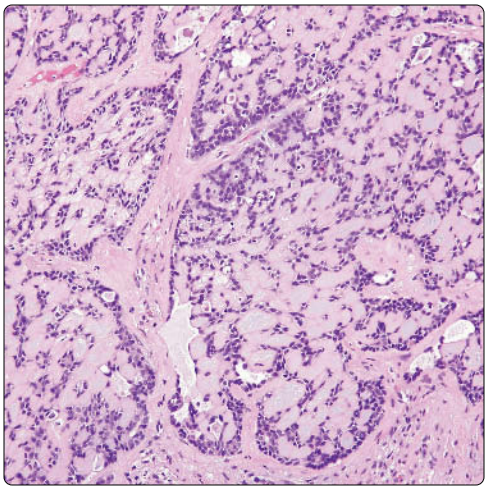

Hyaline Cylinders

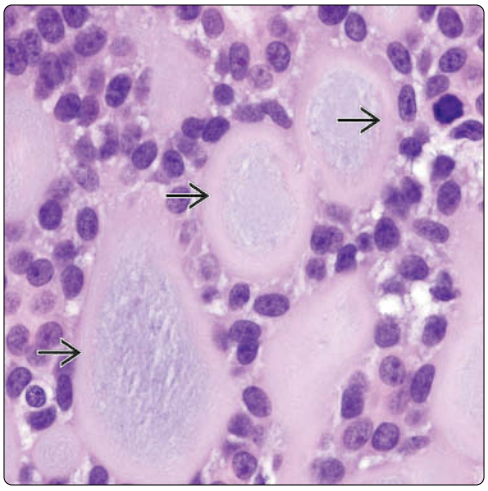

(Left) *Metastatic adenoid cystic carcinoma of the salivary gland to the lung shows strands of epithelial cells with a cylindromatous growth pattern. These tumors can metastasize up to 15 years after removal of the primary tumor and may be impossible to separate from a primary salivary gland-type lung tumor. Clinical history is indispensable for diagnosis.* **(Right)** *Higher magnification of metastatic adenoid cystic carcinoma shows "cylinders" lined by an eosinophilic rim of basal lamina material ⇨.*

Metastatic Sarcoma

KEY FACTS

CLINICAL ISSUES

- Multiple nodules on chest x-ray
- Cough
- Dyspnea
- Lung is most common site of metastases for soft tissue sarcomas from trunk and extremities
- Good prognosis in patients with resectable tumors and in patients with metastases from uterine leiomyosarcoma

MACROSCOPIC

- Bilateral nodules, mostly small and interstitial, most commonly in lower lobes
- Gray-white, whorled, rubbery tissue that bulges from cut surface
- Can show extensive hemorrhage and necrosis
- May show prominent cystic changes

MICROSCOPIC

- **Spindle cell sarcomas**
  - Most common types are leiomyosarcoma, myxofibrosarcoma, synovial sarcoma, osteosarcoma, malignant schwannoma
- **Epithelioid cell sarcomas**
  - Most common types include epithelioid sarcoma, angiosarcoma, alveolar soft parts sarcoma
- **Pleomorphic cell sarcomas**
  - Most common type is pleomorphic high-grade sarcoma (so-called malignant fibrous histiocytoma)
- **Small round blue cell sarcomas**
  - Most common types include rhabdomyosarcoma, Ewing sarcoma/PNET, round cell liposarcoma, small desmoplastic round cell tumor

ANCILLARY TESTS

- Immunohistochemistry is very helpful tool for differential diagnosis
- Most important distinction is between sarcomatoid carcinoma [keratin (+)] and true spindle cell sarcoma

Lung Metastasis of Leiomyosarcoma

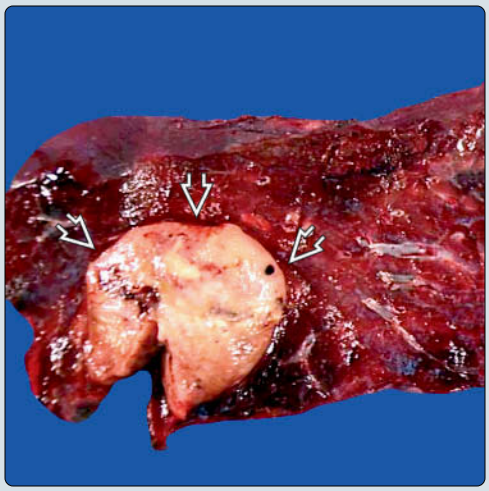

Metastatic Leiomyosarcoma

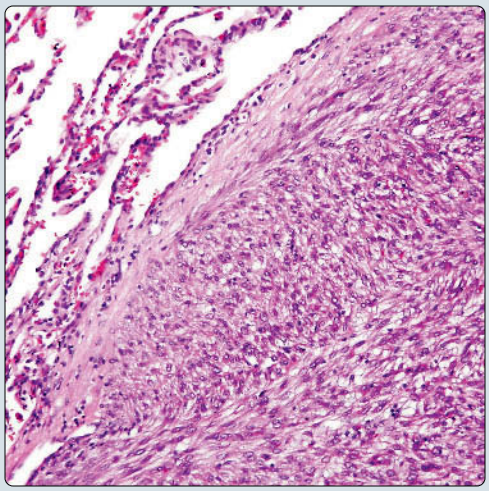

(Left) *Gross appearance of a metastatic leiomyosarcoma from soft tissue to the lung shows a well-circumscribed, round mass that is sharply separated from the surrounding lung parenchyma* ⇨. **(Right)** *Histology of metastatic well-differentiated leiomyosarcoma to the lung shows a well-circumscribed nodule surrounded by lung parenchyma composed of fascicles of atypical spindle cells.*

Endobronchial Metastasis of Osteosarcoma

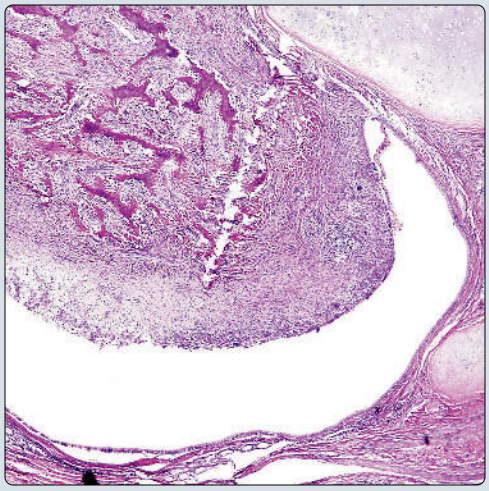

Osteosarcoma Metastasis: High Power

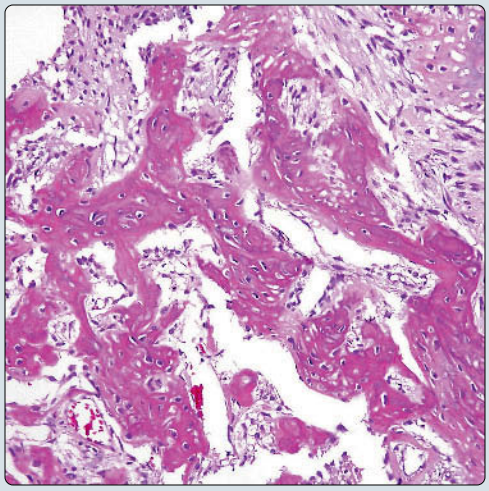

(Left) *Metastases of sarcoma to the lung can present as polypoid endobronchial tumors. This case shows an endobronchial metastasis of osteosarcoma from the femur in an 18-year-old man.* **(Right)** *Higher magnification from metastasis to the lung from osteosarcoma shows abundant immature bony matrix (osteoid) deposition surrounded by atypical spindle cells.*

TERMINOLOGY

Definitions

- Formation of sarcomatous nodules in lung as result of hematogenous spread from distant sites

CLINICAL ISSUES

Presentation

- Multiple nodules on chest x-ray
- Cough, dyspnea, hemoptysis

Natural History

- Lung is most common site of metastases for soft tissue sarcomas from trunk and extremities
- Most common primary source of lung metastasis from soft tissue sarcomas is from lower extremities
- Most common types of metastatic sarcomas to lung are leiomyosarcoma, undifferentiated sarcoma, synovial sarcoma, and liposarcoma

Treatment

- Surgical approaches
  - Surgical excision for solitary or peripheral lesions
  - Adjuvant chemotherapy for multiple and bilateral lesions

Prognosis

- Good prognosis in patients with resectable tumors and in patients with metastases from uterine leiomyosarcoma
- Metastasectomy can double median survival and 3-year survival for patients with metastatic soft tissue sarcoma
- Patient age > 50 years old is adverse prognostic factor

IMAGING

General Features

- Location
  - Usually distributed in lower lobes, bilaterally
- Size
  - Variable, from microscopic to large masses (> 5 cm in diameter)

MACROSCOPIC

General Features

- Bilateral nodules, mostly small and interstitial, most commonly in lower lobes
- Gray-white, whorled, rubbery tissue that bulges from cut surface
- Can show extensive hemorrhage and necrosis
- May show prominent cystic changes
- Can have myxoid or mucinous cut surface or may be rubbery, like cartilage
- Metastases of osteosarcoma may be gritty and hard

MICROSCOPIC

Histologic Features

- May vary depending on type of sarcoma
  - **Spindle cell sarcomas**
    - Fascicles of atypical spindle cells with variable cellularity, pleomorphism, and mitotic activity
    - Most common types: Leiomyosarcoma, myxofibrosarcoma, synovial sarcoma, malignant peripheral nerve sheath tumor, and osteosarcoma
  - **Epithelioid cell sarcomas**
    - Sheets of large round to polygonal atypical cells with abundant cytoplasm resembling carcinoma
    - Most common types include epithelioid sarcoma, angiosarcoma, and alveolar soft part sarcoma
  - **Pleomorphic cell sarcomas**
    - Sheets of large pleomorphic or anaplastic tumor cells with atypical nuclei and abnormal mitoses
    - Most common type is pleomorphic high-grade sarcoma (so-called malignant fibrous histiocytoma)
  - **Small round blue cell sarcomas**
    - Sheets of atypical, undifferentiated small round blue cells
    - Most common types include rhabdomyosarcoma, Ewing sarcoma/PNET, small desmoplastic round cell tumor, and round cell liposarcoma

ANCILLARY TESTS

Immunohistochemistry

- Very helpful tool for differential diagnosis
- Most important distinction is between sarcomatoid carcinoma [keratin (+)] and true spindle cell sarcoma
- Specific antibodies may be of value for further subtyping of tumor and defining cell lineage

Genetic Testing

- Specific chimeric fusion products resulting from genetic translocations can be detected using molecular techniques
  - FISH and PCR can be used to detect (: 6 5 fusion product in Ewing sarcoma or the 6 < 7 6 ; ; fusion product in synovial sarcoma
- Chromosomal translocations can be associated with specific types of sarcomas, i.e., t(x;18) in synovial sarcoma

DIFFERENTIAL DIAGNOSIS

Metastatic Malignant Melanoma

- Can resemble sarcoma due to mixed spindle and epithelioid cell morphology
- Prominent nesting pattern, intracellular melanin pigment, and large eosinophilic nucleoli are characteristic
- Tumor cells react strongly with S100 protein and melanocytic-associated markers (HMB-45, Melan-A, tyrosinase, and MITF)

Primary Lung Sarcoma

- Any type of soft tissue sarcoma can arise as primary in lung; however, this is extremely rare event
- Thorough clinical history to rule out possibility of late or occult metastasis from soft tissue site is indispensable for diagnosis

Sarcomatoid (Spindle Cell) Carcinoma of Lung

- Sheets of pleomorphic and atypical spindle cells, usually in association with preexisting adenocarcinoma or squamous cell carcinoma
- Extensive sampling is recommended to identify well-differentiated adenocarcinoma or squamous cell carcinoma component

Immunohistochemistry

Antibody	Reactivity	Staining Pattern	Comment
Metastatic leiomyosarcoma			
SMAD4	Positive	Cytoplasmic	Should stain strongly and diffusely
Desmin	Positive	Cytoplasmic	May be present in only 50-60% of cases
CK-PAN	Negative	Cytoplasmic	May be positive focally in small percentage of cases
EMA	Negative	Cell membrane & cytoplasm	May be positive in small percentage of cases
Metastatic synovial sarcoma			
CK-PAN	Positive	Cytoplasmic	Usually only focal, weak positivity in scattered cells
EMA	Positive	Cell membrane & cytoplasm	Usually only focal positivity
Bcl-2	Positive	Cytoplasmic	Usually strong and diffuse positivity in majority of tumor cells
CD99	Positive	Cytoplasmic	Present at least focally in > 75% of cases
Metastatic epithelioid sarcoma			
CK-PAN	Positive	Cytoplasmic	Strongly positive in all cases
Vimentin	Positive	Cytoplasmic	Strongly positive in all cases
CD34	Positive	Cytoplasmic	Positive in ~ 50% of cases
Ewing sarcoma/PNET			
CD99	Positive	Cell membrane	Diffusely positive in all cases
FLI-1	Positive	Nuclear	Positive in ~ 70% of cases
CK-PAN	Negative	Not applicable	May be present focally in small number of cases
Metastatic epithelioid angiosarcoma			
CD31	Positive	Cell membrane & cytoplasm	Most specific and sensitive marker for angiosarcoma
CD34	Positive	Cytoplasmic	Sensitive but relatively nonspecific marker
CK-PAN	Positive	Cytoplasmic	Cytokeratins may be positive in high percentage of epithelioid vascular neoplasms
TTF-1	Negative	Not applicable	
Metastatic endometrial stromal sarcoma			
CD10	Positive	Cytoplasmic	Diffuse CD10 positivity in absence of reactivity for H-caldesmon or desmin is characteristic
ERP	Positive	Nuclear	ER/PR positivity is seen in all cases
PRP	Positive	Nuclear	
CK-PAN	Negative	Not applicable	Focal keratin positivity may be seen in rare cases

- Spindle cells are strongly positive for epithelial markers (cytokeratins, EMA, MOC-31, etc.)

Pulmonary Carcinosarcoma

- Biphasic malignant neoplasm composed of true malignant epithelial component (squamous or adenocarcinoma) and true sarcoma component
- Epithelial component must stain with epithelial markers or show ultrastructural features of epithelial differentiation
- Sarcomatous component must resemble well-defined types of sarcomas or be devoid of reactivity for epithelial markers

Pulmonary Blastoma

- Biphasic malignant neoplasm with epithelial component resembling fetal lung and spindle cell sarcomatous component
- Epithelial component is positive for cytokeratin and TTF-1
- Sarcomatous component stains as specific subtype of sarcoma or is composed of primitive spindle cell sarcoma, not otherwise specified

SELECTED REFERENCES

1. Vella JE et al: Review of lung and pleural biopsies received in a gynecologic pathology department over a 14-Yr period. Int J Gynecol Pathol. ePub, 2016
2. Kaifi JT et al: Indications and approach to surgical resection of lung metastases. J Surg Oncol. 102(2):187-95, 2010
3. Nishiyama N et al: Lung metastases from various malignancies combined with primary lung cancer. Gen Thorac Cardiovasc Surg. 58(10):538-41, 2010
4. García Franco CE et al: Long-term results after resection for soft tissue sarcoma pulmonary metastases. Interact Cardiovasc Thorac Surg. 9(2):223-6, 2009
5. Absalon MJ et al: Pulmonary nodules discovered during the initial evaluation of pediatric patients with bone and soft-tissue sarcoma. Pediatr Blood Cancer. 50(6):1147-53, 2008
6. Pfannschmidt J et al: Pulmonary metastasectomy in patients with soft tissue sarcomas: experiences in 50 patients. Thorac Cardiovasc Surg. 54(7):489-92, 2006

Metastasis of Uterine Leiomyosarcoma

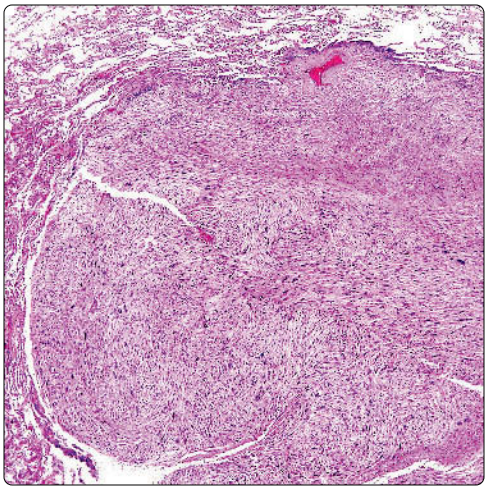

Leiomyosarcoma Metastasis: High Power

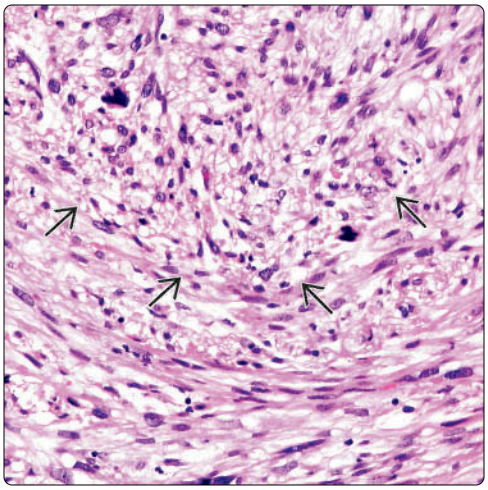

(Left) *Scanning magnification of metastasis of uterine leiomyosarcoma to the lung shows a well-circumscribed nodule composed of atypical spindle cell proliferation that is sharply separated from the surrounding pulmonary parenchyma.* **(Right)** *Higher magnification of pulmonary metastasis of uterine leiomyosarcoma shows fascicles of atypical cells that are cut at right angles resulting in some of the cells appearing round ⇨, while others (below) appear spindled.*

Mitotic Activity

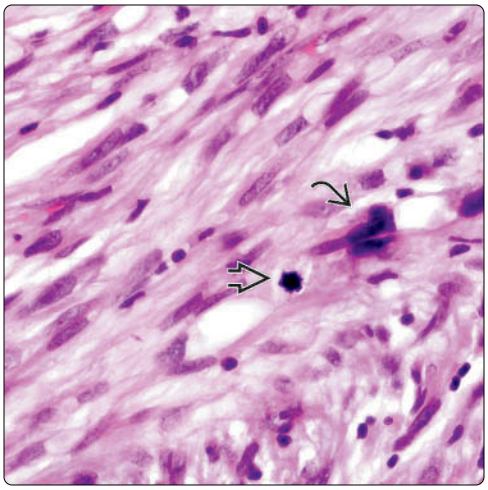

Cigar-Shaped Nuclei

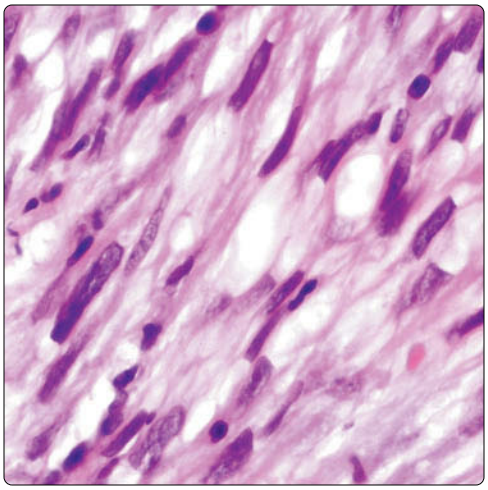

(Left) *Higher magnification of pulmonary metastasis of uterine leiomyosarcoma shows a bizarre tumor cell ⇨ and mitotic figure ⇨. The tumor cells reacted strongly with antibodies for smooth muscle actin, smooth muscle myosin, and desmin.* **(Right)** *Higher magnification of metastatic uterine leiomyosarcoma to the lung shows another characteristic feature of these tumors: The nuclei are cigar-shaped and display blunted ends rather than the tapered ends seen in other types of sarcomas.*

Mitotic Figures

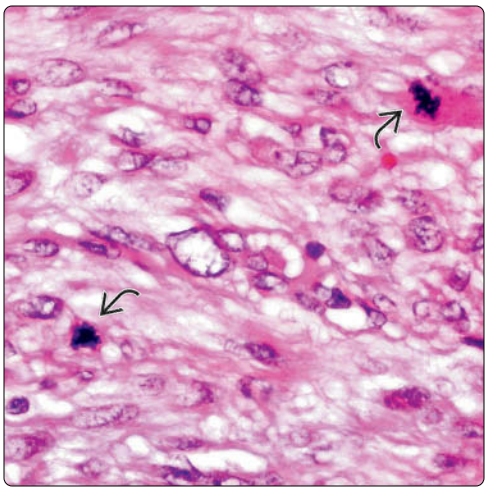

High Mitotic Activity

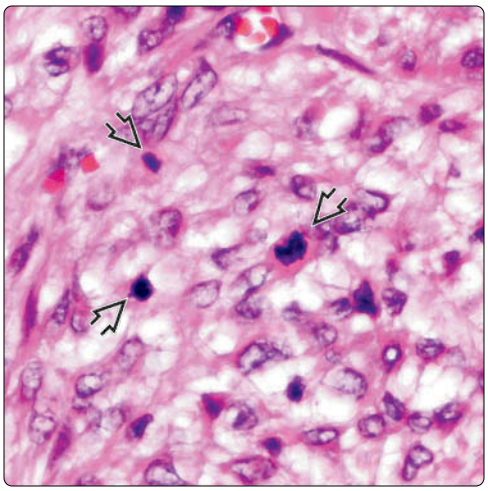

(Left) *Metastasis to the lung from leiomyosarcoma of soft tissue (thigh) shows a population of atypical tumor cells with pleomorphic and vesicular nuclei and scattered mitotic figures ⇨.* **(Right)** *Metastasis of leiomyosarcoma of soft tissue to the lung shows high mitotic activity admixed with a population of atypical spindle cells. This HPF contains 3 mitotic figures ⇨. The tumor also showed extensive areas of tumor necrosis and areas with nuclear pleomorphism.*

Metastatic Osteosarcoma

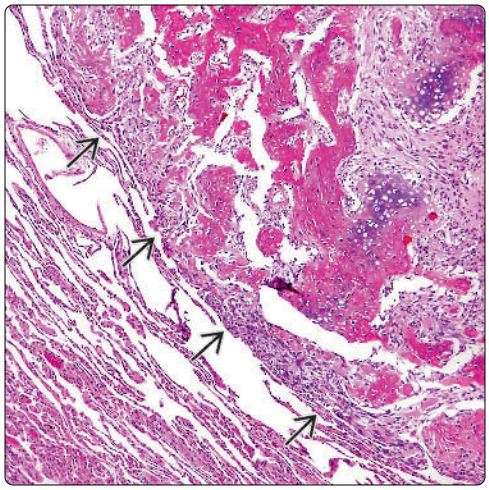

Abundant Osteoid

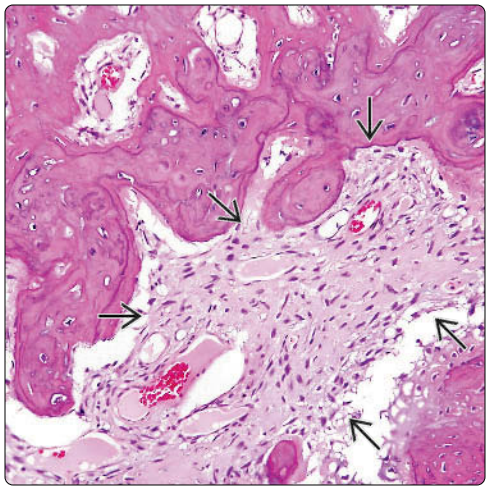

(Left) *Scanning magnification of intrapulmonary metastasis from osteosarcoma of the femur shows a well-circumscribed nodule surrounded by normal lung parenchyma and containing abundant osteoid matrix.* **(Right)** *High magnification of metastasis of osteosarcoma to the lung shows abundant osteoid matrix circumscribing a focus of stromal spindle cell proliferation. Not all metastases from osteosarcoma are well-differentiated and show obvious osteoid matrix as this one does.*

Endobronchial Metastasis

Osteoid Formation

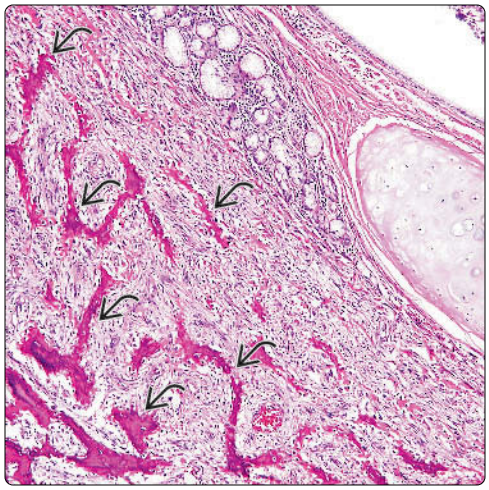

(Left) *Endobronchial metastasis from osteosarcoma of the tibia shows a polypoid tumor mass protruding into the lumen of the bronchus.* **(Right)** *Scanning magnification from the wall of the bronchus shows atypical spindle cell proliferation containing thin, irregular strands of immature osteoid matrix. Benign osseous metaplasia can occasionally occur in a variety of other sarcomas and must be distinguished from osteoid matrix in osteosarcoma.*

Osteoid Matrix in Osteosarcoma

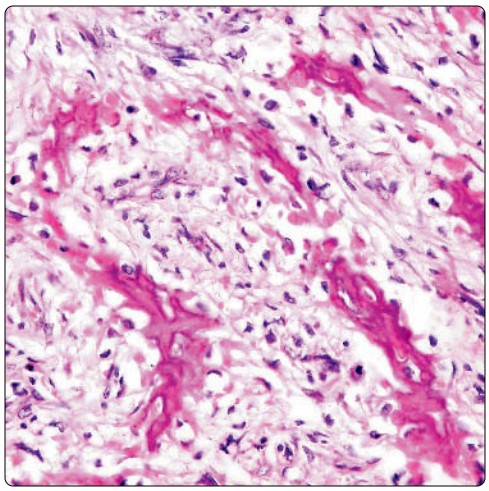

Focus of Osteoid Deposition

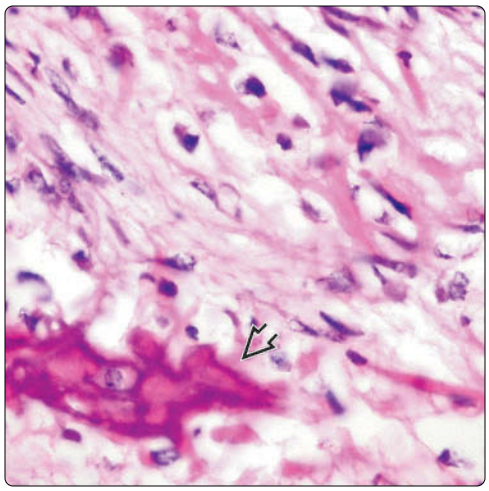

(Left) *Higher magnification from a metastasis of osteosarcoma to the lung shows an immature osteoid matrix surrounded by atypical spindle cell population embedded in abundant collagenous stroma.* **(Right)** *High magnification from metastatic osteosarcoma to the lung shows a small focus of osteoid. The surrounding connective tissue stroma shows a sparse spindle cell population with cytologic atypia. Scattered mitoses were noted in other areas of the tumor.*

Metastatic Alveolar Soft Part Sarcoma

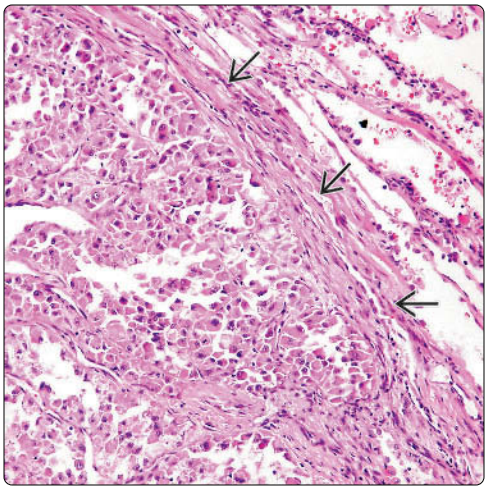

Alveolar Soft Part Sarcoma

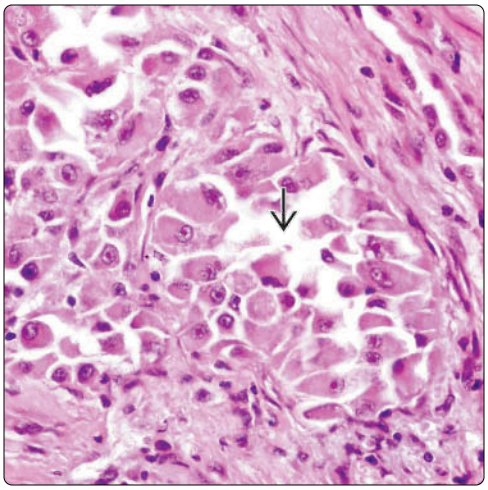

(Left) *Metastasis to the lung of alveolar soft part sarcoma of the thigh shows the proliferation of large epithelioid cells with abundant cytoplasm that are sharply separated from the surrounding pulmonary parenchyma.* **(Right)** *Higher magnification from metastasis of an alveolar soft part sarcoma to the lung shows a vague alveolar pattern with large epithelioid cells aggregating around a central lumen. The lung is a favored site of metastasis for this tumor.*

Polygonal Tumor Cells

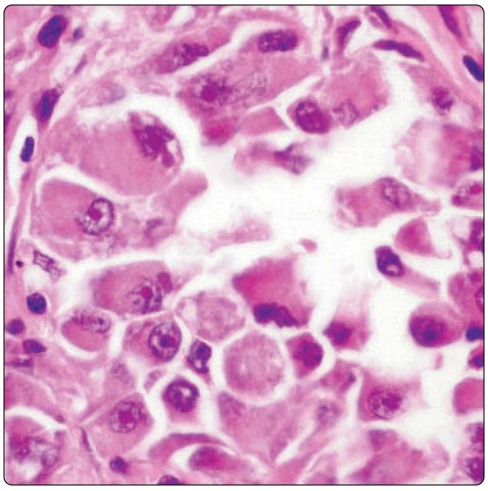

Metastatic Epithelioid Sarcoma

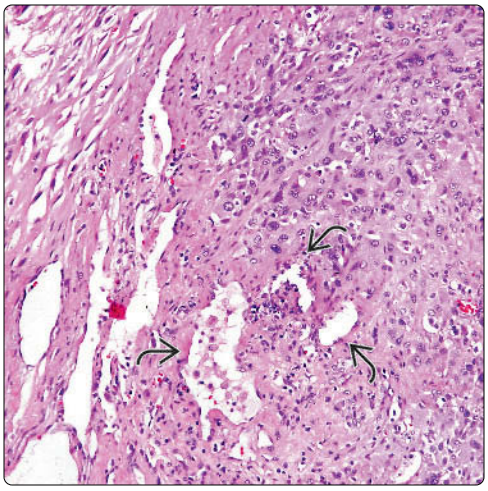

(Left) *High magnification of a metastasis to the lung from an alveolar soft part sarcoma of soft tissue shows a dyscohesive population of large, epithelioid cells with abundant granular cytoplasm. The cells display large round nuclei with prominent eosinophilic nucleoli.* **(Right)** *Lung metastasis of epithelioid sarcoma from the arm in a 32-year-old man shows sheets of large epithelioid cells with abundant cytoplasm surrounding entrapped residual alveolar spaces.*

Sheets of Epithelioid Cells

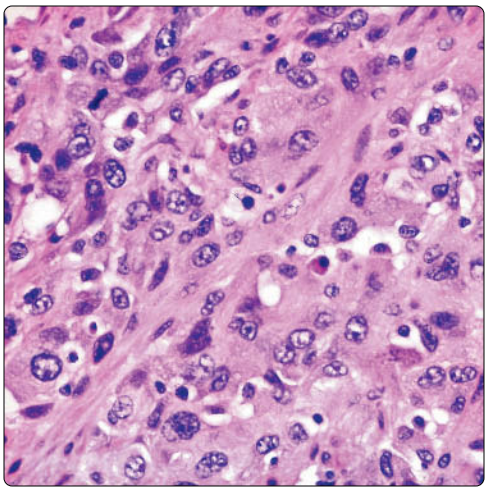

Epithelioid Sarcoma: High Power

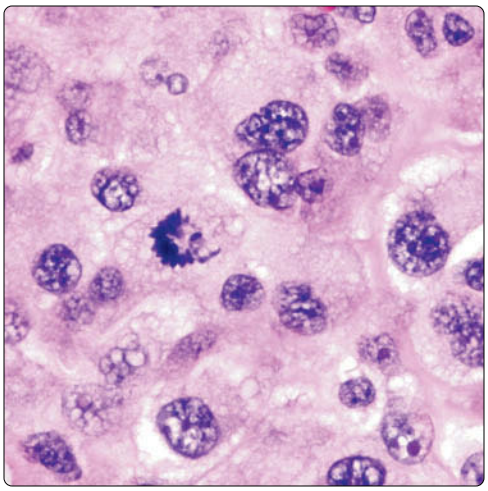

(Left) *High magnification of lung metastases in epithelioid sarcoma shows sheets of large cells with enlarged nuclei and an abundant rim of cytoplasm. These tumor cells were positive for cytokeratin, vimentin, and CD34. The tumors can be easily confused for large cell carcinoma of the lung. Clinical history is indispensable for diagnosis.* **(Right)** *Higher magnification of lung metastasis from epithelioid sarcoma shows large cells with abundant cytoplasm and mitotic activity.*

Epithelioid Angiosarcoma Metastasis

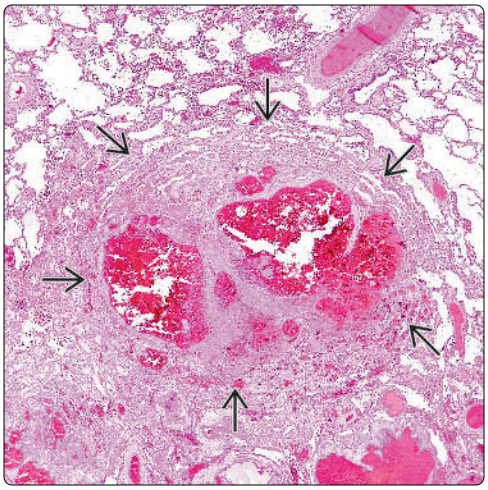

Angiosarcoma: High Power

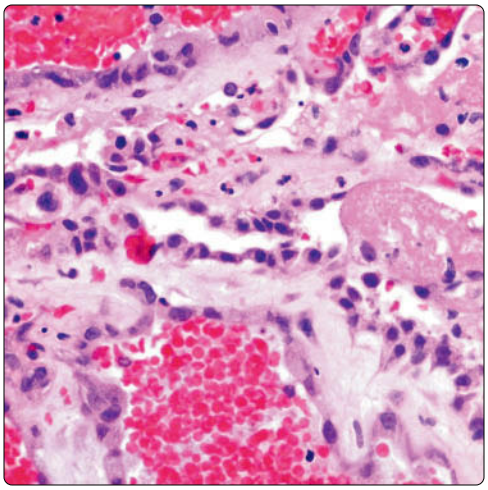

(Left) *Multiple hemorrhagic tumor nodules ⇨ are seen studding the lung parenchyma in this metastasis from an epithelioid angiosarcoma from the heart.* **(Right)** *Higher magnification from a hemorrhagic tumor nodule in lung parenchyma from metastasis of an angiosarcoma of the heart shows poorly formed, anastomosing vascular channels lined by atypical, hyperchromatic endothelial cells. The vascular channels merged with solid areas containing similar cells in the stroma.*

Epithelioid Atypical Cells

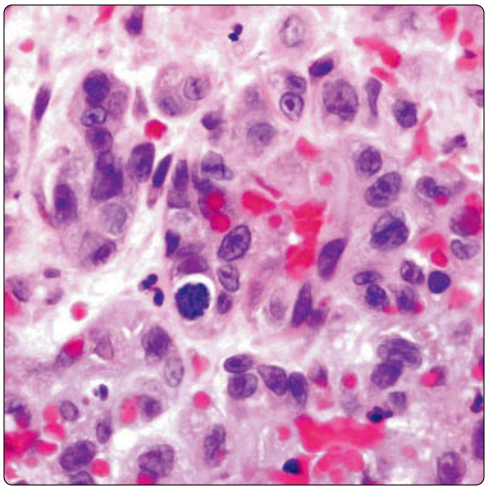

CD31 Immunostaining

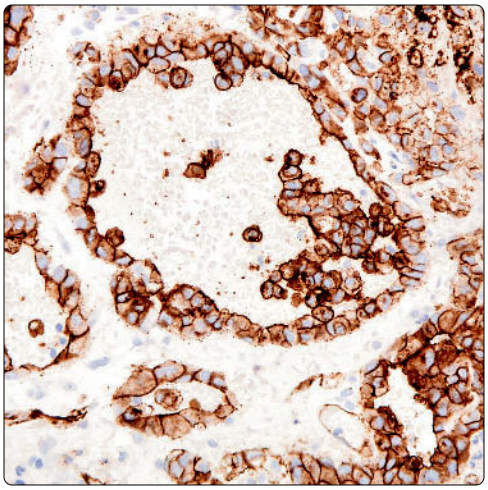

(Left) *A solid focus containing sheets of apparently cohesive epithelioid cells in the stroma is seen in this metastasis to the lung from angiosarcoma of the heart. The tumor cells are round with large nuclei and occasional mitoses, and the cells contain prominent nucleoli and a rim of ample to eosinophilic cytoplasm.* **(Right)** *Immunohistochemical staining of a metastatic angiosarcoma to the lung with CD31 shows strong membrane and cytoplasmic staining for this antibody.*

CK7 Immunostaining

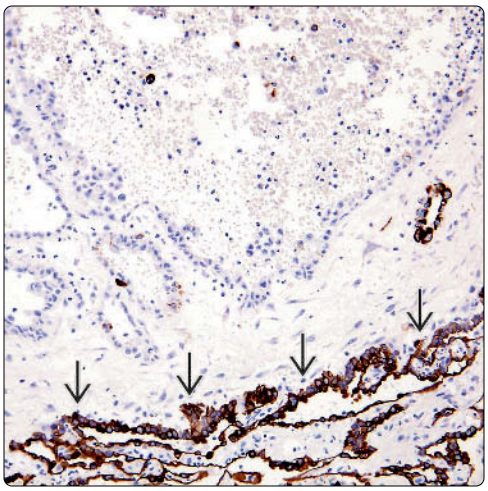

TTF-1 Immunostaining

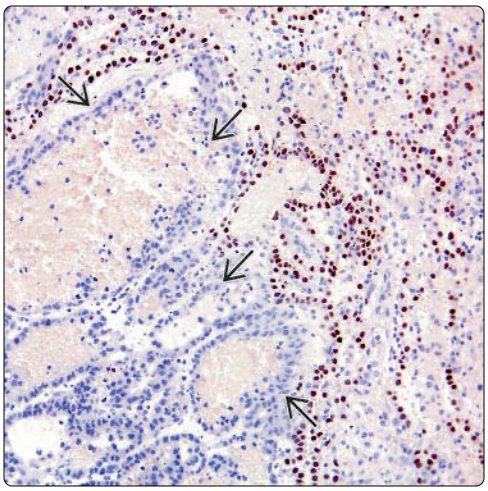

(Left) *Immunohistochemical staining of a metastasis from an angiosarcoma of the heart to the lung with CK7 shows strong positivity of the normal lung respiratory mucosa for this marker ⇨ but negative staining of the tumor cells (above).* **(Right)** *Immunohistochemical staining of metastatic epithelioid angiosarcoma to the lung with the lung-specific marker, TTF-1, shows nuclear positivity in the respiratory epithelium surrounding the tumor but not in the tumor cells ⇨.*

Metastatic Undifferentiated Sarcoma

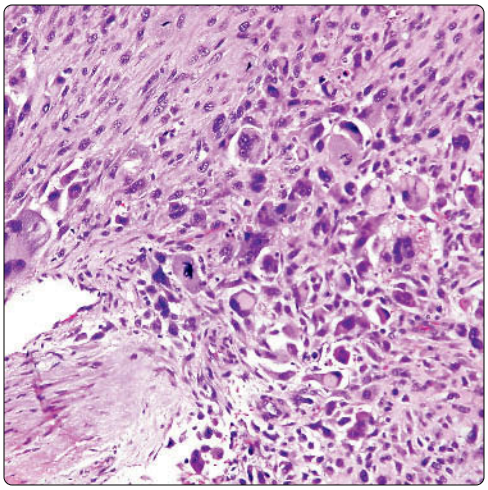

Pleomorphic Tumor Cells

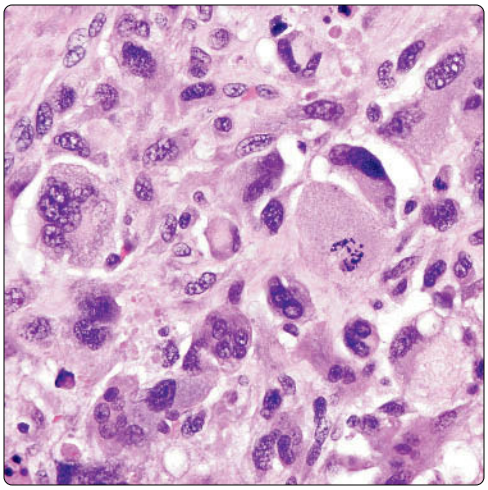

(Left) *Metastasis to the lung from a pleomorphic undifferentiated sarcoma of the thigh ("malignant fibrous histiocytoma") shows a highly pleomorphic tumor cell population destroying the lung parenchyma.* **(Right)** *High magnification of a malignant fibrous histiocytoma-type of metastasis is characterized by the extreme pleomorphism of the tumor cells. This morphologic appearance can be observed in metastases coming from a variety of well-differentiated sarcomas from other sites.*

Abnormal Mitotic Figure

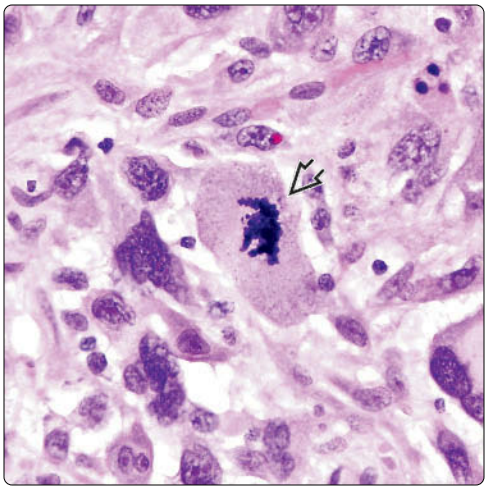

Lipoblast-Like Atypical Cells

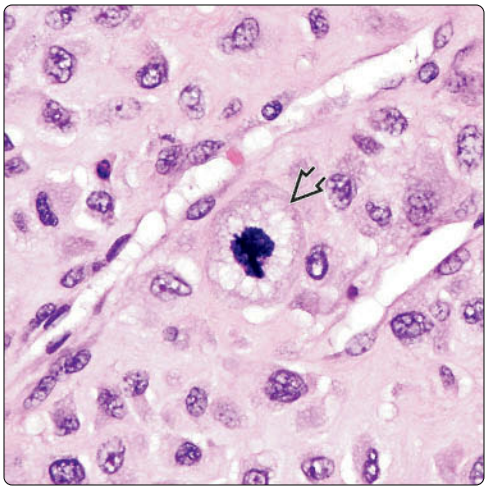

(Left) *Higher magnification of a metastatic, pleomorphic high-grade sarcoma to the lung shows highly atypical tumor cells surrounding an abnormal mitotic figure.* **(Right)** *High-power view of a metastasis from a pleomorphic high-grade sarcoma to the lung shows a large atypical cell with abundant, finely vacuolated cytoplasm resembling a lipoblast. Lipoblast-like atypical cells can be seen in a variety of sarcomas other than liposarcomas and may not be an indication of a liposarcoma metastasis.*

Atypical Multinucleated Cell

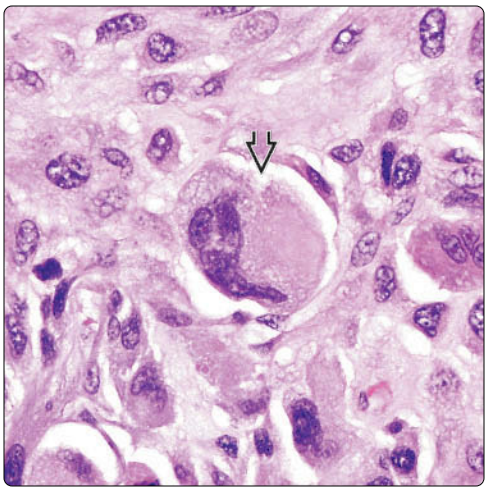

Osteoclast-Like Atypical Giant Cells

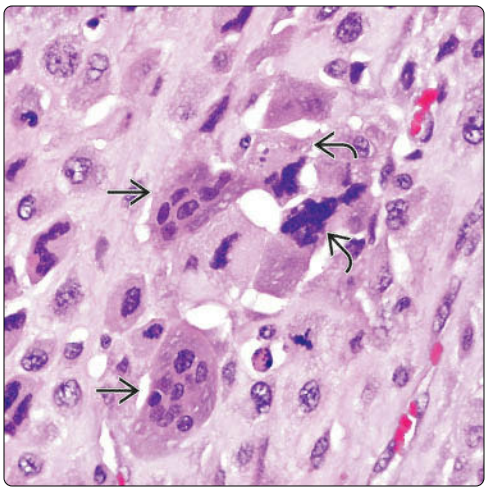

(Left) *High magnification of a lung metastasis from a pleomorphic high-grade sarcoma of soft tissue shows a large, atypical multinucleated cell with abundant eosinophilic cytoplasm reminiscent of a malignant histiocytic cell.* **(Right)** *High magnification of a pulmonary metastasis from a pleomorphic high-grade sarcoma of soft tissue shows benign osteoclast-type multinucleated giant cells alongside malignant, pleomorphic multinucleated giant cells.*

Metastatic Mesenchymal Chondrosarcoma

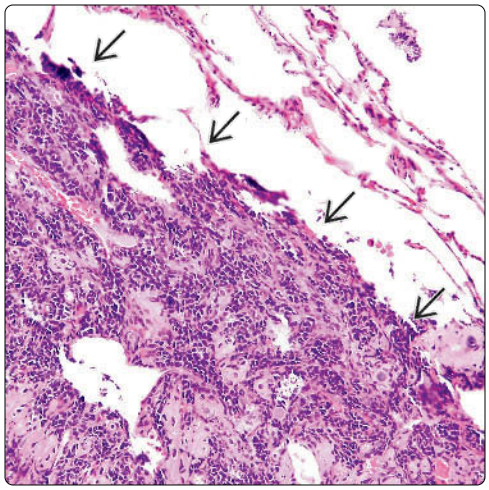

Immature Cartilage Foci

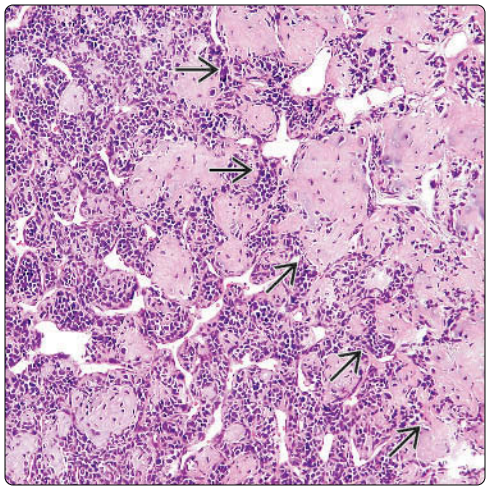

(Left) *Scanning magnification of a lung metastasis from an extraskeletal mesenchymal chondrosarcoma shows a well-circumscribed tumor nodule ⇨ surrounded by normal lung parenchyma.* **(Right)** *Lung metastasis from an extraskeletal mesenchymal chondrosarcoma shows areas of an immature chondroid matrix ⇨ imperceptibly merging with an atypical small round blue cell neoplastic population (left). Numerous ectatic and branching hemangiopericytic vascular spaces are noted throughout.*

Hemangiopericytic Vascular Pattern

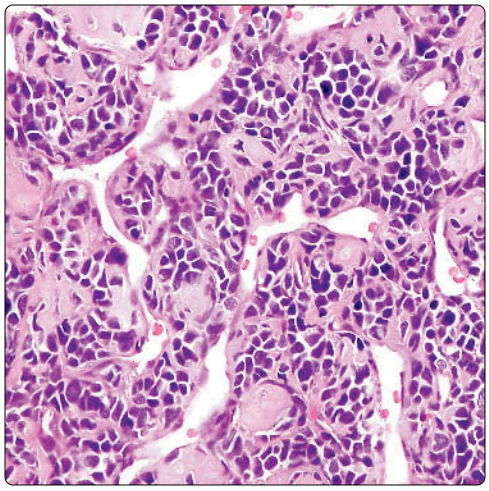

Metastatic Ewing Sarcoma

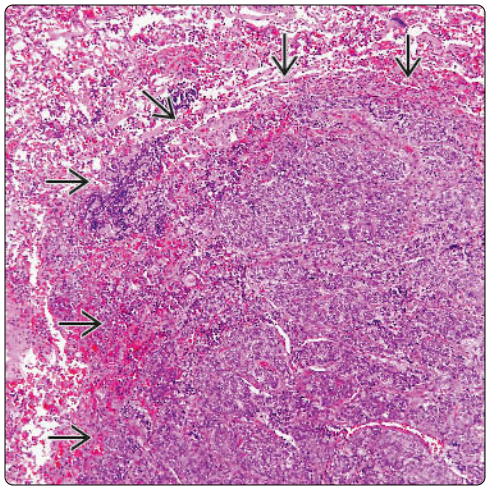

(Left) *High magnification of a pulmonary metastasis from an extraskeletal mesenchymal chondrosarcoma shows a small round blue cell population flanking a proliferation of branching dilated vascular spaces. The hemangiopericytic appearance is quite characteristic for this tumor.* **(Right)** *Scanning magnification shows a pulmonary metastasis from a Ewing sarcoma of the pelvis ⇨. Tumors with similar morphologic features can arise in the soft tissues in a variety of somatic organs and in the pleura.*

Ewing Sarcoma: High Power

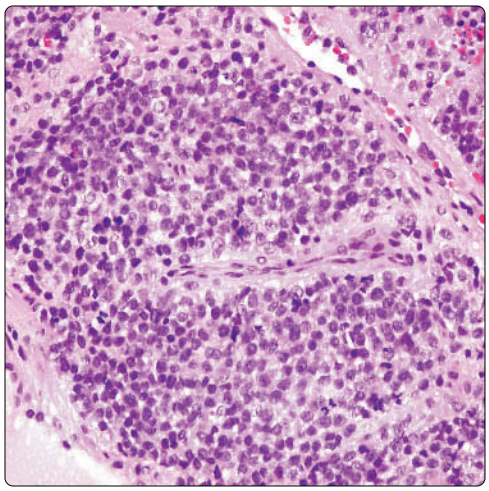

Mitotic Activity

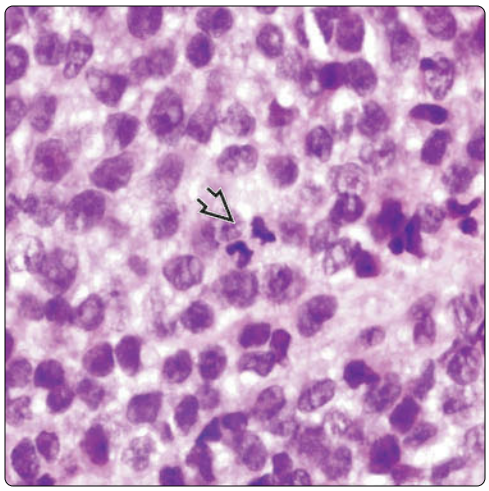

(Left) *Pulmonary metastasis from Ewing sarcoma/PNET shows a dense population of sheets of primitive-appearing small round blue cells. A wide variety of tumors can adopt this morphology. Immunohistochemical and molecular studies are indispensable to determine the exact type of tumor.* **(Right)** *High magnification of a metastasis from a Ewing/PNET to the lung shows sheets of primitive small round blue cells with dense nuclear chromatin and small nucleoli. Notice the mitotic figure ⇨.*

Metastatic Endometrial Stromal Sarcoma

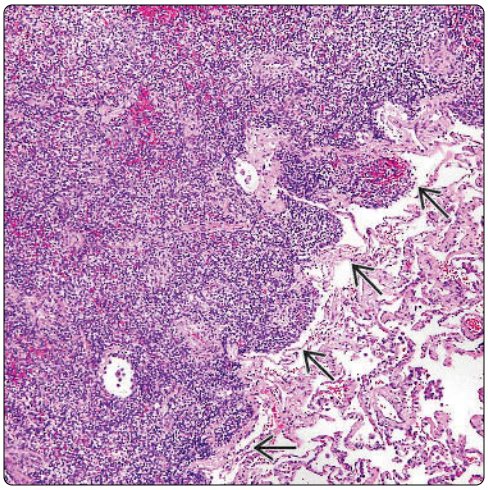

Perivascular Whorling

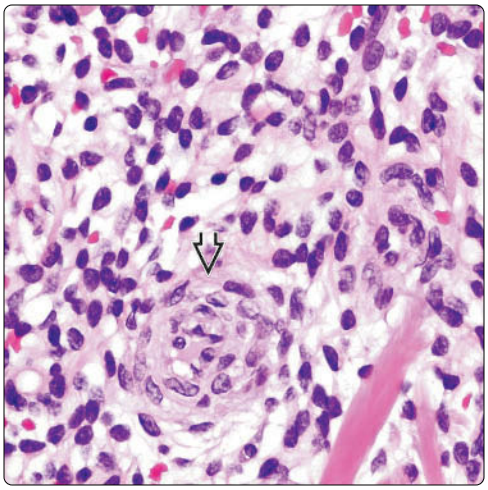

(Left) *Scanning magnification of a pulmonary metastasis from an endometrial stromal sarcoma of the uterus shows a well-demarcated nodule ⇨ showing sheets of small round blue cells without any specific architecture.* **(Right)** *High magnification of pulmonary metastases from endometrial stromal sarcoma of the uterus shows monotonous small round blue cell population surrounding a small vessel ⇨. The presence of these scattered small vessels with thickened walls is a characteristic of this tumor.*

Estrogen Receptor Immunostaining

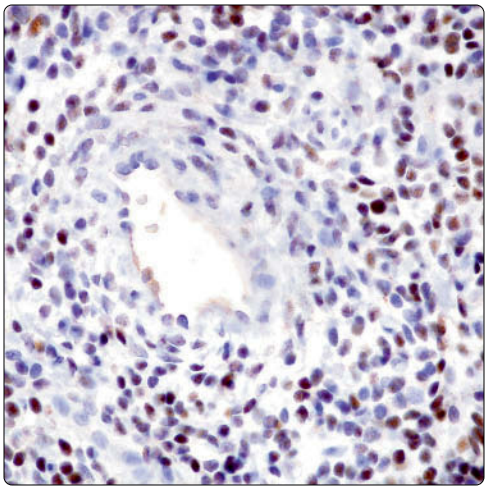

CD10 Immunostaining

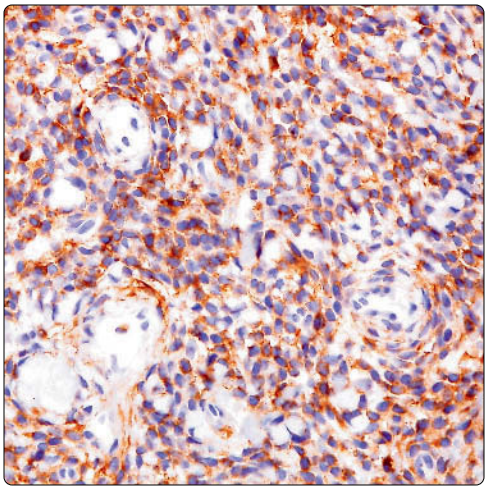

(Left) *Immunohistochemical staining of a pulmonary metastasis from endometrial stromal sarcoma of the uterus for ER shows strong nuclear positivity for this antibody in the majority of the small round blue tumor cells. ER/PR positivity is a distinctive feature of these tumors.* **(Right)** *Immunohistochemical staining of a pulmonary metastasis from endometrial stromal sarcoma from the uterus for CD10 shows cytoplasmic positivity in the majority of the tumor cells.*

Metastatic Myxoid Liposarcoma

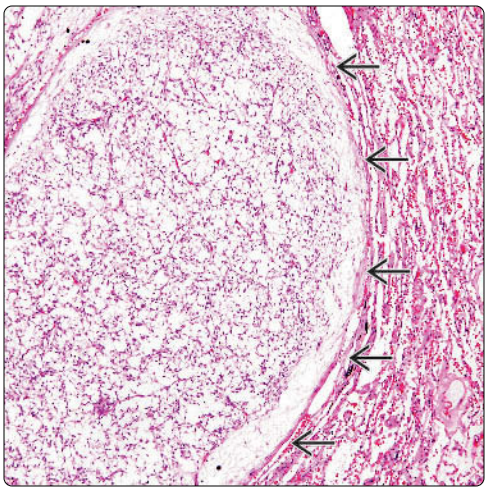

Myxoid Liposarcoma: High Power

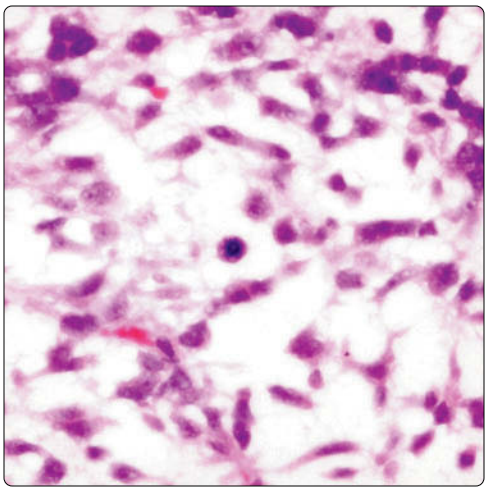

(Left) *Scanning magnification of a pulmonary metastasis from a round cell/myxoid liposarcoma of soft tissue shows a well-circumscribed nodule ⇨ sharply separated from the surrounding lung parenchyma.* **(Right)** *High magnification of a lung metastasis from a round cell/myxoid liposarcoma shows a primitive population of small round blue cells without any distinguishing features of differentiation. Cytogenetic or molecular studies for the demonstration of the CHOP translocation are indicated.*

Metastatic Malignant Melanoma

KEY FACTS

CLINICAL ISSUES

- Lung is frequent site of metastasis for malignant melanoma
- Middle-aged to elderly patients
- Melanoma metastases to lungs are associated with advanced stage and poor prognosis
- Cough, hemoptysis, dyspnea, atelectasis, and pleural effusion

IMAGING

- Multiple, well-defined nodules in periphery of lungs
- Endobronchial metastases

MICROSCOPIC

- Can show large variety of morphologic appearances, including epithelioid, spindle, signet ring cell, rhabdoid, and small cell melanoma
- Hallmark of malignant melanoma is presence of cells with marked cytologic atypia
- Majority of tumor cells are large and pleomorphic with enlarged nuclei and prominent eosinophilic nucleoli
- Cells may also be small and relatively bland-appearing with minimal cytologic atypia
- Frequent mitotic figures; abnormal mitoses are often encountered

ANCILLARY TESTS

- S100 protein is positive in nearly 100% of cases (nuclear and cytoplasmic stain)
- In most cases, melanocytic-associated markers are positive: HMB-45, Melan-A, tyrosinase, MITF
- Aberrant expression of epithelial markers (keratins, CEA, EMA) can be seen in small percentage of cases
- Other markers can also be expressed, including CD10, CD56, CD68, CD99, CD117, calretinin, NSE, vimentin, and Bcl-2, but are nonspecific

Metastatic Melanoma

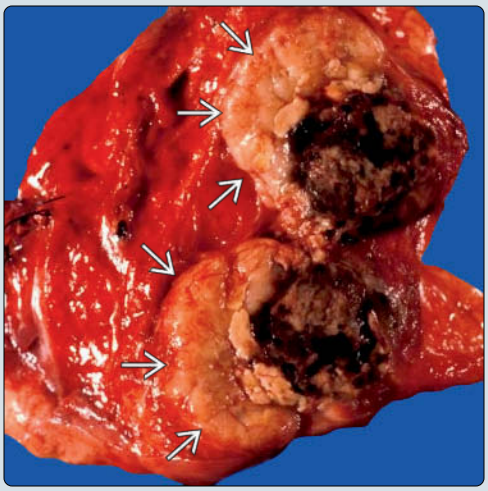

Nested Group of Tumor Cells

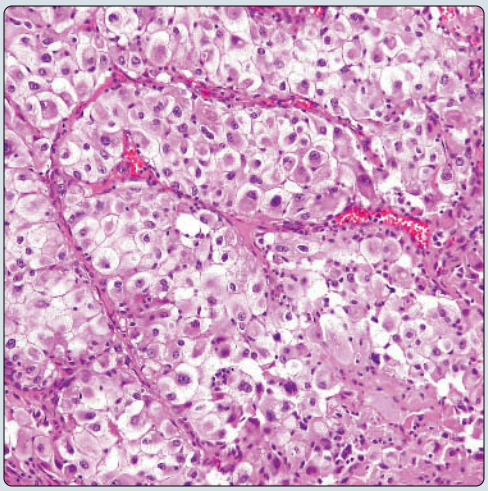

(Left) *Gross appearance of a bisected nodule ➡ containing a lung metastasis of malignant melanoma shows a well-circumscribed, tan nodule with an area of black discoloration due to melanin pigment deposition.* **(Right)** *Histologic appearance of metastatic malignant melanoma in the lung shows nests of large, epithelioid tumor cells with enlarged nuclei, prominent nucleoli, and abundant eosinophilic cytoplasm.*

Atypical Tumor Cells

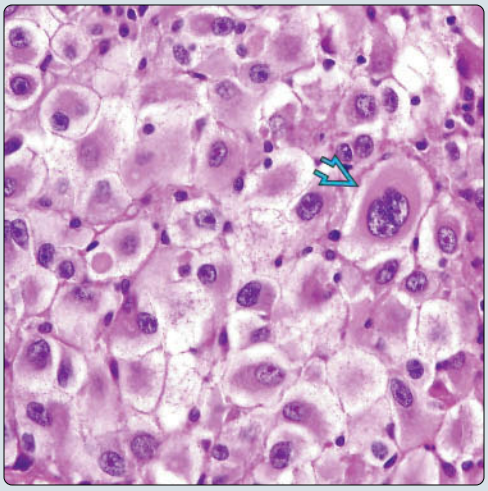

S100 Protein Immunostaining

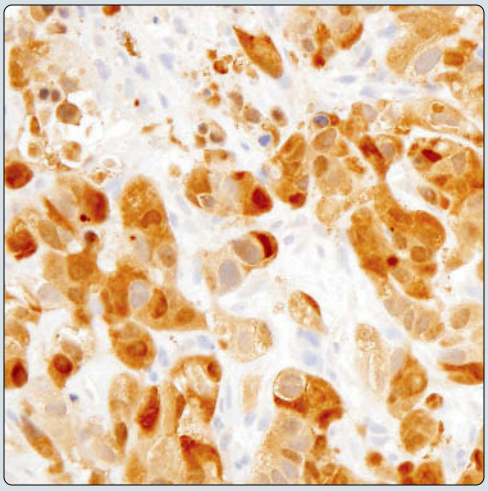

(Left) *Higher magnification of pulmonary metastasis from malignant melanoma shows sheets of large epithelioid cells with atypical nuclei and an abundant rim of eosinophilic cytoplasm. Notice the binucleated cell ⇨, a relatively common feature of melanoma.* **(Right)** *An immunohistochemical stain for S100 protein in metastatic malignant melanoma to the lung shows strong nuclear and cytoplasmic staining of the tumor cells.*

CLINICAL ISSUES

Epidemiology

- Incidence
  - Lung is frequent site of metastasis for malignant melanoma
- Age
  - Middle-aged to elderly patients

Presentation

- Cough, hemoptysis, dyspnea, atelectasis, and pleural effusion

Prognosis

- Melanoma metastases to lungs are associated with advanced stage and poor prognosis

MACROSCOPIC

General Features

- Usually well circumscribed but unencapsulated
- Tan or white, homogeneous cut surface with areas of hemorrhage and necrosis
- Tumors may be deeply pigmented due to heavy melanin deposition

MICROSCOPIC

Histologic Features

- **Epithelioid melanoma**
  - Nests or islands of large epithelioid cells with abundant eosinophilic cytoplasm that may resemble carcinoma
  - Tumor cells contain enlarged nuclei with prominent nucleoli
- **Spindle cell melanoma**
  - Nests or short fascicles of atypical spindle cells resembling sarcoma
  - Differential diagnosis includes sarcomatoid lung carcinoma, metastatic sarcomatoid renal cell carcinoma, and spindle cell sarcoma
- **Mixed spindle and epithelioid cell melanoma**
  - Most common form of metastatic melanoma showing admixture of both spindle and epithelioid cells
  - Can be confused for variety of other primary and metastatic sarcomas in lung
- **Pleomorphic melanoma**
  - Characterized by sheets of pleomorphic and anaplastic tumor cells with bizarre nuclei and frequent abnormal mitoses
  - Tumors may resemble pleomorphic high-grade sarcoma or pleomorphic/anaplastic carcinoma of lung
- **Rhabdoid melanoma**
  - Composed of sheets of large tumor cells with eccentric, densely eosinophilic cytoplasmic inclusions
  - Tumor cells can resemble rhabdomyoblastic cells in rhabdomyosarcoma or in malignant rhabdoid tumor
- **Signet ring cell melanoma**
  - Sheets of tumor cells characterized by signet ring cell morphology
  - Cells will show enlarged, hyperchromatic nuclei displaced to periphery by abundant cytoplasm
- **Small cell melanoma**
  - Dense sheets of monotonous small round tumor cells with hyperchromatic nuclei and scant cytoplasm
  - Tumors can resemble malignant lymphoma, carcinoid tumors, and other small round blue cell tumors

Cytologic Features

- Hallmark of malignant melanoma is presence of cells with marked cytologic atypia
- Majority of tumor cells are large and pleomorphic with enlarged nuclei and prominent eosinophilic nucleoli
- Frequent mitotic figures; abnormal mitoses are often encountered
- Cells may also be small and relatively bland-appearing with minimal cytologic atypia

ANCILLARY TESTS

Immunohistochemistry

- S100 protein is positive in nearly 100% of cases (nuclear and cytoplasmic stain)
- In most cases, melanocytic-associated markers are positive: HMB-45, Melan-A, tyrosinase, MITF
- Aberrant expression of epithelial markers (keratins, CEA, EMA) can be seen in small percentage of cases
- Other markers can also be expressed, including CD10, CD56, CD68, CD99, CD117, calretinin, NSE, vimentin, and Bcl-2, but are nonspecific

DIFFERENTIAL DIAGNOSIS

Sarcomatoid Carcinoma

- Tumor cells are positive for epithelial markers (cytokeratin, EMA, MOC-31) and negative for S100 and melanocytic markers

Metastatic Renal Cell Carcinoma

- Can show similar morphology with nests of tumor cells with abundant eosinophilic or granular cytoplasm
- Tumor cells are positive for cytokeratin, EMA, and RCC marker and negative for melanoma-associated markers and S100

Spindle and Epithelioid Cell Sarcomas

- Tumors such as leiomyosarcoma, epithelioid sarcoma, and synovial sarcoma may resemble melanoma morphologically
- Absence of melanocytic-associated markers and reactivity for other specific lineage-associated markers are helpful adjuncts for diagnosis

Pleomorphic High-Grade Sarcoma

- Usually vimentin positive only and does not express melanocytic-associated markers

SELECTED REFERENCES

1. Chaussende A et al: Endobronchial metastases from melanoma: a survival analysis. Clin Respir J. ePub, 2016
2. Kobayashi S et al: Pulmonary metastasis with endobronchial spread from sinonasal melanoma during a 9-year follow-up. Intern Med. 49(8):777-9, 2010
3. Oliaro A et al: Pulmonary metastasectomy for melanoma. J Thorac Oncol. 5(6 Suppl 2):S187-91, 2010

Nesting Pattern

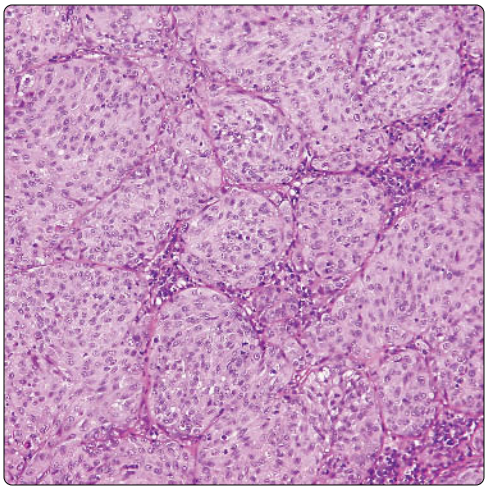

Nests of Atypical Tumor Cells

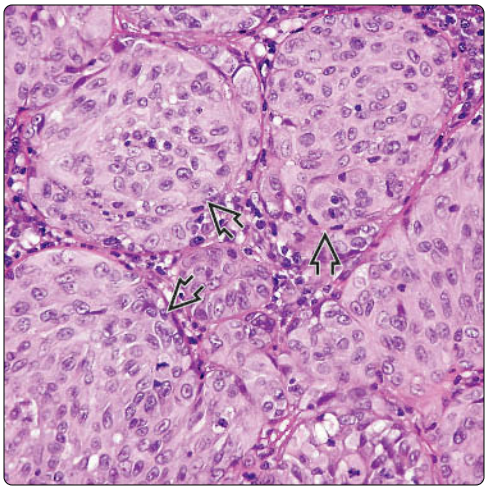

(Left) *Pulmonary metastasis from epithelioid melanoma shows the classic morphology of metastatic melanoma characterized by discrete, well-formed nests or thèques of large epithelioid cells with enlarged nuclei surrounded by abundant cytoplasm.* **(Right)** *Higher magnification of a metastasis to the lung from an epithelioid malignant melanoma of the skin shows discrete nests ⇨ of tumor cells with large, round to oval nuclei surrounded by abundant eosinophilic cytoplasm.*

S100 Protein Immunostaining

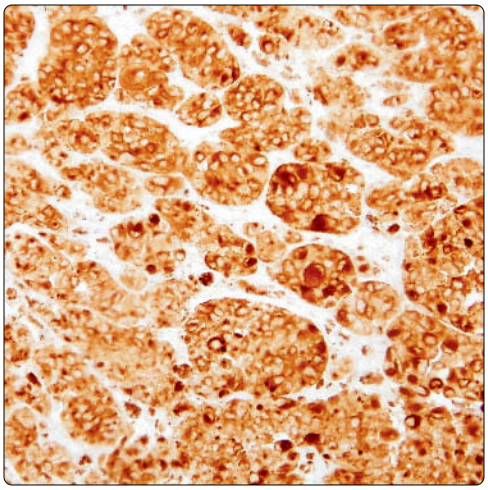

Metastatic Epithelioid Melanoma

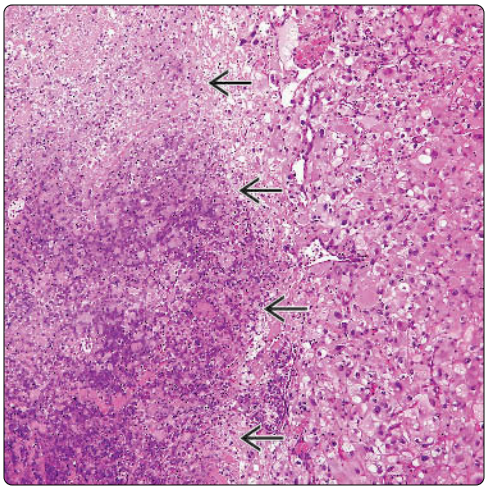

(Left) *Immunohistochemical staining of metastatic malignant melanoma to the lung with S100 protein shows strong cytoplasmic and nuclear positivity in the vast majority of the tumor cells. Notice the nested configuration of the tumor cells highlighted by the stain.* **(Right)** *Metastatic epithelioid malignant melanoma to the lung shows sheets of large, atypical tumor cells flanking an extensive area of necrosis ⇨. Necrosis is a frequent finding in these tumors.*

Large Epithelioid Cells

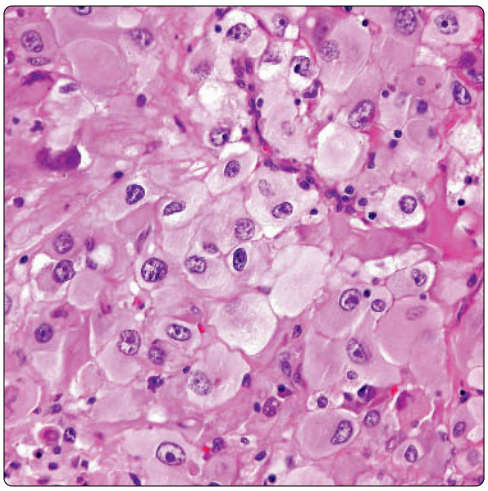

Prominent Nucleoli

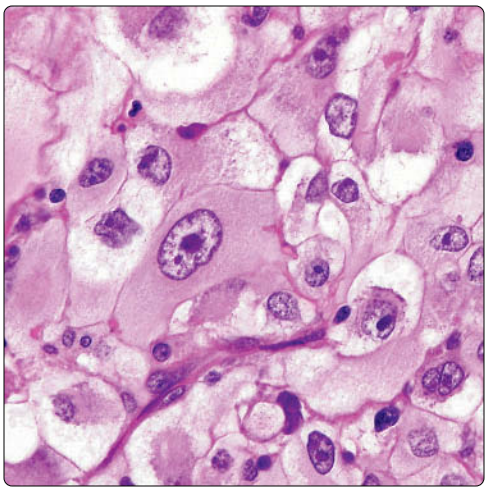

(Left) *Higher magnification of metastasis of epithelioid malignant melanoma to the lung shows characteristic appearance with large cells displaying sharp cell borders giving the appearance of cohesiveness and raising the diagnostic possibility of an epithelial neoplasm (i.e., large cell carcinoma) in the differential diagnosis.* **(Right)** *Higher magnification of metastatic melanoma shows cells with enlarged nuclei, prominent nucleoli, and abundant cytoplasm.*

Metastasis From Spindle Cell Melanoma

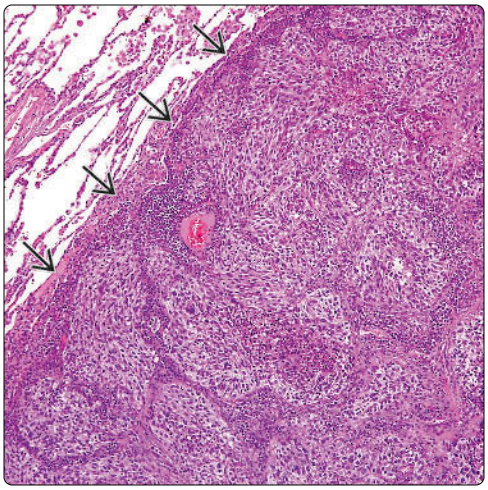

Nests of Spindle Cells

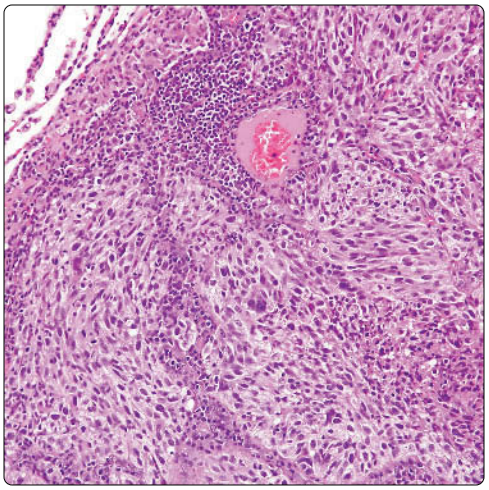

(Left) *Metastasis to the lung from spindle cell melanoma of the forearm shows nests of spindle cells ⇨ that are sharply demarcated from the surrounding lung parenchyma.* **(Right)** *Higher magnification of metastasis from spindle cell melanoma shows well-defined nests of tumor cells. The tumor cells are characterized by their spindle appearance with elongated, tapered nuclei surrounded by a rim of eosinophilic cytoplasm. The nesting patterns are a clue to the diagnosis.*

S100 Protein Immunostaining

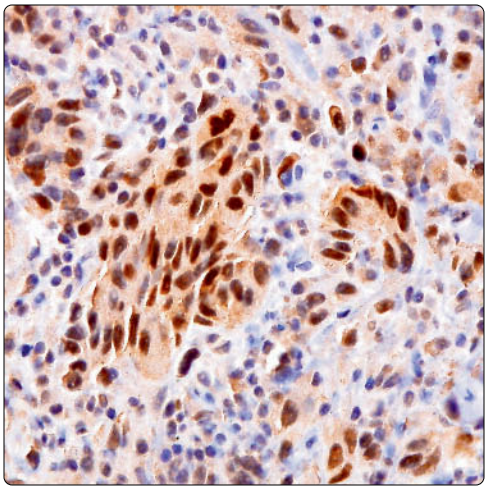

Metastatic Spindle Cell Melanoma

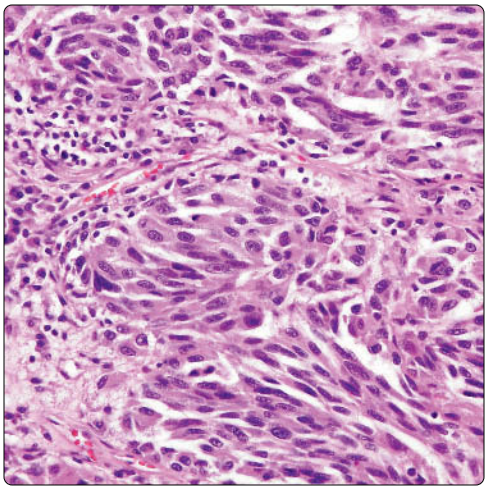

(Left) *Immunohistochemical staining of metastasis to the lung from spindle cell melanoma with S100 shows strong cytoplasmic and nuclear positivity of the spindle tumor cells for this antigen.* **(Right)** *Metastasis to the lung from spindle cell ocular melanoma shows poorly formed nests of tumor cells with a spindle morphology. Spindle cell melanomas may lose their nested pattern and show a fascicular appearance that may be confused for a sarcoma or sarcomatoid carcinoma.*

Fascicular Growth

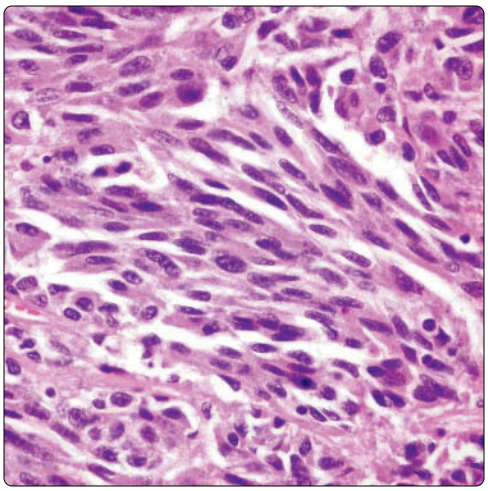

Spindle Cell Melanoma: High Power

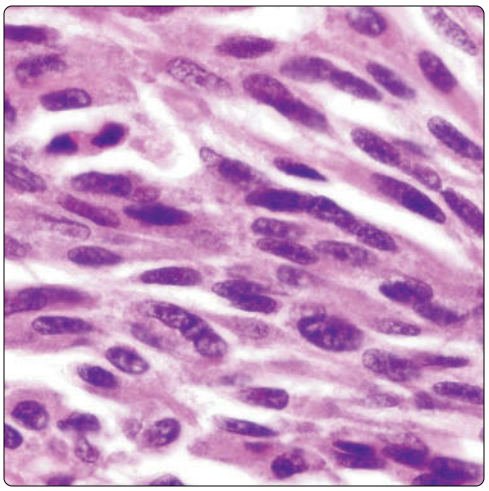

(Left) *Higher magnification of metastatic ocular spindle cell melanoma shows fascicles of tumor cells composed of atypical cells with hyperchromatic nuclei and a scant rim of eosinophilic cytoplasm. Tumors like this may resemble leiomyosarcoma or spindle cell carcinoma.* **(Right)** *Higher magnification of metastasis to the lung from ocular spindle cell melanoma shows spindle cells with hyperchromatic nuclei and occasional nucleoli surrounded by a rim of eosinophilic cytoplasm.*

Endobronchial Metastasis

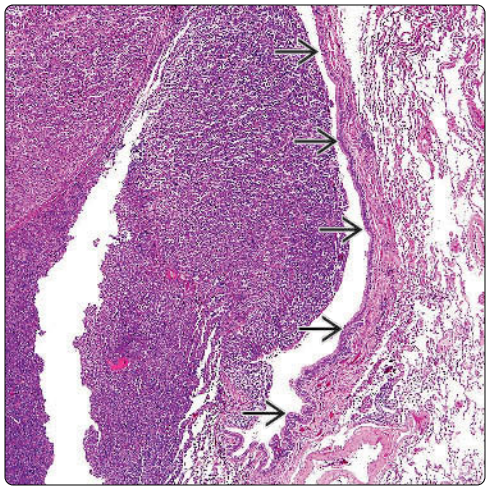

In Situ Focus of Melanoma

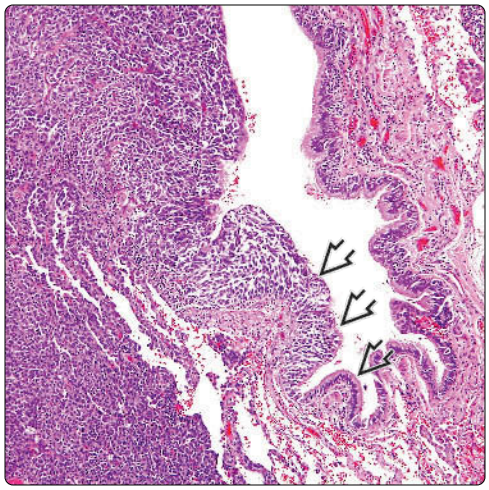

(Left) *Endobronchial metastasis of malignant melanoma shows a polypoid tumor mass growing into the lumen of the bronchus. Notice the distended bronchial lumen lined by a single layer of bronchial epithelium ⇨. Endobronchial metastases of melanoma need to be distinguished from primary lung neoplasms that can show this same growth pattern.* **(Right)** *Endobronchial metastasis of malignant melanoma shows transition between the normal bronchial mucosa and the malignant melanoma ⇨.*

Transition With Bronchial Mucosa

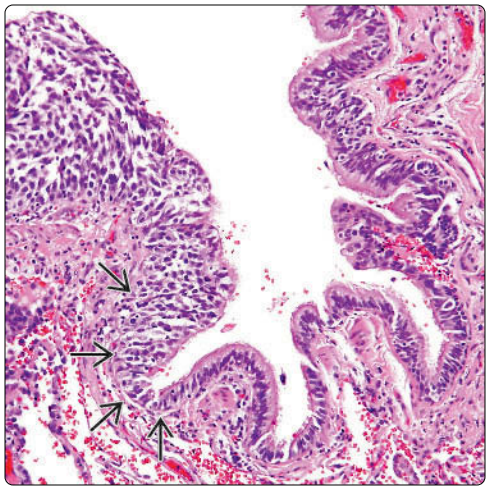

Transition: Higher Magnification

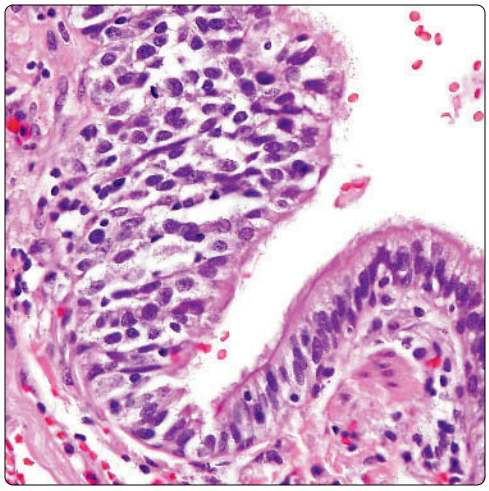

(Left) *Higher magnification of endobronchial metastasis from malignant melanoma shows gradual replacement of the bronchial epithelium by the melanoma cells ⇨. At times, it may be impossible to separate cases like this from a primary malignant melanoma of the bronchus in the absence of a clinical history.* **(Right)** *Higher magnification illustrates the transition between normal bronchial epithelium with tall columnar ciliated cells and endobronchial metastatic malignant melanoma.*

Melanin Pigment Deposition

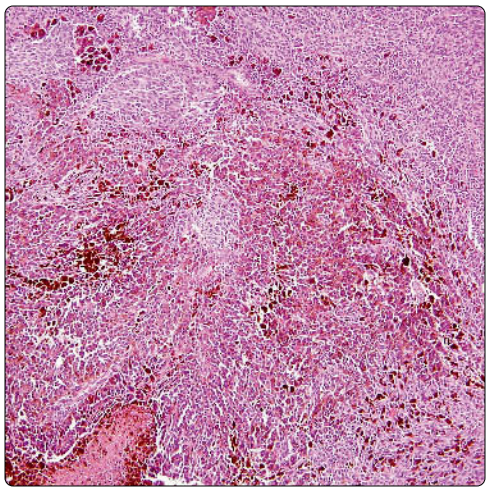

Melanin Pigment: Higher Power

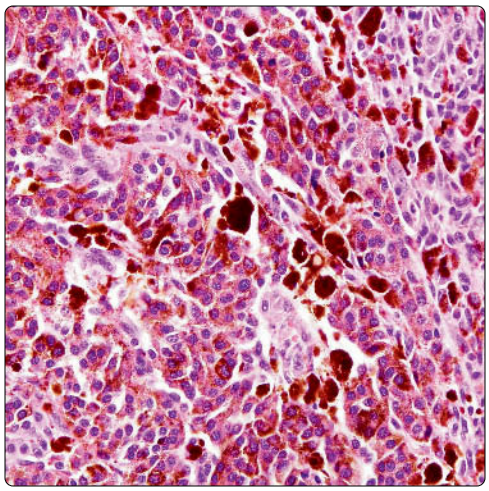

(Left) *Solid area of the tumor in endobronchial metastasis of malignant melanoma shows a heavy deposition of dark melanin pigment. The presence of melanin pigment serves to facilitate the diagnosis in pigmented metastases of malignant melanoma.* **(Right)** *Higher magnification of endobronchial metastasis of pigmented malignant melanoma shows a heavy deposition of dark brown pigment in the cytoplasm of the tumor cells. A hint of nesting pattern of the tumor cells can be appreciated.*

Pseudopapillary Pattern

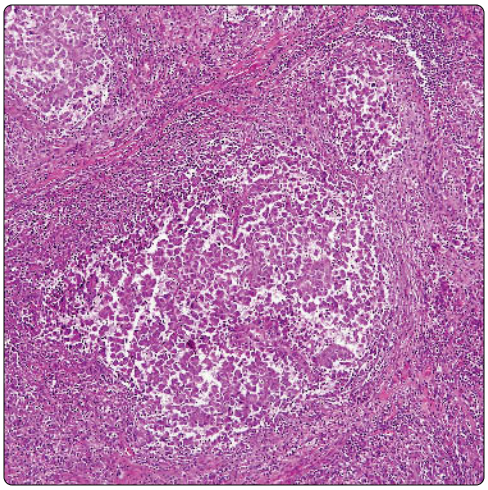

Artifactual Breakdown of Cells

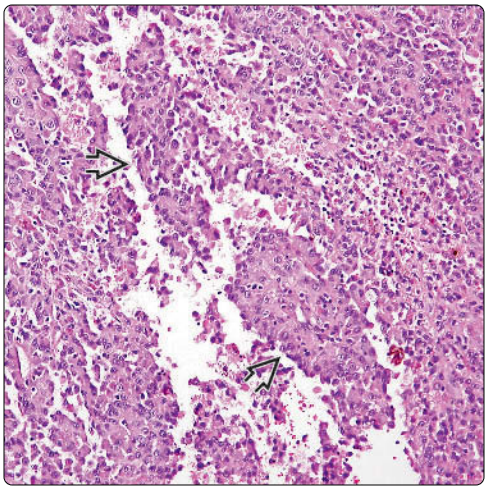

(Left) *Metastatic malignant melanoma to the lung shows a vague pseudopapillary pattern of growth resulting from dehiscence of tumor cells.* **(Right)** *Higher magnification of metastatic malignant melanoma to the lung shows irregular pseudopapillary structures resulting from artifactual breakdown of the tumor cells. Tumors with these features can often be confused for a variety of primary and metastatic papillary carcinomas of the lung.*

S100 Protein Immunostaining

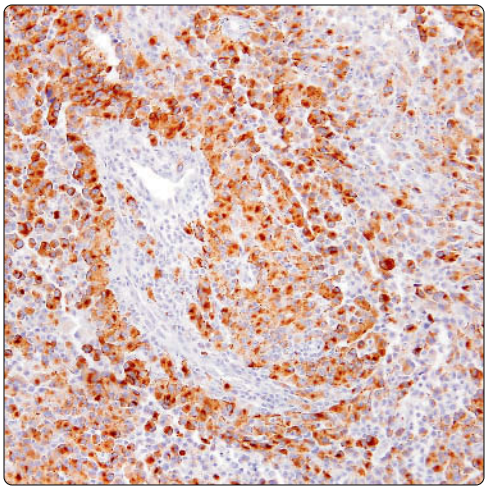

Rhabdoid Malignant Melanoma

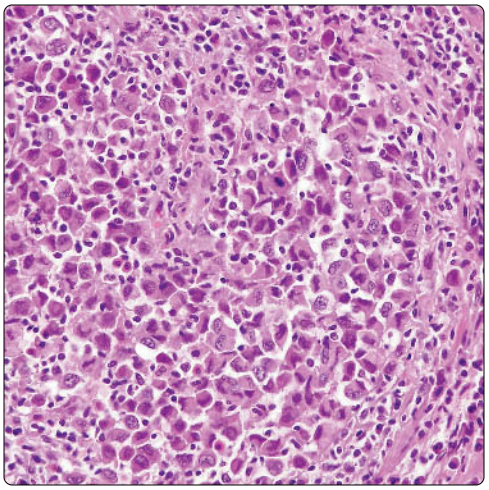

(Left) *Immunohistochemical staining with S100 in pulmonary metastasis of malignant melanoma with a pseudopapillary pattern of growth shows strong nuclear and cytoplasmic positivity in the tumor cells.* **(Right)** *Metastasis to the lung from malignant melanoma shows a dyscohesive population of cells with large nuclei and abundant eccentric cytoplasm imparting the cells with a rhabdoid appearance. The differential diagnosis includes rhabdomyosarcoma and malignant rhabdoid tumor.*

Rhabdoid Melanoma Cells

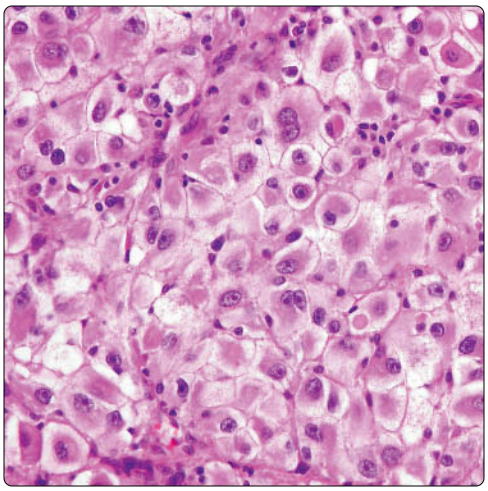

Rhabdoid Cytoplasmic Inclusions

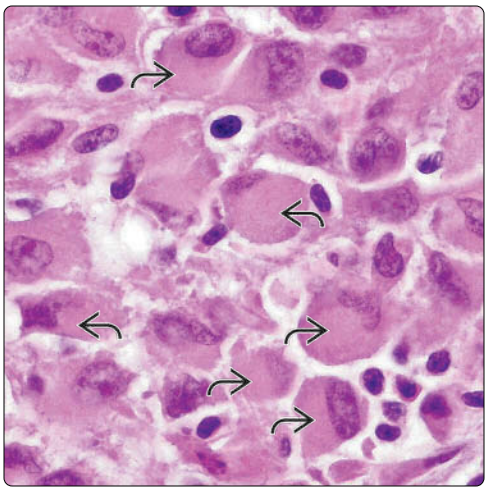

(Left) *Higher magnification of metastasis to the lung from rhabdoid malignant melanoma shows sheets of large tumor cells with abundant cytoplasm and dense eosinophilic cytoplasmic inclusions. These features are nonspecific and can be observed in a wide variety of malignant neoplasms, including neuroendocrine malignancies, sarcomas, and carcinomas.* **(Right)** *Higher magnification of rhabdoid cells in metastatic melanoma of the lung shows characteristic cytoplasmic inclusions.*

Small Cell Variant of Metastatic Melanoma

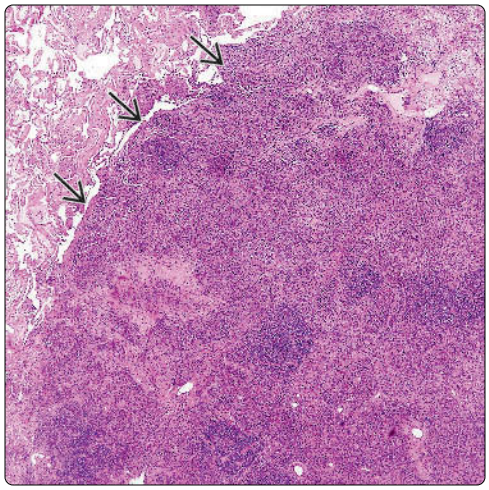

Small Cell Melanoma

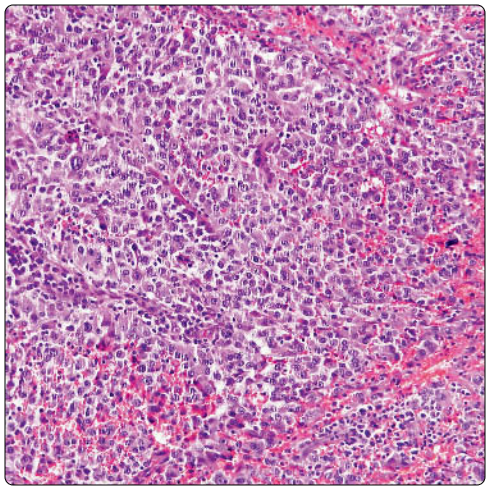

(Left) *Scanning magnification of lung metastasis of malignant melanoma, small cell variant, shows a well-defined tumor nodule separated from the surrounding normal lung parenchyma.* **(Right)** *Higher magnification of pulmonary metastasis from malignant melanoma, small cell variant, shows sheets of uniform small tumor cells with no discernible growth pattern. Tumors like this can be confused for malignant lymphoma or small cell neuroendocrine carcinoma.*

Infiltration of Bronchiole

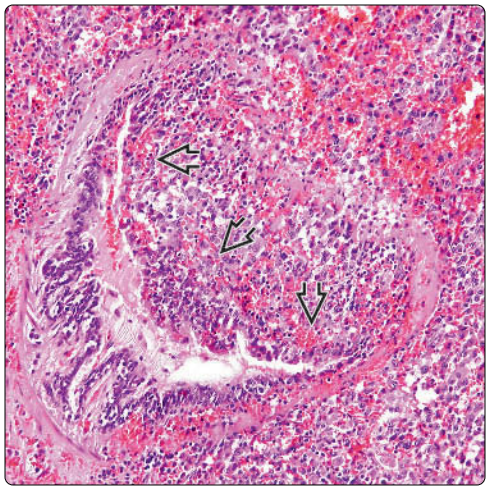

Sheets of Small Cells in Melanoma

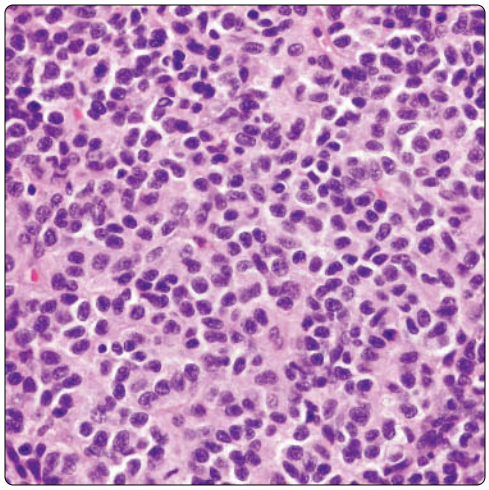

(Left) *Infiltration and destruction of the wall of a bronchiole is seen in this example of pulmonary metastasis of malignant melanoma of small cell type. Epitheliotropism is commonly encountered in malignant melanoma at metastatic sites.* **(Right)** *Metastasis to the lung from malignant melanoma of small cell type shows a monotonous population of small tumor cells simulating a malignant lymphoma, a highly unusual morphologic appearance that can be very difficult to diagnose.*

Small Cells: Higher Magnification

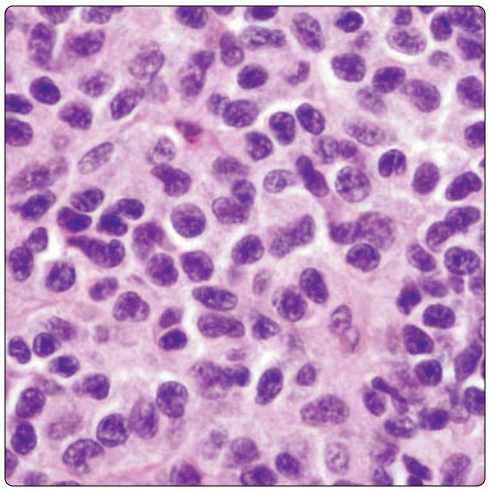

Intracytoplasmic Melanin Pigment

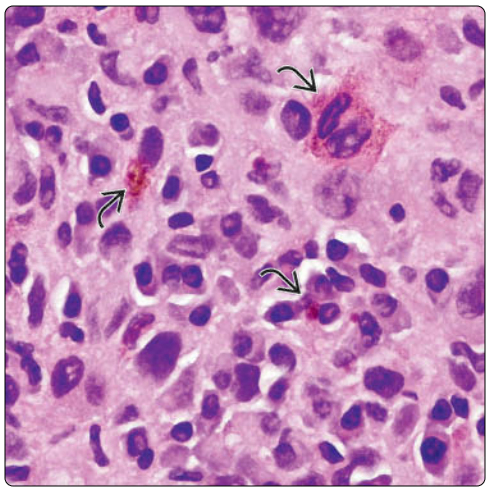

(Left) *Higher magnification of pulmonary metastasis of small cell melanoma shows sheets of small round tumor cells with hyperchromatic nuclei, absent or very inconspicuous nucleoli, paucity of mitotic figures, and an indistinct rim of cytoplasm surrounding the tumor cells.* **(Right)** *Higher magnification from pulmonary metastasis of malignant melanoma, small cell variant, shows a few scattered cells displaying cytoplasmic melanin pigment, a helpful clue for the diagnosis.*

S100 Protein Immunostaining

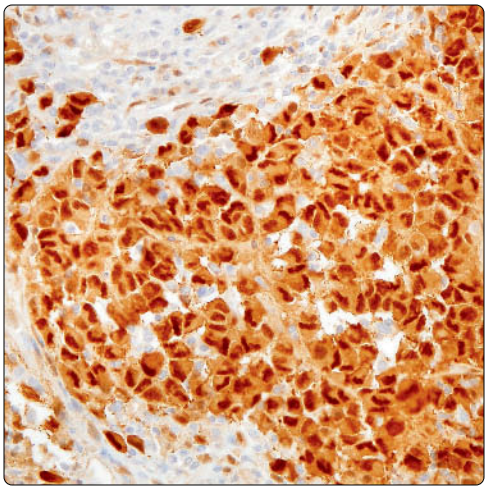

HMB-45 Immunostaining

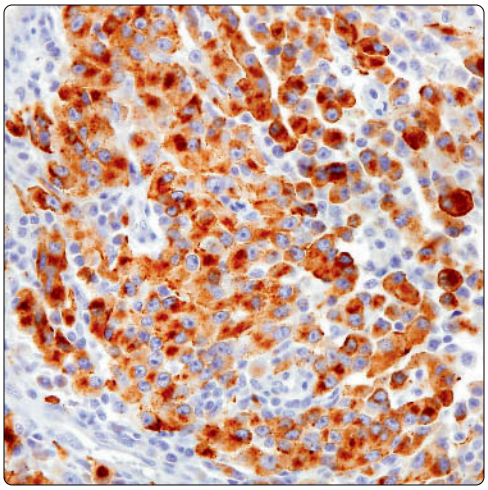

(Left) *Immunohistochemical staining of metastatic malignant melanoma for S100 protein shows strong nuclear and cytoplasmic staining of the tumor cells. This antigen is very sensitive but not very specific for malignant melanoma.* **(Right)** *Immunohistochemical staining of metastatic malignant melanoma to lung with HMB-45 melanoma-associated marker shows strong positivity in the tumor cells. This marker may not always be expressed at metastatic sites and is less sensitive than S100.*

Melan-A Immunostaining

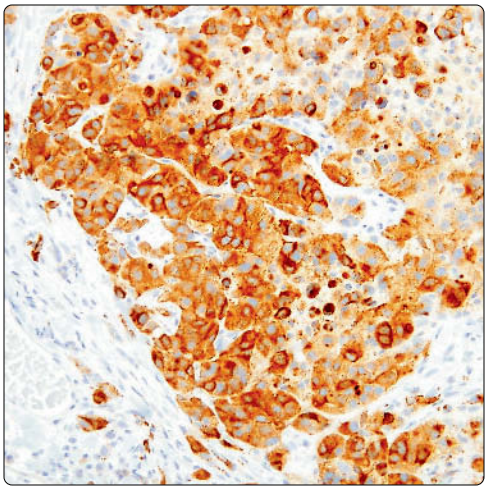

Melan-A Immunostaining

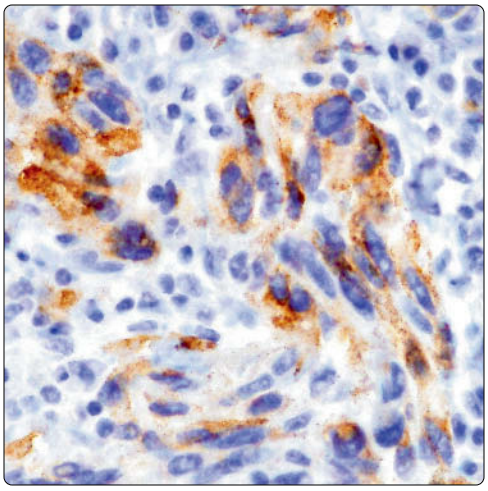

(Left) *Immunohistochemical staining of metastatic melanoma to the lung with Melan-A shows the strong positivity of tumor cells for this marker. Melan-A is a good alternative for a melanocyte-specific marker in the diagnosis of malignant melanoma at metastatic sites.* **(Right)** *Immunohistochemical staining of metastatic spindle cell melanoma with Melan-A (clone A103) shows cytoplasmic positivity in the spindle tumor cells. Use of this antibody can be helpful in HMB-45(-) cases.*

CEA Immunostaining

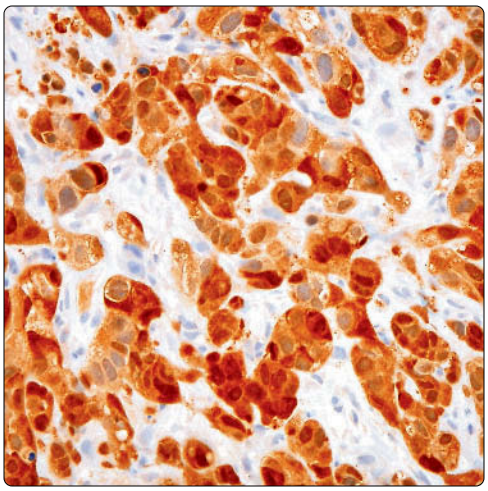

EMA Immunostaining

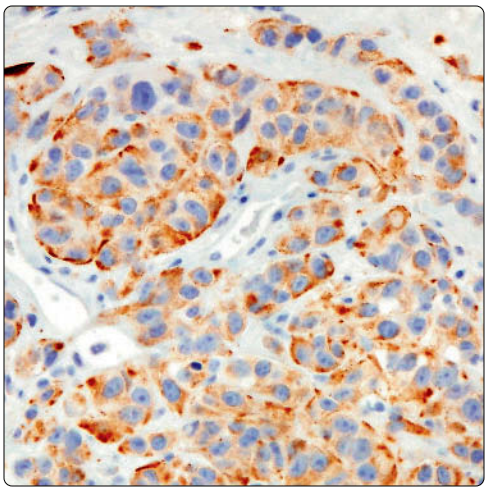

(Left) *Immunohistochemical staining of metastatic malignant melanoma to the lung with CEA polyclonal antibody shows cytoplasmic positivity in the tumor cells. CEA positivity can occur in a subset of malignant melanomas causing diagnostic difficulties that most likely result from cross-reactivity with nonspecific antigens.* **(Right)** *Faint cytoplasmic staining is seen in metastatic melanoma with EMA antibodies. Occasional cases of metastatic melanoma may react with EMA antibodies.*

This page intentionally left blank

PART I
SECTION 4

Nonneoplastic and Systemic Conditions

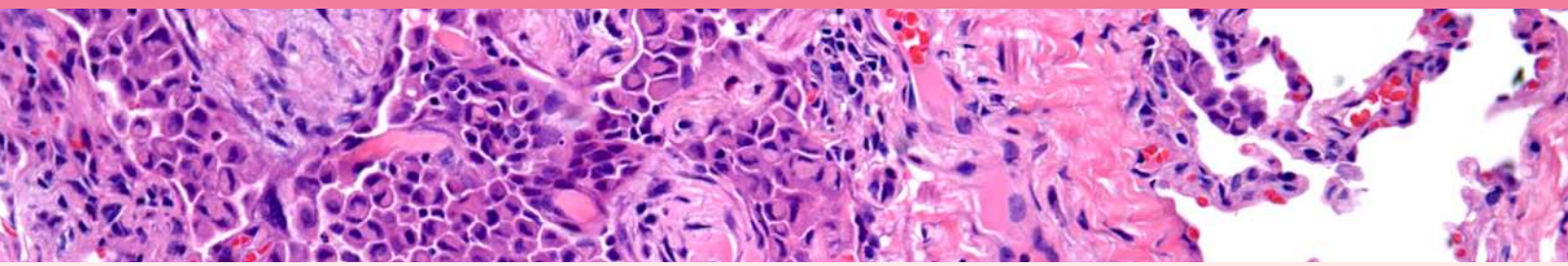

Diffuse Alveolar Damage	**386**
Bronchiolitis Obliterans With Organizing Pneumonia	**390**
Respiratory Bronchiolitis	**394**
Usual Interstitial Pneumonia	**398**
Desquamative Interstitial Pneumonia	**406**
Nonspecific Interstitial Pneumonia	**410**
Extrinsic Allergic Alveolitis	**414**
Allergic Angiitis and Granulomatosis (Churg-Strauss)	**418**
Bronchocentric Granulomatosis	**422**
Wegener Granulomatosis	**426**
Sarcoidosis	**430**
Hard Metal Pneumoconiosis Pneumonitis	**434**
Asbestos-Related Interstitial Fibrosis	**438**
Idiopathic Pulmonary Hemosiderosis	**442**
Alveolar Proteinosis	**444**
Pulmonary Amyloidosis	**448**
Eosinophilic Pneumonia	**452**
Langerhans Cell Histiocytosis	**456**
Erdheim-Chester Disease	**460**
Alveolar Microlithiasis	**464**

Diffuse Alveolar Damage

KEY FACTS

TERMINOLOGY

- Acute inflammatory reaction involving endothelial and epithelial cells of alveolus

CLINICAL ISSUES

- Nonspecific histologic pattern of acute lung injury that may occur in wide variety of clinical settings
- Idiopathic cases are designated acute interstitial pneumonia or Hamman-Rich syndrome
- Clinical syndrome associated with diffuse alveolar damage is known as acute respiratory distress syndrome
- ~ 50% of patients may undergo spontaneous resolution with supportive therapy
- High overall mortality (~ 50% of patients)
- Surviving patients may recover normal lung function or go on to develop interstitial fibrosis

MICROSCOPIC

- Early acute phase characterized by capillary congestion, edema, and intraalveolar hemorrhage
- Formation of hyaline membranes (pink fibrinous material lining alveolar walls) is hallmark of acute phase
- Interstitial inflammatory exudates (lymphocytes, plasma cells, and histiocytes)
- Organizing phase shows proliferation of type II pneumocytes with cytologic atypia
- Fibroblastic proliferation forms fibrinous intraalveolar plugs of granulation tissue reminiscent of organizing pneumonia
- Dense interstitial fibrosis with widening of alveolar septa is seen in late stages

DIAGNOSTIC CHECKLIST

- Morphologic findings are nonspecific and need to be correlated with clinical picture for definitive diagnosis

Gross Appearance of Diffuse Alveolar Damage

Interstitial Edema and Inflammation

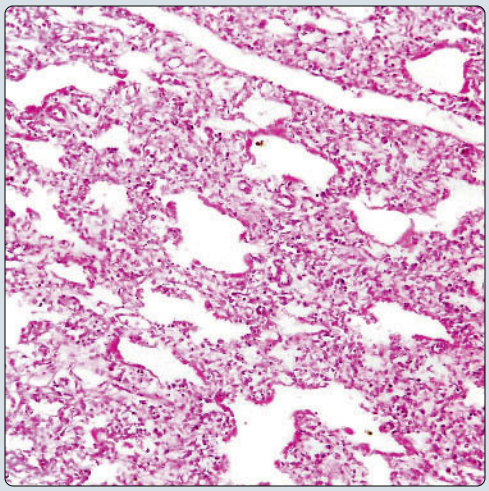

(Left) *Gross appearance of the lung on cut surface in a patient with diffuse alveolar damage (DAD) shows beefy red, congested, and edematous parenchyma.* **(Right)** *Histologic appearance of DAD shows airspaces lined by hyaline membranes and thickened alveolar septa containing inflammatory exudate.*

Interstitial Inflammation

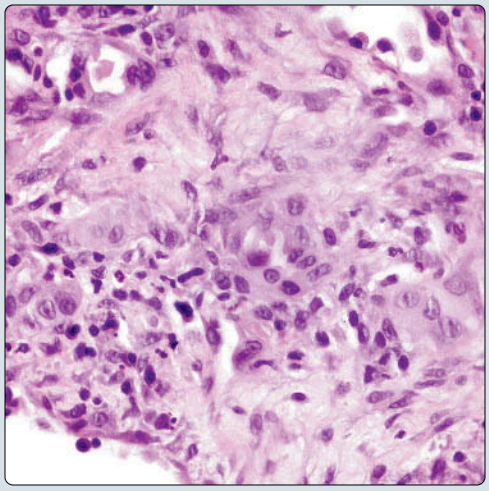

Hyaline Membrane

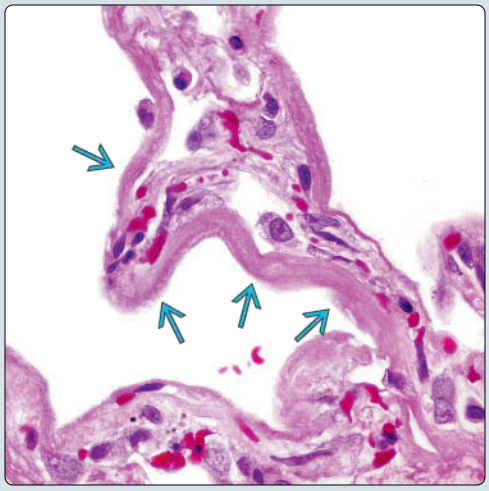

(Left) *Higher magnification from the interstitium of the lung shows stromal edema with early fibroblastic proliferation and acute inflammatory infiltrates.* **(Right)** *Higher power shows the lumen of an alveolar space and the lining of the alveolar wall replaced by a thick, homogeneous eosinophilic layer of fibrin corresponding to the "hyaline membrane".*

TERMINOLOGY

Abbreviations

- Diffuse alveolar damage (DAD)

Synonyms

- Acute respiratory distress syndrome, shock lung, postperfusion lung, hyaline membrane disease

Definitions

- Acute inflammatory reaction involving endothelial and epithelial cells of alveolus

ETIOLOGY/PATHOGENESIS

Etiology

- Can result from variety of lung injuries
  - Bacterial and viral infection
  - Drugs and inhaled toxins
  - Shock, trauma, burns, sepsis, radiation
  - Allograft rejection
  - Collagen vascular disease
  - Idiopathic

CLINICAL ISSUES

Epidemiology

- Age
  - Children to adults

Presentation

- Tachypnea and rapidly progressive dyspnea
- Respiratory failure with noncardiogenic pulmonary edema

Natural History

- Nonspecific histologic pattern of acute lung injury that may occur in wide variety of clinical settings
- Idiopathic cases are designated acute interstitial pneumonia or Hamman-Rich syndrome
- Clinical syndrome associated with DAD is known as acute respiratory distress syndrome
- Rapid clinical onset, usually within 24-48 hours of precipitating event
- ~ 50% of patients may undergo spontaneous resolution with supportive therapy
- Oxygen therapy and mechanical ventilation may play significant role in causing development of tissue injury

Prognosis

- High overall mortality (~ 50% of patients)
- Surviving patients may recover normal lung function or go on to develop interstitial fibrosis

IMAGING

Radiographic Findings

- Bilateral basilar opacities are most common finding

CT Findings

- Intense parenchymal opacification due to lung consolidation or compressive atelectasis in dependent lung
- Ground-glass opacities with inhomogeneous distribution

MACROSCOPIC

General Features

- Markedly enlarged and heavy lungs (3-4x normal weight)
- Dark, red to blue cut surface with marked congestion and edema in early stages

MICROSCOPIC

Histologic Features

- Process is progressive and moves through 3 phases
  - **Exudative (acute) phase**
    - Early acute phase characterized by capillary congestion, edema, and intraalveolar hemorrhage
    - Formation of hyaline membranes (pink fibrinous material lining alveolar walls) is hallmark of acute phase
    - Injury of type I pneumocytes and endothelial cells resulting in exudation of proteins and fluid into interstitium
    - Interstitial inflammatory exudates (lymphocytes, plasma cells, and histiocytes)
    - Microvascular thromboemboli (fibrin thrombi in capillaries or fibrin clots in medium-sized arterioles)
  - **Proliferative (organizing) phase**
    - Organization of exudate with proliferation of type II pneumocytes and fibroblasts
    - Fibroblastic proliferation forms fibrinous intraalveolar plugs of granulation tissue reminiscent of organizing pneumonia
    - Fibroblastic proliferation distends alveolar walls forming loose organizing connective tissue
    - Vascular thromboemboli are present and may lead to peripheral infarcts
  - **Fibrotic (chronic) phase**
    - Seen in patients who survive on ventilator > 3-4 weeks
    - Dense interstitial fibrosis with widening of alveolar septa
    - Squamous metaplasia of bronchiolar epithelium

DIAGNOSTIC CHECKLIST

Pathologic Interpretation Pearls

- Morphologic findings are nonspecific and need to be correlated with clinical picture for definitive diagnosis
- Similar histologic findings can be observed secondarily in other processes unrelated to respiratory distress syndrome
- Histologic phases of DAD may show considerable overlap

SELECTED REFERENCES

1. Cardinal-Fernández P et al: The presence of diffuse alveolar damage on open lung biopsy is associated with mortality in patients with acute respiratory distress syndrome: a systematic review and meta-analysis. Chest. 149(5):1155-64, 2016
2. Beasley MB: The pathologist's approach to acute lung injury. Arch Pathol Lab Med. 134(5):719-27, 2010
3. Kang D et al: Two forms of diffuse alveolar damage in the lungs of patients with acute respiratory distress syndrome. Hum Pathol. 40(11):1618-27, 2009

Diffuse Alveolar Damage: Early Stage

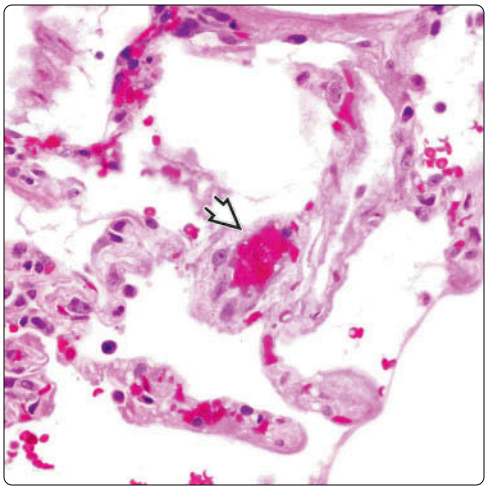

Interstitial Edema

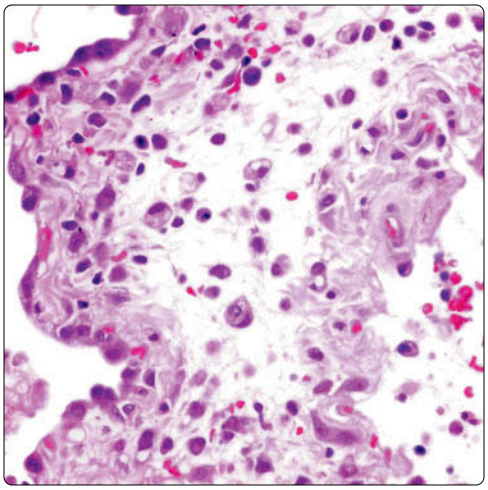

(Left) *Early stage of DAD of the lung shows capillary congestion, edema, and intraalveolar hemorrhage. Microvascular thromboemboli ⇨ composed of fibrin thrombi in capillaries or in medium-sized arterioles can also be observed.* **(Right)** *Interstitial edema is seen in the early stages of DAD, admixed with interstitial inflammatory exudates, including small lymphocytes, plasma cells, and histiocytes.*

Acute Exudative Stage

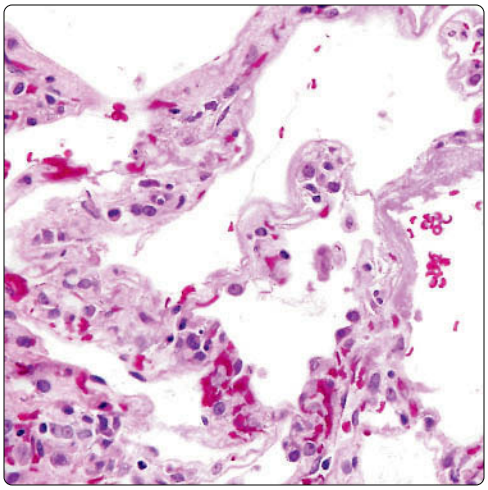

Hyaline Membranes

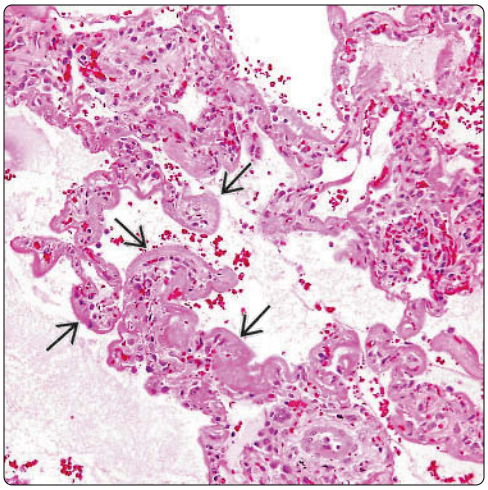

(Left) *Acute exudative stage of DAD shows injury of type II pneumocytes with necrosis of epithelial lining cells and sloughing into the lumen, accompanied by exudation of protein and fluid into the interstitium.* **(Right)** *Hyaline membrane formation is also an early event in the exudative phase of diffuse alveolar damage. The hyaline membranes appear as a layer of pink, amorphous, and homogeneous material ⇨ lining the alveolar lumina.*

Hyaline Membrane

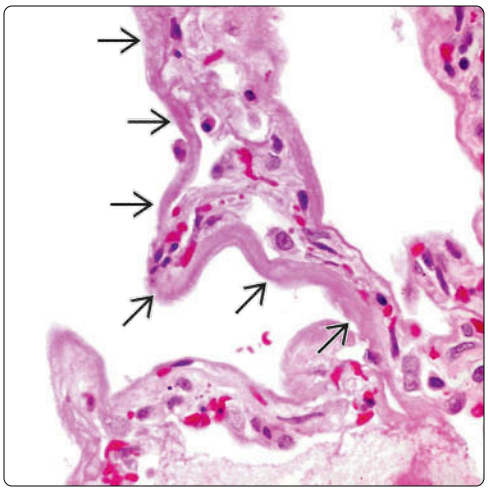

Hyaline Membrane, Higher Power

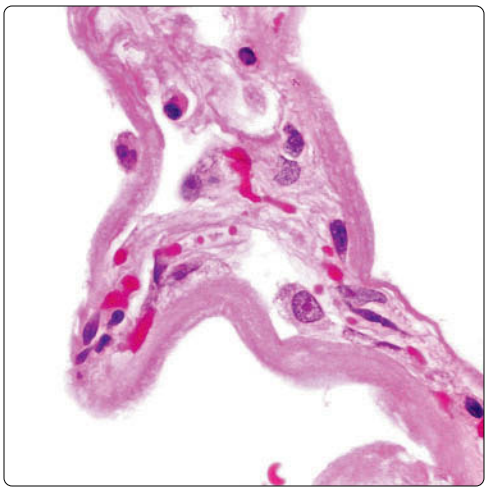

(Left) *Hyaline membrane formation is seen in the early stages of DAD. The hyaline membrane in this case of acute lung injury is characterized by a thick band of homogeneous eosinophilic material ⇨ that lines the alveolar surface and replaces the native respiratory epithelium.* **(Right)** *Higher magnification of the hyaline membrane in DAD shows a thick band of dense, eosinophilic material covering the surface of the alveolar wall.*

Proliferative Phase of Diffuse Alveolar Damage

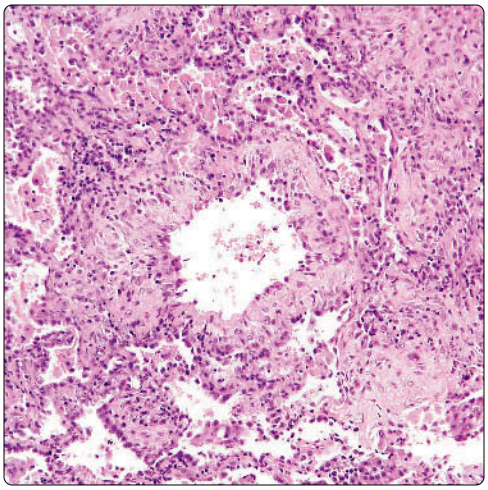

Proliferative Phase, Higher Power

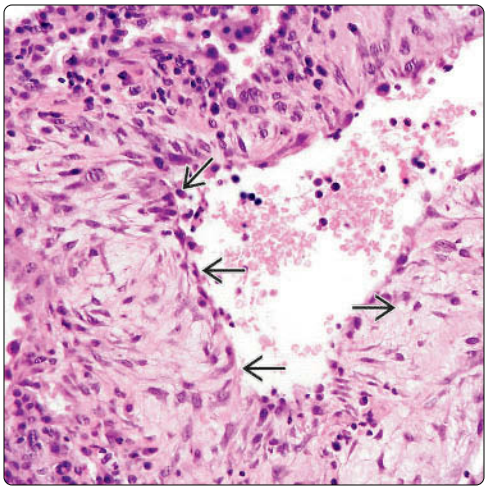

(Left) *Proliferative (organizing) phase of DAD shows organization of the interstitial exudate with proliferation of type II pneumocytes and fibroblasts.* **(Right)** *Higher magnification of proliferative phase of DAD shows fibroblastic proliferation in the wall of the alveoli with residual inflammation and granulation tissue-like changes of the interstitium ⇨. The appearance is reminiscent of fibroblastic foci in usual interstitial pneumonia, but the process is more diffuse.*

Reactive Type II Pneumocytes

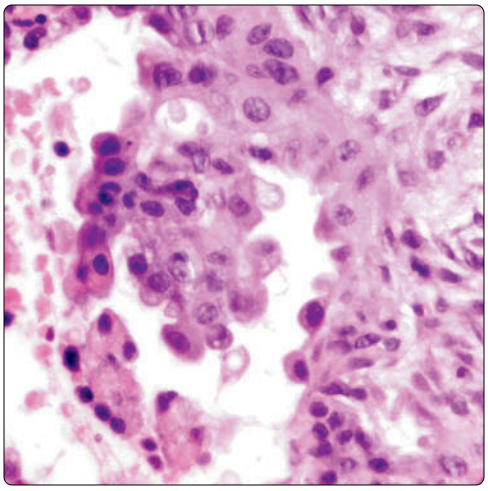

Fibroblastic Plugs

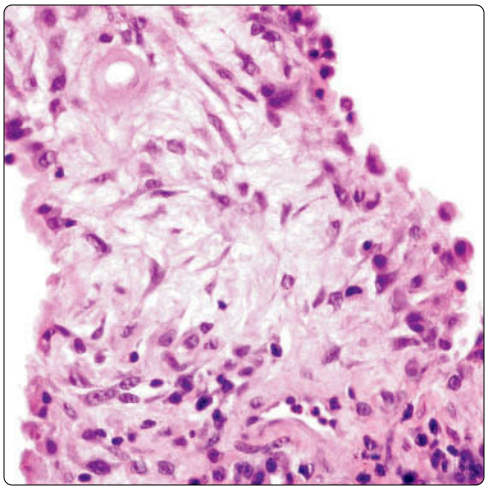

(Left) *Proliferative (organizing) phase of DAD shows reactive proliferation of type II pneumocytes displaying large nuclei with prominent nucleoli, an ample rim of eosinophilic cytoplasm, and marked cytologic atypia.* **(Right)** *Proliferative phase of DAD shows young fibroblastic proliferation in the interstitium of the alveolar walls with spindled fibroblasts embedded in lightly staining myxoid stroma admixed with scattered inflammatory cells.*

Late Phase of Diffuse Alveolar Damage

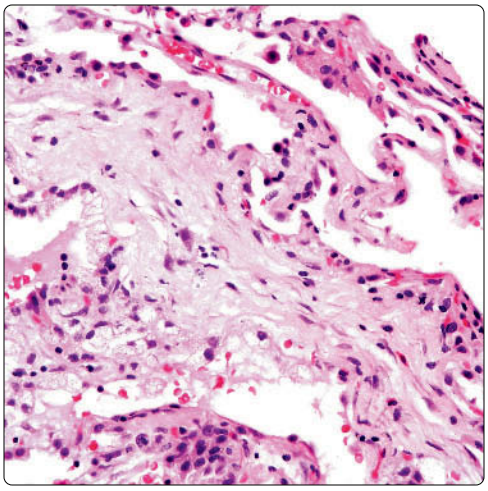

Interstitial Fibrosis

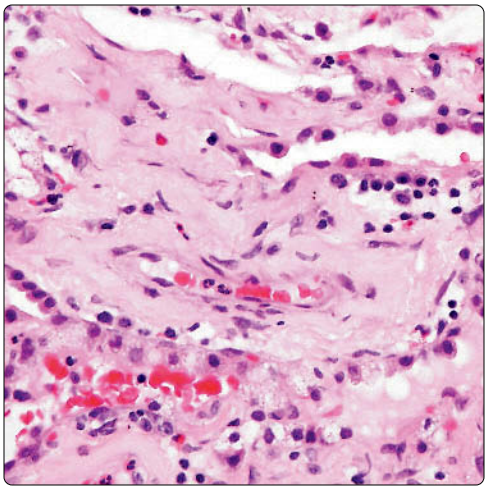

(Left) *Late chronic phase of diffuse alveolar damage may show dense interstitial fibrosis, particularly in patients who have been on a respirator for more than 3-4 weeks. There is widening of the alveolar septa by dense collagenous fibrosis with minimal inflammatory infiltrates and complete disappearance of the hyaline membranes.* **(Right)** *Higher magnification of the chronic phase of DAD shows thickening of alveolar septa by dense fibrosis.*

Bronchiolitis Obliterans With Organizing Pneumonia

KEY FACTS

TERMINOLOGY

- Synonyms: Cryptogenic organizing pneumonia, bronchiolitis obliterans
- Definition
  - Idiopathic interstitial and airway disease process with features of pneumonia

ETIOLOGY/PATHOGENESIS

- No definitive etiology has been specified
- Histopathologic features of bronchiolitis obliterans with organizing pneumonia may be seen secondary to diverse conditions

CLINICAL ISSUES

- Symptoms
  - Cough
  - Dyspnea
  - Fever
  - Flu-like symptoms
- Treatment
  - Corticosteroids
- It may be associated with other conditions including
  - Viral
  - Bacterial
  - Fungal

TOP DIFFERENTIAL DIAGNOSES

- Usual interstitial pneumonitis
- Diffuse alveolar damage
- Organizing diffuse alveolar damage
- Inflammatory pseudotumor

DIAGNOSTIC CHECKLIST

- Loose, young, fibrocollagenous polypoid plugs in alveoli and airway
- Mild inflammatory changes
- Loose organizing fibrosis

Fibrous Plugs | **Airway and Alveolar Involvement**

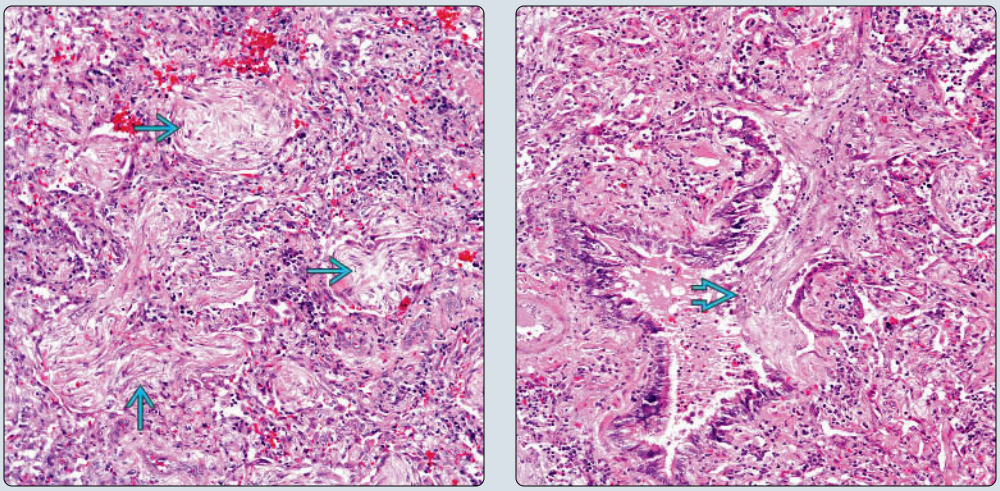

(Left) *Bronchiolitis obliterans with organizing pneumonia (BOOP) is shown with areas of young fibrous plugs in alveolar spaces. These features are characteristic of organizing pneumonia. Note the presence of an inflammatory component.* **(Right)** *Young, fibrous tissue partially obstructs and destroys bronchial lumen and epithelium, respectively. This particular feature is also important in the diagnosis of BOOP.*

Polypoid Plug | **Alveolar Involvement**

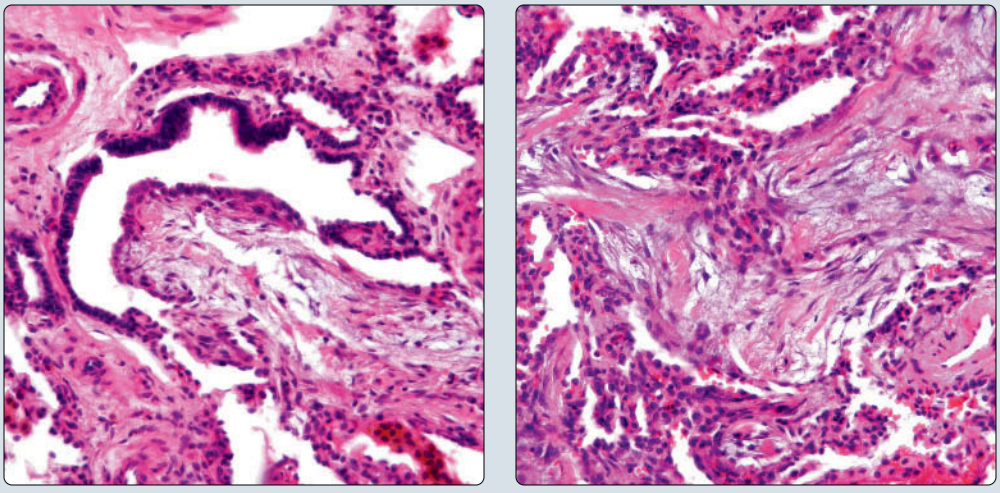

(Left) *The bronchiolitis obliterans component of BOOP is depicted here showing a polypoid plug composed of young fibroblastic cells partially obliterating airway.* **(Right)** *The organizing pneumonia component of BOOP is depicted here showing young fibroblastic plugs involving alveolar spaces. Note there is minimal inflammatory reaction.*

TERMINOLOGY

Abbreviations

- Bronchiolitis obliterans with organizing pneumonia (BOOP)

Synonyms

- Cryptogenic organizing pneumonia, bronchiolitis obliterans

Definitions

- Idiopathic interstitial and airway process with features of pneumonia

ETIOLOGY/PATHOGENESIS

Etiology

- No definitive etiology has been specified for BOOP
- Histopathologic features of BOOP may be seen secondary to diverse conditions

CLINICAL ISSUES

Epidemiology

- Incidence
  - Definitive incidence of BOOP is not known
  - It has been stated at < 10 per 100,000 patient admissions
- Age
  - Usually in adults
- Sex
  - No gender predilection
- Ethnicity
  - No ethnic predilection

Site

- Process may appear in any lung or lung segment

Presentation

- Cough
- Dyspnea
- Fever
- Malaise
- Flu-like symptoms
- Headache

Laboratory Tests

- Leukocytosis
- Elevation of erythrocyte sedimentation rate
- C-reactive protein is positive

Treatment

- Drugs
  - Corticosteroids
  - Azathioprine or cyclophosphamide in some patients who do not respond to steroids

Prognosis

- Most patients respond to corticosteroid therapy

Associated Conditions With Histology of BOOP

- Infectious conditions
  - Viral
  - Bacterial
  - Fungal
- Collagen vascular disease
- Radiation
- Hypersensitivity
- Autoimmune process
- Post lung transplant

MACROSCOPIC

General Features

- Diagnosis of BOOP is essentially done on open biopsy specimens
  - Thus, no specific macroscopic features have been associated with BOOP

MICROSCOPIC

Histologic Features

- Loose organizing fibrosis
- Intraluminal fibrocollagenous polypoid plugs
  - Bronchioles
  - Alveoli
  - Alveolar ducts
- Mild inflammatory changes

DIFFERENTIAL DIAGNOSIS

Usual Interstitial Pneumonitis

- Shows relatively normal areas of lung parenchyma intermixed with areas of interstitial fibrosis
- Usually bilateral and diffuse
- Honeycombing-like changes in lung parenchyma are characteristic of usual interstitial pneumonitis

Organizing Diffuse Alveolar Damage

- May show areas of intraluminal fibrosis similar to BOOP
- Shows hyaline membranes and type II pneumocyte hyperplasia
- Organizing diffuse alveolar damage is diffuse process

Inflammatory Pseudotumor

- Shows predominantly plasma cell or fibrohistiocytic component
- Will not show presence of intraalveolar fibrocollagenous plugs

DIAGNOSTIC CHECKLIST

Clinically Relevant Pathologic Features

- Tissue distribution

Pathologic Interpretation Pearls

- Loose, young, fibrocollagenous polypoid plugs in alveoli and airway
- Mild inflammatory changes
- Loose organizing fibrosis

SELECTED REFERENCES

1. Rojas CM et al: Bronchiolitis obliterans organizing pneumonia in patients with autoimmune rheumatic diseases. Immunol Res. 61(1-2):97-103, 2015
2. Sara AG et al: Bronchiolitis obliterans organizing pneumonia: Pathogenesis, clinical features, imaging and therapy review. Ann Thorac Med. 3(2):67-75, 2008
3. Schlesinger C et al: The organizing pneumonias : a critical review of current concepts and treatment. Treat Respir Med. 5(3):193-206, 2006

(Left) *Low-power view of BOOP shows a well-demarcated area of organization giving the appearance of a nodule within the lung parenchyma. Still, areas of uninvolved lung parenchyma are present.* **(Right)** *BOOP may present as a well-demarcated nodule that partially obliterates the normal lung parenchyma. Note here the presence of a well-demarcated nodule in contrast to normal lung parenchyma.*

Ill-Defined Nodule

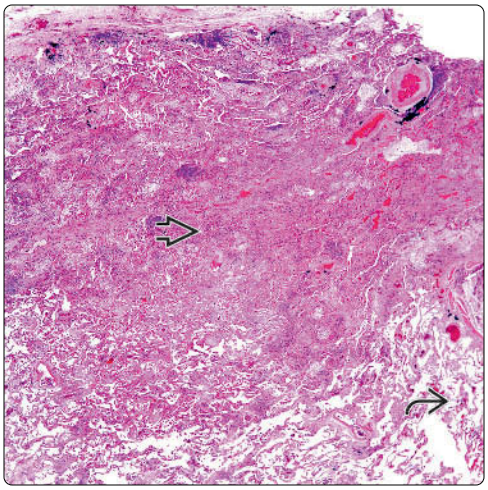

Normal Lung and BOOP

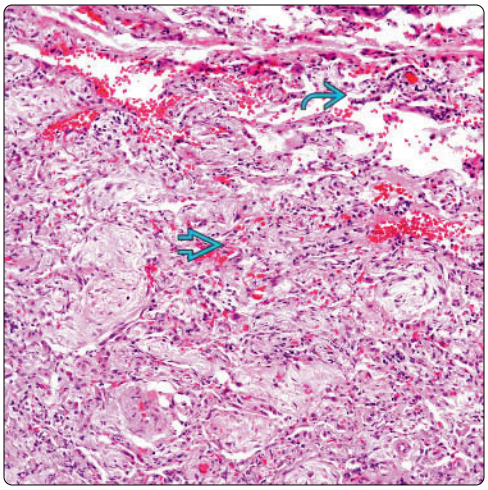

(Left) *Higher magnification shows fibroblastic plugs made of young fibroconnective tissue. These structures are destroying the normal alveolated lung parenchyma. This image may mimic cases of organizing diffuse alveolar damage.* **(Right)** *High-power magnification of a fibroblastic plug shows some spindle cellular proliferation admixed with fibroconnective tissue. Cellular atypia may be seen in some cases.*

Masson Bodies

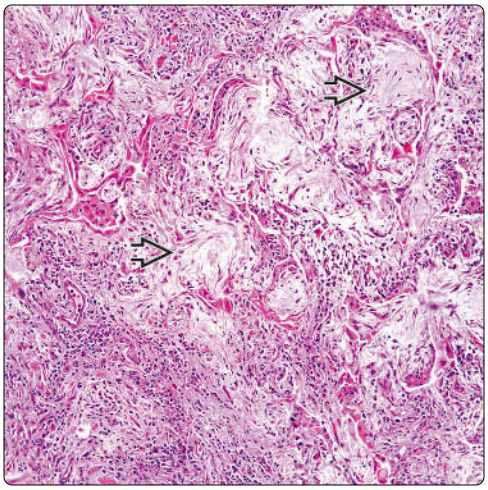

Young Fibroblastic Plugs

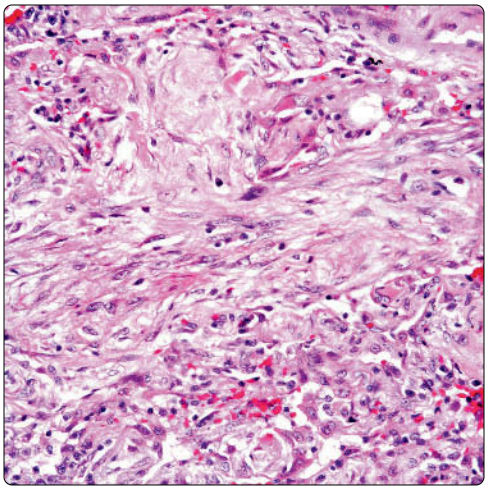

(Left) *Fibroblastic plugs are shown involving alveolar spaces and dispersed haphazardly in the lung parenchyma. In addition, there is hyperplasia of type II pneumocytes.* **(Right)** *One important component in the diagnosis of BOOP is the presence of similar fibroblastic plugs in the airways. Note the presence of polypoid structures filling the airway.*

Hyperplasia of Type II Pneumocytes

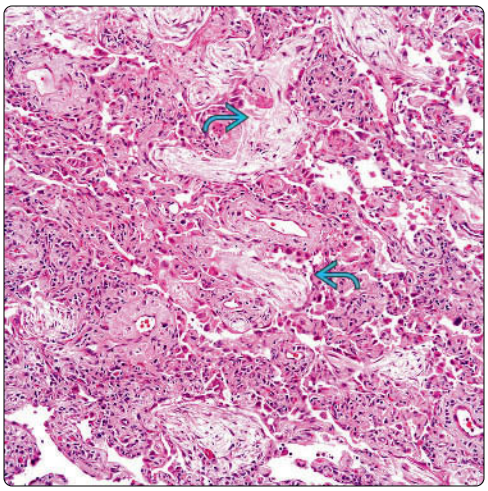

Involvement of Airway

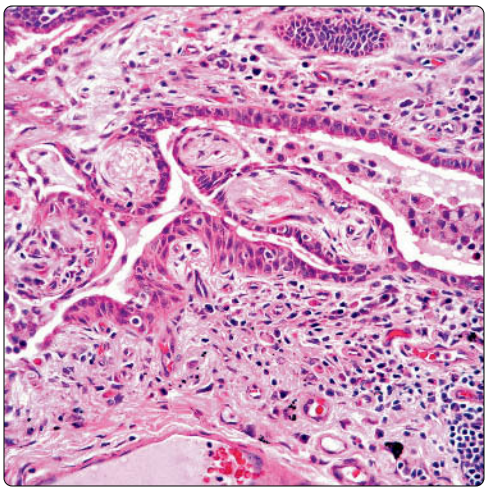

Alveolar Involvement

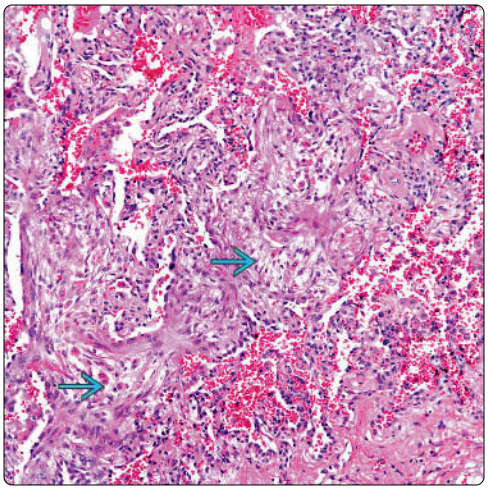

Airway and Alveolar Involvement

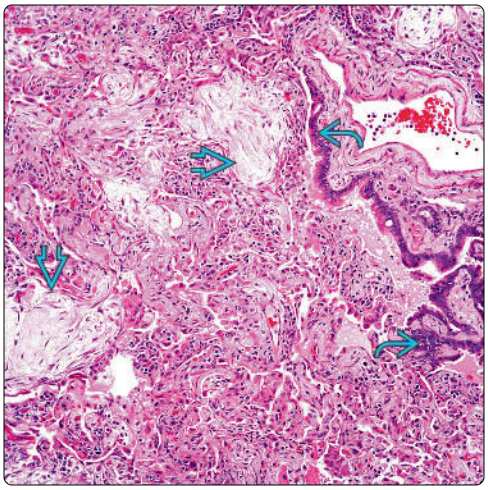

(Left) *BOOP shows the presence of young, fibrous tissue penetrating alveolar spaces. The tissue appears to be dissecting interstitium. Still, areas of uninvolved lung parenchyma are present.* **(Right)** *In some cases of BOOP, the presence of airway obstruction can be difficult to appreciate. In this case, the airway appears to be partially destroyed, and the presence of fibrous plugs appears to be more in the alveolated areas than in the airway.*

Involved and Noninvolved Airway

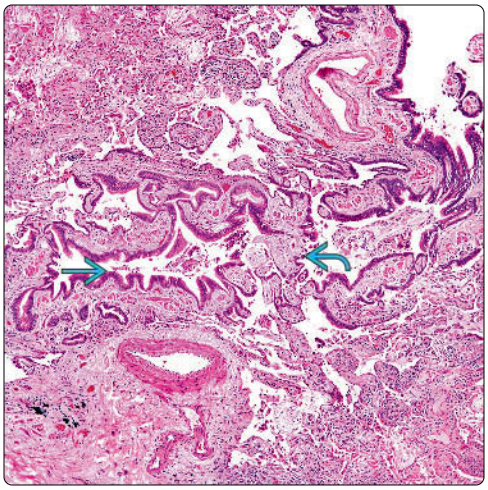

Residual Airway

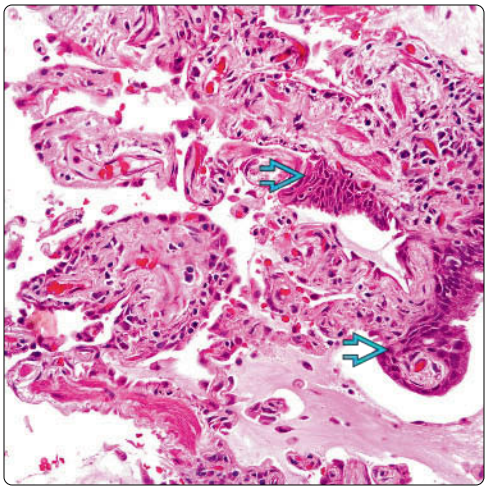

(Left) *In other areas of BOOP, strips of bronchial epithelium are present as well as identifiable airway. In addition, polypoid structures composed of young, fibrous tissue are apparent in the lumen of the airway.* **(Right)** *Closer view shows some of those polypoid structures are composed of fibroconnective tissue and some of them are lined by low cuboidal type of epithelium. In addition, note the presence of residual normal bronchial epithelium .*

Squamous Metaplasia

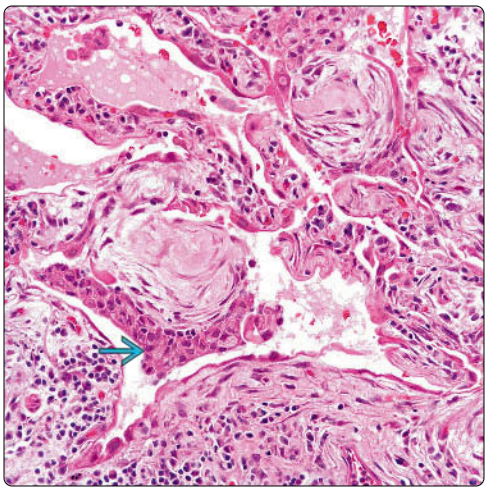

Classic BOOP

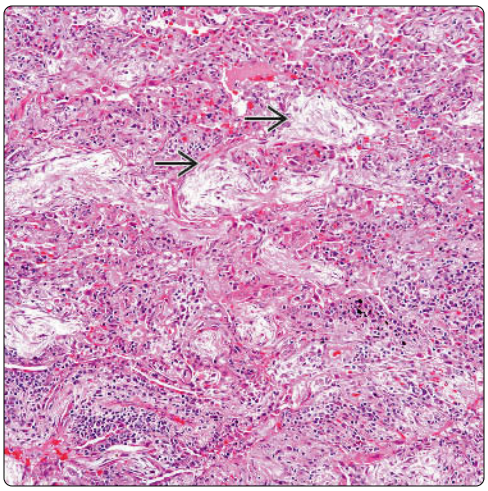

(Left) *Remaining bronchial structure is shown with squamous metaplasia and some polypoid fibrous plugs in this lumen. These features are characteristic of BOOP.* **(Right)** *Areas of BOOP are shown with more conventional areas of organizing pneumonia. Note the presence of the so-called Masson bodies, young fibrocollagenous tissue, and inflammatory infiltrate.*

Respiratory Bronchiolitis

KEY FACTS

TERMINOLOGY

- Respiratory bronchiolitis-interstitial lung disease (RB-ILD)
- Synonym
  - Smoker bronchiolitis
- Definition
  - Mild form of interstitial lung disease

ETIOLOGY/PATHOGENESIS

- Closely associated with smoking history
- Occupational exposure to fumes

CLINICAL ISSUES

- Symptoms
  - Cough
  - Dyspnea
  - Wheezing
  - Flu-like symptoms
- Laboratory findings
  - No specific laboratory findings for RB
  - Pulmonary function tests may be normal
- Treatment
  - Cessation of smoking
  - Corticosteroids

TOP DIFFERENTIAL DIAGNOSES

- Desquamative interstitial pneumonitis
- Langerhans cell histiocytosis
- Usual interstitial pneumonitis

DIAGNOSTIC CHECKLIST

- Collections of pigmented macrophages in lumina of airways
- Collections of intraalveolar macrophages around small airways
- Absence of marked interstitial fibrosis
- Adult individuals without gender or ethnic predilection

Pigmented Macrophages in Airway

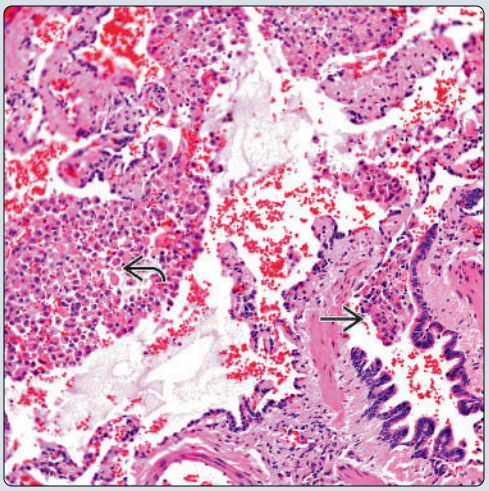

Focal Areas of Scarring

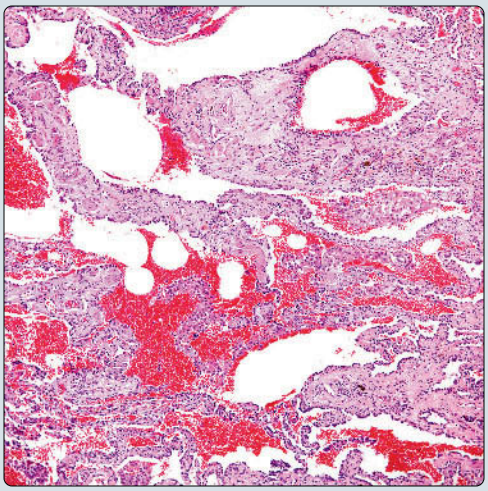

(Left) *Respiratory bronchiolitis shows collections of pigmented macrophages within the airway and in adjacent alveolar spaces.* **(Right)** *Respiratory bronchiolitis-interstitial lung disease (RB-ILD) shows areas of scarring with widening of the interstitium. The normal alveolated architecture is being replaced. Note the collections of alveolar macrophages.*

Partial Destruction of Airway

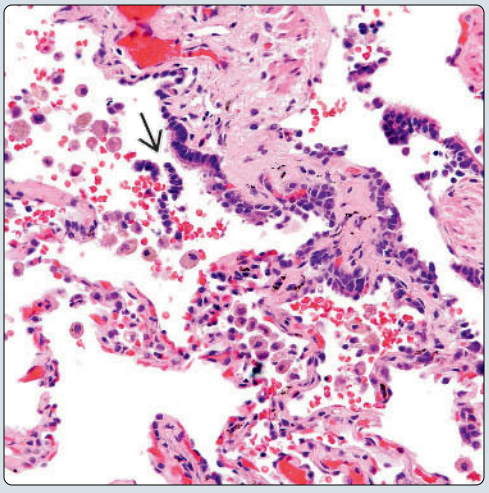

Pigmented Macrophages

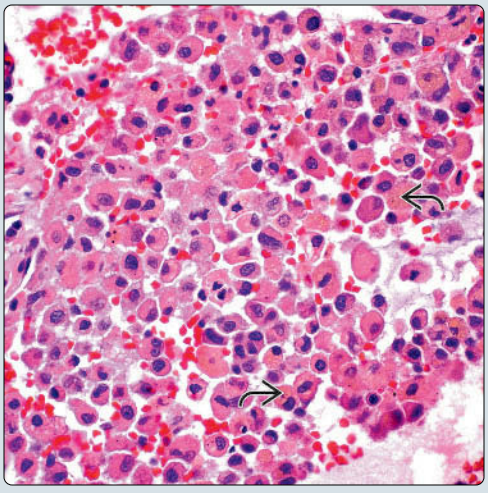

(Left) *RB-ILD shows areas of collections of pigmented macrophages in alveolar spaces and also in the airway. Also note the partial destruction of the small airway.* **(Right)** *High-power magnification shows a collection of macrophages in respiratory bronchiolitis. Note that some of the macrophages show pigment.*

TERMINOLOGY

Abbreviations

- Respiratory bronchiolitis-interstitial lung disease (RB-ILD)

Synonyms

- Smoker bronchiolitis
- Small airway disease

Definitions

- Mild form of interstitial lung disease

ETIOLOGY/PATHOGENESIS

Environmental Exposure

- Closely associated with smoking history
- Occupational exposure to fumes

CLINICAL ISSUES

Epidemiology

- Incidence
  - No hard data
- Age
  - Generally in adults
- Sex
  - No predilection
- Ethnicity
  - No preference

Site

- Small airways of lung parenchyma

Presentation

- Cough
- Dyspnea
- Wheezing
- Flu-like symptoms

Laboratory Tests

- No specific laboratory findings for RB
- Pulmonary function tests may be normal or show only minimal changes

Treatment

- Drugs
  - Corticosteroids
- Cessation of smoking

Prognosis

- Good prognosis

MACROSCOPIC

General Features

- Typically, diagnosis of RB-ILD is made during open lung biopsy

MICROSCOPIC

Histologic Features

- Pigmented macrophages in lumina of airway
- Collections of intraalveolar pigmented macrophages around airways
- Goblet cell metaplasia may be present in bronchial epithelium
- Mild interstitial fibrosis may be present
- Most of alveolated lung parenchyma appears normal
- Absence of marked interstitial fibrosis
- Absence of marked inflammatory changes

DIFFERENTIAL DIAGNOSIS

Desquamative Interstitial Pneumonitis

- More diffuse process
- Prominent collections of intraalveolar macrophages

Langerhans Cell Histiocytosis

- Presence of histiocytic cellular proliferation
- May show prominent eosinophilic component
- Not limited to small airways
- Immunohistochemical study for CD1a will show positive staining in histiocytes

Usual Interstitial Pneumonitis

- Areas of remodeling lung parenchyma
- Honeycombing changes of lung parenchyma
- Extensive areas of interstitial fibrosis

Eosinophilic Pneumonia

- Prominent intraalveolar collections of eosinophils
- Diffuse process
- Presence of collections of intraalveolar macrophages in airway is not feature of eosinophilic pneumonia

Pneumonia

- Prominent acute and chronic inflammatory changes
- More diffuse process
- Histochemical stains for organisms or tissue cultures will lead to correct interpretation

DIAGNOSTIC CHECKLIST

Clinically Relevant Pathologic Features

- Tissue distribution

Pathologic Interpretation Pearls

- Collections of pigmented macrophages in lumina of airways
- Collections of intraalveolar macrophages around small airways
- Absence of marked interstitial fibrosis
- Subtle changes in small airways
- Absence of marked inflammatory changes

SELECTED REFERENCES

1. Margaritopoulos GA et al: Smoking-related idiopathic interstitial pneumonia: A review. Respirology. 21(1):57-64, 2016
2. Crotty Alexander LE et al: Inflammatory diseases of the lung induced by conventional cigarette smoke: a review. Chest. 148(5):1307-22, 2015
3. Kadoch MA et al: Idiopathic interstitial pneumonias: a radiology-pathology correlation based on the revised 2013 American Thoracic Society-European Respiratory Society classification system. Curr Probl Diagn Radiol. 44(1):15-25, 2015
4. Margaritopoulos GA et al: Smoking and interstitial lung diseases. Eur Respir Rev. 24(137):428-35, 2015

Pulmonary Congestion

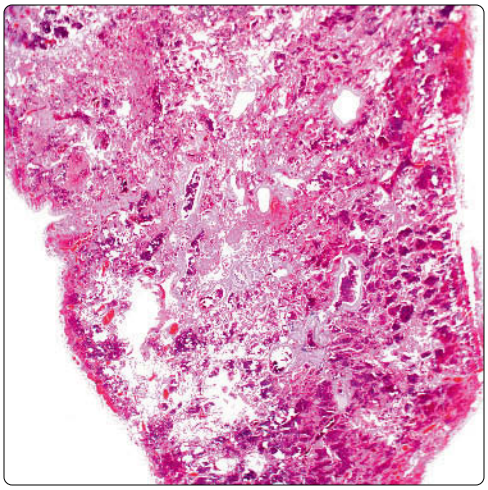

Filling of Alveoli by Red Cells

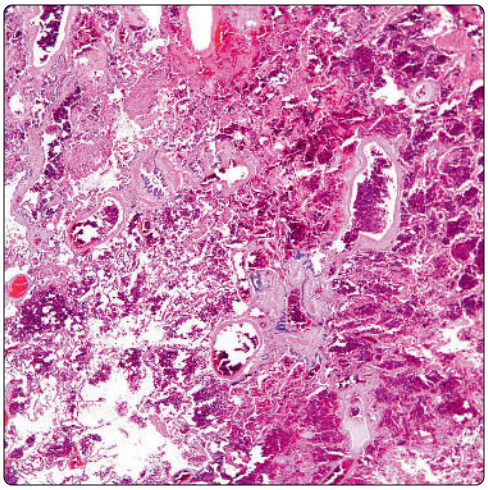

(Left) *Low-power view of a section from lung parenchyma shows extensive congestion. At this power, the diagnostic features of respiratory bronchiolitis are not easily recognized.* **(Right)** *Lung parenchyma is shown with an intraalveolar collection of red cells. The lung parenchyma is congested, probably as a result of the surgical procedure and not necessarily as a feature of respiratory bronchiolitis.*

Red Cells and Macrophages

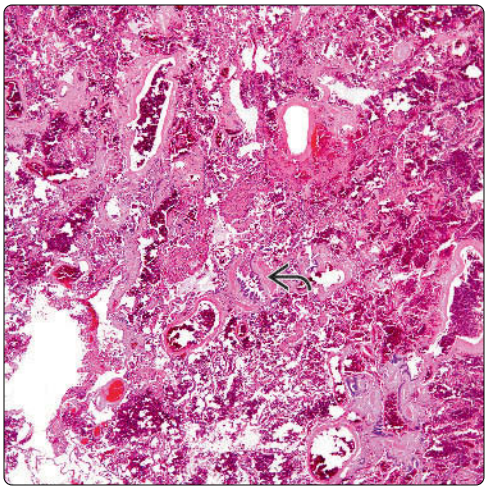

Intraalveolar Red Cells

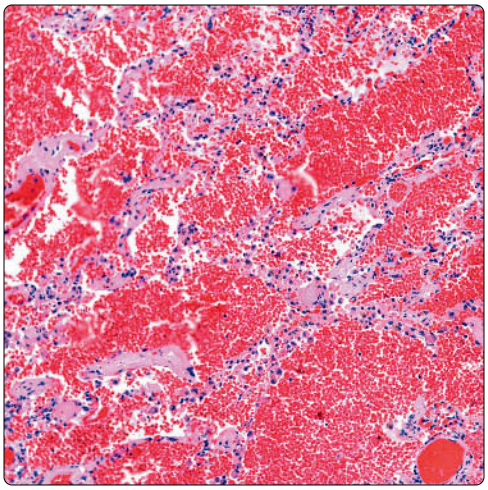

(Left) *Other areas of respiratory bronchiolitis in which collections of red cells are admixed with collections of macrophages are shown. Note the presence of an airway structure.* **(Right)** *In some cases, discrete areas of interstitial fibrosis may be apparent; however, note the presence of intraalveolar red cells with the absence of pigmented macrophages.*

Preservation of Lung Parenchyma

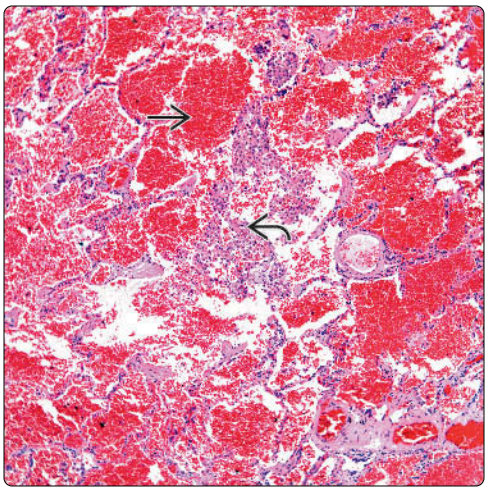

Collection of Macrophages

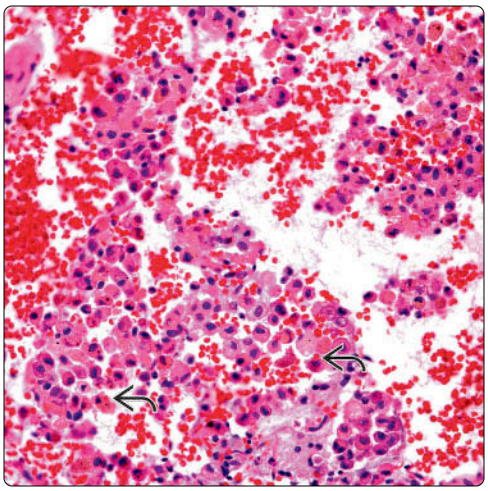

(Left) *Other areas of respiratory bronchiolitis show combined intraalveolar collections of red cells and macrophages. Note that the basic architecture of the lung parenchyma is preserved.* **(Right)** *Closer view shows a collection of macrophages, some of them with pigment in their cytoplasm. Although this is an important feature of respiratory bronchiolitis, by itself, it is not diagnostic.*

Involvement of Airway

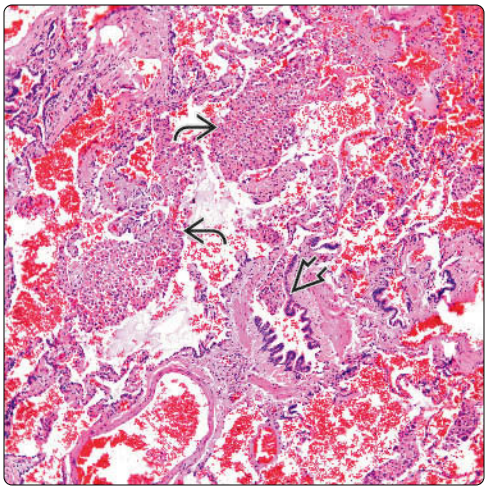

Bronchial Lumen With Macrophages

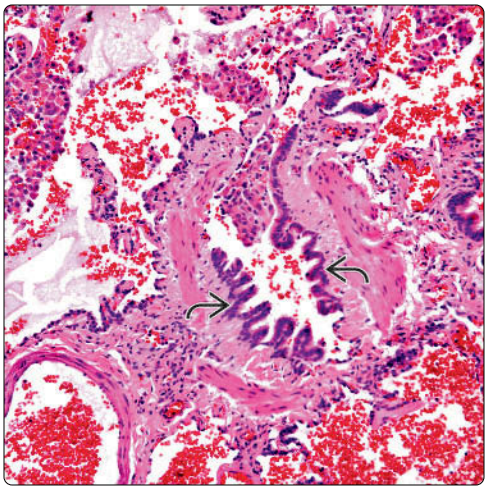

(Left) *Respiratory bronchiolitis shows the most important and characteristic histological features, mainly the presence of pigmented macrophages in the bronchial lumen and collections of pigmented macrophages in the adjacent peribronchial areas.* **(Right)** *Closer view of an airway shows collections of pigmented macrophages. Note that the bronchial epithelium is still within normal limits.*

Basic Airway Architecture Is Preserved

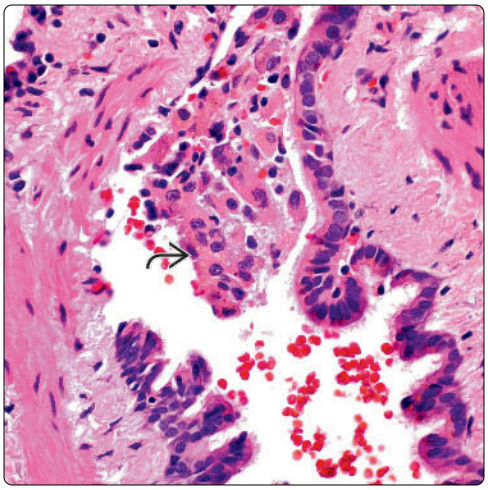

Distorted Airway

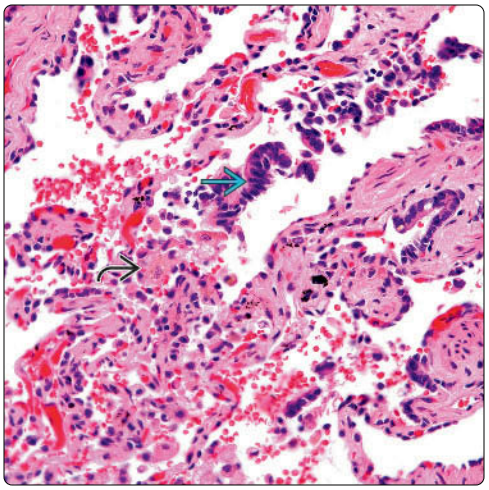

(Left) *High-power view shows the airway containing pigmented macrophages. The bronchial epithelium is still showing ciliated epithelium. This histological feature is important in the diagnosis of respiratory bronchiolitis.* **(Right)** *In some areas of respiratory bronchiolitis, the airway may not show the usual concentric luminal space; rather, the airway is partially distorted yet contains numerous pigmented macrophages.*

Focal Scarring

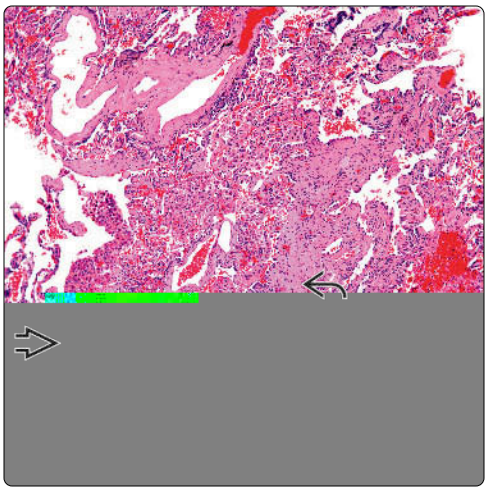

Focal Scarring

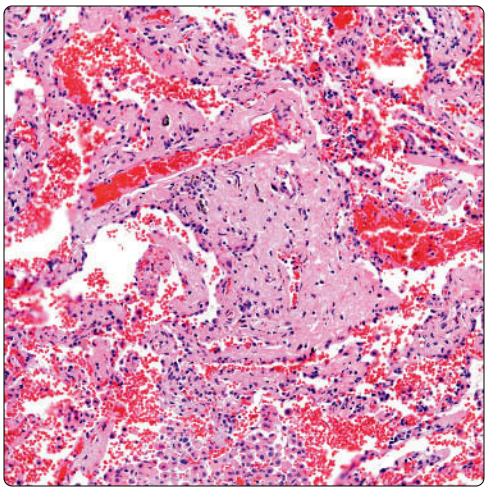

(Left) *Low-power view of respiratory bronchiolitis shows areas with collections of pigmented macrophages and focal scarring with mild inflammatory reaction.* **(Right)** *Areas of scarring may be only focal in cases of respiratory bronchiolitis. Extensive areas of fibrosis or scarring are not features of respiratory bronchiolitis.*

Usual Interstitial Pneumonia

KEY FACTS

TERMINOLOGY

- Pattern of lung damage characterized by bilateral, diffuse, interstitial inflammation and fibrosis

CLINICAL ISSUES

- Insidious onset of dyspnea and nonproductive cough
- Poor prognosis; mean survival range: 3.5-5 years

IMAGING

- HRCT shows reticular pattern with honeycombing involving mainly subpleural lung regions
- In more advanced stages, there is traction bronchiectasis and honeycombing

MICROSCOPIC

- Areas of lung parenchyma showing interstitial inflammation and fibrosis adjacent to areas of normal parenchyma
- Areas of diseased lung are seen in various stages of evolution (temporal heterogeneity)
- Interstitial fibrosis causes widening of alveolar septa due to collagen deposition admixed with inflammatory cells
- Fibroblastic foci are present, composed of loose connective tissue admixed with fibroblastic cells
- Areas of fibrosis with cystic spaces result in honeycombing effect
- Episodes of acute exacerbation may result in foci of diffuse alveolar damage superimposed on UIP

DIAGNOSTIC CHECKLIST

- Temporal heterogeneity (lesions at various stages of evolution) serve to distinguish UIP from NSIP
- Clinical history is indispensable for cases associated with underlying collagen-vascular disease, autoimmune or other disorders
- Scanning magnification showing variegation and admixture of abnormal foci with normal lung parenchyma is diagnostic
- Advanced stages with extensive fibrosis and honeycombing may be impossible to diagnose in absence of history

Gross Appearance

Scanning Magnification

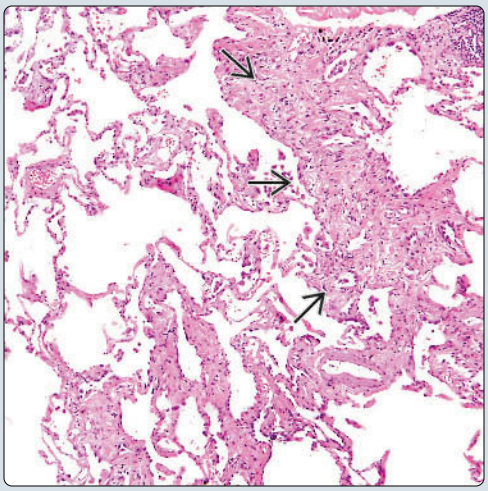

(Left) *Gross appearance of resected lung with advanced usual interstitial pneumonia (UIP) shows massive multicystic changes due to honeycombing of lung parenchyma at the periphery.* **(Right)** *Scanning magnification in UIP shows areas of lung parenchyma with thickened alveolar walls ⇨ surrounded by areas of normal lung parenchyma. The fibrotic alveolar walls contain scattered small lymphocytes and occasional plasma cells.*

Higher Magnification

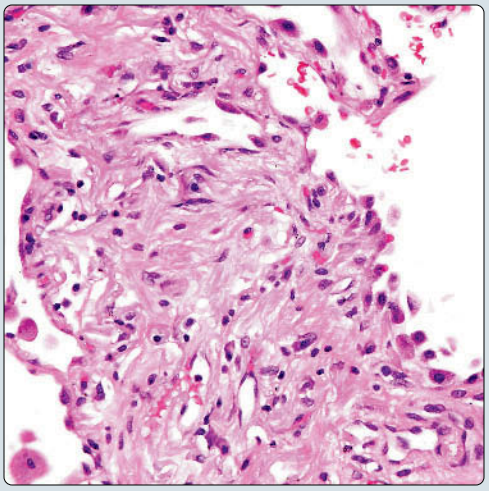

Peripheral Honeycombing

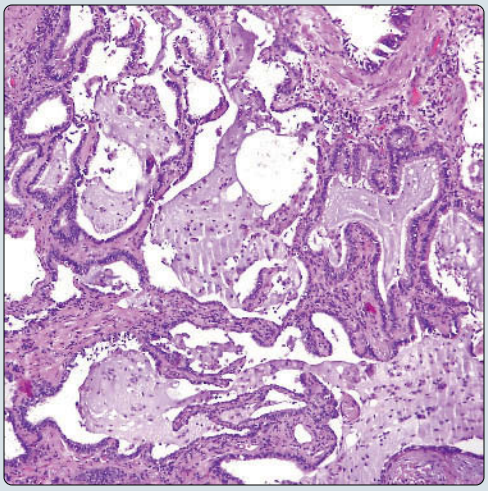

(Left) *Higher magnification of a thickened alveolar wall in UIP shows heavy deposition of collagen fibers admixed with sparse inflammatory infiltrate.* **(Right)** *Area of lung parenchyma in UIP shows honeycombing characterized by dilated air spaces at the periphery of the lung, which are often filled with inspissated mucus. This is usually seen in the more advanced stages of the process.*

TERMINOLOGY

Abbreviations

- Usual interstitial pneumonia (UIP)

Synonyms

- Idiopathic interstitial fibrosis, idiopathic pulmonary fibrosis, cryptogenic fibrosing alveolitis

Definitions

- Pattern of lung damage characterized by bilateral, diffuse, interstitial inflammation and fibrosis

ETIOLOGY/PATHOGENESIS

Pathogenesis

- Unknown (idiopathic)
- May be associated with variety of underlying clinical conditions, including
  - Collagen-vascular disease
  - Drug toxicity
  - Pneumoconiosis and other environmental exposures
  - Autoimmune disorders

CLINICAL ISSUES

Epidemiology

- Incidence
  - ~ 10 cases per 100,000 people per year
- Age
  - 50-70 years

Presentation

- Insidious onset of dyspnea and nonproductive cough
- Bibasilar, late inspiratory crackles
- Clubbing of fingers in > 40% of patients
- Pulmonary hypertension (in late stages)

Treatment

- Surgical approaches
  - Lung transplantation
- Drugs
  - Immunosuppressive and cytotoxic agents have not been very effective
  - Gamma interferon

Prognosis

- Poor prognosis
- Mean survival range: 3.5-5 years
- Respiratory failure is most frequent cause of death

IMAGING

CT Findings

- HRCT shows reticular pattern with honeycombing involving mainly subpleural lung regions
- Intralobular linear opacities with irregular thickening of interlobular septa
- Irregular pleural, vascular, and bronchial interfaces with lung parenchyma
- In more advanced stages, there is traction bronchiectasis and honeycombing
- Typical findings may be seen on HRCT even when chest x-rays appear normal
- Bilateral process with basilar and peripheral predominance

MICROSCOPIC

Histologic Features

- Areas of lung parenchyma showing interstitial inflammation and fibrosis adjacent to areas of normal parenchyma
- Areas of diseased lung are seen in various stages of evolution (temporal heterogeneity)
- Interstitial fibrosis causes widening of alveolar septa due to collagen deposition admixed with inflammatory cells
- Interstitial inflammatory infiltrate includes small lymphocytes, plasma cells, and histiocytes with occasional lymphoid follicles
- Fibroblastic foci are present, composed of loose connective tissue admixed with fibroblastic cells
- Focal accumulation of alveolar macrophages [desquamative interstitial pneumonia (DIP)-like appearance]
- Bronchiolization of alveolar lining ("lambertosis") may be observed
- Squamous metaplasia in areas of scarring can be seen in late stages
- Smooth muscle stromal proliferation may accompany stromal scarring
- Areas of fibrosis with cystic spaces result in honeycombing effect
- Episodes of acute exacerbation may result in foci of diffuse alveolar damage superimposed on UIP

DIAGNOSTIC CHECKLIST

Clinically Relevant Pathologic Features

- Transbronchial biopsies are not useful for evaluation of interstitial fibrosis
- Multiple open lung biopsies are indicated for definitive diagnosis
- Biopsies must be obtained from multiple lobes, avoiding lung apices
- ~ 50% of patients can be diagnosed on clinical and radiologic grounds alone without biopsy

Pathologic Interpretation Pearls

- Temporal heterogeneity (lesions at various stages of evolution) serves to distinguish UIP from nonspecific interstitial pneumonia
- Clinical history is indispensable for cases associated with underlying collagen-vascular disease, autoimmune or other disorders
- Scanning magnification showing variegation and admixture of abnormal foci with normal lung parenchyma is diagnostic
- Advanced stages with extensive fibrosis and honeycombing may be impossible to diagnose in absence of history

SELECTED REFERENCES

1. Chung JH et al: The value of a multidisciplinary approach to the diagnosis of usual interstitial pneumonitis and idiopathic pulmonary fibrosis: radiology, pathology, and clinical correlation. AJR Am J Roentgenol. 206(3):463-71, 2016
2. Borchers AT et al: Idiopathic pulmonary fibrosis-an epidemiological and pathological review. Clin Rev Allergy Immunol. 40(2):117-34, 2011

(Left) *Scanning magnification in a patient with UIP shows focal areas of interstitial fibrosis ⇨ surrounded by areas of spared, normal lung parenchyma. This variegation in histology, with lesions present in different stages of organization, is described as temporal heterogeneity.* **(Right)** *Higher magnification in a patient with UIP shows interstitial fibrosis with widened alveolar septa ⇨ circumscribing normal lung parenchyma.*

Scanning Magnification

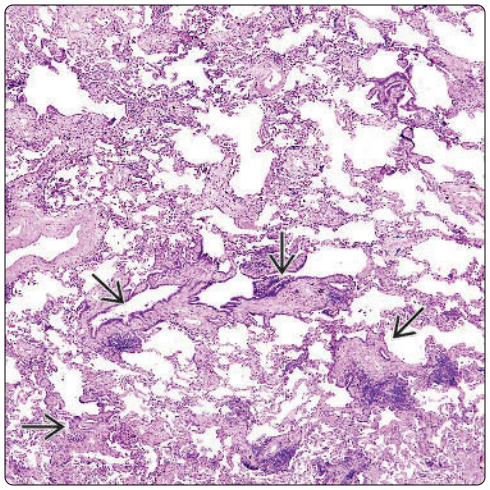

Fibrotic Alveolar Septa

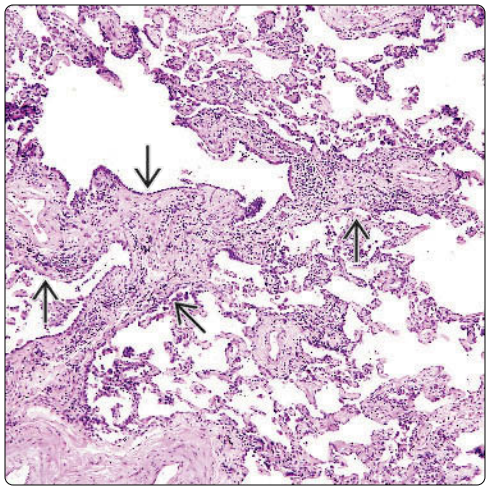

(Left) *Higher magnification of lung involved with UIP shows thickened alveolar septa ⇨ containing a dense lymphoid cell infiltration admixed with fibrous tissue deposition. Notice the normal intervening lung parenchyma ⇨.* **(Right)** *Higher magnification in UIP shows thickened alveolar septa ⇨ with scattered inflammatory cells admixed with fibrous tissue. The thickened alveolar septa circumscribe normal lung parenchyma ⇨.*

Chronic Inflammation

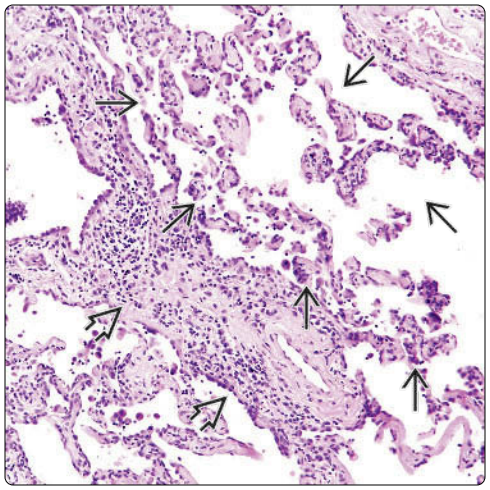

Fibrosis Circumscribing Normal Parenchyma

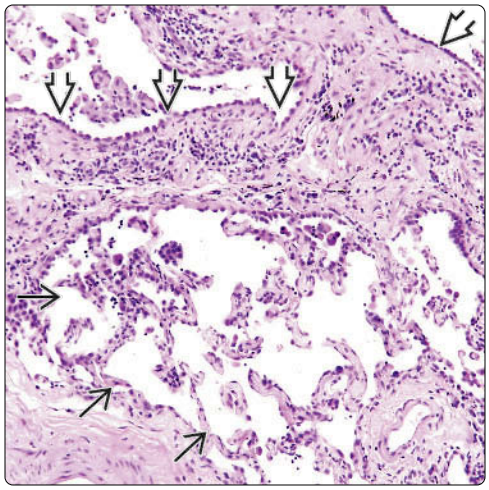

(Left) *Higher magnification in UIP shows thickened alveolar septa with chronic inflammation and fibrosis (top). The underlying entrapped lung parenchyma shows alveolar septa of normal thickness without inflammation or fibrosis ⇨.* **(Right)** *Higher magnification of thickened alveolar septa in UIP shows numerous scattered small lymphocytes and plasma cells embedded in abundant collagenous stroma.*

Normal Airspaces

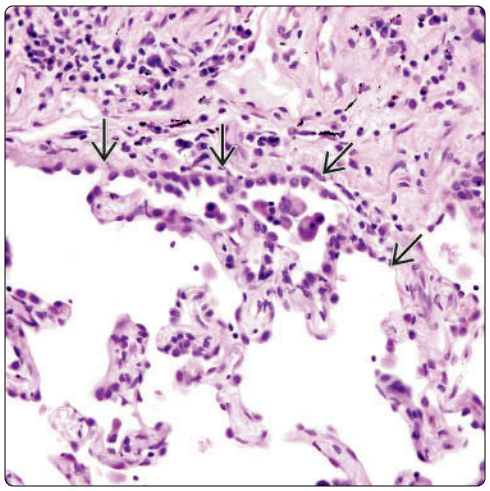

Septal Fibrosis, High Power

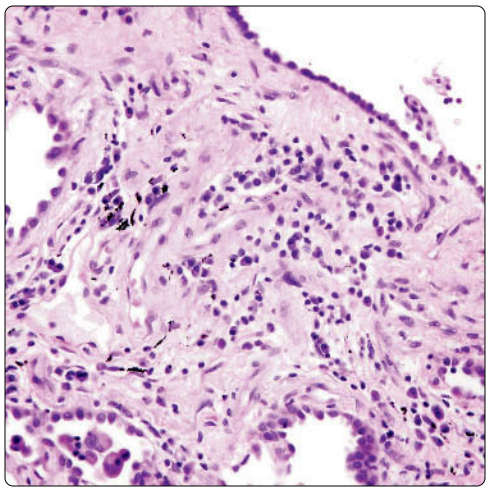

Interstitial Fibrosis

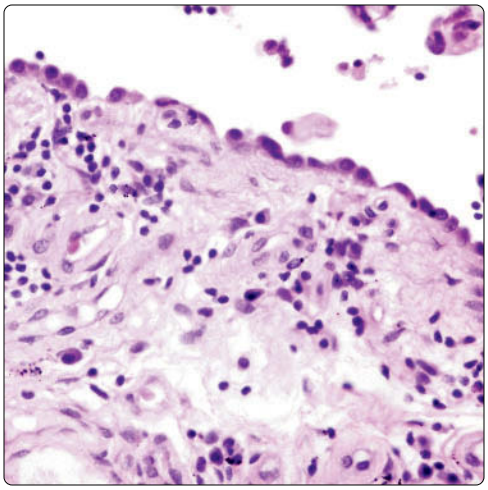

Fibrosis and Chronic Inflammation

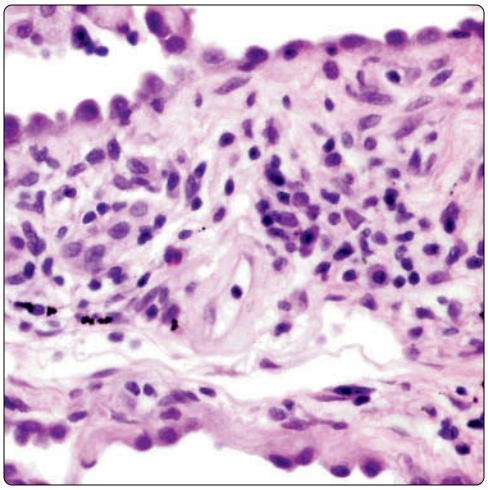

(Left) *Higher magnification in UIP illustrates an area of interstitial fibrosis with scattered inflammatory infiltrate and deposition of early, young collagenous tissue in the interstitium.* **(Right)** *Higher magnification of thickened alveolar septa in a patient with UIP shows mixed inflammatory infiltrate chiefly composed of small lymphocytes and scattered plasma cells and histiocytes deposited around small vessels.*

Hyperplasia of Type II Pneumocytes

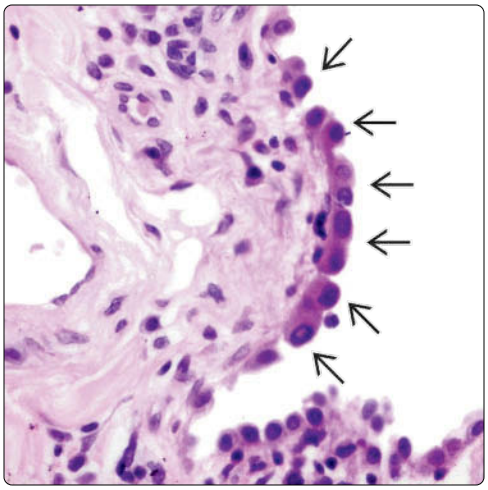

Stromal Lymphoid Aggregates

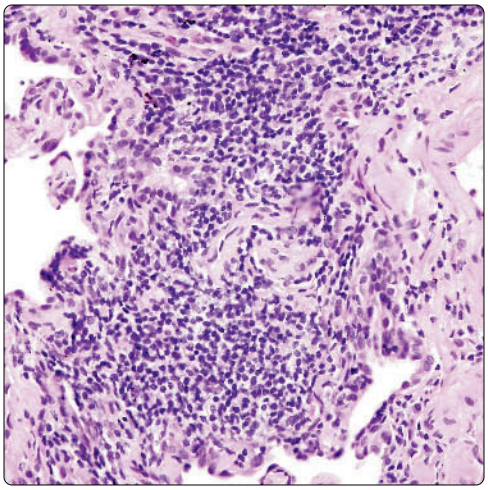

(Left) *Higher magnification of thickened alveolar septa in a patient with UIP shows mixed inflammatory infiltrate with lymphocytes and plasma cells and hyperplasia of type II pneumocytes ⇨ in the alveolar lining cells.* **(Right)** *Lymphoid aggregate is seen in a case of UIP showing widening of alveolar septa with numerous small lymphoid cells. Lymphoid follicle formation with germinal centers should raise the possibility of lymphoid interstitial pneumonia.*

Foci of Bronchiolization

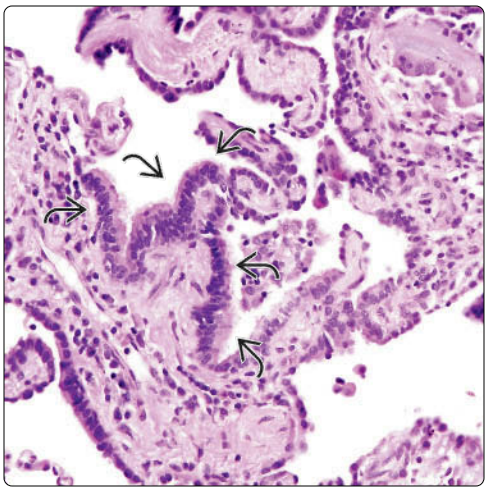

Bronchial Metaplasia

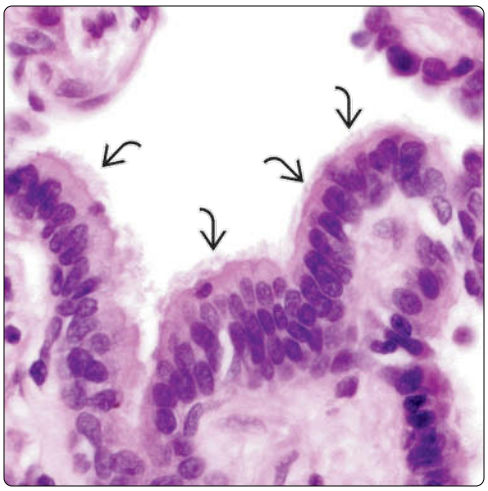

(Left) *Scanning magnification of UIP shows a focus of bronchiolization of alveolar lining ("lambertosis") ⇨, a metaplastic phenomenon in which the alveolar lining cells are transformed into tall columnar ciliated epithelium.* **(Right)** *Higher magnification of a focus of bronchiolar metaplasia ("lambertosis") in a patient with UIP shows tall columnar cells with parallel elongated nuclei and abundant cytoplasm. Notice the surface cilia ⇨.*

Interstitial Fibrosis

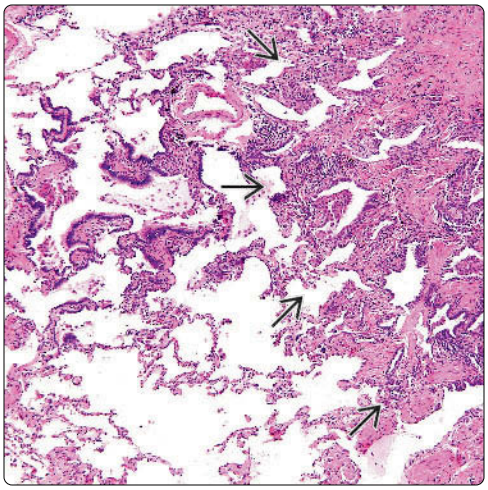

Widening of Alveolar Septa

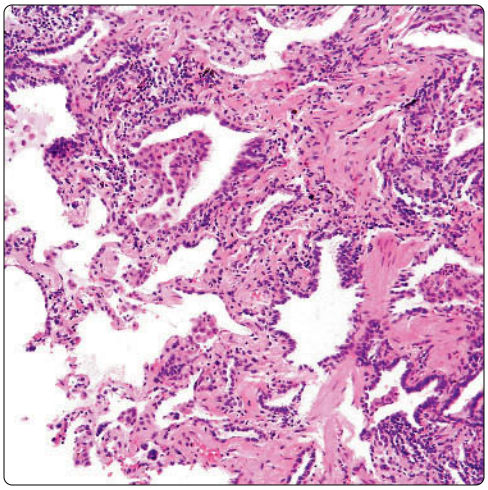

(Left) *Scanning magnification in UIP shows extensive areas of interstitial fibrosis ⇨ blending imperceptibly with normal, uninvolved lung parenchyma at the bottom of the figure. The focal, patchy character of the fibrosing changes is quite typical of usual interstitial fibrosis.* **(Right)** *Higher magnification of UIP shows an area affected by interstitial fibrosis with widening of the alveolar septa and chronic inflammatory infiltrates.*

Interstitial Fibrosis, High Power

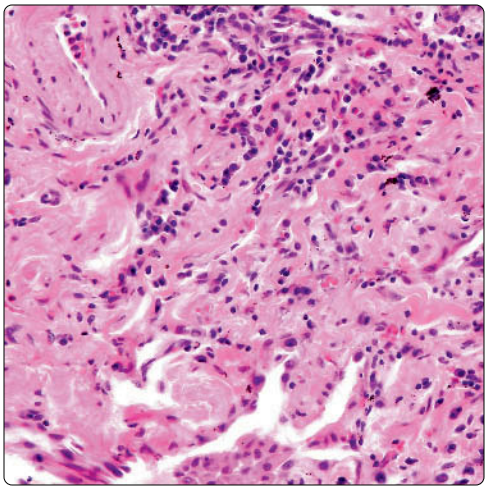

Bronchiolization

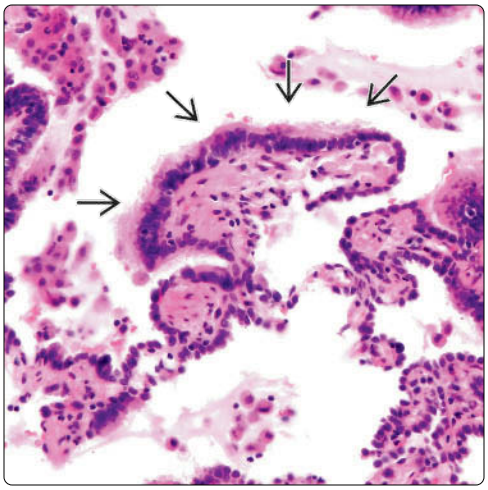

(Left) *Higher magnification of the wall of an alveolus in UIP shows abundant deposition of fibrocollagenous tissue in the interstitium admixed with a mixed inflammatory infiltrate. The thick collagen bundles are arranged in a haphazard fashion.* **(Right)** *Microscopic focus of bronchiolization is seen in a case of UIP. The change is quite subtle and consists of gradual metaplasia of alveolar lining cells into tall, columnar, ciliated epithelium ⇨.*

Fibrosis and DIP-Like Effect

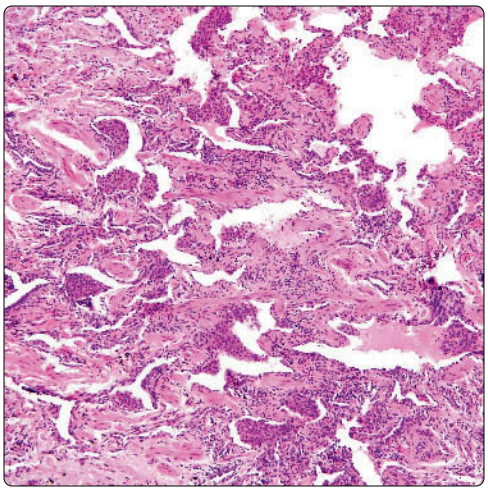

DIP-Like Areas, Higher Power

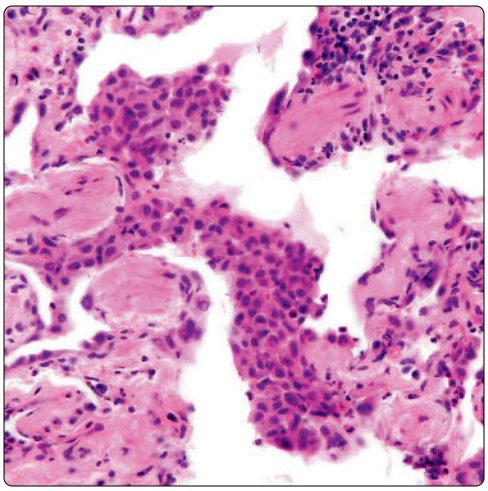

(Left) *Scanning magnification of UIP shows widening of alveolar septa by fibrosis and inflammation and multiple foci of eosinophilic intraalveolar macrophages, resulting in a desquamative interstitial pneumonia (DIP)-like appearance.* **(Right)** *UIP with DIP-like effect shows clusters of alveolar macrophages with abundant eosinophilic cytoplasm within a dilated alveolar lumen. This may be observed focally in UIP and should not be confused with DIP.*

Fibroblastic Focus

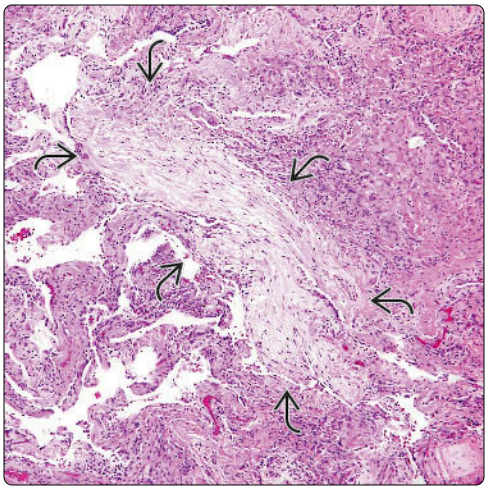

Fibroblastic Focus, High Power

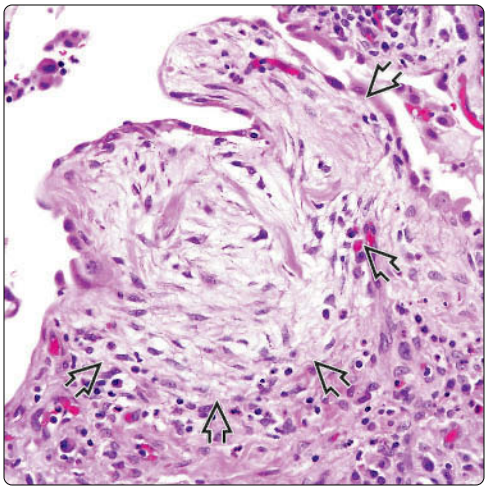

(Left) *Scanning magnification in a case of UIP shows a large fibroblastic focus ⇨. This area is composed of loose connective tissue admixed with fibroblastic cells against a faintly myxoid matrix. Fibroblastic foci are a distinctive feature of UIP.* **(Right)** *Fibroblastic focus ⇨ in UIP shows young collagen admixed with spindled fibroblasts in the interstitium displaying a faintly myxoid background.*

Fibroblastic Focus

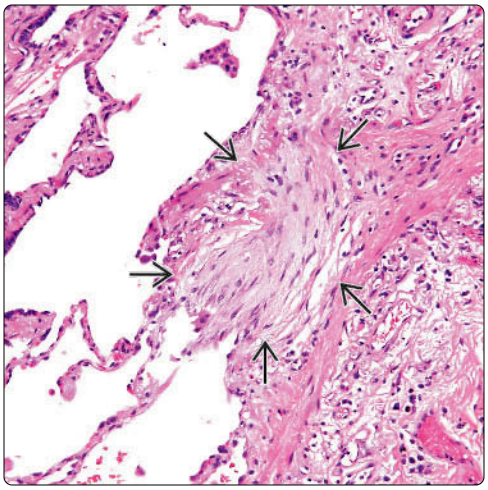

Fibroblastic Focus, High Power

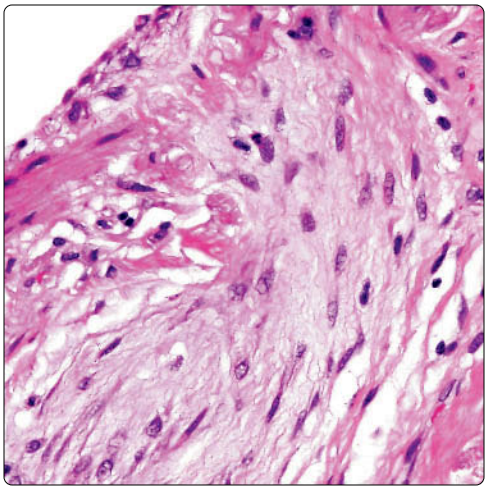

(Left) *Scanning magnification in UIP shows a fibroblastic focus in the wall of the alveolus adjacent to normal pulmonary parenchyma ⇨. Notice the parallel, linear disposition of the spindle fibroblastic cells admixed with the young collagen.* **(Right)** *Higher magnification of the fibroblastic focus in UIP shows bland-appearing spindled fibroblasts embedded in a slightly myxoid young collagenous matrix.*

Fibroblastic Focus

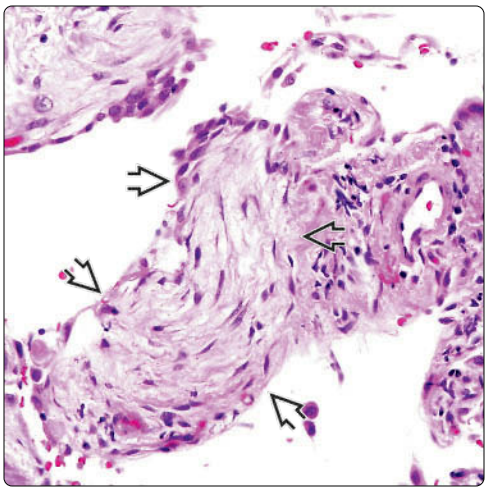

Fibroblastic Focus and DIP-Like Area

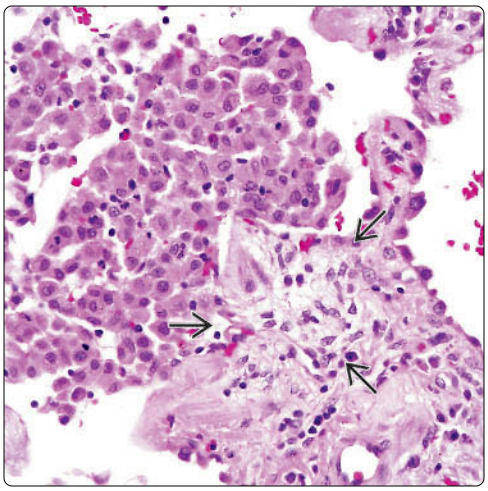

(Left) *Fibroblastic focus located within the wall of an alveolus ⇨ in UIP shows spindled fibroblasts embedded in collagenous matrix. The interstitial location is distinctive as opposed to the intraalveolar location in organizing pneumonia.* **(Right)** *Early fibroblastic focus formation ⇨ in UIP is seen alongside clusters of intraalveolar macrophages with abundant eosinophilic cytoplasm (DIP-like appearance) within the alveolar lumen.*

Advanced Fibrosis

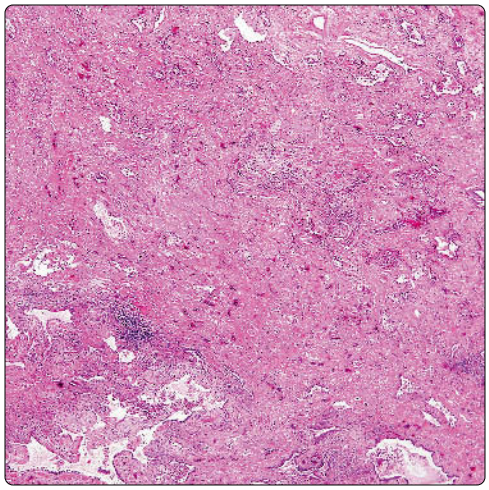

Fibrosis and Entrapped Lung

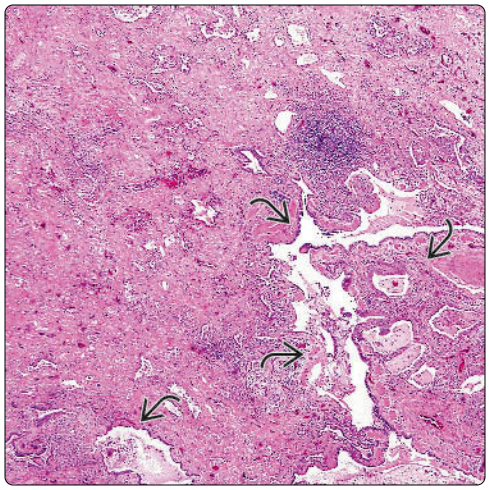

(Left) *End-stage fibrosis in a patient with UIP shows almost total remodeling of lung parenchyma with almost complete obliteration of the underlying architecture and replacement by dense connective tissue.* **(Right)** *Scanning magnification in end-stage idiopathic interstitial fibrosis shows almost total obliteration of lung parenchyma by fibrous tissue with only a few small residual foci of lung parenchyma.*

Advanced Fibrosis

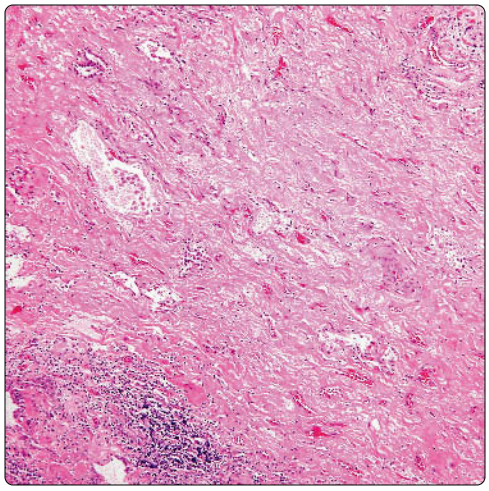

Fibrosis, High Power

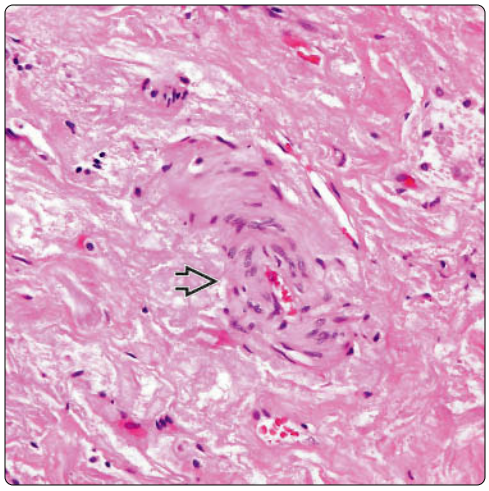

(Left) *Higher magnification from an area of dense fibrosis in end-stage idiopathic pulmonary fibrosis shows almost total replacement of the lung parenchyma by paucicellular collagenous tissue.* **(Right)** *Higher magnification of collagenized area in end-stage idiopathic pulmonary fibrosis shows deposition of mature, paucicellular collagen with a few scattered inflammatory cells in the background. Notice the entrapped small vessel.*

Honeycombing

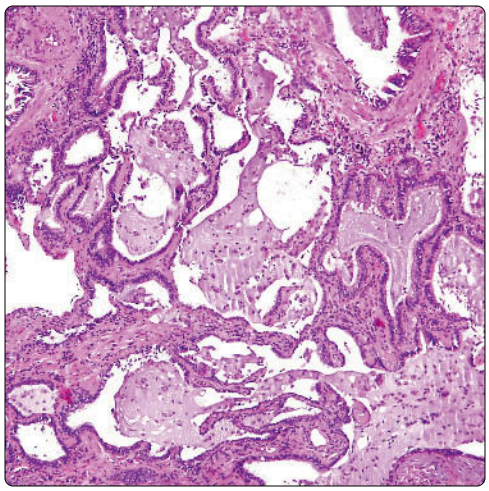

Honeycombing

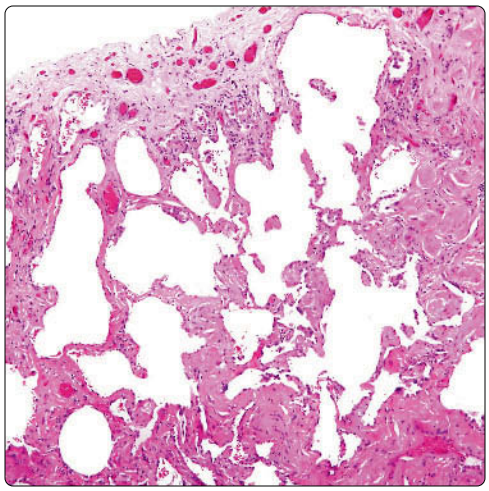

(Left) *Honeycombing of lung parenchyma is seen in advanced stages of idiopathic pulmonary fibrosis and is characterized by massive dilatation of air spaces, which become filled with mucin.* **(Right)** *Scanning magnification in end-stage idiopathic pulmonary fibrosis shows honeycombing of lung parenchyma with dilated airspaces surrounded by fibrotic alveolar septa. It may be difficult to determine the correct diagnosis in such cases without comparison with previous films.*

Advanced Interstitial Fibrosis

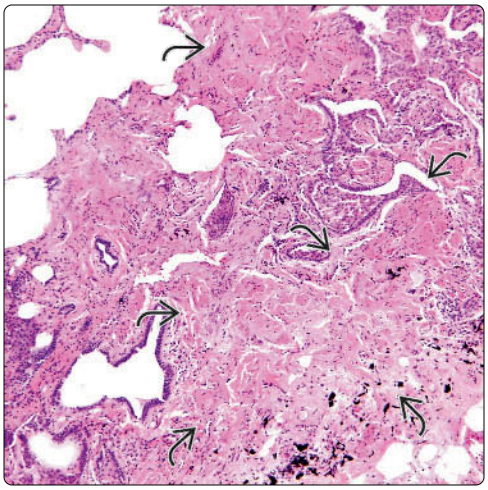

Smooth Muscle Metaplasia

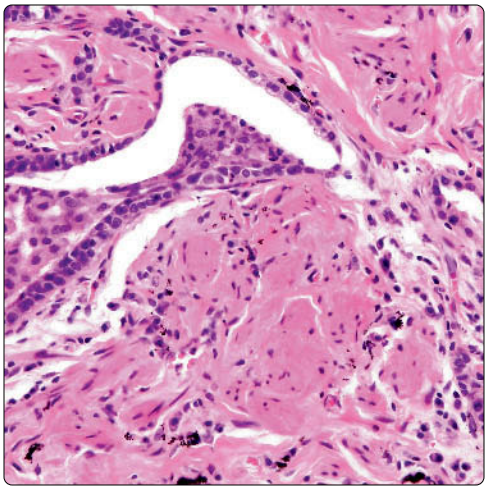

(Left) *Advanced, end-stage changes in idiopathic pulmonary fibrosis show a few residual airspaces surrounded by collagenous stroma with smooth muscle metaplasia.* **(Right)** *Higher magnification of advanced stage of usual interstitial fibrosis shows a residual compressed airspace with multiple small foci of smooth muscle proliferation in the interstitium. Smooth muscle metaplasia is usually a late event in UIP.*

Smooth Muscle Metaplasia

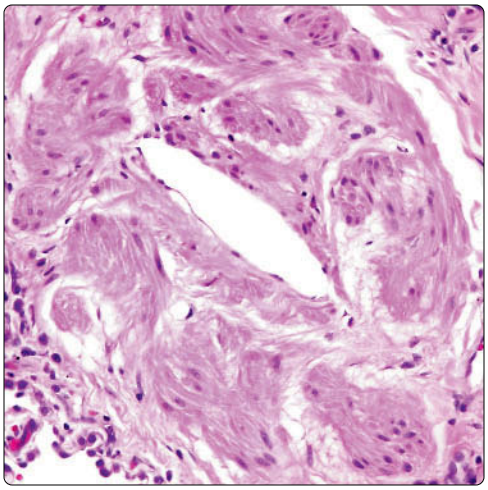

Bronchiolar and Squamous Metaplasia

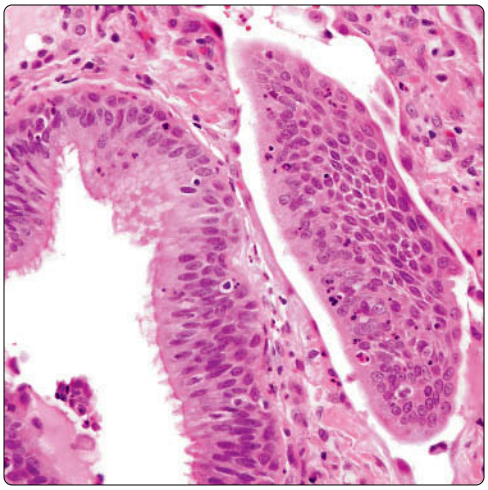

(Left) *Focus of smooth muscle is seen in the pulmonary interstitium of a patient with advanced UIP. The smooth muscle metaplasia can result in a cobblestone gross appearance and has been termed by some as pulmonary cirrhosis.* **(Right)** *Metaplastic phenomena are rather common in end-stage idiopathic pulmonary fibrosis. This image depicts a focus of bronchial metaplasia (left) side-by-side with a focus of squamous metaplasia (right).*

Bronchiolar Metaplasia, High Power

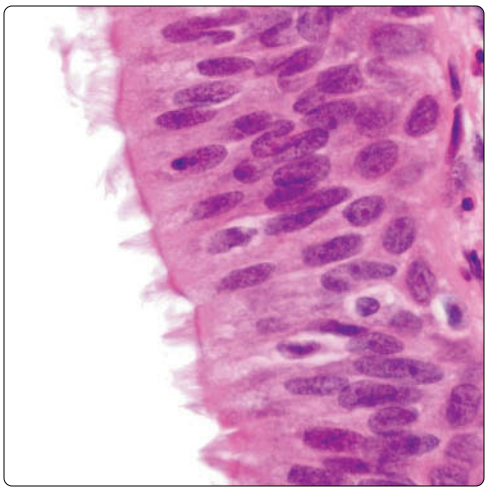

Squamous Metaplasia, High Power

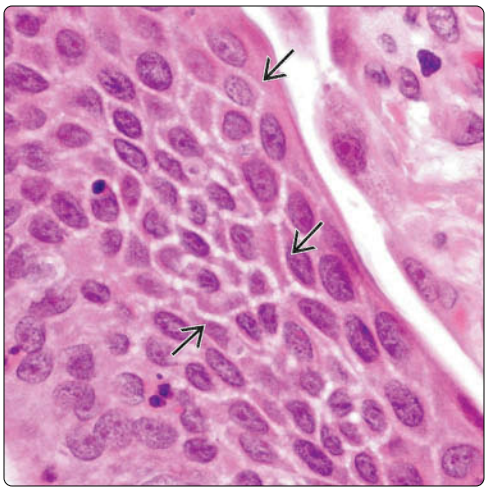

(Left) *Higher magnification of a focus of bronchial metaplasia in end-stage idiopathic pulmonary fibrosis shows columnar cell metaplasia with prominent cilia on the luminal surface.* **(Right)** *Higher magnification of a focus of squamous metaplasia in end-stage idiopathic pulmonary fibrosis shows polygonal cells with large nuclei and pavement-like architecture displaying intercellular bridges.*

Desquamative Interstitial Pneumonia

KEY FACTS

TERMINOLOGY

- Distinctive histologic reaction pattern to lung injury related to cigarette smoking

ETIOLOGY/PATHOGENESIS

- Strong epidemiologic link to cigarette smoking

CLINICAL ISSUES

- Dyspnea
- Cough
- Cessation of smoking generally leads to regression of symptoms and radiologic changes
- Patients with moderate to severe disease respond well to administration of corticosteroids
- Much better survival than usual interstitial pneumonia (UIP) and other interstitial pneumonias
- Unknown
- 40-50 years
- More common in males (2:1)
- Steroids, smoking cessation

IMAGING

- Bilateral and symmetric, panlobular ground-glass pattern seen in lower lung zones on HRCT in 100% of cases

MICROSCOPIC

- Histologic hallmark is diffuse and extensive intraalveolar deposition of alveolar macrophages
- Minimal fibrosis with only mild thickening of alveolar septa and mild chronic inflammatory infiltrate
- Absence of organizing fibroblastic foci
- All lesions in same stage of evolution (absence of "temporal heterogeneity")

ANCILLARY TESTS

- Cells filling alveoli are positive for CD68 macrophage-associated antigen and negative for cytokeratin

(Left) *Scanning magnification shows expansion of alveolar spaces by a dense infiltrate of mononuclear cells with abundant cytoplasm. A bronchiole is note at the bottom right of the image, which also contains "desquamated" macrophages.* **(Right)** *Desquamative interstitial pneumonia shows plugging and distention of airspaces by monotonous infiltrate of alveolar macrophages filling the lumen. Scattered multinucleated cells are also present.*

DIP: Low Power

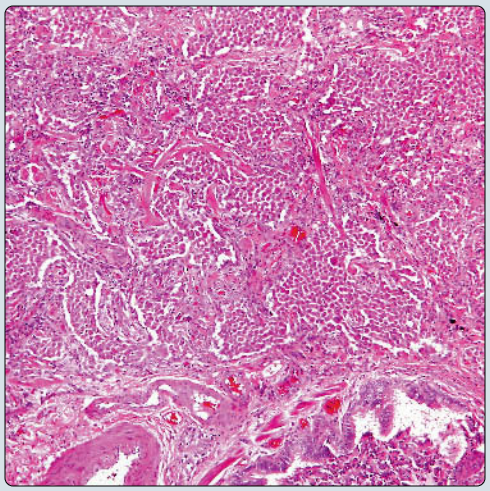

DIP: Medium Power

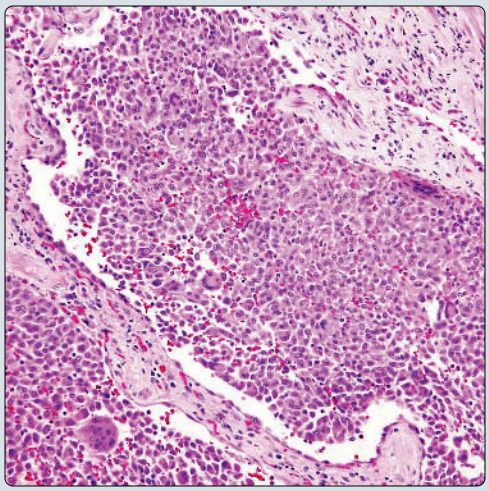

(Left) *Higher power of desquamative interstitial pneumonia shows sheets of macrophages admixed with multinucleated histiocytes lying within the lumen of a distended alveolar space.* **(Right)** *Higher magnification of desquamative interstitial pneumonia shows collection of alveolar macrophages with vesicular nuclei and abundant eosinophilic cytoplasm within the alveolar lumen.*

DIP: High Power

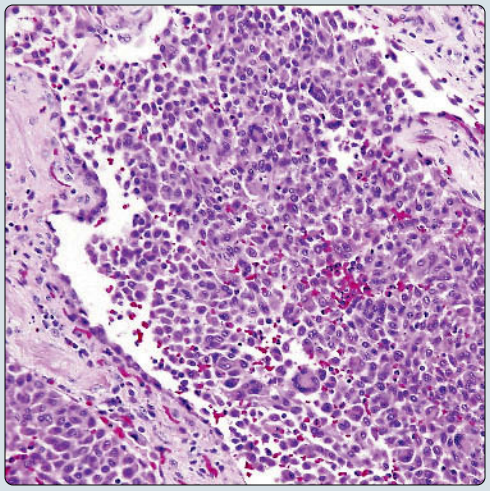

Macrophages in DIP

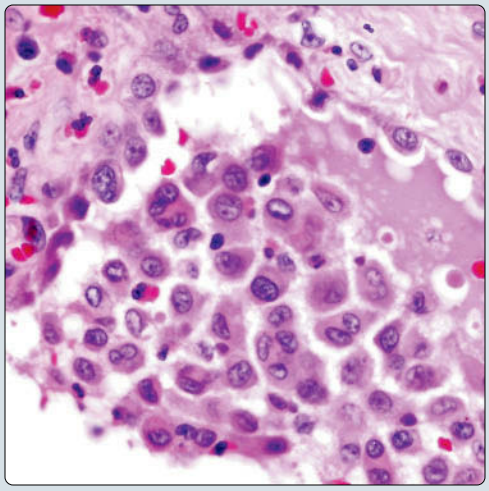

TERMINOLOGY

Abbreviations

- Desquamative interstitial pneumonia (DIP)

Definitions

- Distinctive histologic reaction pattern to lung injury related to cigarette smoking

CLINICAL ISSUES

Epidemiology

- Incidence
  - Unknown
- Age
  - 40-50 years
- Sex
  - More common in males (2:1)

Presentation

- Dyspnea, cough and crackles on ausculattion
- Clubbing of the fingers in 40% of patients

Natural History

- Subacute onset (weeks to months) of symptoms
- Cessation of smoking generally leads to regression of symptoms and radiologic changes
- Patients with moderate to severe disease respond well to administration of corticosteroids

Treatment

- Steroids, smoking cessation

Prognosis

- Much better survival than usual interstitial pneumonia (UIP) and other types of interstitial pneumonias
- Approximately 95% 5-year survival and 70% 10-year survival
- Very small number of patients may progress to diffuse interstitial fibrosis requiring transplantation

IMAGING

Radiographic Findings

- Bilateral symmetric areas of ground-glass opacification in lower lung zones
- Reticular pattern observed in 50% of cases due to localized areas of fibrosis

CT Findings

- Bilateral and symmetric, panlobular ground-glass pattern seen in lower lung zones on HRCT in 100% of cases

MICROSCOPIC

Histologic Features

- Histologic hallmark is diffuse and extensive intraalveolar deposition of alveolar macrophages
- Minimal fibrosis with only mild thickening of alveolar septa and mild chronic inflammatory infiltrate
- Absence of fibroblastic foci
- All lesions in same stage of evolution (absence of "temporal heterogeneity")

Cytologic Features

- Intraalveolar macrophages may contain finely granular brown pigment (hemosiderin)
- Intraalveolar laminated basophilic concretions ("blue bodies") may be present

ANCILLARY TESTS

Immunohistochemistry

- Cells filling alveoli are positive for CD68 macrophage-associated antigen and negative for cytokeratin

DIFFERENTIAL DIAGNOSIS

Usual Interstitial Pneumonia

- UIP may show DIP-like effect with focal areas containing abundant intraalveolar macrophages
- Interstitial fibrosis and inflammation are prominent with active remodeling of lung architecture
- Alternating areas of interstitial fibrosis alongside normal lung parenchyma are characteristic
- Fibroblastic foci are commonly seen
- Smooth muscle proliferation, squamous metaplasia, and honeycombing are common findings in advanced stages

Nonspecific DIP-Like Reaction

- Areas resembling DIP can occur as a nonspecific reaction adjacent to a variety of unrelated lesions, such as tumors, scars, etc.
- Focalized process found incidentally in vicinity of lesions resected for other causes
- Radiologic correlation will not show bilateral symmetric ground-glass opacities

Histiocyte-Rich Infections

- Certain infections such as *Mycobacterium avium intracellulare* (MAI), *Cryptococcus*, and *Rhodococcusequi* may show DIP-like areas
- Special stains for organisms (AFB, GMS, PAS, etc.) will serve to highlight causative agent

DIAGNOSTIC CHECKLIST

Pathologic Interpretation Pearls

- Term "desquamative" is a misnomer; cells filling alveoli are histiocytes, not desquamated epithelial cells
- Process is closely related to respiratory bronchiolitis interstitial lung disease (RB-ILD), a condition also related to smoking
- DIP and RB-ILD may be different stages within same spectrum in response pattern of lung to smoking

SELECTED REFERENCES

1. Madan R et al: Spectrum of smoking-related lung diseases: imaging review and update. J Thorac Imaging. 31(2):78-91, 2016
2. Margaritopoulos GA et al: Smoking-related idiopathic interstitial pneumonia: a review. Respirology. 21(1):57-64, 2016
3. Tazelaar HD et al: Desquamative interstitial pneumonia. Histopathology. 58(4):509-16, 2011
4. Vassallo R et al: Tobacco smoke-related diffuse lung diseases. Semin Respir Crit Care Med. 29(6):643-50, 2008

DIP: Scanning Magnification

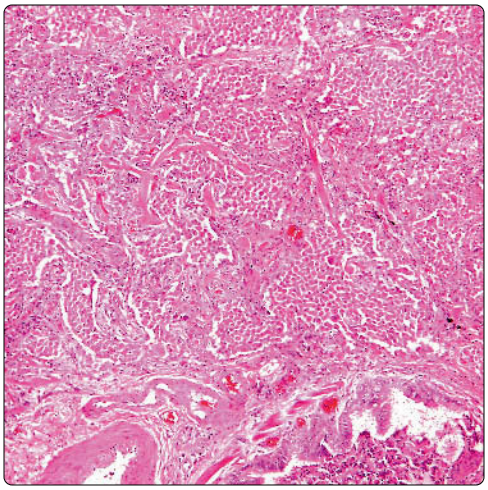

DIP: Sheets of Macrophages

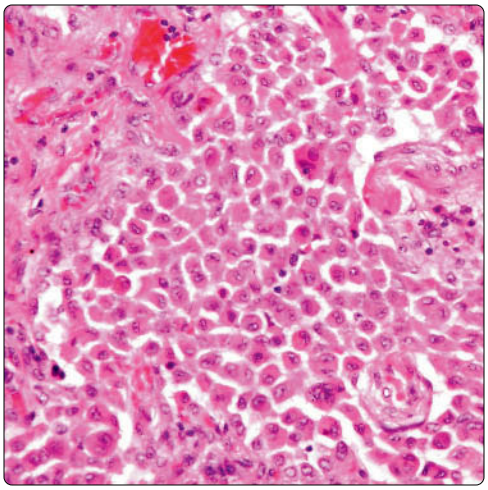

(Left) *Scanning magnification of desquamative interstitial pneumonia shows massive expansion of alveolar spaces by dense, monotonous population of alveolar macrophages completely filling the lumina.* **(Right)** *Higher magnification of desquamative interstitial pneumonia shows a monotonous discohesive population of histiocytic cells that are completely filling the alveolar lumen. Notice absence of lymphocytes, neutrophils, or other types of inflammatory cells admixed with the histiocytes.*

Macrophages in DIP: High Power

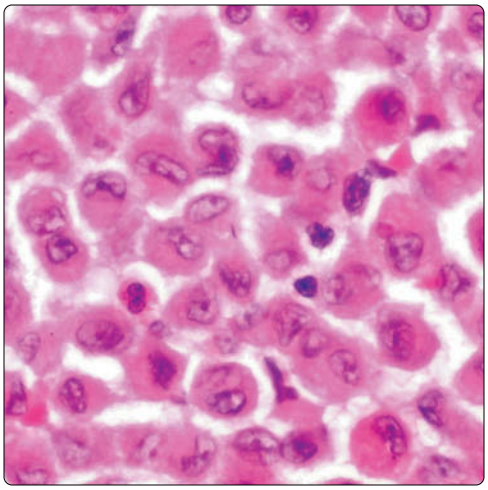

Respiratory Bronchiolitis in DIP

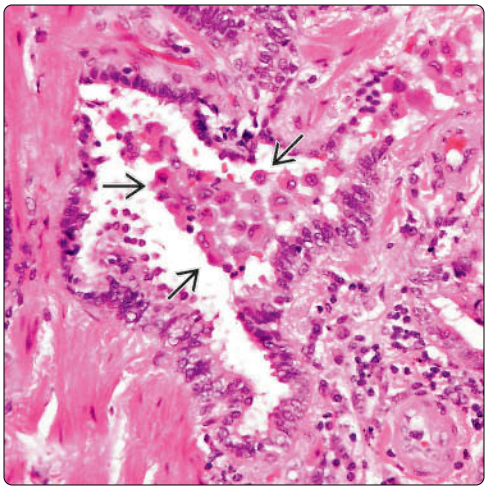

(Left) *Higher magnification of desquamative interstitial pneumonia shows monotonous sheets of histiocytes with irregular nuclei and an abundant rim of eosinophilic cytoplasm. Some of the histiocytes contain finely granular hemosiderin pigment in their cytoplasm.* **(Right)** *Areas adjacent to the infiltrates may show evidence of respiratory bronchiolitis with pigmented macrophages lying within the lumen of small bronchioles ⇨. Desquamative interstitial pneumonia is closely related to cigarette smoking.*

Temporal Uniformity in DIP

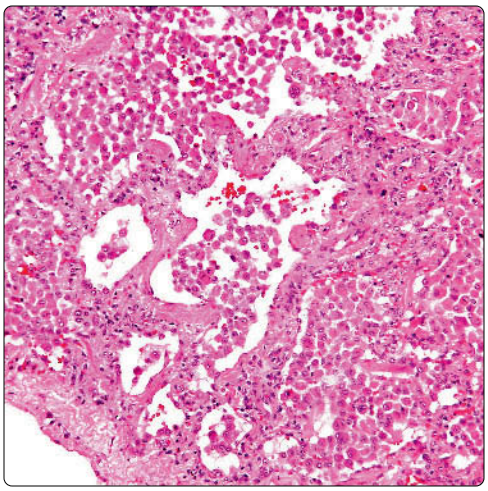

Mild Thickening of Alveolar Septa in DIP

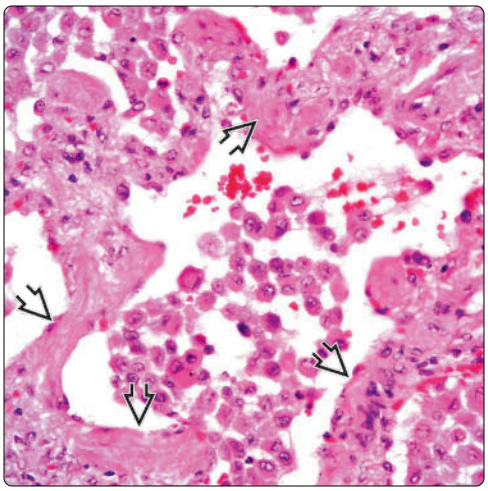

(Left) *Desquamative interstitial pneumonia shows monotonous deposition of alveolar macrophages showing temporal uniformity; i.e., all the lesions are in the same stage of evolution and do not show variability from field to field.* **(Right)** *Higher magnification of desquamative interstitial pneumonia shows minimal fibrosis with only mild thickening of alveolar septa ⇨ and mild chronic inflammatory infiltrates. Notice the absence of organizing fibroblastic foci.*

DIP: Low Power

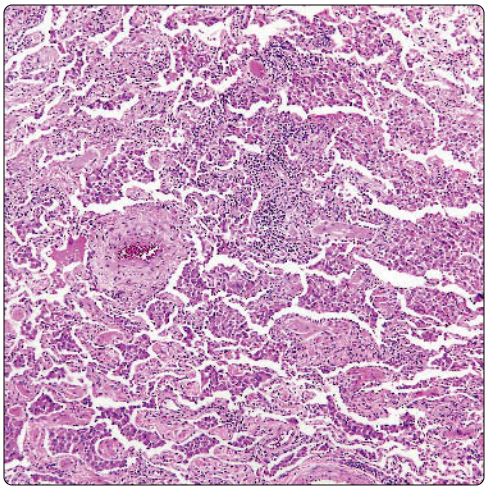

Macrophages in Alveolar Lumen

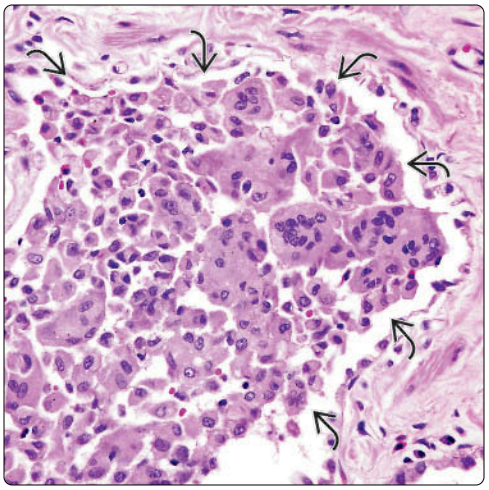

(Left) *Desquamative interstitial pneumonia is characterized by a monotonous deposition of alveolar macrophages filling the alveolar lumina. The process is characterized by minimal interstitial fibrosis and inflammation and displays a uniform histologic appearance (temporal uniformity).* **(Right)** *Higher magnification of desquamative interstitial pneumonia shows a monotonous population of macrophages occupying the alveolar lumen.*

Blue Bodies in DIP

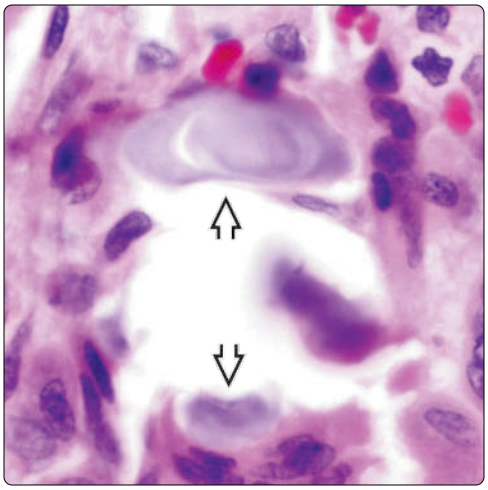

Blue Body in DIP

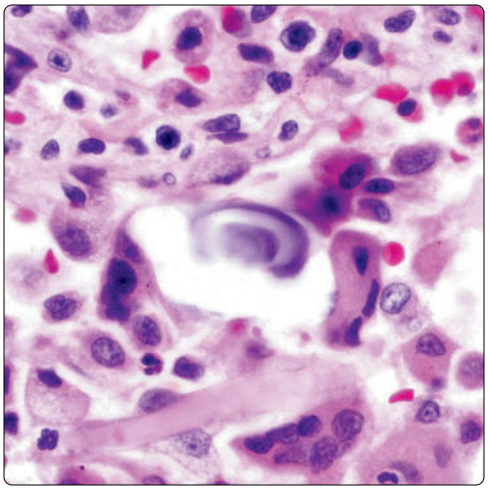

(Left) *Intraalveolar laminated basophilic concretions (so-called blue bodies) can occasionally be identified admixed with the histiocytic infiltrate in desquamative interstitial pneumonia. These are nonspecific inclusions composed mostly of calcium carbonate admixed with mucopolysaccharide matrix and iron.* **(Right)** *Higher magnification shows laminated structure corresponding to basophilic concretion (so-called blue bodies) in desquamative interstitial pneumonia.*

Cytokeratin Staining in DIP

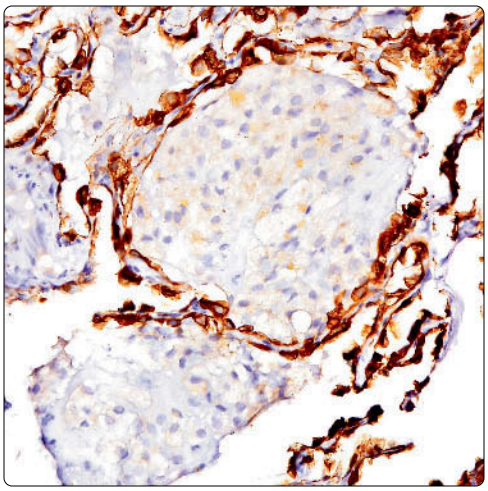

CD68 Staining in DIP

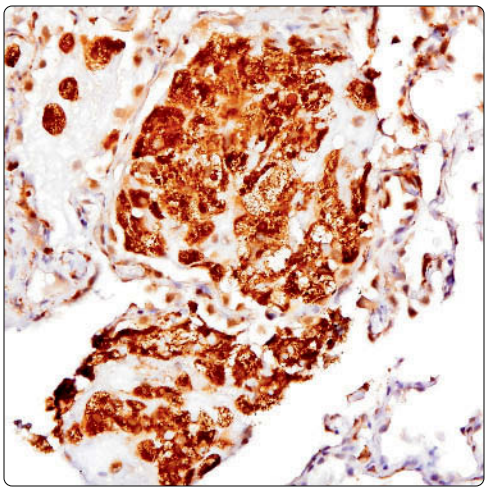

(Left) *Immunohistochemical staining of desquamative interstitial pneumonia for cytokeratin AE1/AE3 shows positivity in the alveolar epithelial cells but is negative in the intraalveolar macrophages. "Desquamative" is a misnomer since the infiltrate is composed of histiocytes and not desquamated epithelial cells.* **(Right)** *Immunohistochemical staining of desquamative interstitial pneumonia with CD68 shows strong positivity in the intraalveolar macrophages.*

KEY FACTS

ETIOLOGY/PATHOGENESIS

- Unknown
- Substantial number of cases are related to underlying collagen-vascular disease

CLINICAL ISSUES

- Age: 25-60 years (average: 50 years)
- Diffuse, bilateral process, predominantly distributed in lower lobes
- Dyspnea, couch, fever
- Disease has insidious onset with slowly progressive exertional dyspnea over 8-18 months
- Dramatic response to corticosteroids during early stages
- > 75% of patients will improve or recover completely following treatment with corticosteroids

MICROSCOPIC

- Process is characterized by interstitial fibrosis and inflammation in varying proportions
- Findings are characterized by absence of temporal heterogeneity (i.e., all lesions in same stage of evolution)
- Underlying lung architecture is often preserved
- 2 major patterns are recognized
  - Cellular pattern is characterized by dense lymphoid infiltration of alveolar septa with preservation of underlying lung architecture
  - Fibrosing pattern is characterized by uniform expansion of alveolar septa by collagen deposition without fibroblastic foci

DIAGNOSTIC CHECKLIST

- Not specific pathologic entity but reaction pattern to unknown underlying stimulus
- Diagnosis of exclusion (i.e., absence of features of usual interstitial pneumonia, desquamative interstitial pneumonia, lymphoid interstitial pneumonia, bronchiolitis obliterans organizing pneumonia, etc.)

(Left) *Nonspecific interstitial pneumonia pattern in the lungs shows uniform thickening of the alveolar septa with a monotonous population of inflammatory cells showing temporal uniformity.* **(Right)** *Higher magnification of nonspecific interstitial pneumonia shows uniform thickening of the alveolar septa by inflammatory elements, including lymphocytes and plasma cells.*

Cellular Nonspecific Interstitial Pneumonia

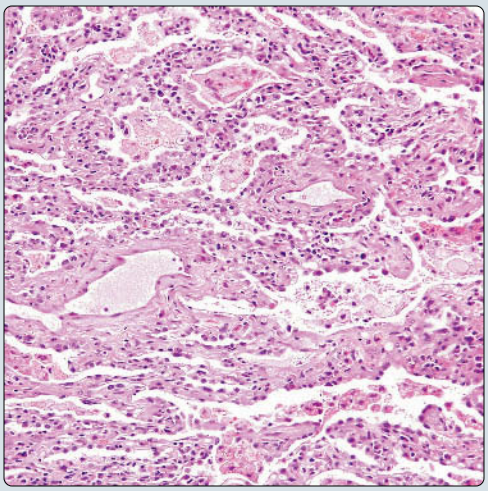

Cellular Nonspecific Interstitial Pneumonia: High Power

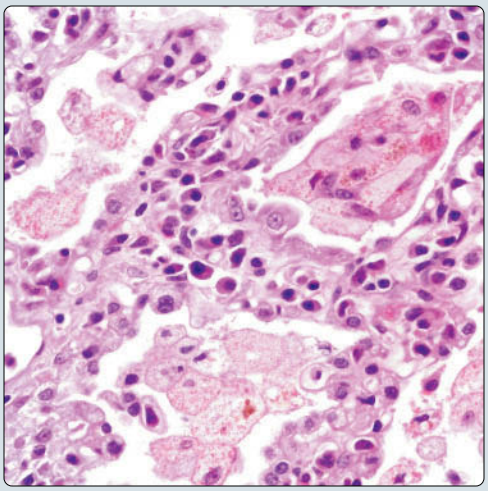

(Left) *The fibrotic form of nonspecific interstitial pneumonia shows a similar diffuse and uniform thickening of alveolar septa due to collagen deposition, but there is absence of dense interstitial lymphoid infiltrates.* **(Right)** *A higher magnification from a case of nonspecific interstitial fibrosis shows thickening of alveolar septa and perivascular deposition of dense connective tissue devoid of lymphoid infiltrates.*

Fibrotic Nonspecific Interstitial Pneumonia

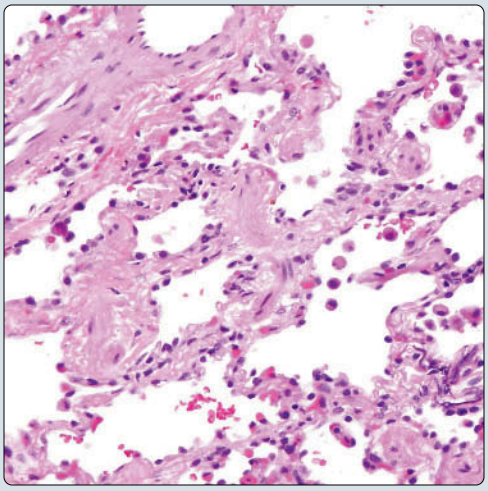

Fibrotic Nonspecific Interstitial Pneumonia: High Power

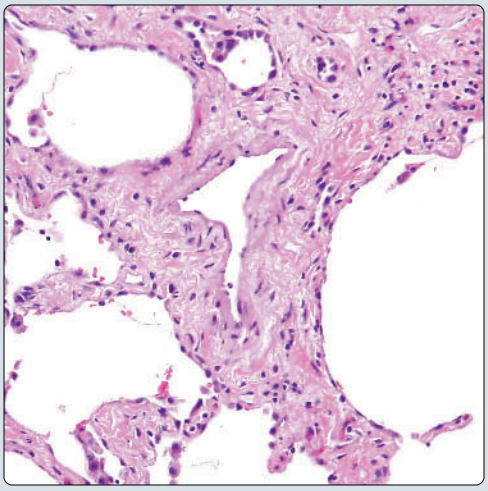

TERMINOLOGY

Abbreviations

- Nonspecific interstitial pneumonia (NSIP)

Definitions

- Special pattern of fibrosing idiopathic interstitial pneumonia with much better prognosis than usual interstitial pneumonia (UIP)

ETIOLOGY/PATHOGENESIS

Etiology

- Unknown
- Substantial number of cases are related to underlying collagen-vascular disease

CLINICAL ISSUES

Site

- Diffuse, bilateral process, predominantly distributed in lower lobes

Presentation

- Dyspnea, cough, fever, and clubbing of fingers (up to 40% of patients)

Natural History

- Disease has insidious onset with slowly progressive exertional dyspnea over 8-18 months
- Dramatic response to corticosteroids during early stages
- Fibrosing histologic variant of NSIP has worse prognosis than nonfibrosing ("cellular") variant
- Average 5-year survival > 80%

Prognosis

- > 75% of patients will improve or recover completely following treatment with corticosteroids
- Patients with fibrosing variant of NSIP may progress to UIP

IMAGING

Radiographic Findings

- Diffuse ground-glass opacities in lower lobes

MICROSCOPIC

Histologic Features

- Process is characterized by interstitial fibrosis and inflammation in varying proportions
- Findings are characterized by absence of temporal heterogeneity (i.e., all lesions in same stage of evolution)
- Underlying lung architecture is often preserved
- 2 major patterns are recognized
  - NSIP with cellular pattern
    - Characterized by mild to moderate interstitial chronic inflammation
    - Inflammatory infiltrate is composed of small lymphocytes and plasma cells
    - Lymphoid aggregates may also be present
  - NSIP with fibrosing pattern
    - Characterized primarily by interstitial deposition of loose or dense fibrous tissue
    - Distribution of fibrous tissue is uniform and monotonous without variation from field to field
    - Absence of fibroblastic foci
    - Pattern of fibrosis may be patchy and discontinuous throughout lung
    - May be combinations of cellular and fibrosing patterns in same biopsy

DIFFERENTIAL DIAGNOSIS

Hypersensitivity Pneumonitis

- Contains scattered, small, poorly formed epithelioid granulomas
- Clinical history of exposure to allergens is important for differential diagnosis

Lymphoid Interstitial Pneumonia (Diffuse BALT Hyperplasia)

- Interstitial infiltration by lymphoid infiltrate is dense and distorts underlying lung architecture
- Lymphoid infiltrate involves interlobular septa, perivascular and peribronchiolar spaces, and pleura
  - Lymphoid infiltrate in cellular NSIP involves mainly alveolar septa with preservation of underlying architecture

Usual Interstitial Pneumonia

- Inflammatory and fibrotic changes are characterized by temporal heterogeneity (i.e., lesions are at varying stages of evolution)
- UIP shows prominent fibroblastic foci, feature not seen in NSIP
- Honeycombing of lung parenchyma is common feature of UIP that should not be seen in NSIP

Collagen-Vascular Diseases

- Clinical history and laboratory tests are important for establishing correct diagnosis

DIAGNOSTIC CHECKLIST

Clinically Relevant Pathologic Features

- Not specific pathologic entity but reaction pattern to unknown underlying stimulus
- Diagnosis of exclusion [i.e., absence of UIP features, desquamative interstitial pneumonia, lymphoid interstitial pneumonia (LIP), bronchiolitis obliterans organizing pneumonia, or other specific process]
- Histologic features may overlap with several other conditions, including LIP, hypersensitivity pneumonitis, and collagen vascular diseases
- Clinical and radiographic correlation is indispensable for diagnosis

SELECTED REFERENCES

1. Belloli EA et al: Idiopathic non-specific interstitial pneumonia. Respirology. 21(2):259-68, 2016
2. Akira M et al: Long-term follow-up high-resolution CT findings in non-specific interstitial pneumonia. Thorax. 66(1):61-5, 2011
3. Sato T et al: Non-specific interstitial pneumonia; as the first clinical presentation of various collagen vascular disorders. Rheumatol Int. 26(6):551-5, 2006
4. Nicholson AG: Classification of idiopathic interstitial pneumonias: making sense of the alphabet soup. Histopathology. 41(5):381-91, 2002

Nonspecific Interstitial Pneumonia

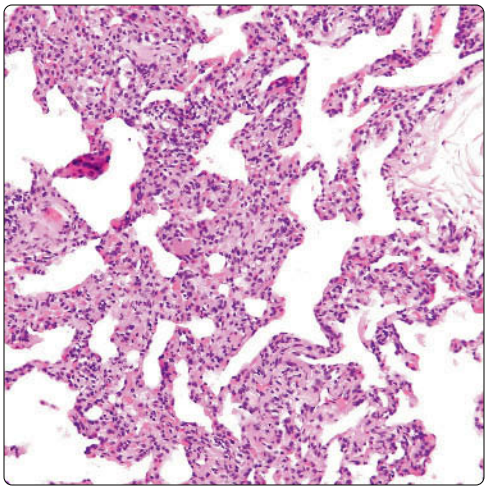

Lack of Temporal Heterogeneity

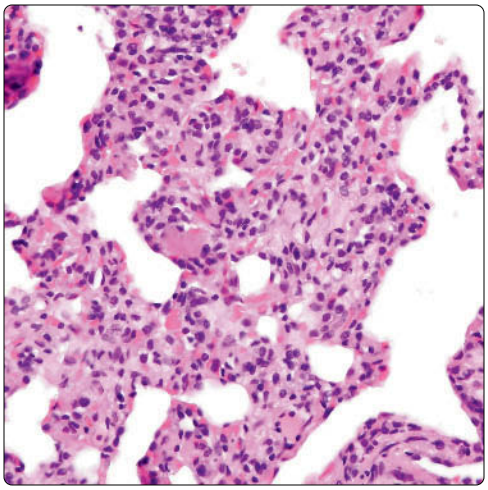

(Left) *Scanning magnification in nonspecific interstitial pneumonia shows moderate thickening of the alveolar septa with interstitial chronic inflammation. The lesions are uniform throughout and show temporal uniformity (i.e., all are at the same stage of evolution), which imparts them with a monotonous appearance.* **(Right)** *Higher magnification in nonspecific interstitial pneumonia shows uniform thickening of the alveolar septa by a monotonous population of lymphoid cells.*

Nonspecific Interstitial Pneumonia: Cellular Variant

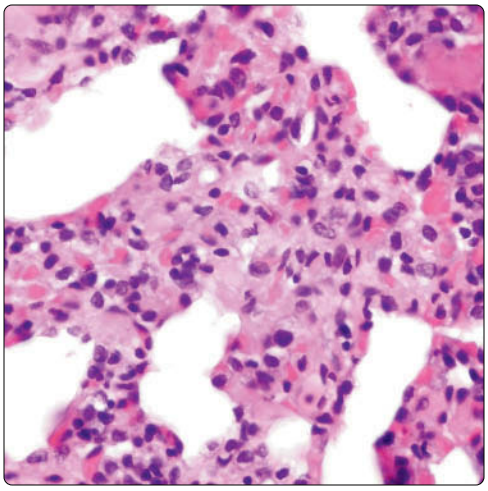

Nonspecific Interstitial Pneumonia: High Power

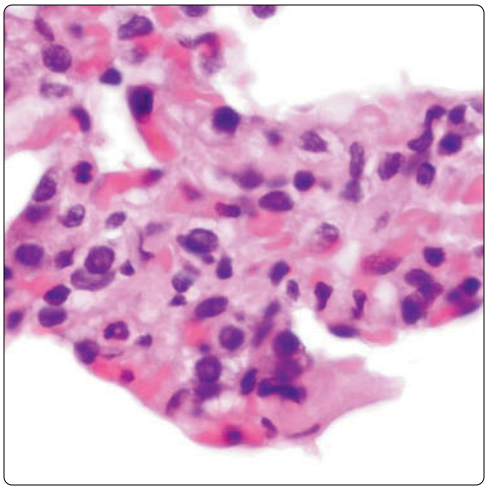

(Left) *Higher magnification of nonspecific interstitial pneumonia shows distended alveolar walls with early collagen deposition and dense lymphoid cell infiltrates. Cases like this need to be distinguished from lymphoid interstitial pneumonia and extrinsic allergic alveolitis.* **(Right)** *Higher magnification from nonspecific interstitial pneumonia with a cellular pattern shows a thickened alveolar wall containing dense inflammatory cell infiltrate.*

Nonspecific Interstitial Pneumonia: Late Cellular Phase

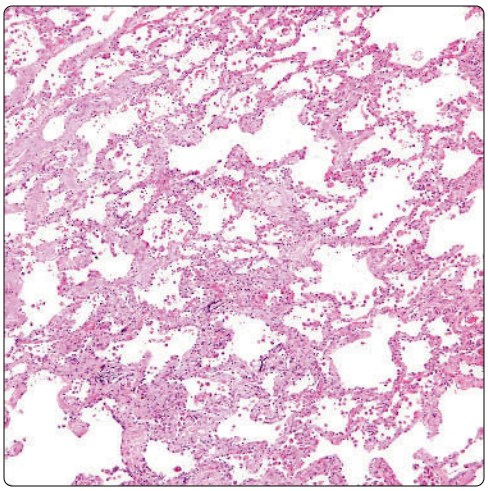

Nonspecific Interstitial Pneumonia: Higher Magnification

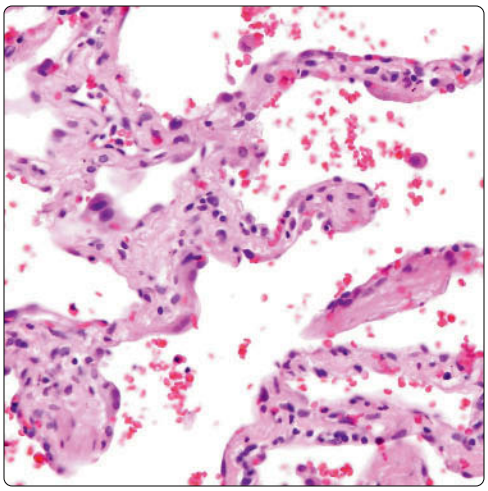

(Left) *Scanning magnification of nonspecific interstitial pneumonia, late cellular phase, shows fibrotic, uniformly distended alveolar walls with a few residual inflammatory elements. The lesions are strikingly similar from area to area and do not show the entrapment of normal lung parenchyma characteristic of usual interstitial pneumonia.* **(Right)** *Higher magnification of the late cellular phase of nonspecific interstitial pneumonia shows fibrotic alveolar septa with some residual lymphocytes.*

Nonspecific Interstitial Pneumonia: Fibrosing Pattern

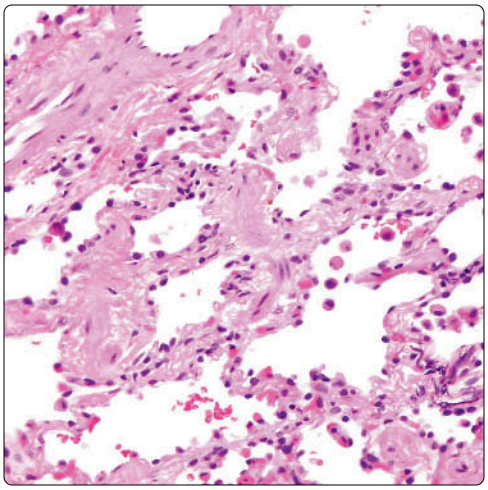

Nonspecific Interstitial Pneumonia: Fibrosing Pattern

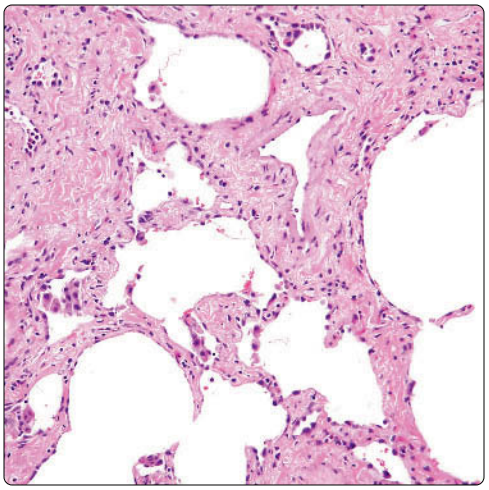

(Left) *Fibrosing pattern of nonspecific interstitial pneumonia shows thickened alveolar septa that are primarily distended by abundant fibrocollagenous tissue. Notice the uniformity of the process, which looks the same throughout, unlike the heterogeneous appearance of usual interstitial pneumonia, which shows lesions in varying stages of evolution.* **(Right)** *Nonspecific interstitial pneumonia, fibrosing pattern, shows thickened alveolar septa with a paucity of inflammatory elements.*

Fibrosing Nonspecific Interstitial Pneumonia: Higher Magnification

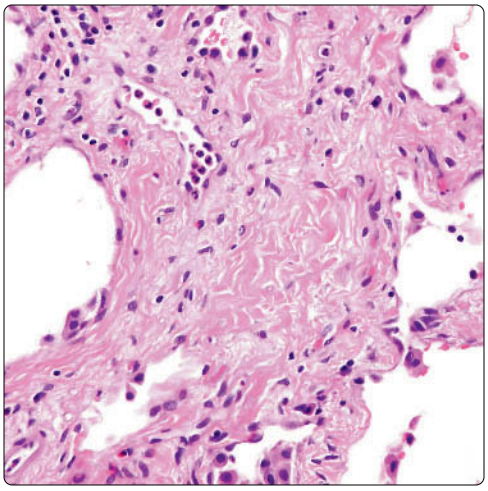

Nonspecific Interstitial Pneumonia: High Power

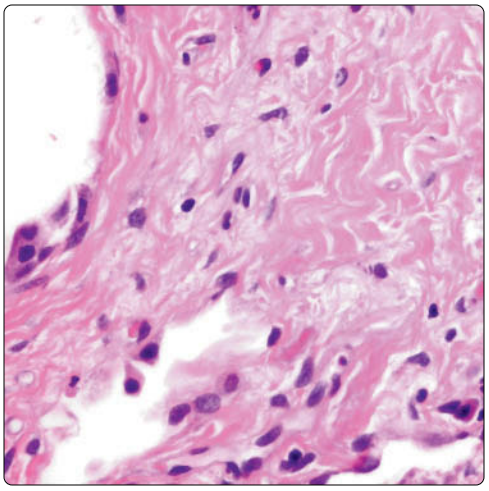

(Left) *Higher magnification of the fibrosing pattern in nonspecific interstitial pneumonia shows thickening of the alveolar septum due to dense collagen deposition. There are still a few small lymphocytes noted, but the damage is predominantly at the expense of collagen deposition.* **(Right)** *Higher magnification of an alveolar wall in the fibrosing pattern of nonspecific interstitial pneumonia shows thick collagen bundles with only a few scattered inflammatory cells.*

Fibrosis of Alveolar Septa

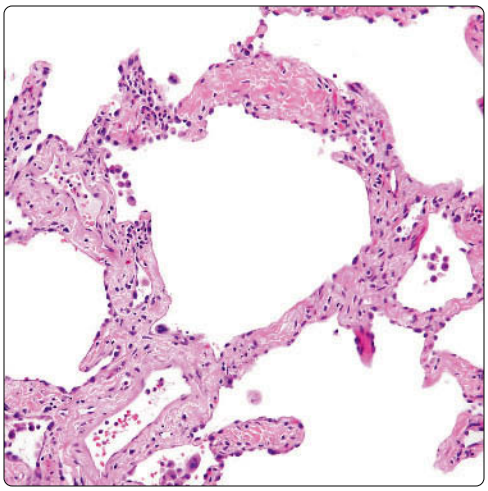

Thickened Alveolar Septa

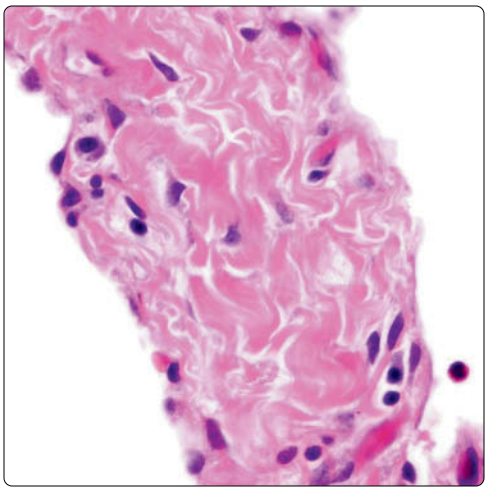

(Left) *Fibrosing pattern of nonspecific interstitial pneumonia shows mildly thickened alveolar walls with few lymphocytes and heavy interstitial collagen deposition. Cases with these features are associated with a poorer prognosis and may lead to honeycombing of the lung.* **(Right)** *Higher magnification of the sclerosing pattern of nonspecific interstitial pneumonia shows heavy interstitial collagen deposition with a few spindled fibroblasts.*

KEY FACTS

TERMINOLOGY

- Hypersensitivity pneumonitis (HP)
- Granulomatous lung disease secondary to inhalation of organic antigens or chemicals

ETIOLOGY/PATHOGENESIS

- History of exposure to organic antigens
- 6 D F F K D U R S R O \ V S [illegible]
- 7 K H U P R D F W L Q R [illegible] workers)
- Animal protein from bird feathers and feces
- HP represents immune complex-mediated (type III) T cell and delayed (type IV) hypersensitivity reaction

CLINICAL ISSUES

- Acute HP
  - 4-6 hours after exposure to antigen
  - Episode may last 12-18 hours
- Chronic HP
  - Patients may have continuous exposure to antigen over longer periods of time
  - Patients may not experience acute episode
  - This type of HP eventually gets biopsied
- Treatment
  - Corticosteroids
- HP is more common in adults with no gender or ethnic predilection

TOP DIFFERENTIAL DIAGNOSES

- Sarcoidosis
- Usual interstitial pneumonitis
- Bronchiolitis obliterans and organizing pneumonia (BOOP)

DIAGNOSTIC CHECKLIST

- Areas of BOOP
- Noncaseous granulomatous inflammation

Masson Bodies and Giant Cells

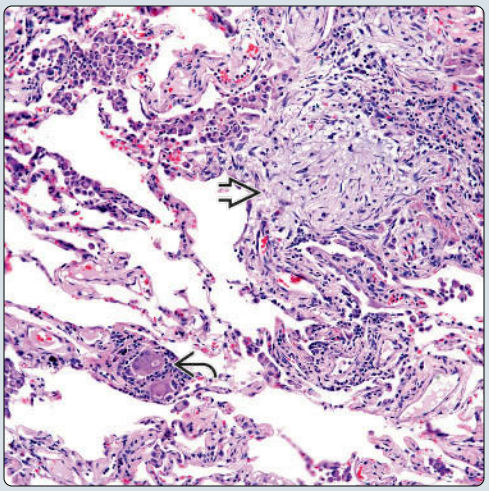

Ill-Defined Granulomas

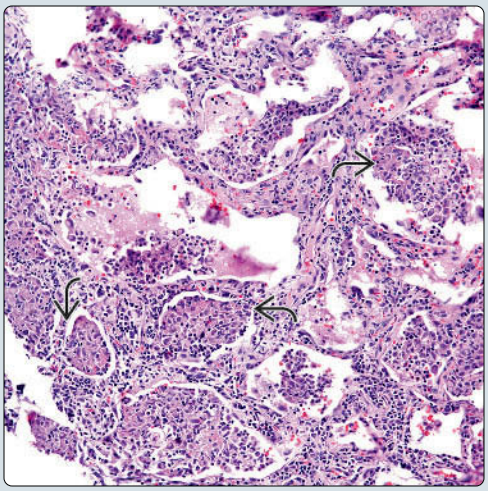

(Left) *Hypersensitivity pneumonitis (HP) shows the 2 most important features for its diagnosis: Areas of bronchiolitis obliterans and the presence of ill-defined granulomas. (Right) In other areas of lung parenchyma, there is a discrete presence of numerous noncaseating granulomas. The presence of ill-defined granulomas is characteristic of HP.*

Pneumonitis

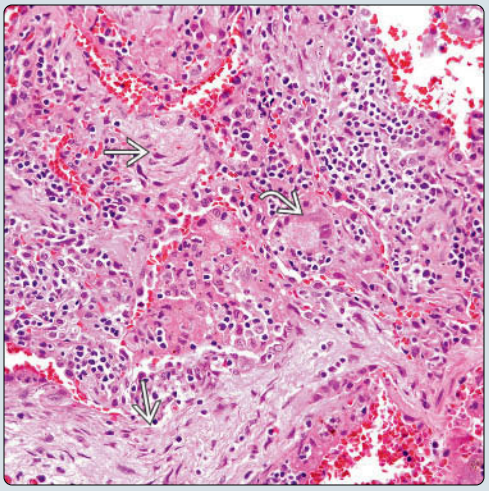

Fibrinoid Nodules

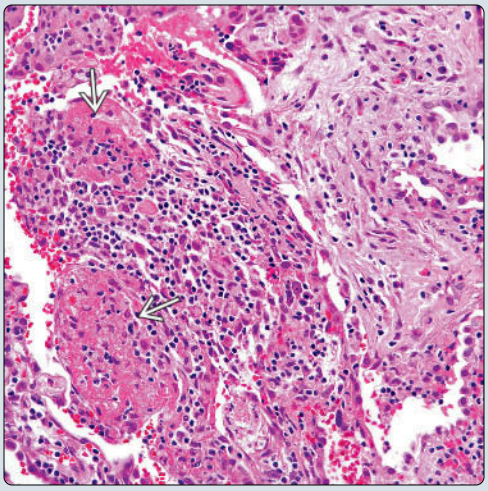

(Left) *HP shows areas of inflammatory reaction, which distorts the normal lung architecture. However, it is possible to identify areas of organizing pneumonia and giant cells. (Right) HP shows areas of organizing pneumonia and marked inflammatory reaction. In addition, there are 2 fibrinoid nodules that may represent ill-defined granulomatous reaction.*

TERMINOLOGY

Synonyms

- Hypersensitivity pneumonitis (HP)

Definitions

- Granulomatous lung disease secondary to inhalation of organic antigens or chemicals

ETIOLOGY/PATHOGENESIS

Environmental Exposure

- History of exposure to organic antigens
  - 6DFFKDURSRO\VSRUD UHFWLYLUJXOD in "farmer's lung" (moldy hay)
  - 7KHUPRDFWLQRP\FHV VDFFKDUL in bagassosis (sugar cane workers)
  - Animal protein from bird feathers and feces
- In unusual cases, HP may develop due to sensitization to fungi- and mite-contaminated flour
- In unusual cases, HP may be due to metalworking fluids

Pathogenesis

- HP represents immune complex-mediated (type III) T cell and delayed (type IV) hypersensitivity reaction

CLINICAL ISSUES

Epidemiology

- Incidence
  - Exact incidence of HP is unknown
    - However, HP may be more prevalent in people exposed to birds
- Age
  - Usually in adults
- Sex
  - No predilection for any particular sex
- Ethnicity
  - No predilection for any particular ethnic group

Site

- Lung without predilection for specific side or lung segment

Presentation

- Cough
- Dyspnea
- Fever
- Chills
- Wheezing
- Malaise

Laboratory Tests

- Pulmonary function tests may be abnormal
- Erythrosedimentation may be elevated
- C protein may be elevated

Natural History

- Acute HP
  - 4-6 hours after exposure to antigen
  - Episode may last 12-18 hours
- Chronic HP
  - Patients may have continuous exposure to antigen over months or years
  - Patients may not experience acute episode
  - This type eventually gets biopsied

Treatment

- Drugs
  - Corticosteroids
- Stop exposure to potential antigen

Prognosis

- Prognosis is good in patients who have not developed pulmonary fibrosis

MACROSCOPIC

General Features

- Diagnosis of HP is generally performed by open lung biopsy

MICROSCOPIC

Histologic Features

- Areas of organizing pneumonia
- Intrabronchial budding of fibrocollagenous tissue
- Noncaseating granulomatous inflammation
- Patchy appearance in lung parenchyma
- Mild inflammatory peribronchial and interstitial changes

DIFFERENTIAL DIAGNOSIS

Sarcoidosis

- Rarely shows combined features of bronchiolitis obliterans and organizing pneumonia (BOOP) and noncaseous granulomatous reaction
- Granulomatous component in HP is rather ill defined in contrast with one seen in sarcoidosis

Usual Interstitial Pneumonitis

- Rarely shows presence of noncaseous granulomatous inflammation
- Shows more extensive areas of pulmonary fibrosis

Bronchiolitis Obliterans and Organizing Pneumonia

- HP shows areas of BOOP
- Combination of BOOP and noncaseous granulomatous inflammation is hallmark of HP

Infectious Process

- Use of histochemical stains (AFB, PAS, and GMS) and tissue cultures are helpful in ruling out such possibility

DIAGNOSTIC CHECKLIST

Clinically Relevant Pathologic Features

- Tissue distribution

Pathologic Interpretation Pearls

- Areas of BOOP
- Noncaseous granulomatous inflammation
- Ill-defined granulomas

SELECTED REFERENCES

1. Cano-Jiménez E et al: Farmer's lung disease. A review. Arch Bronconeumol. 52(6):321-8, 2016
2. Quirce S et al: Occupational hypersensitivity pneumonitis: an EAACI position paper. Allergy. 71(6):765-79, 2016

Focal Granulomas

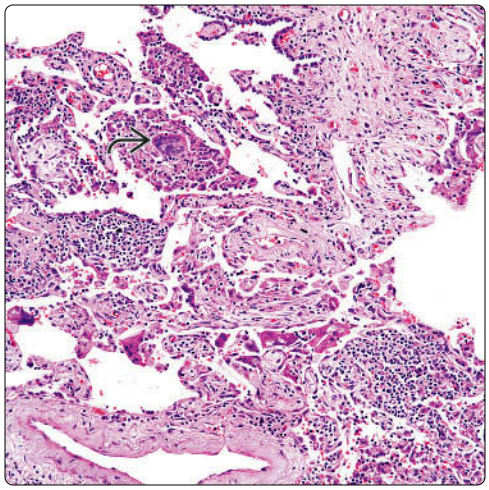

Organizing Pneumonia

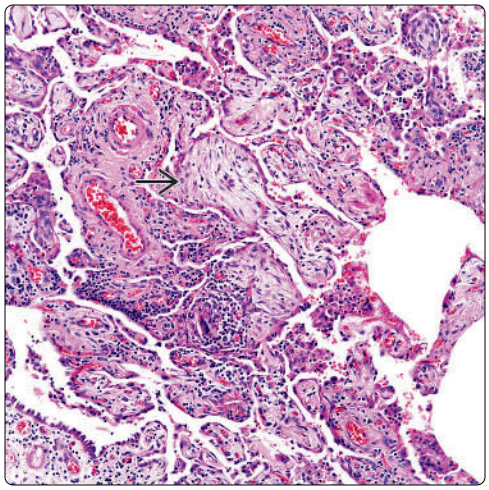

(Left) *HP shows an ill-defined granulomatous reaction, noncaseous type. Adjacent lung parenchyma shows widening of the interstitium with focal areas of fibrosis.* **(Right)** *HP shows areas similar to those seen in organizing pneumonia, namely the presence of fibroblastic polypoid plugs, so-called Masson bodies. There is mild inflammatory infiltrate.*

Organizing Pneumonia and Granulomas

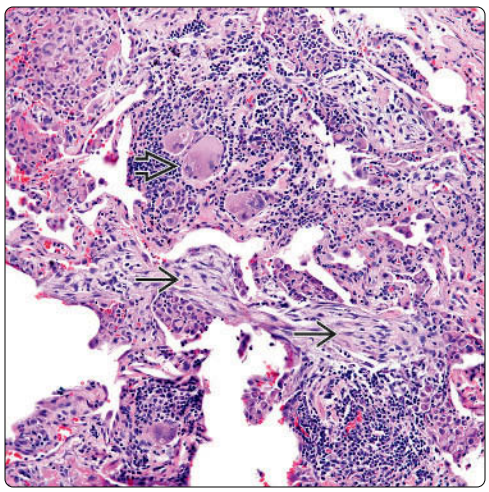

Fibroblastic Plugs

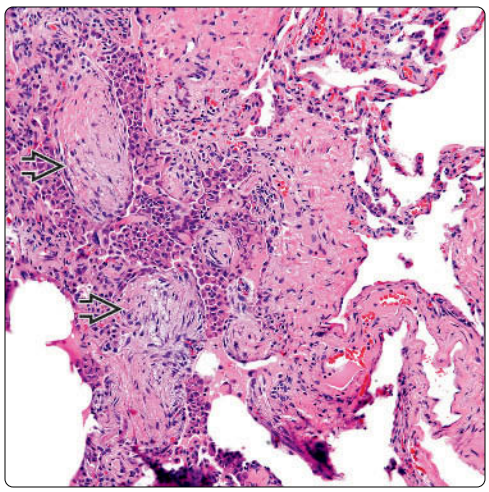

(Left) *The classic features of HP, namely the presence organizing pneumonia and the presence of an ill-defined granulomatous component, are present. These features are diagnostic of HP.* **(Right)** *The presence of young fibroblastic plugs may be the most obvious features in cases of HP. Thus, careful attention should be given to the finding of the granulomatous component in order to diagnose HP.*

Focal Granulomas

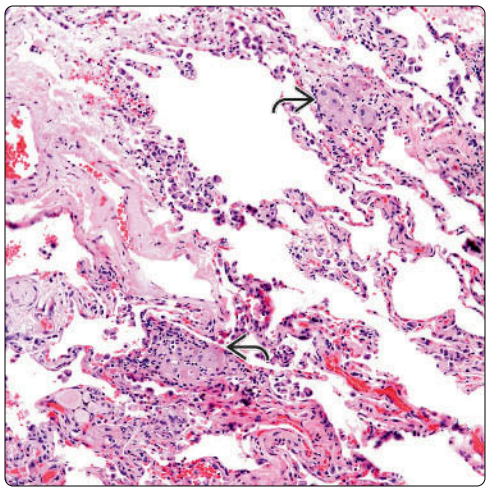

Giant Cells

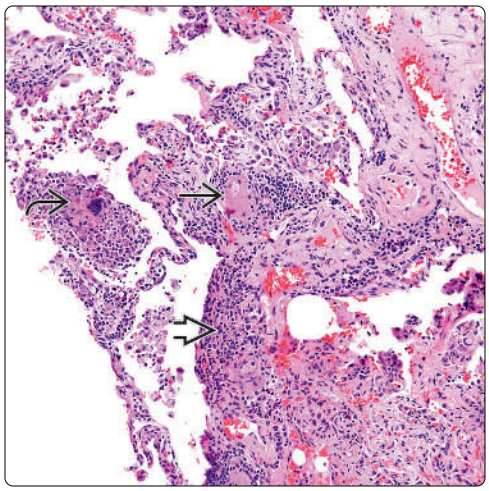

(Left) *Low-power view shows an HP in which the lung appears to be within normal limits; however, note the presence of discrete granulomas. This component can be easily ignored in cases of HP.* **(Right)** *HP shows more inflammatory components, including lymphocytes. There is also the presence of a small granuloma and giant cells embedded in the inflammatory component.*

Mild Scarring

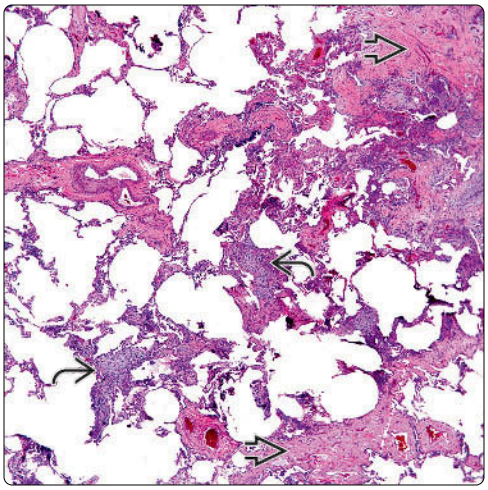

Nodular Pattern

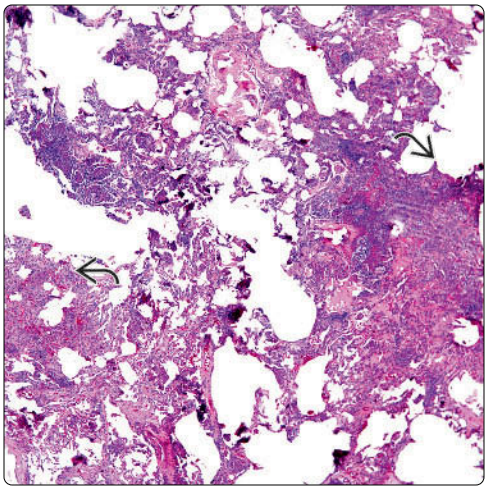

(Left) *Low-power view of HP shows the presence of fibroblastic plugs admixed with areas of relatively uninvolved lung parenchyma. In focal areas, there is mild interstitial scarring.* **(Right)** *Two distinct nodules are present within the lung parenchyma, giving the appearance of organizing pneumonia. Although this is an important histological feature, equally important is the presence of granulomas.*

Inflammatory Component

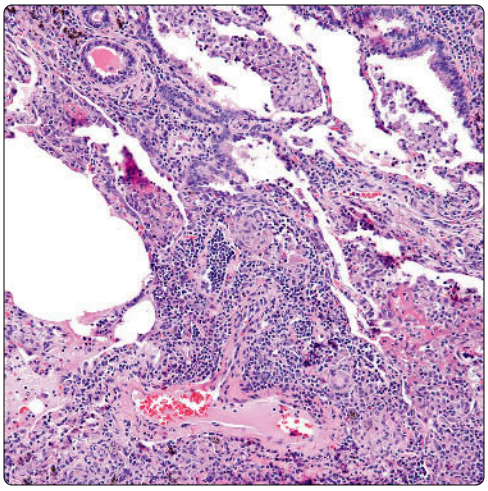

Masson Bodies and Granulomas

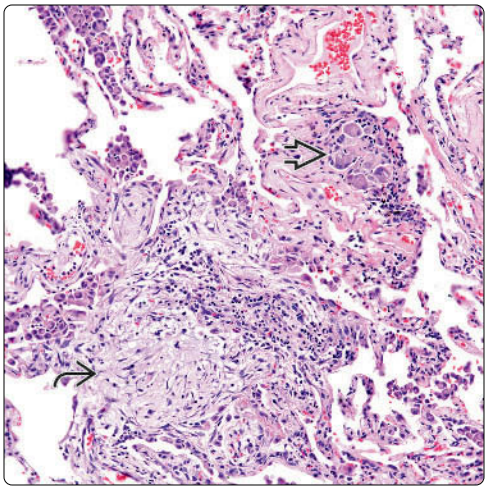

(Left) *HP shows areas with a more inflammatory component, namely lymphocytes. This feature may suggest an infectious or reactive process.* **(Right)** *Closer view at a fibroblastic plug shows the spindle fibroblastic proliferation. In addition, note the presence of a granulomatous component. Adjacent lung parenchyma appears uninvolved.*

Fibrosis

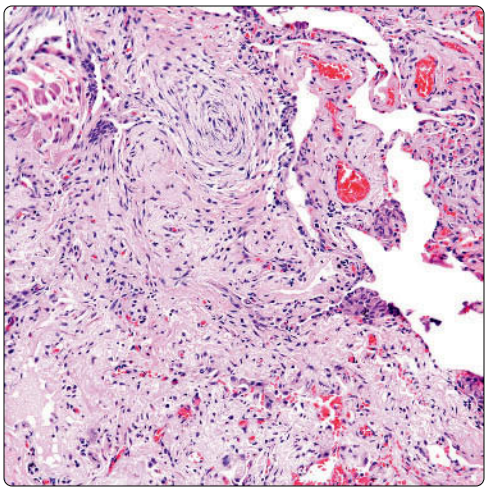

Focal Organizing Pneumonia

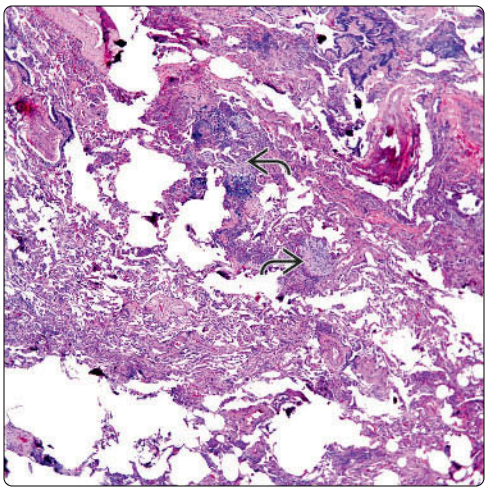

(Left) *In some cases of HP, areas of scarring or fibrosis may be present, suggesting the possibility of developing an interstitial fibrotic lung disease.* **(Right)** *A section of lung parenchyma shows areas of what appear to be "normal" lung parenchyma alternating with areas of focal organizing pneumonia. The presence of areas of organizing pneumonia and a granulomatous component are characteristic of HP.*

Allergic Angiitis and Granulomatosis (Churg-Strauss)

KEY FACTS

TERMINOLOGY

- Systemic process characterized by presence of vasculitis, blood eosinophilia, and asthma

ETIOLOGY/PATHOGENESIS

- No definitive etiology has been defined for Churg-Strauss syndrome
- Probably an autoimmune process
- Small-vessel vasculitis

CLINICAL ISSUES

- Incidence
  - More common in adults
- Since this process is systemic, it may involve different systems, including
  - Respiratory
  - Cardiovascular
  - Gastrointestinal
  - Renal
  - Central nervous
  - Skin
- Laboratory findings
  - Blood eosinophilia
  - p-ANCA commonly positive, although c-ANCA may also be positive in some cases
  - Leukocytosis
  - Elevated erythrosedimentation rate
- Treatment
  - Different therapeutic approaches have been tried depending on particular case
- Prognosis
  - Majority of patients respond to treatment with steroids
  - Churg-Strauss syndrome may follow rapid and severe course unresponsive to treatment

Obliterated Lung Parenchyma

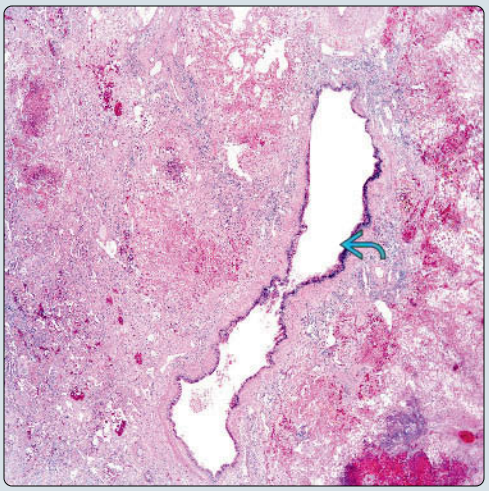

Residual Lung Parenchyma

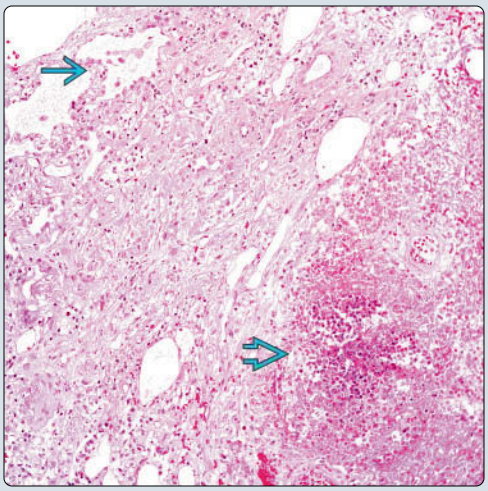

(Left) *Lung parenchyma is shown partially destroyed by a fibrinous infiltrate composed of mixed inflammatory infiltrate. Note the presence of an airway structure that is still identifiable.* **(Right)** *H&E shows transitional areas between relatively uninvolved lung parenchyma with areas in which the lung parenchyma is replaced by eosinophilic abscess.*

Eosinophilic Abscess

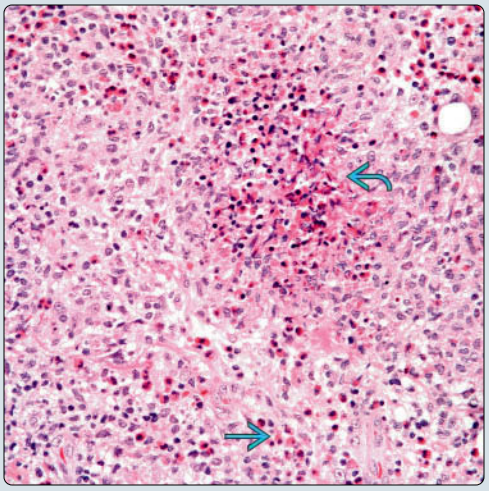

Vasculitis

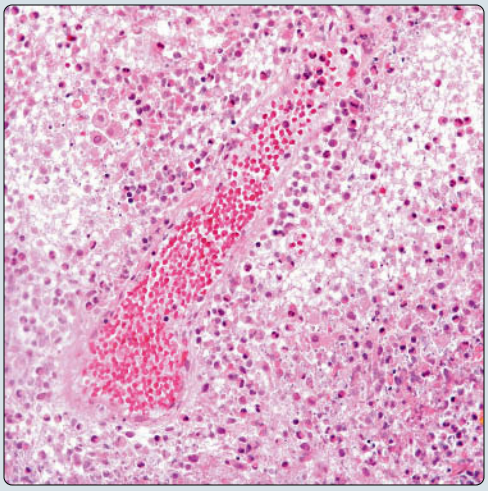

(Left) *The presence of eosinophilic microabscess is a common feature in cases of Churg-Strauss syndrome. Note also the presence of tissue eosinophilia.* **(Right)** *An elongated pulmonary vascular structure is depicted showing marked inflammatory reaction, mainly composed of eosinophils. Note that the wall of the vessels is partially destroyed.*

TERMINOLOGY

Abbreviations

- Allergic angiitis and granulomatosis (AAG)

Synonyms

- Churg-Strauss syndrome

Definitions

- Systemic process characterized by presence of vasculitis, blood eosinophilia, and asthma

ETIOLOGY/PATHOGENESIS

Etiology

- No definitive etiology has been defined for Churg-Strauss syndrome
- Probably an autoimmune process
  - Th2-mediated disease
  - Probably B cells and humoral response
  - ANCA-associated vasculitides
- Small vessel vasculitis

CLINICAL ISSUES

Epidemiology

- Incidence
  - No clear population study has been performed to evaluate exact incidence of this syndrome
  - It is believed that 10% of patients with well-defined vasculitides may have Churg-Strauss syndrome
- Age
  - More common in adults
  - May vary from 3rd to 6th decade of life
- Sex
  - No apparent gender predilection for Churg-Strauss syndrome
- Ethnicity
  - No apparent predilection

Site

- Since this process is systemic, it may involve different systems, including
  - Respiratory system
  - Cardiovascular
  - Gastrointestinal
  - Renal
  - Central nervous system
  - Skin

Presentation

- Rhinitis
- Asthma
- Cough
- Dyspnea

Laboratory Tests

- Blood eosinophilia
- p-ANCA commonly positive, although c-ANCA may also be positive in some cases
  - By indirect immunofluorescence test
  - Image analysis of immunofluorescence patterns: Known as 3rd generation PR3-ANCA and MPO-ANCA
- Elevation of erythrosedimentation rate
- Elevated IgE levels
- Leukocytosis
- Hypergammaglobulinemia

Prognosis

- Majority of patients respond to steroid treatment
- Churg-Strauss syndrome may follow rapid and severe course unresponsive to treatment

MICROSCOPIC

Histologic Features

- Vasculitis
  - This process may affect capillaries, veins, and arteries
- Granulomatous reaction
  - Necrotizing
  - Nonnecrotizing
- Tissue eosinophilia
- Bronchitis
- Fibrinoid pneumonia

DIFFERENTIAL DIAGNOSIS

Wegener Granulomatosis

- Commonly involves kidneys
  - Churg-Strauss commonly involves cardiovascular system
- Commonly has positive c-ANCA
  - Churg-Strauss more commonly has positive p-ANCA

Eosinophilic Pneumonia

- Eosinophilic abscess is more commonly seen in intraalveolar spaces
- Does not show extensive areas of necrosis and granulomatous reaction
- Does not involve other systems, such as cardiovascular system
- Most likely negative for p-ANCA or c-ANCA

Infectious Conditions

- Fungal
  - Special histochemical stains, including PAS and GMS, should be performed; tissue cultures are highly recommended
- Parasitic
  - 6WURQJ\OLGHV VWHUFRUDOLVand 7R[RFDUD
    - Both of these parasites can be identified on light microscopic examination

DIAGNOSTIC CHECKLIST

Clinically Relevant Pathologic Features

- Organ distribution

Pathologic Interpretation Pearls

- Vasculitis
- Granulomatous inflammation
- Asthma

SELECTED REFERENCES

1. Greco A et al: Churg-Strauss syndrome. Autoimmun Rev. 14(4):341-348, 2015

Fibrinoid Exudate

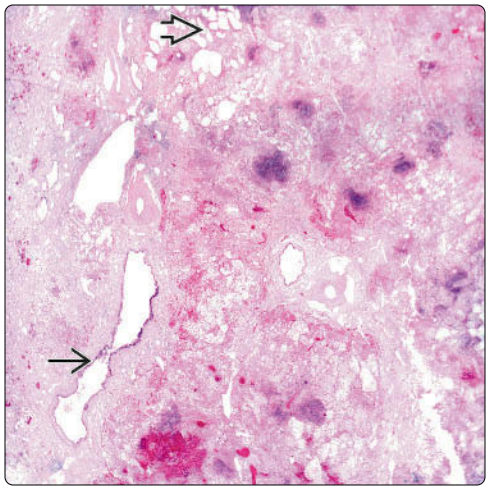

Microabscesses

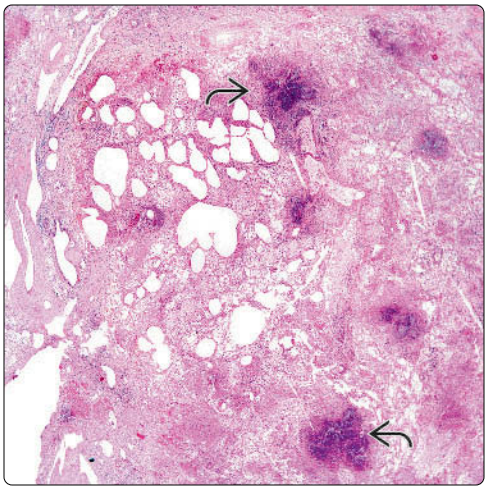

(Left) *Low-power view of Churg-Strauss syndrome shows areas of still recognizable airway structures and alveolated tissue. Most of the lung parenchyma is destroyed by a fibrinous inflammatory infiltrate.* **(Right)** *Churg-Strauss syndrome shows the presence of numerous microabscesses. This feature may be seen in infectious cases as well as in Wegener granulomatosis.*

Tissue Eosinophilia

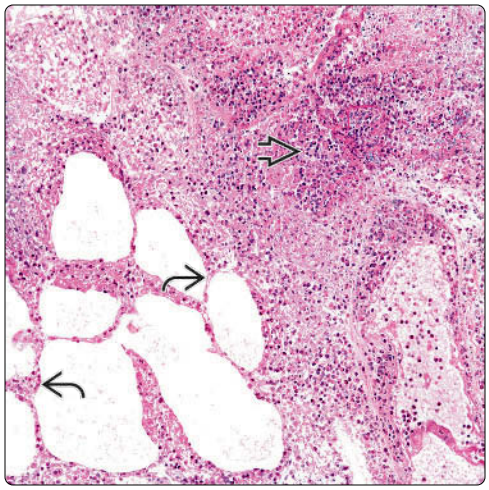

Fibrinoid Exudate With Eosinophils

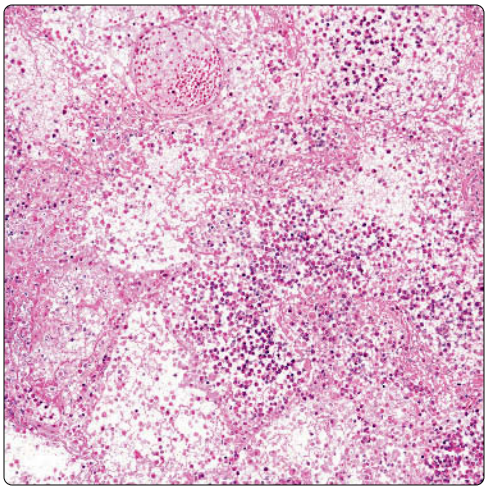

(Left) *Extensive areas of necrosis with eosinophils are shown; however, in some areas, one is still able to identify the outline of alveoli.* **(Right)** *Higher magnification shows the fibrinopurulent infiltrate in the lung parenchyma in Churg-Strauss. At this power, it is difficult to recognize either lung parenchyma or vascular structures.*

Fibrinoid Necrosis

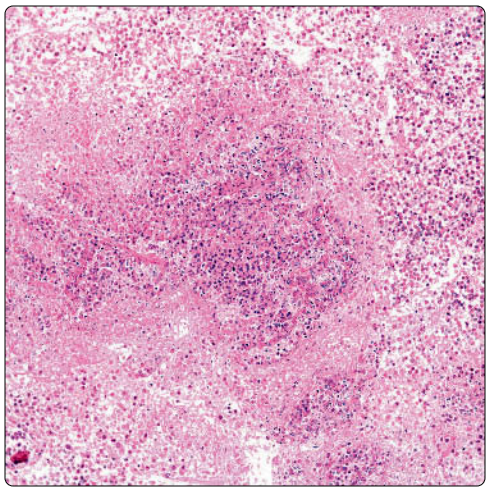

Tissue Eosinophilia

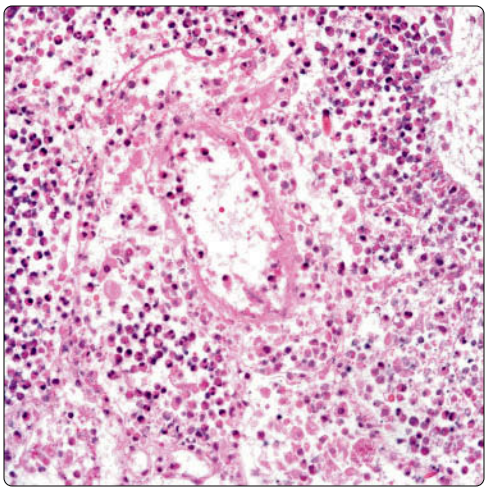

(Left) *Necrosis and microabscesses are commonly seen in cases of Churg-Strauss, as they may also be seen in cases of Wegener granulomatosis.* **(Right)** *High-power magnification shows that the inflammatory infiltrate is composed predominantly of eosinophils. This type of infiltrate should raise the suspicion of Churg-Strauss syndrome in the proper clinical setting.*

Extensive Necrosis

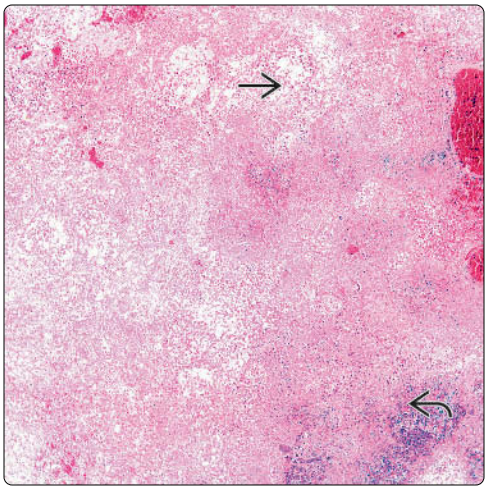

Fibrinoid Exudate

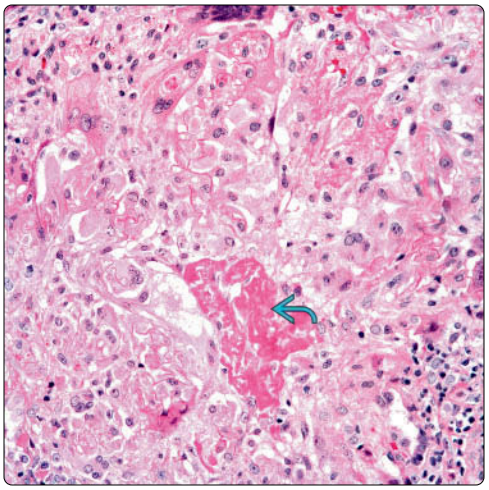

(Left) *Low-power view shows areas of necrosis and fibrinoid exudate destroying lung parenchyma. Similar features may be seen in Wegener granulomatosis.* **(Right)** *High-power view shows areas of focal fibrinoid exudate surrounded by the remains of lung parenchyma with marked inflammatory changes. In this area, eosinophils are only scattered and few.*

Giant Cells and Eosinophils

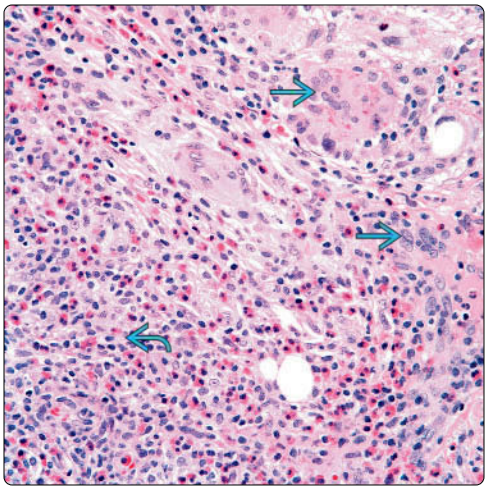

Granulomatous Reaction

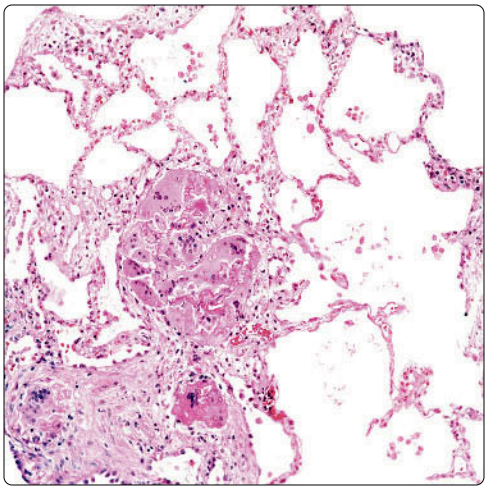

(Left) *Prominent tissue eosinophilia admixed with scattered multinucleated giant cells is a common feature of Churg-Strauss syndrome.* **(Right)** *In areas away from the acute inflammatory reaction and eosinophilia, the presence of granulomas in otherwise uninvolved lung parenchyma is common. Special stains are important to rule out infection.*

Fibrinoid Exudate and Giant Cells

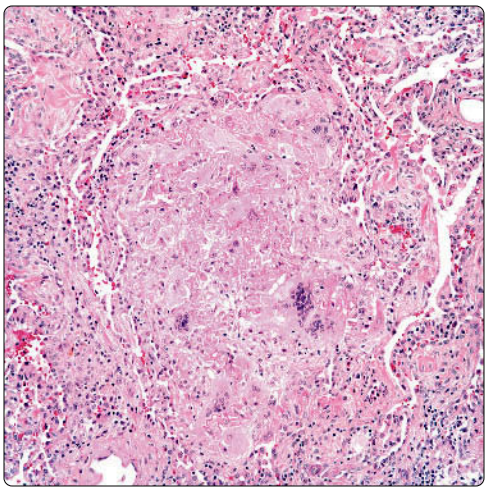

Crystalloid Material

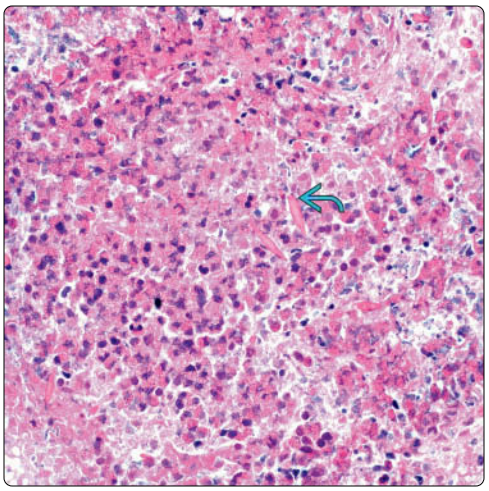

(Left) *High-power view shows a focal granulomatous reaction in Churg-Strauss syndrome. This feature may be seen in cases of infectious origin.* **(Right)** *Areas of tissue necrosis and prominent inflammatory changes are admixed with crystalloid material. These features should also raise suspicion for underlying asthma.*

Bronchocentric Granulomatosis

KEY FACTS

TERMINOLOGY

- Reaction pattern of lung parenchyma characterized by broncho- and bronchiolocentric necrotizing granulomas

ETIOLOGY/PATHOGENESIS

- Infections associated with bronchocentric granulomatosis (BCG) include mycobacteria, fungi ($VSHUJLOOXV, +LVWRSODVPD, etc.), and parasites ((FKLQRFRFFXV)
- Noninfectious causes of BCG include Wegener granulomatosis and rheumatoid arthritis
- Allergic causes of BCG include allergic aspergillosis in association with mucoid impaction

CLINICAL ISSUES

- Most cases are allergic and associated with bronchopulmonary aspergillosis
- ~ 50% of patients have history of chronic asthma
- Infectious cases show more variable findings, ranging from localized consolidation to nodular parenchymal lesions
- Elevated IgE levels and serum precipitins to $VSHUJLOOXV are important clues in allergic cases
- Antinuclear antibody testing is helpful to rule out Wegener granulomatosis
- Cultures are important to rule out specific infectious agents

MICROSCOPIC

- Destruction of walls of small bronchi and bronchioles by necrotizing granulomatous inflammation
- Bronchial walls are replaced by palisading histiocytic reaction
- Abundant necrotic debris seen in lumina of bronchioles with numerous neutrophils and eosinophils
- Impaction of proximal airways by allergic mucin
- Eosinophils are particularly prominent in cases associated with allergic bronchopulmonary aspergillosis
- Multinucleated giant cells may be present, particularly around necrotic debris

Peribronchial Granulomas

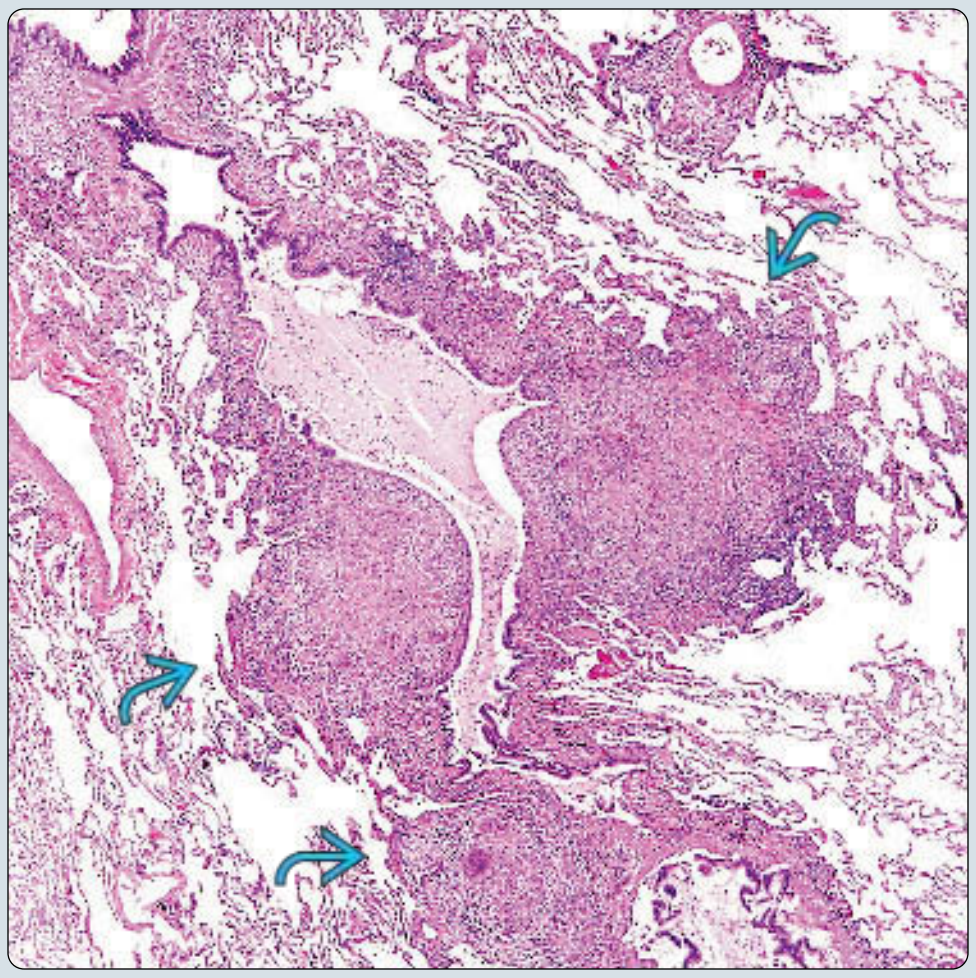

Peribronchial Granuloma: Higher Power

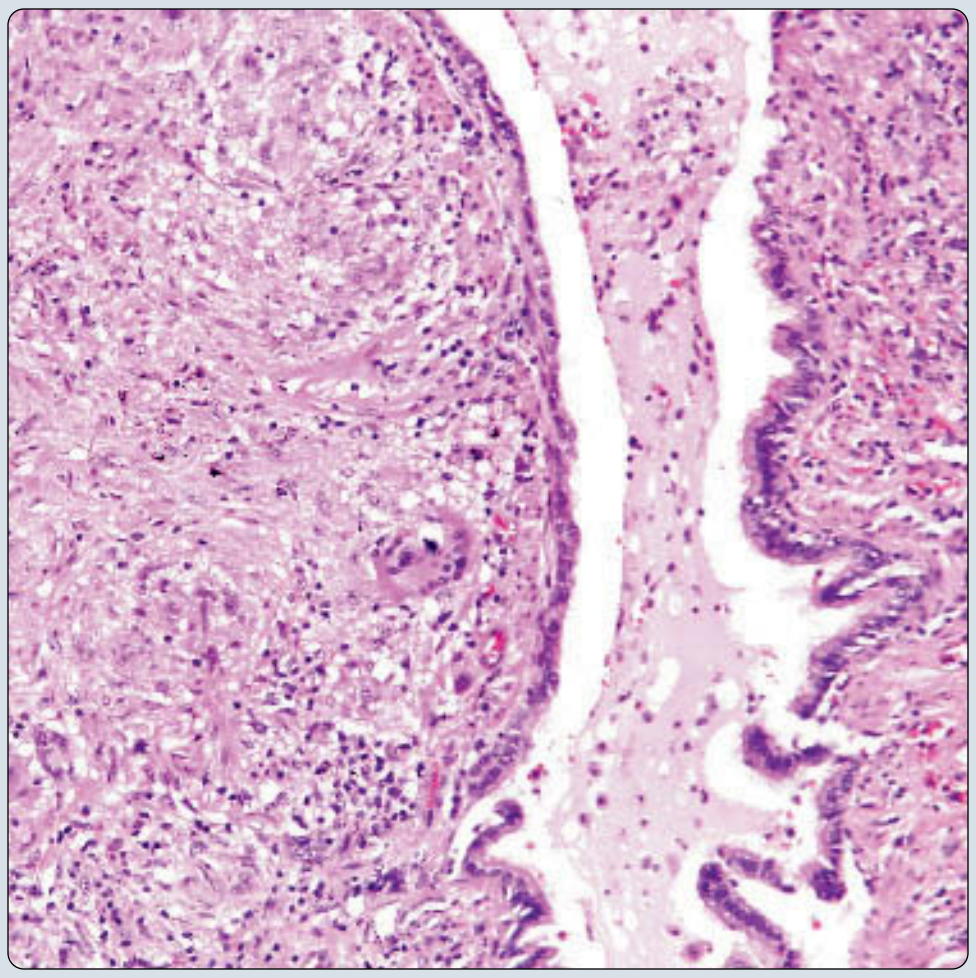

(Left) *Bronchocentric granulomatosis shows multiple epithelioid granulomas ➡ composed of epithelioid histiocytes circumscribing a bronchus.* **(Right)** *Higher magnification of bronchocentric granulomatosis shows epithelioid granulomas with multinucleated giant cells abutting and indenting the epithelial lining of a bronchiole.*

Compression of Bronchiole by Granulomas

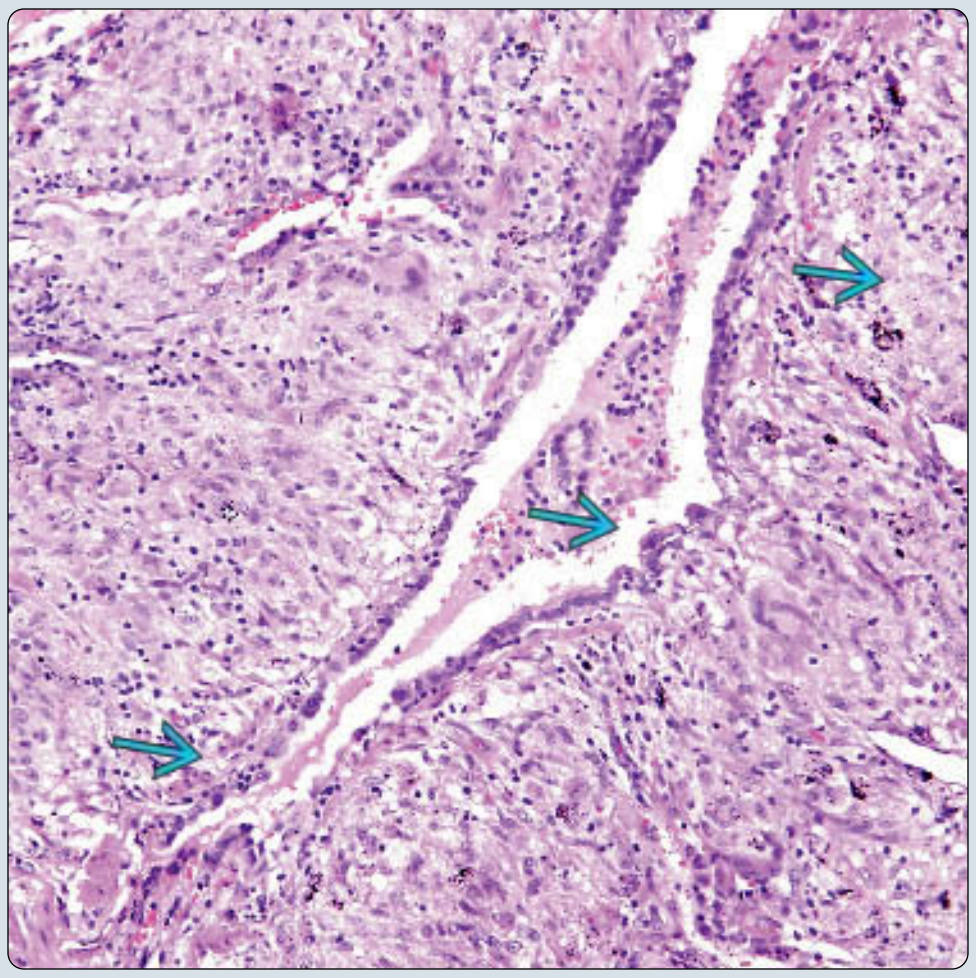

Multinucleated Cell and Necrosis

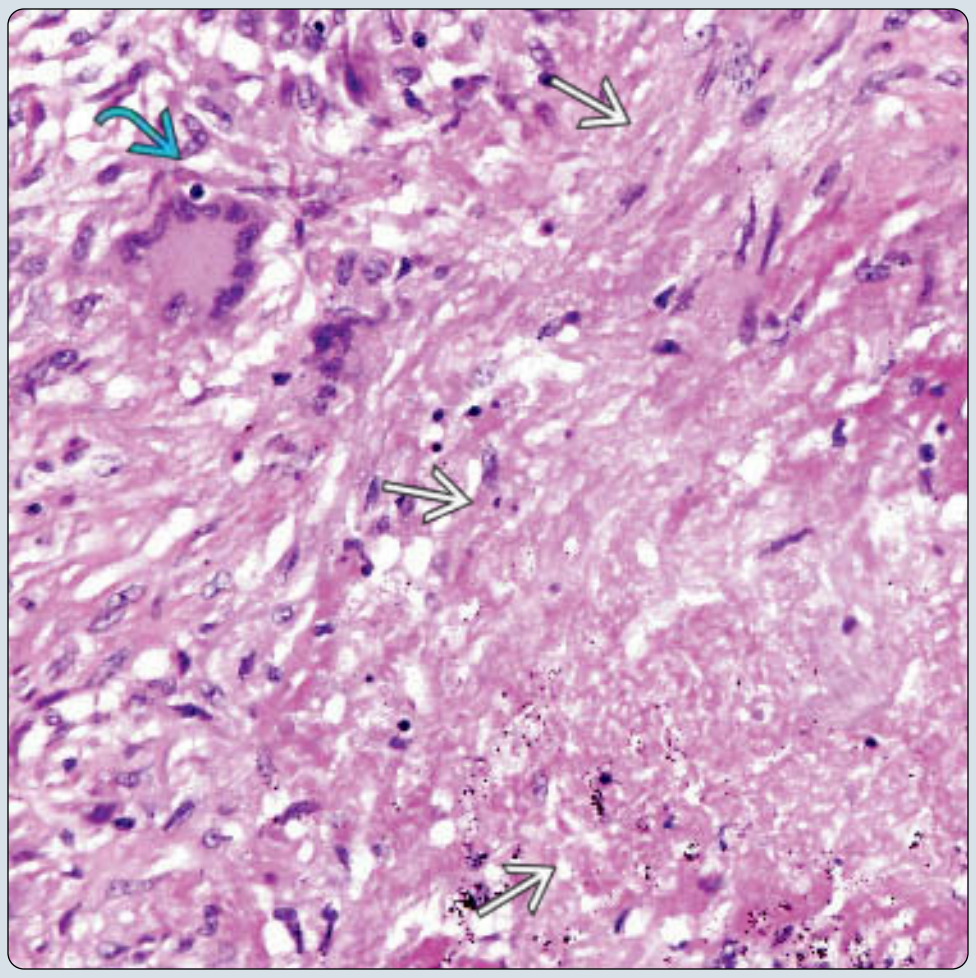

(Left) *H&E shows compression of the lumen in a bronchiole ➡ by sheets of epithelioid histiocytes with multinucleated giant cells that are disposed in dense sheets under the submucosa.* **(Right)** *Higher magnification of peribronchiolar granuloma shows a multinucleated giant cell ➡ surrounded by abundant histiocytes lying adjacent to an area of necrosis ➡.*

TERMINOLOGY

Abbreviations

- Bronchocentric granulomatosis (BCG)

Definitions

- Reaction pattern of lung parenchyma characterized by broncho- and bronchiolocentric necrotizing granulomatous inflammation

ETIOLOGY/PATHOGENESIS

Environmental Exposure

- Process can be related to infectious and noninfectious causes
  - Infections associated with BCG include mycobacteria, fungi ($ V S H U J L O O X V, + L V W R S O D V P D, etc.), and parasites ((F K L Q R F R F F X V)
  - Noninfectious causes of BCG include Wegener granulomatosis and rheumatoid arthritis
  - Allergic causes of BCG include allergic aspergillosis in association with mucoid impaction

CLINICAL ISSUES

Epidemiology

- Incidence
  - Most cases of BCG are allergic and associated with allergic bronchopulmonary aspergillosis
  - ~ 50% of patients have history of chronic asthma

Presentation

- Fever, cough, wheezing
- Peripheral eosinophilia
- Mucoid impaction

Laboratory Tests

- Elevated IgE levels and serum precipitins to $ V S H U J L O O X V are important clues in allergic cases
- Antinuclear antibody testing is helpful to rule out Wegener granulomatosis
- Cultures are important to rule out specific infectious agents

Natural History

- Noninfectious cases occur mainly in asthmatic patients with mucus impaction
- Infectious cases show more variable findings, ranging from localized consolidation to nodular parenchymal lesions

Treatment

- Steroids are treatment of choice for both infectious and noninfectious BCG

MICROSCOPIC

Histologic Features

- Destruction of walls of small bronchi and bronchioles by necrotizing granulomatous inflammation
- Bronchial walls are replaced by palisading histiocytic reaction
- Abundant necrotic debris seen in lumen of bronchioles with numerous neutrophils and eosinophils
- Impaction of proximal airways by allergic mucin
- Early lesions may show only chronic bronchitis with intact bronchial wall
- More advanced lesions will show chronic and acute bronchitis with destruction of normal elastic lamina of bronchioles

Cytologic Features

- Eosinophils are particularly prominent in cases associated with allergic bronchopulmonary aspergillosis
- Multinucleated giant cells may be present, particularly around necrotic debris

DIFFERENTIAL DIAGNOSIS

Wegener Granulomatosis

- May also show prominent bronchocentric distribution with destruction of bronchial walls
  - In addition to bronchocentric granulomas, there will also be evidence of vasculitis and microabscesses
  - Extensive areas of parenchymal necrosis with abundant neutrophilic debris
  - Positive c-ANCA in serum favors Wegener granulomatosis

Sarcoidosis

- Abundant epithelioid granulomas that can occasionally undergo necrotizing changes
- Distribution of granulomas is not restricted to bronchiolar walls and follows lymphangitic distribution
- Absence of allergic mucin, eosinophilia, or organisms on special stains
- Characteristic clinical and radiographic presentation often associated with lymphadenopathy

Foreign Body Granulomas

- Secondary to aspiration
- Can cause necrotizing granulomatous reaction surrounding foreign material
- Complete destruction of bronchial wall is unusual
- Foreign material is usually recognizable under polarized light

DIAGNOSTIC CHECKLIST

Clinically Relevant Pathologic Features

- Most important consideration is to rule out infection or Wegener granulomatosis when encountering bronchocentric granulomas
- History of asthma is most important clue for allergic cases

Pathologic Interpretation Pearls

- BCG resembles any necrotizing granuloma of infectious etiology except that it is bronchiolocentric in distribution
- Chronic bronchitis and scattered nonnecrotizing granulomas are not sufficient for diagnosis in absence of palisaded necrotizing inflammation

SELECTED REFERENCES

1. Periwal P et al: Bronchocentric granulomatosis with extensive cystic lung disease in tuberculosis: An unusual presentation. Lung India. 33(3):320-2, 2016
2. Ward S et al: Bronchocentric granulomatosis: computed tomographic findings in five patients. Clin Radiol. 55(4):296-300, 2000
3. Yousem SA: The histological spectrum of chronic necrotizing forms of pulmonary aspergillosis. Hum Pathol. 28(6):650-6, 1997

Coalescing Granulomas

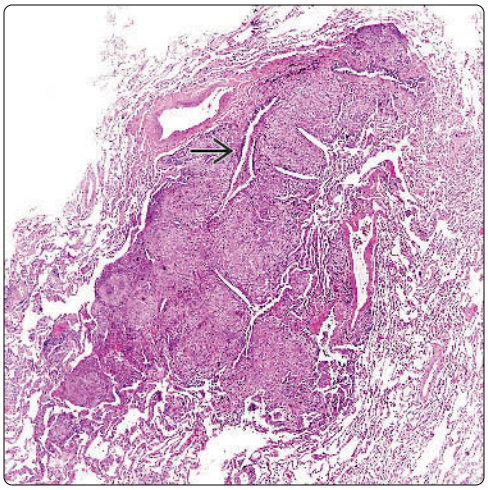

Peribronchiolar Granulomas

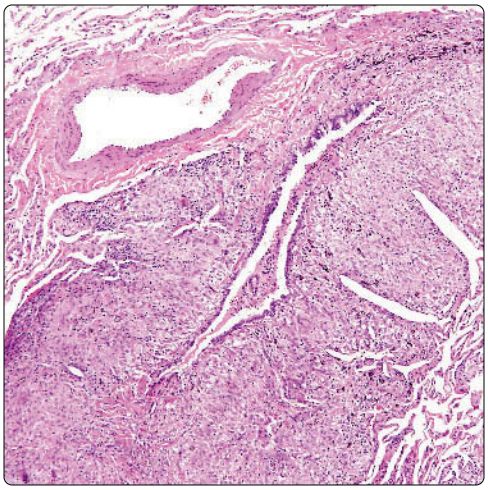

(Left) *Bronchocentric granulomatosis of the lung shows multiple large, epithelioid granulomas coalescing around a bronchiole. The lumen of the bronchiole is collapsed and distorted by the surrounding granulomas.* **(Right)** *Higher magnification of bronchocentric granulomatosis shows dense, epithelioid granulomas surrounding a bronchial lumen. Early lesions do not show necrotizing changes, but there is evidence of bronchitis with inflammatory infiltrate in the bronchial lumen.*

Bronchocentric Granuloma: High Power

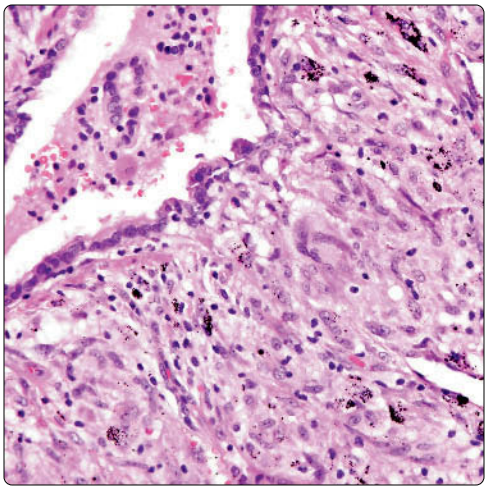

Necrotizing Granuloma

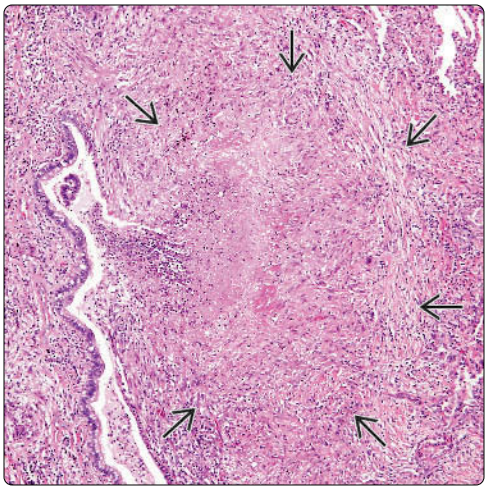

(Left) *Higher magnification of bronchocentric granulomatosis shows a bronchial lumen surrounded by epithelioid histiocytes and a few multinucleated giant cells. The lumen of the bronchus contains scant inflammatory infiltrate admixed with fibrin.* **(Right)** *Bronchocentric granulomatosis shows partial destruction of the wall of a bronchus by granulomatous inflammation. An ill-defined palisading granuloma can be observed adjacent to the bronchial wall.*

Necrotizing Granuloma: High Power

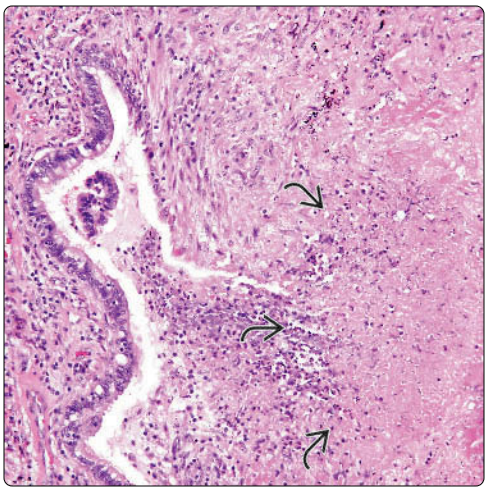

Necrotic Debris in Bronchiolar Lumen

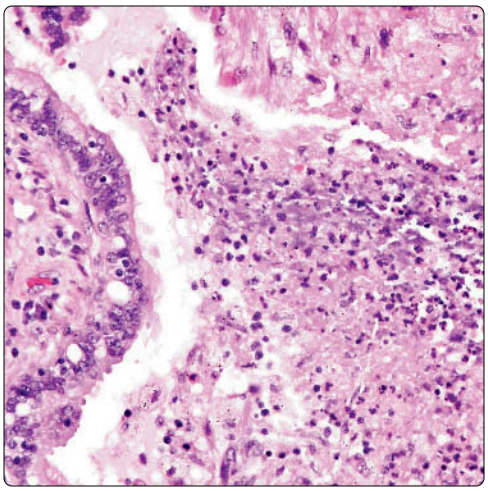

(Left) *Higher magnification of the bronchial wall in bronchocentric granulomatosis shows partial destruction of the wall of the bronchus by severe acute and chronic inflammation with abundant necrotic debris and neutrophilic infiltrate.* **(Right)** *Higher magnification of a bronchial wall in bronchocentric granulomatosis shows acute inflammation with abundant neutrophils, karyorrhexis, and necrotic debris surrounded by a rim of epithelioid histiocytes.*

Destruction of Bronchial Wall

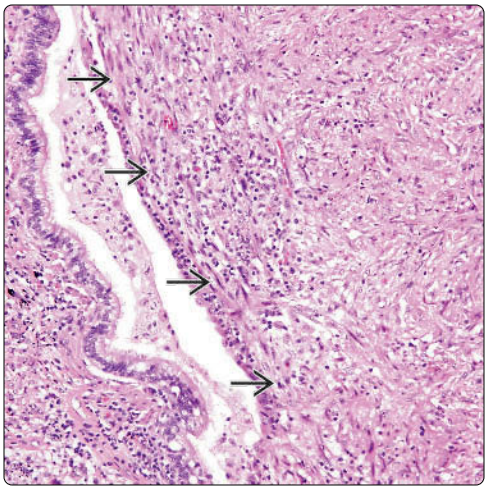

Peribronchial Granuloma

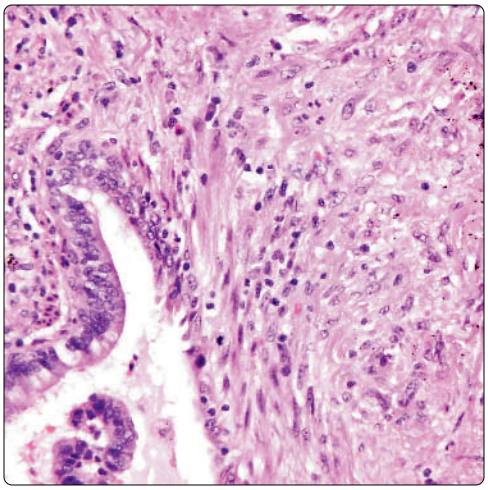

(Left) *Bronchocentric granulomatosis shows partial destruction of the wall of a bronchus by chronic inflammation. The involved wall of the bronchus contains a large epithelioid granuloma ⇨ composed of sheets of large epithelioid histiocytes admixed with scant lymphoid cells.* **(Right)** *Higher magnification of an affected bronchial wall in bronchocentric granulomatosis shows partial destruction and thinning of the wall by adjacent sheets of epithelioid histiocytes.*

Large Epithelioid Granuloma

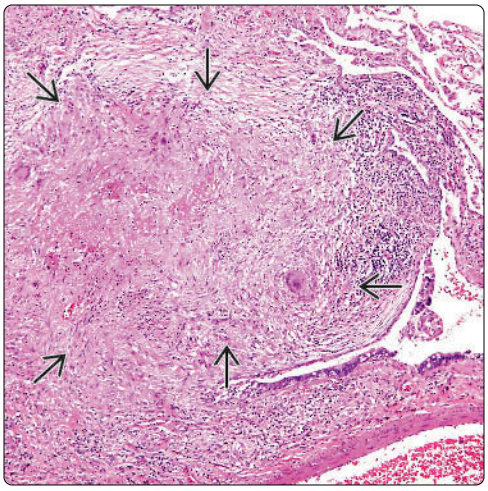

Peribronchial Granuloma: High Power

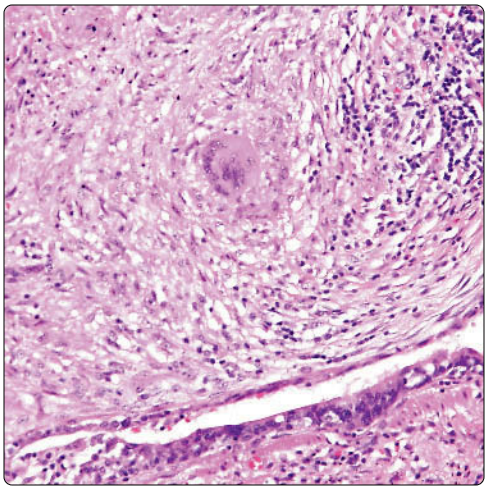

(Left) *Bronchocentric granulomatosis shows compression and distortion of a bronchial lumen by a large epithelioid granuloma ⇨ involving lung parenchyma around the bronchioles.* **(Right)** *Higher magnification of a small bronchiole in bronchocentric granulomatosis shows a large epithelioid granuloma with a multinucleated giant cell and few scattered small lymphocytes. Absence of vasculitis is a helpful clue to distinguish this from Wegener granulomatosis.*

Multinucleated Giant Cell

Necrosis in Bronchocentric Granuloma

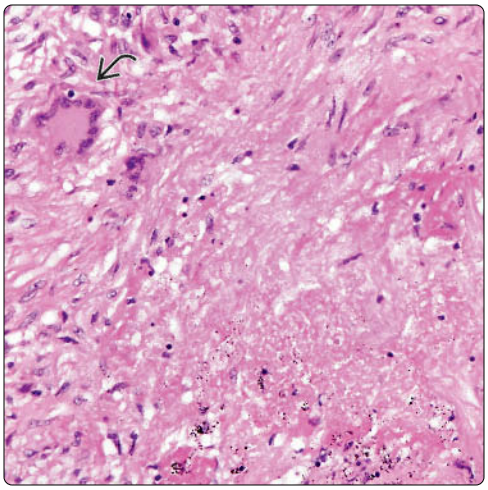

(Left) *Higher magnification of epithelioid granuloma in bronchocentric granulomatosis shows sheets of epithelioid histiocytes with a single multinucleated giant cell in the center ⇨.* **(Right)** *Granulomatous inflammation in the wall of a bronchus in a patient with bronchocentric granulomatosis shows abundant necrotic debris surrounded by palisading histiocytes. Notice the single residual multinucleated giant cell ⇨ at the edges of the necrotic field.*

Wegener Granulomatosis

KEY FACTS

ETIOLOGY/PATHOGENESIS

- No definitive etiology is known for Wegener granulomatosis (WG)

CLINICAL ISSUES

- Incidence
  - More common in adults, usually in 5th decade of life
- Since WG is systemic and can affect any particular system; these sites may include
  - Upper and lower respiratory system
  - Genitourinary system, mainly kidney
  - Ocular system
  - Breast
- Laboratory findings
  - Cytoplasmic antineutrophilic antibody (c-ANCA) is positive in nearly all cases of WG
  - Perinuclear antineutrophilic antibody (p-ANCA) is not as specific as c-ANCA as it may be positive in other conditions
  - Leukocytosis
  - Erythrocyte sedimentation rate is usually elevated
- Treatment
  - Cyclophosphamide and prednisone
  - Trimethoprim and sulfamethoxazole
    - Prolonged maintenance with immunosuppressive therapy
- Prognosis
  - Untreated WG is fatal
  - Treated patients do relatively well, but remissions are common

TOP DIFFERENTIAL DIAGNOSES

- Lymphomatoid granulomatosis
  - Usually shows atypical lymphoid proliferation
- Churg-Strauss syndrome
  - Commonly associated with asthma
- Infectious process

Wegener Granulomatosis With Extensive Necrosis

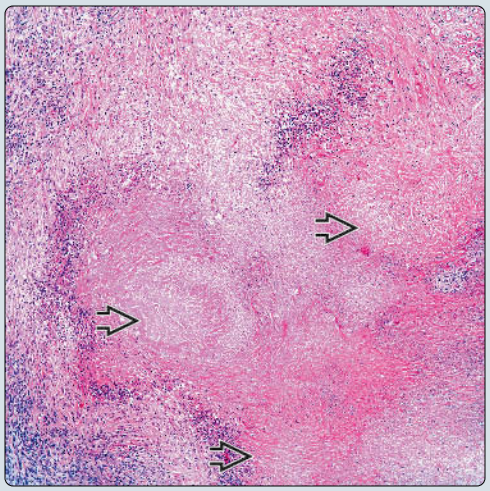

Microabscess Formation

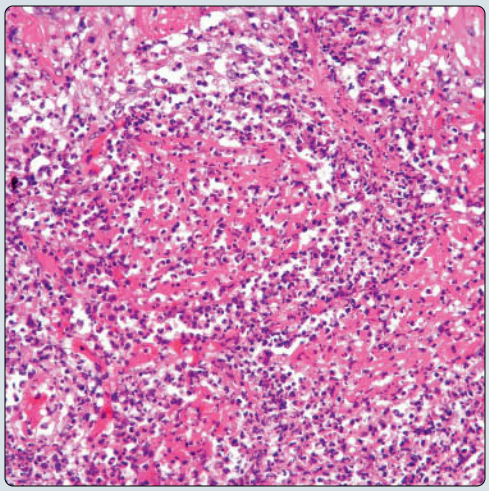

(Left) *Low-power view of Wegener granulomatosis (WG) displays extensive areas of necrosis ⇨; so-called geographic necrosis with total destruction of the normal lung parenchyma.* **(Right)** *WG shows areas in which there is prominent fibrinoid acute inflammatory change destroying normal lung parenchyma.*

Vascular Involvement

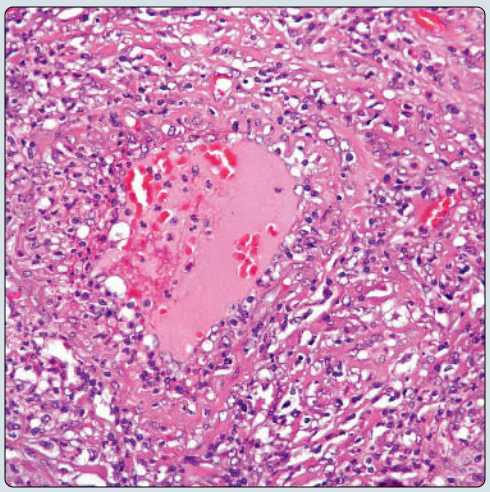

Vasculitis

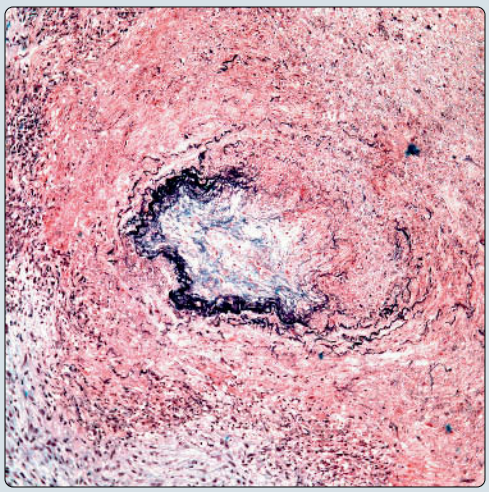

(Left) *WG shows a medium-sized vessel involved by an inflammatory reaction. Note that the entire wall of the vessel is essentially destroyed.* **(Right)** *High-power view of a vessel stained with elastic van Gieson in Wegener granulomatosis shows partial destruction of the vascular wall.*

TERMINOLOGY

Abbreviations

- Wegener granulomatosis (WG)

Synonyms

- Granulomatosis with polyangiitis

Definitions

- Systemic inflammatory process characterized by vasculitis and granulomatous reaction

ETIOLOGY/PATHOGENESIS

Etiology

- No definitive etiology is known for WG

CLINICAL ISSUES

Epidemiology

- Incidence
  - Incidence of this condition varies and can be up to 8 per 1 million people
- Age
  - More common in adults, usually in 5th decade of life
  - Rarely occurs in young people or children
    - In study of 66 children before age 18 with ANCA-associated vasculitis
      - 42% had granulomatous polyangiitis
      - 67% were p-ANCA positive
      - Median age at diagnosis: 11.5 years; median time to diagnosis: 1 month

Site

- Since WG process is systemic, it can affect any particular system
  - Sites may include
    - Upper and lower respiratory system
    - Genitourinary system, mainly kidney
    - Ocular system
    - Breast

Presentation

- Rhinorrhea
- Oral and nasal ulcers
- Cough
- Dyspnea
- Pleuritic pain
- Hemoptysis

Laboratory Tests

- Antineutrophil cytoplasmic antibodies
  - c-ANCA is positive in nearly all cases of WG
  - p-ANCA not as specific as c-ANCA as it may be seen positive in other conditions
- Erythrocyte sedimentation rate is usually elevated
- Leukocytosis
- Thrombocytopenia
- Anemia (normochromic-normocytic)

Prognosis

- Untreated WG is fatal
- Treated patients do relatively well, and remissions are common
- In study of 66 children before age 18, findings were
  - Median follow-up: 5.2 yr
  - Mortality: 6%; mortality rate of 1.2 per 100 person-yr
  - 34% developed end-stage renal disease
  - Renal survival 74%, 70%, and 59% at 1, 5, and 10 years, respectively
  - Relapse-free survival was 57% at 5 years and 34% at 10 years

MACROSCOPIC

General Features

- Multiple bilateral cavitary and solid pulmonary nodules
- Areas of necrosis are usually present

MICROSCOPIC

Histologic Features

- Geographic necrosis
  - Extensive areas of necrosis
  - Microabscesses
- Vasculitis
  - Arteries, veins, &/or capillaries
- Prominent inflammatory response composed of lymphocytes, neutrophils, macrophages, and giant cells
- Granulomatous reaction
  - All types of giant cells may be present

DIFFERENTIAL DIAGNOSIS

Lymphomatoid Granulomatosis

- There is vasculitis, but, usually, infiltrate is more monotonous and atypical
- Extensive areas of geographic necrosis are uncommon
- Immunohistochemical studies are helpful in this diagnosis
  - Lymphoid markers are of utmost importance

Churg-Strauss Syndrome

- Both conditions show evidence of vasculitis
- Most commonly will show positive p-ANCA and negative c-ANCA
- Commonly associated with asthma
- Extensive presence of eosinophils may be seen

Infectious Process

- WG shows necrosis and granulomatous inflammation that may mimic any infectious process

DIAGNOSTIC CHECKLIST

Pathologic Interpretation Pearls

- Geographic necrosis
- Vasculitis
- Granulomatous inflammation

SELECTED REFERENCES

1. Pagnoux C et al: Treatment of granulomatosis with polyangiitis (Wegener's). Expert Rev Clin Immunol. 1-10, 2015
2. Sacri AS et al: Clinical characteristics and outcomes of childhood-onset ANCA-associated vasculitis: a French nationwide study. Nephrol Dial Transplant. 30 Suppl 1:i104-12, 2015

Chest Imaging

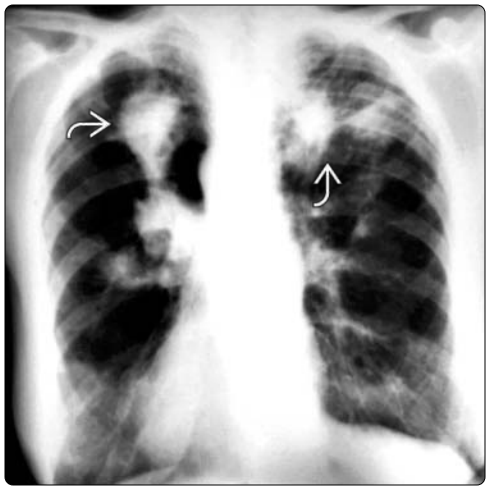

Extensive Necrosis

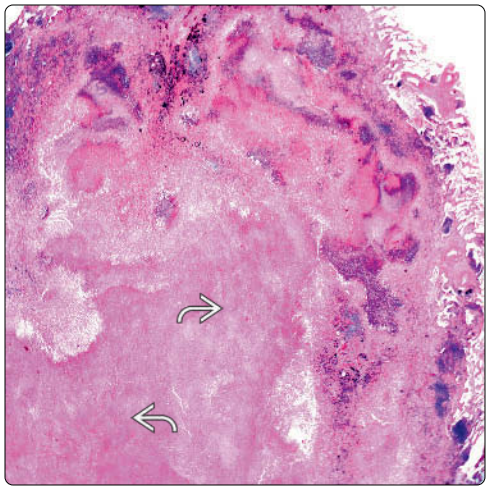

(Left) *Chest x-ray shows bilateral pulmonary involvement. This radiologic image is not diagnostic of WG as it may be seen in other conditions.* **(Right)** *Low-power view of Wegener granulomatosis shows extensive areas of necrosis destroying most of the lung parenchyma. There is very little inflammatory component.*

Microabscesses

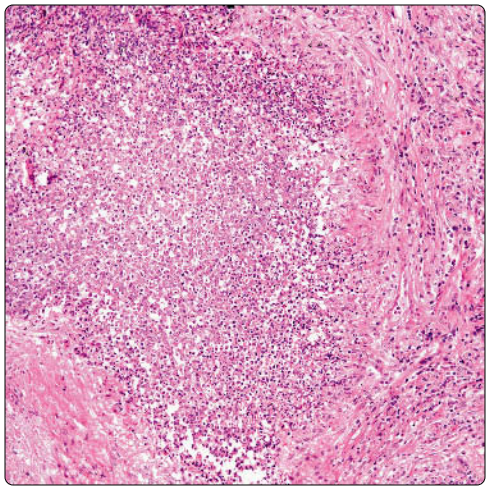

Inflammatory Changes

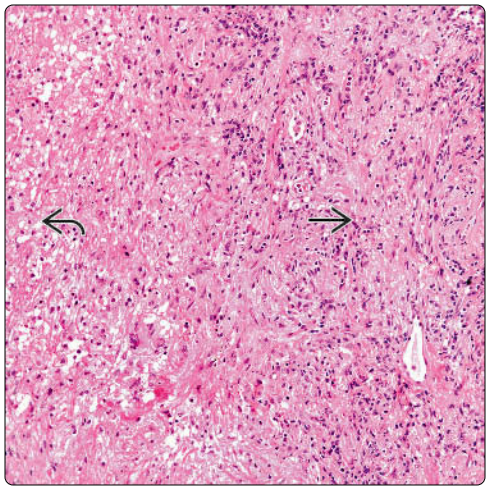

(Left) *Small microabscesses are a common feature in cases of Wegener granulomatosis, and their presence should not dissuade from the diagnosis of WG.* **(Right)** *In other parts of the lung, the necrosis merges with areas of fibrosis and prominent acute inflammatory changes. These features may also be seen in cases of infectious origin.*

Giant Cells

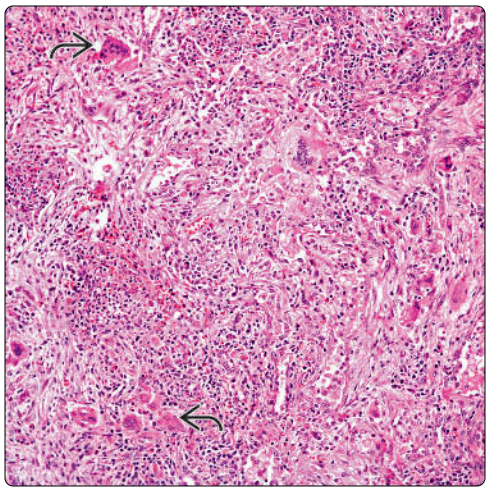

Vasculitis

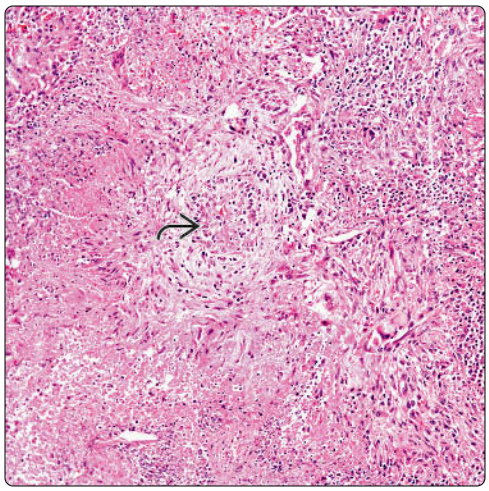

(Left) *WG shows areas of acute inflammation admixed with numerous multinucleated giant cells. This feature may not be present in all the cases of WG.* **(Right)** *Wegener granulomatosis shows a pulmonary vessel that is markedly involved by vasculitis. Adjacent tissue shows prominent acute inflammatory changes.*

Giant Cells

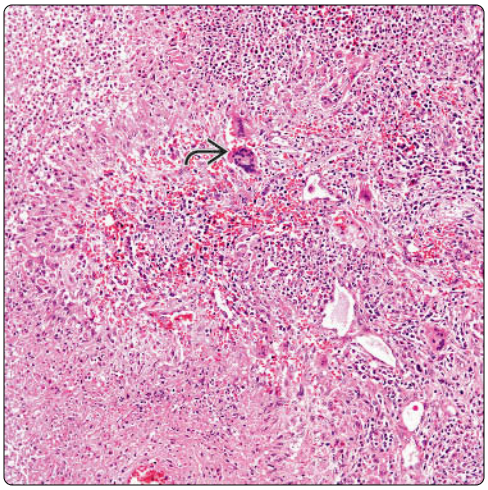

Granulomas

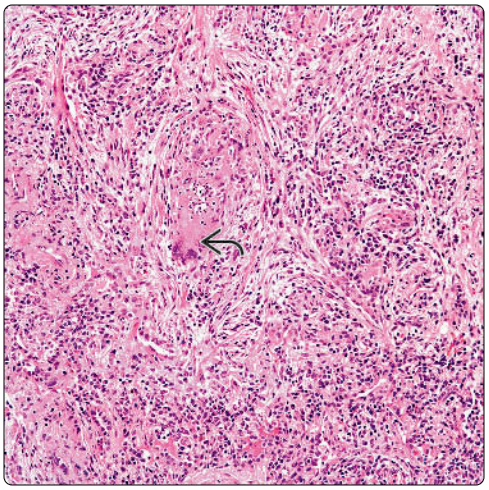

(Left) *Pulmonary parenchyma totally destroyed by acute inflammation shows granulomatous inflammation and the presence of multinucleated giant cells. These features are commonly seen in WG.* **(Right)** *Multinucleated giant cells can be seen singly and without forming a conventional granulomatous reaction embedded in otherwise fibrotic tissue with acute inflammation.*

Acute Inflammation

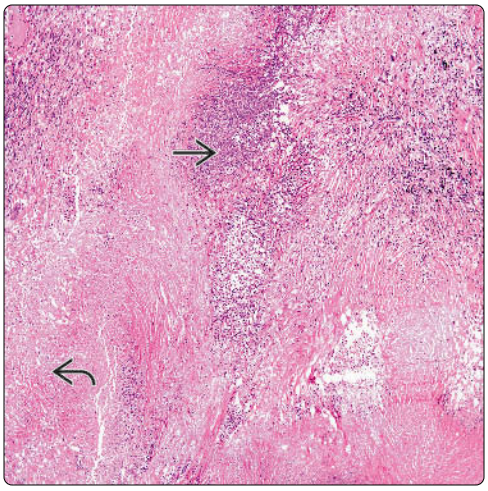

Organizing Pneumonia Areas

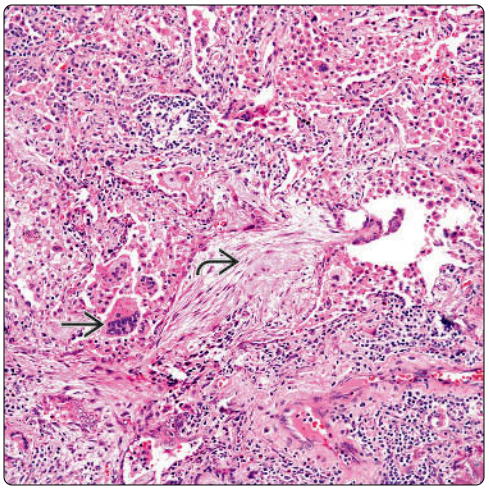

(Left) *Extensive areas of necrosis are admixed with focal areas of acute inflammation. Because these features may be seen in infectious cases, the use of histochemical stains for organisms is required.* **(Right)** *WG shows areas of organizing pneumonia with the presence of Masson bodies. In addition, note the presence of numerous multinucleated giant cells.*

Giant Cells and Other Inflammatory Cells

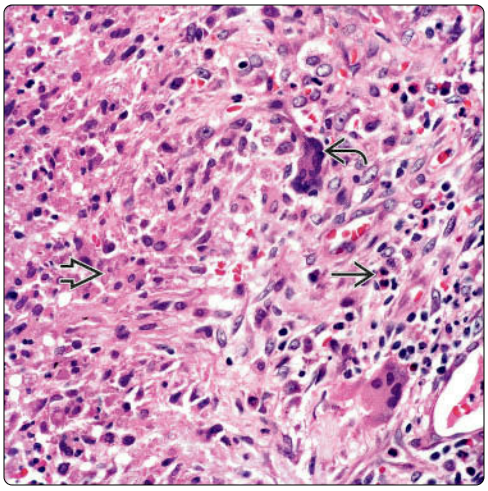

Elastic Stain Showing Vasculitis

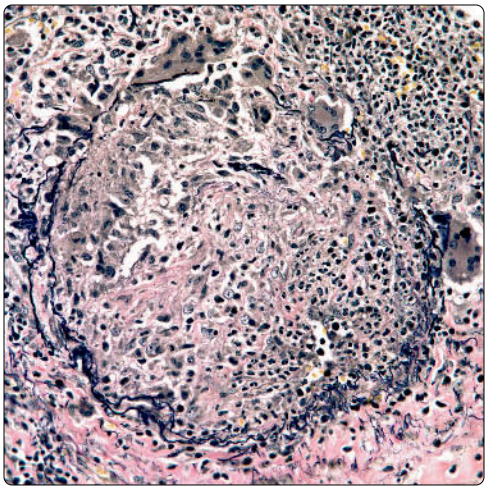

(Left) *High-power view of the inflammatory infiltrate in WG shows multinucleated giant cells, histiocytes, and eosinophils.* **(Right)** *High-power view (elastic van Gieson stain) shows a vessel with destruction of the vascular wall and prominent inflammatory changes (vasculitis). This is an important diagnostic feature of WG.*

Sarcoidosis

KEY FACTS

ETIOLOGY/PATHOGENESIS

- Etiology unknown, but evidence suggests it may represent exaggerated cellular immune response to unidentified antigen
- Multiorgan disease characterized by nonnecrotizing epithelioid granulomas

CLINICAL ISSUES

- Most commonly affected sites include lungs (95% of patients) and lymphatic organs
- May be asymptomatic and discovered incidentally on chest x-rays
- Symptomatic patients may present with insidious chronic disease or acute presentation
- Fatigue, anorexia, weight loss, fever
- Spontaneous resolution is commonly rule

MICROSCOPIC

- Multiple small, nonnecrotizing, interstitial epithelioid granulomas distributed along bronchovascular bundles and interlobular septa
- Nodular sarcoidosis shows confluence of granulomas with large tumor nodule formation
- Granulomas are frequently distributed along bronchial submucosa, accounting for high yield in bronchoscopic biopsies
- Interstitial inflammation is absent or inconspicuous
- Vasculitis and foci of necrosis may sometimes accompany granulomas
- Granulomas are composed of aggregates of epithelioid histiocytes ± multinucleated giant cells

DIAGNOSTIC CHECKLIST

- Special stains for organisms (AFB, PAS, GMS) should routinely be done to rule out infection

Pulmonary Sarcoidosis

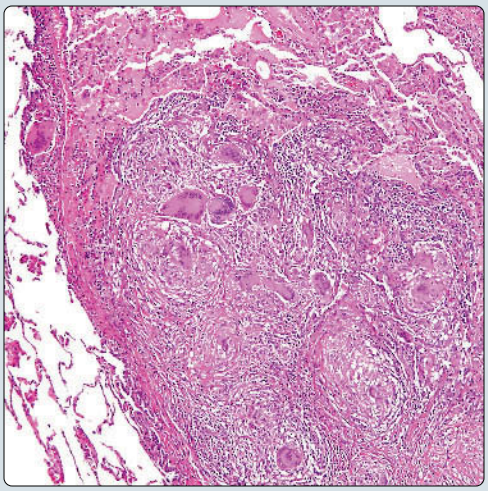

Bronchocentric Distribution

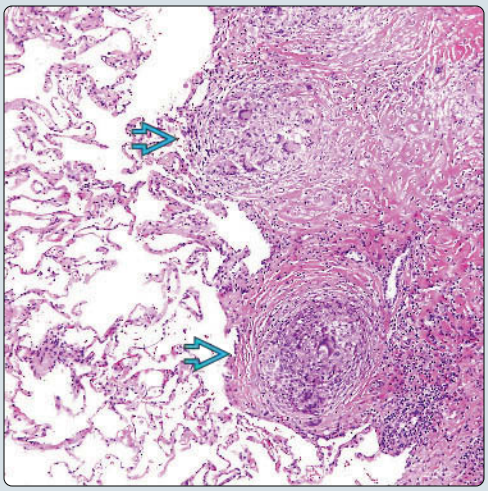

(Left) *Pulmonary sarcoidosis shows well-circumscribed collections of histiocytes without evidence of necrosis and abundant multinucleated giant cells.* **(Right)** *One of the histologic characteristics of pulmonary sarcoidosis is its bronchocentric and perivascular distribution. Notice the well-defined, small, nonnecrotizing epithelioid granulomas.*

Hyalinizing Granulomas

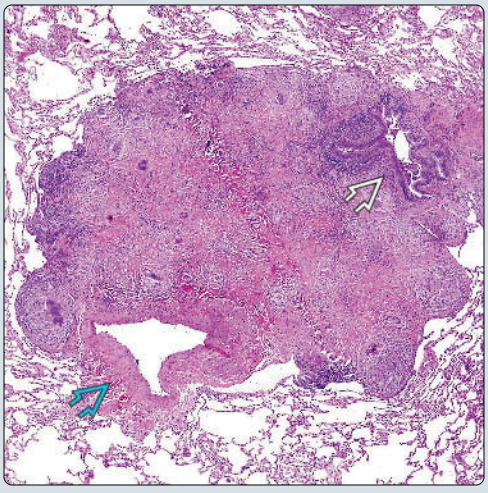

Multinucleated Giant Cells

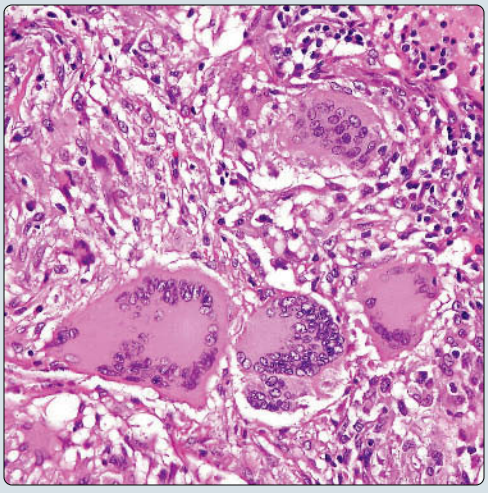

(Left) *Another feature of sarcoidosis in contrast to infectious granulomas is the tendency for the development of extensive stromal sclerosis. Notice the perivascular and peribronchial distribution of the granuloma.* **(Right)** *Higher magnification from sarcoid granuloma of the lung shows numerous histiocytes and large, multinucleated giant cells. Notice the abundance of small uniform nuclei within the giant cells.*

TERMINOLOGY

Definitions

- Multiorgan disease characterized by nonnecrotizing epithelioid granulomas

ETIOLOGY/PATHOGENESIS

Environmental Exposure

- Etiology is unknown, but evidence suggests it may represent exaggerated cellular immune response to unidentified antigen

Genetic Predisposition

- Marked familial clustering of cases

CLINICAL ISSUES

Site

- Most commonly affected sites include lungs (95% of patients) and lymphatic organs
- Other organs involved include liver, spleen, skin, heart, and eyes; CNS may also be involved

Presentation

- Fatigue, anorexia, weight loss, fever

Laboratory Tests

- Hyperglobulinemia due to nonspecific polyclonal activation of B cells by helper T cells
- Elevation of serum levels of angiotensin-converting enzyme

Natural History

- May be asymptomatic and discovered incidentally on chest x-rays
- Symptomatic patients may present with insidious chronic disease or acute presentation
- Spontaneous resolution is commonly rule
- Progressive and disabling organ failure may occur in up to 10% of patients

IMAGING

Radiographic Findings

- Symmetric bilateral hilar and mediastinal lymph node enlargement ± associated interstitial lung abnormalities
- Symmetrical, bilateral, reticulonodular or nodular opacifications mainly involving middle and upper lung zones

CT Findings

- HRCT shows small nodules 2-5 mm in diameter with irregular margins and perilymphatic distribution
- Nodules are distributed along bronchi and pulmonary vessels and along interlobar fissures and interlobular septa

MACROSCOPIC

General Features

- Cut surface shows multiple minute, white nodules distributed along bronchovascular bundles
- Confluence of lesions can lead to formation of large nodules measuring several cm in diameter (nodular sarcoidosis)

MICROSCOPIC

Histologic Features

- Multiple small, nonnecrotizing, interstitial epithelioid granulomas distributed along bronchovascular bundles and interlobular septa
- Nodular sarcoidosis shows confluence of granulomas with large tumor nodule formation
- Granulomas are frequently distributed along bronchial submucosa, accounting for high yield in bronchoscopic biopsies
- Interstitial inflammation is absent or inconspicuous
- Vasculitis and foci of necrosis may sometimes accompany granulomas
- Interstitial fibrosis may develop in small percentage of advanced cases that may lead to end-stage honeycomb lung

Cytologic Features

- Granulomas are composed of aggregates of epithelioid histiocytes ± multinucleated giant cells
- Concentric fibrosis may surround outer layer of epithelioid granulomas in advanced cases
- Granulomas may contain asteroid bodies (star-shaped crystals)
- Schaumann bodies (small lamellar calcifications) are seen in up to 70% of patients
- Rounded, birefringent basophilic calcifications can also be encountered in fibrotic granulomas

DIFFERENTIAL DIAGNOSIS

Fungal Infections

- Majority of deep fungal infections are characterized by necrotizing granulomas
- Clinical history and fungal stain (GMS, PAS) will help identify specific organisms

Mycobacterial Infections

- Tuberculosis usually shows caseating granulomas and organisms on acid-fast stains (AFB, Ziehl-Neelsen)
- 0\FREDFWHULXP DYLXP LQWUDFHOOXODUH may ha areas of necrosis and stain positive for modified Fite-Faraco stains

Berylliosis

- History of exposure to beryllium

SELECTED REFERENCES

1. Sawahata M et al: An epidemiological perspective of the pathology and etiology of sarcoidosis. Sarcoidosis Vasc Diffuse Lung Dis. 33(2):112-116, 2016
2. Iannuzzi MC et al: Sarcoidosis: clinical presentation, immunopathogenesis, and therapeutics. JAMA. 305(4):391-9, 2011
3. Morgenthau AS et al: Recent advances in sarcoidosis. Chest. 139(1):174-82, 2011
4. Hsu RM et al: Histologic, microbiologic, and clinical correlates of the diagnosis of sarcoidosis by transbronchial biopsy. Arch Pathol Lab Med. 120(4):364-8, 1996

(Left) *Pulmonary sarcoidosis shows multiple small, nonnecrotizing, interstitial epithelioid granulomas distributed along bronchovascular bundles. Notice some of the granulomas are in close proximity to the bronchial submucosa, which accounts for the high diagnostic yield on bronchoscopic biopsies.* **(Right)** *Higher magnification of interstitial granulomas in a patient with sarcoidosis shows focal accumulations of epithelioid histiocytes admixed with scattered multinucleated giant cells.*

Bronchovascular Distribution

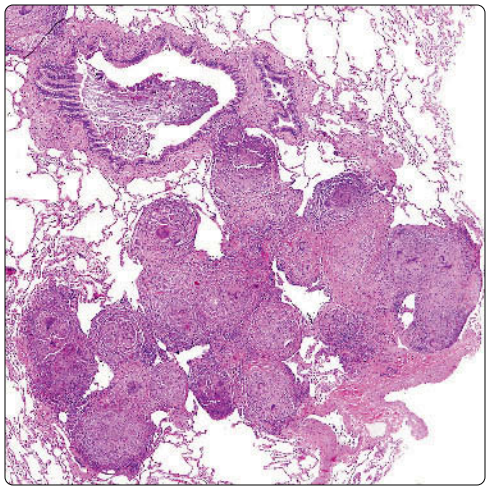

Small Coalescing Granulomas

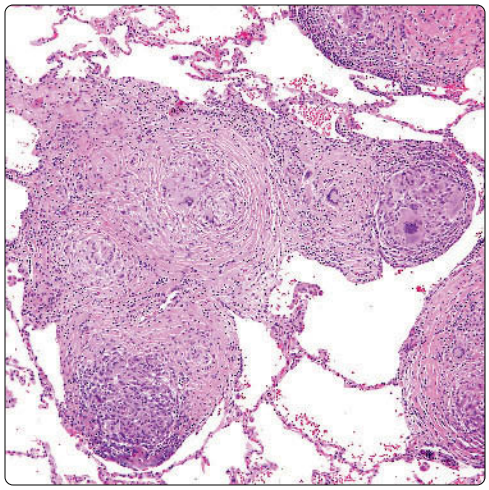

(Left) *Higher magnification of epithelioid granulomas in pulmonary sarcoidosis shows a concentric rim of fibrosis surrounding one of the granulomas ⇨. Notice the sparse inflammatory cells scattered in the interstitium outside of the granulomas.* **(Right)** *Higher magnification of a sclerotic granuloma in pulmonary sarcoidosis shows concentric layers of collagenous tissue circumscribing clusters of epithelioid histiocytes with a few multinucleated giant cells ⇨.*

Fibrosis Surrounding Granuloma

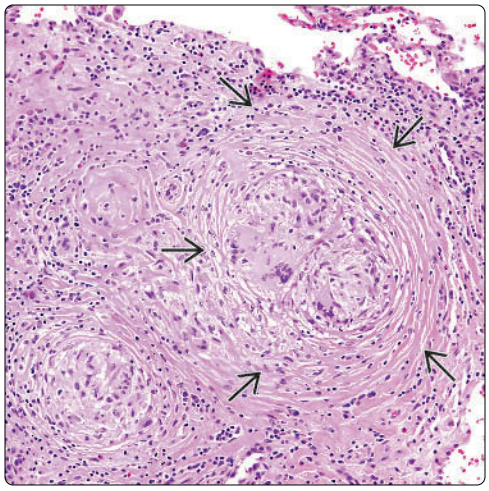

Sclerotic Granuloma

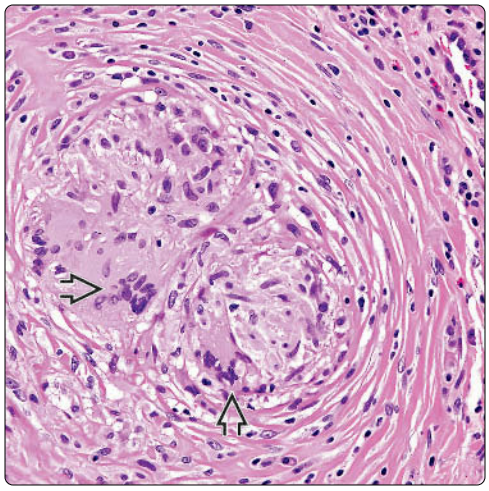

(Left) *Higher magnification of an epithelioid granuloma in pulmonary sarcoidosis shows a concentric arrangement of epithelioid histiocytes around a large multinucleated giant cell with abundant eosinophilic cytoplasm ⇨.* **(Right)** *Sarcoid granuloma of the lung shows a multinucleated giant cell containing a star-shaped asteroid body ⇨. The asteroid bodies are made up of crystals located within the cytoplasm of the giant cells. These structures are very distinctive but nonspecific.*

Epithelioid Granuloma With Giant Cell

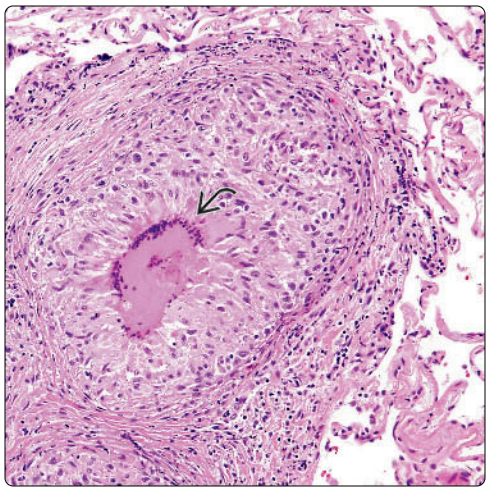

Asteroid Body

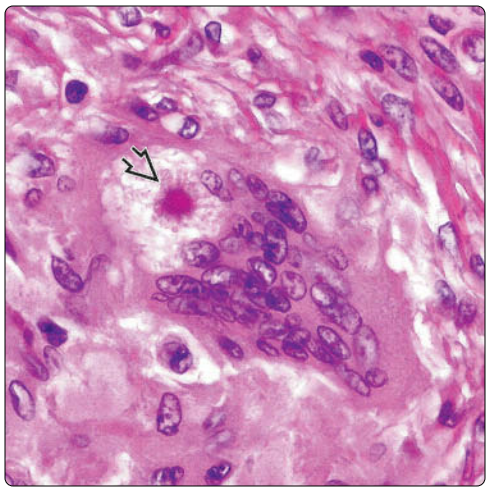

Confluent Granulomas With Fibrosis

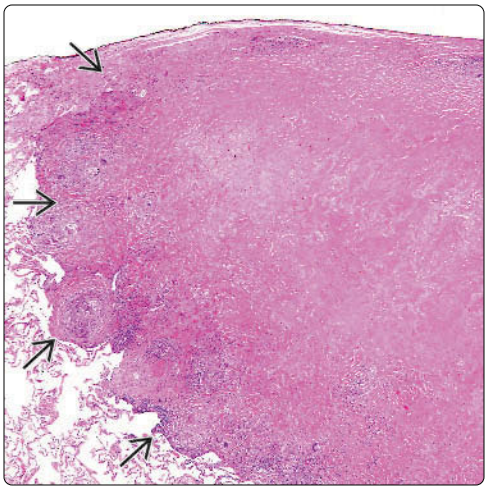

Extensive Stromal Hyalinization

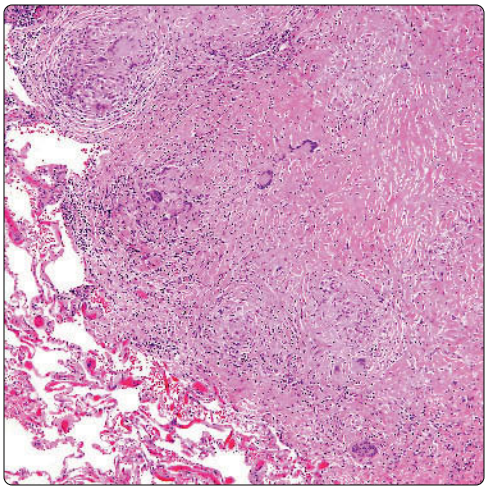

(Left) *Confluence of granulomas in pulmonary sarcoidosis may lead to the formation of a large nodular mass ⇨ that can be confused radiologically for malignancy. Such cases have been termed nodular sarcoidosis.* **(Right)** *Nodular sarcoidosis usually displays extensive stromal hyalinization with only a few scattered multinucleated giant cells remaining admixed with collagenous matrix. The granulomas in such instances may be small and very subtle.*

Scattered Multinucleated Giant Cells

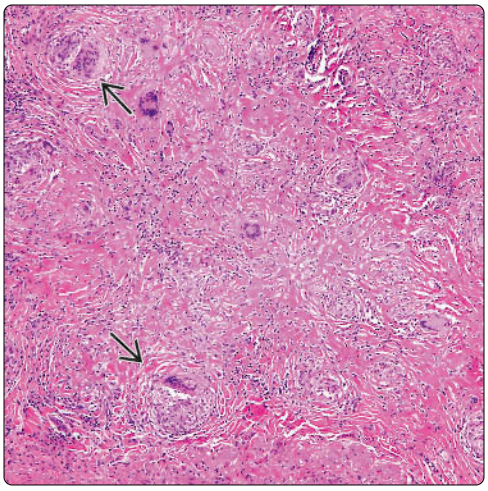

Massive Stromal Sclerosis

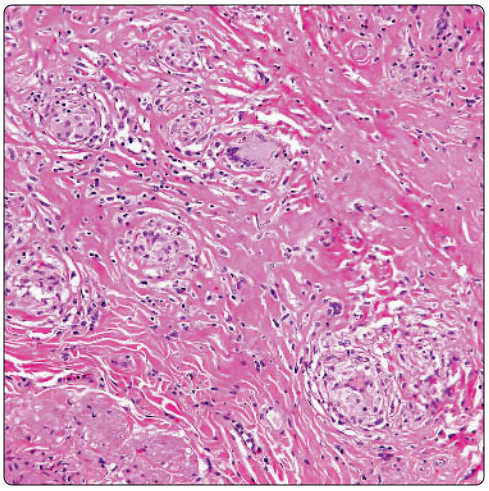

(Left) *Higher magnification of nodular sarcoidosis of the lung shows extensive sclerosis and hyalinization of the stroma with scattered multinucleated giant cells. Discrete, small epithelioid granuloma formation is also noted ⇨.* **(Right)** *Higher magnification of the sclerotic area within a nodular sarcoidosis of the lung shows massive stromal sclerosis due to the deposition of acellular collagen. The small scattered epithelioid granulomas are better appreciated at this magnification.*

Endoscopic Biopsy in Sarcoidosis

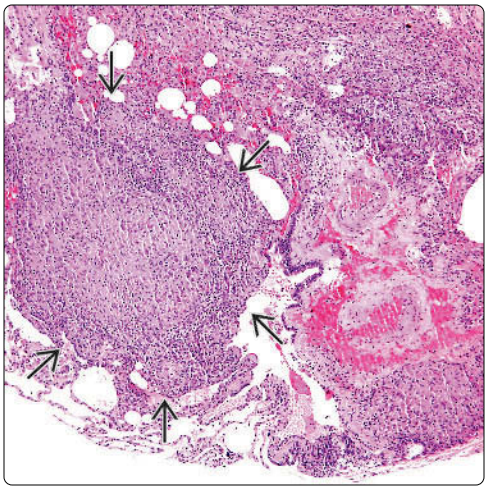

Submucosal Granuloma

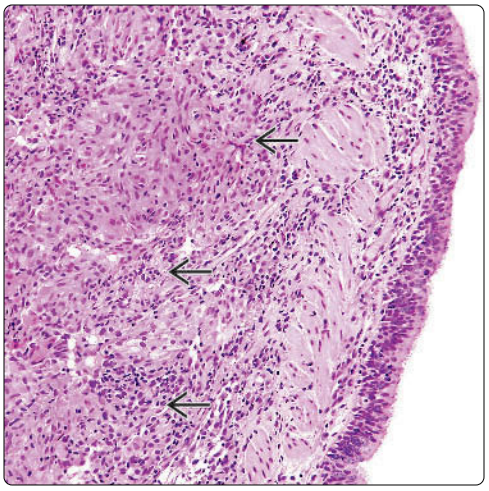

(Left) *Endoscopic biopsy in a patient with scattered interstitial infiltrates on a CT scan suspicious for interstitial fibrosis shows a sarcoid granuloma ⇨ adjacent to the wall of the bronchus. The peribronchial location makes it very easy to identify the granulomas on endoscopic biopsies.* **(Right)** *Sometimes the granulomas are not well-formed, and endoscopic biopsies may yield only ill-defined clusters of epithelioid histiocytes ⇨ without multinucleated giant cells.*

Hard Metal Pneumoconiosis Pneumonitis

KEY FACTS

TERMINOLOGY

- Type of pneumonitis caused by exposure to hard metal (cobalt)

ETIOLOGY/PATHOGENESIS

- Exposure to hard metal
- Hard metal is combination of tungsten with cobalt
- Aluminum has been implicated in this process

CLINICAL ISSUES

- Symptoms
  - Cough
  - Dyspnea
  - Rhinitis
  - Dermatitis
  - Asthma
- Laboratory findings
  - Increased cobalt in urine
  - Increased cobalt in blood
- Treatment
  - Corticosteroids

MICROSCOPIC

- Discrete interstitial fibrosis
- Desquamative interstitial pneumonitis-like changes
- Multinucleated giant cells may be present

TOP DIFFERENTIAL DIAGNOSES

- Usual interstitial pneumonitis
- Desquamative interstitial pneumonitis
- Infectious pneumonia
- Langerhans cell histiocytosis

DIAGNOSTIC CHECKLIST

- Presence of giant cells
- Patchy and subtle nodular appearance
- Inflammatory reaction
- Lymphoid aggregates
- History of exposure to hard metal

(Left) *Low-power view of hard metal pneumonitis shows a patchy and subtle nodular growth pattern. There are at least 2 nodule-like areas within the lung parenchyma.* **(Right)** *Hard metal pneumoconiosis shows areas in which the alveoli are filled with macrophages and in areas widening of the interstitium.*

Nodular Pattern

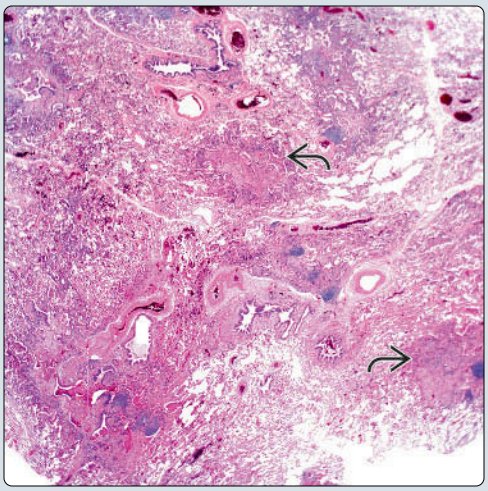

Intraalveolar Macrophages

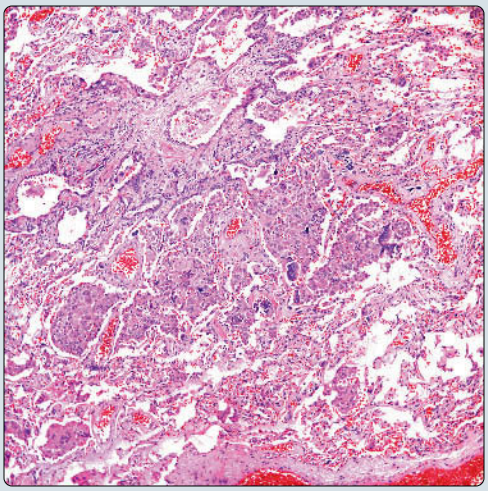

(Left) *Hard metal pneumoconiosis shows desquamative interstitial pneumonitis (DIP)-like reaction areas in which there is a marked presence of pigmented macrophages alternating with areas of fibrosis.* **(Right)** *High-power view of hard metal pneumonitis shows a collection of intraalveolar macrophages admixed with multinucleated giant cells.*

DIP-Like Reaction

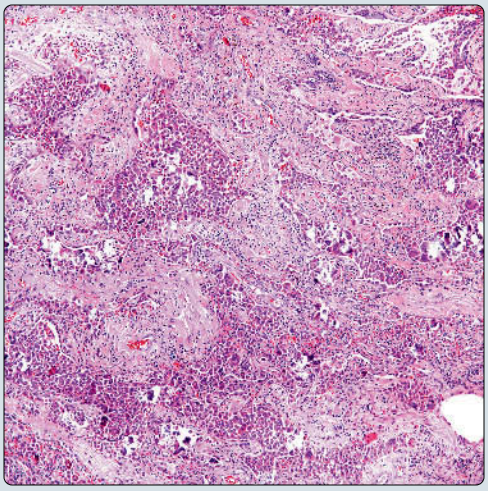

Multinucleated Giant Cells

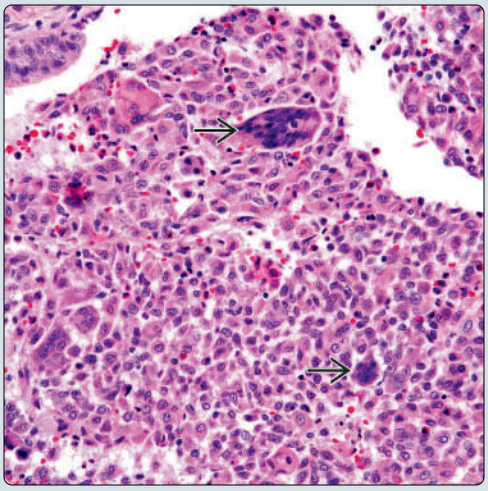

TERMINOLOGY

Synonyms

- Hard metal lung disease, cobalt lung disease

Definitions

- Type of pneumonitis caused by exposure to hard metal (cobalt and others)

ETIOLOGY/PATHOGENESIS

Environmental Exposure

- Exposure to hard metal
  - Hard metal is combination of tungsten with cobalt
  - Aluminum has been implicated

Pathogenesis

- Possibly immunologically mediated disease

CLINICAL ISSUES

Epidemiology

- Incidence
  - No hard data documenting true incidence of hard metal lung disease
- Age
  - Adults are more commonly affected
- Sex
  - No apparent sex predilection
- Ethnicity
  - No apparent ethnic predilection

Site

- Lung without predilection for any side or segment

Presentation

- Cough
- Dyspnea
- Chest pain
- Wheezing
- Rhinitis
- Conjunctivitis
- Dermatitis
- Asthma
- Malaise

Laboratory Tests

- Radiographic features are nonspecific
- Increased cobalt in urine
- Increased cobalt in blood
- IgE antibodies to cobalt may be present in serum

Treatment

- Drugs
  - Corticosteroids
  - In cases not responding to corticosteroids
    - Cyclophosphamide
    - Azathioprine
    - Lung transplantation
  - Most important aspect is to avoid contact with cobalt

Prognosis

- If patients are kept away form further exposure to cobalt and treated with corticosteroids, their prognosis may be good
- Fatal cases have been reported

MACROSCOPIC

General Features

- Diagnosis of this process is performed with open lung biopsy

MICROSCOPIC

Histologic Features

- Subtle nodular or patchy appearance
- Intraalveolar macrophages
- Easily identifiable multinucleated giant cells
- Lymphoid aggregates
- Discrete interstitial fibrosis may be present

DIFFERENTIAL DIAGNOSIS

Usual Interstitial Pneumonitis

- Shows presence of extensive areas of interstitial fibrosis alternating with areas of relatively normal alveolated lung parenchyma
- Does not show multinucleated giant cells

Desquamative Interstitial Pneumonitis

- Generally displays collections of intraalveolar macrophages
- Shows only mild and subtle interstitial fibrosis
- Does not show multinucleated giant cells

Infectious Pneumonia

- Use of special histochemical stains (GMS, PAS, and AFB) and tissue cultures is important to rule out infectious origin
- History of exposure to hard metal will be relevant to point to right interpretation

Langerhans Cell Histiocytosis

- Shows nodular and cystic growth pattern
- Shows giant cells but also displays other inflammatory component in which eosinophils may be prominent
- Immunohistochemical stain for CD1a is helpful in diagnosis of Langerhans cell histiocytosis (LCH)
- History of hard metal exposure will be unusual for LCH

DIAGNOSTIC CHECKLIST

Clinically Relevant Pathologic Features

- Symptom complex

Pathologic Interpretation Pearls

- Presence of giant cells
- Patchy and subtle nodular appearance
- Inflammatory reaction
- Lymphoid aggregates
- History of exposure to hard metal

SELECTED REFERENCES

1. Carney J et al: Aluminum-induced pneumoconiosis confirmed by analytical scanning electron microscopy: a case report and review of the literature. Ultrastruct Pathol. 1-3, 2016

Small Nodule With Fibrosis

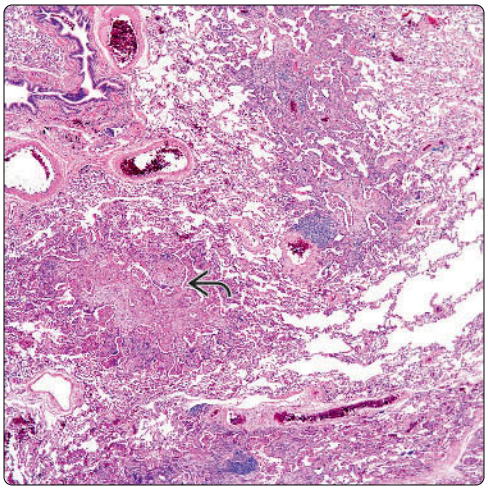

Organizing Pneumonia-Like Areas

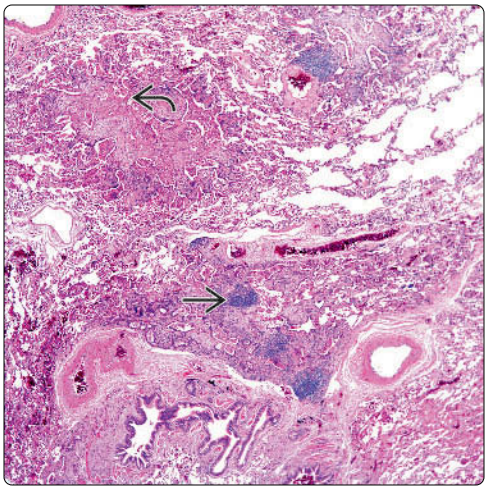

(Left) *Low-power view shows a small nodule, which at this power may suggest the possibility of organizing pneumonia. The remaining lung parenchyma appears within normal limits.* **(Right)** *Hard metal pneumonitis shows areas of organization admixed with areas that show lymphoid aggregates. These features by themselves are not specific and may be seen in other types of pneumonitis.*

Interstitial Fibrosis

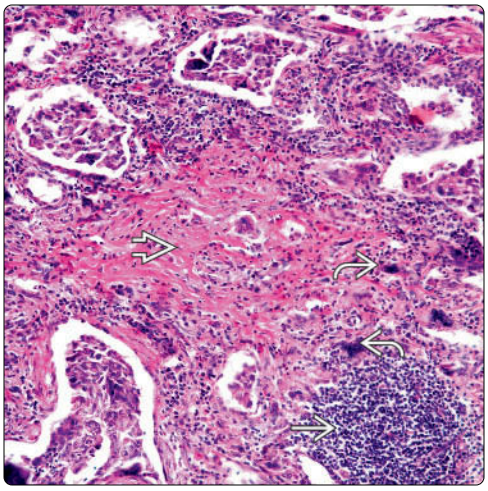

Collections of Macrophages

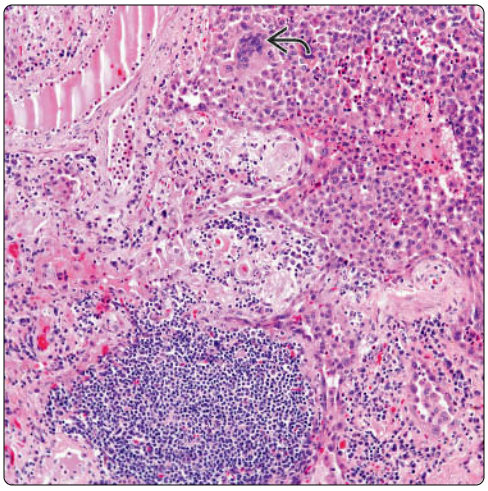

(Left) *Areas of discrete interstitial fibrosis are present. Also note the scattered multinucleated giant cells as well as a small lymphoid aggregate.* **(Right)** *Hard metal pneumonitis shows collections of intraalveolar macrophages, inflammatory changes, and a lymphoid aggregate. Note that in the collections of macrophages, it is possible to identify giant cells.*

Scattered Giant Cells

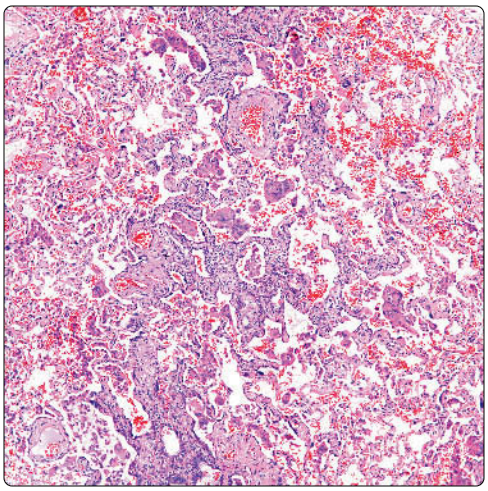

Peribronchial Fibrosis

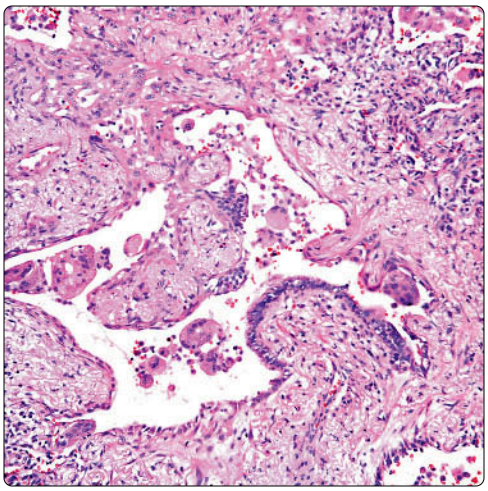

(Left) *Areas with more discrete fibrosis and collections of intraalveolar macrophages can be identified. The presence of scattered giant cells may also be seen.* **(Right)** *High-power view of an airway shows peribronchial fibrosis and intraluminal presence of macrophages and giant cells. Surrounding areas appear to show inflammatory changes.*

Inflammatory Changes

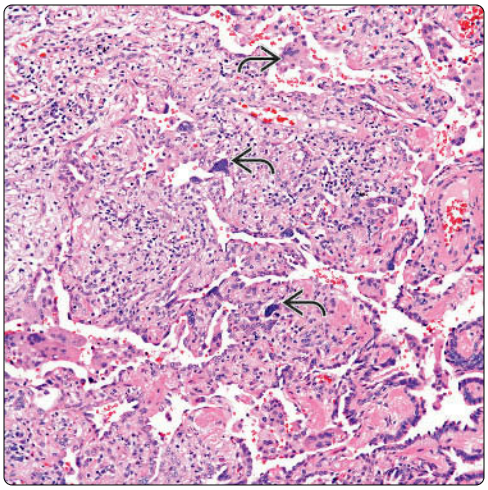

Prominent Scarring

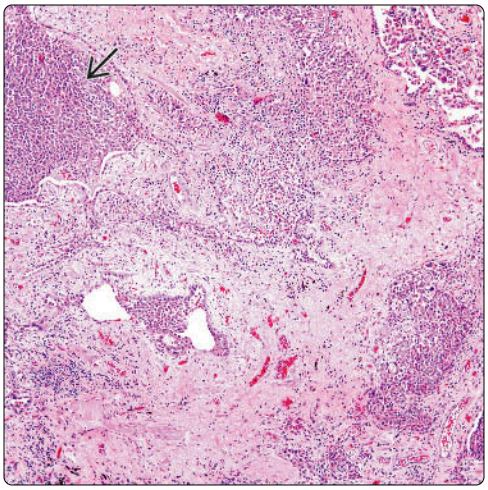

(Left) *Hard metal pneumonitis shows lung parenchyma with marked inflammatory changes and hyperplastic changes of the bronchial and alveolar lining, as well as accumulation of macrophages and giant cells ⇨.* **(Right)** *Areas of prominent scarring can be seen in hard metal pneumonitis. Note the adjacent accumulation of macrophages ⇨.*

Intravascular Macrophages

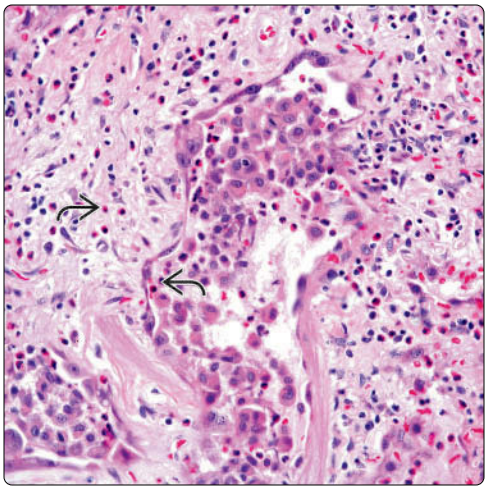

Replacement of Normal Lung Parenchyma

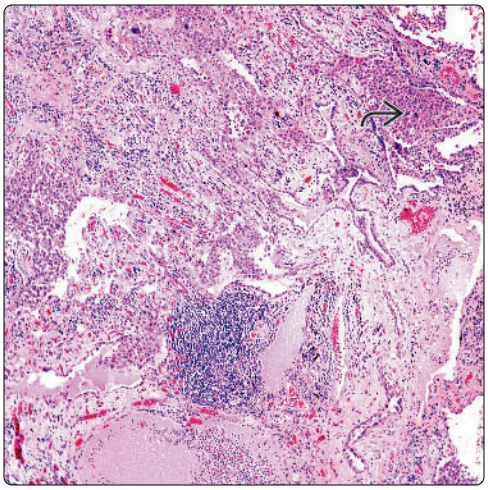

(Left) *Collections of macrophages and eosinophils may also be seen in vascular spaces. Note the presence of eosinophils, not only inside the vessels, but also in adjacent tissue ⇨.* **(Right)** *Hard metal pneumonitis shows a combination of collections of macrophages admixed with giant cells ⇨, inflammatory changes, and lymphoid aggregates.*

Multinucleated Giant Cells

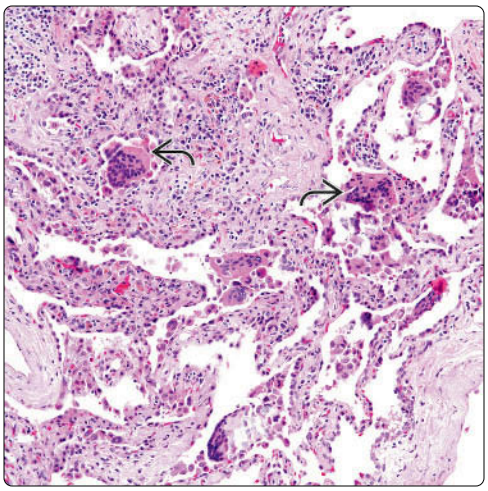

Interstitial Fibrosis

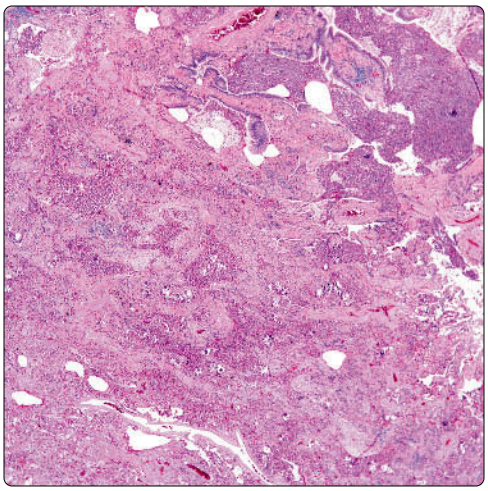

(Left) *This higher magnification shows the collections of macrophages and the obvious presence of multinucleated giant cells ⇨. This is one of the most important histopathological features of hard metal pneumonitis.* **(Right)** *Low-power view of hard metal pneumonitis shows discrete interstitial fibrosis and collections of macrophages. These features may be seen in other types of pneumonitis.*

Asbestos-Related Interstitial Fibrosis

KEY FACTS

ETIOLOGY/PATHOGENESIS

- 2 types of asbestos fibers have been identified
- Serpentine
  - Chrysotile (more common in industry)
  - Somewhat soluble in lung fluids
- Amphibole
  - Amosite
  - Crocidolite

CLINICAL ISSUES

- Latent period
  - Varies from 15-20 years
  - Disease may occur earlier depending on exposure
- Symptoms
  - Shortness of breath, cough, dyspnea
  - Clubbing of finger
  - Pleural effusion
- Laboratory tests
  - Pulmonary functions tests
  - Restrictive disease
- Pulmonary fibrosis may progress
- Linked to increased risk for development of lung cancer and malignant mesothelioma

MICROSCOPIC

- Interstitial fibrosis
- Peribronchiolar fibrosis
- Round atelectasis
- Identification of asbestos bodies or fibers in lung parenchyma

ANCILLARY TESTS

- X-ray diffraction analysis should show asbestos bodies
- Mass spectrometry may also identify asbestos bodies
- Histochemical stains for iron in tissue sections will disclose asbestos bodies

Interstitial Fibrosis in Asbestosis

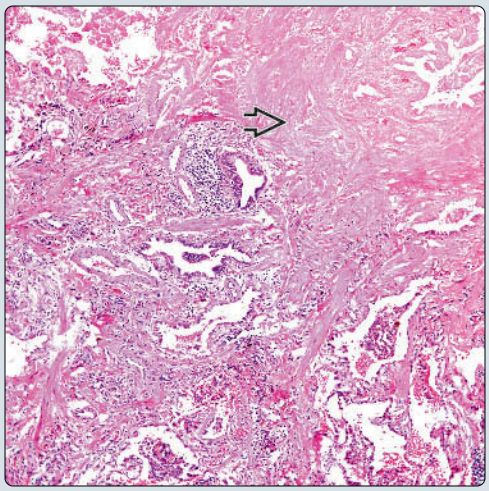

Asbestos Bodies in Alveolar Lumina

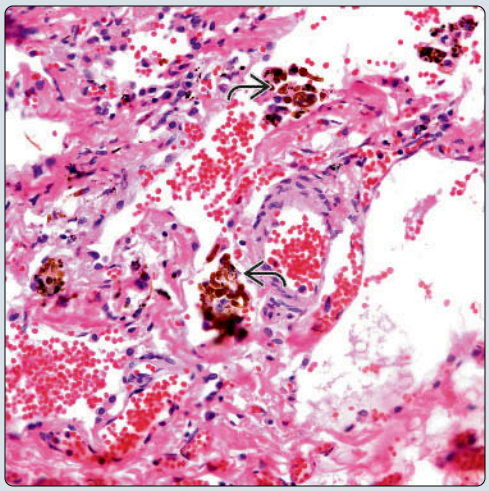

(Left) *Low-power magnification of lung shows extensive areas of interstitial fibrosis. The normal lung architecture has been replaced by fibrocollagenous tissue. A few distorted airspaces are present (bottom) and a small bronchiole is present at the center of the field.* **(Right)** *Closer magnification of lung tissue shows numerous asbestos bodies floating within the lumina of the airspaces. There is discrete interstitial fibrosis and minimal inflammatory reaction.*

Ferruginous Bodies

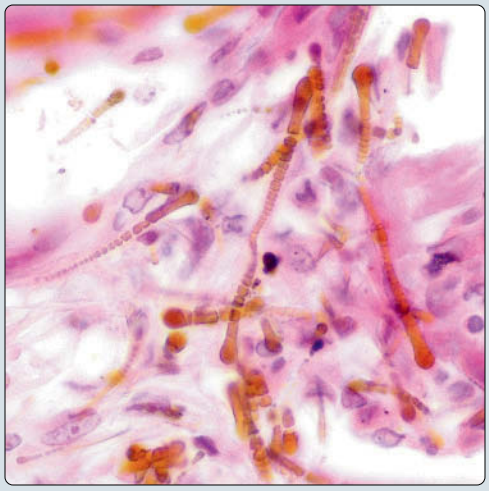

Asbestos Body

(Left) *Cluster of ferruginous bodies (asbestos particles) is seen in an advanced case of pulmonary asbestosis with advanced interstitial fibrosis. The structures have a rusty yellowish color due to the coating with an iron protein coat.* **(Right)** *A typical asbestos body is seen in the center of the field. It is composed of a string of rusty-orange, beaded small particles. Many of these particles can also show characteristic bulbous ends.*

TERMINOLOGY

Synonyms

- Asbestosis

Definitions

- Interstitial pulmonary fibrosis secondary to inhalation of asbestos dust

ETIOLOGY/PATHOGENESIS

Environmental Exposure

- Combination of hydrated silicates
  - Silica, iron, magnesium
- 2 types of asbestos fibers have been identified
  - Serpentine
    - Chrysotile (more common in industry)
  - Amphibole
    - Amosite
    - Crocidolite

CLINICAL ISSUES

Epidemiology

- Age
  - Usually occurs in adults
- Sex
  - More common in males

Site

- Lung and pleura

Presentation

- Shortness of breath, cough, dyspnea
- Clubbing of fingers
- Pleural effusion

Laboratory Tests

- Pulmonary function test
  - Restrictive disease

Natural History

- Latent period
  - Varies from 15-20 years
  - Disease may occur earlier depending on exposure

Treatment

- No specific treatment for asbestosis
- Cessation of exposure

Prognosis

- Pulmonary fibrosis may progress
  - May be fatal in patients with severe pulmonary fibrosis
- Linked to increased risk for development of lung cancer and malignant mesothelioma

IMAGING

Radiographic Findings

- Bilateral interstitial opacities

MICROSCOPIC

Histologic Features

- Interstitial fibrosis
  - Nonuniform interstitial fibrosis
  - Honeycombing of lung parenchyma
  - Residual areas of uninvolved lung parenchyma
- Peribronchiolar fibrosis
- Round atelectasis
- Identification of asbestos bodies or fibers in lung parenchyma

ANCILLARY TESTS

Identification of Asbestos Bodies

- X-ray diffraction analysis should show asbestos bodies
- Mass spectrometry may also identify asbestos bodies
- Histochemical stains for iron in tissue sections will disclose asbestos bodies

DIFFERENTIAL DIAGNOSIS

Usual Interstitial Pneumonitis

- Both conditions may share similar histological features
- Does not show asbestos bodies

Desquamative Interstitial Pneumonitis

- Shows more homogeneous pattern of intraalveolar macrophages and fibrosis
- Shows more subtle interstitial fibrosis
- Negative results for asbestos bodies using iron stains

DIAGNOSTIC CHECKLIST

Clinically Relevant Pathologic Features

- Age distribution
- Radiographic appearance

Pathologic Interpretation Pearls

- Usual interstitial pneumonia type of interstitial fibrosis
- Identification of asbestos bodies in tissue
  - Histochemical stains for iron
  - X-ray diffraction analysis
  - Mass spectrometry

SELECTED REFERENCES

1. Bhattacharjee P et al: Risk of occupational exposure to asbestos, silicon and arsenic on pulmonary disorders: Understanding the genetic-epigenetic interplay and future prospects. Environ Res. 147:425-34, 2016
2. Gulati M et al: Asbestosis and environmental causes of usual interstitial pneumonia. Curr Opin Pulm Med. 21(2):193-200, 2015
3. Markowitz S: Asbestos-related lung cancer and malignant mesothelioma of the pleura: selected current issues. Semin Respir Crit Care Med. 36(3):334-46, 2015
4. Antonescu-Turcu AL et al: Parenchymal and airway diseases caused by asbestos. Curr Opin Pulm Med. 16(2):155-61, 2010
5. Brody AR: Asbestos and lung disease. Am J Respir Cell Mol Biol. 42(2):131-2, 2010
6. Roggli VL et al: Pathology of asbestosis- An update of the diagnostic criteria: Report of the asbestosis committee of the college of american pathologists and pulmonary pathology society. Arch Pathol Lab Med. 134(3):462-80, 2010

Interstitial Fibrosis, Low Power

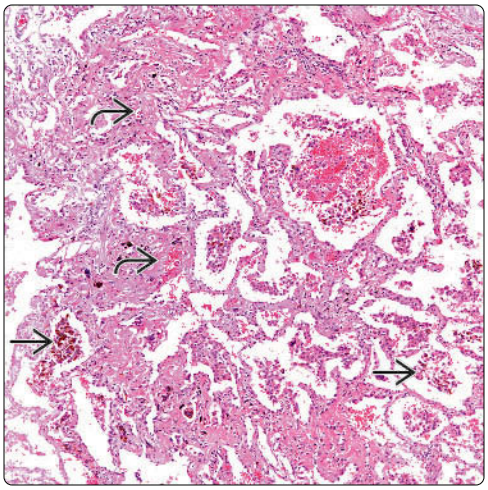

Interstitial Fibrosis, High Power

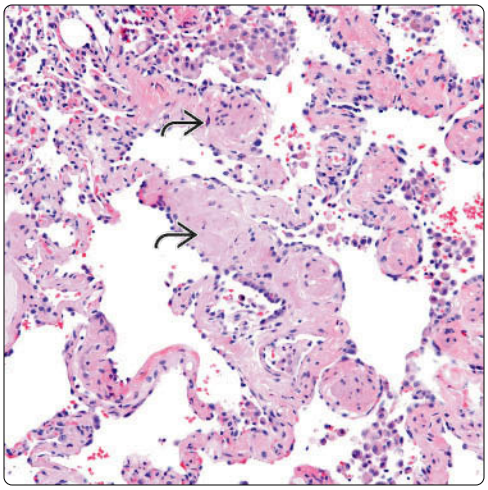

(Left) *Low-power magnification of lung shows the presence of marked interstitial fibrosis with collections of pigmented macrophages within some of the alveolar spaces.* **(Right)** *Interstitial pulmonary fibrosis can be prominent, mimicking the histological features of usual interstitial pneumonia (UIP). However, the identification of asbestos bodies helps to establish the diagnosis of asbestos-related pulmonary fibrosis.*

Interstitial Fibrosis Due to Asbestos

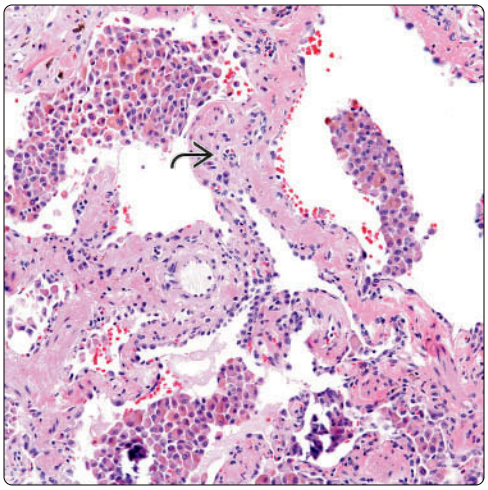

Residual Airspaces

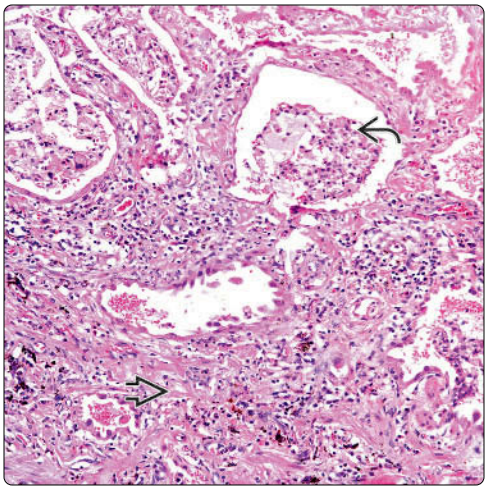

(Left) *This lung biopsy specimen shows extensive areas of fibrosis with collections of pigmented macrophages within airspaces. These changes are similar to those seen in UIP.* **(Right)** *Extensive areas of fibrosis replace the lung parenchyma with only focal areas of residual airspaces containing focal collections of macrophages.*

Area of Severe Interstitial Fibrosis

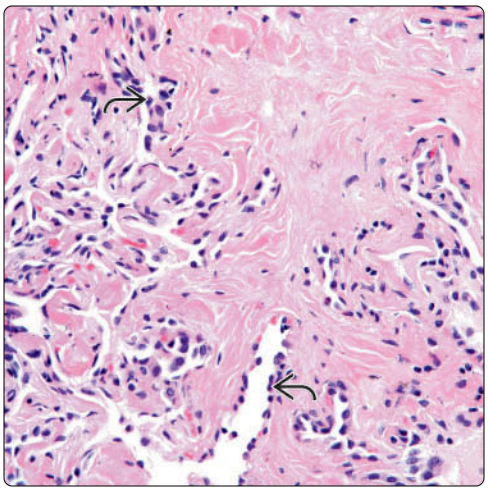

Bronchiolitis in Asbestosis

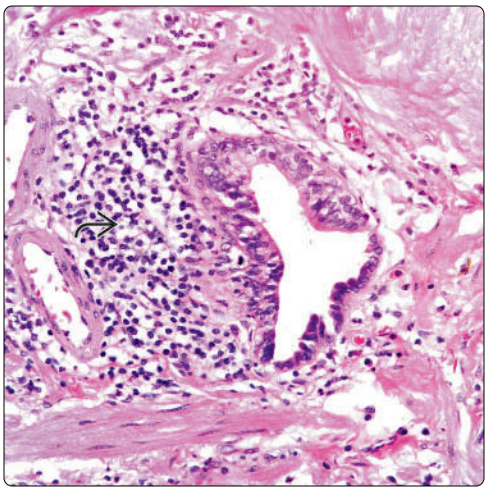

(Left) *Closer view shows marked interstitial fibrosis with entrapment of residual alveolar lining. These features are indistinguishable from other interstitial fibrotic lung diseases and, in the absence of asbestos bodies, may be confused for idiopathic pulmonary fibrosis.* **(Right)** *Residual airway shows peribronchiolar inflammation composed mainly of lymphocytes. This feature is commonly seen in cases of asbestosis.*

Pleural Fibrosis

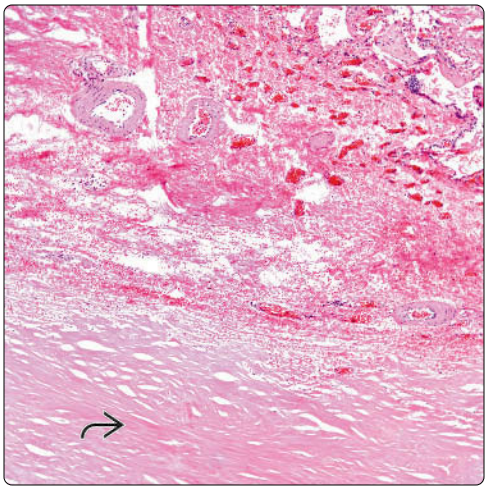

Pleural Plaque in Asbestosis

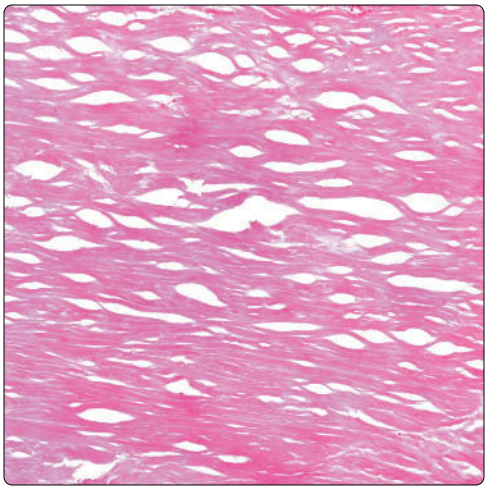

(Left) *Asbestosis in the lung is not limited to lung parenchyma as the process may also involve pleura. Note the presence of a pleural plaque, which is composed essentially of dense hyaline matrix.* **(Right)** *Closer view of a pleural plaque shows dense hyalinization with minimal cellular reaction. This is a common finding in cases of asbestos exposure.*

Extensive Interstitial Fibrosis

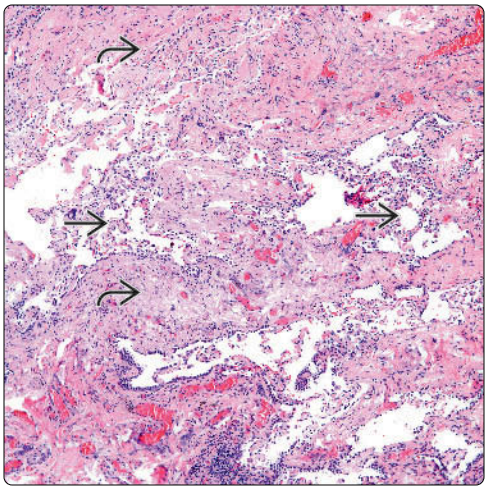

Fibrosis With Anthracosis

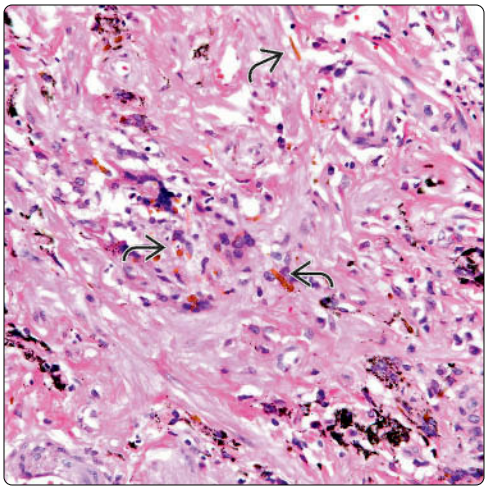

(Left) *In some cases of pulmonary asbestosis, the lung parenchyma may be extensively replaced by dense fibroconnective tissue, leaving only focal areas of of uninvolved lung parenchyma.* **(Right)** *Extensive areas of fibrosis with anthracotic pigment and numerous asbestos bodies are shown. Asbestos bodies are generally found in areas containing viable lung parenchyma.*

Asbestos Bodies in Alveolar Spaces

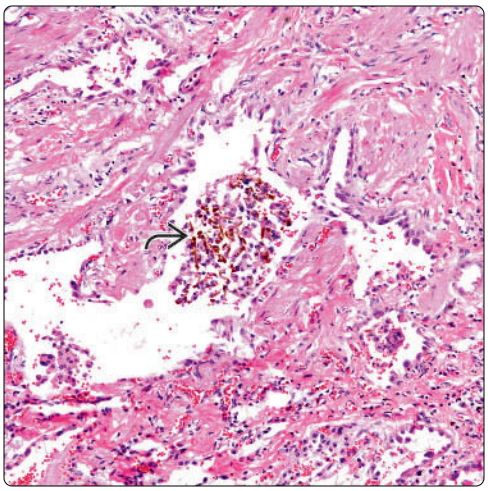

Asbestos Bodies, Higher Magnification

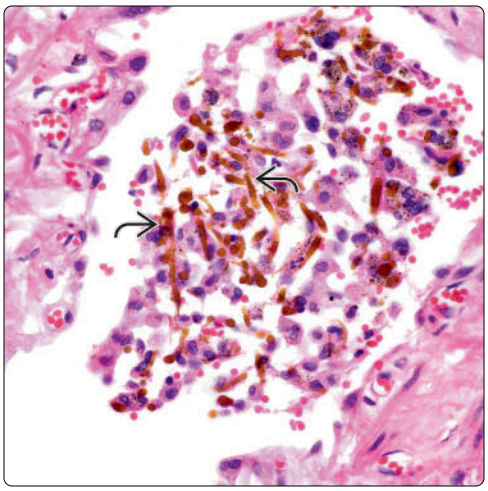

(Left) *Numerous asbestos bodies are floating within airspaces. The finding of asbestos bodies is essential for the diagnosis of asbestosis.* **(Right)** *Closer magnification demonstrates numerous asbestos bodies admixed with macrophages. This is the most important finding in cases of asbestosis. The asbestos bodies display a yellow-red color and are elongated with bulbous heads.*

Idiopathic Pulmonary Hemosiderosis

KEY FACTS

TERMINOLOGY

- Intrapulmonary hemorrhage of unknown etiology that is unassociated with other systemic manifestations

ETIOLOGY/PATHOGENESIS

- Unknown
- No immunologic mechanism has been identified
- Familial clustering has been reported, supporting genetic susceptibility

CLINICAL ISSUES

- Affects children more commonly than adults
- ~ 20% of patients are adults > 30 years old
- Male predominance (M:F = 2:1) in adults
- Equal gender distribution in children
- Hemoptysis
- Iron deficiency anemia
- Cough
- Dyspnea
- Localized to lungs; no systemic involvement
- Sudden onset of cough and hemoptysis in child or young adult
- No evidence of systemic disease or laboratory test abnormalities
- Episodes of pulmonary hemorrhage are recurrent and intermittent
- 25% of patients die rapidly due to massive hemorrhage
- 50% of patients develop chronic disease with persistent anemia and eventual interstitial fibrosis
- 25% of patients recover completely without recurrence

MICROSCOPIC

- Hemorrhage diffusely involving alveolar spaces
- Abundance of intraluminal hemosiderin-laden macrophages within bronchial lumina
- Iron stains are strongly positive in alveolar macrophages

Massive Intraalveolar Hemorrhage

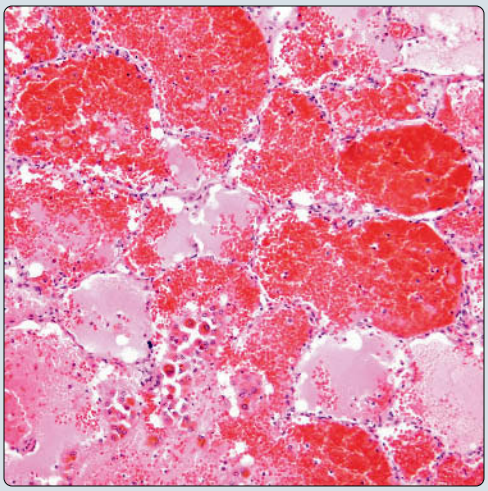

Alveoli Filled With Pigmented Macrophages

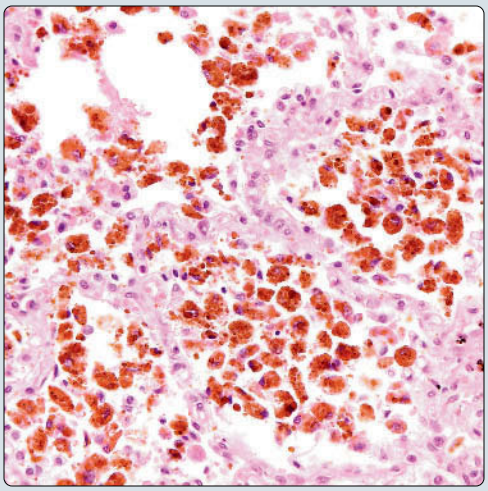

(Left) *Histologic appearance of the lung in idiopathic pulmonary hemosiderosis shows massive fresh intraalveolar hemorrhage. The underlying alveolar architecture of the lung is preserved.* **(Right)** *Idiopathic pulmonary hemosiderosis shows abundance of intraluminal hemosiderin-laden macrophages in alveolar lumina.*

Preserved Alveolar Walls

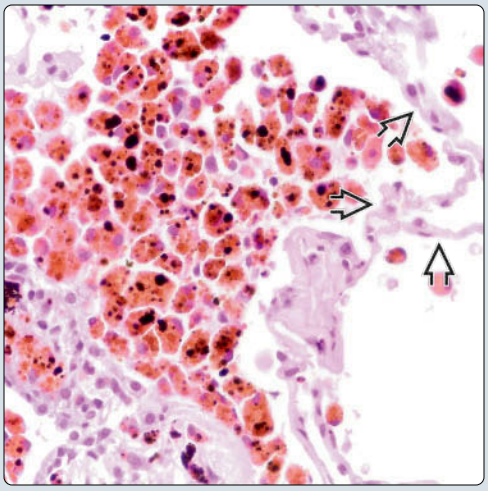

Hemosiderin-Laden Macrophages

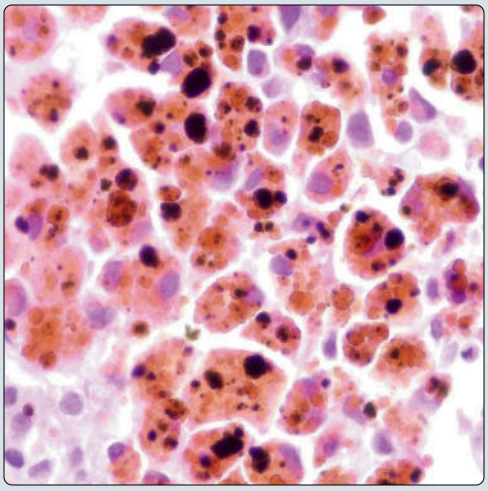

(Left) *Higher magnification of an airspace in idiopathic pulmonary hemosiderosis shows normal alveolar walls ⇨ devoid of interstitial fibrosis or inflammation.* **(Right)** *Higher magnification shows hemosiderin-laden macrophages containing ingested brown pigment and coarse granules of iron pigment within their cytoplasm.*

TERMINOLOGY

Abbreviations

- Idiopathic pulmonary hemosiderosis (IPH)

Synonyms

- Idiopathic pulmonary hemorrhage

Definitions

- Intrapulmonary hemorrhage of unknown etiology that is unassociated with other systemic manifestations

ETIOLOGY/PATHOGENESIS

Etiology

- Unknown
- No immunologic mechanism has been identified
- Familial clustering has been reported, supporting genetic susceptibility

CLINICAL ISSUES

Epidemiology

- Age
  - Affects children more commonly than adults
  - ~ 20% of patients are adults, usually < 30 years old
- Sex
  - Male predominance (M:F = 2:1) in adults
  - Equal sex distribution in children

Site

- Localized to lungs; no systemic involvement

Presentation

- Hemoptysis with iron deficiency anemia
- Cough and dyspnea
- Acute phase may lead to fulminant hemoptysis with respiratory failure; chronic phase may lead to pulmonary fibrosis

Laboratory Tests

- ANCA and antibasement membrane antibodies (ABMA) tests are negative
- Absence of immune complexes
- Normal renal function tests

Natural History

- Sudden onset of cough and hemoptysis in child or young adult
- No evidence of systemic disease or laboratory test abnormalities
- Episodes of pulmonary hemorrhage are recurrent and intermittent
- 25% of patients die rapidly due to massive hemorrhage
- 50% of patients develop chronic disease with persistent anemia and eventual interstitial fibrosis
- 25% of patients recover completely without recurrence

Treatment

- Drugs
  - Corticosteroids

Prognosis

- Patients can show variable response to steroid therapy
- Median survival: 3-5 years

IMAGING

General Features

- Diffuse bilateral consolidation

Radiographic Findings

- Acute phase: Diffuse ground-glass infiltrates predominantly in lower lobes
- Chronic phase: Parenchymal reticulonodular infiltrates with fibrosis

MACROSCOPIC

General Features

- Cut section of lung shows dark brown, homogeneous, indurated parenchyma

MICROSCOPIC

Histologic Features

- Hemorrhage diffusely involving alveolar spaces
- Abundance of intraluminal hemosiderin-laden macrophages within bronchial lumina
- Interstitial thickening seen in more advanced stages with type II pneumocyte hyperplasia and interstitial fibrosis
- Minimal interstitial inflammation

ANCILLARY TESTS

Electron Microscopy

- No evidence of immunoglobulin deposits by ultrastructure

Histochemistry

- Iron stains are strongly positive in alveolar macrophages

DIFFERENTIAL DIAGNOSIS

Goodpasture Syndrome

- Has both lung and kidney involvement
- Due to circulating ABMA
- Serologic studies demonstrate antiglomerular basement membrane (anti-GBM) antibodies
- Linear deposition of IgG and complement can be demonstrated in basement membrane of alveoli by immunofluorescence

DIAGNOSTIC CHECKLIST

Pathologic Interpretation Pearls

- IPH cannot be distinguished on routine histology from Goodpasture syndrome
- Serologic studies to demonstrate circulating ABMA or immunofluorescence detection of anti-GBM antibodies are required for diagnosis

SELECTED REFERENCES

1. Taytard J et al: New insights into pediatric idiopathic pulmonary hemosiderosis: the French RespiRare(R) cohort. Orphanet J Rare Dis. 8(1):161, 2013
2. Le Clainche L et al: Long-term outcome of idiopathic pulmonary hemosiderosis in children. Medicine (Baltimore). 79(5):318-26, 2000
3. Cohen S: Idiopathic pulmonary hemosiderosis. Am J Med Sci. 317(1):67-74, 1999

KEY FACTS

TERMINOLOGY

- Nonneoplastic condition in which alveoli are filled with proteinaceous material

ETIOLOGY/PATHOGENESIS

- May be associated with
  - Infections, immunosuppression, malignancies

CLINICAL ISSUES

- Presentation
  - Cough
  - Dyspnea
  - Chest pain
  - Fever
- Treatment
  - Pulmonary lavage
  - Spontaneous remission in some cases

IMAGING

- Reticulonodular pattern
- Small acinar pattern
- Focal consolidation

MICROSCOPIC

- Alveolar filling by proteinaceous material
- Preservation of normal alveolar architecture
- Proteinaceous material is positive for periodic acid-Schiff (PAS)

TOP DIFFERENTIAL DIAGNOSES

- 3QHXPRF\VWLV pneumonia
  - Silver stains will show presence of organisms
  - PAS histochemical stain is negative
- Pulmonary edema
  - Pulmonary edema fluid is negative for PAS histochemical stain

Alveolar Proteinosis

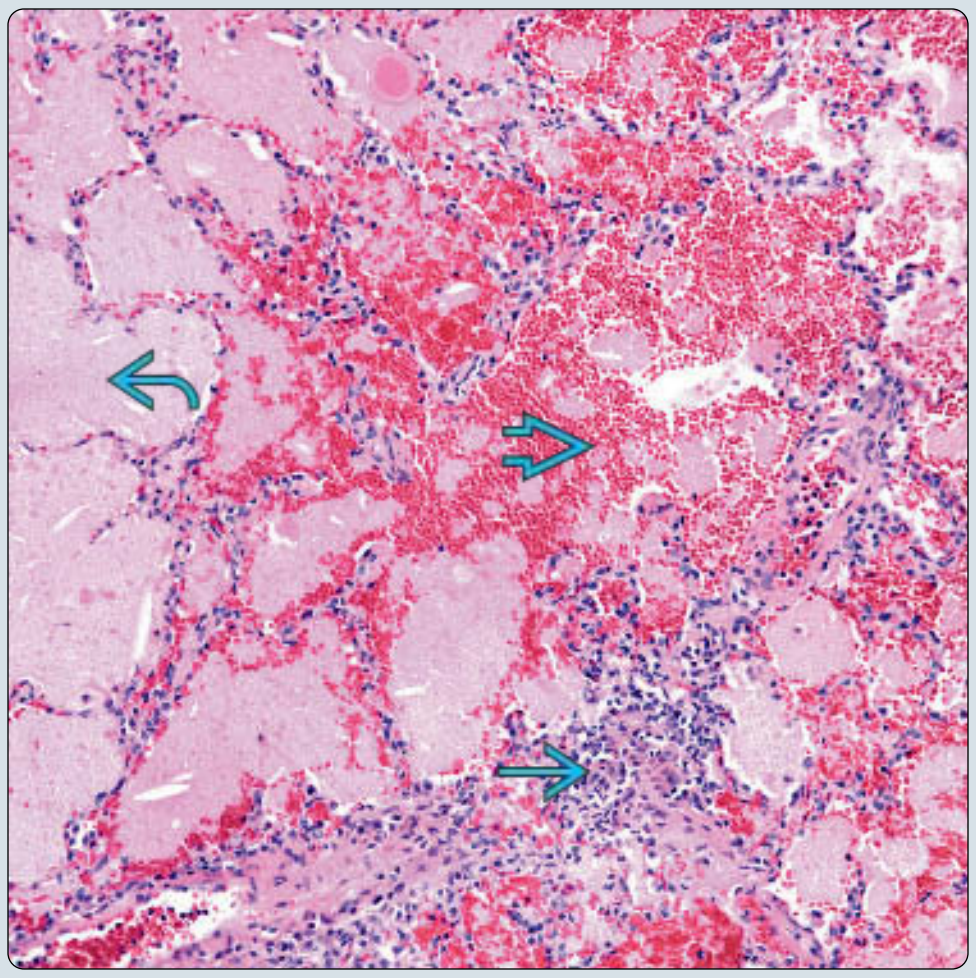

Alveolar Filling

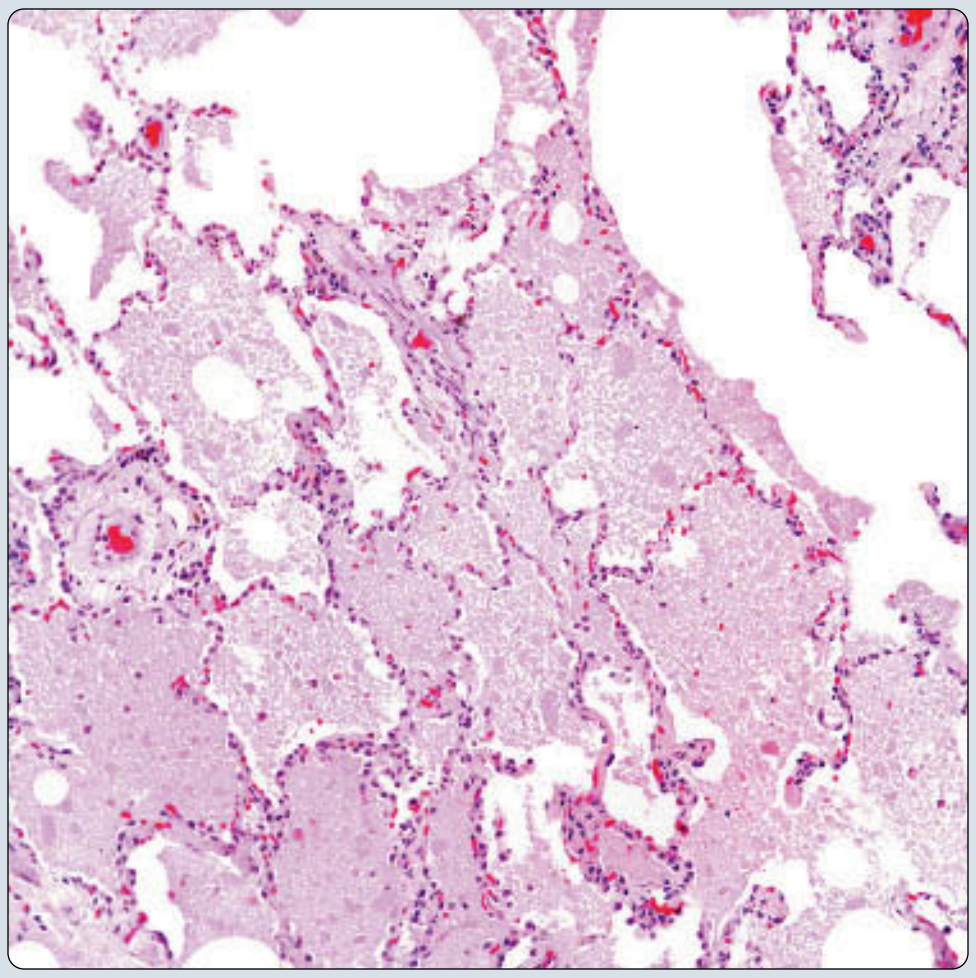

(Left) *Pulmonary alveolar proteinosis (PAP) shows alveolar filling by a proteinaceous material → as well as fresh blood →. In addition, a mild inflammatory infiltrate is also present →.* **(Right)** *PAP shows alveolar filling; however, note that the basic architecture of the lung parenchyma is preserved.*

Airway Involvement

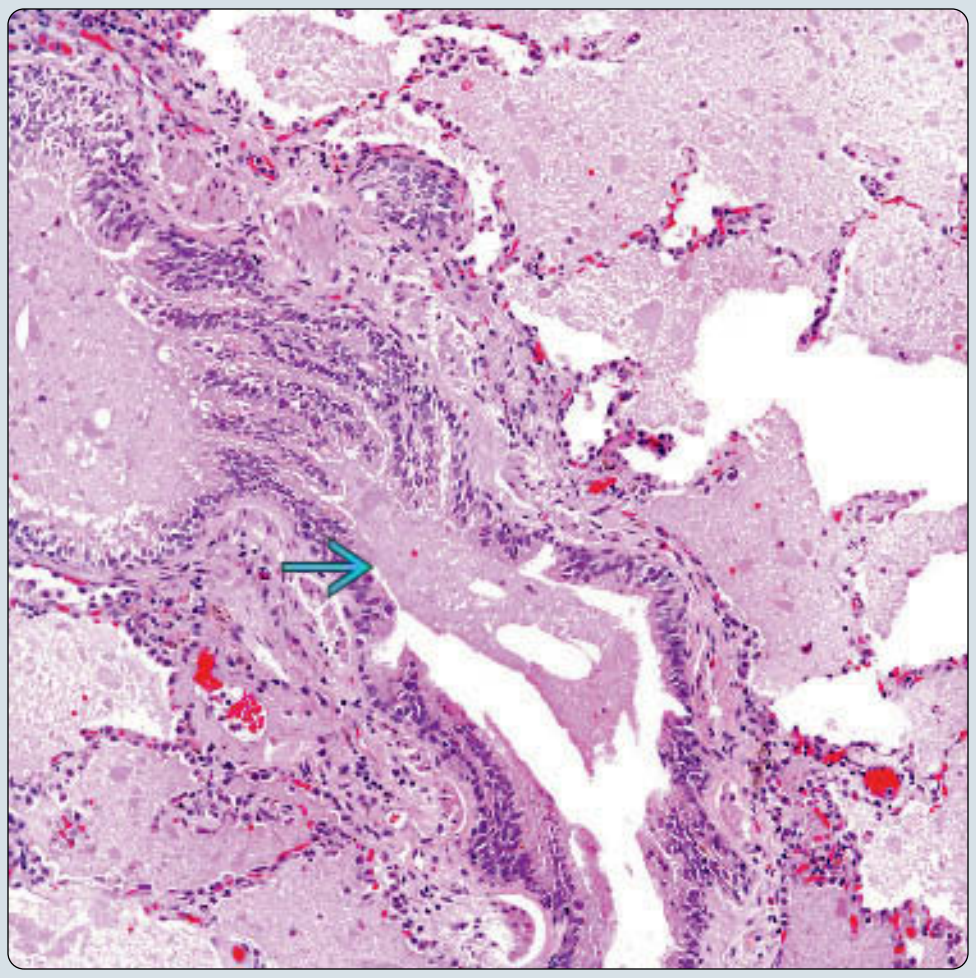

Intraalveolar Acellular Material

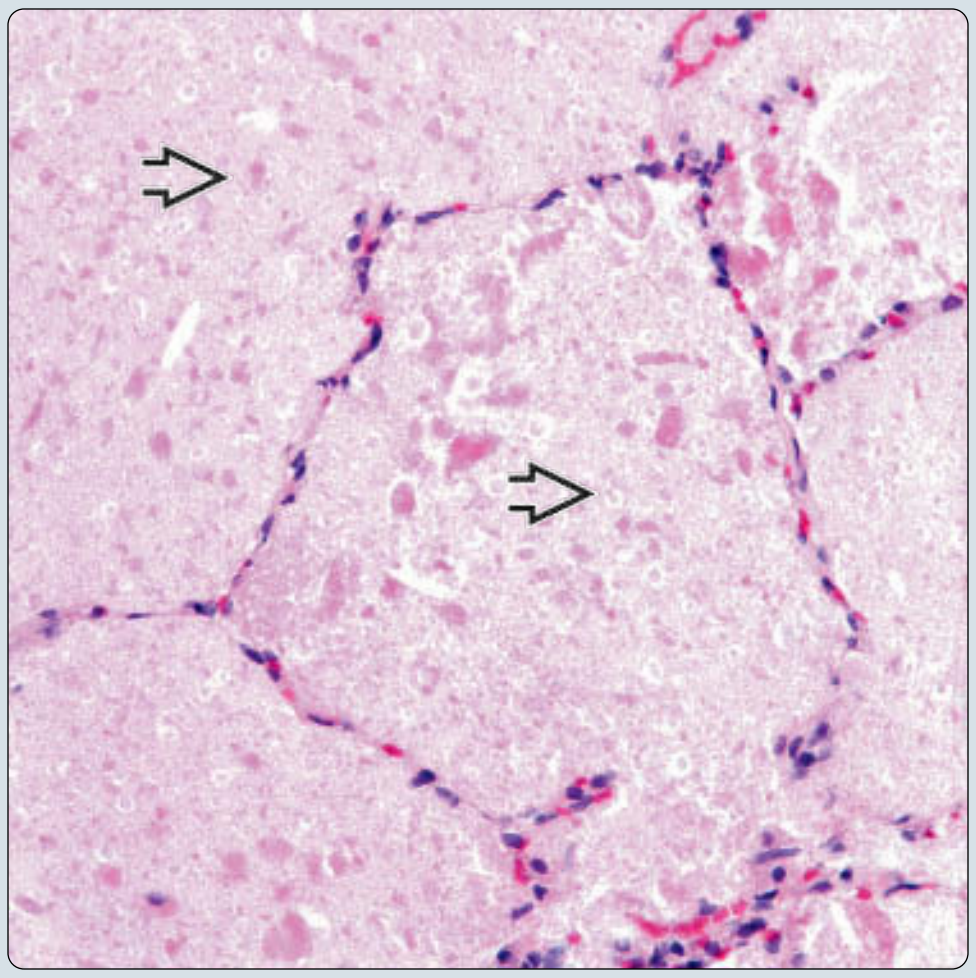

(Left) *PAP shows in addition to the alveolar filling by the proteinaceous material; involvement of the airway → is by the same process.* **(Right)** *High-power view of PAP shows complete filling of the alveolar spaces by granular acellular proteinaceous material →.*

TERMINOLOGY

Abbreviations

- Pulmonary alveolar proteinosis (PAP)

Definitions

- Nonneoplastic condition in which alveoli are filled with proteinaceous material

ETIOLOGY/PATHOGENESIS

Etiology

- PAP has been seen in association with
  - Infectious conditions
  - Immunosuppression
  - Hematologic malignancies
- Abundant deposition of surfactant and lipoprotein in alveoli
- Autoimmune form of PAP may account for ~ 90% of cases

CLINICAL ISSUES

Epidemiology

- Incidence
  - Condition of unusual occurrence
- Age
  - Condition has been reported to occur in any age group
- Sex
  - No gender predilection

Presentation

- Cough
- Dyspnea
- Chest pain
- Fever

Treatment

- Spontaneous remission in some cases
- Pulmonary lavage
  - 50% of patients may experience complete remission
  - Treatment of underlying associated condition is highly important

Prognosis

- Generally good prognosis
- Depends on associated condition
- Some patients may not respond to treatment

IMAGING

General Features

- Reticulonodular pattern
- Small acinar pattern
- Focal consolidation

MICROSCOPIC

Histologic Features

- Alveolar filling by proteinaceous material
- Preservation of normal alveolar architecture
- No evidence of interstitial fibrosis
- Proteinaceous material is positive for periodic acid-Schiff (PAS)

DIFFERENTIAL DIAGNOSIS

Pneumocystis Pneumonia

- Silver stains will show presence of organisms
- PAS histochemical stain is negative
- 3 Q H X P R F \ V W L V pneumonia and PAP may be associated with immunosuppression
- In both conditions, there is filling of alveolar spaces by acellular material

DIAGNOSTIC CHECKLIST

Pathologic Interpretation Pearls

- Granular proteinaceous material filling alveolar spaces
- Intraalveolar proteinaceous material is positive for PAS histochemical stain

SELECTED REFERENCES

1. Papiris SA et al: Pulmonary alveolar proteinosis: time to shift? Expert Rev Respir Med. 9(3):337-49, 2015

Immunohistochemistry

Antibody	Reactivity	Staining Pattern	Comment
CD68	Negative		May be positive in alveolar macrophages
S100	Negative		May be positive in alveolar macrophages
AE1/AE3	Negative		In proteinaceous material
TTF-1	Positive	Nuclear	In the alveolar lining
Surfactant	Positive	Granular	In some cases, in the proteinaceous material

Histochemical Features

Stain	Result
PAS	Positive in proteinaceous material
PAS-D	Negative in proteinaceous material
Mucicarmine	Negative
Silver stains for organisms	Negative

Acellular Material in Airway

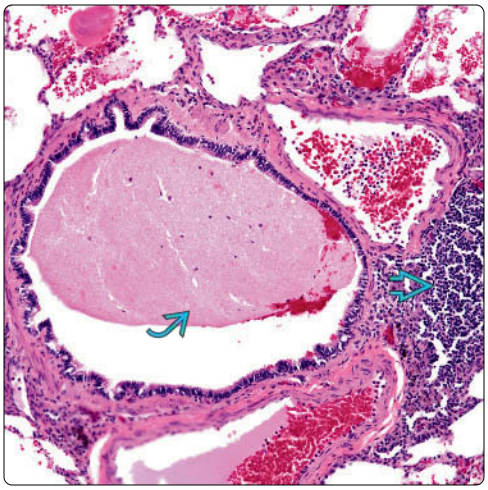

Involvement of Alveoli and Airway

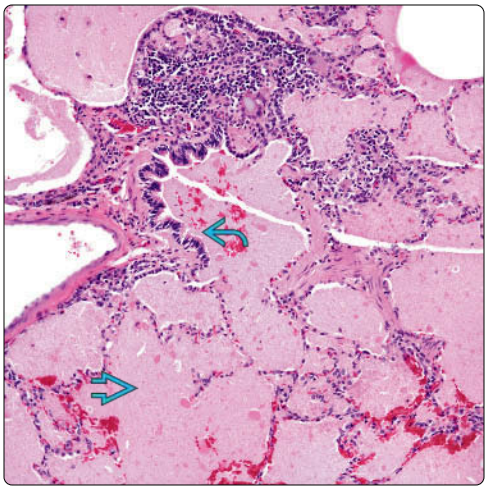

(Left) *In some cases of PAP, the lumen of the airway may also be involved. Adjacent structures are within normal limits; a lymphoid aggregate is also present.* **(Right)** *In areas, the airway may appear to be involved and partially destroyed in PAP. The adjacent alveolar spaces show the typical alveolar filling.*

Hemorrhagic Areas

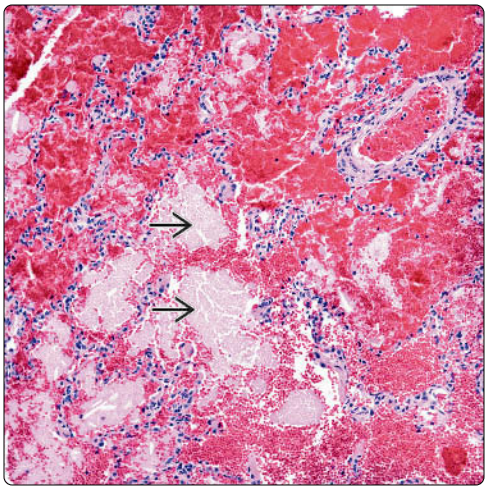

Blood and Proteinaceous Material

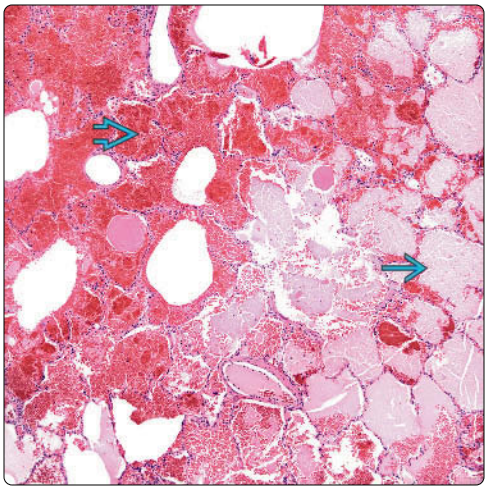

(Left) *PAP shows extensive areas of hemorrhage almost obscuring the process. In a few areas, it is still possible to identify diagnostic areas. These findings may pose a problem in making a definitive diagnosis.* **(Right)** *In some cases, the areas of hemorrhage and PAP have a clear demarcation, thus making the interpretation of PAP easier.*

Cholesterol Cleft Granulomas

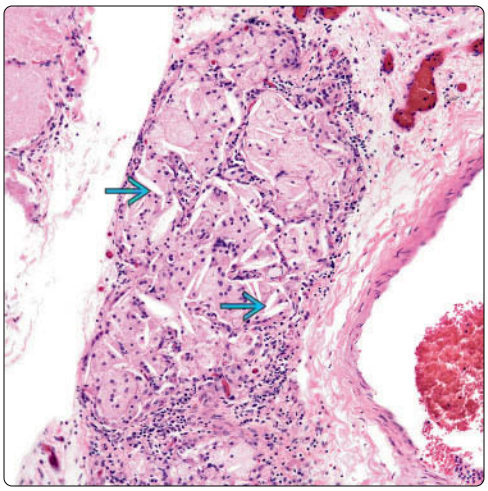

Pneumonitis

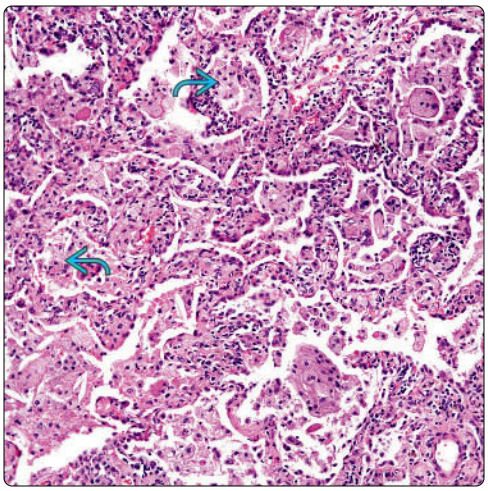

(Left) *PAP shows areas containing cholesterol-cleft granuloma. This feature is also rather unusual since in the majority of cases of PAP no reactive changes are associated with it.* **(Right)** *Adjacent lung parenchyma in PAP may show areas of pneumonitis with the accumulation of alveolar macrophages.*

Intraalveolar Macrophages

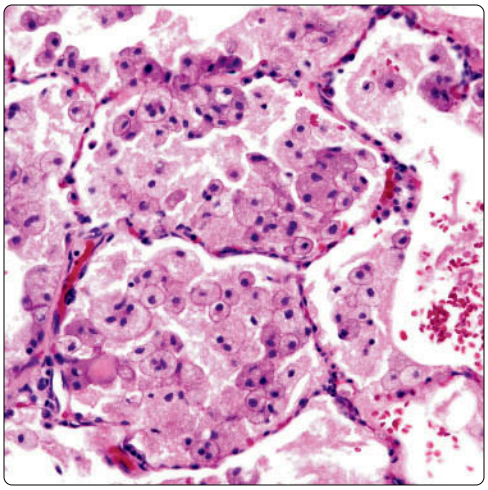

Macrophages and Proteinosis

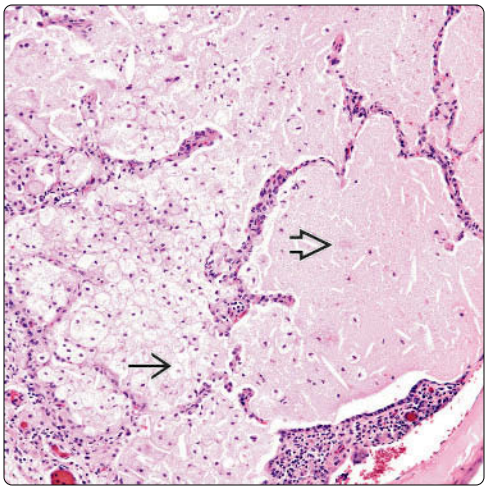

(Left) *PAP shows an area in which the alveoli are filled with foamy macrophages. No proteinaceous material is present within the alveoli.* **(Right)** *In some cases, the classic features of PAP are present and admixed with numerous macrophages. These findings may suggest the possibility of obstructive pneumonia with edematous changes.*

Airway and Alveoli Involvement

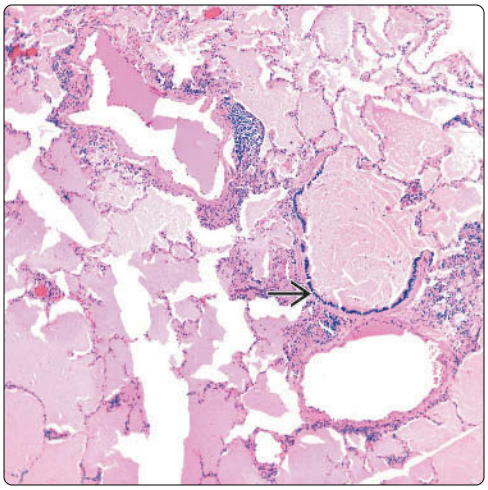

Preservation of Lung Architecture

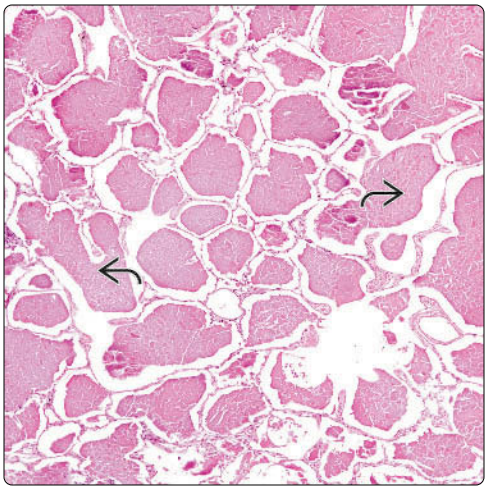

(Left) *PAP is shown partially destroying an airway, which is also filled with the proteinaceous material. Although the name PAP implies alveolar disease, the process may also involve airway structures.* **(Right)** *In PAP, the preservation of the normal lung architecture is a conventional feature. However, the alveoli are filled with proteinaceous material.*

Proteinaceous Material

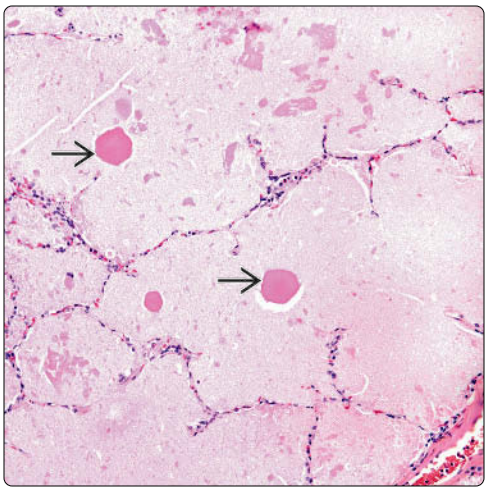

Inflammatory Component

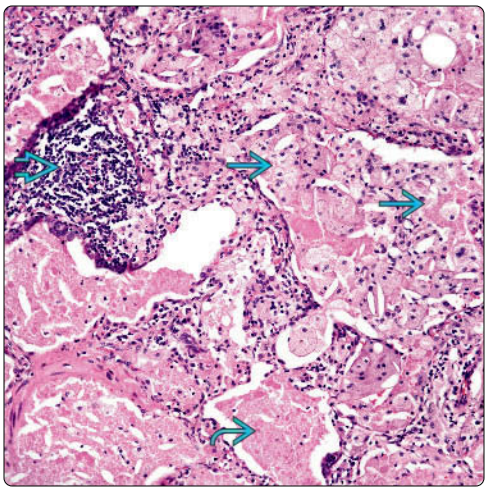

(Left) *Higher magnification of PAP shows the classic granular proteinaceous material with small clumps of bright eosinophilic material. There is no cellularity, including macrophages.* **(Right)** *PAP shows areas of focal lymphoid aggregate, intraalveolar foamy macrophages, and classic proteinaceous material.*

Pulmonary Amyloidosis

KEY FACTS

TERMINOLOGY

- Nonneoplastic process characterized by deposition of amorphous proteinaceous material that may involve lung either primarily or secondarily

ETIOLOGY/PATHOGENESIS

- Secondary to
  - Systemic amyloidosis
  - Light chain disease
  - Multiple myeloma
  - Mucosa-associated lymphoid tissue (MALT) lymphoma of lung
  - Sjögren syndrome
  - Familial neuropathy
  - Gaucher disease

MICROSCOPIC

- Several distinct patterns of amyloid deposition
  - Nodular
  - Interstitial
  - Diffuse
  - Plaque-like
- Cytologic features
  - Amorphous acellular material
  - Presence of giant cells toward periphery of lesion
  - Ossification may be present
  - Inflammatory reaction

ANCILLARY TESTS

- Congo red: Positive
- Crystal violet: Positive, metachromatic

TOP DIFFERENTIAL DIAGNOSES

- Hyalinizing granuloma of lung
- Alveolar proteinosis
- Intrapulmonary solitary fibrous tumor
- Pneumocystis pneumonia
- Pneumonia

Amyloid With Vascular Proliferation

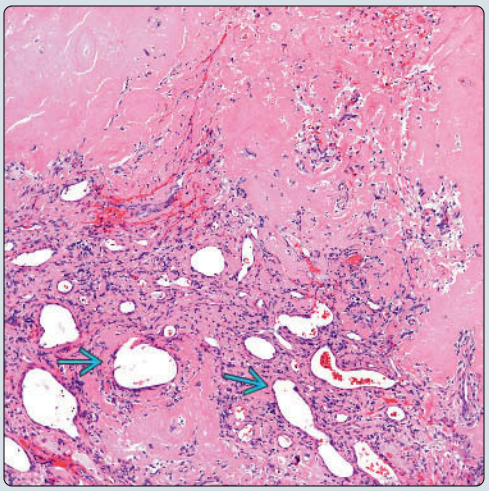

Nodular Amyloid

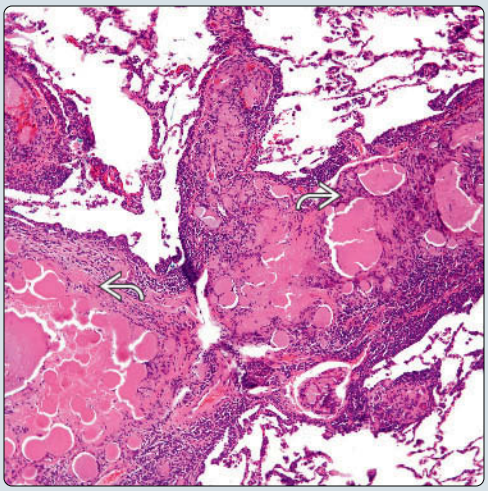

(Left) *Pulmonary amyloid shows destruction of the lung parenchyma by a deposition of amorphous acellular material. In addition, there is a spindle cell component with dilated vascular spaces, which could mimic a vascular neoplasm.* **(Right)** *Low-power view demonstrates lung parenchyma with nodules of different sizes composed of amorphous acellular material replacing lung parenchyma.*

Presence of Giant Cells

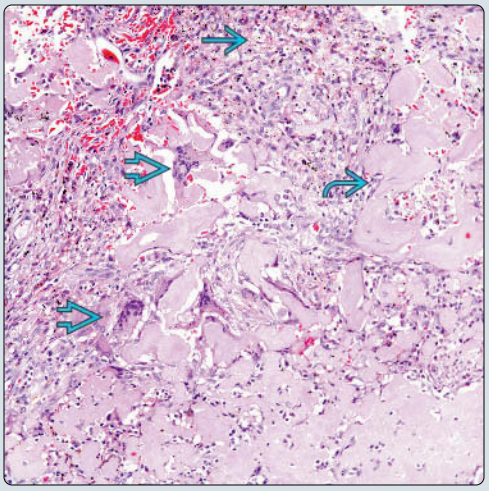

Amorphous Acellular Material

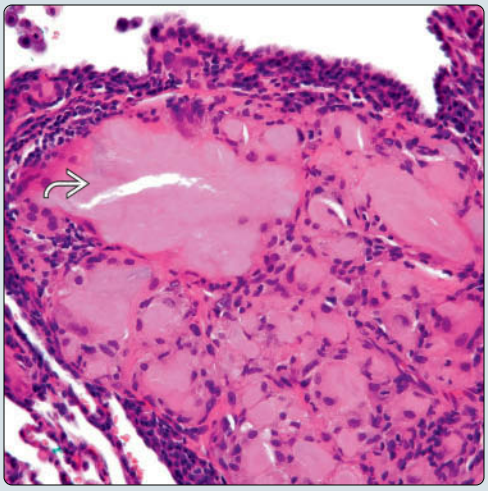

(Left) *Pulmonary amyloid shows a combination of amorphous acellular material admixed with the presence of cellular areas composed of histiocytes and multinucleated giant cells.* **(Right)** *A closer view of the amorphous material replacing normal lung parenchyma is shown. The material is acellular with a haphazard distribution.*

TERMINOLOGY

Synonyms

- Amyloidoma

Definitions

- Nonneoplastic process characterized by deposition of amorphous proteinaceous material that may involve lung either primarily or secondarily

ETIOLOGY/PATHOGENESIS

May Develop Secondary to

- Systemic amyloidosis
- Light chain disease
- Multiple myeloma
- Waldenström macroglobulinemia
- Familial neuropathy
- Niemann-Pick disease
- Gaucher disease
- Sjögren syndrome
- Mucosa-associated lymphoid tissue (MALT) lymphoma of lung

CLINICAL ISSUES

Epidemiology

- Incidence
  - Rare condition in lung
- Age
  - Generally affects adults
- Sex
  - No apparent gender predilection
- Ethnicity
  - No apparent ethnic predilection

Site

- Lung

Presentation

- Dyspnea
- Cough
- Chest pain
- Asymptomatic

Laboratory Tests

- Potassium permanganate oxidation technique
  - Separates amyloid type AA from other forms of amyloid

Treatment

- Surgical approaches
  - Surgical resection of tumor nodules is usually performed

Prognosis

- Depends on clinical background, such as whether patient has systemic amyloidosis or any other disease associated with amyloid deposition

MACROSCOPIC

General Features

- Lung parenchyma can have 1 or more pulmonary nodules

Size

- Varies; between 1 and > 10 cm

MICROSCOPIC

Histologic Features

- Several distinct patterns of amyloid deposition in lung
  - Nodular
  - Interstitial
  - Diffuse
  - Plaque-like

Cytologic Features

- Amorphous acellular material
- Presence of giant cells toward periphery of lesion
- Ossification may be present
- Inflammatory reaction, namely plasma cells

ANCILLARY TESTS

Histochemistry

- Congo red: Positive
  - Characteristic apple-green birefringence under polarized light
- Crystal violet: Positive, metachromatic
- PAS: Negative
- GMS: Negative

Immunohistochemistry

- Kappa: Polyclonal
- Lambda: Polyclonal
- CD34: Negative

DIFFERENTIAL DIAGNOSIS

Hyalinizing Granuloma of Lung

- Shows negative staining for Congo red
- Composed of thick collagen
- More fibrosing process than pulmonary amyloidosis

Alveolar Proteinosis

- Negative for Congo red
- Classically has proteinaceous material within alveolar spaces only
- Positive staining for PAS, while amyloid is negative
- Neither giant cells nor interstitial involvement

DIAGNOSTIC CHECKLIST

Pathologic Interpretation Pearls

- Amorphous material: Congo red histochemical stain (+)
- Giant cells: Usually in periphery
- Plasma cells

SELECTED REFERENCES

1. de Almeida RR et al: Respiratory tract amyloidosis. state-of-the-art review with a focus on pulmonary involvement. Lung. 193(6):875-83, 2015
2. Scala R et al: Amyloidosis involving the respiratory system: 5-year's experience of a multi-disciplinary group's activity. Ann Thorac Med. 10(3):212-6, 2015
3. Tada L et al: Recurrent pleural effusions occurring in association with primary pulmonary amyloidosis. Case Rep Pulmonol. 2015:421201, 2015
4. Hui AN et al: Amyloidosis presenting in the lower respiratory tract. Clinicopathologic, radiologic, immunohistochemical, and histochemical studies on 48 cases. Arch Pathol Lab Med. 110(3):212-8, 1986

Destruction of Normal Lung Parenchyma

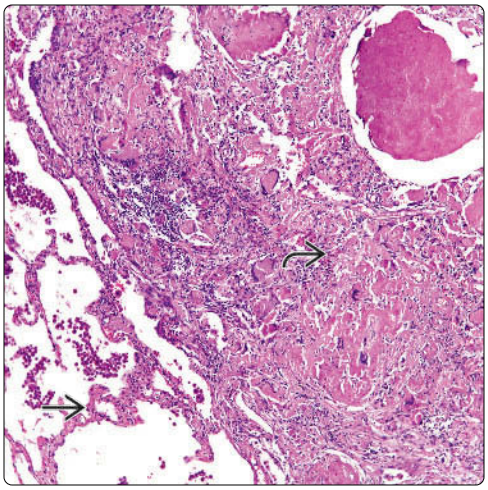

Presence of Giant Cells

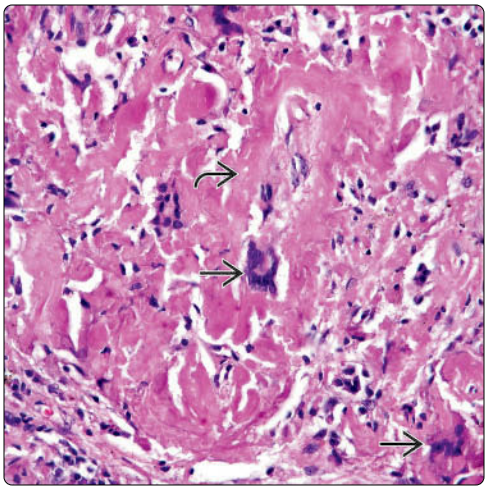

(Left) *Low magnification of amyloid deposition in the lung shows both uninvolved lung parenchyma and extensive areas of lung parenchyma replaced by amyloid.* **(Right)** *Closer view of amyloid deposition in the lung shows areas composed of acellular material; however, note the presence of multinucleated giant cells admixed with the amorphous material.*

Interstitial Distribution

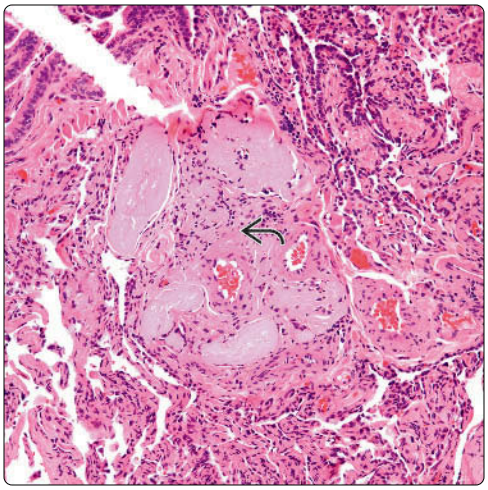

Predominantly Interstitial Involvement

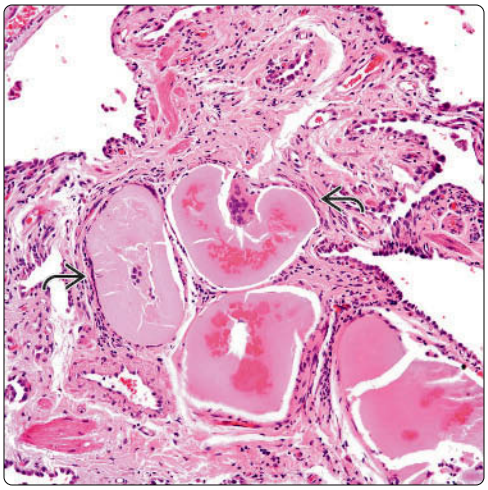

(Left) *In some cases, the presence of amyloid may not be so obvious, and the amorphous material may be deposited in a more interstitial distribution. In such cases, the diagnosis of pulmonary amyloidosis can be easily missed.* **(Right)** *Amyloid deposition in a pattern predominantly involving the interstitium is shown. Note that the adjacent lung parenchyma seems to be within normal limits.*

Distorted Lung Parenchyma

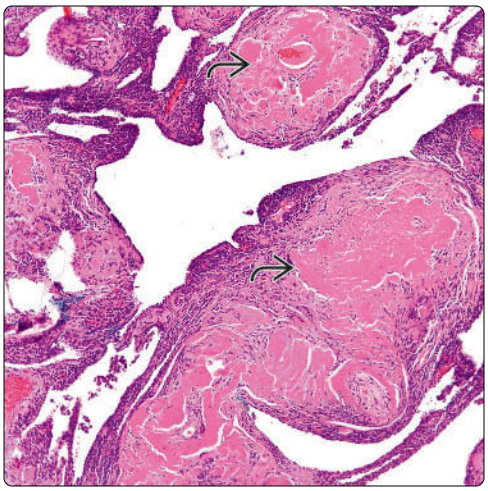

Inflammatory Reaction

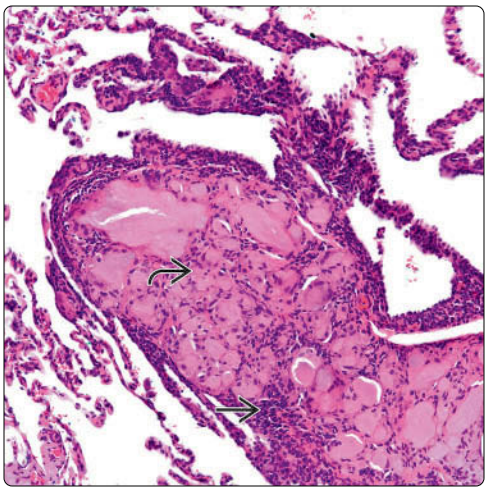

(Left) *In some cases of amyloid deposition, the normal architecture of the lung parenchyma is distorted, which can give the impression of fibrotic interstitial lung disease.* **(Right)** *Lung parenchyma with amyloid deposition and a rim of inflammatory reaction is shown. Also note the presence of a mild inflammatory reaction within the amyloid.*

Focal Residual Areas of Lung Parenchyma

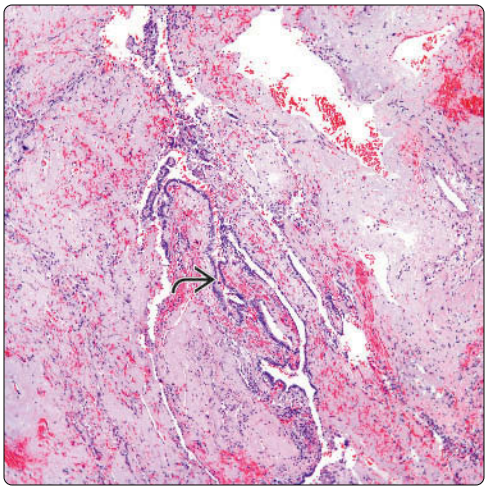

Replacement of Lung Architecture

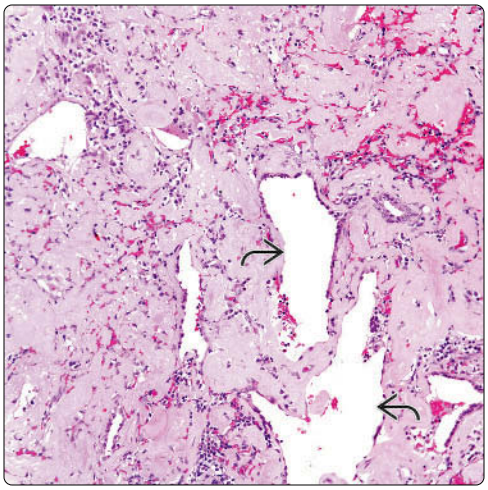

(Left) *In some cases of amyloid deposition, there are only focal residual areas of normal lung tissue, as in this case with focal areas of respiratory epithelium within the amyloid.* **(Right)** *In some cases, amyloid deposition may show ectatic spaces that can mimic dilated vascular structures, which could be easily mistaken for a vascular neoplasm.*

Minimal Inflammatory Reaction

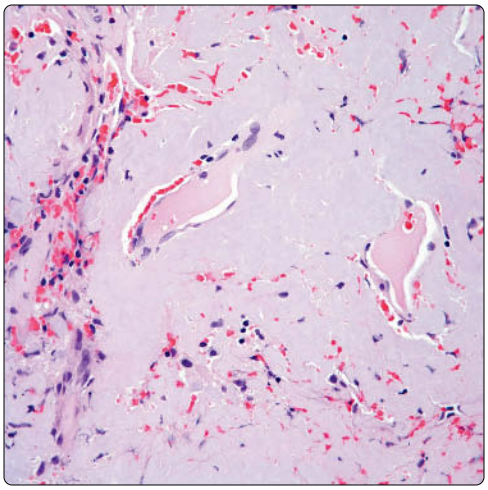

Amyloid Associated With Cellular Areas

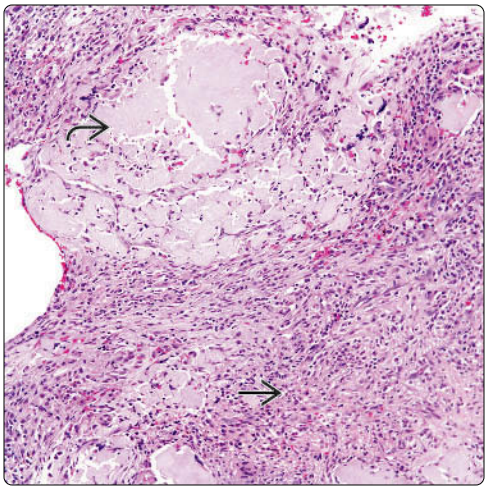

(Left) *Higher magnification of amyloid displays amorphous material with minimal inflammatory reaction. This histologic feature is characteristic, and a Congo red stain must be requested for further evaluation.* **(Right)** *Focal areas of lung parenchyma are obliterated by amyloid deposition. However, note the presence of a spindle cell proliferation, which by itself could be mistaken for a spindle cell neoplasm.*

Metaplastic Bone Formation

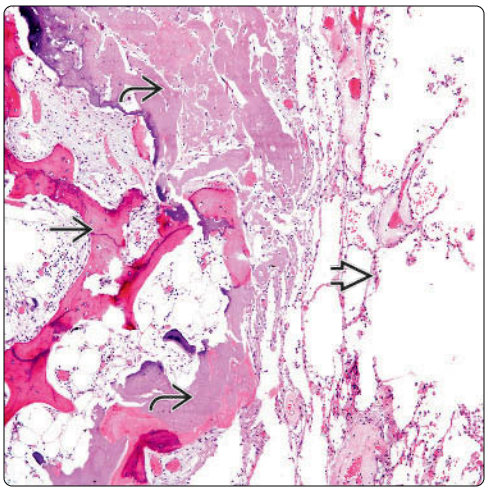

Focal Areas With Lymphoid Aggregates

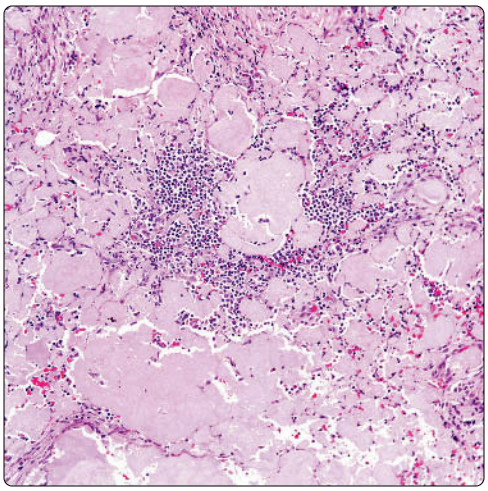

(Left) *Another rather unusual histological feature of amyloid in the lung is the presence of metaplastic bone. Note the presence of normal lung parenchyma, metaplastic bone, and amyloid.* **(Right)** *Extensive areas of amyloid admixed with an inflammatory reaction predominantly composed of lymphocytes are seen. Because in some cases amyloid may be associated with lymphoma or plasma cell malignancy, it is very important to carefully rule out these possibilities.*

Eosinophilic Pneumonia

KEY FACTS

TERMINOLOGY

- Synonyms
  - Loeffler syndrome
- Definition
  - Patchy pulmonary infiltrates characterized by presence of eosinophils as main inflammatory component

ETIOLOGY/PATHOGENESIS

- Parasites
- Ingestants and inhalants
- Fungal infections
- Drug toxicity
- Unknown etiology

CLINICAL ISSUES

- Presentation
  - Simple (Loeffler syndrome)
  - Tropical
  - Chronic
  - Acute
- Treatment
  - Depends on etiology of process
- Prognosis
  - Most patients follow recovery process

MICROSCOPIC

- Histological features
  - Filling of alveolar spaces by eosinophils and macrophages
  - Intraalveolar acellular exudate
  - Eosinophilic intraalveolar necrosis may be present

TOP DIFFERENTIAL DIAGNOSES

- Churg-Strauss syndrome
- Langerhans cell histiocytosis
- Dirofilariasis
- Fibrinous pneumonitis

(Left) *Eosinophilic pneumonia shows pulmonary parenchyma with a fibrinous intraalveolar exudate. Note the presence of numerous inflammatory cells in the center of the exudate.* **(Right)** *Higher magnification shows numerous eosinophils admixed with macrophages. This finding is essential for the diagnosis of eosinophilic pneumonia.*

Intraalveolar Eosinophils

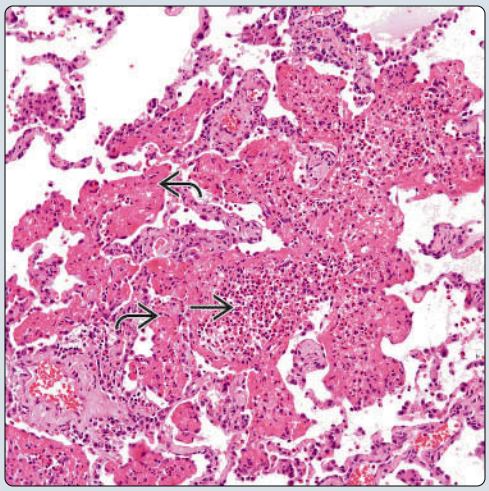

Alveolar Filling With Eosinophils

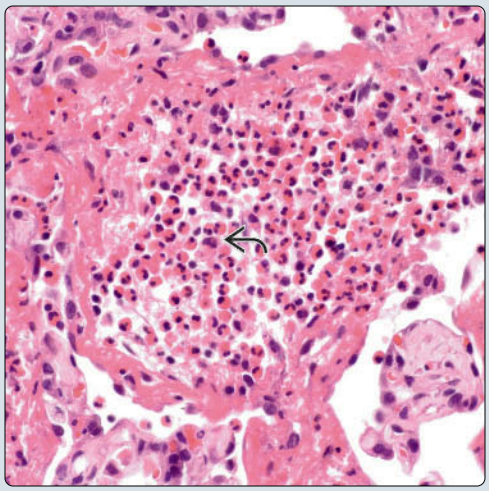

(Left) *Pulmonary eosinophilic pneumonia shows a fibrinous eosinophilic plug filling alveolar space. This closely resembles an eosinophilic abscess. Note the peripheral presence of more easily identifiable eosinophils.* **(Right)** *Eosinophilic pneumonia shows marked areas of eosinophils admixed with fibrinous exudate and other inflammatory cells. The outlines of alveolar spaces are still noted.*

Fibrinous Eosinophilic Plug

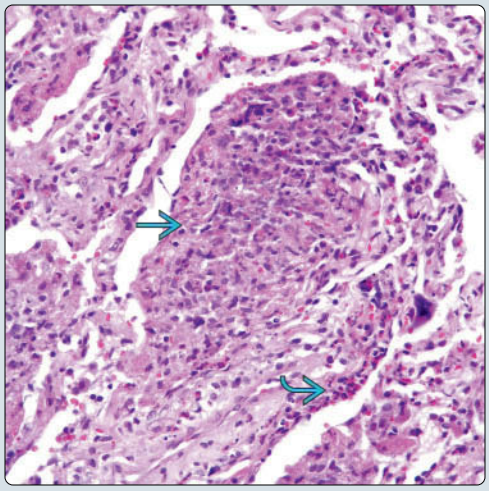

Marked Presence of Eosinophils

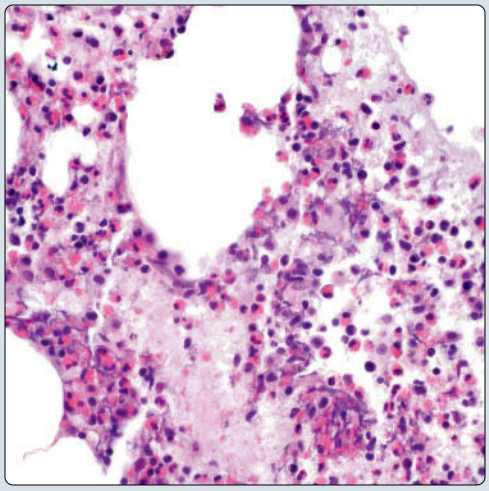

TERMINOLOGY

Synonyms

- Loeffler syndrome

Definitions

- Patchy pulmonary infiltrates characterized by presence of eosinophils as main inflammatory component

ETIOLOGY/PATHOGENESIS

Causes

- Parasites
  - $VFDULV
  - Filarioidea
  - 6WURQJ\ORLGHV
  - 7R[RFDUD
- Ingestants and inhalants
  - L-tryptophan
  - Cocaine
- Fungal infections
  - $VSHUJLOOXV
  - &DQGLGD
  - &XUYXODULD
- Drug toxicity
  - Antibiotics
- Unknown etiology

CLINICAL ISSUES

Presentation

- Symptomatology will depend on type of process
  - Simple (Loeffler syndrome)
    - Self-limited
    - Fleeting pulmonary infiltrates
  - Tropical
    - Fever
    - Cough
    - Dyspnea
  - Chronic
    - Fever
    - Chills
    - Dyspnea
    - Weight loss
    - History of asthma
  - Acute
    - Fever
    - Marked respiratory difficulty

Laboratory Tests

- Peripheral eosinophilia in chronic phase
- Elevated IgE in serum in chronic phase

Natural History

- Eosinophilic pneumonia can present in 4 different forms
  - Simple (Loeffler syndrome)
  - Tropical
  - Chronic
  - Acute

Prognosis

- Will depend on etiology of process
- Most patients follow recovery process

IMAGING

Radiographic Findings

- Fleeting pulmonary infiltrates

MICROSCOPIC

Histologic Features

- Filling of alveolar spaces by eosinophils and macrophages
- Charcot-Leyden crystal may be present
- Intraalveolar acellular exudate
- Eosinophilic intraalveolar necrosis may be present
- Bronchiolitis obliterans and organizing pneumonia (BOOP) areas may be present
- Areas of diffuse alveolar damage may be present

DIFFERENTIAL DIAGNOSIS

Churg-Strauss Syndrome

- Infiltrates in eosinophilic pneumonia are intraalveolar
- Eosinophilic pneumonia does not show vasculitis
- Eosinophilic pneumonia does not show positive p-ANCA in serum

Langerhans Cell Histiocytosis

- Multiple pulmonary nodules, whereas eosinophilic pneumonia shows fleeting infiltrates
- Typical nodules (so-called Medusa head)
- Positive staining for S100 protein and CD1a

Dirofilariasis

- Usually presents with necrotizing intrapulmonary nodule
- Identification of parasite within necrotizing nodule is diagnostic of dirofilariasis
- Eosinophilic infiltrate may be seen in periphery of necrotizing nodule

Fibrinous Pneumonitis

- Lacks presence of eosinophils
- Fleeting pulmonary infiltrates would be unusual finding
- Clinical background of fibrinous pneumonitis is different

DIAGNOSTIC CHECKLIST

Clinically Relevant Pathologic Features

- Symptom complex
- Tissue distribution

Pathologic Interpretation Pearls

- Intraalveolar presence of eosinophilic infiltrate

SELECTED REFERENCES

1. Akkanti B et al: Acute eosinophilic pneumonia. BMJ Case Rep. 2016, 2016
2. Larranaga JM et al: Acute eosinophilic pneumonia as a complication of influenza A (H1N1) pulmonary infection. Sarcoidosis Vasc Diffuse Lung Dis. 33(1):95-7, 2016
3. Sergew A et al: Current approach to diagnosis and management of pulmonary eosinophilic syndromes: eosinophilic pneumonias, eosinophilic granulomatosis with polyangiitis, and hypereosinophilic syndrome. Semin Respir Crit Care Med. 37(3):441-56, 2016

Fibrinous Exudate

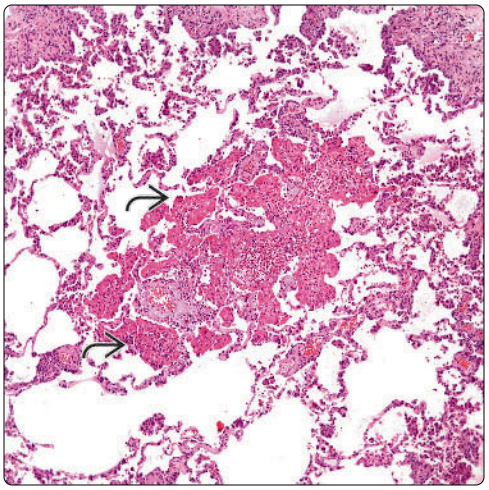

Areas of Perivascular Involvement

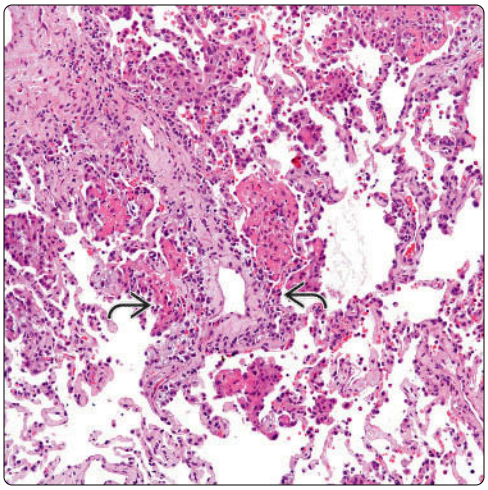

(Left) *Low-power magnification of eosinophilic pneumonia shows a fibrinous inflammatory exudate predominantly in an intraalveolar location. This feature may be seen in some cases of acute fibrinous pneumonia.* **(Right)** *In other areas, the fibrinous exudate is also found around perivascular structures, giving the impression of an inflammatory vascular process.*

Vascular Structures With Inflammation

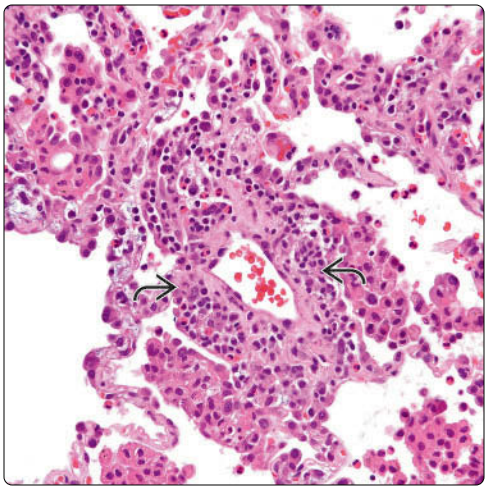

Pleural Involvement

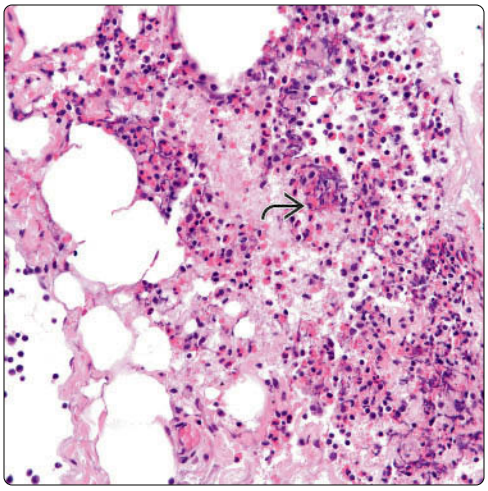

(Left) *In some cases of eosinophilic pneumonia away from the eosinophilic abscesses that are commonly seen, the inflammatory response may be more subtle, showing a perivascular inflammatory reaction without the fibrinous exudate.* **(Right)** *In addition to the commonly seen intraalveolar eosinophilic abscess, an eosinophilic reaction is also seen toward the periphery of the lung into the visceral pleura.*

Interstitial Involvement

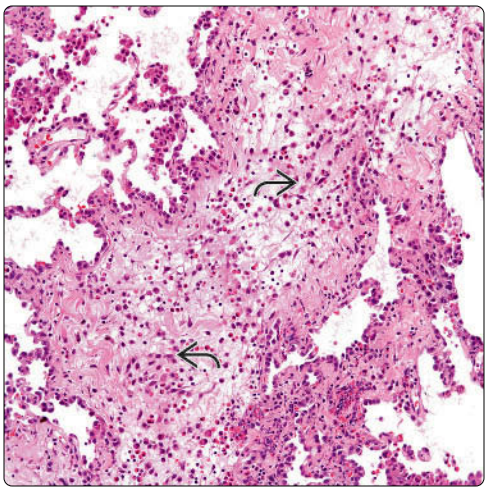

Mixed Inflammatory Response

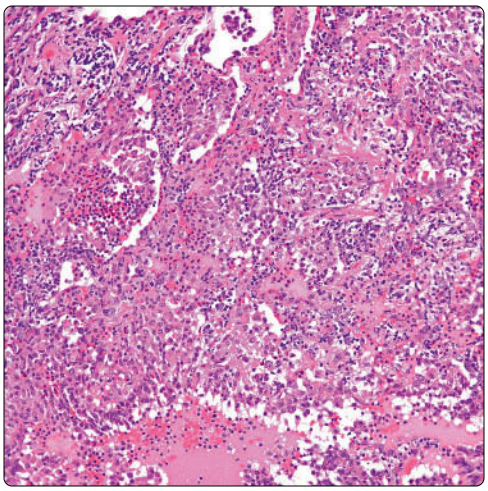

(Left) *Eosinophilic pneumonia shows extensive deposition of inflammatory cells, predominantly composed of eosinophils. The eosinophilic infiltrate involves the pulmonary septum.* **(Right)** *Eosinophilic pneumonia shows areas of organization. The eosinophilic infiltrate is mixed with other inflammatory cells and macrophages, obscuring the diagnosis.*

Collapsed Lung Parenchyma

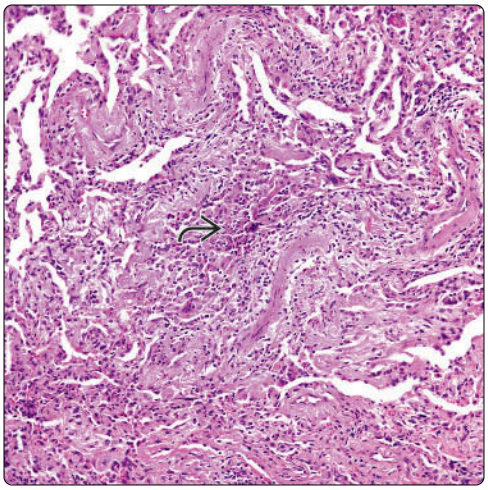

Focal Eosinophilic Abscess

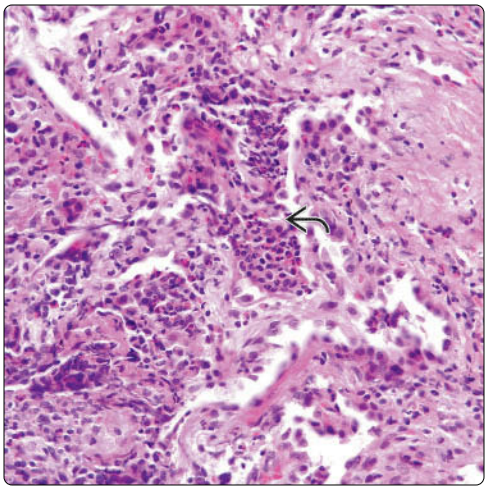

(Left) *In some cases of eosinophilic pneumonia, the lung parenchyma is collapsed, and the presence of the eosinophilic abscess is not readily observed, making the diagnosis more challenging.* **(Right)** *Eosinophilic pneumonia shows an eosinophilic abscess in the background of collapsed alveolar structures.*

Pneumonia Pattern

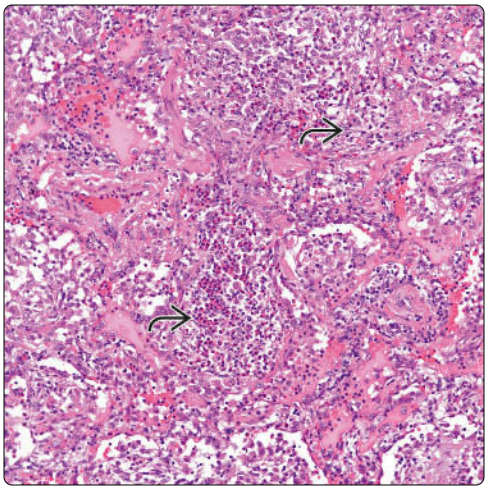

Eosinophilic Abscess

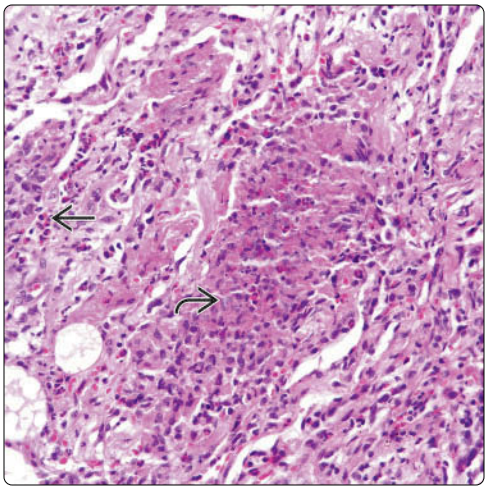

(Left) *Eosinophilic pneumonia shows alveolar filling of inflammatory cells predominantly composed of eosinophils. At this magnification, this process can easily be mistaken for a conventional pneumonia.* **(Right)** *Classic eosinophilic abscess in an eosinophilic pneumonia is shown. Adjacent to the abscess are numerous interstitial eosinophils.*

Intraalveolar Fibrinous Exudate

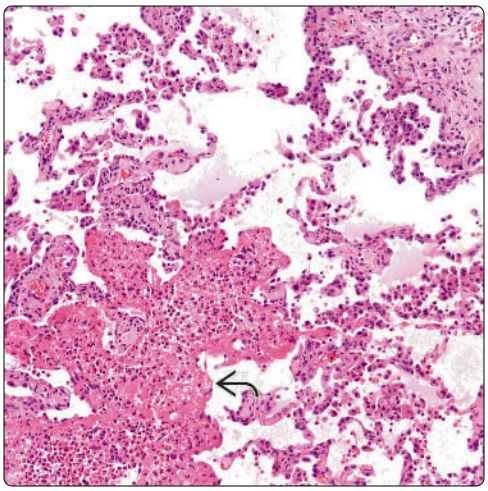

Eosinophils Embedded in Fibrinous Exudate

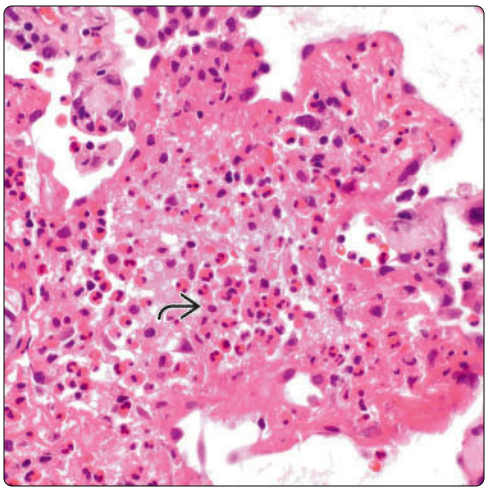

(Left) *Eosinophilic pneumonia shows conventional features of intraalveolar fibrinous exudate. The cellular proliferation within the fibrinous exudate is composed predominantly of eosinophils.* **(Right)** *Higher magnification demonstrates that the fibrinous exudates contain numerous eosinophils, which are essential for the diagnosis of eosinophilic pneumonia.*

Langerhans Cell Histiocytosis

KEY FACTS

TERMINOLOGY

- Proliferation of Langerhans cells that form multiple interstitial, bilateral, peribronchiolar pulmonary nodules

ETIOLOGY/PATHOGENESIS

- 95% of patients are cigarette smokers, suggesting link with cigarette smoking

CLINICAL ISSUES

- 18-40 years
- Predominantly affects upper and mid zones of lungs
- Asymptomatic in ~ 15% of patients

MICROSCOPIC

- Interstitial proliferation of Langerhans cells distributed along small airways (bronchioles and alveolar ducts)
- Larger lesions produce stellate-shaped or round nodules around bronchioles
- Lesions may be paucicellular or contain abundant Langerhans cells
- Nodular lesions may show cystic changes and cavitation
- Langerhans cells show round to oval nuclei with frequent nuclear irregularities and nuclear infolding (grooves)
- Langerhans cells are accompanied by abundant eosinophils
- Lesions are often accompanied by evidence of respiratory bronchiolitis
- Multinucleated histiocytes may accompany cellular infiltrate
- Late or more advanced lesions may be almost totally devoid of Langerhans cells and replaced by stromal fibrosis

ANCILLARY TESTS

- Langerhans cells are positive for S100 protein and CD1a
- Zipper-like structures (Birbeck granules) are pathognomonic on electron microscopy

Langerhans Cell Histiocytosis of Lung: Stellate Scar

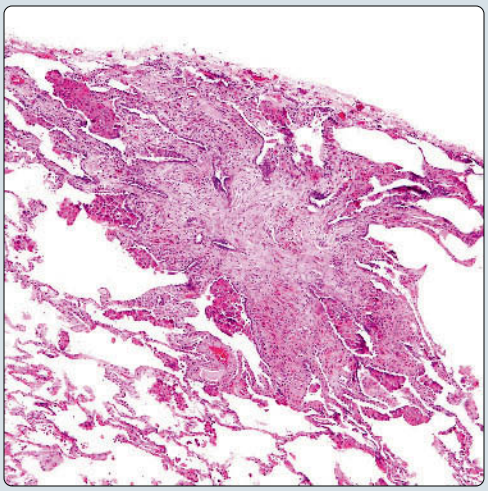

Langerhans Cell Histiocytosis: Higher Magnification

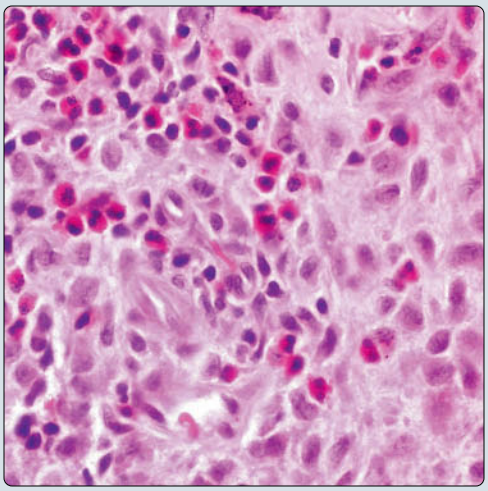

(Left) *Histologic appearance of a focus of Langerhans cell histiocytosis shows a stellate-shaped area in the periphery of the lung with sparse cellular proliferation.* **(Right)** *Higher magnification of a pulmonary focus of Langerhans cell histiocytosis shows proliferation of small, spindled Langerhans cells admixed with abundant eosinophils.*

CD1a Immunostaining

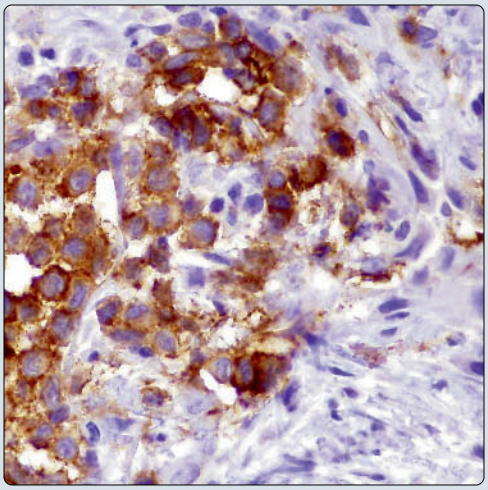

S100 Protein Immunostaining

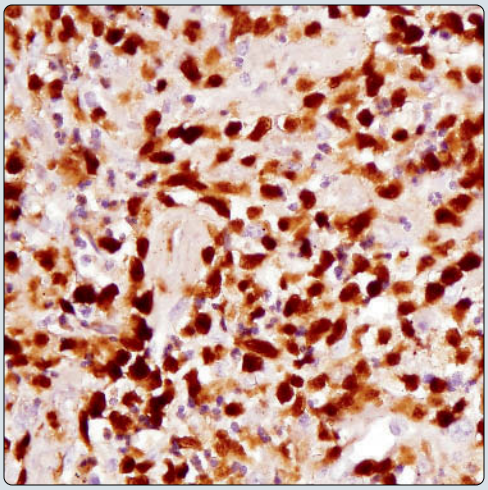

(Left) *Immunohistochemical staining with CD1a antibody in Langerhans cell histiocytosis of the lung shows strong membrane staining of the histiocytes by this antibody.* **(Right)** *Immunohistochemical staining of Langerhans cell histiocytosis of the lung with S100 protein antibody shows strong nuclear staining of the Langerhans cells with this antibody.*

TERMINOLOGY

Synonyms

- Eosinophilic granuloma, Langerhans cell granulomatosis, histiocytosis X

Definitions

- Proliferation of Langerhans cells that form multiple interstitial, bilateral, peribronchiolar pulmonary nodules

ETIOLOGY/PATHOGENESIS

Pathogenesis

- Clonality studies in lung have suggested both reactive and neoplastic process
- 95% of patients are cigarette smokers, suggesting link with cigarette smoking

CLINICAL ISSUES

Epidemiology

- Incidence
  - Highest incidence is in cigarette smokers (95% of patients)

Site

- Predominantly affects upper and midzones of lungs

Presentation

- Cough, dyspnea, chest pain
- Systemic symptoms (malaise, fever, weight loss)

Natural History

- Some patients may experience spontaneous remissions, while others may progress to end-stage pulmonary fibrosis
- Disease often regresses with cessation of smoking

Treatment

- Steroids, cessation of smoking
- Immunosuppressive therapy in refractory cases
- Spontaneous resolution in some cases

Prognosis

- Usually reversible with cessation of smoking
- 15% of patients show progressive disease that may be fatal

IMAGING

Radiographic Findings

- Interstitial process with predilection for mid and upper lobes of lung with sparing of costophrenic angles

CT Findings

- HRCT shows small nodules and cystic spaces showing upper and mid lung patchy distribution

MACROSCOPIC

General Features

- Usually seen as small (2-mm diameter) nodules
- Advanced stages may show extensive interstitial fibrosis

MICROSCOPIC

Histologic Features

- Interstitial proliferation of Langerhans cells distributed along small airways (bronchioles and alveolar ducts)
- Larger lesions produce stellate-shaped or round nodules around bronchioles
- Lesions may be paucicellular or contain abundant Langerhans cells
- Nodular lesions may show cystic changes and cavitation
- Lesions are often accompanied by evidence of respiratory bronchiolitis

Cytologic Features

- Langerhans cells show round to oval nuclei with frequent nuclear irregularities and nuclear infolding (grooves)
- Langerhans cells are accompanied by abundant eosinophils
- Multinucleated histiocytes may accompany cellular infiltrate
- Late or more advanced lesions may be almost totally devoid of Langerhans cells and replaced by stromal fibrosis

ANCILLARY TESTS

Immunohistochemistry

- Langerhans cells are positive for S100 protein, Langerin, and CD1a

Electron Microscopy

- Zipper-like structures (Birbeck granules) are pathognomonic

DIFFERENTIAL DIAGNOSIS

Eosinophilic Pneumonia

- Intraalveolar infiltrate of eosinophils without Langerhans cells

DIAGNOSTIC CHECKLIST

Clinically Relevant Pathologic Features

- In healed cases, diagnosis is based on presence of stellate peribronchiolar scarring in setting of typical HRCT changes

Pathologic Interpretation Pearls

- Stellate peribronchiolar lesions with cystic changes in upper lobes of lung are characteristic
- Admixture of eosinophils with mononuclear cells displaying prominent nuclear infolding is also characteristic

SELECTED REFERENCES

1. DeMartino E et al: Langerhans cell histiocytosis and other histiocytic diseases of the lung. Clin Chest Med. 37(3):421-30, 2016
2. Li CW et al: Pulmonary Langerhans cell histiocytosis: analysis of 14 patients and literature review. J Thorac Dis. 8(6):1283-9, 2016
3. Roden AC et al: Pulmonary Langerhans cell histiocytosis: an update from the pathologists' perspective. Arch Pathol Lab Med. 140(3):230-40, 2016
4. Tazi A et al: The natural history of adult pulmonary Langerhans cell histiocytosis: a prospective multicentre study. Orphanet J Rare Dis. 10:30, 2015
5. Wei P et al: Pulmonary langerhans cell histiocytosis: case series and literature review. Medicine (Baltimore). 93(23):e141, 2014

Focus of Langerhans Cell Histiocytosis in Lung

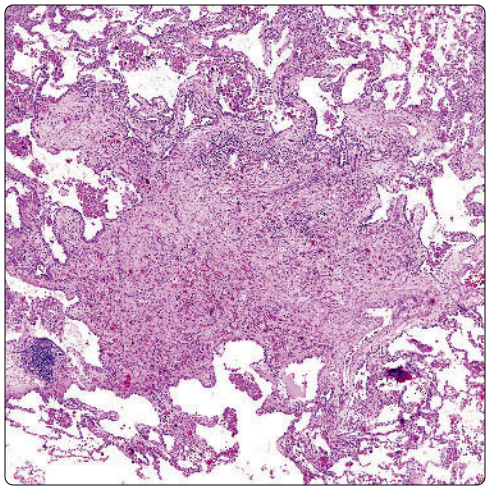

Langerhans Cell Histiocytosis: Higher Magnification

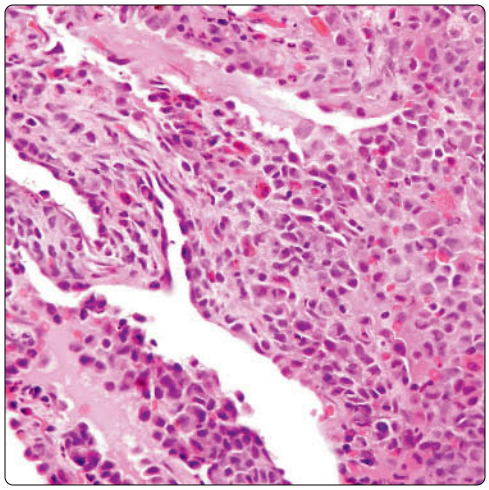

(Left) *Scanning magnification of a pulmonary lesion in Langerhans cell histiocytosis shows a characteristic stellate-shaped area of consolidation of lung parenchyma by a monotonous population of small, round to oval cells. The lesions show a tendency to follow the distribution of bronchioles and vascular bundles.* **(Right)** *Higher magnification of a pulmonary lesion in Langerhans cell histiocytosis shows a dense population of Langerhans cells admixed with eosinophils and hemosiderin-laden macrophages.*

Langerhans Cell Histiocytosis: Cellular Detail

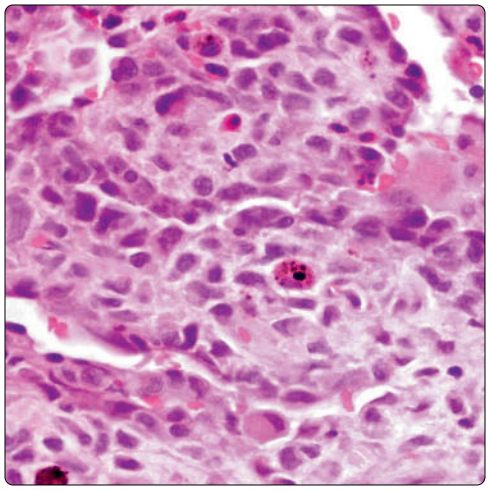

Nuclear Grooving

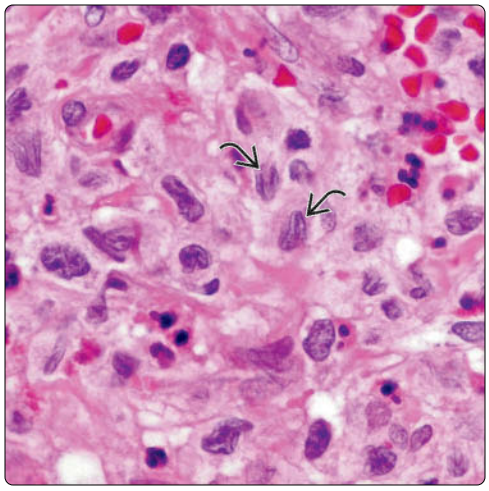

(Left) *High magnification of a pulmonary lesion of Langerhans cell histiocytosis shows interstitial infiltration by Langerhans cell proliferation. Interstitial spread of the process may lead to symptoms.* **(Right)** *Higher magnification of pulmonary Langerhans cell histiocytosis shows histiocytic cells with elongated nuclei surrounded by an ample rim of eosinophilic cytoplasm. The nuclei show a cerebriform appearance with occasional faint longitudinal nuclear grooves* ⇄.

S100 Protein Immunostaining

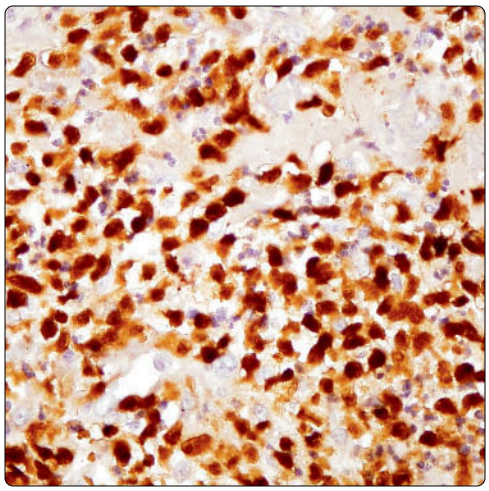

CD1a Immunostaining

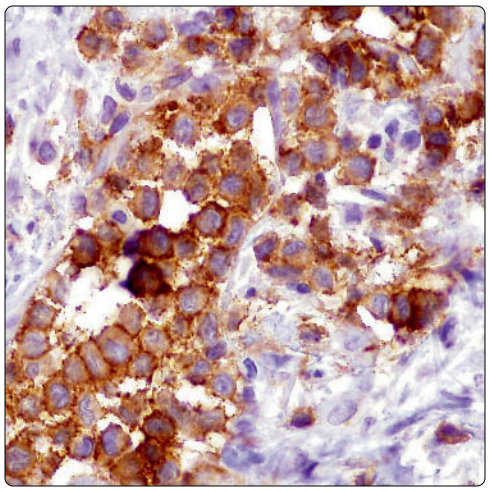

(Left) *Immunohistochemical staining for S100 protein in pulmonary Langerhans cell histiocytosis shows nuclear positivity in the Langerhans cells scattered throughout the lesion.* **(Right)** *Immunohistochemical staining for CD1a in pulmonary Langerhans cell histiocytosis shows strong membrane positivity in the Langerhans cells. The combination of S100 protein positivity with CD1a positivity in the same cells, in the appropriate setting, is diagnostic of this condition.*

Langerhans Cell Histiocytosis Nodule in Lung

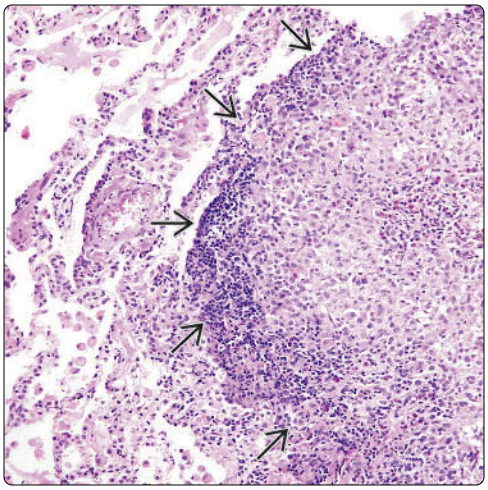

Higher Magnification

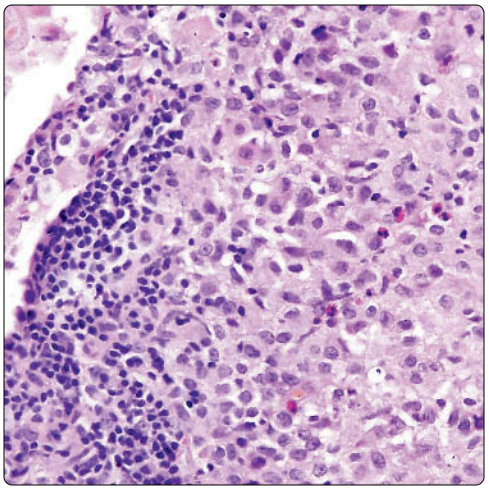

(Left) *Scanning magnification of a nodular lesion ⇨ in pulmonary Langerhans cell histiocytosis shows a well-demarcated nodule composed of sheets of epithelioid cells that are sharply demarcated from the surrounding pulmonary parenchyma.* **(Right)** *Higher magnification of a nodular lesion in a patient with pulmonary Langerhans cell histiocytosis shows sheets of monotonous tumor cells with round to oval nuclei and abundant lightly eosinophilic cytoplasm.*

Scattered Eosinophils

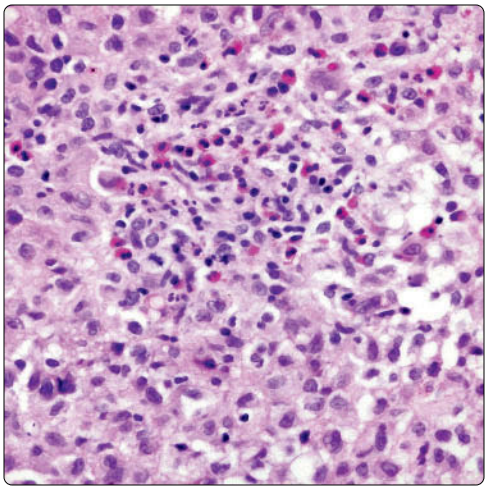

Langerhans Cells: High Power

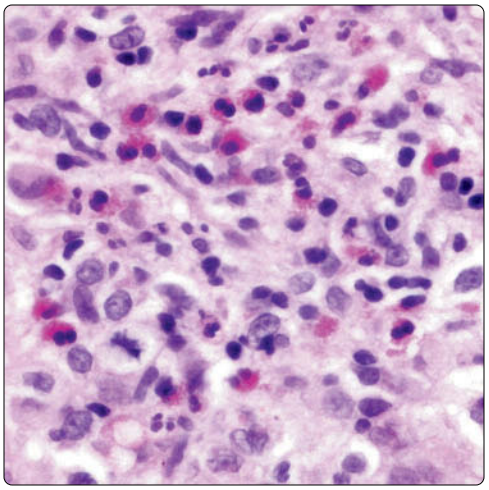

(Left) *Higher magnification of pulmonary Langerhans cell histiocytosis shows sheets of round to oval cells with abundant lightly eosinophilic cytoplasm admixed with scattered eosinophils.* **(Right)** *Higher magnification of a pulmonary lesion in Langerhans cell histiocytosis shows sheets of Langerhans cells with round to oval nuclei surrounded by an ample rim of lightly eosinophilic cytoplasm. There are numerous mature eosinophils scattered in the background.*

Nuclear Grooves and Convolutions

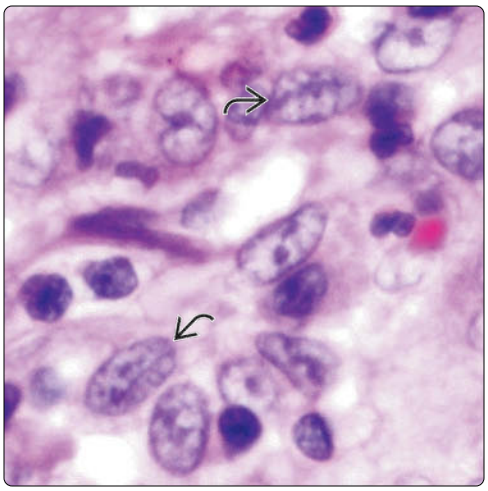

Central Focus of Cavitation

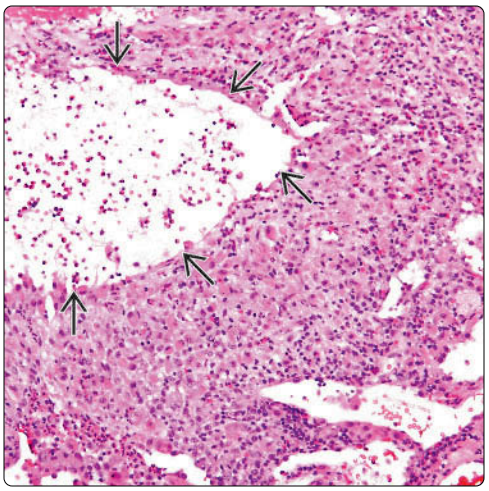

(Left) *Higher magnification of pulmonary Langerhans cell histiocytosis shows oval to spindle cells with vesicular nuclei that display nuclear convolutions and occasional longitudinal nuclear grooves ⇨. Nuclear convolutions and longitudinal nuclear grooves are 2 of the distinguishing features of Langerhans cells at the microscopic level.* **(Right)** *Pulmonary Langerhans cell histiocytosis shows a focus of central cavitation ⇨ (a characteristic feature of this process) frequently observed on CT scans.*

Erdheim-Chester Disease

KEY FACTS

TERMINOLOGY

- Rare histiocytic infiltrative disorder that most commonly affects bones but may affect other organs, including lung

CLINICAL ISSUES

- Bone involvement is most common site
- 50% of patients have extraskeletal involvement, including lungs
- Progressive disorder; morbidity and mortality depend on presence or absence of extraskeletal involvement
- Pulmonary involvement may precede skeletal manifestations in some cases
- Development of clearly delimited bilateral and symmetrical metaphyseal and diaphyseal areas of cortical sclerosis of long bones is classic

IMAGING

- Diffuse interstitial bilateral infiltrates with thickening of pleura and interlobular septa
- Characteristic radiographic finding is interstitial opacities with thickening of interlobular fissures and septa in lung
- Symmetrical osteosclerosis of diaphyses of long bones

MICROSCOPIC

- Diffuse infiltration of histiocytes along lymphatic routes, including pleura, septa, and perivascular and peribronchiolar interstitium
- Characteristic thickening of pleura that tracks into lung parenchyma along interlobular septa

ANCILLARY TESTS

- Histiocytes are positive for CD68 and factor XIIIa
- Scattered S100(+) cells may be identified

Cut Surface of Erdheim-Chester Disease

Erdheim-Chester Disease of Lung

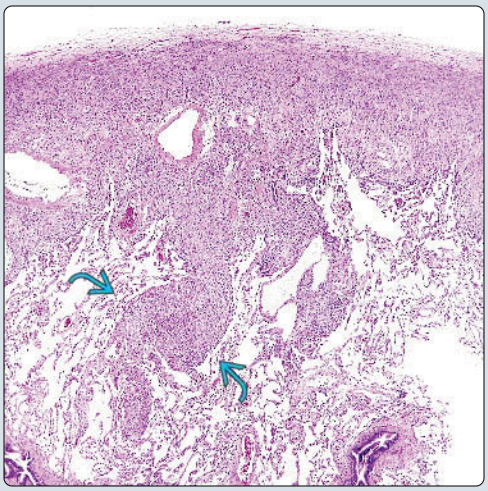

(Left) *Gross appearance of the lung in Erdheim-Chester disease shows thickened interlobular septa with dilatation of airspaces.* **(Right)** *Scanning magnification of a lung section involved with Erdheim-Chester disease shows massive thickening of the pleura by histiocytic infiltrate with characteristic "tongues" dipping into the underlying lung parenchyma.*

Widened Interlobular Septa

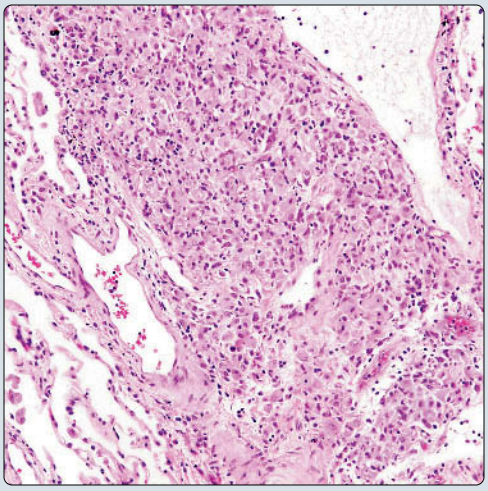

High Power, Erdheim-Chester Disease

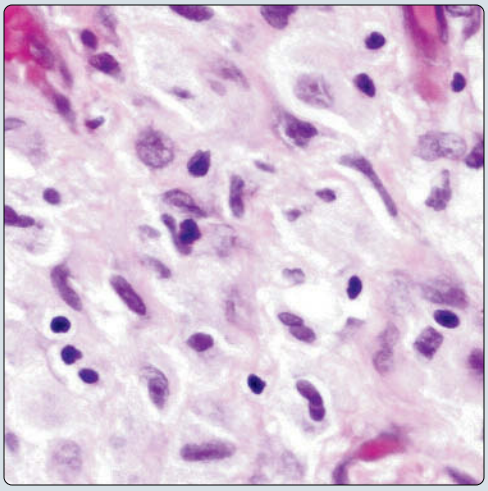

(Left) *Erdheim-Chester disease of the lung shows characteristic widening of the interlobular septa by diffuse infiltration of foamy histiocytes.* **(Right)** *Higher magnification of Erdheim-Chester disease of the lung shows bland-appearing histiocytic proliferation admixed with scattered small lymphocytes in a loose collagenous stroma.*

TERMINOLOGY

Synonyms

- Chester-Erdheim disease, lipoid granulomatosis

Definitions

- Rare histiocytic infiltrative disorder that most commonly affects bones but may affect other organs, including lung

ETIOLOGY/PATHOGENESIS

Etiology

- Unknown
- Has been proposed to be "macrophage counterpart" of Langerhans cell histiocytosis
- Study using HUMARA assay has demonstrated monoclonality in histiocytic cells in some cases

CLINICAL ISSUES

Epidemiology

- Age
  - 25-70 years of age

Site

- Bone involvement is most common manifestation
- Extraskeletal involvement is seen in 50% of patients, including lung and pleura, central nervous system, kidney, retroperitoneum, skin, heart, and pericardium

Presentation

- Dyspnea, fever, weight loss, and bone pain

Natural History

- Pulmonary involvement may precede skeletal manifestations in some cases, but eventually all patients develop skeletal manifestations
- Progressive disorder; morbidity and mortality depend on presence or absence of extraskeletal involvement

Prognosis

- ~ 60% of patients die due to respiratory failure

IMAGING

Radiographic Findings

- Characteristic radiographic finding is interstitial opacities with thickening of interlobular fissures and septa in lung
- Symmetrical osteosclerosis of diaphyses of long bones is classic finding that helps confirm diagnosis

CT Findings

- Interlobular septal thickening with areas of ground-glass attenuation and centrilobular, nodular opacities
- Pleural thickening and pleural or pericardial effusion

MICROSCOPIC

Histologic Features

- Diffuse infiltration of histiocytes along lymphatic routes, including pleura, septa, and perivascular and peribronchiolar interstitium
- Characteristic thickening of pleura that tracks into lung parenchyma along interlobular septa
- Histiocytic cell infiltrate is admixed with stromal fibrosis in varying degrees

Cytologic Features

- Histiocytes are generally small with round or oval nuclei and scant rim of cytoplasm
- Histiocytes may be accompanied by small lymphocytes, plasma cells, and eosinophils
- Absence of nuclear atypia, mitotic figures, or anaplasia
- Absence of osteoclastic giant cells or grooved, convoluted nuclei

ANCILLARY TESTS

Immunohistochemistry

- Histiocytes are positive for CD68 and factor XIIIa
- Scattered S100(+) cells may be identified
  - Stains for CD1a, CD45RB, and CD21 are negative

Electron Microscopy

- Cells show cytoplasmic phagolysosomes containing lipid
- No Birbeck granules are identified

DIFFERENTIAL DIAGNOSIS

Langerhans Cell Histiocytosis

- Histiocytic cells have oval nuclei with longitudinal grooves and nuclear convolutions
- Prominent eosinophilic infiltration is present admixed with histiocytic cells
- Osteoclastic giant cells are often present admixed with infiltrate
- Histiocytic cells are positive for CD1a and S100 protein
- Histiocytic cells contain distinctive organelles (Birbeck granules) on electron microscopy

Sinus Histiocytosis With Massive Lymphadenopathy (Rosai-Dorfman Disease)

- Histiocytic disorder of unknown etiology that can also involve lung
- Usually forms well-circumscribed lesions without pleural involvement or septal distribution
- Histiocytes are large with enlarged, vesicular nuclei and abundant cytoplasm
- Histiocytic cells are accompanied by abundant plasma cells, display prominent emperipolesis, and are strongly positive for S100 protein

SELECTED REFERENCES

1. Cives M et al: Erdheim-Chester disease: a systematic review. Crit Rev Oncol Hematol. 95(1):1-11, 2015
2. Arnaud L et al: Pulmonary involvement in Erdheim-Chester disease: a single-center study of thirty-four patients and a review of the literature. Arthritis Rheum. 62(11):3504-12, 2010
3. Bisceglia M et al: Erdheim-Chester disease: clinical and pathologic spectrum of four cases from the Arkadi M. Rywlin slide seminars. Adv Anat Pathol. 10(3):160-71, 2003
4. Chetritt J et al: Chester-Erdheim disease: a neoplastic disorder. Hum Pathol. 30(9):1093-6, 1999
5. Egan AJ et al: Erdheim-Chester disease: clinical, radiologic, and histopathologic findings in five patients with interstitial lung disease. Am J Surg Pathol. 23(1):17-26, 1999

Pleural Thickening in Erdheim-Chester

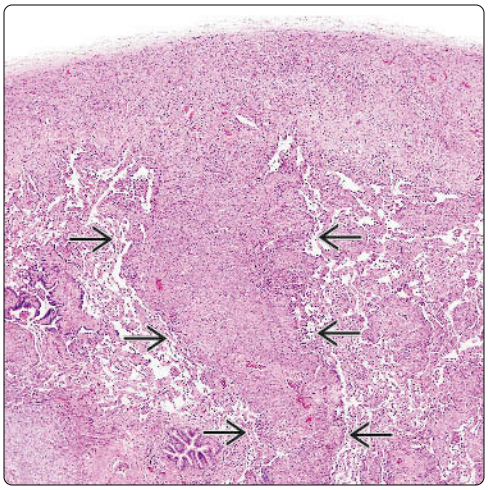

Pleural Involvement

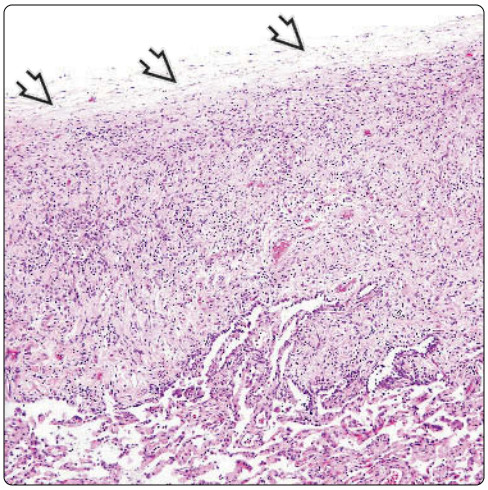

(Left) *Characteristic appearance of Erdheim-Chester disease of the lung shows a thickened pleura in continuity with a widened interlobular septa* ⇨ *containing a proliferation of histiocytes.* **(Right)** *Higher magnification of the pleura in pulmonary involvement by Erdheim-Chester disease shows dramatic widening* ⇨ *by a proliferation of small histiocytes. A few admixed small lymphocytes are also present against a mildly fibrotic stroma.*

Perivascular Infiltration

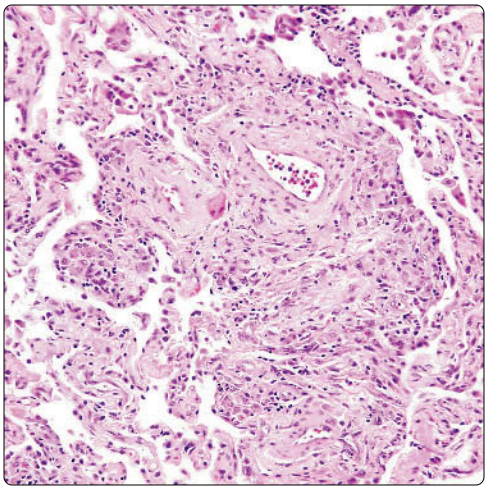

Erdheim-Chester, Higher Magnification

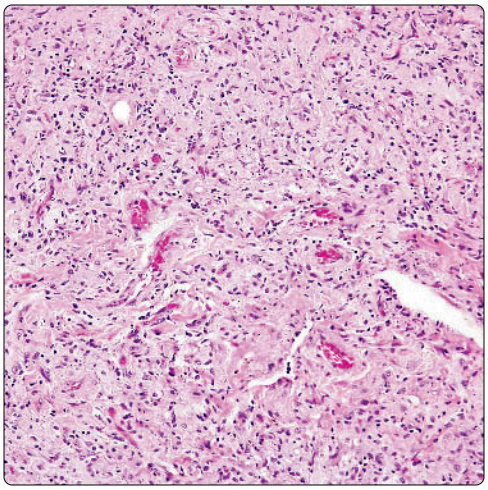

(Left) *Erdheim-Chester disease of the lung shows widening of the perivascular interstitium by the proliferation of small histiocytes admixed with variable degrees of stromal sclerosis.* **(Right)** *Higher magnification of lung infiltrate in a patient with Erdheim-Chester disease shows a mononuclear cell population primarily composed of histiocytes admixed with scattered small lymphocytes, plasma cells, and occasional eosinophils. The histiocytic infiltrate is accompanied by stromal fibrosis.*

Bland Histiocytic Cell Population

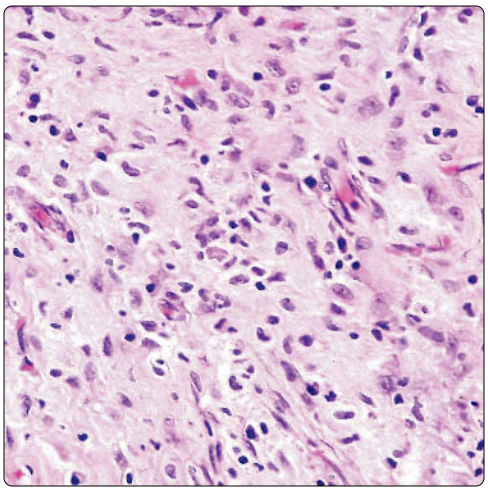

Higher Power View

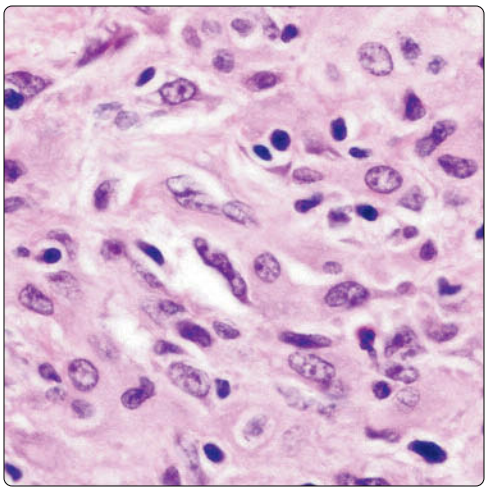

(Left) *Higher magnification of lung involvement in a patient with Erdheim-Chester disease shows a sparse population of small lymphocytes scattered between small histiocytes.* **(Right)** *Higher magnification of lung involved with Erdheim-Chester disease shows histiocytic proliferation characterized by round to oval nuclei surrounded by a scant rim of amphophilic to eosinophilic cytoplasm. A few rare cells can show multinucleation, but nuclear atypia and mitoses are not encountered.*

Pleural Widening in Erdheim-Chester

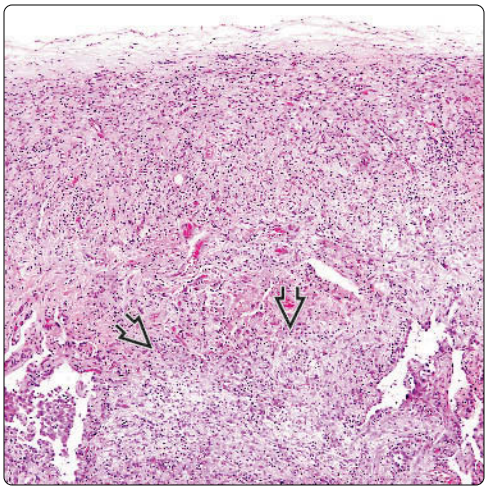

Bland Histiocytes in Erdheim-Chester

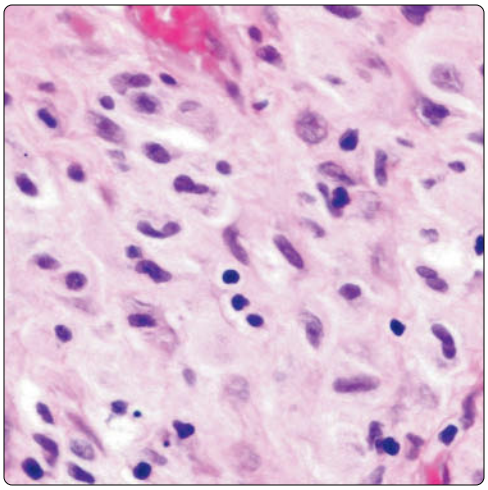

(Left) *Histologic appearance of Erdheim-Chester disease of the lung shows massive widening of the pleura by the proliferation of small, bland-appearing histiocytes that extend along the interlobular septa into the lung parenchyma* ⇨. **(Right)** *Higher magnification of Erdheim-Chester disease involving the lung shows a bland-appearing population of histiocytes admixed with a few scattered small lymphocytes. The histiocytes are singly scattered in a dense collagenous matrix.*

S100 Protein Immunopositivity

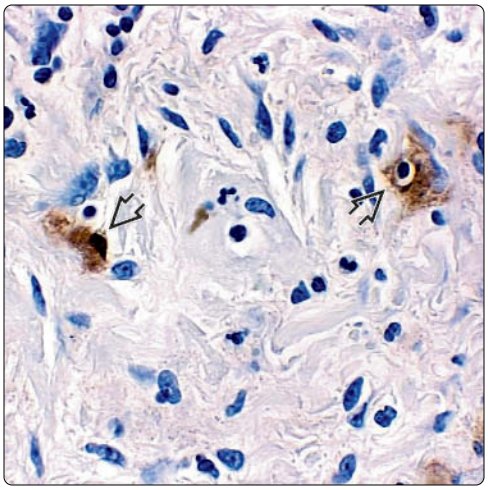

CD68(+) Immunostaining

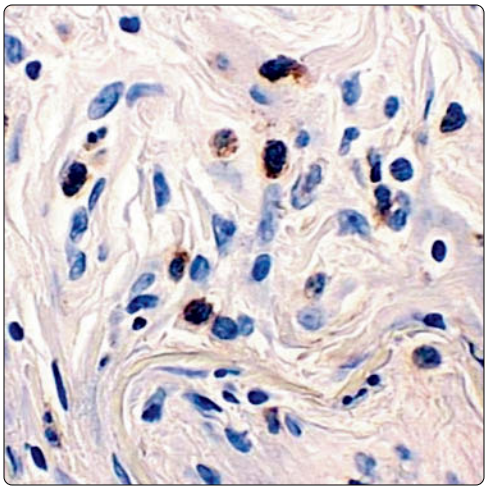

(Left) *Immunohistochemical staining of Erdheim-Chester disease with S100 protein shows a few cells* ⇨ *displaying nuclear and cytoplasmic positivity for this antigen.* **(Right)** *Immunohistochemical staining of Erdheim-Chester disease involving the lung for CD68 shows scattered small histiocytes that stain positive for this antibody. The cells are negative for CD1a antibodies and do not otherwise display the cytological or ultrastructural features of Langerhans cells.*

Chest CT Scan in Erdheim-Chester

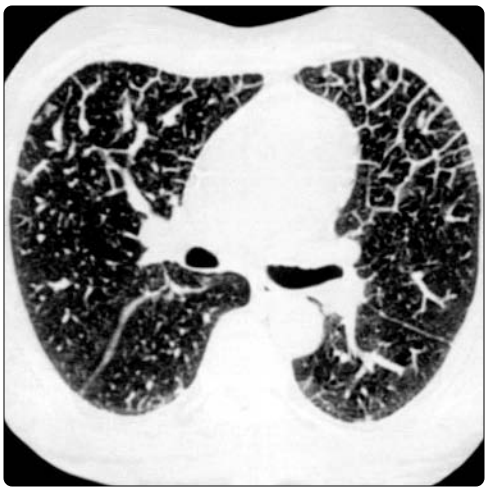

Symmetrical Osteosclerosis of Long Bones

(Left) *CT scan of the chest in a patient with Erdheim-Chester disease shows a typical radiographic image characterized by interlobular septal thickening with areas of ground-glass attenuation.* **(Right)** *Radiograph of the hand and forearm shows characteristic symmetrical osteosclerosis of the long bones. This radiographic appearance is typical for Erdheim-Chester disease and permits confirmation of the histologic diagnosis.*

Alveolar Microlithiasis

KEY FACTS

TERMINOLOGY

- Extensive deposition of microliths in alveolar spaces

ETIOLOGY/PATHOGENESIS

- Rare condition of unknown etiology
- Familial pattern has been observed in some cases
- Can occur at any age

CLINICAL ISSUES

- Decrease in respiratory performance
- No metabolic abnormalities
- No specific treatment
- Variable
- Protracted course
- Rapid course with respiratory failure and death
- No specific treatment

IMAGING

- Sandstorm pattern

MICROSCOPIC

- Intraalveolar deposition of spherical calcifications
- Each calcospherite measures about 250-750 µm
- Laminated bodies with onion skin features
- Chemical analysis shows calcospherites to be made of phosphorus and calcium

TOP DIFFERENTIAL DIAGNOSES

- Metastatic calcification (dendritic calcification)
  - Absence of calcospherites in intraalveolar spaces
- Corpora amylacea
  - Onion skin features of microlithiasis are not present in corpora amylacea
  - Corpora is usually not intraalveolar location

DIAGNOSTIC CHECKLIST

- Intraalveolar calcospherites with onion skin features

(Left) *Low-power view of alveolar microlithiasis shows the main bronchus ⇨ and adjacent bronchial glands not involved by the process ⇨.* **(Right)** *Pulmonary microlithiasis shows numerous calcospherites ⇨ in an intraalveolar location. This is the classic pattern of pulmonary alveolar microlithiasis.*

Uninvolved Airway

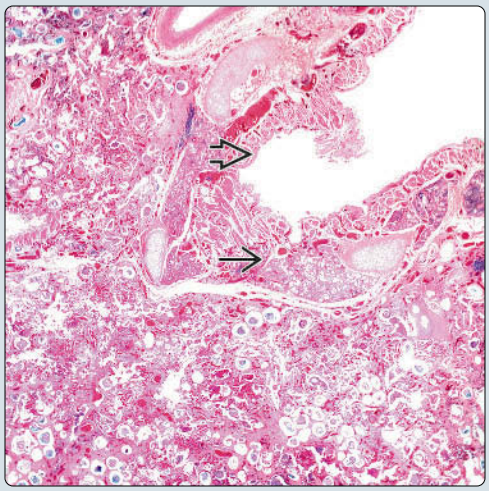

Alveolar Filling

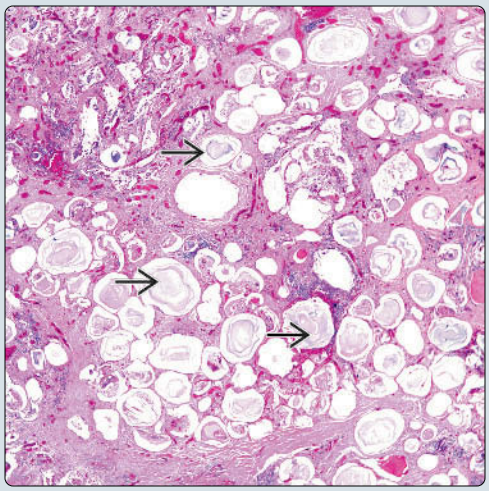

(Left) *Alveolar microlithiasis shows metaplastic bone formation ⇨. Note the presence of microliths filling alveolar spaces contrary to bone destroying lung parenchyma.* **(Right)** *Higher magnification of a microlith shows the typical morphological characteristics of an onion skin-like morphology.*

Metaplastic Bone

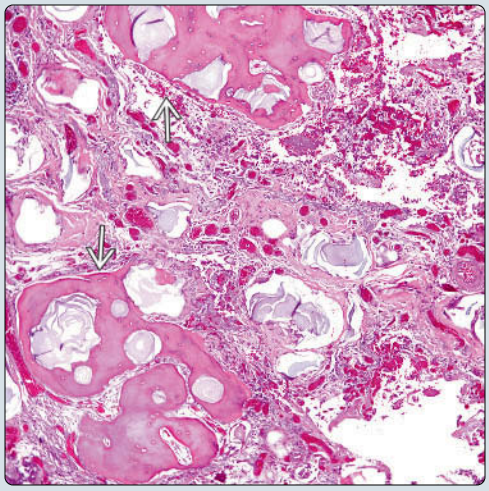

Microlith

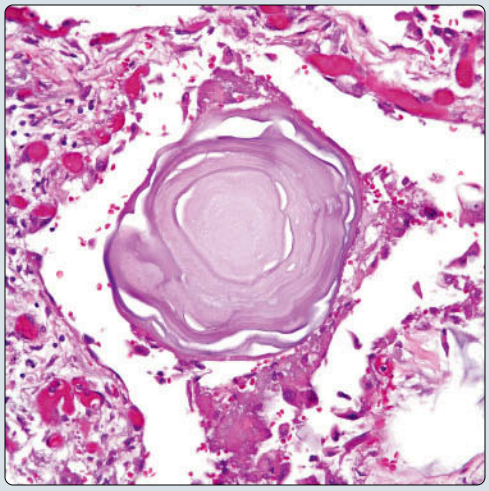

TERMINOLOGY

Synonyms

- Pulmonary microlithiasis

Definitions

- Extensive deposition of microliths in alveolar spaces

ETIOLOGY/PATHOGENESIS

Etiology

- Rare condition of unknown etiology
- Familial pattern has been observed in some cases

CLINICAL ISSUES

Presentation

- Cough
- Shortness of breath
- Malaise
- Fatigue
- Decrease in respiratory performance
- No metabolic abnormalities

Laboratory Tests

- Normal calcium and phosphates in serum
- No signs of hyperparathyroidism
- Decreased pulmonary function tests

Prognosis

- Variable
  - Protracted course
  - Rapid course with respiratory failure and death

IMAGING

General Features

- Sandstorm pattern

MACROSCOPIC

General Features

- Honeycomb changes in lung parenchyma

MICROSCOPIC

Histologic Features

- Intraalveolar deposition of spherical calcifications
- Each calcospherite measures about 250-750 µm
- Laminated bodies with onion skin features
- Interstitial fibrosis may be seen
- Areas of ossification may be present
- Minimal inflammatory reaction
- Chemical analysis shows calcospherites to be made of phosphorus and calcium

DIFFERENTIAL DIAGNOSIS

Metastatic Calcification (Dendritic Calcification)

- Calcification follows alveolar wall and interstitium
- Absence of calcospherites in intraalveolar spaces
- Generally, there is history of underlying condition but not with microlithiasis
- Chemical analysis of metastatic calcification and that of microlithiasis is different

Corpora Amylacea

- Less extensive distribution than microlithiasis
- Onion skin features of microlithiasis are not present in corpora amylacea
- Overall, presence of corpora amylacea is haphazard and commonly involves interstitium
- Presence of corpora amylacea may be seen in otherwise normal lung
- Chemical analysis of corpora amylacea is different

DIAGNOSTIC CHECKLIST

Pathologic Interpretation Pearls

- Intraalveolar calcospherites with onion skin features

SELECTED REFERENCES

1. Castellana G et al: Pulmonary alveolar microlithiasis: review of the 1022 cases reported worldwide. Eur Respir Rev. 24(138):607-20, 2015
2. Moran CA et al: Pulmonary alveolar microlithiasis. A clinicopathologic and chemical analysis of seven cases. Arch Pathol Lab Med. 121(6):607-11, 1997

Histochemical Features

Stain	Result
PAS	Negative
D-PAS	Negative
Mucicarmine	Negative
Iron	May show positive staining in some microliths
Von Kossa	Positive in microliths
Chemical Analysis*	
Calcium	High in chemical analysis
Phosphorus	High in chemical analysis

%HVW SURFHGXUH WR GHWHUPLQH WKH FRPSRVLWLRQ RI WKH PLFURROLWKV

Honeycomb Appearance

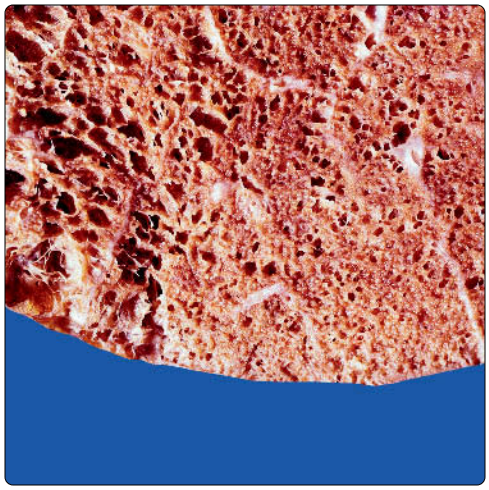

Uninvolved Bronchial Glands

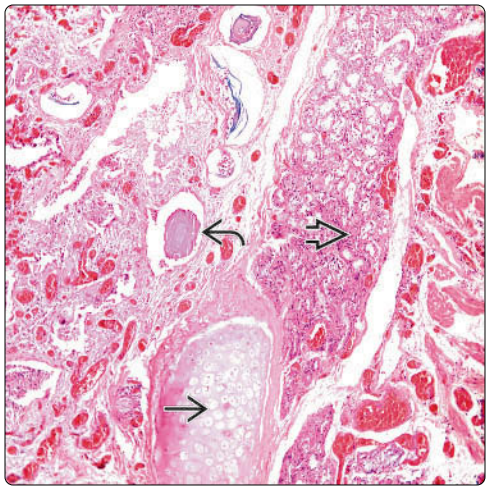

(Left) *Portion of lung shows a honeycomb appearance. Although this is not the classic pattern of alveolar microlithiasis, it may be seen in some advanced cases. Similar features may be seen in cases of pulmonary fibrosis.* **(Right)** *Low-power view of the bronchial wall shows the bronchial cartilage and endobronchial glands not involved by the process, which is essentially an intraalveolar process. Thus, bronchial biopsies will rarely be diagnostic of this process.*

Prominent Vasculature

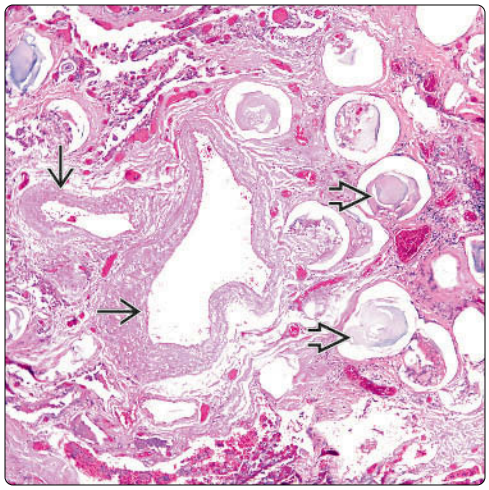

Focal Interstitial Fibrosis

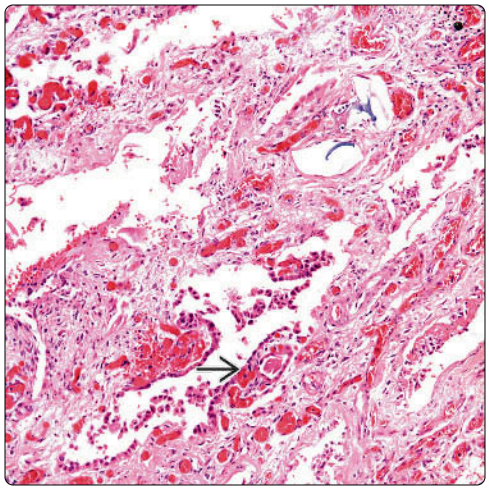

(Left) *Lung parenchyma shows prominent dilated vascular structures not involved by the process. Adjacent alveolar structures are filled with microliths. This is the classic pattern of distribution of this unusual process.* **(Right)** *Uninvolved lung parenchyma shows areas of fibrosis with only remnants of epithelial lining. No microliths are present. Even in resected material, skip areas of uninvolved lung parenchyma will be present.*

Inflammatory Changes

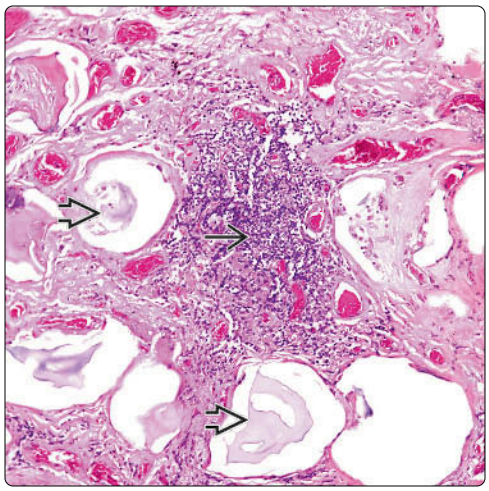

Ossification

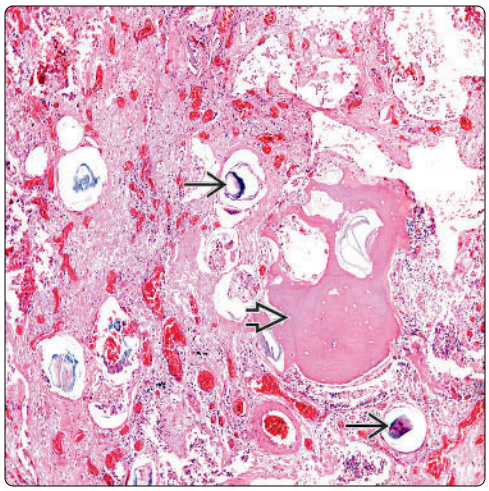

(Left) *Alveolar microlithiasis shows areas of fibrosis with chronic inflammation. Adjacent alveolar structures are filled with microliths. The microliths do not show the classic structural features and may be confused with foreign material.* **(Right)** *A common finding in alveolar microlithiasis is the presence of ossification. Note the difference between the 2 processes. In the ossified component, one can still see bone rims.*

Degenerated Microliths

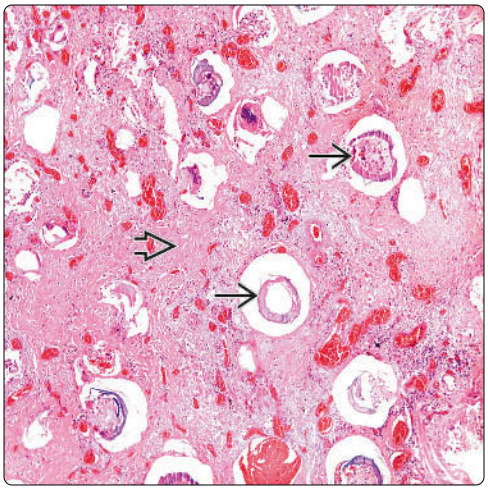

Numerous Microliths

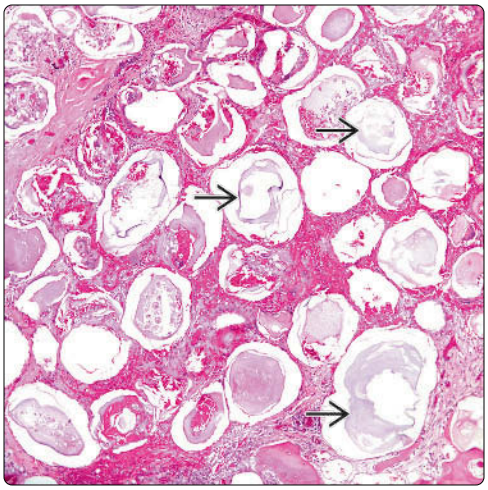

(Left) *Alveolar microlithiasis shows degenerated microliths ⇨. Extensive fibrosis of the lung parenchyma is also present ⇨. This pattern may suggest a fibrotic lung disease with foreign material.* **(Right)** *Alveolar microlithiasis shows numerous microliths with a more cartilaginous appearance ⇨. The morphological features of the microliths are different from the classic ones showing the onion skin features.*

Microliths and Interstitial Fibrosis

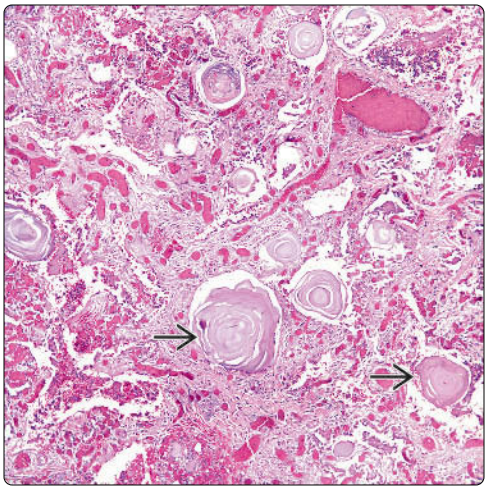

Onion Skin-Like Appearance

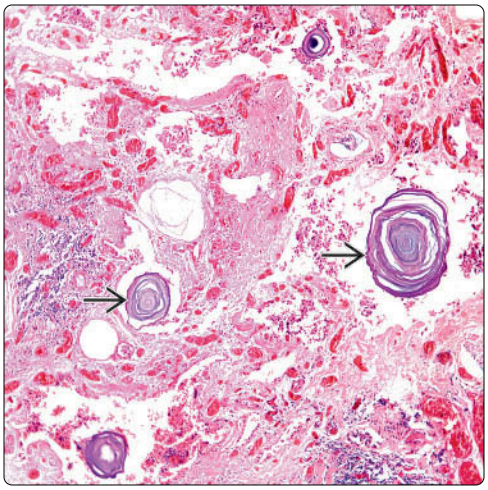

(Left) *Low-power view of alveolar microlithiasis shows only a few microliths ⇨ embedded in a predominantly fibrotic lung parenchyma. Although the number of microliths is not prominent, their morphology is classic and diagnostic of alveolar microlithiasis.* **(Right)** *Typical appearance of microliths in alveolar microlithiasis shows the classic onion skin changes ⇨. Even though they are not numerous, they are diagnostic.*

Degenerative Changes

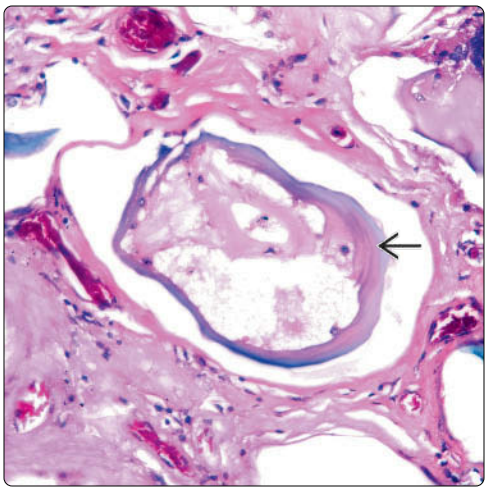

Classic Microlith

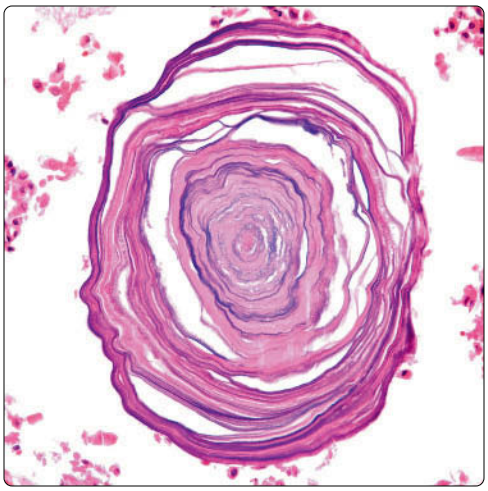

(Left) *High-power view of a microlith shows degenerative changes in which the structure has only a thin rim of calcification ⇨. The onion skin pattern is not present. These degenerative changes in the microliths may be related to the long course of the process.* **(Right)** *High-power view of a microlith in alveolar microlithiasis shows the onion skin changes of this structure. This morphological appearance is classic and diagnostic of alveolar microlithiasis.*

This page intentionally left blank

PART I
SECTION 5

Parasitic Disorders

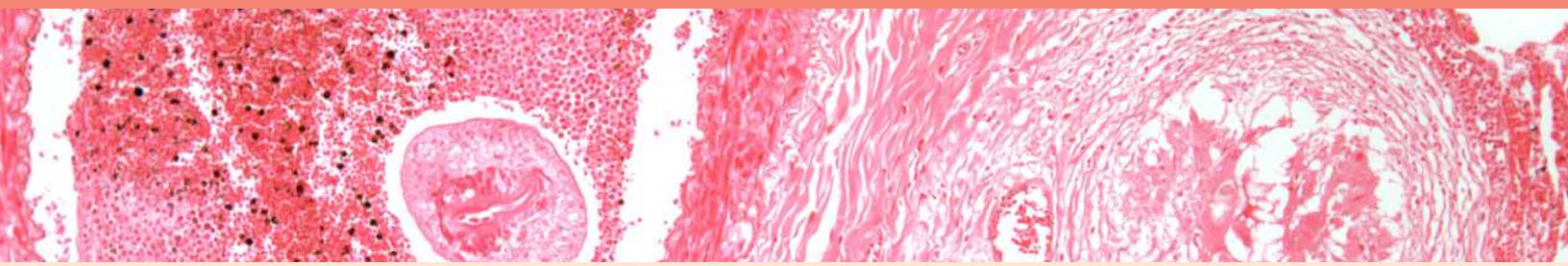

Strongyloidiasis	**470**
Dirofilariasis	**474**
Schistosomiasis	**478**
Echinococcosis (Hydatid Cyst)	**482**
Paragonimiasis	**486**

Strongyloidiasis

KEY FACTS

TERMINOLOGY

- Synonyms
  - Cochin China diarrhea, thread worm infection
- Definition
  - Parasitic infection caused by nematode

ETIOLOGY/PATHOGENESIS

- 3 cycles of infection
  - Direct
  - Indirect
  - Autoinfection

CLINICAL ISSUES

- Epidemiology
  - Worldwide distribution
  - More common in tropical countries
  - High in conditions that promote fecal contamination
- Symptoms
  - Urticaria
  - Cough
  - Dyspnea
  - Hemoptysis
  - Bronchopneumonia
  - Intermittent diarrhea
- Laboratory tests
  - Eosinophilia
  - Leukocytosis
  - Feces study is important in diagnosis
  - Enzyme-linked immunosorbent assays for IgG antibodies to antigens of larvae of 6 W U R Q J \ O R L G H V

MICROSCOPIC

- Inflammatory reaction with prominent eosinophils
- Suppurative exudate
- Presence of larvae
- Presence of adult worm

Aspirate With Larva

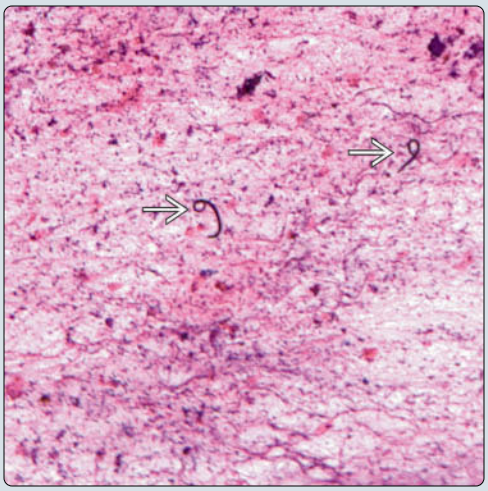

Solitary Larva

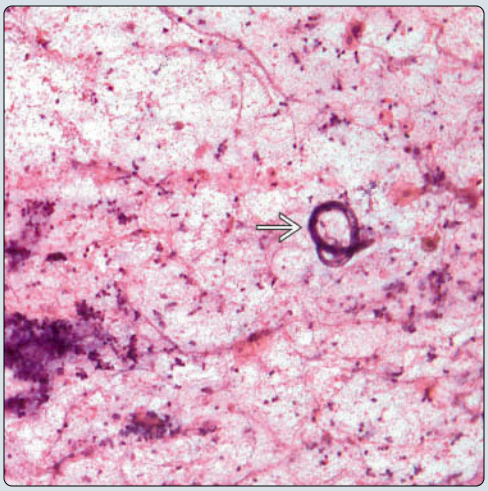

(Left) *Pulmonary aspirate shows the presence of several larvae of strongyloidiasis in a necrotic background. Some strings of fibroconnective tissue may be confused with larvae.* **(Right)** *Pulmonary aspirate shows the presence of a solitary larva of strongyloides accompanied by several exfoliated epithelial cells in a fibrinous background.*

Airway With Parasite

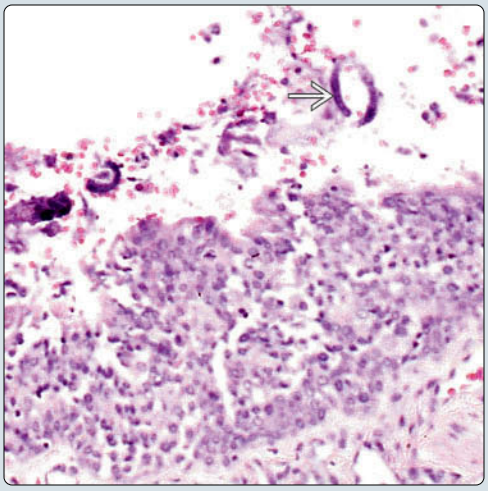

Larva of *Strongyloides*

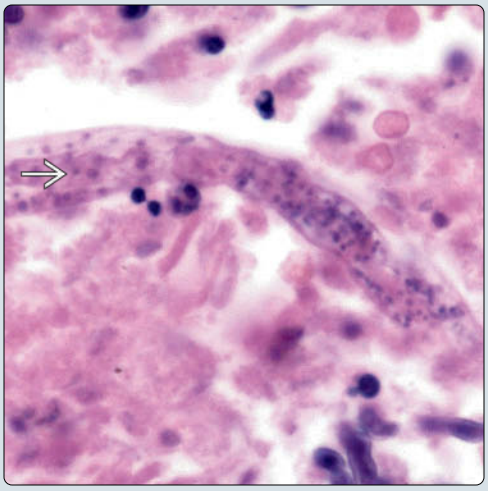

(Left) *Low-power view of a pulmonary airway shows respiratory epithelium with inflammatory changes and focal necrosis. Even at this power, it is possible to identify some filariform larvae.* **(Right)** *High-power view shows rhabditiform larvae of Strongyloides admixed with necrosis. The rhabditiform larva is most commonly encountered on histological examinations.*

TERMINOLOGY

Synonyms

- Cochin China diarrhea, thread worm infection

Definitions

- Parasitic infection caused by nematode

ETIOLOGY/PATHOGENESIS

Infectious Agents

- 6WURQJ\ORLGHV VWHUFRUDOLV

3 Cycles of Infection

- Direct
  - Filariform larvae penetrate skin
    - Cutaneous phase may last few days
- Indirect
  - Rhabditiform larvae mature into free-living males and females in soil
- Autoinfection
  - Rhabditiform larvae become infective filariform larvae in intestine or skin of host

CLINICAL ISSUES

Epidemiology

- Incidence
  - Worldwide distribution
  - More common in tropical countries
  - High in conditions that promote fecal contamination
- Age
  - Affects any age group
- Sex
  - Infection may be more common in males
- Ethnicity
  - No ethnic predisposition

Presentation

- Skin itching
- Urticaria
- Low-grade fever
- Cough
- Dyspnea
- Hemoptysis
- Bronchopneumonia
- Intermittent diarrhea
- Constipation
- Anemia
- Asymptomatic

MICROSCOPIC

Histologic Features

- Inflammatory reaction with prominent eosinophils
- Suppurative exudate
- Presence of larvae
- Presence of adult worm

DIFFERENTIAL DIAGNOSIS

Parasitic Infections

- Hookworm
- Ascariasis
  - Morphology and size of those parasites are different from 6WURQJ\ORLGHV

Bronchopneumonia

- Even though there may be inflammatory component, bacterial pneumonia will lack presence of larvae

Dirofilaria immitis

- 'LURILODULD is larger parasite
- Dirofilaria generally form necrotic tumor nodules
- Presence of larvae would be more in keeping with 6WURQJ\ORLGHV

SELECTED REFERENCES

1. Ostera G et al: Strongyloidiasis: Risk and healthcare access for Latin American immigrants living in the united states. Curr Trop Med Rep. 3:1-3, 2016
2. Toledo R et al: Strongyloidiasis with emphasis on human infections and its different clinical forms. Adv Parasitol. 88:165-241, 2015

Diagnostic Methods for Identification of Strongyloidiasis

Method	Result
Fresh stools	Identification of larvae or adult worm
Tissue biopsy	Identification of larvae or adult worm
Aspirates	Identification of larvae
Enzyme-linked immunosorbent assays for IgG antibodies	May be elevated

Histochemical Features

Stain	Result
Hematoxylin & eosin	Identifies larvae and adult worm
Movat	Accentuates outlines of adult worm
Giemsa	Identifies larvae
Papanicolaou stain	Identifies larvae

Ill-Defined Granuloma

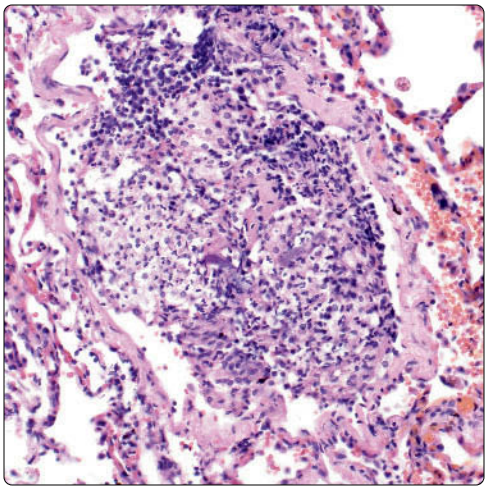

Lung Parenchyma With Larva

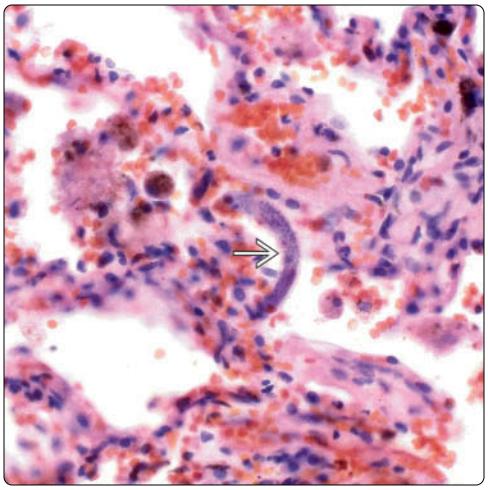

(Left) *Pulmonary parenchyma shows focal areas of an ill-defined granulomatous reaction. Such a finding is unusual in cases of strongyloidiasis.* **(Right)** *Pulmonary parenchyma shows a rhabditiform larva of Strongyloides. Note the absence of reactive changes in the adjacent lung parenchyma. In some cases, the parasites are not numerous and are difficult to identify.*

Eggs of *Strongyloides*

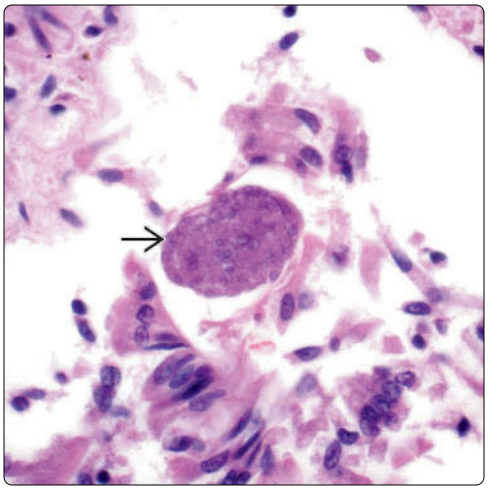

Larva in Fibrinous Exudate

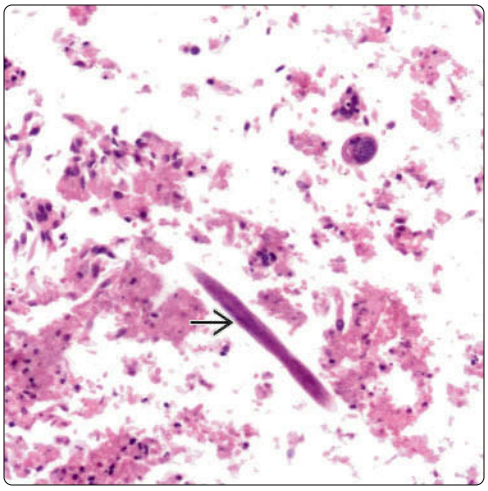

(Left) *High power shows Strongyloides eggs admixed with epithelial cells most likely exfoliated from the bronchial respiratory epithelium. Once again, the reaction is not marked.* **(Right)** *A single rhabditiform larva of Strongyloides is present. In this particular case, there is an associated inflammatory reaction with some destruction of the normal lung architecture.*

Aspiration Cytology

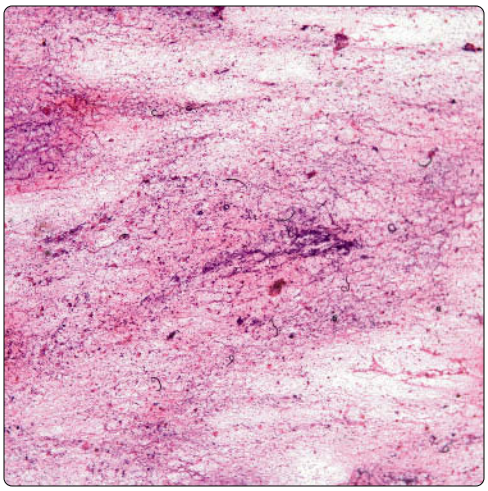

Aspiration Cytology

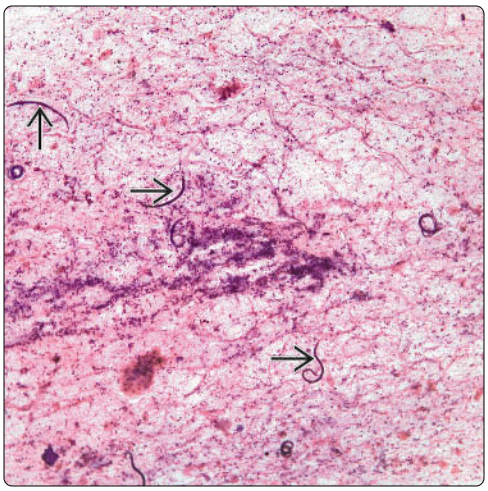

(Left) *The diagnosis of pulmonary strongyloidiasis can also be accomplished by aspiration cytology. This aspiration depicts the presence of inflammatory cells and numerous Strongyloides forms, difficult to visualize at this power.* **(Right)** *On higher magnification, the presence of filariform larvae of Strongyloides is easily detected, and they are admixed with epithelial and inflammatory cells.*

Larva of *Strongyloides*

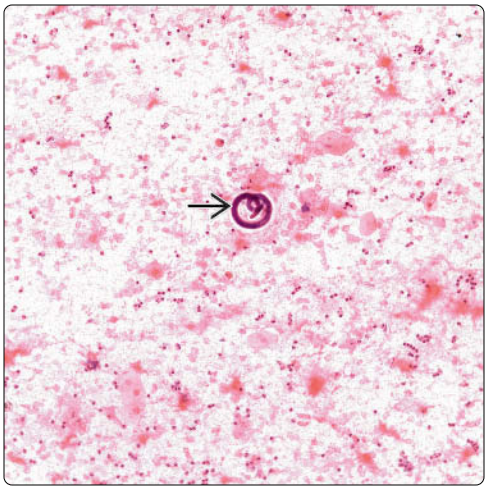

Strongyloides

(Left) *Pulmonary aspirate shows numerous cellular debris admixed with blood and a single rhabditiform larva of Strongyloides, which is enough to establish a diagnosis of pulmonary infection.* **(Right)** *High-power magnification shows a filariform larva of Strongyloides. Similar features may be seen in filarial diseases. Note the absence of a prominent inflammatory reaction in this lung aspirate.*

Intestinal Mucosa With Parasite

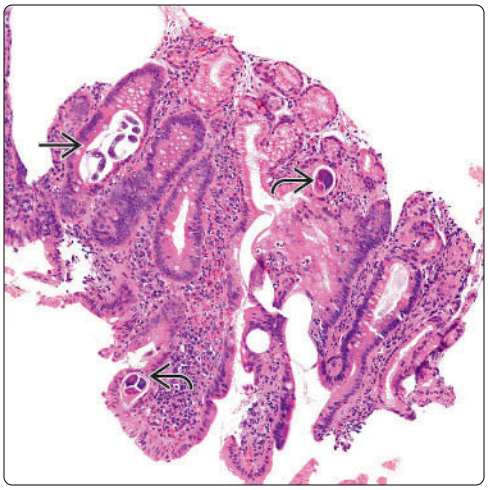

Numerous Parasites in Intestine

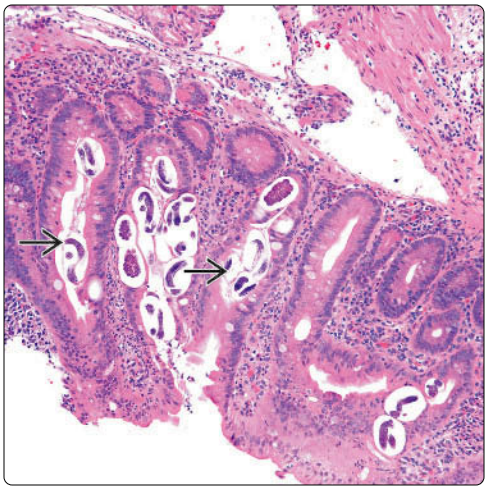

(Left) *Low-power magnification shows a duodenal biopsy in which the glands are filled with numerous filariform larvae of Strongyloides. Also note the presence of adult parasites.* **(Right)** *In this high magnification, the glandular component of the duodenum is filled with numerous filariform larvae of Strongyloides, similar to those encountered in the lung parenchyma.*

Larvae of *Strongyloides*

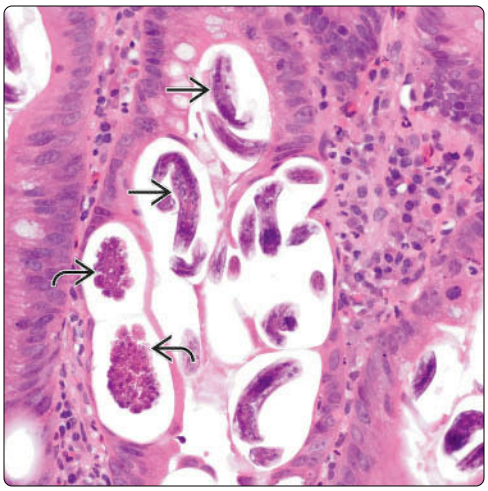

Adult Parasite



(Left) *High-power view shows numerous rhabditiform larvae of Strongyloides. Also note the presence of eggs of Strongyloides.* **(Right)** *High-power view shows an adult Strongyloides. This finding appears to be more commonly seen in intestinal biopsies than in pulmonary infection.*

Dirofilariasis

KEY FACTS

ETIOLOGY/PATHOGENESIS

- Caused by 'LURILODULD LPPLWLV
- Dirofilariasisis more common in dogs
- Humans are accidental hosts

CLINICAL ISSUES

- Uncommon infectious condition
- Can occur at any age, and infection has been described in children and adults
  - More common in adults
- May be more common in males than in females
- As it occurs in dogs, worms lodge in heart but die before reaching maturity
- Worms pass into pulmonary arteries
- Peripheral lung lesions are by far more common
- Clinical presentation
  - Cough
  - Dyspnea
  - Wheezing
  - Chest pain
  - Fever
- Laboratory findings
  - Eosinophilia may be present in 10-15% of patients
- Treatment
  - Complete surgical resection is curative

MICROSCOPIC

- Histological features
  - Well-demarcated necrotic nodule
  - Intravascular presence of nonviable worms
  - Worms may be present in necrotic tissue and not in vessels
  - Prominent inflammatory reaction
  - Nonnecrotizing granulomas may be present

Necrotic Nodule | **Parasite and Necrosis**

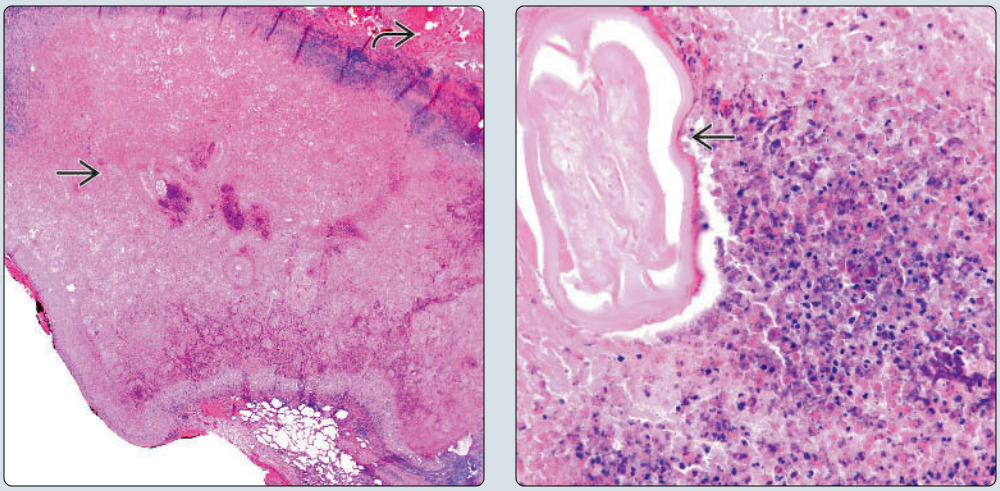

(Left) *Low-power view of a necrotic pulmonary nodule shows that the nodule is well demarcated and destroys normal lung parenchyma. A little rim of normal lung parenchyma is still present.* **(Right)** *High-power view of a nonviable worm typical of dirofilariasis is present. The worm is embedded in necrotic material, which makes it difficult to identify.*

Parasites | **Elastic Stain Highlighting Parasite**

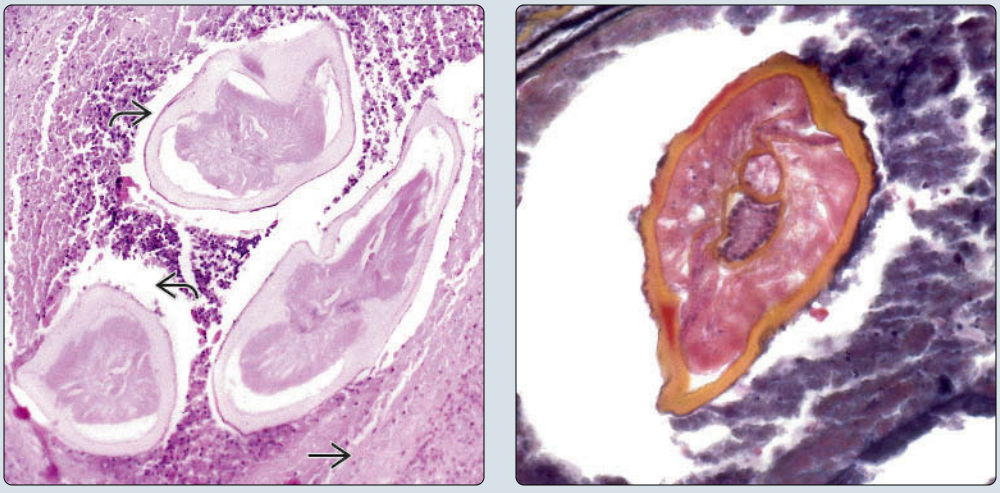

(Left) *Pulmonary dirofilariasis shows the classic pulmonary nodule with extensive necrosis and the presence of several worms typical of Dirofilaria immitis. Even with the conventional stain, it is possible to distinguish the elastic of the pulmonary vessel.* **(Right)** *High-power view of an elastic histochemical stain highlights the presence of Dirofilaria immitis. Note the thick cuticle and the presence of internal organs, which are easier to identify with the Movat stain.*

Necrotic Nodule

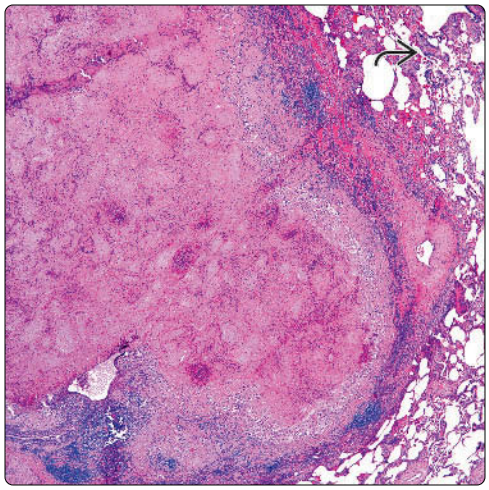

Squamous Metaplasia

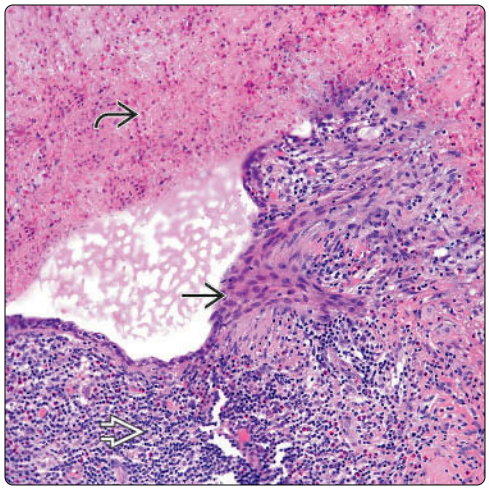

(Left) *Low-power view of a well-demarcated pulmonary nodule shows destruction of normal lung parenchyma. The nodule shows extensive necrosis with a rim of normal lung parenchyma.* **(Right)** *Necrotic pulmonary nodule replacing lung parenchyma also shows focal areas of squamous metaplastic changes accompanied by an inflammatory reaction.*

Giant Cells

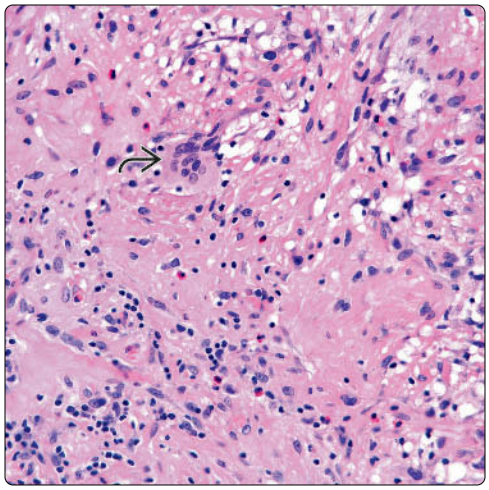

Eosinophilic Inflammatory Response

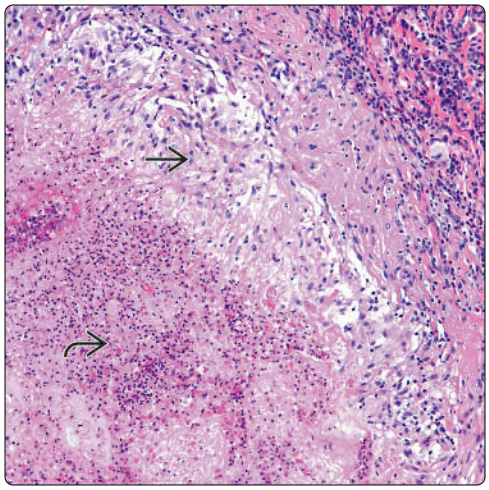

(Left) *High-power view of the peripheral aspect of the necrotic pulmonary nodule shows histiocytic reaction and the presence of multinucleated giant cells. Such features may be seen in other infectious conditions.* **(Right)** *Intermediate-power view shows the interface between areas of necrosis with prominent eosinophilic inflammatory reaction and areas of a histiocytic reaction. These features also suggest the possibility of another pulmonary infection.*

Extensive Necrosis

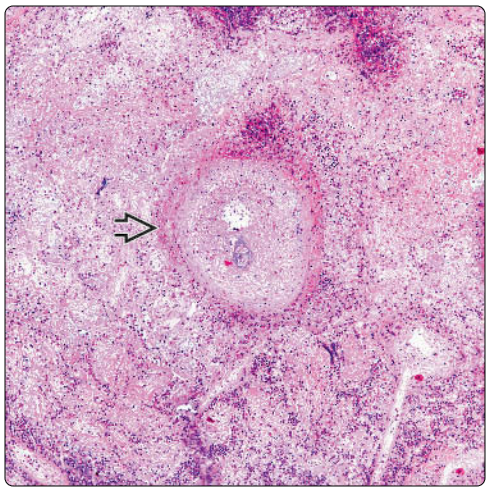

Parasite in Necrotic Background

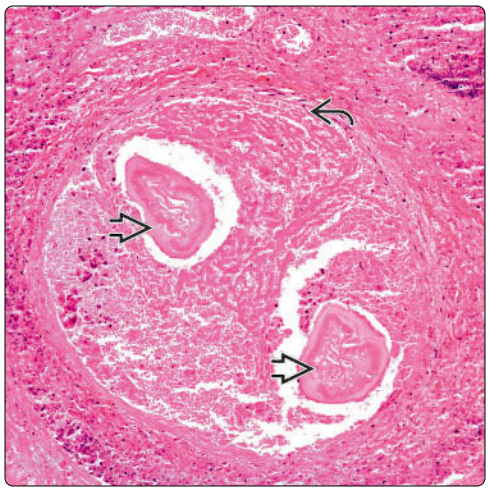

(Left) *Pulmonary dirofilariasis shows a nodule with extensive necrosis and inflammatory reaction. Note the presence, even with the conventional stain, of an obstructed pulmonary vessel.* **(Right)** *Two worms of Dirofilaria are present embedded in a necrotic background. Still, the outlines of a pulmonary vessel can be recognized. This is a typical presentation of Dirofilaria.*

Single Parasite in Necrotic Nodule

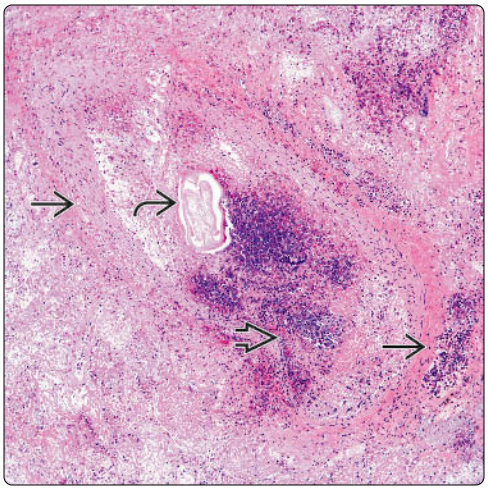

Large Pulmonary Vessel and Parasite

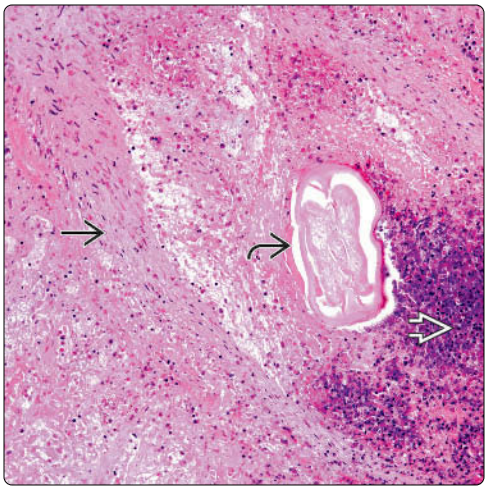

(Left) *Pulmonary dirofilariasis shows the classic pulmonary nodule with extensive necrosis. Note the outline of the pulmonary vessel ⇨, which is filled with necrotic material ⇨, and in the center, the presence of Dirofilaria immitis ⇨.* **(Right)** *High-power magnification shows the parasite of Dirofilaria immitis ⇨ embedded in necrotic material ➡ and within a large pulmonary vessel ⇨. The salient feature of Dirofilaria immitis here is the presence of a thick cuticle.*

Two Distinct Parasites

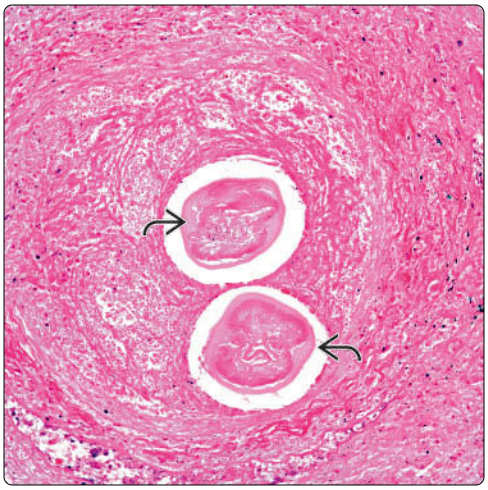

Movat Stain Highlights Parasites

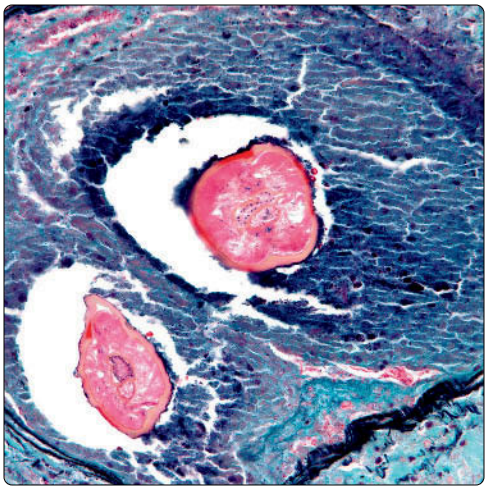

(Left) *In some cases, the presence of Dirofilaria is more obvious as in this low-power view of 2 worms ⇨ that have a targetoid appearance.* **(Right)** *In some cases, the use of other histochemical stains, such as Movat, are important in highlighting the worms and distinguishing their internal organs.*

Elastic Stain Highlights Parasites

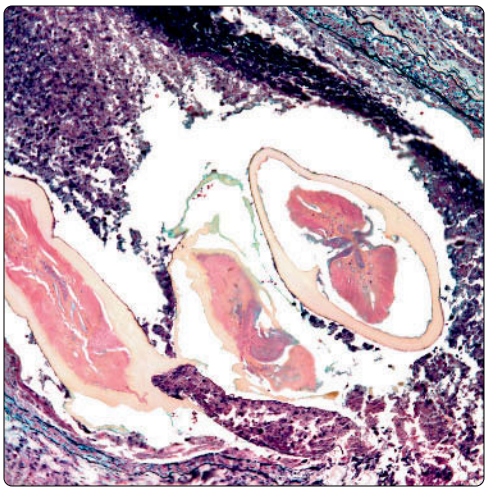

Organizing Pneumonia

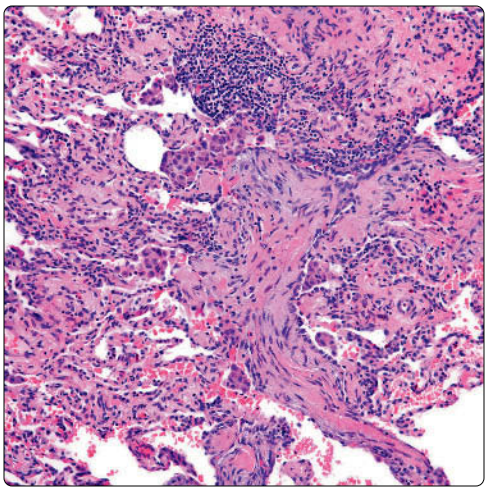

(Left) *Another histochemical stain that may be useful in the identification of the parasites, mainly when there is a lot of necrotic material, is an elastic stain, which not only highlights the parasite but also the remains of the affected vessel.* **(Right)** *Adjacent lung parenchyma in cases of dirofilariasis may show different features, including organizing pneumonia, as it is depicted in this case. Other features may also include nonnecrotizing lung nodules.*

Schistosomiasis

KEY FACTS

TERMINOLOGY

- Synonym
  - Bilharziasis
- Definition
  - Infection caused by Trematoda (flukes)

ETIOLOGY/PATHOGENESIS

- 3 most common types that affect humans are
  - 6 F K L V W R V R P D K (Urinary tract)
  - 6 F K L V W R V R P D (Intestinal tract)
  - 6 F K L V W R V R P D (Intestinal tract)
- Pathogenesis
  - Snails are intermediate host
  - 6 F K L V W R V R P D via portal-systemic collateral veins to lung

CLINICAL ISSUES

- Acute phase
- Chronic phase
- Laboratory findings
  - Eosinophilia
  - Possible false-positive HIV test
- Treatment
  - Good if treated early and patient not immunocompromised
  - Can be fatal in some cases

MICROSCOPIC

- Granulomatous inflammation
- Presence of 6 F K L V W R V R P D

TOP DIFFERENTIAL DIAGNOSES

- Fungal granulomatous infection
- Pulmonary tuberculosis
- Pulmonary hypertension
- Bacterial bronchopneumonia

Granulomatous Inflammation

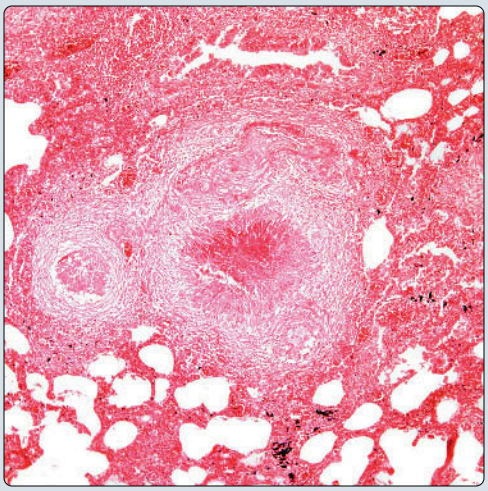

Thickening of Vasculature

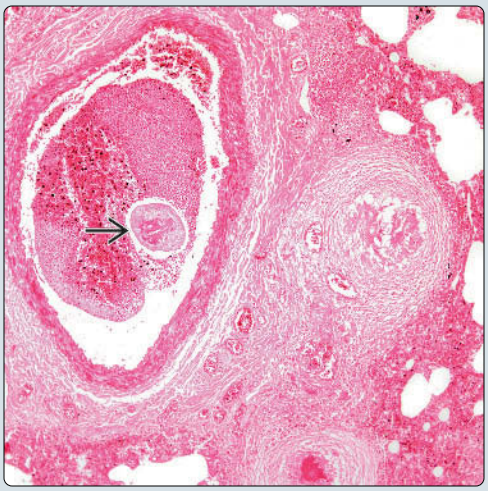

***(Left)** Lung parenchyma with an easily identifiable granulomatous reaction shows that the center of the granulomas contain necrosis and hemorrhage. These changes can be seen in other infections as well. **(Right)** In other portions of the lung parenchyma, the vessels are dilated, containing blood and, in some cases, schistosomes, as in this case where the parasite ⇨ is admixed with blood within the vessel.*

Necrotic Granuloma

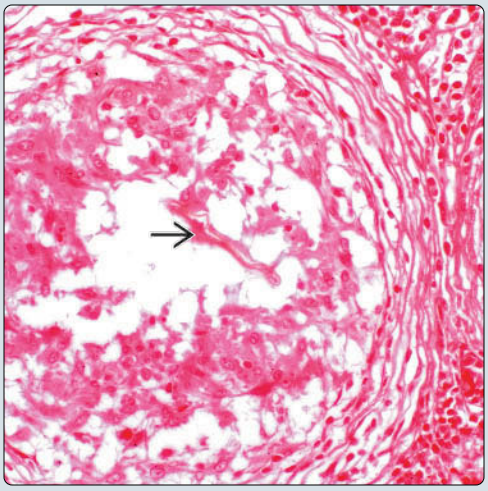

Schistosoma With Necrosis

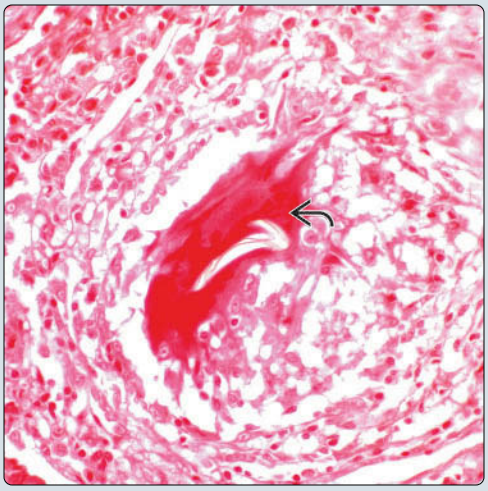

***(Left)** High-power view of the central necrosis of the granulomatous reaction shows the outlines of Schistosoma ⇨. This organism can be easily missed in a cursory review. **(Right)** Higher magnification shows a not so well-preserved Schistosoma ⇨ embedded in a central area of necrosis. Schistosoma is not well preserved in the lungs, in contrast to other organs, which can make identification difficult.*

TERMINOLOGY

Synonyms

- Bilharziasis

Definitions

- Infection caused by Trematoda (flukes)

ETIOLOGY/PATHOGENESIS

Infectious Agents

- 3 most common types affecting humans are
  - 6 F K L V W R V R P D K D H P D W R E L X P (urinary tract)
  - 6 F K L V W R V R P D P D Q V R Q L (intestinal tract)
  - 6 F K L V W R V R P D M D S R Q L F X P (intestinal tract)
    - Snails are intermediate host

Pathogenesis in Pulmonary Schistosomiasis

- 6 F K L V W R V R P D eggs travel via portal-systemic collateral veins to lung

CLINICAL ISSUES

Presentation

- Acute phase
  - Fever
  - Cough
  - Asthma-like symptoms
  - Urticaria
  - Diarrhea
  - Hepatomegaly
  - Splenomegaly
  - Lymphadenopathy
- Chronic phase
  - Acute symptoms subside over period of weeks
  - Patients may be asymptomatic

Prognosis

- Good if treated early and patients not immunocompromised
- Can follow aggressive course in immunocompromised individuals

MICROSCOPIC

Histologic Features

- Granulomatous reaction
- Granulomatous endarteritis
- Thickening of pulmonary vasculature
- 6 F K L V W R V R P D eggs deposited in arterioles
- Acute inflammatory reaction

DIFFERENTIAL DIAGNOSIS

Fungal Granulomatous Infection

- Presence of fungal organisms demonstrated by fungal stains
- Fungal organisms present within granulomatous reaction
- Unusual for fungal infection to show organisms only within vessels

Pulmonary Tuberculosis

- Histochemical stains for acid-fast bacilli aid identification of bacilli
- Thickening of pulmonary vasculature is unusual
- Acid-fast bacilli are distributed haphazardly rather than in pulmonary vessels

Pulmonary Hypertension

- As in schistosomiasis, thickening of pulmonary vasculature is feature of pulmonary hypertension
  - However, 6 F K L V W R V R P D eggs are absent

DIAGNOSTIC CHECKLIST

Clinically Relevant Pathologic Features

- Symptom complex
  - Pulmonary hypertension
  - Hepatosplenomegaly

Pathologic Interpretation Pearls

- Granulomatous endarteritis
- Presence of 6 F K L V W R V R P D eggs in vessels is of utmost importance

SELECTED REFERENCES

1. Weerakoon KG et al: Advances in the diagnosis of human schistosomiasis. Clin Microbiol Rev. 28(4):939-67, 2015
2. Papamatheakis DG et al: Schistosomiasis-associated pulmonary hypertension. Pulm Circ. 4(4):596-611, 2014
3. Graham BB et al: Schistosomiasis-associated pulmonary hypertension: pulmonary vascular disease: the global perspective. Chest. 137(6 Suppl):20S-29S, 2010

Diagnostic Aids

Study	Description	Result
Stool examination	Fresh stools	Identification of 6 F K L V W R V R P D eggs
Urine test	Fresh urine	Identification of 6 F K L V W R V R P D eggs
Kato method	Quantification of eggs in fresh stools	Identification of 6 F K L V W R V R P D eggs
Tissue biopsy	Tissue of gastrointestinal, genitourinary, or pulmonary tract	Identification of 6 F K L V W R V R P D eggs
Hematoxylin & eosin stain	From any tissue	Identification of 6 F K L V W R V R P D eggs
Ziehl-Neelsen stain	Shells and spines of 6 F K L V W R V R P D eggs are acid-fast	Helps highlight 6 F K L V W R V R P D eggs

Granulomatous Reaction

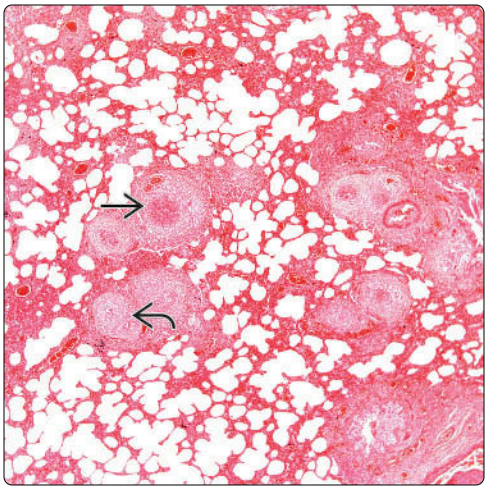

Necrotizing Granulomas

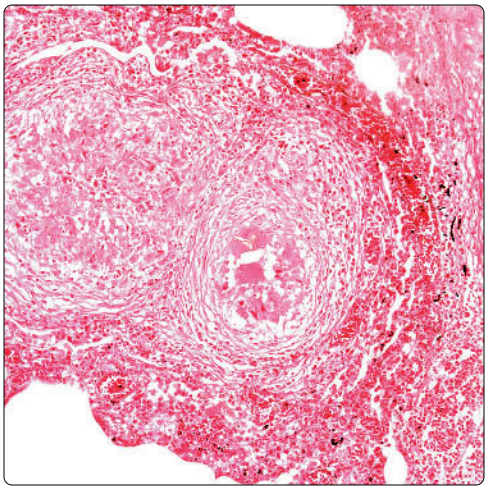

(Left) *Low-power view of a section of lung shows a florid granulomatous reaction. Note that part of the granulomatous area has central necrosis ⇨ while other areas do not contain caseous material ⇨. Remaining portions of lung are within normal limits.* **(Right)** *Higher magnification of the granulomatous reactions shows central necrosis, and it is in these areas that the parasite will most likely be identifiable. However, similar features may also be seen in other infections.*

Nonnecrotizing Granulomas

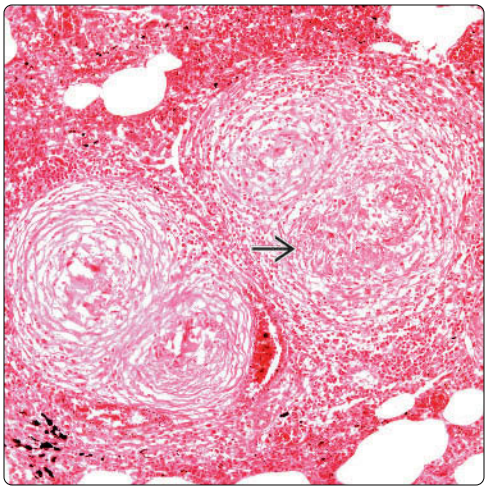

Central Necrosis With Schistosoma

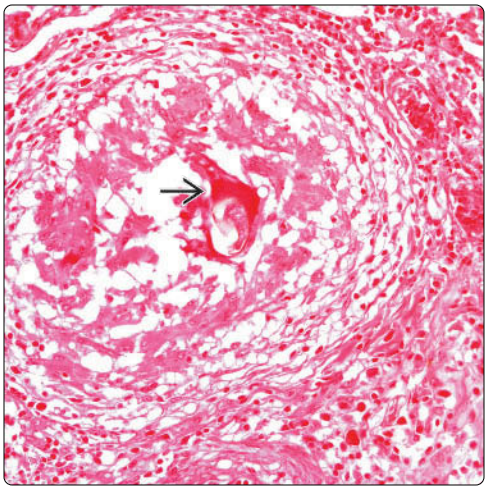

(Left) *In some areas, the granulomas are tightly packed, almost mimicking the granulomas seen in sarcoidosis. Note, however, the presence of central necrosis and acute inflammation ⇨. These features would be unusual for sarcoid granulomas.* **(Right)** *Usually schistosomes are encountered in areas of central necrosis within the granulomatous reaction. In this case, the parasite ⇨ is admixed with necrosis. However, the parasite is not well preserved and can be easily missed.*

Fragments of Parasite

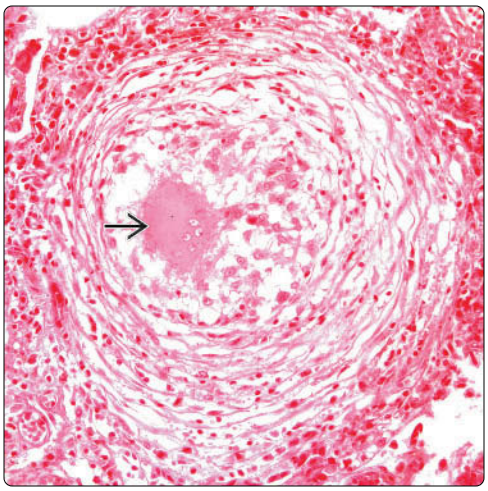

Central Necrosis and Parasite

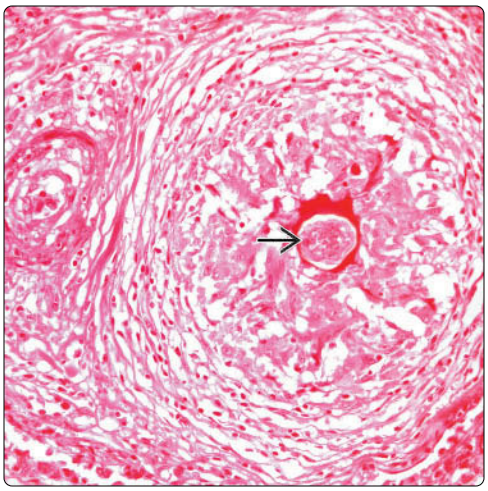

(Left) *Unlike granulomas containing fragments of the parasite, some granulomas do not show evidence of parasitic infection. Essentially, such granulomas show central necrosis with the presence of multinucleated giant cells ⇨.* **(Right)** *In some granulomas, the parasite ⇨ is more easily identifiable. In this granuloma with concentric fibrosis and central necrosis, for example, the organism is easily diagnosed.*

Ill-Defined Parasite

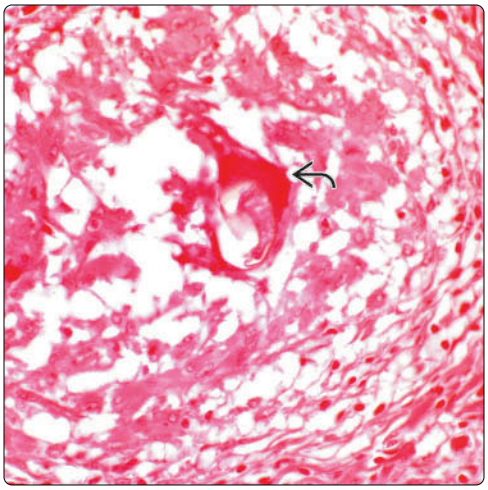

Giant Cells

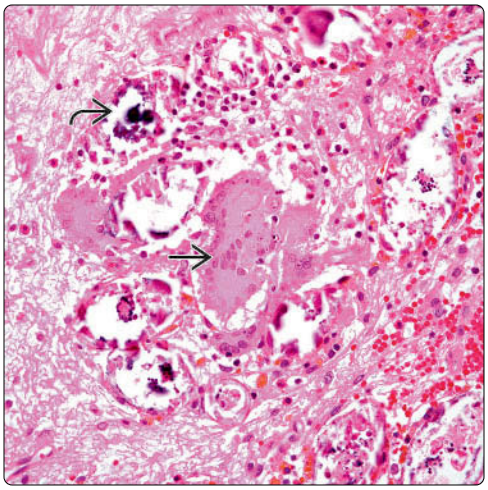

(Left) *In other granulomas, one can see only the outlines of the organism, making the diagnosis more difficult since the remnants can be easily dismissed as foreign material or artifact.* **(Right)** *Other areas of the lung parenchyma may show numerous multinucleated giant cells with calcifications. In these areas, it is also possible to identify the presence of Schistosoma.*

Numerous Parasites

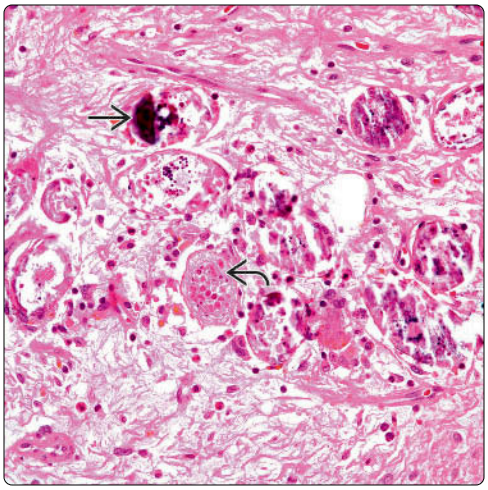

Easily Recognized Schistosoma

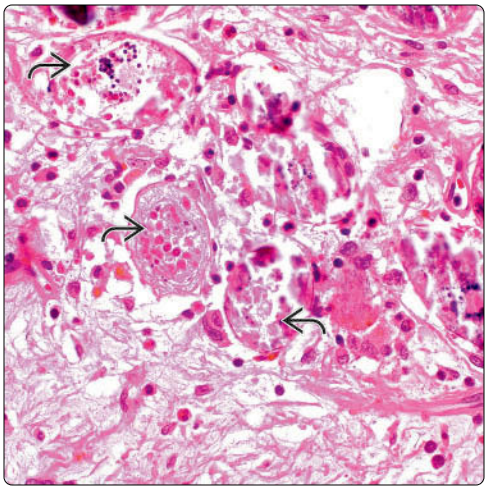

(Left) *In some unusual cases, parasites are easily identifiable admixed with mild inflammatory changes and the presence of calcifications.* **(Right)** *High-power view of Schistosoma demonstrates classic organisms. Unfortunately, such cases are few since in most cases the intact parasite is hard to identify. In many cases, the presence of granulomas and marked inflammatory changes may obscure the parasites.*

Marked Inflammation

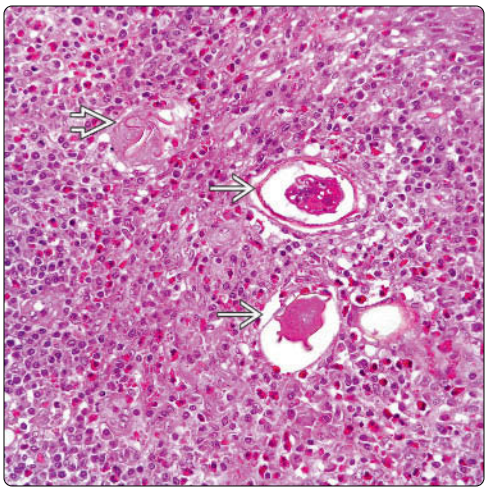

Schistosoma and Giant Cell

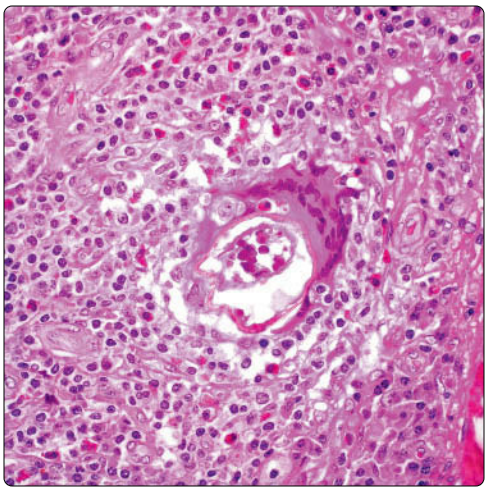

(Left) *Well-preserved parasites of Schistosoma in association with marked chronic inflammatory reaction. Note the presence of a not-so-well-preserved parasite.* **(Right)** *Higher magnification shows a Schistosoma associated in close proximity with a multinucleated giant cell. Both are embedded in a prominent chronic inflammatory reaction.*

Echinococcosis (Hydatid Cyst)

KEY FACTS

TERMINOLOGY

- Synonyms
  - Hydatidosis, echinococcosis
- Definition
  - Infectious condition caused by tapeworms

ETIOLOGY/PATHOGENESIS

- 4 types of (FKLQRFRFFXV
  - (FKLQRFRFFXV JUDQXORVXV
  - (FKLQRFRFFXV PXOWLORFXODULV
  - (FKLQRFRFFXV YRJHOL
  - (FKLQRFRFFXV ROLJDUWKUXV

CLINICAL ISSUES

- Epidemiology
  - Worldwide distribution
  - Predominantly in sheep- and cattle-raising regions
- Symptoms
  - Cough
  - Dyspnea
  - Hemoptysis
  - Pneumothorax
- Infection can also involve
  - Liver
  - Brain
  - Spleen
  - Kidney
  - Bone
- Natural history
  - Eggs can contaminate fruits, vegetables, water, or hands

TOP DIFFERENTIAL DIAGNOSES

- Schistosomiasis
- Dirofilariasis
- Strongyloidiasis

Laminated Structure

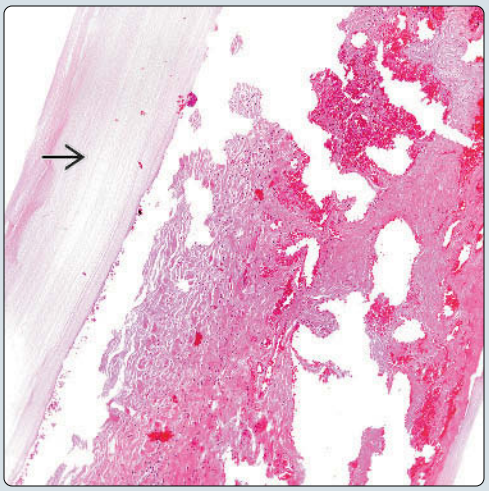

Thin Germinal Layer

(Left) *Lung parenchyma shows on 1 side of a laminated structure of hyaline material, characteristic of an echinococcal cyst.* **(Right)** *Closer view shows that the cystic lesion is rimmed by a very thin germinal layer. Still, the laminated nature of the cystic structure can be identified.*

Cystic Structure

Inflammatory Reaction

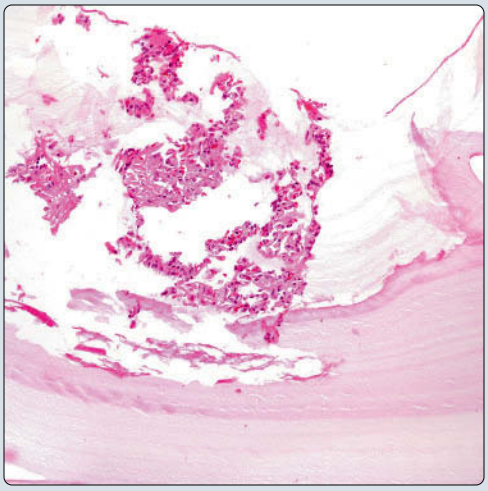

(Left) *Cystic structure with large buds in the surface is shown. These changes are common in echinococcal infection.* **(Right)** *Echinococcal cyst shows a laminated structure with cystic change containing numerous epithelial and inflammatory cells.*

TERMINOLOGY

Synonyms

- Hydatidosis, echinococcosis

Definitions

- Infectious condition caused by tapeworms

ETIOLOGY/PATHOGENESIS

Infectious Agents

- (FKLQRFRFFXV
  - 4 types
    - (FKLQRFRFFXV JUDQXORVXV
    - (FKLQRFRFFXV PXOWLORFXODULV
    - (FKLQRFRFFXV YRJHOL
    - (FKLQRFRFFXV ROLJDUWKUXV

CLINICAL ISSUES

Epidemiology

- Incidence
  - Worldwide distribution
    - Predominantly in sheep- and cattle-raising regions
- Age
  - Can occur in any age group
- Sex
  - M < F
- Ethnicity
  - No ethnic predilection

Presentation

- Symptoms
  - Cough
  - Chest pain
  - Dyspnea
  - Hemoptysis
  - Pneumothorax
- Infection can involve
  - Lung
  - Liver
  - Brain
  - Spleen
  - Kidney
  - Bone
- Patients may be asymptomatic

Natural History

- Eggs can contaminate fruits, vegetables, water, or hands

Treatment

- Surgical approaches
  - Complete surgical resection of cyst
- Drugs
  - Albendazole
  - Combined mebendazole with praziquantel

Prognosis

- Good after treatment
- Can develop serious morbidity

IMAGING

General Features

- Cystic lesion

MACROSCOPIC

General Features

- Unilocular or multilocular cysts
- Thin walls
- Light tan fluid contents

MICROSCOPIC

Histologic Features

- Bronchopneumonia
- Abscess formation
- Identification of parasite
  - Cystic structures
  - Laminations of cyst wall
  - Outer laminated membrane
  - Thin germinal membrane
  - Calcareous corpuscles

DIFFERENTIAL DIAGNOSIS

Other Parasitic Infections

- Strongyloidiasis
  - Commonly shows presence of larvae
- Dirofilariasis ('LURILODULD LPPLWLV
  - Does not present as cystic lesion
  - Usually necrotic granuloma
- Schistosomiasis
  - Does not present as unilocular or multilocular cyst
  - Morphology of 6FKLVWRVRPD differs from (FKLQRFRFFXV

Bacterial Bronchopneumonia

- Abscess formation and acute inflammation may be seen in both bacterial bronchopneumonia and echinococcosis
- Identification of bacterial organisms
- Absence of hydatid cyst

DIAGNOSTIC CHECKLIST

Pathologic Interpretation Pearls

- Unilocular or multilocular cyst
- Identification of parasite
- Cystic structures
- Laminations of wall of cyst
- Identification of thin germinal membrane and laminated outer membrane

SELECTED REFERENCES

1. Erbey F et al: Coexistence of non-Hodgkin's lymphoma and cyst hydatid disease and successful medical treatment. J Pediatr Hematol Oncol. 32(6):524, 2010
2. Matsumoto J et al: Primary alveolar echinococcosis: course of larval development and antibody responses in intermediate host rodents with different genetic backgrounds after oral infection with eggs of Echinococcus multilocularis. Parasitol Int. 59(3):435-44, 2010
3. Mehta KD et al: Comparative evaluation of thoracoscopy versus thoracotomy in the management of lung hydatid disease. World J Surg. 34(8):1828-31, 2010

Cystic Lesion

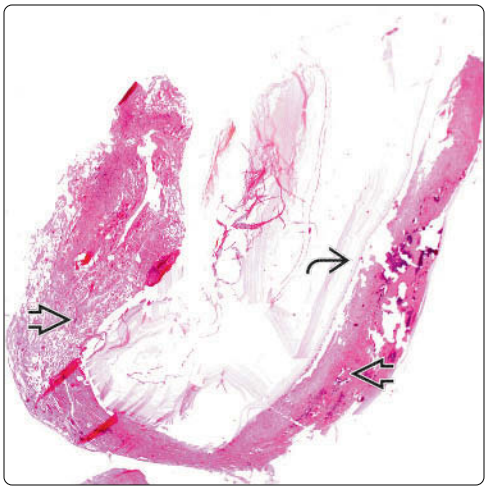

Hydatid Cyst

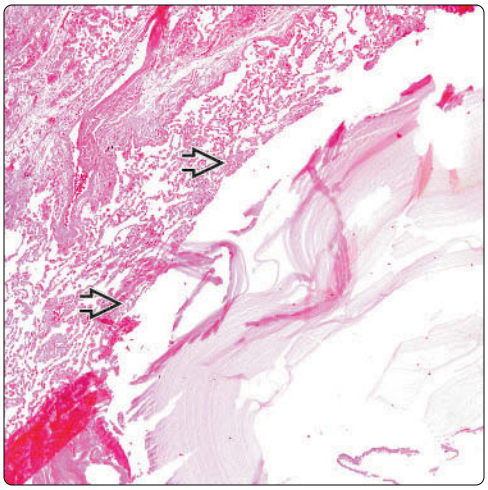

(Left) *Low-power view of a pulmonary cystic lesion shows pulmonary parenchyma surrounding the cyst. Even at this power, it is possible to identify the presence of a well-formed outer layer of the cyst.* **(Right)** *Different view shows a pulmonary hydatid cyst in which the classic laminated wall is not easily identifiable. The cyst appears to be surrounded just by alveolated lung parenchyma.*

Cystic Wall

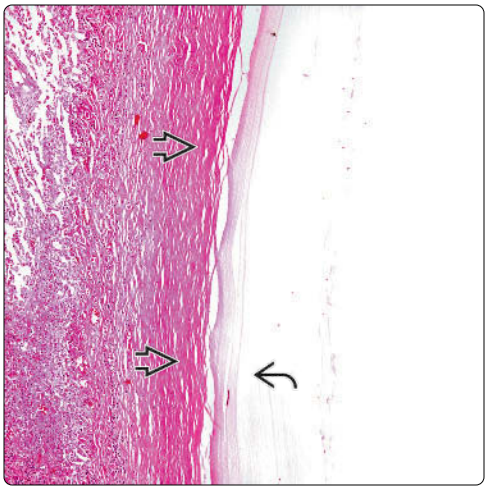

Laminated Cystic Structure

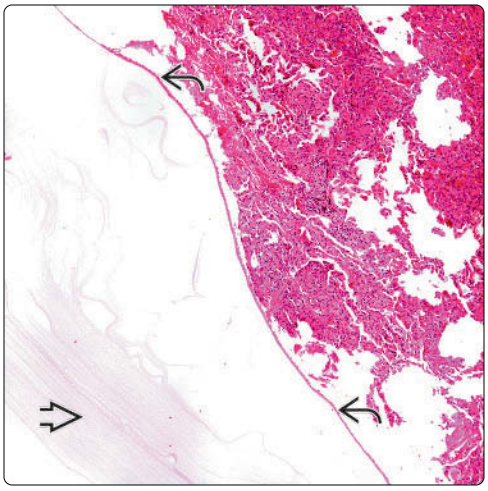

(Left) *In some cases of hydatid cyst, the cystic wall also appears to be surrounded by dense fibrous connective tissue forming a capsule around the cystic structure. Even at this magnification, the classic laminations of the cystic wall can be identified.* **(Right)** *A hydatid cyst composed of a laminated cystic structure with a very thin germinal layer is shown. Note that the cystic structure here is not surrounded by dense fibrous connective tissue.*

Hydatid Cyst

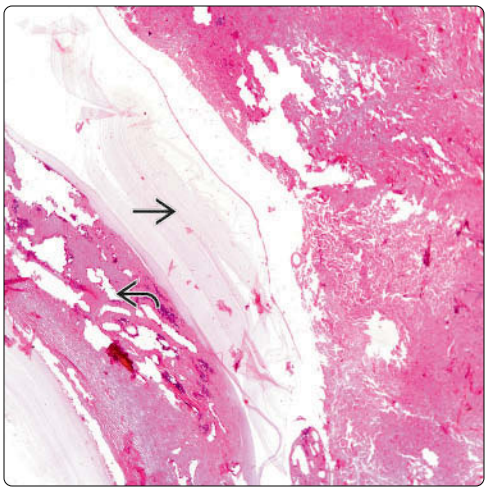

Thin Germinal Layer

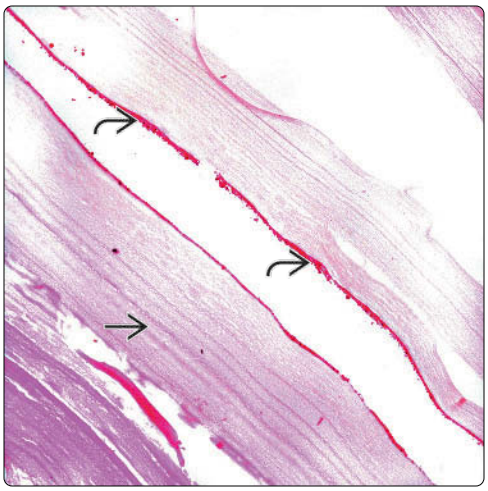

(Left) *Low-power view shows a hydatid cyst in which the surrounding lung parenchyma appears congested with dilated vascular spaces. Note that the hydatid cyst is easily identifiable.* **(Right)** *Closer view shows that the hydatid cyst contains a laminated wall and a thin germinal layer. Note the absence of any inflammatory changes within the wall of the cyst. The features are characteristic of echinococcosis.*

Inflammatory Reaction

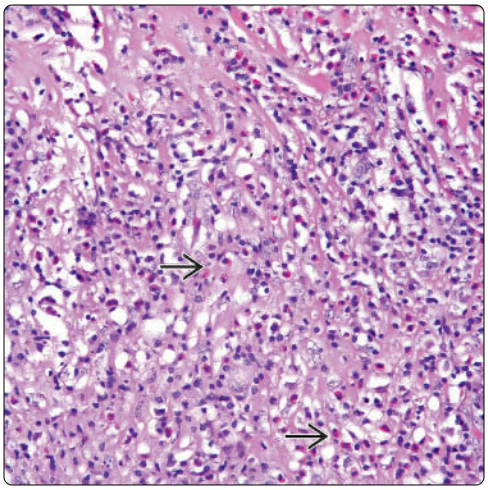

Necrotic Changes

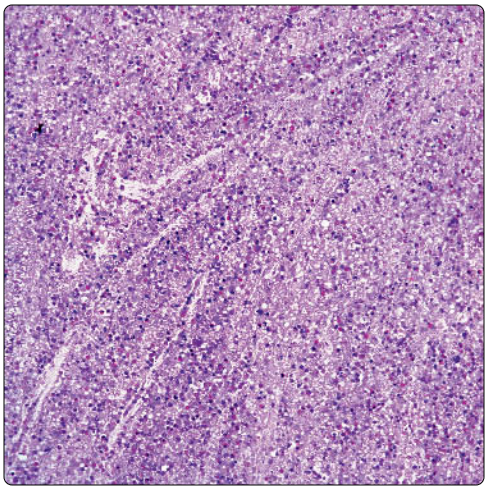

(Left) *Areas adjacent to the hydatid cyst may show inflammation with marked eosinophils, as are present in this particular case.* **(Right)** *In other areas, the presence of viable cystic structures may not be readily identifiable, and prominent areas of necrosis can obscure the diagnosis.*

Calcification

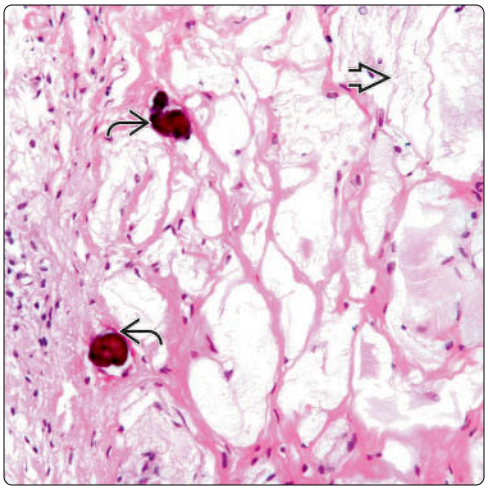

Multinucleated Giant Cells

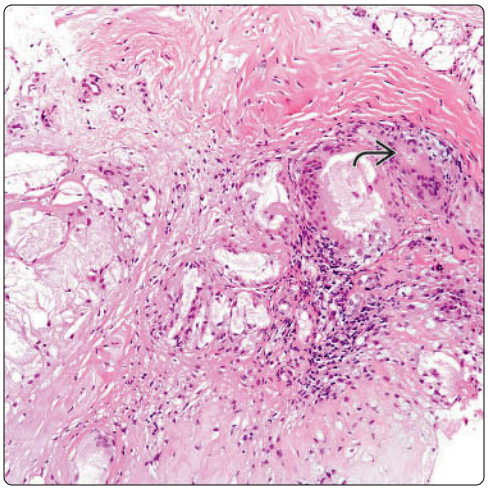

(Left) *The presence of calcifications and areas of myxoid change are not common but may occur in some cases in areas adjacent to the cyst. These features are not specific for the diagnosis of echinococcosis.* **(Right)** *The presence of a granulomatous reaction in the form of multinucleated giant cells, although not common, may be seen in some cases. Note how the multinucleated giant cells are admixed with myxoid changes and inflammatory reaction.*

Multinucleated Giant Cells

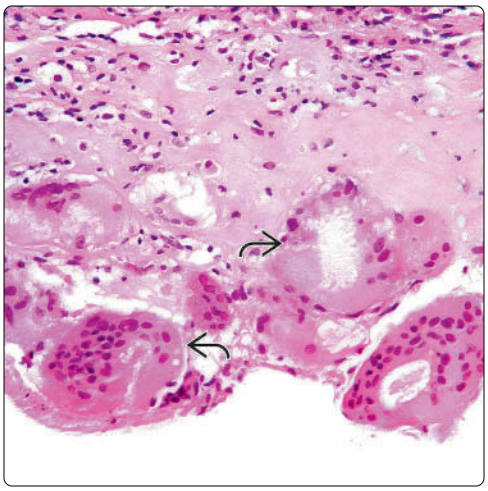

Echinococcal Cyst

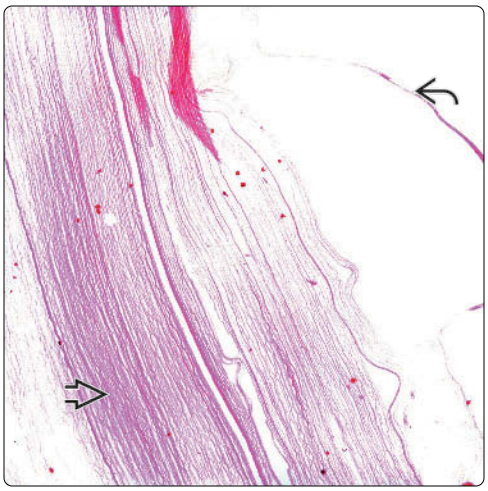

(Left) *In some cases, the presence of multinucleated giant cells is easily recognizable and may be misleading for another infectious condition. Proper identification of the cyst is necessary for diagnosis.* **(Right)** *Classic features of the echinococcal cyst include a laminated wall and a thin germinal layer. Note the absence of any inflammatory changes within the wall of the cyst.*

Paragonimiasis

KEY FACTS

TERMINOLOGY

- Synonyms: Pulmonary distomiasis, lung fluke disease, parasitic hemoptysis, tojil (earth-borne disease), and gregarinosis
- Infectious condition caused by trematode

ETIOLOGY/PATHOGENESIS

- Raw or partially cooked crab or crayfish
- Contaminated drinking water
- Infectious agent; most common in humans are
  - 3 D U D J R Q L P X V (Asia)
  - 3 D U D J R Q L P X V (Latin America)

CLINICAL ISSUES

- Infection can involve
  - Lung
  - Brain
  - Skin/subcutis
- Laboratory results
  - Eosinophilia
- Treatment
  - Surgical resection
- Alternative treatment
  - Praziquantel
  - Bithionol

IMAGING

- Pulmonary mass

MICROSCOPIC

- Identification of parasite or eggs
- Granulomatous reaction
- Necrosis
- Identification of parasites
  - Sputum
  - Feces
  - Tissue

(Left) *CT scan of the thorax shows intrapulmonary nodules ➡. This presentation may be confused with other conditions, including neoplastic processes.* **(Right)** *Numerous paracytic structures are present ⇨ admixed with calcifications ⇨ and minimal inflammatory reaction. These features are in keeping with paragonimiasis.*

CT Scan

Numerous Parasites

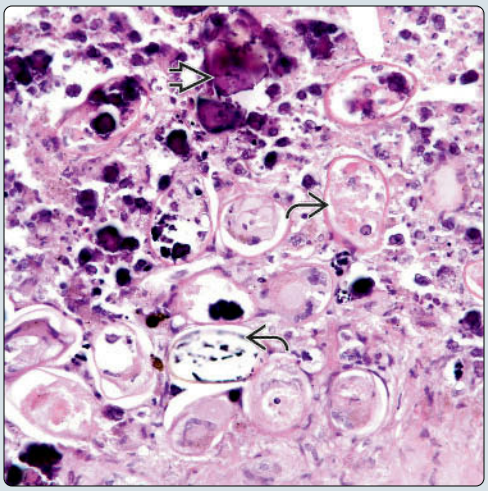

(Left) *Cystic structure shows a thick capsule and extensive fibrinous material admixed with calcifications and eggs or Paragonimus ⇨. In some cases, the presence of calcifications may make the identification of the parasite much more difficult.* **(Right)** *Cystic lesion shows a thickened wall containing areas of calcification and numerous eggs of Paragonimus westermani ➡. There is very little inflammatory reaction present.*

Calcification

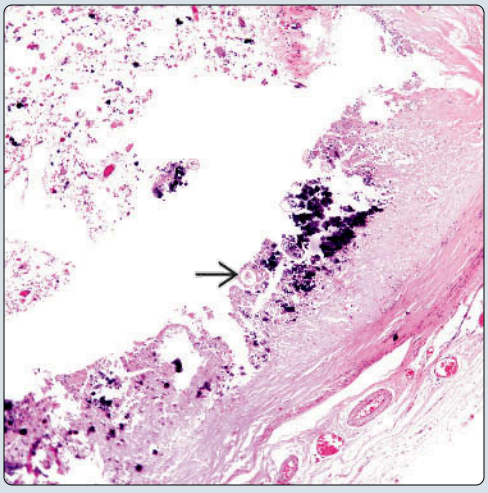

Parasites

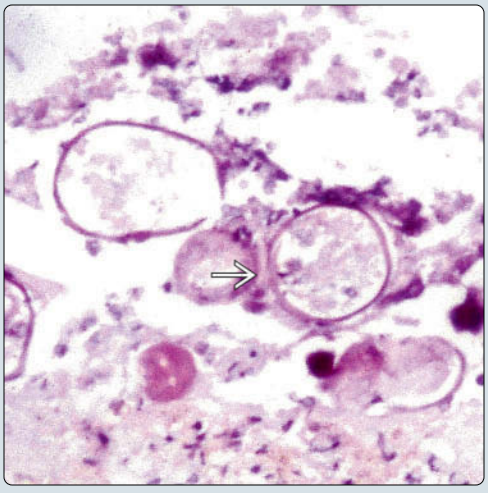

TERMINOLOGY

Synonyms

- Pulmonary distomiasis, lung fluke disease, parasitic hemoptysis, tojil (earth-borne disease), and gregarinosis

Definitions

- Infectious condition caused by trematode

ETIOLOGY/PATHOGENESIS

Environmental Exposure

- Raw or partially cooked crab or crayfish
- Contaminated drinking water

Infectious Agents

- Although there are numerous species of 3 D U D J R Q L P X V, most common in humans is
  - 3 D U D J R Q L P X V Z H V W H U P D Q L (Asia)
  - 3 D U D J R Q L P X V P H [L F D Q X V (Latin America)
    - Requires 7 different phases in life cycle
    - Requires 3 hosts to complete life cycle
    - Incubation period is ~ 70 days

CLINICAL ISSUES

Epidemiology

- Incidence
  - Worldwide distribution
- Age
  - More common in younger patients
- Sex
  - Males appear to be more commonly infected
- Ethnicity
  - No ethnic predilection

Site

- Infection can involve
  - Lung
  - Brain
  - Skin/subcutis

Presentation

- Symptoms
  - Abdominal pain
  - Diarrhea
  - Nausea
  - Vomiting
  - Fatigue
  - Fever
  - Cough
  - Night sweats
  - Chest pain
  - Hemoptysis
  - Hydropneumothorax
- Asymptomatic

Laboratory Tests

- Eosinophilia

Treatment

- Surgical approaches
  - Surgical resection
- Drugs
  - Praziquantel
  - Bithionol

Prognosis

- Good

IMAGING

General Features

- Pulmonary mass

MACROSCOPIC

General Features

- Necrotic mass
- Well circumscribed but not encapsulated
- Soft and light tan in color

Size

- May vary from 1 cm to > 5 cm

MICROSCOPIC

Histologic Features

- Abscess formation
- Tissue eosinophilia
- Necrosis
- Hemorrhage
- Granulomatous reaction
- Identification of parasite or eggs

DIFFERENTIAL DIAGNOSIS

Other Parasites

- & O R Q R U F K L V V L Q H Q V L V
-) D V F L R O D K H S D W L F D
- 6 F K L V W R V R P D
  - Size of eggs and morphology of 3 D U D J R Q L P X V spp. are different

DIAGNOSTIC CHECKLIST

Pathologic Interpretation Pearls

- Identification of parasite
  - Sputum
  - Feces
  - Tissue

SELECTED REFERENCES

1. Lane MA et al: Human paragonimiasis in North America following ingestion of raw crayfish. Clin Infect Dis. 49(6):e55-61, 2009
2. Osaki T et al: Pulmonary Paragonimus westermani with false-positive fluorodeoxyglucose positron emission tomography mimicking primary lung cancer. Gen Thorac Cardiovasc Surg. 55(11):470-2, 2007
3. Yoo IeR et al: Two cases of pulmonary paragonimiasis on FDG-PET CT imaging. Ann Nucl Med. 20(4):311-5, 2006
4. Choo JD et al: Chronic cerebral paragonimiasis combined with aneurysmal subarachnoid hemorrhage. Am J Trop Med Hyg. 69(5):466-9, 2003
5. Dainichi T et al: A case of cutaneous paragonimiasis with pleural effusion. Int J Dermatol. 42(9):699-702, 2003
6. Meehan AM et al: Severe pleuropulmonary paragonimiasis 8 years after emigration from a region of endemicity. Clin Infect Dis. 35(1):87-90, 2002

Chest Films

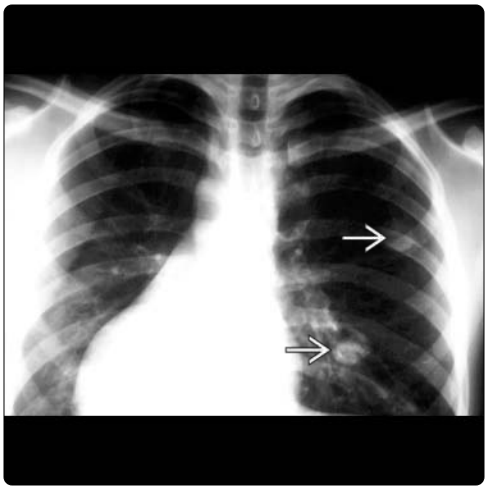

Chest Films

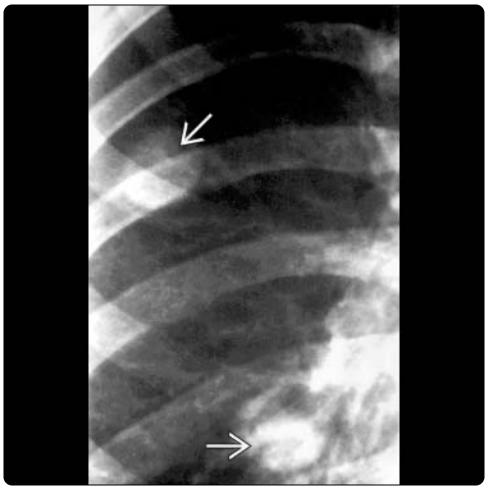

(Left) *Chest radiograph shows intrapulmonary nodules. This appearance may be confused with metastatic tumors of the lung.* **(Right)** *Closer view of chest radiograph of the lung fields demonstrates the presence of intrapulmonary nodules, raising the possibility of a malignant neoplasm involving lung parenchyma.*

Macroscopic Features

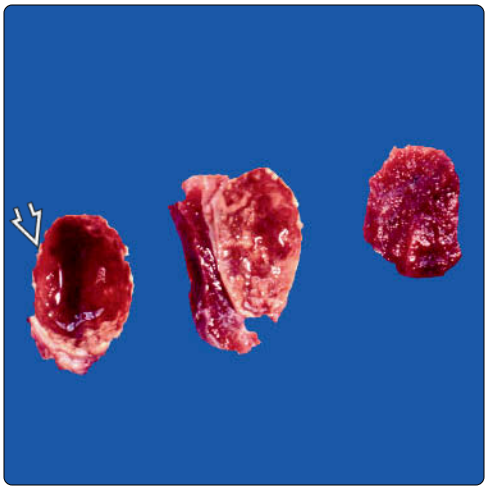

Extensive Calcification

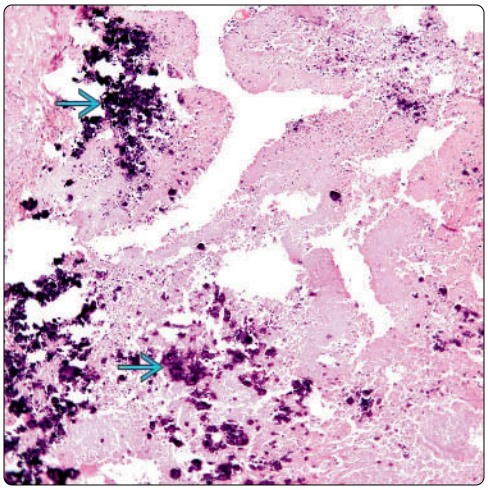

(Left) *Wedge resection of a pulmonary nodule of paragonimiasis shows a cystic structure with a thick capsule. The cyst appears to be hemorrhagic and somewhat yellowish. Adjacent lung parenchyma is congested.* **(Right)** *Low-power view of pulmonary paragonimiasis shows extensive areas of fibrinous exudate accompanied by areas of calcification. At this power, it is difficult to identify the presence of the organisms.*

Parasites

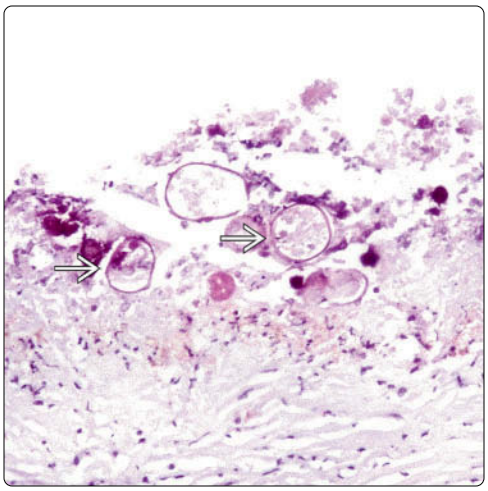

Parasites and Calcifications

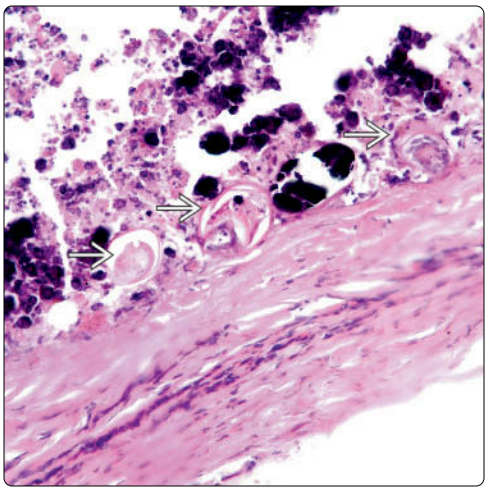

(Left) *Cystic lesion shows a thickened wall containing areas of calcification and numerous eggs of P. westermani. There is very little inflammatory reaction present.* **(Right)** *High-power magnification shows collapsed eggs of Paragonimus admixed with calcifications. Note there is minimal associated inflammatory change.*

Numerous Parasites

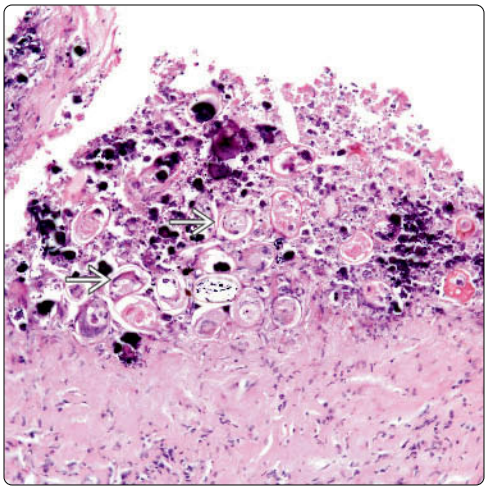

Thick Shell

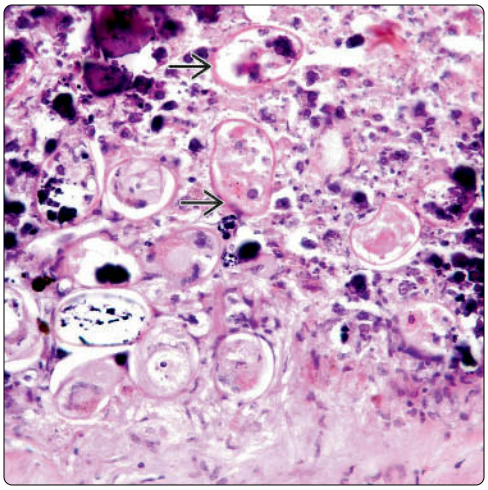

(Left) *Different view of a cystic structure demonstrates numerous eggs of Paragonimus admixed with calcifications.* **(Right)** *High-power view of eggs of Paragonimus shows a thickened shell and operculum. These characteristics are important in order to differentiate Paragonimus from other parasites.*

Parasite Eggs

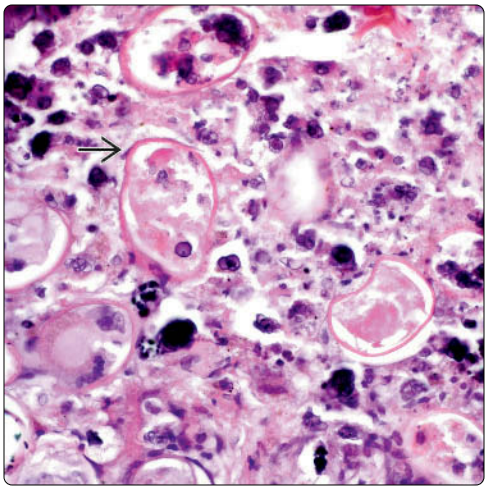

Brain Infection

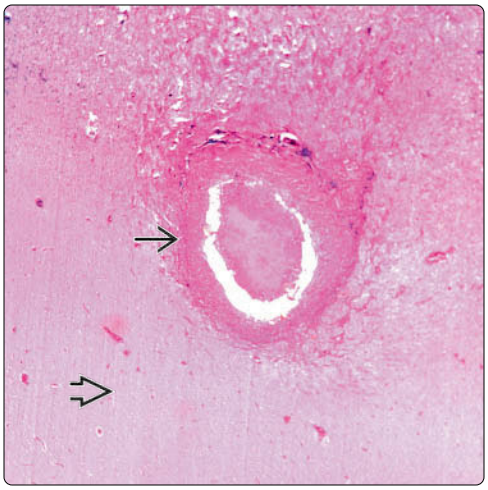

(Left) *Eggs of Paragonimus admixed with calcifications and mild inflammatory reaction are shown. The features of a thickened shell and operculum are characteristics of Paragonimus.* **(Right)** *Paragonimus in the brain shows a cystic lesion with central necrosis and mild inflammatory reaction. Note the rest of the glial tissue does not show marked inflammatory changes.*

Brain Infection

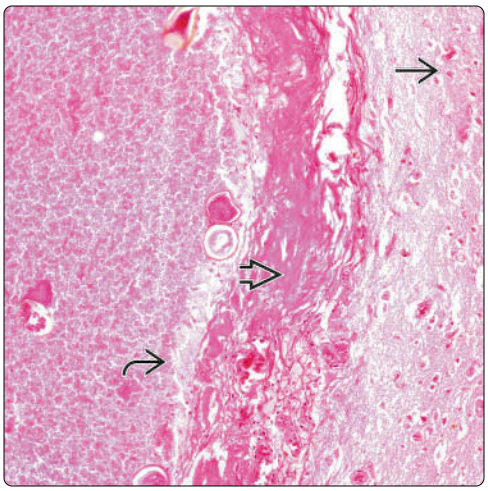

Collapsed Eggs

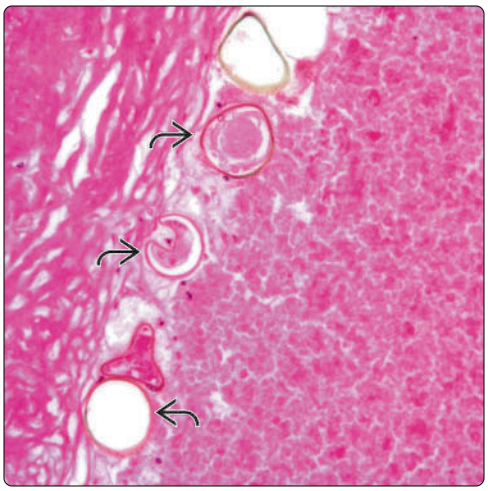

(Left) *Higher magnification of Paragonimus in the brain shows a distinct interphase between the cystic lesion and the normal glial tissue. Note the presence of a thickened capsule.* **(Right)** *Higher magnification of Paragonimus in the brain shows the presence of numerous collapsed eggs of Paragonimus. Note the presence of a thickened shell, which is a characteristic of the eggs of Paragonimus.*

This page intentionally left blank

PART I
SECTION 6

Infectious Diseases

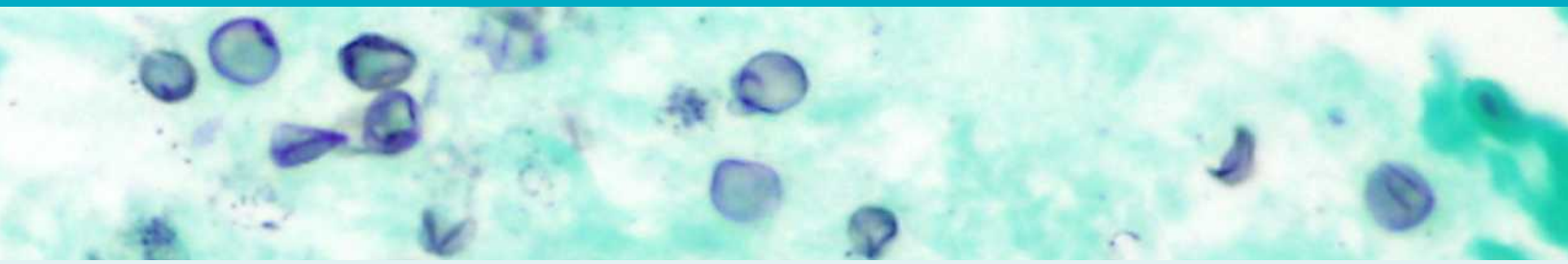

Cryptococcosis	**492**
Coccidioidomycosis	**496**
Pneumocystosis	**500**
Blastomycosis	**504**
Histoplasmosis	**506**
Tuberculosis	**510**
Herpes Simplex Virus	**514**
Cytomegalovirus	**518**
Adenovirus	**522**
Measles Pneumonia	**524**
Sporotrichosis	**528**
Klebsiella Pneumonia	**530**
SARS Pneumonia	**534**
Nocardiosis	**536**
Actinomycosis	**538**
Aspergillosis	**540**
Botryomycosis	**546**
Malakoplakia	**548**

Cryptococcosis

KEY FACTS

TERMINOLOGY

- Lung infection caused by inhalation of *Cryptococcus neoformans* spores

CLINICAL ISSUES

- Acute pulmonary infection can be asymptomatic or self-limited
- Progressive infection is seen in immunocompromised hosts and involves lungs and meninges

MACROSCOPIC

- Well-defined nodules (cryptococcomas) show central necrosis and cavitation but absence of calcifications
- Nodules may be minute, resembling miliary tuberculosis
- Areas of patchy consolidation can be seen that display mucoid cut surface

MICROSCOPIC

- Nodular granulomatous lesions with multinucleated giant cells containing intracellular organisms
- Nodular lesions may progress to form necrotizing granulomas with palisading histiocytes
- Multiple organisms can be seen lying free within alveolar spaces with no inflammation in alveolar walls
- *C. neoformans* yeast are small (4-6 µm in diameter), eosinophilic, round to oval, and occasionally appear refractile with single budding
- Cells appear to be surrounded by halo that actually represents mucinous capsule
- Capsule-deficient variant of *C. neoformans* is found in immunocompromised patients

ANCILLARY TESTS

- Organisms stain with silver stains (GMS) and PAS
- Capsule of organisms stains strongly with mucicarmine and Alcian blue stains
- Capsule-deficient variant of *C. neoformans* stains with Fontana-Masson stain

Pulmonary Cryptococcomas

Cryptococcal Organisms: H&E

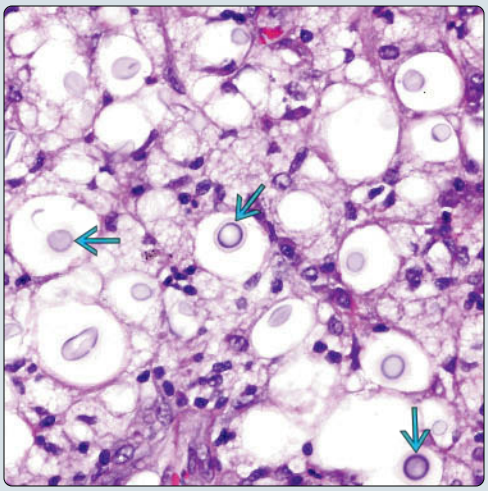

(Left) *Gross appearance of cryptococcal infection in the lung shows multiple cryptococcomas distributed in the periphery of the upper lobe. The nodules are sharply separated from the surrounding uninvolved pulmonary parenchyma.* **(Right)** *Histologic appearance of cryptococcal organisms shows round to oval yeasts with a double refractile capsule surrounding a central translucent core. The yeast are surrounded by abundant foamy histiocytes.*

***Cryptococcus*: GMS Stain**

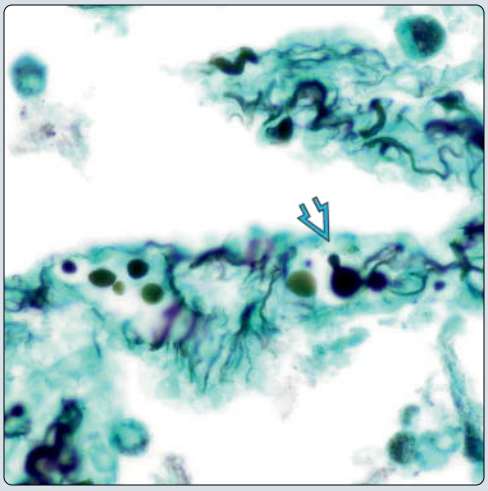

***Cryptococcus*: Mucicarmine Stain**

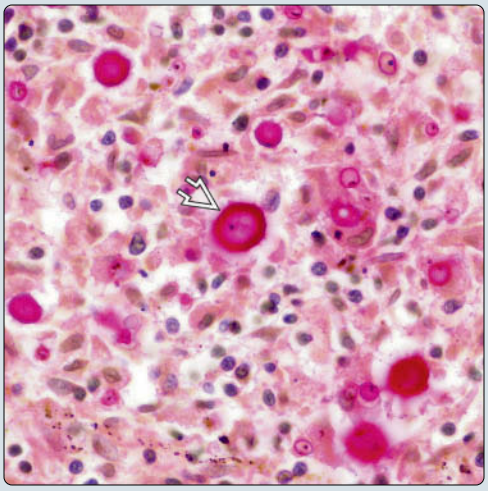

(Left) *A yeast of Cryptococcus is seen in the center of the field in this lung biopsy. The organism is stained with Gomori methenamine silver and shows a small narrow bud.* **(Right)** *Cryptococcal yeast are seen that stain bright red with the mucicarmine stain. The stain specifically highlights the lipid content of the capsule.*

TERMINOLOGY

Definitions

- Lung infection caused by inhalation of &U\SWRFRFFXV QHRIRUPDQV spores

ETIOLOGY/PATHOGENESIS

Environmental Exposure

- Organisms are found in soil, especially soil contaminated with pigeon droppings

CLINICAL ISSUES

Epidemiology

- Incidence
  - Worldwide distribution; unknown incidence

Presentation

- Acute pulmonary infection is most often asymptomatic
- Progressive infection is accompanied by cough, fever, pleuritic pain, and weight loss

Natural History

- Acute pulmonary infection can be asymptomatic or self-limited
- Progressive infection is seen in immunocompromised hosts and involves lungs and meninges
- Sequel of self-limited infection is formation of small subpleural fibrocaseous nodules without calcifications

Treatment

- Surgical approaches
  - Surgical excision of pulmonary nodules may be helpful to reduce mortality
- Drugs
  - Amphotericin B, fluconazole

Prognosis

- Good response to antifungal agents

IMAGING

General Features

- Morphology
  - Multifocal peripheral pulmonary nodules predominantly in upper lobes
  - Unilateral or bilateral parenchymal consolidation
  - Immunocompromised patients may show diffuse, bilateral, reticular, or nodular interstitial opacities or miliary nodules
  - Fibrosis and calcification are not associated with cryptococcosis

MACROSCOPIC

General Features

- Well-defined nodules (cryptococcomas) show central necrosis and cavitation but absence of calcifications
- Nodules may be minute, resembling miliary tuberculosis
- Areas of patchy consolidation can be seen that display mucoid cut surface

MICROSCOPIC

Histologic Features

- Reaction pattern of lung to organisms depends on immune status of patient
  - Immunocompetent patients generally develop granulomatous reaction to organisms
    - Nodular granulomatous lesions with multinucleated giant cells containing intracellular organisms
    - Nodular lesions may progress to form necrotizing granulomas with palisading histiocytes
    - Granulomatous lesions may exhibit prominent stromal fibrosis
  - Immunocompromised patients will not exhibit granulomatous response to organisms
    - Multiple organisms can be seen lying free within alveolar spaces with no inflammation in alveolar walls

Cytologic Features

- & QHRIRUPDQV yeast are small (4-6 µm in diameter), eosinophilic, round to oval, occasionally appear refractile, and are easily seen on H&E stains
  - Characterized by single budding attached by narrow base to parent cell
- Cells appear to be surrounded by halo that actually represents mucinous capsule
- Capsule-deficient variant of & QHRIRUPDQV is found in immunocompromised patients

ANCILLARY TESTS

Histochemistry

- Organisms stain with silver stains (GMS) and PAS
- Capsule of organisms stains strongly with mucicarmine and Alcian blue stains
- Capsule-deficient variant of & QHRIRUPDQV stains with Fontana-Masson stain

DIFFERENTIAL DIAGNOSIS

Other Fungal Infections

- & QHRIRUPDQV can be mistaken for any yeast-forming fungus but is only one with true mucinous capsule
- Capsule-deficient variant of & QHRIRUPDQV can be confused for +LVWRSODVPD, %ODVWRP\FHV, &RFFLGLRLGHV
  - Fontana-Masson stain is useful to identify wall of organism and separate it from other fungi
- Blastomycosis can be distinguished from cryptococcosis due to its broad-based budding yeast

DIAGNOSTIC CHECKLIST

Pathologic Interpretation Pearls

- Only fungus that stains positive with mucicarmine stain

SELECTED REFERENCES

1. Haddad N et al: Pulmonary cryptococcoma: a rare and challenging diagnosis in immunocompetent patients. Autops Case Rep. 5(2):35-40, 2015
2. Bavishi AV et al: A case of pulmonary cryptococcosis caused by capsule-deficient cryptococcus neoformans in an immunocompetent patient. Respir Care. 55(7):937-41, 2010
3. Goldman JD et al: Cryptococcosis in the immunocompetent patient. Respir Care. 55(11):1499-503, 2010

Granulomatous Inflammation of Lung

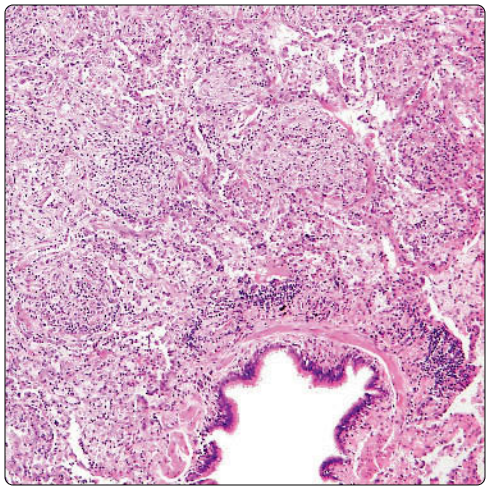

Organisms in Multinucleated Giant Cell

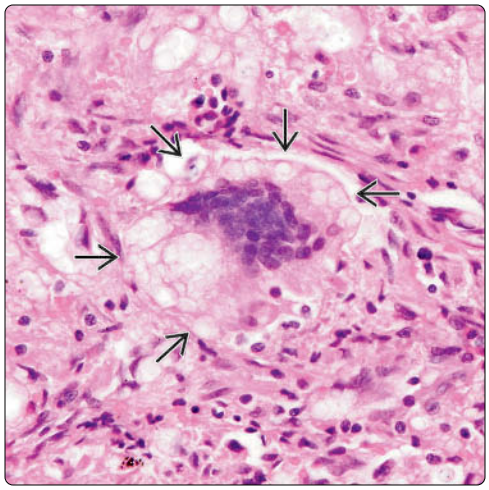

(Left) *Nodular granulomatous lesion in the lung of an immunocompetent patient with cryptococcosis shows sheets of epithelioid histiocytes surrounding a bronchus. Advanced lesions will undergo central necrosis and cavitation with peripheral palisading of histiocytes.* **(Right)** *Higher magnification of a granulomatous lesion in an immunocompetent patient with cryptococcosis shows numerous organisms located within the cytoplasm of a multinucleated giant cell ⇨.*

Infection in Immunocompromised Patient

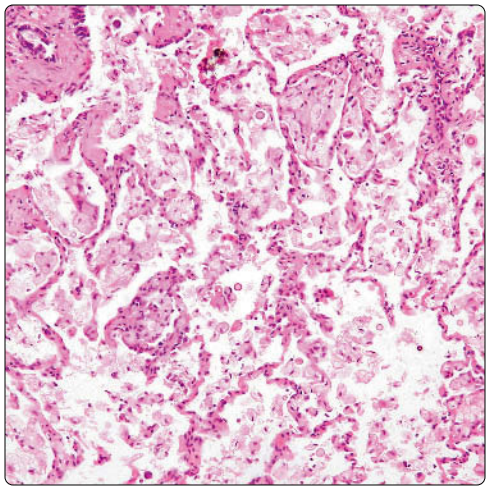

Cryptococcus Within Alveolar Space

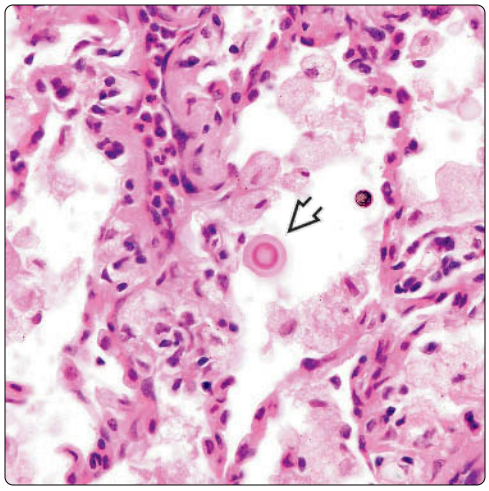

(Left) *Scanning magnification of cryptococcal pneumonia in an immunocompromised patient shows minimal reaction of lung parenchyma with no inflammatory response and abundant organisms lying free within the alveolar lumina.* **(Right)** *Higher magnification of cryptococcal pneumonia in an immunocompromised patient shows minimal inflammatory reaction and organisms lying free within the alveolar lumina ⇨. The organisms can be easily visualized on H&E without the need for special stains.*

Cryptococcosis in AIDS Patient

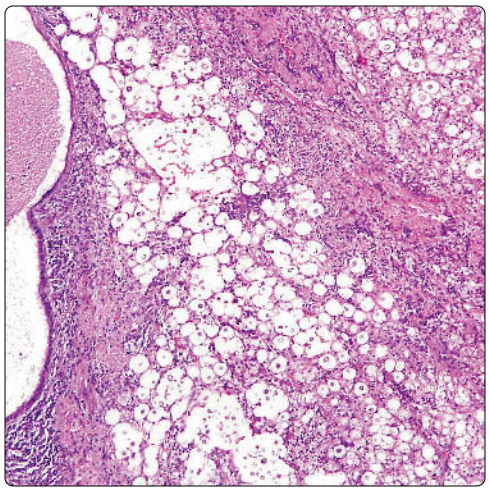

Cryptococcal Organisms

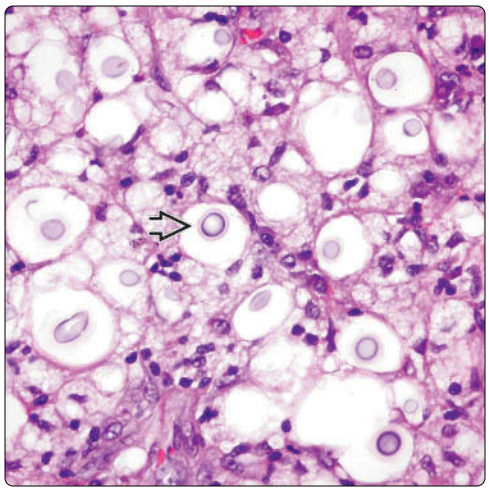

(Left) *Cryptococcal pneumonia in an AIDS patient shows multiple organisms lying free within the alveolar lumina.* **(Right)** *Higher magnification of cryptococcal pneumonia in an immunocompromised patient with AIDS shows numerous round to oval yeast with refractile cell walls and halo effect ⇨ caused by the presence of a thick mucinous capsule. There are numerous foamy macrophages seen admixed with the organisms. Cases like this can be confused with lipoid pneumonia.*

***Cryptococcus* Yeast**

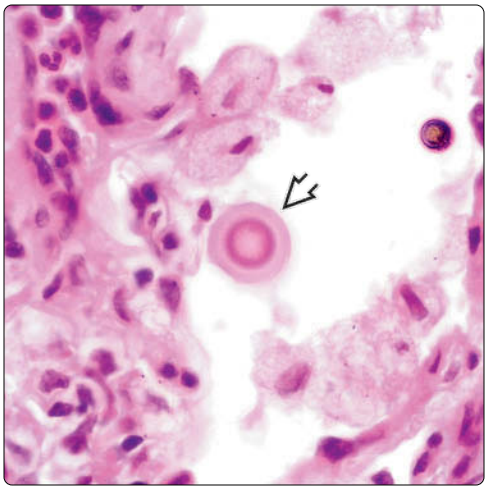

Capsule-Deficient Variant

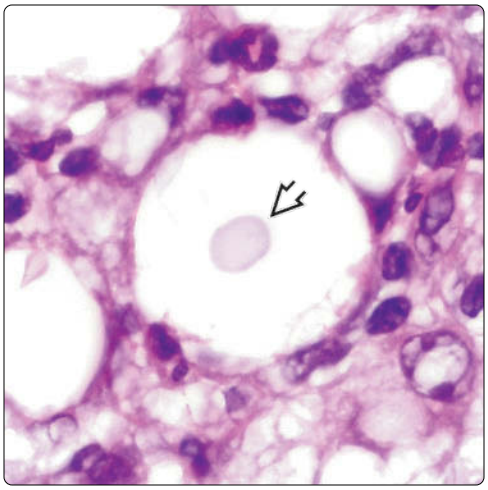

(Left) *High magnification in cryptococcal pneumonia shows the classic appearance of Cryptococcus, displaying round yeast ⇨ with a halo around the nucleus caused by the presence of a thick mucinous capsule. The capsule can be highlighted with mucicarmine.* **(Right)** *Higher magnification shows a capsule-deficient variant of Cryptococcus ⇨ in the lung. The absence of a thick capsule allows these forms to be easily mistaken for other types of yeast, including histoplasmosis, blastomycosis, etc.*

***Cryptococcus*: GMS Stain**

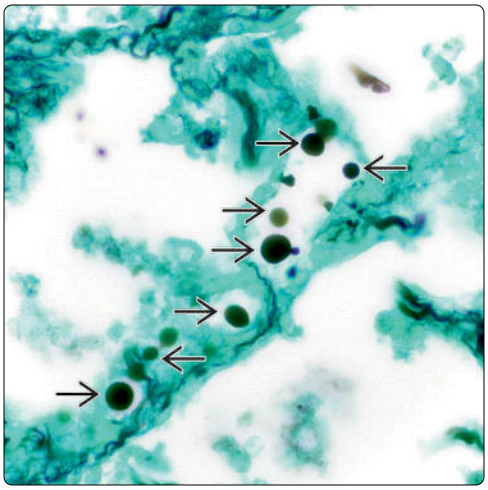

***Cryptococcus* Budding Yeast**

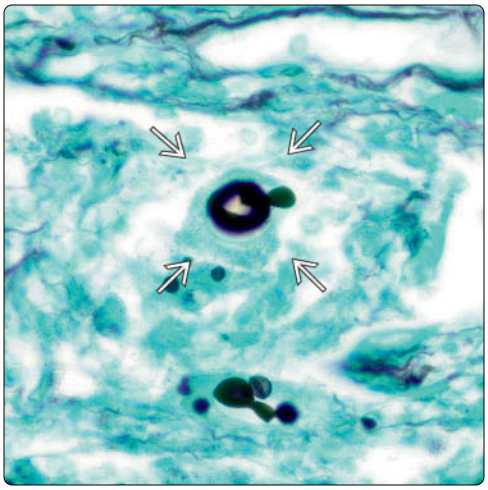

(Left) *Histochemical staining with Grocott methenamine silver (GMS) stain in a patient with pulmonary cryptococcosis shows numerous small yeast lying free within the airspaces ⇨.* **(Right)** *Higher magnification of cryptococcal pneumonia in an immunocompromised patient with AIDS, stained with Gomori methenamine silver (GMS), shows a budding yeast ➡. The budding yeasts in cryptococcosis are characterized by single buds attached to the parent cell by a narrow base.*

***Cryptococcus*: Mucicarmine Stain**

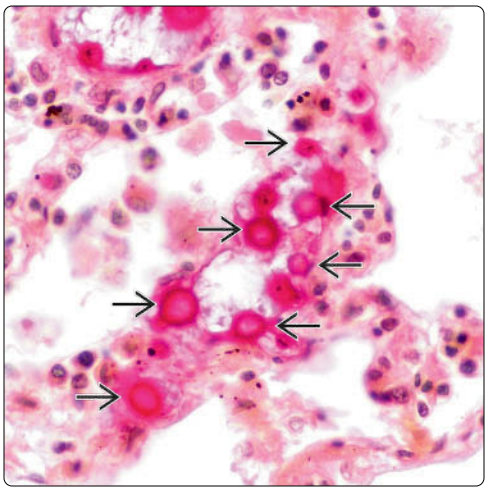

Mucicarmine Stain: High Power

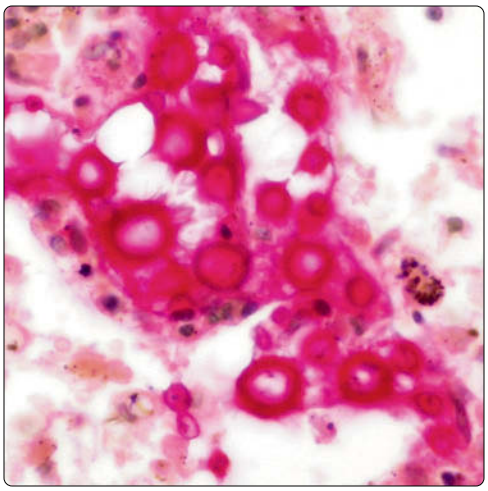

(Left) *Cryptococcal pneumonia stained with mucicarmine displays multiple organisms that show strong positivity ⇨. Mucicarmine may be very useful in the context of differentiating Cryptococcus from other fungal organisms, as this is the only fungus that contains a mucicarmine positive capsule.* **(Right)** *Higher magnification of cryptococcal pneumonia stained with mucicarmine histochemical reaction shows accentuation of the capsule by the stain.*

Coccidioidomycosis

KEY FACTS

TERMINOLOGY

- Pulmonary infection caused by inhalation of fungal spores of *Coccidioides immitis*
- a.k.a. San Joaquin Valley fever

CLINICAL ISSUES

- Organism is endemic in Southwestern United States, Mexico, and Central and South America
- Pulmonary infection may be acute, persistent, or chronic
- Chronic progressive infection can mimic tuberculosis with miliary dissemination and high mortality
- Solitary cavitary nodules with thin walls may be seen in upper lobes in up to 70% of cases
- Extrapulmonary dissemination can occur in pregnant women and immunosuppressed patients

MICROSCOPIC

- Primary pulmonary infection is characterized by acute suppurative pneumonia with neutrophilic infiltrates
- Granulomatous lesions are characterized by solid epithelioid granulomas that can cavitate and undergo central necrosis
- Organism is characterized by large, round to oval spherule (30-100 µm) containing multiple endospores
- Immature spherules lack endospores
- Mature spherules have 1-2 µm thick refractile wall
- Immature spherules lack endospores
- Endospores are 2-5 µm in diameter and have punctate cytoplasmic inclusions that are PAS(+) and GMS(-)
- Vegetative forms consist of 2-4 µm thick septate branching hyphae and 2-5 µm barrel-shaped arthroconidia
- Necrotizing granulomas may be multiple or solitary and have fibrotic rim surrounding central necrotic zone

ANCILLARY TESTS

- GMS stains both mature spherules and endospores
- Immature spherules are PAS(+)

Lung Cavitation in Coccidioidomycosis

Spherules Filled With Endospores

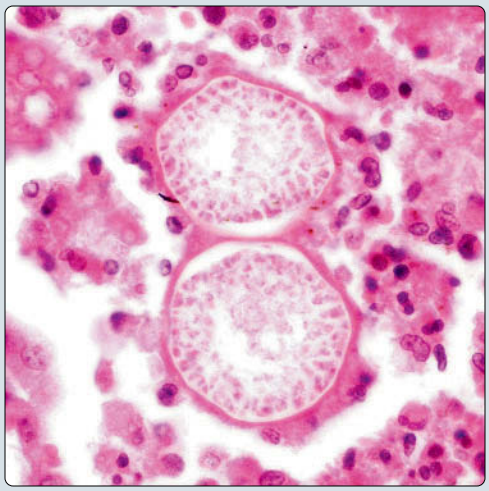

(Left) *Cut surface of the lung in a patient with cavitary lesions due to coccidioidomycosis shows large, thin-walled subpleural cavities lined by fibrous tissue with necrotic debris.* **(Right)** *Histologic appearance of coccidioidomycosis in the lung shows 2 large round spherules surrounded by a thin capsule and containing numerous endospores.*

Immature Empty Spherules

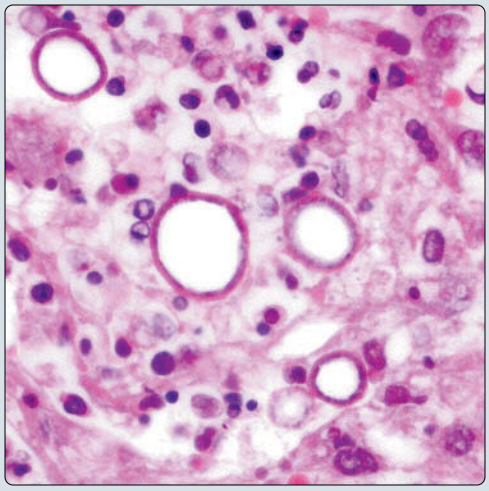

***Coccidioides*, PAS Stain**

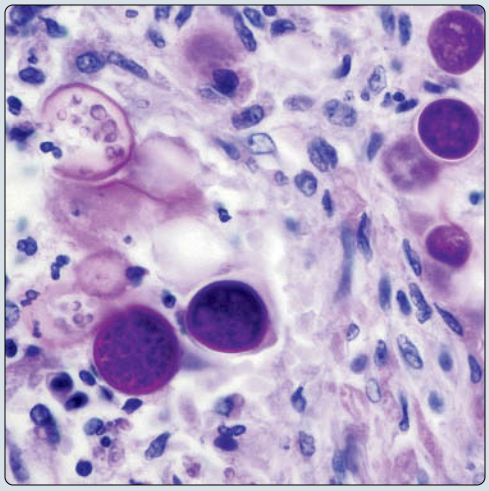

(Left) *Higher magnification in pulmonary coccidioidomycosis shows empty immature spherules with thick membranes circumscribing an empty lumen devoid of endospores.* **(Right)** *Higher magnification of immature spherules in coccidioidomycosis infection of the lung stained with PAS highlights the organisms; notice the small endospores contained within the spherules.*

TERMINOLOGY

Synonyms

- San Joaquin Valley fever

Definitions

- Pulmonary infection caused by inhalation of fungal spores of &RFFLGLRLGHV LPPLWLV

CLINICAL ISSUES

Epidemiology

- Incidence
  - Organism is endemic in Southwestern United States, Mexico, and Central and South America

Presentation

- Majority of patients are asymptomatic
- Fever, cough, pleuritic pain, myalgias, and arthralgias
- Erythema nodosum or erythema multiforme (in 20% of patients)

Laboratory Tests

- Serum IgM antibodies to & LPPLWLV can be detected 2-3 weeks after onset of infection in 75% of patients
- Serum IgG antibodies are detected in later stages in up to 90% of patients

Natural History

- Pulmonary infection may be acute, persistent, or chronic
- Acute infection develops 1-4 weeks following inhalation of spores and leads to fungal pneumonia
- Chronic progressive infection can mimic tuberculosis with miliary dissemination and high mortality
- Residual localized pulmonary nodule (coccidioidoma) can be seen as sequel of resolved primary infection
- Solitary cavitary nodules with thin walls may be seen in upper lobes in up to 70% of cases
- Extrapulmonary dissemination can occur in pregnant women and immunosuppressed patients

Treatment

- Drugs
  - Amphotericin B

Prognosis

- Most patients recover spontaneously without evidence of persistent disease
- Persistent pneumonia in immunosuppressed patients can be fatal and requires antifungal treatment

IMAGING

Radiographic Findings

- Patchy, unilateral perihilar, or lower lobe parenchymal consolidation is seen in primary pulmonary infection
- Multifocal, peripheral, subpleural nodules may also occur
- Healing will produce solitary pulmonary nodules or thin-walled cavities

MACROSCOPIC

General Features

- Chronic progressive coccidioidal pneumonia is characterized by consolidation and cavitary lesions
- Fibrous-walled cavities may contain gray-brown, friable fungus balls
- Coccidioidoma is characterized by discrete, well-demarcated lesion without calcifications

MICROSCOPIC

Histologic Features

- Primary pulmonary infection is characterized by acute suppurative pneumonia with neutrophilic infiltrates
- Granulomatous lesions are characterized by solid epithelioid granulomas that can cavitate and undergo central necrosis
- Necrotizing granulomas may be multiple or solitary and have fibrotic rim surrounding central necrotic zone
- Necrotizing granulomas show peripheral palisading of histiocytes admixed with multinucleated giant cells
- Mature spherules may be difficult to identify in necrotizing granulomas and may only contain few immature spherules
- Immature spherules may become lined with eosinophilic radiating material resulting in Splendore-Hoeppli phenomenon

Cytologic Features

- Organism is characterized by large, round to oval spherule (30-100 µm) containing multiple endospores
- Mature spherules have 1-2 µm thick refractile wall
- Immature spherules lack endospores
- Endospores are 2-5 µm in diameter and have punctate cytoplasmic inclusions that are PAS(+) and GMS(-)
- Under certain conditions, endospores can germinate within host tissue, resulting in vegetative forms
- Vegetative forms consist of 2-4 µm thick septate branching hyphae and 2-5 µm barrel-shaped arthroconidia

ANCILLARY TESTS

Histochemistry

- GMS stains both mature spherules and endospores
- Immature spherules are PAS(+)

DIFFERENTIAL DIAGNOSIS

Histoplasmosis

- Yeast form of +LVWRSODVPD FDSVXODWXP may resemble endospores in & LPPLWLV but are characterized by presence of buds

Blastomycosis

- Yeast forms of %ODVWRP\FHV GHUPDWLGLV may resemble endospores of & LPPLWLV but are characterized by broad-based budding forms

SELECTED REFERENCES

1. Ampel NM: New perspectives on coccidioidomycosis. Proc Am Thorac Soc. 7(3):181-5, 2010
2. Spinello IM et al: Pulmonary coccidioidomycosis. Semin Respir Crit Care Med. 29(2):166-73, 2008

Large Necrotizing Granuloma

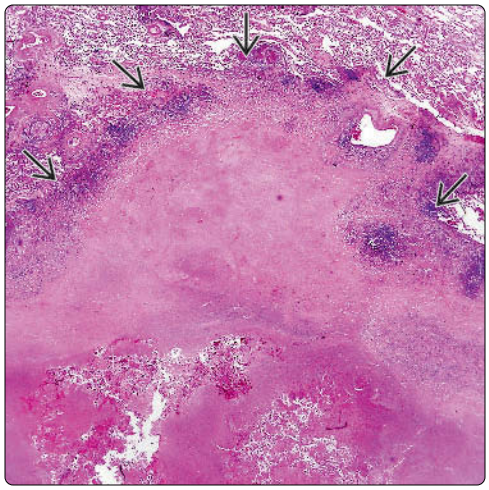

Scattered Small Granulomas

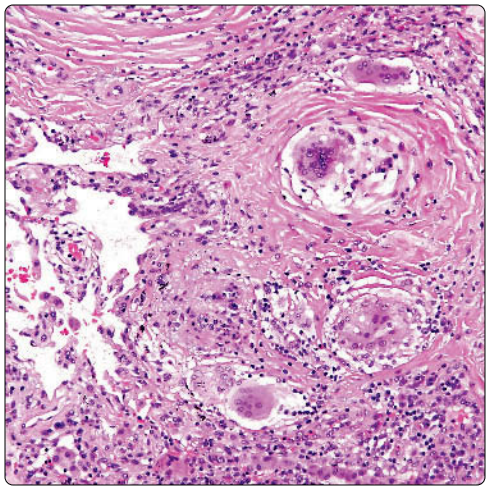

(Left) *Granulomatous lesion in pulmonary coccidioidomycosis shows a well-circumscribed nodule (coccidioidoma) with extensive central necrosis and peripheral palisading of histiocytes.* **(Right)** *Scattered small epithelioid granulomas with multinucleated giant cells are seen in pulmonary coccidioidomycosis. Organisms are not numerous in granulomatous lesions and are often found within the areas of necrosis. They can be easily visualized with H&E without the need for special stains.*

Degenerating Spherule

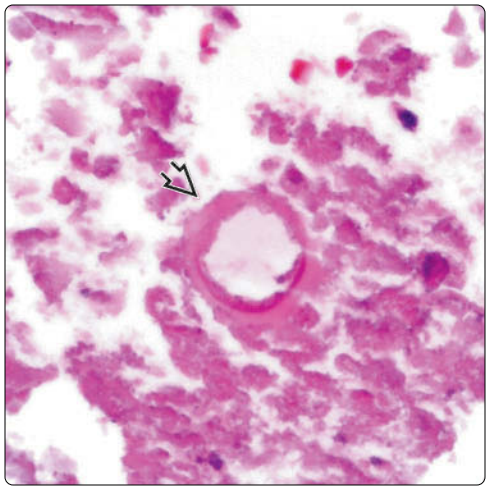

Acute Suppurative Pneumonia

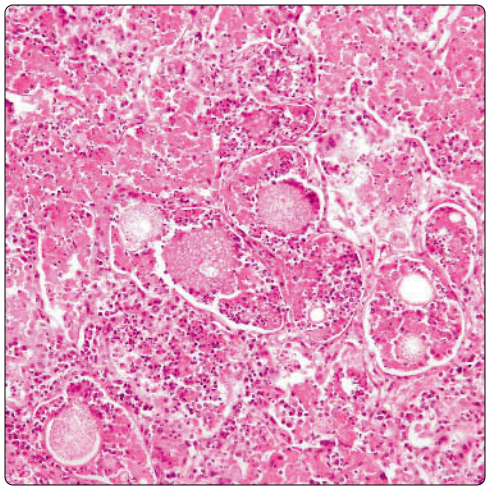

(Left) *Higher magnification of the organism in pulmonary coccidioidomycosis with localized granulomatous reaction (coccidioidoma) shows a single degenerating spherule devoid of endospores. The extensive necrosis often makes it difficult to identify viable organisms in these cases.* **(Right)** *Typical reaction in primary pulmonary infection with Coccidioides immitis shows acute suppurative pneumonia with neutrophilic infiltrates and abundant organisms lying within alveolar lumina.*

Organisms in Acute Infection

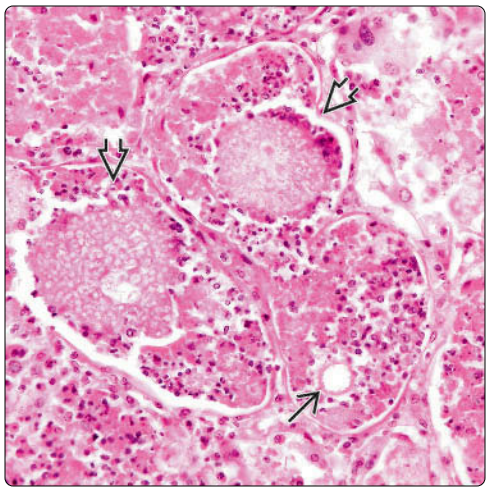

Organisms Within Alveolar Lumina

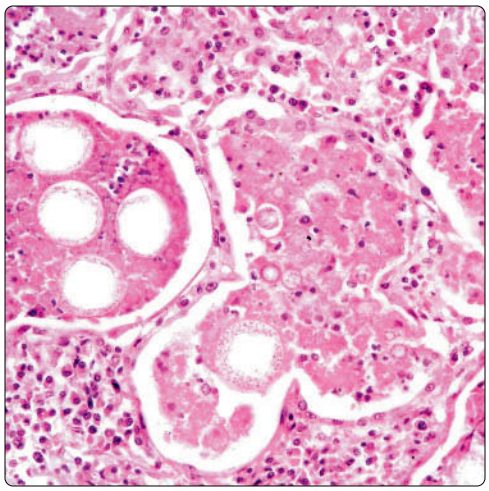

(Left) *Higher magnification of acute infection by coccidioidomycosis in the lung shows 2 large spherules filled with numerous endospores and surrounded by abundant neutrophilic infiltrates. Notice also a smaller empty spherule corresponding to an immature organism.* **(Right)** *Acute suppurative pneumonia in a patient with acute coccidioidomycosis shows multiple large spherules within distended alveolar lumina. Notice the intense neutrophilic infiltration in the interstitium.*

***Coccidioides* Spherule With Endospores**

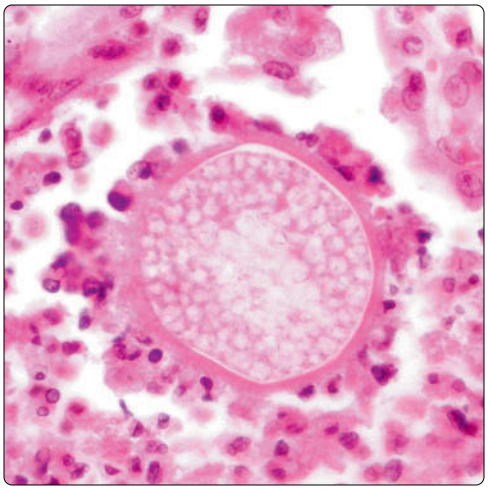

Spherules in Alveolar Spaces

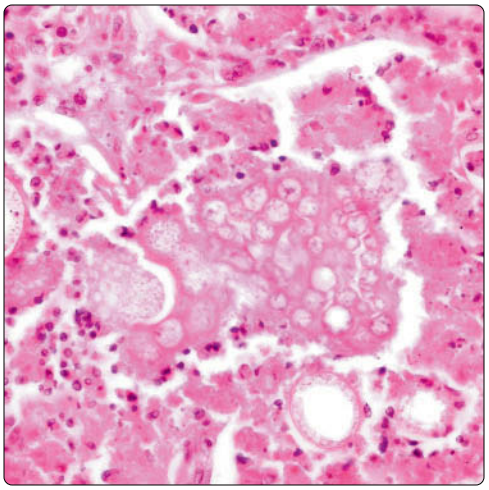

(Left) *Pulmonary coccidioidomycosis shows a large, round spherule filled with endospores. Notice Splendore-Hoeppli phenomenon characterized by radiating clusters of neutrophils admixed with fibrinous exudate along the outer surface of the structure.* **(Right)** *Pulmonary coccidioidomycosis shows destruction of alveolar walls by acute fibrinopurulent exudate admixed with mature and immature spherules. Some spherules have ruptured, releasing their endospores.*

Immature Spherules Within Alveoli

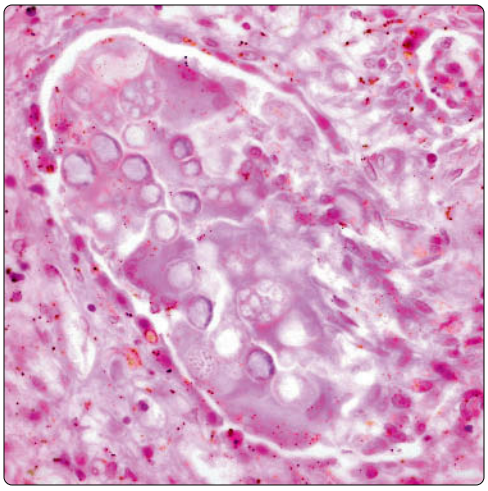

Immature Spherules

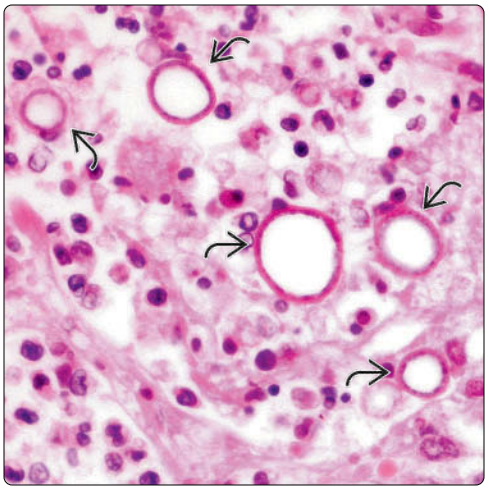

(Left) *Pulmonary coccidioidomycosis shows infiltration and dilatation of alveolar lumen by clusters of immature spherules. There is little inflammatory infiltration in this immunocompromised patient with AIDS.* **(Right)** *Primary pulmonary infection by coccidioidomycosis shows scattered immature spherules of Coccidioides immitis admixed with suppurative neutrophilic exudate. Notice the thin wall of the spherules ⇨, which are empty and devoid of endospores.*

Chronic Infection With Immature Spherules

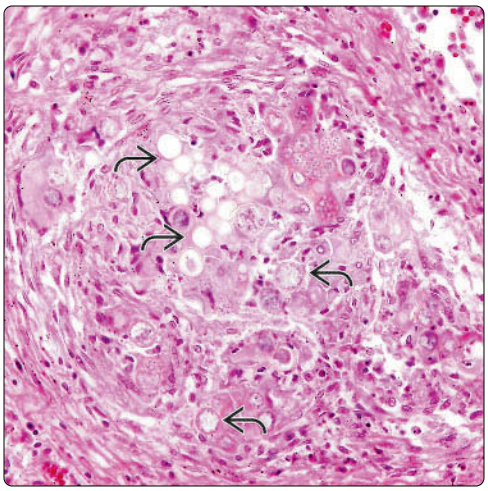

***Coccidioides*, PAS Stain**

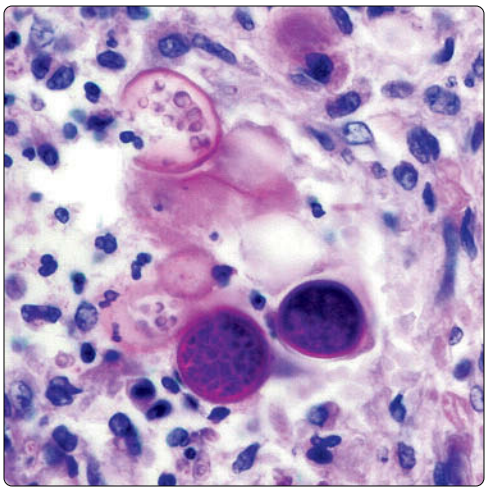

(Left) *Chronic infection with coccidioidomycosis in the lung shows small epithelioid granuloma containing multiple immature spherules ⇨ devoid of endospores. The organisms are admixed with multinucleated giant cells.* **(Right)** *Histochemical stain for PAS in chronic pulmonary coccidioidomycosis highlights the organisms. Notice the stain is strongly positive in the endospores as well as in the large spherules. Immature spherules also stain with the PAS stain.*

KEY FACTS

TERMINOLOGY

- Lung infection caused by fungus 3 Q H X P R F \ V W L V M L U R Y H F L (formerly 3 Q H X P R F \ V W L V F D U L Q L L

CLINICAL ISSUES

- Infantile form (plasma cell interstitial pneumonia) affects premature and malnourished infants
- Adult (sporadic) form occurs in AIDS patients and other immunocompromised patients with impaired CD4(+) lymphoid cells
- Insidious onset with respiratory and generalized symptoms of fever, dyspnea, tachypnea, cough, weight loss, and fatigue
- Favorable prognosis when appropriately treated; relapses are common in AIDS patients
- Infection is acquired by inhalation with primary infection occurring early in life and remaining latent in host
- Reinfection occurs when host becomes immunocompromised
- Survival rates of 50-90% with appropriate treatment

IMAGING

- HRCT shows characteristic symmetrical, bilateral ground-glass opacities with geographic distribution

MICROSCOPIC

- Typical pattern is characterized by foamy, granular eosinophilic intraalveolar exudates containing organisms
- Alveolar exudate is composed of fibrin admixed with abundant trophozoites and cysts, surfactant, and cellular debris
- Cysts are oval (4-7 µm) with collapsed or crescentic forms and exhibit grooves, folds, and dark-staining central dots

ANCILLARY TESTS

- Cysts are best stained in tissues with GMS
- Antibodies against pneumocystis can be used to highlight organisms in tissue sections by immunoperoxidase technique

Pulmonary Pneumocystosis

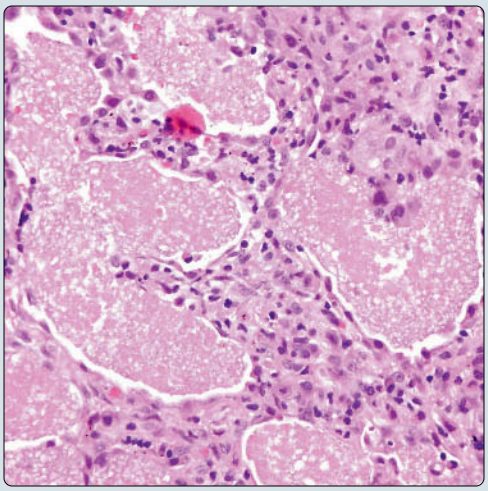

Frothy Exudate

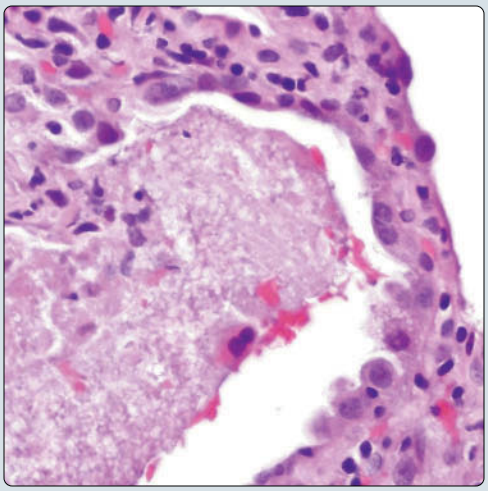

(Left) *Pulmonary pneumocystosis shows expansion of alveolar spaces by dense, frothy and granular eosinophilic exudate. The alveolar walls are distended and contain abundant inflammatory cells.* **(Right)** *Higher magnification from a lesion in a patient with pulmonary pneumocystosis shows dense, frothy intraalveolar exudate. The alveolar wall is lined by swollen and hyperplastic type II pneumocytes.*

GMS Stain

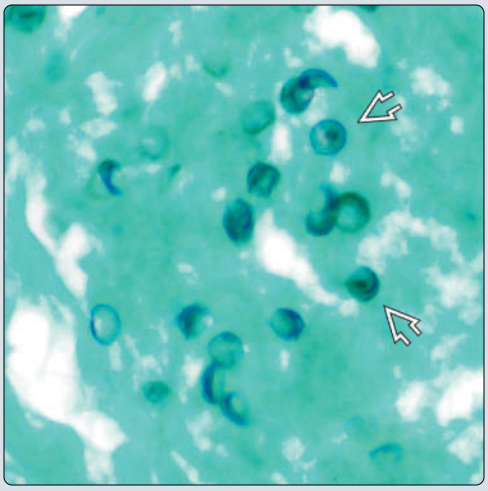

Navicular Cells

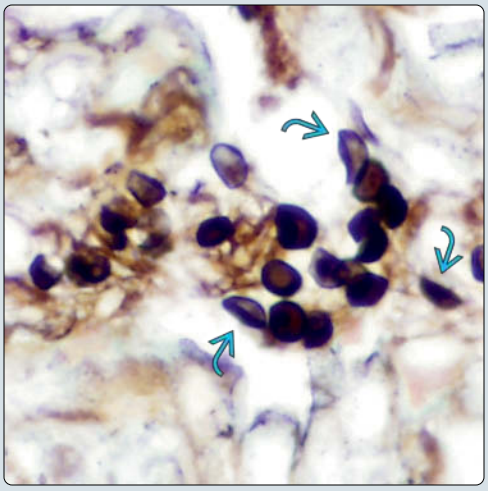

(Left) *Histochemical stain for GMS in pulmonary pneumocystosis shows the typical organisms with crescentic forms as well as some cysts with dark-staining central dots ➡. (Right) Another example of pulmonary pneumocystosis stained with Gomori methenamine silver shows the organisms stained dark brown. Navicular cells (boat-shaped) half-crescent forms are present ⇨.*

TERMINOLOGY

Abbreviations

- Pneumocystosis pneumonia (PCP)

Definitions

- Lung infection caused by fungus *Pneumocystis jirovecii* (formerly *Pneumocystis carinii*)

CLINICAL ISSUES

Natural History

- Infection is acquired by inhalation with primary infection occurring early in life and remaining latent in host
- Reinfection occurs when host becomes immunocompromised
- 2 major clinical forms
  - Infantile form (plasma cell interstitial pneumonia) affects premature and malnourished infants
  - Adult (sporadic) form occurs in AIDS patients and other immunocompromised patients with impaired CD4(+) lymphoid cells
    - Insidious onset with respiratory and generalized symptoms of fever, dyspnea, tachypnea, cough, weight loss, and fatigue
- Favorable prognosis when appropriately treated; relapses are common in AIDS patients

IMAGING

Radiographic Findings

- Early stages show fine pattern of ground-glass opacities involving perihilar regions
- Untreated cases progress to perihilar or diffuse bilateral airspace consolidation involving mainly lower lobes

CT Findings

- HRCT shows characteristic symmetrical, bilateral ground-glass opacities with geographic distribution
- AIDS patients show tendency to develop bilateral thin-walled cysts in 30% of cases showing subpleural distribution
- Atypical cases may show nodules, thick-walled cavities, and focal or asymmetric areas of consolidation

MACROSCOPIC

General Features

- Consolidation of pulmonary parenchyma with pale-gray or tan granular cut surface
- Nodules or cavities may occasionally be identified
- Small subpleural blebs and cysts are often noted in upper lobes

MICROSCOPIC

Histologic Features

- Histologic reaction patterns can be quite variable
  - Typical pattern is characterized by foamy, granular eosinophilic intraalveolar exudates containing organisms
    - Alveolar exudate is composed of fibrin admixed with abundant trophozoites and cysts, surfactant, and cellular debris
    - Alveolar exudate may be focal or diffuse and can be accompanied by mild interstitial inflammation and type II pneumocyte hyperplasia
  - Atypical patterns
    - Dense interstitial lymphoid infiltrates (lymphoid interstitial pneumonia-like pattern), which may obscure alveolar exudates
    - Interstitial fibrosis and organizing pneumonia may be seen in resolving phase of process
    - Diffuse alveolar damage pattern with hyaline membranes
    - Absence of characteristic foamy alveolar exudate can be seen in up to 50% of non-HIV patients
    - Miliary pattern of involvement with multiple small, scattered foci of PCP
    - Cavitary lesions (including subpleural blebs), intraparenchymatous cysts, or necrotizing granulomas may be seen
    - Granulomatous pattern with clusters of epithelioid histiocytes and multinucleated giant cells lining alveolar walls
    - Interstitial microcalcifications can be seen in small percentage of patients and should raise possibility of PCP
    - Vascular invasion by exudate containing organisms and vasculitis can be seen in small percentage of patients

Cytologic Features

- Organisms have 3 life stages: Sporozoites, trophozoites, and cysts
- Cysts are most commonly encountered and are oval (4-7 µm) with collapsed or crescentic forms
- Cysts may display prominent grooves or folds and small, darkly staining, dot-like structures at their centers

ANCILLARY TESTS

Histochemistry

- Cysts are best stained in tissues with GMS
- Trophozoites are seen only in smears stained with Giemsa (Diff-Quik)

Immunohistochemistry

- Antibodies against pneumocystis can be used to highlight organisms in tissue sections by immunoperoxidase technique

DIFFERENTIAL DIAGNOSIS

Histoplasmosis

- *Histoplasma capsulatum* may show similar morphology to *Pneumocystis jirovecii*, including central dark dots
  - *Pneumocystis jirovecii* lacks budding forms unlike *Histoplasma capsulatum* which is characterized by budding yeast

SELECTED REFERENCES

1. Fauchier T et al: Detection of Pneumocystis jirovecii by quantitative PCR To differentiate colonization and pneumonia in immunocompromised HIV-positive and HIV-negative patients. J Clin Microbiol. 54(6):1487-95, 2016
2. Matsumura Y et al: Clinical characteristics of Pneumocystis pneumonia in non-HIV patients and prognostic factors including microbiological genotypes. BMC Infect Dis. 11(1):76, 2011

Pulmonary Pneumocystosis

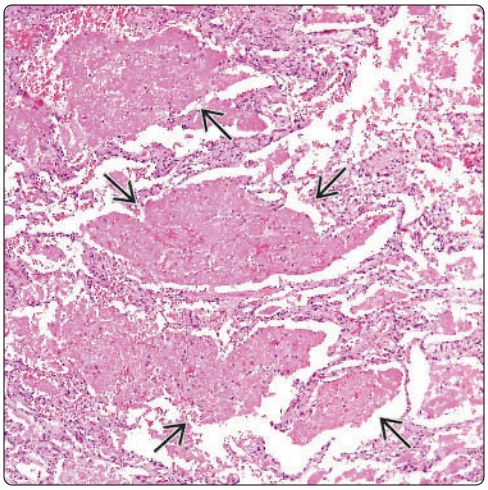

Frothy Intraalveolar Exudates

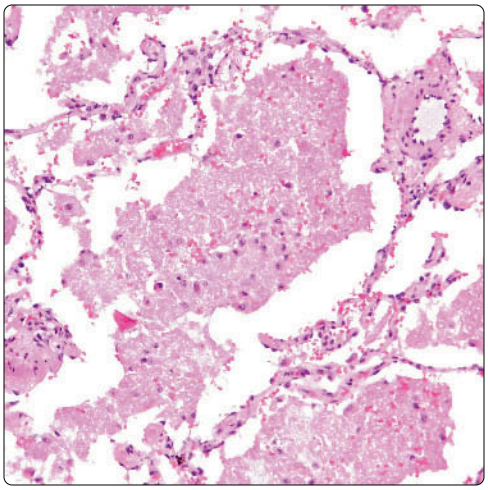

(Left) *Typical histologic appearance of pulmonary pneumocystosis is characterized by foamy, granular eosinophilic intraalveolar exudates ⇨ containing abundant organisms. The organisms cannot be easily visualized on routine microscopy and usually require the use of special stains.* **(Right)** *Typical appearance of pulmonary pneumocystosis shows frothy intraalveolar eosinophilic exudates. Notice the lack of damage or inflammation in the alveolar walls.*

Frothy Exudate: High Power

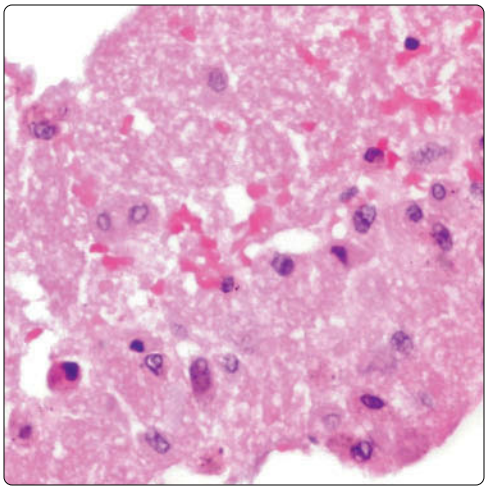

Hyaline Membranes

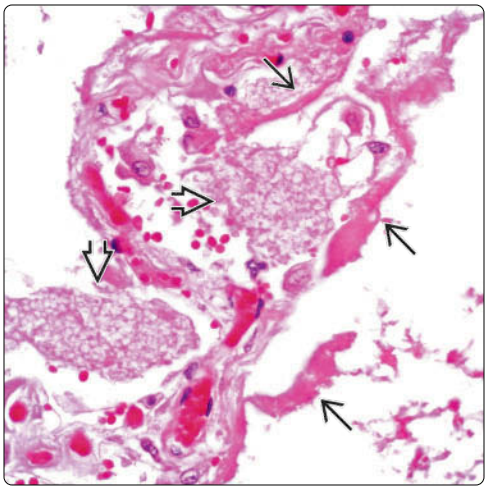

(Left) *Higher magnification of the frothy intraalveolar exudate shows mostly fibrin admixed with a few scattered inflammatory cells. Numerous small, round "ghosts" of cells are seen in the background, which correspond to the unstained organisms.* **(Right)** *Acute pulmonary pneumocystosis is characterized by diffuse alveolar damage associated with intraalveolar exudates. Notice the frothy alveolar exudates ⇨ and the hyaline membranes lining the alveoli ⇨.*

Hyperplastic Type II Pneumocytes

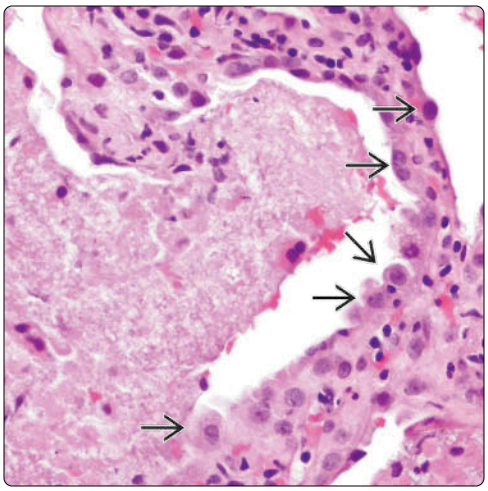

Dense Lymphoid Infiltrate

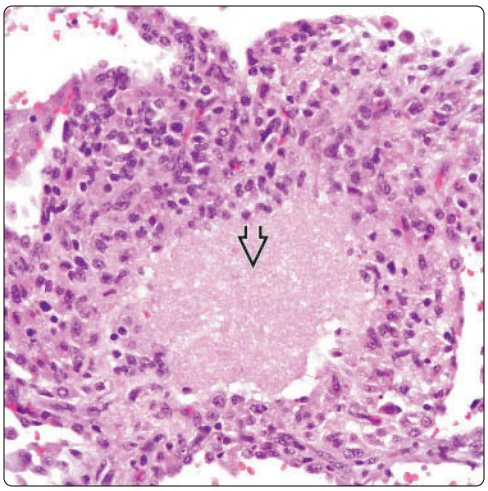

(Left) *Acute pulmonary pneumocystosis shows abundant frothy intraalveolar exudate and hyperplasia of type II pneumocytes in the lining of the airspace ⇨.* **(Right)** *Pulmonary pneumocystosis simulating lymphoid interstitial pneumonia shows frothy intraalveolar exudate within the alveolar lumen ⇨ surrounded by a dense lymphoid infiltrate that is distending and replacing the alveolar walls. Cases like this may be confused for lymphoid interstitial pneumonia if the exudate is overlooked.*

Granulomatous Pneumocystosis

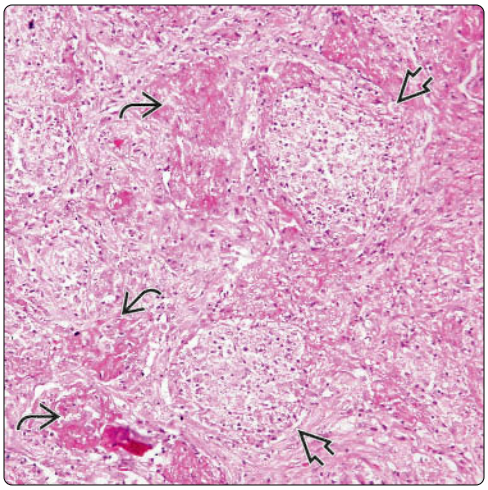

Interstitial Calcification

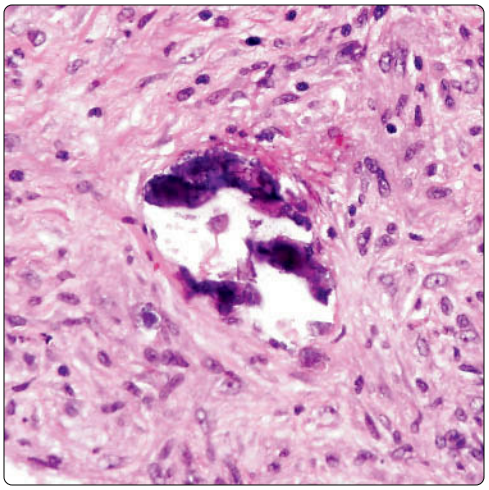

(Left) *Pulmonary pneumocystosis with granulomatous reaction shows well-formed epithelioid granulomas ⇨ adjacent to discrete foci containing frothy eosinophilic exudates ⇨. The granulomas can sometimes obscure the diagnosis when the exudates are minimal.* **(Right)** *Stromal calcification is seen in a case of granulomatous pulmonary pneumocystosis. Interstitial calcifications can be seen in a small proportion of patients with pneumocystosis and are a helpful clue for diagnosis.*

GMS Stain

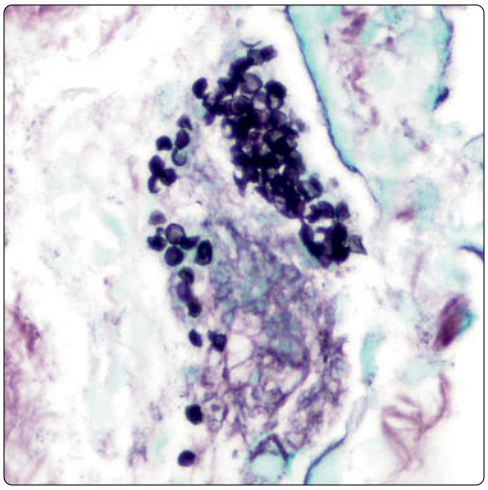

GMS Stain

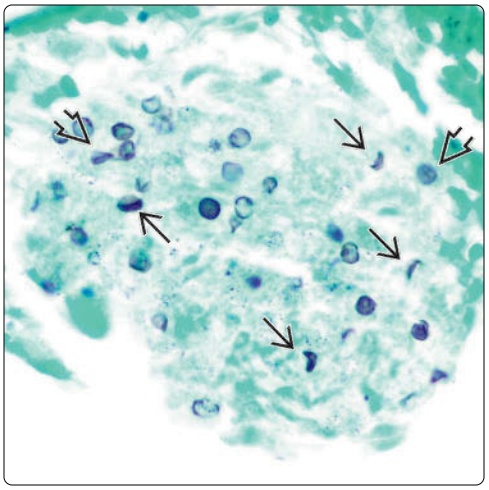

(Left) *Pulmonary pneumocystosis stained with GMS shows numerous small, round organisms lying within the alveolar exudate.* **(Right)** *Pulmonary pneumocystosis stained with GMS shows small, oval cysts. The cysts can display collapsed or crescentic forms ⇨ and have been described as disc or boat-shaped. They can also display distinctive longitudinal grooves or folds ⇨.*

GMS Stain

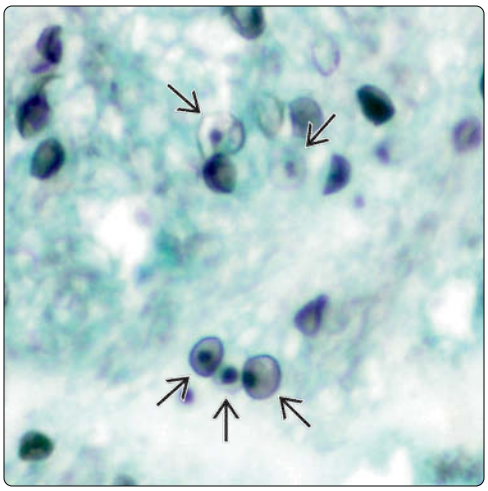

Pneumocystis Immunostaining

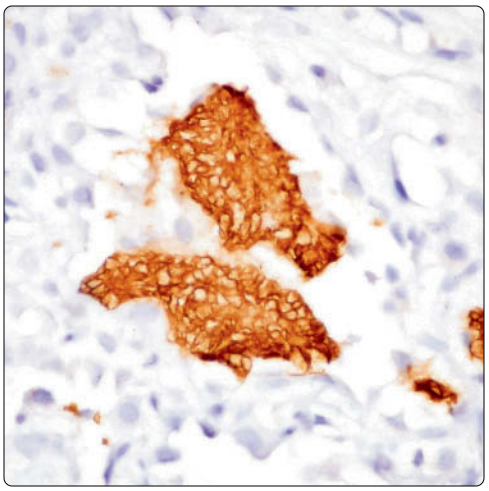

(Left) *Pulmonary pneumocystosis stained with GMS stain shows another characteristic feature of the cysts, which is the presence of dark-staining central "dots" ⇨.* **(Right)** *Immunohistochemical staining in pulmonary pneumocystosis with antibodies against pneumocystis shows multiple organisms lying within the alveolar lumina. The organisms show a dark brown reaction with this antibody.*

Blastomycosis

KEY FACTS

TERMINOLOGY

- Pulmonary infection caused by inhalation of % O D V W R P \ F H V G H U P D W L W L G L V {

CLINICAL ISSUES

- Geographic distribution in USA: Mississippi, Missouri, and Ohio River Valley
- Acute infection is usually self-limited and may simulate bacterial pneumonia
- Chronic infection presents with gradual onset of cough, low-grade fever, hemoptysis, weight loss, and pleuritic pain
- Infection may be acute or chronic; most often self-limited and accompanied by flu-like symptoms
- Some cases in acute phase may lead to respiratory distress syndrome and cavitary lesions
- Extrapulmonary hematogenous spread may occur to variety of organs, in particular skin and bone
- Not common infection in immunocompromised patients, but disease is more aggressive in HIV(+) patients
- Advanced chronic cases may lead to development of sclerosing mediastinitis

MICROSCOPIC

- Typical reaction of lung parenchyma to % G H U P D W L W L G L V suppuration with abscess formation
- Advanced stages show necrotizing palisading granulomas
- Organisms are round to oval budding yeasts measuring 8-15 µm with thick, refractile cell walls
- Organisms stain positive with GMS and may also stain positive for PAS

ANCILLARY TESTS

- Direct immunofluorescence or immunohistochemistry in deparaffinized tissue sections is sensitive way to make diagnosis
- Organisms stain positive with GMS and may also stain positive for PAS

Epithelioid Granuloma

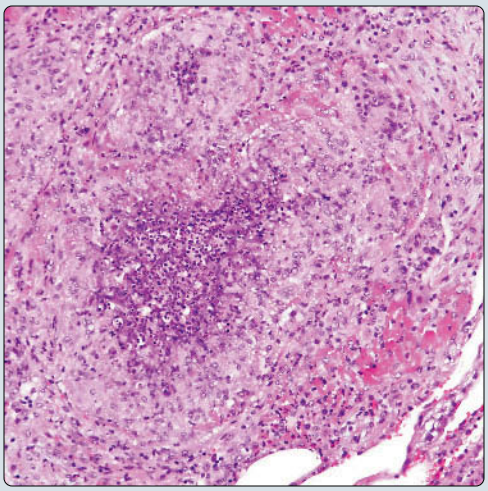

Yeast Forms

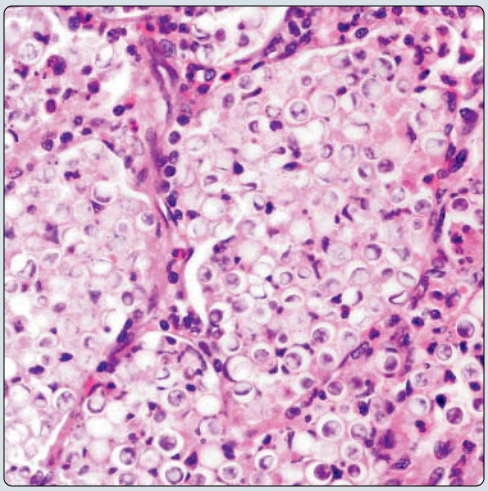

(Left) *Scanning magnification of a suppurative, epithelioid granuloma in pulmonary blastomycosis shows a dense collection of epithelioid histiocytes with central necrosis and neutrophilic infiltrates.* **(Right)** *Higher magnification from an acute lesion of pulmonary blastomycosis shows numerous yeast forms stuffing the alveolar lumina. The organisms are easily recognized on routine histology due to their thick, refractile cell walls.*

High Power: Hematoxylin and Eosin

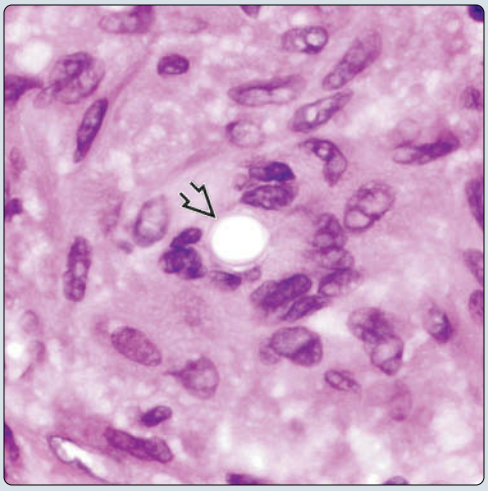

GMS Stain

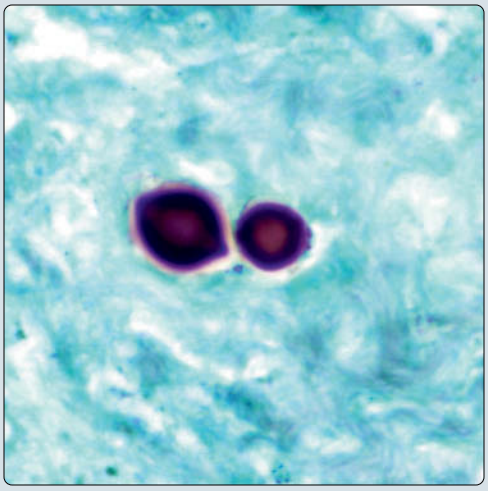

(Left) *Higher magnification from an epithelioid granuloma in pulmonary blastomycosis shows abundant epithelioid histiocytes surrounding a large (~ 10 µm), oval yeast form ⇨ with a thin refractile capsule.* **(Right)** *Pulmonary blastomycosis stained with GMS shows round to oval yeast with thick walls.*

TERMINOLOGY

Synonyms

- North American blastomycosis

Definitions

- Pulmonary infection caused by inhalation of % O D V W R P \ F H V G H U P D W L W L G L V {fungus

ETIOLOGY/PATHOGENESIS

Environmental Exposure

- Natural habitat for fungus is most likely wood

CLINICAL ISSUES

Epidemiology

- Incidence
  - Geographic distribution in USA: Mississippi, Missouri, and Ohio River Valley
  - Mostly restricted to North America, although cases have been described in other countries in South America, Asia, and Middle East
- Age
  - Young adults
- Sex
  - Male predilection

Presentation

- Acute infection is usually self-limited and may simulate bacterial pneumonia
- Chronic infection presents with gradual onset of cough, low-grade fever, hemoptysis, weight loss, and pleuritic pain

Laboratory Tests

- Culture is most definitive way to establish the diagnosis but may take up to 3 weeks to be positive

Natural History

- Infection may be acute or chronic; most often self-limited and accompanied by flu-like symptoms
- Some cases in acute phase may lead to respiratory distress syndrome and cavitary lesions
- Extrapulmonary hematogenous spread may occur to variety of organs, in particular skin and bone
- Not common infection in immunocompromised patients, but disease is more aggressive in HIV(+) patients
- Advanced chronic cases may lead to development of sclerosing mediastinitis

Treatment

- Drugs
  - Amphotericin B used in severe life-threatening infections
  - Ketoconazole used in mild or moderate infections

Prognosis

- Acute primary blastomycosis usually self-limited

IMAGING

Radiographic Findings

- Focal or diffuse parenchymal consolidation affecting upper lobes
- Solitary or multiple nodules can occur in ~ 30% of patients
- Single or multiple cavities can be seen in 15-20% of patients
- Pleural effusion and pleural thickening seen in up to 15% of patients

CT Findings

- Localized mass with air bronchograms
- Hilar &/or mediastinal lymphadenopathy

MACROSCOPIC

General Features

- Lesions may be nodular and localized or diffuse with miliary pattern of spread
- Chronic lesions show fibrosis and hyalinization of nodules with cavitation similar to other fungal processes

MICROSCOPIC

Histologic Features

- Typical reaction of lung parenchyma to % G H U P D W L W L G L V is suppuration with abscess formation
- Advanced stages show necrotizing palisaded granulomas
- Granulomas may become fibrotic and cavitary, but calcification is very uncommon

Cytologic Features

- Organisms are round to oval yeasts measuring 8-15 µm with thick, refractile cell walls
- Yeasts frequently show budding with broad base attached to parent cell
- Organisms are more numerous in suppurative than in granulomatous lesions

ANCILLARY TESTS

Immunofluorescence

- Direct immunofluorescence or immunohistochemistry in deparaffinized tissue sections is sensitive way to make diagnosis

Histochemistry

- Organisms stain positive with GMS and may also stain positive for PAS

DIFFERENTIAL DIAGNOSIS

Cryptococcosis

- Does not show broad-based budding yeast, and capsule-deficient variant is negative for mucicarmine stains
- Capsule-deficient & U \ S W R F R F F X V is positive with Fontana-Masson stain (unlike blastomycosis, which is negative)

SELECTED REFERENCES

1. Bariola JR et al: Pulmonary blastomycosis. Semin Respir Crit Care Med. 32(6):745-53, 2011
2. Mukhopadhyay S: Role of histology in the diagnosis of infectious causes of granulomatous lung disease. Curr Opin Pulm Med. 17(3):189-96, 2011
3. Patel AJ et al: Diagnosis of blastomycosis in surgical pathology and cytopathology: correlation with microbiologic culture. Am J Surg Pathol. 34(2):256-61, 2010

KEY FACTS

TERMINOLOGY

- Disease caused by inhalation of + L V W R S O D V P D F D S V X O D W [illegible] fungus

CLINICAL ISSUES

- Clinical forms of histoplasmosis include benign, self-limited, acute, chronic, progressive disseminated, and with mediastinal involvement
- Immunosuppressed patients generally develop progressive disseminated disease involving other organs
- Most patients with primary pulmonary infection are asymptomatic (75% of patients)
- Patients with acute pulmonary histoplasmosis present with self-limited disease in upper lobes that resolves spontaneously
- Symptoms usually develop 2 weeks after exposure and include fever, chills, cough, and muscle pain

MICROSCOPIC

- Acute infection characterized by acute fibrinous pneumonia with abundant organisms within macrophages in alveolar spaces
- Disseminated infection characterized by granulomatous inflammation that may show central areas of necrosis
- Granulomas may show characteristic lamellar patten of concentric fibrosis with progressive stages of calcification
- Organisms are round or oval, small (2-4 µm), uninucleated, and devoid of capsule, with single narrow-based buds
- Organisms can also show small, dark-staining central "dot" similar to those seen in 3 Q H X P R F \ V W L V
- Cytoplasm of yeast can be retracted from cell wall, forming "halo" that resembles capsule
- Organisms are highlighted in tissue sections with GMS stains
- PAS also stains + L V W R S O D V P D but more weakly

(Left) *Gross appearance of a pulmonary Histoplasma granuloma shows a distinctive lamellar pattern of concentric fibrosis with progressive stages of calcification.* **(Right)** *Histologic appearance of an old hyalinized Histoplasma granuloma of the lung shows concentric layers of fibrotic and calcified material surrounding a hyalinized central core.*

***Histoplasma* Granuloma**

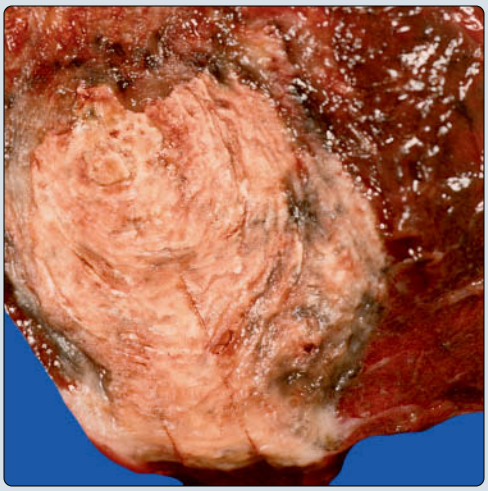

Old Hyalinized Granuloma

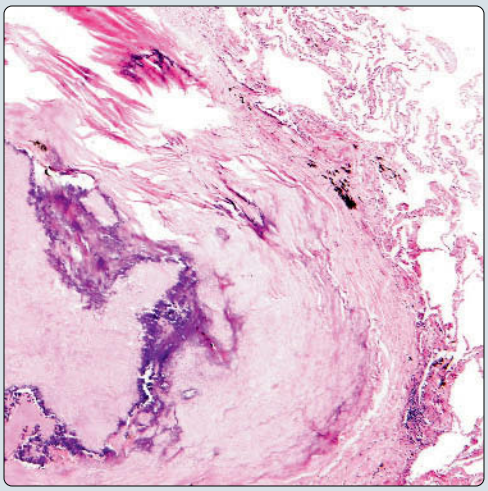

(Left) *Active lesions show necrotizing and nonnecrotizing epithelioid granulomas with abundant multinucleated giant cells.* **(Right)** *GMS highlights the organisms in pulmonary histoplasmosis, showing numerous clustered small yeasts devoid of a capsule with occasional single narrow-based buds.*

Active Granuloma

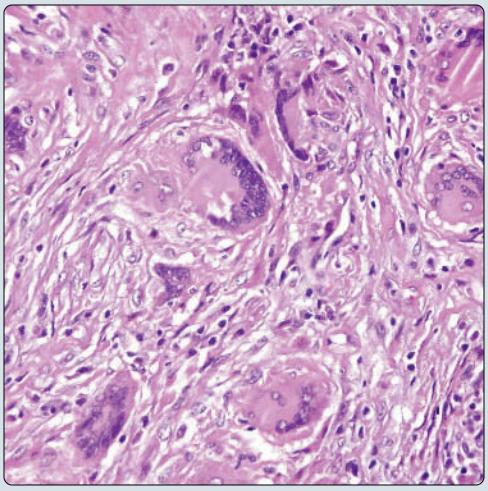

GMS Stain in Histoplasmosis

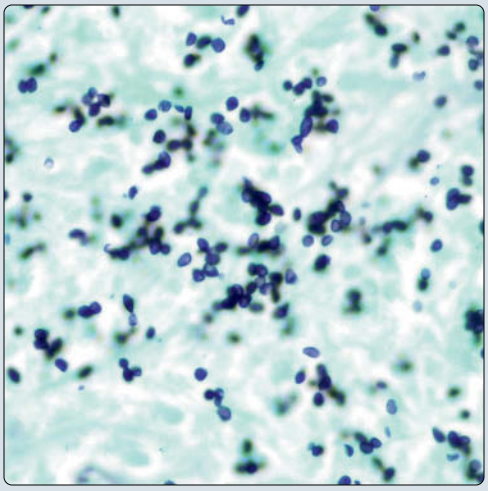

ETIOLOGY/PATHOGENESIS

Environmental Exposure

- Fungus lives in soil and is endemic to south central United States, especially Mississippi and Ohio Valleys
- Infection caused by inhalation of infected dust, most commonly from bird droppings

CLINICAL ISSUES

Presentation

- Clinical forms of histoplasmosis include benign, self-limited, acute, chronic, progressive disseminated, and with mediastinal involvement
- Most patients with primary pulmonary infection are asymptomatic (75% of patients)
- Patients with acute pulmonary histoplasmosis present with self-limited disease in upper lobes that resolves spontaneously
- Patients exposed to large inoculum may develop life-threatening infection with acute respiratory distress syndrome
- Symptoms usually develop 2 weeks after exposure and include fever, chills, cough, and muscle pain
- Complications of infection include calcified pulmonary nodules, chronic cavitary lesions, or mediastinal fibrosis
- Immunosuppressed patients generally develop progressive disseminated disease involving other organs

Treatment

- Drugs
  - Progressive disseminated disease requires treatment with antifungal agents, such as amphotericin B, ketoconazole, etc.

Prognosis

- Acute primary infection is self-limited and resolves spontaneously without treatment
- Progressive disseminated disease in immunocompromised patients is associated with 80% mortality without treatment

MACROSCOPIC

General Features

- In acute histoplasmosis, cut section shows patchy pneumonia
- Disseminated histoplasmosis characterized by congestion and scattered granulomas on cut section
- Chronic histoplasmosis shows diffuse, bilateral infiltrates associated with cavitary lesions resembling tuberculosis
- Solitary lesions (histoplasmoma) are round, subpleural, and show pattern of laminated, concentric calcification

MICROSCOPIC

Histologic Features

- Acute infection characterized by acute fibrinous pneumonia with abundant organisms within macrophages in alveolar spaces
- Disseminated infection characterized by granulomatous inflammation that may show central areas of necrosis
- Occasionally small, solid, nonnecrotizing epithelioid granulomas may develop that can mimic sarcoidosis
- Chronic infection characterized by formation of necrotizing granulomas
- Granulomas may show characteristic lamellar patten of concentric fibrosis with progressive stages of calcification
- Histoplasmomas consist of large necrotizing granulomas surrounded by fibrous capsule with large central zones of necrosis that may become calcified
- Disseminated form in immunosuppressed patients shows extensive tissue infiltration with abundant organisms and no tissue reaction

Cytologic Features

- + L V W R S O D V P D is seen in tissues in yeast form and is usually multiple and clustered
- Organisms are round or oval, small (2-4 µm), uninucleated, and devoid of capsule with single narrow-based buds
- Organisms can also show small, dark-staining central "dot" similar to those seen in 3 Q H X P R F \ V W L V
- Cytoplasm of yeast can be retracted from cell wall, forming "halo" that resembles capsule
- Organisms are extremely rare in tissue sections and require use of special stains to visualize
- Organisms are usually present in centers of necrotizing granulomas or within macrophages

ANCILLARY TESTS

Histochemistry

- Organisms are best stained with GMS
- PAS stains will also identify organisms, particularly in acute infection when they are numerous

Immunofluorescence

- Direct immunofluorescence on histologic sections can help establish diagnosis

DIFFERENTIAL DIAGNOSIS

Pneumocystosis

- 3 Q H X P R F \ V W L V M L U R Y H F L may show identical morphology to histoplasma (including central "dots") but is not found within large necrotizing granulomas

Blastomycosis

- % O D V W R P \ F H V G H U P D W L W L G L V may show identical morph + L V W R S O D V P D but is characterized by broad-based budding yeast and thicker walls

Capsule-Deficient *Cryptococcus*

- Cell walls are strongly positive for Fontana-Masson and may also be weakly positive for mucicarmine

SELECTED REFERENCES

1. Gailey MP et al: A cytomorphometric analysis of pulmonary and mediastinal granulomas: differentiating histoplasmosis from sarcoidosis by fine-needle aspiration. Cancer Cytopathol. 123(1):51-8, 2015
2. Knox KS: Perspective on coccidioidomycosis and histoplasmosis. Am J Respir Crit Care Med. 189(6):752-3, 2014
3. Mukhopadhyay S: Role of histology in the diagnosis of infectious causes of granulomatous lung disease. Curr Opin Pulm Med. 17(3):189-96, 2011
4. Hage CA et al: Pulmonary histoplasmosis. Semin Respir Crit Care Med. 29(2):151-65, 2008

Necrotizing Palisaded Granuloma

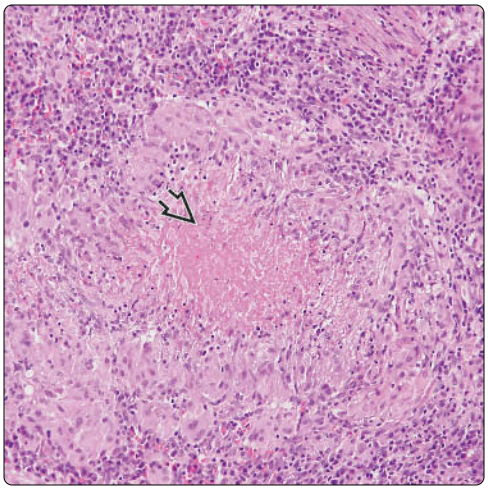

Edge of Necrotizing Granuloma

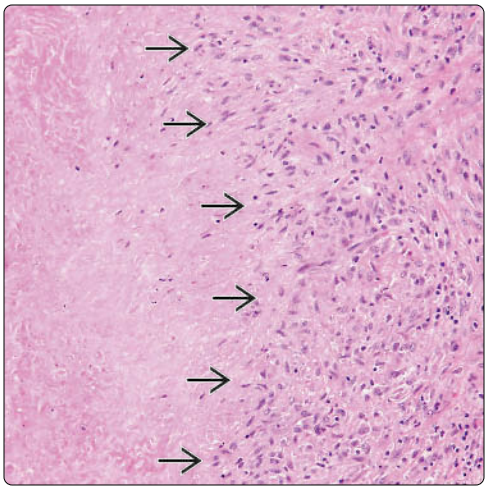

(Left) *Necrotizing palisading granuloma in pulmonary histoplasmosis shows a well-defined collection of epithelioid histiocytes surrounding a centrally necrotic area. The organisms cannot be visualized on routine histology and require the use of special stains for identification.* **(Right)** *Higher magnification of a palisaded necrotizing granuloma in a patient with pulmonary histoplasmosis shows a necrotic center bordered by a rim of palisaded histiocytes.*

Suppurative Granuloma

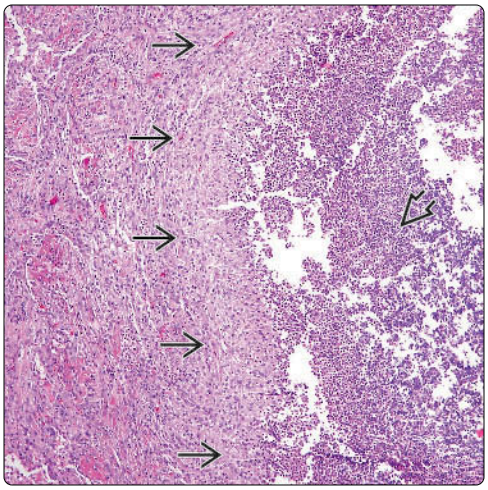

Higher Magnification of Suppurative Granuloma

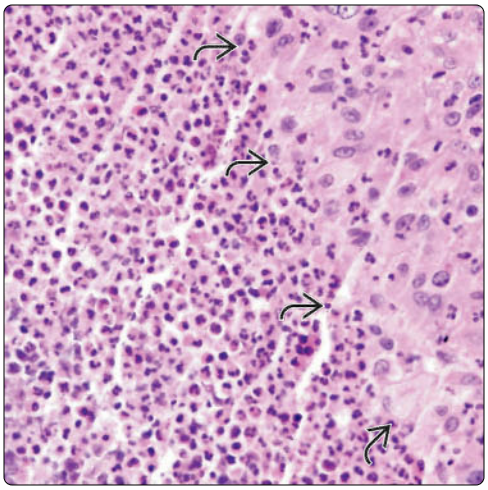

(Left) *Suppurative granuloma in pulmonary histoplasmosis shows a well-defined rim of epithelioid histiocytes circumscribing a dense zone of suppuration containing abundant neutrophilic infiltrates.* **(Right)** *Higher magnification of a suppurative granuloma in pulmonary histoplasmosis shows a rim of epithelioid histiocytes showing a sharp transition with a central area of suppuration. Sheets of neutrophils are seen, but organisms could not be visualized on routine stains.*

Nonnecrotizing Epithelioid Granuloma

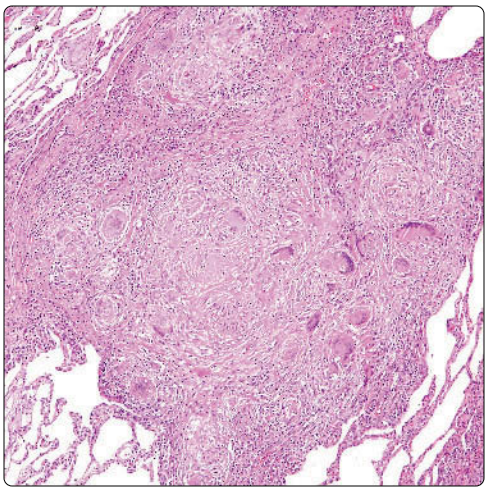

Multinucleated Giant Cells

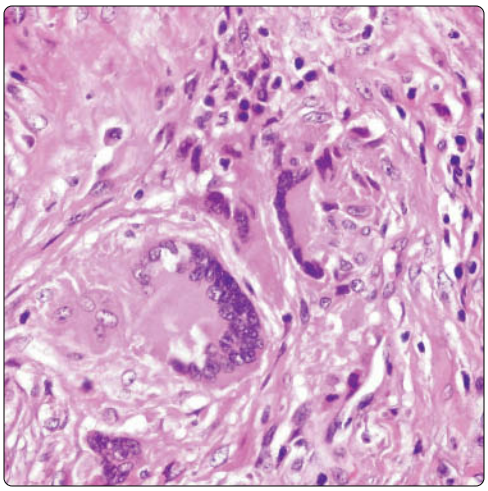

(Left) *Nonnecrotizing epithelioid granuloma (so-called productive granuloma) in a patient with pulmonary histoplasmosis shows focalized accumulation of epithelioid histiocytes devoid of central areas of necrosis. Cases like this can mimic sarcoidosis, but special stains will reveal evidence of the characteristic organisms.* **(Right)** *Higher magnification of nonnecrotizing epithelioid granuloma in a patient with pulmonary histoplasmosis shows multinucleated giant cells.*

Solitary Necrotizing Granuloma

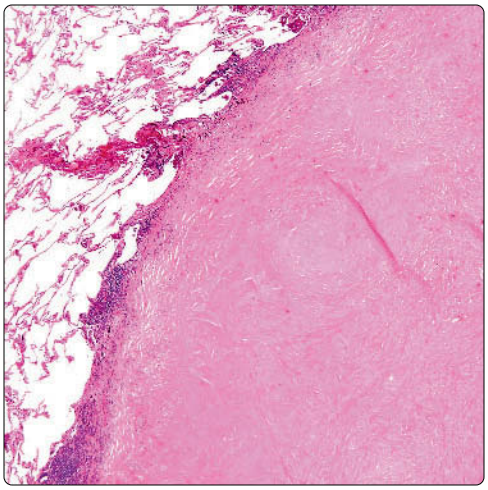

Hyalinizing Granuloma

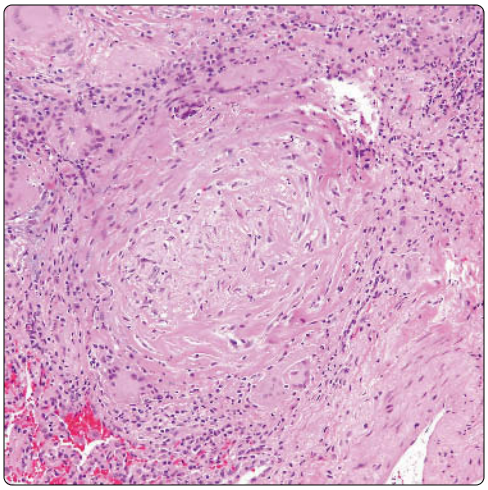

(Left) *Solitary histoplasmoma in pulmonary histoplasmosis shows a characteristic well-circumscribed nodule that is sharply separated from the surrounding lung parenchyma with extensive central areas of necrosis.* **(Right)** *Hyalinizing granuloma in a patient with pulmonary histoplasmosis shows a well-circumscribed collection of epithelioid histiocytes with concentric layers of hyalinized collagen. Progression of the process leads to formation of a fibrous capsule and calcification.*

Higher Magnification of Hyalinizing Granuloma

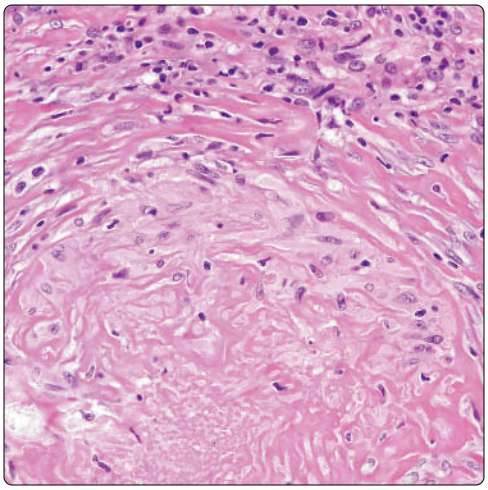

GMS Stain in Necrotizing Granuloma

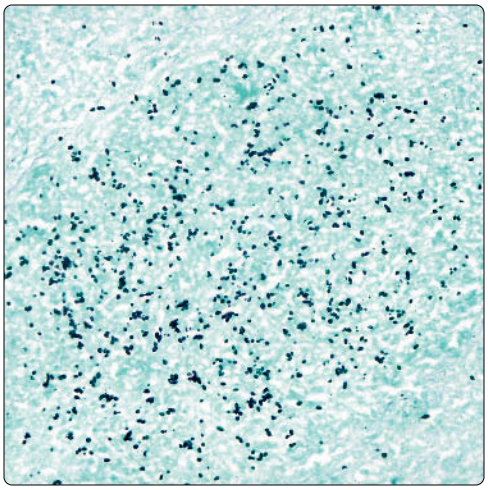

(Left) *Higher magnification of a fibrosing granuloma in pulmonary histoplasmosis shows dense deposits of hyalinized collagen arranged in layers around the periphery of the granuloma.* **(Right)** *GMS stain in a necrotizing granuloma of a patient with pulmonary histoplasmosis shows numerous organisms forming clusters in the central portion of the granuloma. The number of organisms can vary and decreases with the age of the lesions.*

Budding Yeast Stained With GMS

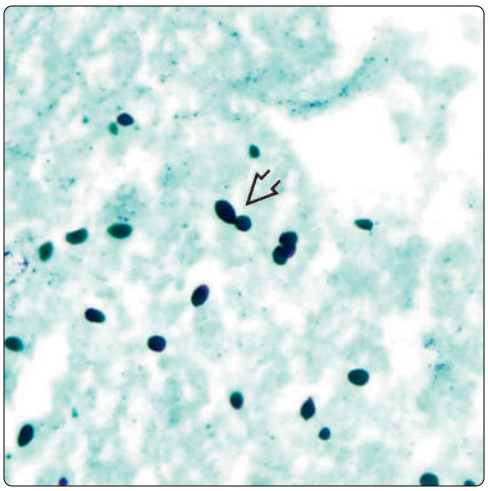

Small Yeast, PAS Stain

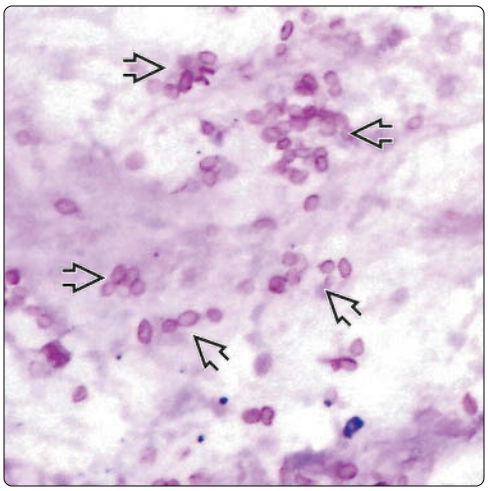

(Left) *Higher magnification of pulmonary histoplasmosis stained with GMS shows small, round to oval yeast devoid of a capsule. One of the organisms shows budding, with a single narrow-based bud.* **(Right)** *High magnification of pulmonary histoplasmosis stained with PAS stain shows numerous clusters of scattered small yeasts. Notice that the organisms stain much less intensely than with the GMS stain.*

Tuberculosis

KEY FACTS

TERMINOLOGY

- Tuberculosis (TB)
- Lung infection caused by inhalation of 0\FREDFWHULXP WXEHUFXORVLV

CLINICAL ISSUES

- Primary infection usually asymptomatic and leads to formation of Ghon complex (apical nodule with calcification) and hilar lymphadenopathy
- Progressive primary TB occurs when primary foci do not involute and progress to disseminated, cavitary lesions
- Most common mechanism of secondary TB is reactivation of latent focus of infection
- Often associated with chronic, debilitating diseases or immunosuppressive states (AIDS, transplant, cancer, diabetes, alcoholism)
- ~ 1/3 of world's population is infected with TB; more prevalent in underdeveloped countries
- ~ 10% of HIV-infected patients will develop active disease annually

MICROSCOPIC

- Basic pathologic manifestation of TB is granulomatous inflammation, with necrotizing, palisading epithelioid granulomas
- Palisading granulomas can progress to complete fibrosis and calcification
- Necrotizing granulomas may enlarge to form cavities with central liquefaction that may range from 3-10 cm in diameter
- Mycobacteria are slender rods measuring 4 µm in length; they cannot be visualized on routine histology and require special stains

ANCILLARY TESTS

- Best stain for 0 WXEHUFXORVLV is Ziehl-Neelsen, which stains acid-fast bacilli
- Mycobacterial DNA can be demonstrated by PCR

Gross Appearance of Pulmonary Tuberculosis

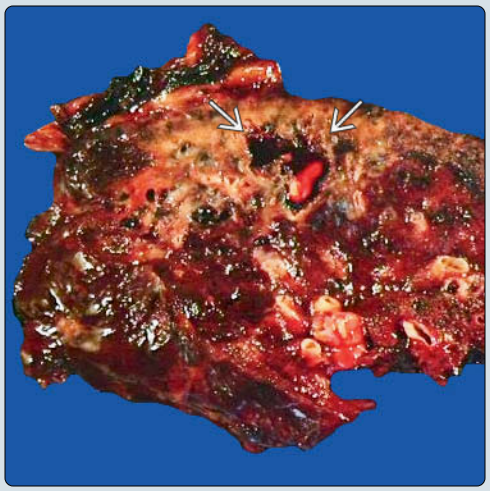

Necrotizing Granuloma

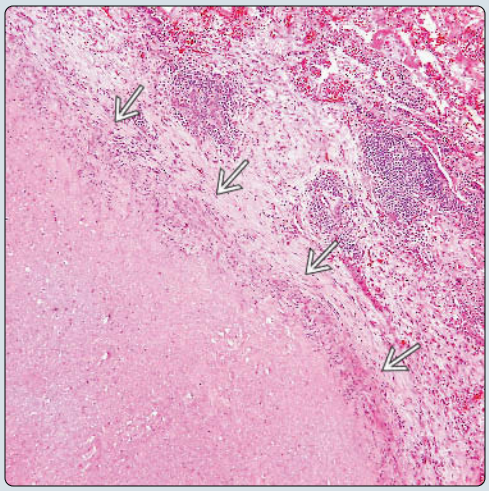

(Left) *Gross photo of the lung in active pulmonary tuberculosis shows subpleural areas of consolidation with cavitary lesions containing caseous material in the lumen ➡.* **(Right)** *The hallmark of tuberculosis in the lung is the presence of necrotizing granulomas ➡, which contain abundant, necrotic, "cheesy" material (so-called caseous necrosis).*

Caseating Granuloma

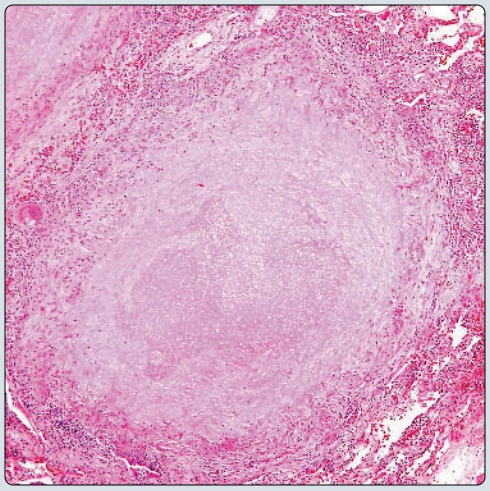

Acid-Fast Bacilli

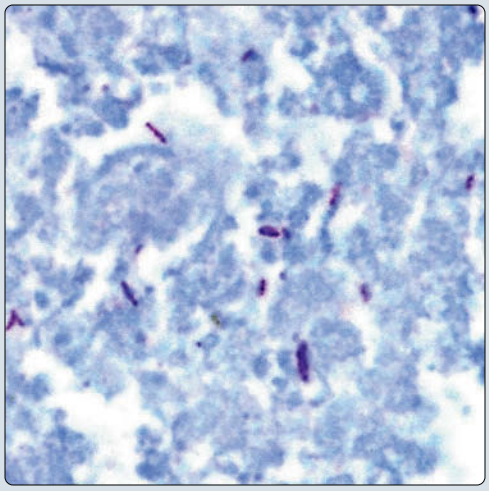

(Left) *Typical histologic appearance of pulmonary tuberculosis characterized by necrotizing caseating granuloma shows peripheral palisading of histiocytes surrounding a necrotic center.* **(Right)** *Ziehl-Neelsen stain for acid-fast bacilli shows a few slender rods that stain brightly red. Identification of the organisms may be quite difficult and requires extensive search, particularly in the areas of necrosis.*

TERMINOLOGY

Abbreviations

- Tuberculosis (TB)

Definitions

- Lung infection caused by inhalation of 0\FREDFWHULXP WXEHUFXORVLV

ETIOLOGY/PATHOGENESIS

Infectious Agents

- TB transmitted through inhalation of airborne droplets contaminated with bacillus

CLINICAL ISSUES

Epidemiology

- Incidence
  - ~ 1/3 of world's population is infected with TB; more prevalent in underdeveloped countries
  - ~ 10% of HIV-infected patients will develop active disease annually

Presentation

- Primary TB is defined as infection occurring in previously uninfected host
  - Primary infection is usually asymptomatic and leads to formation of Ghon complex (apical nodule with calcification) and hilar lymphadenopathy
  - Progressive primary TB occurs when primary foci do not involute and progress to disseminated, cavitary lesions
  - Fulminant infection with dissemination via bloodstream can lead to miliary TB
- Secondary or chronic TB is defined as active disease developing in previously sensitized host
  - Most common mechanism of secondary TB is reactivation of latent focus of infection
  - May also be result of massive reinfection from external source
  - Symptoms include cough, weight loss, fatigue, and fever with cavitary lesions in upper lobes
  - Often associated with chronic, debilitating diseases or immunosuppressive states (AIDS, transplant, cancer, diabetes, alcoholism)

Prognosis

- Mortality rate for active TB is ~ 50% if left untreated
- Poor prognosis in patients with drug-resistant strains and in AIDS patients

IMAGING

Radiographic Findings

- Most common manifestation of primary TB is focal apical airspace consolidation with hilar lymphadenopathy (Ranke complex)
- Postprimary tuberculosis shows lobular and peribronchial consolidation, cavitation, and intraparenchymatous nodules

CT Findings

- Mediastinal lymph nodes characteristically display low-density centers with peripheral rim enhancement
- Consolidation with variably sized cavities with thick walls
- Small nodular opacities with centrilobular distribution associated with branching opacities (tree-in-bud appearance)
- Miliary TB shows randomly distributed small nodules, usually too numerous to count

MACROSCOPIC

General Features

- Cut section often displays consolidation resembling bacterial pneumonia with areas of caseous (i.e., cheese-like) necrosis
- Advanced lesions are characterized by cavitation that may often lead to erosion into bronchus with intrabronchial spread
- Cavitation is often distributed in upper lobes; cavities have thick walls and measure 3-10 cm in diameter
- Can also present as mass or circumscribed nodule (tuberculoma) with central necrosis, calcification, or fibrosis
- Miliary TB is characterized by numerous small (1-2 mm) nodules diffusely distributed throughout lungs

MICROSCOPIC

Histologic Features

- Basic pathologic manifestation of TB is granulomatous inflammation, with necrotizing, palisading epithelioid granulomas

Cytologic Features

- Mycobacteria are slender rods measuring 4 µm in length, which cannot be visualized on routine histology and require special stains

ANCILLARY TESTS

Histochemistry

- Best stain for 0 WXEHUFXORVLV is Ziehl-Neelsen stain, which stains acid-fast bacilli

PCR

- PCR detects mycobacterial DNA, but positive reaction is not accepted as valid unless at least 1 organism can be visualized in tissue

SELECTED REFERENCES

1. Bhurayanontachai R et al: Factors influencing development and mortality of acute respiratory failure in hospitalized patient with active pulmonary tuberculosis: a 10-year retrospective review. J Thorac Dis. 8(7):1721-30, 2016
2. Subotic D et al: Surgery and pleuro-pulmonary tuberculosis: a scientific literature review. J Thorac Dis. 8(7):E474-85, 2016
3. Alsumrain M et al: Intracavitary and endobronchial tuberculosis. ScientificWorldJournal. 11:130-2, 2011
4. Sia IG et al: Current concepts in the management of tuberculosis. Mayo Clin Proc. 86(4):348-61, 2011
5. WHO global tuberculosis control report 2010: Summary. Cent Eur J Public Health. 18(4):237, 2010

Confluent Areas of Necrosis

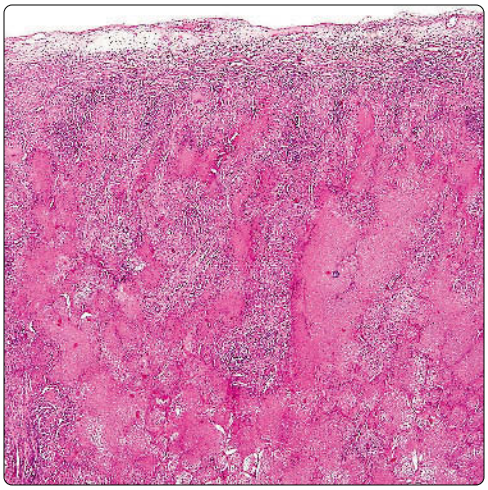

Liquefactive Necrosis

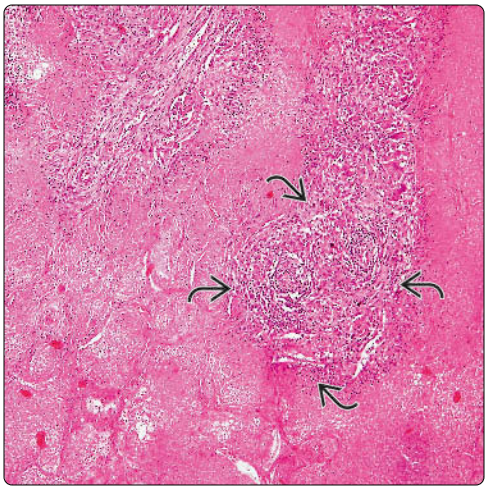

(Left) *Scanning magnification of area of consolidation of the lung in postprimary tuberculosis shows extensive, confluent areas of necrosis of lung parenchyma with liquefaction and intervening areas of granulomatous inflammation.* **(Right)** *Higher magnification of an area of liquefactive necrosis in pulmonary tuberculosis shows abundant, pink, fibrinopurulent exudate surrounding an epithelioid granuloma ⇨. There is complete loss of underlying pulmonary architecture in the area of necrosis.*

Necrotic Fibrinopurulent Exudate

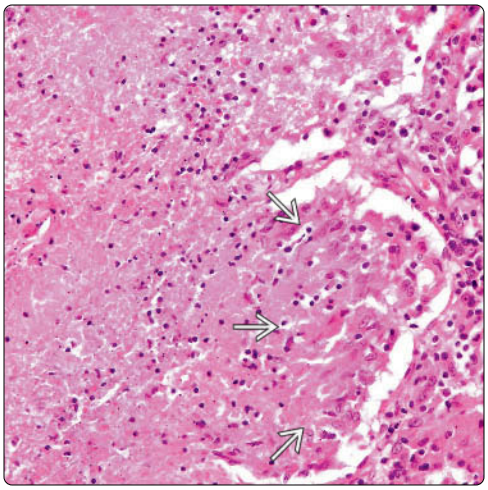

Multinucleated Giant Cells

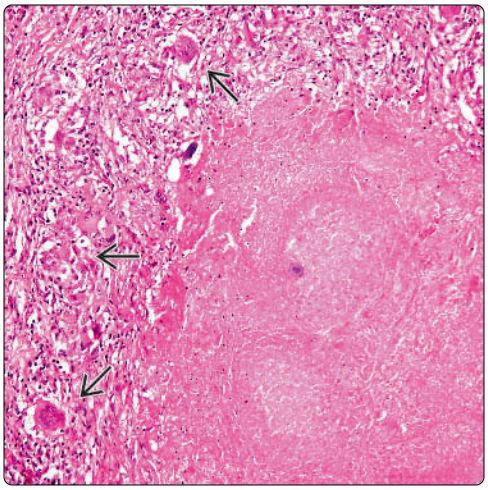

(Left) *Higher magnification from an area of liquefactive necrosis in postprimary pulmonary tuberculosis shows necrotic fibrinopurulent exudate focally admixed with a residual epithelioid histiocytic granuloma ➡.* **(Right)** *A necrotizing palisaded granuloma with central focus of caseous necrosis is seen in this patient with an advanced lesion of postprimary tuberculosis. Notice the epithelioid histiocytes at the periphery of the granuloma and scattered, multinucleated giant cells ⇨.*

Multinucleated Giant Cells: High Power

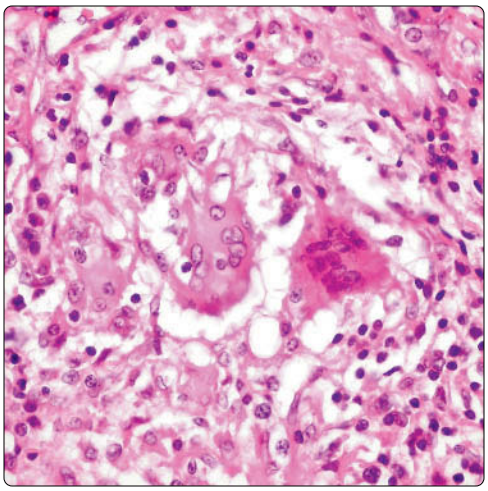

Acid-Fast Bacilli

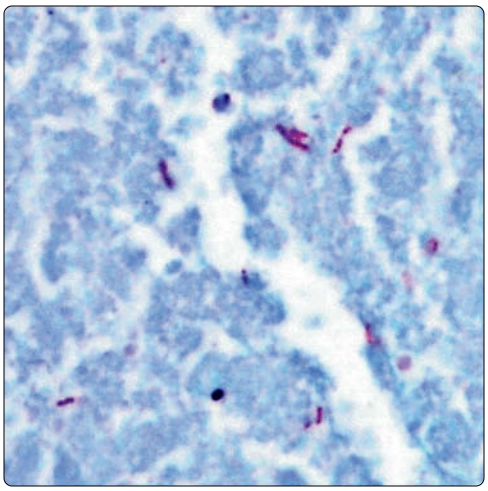

(Left) *Higher magnification from the edges of a large, necrotizing, palisaded granuloma in postprimary pulmonary tuberculosis shows several Langhans-type multinucleated giant cells.* **(Right)** *Higher magnification of the center of a granuloma in cavitating pulmonary tuberculosis shows a few slender, acid-fast organisms (stained in red). The mycobacteria are slender rods that cannot be visualized on routine microscopy and are usually quite scanty.*

Miliary Tuberculosis

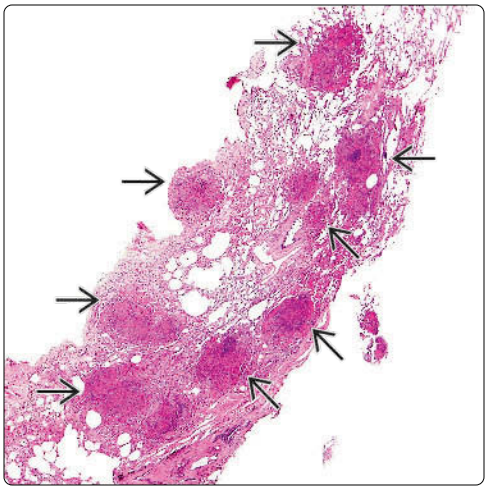

Necrotizing Granuloma

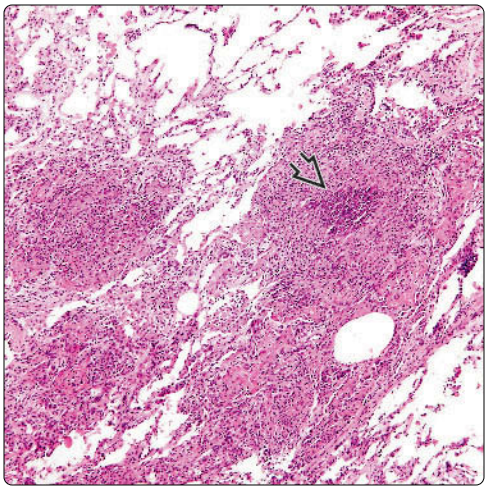

(Left) *Scanning magnification shows miliary pattern of spread in pulmonary tuberculosis, with multiple microscopic nodules ⇨ scattered throughout the lung parenchyma.* **(Right)** *Higher magnification of lung parenchyma involved with miliary tuberculosis shows multiple small nodules containing epithelioid granulomas admixed with inflammatory infiltrates in the surrounding lung parenchyma. Notice one of the granulomas ⇨ has a focus of necrosis and suppuration.*

Central Calcification

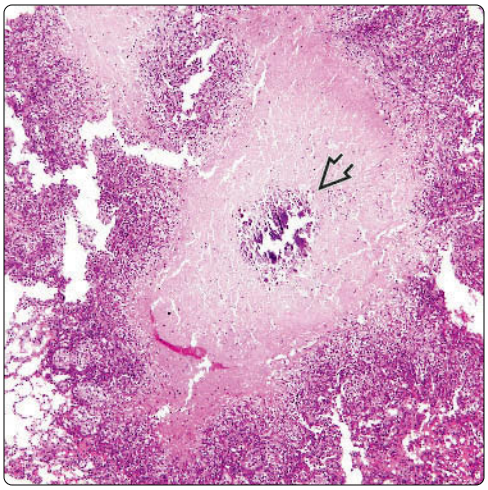

Calcification: High Power

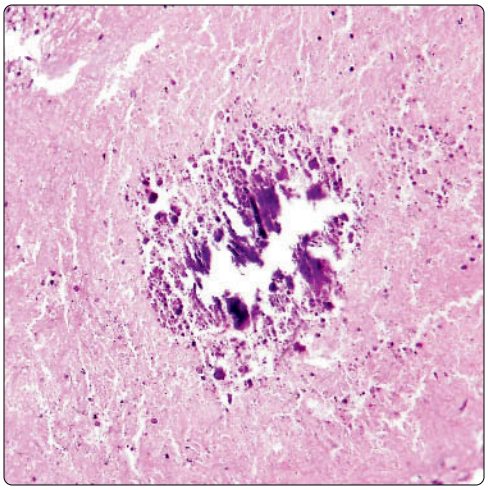

(Left) *Necrotizing palisaded granuloma in a patient with postprimary pulmonary tuberculosis shows a central area of extensive necrosis with a central focus of calcification ⇨. Foci of fibrosis and calcification are a common occurrence in old, necrotizing, palisaded granulomas in pulmonary tuberculosis.* **(Right)** *Higher magnification from the center of a necrotizing palisaded granuloma in pulmonary tuberculosis shows irregular areas of dystrophic calcification.*

Submucosal Granuloma

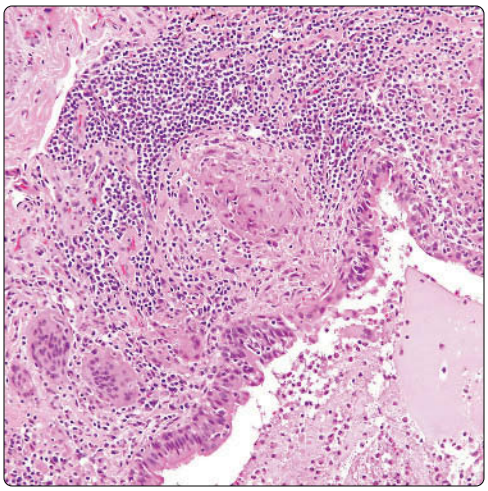

Bronchocentric Distribution

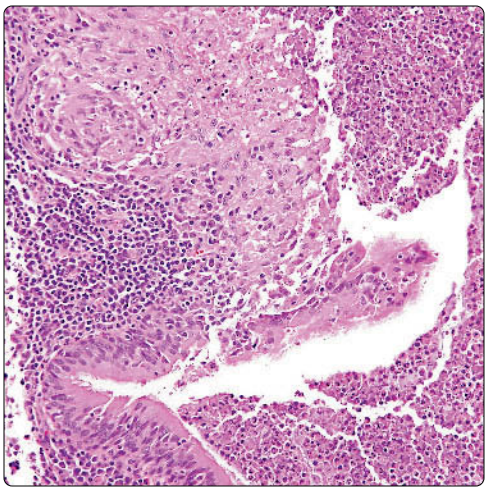

(Left) *Scanning magnification shows a bronchus with multiple small, epithelioid granulomas surrounding the bronchial wall in a patient with postprimary pulmonary tuberculosis. Notice that there is early involvement of the mucosa of the bronchus by the inflammation resembling a pattern of bronchocentric granulomatosis.* **(Right)** *Higher magnification shows bronchocentric granulomatosis-like pattern of involvement of the bronchial wall in a patient with pulmonary tuberculosis.*

Herpes Simplex Virus

KEY FACTS

TERMINOLOGY

- Lung infection caused by double-stranded DNA HSV-1

CLINICAL ISSUES

- In infants, disease is transmitted by mother during passage of fetus through infected birth canal
- In adults, infection may be due to contamination from mucocutaneous sources or reactivation of latent infection

IMAGING

- Patchy ground-glass opacities and consolidation with pleural effusion
- Findings are typically diffuse and bilateral

MICROSCOPIC

- Pattern of involvement in lung may present as necrotizing pneumonia or as diffuse interstitial pneumonitis
- HSV diffuse interstitial pneumonitis closely resembles diffuse alveolar damage
- Infected cells are characterized by presence of intranuclear inclusions
  - Cowdry type A inclusions: Eosinophilic intranuclear inclusion separated from nuclear membrane by halo
  - Cowdry type B inclusions: Homogeneous, amphophilic, and glassy intranuclear inclusions
- Multinucleated epithelial cells with multiple eosinophilic intranuclear inclusions may also be present
- Miliary pattern of spread can be seen in cases of hematogenous dissemination of HSV to lungs
- Herpetic foci show extensive necrosis and karyorrhectic debris with hemorrhage and neutrophilic infiltration

ANCILLARY TESTS

- Antibodies to HSV using formalin-fixed, paraffin-embedded tissue sections are quite sensitive
- Virus particles are encapsulated and targetoid and measure 100-110 nm by electron microscopy

Hemorrhagic Pneumonia Due to HSV

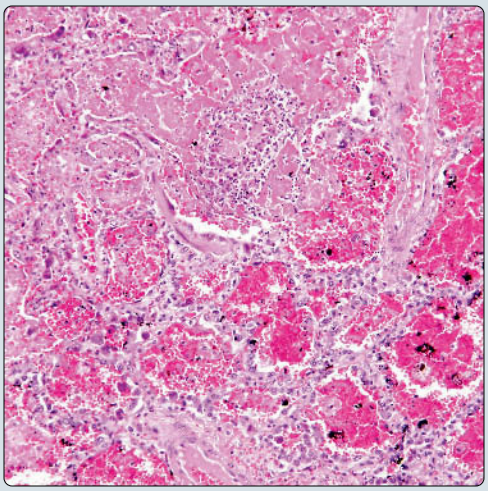

Virally Infected Cell

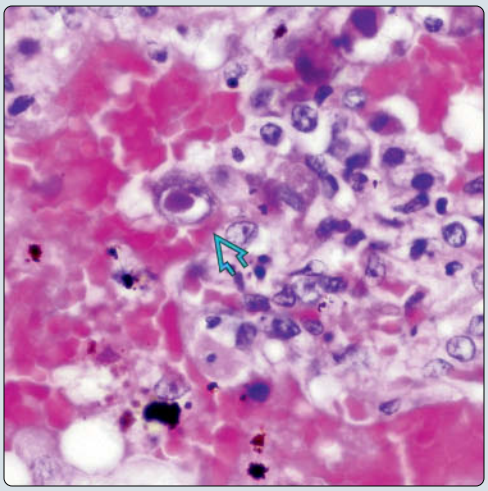

(Left) *Histologic appearance of hemorrhagic necrotizing pneumonia in a patient with herpes simplex virus (HSV) infection shows extensive destruction of lung parenchyma with fibrinous intraalveolar exudates.* **(Right)** *A virally infected cell is seen in this example of hemorrhagic HSV pneumonia. The cell contains a large, densely eosinophilic intranuclear inclusion.*

Viral Inclusion

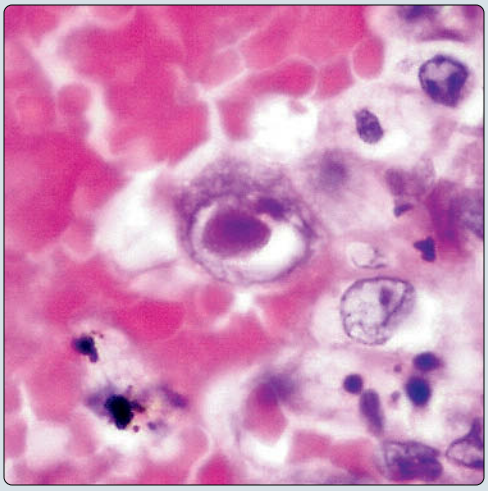

Multiple Viral Inclusions

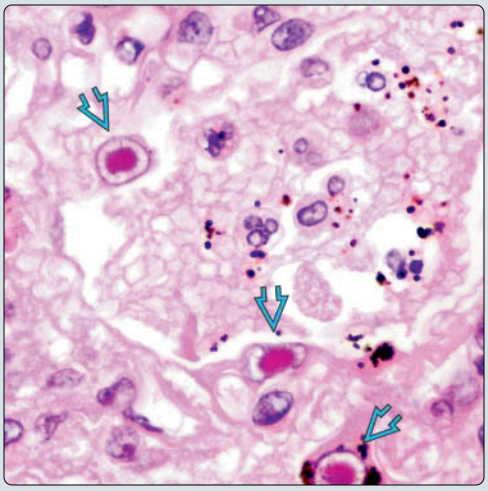

(Left) *Higher magnification of acute necrotizing and hemorrhagic HSV pneumonia shows a characteristic viral inclusion composed of dense eosinophilic intranuclear mass surrounded by a clear halo.* **(Right)** *Another example of viral pneumonia due to HSV shows numerous scattered cells displaying prominent cytopathic effect with bright red, large intranuclear inclusions.*

TERMINOLOGY

Abbreviations

- Herpes simplex virus (HSV)

Definitions

- Lung infection caused by double-stranded DNA HSV-1

ETIOLOGY/PATHOGENESIS

Infectious Agents

- Most cases of neonatal disease are acquired from infected mothers during labor
- Adult HSV pneumonia is most often caused by inhalation of viral particles from mucocutaneous lesions in oropharynx

CLINICAL ISSUES

Epidemiology

- Incidence
  - HSV pneumonia is seen in neonates as well as in immunosuppressed patients
  - Incidence of neonatal HSV infection is ~ 1 in every 3,000 deliveries
  - Disseminated HSV infection develops in ~ 25% of infected neonates
- Age
  - Wide range, from neonates to elderly patients

Presentation

- HSV pneumonia is most often preceded by mucocutaneous infection
- Newborn infants, severely immunosuppressed or burned patients, and patients with trauma are at highest risk for infection
- Infants with disseminated neonatal infection show signs and symptoms about 1 week after birth
- In adults, disseminated infection produces acute hemorrhagic bronchopneumonia

Prognosis

- Primary HSV infection of upper respiratory tract usually resolves spontaneously without treatment
- Infection in immunosuppressed patients requires treatment with antiviral drugs
- Disseminated disease in neonates carries 30% mortality rate

IMAGING

CT Findings

- Patchy ground-glass opacities and consolidation with pleural effusion
- Findings are typically diffuse and bilateral

MACROSCOPIC

General Features

- Cut section shows heavy, congested, and firm lungs with multiple necrotic and hemorrhagic nodules
- Hematogenous dissemination will produce miliary pattern of distribution of lesions

MICROSCOPIC

Histologic Features

- Pattern of involvement in lung may present as necrotizing pneumonia or as diffuse interstitial pneumonitis resembling diffuse alveolar damage
- Miliary pattern of spread can be seen in cases of hematogenous dissemination of HSV to lungs
- Herpetic foci show extensive necrosis and karyorrhectic debris with hemorrhage and neutrophilic infiltration

Cytologic Features

- Infected cells are characterized by presence of intranuclear inclusions
  - Cowdry type A inclusions
    - Eosinophilic intranuclear inclusion separated from nuclear membrane by halo
  - Cowdry type B inclusions
    - Homogeneous, amphophilic, and glassy intranuclear inclusions
- Multinucleated epithelial cells with multiple eosinophilic intranuclear inclusions may also be present

ANCILLARY TESTS

Immunohistochemistry

- Antibodies to HSV using formalin-fixed, paraffin-embedded tissue sections are quite sensitive

Electron Microscopy

- Virus particles are encapsulated and measure ~ 100-110 nm in diameter
- Virus particles have targetoid appearance and are arranged in lattice-like pattern

DIFFERENTIAL DIAGNOSIS

Adenovirus

- Intranuclear inclusions identical to HSV but also contains "smudge" cells not seen in HSV

Measles

- Similar inclusions to HSV but inclusions are both intranuclear and cytoplasmic, unlike HSV, in which they are exclusively intranuclear

Varicella-Zoster

- Produce identical inclusions to HSV; can only be distinguished by immunohistochemistry or molecular methods

SELECTED REFERENCES

1. Bonizzoli M et al: Human herpesviruses respiratory infections in patients with acute respiratory distress (ARDS). Med Microbiol Immunol. 205(4):371-9, 2016
2. Tachikawa R et al: Detection of herpes viruses by multiplex and real-time polymerase chain reaction in bronchoalveolar lavage fluid of patients with acute lung injury or acute respiratory distress syndrome. Respiration. 87(4):279-86, 2014
3. Chong S et al: Herpes simplex virus pneumonia: high-resolution CT findings. Br J Radiol. 83(991):585-9, 2010
4. Witt MN et al: Occurrence of HSV-1-induced pneumonitis in patients under standard immunosuppressive therapy for rheumatic, vasculitic, and connective tissue disease. BMC Pulm Med. 9:22, 2009

Hemorrhagic HSV Pneumonia

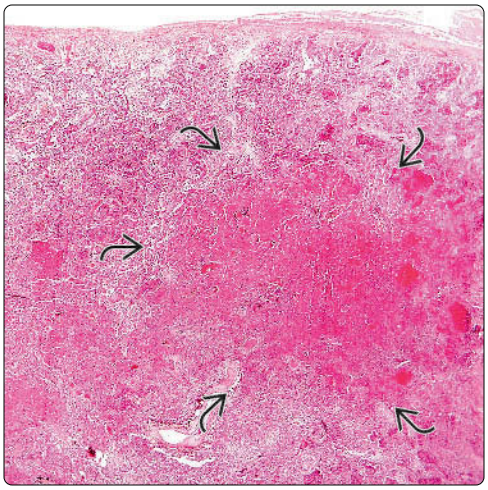

Diffuse Hemorrhage

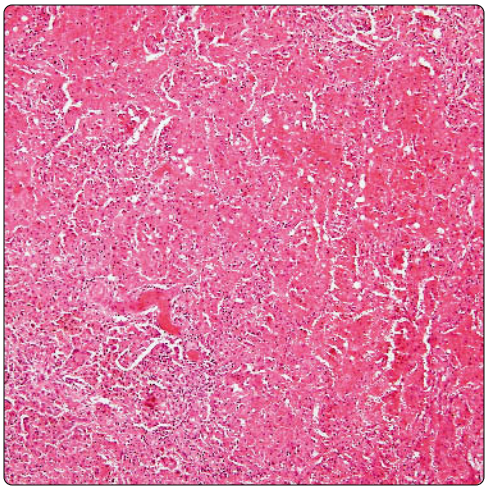

(Left) *Scanning magnification of hemorrhagic necrotizing pneumonia in a patient with HSV infection shows complete destruction of the airways with irregular areas of hemorrhage and necrosis.* **(Right)** *Higher magnification of hemorrhagic necrotizing pneumonia in a patient with HSV infection shows complete destruction of lung parenchyma with loss of the normal alveolar architecture and sparse inflammatory infiltrates.*

Necrotizing HSV Pneumonia

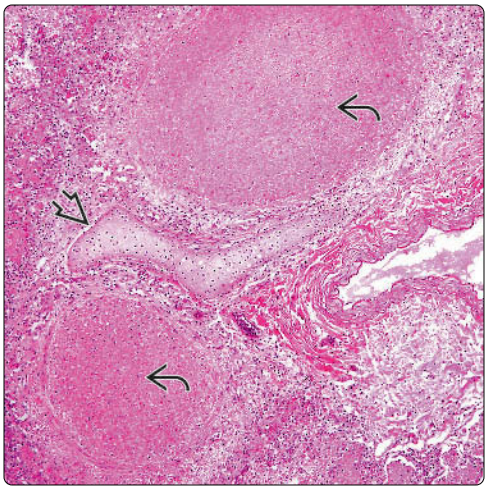

Intranuclear Inclusion

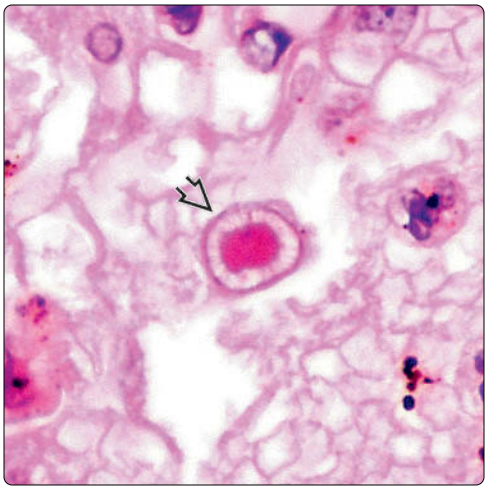

(Left) *Scanning magnification of the lung in a patient with necrotizing HSV pneumonia shows well-defined nodular areas of necrosis separated by a residual cartilaginous plate. Necrotizing HSV pneumonia is usually airway centered and involves bronchi and bronchioles.* **(Right)** *Higher magnification from the edge of an area of necrosis in necrotizing HSV pneumonia shows a characteristic intranuclear inclusion with peripherally marginated nuclear chromatin.*

Necrotizing HSV Pneumonia

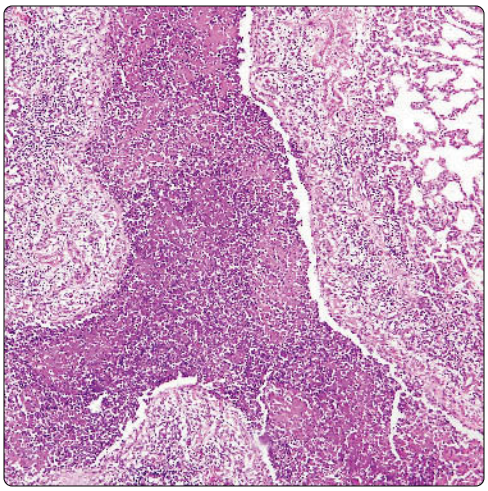

Necrotizing Tracheobronchitis

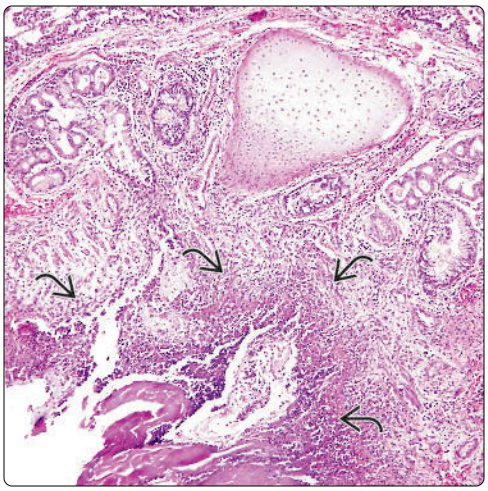

(Left) *Scanning magnification of lung involved with necrotizing HSV pneumonia shows complete destruction of the bronchial lining mucosa by dense inflammatory infiltrates with filling of the bronchial lumen by abundant fibrinopurulent exudate.* **(Right)** *Necrotizing tracheobronchitis and bronchiolitis in a patient with HSV pneumonia shows extensive destruction of the wall of the bronchus by inflammatory exudate.*

Diffuse Alveolar Damage Pattern in HSV Pneumonia

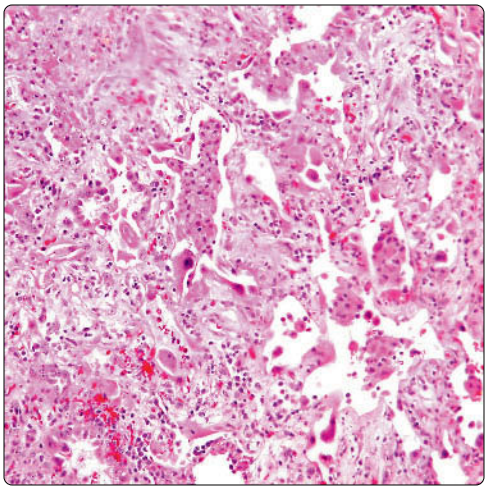

Hyaline Membrane in HSV Pneumonia

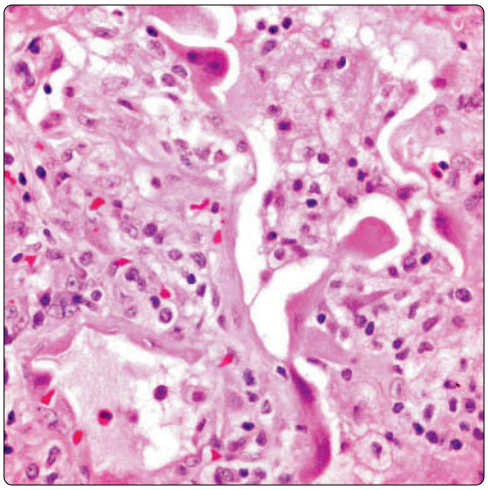

(Left) *Diffuse interstitial pneumonia with diffuse alveolar damage pattern in a lung infected with HSV shows preservation of lung alveolar architecture with thickening of alveolar septa by chronic inflammatory cell infiltrates.* **(Right)** *Higher magnification of HSV pneumonia with diffuse interstitial pattern shows hyaline membrane formation, interstitial edema, and pneumocyte hyperplasia, all features seen in diffuse alveolar damage.*

Hyaline Membrane

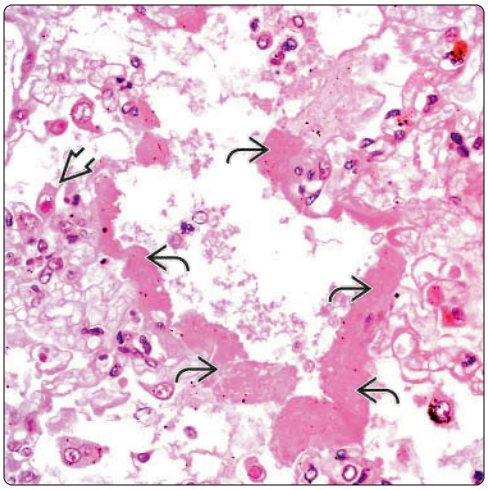

Intranuclear Inclusion in HSV Pneumonia

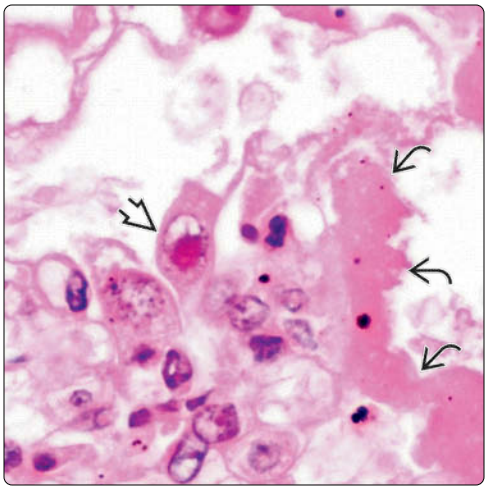

(Left) *Interstitial pattern of involvement in HSV pneumonia shows thick, eosinophilic hyaline membranes lining the wall of an alveolus. Notice an infected cell containing a large, bright eosinophilic inclusion.* **(Right)** *Higher magnification of HSV pneumonia with interstitial pattern of involvement shows a large intranuclear inclusion surrounded by a clear halo adjacent to a hyaline membrane.*

Multinucleated Giant Cell

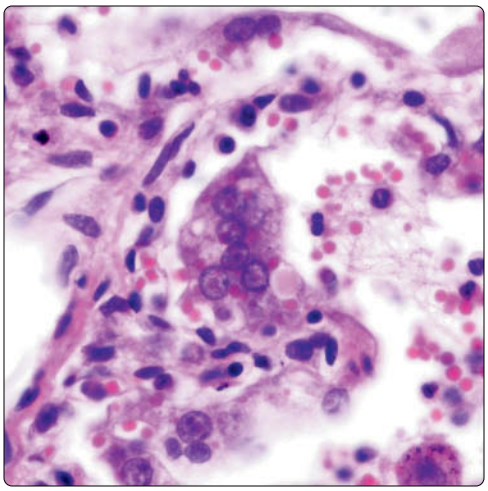

Multinucleated Giant Cell With Inclusions

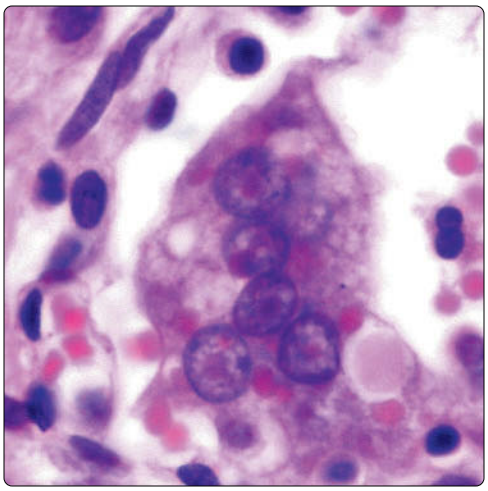

(Left) *Infected epithelial multinucleated giant cell in the lung of a patient infected with HSV shows multiple small, uniform nuclei containing round, eosinophilic inclusions. Similar cells can also be seen in varicella-zoster and measles infection.* **(Right)** *Higher magnification of multinucleated giant cell in the lung of a patient with HSV infection shows uniform, small nuclei containing small, intranuclear inclusions.*

Cytomegalovirus

KEY FACTS

CLINICAL ISSUES

- One of most common opportunistic infections in AIDS and organ transplant patients
- Diagnosis of CMV pneumonia based on evaluation of lung biopsy or bronchoalveolar lavage specimens
- Disseminated CMV infection can cause pneumonitis, hepatitis, adrenalitis, encephalitis, leukopenia, and other systemic manifestations
- Seen in congenital, perinatal, childhood, and adulthood
- CMV pneumonitis causes fever, nonproductive cough, and shortness of breath with hypoxemia
- Disseminated CMV infection can cause pneumonitis, hepatitis, adrenalitis, encephalitis, leukopenia, and other systemic manifestations
- CMV can cause variety of infections that affect multiple organs, including liver, lung, CNS, lymph nodes, etc.

MICROSCOPIC

- Cytopathic effects of CMV involve both nucleus and cytoplasm of infected cells and lead to cytomegaly
- Can infect large variety of cell types in lung, including pneumocytes, endothelial cells, fibroblasts, and macrophages
- Intranuclear inclusions in CMV are larger than cytoplasmic inclusions and may measure up to 20 µm in diameter
- Nuclear inclusions are usually basophilic, round to oval, and show peripheral halo with accentuation of nuclear membrane
- Cytoplasmic inclusions are basophilic to eosinophilic and smaller than intranuclear inclusions (1-3 µm in diameter)

ANCILLARY TESTS

- Anti-CMV antibodies by immunoperoxidase technique are sensitive and specific
- DNA in situ hybridization for CMV is another sensitive and reliable method for identification of CMV

CMV Infection of Lung

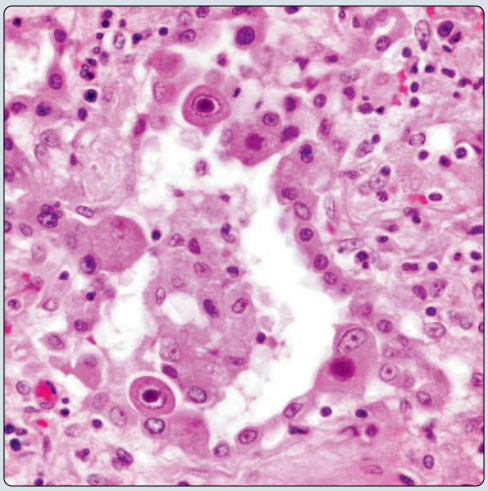

Intranuclar Inclusion

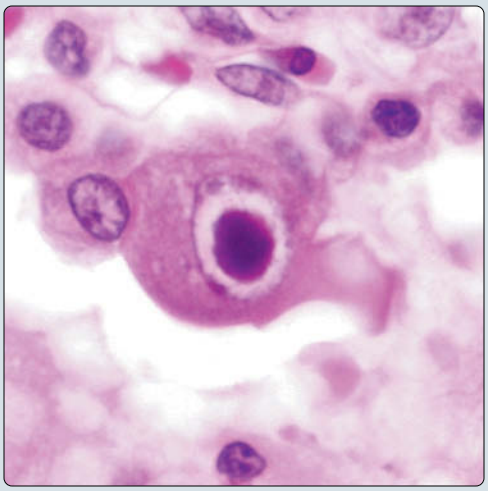

(Left) *Histologic appearance of CMV pneumonitis in an immunosuppressed patient shows interstitial inflammation with a few alveolar lining cells containing the characteristic viral intranuclear inclusions.* **(Right)** *Higher magnification of cytopathic effect in CMV pneumonia shows a cell displaying cytomegaly with a large, single intranuclear inclusion surrounded by a clear halo in the periphery.*

Multiple Intranuclear Inclusions

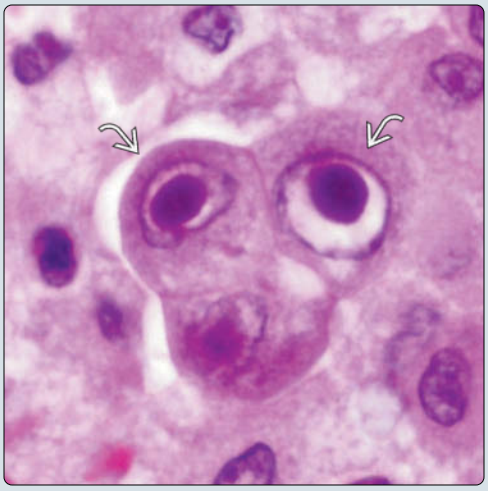

CMV Immunohistochemistry

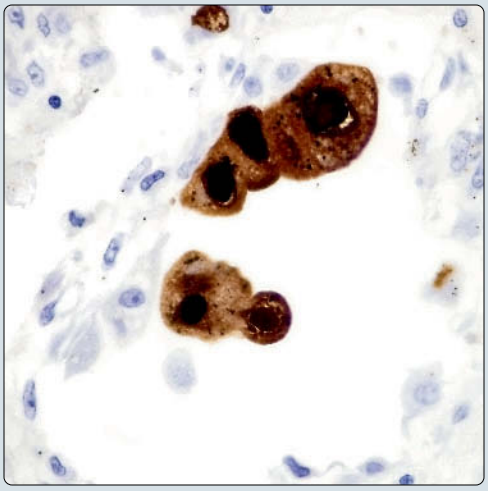

(Left) *Three fused bronchial epithelial cells are present that contain large, deeply eosinophilic intranuclear inclusions. In 2 of them, a clear halo is present in the nucleus surrounding the inclusion.* **(Right)** *CMV can be detected in tissues by immunoperoxidase. The CMV antibody will strongly stain the nuclear inclusions dark brown.*

TERMINOLOGY

Abbreviations

- Cytomegalovirus (CMV)

Definitions

- Infection of lung caused by CMV

ETIOLOGY/PATHOGENESIS

Infectious Agents

- Double-stranded DNA herpesvirus with icosahedral capsid that contains 120 capsomeres
- Measures 120-200 nm and has envelope derived from nuclear membrane

CLINICAL ISSUES

Epidemiology

- Incidence
  - One of most common opportunistic infections in AIDS and organ transplant patients
- Age
  - Seen in congenital, perinatal, childhood, and adulthood

Presentation

- CMV pneumonitis causes fever, nonproductive cough, and shortness of breath with hypoxemia
- Diagnosis of CMV pneumonia based on evaluation of lung biopsy or bronchoalveolar lavage specimens
  - Presence of CMV in blood, urine, or sputum is not evidence of CMV pneumonia; tissue confirmation required for diagnosis

Natural History

- Primary infection can occur in utero or shortly after birth and is generally asymptomatic, leading to latent status
- Immune deficiency or immunosuppression causes CMV to reactivate and disseminate
- Reactivation may lead to minimal disease or be symptomatic to fulminant depending on degree of immunodeficiency
- CMV can cause variety of infections that affect multiple organs, including liver, lung, CNS, lymph nodes, etc.

Prognosis

- CMV pneumonia can be fatal in immunosuppressed patients

IMAGING

Radiographic Findings

- Bilateral nodular or reticular interstitial opacities
- Pleural effusions may be seen in ~ 1/3 of patients

CT Findings

- HRCT studies show consolidation with micronodules, ground-glass opacities, and irregular reticular opacities

MICROSCOPIC

Histologic Features

- Patterns of lung involvement in CMV
  - Minimal disease characterized by scattered or isolated CMV inclusions without significant changes in lung parenchyma
  - Miliary disease characterized by miliary pattern of distribution with microscopic nodules containing chronic inflammation and viral inclusions
  - Diffuse interstitial pneumonitis characterized by interstitial inflammation that may progress to diffuse alveolar damage

Cytologic Features

- Cytopathic effects of CMV involve both nucleus and cytoplasm of infected cells and lead to cytomegaly
- Can infect large variety of cell types in lung, including pneumocytes, endothelial cells, fibroblasts, and macrophages
- Intranuclear inclusions are larger than cytoplasmic inclusions and may measure up to 20 µm in diameter
- Nuclear inclusions are usually basophilic, round to oval, and show peripheral halo with accentuation of nuclear membrane
- Cytoplasmic inclusions are basophilic to eosinophilic and smaller than intranuclear inclusions (1-3 µm in diameter)

ANCILLARY TESTS

Immunohistochemistry

- Anti-CMV antibodies by immunoperoxidase technique are sensitive and specific

In Situ Hybridization

- DNA in situ hybridization is another sensitive and reliable method for identification of CMV

DIFFERENTIAL DIAGNOSIS

Other Viral Pneumonias

- Other viral pneumonias with cytopathic inclusions lack cytomegaly and distinct large basophilic intranuclear inclusions of CMV

DIAGNOSTIC CHECKLIST

Pathologic Interpretation Pearls

- CMV inclusions may be very scant and difficult to recognize; immunohistochemical staining should be done routinely for identification in suspected cases
- Mixed infections are often encountered in immunosuppressed patients; attention must be paid for other signs of pathogens in patients with CMV
- CMV and pneumocystosis are a common and frequent combination in AIDS patients

SELECTED REFERENCES

1. Santos CA et al: Incidence, Risk Factors and Outcomes of Delayed-onset Cytomegalovirus Disease in a Large Retrospective Cohort of Lung Transplant Recipients. Transplantation. 99(8):1658-66, 2015
2. Torres HA et al: Fatal cytomegalovirus pneumonia in patients with haematological malignancies: an autopsy-based case-control study. Clin Microbiol Infect. 14(12):1160-6, 2008
3. Drew WL: Laboratory diagnosis of cytomegalovirus infection and disease in immunocompromised patients. Curr Opin Infect Dis. 20(4):408-11, 2007
4. Tang HJ et al: Opportunistic infections in adults with acquired immunodeficiency syndrome: a comparison of clinical and autopsy findings. J Microbiol Immunol Infect. 39(4):310-5, 2006

Miliary CMV Infection

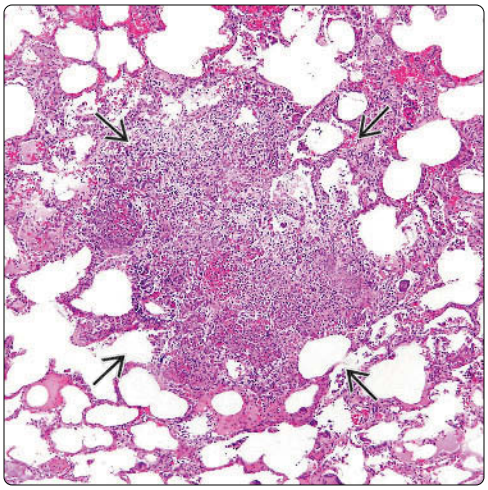

Intranuclear Inclusion

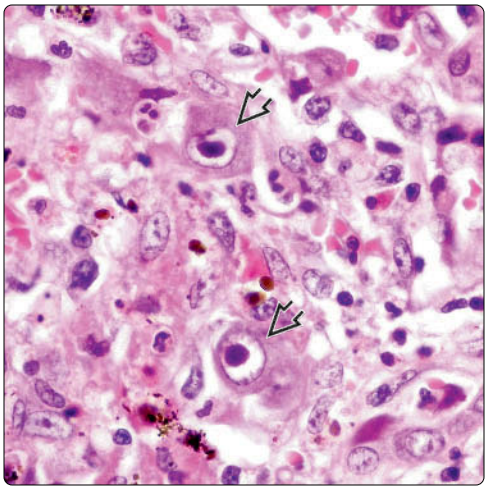

(Left) *Scanning magnification of miliary form of CMV infection in the lung shows a small cellular nodule ⇨ that is well delimited from the surrounding pulmonary parenchyma and contains dense inflammatory infiltrates.* **(Right)** *Higher magnification from the center of the nodule in miliary form of CMV pulmonary infection shows dense inflammatory cell infiltrates with a few scattered cells displaying cytomegaly and large, densely basophilic intranuclear inclusions ⇨.*

Diffuse Pattern of Infection

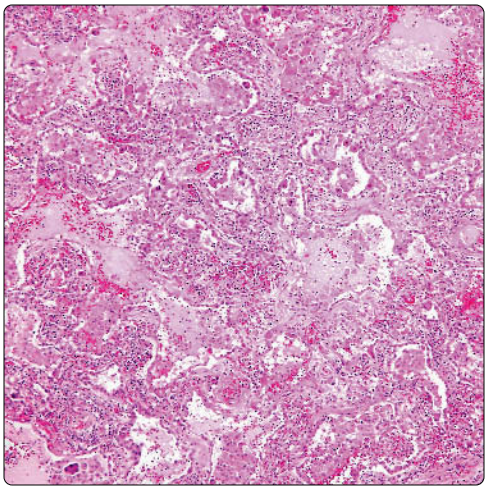

Hyaline Membranes

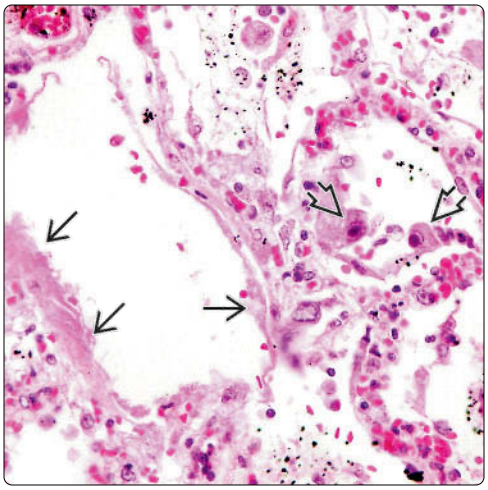

(Left) *Scanning magnification in CMV lung infection with a diffuse interstitial pneumonic pattern shows thickening and expansion of alveolar septa by dense inflammatory cell infiltrates and filling of the alveolar lumina by eosinophilic fibrinous material.* **(Right)** *Higher magnification of diffuse interstitial CMV pneumonitis shows hyaline membrane formation lining the walls of an alveolar space ⇨. Notice that the contiguous alveolar space contains 2 cells with prominent basophilic intranuclear inclusions ⇨.*

Massive CMV Infection

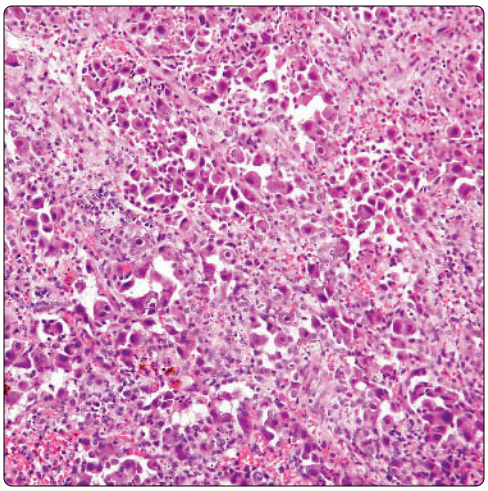

Abundant Inclusions

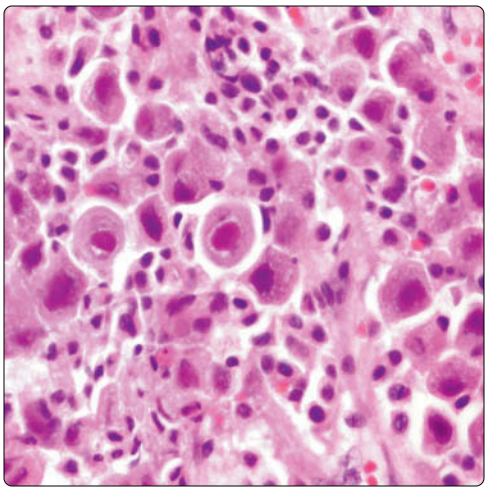

(Left) *Massive superinfection by CMV in an infant with AIDS shows a massive accumulation of cells with marked viral cytopathic effect. The infected cells are forming sheets and show characteristic cytomegaly with large viral inclusions. On cursory examination, the sheets of cells can be confused for a malignant process.* **(Right)** *Higher magnification of massive CMV pneumonitis in a child with AIDS shows sheets of large cells with viral cytopathic effect and large basophilic intranuclear inclusions.*

Nuclear Inclusion

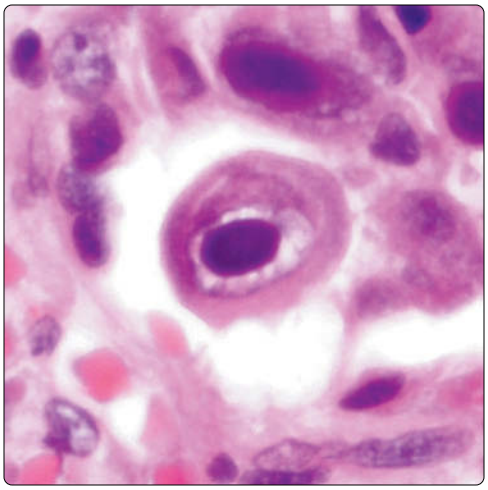

"Owl-Eyed" Intranuclear Inclusion

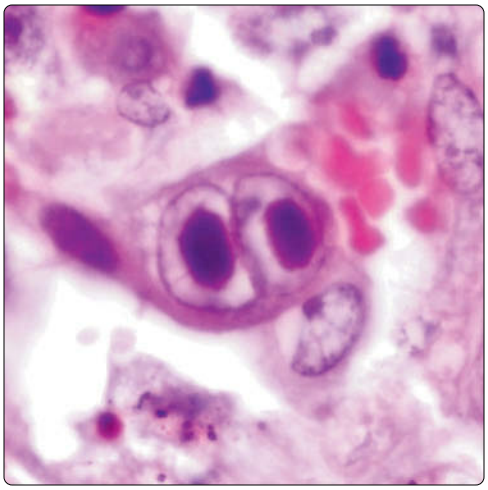

(Left) *Viral cytopathic effect in CMV pneumonia is characterized by a single, large basophilic intranuclear inclusion that is surrounded by a clear halo. There is usually accentuation of the nuclear membrane. The inclusions can be round or oval.* **(Right)** *Cytopathic effect in CMV pneumonitis shows 2 cells side-by-side displaying characteristic "owl-eyed" double nuclear inclusions surrounded by a clear halo. The appearance of these cells is reminiscent of the Reed-Sternberg cell.*

Cytoplasmic Inclusion

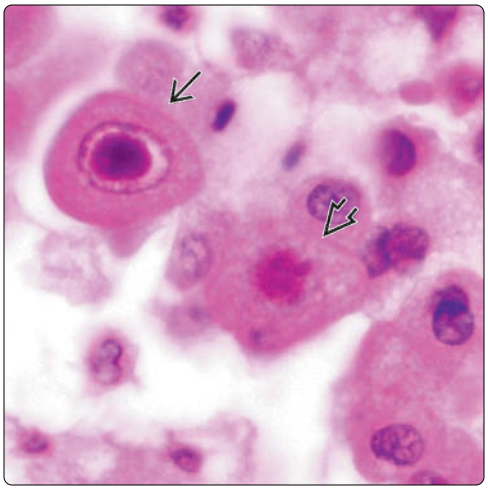

Crescentic Inclusion

(Left) *Cytopathic effect in CMV pneumonitis shows 1 cell with classic basophilic intranuclear inclusion ⇨ lying next to another cell lacking a basophilic intranuclear inclusion but containing a smaller, eosinophilic cytoplasmic inclusion ⇨.* **(Right)** *Cytopathic effect in CMV pneumonitis shows an infected cell containing a boat-shaped, crescentic intranuclear inclusion. Notice the clear halo surrounding the inclusion and the accentuation of the nuclear membrane.*

IHC Stain for CMV

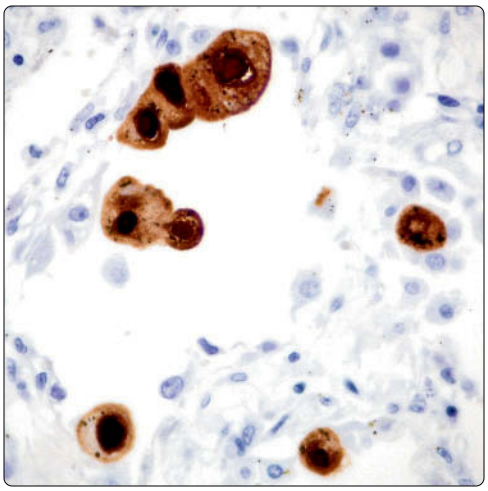

Positive CMV Inclusion by IHC

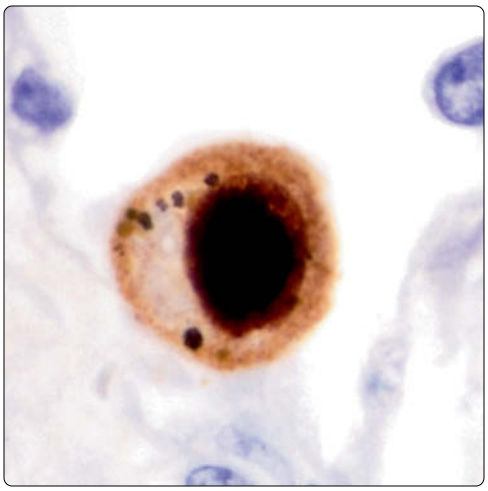

(Left) *IHC staining for CMV in a patient with CMV pneumonitis shows strong positivity in several scattered infected cells. Infected cells may be few in some cases of CMV pneumonitis and can be easily missed on histopathologic examination; routine use of immunohistochemistry is therefore recommended for proper identification in suspected cases.* **(Right)** *Higher magnification shows positive staining for CMV antibody by immunohistochemistry in CMV pneumonitis.*

Adenovirus

KEY FACTS

ETIOLOGY/PATHOGENESIS

- > 50 known serotypes
  - Serotypes 3, 7, and 21 are more common in children
  - Serotypes 3, 4, and 7 are more common in adults

CLINICAL ISSUES

- Accounts for ~ 10% of all pneumonias in children and infants
- Epidemics have been reported in military personnel
- Presentation
  - Fever
  - Dyspnea
  - Chills
  - Myalgias
  - Pharyngitis

MICROSCOPIC

- 2 major patterns of lung injury
  - Necrotizing bronchitis/bronchiolitis with necrosis of walls of airways due to severe acute inflammatory infiltrate
  - Acute necrotizing alveolitis with hyaline membranes and fibrinous alveolar exudates resembling diffuse alveolar damage
- "Smudge cell"
  - Basophilic inclusion that obscures nuclear membrane and fills entire nucleus
- Intranuclear eosinophilic inclusions
  - Surrounded by halo separating them from nuclear membrane (similar to those seen in herpes simplex virus)

ANCILLARY TESTS

- Paracrystalline arrays of virions by electron microscopy
- DNA in situ hybridization for identification of virus
- Immunohistochemical stain for adenovirus
- Serologic demonstration of IgM antibody or 4x increase in IgG antibody

Edema and Inflammatory Exudate

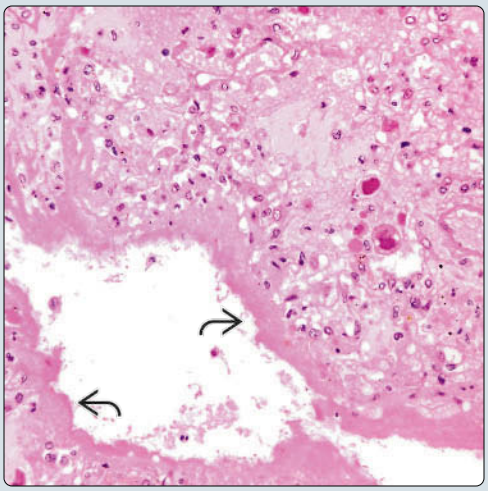

Viral Particles

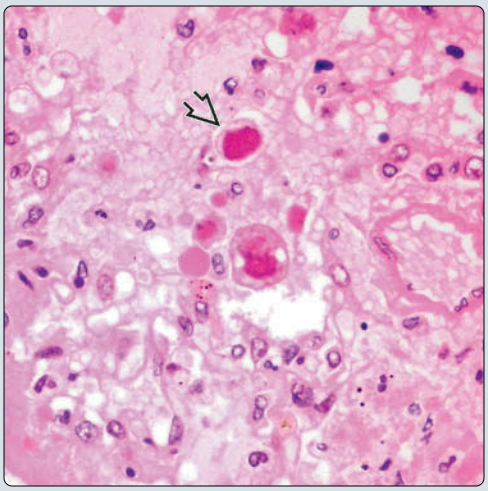

(Left) *Histologic appearance of acute necrotizing alveolitis in a patient with adenovirus pneumonia shows interstitial edema with inflammatory exudates and hyaline membrane formation similar to diffuse alveolar damage.* **(Right)** *Higher magnification of adenovirus pneumonia shows several intranuclear eosinophilic inclusions. The presence of "smudge cells" (eosinophilic inclusions filling the nucleus) is distinctive for adenovirus.*

Cowdry Inclusion

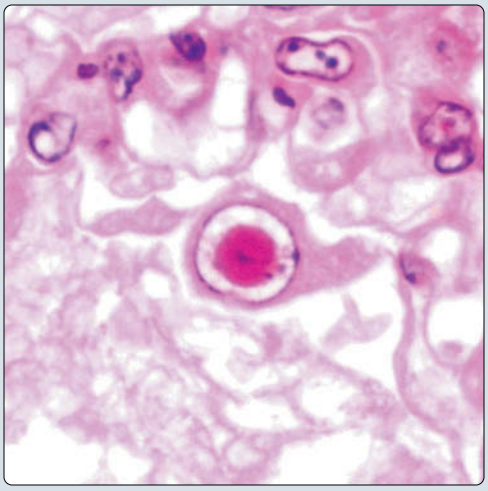

Immunostain for Adenovirus

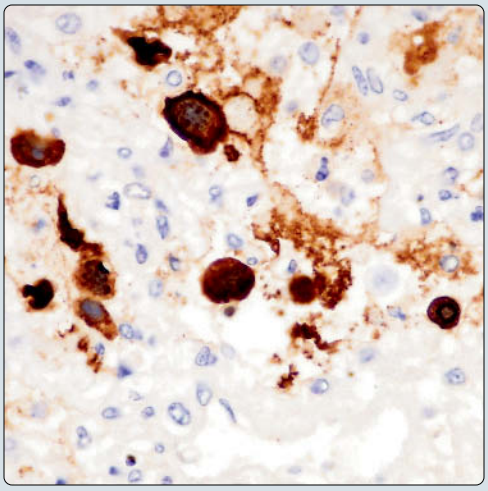

(Left) *Cowdry type A intranuclear eosinophilic inclusion in adenovirus pneumonia shows a characteristic clear halo, separating it from the nuclear envelope. Identical inclusions can be seen in herpes simplex virus pneumonia.* **(Right)** *Immunohistochemical staining with antibodies to adenovirus shows strong positivity in the intranuclear inclusions.*

TERMINOLOGY

Definitions

- Pulmonary infection caused by adenovirus

ETIOLOGY/PATHOGENESIS

Infectious Agents

- > 50 known serotypes
  - Serotypes 3, 7, and 21 are most common in children
  - Serotypes 3, 4, and 7 are most common in adults

CLINICAL ISSUES

Epidemiology

- Incidence
  - Accounts for ~ 10% of all pneumonias in children and infants
  - Epidemics have been reported in military personnel
  - Common in immunocompromised patients

Presentation

- Acute respiratory disease
  - Fever
  - Chills
  - Myalgias
  - Pharyngitis and tracheobronchitis
- Adenovirus pneumonia
  - Similar symptoms to other types of pneumonia
  - May be fatal in immunosuppressed patients, particularly transplant and AIDS patients

Treatment

- Drugs
  - Medical support and management of symptoms
  - Severe cases may be treated with intravenous ribavirin
  - Vaccines for serotypes 4 and 7 have been used with success in military personnel

Prognosis

- Can resolve spontaneously, leaving some sequelae, or may progress to death over 2-3 weeks
  - Sequelae of disease include bronchiectasis, bronchiolitis obliterans, or chronic lung disease
- Adenovirus pneumonia in immunocompromised patients is almost always fatal

IMAGING

Radiographic Findings

- Bilateral, multifocal, lobar, or segmental pneumonia with bronchial wall thickening and hyperaeration

MACROSCOPIC

General Features

- Lungs are heavy and edematous
- Mucosa in main bronchi is generally congested and hemorrhagic
- Cut surface of lung may show yellow friable nodules corresponding to necrotic foci

MICROSCOPIC

Histologic Features

- 2 major patterns of lung injury
  - Necrotizing bronchitis/bronchiolitis
    - Necrosis of walls of airways due to severe acute inflammatory infiltrate
    - Airway lumina are filled with necrotic eosinophilic debris and fibrinopurulent exudate
    - Mucosa of bronchioles is denuded and necrotic
  - Necrotizing alveolitis
    - Acute necrotizing alveolitis with hyaline membranes and fibrinous alveolar exudates resembling diffuse alveolar damage
    - Walls of alveoli show interstitial edema and neutrophilic and mononuclear inflammatory infiltrates

Cytologic Features

- 2 types of intranuclear inclusions
  - Cowdry type A intranuclear eosinophilic inclusions
    - Surrounded by halo separating them from nuclear membrane
  - "Smudge cells"
    - Dark eosinophilic to basophilic inclusion that obscures nuclear membrane and fills entire nucleus

ANCILLARY TESTS

Immunohistochemistry

- Immunohistochemistry and DNA in situ can be used in formalin-fixed paraffin-embedded tissue for specific diagnosis

Electron Microscopy

- Characteristic paracrystalline arrays of virions that measure 70-90 nm in diameter

PCR

- Molecular assays with gene amplification or DNA in situ hybridization can be used for identification

Culture

- Optimal way to establish diagnosis
  - Provides added advantage of serotyping

Serologic Testing

- Requires demonstration of IgM antibody or 4x increase in IgG antibody

DIAGNOSTIC CHECKLIST

Pathologic Interpretation Pearls

- Eosinophilic intranuclear inclusions are identical to those seen in herpes simplex virus or cytomegalovirus
- Identification of "smudge cells" is helpful for distinguishing adenovirus from other viral infections

SELECTED REFERENCES

1. Pavia AT: Viral infections of the lower respiratory tract: old viruses, new viruses, and the role of diagnosis. Clin Infect Dis. 52 Suppl 4:S284-9, 2011
2. Trei JS et al: Spread of adenovirus to geographically dispersed military installations, May-October 2007. Emerg Infect Dis. 16(5):769-75, 2010
3. Chong DC et al: Respiratory viruses in pediatric necropsies: an immunohistochemical study. Pediatr Dev Pathol. 12(3):211-6, 2009

Measles Pneumonia

KEY FACTS

ETIOLOGY/PATHOGENESIS

- Causative agent is single-stranded, enveloped virus of family Paramyxoviridae, genus 0 R U E L O O L Y L U X V

CLINICAL ISSUES

- Exposure in children < 6 years of age usually results in lifelong immunity
- Pulmonary complications usually occur in immunocompromised or debilitated patients and may progress to fatal pneumonia

MICROSCOPIC

- Necrotizing bronchiolitis with extensive destruction of epithelial lining of bronchioles
- Squamous metaplasia of bronchial and bronchiolar lining epithelium
- Giant cell interstitial pneumonia with numerous multinucleated epithelial giant cells
- Interstitial mononuclear inflammatory cell infiltrate
- Abundant intraalveolar exudate with hyaline membrane formation indistinguishable from diffuse alveolar damage
- Giant cells can show up to 60 nuclei and are prominently enlarged (up to 100 µm in diameter)
- Multinucleated giant cells contain homogeneous, small eosinophilic intranuclear and cytoplasmic inclusions

ANCILLARY TESTS

- Presence of virus can be confirmed by immunohistochemistry using specific measles antibodies
- Viral particles can be identified in cells by using specific probes by DNA in situ hybridization

TOP DIFFERENTIAL DIAGNOSES

- Varicella-Zoster virus infection
- Parainfluenza and respiratory syncytial virus infection

Respiratory Epithelium

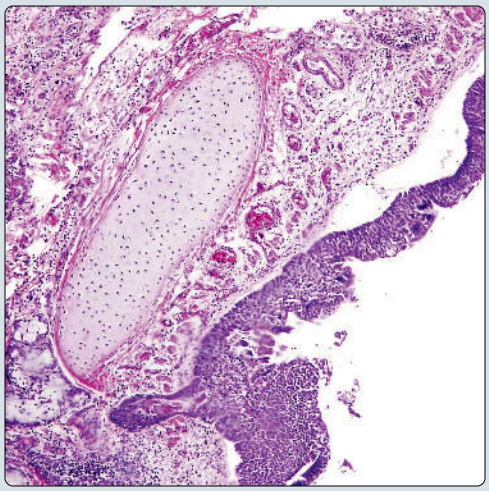

Interstitial Pneumonia-Like Pattern

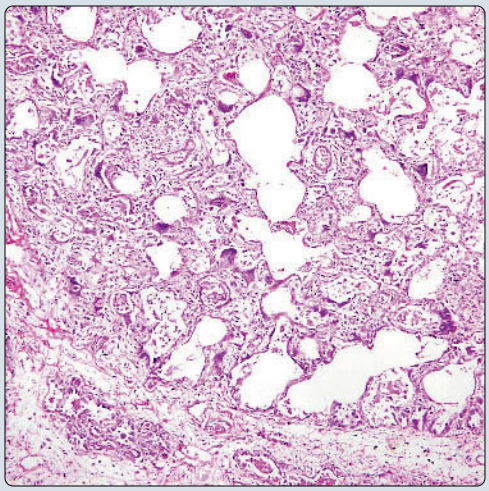

(Left) *Respiratory mucosa shows areas of acute inflammatory changes. However, this type of reaction may be seen in many different entities and does not represent a specific feature.* **(Right)** *Histological appearance on scanning magnification of giant cell interstitial pneumonia in a patient with measles infection shows expansion of alveolar walls by mononuclear cell infiltrate admixed with giant cells.*

Scattered Giant Cells

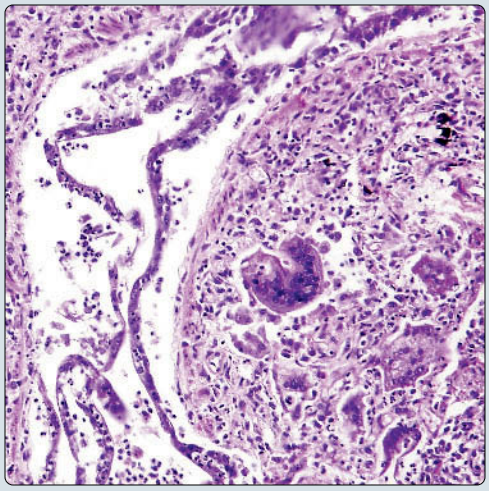

Giant Cells

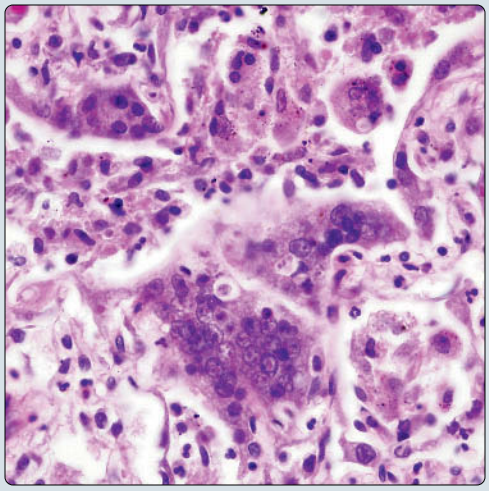

(Left) *Lung parenchyma shows the presence of an inflammatory reaction and the presence of several multinucleated giant cells.* **(Right)** *Higher magnification of the infiltrate in giant cell interstitial pneumonia due to measles shows multinucleated giant cells containing abundant small, uniform nuclei surrounded by inflammatory cell infiltrate.*

TERMINOLOGY

Definitions

- Highly contagious pulmonary infection caused by measles virus (rubeola)

ETIOLOGY/PATHOGENESIS

Infectious Agents

- Causative agent is single-stranded, enveloped virus of family Paramyxoviridae, genus 0 R U E L O O L Y L U X V
- Virus is spread by aerosols and droplets from respiratory secretions of acute cases

CLINICAL ISSUES

Epidemiology

- Incidence
  - Worldwide infection, particularly prevalent in underdeveloped countries
  - Recrudescence has occurred in some urban areas of USA due to diminished use of vaccine
  - Mortality is 1 in 1,000 patients
- Age
  - Children and young adults

Presentation

- Prodromal period consists of fever, cough, rhinorrhea, and conjunctivitis, with Koplik spots in buccal mucosa
- Erythematous maculopapular rash develops 3 days after onset and involves face, trunk, and extremities
- Pulmonary complications include secondary pneumonia, giant cell pneumonia, and atypical pneumonia

Natural History

- Exposure in children < 6 years of age usually results in lifelong immunity
- Most adults have lifelong immunity either due to vaccination or previous exposure
- Clinical infection has incubation period of 1-2 weeks followed by prodromal period and skin rash
- Symptoms usually resolve spontaneously over period of days with complete resolution
- Pulmonary complications usually occur in immunocompromised or debilitated patients and may progress to fatal pneumonia

Treatment

- Drugs
  - Immune globulin may be helpful if administered within 1st week of exposure

Prognosis

- Measles pneumonia can be fatal in immunocompromised patients

MICROSCOPIC

Histologic Features

- Necrotizing bronchiolitis with extensive destruction of epithelial lining of bronchioles
- Squamous metaplasia of bronchial and bronchiolar lining epithelium
- Giant cell interstitial pneumonia with numerous multinucleated epithelial giant cells
- Interstitial mononuclear inflammatory cell infiltrate
- Proliferation of alveolar type II pneumocytes
- Abundant intraalveolar exudate with hyaline membrane formation indistinguishable from diffuse alveolar damage
- Secondary bacterial pneumonia can superimpose as complication of measles pneumonia

Cytologic Features

- Viral cytopathic changes involving tracheal and bronchial mucosal epithelial cells
- Giant cells can show up to 60 nuclei and are prominently enlarged (up to 100 µm in diameter)
- Multinucleated giant cells contain homogeneous, small eosinophilic intranuclear and cytoplasmic inclusions

ANCILLARY TESTS

Immunohistochemistry

- Presence of virus can be confirmed by immunohistochemistry using specific measles antibodies

In Situ Hybridization

- Viral particles can be identified in cells by using specific probes by DNA in situ hybridization

Serologic Testing

- Detection of viral antigens can be accomplished by hemagglutination inhibition, neutralization, or enzyme immunoassay
- Presence of specific IgM antibodies can be used to diagnose recent infection

Electron Microscopy

- Nuclear inclusions resemble tubular or rod-shaped particles with blunt tips

DIFFERENTIAL DIAGNOSIS

Parainfluenza and Respiratory Syncytial Virus Infection

- Also produces giant cell interstitial pneumonia similar to that of measles
  - Viral inclusions in parainfluenza virus and respiratory syncytial virus pneumonia are only cytoplasmic, not intranuclear
  - Definitive diagnosis requires viral isolation, demonstration of viral antigen, serologic testing, or ultrastructural examination

Varicella-Zoster Virus Infection

- Also characterized by giant cell interstitial pneumonia similar to that of measles
  - Inclusions in varicella-zoster pneumonia are similar to intranuclear inclusions in measles, but cytoplasmic inclusions are not seen

SELECTED REFERENCES

1. Piastra M et al: Measles-induced respiratory distress, air-leak and ARDS. Eur J Clin Microbiol Infect Dis. 29(2):181-5, 2010
2. Moussallem TM et al: Lung involvement in childhood measles: severe immune dysfunction revealed by quantitative immunohistochemistry. Hum Pathol. 38(8):1239-47, 2007

(Left) *Scanning magnification of lung parenchyma in a patient with measles infection shows a well-circumscribed area of consolidation ⇨ merging with the adjacent lung parenchyma. The area of consolidation contains heavy inflammatory cell infiltrates.* **(Right)** *Higher magnification of lung with giant cell interstitial pneumonia in a patient with measles shows intraalveolar inflammatory infiltrates and thickening of the walls of the alveoli secondary to inflammation and giant cells.*

Acute Pneumonia

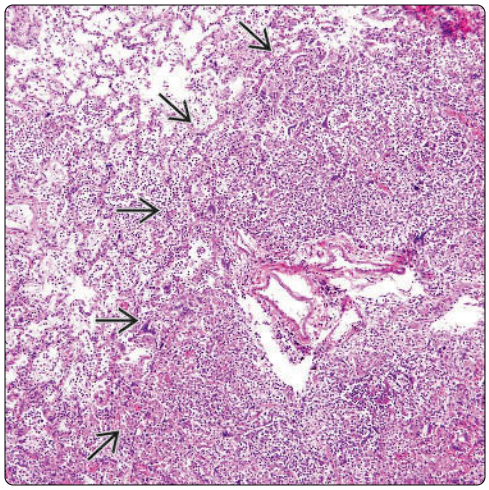

Acute Inflammation and Giant Cells

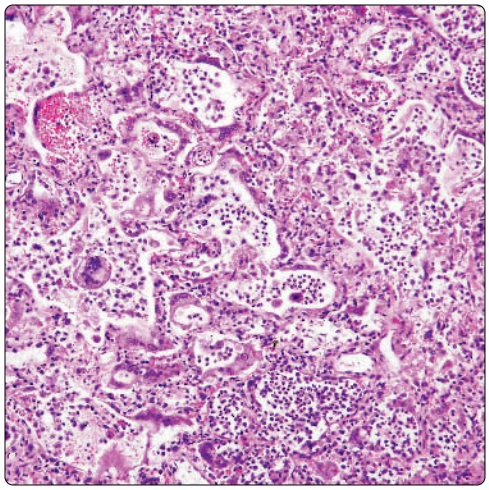

(Left) *Higher magnification of giant cell interstitial pneumonia in a patient with measles shows numerous giant cells with multiple nuclei. The nuclei of the giant cells ⇨ characteristically wrap around the alveolar walls and surround the inflammatory cells in the lumen.* **(Right)** *Giant cells in measles giant cell interstitial pneumonia show a large number of small, round, uniform nuclei, most of which contain small eosinophilic intranuclear inclusions.*

Multinucleated Giant Cells

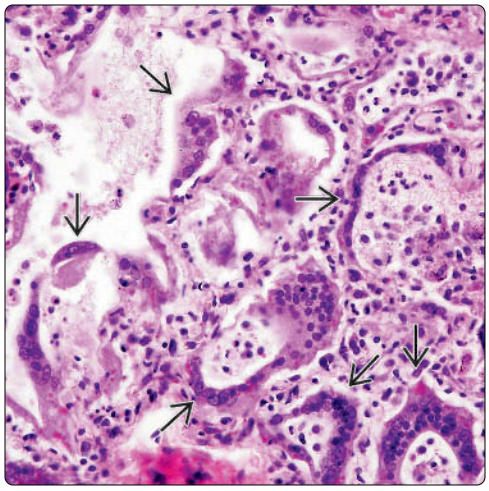

Viral Pneumonia

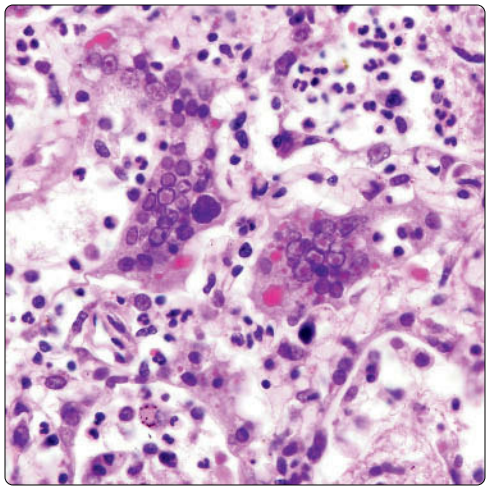

(Left) *Higher magnification of a giant cell in measles interstitial pneumonia shows multiple small nuclei and scattered intracytoplasmic and intranuclear inclusions. The giant cells are not histiocytic in origin but rather are modified epithelial cells.* **(Right)** *Higher magnification of a multinucleated epithelial giant cell in measles giant cell interstitial pneumonia shows small eosinophilic intranuclear inclusions with a targetoid appearance ⇨. Notice similar inclusions within the cytoplasm ⇨.*

Multinucleated Giant Cells

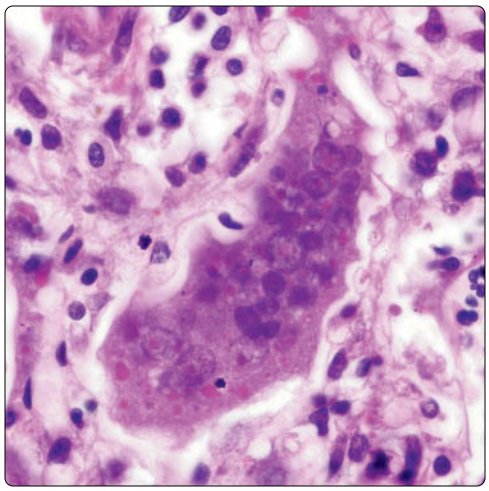

Intranuclear Inclusions

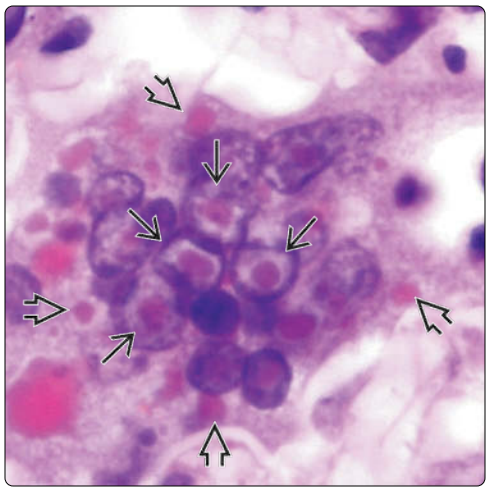

Squamous Metaplasia

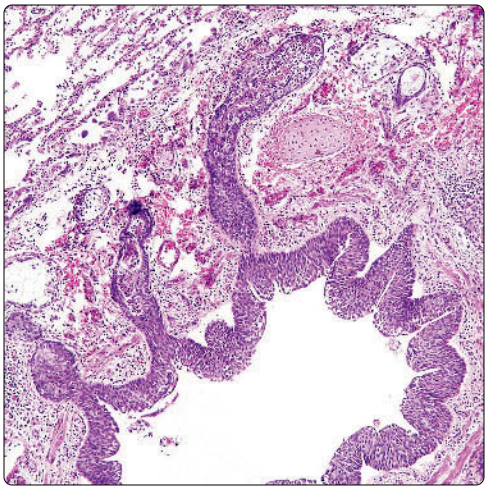

Atypical Squamous Epithelium

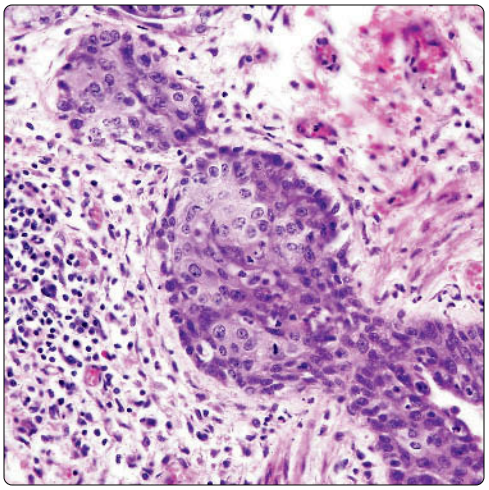

(Left) *Scanning magnification of the lung in a patient with measles pneumonia shows severe acute and chronic inflammation of a bronchus with extensive squamous metaplasia of the bronchial lining mucosa.* **(Right)** *Higher magnification of the wall of a secondary bronchus in a patient with measles pneumonia shows squamous metaplasia of the lining epithelium. The islands of squamous metaplasia are surrounded by chronic inflammation mainly composed of a mononuclear cell infiltrate.*

Inflammation and Giant Cells

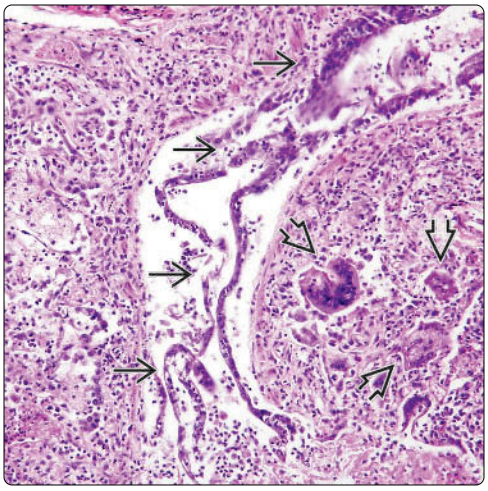

Acute Inflammation

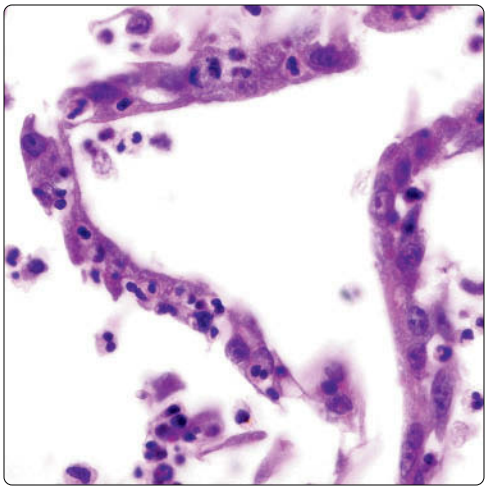

(Left) *Section of lung in a patient with pulmonary involvement by measles pneumonia shows necrotizing bronchiolitis with extensive destruction of the bronchiolar mucosa. Notice a few scattered multinucleated giant cells distributed throughout the adjacent parenchyma.* **(Right)** *Higher magnification from focus of necrotizing bronchiolitis in patient with measles pneumonia shows infiltration of mucosa by mononuclear cell inflammatory infiltrate.*

Edema and Inflammation

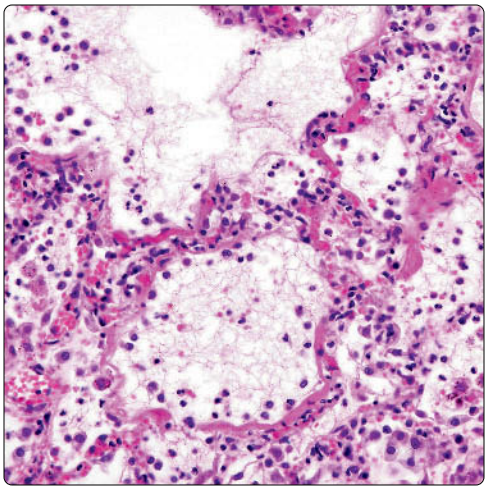

Hyaline Membrane

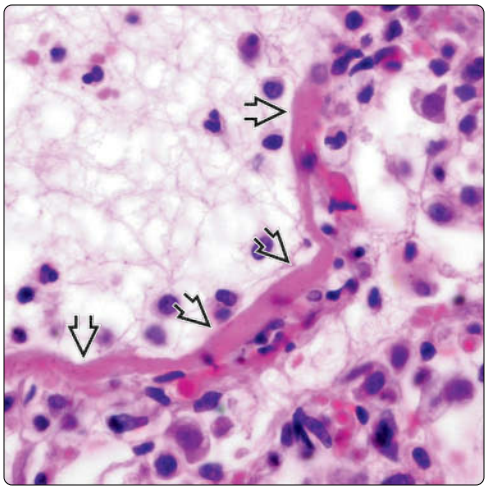

(Left) *Acute lung injury in a patient with measles pneumonia shows edema and congestion of alveolar septa with dense mononuclear cell inflammatory infiltrates. The alveolar lumina contain edema fluid and scattered inflammatory cells and are lined by a thin layer of dense eosinophilic material similar to that seen in diffuse alveolar damage.* **(Right)** *Higher magnification from measles pneumonia displays dense eosinophilic hyaline membrane lining the wall of an alveolar space.*

Sporotrichosis

KEY FACTS

TERMINOLOGY

- Chronic mycotic infection

ETIOLOGY/PATHOGENESIS

- *Sporothrix schenckii* (*Sporotrichum schenckii*)

CLINICAL ISSUES

- Infection predominantly affects
  - Skin
  - Lymph nodes
- Infections may also involve
  - Lung
  - Bone
  - Mucosal membranes
- Process may start as penetrating wound

MICROSCOPIC

- Suppurative pneumonia
- Granulomatous inflammation
- Abscess formation
- Asteroid bodies
- Fungal organisms
  - Numerous budding yeasts
  - Splendore-Hoeppli phenomenon

TOP DIFFERENTIAL DIAGNOSES

- Histoplasmosis
  - Splendore-Hoeppli phenomenon would be unusual in histoplasmosis
  - Asteroid bodies would be unusual in histoplasmosis
- Cryptococcal pneumonia
  - *Cryptococcus* would show positive staining for mucicarmine
- Coccidioidomycosis
  - Size of *Coccidioides* is large in comparison to Sporotrichum

(Left) *Low-power view of pulmonary sporotrichosis shows areas of necrosis with a rim of fibrosis with acute and chronic inflammation. Note the presence of uninvolved lung parenchyma.* **(Right)** *Higher magnification of pulmonary sporotrichosis shows areas of abscess formation and granulomatous reaction with presence of multinucleated giant cells.*

Pulmonary Necrosis

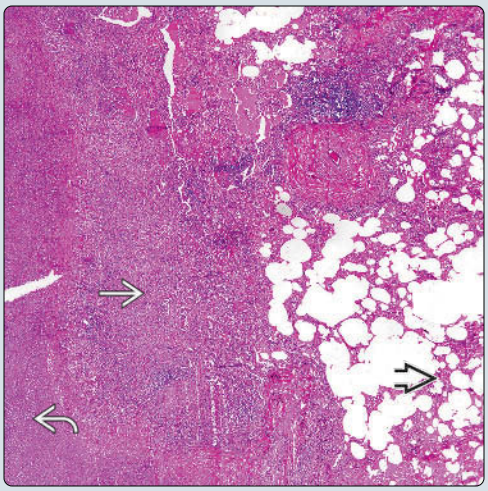

Granulomatous Inflammation

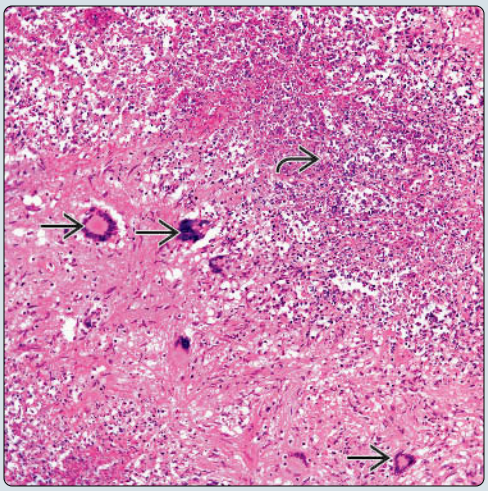

(Left) *Pulmonary sporotrichosis shows acute inflammatory changes and granulomatous inflammation with numerous multinucleated giant cells.* **(Right)** *Silver stain shows the presence of numerous budding yeast forms. There is narrow budding, which is characteristic of sporotrichosis.*

Multinucleated Giant Cells

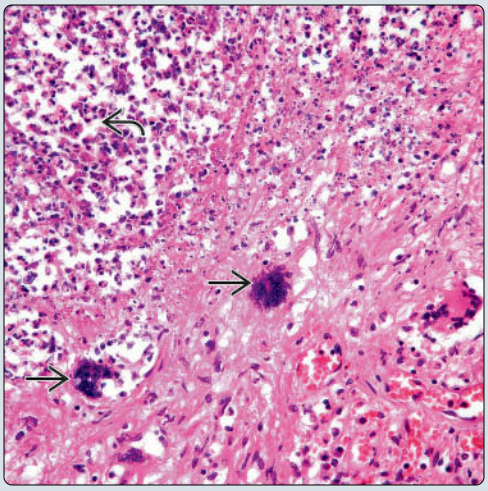

Fungal Organisms

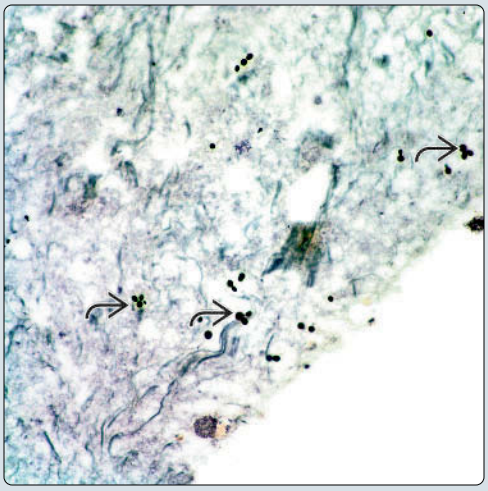

TERMINOLOGY

Definitions

- Chronic mycotic infection

ETIOLOGY/PATHOGENESIS

Infectious Agents

- *Sporothrix schenckii* (*Sporotrichum schenckii*)

CLINICAL ISSUES

Epidemiology

- Incidence
  - Worldwide distribution with variable prevalence
- Age
  - Any age group may be affected

Site

- Infection predominantly affects
  - Skin, lymph nodes
- Infection may also involve
  - Lung
  - Bone
  - Mucosal membranes
    - Nose, mouth, pharynx

Presentation

- Fever, dyspnea, chest pain

Laboratory Tests

- Blood and tissue cultures

Natural History

- May start as penetrating wound

Treatment

- Surgical approaches
  - In some cases, wedge resection or even lobectomy
- Drugs
  - Antifungal treatment

Prognosis

- May be fatal in immunocompromised patients with widespread infection

MICROSCOPIC

Histologic Features

- Suppurative pneumonia
- Granulomatous inflammation
- Abscess formation
  - Presence of fungal organisms
  - Asteroid bodies
  - Splendore-Hoeppli phenomenon

DIFFERENTIAL DIAGNOSIS

Other Infectious Diseases

- Histoplasmosis
  - Splendore-Hoeppli and asteroid bodies unusual in histoplasmosis
  - Cultures reveal correct fungal organisms
- Cryptococcal pneumonia
  - Mucicarmine stain positive in cryptococcal infections but negative in sporotrichosis
  - Tissue cultures reveal correct organism
- Coccidioidomycosis
  - *Coccidioides* is larger fungal organism
  - *Coccidioides* shows presence of endospores, which are not present in sporotrichosis
- Bacterial pneumonia
  - Suppurative pneumonia may be seen in both bacterial pneumonia and sporotrichosis
  - GMS and PAS histochemical stains negative
- Atypical mycobacterial disease
  - Suppurative pneumonia may be seen in both atypical mycobacterial disease and sporotrichosis
  - Acid-fast histochemical stains positive for presence of acid-fast bacilli
  - GMS and PAS histochemical stains negative

DIAGNOSTIC CHECKLIST

Pathologic Interpretation Pearls

- Fungal organisms
- Asteroid bodies
- Splendore-Hoeppli phenomenon
- Numerous yeasts
- Budding yeasts

SELECTED REFERENCES

1. Hussein MR: Mucocutaneous Splendore-Hoeppli phenomenon. J Cutan Pathol. 35(11):979-88, 2008
2. Schubach A et al: Epidemic sporotrichosis. Curr Opin Infect Dis. 21(2):129-33, 2008
3. Zeegelaar JE et al: Imported tropical infectious ulcers in travelers. Am J Clin Dermatol. 9(4):219-32, 2008

Histochemical Features

Stain	Result
GMS	Positive staining of fungal organisms
PAS	Highlights fungal organisms
Mucicarmine	Negative staining of fungal organisms
Acid-fast bacilli	Negative
Fite-Faraco	Negative

Tissue culture is the most important study to define the type of fungal organism.

Klebsiella Pneumonia

KEY FACTS

TERMINOLOGY

- Synonym
  - Friedlander pneumonia
- Definition
  - Infectious condition caused by gram-negative bacteria

ETIOLOGY/PATHOGENESIS

- *Klebsiella pneumoniae*
  - Nonmotile, usually encapsulated bacillus
  - > 80 different types

CLINICAL ISSUES

- *Klebsiella* pneumonia appears to be more common in
  - Hospitalized patients
  - Nursing homes
  - Alcoholics
  - Diabetics
  - Individuals with poor hygiene
- Presentation
  - Fever
  - Cough
  - Hemoptysis
  - Chest pain
  - Malaise
  - Weight loss
- Prognosis
  - Depends on setting in which illness occurs
  - May be fatal in 20-60% of patients
- Treatment
  - Antibiotics

MICROSCOPIC

- Mucicarminophilic exudate
- Abscess formation
- Cavitation
- Gram-negative bacilli

Congestion and Hemorrhage

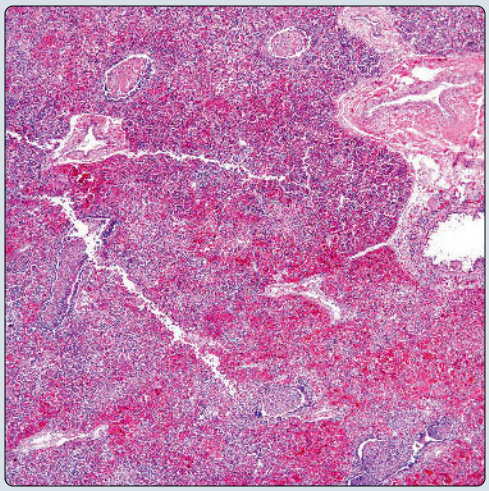

Acute Pneumonia

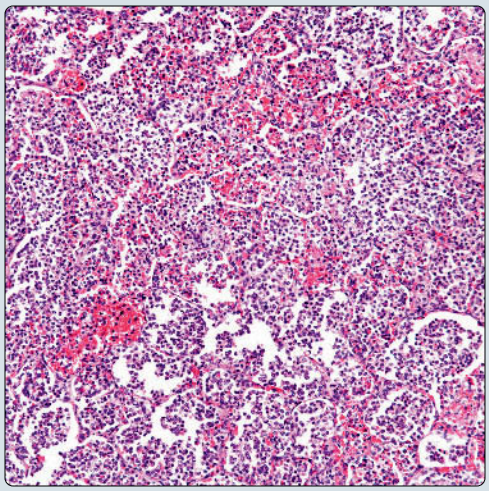

(Left) *Low-power view of a section of lung parenchyma shows extensive areas of congestion and inflammation. Note the absence of alveolated tissue.* **(Right)** *Higher magnification shows areas of abscess formation with prominent acute inflammation and fibrinous exudate. These features, although not pathognomonic of Klebsiella pneumonia, are suggestive.*

Acute Pneumonia

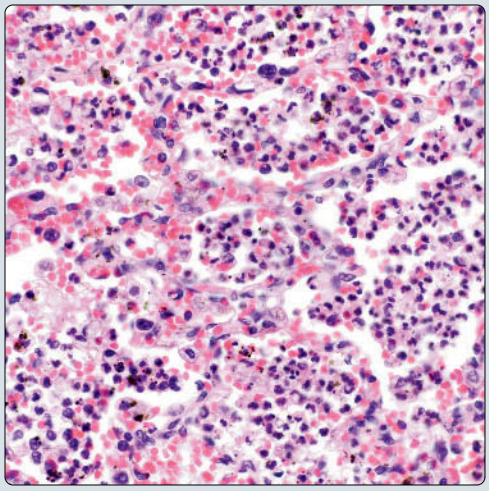

***Klebsiella* Organisms**

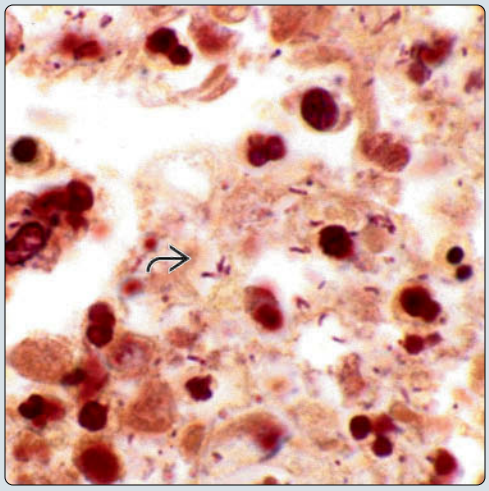

(Left) *Higher magnification of Klebsiella pneumonia shows marked acute inflammatory infiltrate filling the alveolar spaces. On morphological ground alone, it is very difficult to identify the organisms.* **(Right)** *The Brown-Hopps histochemical stain is useful in the diagnosis of Klebsiella pneumonia, as it may demonstrate the presence of bacterial forms, which may not be readily identifiable in the conventional H&E. Note the presence of numerous organisms compatible with Klebsiella.*

TERMINOLOGY

Synonyms

- Friedlander pneumonia

Definitions

- Infectious condition caused by gram-negative bacteria

ETIOLOGY/PATHOGENESIS

Infectious Agents

- .OHEVLHOOD SQHXPRQLDH
  - Nonmotile, usually encapsulated bacillus
  - > 80 different types

CLINICAL ISSUES

Epidemiology

- Incidence
  - .OHEVLHOOD pneumonia appears to be more common in
    - Hospitalized patients
    - Nursing homes
    - Alcoholics
    - Diabetic patients
    - Individuals with poor oral hygiene
- Age
  - More common in adults
- Sex
  - No sex predilection
- Ethnicity
  - No ethnic predisposition

Site

- Posterior segment of right upper lobe is more commonly affected

Presentation

- Fever
- Cough
- Hemoptysis
- Chest pain
- Malaise
- Weight loss

Laboratory Tests

- Leukocytosis
- Increased erythrocyte sedimentation rate
- Cultures positive for gram-negative bacilli

Treatment

- Drugs
  - Antibiotics

Prognosis

- Depends on setting in which illness occurs
- May be fatal in 20-60% of patients

IMAGING

Radiographic Findings

- Bilateral multifocal consolidations or cavitations

MACROSCOPIC

General Features

- Necrosis
- Hemorrhage
- Abscess formation

MICROSCOPIC

Histologic Features

- Alveolar destruction
- Prominent polymorphonuclear leukocyte reaction
- Edematous fluid mixed with mononuclear cells
- Mucicarminophilic exudate
- Abscess formation
- Pulmonary gangrene

Cytologic Features

- Consolidation with acute inflammation
- Cavitation
- Abscess formation

DIFFERENTIAL DIAGNOSIS

Bacterial Pneumonia

- Gram stain distinguishes gram-positive from gram-negative pneumonia
- Bacterial cultures help in identifying .OHEVLHOOD
- Mucicarminophilic exudate appears to be more common in .OHEVLHOOD pneumonia

Pulmonary Tuberculosis

- Although tuberculosis may show areas of cavitation, Gram stain is negative
- Tuberculosis stains positive for acid-fast bacilli
- Tuberculosis shows specific culture results

Carcinoma

- In some cases, cavitation may occur in cases of non-small cell carcinoma
- Identification of malignant cells is of utmost importance

DIAGNOSTIC CHECKLIST

Pathologic Interpretation Pearls

- Mucicarminophilic exudate
- Cavitation
- Abscess formation
- Gram-negative bacilli
- Positive cultures

SELECTED REFERENCES

1. Melot B et al: Bacteremic community-acquired infections due to Klebsiella pneumoniae: clinical and microbiological presentation in New Caledonia, 2008-2013. Int J Infect Dis. 41:29-31, 2015
2. Lee CC et al: Different clinical presentation of community-onset bacteremia among human immunodeficiency virus-infected and human immunodeficiency virus-uninfected adults in the ED. Am J Emerg Med. 32(10):1241-7, 2014

(Left) *Low-power view of Klebsiella pneumonia shows extensive congestion and fibrinous exudate admixed with inflammatory reaction. These features, although not specific for Klebsiella pneumonia, should prompt the use of cultures and special stains.* **(Right)** *High-power view of lung parenchyma shows areas of fibrinous exudate and a prominent inflammatory component with abscess formation. The use of special histochemical stains for bacteria is warranted in such cases.*

Acute Pneumonia

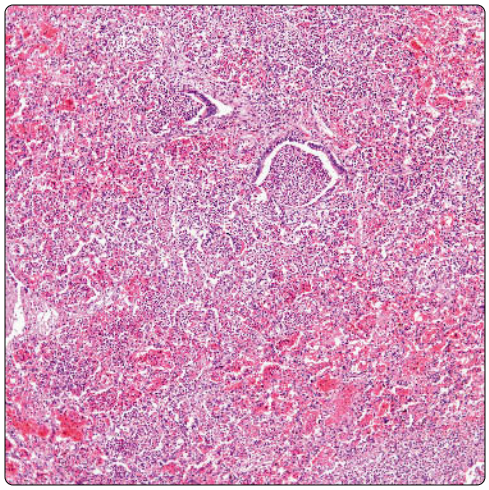

Fibrinous Exudate

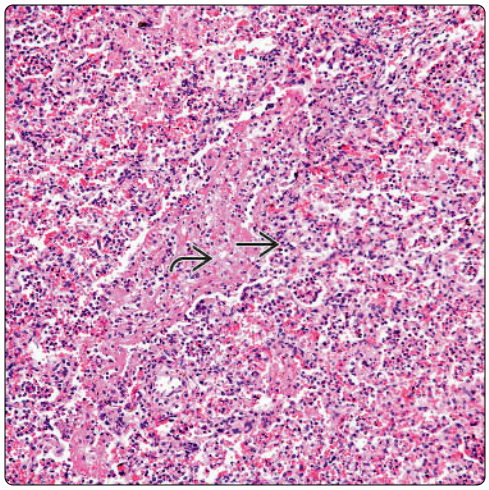

(Left) *Klebsiella pneumonia shows abscess formation within the airway, while the adjacent lung parenchyma shows congestion and inflammatory changes.* **(Right)** *Closer view of the inflammatory component shows that it consists of acute inflammatory cells admixed with red cells. Once again, even though these changes are not specific for Klebsiella pneumonia, they should raise the possibility of this diagnosis in the right setting.*

Abscess Formation

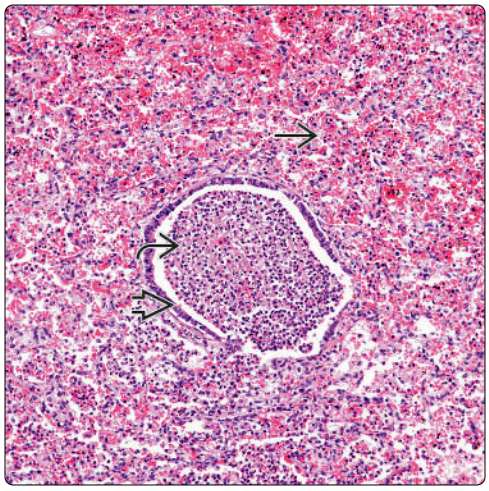

Acute Inflammation

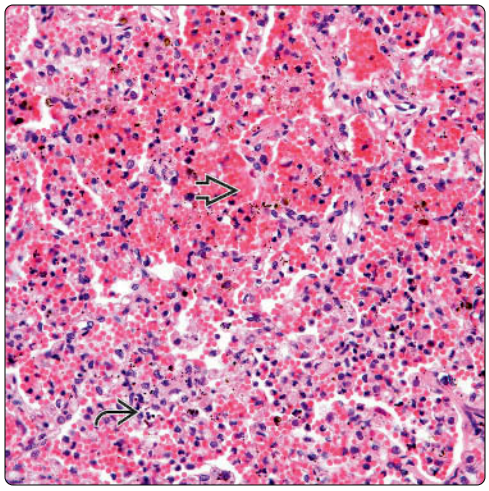

(Left) *Klebsiella pneumonia shows extensive areas of fibrinous component admixed with acute inflammatory cells. The process is clearly infectious and requires the use of cultures and special histochemical stains for identification of the organism.* **(Right)** *High-power magnification shows that alveoli are filled with acute inflammatory cells. Basically, the normal lung parenchyma is destroyed by the infectious process.*

Acute Pneumonia

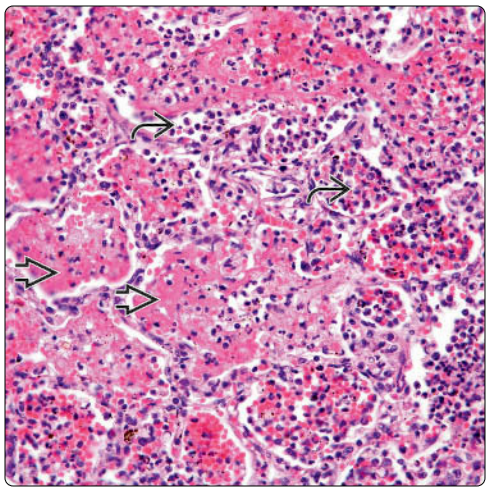

Acute Pneumonia

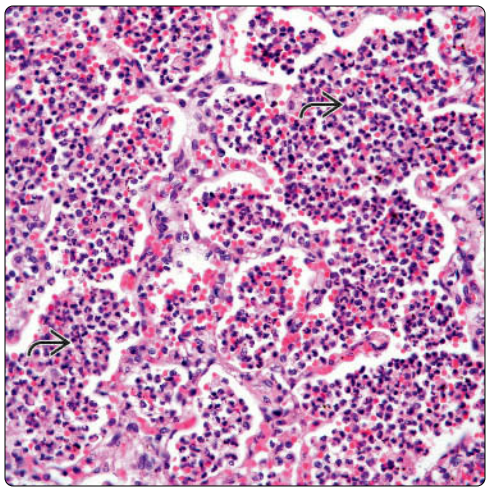

Fibrinous Acute Pneumonia

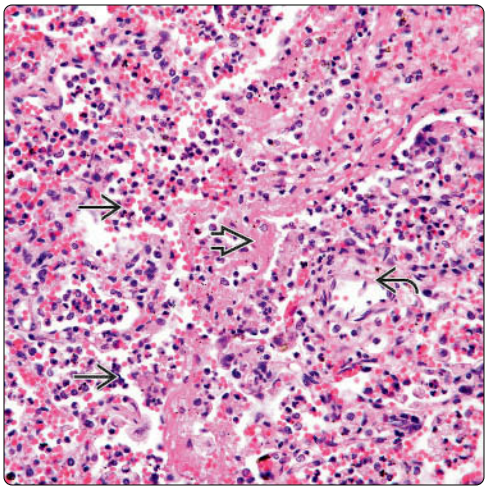

Airway Destruction

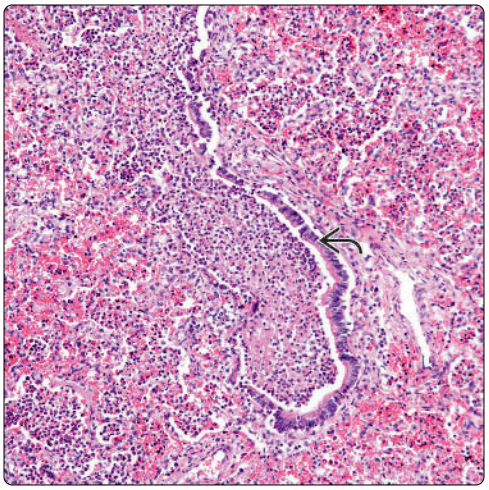

(Left) *In some cases of Klebsiella pneumonia, the basic alveolar outline is not recognizable due to the inflammatory process. In this case, the acute inflammatory cells are admixed with fibrin, leaving only a few recognizable structures, such as pulmonary vessels.* **(Right)** *Klebsiella pneumonia shows partial destruction of the airway. Note the presence of abscess formation and the destruction of the adjacent normal lung parenchyma.*

Bronchial Erosion

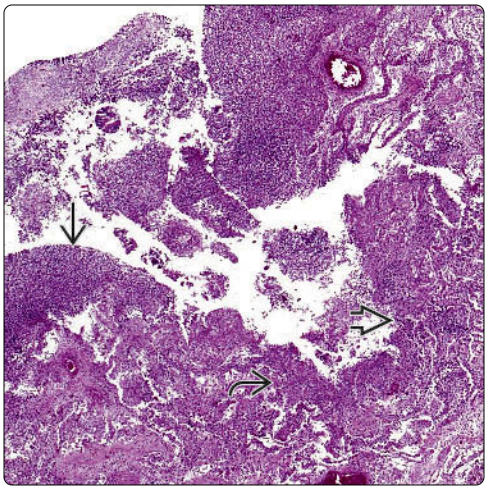

Alveoli With Acute Inflammatory Cells

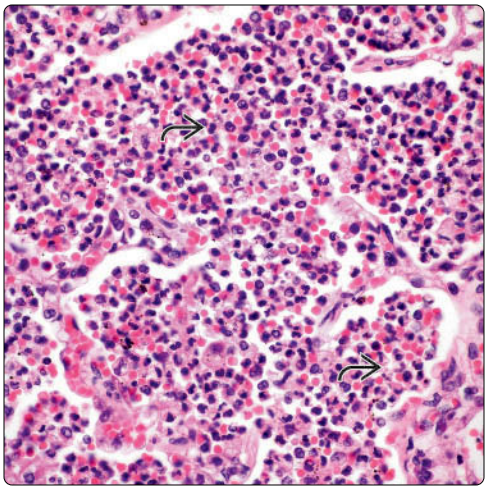

(Left) *Klebsiella pneumonia involving main bronchi shows erosion and destruction of the normal mucosa and the presence of abscess formation. These changes may be seen in small biopsy specimens.* **(Right)** *The involvement of the lung parenchyma characterized by alveoli filled with acute inflammatory cells is the most common pattern in cases of Klebsiella pneumonia.*

Mucicarmine Stain

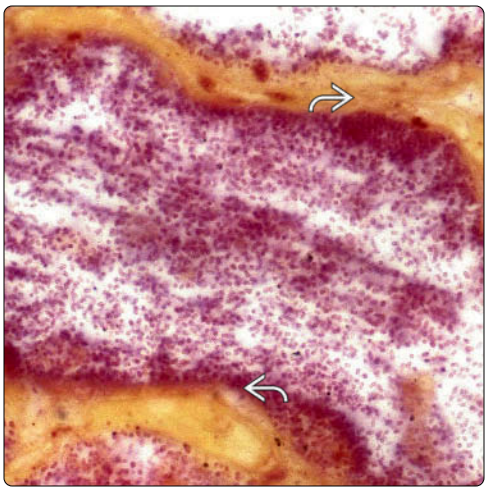

Brown-Hopps Stain

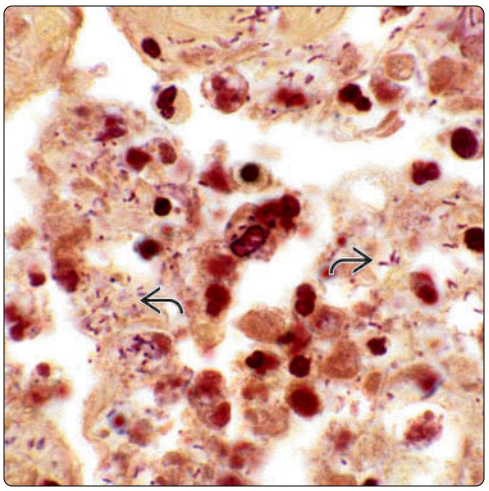

(Left) *Mucin histochemical stain shows the classic mucicarminophilic exudate that is commonly seen in cases of Klebsiella pneumonia. Such a finding is helpful in making the diagnosis.* **(Right)** *The Brown-Hopps histochemical stain is useful in the diagnosis of Klebsiella pneumonia, as it may demonstrate the presence of bacterial forms, which may not be readily identifiable in the conventional H&E. Note the presence of numerous organisms compatible with Klebsiella.*

SARS Pneumonia

KEY FACTS

TERMINOLOGY

- Severe acute respiratory syndrome (SARS)

ETIOLOGY/PATHOGENESIS

- Etiological agent
  - SARS coronavirus (SARS-CoV)
- SARS can be transmitted by
  - Direct contact
  - Droplet
  - Airborne route

CLINICAL ISSUES

- Symptomatology
  - Flu-like symptoms
- Prognosis
  - Mortality: ~ 10%
  - More fatal cases in elderly patients > 60 yr of age
  - Mortality in younger individuals < 10%

ANCILLARY TESTS

- Identification of viral particles by electron microscopy
- Identification of viral particles by FISH or PCR

TOP DIFFERENTIAL DIAGNOSES

- Avian influenza A (H5N1)
  - Avian influenza follows more aggressive course
  - Extensive necrosis and hemorrhage in lung parenchyma
  - Multinucleated giant cells are not commonly seen in avian influenza

DIAGNOSTIC CHECKLIST

- Diffuse alveolar damage (DAD)
- Organizing phase of DAD
- Multinucleated giant cells

Congestion and Edema

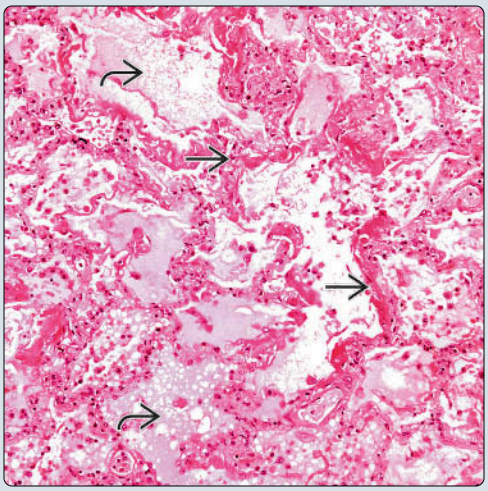

Focal Pneumocyte Type II Hyperplasia

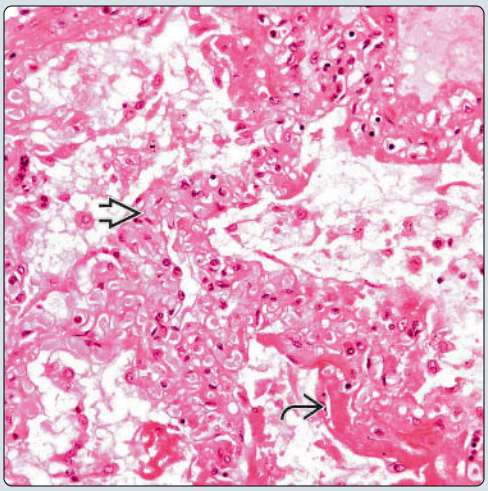

(Left) *SARS infection shows extensive areas of congestion, edema, and hyaline membranes. All these features are compatible with diffuse alveolar damage (DAD) caused by SARS-CoV.* **(Right)** *SARS shows the classic features of hyaline membranes and pneumocyte type II hyperplasia, which are compatible with DAD.*

DAD Changes

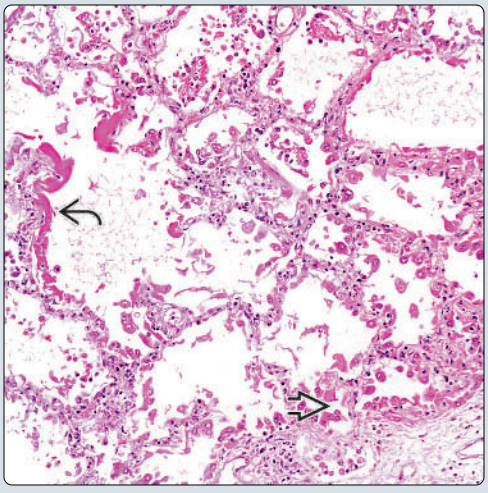

Hyaline Membranes

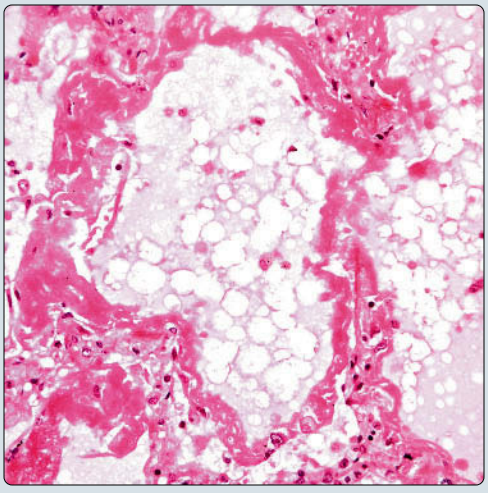

(Left) *In other areas, features of DAD are more apparent. Note the presence of type II pneumocyte hyperplasia and hyaline membranes.* **(Right)** *Alveolar walls entirely lined by a hyaline membrane are commonly seen in fulminant cases of DAD as shown here.*

TERMINOLOGY

Abbreviations

- Severe acute respiratory syndrome (SARS)

Definitions

- Infectious viral disease

ETIOLOGY/PATHOGENESIS

Infectious Agents

- SARS coronavirus (SARS-CoV)
- Single-stranded RNA virus
- Virus has also been isolated from
  - Urine
  - Feces

Pathogenesis

- Highly complex
- May involve
  - Immune system
  - Hyperinduction of chemokines and cytokines
  - Insufficient interferon reaction
  - Compromised cellular immune response
  - Metallopeptidase (ACE2) identified as functional receptor for SARS-CoV
- SARS can be transmitted by
  - Direct contact
  - Droplet
  - Airborne route

CLINICAL ISSUES

Epidemiology

- Incidence
  - Difficult to establish but at end of initial epidemic of 2003, > 8,000 probable cases had been reported
- Age
  - Affects any age group
- Sex
  - No gender predilection
- Ethnicity
  - Probably more common in China

Presentation

- Flu-like symptoms
- Fever
- Cough
- Chills
- Malaise
- Shortness of breath

Treatment

- No specific treatment
- Some patients treated with steroids
- Antiviral therapy

Prognosis

- Mortality: ~ 10%
- Elderly patients (> 60 yr of age) may account for 50% of fatal cases
- In younger patients, mortality has been estimated to be < 10%
- Mortality appears to be higher in males than females

MACROSCOPIC

General Features

- Congested lungs

MICROSCOPIC

Histologic Features

- Diffuse alveolar damage (DAD)
  - Pneumocyte type II hyperplasia
  - Hyaline membranes
- Organizing phase of DAD
  - Hyaline membranes
  - Fibroblastic plugs in alveolar spaces
  - Pneumocyte type II hyperplasia
- Bronchiolitis obliterans and organizing pneumonia
- Multinucleated giant cells
- Other organs may also be affected, including
  - Gastrointestinal tract
  - Hematopoietic
  - Central nervous system
  - Skeletal muscle
  - Heart
  - Thyroid
  - Testes

ANCILLARY TESTS

In Situ Hybridization

- Identification of viral particles

PCR

- Identification of viral particles

Electron Microscopy

- Identification of viral particles

DIFFERENTIAL DIAGNOSIS

Avian Influenza A (H5N1)

- Although it also shows DAD, avian influenza follows more aggressive course with marked necrosis and hemorrhage in lungs
- Multinucleated giant cells present in SARS are not present in avian influenza

DIAGNOSTIC CHECKLIST

Pathologic Interpretation Pearls

- Diffuse alveolar damage
- Organizing phase of DAD
- Multinucleated giant cells

SELECTED REFERENCES

1. Gogna A et al: Severe acute respiratory syndrome: 11 years later--a radiology perspective. AJR Am J Roentgenol. 203(4):746-8, 2014
2. Cleri DJ et al: Severe acute respiratory syndrome (SARS). Infect Dis Clin North Am. 24(1):175-202, 2010
3. Hui DS et al: Severe acute respiratory syndrome and coronavirus. Infect Dis Clin North Am. 24(3):619-38, 2010

Nocardiosis

KEY FACTS

ETIOLOGY/PATHOGENESIS

- 1RFDUGLD DVWHURLGHV
  - Aerobic, partially acid-fast branching actinomycete
  - Rarely measures > 1 μm in diameter
- Other types of 1RFDUGLD may also be pathogenic agent

CLINICAL ISSUES

- Nocardiosis predominantly affects
  - Lungs
  - Brain
  - Meninges
- Epidemiology
  - Worldwide
  - More common in adults
  - No gender predilection
  - No ethnic predilection
- Presentation
  - Fever
  - Dyspnea

MICROSCOPIC

- Acute suppurative pneumonia
- Abscess formation
- Filamentous organisms
- Branching at right angles
- Positive staining for
  - Gram stain
  - GMS stain
  - Ziehl-Neelsen stain
  - Fite-Faraco

DIAGNOSTIC CHECKLIST

- Positive staining for
  - Gram
  - Ziehl-Neelsen

Abscess Formation

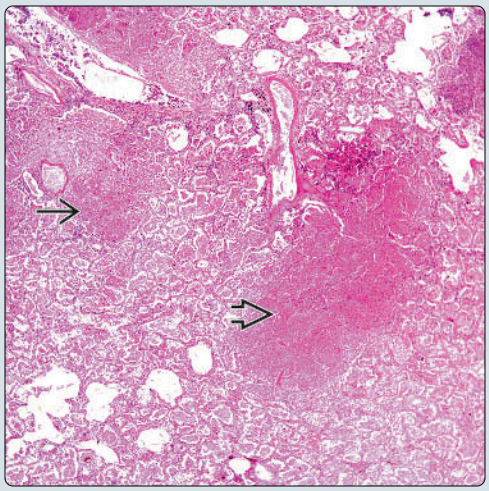

Acute Pneumonia

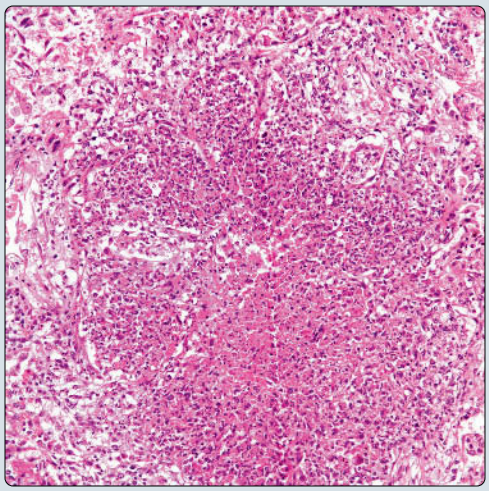

(Left) *Low-power view of a suppurative pneumonia shows abscess formation. The remaining portions of the lung show acute inflammatory changes and a small developing abscess.* **(Right)** *Closer view at a pulmonary abscess caused by nocardiosis shows the presence of severe acute inflammation. The presence of organisms is not apparent in conventional H&E stains.*

Positive Gram Stain

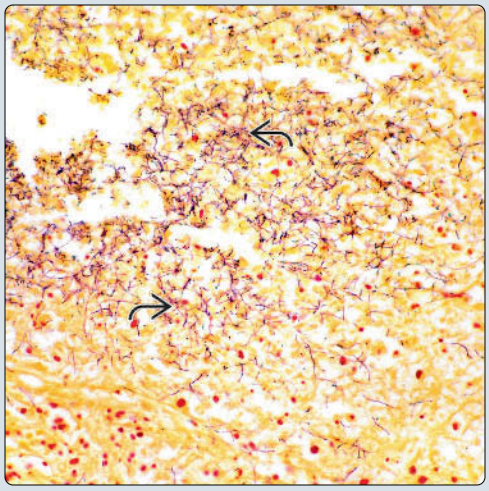

Positive Ziehl-Neelsen

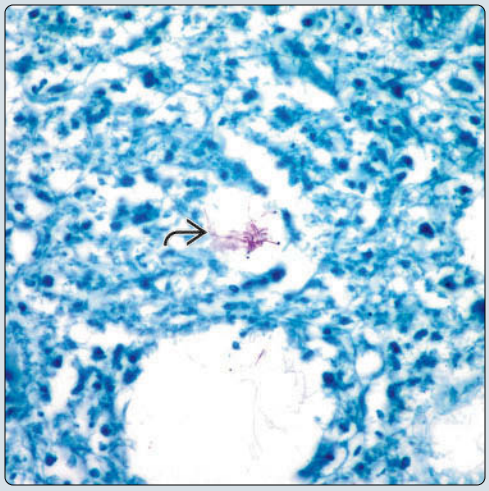

(Left) *Gram histochemical stains show numerous filamentous bacterial organisms embedded in a pulmonary abscess. Gram stain is important in demonstrating nocardiosis.* **(Right)** *A cluster of organisms is present with the Ziehl-Neelsen stain.*

TERMINOLOGY

Definitions

- Infectious condition

ETIOLOGY/PATHOGENESIS

Infectious Agents

- 1RFDUGLD DVWHURLGHV
  - Aerobic, partially acid-fast branching actinomycete
  - Rarely measures > 1 μm in diameter
- Other types of 1RFDUGLD may also be pathogenic agent

CLINICAL ISSUES

Epidemiology

- Incidence
  - Worldwide distribution
- Age
  - More common in adults
- Sex
  - No gender predilection
- Ethnicity
  - No ethnic predilection

Site

- Nocardiosis predominantly affects
  - Lungs
  - Brain
  - Meninges

Presentation

- Fever
- Dyspnea
- Chest pain
- Weight loss
- Anorexia
- General malaise

Prognosis

- If treated early, prognosis may be good
- If spreads to brain and meninges, may be fatal

MICROSCOPIC

Histologic Features

- Acute suppurative pneumonia
- Abscess formation

DIFFERENTIAL DIAGNOSIS

Other Infectious Conditions

- Bacterial pneumonia
  - Both infections may share similar histopathological features
  - Presence of acid-fast organisms with special stains is more typical of 1RFDUGLD
  - Tissue cultures would reveal correct organism
- Atypical mycobacterial disease
  - Both infections may share similar histopathological features
  - Bacilli of mycobacterial infection are short
  - Bacilli of mycobacterial disease are negative for Gram stains
  - Tissue cultures would reveal correct organism
- Actinomycosis
  - Presence of granules may aid in separating 1RFDUGLD from other actinomyces as 1RFDUGLD would not show granules
- Other fungal infections
  - GMS positivity may be shared by other fungal organisms
  - Acid-fast histochemical stains are negative in other fungal infections
  - Gram stain may also be negative in other common fungal infections

DIAGNOSTIC CHECKLIST

Pathologic Interpretation Pearls

- Suppurative pneumonia
- Abscess formation
- Delicate filamentous organisms
- Branching at right angles
- Absence of granules
- Positive staining for
  - Gram
  - GMS
  - Ziehl-Neelsen
  - Fite-Faraco

SELECTED REFERENCES

1. Kandi V: Human nocardia infections: a review of pulmonary nocardiosis. Cureus. 7(8):e304, 2015
2. Ambrosioni J et al: Nocardiosis: updated clinical review and experience at a tertiary center. Infection. 38(2):89-97, 2010
3. Rodrigues C et al: [Thoracic nocardiosis.] Rev Port Pneumol. 15(6):1199-204, 2009

Histochemical Features

Stain	Result
Gram	Positive staining of organism
GMS	Positive staining of organism
Ziehl-Neelsen/Fite-Faraco	Positive staining of organism
PAS	Negative
Gridley	Negative

7LVVXH FXOWXUHV DUH WKH EHVW PHWKRG WR LGHQWLI\ WKH RUJDQLVPV

Actinomycosis

KEY FACTS

ETIOLOGY/PATHOGENESIS

- *Actinomyces israelii*
  - Common saprophyte of mouth and tonsils
- Other types isolated from infections include
  - *Actinomyces naeslundii*
  - *Actinomyces propionicus*
  - *Actinomyces eriksonii*

CLINICAL ISSUES

- May involve following areas
  - Cervicofacial area
  - Lungs
  - Abdomen

MICROSCOPIC

- Suppurative pneumonia
- Abscess formation
- Presence of "sulfur" granules in abscess

TOP DIFFERENTIAL DIAGNOSES

- Nocardiosis
  - Absence of "sulfur" granules
- *Candida* infection
  - Absence of "sulfur" granules
  - *Candida* is weakly gram positive
- Aspergillosis
  - Absence of "sulfur" granules
  - Numerous hyphae branching at 45°
- Histoplasmosis
  - Absence of "sulfur" granules
  - *Histoplasma* usually presents as numerous small budding yeast organisms

Acute Pneumonia

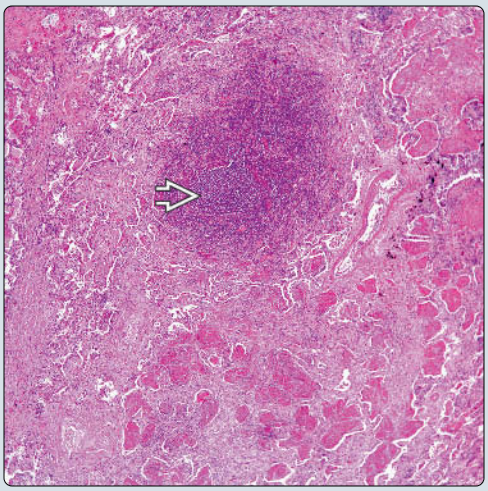

Abscess With Organism

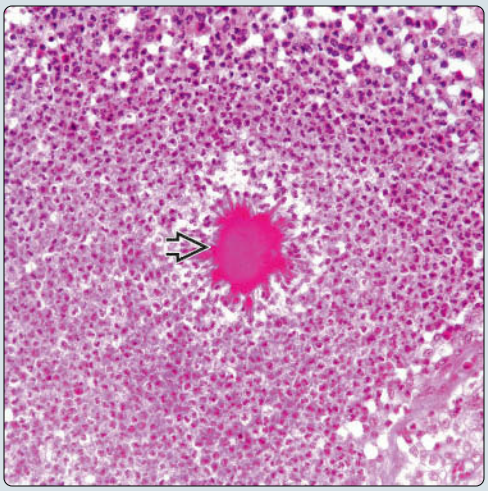

(Left) *Low-power view shows suppurative pneumonia with abscess formation. The rest of the lung parenchyma shows acute fibrinous pneumonia.* **(Right)** *High-power view of the abscess shows the presence of acute inflammatory cells. Actinomycosis with the characteristic grains is present in the center.*

***Actinomyces* Organism**

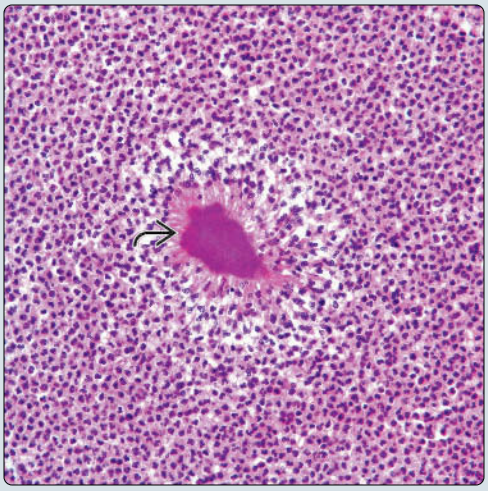

Gram Stain of Organism

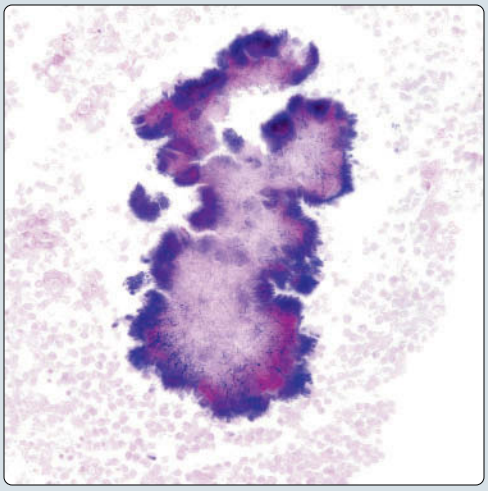

(Left) *High-power view of actinomycosis embedded in an abscess shows the presence of the purple color of the organism and the characteristic granular appearance.* **(Right)** *Actinomycosis in a Gram stain shows a purple color. It is possible to observe the presence of filamentous organisms.*

TERMINOLOGY

Definitions

- Chronic suppurative infectious condition

CLINICAL ISSUES

Epidemiology

- Incidence
  - Worldwide distribution
- Age
  - Affects any age group but may be more common in adults
- Sex
  - No gender predilection
- Ethnicity
  - No ethnic predilection

Site

- May involve
  - Cervicofacial area
  - Lungs
  - Abdomen

Presentation

- Fever
- Dyspnea
- Cough
- Chest pain
- Suppurative skin lesion in cervicofacial area

Laboratory Tests

- Tissue cultures
- Anaerobic cultures

Treatment

- Drugs
  - Broad-spectrum antibiotics

Prognosis

- Good if treated early
- May be difficult to control in immunocompromised patients

MICROSCOPIC

Histologic Features

- Suppurative pneumonia
- Abscess formation
- Presence of "sulfur" granules in abscess
  - Deep purple granules
  - Round to oval granules
  - 100-300 µm in diameter
- Identification of gram-positive filamentous organisms

DIFFERENTIAL DIAGNOSIS

Nocardiosis

- Absence of "sulfur" granules
- Tissue cultures would reveal correct organism

Candida Infection

- Absence of granules
- In unusual circumstances, & D Q G L G D may be weakly positive for Gram stain
- Tissue cultures would reveal correct organism

Aspergillosis Infection

- Absence of "sulfur" granules
- Unusual for $ V S H U J L O O X V to be positive for Gram stain
- Tissue cultures would reveal correct organism

Histoplasmosis

- Unusual for + L V W R S O D V P D to show acute suppurative pneumonia
- Negative for Gram stain
- Absence of "sulfur" granules
- More commonly shows granulomatous reaction
- Tissue cultures would reveal correct organism

DIAGNOSTIC CHECKLIST

Pathologic Interpretation Pearls

- Suppurative pneumonia
- Abscess formation
- Presence of "sulfur" granules
- Filamentous bacteria

SELECTED REFERENCES

1. Qiu L et al: Pulmonary actinomycosis imitating lung cancer on (18)F-FDG PET/CT: a case report and literature review. Korean J Radiol. 16(6):1262-5, 2015
2. Skehan N et al: Endobronchial actinomycosis: successful treatment with oral antibiotics. BMJ Case Rep. 2015, 2015
3. Valour F et al: Actinomycosis: etiology, clinical features, diagnosis, treatment, and management. Infect Drug Resist. 7:183-97, 2014

Histochemical Features

Stain	Result
Gram	Positive staining of filamentous organism
GMS	Positive staining of organism
PAS	Negative
Gridley	Negative
Ziehl-Neelsen	Negative
Mucicarmine	Negative

7LVVXH FXOWXUHV DUH WKH EHVW PHWKRG WR VHSDUDWH WKH RUJDQLVPV IURP RWKHU LQIHFWL

Aspergillosis

KEY FACTS

TERMINOLOGY

- Infection caused by fungus species $ V S H U J L O O X V

CLINICAL ISSUES

- Fungus balls may be asymptomatic and discovered incidentally or can present with massive, life-threatening hemoptysis
- Immunosuppressed patients with acute invasive aspergillosis present with cough, fever, and pleuritic pain; infection simulates bacterial bronchopneumonia

MACROSCOPIC

- Fungus balls appear as friable greenish to brown soft material lying within distended cavity
- Necrotizing tracheobronchitis is characterized by formation of shaggy pseudomembrane growing along mucosa of trachea
- Acute invasive aspergillosis is characterized by target lesion corresponding to area of infarction surrounded by hemorrhagic rim

MICROSCOPIC

- Acute invasive aspergillosis shows foci of necrotic and hemorrhagic parenchyma associated with occlusion of vessel lumina by hyphae
- Wedge-shaped infarcts can also occur when large arteries are occluded by fungus
- Chronic necrotizing aspergillosis shows large areas of parenchymal consolidation by necrotizing granulomas containing fungal hyphae
- Bronchocentric granulomatosis pattern characterized by necrotizing granulomas surrounding bronchiolar walls
- Conidial or fruiting heads occur in lesions exposed to air and consist of vesicle with sterigmata surrounded by chains of conidia
- Organisms consist of septate hyphae 3-6 µm in width that branch at acute angles (45°)
- Birefringent calcium oxalate crystals may be encountered admixed with hyphal elements

Fungus Ball (Aspergilloma)

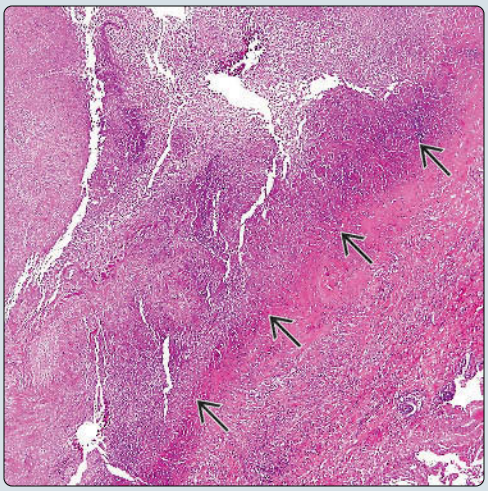

Aspergillosis, High Power

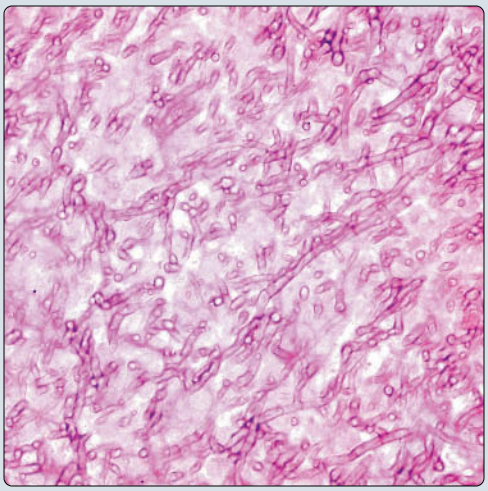

(Left) *Fungus ball in pulmonary aspergilloma shows a cavity containing abundant necrotic material admixed with numerous layers of hyphal forms of aspergillus.* **(Right)** *Higher magnification from the necrotic center of a fungus ball (aspergilloma) shows numerous slender and septate hyphae that branch at acute angles.*

GMS Stain in Aspergillosis

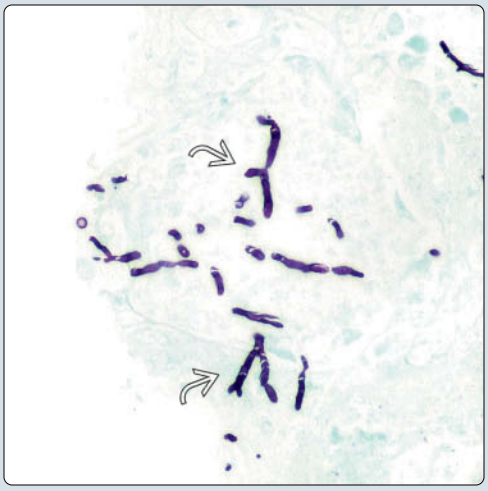

Calcium Oxalate Crystals

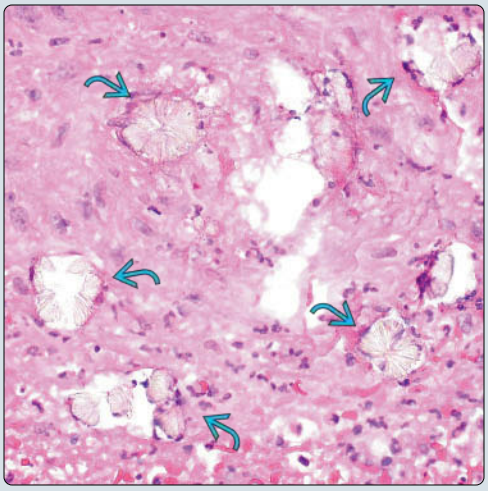

(Left) *Higher magnification from aspergillosis stained with GMS shows hyphal organisms, some of which show the characteristic branching at acute angles.* **(Right)** *Birefringent calcium oxalate crystals are a common finding in cases of pulmonary aspergillosis and are characterized by their radiating, star-shaped configuration, often found admixed with fibrin and necrotic debris.*

TERMINOLOGY

Definitions

- Infection caused by fungus of species $ V S H U J L O O X V

ETIOLOGY/PATHOGENESIS

Infectious Agents

- Most common species: $ V S H U J L O O X V I X P L J D W X V, $ V S H U J L O O X V I O D Y X V, and $ V S H U J L O O X V Q L J H U

CLINICAL ISSUES

Presentation

- Several clinical forms of aspergillosis
  - Colonizing (saprophytic) form in which preexisting cavities are secondarily colonized by organisms, which form fungus ball
  - Allergic bronchopulmonary aspergillosis seen in patients with asthma or cystic fibrosis
  - Acute invasive aspergillosis tends to occur preferentially in immunocompromised patients
  - Chronic necrotizing aspergillosis seen in patients with chronic underlying lung disease, such as COPD or collagen vascular disorders
- Fungus balls may be asymptomatic and discovered incidentally or can present with massive, life-threatening hemoptysis
- Immunosuppressed patients with acute invasive aspergillosis present with cough, fever, and pleuritic pain; simulates bacterial bronchopneumonia

Laboratory Tests

- Serum precipitins against $ V S H U J L O O X V can be found in > 95% of patients with fungus balls
- Sputum cultures can help identify organisms in patients with fungus balls but may not be helpful in invasive aspergillosis

Treatment

- Drugs
  - Amphotericin B is drug of choice for acute invasive aspergillosis and chronic necrotizing aspergillosis

IMAGING

Radiographic Findings

- Aspergilloma (fungus ball) shows soft tissue nodule within preexistent pulmonary cavity or bronchiectatic airway
  - Fungus ball is usually outlined by crescent of air along its nondependent surface (air crescent sign)
- Invasive aspergillosis shows multifocal opacities with ill-defined borders that may progress to large foci of consolidation

CT Findings

- Invasive aspergillosis shows focal or multifocal nodular opacities surrounded by ground-glass attenuation (halo sign)

MACROSCOPIC

General Features

- Fungus balls appear as friable greenish to brown soft material lying within distended cavity
- Necrotizing tracheobronchitis is characterized by formation of shaggy pseudomembrane growing along mucosa of trachea
- Acute invasive aspergillosis is characterized by target lesion corresponding to area of infarction surrounded by hemorrhagic rim
- Bronchopneumonic form is characterized by lobular consolidation with filling of alveolar spaces by acute inflammatory exudate admixed with fungal elements
- Extrinsic allergic alveolitis pattern is caused by small granulomas with foci of early interstitial fibrosis and inflammation

MICROSCOPIC

Histologic Features

- **Fungus ball (aspergilloma)**
  - Masses of mycelia that grow in layers within cavity
- **Necrotizing pseudomembranous tracheobronchitis**
  - Pseudomembrane lining mucosa contains mixture of mucus, inflammatory cells, necrotic tissue, and fungal hyphae with conidial heads
- **Acute invasive aspergillosis**
  - Foci of necrotic, infarcted, and hemorrhagic parenchyma associated with occlusion of vessel lumina by fungal hyphae
  - Wedge-shaped infarcts can also occur when large arteries are occluded by fungus
  - Infarcts lead to progressive cavitation in which fungus balls later develop
- **Chronic necrotizing aspergillosis**
  - Large areas of parenchymal consolidation by necrotizing granulomas containing fungal hyphae
  - Bronchocentric granulomatosis pattern characterized by necrotizing granulomas surrounding bronchiolar walls
  - Extrinsic allergic alveolitis pattern may occur in response to chronic infection and shows small granulomas with focal interstitial fibrosis

Cytologic Features

- Organisms consist of septate hyphae 3-6 µm in width that branch at acute angles (45°)
- Hyphae may undergo degenerative changes, such as swollen hyphal segments, that may make it difficult to distinguish them from other fungi
- Conidial or fruiting heads occur in lesions exposed to air and consist of vesicle with sterigmata surrounded by chains of conidia
- In chronic granulomatous lesions, hyphae may be surrounded by proteinaceous debris with Splendore-Hoeppli phenomenon
- Birefringent calcium oxalate crystals may be encountered admixed with hyphal elements

Clinical Spectrum of Pulmonary Aspergillosis

Clinical Type	Clinical Setting
Invasive aspergillosis	Severely immunocompromised patients
	Neutropenia
	Heart and lung transplant recipients
	Critically ill patients
	Patients on steroids
	Massive exposure to fungal spores
Chronic pulmonary aspergillosis	Patients without obvious immune compromise but with underlying lung conditions
	Chronic obstructive pulmonary disease
	Sarcoidosis
	Tuberculosis or other mycobacterial infections
	Cystic fibrosis
	Bronchiectasis
Allergic bronchopulmonary aspergillosis	Immunological pulmonary disorder in patients with asthma caused by hypersensitivity to $ V S H U J L O O X V

ANCILLARY TESTS

Histochemistry

- Organisms are best highlighted with PAS and GMS stains

PCR

- Multiplex real-time PCR assay for mutations in & < 3 $ can help differentiate susceptible from resistant $ I X P L J D W X V strains
  - Multiplex RT-PCR can be successfully employed in sputum samples and bronchioloalveolar lavage fluid samples
- PCR detection of serum $ V S H U J L O O X V DNA can be used for early diagnosis and therapy of invasive aspergillosis in high-risk patients

Serologic Testing

- Serum galactomannan assay for detection of $ V S H U J L O O X V antigen is reliable marker of invasive aspergillosis
- Detection of β-glucan, an antifungal antigen, has auxiliary role in diagnosis and can help confirm results of galactomannan test

DIFFERENTIAL DIAGNOSIS

Fusarium Infection

-) X V D U L X P has wider hyphae (3-8 µm) that branch at 90° angles and show constrictions at branching points
- Some branches in) X V D U L X P hyphae can show small ovoid conidia at their tips or located laterally on short conidiophores
- Morphologic overlap between) X V D U L X P and $ V S H U J L O O X V can be significant; definitive diagnosis may require cultures or other methods

Pseudallescheria boydii Infection

- 3 V H X G D O O H V F K H U L D has slightly thinner hyphae (2-5 µm) than $ V S H U J L O O X V and more haphazard branching pattern
- 3 E R \ G L L may show vesicles and oval conidia measuring 5-10 µm that grow on short conidiophores
- Morphologic overlap with $ V S H U J L O O X V can be significant; definitive diagnosis requires culture, immunohistochemistry, or direct immunofluorescence

Zygomycetes Infection

- = \ J R P \ F H W H V have broad hyphae that range from 5-25 µm and appear twisted, folded, or swollen with irregular branching pattern

SELECTED REFERENCES

1. Aguado JM et al: Serum galactomannan versus a combination of galactomannan and polymerase chain reaction-based Aspergillus DNA detection for early therapy of invasive aspergillosis in high-risk hematological patients: a randomized controlled trial. Clin Infect Dis. 60(3):405-14, 2015
2. Chong GL et al: Validation of a new Aspergillus real-time PCR assay for direct detection of Aspergillus and azole resistance of Aspergillus fumigatus on bronchoalveolar lavage fluid. J Clin Microbiol. 53(3):868-74, 2015
3. Kosmidis C et al: The clinical spectrum of pulmonary aspergillosis. Thorax. 70(3):270-7, 2015
4. Muñoz P et al: Invasive aspergillosis among heart transplant recipients: a 24-year perspective. J Heart Lung Transplant. 33(3):278-88, 2014
5. Agarwal R et al: Allergic bronchopulmonary aspergillosis: review of literature and proposal of new diagnostic and classification criteria. Clin Exp Allergy. 43(8):850-73, 2013
6. Tochigi N et al: Histopathological implications of Aspergillus infection in lung. Mediators Inflamm. 2013:809798, 2013
7. Chai LY et al: Recent advances in invasive pulmonary aspergillosis. Curr Opin Pulm Med. 17(3):160-6, 2011
8. Ader F: Invasive pulmonary aspergillosis in patients with chronic obstructive pulmonary disease: an emerging fungal disease. Curr Infect Dis Rep. 12(6):409-16, 2010

Ischemic Infarction With Thrombosis

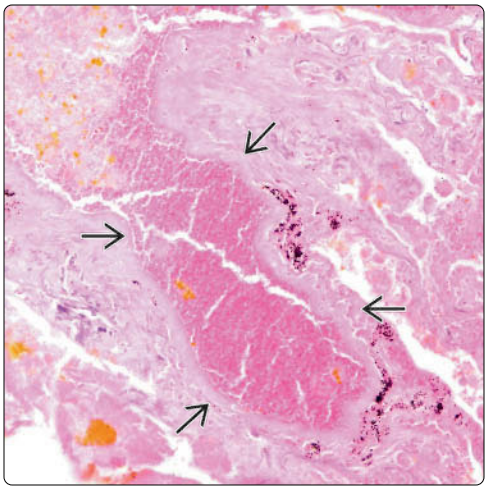

Aspergillus Organisms, High Power

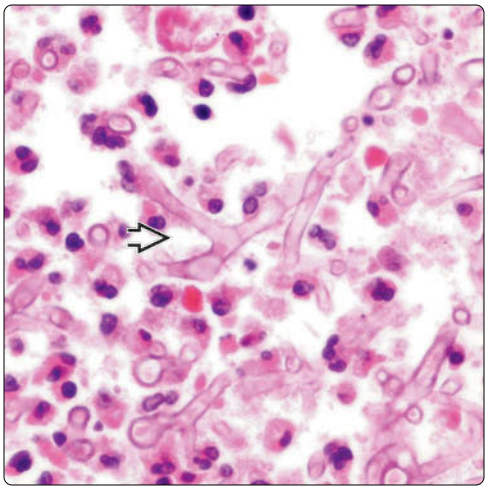

(Left) *Acute invasive pulmonary aspergillosis shows an occluded vessel ⇨ surrounded by an extensive area of ischemic infarction due to plugging of the lumen with fungal organisms.* **(Right)** *Higher magnification from the center of the vessel shows branching septate hyphae ⇨ admixed with necrotic debris and scattered red blood cells. The areas of infarction caused by the occlusion of vessels may eventually lead to cavitation followed by the development of fungus balls.*

Necrotizing Palisaded Granuloma

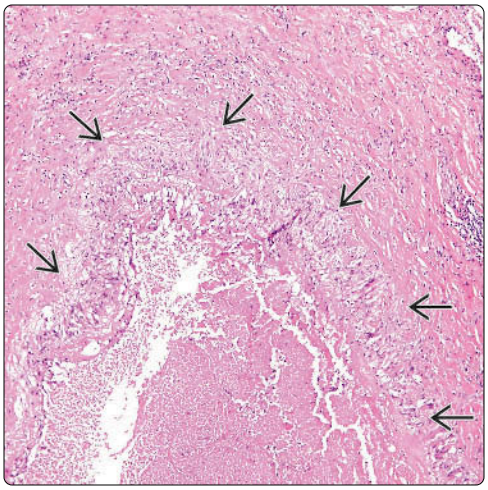

Necrotizing Granuloma With Organisms

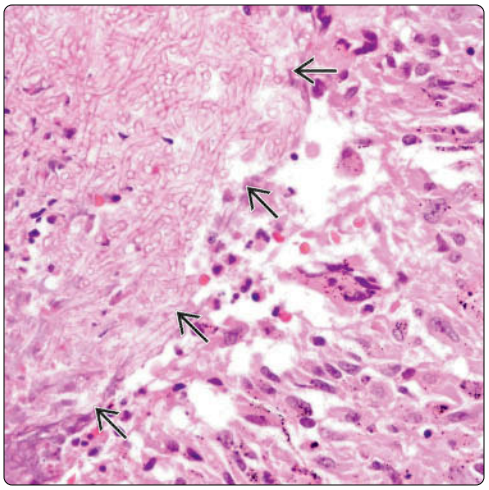

(Left) *Necrotizing palisaded granuloma ⇨ circumscribing an area of necrosis is seen admixed with abundant hyphal organisms in chronic necrotizing pulmonary aspergillosis. The granulomas can sometimes involve the bronchiolar walls, resulting in a pattern of bronchocentric granulomatosis.* **(Right)** *Higher magnification from the edge of a necrotizing granuloma in chronic necrotizing aspergillosis shows abundant epithelioid histiocytes circumscribing a mass of tangled hyphal organisms ⇨.*

Prominent Squamous Metaplasia

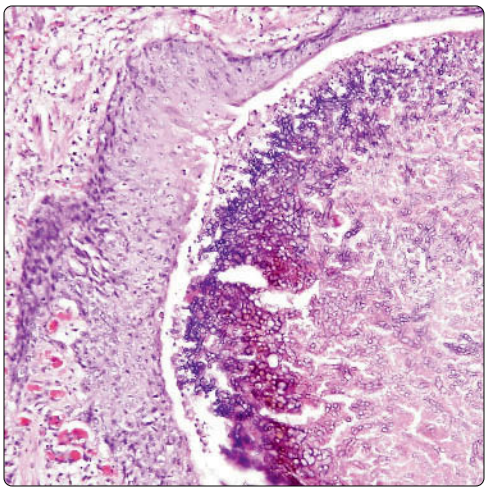

Squamous Metaplasia, Higher Power

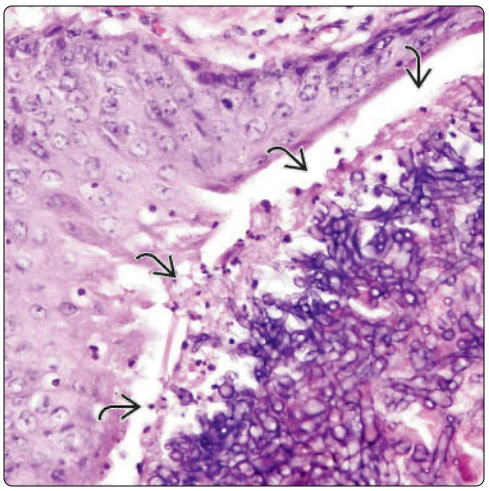

(Left) *A dilated bronchiole with extensive squamous metaplasia of the lining epithelium shows masses of hyphal forms plugging the lumen in a case of chronic necrotizing pulmonary aspergillosis.* **(Right)** *Higher magnification of the wall of a dilated bronchiole in a patient with chronic necrotizing pulmonary aspergillosis shows extensive squamous metaplasia of the lining bronchiolar epithelium. Notice the masses of hyphal organisms plugging the lumen ⇨.*

Angioinvasive Aspergillosis

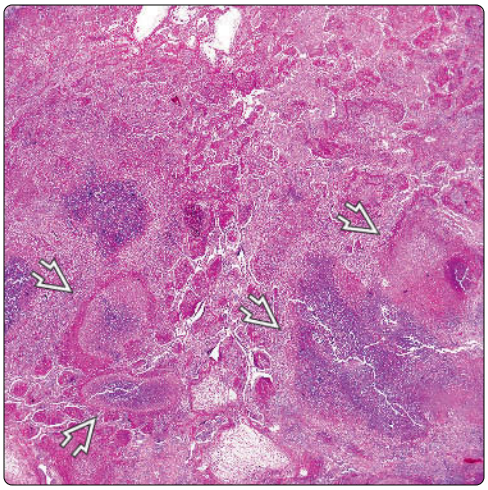

Angioinvasive Aspergillosis, High Power

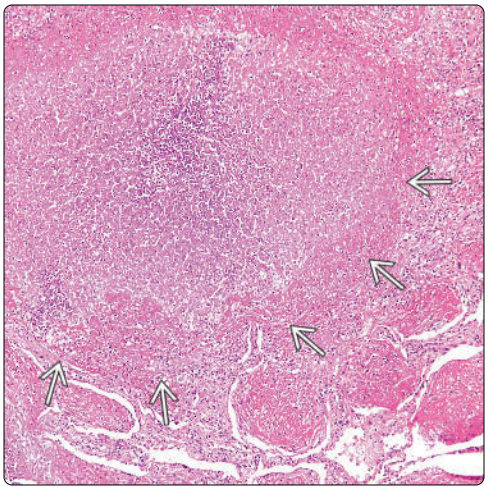

(Left) *Lung parenchyma shows angioinvasive aspergillosis. There are several dilated spaces filled with necrotic debris and fibrin filled with organisms ➡. (Right) Higher magnification of same case shows destruction of vessel wall by a necrotizing process with central areas of necrosis admixed with abundant polymorphonuclear leukocytic infiltrates ➡. Notice the fibrinous exudate is extending into adjacent alveolar spaces.*

Focus of Necrosis With Few Organisms

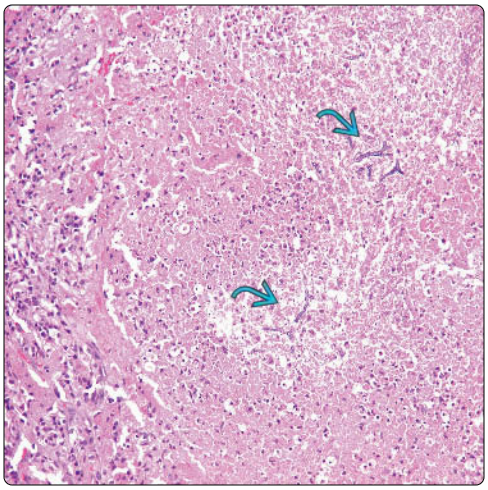

Aspergillus Organisms (PAS Stain)

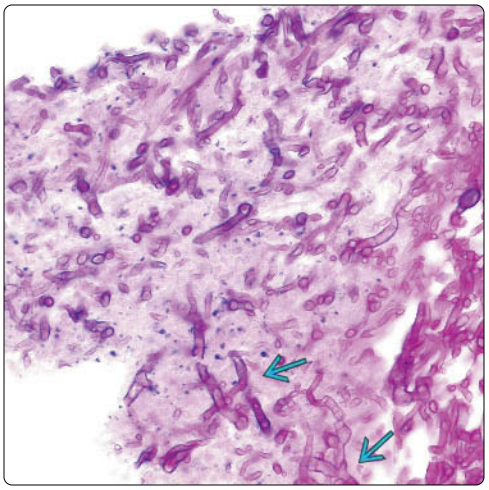

(Left) *Higher magnification of a focus of necrosis in pulmonary aspergillosis shows abundant necrotic debris admixed with fibrinopurulent exudate. There are a few scattered branching hyphal organisms ⇨ seen scattered in the inflammatory infiltrate.* **(Right)** *Histochemical stain for PAS shows numerous scattered, yeast-like forms and hyphae, some of which display branching at 45° angles ⇨.*

Aspergilloma

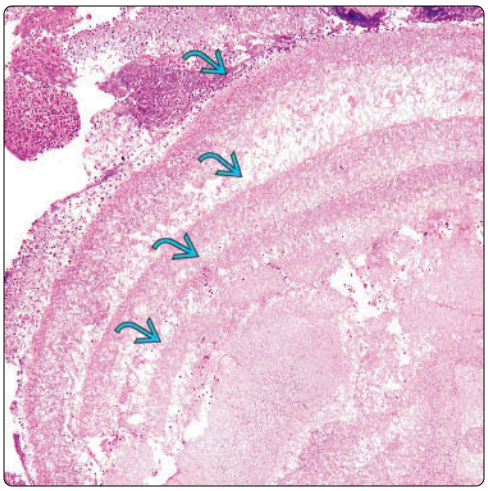

Granulomatous Response to *Aspergillus*

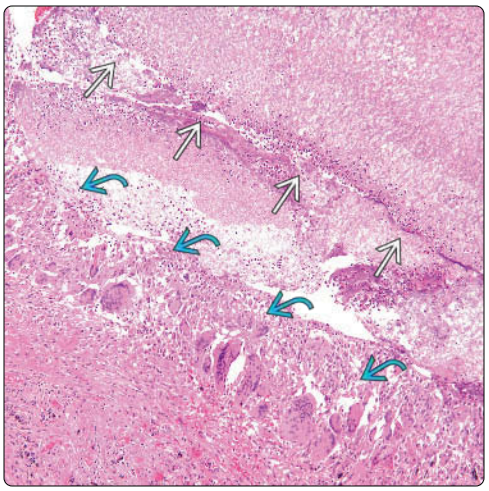

(Left) *Scanning magnification in pulmonary aspergilloma shows concentric layers ⇨ of dense fibrin admixed with the fungal organisms, adopting a laminated appearance.* **(Right)** *Another area in the preceding example shows a florid granulomatous response to the fungus ball ➡ with a wall of multinucleated giant cells ⇨ that are attempting to wall-off the organisms.*

Botryomycosis

KEY FACTS

TERMINOLOGY

- Chronic, purulent, granulomatous bacterial infection

ETIOLOGY/PATHOGENESIS

- Can be caused by different bacterial organisms
- 6WDSK\ORFRFFXV DXUHXV
- 3VHXGRPRQDV DHUXJLQRVD
- (VFKHULFKLD FROL
- 3URWHXV YXOJDULV

CLINICAL ISSUES

- Symptoms
  - Ulcers
  - Draining sinuses
  - Fever
  - Chest pain
  - Hemoptysis
- More common in patients with
  - Immunodeficiency
  - Diabetes
  - Alcoholism
  - Poor hygiene

IMAGING

- Discrete pulmonary mass
- Cavitary pulmonary lesion

MICROSCOPIC

- Abscess formation
- Splendore-Hoeppli phenomenon
- Purulent inflammatory reaction
- Granules within abscess
- Nonfilamentous bacteria

TOP DIFFERENTIAL DIAGNOSES

- Actinomycosis
- Nocardiosis

Botriomycotic Abscess | **Higher Magnification**

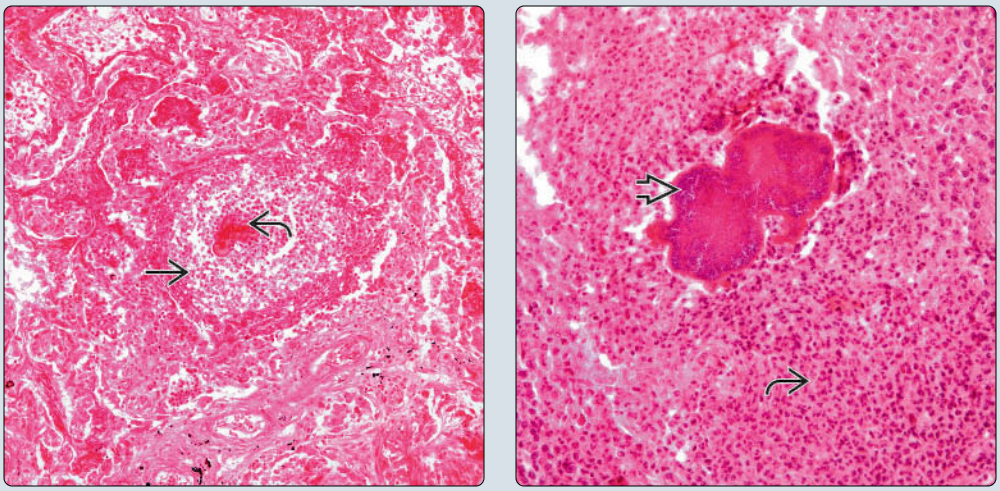

(Left) *Pulmonary botryomycosis shows abscess formation filling the alveolar space. At the center, there is bacterial infection, typical of botryomycosis.* **(Right)** *Higher magnification from botriomycotic abscess in the lung is shown. Pulmonary botryomycosis shows abscess formation, and in the center of the abscess there is an eosinophilic clump of bacterial organisms.*

Sulfur Granule-Like Cluster | **Giemsa Stain**

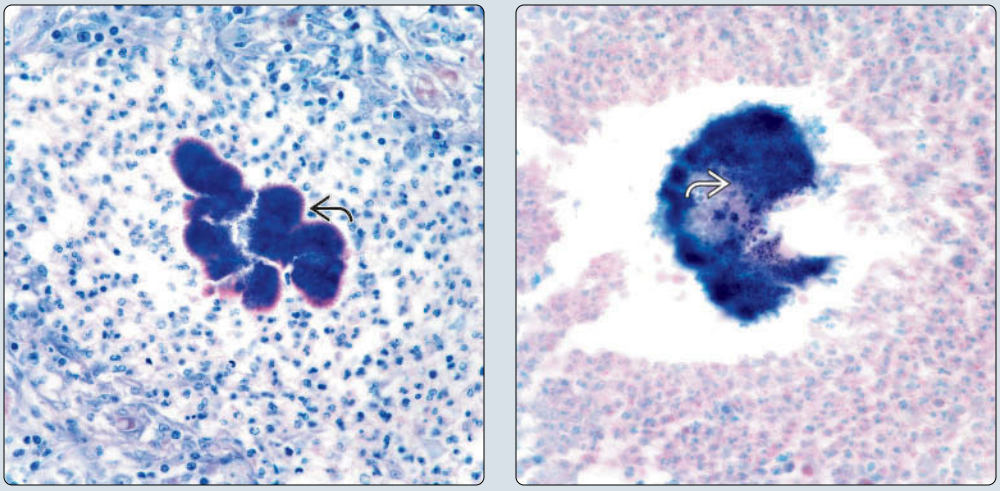

(Left) *A Giemsa stain highlights a clump of bacteria resembling a sulfur granule in botryomycosis. The cluster of bacteria is present in the center of an abscess.* **(Right)** *Higher magnification of botriomycotic abscess stained with Giemsa shows the presence of the characteristic grains, a feature of botryomycosis.*

TERMINOLOGY

Definitions

- Chronic, purulent, granulomatous bacterial infection

ETIOLOGY/PATHOGENESIS

Infectious Agents

- Can be caused by different bacterial organisms
  - 6WDSK\ORFRFFXV DXUHXV
  - 3VHXGRPRQDV DHUXJLQRVD
  - (VFKHULFKLD FROL
  - 3URWHXV YXOJDULV

Pathogenesis

- Not well understood; possibilities include
  - Decreased T- and B-lymphocyte function
  - Unusual tissue response
  - Foreign body

CLINICAL ISSUES

Site

- Ordinarily more common in skin and subcutaneous tissue
- Can involve different anatomic areas
  - Lung
  - Upper respiratory tract
  - Liver
  - Kidney
  - Brain
  - Lymph node

Presentation

- Ulcers
- Draining sinuses
- Fever
- Chest pain
- Hemoptysis

Natural History

- More common in patients with
  - Immunodeficiency
  - Diabetes
  - Alcoholism
  - Poor hygiene

Treatment

- Surgical approaches
  - Surgical excision of affected tissue
- Drugs
  - Antibiotics
- Best results may be obtained with combination of surgical resection and long-term antibiotic therapy

Prognosis

- Depends on setting in which infection occurs

IMAGING

General Features

- Discrete pulmonary mass
- Cavitary pulmonary lesion

MICROSCOPIC

Histologic Features

- Abscess formation
- Splendore-Hoeppli phenomenon
- Purulent inflammatory reaction
- Granules within abscess
- Nonfilamentous bacteria

DIFFERENTIAL DIAGNOSIS

Actinomycosis

- True fungi shown on silver stains
- May show granules
- May show Splendore-Hoeppli phenomenon

Nocardiosis

- Granules and nonfilamentous bacteria will be unusual in 1RFDUGLD infections
- Fite stains will show presence of filamentous bacteria

SELECTED REFERENCES

1. Ariza-Prota MA et al: Primary pulmonary botryomycosis: a bacterial lung infection mimicking lung cancer. Int J Tuberc Lung Dis. 17(7):992-4, 2013
2. Heyndrickx M et al: Pulmonary botryomycosis on a lung cavity: a rare pulmonary infection mimicking cancer. Gen Thorac Cardiovasc Surg. 60(9):607-9, 2012

Histochemical Features

Stain	Result
Giemsa	Shows presence of granules and enhances Splendore-Hoeppli phenomenon
Brown-Hopps	Shows presence of granules
Luxol fast	Enhances Splendore-Hoeppli phenomenon
Ziehl-Neelsen	Enhances Splendore-Hoeppli phenomenon; negative for acid-fast bacilli or filamentous bacteria
GMS	Negative for fungal organisms
PAS	Enhances Splendore-Hoeppli phenomenon but negative for fungal organisms
Gridley	Negative for fungal organisms
Tissue cultures	Most important study to isolate specific type of organism

Malakoplakia

KEY FACTS

TERMINOLOGY

- Distinctive chronic inflammatory process characterized by histiocytic proliferation admixed with microcalcifications (Michaelis-Gutmann bodies)

ETIOLOGY/PATHOGENESIS

- Response to infection with 5 K R G R F R F, F X V F K H T X L F K L D F R, O L $ F L Q H W R E D F W H U
- 5 H T X L is aerobic, usually gram-positive coccobacillus of worldwide distribution found in soil and feces of animals, especially horses
- Human infection is acquired through inhalation of contaminated soil

CLINICAL ISSUES

- Most cases reported are associated with 5 H T X L infection in AIDS patients or immunocompromised hosts
- Presentation
  - Cough, fever, dyspnea

MICROSCOPIC

- Sheets of histiocytes admixed with inflammatory cells, particularly plasma cells
- Abscess formation with abundant fibrinopurulent exudate
- Histiocytes have large round to oval nuclei with vesicular chromatin and abundant eosinophilic cytoplasm
- Scattered small calcific structures (Michaelis-Gutmann bodies) can be seen within histiocytes or in interstitium
  - Round to oval structures with concentric targetoid appearance
  - Small round to oval structures with glassy homogeneous appearance

ANCILLARY TESTS

- Michaelis-Gutmann bodies can be readily identified with alizarin red or von Kossa calcium stains
- In case of 5 H T X L infection, organisms can be stained with tissue Gram stains (Brown and Brenn stain; Brown and Hopps stain)

Pulmonary Malakoplakia

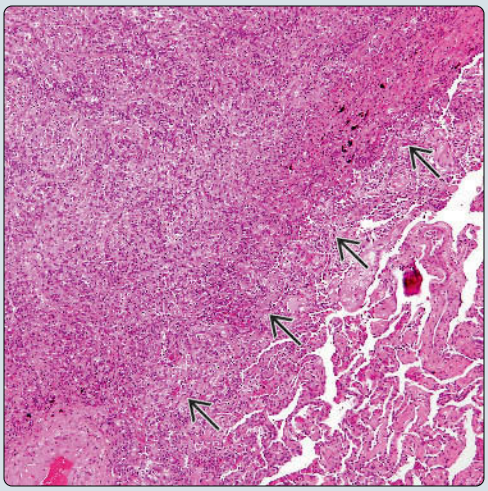

Dense Histiocytic Reaction

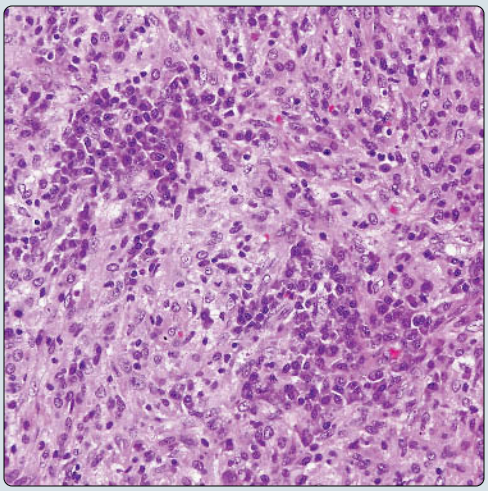

(Left) *Histologic appearance of pulmonary malakoplakia due to Rhodococcus equi infection shows normal pulmonary parenchyma flanked by an area of consolidation ⇨ that contains a dense histiocytic reaction.* **(Right)** *Higher magnification in pulmonary malakoplakia shows a dense histiocytic proliferation admixed with other inflammatory cells, including clusters of plasma cells and small lymphocytes.*

Michaelis-Gutmann Body

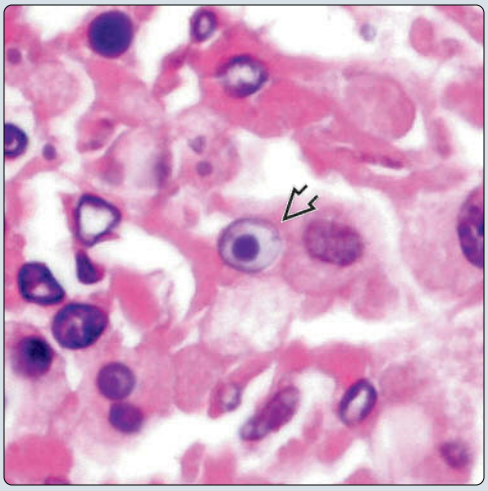

von Kossa Stain

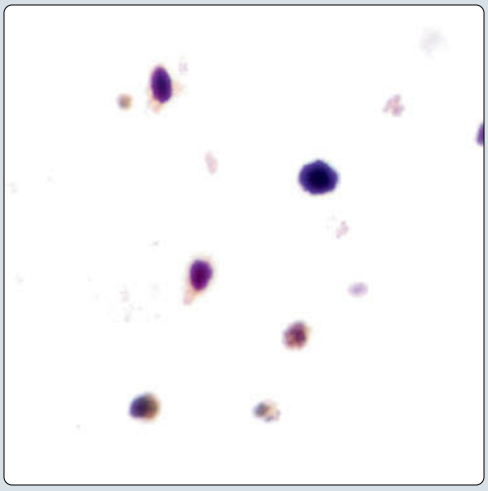

(Left) *Higher magnification of lung infection by malakoplakia shows sheets of histiocytes with occasional small, concentric, and targetoid calcific bodies with a central core ⇨ (Michaelis-Gutmann bodies).* **(Right)** *A von Kossa histochemical reaction for calcium highlights scattered Michaelis-Gutmann bodies through the infiltrate (black dots indicates the positive reaction).*

TERMINOLOGY

Definitions

- Distinctive chronic inflammatory process characterized by histiocytic proliferation admixed with microcalcifications (Michaelis-Gutmann bodies)

ETIOLOGY/PATHOGENESIS

Infectious Agents

- Response to infection with 5KRGRFRFFXV HTXL, (VFKHULFKLD FROL, and $FLQHWREDFWHU
- 5 HTXL is aerobic, usually gram-positive coccobacillus of worldwide distribution found in soil and feces of animals, especially horses
- Human infection is acquired through inhalation of contaminated soil

CLINICAL ISSUES

Epidemiology

- Incidence
  - Most cases reported are associated with 5 HTXL infection in AIDS patients or immunocompromised hosts
- Age
  - Adults between 30-60 years of age

Presentation

- Cough, fever, dyspnea, chest pain

MACROSCOPIC

General Features

- Lesions are more often solitary, although multifocal and bilateral lesions can sometimes be encountered
- Cut section shows well-circumscribed yellow-cream area of consolidation that can simulate neoplasm
- Lesions can show cavitation lined by thick capsule and forming abscess

MICROSCOPIC

Histologic Features

- Sheets of histiocytes admixed with inflammatory cells, particularly plasma cells
- Abscess formation with abundant fibrinopurulent exudate

Cytologic Features

- Histiocytes have large round to oval nuclei with vesicular chromatin and abundant eosinophilic cytoplasm
- Scattered small calcific structures (Michaelis-Gutmann bodies) can be seen within histiocytes or in interstitium
  - Michaelis-Gutmann bodies consist of concentric, laminated foci of calcifications, 2-10 µm in diameter
    - Round to oval structures with targetoid appearance showing dark peripheral rim surrounding clear halo and containing dark central zone
    - Small gray-blue round or oval structures with glassy homogeneous appearance

ANCILLARY TESTS

Histochemistry

- Michaelis-Gutmann bodies can be readily identified with alizarin red or von Kossa calcium stains
- In case of 5 HTXL infection, organisms can be stained with tissue Gram stains (Brown and Brenn stain; Brown and Hopps stain)
- Organisms are also weakly acid-fast positive and can be seen on modified Fite-Faraco stain but do not stain with Ziehl-Neelsen stain
- Organisms can also be identified by PCR

Electron Microscopy

- Michaelis-Gutmann bodies consist of large phagolysosomes that contain fragments of bacterial organisms

DIFFERENTIAL DIAGNOSIS

Mycobacterial Pneumonia

- 0\FREDFWHULXP DYLXP LQWUDFHOOXODUH (MAI) i present with sheets of foamy histiocytes admixed with inflammatory infiltrates
  - MAI infection shows abundant foamy cytoplasm in macrophages rather than dense eosinophilic cytoplasm of malakoplakia
  - Organisms in MAI are strongly positive with AFB and modified AFB (Fite-Faraco) stains
  - MAI infection lacks Michaelis-Gutmann bodies

Lipid Storage Disorders

- Gaucher disease or Niemann-Pick disease can show prominent histiocytic infiltrates in lung parenchyma, similar to malakoplakia
  - Infiltrates in storage diseases are usually diffuse rather than localized and form discrete mass as in malakoplakia
  - PAS stains will highlight intracytoplasmic inclusions (Michaelis-Gutmann bodies) in malakoplakia but not in storage disease
  - Histiocytes in Gaucher disease show characteristic wrinkled-paper appearance
  - Clinical history and specialized testing are necessary for specific diagnosis of storage disease

Rosai-Dorfman Disease

- Will also form discrete localized tumor masses composed of sheets of histiocytes admixed with plasma cells
  - Histiocytes may show enlarged atypical nuclei with emperipolesis
  - Prominent cuffing of vessel walls by sheets of plasma cells
  - Not associated with Michaelis-Gutmann bodies
  - Histiocytes stain strongly positive for S100 protein
    - Histiocytes in malakoplakia are uniformly negative for S100 protein

SELECTED REFERENCES

1. Mulè A et al: Pulmonary malacoplakia at early stage: use of polymerase chain reaction for detection of Rhodococcus equi. Int J Immunopathol Pharmacol. 25(3):703-12, 2012
2. Guerrero MF et al: Pulmonary malacoplakia associated with Rhodococcus equi infection in patients with AIDS: case report and review. Clin Infect Dis. 28(6):1334-6, 1999

(Left) *Scanning magnification of a focus of pulmonary malakoplakia shows a well-circumscribed area composed of sheets of large histiocytic cells separated from the normal lung parenchyma by a fibrotic band of connective tissue.* **(Right)** *Higher magnification of pulmonary malakoplakia shows sheets of histiocytes with abundant eosinophilic cytoplasm. Notice a few scattered Michaelis-Gutmann bodies in the background; they can sometimes be hard to find without the aid of special stains.*

Focus of Pulmonary Malakoplakia

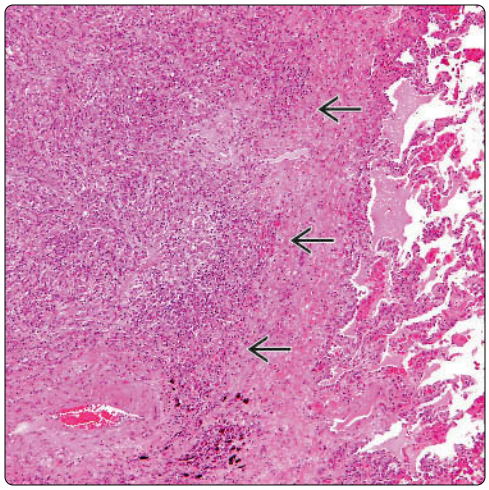

Sheets of Histiocytes

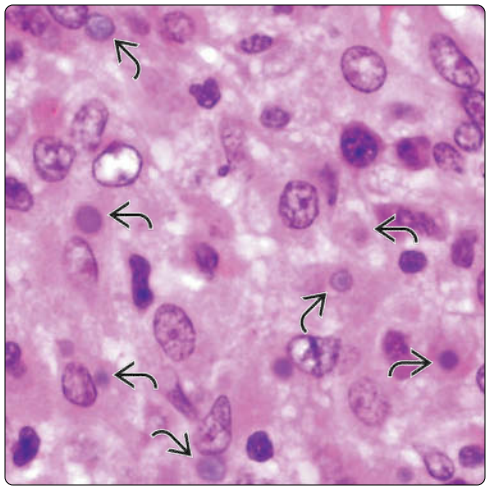

(Left) *Heavy plasma cell infiltrates can often be seen in pulmonary malakoplakia. Such cases can be confused for extranodal Rosai-Dorfman disease involving the lung. Absence of reactivity of the surrounding histiocytes for S100 protein will help rule out that diagnostic possibility.* **(Right)** *Periphery of the lesion in a case of pulmonary malakoplakia shows organizing pneumonia with hyperplasia of type II pneumocytes and intraalveolar fibrin plugs with fibroblastic proliferation.*

Plasma Cell Infiltrates

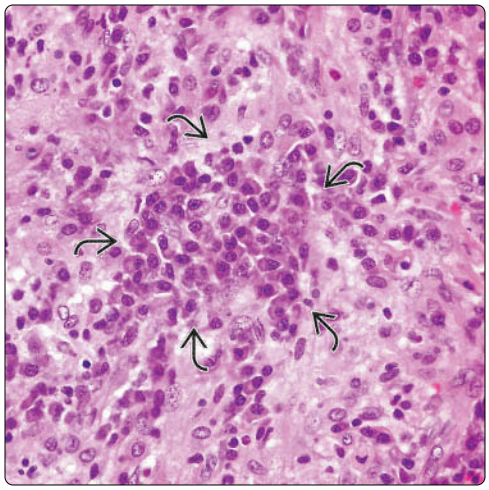

Organizing Pneumonia

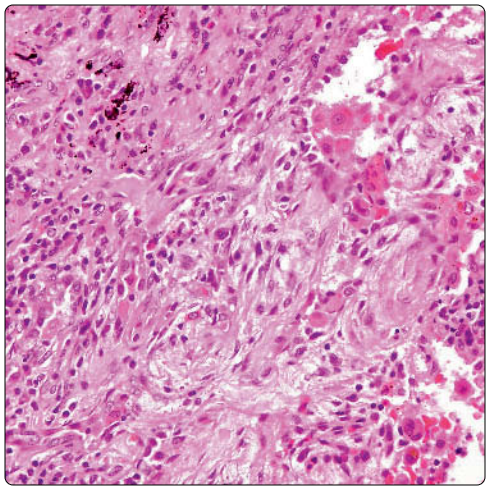

(Left) *Spindling of the histiocytes showing a vague storiform pattern is seen in this example of pulmonary malakoplakia. Cases such as this can be confused for inflammatory pseudotumor of the plasma cell type. Careful attention and identification of Michaelis-Gutmann bodies is indispensable for correct diagnosis.* **(Right)** *Higher magnification of pulmonary malakoplakia shows scattered histiocytes with oval to spindle-shaped nuclei admixed with abundant mature plasma cells.*

Storiform Pattern

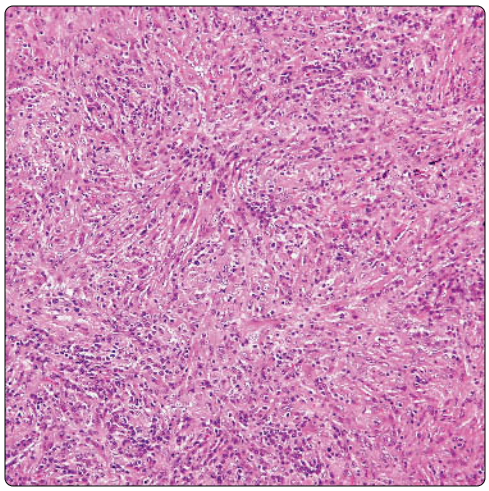

Histiocytes Admixed With Plasma Cells

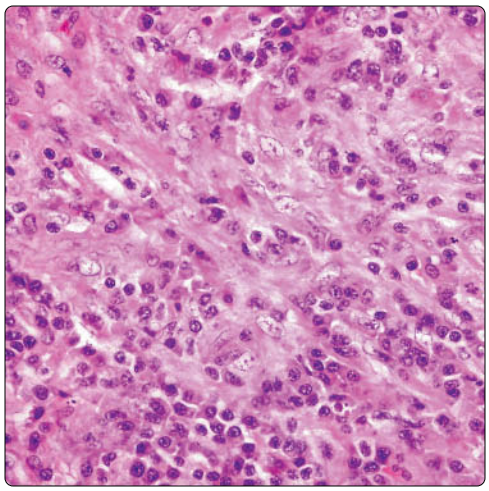

Sheets of Histiocytes

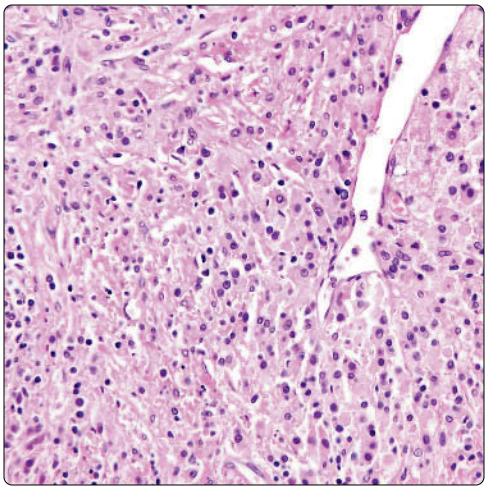

Michaelis-Gutmann Bodies

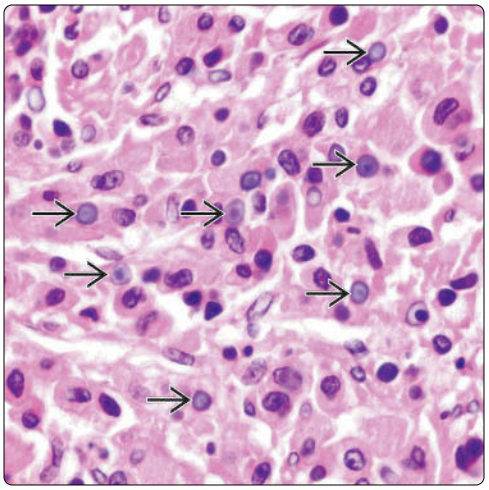

(Left) *Typical appearance of histiocytic reaction in pulmonary malakoplakia shows sheets of histiocytes admixed with other chronic inflammatory cells. The process resembles a xanthogranulomatous inflammation, inflammatory pseudotumor, or Rosai-Dorfman disease.* **(Right)** *Higher magnification of pulmonary malakoplakia shows sheets of histiocytic cells admixed with other inflammatory cell elements. There are multiple small round gray-blue structures scattered throughout ⇨.*

Concentric Michaelis-Gutmann Body

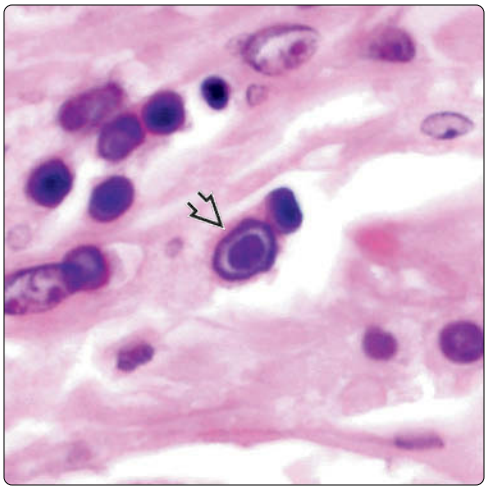

Scattered Michaelis-Gutmann Bodies

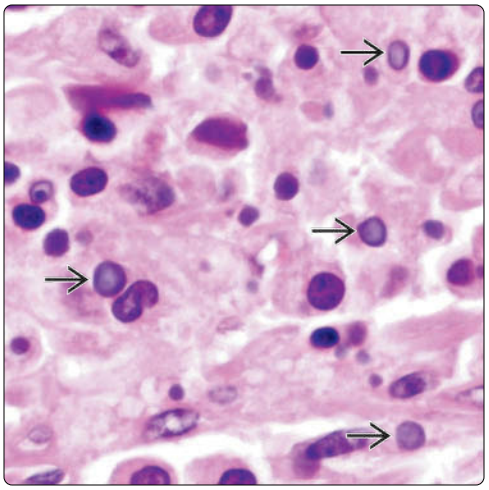

(Left) *Characteristic histologic appearance of a Michaelis-Gutmann body ⇨ shows a target-shaped structure composed of concentric laminations containing a dark central core surrounded by a halo. Such bodies may be found within macrophages or lying free in the interstitium.* **(Right)** *Michaelis-Gutmann bodies are not always laminated or with a target-like appearance but may be homogeneous with a light glassy center ⇨. They may be quite difficult to find, requiring special stains.*

von Kossa Calcium Stain



Alizarin Red Stain for Calcium

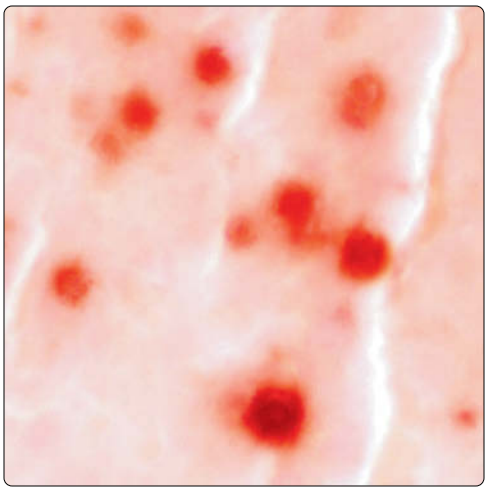

(Left) *Michaelis-Gutmann bodies can be readily identified with the use of histochemical stains. One of the most useful stains is the von Kossa calcium stain, which stains the small, dot-like structures dark brown or black.* **(Right)** *Another useful stain for identifying Michaelis-Gutmann bodies in pulmonary malakoplakia is alizarin red, which stains these structures bright red-orange. Other stains that may be used include PAS, GMS, and Giemsa.*

This page intentionally left blank

PART II
SECTION 1

Neoplasms, Benign

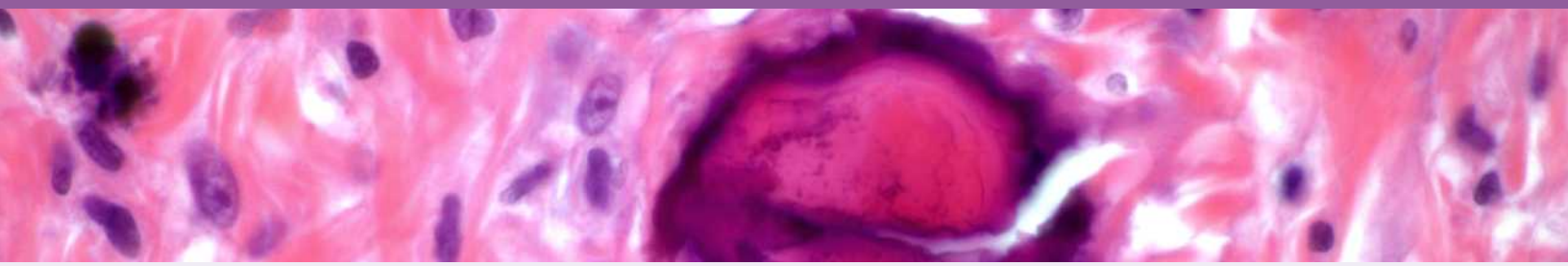

Mesothelial Hyperplasia	**554**
Solitary Fibrous Tumor	**558**
Calcified Fibrous Pseudotumor	**568**

Mesothelial Hyperplasia

KEY FACTS

TERMINOLOGY

- Proliferation of benign reactive mesothelial cells lining pleural surface

CLINICAL ISSUES

- Incidental finding in pleural biopsy specimens done for other causes
- Finding in pleural fluid cytology for assessment of pleural effusion
- Usually regresses spontaneously when stimulus is removed
- May arise in pericardium forming small excrescences [cardiac monocytic incidental cardiac excrescences (MICE)]

MICROSCOPIC

- Focal thickening of pleural surface by sheets of mesothelial cells
- Formation of small papillary excrescences that project into free pleural space
- Process is confined to surface of pleura and does not invade underlying structures
- Variable nuclear enlargement with mild increase in chromatin pattern
- Nucleolar prominence
- Variable mitotic activity

DIAGNOSTIC CHECKLIST

- Small and focal process; generally seen as incidental finding
- Demonstration of absence of invasion is most important feature for distinguishing from early malignant mesothelioma
- Role of immunohistochemistry is very limited for separating mesothelial hyperplasia from malignant mesothelioma
- Reactive, hyperplastic mesothelial cells share same markers with malignant mesothelioma
  - No molecular or cytogenetic markers are available for distinguishing between them

Cytologic Smear From Pleural Effusion

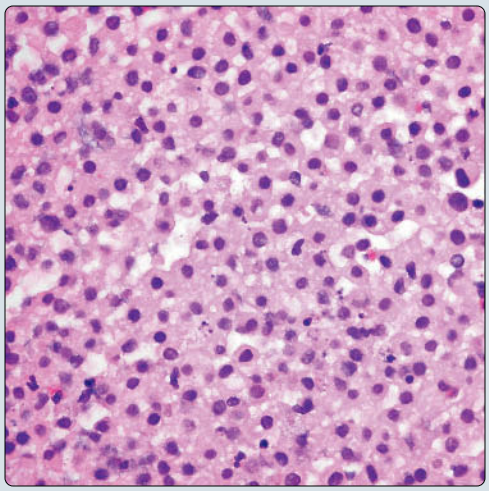

Cytologic Smear: High Power

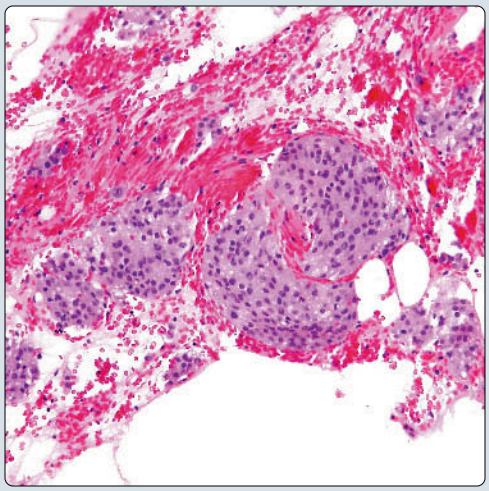

(Left) *Mesothelial hyperplasia shows sheets of monotonous mesothelial cells with mild cytologic atypia and abundant pale eosinophilic cytoplasm. The cells are quite monotonous.* **(Right)** *Higher magnification of smear from this pleural effusion shows an abortive papillary configuration made up of small, round to polygonal epithelioid cells with bland-appearing nuclei and abundant eosinophilic cytoplasm.*

Papillary Protrusions

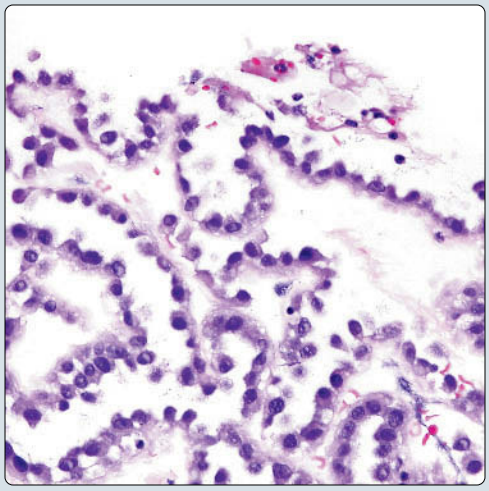

Reactive Mesothelial Cells

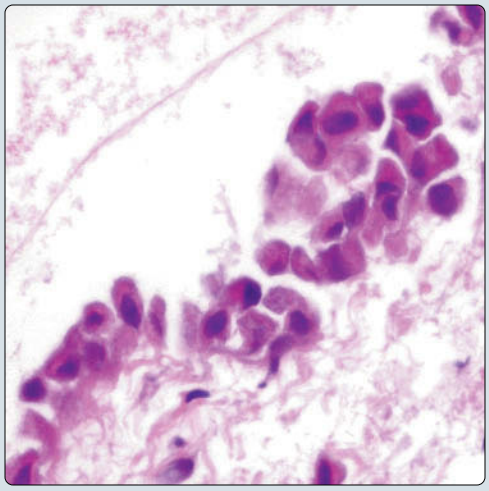

(Left) *Histologic section from pleural biopsy in a patient with pleural effusion of unknown etiology shows small papillary protrusions on the surface of the pleura composed of monotonous cuboid cells with hyperchromatic nuclei and scant cytoplasm.* **(Right)** *Higher magnification from another focus of mesothelial hyperplasia shows focal piling up of round to polygonal cells with dark nuclei and an abundant rim of eosinophilic cytoplasm. Notice the cells are confined to the surface and do not invade into the wall.*

TERMINOLOGY

Abbreviations

- Mesothelial hyperplasia (MH)

Definitions

- Proliferation of benign reactive mesothelial cells lining pleural surface

ETIOLOGY/PATHOGENESIS

Pathogenesis

- Reaction to injury, such as recurrent effusions, inflammation, or neoplasia
- As result of surgical procedures, such as in cardiac monocytic incidental cardiac excrescences (MICE)

CLINICAL ISSUES

Presentation

- Asymptomatic
- Incidental finding in pleural biopsies done for other causes
- Finding in pleural fluid cytology for assessment of pleural effusion
- May arise in pericardium forming small excrescences (cardiac MICE)

Prognosis

- Usually regresses spontaneously when stimulus is removed

MICROSCOPIC

Histologic Features

- Focal thickening of pleural surface by sheets of mesothelial cells
- Formation of small papillary excrescences that project into free pleural space
- Process is confined to surface of pleura and does not invade underlying structures
- When in pericardium (cardiac MICE), lesions are composed of reactive mesothelial cells admixed with epithelioid histiocytes

Cytologic Features

- Variable nuclear enlargement with mild increase in chromatin pattern, nucleolar prominence, and variable mitotic activity
- Process may vary in cytological composition
  - Simple MH composed of bland-appearing cuboidal mesothelial cells
  - Atypical MH composed of atypical mesothelial cells with complex architecture

DIFFERENTIAL DIAGNOSIS

Malignant Mesothelioma, Early Stage

- Differs from hyperplasia by showing infiltration of underlying fat, muscle, or adjacent tissues
- Presence of tumor cell necrosis favors mesothelioma

Metastatic Papillary Carcinoma

- May resemble metastasis from papillary carcinoma of thyroid, lung, ovary, uterus, or breast
- Thorough clinical history is essential to rule out tumor at another location
- Immunohistochemical stains may help in differential diagnosis
  - TTF-1 positivity favors carcinoma metastatic from lung or thyroid
  - ERP/PRP positivity favors uterine, ovarian, or breast carcinoma

Müllerian Rests and Proliferations

- Pleural endometriosis
  - Rare condition, usually in young women of child-bearing age
  - Well-formed glandular structures are predominantly seen in endometriosis
  - Glandular structures are surrounded by dense spindle cell stroma in endometriosis

DIAGNOSTIC CHECKLIST

Clinically Relevant Pathologic Features

- Nuclear features
  - Mild to moderate nuclear atypia with occasional prominent nucleoli
- Tissue distribution
  - Focal, usually forms skip lesions
- Invasive pattern
  - Usually confined to surface of pleura; invasion or infiltration of fat, muscle, or lung parenchyma signifies malignancy

Pathologic Interpretation Pearls

- Small and focal process; generally seen as incidental finding
- Demonstration of absence of invasion is most important feature for distinguishing from early malignant mesothelioma
- Role of immunohistochemistry is very limited for separating MH from malignant mesothelioma
  - Reactive, hyperplastic mesothelial cells mostly share same markers with malignant mesothelioma
  - Molecular detection of p16/CDKN2A has not been sufficiently specific or consistent to separate benign from malignant
  - Strong Ki-67 labeling (> 9%) favors malignant mesothelioma over MH

SELECTED REFERENCES

1. Henderson DW et al: Challenges and controversies in the diagnosis of mesothelioma: part 1. Cytology-only diagnosis, biopsies, immunohistochemistry, discrimination between mesothelioma and reactive mesothelial hyperplasia, and biomarkers. J Clin Pathol. 66(10):847-53, 2013
2. Taheri ZM et al: The diagnostic value of Ki-67 and repp86 in distinguishing between benign and malignant mesothelial proliferations. Arch Pathol Lab Med. 132(4):694-7, 2008
3. Cagle PT et al: Differential diagnosis of benign and malignant mesothelial proliferations on pleural biopsies. Arch Pathol Lab Med. 129(11):1421-7, 2005
4. Attanoos RL et al: The use of immunohistochemistry in distinguishing reactive from neoplastic mesothelium. A novel use for desmin and comparative evaluation with epithelial membrane antigen, p53, platelet-derived growth factor-receptor, P-glycoprotein and Bcl-2. Histopathology. 43(3):231-8, 2003
5. Cury PM et al: The use of histological and immunohistochemical markers to distinguish pleural malignant mesothelioma and in situ mesothelioma from reactive mesothelial hyperplasia and reactive pleural fibrosis. J Pathol. 189(2):251-7, 1999

Diffuse Mesothelial Hyperplasia

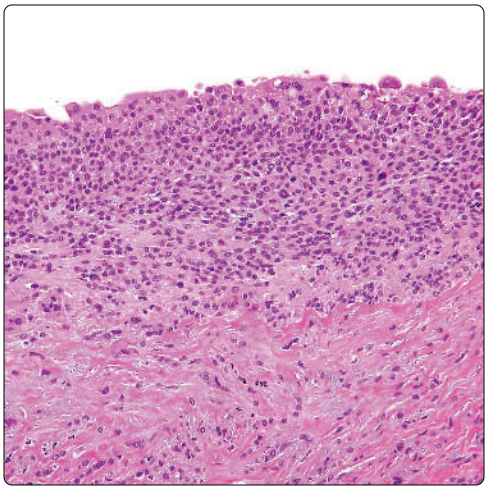

Papillary Mesothelial Hyperplasia

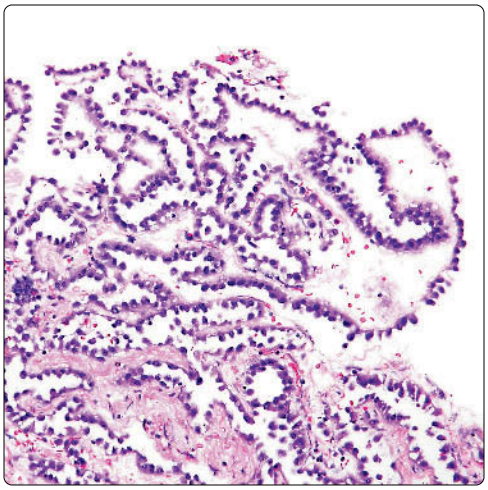

(Left) *Diffuse-type mesothelial hyperplasia is seen with thickening of the pleural surface caused by sheets of epithelioid cells in a diffuse, solid pattern. Notice the sharp demarcation from the underlying pleural connective tissue.* **(Right)** *In papillary-type mesothelial hyperplasia, hyperplastic mesothelial cells are forming small papillary fronds lined by a single layer of cells. This process may be confused for malignant mesothelioma or a metastasis from papillary carcinoma.*

Sheets of Mesothelial Cells

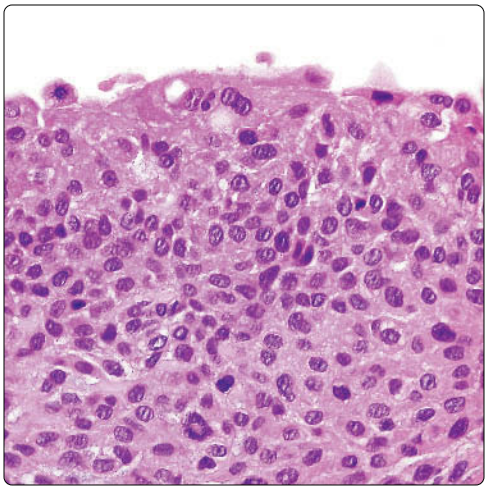

Small Abortive Papillae

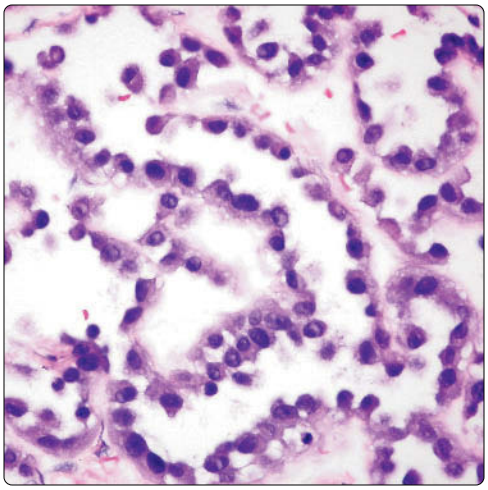

(Left) *In this diffuse-type mesothelial hyperplasia, high magnification shows solid mesothelial hyperplasia with sheets of round to polygonal cells with mild atypia. No papillary structures are seen.* **(Right)** *In papillary-type mesothelial hyperplasia, high magnification of papillary fronds shows a single layer of hyperchromatic cells lining the papillae. The cells contain enlarged nuclei with a dense chromatin pattern and often display a hobnail configuration.*

Mild Cytologic Atypia

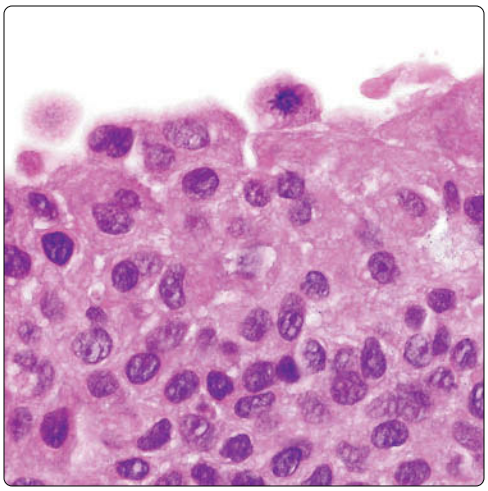

Mild Atypia and Nucleoli

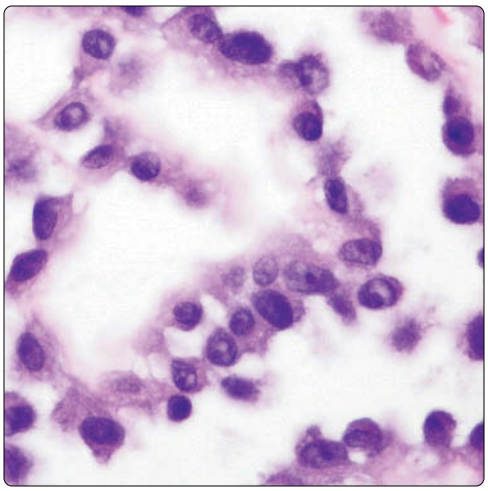

(Left) *Higher magnification of solid mesothelial hyperplasia shows cells with enlarged nuclei, prominent nucleoli, and a dense chromatin pattern in this diffuse-type mesothelial hyperplasia. Some of the cells contain a single small nucleolus.* **(Right)** *Higher magnification of papillary mesothelial hyperplasia shows cells with enlarged, atypical nuclei and small nucleoli in this papillary-type mesothelial hyperplasia. Some of the cells can show prominent eosinophilic nucleoli.*

Atypical Mesothelial Hyperplasia

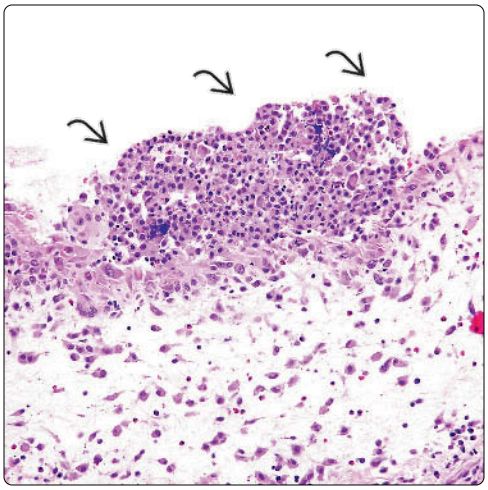

Atypical Hyperplasia: Higher Magnification

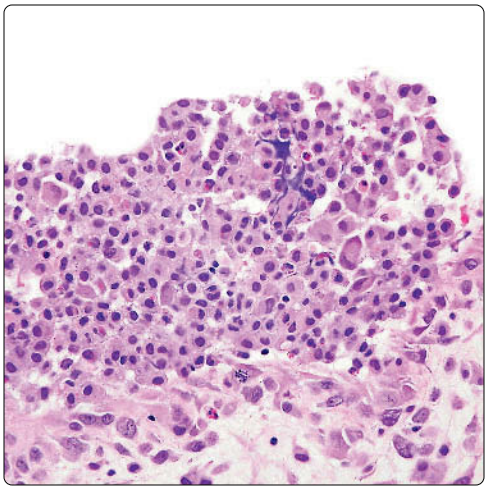

(Left) *Focus of pleural atypical mesothelial hyperplasia is characterized by focal thickening of the pleural surface by proliferation of atypical round epithelioid cells. Small foci like this can be mistaken for metastatic carcinoma.* **(Right)** *High magnification shows densely packed epithelioid cells with abundant eosinophilic cytoplasm. There is some degree of nuclear pleomorphism and cytologic atypia noted.*

Atypical Hyperplasia: Mitosis

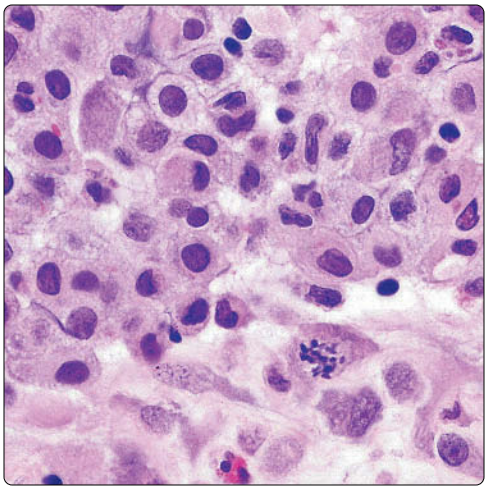

Pseudoinvasion

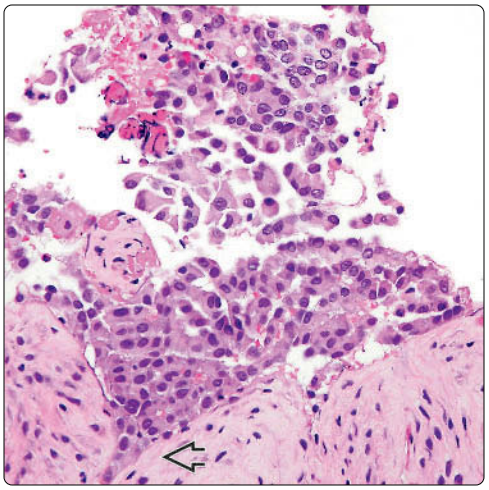

(Left) *Higher magnification shows significant cytologic atypia with enlarged, hyperchromatic nuclei and an abnormal mitosis. The cells show some degree of nuclear pleomorphism with variation in size and shape of the mesothelial cells.* **(Right)** *Atypical mesothelial hyperplasia of the pleura shows densely packed proliferation of epithelioid cells along the pleural surface. The area toward the base is suggestive of a focus of invasion.*

Calretinin Immunostaining

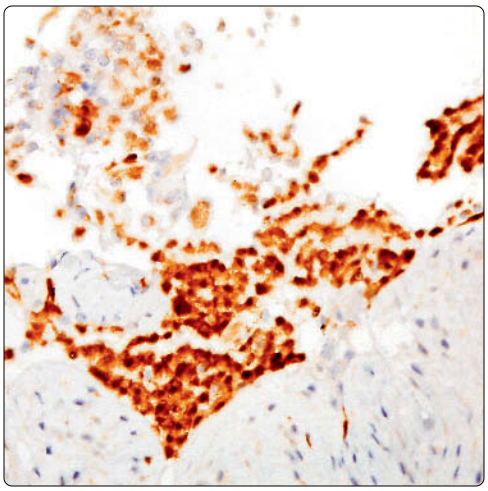

Ki-67 Immunostaining

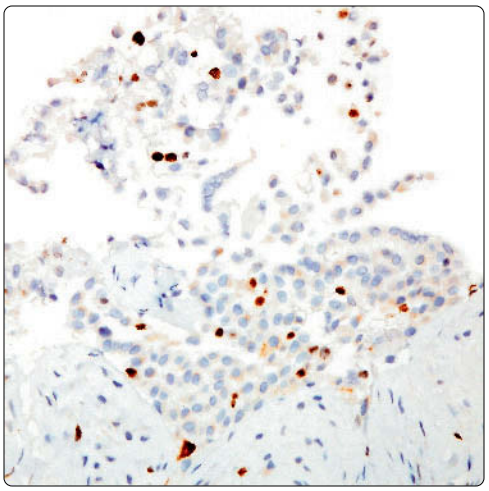

(Left) *Immunohistochemical staining shows positive nuclear and cytoplasmic staining of the epithelioid cells for calretinin antibodies.* **(Right)** *Immunoperoxidase staining shows scattered nuclear positivity in a few of the epithelioid cells (< 5%) for the proliferation marker, Ki-67.*

Solitary Fibrous Tumor

KEY FACTS

CLINICAL ISSUES

- Asymptomatic; incidental finding on routine chest x-ray
- Cough
- Pleuritic pain
- Dyspnea
- Hypoglycemia (5% of patients)
- Pulmonary osteoarthropathy with clubbing of fingers

MICROSCOPIC

- Bland-appearing spindle cell proliferation
- Variegation in growth patterns within same tumor
- Stroma is highly vascularized with angiofibromatous or hemangiopericytic vascular pattern
- Spindle cell areas are variably admixed with areas of stromal hyalinization
- Most distinctive pattern of hyalinization is characterized by parallel linear deposits of rope-like collagen separating tumor cells
- Oval to spindle cells with scant cytoplasm and oval nuclei with dense chromatin pattern
- Very low mitotic activity (1-3 per 10 HPF)
- Cells are positive for vimentin, CD34, Bcl-2, CD99, and STAT6

ANCILLARY TESTS

- Intrachromosomal inversion (12)(q13q13) causes characteristic gene fusion of *NAB2-STAT6*

DIAGNOSTIC CHECKLIST

- Circumscription and encapsulation
- Bland-appearing spindle cell proliferation with prominent vascular pattern and variable degrees of stromal sclerosis
- Fascicular, short storiform, hemangiopericytic, neural palisading, and synovial sarcoma-like growth patterns
- Different histologic growth patterns may be seen in same lesion in different proportions

Gross Appearance

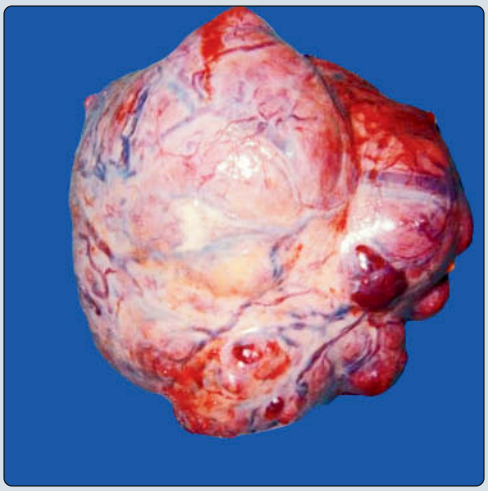

Histologic Appearance

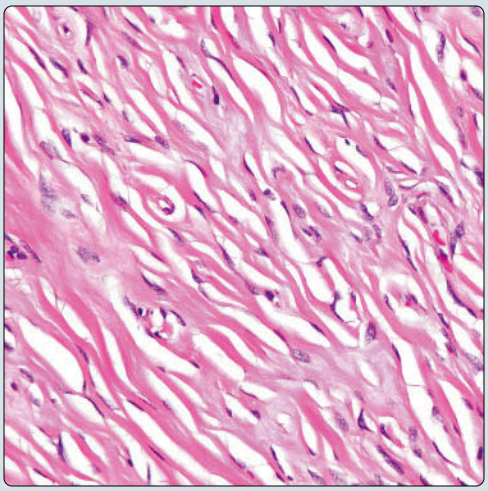

(Left) *Typical gross appearance of solitary fibrous tumor (SFT) of the pleura shows a lobulated, well-circumscribed, firm mass covered by a thin, shiny capsule with striking vascular markings.* **(Right)** *Characteristic histologic appearance of SFT shows scant, bland-appearing spindle cells separated by parallel linear arrays of dense keloidal collagen, described as rope-like or the so-called patternless pattern.*

High-Power Magnification

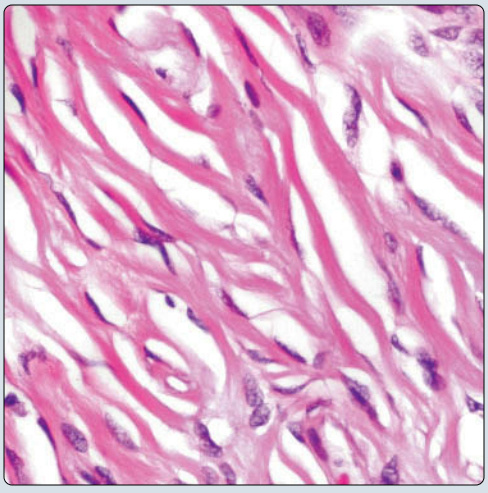

STAT6 Immunohistochemical Stain

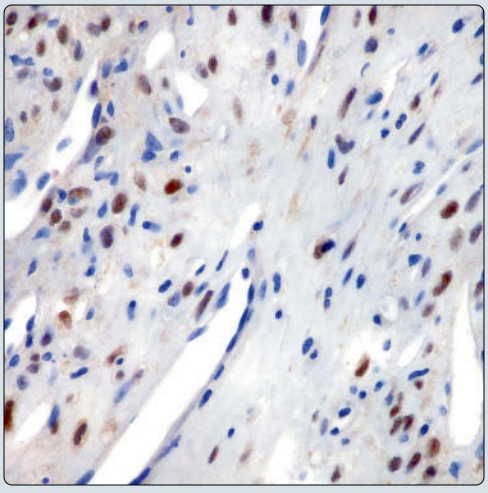

(Left) *Higher magnification of SFT shows bland spindle cells flanking linear strands of dense keloidal collagen. The spindle cells have small, oval nuclei with a dense chromatin pattern and absence of nucleoli or mitotic figures.* **(Right)** *Immunohistochemical stain for STAT6 shows strong nuclear positivity of the tumor cells in SFT. This marker has replaced CD34 as the marker of choice for making this diagnosis.*

TERMINOLOGY

Abbreviations

- Solitary fibrous tumor (SFT)

Synonyms

- Submesothelial fibroma; localized fibrous tumor

Definitions

- Benign neoplastic proliferation of submesothelial fibroblastic cells

ETIOLOGY/PATHOGENESIS

Pathogenesis

- Arises from submesothelial fibroblasts
- No relationship with asbestos exposure

CLINICAL ISSUES

Presentation

- Asymptomatic; incidental finding on routine chest x-ray
- Cough
- Dyspnea
- Pleuritic pain
- Hypoglycemia (in 5% of patients)
- Pulmonary osteoarthropathy with clubbing of fingers
- Most commonly presents in adults with no sex predilection

Treatment

- Surgical excision

Prognosis

- Excellent prognosis following complete excision with clear margins
- ~ 10% of cases may be malignant
- Malignant cases can show invasion of adjacent structures and recurrences
- Only rare cases metastasize

MACROSCOPIC

General Features

- Well circumscribed and encapsulated
- Smooth and glistening outer surface
- Sessile, broad-based pleural mass
- Pedunculated mass attached to pleural surface by short pedicle
- Rubbery, homogeneous, and whorled cut surface
- Size: 5-20 cm in greatest diameter
- Invasive tumors tend to behave aggressively

MICROSCOPIC

Histologic Features

- Bland-appearing spindle cell proliferation
- Variegation in growth patterns
  - Fascicular spindle cell pattern
  - Short storiform pattern
  - Patternless pattern (i.e., linear rope-like pattern of stromal sclerosis)
  - Hemangiopericytomatous pattern
  - Angiofibromatous pattern
  - Herringbone pattern
  - Dense hypercellular (synovial sarcoma-like) pattern
  - Paucicellular (diffusely sclerotic) pattern
- May incorporate entrapped air spaces at interphase with lung parenchyma
- May show prominent myxoid stromal changes
- May contain metaplastic bone or abnormal collagen ("amianthoid") fibers
- Highly vascularized stroma with angiofibromatous or hemangiopericytic vascular pattern
- Most distinctive pattern of hyalinization is characterized by parallel linear deposits of rope-like collagen separating tumor cells
- Areas with degeneration of collagen may simulate tumor cell necrosis
- Invasiveness, increased mitotic activity (> 4 per 10 HPF), nuclear pleomorphism, and areas of necrosis correlate with malignant behavior
- Occasional histologically low-grade tumors can rarely also metastasize

Cytologic Features

- Oval to spindle cells with scant cytoplasm and oval nuclei with dense chromatin pattern
- Spindle cells may show wavy nuclei resembling schwannian cells
- Nuclei may be small and round in areas of sclerosis
- Multinucleated giant cells may be present
- Very low mitotic activity (1-3 per 10 HPF)
- Mitotic activity > 4 mitoses per 10 HPF should raise suspicion of malignancy
- Care must be taken to distinguish between areas of tumor cell necrosis and areas of degeneration of collagen

ANCILLARY TESTS

Immunohistochemistry

- Cells are positive for vimentin, CD34, Bcl-2, and CD99
- Nuclear positivity with STAT6 antibody

Genetic Testing

- Intrachromosomal inversion (12)(q13q13) causes characteristic gene fusion of *NAB2-STAT6*

DIFFERENTIAL DIAGNOSIS

Sarcomatoid Mesothelioma

- More pronounced cytologic atypia, nuclear pleomorphism, and mitotic activity are seen in sarcomatoid mesothelioma
- Diffuse, as opposed to localized, growth pattern in sarcomatoid mesothelioma
- Strong cytokeratin and calretinin positivity favors sarcomatoid mesothelioma
- Strong STAT6 nuclear positivity favors solitary fibrous tumor

Pleural Monophasic Synovial Sarcoma

- More pronounced cytologic atypia and mitotic activity are seen in synovial sarcoma
- Invasive features favor synovial sarcoma over solitary fibrous tumor
- Cytokeratin and EMA positivity is typically seen in synovial sarcoma but not in solitary fibrous tumor

Immunohistochemistry

Antibody	Reactivity	Staining Pattern	Comment
STAT6	Positive	Nuclear	Diffuse, strong nuclear staining in all cells
CD34	Positive	Cytoplasmic	Positive in 60-90% of cases
Bcl-2	Positive	Cytoplasmic	Strongly positive in 80-100% of cases
CD99	Positive	Cytoplasmic	Positive in 60-80% of cases
AE1/AE3	Negative		May be rarely positive in some cases
Actin-sm	Negative		May be rarely positive in some cases
S100	Negative		
Caldesmon	Negative		
Vimentin	Positive	Cytoplasmic	Nonspecific, not very useful for diagnosis

Histologic Growth Patterns in Solitary Fibrous Tumors

Solid Spindle Cell Component	Diffuse Sclerosing Component
Fascicular spindle cell growth pattern	Fine linear pattern of intercellular sclerosis
Short storiform pattern of growth	Coarse linear pattern of sclerosis (rope-like collagen)
Hemangiopericytic growth pattern	Diffuse, confluent areas of sclerosis
Herringbone growth pattern	Angiofibromatous growth pattern
Wavy neural growth pattern	Myxoid stromal changes
Synovial sarcoma-like cellular growth pattern	Metaplastic bone and "amianthoid" fibers
Neural-type palisaded growth pattern	Degeneration of collagen resembling necrosis

- Most synovial sarcomas are positive for Bcl-2 and CD99 but negative for STAT6
- Cytogenetic translocation (x;18) is characteristic of synovial sarcoma and is absent in solitary fibrous tumor

Metastatic Spindle Cell Melanoma

- More pronounced nuclear pleomorphism with prominent nucleoli and scattered mitoses
- Nesting pattern of tumor cells; melanin pigment
- Positivity for melanocytic-associated markers (S100 protein, HMB45, Melan-A, tyrosinase, etc.)

Other Metastatic Spindle Cell Sarcomas

- Clinical history of spindle cell sarcoma elsewhere
- Positivity for specific immunohistochemical differentiation markers (S100, desmin, SMA, myogenin, MDM2, etc.)
- Negative nuclear staining for STAT6

DIAGNOSTIC CHECKLIST

Clinically Relevant Pathologic Features

- Circumscription and encapsulation
- Pulmonary osteoarthropathy with clubbing of fingers
- Hypoglycemia
- Often found incidentally on routine chest x-rays

Pathologic Interpretation Pearls

- Bland-appearing spindle cell proliferation with prominent vascular pattern and variable degrees of stromal sclerosis
- Fascicular, short storiform, hemangiopericytic, neural palisading, and synovial sarcoma-like growth patterns
- Variegation of histologic growth patterns within same lesion
- Immunohistochemical positivity for CD34, Bcl-2, CD99, and STAT6

SELECTED REFERENCES

1. Creytens D et al: Nuclear expression of STAT6 in dedifferentiated liposarcomas with a solitary fibrous tumor-like morphology: a diagnostic pitfall. Appl Immunohistochem Mol Morphol. 23(6):462-3, 2015
2. Ouladan S et al: Differential diagnosis of solitary fibrous tumors: A study of 454 soft tissue tumors indicating the diagnostic value of nuclear STAT6 relocation and ALDH1 expression combined with in situ proximity ligation assay. Int J Oncol. 46(6):2595-605, 2015
3. Doyle LA et al: Nuclear expression of STAT6 distinguishes solitary fibrous tumor from histologic mimics. Mod Pathol. 27(3):390-5, 2014
4. Cardillo G et al: Solitary fibrous tumors of the pleura: an analysis of 110 patients treated in a single institution. Ann Thorac Surg. 88(5):1632-7, 2009
5. Liu CC et al: Solitary fibrous tumors of the pleura: clinicopathological characteristics, immunohistochemical profiles, and surgical outcomes with long-term follow-up. Thorac Cardiovasc Surg. 56(5):291-7, 2008
6. Schirosi L et al: Pleuro-pulmonary solitary fibrous tumors: a clinicopathologic, immunohistochemical, and molecular study of 88 cases confirming the prognostic value of de Perrot staging system and p53 expression, and evaluating the role of c-kit, BRAF, PDGFRs (alpha/beta), c-met, and EGFR. Am J Surg Pathol. 32(11):1627-42, 2008
7. Sung SH et al: Solitary fibrous tumors of the pleura: surgical outcome and clinical course. Ann Thorac Surg. 79(1):303-7, 2005
8. Fukasawa Y et al: Solitary fibrous tumor of the pleura causing recurrent hypoglycemia by secretion of insulin-like growth factor II. Pathol Int. 48(1):47-52, 1998
9. Suster S et al: Expression of bcl-2 oncoprotein in benign and malignant spindle cell tumors of soft tissue, skin, serosal surfaces, and gastrointestinal tract. Am J Surg Pathol. 22(7):863-72, 1998
10. Moran CA et al: The spectrum of histologic growth patterns in benign and malignant fibrous tumors of the pleura. Semin Diagn Pathol. 9(2):169-80, 1992
11. England DM et al: Localized benign and malignant fibrous tumors of the pleura. A clinicopathologic review of 223 cases. Am J Surg Pathol. 13(8):640-58, 1989

Storiform Pattern

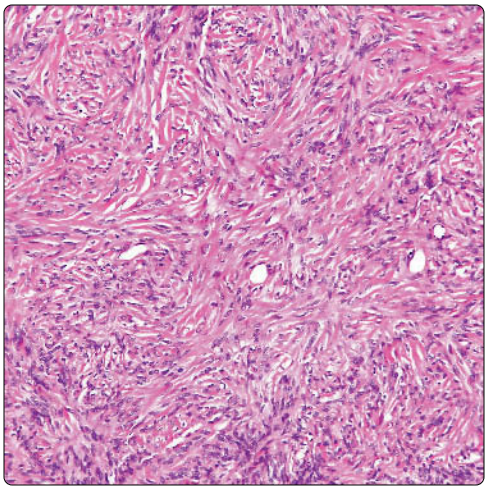

Storiform Pattern: Higher Magnification

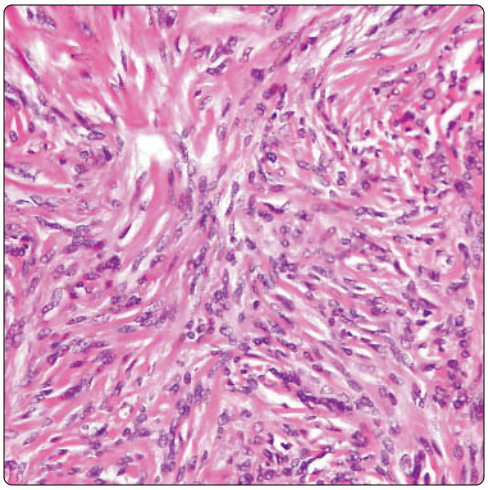

(Left) *SFT of the pleura shows cellular proliferation with a storiform pattern of growth. Tumors with this growth pattern can be easily confused with fibrohistiocytic neoplasms.* **(Right)** *High magnification of SFT of the pleura shows a storiform pattern of growth. Short fascicles of small spindle cells are seen radiating from the center in a pinwheel fashion along with the surrounding stromal collagen fibers.*

Rope-Like Sclerosing Pattern

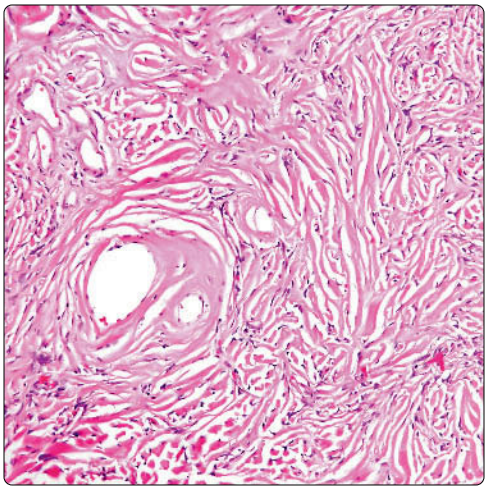

Rope-Like Pattern: High Power

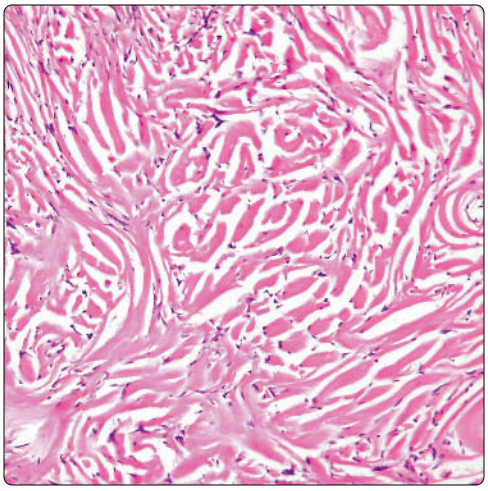

(Left) *Typical appearance of SFT of the pleura is characterized by rope-like strands of acellular, hyalinized collagen flanked by small hyperchromatic spindle cells. The parallel arrangement of the strands of collagen is quite characteristic for this tumor.* **(Right)** *High magnification of a typical sclerosing pattern in SFT of the pleura shows parallel strands of rope-like keloidal collagen flanked by small spindle cells.*

Stromal Fibrosis

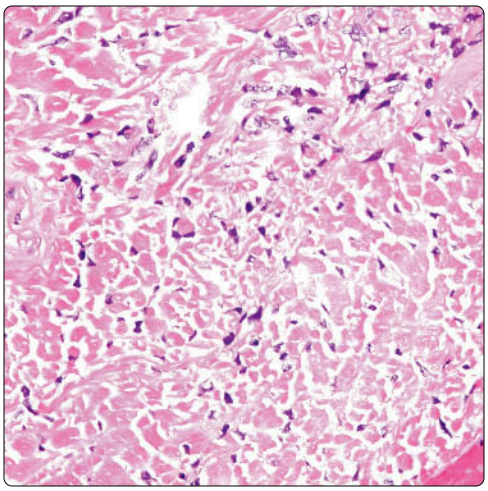

Advanced Stromal Fibrosis

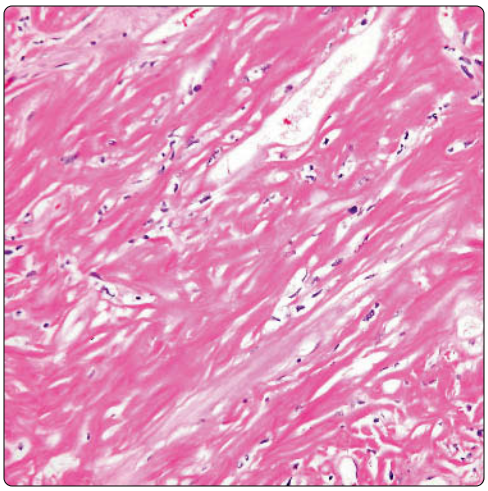

(Left) *A more advanced stage of stromal sclerosis is seen in SFT of the pleura showing abundant collagen deposition with few scattered residual round to oval nuclei compressed by the stromal collagen.* **(Right)** *Advanced stage of stromal collagen deposition in SFT of the pleura shows acellular bands of hyalinized intercellular collagen with very few scattered small spindle cells in the background.*

Neural Wavy Pattern

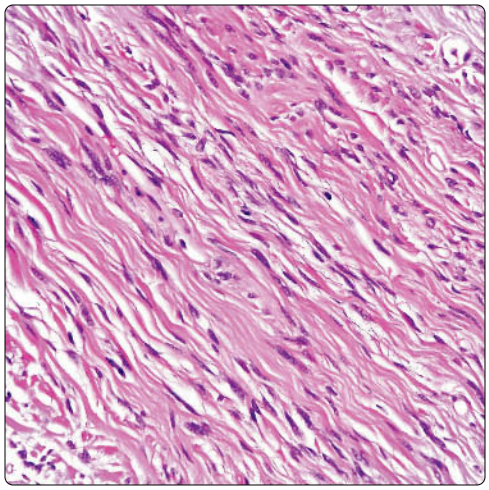

Neural Wavy Pattern: High Power

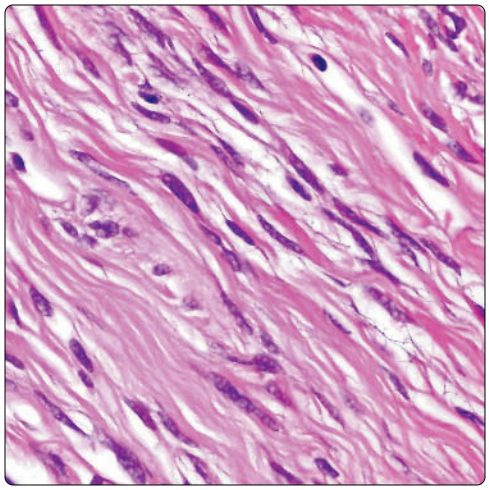

(Left) *This neural-like appearance of SFT of the pleura is characterized by longitudinal fascicles of spindle cells with wavy nuclei. Tumors with this appearance can closely resemble peripheral nerve sheath tumors.* **(Right)** *Higher magnification of SFT of the pleura with a neural-like appearance shows elongated spindle cells with wavy nuclei and tapering cell processes simulating a schwannian neoplasm.*

Myxoid Stroma

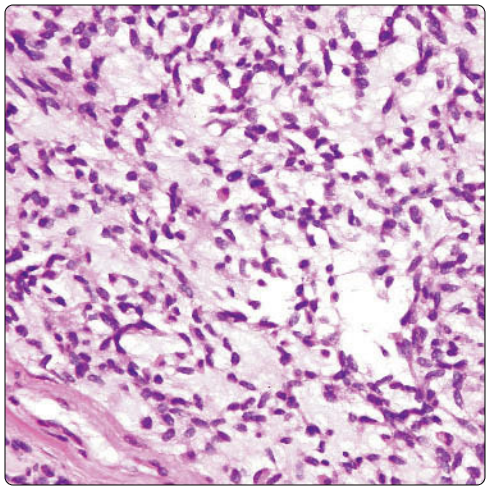

Myxoid Stroma: High Power

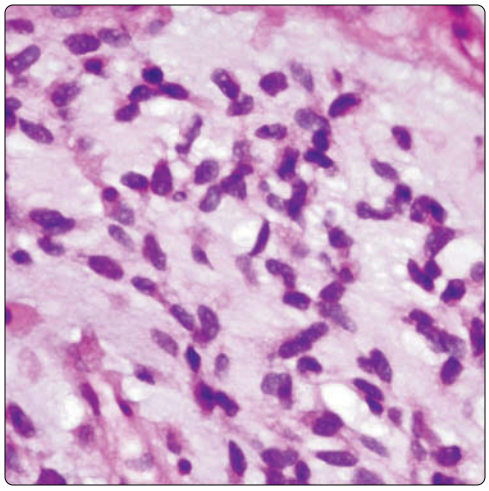

(Left) *SFT of the pleura shows prominent myxoid stroma surrounding the tumor cell population. The tumor cells are composed of small, spindle to stellate cells with dark nuclei and an inconspicuous rim of cytoplasm.* **(Right)** *High magnification of SFT of the pleura with prominent myxoid stroma shows a bland-appearing proliferation of small, stellate to spindle cells with hyperchromatic nuclei and a scant, indistinct rim of cytoplasm.*

Peritheliomatous Distribution

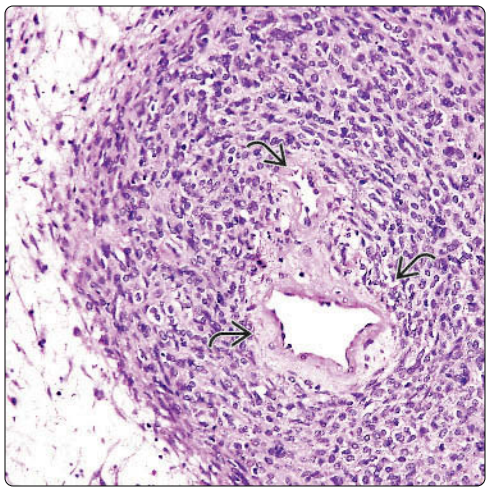

Epithelioid Variant of SFT

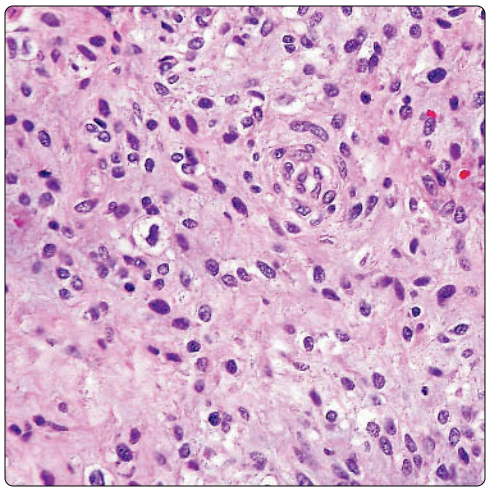

(Left) *SFT of the pleura with epithelioid cell morphology shows peritheliomatous distribution of round epithelioid tumor cells. Notice the entrapment of small, dilated vascular spaces in the center of the cellular nodule.* **(Right)** *Higher magnification of SFT of the pleura with epithelioid features shows a monotonous population of round epithelioid cells with an abundant rim of eosinophilic cytoplasm.*

Hemangiopericytic Pattern

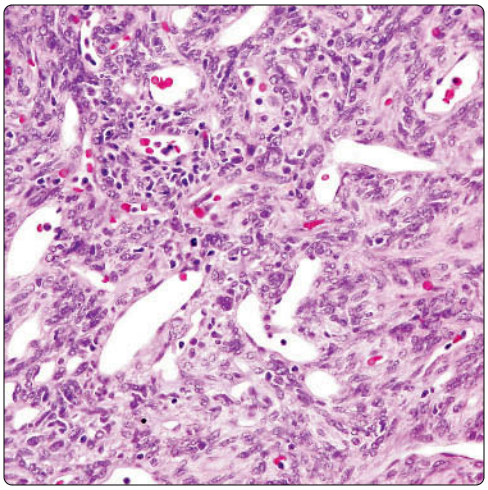

Hemangiopericytic Pattern: High Power

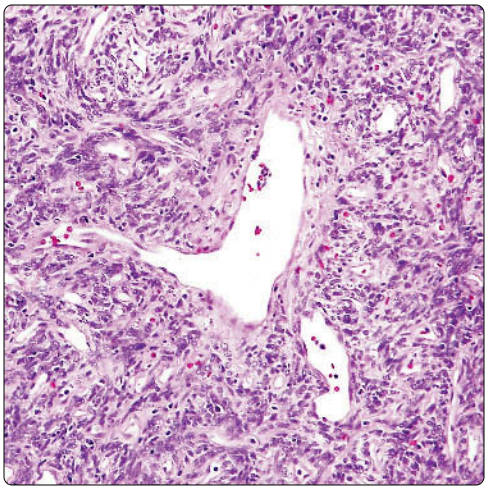

(Left) *SFT of the pleura shows abundant branching small vessels with patent lumina resulting in a striking hemangiopericytoma-like appearance. The hemangiopericytoma variant of SFT is another typical morphologic manifestation of these tumors.* **(Right)** *Higher magnification of SFT of the pleura with hemangiopericytoma-like growth pattern shows a dilated small vessel branching at right angles, resulting in a "staghorn" appearance.*

Angiofibromatous Pattern

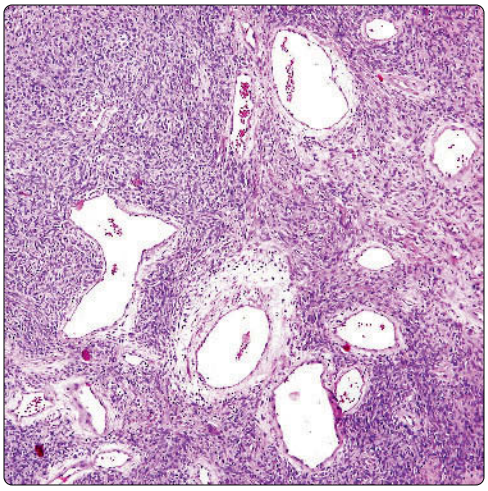

Angiofibromatous Pattern: High Power

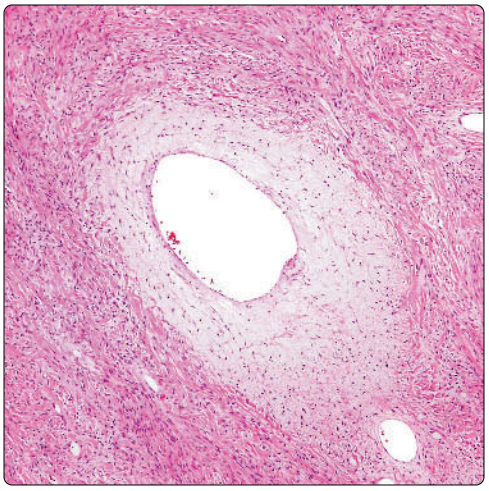

(Left) *SFT of the pleura shows multiple dilated small vessels with wide patent lumina and perivascular stromal sclerosis resulting in an angiofibromatous growth pattern.* **(Right)** *SFT of the pleura with angiofibromatous pattern of growth shows a dilated vessel in the center with perivascular sclerosis and edema and solid spindle cell proliferation circumferentially surrounding the dilated vascular space.*

Epithelioid Variant of SFT

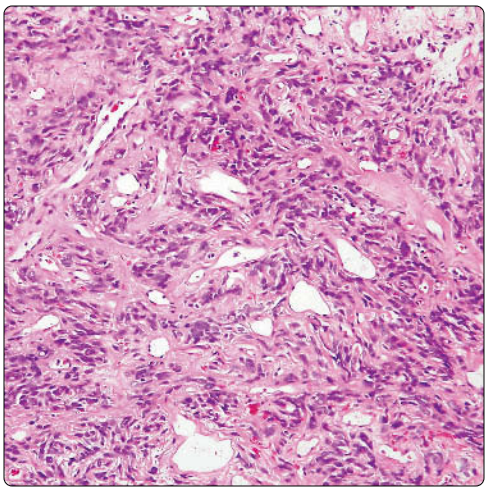

Hemangiopericytic Growth Pattern

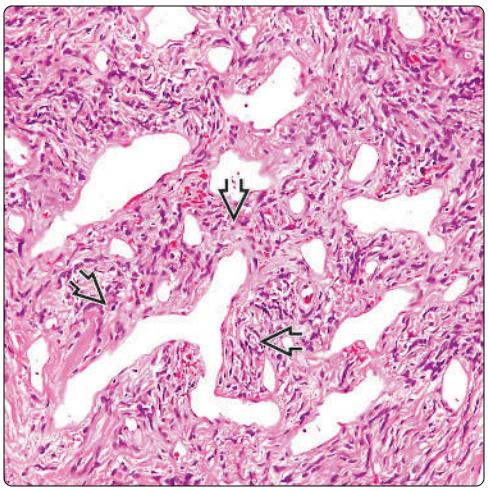

(Left) *SFT of the pleura shows a dense population of plump epithelioid cells surrounding small dilated vascular spaces with patent lumina.* **(Right)** *SFT of the pleura with prominent hemangiopericytic growth pattern shows a dense population of spindle cells in the stroma surrounding irregular, branching, and dilated vascular spaces with open lumina displaying an occasional "staghorn" configuration.*

Entrapment of Airspaces at Periphery

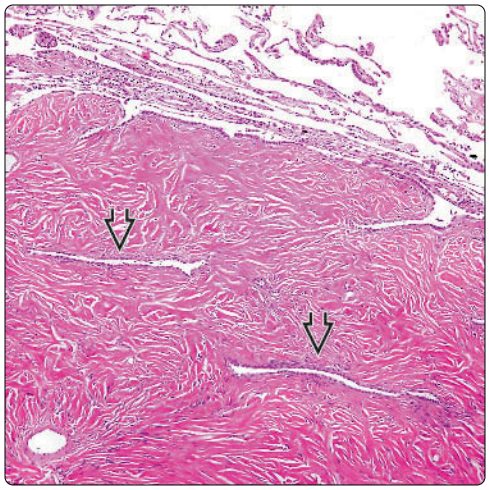

Entrapment of Airspaces: High Power

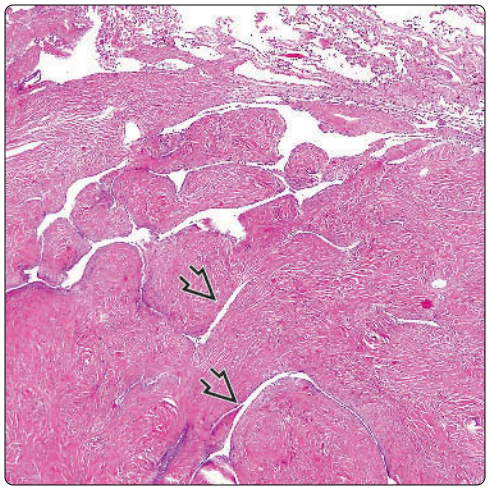

(Left) *SFT of the pleura shows entrapment of airspaces within the tumor ⇨ near the interface between the lung and the tumor. The entrapped airspaces can simulate a biphasic malignant neoplasm.* **(Right)** *SFT of the pleura shows entrapped airspaces deep within the tumor and away from the adjacent lung parenchyma ⇨. The distribution of these epithelial-lined structures primarily at the periphery of the lesion is quite characteristic.*

Entrapped Airspaces

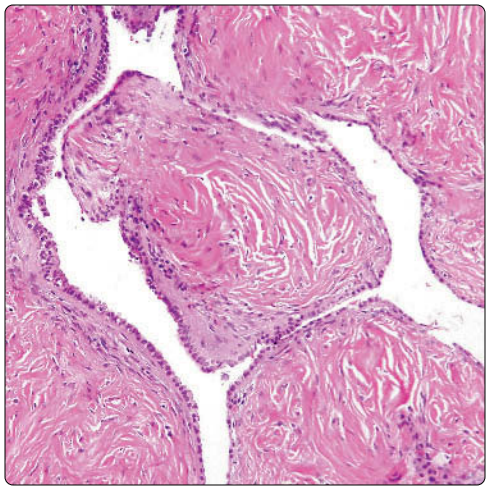

Entrapped Airspaces With Fibrosis

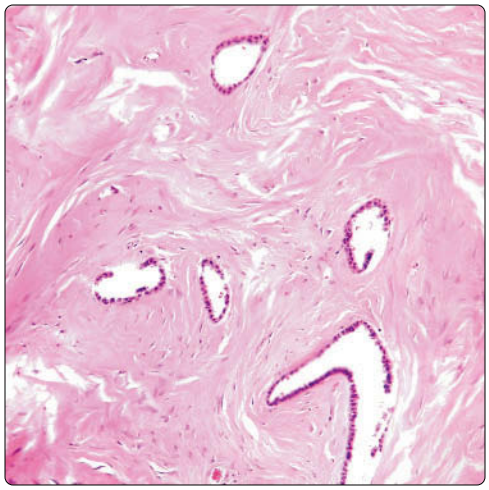

(Left) *Higher magnification of entrapped airspaces in SFT of the pleura shows luminal spaces lined by columnar epithelium and surrounding fibrous tissue cores containing dense hyalinized collagen.* **(Right)** *SFT of the pleura shows a more advanced stage of entrapment of airspaces within the substance of the tumor. In this example, the stroma surrounding the entrapped airspaces is completely sclerotic.*

Entrapped Airspace

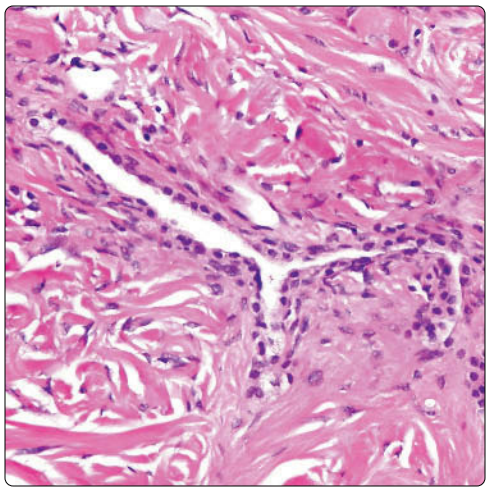

Entrapped Airspace

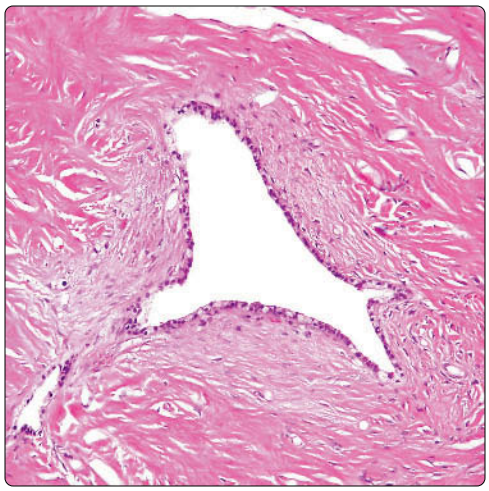

(Left) *Higher magnification of residual entrapped airspace in SFT of the pleura shows atrophy of the epithelial lining in the luminal side of the structure, which is lined primarily by a single layer of small, cuboidal epithelial cells.* **(Right)** *Entrapped airspace in SFT of the pleura shows an irregularly dilated luminal space lined by variable epithelium ranging from flat to cuboidal to tall columnar epithelium.*

Cellular Variant of SFT

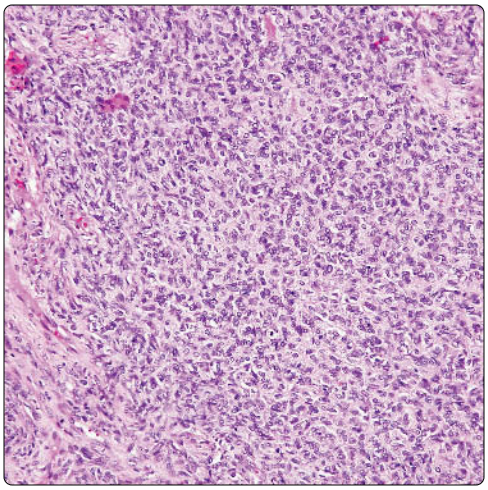

Cellular Variant of SFT: High Power

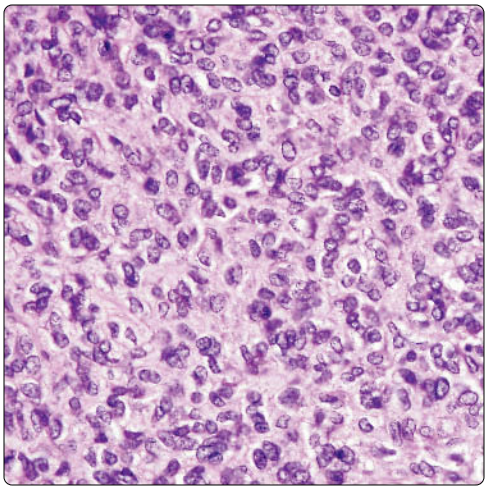

(Left) *SFT of the pleura growing as diffuse sheets of cells shows dense cellularity. The tumor cells are small and mostly round epithelioid rather than the conventional spindle cells commonly observed in these tumors.* **(Right)** *Higher magnification of SFT of the pleura characterized by a predominantly round cell population shows densely packed round to oval cells with vesicular nuclei surrounded by a scant rim of amphophilic cytoplasm.*

Storiform Pattern

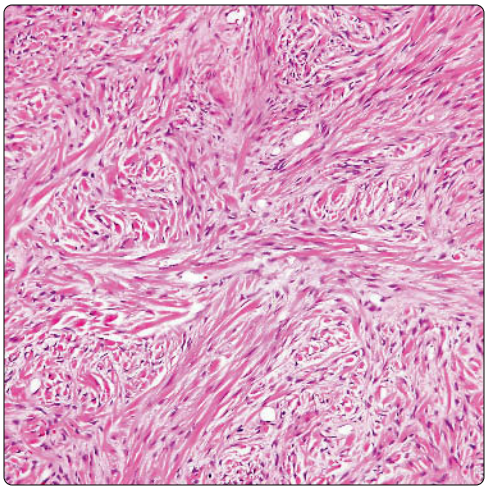

High-Power Magnification

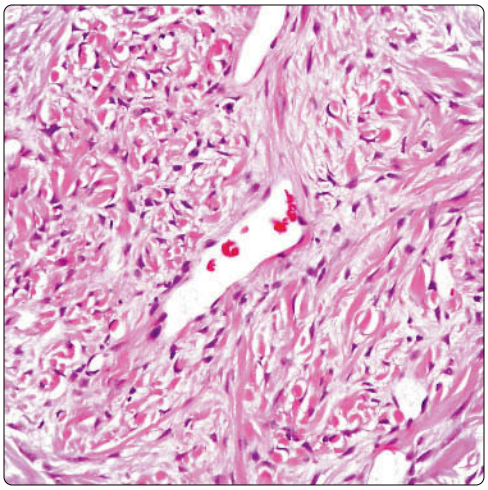

(Left) *SFT of pleura shows a proliferation of small spindle cells set against a background of hyalinized stromal collagen. The lesion is quite cellular and uniform with even distribution of the short spindle cells among the collagen fibers.* **(Right)** *High magnification of SFT of the pleura shows a uniform population of small, dark spindle cells set against a heavily collagenized stroma. Despite the heavy collagenization, the lesion is quite cellular.*

Storiform Pattern

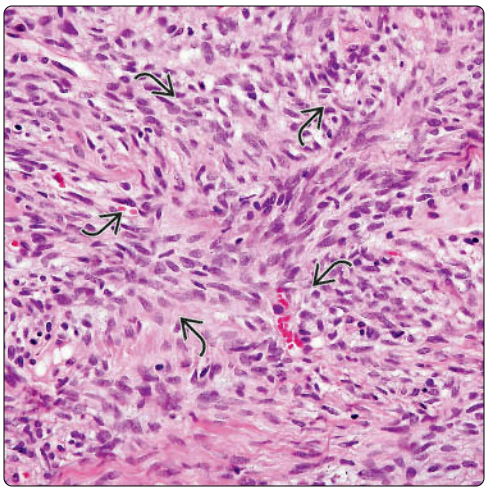

Spindle Cells: High Power

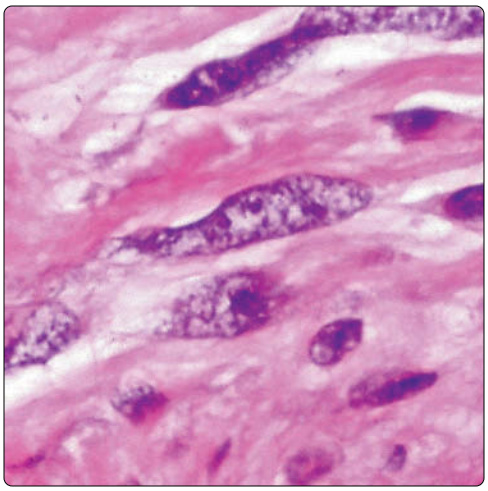

(Left) *SFT of the pleura shows a cellular spindle cell proliferation with a discrete storiform growth pattern. The spindle cells seem to be radiating from the central portion of the spindle cell fascicles like the spokes of a wheel.* **(Right)** *High magnification of SFT of the pleura shows spindle cells with elongated nuclei, a dispersed chromatin pattern, and multiple small nucleoli surrounded by a scant rim of amphophilic cytoplasm.*

Cellular Variant of SFT

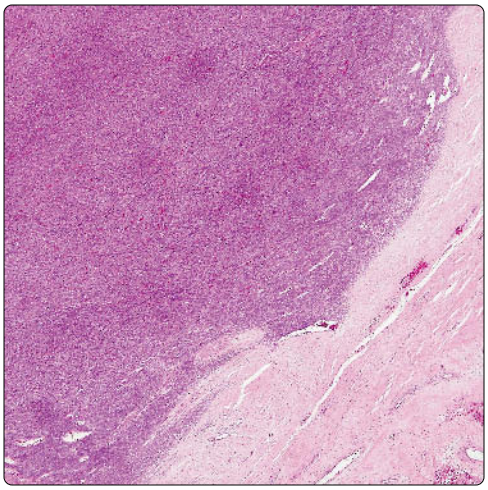

Synovial Sarcoma-Like SFT

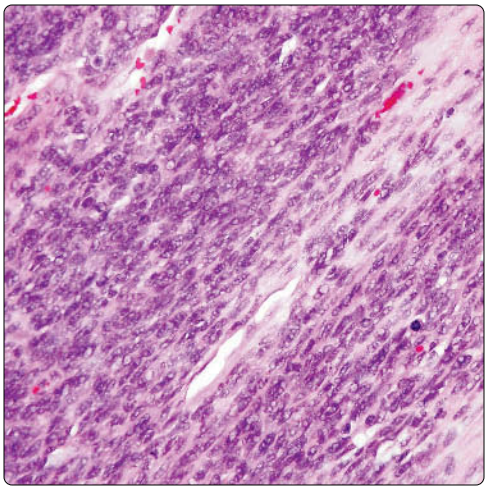

(Left) *Densely cellular, synovial sarcoma-like variant of SFT of the pleura shows solid proliferation of tightly packed spindle cells on scanning magnification.* **(Right)** *Higher magnification of a cellular spindle cell variant of SFT of the pleura shows sheets of hyperchromatic spindle cells with very little intervening stroma. Scattered mitotic figures can also be seen in these tumors, highlighting the similarity with synovial sarcoma.*

Cellular SFT: High Power

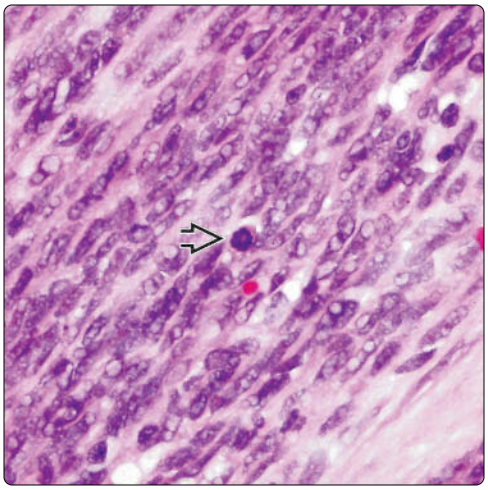

Cellular SFT

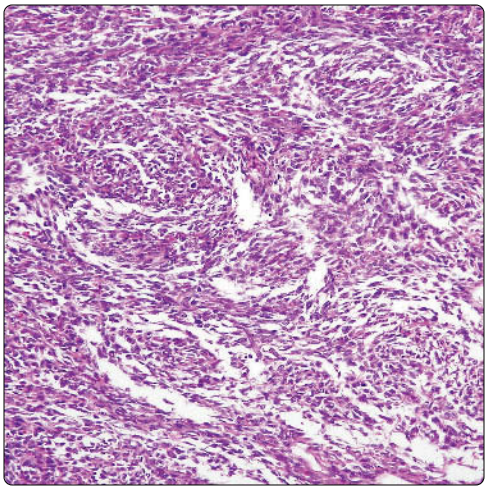

(Left) *Higher magnification of a cellular variant of SFT of the pleura shows a monotonous population of spindle cells with vesicular nuclei and occasional mitotic figures ⇨. Tumors with these features can be easily mistaken for examples of synovial sarcoma of the pleura.* **(Right)** *SFT of the pleura shows solid spindle cell proliferation with little intervening stroma that may closely resemble monophasic synovial sarcoma.*

Cellular SFT: High Power

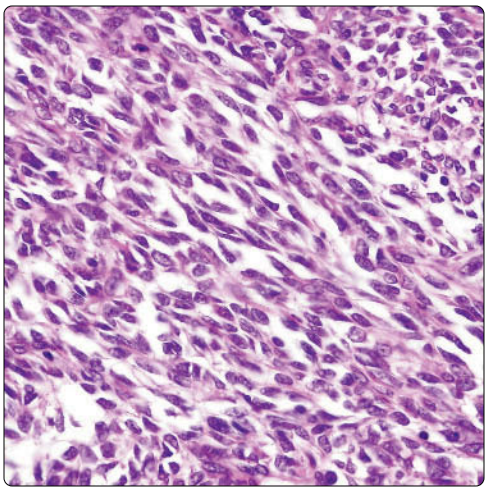

Spindle Cells in Cellular SFT

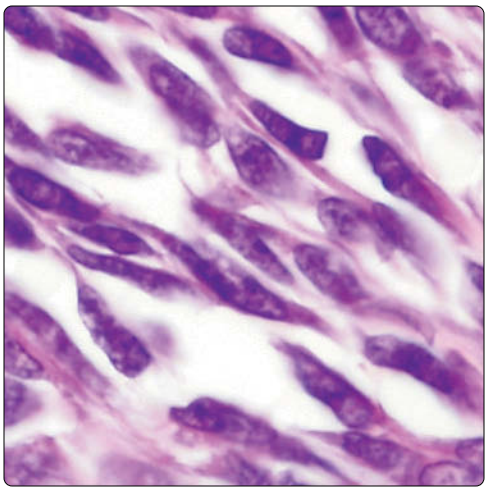

(Left) *Higher magnification of SFT of the pleura composed of a monotonous proliferation of spindle cells with little intervening stroma closely resembles monophasic synovial sarcoma.* **(Right)** *Detail of the spindle cells in a cellular variant of SFT of the pleura resembling monophasic synovial sarcoma shows hyperchromatic spindle cells with a dense chromatin pattern, inconspicuous nucleoli, and tapered cytoplasmic processes.*

STAT6 Positivity

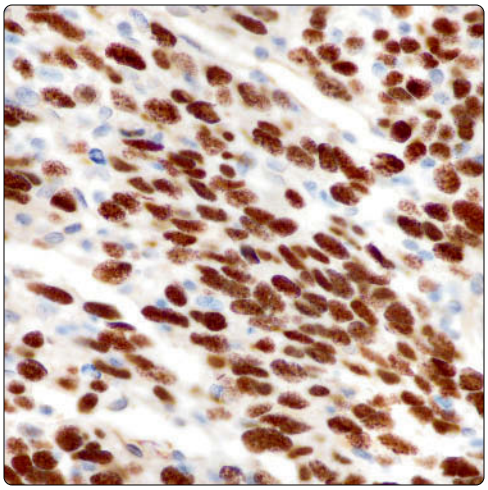

SMA Positivity

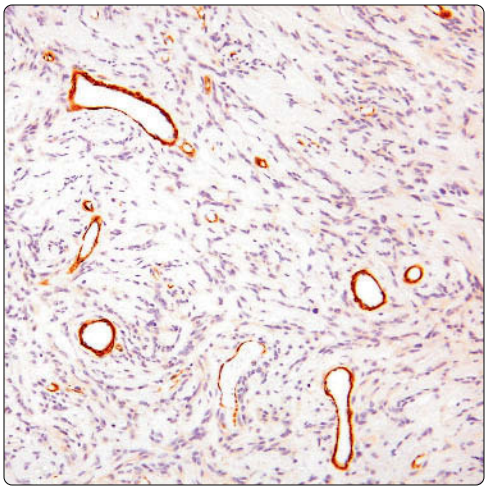

(Left) *Immunohistochemical stain for STAT6 shows strong nuclear positivity of the tumor cells for this antibody in SFT. This currently represents the marker of choice for establishing the diagnosis of SFT and shows high sensitivity and specificity.* **(Right)** *Immunohistochemical staining for smooth muscle actin (SMA) in SFT of the pleura highlights the positive staining of the muscle layer of small vessels but shows negative staining in the tumor cells.*

Bcl-2 Positivity

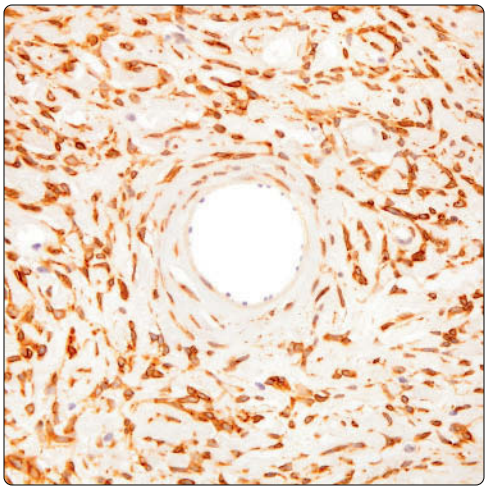

Bcl-2 Positivity: High Power

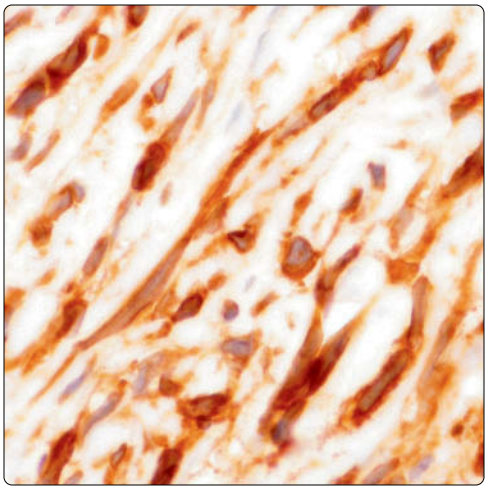

(Left) *Immunohistochemical staining of SFT of the pleura with antibodies to Bcl-2 shows strong positivity of the tumor cells for this marker. Notice the concentric arrangement of the positive tumor cells surrounding the vessel wall (center).* **(Right)** *Immunohistochemical staining for Bcl-2 in SFT of the pleura shows strong cytoplasmic positivity of the spindle cells for this marker. Nearly 100% of cases of SFT are positive for this marker.*

CD34 Positivity

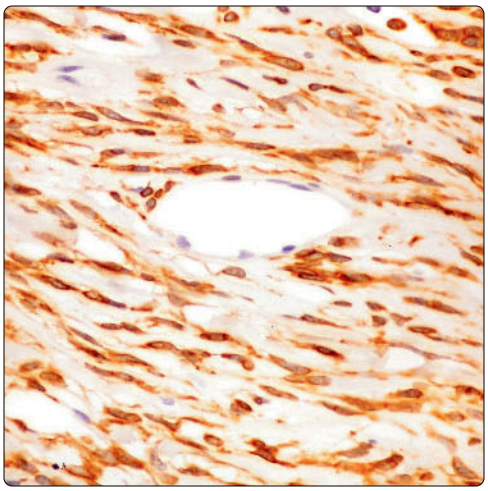

CD34 Positivity: High Power

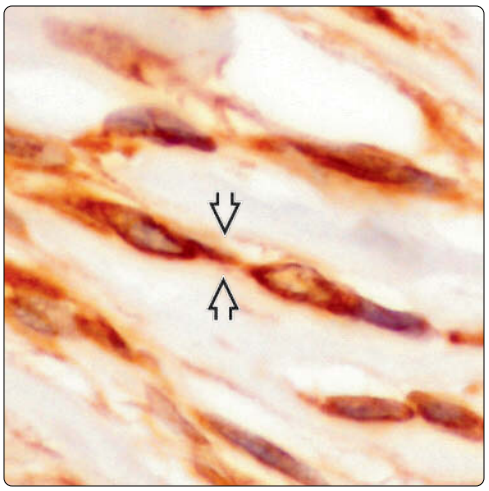

(Left) *Immunohistochemical staining of SFT of the pleura for CD34 shows positive staining in the majority of the tumor cells. CD34 stains positively in ~ 60-80% of SFT cases.* **(Right)** *Immunohistochemical staining for CD34 in SFT of the pleura shows a positive cytoplasmic rim in 2 adjacent tumor cells that appear to be touching each other via slender cytoplasmic prolongations ⇨.*

Calcified Fibrous Pseudotumor

KEY FACTS

TERMINOLOGY

- Calcified fibrous pseudotumor (CFPT)

CLINICAL ISSUES

- Cough
- Chest pain
- Shortness of breath
- Asymptomatic

MACROSCOPIC

- Single pleural mass
- Multiple pleural nodules

MICROSCOPIC

- Dense fibrocollagenous tissue
- Psammoma bodies
- Dystrophic calcifications
- Lymphoplasmacytic inflammatory reaction
- Absence of nuclear atypia or mitotic activity
- Absence of necrosis &/or hemorrhage

TOP DIFFERENTIAL DIAGNOSES

- Solitary fibrous tumor
  - Shows different growth pattern in same tumor
  - Positive staining for Bcl-2
  - Rarely shows dystrophic calcification &/or psammoma bodies
- Sarcomatoid mesothelioma
  - Shows diffuse pleural involvement
  - Shows nuclear atypia and mitotic activity
  - Positive for CK-PAN
- Fibrous plaque
  - CFPT generally shows psammoma bodies &/or dystrophic calcification

Calcifications | **Fibrous Stroma**

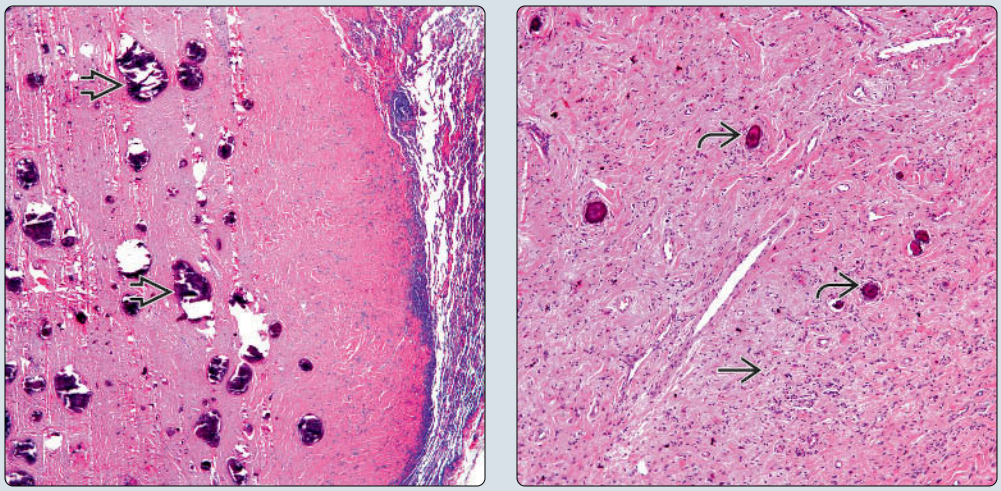

(Left) *Low-power view shows a calcified fibrous pseudotumor of the pleura. Note the presence of numerous calcifications embedded in a fibrous stroma with mild inflammatory changes.* **(Right)** *The tumor is composed of a bland spindle cell proliferation with scattered inflammatory cells and the presence of psammomatous calcifications.*

Predominantly Collagenous Stroma | **Calcifications Embedded in Fibrous Stroma**

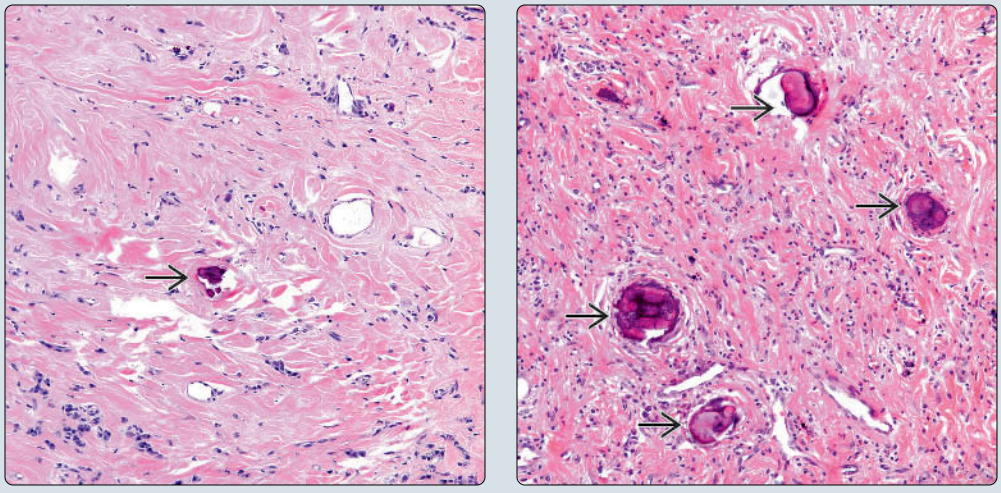

(Left) *Calcified fibrous pseudotumor (CFPT) shows extensive collagenization of the stroma with mild inflammatory reaction and only focal calcification. Even though there is only 1 calcification, its presence should raise the suspicion of CFPT.* **(Right)** *CFPT shows more conventional features of collagenous stroma with fibroblastic component and obvious calcifications. This is the classic view of a CFPT of the pleura.*

Rim of Inflammatory Reaction

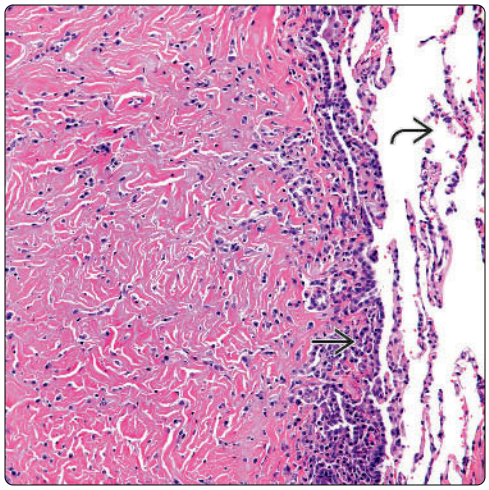

Scattered Calcifications

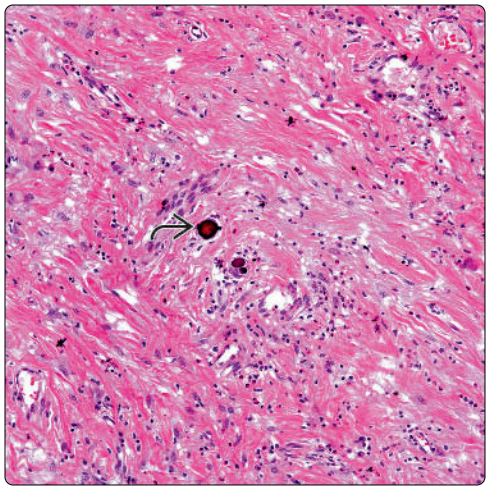

(Left) *Calcifying pseudotumor of the pleura shows good circumscription from the lung parenchyma. The tumor is not encapsulated and has a rim of inflammatory infiltrate.* **(Right)** *The presence of calcifications may be very subtle. In some areas, there may only be a few, while in other areas there may be multiple.*

Collagenous Stroma

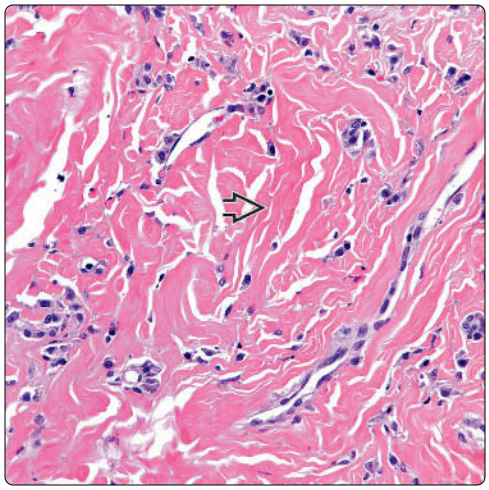

Inflammatory Reaction

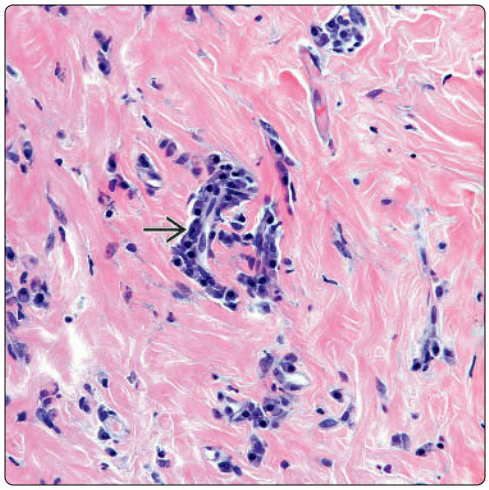

(Left) *CFPT shows extensive areas of hyalinization with only focal areas of inflammatory reaction. This pattern could easily be confused with a solitary fibrous tumor of the pleura. The presence of calcifications are important in arriving at a correct interpretation.* **(Right)** *High-power view of CFPT shows extensive hyalinization with a cluster of inflammatory cells, namely plasma cells. Note the absence of calcifications in these areas.*

Small Capillaries

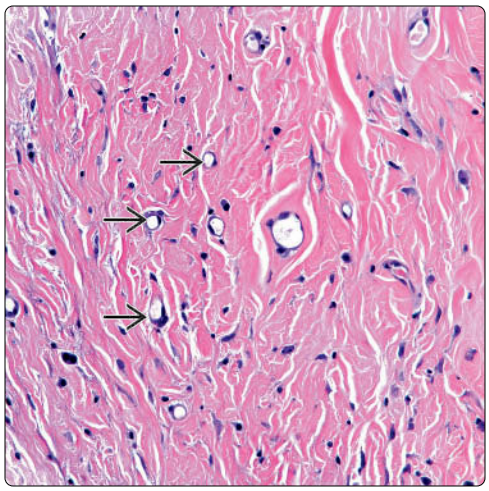

Focal Calcification

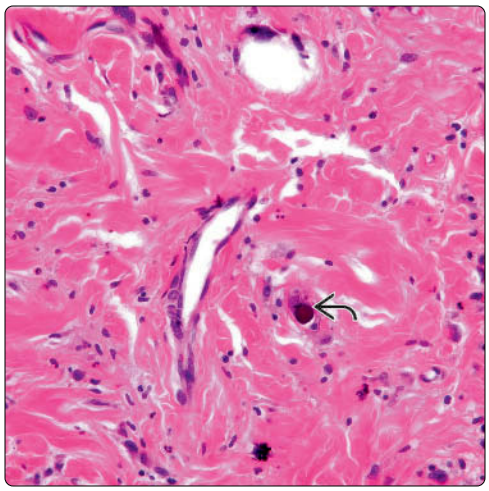

(Left) *CFPT shows collagenization with proliferation of small capillaries. Very minimal inflammatory reaction is seen. This growth pattern may also be seen in cases of solitary fibrous tumors of the pleura.* **(Right)** *Extensive collagenization with little cellularity is shown. Note the presence of a small calcification and also the presence of dilated blood vessels.*

Extensive Hyalinization

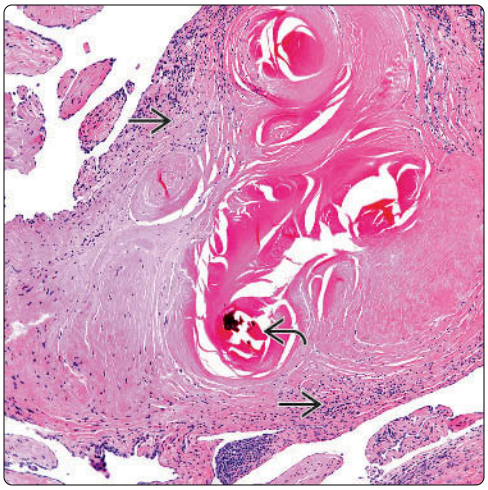

Dense Collagen

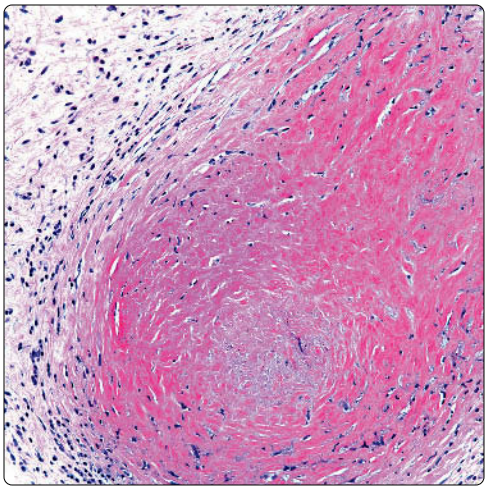

(Left) *Some cases may show extensive areas of collagenization with only focal calcifications. Note the presence of a spindle cell proliferation.* **(Right)** *In some other areas, there is only dense collagen deposition with no calcifications. The presence of calcifications is important for the diagnosis.*

Predominantly Collagenous Stroma

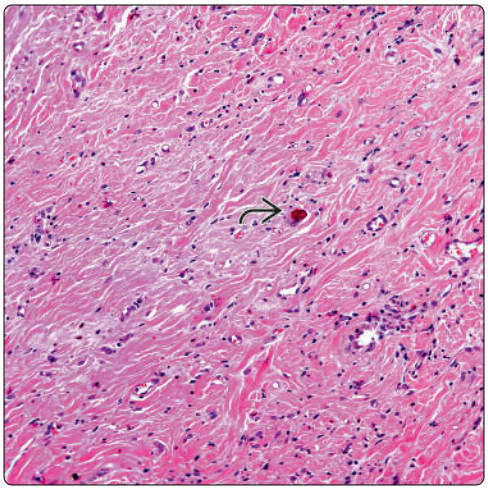

Calcification

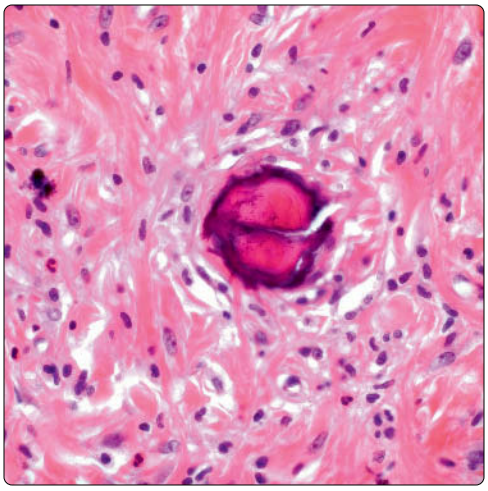

(Left) *Only a small calcification is present in this tumor. Otherwise, these features may be seen in other mesenchymal neoplasms, mainly solitary fibrous tumor.* **(Right)** *In this high-power view of a calcification in a CFPT, the calcification is similar to those described as psammoma bodies, which can be seen in neoplastic and nonneoplastic conditions. However, in this setting it is diagnostic of CFPT.*

Increased Eosinophils

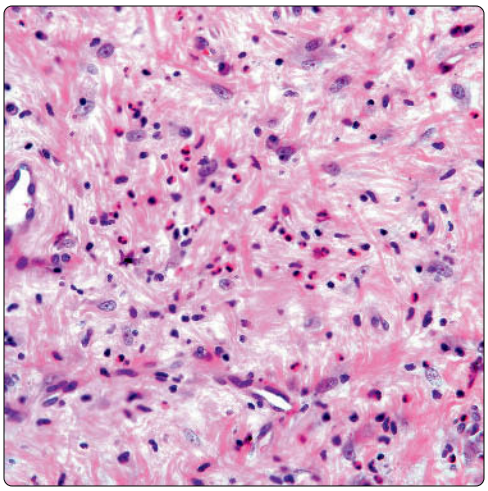

Small Calcifications

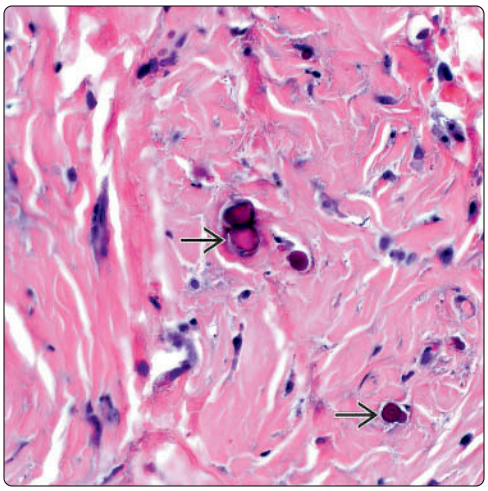

(Left) *Inflammatory reaction with presence of numerous eosinophils is commonly encountered in these tumors.* **(Right)** *In some cases of CFPT of the pleura, the calcification may not be so obvious and large. In this case, the calcifications are rather small and embedded in a collagenous stroma. These features are common in CFPT of the pleura.*

This page intentionally left blank

PART II
SECTION 2

Neoplasms, Malignant, Primary

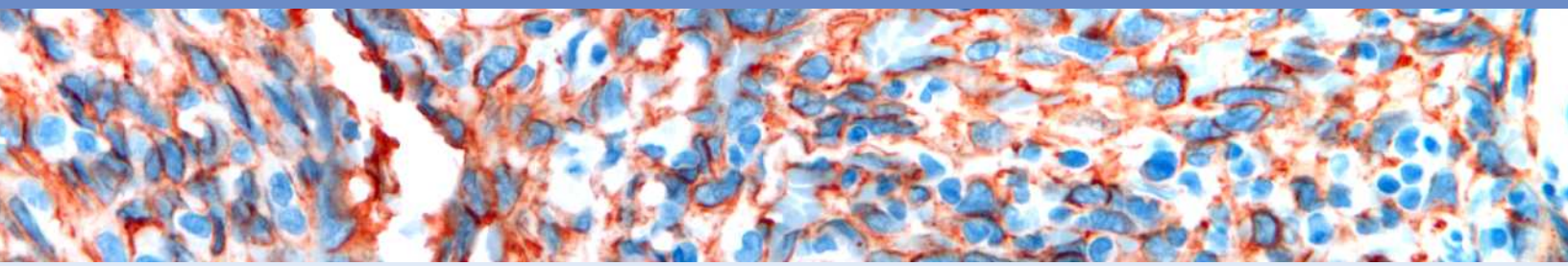

Epithelial Neoplasms

Overview of Malignant Pleural Neoplasms	**574**
Malignant Mesothelioma	**576**
Pseudomesotheliomatous Adenocarcinoma	**584**
Mucoepidermoid Carcinoma of Pleura	**590**
Angiosarcoma	**596**
Synovial Sarcoma	**602**
Malignant Solitary Fibrous Tumor (Fibrosarcoma)	**608**
Smooth Muscle Tumors of Pleura	**614**
Desmoplastic Small Round Cell Tumor	**620**

TERMINOLOGY

Definitions

- Malignant pleural neoplasms may be primary or secondary
  - Primary malignant pleural neoplasms
    - Malignant mesothelioma (most common primary malignant pleural neoplasm)
    - Malignant lymphoma of pleura (primary effusion lymphoma and pyothorax-associated lymphoma)
    - Primary mesenchymal tumors of pleura
  - Secondary pleural neoplasms
    - Metastases to pleura are most common type of malignancy involving pleura
    - Metastases from lung carcinoma are most common type of secondary tumor of pleura
    - Other common types of pleural metastases include breast, kidney, gastrointestinal, and female genital tract cancer

ETIOLOGY/PATHOGENESIS

Etiology

- Occupational exposure to asbestos has been established as most important cause for development of malignant mesothelioma
  - Asbestos-related mesotheliomas are associated with long latency period (30-40 years)
  - Asbestos fiber types are associated with varying degrees of carcinogenicity
    - Amphiboles (amosite and crocidolite) are most potent ones; crocidolite is more dangerous of 2
    - Chrysotile is least potent carcinogen among asbestos fibers and associated with lowest risk
- Syrian monkey virus (SV40) has been associated with development of mesothelioma in exposed individuals
  - SV40 induces breaks in human DNA strands in human mesothelial cells inactivating tumor suppressor *TP53* and *RB1* (RB) genes
  - SV40 was found in contaminated polio vaccines during 1950s and 1960s, spreading to millions of people
  - Role of latent infection with SV40 for causing malignant mesothelioma still remains to be established
- Other causes of mesothelioma include nonasbestos fiber, erionite (found only in Cappadocia, Turkey), and ionizing radiation

EPIDEMIOLOGY

Age Range

- Malignant mesothelioma can occur in any age group from children to adults
- Most prevalent in adults > 60 years of age

Gender

- Marked male predilection (in USA, M:F = 9:1)

Incidence

- Incidence in men in USA is ~ 20 per 1 million persons per year
- Incidence in women in USA is ~ 2-3 per 1 million persons per year
- Incidence in other countries is higher; e.g., in Australia and UK it is ~ 50-60 per 1 million persons per year

CLINICAL IMPLICATIONS

Clinical Presentation

- Most common presenting symptoms are recurrent pleural effusions, progressive dyspnea, and chest pain
- Constitutional symptoms include malaise, weight loss, weakness, and fatigue

Clinical Risk Factors

- Certain occupations are associated with higher risk of exposure to asbestos
  - Workers in shipyard industry
  - Workers in insulation and heating trades and construction workers
  - Workers in mining and milling industry of asbestos
- Marked increase in incidence is observed when risk factors are combined with cigarette smoking

Gross Appearance

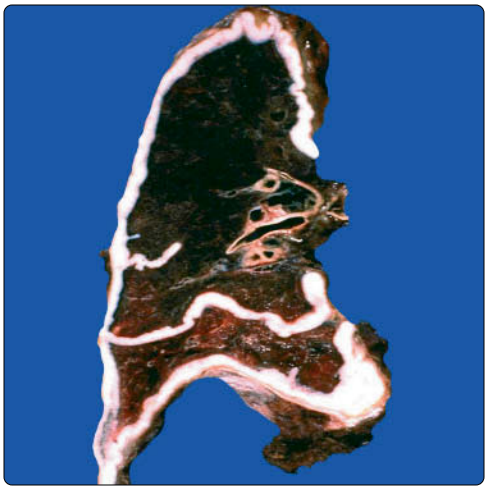

Ultrastructure of Asbestos Fiber

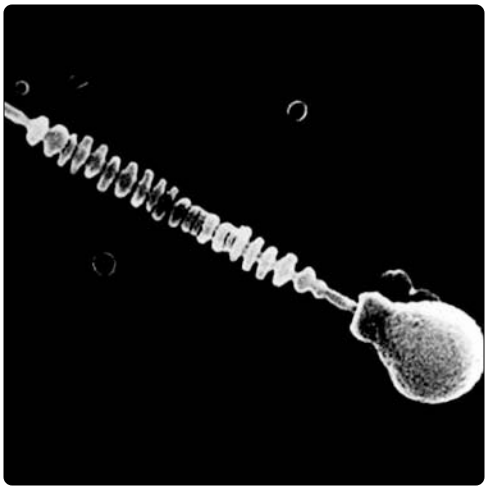

(Left) *Cut section of the lung in a patient with malignant pleural mesothelioma shows a thick rind of whitish tumor tissue surrounding the outer surface of the lung and extending along the interlobar fissures.* **(Right)** *Scanning electron micrograph of an asbestos fiber measuring ~ 35 µm in length shows a bulb-shaped end attached to a longitudinal core with a beaded appearance.*

Staging

- AJCC (7th edition) pathologic staging
  - Primary tumor (T)
    - TX
      - Primary tumor cannot be assessed
    - T0
      - No evidence of primary tumor
    - T1
      - Tumor limited to ipsilateral parietal pleura ± mediastinal or diaphragmatic pleural involvement
    - T1a
      - No involvement of visceral pleura
    - T1b
      - Tumor also involving visceral pleura
    - T2
      - Tumor involving each of ipsilateral pleural surfaces with at least involvement of diaphragm or of underlying lung parenchyma
    - T3
      - Locally advanced but potentially resectable tumor involving all ipsilateral pleural surfaces and extension into fat, fascia, chest wall, or pericardium
    - T4
      - Locally advanced and technically unresectable tumor with extension through chest wall, diaphragm, mediastinum, spine, pericardium
  - Regional lymph nodes (N)
    - NX
      - Regional lymph nodes cannot be assessed
    - N0
      - No regional lymph node metastases
    - N1
      - Metastases in ipsilateral bronchopulmonary or hilar lymph nodes
    - N2
      - Metastases in subcarinal or ipsilateral mediastinal lymph nodes (including internal mammary and peridiaphragmatic nodes)
    - N3
      - Metastases in contralateral mediastinal or internal mammary nodes and ipsilateral or contralateral supraclavicular lymph nodes
  - Metastases (M)
    - M0
      - No distant metastases
    - M1
      - Distant metastases

Prognostic Factors

- Histologic type
  - Pure epithelioid mesothelioma is associated with slightly better outcome
  - Sarcomatoid and biphasic mesotheliomas are associated with more aggressive course
- Presenting symptoms (chest pain, dyspnea, and weight loss) are associated with worse prognosis
- Younger age at presentation, low stage, and good performance status are associated with better prognosis

MACROSCOPIC

General Features

- Pleural mesothelioma shows tendency to spread along pleural surface
  - Initial manifestation may be as multiple tiny nodules studding visceral or parietal pleura
  - Over time, nodules enlarge and become confluent, forming plaques and larger nodules
  - In more advanced stages, entire pleural surface is covered by rind of tumor that may vary in thickness
  - Tumor tends to invade pleural fissures and infiltrate surface of lung parenchyma
  - Tumor eventually spreads to regional and intrathoracic lymph nodes
  - Invasion of chest wall fat and muscle is characteristic
  - Spread through diaphragm can occasionally occur, leading to seeding of peritoneal cavity, and ascites
- Rarely, mesothelioma may grow as localized, sharply circumscribed mass, termed localized malignant mesothelioma
  - Such tumors are generally associated with better prognosis

MICROSCOPIC

General Features

- Malignant mesothelioma is divided histopathologically into epithelioid, sarcomatoid, and mixed (biphasic) types
- Special histologic variants of mesothelioma include desmoplastic, lymphohistiocytic, and deciduoid types
- Well-differentiated papillary mesothelioma is distinct variant with papillary architecture and absence of invasion and indolent behavior

Molecular Genetic Alterations

- Inactivation of *CDKN2A*/ARF locus at 9p21 leading to loss of p16 expression is frequent finding
- Deletions at 3p21 is common in epithelioid mesothelioma but rare in sarcomatoid and biphasic tumors

SELECTED REFERENCES

1. Campbell NP et al: Update on malignant pleural mesothelioma. Semin Respir Crit Care Med. 32(1):102-10, 2011
2. Kao SC et al: Molecular biomarkers in malignant mesothelioma: state of the art. Pathology. 43(3):201-12, 2011
3. Suster S et al: Malignant mesothelioma: current status of histopathologic diagnosis and molecular profile. Expert Rev Mol Diagn. 5(5):715-23, 2005

Malignant Mesothelioma

KEY FACTS

TERMINOLOGY

- Malignant neoplasm arising in serosal surfaces

ETIOLOGY/PATHOGENESIS

- Mesotheliomas have been linked closely to asbestos exposure

CLINICAL ISSUES

- Rare tumor accounting for ~ 4-7 cases per million individuals
- More common in 5th and 6th decades of life
- Weight loss
- Chest pain
- General malaise
- Extrapulmonary pneumonectomy
- Decortication
- More common in men

MICROSCOPIC

- Tubulopapillary
- Sarcomatoid
- Biphasic
- Clear cell
- Deciduoid
- Adenomatoid
- Glandular
- Mucohyaline
- Cartilaginous and osseous metaplasia
- Desmoplastic
- Lymphohistiocytic

TOP DIFFERENTIAL DIAGNOSES

- Adenocarcinoma
- Sarcoma
- Synovial sarcoma

Extrapleural Pneumonectomy

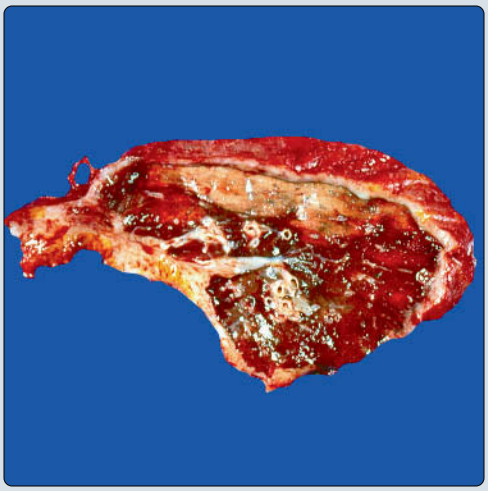

Sarcomatoid Mesothelioma

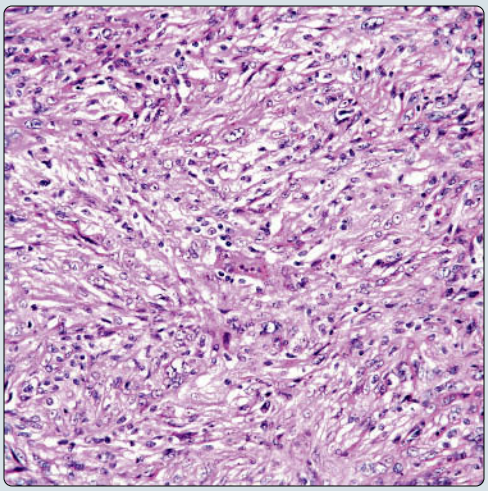

(Left) *Extrapulmonary pneumonectomy consisting of both visceral and parietal pleurae, lung, and portions of diaphragm and pericardium is shown. Note the marked pleural thickening.* **(Right)** *Sarcomatoid malignant mesothelioma shows a spindle cell proliferation closely mimicking the features of a mesenchymal neoplasm.*

Muscle Invasion

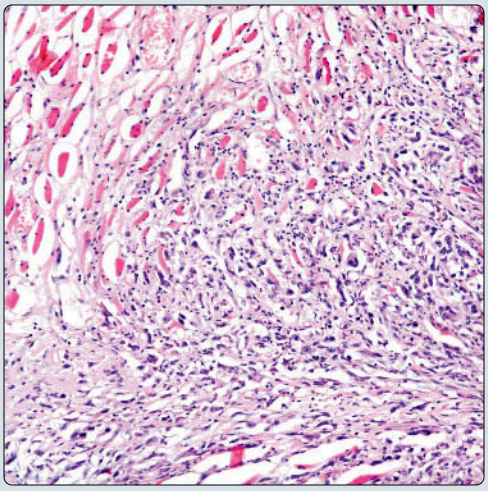

Positive Keratin

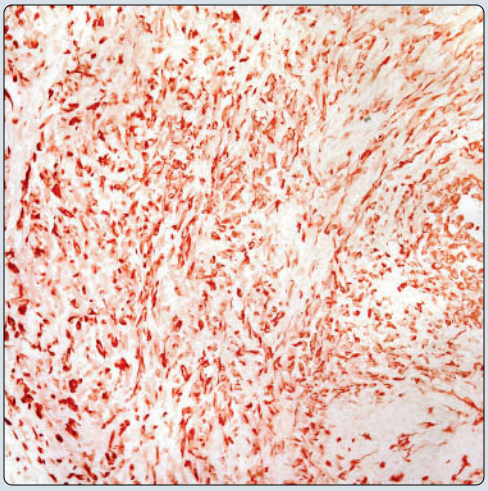

(Left) *Sarcomatoid malignant mesothelioma is shown invading into the skeletal muscle. This particular feature is one of the most important to determine malignancy in difficult cases.* **(Right)** *Sarcomatoid malignant mesothelioma shows strong positive reaction in tumor cells for keratin.*

TERMINOLOGY

Synonyms

- Epithelioma
  - Term used in older literature

Definitions

- Malignant neoplasm arising in serosal surfaces

ETIOLOGY/PATHOGENESIS

Environmental Exposure

- Mesotheliomas have been linked closely to asbestos exposure

Other Possible Etiologies

- Viral infection SV40
- De novo

CLINICAL ISSUES

Epidemiology

- Incidence
  - Rare tumor accounting for ~ 4-7 cases per million individuals
- Age
  - More common in 5th and 6th decades of life
- Sex
  - More common in men

Presentation

- Weight loss
- Chest pain
- Cough
- Shortness of breath
- Pleural effusion

Treatment

- Surgical approaches
  - Extrapulmonary pneumonectomy
  - Decortication
  - Pleural peeling
- Adjuvant therapy
  - Chemotherapy

Prognosis

- Poor
  - Average survival: 12-18 months

MACROSCOPIC

General Features

- Diffuse thickening of pleura
- In rare cases, tumor will present as localized pleural-based tumor

MICROSCOPIC

Histologic Features

- Homogeneous cellular proliferation without much mitotic activity or cellular pleomorphism

Predominant Pattern/Injury Type

- Tubulopapillary
- Sarcomatoid
- Biphasic

Predominant Cell/Compartment Type

- Epithelial
- Spindle

Other Growth Patterns

- Clear cell
  - This pattern is characterized by presence of cellular proliferation in which cells show clear cytoplasm
  - Low mitotic count
  - Most of these tumors do not show extensive areas of necrosis
- Deciduoid
  - This pattern is composed of medium-sized cells with eccentric nuclei and inconspicuous nucleoli
  - Low mitotic count
  - Necrosis and prominent nuclear atypia are not common
- Adenomatoid
  - Cords of neoplastic cells forming cystic spaces
  - Signet ring cell-like
  - Low mitotic count
  - Areas of necrosis or hemorrhage are not common
- Glandular
  - Prominent glandular component
  - Glands of different sizes
  - Most closely mimics adenocarcinoma
- Mucohyaline
  - Extensive pools of mucoid material
  - Neoplastic cells embedded or floating in pools of mucoid material
- Cartilaginous and osseous metaplasia
  - Very unusual growth pattern
  - Tumor shows extensive areas of cartilaginous or osseous differentiation
  - Numerous osteoclast giant cells
- Desmoplastic
  - Low cellularity
  - Easily mistaken for benign tumor
  - Neoplastic cells, either spindle or oval, dissecting fibrocollagen
  - Areas of necrosis are not readily apparent
- Lymphohistiocytic
  - Mixture of epithelioid cells, lymphocytes, and histiocytes
  - May mimic thymoma or lymphoma

ANCILLARY TESTS

Electron Microscopy

- Elongated microvilli
- Well-developed cell junctions

DIFFERENTIAL DIAGNOSIS

Metastatic Adenocarcinoma

- Shows positive staining for carcinomatous epitopes, including CEA, MOC-31, and BER-EP4
- History of primary tumor elsewhere is important

Sarcoma

- Sarcomas encasing lung parenchyma are rather unusual

Immunohistochemistry

Antibody	Reactivity	Staining Pattern	Comment
CK-PAN	Positive	Cytoplasmic	
CK5/6	Positive	Cytoplasmic	In epithelioid neoplasms; also positive in squamous cell carcinomas
Calretinin	Positive	Nuclear & cytoplasmic	In epithelioid neoplasms/focally in sarcomatoid
HBME-1	Positive	Cytoplasmic	Also positive in carcinomas
WT1	Positive	Nuclear	Also positive in carcinomas
Thrombomodulin	Positive	Cytoplasmic	Also positive in carcinomas
Mesothelin	Positive	Cell membrane	Also positive in carcinomas
p63	Positive	Nuclear	Also positive in squamous cell carcinoma
D2-40	Positive	Cytoplasmic	
MDM2	Positive	Nuclear	In some cases
CD10	Positive	Cytoplasmic	Also positive in other carcinomas
CEA-M	Negative		
CD15	Negative		
EpCAM/BER-EP4/CD326	Negative		In 27% of mesotheliomas, may be positive
MOC-31	Negative		May be seen focally positive in some mesotheliomas
TTF-1	Negative		
NAPSIN-A	Negative		

Histochemical Features

Stain	Reactivity
PAS	Positive
PAS-D	Negative
Mucicarmine	Negative
Iron	Identifies ferruginous bodies in lung parenchyma

Molecular Features

FISH	Mutation Analysis
Loss of p16 tumor suppressor (*CDKN2A*) through homozygous deletions of 9p21	In ~ 50% of mesotheliomas
BAP1	In ~ 30-40% of mesotheliomas

- It would be unusual for mesothelioma to stain with mesenchymal markers other than vimentin
- Clinical history is important to rule out metastasis

Synovial Sarcoma

- Either mono- or biphasic tumors may mimic mesothelioma
- Monophasic tumors will show positive staining for Bcl-2, which would be unusual in mesothelioma
- Synovial sarcoma shows characteristic X;18 translocation

Thymoma

- In cases of lymphohistiocytic mesothelioma
  - Use of immunohistochemical studies shows strong p63 positivity in thymoma
- Although thymomas may occur as pleural tumors, they are more common in anterior mediastinum

DIAGNOSTIC CHECKLIST

Clinically Relevant Pathologic Features

- Invasive pattern
  - Penetration of tumor cells into fat

SELECTED REFERENCES

1. Nasu M et al: High incidence of somatic BAP1 alterations in sporadic malignant mesothelioma. J Thorac Oncol. 10(4):565-76, 2015
2. Hwang H et al: p16 FISH deletion in surface epithelial mesothelial proliferations is predictive of underlying invasive mesothelioma. Am J Surg Pathol. 38(5):681-8, 2014
3. Wu D et al: Diagnostic usefulness of p16/CDKN2A FISH in distinguishing between sarcomatoid mesothelioma and fibrous pleuritis. Am J Clin Pathol. 139(1):39-46, 2013
4. Arrossi AV et al: Histologic assessment and prognostic factors of malignant pleural mesothelioma treated with extrapleural pneumonectomy. Am J Clin Pathol. 130(5):754-64, 2008

Sarcomatoid Mesothelioma

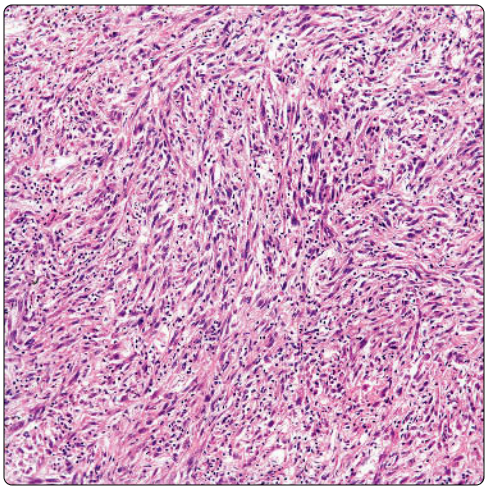

Sarcomatoid Mesothelioma

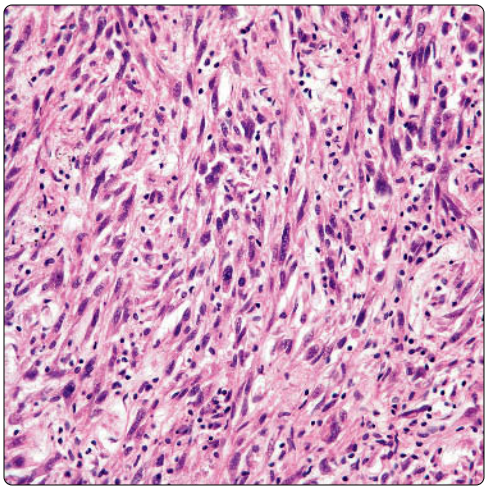

(Left) *Intermediate-power view shows the spindle cellular proliferation with a vague storiform pattern admixed with inflammatory cells. This pattern is indistinguishable from any other high-grade sarcoma.* **(Right)** *Higher magnification shows spindle cells with marked cellular atypia and scattered mitotic figures. This pattern closely mimics any pleomorphic sarcoma or malignant fibrous histiocytoma.*

Ferruginous Bodies

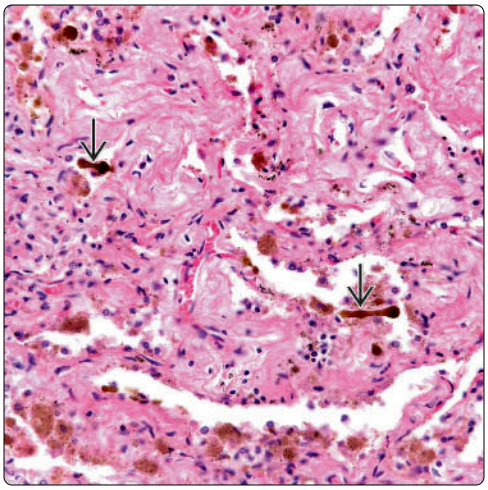

Sarcomatoid Mesothelioma

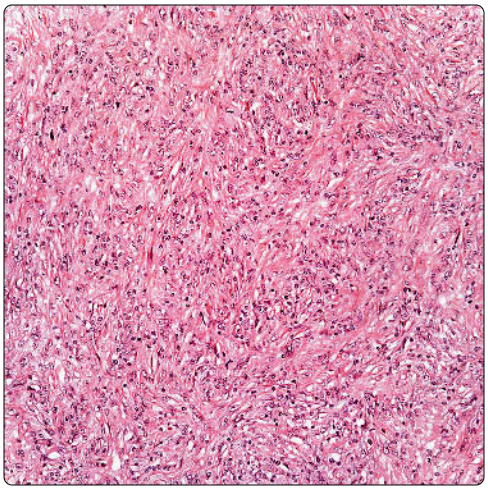

(Left) *Adjacent lung parenchyma shows numerous ferruginous bodies ⇨. In many cases, these structures can be easily identified with conventional H&E stains. However, in cases in which these structures are not readily recognizable, the use of iron histochemical stains is recommended.* **(Right)** *Sarcomatoid mesothelioma shows more bland spindle cell proliferation admixed with inflammatory cells. This growth pattern is reminiscent of fibrosarcoma.*

Sarcomatoid Mesothelioma

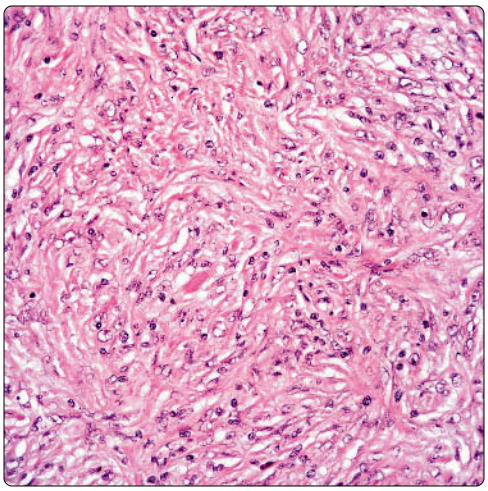

Desmoplastic Mesothelioma

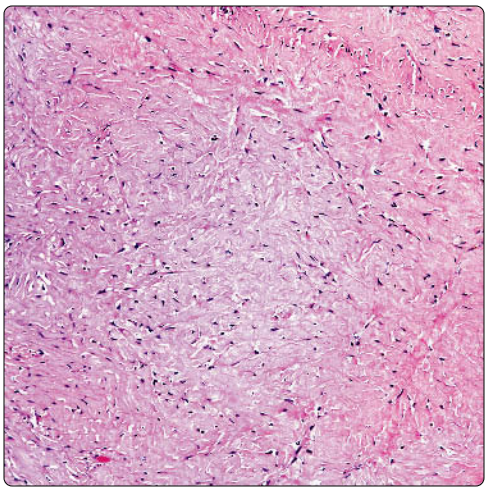

(Left) *Sarcomatoid mesothelioma is shown with desmoplastic features. In a cursory evaluation, this tumor can be easily confused for a benign fibrous pleurisy. Careful review of the histology usually leads to a correct interpretation. However, in some cases, the cellularity may be scant.* **(Right)** *Desmoplastic mesothelioma shows prominent hyalinized stroma with only minimal cellular proliferation. On cursory review, this type of mesothelioma can be easily misdiagnosed.*

Desmoplastic Mesothelioma

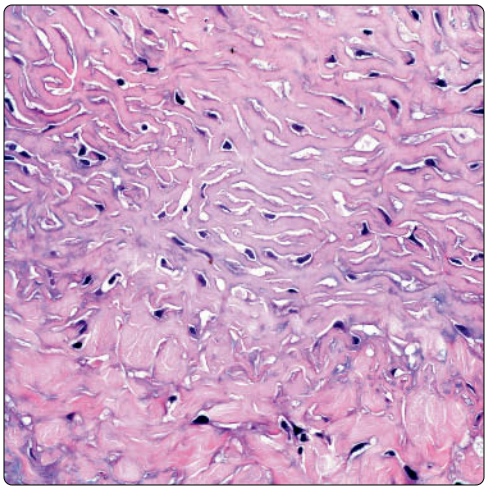

Desmoplastic Mesothelioma

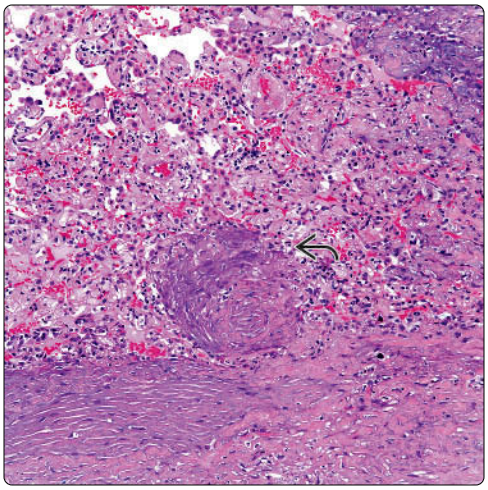

(Left) *Closer magnification of a desmoplastic mesothelioma shows abundant collagen deposition with a subtle spindle cell component. However, there is no evidence of nuclear atypia or mitotic activity.* **(Right)** *One additional feature that may be helpful in the diagnosis of desmoplastic mesothelioma is the penetration of the tumor into adipose tissue or into lung parenchyma.*

Epithelioid Mesothelioma

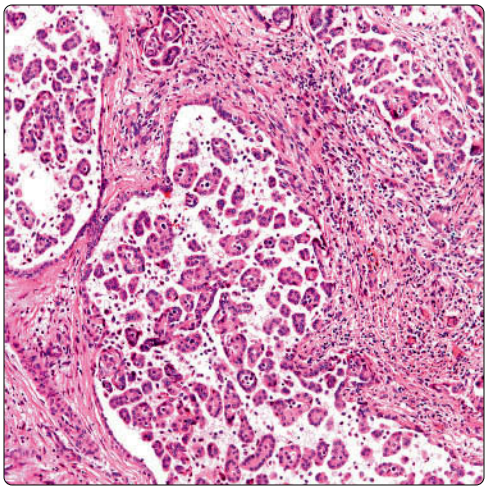

Epithelioid Mesothelioma

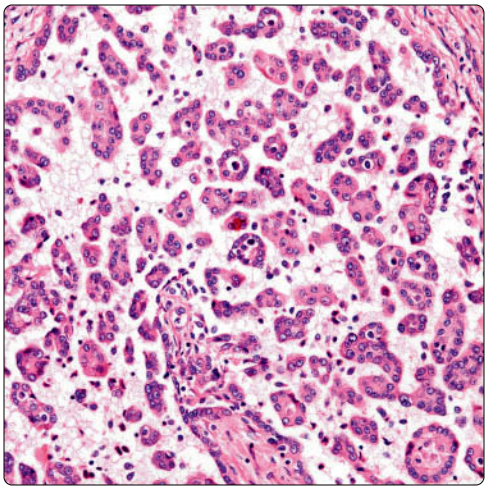

(Left) *Epithelioid malignant mesothelioma on intermediate-power view shows the presence of a papillary tumor dissecting areas of fibroconnective tissue. This histological growth pattern should raise the suspicion of malignant mesothelioma.* **(Right)** *Higher magnification shows tumor cells arranged in small papillary projections. Note the presence of a homogeneous cellular proliferation without much nuclear atypia or mitotic figures.*

Epithelioid Mesothelioma

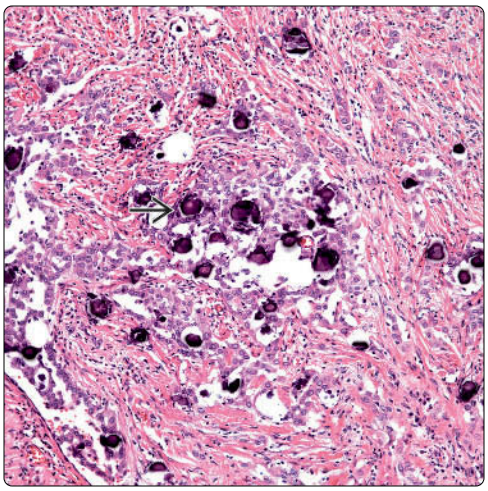

Cytokeratin 5/6

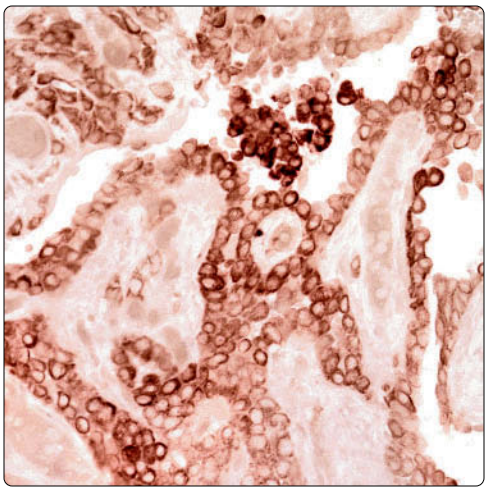

(Left) *Higher magnification shows psammoma bodies closely admixed with neoplastic cells. In the tubulopapillary growth pattern, it is common to identify psammoma bodies. However, these calcifications may be seen in calcifying fibrous pseudotumor of the pleura.* **(Right)** *Immunohistochemical study for CK5/6 shows strong positive staining in tumor cells.*

Calretinin

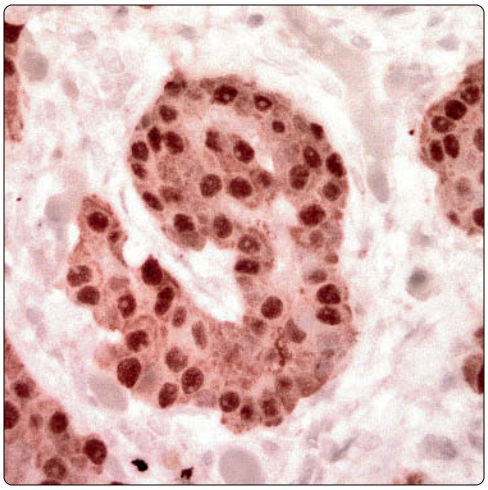

Clear Cell Mesothelioma

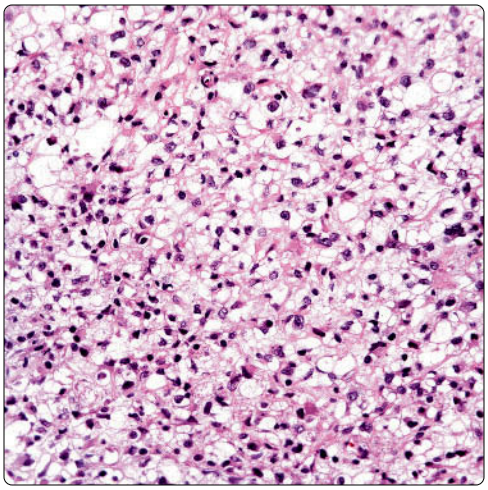

(Left) *Calretinin and cytokeratin 5/6 are commonly used in the work-up of mesothelioma, and their interpretation should be performed while taking into account the results of other carcinomatous epitopes.* **(Right)** *High magnification of a malignant mesothelioma shows prominent clear cells with round to oval nuclei and clear cytoplasm. This pattern can mimic metastatic renal cell carcinoma.*

Clear Cell Mesothelioma

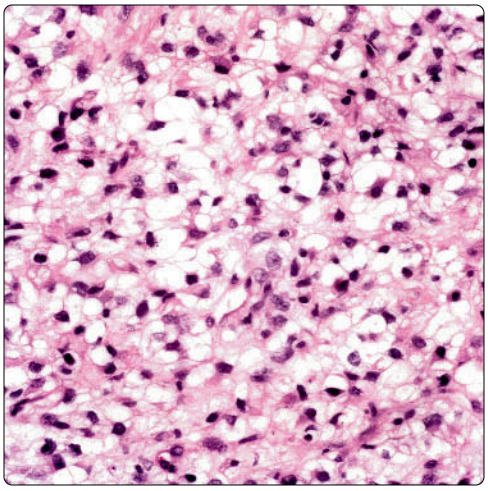

Lymphohistiocytoid Mesothelioma

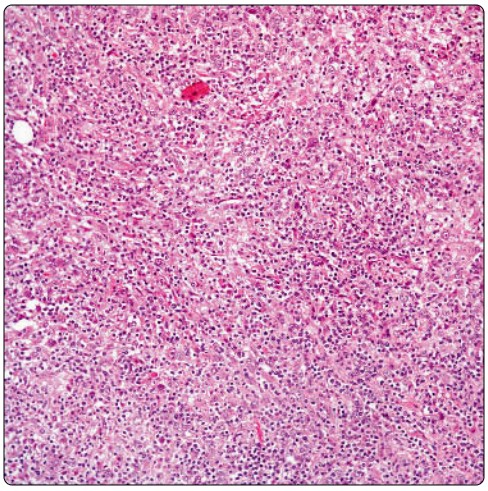

(Left) *A closer view shows malignant cells with clear cytoplasm and round nuclei. Note the absence of cellular pleomorphism and mitotic activity. Similar features may be seen in metastatic carcinomas of renal or thyroid origin.* **(Right)** *Low-power view shows a lymphohistiocytoid mesothelioma in which tumor cells are admixed with a prominent lymphoid component.*

Lymphohistiocytoid Mesothelioma

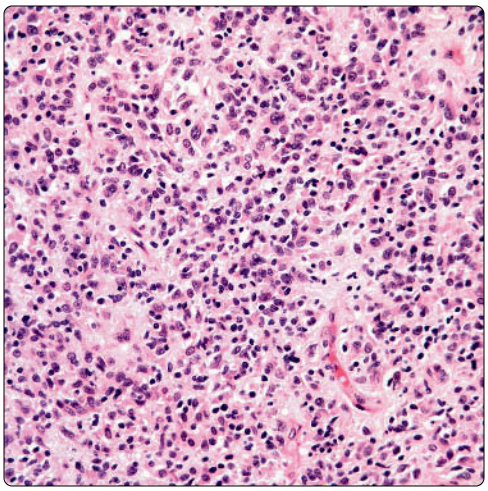

Histiocytoid Appearance

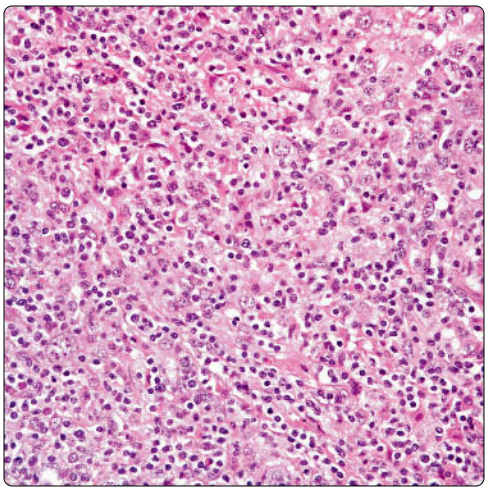

(Left) *High-power view clearly shows the presence of epithelioid cells admixed with lymphocytes, thus giving the impression of a lymphohistiocytic type of proliferation. Similar features may be seen in pleural thymomas.* **(Right)** *A different view shows a lymphohistiocytoid mesothelioma in which the tumor cells have a more histiocytoid appearance with lobulated nuclei and small nuclei. The tumor does not show marked nuclear atypia or increased mitotic activity.*

Osteocartilaginous Mesothelioma

(Left) *Intermediate magnification shows a tumor composed of spindle cells, osteoid, and cartilage. This is the so-called mesothelioma with osseous and cartilaginous differentiation.* **(Right)** *Higher magnification shows the presence of osteoid and cartilage admixed with spindle cells. This variant of mesothelioma can be easily confused with metastasis from skeletal osteosarcoma.*

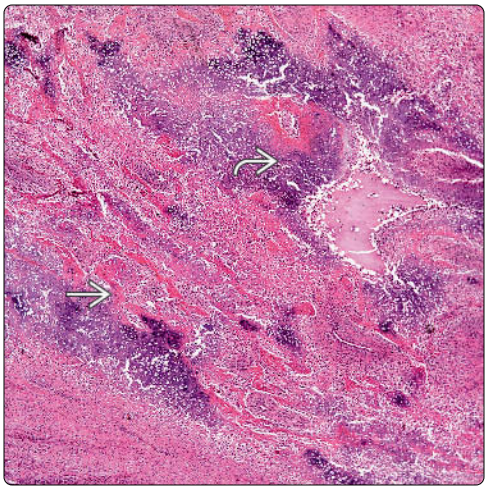

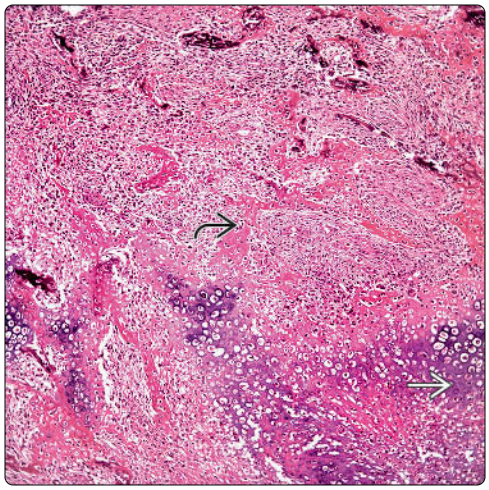

Epithelioid Transitional Mesothelioma

(Left) *Intermediate-power view of a malignant mesothelioma shows neoplastic cells with areas of necrosis. These morphologic features have also been referred to as transitional mesothelioma.* **(Right)** *High-power view shows pleomorphic cells with marked nuclear atypia and scattered mitotic figures. Although the features are of an epithelioid mesothelioma, these tumors are often difficult to classify.*

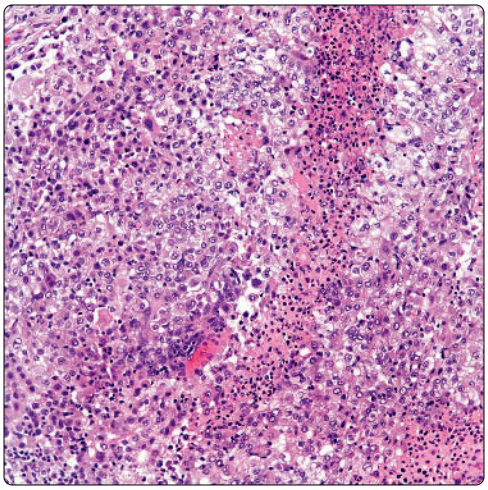

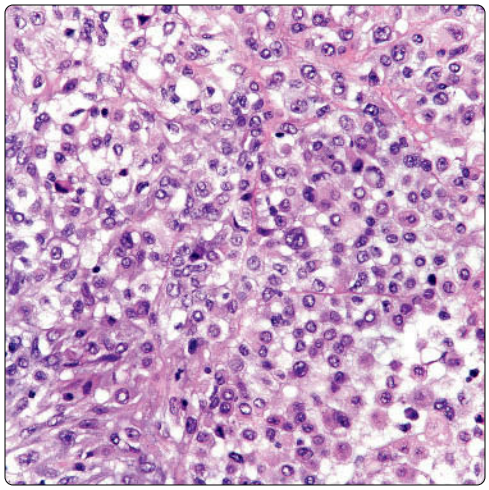

Mucinous Mesothelioma

(Left) *Intermediate-power view shows a malignant mesothelioma with prominent mucinous component and neoplastic cells floating in pools of mucin. Because of the presence of extensive areas of mucoid deposition, this tumor may be confused with adenocarcinomas.* **(Right)** *High-power view shows a mesothelioma with extensive extracellular deposition of mucoid material. Note the presence of clusters of neoplastic cells of mesothelial origin floating in the pools of mucin.*

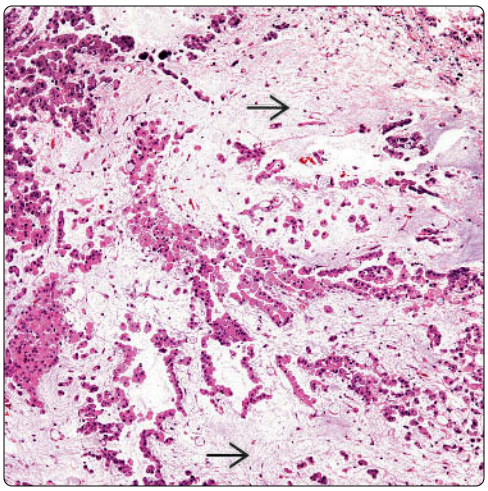

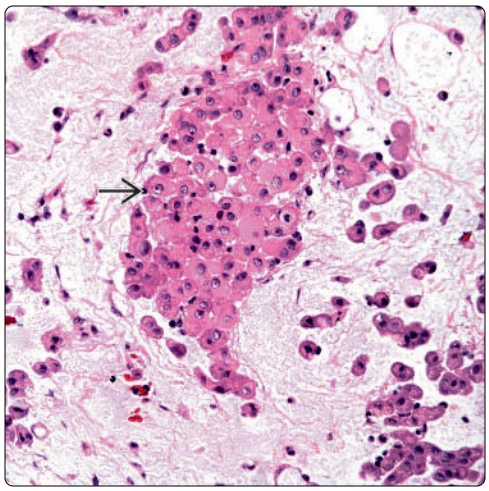

Glandular Mesothelioma

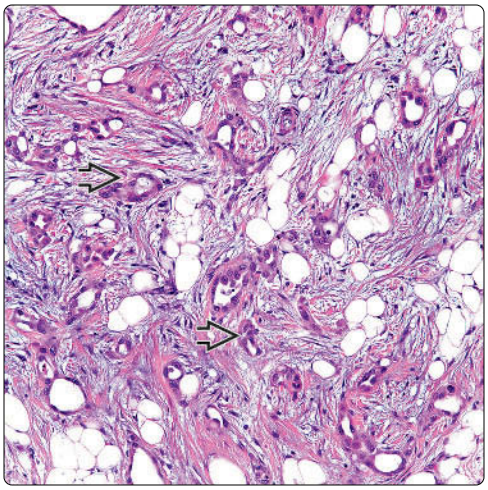

Glandular Mesothelioma

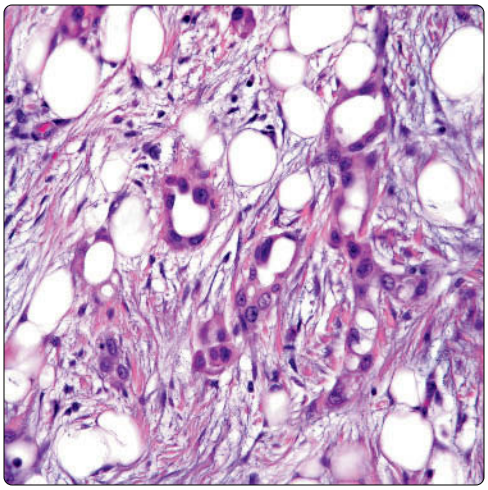

(Left) *Higher magnification shows glandular proliferation involving fibroconnective and adipose tissue in a malignant mesothelioma.* **(Right)** *Higher magnification shows malignant glands with minimal cytological atypia and virtual absence of mitotic activity. This pattern mimics an adenomatoid tumor, and care must be used in not confusing this pattern with a benign adenomatoid tumor.*

Epithelioid Mesothelioma

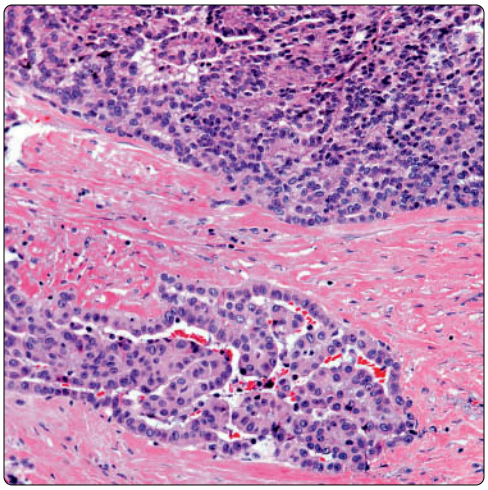

Epithelioid Mesothelioma

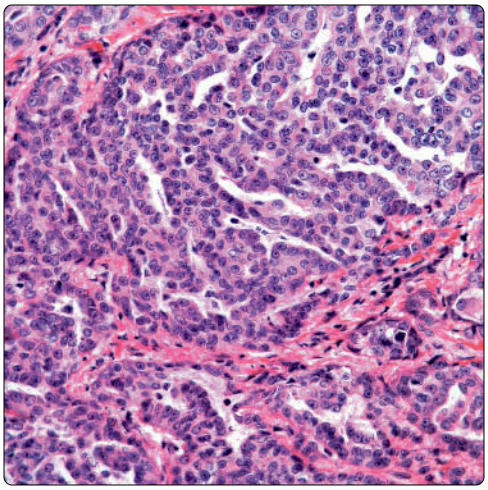

(Left) *High-power view of a malignant mesothelioma shows a homogeneous cellular proliferation with absence of mitotic activity and nuclear pleomorphism. This is one of the most common histological growth patterns of malignant mesothelioma.* **(Right)** *Low-power view shows a neoplastic cellular proliferation arranged in short papillary projections and tubules. Note the absence of marked nuclear atypia or mitotic activity.*

Mixed Mesothelioma

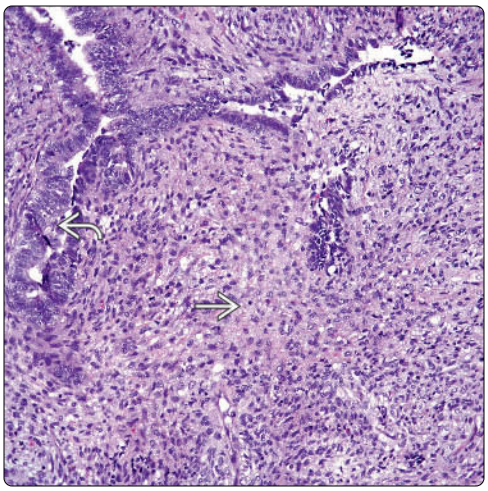

Mixed Mesothelioma

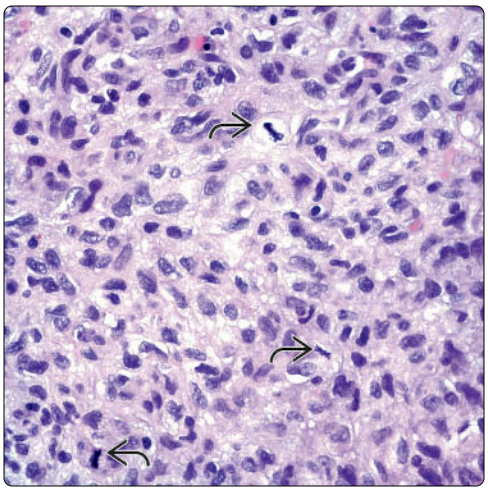

(Left) *Biphasic malignant mesothelioma shows 2 distinct components: Epithelioid and sarcomatoid. In some cases, the epithelioid component may be minimal, and the tumor may have a predominant sarcomatoid component.* **(Right)** *Closer magnification shows the sarcomatoid component in a biphasic mesothelioma. Note the presence of prominent cellular and nuclear atypia. Mitotic figures are easily identified.*

Pseudomesotheliomatous Adenocarcinoma

KEY FACTS

TERMINOLOGY

- Malignant epithelial neoplasm of lung origin growing along pleural surface

ETIOLOGY/PATHOGENESIS

- Has been linked to
  - Tobacco use
  - Asbestos exposure
  - Iron exposure
  - Stone dust exposure

CLINICAL ISSUES

- Cough
- Shortness of breath
- Chest pain
- Weight loss
- Pleural effusion

MACROSCOPIC

- Thickening of pleura
- Encasement of lung parenchyma
- Tumor growth along pulmonary septum
- Discrete peripheral intrapulmonary tumor

MICROSCOPIC

- Glandular formation
- Desmoplastic reaction
- Papillary pattern in some cases

TOP DIFFERENTIAL DIAGNOSES

- Mesothelioma, epithelioid type
  - Immunohistochemistry: Carcinomatous epitopes (+) (CEA-M, TAG72, MOC-31, CD15, TTF-1)

(Left) *In this pseudomesotheliomatous adenocarcinoma, note the presence of diffuse pleural thickening, as well as the presence of distinct intrapulmonary nodules.* **(Right)** *Pleura shows marked inflammatory reaction with presence of blood and fibrin. The pleura also shows areas of fibrosis with ectatic vessels and only nests of tumor cells.*

Macroscopic Features

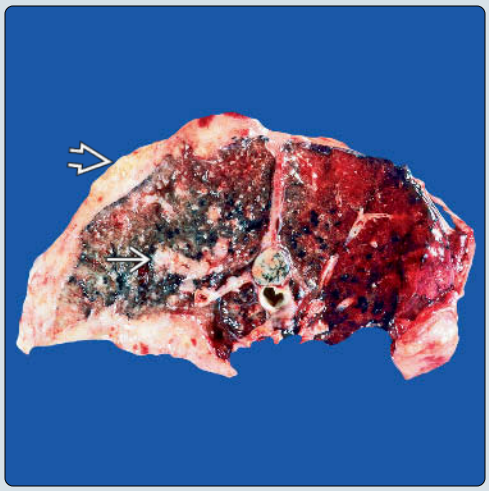

Prominent Pleuritis

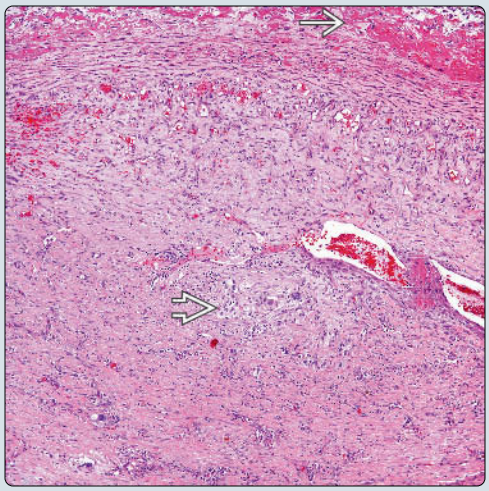

(Left) *Malignant glands are shown invading fibroconnective tissue of the pleura. Note the presence of malignant cells, some of them showing intracytoplasmic mucin.* **(Right)** *Nests of neoplastic cells are shown embedded in a fibrous stroma, which represents the fibrous pleurisy in the background of the neoplastic cells.*

Malignant Glandular Component

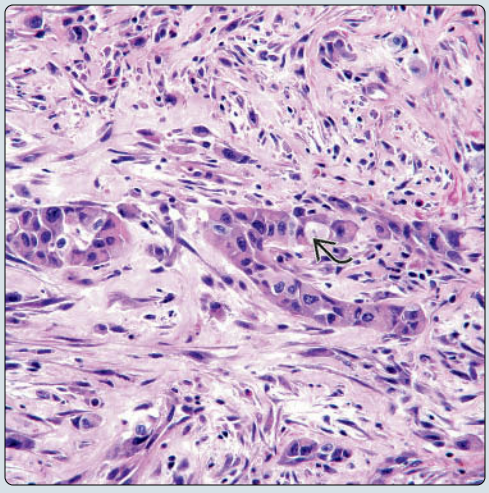

Neoplastic Cells

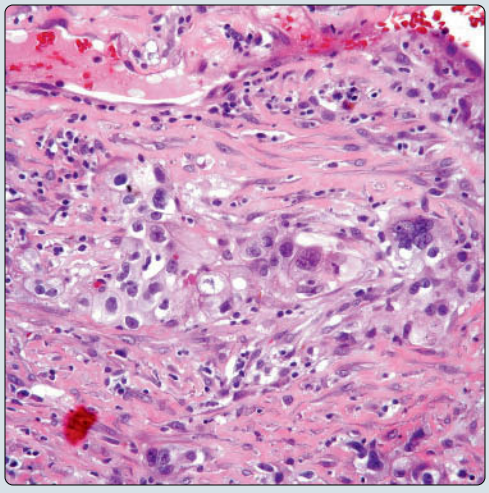

TERMINOLOGY

Definitions

- Malignant epithelial neoplasm of lung origin growing along pleural surface

ETIOLOGY/PATHOGENESIS

Environmental Exposure

- Has been linked to
  - Tobacco smoke
  - Asbestos exposure
  - Iron exposure
  - Stone dust exposure

CLINICAL ISSUES

Epidemiology

- Incidence
  - Tumor of rare occurrence
- Age
  - Majority of patients are > 50 years old
- Sex
  - May be more common in men

Presentation

- Cough
- Shortness of breath
- Chest pain
- Weight loss
- Pleural effusion

Treatment

- Surgical approaches
  - Extrapleural pneumonectomy may be considered
- Adjuvant therapy
  - Chemotherapy
  - May depend on molecular results

Prognosis

- Poor with survival of < 18 months

IMAGING

General Features

- Tumor mimics radiographic findings of mesothelioma
- Diffuse pleural thickening
- Small intrapulmonary tumor may be present

CT Findings

- Encasement of lung
- Involvement of lung parenchyma

MACROSCOPIC

General Features

- Thickening of pleura
- Encasement of lung parenchyma
- Tumor growth along pulmonary septum
- Discrete peripheral intrapulmonary tumor

MICROSCOPIC

Histologic Features

- Glandular formation
- Desmoplastic reaction
- Papillary pattern in some cases
- Cellular atypia
- Mitotic figures

Predominant Pattern/Injury Type

- Infiltrative

Predominant Cell/Compartment Type

- Epithelial

DIFFERENTIAL DIAGNOSIS

Mesothelioma, Epithelioid Type

- Both tumors may shows similar histopathological features
- Histochemical studies are important (PAS-D and mucicarmine)
- Immunohistochemistry: Carcinomatous epitopes (+) (CEA-M, TAG72, MOC-31, CD15, TTF-1)

Adenocarcinoma of Extrathoracic Origin

- In this setting, relevant clinical history is of utmost importance
- Use of different immunohistochemical panel to determine primary site should be undertaken

DIAGNOSTIC CHECKLIST

Clinically Relevant Pathologic Features

- Gross appearance

Pathologic Interpretation Pearls

- Glandular proliferation
- Glands with cellular atypia and mitotic figures
- CEA-M, TAG72, CD15, MOC-31, TTF-1 (+)

SELECTED REFERENCES

1. Dodson RF et al: Analysis of asbestos concentration in 20 cases of pseudomesotheliomatous lung cancer. Ultrastruct Pathol. 39(1):13-22, 2015
2. Kaira K et al: Pseudomesotheliomatous adenocarcinoma of the lung with synchronous gastric and esophageal cancer. Australas Radiol. 51 Suppl:B265-7, 2007
3. Pardo J et al: Pseudomesotheliomatous carcinoma of the lung with a distinct morphology, immunohistochemistry, and comparative genomic hybridization profile. Ann Diagn Pathol. 11(4):241-51, 2007
4. Kobashi Y et al: Clinicopathological analysis of lung cancer resembling malignant pleural mesothelioma. Respirology. 10(5):660-5, 2005
5. Attanoos RL et al: 'Pseudomesotheliomatous' carcinomas of the pleura: a 10-year analysis of cases from the Environmental Lung Disease Research Group, Cardiff. Histopathology. 43(5):444-52, 2003
6. Attems JH et al: Pseudomesotheliomatous adenocarcinoma of the lung with rhabdoid features. Pathol Res Pract. 197(12):841-6, 2001
7. Shah IA et al: Pseudomesotheliomatous carcinoma involving pleura and peritoneum: A clinicopathologic and immunohistochemical study of three cases. Ann Diagn Pathol. 3(3):148-59, 1999
8. Koss MN et al: Adenocarcinoma simulating mesothelioma: a clinicopathologic and immunohistochemical study of 29 cases. Ann Diagn Pathol. 2(2):93-102, 1998
9. Koss M et al: Pseudomesotheliomatous adenocarcinoma: a reappraisal. Semin Diagn Pathol. 9(2):117-23, 1992
10. Harwood TR et al: Pseudomesotheliomatous carcinoma of the lung. A variant of peripheral lung cancer. Am J Clin Pathol. 65(2):159-67, 1976

Immunohistochemistry

Antibody	Reactivity	Staining Pattern	Comment
CEA-M	Positive	Cytoplasmic	
CD15	Positive	Cytoplasmic	
MOC-31	Positive	Cytoplasmic	
EpCAM/BER-EP4/CD326	Positive	Cell membrane & cytoplasm	May be positive in ~ 25% of mesotheliomas
EMA	Positive	Cell membrane	
TTF-1	Positive	Nuclear	If of lung origin
NAPSIN-A	Positive	Cytoplasmic	
Surfactant-A	Positive	Cytoplasmic	
CK-PAN	Positive	Cytoplasmic	
CK7	Positive	Cytoplasmic	
CK-LMW-NOS			
CK20	Negative		
CDX-2	Negative		
TAG72	Positive	Cell membrane & cytoplasm	
Calretinin	Negative		May be positive in some carcinomas
CK5/6	Negative		
p63	Negative		
D2-40	Negative		
WT1	Negative		May show positive staining in some cases
p40	Negative		
Desmocollin-3	Negative		
pax-8	Negative		

Histochemical Features

Stain	Result
PAS	May show positive staining for intracellular glycogen
PAS-D	Positive for intracellular mucin
Mucicarmine	Positive for intracellular mucin
Iron	Positive in cases of asbestos exposure

Molecular Features

FISH	Result
EGFR	May be positive
KRAS	May be positive
ROS1	May be positive
ALK	May be positive
BRAF	May be positive
PIK3CA	May be positive

Clear Cells

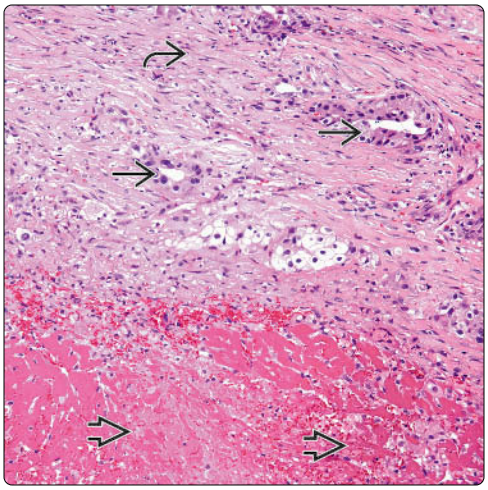

Cords of Neoplastic Cells

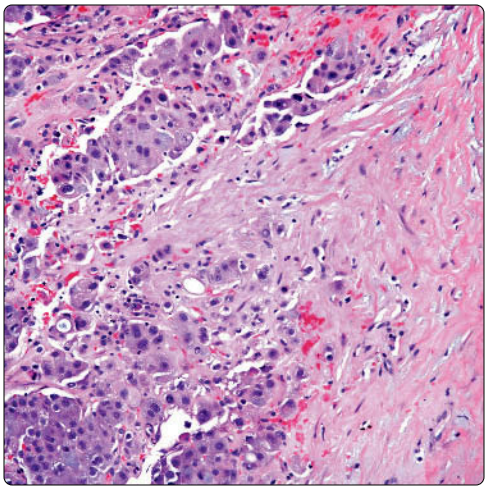

(Left) *This case of pseudomesotheliomatous adenocarcinoma of the lung shows areas of fibrinous pleuritis. Adjacent fibrocollagen is infiltrated by neoplastic cells forming small glands. Note the fibrocollagenous stroma with mild inflammatory infiltrate.* **(Right)** *Neoplastic cellular proliferation arranged in cords is shown invading fibroconnective tissue of the pleura. This pattern may be seen in some cases of mesothelioma.*

Small Glandular Proliferation

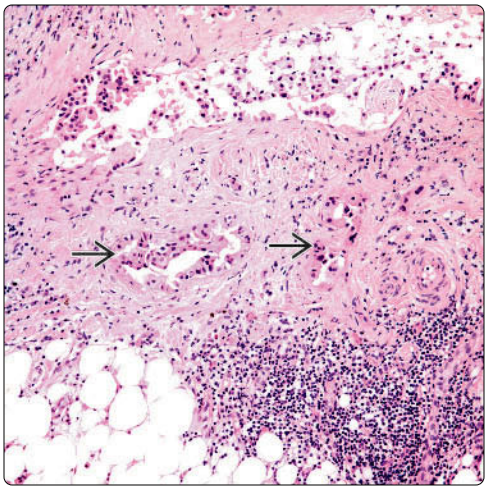

Solid Growth Pattern

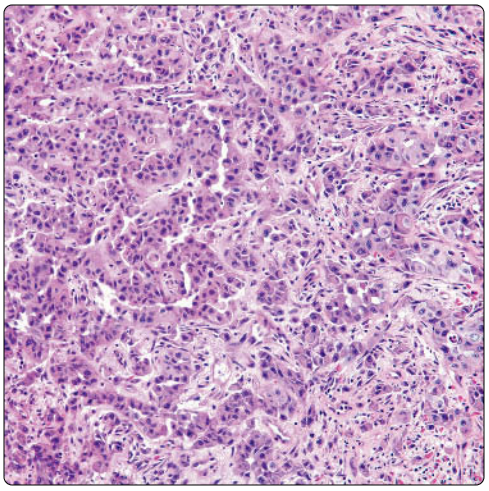

(Left) *Pleural tissue with adipose tissue is invaded by a glandular proliferation. This feature may also be seen in cases of mesothelioma, thus the need for immunohistochemical stains.* **(Right)** *Solid neoplastic cellular proliferation is composed of medium-sized cells with ample eosinophilic cytoplasm. The growth pattern closely mimics mesothelioma.*

Neoplastic Cells Admixed With Fibrin

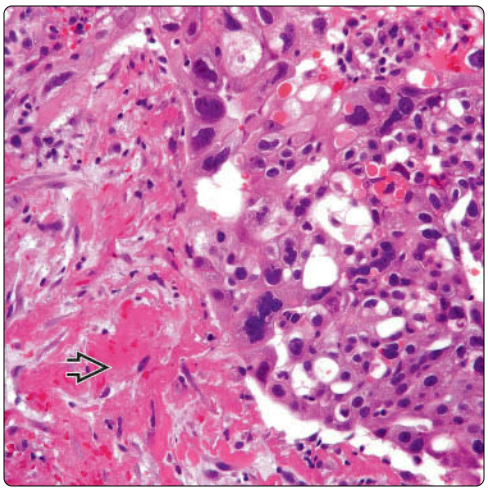

Marked Cellular Pleomorphism

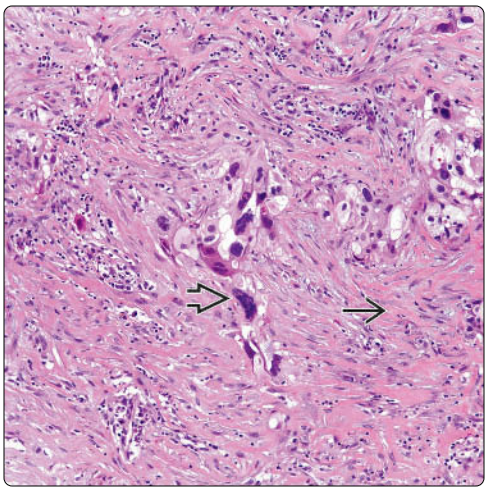

(Left) *A more pleomorphic malignant component admixed with areas of fibrinoid pleuritis is shown. This feature is more common in adenocarcinomas than in mesotheliomas.* **(Right)** *Clusters of malignant cells are shown embedded in a fibrous stroma, giving the appearance of a biphasic mesothelioma. It is important to keep this feature in mind to avoid an incorrect diagnosis.*

Reactive Atypia

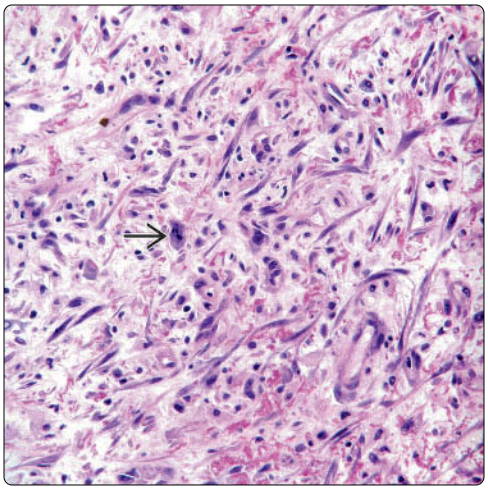

Giant Cells

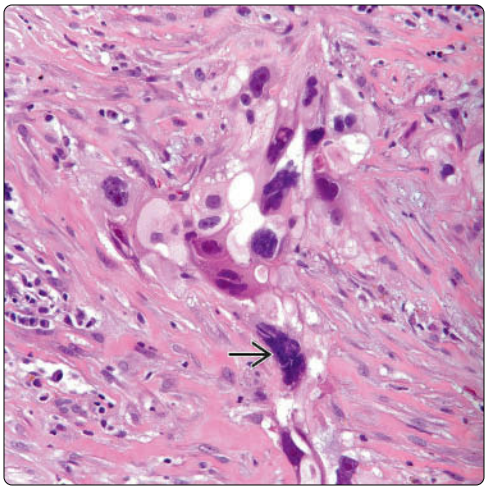

(Left) *Prominent reactive changes are shown in the pleura mixed with neoplastic cells, some of them with atypical mitotic figures ⇨. This pattern could be misinterpreted as biphasic cellular proliferation and diagnosed as mesothelioma.* **(Right)** *Pseudomesotheliomatous adenocarcinoma shows prominent cellular atypia, namely cells with prominent nucleoli and multinucleated malignant cells ⇨. These features are unusual for mesotheliomas.*

Vacuolated Neoplastic Cells

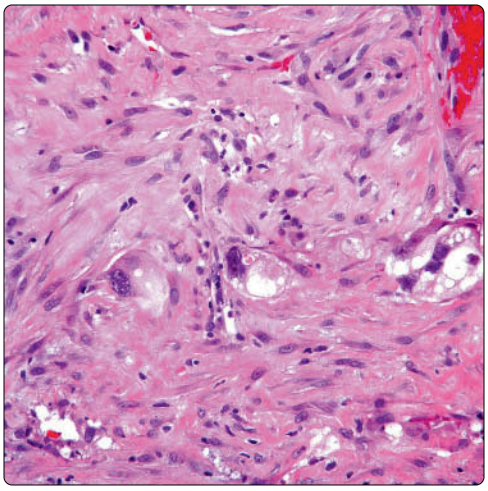

Glandular Proliferation

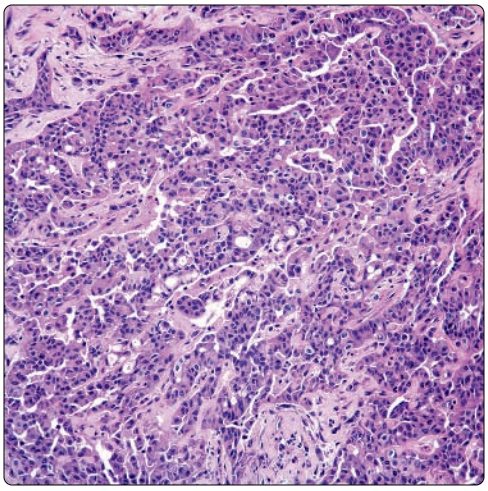

(Left) *In cases of limited tissue for analysis, the presence of single malignant cells embedded in a fibrous stroma would prompt the use of immunohistochemical stains.* **(Right)** *More conventional features of adenocarcinoma are shown. The tumor is showing cords and glandular formation.*

Cluster of Neoplastic Cells

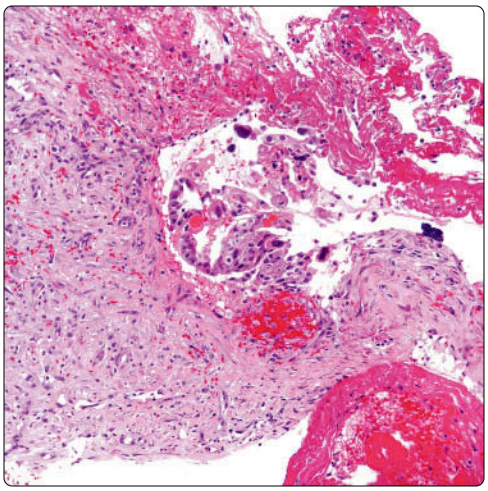

Pleural Surface

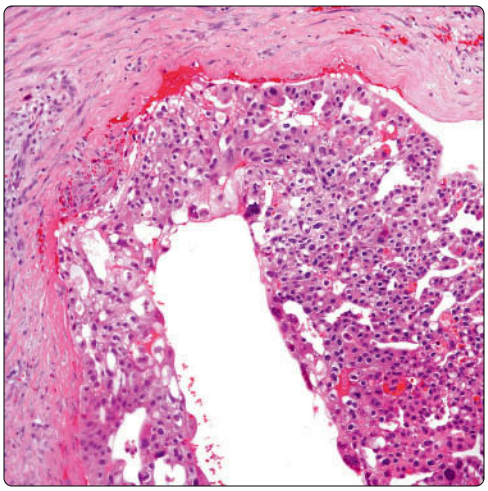

(Left) *Pseudomesotheliomatous adenocarcinoma shows only a cluster of neoplastic cells. Note the presence of extensive areas of fibrinous and fibrous pleurisy.* **(Right)** *Pseudomesotheliomatous adenocarcinoma shows the neoplastic cellular proliferation growing along the pleural surface in a manner similar to mesothelioma.*

Fibrous Pleurisy

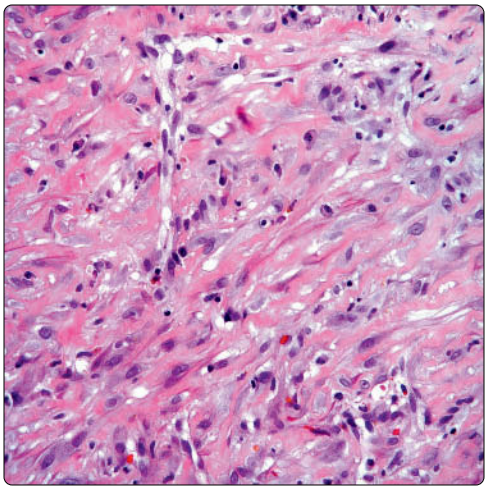

Malignant Glands

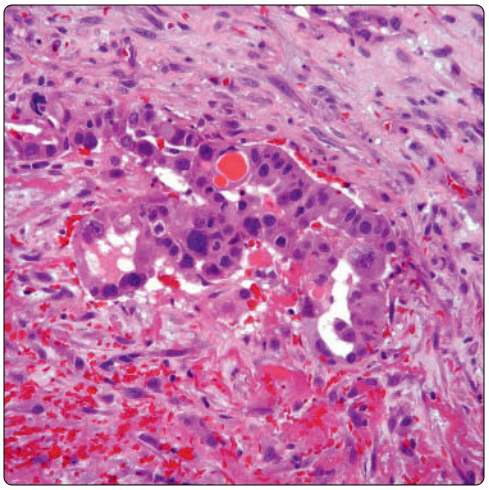

(Left) *Extensive areas of fibrous pleurisy may be seen in cases of pseudomesotheliomatous adenocarcinoma. Care must be exercised not to misconstrue this fibrous pleuritis for a biphasic mesothelioma.* **(Right)** *Unequivocal presence of malignant glandular component is shown embedded in a fibrous stroma containing also blood, fibroblasts, and fibrin.*

Intracellular Mucin

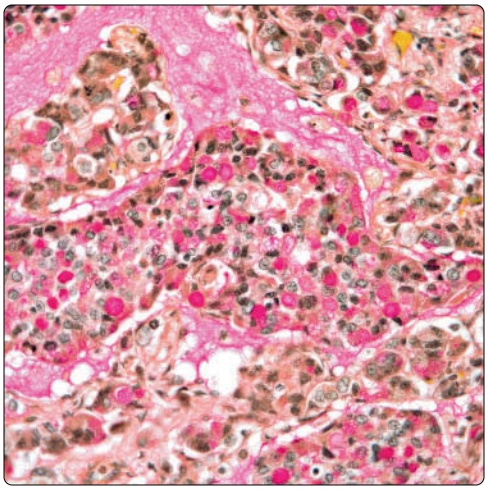

TTF-1 Positivity

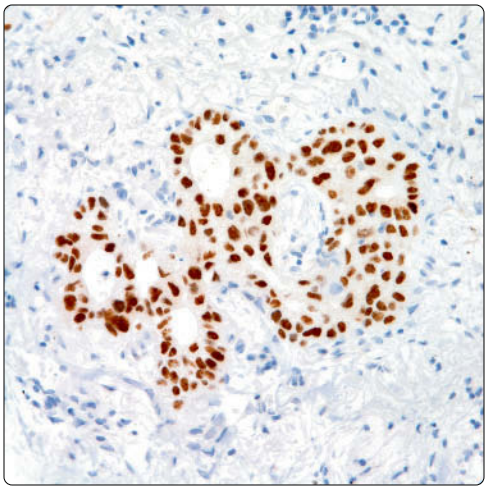

(Left) *The presence of intracellular mucin is one important feature in favor of the diagnosis of adenocarcinoma, as illustrated in this case.* **(Right)** *Positive nuclear staining for TTF-1 is strong evidence in favor of adenocarcinoma of lung origin.*

TAG72 Positivity

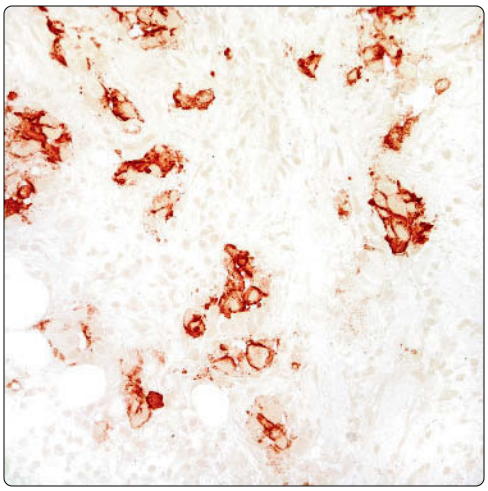

CD15 Positivity

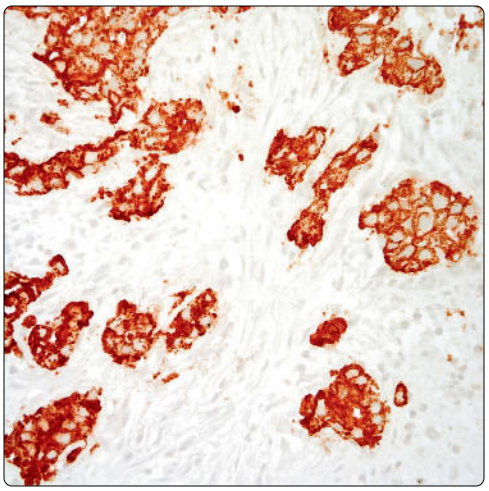

(Left) *Immunohistochemical stain for TAG72 shows positive staining in tumor cells. Positive staining for this antibody is considered diagnostic of adenocarcinoma.* **(Right)** *Immunohistochemical stain for CD15 (LeuM1) in this setting is in keeping with the diagnosis of adenocarcinoma.*

Mucoepidermoid Carcinoma of Pleura

KEY FACTS

TERMINOLOGY

- Mucoepidermoid carcinoma (MEC)

CLINICAL ISSUES

- Symptoms
  - Chest pain
  - Shortness of breath
  - Cough
  - Dyspnea

IMAGING

- Pleural-based mass
- Diffuse involvement of pleura has not been recorded for these tumors

MICROSCOPIC

- Epidermoid component without keratinization
- Mucus-secreting cells admixed with epidermoid component
- Mild cellular atypia
- Low mitotic activity
- Possible sclerotic stroma

TOP DIFFERENTIAL DIAGNOSES

- Adenocarcinoma
  - MEC lacks presence of malignant glandular component
- Squamous cell carcinoma
  - Presence of keratinization unusual in MEC
  - Mucus-producing cells (mucocytes) admixed with epidermoid component in MEC
- Synovial sarcoma
  - Spindle cell component in synovial sarcoma is malignant
  - Sclerotic component in MEC is fibroblastic benign

Adipose Tissue Invasion

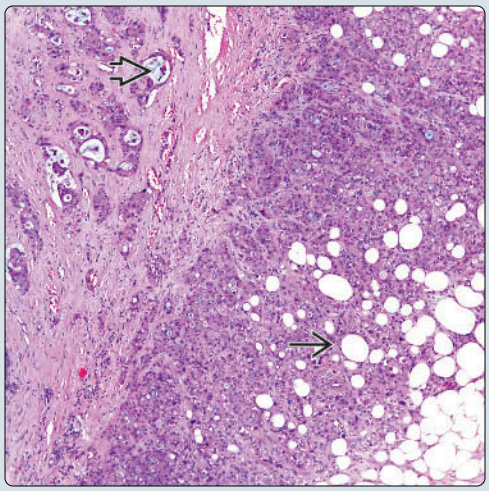

Mucus-Secreting Cells

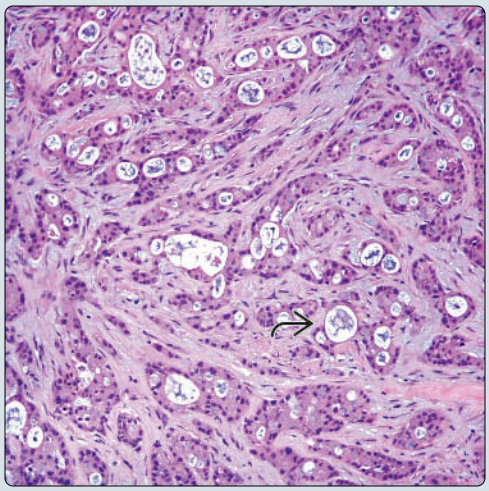

(Left) *Pleural mucoepidermoid carcinoma (MEC) shows invasion of the tumor into the adipose tissue. Similar features may also be seen in mesotheliomas. However, note the presence of cystic structures containing mucin.* **(Right)** *MEC of the pleura shows more conventional areas of the epidermoid component with the presence of mucinous cells. Even at this power, one can see the oncocytic features present in this tumor.*

Intraluminal Mucus Secretion

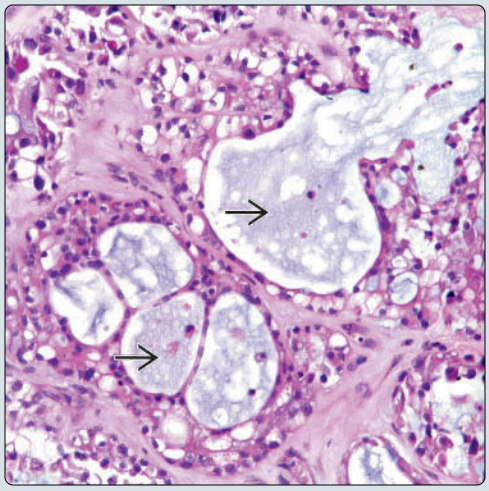

Pseudoglandular Formation

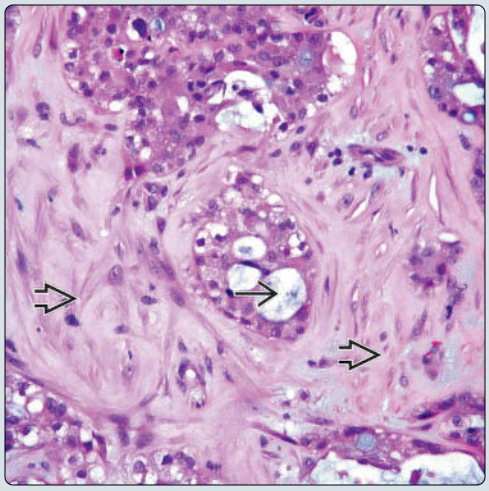

(Left) *MEC shows gland-like structures of different sizes with mucoid material. The neoplastic cellular proliferation is rather homogeneous.* **(Right)** *Closer view shows the neoplastic cells arranged in a pseudoglandular pattern with intraluminal mucin. Note the desmoplastic reaction around the tumor cells.*

TERMINOLOGY

Abbreviations

- Pleural mucoepidermoid carcinoma (MEC)

Definitions

- Primary salivary gland-type tumor of pleura

ETIOLOGY/PATHOGENESIS

Etiology

- Although etiology of this tumor in pleura is unknown, it is possible that it may arise from entrapped glands in pleura

CLINICAL ISSUES

Epidemiology

- Incidence
  - Exceedingly rare tumor in pleura
- Age
  - Has been described only in adults
- Sex
  - No predilection

Presentation

- Chest pain
- Shortness of breath

Treatment

- Surgical approaches
  - Complete resection of tumor
    - Lobectomy
    - Decortication
    - Simple resection of pleural tumor
- Adjuvant therapy
  - Possible chemotherapy

Prognosis

- May be good depending on histological grade of tumor
- Difficult to assess due to few cases reported

IMAGING

General Features

- Pleural-based mass
- Diffuse involvement of pleura has not been recorded for these tumors

MACROSCOPIC

General Features

- Tumor mass well circumscribed and attached to pleura

Size

- May vary from 2 cm to > 5 cm

MICROSCOPIC

Histologic Features

- Epidermoid component without keratinization
- Mucus-secreting cells admixed with epidermoid component
- Mild cellular atypia
- Low mitotic activity
- Possible sclerotic stroma

Predominant Pattern/Injury Type

- Squamoid

Predominant Cell/Compartment Type

- Epithelial, squamous

DIFFERENTIAL DIAGNOSIS

Adenocarcinoma

- Peripheral adenocarcinoma shows presence of intrapulmonary mass
- Shows presence of neoplastic glandular proliferation
- Does not show presence of intermediate cells

Squamous Cell Carcinoma

- Presence of keratinization is unusual and favors squamous cell carcinoma over MEC
- Mucus-producing cells (mucocytes) admixed with epidermoid component in MEC

Synovial Sarcoma

- Spindle cell component in synovial sarcoma is malignant
- Sclerotic component in MEC is fibroblastic benign

Mesothelioma

- Keratin 5/6 may be positive in both tumors
- Mesothelioma will not show presence of mucus-producing cells
- Spindle cell component in mesothelioma is positive for keratin
- Mesothelioma will present in vast majority of cases with diffuse pleural thickening

Metastatic Mucoepidermoid Carcinoma

- Clinical history of previous head and neck MEC is of utmost importance

DIAGNOSTIC CHECKLIST

Clinically Relevant Pathologic Features

- Gross appearance

Pathologic Interpretation Pearls

- Epidermoid component without keratinization
- Mucus-secreting cells (mucocytes) admixed with epidermoid component
- Focal oncocytic features may be seen
- In sclerosing variant, spindle cell stroma is benign

SELECTED REFERENCES

1. Falk N et al: Primary pulmonary salivary gland-type tumors: a review and update. Adv Anat Pathol. 23(1):13-23, 2016
2. Yamamoto T et al: Surgical treatment of mucoepidermoid carcinoma of the lung: 20 years' experience. Asian Cardiovasc Thorac Ann. 24(3):257-61, 2016
3. Huo Z et al: Primary pulmonary mucoepidermoid carcinoma: histopathological and molecular genetic studies of 26 cases. PLoS One. 10(11):e0143169, 2015
4. Komiya T et al: Primary lung mucoepidermoid carcinoma: analysis of prognostic factors using Surveillance, Epidemiology, and End Results Program (SEER). Clin Respir J. ePub, 2015
5. Moran CA et al: Primary mucoepidermoid carcinoma of the pleura. A clinicopathologic study of two cases. Am J Clin Pathol. 120(3):381-5, 2003

Immunohistochemistry

Antibody	Reactivity	Staining Pattern	Comment
CK-PAN	Positive	Cytoplasmic	Also positive in other carcinomas
CK8/18/CAM5.2	Positive	Cytoplasmic	
CK8/18/CAM5.2			
p63	Positive	Nuclear	Also positive in squamous cell carcinomas
p40	Positive	Nuclear	
Desmocollin-3	Negative		May be positive in some cases
EMA	Positive	Cell membrane	Also positive in other carcinomas
CK5/6	Positive	Cytoplasmic	Also positive in mesotheliomas and squamous cell carcinomas
CEA-M	Positive	Cytoplasmic	
Vimentin	Positive	Cytoplasmic	In spindle cell component of sclerotic areas
Androgen receptor	Positive	Nuclear	In some cases
CD15	Positive	Cytoplasmic	In epidermoid component
D2-40	Negative		
TTF-1	Negative		
NAPSIN-A	Negative		
Surfactant-A	Negative		
S100	Negative		
Actin-HHF-35	Negative		
Desmin	Negative		
pax-8	Negative		
WT1	Negative		
Bcl-2	Negative		
CD34	Negative		

Histochemical Features

Stain	Result
PAS	Positive in some cell for glycogen content
PAS-D	Positive for intracellular mucin in mucinophages
Mucicarmine	Positive for intracellular mucin in mucinophages

Molecular Features

FISH	Result
MAML2 on chromosome 11q21	40-75% of cases
t(11;19)(21;p13) involving CREB-regulated transcription coactivator on chromosome 19p13	

Gland-Like Areas

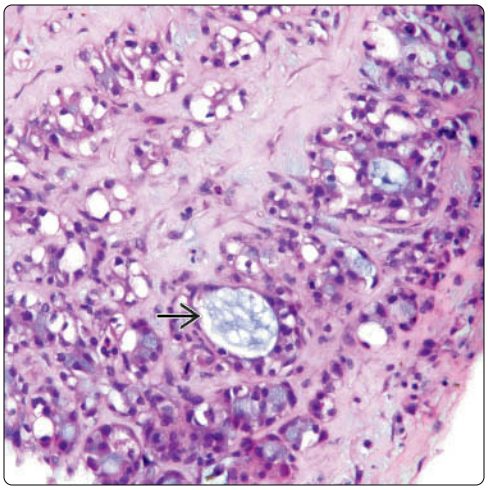

Cords of Neoplastic Cells

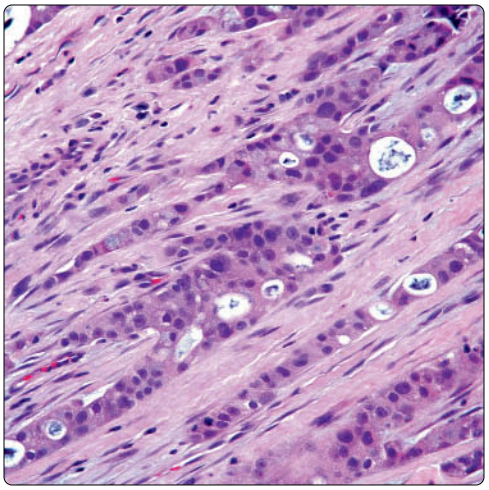

(Left) *MEC with a more nested pattern and 1 obvious dilated, gland-like structure. The cellular proliferation has rather oncocytic and clear cell features. This growth pattern is unusual for conventional mesotheliomas or adenocarcinomas.* **(Right)** *In some areas, the pattern of growth is that of cords of neoplastic cells embedded in a collagenous stroma. The tumor does not show evidence of increased mitotic activity or necrosis.*

Cystic Changes

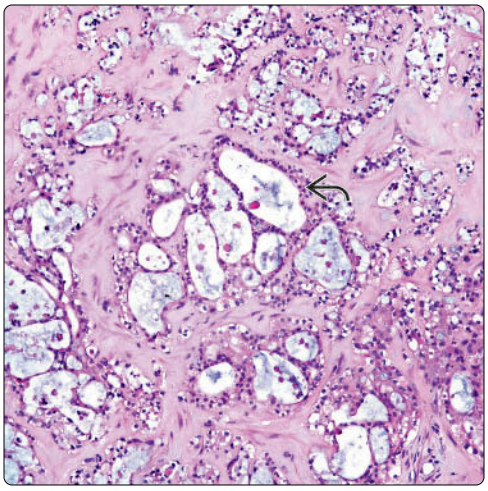

Clear Cells

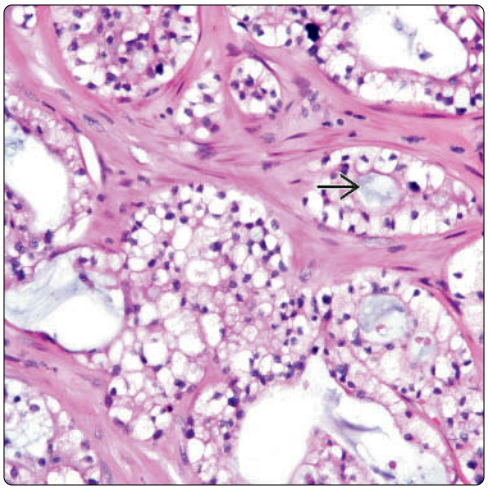

(Left) *In some areas, the neoplastic cells are seen in association with cystic areas, which contain flattened epithelium.* **(Right)** *Pleural MEC with prominent clear cell features is shown. This feature may be only focal in these tumors. Note the presence of intraluminal mucin.*

Tumor Invasion

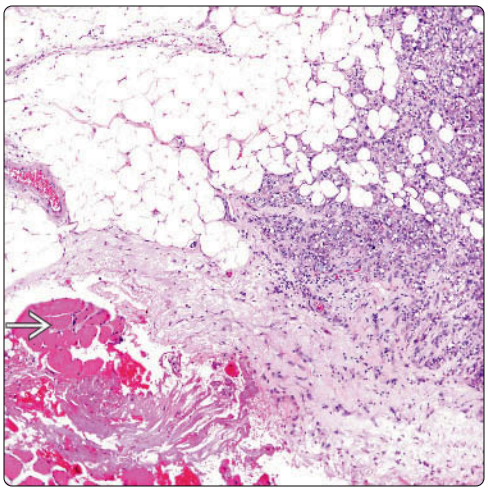

Adipose Tissue Invasion

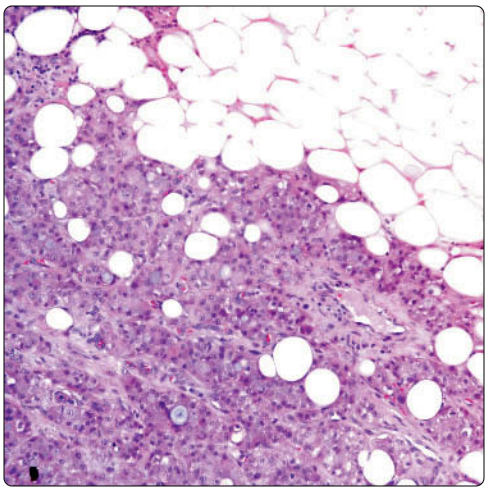

(Left) *MEC of the pleura invading into adipose tissue is shown. Note the presence of skeletal muscle near the adipose tissue. The presence of invasion in these structures is unequivocal evidence of aggressiveness.* **(Right)** *Higher magnification of pleural MEC shows unequivocal evidence of tumor invasion into adipose tissue. Note the presence of areas of tumor cells with mucous secretion.*

Sclerotic Areas

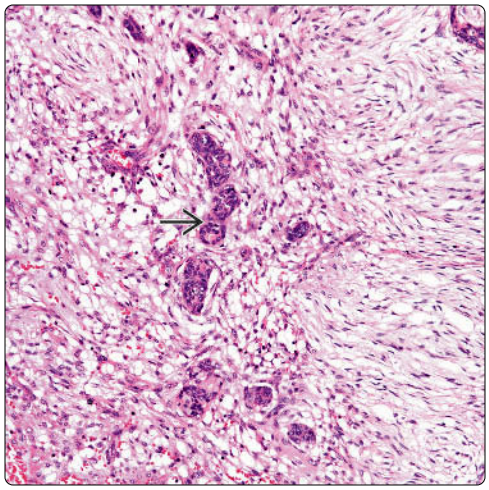

Nonneoplastic Sclerotic Areas

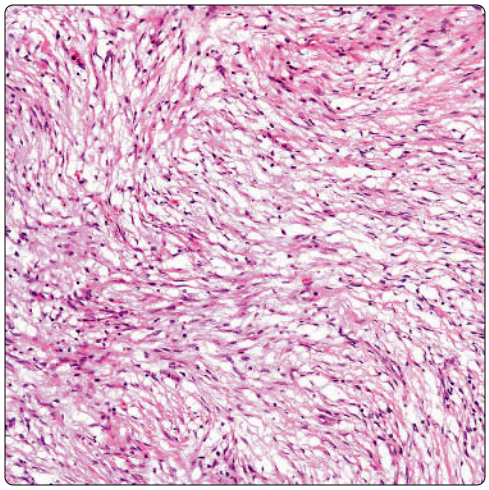

(Left) *Sclerosing MEC with extensive areas of spindle fibroblastic proliferation is shown. In some areas, the presence of an epidermoid component may be only minimal.* **(Right)** *Closer view of the sclerosing areas shows fibroconnective tissue with fibroblastic proliferation. Note the absence of cellular atypia or mitotic activity.*

Presence of Mucus-Secreting Cells

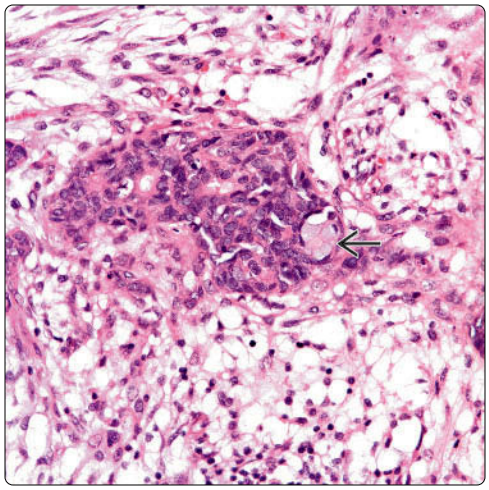

Epidermoid Cells and Mucocytes

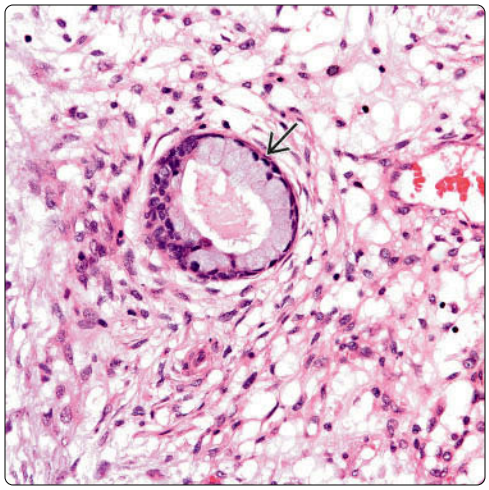

(Left) *Closer view of the epithelial component of a sclerosing variant of MEC shows the neoplastic cells with vague epidermoid features and only focal mucus-producing cells.* **(Right)** *Different view of the epithelial component of a sclerosing variant of MEC shows a classic area of epidermoid cells and mucus-producing cells embedded in a collagenous stroma. The use of histochemical stain for mucin, such as mucicarmine, shows positive staining in these areas.*

Nonkeratinizing Tumor

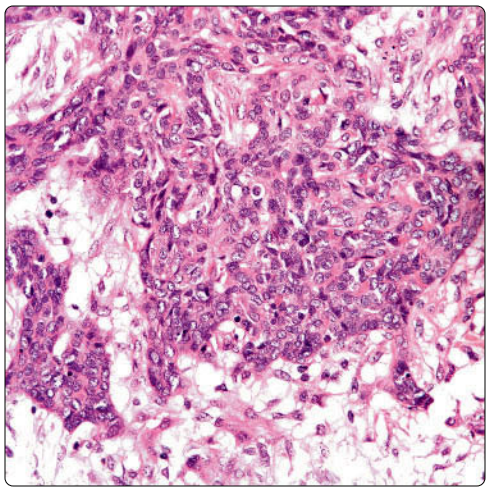

Metaplastic Bone

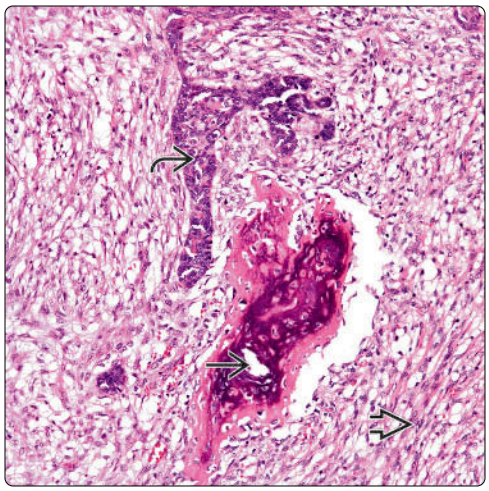

(Left) *Closer view at the epithelial component of a MEC sclerosing variant shows the epidermoid component with mild to moderate nuclear atypia and scattered mitotic figures. These features may also be seen in cases of metastatic squamous cell carcinomas to the pleura.* **(Right)** *Sclerosing MEC shows the classic sclerosed areas with islands of epidermoid carcinoma and metaplastic bone formation.*

Strands of Tumor Cells

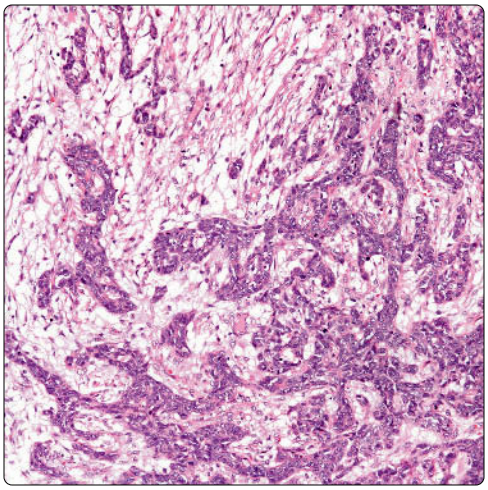

Immunostain for Keratin 5/6

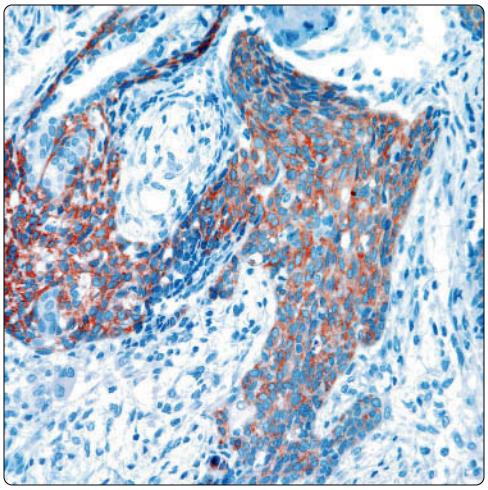

(Left) *Pleural MEC shows strands of malignant cells arranged in a haphazard manner admixed embedded in a fibrous stroma rich in fibroblasts, giving the appearance of a biphasic tumor.* **(Right)** *Keratin 5/6 shows strong positive reaction in the tumor cells of the nonkeratinizing component of a pleural MEC.*

Pleural Tumor

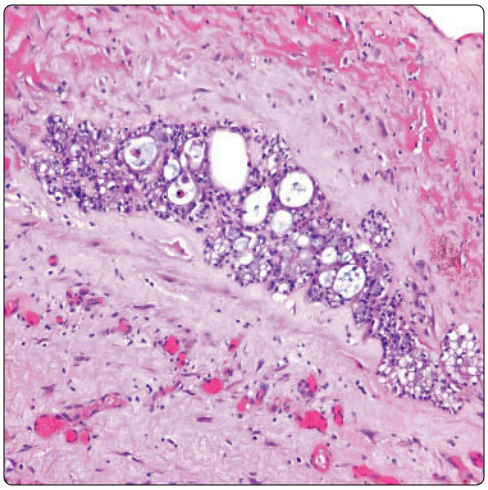

Fibrinous Pleuritis

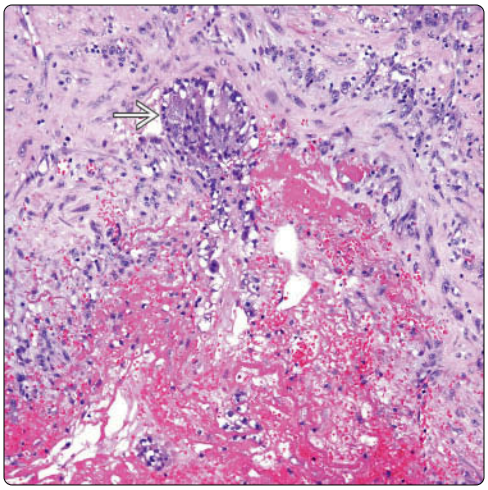

(Left) *Low-power view of a pleural MEC in which only a small focus of tumor is present and embedded in a fibrous pleura is shown. Note the surface of the pleura shows some inflammatory changes.* **(Right)** *Pleural MEC in which the pleura shows extensive areas of fibrinous pleuritis is shown. Note the small focus of MEC ⇒. These features may obscure the true nature of this process.*

Cords of Neoplastic Cells

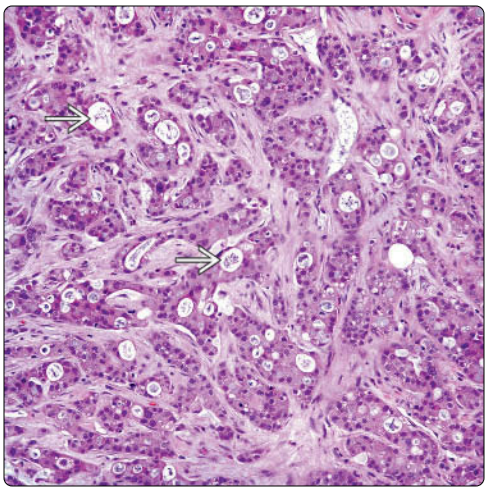

Epidermoid and Mucus-Secreting Cells

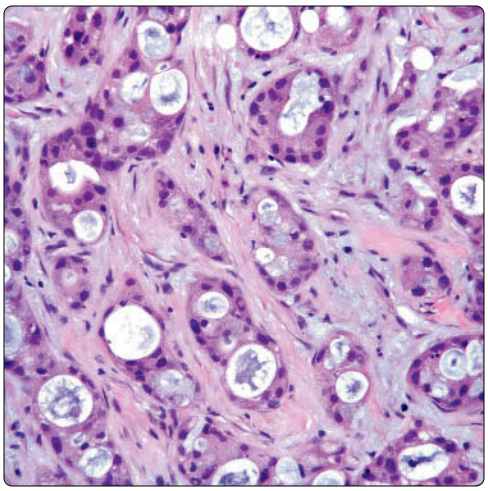

(Left) *Pleural MEC arranged in cords of neoplastic cells with prominent oncocytic changes is shown. Also note the presence of intraluminal mucin ⇒.* **(Right)** *Higher magnification of a pleural MEC in which the tumor shows mild nuclear atypia, mucus-secreting cells, and intraluminal mucin is shown. Note the absence of marked nuclear atypia and mitotic activity.*

Angiosarcoma

KEY FACTS

CLINICAL ISSUES

- Chest pain, dyspnea, and recurrent hemorrhagic pleural effusion
- Age range: 22-79 years (average: 57 years)

MACROSCOPIC

- Diffuse, plaque-like growth encasing pleura
- Abundant hemorrhage and necrosis
- Infiltration of adjacent structures

MICROSCOPIC

- Solid atypical epithelioid or spindle cell proliferation
- Anastomosing vessel-like channels lined by atypical cells
- Extensive hemorrhage and necrosis
- Enlarged nuclei with dense chromatin pattern
- Prominent nucleoli
- Frequent mitoses, including atypical (abnormal) mitoses
- Cells may be predominantly epithelioid (epithelioid variant of angiosarcoma) and resemble epithelial neoplasm
- Conventional type is composed of spindle and pleomorphic tumor cells resembling spindle cell sarcoma
- CD31, FLI-1, ERG, and CD34 positive in tumor cells
- Cytokeratin may be positive in cells of epithelioid variant
- Tumor cells are negative for most conventional mesothelioma markers

DIAGNOSTIC CHECKLIST

- May simulate malignant mesothelioma radiologically and histologically
- Characterized by recurrent hemorrhagic pleural effusion
- Prognosis is similar to that of malignant mesothelioma
- Not associated with asbestos exposure
- Look for extensive areas of hemorrhage and necrosis
- Look for anastomosing vessel-like channels lined by atypical endothelial cells
- CD31, FLI-1, or ERG positivity in tumor cells is diagnostic
- Think of this possibility when other tumor markers are equivocal or incomplete for malignant mesothelioma

Pleural Angiosarcoma, Low Power

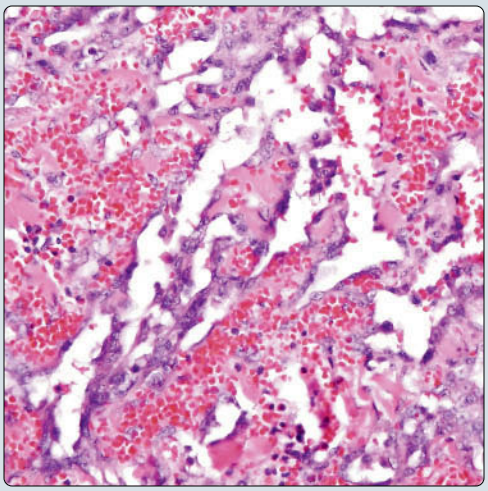

Pleural Angiosarcoma, High Power

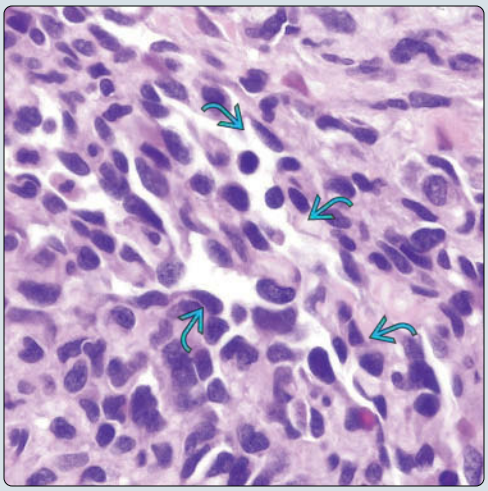

(Left) *Low power of a pleural angiosarcoma shows anastomosing vascular channels lined by plump, atypical endothelial cells and containing scattered red blood cells in their lumina. The intervening stroma is highly hemorrhagic.* **(Right)** *Higher magnification from a more cellular area in pleural angiosarcoma shows primitive vascular channels lined by atypical endothelial cells and surrounded by a very cellular stroma.*

Cellular Detail in Pleural Angiosarcoma

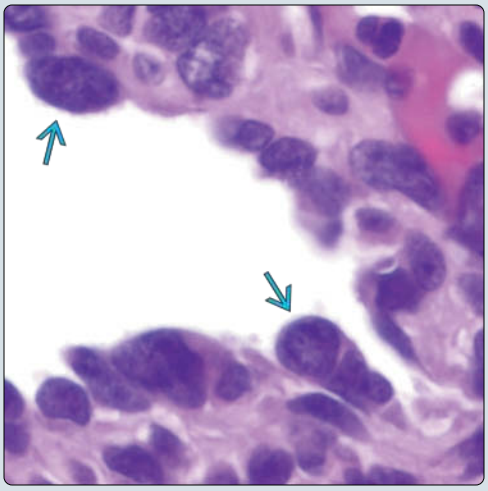

ERG Immunostaining

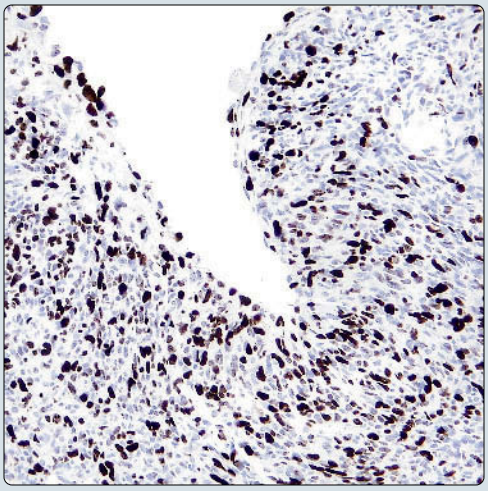

(Left) *Higher magnification shows the cellular detail in pleural angiosarcoma. Vascular channels are lined by large, hyperchromatic endothelial cells with enlarged, atypical nuclei and occasional nucleoli. Some of the cells bulge from the surface resembling hobnails.* **(Right)** *An immunohistochemical stain for the vascular endothelial-associated antigen, ERG, shows strong nuclear positivity in the cells lining the lumen of a vessel as well as the proliferating cells in the surrounding stroma.*

TERMINOLOGY

Abbreviations

- Angiosarcoma (AS)

Definitions

- Malignant pleural neoplasm showing evidence of vascular endothelial differentiation

ETIOLOGY/PATHOGENESIS

Unknown

- No association with occupational exposure to asbestos

CLINICAL ISSUES

Presentation

- Chest pain, dyspnea, and recurrent hemorrhagic pleural effusion
- Age range: 22-79 years (average: 57 years)

Treatment

- Surgical excision, radiation therapy, chemotherapy

Prognosis

- Highly aggressive tumor with poor prognosis
- Median survival: ~ 12 months

MACROSCOPIC

General Features

- Diffuse, plaque-like thickening encasing pleura
- Abundant hemorrhage and necrosis
- Infiltration of adjacent structures

MICROSCOPIC

Histologic Features

- Solid atypical epithelioid or spindle cell proliferation
- Anastomosing vessel-like channels lined by atypical cells
- Extensive hemorrhage and necrosis
- Infiltration of adjacent structures

Cytologic Features

- Enlarged nuclei with dense chromatin pattern and prominent nucleoli
- Frequent mitoses, including atypical (abnormal) mitoses
- Cells may be predominantly epithelioid (epithelioid variant of AS) and resemble epithelial neoplasm
- Conventional type is composed of spindle and pleomorphic tumor cells resembling spindle cell sarcoma

ANCILLARY TESTS

Immunohistochemistry

- CD31, CD34, FLI-1, ERG, and FVIIIRAg positive in tumor cells
- Cytokeratin may be positive in tumor cells of epithelioid variant of AS
- Tumor cells are negative for most conventional mesothelioma markers

DIFFERENTIAL DIAGNOSIS

Epithelioid Malignant Mesothelioma

- AS tends to be more hemorrhagic than mesothelioma
- Presence of vessel-like spaces lined by atypical cells is rare in mesothelioma and typical of AS
- CD31, FLI-1, and ERG are negative in mesothelioma
- Tumor cells in mesothelioma are positive for calretinin, CK5/6, WT1, HBME-1, and other mesothelioma markers

Metastatic Adenocarcinoma

- Solid growth pattern and epithelioid cell features in AS may simulate metastasis of carcinoma
- Epithelioid AS may be positive for cytokeratin
- Anastomosing vessel-like channels favor AS
- Tumor cells will be positive for variety of epithelial markers in metastatic carcinoma, such as EMA/MUC1, CEA-M, MOC-31, TTF-1, etc.
  - Tumor cells will be positive for CD31, CD34, FLI-1, and ERG in AS

Metastatic Amelanotic Melanoma

- Prominent nesting of tumor cells is typical of melanoma
- Intranuclear inclusions, binucleation, and pleomorphic cells with prominent nucleoli are more frequent in melanoma
- Melanoma positive for S100, HMB-45, and MART-1
  - AS will be positive for CD31, FLI-1, ERG, and CD34; negative for melanocytic markers

DIAGNOSTIC CHECKLIST

Clinically Relevant Pathologic Features

- May simulate radiologically and histologically malignant mesothelioma
- Characterized by recurrent hemorrhagic pleural effusion
- May be of epithelioid or conventional (spindle cell) type
- Prognosis is similar to that of malignant mesothelioma
- Not associated with asbestos exposure

Pathologic Interpretation Pearls

- Look for extensive areas of hemorrhage and necrosis
- Look for anastomosing vessel-like channels lined by atypical endothelial cells
- CD31, FLI-1, or ERG positivity in tumor cells is diagnostic
  - Think of this possibility when other tumor markers are equivocal or incomplete for malignant mesothelioma

SELECTED REFERENCES

1. Anderson T et al: Thoracic epithelioid malignant vascular tumors: a clinicopathologic study of 52 cases with emphasis on pathologic grading and molecular studies of WWTR1-CAMTA1 fusions. Am J Surg Pathol. 39(1):132-9, 2015
2. Dainese E et al: Primary pleural epithelioid angiosarcoma. a case report and review of the literature. Pathol Res Pract. 206(6):415-9, 2010
3. Kurtz JE et al: Diffuse primary angiosarcoma of the pleura: a case report and review of the literature. Sarcoma. 8(4):103-6, 2004
4. Zhang PJ et al: Malignant epithelioid vascular tumors of the pleura: report of a series and literature review. Hum Pathol. 31(1):29-34, 2000
5. Falconieri G et al: Pseudomesotheliomatous angiosarcoma: a pleuropulmonary lesion simulating malignant pleural mesothelioma. Histopathology. 30(5):419-24, 1997
6. Lin BT et al: Malignant vascular tumors of the serous membranes mimicking mesothelioma. A report of 14 cases. Am J Surg Pathol. 20(12):1431-9, 1996

Pleural Angiosarcoma, Scanning Magnification

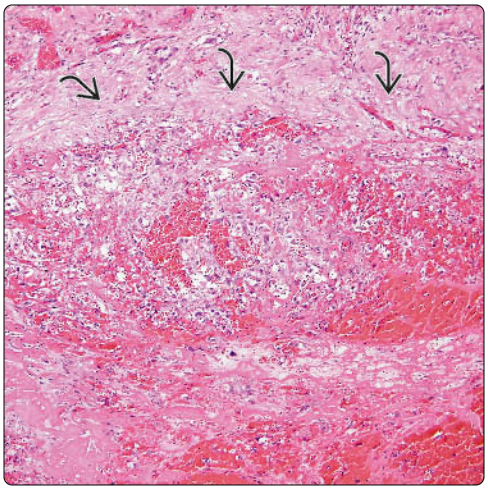

Pleural Angiosarcoma, High Magnification

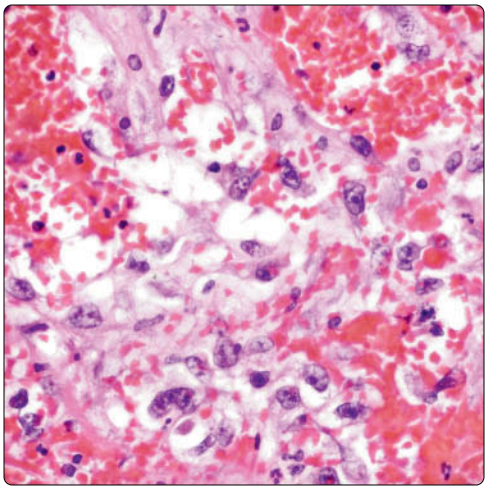

(Left) *The pleura in conventional pleural angiosarcoma is replaced by an extensively hemorrhagic process. A sparsely cellular proliferation is seen in the center, containing scattered large cells admixed with abundant red blood cells.* **(Right)** *High-power view of pleural angiosarcoma shows scattered atypical cells with large, hyperchromatic nuclei and prominent basophilic nucleoli. Note the blood lakes containing abundant red blood cells interspersed with the atypical tumor cells.*

Solid Area in Angiosarcoma

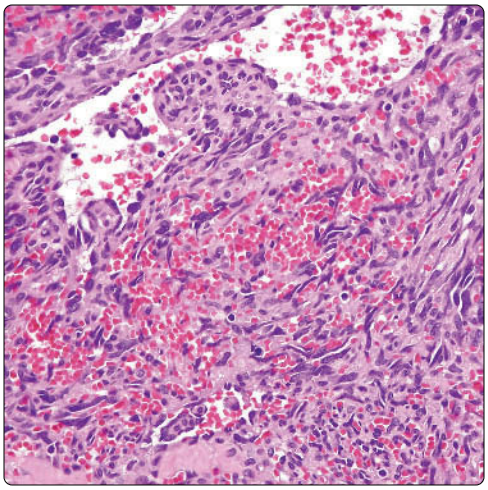

Primitive Vascular Space

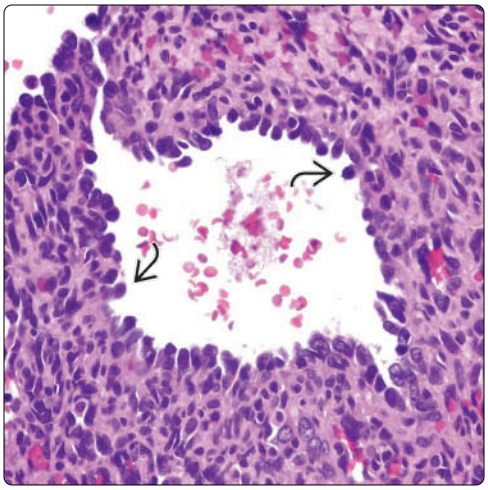

(Left) *Multiple anastomosing vessel-like channels separated by abundant extravasated red blood cells are seen in conventional pleural angiosarcoma. Some of the atypical cells in the stroma are spindle-shaped.* **(Right)** *A malformed blood vessel is seen in the center of the field lined by large, hyperchromatic, and atypical vascular endothelial cells in conventional pleural angiosarcoma. Note the cells protruding into the vessel lumen in a hobnail fashion.*

Dilated Vascular Space

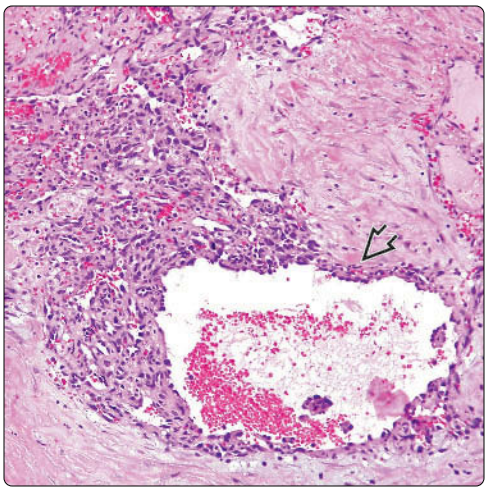

Vascular Space, Higher Magnification

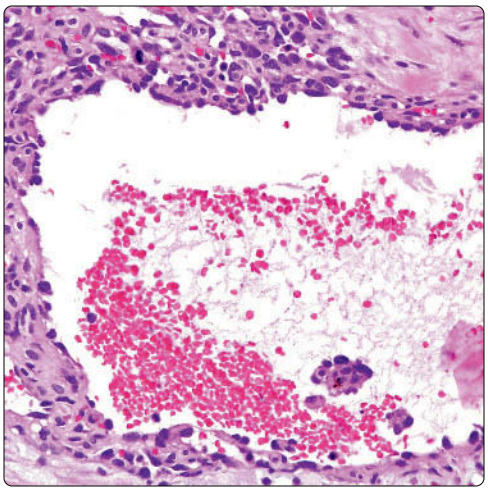

(Left) *Solid areas (left) in conventional pleural angiosarcoma merge imperceptibly with vessel-like spaces. Note the dilated vessel at the bottom, which appears to be originating from the solid proliferation on the left.* **(Right)** *A large dilated and abnormal vessel is seen in the center of the field lined by atypical endothelial cells characterized by large, round to oval, hyperchromatic nuclei with scant cytoplasm in conventional pleural angiosarcoma.*

Angiosarcoma, Solid Pattern

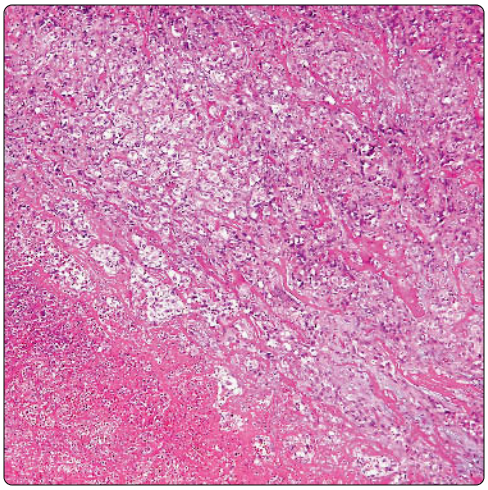

Solid Pattern, High Power

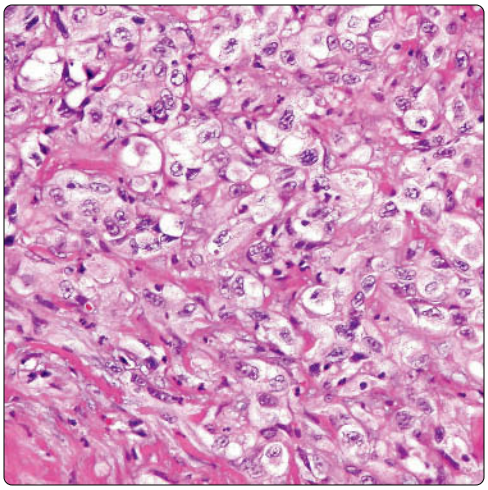

(Left) *The pleura is replaced by sheets of large, solid epithelioid cells devoid of recognizable vascular spaces in pleural angiosarcoma of the epithelioid type.* **(Right)** *High power shows solid sheets of large, epithelioid cells with abundant clear to lightly eosinophilic cytoplasm containing large, atypical nucleoli in epithelioid pleural angiosarcoma. Notice the absence of well-formed anastomosing vascular spaces lined by atypical endothelial cells.*

Epithelioid Angiosarcoma

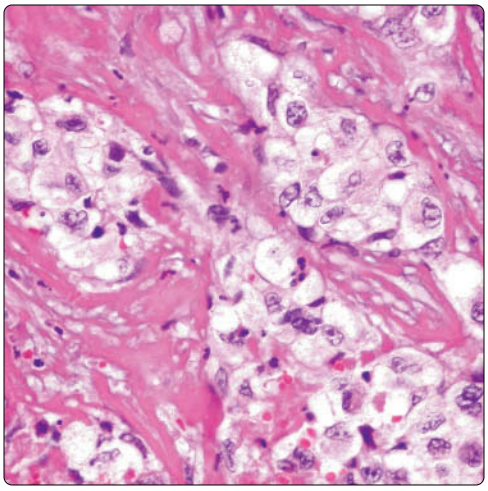

Epithelioid Angiosarcoma, High Power

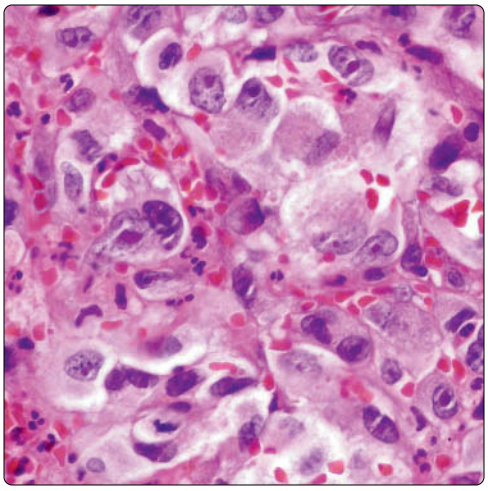

(Left) *Small solid nests of large epithelioid cells are seen, separated by bands of fibroconnective tissue in the stroma of a pleural angiosarcoma, epithelioid type. The cohesive and well-demarcated nature of these cell islands is reminiscent of a metastatic carcinoma.* **(Right)** *Nests of large, atypical epithelioid cells are seen in epithelioid pleural angiosarcoma. The cells contain abundant eosinophilic cytoplasm. The cell nuclei are large and hyperchromatic with prominent nucleoli.*

Infiltration of Fat

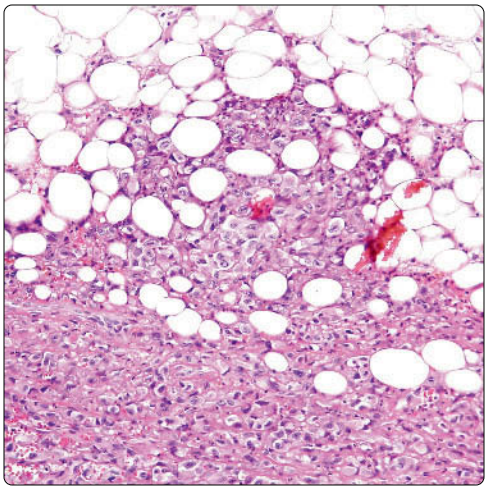

Infiltration of Muscle

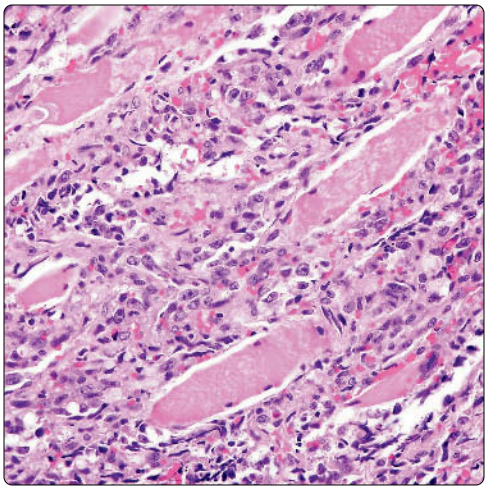

(Left) *Tumor is seen to infiltrate the subpleural adipose tissue in pleural angiosarcoma of epithelioid type. Note how the adipocytes are spared by the infiltrating tumor cells.* **(Right)** *Extensive infiltration of skeletal muscle of the diaphragm is seen in a pleural epithelioid angiosarcoma. The skeletal muscle shows degeneration of the cytoplasm with loss of cross striations; however, it is not destroyed by the infiltrating epithelioid angiosarcoma tumor cells.*

Angiosarcoma, Solid Pattern

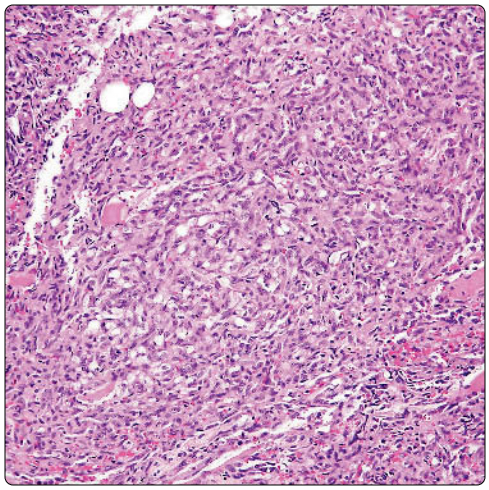

Solid Pattern, High Power

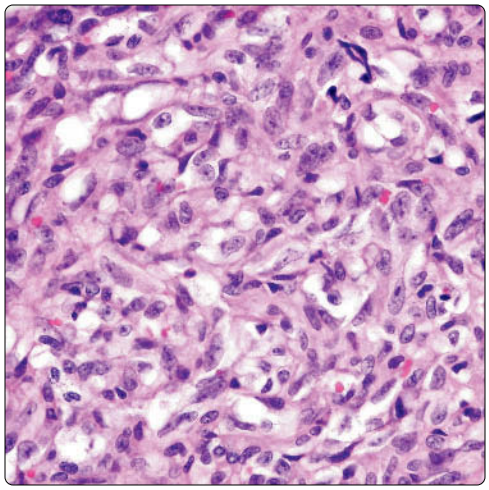

(Left) *The pleura is replaced by a dense, solid cellular proliferation composed of sheets of large, epithelioid cells with abundant cytoplasm and large hyperchromatic nuclei in a pleural angiosarcoma of epithelioid type.* **(Right)** *High magnification shows sheets of large, epithelioid cells with abundant cytoplasm and large cell nuclei with prominent nucleoli in pleural epithelioid angiosarcoma. Notice the absence of angioformative elements and the cohesive aspect of the cell population.*

Intracytoplasmic Vacuoles

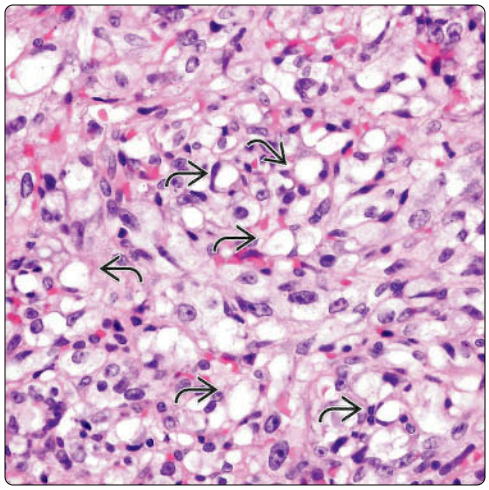

Cytoplasmic Vacuoles, High Power

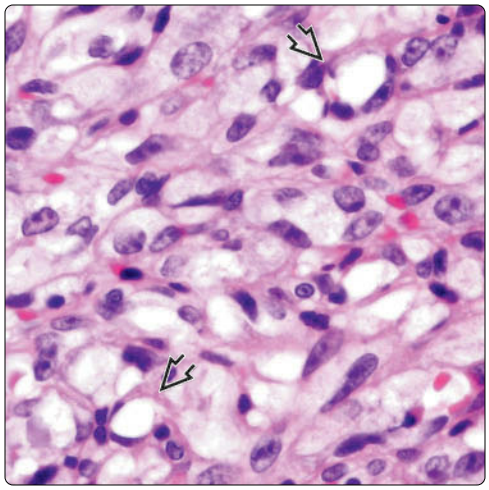

(Left) *This tumor shows an interesting feature: The presence of multiple large, epithelioid cells with prominent clear cytoplasmic vacuoles ⇨ simulating fat cells in epithelioid pleural angiosarcoma.* **(Right)** *Prominent cytoplasmic vacuolization is seen in this example of pleural angiosarcoma, epithelioid type. In some areas, the vacuoles displace the nuclei of the tumor cells toward the periphery of the cell, imparting them with a signet ring cell appearance ⇨.*

Immunohistochemistry for CD31

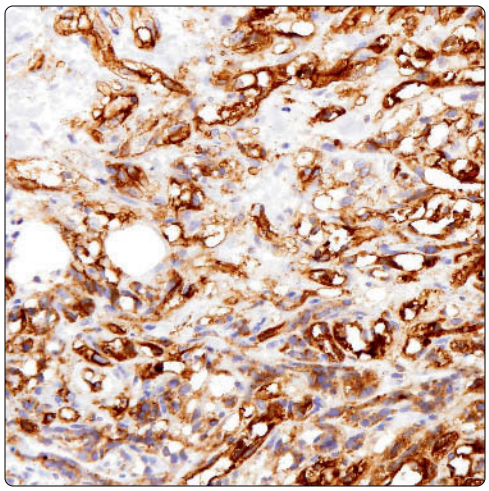

Immunohistochemistry for FVIIIRAg

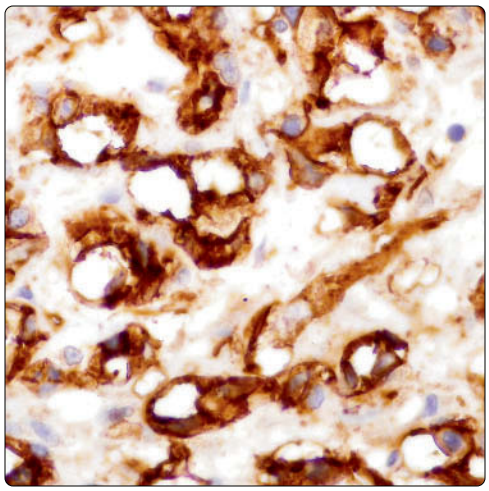

(Left) *Immunoperoxidase stain for CD31 shows positive cytoplasmic staining of the tumor cells for this antigen in a pleural angiosarcoma of epithelioid type.* **(Right)** *Immunoperoxidase stain for FVIIIRAg shows strong cytoplasmic staining of the epithelioid tumor cells in epithelioid pleural angiosarcoma. FVIIIRAg shows a tendency to stain the circumference of the cytoplasmic vacuoles, highlighting the boundaries of these structures.*

Angiosarcoma, Solid Pattern

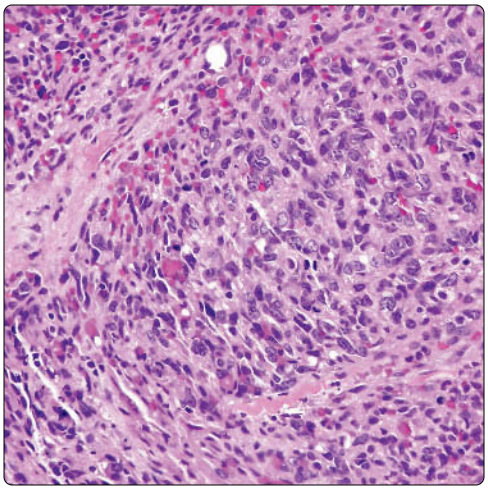

Abortive Vascular Lumina

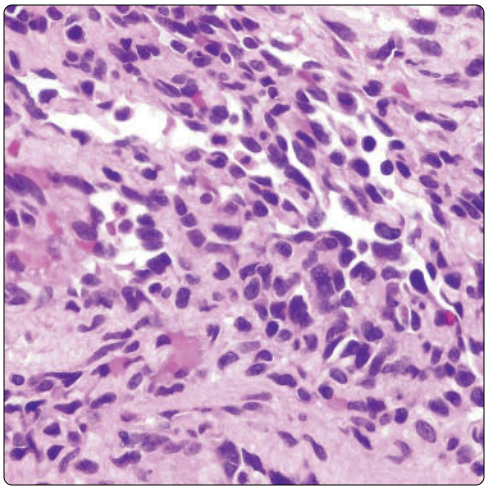

(Left) *The pleura is replaced by a solid proliferation of large atypical cells showing nuclear pleomorphism and focal spindling of the tumor cells in this example of pleural angiosarcoma, conventional type.* **(Right)** *This focus shows primitive, abortive, and anastomosing vessel-like spaces lined by large, atypical endothelial cells with oval to spindle nuclei in pleural angiosarcoma. Note that similar cells are also seen infiltrating the stroma and outside of the vessel-like lumina.*

Large Irregular Vessels

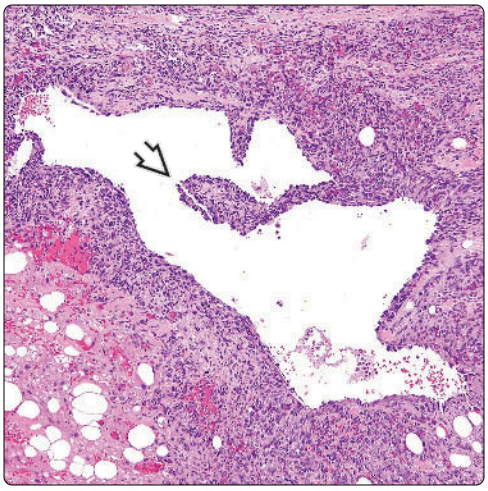

Anastomosing Vascular Pattern

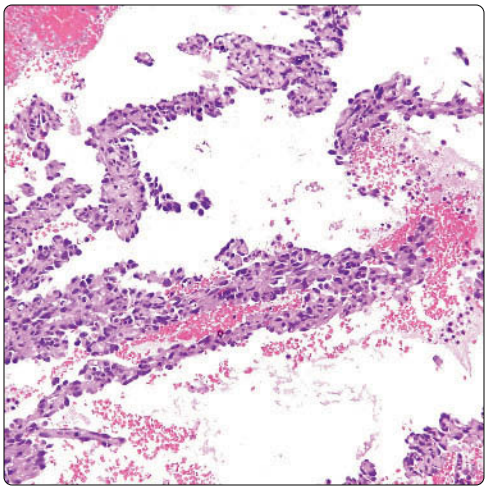

(Left) *There is a large, dilated space in the center of the field representing an abnormal, neoplastic vessel lined by atypical vascular endothelial cells in pleural angiosarcoma, conventional type. A focal projection into the lumen with pseudopapillary appearance is noted.* **(Right)** *Strands of tumor cells adopting a pseudopapillary appearance are seen projecting into an empty lumen in pleural angiosarcoma, conventional type. The structures are lined by atypical endothelial cells.*

Immunohistochemistry for CD31

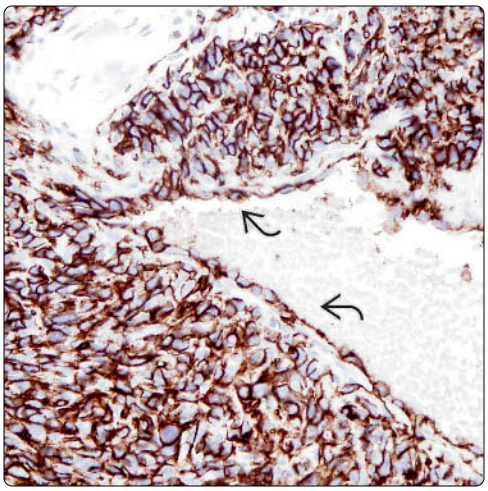

Immunohistochemistry for FLI-1

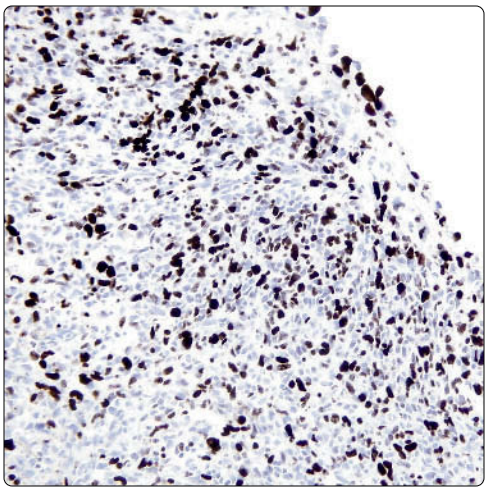

(Left) *Immunoperoxidase stain for CD31 shows strong cytoplasmic positivity of the tumor cells for this marker in a pleural angiosarcoma, conventional type. Notice that the cells lining the dilated vascular spaces are also strikingly positive.* **(Right)** *Immunohistochemical staining of pleural angiosarcoma shows strong nuclear positivity of the tumor cells for FLI-1 antibody.*

Synovial Sarcoma

KEY FACTS

CLINICAL ISSUES

- Chest pain, pleural effusion
- Pleural-based mass on CT scan
- Age range: 10-50 years (average: 25 years)

MACROSCOPIC

- Large, well-circumscribed, pleural-based mass
- May extend along pleural surface mimicking malignant mesothelioma
- May show cystic and hemorrhagic changes

MICROSCOPIC

- May be biphasic or monophasic
- Biphasic tumors are composed of cleft-like and glandular structures with intraluminal eosinophilic proteinaceous material admixed with population of atypical spindle cells
- Monophasic tumors are composed of monotonous atypical spindle cell proliferation with herringbone, storiform, or hemangiopericytic growth patterns
- Variable mitotic activity (range: 2-10 mitoses per 10 HPF)
- Spindle cell population is very monotonous and uniform
- Absence of nuclear pleomorphism or prominent nucleoli
- Glands lined by tall columnar cells with abundant cytoplasm in biphasic type
- Focal (patchy) positivity for epithelial markers (cytokeratin and EMA)
- Strong positivity for Bcl-2 and CD99
- Shares many markers with malignant mesothelioma, including calretinin and HBME-1
- Some cases may be positive for CD34
- Characteristic chromosomal translocation, t(X;18)(SYT-SSX) seen in > 80% of cases
- Distinctive translocation may be assayed by FISH, PCR, or DNA in situ hybridization

Gross Appearance of Synovial Sarcoma

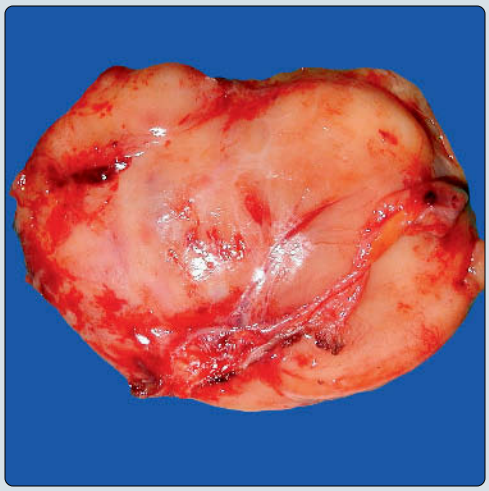

Fascicular/Herringbone Appearance

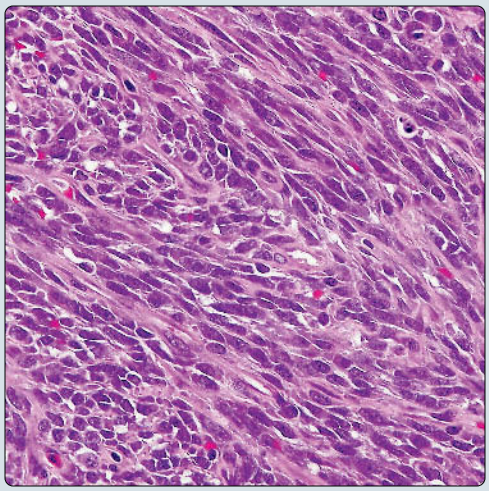

(Left) *Gross appearance of primary synovial sarcoma of the pleura shows a well-circumscribed mass with a fleshy and soft appearance and a lobulated external surface.* **(Right)** *Typical histologic appearance of monophasic synovial sarcoma of the pleura shows monotonous fascicles of spindle cells almost completely devoid of connective tissue stroma.*

Hemangiopericytic Vascular Pattern

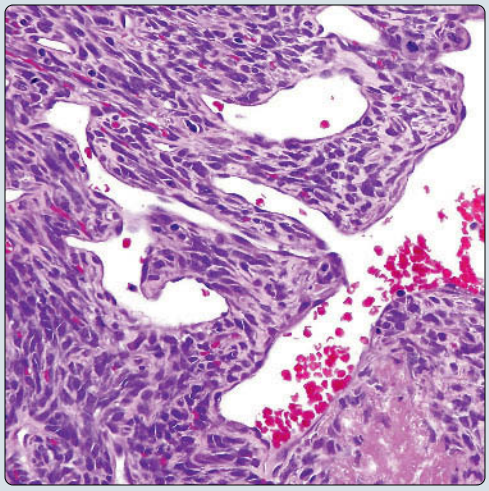

Uniform Spindle Cell Population

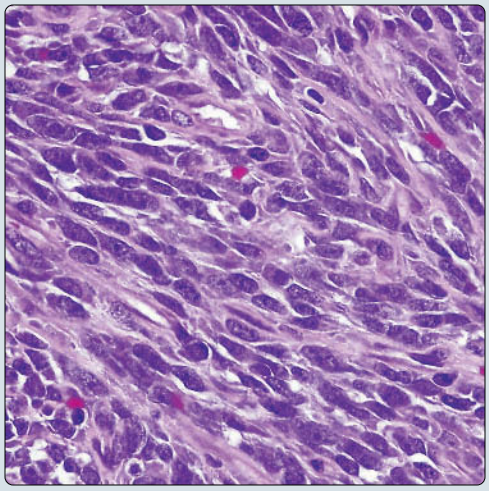

(Left) *Synovial sarcomas often adopt a hemangiopericytoma-like vascular pattern characterized by small branching vessels with patent lumina that are surrounded by a dense spindle cell population.* **(Right)** *The cytologic hallmark of synovial sarcoma is its uniform cell population composed of tightly packed oval to spindle cells with a dense chromatin pattern and scant cytoplasm without any intervening stroma.*

TERMINOLOGY

Abbreviations

- Synovial sarcoma (SS)

Definitions

- Pleural malignant neoplasm composed of nonmesothelial cells showing epithelial differentiation with distinctive spindle cell pattern of growth and chromosomal translocation

CLINICAL ISSUES

Presentation

- Chest pain, pleural effusion
- Pleural-based mass on CT scan
- Age range: 10-50 years (average: 25 years)

Prognosis

- Similar prognosis to soft tissue counterpart
- Aggressive behavior with local recurrence and metastases

MACROSCOPIC

General Features

- Large, well-circumscribed, pleural-based mass
- May extend along pleural surface mimicking malignant mesothelioma
- May show cystic and hemorrhagic changes

MICROSCOPIC

Histologic Features

- May be biphasic or monophasic
- Biphasic tumors are composed of cleft-like and glandular structures with intraluminal eosinophilic proteinaceous material admixed with population of atypical spindle cells
- Monophasic tumors are composed of monotonous atypical spindle cell proliferation with herringbone, storiform, or hemangiopericytic growth patterns
- Poorly differentiated variants are characterized by round epithelioid cells rather than spindle cells
- Variable mitotic activity (range: 2-10 mitoses per 10 HPF)
- May display hemorrhage and necrosis

Cytologic Features

- Spindle cell population is very monotonous and uniform
- Absence of nuclear pleomorphism or prominent nucleoli
- Glands lined by tall columnar cells with abundant cytoplasm in biphasic type
- Absence of marked anaplasia or multinucleated tumor cells

ANCILLARY TESTS

Immunohistochemistry

- Focal (patchy) positivity for epithelial markers (cytokeratin and EMA)
- Strong positivity for Bcl-2, CD99, and TLE1
- Shares many markers with malignant mesothelioma, including calretinin and HBME-1
- May also stain with calponin and CD117

Genetic Testing

- Characteristic chromosomal translocation, t(X;18)(SYT-SSX) seen in > 80% of cases
- Distinctive translocation may be demonstrated by FISH, PCR, or DNA in situ hybridization

DIFFERENTIAL DIAGNOSIS

Biphasic Malignant Mesothelioma

- Both tumors share cytokeratin, EMA, calretinin, and HMBE-1 positivity
- WT1 is positive in mesothelioma but consistently negative in SS
- Cytogenetic studies demonstrate t(X;18) in all SSs; translocation is negative in mesothelioma

Sarcomatoid Malignant Mesothelioma

- Can be confused for monophasic spindle cell variant of SS
- Cell population more uniform in SS than in sarcomatoid mesothelioma
- Both can be negative for epithelial (keratin, EMA) and mesothelial (calretinin, WT1, HBME-1) markers
- Demonstration of t(X;18) is most reliable way for separating them

Solitary Fibrous Tumor/Malignant Solitary Fibrous Tumor

- Bcl-2, CD99, and CD34 reactivity can be shared by both SS and sarcomatoid mesothelioma
- Focal keratin or EMA positivity favors SS
- Demonstration of t(X;18) can help make definitive diagnosis of SS in equivocal cases

DIAGNOSTIC CHECKLIST

Clinically Relevant Pathologic Features

- More frequent in young adults than in mature or elderly patients
- Aggressive behavior with frequent recurrences and metastases

Pathologic Interpretation Pearls

- Uniformity of spindle cell population is important key for diagnosis of SS
- Demonstration of t(X;18) by molecular techniques is of value in equivocal cases

SELECTED REFERENCES

1. Falkenstern-Ge RF et al: Primary pulmonary synovial sarcoma: a rare primary pulmonary tumor. Lung. 192(1):211-4, 2014
2. Bégueret H et al: Primary intrathoracic synovial sarcoma: a clinicopathologic study of 40 t(X;18)-positive cases from the French Sarcoma Group and the Mesopath Group. Am J Surg Pathol. 29(3):339-46, 2005
3. Aubry MC et al: Primary monophasic synovial sarcoma of the pleura: five cases confirmed by the presence of SYT-SSX fusion transcript. Am J Surg Pathol. 25(6):776-81, 2001
4. Miettinen M et al: Calretinin and other mesothelioma markers in synovial sarcoma: analysis of antigenic similarities and differences with malignant mesothelioma. Am J Surg Pathol. 25(5):610-7, 2001
5. Nicholson AG et al: Synovial sarcoma of the pleura and its differentiation from other primary pleural tumours: a clinicopathological and immunohistochemical review of three cases. Histopathology. 33(6):508-13, 1998

Dense Spindle Cell Population

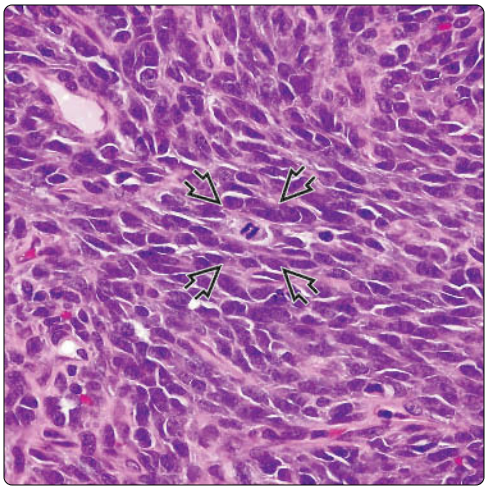

Mitotic Figure in Synovial Sarcoma

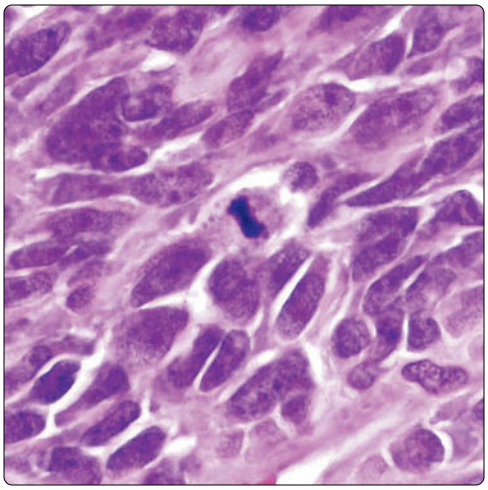

(Left) *Low magnification of monophasic synovial sarcoma of the pleura shows a monotonous population of spindle cells. A mitotic figure is seen in the center of the field* ⇨. **(Right)** *High magnification of monophasic synovial sarcoma of the pleura shows a monotonous population of atypical spindle cells. Notice the mitotic figure in the center. Mitotic activity can vary considerably in these tumors, from very scanty to > 10 mitoses per 10 HPF.*

Fascicular Pattern

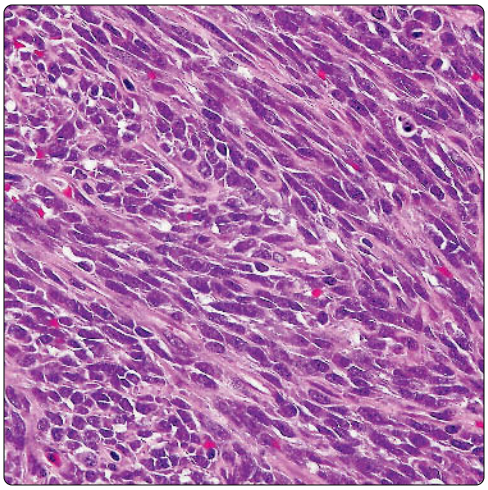

Atypical Cells: High Power

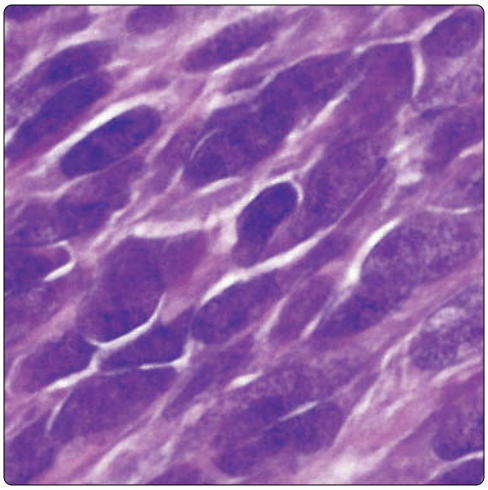

(Left) *Monophasic synovial sarcoma of the pleura shows fascicles of monotonous spindle cells without significant vascular markings and exhibiting a herringbone pattern of growth. This appearance can closely resemble that of sarcomatoid malignant mesothelioma.* **(Right)** *High magnification of monophasic synovial sarcoma of the pleura shows the monotonous character of the atypical spindle cells with uniform nuclei showing a dispersed chromatic pattern and inconspicuous nucleoli.*

Hemangiopericytic Vascular Pattern

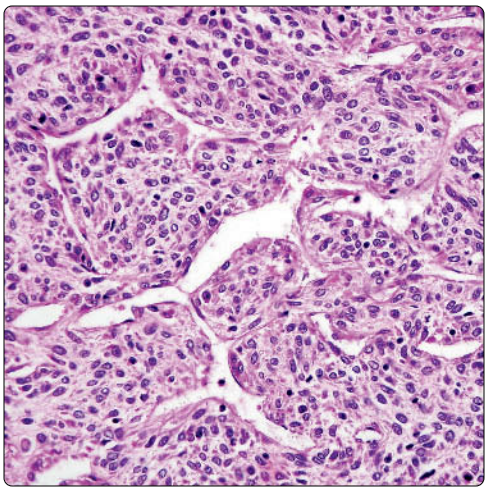

Small Branching Vessel

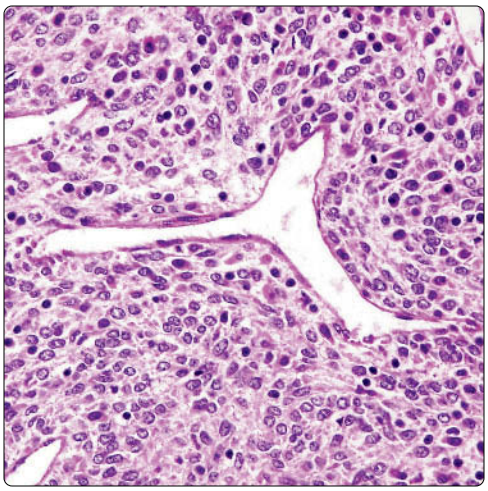

(Left) *Monophasic synovial sarcoma of the pleura shows a prominent hemangiopericytoma-like growth pattern. Multiple branching vessels with patent lumina are noted surrounded by the atypical spindle cells.* **(Right)** *High magnification of monophasic synovial sarcoma of the pleura with hemangiopericytoma-like growth patterns shows a small branching vessel with patent lumina surrounded by a dense population of monotonous spindle cells.*

Herringbone Pattern

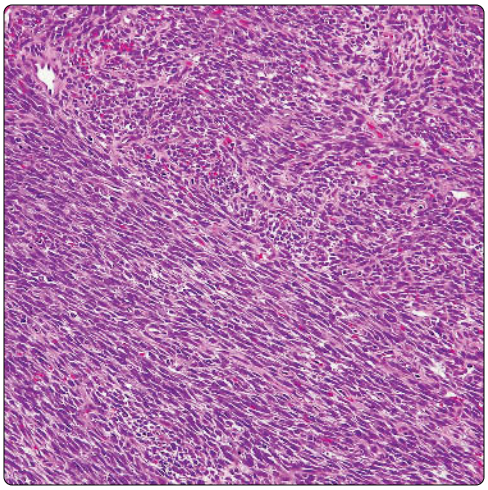

Fascicles of Spindle Cells

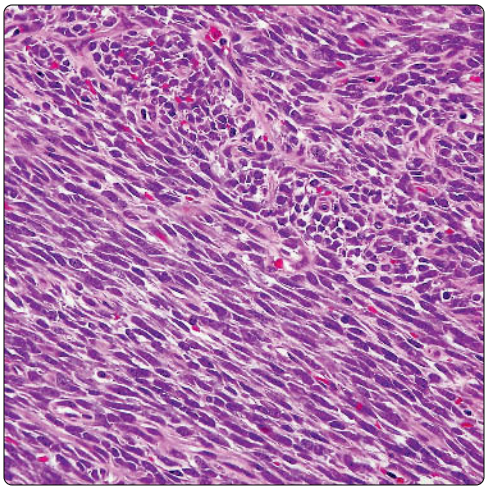

(Left) *Scanning magnification of monophasic synovial sarcoma of the pleura shows fascicles of monotonous atypical spindle cells arranged in a herringbone pattern. The dense and monotonous atypical spindle cell proliferation is characteristic for this tumor.* **(Right)** *Scanning magnification of monophasic synovial sarcoma of the pleura shows fascicles of parallel tumor cells with a very monotonous appearance and scant intercellular stroma.*

Storiform Pattern

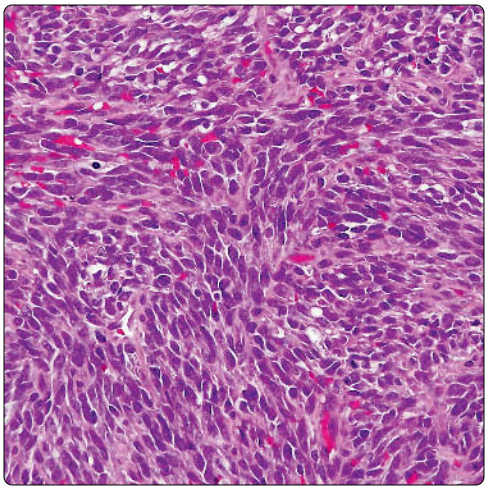

Myxoid Matrix

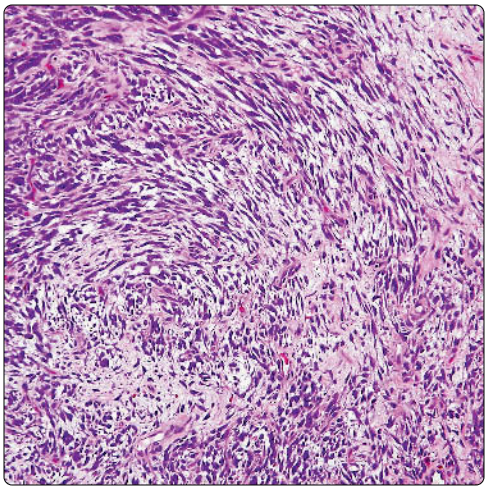

(Left) *Monophasic synovial sarcoma of the pleura shows intersecting fascicles of monotonous tumor cells with a vague storiform pattern and a few scattered mitotic figures. This histologic appearance can closely resemble a "fibrohistiocytic" tumor.* **(Right)** *Monophasic synovial sarcoma of the pleura shows prominent myxoid intercellular matrix. This type of change is often seen in treated tumors that have been radiated prior to surgery or as a result of adjuvant chemotherapy.*

Hemangiopericytic Vascular Pattern

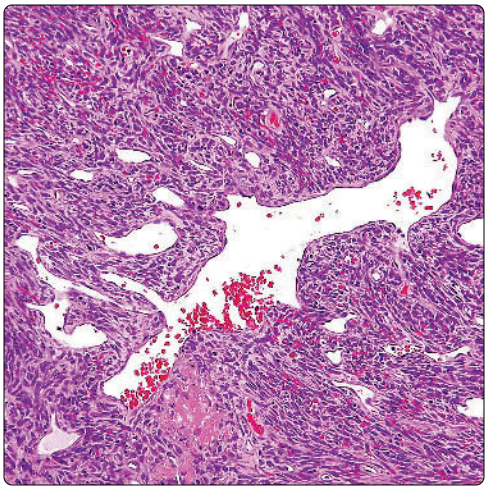

Mitotic Activity

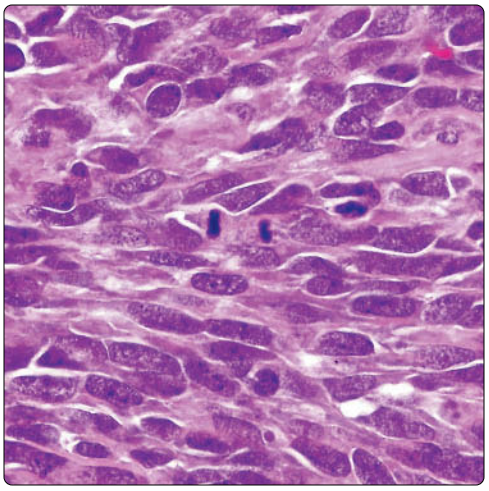

(Left) *Monophasic synovial sarcoma of the pleura shows a focal hemangiopericytic growth pattern with branching vessels adopting a staghorn configuration. Tumors with these features were previously diagnosed as hemangiopericytoma.* **(Right)** *High magnification in monophasic synovial sarcoma of the pleura shows a monotonous population of tumor cells with tapered nuclei showing a dense chromatin pattern with inconspicuous nucleoli and scattered mitotic figures.*

Myxoid Stromal Background

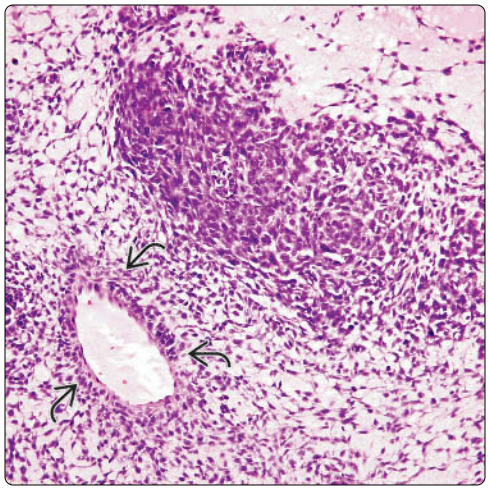

Dense Spindle Cell Population

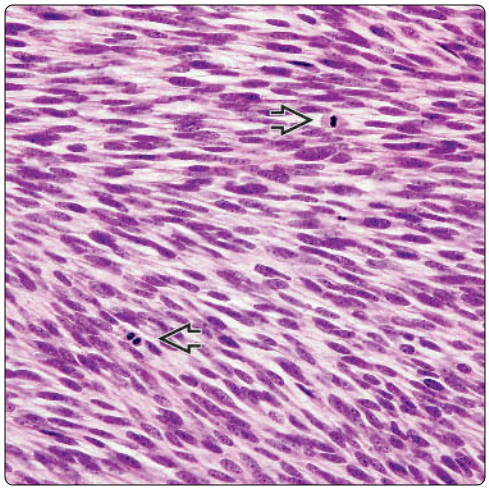

(Left) *Synovial sarcoma of the pleura shows alternating hypercellular and paucicellular areas. Notice a dense cuff of tumor cells surrounding a small vessel. (Right) High magnification of a cellular area in monophasic synovial sarcoma of the pleura shows a monotonous population of hyperchromatic spindle cells. Notice the monotonous appearance of the spindle cells, which are devoid of significant nuclear pleomorphism. Scattered mitoses are present throughout the tumor.*

Areas of Tumor Necrosis

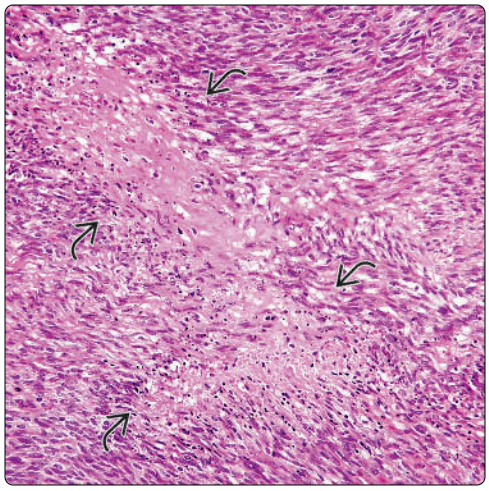

Stromal Hyalinization

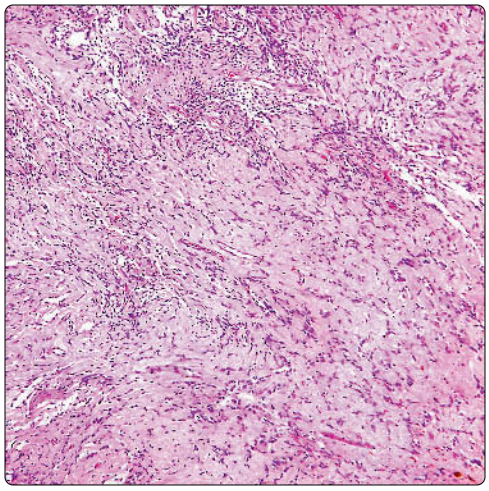

(Left) *Synovial sarcoma of the pleura shows a focus of coagulative tumor cell necrosis. Notice the monotonous spindle tumor cells surrounding the area of necrosis.* **(Right)** *Synovial sarcoma of the pleura shows an area displaying striking stromal sclerosis with a sparse spindle cell population embedded in abundant collagenized stroma. Striking stromal hyalinization is rare in monophasic synovial sarcoma and is most often seen in cases after radiation or chemotherapy.*

Hyalinization: Higher Magnification

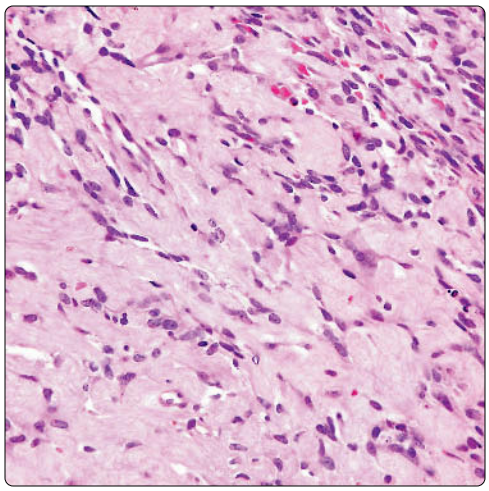

Myxoid Stroma

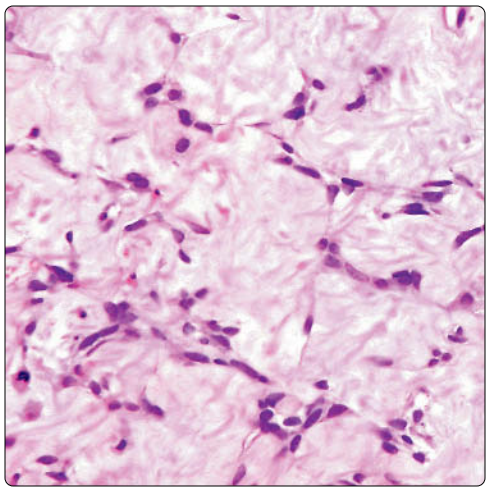

(Left) *Synovial sarcoma of the pleura with stromal sclerosis shows hyperchromatic spindle cells separated by abundant hyalinized stroma. Tumors with these features can be mistaken for solitary fibrous tumor, fibrosarcoma, and other types of spindle cell sarcomas.* **(Right)** *Synovial sarcoma of the pleura with stromal hyalinization shows a sparse population of hyperchromatic spindle cells embedded in abundant hyalinized connective tissue stroma.*

Cytokeratin AE1/AE3 Immunostaining

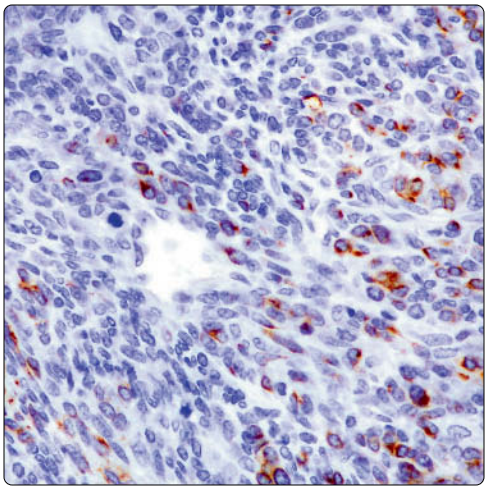

Bcl-2 Immunostaining

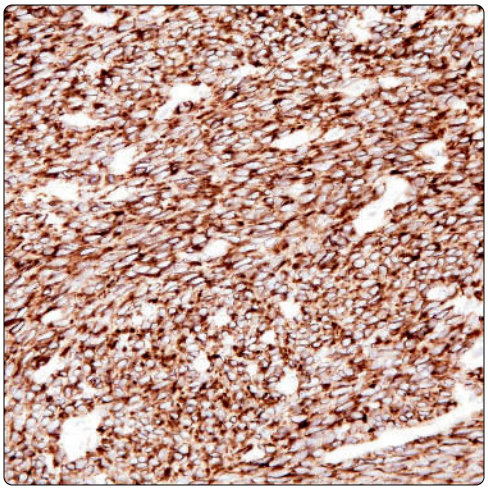

(Left) *Immunohistochemical stain for cytokeratin in monophasic synovial sarcoma of the pleura shows focal cytoplasmic positivity in scattered tumor cells. This is the typical staining pattern for cytokeratin in synovial sarcoma.* **(Right)** *Immunohistochemical staining of monophasic synovial sarcoma of the mediastinum for BCL2 oncogene shows strong positivity of the tumor cells. This marker is strongly expressed in practically all cases of monophasic synovial sarcoma.*

EMA Immunostaining

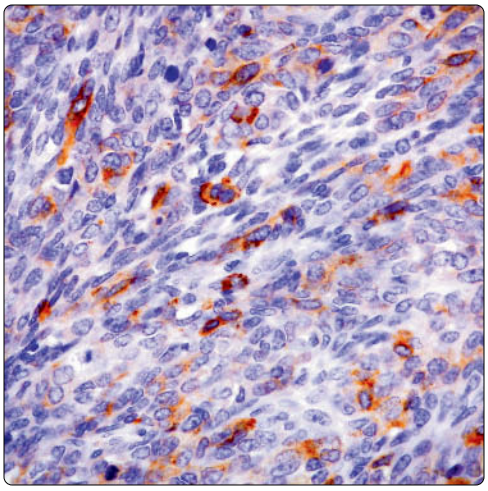

Calponin Immunostaining

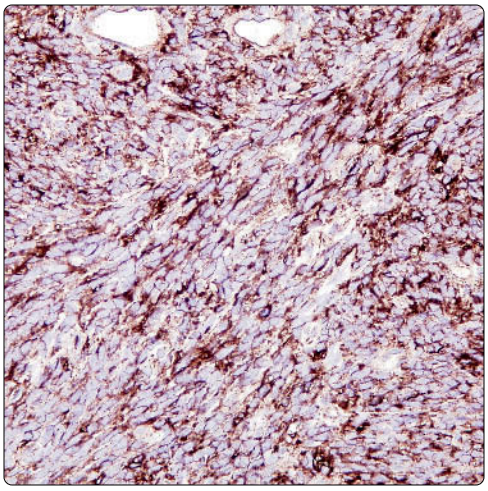

(Left) *Immunohistochemical stain for EMA is shown in monophasic synovial sarcoma of the pleura. The staining is patchy and often weak. EMA, however, may be a more sensitive marker for synovial sarcoma in cases that are keratin negative.* **(Right)** *Immunohistochemical staining of monophasic synovial sarcoma of the mediastinum shows positive staining of the tumor cells for calponin.*

S100 Protein Immunostaining

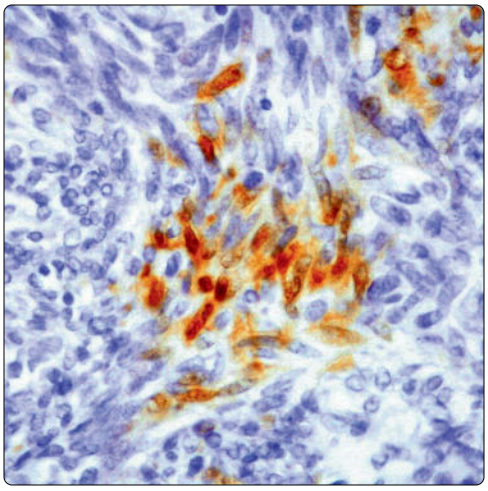

FISH for SYT-SSX Fusion

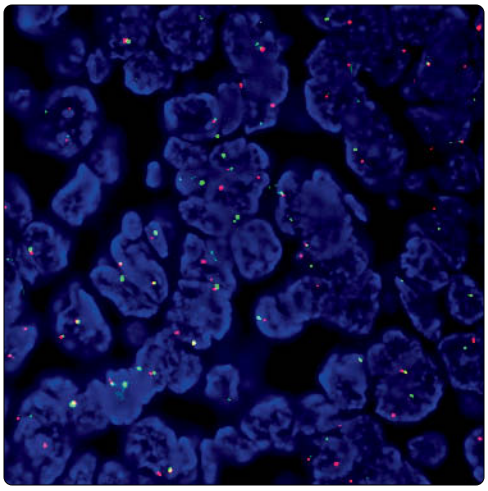

(Left) *Immunohistochemical stain for S100 protein shows monophasic synovial sarcoma. Notice focal nuclear positivity in a cluster of tumor cells. Up to 30% of monophasic synovial sarcoma has been reported to stain positive for this marker in one study.* **(Right)** *Fluorescence in situ hybridization assay in a case of monophasic synovial sarcoma of the pleura demonstrates t(X;18) translocation by detecting the SYT-SSX fusion transcripts.*

Malignant Solitary Fibrous Tumor (Fibrosarcoma)

KEY FACTS

TERMINOLOGY

- Malignant neoplastic proliferation of submesothelial fibroblasts

CLINICAL ISSUES

- Cough, pleuritic pain, dyspnea
- Usually aggressive behavior similar to high-grade sarcomas

MACROSCOPIC

- Diffuse growth
- Poorly circumscribed
- Invasion of adjacent structures
- Areas of necrosis
- Hemorrhage

MICROSCOPIC

- Dense, atypical spindle cell proliferation
- Fascicular, herringbone, storiform, and hemangiopericytic growth patterns
- May contain foci of "dedifferentiation"
- Areas of typical, low-grade solitary fibrous tumor (SFT) must be identified to make diagnosis
- Atypical spindle cells with enlarged, hyperchromatic nuclei
- Marked nuclear pleomorphism
- Prominent nucleoli
- Tumor cell necrosis
- Bizarre giant cells and multinucleated cells
- Immunohistochemical stains are of limited value for diagnosis because markers associated with SFT may lose their expression in poorly differentiated variants
- Better differentiated areas stain positive for CD34, Bcl-2, CD99, and vimentin
- p53 and Ki-67 may show increased positivity in poorly differentiated areas

DIAGNOSTIC CHECKLIST

- Malignant SFT (MSFT) is largely diagnosis of exclusion

Malignant Solitary Fibrous Tumor

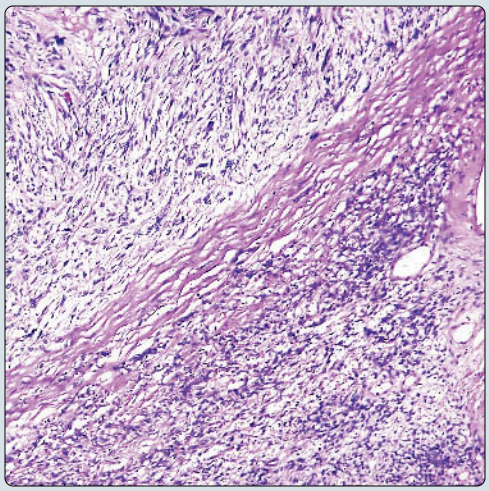

Malignant Solitary Fibrous Tumor: Higher Power

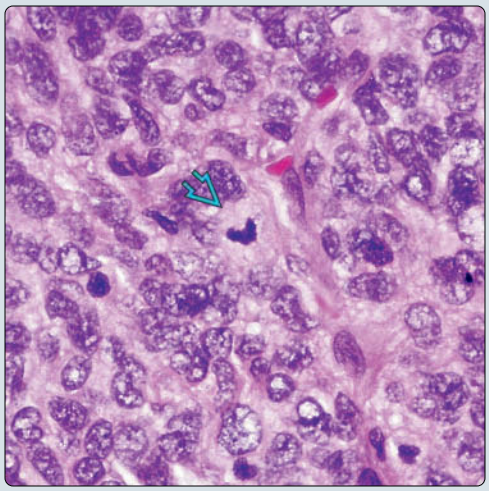

(Left) *Scanning magnification of a malignant pleural solitary fibrous tumor shows hypocellular areas corresponding to conventional solitary fibrous tumor (top) alongside more hypercellular areas containing atypical cells (bottom).* **(Right)** *Higher magnification in malignant solitary fibrous tumor of the pleura shows an atypical cell population with hyperchromatic nuclei and scattered mitoses.*

Pleomorphic Tumor Cells: High Power

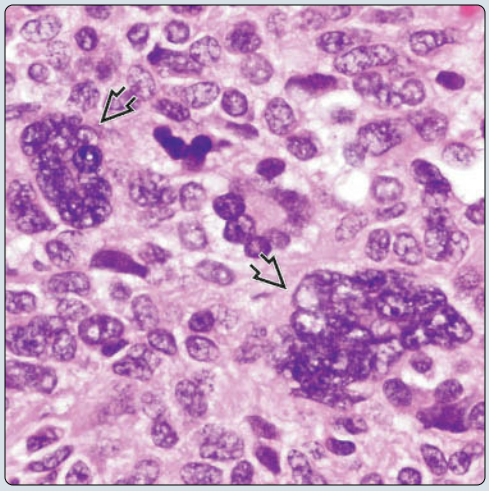

Bizarre Multinucleated Tumor Cell

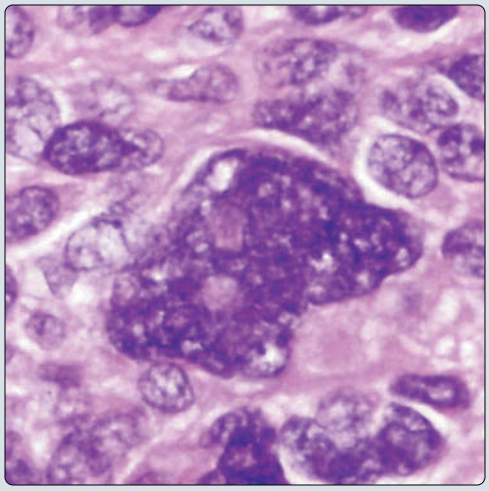

(Left) *High power of malignant solitary fibrous tumor of the pleura shows highly atypical, pleomorphic, multinucleated tumor cells. Notice the more bland-appearing mononuclear cells in the background.* **(Right)** *Malignant solitary fibrous tumor of the pleura shows an example of a bizarre multinucleated tumor cells containing multiple atypical nuclei resembling a polykaryosome.*

TERMINOLOGY

Abbreviations

- Malignant solitary fibrous tumor (MSFT)

Synonyms

- Pleural fibrosarcoma

Definitions

- Malignant neoplastic proliferation of submesothelial fibroblasts

CLINICAL ISSUES

Presentation

- Cough, pleuritic pain, dyspnea

Prognosis

- Usually aggressive behavior similar to high-grade sarcomas

MACROSCOPIC

General Features

- Diffuse growth, poorly circumscribed with infiltration of adjacent structures
- Areas of hemorrhage and necrosis
- May spread along pleural surface in fashion reminiscent of malignant mesothelioma

MICROSCOPIC

Histologic Features

- Fascicular, herringbone, storiform, and hemangiopericytic growth patterns
- May contain foci of "dedifferentiation"
- Areas of typical, low-grade SFT must be identified to make diagnosis
- Infiltration of fat and surrounding tissues
- High mitotic activity (> 3 mitoses per 10 HPF)

Cytologic Features

- Atypical spindle cells with enlarged, hyperchromatic nuclei
- Marked nuclear pleomorphism, prominent nucleoli, and tumor cell necrosis
- Bizarre giant cells and multinucleated cells

ANCILLARY TESTS

Immunohistochemistry

- Immunohistochemical stains are of limited value because markers associated with SFT may lose their expression in poorly differentiated variants
- Better differentiated areas stain positive for CD34, Bcl-2, CD99, and vimentin
- p53 and Ki-67 may show increased positivity in poorly differentiated areas

DIFFERENTIAL DIAGNOSIS

Sarcomatoid Mesothelioma

- Most sarcomatoid mesotheliomas are positive for cytokeratin
- Need to identify areas typical for SFT to diagnose MSFT

Pleural Synovial Sarcoma

- Spindle cell population is much more monotonous and uniform in synovial sarcoma
- No nuclear pleomorphism or giant cells seen in synovial sarcoma
- Synovial sarcoma is positive for cytokeratin and EMA
- Identification of t(x;18) by molecular techniques is diagnostic of synovial sarcoma and is absent in MSFT

Malignant Peripheral Nerve Sheath Tumor

- Histologic features may be very similar for both in high-grade tumors
- Electron microscopy of malignant peripheral nerve sheath tumor is distinctive and characterized by interdigitating cytoplasmic processes with basal lamina material

Metastatic Malignant Melanoma

- Immunohistochemical positivity for S100 protein, HMB-45, and Melan-A is seen in melanoma

Metastatic Spindle Cell Sarcoma of Soft Tissue

- History of previous tumor elsewhere and bilateral lesions will favor metastasis

Metastatic Sarcomatoid Renal Cell Carcinoma

- Renal cell carcinoma will show positivity for cytokeratin, EMA, and CD10

DIAGNOSTIC CHECKLIST

Clinically Relevant Pathologic Features

- Diffuse infiltrative growth, areas of hemorrhage and necrosis and absence of capsule
- Mitotic rate > 3 mitoses per 10 HPF and presence of atypical mitoses
- Enlarged, hyperchromatic nuclei with prominent nucleoli and multinucleated tumor cells

Pathologic Interpretation Pearls

- MSFT is largely diagnosis of exclusion
- Other types of malignant spindle cell tumors of pleura must be ruled out 1st
- Immunohistochemical stains are not very specific in this setting and may be of limited value
- Most important feature for histologic diagnosis is identifying areas showing typical features of benign SFT

SELECTED REFERENCES

1. Hélage S et al: Solitary fibrous tumor of the pleura: can computed tomography features help predict malignancy? A series of 56 patients with histopathological correlates. Diagn Interv Imaging. 97(3):347-53, 2016
2. Cardillo G et al: Solitary fibrous tumors of the pleura: an analysis of 110 patients treated in a single institution. Ann Thorac Surg. 88(5):1632-7, 2009
3. Mosquera JM et al: Expanding the spectrum of malignant progression in solitary fibrous tumors: a study of 8 cases with a discrete anaplastic component--is this dedifferentiated SFT? Am J Surg Pathol. 33(9):1314-21, 2009
4. Hanau CA et al: Solitary fibrous tumor: histological and immunohistochemical spectrum of benign and malignant variants presenting at different sites. Hum Pathol. 26(4):440-9, 1995
5. Moran CA et al: The spectrum of histologic growth patterns in benign and malignant fibrous tumors of the pleura. Semin Diagn Pathol. 9(2):169-80, 1992

Biphasic Appearance

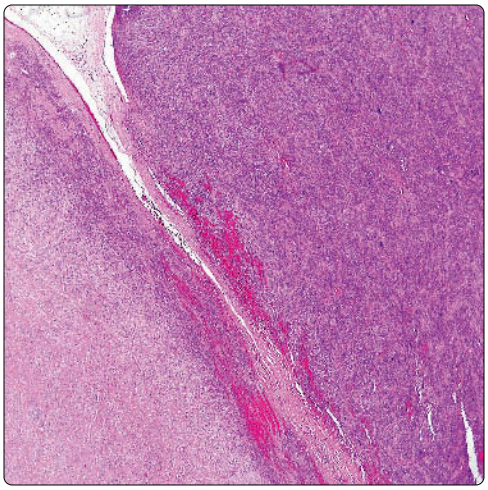

Benign Solitary Fibrous Tumor Component

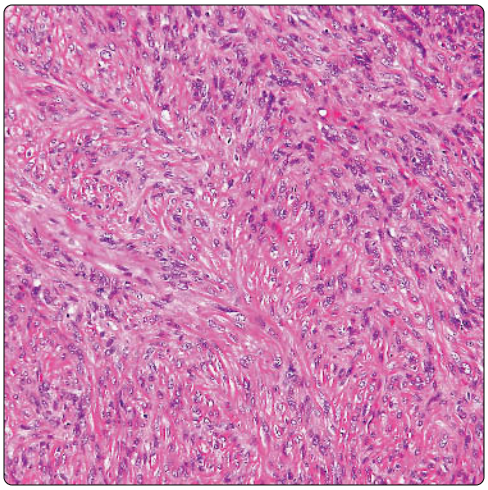

(Left) *Malignant solitary fibrous tumor of the pleura shows a biphasic appearance with an area resembling conventional, benign solitary fibrous tumor (left) merging with hypercellular areas containing malignant elements (right).* **(Right)** *Preexisting benign solitary fibrous tumor component in malignant solitary fibrous tumor of pleura shows bland-appearing spindle cell proliferation devoid of cytologic atypia, nuclear pleomorphism, or any significant mitotic activity.*

Malignant Solitary Fibrous Tumor Component

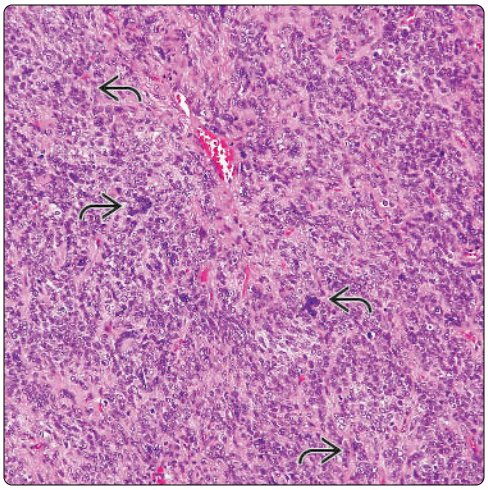

Malignant Solitary Fibrous Tumor: Higher Power

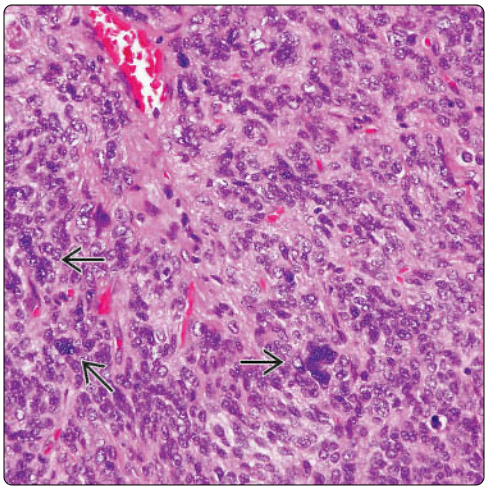

(Left) *Hypercellular, malignant component in malignant solitary fibrous tumor of pleura shows increased cellularity with significant nuclear pleomorphism. Notice the scattered, large pleomorphic and multinucleated tumor cells.* **(Right)** *High-power view of a malignant solitary fibrous tumor of the pleura shows atypical spindle cell proliferation characterized by spindle cells with a dense chromatin pattern and occasional mitotic figures. Notice the large tumor cells with multiple nuclei.*

Bizarre Tumor Cells

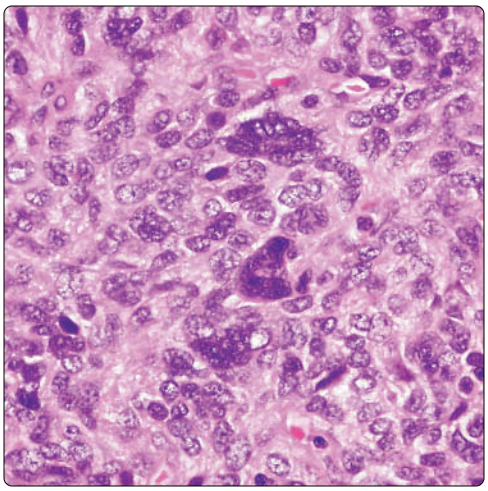

Multinucleated Tumor Cells

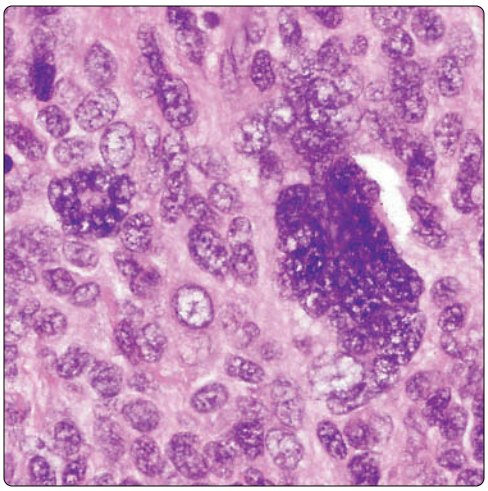

(Left) *High-power view of a malignant solitary fibrous tumor shows numerous bizarre multinucleated tumor cells with multiple enlarged nuclei. The nuclei in these cells show a dense chromatin pattern and vesiculation and contain scanty cytoplasm.* **(Right)** *High-power view of a malignant solitary fibrous tumor of the pleura shows a large multinucleated tumor cell. The giant tumor cell contains > 20 nuclei and resembles a polykaryosome of Warthin-Finkeldey giant cell.*

Abnormal Nuclear Morphology

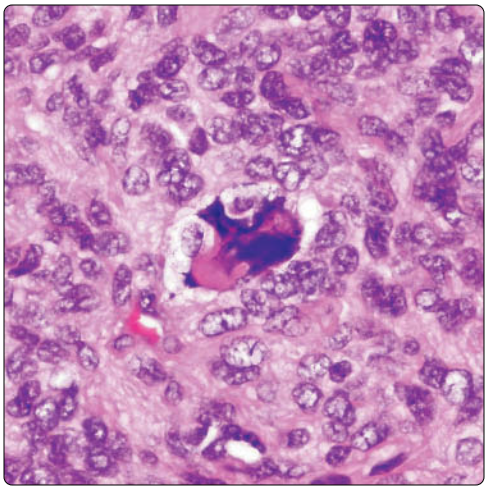

Mitotic Figure

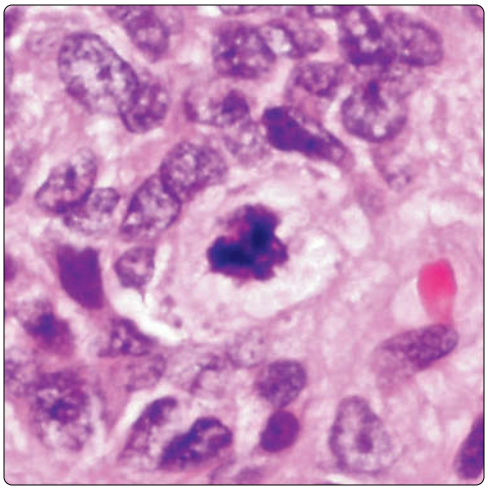

(Left) *Malignant solitary fibrous tumor of the pleura shows a bizarre, pleomorphic tumor cell with huge smudged nucleoli and retraction artifact surrounding the nucleus. Notice the monotonous population of mononuclear atypical cells surrounding the pleomorphic tumor cell.* **(Right)** *High magnification of malignant solitary fibrous tumor of the pleura (pleural fibrosarcoma) shows an abnormal mitotic figure within the mononuclear cell component of the tumor (center).*

Pleomorphic Tumor Cells

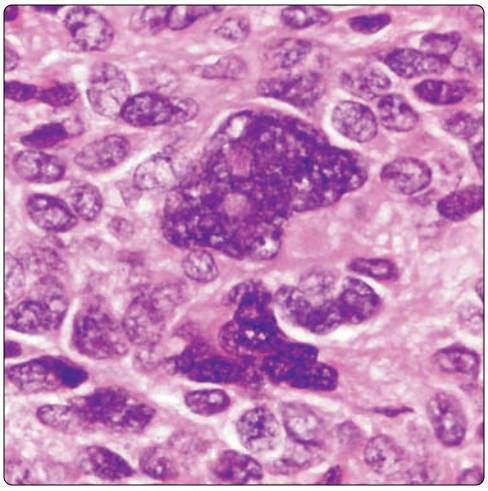

Pleomorphic Tumor Cell

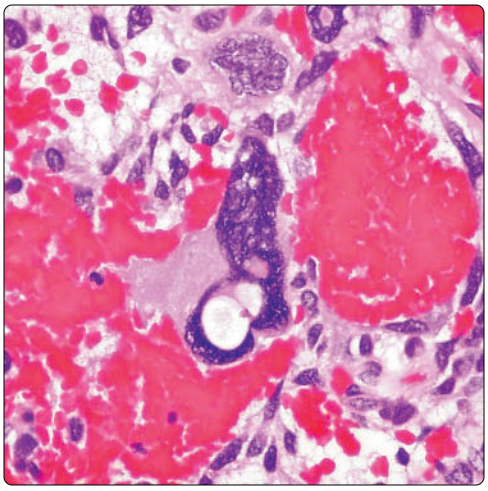

(Left) *High magnification of a malignant solitary fibrous tumor of the pleura shows several bizarre, hyperchromatic, and multinucleated tumor cells similar to the ones commonly observed in malignant fibrous histiocytoma.* **(Right)** *High magnification of a malignant solitary fibrous tumor of the pleura shows a bizarre tumor cell with intranuclear cytoplasmic inclusions. The appearance of the tumor cells and the abundant hemorrhage can closely simulate choriocarcinoma.*

Multinucleated Tumor Cell

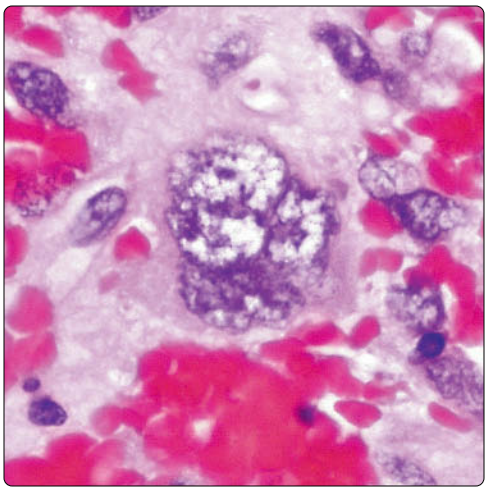

Area of Necrosis

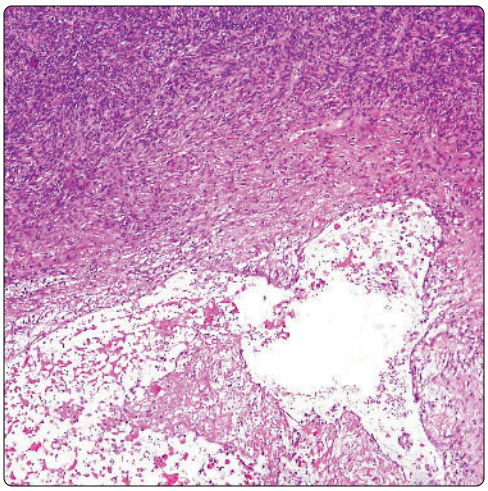

(Left) *High magnification of a malignant solitary fibrous tumor of the pleura shows a multinucleated tumor cell with vesicular nuclei and large eosinophilic nucleoli. These tumor cells can closely resemble the Reed-Sternberg cells seen in Hodgkin lymphoma.* **(Right)** *Malignant solitary fibrous tumor of the pleura shows an area of tumor cell necrosis adjacent to solid proliferation of atypical tumor cells.*

Fibrosarcomatous Appearance

Pleomorphic Tumor Cell

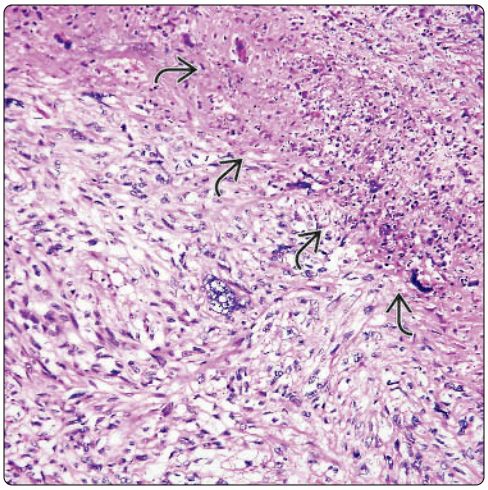

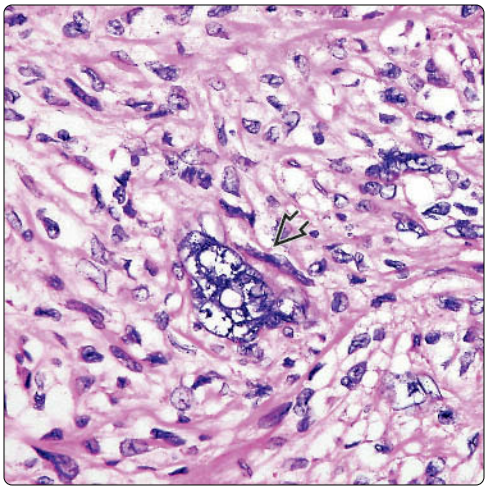

(Left) *Malignant solitary fibrous tumor of pleura shows a fibrosarcomatous appearance with fascicles of atypical spindle cells circumscribing an area of tumor cell necrosis.* **(Right)** *Fibrosarcomatous variant of malignant solitary fibrous tumor of the pleura shows a large pleomorphic tumor cell. The surrounding cell population is composed of mildly atypical spindle cells with hyperchromatic nuclei surrounded by a scant rim of amphophilic cytoplasm.*

Collagenized Stroma

Atypical Spindle Cells

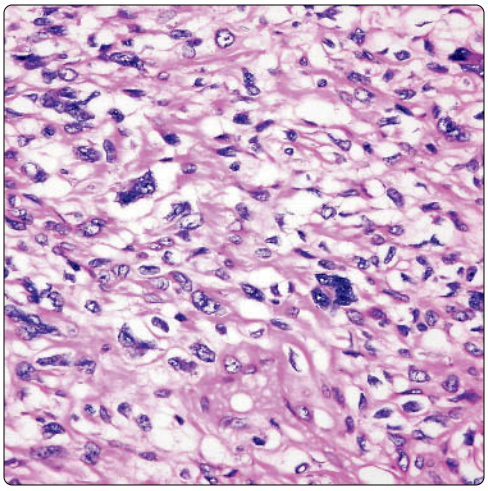

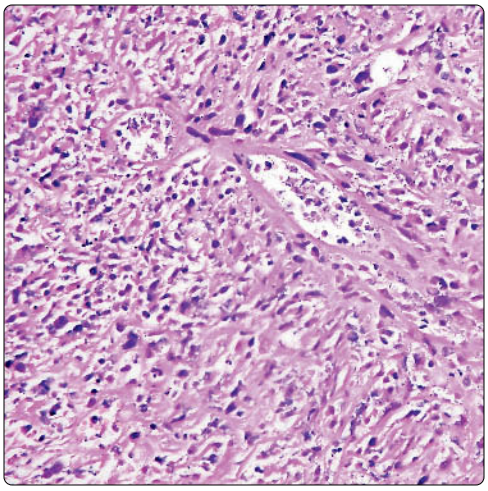

(Left) *Malignant solitary fibrous tumor of the pleura shows atypical spindle cell proliferation with collagenized stroma. Notice the scattered large, atypical, and often multinucleated tumor cells interspersed with the fibroblast-like spindle cells.* **(Right)** *Malignant solitary fibrous tumor of the pleura shows proliferation of atypical spindle cells with early features of tumor cell necrosis, apoptosis, and karyorrhexis.*

Pleomorphic Cell Population

Necrotic and Apoptotic Cells

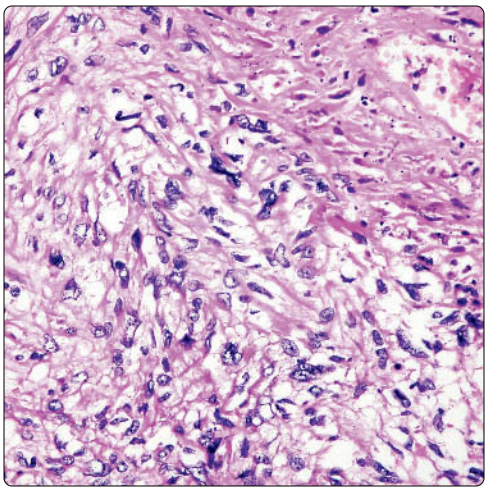

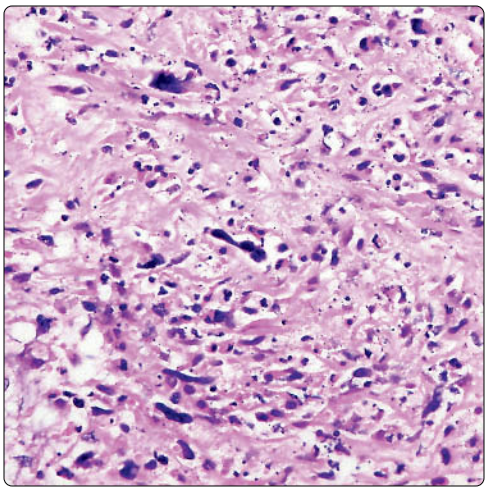

(Left) *Malignant solitary fibrous tumor of the pleura shows spindle cell proliferation with scattered mitotic figures and areas of necrosis embedded within abundant fibrous stroma. The tumor essentially resembles fibrosarcoma.* **(Right)** *High magnification of malignant solitary fibrous tumor of the pleura shows necrotic and dying spindle tumor cells and abundant scattered apoptotic bodies. Very few viable spindle tumor cells are seen in this field.*

Tumor Cell Necrosis

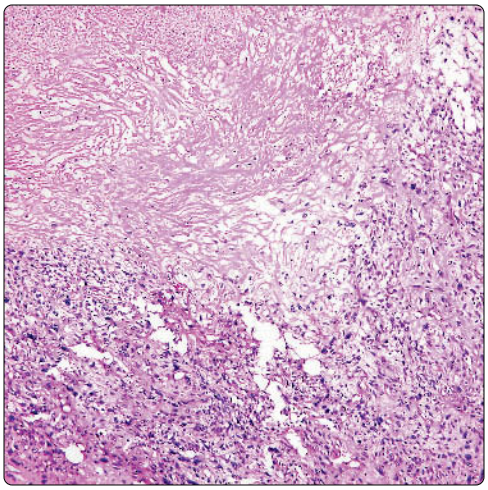

Spindle Cell Area

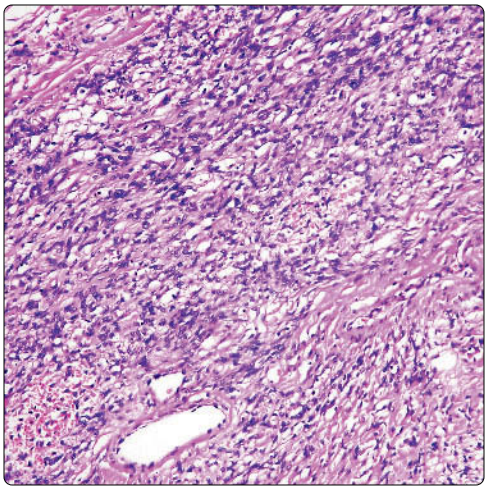

(Left) *Malignant solitary fibrous tumor of the pleura shows extensive areas of tumor cell necrosis (top). The viable portions of the tumor (bottom) are composed of an atypical spindle cell proliferation with collagenized stroma.* **(Right)** *Area of malignant solitary fibrous tumor shows a spindle cell population with preservation of the features of conventional solitary fibrous tumor and only early evidence of cytologic atypia.*

Fibrosarcoma-Like Appearance

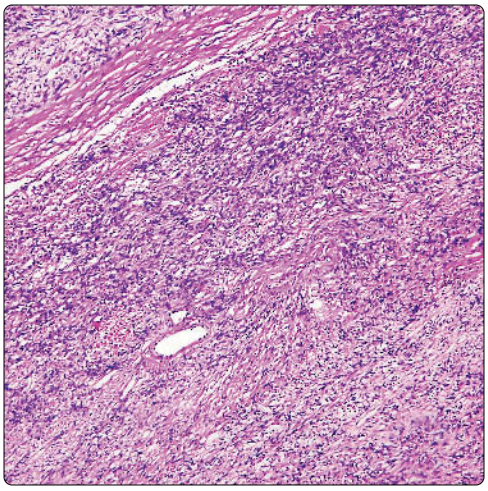

Myxoid Changes

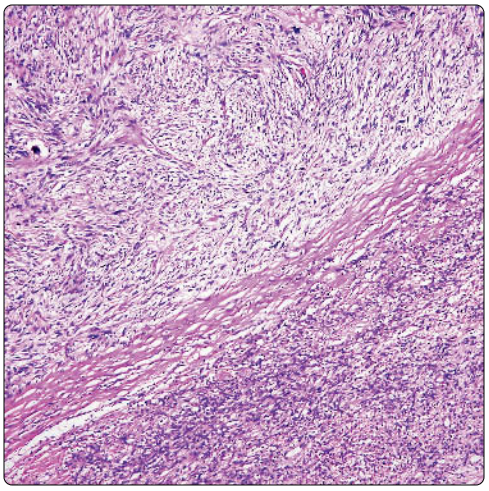

(Left) *Malignant solitary fibrous tumor of pleura shows fascicles of atypical spindle cells reminiscent of fibrosarcoma. Some of the original architecture of solitary fibrous tumor is still preserved in this area.* **(Right)** *Malignant solitary fibrous tumor of the pleura shows 2 distinct areas; a portion of the tumor (top) shows some myxoid stromal features and contains scattered large, atypical tumor cells, while a portion of the tumor (bottom) shows increased cellularity and atypia.*

Focus of Necrosis

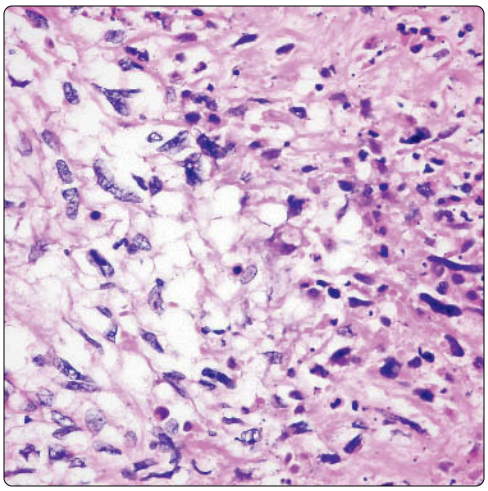

Pleomorphic Tumor Cells

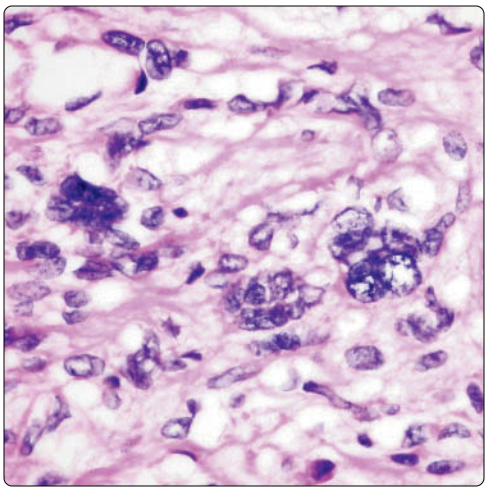

(Left) *Area of malignant solitary fibrous tumor shows viable tumor surrounded by extensive area of tumor cell necrosis. The viable tumor cells (left) show a dispersed chromatin pattern with prominent eosinophilic nucleoli.* **(Right)** *Malignant solitary fibrous tumor shows marked cytologic atypia with large, multinucleated tumor cells with vesicular and hyperchromatic nuclei surrounded by mononuclear oval to spindle atypical cells embedded in collagenous stroma.*

Smooth Muscle Tumors of Pleura

KEY FACTS

CLINICAL ISSUES

- Incidence
  - Exceedingly rare tumors in pleura
  - Tumor affects individuals in wide range of ages: 20-70 years
- Symptoms
  - Chest pain
  - Empyema
  - Asymptomatic
  - Dyspnea
  - Cough

MACROSCOPIC

- Pleural-based tumors
- Diffuse involvement of pleura can occur

MICROSCOPIC

- Spindle cell proliferation
- Fascicular pattern
- Variable mitotic activity
- Necrosis

TOP DIFFERENTIAL DIAGNOSES

- Solitary fibrous tumor
  - Shows positive staining for CD34 and Bcl-2
  - Shows different growth patterns in same tumor
- Peripheral nerve sheath tumor
  - May show positive staining for S100 protein
  - Would be most unusual for PNST to show positive staining for desmin &/or smooth muscle actin
- Desmoid tumor
  - Spindle cell proliferation of desmoid tumor is fibroblastic
  - Would be unusual to show strong positive staining for desmin or smooth muscle actin

Spindle and Epithelioid Areas

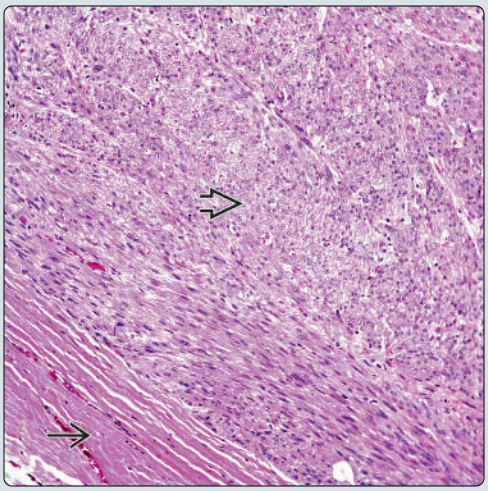

Focal Clear Cells

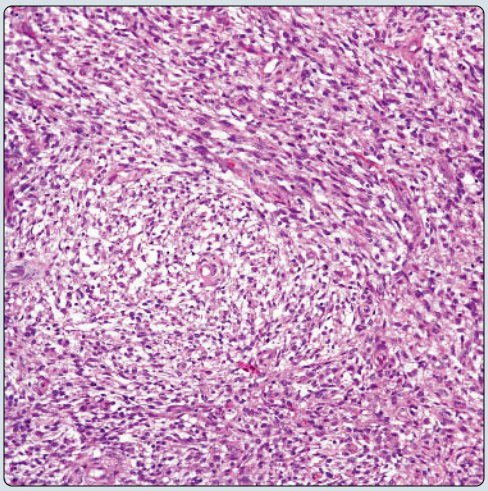

(Left) *Pleural leiomyosarcoma shows the classic fascicular growth pattern composed of spindle cells. One is still able to recognize some residual pleural tissue.* **(Right)** *Leiomyosarcoma shows the classic fascicular growth pattern admixed with areas in which the tumor cells have some clearing of the cytoplasm.*

Mitotic Activity

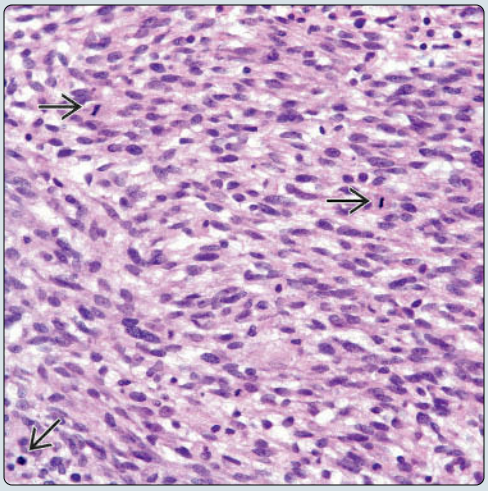

Spindle Cell Proliferation

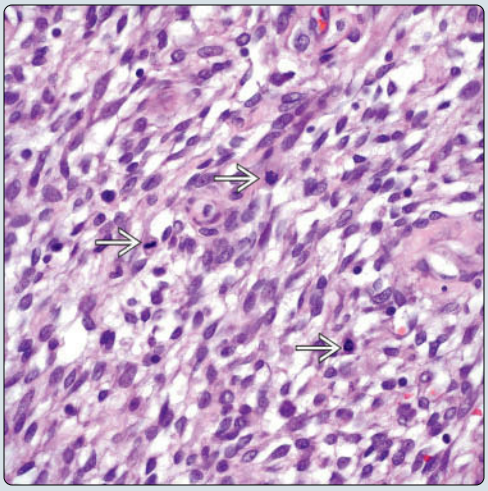

(Left) *Higher magnification of a pleural leiomyosarcoma shows a spindle cell proliferation with nuclear atypia and scattered mitotic figures.* **(Right)** *Spindle cell proliferation with easily identifiable mitotic figures is shown. In this high-power field, 3 mitotic figures are present.*

TERMINOLOGY

Synonyms

- Leiomyoma, leiomyosarcoma

Definitions

- Spindle cell tumor with muscle differentiation

CLINICAL ISSUES

Epidemiology

- Incidence
  - Exceedingly rare tumors in pleura
- Age
  - Tumor affects individuals in wide range of ages: 20-70 years
- Sex
  - No apparent gender predilection

Presentation

- Chest pain
- Dyspnea
- Cough
- Empyema
- Asymptomatic

Treatment

- Surgical approaches
  - Complete surgical resection
- Adjuvant therapy
  - In high-grade tumors, chemotherapy may be considered

Prognosis

- Depends on grade of tumor
  - Higher grade tumors have poor prognosis

IMAGING

General Features

- Pleural-based mass
- Thickening of pleura
- Absent intrapulmonary mass
- Pleural effusion

MACROSCOPIC

General Features

- Pleural-based tumors
- Diffuse involvement of pleura can occur
- Firm, white, and homogeneous surface
- Areas of hemorrhage &/or necrosis may be present

Size

- 10-18 cm

MICROSCOPIC

Histologic Features

- Spindle cell proliferation
- Fascicular pattern
- Variable mitotic activity
- Variable nuclear atypia
- Necrosis
- Hemorrhage

Predominant Pattern/Injury Type

- Sarcomatoid

Predominant Cell/Compartment Type

- Myoid

ANCILLARY TESTS

Electron Microscopy

- Ultrastructural studies may show
  - Cytoplasmic myofilaments with focal densities
  - Abundant mitochondria
  - Bundles of intermediate filaments
  - Prominent rER

DIFFERENTIAL DIAGNOSIS

Solitary Fibrous Tumor

- Positive staining for CD34 and Bcl-2
- Different growth patterns in same tumor
- Would be unusual for solitary fibrous tumor to show strong positive reaction for desmin and smooth muscle actin

Peripheral Nerve Sheath Tumor

- May show positive staining for S100 protein
- Would be most unusual for peripheral nerve sheath tumor to show positive staining for desmin &/or smooth muscle actin

Desmoid Tumor

- Spindle cell proliferation of desmoid tumor is fibroblastic
- Desmoid tumors would be unusual to show strong positive staining for desmin or smooth muscle actin

Malignant Mesothelioma, Sarcomatoid Type

- Mesothelioma may show positive staining for keratin, keratin 5/6, and calretinin, among others
- Ultrastructural studies for mesothelioma would show epithelial differentiation

Sarcomatoid Carcinoma

- Likely will show intrapulmonary involvement
- May show staining for keratin 7, TTF-1, &/or p40

Metastatic Leiomyosarcoma

- Clinical history is of utmost importance
- Intrapulmonary leiomyosarcoma may involve pleura by direct extension

Synovial Sarcoma, Monophasic Type

- Would show positive staining for keratin, EMA, and Bcl-2
- Has specific molecular signature

DIAGNOSTIC CHECKLIST

Clinically Relevant Pathologic Features

- Mitotic rate

Pathologic Interpretation Pearls

- Fascicular growth pattern
- Interlacing fascicles of elongated cells intersecting at right angles
- Mitotic count

Immunohistochemistry

Antibody	Reactivity	Staining Pattern	Comment
Desmin	Positive	Cytoplasmic	Staining will vary depending on grade of tumor
Actin-sm	Positive	Cytoplasmic	Variable staining; can also be positive in some carcinomas
Caldesmon	Positive	Cytoplasmic	Stronger staining in lower grade tumors
CD34	Negative		
CD31	Negative		
STAT6	Negative		
Bcl-2	Negative		
S100	Negative		
CK-PAN	Negative		May be positive in low-grade tumors
EMA	Negative		
CK5/6	Negative		
CK7	Negative		
Calretinin	Negative		
p40	Negative		
TTF-1	Negative		
D2-40	Negative		
FLI-1	Negative		
SOX10	Negative		
Myoglobin	Negative		
WT1	Negative		

Molecular Features

FISH/Cytogenetics	Result
Alternative lengthening of telomerase (ALT) phenotype	May be associated with aggressive histology and poor outcome
MDM12 protein expression	May have oncogene role

GRADING

Uncertain Malignant Potential to Low Grade

- Spindle cells
- Fascicular growth pattern
- Mild nuclear atypia
- Scattered mitotic figures
- Absent necrosis &/or hemorrhage

Intermediate Grade

- Spindle cells
- Fascicular growth pattern
- Moderate nuclear atypia
- Necrosis &/or hemorrhage are present
- Mitotic activity easily identified
  - < 10 per 10 HPF

High Grade

- Disorganized spindle cell proliferation
- Prominent nuclear atypia
- Atypical mitosis easily identified and numerous
- Necrosis &/or hemorrhage easily identified

SELECTED REFERENCES

1. Rais G et al: Primary pleural leiomyosarcoma with rapid progression and fatal outcome: a case report. J Med Case Rep. 6:101, 2012
2. Andino L et al: Pleuropulmonary desmoid tumors: immunohistochemical comparison with solitary fibrous tumors and assessment of beta-catenin and cyclin D1 expression. Arch Pathol Lab Med. 130(10):1503-9, 2006
3. Rdzanek M et al: Spindle cell tumors of the pleura: differential diagnosis. Semin Diagn Pathol. 23(1):44-55, 2006
4. Al-Daraji WI et al: Primary smooth muscle tumor of the pleura: a clinicopathological case report with ultrastructural observations and a review of the literature. Ultrastruct Pathol. 29(5):389-98, 2005
5. Gladish GW et al: Primary thoracic sarcomas. Radiographics 22(3):621-37, 2002.
6. Takeshima Y et al: Extra-abdominal desmoid tumor presenting as an intrathoracic tumor: case report and literature review. Pathol Int. 51(10):824-8, 2001
7. Kubota Y et al: Myofibroblastic sarcoma of the pleura in a pig. J Vet Med Sci. 62(8):913-6, 2000
8. Proca DM et al: Smooth muscle tumor of the pleura. A case report and review of the literature. Arch Pathol Lab Med. 124(11):1688-92, 2000
9. Wilson RW et al: Desmoid tumors of the pleura: a clinicopathologic mimic of localized fibrous tumor. Mod Pathol. 12(1):9-14, 1999
10. Moran CA et al: Smooth muscle tumours of the pleura. Histopathology. 30(1):97-8, 1997

Epithelioid Areas

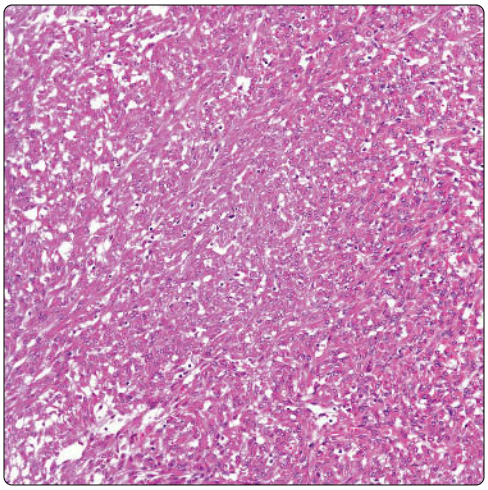

Low-Grade Leiomyosarcoma

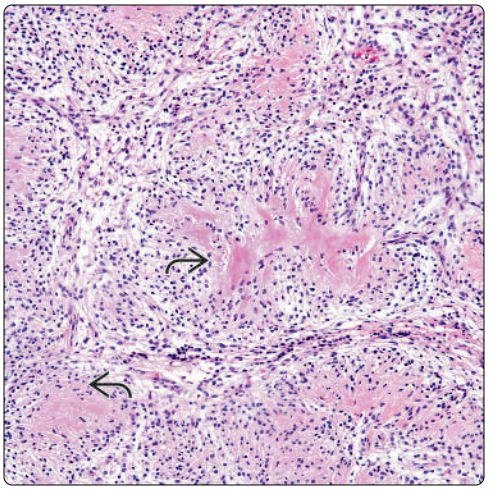

(Left) *Low-power view of a low-grade leiomyosarcoma of the pleura shows a spindle cell proliferation with striking muscle appearance. Note the absence of hemorrhage or necrosis.* **(Right)** *Low-grade leiomyosarcoma shows a bland spindle cell proliferation with areas resembling the so-called amianthoid fibers.*

Neural-Like Pattern

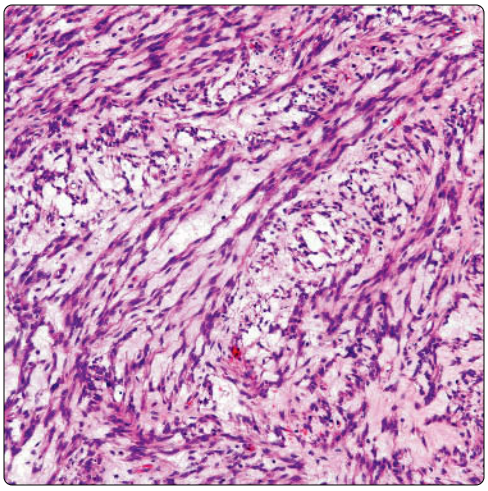

Pseudoglandular Appearance

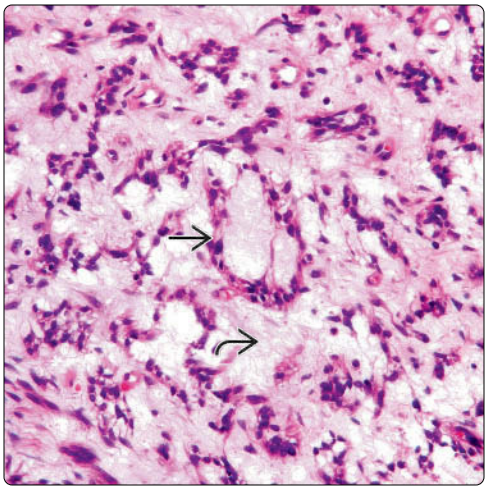

(Left) *Low-grade leiomyosarcoma of the pleura shows a spindle cell proliferation closely mimicking a neural tumor. Necrosis and hemorrhage are absent.* **(Right)** *Low-grade leiomyosarcoma with areas mimicking a glandular space is shown with some myxoid changes.*

Cystic Changes

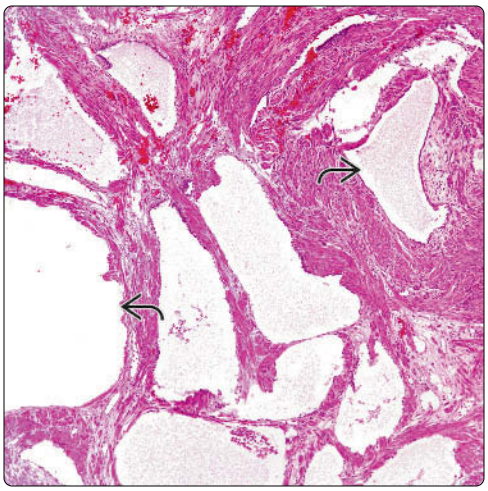

Solid and Cystic Areas

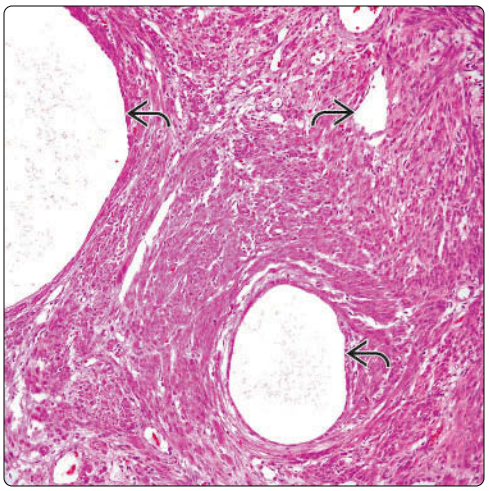

(Left) *Low-grade leiomyosarcoma shows prominent cystic changes. Some of these cystic structures may be lined by flattened epithelium.* **(Right)** *Low-grade leiomyosarcoma is seen with a more solid component and only focal small cystic structures. In these areas, the nuclear atypia and mitotic activity may not be prominent.*

Collagenous Stroma

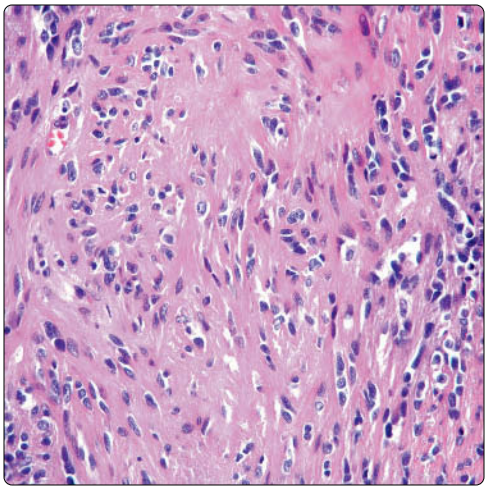

Mitotic Activity

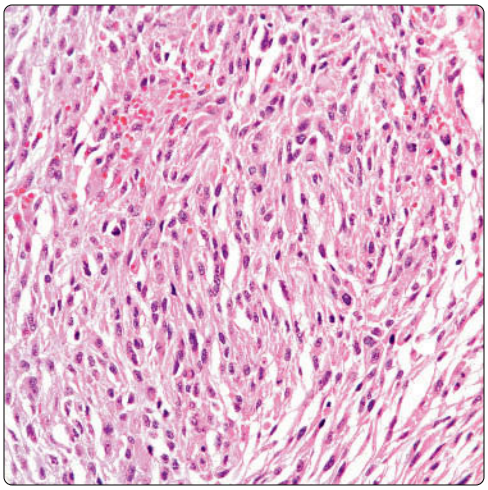

(Left) *Intermediate-grade leiomyosarcoma shows moderate nuclear atypia and spindle cells dissecting into collagenous tissue.* **(Right)** *Higher magnification shows mitotic activity and nuclear atypia. Note that the tumor still preserves a good fascicular arrangement, but the presence of nuclear pleomorphism and mitotic activity is a clue for a higher grade tumor.*

Extensive Necrosis

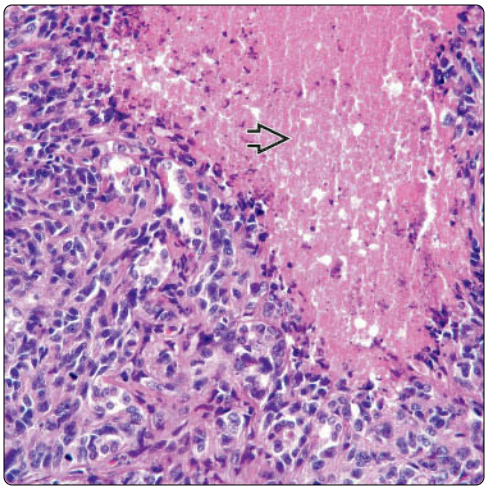

Nuclear Atypia and Mitosis



(Left) *High-grade leiomyosarcoma of the pleura shows areas of necrosis ⇨. Note the marked nuclear atypia, cellular pleomorphism, and mitotic activity.* **(Right)** *Higher magnification of a high-grade leiomyosarcoma shows prominent cellular and nuclear atypia as well as increased mitotic activity ↷.*

Fascicular Growth Pattern

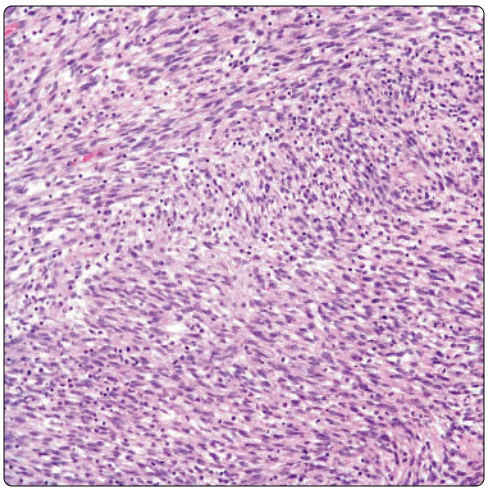

Thrombotic Vessels

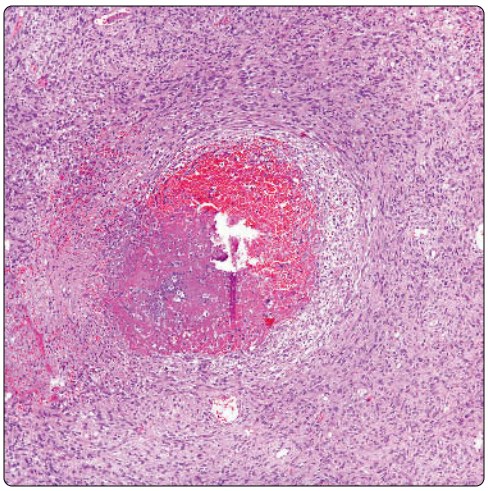

(Left) *More conventional features of leiomyosarcoma of the pleura show intersecting fascicles of tumor cells, which are typical for leiomyosarcomas.* **(Right)** *Leiomyosarcoma shows areas of thrombosed vessels. However, a viable tumor is around the vessel.*

Extensive Necrosis

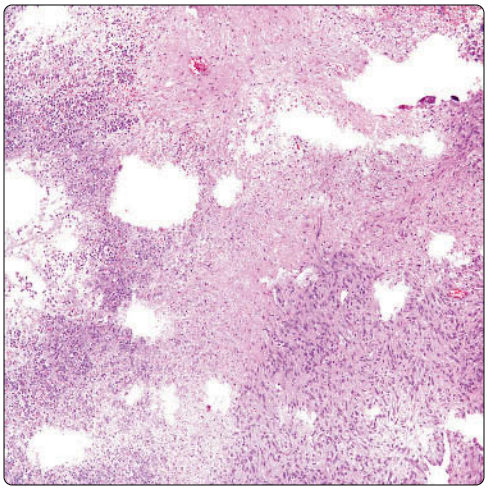

Solid Spindle Cell

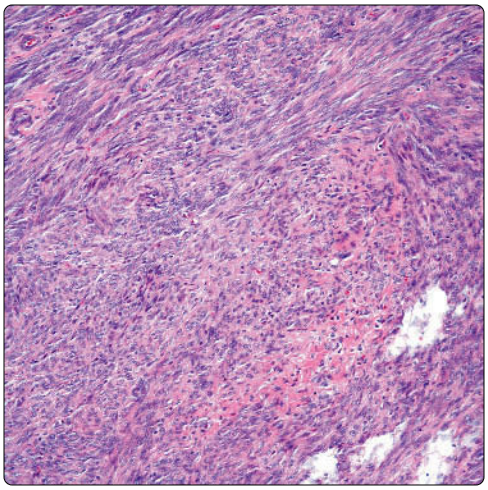

(Left) *Leiomyosarcoma shows extensive necrosis. Only a small focal area of the viable tumor is present, enough for diagnosis.* **(Right)** *Leiomyosarcoma shows a solid spindle cell proliferation and areas of fibrocollagenous stroma. Note the presence of nuclear atypia.*

Solid Growth Pattern

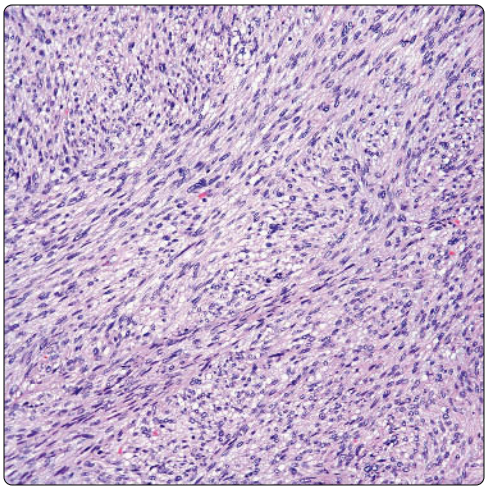

Positive Staining for Caldesmon

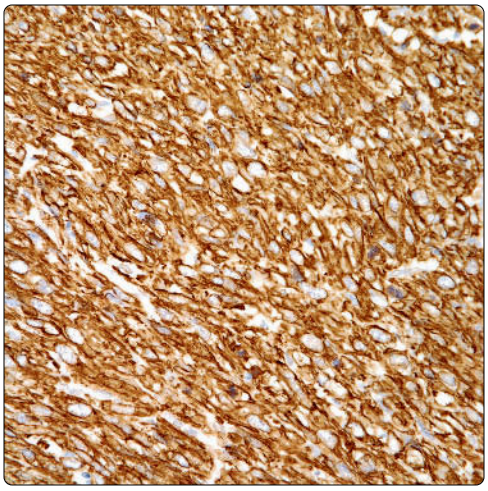

(Left) *Leiomyosarcoma shows a solid growth pattern composed of interlacing fascicles of tumor cells. Mitotic activity and nuclear atypia are present.* **(Right)** *Immunohistochemical stain for caldesmon in leiomyosarcoma shows a strong positive reaction in the spindle tumor cells.*

Positive Staining for Desmin

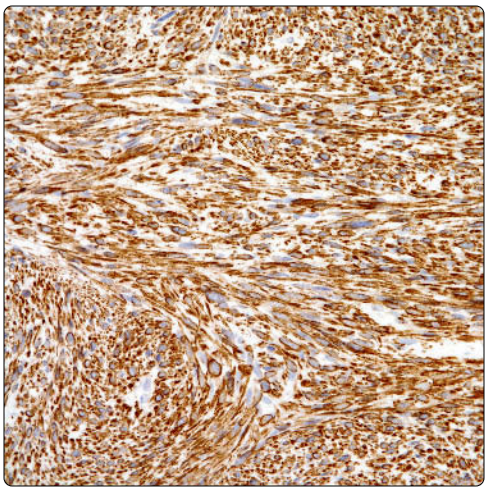

Positive Staining for Actin

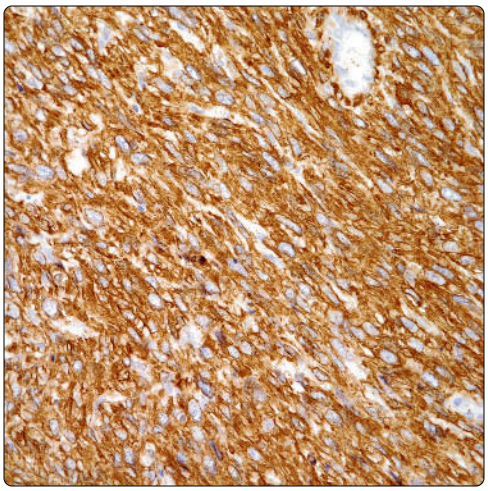

(Left) *Immunohistochemical stain for desmin shows positive staining in the spindle cells of leiomyosarcoma.* **(Right)** *Immunohistochemical stain for actin shows a strong positive reaction in the spindle cells of leiomyosarcoma.*

Desmoplastic Small Round Cell Tumor

KEY FACTS

CLINICAL ISSUES

- Most common in children and young adults (median age: 20 years)
- Male predilection
- Large pleural-based mass on chest x-rays and CT scans
- Poor prognosis
- Median survival is 24 months

MACROSCOPIC

- Large, bulky tumors (> 10 cm in greatest dimension)
- Firm, homogeneous cut surface with hemorrhage and necrosis

MICROSCOPIC

- Nests, trabeculae, or sheets of small round blue cells embedded in abundant desmoplastic fibrous stroma
- Rosette-like structures
- Small to intermediate-sized round to oval cells with scant cytoplasm
- High mitotic rate, often with atypical (abnormal) mitoses
- Staining pattern is polyphenotypic
- Vimentin, keratin, desmin, EMA, and WT1 consistently stain tumor cells in ~ 90% of cases
- Staining pattern for desmin and vimentin is characteristically dot-like and paranuclear
- May also show focal positivity for CD56, NSE, chromogranin, synaptophysin, and S100 protein
- Shows t(11:22)(p13;q12), similar to Ewing sarcoma/PNET
- Unlike Ewing sarcoma, site on chromosome 11 is *WT1* gene rather than *FLI1* gene
- Nests may display peripheral palisading of tumor cells and retraction artifact

TOP DIFFERENTIAL DIAGNOSES

- Peripheral neuroectodermal tumor/Ewing sarcoma
- Metastatic neuroendocrine carcinoma
- Malignant lymphoma

Scanning Magnification

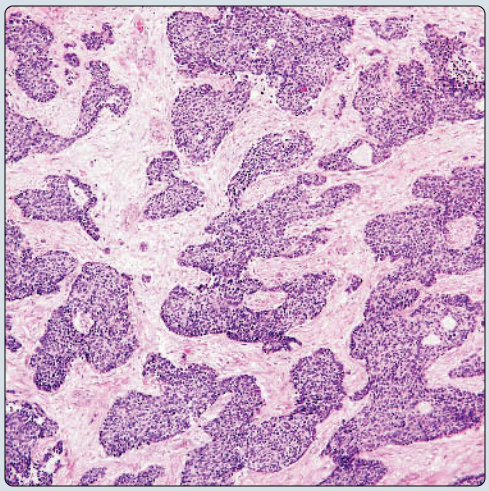

Higher Magnification

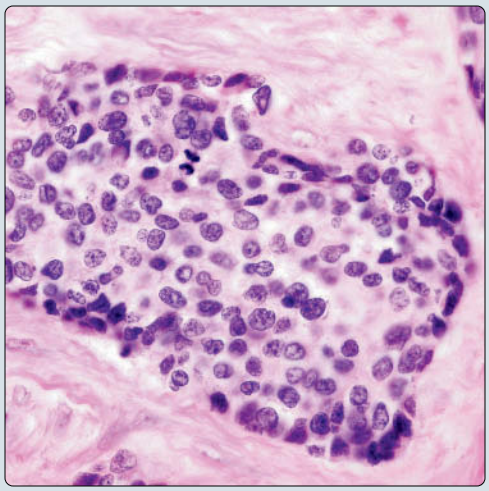

(Left) *Desmoplastic small round cell tumor (DSRCT) of the pleura shows islands of small round blue tumor cells surrounded by abundant, paucicellular, and desmoplastic connective tissue stroma.* **(Right)** *Small island of tumor cells in DSRCT shows primitive small blue cells with dispersed nuclear chromatin, small inconspicuous nucleoli, and occasional mitoses.*

Cytokeratin Immunostaining

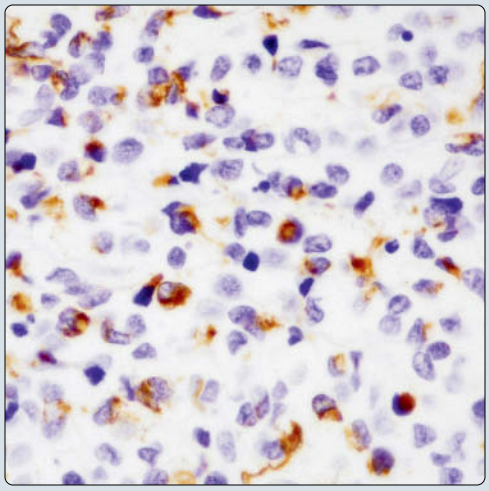

Desmin Immunohistochemistry

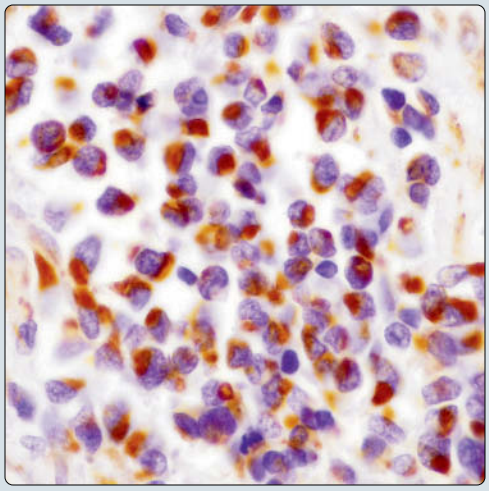

(Left) *Immunohistochemical stains with pan-cytokeratin shows dot-like paranuclear staining of the tumor cells.* **(Right)** *Immunohistochemical staining shows strong dot-like, paranuclear positivity for desmin in the tumor cells.*

TERMINOLOGY

Abbreviations

- Desmoplastic small round cell tumor (DSRCT)

Synonyms

- Desmoplastic small cell tumor with divergent differentiation
- Polyphenotypic small round cell tumor

Definitions

- Malignant neoplasm arising in serosal surfaces with distinctive histology composed of primitive small round blue cells embedded in abundant desmoplastic stroma

ETIOLOGY/PATHOGENESIS

Unknown

- May represent primitive mesothelial neoplasm (i.e., "mesoblastoma")

CLINICAL ISSUES

Presentation

- Male predilection
- Large pleural-based mass on chest x-rays and CT scans
- Most common in children and young adults (median age: 20 years)

Treatment

- Surgical excision and chemotherapy

Prognosis

- Poor prognosis with frequent local recurrence; rarely metastasizes
- Median survival is 24 months

MACROSCOPIC

General Features

- Large, bulky tumors (> 10 cm in greatest dimension) that often grow in multinodular fashion
- Firm, homogeneous cut surface with hemorrhage and necrosis

MICROSCOPIC

Histologic Features

- Nests, cords, or sheets of small round blue cells embedded in abundant fibrous stroma
- Nests may display peripheral palisading of tumor cells and retraction artifact

Cytologic Features

- Small to intermediate-sized round to oval cells with scant cytoplasm
- Round to oval, hyperchromatic nuclei with small nucleoli
- High mitotic rate, often with atypical (abnormal) mitoses

ANCILLARY TESTS

Immunohistochemistry

- Vimentin, keratin, desmin, EMA, and WT1 consistently stain tumor cells in > 90% of cases
- Staining pattern for desmin and vimentin is characteristically dot-like and paranuclear
- May also show positivity for CD56, CD99, NSE, chromogranin, synaptophysin, and S100 protein

Genetic Testing

- Shows t(11:22)(p13;q12), similar to Ewing sarcoma/peripheral neuroectodermal tumor (PNET)

DIFFERENTIAL DIAGNOSIS

Peripheral Neuroectodermal Tumor/Ewing Sarcoma

- Similar cell population in both, but prominent desmoplastic stroma is not seen in PNET
- PNET does not show polyphenotypic expression of markers such as desmin, keratin, and WT1
- PNET is strongly positive for CD99 in almost 100% of cases; CD99 is only seen in 20% of cases of DSRCT
- Translocation in PNET is t(11:22)(p24;q12); translocation in DSRCT is t(11:22)(p13;q12)

Metastatic Neuroendocrine Carcinoma

- Neuroendocrine carcinoma stains positive for neuroendocrine markers, such as chromogranin, CD56, and synaptophysin
- Neuroendocrine carcinomas do not express desmin or WT1

Malignant Lymphoma

- Lymphomas show dyscohesive pattern of growth without striking desmoplasia
- Expresses CD45 and variety of other lymphoid markers, such as CD3, CD20, CD30, CD43, etc.
- Does not express keratin, desmin, WT1, and EMA

DIAGNOSTIC CHECKLIST

Clinically Relevant Pathologic Features

- Preferentially affects children and young adults, although it can also occur in older patients

Pathologic Interpretation Pearls

- Distinctive combination of nests of small round blue cells surrounded by abundant desmoplastic fibrous stroma
- Distinctive pattern of immunohistochemical staining: Keratin, EMA, desmin, and WT1 positive
- Distinctive cytogenetic translocation, t(11:22)(p13;q12)

SELECTED REFERENCES

1. Machado I et al: Defining Ewing and Ewing-like small round cell tumors (SRCT): the need for molecular techniques in their categorization and differential diagnosis. A study of 200 cases. Ann Diagn Pathol. 22:25-32, 2016
2. Lettieri CK et al: Incidence and outcomes of desmoplastic small round cell tumor: results from the surveillance, epidemiology, and end results database. J Cancer Epidemiol. 2014:680126, 2014
3. Lae ME et al: Desmoplastic small round cell tumor: a clinicopathologic, immunohistochemical, and molecular study of 32 tumors. Am J Surg Pathol. 26(7):823-35, 2002
4. Ordóñez NG: Desmoplastic small round cell tumor: I: a histopathologic study of 39 cases with emphasis on unusual histological patterns. Am J Surg Pathol. 22(11):1303-13, 1998
5. Parkash V et al: Desmoplastic small round cell tumor of the pleura. Am J Surg Pathol. 19(6):659-65, 1995
6. Ladanyi M et al: Fusion of the EWS and WT1 genes in the desmoplastic small round cell tumor. Cancer Res. 54(11):2837-40, 1994

Islands of Tumor Cells

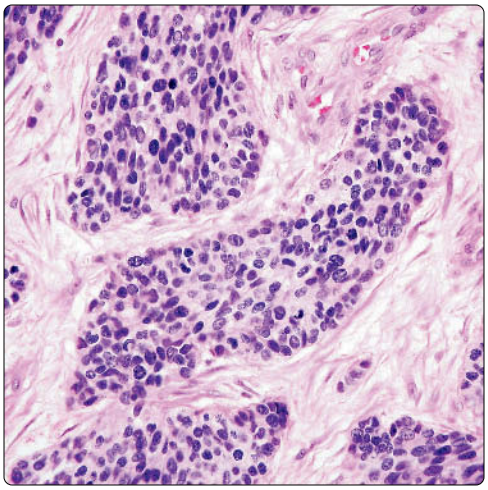

Tumor Cells, Higher Magnification

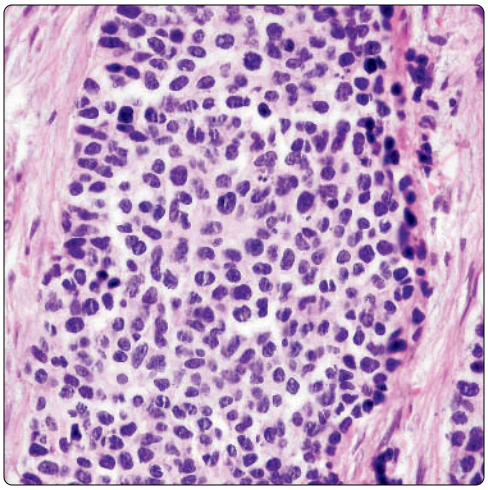

(Left) *DSRCT shows irregular islands of tumor cells surrounded by dense fibroconnective tissue stroma. There is a hint of peripheral palisading in the tumor cell islands.* **(Right)** *High magnification of DSRCT of the pleura shows a primitive cell population of small round blue cells with scant cytoplasm and scattered mitotic figures. The tumor lobules are sharply demarcated from the surrounding connective tissue stroma.*

Cytokeratin Immunohistochemistry

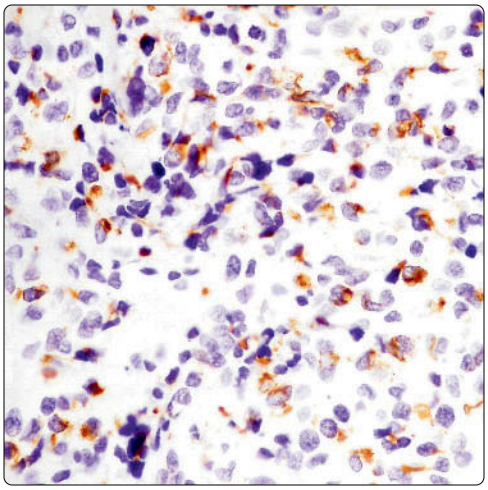

Desmin Immunohistochemistry

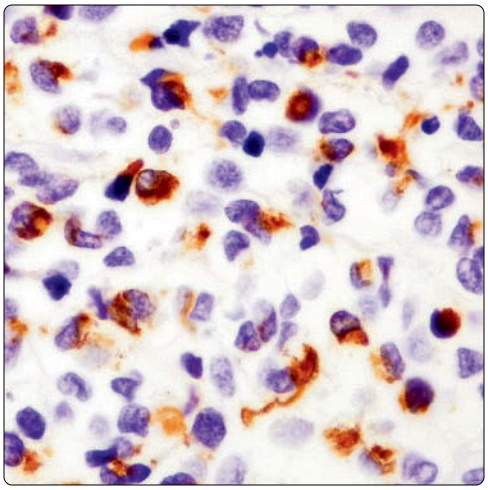

(Left) *Immunohistochemical staining of DSRCT of the pleura for cytokeratin stain shows cytoplasmic positivity in the majority of the tumor cells for this marker.* **(Right)** *Immunohistochemical staining of DSRCT of the pleura for desmin shows cytoplasmic positivity in the majority of the tumor cells. The staining pattern is dot-like and paranuclear (Golgi zone) and very distinctive for this tumor.*

Vimentin Immunohistochemistry

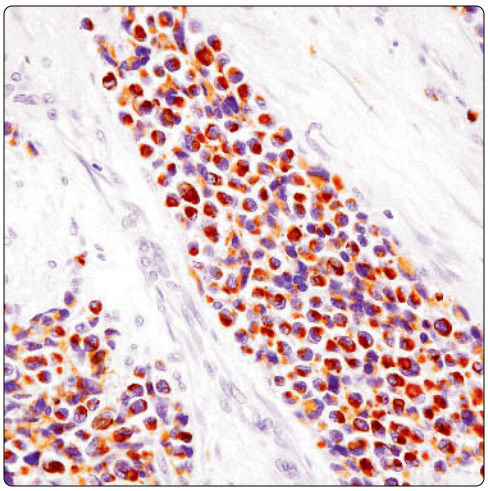

CD99 Negative Staining

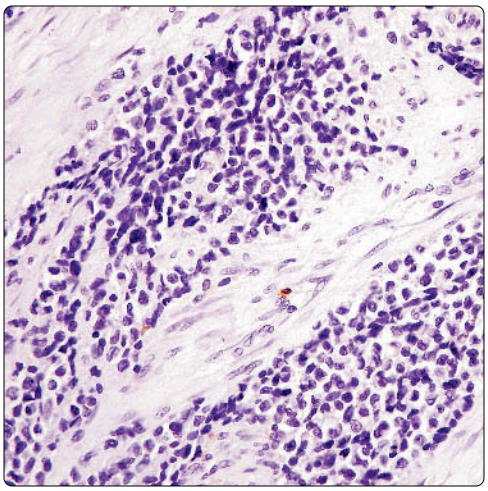

(Left) *Immunohistochemical staining of DSRCT of the pleura for vimentin shows the majority of the tumor cells are positive for this marker and display a distinctive dot-like, paranuclear (Golgi zone) staining pattern.* **(Right)** *Immunohistochemical staining of DSRCT for CD99 shows a negative reaction in the tumor cells. This serves to distinguish this tumor from peripheral neuroectodermal tumor/Ewing sarcoma and lymphoblastic lymphoma.*

Lobular Architecture

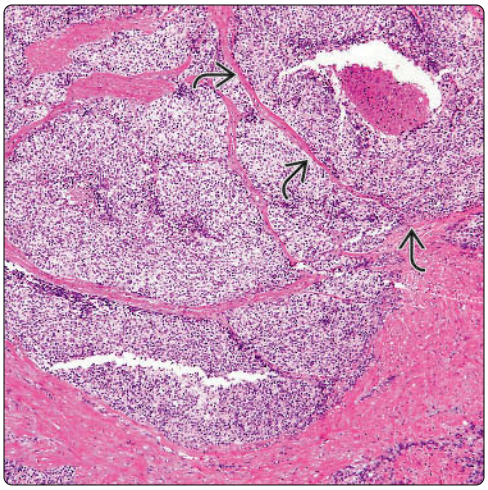

Higher Magnification

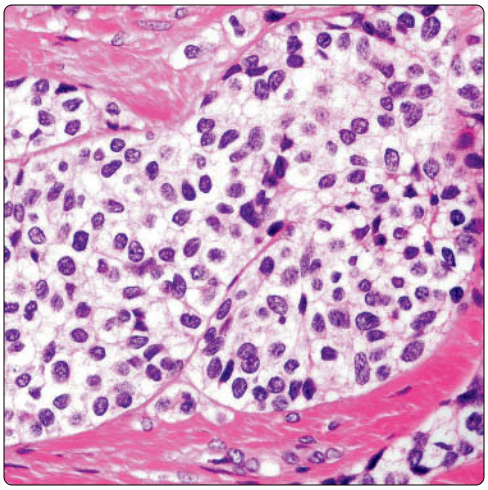

(Left) *DSRCT of the pleura shows lobular architecture with foci of comedonecrosis. The lobules are separated by broad bands of dense fibroconnective tissue.* **(Right)** *High magnification of DSRCT of the pleura shows islands of primitive small blue cells surrounded by a clear cytoplasmic halo. Tumors with this feature can be confused for a metastasis from clear cell carcinoma.*

Stromal Retraction Artifact

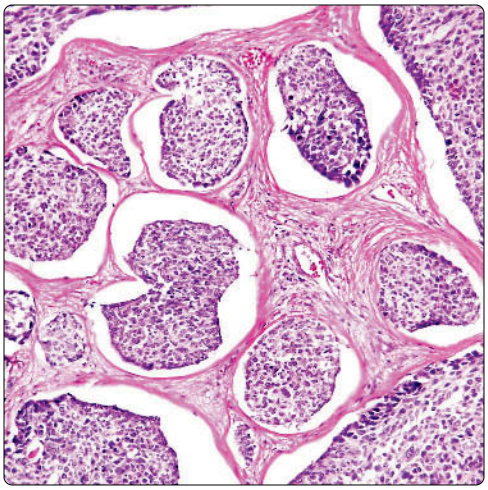

Higher Magnification, Retraction Artifact

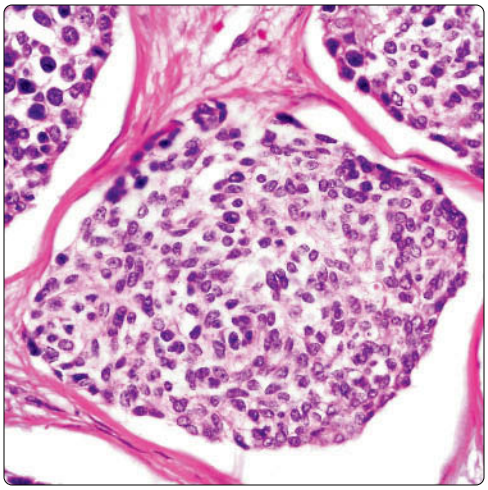

(Left) *DSRCT shows islands of small blue cells with prominent stromal retraction artifact. The nesting appearance in this tumor is reminiscent of the zellballen or neuroendocrine growth pattern observed in neuroendocrine neoplasms.* **(Right)** *High magnification of DSRCT shows a nest of small round blue tumor cells surrounded by bands of collagenous stroma. This image can be confused for a neuroendocrine tumor.*

Spindling of Tumor Cells

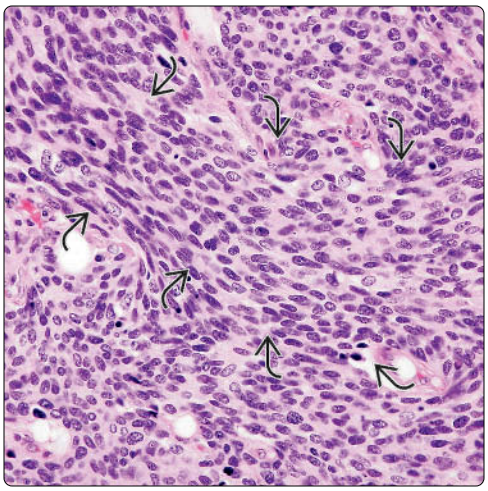

Stromal Hyalinization

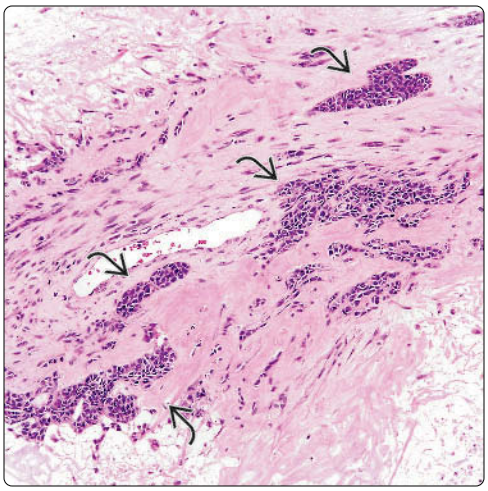

(Left) *DSRCT shows spindling of the tumor cells. Tumors with these features can be mistaken for other types of spindle cell tumors involving the pleura, including sarcomatoid malignant mesothelioma.* **(Right)** *DSRCT shows extensive stromal hyalinization with only small, residual islands of tumor cells present in the stroma. Such tumors can be mistaken for metastases of poorly differentiated carcinoma.*

This page intentionally left blank

PART II
SECTION 3

Other Lesions of Pleura

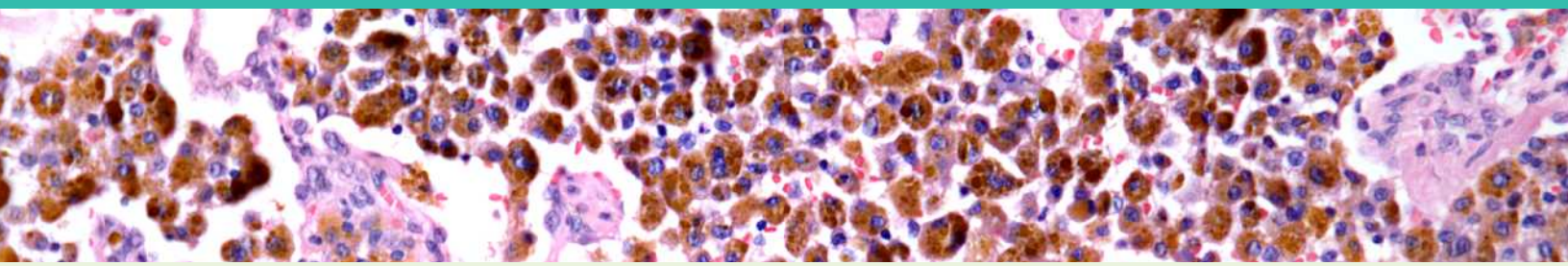

Pleural Endometriosis 626

KEY FACTS

TERMINOLOGY

- Endometrioma, deciduosis

CLINICAL ISSUES

- Incidence
  - Unusual occurrence in thoracic cavity
  - Predominantly in women of reproductive age
  - May be seen in older postmenopausal women
- Symptoms
  - Cough
  - Pleuritic pain
  - Shortness of breath
  - Hemoptysis

IMAGING

- Pleuropulmonary nodules
- Pleural-based mass
- Intrapulmonary nodules

MICROSCOPIC

- Glands in proliferative endometrial phase
- Plasma cells in stromal component
- Medium-sized dilated vessels in stromal component
- Myxoid or edematous changes in stroma
- Cystic changes

TOP DIFFERENTIAL DIAGNOSES

- Pleuropulmonary blastoma
  - More common in younger individuals (< 20 years old)
  - Commonly cystic neoplasm
- Adenocarcinoma
  - Glandular proliferation in endometriosis is embedded in cellular stroma
  - Glands in endometriosis have appearance of proliferative phase of endometrial cycle
- Biphasic pulmonary blastoma
  - Both components in biphasic blastoma are malignant

Glandular Proliferation

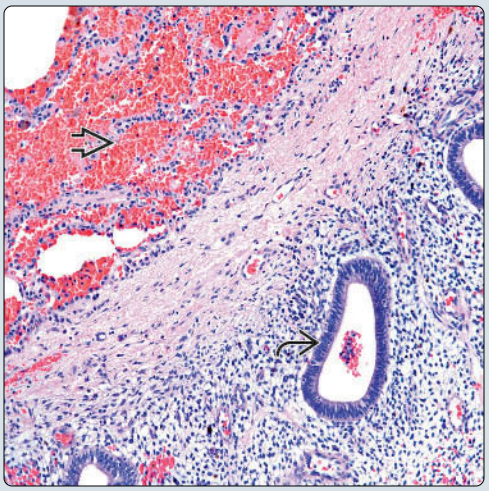

Cellular Stroma

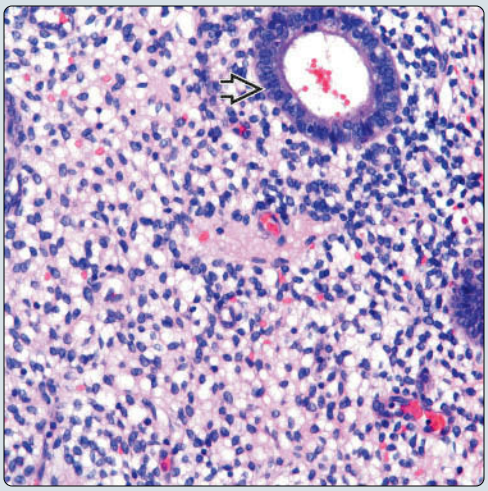

(Left) *Pleuropulmonary endometriosis shows the classic features of endometrial glands ⇨ embedded in a cellular stroma. Note the presence of adjacent lung parenchyma ⇨ with congestion.* **(Right)** *Higher magnification of pulmonary endometriosis shows a glandular structure ⇨ with the appearance of an endometrial gland in the proliferative phase embedded in a cellular stroma.*

Dilated Glands

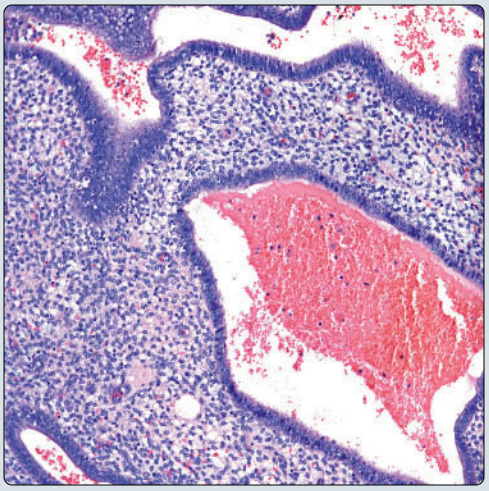

Decidual Reaction

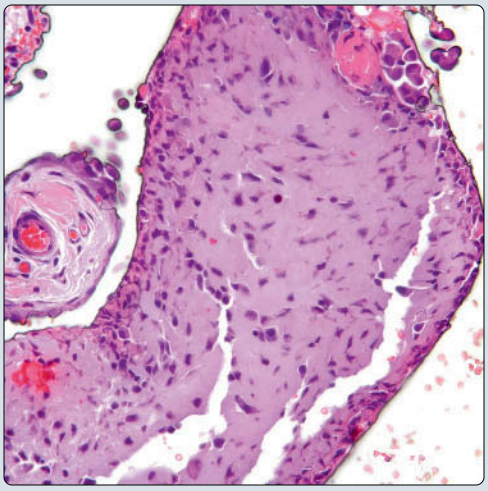

(Left) *Dilated glandular elements in pulmonary endometriosis show blood in the lumen. Note the stromal tissue that looks "immature." In some cases, these findings can be confused with pleuropulmonary blastoma.* **(Right)** *High-power magnification of pulmonary endometriosis shows exclusively decidualized tissue. There is no cellular atypia or mitotic activity. However, this process can be easily confused with hemangioendothelioma; thus the use of immunohistochemistry is helpful.*

TERMINOLOGY

Synonyms

- Endometrioma, deciduosis

Definitions

- Benign glandular proliferation of ectopic endometrial tissue in pleura

CLINICAL ISSUES

Epidemiology

- Incidence
  - Unusual occurrence in thoracic cavity
- Age
  - Predominantly in women of reproductive age
  - May be see in older postmenopausal women

Presentation

- Cough
- Pleuritic pain
- Shortness of breath
- Hemoptysis

Treatment

- Surgical approaches
  - Complete surgical resection

Prognosis

- Excellent

IMAGING

General Features

- Pleuropulmonary nodules
- Pleural-based mass
- Intrapulmonary nodule

MICROSCOPIC

Histologic Features

- Glandular proliferation
- Glands in proliferative endometrial phase
- Glands with mitotic figures
- Mesenchymal-like stromal component
- Plasma cells in stromal component
- Medium-sized dilated vessels in stromal component
- Myxoid or edematous changes in stroma
- Cystic changes

Predominant Pattern/Injury Type

- Biphasic

Predominant Cell/Compartment Type

- Epithelial

DIFFERENTIAL DIAGNOSIS

Pleuropulmonary Blastoma

- More common in younger individuals (< 20 years old)
- Commonly intrapulmonary cystic neoplasm
- Epithelial component in both endometriosis and pleuropulmonary blastoma (PPB) is benign
- Spindle cell component in PPB is mesenchymal and commonly shows muscle differentiation
- Presence of scattered plasma cells is commonly seen in endometriosis
- Estrogen and progesterone receptors are positive in endometriosis and negative in PPB

Adenocarcinoma

- Glandular proliferation in endometriosis is embedded in cellular stroma
- Glands in endometriosis have appearance of proliferative phase of endometrial cycle
- Glandular component of endometriosis is benign

Biphasic Pulmonary Blastoma

- Both components in biphasic blastoma are malignant
- Mesenchymal component in blastoma is that of sarcoma
- Pulmonary blastoma generally is not cystic tumor

Biphasic Mesothelioma

- Both components of mesothelioma (epithelioid and sarcomatoid) are malignant
- Sarcomatoid component in mesothelioma would be more atypical and may show pleomorphic features
- Immunohistochemical studies will lead to correct interpretation

DIAGNOSTIC CHECKLIST

Clinically Relevant Pathologic Features

- Gross appearance

Pathologic Interpretation Pearls

- Glands with appearance of proliferative phase of endometrial cycle
- Cellular stromal component
- Myxoid changes of stroma
- Prominent dilated vessels in stroma
- Scattered plasma cells in stroma

SELECTED REFERENCES

1. Ghigna MR et al: Thoracic endometriosis: clinicopathologic updates and issues about 18 cases from a tertiary referring center. Ann Diagn Pathol. 19(5):320-5, 2015
2. Hwang SM et al: Clinical features of thoracic endometriosis: a single center analysis. Obstet Gynecol Sci. 58(3):223-31, 2015
3. Trehan K et al: Recurrent thoracic endometriosis with extensive adhesions after talc pleurodesis. Surgery. 158(6):1740-1, 2015
4. Augoulea A et al: Thoracic endometriosis syndrome. Respiration. 75(1):113-9, 2008
5. Costa F et al: [Thoracic endometriosis.] Rev Port Pneumol. 14(3):427-35, 2008
6. Kervancioglu S et al: Bronchial artery embolization in the management of pulmonary parenchymal endometriosis with hemoptysis. Cardiovasc Intervent Radiol. 31(4):824-7, 2008
7. Derman AY et al: Endometrioma presenting as a cavitary lung mass with intense 18F-FDG uptake on PET-CT. J Thorac Imaging. 22(2):172-5, 2007
8. Flieder DB et al: Pleuro-pulmonary endometriosis and pulmonary ectopic deciduosis: a clinicopathologic and immunohistochemical study of 10 cases with emphasis on diagnostic pitfalls. Hum Pathol. 29(12):1495-503, 1998
9. Karpel JP et al: Pulmonary endometriosis. Lung. 163(3):151-9, 1985
10. Foster DC et al: Pleural and parenchymal pulmonary endometriosis. Obstet Gynecol. 58(5):552-6, 1981

Chest Film

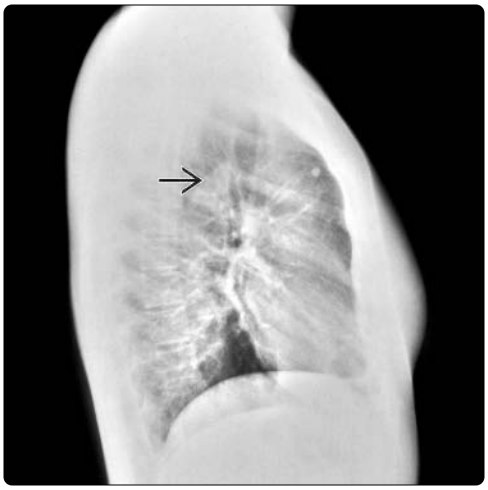

Macroscopic Features

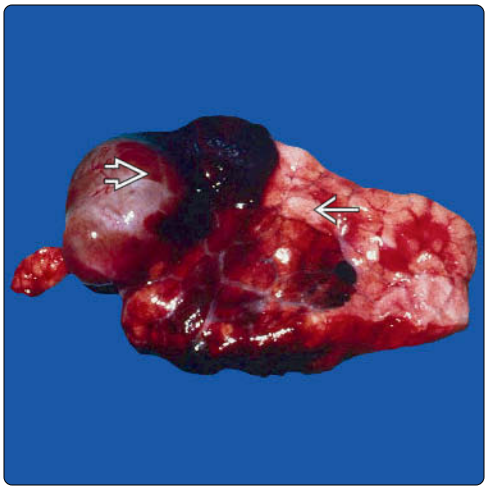

(Left) *Lateral view of a chest x-ray shows a pulmonary lesion of pulmonary endometriosis. However, there are not specific features for the diagnosis of endometriosis of the thoracopulmonary region.* **(Right)** *Gross photograph shows pulmonary endometriosis. Note the cystic hemorrhagic lesion attached to the lung parenchyma. Although cystic hemorrhagic changes raise the suspicion of endometriosis, histopathologic examination is required.*

Dilated Blood Vessels

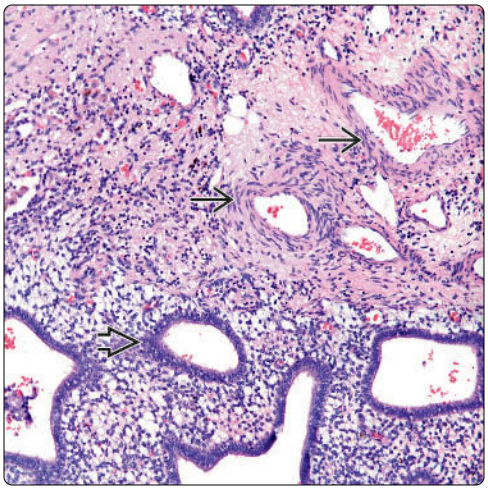

Cellular Stroma

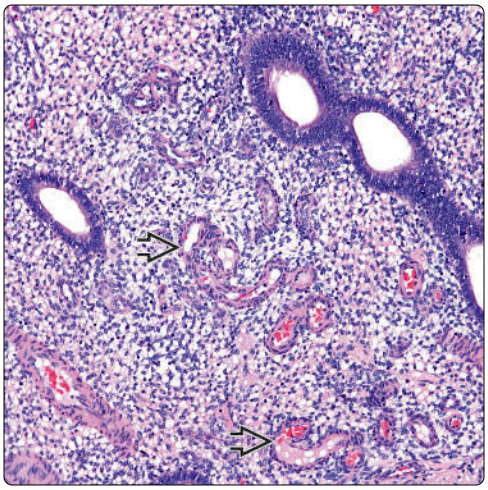

(Left) *Pulmonary endometriosis shows a biphasic cellular population, one composed of endometrial glands and the other composed of stromal elements with dilated blood vessels.* **(Right)** *Pleuropulmonary endometriosis shows typical features of endometrial gland embedded in a cellular stroma. Note the presence of numerous stromal vessels.*

Prominent Cellular Stroma

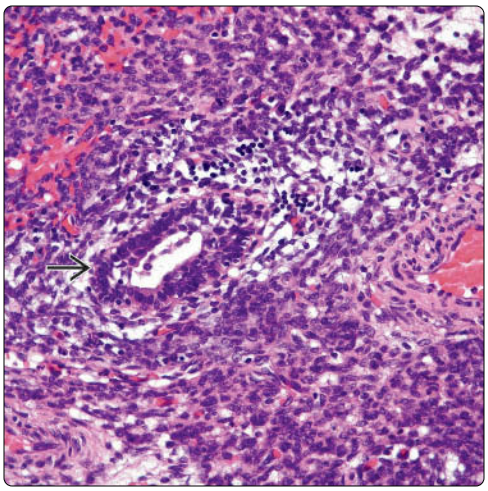

Edematous Change

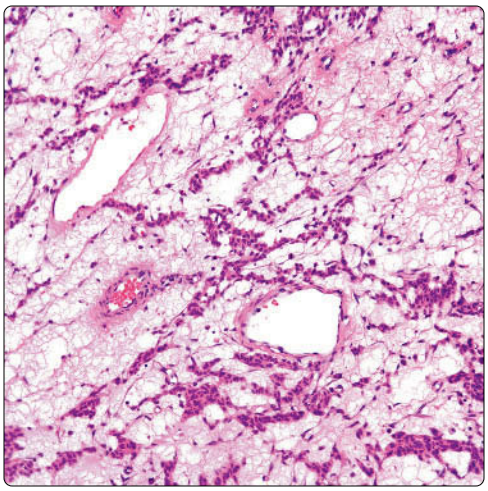

(Left) *In some cases of pleuropulmonary endometriosis, the stromal tissue may be extensive with only scattered glands. In these cases, extensive search for the endometrial glands is warranted.* **(Right)** *Pleuropulmonary endometriosis shows extensive edematous reaction with stromal cells. No endometrial glands are present.*

Thrombosed Vessels

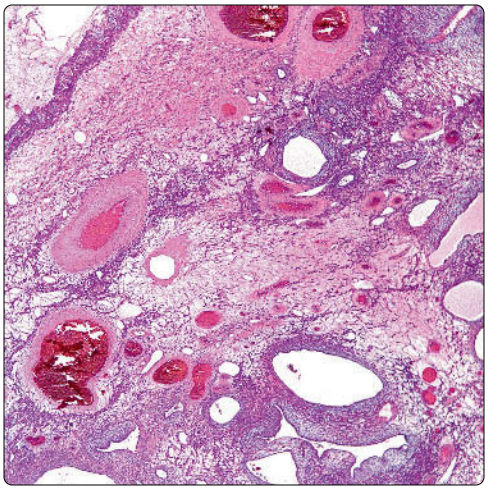

Absence of Glands

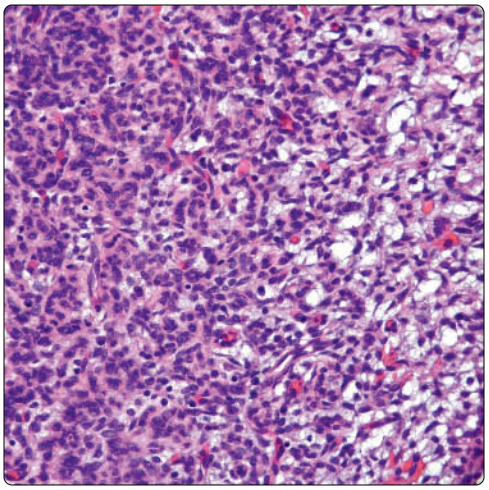

(Left) *Pulmonary endometriosis shows predominantly edematous changes in the stroma with dilated and congested blood vessels.* **(Right)** *The stromal component of pulmonary endometriosis shows spindle cells admixed with histiocytes and scattered plasma cells. The presence of plasma cells is not marked, and their findings are an important histological feature for the diagnosis of endometriosis.*

Gland With Mitotic Activity

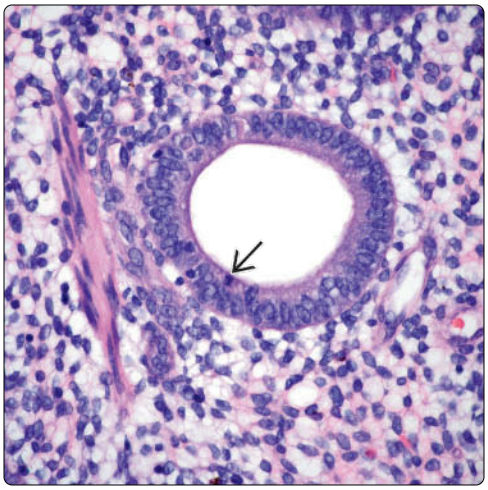

Hemorrhagic Changes

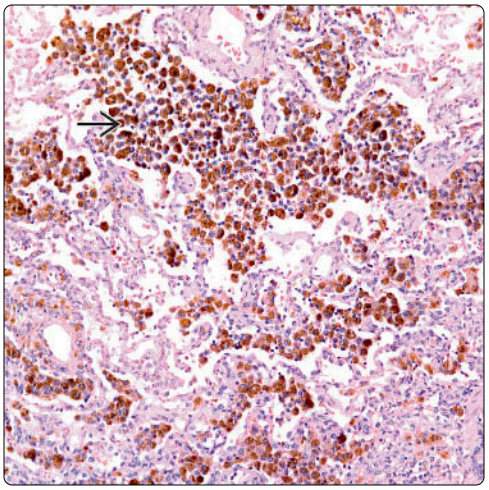

(Left) *High-power view of a gland in pulmonary endometriosis shows mitotic activity ⇨. The appearance of this gland is reminiscent of the proliferative phase of the endometrial cycle.* **(Right)** *Lung parenchyma shows numerous hemosiderin-laden macrophages ⇨. This feature may represent hemorrhagic changes due to the endometriotic process.*

Positive ER Stain

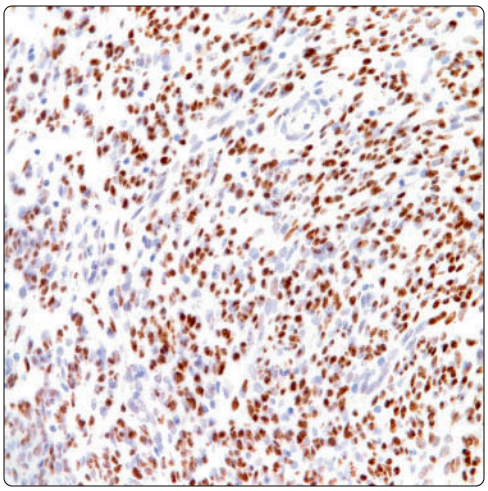

Positive WT1 Stain

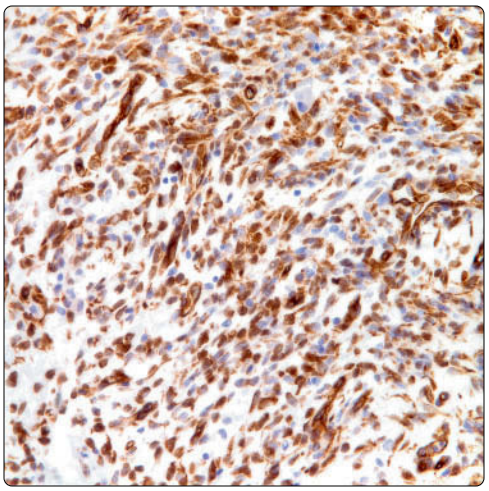

(Left) *Estrogen receptor (ER) immunohistochemical stain shows strong positive nuclear staining in endometriosis.* **(Right)** *WT1 immunohistochemical stain shows strong positive staining in endometriosis. These stains coupled with the negative staining for other specific markers are compatible with the diagnosis of endometriosis.*

This page intentionally left blank

PART III
SECTION 1

Neoplasms, Benign

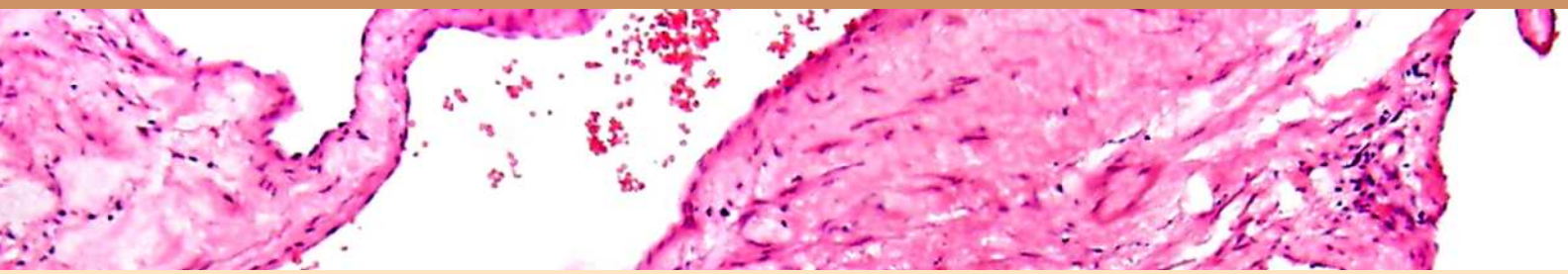

Lymphangioma	**632**
Hemangioma	**636**
Paraganglioma	**640**

Lymphangioma

KEY FACTS

TERMINOLOGY

- Benign, tumor-like proliferation of lymphatic vessels

CLINICAL ISSUES

- Neck mass with extension into mediastinum (75% of patients)
- Anterior mediastinal mass (15% of patients)
- Cough
- Dyspnea
- Majority of patients are pediatric, < 2 years of age
- Up to 50% of cases may be present at birth
- Rapid enlargement of mass can be observed following upper respiratory tract infection that blocks lymphatic drainage
- Surgery is usually curative

IMAGING

- Large "soft" multicystic mass extending from neck into mediastinum
- Variable size (range: 2-20 cm)
- Usually large, cystic, with variable sized cysts
- Lack of capsule allows tumor to infiltrate surrounding tissues

MICROSCOPIC

- Lesions may be of 3 types: Capillary, cavernous, or cystic lymphangioma
- Composed of solid proliferation of small, capillary-sized lymphatic channels
- Lymphoid aggregates present in stroma
- Lumen of lymphatic spaces may be filled with clear proteinaceous fluid containing small lymphocytes
- Walls of dilated lymphatic channels may show smooth muscle hyperplasia
- Coalescence of dilated lymphatic channels leads to formation of large multicystic mass

Cystic Lymphangioma

Dilated Lymphatic Spaces

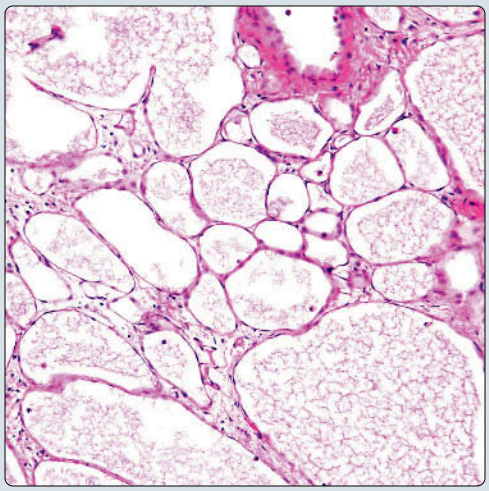

(Left) *Gross appearance of cystic lymphangioma (cystic hygroma) in the anterior mediastinum of a child shows a well-circumscribed, distended cystic structure with a smooth and shiny outer surface.* **(Right)** *Histologic appearance of lymphangioma of an anterior mediastinum shows dilated cystic spaces lined by a layer of flattened endothelial cells and containing proteinaceous fluid in their lumina.*

Dense Lymphoid Infiltrates

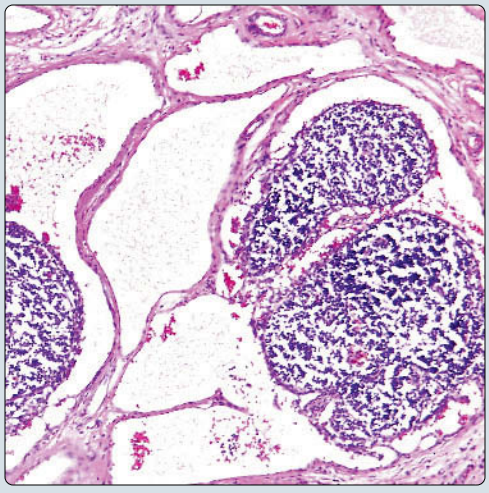

Thin-Walled Vascular Spaces

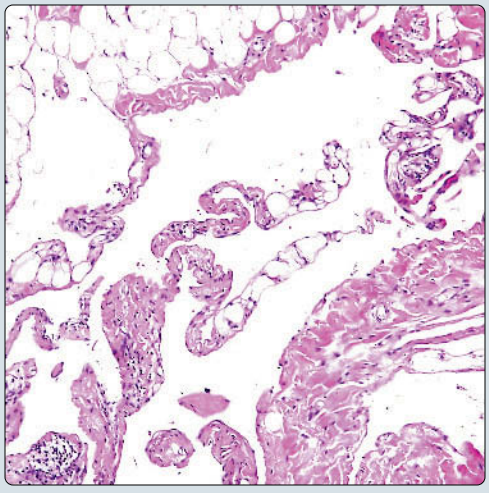

(Left) *Dense lymphoid infiltrates in the walls of dilated lymphatic spaces is a common finding in mediastinal lymphangioma.* **(Right)** *Most cases show an admixture of thin-walled vascular spaces with thick muscular walls corresponding to entrapped veins. Entrapment of fat between the vessels is a frequent finding.*

TERMINOLOGY

Synonyms

- Cystic lymphangioma, cavernous lymphangioma, cystic hygroma, capillary lymphangioma

Definitions

- Benign, tumor-like proliferation of lymphatic vessels

ETIOLOGY/PATHOGENESIS

Developmental Anomaly

- Most likely represents hamartomatous process arising from sequestration of lymphatic tissue without connection to lymphatic system
- May occur as congenital malformation of lymphatic vascular channels

CLINICAL ISSUES

Site

- Neck mass with extension into mediastinum (75% of patients)
- Anterior mediastinal mass (15% of patients); can also arise in posterior and middle mediastinum
- May present as diffuse or multifocal process (lymphangiomatosis)

Presentation

- Cough, dyspnea
- May be asymptomatic and discovered incidentally on routine chest x-ray
- Majority of patients are pediatric, < 2 years of age; up to 50% of cases may be present at birth

Prognosis

- Surgery is usually curative
- May show repeated recurrences after surgery and require multiple surgical interventions

IMAGING

CT Findings

- Heterogeneous enhancement uncommon
- CECT is best imaging tool to help characterize mass in relation to surrounding structures

MACROSCOPIC

General Features

- Lobulated, well-circumscribed mass with multicystic cut surface
- Infiltrative borders may be seen
- Cysts of varying sizes lined by fibrous walls of varying thickness
- Cystic spaces may be filled with proteinaceous clear fluid
- Lesions composed predominantly of capillary-sized vessels may show solid, spongy cut surface

MICROSCOPIC

Histologic Features

- Lesions may be of 3 types: Capillary, cavernous, or cystic lymphangioma
- **Capillary lymphangioma**
  - Composed of solid proliferation of small, capillary-sized lymphatic channels
  - Lymphatic vessels display attenuated layer of endothelium
  - Lumen of lymphatic spaces may be filled with clear proteinaceous fluid containing small lymphocytes
  - Lymphoid aggregates present in stroma
  - Least common type of mediastinal lymphangioma
- **Cavernous lymphangioma**
  - Characterized by grossly distended lymphatic channels
  - Hemorrhage into lumen may simulate cavernous hemangioma
  - Lymphoid aggregates and lymphoid follicles commonly seen in stroma
  - Can become secondarily inflamed
  - Walls of dilated lymphatic channels may show smooth muscle hyperplasia
- **Cystic lymphangioma (cystic hygroma)**
  - Coalescence of dilated lymphatic channels leads to formation of large multicystic mass
  - Walls of cysts may show fibrosis or sclerosis, inflammation and lymphoid follciles
  - Walls of cyst may contain entrapped fat

DIFFERENTIAL DIAGNOSIS

Hemangioma

- Smooth or lobulated mass with sharp margins
- May contain phleboliths in up to 10% of cases
- Responds to steroids and may involute spontaneously

Cystic Teratoma

- Heterogeneous mass with fat and calcifications on imaging studies
- Multiple fluid levels on chest x-ray
- Histologically displays mature elements derived from all 3 germ layers

Bronchogenic Cyst

- Usually unilocular subcarinal mass
- May contain calcifications in wall
- Cyst lining composed of ciliated columnar epithelium

Multilocular Thymic Cyst

- Usually occurs in older individuals
- Multilocular cystic mass often with firm adhesions to surrounding structures
- Shows prominent inflammation, hemorrhage, fibrosis, and lymphoid follicular hyperplasia in stroma
- Cyst lining is in continuity with dilated Hassall corpuscles

SELECTED REFERENCES

1. Teramoto K et al: Mediastinal cavernous lymphangioma in an adult. Gen Thorac Cardiovasc Surg. 56(2):88-90, 2008
2. Bossert T et al: Giant cystic lymphangioma of the mediastinum. Eur J Cardiothorac Surg. 21(2):340, 2002
3. Awad WI et al: Concurrent cysts of the mediastinum, pleura and neck. Eur J Cardiothorac Surg. 20(4):861-3, 2001
4. Oshikiri T et al: Five cases of the lymphangioma of the mediastinum in adult. Ann Thorac Cardiovasc Surg. 7(2):103-5, 2001
5. Charruau L et al: Mediastinal lymphangioma in adults: CT and MR imaging features. Eur Radiol. 10(8):1310-4, 2000

Proteinaceous Material

Cystic Spaces With Fibrosis

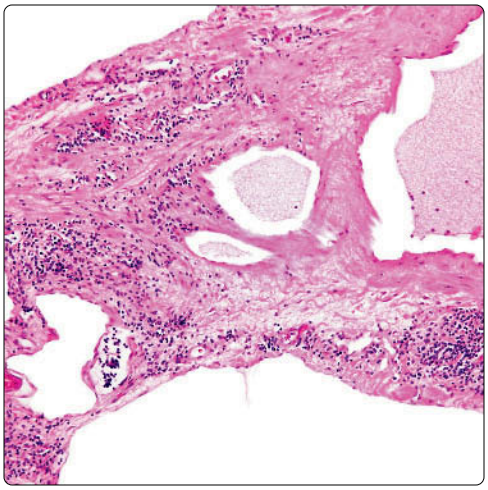

(Left) *Cystic lymphangioma of the mediastinum shows dilated lymphatic spaces filled with homogeneous eosinophilic, proteinaceous material. Notice the walls of the cysts are thickened by fibrosis and contain focal lymphoid infiltrates.* **(Right)** *Cystic lymphangioma of the mediastinum shows multiple dilated lymphatic spaces of varying sizes lined by a flattened layer of endothelial cells. The walls of the cyst show fibrosis and scattered lymphoid cells.*

Complex Vessels

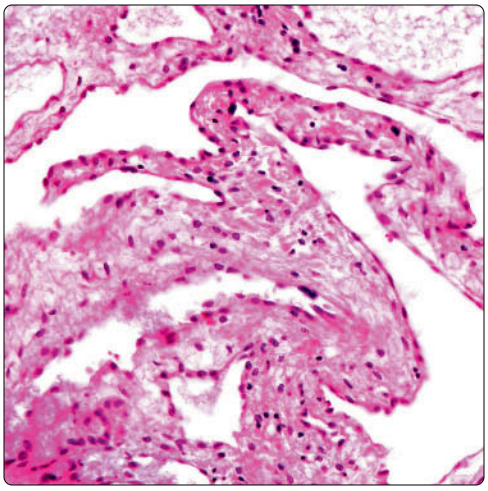

Intraluminal Lymphocytes

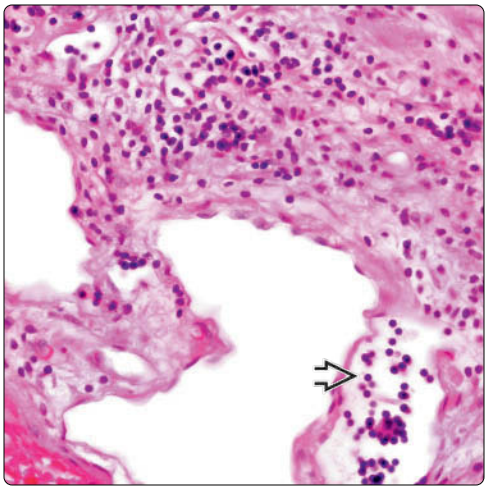

(Left) *Cystic lymphangioma of the mediastinum shows complex, dilated vessel lumina lined by a single layer of flattened endothelial cells. The walls of the vessels are thickened by fibrosis and contain scattered lymphocytes.* **(Right)** *High magnification of cystic lymphangioma of the mediastinum shows lymphatic vessels lined by a layer of flattened endothelial cells. One of the vessels contains scattered small lymphocytes in the lumen.*

Proliferation of Capillary Vessels

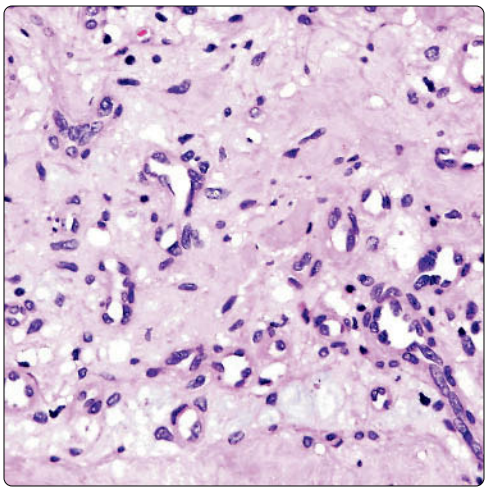

Fibrosis of Walls

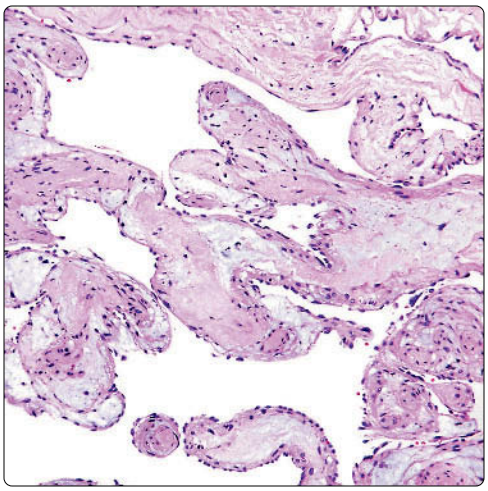

(Left) *Capillary lymphangioma of the mediastinum shows proliferation of small, capillary-sized vessels amid connective tissue stroma. Focal areas like this can be seen occasionally in cystic lymphangiomas of the mediastinum.* **(Right)** *Cystic lymphangioma of the mediastinum with fibrosis of the vessel walls shows irregular vascular lumina that contain variably hyalinized stroma with focal areas of stromal edema. A prominent endothelial cell layer is seen lining the vessels.*

Stromal Fibrosis

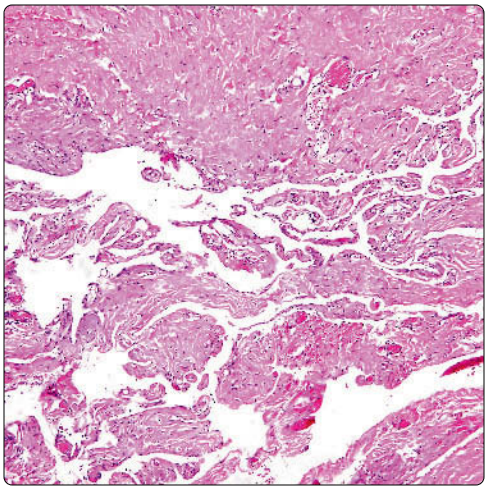

Complex Dilated Vascular Spaces

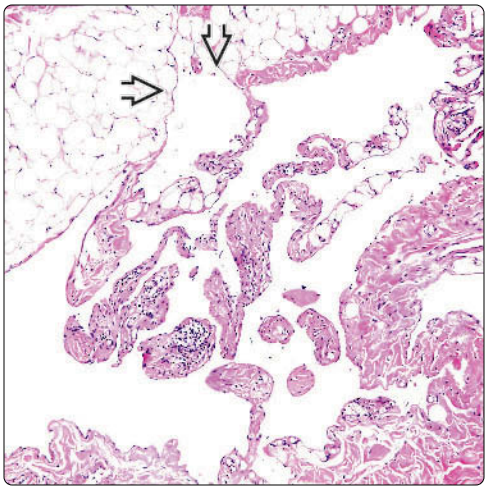

(Left) *Scanning magnification of lymphangioma of the mediastinum with prominent fibrosis shows empty anastomosing vascular channels surrounded by abundant connective tissue. The vascular nature of the lesion can be easily missed on cursory examination.* **(Right)** *High magnification of cystic lymphangioma shows complex dilated vascular spaces lined by a single layer of flattened endothelial cells. Notice the vascular spaces dissecting among the fat ⇨.*

Entrapped Adipose Tissue

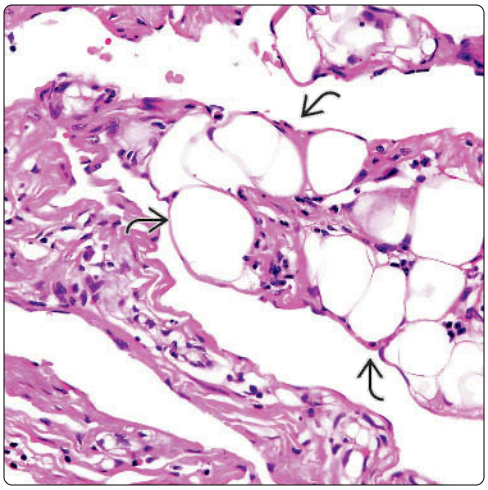

Luminal Proteinaceous Material

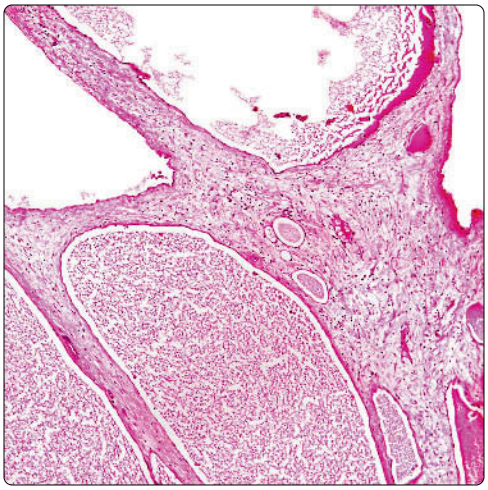

(Left) *Lymphangioma of the mediastinum shows lymphatic spaces containing entrapped mature adipocytes ⇨. The adipocytic component may be quite prominent and lead to confusion with an angiolipomatous lesion.* **(Right)** *Cystic lymphangioma of the mediastinum shows dilated lymphatic spaces containing eosinophilic proteinaceous material in their lumina. Notice the walls of the dilated vascular spaces are thickened by fibrosis and contain scattered inflammatory cells.*

Lymphoid Follicles With Germinal Centers

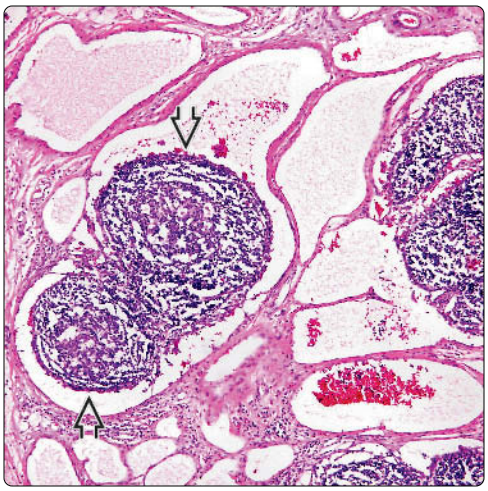

Granulation Tissue

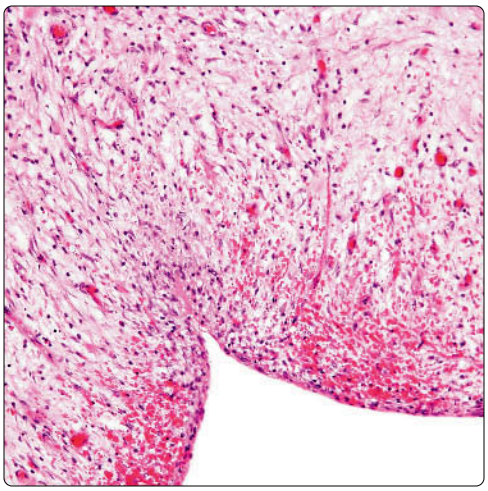

(Left) *Cystic lymphangioma of the mediastinum shows dilated vascular spaces with a few scattered lymphoid follicles with well-formed germinal centers in the stroma ⇨.* **(Right)** *Cystic lymphangioma of the mediastinum shows a thickened wall of a dilated lymphatic vessel with edema, hemorrhage, acute and chronic inflammation, and granulation tissue. Secondary inflammation in mediastinal lymphangiomas may lead to scarring and fibrous adhesions.*

Hemangioma

KEY FACTS

CLINICAL ISSUES

- Rare tumor
- Affects broad age range, from newborns to old age
- More frequent in children and young adults
- Anterior and posterior mediastinum
- Some cases may be diffuse and multifocal (hemangiomatosis)
- Dyspnea
- Cough
- Chest pain
- Benign lesions that usually produce symptoms through compression
- Rarely invasive but unencapsulated; may infiltrate mediastinal structures
- Some cases may regress spontaneously
- Most cases are cured by simple surgical excision

IMAGING

- Anterior mediastinum most common location
- Posterior mediastinum in 1/4 of cases

MICROSCOPIC

- **Capillary hemangiomas**
  - Lobular growth pattern separated by thin fibroconnective tissue bands
  - Lobules composed of solid, cellular proliferation of endothelial cells with compressed vascular lumina
  - Rare mitotic figures can occasionally be found
- **Cavernous hemangiomas**
  - Large, ectatic vessels filled with blood seen on scanning magnification
  - Stroma separating vessels may contain prominent smooth muscle proliferation
  - Areas showing admixture of fibrosis, smooth muscle, and mature fat are commonly seen
  - Cellular proliferation can dissect focally into adjacent fibroadipose tissue

Mediastinal Hemangioma | **Cavernous Hemangioma**

(Left) *Mediastinal hemangioma shows characteristic admixture of dilated blood vessels with stromal elements, including fibroconnective tissue and mature adipose tissue.* **(Right)** *Cavernous hemangioma of the mediastinum shows large, dilated vascular spaces lined by small, flattened endothelial cells containing extravasated red blood cells.*

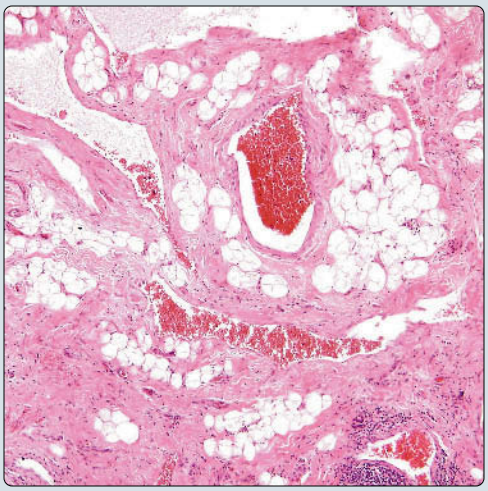

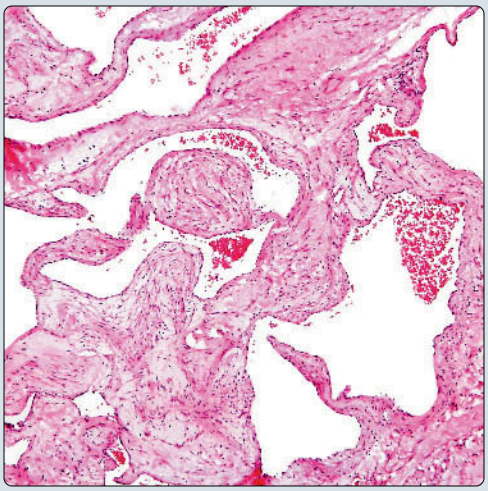

Capillary Hemangioma | **Lymphoid Infiltrates**

(Left) *This example of mediastinal hemangioma is composed of a tightly packed proliferation of numerous small, capillary-sized vessels that are growing in a lobular configuration.* **(Right)** *This mediastinal hemangioma shows dilated, thin-walled vessels containing abundant dense lymphoid infiltrates in their walls, giving a superficial resemblance to a lymphangioma*

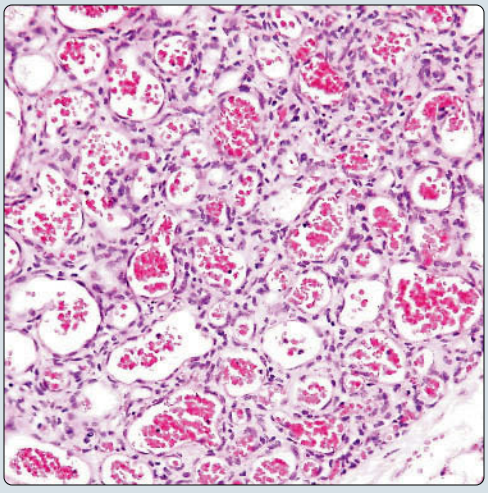

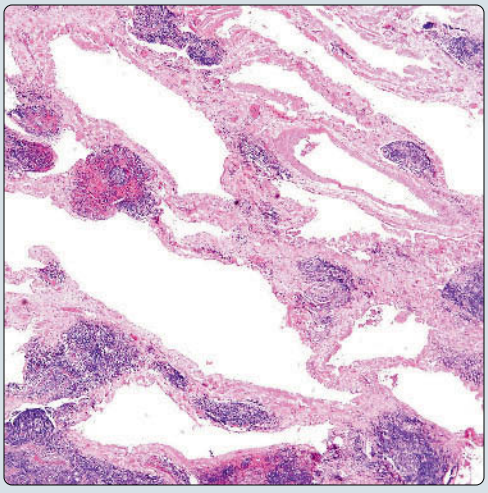

TERMINOLOGY

Definitions

- Benign, neoplastic vascular proliferation

CLINICAL ISSUES

Epidemiology

- Age
  - Affects broad age range, from newborns to old age
  - More frequent in children and young adults

Site

- Anterior and posterior mediastinum
- Some cases may be diffuse and multifocal (hemangiomatosis)

Presentation

- Dyspnea, cough, chest pain
- ~ 15% of patients may be asymptomatic, and lesion is discovered on routine chest x-ray
- Incidental finding at autopsy

Natural History

- Benign lesions that usually produce symptoms through compression
- Rarely invasive, but unencapsulated; may infiltrate mediastinal structures
- Some cases are associated with multiorgan, systemic involvement (hemangiomatosis)
- Some cases may regress spontaneously

Treatment

- Surgical excision; sclerotherapy

Prognosis

- Most cases are cured by simple surgical excision
- Expectant approach may be warranted in children due to possibility of spontaneous regression

IMAGING

General Features

- Location
  - Anterior mediastinum most common location
  - Posterior mediastinum in 1/4 of cases

Radiographic Findings

- Smooth or lobulated mass with sharp borders
- Phleboliths can be present in up to 10% of cases

MACROSCOPIC

General Features

- Well circumscribed and unencapsulated
- Some tumors may show infiltration of adjacent structures
- Cystic and hemorrhagic cut surface

Size

- Variable size: 2-20 cm

MICROSCOPIC

Histologic Features

- **Capillary hemangiomas**
  - Lobular growth pattern separated by thin fibroconnective tissue bands
  - Lobules composed of solid, cellular proliferation of endothelial cells with compressed vascular lumina
  - Cells contain round to oval nuclei with peripheral margination of chromatin and small, eccentric nucleoli
  - Small, compressed, and slit-like capillary vessels identified adjacent to solid areas
  - Rare mitotic figures can occasionally be found
  - Regressive changes, including hyalinization, cystic changes, and fatty overgrowth, are commonly seen
- **Cavernous hemangiomas**
  - Large, ectatic vessels filled with blood seen on scanning magnification
  - Stroma separating vessels may contain prominent smooth muscle proliferation
  - Areas showing admixture of fibrosis, smooth muscle, and mature fat are commonly seen
  - Focal inflammatory stromal changes with lymphocytes and plasma cells may be present
  - May contain foci of dystrophic calcification

DIFFERENTIAL DIAGNOSIS

Lymphangioma

- Ectatic lymphatics filled with homogeneous proteinaceous eosinophilic material (chyle)
- Inflammatory interstitial lymphoid infiltrate with well-formed follicles and prominent germinal centers in stroma

Thymolipoma

- Absence of vascular component

Epithelioid Hemangioendothelioma

- Solid proliferation of large, atypical epithelioid cells with enlarged nuclei, prominent nucleoli, and abundant cytoplasm
- Prominent intracytoplasmic vacuoles are seen, sometimes containing red blood cells in their lumina
- Myxoid degeneration of stroma may simulate cartilaginous matrix

Angiomyolipoma

- Vascular proliferation containing entrapped fat and smooth muscle
- Smooth muscle proliferation is characteristically distributed concentrically around vessel walls

SELECTED REFERENCES

1. Ampollini L et al: Cavernous hemangioma of the posterior mediastinum. Ann Thorac Surg. 90(6):e96, 2010
2. Sakurai K et al: Thoracic hemangiomas: imaging via CT, MR, and PET along with pathologic correlation. J Thorac Imaging. 23(2):114-20, 2008
3. Yamazaki A et al: Cavernous hemangioma of the anterior mediastinum: case report and 50-year review of Japanese cases. Jpn J Thorac Cardiovasc Surg. 54(5):221-4, 2006
4. Moran CA et al: Mediastinal hemangiomas: a study of 18 cases with emphasis on the spectrum of morphological features. Hum Pathol. 26(4):416-21, 1995

Capillary Hemangioma

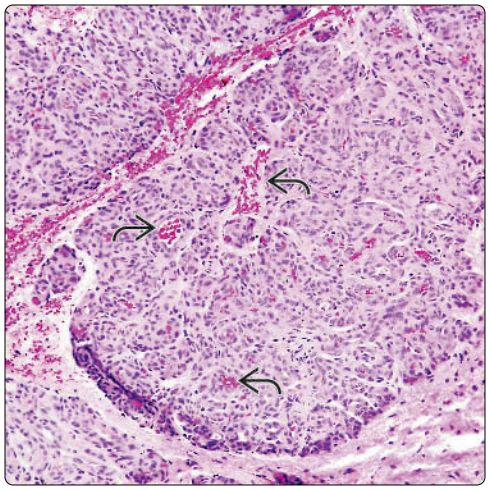

Capillary Hemangioma, High Power

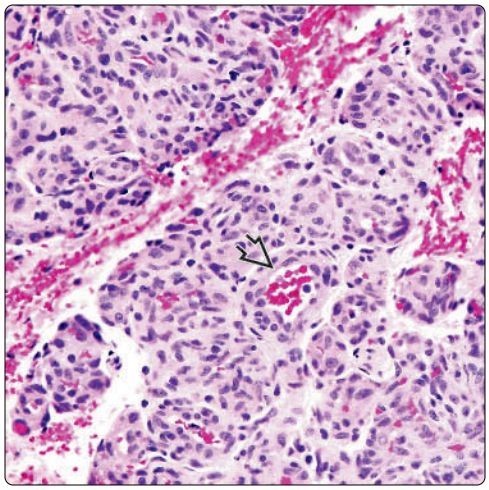

(Left) *Capillary-type hemangioma of the anterior mediastinum shows cellular lobules composed of a proliferation of small round cells with occasional small vessels displaying patent lumina filled with red blood cells.* **(Right)** *Higher magnification of capillary-type hemangioma of the mediastinum shows solid proliferation of small round, endothelial cells with compressed vascular lumina. Notice the occasional small vessel with patent lumen containing a few red blood cells.*

Mitosis in Capillary Hemangioma

Lobular Capillary Hemangioma

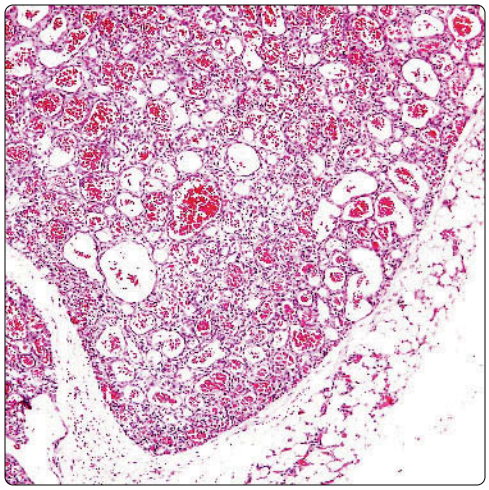

(Left) *High magnification of cellular capillary hemangioma of the mediastinum shows nuclear detail of the endothelial cells with dispersed chromatin and absence of nucleoli or cellular atypia. Notice the single mitotic figure in the center of the field.* **(Right)** *Capillary hemangioma of the mediastinum shows numerous scattered small vascular spaces with open lumina containing red blood cells. These lesions can closely resemble lobular capillary hemangiomas of the skin.*

Solid Growth Pattern

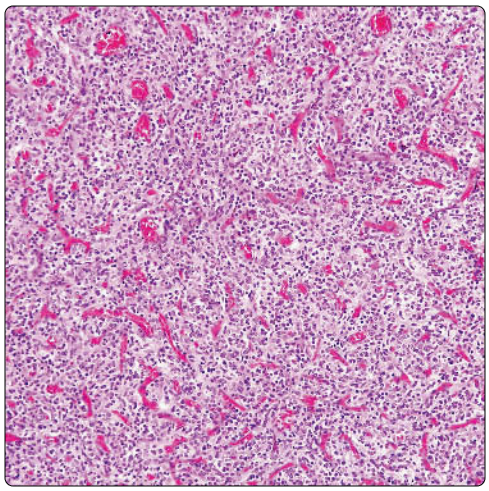

Solid Pattern, Higher Magnification

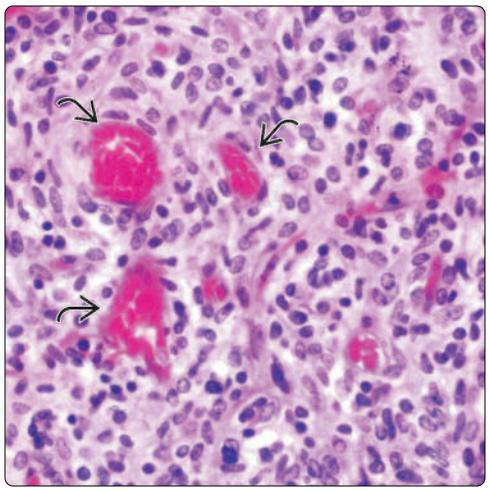

(Left) *Scanning magnification of capillary hemangioma of the mediastinum shows solid sheets of monotonous, small, round endothelial cells with numerous compressed, slit-like vascular lumina filled with red blood cells. The lesion may be difficult to recognize as a vascular neoplasm.* **(Right)** *High magnification of capillary hemangioma of the mediastinum shows an area with solid growth pattern. Notice a few small vessels with patent lumina are filled with red blood cells.*

Hemangioma With Smooth Muscle

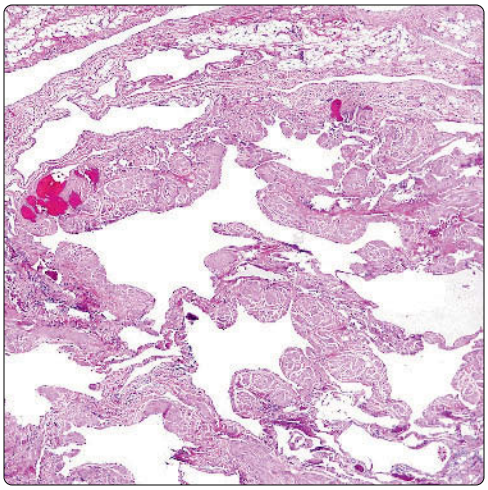

Thin-Walled Vessels

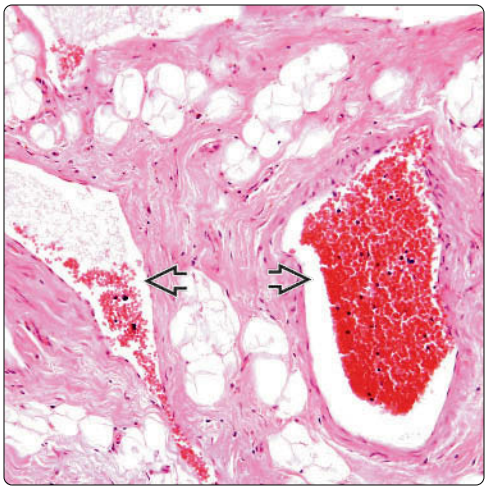

(Left) *Cavernous hemangioma of the anterior mediastinum in a 2-year-old child shows large, dilated, and irregular vascular spaces lined by a flattened layer of endothelial cells and separated by thick, fibrous walls containing smooth muscle bundles.* **(Right)** *Cavernous hemangioma of the anterior mediastinum shows dilated cavernous spaces filled with red blood cells. Notice the extensive fibrosis and entrapment of mature adipose tissue in the walls of the dilated vascular spaces.*

Hemangioma With Muscular Hyperplasia

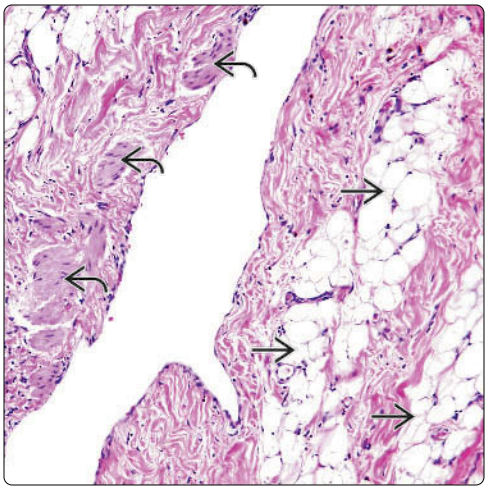

Entrapped Adipose Tissue

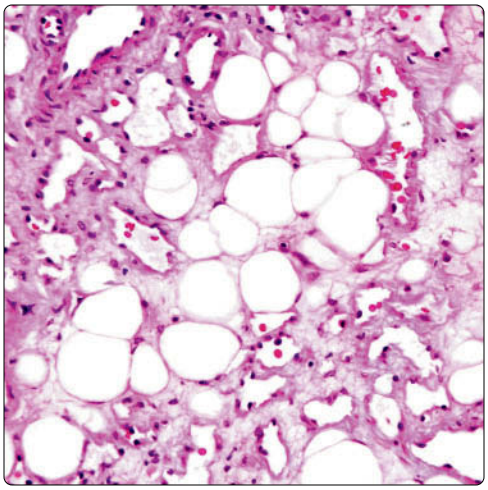

(Left) *Cavernous hemangioma of the anterior mediastinum shows a dilated vascular space lined by a flattened layer of endothelial cells. Notice the walls flanking the vascular space show fibrosis, muscular hyperplasia, and entrapped mature adipose tissue elements.* **(Right)** *High magnification of cavernous hemangioma of the mediastinum shows infiltration of the fat at the edges of the lesion by a proliferation of small vascular channels lined by small endothelial cells.*

Smooth Muscle Proliferation

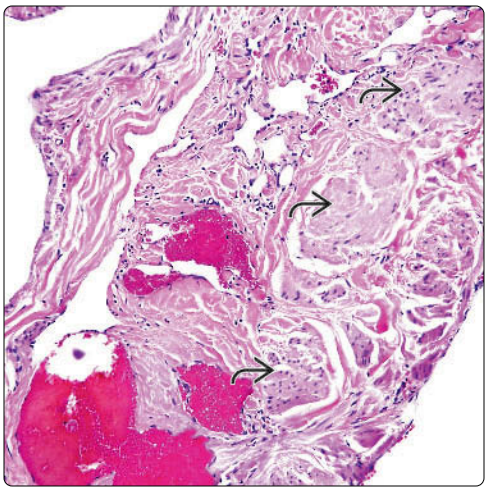

Lymphoid Infiltrates in Hemangioma

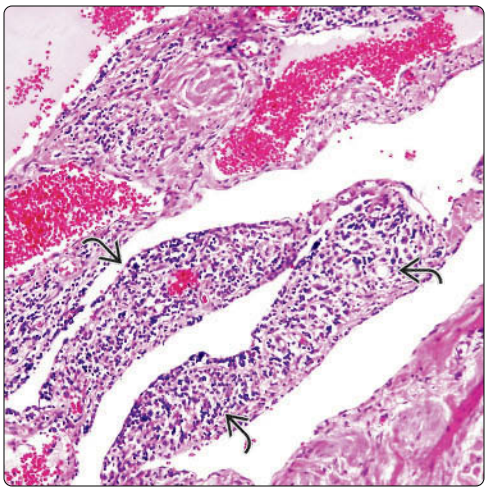

(Left) *Cavernous hemangioma of the mediastinum shows detail of the wall of the vascular spaces showing fibrosis and proliferation of bundles of smooth muscle.* **(Right)** *Cavernous hemangioma of the mediastinum shows dilated vascular spaces flanked by connective tissue containing prominent inflammatory cell infiltrate. Notice the inflammatory cells are diffusely scattered throughout and do not form discrete lymphoid follicles with germinal centers.*

Paraganglioma

KEY FACTS

TERMINOLOGY

- Synonyms
  - Extraadrenal paraganglioma, carotid body tumor

CLINICAL ISSUES

- Incidence
  - May occur at any age
  - More common in 3rd decade of life
  - May occur in anterior and posterior mediastinum
- Symptomatology
  - Dyspnea
  - Headache
  - Hypertension
  - Diaphoresis
  - Part of multiple endocrine neoplasia syndrome
- Treatment and prognosis
  - In majority of cases, complete surgical resection is curative

TOP DIFFERENTIAL DIAGNOSES

- Neuroendocrine carcinoma
- Ectopic parathyroid tumor
- Thymic carcinoma
- Alveolar soft part sarcoma

DIAGNOSTIC CHECKLIST

- Zellballen growth pattern
- Prominent cellular atypia
- Macronuclei
- Rare mitotic activity

Nested Pattern

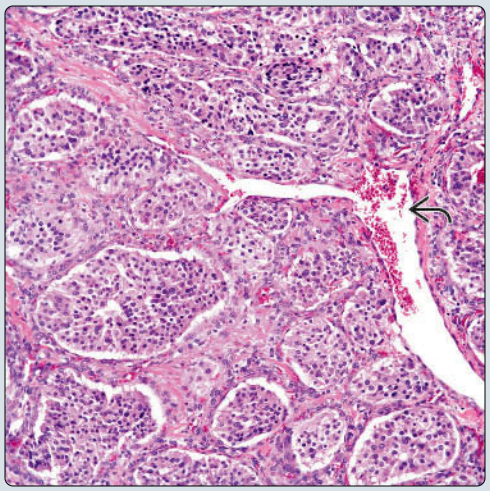

Nuclear Atypia

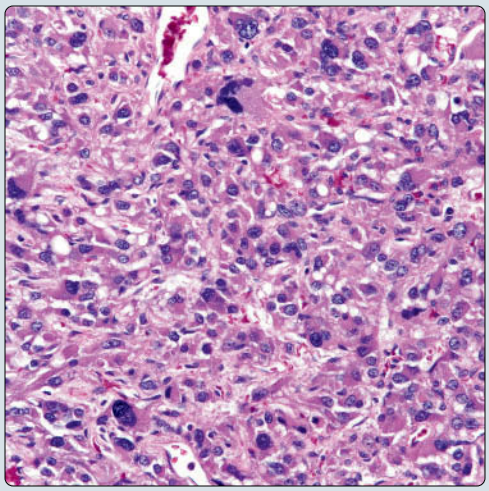

(Left) *Mediastinal paraganglioma shows the typical nesting pattern of growth. Note the presence of a dilated vascular structure. These findings are typical for paraganglioma.* **(Right)** *Mediastinal paraganglioma shows the presence of marked nuclear atypia and macronuclei and a lack of mitotic activity.*

GATTA-3

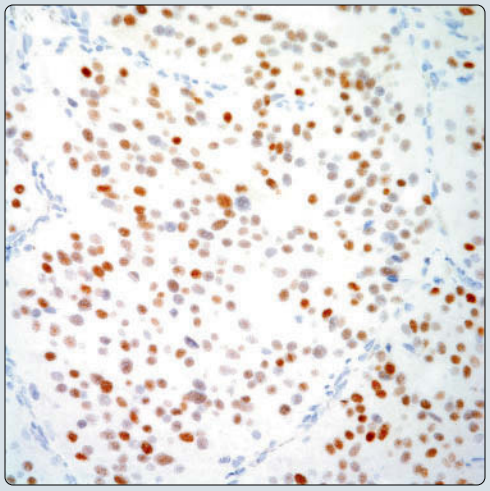

Positive Synaptophysin

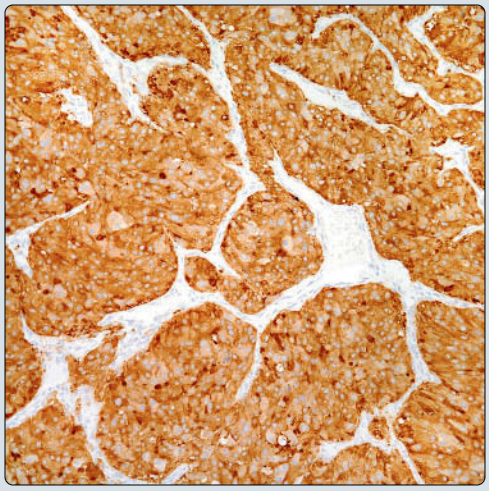

(Left) *Immunohistochemical stain for GATTA-3 shows nuclear positive staining in paraganglioma.* **(Right)** *Immunohistochemical stain for synaptophysin in paraganglioma shows strong positive reaction in tumor cells.*

TERMINOLOGY

Synonyms

- Extraadrenal paraganglioma, carotid body tumor
- Intrathoracic pheochromocytoma

Definitions

- Neuroendocrine neoplasm

ETIOLOGY/PATHOGENESIS

Etiology

- These tumors may originate from normal paraganglia

CLINICAL ISSUES

Epidemiology

- Incidence
  - Unusual tumors in mediastinal compartment
    - Succinate dehydrogenase (SDH) subunits need to be evaluated in case of hereditary paragangliomas
      - It has been stated that SDHB mutations may be associated with malignancy
      - SDH subunits B and D have been described in mediastinal paragangliomas
      - All subunits A,B,C,and D may be involved in hereditary paragangliomas
- Age
  - May occur at any age
  - More common in 3rd decade of life
- Sex
  - No gender predilection
  - Some studies have reported slight predominance in male patients

Site

- Paragangliomas may occur in anterior and posterior mediastinum
- Metachronous tumors may occur
- Synchronous tumors may occur

Presentation

- Chest pain
- Cough
- Difficulty in swallowing
- Dyspnea
- Headache
- Hypertension
- Diaphoresis
- Part of multiple endocrine neoplasia syndrome
- Some patients may be asymptomatic
- Some patients may present with metastatic disease at diagnosis
  - Metastasis can occur in lymph nodes, lung, and bone
- Tumors may occur as part of so-called Carney triad

Treatment

- Complete surgical resection
- Adjuvant therapy in selected cases

Prognosis

- In majority of cases, complete surgical resection is curative
- In some cases, paragangliomas behave aggressively with metastatic disease leading to death
- Some authors argue that incidence of metastasis depends on length of follow-up
- Extent of tumor, well circumscribed or infiltrative, may correlate with prognosis
- Histology alone is not good predictor of prognosis

MACROSCOPIC

General Features

- Soft, irregular
- Tan to light brown

Size

- Varies from 2 cm to > 10 cm in diameter

MICROSCOPIC

Histologic Features

- So-called zellballen growth pattern
- Nested pattern
- Spindle cell pattern
- Presence of large cells with macronuclei and bizarre shapes
- Granular-like cells may be prominent
- Melanin pigment may also be seen
- Mitotic activity is rare
- Extensive areas of hyalinization may be present
- Ectatic vessels
- Cystic changes may occur

DIFFERENTIAL DIAGNOSIS

Well-Differentiated Neuroendocrine Carcinoma (Carcinoid Tumor)

- Neuroendocrine carcinomas generally show positive staining for pan keratin
- Neuroendocrine carcinomas would display mitotic activity
- Paragangliomas and neuroendocrine carcinomas share similar immunophenotype with neuroendocrine markers

Ectopic Parathyroid Tumor

- Generally positive for keratin markers
- Rarely displays cellular atypia of paragangliomas
- Parathyroid tumors generally show positive staining for PTH, whereas paragangliomas are negative

Thymic Carcinoma

- Displays more cellular atypia and mitotic activity
- Generally is negative for neuroendocrine markers
- Growth pattern of thymic carcinoma is not of zellballen type

Alveolar Soft Part Sarcoma

- Alveolar soft part sarcoma (ASPS) has been only rarely reported in mediastinum
- ASPS may show focal staining for S100 protein
- ASPS is negative for neuroendocrine markers such as chromogranin and synaptophysin
- ASPS would show intracytoplasmic rhomboid crystals in tumor cells

Immunohistochemistry

Antibody	Reactivity	Staining Pattern	Comment
Chromogranin-A	Positive	Cytoplasmic	Strongly positive
Synaptophysin	Positive	Not applicable	Strongly positive
CD56	Positive	Cytoplasmic	Strongly positive
NFP	Positive	Cytoplasmic	In ~ 50% of cases
GATA3	Positive	Nuclear	In ~ 15-20% of cases
S100	Positive	Nuclear	In sustentacular cells
Enkephalin	Positive	Cytoplasmic	In ~ 50% of cases
NSE	Positive	Cytoplasmic	Strongly positive
CK-PAN	Negative		It may be focally positive in some gangliocytic paragangliomas
CK-LMW-NOS	Negative		
CK-HMW-NOS	Negative		
TTF-1	Negative		
PTH	Negative		
NAPSIN-A	Negative		
CEA-M	Negative		
Calretinin	Negative		

Histochemical Features

Stain	Result
PAS	Negative
PAS-D	Negative
Mucicarmine	Negative
Grimelius	Positive

Ultrastructural Features

Electron microscopic findings	Numerous neurosecretory granules in cytoplasm of cells

DIAGNOSTIC CHECKLIST

Clinically Relevant Pathologic Features

- Mitotic rate
- Nuclear features
- Growth pattern

Pathologic Interpretation Pearls

- Zellballen growth pattern
- Prominent cellular atypia
- Macronuclei
- Rare mitotic activity

SELECTED REFERENCES

1. Giblett N et al: Carney's triad with paraganglioma. Br J Oral Maxillofac Surg. 54(1):e15-6, 2016
2. Kornaczewski ER et al: Utility of FDG-PET imaging in screening for succinate dehydrogenase B and D mutation-related lesions. Clin Endocrinol (Oxf). 85(2):172-9, 2016
3. Currás-Freixes M et al: Recommendations for somatic and germline genetic testing of single pheochromocytoma and paraganglioma based on findings from a series of 329 patients. J Med Genet. 52(10):647-56, 2015
4. Mehta CK et al: Rare middle mediastinal paraganglioma mimicking metastatic neuroendocrine tumor. Ann Thorac Surg. 100(2):702-5, 2015
5. Bickmann JK et al: Phenotypic variability and risk of malignancy in SDHC-linked paragangliomas: lessons from three unrelated cases with an identical germline mutation (p.Arg133*). J Clin Endocrinol Metab. 99(3):E489-96, 2014
6. Else T et al: The clinical phenotype of SDHC-associated hereditary paraganglioma syndrome (PGL3). J Clin Endocrinol Metab. 99(8):E1482-6, 2014
7. Takahashi T et al: Superior mediastinal paraganglioma associated with von Hippel-Lindau syndrome: report of a case. World J Surg Oncol. 12:74, 2014
8. Weissferdt A et al: Thymic neuroendocrine tumors (paraganglioma and carcinoid tumors): a comparative immunohistochemical study of 46 cases. Hum Pathol. 45(12):2463-70, 2014
9. Parisinos CA et al: Mediastinal paraganglioma: time to panic? BMJ Case Rep. 2011
10. Ortega PF et al: Cystic paraganglioma of the anterior mediastinum. Ann Diagn Pathol. 14(5):341-6, 2010
11. Wald O et al: Paraganglioma of the mediastinum: challenges in diagnosis and surgical management. J Cardiothorac Surg. 5:19, 2010
12. Brown ML et al: Mediastinal paragangliomas: the Mayo Clinic experience. Ann Thorac Surg. 86(3):946-51, 2008
13. Plaza JA et al: Sclerosing paraganglioma: report of 19 cases of an unusual variant of neuroendocrine tumor that may be mistaken for an aggressive malignant neoplasm. Am J Surg Pathol. 30(1):7-12, 2006
14. Kimani S et al. Hereditary paraganglioma-pheochromocytoma syndromes. GeneReviews. 1993-2016
15. Moran CA et al: Mediastinal paragangliomas. A clinicopathologic and immunohistochemical study of 16 cases. Cancer. 72(8):2358-64, 1993

Subtle HPC Pattern

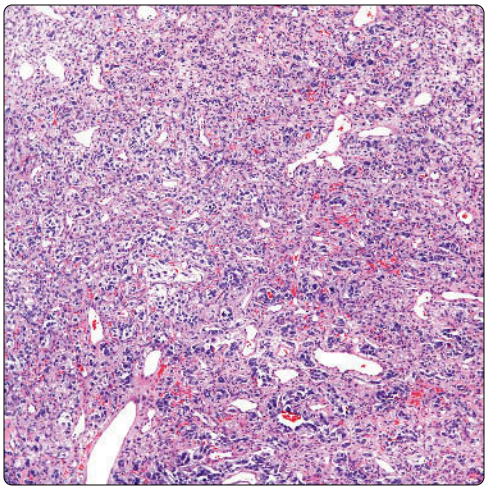

So-Called Zellballen

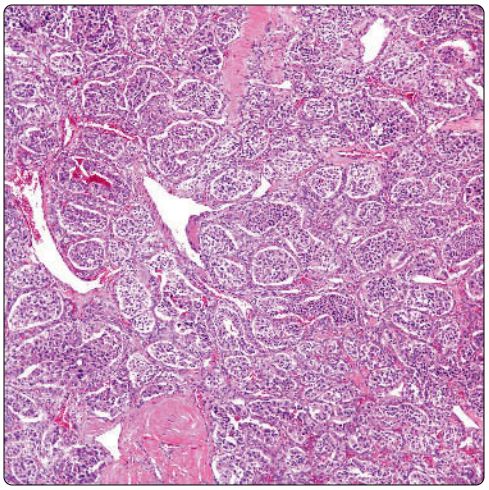

(Left) *Mediastinal paraganglioma shows tumor cells growing in nests with the presence of numerous ectatic blood vessels giving a hemangiopericytoma (HPC)-like pattern.* **(Right)** *Paraganglioma shows the classic so-called zellballen growth pattern. Note the discrete fibroconnective tissue separating the nests of tumor cells.*

Subtle HPC Pattern

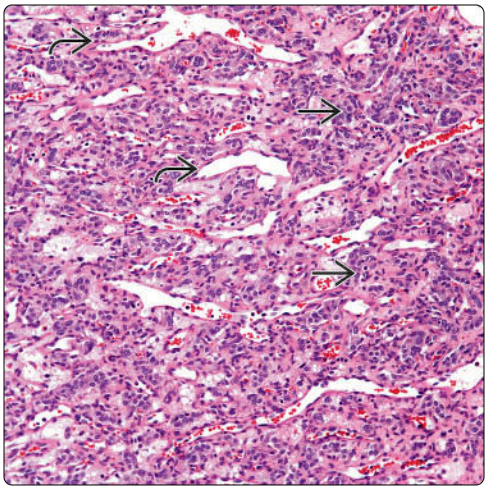

Nested Pattern

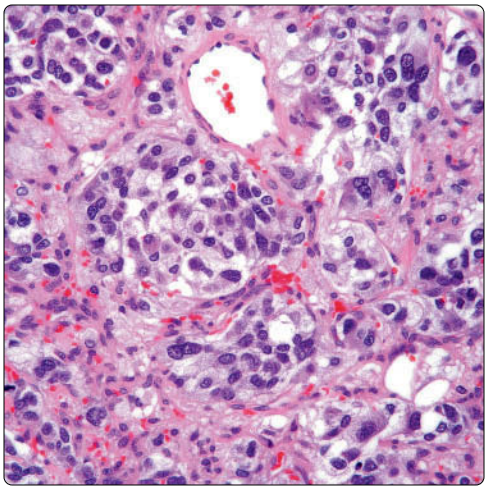

(Left) *Mediastinal paraganglioma shows a more vascular differentiation ⇨, almost mimicking a primary vascular neoplasm. However, note the presence of the neuroendocrine cellular proliferation ⇨ around the numerous ectatic blood vessels.* **(Right)** *Mediastinal paraganglioma shows a cellular proliferation composed of rather small cells with a moderate amount of cytoplasm, round nuclei, and inconspicuous nucleoli growing in a nested pattern.*

Subtle Spindle Cell Component

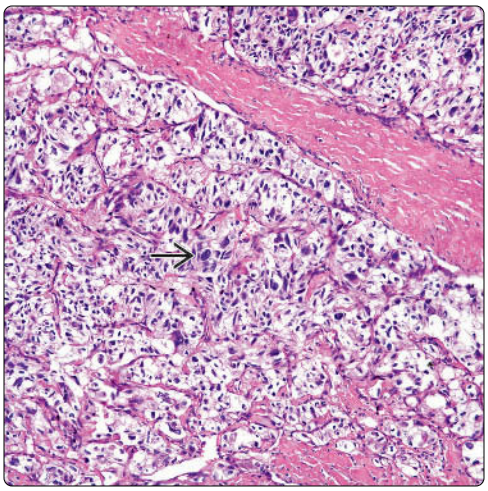

Spindle Cell Component

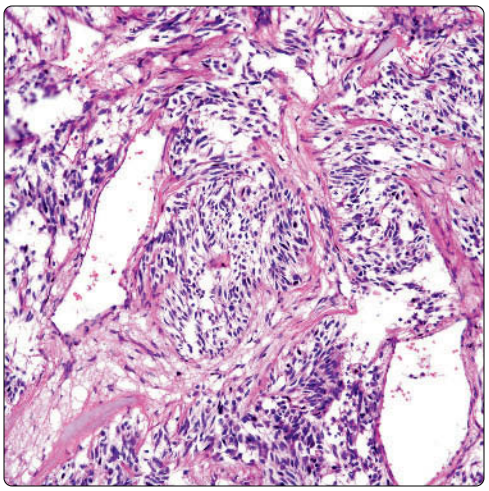

(Left) *Paraganglioma shows a subtle spindle cell component arranged in nests of tumor cells. Note the presence of cells with macronuclei ⇨ and also the presence of bands of fibroconnective tissue.* **(Right)** *Paraganglioma shows a more prominent spindle cell component. The tumor still preserves a nested pattern, and also note the presence of ectatic blood vessels admixed with the tumor.*

Extensive Hyalinization

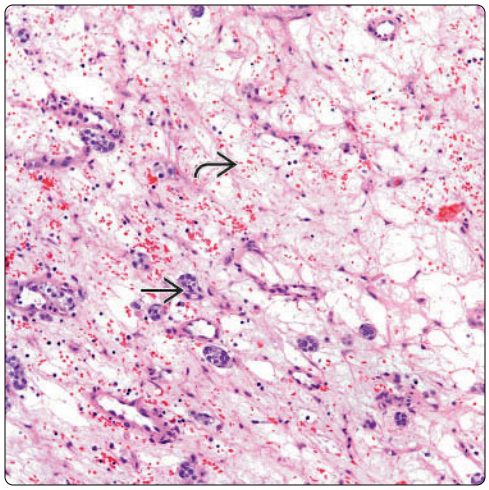

Scattered Cells in Hyalinized Background

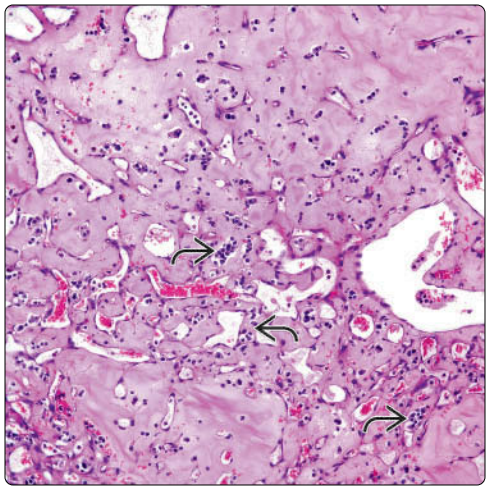

(Left) *Mediastinal paraganglioma shows extensive areas of edematous tissue and only scattered nests of tumor cells. These features may pose a problem in making an unequivocal diagnosis of paraganglioma.* **(Right)** *Dense collagenization with numerous dilated vascular channels mimics a vascular neoplasm. However, note the presence of clusters of neuroendocrine cells.*

Areas of Fibrosis

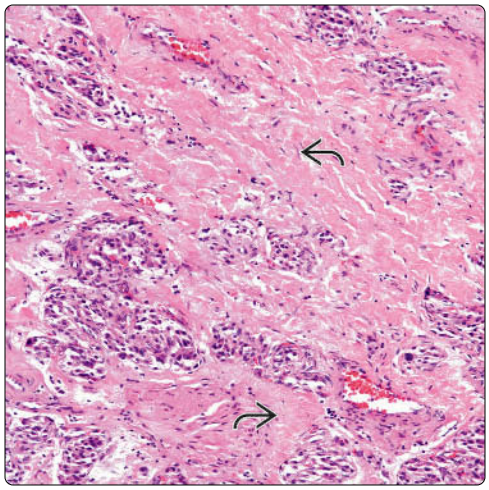

Hyalinization of Vascular Spaces

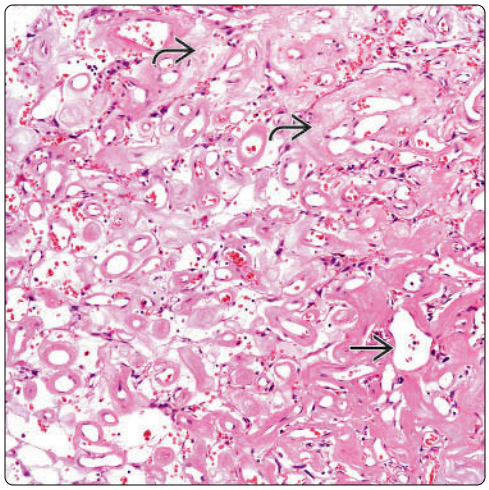

(Left) *Mediastinal paraganglioma is shown with extensive areas of fibroconnective tissue. This feature may be seen in several other neuroendocrine tumors, including paragangliomas.* **(Right)** *Mediastinal paraganglioma shows the presence of extensive areas of collagenization alternating with a prominent vessel proliferation. Similar histological features may be seen in other nonneuroendocrine tumors.*

Solid Oncocytic Change

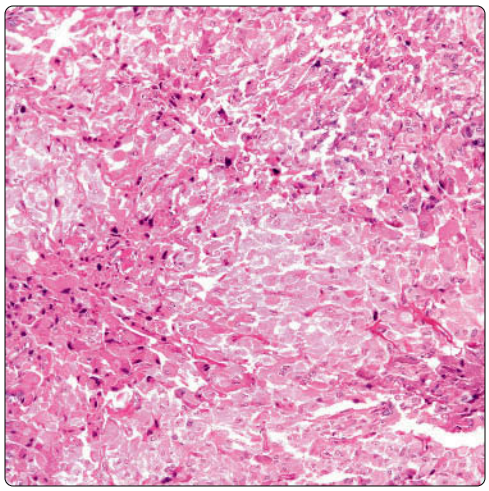

Granular Cell Change

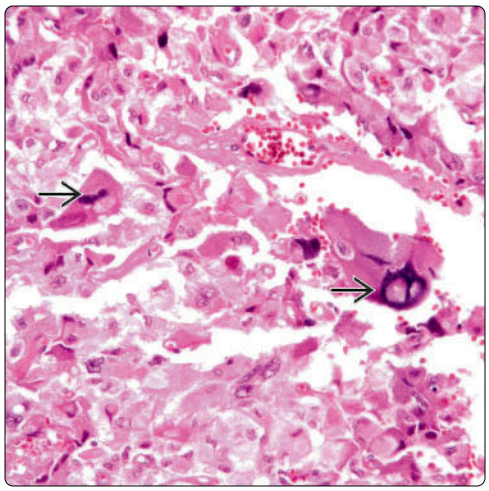

(Left) *Mediastinal paraganglioma shows prominent oncocytic and granular cell features. These types of cellular proliferation are unusual and can give rise to a wide differential diagnosis.* **(Right)** *Mediastinal paraganglioma is shown with oncocytic and granular cell changes. Note the presence of larger cells with ample cytoplasm and bizarre nuclei but without mitotic activity.*

Solid Pattern and Nuclear Atypia

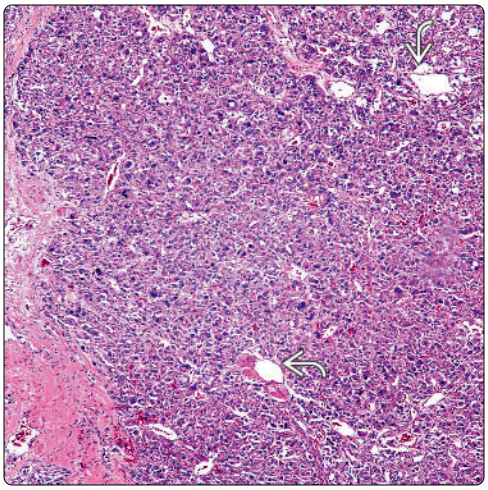

Hemosiderin Pigment

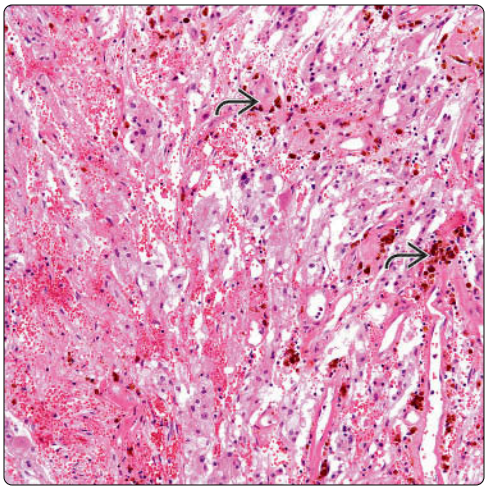

(Left) *Mediastinal paraganglioma shows diffuse growth pattern with only a few scattered ectatic blood vessels.* **(Right)** *Mediastinal paraganglioma is shown with extensive areas of hemorrhage and hemosiderin pigment. In such cases, it may be difficult to identify neuroendocrine cells, and the use of immunohistochemistry is required.*

Positive Chromogranin

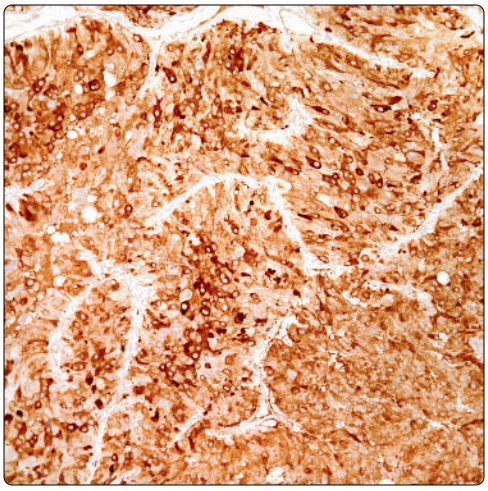

Sustentacular Cells

(Left) *Immunohistochemical stain for chromogranin shows strong positive staining in tumor cells of paraganglioma.* **(Right)** *Immunohistochemical stain is shown for S100 protein decorating sustentacular cells in a paraganglioma.*

Metastatic Paraganglioma

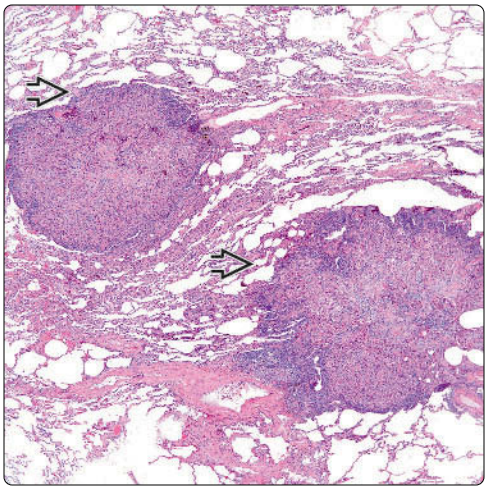

Metastatic Paraganglioma

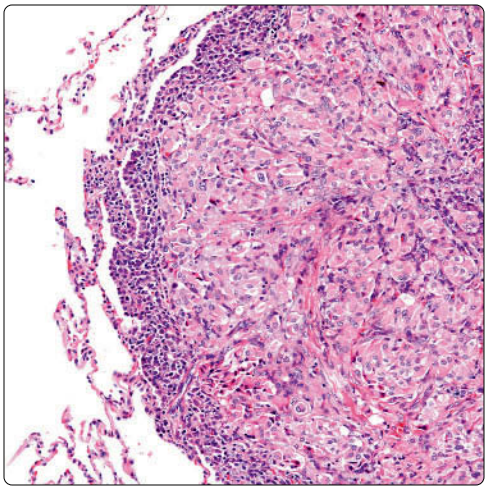

(Left) *Metastatic paraganglioma to lung is shown. Note the presence of 2 separate tumor nodules replacing lung parenchyma.* **(Right)** *Higher magnification of 1 nodule replacing lung parenchyma is shown. Note the sharp demarcation of the tumor nodule as well as the neuroendocrine morphology.*

PART III
SECTION 2

Neoplasms, Malignant, Primary

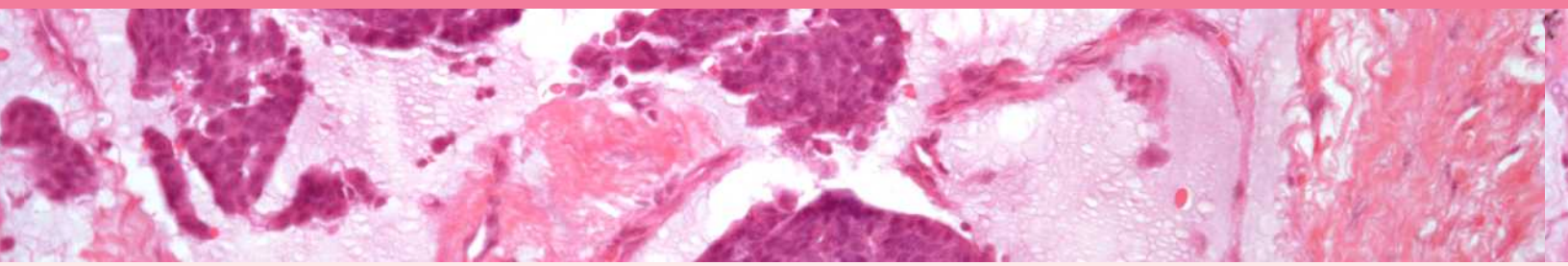

Epithelial Neoplasms

Overview of Malignant Thymic Neoplasms **648**
Thymoma **650**
Atypical Thymoma **666**
Thymic Carcinoma **676**
Neuroendocrine Carcinomas of Thymus **690**

Germ Cell Tumors

Mediastinal Teratoma **696**
Mediastinal Seminoma **702**
Yolk Sac Tumor **708**
Choriocarcinoma **714**
Embryonal Carcinoma **720**

Hematopoietic Malignancies

Hodgkin Lymphoma of Mediastinum **726**
Diffuse Large Cell Lymphoma of Mediastinum **734**
Lymphoblastic Lymphoma **748**
MALT Lymphoma of Thymus **754**

Mesenchymal Neoplasms

Liposarcoma **758**
Leiomyosarcoma **768**
Synovial Sarcoma **774**
Neurofibroma **786**
Peripheral Nerve Sheath Tumor **790**
Solitary Fibrous Tumor/Fibrosarcoma **796**
Epithelioid Hemangioendothelioma **806**
Mesenchymal Chondrosarcoma **812**
Chordoma **816**
Alveolar Soft Part Sarcoma **822**
Rhabdomyosarcoma **828**

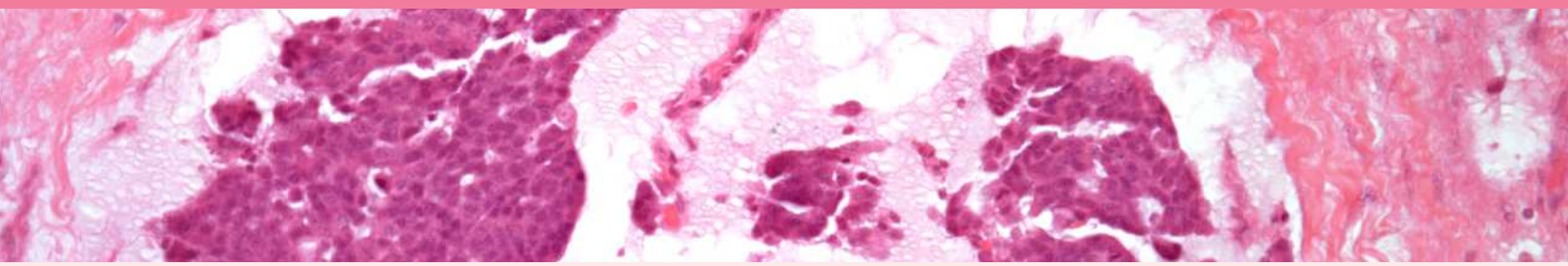

Sympathetic Nervous System Tumors

Ganglioneuroma **834**
Neuroblastoma/Ganglioneuroblastoma **838**
Ependymoma **844**

Other Tumors

Ectopic Parathyroid Tumor **848**
Ectopic Thyroid Tumor **854**

TERMINOLOGY

Definitions

- Primary malignant thymic neoplasms are derived from thymic epithelium, stroma, germ cells, or lymphoid component and include
  - Primary thymic epithelial neoplasms
    - Well-differentiated primary thymic epithelial neoplasms (thymoma)
    - Moderately differentiated primary thymic epithelial neoplasms (atypical thymoma)
    - Poorly differentiated primary thymic epithelial neoplasms (thymic carcinoma)
  - Thymic lymphoproliferative disorders
    - Hodgkin disease
    - Lymphoblastic lymphoma
    - Mediastinal diffuse large B-cell lymphoma
    - Other types of mediastinal lymphomas
  - Germ cell tumors arising in mediastinum
    - Teratomatous lesions
    - Seminoma
    - Yolk sac tumor
    - Choriocarcinoma
    - Embryonal carcinoma
  - Neuroendocrine carcinomas of thymus
    - Well-differentiated neuroendocrine carcinoma (thymic carcinoid)
    - Moderately differentiated neuroendocrine carcinoma (atypical carcinoid of thymus)
    - Poorly differentiated neuroendocrine carcinoma (small cell and large cell neuroendocrine carcinomas)
  - Sarcomas
    - Liposarcoma
    - Leiomyosarcoma
    - Epithelioid hemangioendothelioma
    - Chondrosarcoma
    - Osteosarcoma
    - Chordoma
    - Fibrosarcoma and malignant fibrous histiocytoma
    - Synovial sarcoma
    - Malignant peripheral nerve sheath tumors
    - Rhabdomyosarcoma
    - Alveolar soft parts sarcoma
    - Mesenchymal chondrosarcoma

EPIDEMIOLOGY

Age Range

- Affect all age groups but more common in middle-aged adults (40-50 years)

Incidence

- Rare tumors
  - Metastases to mediastinum outnumber primary malignancies 9:1

Natural History

- Thymomas are slow-growing tumors; prognosis is largely dependent on status of capsular integrity at time of resection
  - Most thymomas are found in stage I (noninvasive, completely encapsulated)
  - All histologic types have capability to invade, recur, and metastasize
  - Overall recurrence rate for thymoma is 10% with mean time to recurrence being 6 years (range: 1-16 years)
  - Survival after recurrence is usually good if adequately treated, with up to 65% 10-year survival after treatment of recurrence
  - Atypical thymomas (WHO type B3) are associated with higher incidence and earlier recurrences
  - Increased survival is also closely associated with completeness of excision
    - Incompletely excised tumors are associated with shorter survival
    - Completely excised tumors are associated with more favorable survival, independent of stage or histology
  - Metastases are rare in thymoma and more often occur in intrathoracic lymph nodes, lung, and pleura

WHO Type A Thymoma

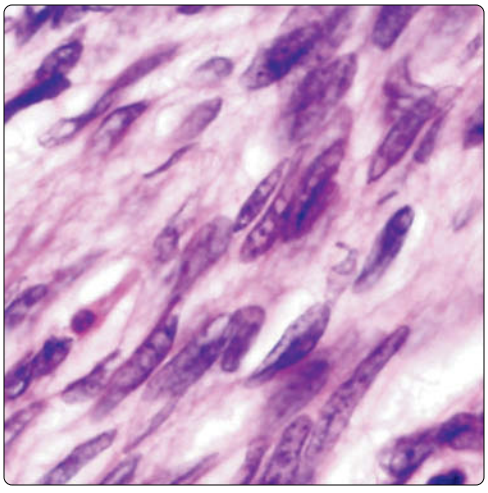

WHO Type B Thymoma

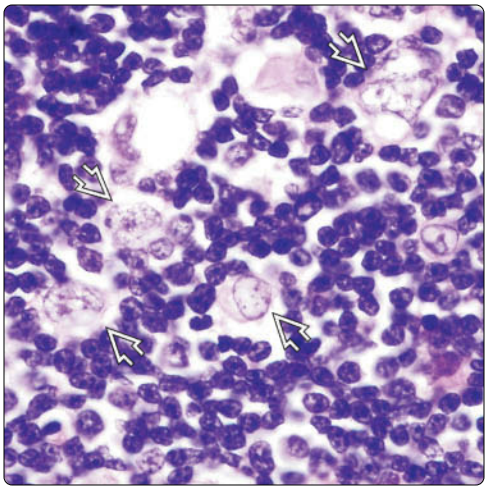

(Left) *WHO type A thymoma (spindle cell thymoma) shows characteristic cytomorphology of the tumor cells with elongated spindle cells displaying nuclei that contain dispersed chromatin and absence of nucleoli.* **(Right)** *WHO type B thymoma (lymphocyte rich) shows large epithelioid cells ➪ with vesicular nuclei and an indistinct rim of amphophilic cytoplasm surrounded by a dense population of small lymphocytes.*

Modified Masaoka Staging for Thymoma

Stage	Description
Stage I	Grossly and microscopically completely encapsulated (including microscopic invasion **into** capsule)
Stage IIa	Microscopic transcapsular invasion
Stage IIb	Microscopic invasion into thymic or surrounding fat, or grossly adherent but not breaking through mediastinal pleura or pericardium
Stage III	Microscopic invasion of neighboring organs (pericardium, great vessels, lung)
Stage IVa	Pleural or pericardial dissemination
Stage IVb	Hematogenous or lymphatic dissemination

Koga K et al. A review of 79 thymomas: modification of staging system and reappraisal of conventional division into invasive and non-invasive thymoma. Pathol Int. 44:359-367, 1994.

  - Intrathoracic metastases are seen in ~ 10% of patients with thymoma
  - Distant metastases are extremely rare in thymoma (~ 1-2% of patients)
  - Distant metastases are associated with poor prognosis (average survival after metastases: 1.5-3.0 years)
  - All histologic types are associated with potential for metastases
- Mortality in thymoma is in order of 10% of patients
  - Thymoma deaths usually occur late in disease, between 10-15 years after initial diagnosis
- Thymic carcinomas are, in general, highly aggressive tumors with short patient survival and poor response to treatment
  - Low-grade variants of thymic carcinoma (i.e., mucoepidermoid, well-differentiated squamous cell carcinoma) may have good prognosis
  - High-grade histologic variants (small cell carcinoma, lymphoepithelioma-like carcinoma, clear cell carcinoma) are rapidly fatal and refractory to treatment

CLINICAL IMPLICATIONS

Clinical Presentation

- Majority of mediastinal tumors present with symptoms referable to compression of mediastinal structures by expanding mass
  - Cough
  - Chest pain
  - Dyspnea
  - Superior vena cava syndrome
- Significant number of thymomas can be asymptomatic and discovered incidentally on routine chest x-rays
- Thymomas are commonly associated with paraneoplastic syndromes, myasthenia gravis in particular

MACROSCOPIC

General Features

- Size
  - Most mediastinal tumors reach large size before they become symptomatic (> 10 cm in greatest diameter)
    - Thymomas are often discovered as incidental finding and when they are still small in patients undergoing coronary artery bypass graft surgery
- Sections to be submitted
  - It is recommended to submit at least 1 section per cm of greatest diameter of lesion
  - Cystic lesions are best sampled extensively to make sure microscopic focus of burned-out neoplasm in walls of cysts is not missed
  - Thymomas require inking and extensive sampling of capsule for staging and identification of invasion
- Mediastinal compartments
  - Certain types of tumors have special predilection for various mediastinal compartments
    - Anterior-superior mediastinum: Thymoma, thymic carcinoma, lymphoma, germ cell tumors, multilocular thymic cysts
    - Middle mediastinum: Lymphomas, Castleman disease, mediastinal cysts, sarcomas, metastases to mediastinum
    - Posterior mediastinum: Neurogenic tumors, sarcomas, lymphomas

SELECTED REFERENCES

1. Suster S et al: The mediastinum. In Weidner N et al: Modern Surgical Pathology. 2nd ed. Philadelphia: Saunders Elsevier. 454-516, 2009
2. Marchevsky AM et al: Evidence-based pathology and the pathologic evaluation of thymomas: the World Health Organization classification can be simplified into only 3 categories other than thymic carcinoma. Cancer. 112(12):2780-8, 2008
3. Suster S et al: Histologic classification of thymoma: the World Health Organization and beyond. Hematol Oncol Clin North Am. 22(3):381-92, 2008
4. Suster S et al: Thymoma classification: current status and future trends. Am J Clin Pathol. 125(4):542-54, 2006
5. Suster S: Thymic carcinoma: update of current diagnostic criteria and histologic types. Semin Diagn Pathol. 22(3):198-212, 2005

Thymoma

KEY FACTS

CLINICAL ISSUES

- Majority of thymomas are very low-grade malignant neoplasms with generally indolent behavior
- Status of capsular integrity is most important determinant factor for prognosis
- Best chance for cure is complete surgical excision with negative margins

MICROSCOPIC

- WHO classification system is based predominantly on cell type, cytologic atypia, and proportion of lymphocytes to epithelial cells: Thymoma type A, AB, B1, B2, B3, and thymic carcinoma
- 2 basic cell types are recognized: Spindle/oval and round/epithelioid
  - Type A thymoma: Composed of oval or spindle cells with scattered nuclear chromatin and inconspicuous or absent nucleoli without mitotic activity
  - Type AB thymoma: Composed of oval or spindle cells identical to those seen in type A but admixed with abundant small lymphocytes
  - Type B1 thymoma: Composed of round/epithelioid cells with single small eosinophilic nucleoli and abundant cytoplasm, admixed with numerous small T lymphocytes
  - Type B2 thymoma: Composed of approximately equal admixture of round epithelial cells and small lymphocytes
  - Type B3 thymoma: Composed of sheets of large epithelioid cells admixed with scant lymphocytes

DIAGNOSTIC CHECKLIST

- Types A, AB, B1, and B2 in WHO classification observe similar behavior; prognosis is determined by status of capsular integrity
- Type B3 thymoma in WHO classification has slightly more aggressive biologic behavior with frequent invasion at time of diagnosis and earlier recurrences

Graphic

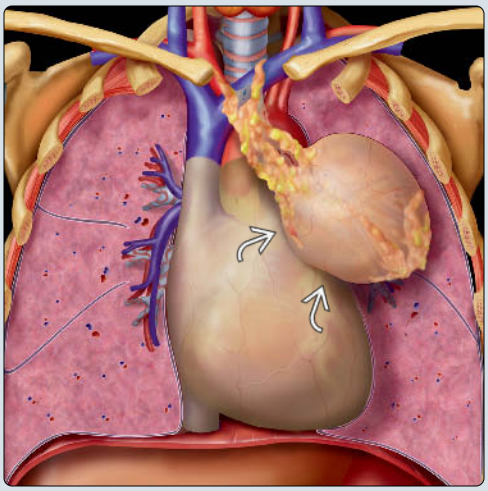

Gross Appearance

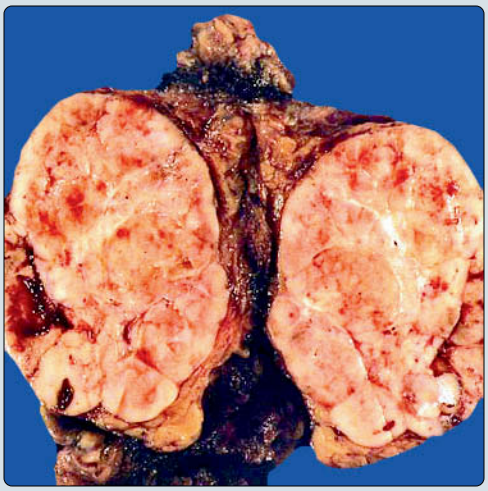

(Left) *Graphic of the chest cavity shows a round to ovoid, well-circumscribed thymoma in the anterior mediastinal compartment on top of the pericardium and protruding onto the left hemithorax.* **(Right)** *Gross appearance of bisected thymoma shows a well-circumscribed, fleshy, lobulated mass composed of tan-white, homogeneous rubbery tissue with focal areas of congestion and hemorrhage.*

Thymoma Composed of Spindle Cells

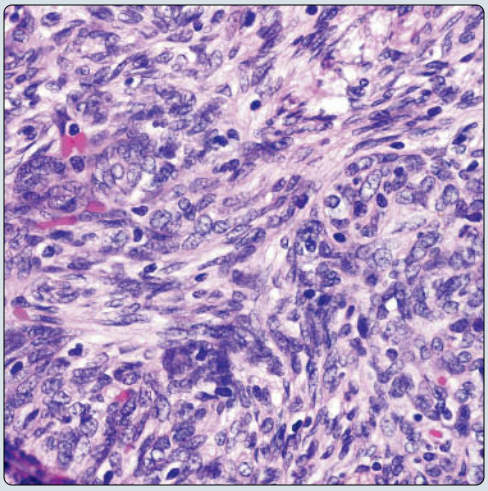

Thymoma Composed of Round/Epithelioid Cells

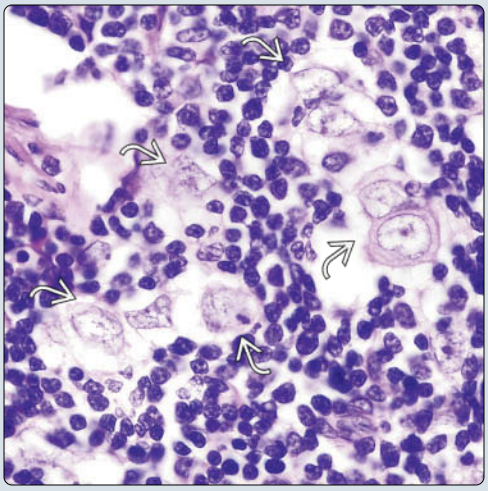

(Left) *Spindle cell thymoma (WHO type A) is composed of spindle cells with elongated nuclei, dispersed chromatin, and absence of nucleoli. The spindle cells usually predominate, and stromal lymphocytes are very scant.* **(Right)** *Lymphocyte-rich thymoma (WHO type B1) shows a few scattered large, epithelioid cells with large vesicular nuclei and small eosinophilic nucleoli. The large epithelioid cells are surrounded by abundant small T lymphocytes.*

TERMINOLOGY

Synonyms

- Primary thymic epithelial neoplasm

Definitions

- Primary thymic epithelial neoplasm composed of thymic epithelial cells admixed in varying proportions with nonneoplastic immature T lymphocytes

ETIOLOGY/PATHOGENESIS

Pathogenesis

- Unknown
- Close association with myasthenia gravis and other autoimmune disorders

CLINICAL ISSUES

Presentation

- Chest pain
- Shortness of breath
- Paraneoplastic syndrome (myasthenia gravis, hypogammaglobulinemia, pure red cell aplasia, Cushing syndrome, etc.)
- Superior vena cava syndrome
- Asymptomatic in up to 30% of cases
- Incidental finding on routine chest x-ray or during coronary artery bypass surgery

Natural History

- Majority of thymomas are very low-grade malignant neoplasms with generally indolent behavior
- Size and status of capsular integrity: Most important determinant factors for prognosis
- Invasive tumors are associated with more aggressive behavior
- Incompletely excised tumors have tendency to recur locally and spread along chest cavity
- Recurrences can take place many years after initial resection (i.e., > 10-15 years)
- Most common sites for metastases are lung, pleura, and thoracic lymph nodes
- Extrathoracic metastases are extremely rare (< 2% of cases)

Treatment

- Complete surgical excision for noninvasive tumors
- Radiation therapy for incompletely resected tumors
- Surgical excision + postoperative radiation therapy for invasive tumors
- Repeat surgical excision + radiation for recurrent tumors
- Combination chemotherapy for advanced stage and metastatic tumors
- Best chance for cure is complete surgical excision with negative margins

Prognosis

- Most important prognostic factor is clinical staging (modified Masaoka staging)
- 80-90% survival at 15 years with stages I and II
- 70% survival at 15 years with stage III
- 60% survival at 5 years with stage IV
- Stages I and II include infiltration of capsule and minimal invasion of perithymic fat (collectively regarded as noninvasive tumors; confined to anterior mediastinum)
- Stages III and IV include infiltration of adjacent or neighboring structures, implants, and distant metastases (collectively regarded as invasive)

IMAGING

General Features

- Best diagnostic clue
  - Smooth or lobulated anterior mediastinal mass
- Location
  - Generally anterior mediastinum
  - May also occur in posterior mediastinum
  - May arise ectopically in pulmonary hilum, pleura, or head and neck
- Size
  - Usually between 4-15 cm

Radiographic Findings

- Round or oval anterior mediastinal mass
- Usually centered over heart; best seen on lateral view
- Linear and peripheral calcifications in capsule (10% of patients)

MR Findings

- T1WI: Isointense relative to muscle
- T2WI: Hyperintense, approaching that of fat

CT Findings

- CECT best imaging tool for thymoma
- Oval or lobulated mass within anterior mediastinum
- Homogeneous enhancement is common in small tumors
- Heterogeneous enhancement more common in large tumors
- Thin and linear calcifications seen within capsule in 1/3 of patients
- Cystic changes and necrosis common in larger tumors
- Obliteration of mediastinal fat planes or mediastinal structures seen in invasive tumors

MACROSCOPIC

General Features

- Generally well-circumscribed, encapsulated, solid tumor
- Homogeneous tan-white, rubbery tissue on cut surface
- Lobulated cut surface
- May be cystic and multilocular
- May contain calcifications in capsule or within tumor
- Rarely can be multifocal
- Can be ectopically located in posterior mediastinum, lung, neck, or pleura
- Can show areas of necrosis and hemorrhage
- Invasive tumors usually compromise adjacent structures, including large vessels, pericardium, pleura
- Distant metastases are rare

Sections to Be Submitted

- At least 1 section per cm of greatest tumor diameter
- Take additional sections if tumor shows variegated appearance
- Sample solid areas in cyst walls in multicystic tumors

- Always include sections of inked outer surface of specimen
- Coordination with surgeon should be sought to establish "true" margins to be sampled
- Any structures attached to specimen (i.e., pleura, lung, large vessels) should be inked and sampled separately as they represent "true" margins

MICROSCOPIC

Histologic Features

- Histologic classification is controversial
- Currently 2 systems are in use: Suster & Moran classification and WHO classification
- Suster & Moran classification: Based on degree of organotypical differentiation, divided into 3-tiered system
  - Well-differentiated (thymoma)
  - Moderately differentiated (atypical thymoma)
  - Poorly differentiated (thymic carcinoma)
- WHO classification is based primarily on cell type, cytologic atypia, and proportion of lymphocytes to epithelial cells
  - WHO type A: Composed of spindle cells without cytologic atypia
  - WHO type AB: Composed of spindle cells admixed with abundant lymphocytes
  - WHO type B1: Composed of round, epithelioid cells admixed with abundant lymphocytes
  - WHO type B2: Composed of round, epithelioid cells admixed with equal amounts of lymphocytes
  - WHO type B3: Composed predominantly of epithelial cells with cytologic atypia and few lymphocytes
- WHO classification has series of other distinctive histologic types that do not fit into standard categories
  - "Metaplastic" thymoma
  - Multifocal thymoma
  - Microscopic thymoma
  - Micronodular thymoma
  - Anaplastic thymoma
- Older (traditional) classification by Bernatz et al is still used today by some and divides these tumors based on their cell composition
  - Lymphocyte-rich thymoma
  - Mixed, lymphoepithelial thymoma
  - Epithelial-rich thymoma
  - Spindle cell thymoma

Cytologic Features

- 2 basic cell types are recognized
  - Oval/spindle cells (types A, AB)
  - Round/epithelioid cells (types B1-3)
- Type A thymoma is composed of oval or spindle cells with scattered nuclear chromatin and inconspicuous or absent nucleoli and no mitotic activity
  - Spindle cell thymoma usually contains few lymphocytes
  - Majority of spindle cell thymomas are low grade and encapsulated
  - Invasive or atypical spindle cell thymoma can follow aggressive behavior
  - Distant metastases and death can occur in some cases of spindle cell thymoma
- Type AB thymoma is composed of oval or spindle cells similar to those in type A but admixed with abundant small lymphocytes
  - Spindle cells do not display mitotic activity
  - Lymphocytes admixed with epithelial cells are of T-cell type
  - Tumors usually contain admixture of lymphocyte-rich and lymphocyte-poor areas
  - Tumors may be composed exclusively of lymphocyte-rich areas and be confused for B1 thymoma
- Type B1 thymoma is composed of round/epithelioid cells with single small eosinophilic nucleoli and abundant cytoplasm, admixed with numerous small T lymphocytes
  - Small lymphocytes predominate and overshadow epithelial cells
  - Contains frequent dilated perivascular spaces and areas of medullary differentiation
  - Equivalent to lymphocyte-rich or lymphocyte-predominant in traditional classification (Bernatz)
- Type B2 thymoma is composed of approximately equal admixture of round epithelial cells and small lymphocytes
  - Epithelial cells may show mild enlargement of nuclei
  - Admixtures with B1 areas may be seen in ~ 30% of cases
  - Equivalent to mixed lymphoepithelial thymoma of traditional classification (Bernatz)
- Type B3 thymoma is composed of sheets of large epithelioid cells admixed with scant lymphocytes
  - Epithelial cells may vary in size and are characterized by nuclear enlargement with dense chromatin pattern and prominent nucleoli
  - Rare mitoses can be encountered in epithelial cells
  - Cell nuclei show tendency to display raisin-like configuration
  - Cytoplasm of tumor cells is usually abundant, eosinophilic, and with sharp cell borders
  - Tendency for epithelial cells to palisade around perivascular spaces
  - Tumor cells can also be oval or spindle with similar nuclear features
- Type A thymomas may exhibit unusual growth patterns
  - Hemangiopericytic growth pattern
  - Micronodular growth pattern with lymphoid B-cell hyperplasia
  - Biphasic pattern with pseudosarcomatous stroma (metaplastic thymoma)
  - Skin adnexal-like (adenoid) growth pattern
  - Sclerosing growth pattern
  - Rosette-forming growth pattern
- Type B thymomas may exhibit unusual features
  - Extensive multilocular thymic cyst-like changes
  - Areas of infarction, hemorrhage, and necrosis
  - Massive infiltration by plasma cells in stroma
  - Clear cell changes
  - Starry-sky appearance simulating lymphoma
- Mixed thymomas
  - Thymomas may show frequent admixtures of various histologic types within same lesion due to tumor heterogeneity
    - Most common admixtures are between types B1 + B2 and types B2 + B3

  - Mixed thymomas are reported by providing percentage of various types present
- Unusual types of thymoma
  - Metaplastic thymoma (thymoma with pseudosarcomatous stroma)
    - Characterized by islands of polygonal thymic epithelial cells separated by abundant spindle cell stroma devoid of cytologic atypia
    - Thymic epithelial cells can display mild atypia but no mitotic activity
    - Tumors are generally encapsulated and well circumscribed
    - Epithelial cells stain for keratin and p63; spindle stromal cells stain for SMA and vimentin and may be focally positive for EMA but are negative for keratin and p63
    - Majority of these tumors are cured by simple surgical excision; rare tumors can be invasive
  - Micronodular thymoma with lymphoid hyperplasia
    - Composed of discrete nodular islands of oval to spindle thymic epithelial cells separated by abundant lymphoid stroma
    - Lymphoid stroma is primarily composed of small B lymphocytes and plasma cells with hyperplastic lymphoid follicles with germinal centers
    - Clinical behavior is related to status of capsular integrity and invasiveness
  - Anaplastic thymoma
    - Well-circumscribed and encapsulated B-type thymoma with foci containing cells displaying marked anaplasia

Lymphatic/Vascular Invasion

- Very rare; unknown significance but generally associated with worse prognosis

Margins

- Very difficult to determine without assistance of surgeon
- True resection margins need to be inked or tagged by surgeon before submitting to pathology
- Inked anterior surface does not represent margin unless it was invading at time of surgery
- True margins need to be inked for proper assessment

Lymph Nodes

- Thymoma rarely metastasizes to lymph nodes
- Majority of lymph node metastases in thymoma are to mediastinal nodes
- Other intrathoracic lymph nodes may also be involved more rarely by metastatic thymoma

DIFFERENTIAL DIAGNOSIS

Lymphoblastic Lymphoma

- Does not show scattered keratin-positive cells admixed with immature T lymphocytes
- Rapid growth with sudden onset of symptoms
  - Thymoma is slow-growing tumor with slowly progressive symptoms
- Most common ages for lymphoblastic lymphoma are childhood and adolescence
  - Most common age for thymoma is middle-aged adults; rare in children and adolescents

Acquired Multilocular Thymic Cyst

- Multilocular cysts do not contain discrete areas attached to walls of cysts showing typical type B thymoma
  - Type A thymoma can undergo massive cystic changes, but cells lining cysts are spindle cells
- Small cuboidal or squamous epithelial cells lining cysts in continuity with dilated Hassall corpuscles
- Prominent lymphoid follicular hyperplasia and severe acute and chronic inflammation with cholesterol cleft granulomas

Hemangiopericytoma/Solitary Fibrous Tumor

- Spindle cells in solitary fibrous tumors are not keratin positive
- Spindle cells in solitary fibrous tumor are CD34, Bcl-2, and CD99 positive
- Characteristic linear pattern of stromal collagenization resulting in deposition of rope-like collagen separating spindle cells
- Devoid of immature T cells
  - Spindle cell thymoma may contain variable number of immature T cells admixed with epithelial cells

Neuroendocrine Carcinomas

- Positive for neuroendocrine markers
  - Rosette-like structures in thymoma are only positive for cytokeratin
- Thymic carcinoids usually show increased mitotic activity and tumor cells necrosis
- Tumor cells in carcinoids show characteristic stippled (salt and pepper) chromatin pattern
- Other features of thymic carcinoids include nested growth pattern (zellballen) and formation of trabeculae, ribbons, and festoons

DIAGNOSTIC CHECKLIST

Clinically Relevant Pathologic Features

- Encapsulation/circumscription
- Presence or absence of cytologic atypia in epithelial cells
- Size of tumor
- Clinical stage
- Presence or absence of myasthenia gravis

Pathologic Interpretation Pearls

- Great variation in histologic appearance due to tumor heterogeneity
- Identification of scattered keratin-positive neoplastic cells in lymphocyte-rich tumors
- Hemorrhage and necrosis may be seen in encapsulated low-grade, well-differentiated tumors; not to be mistaken for ominous sign
- Capsular invasion is most significant prognostic factor
- Rarely, thymoma may be devoid of capsule; should not be overinterpreted for invasion
- Types A, AB, B1, and B2 in WHO classification observe similar behavior; prognosis is determined by status of capsular integrity
- Type B3 thymoma in WHO classification has slightly more aggressive biologic behavior with frequent invasion at time of diagnosis and earlier recurrences

Immunohistochemistry

Antibody	Reactivity	Staining Pattern	Comment
AE1/AE3	Positive	Cytoplasmic	Stains neoplastic thymic epithelial cells in all histologic types
p63	Positive	Nuclear	Stains neoplastic thymic epithelial cells in all histologic types
CK19	Positive	Cytoplasmic	Stains neoplastic cells in all histologic types of thymoma
CD1a	Positive	Cytoplasmic	Stains immature T lymphocytes
TdT	Positive	Nuclear	Stains immature T lymphocytes
CD3	Positive	Cytoplasmic	Stains T lymphocytes
CD99	Positive	Cytoplasmic	Stains immature T lymphocytes
CD20	Positive	Cytoplasmic	May be positive in spindle cells in thymoma (WHO types A and AB) and also highlights small subpopulation of B lymphocytes
Bcl-2	Positive	Cytoplasmic	May be positive in spindle cell thymoma (WHO types A and AB)
CD5	Negative	Cytoplasmic	Negative in epithelial cells of most thymomas, except WHO B3
CD117	Negative	Cytoplasmic	Negative in epithelial cells of most thymomas; stains germ cells and mast cells within tumor; may be positive in WHO B3

Histologic Classification Systems for Thymoma

Suster & Moran Classification	WHO 2015 Classification
Well-differentiated thymic epithelial neoplasm (thymoma)	WHO type A (spindle cell)
Well-differentiated thymic epithelial neoplasm (thymoma)	WHO Type AB (spindle cell with abundant lymphocytes)
Well-differentiated thymic epithelial neoplasm (thymoma)	WHO type B1 (lymphocyte predominant)
Well-differentiated thymic epithelial neoplasm (thymoma)	WHO type B2 (lymphoepithelial)
Moderately differentiated thymic epithelial neoplasm (atypical thymoma)	WHO type B3 (epithelial rich)
Poorly differentiated thymic epithelial neoplasm (thymic carcinoma)	Thymic carcinoma

Classification of Thymoma According to Grades of Differentiation (Suster & Moran)

Diagnosis	Differentiation Grade	Features
Organotypical thymoma	Well-differentiated thymic neoplasm	Preservation of organotypical features of thymic differentiation; no cytologic evidence of atypia
Atypical thymoma	Moderately differentiated thymic neoplasm	Partial preservation of organotypical features of differentiation of thymus; mild to moderate cytologic atypia
Thymic carcinoma	Poorly differentiated thymic neoplasm	Loss of organotypical features of differentiation of thymus; overt cytologic evidence of malignancy

SELECTED REFERENCES

1. Roden AC et al: Modified Masaoka stage and size are independent prognostic predictors in thymoma and modified Masaoka stage is superior to histopathologic classifications. J Thorac Oncol. 10(4):691-700, 2015
2. Travis WB et al: WHO Classification of Tumors of the Lung, Pleura, Thymus and Heart. Lyon: IARC, 2015
3. Roden AC et al: Reproducibility of 3 histologic classifications and 3 staging systems for thymic epithelial neoplasms and its effect on prognosis. Am J Surg Pathol. 39(4):427-41, 2015
4. Miki Y et al: Type AB thymoma is not a mixed tumor of type A and type B thymomas, but a distinct type of thymoma. Virchows Arch. 464(6):725-34, 2014
5. Wang H et al: Classification of thymic epithelial neoplasms is still a challenge to thoracic pathologists: a reproducibility study using digital microscopy. Arch Pathol Lab Med. 138(5):658-63, 2014
6. Wang Z et al: Clinicopathological features of type AB thymoma with liver metastases. Int J Clin Exp Pathol. 7(12):8700-5, 2014
7. Casey EM et al: Clinical management of thymoma patients. Hematol Oncol Clin North Am. 22(3):457-73, 2008
8. Marchevsky AM et al: Evidence-based pathology and the pathologic evaluation of thymomas: the World Health Organization classification can be simplified into only 3 categories other than thymic carcinoma. Cancer. 112(12):2780-8, 2008
9. Suster S et al: Histologic classification of thymoma: the World Health Organization and beyond. Hematol Oncol Clin North Am. 22(3):381-92, 2008
10. Verghese ET et al: Interobserver variation in the classification of thymic tumours--a multicentre study using the WHO classification system. Histopathology. 53(2):218-23, 2008
11. Wick MR: Prognostic factors for thymic epithelial neoplasms, with emphasis on tumor staging. Hematol Oncol Clin North Am. 22(3):527-42, 2008
12. Suster S et al: Thymoma classification: current status and future trends. Am J Clin Pathol. 125(4):542-54, 2006
13. Suster S et al: Problem areas and inconsistencies in the WHO classification of thymoma. Semin Diagn Pathol. 22(3):188-97, 2005
14. Rieker RJ et al: Histologic classification of thymic epithelial tumors: comparison of established classification schemes. Int J Cancer. 98(6):900-6, 2002

Spindle Cell Thymoma (WHO Type A)

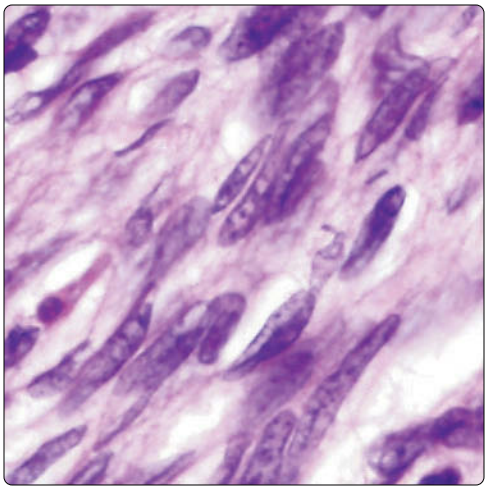

Lymphocyte-Rich Spindle Cell Thymoma (WHO Type AB)

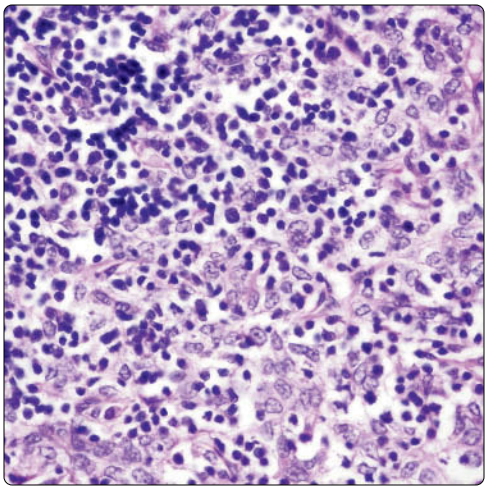

(Left) *Spindle cell thymoma (WHO type A) is composed of spindle cells with elongated nuclei showing dispersed chromatin pattern and absent or very inconspicuous nucleoli and an indistinct rim of lightly eosinophilic to amphophilic cytoplasm.* **(Right)** *Lymphocyte-rich spindle cell thymoma (type AB thymoma) is composed of small spindle cells admixed with numerous small lymphocytes; the tumor can closely resemble a B1 thymoma on scanning magnification because of the abundance of lymphocytes.*

Lymphocyte-Rich Thymoma (WHO Type B1)

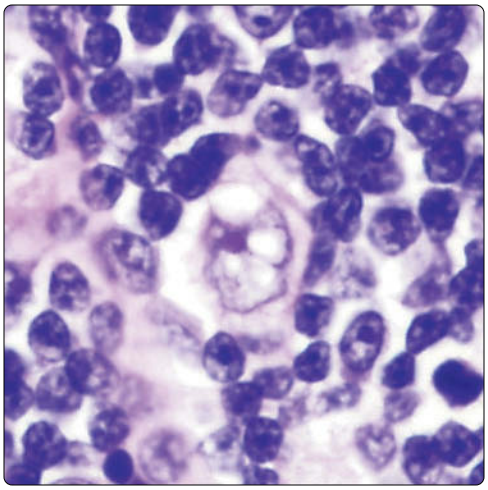

Lymphoepithelial Thymoma (WHO Type B2)

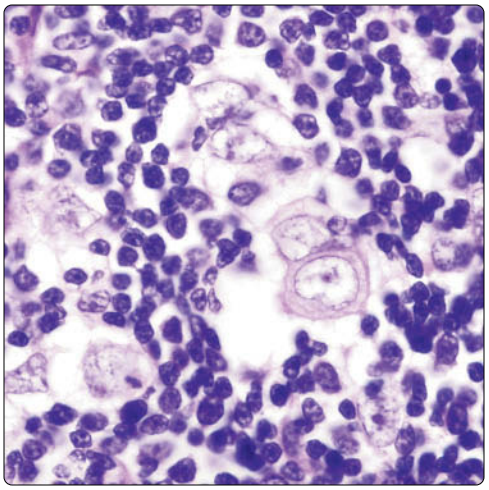

(Left) *WHO type B1 thymoma is composed of large, round epithelioid cells with large, vesicular nuclei containing single prominent eosinophilic nucleoli and surrounded by an indistinct rim of amphophilic cytoplasm.* **(Right)** *Lymphoepithelial thymoma (WHO type B2) is composed of similar cells to WHO type B1, except they are more numerous & easily spotted on intermediate magnification. The nuclei are large with vesicular chromatin and eosinophilic nucleoli and have a rim of lightly eosinophilic to amphophilic cytoplasm.*

Atypical Thymoma (WHO Type B3)

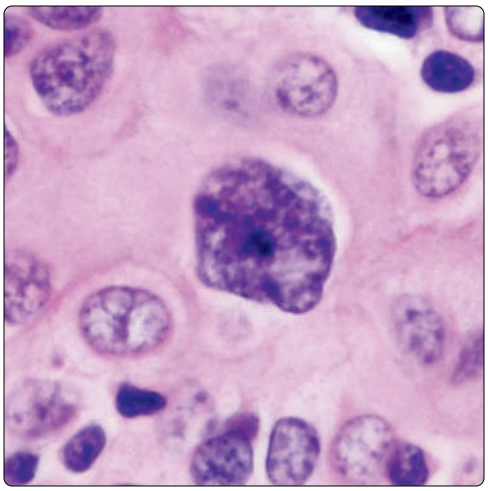

Atypical Thymoma (WHO Type B3)

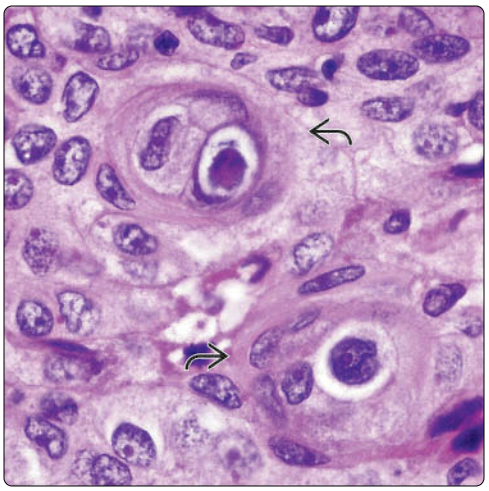

(Left) *WHO type B3 thymoma shows sheets of large epithelioid to polygonal cells with enlarged nuclei, marked increase in nuclear chromatin, prominent nucleoli, and abundant eosinophilic cytoplasm with sharp cell borders.* **(Right)** *WHO type B3 thymoma may show foci of abortive squamous differentiation, showing large, round to polygonal cells with large nuclei and prominent nucleoli. Notice the tight apposition and moulding of the cells forming abortive squamous eddies.*

Spindle Cell Thymoma

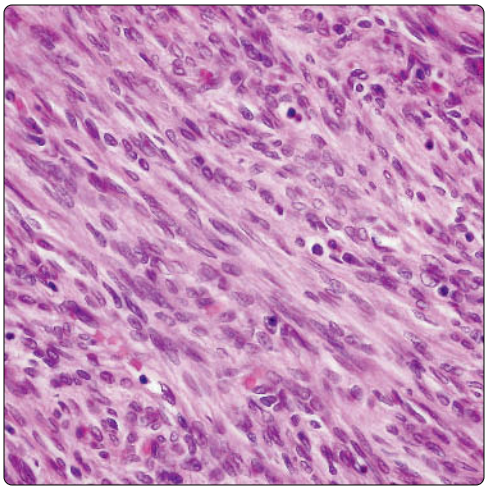

Spindle Cell Thymoma

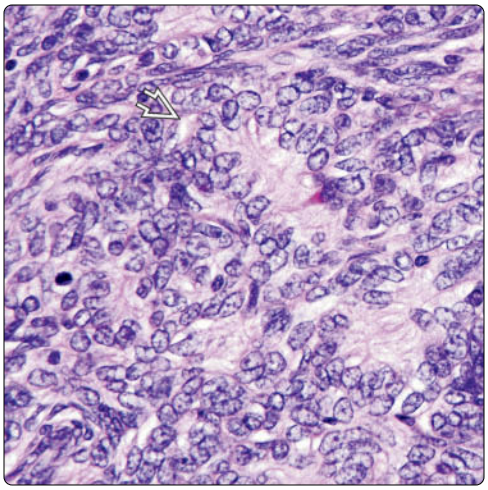

(Left) *Spindle cell thymoma (WHO type A) shows fascicles of bland-appearing spindle cells admixed with a few scattered small lymphocytes.* **(Right)** *The cells in spindle cell thymoma may also show plump oval nuclei with dispersed chromatin and absence of nucleoli. The cytoplasm in these spindle cells is inconspicuous, and occasionally they can aggregate around an empty center, forming pseudorosette-like structures.*

Spindle Cell Thymoma, Storiform Pattern

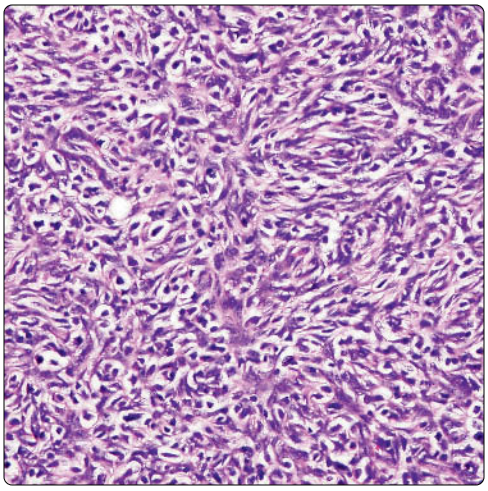

Spindle Cell Thymoma, Microcystic

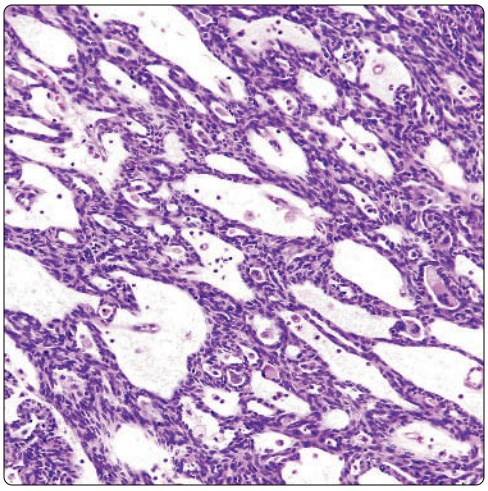

(Left) *A short storiform pattern is appreciated in this example of spindle cell thymoma (WHO type A). Notice the sprinkling of small lymphocytes in the background. This growth pattern can be confused for a fibrohistiocytic neoplasm or a solitary fibrous tumor of the mediastinum.* **(Right)** *Spindle cell thymoma (WHO type A) shows a striking microcystic pattern of growth with small, abortive, gland-like structures. The microcysts are primarily composed of dilated perivascular spaces.*

Spindle Cell Thymoma, Macrocystic

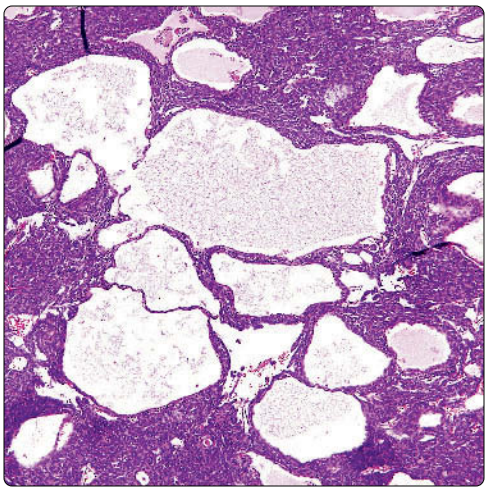

Spindle Cell Thymoma, Capsular Invasion

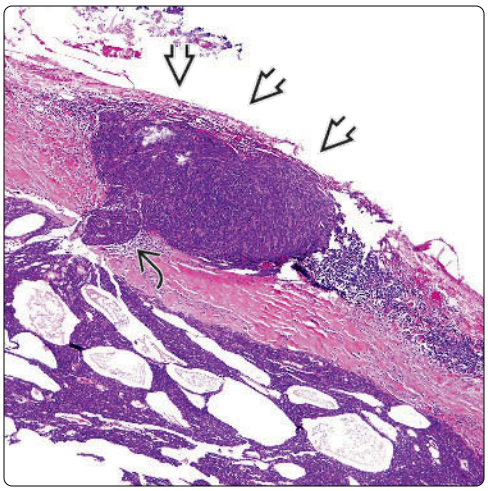

(Left) *Spindle cell thymoma (WHO type A) shows a macrocystic pattern of growth with large, irregular cystic spaces lined by the thymic epithelial cells. The macrocysts are caused by the confluence and coalescence of smaller, dilated perivascular spaces.* **(Right)** *Spindle cell thymoma (WHO type A) shows capsular invasion by tumor. Notice the solid nodule traversing the fibrous capsule of the thymus that is still attached to the underlying main tumor mass by a short pedicle.*

Spindle Cell Thymoma, Hemangiopericytic

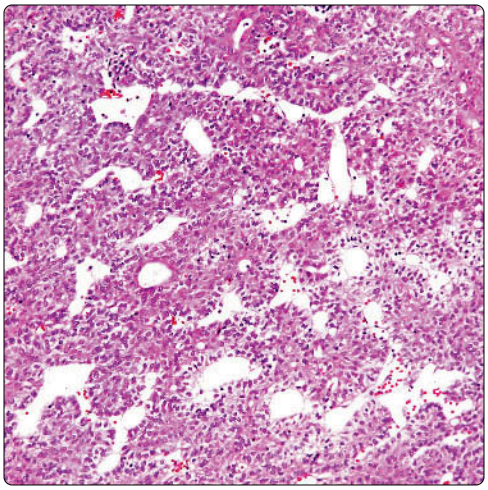

Spindle Cell Thymoma, Papillary

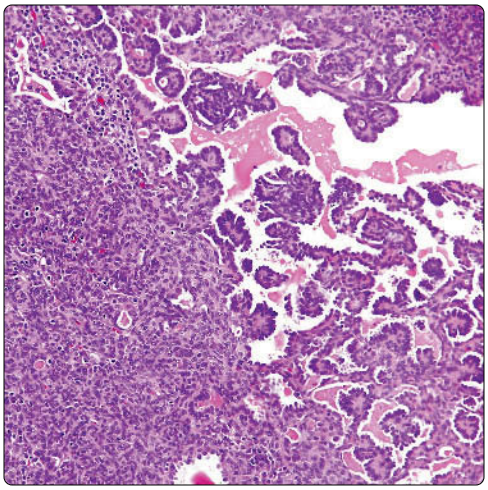

(Left) *Spindle cell thymoma (WHO type A) shows a striking hemangiopericytoma-like vascular pattern. Notice numerous small to medium-sized vascular spaces displaying open lumina and occasional branching of vessels.* **(Right)** *Spindle cell thymoma (WHO type A) shows prominent papillary structures (right 1/2 of field) that gradually merge with solid, spindle cell component on the left side. These tumors can be confused for metastatic papillary carcinoma.*

Spindle Cell Thymoma With Rosettes

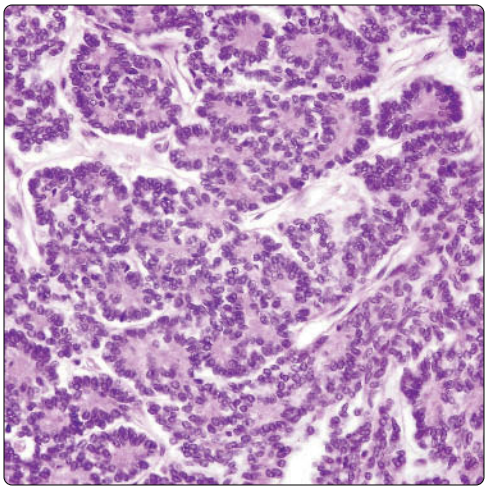

Rosettes, High Power

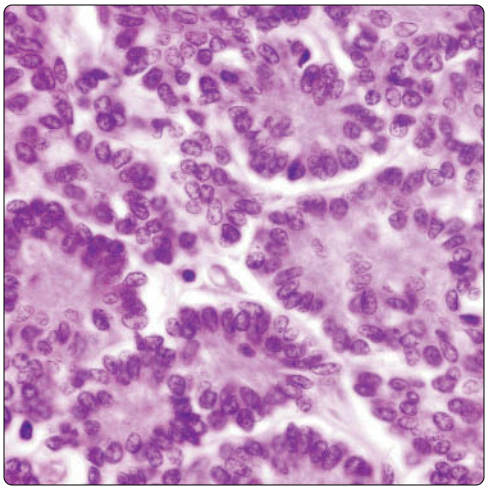

(Left) *Spindle cell thymoma (WHO type A) shows numerous small, rosette-like structures with striking palisading of nuclei in the periphery and central cores containing amorphous material.* **(Right)** *High-power view of spindle cell thymoma with epithelial rosettes shows rosette-like structures displaying peripheral palisading of nuclei and central cores containing pink, amorphous material. These tumors may be confused for primary or metastatic neuroendocrine neoplasms.*

Spindle Cell Thymoma, Adenoid Pattern

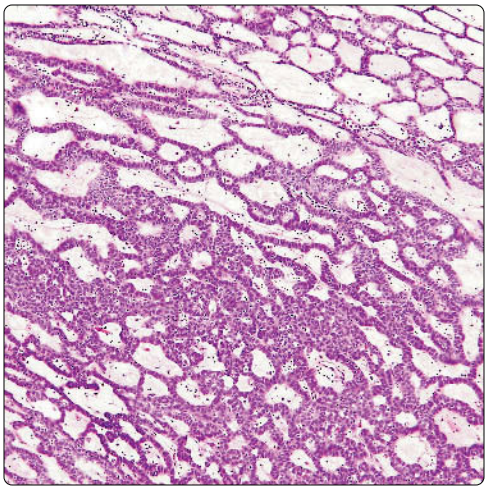

Adenoid Pattern, High Power

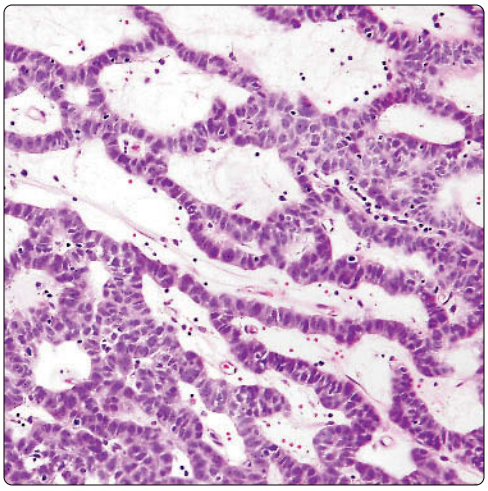

(Left) *Spindle cell thymoma (WHO type A) shows a delicate, lace-like pattern composed of cords and rows of single cells adopting a net-like configuration reminiscent of a benign skin adnexal tumor.* **(Right)** *High-power view of spindle cell thymoma shows an adenoid, lace-like arrangement of tumor cells. The cells are oval to spindle and adopt a palisaded appearance. A few scattered small lymphocytes are also present. The image is reminiscent of a benign skin adnexal tumor.*

Micronodular Thymoma

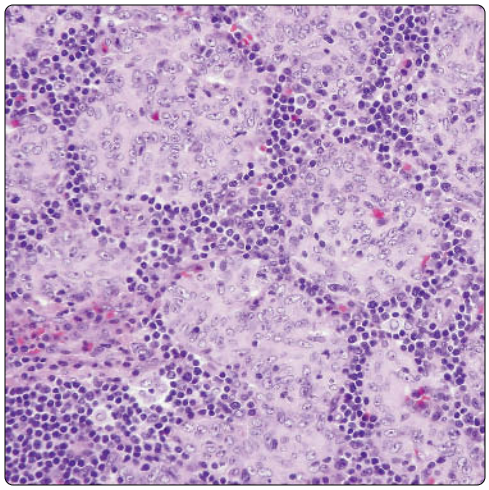

Micronodular Thymoma, High Power

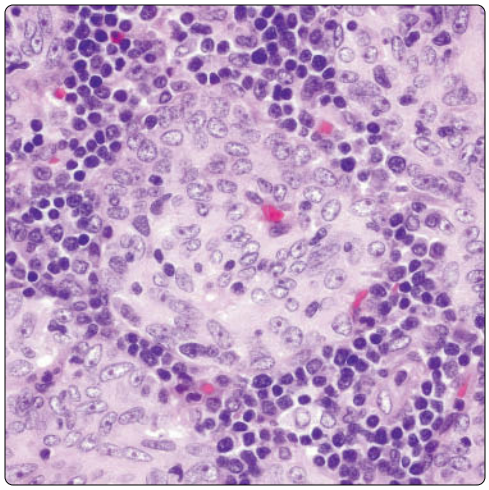

(Left) *Micronodular thymoma with lymphoid B-cell hyperplasia shows discrete, small nodules against a background of small lymphocytes in the stroma.* **(Right)** *High-power view of micronodule in micronodular thymoma shows cells with oval nuclei surrounded by an indistinct rim of amphophilic cytoplasm. The cells surrounding the nodule are polyclonal B lymphocytes. This image can be confused for a metastatic carcinoma to mediastinal lymph node.*

Micronodular Thymoma, Germinal Center

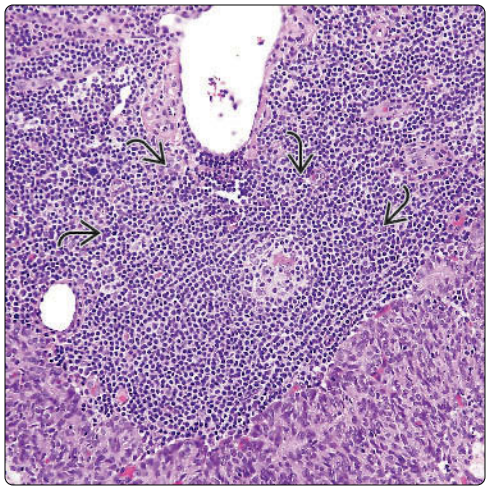

Sclerosing Spindle Cell Thymoma

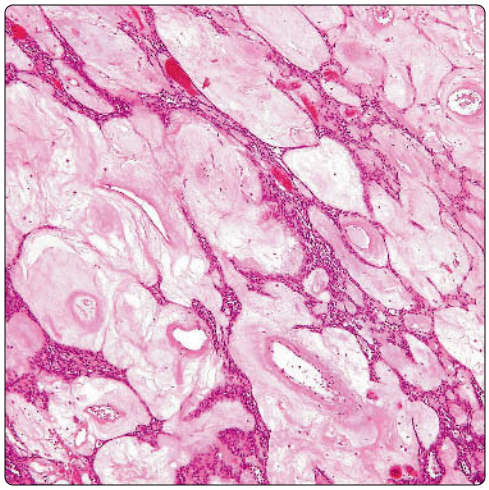

(Left) *Micronodular thymoma with lymphoid B-cell hyperplasia shows a hyperplastic lymphoid follicle with reactive germinal center. The solid nodule beneath is composed mainly of spindle to oval cells with scant cytoplasm.* **(Right)** *Spindle cell thymoma (WHO type A) shows massive dilatation of perivascular spaces with abundant hyalinization and sclerosis. Notice fibroepitheliomatous appearance caused by strands of epithelial cells circumscribing hyalinized stroma.*

Rhabdomyomatous Thymoma

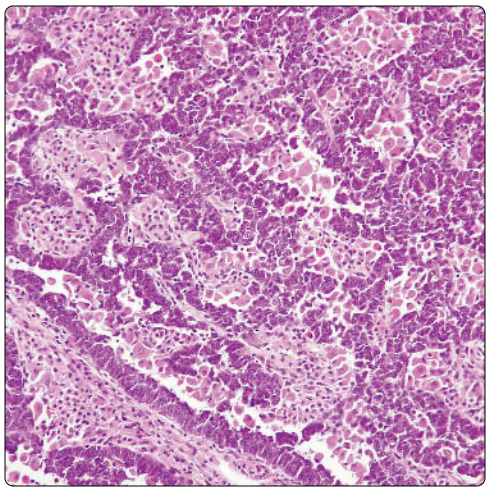

Rhabdomyomatous Thymoma, High Power

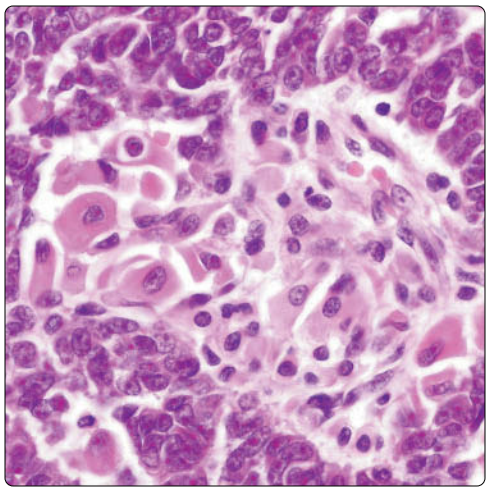

(Left) *Rhabdomyomatous variant of thymoma shows a biphasic appearance on scanning magnification. There are strands and cords of oval to spindle epithelial tumor cells circumscribing clusters of large eosinophilic cells.* **(Right)** *High-power view of rhabdomyomatous thymoma shows large rhabdoid cells in the center characterized by small, oval nuclei surrounded by an ample rim of densely eosinophilic cytoplasm. These cells express desmin and correspond to myoid cells of the thymus.*

Metaplastic Thymoma

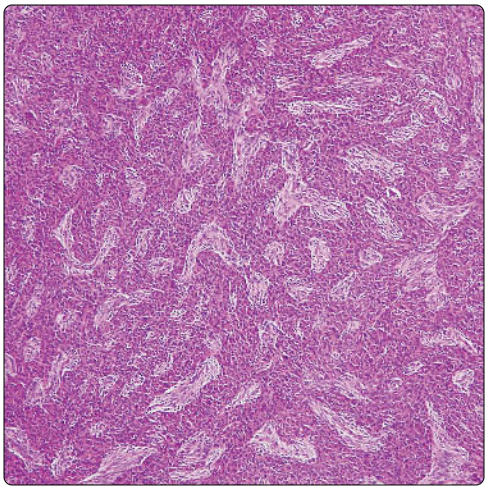

Metaplastic Thymoma

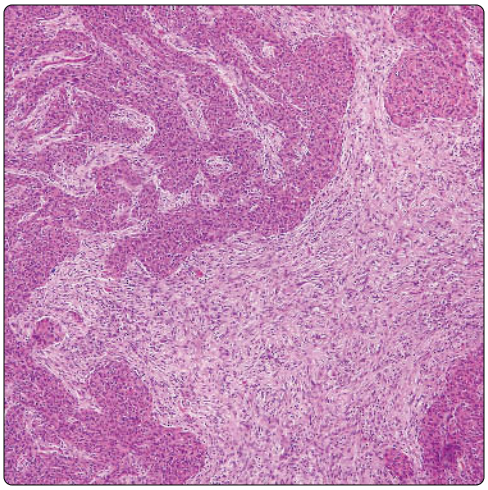

(Left) *Spindle cell thymoma with pseudosarcomatous stroma (so-called metaplastic thymoma) shows a sieve-like architecture with anastomosing cords and trabeculae of epithelial tumor cells circumscribing stromal areas containing a spindle cell population.* **(Right)** *Thymoma with pseudosarcomatous stroma shows a sharp demarcation between the epithelial component (periphery) and the spindle cell stromal component (center).*

Metaplastic Thymoma, Epithelial Component

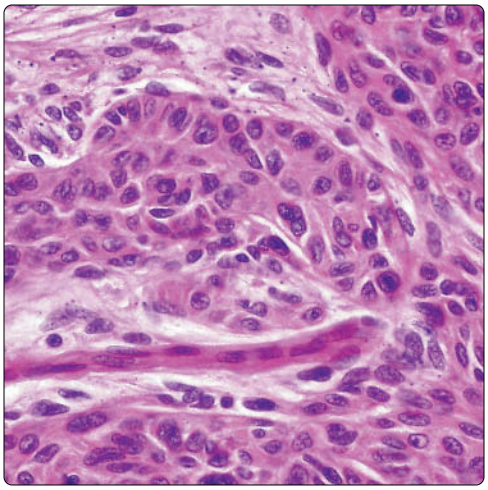

Metaplastic Thymoma, Stromal Component

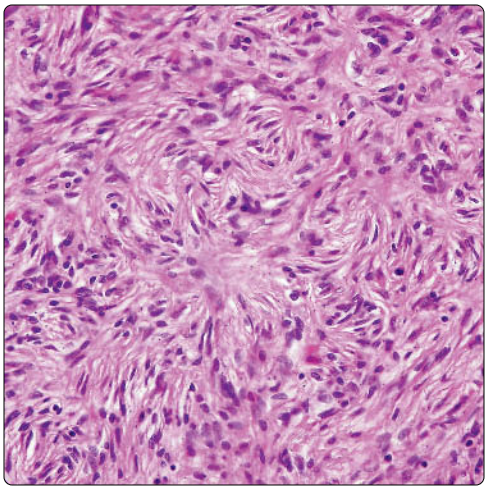

(Left) *High magnification of epithelial component is shown in thymoma with pseudosarcomatous stroma (metaplastic thymoma). Notice the large, oval to round nuclei with prominent nucleoli.* **(Right)** *High magnification of stromal component of spindle cell thymoma with pseudosarcomatous stroma shows a storiform pattern of growth. Notice the bland appearance of the spindle cells, the absence of nuclear pleomorphism and mitoses, and the lack of necrosis.*

Metaplastic Thymoma, Atypia

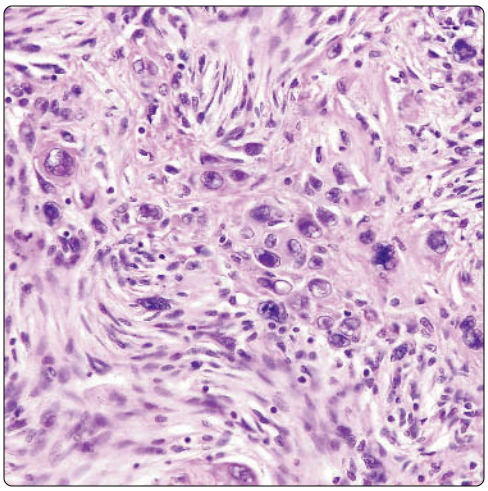

Atypical Areas, High Power

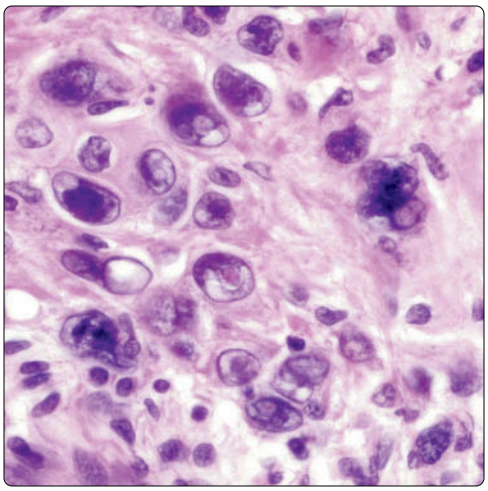

(Left) *Epithelial component in thymoma with pseudosarcomatous stroma (metaplastic thymoma) shows marked cytologic atypia in many of the tumor cells. Notice that the spindle cell stroma surrounding the tumor cell island lacks mitotic activity or nuclear pleomorphism.* **(Right)** *High magnification of atypical epithelial component in thymoma with pseudosarcomatous stroma (metaplastic thymoma) shows enlarged tumor cells with large nuclei and prominent nucleoli.*

Lymphocyte-Rich Spindle Cell Thymoma

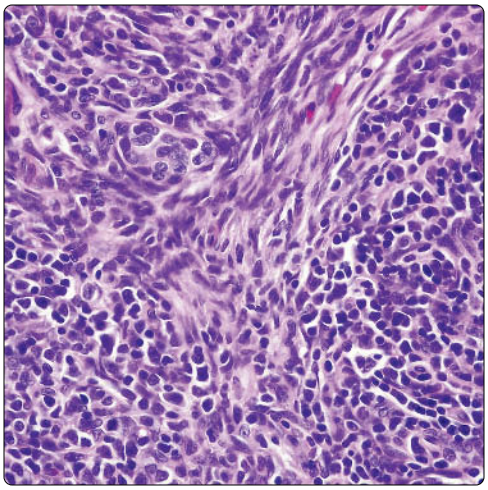

Lymphocyte-Rich Spindle Cell Thymoma

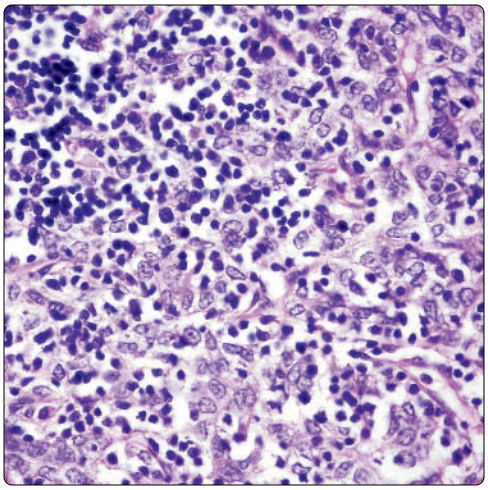

(Left) *Lymphocyte-rich spindle cell thymoma (WHO type AB) shows storiform fascicle of spindle cells (center) with few lymphocytes surrounded by areas containing scattered spindle cells admixed with numerous lymphocytes.* **(Right)** *High-power view of lymphocyte-rich spindle cell thymoma (WHO type AB) shows scattered small spindle epithelial cells admixed with numerous scattered small lymphocytes. The small spindle cells show identical nuclear features to those in the fascicular areas.*

Entrapped Glands

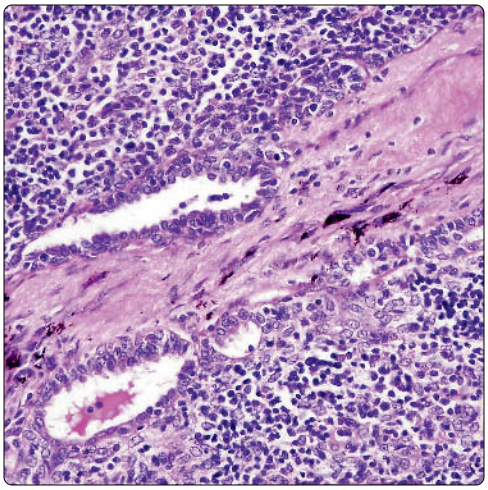

Spindle Cells, High Power

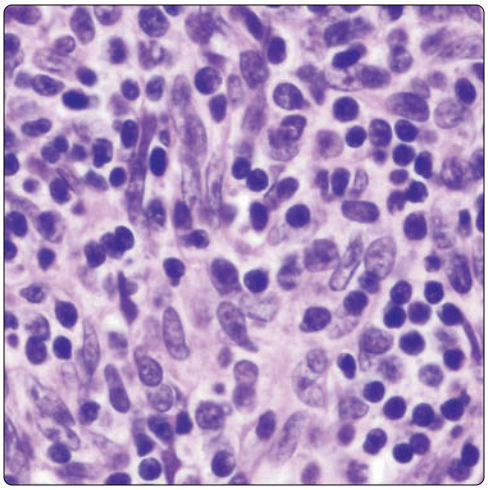

(Left) *Lymphocyte-rich spindle cell thymoma shows focal glandular structures admixed with the spindle cell population. Similar gland-like structures are commonly seen in conventional spindle cell thymoma and should not be confused for metastatic adenocarcinoma.* **(Right)** *High-power view of lymphocyte-rich spindle cell thymoma shows oval to spindle-shaped nuclei with dispersed chromatin and absent or inconspicuous nucleoli identical to those of conventional spindle cell thymoma. Notice the abundant lymphocytes.*

CD1a(+) Lymphocytes

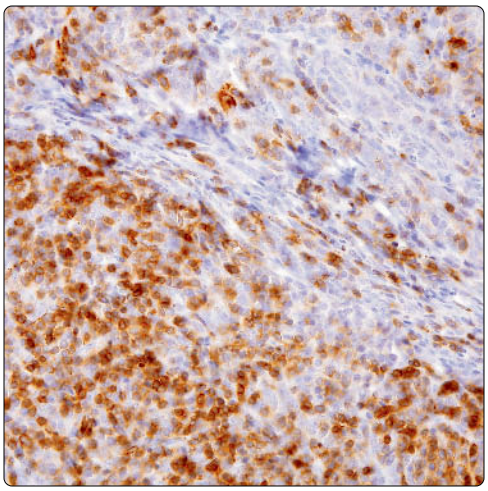

p63(+) Spindle Cells

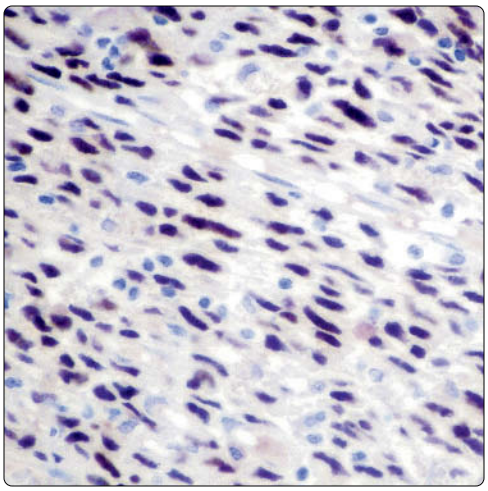

(Left) *Immunohistochemical staining of lymphocyte-rich spindle cell thymoma (WHO type AB) for the lymphoid marker CD1a highlights numerous immature T lymphocytes admixed with the spindle cells.* **(Right)** *Immunohistochemical staining of lymphocyte-rich spindle cell thymoma (WHO type AB) with p63 antibody shows strong nuclear positivity in the spindle thymic epithelial cells. Notice how the stain highlights the elongated, oval to spindle shape of the nuclei in the tumor cells.*

Lymphocyte-Rich Thymoma, Lobulation

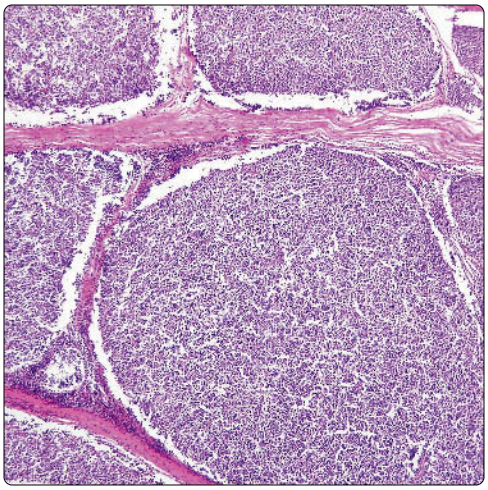

Lymphocyte-Rich Thymoma, Higher Power

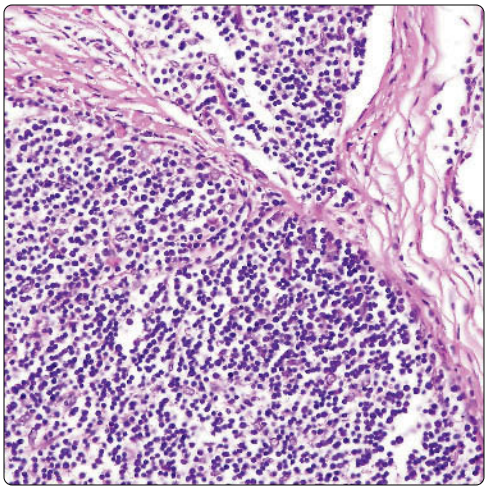

(Left) *Lymphocyte-rich thymoma (WHO type B1) shows round lobules of tumor tissue containing abundant lymphocytes. The lobules are circumscribed by broad bands of fibroconnective tissue.* **(Right)** *Higher magnification of round cellular lobule in lymphocyte-rich thymoma (WHO type B1) shows a predominantly lymphoid cell population. The lobules are separated by thin bands of fibrocollagenous tissue. These tumors can be easily mistaken for lymphocytic lymphomas.*

Lymphocyte-Rich Thymoma

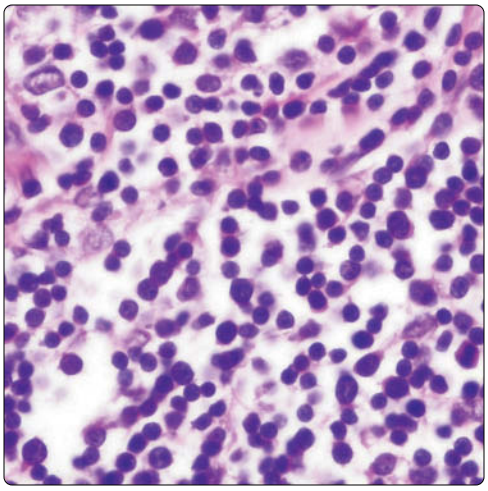

Epithelial Cell Surrounded by Lymphocytes

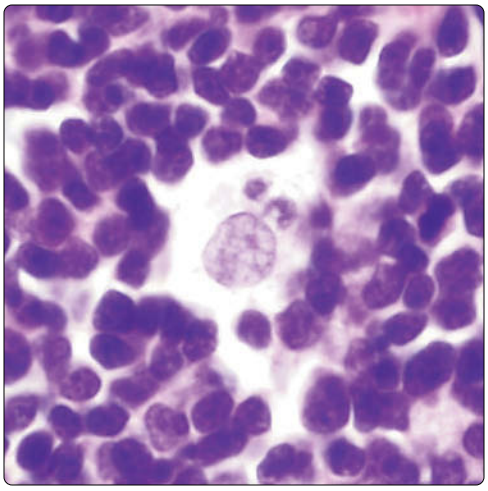

(Left) *High magnification of lymphocyte-rich thymoma (WHO type B1) shows a monotonous population of small lymphocytes with only rare, scattered cells with larger nuclei and an indistinct rim of cytoplasm.* **(Right)** *High magnification of lymphocyte-rich thymoma (WHO type B1) shows a large neoplastic epithelial cell in the center surrounded by a dense population of small lymphocytes.*

Dilated Perivascular Space

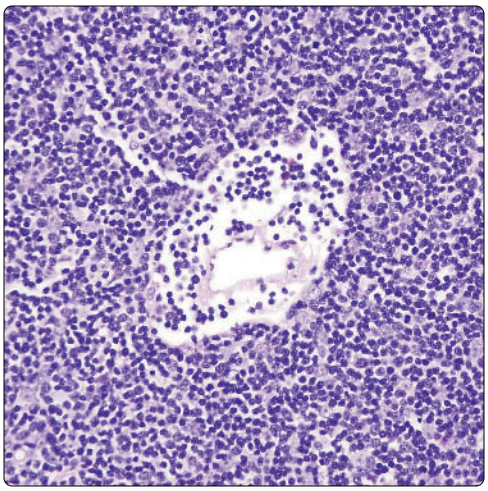

Area of Medullary Differentiation

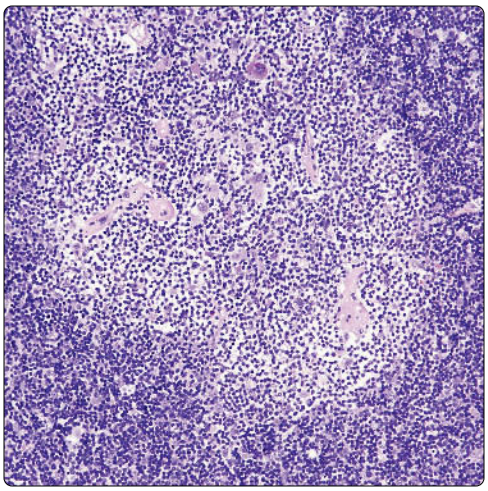

(Left) *Lymphocyte-rich thymoma (WHO type B1) shows a dilated perivascular space (center of the field) filled with scattered small lymphocytes. Notice the small vessel lumen floating inside the empty perivascular space.* **(Right)** *Lymphocyte-rich thymoma (WHO type B1) shows an area of medullary differentiation (center). This area is sparsely cellular and contains fewer lymphocytes than the surrounding parenchyma, as well as areas of hyalinization with abortive Hassall corpuscles.*

Starry-Sky Appearance

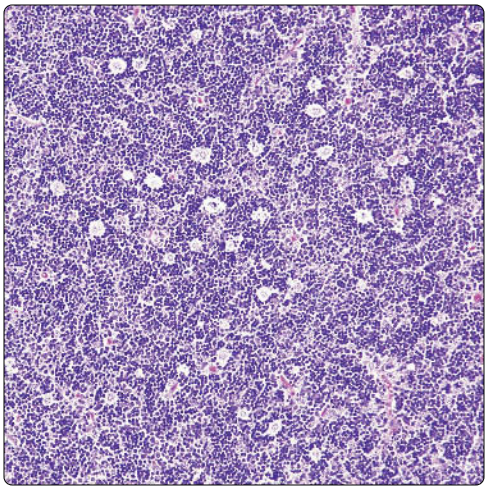

Starry-Sky Appearance, High Power

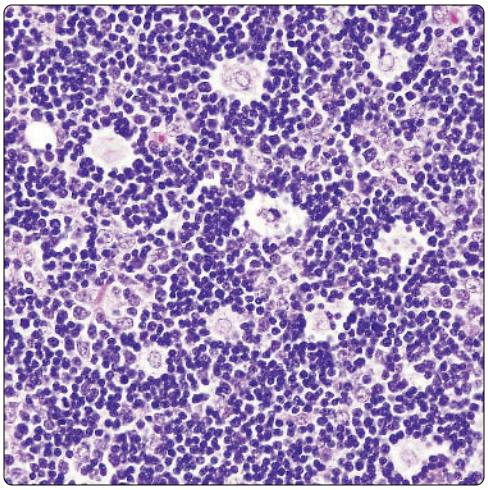

(Left) *Lymphocyte-rich thymoma (WHO type B1) shows prominent starry-sky appearance. These tumors can be easily confused for lymphoblastic lymphoma, which are also often characterized by this histologic appearance.* **(Right)** *Lymphocyte-rich thymoma (WHO type B1) shows starry-sky appearance represented by the large cells surrounded by clear spaces. This appearance is caused by an abundance of tingible-body macrophages.*

Organoid Thymoma

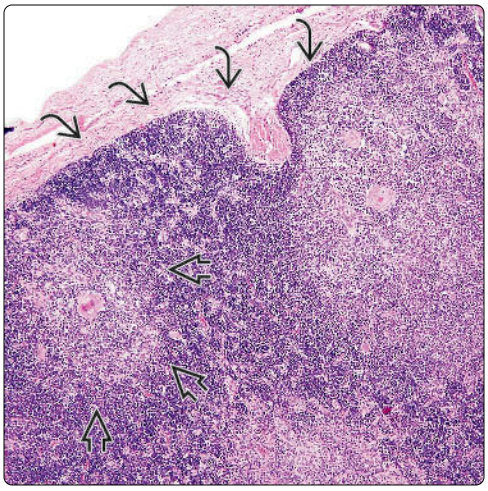

Hassall Corpuscle

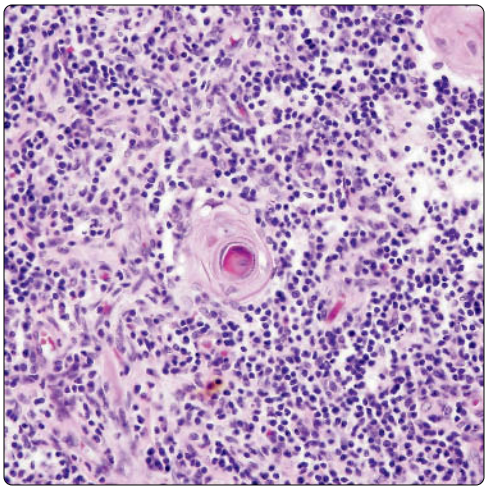

(Left) *Lymphocyte-rich thymoma (WHO type B1) shows well-developed and sharply defined areas resembling the normal cortex ⇨ circumscribing lighter areas resembling the thymic medulla ⇨. Tumors with these features were termed organoid and predominantly cortical thymoma in prior terminology.* **(Right)** *High-power view shows Hassall corpuscle within an area of medullary differentiation in lymphocyte-rich thymoma (WHO type B1; organoid thymoma).*

Necrosis

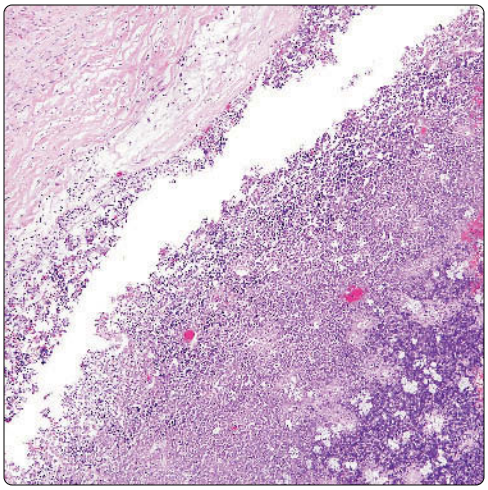

Vascular Invasion

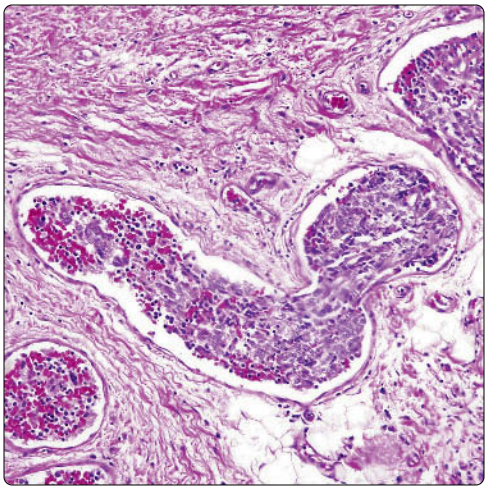

(Left) *Area of necrosis and infarction is seen in lymphocyte-rich (WHO type B1) thymoma. This is caused by vasoocclusive phenomena in the vicinity of the infarcted areas of tumors with cystic changes. This should not be confused for a sign of malignancy or more aggressive behavior.* **(Right)** *Focus of vascular invasion in lymphocyte-rich thymoma (WHO type B2) is shown. The significance of this finding is unknown, but it is believed to be associated with more aggressive behavior.*

Lymphoepithelial Thymoma (WHO Type B2)

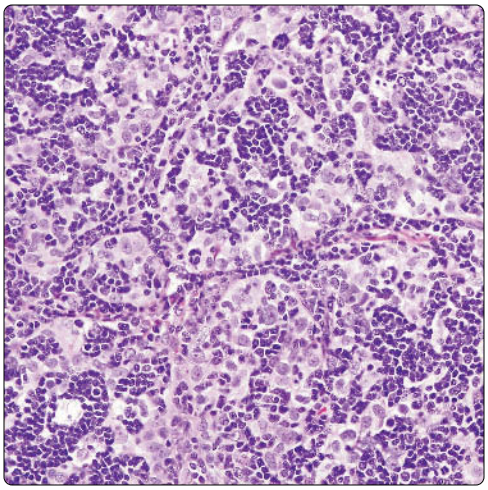

Lymphoepithelial Thymoma, High Power

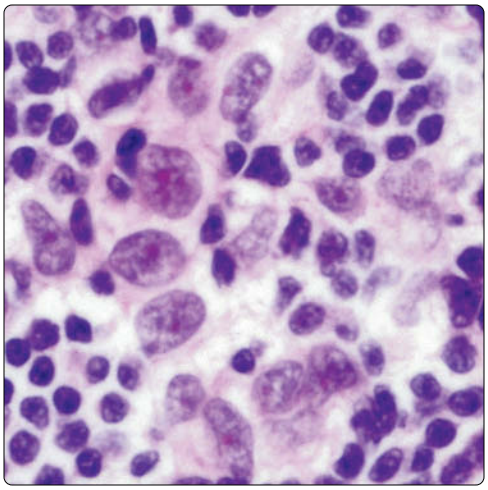

(Left) *Mixed lymphoepithelial (WHO type B2) thymoma shows approximately equal admixture of lymphocytes with neoplastic epithelial cells.* **(Right)** *Higher magnification of mixed lymphoepithelial thymoma (WHO type B2) shows abundant large, round to oval epithelial cells displaying vesicular nuclei with prominent eosinophilic nucleoli and indistinct rim of amphophilic cytoplasm. Note the variation in size and shape of the epithelial cells.*

Lymphoepithelial Thymoma, Epithelial Cells

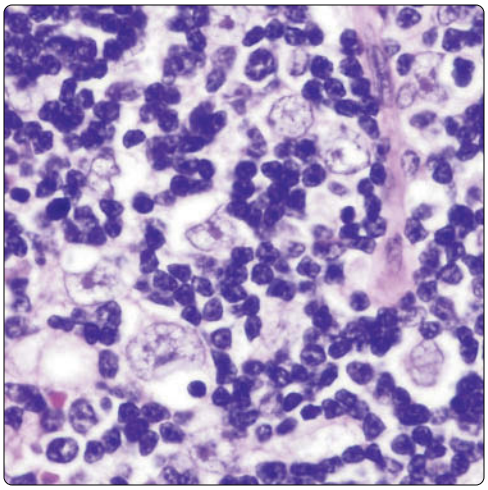

Epithelial Cell, High Power

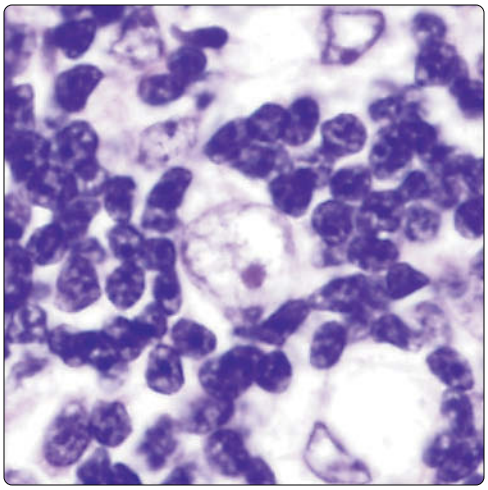

(Left) *Another example of mixed lymphoepithelial thymoma (WHO type B2) shows a large number of thymic epithelial cells admixed with small lymphocytes.* **(Right)** *High power of mixed lymphoepithelial thymoma (WHO type B2) shows a large epithelial cell in the center surrounded by small lymphocytes. The large cell in the center of the field shows a vesicular nucleus with prominent eosinophilic nucleolus.*

Combination WHO Type B2 + B3

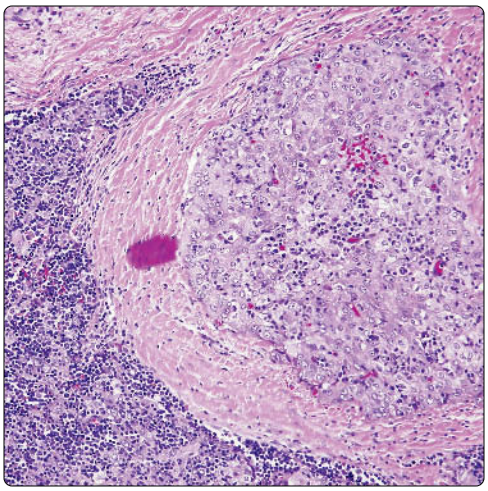

Atypical Focus, High Power

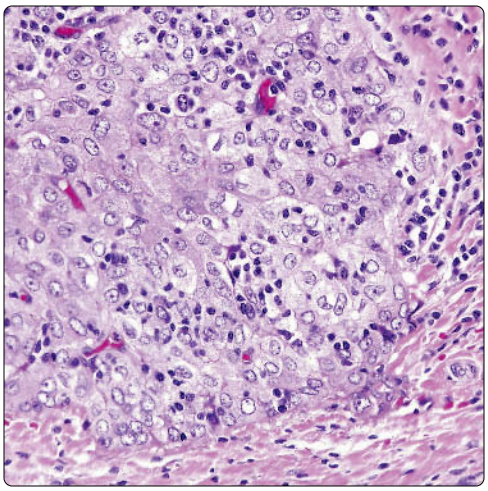

(Left) *Combinations of thymoma WHO type B2 and B3 are seen in ~ 30% of cases. The nodule on the right corresponds to a focus of atypical thymoma (WHO type B3). The areas on the left show lymphoepithelial thymoma (WHO type B2) and contain a higher density of small lymphocytes.* **(Right)** *Higher magnification shows a nodule with atypical thymoma (WHO type B3) in a combined thymoma, type B2 + B3. Notice the large size of the epithelial cells.*

(Left) *Lymphocyte-rich thymoma with starry-sky appearance simulating lymphoblastic lymphoma shows striking nuclear positivity in small lymphocytes for TdT, not to be confused with lymphoblastic lymphoma.* **(Right)** *Immunoperoxidase stain for cytokeratin AE1/AE3 in lymphocyte-rich thymoma simulating lymphoblastic lymphoma shows scattered, isolated, keratin-positive tumor cells. Identification of keratin-positive cell population is critical for making the correct diagnosis.*

TdT Immunostain

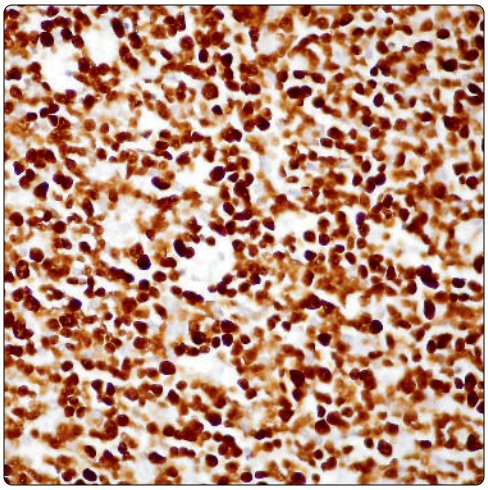

Cytokeratin AE1/AE3

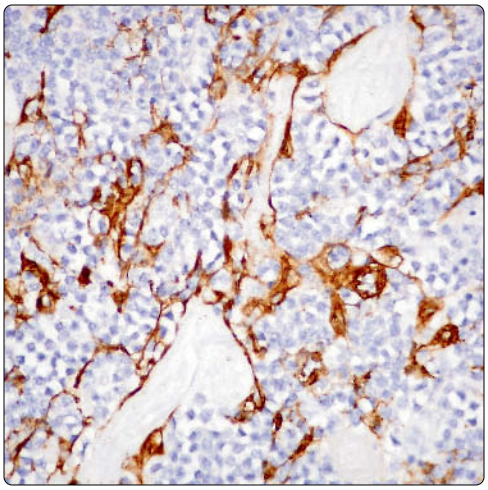

(Left) *Strong membrane positivity for CD3 is observed in this lymphocyte-rich thymoma (WHO type B1). A similar pattern of staining should also be expected for CD1a, a marker of immature T cells.* **(Right)** *Positive staining of the tumor cells for CD99 is seen in this lymphocyte-rich thymoma (WHO type B1). CD99 is a marker of T lymphoblasts and can be used in lieu of CD1a or TdT for the demonstration of immature T-lymphoblastic cells in lymphocyte-rich thymomas.*

CD3 Immunostaining

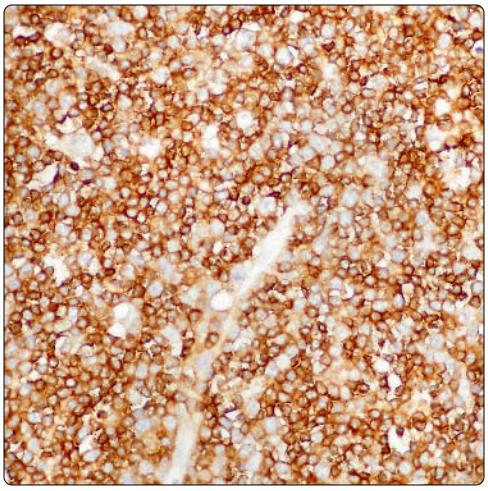

CD99 Stain in Lymphocytes

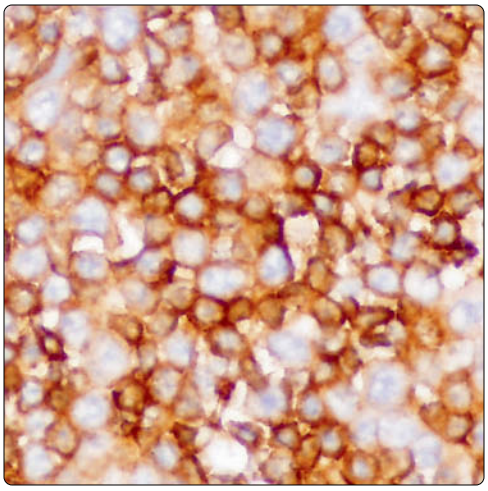

(Left) *Cluster of small lymphocytes is seen to stain with CD20, a B-cell marker. This represents residual islands of the native thymic B-cell lymphoid cell population that can give rise to MALT lymphomas in the thymus.* **(Right)** *Lymphocyte-rich thymoma (WHO type B1) shows a network of scattered keratin-positive thymic epithelial cells against a background of small lymphocytes. The distribution of the scattered keratin-positive cells identifies them as the neoplastic epithelial component.*

CD20(+) Lymphocytes

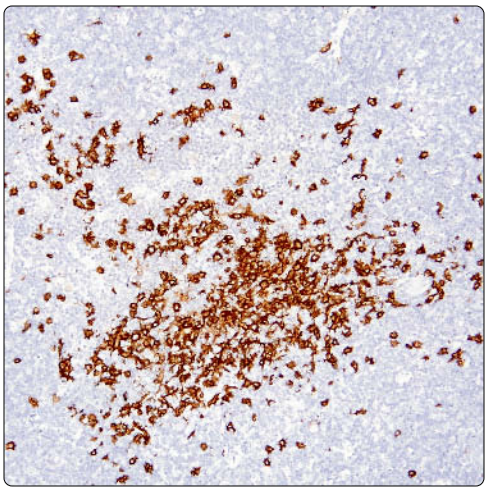

Cytokeratin Staining

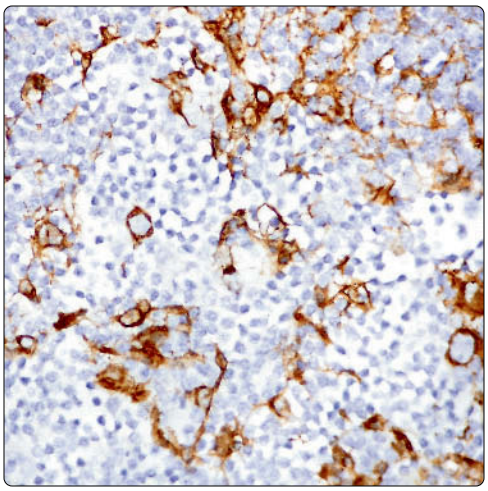

Multilocular Cystic Changes

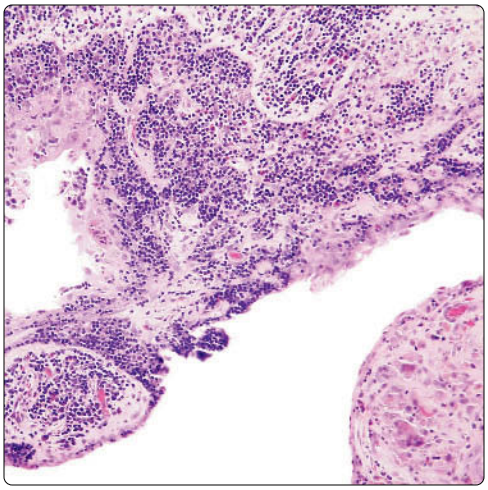

Cystic Changes, High Power

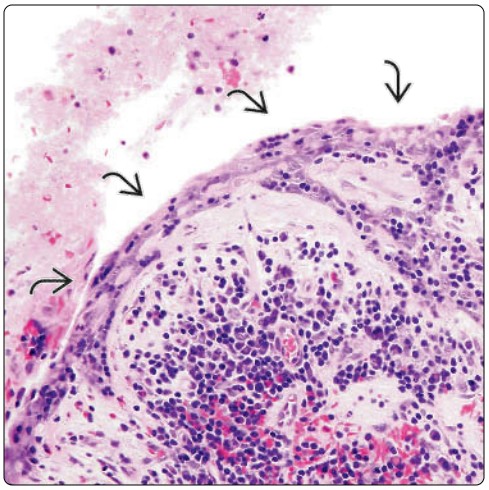

(Left) *Lymphocyte-rich (WHO type B1) thymoma shows secondary multilocular cystic changes in the surrounding, uninvolved residual thymus. The epithelial lining of the cysts is in continuity with dilated Hassall corpuscles and devoid of cytologic atypia.* **(Right)** *High-power view of lymphocyte-rich thymoma shows secondary multilocular thymic cyst-like changes. Notice hemorrhage and inflammation in the wall of the cyst and the flattened squamous epithelial lining.*

Lymph Node Metastasis

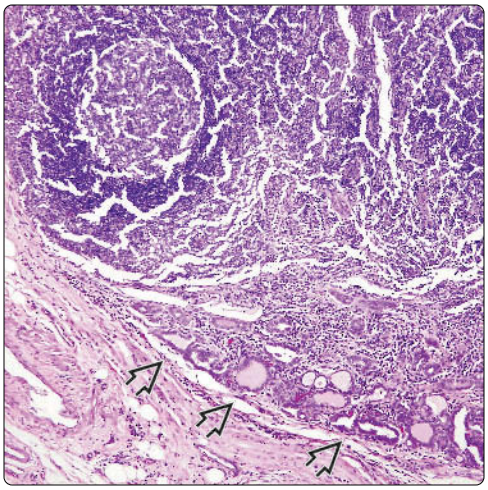

Lymph Node Metastasis, High Power

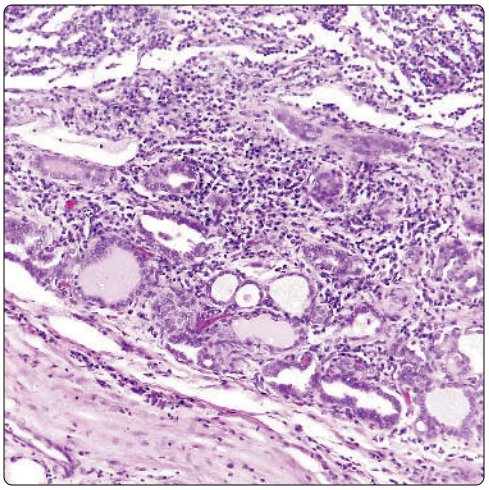

(Left) *Metastasis of spindle cell thymoma to a mediastinal lymph node is seen. Notice the gland-like structures in the lymph node sinus percolating into the node adjacent to a follicle with a germinal center.* **(Right)** *High-power view shows lymph node metastasis from spindle cell thymoma (WHO type A) to mediastinal lymph node. Notice solid nests of spindle cells admixed with cyst-like structures within the lymph node sinus.*

Capsular Invasion

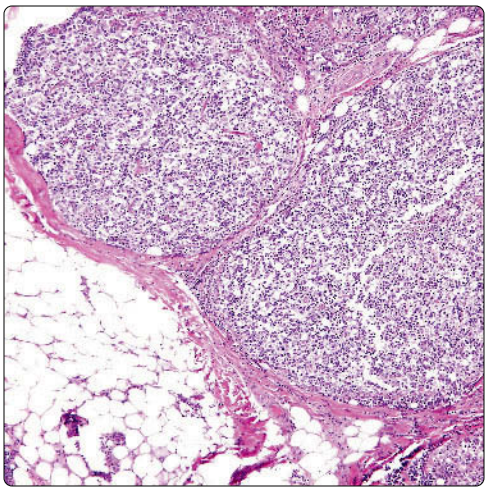

Invasion of Fat

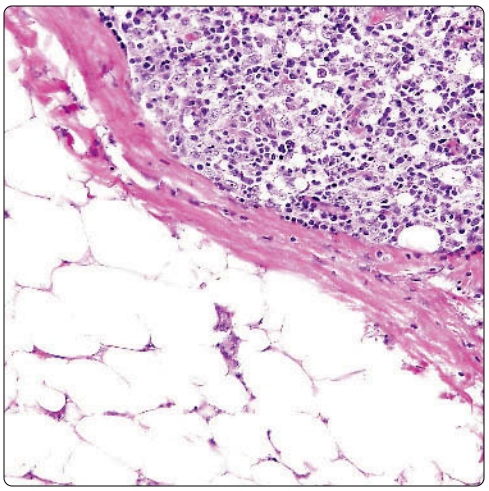

(Left) *Invasion of the capsule into mediastinal fat is noted in this example of mixed lymphoepithelial thymoma (WHO type B2). Notice preservation of the lobular architecture. This focus would be considered as microinvasion (stage IIA) in the modified Masaoka staging by Koga et al. The tumor would be thus classified as noninvasive because it does not yet invade neighboring organs.* **(Right)** *High-power view shows microinvasive lymphoepithelial thymoma infiltrating perithymic fat.*

Atypical Thymoma

KEY FACTS

TERMINOLOGY

- WHO type B3, polygonal cell thymoma, epithelial-rich thymoma
- Moderately differentiated thymic epithelial neoplasm, intermediate between thymoma and thymic carcinoma

CLINICAL ISSUES

- Intermediate biologic potential between thymoma and thymic carcinoma
- Earlier recurrences
- More often invasive at time of presentation

MICROSCOPIC

- Confluent sheets of cells with scant lymphocytes
- Prominent perivascular spaces
- Foci of squamous differentiation
- Large epithelioid tumor cells with abundant cytoplasm and sharp cell borders
- Large nuclei with dense chromatin pattern
- "Raisinoid" nuclei with wrinkled nuclear membrane
- Prominent nucleoli
- Scattered mitoses
- Cells may also be spindle or oval, with nucleoli and moderate cytologic atypia
- Lymphocytes are mainly mature T cells
- Cells can show prominent cytoplasmic clearing

TOP DIFFERENTIAL DIAGNOSES

- Well-differentiated squamous cell carcinoma
- Thymoma, mixed lymphoepithelial (WHO type B2)
- Squamous cell carcinoma of lung origin

DIAGNOSTIC CHECKLIST

- Confluent sheets of epithelioid cells with scant lymphocytes
- Perivascular spaces
- Large epithelioid cells with sharp cell borders

Perivascular Spaces

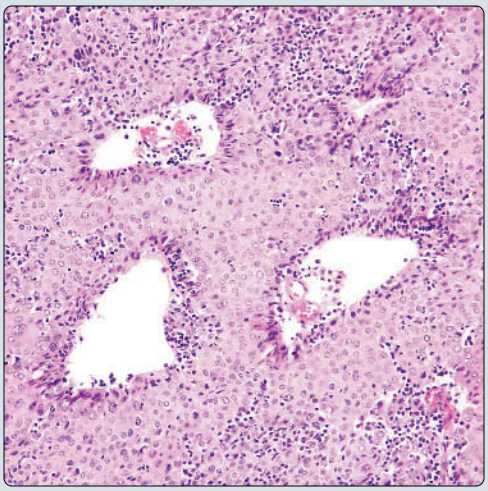

Polygonal Epithelial Cells

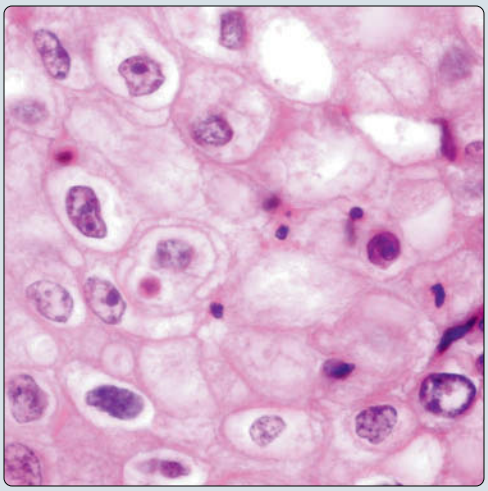

(Left) *Atypical thymoma (WHO type B3) shows sheets of large, thymic epithelial cells with dilated perivascular spaces and a sprinkling of lymphocytes in the background. The tumor has an overall pink appearance on scanning magnification.* **(Right)** *Higher magnification of atypical thymoma (WHO B3) shows sheets of large, polygonal cells with irregular nuclei with prominent nucleoli, abundant eosinophilic cytoplasm, and sharp cell membranes.*

Nuclear Pleomorphism

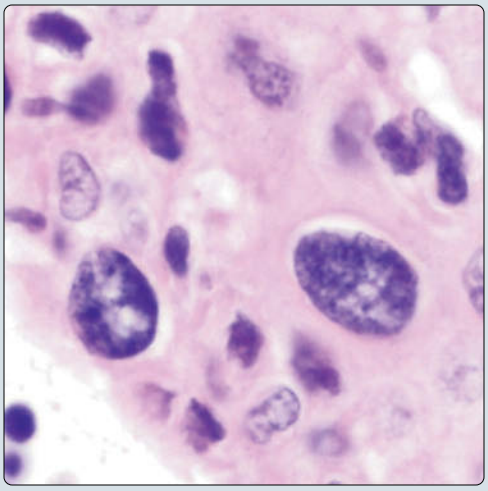

Foci of Squamoid Differentiation

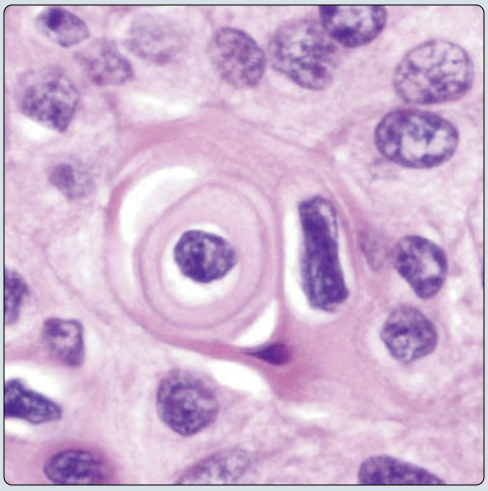

(Left) *Higher magnification of atypical thymoma (WHO B3) shows marker cell pleomorphism with variation in size and shape of the tumor cells, from small cells to larger cells with enlarged nuclei showing dense chromatin pattern.* **(Right)** *Microscopic foci of abrupt squamoid differentiation (center), often showing intercellular bridges, are often seen in atypical thymomas (WHO B3).*

TERMINOLOGY

Abbreviations

- Atypical thymoma (AT)

Synonyms

- WHO type B3, polygonal cell thymoma, epithelial-rich thymoma

Definitions

- Moderately differentiated thymic epithelial neoplasm, intermediate between thymoma and thymic carcinoma

CLINICAL ISSUES

Site

- Anterior-superior mediastinum

Presentation

- Cough, chest pain, dyspnea, and superior vena cava syndrome
- Association with myasthenia gravis

Treatment

- Surgical excision

Prognosis

- Intermediate between encapsulated thymoma and thymic carcinoma
- Earlier recurrences and frequent evidence of invasion at time of initial diagnosis

MACROSCOPIC

General Features

- Large, solid mass
- Hemorrhage and necrosis are rarely present

Sections to Be Submitted

- 1 section per cm of greatest tumor dimension
- Inked margins of resection
- Sections should be taken from periphery of tumor

Size

- Variable; 3-20 cm

MICROSCOPIC

Histologic Features

- Confluent sheets of epithelioid cells with scant lymphocytes
- Prominent perivascular spaces
- Palisading of epithelial tumor cells around perivascular spaces
- Foci of squamous differentiation
- Large epithelioid tumor cells with abundant cytoplasm and sharp cell borders
- Large nuclei with dense chromatin pattern and prominent nucleoli
- "Raisinoid" nuclei with wrinkled nuclear membrane
- Scattered mitoses
- Cells may also be spindle or oval with moderate cytologic atypia
- Cells can show prominent cytoplasmic clearing
- Cells show variable size, from small round cells the size of a lymphocyte to large polygonal cells the size of a histiocyte

ANCILLARY TESTS

Immunohistochemistry

- Tumor cells are strongly positive for cytokeratins, p40, and p63
- MIB-1 proliferation marker shows increased proliferative activity (10-20% nuclear positivity)
- Lymphocytes stain mostly as immature T cells

DIFFERENTIAL DIAGNOSIS

Well-Differentiated Squamous Cell Carcinoma

- Atypical thymoma grows as sheets of uniform tumor cells rather than tumor cell islands
- More extensive keratinization
- Does not have dilated perivascular spaces
- Lymphocytes are B-cell type

Thymoma, Mixed Lymphoepithelial (WHO Type B2)

- More abundant lymphocytes
- Nuclei not as hyperchromatic
- Absence of squamous differentiation

Squamous Cell Carcinoma of Lung Origin

- Radiological evidence of lung tumor mass
- Absence of T lymphocytes

DIAGNOSTIC CHECKLIST

Clinically Relevant Pathologic Features

- Extent of invasiveness

Pathologic Interpretation Pearls

- Confluent sheets of epithelioid cells with scant lymphocytes
- Perivascular spaces
- Large epithelioid cells with sharp cell borders

SELECTED REFERENCES

1. Wu J et al: The enlightenments from ITMIG Consensus on WHO histological classification of thymoma and thymic carcinoma: refined definitions, histological criteria, and reporting. J Thorac Dis. 8(4):738-43, 2016
2. Roden AC et al: Reproducibility of 3 histologic classifications and 3 staging systems for thymic epithelial neoplasms and its effect on prognosis. Am J Surg Pathol. 39(4):427-41, 2015
3. Weis CA et al: The impact of thymoma histotype on prognosis in a worldwide database. J Thorac Oncol. 10(2):367-72, 2015
4. Wu M et al: Immunohistochemical detection of p63 and XIAP in thymic hyperplasia and thymomas. Am J Clin Pathol. 131(5):689-93, 2009
5. Suster S et al: Histologic classification of thymoma: the World Health Organization and beyond. Hematol Oncol Clin North Am. 22(3):381-92, 2008
6. Shiraishi J et al: Atypical thymoma (WHO B3) with neuroendocrine differentiation: report of a case. Virchows Arch. 449(2):234-7, 2006
7. Baran JL et al: Atypical thymoma: a report of seven patients. Ann Thorac Surg. 78(2):411-6, 2004
8. Pomplun S et al: Immunohistochemical markers in the differentiation of thymic and pulmonary neoplasms. Histopathology. 40(2):152-8, 2002
9. Kondo K et al: Two cases of repeatedly recurrent atypical thymoma. Chest. 115(1):282-5, 1999
10. Suster S et al: Primary thymic epithelial neoplasms: spectrum of differentiation and histological features. Semin Diagn Pathol. 16(1):2-17, 1999
11. Suster S et al: Thymoma, atypical thymoma, and thymic carcinoma. A novel conceptual approach to the classification of thymic epithelial neoplasms. Am J Clin Pathol. 111(6):826-33, 1999

Lobulation

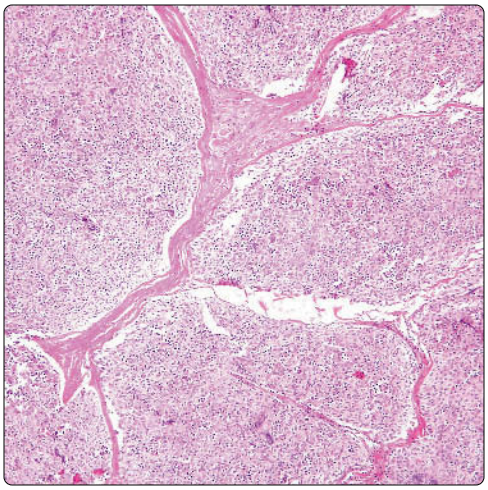

Sheet of Polygonal cells

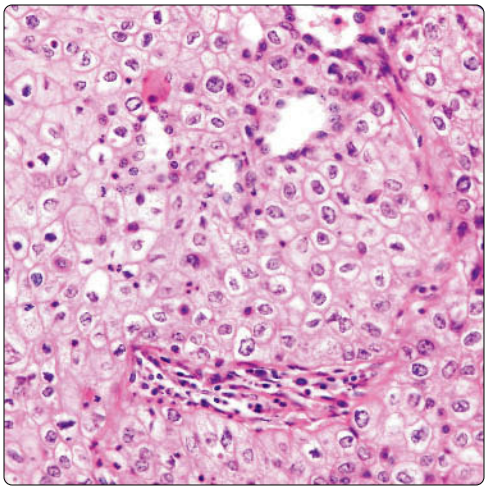

(Left) *Scanning magnification of atypical thymoma (WHO type B3) shows a monotonous population of epithelial cells with preservation of lobular architecture and thick, fibrous bands separating the tumor cell lobules.* **(Right)** *Atypical thymoma (WHO type B3) shows sheets of large, monotonous, round to polygonal epithelial cells with abundant eosinophilic cytoplasm and sharp cell borders. The nuclei of the cells are large, hyperchromatic, and have numerous nuclear irregularities.*

Dilated Perivascular Spaces

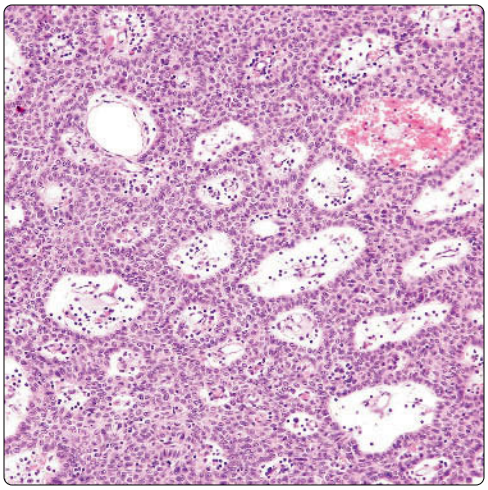

Pleomorphic Cell Population

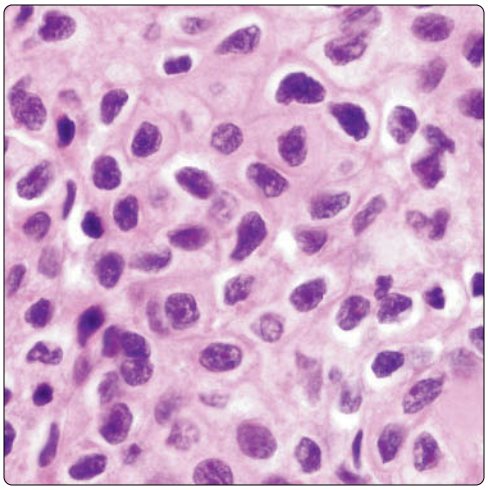

(Left) *Scanning magnification of atypical thymoma (WHO type B3) shows numerous small, dilated perivascular spaces surrounded by a monotonous population of epithelial cells. Note the palisading of epithelial cells around perivascular spaces.* **(Right)** *High magnification of atypical thymoma (WHO type B3) shows cells with large, irregular nuclei and dense chromatin pattern. The nuclei are surrounded by an ample rim of eosinophilic cytoplasm and show sharply defined cell borders.*

Atypical Cells

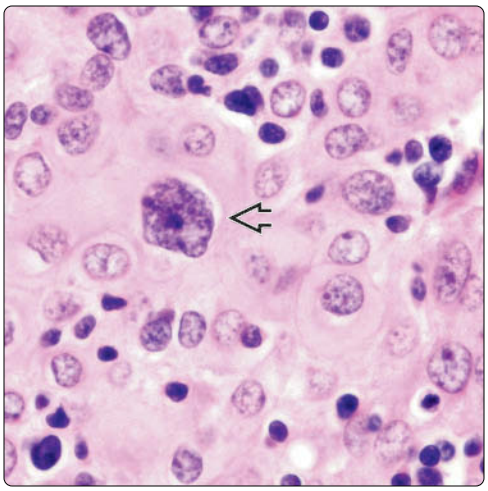

Mitotic Figure

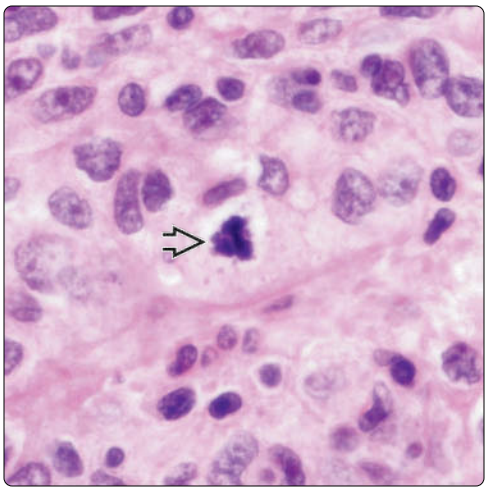

(Left) *High magnification of atypical thymoma (WHO type B3) shows large cells with enlarged nuclei. The cells contain abundant eosinophilic cytoplasm. Note the large, atypical cell ⇨ with prominent nucleolus and cerebriform nuclear convolutions.* **(Right)** *Atypical thymoma (WHO type B3) shows sheets of large epithelioid cells with abundant cytoplasm. The cells show a dense chromatin pattern and eosinophilic nucleoli. Notice the abnormal mitotic figure ⇨ in the center of the field.*

Dyskeratotic Cell

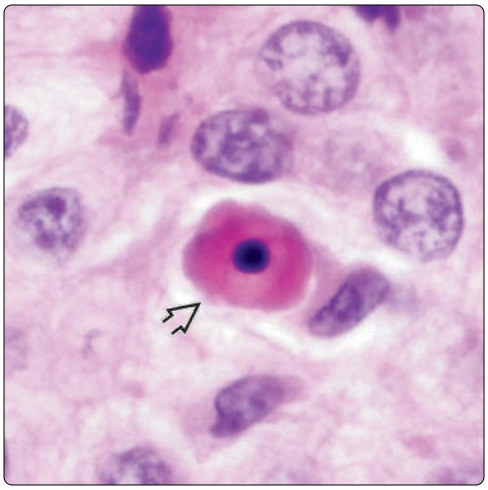

Multinucleated Tumor Cell

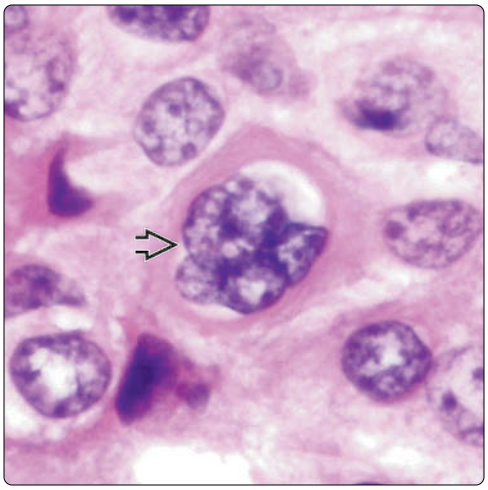

(Left) *Higher magnification of atypical thymoma (WHO type B3) shows round epithelial cells with hyperchromatic nuclei. Note the single-cell keratinization ⇨ in the center of the field.* **(Right)** *High magnification of atypical thymoma (WHO type B3) shows a multinucleated cell ⇨. The nuclei are large, irregular, hyperchromatic, overlapping, and resemble those of the surrounding mononuclear cells.*

Variable Nuclear Morphology

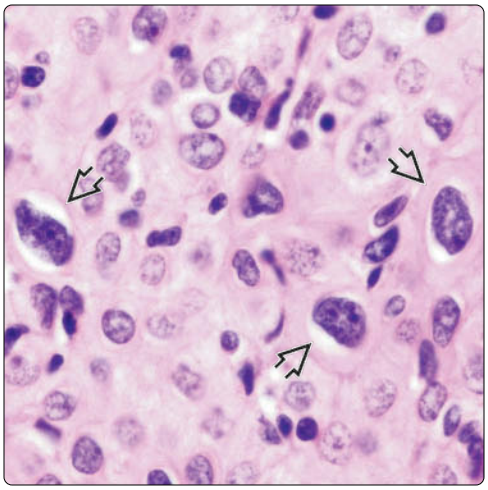

Nuclear Pleomorphism

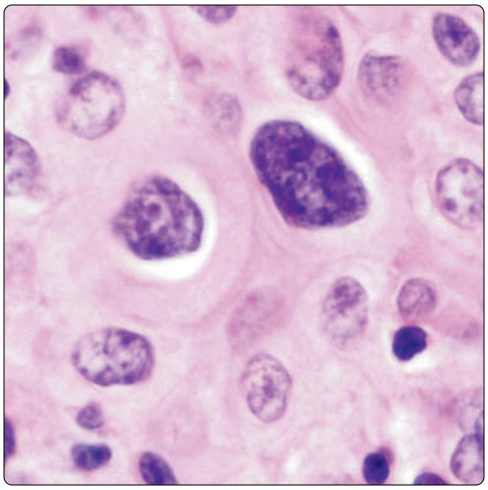

(Left) *Atypical thymoma (WHO type B3) shows numerous large, atypical cells admixed with smaller epithelioid cells. The large cells ⇨ show irregular nuclei with dense chromatin pattern, multiple small nucleoli, and irregularities of the nuclear envelope.* **(Right)** *Higher magnification of atypical thymoma (WHO type B3) shows large, atypical cells with enlarged, irregular nuclei containing a dense chromatin pattern and multiple small nucleoli. Note the clear perinuclear halos.*

Atypical Cell

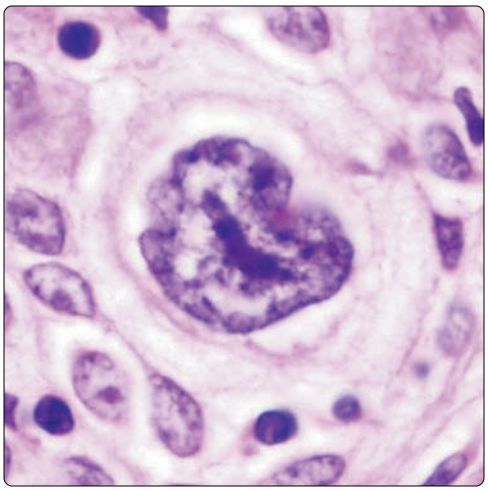

Atypical Cell

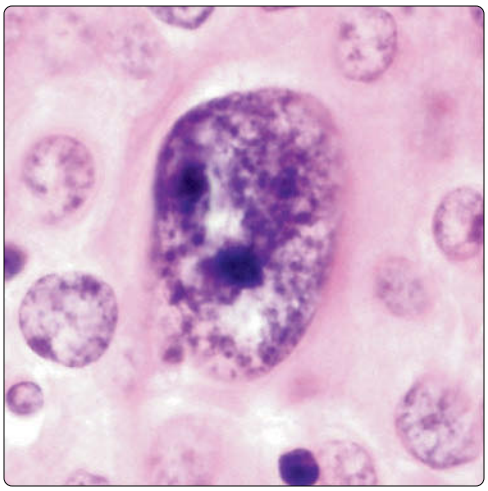

(Left) *High magnification of atypical thymoma (WHO type B3) shows a single enlarged nucleus with irregular nuclear contours and a single prominent nucleolus.* **(Right)** *High magnification of atypical thymoma (WHO type B3) shows a monster cell ~ 4x the size of the adjoining cells. This large cell shows dense nuclear chromatin and 2 large nucleoli and is surrounded by an ample rim of eosinophilic cytoplasm.*

Mixed Epithelioid and Spindle Morphology

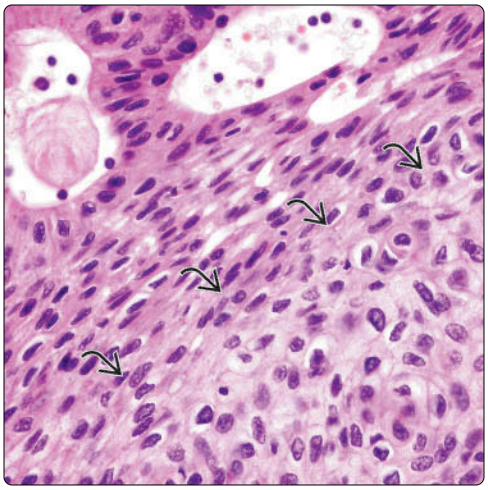

Spindling of Tumor Cells

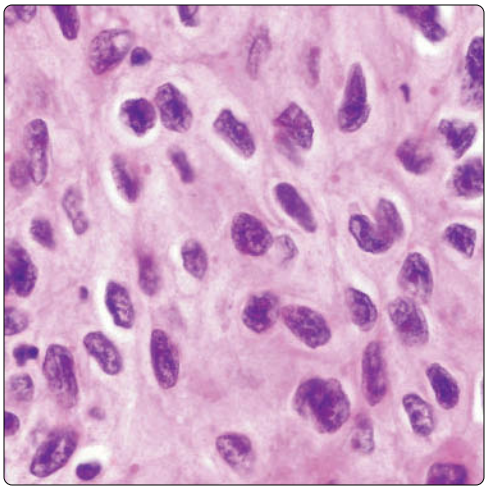

(Left) *Atypical thymoma (WHO type B3) shows transitions between conventional epithelioid areas and areas showing prominent spindling of the tumor cells beneath 2 small perivascular spaces.* **(Right)** *High magnification of atypical thymoma (WHO type B3) shows spindling of the tumor cells. Notice the elongated shape of the cell nuclei and the dense chromatin pattern. Some of the cells contain perinuclear halos and show sharp cell borders.*

Spindle Cell Type

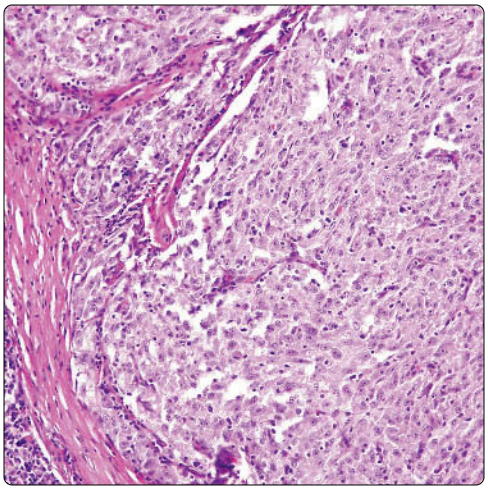

Spindle Cells: Higher Magnification

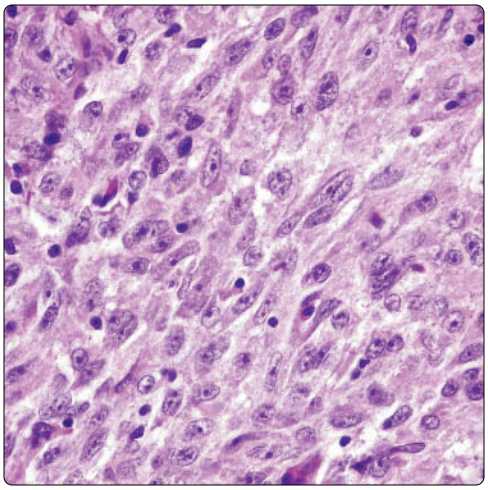

(Left) *Scanning magnification of atypical thymoma (WHO type B3), spindle cell type, shows preserved lobular architecture and sprinkling of small lymphocytes, 2 of the organotypical features of the thymus.* **(Right)** *High magnification of atypical thymoma (WHO type B3), spindle cell type, shows relatively uniform population of spindle cells admixed with a few scattered small lymphocytes. The spindle cells display prominent eosinophilic nucleoli.*

Atypical Spindle Cells

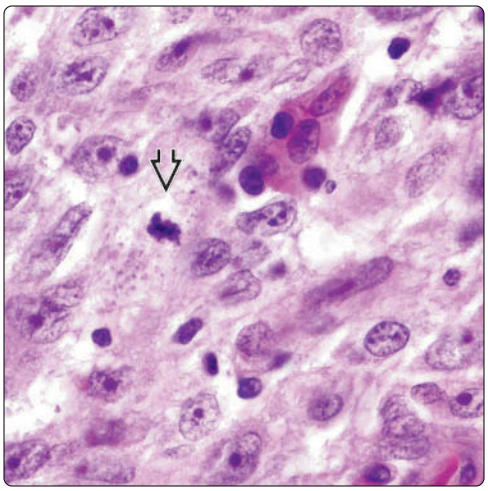

Atypical Spindle Cells

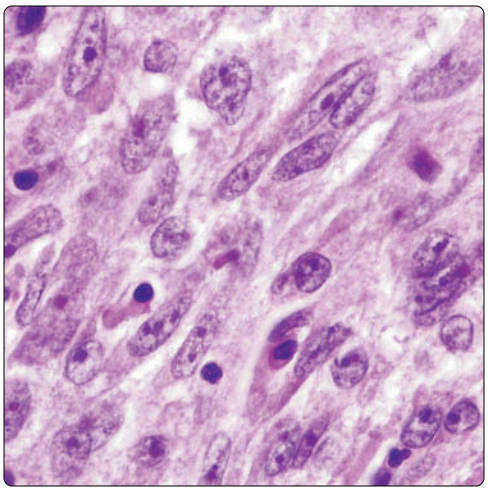

(Left) *High magnification of atypical thymoma (WHO type B3), spindle cell type, shows oval to spindle cells with scattered nuclear chromatin and prominent nucleoli. Notice atypical mitosis toward the center of the field.* **(Right)** *High magnification of atypical thymoma (WHO type B3), spindle cell type, shows a population of atypical spindle cells with a few scattered small lymphocytes. The atypical spindle cells show dispersed nuclear chromatin with prominent eosinophilic nucleoli.*

Transitions Between B2/B3 Thymoma

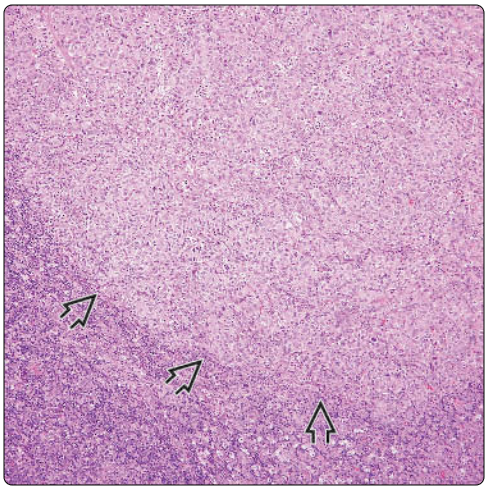

B2/B3 Thymoma

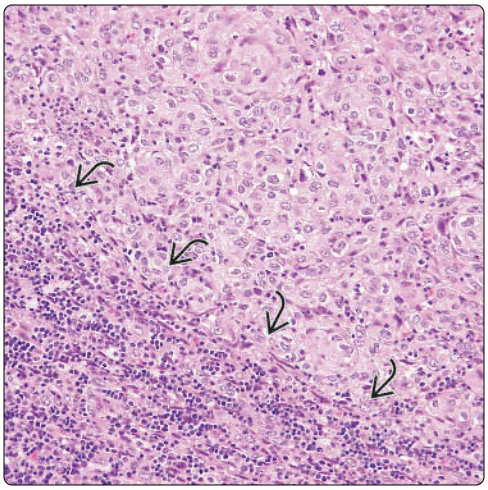

(Left) *Atypical thymoma (WHO type B3) shows transition from adjacent focus of lymphoepithelial thymoma (WHO type B2). Notice the larger cells with fewer lymphocytes in the atypical thymoma component.* **(Right)** *High magnification shows interface between atypical thymoma (WHO type B3) (top) and lymphoepithelial thymoma (WHO type B2) (bottom). Note the smaller cells with increased number of lymphocytes in the type B2 thymoma component.*

Transition Between A/B3 Thymoma

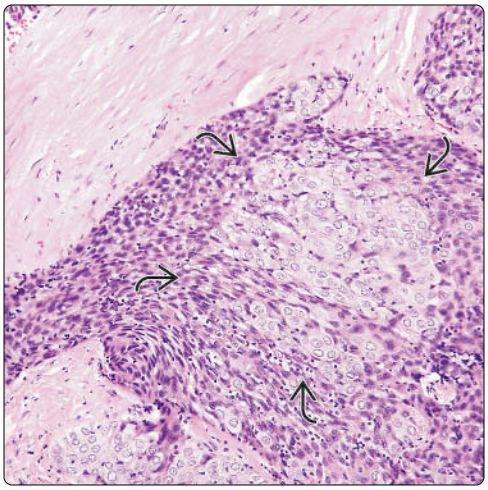

Transition Between A/B3 Thymoma

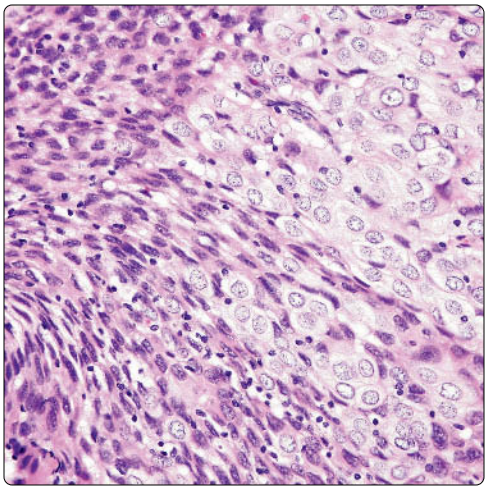

(Left) *Scanning magnification shows transitions between spindle cell thymoma (WHO type A) and atypical thymoma (WHO type B3).* **(Right)** *High magnification shows transitions between spindle cell thymoma (WHO type A) (left) and atypical thymoma (WHO type B3) (right). Note the character of the cells on the right, which are composed of a population of round cells with enlarged nuclei and an abundant rim of pale, lightly eosinophilic cytoplasm.*

Transition Between B3/Thymic Carcinoma

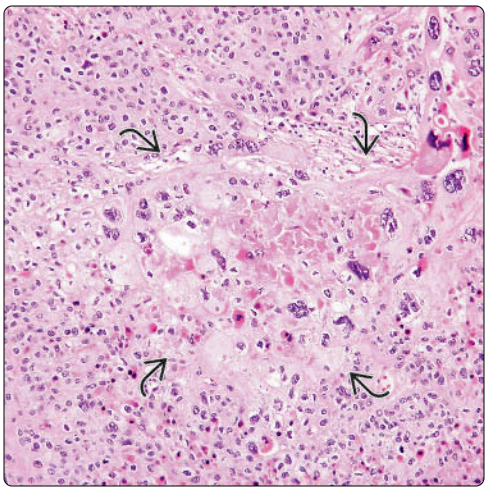

Well-Differentiated Squamous Carcinoma

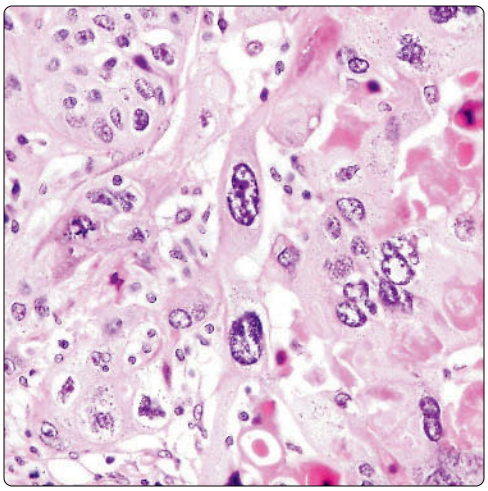

(Left) *Scanning magnification of mediastinal mass shows transition between atypical thymoma (WHO type B3) and well-differentiated squamous cell carcinoma of the thymus.* **(Right)** *High magnification of mediastinal tumor shows transition between atypical thymoma (left) and well-differentiated squamous cell carcinoma (right). Note the striking nuclear pleomorphism, abnormal mitosis, and abundant single cell keratinization in the squamous cell carcinoma component.*

Foci of Squamous Differentiation

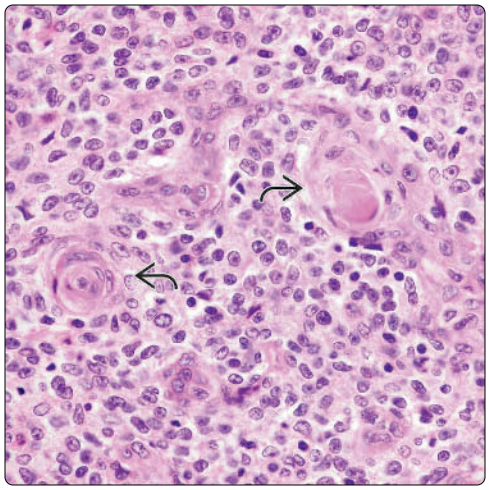

Squamous Differentiation

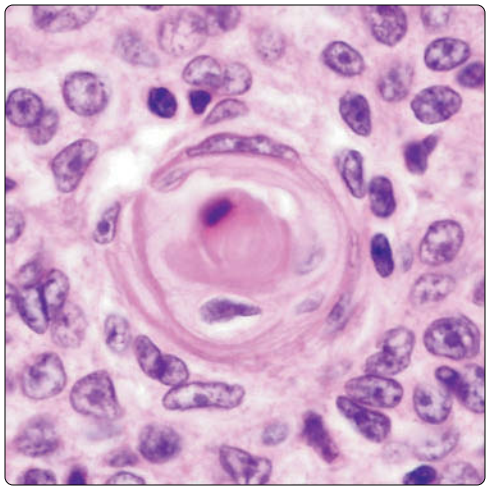

(Left) *Atypical thymoma (WHO type B3) shows foci of squamous differentiation ⇨. The small foci of keratinization show concentric arrangement of squamoid cells.* **(Right)** *High magnification of a focus of keratinization in atypical thymoma (WHO type B3) shows concentric layering of squamoid cells with a small focus of central keratinization. The cells surrounding this focus show enlarged nuclei with prominent nucleoli.*

Epidermoid Appearance

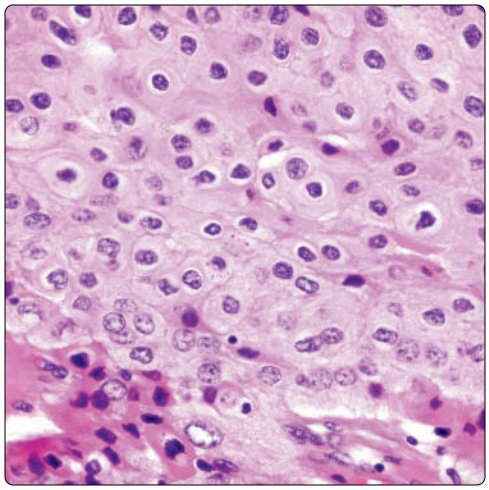

Focus of Keratinization

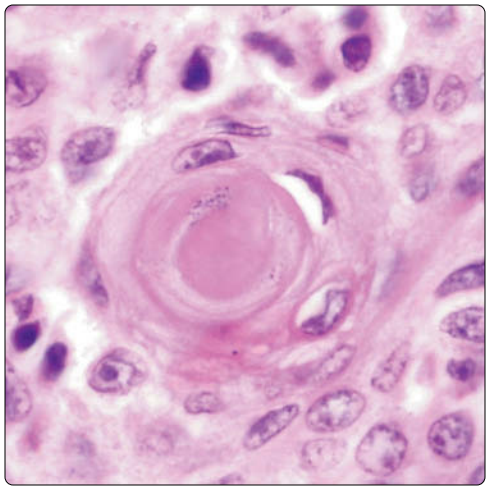

(Left) *Atypical thymoma (WHO type B3) shows striking epidermoid appearance of the tumor cells, with large, epithelioid cells and abundant cytoplasm displaying a pavement-like architecture with sharp cell membranes.* **(Right)** *Focus of keratinization in atypical thymoma (WHO type B3) shows concentric layering of epidermoid cells with a central focus of keratinization and keratin pearl formation.*

Foci of Squamous Differentiation

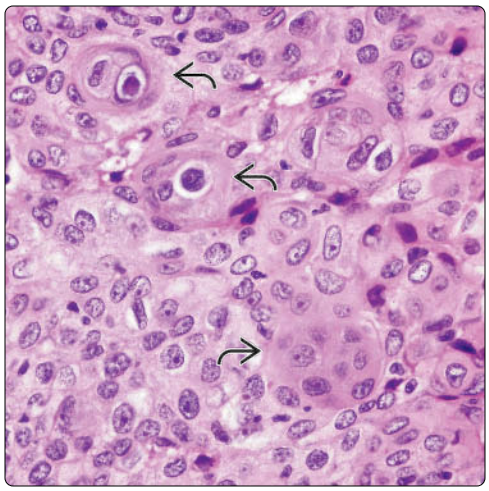

Foci of Squamous Differentiation

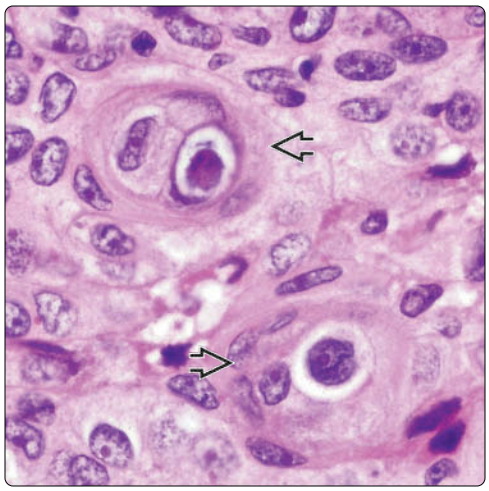

(Left) *Multiple foci of keratinization in atypical thymoma (WHO type B3) show small clusters of tumor cells displaying concentric arrangement of epithelial cells ⇨ admixed with sheets of epithelioid cells.* **(Right)** *High magnification of atypical thymoma (WHO type B3) shows concentric arrangement of squamoid cells displaying enlarged nuclei with prominent nucleoli and surrounded by an ample rim of eosinophilic cytoplasm ⇨.*

Clearing of Tumor Cells

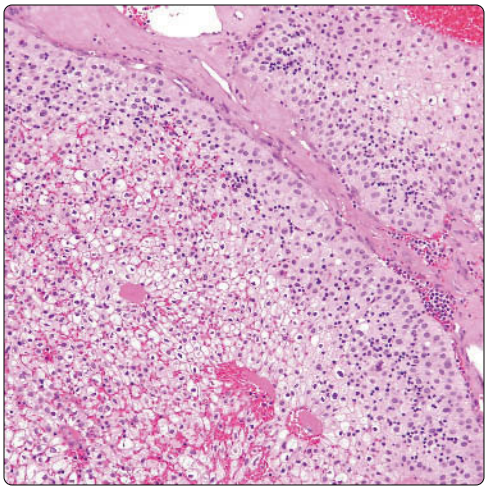

Clearing of Tumor Cells

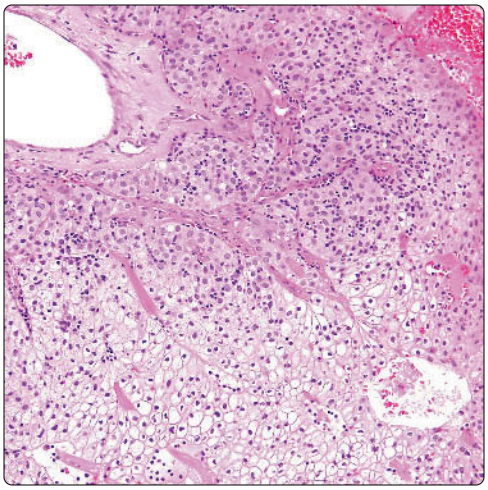

(Left) *Scanning magnification of atypical thymoma (WHO type B3) shows tumor lobules separated by broad bands of connective tissue and displaying prominent clearing of the cytoplasm of the tumor cells.* **(Right)** *High magnification of atypical thymoma (WHO type B3) shows conventional areas (top) of monotonous epithelioid cells with abundant eosinophilic cytoplasm merging with areas in which the tumor cells display prominent cytoplasmic clearing (bottom).*

Clear Cells: Higher Magnification

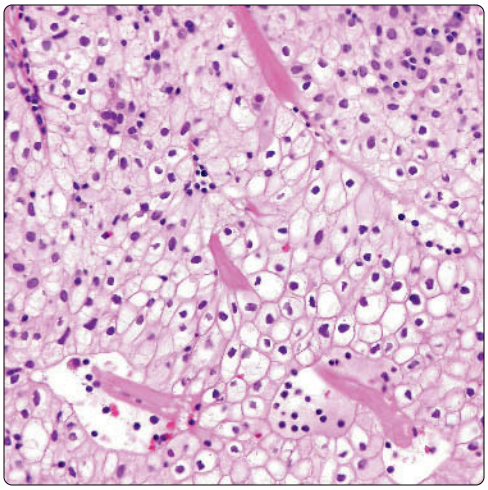

Clear Cells

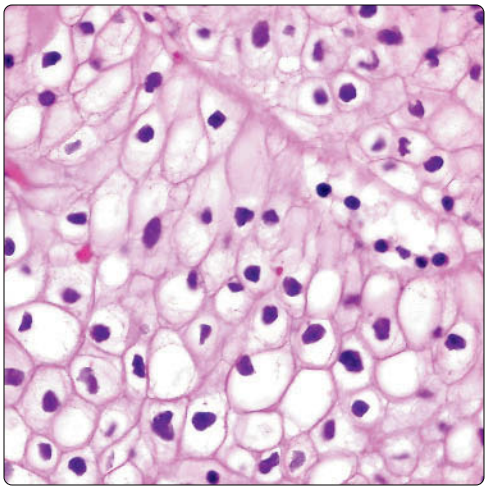

(Left) *Atypical thymoma (WHO type B3) shows sheets of monotonous tumor cells with prominent clearing of the cytoplasm imparting the tissue with a plant-like appearance.* **(Right)** *High magnification of atypical thymoma (WHO type B3) shows cells with hyperchromatic nuclei with irregular ("raisinoid") nuclear contours and abundant, optically clear cytoplasm bounded by a thick, eosinophilic cell membrane.*

Intercellular Bridges

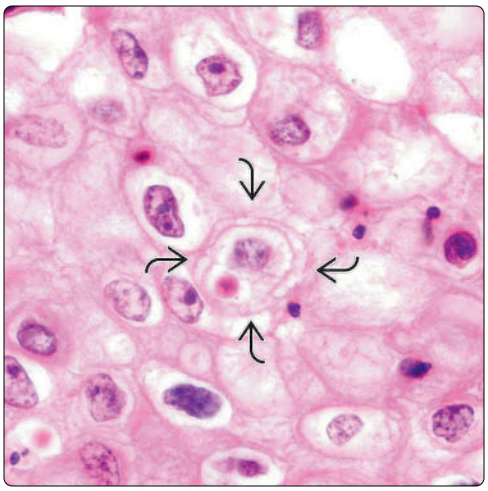

Mitotic Figures

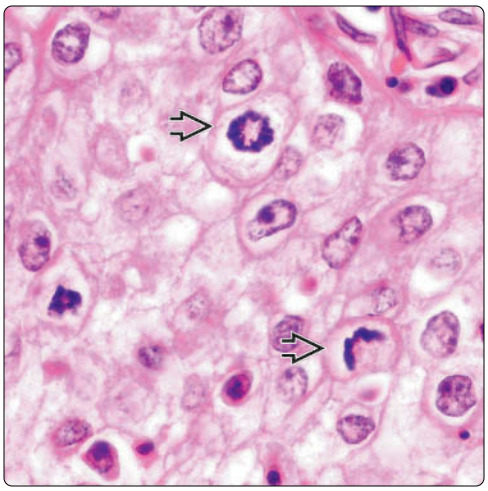

(Left) *Atypical thymoma (WHO type B3) shows prominent clearing of the cytoplasm of the tumor cells. The cell in the center ⇨ shows a hint of intercellular bridges. Notice the raisin-like appearance of the nuclei in the surrounding cells due to irregularities of the nuclear envelope.* **(Right)** *High magnification shows atypical thymoma (WHO type B3) with clearing of the cytoplasm. Note 2 cells in mitosis ⇨ and the presence of sharp cytoplasmic cell borders.*

Infiltration of Perithymic Fat

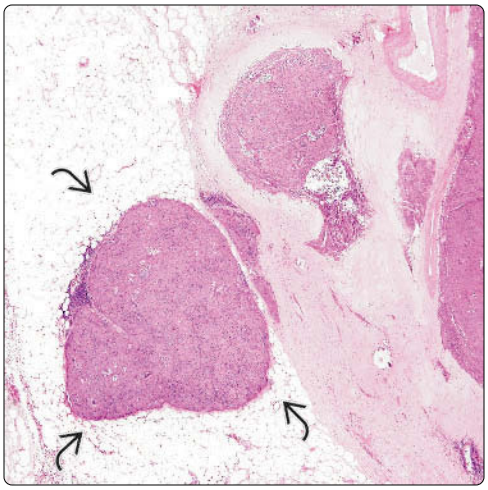

Infiltration of Fat

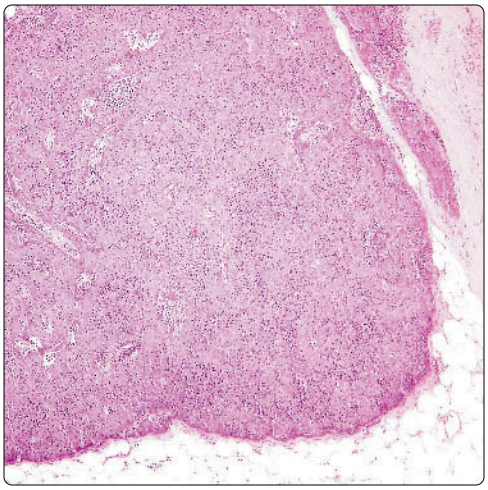

(Left) *Scanning magnification of atypical thymoma (WHO type B3) shows infiltration of the capsule and mediastinal fat by tumor.* **(Right)** *High magnification of invasive atypical thymoma (WHO type B3) shows lobule of tumor cells penetrating into the mediastinal fat. The invasive focus retains the features of the original tumor and shows sheets of monotonous epithelial cells with a sprinkling of small, immature lymphocytes.*

Lung Invasion

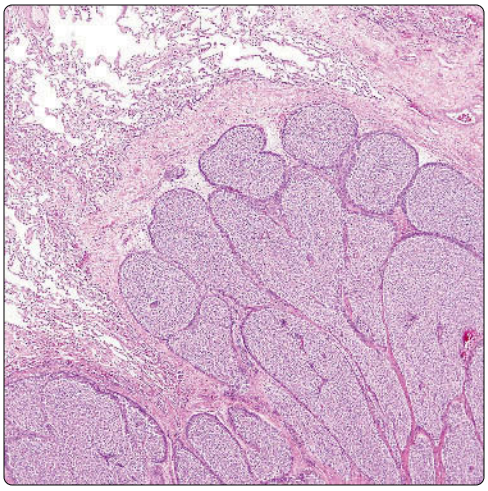

Lung Invasion

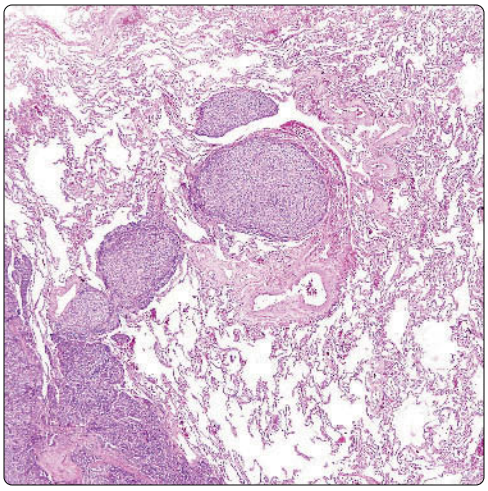

(Left) *Invasive atypical thymoma (WHO type B3) shows small lobules of tumor cells infiltrating the pleural surface and pushing into lung parenchyma.* **(Right)** *Infiltration of lung parenchyma by atypical thymoma (WHO type B3) shows small tumor cell islands lying within lung parenchyma. Notice the preservation of the lobular architecture in the tumor cell islands with infiltration and displacement of surrounding air spaces.*

Capsular Invasion

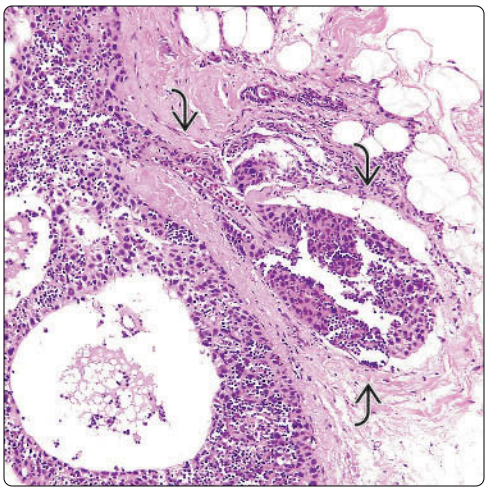

Vascular Invasion

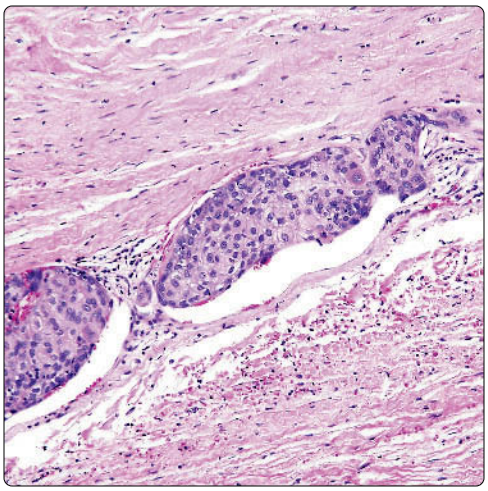

(Left) *Atypical thymoma (WHO type B3) shows through-and-through infiltration of the fibrous capsule by tumor into the adjacent mediastinal fat.* **(Right)** *Vascular invasion in atypical thymoma (WHO type B3) is characterized by multiple tumor emboli within the lumen of small vessels. The tumor emboli are composed of large epithelioid cells with abundant cytoplasm that are partially attached to the vessel walls.*

Cytokeratin AE1/AE3 Immunostaining

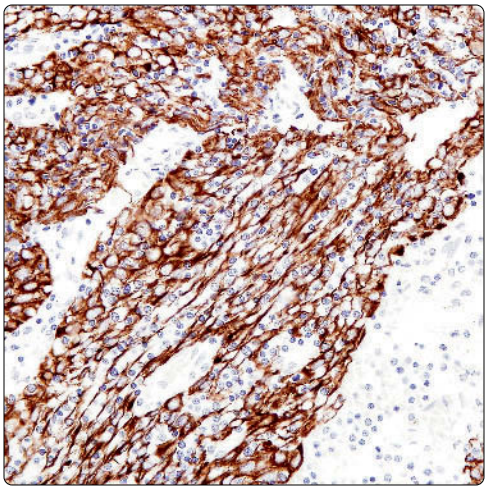

CK19 Immunostaining

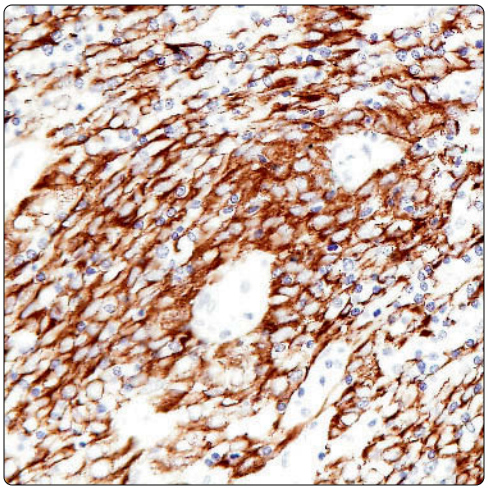

(Left) *Atypical thymoma (WHO type B3) shows strong cytoplasmic positivity in the majority of the tumor cells with cytokeratin AE1/AE3 antibody.* **(Right)** *Atypical thymoma (WHO type B3) shows strong positivity of the tumor cells with antibodies against CK19, which intensely stains the majority of primary thymic epithelial neoplasms, including atypical thymoma.*

p63 Immunostaining

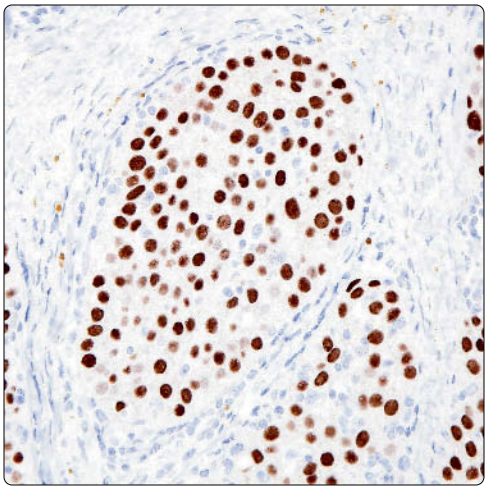

Ki-67 Immunostaining

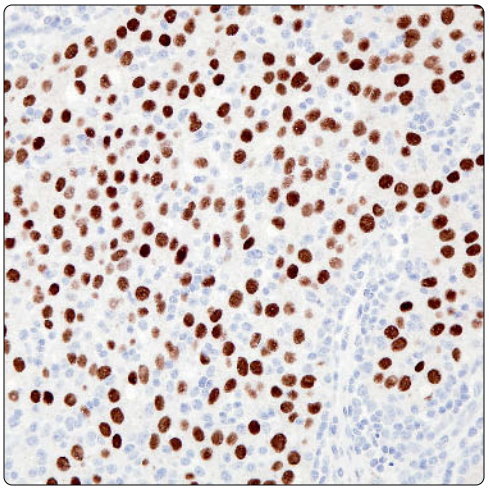

(Left) *Immunohistochemical staining of atypical thymoma (WHO type B3) with p63 shows strong positive nuclear staining of the tumor cells.* **(Right)** *Immunohistochemical staining of atypical thymoma (WHO type B3) with the proliferation marker Ki-67 shows strong nuclear staining in a large number of the tumor cells. Proliferative activity is often increased in atypical thymoma.*

CD1a(+) Small Lymphocytes

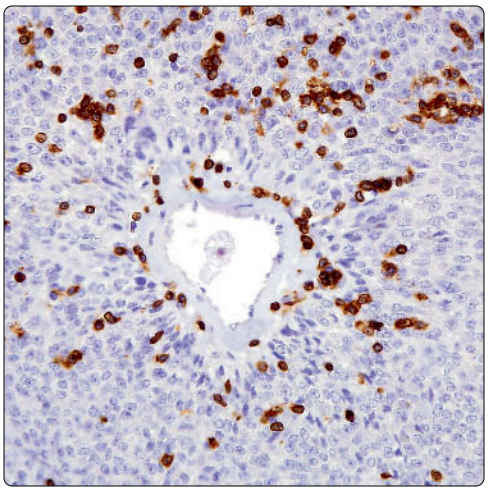

CD5 Immunostaining of Epithelial Cells

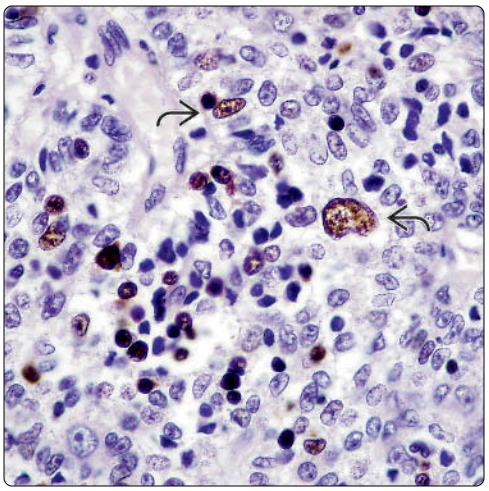

(Left) *Immunohistochemical staining of atypical thymoma (WHO type B3) with CD1a shows a few scattered, positive small lymphocytes.* **(Right)** *Immunohistochemical staining of atypical thymoma (WHO type B3) with CD5 shows a few positive small lymphocytes, as well as a few positive epithelial cells. The cells in atypical thymoma can also react with CD5. This marker is therefore not helpful in separating this tumor from thymic carcinoma.*

Thymic Carcinoma

KEY FACTS

CLINICAL ISSUES

- Generally poor prognosis
- High-grade tumors have median survival of 18 months

MACROSCOPIC

- Commonly contain areas of hemorrhage and necrosis
- Usually invasive, unencapsulated, and poorly circumscribed
- Cystic degeneration can be seen in some subtypes (basaloid, mucoepidermoid)

MICROSCOPIC

- Closely resembles other types of carcinoma
  - Well-differentiated squamous cell carcinoma of thymus
  - Basaloid carcinoma
  - Mucoepidermoid carcinoma
  - Poorly differentiated, nonkeratinizing (lymphoepithelioma-like) carcinoma
  - Adenocarcinoma of thymus
  - Papillary carcinoma
  - Clear cell carcinoma
  - Spindle cell (sarcomatoid) carcinoma
  - Carcinosarcoma
  - Anaplastic carcinoma

TOP DIFFERENTIAL DIAGNOSES

- Atypical thymoma (WHO type B3)
- Metastatic carcinoma of lung
- Metastatic carcinoma from other organs

DIAGNOSTIC CHECKLIST

- Thymic carcinoma is diagnosis of **exclusion**
- No pathognomonic features permitting diagnosis based on histology because tumors resemble carcinomas from other organs
- Demonstration of absence of tumor elsewhere is required for definitive diagnosis

Gross Appearance

Well-Differentiated Squamous Cell Thymic Carcinoma

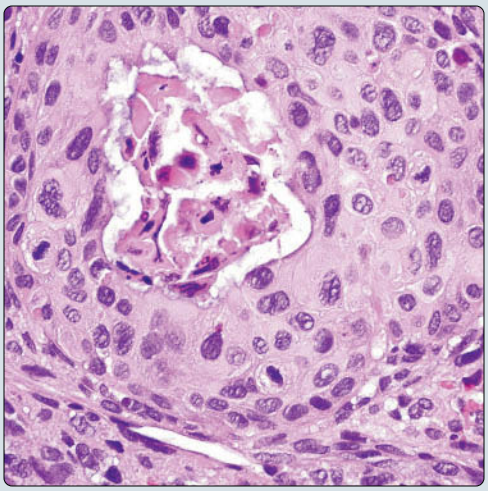

(Left) *Gross photo of squamous cell carcinoma of the thymus shows a solid tumor surrounded by areas of hemorrhage, necrosis, and cystic degeneration.* **(Right)** *High magnification of thymic squamous cell carcinoma shows a well-differentiated focus of keratinization surrounded by large atypical cells with sharp cell borders and occasional intercellular bridges.*

Lymphoepithelioma-Like Carcinoma

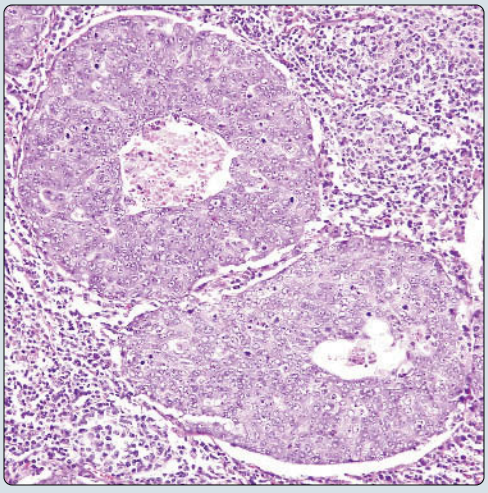

Poorly Differentiated Cells

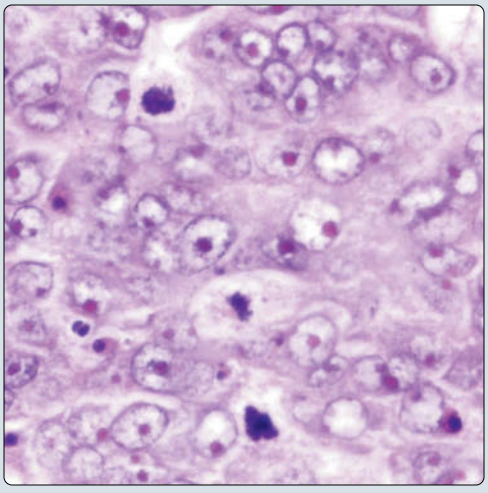

(Left) *Poorly differentiated nonkeratinizing squamous cell carcinoma, a.k.a. lymphoepithelioma-like carcinoma, is characterized by tumor islands with central comedo-like areas of necrosis surrounded by dense lymphoid infiltrates.* **(Right)** *Higher magnification of lymphoepithelioma-like carcinoma of the thymus shows tumor cells containing large, round to oval, vesicular nuclei with prominent eosinophilic nucleoli and frequent mitotic figures.*

TERMINOLOGY

Abbreviations

- Thymic carcinoma (TC)

Synonyms

- Malignant thymoma type II
- WHO type C thymoma
- Poorly differentiated (high-grade) thymic epithelial neoplasm

Definitions

- Primary thymic epithelial neoplasm showing overt cytologic features of malignancy with loss of organotypical features of thymic differentiation

ETIOLOGY/PATHOGENESIS

Pathogenesis

- Unknown
- Some cases may arise from malignant degeneration of preexisting thymoma

CLINICAL ISSUES

Epidemiology

- Incidence
  - Extremely rare neoplasm; accounts for < 1% of thymic tumors
- Age
  - Affects all age groups but is most frequent between 30-60 years
- Sex
  - Slight male predilection (M:F = 1.5:1.0)

Presentation

- Incidental finding in small subset of cases
- Anorexia
- Weight loss
- Chest pain
- Shortness of breath
- Not associated with paraneoplastic syndromes

Natural History

- Highly aggressive neoplasm

Treatment

- Options, risks, complications
  - Treatment related to grade and stage
- Surgical approaches
  - Surgical resection may be curative for low-grade, encapsulated lesions
  - Surgical excision may be indicated in larger tumors for debulking or palliation of symptoms
- Adjuvant therapy
  - Radiation and chemotherapy used in high-grade or high-stage tumors

Prognosis

- Generally poor prognosis
- High-grade tumors have median survival of 18 months
- Usual sites of metastases include lymph nodes, bone, lung, pleura, liver, and brain

IMAGING

General Features

- Lobulated, marginated, anterior mediastinal mass

Radiographic Findings

- Calcification in 10-40% of cases
- Obscuring of mediastinal fat plane
- Extension to pericardium and pleura
- Extrathymic metastases often present
- Invasion into great vessels and mediastinal structures seen in ~ 40% of cases

CT Findings

- Best imaging tool for thymic carcinoma
- Usually heterogeneous enhancement with areas of necrosis
- Unenhanced images for screening purposes followed by contrast-enhanced scans

MACROSCOPIC

General Features

- Commonly contain areas of hemorrhage and necrosis
- Usually invasive, unencapsulated, and poorly circumscribed
- Cystic degeneration can be seen in some subtypes (basaloid, mucoepidermoid)

Sections to Be Submitted

- Sections should include tumor with capsule (1 per centimeter of greatest diameter) as well as infiltrating margins and any included lymph nodes or surrounding structures

MICROSCOPIC

Histologic Features

- **Well-differentiated squamous cell carcinoma of thymus**
  - Identical histologic features to squamous cell carcinoma arising at other locations
  - Must first rule out metastasis from other organ or occult primary site
  - Stage-by-stage has better prognosis than squamous cell carcinoma of lung with massive mediastinal compromise
- **Basaloid carcinoma**
  - Small hyperchromatic round to oval tumor cells with prominent peripheral palisading of nuclei
  - Often associated with cystic changes; tumor cells can be tracked to lining of cysts
  - Usually associated with low-grade behavior but can also metastasize distantly
- **Mucoepidermoid carcinoma**
  - Admixture of squamous, intermediate, and mucinous cells with cribriform cystic spaces filled with mucin
  - Mucinous cysts and individual mucocytes are highlighted by mucicarmine stains
  - Frequently associated with cystic changes of thymus
  - Most cases are well differentiated; however, moderate and poorly differentiated variants also exist and are associated with more aggressive behavior
- **Poorly differentiated, nonkeratinizing (lymphoepithelioma-like) carcinoma**
  - Most frequent type of thymic carcinoma in Western patients

- Poorly differentiated tumor cells with large hyperchromatic nuclei with prominent eosinophilic nucleoli and frequent mitotic figures; resembles poorly differentiated carcinoma (lymphoepithelioma) of nasopharynx
- Large tumor cell islands characterized by central comedo-like areas of necrosis
- Some cases are characterized by dense lymphoplasmacellular stromal infiltrates; others are devoid of lymphoid stroma
- Can often show admixtures with areas of spindle cell thymoma (WHO type A)
- Some cases in children and adolescents may be associated with Epstein-Barr virus

- **Adenosquamous carcinoma**
  - Biphasic glandular and squamous components
  - High-grade tumor usually associated with poor prognosis
  - May harbor "myoid" cell component (rhabdomyomatous carcinoma of thymus)
- **Adenocarcinoma of thymus**
  - Very rare variant (few cases reported)
  - May be of mucinous and nonmucinous type; mucinous variant resembles colloid carcinoma in other organs
  - Metastasis from distant or occult primary must be stringently ruled out before making this diagnosis
- **Papillary carcinoma**
  - Very rare type; very few cases reported in literature
  - Often associated with areas of spindle cell thymoma (WHO type A)
  - Papillary areas may display very low-grade cytologic features
- **Clear cell carcinoma**
  - Characterized by large cells with abundant clear cytoplasm
  - Can display very aggressive behavior
  - Most cases represent secondary clear cell changes in squamous cell carcinoma
  - Care must be taken to exclude metastasis from clear cell carcinoma of lung, kidney, adrenal, or other organs
- **Spindle cell (sarcomatoid) carcinoma**
  - Composed of highly atypical spindle epithelial cells with high nuclear grade and brisk mitotic activity
  - Majority are seen in association with preexisting areas of spindle cell thymoma (WHO type A)
  - Aggressive behavior with frequent distant metastases
- **Carcinosarcoma**
  - True mixed tumor with both malignant epithelial (carcinomatous) component and malignant sarcomatous component
  - Most frequent sarcomatous component is rhabdomyosarcoma; most frequent carcinomatous component is poorly differentiated adenocarcinoma
  - Highly aggressive tumor with high mortality
- **Anaplastic carcinoma**
  - Bizarre tumor cells with marked nuclear atypia and abnormal mitotic figures
  - Diagnosis of exclusion: Needs demonstration of epithelial lineage of tumor cells by either immunohistochemistry or electron microscopy
  - Rare foci of differentiated squamous carcinoma or adenocarcinoma can be occasionally identified
  - Highly aggressive behavior
- **Neuroendocrine carcinoma**
  - Well, moderately, or poorly differentiated types
- **Other rare types of thymic carcinoma**
  - Rhabdoid carcinoma of thymus: Characterized by eccentric globular eosinophilic cytoplasmic inclusions
  - Hepatoid carcinoma of thymus: Tumor cells resemble hepatocytes
  - Desmoplastic carcinoma of thymus: Characterized by prominent desmoplastic stroma entrapping squamoid elements

Predominant Cell/Compartment Type

- Epithelial

Grade

- Low-grade and high-grade types, depending on degree of cytologic atypia, mitotic activity, and amount of necrosis

ANCILLARY TESTS

Cytology

- As screening tool to confirm presence of malignant cells

Frozen Sections

- To confirm presence of cytologic atypia, mitotic activity, and necrosis; not for definitive diagnosis

Genetic Testing

- Several nonrecurrent chromosomal losses and gains have been reported but are not useful for diagnosis or prognosis

DIFFERENTIAL DIAGNOSIS

Atypical Thymoma (WHO Type B3)

- May be difficult to distinguish from low-grade, well-differentiated squamous cell carcinoma of thymus
  - Should not show marked cytologic atypia or overt features of malignancy
  - Contains perivascular spaces and immature T lymphocytes
  - Usually lacks vascular invasion and necrosis

Metastatic Carcinoma of Lung

- Well-differentiated squamous cell carcinoma of lung can metastasize massively to mediastinal lymph nodes
- Bronchoscopy with bilateral bronchial brushings and washings are necessary to rule out primary bronchial squamous cell carcinoma
- Immunohistochemical stains for TTF-1 may be helpful for identifying pulmonary metastases of adenocarcinoma

Metastatic Carcinoma from Other Organs

- Carcinomas in mediastinum are statistically more likely to represent metastases from other organs rather than primary tumors of thymus
  - Thorough clinical and radiographic examination is required to rule out possibility of occult or late metastasis from distant primary before rendering diagnosis of thymic carcinoma

Immunohistochemistry

Antibody	Reactivity	Staining Pattern	Comment
CK-PAN	Positive	Cytoplasmic	Used to confirm epithelial nature of tumor cells
CD5	Positive	Cytoplasmic	Stains neoplastic epithelial cells in thymic carcinoma
C117	Positive	Cell membrane & cytoplasm	Positivity demonstrated in neoplastic epithelial cells in 80% of cases of squamous cell thymic carcinoma in 1 study; up to 20% of pulmonary squamous cell carcinomas may also be positive; not studied in other variants of thymic carcinoma
Chromogranin-A	Positive	Cytoplasmic	Can be focally positive in some cases of nonneuroendocrine-type thymic carcinoma as result of aberrant differentiation
Ki-67	Positive	Nuclear	Expressed in > 50% of tumor cell nuclei in high-grade tumors; < 10% nuclear positivity in low-grade tumors
Calretinin	Positive	Cytoplasmic	~ 30% of thymic carcinomas are positive for calretinin, mesothelin, and CK5/6
CD3	Negative	Not applicable	T-cell markers are generally negative in lymphoid cells of thymic carcinoma; lymphocytes in thymic carcinoma are of B-cell type

Classification of Thymic Carcinoma According to Histologic Grade

Low-Grade Tumors	High-Grade Tumors
Well-differentiated squamous cell carcinoma	Poorly differentiated, nonkeratinizing (lymphoepithelioma-like) carcinoma
Basaloid carcinoma	Clear cell carcinoma
Well-differentiated mucoepidermoid carcinoma	Poorly differentiated mucoepidermoid carcinoma
Papillary carcinoma	Sarcomatoid (spindle cell) carcinoma
	Carcinosarcoma
	Anaplastic carcinoma
	Adenocarcinoma

DIAGNOSTIC CHECKLIST

Clinically Relevant Pathologic Features

- Thymic carcinoma is diagnosis of **exclusion**
- No pathognomonic features permitting diagnosis based on histology because tumors resemble carcinomas from other organs
- Demonstration of absence of tumor elsewhere is required for definitive diagnosis

Pathologic Interpretation Pearls

- Islands of poorly differentiated cells with central comedo-like areas of necrosis characterize poorly differentiated nonkeratinizing (lymphoepithelioma-like) squamous cell carcinoma
- Areas of transition with well-differentiated or atypical thymoma can be seen in significant number of cases

SELECTED REFERENCES

1. Weissferdt A et al: Neuroendocrine differentiation in thymic carcinomas: a diagnostic pitfall: an immunohistochemical analysis of 27 cases. Am J Clin Pathol. 145(3):393-400, 2016
2. Marchevsky AM et al: Thymic epithelial neoplasms: a review of current concepts using an evidence-based pathology approach. Hematol Oncol Clin North Am. 22(3):543-62, 2008
3. Rieker RJ et al: An institutional study on thymomas and thymic carcinomas: experience in 77 patients. Thorac Cardiovasc Surg. 56(3):143-7, 2008
4. Suster S et al: Histologic classification of thymoma: the World Health Organization and beyond. Hematol Oncol Clin North Am. 22(3):381-92, 2008
5. Ra SH et al: Mucinous adenocarcinomas of the thymus: report of 2 cases and review of the literature. Am J Surg Pathol. 31(9):1330-6, 2007
6. Nakagawa K et al: Immunohistochemical KIT (CD117) expression in thymic epithelial tumors. Chest. 128(1):140-4, 2005
7. Suster S: Thymic carcinoma: update of current diagnostic criteria and histologic types. Semin Diagn Pathol. 22(3):198-212, 2005
8. Chalabreysse L et al: Thymic carcinoma: a clinicopathological and immunohistological study of 19 cases. Histopathology. 44(4):367-74, 2004
9. Pan CC et al: KIT (CD117) is frequently overexpressed in thymic carcinomas but is absent in thymomas. J Pathol. 202(3):375-81, 2004
10. Choi WW et al: Adenocarcinoma of the thymus: report of two cases, including a previously undescribed mucinous subtype. Am J Surg Pathol. 27(1):124-30, 2003
11. Pan CC et al: Expression of calretinin and other mesothelioma-related markers in thymic carcinoma and thymoma. Hum Pathol. 34(11):1155-62, 2003
12. Suster S et al: Spindle cell thymic carcinoma: clinicopathologic and immunohistochemical study of a distinctive variant of primary thymic epithelial neoplasm. Am J Surg Pathol. 23(6):691-700, 1999
13. Suster S et al: Primary thymic epithelial neoplasms showing combined features of thymoma and thymic carcinoma. A clinicopathologic study of 22 cases. Am J Surg Pathol. 20(12):1469-80, 1996
14. Suster S et al: Thymic carcinoma. A clinicopathologic study of 60 cases. Cancer. 67(4):1025-32, 1991

(Left) *Core biopsy of well- to moderately differentiated squamous cell carcinoma of the thymus shows connective tissue containing islands of atypical cells. The surrounding stroma shows chronic inflammation and desmoplasia.* **(Right)** *High magnification of primary squamous cell carcinoma of the thymus shows islands of large tumor cells with hyperchromatic nuclei and abundant cytoplasm and containing scattered mitotic figures.*

Squamous Cell Carcinoma, Core Biopsy

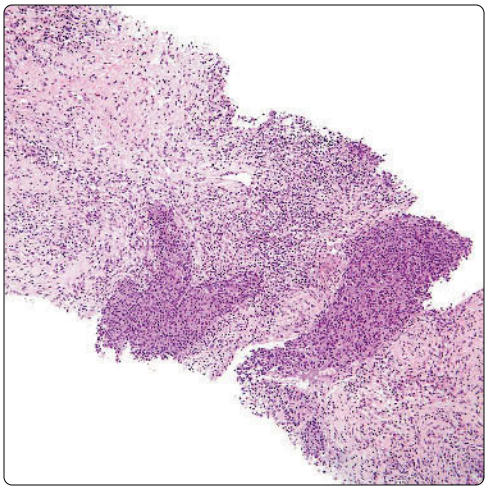

Well-Differentiated Squamous Cell Carcinoma

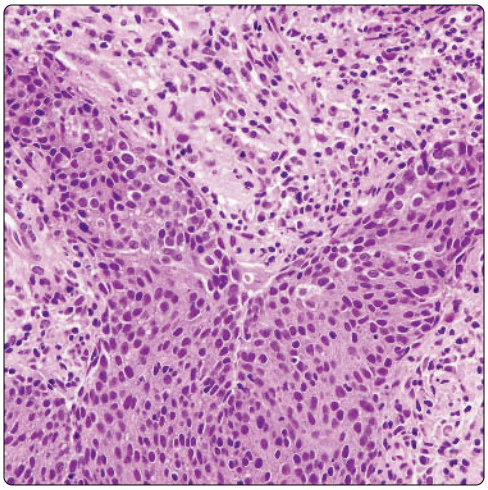

(Left) *Squamous cell carcinoma of the thymus shows a pavement-like arrangement of the tumor cells admixed with numerous apoptotic cells ⇨. The tumor cells expressed CK5/6 and p63 by immunohistochemistry, supporting a squamous epithelial origin.* **(Right)** *High magnification of well-differentiated squamous cell carcinoma of the thymus shows large cells with sharp cell membranes and focal clearing of the cytoplasm. The tumor cells show a pavement-like architecture.*

Squamous Cell Carcinoma Island

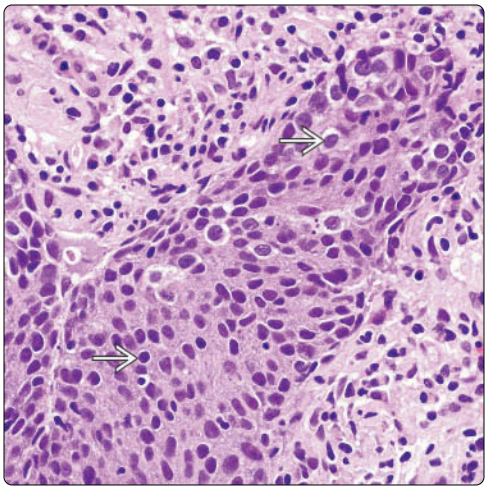

Sheets of Squamous Tumor Cells

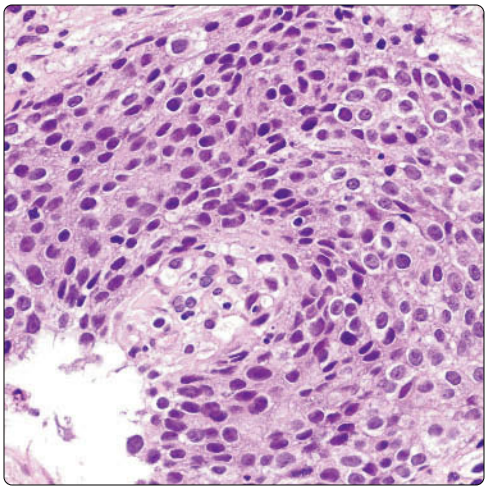

(Left) *Small island of tumor cells in well-differentiated squamous cell carcinoma of the thymus shows foci displaying single cell keratinization ⇨ and a central area of horn pearl formation ⇨.* **(Right)** *High magnification of focus of keratinization in squamous cell carcinoma of the thymus shows large atypical cells with sharp cell borders and occasional intercellular bridges. Notice central focus of abrupt keratinization ⇨.*

Focus of Keratinization

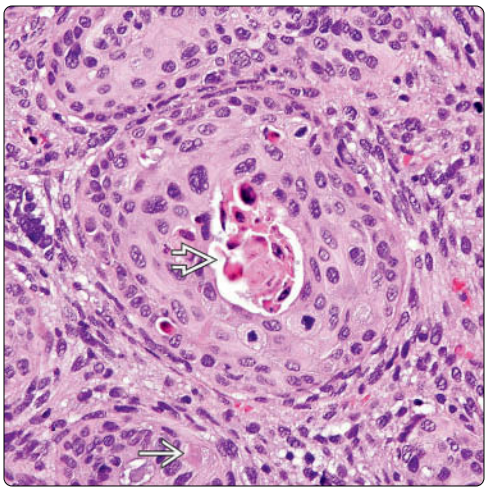

Intercellular Bridges

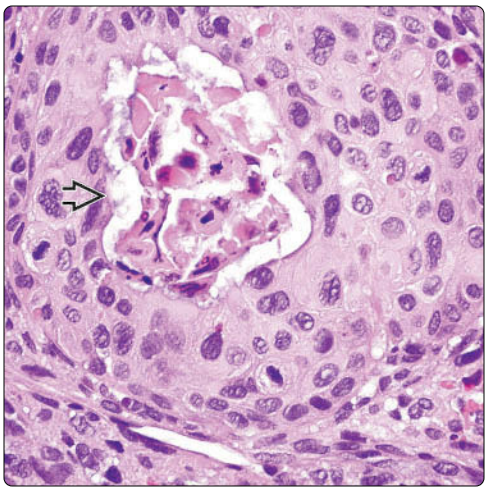

Mucoepidermoid Carcinoma

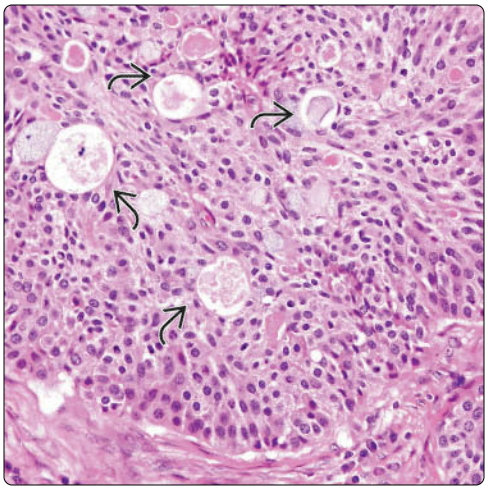

Scattered Mucocytes

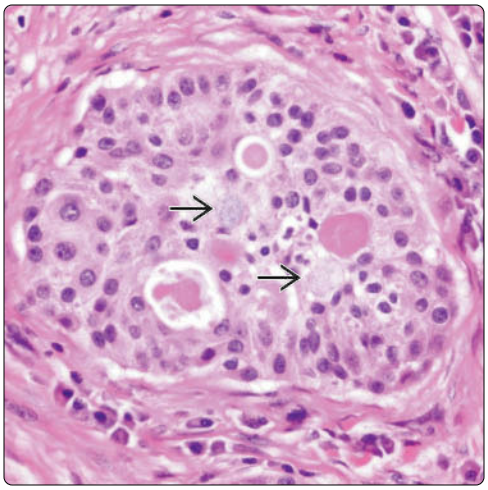

(Left) *Primary mucoepidermoid carcinoma of the thymus shows sheets of squamoid intermediate cells dotted by small mucinous cysts admixed with scattered individual mucocytes.* **(Right)** *High magnification from a small tumor cell island in a well-differentiated mucoepidermoid carcinoma of the thymus shows cohesive squamoid cells with small mucinous cysts and occasional singly scattered mucocytes.*

Cystic Spaces Filled With Mucin

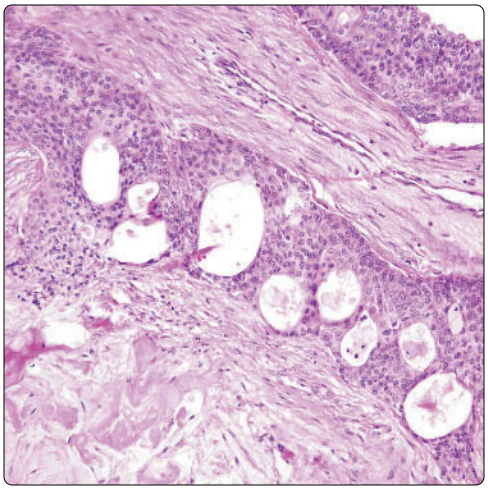

Mucin-Secreting Cells

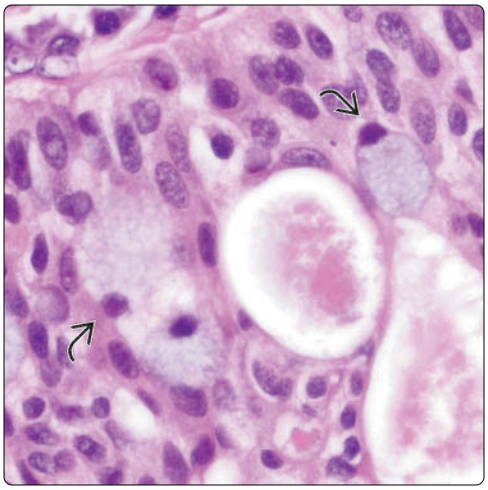

(Left) *Cords of tumor cells with cribriform-like cystic spaces filled with mucin are seen in this example of well-differentiated mucoepidermoid carcinoma of the thymus.* **(Right)** *High magnification of well-differentiated mucoepidermoid carcinoma of the thymus shows a cohesive population of squamoid epithelial cells containing mucinous microcysts surrounded by mucocytes that are filled with abundant light bluish mucin content.*

Cystic Changes

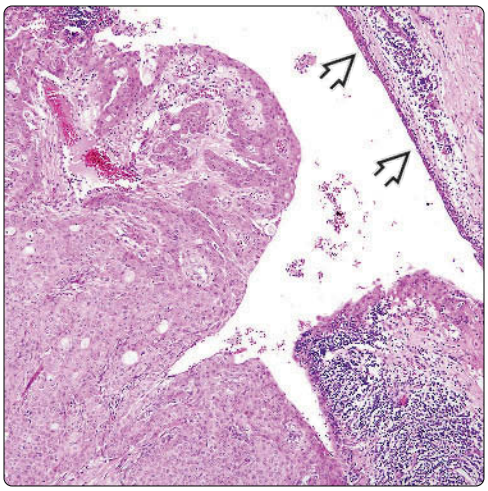

Cystic Mucoepidermoid Carcinoma

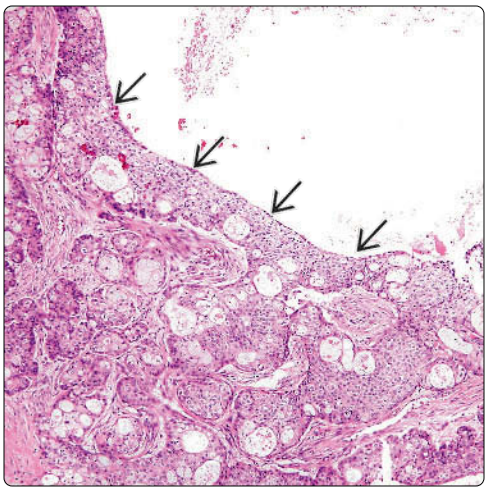

(Left) *Cystic area in moderately differentiated mucoepidermoid carcinoma of the thymus shows a flat cuboidal epithelial lining slowly merging with solid sheets of epithelioid tumor cells on the left of the image.* **(Right)** *Example of cystic mucoepidermoid carcinoma of the thymus shows dilated cystic lumen (top right) flanked by sheets and lobules of tumor cells displaying mucoepidermoid features. In some cases, the tumor may originate from the lining of the cyst.*

Invasive Component

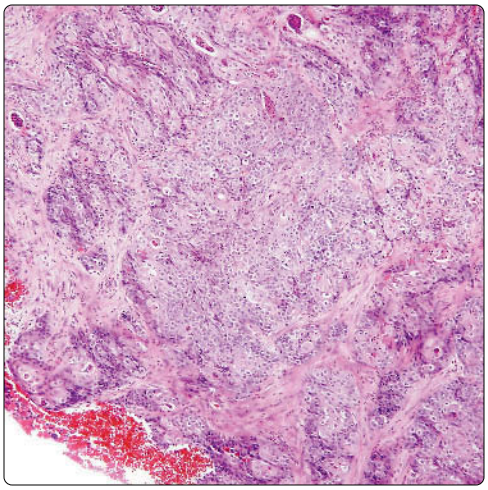

Sheets of Poorly Differentiated Cells

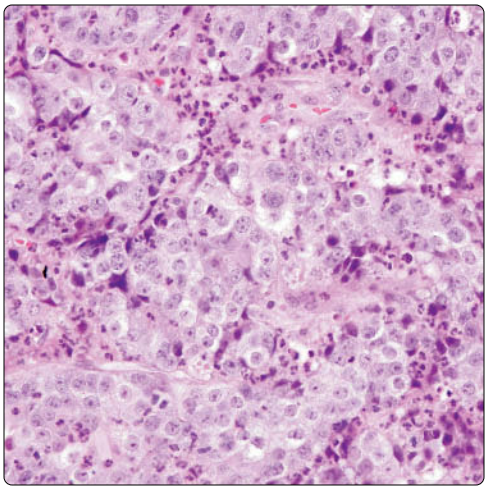

(Left) *Scanning magnification of poorly differentiated mucoepidermoid carcinoma of the thymus shows sheets and small islands of tumor cells embedded in fibrous stroma.* **(Right)** *High magnification of poorly differentiated mucoepidermoid carcinoma of the thymus shows sheets of monotonous tumor cells without evidence of luminal differentiation or other distinctive lineage. There is an inflammatory cell infiltrate in the interstitium.*

Invasive Islands

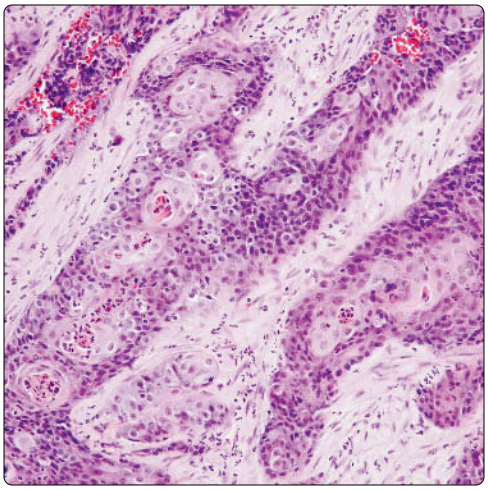

Vascular Invasion

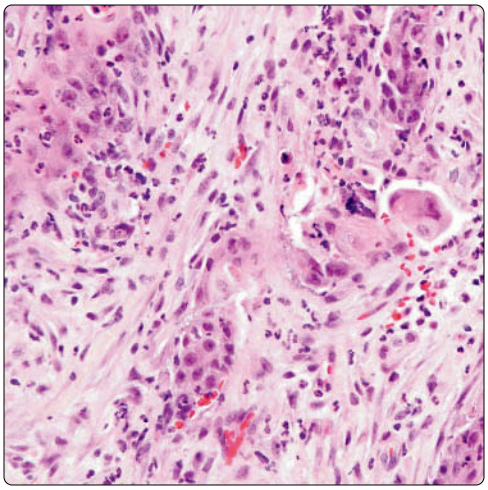

(Left) *Moderate to poorly differentiated mucoepidermoid carcinoma of the thymus shows immature intermediate cells merging with better differentiated epidermoid cells set against a desmoplastic stroma.* **(Right)** *High magnification of poorly differentiated mucoepidermoid carcinoma of the thymus shows infiltration of vascular lumina by carcinoma cells. Vascular and lymphatic involvement is a common event in these tumors.*

Tumor Embolus in Vascular Lumen

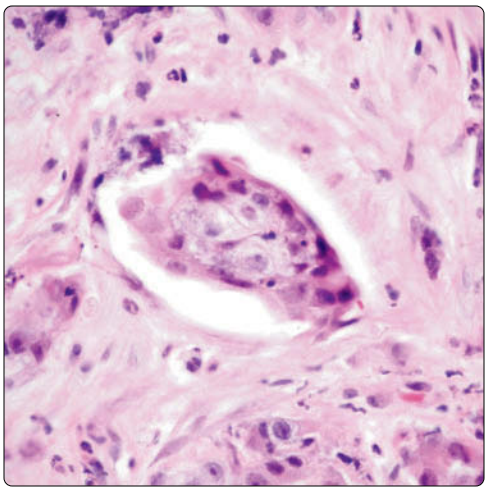

Mucicarmine Stain

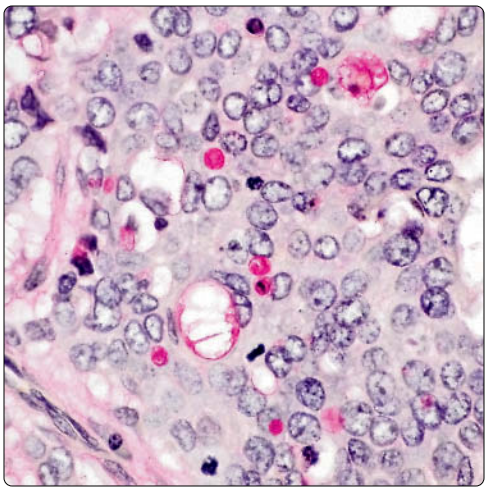

(Left) *High magnification of focus of lymphatic invasion in poorly differentiated mucoepidermoid carcinoma of the thymus is shown. Notice the clearly squamoid appearance of the tumor embolus within the vessel lumen.* **(Right)** *Mucicarmine stain in poorly differentiated mucoepidermoid carcinoma of the thymus shows focal cytoplasmic positivity (red) of scattered tumor cells, corresponding to intracellular mucin.*

Basaloid Carcinoma

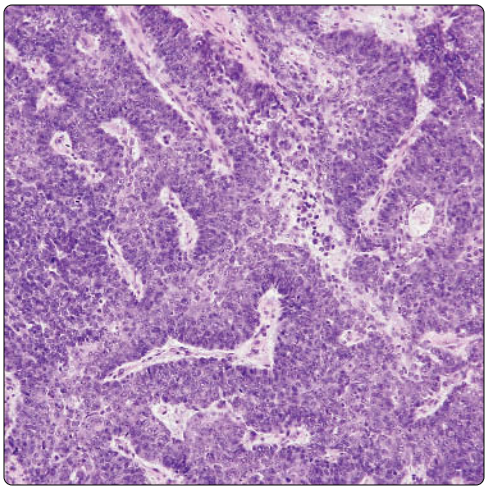

Anastomosing Basaloid Strands

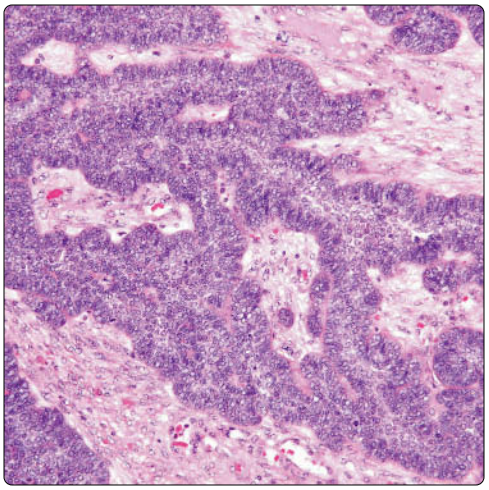

(Left) *Scanning magnification in basaloid carcinoma of the thymus shows anastomosing cords of hyperchromatic tumor cells displaying prominent peripheral palisading of nuclei.* **(Right)** *Higher magnification of basaloid carcinoma of the thymus shows a monotonous population of round to oval tumor cells with clear nuclear chromatin and peripheral palisading of nuclei. The striking peripheral palisading of nuclei is reminiscent of basal cell carcinoma of the skin.*

Cystic Changes in Basaloid Carcinoma

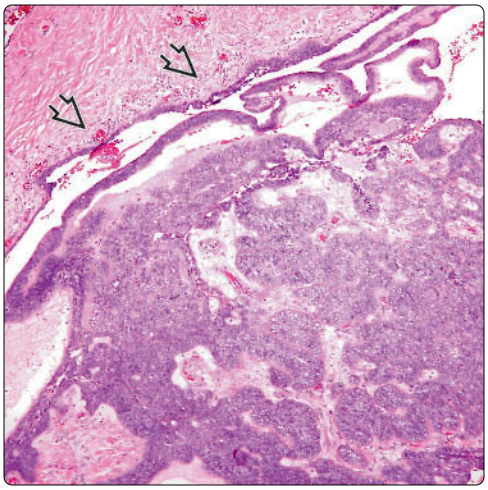

Peripheral Palisading of Nuclei

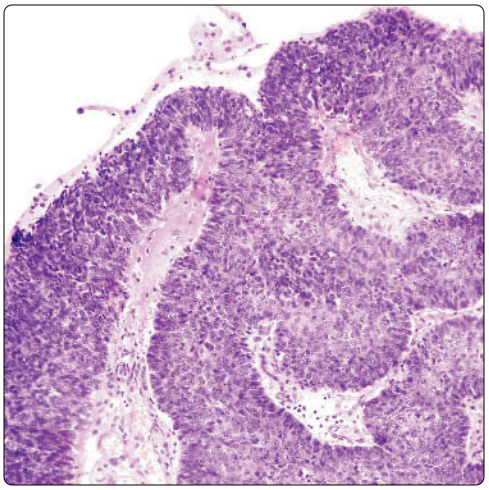

(Left) *Scanning magnification of basaloid carcinoma of the thymus shows early cystic changes that can be seen at the periphery of the lesion ⇨. The lining of the cysts may or may not contain the same type of epithelium as the solid part of the tumor.* **(Right)** *Cords of monotonous tumor cells with peripheral palisading of nuclei are seen in this basaloid carcinoma of the thymus. The tumor cells are quite monotonous, and no nuclear pleomorphism is appreciated.*

Primitive Cell Population

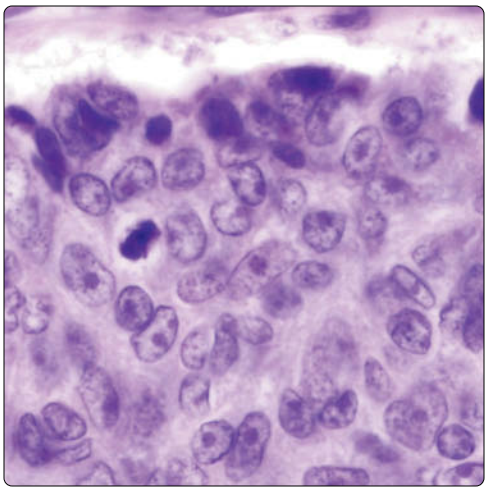

Focus of Abrupt Keratinization

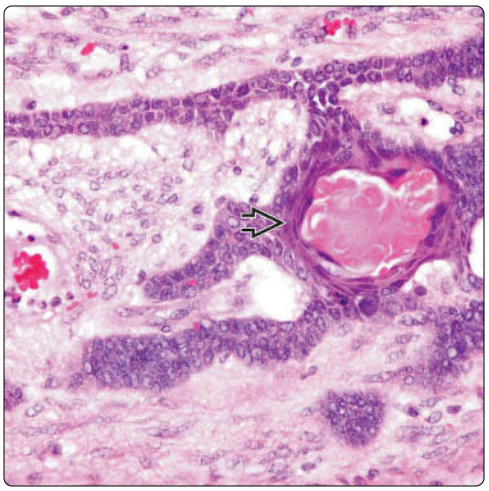

(Left) *Higher magnification of basaloid carcinoma of the thymus shows primitive-appearing round to oval tumor cells, with large oval nuclei and prominent central eosinophilic nucleoli. The tumor shows frequent mitotic figures.* **(Right)** *Basaloid carcinoma of the thymus shows a focus of abrupt keratinization ⇨ with keratin pearl formation in the center of the lumen. The rest of the tumor cells appear as primitive, undifferentiated small cells.*

Clear Cell Carcinoma

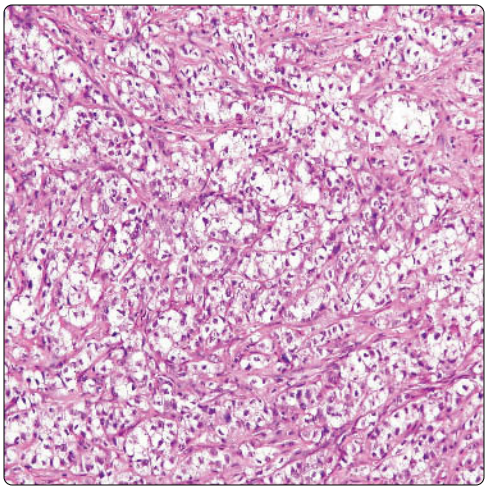

Clear Cells: High Power

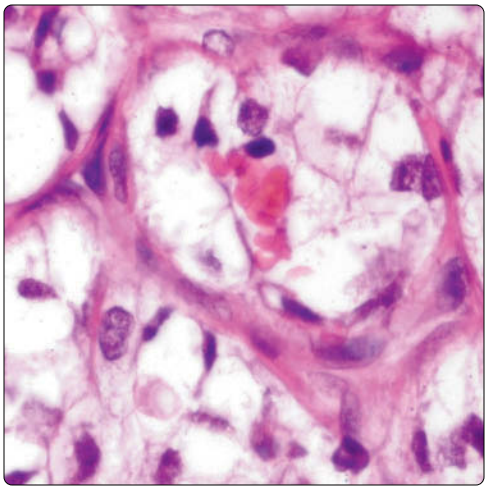

(Left) *Scanning magnification in clear cell carcinoma of the thymus shows sheets of large tumor cells with abundant clear cytoplasm. Tumors with this histologic appearance may closely resemble metastatic clear cell renal cell carcinoma.* **(Right)** *High magnification of clear cell carcinoma of the thymus shows large cells with abundant water-clear cytoplasm and centrally placed small nuclei with vesicular chromatin and inconspicuous nucleoli.*

Squamoid Clear Cell Carcinoma

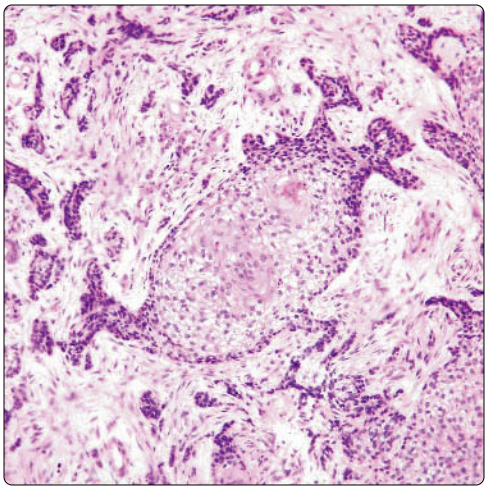

Clear Cells: High Power

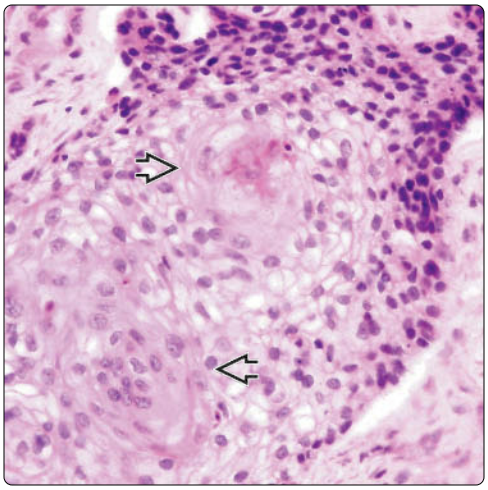

(Left) *Scanning magnification of tumor cell island in clear cell carcinoma of the thymus shows central clearing of the cytoplasm with condensation of dark small nuclei toward the periphery. Notice small infiltrating islands of tumor cells surrounded by desmoplastic stroma.* **(Right)** *Higher magnification of clear cell carcinoma of the thymus shows transition between the clear cells and areas showing more epidermoid features ⇨.*

Clear Cell Carcinoma

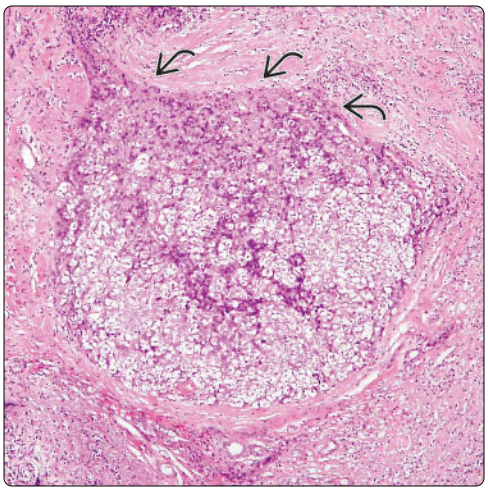

Clear Cells: Higher Power

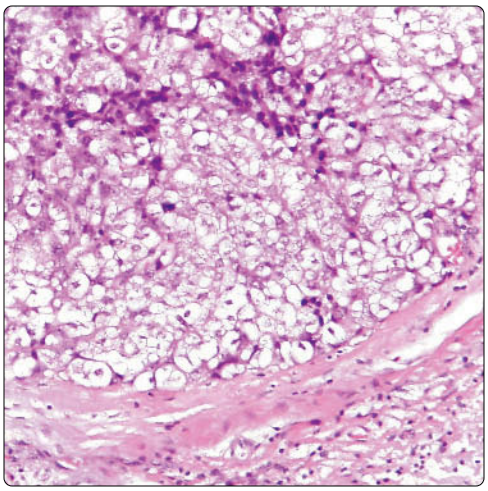

(Left) *Clear cell carcinoma of the thymus shows a well-circumscribed tumor lobule composed of clear tumor cells admixed with cells displaying more conventional eosinophilic cytoplasm ⇨. Notice the angulated character of the tumor cell nodule reminiscent of the growth pattern seen in thymoma.* **(Right)** *High magnification of clear cell carcinoma of the thymus shows large, round tumor cells with abundant water-clear cytoplasm and small, centrally placed nuclei.*

Spindle Cell Carcinoma

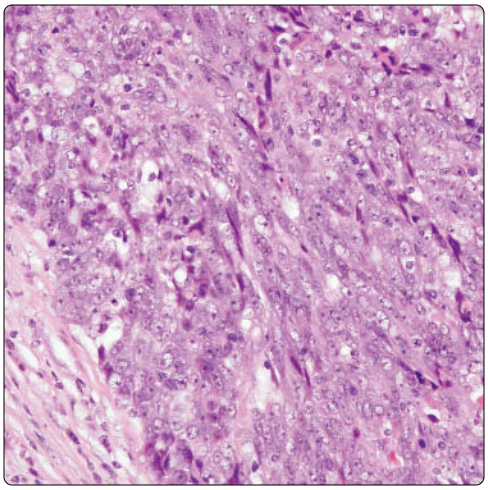

Spindle Cell Carcinoma: High Power

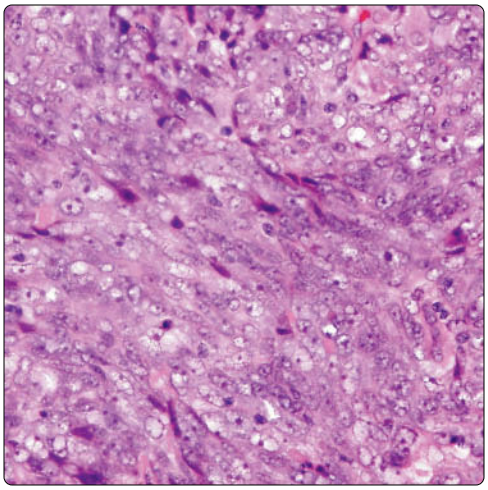

(Left) *Spindle cell (sarcomatoid) carcinoma of the thymus shows dense spindle cell population disposed in longitudinal fascicles with oval nuclei displaying prominent eosinophilic nucleoli.* **(Right)** *High magnification of spindle cell carcinoma of the thymus shows round to oval nuclei with vesicular chromatin pattern and prominent, central eosinophilic nucleoli. The cells contain a rim of eosinophilic cytoplasm and display scattered mitotic figures.*

Spindle Cell Carcinoma

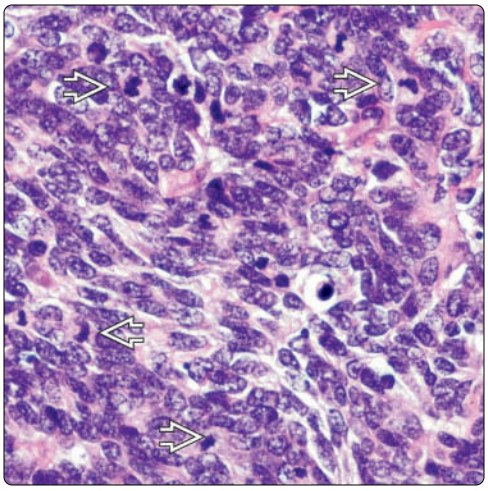

Carcinosarcoma

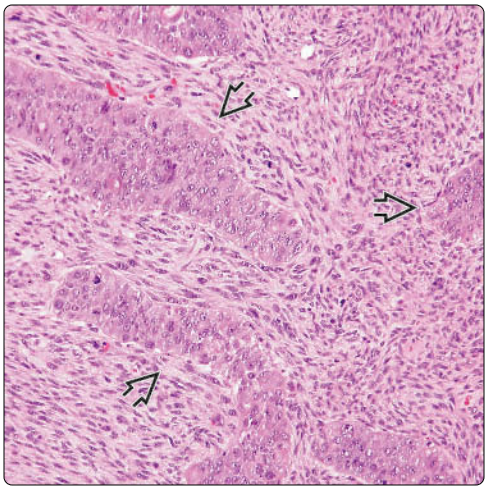

(Left) *High magnification of spindle cell (sarcomatoid) carcinoma of the thymus shows neoplastic spindle cells characterized by oval to spindled hyperchromatic nuclei with occasional small nucleoli and a scant rim of cytoplasm. Notice frequent mitotic figures ⇨.* **(Right)** *Carcinosarcoma of the thymus shows a biphasic malignant neoplasm composed of well-defined islands of cohesive epithelial cells ⇨ surrounded by a densely cellular spindle cell stroma.*

Epithelial Island

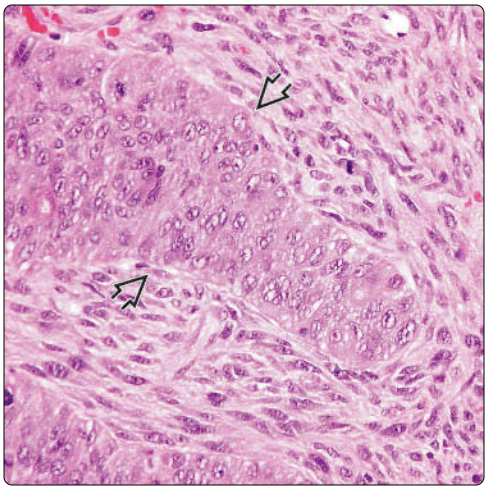

Sarcomatous and Epithelial Components

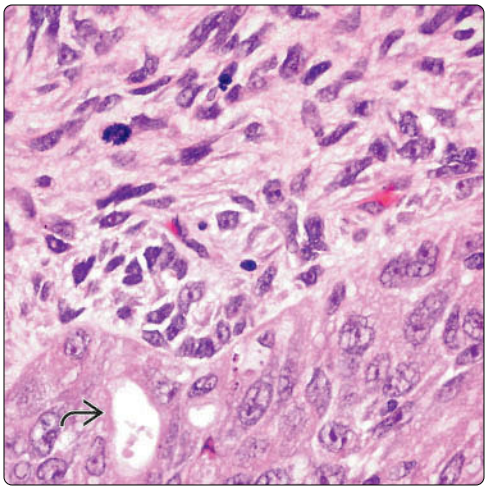

(Left) *High magnification of carcinosarcoma of the thymus shows an island of epithelioid cells ⇨, corresponding to a poorly differentiated carcinomatous component, surrounded by atypical spindle cell, sarcomatous elements.* **(Right)** *High magnification of carcinosarcoma of the thymus shows an island of epithelial tumor cells with focal abortive lumen formation ⇨. The sarcomatous element in the surrounding stroma is composed of keratin-negative spindle cells.*

Lymphoepithelioma-Like Carcinoma

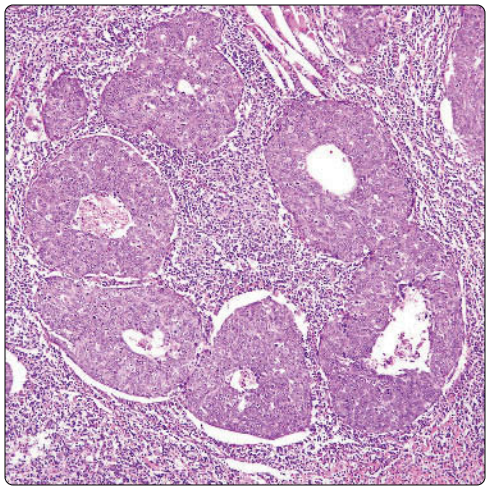

Comedo-Like Central Necrosis

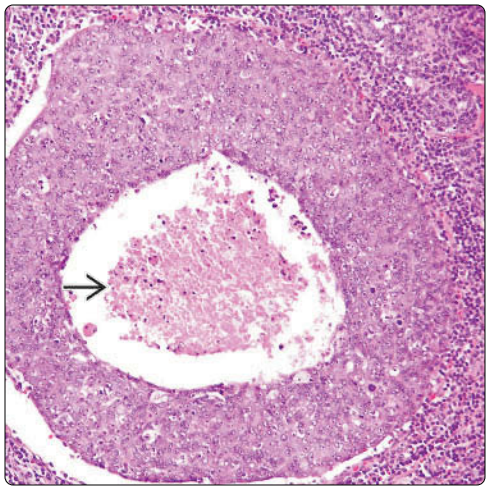

(Left) *Lymphoepithelioma-like carcinoma of the thymus shows a cluster of round tumor cell islands with central comedo-like areas of necrosis. Notice the dense lymphoplasmacellular infiltrate surrounding the tumor cell islands, characteristic of this lesion.* **(Right)** *Island of tumor cells in lymphoepithelioma-like carcinoma of the thymus shows characteristic comedo-like area of necrosis. The tumor cells in this lobule are monotonous with numerous mitoses.*

Atypical Tumor Cells

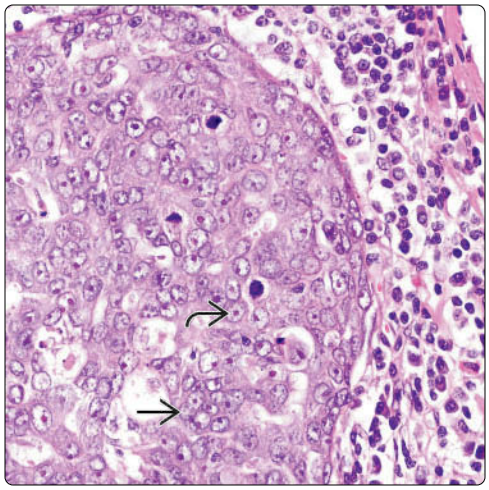

Scattered Mitoses

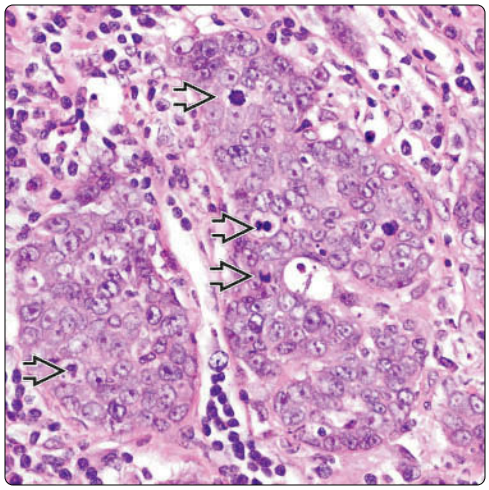

(Left) *High magnification of lymphoepithelioma-like carcinoma of the thymus shows a small island of monotonous tumor cells. Notice focal overlapping of nuclei and prominent, mostly centrally placed eosinophilic nucleoli.* **(Right)** *Small islands of lymphoepithelioma-like carcinoma of the thymus show scattered atypical mitoses. Notice the dense lymphoplasmacellular infiltration in the surrounding stroma.*

Vesicular Nuclei and Central Nucleoli

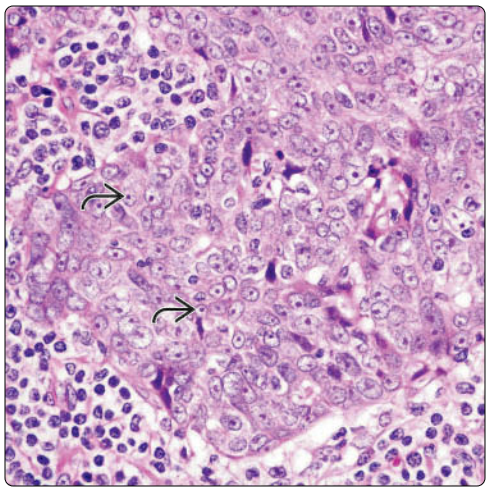

Poorly Differentiated Cells

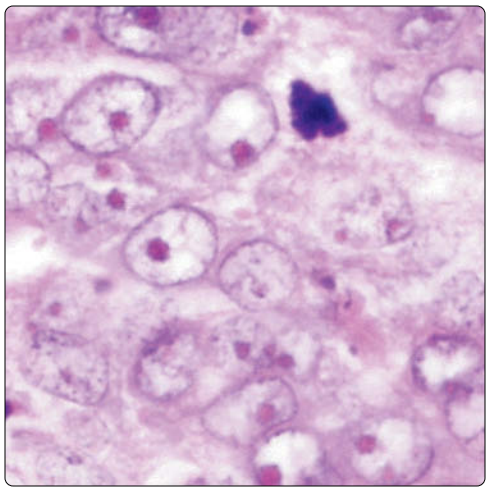

(Left) *Lymphoepithelioma-like carcinoma of the thymus shows nuclear detail of the cells. Notice small, round, centrally placed nucleoli and dense lymphoid infiltrate in the surrounding stroma. The cells in this infiltrate are polyclonal small lymphocytes.* **(Right)** *High magnification of lymphoepithelioma-like carcinoma of the thymus shows cells with round to oval nuclei with vesicular chromatin and prominent eosinophilic nucleoli and an indistinct rim of cytoplasm.*

Tumor Islands With Central Necrosis

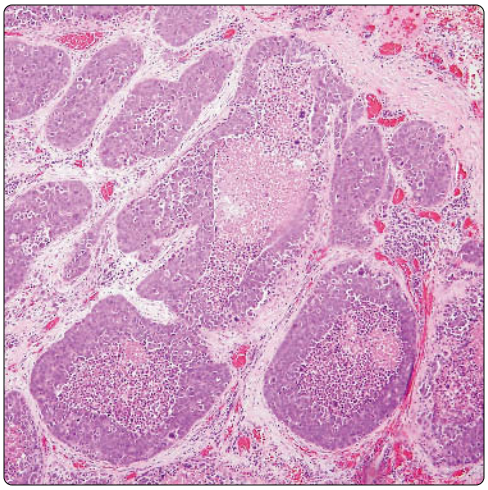

Tumor Island: Higher Power

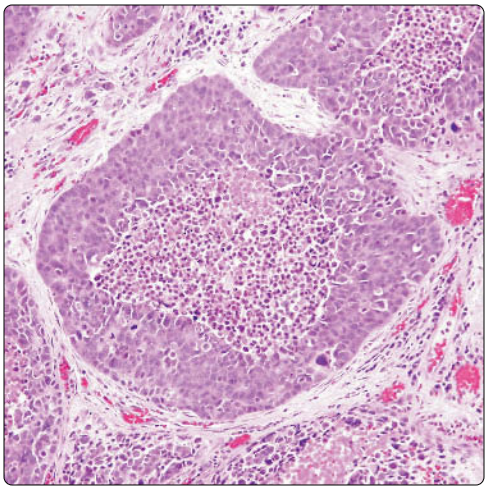

(Left) *Scanning magnification of lymphoepithelioma-like carcinoma of the thymus (poorly differentiated, nonkeratinizing squamous cell carcinoma) shows tumor cell islands with extensive, comedo-like areas of necrosis.* **(Right)** *High magnification of lymphoepithelioma-like carcinoma of the thymus shows an island of monotonous tumor cells with a prominent comedo-like area of necrosis. Central comedo-like areas of necrosis are characteristic for this tumor.*

Confluent Areas of Necrosis

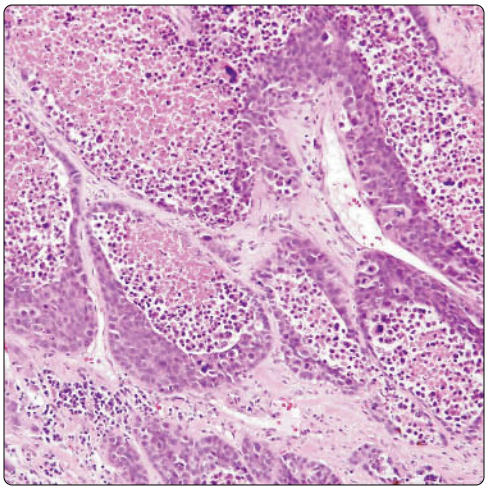

Vascular Invasion

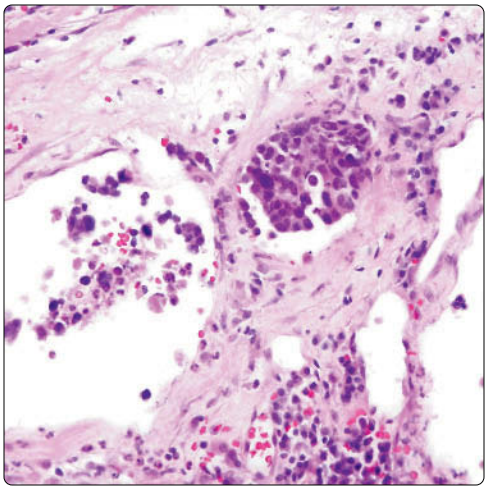

(Left) *Lymphoepithelioma-like carcinoma of the thymus (poorly differentiated, nonkeratinizing squamous cell carcinoma) shows extensive central areas of necrosis within the tumor cell islands.* **(Right)** *Focus of vascular invasion is seen in lymphoepithelioma-like carcinoma of the thymus. Vascular invasion is a common finding in these tumors and accounts in part for the highly aggressive clinical behavior of these neoplasms when arising in the thymus.*

Desmoplastic Stroma

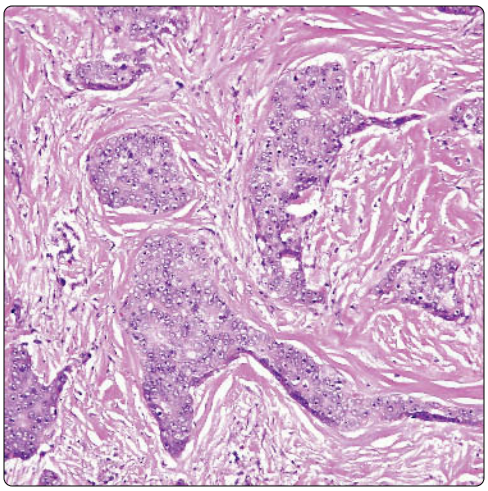

Island of Primitive Cells

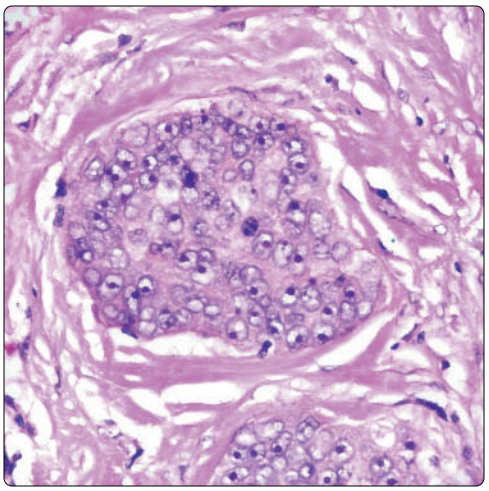

(Left) *Lymphoepithelioma-like carcinoma of the thymus shows islands of tumor cells surrounded by a paucicellular desmoplastic stroma. Not all lymphoepithelioma-like carcinomas of the thymus contain an abundant lymphoid infiltrate; the diagnosis is established based on the cytology of the tumor cells.* **(Right)** *High magnification shows a tumor cell island in lymphoepithelioma-like carcinoma of the thymus. Notice the absence of dense lymphoid stromal infiltrate.*

Anaplastic Carcinoma

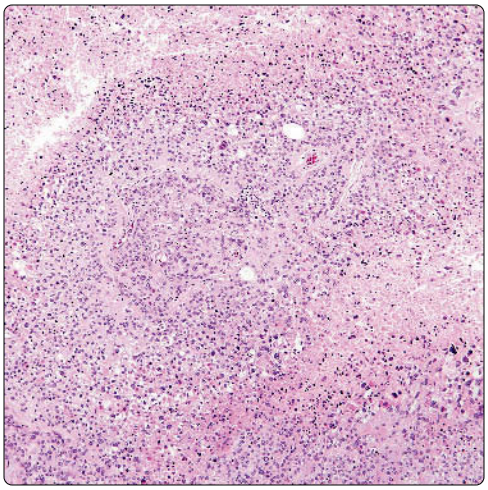

Anaplastic Carcinoma

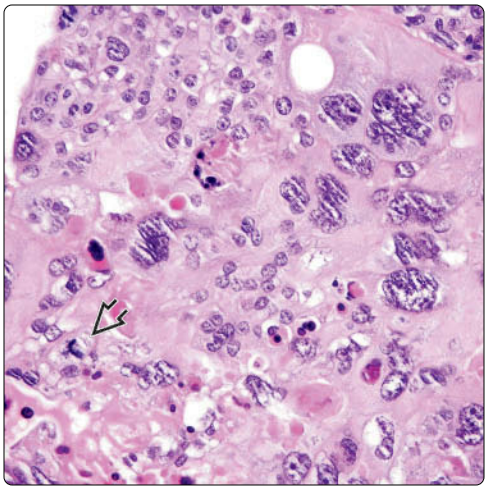

(Left) *Anaplastic carcinoma of the thymus shows sheets of large atypical tumor cells associated with extensive areas of tumor necrosis. No recognizable architecture is appreciated on scanning magnification.* **(Right)** *High magnification of anaplastic carcinoma of the thymus shows bizarre giant tumor cells located toward the center of the field surrounded by smaller, atypical tumor cells. Notice the tripolar mitosis.*

Bizarre Tumor Cells

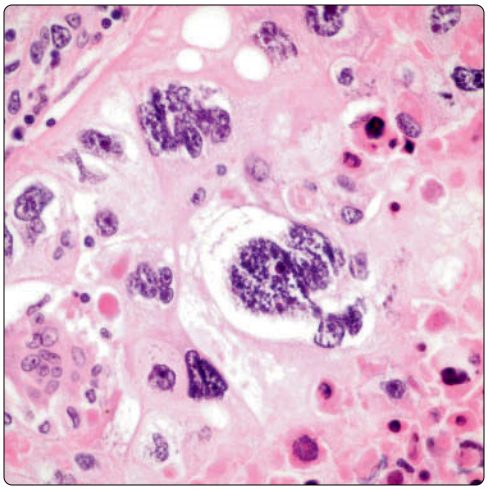

Bizarre Tumor Cells

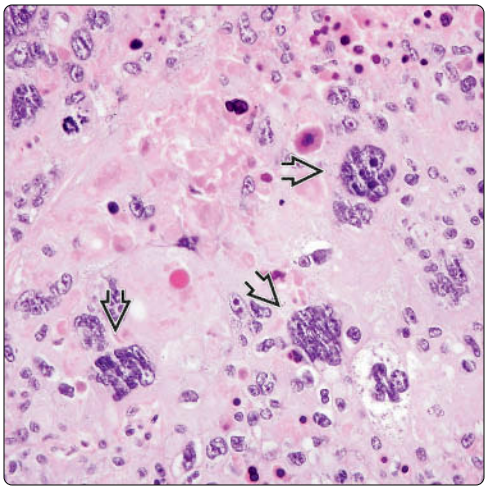

(Left) *High magnification of anaplastic carcinoma of the thymus shows bizarre pleomorphic and multinucleated tumor cells admixed with abundant necrotic and apoptotic cells.* **(Right)** *Anaplastic carcinoma of the thymus shows sheets of atypical tumor cells with scattered large, multinucleated and multilobated anaplastic tumor cells. Notice the total absence of organization or other features of differentiation. Tumors like this can resemble pleomorphic sarcomas.*

Multinucleated Tumor Cells

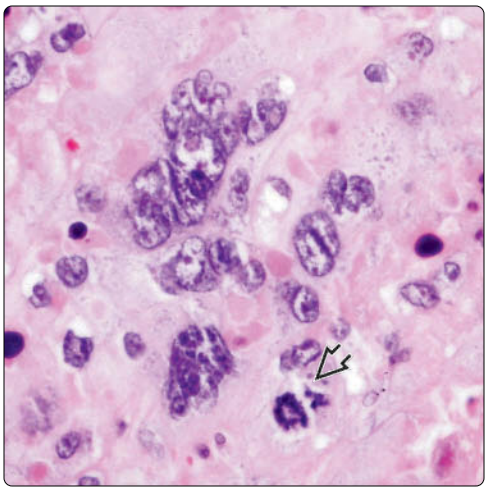

Pleomorphic Tumor Cells

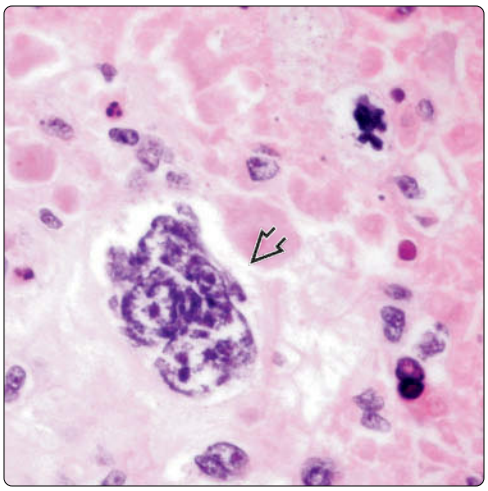

(Left) *High magnification of anaplastic carcinoma of the thymus shows characteristic bizarre, multilobated and multinucleated tumor cells. Notice abnormal mitosis.* **(Right)** *High magnification of a bizarre pleomorphic tumor cell in anaplastic carcinoma of the thymus shows multiple nuclei with prominent nucleoli and ill-defined cell borders. Notice the extensive areas of necrosis surrounding the multinucleated tumor cell.*

AE1/AE3 Cytokeratin Immunostaining

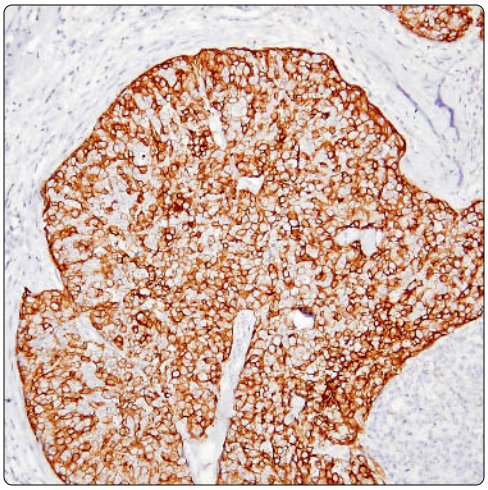

CD117 Immunostaining

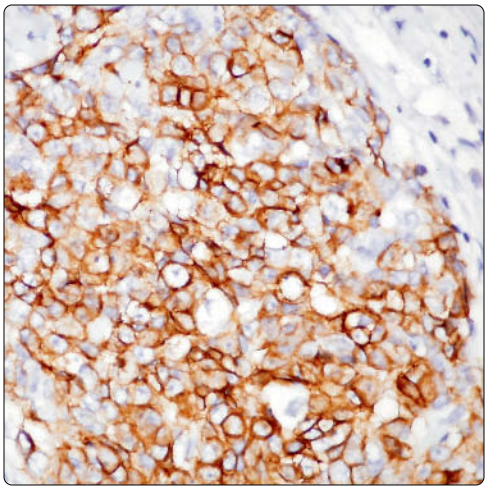

(Left) *Immunohistochemical stain for broad-spectrum cytokeratin AE1/AE3 in lymphoepithelioma-like carcinoma of the thymus shows strong staining in an island of tumor cells.* **(Right)** *Immunohistochemical staining for CD117 in primary thymic carcinoma, lymphoepithelioma-like type, shows strong membrane staining of the tumor cells for this antigen. This finding is encountered mostly in thymic tumors of squamous cell lineage.*

CD5 Immunostaining

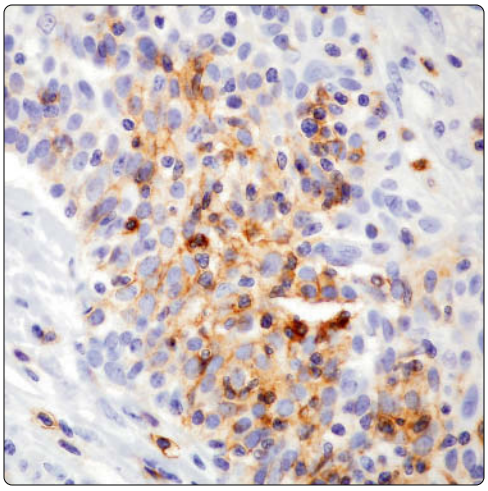

MOC-31 Immunostaining

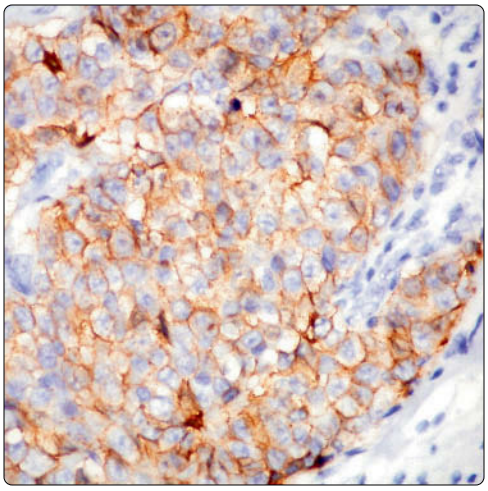

(Left) *Immunohistochemical staining of thymic carcinoma with CD5 shows focal membrane and cytoplasmic staining in some of the tumor cells. Not all types of thymic carcinoma stain for this marker, and many other types of nonthymic cancers can be positive as well.* **(Right)** *Immunohistochemical staining for MOC-31, an epithelium-associated marker, in poorly differentiated thymic carcinoma shows faint staining in a cluster of tumor cells.*

CD99 Immunostaining

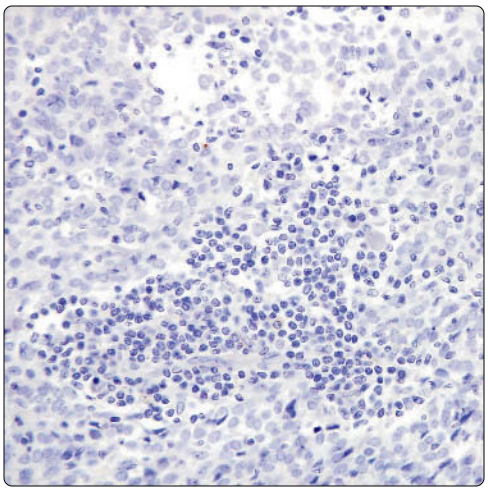

CD20 Immunostaining

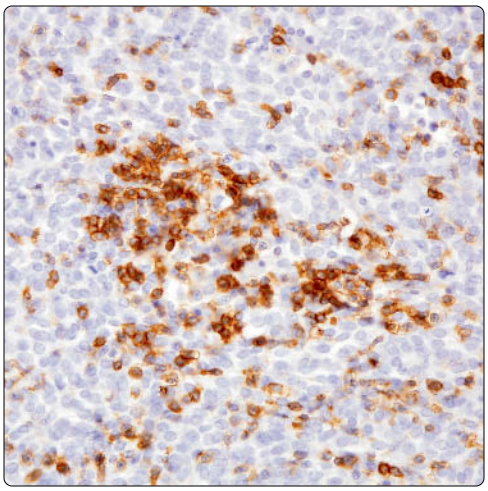

(Left) *Immunohistochemical staining for CD99 in poorly differentiated thymic carcinoma shows complete absence of reactivity in the small lymphocytes admixed with the tumor cells for this marker. CD99 is a marker of immature T lymphoblasts commonly seen in thymomas.* **(Right)** *Immunohistochemical staining for CD20 in poorly differentiated thymic carcinoma shows numerous positive small lymphocytes in clusters and scattered singly within the malignant thymic epithelial cell population.*

Neuroendocrine Carcinomas of Thymus

KEY FACTS

TERMINOLOGY

- Synonyms: Carcinoid tumor, atypical carcinoid, small cell carcinoma
- Malignant neoplasms that range from low- to high-grade malignancies

CLINICAL ISSUES

- Incidence
  - Thymic neuroendocrine carcinomas represent ~ 5% of all mediastinal tumors
  - Can occur at any age
- Symptoms
  - Paraneoplastic syndromes
  - Multiple endocrine neoplasia type II
  - Cushing syndrome
- Prognosis depends on grade and surgical stage of neoplasm at time of diagnosis
  - Well-differentiated neuroendocrine carcinoma: 5-year survival ~ 50%
  - Moderately differentiated neuroendocrine carcinoma: 5-year survival ~ 25%
  - Poorly differentiated neuroendocrine carcinoma: 5-year survival 0%
- Treatment
  - Complete surgical resection
  - Surgical resection followed by chemotherapy in higher grade tumors

TOP DIFFERENTIAL DIAGNOSES

- Paraganglioma
- Ectopic parathyroid tumor
- Thymic carcinoma

DIAGNOSTIC CHECKLIST

- Nesting growth pattern
- Mitotic activity
- Presence of necrosis

Thymic Remnants | **Low-Grade Neuroendocrine Carcinoma**

(Left) *Low-power view of a neuroendocrine carcinoma of the thymus is shown. Note the presence of remnants of thymic tissue ⇨ clearly separated from the tumor ⇨.* **(Right)** *Well-differentiated neuroendocrine carcinoma (carcinoid tumor) shows a cellular proliferation arranged in cords and nests.*

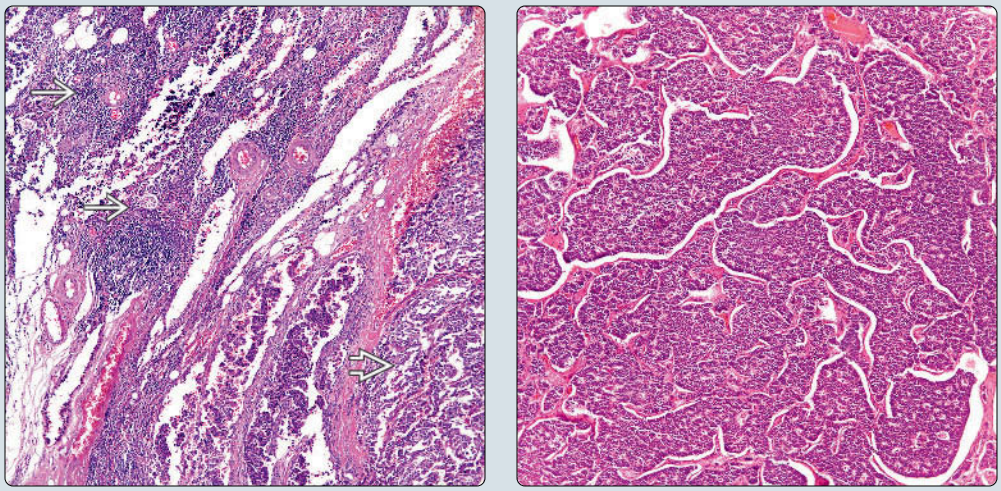

Pseudoglandular Pattern | **Low-Grade Neuroendocrine Carcinoma**

(Left) *Low-grade neuroendocrine carcinoma shows areas of a pseudoglandular pattern. However, the tumor does not show necrosis or increased mitotic activity.* **(Right)** *High-power magnification of a well-differentiated neuroendocrine carcinoma (carcinoid tumor) shows a homogeneous cellular proliferation without nuclear atypia or mitotic activity.*

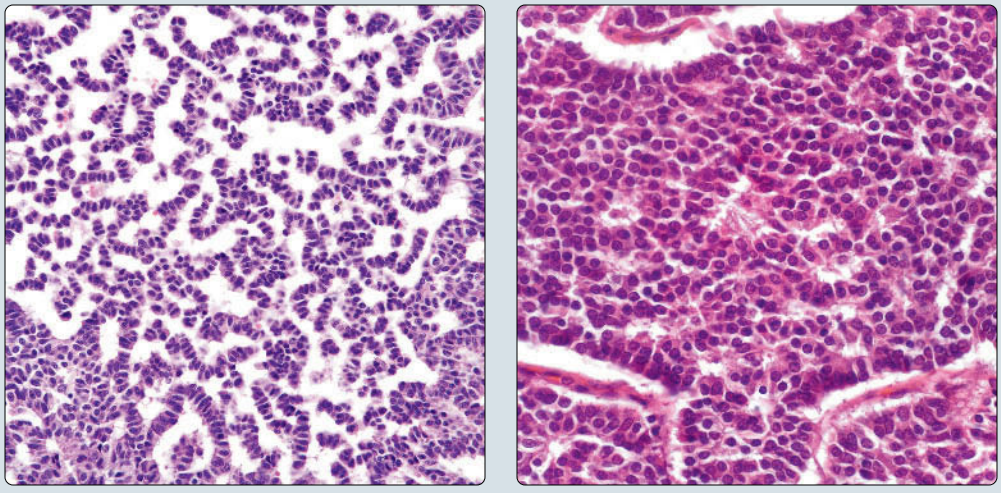

TERMINOLOGY

Abbreviations

- Well-differentiated neuroendocrine carcinoma (WDNECa)
- Moderately differentiated neuroendocrine carcinoma (MDNECa)
- Poorly differentiated neuroendocrine carcinoma (PDNECa)

Synonyms

- Carcinoid tumor, atypical carcinoid, small cell carcinoma

Definitions

- Malignant neuroendocrine neoplasms that range from low- to high-grade malignancies

ETIOLOGY/PATHOGENESIS

Etiology

- Probably originating from Kulchitsky cells

CLINICAL ISSUES

Epidemiology

- Incidence
  - Thymic NECas represent ~ 5% of all mediastinal tumors
- Age
  - NECas can occur in any age group
- Sex
  - No specific gender predilection for thymic NECas

Site

- Anterior mediastinum

Presentation

- Chest pain
- Cough
- Dyspnea
- Cushing syndrome
- Multiple endocrine neoplasia type II
- Proximal myopathy
- Polyarthropathy
- Peripheral neuropathy
- Incomplete Sipple syndrome
- Antidiuretic hormone secretion
- Eaton-Lambert syndrome
- Hypertrophic osteoarthropathy
- Adrenocorticotropic hormone secretion (ACTH)
- Paraneoplastic syndromes

Treatment

- Complete surgical resection
- Depending on grade of tumor
  - Surgical resection followed by chemotherapy
  - In poorly differentiated tumors (small cell carcinoma): Chemotherapy

Prognosis

- Depends on grade and surgical stage of neoplasm at time of diagnosis
  - WDNECa: 5-year survival ~ 50%
  - MDNECa: 5-year survival ~ 25%
  - PDNECa: 5-year survival 0%
    - Association of ACTH production and NECa in young patients may be followed by more aggressive behavior

MACROSCOPIC

General Features

- Tan to brown color
- Soft consistency
- Well-defined, but not encapsulated, tumor
- Areas of hemorrhage &/or necrosis may be present
- Minority of cases will present with cystic changes

Sections to Be Submitted

- Important to document transitional areas of tumor and normal thymus
- Important to document presence of necrosis &/or hemorrhage

Size

- Variable size from few cm to > 10 cm in diameter

MICROSCOPIC

Histologic Features

- Nesting, spindle cell, oncocytic, or angiomatoid growth pattern
- Pigmented, cystic

DIFFERENTIAL DIAGNOSIS

Paraganglioma

- Paraganglioma and NECa may share similar immunophenotype in terms of neuroendocrine markers
- Usually negative for keratin markers
- May show presence of prominent nuclear atypia, but mitotic activity is rare

Ectopic Parathyroid Tumor

- May also share similar immunophenotype
- May show presence of chief and oncocytic cells
- Generally shows positive staining for PTH
- Shows positive staining for PAS

Thymoma

- May show areas that histologically mimic neuroendocrine tumor
- Generally negative for neuroendocrine markers

Thymic Carcinoma

- Usually negative for neuroendocrine markers
- Histology of thymic carcinoma is different from neuroendocrine pattern seen in neuroendocrine tumors

Metastatic Neuroendocrine Carcinoma

- Clinical history important in arriving at specific site of origin
- Use of immunohistochemical studies in some cases may provide clue for site of origin

DIAGNOSTIC CHECKLIST

Clinically Relevant Pathologic Features

- Nuclear features, mitotic rate, invasive pattern

Immunohistochemistry

Antibody	Reactivity	Staining Pattern	Comment
CK-HMW-NOS	Positive	Cytoplasmic	Not specific for neuroendocrine tumors
CK-LMW-NOS	Positive	Cytoplasmic	Not specific for neuroendocrine tumors
Chromogranin-A	Positive	Cytoplasmic	
Synaptophysin	Positive	Cytoplasmic	
CD56	Positive	Cytoplasmic	
p53	Positive	Nuclear & cytoplasmic	In < 5% of cases
S100	Positive	Nuclear & cytoplasmic	In some cases
PTH	Positive	Cytoplasmic	Focal in some cases
Calcitonin	Positive	Cytoplasmic	Focal in some cases
TTF-1	Positive	Nuclear	In ~ 15% of cases
pax-8	Positive	Nuclear	In ~ 30% of cases
Ki-67	Positive	Nuclear	Varies depending on grade of tumor
GATA3	Negative		
NAPSIN-A	Negative		

Classification of Thymic Neuroendocrine Carcinomas

Traditional Classification	WHO Classification	Moran and Suster Classification
Carcinoid	Well-differentiated neuroendocrine carcinoma	Well-differentiated neuroendocrine carcinoma (low grade)
Atypical carcinoid	Well-differentiated neuroendocrine carcinoma	Moderately differentiated neuroendocrine carcinoma (intermediate grade)
Small cell carcinoma	Poorly differentiated neuroendocrine carcinoma	Poorly differentiated neuroendocrine carcinoma (high grade)

Histological Classification of Thymic Neuroendocrine Carcinomas*

Tumor Type	Histological Feature
Well-differentiated neuroendocrine carcinoma	Well-developed neuroendocrine pattern
	Mild cellular atypia
	0-3 mitotic figures x 10 HPF
	Only focal necrosis
Moderately differentiated neuroendocrine carcinoma	Focal preservation of neuroendocrine pattern
	Mixture of nesting and diffuse growth patterns
	Moderate cellular atypia
	4-10 mitotic figures x 10 HPF
	Necrosis in form of comedo-like necrosis
Poorly differentiated neuroendocrine carcinoma	Complete loss of neuroendocrine growth pattern
	Marked cellular atypia
	> 10 mitotic figures x 10 HPF
	Necrosis

**On resected specimens.*

Pathologic Interpretation Pearls

- Nesting growth pattern, mitotic activity, necrosis

SELECTED REFERENCES

1. Weissferdt A et al: Comparative immunohistochemical analysis of pulmonary and thymic neuroendocrine carcinomas using PAX8 and TTF-1. Mod Pathol. 26(12):1554-60, 2013
2. Moran CA et al: Neuroendocrine carcinomas (carcinoid tumor) of the thymus. A clinicopathologic analysis of 80 cases. Am J Clin Pathol. 114(1):100-10, 2000

Low-Grade Neuroendocrine Carcinoma



Spindle Cell Neuroendocrine Carcinoma

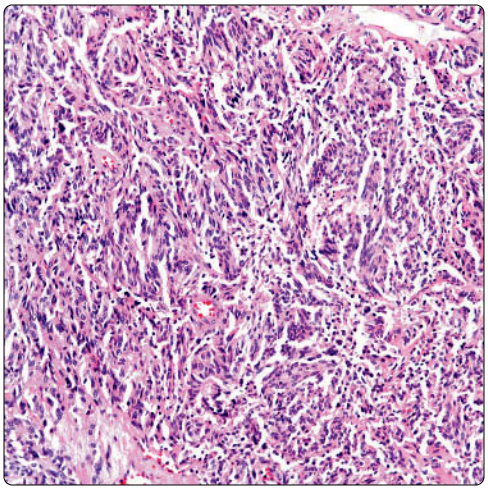

(Left) *Well-differentiated neuroendocrine carcinoma shows a well-organized pattern of growth without the presence of necrosis. Scattered rosettes are present in this tumor.* **(Right)** *Well-differentiated neuroendocrine carcinoma with spindle cell features is shown. This histology is also commonly encountered in these tumors. The presence of mitosis and necrosis are important to determine the grade of the tumor.*

Mucinous Neuroendocrine Carcinoma

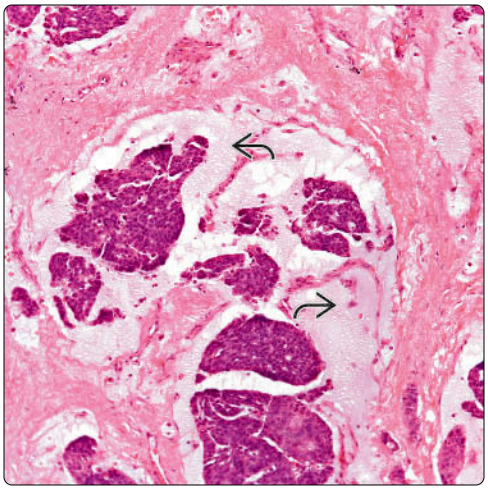

Cystic Neuroendocrine Carcinoma

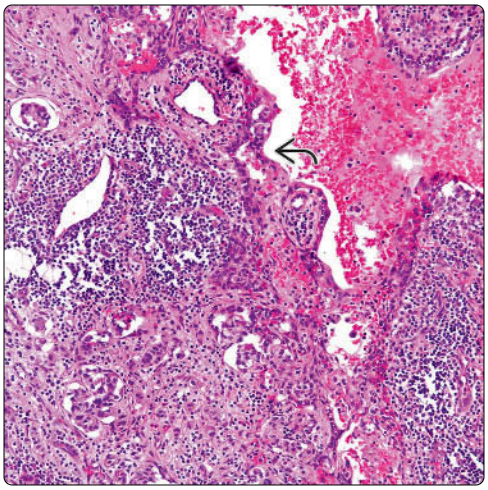

(Left) *Well-differentiated neuroendocrine carcinoma is shown with prominent mucinous changes in the stroma. This feature is unusual in these tumors in a mediastinal location.* **(Right)** *Well-differentiated neuroendocrine carcinoma with prominent cystic changes similar to those described in multilocular thymic cysts is shown. The presence of cystic neuroendocrine carcinomas in the mediastinum is rare.*

Clear Cell Neuroendocrine Carcinoma

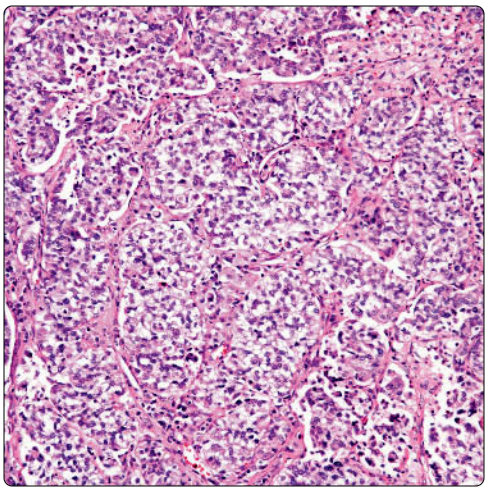

Angiomatoid Neuroendocrine Carcinoma

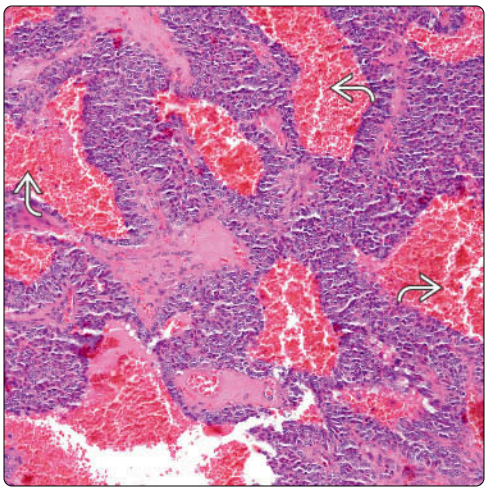

(Left) *Well-differentiated neuroendocrine carcinoma shows striking clear cell features. Still, the tumor shows a subtle nesting pattern of growth.* **(Right)** *Well-differentiated neuroendocrine carcinoma is shown with the presence of ectatic spaces containing blood and mimicking a vascular neoplasm. This is the so-called angiomatoid variant of neuroendocrine carcinoma.*

Imaging and Gross Thymic Neuroendocrine Carcinoma

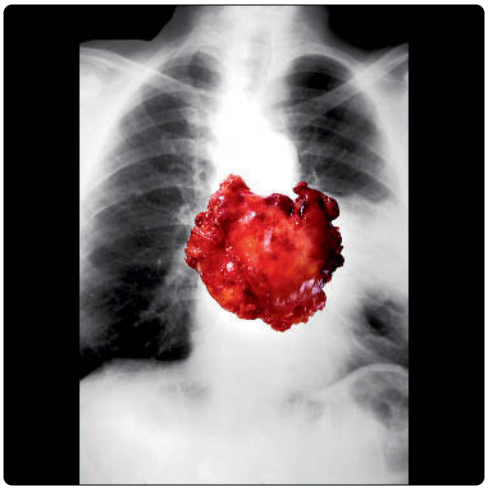

Thymic Neuroendocrine Carcinoma

(Left) *Thoracic radiograph shows an anterior mediastinal tumor. Superimposed is the actual specimen resected from this patient recapitulating the actual radiological imaging.* **(Right)** *Gross photograph shows the bisected anterior mediastinal tumor in the previously displayed radiograph. Note the presence of hemorrhagic areas as well as focal necrotic areas, which are common findings in these tumors.*

Intermediate-Grade Neuroendocrine Carcinoma

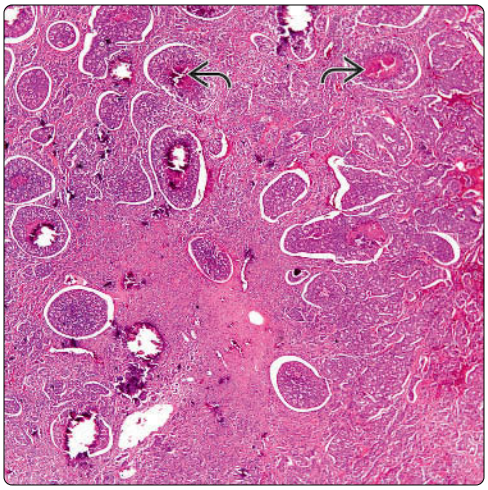

Intermediate-Grade Neuroendocrine Carcinoma

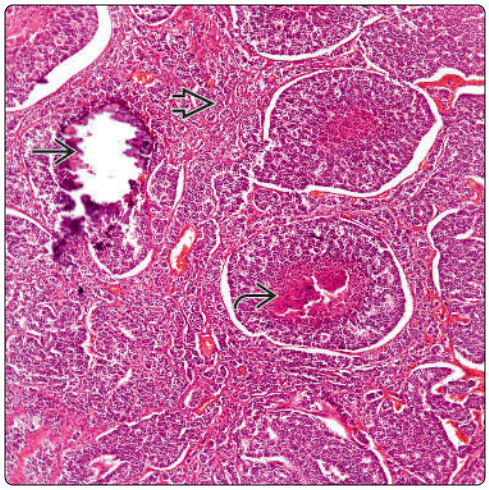

(Left) *Low-power view of moderately differentiated neuroendocrine carcinoma (atypical carcinoid) shows evidence of comedo-like necrosis. This feature by itself is diagnostic of a moderately differentiated tumor.* **(Right)** *Moderately differentiated neuroendocrine carcinoma (atypical carcinoid) shows comedo-like necrosis as well as central calcification. In addition, note the presence of a more diffuse growth pattern.*

Oncocytic Intermediate-Grade Neuroendocrine Carcinoma

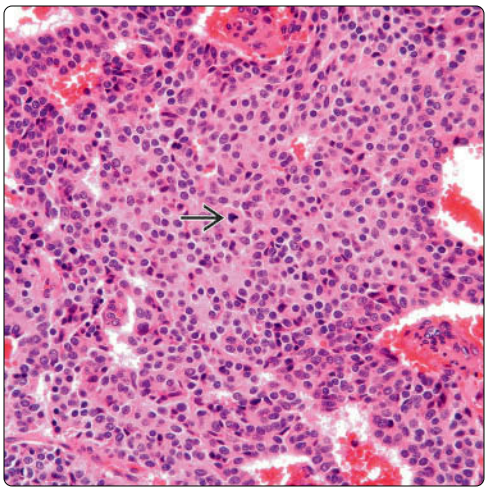

Spindle Cell Intermediate-Grade Neuroendocrine Carcinoma

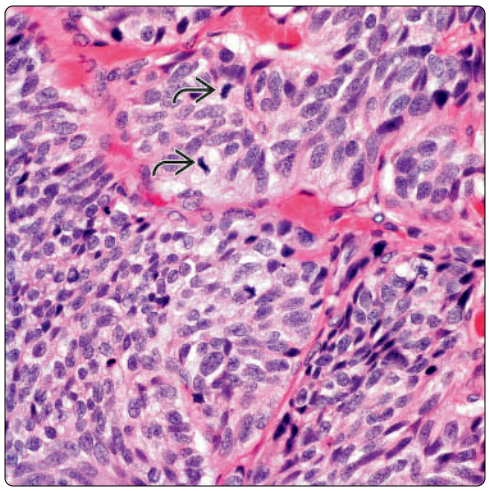

(Left) *Moderately differentiated neuroendocrine carcinoma (atypical carcinoid) shows oncocytic changes and mitotic activity. The presence of mitotic activity is an important feature for the grading of these tumors.* **(Right)** *Spindle cell moderately differentiated neuroendocrine carcinoma shows numerous mitotic figures. A moderately differentiated tumor may be seen in any histological subtype.*

Mucinous Neuroendocrine Carcinoma

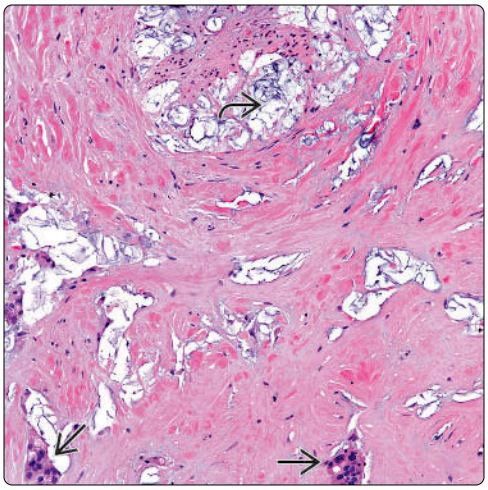

Sclerotic Neuroendocrine Carcinoma



(Left) *Mucinous neuroendocrine carcinoma is shown in which the cellular component is rather scant. The tumor is composed essentially of mucinous material and fibroconnective tissue. Note the presence of clusters of neuroendocrine cells.* **(Right)** *Neuroendocrine carcinoma is shown with prominent sclerotic changes. These changes may be seen in other neuroendocrine mediastinal tumors as well.*

Intermediate-Grade Neuroendocrine Carcinoma

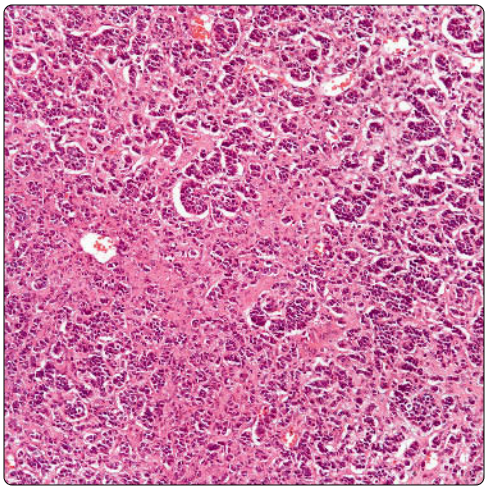

Chromogranin Stain

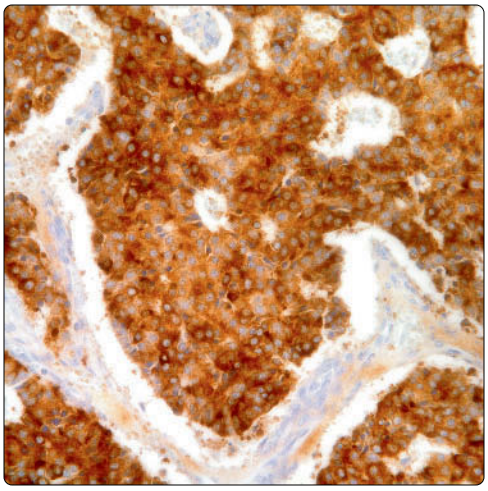

(Left) *Moderately differentiated neuroendocrine carcinoma (atypical carcinoid) shows a loss of the organoid pattern, and the tumor shows a disorganized pattern of growth.* **(Right)** *Chromogranin-A shows strong positive staining in neuroendocrine carcinomas; thus, it is a useful marker for these tumors. However, it is important to keep in mind that chromogranin staining may also be positive in other neuroendocrine tumors.*

High-Grade Neuroendocrine Carcinoma

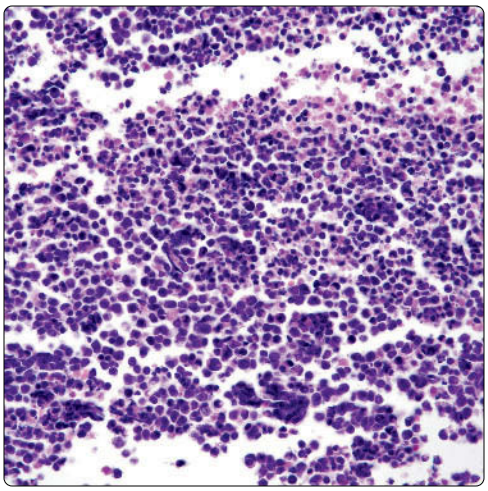

High-Grade Neuroendocrine Carcinoma

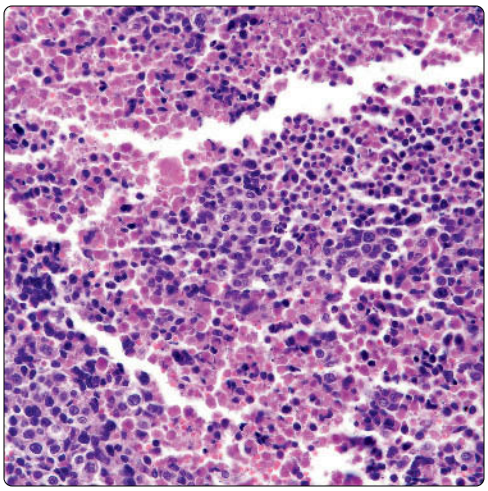

(Left) *High-grade neuroendocrine carcinoma, small cell type, shows a sheets of malignant cells. Subtle necrosis and nuclear molding are present, the same as when these tumors occur in the lung.* **(Right)** *High-grade neuroendocrine carcinoma, small cell type, shows more prominent areas of necrosis admixed with malignant cells embedded in the necrotic material.*

Mediastinal Teratoma

KEY FACTS

ETIOLOGY/PATHOGENESIS

- Some authors have proposed possibility of ectopically misplaced germ cells

CLINICAL ISSUES

- Incidence
  - Most common germ cell tumors in anterior mediastinum
  - ~ 45% of all mediastinal germ cell tumors
  - More common in young individuals
  - Most common germ cell tumor in children
  - May be more common in male patients (~ 2:1)
  - Teratomas with malignant component may be more common in male patients
- Symptoms
  - Precocious puberty
  - Hematologic conditions
  - Chest pain
  - Dyspnea
  - Asymptomatic

IMAGING

- Calcifications in 20-40% of cases
- Fat-fluid levels are considered classic for teratomas

MACROSCOPIC

- Cyst and solid tumors
- Presence of hair or teeth
- Presence of sebaceous material
- Sampling is of utmost importance

MICROSCOPIC

- Mature elements derived from 3 germ cell layers
  - Mature teratoma
  - Immature teratoma
  - Teratomas with malignant component
  - Determine percentage of each element

Glial Tissue

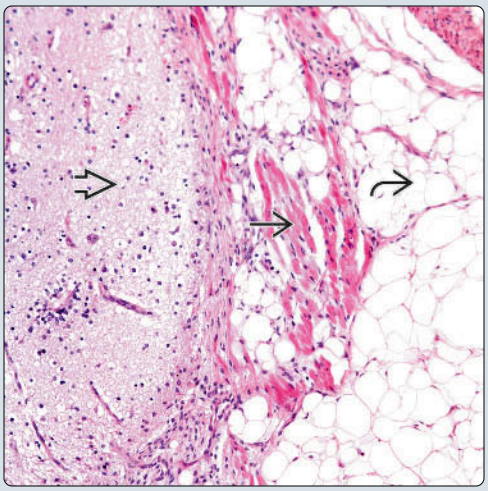

Mature Epithelium

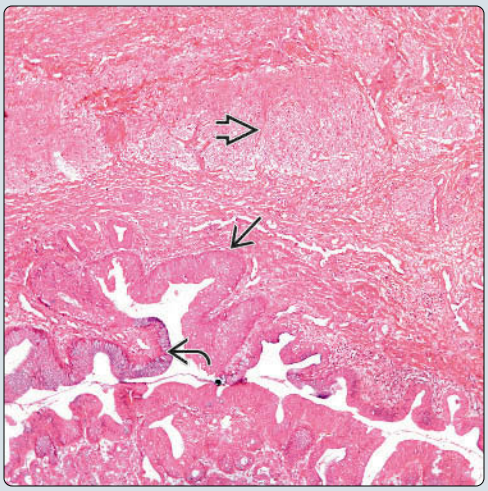

(Left) *Mediastinal teratoma shows mature glial tissue adjacent to fibers of skeletal muscle and mature adipose tissue. Note that all tissues are mature.* **(Right)** *Mediastinal mature teratoma is shown with presence of cystic structures lined by squamous and glandular epithelium. Mature glial tissue is also present.*

Enteric Glands

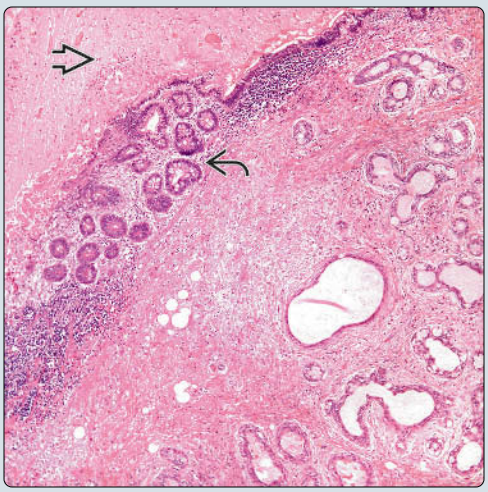

Mature Cartilage

(Left) *Mature teratoma is shown with focal necrotic area. In addition, the tumor shows mature enteric glands and other cystic structures lined by mature epithelium.* **(Right)** *Mature teratomas are shown with presence of cartilage. Even though cartilage is a common component of teratomas, it is generally not extensive and may show focal cellular atypia.*

TERMINOLOGY

Definitions

- Neoplasm showing tissues derived from 3 germinal layers
  - At least 2 must be present

ETIOLOGY/PATHOGENESIS

Etiology

- Although unequivocal explanation for occurrence of mediastinal germ cell tumors is not available, some authors have proposed possibility of ectopically misplaced germ cells

CLINICAL ISSUES

Epidemiology

- Incidence
  - Most common germ cell tumors in anterior mediastinum
  - ~ 45% of all mediastinal germ cell tumors
- Age
  - More common in young individuals
  - Teratomas are most common germ cell tumor in children
- Sex
  - Mature teratomas may be more common in male patients (~ 2:1)
  - Teratomas with malignant component may be more common in male patients

Site

- Teratomas more common in anterior mediastinum
- Posterior mediastinum may be site in unusual cases

Presentation

- Cough
- Chest pain
- Dyspnea
- Hemoptysis
- Klinefelter syndrome
- Hematologic conditions
- Precocious puberty
- Asymptomatic

Treatment

- Surgical approaches
  - Mature teratomas: Complete surgical resection
  - Immature teratomas: Chemotherapy may be used
  - Teratomas with another malignant component: Chemotherapy

Prognosis

- Mature teratomas: Prognosis is good in majority of cases
- Immature teratomas: Depends on clinical stage
- Teratomas with another malignant component: Clinical stage, type, and percentage of malignant component are important parameters to determine prognosis

IMAGING

General Features

- Calcification in 20-40% of cases
- Fat-fluid levels are considered classic for teratomas

MACROSCOPIC

General Features

- Cyst and solid tumors
- Presence of hair or teeth
- Presence of sebaceous material

Sections to Be Submitted

- Sections from solid and cystic areas must be evaluated
- Reasonable number of sections needs to be submitted for histological evaluation

Size

- Vary in size from few centimeters to > 15 cm in diameter

MICROSCOPIC

Histologic Features

- Mature teratoma
  - Mature elements derived from 3 germ cell layers
  - Pancreatic tissue is commonly seen
  - Presence of skin adnexa is commonly seen
- Immature teratoma
  - Presence of neural tubules
  - Presence of rosettes
- Teratomas with malignant component
  - Seminoma
  - Yolk sac tumor
  - Embryonal carcinoma
  - Choriocarcinoma
  - Another malignant epithelial component: Adenocarcinoma, etc.
- Presence of malignant mesenchymal component
  - Angiosarcoma
  - Rhabdomyosarcoma
  - Osteosarcoma
  - Chondrosarcoma

Predominant Pattern/Injury Type

- Biphasic

Predominant Cell/Compartment Type

- Germ, nonseminomatous

DIFFERENTIAL DIAGNOSIS

Sarcoma

- Pure malignant mesenchymal neoplasms (sarcomas) do not show other type of epithelial differentiation

Carcinoma

- Strictly malignant epithelial tumors; do not show other germinal layer components

Other Germ Cell Tumor

- Presence of at least 2 different germ cell layers is diagnostic of teratoma

DIAGNOSTIC CHECKLIST

Clinically Relevant Pathologic Features

- Gross appearance

Immunohistochemistry

Antibody	Reactivity	Staining Pattern	Comment
S100	Positive	Nuclear & cytoplasmic	In neural component of mature and immature teratomas
NSE	Positive	Cytoplasmic	In neural or epithelial components
GFAP	Positive	Cytoplasmic	In neural components
CK-PAN	Positive	Cytoplasmic	In epithelial components
Desmin	Positive	Cytoplasmic	In muscle components
MYOD1	Positive	Cytoplasmic	Rhabdomyoblastic differentiation
Myoglobin	Positive	Cytoplasmic	Rhabdomyoblastic differentiation
FVIIIRAg	Positive	Cytoplasmic	Vascular differentiation
CD31	Positive	Cytoplasmic	Vascular differentiation
α-fetoprotein	Positive	Cytoplasmic	If yolk sac or embryonal carcinoma is present
PLAP	Positive	Cytoplasmic	If seminoma is present
HCG	Positive	Cytoplasmic	If choriocarcinoma is present
Chromogranin-A	Positive	Cytoplasmic	If neuroendocrine elements are present
Synaptophysin	Positive	Cytoplasmic	If neuroendocrine or neural elements are present
CD34	Positive	Cytoplasmic	If vascular elements are present
CK5/6	Positive	Cytoplasmic	In squamous elements
p63	Positive	Nuclear	In squamous elements
CEA-M	Positive	Cytoplasmic	In carcinomatous as well as normal glandular elements
PLACEN_LACT	Positive	Cytoplasmic	Germ cell components
CD30	Positive	Golgi zone	If embryonal carcinoma is present
CD117	Positive	Nuclear & cytoplasmic	In seminomatous components

Histological Classification of Mediastinal Teratomas

Tumor	Definition
Mature teratoma	Only mature elements representing different germ layers
Immature teratoma	Mature elements admixed with neural tubules &/or rosettes
Teratoma with malignant component	
Type I	Teratomas with another germ cell component (seminoma, yolk sac tumor, embryonal carcinoma, choriocarcinoma)
Type II	Teratomas with malignant epithelial non-germ cell component (squamous cell carcinoma, adenocarcinoma, small cell carcinoma, etc.)
Type III	Teratoma with malignant mesenchymal component (rhabdomyosarcoma, osteosarcoma, angiosarcoma, etc.)
Type IV	Teratoma with any combination of above
Mature teratomas	Represent ~ 65% of all cases
Immature teratomas	Represent ~ 5% of all cases
Teratomas with malignant component	Represent ~ 30% of all cases

Pathologic Interpretation Pearls

- Presence of following features should help in diagnosis
  - Tissues from different germ cell layers
  - Neural tubules &/or rosettes
  - Malignant mesenchymal components
- Determine percentage of different components: Mature, immature, and malignant

SELECTED REFERENCES

1. Barksdale EM Jr et al: Teratomas in infants and children. Curr Opin Pediatr. 21(3):344-9, 2009
2. El Mesbahi O et al: Chemotherapy in patients with teratoma with malignant transformation. Eur Urol. 51(5):1306-11; discussion 1311-2, 2007
3. Malagón HD et al: Germ cell tumors with sarcomatous components: a clinicopathologic and immunohistochemical study of 46 cases. Am J Surg Pathol. 31(9):1356-62, 2007
4. Romagnani E et al: Mediastinal mature teratoma with an immature component–what about the treatment?. Ann Oncol. 17(10):1602-4, 2006
5. Moeller KH et al: Mediastinal mature teratoma: imaging features. AJR Am J Roentgenol. 169(4):985-90, 1997
6. Moran CA et al: Primary germ cell tumors of the mediastinum: I. Analysis of 322 cases with special emphasis on teratomatous lesions and a proposal for histopathologic classification and clinical staging. Cancer. 80(4):681-90, 1997

Macroscopic Features

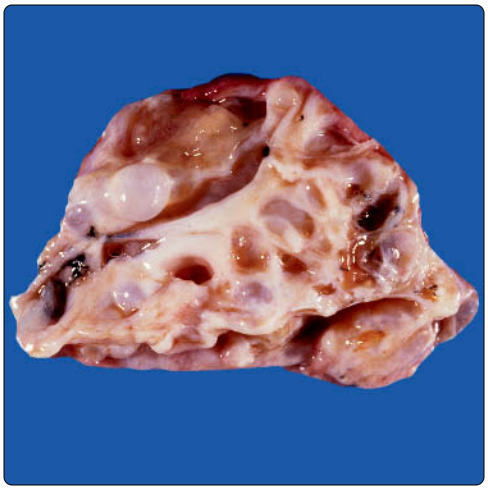

Cystic Changes

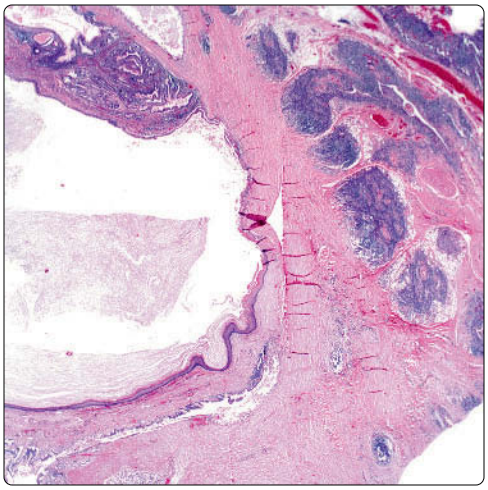

(Left) *Gross photograph shows a mediastinal teratoma. Note the presence of cystic structures admixed with solid areas. Because there are no macroscopic features to separate immature from other possible malignant components, it is very important to properly sample these tumors.* **(Right)** *Low-power view shows a mediastinal teratoma displaying cystic structures and solid areas, all of them with mature elements.*

Pancreatic Tissue

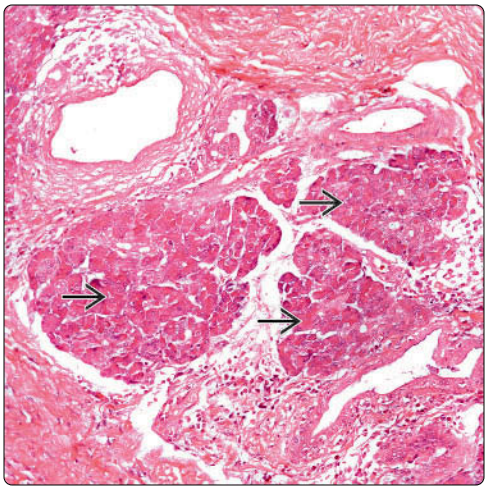

Dermal Tissue

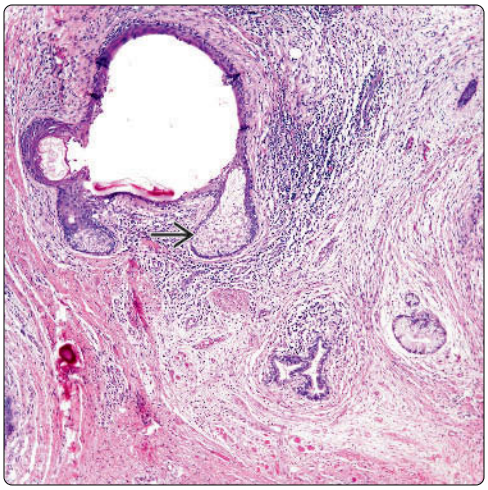

(Left) *Mature teratoma shows acinar structures compatible with pancreas. Pancreas is a common component in mediastinal teratomas, and, in some cases, it may be a functioning pancreas.* **(Right)** *Mediastinal mature teratoma shows skin appendages admixed with other mature cystic elements embedded in a fibroconnective tissue stroma. These structures are invariably present in the great majority of mature teratomas.*

Cartilage and Adipose Tissue

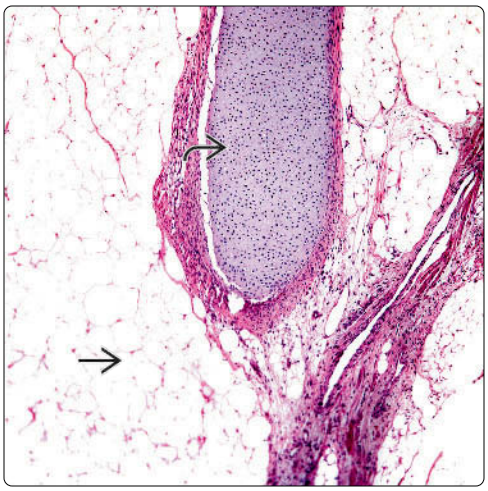

Dermal Appendages

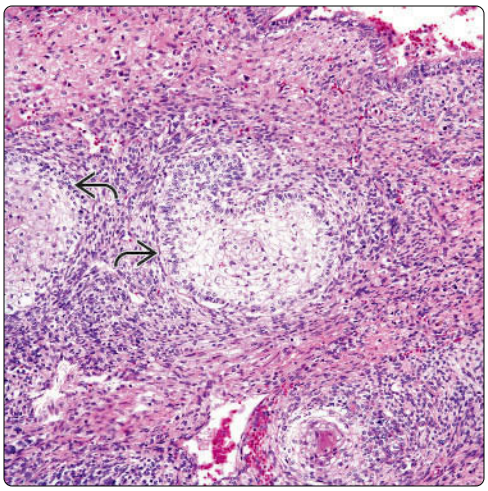

(Left) *Mature teratoma shows 2 classic mature component in these tumors: Mature cartilage and mature adipose tissue.* **(Right)** *Mature teratoma shows dense fibroconnective tissue with only focal dermal appendages. This feature is commonly seen in mature teratomas.*

Macroscopic Features

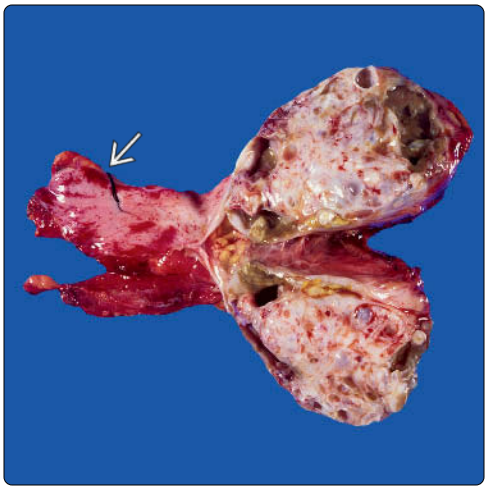

Immature Teratoma

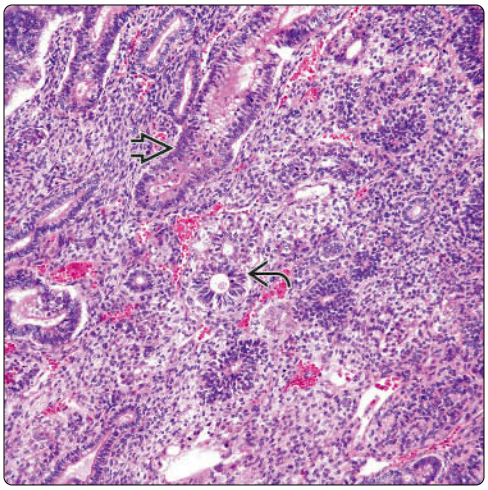

(Left) *Gross photograph shows an immature mediastinal teratoma. Although this particular tumor shows more solid than cystic areas, there is really not a way to separate mature from immature tumors. However, the presence of solid areas should be suspicious for immature or other malignant components. Note the presence of residual thymic gland.* **(Right)** *Immature teratoma shows areas of rosette formation and neurotubules embedded in an immature stromal tissue.*

Neural Structures

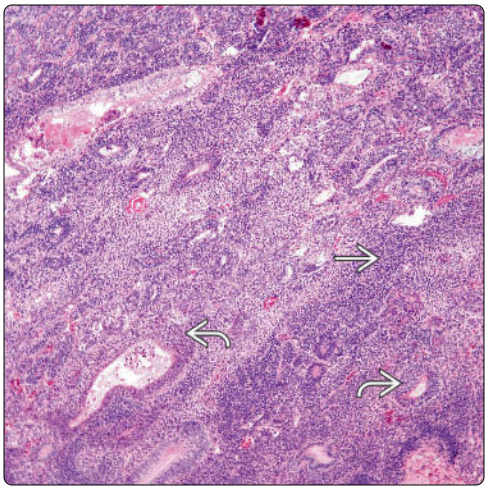

Neural Rosettes

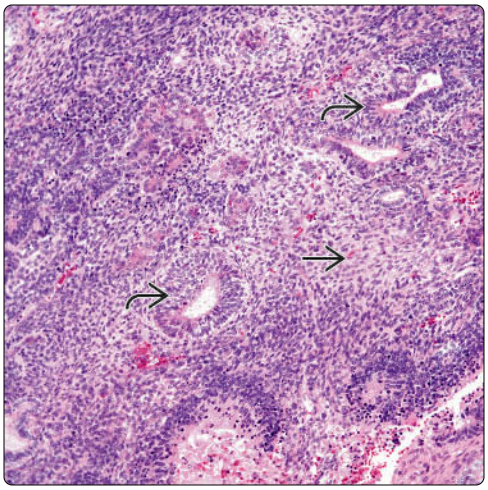

(Left) *Mediastinal immature teratoma shows prominent solid areas with only scattered tubular neural structures.* **(Right)** *Closer view shows a mediastinal immature teratoma displaying solid and classic areas of immature neural differentiation. This feature is reminiscent of that seen in cases of neuroblastoma, and often there is more cellular atypia and mitotic activity.*

Neural Rosettes and Cartilage

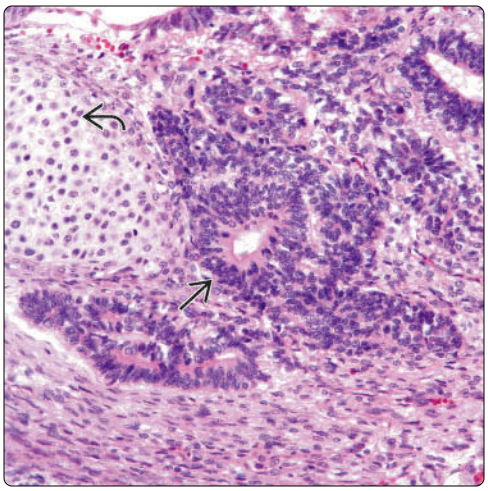

Immature Elements

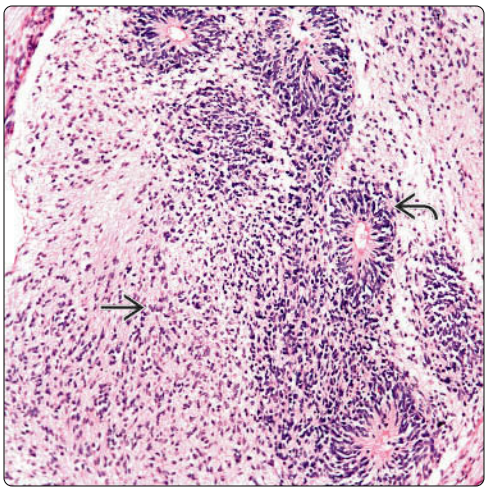

(Left) *Mediastinal immature teratoma is shown with neural rosettes admixed with cartilage. It is common to see mature and immature elements admixed with each other. Pure immature teratomas are extremely rare, if any exist at all.* **(Right)** *Solid highly atypical areas of neural tissue are shown admixed with neural rosettes. These histological features are classic for the diagnosis of immature teratoma.*

Macroscopic Features

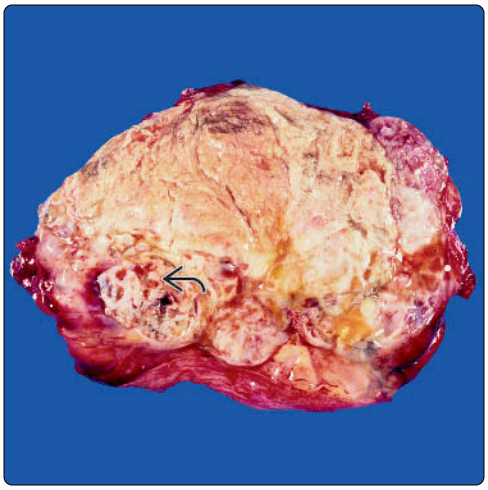

Yolk Sac Component

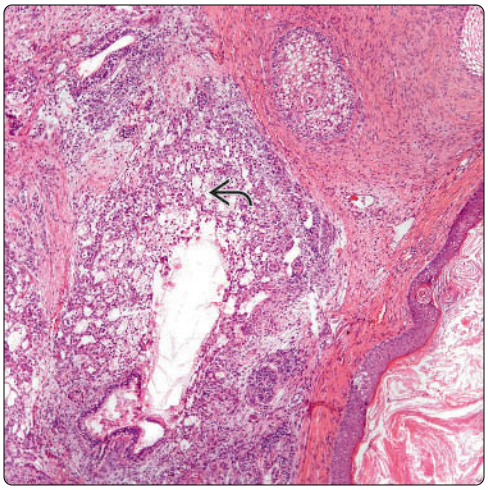

(Left) *Gross photograph shows a mediastinal teratoma with a malignant component. Once again, the presence of solid areas should raise the suspicion of a possible malignant component. Ample sampling is crucial for this diagnosis. Note that this tumor also shows cystic areas ⇨.* **(Right)** *Light microscopy shows a mediastinal teratoma with a malignant component. In this particular case, the malignant component is that of a yolk sac tumor ⇨. This corresponds to type I.*

Yolk Sac Tumor and Mature Elements

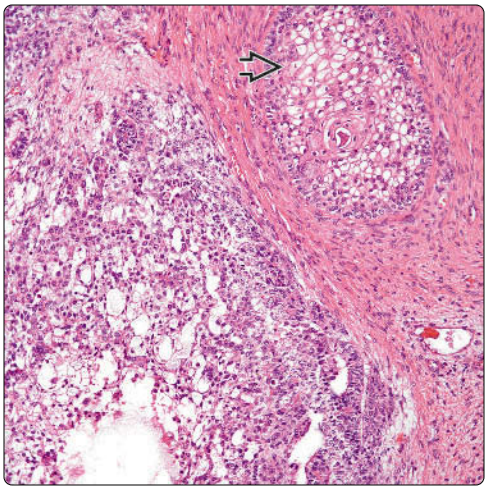

Adenocarcinoma Component

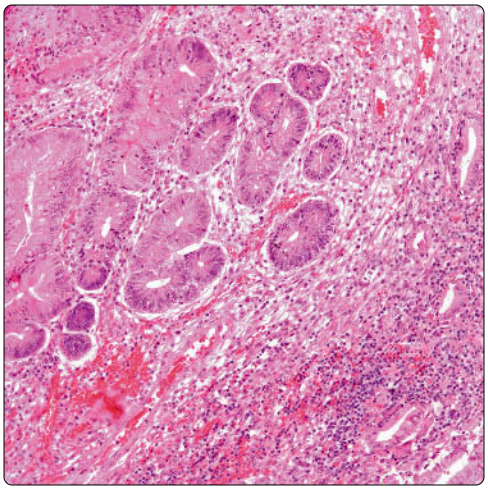

(Left) *Closer view shows the yolk sac component of this teratomatous lesion. The tumor also displays mature elements in the form of appendages ⇨. This type of teratoma corresponds to type I, which is a teratoma associated with another germ cell tumor.* **(Right)** *Mediastinal teratoma is shown with a malignant component. In this case, the malignant component is adenocarcinoma, a malignant epithelial component. This corresponds to type II.*

Angiosarcomatous Component

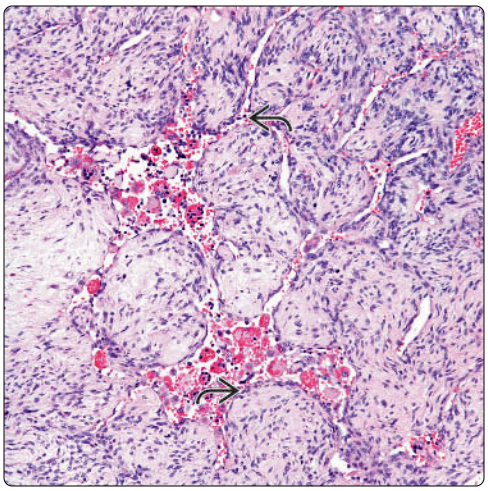

Rhabdomyoblastic Component

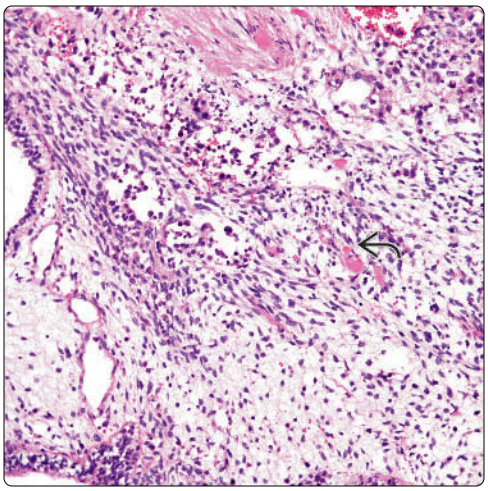

(Left) *Type III teratoma is shown with a malignant mesenchymal component. Note the anastomosing vascular channels ⇨ in keeping with angiosarcoma.* **(Right)** *Mediastinal teratoma is shown with a malignant component of type III. Note the presence of rhabdomyoblastic differentiation ⇨. In some cases, the malignant mesenchymal component may be of the undifferentiated type.*

Mediastinal Seminoma

KEY FACTS

TERMINOLOGY

- Synonym
  - Thymic seminoma

ETIOLOGY/PATHOGENESIS

- Probably misplaced germ cells in anterior mediastinum

CLINICAL ISSUES

- Incidence
  - May account for ~ 37% of all germ cell tumors
  - Majority of tumors occur in young adults aged 20-30 years
  - Almost exclusive occurrence in men
- Symptoms
  - Gynecomastia
  - Superior vena cava syndrome
  - Chest pain

MACROSCOPIC

- Large tumors
- Cystic tumor can occur in < 10% of cases

TOP DIFFERENTIAL DIAGNOSES

- Carcinoma
- Lymphoma
- Melanoma
- Thymoma
- Metastatic seminoma of testicular origin

DIAGNOSTIC CHECKLIST

- Sheets of neoplastic cells
- Inflammatory component (lymphocytes)
- Cells with clear or eosinophilic cytoplasm
- PLAP, SALL4, OCT3 positive immunohistochemical study

Macroscopic Features

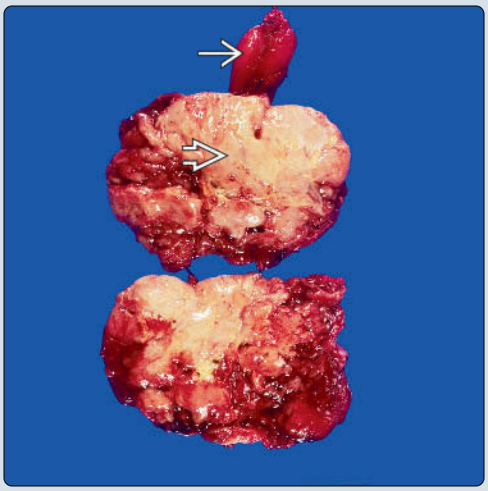

Classic Seminoma

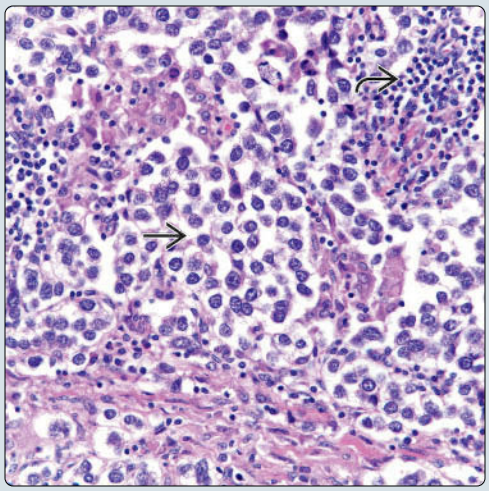

(Left) *Gross photograph of a thymic seminoma shows a soft, light brown to tan tumor with a homogeneous, fleshy surface. On the upper portion, one can still see grossly identifiable remnants of the thymic gland.* **(Right)** *High-power view of a thymic seminoma displays sheets of neoplastic cells with a discrete inflammatory reaction composed of lymphocytes.*

SALL4 Immunohistochemistry

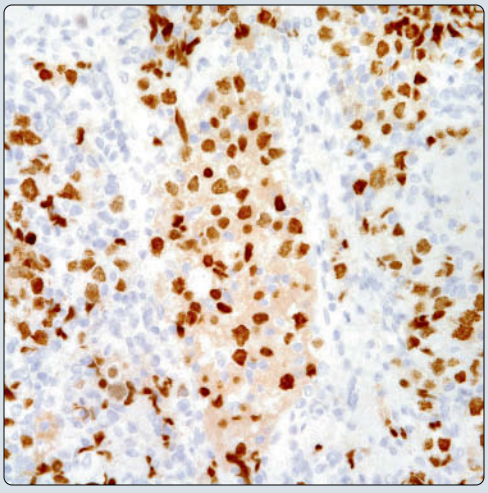

PLAP Immunohistochemistry

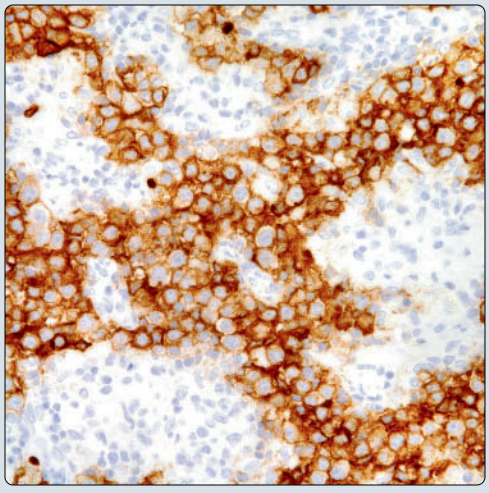

(Left) *SALL4 shows strong positive nuclear reaction in seminoma cells.* **(Right)** *Thymic seminoma shows strong positive reaction in tumor cells for placental-like alkaline phosphatase.*

TERMINOLOGY

Synonyms

- Thymic seminoma, germinoma

Definitions

- Malignant germ cell tumor

ETIOLOGY/PATHOGENESIS

Etiology

- Unknown, but some theories have postulated misplaced germ cells in anterior mediastinum as origin

CLINICAL ISSUES

Epidemiology

- Incidence
  - Difficult to determine exact incidence
  - 2nd most common germ cell tumor after teratomas
  - May account for ~ 37% of all germ cell tumors
- Age
  - Majority of tumors occur in young adults aged 20-30 years
  - Highly unusual in patients < 12 years old
  - Minority of cases in patients > 60 years old
- Sex
  - Almost exclusive occurrence in males
  - Only a few cases reported in females

Site

- Anterior mediastinal tumor
- Rarely in posterior mediastinum

Presentation

- Shortness of breath
- Cough
- Chest pain
- Hemoptysis
- Superior vena cava syndrome
- Gynecomastia
- Pulmonic stenosis
- Ventricular septal defect
- Congenital absence of thoracic hemivertebrae
- In some cases, patients may be asymptomatic

Treatment

- Chemotherapy
- Radiation therapy

Prognosis

- Depends on clinical staging
- May be better in younger than in older patients

IMAGING

General Features

- Large, bulky tumors
- Well marginated
- May extend to both sides of midline

CT Findings

- Homogeneous attenuation equal to soft tissue

MACROSCOPIC

General Features

- Large tumors
- Slightly lobulated, firm, and tan
- Cystic tumor can occur in < 10% of cases

Size

- Vary from a few cm to > 15 cm in greatest dimension

MICROSCOPIC

Histologic Features

- Sheets or discrete nesting pattern
- Medium-sized cells
- Clear or lightly eosinophilic cytoplasm
- Inflammatory infiltrate (lymphocytes)

Predominant Pattern/Injury Type

- Sheets

Predominant Cell/Compartment Type

- Germ, seminomatous

DIFFERENTIAL DIAGNOSIS

Thymic Carcinoma

- Displays lobulation and more cellular pleomorphism
- Extensive areas of hyalinization may be present
- Positive reaction for common germ cell markers, such as PLAP, SALL4, OCT3, and CD117 (c-kit), will be unusual

Mediastinal B-Cell Lymphoma

- May show extensive areas of fibrosis
- Shows negative staining for keratin and other common germ cell markers (PLAP, etc.)

Melanoma

- Shows positive staining for S100 protein and MART-1; negative for keratin and PLAP

Thymoma

- Shows classic features of lobulation and mixed biphasic cellular components
- EMA is commonly negative in thymomas while positive in seminomas
- Germ cell markers are generally negative in thymomas

Metastatic Seminoma of Testicular Origin

- Rarely metastasizes as bulky anterior mediastinal tumor
- May metastasize to mediastinal lymph nodes
- Identical histopathological and immunohistochemical features for both tumors (mediastinal and testicular)

DIAGNOSTIC CHECKLIST

Clinically Relevant Pathologic Features

- Age distribution

Pathologic Interpretation Pearls

- Sheets of neoplastic cells
- Inflammatory component (lymphocytes)
- Cells with clear or eosinophilic cytoplasm
- PLAP, SALL4, OCT3 positive immunohistochemical study

Immunohistochemistry

Antibody	Reactivity	Staining Pattern	Comment
PLAP	Positive	Cytoplasmic	
CK8/18/CAM5.2	Positive	Cytoplasmic	
CD117	Positive	Nuclear & cytoplasmic	
HPL	Positive	Cytoplasmic	
CK-PAN	Positive	Cytoplasmic	Weak
HCG	Positive	Cytoplasmic	Scattered cells
SALL4	Positive	Cytoplasmic	
POU5F1	Positive	Cytoplasmic	
Glypican-3	Negative		In some cases, focal weak positive staining may be seen
α-fetoprotein	Negative		

Histological, Histochemical, and Molecular Features

Feature	Percentage/Result
Thymic remnants	~ 27% of cases
Noncaseous granulomatous inflammation	~ 46% of cases
Lymphoid hyperplasia	~ 10% of cases
Cystic changes	< 10% of cases
Syncytiotrophoblastic component	< 5% of cases
Necrosis	~ 25% of cases
K-ras-2 genotype	Normal in ~ 90% of cases
Mutation in codon 13	In a few cases
PAS	Positive for intracytoplasmic glycogen
PAS-D	Negative for intracellular mucin
Mucicarmine	Negative for intracellular mucin

Clinical Staging of Mediastinal Germ Cell Tumors

Stage	Description
I	Well-circumscribed tumor ± focal adhesions to pleura or pericardium but without microscopic evidence of invasion into adjacent structures
II	Tumor confined to mediastinum with macroscopic &/or microscopic evidence of infiltration into adjacent structures (pleura, pericardium, great vessels)
III	Tumor with metastases
IIIA	With metastases to intrathoracic organs (lymph nodes, lung, etc.)
IIIB	With extrathoracic metastases

SELECTED REFERENCES

1. Weissferdt A et al: Mediastinal seminoma with florid follicular lymphoid hyperplasia: a clinicopathological and immunohistochemical study of six cases. Virchows Arch. 466(2):209-15, 2015
2. Weissferdt A et al: Primary mediastinal seminomas: a comprehensive immunohistochemical study with a focus on novel markers. Hum Pathol. 46(3):376-83, 2015
3. Weissferdt A et al: Combined thymoma-thymic seminoma. Report of 2 cases of a heretofore unreported association. Hum Pathol. 45(10):2168-72, 2014
4. Weissferdt A et al: Primary mediastinal "thymic" seminomas. Adv Anat Pathol. 19(2):75-80, 2012
5. Moran CA: Germ cell tumors of the mediastinum. Pathol Res Pract. 195(8):583-7, 1999
6. Suster S et al: Germ cell tumors of the mediastinum and testis: a comparative immunohistochemical study of 120 cases. Hum Pathol. 29(7):737-42, 1998
7. Moran CA et al: Primary germ cell tumors of the mediastinum: II. Mediastinal seminomas--a clinicopathologic and immunohistochemical study of 120 cases. Cancer. 80(4):691-8, 1997
8. Moran CA et al: Mediastinal seminomas with prominent cystic changes. A clinicopathologic study of 10 cases. Am J Surg Pathol. 19(9):1047-53, 1995
9. Rosado-de-Christenson ML et al: From the archives of the AFIP. Mediastinal germ cell tumors: radiologic and pathologic correlation. Radiographics. 12(5):1013-30, 1992

Residual Thymus

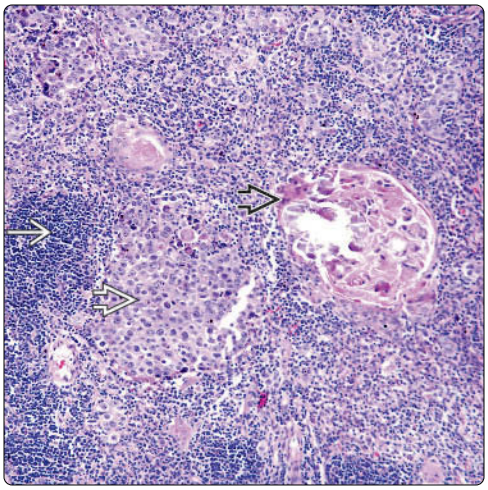

Follicular Hyperplasia

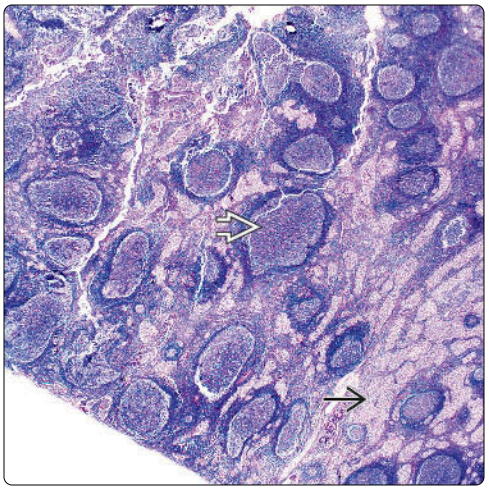

(Left) *Thymic seminoma shows neoplastic cells admixed with lymphoid residual thymus and Hassall corpuscles. In some areas, the mixture of neoplastic and nonneoplastic cells is more subtle.* **(Right)** *Low-power view of a thymic seminoma shows the presence of marked follicular hyperplasia and, within hyperplastic follicles, neoplastic seminoma cells. This pattern can be confused with a mediastinal lymphoma.*

Germinal Centers

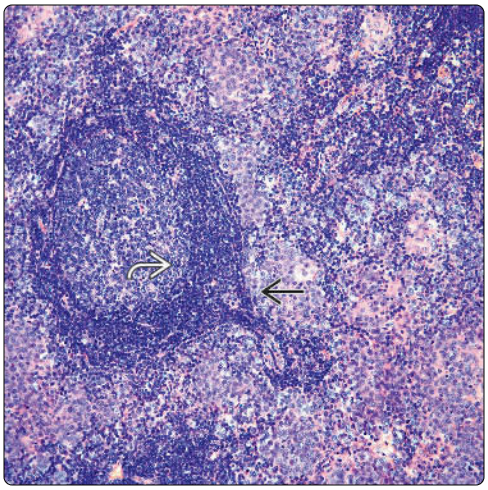

Granulomatous Reaction

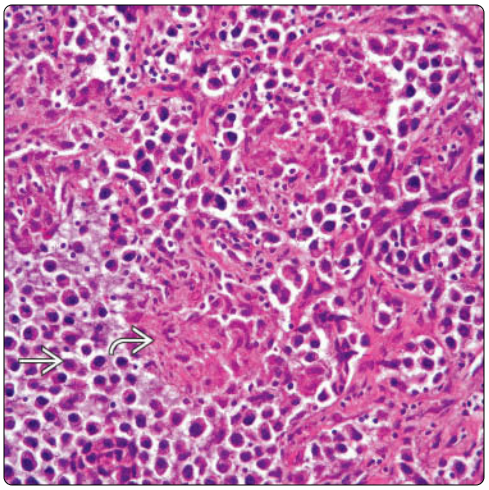

(Left) *High-power view of a mediastinal seminoma demonstrates the difference between the 2 populations of cells, clearly distinguishing the neoplastic seminomatous component from the hyperplastic lymphoid follicle.* **(Right)** *Higher magnification of a mediastinal seminoma shows close association between the ill-defined granulomas and the neoplastic cells.*

Classic Seminoma

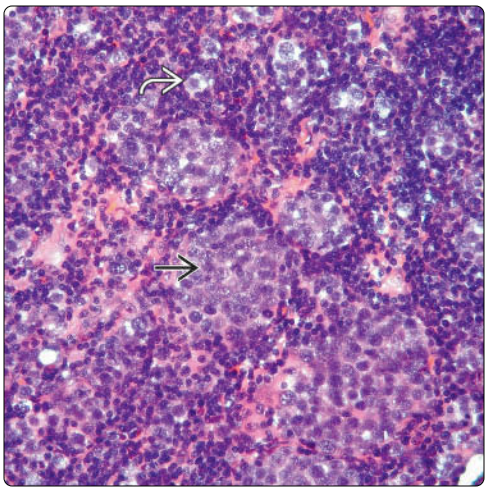

Necrotic Tumor

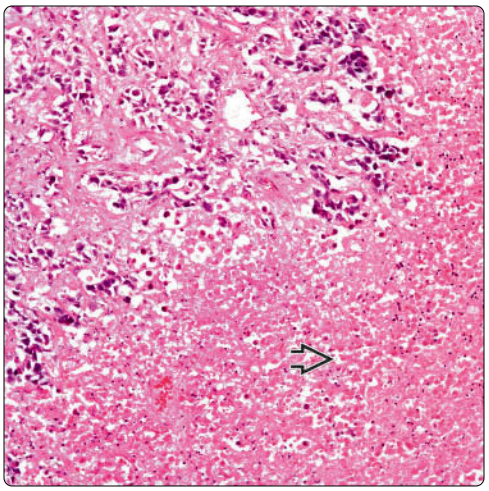

(Left) *Thymic seminoma displays numerous clusters of neoplastic cells embedded in a lymphoid stroma. In some areas of heavy lymphoid component, there are neoplastic cells intimately admixed with lymphocytes.* **(Right)** *Seminoma with extensive areas of necrosis is shown. In this setting, many times it is difficult to identify classic seminoma cells, thus the need for immunohistochemical studies.*

Cystic Seminoma

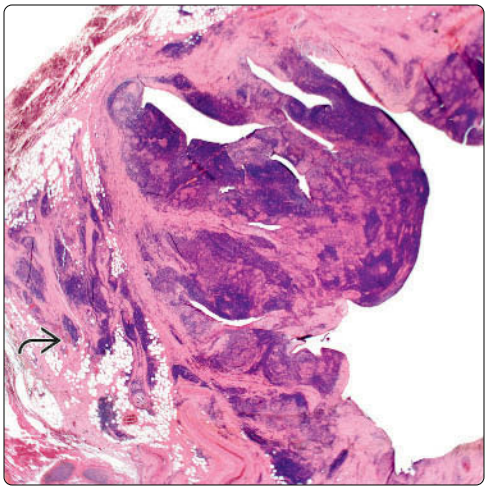

Cystic Seminoma

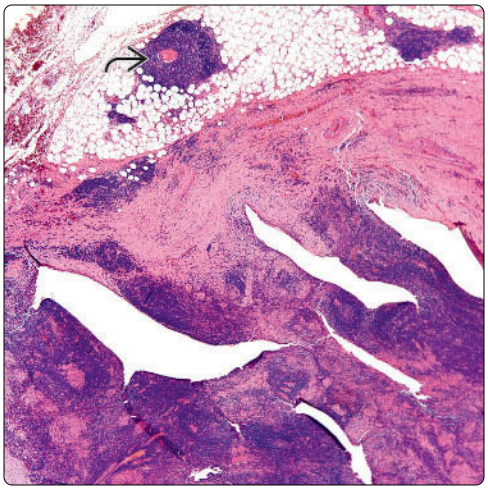

(Left) *Low-power view of a thymic cystic seminoma mimics a benign thymic cystic lesion. Note that the cystic walls show a dense inflammatory reaction admixed with a noncaseous granulomatous reaction and adjacent remnants of thymic tissue.* **(Right)** *Hematoxylin & eosin stain shows a cystic seminoma in which the walls are heavily infiltrated by a dense inflammatory reaction, making it difficult to observe the neoplastic cells. Residual thymus is present.*

Residual Thymic Tissue

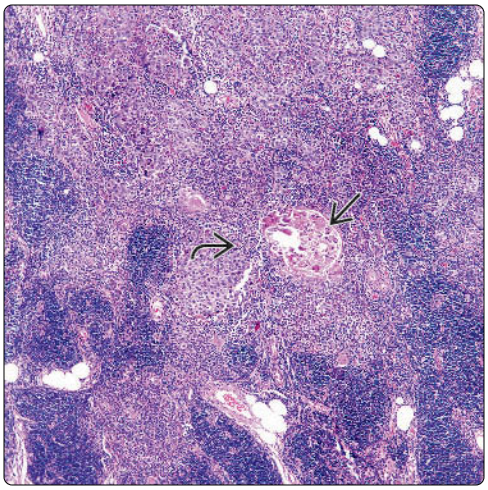

Granulomatous Reaction

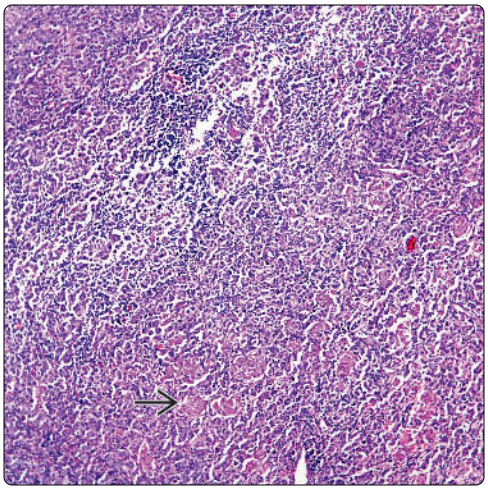

(Left) *Seminoma cells are shown intimately admixed with thymic tissue. Note the presence of a Hassall corpuscle admixed with the neoplastic cells.* **(Right)** *Low-power view of a thymic seminoma displays sheets of neoplastic cells without any particular growth pattern. Discrete, noncaseous, ill-defined granulomas are present. This pattern can be easily confused with a lymphoma.*

Classic Seminoma

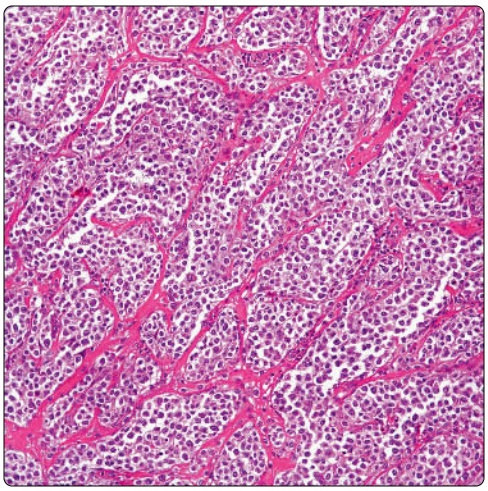

Clear Cells

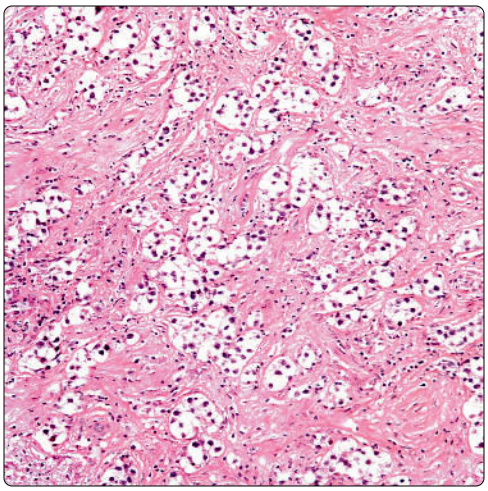

(Left) *Seminoma with a nested growth pattern is shown. Similar primary tumors of the mediastinum may have a similar growth pattern, namely, neuroendocrine carcinomas.* **(Right)** *Closer view shows a thymic seminoma in which the neoplastic cells display marked clearing of the cytoplasm. The intervening stroma does not show a marked inflammatory reaction.*

Clear Cells

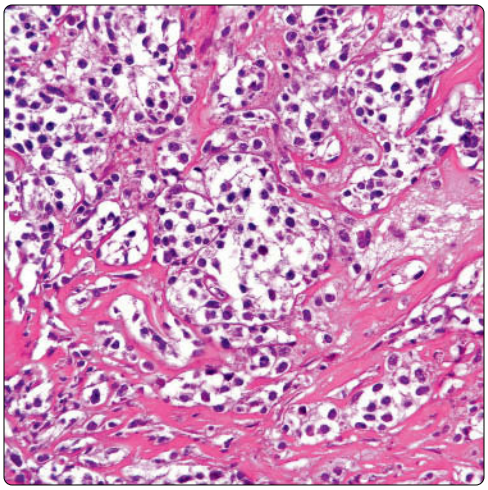

Lymphocytic Component

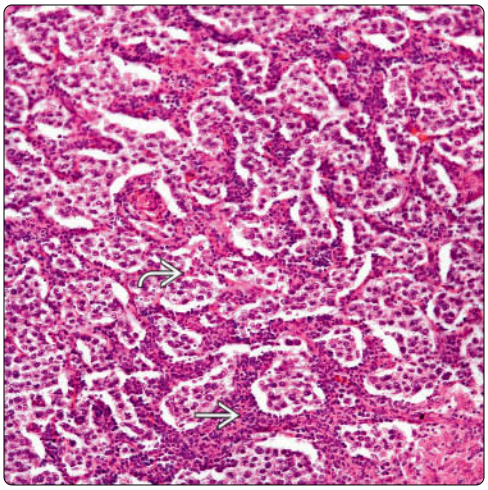

(Left) *Higher magnification shows seminoma cells with prominent clear cytoplasm. In these cases, glycogen is more likely to be identified on PAS stains.* **(Right)** *Classic growth pattern of seminoma shows islands of tumor cells separated by thin fibroconnective tissue with inflammatory cells, mainly lymphocytes.*

Classic Seminoma

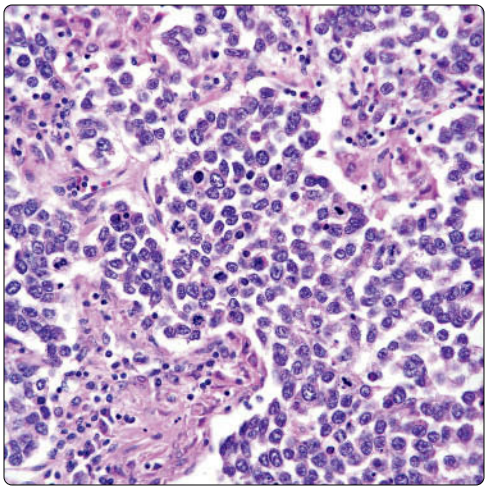

Multinucleated Giant Cells

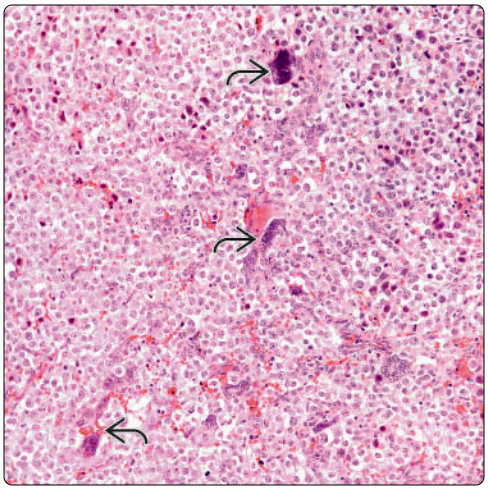

(Left) *The classic appearance of a thymic seminoma is shown in which the cells are oval with light eosinophilic cytoplasm, some with nucleoli and others with numerous chromocenters. Mitotic figures are present. Note the delicate fibroconnective tissue with mild inflammatory infiltrate.* **(Right)** *Thymic seminoma shows focal presence of multinucleated syncytiotrophoblastic cells. This is another uncommon feature of these tumors, seen in < 10% of cases.*

Invasive Seminoma

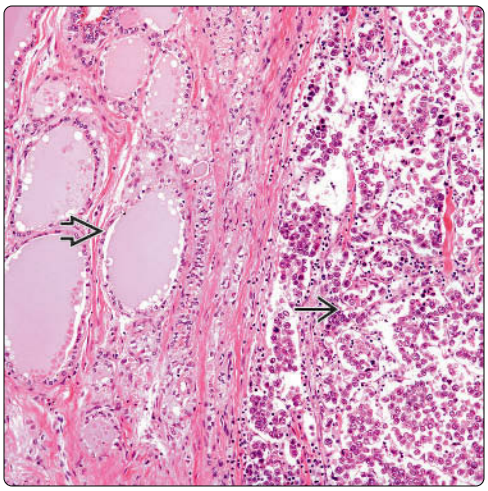

Invasive Seminoma

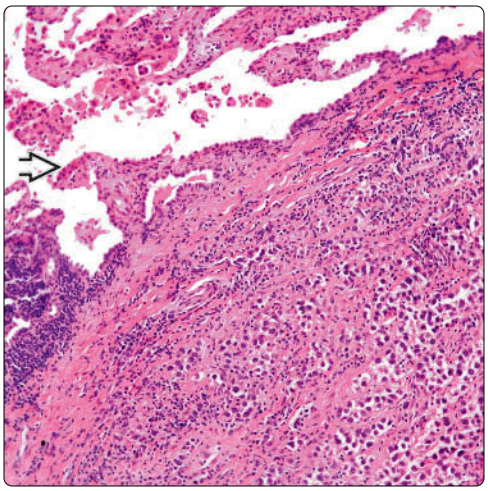

(Left) *Hematoxylin & eosin stain shows a thymic seminoma invading the thyroid gland. Note the presence of thyroid follicles adjacent to areas of seminomatous infiltration. This is an unusual site of metastatic disease.* **(Right)** *Thymic seminoma infiltrates into lung parenchyma. This is a more common site of spreading of thymic seminomas, which usually infiltrate intrathoracic structures first.*

Yolk Sac Tumor

KEY FACTS

TERMINOLOGY

- Yolk sac tumor (YST)
- Endodermal sinus tumor, infantile type embryonal carcinoma

CLINICAL ISSUES

- Most common nonseminomatous germ cell tumor in mediastinum
- May account for ~ 20% of all nonteratomatous germ cell tumors in mediastinum
- Tumor is more common in young adults in 3rd decade of life
- YSTs appear predominantly in males

MACROSCOPIC

- Variable size from few cm to > 20 cm in diameter
- Rarely, YST may present as cystic anterior mediastinal tumor

MICROSCOPIC

- Reticulated
- Cells growing in multiple communicating channels resembling immature glomeruli (Schiller-Duval bodies)
- Numerous intracellular and extracellular hyaline globules
- Loose reticular network

TOP DIFFERENTIAL DIAGNOSES

- Embryonal carcinoma
- Sarcoma
- Metastatic carcinoma
- Multilocular thymic cyst

(Left) *A yolk sac tumor (YST) is seen with the typical appearance of a neoplastic cellular proliferation and a Schiller-Duval body.* **(Right)** *High-power view of a YST shows a reticular growth pattern composed of small cells without much nuclear pleomorphism. Note the presence of mitotic activity.*

Schiller Duval Bodies

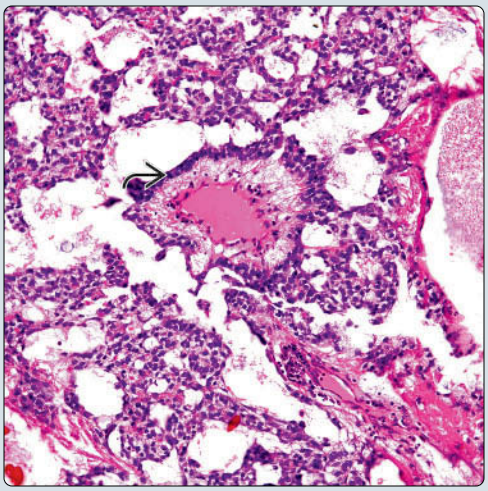

Reticular Pattern

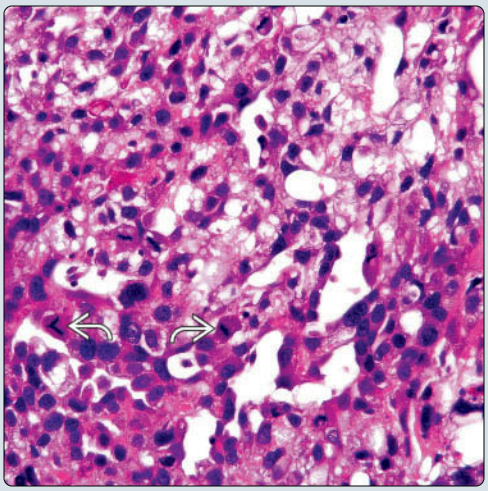

(Left) *Immunohistochemical stain for glypican-3 shows positive staining in tumors cells of YST.* **(Right)** *Immunohistochemical stain for AFP shows positive staining in tumor cells of YST.*

Glypican-3

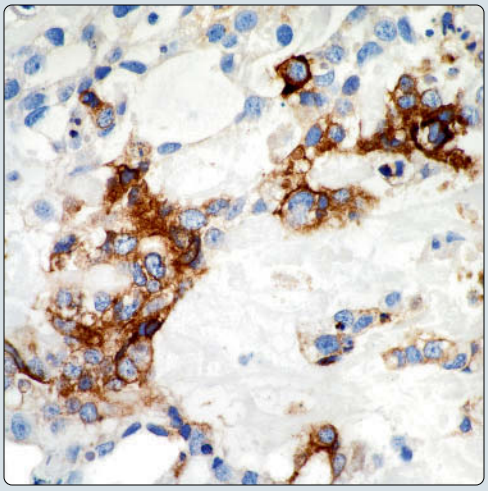

α-Fetoprotein

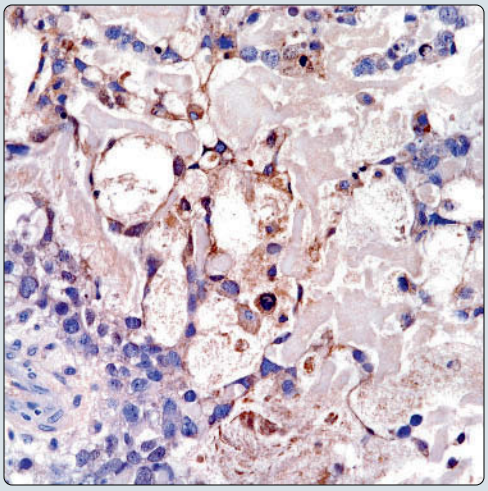

TERMINOLOGY

Abbreviations

- Yolk sac tumor (YST)

Synonyms

- Endodermal sinus tumor, infantile-type embryonal carcinoma

Definitions

- Malignant germ cell tumor

ETIOLOGY/PATHOGENESIS

Unknown Etiology

- Some authors have stated possibility of misplaced germ cells in mediastinum

CLINICAL ISSUES

Epidemiology

- Incidence
  - Most common nonseminomatous germ cell tumor in mediastinum
  - May account for ~ 20% of all nonteratomatous germ cell tumors in mediastinum
- Age
  - Tumor is more common in young adults in 3rd decade of life
- Sex
  - Appears to occur predominantly in males

Site

- Anterior mediastinum

Presentation

- Cough
- Difficulty breathing
- Superior vena cava syndrome
- Chest pain
- Klinefelter syndrome
- Sexual precocity
- Idiopathic thrombocytopenia
- Acute megakaryoblastic leukemia
- Malignant histiocytosis
- Patients may also be asymptomatic

Laboratory Tests

- Increased α-fetoprotein in serum

Treatment

- Options, risks, complications
  - Surgery, if possible
  - Chemotherapy, platinum based

Prognosis

- Poor
  - Survival: ~ 6-24 months

IMAGING

General Features

- Heterogeneous attenuation

MACROSCOPIC

General Features

- Significant necrosis and hemorrhage

Sections to Be Submitted

- ~ 1 section per cm of tumor
- Include transitional areas of thymus (if present) and tumor

Size

- Variable, from few cm to > 20 cm in diameter
- Rarely, YST may present as cystic anterior mediastinal tumor

MICROSCOPIC

Histologic Features

- Cells growing in multiple communicating channels resembling immature glomeruli (Schiller-Duval bodies)
- Numerous intracellular and extracellular hyaline globules
- Loose reticular network

Predominant Pattern/Injury Type

- Reticulated

Predominant Cell/Compartment Type

- Germ, nonseminomatous

ANCILLARY TESTS

Histochemistry

- PAS
  - Reactivity: Positive
  - Staining pattern: Cytoplasmic inclusion
- Mucicarmine
  - Reactivity: Negative
  - Staining pattern: Not applicable
- PAS diastase
  - Reactivity: Negative
  - Staining pattern: Not applicable

Electron Microscopy

- Large amounts of basal lamina outlining cells
- Zonula occludens junctions joining cells

DIFFERENTIAL DIAGNOSIS

Embryonal Carcinoma

- Most often shows presence of nucleoli in tumor cells
- More nuclear pleomorphism
- More often shows abortive, gland-like structures
- Most likely shows positive staining for CD30
- Both tumors may show similar immunophenotype

Metastatic Carcinoma

- In metastatic carcinoma of liver origin, it is likely that tumor may show bile, while YST does not
- Generally, carcinomas will not show conventional areas of YST
- History of carcinoma is ultimately most reliable information

Sarcoma

- YST with spindle cell morphology also shows conventional areas of YST but will be absent in true sarcomas

Immunohistochemistry

Antibody	Reactivity	Staining Pattern	Comment
α-fetoprotein	Positive	Cytoplasmic	
AE1/AE3	Positive	Cytoplasmic	
CEA-M	Positive	Cytoplasmic	
EMA	Positive	Cell membrane	Variable
SALL4	Positive	Cytoplasmic	
Glypican-3	Positive	Cytoplasmic	
PLAP	Positive	Cytoplasmic	Variable
LEU-7	Positive	Cytoplasmic	Variable
CK8/18/CAM5.2	Positive	Cytoplasmic	
CD30	Negative	Not applicable	

Histological Growth Patterns

Pattern	Frequency
Reticular pattern of growth with Schiller-Duval bodies	Most common
Hepatoid variant	Unusual
Intestinal variant	Unusual
Spindle cell variant	Unusual
Cystic	Unusual

Clinical Staging of Mediastinal Germ Cell Tumors

Stage	Description
I	Well-circumscribed tumor ± focal adhesions to pleura or pericardium and without microscopic evidence of invasion into adjacent structures
II	Tumor confined to mediastinum with macroscopic &/or microscopic evidence of infiltration into adjacent structures, such as pleura, pericardium, and great vessels
III	Tumor metastases
IIIA	With metastases to intrathoracic organs (lymph nodes, lung, etc.)
IIIB	With extrathoracic metastases

- True sarcomas rarely will show positive staining for keratin and generally are negative for AFP
- Positive staining for mesenchymal markers, such as desmin, SMA, and others will be against YST

Multilocular Thymic Cyst

- Similar cystic features
- Does not display any atypical cellular proliferation
- Ample sectioning is important in these cases

Mixed Germ Cell Tumor

- YST is often accompanied by another germ cell tumor
- Most common association is with embryonal carcinoma
- Ample sampling is important in these cases

DIAGNOSTIC CHECKLIST

Clinically Relevant Pathologic Features

- Age distribution
  - Most common in young men

Pathologic Interpretation Pearls

- Schiller-Duval bodies
- Extracellular and intracellular hyaline bodies

SELECTED REFERENCES

1. Malagón HD et al: Germ cell tumors with sarcomatous components: a clinicopathologic and immunohistochemical study of 46 cases. Am J Surg Pathol. 31(9):1356-62, 2007
2. Moran CA: Germ cell tumors of the mediastinum. Pathol Res Pract. 195(8):583-7, 1999
3. Suster S et al: Germ cell tumors of the mediastinum and testis: a comparative immunohistochemical study of 120 cases. Hum Pathol. 29(7):737-42, 1998
4. Moran CA et al: Hepatoid yolk sac tumors of the mediastinum: a clinicopathologic and immunohistochemical study of four cases. Am J Surg Pathol. 21(10):1210-4, 1997
5. Moran CA et al: Mediastinal yolk sac tumors associated with prominent multilocular cystic changes of thymic epithelium: a clinicopathologic and immunohistochemical study of five cases. Mod Pathol. 10(8):800-3, 1997
6. Moran CA et al: Primary germ cell tumors of the mediastinum: III. Yolk sac tumor, embryonal carcinoma, choriocarcinoma, and combined nonteratomatous germ cell tumors of the mediastinum--a clinicopathologic and immunohistochemical study of 64 cases. Cancer. 80(4):699-707, 1997

Macroscopic Features

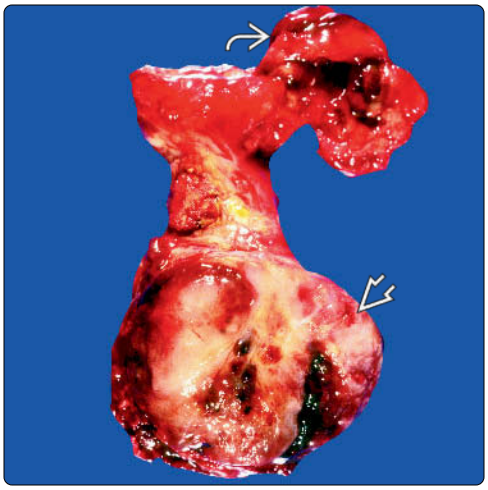

Reticular Pattern

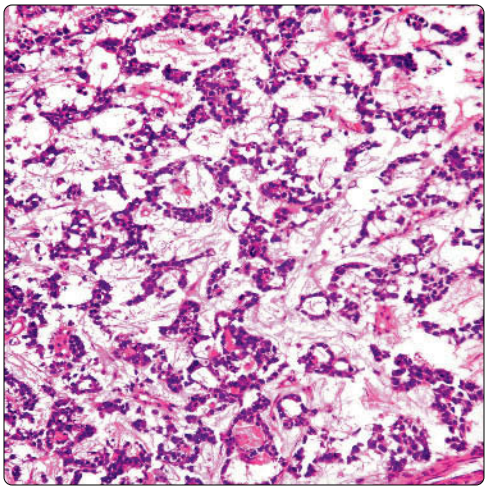

(Left) *Gross photograph shows a mediastinal YST. The tumor is fleshy with focal areas of hemorrhage. Note the presence of a residual portion of the thymus.* **(Right)** *YST shows a neoplastic cellular proliferation embedded in a myxoid stroma. The tumor does not show much in terms of cellular atypia or mitotic activity.*

Extensive Hyaline Changes

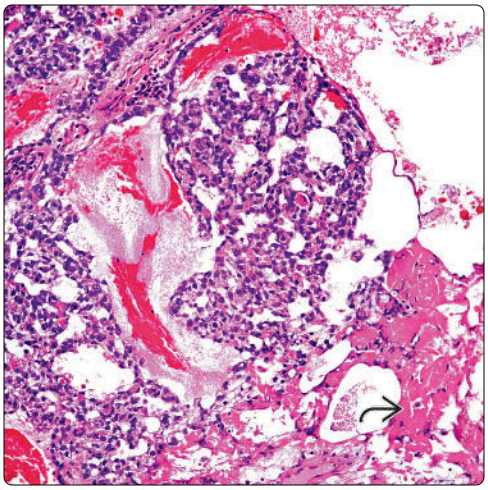

Adenomatoid-Like Pattern

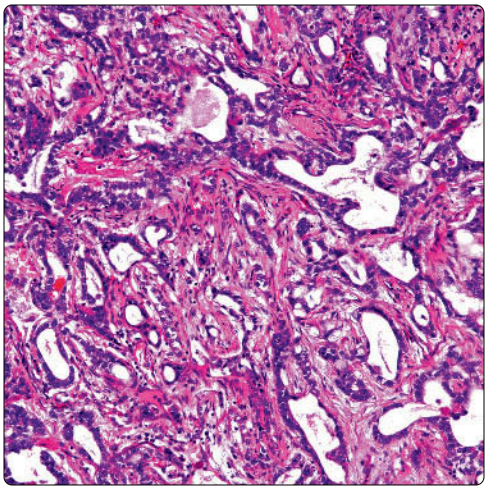

(Left) *YST shows a neoplastic cellular proliferation composed of rather small cell areas admixed with fibrinoid material.* **(Right)** *YST shows a reticular growth pattern in which there are alternating small pseudoglands lined by low cuboidal neoplastic cells and separated by fibrocollagenous tissue.*

Solid Pattern

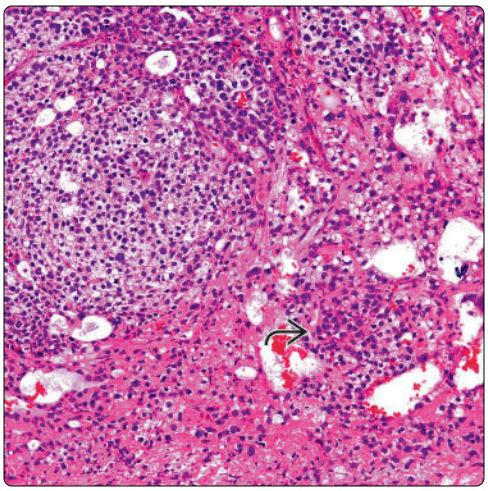

Schiller-Duval Bodies

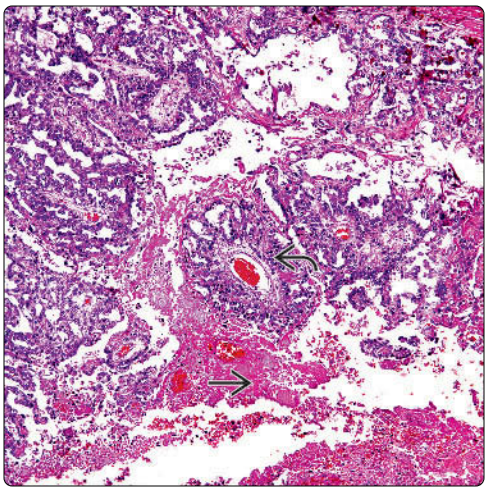

(Left) *YST with an area in which the neoplastic cell acquires a clear cytoplasm is shown. In some areas, the tumor cells are admixed with fibrinoid inflammatory material.* **(Right)** *YST with more conventional areas and presence of necrosis is shown. Note the presence of a Schiller-Duval body. These features are typical of YST.*

Extensive Necrosis

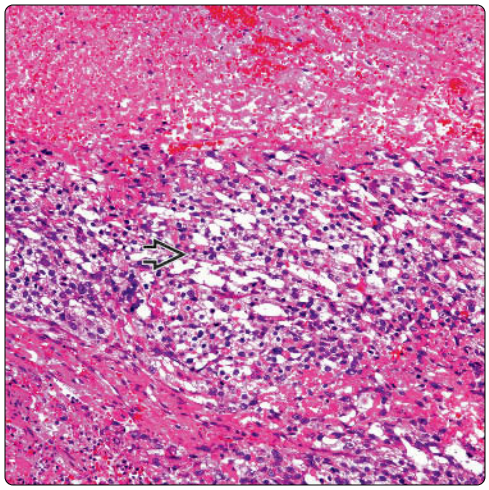

Spindle Cell Pattern

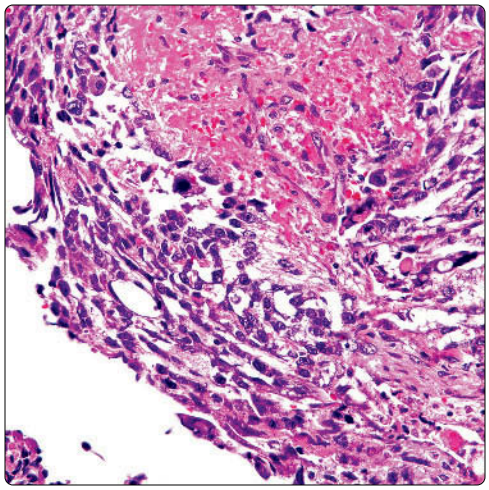

(Left) *YST with extensive areas of necrosis is shown. However, one is still able to recognize a neoplastic cellular proliferation composed of rather smaller cells.* **(Right)** *YST with marked spindle cell component and necrosis is shown. This type of growth pattern can easily be missed for a mesenchymal neoplasm.*

Solid Pattern

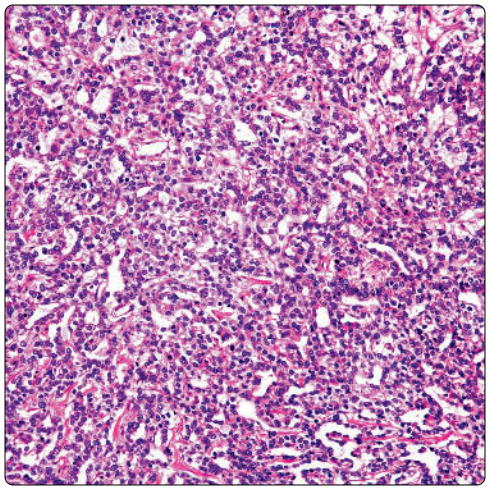

Solid and Glandular Patterns

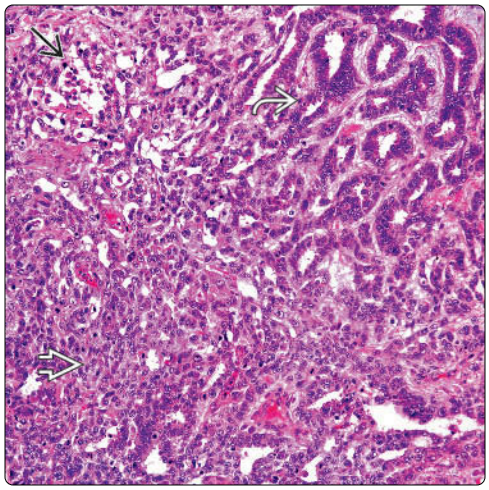

(Left) *YST with more solid areas is shown. The neoplastic cellular proliferation is composed of small cells without any particular growth pattern.* **(Right)** *In some cases of YST, solid areas can alternate with more glandular components. However, note the presence of more conventional areas.*

Solid and Oncocytic Features

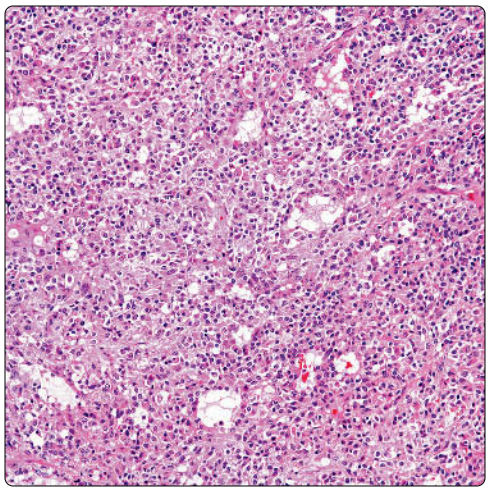

Oncocytic Features

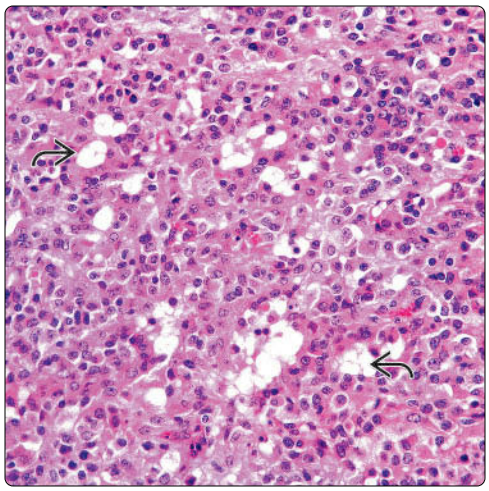

(Left) *YST shows a homogeneous cellular proliferation of medium-sized cells with eosinophilic cytoplasm. This is the so-called hepatoid variant.* **(Right)** *YST with a more solid pattern composed of medium-sized cells with round nuclei and eosinophilic cytoplasm is shown. This is the so-called hepatoid variant. Some areas resemble fat droplets.*

Papillary Features

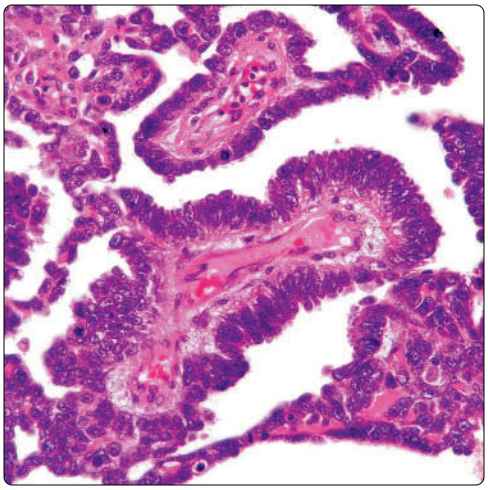

Hyaline Globules

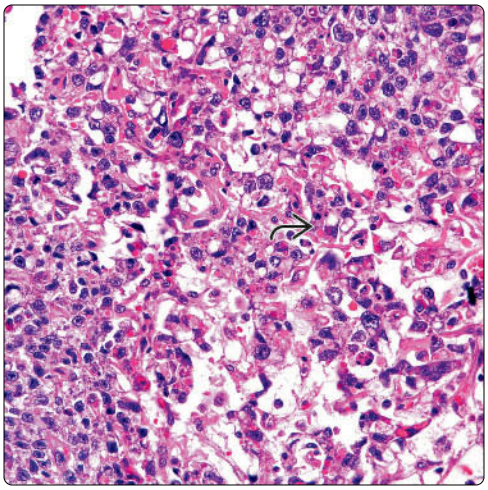

(Left) *YST with papillary-like structures resembling intestinal villi is shown. This represents the so-called intestinal variant of this tumor.* **(Right)** *In other areas, the tumor shows more conventional areas of YST, mainly the presence of intra- and extracellular hyaline globules.*

Pseudoglandular Pattern

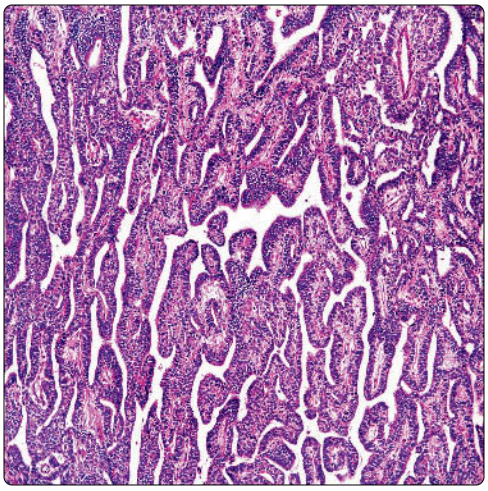

Pseudoglandular Pattern

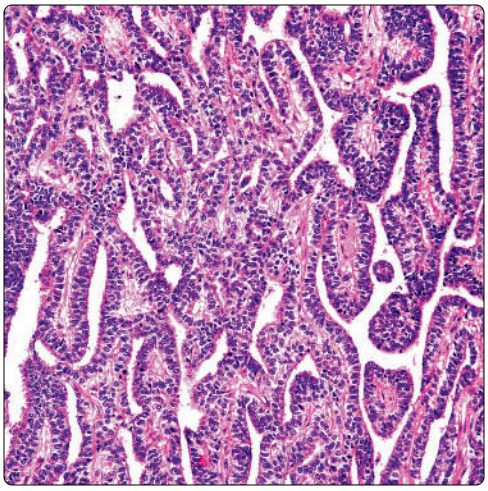

(Left) *YST with a prominent pseudoglandular formation is shown. There appears to be anastomosing glandular structures.* **(Right)** *Higher magnification shows these pseudoglands to be lined by a low cuboidal type of neoplastic cells. There is very little intervening stroma, and no vasculature is identified.*

Immature Tubules

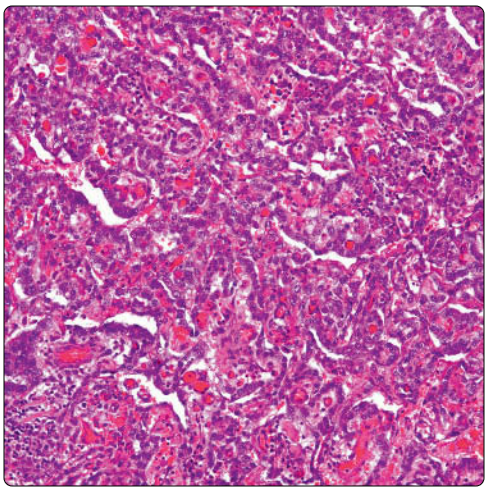

Mitotic Activity

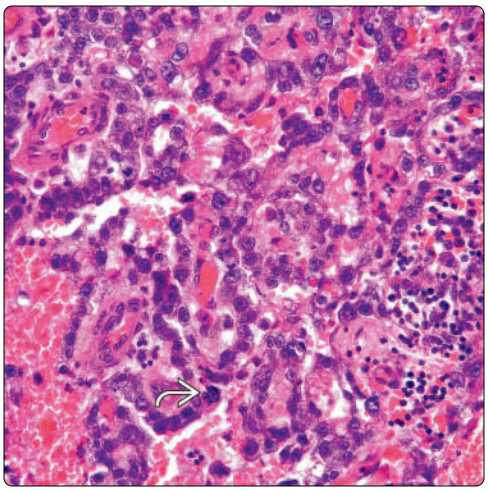

(Left) *YST with prominent tubular formation, which is separated by thin fibrocollagenous tissue, is shown. There is not a well-defined growth pattern.* **(Right)** *Higher magnification shows that the neoplastic cells are rather small and homogeneous. However, a few mitotic figures can still be identified.*

Choriocarcinoma

KEY FACTS

TERMINOLOGY

- Chorioepithelioma

CLINICAL ISSUES

- Incidence
  - May represent least common of all germ cell tumors in mediastinum
  - Represents < 5% of all germ cell tumors of mediastinum
  - Choriocarcinomas appear to be more common in 3rd and 4th decades of life
  - Choriocarcinomas are more common in men
- Symptoms
  - Cough
  - Dyspnea
  - Gynecomastia
  - Chest pain
  - Superior vena cava syndrome
- Laboratory findings
  - Increased hCG in serum

IMAGING

- Anterior mediastinal mass

MACROSCOPIC

- Large bulky tumors
- Extensive areas of hemorrhage and necrosis

MICROSCOPIC

- Hemorrhage
- Necrosis
- Cytotrophoblast
- Syncytiotrophoblast

Extensive Hemorrhagic Areas

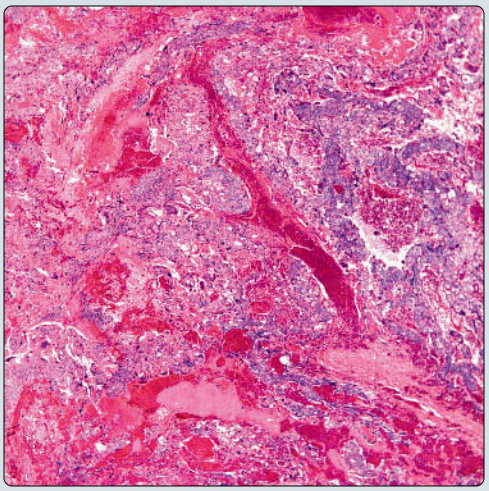

Biphasic Population

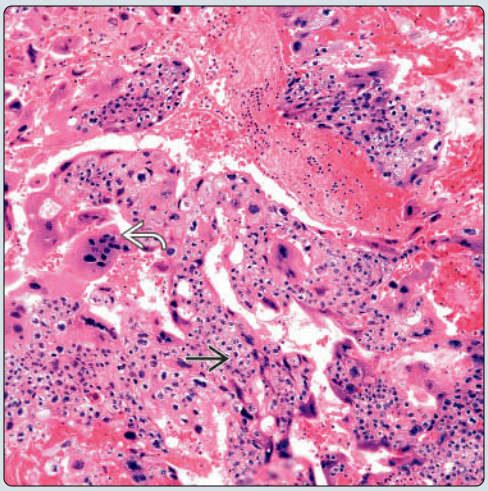

(Left) *Primary mediastinal choriocarcinoma is seen with areas of hemorrhage admixed with neoplastic cellular proliferation without a specific growth pattern.* **(Right)** *Choriocarcinoma with areas of hemorrhage admixed with a biphasic cellular proliferation is composed of large multinucleated cells (syncytiotrophoblasts) and round cells (cytotrophoblasts).*

Cyto- and Syncytiotrophoblast

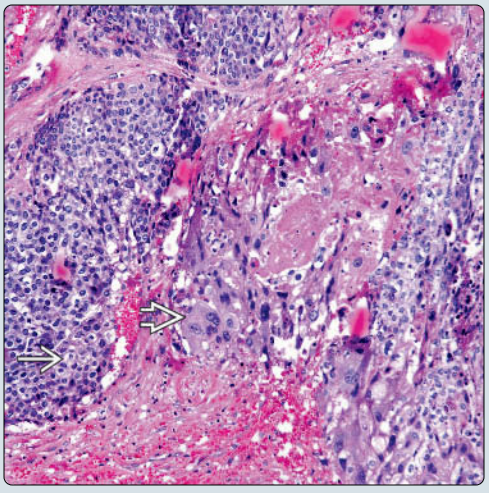

Multinucleated Giant Cells

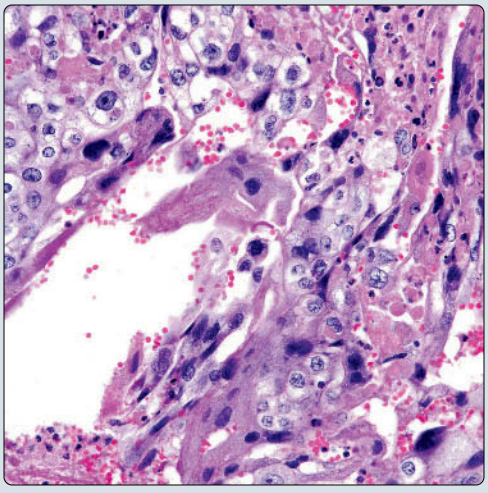

(Left) *Closer view of the dual components of a choriocarcinoma cytotrophoblast and syncytiotrophoblast shows that adjacent areas of necrosis and hemorrhage are present.* **(Right)** *Closer view at the syncytiotrophoblastic component of a choriocarcinoma shows multinucleated giant cells with ample cytoplasms and pyknotic nuclei.*

TERMINOLOGY

Synonyms

- Chorioepithelioma

Definitions

- Malignant germ cell tumor

ETIOLOGY/PATHOGENESIS

Etiology

- Misplaced germ cells in mediastinum
- Unknown etiology

CLINICAL ISSUES

Epidemiology

- Incidence
  - May represent most common of all germ cell tumors in mediastinum
  - Accounts for < 5% of all germ cell tumors of mediastinum
- Age
  - More common in 3rd and 4th decades of life
- Sex
  - More common in male patients

Presentation

- Cough
- Dyspnea
- Gynecomastia
- Chest pain
- Superior vena cava syndrome

Laboratory Tests

- Increased hCG in serum

Treatment

- Chemotherapy
- Surgical debulking if necessary

Prognosis

- Poor
- Usually patients die within 12-18 months
- At time of diagnosis, most patients already have widespread metastatic disease

IMAGING

General Features

- Location
  - Anterior mediastinal mass
  - No pathognomonic features to separate choriocarcinoma from other nonseminomatous germ cell tumors

MACROSCOPIC

General Features

- Large bulky tumors
- Extensive areas of hemorrhage and necrosis

Sections to Be Submitted

- Due to presence of extensive necrosis and hemorrhage, extensive sampling is required

Size

- Varies from few centimeters to large tumors of > 10 cm in diameter

MICROSCOPIC

Histologic Features

- Hemorrhage, necrosis
- Cytotrophoblast, syncytiotrophoblast
- Marked nuclear atypia
- Pleomorphism
- Mitotic activity

Predominant Pattern/Injury Type

- Hemorrhagic

Predominant Cell/Compartment Type

- Germ, nonseminomatous

DIFFERENTIAL DIAGNOSIS

Pleomorphic Carcinoma of Lung Origin

- Primary lung carcinomas may express hCG just like choriocarcinomas
- Choriocarcinomas are usually tumors of younger patients, in contrast to lung carcinoma
- Choriocarcinomas are bulky anterior mediastinal masses, which may spread to lung
- Lung carcinoma presents predominantly with lung mass
- Pleomorphic carcinoma is more common in older individuals
- Pleomorphic carcinoma may show ectopic production of hCG
- Pleomorphic carcinoma shows sarcomatous component with multinucleated giant cells
- Choriocarcinoma shows presence of cyto- and syncytiotrophoblastic cells

Metastatic Choriocarcinoma of Gonadal Origin

- Histology in both primary and metastatic disease is similar
- Immunophenotype of both tumors is same
- In some cases of primary testicular choriocarcinoma, tumor may have undergone regression, "burned-out"
- It would be unusual for metastases to present with bulky anterior mediastinal mass
- Clinical history would be very important

Thymic Carcinoma

- Most thymic carcinomas do not show marked pleomorphism present in choriocarcinomas
- Presence of cyto- and syncytiotrophoblastic components are not present in thymic carcinoma
- Positive staining for hCG would be unusual in thymic carcinoma

Giant Cell Carcinoma

- Usually shows malignant multinucleated giant cells not of syncytiotrophoblastic type of choriocarcinoma
- Commonly shows cannibalism by giant cells

Immunohistochemistry

Antibody	Reactivity	Staining Pattern	Comment
CK8/18/CAM5.2	Positive	Cytoplasmic	
α-fetoprotein	Positive	Cytoplasmic	Only focal in some cases
CEA-M	Positive	Cytoplasmic	Only focal in some cases
EMA	Positive	Cell membrane	Focal
HPL	Positive	Cytoplasmic	Focal in some cases
CK-PAN	Positive	Cytoplasmic	
Vimentin	Positive	Cytoplasmic	
HCG-α	Positive	Cytoplasmic	
HCG-β	Positive	Cytoplasmic	
CD15	Negative		May show focal positive cells in some cases
PLAP	Negative		May be focally positive in some cases
CD30	Negative		
TTF-1	Negative		
S100	Negative		
CDX-2	Negative		
Calretinin	Negative		

Histochemical Features

Stain	Result
PAS	Focally positive in cytotrophoblastic component in some cases
PAS-D	Negative for intracellular mucin
Mucicarmine	Negative for intracellular mucin

Clinical Staging of Mediastinal Germ Cell Tumors

Stage	Tumor Extension
I	Well-circumscribed tumor ± focal adhesions to pleura or pericardium and without microscopic evidence of invasion into adjacent structures
II	Tumor confined to mediastinum with macroscopic &/or microscopic evidence of infiltration into adjacent structures, such as pleura, pericardium, and great vessels
III	Tumor with metastases
IIIA	With metastases to intrathoracic organs (lymph nodes, lung, etc.)
IIIB	With extrathoracic metastases

- May show ectopic production of hCG
- Does not show presence cytotrophoblastic component

Mixed Germ Cell Tumor

- Choriocarcinoma may be component of another germ cell tumor
- Extensive sampling is required in order to properly rule out mixed germ cell tumor
- Presence of high hCG in serum should prompt search for choriocarcinomatous component

DIAGNOSTIC CHECKLIST

Clinically Relevant Pathologic Features

- Gross appearance
- Increase hCG in serum

Pathologic Interpretation Pearls

- Hemorrhage and necrosis
- Presence of cyto- and syncytiotrophoblastic cells
- Positive staining for hCG
- Marked pleomorphism
- Anterior mediastinal mass

SELECTED REFERENCES

1. Moran CA et al: Primary germ cell tumors of the mediastinum: III. Yolk sac tumor, embryonal carcinoma, choriocarcinoma, and combined nonteratomatous germ cell tumors of the mediastinum--a clinicopathologic and immunohistochemical study of 64 cases. Cancer. 80(4):699-707, 1997
2. Moran CA et al: Primary mediastinal choriocarcinomas: a clinicopathologic and immunohistochemical study of eight cases. Am J Surg Pathol. 21(9):1007-12, 1997

Macroscopic Features

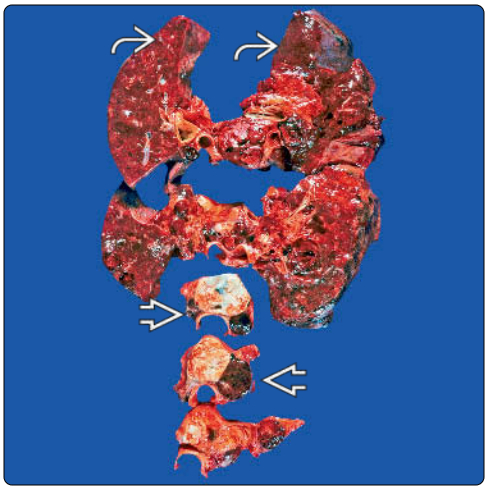

Extensive Hemorrhage

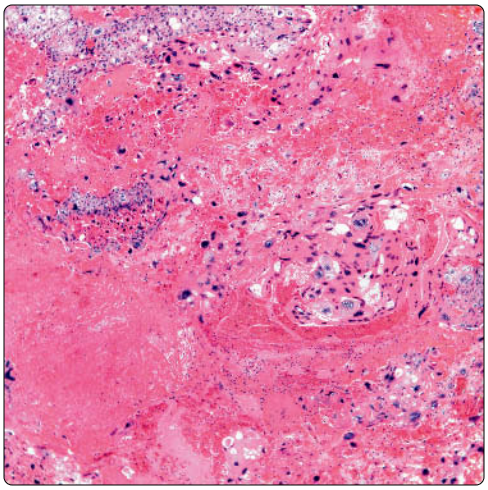

(Left) *Gross photograph of a primary mediastinal choriocarcinoma (autopsy material) shows the presence of a bulky, fleshy, and hemorrhagic tumor mass* ⇨. *Adjacent lungs do not show evidence of metastatic disease* ⇨. **(Right)** *Extensive areas of hemorrhage with clusters of neoplastic cells are shown. Some of the neoplastic cells are multinucleated and of the syncytiotrophoblastic type, whereas the majority represent cytotrophoblastic cells.*

Focus of Malignant Cells

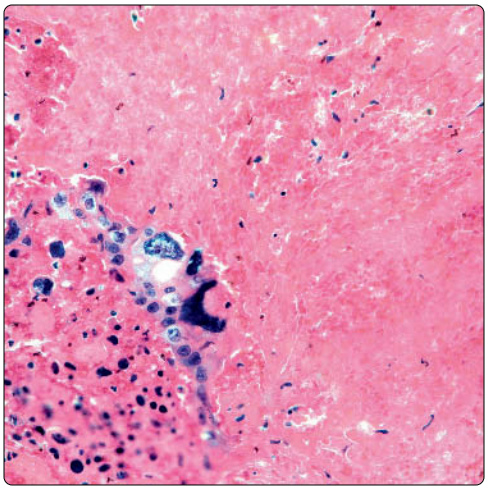

Scattered Malignant Cells

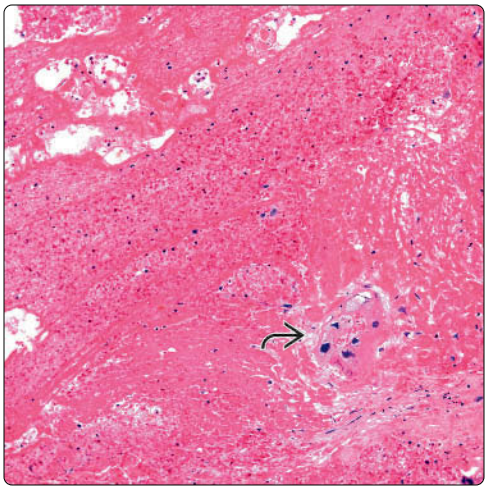

(Left) *Extensive areas of hemorrhage contain a cluster of neoplastic cells of the cytotrophoblastic and syncytiotrophoblastic type.* **(Right)** *Choriocarcinoma is shown with extensive areas of hemorrhage, which at times may obscure the neoplastic nature of the process. Here, only a cluster of neoplastic cells* ⇨ *floating in the hemorrhage is observed.*

Cellular Pleomorphism

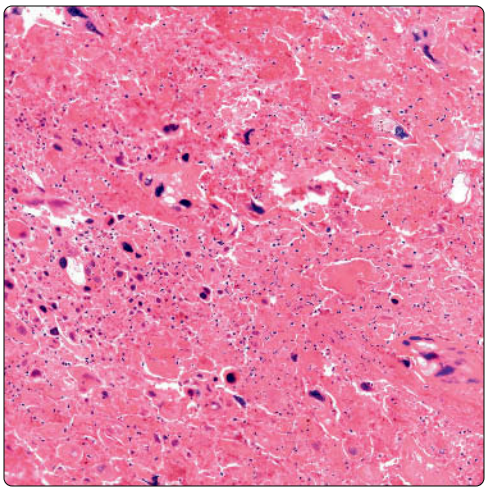

Strands of Malignant Cells

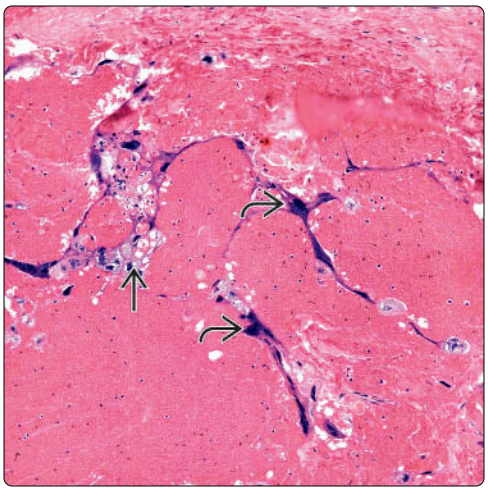

(Left) *Choriocarcinoma with areas of hemorrhage shows single cells distributed haphazardly. Note the marked nuclear pleomorphism. These features are also suggestive of choriocarcinoma.* **(Right)** *Choriocarcinoma with areas of hemorrhage is shown, but one is still able to recognize 2 different populations of tumors cells. The giant cells represent syncytiotrophoblasts* ⇨, *and the round cells represent cytotrophoblasts* ⇨.

Dual Component

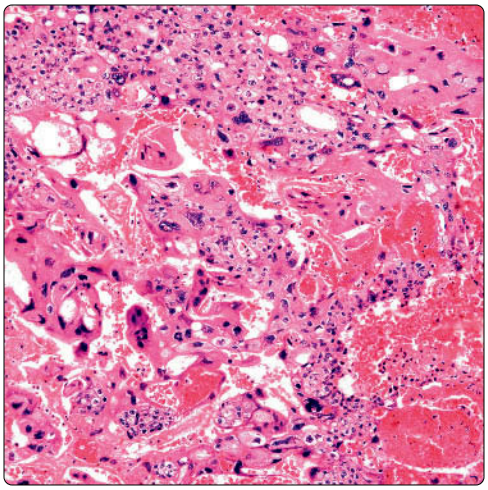

Multinucleated Cells

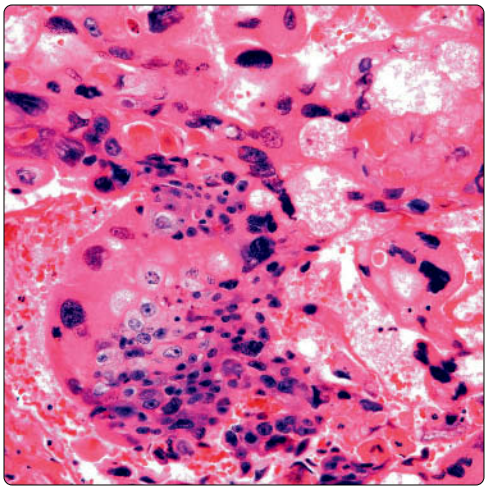

(Left) *Choriocarcinoma with presence of 2 distinct cellular proliferations is composed of round cells with clear cytoplasm and multinucleated giant cells. More nuclear pleomorphism is present in the giant cells.* **(Right)** *Choriocarcinoma with mononucleated and multinucleated cells shows vague squamoid features. The tumor shows a subtle deciduoid-like appearance.*

Cytotrophoblastic Component

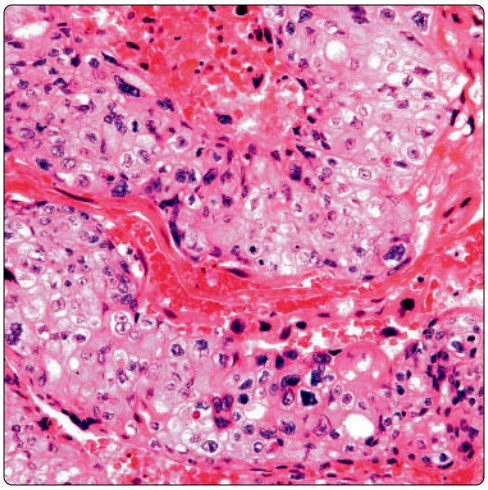

Dual Component With Hemorrhage

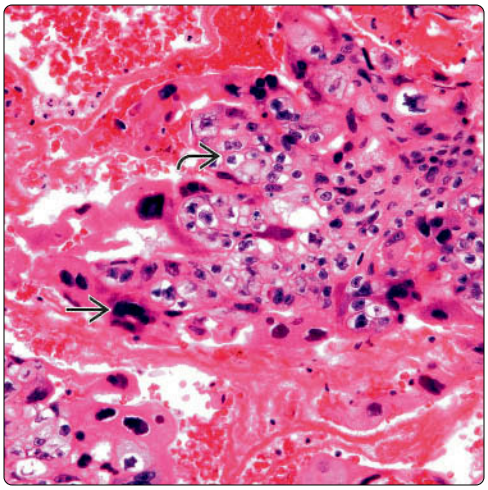

(Left) *Cords of neoplastic cells, predominantly of the cytotrophoblastic type, are composed of medium-sized cells with round nuclei and prominent nucleoli. Scattered larger cells are also present.* **(Right)** *More conventional areas composed of cytotrophoblastic ⇨ and syncytiotrophoblastic ⇨ cells are seen embedded in a fibrinoid hemorrhagic background, typical of choriocarcinoma.*

Extensive Hemorrhage

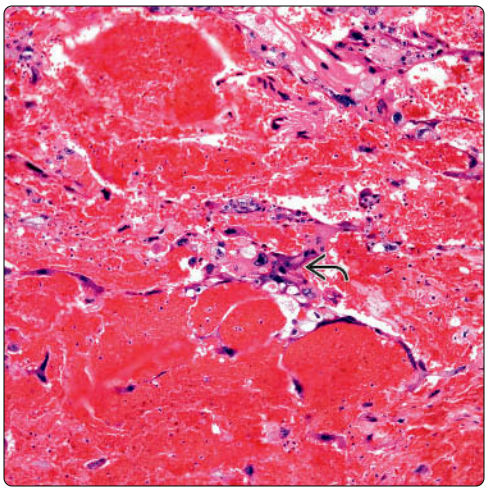

Focal Solid Component

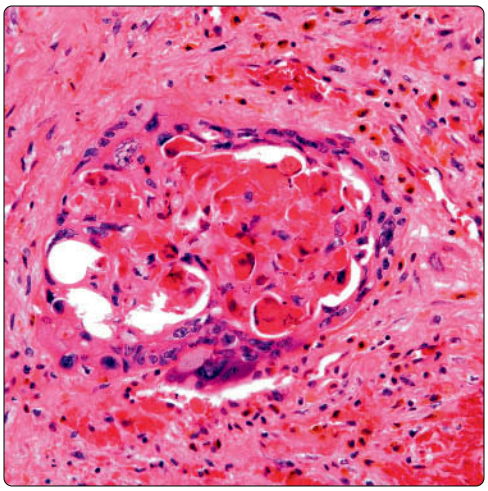

(Left) *Choriocarcinoma shows extensive areas of hemorrhage. However, conventional neoplastic cellular proliferation is also present ⇨.* **(Right)** *Choriocarcinoma shows focal cystic areas. However, the cellular proliferation is composed of mononuclear and multinucleated cells, typical of choriocarcinoma.*

Fibrinoid Necrosis

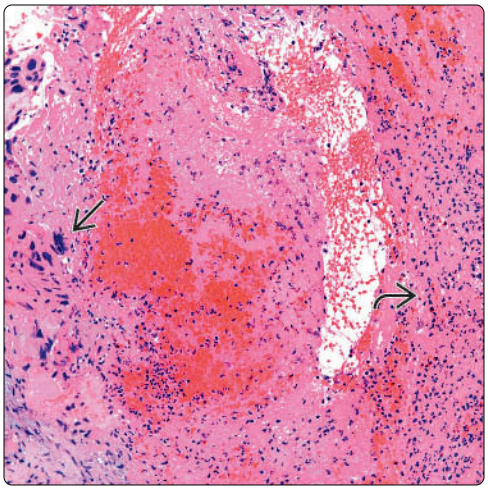

Viable Tumor

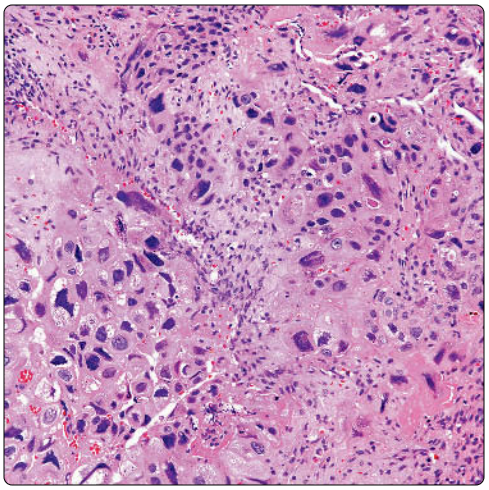

(Left) *Choriocarcinoma is shown with extensive fibrinoid necrosis and prominent inflammatory cells.* *However, the presence of a neoplastic process composed of multinucleated giant cells is apparent.* **(Right)** *In some areas, the tumoral cells are more viable without evidence of necrosis or hemorrhage. Nevertheless, the dual neoplastic population of cells is still present.*

Brain Metastasis

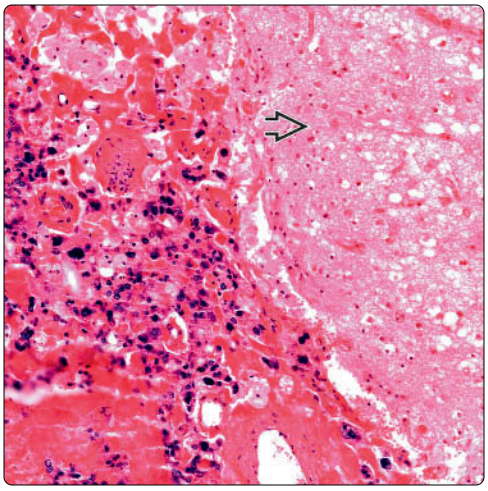

Predominant Mononuclear Cells

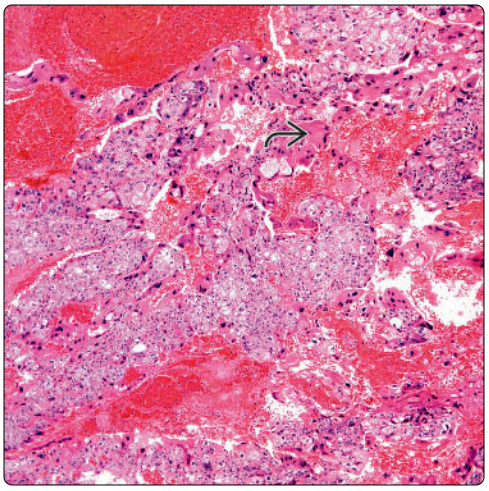

(Left) *Metastatic mediastinal choriocarcinoma to the brain shows that the histology of the mediastinal tumor is similar to the metastatic tumor.* **(Right)** *Choriocarcinoma shows extensive hemorrhage and predominantly syncytial cells (mononuclear cells) with clear cytoplasm. Only scattered syncytiotrophoblastic cells are present.*

Multinucleated Giant Cells

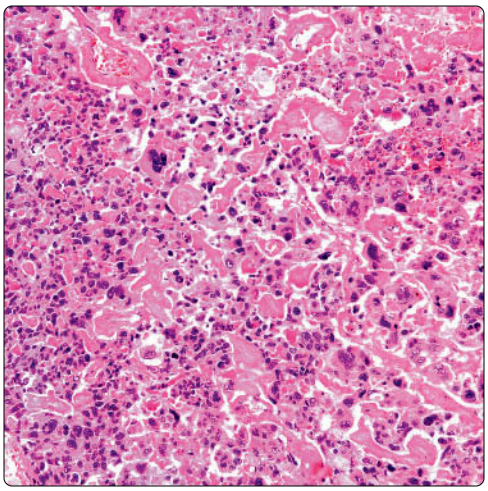

HCG-Positive Stain

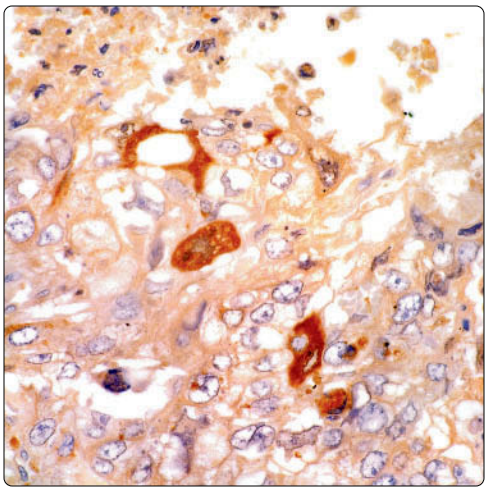

(Left) *Choriocarcinoma shows a dual neoplastic cellular proliferation composed of round mononuclear cells and multinucleated giant cells admixed with areas containing amorphous material.* **(Right)** *HCG immunohistochemical staining shows positive reaction in the syncytiotrophoblastic component of a choriocarcinoma.*

Embryonal Carcinoma

KEY FACTS

TERMINOLOGY

- Embryonal carcinoma adult type

CLINICAL ISSUES

- Incidence
  - Unusual tumor in its pure form
  - More often accompanied with another germ cell tumor, mainly yolk sac tumor
  - May account for no more than 10% of all mediastinal germ cell tumors
  - More common in young adults; unusual in older individuals
  - More common in 3rd decade of life
  - More common in male patients
- Symptoms
  - Chest pain
  - Cough
  - Dyspnea
  - Klinefelter syndrome
  - Hematologic dyscrasias
  - Chromosomal abnormalities

MICROSCOPIC

- Gland-like appearance
- Sheets of neoplastic cells
- Primitive cellular proliferation
- Cells with prominent nucleoli
- Extensive necrosis
- Prominent cellular atypia and mitotic activity

TOP DIFFERENTIAL DIAGNOSES

- Anaplastic large cell lymphoma
- Metastatic adenocarcinoma of lung origin

Glandular Features

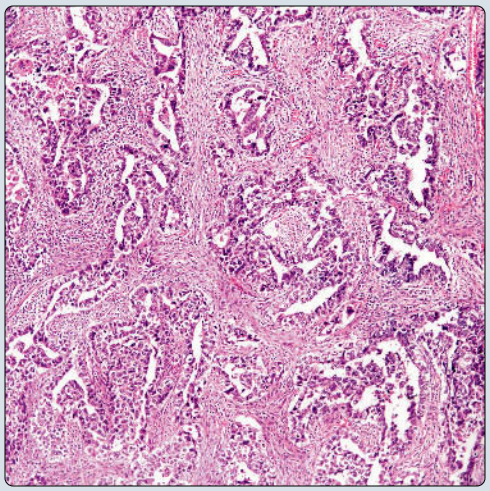

Cellular Atypia

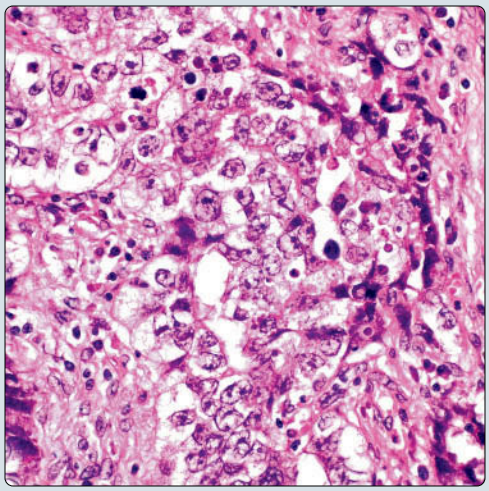

(Left) *Embryonal carcinoma shows the typical glandular arrangement of neoplastic cells separated by inflamed fibroconnective tissue.* **(Right)** *Closer view of the neoplastic cells shows medium-sized cells with round to oval vesiculated nuclei and prominent nucleoli. These features are typical of embryonal carcinoma.*

Prominent Nucleoli

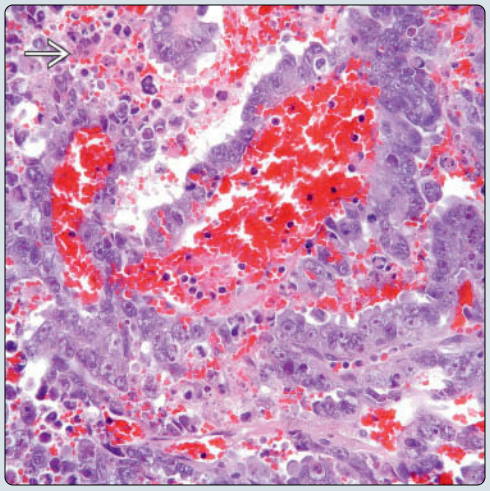

CD30

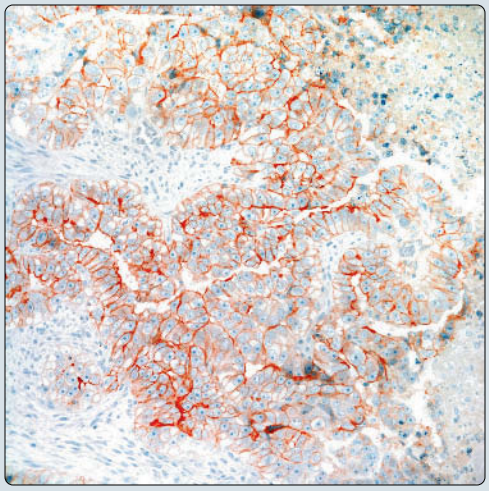

(Left) *Closer view of an embryonal carcinoma shows glandular-like elements composed of pleomorphic cells with prominent nucleoli. Numerous apoptotic cells are also present.* **(Right)** *Embryonal carcinoma shows a strong positive reaction in tumor cells. Note the membranous staining of CD30 decorating tumor cells.*

TERMINOLOGY

Abbreviations

- Embryonal carcinoma (EC)

Synonyms

- EC adult type

Definitions

- Malignant germ cell tumor

ETIOLOGY/PATHOGENESIS

Etiology

- Although definitive etiology is unknown, misplaced germ cells in mediastinum may be origin of these tumors

CLINICAL ISSUES

Epidemiology

- Incidence
  - Unusual tumor in its pure form
  - More often accompanied with another germ cell tumor, mainly yolk sac tumor (YST)
  - May account for no more than 10% of all germ cell tumors of mediastinum
- Age
  - Tumor is more common in young adults
  - More common in 3rd decade of life
  - Unusual in older individuals
- Sex
  - More common in male patients
  - Unusual cases in female patients have been described

Presentation

- Chest pain
- Cough
- Dyspnea
- Klinefelter syndrome
- Hematologic dyscrasias
- Chromosomal abnormalities

Treatment

- Chemotherapy
- Cis platinum-based therapy
- Surgical debulking if appropriate

Prognosis

- Poor
- May depend on clinical staging

IMAGING

General Features

- Anterior mediastinal tumor
- Bulky tumor indistinguishable from other nonteratomatous germ cell tumors

MACROSCOPIC

General Features

- Large, ill-defined tumors
- Extensive necrosis and hemorrhage

Sections to Be Submitted

- Extensive sampling is required
- Possible sites of involvement
  - Lung
  - Pericardium
  - Lymph nodes
  - Diaphragm

Size

- Variable from few centimeters to > 10 cm in diameter

MICROSCOPIC

Histologic Features

- Gland-like appearance
- Sheets of neoplastic cells
- Primitive cellular proliferation
- Cells with prominent nucleoli
- Extensive necrosis
- Prominent cellular atypia and mitotic activity

Predominant Pattern/Injury Type

- Necrosis

Predominant Cell/Compartment Type

- Germ, nonseminomatous

ANCILLARY TESTS

Electron Microscopy

- Intercellular junctions and desmosomes
- Tight junctions and telolysosomes

DIFFERENTIAL DIAGNOSIS

Metastatic Adenocarcinoma of Lung Origin

- Glands in adenocarcinoma are better formed
- Glands in adenocarcinoma may show positive intracellular mucin
- Adenocarcinoma of lung origin may show TTF-1 positivity
- Lung adenocarcinomas are more common in older patients, unlike young age in EC
- Would be highly unusual for lung adenocarcinoma to show positive staining for CD30

Seminoma

- Seminomas show more cohesive growth pattern
- Seminomas rarely show extensive areas of necrosis
- EC may show positive staining for CD30 while being negative in seminomas
- EC shows more prominent nuclear atypia and mitotic activity

Yolk Sac Tumor

- YST and EC may show similar histopathological pattern
- YST and EC may show similar immunophenotype
- Presence of prominent nucleoli in EC may help in separating these tumors

Mixed Germ Cell Tumor

- Extensive sampling is of utmost importance
- EC is often accompanied with another germ cell tumor, namely YST

Immunohistochemistry

Antibody	Reactivity	Staining Pattern	Comment
α-fetoprotein	Positive	Cytoplasmic	Also positive in yolk sac tumors
PLAP	Positive	Cytoplasmic	In some cases, patchy and focal
SALL4	Positive	Nuclear	In some cases
NSE	Positive	Cytoplasmic	Not specific
LEU-7	Positive	Cytoplasmic	In some cases
CK-PAN	Positive	Cytoplasmic	Also positive in other epithelial tumors
CK8/18/CAM5.2	Positive	Cytoplasmic	Also positive in other epithelial tumors
CD30	Positive	Golgi zone	Not in all cases; also positive in anaplastic large cell lymphoma
EMA	Positive	Cell membrane	Positive in other epithelial tumors
CEA-M	Negative		
TTF-1	Negative		
CD15	Negative		
CD5	Negative		
HPL	Negative		May be focally positive in some cases
CD20	Negative		
ALK1	Negative		

Clinical Staging of Germ Cell Tumors of Mediastinum

Stage	Description
I	Well-circumscribed tumor ± focal adhesions to pleura or pericardium and without microscopic evidence of invasion into adjacent structures
II	Tumor confined to mediastinum with macroscopic &/or microscopic evidence of infiltration into adjacent structures, such as pleura, pericardium, and great vessels
III	Tumor with metastases
IIIA	With metastases to intrathoracic organs (lymph nodes, lung, etc.)
IIIB	With extrathoracic metastases

Histochemical Features

Stain	Result
PAS	Positive for intracellular glycogen
PAS-D	Negative for intracellular mucin
Mucicarmine	Negative for intracellular mucin

Thymic Carcinoma

- Some high-grade carcinomas of thymus may share some histopathological features
- Thymic carcinoma does not show staining for α-fetoprotein or CD30

Anaplastic Large Cell Lymphoma

- Anaplastic large cell lymphoma and EC may show positive staining for CD30 and EMA/MUC1
- Does not show positive staining for α-fetoprotein

DIAGNOSTIC CHECKLIST

Clinically Relevant Pathologic Features

- Gross appearance
- Extensive areas of hemorrhage and necrosis
- Bulky, slightly lobulated tumor

Pathologic Interpretation Pearls

- Gland-like growth pattern
- Embryonic type of epithelium
- Prominent nucleoli
- Nuclear pleomorphism and mitotic activity
- Extensive necrosis

SELECTED REFERENCES

1. Moran CA: Germ cell tumors of the mediastinum. Pathol Res Pract. 195(8):583-7, 1999
2. Weidner N: Germ-cell tumors of the mediastinum. Semin Diagn Pathol. 16(1):42-50, 1999

Macroscopic Features

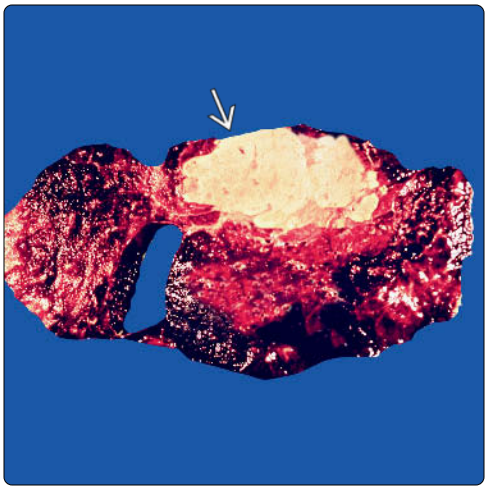

Solid and Gland-Like Features

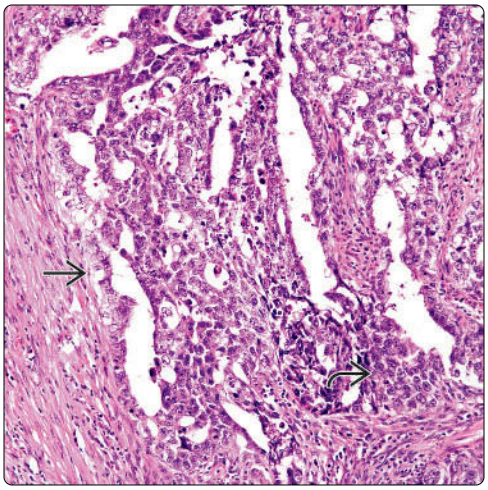

(Left) *Gross photograph shows a fairly well-circumscribed but not encapsulated tumor mass ➡ involving the thymic gland. The tumor is yellowish and lacks extensive areas of necrosis or hemorrhage.* **(Right)** *This embryonal carcinoma shows typical features of pseudoglandular ⇨ appearance and solid areas ⇨. These features are invariably seen in this tumor.*

Poorly Differentiated Areas

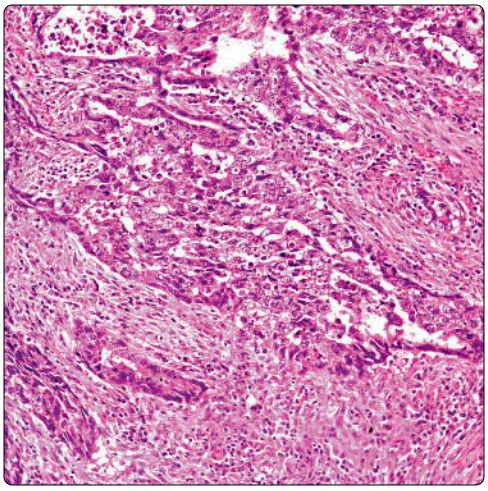

Mitotic Activity

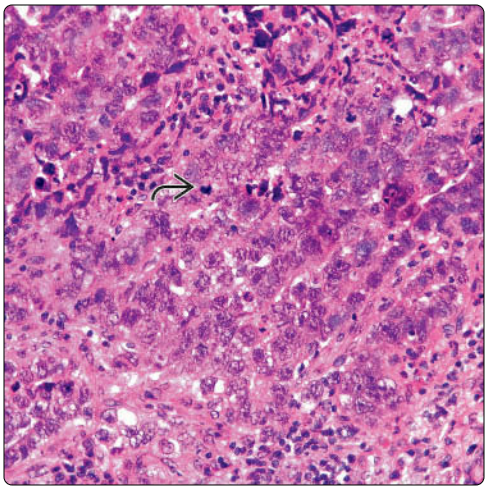

(Left) *Embryonal carcinoma shows neoplastic glandular structures dissecting fibroconnective tissue. This pattern can be seen in adenocarcinomas.* **(Right)** *This embryonal carcinoma shows solid areas. The neoplastic cells show medium-sized cells with eosinophilic cytoplasm, round vesiculated nuclei, and prominent nucleoli. Atypical mitotic figures are present ⇨.*

Haphazard Pattern

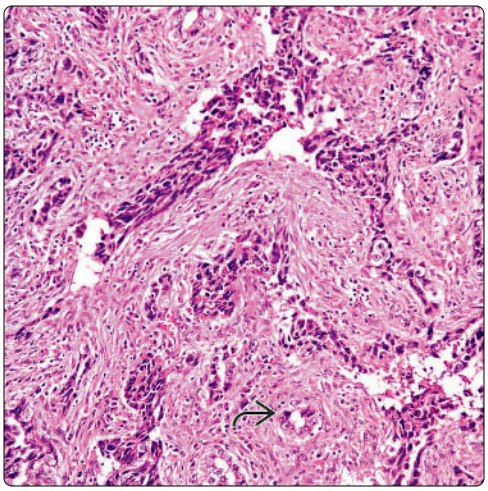

Small Gland-Like Areas

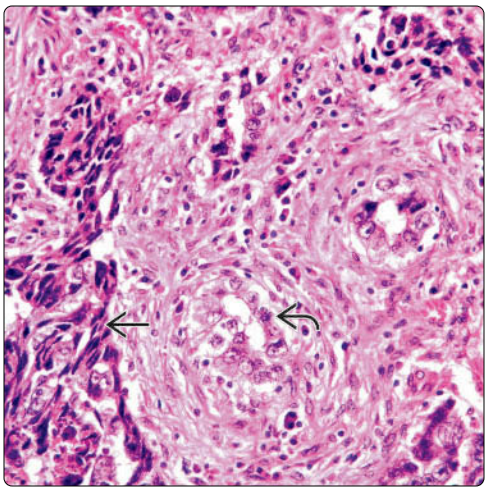

(Left) *Islands of tumor cells are dissecting fibroconnective tissue, giving the appearance of an epithelial neoplasm, namely squamous cell carcinoma. Note that the small glandular structures ⇨ are more in keeping with embryonal carcinoma.* **(Right)** *Higher magnification shows the contrast between the glandular structures ⇨ and the compressed islands of tumor cells ⇨.*

Focal Necrosis

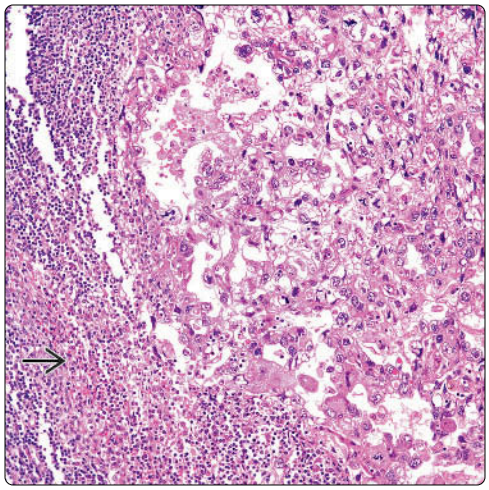

Extensive Necrosis

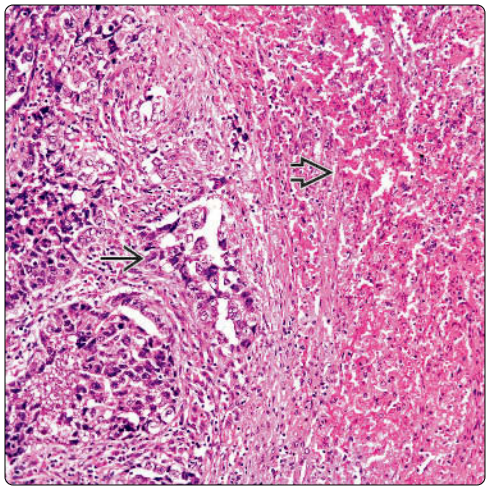

(Left) *In some cases, embryonal carcinoma may not show areas of necrosis but rather an inflammatory reaction composed mainly of lymphocytes and plasma cells.* **(Right)** *A common feature of embryonal carcinoma is the presence of extensive areas of necrosis. Note the transition areas with tumor cells.*

Hemorrhagic Areas

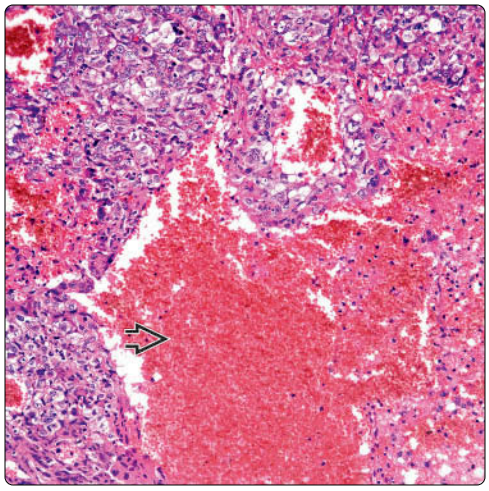

Focal Gland-Like Areas

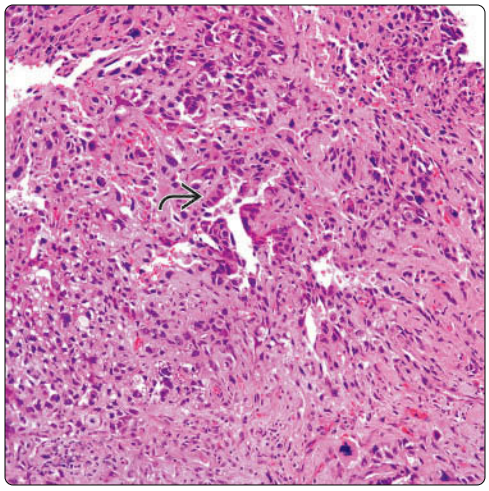

(Left) *Embryonal carcinoma may also show extensive areas of hemorrhage, which, in some cases, may obscure the nature of the neoplasm.* **(Right)** *Fibroconnective tissue infiltrated by neoplastic cells, which are in sheets and in focal areas, are seen forming pseudoglandular structures. This pattern can be confused for adenocarcinoma.*

Focal Pseudopapillary Areas

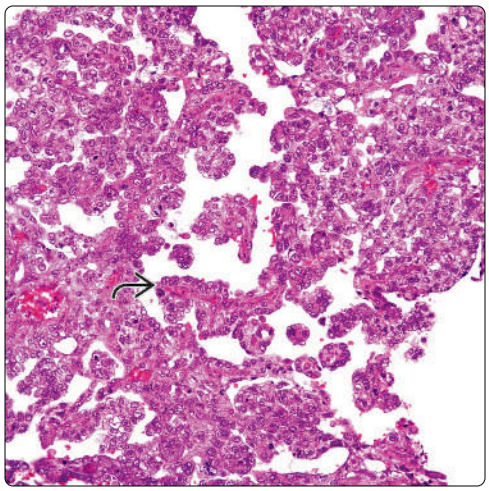

Sheets of Neoplastic Cells

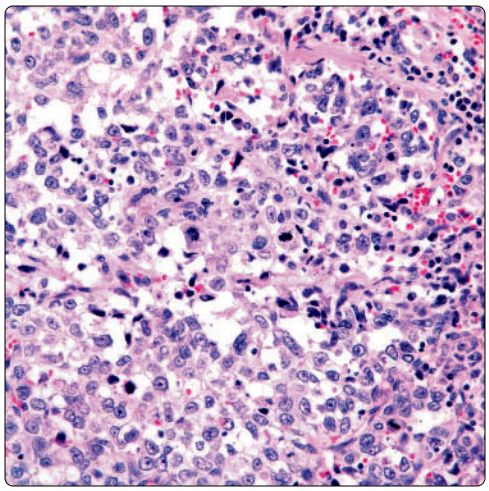

(Left) *Embryonal carcinoma shows cords of neoplastic cells, and, in focal areas, these cords acquire a pseudopapillary appearance.* **(Right)** *Embryonal carcinoma with a solid growth pattern is composed of medium-sized cells with prominent nucleoli. Numerous mitotic figures are easily identified.*

Cellular Atypia and Mitotic Activity

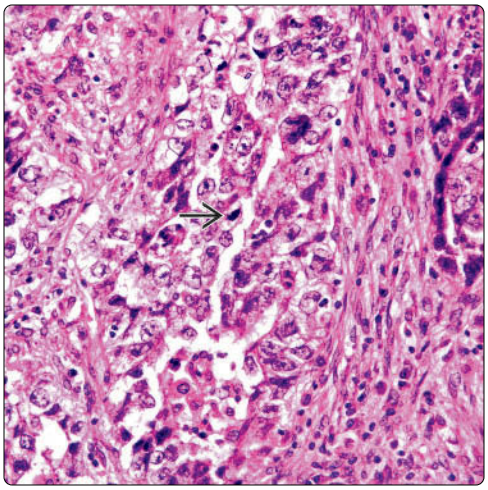

Large Cell With Vesiculated Cytoplasm

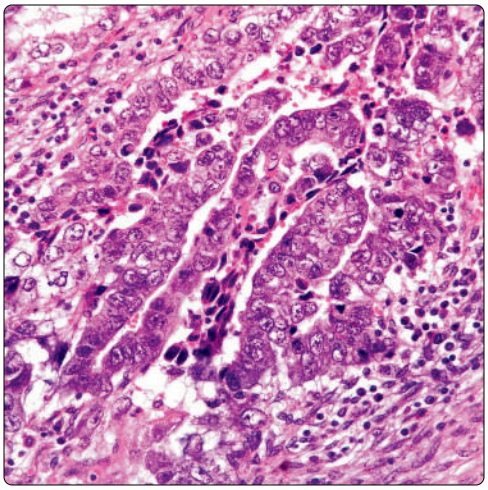

(Left) *This closer view shows neoplastic cells of embryonal carcinoma that are medium sized with round to oval vesiculated nuclei and prominent nucleoli. Mitoses are easily identified ⇨.* **(Right)** *High magnification shows neoplastic cells arranged in cords with little intervening stroma. No necrosis is present, but atypical mitotic figures are seen.*

Prominent Gland-Like Features

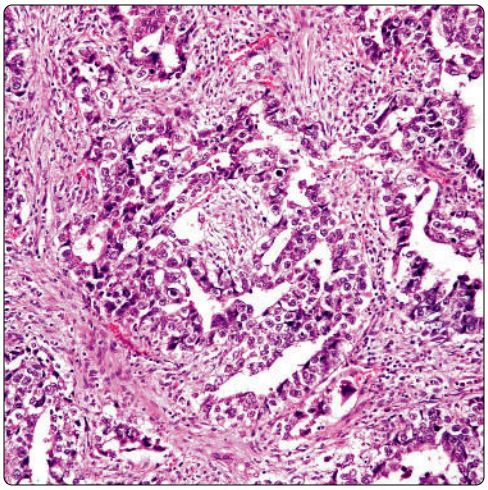

Solid and Gland-Like Areas

(Left) *Embryonal carcinoma shows a back-to-back glandular-like appearance. Note that the neoplastic cells have prominent nucleoli and a vesicular cytoplasm.* **(Right)** *Embryonal carcinoma with a pseudoglandular arrangement shows cells with a clear cytoplasm; even at this magnification, it is easy to observe nuclear atypia and mitotic activity.*

Focal Pseudoglandular Areas

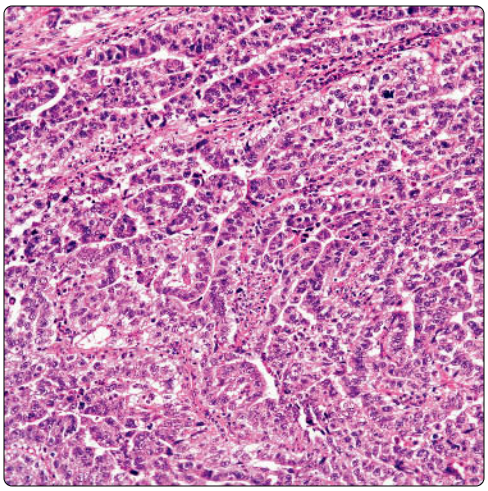

Neoplastic Cells in Fibrous Stroma

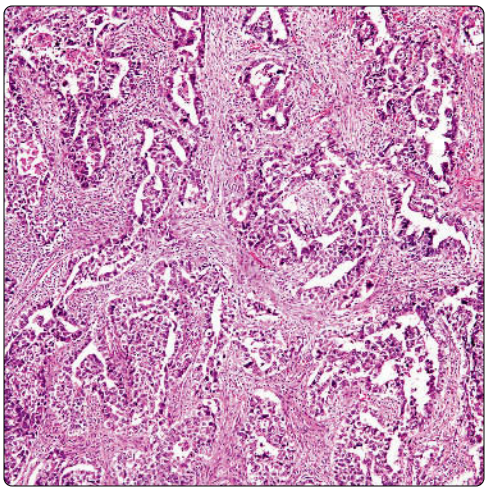

(Left) *Embryonal carcinoma shows cords and a pseudoglandular arrangement of neoplastic cells. This appearance can easily be confused with a metastatic carcinoma.* **(Right)** *Embryonal carcinoma shows the classic glandular appearance in which glands are separated by bands of fibroconnective tissue.*

Hodgkin Lymphoma of Mediastinum

KEY FACTS

CLINICAL ISSUES

- Asymptomatic in ~ 50% of patients (incidental finding on chest x-ray or CT scan)
- More frequent in young patients; female predilection
- Chest pain and dyspnea
- Fever and night sweats (type B symptoms) present in ~ 30% of patients

MACROSCOPIC

- Hodgkin lymphoma (HL) may involve mediastinal lymph nodes or thymus proper
- When involving thymus, tumor tends to be well circumscribed and encapsulated
- When involving thymus, cystic changes may be prominent in tumor

MICROSCOPIC

- Nodular sclerosing subtype is most common variant encountered in mediastinum
- Ill-defined, cellular nodules separated by broad bands of fibrous tissue
- Admixture of small lymphocytes, plasma cells, eosinophils, histiocytes, and Reed-Sternberg cells and their variants
- "Syncytial" variant of HL shows sheets of "lacunar" Reed-Sternberg cells surrounding areas of necrosis
- Classic Reed-Sternberg cells are large, binucleated, and display characteristic "owl-eyed" large eosinophilic nucleoli
- Mononuclear variants (Hodgkin cells) have large single nucleus with prominent eosinophilic nucleolus
- "Lacunar" Reed-Sternberg cells are characterized by clear halo surrounding nucleus

ANCILLARY TESTS

- Reed-Sternberg cells and their variants are positive for CD30 and CD15
  - Negative for CD3, CD20, and CD45

CT Scan in Mediastinal Hodgkin Lymphoma

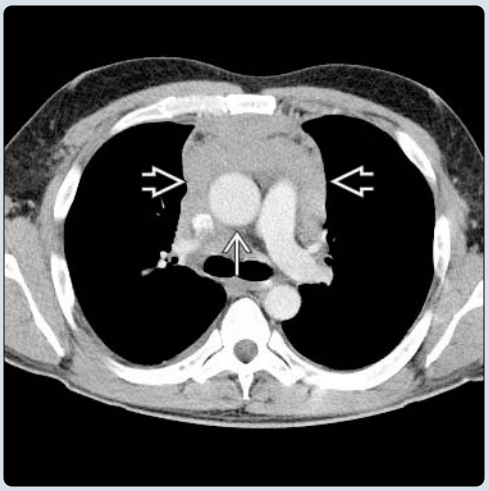

Nodular Sclerosing Hodgkin Lymphoma

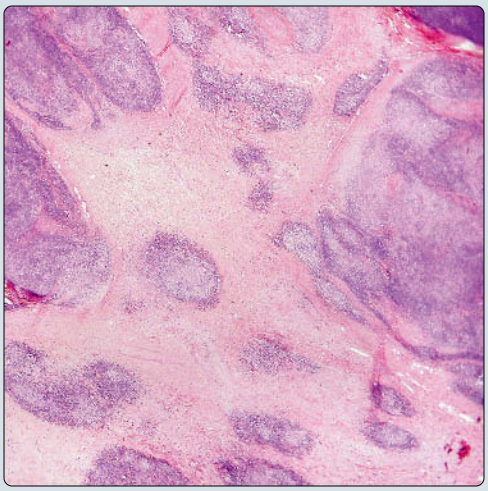

(Left) *Axial contrast-enhanced CT shows a soft tissue anterior mediastinal mass ⇨, which surrounds the aorta ⇨ and other vascular structures without obstruction. This is typical of Hodgkin lymphoma (HL).* **(Right)** *Scanning magnification shows nodules of varying sizes composed of a dense lymphoid cell population surrounded by bands of dense collagenized tissue, typical of nodular sclerosing HL.*

Reed-Sternberg Cell

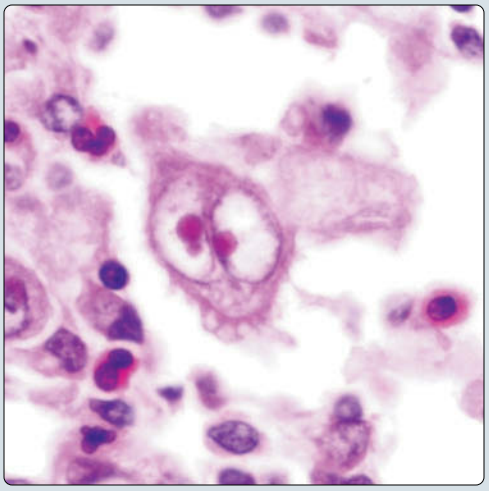

CD30 Stain in Reed-Sternberg Cell

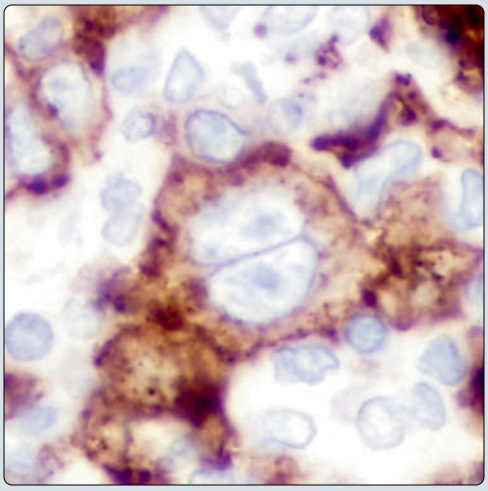

(Left) *A classic Reed-Sternberg cell is seen (center of the field) in HL. Notice the large nuclei with prominent "owl-eyed" nucleoli and scattered eosinophils surrounding them.* **(Right)** *Immunohistochemical stain for CD30 antigen shows membrane and cytoplasmic staining of a large, binucleated Reed-Sternberg cell (center) in HL.*

TERMINOLOGY

Abbreviations

- Hodgkin lymphoma (HL)

Synonyms

- Hodgkin disease
- Classic Hodgkin lymphoma (CHL)

Definitions

- Malignant proliferation of CD30/CD15(+) lymphoreticular cells of B-cell lineage intimately admixed with other reactive cellular elements arising within mediastinal lymph nodes &/or thymus

CLINICAL ISSUES

Presentation

- Asymptomatic in ~ 50% of patients (incidental finding on chest x-ray or CT scan)
- More frequent in young patients; female predilection
- Chest pain and dyspnea
- Advanced cases may present with superior vena cava syndrome
- Fever and night sweats (type B symptoms) present in ~ 30% of patients
- Disease may involve mediastinal lymph nodes, thymus, or both

Treatment

- Radiation therapy is effective for patients in stages I and II
- Advanced stages and bulky mediastinal disease require combination chemotherapy

Prognosis

- Mediastinal HL is curable disease for patients with stages I or II disease
- ~ 95% of patients with stage IA or IIA disease and small tumor burden will be alive and free of disease at 10 years
- Patients who fail chemotherapy for advanced disease and suffer relapse have poor prognosis

IMAGING

General Features

- Chest x-rays show solid, lobulated, anterior mediastinal mass
- Tumors can show multicystic changes on imaging studies
- Prevascular and paratracheal lymph nodes are most commonly affected

CT Findings

- Multiple rounded soft tissue masses or bulky soft tissue masses
- Displacement, compression, and invasion of mediastinal or chest wall structures

MACROSCOPIC

General Features

- HL may involve mediastinal lymph nodes or thymus proper
- When involving thymus, tumor tends to be well circumscribed and encapsulated
- Nodular, gray-white, homogeneous, and rubbery tissue on cut section
- When involving thymus, tumor may show prominent cystic changes

Sections to Be Submitted

- 1 block per centimeter of largest tumor diameter
- In cystic lesions, sample amply solid areas in cyst walls

MICROSCOPIC

Histologic Features

- Nodular sclerosing subtype is most common variant encountered in mediastinum
  - Ill-defined, cellular nodules separated by broad bands of fibrous tissue
  - Admixture of small lymphocytes, plasma cells, eosinophils, histiocytes, and Reed-Sternberg cells and their variants
  - Epithelial-lined cysts containing solid areas with characteristic lymphoreticular proliferation in cyst walls
  - Entrapped, hyperplastic thymic epithelium can be encountered within tumor in cases arising in thymus
  - Sclerosis can be massive, resulting in large expanses of acellular collagenous stroma with small islands containing characteristic tumor cells
  - Pattern of sclerosis may be fine and reticular, resulting in "compartmentalization" of tumor cells reminiscent of diffuse large B-cell lymphoma of mediastinum with sclerosis
- Syncytial variant of nodular sclerosis Hodgkin lymphoma
  - Sheets of "lacunar" Reed-Sternberg cells surrounding areas of necrosis

Cytologic Features

- Identification of Reed-Sternberg cells is required for diagnosis
  - Classic Reed-Sternberg cells are large, binucleated, and display characteristic "owl-eyed" large eosinophilic nucleoli
  - Mononuclear variants (Hodgkin cells) have large single nucleus with prominent eosinophilic nucleolus
  - "Lacunar" Reed-Sternberg cells are characterized by clear halo surrounding nucleus
  - Reed-Sternberg cells may show bizarre forms due to extensive degenerative changes
    - Anaplastic tumor cells with abundant cytoplasm reminiscent of pleomorphic high-grade sarcoma
    - Degenerating cells with pyknotic, hyperchromatic nuclei ("mummy" cells)

ANCILLARY TESTS

Immunohistochemistry

- Reed-Sternberg cells and their variants are positive for CD30 and CD15
  - Negative for CD3, CD20, and CD45

DIFFERENTIAL DIAGNOSIS

Germ Cell Tumor

- Seminoma, embryonal carcinoma, yolk sac tumor
- Elevated oncofetal proteins (AFP, PLAP, HCG, etc.) in serum

Immunohistochemistry

Antibody	Reactivity	Staining Pattern	Comment
CD30	Positive	Cell membrane & cytoplasm	Membranous and dot-like, paranuclear cytoplasmic positivity is distinctive pattern of staining for RS cells
CD15	Positive	Cell membrane & cytoplasm	Not as sensitive as CD30 for RS cells; can stain many other types of cells (i.e., granulocytes, etc.)
pax-5	Positive	Nuclear	pax-5 nuclear (faint) staining of Hodgkin cells is helpful to demonstrate B-cell lineage and distinguish HL from CD30/CD15(+), CD45/CD20(-) peripheral T-cell lymphoma
CD3	Negative	Not applicable	CD3 helps rule out peripheral T-cell lymphoma, especially when there is atypical medium-sized population of lymphocytes in background
CD20	Negative	Not applicable	CD20 is usually negative in RS cells; most CD30(+) large cell lymphomas of mediastinum are of B-cell type [CD20(+)]
CD45	Negative	Not applicable	RS cells are CD45(-), unlike diffuse large B-cell lymphoma in which cells are always positive

HL = Hodgkin lymphoma; RS = Reed-Sternberg.

- Absence of regional or generalized lymphadenopathy
- Absence of Reed-Sternberg cells

Thymoma

- Epithelial cells in thymoma are devoid of cytologic atypia or multinucleation
- Monotonous lymphoid cell infiltrate (immature T cells) seen in thymoma
- Absence of Reed-Sternberg cells in thymoma
- Large epithelioid cells in thymoma stain for cytokeratin rather than for CD30

Diffuse Large Cell Lymphoma of Mediastinum

- Pattern of sclerosis characterized by small compartments rather than large lobules
- Neoplastic cell population is more uniform than in HL, without eosinophils, histiocytes, and plasma cells
- Atypical tumor cells positive for CD20 and CD45 and negative for CD15 and CD30

Anaplastic Large Cell Lymphoma

- Tumor cells can look indistinguishable from Reed-Sternberg cells
- Cell population is more uniform and homogeneous
- Nodularity and sclerosis are not prominent features
- Tumor cells CD30(+) but CD15(-)
- Tumor cells may type as either T or B and may be ALK1(+)
- Can be confused for "syncytial" variant of HL; confirmation by immunohistochemistry is recommended

DIAGNOSTIC CHECKLIST

Clinically Relevant Pathologic Features

- Age distribution
  - Younger age group (children and adolescents)
- Gross appearance
  - Multinodular, lobulated, and infiltrative mass
  - Frequently displays prominent multicystic changes
  - Homogeneous, fleshy cut surface
- Invasive pattern
  - Often infiltrates adjacent organs (lung, pleura, pericardium)
  - Painless cervical and supraclavicular lymphadenopathy
- Nuclear features
  - Diagnosis based on identification of Reed-Sternberg cells
  - HL has large mono- or multinucleated cells with single or multiple prominent eosinophilic nucleoli
- Immunohistochemistry
  - Reed-Sternberg cells positive for CD30 and CD15

Pathologic Interpretation Pearls

- Reed-Sternberg cells must be present in appropriate milieu for diagnosis
- Diagnosis is best confirmed by immunohistochemistry
- Tumors can undergo extensive stromal sclerosis or massive cystic changes that will mask underlying disease

SELECTED REFERENCES

1. Piña-Oviedo S et al: Primary mediastinal classical Hodgkin lymphoma. Adv Anat Pathol. 23(5):285-309, 2016
2. Yamamoto W et al: Clinicopathological analysis of mediastinal large B-cell lymphoma and classical Hodgkin lymphoma of the mediastinum. Leuk Lymphoma. 54(5):967-72, 2013
3. Suster S et al: The Mediastinum. In Weidner et al: Modern Surgical Pathology. 2nd ed. Philadelphia: Saunders Elsevier. 454-516; 2009
4. Ng AK et al: Long-term results of a prospective trial of mantle irradiation alone for early-stage Hodgkin's disease. Ann Oncol. 17(11):1693-7, 2006
5. Krasin MJ et al: Patterns of treatment failure in pediatric and young adult patients with Hodgkin's disease: local disease control with combined-modality therapy. J Clin Oncol. 23(33):8406-13, 2005
6. Brice P et al: Advanced Hodgkin disease with large mediastinal involvement can be treated with eight cycles of chemotherapy alone after a major response to six cycles of chemotherapy: a study of 82 patients from the Groupes d'Etudes des Lymphomes de l'Adulte H89 trial. Cancer. 92(3):453-9, 2001
7. Enrici RM et al: Long-term results of 60 patients with pathologic stage I & IIA Hodgkin's disease treated with exclusive mantle radiation therapy. Eur J Haematol. 63(2):126-33, 1999
8. Glick RD et al: Lymphomas of the anterior mediastinum. Semin Pediatr Surg. 8(2):69-77, 1999
9. Higgins JP et al: CD30 expression is common in mediastinal large B-cell lymphoma. Am J Clin Pathol. 112(2):241-7, 1999
10. Roth SL et al: Contiguous pattern spreading in patients with Hodgkin's disease. Radiother Oncol. 47(1):7-16, 1998
11. Suzuki K et al: Isolated mediastinal Hodgkin's disease mimicking thymoma: report of a case. Surg Today. 28(2):213-6, 1998

Nodular Sclerosing Hodgkin Lymphoma

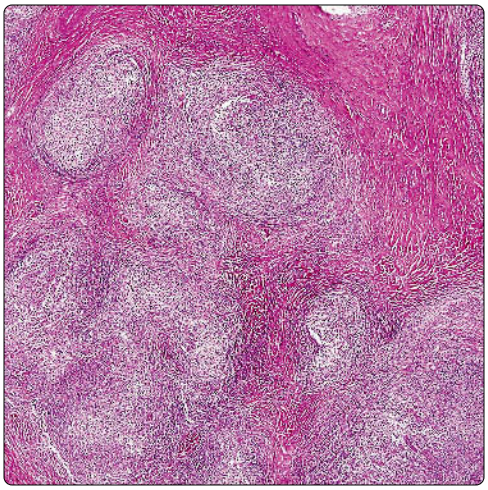

Hodgkin Lymphoma Nodule

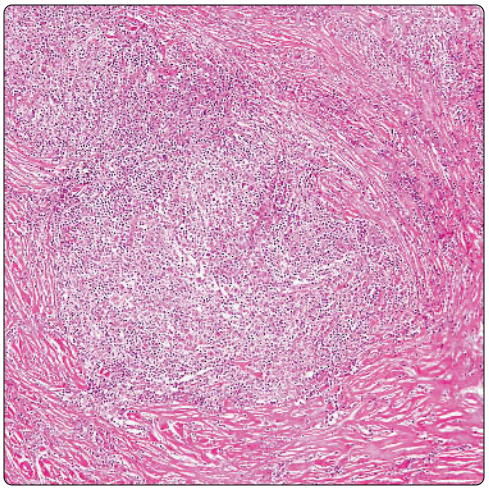

(Left) *Scanning magnification of typical example of nodular sclerosis HL shows several round cellular nodules separated by broad bands of dense fibroconnective tissue. Nodules are ill defined and of varying sizes.* **(Right)** *High magnification of nodular sclerosis HL shows a round cellular nodule containing a mixed population of cells and surrounded by dense fibroconnective tissue. The cell population within the nodule appears to be mixed.*

Nodular Sclerosis Hodgkin Lymphoma

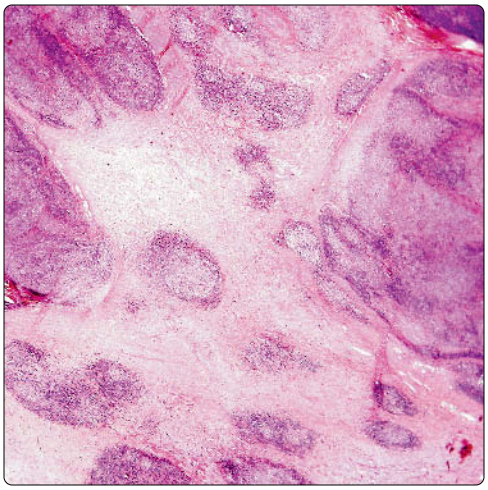

Perinodular Fibrosis

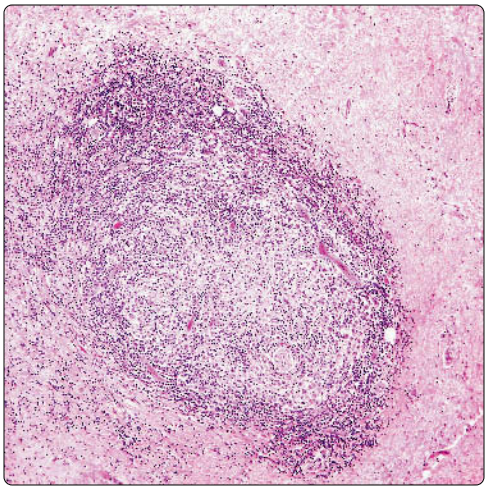

(Left) *Scanning magnification of nodular sclerosis HL shows more advanced fibrosis separating smaller nodules and creating large expanses of acellular connective tissue. A similar picture may be seen in other sclerosing tumors, such as seminoma.* **(Right)** *High power of nodular sclerosis HL shows a cellular nodule composed of an atypical cell population admixed with small lymphocytes, plasma cells, and eosinophils and surrounded by dense fibrous tissue.*

Cystic Changes

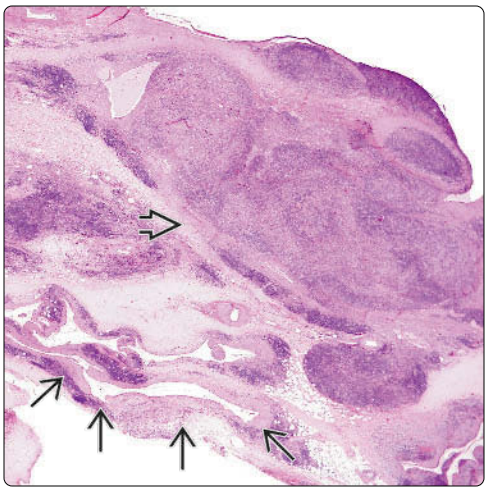

Cystic Mediastinal Hodgkin Lymphoma

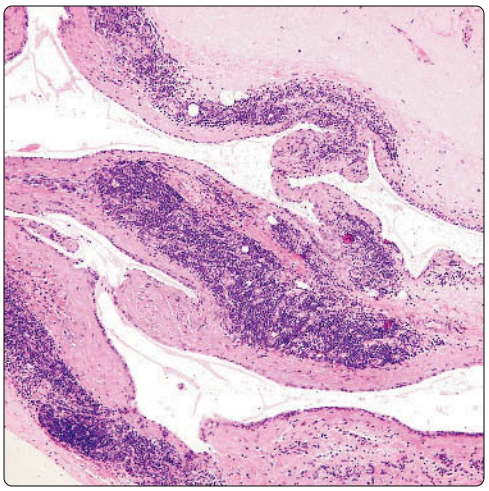

(Left) *Cystic HL shows a solid cellular nodule with neoplastic components in the wall of a large cyst and several smaller dilated cystic spaces noted toward the bottom of the field.* **(Right)** *The cystic spaces in cystic HL are lined by a single layer of simple cuboidal epithelium. The walls of the cysts harbor a dense lymphoid infiltrate containing lymphocytes, plasma cells, histiocytes, eosinophils, and scattered Reed-Sternberg cells.*

Nodular Sclerosing Hodgkin Lymphoma

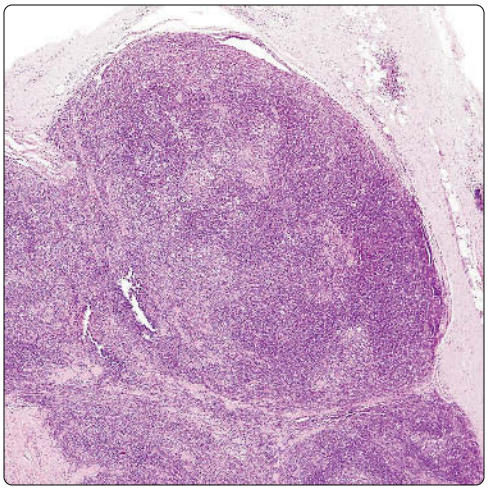

Lacunar Cells

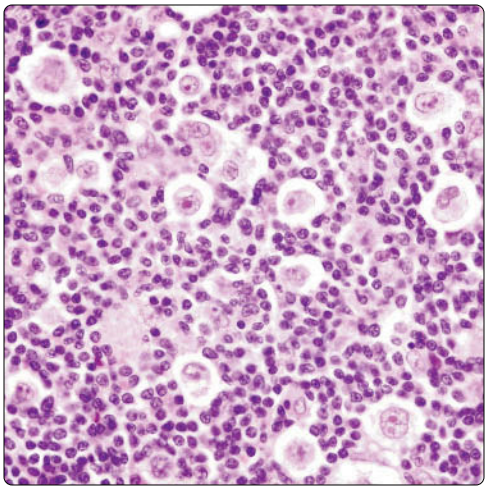

(Left) *Nodular sclerosis HL of the mediastinum shows sharp delineation of the round cellular nodule from the surrounding connective tissue, with sharp circumscription from the surrounding bands of fibrous tissue.* **(Right)** *High magnification of nodular sclerosis HL shows a dense lymphoid cell population punctuated by larger cells with clear halos ("lacunar" cells). Notice the large nuclei and prominent eosinophilic nucleoli within the "lacunar" cells.*

Mononuclear Hodgkin Cell

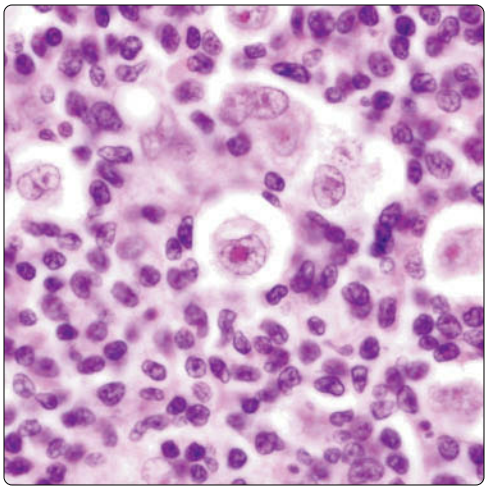

Binucleated Reed-Sternberg Cell

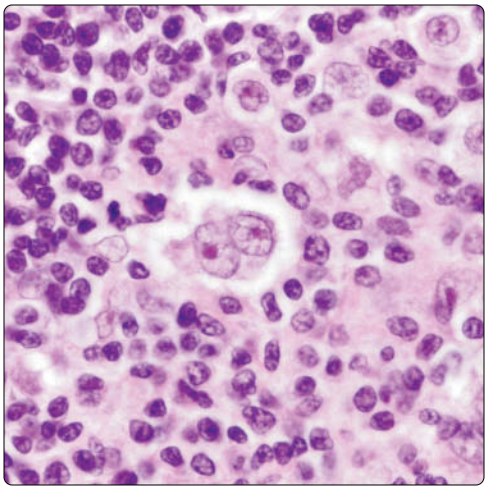

(Left) *High magnification of nodular sclerosis HL shows a characteristic mononuclear Reed-Sternberg cell. Notice the large nucleus with a clear halo and large, prominent single eosinophilic nucleolus.* **(Right)** *Higher magnification of nodular sclerosis HL shows a classic binucleated Reed-Sternberg cell. Notice the 2 large nuclei, each containing a single prominent eosinophilic nucleolus. The surrounding cell population is composed primarily of small lymphocytes.*

Entrapped Thymus

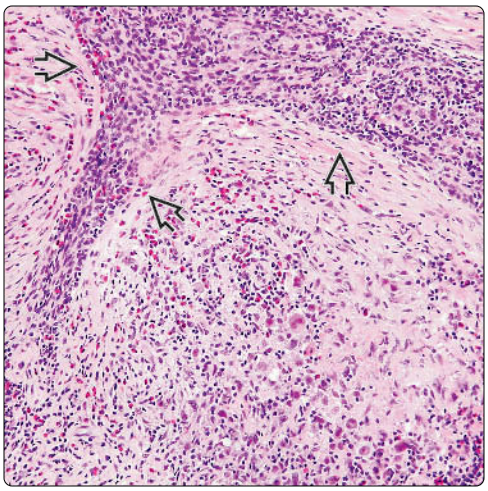

Mixed Infiltrate

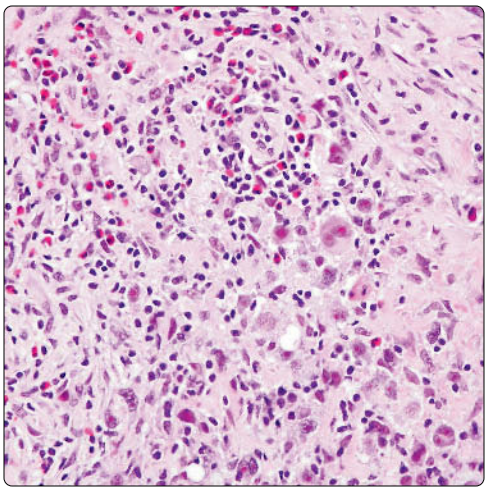

(Left) *Nodular sclerosis HL is seen involving the thymus. Notice entrapped hyperplastic thymic epithelium circumscribing the lymphoid cellular proliferation underneath with scattered prominent eosinophils.* **(Right)** *High magnification of nodular sclerosis HL involving the thymus shows a mixed cell population with small lymphocytes, abundant eosinophils, and scattered mononuclear and binucleated Reed-Sternberg cells.*

Multinucleated Reed-Sternberg Cell

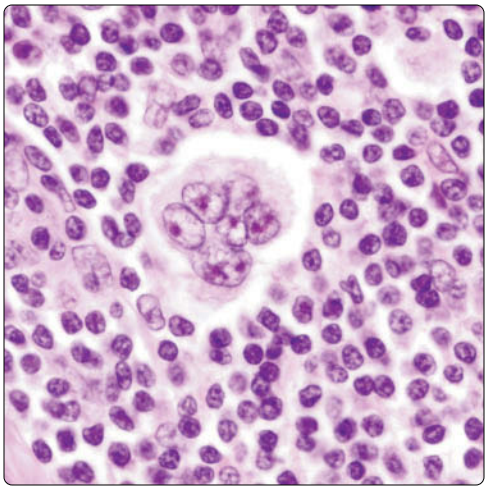

Binucleated Reed-Sternberg Cell

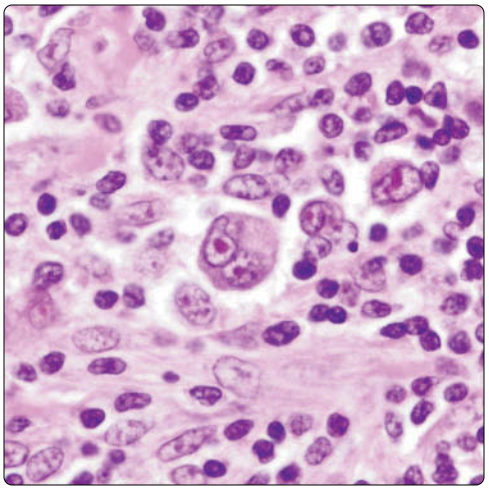

(Left) *Nodular sclerosis HL shows a Reed-Sternberg cell containing 6 nuclei (center of the field), each harboring a large, prominent eosinophilic nucleolus; the nuclei are surrounded by an indistinct rim of amphophilic cytoplasm.* **(Right)** *Nodular sclerosis HL shows a typical binucleated Reed-Sternberg cell with the characteristic "owl-eyed" nucleoli. Notice a few mononuclear variants of Reed-Sternberg cells (Hodgkin cells) lying in the vicinity.*

Pleomorphic Reed-Sternberg Cells

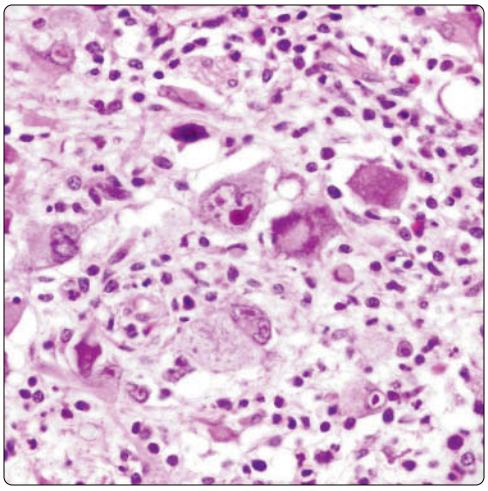

Anaplastic Morphology

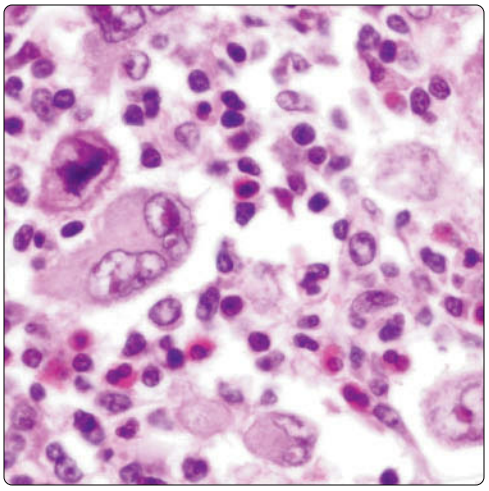

(Left) *Pleomorphic type of Reed-Sternberg cell in nodular sclerosis HL shows bizarre shapes, abundant dense eosinophilic cytoplasm, and prominent eosinophilic nucleoli surrounded by a mixed lymphoid cell population.* **(Right)** *Another example of anaplastic morphology in HL shows large, bizarre tumor cells, some of which contain multiple nuclei with prominent eosinophilic nucleoli. Notice the eosinophils surrounding the large atypical cells.*

Degenerating Reed-Sternberg Cell

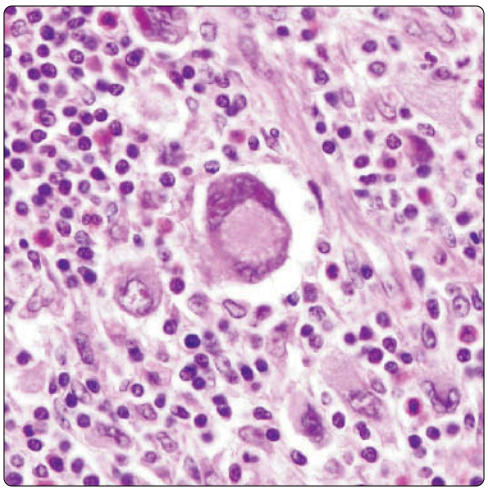

"Mummy" Cells

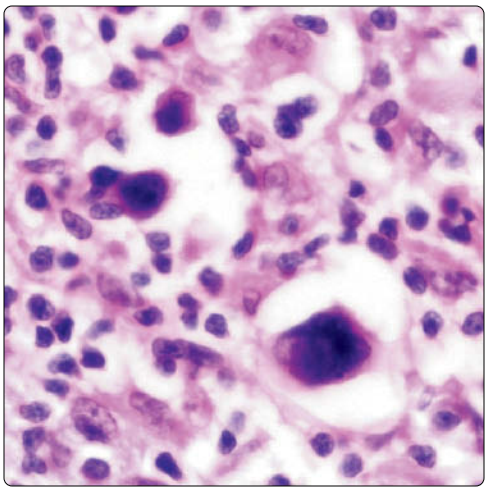

(Left) *Nodular sclerosis HL shows a degenerating, multinucleated Reed-Sternberg cell (center of the field) displaying abundant cytoplasm reminiscent of atypical cells seen in high-grade pleomorphic sarcomas (malignant fibrous histiocytoma).* **(Right)** *Nodular sclerosis HL shows hyperchromatic nuclei ("mummy" cells) present in Reed-Sternberg cells. The surrounding cell population is composed of lymphocytes, histiocytes, and plasma cells.*

Interstitial Sclerosis

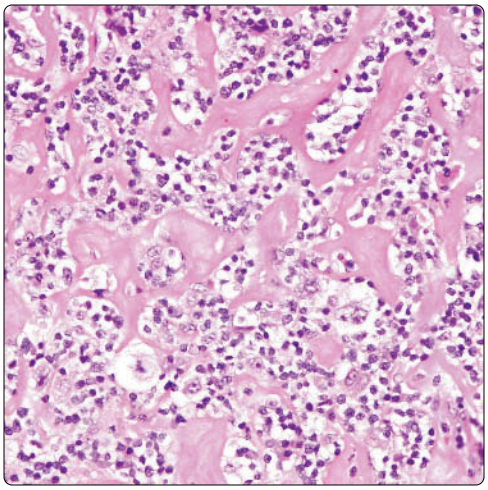

Interstitial Sclerosis: High Power

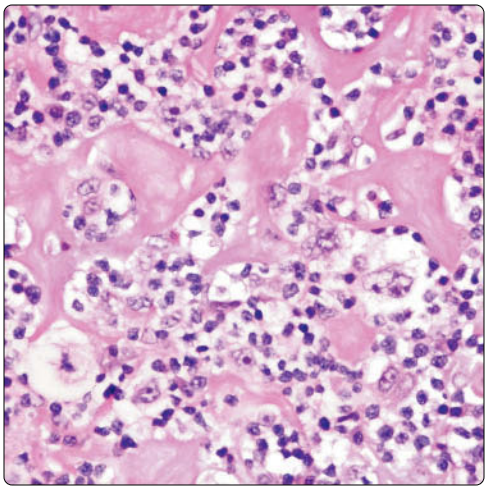

(Left) *Nodular sclerosis HL with an unusual pattern of fine interstitial sclerosis is shown in mediastinal HL, resulting in a compartmentalization effect reminiscent of diffuse large B-cell lymphoma of the mediastinum. Note fine bands of fibrous tissue separating the lymphoid cell population.* **(Right)** *High magnification of nodular sclerosis HL shows small islands of lymphoid cells with a few large, atypical mono- and multinucleated Reed-Sternberg cells.*

Syncytial Variant of Hodgkin Lymphoma

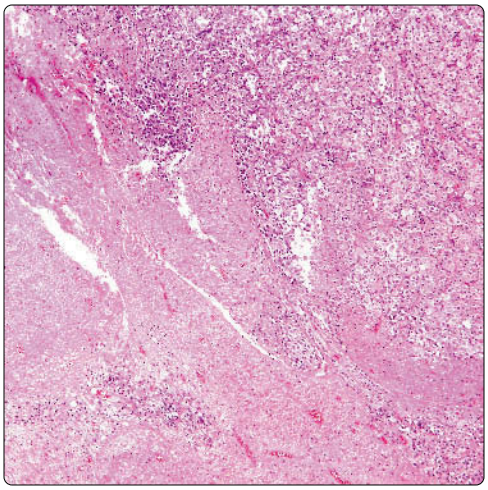

Necrosis in Syncytial Variant of Hodgkin Lymphoma

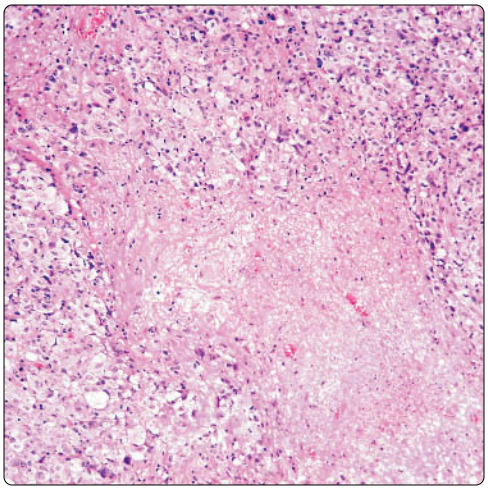

(Left) *Syncytial variant of HL of the mediastinum shows solid cellular areas (top right) separated from extensive areas of tumor cell necrosis (bottom half). The cells in the cellular areas form solid sheets and circumscribe the areas of necrosis.* **(Right)** *Syncytial variant of HL of the mediastinum shows sheets of large, atypical mononuclear cells surrounding a central, irregular area of necrosis. Notice the monotonous nature of the mononuclear cells.*

Syncytial Variant: High Power

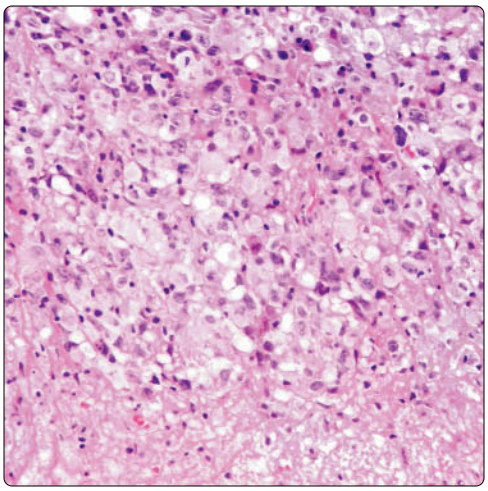

Mononuclear Hodgkin Cells

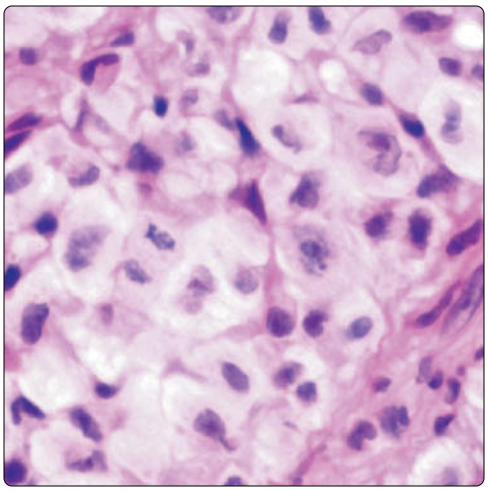

(Left) *High magnification of syncytial variant of HL shows solid cellular areas composed of an atypical cell population. Notice the uniformity and monotony of the tumor cell population. Such areas can closely resemble diffuse large B-cell lymphoma of the mediastinum.* **(Right)** *Higher magnification of syncytial variant of HL shows solid sheets of mononuclear lacunar Reed-Sternberg cells with enlarged nuclei and prominent clear cytoplasmic halos.*

CD3 Immunostaining

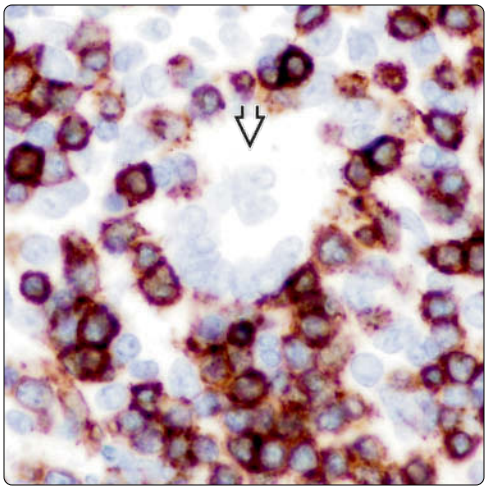

CD45 Immunostaining

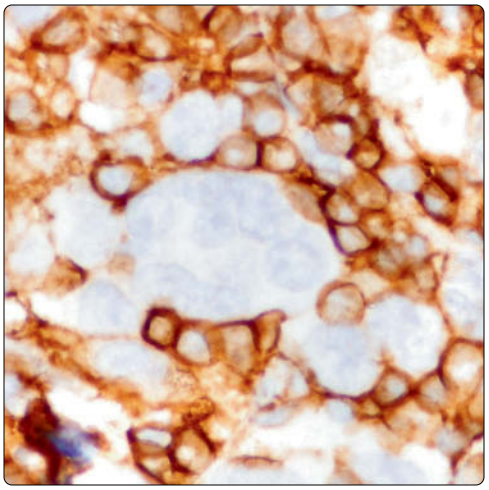

(Left) *Immunoperoxidase stain for CD3 highlights small T lymphocytes in HL. Notice the rosette-like distribution of CD3(+) T lymphocytes around a Reed-Sternberg cell.* **(Right)** *Immunohistochemical staining of HL of the mediastinum for CD45 shows staining of the small lymphocytes in the periphery but negative staining of the large, multinucleated Reed-Sternberg cell in the center of the field.*

CD15 Immunostaining

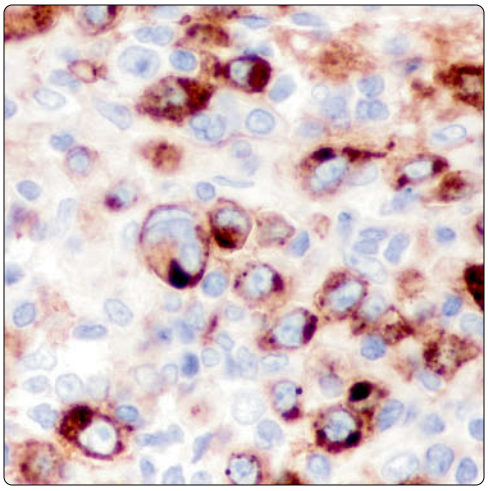

CD30 Immunostaining

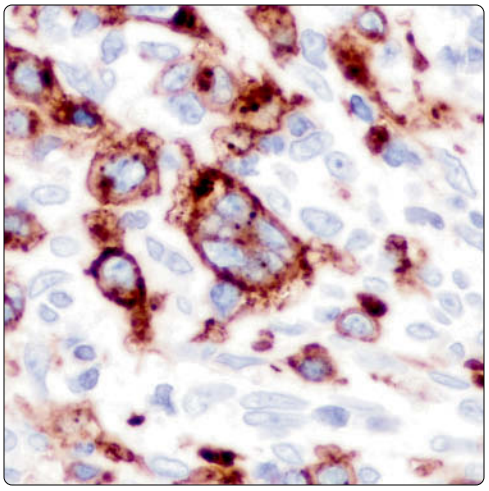

(Left) *Immunohistochemical staining of HL shows positivity for CD15 (Leu-M1) in scattered Reed-Sternberg cells. Notice that the staining pattern is both membranous and paranuclear, with Golgi zone distribution.* **(Right)** *Immunohistochemical staining shows positivity of Reed-Sternberg cells in HL for CD30. Notice the membrane and dot-like paranuclear pattern of staining of the large, multinucleated Reed-Sternberg cell in the center of the field.*

CD30 Positivity in Reed-Sternberg Cell

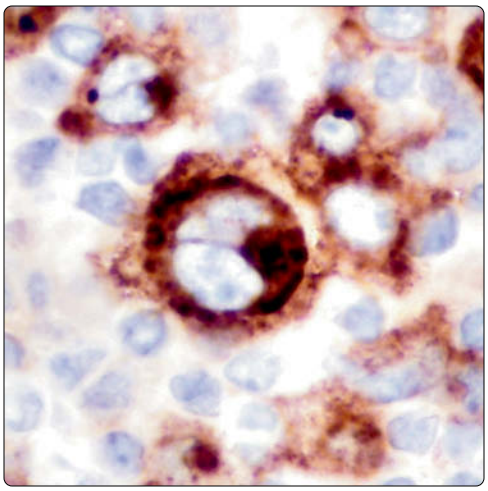

pax-5 Positivity in Reed-Sternberg Cells

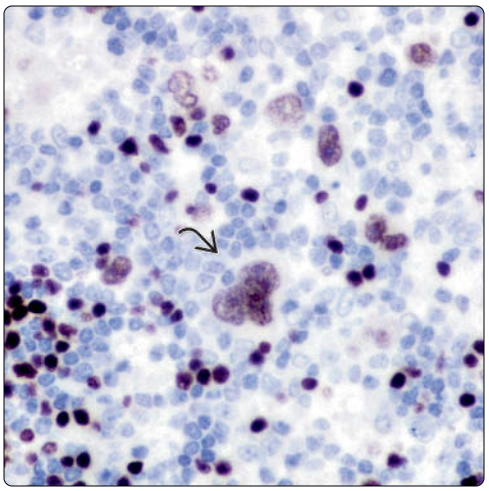

(Left) *Immunoperoxidase stain shows membranous, cytoplasmic, and dot-like paranuclear positivity for CD30 in a large, binucleated Reed-Sternberg cell in the center of the field in classic HL.* **(Right)** *Immunohistochemical staining for pax-5 shows positive nuclear staining in Reed-Sternberg cells in classic HL. This serves to identify these cells as of B-cell lineage in equivocal cases and supports a diagnosis of HL over that of T-cell lymphoma.*

Diffuse Large Cell Lymphoma of Mediastinum

KEY FACTS

CLINICAL ISSUES

- Predominantly affects women in 3rd decade of life
- Presents with rapidly growing, large (> 10 cm in diameter), infiltrative anterior mediastinal mass
- Rarely involves peripheral lymph nodes, bone marrow, or other lymphoid organs
- Commonly presents with superior vena cava syndrome, pleural effusion, and airway obstruction
- Relapses involve variety of extrathoracic sites, including kidneys, adrenals, liver, and central nervous system

MICROSCOPIC

- Nuclei may show great variability, from centroblastic to immunoblastic morphology
- Nuclear pleomorphism with bizarre forms can often be found
- Crushing artifact is common finding in small endoscopic biopsies or core needle biopsies
- Stromal sclerosis may be fine and delicate or coarse, separating tumor cells into small nests
- Consistent B-cell phenotype: CD19(+), CD20(+), CD22(+), CD79-α(+)
- Other markers: May show CD30(+) when using heat-induced epitope retrieval techniques; generally Bcl-6(+), variably Bcl-2(+)
- Negative markers: Ig, CD5, CD15, CD21, CD30 (in multinucleated tumor cells), EBV
- Other lymphoid markers: CD45(+), HLA-DR(+), IgG or IgA (+), may show κ or λ light chain restriction
- Reed-Sternberg-like cells and small multinucleated or multilobated cells can also be seen
- Cells can be spindled, signet ring, clear, or pleomorphic
- Tumors involving thymus may contain entrapped benign thymic epithelial elements

ANCILLARY TESTS

- May show κ or λ light chain restriction

Gross Appearance

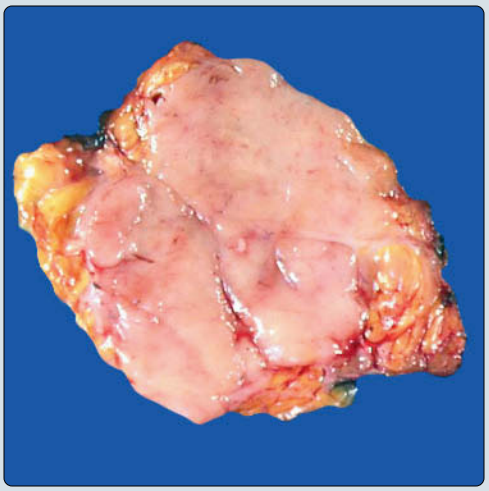

Atypical Lymphoid Cells

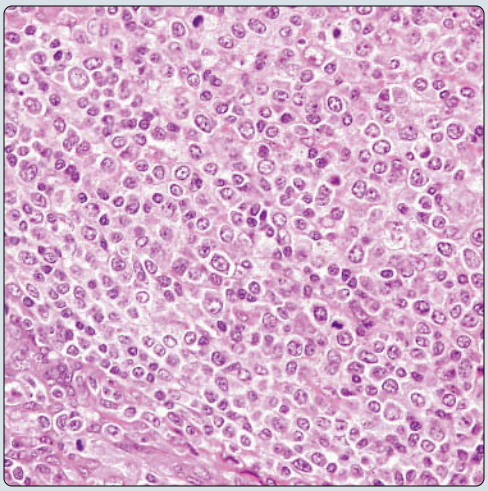

(Left) *Gross photograph of mediastinal diffuse large cell lymphoma (MDLCL) shows an ill-defined mass with tan-white, lobulated, and homogeneous cut surface with a fish-flesh appearance.* **(Right)** *Sheets of large, atypical lymphoid cells are seen in this example of MDLCL. The tumor cells marked positively with B-cell antigens, including CD20, CD79a, and Bcl-6.*

Sclerosis

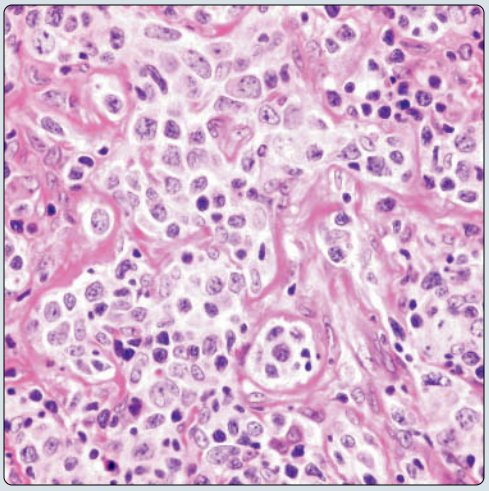

Higher Magnification

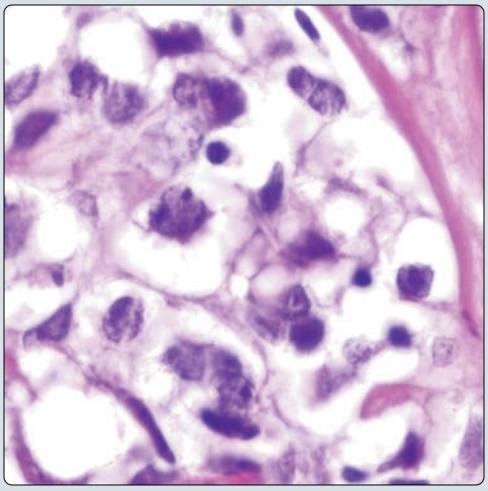

(Left) *The histologic appearance of mediastinal diffuse large cell lymphoma is characterized in a significant number of cases by the formation of small islands or nests of large tumor cells separated by thin, collagenized, fibrous septa imparting a striking nested appearance.* **(Right)** *The tumor cells in MDLCL are characterized by enlarged, hyperchromatic nuclei with prominent nucleoli and rim of amphophilic or lightly eosinophilic cytoplasm.*

TERMINOLOGY

Synonyms

- Mediastinal large B-cell lymphoma; mediastinal diffuse large cell lymphoma (MDLCL); diffuse large cell lymphoma with sclerosis

Definitions

- Primary large cell lymphoma arising from native thymic lymphoid B-cell population

ETIOLOGY/PATHOGENESIS

Pathogenesis

- Derived from extranodal, mucosa-associated, native lymphoid cell population originating in medullary compartment of thymus
- In some cases, may represent progression from extranodal marginal zone B-cell lymphoma (MALToma) of thymus
- Gene expression profiling has demonstrated 30% similarity of gene expression with classic Hodgkin lymphoma

CLINICAL ISSUES

Epidemiology

- Incidence
  - Represents ~ 6% of all large cell lymphomas in adults
  - Represents ~ 25% of all childhood non-Hodgkin lymphomas
- Age
  - Most commonly occurs in young adults (range: 15-73 years; median: 32 years)
  - Can also occur in children and adolescents
- Sex
  - Predilection for women

Presentation

- Distinctive clinicopathologic syndrome
  - Predominantly affects women in 3rd decade of life
  - Presents with rapidly growing, large (> 10 cm in diameter), infiltrative anterior mediastinal mass
  - Rarely involves peripheral lymph nodes, bone marrow, or other lymphoid organs
  - Commonly presents with superior vena cava syndrome, pleural effusion, and airway obstruction
  - Relapses involve variety of extrathoracic sites, including kidneys, adrenals, liver, and central nervous system

Treatment

- Combination chemotherapy ± radiation therapy

Prognosis

- Despite high-grade histology and aggressive presentation, diffuse large cell lymphoma of mediastinums respond well to combination chemotherapy
- Recent studies have shown remission rates of nearly 80% and disease-free survival of 60% at 3 years

IMAGING

Radiographic Findings

- Mediastinal widening with pleural effusion

CT Findings

- Large mediastinal mass obscuring borders of heart and great vessels

MACROSCOPIC

General Features

- Bulky mediastinal disease with infiltration of lung, pleura, pericardium, and chest wall
- Homogeneous rubbery cut surface; may show areas of hemorrhage and necrosis

MICROSCOPIC

Histologic Features

- Most cases are characterized by sheets of large lymphoid cells with prominent nucleoli and pale cytoplasm
- May show unusual histologic features, including following subtypes
  - Clear cell mediastinal lymphoma
    - Sheets of large CD20(+) lymphoid cells with large nuclei and prominent nucleoli surrounded by ample rim of water-clear cytoplasm
    - Clear cell lymphoma may resemble metastases of renal cell carcinoma and other clear cell malignant neoplasms
  - Spindle cell mediastinal lymphoma
    - Sheets or fascicles of CD20(+) spindle cells with elongated, hyperchromatic nuclei
    - May show prominent storiform pattern resembling malignant fibrohistiocytic neoplasms
    - May be confused for variety of spindle cell sarcomas
  - Pleomorphic mediastinal large cell lymphoma
    - Sheets of bizarre CD20(+) pleomorphic tumor cells with atypical multinucleated and multilobated cells
    - May resemble variety of high-grade pleomorphic sarcomas
  - Large cell mediastinal lymphoma with marked tropism for germinal centers ("germinotropic lymphoma")
    - Clusters of large CD20(+) atypical lymphoid cells encroaching on germinal centers and replacing follicular center cells
    - Irregular replacement of follicles by large, atypical lymphoid cells in fashion reminiscent of progressive transformation of germinal centers
    - Atypical lymphoid cells are found within lymphoid follicles without involvement of interfollicular areas
    - Germinotropic lymphoma may be confused for mediastinal seminoma, metastatic carcinoma, or melanoma
  - Signet ring cell mediastinal lymphoma
    - Sheets or singly scattered CD20(+) lymphoid cells displaying prominent signet ring cell features admixed with lymphoid cells
    - May be confused for liposarcoma or metastases of signet ring cell carcinoma
  - Mediastinal large B-cell lymphoma with Hodgkin-like or anaplastic large cell lymphoma-like features
    - Sheets of large anaplastic CD20(+) lymphoid cells with indented nuclei and prominent eosinophilic nucleoli

  - Sheets of Reed-Sternberg-like multinucleated or multilobated B-lymphoid cells with prominent eosinophilic nucleoli
  - Tumor cells may be CD30(+) but are also CD20(+) and ALK1(-) and T-cell markers (-)
- Diffuse large B-cell lymphoma with sclerosis
  - Nests of large, atypical CD20(+) lymphocytes surrounded by variable degrees of stromal collagenization, creating compartmentalized growth pattern
  - Stromal sclerosis may be fine and delicate or coarse, separating tumor cells into small nests
  - Advanced stages of collagenization may show extensive paucicellular stromal sclerosis with few residual atrophic tumor cells
  - May be confused for carcinoma or melanoma due to nested growth pattern
- Other unusual histologic features
  - Residual thymic epithelial islands may show hyperplastic features and undergo cystic changes
  - Sheets of atypical B lymphocytes may show degenerative changes, resulting in pseudoalveolar growth pattern
  - Tumor cells may show angiocentric distribution around vessel walls with plugging of vessel wall lumen
  - Some cases show overlapping morphologic and genetic features with Hodgkin lymphoma (so-called gray-zone lymphoma)

Cytologic Features

- Nuclei may show great variability, from centroblastic to immunoblastic morphology
- Nuclear pleomorphism with bizarre forms can often be found
- Reed-Sternberg-like cells and small multinucleated or multilobated cells can also be seen
- Cells can be spindled, signet ring, clear, or pleomorphic
- Crushing artifact is common finding in small endoscopic biopsies or core needle biopsies
- Tumors involving thymus may contain entrapped benign thymic epithelial elements
- Tumor cell necrosis is frequent finding in large tumors
- Tumor cells often show extensive infiltration of adjacent structures with sparing and preservation of mediastinal fat

ANCILLARY TESTS

Immunohistochemistry

- Consistent B-cell phenotype: CD19(+), CD20(+), CD22(+), CD79-α(+)
- Other lymphoid markers: CD45(+), HLA-DR(+), IgG or IgA (+)
- Other markers: May show weak CD30 positivity when using heat-induced epitope retrieval techniques; generally Bcl-6(+), variably Bcl-2(+)
- Negative markers: Ig, EBV, CD5, CD15, CD21, CD30 (in multinucleated tumor cells)
- Immunoexpression of MAL is seen in 50% of cases
- May show κ or λ light chain restriction

Genetic Testing

- Frequent chromosomal gains: 2p, 6p, 7q, 9p, 12, and X
- Most important cytogenetic abnormality is gain of chromosome arm 9p observed in up to 75% of cases, leading to overexpression of c-REL
- Aberrations of chromosome X are seen in up to 87% of cases
- Bcl-2 rearrangements observed in up to 30% of cases
- Overexpression of *MAL* gene is believed to be specific for MDLCL, although it is shared with classic Hodgkin lymphoma
- Immunoglobulin gene rearrangements are present
- Absence of Epstein-Barr virus genome

DIFFERENTIAL DIAGNOSIS

Thymic Carcinoma and Metastatic Carcinoma

- Tumor cells are cohesive and positive for epithelial markers (cytokeratins, etc.) in thymic carcinoma
- Metastatic renal cell carcinoma is positive for cytokeratins, EMA, CD10, and vimentin
- Thymic carcinoma and metastatic carcinoma tend to occur at older age

Anaplastic Large Cell Lymphoma

- Sclerosis and compartmentalization are not features of anaplastic large cell lymphoma (ALCL)
- Immunophenotype of ALCL is CD30(+), ALK1(+)
- Staining for CD30 in neoplastic cells is stronger and more diffuse in ALCL than in MDLCL
- ALCL is characterized by t(2;5) translocation

Hodgkin Lymphoma

- Mixed cell infiltrate with eosinophils, plasma cells, and small lymphocytes
- Reed-Sternberg cells are CD15/CD30(+) and CD19(-), CD20(-), and CD22(-)

Metastatic Amelanotic Malignant Melanoma

- Melanoma cells are positive for S100 protein and other melanocytic markers (HMB-45, Melan-A, tyrosinase, etc.)
  - Melanoma cells are CD20 and CD45 (-)

Mediastinal Seminoma

- Tumor cells have large vesicular nuclei with prominent irregular nucleoli due to presence of nucleolonemata
- Tumor cells are PLAP(+), OCT4(+), D2-40(+), CD20(-), and CD45(-)

Sarcoma

- Usually occurs in older age group than MDLCL
- Pleomorphic sarcomas are negative for lymphoid markers (CD20, CD45)

DIAGNOSTIC CHECKLIST

Clinically Relevant Pathologic Features

- Age distribution
  - Young adults (3rd-4th decades)
- Gross appearance
  - Large bulky masses with extensive infiltration of local structures (lung, pleura, pericardium, diaphragm, etc.)
- Metastatic distribution
  - Unusual distribution of extrathoracic metastases: Kidneys, adrenals, liver, pancreas, ovaries, CNS

Immunohistochemistry

Antibody	Reactivity	Staining Pattern	Comment
CD20	Positive	Cell membrane	Strongly positive in all cases of MDLCL
CD45	Positive	Cytoplasmic	Positive in majority of cases of MDLCL
CD19	Positive	Cytoplasmic	Positive in majority of cases of MDLCL
CD22	Positive	Cytoplasmic	Positive in majority of cases of MDLCL
CD79-α	Positive	Cytoplasmic	Positive in all cases of MDLCL
HLA-DR	Positive	Cytoplasmic	Positive in majority of cases of MDLCL
Bcl-2	Positive	Nuclear	Positive in majority of cases of MDLCL
Bcl-6	Positive	Nuclear	Positive in majority of cases of MDLCL
CD5	Negative	Not applicable	Helpful for differentiating MDLCL from follicular lymphoma
CD10	Negative	Not applicable	May be positive in 50% of MDLCL
CD15	Negative	Not applicable	Helpful for differentiating MDLCL from Hodgkin lymphoma
CD21	Negative	Not applicable	Helpful for differentiating MDLCL from conventional nodal-based DLCL
ALK1	Negative	Not applicable	Useful for differentiating MDLCL from ALCL
CD30	Equivocal	Cytoplasmic	Positivity in MDLCL is weak and cytoplasmic, rather than strong and paranuclear as in ALCL

ALCL = anaplastic large cell lymphoma; DLCL = diffuse large cell lymphoma; MDLCL = mediastinal diffuse large cell lymphoma.

Pathologic Interpretation Pearls

- Core biopsies are often difficult to diagnose due to distortion by sclerosis or necrosis
- Care must be taken not to misinterpret keratin (+), entrapped, residual thymic epithelium for evidence of carcinoma on small biopsies
- Nested, compartmentalized appearance should not be mistaken for other types of tumors
- High level of suspicion should exist in proper clinicopathologic context
  - Young female patient
  - Rapidly growing and extensively invasive anterior mediastinal mass
  - No peripheral lymphadenopathy
- Immunohistochemical stains are critical for diagnosis
  - CD20/CD45(+)
  - May be weakly and focally positive for CD30 using heat-induced epitope retrieval
  - CD5(-), CD10(-), CD15(-), CD21(-)
  - Negative for other markers of differentiation (keratins, CEA, EMA, S100 protein, HMB-45, PLAP, etc.)
  - Overexpression of *MAL* gene is seen in 50% of cases and is considered specific for MDLCL, but it can also be observed in 30% of nodular sclerosing Hodgkin lymphoma
- Molecular studies may be of limited value
  - No rearrangements of T-cell receptor β chain gene constant region
  - No distinctive cytogenetic chromosomal translocations
  - May show Ig heavy or light chain gene rearrangements
  - Absence of t(2;5) may help to distinguish MDLCL from ALCL in equivocal cases

SELECTED REFERENCES

1. Vitolo U et al: Extranodal diffuse large B-cell lymphoma (DLBCL) and primary mediastinal B-cell lymphoma: ESMO Clinical Practice Guidelines for diagnosis, treatment and follow-up. Ann Oncol. ePub, 2016
2. Bhatt VR et al: Primary mediastinal large B-cell lymphoma. Cancer Treat Rev. 41(6):476-85, 2015
3. Dunleavy K et al: Emerging biological insights and novel treatment strategies in primary mediastinal large B-cell lymphoma. Semin Hematol. 52(2):119-125, 2015
4. Faris JE et al: Primary mediastinal large B-cell lymphoma. Clin Adv Hematol Oncol. 7(2):125-33, 2009
5. Fietz T et al: Treatment of primary mediastinal large B cell lymphoma with an alternating chemotherapy regimen based on high-dose methotrexate. Ann Hematol. 88(5):433-9, 2009
6. Dunphy CH et al: Primary mediastinal B-cell lymphoma: detection of BCL2 gene rearrangements by PCR analysis and FISH. J Hematop. 1(2):77-84, 2008
7. Massoud M et al: Primary mediastinal large B-cell lymphomas treated with dose-intensified CHOP alone or CHOP combined with radiotherapy. Leuk Lymphoma. 49(8):1510-5, 2008
8. Rodríguez J et al: Primary mediastinal B-cell lymphoma: treatment and therapeutic targets. Leuk Lymphoma. 49(6):1050-61, 2008
9. Kimm LR et al: Frequent occurrence of deletions in primary mediastinal B-cell lymphoma. Genes Chromosomes Cancer. 46(12):1090-7, 2007
10. Renné C et al: High expression of several tyrosine kinases and activation of the PI3K/AKT pathway in mediastinal large B cell lymphoma reveals further similarities to Hodgkin lymphoma. Leukemia. 21(4):780-7, 2007
11. Hamlin PA et al: Primary mediastinal large B-cell lymphoma: optimal therapy and prognostic factor analysis in 141 consecutive patients treated at Memorial Sloan Kettering from 1980 to 1999. Br J Haematol. 130(5):691-9, 2005
12. Traverse-Glehen A et al: Mediastinal gray zone lymphoma: the missing link between classic Hodgkin's lymphoma and mediastinal large B-cell lymphoma. Am J Surg Pathol. 29(11):1411-21, 2005
13. Savage KJ et al: The molecular signature of mediastinal large B-cell lymphoma differs from that of other diffuse large B-cell lymphomas and shares features with classical Hodgkin lymphoma. Blood. 102(12):3871-9, 2003
14. Suster S: Primary large-cell lymphomas of the mediastinum. Semin Diagn Pathol. 16(1):51-64, 1999
15. Suster S et al: Pleomorphic large cell lymphomas of the mediastinum. Am J Surg Pathol. 20(2):224-32, 1996
16. Suster S: Large cell lymphoma of the mediastinum with marked tropism for germinal centers. Cancer. 69(12):2910-6, 1992

Sclerosis

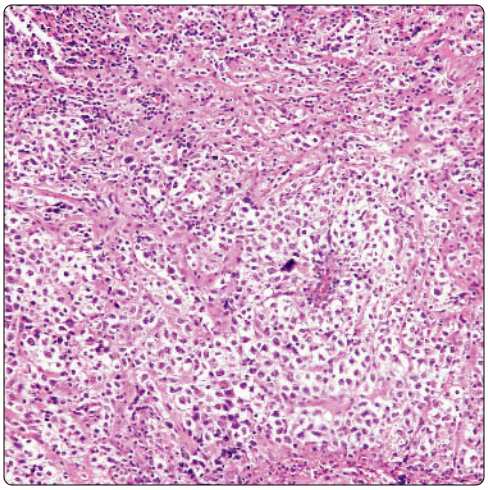

Sclerosis: Higher Magnification

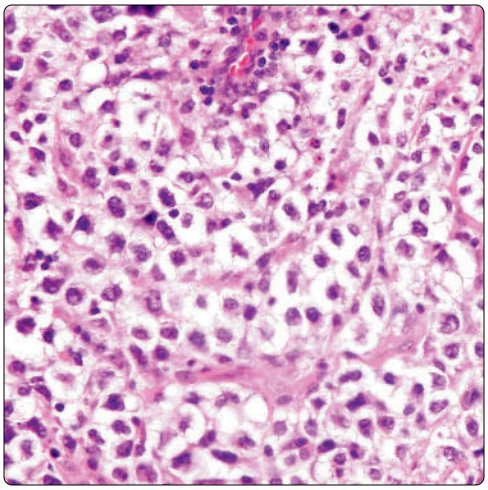

(Left) *MDLCL with sclerosis shows sheets and ill-defined nests of large, dyscohesive tumor cells separated by thin strands of fibroconnective tissue.* **(Right)** *Higher magnification of MDLCL shows discrete small nests of tumor cells separated by thin fibrovascular septa, resulting in a compartmentalized appearance. A similar appearance can be observed in metastatic amelanotic malignant melanoma.*

Nests of Tumor Cells

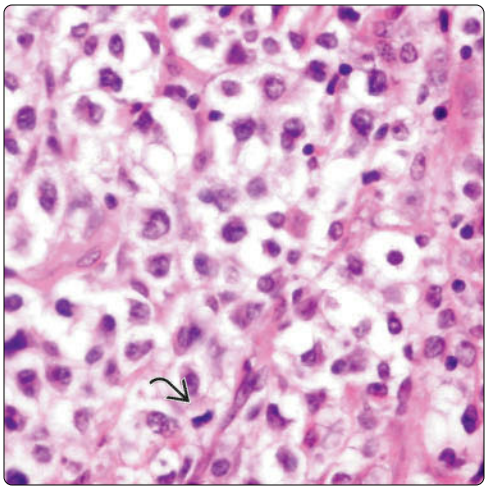

Higher Magnification

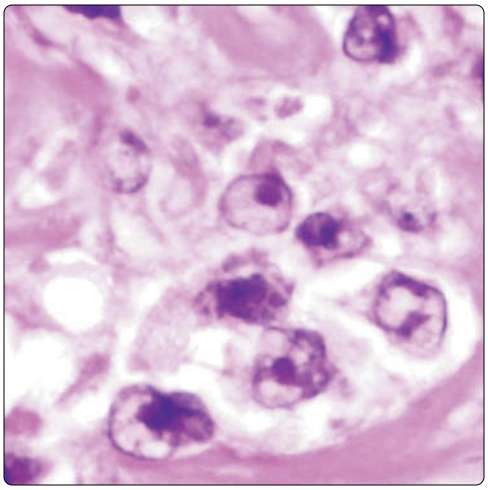

(Left) *High magnification of MDLCL with sclerosis shows large lymphoid cells surrounded by a clear halo with occasional scattered mitotic figures.* **(Right)** *Higher magnification of MDLCL with sclerosis shows large, atypical lymphoid cells with vesicular nuclei and prominent single eosinophilic nucleoli. The cells are surrounded by an ample rim of clear or amphophilic cytoplasm.*

CD20 Positivity

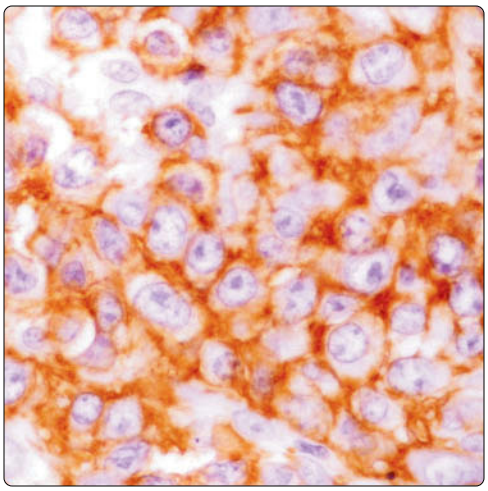

CD45 Positivity

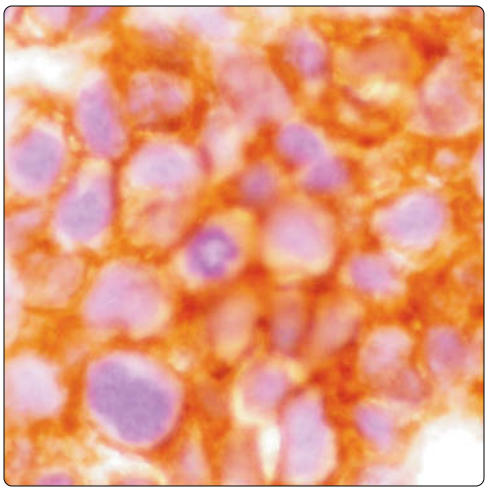

(Left) *Immunohistochemical stain for CD20 shows positive membrane staining in the large, atypical lymphoid cells in MDLCL.* **(Right)** *Immunohistochemical staining for CD45 shows strong positivity of the tumor cells in MDLCL. Positivity for this marker, together with CD20 positivity and negative staining for CD15/CD30, is helpful for distinguishing this tumor from mediastinal Hodgkin lymphoma in equivocal cases.*

Crush Artifact on Core Biopsy

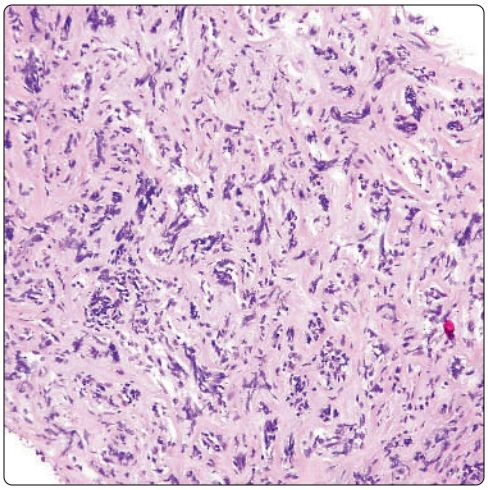

Higher Magnification: Core Biopsy

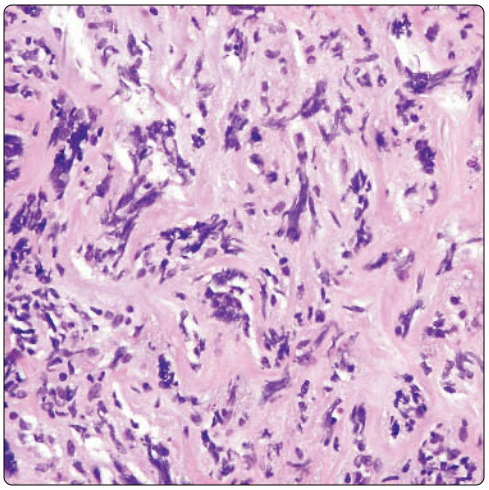

(Left) *Core biopsy of a large anterior mediastinal mass came from a patient with MDLCL with sclerosis. Note the abundant fibrous tissue containing mainly crushed and distorted cells.* **(Right)** *Higher magnification of a core biopsy of anterior mediastinal mass in a patient with MDLCL with sclerosis shows numerous crushed cells embedded in fibrous tissue. This picture is highly suggestive of mediastinal lymphoma in the proper clinical setting.*

Higher Magnification: Crush Artifact

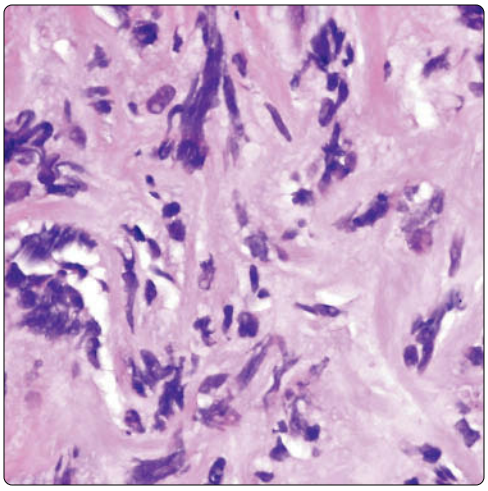

CD20 Positivity in Crush Artifact

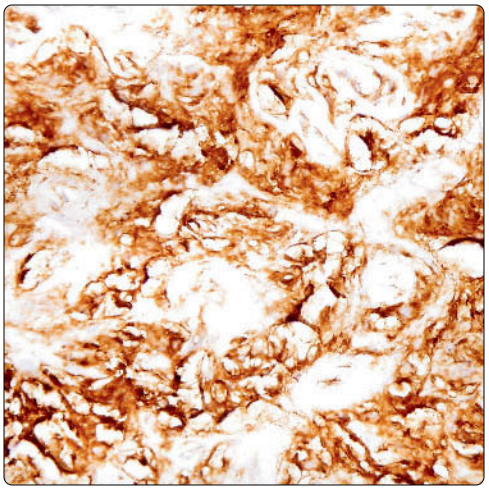

(Left) *Higher magnification of MDLCL core biopsy shows extensively distorted cells, mainly composed of crushed lymphocytes surrounded by dense collagenous tissue. Biopsies like this may be very hard to interpret due to the extensive tissue distortion that precludes evaluation of nuclear detail.* **(Right)** *Immunohistochemical staining for CD20 in a core biopsy of MDLCL shows strong positivity of the crushed tumor cells.*

Sclerosis and Crush Artifact

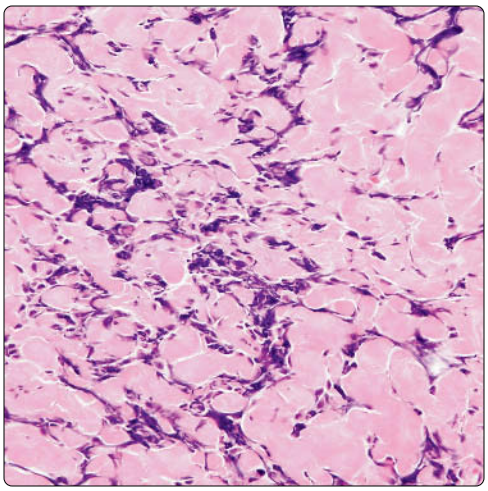

CD20 Positivity in Crush Artifact

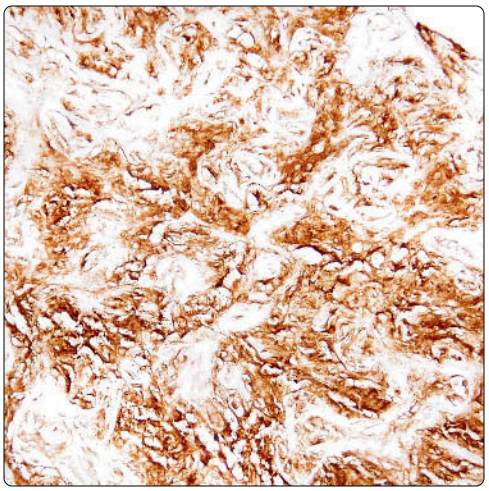

(Left) *Extensive distortion of tumor cells is seen in this mediastinal biopsy from a patient with MDLCL with sclerosis. The sclerosis in this case takes the form of small rounded balls of collagen that crush and distort the surrounding tumor cells.* **(Right)** *Immunohistochemical staining with CD20 in MDLCL highlights the lymphoid cells lying between the collagen bundles.*

Sheet-Like Growth Pattern

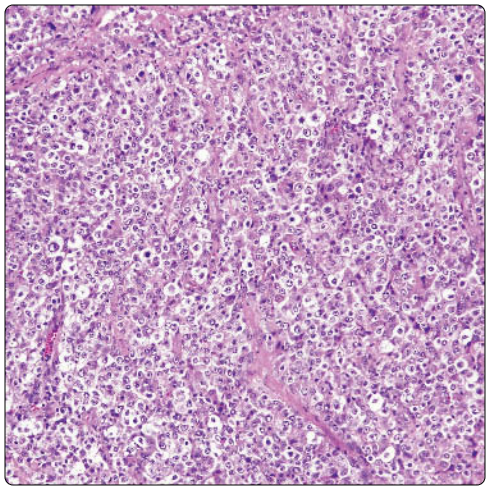

Higher Magnification

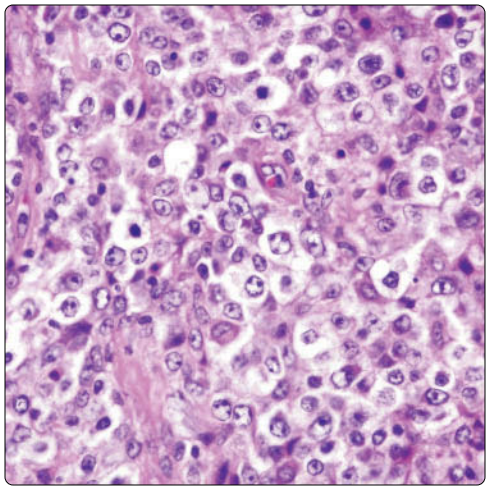

(Left) *Mediastinal MDLCL shows sheets of large, atypical lymphoid cells with very little intervening stroma. Striking sclerosis and compartmentalization are not features seen in this case.* **(Right)** *MDLCL shows sheets of large, atypical lymphoid cells. Cases devoid of stromal sclerosis, such as this, are more readily recognizable as a malignant lymphoma on routine histopathologic examination than those with prominent sclerotic fibrous bands.*

Atypical Lymphoid Cells

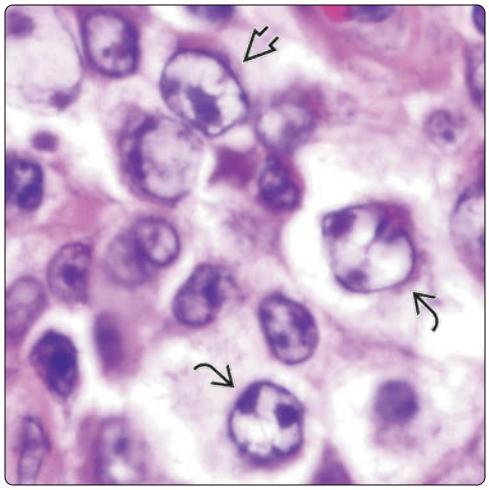

Mitotic Activity

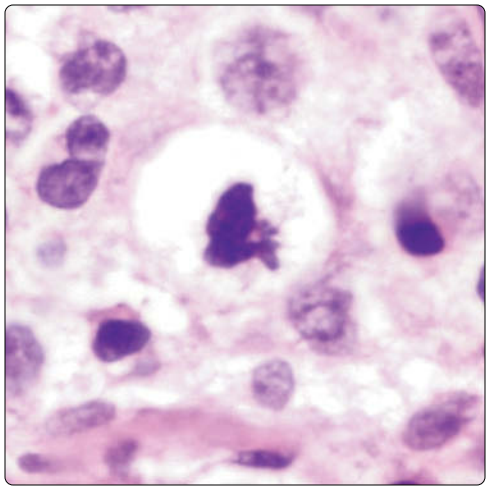

(Left) *High magnification of MDLCL shows atypical lymphoid cells. Some of the cells contain a single prominent nucleolus; others show multiple nucleoli.* **(Right)** *High magnification of MDLCL shows large, atypical lymphoid cells and an abnormal mitotic figure (center). Mitotic activity may vary in these tumors from minimal to > 10 mitoses per 10 HPF.*

Multinucleated Cells

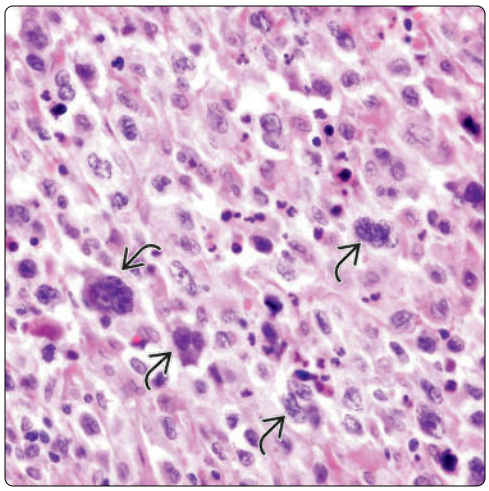

Multinucleated Cell: Higher Magnification

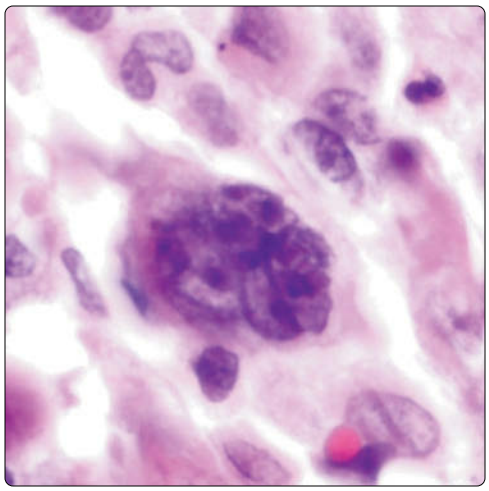

(Left) *MDLCL shows sheets of atypical lymphoid cells containing a few scattered, larger, multinucleated cells.* **(Right)** *High magnification of MDLCL shows a large, multinucleated tumor cell. The cell is characterized by multiple overlapping nuclei with prominent eosinophilic nucleoli and is surrounded by a scant rim of amphophilic cytoplasm. These cells display a close resemblance to Reed-Sternberg cells.*

Pleomorphic Mediastinal Lymphoma

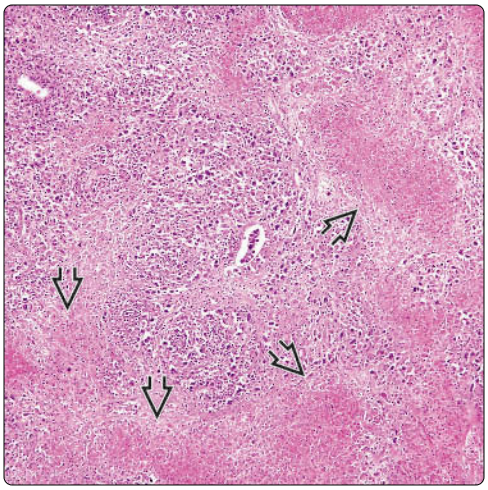

Pleomorphic MDLCL: Higher Magnification

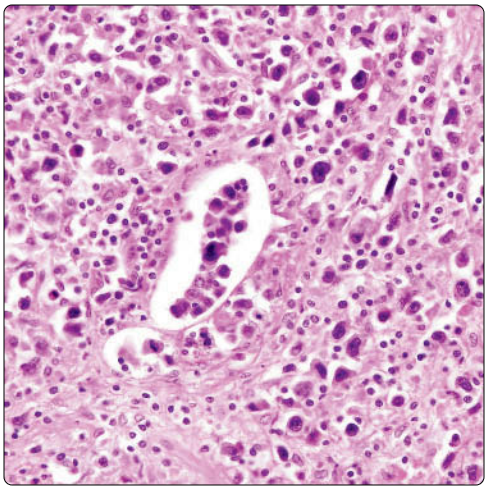

(Left) *Pleomorphic MDLCL shows extensive areas of necrosis ⇨. The residual tumor cell population shows marked nuclear pleomorphism.* **(Right)** *Pleomorphic MDLCL shows large tumor cells with bizarre, hyperchromatic nuclei. The size of the pleomorphic tumor cells is at least 4x that of a normal immunoblast. For comparison, note the smaller atypical lymphocytes scattered in the vicinity.*

Pleomorphic Lymphoma: High Grade

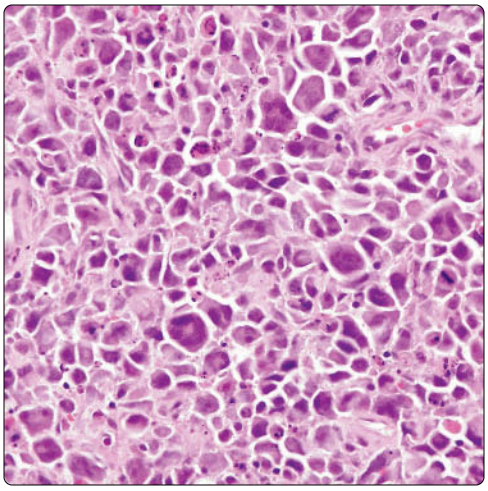

Pleomorphic Tumor Cells

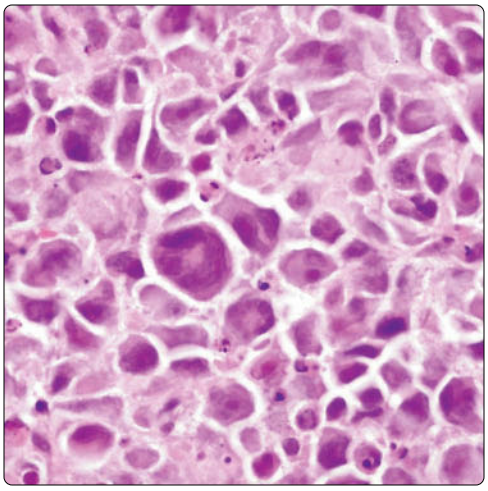

(Left) *Pleomorphic MDLCL shows a population of bizarre tumor cells simulating a pleomorphic high-grade sarcoma (a.k.a. malignant fibrous histiocytoma). The large size of the tumor cells is uncharacteristic of lymphoma.* **(Right)** *High magnification of pleomorphic MDLCL shows atypical nuclear features, including bizarre pleomorphic nuclei, occasional "tadpole" cells, and bizarre, multinucleated cells.*

Emperipolesis

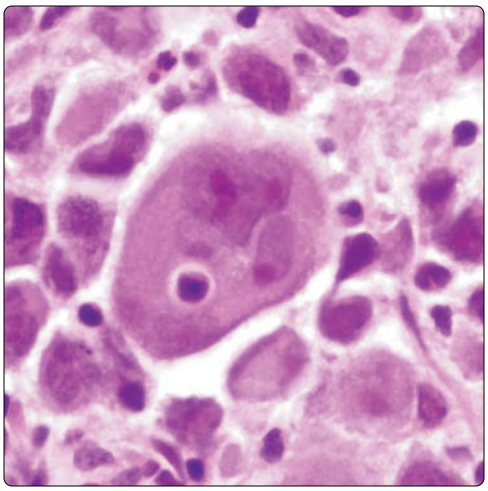

CD20 Positivity in Pleomorphic MDLCL

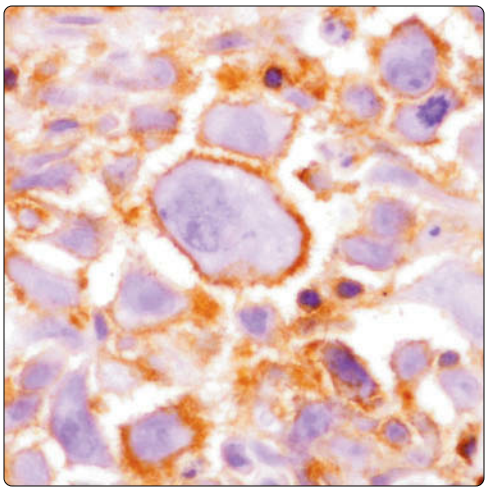

(Left) *High magnification of pleomorphic MDLCL shows a large tumor cell (center) with multiple nuclei and phagocytosis of a small lymphocyte (emperipolesis). Similar cells are a common finding in "fibrohistiocytic" sarcomas.* **(Right)** *Immunohistochemical staining for CD20 in MDLCL shows nice membrane staining of the tumor cells, including the bizarre multinucleated cell in the center.*

MDLCL Resembling ALCL

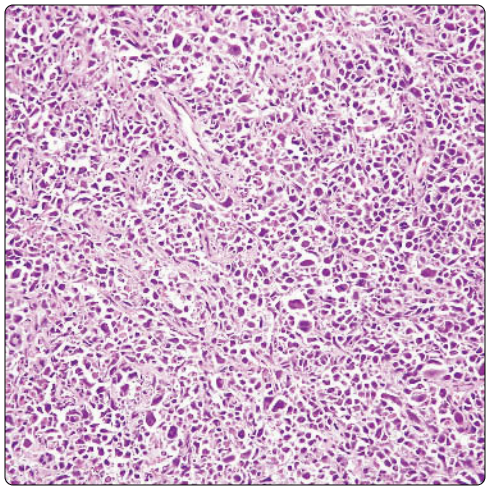

Kidney-Shaped Nuclei

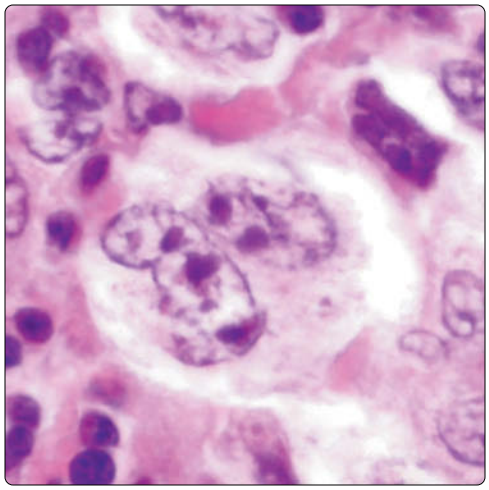

(Left) *MDLCL resembling anaplastic large cell lymphoma (ALCL) shows a population of tumor cells that contains scattered larger cells admixed with smaller atypical lymphocytes.* **(Right)** *High magnification of large tumor cells in MDLCL shows cells with kidney-shaped nuclei containing a vesicular chromatin pattern and multiple large eosinophilic nucleoli closely resembling Reed-Sternberg cells.*

MDLCL Resembling ALCL

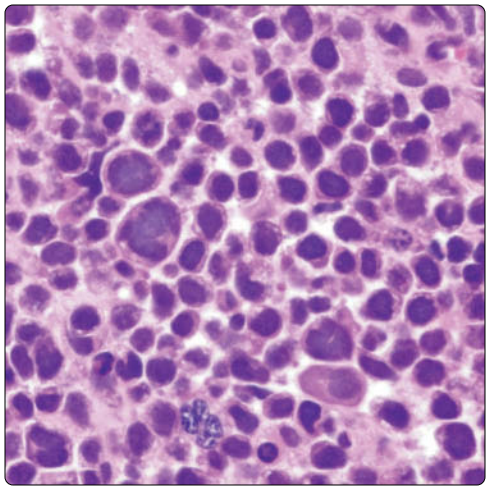

Anaplastic Tumor Cells

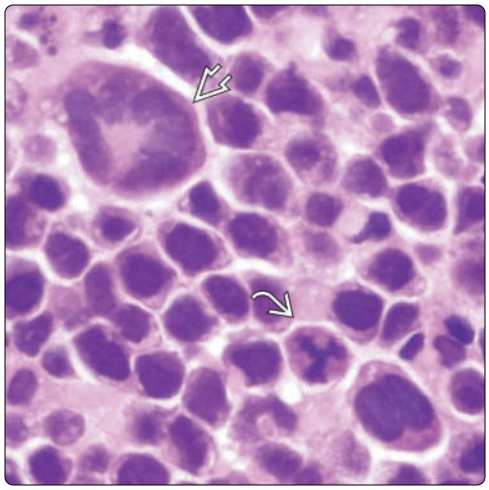

(Left) *MDLCL resembling ALCL shows hyperchromatic tumor cells admixed with smaller atypical lymphocytes resembling a metastasis from an anaplastic carcinoma.* **(Right)** *High magnification of MDLCL resembling ALCL shows tumor cells with irregular, horseshoe-shaped nuclei similar to those seen in ALCL. Notice the tripolar mitosis.*

CD20 Positivity in Anaplastic Lymphoma

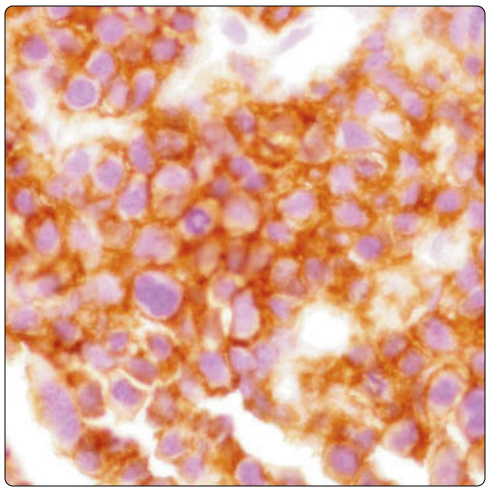

CD20 Positivity: Higher Magnification

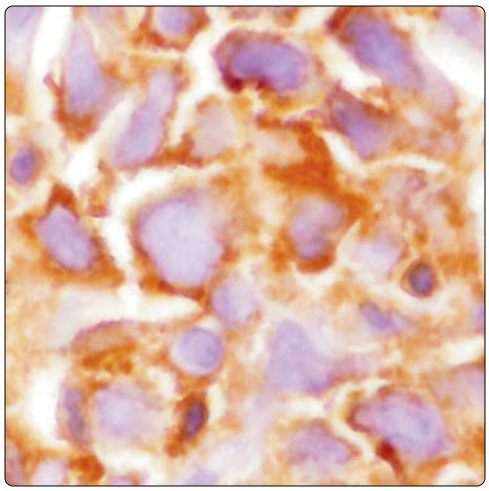

(Left) *MDLCL resembling ALCL shows strong membrane positivity for CD20 antibody by immunohistochemistry. The tumor cells in this case were negative for CD30, ALK1, and a variety of T-cell markers.* **(Right)** *Immunohistochemical staining for CD20 in MDLCL resembling ALCL is shown. This marker labels the large, anaplastic, and Reed-Sternberg-like cells.*

Clear Cell Mediastinal Lymphoma

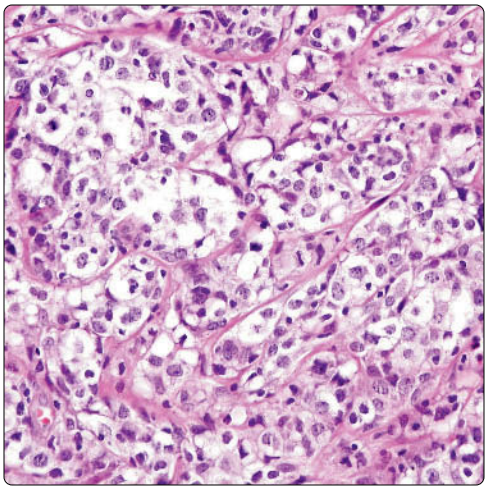

Clear Cell Lymphoma: Higher Magnification

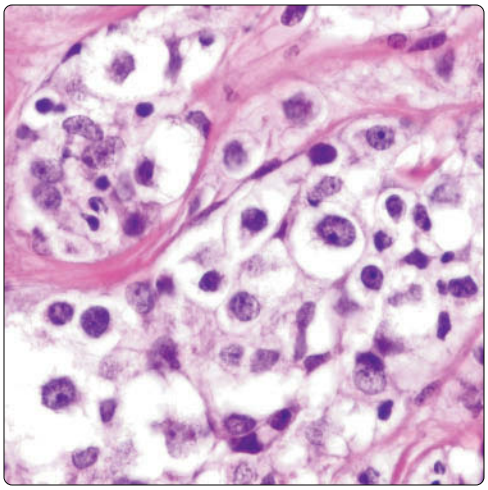

(Left) *Clear cell MDLCL shows nests of large tumor cells separated by thin fibrous bands. Notice the abundant water-clear, empty cytoplasm that surrounds the nuclei of the tumor cells.* **(Right)** *High magnification of MDLCL, clear cell type, shows nests of tumor cells with abundant clear cytoplasm simulating a metastasis from clear cell renal cell carcinoma or some other type of clear cell carcinoma.*

Clear Cell Lymphoma: Cytology

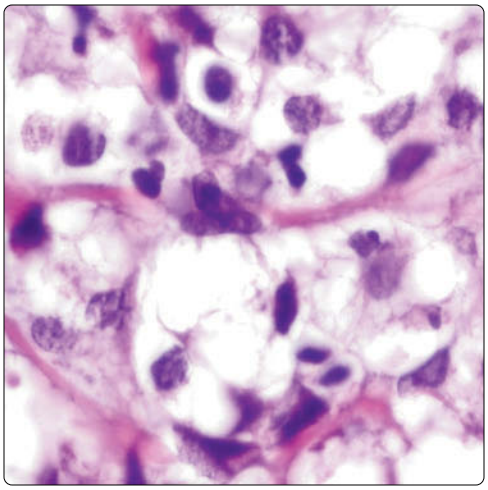

CD20 Positivity in Clear Cell Lymphoma

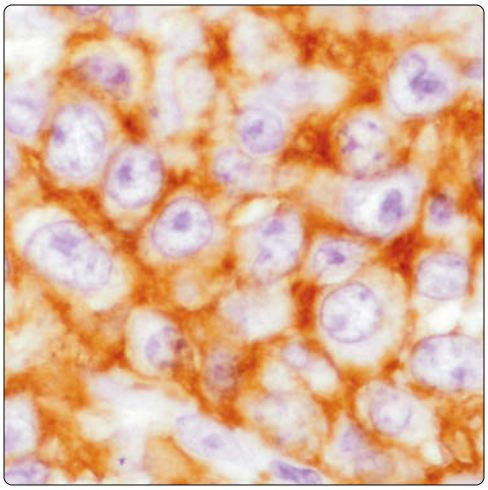

(Left) *High magnification of MDLCL, clear cell type, shows nuclear detail of the tumor cells, which are surrounded by abundant clear cytoplasmic rims. It may be very difficult to distinguish this image from a metastasis of clear cell renal cell carcinoma without the use of special stains.* **(Right)** *Immunohistochemical staining for CD20 in MDLCL, clear cell type, shows membrane positivity in the tumor cells.*

Sclerosis

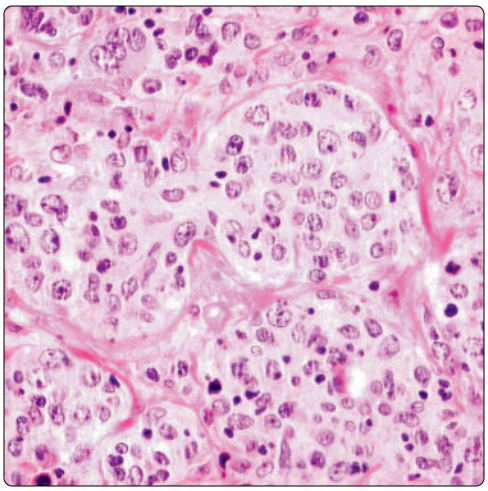

Sclerosis: Higher Magnification

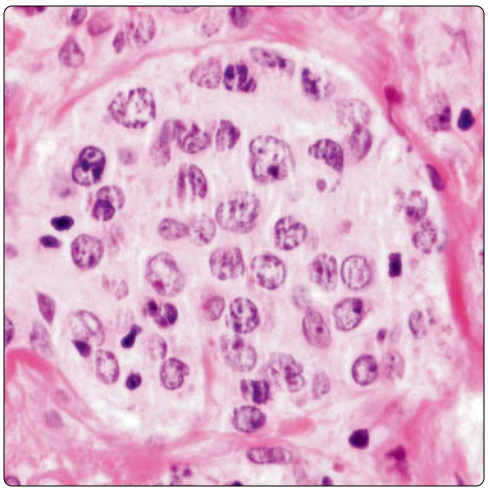

(Left) *MDLCL with sclerosis, clear cell type, shows compartmentalizing effect created by thin bands of fibrous tissue. Notice the abundant clear cytoplasm surrounding the tumor cells.* **(Right)** *High magnification of an island of tumor cells in MDLCL, clear cell type, shows atypical lymphoid cells surrounded by an indistinct rim of clear or amphophilic cytoplasm. The nested appearance of the cells is reminiscent of melanoma.*

Germinotropic Mediastinal Lymphoma

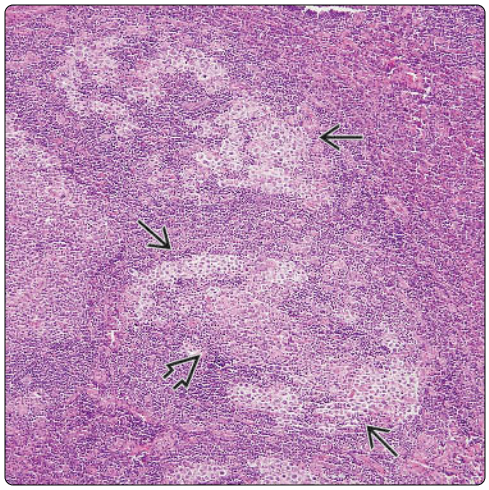

Germinotropic Mediastinal Lymphoma

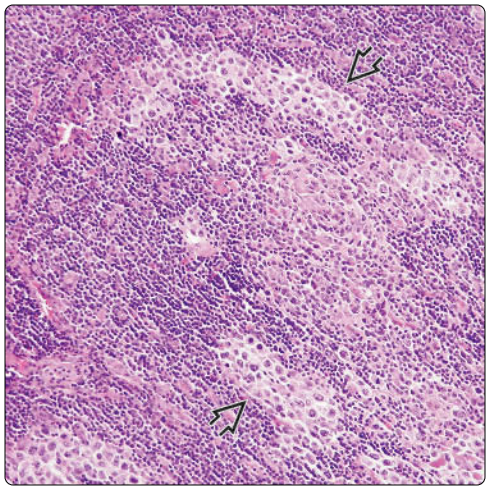

(Left) *MDLCL with marked tropism for germinal centers (germinotropic lymphoma) shows irregular replacement of lymphoid follicles and germinal centers by clusters and nests of large tumor cells.* **(Right)** *MDLCL with marked tropism for germinal centers (germinotropic lymphoma) shows progressive and gradual replacement of the germinal center in the lymphoid follicle by discrete clusters and islands of large tumor cells.*

Germinotropic Lymphoma: Higher Magnification

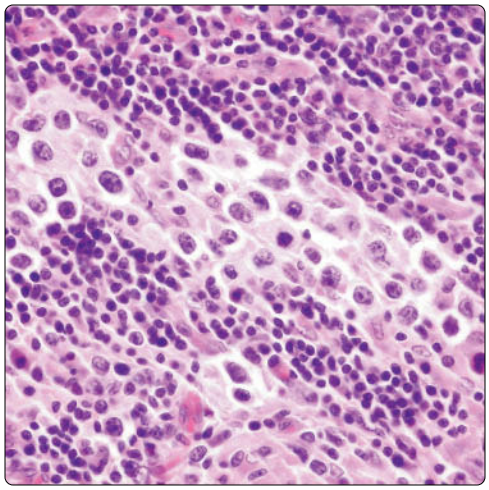

Germinotropic Lymphoma: Cellular Detail

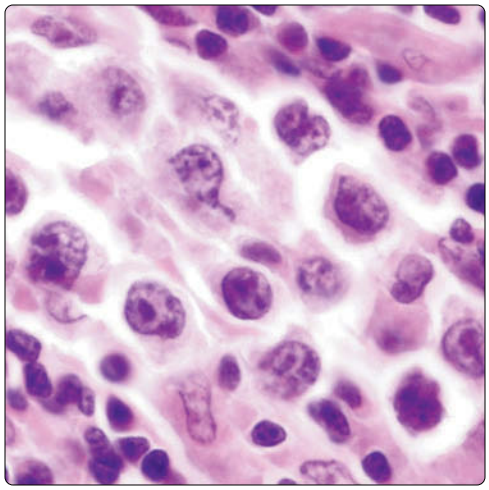

(Left) *High magnification of MDLCL with marked tropism for germinal centers (germinotropic lymphoma) shows a cluster of large, atypical lymphoid cells disrupting the follicle mantle zone.* **(Right)** *High magnification in MDLCL with marked tropism for germinal centers (germinotropic lymphoma) shows large, atypical lymphoid cells with irregular nuclei and prominent eosinophilic nucleoli surrounded by a scant rim of cytoplasm.*

Germinotropic Lymphoma: Low Power

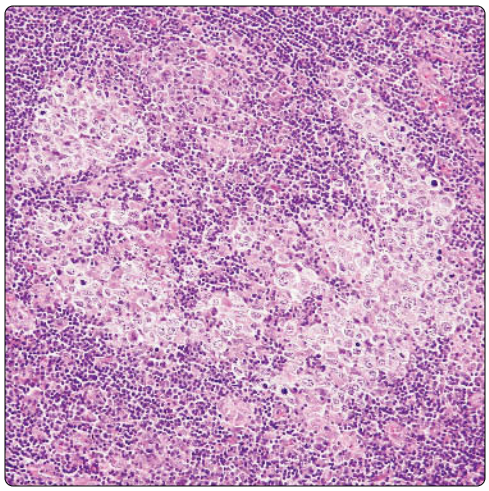

Germinotropic Lymphoma: Higher Power

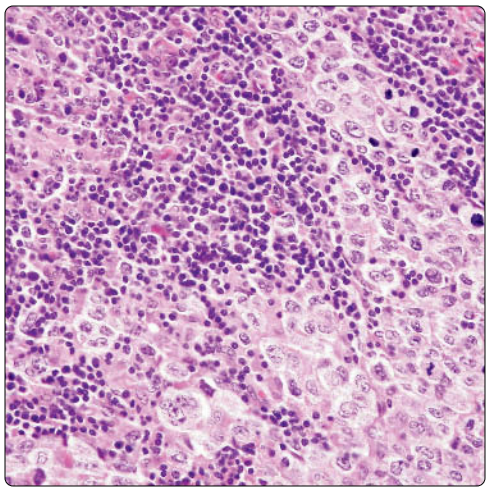

(Left) *MDLCL with marked tropism for germinal centers (germinotropic lymphoma) shows almost complete replacement of the follicle by sheets and clusters of large, atypical lymphoid cells. A similar morphologic appearance can be observed in mediastinal seminoma.* **(Right)** *Higher magnification of MDLCL with marked tropism for germinal centers shows progressive replacement of the germinal center by tumor cells.*

Mediastinal Spindle Cell Lymphoma

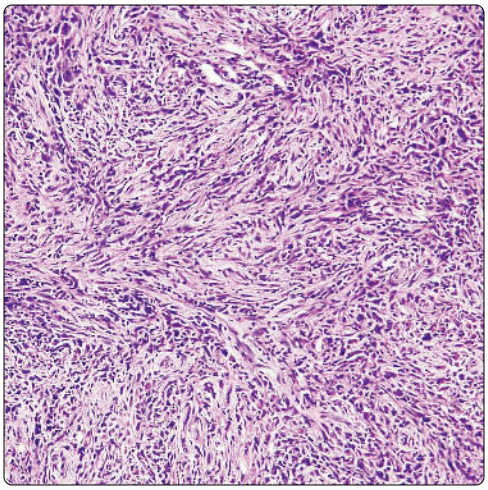

Storiform Pattern

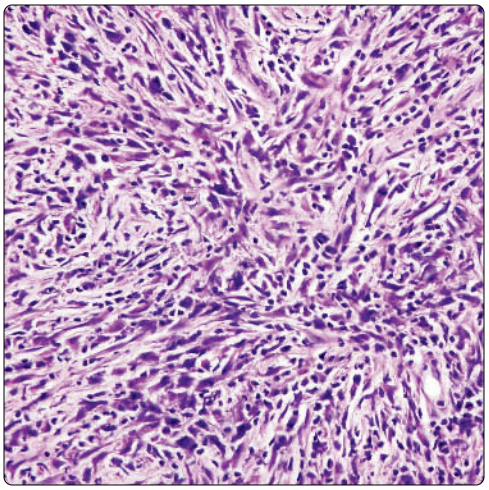

(Left) *MDLCL, spindle cell type, shows atypical spindle cell proliferation that on scanning magnification closely resembles a spindle cell sarcoma.* **(Right)** *MDLCL with sarcomatoid appearance shows fascicles of atypical spindle cells with a vague storiform pattern simulating a malignant fibrohistiocytic tumor. Tumors like this can be easily mistaken for a variety of spindle cell sarcomas.*

Fascicular Appearance

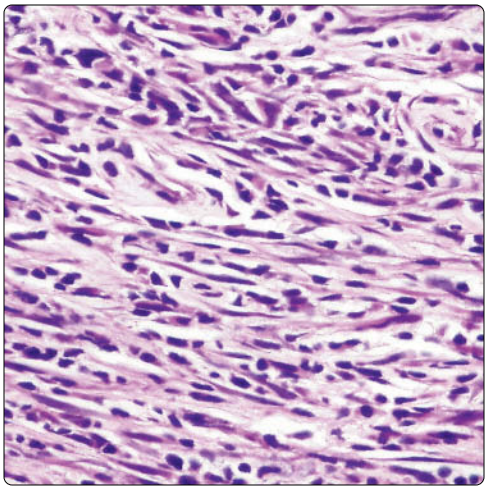

CD20 Positivity in Spindle Cell Lymphoma

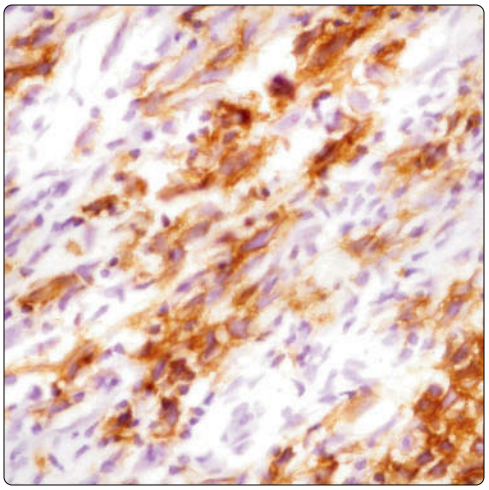

(Left) *High magnification of MDLCL with prominent spindling of the tumor cells shows a fascicular appearance of elongated spindle cells admixed with small lymphocytes simulating a spindle cell sarcoma.* **(Right)** *Immunohistochemical staining for CD20 in MDLCL with prominent spindling of the tumor cells shows positive staining of elongated, spindle tumor cells for this antibody.*

Signet Ring Cell Lymphoma

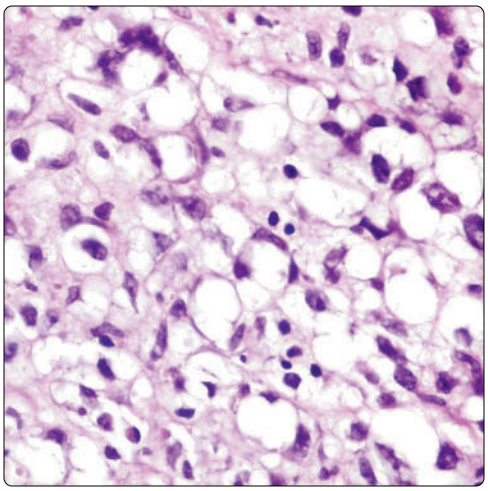

Signet Ring Cell Lymphoma: High Power

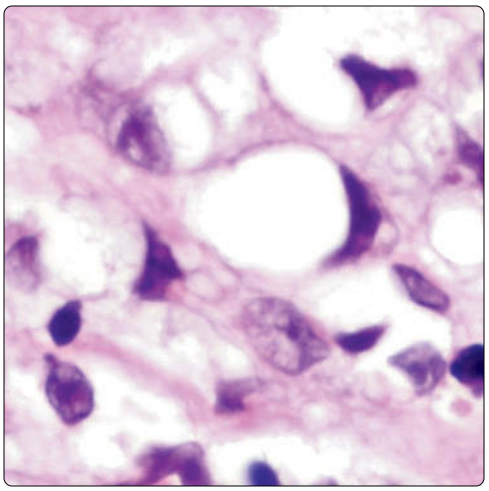

(Left) *MDLCL with signet ring cells shows sheets of large vacuolated cells that resemble adipocytes admixed with a few scattered small lymphocytes. The morphologic appearance depicted here may closely simulate a liposarcoma.* **(Right)** *Higher magnification of MDLCL shows a few signet ring cell lymphocytes with large hyperchromatic nuclei displaced to the periphery. The cells were CD20(+).*

Stromal Sclerosis

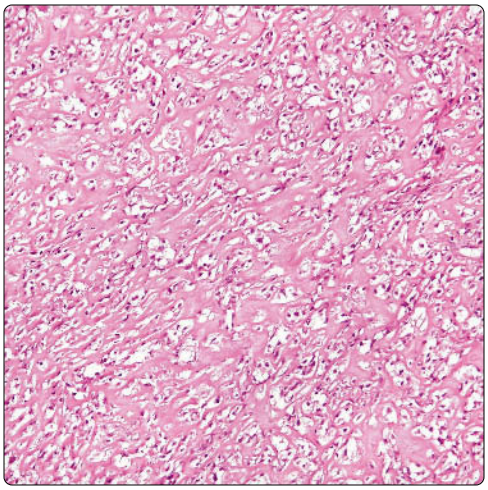

Extensive Stromal Sclerosis

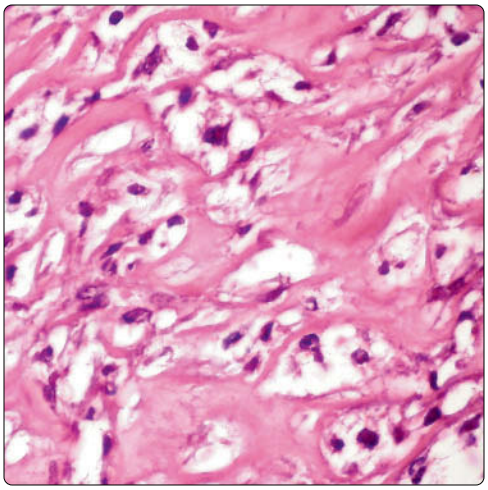

(Left) *MDLCL shows an extensive pattern of stromal sclerosis. Notice lattice-like appearance due to prominent deposition of intercellular stromal collagen.* **(Right)** *High magnification of MDLCL with sclerosis shows extensive stromal deposition of collagen surrounding the lymphoid tumor cells. Tumors with these features may be confused for idiopathic sclerosing mediastinitis or for a sclerosing epithelioid fibrosarcoma arising in the mediastinum.*

Advanced Stromal Sclerosis

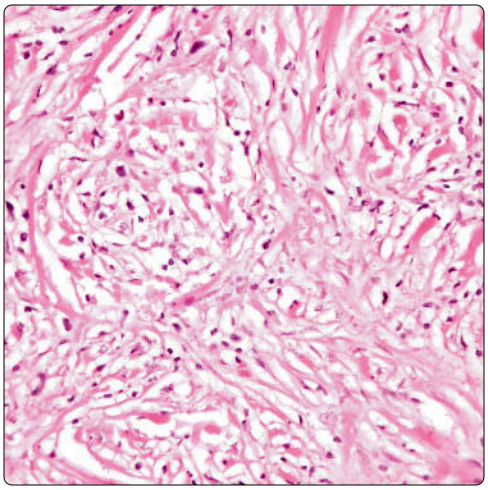

Perivascular Cuffing

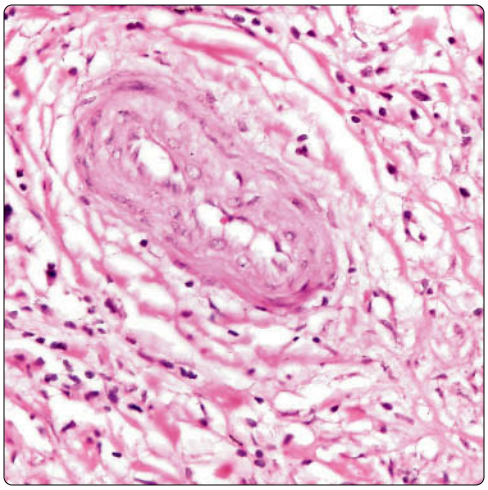

(Left) *The concentric pattern of stromal sclerosis in MDLCL, as seen in this biopsy, can resemble a solitary fibrous tumor of the mediastinum due to the rope-like pattern of distribution of the collagen fibers.* **(Right)** *High magnification of MDLCL with sclerosis shows a concentric pattern of collagen deposition. Notice the perivascular distribution of the sclerosis and a few scattered residual lymphocytes.*

Entrapment of Thymic Epithelium

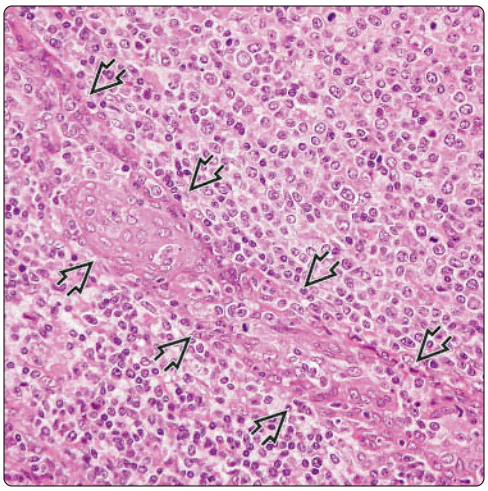

Entrapped Thymic Epithelium

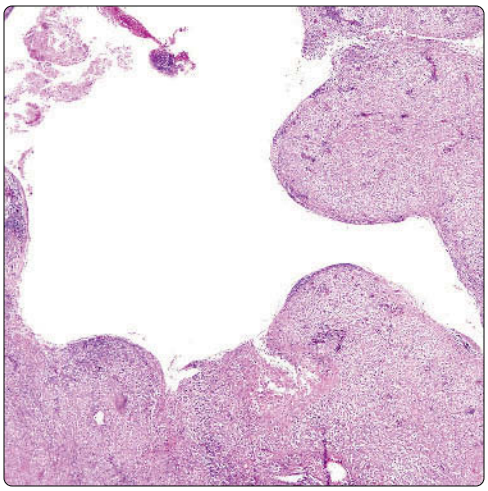

(Left) *MDLCL shows entrapped residual thymic epithelium within the tumor ⇨. Notice the elongated character of the thymic epithelial rests. Positive keratin stains may lead to confusion with thymoma or carcinoma in such cases.* **(Right)** *MDLCL with cystic changes shows dilatation of entrapped thymic epithelium resulting in large cystic spaces. Fortunately, this is usually only a focal event in these tumors.*

Wreath-Like Multinucleated Tumor Cell

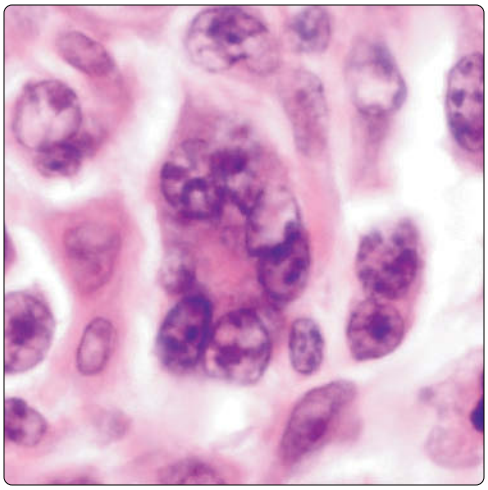

Binucleated Tumor

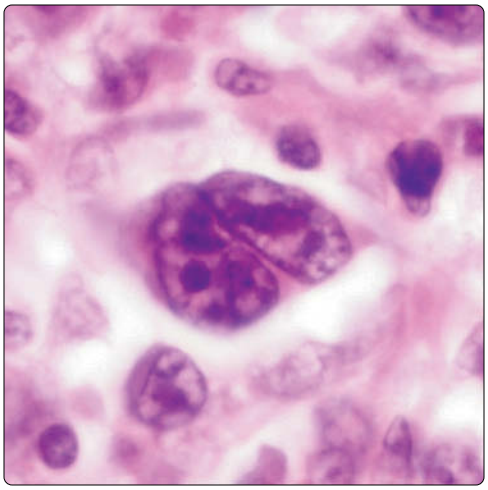

(Left) *MDLCL may show a wide spectrum of cells, including multinucleated cells with a wreath-like disposition of nuclei (center) that can sometimes resemble Touton giant cells.* **(Right)** *MDLCL shows classic binucleate Reed-Sternberg-like cells. This cell was positive for CD20 and negative for CD15 and CD30. The rest of the tumor marked as a conventional diffuse large B-cell lymphoma.*

Reed-Sternberg-Like Cell

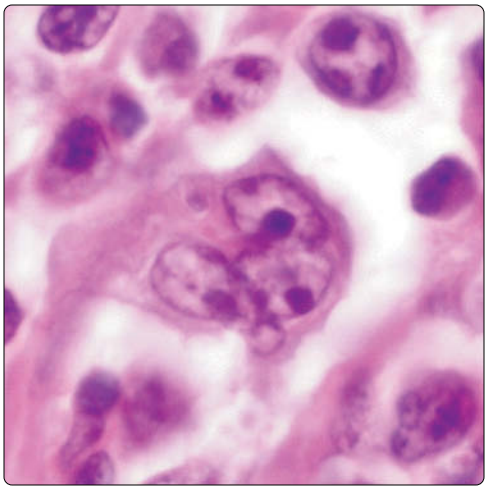

Bizarre Multinucleated Tumor Cells

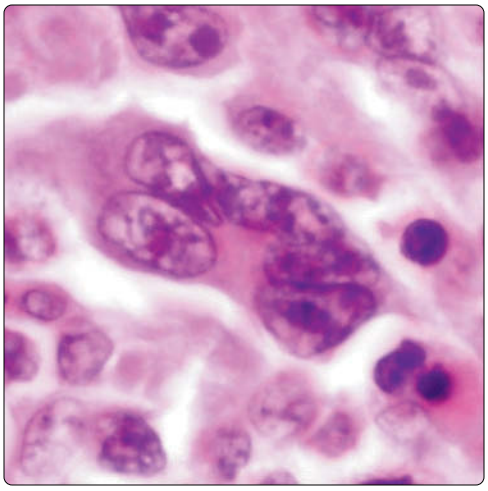

(Left) *MDLCL shows a Reed-Sternberg-like cell with 3 nuclei, each displaying a prominent eosinophilic nucleolus. The milieu of this tumor, however, was incompatible with Hodgkin lymphoma and showed abundant large immunoblastic cells with B-cell phenotype.* **(Right)** *MDLCL shows bizarre, multinucleated, CD20(+) cells with atypical nuclei and prominent eosinophilic nucleoli.*

Pseudoalveolar Growth Pattern

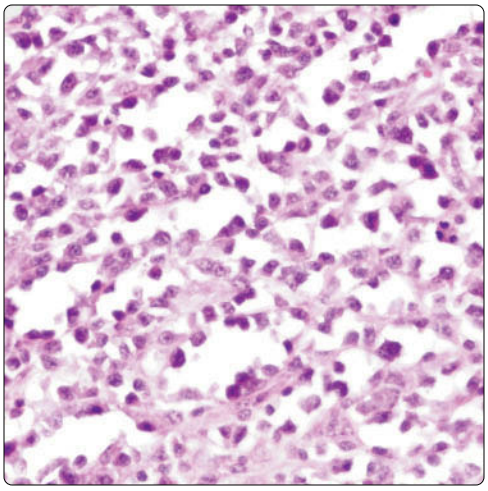

Infiltration of Mediastinal Fat

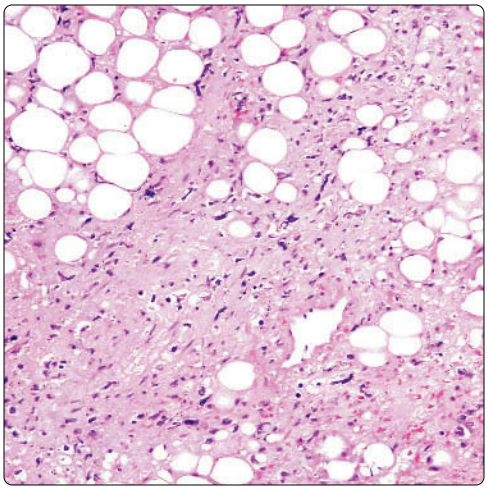

(Left) *MDLCL shows an unusual architectural pattern characterized by artifactual separation of the tumor cells, resulting in a pseudoalveolar pattern of growth. Tumors like this can be mistaken for metastases of alveolar rhabdomyosarcoma to the mediastinum.* **(Right)** *MDLCL with sclerosis shows a distinctive pattern of infiltration of mediastinal fat with preservation and sparing of the adipocytes.*

Lymphoblastic Lymphoma

KEY FACTS

ETIOLOGY/PATHOGENESIS

- Neoplastic proliferation of blastic precursor lymphocytes

CLINICAL ISSUES

- Occurs more commonly in children than in adults
- Anterior superior and middle mediastinum
- Rapidly enlarging mediastinal mass
- Aggressive clinical course
- Rapid progression, often with superior vena cava syndrome
- Frequent relapses
- Short survival

MICROSCOPIC

- Diffuse sheets of immature lymphoid cells
- Infiltration of lymph node capsule and mediastinal fat with single file arrangement of tumor cells
- Starry-sky appearance due to numerous tingible body macrophages
- Crush artifact
- Lymphoblasts show large immature nuclei with dense chromatin and small inconspicuous or absent nucleoli
- Lymphoblasts can be convoluted or nonconvoluted
- Almost all precursor lymphocytes (T and B) express nuclear enzyme, terminal deoxynucleotidyl transferase (TdT)
- Precursor lymphocytes also express CD34 and CD99

ANCILLARY TESTS

- Favorable prognosis: t(12;21)(p13;q22)
- Intermediate prognosis: t(1;19)(q23;p13)
- Poor prognosis: t(9;22)(q34;q11), BCR/ABL, t(v;11q23)

TOP DIFFERENTIAL DIAGNOSES

- Burkitt lymphoma
- B-cell chronic lymphocytic leukemia/small lymphocytic lymphoma
- Lymphocyte-rich thymoma (WHO type B1)
  - Most important stain is pancytokeratin to identify scattered neoplastic thymic epithelial cells

Lymphoblastic Lymphoma: Low Power

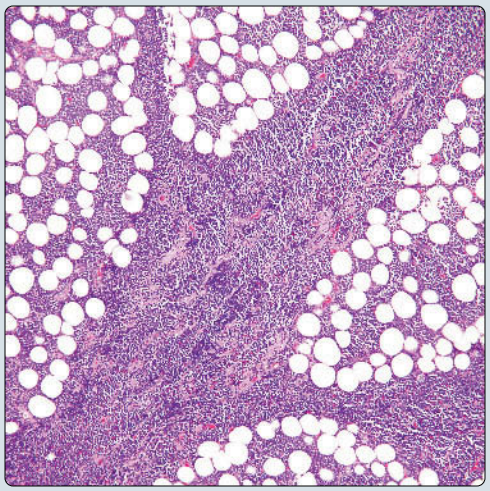

Sheets of Tumor Cells

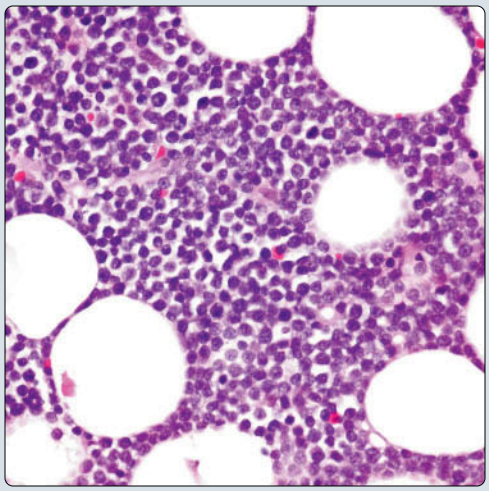

(Left) *Scanning magnification in lymphoblastic lymphoma of the mediastinum shows sheets of monotonous small round blue tumor cells diffusely infiltrating the tissues and entrapping mediastinal fat.* **(Right)** *Higher magnification of lymphoblastic lymphoma of the mediastinum shows monotonous population of primitive tumor cells. Entrapment of the fat without destroying it is characteristic for this tumor.*

Convoluted Lymphocytes

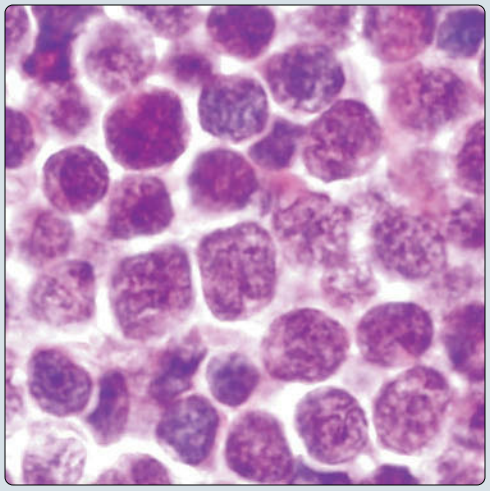

Round Lymphocytes

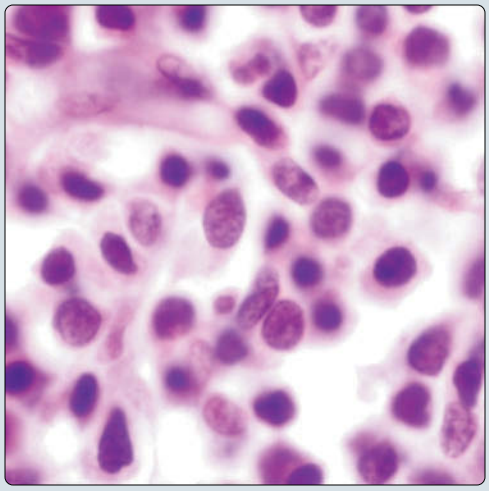

(Left) *High magnification of T-lymphoblastic lymphoma of the mediastinum, convoluted type, shows primitive nuclei with deep nuclear convolutions and nuclear membrane irregularities.* **(Right)** *High magnification of nonconvoluted T-lymphoblastic lymphoma of the mediastinum shows primitive nuclei with dense chromatin pattern and with smooth nuclear contours.*

TERMINOLOGY

Abbreviations

- Lymphoblastic lymphoma (LBL)

Synonyms

- Lymphoblastic lymphoma/leukemia, lymphoma of precursor lymphocytes

Definitions

- Diffuse lymphoma of immature or precursor lymphocytes, predominantly of T-cell type

ETIOLOGY/PATHOGENESIS

Pathogenesis

- Neoplastic proliferation of blastic precursor lymphocytes
- Associations with prior radiation, Down syndrome, and other genetic diseases have been noted
- Phenotype can be either of T-precursor cell type or B-precursor cell type

CLINICAL ISSUES

Epidemiology

- Incidence
  - Occurs more commonly in children than in adults
    - ~ 3 cases per 100,000 children
    - 75% of affected children are under 15 years of age
    - Peak incidence in children is between 2-5 years old
    - More frequent in males than females
  - Also affects men in 3rd decade of life
  - Can rarely occur in older individuals over age of 60 years

Site

- Anterior superior and middle mediastinum
- Supradiaphragmatic, supraclavicular, cervical, and axillary lymph nodes

Presentation

- Rapidly enlarging mediastinal mass
- Aggressive clinical course
  - Rapid progression, often with superior vena cava syndrome
  - Frequent relapses
  - Short survival
  - Generally diagnosed in advanced stages (stage III or IV)
  - Dissemination to other organs is common
    - Central nervous system (most common site of relapse)
    - Skin, testes, eyes, kidneys, breast, and lungs
    - Bone marrow involvement occurs early in disease
    - Leukemic phase with circulating blasts in peripheral blood occurs shortly after initial diagnosis

IMAGING

General Features

- Location
  - Superior mediastinal nodes (prevascular & paratracheal)

Radiographic Findings

- Bulky mediastinal bilateral hilar lymphadenopathy
- Pleural effusion may be seen due to lymphatic or venous obstruction

CT Findings

- CECT: Imaging modality of choice
- Slight to moderate uniform enhancement following intravenous contrast

MICROSCOPIC

Histologic Features

- Diffuse sheets of immature lymphoid cells
- Pseudonodular pattern due to compartmentalization by thin strands of fibrous tissue
- Infiltration of lymph node capsule and mediastinal fat with single-file arrangement of tumor cells
- Starry-sky appearance due to numerous tingible body macrophages
- Crush artifact
- Occasional spared, residual lymphoid follicles with germinal centers may become entrapped by lymphoblastic proliferation

Cytologic Features

- Lymphoblasts show large immature nuclei with dense chromatin and small, inconspicuous or absent nucleoli
  - High nuclear:cytoplasmic ratio
- Lymphoblasts can be convoluted or nonconvoluted
  - Convoluted lymphoblasts show multiple, complex nuclear indentations
  - Nonconvoluted lymphoblasts show smooth nuclear contours
- Frequent mitotic figures

ANCILLARY TESTS

Immunohistochemistry

- Almost all precursor lymphocytes (T and B) express the nuclear enzyme terminal deoxynucleotidyl transferase (TdT)
- Precursor lymphocytes also express CD34 and CD99
- 90% of cases correspond to T-cell precursor lymphoblasts and express CD3 and CD43
- 10% of cases correspond to B-cell precursor lymphoblasts and express CD10, CD19, CD20, CD22, and CD79a

Genetic Testing

- Various cytogenetic abnormalities
  - Favorable prognosis: t(12;21)(p13;q22)
  - Intermediate prognosis: t(1;19)(q23;p13)
  - Poor prognosis: t(9;22)(q34;q11), BCR/ABL, t(v;11q23)

Electron Microscopy

- Round to oval cells with smooth surfaces and no cytoplasmic processes
- Convoluted nuclei with deep indentations and scant cytoplasm with few organelles

Molecular Diagnosis

- t(12;21) is most frequent translocation in B-precursor ALL in children (25% of cases)
  - Molecular demonstration of fusion of TEL at 12p13 to AML1 at 21q22

Immunohistochemistry

Antibody	Reactivity	Staining Pattern	Comment
TdT	Positive	Nuclear	All LBLs show nuclear positivity for TdT regardless of whether they are of T- or B-cell lineage
CD99	Positive	Cell membrane & cytoplasm	All LBLs express CD99: Caution should be exercised not to mistake this finding for evidence of a small round blue cell tumor in the Ewing/PNET family
CD43	Positive	Cell membrane & cytoplasm	Most LBL of either T- or B-cell lineage express cytoplasmic CD43
CD1a	Positive	Cytoplasmic	Positive in T-cell precursor LBL
CD3	Positive	Cytoplasmic	Positive in T-cell precursor LBL
CD10	Positive	Cytoplasmic	May be positive in both T- and B-cell precursor LBL
CD19	Positive	Cytoplasmic	Positive in B-cell precursor LBL
CD20	Positive	Cytoplasmic	Positive in B-cell precursor LBL
CD22	Positive	Cytoplasmic	Positive in B-cell precursor LBL
CD45	Negative	Not applicable	Usually negative in LBL by immunohistochemistry but may be detected by flow cytometry

- t(9;22) is frequently demonstrated in T-precursor ALL in adults (30% of cases)
  - Molecular demonstration of BCR/ABL

DIFFERENTIAL DIAGNOSIS

Burkitt Lymphoma

- Also occurs in children and shows diffuse sheets of immature lymphoid cells
- Cells have round nonconvoluted nuclei with multiple prominent nucleoli and basophilic cytoplasm
- Starry-sky pattern may be prominent in both Burkitt and LBL
- Lymphocytes negative for TdT and CD99, positive for CD10, CD20, and CD45; show κ/λ light chain restriction

B-Cell Chronic Lymphocytic Leukemia/Small Lymphocytic Lymphoma

- Occurs mostly in elderly patients rather than in children
- Cells are small and uniform, and mitoses are rare
- No starry-sky appearance or crush artifact
- Cells show CD5(+) mature B-cell phenotype as well as κ/λ light chain restriction
- Cells negative for TdT and CD99

Lymphocyte-Rich Thymoma (WHO Type B1)

- Can show similar histology due to high content of immature T lymphocytes
- Lymphocytes positive for TdT and CD99
- May also show starry-sky appearance
- Usually lobulated and does not infiltrate capsule or perithymic fat in single file arrangement
- Clinically, tumors slow growing and do not present clinically with rapid growth and widespread infiltration of surrounding structures
- Flow cytometry studies may mistakenly be misinterpreted as LBL due to high content of immature T lymphoblasts
- Most important test is immunoperoxidase stain for pancytokeratin to identify scattered neoplastic thymic epithelial cells

DIAGNOSTIC CHECKLIST

Clinically Relevant Pathologic Features

- Age distribution
  - More common in children and young adults
  - Rarely can occur in older adults
- Clinical presentation
  - Rapidly growing mediastinal mass
  - Shortness of breath, chest pain, and superior vena cava syndrome
  - Often presents as medical emergency
- Histologic findings
  - Sheets of primitive lymphoid cells with dispersed chromatin pattern and inconspicuous or absent nucleoli
  - Starry-sky appearance and crush artifact
  - Infiltration of mediastinal fat with preservation of fat cells
  - High mitotic activity
  - Prominent nuclear convolutions in high percentage of cases
- Special studies
  - Nuclear TdT positivity and membranous CD99 positivity in tumor cells
  - Absence of keratin(+) epithelial cells admixed with lymphoid cell infiltrate
  - Molecular demonstration of t(12;21) or t(9;22)

Pathologic Interpretation Pearls

- Large diffusely infiltrative "small blue cell tumor" in mediastinal location in a child
- Cells with primitive nuclei with scant cytoplasm and absent or inconspicuous nucleoli
- TdT/CD99(+) in absence of keratin (+) cells in background

SELECTED REFERENCES

1. Bassan R et al: Lymphoblastic lymphoma: an updated review on biology, diagnosis, and treatment. Eur J Haematol. 96(5):447-60, 2016

Sheets of Small Round Blue Cells

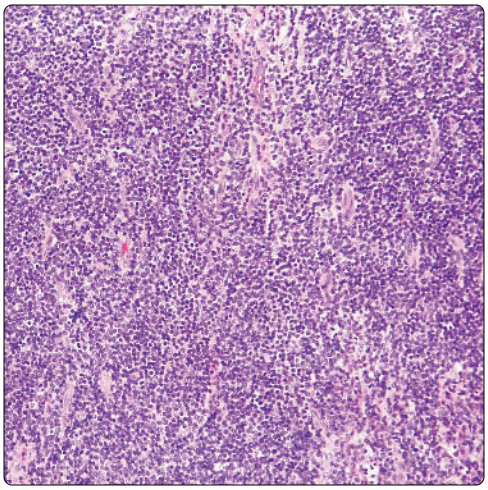

Lymphoblastic Cells

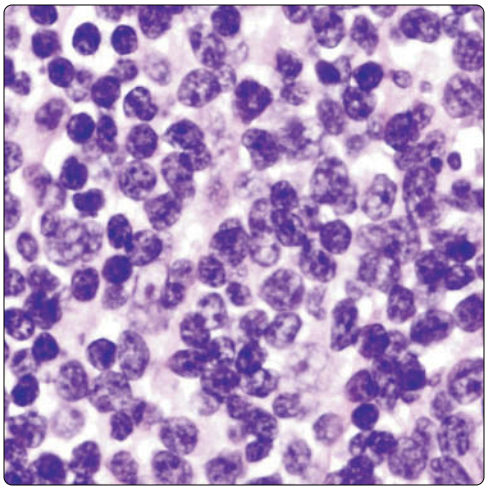

(Left) *Scanning magnification of lymphoblastic lymphoma of the mediastinum shows sheets of small hyperchromatic lymphoid cells.* **(Right)** *High magnification of lymphoblastic lymphoma of the mediastinum shows primitive lymphoid cells with round to oval nuclei, a dense chromatin pattern, and absent or inconspicuous nucleoli surrounded by a scant rim of amphophilic cytoplasm. The absence of nucleoli and primitive appearance of the nuclei are characteristic of this tumor.*

Pseudolobular Appearance

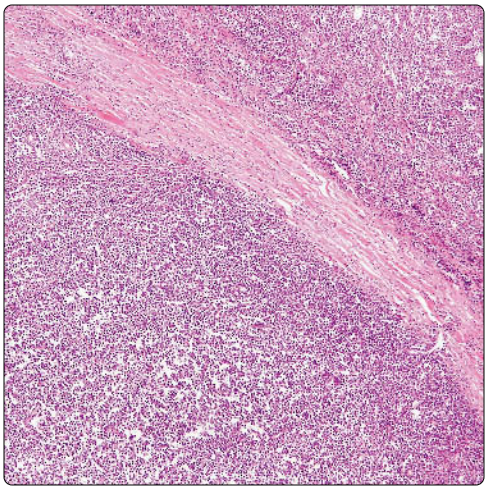

Sheets of Monotonous Tumor Cells

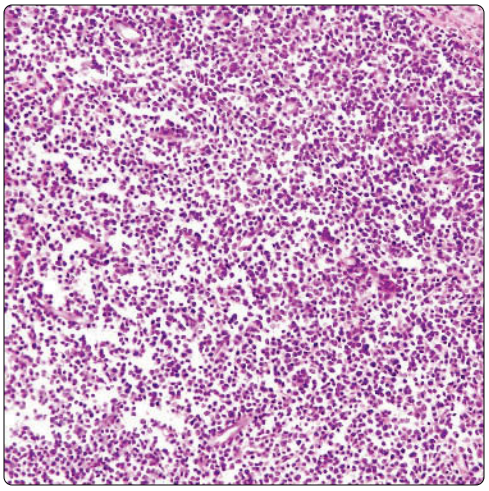

(Left) *Lymphoblastic lymphoma of mediastinum shows a dense fibrous connective tissue band separating the tumor into pseudolobules. The pseudolobular appearance is reminiscent of the architecture typically seen in lymphocyte-rich thymoma. Absence of keratin-positive cells serves to distinguish it from thymoma.* **(Right)** *High magnification of lymphoblastic lymphoma of the mediastinum shows sheets of monotonous lymphoid cells without any intervening stroma.*

Starry-Sky Appearance

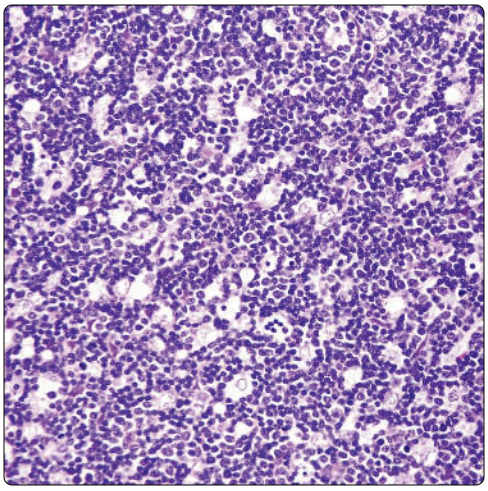

Tingible Body Macrophages

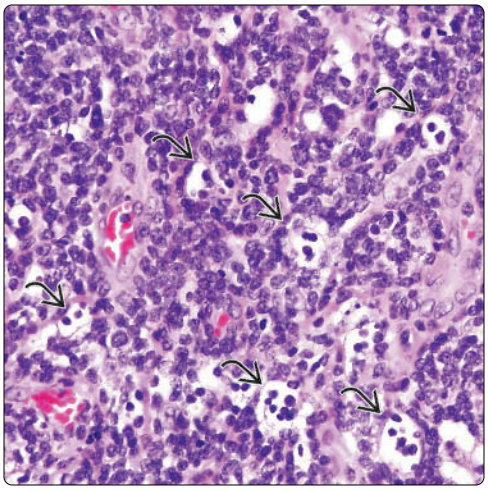

(Left) *Lymphoblastic lymphoma of the mediastinum shows a prominent starry-sky appearance due to tingible body macrophages. A similar appearance can be observed in cases of lymphocyte-rich thymoma and in thymus glands undergoing stress involution.* **(Right)** *High magnification of lymphoblastic lymphoma shows starry-sky appearance due to multiple tingible body macrophages. The surrounding population is composed of immature T lymphoblasts.*

Crush Artifact

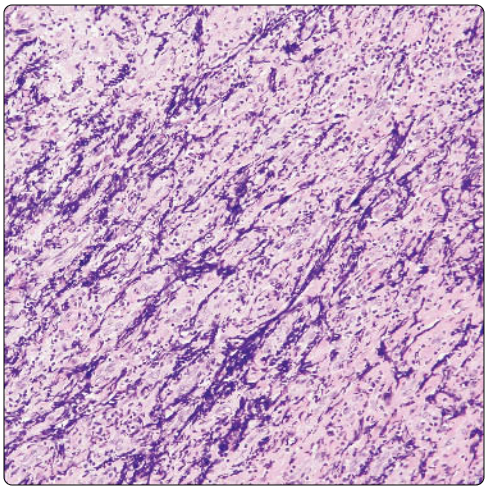

Crush Artifact: High Power

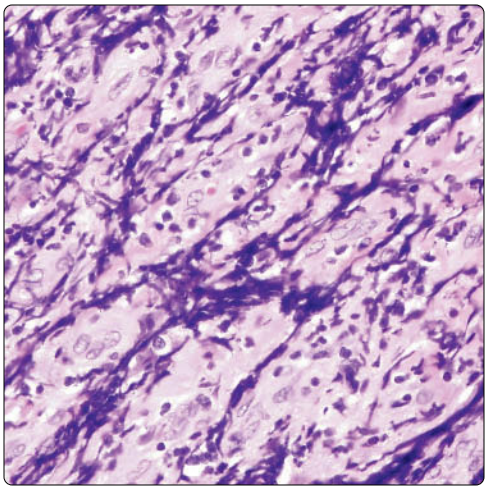

(Left) *Typical appearance of lymphoblastic lymphoma of the mediastinum in a core needle biopsy sample shows distortion of the tumor cells due to crush artifact. Biopsies like this may be difficult to distinguish from other types of lymphomas or metastatic carcinoma.* **(Right)** *High magnification shows lymphoblastic lymphoma with extensive distortion due to crush artifact. Notice the purplish blue streaking of the nuclear chromatin in the stroma separating a few viable cells.*

Single File Arrangement of Tumor Cells

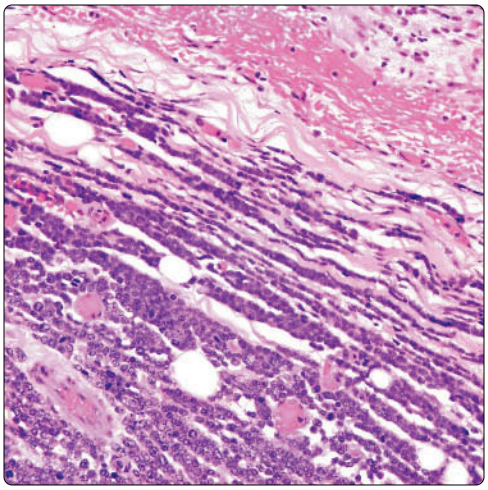

Single File Arrangement

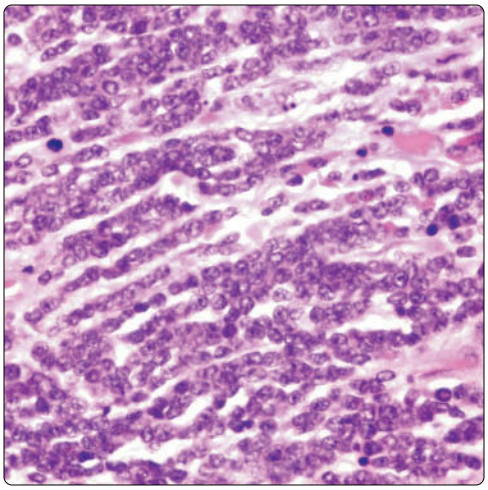

(Left) *Section taken from the periphery of a lymphoblastic lymphoma of the mediastinum shows a linear, single file arrangement of the tumor cells reminiscent of metastatic invasive lobular carcinoma of the breast.* **(Right)** *High magnification of lymphoblastic lymphoma of the mediastinum shows a single file pattern of infiltration of the tumor cells. Notice the primitive appearance of the nuclei and the absence of "molding" of the tumor cells.*

Infiltration of Mediastinal Fat

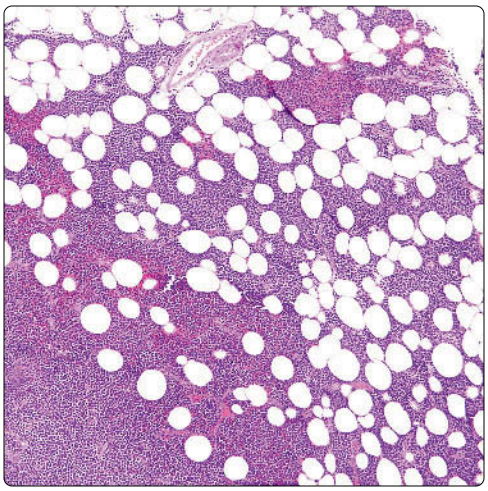

Entrapment of Fat

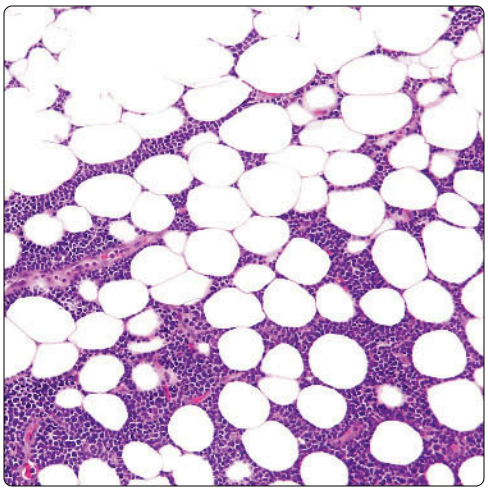

(Left) *Lymphoblastic lymphoma of the mediastinum shows characteristic pattern of infiltration of mediastinal fat at the periphery of the lesion. The tumor cells infiltrate and encircle the adipocytes without destroying them.* **(Right)** *High magnification of lymphoblastic lymphoma of the mediastinum shows infiltration with preservation of mediastinal fat. This feature can help separate lymphoblastic lymphoma from lymphocyte-rich thymoma on frozen sections.*

TdT Immunostaining

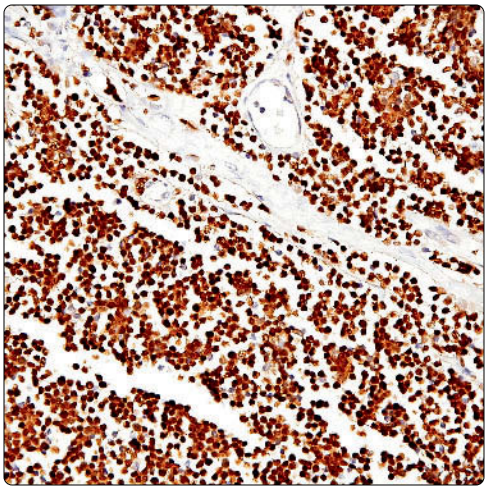

TdT Immunostaining: High Power

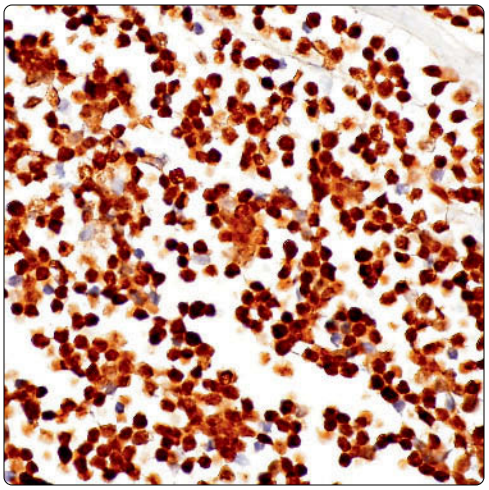

(Left) *Immunohistochemical staining of lymphoblastic lymphoma of the mediastinum for TdT shows strong nuclear positivity in the majority of tumor cells.* **(Right)** *High magnification of lymphoblastic lymphoma of the mediastinum shows positive nuclear staining of the tumor cells with antibodies for TdT. Absence of keratin-positive cells admixed with the lymphoid cells in this sample will allow accurate distinction of this tumor from a lymphocyte-rich thymoma.*

CD3 Immunostaining

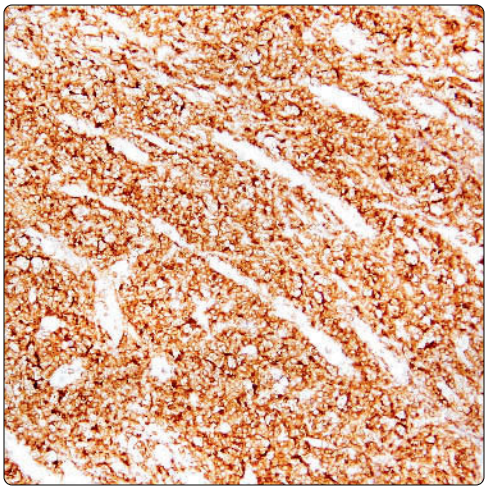

CD99 Immunostaining

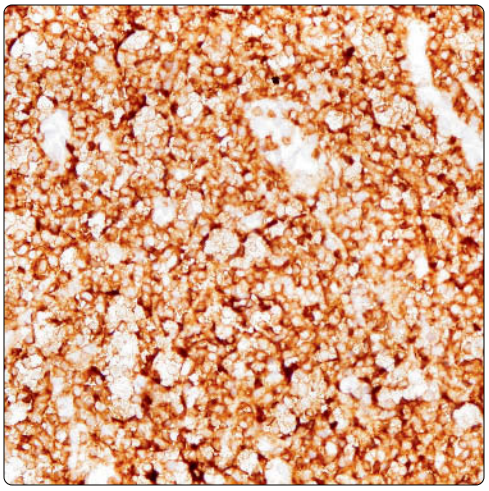

(Left) *Immunoperoxidase stain for CD3 in mediastinal lymphoblastic lymphoma shows strong positivity in all the tumor cells. The CD3 positivity together with TdT nuclear positivity identifies this tumor as a T-lymphoblastic lymphoma/leukemia.* **(Right)** *Immunohistochemical staining for CD99 in mediastinal lymphoblastic lymphoma shows cytoplasmic positivity of the tumor cells. CD99 strongly labels immature T lymphoblasts and can be used in lieu of TdT.*

CD43 Immunostaining

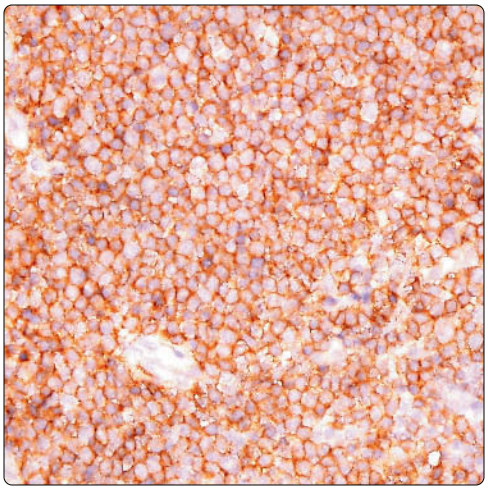

CD10 Immunostaining

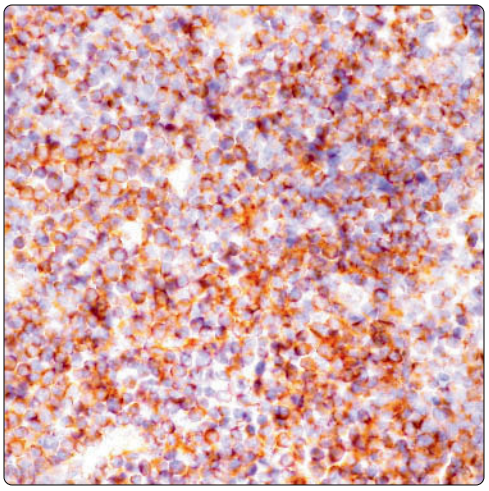

(Left) *Immunohistochemical staining for CD43 in T-lymphoblastic lymphoma of the mediastinum shows strong membrane staining in the tumor cells. This marker is associated with a more aggressive biologic behavior.* **(Right)** *Immunohistochemical staining with CD10 in mediastinal lymphoblastic lymphoma shows positive cytoplasmic staining of the tumor cells. CD10 positivity can be observed in lymphoblastic lymphoma of both B- and T-cell lineage.*

MALT Lymphoma of Thymus

KEY FACTS

TERMINOLOGY

- Low-grade lymphoma derived from distinct native population of thymic postgerminal center stage parafollicular B cells

ETIOLOGY/PATHOGENESIS

- Believed to represent thymic counterpart of distinctive type of extranodal marginal zone lymphoma of mucosa-associated lymphoid tissue (MALToma)

CLINICAL ISSUES

- Generally excellent prognosis with long-term survival
- Some cases may give rise to development of diffuse large cell lymphoma
- Indolent growth with protracted clinical course
- Asymptomatic in > 50% of cases
- Chest pain and shortness of breath in larger lesions
- Indolent growth with protracted clinical course (> 80% 5-year survival)

MICROSCOPIC

- Monotonous proliferation of small lymphoid cells in interfollicular distribution
- Lymphoid cell population is admixed with reactive, hyperplastic lymphoid follicles
- Lymphoid cells infiltrate residual epithelial structures (i.e., Hassall corpuscles), creating lymphoepithelial lesions
- Residual thymic epithelium may undergo cystic degeneration resulting in multiple thymic cysts
- Small lymphocytes can infiltrate surrounding perithymic fat at edges of lesion
- Lymphoid cells display slightly irregular nuclei surrounded by clear, cytoplasmic halos
- Lymphoid cells may display plasmacytoid features
- Rare mitotic figures may be present
- Colonization of germinal centers by neoplastic small mantle zone lymphocytes

(Left) *MALT lymphoma of the thymus shows sheets of small lymphoid cells with clear perinuclear halos cuffing a dilated cystic space. The cystic space is lined by a layer of flattened cuboidal epithelium.* **(Right)** *Lymphoid follicular hyperplasia is a consistent finding in MALT lymphomas and is characterized by enlarged lymphoid follicles with germinal centers. The lymphoid follicle in the center is surrounded by sheets of monotonous lymphocytes.*

Cystic Changes

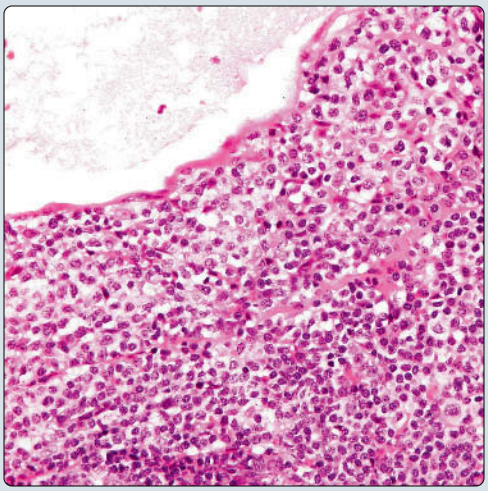

Lymphoid Follicular Hyperplasia

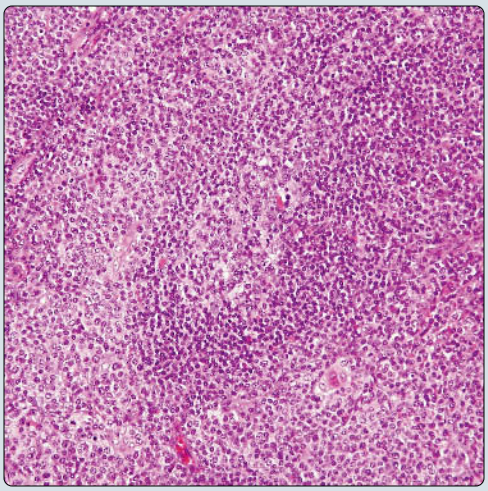

(Left) *Lymphoepithelial lesions involving Hassall corpuscles of the thymus are a distinctive feature in MALT lymphoma. This example shows infiltration and cuffing of a small Hassall corpuscle ⇨ by monotonous lymphoid cells.* **(Right)** *The neoplastic cell population in MALT lymphoma can be quite variable. This case shows a distinctive monocytoid appearance of the tumor cells characterized by a clear cytoplasmic halo surrounding the nuclei of the lymphocytes.*

Lymphoepithelial Lesions

Sheets of Monocytoid Lymphocytes

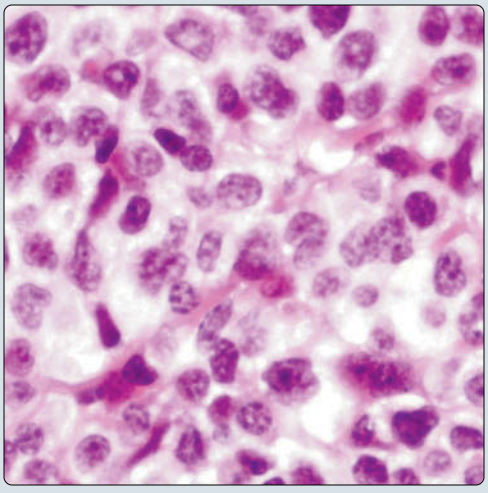

TERMINOLOGY

Abbreviations

- Mucosa-associated lymphoid tissue (MALT) lymphoma

Synonyms

- Monocytoid B-cell lymphoma
- Parafollicular B-cell lymphoma
- Marginal zone lymphoma

Definitions

- Low-grade lymphoma derived from distinct native population of thymic postgerminal center stage parafollicular B cells

CLINICAL ISSUES

Presentation

- Asymptomatic in > 50% of cases
- Chest pain and shortness of breath in larger lesions
- Indolent growth with protracted clinical course (> 80% 5-year survival)
- Often associated with Sjögren syndrome and polyclonal hypergammaglobulinemia
- Predilection for middle-aged women

Treatment

- Surgical excision

Prognosis

- Generally excellent prognosis with long-term survival
- Some cases may give rise to development of diffuse large cell lymphoma

MACROSCOPIC

General Features

- Diffusely enlarged thymus with homogeneous, rubbery cut surface
- May display secondary cystic changes

Size

- 5-10 cm in greatest dimension

MICROSCOPIC

Histologic Features

- Monotonous proliferation of small lymphoid cells in interfollicular distribution
- Lymphoid cell population is admixed with reactive, hyperplastic lymphoid follicles
- Lymphoid cells infiltrate residual epithelial structures (i.e., Hassall corpuscles), creating lymphoepithelial lesions
- Residual thymic epithelium may undergo cystic degeneration resulting in multiple thymic cysts
- Small lymphocytes can infiltrate surrounding perithymic fat at edges of lesion
- Colonization of germinal centers by neoplastic small mantle zone lymphocytes

Cytologic Features

- Lymphoid cells display slightly irregular nuclei surrounded by clear, cytoplasmic halos
- Lymphoid cells often display plasmacytoid features
- Rare mitotic figures may be present

ANCILLARY TESTS

Immunohistochemistry

- Positive for CD11c, CD19, CD20, CD22, CD24, CD43, CD79-α, Bcl-2, pax-5, and IgA
- Negative for CD5, CD10, CD21, CD23, CD25, CD35, cyclin-D1, Bcl-6, and *AP12-MALT1* gene fusion

DIFFERENTIAL DIAGNOSIS

Thymic Lymphoid Hyperplasia

- Most often associated with autoimmune disorders such as myasthenia gravis
- Preservation of normal underlying corticomedullary architecture of thymus
- Absence of lymphoepithelial lesions
- Absence of monocytoid B-cell population surrounding follicles
- Absence of infiltration of perithymic fat by small lymphocytes

Small Lymphocytic Lymphoma/Chronic Lymphocytic Leukemia

- Characterized by diffuse effacement of underlying architecture without follicles or germinal centers
- Neoplastic lymphocytes are positive for CD5 and CD23

Follicular Lymphoma

- Enlarged follicles showing uniform population of transformed germinal center cells
- Cells within follicles are strongly positive for Bcl-2, CD10, and Bcl-6

DIAGNOSTIC CHECKLIST

Pathologic Interpretation Pearls

- Enlargement of thymus with prominent lymphoid follicles but with effacement of underlying native architecture
- Gross and microscopic cystic changes
- Lymphoepithelial lesions
- Monotonous interfollicular population of lymphoid cells with monocytoid features

SELECTED REFERENCES

1. Muramatsu T et al: Thymic and pulmonary mucosa-associated lymphoid tissue lymphomas. Ann Thorac Surg. 95(3):e69-70, 2013
2. Weissferdt A et al: Primary MALT-type lymphoma of the thymus: a clinicopathological and immunohistochemical study of six cases. Lung. 189(6):461-6, 2011
3. Braham E et al: Thymic marginal zone B-cell lymphoma of mucosa-associated lymphoid tissue-type in a patient with Sjögren's syndrome and cryoglobulinaemia. Pathology. 41(7):701-3, 2009
4. Inagaki H et al: Primary thymic extranodal marginal-zone B-cell lymphoma of mucosa-associated lymphoid tissue type exhibits distinctive clinicopathological and molecular features. Am J Pathol. 160(4):1435-43, 2002
5. Parrens M et al: Mucosa-associated lymphoid tissue of the thymus hyperplasia vs lymphoma. Am J Clin Pathol. 117(1):51-6, 2002
6. McCluggage WG et al: Low-grade B-cell lymphoma of mucosa-associated lymphoid tissue (MALT) of thymus. Hum Pathol. 31(2):255-9, 2000
7. Suster S et al: Malignant thymic neoplasms that may mimic benign conditions. Semin Diagn Pathol. 12(1):98-104, 1995

Cystic Spaces

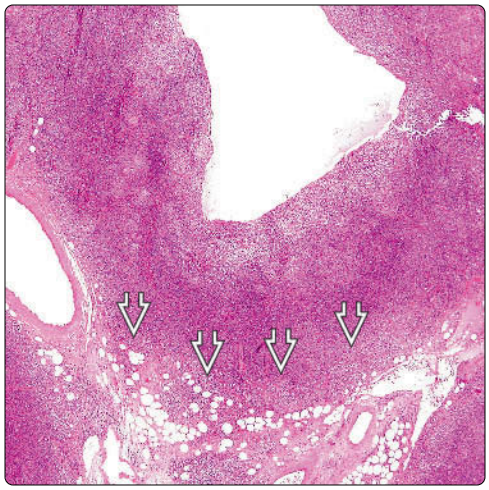

Cystic Space

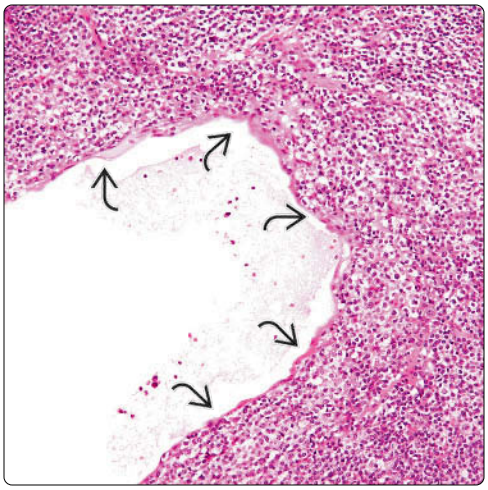

(Left) *Scanning magnification in MALT lymphoma of the thymus shows cystically dilated spaces surrounded by a dense, monotonous lymphoid cell population. The lymphocytes are not confined to the thymus and are seen percolating into the surrounding fat.* **(Right)** *MALT lymphoma of the thymus shows a dilated cystic space lined by a single layer of flattened cuboidal epithelium. The cyst is surrounded by monotonous sheets of small lymphocytes.*

Lymphoid Follicle

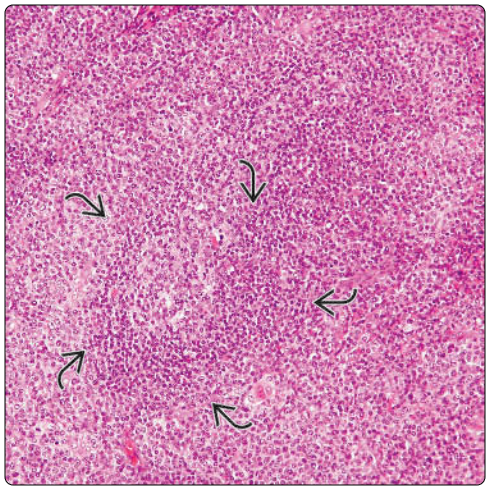

Reactive Germinal Center

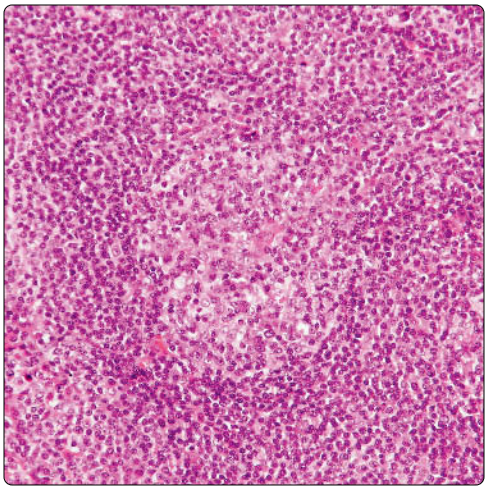

(Left) *MALT lymphoma of the thymus shows sheets of monotonous small lymphocytes circumscribing a lymphoid follicle with a reactive germinal center. The lymphoid cells surrounding the lymphoid follicle show striking perinuclear clearing.* **(Right)** *High-power magnification of MALT lymphoma of the thymus shows a lymphoid follicle with a reactive germinal center surrounded by a monotonous population of small lymphocytes.*

Monotonous Monocytoid Cells

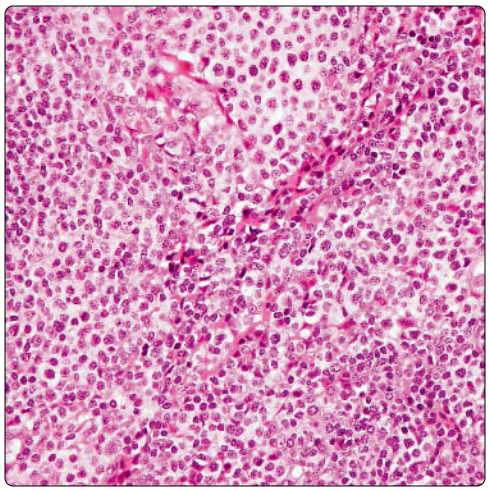

Infiltration of Fat

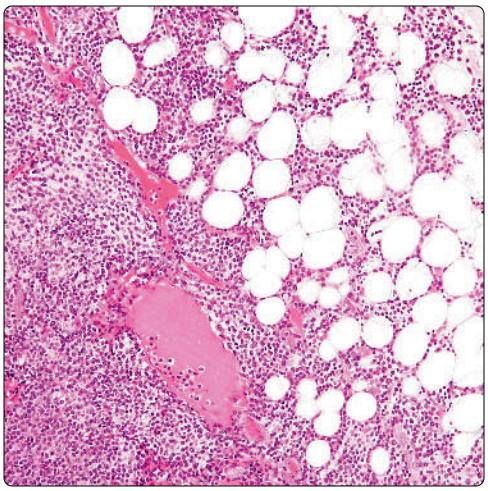

(Left) *High magnification of MALT lymphoma of the thymus shows sheets of monotonous lymphoid cells with minimal nuclear irregularities. Notice the spacing between the cells caused by the presence of clear, perinuclear halos.* **(Right)** *Scanning magnification in MALT lymphoma of the thymus shows infiltration of perithymic adipose tissue by small lymphocytes. Notice percolation of small lymphocytes among the fat cells with preservation of the normal fat.*

Monotonous Small Lymphocytes

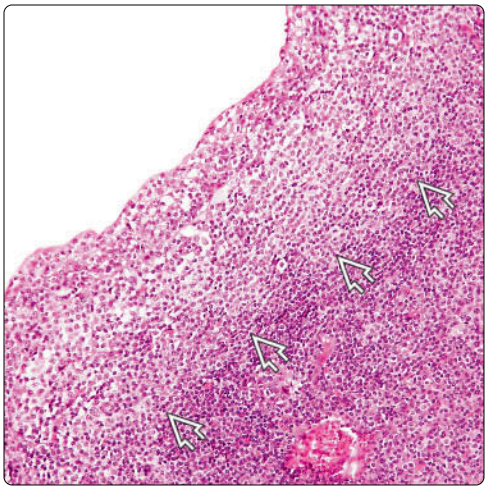

Mitotic Figure

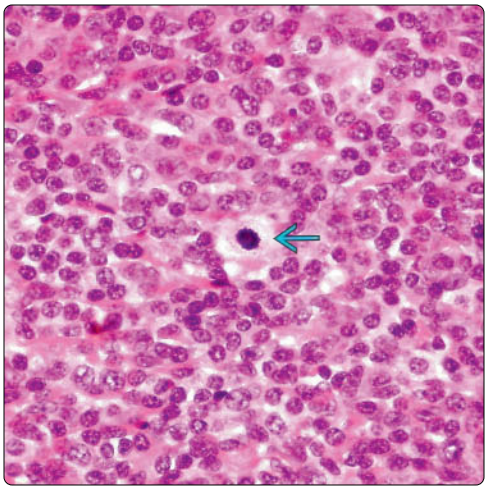

(Left) *Scanning magnification of MALT lymphoma of the thymus shows a band of monotonous lymphoid cells against the lining of a cystic cavity (top left). Notice the lighter staining quality due to an abundance of cytoplasm in the tumor cells.* **(Right)** *MALT lymphoma of the thymus shows sheets of monotonous small lymphocytes. Notice the rare mitotic figure in the center of the field.*

Monocytoid Cells

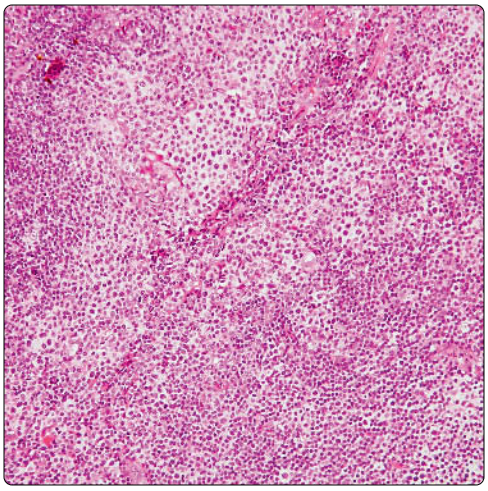

Tumor Cells: High Power

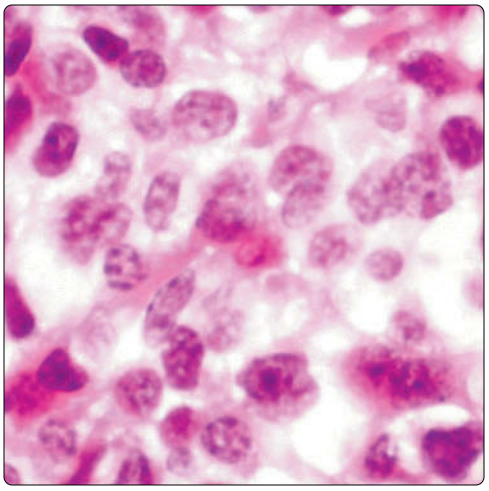

(Left) *MALT lymphoma of the thymus shows sheets of monotonous lymphoid cells with distinctive fried-egg appearance due to clear perinuclear halos surrounding the individual tumor cells.* **(Right)** *High magnification of MALT lymphoma of the thymus shows a population of monotonous small lymphocytes with minimal nuclear irregularities and dispersed nuclear chromatin pattern. The cells are separated from each other by an ample rim of amphophilic cytoplasm.*

Lymphoepithelial Lesions

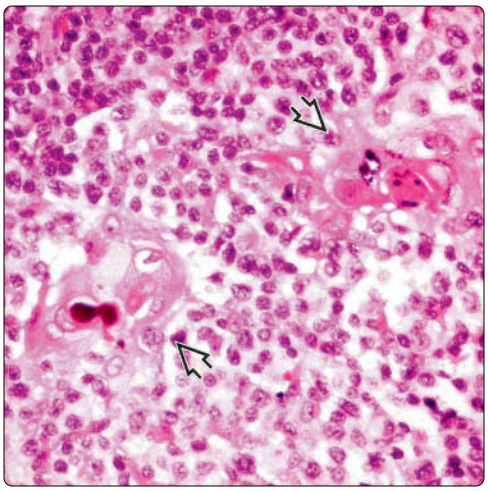

Entrapped Hassall Corpuscle

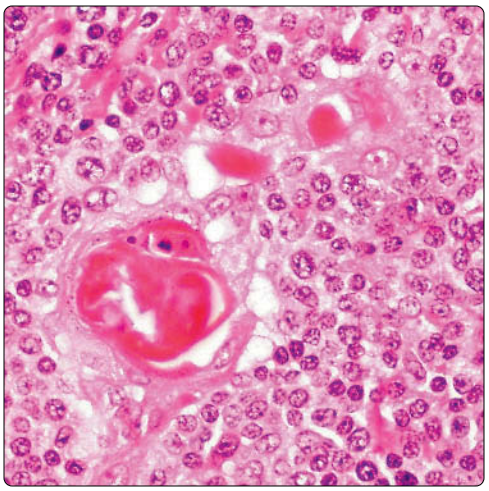

(Left) *MALT lymphoma of the thymus shows entrapment of Hassall corpuscles by dense lymphoid cell infiltrate creating characteristic lymphoepithelial lesions.* **(Right)** *High magnification of MALT lymphoma of the thymus shows a distinctive lymphoepithelial lesion. Notice entrapment of Hassall corpuscle (center) by the dense lymphoid cell population with infiltration and percolation of individual small lymphocytes into the epithelium.*

Liposarcoma

KEY FACTS

CLINICAL ISSUES

- Rare tumor
- Broad age range; from children to adults (mean age: 43 years)
- Anterior and posterior mediastinum
- Dyspnea
- Chest pain
- Recurrences in 33% of cases
- Myxoid/round cell, dedifferentiated, and pleomorphic liposarcomas are associated with more aggressive behavior
- Large, infiltrative, and unresectable tumors are associated with worse prognosis
- Asymptomatic in up to 1/3 of patients

MICROSCOPIC

- Well-differentiated lipoma-like liposarcoma/atypical lipomatous tumor
- Myxoid/round cell liposarcoma
- Dedifferentiated liposarcoma
- Pleomorphic liposarcoma

ANCILLARY TESTS

- Lipoblasts and atypical cells in well-differentiated lipoma-like liposarcoma and dedifferentiated liposarcoma are positive for MDM2 and CDK4
- Well-differentiated liposarcoma and dedifferentiated liposarcoma show amplification of *MDM2* at 12q14-15 region
- Myxoid liposarcoma shows translocation in t(12;16)(q13;p11) with generation of FUS-DDIT3 fusion protein

TOP DIFFERENTIAL DIAGNOSES

- Lipoma and thymolipoma
- Low-grade spindle cell tumors
- High-grade pleomorphic sarcomas
- Small round blue cell tumors

Gross Appearance

Well-Differentiated Liposarcoma

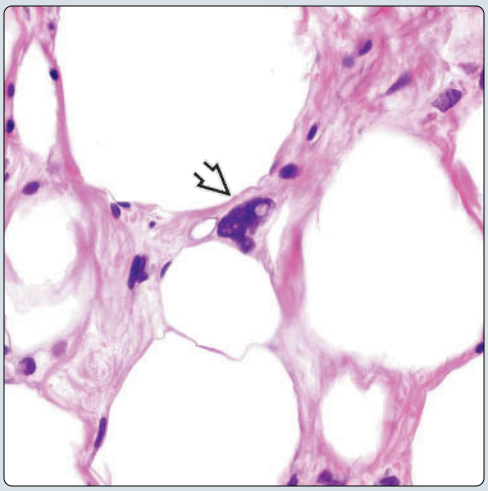

(Left) *Gross appearance of dedifferentiated liposarcoma of the mediastinum shows a well-circumscribed, lobulated mass with an admixture of fleshy white (dedifferentiated) & myxoid (well-differentiated) areas.* **(Right)** *Histologic appearance of well-differentiated liposarcoma of the anterior mediastinum shows atypical lipoblast ⇨ surrounded by normal-appearing adipocytic cells.*

Dedifferentiated Liposarcoma

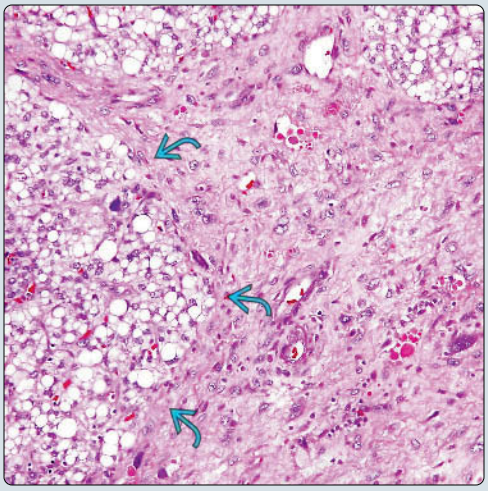

Low-Grade Dedifferentiated Component

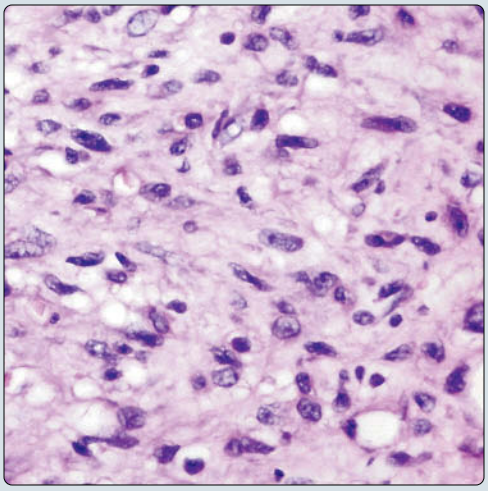

(Left) *Dedifferentiated liposarcoma is a relatively common type of liposarcoma in the mediastinum. This case shows transitions between well-differentiated liposarcoma ⇨ and adjacent low-grade spindle cell dedifferentiated liposarcoma.* **(Right)** *Higher magnification from the low-grade dedifferentiated component in dedifferentiated liposarcoma shows an atypical spindle cell proliferation without features of adipogenic differentiation.*

TERMINOLOGY

Synonyms

- Atypical lipomatous tumor

Definitions

- Malignant neoplastic proliferation of adipocytic cells

CLINICAL ISSUES

Epidemiology

- Incidence
  - Rare tumor
- Age
  - Broad age range; children to adults (mean: 43 years)
- Sex
  - Slight predilection for males

Site

- Anterior and posterior mediastinum
- More common in anterior mediastinum

Presentation

- Cough
- Dyspnea
- Chest pain
- Asymptomatic in up to 1/3 of patients
- May be incidental finding on routine chest x-ray or at autopsy

Treatment

- Surgical excision

Prognosis

- Depends on stage and histologic type
- Recurrences in 33% of cases
- Large, infiltrative, and unresectable tumors are associated with worse prognosis
- Myxoid/round cell, dedifferentiated and pleomorphic liposarcomas are associated with more aggressive behavior
- Round cell and pleomorphic liposarcomas are associated with distant metastases and high mortality
- Well-differentiated liposarcomas can recur 15-20 years after initial diagnosis

MACROSCOPIC

General Features

- Well-differentiated tumors are lobulated, well circumscribed, and thinly encapsulated with soft, yellowish cut surface
- Poorly differentiated tumors are irregular, infiltrative, with yellow-white firm cut surfaces and areas of hemorrhage and necrosis

Sections to Be Submitted

- 1 section per centimeter of largest tumor diameter
- Additional sections must be submitted in tumors suspected of corresponding to dedifferentiated liposarcomas to identify lipogenic elements

Size

- 5-30 cm

MICROSCOPIC

Histologic Features

- **Well-differentiated lipoma-like liposarcoma/atypical lipomatous tumor**
  - Sheets of mature-appearing adipocytes ± scattered atypical lipoblastic cells
  - Areas of densely collagenized stroma containing atypical lipoblasts and spindle cells
  - Thymoliposarcoma is characterized by admixture of normal thymus with atypical lipomatous areas
  - Scattered lymphoid aggregates or lymphoid follicles
- **Myxoid/round cell liposarcoma**
  - Scattered small, stellate or round cells embedded in abundant myxoid matrix
  - Prominent arborizing (chicken-wire) vascular pattern of small branching vessels in stroma
  - Round cell variant characterized by increased cellularity with emergence of dense sheets of primitive, hyperchromatic small round cells
  - Pulmonary-edema pattern with dilated spaces filled with serum may be seen in these tumors
- **Dedifferentiated liposarcoma**
  - Well-differentiated liposarcoma that shows emergence of nonlipogenic atypical spindle cell component
  - Low-grade dedifferentiated component shows bland-appearing spindle cell proliferation with low mitotic rate
  - High-grade dedifferentiated component shows pleomorphic tumor cells with atypical mitoses simulating malignant fibrous histiocytoma
  - Dedifferentiated component may be heterologous (i.e., rhabdo-, leio-, or osteosarcomatous)
  - Dedifferentiated component may show foci of spindle cells showing distinctive whorling pattern that resembles meningioma
- **Pleomorphic liposarcoma**
  - High-grade pleomorphic sarcoma with focal areas containing lipoblastic elements
  - Bizarre lipoblasts and multinucleated floret-type giant cells
- **Pleomorphic myxoid liposarcoma**
  - Shows areas of myxoid liposarcoma admixed with pleomorphic tumor cells
  - More aggressive behavior than conventional myxoid liposarcoma
  - Rare morphologic variant more often seen in mediastinum

Cytologic Features

- Majority of cells in well-differentiated liposarcoma resemble normal mature adipocytes
- Well-differentiated liposarcoma may contain atypical, multinucleated adipocytes
- Well-differentiated liposarcoma often contains floret-type multinucleated cells
- Sclerosing areas in well-differentiated liposarcoma contain floret-type cells and bland-appearing spindle stromal cells
- Lipoblasts may vary from small, signet ring lipoblasts to multivacuolated adipocytes with multiple enlarged, atypical nuclei

- Round cell liposarcoma shows primitive small round blue cells with scant cytoplasm
- Pleomorphic liposarcoma contains bizarre, anaplastic, and multinucleated atypical lipoblastic cells

ANCILLARY TESTS

Immunohistochemistry

- Mature adipocytes are S100 protein positive
- Lipoblasts and atypical cells in well-differentiated lipoma-like liposarcoma and dedifferentiated liposarcoma are MDM2 and CDK4 positive

Genetic Testing

- Supernumerary ring and giant marker chromosomes are seen in well-differentiated and dedifferentiated liposarcoma
- Random and nonrandom telomeric association can also be seen in well-differentiated liposarcoma
- Characteristic t(12;16)(q13;p11) is present in > 90% of myxoid and round cell liposarcomas
  - t(12;16) in myxoid/round cell liposarcoma leads to fusion of *DDIT3* (CHOP) and *FUS* genes with generation of FUS/DDIT3 hybrid protein
- Variant chromosomal translocation t(12;22)(q13;q12) is also present in myxoid liposarcoma in which *DDIT3* fuses with *EWSR1* (EWS)
- No distinctive cytogenetic markers have been observed in pleomorphic liposarcoma

Molecular Diagnostics

- FISH for *MDM2* shows consistent amplification in 12q14-15 in well-differentiated and dedifferentiated liposarcomas
- Neighboring genes, such as *CDK4*, *TSPAN31* (SAS), and *HMGA2* (HMGIC), can also be amplified in well-differentiated and dedifferentiated liposarcomas
- 12q14-15 amplification is not observed in benign tumors and may serve to distinguish well-differentiated liposarcoma from lipoma
- FISH for detection of *FUS/DDIT3* fusion product is helpful in confirming diagnosis of myxoid/round cell liposarcoma
- Amplification of *MDM2* can be observed in ~ 1/3 of pleomorphic liposarcomas

DIFFERENTIAL DIAGNOSIS

Lipoma and Thymolipoma

- Mediastinal lipomas are small and well-circumscribed, completely encapsulated lesions
  - Absence of areas of sclerosis, lipoblasts, floret-type multinucleated cells, or signet ring lipoblastic cells
- Thymolipoma shows admixture of mature adipose tissue with entrapped involuted thymic remnants

Low-Grade Spindle Cell Tumors

- May be difficult to distinguish from low-grade dedifferentiated liposarcoma
  - Low-grade dedifferentiated liposarcoma is positive for MDM2 or CDK4
- Low-grade spindle cell sarcomas of mediastinum lack well-differentiated adipocytic component
- Solitary fibrous tumors are positive for CD34 and Bcl-2
- Schwannomas and neurofibromas are S100 protein positive
- Spindle cell thymomas are positive for cytokeratin
- Leiomyomas and low-grade leiomyosarcomas are positive for desmin and smooth muscle actin

High-Grade Sarcomas

- May be difficult to distinguish from high-grade dedifferentiated liposarcoma or pleomorphic liposarcoma
- Nonlipogenic high-grade sarcomas lack lipoblastic cells or well-differentiated adipocytic components

Small Round Blue Cell Tumors

- May be confused with round cell liposarcoma
- Small round blue cell tumors [Ewing/primitive neuroectodermal tumor (PNET), small desmoplastic round blue cell tumor, neuroblastoma, rhabdomyosarcoma] usually lack myxoid stroma
- Ewing/PNET are positive for CD99 (c-mic2)
- Small desmoplastic round blue cell tumors are polyphenotypic (positive for vimentin, cytokeratin, desmin, synaptophysin, EMA, and other markers)
- Neuroblastoma is positive for NSE
- Rhabdomyosarcoma is positive for desmin, MYOD1, and myogenin
- Small round blue cell tumors lack *DDIT3* translocation

DIAGNOSTIC CHECKLIST

Clinically Relevant Pathologic Features

- Histologic tumor type influences biologic behavior
- Myxoid/round cell liposarcoma and pleomorphic liposarcoma have worse prognosis
- Assessment of margins and adequacy of excision may be very difficult to assess in well-differentiated neoplasms

Pathologic Interpretation Pearls

- Well-differentiated adipocytic tumors in mediastinum are best regarded as well-differentiated liposarcoma irrespective of histology
- Extensive sampling may be required to identify low-grade, well-differentiated liposarcomatous component in dedifferentiated liposarcomas

SELECTED REFERENCES

1. Ortega P et al: Liposarcomas of the posterior mediastinum: clinicopathologic study of 18 cases. Mod Pathol. 28(5):721-31, 2015
2. Alaggio R et al: Liposarcomas in young patients: a study of 82 cases occurring in patients younger than 22 years of age. Am J Surg Pathol. 33(5):645-58, 2009
3. Coulibaly B et al: Recurrent dedifferentiated liposarcoma of mediastinum involving lung and pleura. Interact Cardiovasc Thorac Surg. 9(4):741-2, 2009
4. Fukai R et al: A dedifferentiated liposarcoma of the anterior mediastinum. Int J Clin Oncol. 14(2):174-7, 2009
5. Hahn HP et al: Primary mediastinal liposarcoma: clinicopathologic analysis of 24 cases. Am J Surg Pathol. 31(12):1868-74, 2007
6. Adachi T et al: Immunoreactivity of p53, mdm2, and p21WAF1 in dedifferentiated liposarcoma: special emphasis on the distinct immunophenotype of the well-differentiated component. Int J Surg Pathol. 9(2):99-109, 2001
7. Klimstra DS et al: Liposarcoma of the anterior mediastinum and thymus. a clinicopathologic study of 28 cases. Am J Surg Pathol. 19(7):782-91, 1995

Well-Differentiated Lipoma-Like Liposarcoma

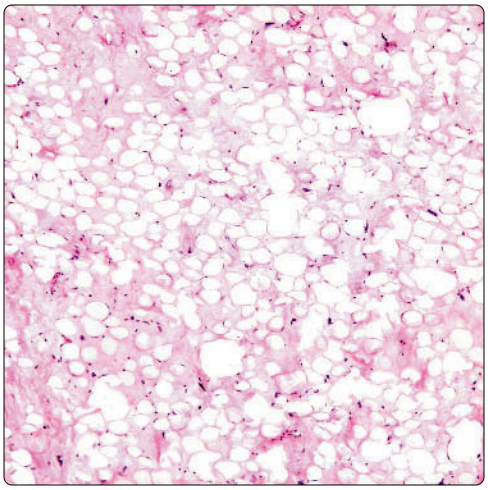

Lipoblastic Cell in Well-Differentiated Liposarcoma

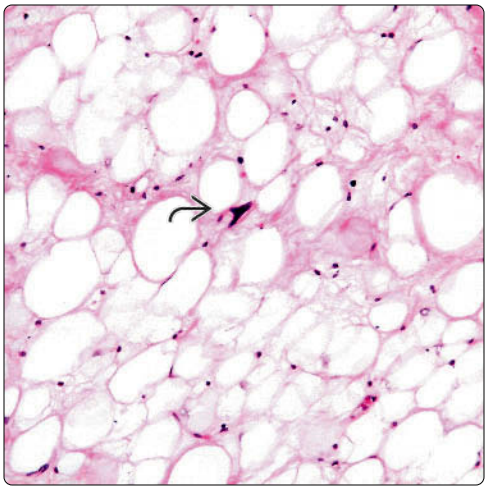

(Left) *Scanning magnification of well-differentiated lipoma-like liposarcoma/atypical lipomatous tumor of the mediastinum shows a monotonous, evenly spaced population of mature, normal-appearing adipocytes. The lesion resembles a lipoma.* **(Right)** *Higher magnification of well-differentiated lipoma-like liposarcoma/atypical lipomatous tumor of the mediastinum shows a rare atypical cell admixed with the surrounding normal-appearing, mature adipocytic cells.*

Lipoblasts in Well-Differentiated Liposarcoma

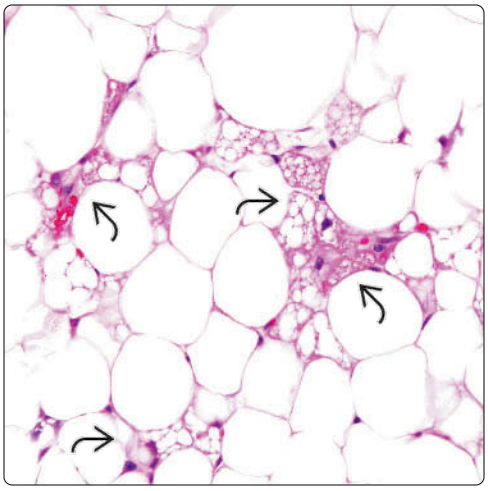

Multivacuolated Lipoblast

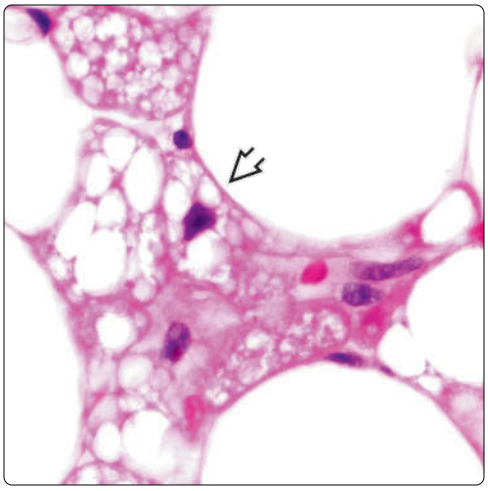

(Left) *Scanning magnification of well-differentiated lipoma-like liposarcoma/atypical lipomatous tumor of the mediastinum shows a uniform population of mature adipocytes admixed with a few multivacuolated adipocytes.* **(Right)** *High magnification of well-differentiated lipoma-like liposarcoma/atypical lipomatous tumor of the mediastinum shows multivacuolated lipoblasts. Notice the slightly atypical nuclei surrounded by multiple cytoplasmic vacuoles.*

Scattered Atypical Lipoblastic Cells

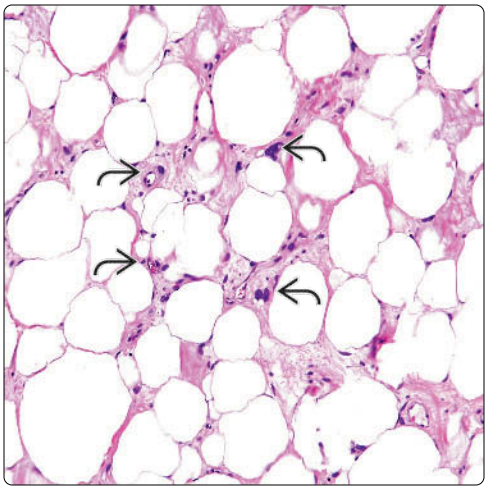

Atypical Lipoblast

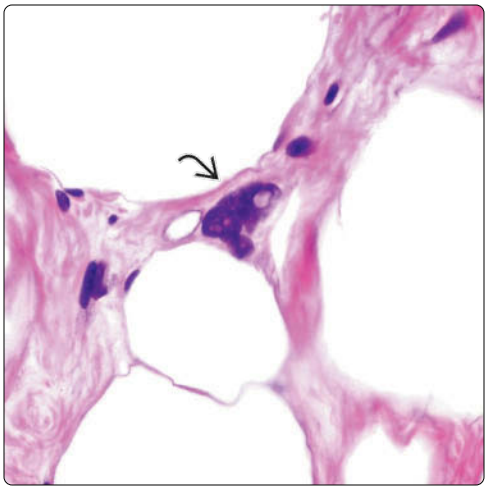

(Left) *Scanning magnification of well-differentiated lipoma-like liposarcoma/atypical lipomatous tumor of the mediastinum shows a uniform population of normal-appearing fat with a few scattered larger, atypical cells.* **(Right)** *High magnification of well-differentiated lipoma-like liposarcoma/atypical lipomatous tumor of the mediastinum shows mature adipocytes surrounding a large, atypical lipoblastic cell. Notice the dense nuclear chromatin and irregularly shaped nucleus.*

Floret Cell

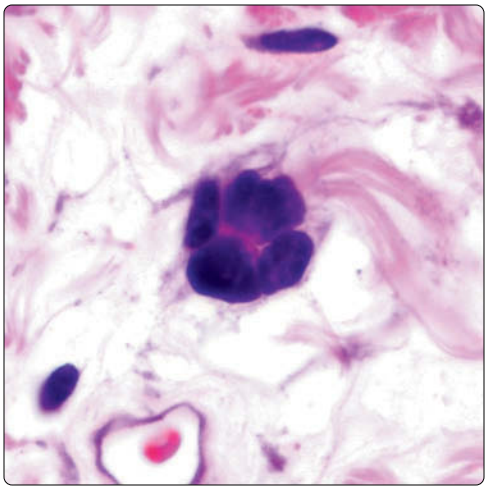

Multinucleated Lipoblast

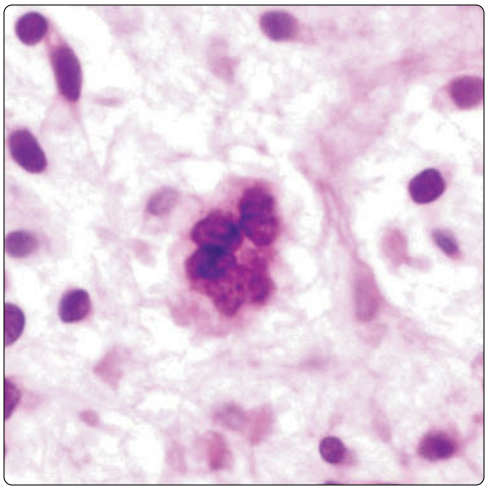

(Left) *Floret-type atypical cell in mediastinal well-differentiated lipoma-like liposarcoma shows multiple large, hyperchromatic nuclei disposed toward the periphery, resembling the petals of a flower.* **(Right)** *Another variation on the theme of the floret-type multinucleated lipoblast in mediastinal liposarcoma shows multiple nuclei surrounded by multivacuolated cytoplasm. These cells are common in well-differentiated lipoma-like liposarcoma/atypical lipomatous tumor.*

Lipoblastic Cell

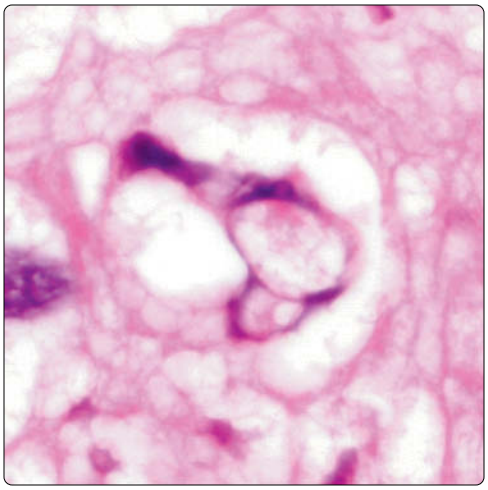

Atypical Lipoblastic Cells

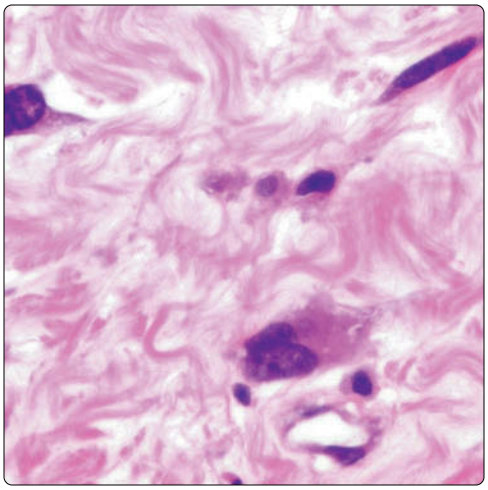

(Left) *Large multivacuolated lipoblast in well-differentiated lipoma-like liposarcoma/atypical lipomatous tumor of the mediastinum shows multiple large cytoplasmic and intranuclear vacuoles.* **(Right)** *Lipoblastic cell in the sclerosing portion of a well-differentiated lipoma-like liposarcoma/atypical lipomatous tumor of the mediastinum shows multinucleation with a single intranuclear vacuole but devoid of any discernible cytoplasmic vacuolization.*

Intranuclear Vacuoles in Lipoblast

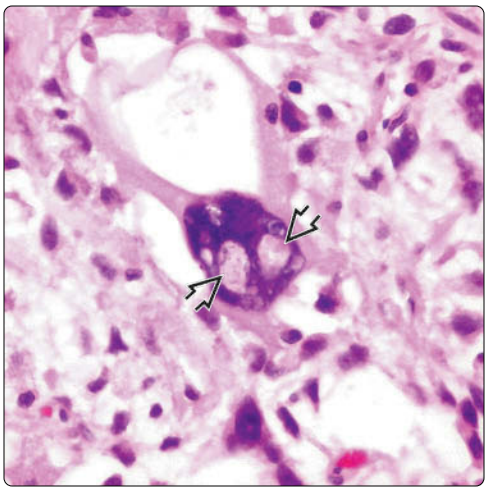

Intranuclear Vacuole

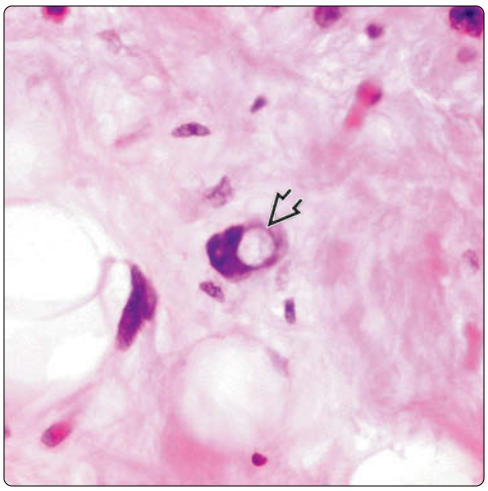

(Left) *Atypical lipoblastic cell in a well-differentiated lipoma-like liposarcoma of the mediastinum is characterized by a single, large, atypical nucleus with a dense chromatin pattern and multiple intranuclear vacuoles caused by invaginations of the cytoplasm (pseudoinclusions).* **(Right)** *Sclerosing portion of well-differentiated lipoma-like liposarcoma of the mediastinum shows a signet ring cell lipoblast containing a single cytoplasmic vacuole that displaces the nucleus to the periphery.*

Sclerosing Liposarcoma

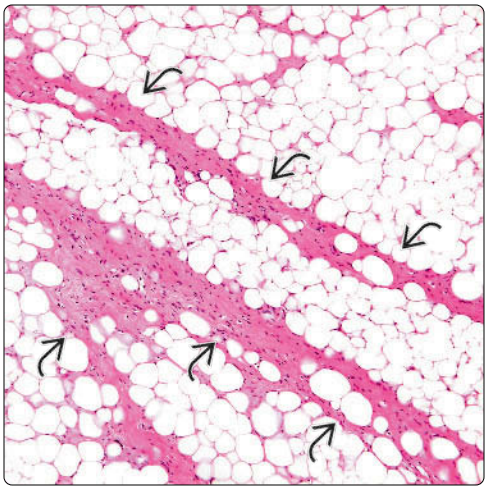

Sclerosing Liposarcoma: High Power

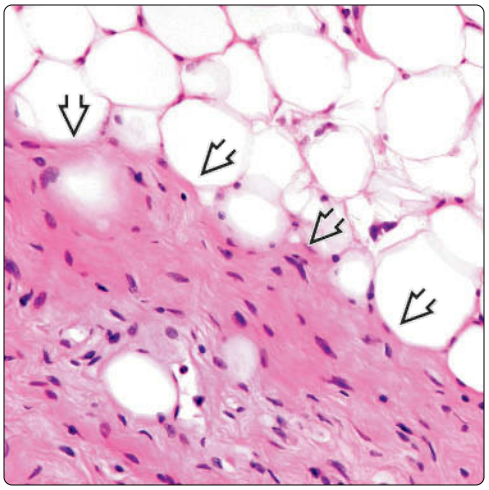

(Left) *Sclerosing well-differentiated lipoma-like liposarcoma of the mediastinum shows thin fibrous bands dissecting the fatty tissue.* **(Right)** *High magnification of the sclerosing portion of well-differentiated lipoma-like liposarcoma/atypical lipomatous tumor of the mediastinum shows dense collagen deposition with numerous small, hyperchromatic spindle cells admixed with small, round, more primitive cells.*

Sclerosing Liposarcoma

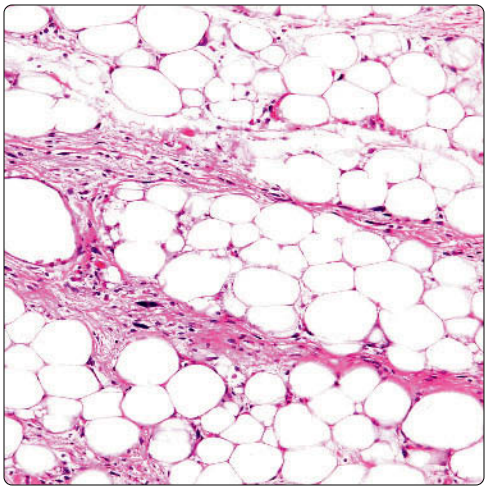

Atypical Lipoblastic Cells

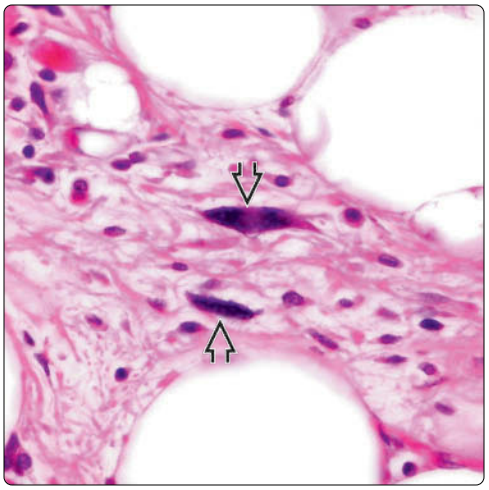

(Left) *Scanning magnification of well-differentiated lipoma-like liposarcoma/atypical lipomatous tumor of the mediastinum with sclerosis shows dense fibrous bands dissecting in-between the adipocytes that contain atypical, hyperchromatic cells.* **(Right)** *Higher magnification of well-differentiated lipoma-like liposarcoma of the mediastinum with sclerosis shows atypical spindle cells lying within the area of sclerosis. The atypical cells display large hyperchromatic nuclei.*

Liposarcoma With Sclerosis

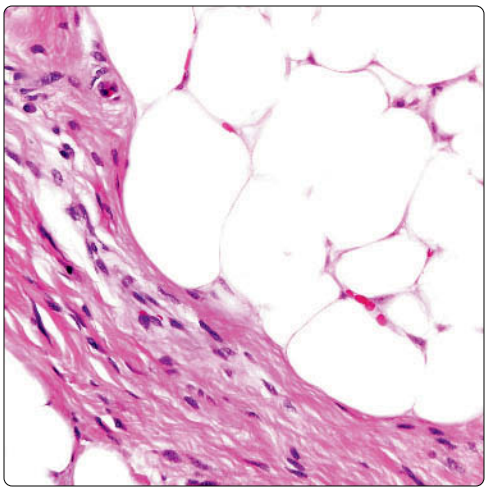

"Inflammatory" Liposarcoma

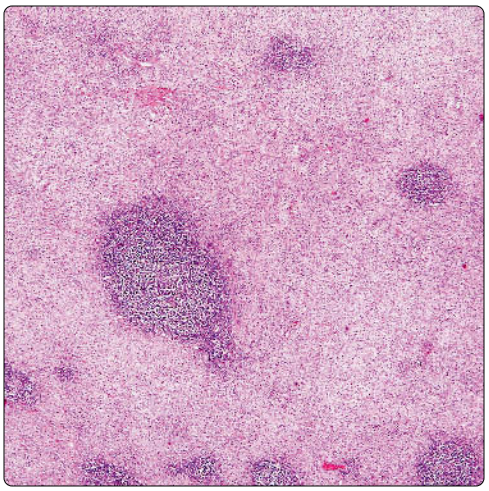

(Left) *Area of sclerosis within well-differentiated lipoma-like liposarcoma/atypical lipomatous tumor of the mediastinum shows a well-defined band of stromal fibrosis that is sharply separated from the surrounding adipose tissue.* **(Right)** *The "inflammatory" variant of well-differentiated liposarcoma is characterized by the deposition of dense lymphoid infiltrates with germinal centers that are scattered among the tumor cells and can sometimes obscure the neoplastic cell population.*

Dedifferentiated Liposarcoma: Low Grade

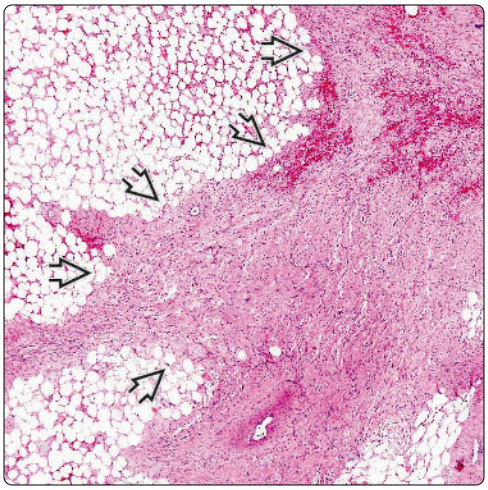

Edge of Dedifferentiated Liposarcoma

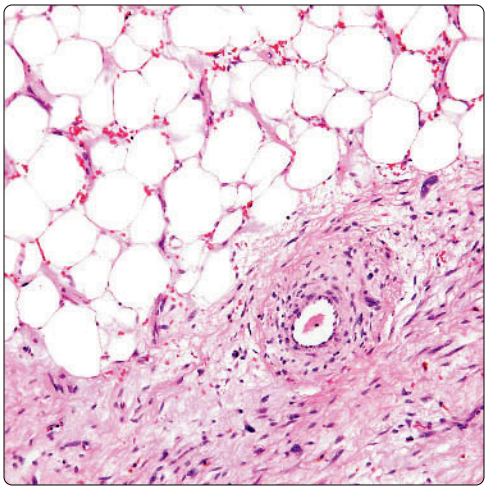

(Left) *Scanning magnification of low-grade dedifferentiated liposarcoma of the mediastinum shows well-differentiated lipoma-like liposarcoma merging with solid areas containing an atypical spindle cell population.* **(Right)** *Higher magnification in low-grade dedifferentiated liposarcoma of the mediastinum shows mature adipose elements (top) merging with a more solid, spindle cell population (bottom). Notice the low-grade appearance of the spindle cells in the dedifferentiated areas.*

Low-Grade Dedifferentiated Liposarcoma

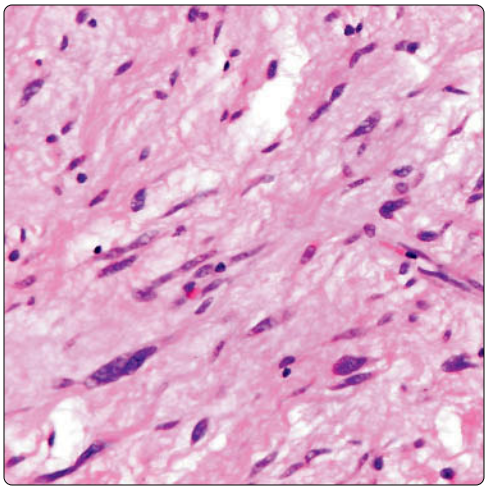

Smooth Muscle Dedifferentiation

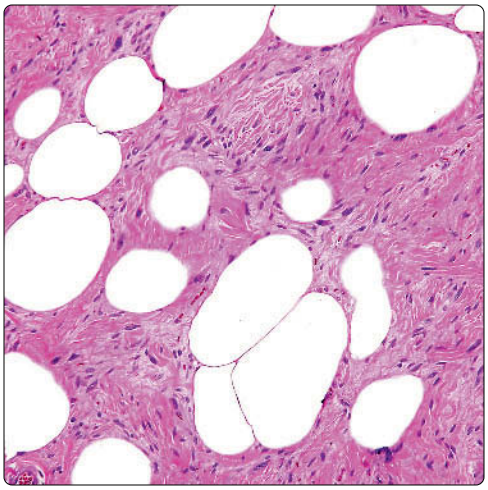

(Left) *Higher magnification of low-grade dedifferentiated liposarcoma of the mediastinum shows mildly atypical spindle cell population embedded in heavily hyalinized stroma.* **(Right)** *Area of dedifferentiated liposarcoma of the mediastinum shows spindle cell proliferation with smooth muscle differentiation percolating in-between the normal residual adipose tissue in the tumor. The smooth muscle most likely is an expression of aberrant differentiation in these tumors.*

High-Grade Dedifferentiated Liposarcoma

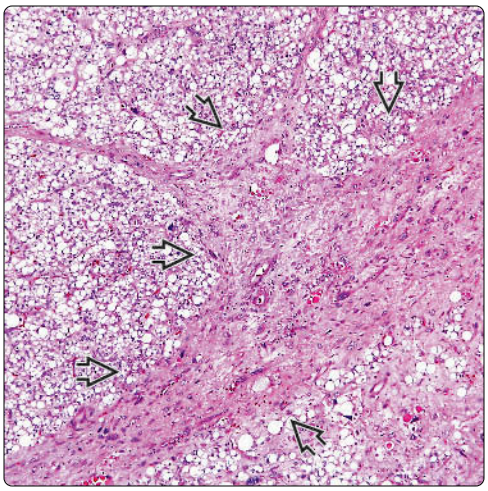

High-Grade Dedifferentiated Liposarcoma

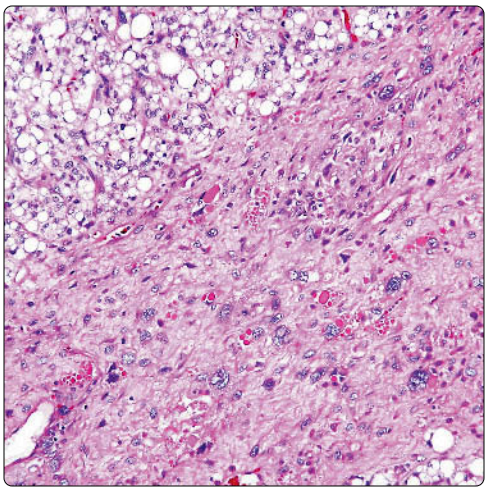

(Left) *Scanning magnification in high-grade dedifferentiated liposarcoma of the mediastinum shows preserved mature-appearing areas of lipoma-like liposarcoma surrounding irregular fibrous strands that contain a population of bizarre, pleomorphic tumor cells.* **(Right)** *High magnification of high-grade dedifferentiated liposarcoma shows a population of bizarre, atypical tumor cells that closely resemble a malignant fibrous histiocytoma.*

Myxoid Liposarcoma

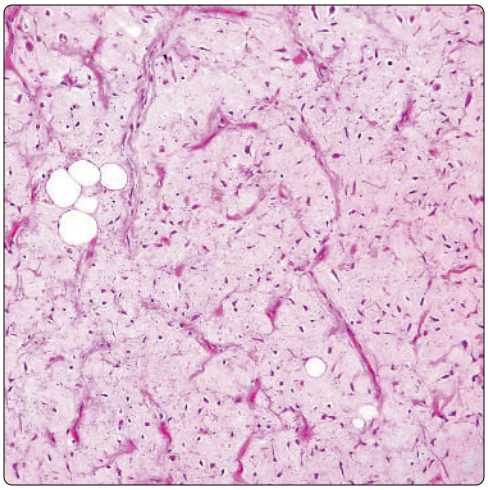

Myxoid Liposarcoma: Higher Magnification

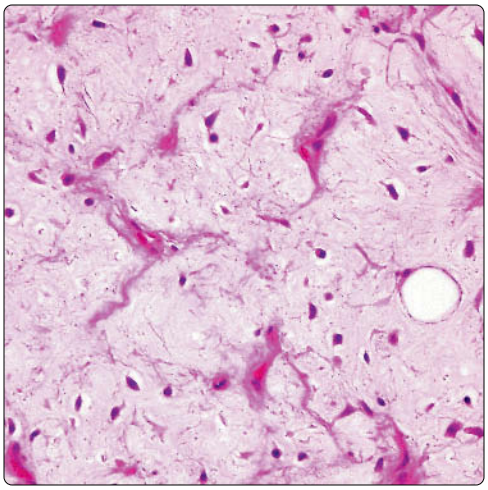

(Left) *Scanning magnification of myxoid liposarcoma of the mediastinum shows a population of small round or stellate cells embedded in abundant myxoid matrix. Notice the arborizing capillary network scattered in the myxoid stroma.* **(Right)** *High magnification of myxoid liposarcoma of the mediastinum shows small, primitive, spindle to stellate, hyperchromatic cells suspended in an abundant myxoid matrix. Notice the small branching vessels displaying a chicken-wire configuration.*

Small Cells in Myxoid Liposarcoma

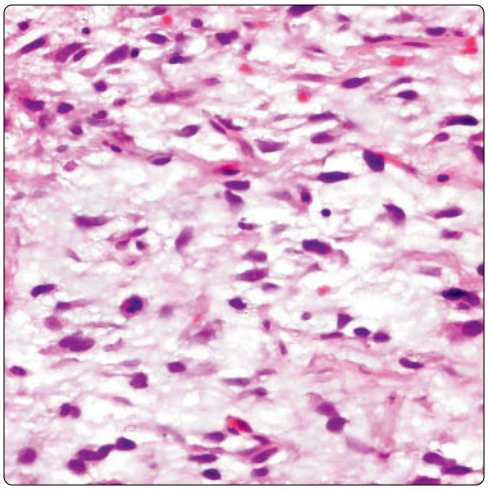

Signet Ring Cell Lipoblasts

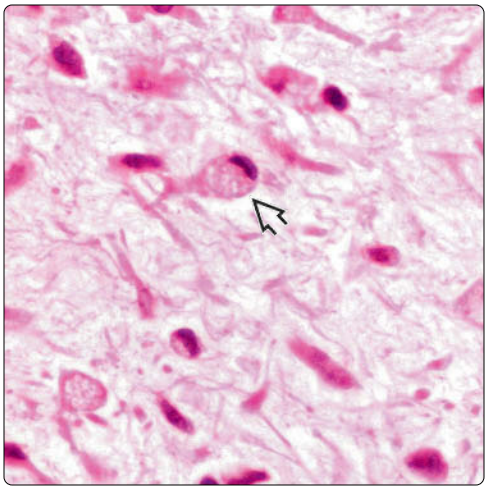

(Left) *Myxoid liposarcoma of the mediastinum shows a population of small round cells and short, hyperchromatic spindle cells lying within a myxoid stroma.* **(Right)** *High magnification of myxoid liposarcoma of the mediastinum shows small, round, and spindle cells suspended in abundant myxoid stroma. A few of the cells show a prominent single intracytoplasmic vacuole that pushes the nucleus to the periphery, adopting a signet ring cell appearance.*

Myxoid Liposarcoma With Atypia

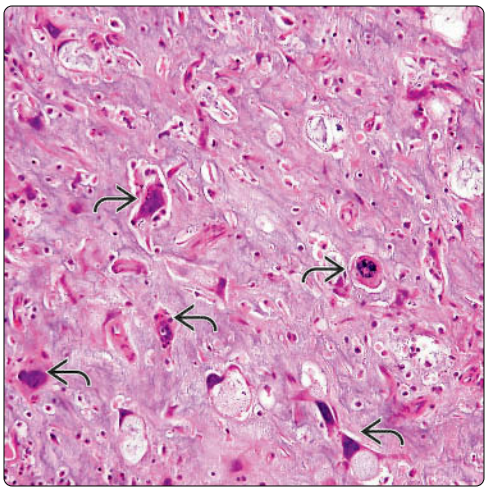

Abnormal Mitosis

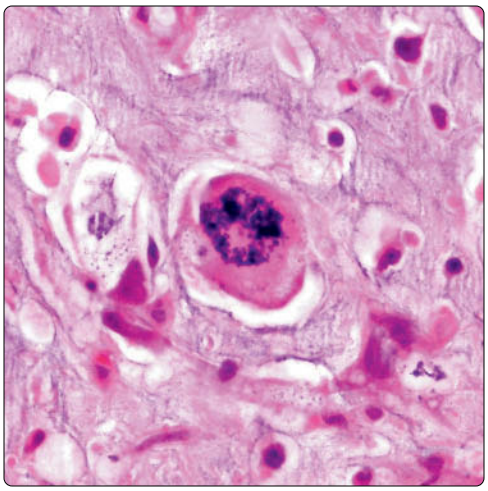

(Left) *Myxoid liposarcoma of the mediastinum with pleomorphic tumor cells shows scattered small cells, abundant myxoid stroma, and a few larger, atypical tumor cells.* **(Right)** *Myxoid pleomorphic liposarcoma of the mediastinum shows a large, atypical tumor cell with an abnormal mitosis (center) surrounded by abundant myxoid matrix. These tumors have been shown to occur with more frequency in the anterior mediastinum and behave more aggressively.*

Round Cell Liposarcoma

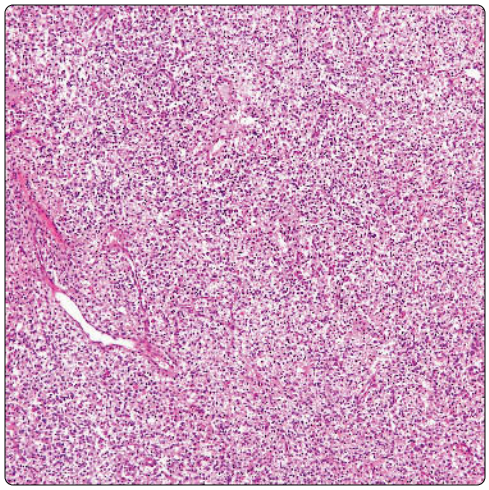

Round Cell Liposarcoma: High Power

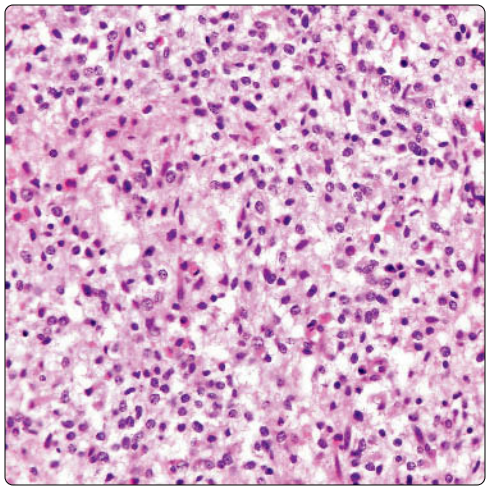

(Left) *Round cell liposarcoma of the mediastinum shows a hypercellular small round cell population without any discernible histologic growth pattern. Tumors with these features can be confused for other small round blue cell tumors, including lymphomas, rhabdomyosarcoma, Ewing/PNET, etc.* **(Right)** *High magnification of round cell liposarcoma of the mediastinum shows a monotonous population of primitive small round blue cells. The tumor is very cellular and contains hardly any stroma.*

Pulmonary Edema-Like Pattern

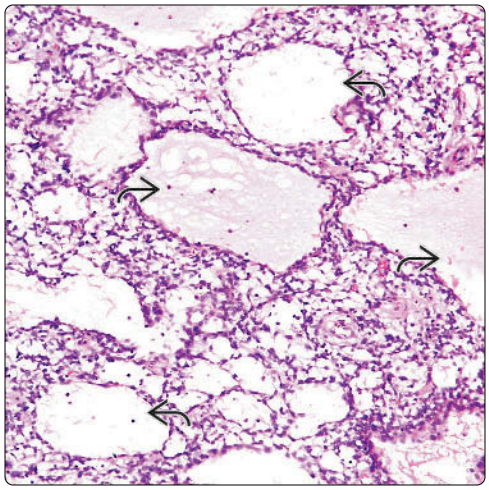

Myxoid Liposarcoma: High Power

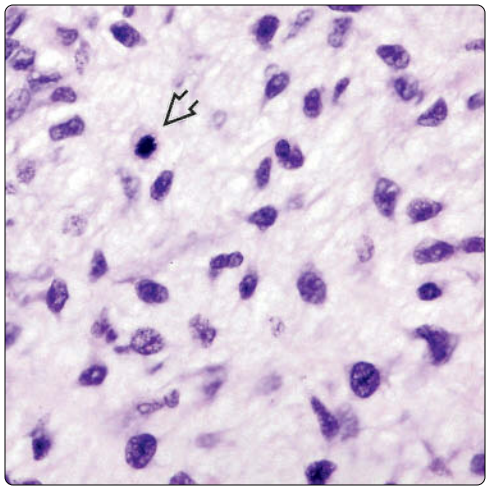

(Left) *Pulmonary edema-like pattern of growth in round cell liposarcoma of the mediastinum is characterized by dilated cystic spaces filled with serum* ⇨ *and surrounded by the small round blue cells.* **(Right)** *High magnification of round cell liposarcoma of the mediastinum shows a primitive-appearing small round blue cell population embedded in abundant, lightly staining myxoid stroma. The cells have hyperchromatic nuclei; notice the mitotic figure* ⇨.

Myxoid/Round Cell Liposarcoma

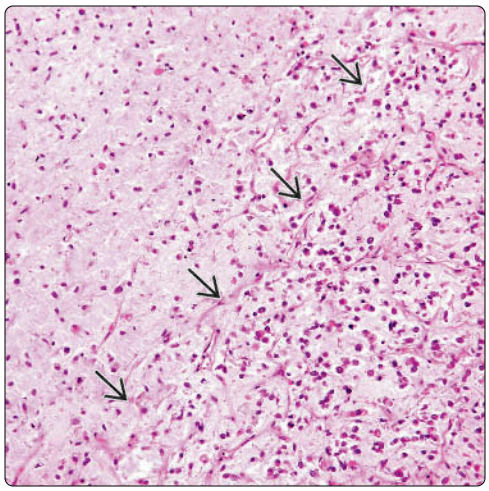

Chicken-Wire Vascular Pattern

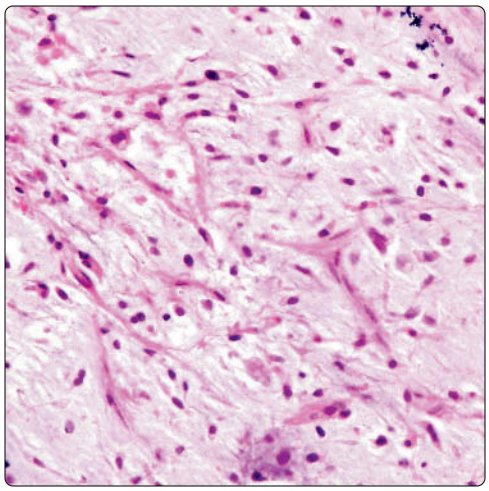

(Left) *Transitions between myxoid liposarcoma and areas with increased cellularity (round cell liposarcoma) are present in this example of round cell liposarcoma of the mediastinum. Notice the gradual increase of cellularity toward the right side of the field* ⇨. **(Right)** *Residual plexiform pattern of vessels (chicken wire) is noted focally in a round cell liposarcoma of the anterior mediastinum. Notice, however, the increase in the number of small round and spindle cells in the background.*

Pleomorphic Liposarcoma

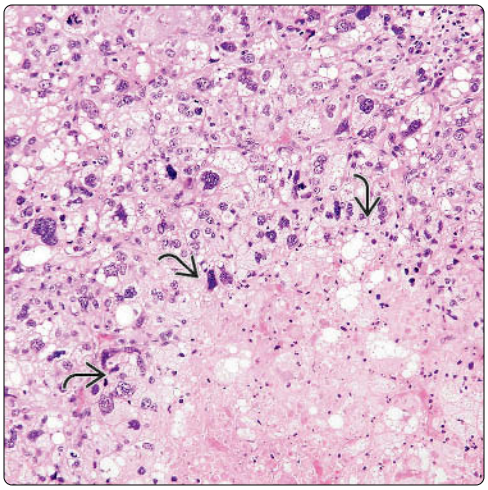

Striking Nuclear Pleomorphism

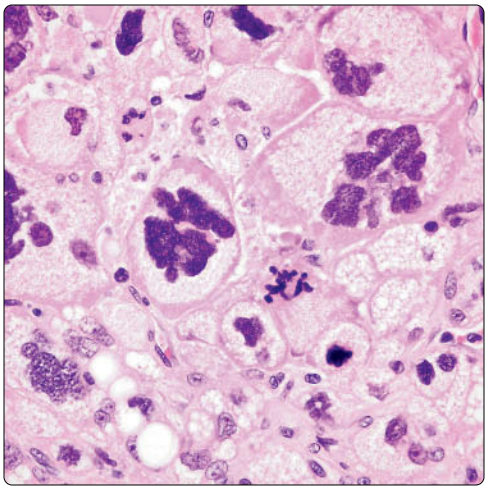

(Left) *Pleomorphic liposarcoma of the mediastinum shows a population of bizarre tumor cells surrounding an area of necrosis. The viable areas of the tumor resemble a pleomorphic high-grade sarcoma.* **(Right)** *High magnification from a cellular area of the tumor in pleomorphic liposarcoma shows bizarre, pleomorphic cells with multiple or multilobated nuclei and scattered abnormal mitotic figures. Notice the prominent cytoplasmic vacuoles in the tumor cells.*

Multivacuolated Lipoblast

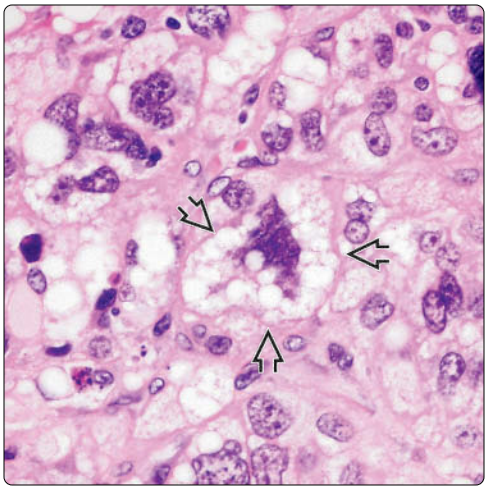

Pleomorphic Lipoblasts

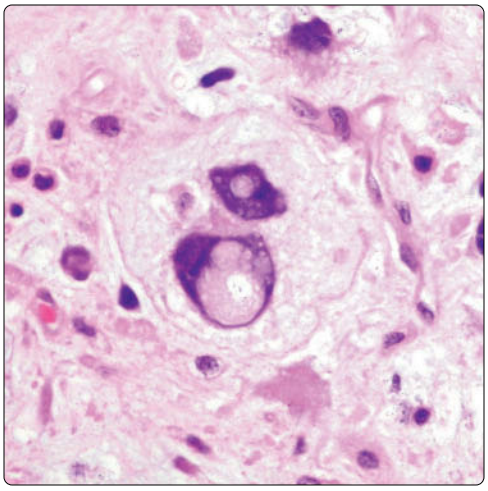

(Left) *High magnification in pleomorphic liposarcoma of the mediastinum shows a pleomorphic tumor cell with large, hyperchromatic nucleus. Notice nuclear scalloping by multiple fatty vacuoles in the cytoplasm; the latter is evidence of lipoblastic differentiation and serves to separate these tumors from malignant fibrous histiocytoma.* **(Right)** *High magnification of a tumor cell in pleomorphic liposarcoma shows multiple nuclei surrounded by abundant vacuolated cytoplasm. Notice the intranuclear vacuoles.*

Bizarre Multinucleated Cells

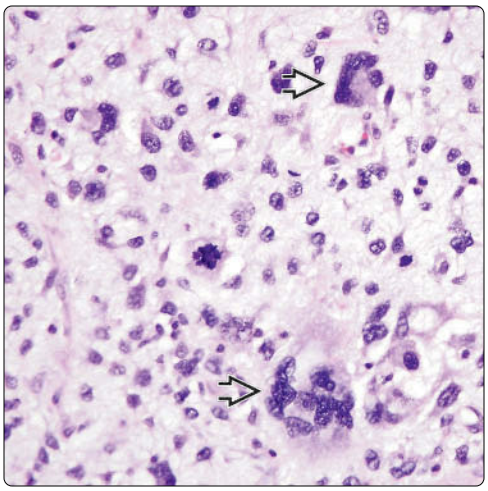

Bizarre Lipoblasts: Higher Magnification

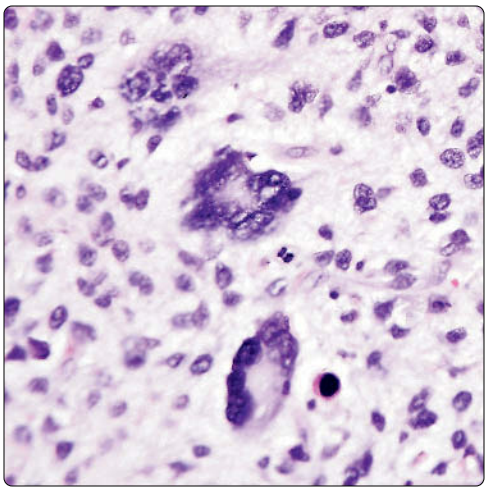

(Left) *Example of myxoid/round cell liposarcoma with pleomorphic tumor cells shows scattered, bizarre multinucleated cells set against a myxoid background. Also note the small round blue cells corresponding to the round cell liposarcoma component.* **(Right)** *High magnification of myxoid/round cell liposarcoma of the mediastinum with pleomorphic component shows bizarre, multinucleated lipoblastic tumor cells with dark-staining nuclei.*

Leiomyosarcoma

KEY FACTS

CLINICAL ISSUES

- Incidence
  - More common in adults
  - Range: 25-70 years of age
- Anatomic site
  - Tumor may appear in anterior or posterior mediastinum
- Treatment
  - Complete surgical resection of tumor
  - Depending on surgical staging, radiation or chemotherapy may be considered
- Symptoms
  - Chest pain
  - Dyspnea
  - Cough
  - Pleural effusion
  - Asymptomatic

MICROSCOPIC

- Solid spindle cellular proliferation
- Spindle cells with cigar-like nuclei and eosinophilic cytoplasm
- Variable nuclear atypia depending on degree of differentiation (grade of tumor)
- Mitotic activity and necrosis

ANCILLARY TESTS

- Positive immunohistochemical stains for muscle markers positive
- Presence of cytoplasmic myofilaments by electron microscopy

TOP DIFFERENTIAL DIAGNOSES

- Solitary fibrous tumor
- Monophasic synovial sarcoma
- Spindle cell thymoma
- Metastatic leiomyosarcoma

Macroscopic Features

Residual Thymic Epithelium

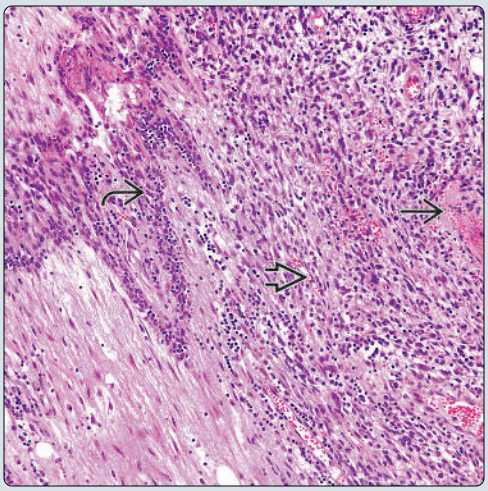

(Left) *Anterior mediastinal leiomyosarcoma shows a fairly homogeneous tumor mass with focal areas of hemorrhage.* **(Right)** *Mediastinal leiomyosarcoma shows a malignant spindle cell proliferation with areas of necrosis. Note the presence of residual thymic epithelium.*

Mitotic Activity

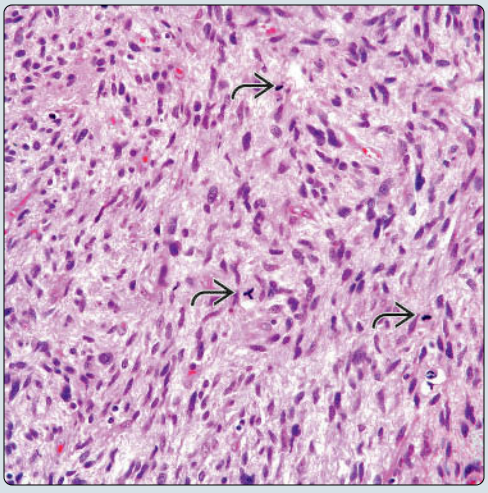

Hemorrhage

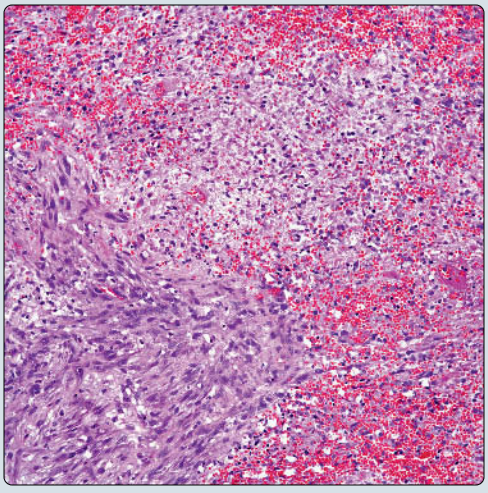

(Left) *Mediastinal leiomyosarcoma shows prominent nuclear atypia and numerous mitotic figures. These features are similar to those tumors occurring in soft tissues.* **(Right)** *Leiomyosarcoma shows areas of necrosis and hemorrhage. These features are commonly seen in high-grade neoplasms.*

TERMINOLOGY

Abbreviations

- Leiomyosarcoma (LMS)

Synonyms

- Malignant smooth muscle tumor

Definitions

- Malignant mesenchymal neoplasm of smooth muscle origin

CLINICAL ISSUES

Epidemiology

- Incidence
  - Unusual tumor in mediastinal compartment
- Age
  - More common in adults
  - Range: 25-70 years old
- Sex
  - There is no sex predilection although LMS may be slightly more common in male patients

Site

- Tumor may appear in anterior or posterior mediastinum

Presentation

- Chest pain
- Dyspnea
- Cough
- General malaise
- Superior vena cava syndrome (unusual)
- Pleural effusion
- Asymptomatic

Treatment

- Surgical approaches
  - Complete surgical resection of tumor
- Adjuvant therapy
  - Depending on surgical staging, radiation or chemotherapy may be considered

Prognosis

- Depends on staging of tumor
  - Patients with advanced stage may follow more aggressive behavior
  - Patients with more limited disease (early stage) may follow more favorable outcome

IMAGING

General Features

- Mediastinal mass
  - Tumor may be in anterior or posterior mediastinum
  - Tumor may encase great vessels
  - Tumor may extend into adjacent structures

MACROSCOPIC

General Features

- Well-defined but not encapsulated tumors
- Rubbery tumor mass at cut surface
- May show cystic changes
- Light brown to tan in color
- Necrosis &/or hemorrhage may be present

Size

- Varies from 5 cm to > 12 cm in greatest diameter

MICROSCOPIC

Histologic Features

- Solid spindle cellular proliferation
- Spindle cells with cigar-like nuclei and eosinophilic cytoplasm
- Variable nuclear atypia depending on degree of differentiation (grade of tumor)
- Variable mitotic activity depending on degree of differentiation (grade of tumor)
- Necrosis &/or hemorrhage
- Infiltrative growth pattern

ANCILLARY TESTS

Electron Microscopy

- Some ultrastructural features that may be associated include
  - Cytoplasmic myofilaments with focal densities
  - Abundant mitochondria
  - Bundles of intermediate filaments
  - Prominent rough endoplasmic reticulum

DIFFERENTIAL DIAGNOSIS

Solitary Fibrous Tumor

- Tumor shows different growth patterns
- Immunohistochemical studies for CD34 and Bcl-2 are commonly seen positive
- Immunohistochemical stains for muscle differentiation are usually negative

Monophasic Synovial Sarcoma

- Generally shows negative staining for muscle markers
- Shows positive staining for EMA &/or keratin
- Specific molecular signature feature

Spindle Cell Thymoma

- Shows lymphocytes
- Lacks increased mitotic activity
- Shows negative staining for muscle markers
- Generally strong positivity for keratin and negative for EMA

Metastatic Leiomyosarcoma

- Clinical and radiological evaluation are of utmost importance
- Clinical history of previous LMS in soft tissue would lead to correct interpretation

Leiomyoma

- Grossly, leiomyomas usually do not show areas of necrosis &/or hemorrhage
- Lacks presence of increased mitotic activity &/or cellular atypia
- Both tumors may show similar immunophenotype

Germ Cell Tumor

- Essentially teratoma with malignant component (LMS)

Immunohistochemistry

Antibody	Reactivity	Staining Pattern	Comment
Actin-HHF-35	Positive	Cytoplasmic	In majority of cases
Desmin	Positive	Cytoplasmic	In high-grade tumors, it may be negative
Caldesmon	Positive	Cytoplasmic	In better differentiated tumors
Vimentin	Positive	Cytoplasmic	Not specific
AE1/AE3	Negative		May be positive in some cases
MYOD1	Negative		
Myoglobin	Negative		
CD34	Negative		
CD31	Negative		
EMA	Negative		
STAT6	Negative		
CK5/6	Negative		
FLI-1	Negative		
SOX10	Negative		
S100	Negative		
CD68	Negative		May show positive staining in inflammatory component
CD99	Negative		

Molecular Features

FISH/Cytogenetics	Result
Alternative lengthening of telomerase phenotype	May be associated with aggressive histology and poor outcome
MDM12 protein expression	May have oncogene role

- Presence of other germ cell layer component in teratoma
- Requires complete surgical resection to make unequivocal diagnosis
- Reasonable sampling if in doubt

Lipomatous Tumor With Muscle Differentiation

- Presence of extensive areas of lipomatous component would be unusual in LMS

DIAGNOSTIC CHECKLIST

Clinically Relevant Pathologic Features

- Mitotic rate
- Spindle cell proliferation
- Necrosis
- Infiltrative growth pattern

Pathologic Interpretation Pearls

- Solid spindle cellular proliferation
- Cigar-like nucleus
- Subtle storiform pattern with cross sections of tumor at right angles
- Increase mitotic activity
- Presence of necrosis

SELECTED REFERENCES

1. Chen F et al: Complete resection of a giant mediastinal leiomyosarcoma. Ann Thorac Surg. 99(3):e69-71, 2015
2. Liao CY et al: Primary leiomyosarcoma of the anterior mediastinum. QJM. 108(5):429-30, 2015
3. Liau JY et al: Leiomyosarcoma with alternative lengthening of telomeres is associated with aggressive histologic features, loss of ATRX expression, and poor clinical outcome. Am J Surg Pathol. 39(2):236-44, 2015
4. Labarca E et al: Superior vena cava syndrome due to a leiomyosarcoma of the anterior mediastinum: A case report and literature overview. Int J Surg Case Rep. 5(12):984-7, 2014
5. Weissferdt A et al: Lipomatous tumors of the anterior mediastinum with muscle differentiation: a clinicopathological and immunohistochemical study of three cases. Virchows Arch. 464(4):489-93, 2014
6. Ravegnini G et al: MED12 mutations in leiomyosarcoma and extrauterine leiomyoma. Mod Pathol. 26(5):743-9, 2013
7. Iwata T et al: Primary leiomyosarcoma of the anterior mediastinum encasing the aortic arch, left common carotid and left subclavian arteries. Ann Thorac Cardiovasc Surg. 18(2):140-3, 2012
8. Lee DH et al: Leiomyosarcoma of the posterior mediastinum extending into the adjacent spinal canal. Korean J Thorac Cardiovasc Surg. 45(3):192-5, 2012
9. Conner WC et al: Surgical management of leiomyosarcoma of the mediastinum. Ann Thorac Surg. 77(1):334-6, 2004
10. Eroğlu A et al: Primary leiomyosarcoma of the anterior mediastinum. Eur J Cardiothorac Surg. 21(5):943-5, 2002
11. Auliac JB et al: [Mediastinal leiomyosarcoma.] Rev Mal Respir. 16(2):210-3, 1999
12. Moran CA et al: Primary leiomyosarcomas of the lung: a clinicopathologic and immunohistochemical study of 18 cases. Mod Pathol. 10(2):121-8, 1997
13. Moran CA et al: Malignant smooth muscle tumors presenting as mediastinal soft tissue masses. A clinicopathologic study of 10 cases. Cancer. 74(8):2251-60, 1994
14. Van Schil PE et al: Primary mediastinal leiomyosarcoma. Thorac Cardiovasc Surg. 41(6):377-8, 1993

Residual Thymus

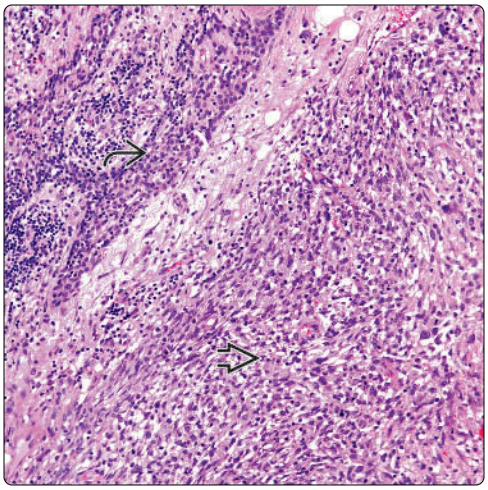

Solid Spindle Cell Proliferation

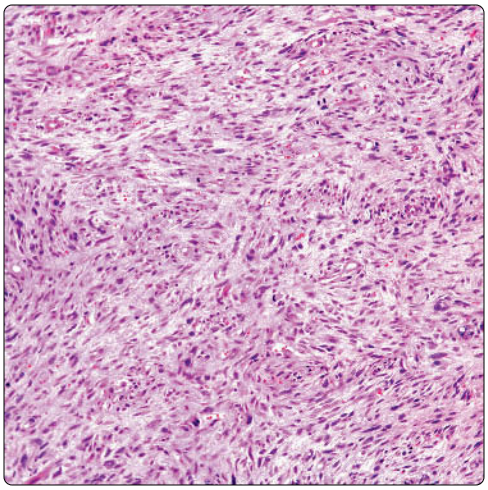

(Left) *Mediastinal leiomyosarcoma shows a malignant spindle cell proliferation. Also note the presence of residual thymic epithelium.* **(Right)** *Mediastinal leiomyosarcoma is shown with a solid spindle cellular proliferation and vague storiform pattern. The tumor shows marked nuclear atypia; however, this pattern may also be seen in some other high-grade sarcomas.*

Subtle Vasculature

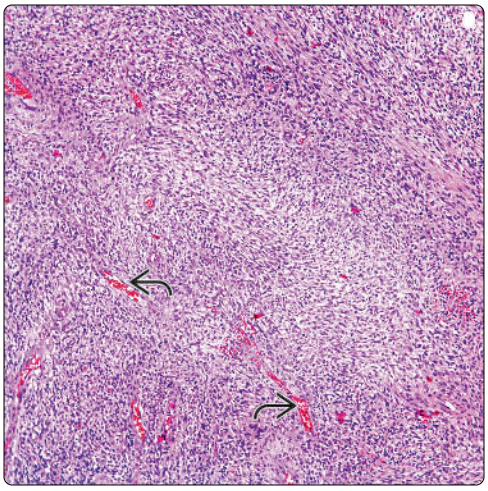

Marked Pleomorphism

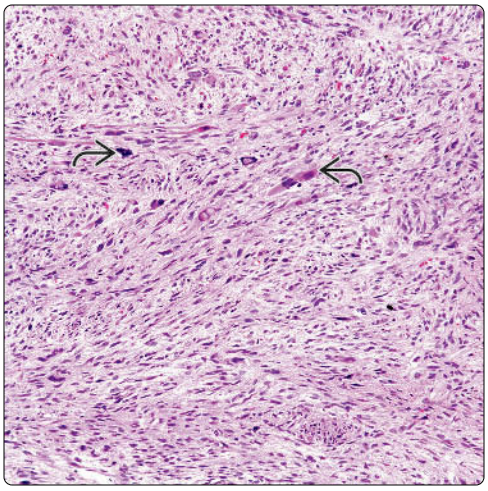

(Left) *Leiomyosarcoma is seen with the typical fascicular growth pattern. Scattered blood vessels are also present.* **(Right)** *Mediastinal leiomyosarcoma displays cellular pleomorphism and prominent nuclear atypia; this pattern is highly suggestive of leiomyosarcoma. These features are more commonly seen in high-grade tumors.*

Giant Cells

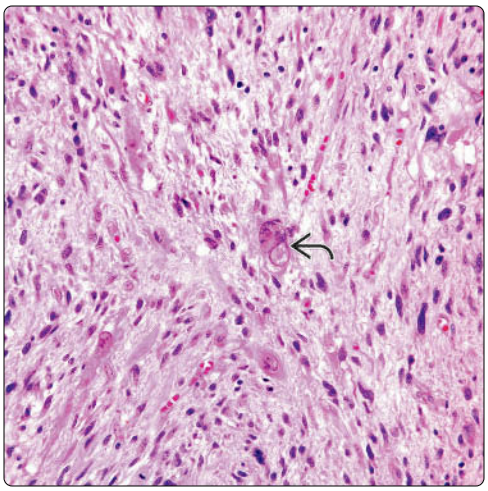

Malignant Vasculitis

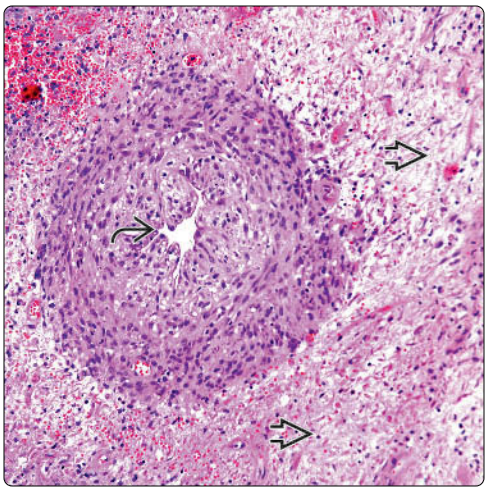

(Left) *High-power view shows prominent nuclear atypia and binucleated cells with intracytoplasmic inclusions in association with a spindle cell proliferation. These features are of high-grade tumors.* **(Right)** *High-grade leiomyosarcoma shows areas of degeneration and necrosis. Note the thin-walled vessel surrounded by the tumor.*

Extensive Necrosis

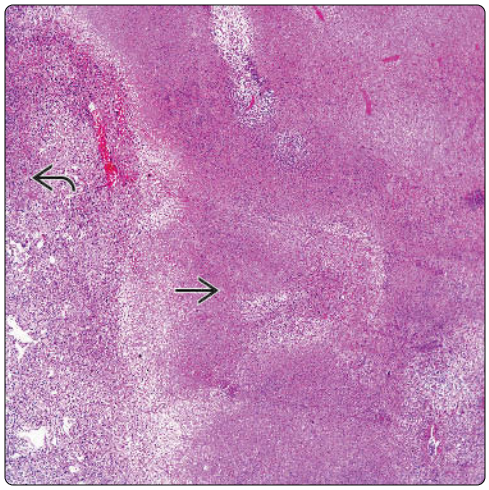

Focal Viable Tumor

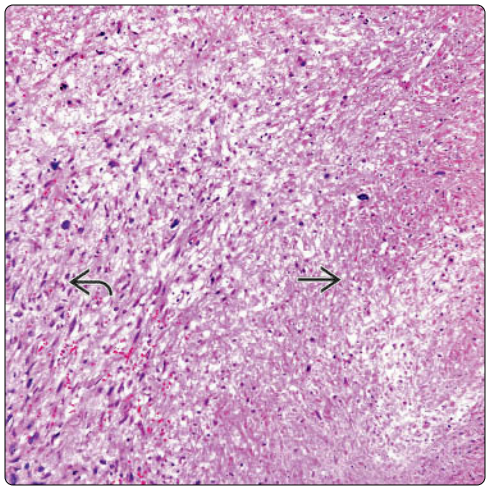

(Left) *Mediastinal leiomyosarcoma shows extensive areas of necrosis. Areas of viable tumor are also present. In some cases, extensive necrosis may obscure the true nature of the neoplasm. The presence of necrosis is a feature of high-grade tumors.* **(Right)** *High-power view shows a malignant spindle cellular proliferation admixed with extensive necrosis. These features are diagnostic of a high-grade sarcoma.*

HPC Pattern

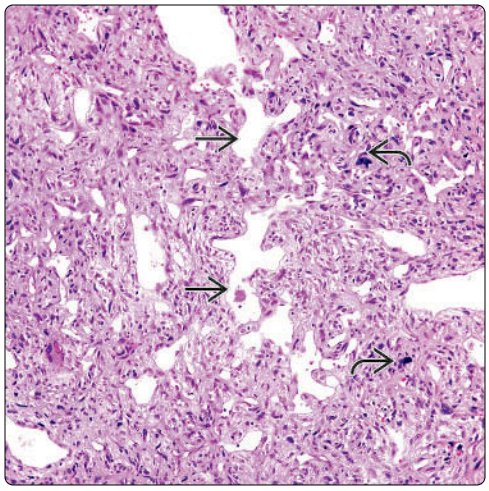

Fibrinous Necrosis

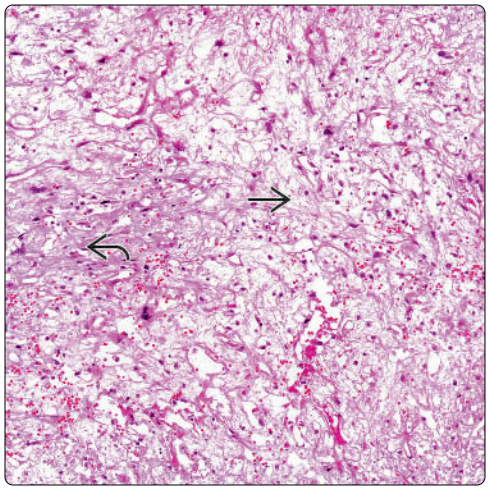

(Left) *Mediastinal leiomyosarcoma shows prominent vascular channels mimicking a hemangiopericytoma (HPC). Note the nuclear atypia. The HPC pattern is commonly seen in leiomyosarcomas.* **(Right)** *Some cases of mediastinal leiomyosarcoma may show extensive fibrinous necrosis with only focal areas of an atypical cellular proliferation, making the diagnosis more difficult.*

Infiltrative Growth Pattern

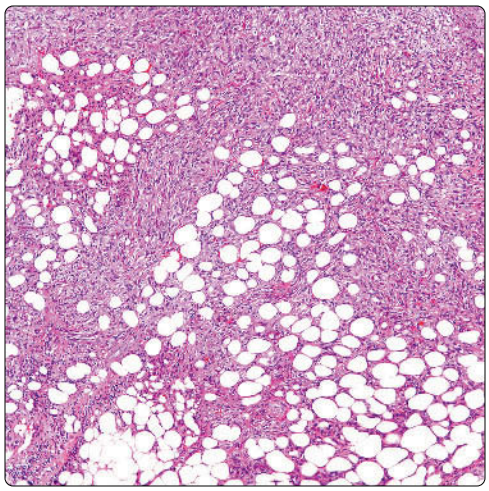

Epithelioid Appearance

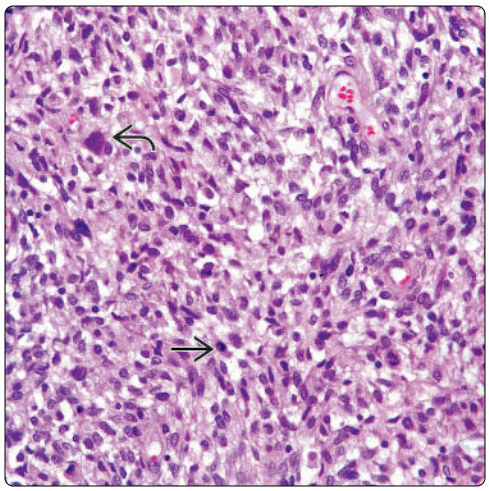

(Left) *Mediastinal leiomyosarcoma is seen infiltrating mediastinal adipose tissue. This feature may be seen in some other tumors, mainly of epithelial origin, such as thymoma.* **(Right)** *High-power view of a high-grade leiomyosarcoma shows nuclear atypia, scattered multinucleated giant cells, and mitotic figures.*

Fascicular Growth Pattern

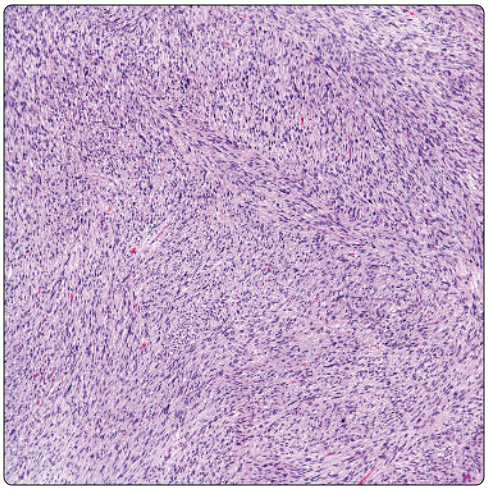

Nuclear Atypia

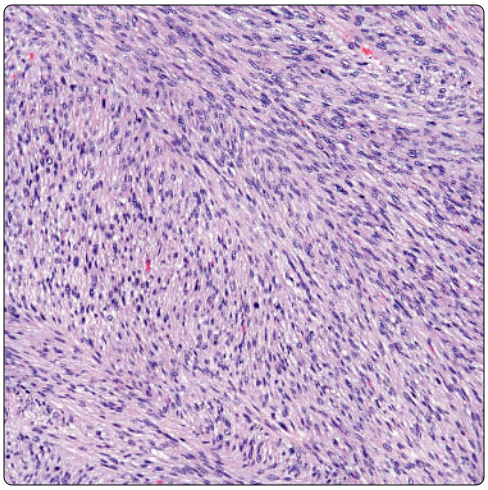

(Left) *Classic low-power presentation of leiomyosarcoma shows interlacing fascicles of malignant spindle cells.* **(Right)** *Closer view of a leiomyosarcoma shows marked nuclear atypia and scattered mitotic activity. Note the presence of interlacing fascicles of tumor cells.*

Mitotic Activity

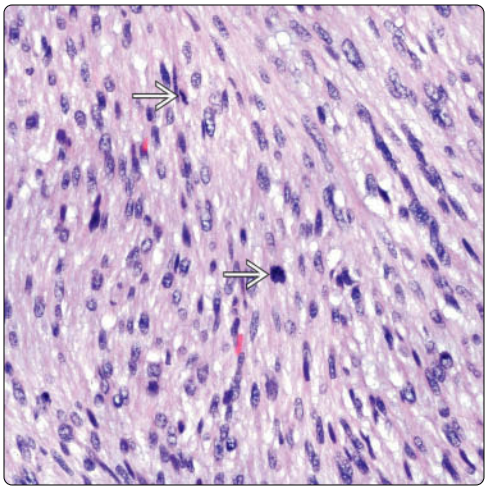

Immunostain for Smooth Muscle Actin

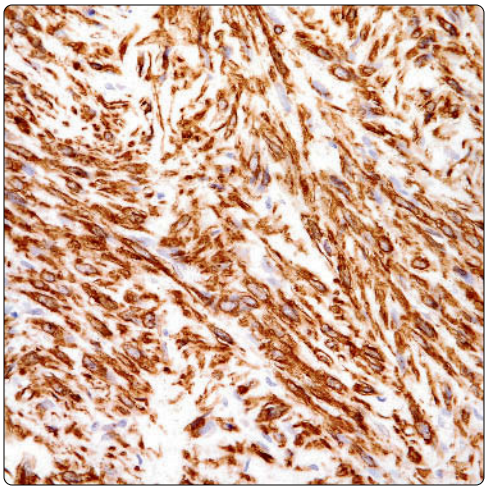

(Left) *Leiomyosarcoma shows easily identifiable mitotic figures* ➡ *in addition to nuclear atypia and cellular pleomorphism.* **(Right)** *Leiomyosarcoma shows strong positive reaction in tumor cells for smooth muscle actin.*

Immunostain for Desmin

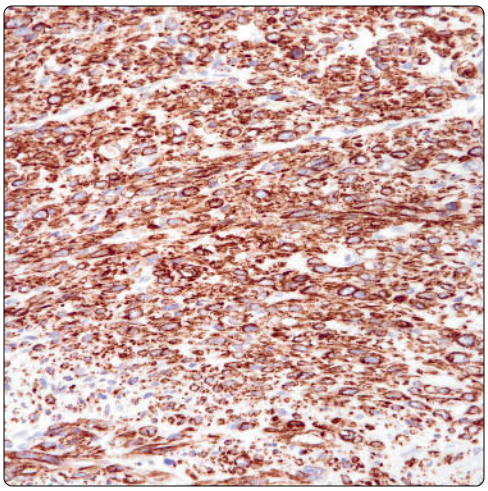

Immunostain for Caldesmon

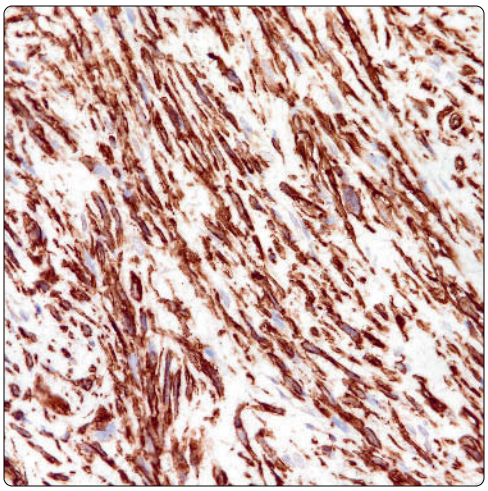

(Left) *Leiomyosarcoma shows strong positive reaction in tumor cells for desmin.* **(Right)** *Leiomyosarcoma shows strong positive reaction in tumor cells for caldesmon.*

Synovial Sarcoma

KEY FACTS

CLINICAL ISSUES

- Predilection for young adults (median: 35 years)
- Female predilection (2:1)
- Aggressive behavior similar to soft tissue counterpart
- Broad age range: 3-83 years
- May involve all mediastinal compartments: Anterior, middle, and posterior

MICROSCOPIC

- Uniform and monotonous proliferation of atypical oval to spindle cells with minimal stroma
- Glandular structures may be very focal or may predominate
- Fascicular growth pattern with herringbone appearance is most common histologic pattern of growth
- Many tumors show, at least focally, prominent hemangiopericytomatous growth pattern
- Other growth patterns include storiform, palisading, and sclerosing
- Stromal changes may include fibrosis, calcifications, and myxoid changes

ANCILLARY TESTS

- Pattern of cytokeratin positivity in monophasic spindle cell tumors is usually weak and focal (patchy)
- Spindle cells
  - Strongly and diffusely stain for Bcl-2
  - Usually stain for CD99
  - May be positive for S100 protein in 30% of cases
  - Negative for actin, desmin, CD34, HMB-45, CEA, MOC-31, and p63
- (X;18)(p11;q11) translocation is characteristically present in > 80% of cases

Monophasic Synovial Sarcoma | **Biphasic Synovial Sarcoma**

(Left) *Monophasic spindle cell variant of synovial sarcoma of the mediastinum shows a monotonous population of atypical spindle cells with scant stroma.* **(Right)** *Biphasic variant of synovial sarcoma of the mediastinum shows admixture of well-formed glandular structures with a monotonous population of atypical spindle cells.*

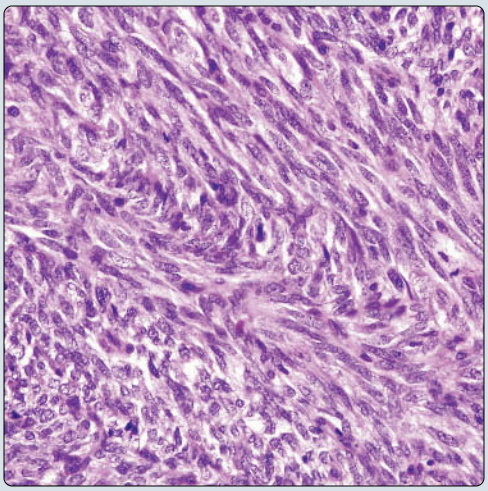

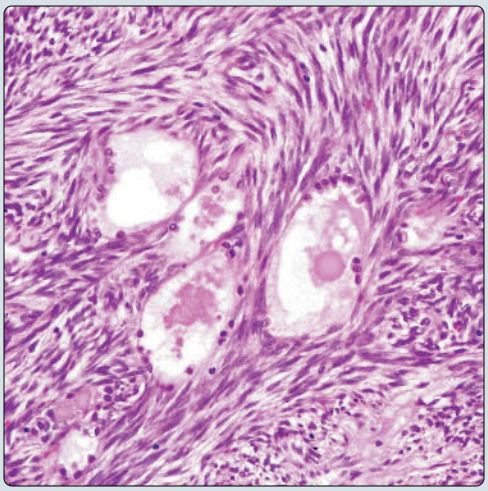

Hemangiopericytic Vascular Pattern | **AE1/AE3 Cytokeratin Immunostaining**

(Left) *A common pattern observed in synovial sarcoma of the mediastinum is characterized by a proliferation of anastomosing vascular spaces with a branching, staghorn configuration surrounded by a dense spindle cell population.* **(Right)** *AE1/AE3 cytokeratin immunostaining shows characteristic patchy positivity in scattered spindle cells in synovial sarcoma.*

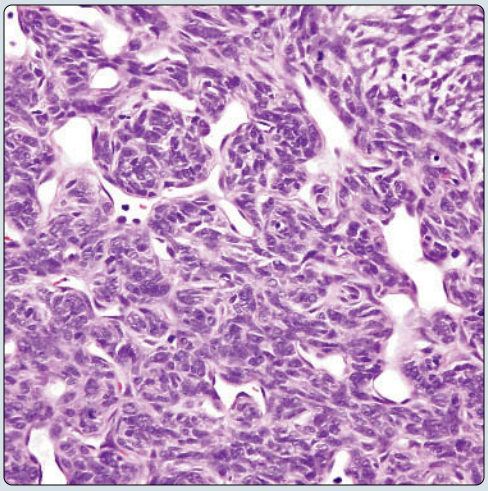

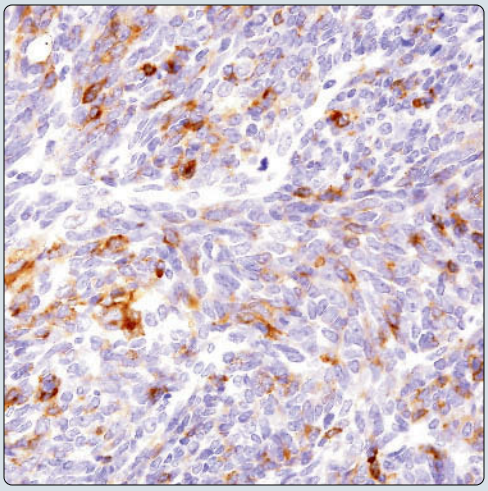

TERMINOLOGY

Abbreviations

- Synovial sarcoma (SS)

Synonyms

- Primary carcinoma of soft tissue

Definitions

- Primary malignant epithelial neoplasm arising from soft tissues

ETIOLOGY/PATHOGENESIS

Pathogenesis

- Unknown; unrelated to synovium or synovial cells
- Pluripotential mesenchymal cells capable of aberrant epithelial differentiation

CLINICAL ISSUES

Epidemiology

- Incidence
  - Rare tumor
- Age
  - Broad range: 3-83 years
  - Predilection for young adults (median: 35 years)
- Sex
  - Female predilection (2:1)

Site

- May involve all mediastinal compartments: Anterior, middle, and posterior

Presentation

- Cough, chest pain, pleural effusion, shortness of breath, and neck or back pain

Treatment

- Surgical excision

Prognosis

- Aggressive behavior similar to soft tissue counterpart
- Local recurrences and distant metastases to lung, lymph nodes, liver, and epidural space

IMAGING

General Features

- Tumors may present as well circumscribed or infiltrative masses with focal calcifications

CT Findings

- Well-circumscribed mediastinal mass with low attenuation
- Pleural effusion

MACROSCOPIC

General Features

- Usually well-circumscribed, fleshy tumors surrounded by thin, fibrous capsule
- May be infiltrative and extend into surrounding structures, such as lung, pleura, pericardium, chest wall, and ribs
- Cut section shows gray-white to tan, homogeneous soft tissue with gelatinous consistency
- Some cases may undergo extensive cystic changes
- May contain scattered calcifications
- Can show focal hemorrhage and necrosis

Sections to Be Submitted

- 1 section per each centimeter of largest tumor diameter

Size

- 5-20 cm

MICROSCOPIC

Histologic Features

- **Monophasic (spindle cell) synovial sarcoma**
  - Uniform and monotonous proliferation of atypical oval to spindle cells with minimal stroma
  - Spindle cells show vesicular or hyperchromatic nuclei with coarse chromatin pattern and inconspicuous nucleoli
  - Mitotic activity may vary from low (1 mitosis per 10 HPF) to high (> 10 mitoses per 10 HPF)
  - Fascicular growth pattern with herringbone appearance is most common histologic pattern of growth
  - Many tumors show, at least focally, prominent hemangiopericytomatous growth pattern
  - Other growth patterns include storiform, palisading, sclerosing, nesting, and rhabdoid
  - Stromal changes may include fibrosis, calcifications, and myxoid changes
  - Poorly differentiated variant characterized by round cell, epithelioid morphology rather than spindle cells
  - Some tumors can show prominent hemorrhage and necrosis
  - Secondary cystic changes are often seen in monophasic tumors
- **Biphasic synovial sarcoma**
  - Shows admixture of well-formed glandular structures and spindle cells
  - Spindle cell component surrounding glands has identical features to those seen in monophasic variant
  - Glandular structures may be very focal or may predominate
  - Glandular structures are lined by large, round to polygonal or columnar epithelial cells
  - Glandular cells are round to oval nuclei with abundant eosinophilic cytoplasm
  - Glands may contain dense, homogeneous eosinophilic secretions in lumen
  - Glandular structures may adopt tubulopapillary pattern with intraluminal papillary infoldings
  - Glandular structures can display prominent cytoplasmic clearing of tumor cells

ANCILLARY TESTS

Immunohistochemistry

- All biphasic tumors show strong keratin positivity in glandular component
- Monophasic tumors are frequently, but not always, positive for cytokeratin stains
- Pattern of cytokeratin positivity in monophasic spindle cell tumors is usually weak and focal (patchy)

- EMA shows similar pattern and distribution as cytokeratin
- Low molecular weight cytokeratins are more sensitive than broad-spectrum cytokeratins for monophasic tumors
- Spindle cells
  - Strongly express vimentin
  - Strongly and diffusely stain for Bcl-2
  - Usually stain for CD99
  - May be positive for calretinin and calponin
  - May be positive for S100 protein in 30% of cases
  - Negative for actin, desmin, CD34, HMB-45, CEA, MOC-31, and p63

Genetic Testing

- (X;18)(p11;q11) translocation characteristically present in > 80% of cases
- Other complex translocations may be found infrequently
- FISH and RT-PCR useful for detecting translocations in paraffin-embedded tissues
- 2/3 contain *SYT/SSX1* fusion
- 1/3 contains *SYT/SSX2* fusion
- Rare cases may show *SYT/SSX4* fusion
- Cases with *SYT/SSX2* fusion are associated with better prognosis

Electron Microscopy

- Glandular epithelial component shows similar features to adenocarcinoma
- Monophasic spindle cell component shows closely apposed cell membranes, frequent desmosomal junctions, and occasional surface microvilli
- Monophasic spindle cell component does not contain abundant rough endoplasmic reticulum or other features of fibroblastic cells

DIFFERENTIAL DIAGNOSIS

Metastatic Adenocarcinoma

- Clinical history is helpful for diagnosis
- Metastatic adenocarcinoma will usually not contain stromal, atypical spindle cell component

Pulmonary Blastoma

- Only rarely will secondarily involve mediastinum, but bulk of tumor will be centered in lung
- Cells lining glands in pulmonary blastoma show subnuclear clearing simulating fetal lung
- Most biphasic pulmonary blastomas are characterized by squamoid morules located at base of glands
- Spindle cell component in pulmonary blastoma is negative for epithelial markers (keratin, EMA)

Thymic Carcinosarcoma

- Spindle cell component in thymic carcinosarcoma is negative for epithelial markers (keratin, EMA)
- Glandular component in thymic carcinosarcoma displays pronounced nuclear atypia
- Negative for t(X;18) translocation

Biphasic Pleural Mesothelioma

- Usually grows as diffuse, plaque-like process covering pleural surface, rather than discrete, well-circumscribed tumor mass
- Spindle cell component in pleural mesothelioma shows marked cytologic atypia and nuclear pleomorphism
- Spindle cells in pleural mesothelioma are negative for Bcl-2 and CD99

Spindle Cell Thymoma

- Slow-growing tumor that is usually encapsulated and noninvasive
- Absence of cytologic atypia or mitotic activity in spindle cells
- Lobular architecture with fibrous bands separating lobules
- Presence of immature T lymphocytes
- Spindle cells are negative for vimentin, CD99, and Bcl-2

Spindle Cell Thymic Carcinoma

- Marked cytologic atypia, nuclear pleomorphism, and mitotic activity
- Spindle cells are negative for Bcl-2 and CD99
- Absence of t(X;18) translocation

Malignant Peripheral Nerve Sheath Tumor

- Commonly arises in background of neurofibromatosis
- Grossly associated with nerve trunks
- Spindle cells are negative for cytokeratins and CD99
- Electron microscopy shows complex interdigitating cytoplasmic processes invested by basal lamina material
- Absence of t(X;18) translocation

Solitary Fibrous Tumor

- Usually shows variegation in growth patterns within same tumor and lack of uniformity of cell population
- Commonly shows variable degrees of stromal fibrosis, including characteristic, rope-like deposition of keloidal collagen
- Spindle cells are positive for CD34
- Spindle cells are negative for cytokeratins and EMA
- Absence of t(X;18) translocation

Metastasis of Synovial Sarcoma of Soft Tissue to Mediastinum

- Clinical history is only means for making this distinction

DIAGNOSTIC CHECKLIST

Pathologic Interpretation Pearls

- Uniform and monotonous population of cells with minimal nuclear pleomorphism
- Prominent herringbone and hemangiopericytic growth pattern
- Cytokeratin and EMA staining usually focal and patchy; may be difficult to demonstrate
- Strong and diffuse positivity for Bcl-2 is seen in almost all cases

SELECTED REFERENCES

1. Lan T et al: Primary pleuropulmonary and mediastinal synovial sarcoma: a clinicopathologic and molecular study of 26 genetically confirmed cases in the largest institution of southwest China. Diagn Pathol. 11(1):62, 2016
2. Katakura H et al: Mediastinal synovial sarcoma. Thorac Cardiovasc Surg. 57(3):183-5, 2009
3. Jeganathan R et al: Primary mediastinal synovial sarcoma. Ulster Med J. 76(2):109-11, 2007
4. Suster S et al: Expression of bcl-2 oncoprotein in benign and malignant spindle cell tumors of soft tissue, skin, serosal surfaces, and gastrointestinal tract. Am J Surg Pathol. 22(7):863-72, 1998

Dense Spindle Cell Pattern

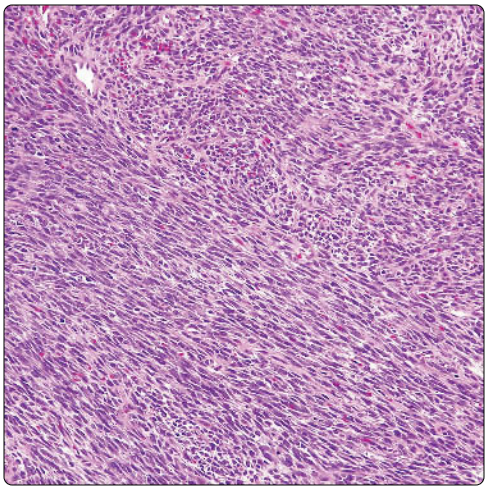

Monotonous Spindle Cell Population

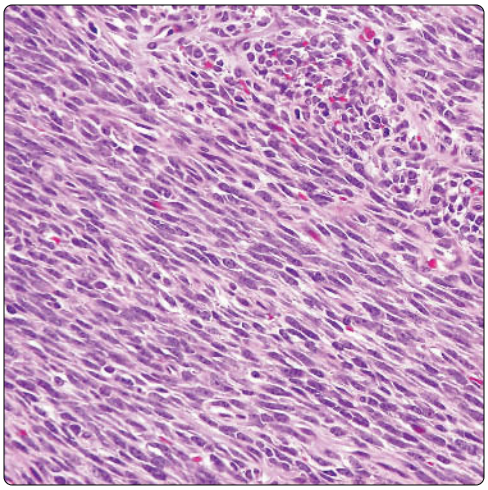

(Left) *Scanning magnification of monophasic spindle cell synovial sarcoma of the mediastinum shows a monotonous population of atypical spindle cells with a fascicular growth pattern.* **(Right)** *Monophasic spindle cell synovial sarcoma of the mediastinum shows a monotonous population of atypical spindle cells. This histologic picture can be seen in a wide variety of other spindle cell sarcomas, including fibrosarcoma and malignant peripheral nerve sheath tumor.*

Higher Magnification, Spindle Cells

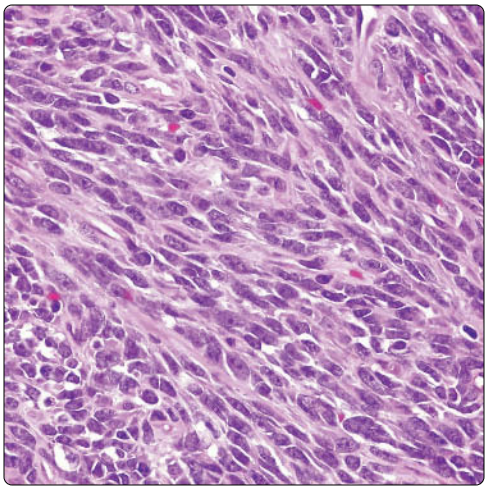

Mitotic Figure

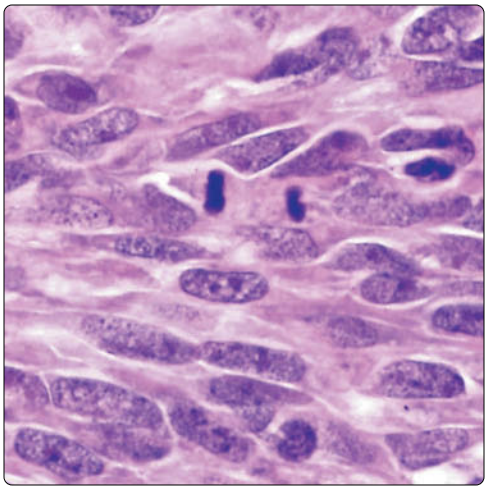

(Left) *Higher magnification of spindle cell monophasic synovial sarcoma of the mediastinum shows a monotonous population of atypical spindle cells. Notice the absence of stroma and the uniform appearance of the spindle cells.* **(Right)** *High magnification of monophasic synovial sarcoma of the mediastinum shows atypical spindle cells with tapered ends, small nucleoli, and a scattered chromatin pattern that is surrounded by a scant rim of cytoplasm and contains scattered mitotic figures.*

Cytokeratin AE1/AE3 Immunostaining

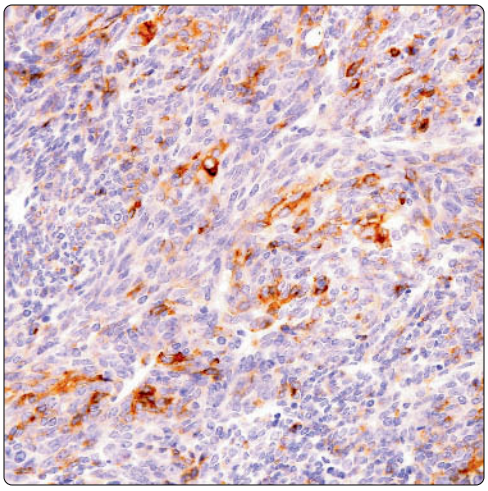

Bcl-2 Immunostaining

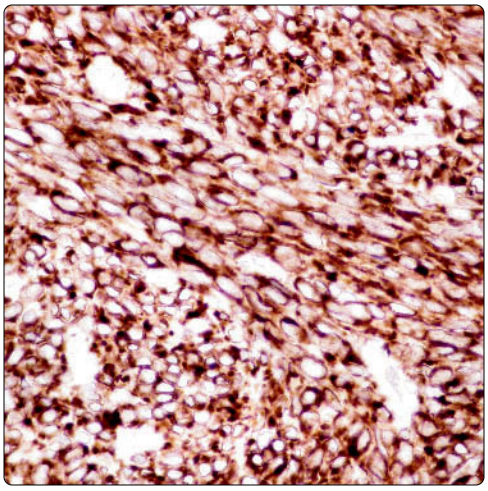

(Left) *Immunohistochemical staining for AE1/AE3 cytokeratin in monophasic spindle cell synovial sarcoma of the mediastinum shows spotty positivity in scattered tumor cells, a distinctive staining pattern for this tumor.* **(Right)** *Immunohistochemical staining of spindle cell synovial sarcoma of the mediastinum for Bcl-2 oncogene shows strong cytoplasmic staining of virtually every cell with this antibody. This diffuse pattern of staining is distinctive for this tumor.*

Herringbone Pattern

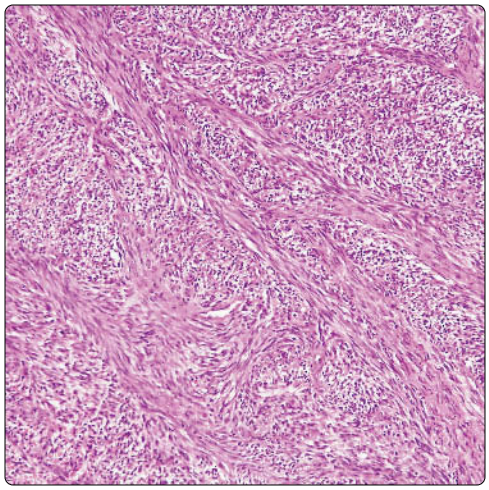

Herringbone Pattern: High Power

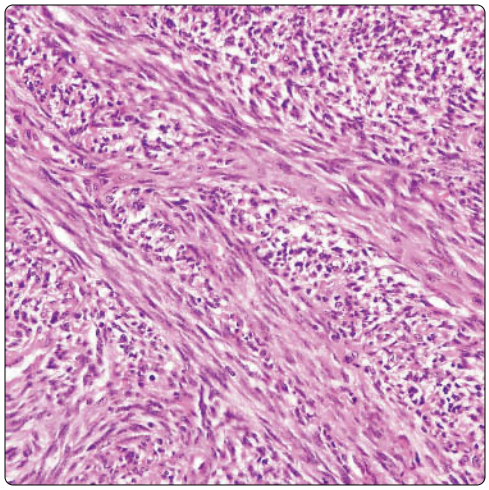

(Left) *Scanning magnification of monophasic synovial sarcoma of the mediastinum shows prominent herringbone pattern of growth, with short fascicles of spindle cells intersecting longer, longitudinal fascicles at acute angles.* **(Right)** *High magnification of monophasic synovial sarcoma of the mediastinum with prominent herringbone pattern shows a monotonous population of atypical spindle cells forming intersecting fascicles that appear to be cut at right angles.*

Monophasic Synovial Sarcoma

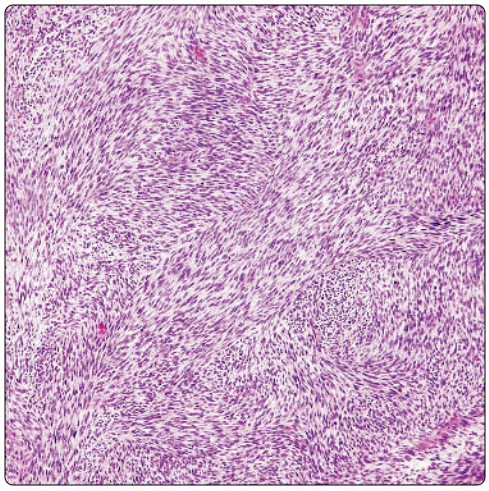

Herringbone Pattern

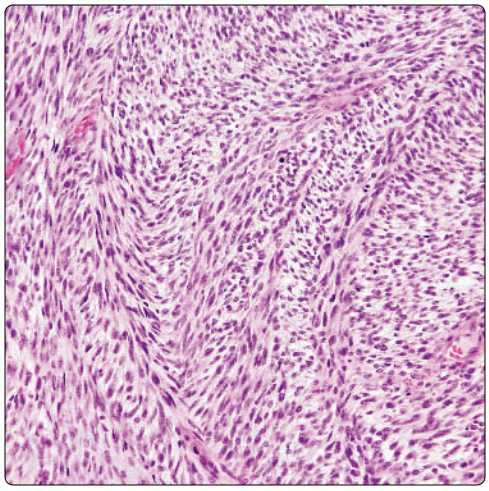

(Left) *Monophasic synovial sarcoma of the mediastinum with a prominent herringbone pattern of growth shows short fascicles of monotonous atypical spindle cells intersecting one another. This image is virtually indistinguishable from that of a malignant peripheral nerve sheath tumor.* **(Right)** *High magnification in monophasic synovial sarcoma of the mediastinum with prominent herringbone pattern shows a monotonous population of atypical spindle cells intersecting one another at acute angles.*

Cytokeratin AE1/AE3 Immunostaining

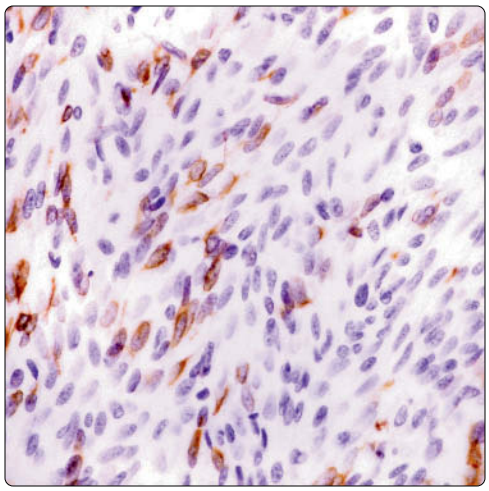

Bcl-2 Immunostaining

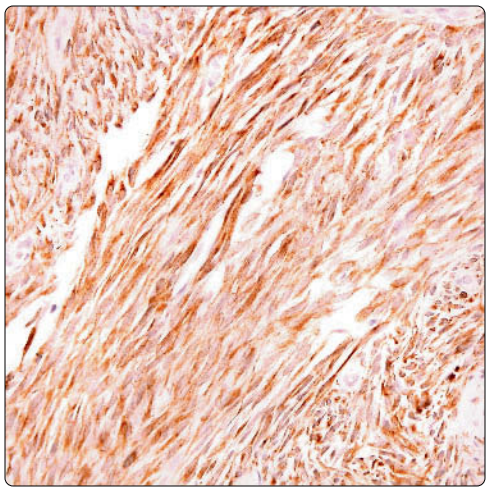

(Left) *Immunohistochemical staining for cytokeratin AE1/AE3 in monophasic synovial sarcoma of the mediastinum with prominent herringbone pattern shows scattered keratin-positive spindle cells.* **(Right)** *Immunohistochemical staining for Bcl-2 oncogene of monophasic synovial sarcoma of the mediastinum with prominent herringbone pattern shows strong and diffuse positivity in the majority of the tumor cells.*

Hemangiopericytic Vascular Pattern

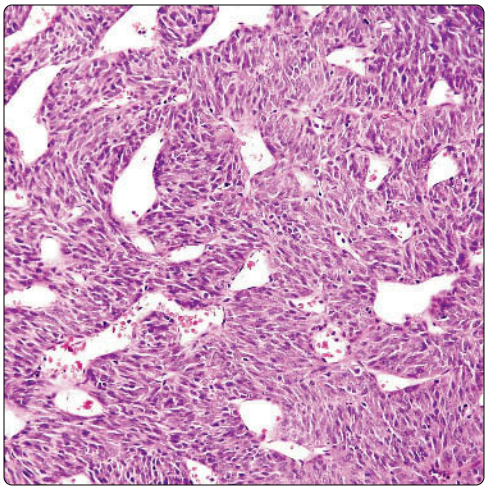

Branching Vessels

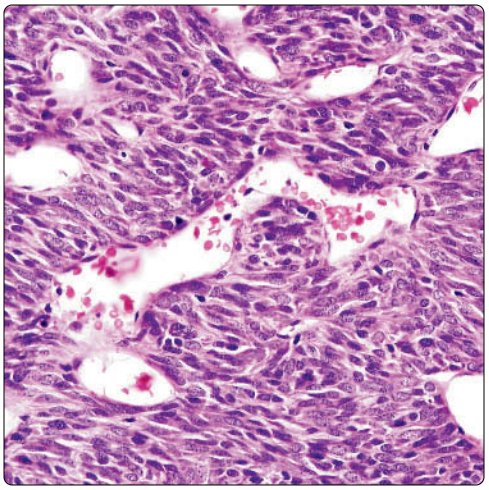

(Left) *Scanning magnification of monophasic synovial sarcoma of the mediastinum with a prominent hemangiopericytic growth pattern shows a dense spindle cell population flanking small, dilated vascular spaces with open lumina.* **(Right)** *Monophasic synovial sarcoma of the mediastinum with a prominent hemangiopericytic growth pattern shows branching small to medium vessels with open lumina, a histologic picture indistinguishable from hemangiopericytoma.*

Hemangiopericytic Vascular Pattern

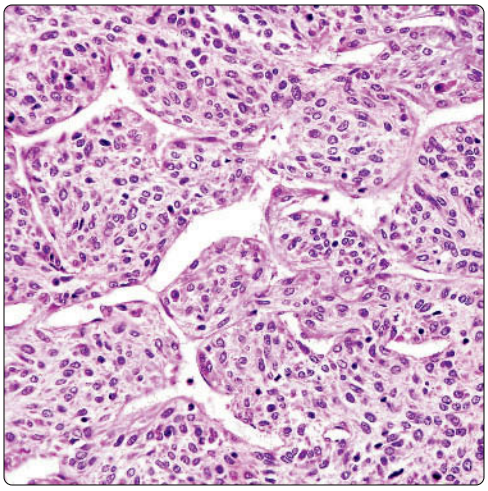

Branching Vessels

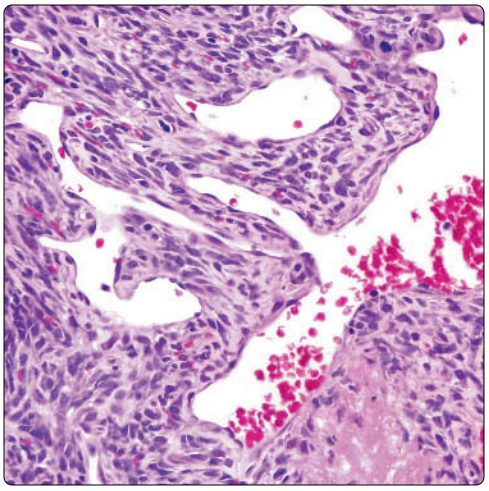

(Left) *Monophasic synovial sarcoma of the mediastinum with a prominent hemangiopericytomatous growth pattern shows vascular spaces that appear to branch at right angles. Tumors like this can be easily mistaken for solitary fibrous tumors.* **(Right)** *Monophasic synovial sarcoma of the mediastinum with a prominent hemangiopericytic growth pattern shows branching vessels with open lumina and a complex, antler-like or staghorn pattern of growth.*

Hemangiopericytic Vascular Pattern

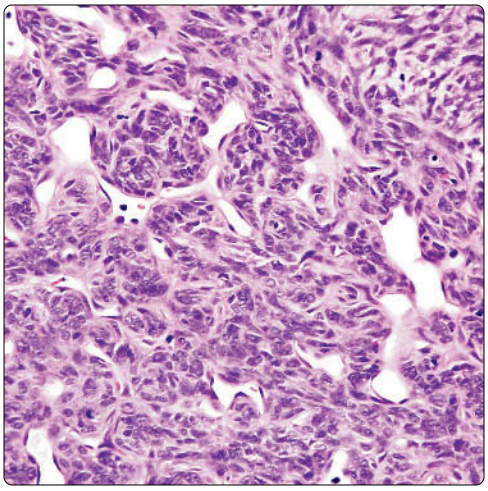

Vimentin Immunostaining

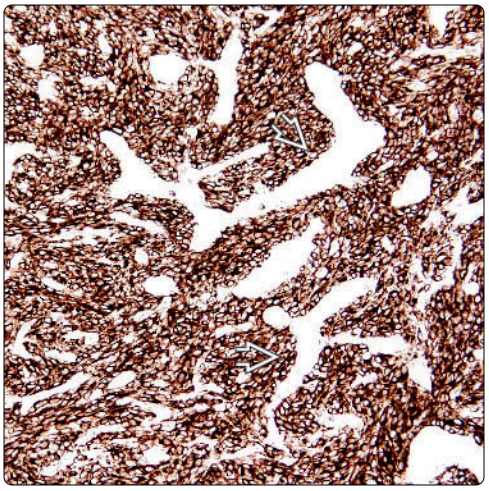

(Left) *Monophasic synovial sarcoma of the mediastinum with a prominent hemangiopericytic growth pattern shows multiple small vessels with open lumina and a complex branching luminal pattern.* **(Right)** *Immunohistochemical staining for vimentin in monophasic synovial sarcoma of the mediastinum shows strong positivity of the tumor cells and highlights the prominent, branching, hemangiopericytoma-like vessels in the background* ⇨.

Storiform Pattern

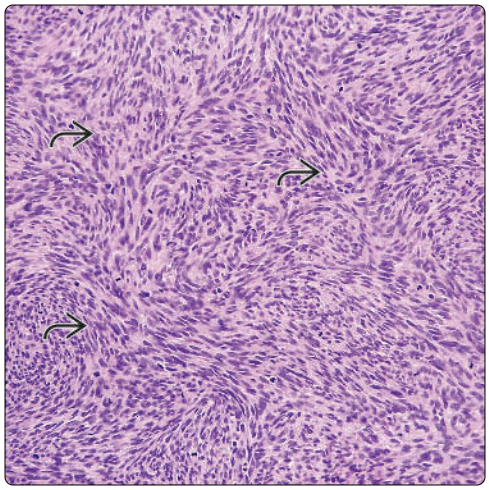

Higher Magnification

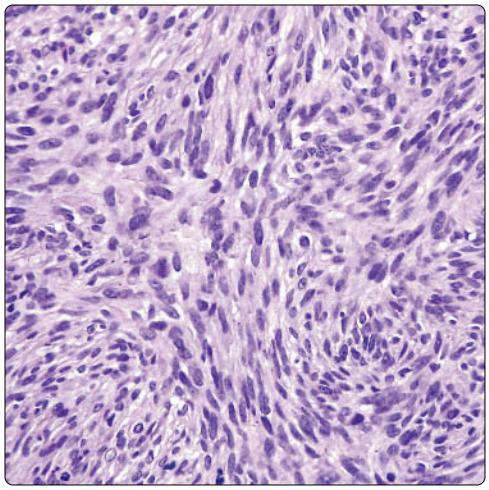

(Left) *Scanning magnification of monophasic synovial sarcoma of the mediastinum with prominent storiform growth pattern shows interlacing fascicles of spindle cells with a pinwheel distribution. Tumors with these features are easily mistaken for malignant fibrous histiocytoma.* **(Right)** *High magnification of monophasic synovial sarcoma of the mediastinum with prominent storiform pattern shows detail of storiform (mat-like) fascicle of spindle cells.*

Storiform Pattern

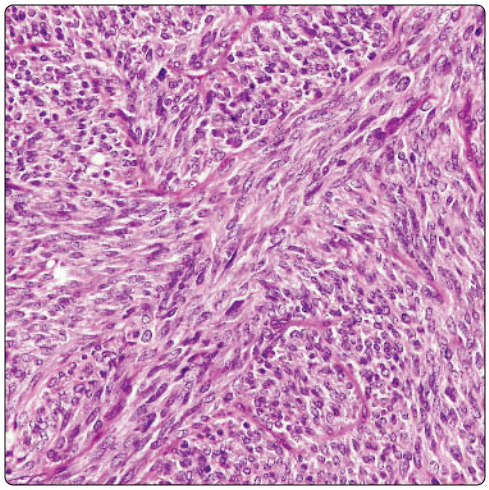

Cytokeratin AE1/AE3 Immunostaining

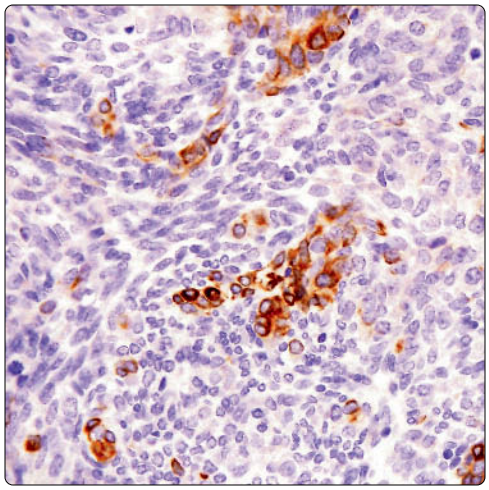

(Left) *Scanning magnification of monophasic synovial sarcoma of the mediastinum with prominent storiform pattern shows atypical spindle cells that seem to be radiating from a central spoke in a pinwheel fashion reminiscent of fibrohistiocytic tumors.* **(Right)** *Immunohistochemical staining for broad-spectrum cytokeratin (keratin AE1/AE3) in monophasic synovial sarcoma of the mediastinum with prominent storiform pattern shows focal staining of the tumor cells.*

Storiform Pattern

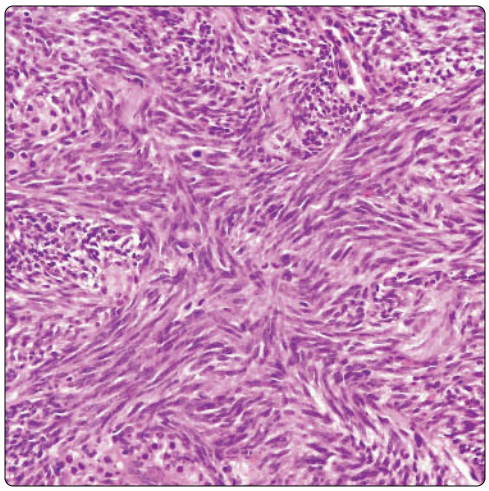

Storiform Pattern

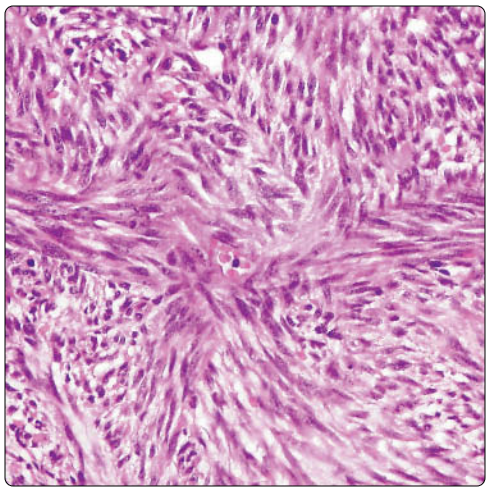

(Left) *Scanning magnification of monophasic synovial sarcoma of the mediastinum with prominent storiform pattern shows striking storiform architecture. The uniformity of the tumor cells, absence of pleomorphism, and significant mitotic activity bear a superficial resemblance to dermatofibrosarcoma protuberans in this tumor.* **(Right)** *High magnification of monophasic synovial sarcoma of the mediastinum with prominent storiform pattern shows a bland appearance and monotony of the tumor cells.*

Palisading of Nuclei

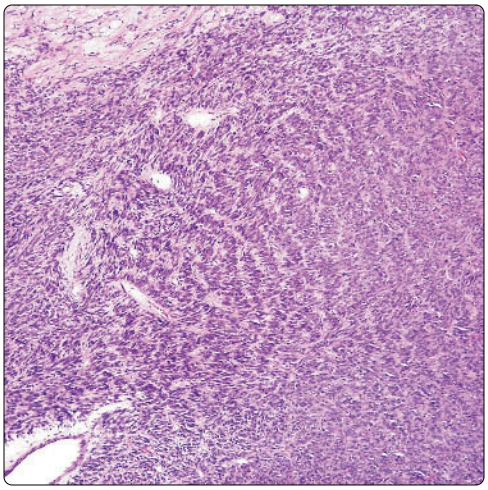

Palisading of Nuclei

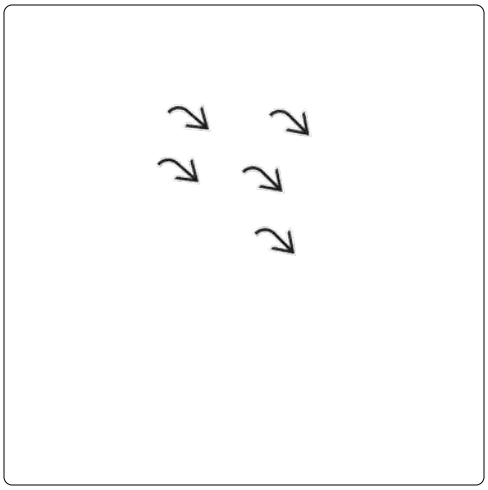

(Left) *Scanning magnification shows monophasic, spindle cell synovial sarcoma of the mediastinum characterized by striking nuclear palisading of the cells. Tumors with these features can closely resemble malignant peripheral nerve sheath tumors.* **(Right)** *Higher magnification of monophasic synovial sarcoma of the mediastinum shows striking palisading of nuclei. The tumor cells are quite monotonous and merge imperceptibly with more traditional fascicular areas in the vicinity.*

Neural-Like Appearance

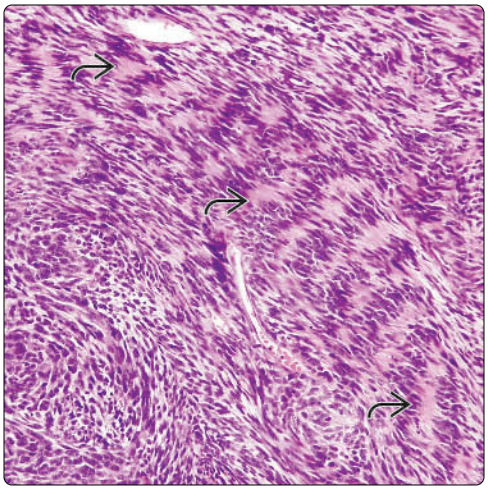

Neural-Like Wavy Nuclei

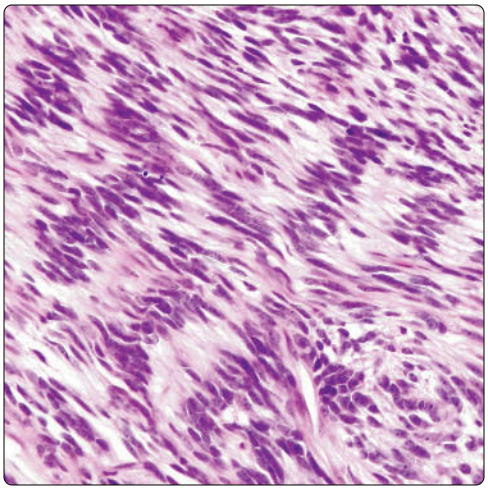

(Left) *Scanning magnification of monophasic synovial sarcoma of the mediastinum with striking palisading of tumor cells shows structures that are reminiscent of Verocay bodies.* **(Right)** *High magnification of monophasic synovial sarcoma of the mediastinum with striking palisading shows detail of nuclear palisades resembling Verocay bodies. Tumors with these features can be easily mistaken for malignant peripheral nerve sheath tumors.*

Nesting Pattern

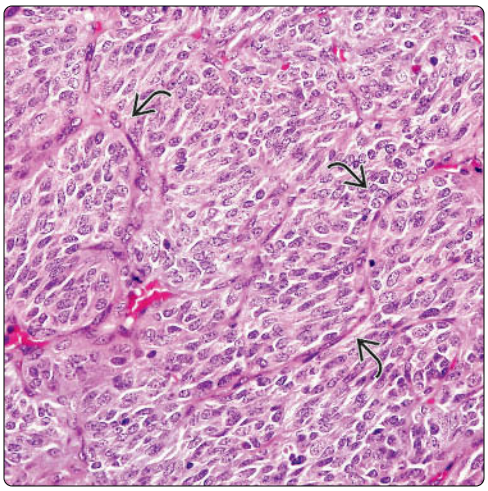

Nesting Pattern

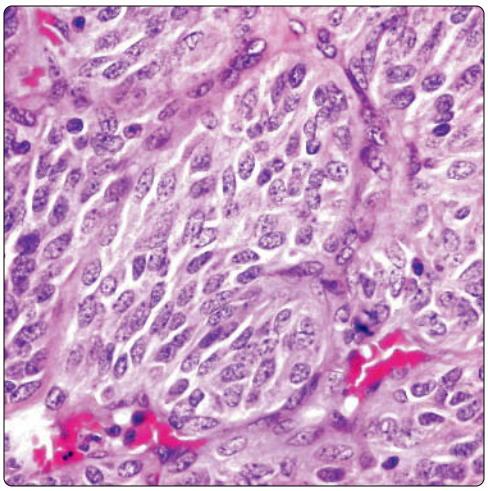

(Left) *Monophasic synovial sarcoma of the mediastinum with prominent nesting pattern shows discrete nests of tumor cells separated by thin fibrovascular septa. Tumors with these features can closely resemble metastatic malignant melanoma to the mediastinum.* **(Right)** *High magnification of monophasic synovial sarcoma of the mediastinum with a prominent nesting pattern shows a monotonous population of spindle tumor cells surrounded by a thin fibrovascular septa.*

Poorly Differentiated Synovial Sarcoma

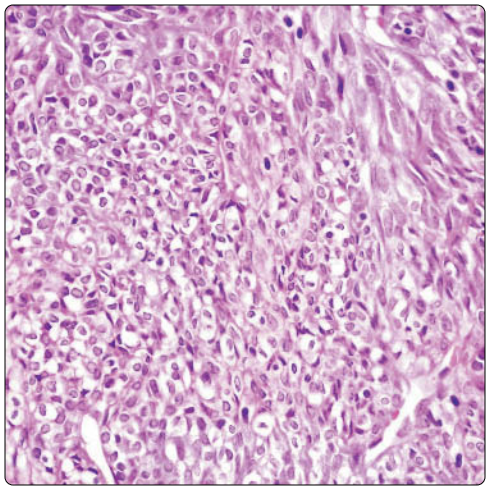

Round Cells

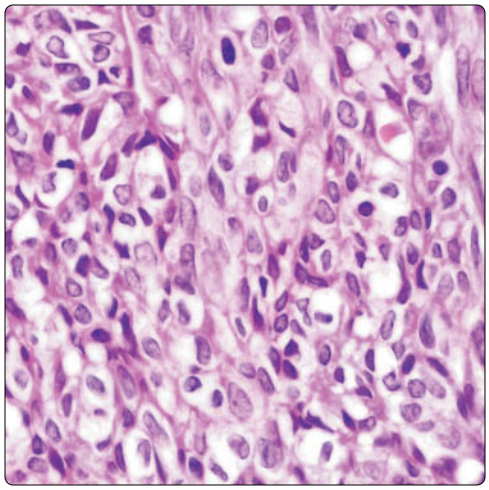

(Left) *Scanning magnification of poorly differentiated synovial sarcoma of the mediastinum is characterized by sheets of monotonous round, epithelioid tumor cells. These tumors can be mistaken for a variety of small round blue cell tumors.* **(Right)** *High magnification of poorly differentiated synovial sarcoma of the mediastinum shows round tumor cells with small, uniform nuclei with minimal nuclear atypia, surrounded by a clear cytoplasmic halo.*

Lobular Configuration

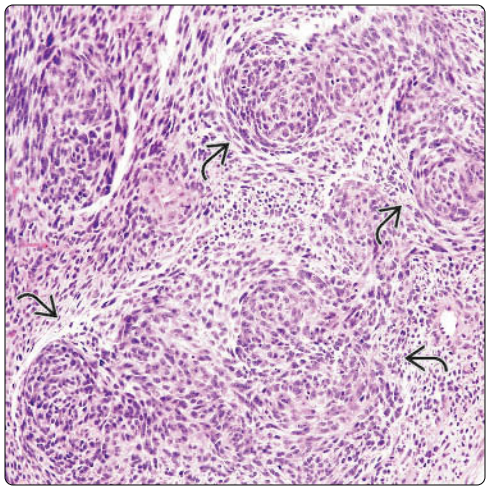

Poorly Differentiated Synovial Sarcoma

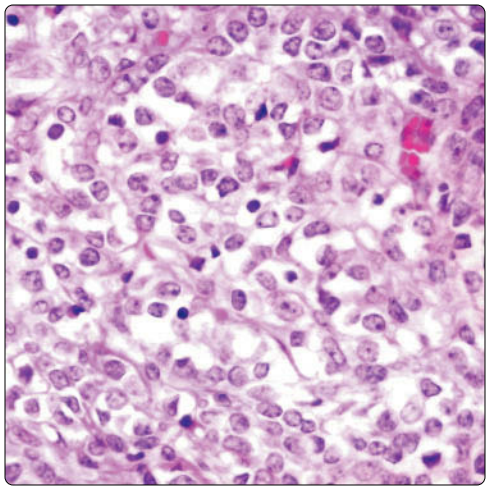

(Left) *Scanning magnification of poorly differentiated synovial sarcoma of the mediastinum shows ill-defined lobules composed of round, epithelioid tumor cells admixed with a few spindle cells in the background. The tumor bears a superficial resemblance to epithelioid malignant peripheral nerve sheath tumors.* **(Right)** *Higher magnification of poorly differentiated synovial sarcoma of the mediastinum shows a monotonous population of bland-appearing, small round blue cells.*

Rhabdoid Cells

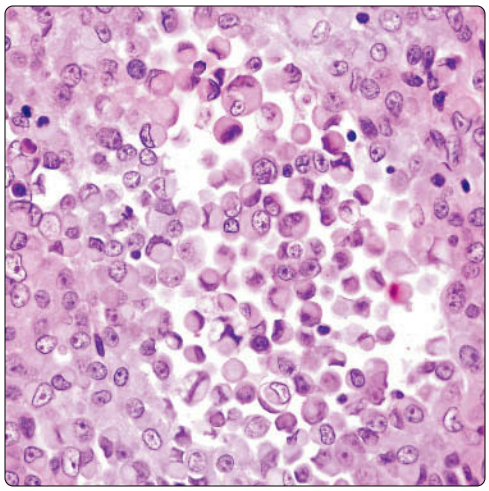

Rhabdoid Cells: High Power

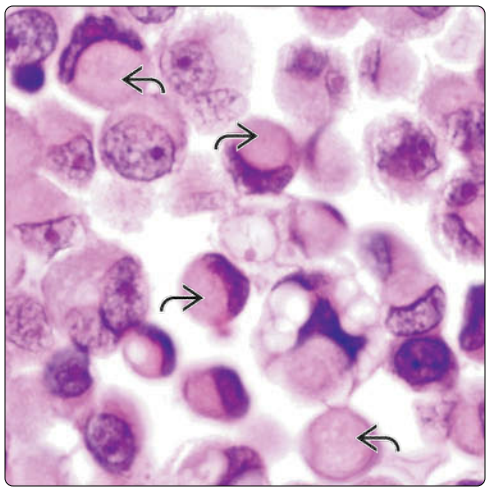

(Left) *Poorly differentiated synovial sarcoma of the mediastinum, rhabdoid cell variant, shows sheets of small round blue cells displaying prominent eosinophilic cytoplasmic inclusions indistinguishable from those seen in rhabdoid tumors.* **(Right)** *Higher magnification of poorly differentiated synovial sarcoma of the mediastinum, rhabdoid type, shows rhabdoid cells characterized by nuclei displaced to the periphery by globular cytoplasmic accumulations of intermediate filaments.*

Cystic Changes

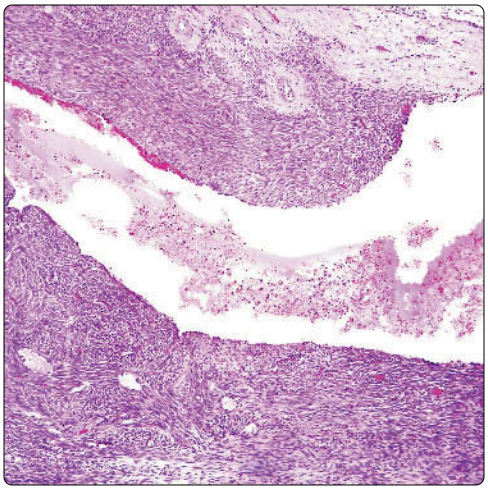

Areas of Necrosis

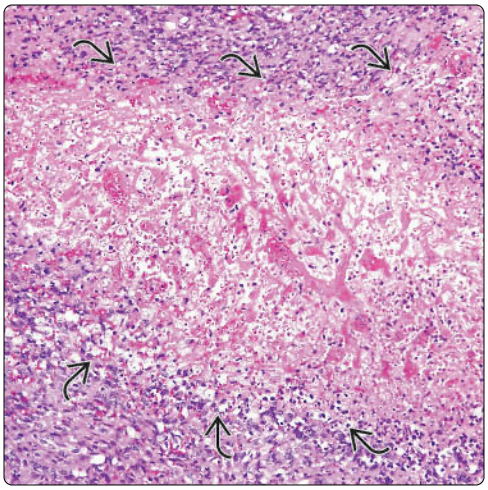

(Left) *Monophasic synovial sarcoma of the mediastinum with secondary cystic changes shows a large cystic space flanked by a dense spindle cell population. The tumors can show massive, gross cystic changes and be mistaken clinically for cystic teratomas.* **(Right)** *Focal areas of necrosis are seen in poorly differentiated synovial sarcoma of the mediastinum. Necrosis is not a common feature of mediastinal synovial sarcoma and is often associated with a more aggressive behavior.*

Myxoid Stromal Changes

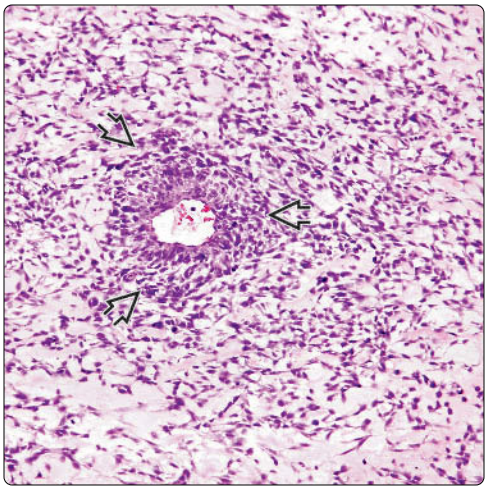

Myxoid Changes: High Power

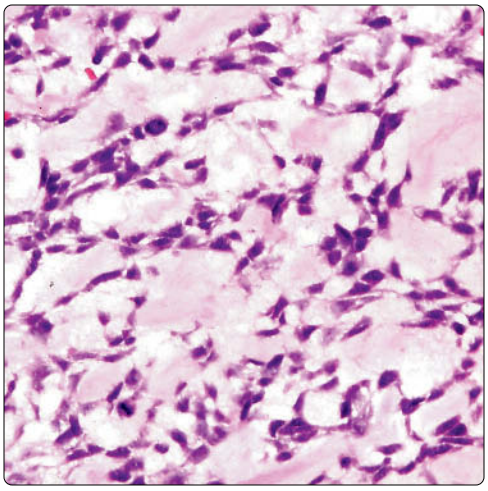

(Left) *Prominent myxoid stromal changes are seen in this monophasic synovial sarcoma of the mediastinum. Tumors with these features may be confused with fibromyxoid sarcomas and myxoid malignant fibrous histiocytoma. Notice perivascular cuffing by the tumor cells.* **(Right)** *High magnification of monophasic synovial sarcoma of the mediastinum with prominent myxoid stromal changes shows a lightly staining myxoid matrix separating the spindle tumor cells.*

Artifactual Clefting

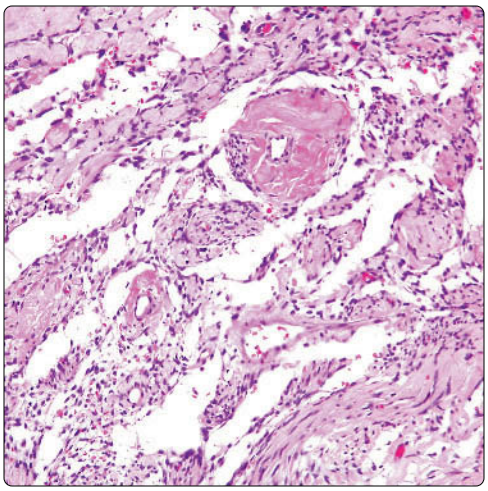

Stromal Collagenization

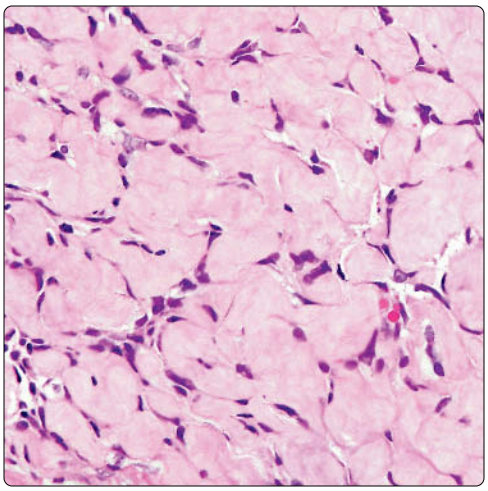

(Left) *Monophasic synovial sarcoma of the mediastinum shows artifactual clefting and separation of the stroma resulting in a pseudovascular appearance that may be mistaken for a malignant vascular neoplasm (i.e., angiosarcoma).* **(Right)** *Monophasic synovial sarcoma of the mediastinum shows extensive stromal collagenization resulting in scattered spindle cells separated by hyalinized matrix. Tumors with these features may be mistaken for fibrosarcoma or solitary fibrous tumors.*

Biphasic Synovial Sarcoma

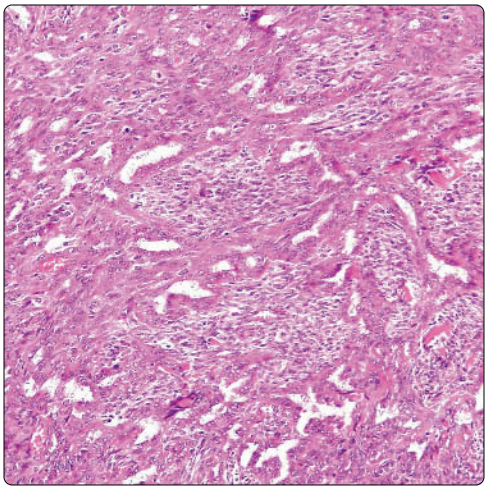

Cytokeratin AE1/AE3 Immunostaining

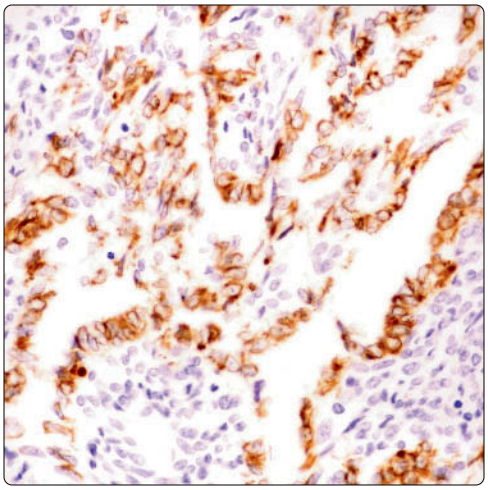

(Left) *Biphasic synovial sarcoma of the mediastinum shows evenly dispersed, small glands with open lumina separated by dense, atypical spindle cell stroma.* **(Right)** *Immunohistochemical staining for cytokeratin AE1/AE3 in biphasic synovial sarcoma of the mediastinum highlights the cells lining the glandular spaces. The glandular cells in biphasic synovial sarcoma stain very strongly for cytokeratin, unlike the spindle cells that generally display only focal positivity.*

Biphasic Synovial Sarcoma

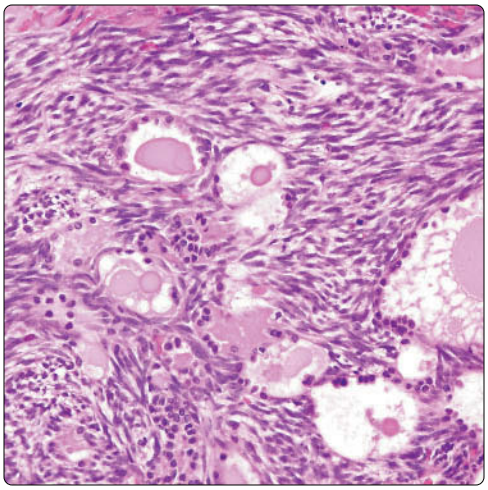

Glands: High Power

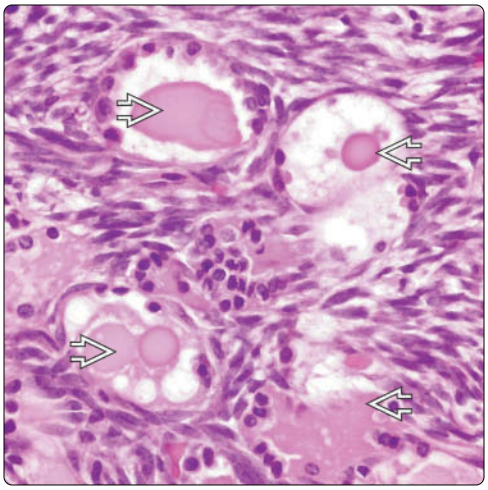

(Left) *Biphasic synovial sarcoma of the mediastinum is composed of small glands lined by small cuboidal or hobnailed tumor cells and is seen with proteinaceous secretions in their lumina. Notice the monotonous spindle cell proliferation surrounding the glands.* **(Right)** *High magnification of biphasic synovial sarcoma of the mediastinum shows small glands lined by hobnailed cells and displaying eosinophilic proteinaceous secretions in their lumina.*

Biphasic Synovial Sarcoma

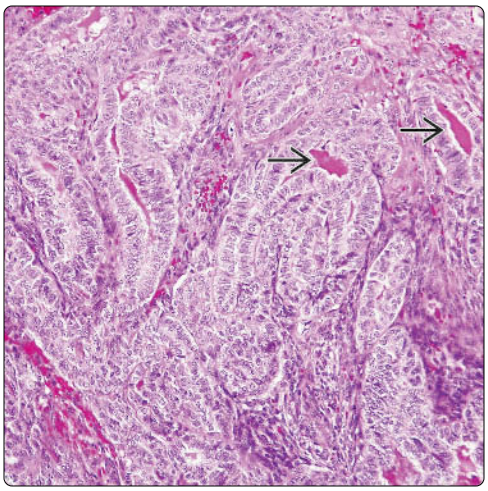

Biphasic Tumor: High Power

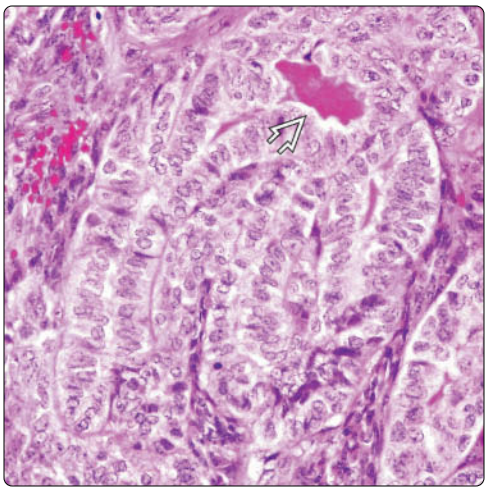

(Left) *Biphasic synovial sarcoma of the mediastinum shows large glandular structures with collapsed lumina lined by tall columnar cells. Notice the residual abortive glandular lumina filled with eosinophilic secretion.* **(Right)** *High magnification of biphasic synovial sarcoma of the mediastinum shows collapsed glandular structures lined by tall columnar cells with clear cytoplasm. Notice the residual small lumen filled with proteinaceous material in one of the glands.*

Biphasic Synovial Sarcoma

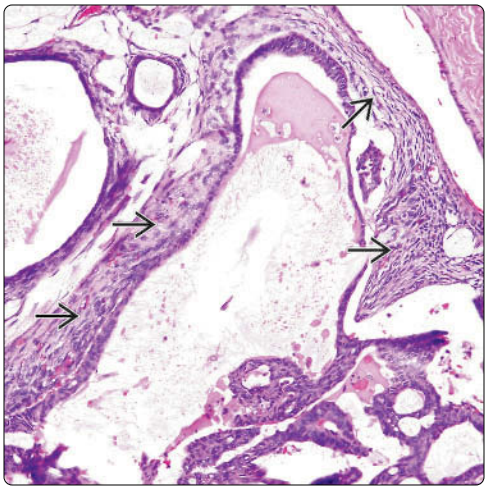

Cytokeratin AE1/AE3 Immunostaining

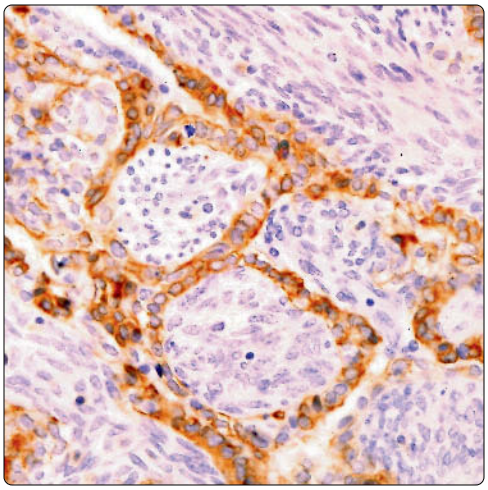

(Left) *Biphasic synovial sarcoma of the mediastinum shows intestinal-type glands with dilated lumina and mucinous luminal contents. Cases like this can be easily mistaken for metastases from adenocarcinomas of enteric origin, except for the fact that the glands are surrounded by a thin layer of atypical spindle cells.* **(Right)** *Immunohistochemical staining for cytokeratin AE1/AE3 in biphasic synovial sarcoma of the mediastinum shows negative staining of the spindle cells.*

Biphasic Synovial Sarcoma

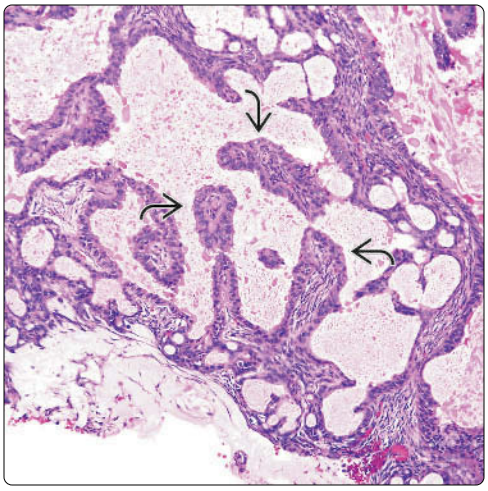

Papillary Structures

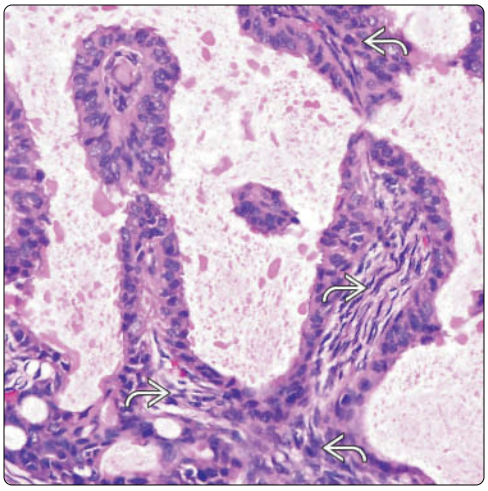

(Left) *Scanning magnification of biphasic synovial sarcoma of the mediastinum with intestinal-type glands shows focal papillary formations protruding into the lumen of the dilated glands.* **(Right)** *High magnification of biphasic synovial sarcoma of the mediastinum with intestinal-type glands shows papillary formation protruding into the lumen of the glandular spaces. Notice the spindle cell stroma in the cores of the papillae and the mucinous content in the lumen.*

Biphasic Synovial Sarcoma

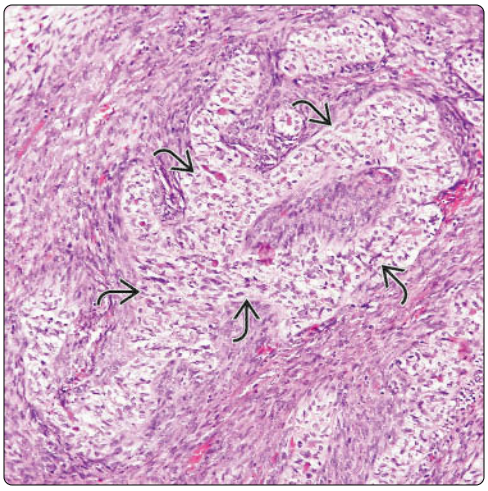

Epithelioid Elements: High Power

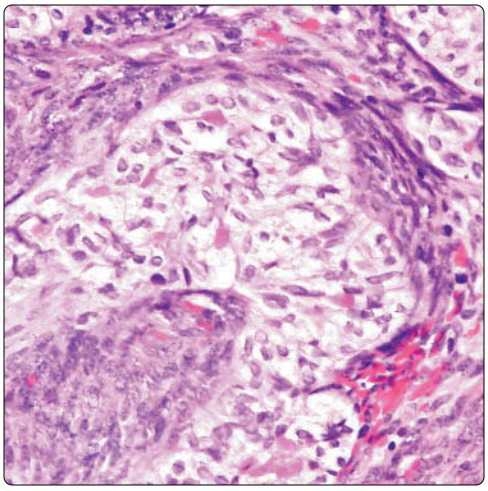

(Left) *Scanning magnification of unusual variant of biphasic synovial sarcoma of the mediastinum shows areas characterized by clear cells surrounded by a dense, monotonous, atypical spindle cell proliferation.* **(Right)** *Higher magnification of unusual variant of biphasic synovial sarcoma of the mediastinum shows islands of large, clear cells with abundant water-clear cytoplasm surrounded by a dense, monotonous, atypical spindle cell population.*

Neurofibroma

KEY FACTS

TERMINOLOGY

- Neurofibroma (NF)

ETIOLOGY/PATHOGENESIS

- Proliferation of perineural fibroblasts, Schwann cells, and neurites

CLINICAL ISSUES

- 1 of most common neural tumors
- Usually adults in 3rd or 4th decade of life
- Location
  - Posterior mediastinum
- Symptoms
  - Chest pain
  - Dyspnea
  - Cough
  - Neurofibromatosis
  - Some patients may be asymptomatic
- Treatment
  - Complete surgical resection
- Prognosis
  - Good

TOP DIFFERENTIAL DIAGNOSES

- Schwannoma
- Neurofibrosarcoma
- Ganglioneuroma
- Solitary fibrous tumor
- Leiomyoma

DIAGNOSTIC CHECKLIST

- Spindle cell proliferation without mitotic activity
- Loose fibrocollagenous or myxoid stroma
- Lack of mitotic activity
- Absence of necrosis

(Left) *Mediastinal neurofibroma shows a classic spindle cell proliferation embedded in a rather loose fibroconnective tissue admixed with dilated vascular structures.* **(Right)** *High-power view of a mediastinal neurofibroma shows a spindle cell proliferation admixed with fibrocollagenous tissue. Note the absence of cellular pleomorphism.*

Spindle Cell Proliferation

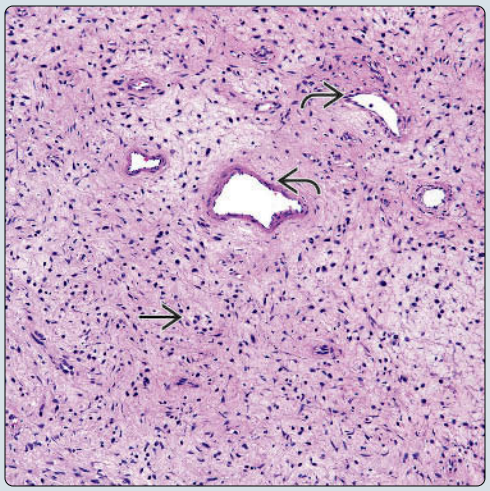

Fibrocollagenous Component

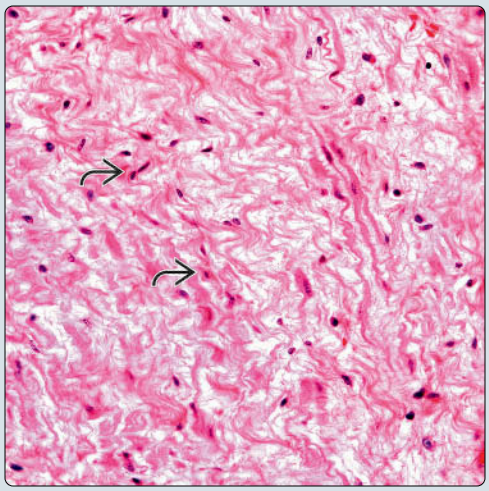

(Left) *Neurofibroma shows a "globular" architecture composed of extensive areas of what appear to be Wagner-Meissner bodies.* **(Right)** *Neurofibroma shows solid areas composed of spindle cells alternating with other areas with myxoid change.*

Neurotized-Like Areas

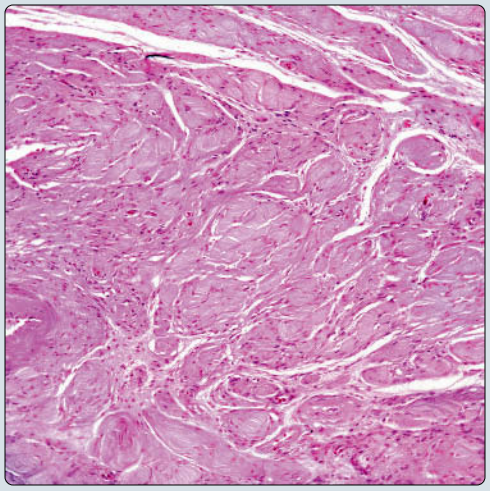

Focal Myxoid Change

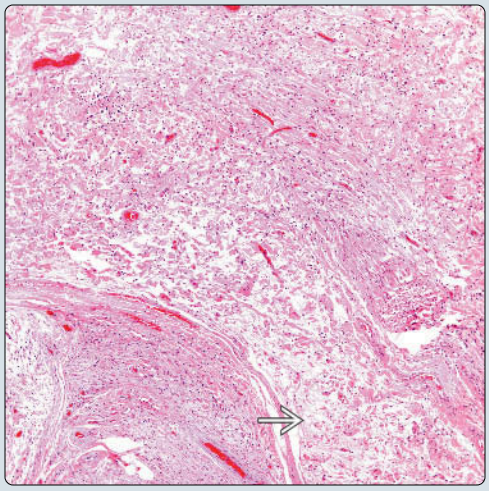

TERMINOLOGY

Abbreviations

- Neurofibroma (NF)

Definitions

- Benign neural neoplasm

ETIOLOGY/PATHOGENESIS

Pathogenesis

- Proliferation of perineural fibroblasts, Schwann cells, and neurites

CLINICAL ISSUES

Site

- Posterior mediastinum

Presentation

- Chest pain
- Dyspnea
- Cough
- Neurofibromatosis (von Recklinghausen disease)
- Some patients may be asymptomatic

Treatment

- Surgical approaches
  - Complete surgical resection

Prognosis

- Good

MACROSCOPIC

General Features

- Well circumscribed but not encapsulated
- Light tan in color

Sections to Be Submitted

- In cases of patients with history of neurofibromatosis, careful sampling to rule out sarcoma

Size

- Variable size
- May be up to or > 10 cm in diameter

MICROSCOPIC

Histologic Features

- Spindle cell proliferation
- Wavy nuclei and pointed ends
- Loose fibroconnective tissue
- Absent mitotic activity
- In some cases, stroma may be myxoid
- Occasional Wagner-Meissner bodies may be seen
- Pacini corpuscles may be seen
- Mucin-producing glands may be seen focally
- Melanin pigment may be present

DIFFERENTIAL DIAGNOSIS

Schwannoma

- Shows presence of Verocay bodies in contrast to NF
- S100 protein is generally strongly positive in schwannomas in contrast to NF

Neurofibrosarcoma

- Usually shows presence of increased mitotic activity
- May also show presence of areas of necrosis, which would be unusual in NF

Ganglioneuroma

- Generally has presence of ganglion cells in contrast to NF, which lacks their presence

Solitary Fibrous Tumor

- Usually shows different growth pattern in same tumor
- Usually positive for CD34 and Bcl-2, which are negative in NF

Leiomyoma

- Both tumors may show similar histologic features with lack of mitotic activity
- Shows positive staining for actin, whereas NF is negative
- Leiomyoma in posterior mediastinum is rare

DIAGNOSTIC CHECKLIST

Clinically Relevant Pathologic Features

- Mitotic rate
- Nuclear features

Pathologic Interpretation Pearls

- Spindle cell proliferation without mitotic activity
- Loose fibrocollagenous or myxoid stroma

SELECTED REFERENCES

1. Ueda K et al: Computed tomography (CT) findings in 88 neurofibromatosis 1 (NF1) patients: prevalence rates and correlations of thoracic findings. Eur J Radiol. 84(6):1191-5, 2015

Immunohistochemistry

Antibody	Reactivity	Staining Pattern	Comment
S100	Positive	Nuclear & cytoplasmic	May be focal and weak
NFP	Positive	Nuclear & cytoplasmic	May be focal and weak
NSE	Positive	Cytoplasmic	Not specific
CD34	Negative		May be positive in vascular spaces
AE1/AE3	Negative		
Actin-HHF-35	Negative		May show focal positive staining around vessels

Macroscopic Features

Spindle Cell Proliferation

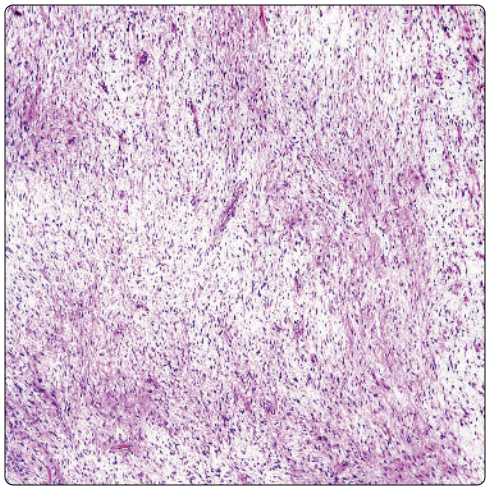

(Left) *Mediastinal neurofibromas are usually well-circumscribed tumors of whitish color and homogeneous surface. Note the absence of necrosis &/or hemorrhage; such features should alert one to the possibility of malignancy.* **(Right)** *Neurofibroma shows a monotonous bland spindle cell proliferation with scattered compressed blood vessels. No necrosis or hemorrhage is normally seen in these tumors.*

Lobular Pattern

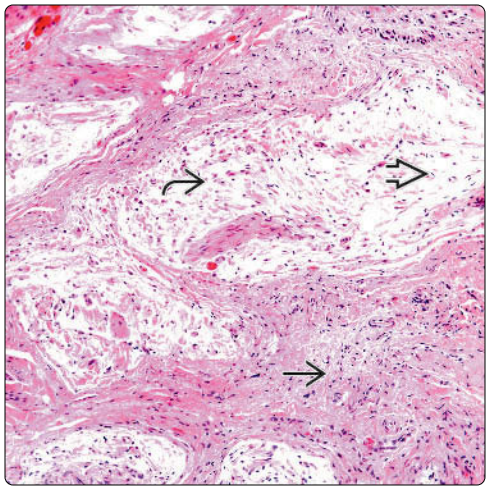

Degenerative Changes

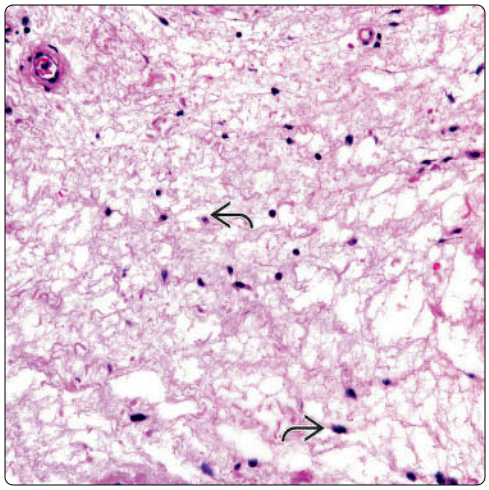

(Left) *In some cases, neurofibromas may adopt a rather lobular growth pattern in which lobules are separated by fibrocollagenous tissue. A subtle myxoid change may be seen in some areas.* **(Right)** *Mediastinal neurofibroma is shown with prominent myxoid changes and very little cellular component. However, the spindle cells are still recognizable, and the tumor does not show necrosis &/or hemorrhage.*

Crush Artifact and Spindle Cells

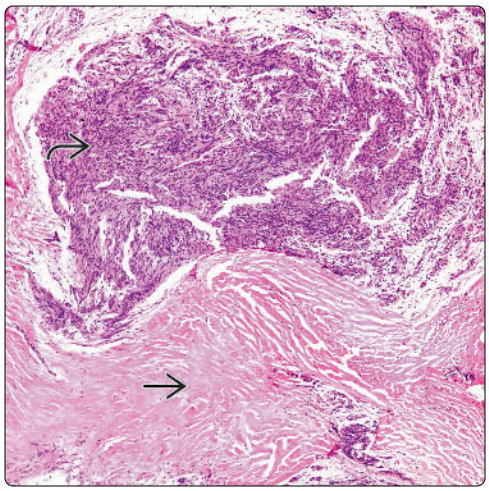

Vascular Proliferation

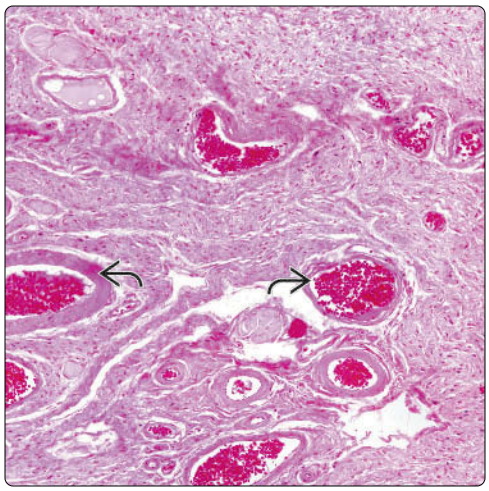

(Left) *Mediastinal neurofibroma shows extensive dense fibrocollagen, and the neurofibroma is composed of a rather solid spindle cellular proliferation. Some of these cellular areas can be confused for malignancy.* **(Right)** *Mediastinal neurofibroma is shown with extensive areas of vascular dilatation, almost mimicking a vascular neoplasm such as cavernous hemangioma.*

Vascular Hyalinization

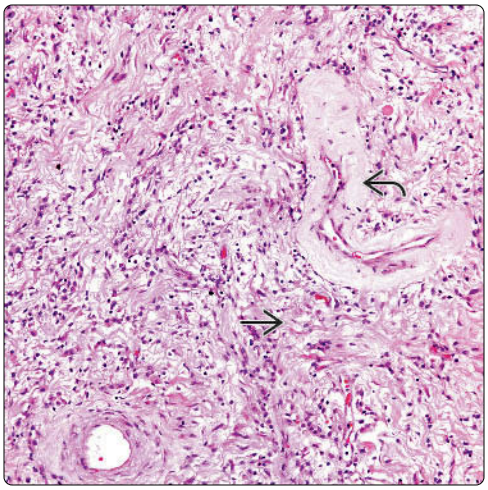

Absence of Mitotic Activity

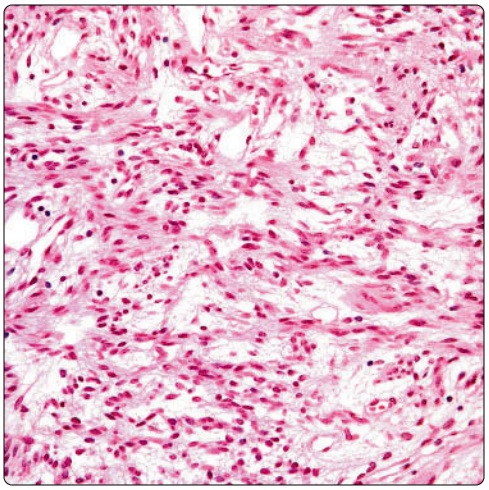

(Left) *Neurofibroma shows compressed blood vessels. Note the perivascular collagenization of the vessels as well as the spindle cellular proliferation admixed with some inflammatory cells.* **(Right)** *Mediastinal neurofibroma shows predominantly spindle cellular proliferation with loose fibroconnective tissue and focal myxoid changes. Note the absence of cellular pleomorphism.*

Solid Spindle Cell Component

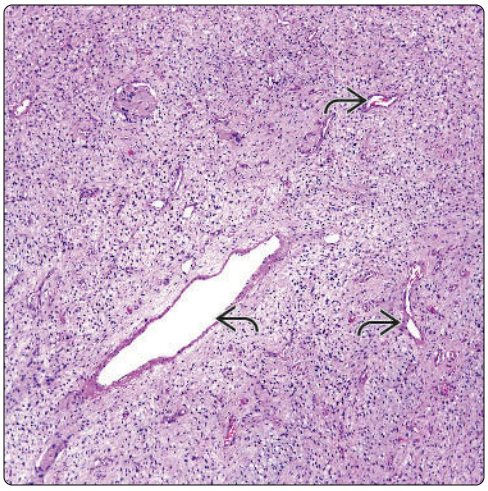

Wagner-Meissner Bodies

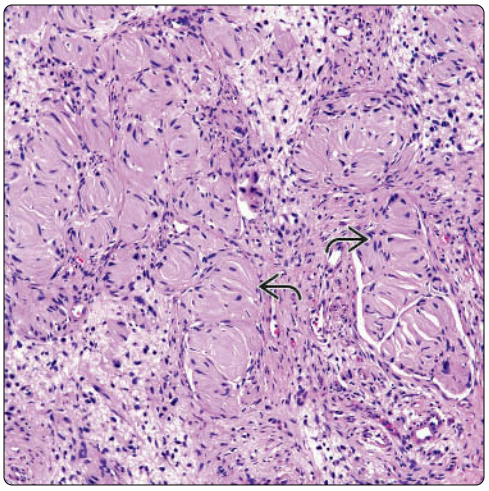

(Left) *Mediastinal neurofibroma shows a spindle cellular proliferation in a more solid growth pattern. Note the presence of several blood vessels of different sizes.* **(Right)** *Mediastinal neurofibroma is shown with the presence of Wagner-Meissner bodies. In general, the presence of Wagner-Meissner bodies is not a common finding and may help in the diagnosis.*

Focal Pigmented Areas

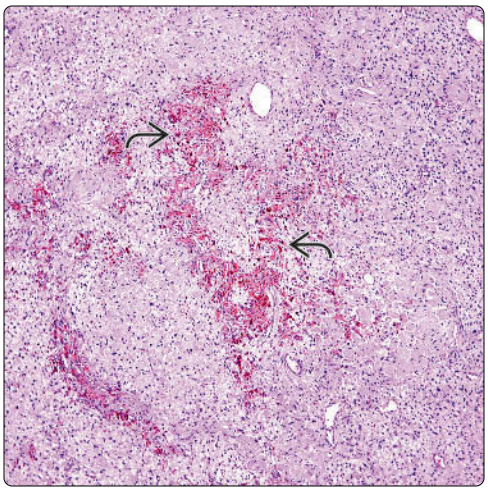

Melanin Pigment

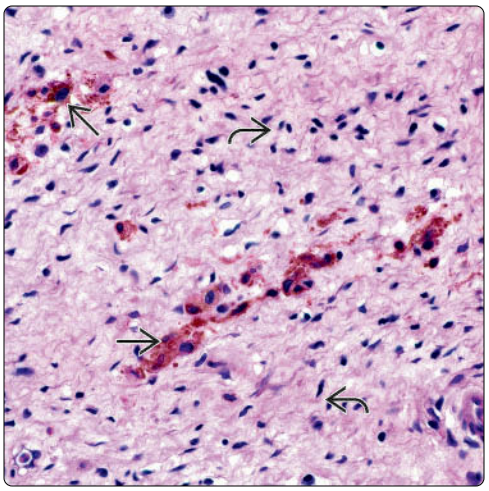

(Left) *Mediastinal neurofibroma is shown with focal areas of melanin pigment. This feature may be mistaken for melanoma; however, neurofibromas lack cellular atypia &/or mitotic figures.* **(Right)** *High power shows a mediastinal neurofibroma in which the melanin pigment is more focal. Note the classic histological features of neurofibroma.*

Peripheral Nerve Sheath Tumor

KEY FACTS

TERMINOLOGY

- Peripheral nerve sheath tumor
- Synonyms: Malignant schwannoma, neurofibrosarcoma, neurogenic sarcoma

CLINICAL ISSUES

- These tumors are more common in posterior mediastinum but can also occur in anterior mediastinum
- Symptoms
  - Chest pain
  - Cough
  - Dyspnea
  - Neurofibromatosis
- Prognosis
  - These tumors follow aggressive behavior, and prognosis is poor
  - Worse prognosis in patients with neurofibromatosis
- Incidence
  - Unusual in mediastinal location
  - May account for ~ 5% of all mediastinal tumors

ANCILLARY TESTS

- Schwannian differentiation by electron microscopy may be seen

TOP DIFFERENTIAL DIAGNOSES

- Neurofibroma
- Leiomyosarcoma
- Solitary fibrous tumor
- Schwannoma
- Triton tumor

DIAGNOSTIC CHECKLIST

- Solid spindle cellular proliferation
- Perivascular hyalinization
- Hemorrhage &/or necrosis
- Nuclear atypia and mitotic activity

Solid Spindle Cell Component

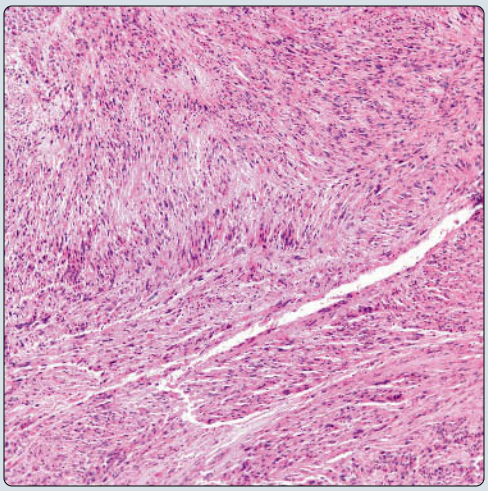

Slight Lobulation

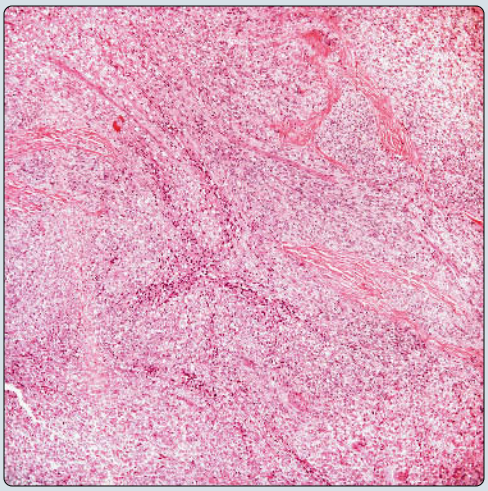

(Left) *Mediastinal peripheral nerve sheath tumor (PNST) shows a solid spindle cell proliferation with a vague herringbone-like pattern of growth.* **(Right)** *Malignant PNST (MPNST) of the mediastinum shows slight lobulation in which tumor cells appear to be separated by bands of fibrocollagen.*

Epithelioid Cellular Proliferation

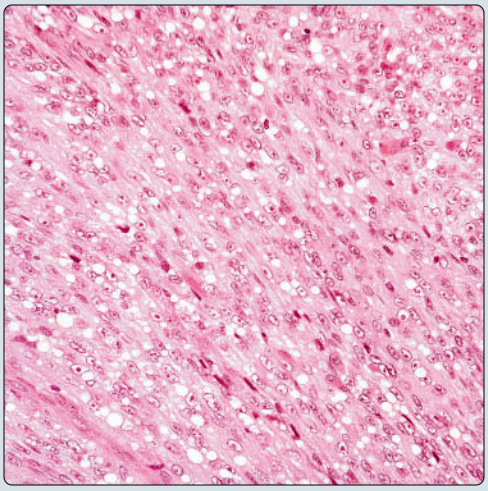

Mitotic Activity

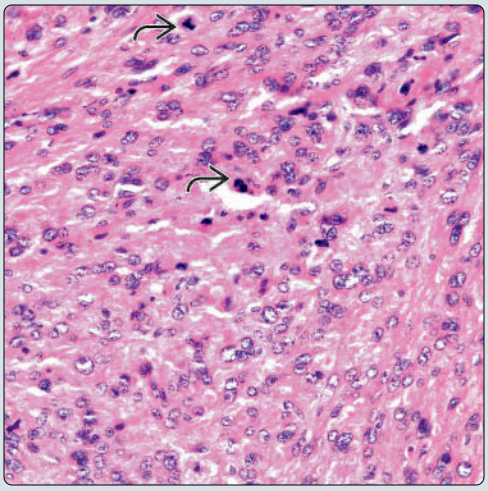

(Left) *High-power view of a mediastinal MPNST in which the cells show an oval to spindle cell nuclei with prominent nucleoli and a few apoptotic cells.* **(Right)** *High-power view of a mediastinal PNST shows more epithelioid areas with cellular pleomorphism, nuclear atypia, and mitotic activity.*

TERMINOLOGY

Abbreviations

- Peripheral nerve sheath tumor (PNST)

Synonyms

- Malignant schwannoma, neurofibrosarcoma, neurogenic sarcoma

Definitions

- Malignant tumor of neural sheath origin

ETIOLOGY/PATHOGENESIS

Etiology

- These tumors may occur as manifestation of neurofibromatosis (von Recklinghausen disease)
- PNST may also occur post radiation

CLINICAL ISSUES

Epidemiology

- Incidence
  - Unusual in mediastinal location
  - May account for ~ 5% of all mediastinal tumors
- Age
  - More common in adults in 3rd, 4th, and 5th decades of life
- Sex
  - No apparent gender predilection
  - Patients with neurofibromatosis are commonly male and young adults

Site

- More common in posterior mediastinum but can also occur in anterior mediastinum

Presentation

- Chest pain
- Cough
- Dyspnea
- Neurofibromatosis

Treatment

- Surgical approaches
  - Complete surgical resection
- Adjuvant therapy
  - Radiation &/or chemotherapy will be determined on individual basis and depending on extent of tumor at time of diagnosis

Prognosis

- Tumors follow aggressive behavior, and prognosis is poor
- Worse prognosis in patients with neurofibromatosis

IMAGING

General Features

- Mediastinal mass
  - More commonly in posterior mediastinum
  - Unusual cases may occur in anterior mediastinum

MACROSCOPIC

General Features

- Lobulated large but not encapsulated tumors
- Light tan in color
- Areas of necrosis and hemorrhage may be seen

Size

- Usually > 5 cm in diameter

MICROSCOPIC

Histologic Features

- Solid spindle cellular proliferation
- Wavy or comma-shaped nuclei
- Nuclear palisading
- Tactoid differentiation
- Cellular pleomorphism with mitotic activity
- Areas of hemorrhage &/or necrosis may be seen
- Perivascular hyalinization
- Heterologous elements may be seen
  - Muscle, cartilage, bone

ANCILLARY TESTS

In Situ Hybridization

- No definitive molecular signature has been determined in these tumors

Electron Microscopy

- Possible schwannian differentiation, which may include
  - Cell processes coated with lamina
  - Abundant rER
  - Well-developed Golgi apparatus
  - Secondary lysosomes
  - Microtubules

DIFFERENTIAL DIAGNOSIS

Neurofibroma

- Does not show increase in mitotic activity or cellular pleomorphism
- Rarely shows areas of necrosis, and when present, they are focal

Leiomyosarcoma

- Does not show nuclear palisading or tactoid differentiation
- Commonly shows positive staining for muscle markers in contrast to PNST

Solitary Fibrous Tumor

- Shows more than 1 growth pattern in same tumor
- Commonly shows positive staining for CD34 and Bcl-2 in contrast to PNST

Schwannoma

- Generally schwannomas lack increase mitotic activity
- Generally schwannomas lack extensive areas of necrosis
- Schwannomas usually show strong positive reaction for S100 protein

Triton Tumor

- Triton tumor would show presence of rhabdomyoblastic differentiation

Immunohistochemistry

Antibody	Reactivity	Staining Pattern	Comment
S100	Positive	Nuclear	In < 50% of cases and focal
NFP	Positive	Cytoplasmic	In some cases and not specific
NSE	Positive		In some cases and not specific
Vimentin	Positive	Cytoplasmic	Not specific
STAT6	Negative		
CD34	Negative		May show focal, weakly positive staining in some cases
Actin-HHF-35	Negative		
Desmin	Negative		
Actin-sm	Negative		
MYOD1	Negative		
Myoglobin	Negative		
Caldesmon	Negative		
CK-PAN	Negative		In some cases, focal, weak positive reaction may be seen
CK5/6	Negative		
SOX10	Negative		
Bcl-2	Negative		
TFE3	Negative		
TFEB	Negative		
CD99	Negative		
FLI-1	Negative		

Molecular Features

FISH	Result
EGFR overexpression	May play role in development
NF1 mutation	May be present in some cases
PTEN overexpression	May play role in development

- Immunostains for muscle markers would show positive staining in rhabdomyoblastic differentiation

Extraskeletal Ewing Sarcoma

- Extraskeletal Ewing sarcoma shows neoplastic small round cell proliferation
- Distinct immunohistochemical and molecular features

DIAGNOSTIC CHECKLIST

Clinically Relevant Pathologic Features

- Mitotic rate
- Invasive pattern
- Nuclear features
- Necrosis

Pathologic Interpretation Pearls

- Solid spindle cellular proliferation
- Palisading of nuclei
- Tactoid differentiation
- Perivascular hyalinization
- Hemorrhage &/or necrosis
- Nuclear atypia and mitotic activity

SELECTED REFERENCES

1. Montano N et al: Tumors of the peripheral nervous system: analysis of prognostic factors in a series with long-term follow-up and review of the literature. J Neurosurg. 1-9, 2015
2. Tatci E et al: The role of FDG PET/CT in evaluation of mediastinal masses and neurogenic tumors of chest wall. Int J Clin Exp Med. 8(7):11146-52, 2015
3. Bicakcioglu P et al: Intrathoracic neurogenic tumors. Thorac Cardiovasc Surg. 62(2):147-52, 2014
4. Thway K et al: Malignant peripheral nerve sheath tumor: pathology and genetics. Ann Diagn Pathol. 18(2):109-16, 2014
5. Wu J et al: EGFR-STAT3 signaling promotes formation of malignant peripheral nerve sheath tumors. Oncogene. 33(2):173-80, 2014
6. Kubiena H et al: Peripheral neural sheath tumors (PNST)--what a radiologist should know. Eur J Radiol. 82(1):51-5, 2013
7. Keng VW et al: PTEN and NF1 inactivation in Schwann cells produces a severe phenotype in the peripheral nervous system that promotes the development and malignant progression of peripheral nerve sheath tumors. Cancer Res. 72(13):3405-13, 2012
8. Shimizu J et al: A case of intrathoracic giant malignant peripheral nerve sheath tumor in neurofibromatosis type I (von Recklinghausen's disease). Ann Thorac Cardiovasc Surg. 14(1):42-7, 2008
9. Patel VS et al: Intrathoracic peripheral nerve sheath tumors in patients with neurofibromatosis type 1 (von Recklinghausen disease). J Thorac Cardiovasc Surg. 131(3):736-7, 2006
10. Takeda S et al: Intrathoracic neurogenic tumors--50 years' experience in a Japanese institution. Eur J Cardiothorac Surg. 26(4):807-12, 2004

Macroscopic Features

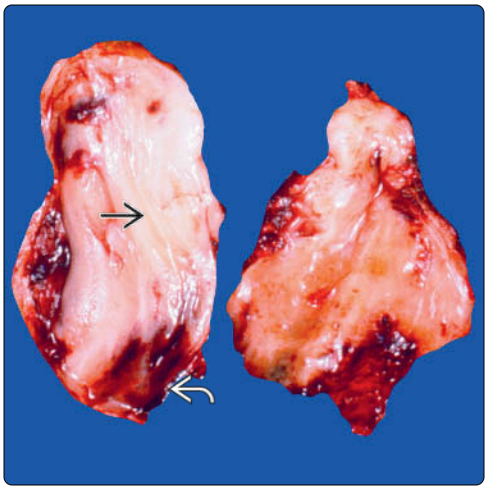

Fascicular Pattern

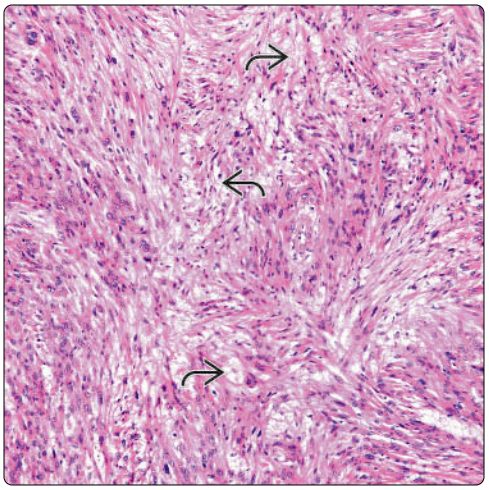

(Left) *Mediastinal PNST shows areas of hemorrhage and possibly necrosis. In addition, more viable areas of tumor show a fish flesh-like appearance. These features are of great importance and should be sampled properly.* **(Right)** *Low-power view shows a mediastinal PNST displaying a spindle cell proliferation arranged in fascicle with a vague storiform pattern. In some areas, there is an appearance of clear cells, possibly an artifact of fixation.*

Sclerotic Areas

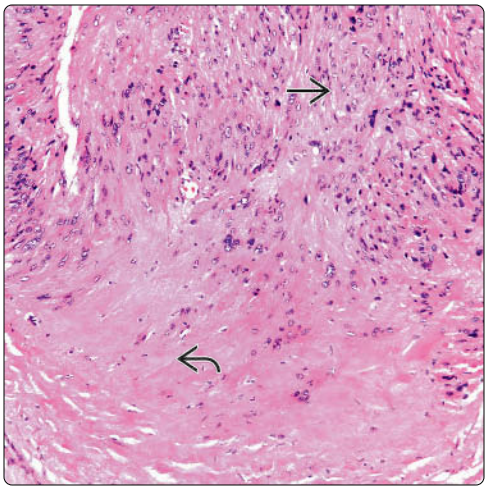

Perivascular Arrangement

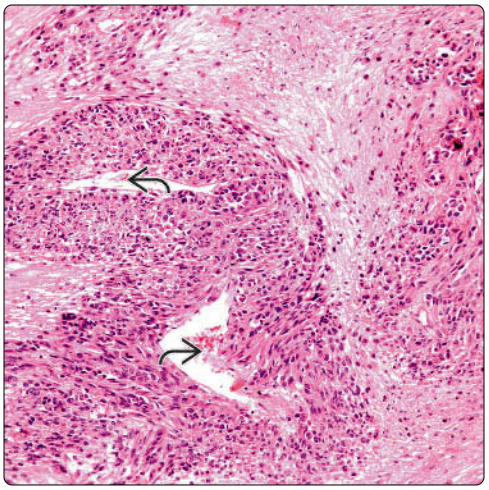

(Left) *Mediastinal PNST shows hypo- and hypercellular areas. The hypocellular areas show dense fibrocollagenous tissue, while the hypercellular areas show a more epithelioid cellular proliferation.* **(Right)** *Mediastinal PNST is shown with prominent arrangement of tumor cells around vascular structures. This feature in particular is very common in these tumors and should alert one to the possibility of PNST. Adjacent areas are hypocellular.*

Perivascular Hyalinization

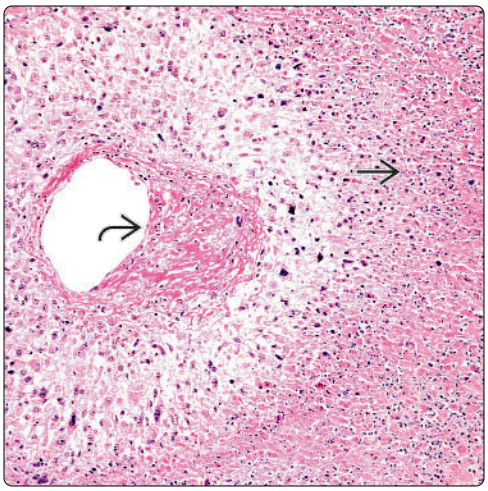

Extensive Necrosis

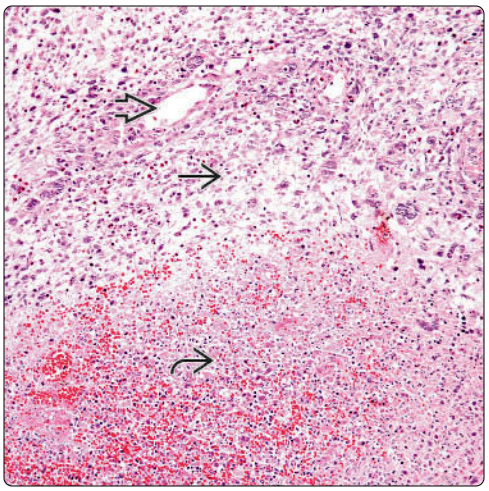

(Left) *The presence of perivascular hyalinization and tumor arrangement around vascular structures is a common feature of PNST. Note the concentric arrangement of tumor cells around the blood vessels and the adjacent tumor necrosis.* **(Right)** *PNST displays extensive areas of necrosis merging with a viable tumor. The tumor has a vague myxoid appearance with an ectatic vascular structure.*

Prominent Hyalinization

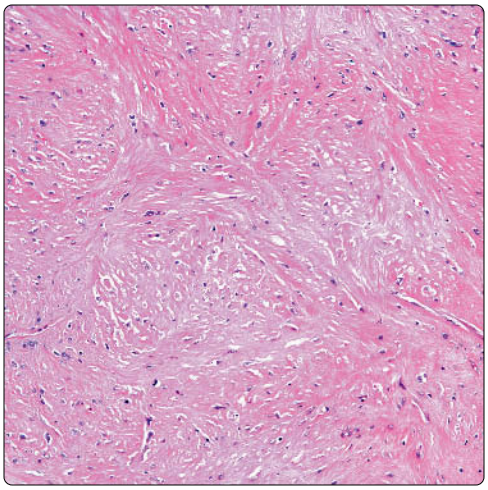

Cellular Pleomorphism

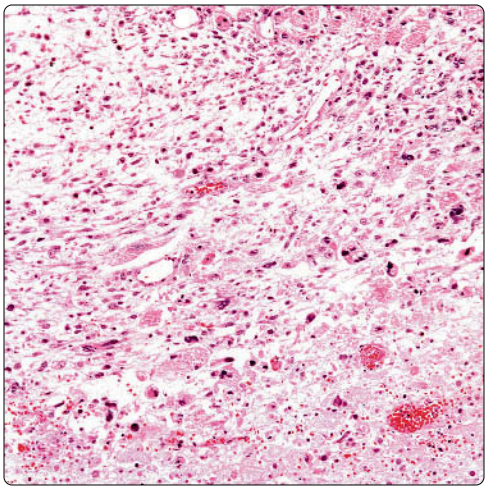

(Left) *Extensive areas of dense collagenization may be present in mediastinal PNST, which may obscure the true nature of the neoplasm. However, in most of the cases, these areas are only focal.* **(Right)** *Mediastinal PNST is shown with marked cellular and nuclear pleomorphism. Pyknotic nuclei, as well as mitotic figures, are present.*

Epithelioid Cellular Proliferation

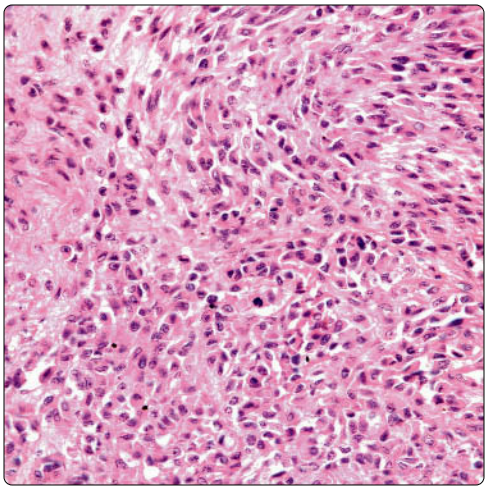

Mitotic Activity

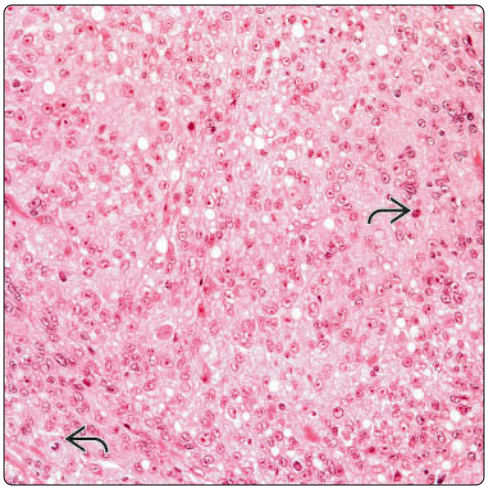

(Left) *High-power view shows an epithelioid PNST composed of oval cells arranged in a subtle nested pattern. This growth pattern can be easily confused with a tumor of epithelial origin.* **(Right)** *Epithelioid PNST is composed of oval cells with moderate light eosinophilic cytoplasm and prominent nucleoli. Mitotic figures are easily encountered. Note that the neoplastic cellular proliferation has vague epithelioid features.*

Neurofibroma-Like Areas

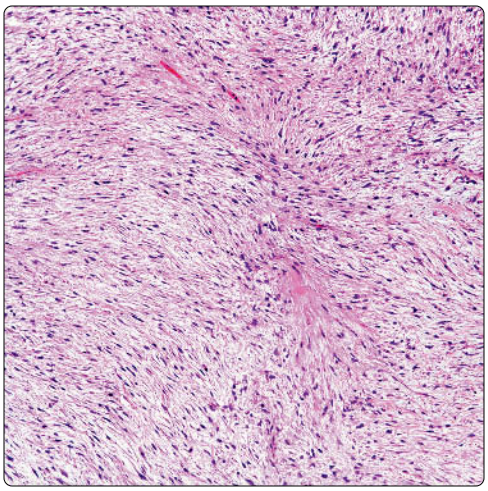

Myxoid Changes

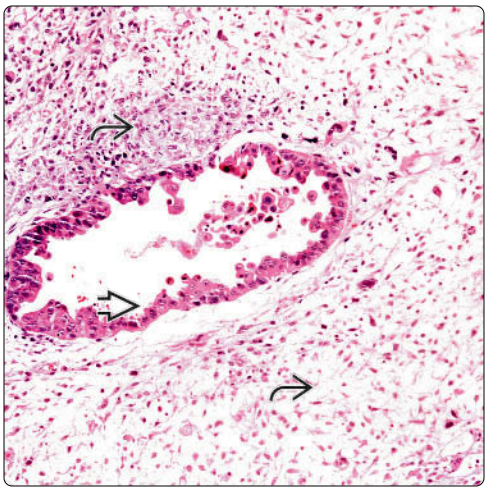

(Left) *In some cases of PNST, the cellularity closely mimics that of benign neurofibroma. In this case, there is no evidence of necrosis and hemorrhage.* **(Right)** *PNST shows glandular differentiation. The neoplastic cellular proliferation around the glandular structure shows myxoid changes, as well as nuclear atypia and mitotic figures.*

Nodular Pattern

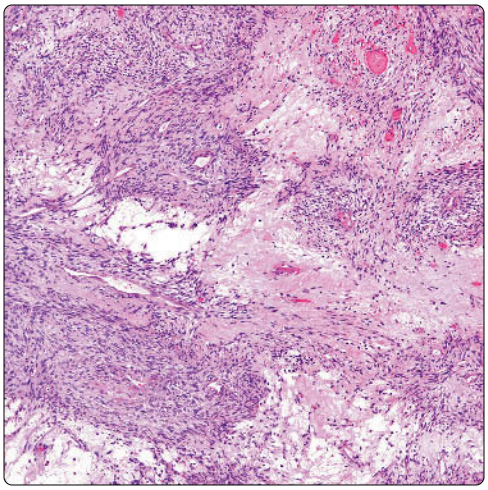

Fibrinoid Necrosis

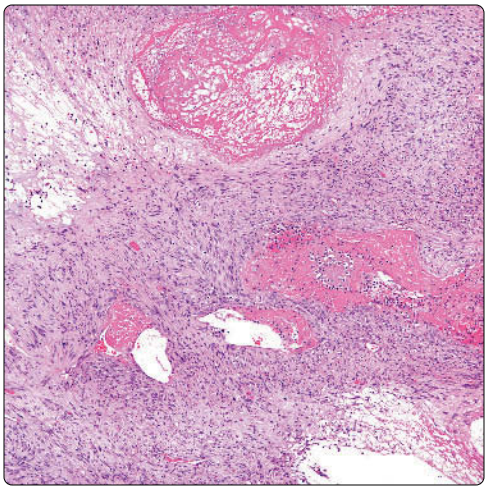

(Left) *Mediastinal MPNST shows a subtle nodular pattern in which tumor cells are arranged around vascular structures and separated by areas of a fibrillary-like acellular material.* **(Right)** *Mediastinal MPNST shows areas of fibrinoid necrosis and cellular areas composed of spindle cells. Note the presence of ectatic vascular structures.*

Hypo- and Hypercellular Areas

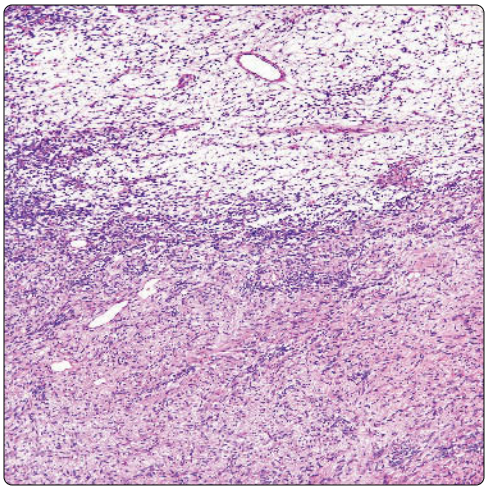

Spindle Cell Component

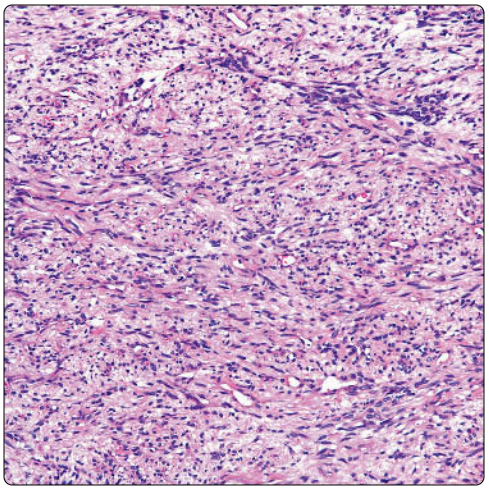

(Left) *Mediastinal MPNST shows solid spindle cell areas alternating with areas in which the cellularity is much less.* **(Right)** *The spindle cell component is composed of cells with elongated nuclei and arranged in a wavy pattern, similar to that seen in neurofibromas.*

Extensive Necrosis

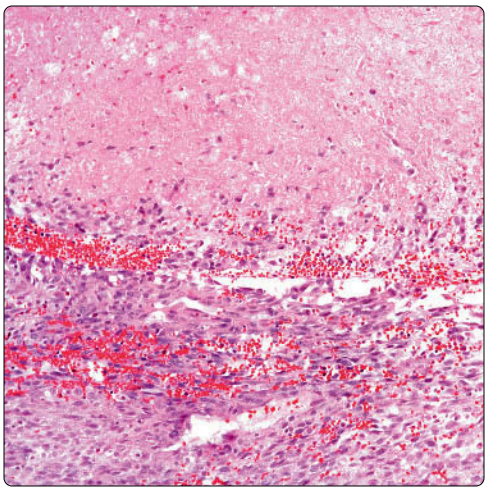

Mitotic Activity

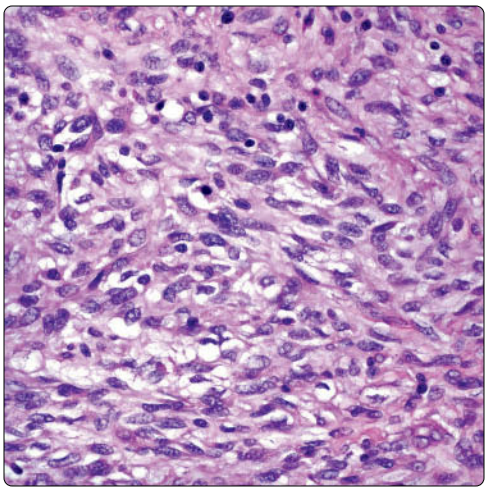

(Left) *The presence of necrosis and an atypical spindle cell proliferation, as seen here, are a couple of highly important features in the diagnosis of MPNST.* **(Right)** *Higher magnification of the spindle cell component shows nuclear atypia and mitotic activity.*

Solitary Fibrous Tumor/Fibrosarcoma

KEY FACTS

CLINICAL ISSUES

- Most common mesenchymal spindle cell tumor of anterior mediastinum
- Cough
- Chest pain
- Dyspnea
- Hypoglycemia
- May be discovered incidentally on routine imaging studies
- Majority of cases reported in mediastinum behaved more aggressively than those at other locations
- Histology may not show strict correlation with prognosis
- In general, cytologic atypia, mitotic activity, necrosis, and invasion are associated with aggressive behavior

MICROSCOPIC

- Fascicles of bland-appearing spindle cells with small, dark nuclei generally devoid of mitotic activity
- Usually shows short storiform pattern resembling fibrohistiocytic tumors
- Small to medium-sized branching vessels with open lumina and staghorn appearance
- Hypercellular areas with increased number of nuclei are seen alongside hypocellular areas
- Haphazard distribution of spindle cells separated by keloidal-like strands of collagen
- Large dilated vessels are seen surrounded by dense collagenous tissue
- Advanced cases may show extensive areas of sclerosis and collagenization
- Tumors cells are strongly positive for STAT6, CD34, Bcl-2, vimentin, and CD99
- Tumor cells are generally negative for cytokeratins, SMA, desmin, S100 protein, and other differentiation markers
- Tumors are characterized by large variegation of histologic growth patterns that may resemble other types of spindle cell tumors

Gross Appearance

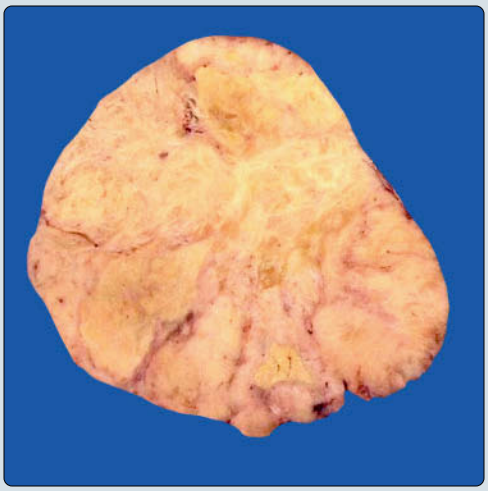

Bland Spindle Cells

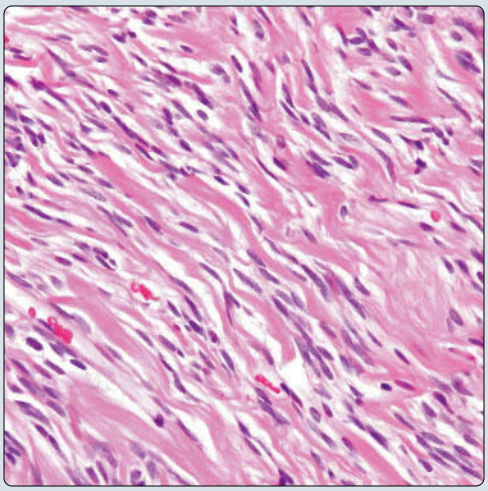

(Left) *Gross photo of solitary fibrous tumor of the mediastinum shows a well-circumscribed mass with a lobulated, tan-white, homogeneous cut surface and focal areas of necrosis.* **(Right)** *Solitary fibrous tumors are characterized by a proliferation of bland-appearing spindle cells with dense nuclear chromatin but absence of nucleoli or nuclear pleomorphism.*

Rope-Like Collagenous Pattern

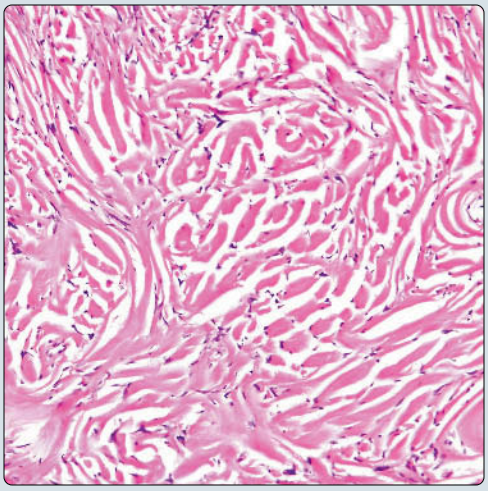

Hemangiopericytic Vascular Pattern

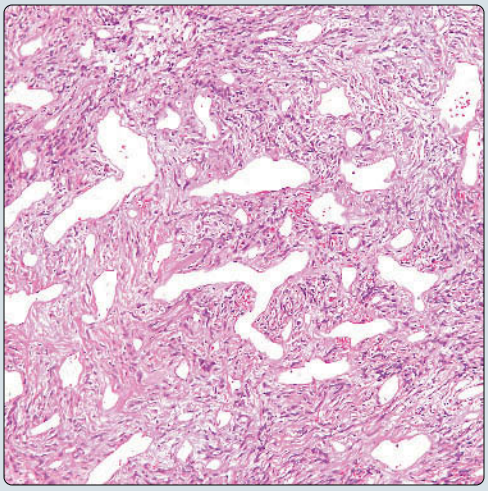

(Left) *Characteristic histologic appearance of solitary fibrous tumor shows parallel linear arrays of rope-like collagen strands flanked by small, bland-appearing spindle cells. This is the most common pattern of growth seen in solitary fibrous tumors.* **(Right)** *Another common growth pattern observed in solitary fibrous tumors is characterized by a proliferation of small branching vessels with patent lumina (so-called hemangiopericytic growth pattern).*

TERMINOLOGY

Abbreviations

- Solitary fibrous tumor (SFT)

Synonyms

- Localized fibrous tumor, malignant solitary fibrous tumor, mediastinal fibroma, mediastinal fibrosarcoma, hemangiopericytoma, fibrous mesothelioma

Definitions

- Neoplastic, tumor-forming proliferation of dendritic fibroblasts

CLINICAL ISSUES

Site

- Most common mesenchymal spindle cell tumor of anterior mediastinum
- May also occur in posterior and middle mediastinal compartments

Presentation

- Cough, chest pain, dyspnea, hypoglycemia
- May be asymptomatic and discovered on routine imaging studies

Treatment

- Surgical excision

Prognosis

- Large and poorly circumscribed tumors may recur, metastasize, and lead to death
- Histology may not show strict correlation with prognosis
- In general, cytologic atypia, mitotic activity, necrosis, and invasion are associated with aggressive behavior

MACROSCOPIC

General Features

- Most tumors are well circumscribed, firm, and lobulated
- Larger tumors are usually infiltrative and adherent to lung and pleura
- May be attached to thymus by short fibrous pedicle
- Tan-gray, whorled appearance on cut surface
- Larger tumors may show areas of hemorrhage and necrosis
- Gross cystic changes can also be seen on cut surface

Size

- 4-25 cm

MICROSCOPIC

Histologic Features

- Tumors are characterized by large variegation of histologic growth patterns that may resemble other types of spindle cell tumors
- **Fascicular pattern**
  - Fascicles of bland-appearing spindle cells with small, dark nuclei generally devoid of mitotic activity
  - Fascicles may resemble those seen in smooth muscle or neural tumors
- **Storiform pattern**
  - Usually shows short storiform pattern resembling fibrohistiocytic tumors
  - Storiform pattern is usually only focal and admixed with other areas
- **Hemangiopericytic pattern**
  - Small to medium-sized branching vessels with open lumina and staghorn appearance
  - Tumors with these features were commonly labeled hemangiopericytoma in previous years
- **Alternating hypo- and hypercellular areas**
  - Hypercellular areas with increased number of nuclei are seen alongside hypocellular areas
  - This growth pattern may resemble malignant peripheral nerve sheath tumors or synovial sarcoma
- **Neural-like growth pattern**
  - Fascicles composed of wavy nuclei, areas with focal palisading of nuclei, and areas resembling Verocay bodies
  - Easily confused for schwannian neoplasms
- **Herringbone pattern**
  - Short fascicles of spindle cells are seen emanating from central area reminiscent of herringbone
  - Can simulate fibrosarcoma, malignant peripheral nerve sheath tumor, and synovial sarcoma
- **Patternless pattern**
  - Haphazard distribution of spindle cells separated by keloidal-like strands of collagen
  - Thin, rope-like strands of keloidal collagen, usually showing parallel distribution, are characteristic
- **Dense hypercellular pattern**
  - Densely packed sheets of spindle cells with little intervening stroma
  - This growth pattern closely resembles monophasic synovial sarcoma
- **Epithelioid growth pattern**
  - Sheets or nests of round, epithelioid cells with round nuclei
  - This pattern may be confused for melanoma and metastatic carcinoma
- **Angiofibromatous pattern**
  - Large, dilated vessels are seen surrounded by dense collagenous tissue
  - Advanced cases may show extensive areas of sclerosis and collagenization
- **Unusual stromal changes**
  - Stromal calcification, metaplastic bone formation, cartilaginous differentiation
  - Extensive degeneration of collagen simulating tumor necrosis
  - Cystic degeneration of stroma
  - Hemorrhage and necrosis
  - Stromal myxoid changes may be prominent and extensive
  - Irregular stellate deposits of dense collagen (so-called amianthoid fibers)

Cytologic Features

- Spindle cells are usually small and bland-appearing with evenly dispersed chromatin and absent or inconspicuous nucleoli
- Mitotic activity is generally very low (< 3 per 10 HPF)

Immunohistochemistry

Antibody	Reactivity	Staining Pattern	Comment
STAT6	Positive	Nuclear	Antibody of choice for diagnosis; stains 100% of cases
CD34	Positive	Cytoplasmic	Stains 60-90% of cases
Bcl-2	Positive	Cytoplasmic	Stains 90-100% of cases
CD99	Positive	Cytoplasmic	Stains 60-70% of cases
Vimentin	Positive	Cytoplasmic	Stains 100% of cases
AE1/AE3	Negative	Not applicable	Should not be positive in these tumors
Desmin	Negative	Not applicable	Negative in tumor cells
S100	Negative	Not applicable	Should not be positive in tumor cells

- Giant cells of osteoclast-type or multinucleated tumor cells may be seen
- Malignant cases may show marked nuclear pleomorphism and high mitotic activity
- Cells may rarely adopt round, epithelioid appearance with abundant rim of eosinophilic cytoplasm

Ancillary Techniques

- Immunohistochemistry
  - Strongly positive for CD34, Bcl-2, CD99, and vimentin
  - Strong nuclear positivity for STAT6
  - Generally negative for cytokeratins, SMA, desmin, S100 protein, and other differentiation markers
- Electron microscopy
  - Ultrastructural features of fibroblastic cells with dendritic cytoplasmic prolongations

DIFFERENTIAL DIAGNOSIS

Hemangiopericytoma

- Older term used to designate tumors with distinctive branching pattern of vessels
- Term "hemangiopericytoma" has been replaced by "solitary fibrous tumor" as most cases represent examples of SFT cases
- Hemangiopericytoma and SFT are currently regarded as synonymous terms in soft tissue locations

Synovial Sarcoma

- High cellularity with marked cytologic atypia and variable mitotic activity
- Monotonous spindle cell population with very scant connective tissue stroma
- Tumor cells show focal cytokeratin and EMA positivity
- Show distinctive t(X;18) translocation
- May be very difficult to distinguish from SFT in some cases, requiring molecular studies for confirmation

Peripheral Nerve Sheath Tumors

- Fascicular proliferation composed of spindle cells with wavy nuclei
- Association with neurofibromatosis and nerve trunks
- S100 protein positivity in spindle cells
- Complex, interdigitating slender dendritic prolongations seen on ultrastructural examination

Spindle Cell Thymoma

- Fascicular spindle cell proliferation separated by broad fibrous bands into lobules
- Usually shows minor component of scattered, small T lymphocytes
- May display rosette-like structures or microcystic growth pattern
- Spindle cells are positive for cytokeratins and negative for CD34 and STAT6

Sarcomatoid Malignant Mesothelioma

- Atypical spindle cell proliferation with marked nuclear pleomorphism and high mitotic activity
- Focal positivity of spindle cells for keratin and calretinin
- Diffuse growth pattern with spread along pleural surface
- Occupational history of previous asbestos exposure

Pleomorphic High-Grade Sarcoma

- Histologic appearance can be indistinguishable from that of malignant solitary fibrous tumors
- Lacks well-preserved areas showing features of solitary fibrous tumors
- Lacks cells positive for STAT6, CD34, and Bcl-2

DIAGNOSTIC CHECKLIST

Clinically Relevant Pathologic Features

- Well-circumscribed mass in anterior mediastinum
- History of hypoglycemia or clubbing of fingers

Pathologic Interpretation Pearls

- Bland-appearing spindle cell population with variegation of histologic growth patterns within same tumor
- Prominent hemangiopericytomatous growth pattern admixed with other growth patterns
- Prominent vascularity of stroma with perivascular hyalinization and sclerosis
- Striking, rope-like linear deposition of keloidal collagen flanking spindle cells

SELECTED REFERENCES

1. Guseva NV et al: The NAB2-STAT6 gene fusion in solitary fibrous tumor can be reliably detected by anchored multiplexed PCR for targeted next-generation sequencing. Cancer Genet. 209(7-8):303-12, 2016
2. Thway K et al: The current status of solitary fibrous tumor: diagnostic features, variants, and genetics. Int J Surg Pathol. 24(4):281-92, 2016
3. Milano MT et al: Thoracic malignant solitary fibrous tumors: A population-based study of survival. J Thorac Dis. 3(2):99-104, 2011

Short Storiform Pattern

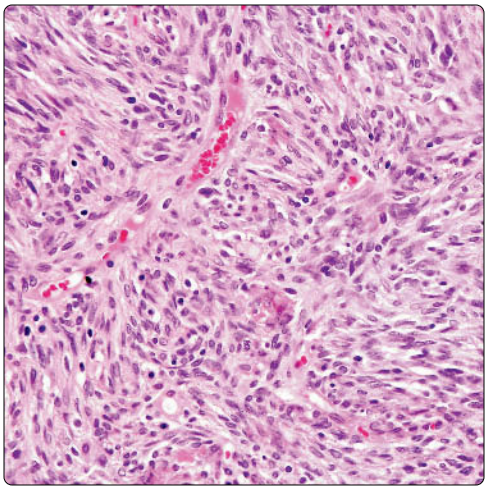

Stromal Collagen

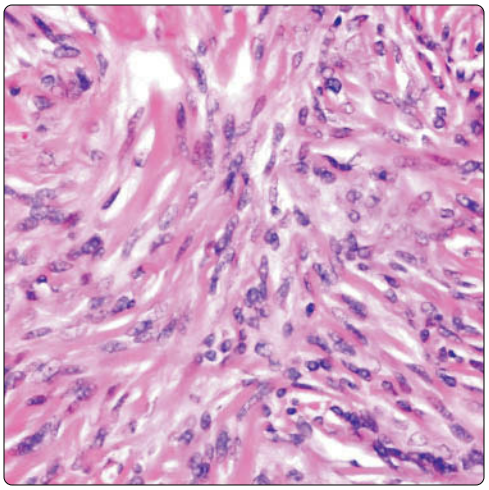

(Left) *Solitary fibrous tumor of the mediastinum shows a vague storiform pattern with overlapping fascicles of spindle cells that appear to emanate from a central spoke. The morphologic appearance of this tumor is reminiscent of a fibrohistiocytic neoplasm.* **(Right)** *High magnification of a solitary fibrous tumor of the mediastinum with a storiform growth pattern shows a bland-appearing spindle cell population separated by thin linear strands of keloidal collagen.*

Rope-Like Strands of Collagen

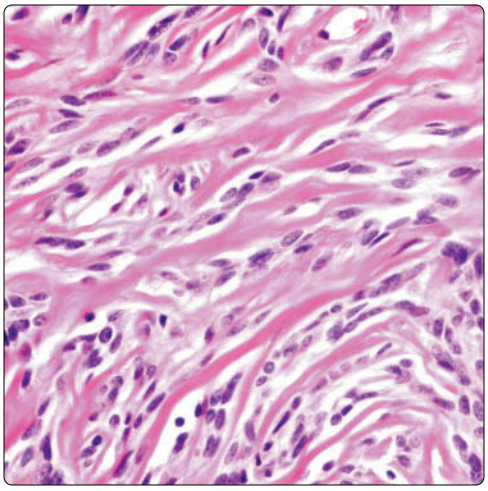

Neural-Like Wavy Nuclei

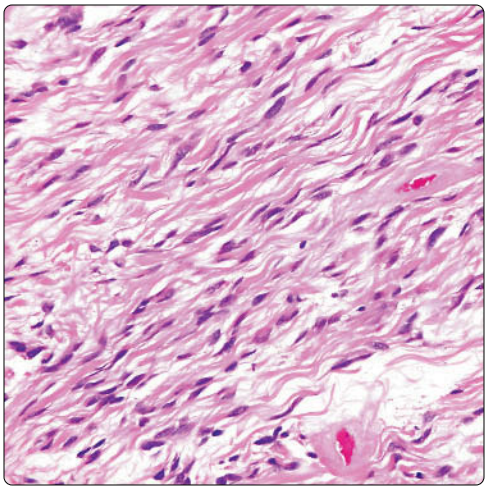

(Left) *High magnification of solitary fibrous tumor of the mediastinum shows the characteristic histologic appearance composed of bland spindle cells flanked by thin, rope-like strands of collagen disposed in parallel linear arrays.* **(Right)** *Solitary fibrous tumor of the anterior mediastinum shows fascicles of spindle cells lying within loose connective tissue stroma. Notice the prominent wavy appearance of the spindle cells, reminiscent of that which is commonly observed in schwannian tumors.*

Rope-Like Pattern of Collagenization

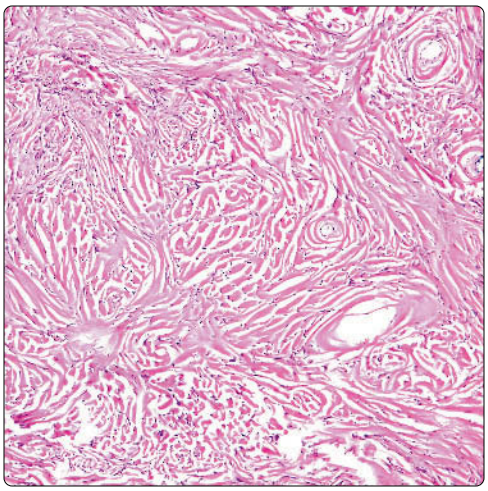

Parallel Rows of Collagenized Stroma

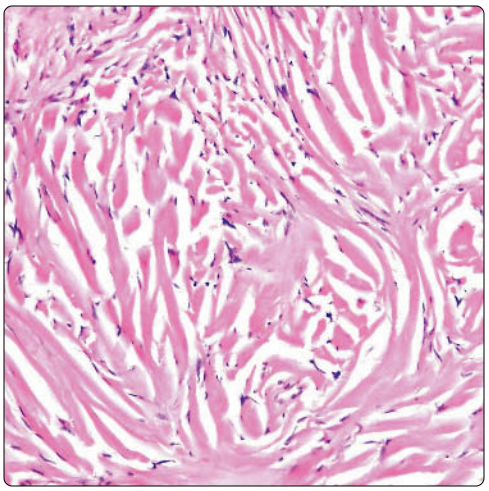

(Left) *Characteristic low-power appearance of a solitary fibrous tumor shows parallel arrays of thin, rope-like strands of keloidal collagen flanked by small spindle cells. This has often been referred to as the patternless pattern of growth in these tumors.* **(Right)** *High magnification of a solitary fibrous tumor shows a patternless pattern characterized by parallel, linear arrays of thin keloidal collagen separating the tumor cells. This pattern of growth is fairly typical for this tumor.*

Hypercellular and Hypocellular Areas

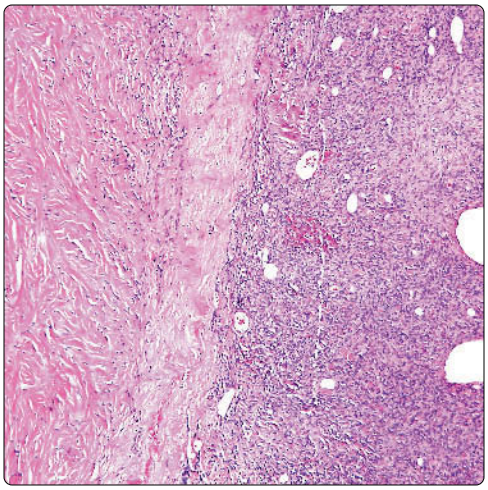

Irregular Stromal Sclerosis

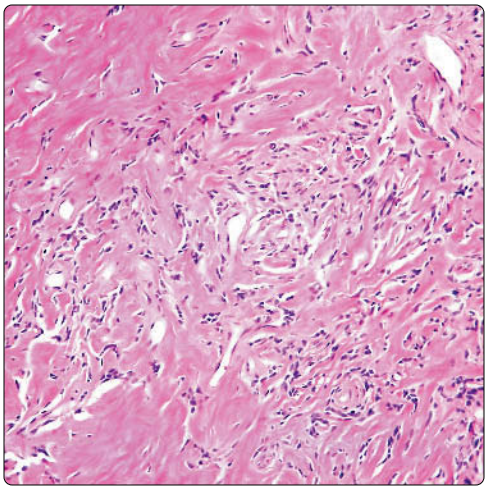

(Left) *Scanning magnification in solitary fibrous tumor of the mediastinum shows an abrupt transition between the hypercellular area (right) and hypocellular, sclerotic area (left). Alternating cellular and hypocellular areas is a common theme in these tumors.* **(Right)** *Solitary fibrous tumor of the mediastinum shows a scant spindle cell population admixed with areas of stromal sclerosis. Notice the irregular distribution of the areas of sclerosis with haphazard arrangement of the spindle cells.*

Solid Hypercellular Growth Pattern

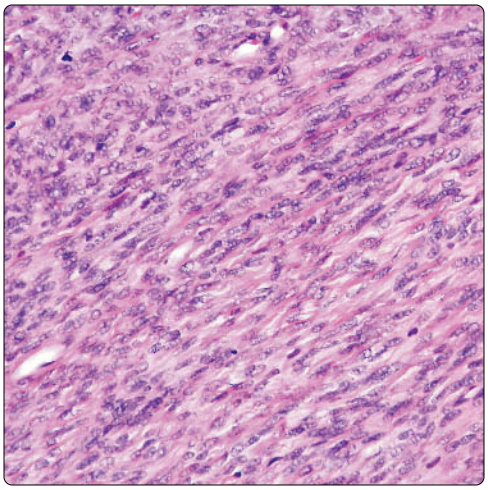

Cellular and Sclerotic Patterns

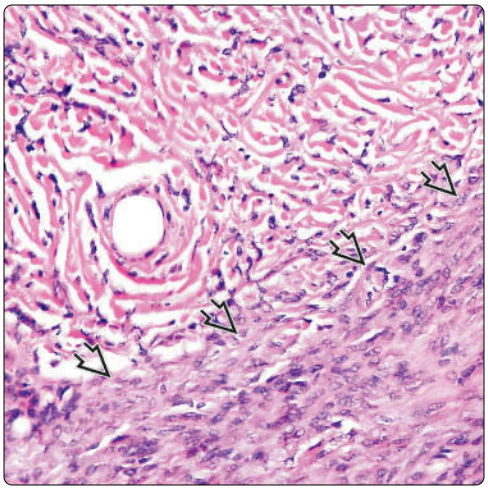

(Left) *Solitary fibrous tumor of the mediastinum shows a solid, hypercellular pattern of growth with sheets of monotonous spindle cells with little intervening stroma. Tumors with this appearance can be easily mistaken for synovial sarcoma.* **(Right)** *High magnification of a solitary fibrous tumor with a solid hypercellular growth pattern ⇨ shows a transition with a more classic sclerosing pattern (top) displaying the characteristic rope-like strands of collagen.*

Perivascular Hyalinization

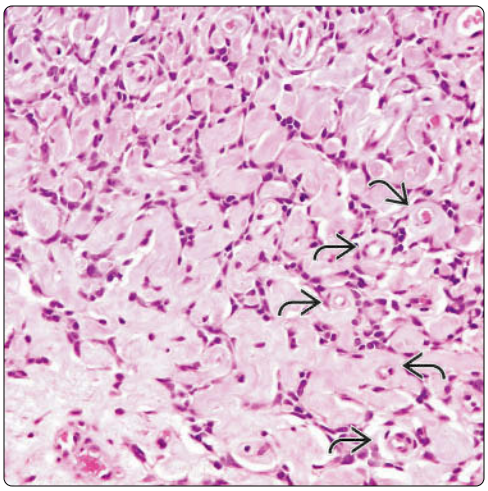

Myxoid Stromal Changes

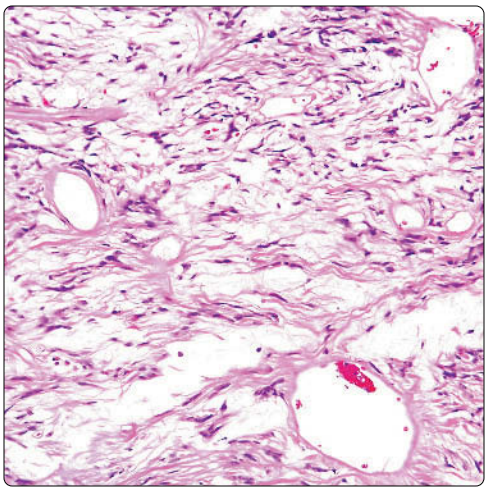

(Left) *Solitary fibrous tumor of the mediastinum shows a micronodular pattern of sclerosis with dense collagen deposition around small vessels ⇨. The spindle tumor cells appear compressed and evenly dispersed around these micronodular structures.* **(Right)** *Solitary fibrous tumor of the mediastinum shows prominent myxoid stromal deposition. Tumors with this morphologic appearance may be mistaken for myxofibrosarcoma, myxoid neurofibroma, or myxoid malignant fibrous histiocytoma (MFH).*

Hemangiopericytic Vascular Pattern

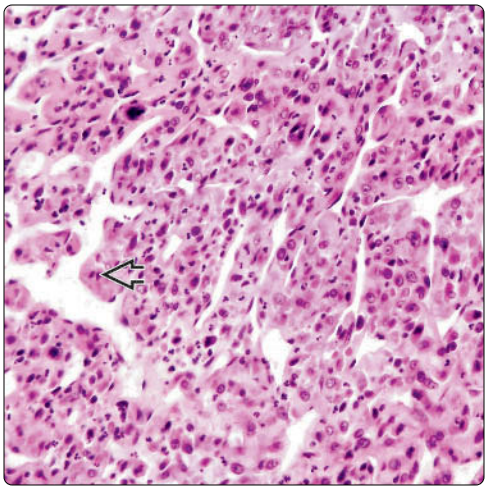

Hemangiopericytic Vascular Pattern

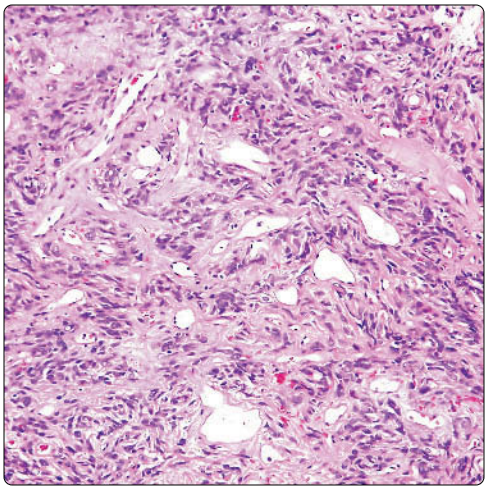

(Left) *Solitary fibrous tumor of the mediastinum shows a striking hemangiopericytic pattern of growth with numerous slit-like vessels that appear to show complex branching of their lumina. Some of the vessels may adopt an antler-like (or staghorn) configuration.* **(Right)** *Solitary fibrous tumor of the mediastinum shows prominent hemangiopericytic pattern of growth characterized by numerous small vessels with open lumina surrounded by a dense spindle cell population.*

Herringbone Pattern

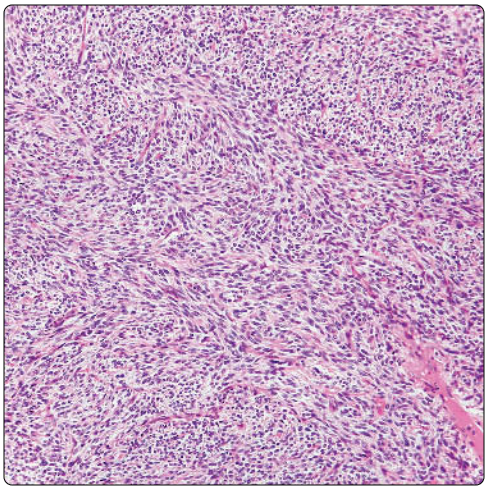

Herringbone Pattern

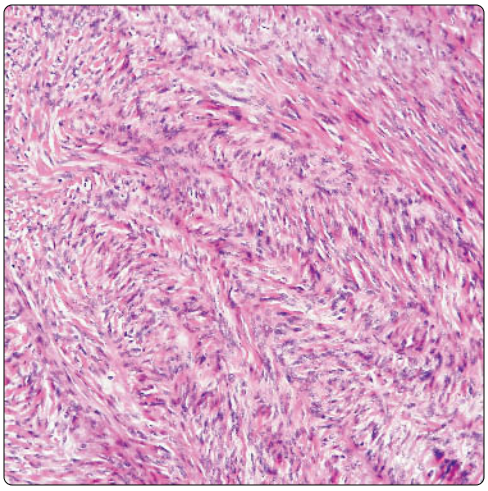

(Left) *Solitary fibrous tumor of the mediastinum with a prominent herringbone pattern of growth shows a dense population of spindle cells with short fascicles that appear to be branching off from central spokes.* **(Right)** *High magnification of solitary fibrous tumor of the mediastinum shows a prominent herringbone pattern of growth. Tumors with these features can resemble other soft tissue sarcomas such as malignant peripheral nerve sheath tumors and synovial sarcoma.*

Epithelioid Growth Pattern

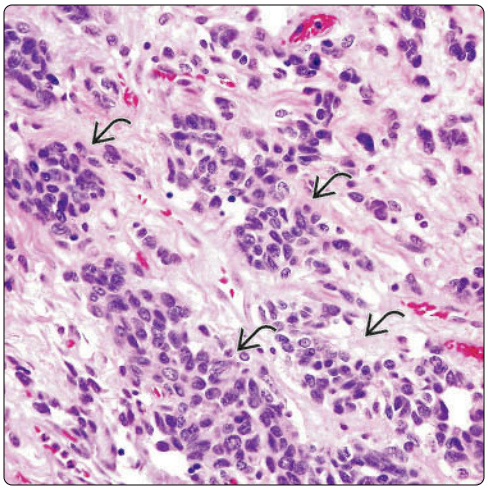

Epithelioid Cells

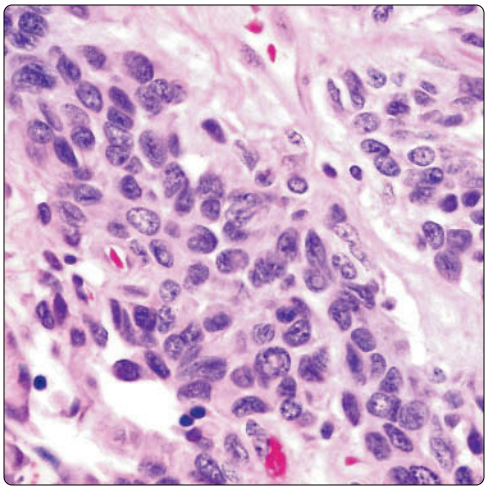

(Left) *Solitary fibrous tumor, epithelioid variant, shows nests of round tumor cells with large, round nuclei surrounded by a rim of lightly eosinophilic cytoplasm.* *This histologic appearance is quite rare in solitary fibrous tumors and may cause confusion with a malignant epithelial neoplasm.* **(Right)** *High magnification of solitary fibrous tumor of the mediastinum with epithelioid features shows nests of large epithelioid cells with large, round nuclei surrounded by eosinophilic cytoplasm.*

(Left) *Immunohistochemical staining for CD34 in solitary fibrous tumor of the mediastinum shows positivity of the spindle cells in a targetoid distribution around a dilated, small blood vessel.* **(Right)** *Immunohistochemical staining for STAT6 shows nuclear positivity of the tumor cells in solitary fibrous tumor for this antibody. This marker is quite specific and is currently regarded as the marker of choice for establishing the diagnosis.*

CD34 Immunostaining

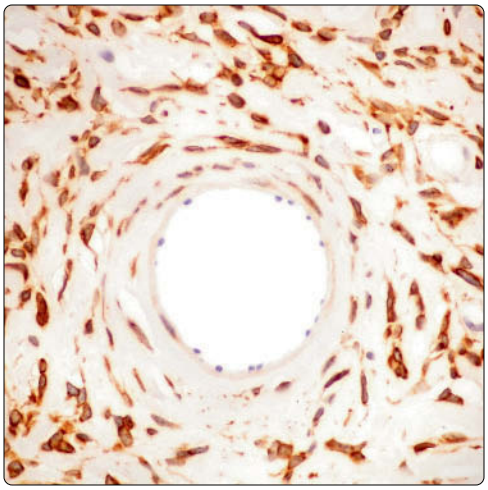

STAT6 Immunostaining

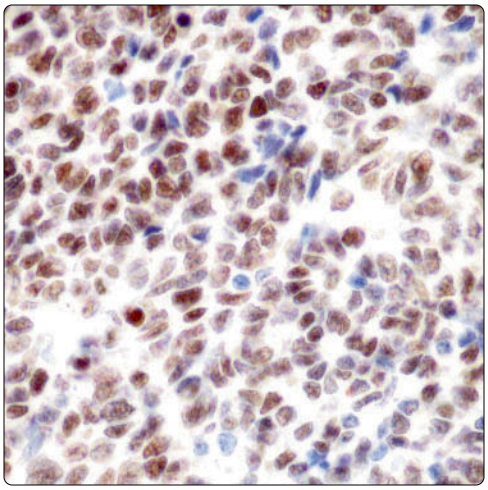

(Left) *Immunohistochemical staining for smooth muscle actin (SMA) in solitary fibrous tumor of the mediastinum shows strong positivity in vessel walls but negative staining in the spindle tumor cells.* **(Right)** *High magnification shows immunohistochemical staining of the spindle cells in solitary fibrous tumor of the mediastinum for CD34. Notice the slender dendritic cytoplasmic prolongations that taper off gradually and interconnect with the cell processes from adjoining cells.*

SMA Immunostaining

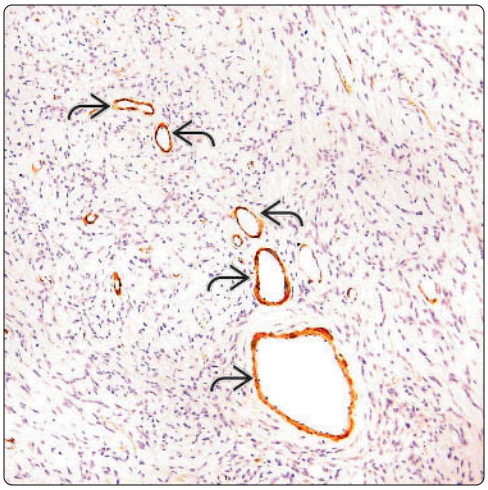

CD34 Staining of Dendritic Processes

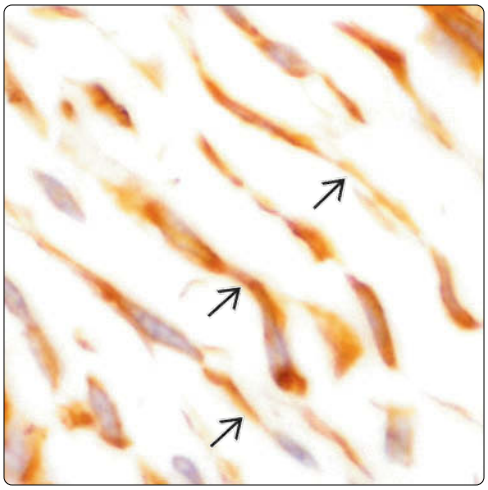

(Left) *Immunohistochemical staining for Bcl-2 oncogene in solitary fibrous tumor of the mediastinum shows strong cytoplasmic positivity in the majority of the tumor cells for this marker. Notice the empty vessel lumina and absence of staining of vascular endothelium.* **(Right)** *Immunohistochemical staining for Bcl-2 oncogene in solitary fibrous tumor of the mediastinum shows the branching, antler-like blood vessel outlined by the positive tumor cells.*

Bcl-2 Immunostaining

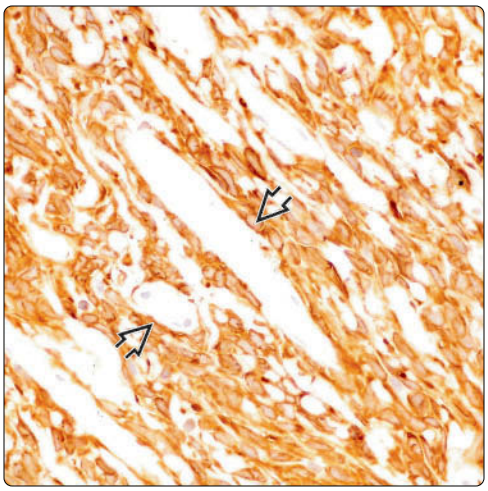

Bcl-2 Immunostaining

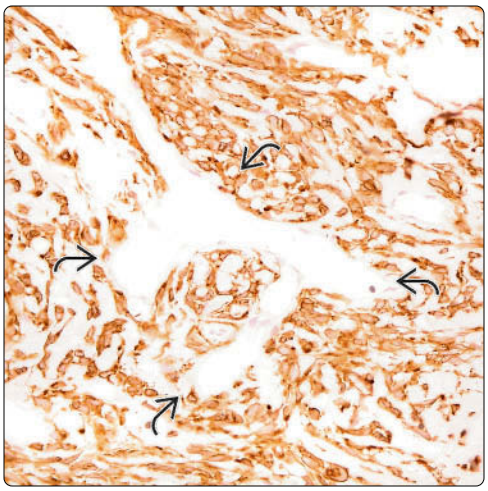

Advanced Sclerosis

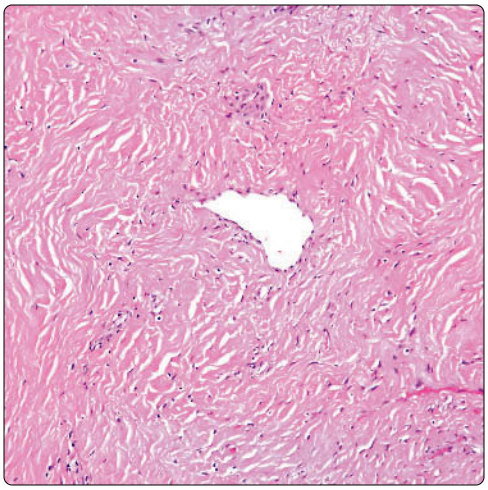

Acellular Areas

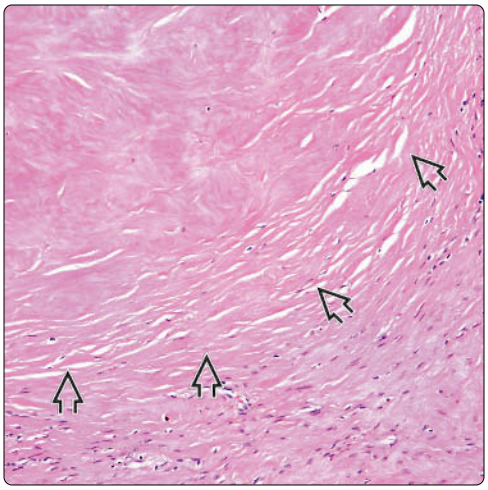

(Left) *Advanced stage of sclerosis in solitary fibrous tumor of the mediastinum shows abundant collagen deposition. Notice the cells are compressed by the collagen and appear as small, round dots in the background rather than spindle cells.* **(Right)** *Solitary fibrous tumor of the mediastinum shows a more advanced degree of stromal sclerosis with dense, homogeneous acellular areas resembling amyloid deposits ⇨. Notice the residual scattered spindle cells (bottom).*

Keloidal Collagen

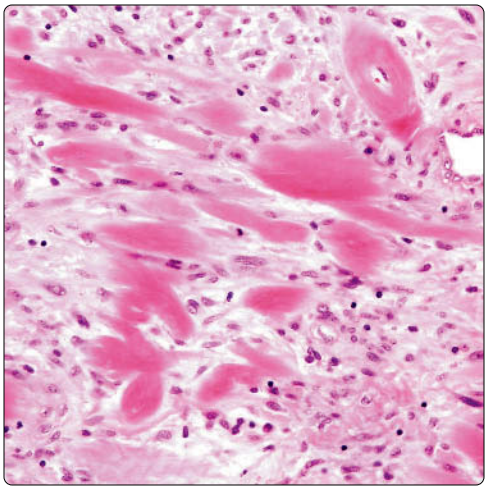

Perivascular Hyalinization

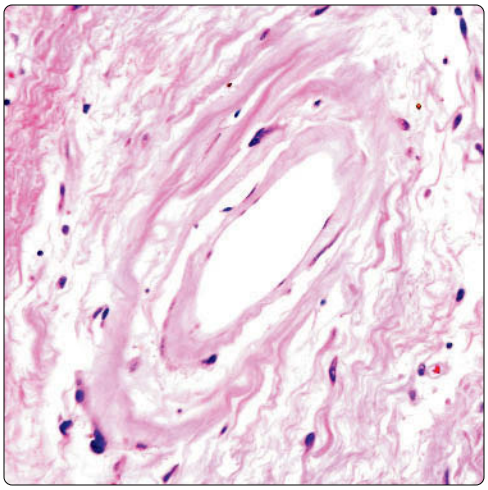

(Left) *Solitary fibrous tumor of the mediastinum shows focal deposits of thick, keloidal collagen bundles. Extensive deposition of collagen fibers in the stroma may result in a histologic picture reminiscent of sclerosing mediastinitis.* **(Right)** *Solitary fibrous tumor of the mediastinum shows dilated vessels with prominent perivascular hyalinization imparting the lesion with an angiofibromatous appearance. Foci like this are commonly observed in areas of stromal sclerosis.*

Mitotic Figure

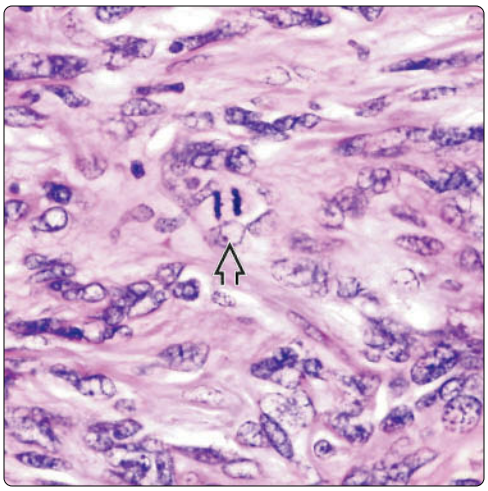

Spindle Cells: Higher Magnification

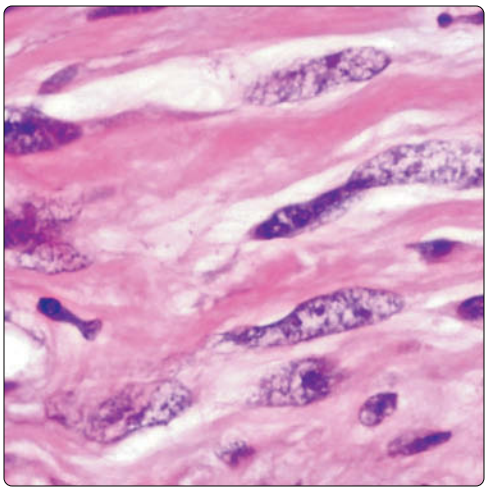

(Left) *High magnification in a solitary fibrous tumor of the mediastinum shows spindle cell population with minimal nuclear pleomorphism. Scattered mitoses can be commonly observed ⇨ but are usually < 3 per 10 HPF.* **(Right)** *Higher magnification in a solitary fibrous tumor of the mediastinum shows bland-appearing spindle cells embedded in a collagenous stroma. The cells show features indistinguishable from those of conventional fibroblasts.*

Mixed Benign/Malignant Solitary Fibrous Tumor

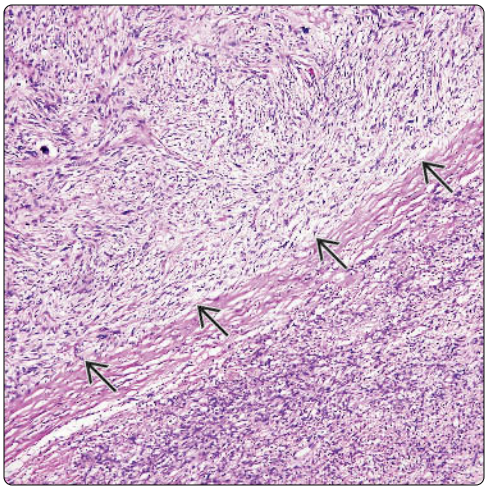

Storiform Pattern in Malignant Solitary Fibrous Tumor

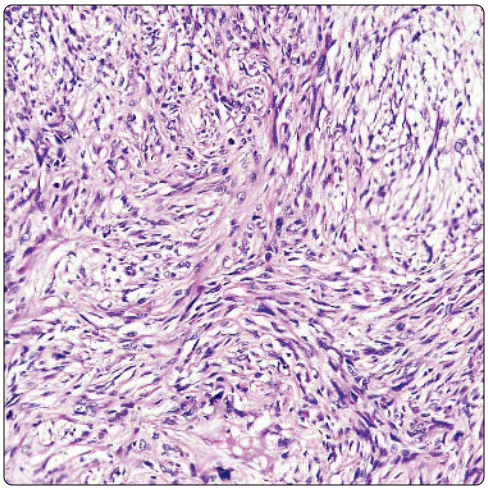

(Left) *Scanning magnification of malignant solitary fibrous tumor of the mediastinum shows transitions between the well-differentiated area in the bottom and a high-grade, poorly differentiated area at the top containing more pronounced nuclear pleomorphism and increased mitotic activity.* **(Right)** *Malignant solitary fibrous tumor of the mediastinum shows an area with a striking storiform pattern simulating the appearance of an MFH.*

Area of Necrosis in Malignant Solitary Fibrous Tumor

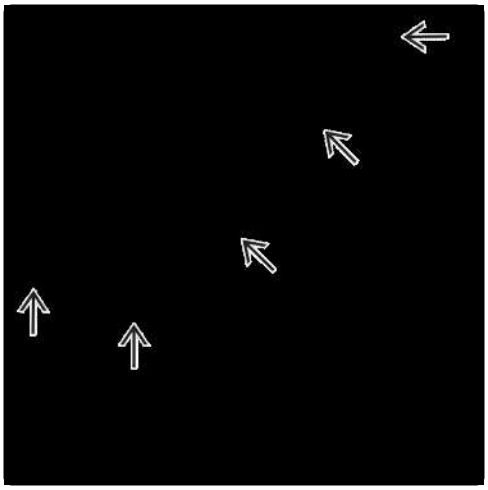

Malignant Solitary Fibrous Tumor

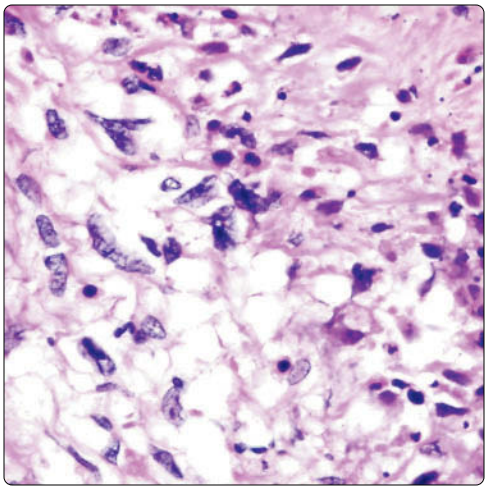

(Left) *Malignant solitary fibrous tumor of the mediastinum shows an area of tumor necrosis with irregular, jagged borders surrounded by a highly atypical spindle and pleomorphic tumor cell population.* **(Right)** *Higher magnification shows the interphase between the tumor and a focus of necrosis in a malignant solitary fibrous tumor of the mediastinum. Notice the marked cytologic atypia of the spindle tumor cells displaying irregular, hyperchromatic nuclei.*

Nuclear Pleomorphism

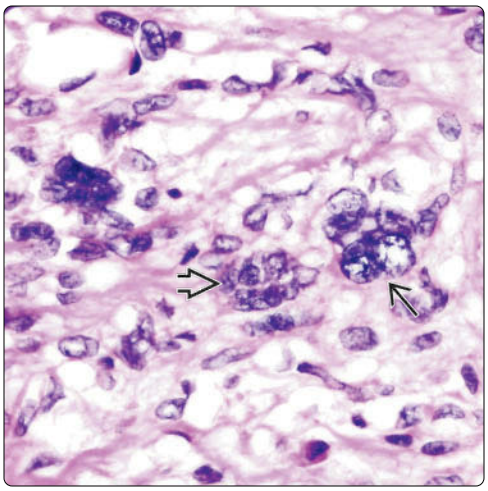

Bizarre Nuclear Forms

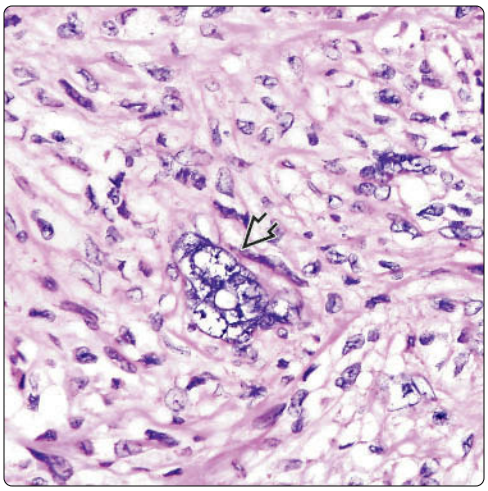

(Left) *Marked nuclear pleomorphism is displayed by the tumor cells in this example of malignant solitary fibrous tumor of the mediastinum. Notice that some of the cells show multilobated nuclei, while others are multinucleated.* **(Right)** *Malignant solitary fibrous tumor of the mediastinum shows an atypical spindle cell population embedded in collagenous stroma, containing scattered large, pleomorphic tumor cells with bizarre nuclei that display a vesicular chromatin pattern.*

Mitotic Activity

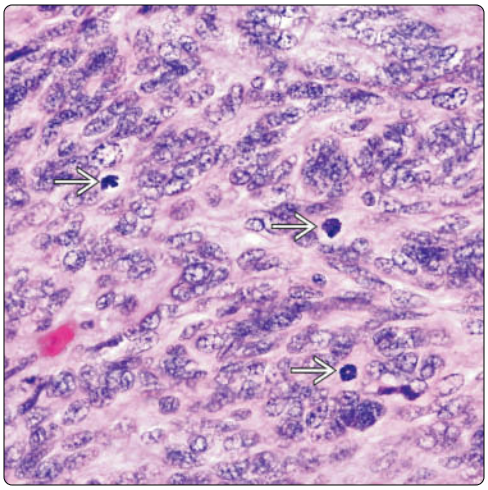

Mitoses in Malignant Solitary Fibrous Tumor

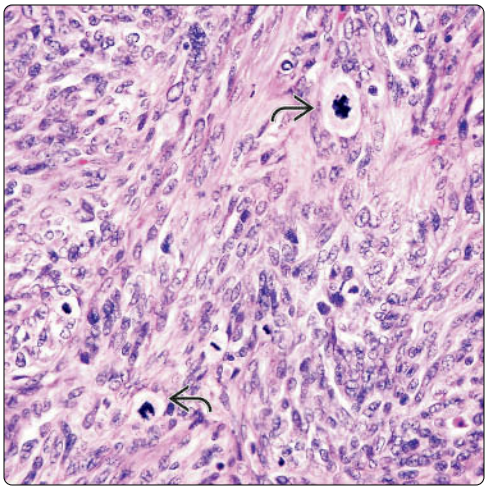

(Left) *Malignant solitary fibrous tumor of the mediastinum shows a monotonous, highly cellular spindle tumor cell population that closely resembles a monophasic synovial sarcoma. Notice the frequent mitoses scattered throughout the field* ⇉. **(Right)** *Malignant solitary fibrous tumor of the mediastinum shows a highly cellular atypical spindle cell population adopting a fascicular pattern of growth and containing scattered abnormal mitotic figures* ⇉.

Area of Necrosis in Malignant SFT

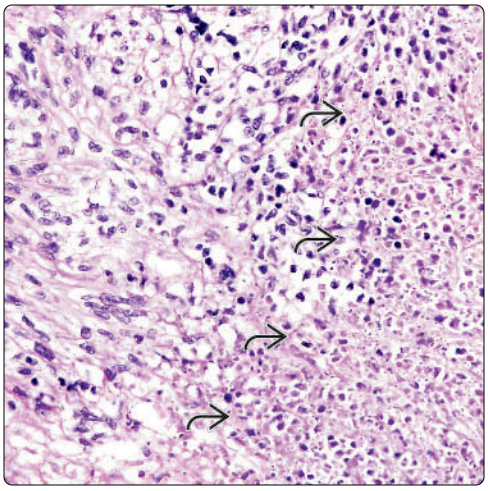

Bizarre Multilobated Tumor Cells

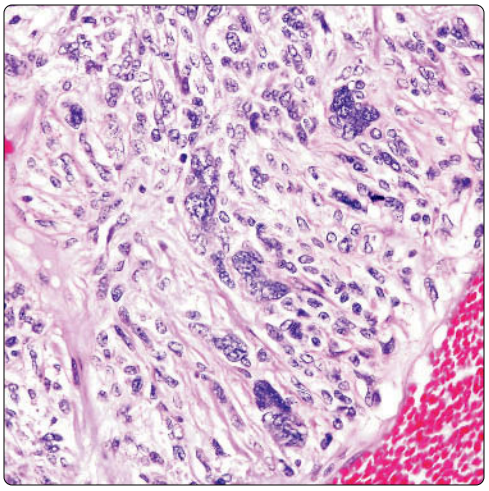

(Left) *Malignant solitary fibrous tumor of the mediastinum shows atypical tumor cell population (left) containing areas of coagulation necrosis* ⇉. **(Right)** *Malignant solitary fibrous tumor of the mediastinum shows an atypical spindle tumor cell population admixed with numerous larger, bizarre, multilobated and multinucleated tumor cells. The appearance of this tumor is reminiscent of that of a pleomorphic high-grade sarcoma (a.k.a. malignant fibrous histiocytoma).*

Multinucleated Atypical Cells

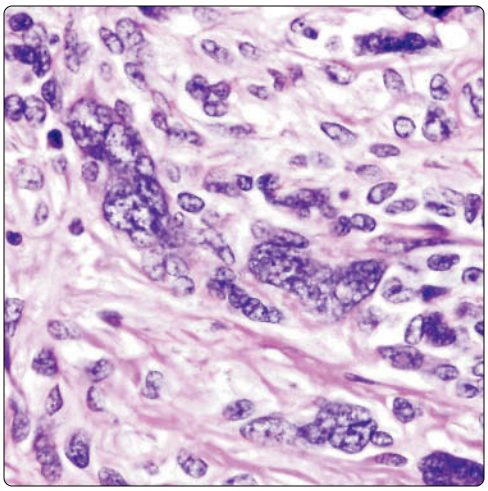

Bizarre Nuclear Morphology

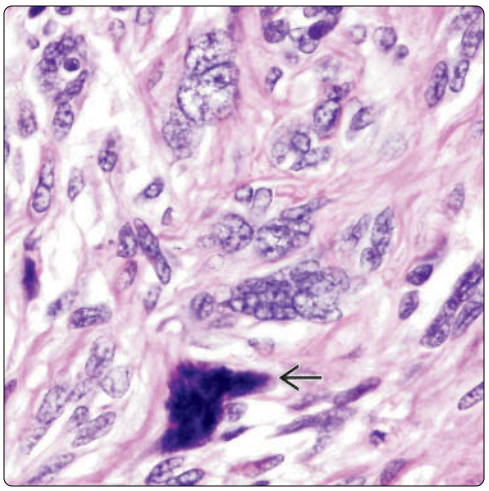

(Left) *Malignant solitary fibrous tumor of the mediastinum shows multiple large tumor cells with multiple hyperchromatic nuclei. Contrast this with the smaller, bland-appearing cells observed in the background.* **(Right)** *Malignant solitary fibrous tumor of the mediastinum shows atypical multinucleated tumor cells scattered between the atypical spindle cells. Notice the multinucleated tumor cell at the bottom with darkly stained basophilic nuclei* ⇉.

Epithelioid Hemangioendothelioma

KEY FACTS

TERMINOLOGY

- Epithelioid hemangioendothelioma (EH)

CLINICAL ISSUES

- Incidence
  - Unusual tumor in mediastinal compartment
  - May account for < 1% of all mediastinal tumors
  - May affect individuals ranging from < 20 to > 60 years of age
  - Some series have reported slight male predominance for occurrence of this tumor
- Symptoms
  - Chest pain
  - Cough
  - Dyspnea
  - Asymptomatic
- Prognosis
  - Tumor may follow protracted course with recurrences
  - In some cases, it may follow rapid course with metastatic disease in or outside of thorax

ANCILLARY TESTS

- Presence of Weibel-Palade bodies by EM

TOP DIFFERENTIAL DIAGNOSES

- Chordoma
- Myxoid chondrosarcoma
- Seminoma
- Thymic carcinoma

DIAGNOSTIC CHECKLIST

- Cords of epithelioid cells
- Low mitotic rate of no more than 1-2 x 10 HPF
- Chondromyxoid stroma
- Absent necrosis, and, if present, it would be focal

(Left) *Mediastinal epithelioid hemangioendothelioma (EH) displays a solid neoplastic cellular proliferation. However, note the presence, even at this magnification, of several slits that may represent vascular spaces.* **(Right)** *High-power view shows a mediastinal EH in which the tumor shows prominent vascular channels lined by atypical endothelial cells. This feature is typical for the diagnosis of EH.*

Solid Growth Pattern



Vascular Spaces

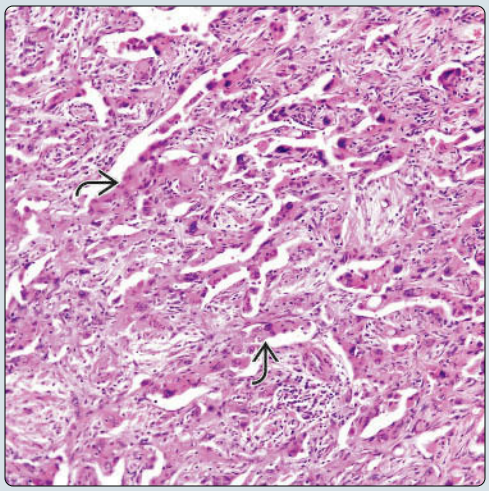

(Left) *Mediastinal EH shows extensive hyalinization with only clusters of neoplastic cells in the center. This is a common finding in these tumors.* **(Right)** *Mediastinal EH shows areas in which there is nuclear atypia and scattered multinucleated giant cells. Note the presence of vascular spaces and absence of mitotic activity.*

Prominent Hyalinization

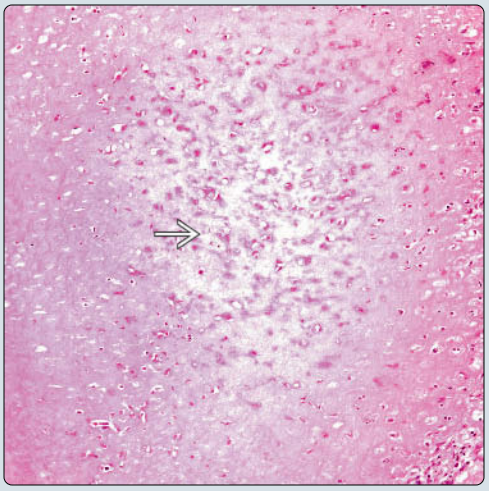

Nuclear Atypia

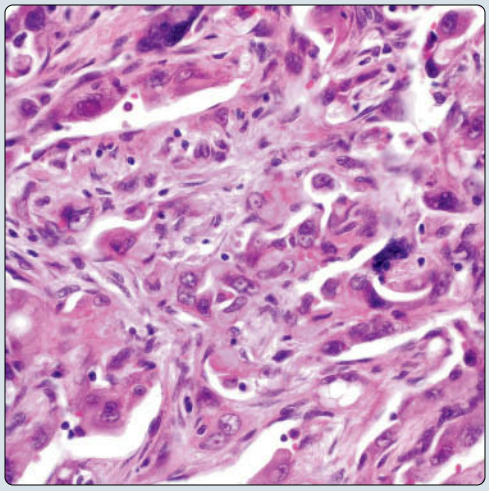

TERMINOLOGY

Abbreviations

- Epithelioid hemangioendothelioma (EH)

Definitions

- Vascular neoplasm of intermediate malignant potential

ETIOLOGY/PATHOGENESIS

Etiology

- Although well known to be tumor of vascular origin, its etiology is still unknown

CLINICAL ISSUES

Epidemiology

- Incidence
  - Unusual tumor in mediastinal compartment
  - May account for < 1% of all mediastinal tumors
- Age
  - Wide range from younger patients (< 20 years old) to older patients (> 60 years old)
- Sex
  - No apparent sex predilection
    - However, in some series of cases there has been slight male predominance
- Ethnicity
  - No apparent ethnic predilection

Presentation

- Chest pain
- Cough
- Dyspnea
- Asymptomatic

Treatment

- Surgical approaches
  - Complete resection of tumor
- Adjuvant therapy
  - Radiation &/or chemotherapy may be considered depending on extent of tumor at time of diagnosis

Prognosis

- Tumor may follow protracted course with recurrences
- In some cases, may follow rapid course with metastatic disease within thoracic cavity or outside of thorax

IMAGING

General Features

- Mediastinal mass
- It can be in either anterior or posterior compartment

MACROSCOPIC

General Features

- Well circumscribed, encapsulated
- Some tumors may be locally infiltrative

Size

- Tumors may vary in size from 3 cm to > 10 cm in diameter

MICROSCOPIC

Histologic Features

- Nests and cords of medium-sized, round to oval epithelioid cells
- Inconspicuous nucleoli
- Cytoplasmic vacuolization
- Rare mitotic activity with no more than 1 x 10 HPF
- Basophilic myxoid matrix resembling hyaline cartilage
- Collagenized stroma
- Necrosis is rare, and, when present, it is focal
- Focal ossification may be seen

ANCILLARY TESTS

Electron Microscopy

- Presence of Weibel-Palade bodies

DIFFERENTIAL DIAGNOSIS

Chordoma

- May show chondromyxoid matrix
- Negative for vascular markers (CD34, CD31, factor VIII)

Myxoid Chondrosarcoma

- May have presence of well-formed cartilage, while EH does not
- Positive for S100 protein, while EH is not
- Negative for vascular markers

Seminoma

- Unusual for seminomas to show chondromyxoid matrix
- Positive for keratin and PLAP, while that would be unusual for EH
- Seminomas are negative for vascular markers

Thymic Carcinoma

- Shows more cellular atypia and mitotic activity than EH
- Generally negative for vascular markers and positive for epithelial markers, in contrast to EH

Angiosarcoma

- Angiosarcoma will show more solid areas
- Angiosarcoma will show more nuclear atypia and increased mitotic activity
- Necrosis and hemorrhage are more common in angiosarcoma

DIAGNOSTIC CHECKLIST

Clinically Relevant Pathologic Features

- Mitotic rate
  - In EH, mitotic rate is low or absent (1 x 10 HPF)
- Cytoplasmic features
  - In some cases, it is possible to identify presence of red cells being engulfed by epithelioid cells

Pathologic Interpretation Pearls

- Cords of epithelioid cells
- Low mitotic rate of no more than 1-2 x 10 HPF
- Chondromyxoid stroma
- Absent necrosis, and, if present, it would be focal

Immunohistochemistry

Antibody	Reactivity	Staining Pattern	Comment
CD31	Positive	Cytoplasmic	Strong reaction in epithelioid cells
FVIIIRAg	Positive	Cytoplasmic	Strong reaction in epithelioid cells
Vimentin	Positive	Cytoplasmic	
CD34	Positive	Cytoplasmic	Only in few cases, and it is focal
ERG	Positive	Cytoplasmic	
TFE3	Positive	Cytoplasmic	In some cases
D2-40	Positive	Cytoplasmic	In some cases
FLI-1	Positive	Cytoplasmic	In some cases
EMA	Negative		Focally positive in some cases
CK8/18/CAM5.2	Negative		It may be focally positive in some cases
Actin-HHF-35	Negative		
Desmin	Negative		
CK5/6	Negative		
CD99	Negative		
GATA3	Negative		
S100	Negative		

Molecular Features

FISH/RT-PCR	Result
WW domain-transcription regulator 1 WWTR1 Calmodulin-binding transcription activator 1: CAMTA1 translocations	Positive in some cases
Yes-associated protein 1 (YAP1)-transcription factor E3 (*TFE3*) gene fusion	Positive in some cases
1p36.3 and 3q25	Translocations

Ultrastructural Features

Electron Microscopy	Result
Weibel-Palade bodies	Present

Histochemical Features

Stain	Result
PAS	Negative
PAS-D	Negative
Mucicarmine	Negative

SELECTED REFERENCES

1. Kumar A et al: Mediastinal epithelioid hemangioendothelioma. Am J Respir Crit Care Med. 193(4):e7-8, 2016
2. Lee SJ et al: Epithelioid hemangioendotheliomas with TFE3 gene translocations are compossible with CAMTA1 gene rearrangements. Oncotarget. 16;7(7):7480-8, 2016
3. Doyle LA et al: Nuclear expression of CAMTA1 distinguishes epithelioid hemangioendothelioma from histologic mimics. Am J Surg Pathol. 40(1):94-102, 2015
4. Patel NR et al: Molecular characterization of epithelioid haemangioendotheliomas identifies novel WWTR1-CAMTA1 fusion variants. Histopathology. 67(5):699-708, 2015
5. Puls F et al: YAP1-TFE3 epithelioid hemangioendothelioma: a case without vasoformation and a new transcript variant. Virchows Arch. 466(4):473-8, 2015
6. Shibuya R et al: CAMTA1 is a useful immunohistochemical marker for diagnosing epithelioid hemangioendothelioma. Histopathology. ;67(6):827-35, 2015
7. Tanas MR et al: Mechanism of action of a WWTR1(TAZ)-CAMTA1 fusion oncoprotein. Oncogene. 18;35(7):929-38, 2015
8. Sardaro A et al: Epithelioid hemangioendothelioma: an overview and update on a rare vascular tumor. Oncol Rev. 8(2):259, 2014
9. Suster S et al: Epithelioid hemangioendothelioma of the anterior mediastinum. Clinicopathologic, immunohistochemical, and ultrastructural analysis of 12 cases. Am J Surg Pathol. 18(9):871-81, 1994
10. Weidner N: Atypical tumor of the mediastinum: epithelioid hemangioendothelioma containing metaplastic bone and osteoclastlike giant cells. Ultrastruct Pathol. 15(4-5):481-8, 1991
11. Lamovec J et al: Epithelioid hemangioendothelioma of the anterior mediastinum with osteoclast-like giant cells. Light microscopic, immunohistochemical, and electron microscopic study. Am J Clin Pathol. 93(6):813-7, 1990

Solid Growth Pattern

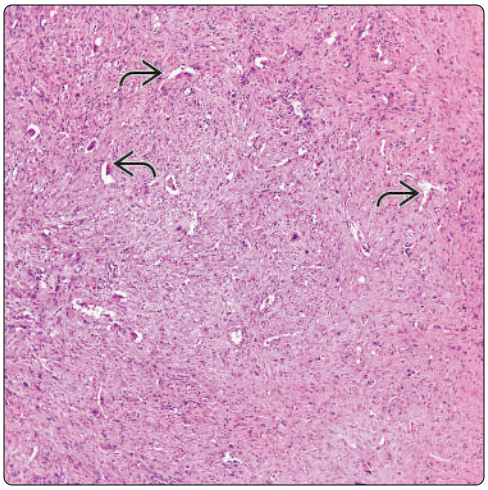

Spindle Cell Component

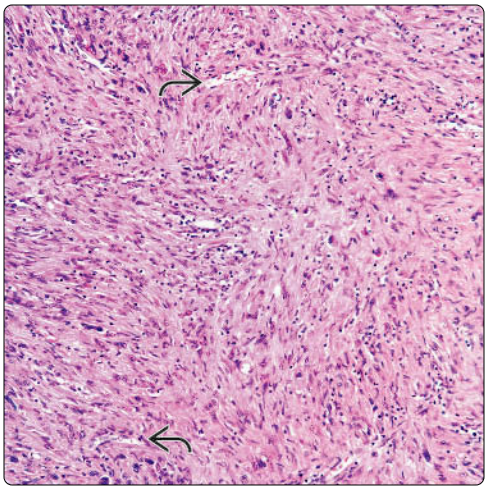

(Left) *Mediastinal EH shows a solid neoplastic cellular proliferation in which there are several vascular channels that are readily visible, which should raise the suspicion of a vascular neoplasm.* **(Right)** *Mediastinal EH shows a prominent spindle cell component with some vascular spaces. These particular features may be seen in other neoplasms not necessarily of vascular origin.*

Chondromyxoid Changes

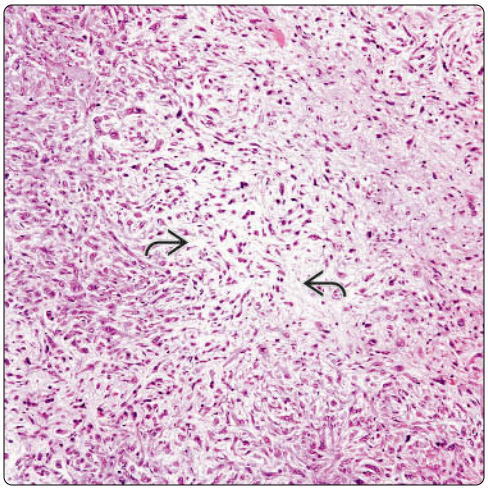

Multinucleated Giant Cells

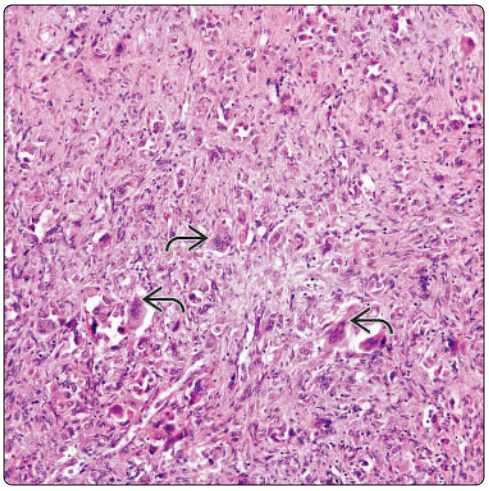

(Left) *Mediastinal EH is shown in which the neoplastic cellular proliferation is embedded in a myxoid or chondromyxoid background. These features, although common in other organs, are not so common in the mediastinum.* **(Right)** *Mediastinal EH shows the presence of numerous large multinucleated giant cells. This feature is rather common in mediastinal EH.*

Vascular Proliferation

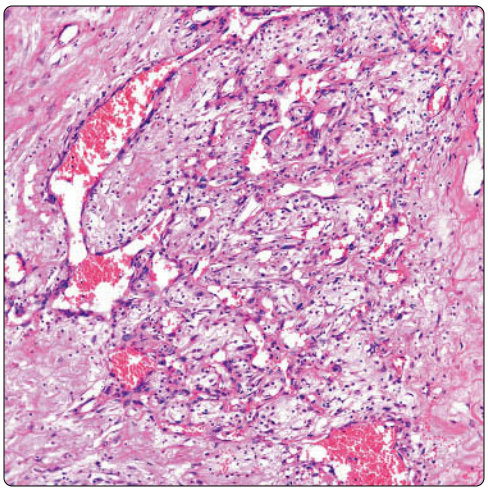

Vascular Channels

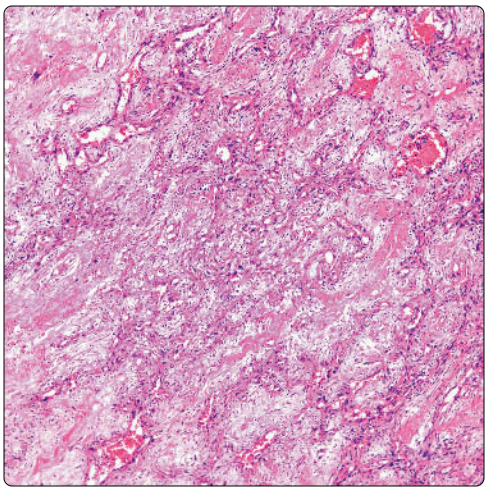

(Left) *Mediastinal EH shows more conventional features of a vascular tumor, namely the presence of anastomosing vascular channels. However, similar features may be seen in angiosarcomas.* **(Right)** *Mediastinal EH is shown in which the interanastomosing vascular channels are dissecting fibroconnective tissue. This histological pattern may be seen in other mediastinal tumors.*

Inflammatory Reaction

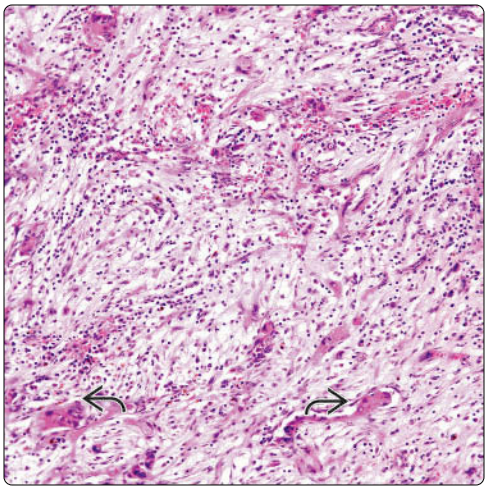

Pseudopapillary Pattern

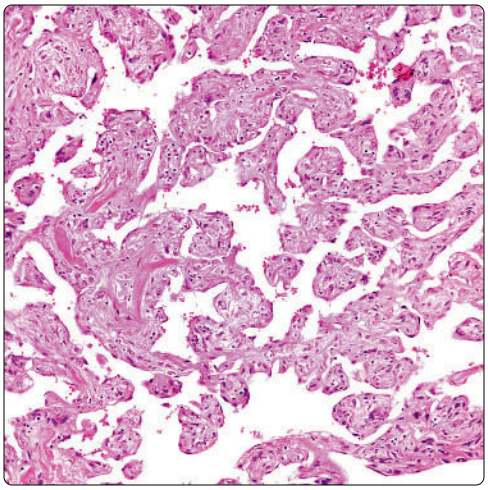

(Left) *Mediastinal EH is shown with prominent loose fibroconnective tissue and inflammatory reaction. Note the presence of vascular channels lined by atypical endothelium.* **(Right)** *Mediastinal EH displays a pseudopapillary growth pattern. These structures in fact represent vascular channels. This feature may be seen in low-grade angiosarcomas.*

Extensive Hyalinization

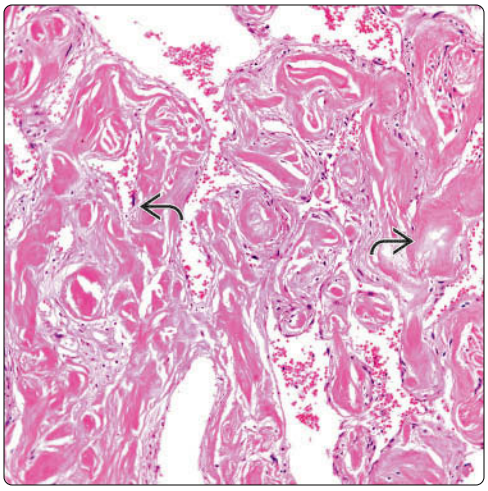

Vascular Slits

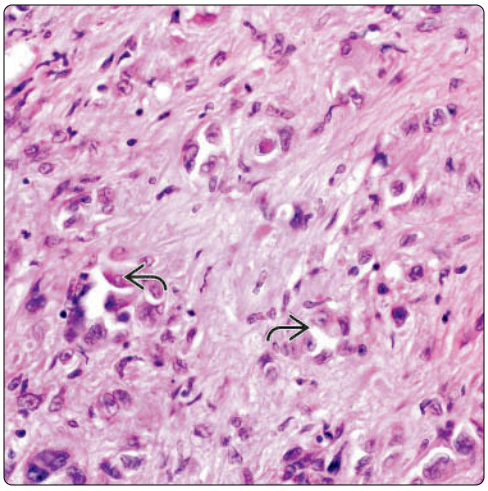

(Left) *Mediastinal EH is shown with extensive hyalinization. This feature, although unusual, may be seen in mediastinal EH and may make the diagnosis difficult.* **(Right)** *High-power magnification shows a mediastinal EH in which there are numerous vascular structures lined by neoplastic endothelial cells. However, mitotic activity is absent.*

Endothelial Cell Proliferation

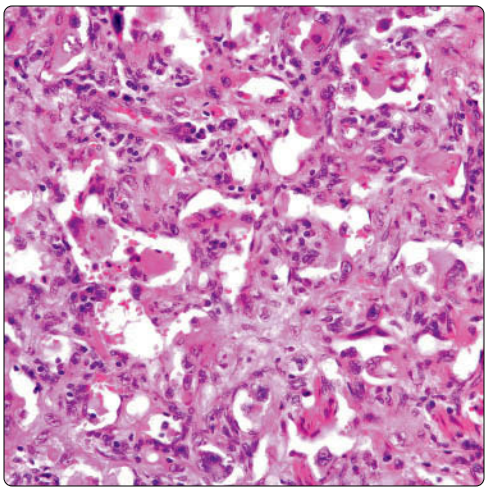

Immunostain for CD31

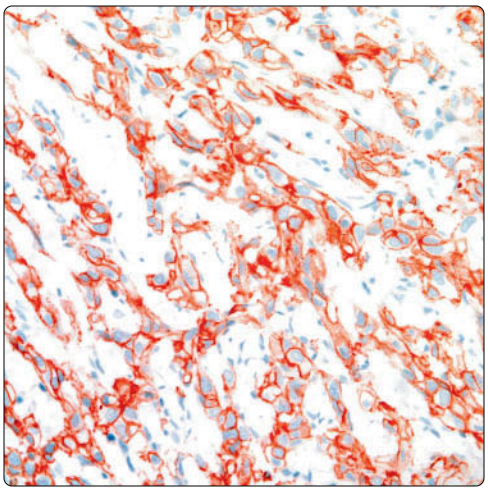

(Left) *Mediastinal EH shows a complex arrangement of vascular structures with an atypical endothelial cellular proliferation. Note the absence of necrosis and hemorrhage or marked nuclear pleomorphism.* **(Right)** *Mediastinal EH shows a strong positive reaction in neoplastic cells for a vascular marker (CD31). These immunohistochemical markers are of help in corroborating the vascular nature of the neoplasm.*

Areas of Necrosis

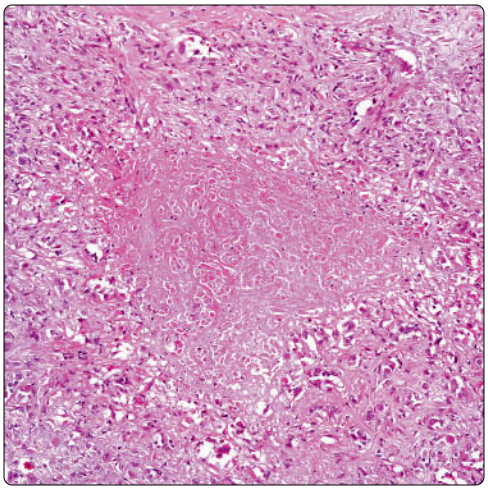

Solid Spindle Cell Pattern

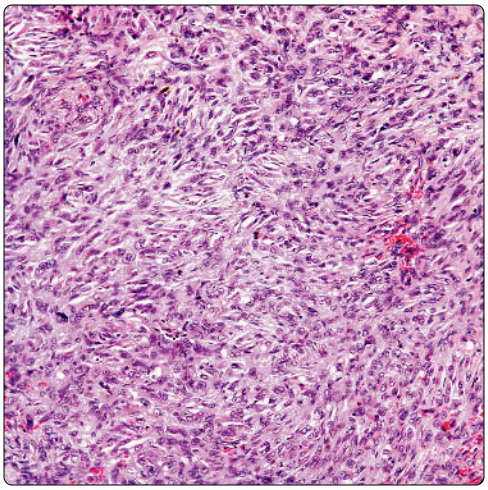

(Left) *Mediastinal EH shows areas of necrosis mimicking comedo-like necrosis. Note the vascular neoplasm around the necrotic area. The presence of necrosis is not a common feature, and usually it is not extensive.* **(Right)** *Mediastinal EH shows prominent solid spindle cell proliferation similar to that seen in other sarcomas. This feature may be focal or occupy extensive areas of the tumor.*

Metaplastic Bone

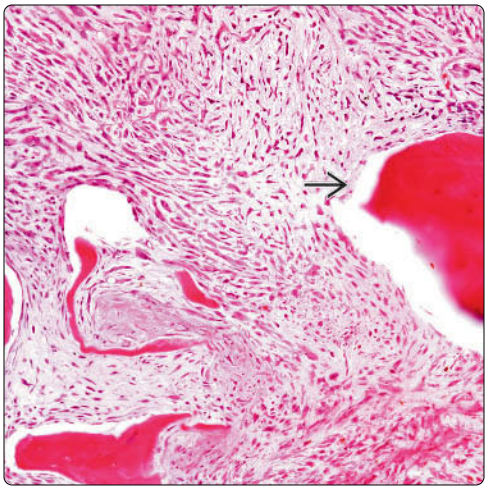

Solid and Hyalin Changes

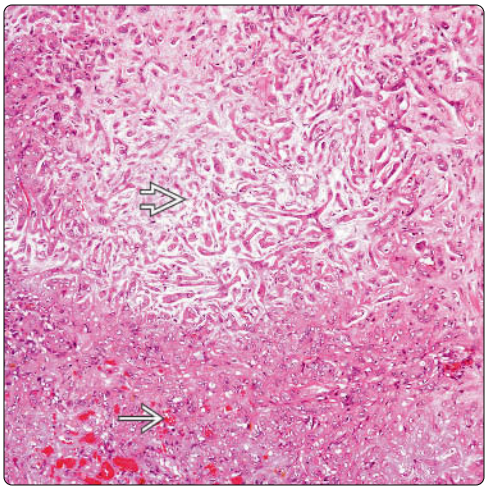

(Left) *A common finding in mediastinal EH is the presence of metaplastic bone formations ⇨. However, note the presence of myxohyaline changes and the proliferation of tumor cells in cords.* **(Right)** *Mediastinal EH shows transitional areas of solid component ➡ and areas of myxohyaline changes ➡. This feature is common in these tumors.*

Papillary-Like Areas

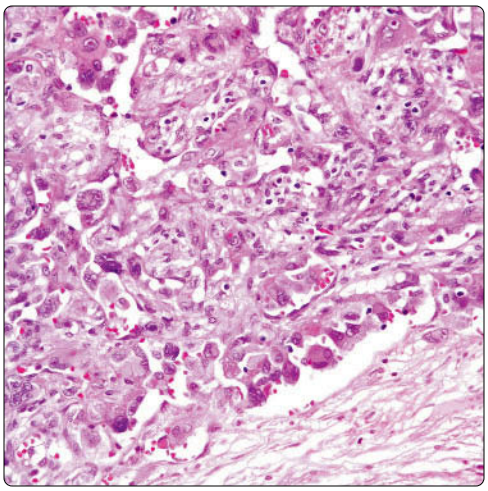

Extravasated Red Cells

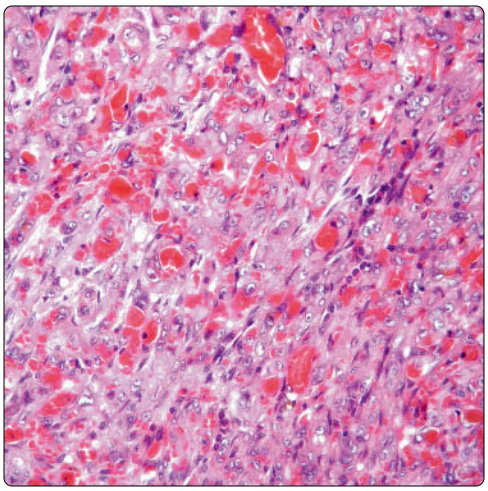

(Left) *Mediastinal EH shows areas in which the tumor cells show a papillary-like pattern. Note the presence of intranuclear inclusion in some of the tumor cells.* **(Right)** *Mediastinal EH shows a solid growth pattern with marked presence of red cells. Also note that some of the red cells have been engulfed by the neoplastic cells.*

Mesenchymal Chondrosarcoma

KEY FACTS

TERMINOLOGY

- Biphasic malignant neoplasm composed of primitive neoplastic small round blue cell population admixed with islands of mature cartilage

CLINICAL ISSUES

- Extremely rare tumor
- Predilection for young adults (15-35 years)
- Slight female predilection
- Incidental finding on routine chest x-rays
- Aggressive malignancy
- ~ 50% 5-year survival rate
- May also occur in young children
- Metastasizes in high percentage of cases

MACROSCOPIC

- Well-circumscribed, multilobated soft tissue mass
- Cut surface shows fleshy, gray-white homogeneous tissue with calcified and cartilaginous foci
- May contain small foci of hemorrhage and necrosis
- Average size: 5-8 cm

MICROSCOPIC

- Sheets of primitive round, oval, or spindle cells
- Foci of cartilaginous differentiation showing abrupt transitions with surrounding round/spindle cells
- Cartilaginous foci may often show areas of calcification and ossification
- Primitive spindle cell component may adopt prominent hemangiopericytic growth pattern
- Undifferentiated tumor cell component
  - Usually negative for S100 protein
  - Shows CD99 membranous positivity
- Primitive small round/spindle cell component shows positivity for SOX9
- Recurrent *HEY1-NCOA2* gene fusion can be demonstrated by FISH and is currently regarded as diagnostic of mesenchymal chondrosarcoma

Gross Appearance

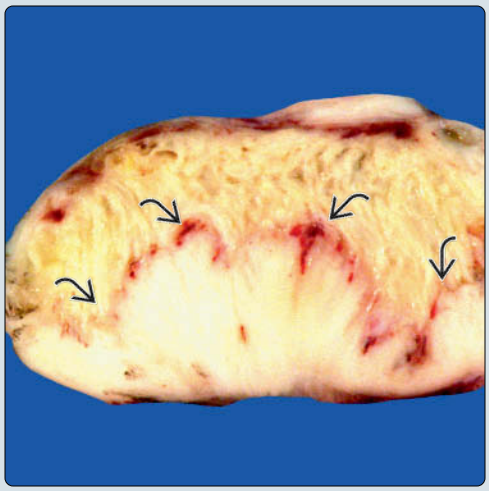

Islands of Immature Cartilage

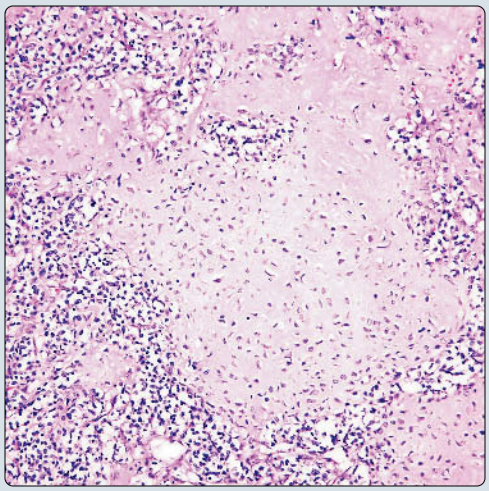

(Left) *Gross photo of mesenchymal chondrosarcoma (MC) of the mediastinum shows a well-circumscribed mass with a fleshy cut surface and areas of immature cartilage formation.* **(Right)** *Classic histologic appearance of MC shows an island of immature cartilage (center) and abrupt transitions with surrounding small round blue cells.*

Hemangiopericytic Vascular Pattern

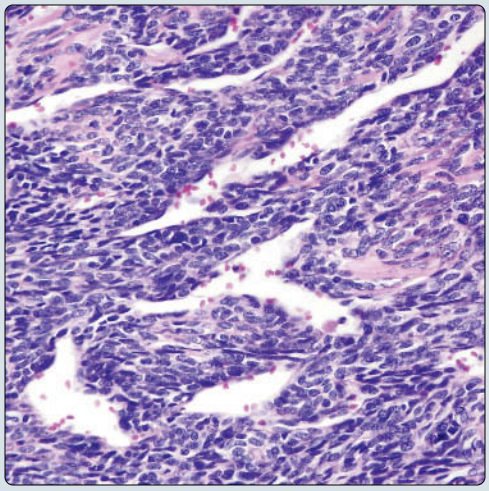

Primitive Spindle Cells

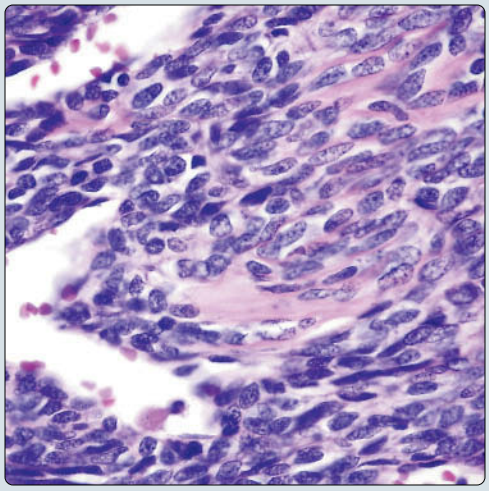

(Left) *MC is one of the tumors characterized by a hemangiopericytic vascular pattern, with small branching vessels with open lumina surrounded by a dense spindle cell population.* **(Right)** *Higher magnification of mediastinal MC shows a primitive population of small spindle cells with dense chromatin pattern and absent or inconspicuous nucleoli.*

TERMINOLOGY

Abbreviations

- Mesenchymal chondrosarcoma (MC)

Definitions

- Biphasic malignant neoplasm composed of primitive neoplastic small round blue cell population admixed with islands of mature cartilage

ETIOLOGY/PATHOGENESIS

Pathogenesis

- Originally believed to represent variant of chondrosarcoma due to presence of mature cartilage
- Currently regarded as closely related to primitive neuroectodermal tumors (PNET) or Ewing sarcoma

CLINICAL ISSUES

Epidemiology

- Age
  - Predilection for young adults (15-35 years)

Presentation

- Back pain, dyspnea; often asymptomatic
- Incidental finding on routine chest x-rays

Prognosis

- Aggressive malignancy with ~ 50% 5-year survival rate
- Metastasizes in high percentage of cases, most commonly to lung

IMAGING

General Features

- Well-defined soft tissue mass in paraspinal location
- May protrude into or involve posterior mediastinum
- Irregular radiopaque stippling due to focal calcifications

MACROSCOPIC

General Features

- Well-circumscribed, multilobated soft tissue mass
- Cut surface shows fleshy, gray-white homogeneous tissue with calcified and cartilaginous foci
- May contain small foci of hemorrhage and necrosis

MICROSCOPIC

Histologic Features

- Sheets of primitive round, oval, or spindle cells
- Foci of cartilaginous differentiation showing abrupt transitions with surrounding round/spindle cells
  - Cartilaginous foci are composed of mature hyaline cartilage and may show foci of calcification
- Primitive spindle cell component may adopt prominent hemangiopericytic growth pattern

Cytologic Features

- Primitive cells may have round or ovoid, elongated, and hyperchromatic nuclei with scant cytoplasm
- Primitive tumor cells usually display low mitotic activity

ANCILLARY TESTS

Immunohistochemistry

- Cartilaginous areas show strong positive staining for S100 protein
- Undifferentiated tumor cell component
  - Usually negative for S100 protein
  - Shows CD99 membranous positivity
- Primitive small round/spindle cell component shows positivity for SOX9

Genetic Testing

- Some cases show t(11;22)(q24;q12) translocation typical of Ewing sarcoma/primitive neuroectodermal tumor family
- Recurrent *HEY1-NCOA2* gene fusion can be demonstrated by FISH and is currently regarded as diagnostic of mesenchymal chondrosarcoma

Electron Microscopy

- Undifferentiated cells have scant cytoplasmic organelles
- Tumor cells show closely apposed cell membranes and desmosome-type junctions

DIFFERENTIAL DIAGNOSIS

Ewing Sarcoma/Primitive Neuroectodermal Tumor

- Lack foci of cartilaginous differentiation or ossification
- Generally more aggressive lesions, with invasion and destruction of adjacent structures

Hemangiopericytoma/Solitary Fibrous Tumor

- Usually lacks foci of cartilaginous differentiation
- Strong CD34 and Bcl-2 positivity

Synovial Sarcoma

- Positive for epithelial markers (cytokeratin, EMA)
- (X;18) translocation

DIAGNOSTIC CHECKLIST

Clinically Relevant Pathologic Features

- Paraspinal or posterior mediastinal mass in young patients
- Well-circumscribed lesion with stippled calcifications
- Slow, indolent growth

Pathologic Interpretation Pearls

- Biphasic appearance with primitive small round blue cell component admixed with cartilaginous foci
- Sheets of dense small round blue cells or hyperchromatic spindle cells with abrupt transitions with cartilaginous foci
- Prominent hemangiopericytomatous growth pattern

SELECTED REFERENCES

1. Wang L et al: Identification of a novel, recurrent HEY1-NCOA2 fusion in mesenchymal chondrosarcoma based on a genome-wide screen of exon-level expression data. Genes Chromosomes Cancer. 51(2):127-39, 2012
2. Fanburg-Smith JC et al: Reappraisal of mesenchymal chondrosarcoma: novel morphologic observations of the hyaline cartilage and endochondral ossification and beta-catenin, Sox9, and osteocalcin immunostaining of 22 cases. Hum Pathol. 41(5):653-62, 2010
3. Wehrli BM et al: Sox9, a master regulator of chondrogenesis, distinguishes mesenchymal chondrosarcoma from other small blue round cell tumors. Hum Pathol. 34(3):263-9, 2003
4. Suster S et al: Malignant cartilaginous tumors of the mediastinum: clinicopathological study of six cases presenting as extraskeletal soft tissue masses. Hum Pathol. 28(5):588-94, 1997

Small Round Blue Cell Tumor

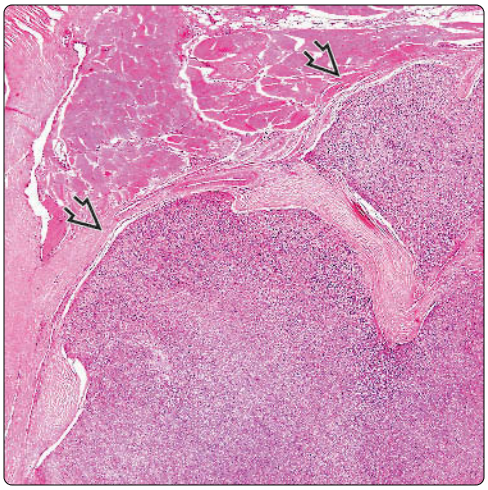

Small Cells Admixed With Cartilage

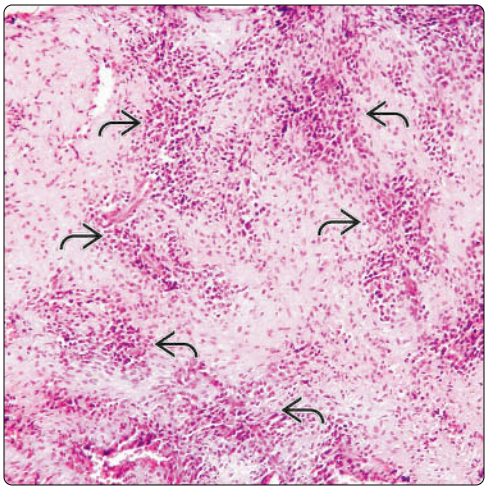

(Left) *Scanning magnification of MC of the mediastinum shows sharp circumscription from surrounding skeletal muscle and displays a marked lobular configuration, resembling a small round blue cell tumor.* **(Right)** *Central portion of MC of the mediastinum shows irregular, pale-staining areas with an immature chondroid matrix circumscribing more cellular areas that are composed of primitive, small round blue cells.*

Primitive Small Round Blue Cells

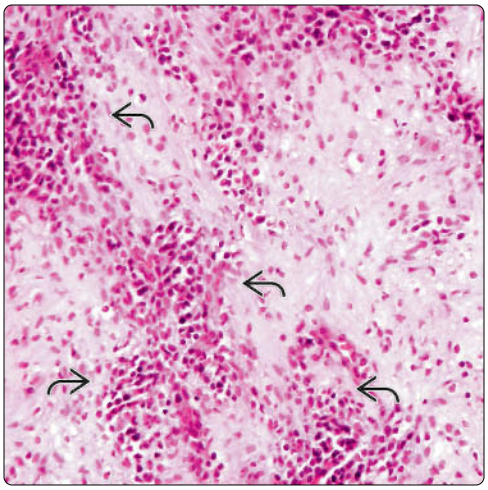

Small Round Cells and Cartilaginous Matrix

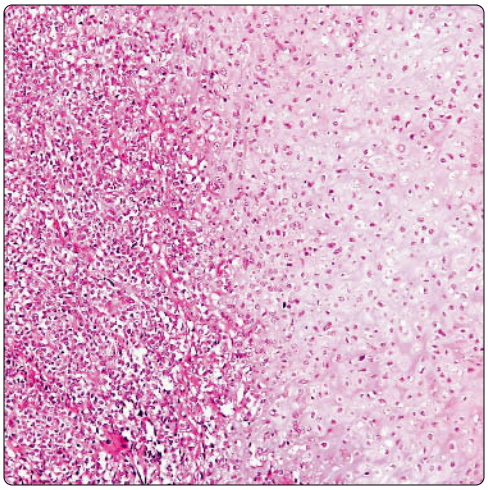

(Left) *High magnification from the central portion of MC of the mediastinum shows a monotonous and primitive small round blue cell population circumscribing pale, paucicellular areas composed of immature chondroid matrix.* **(Right)** *High magnification of MC of the mediastinum shows an abrupt transition between a primitive small round blue cell population (left) and well-formed cartilaginous elements (right).*

Small Round Blue Cells: High Power

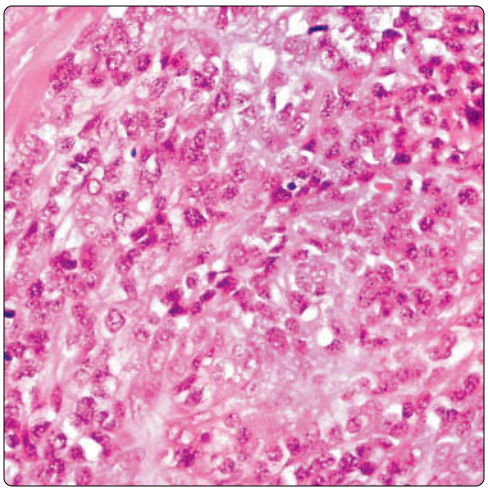

Cartilaginous Elements

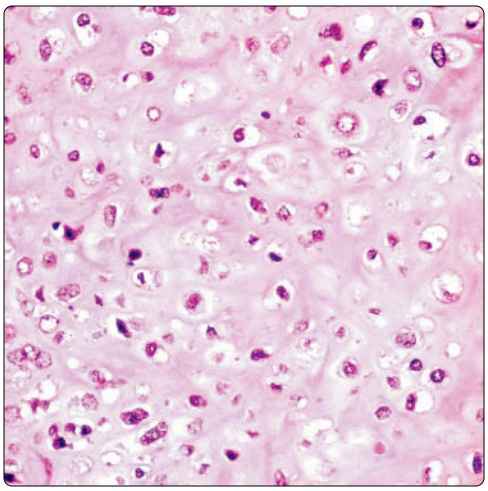

(Left) *High magnification of MC of the mediastinum shows monotonous, primitive small round blue cell population. The cells are indistinguishable from other round blue cell tumors such as Ewing sarcoma/PNET, embryonal rhabdomyosarcoma, neuroblastoma, and lymphoblastic lymphoma.* **(Right)** *High magnification of MC of the mediastinum shows details of cartilaginous elements within the tumor, with mature chondrocytes suspended within empty lacunae.*

Transitions With Immature Cartilage

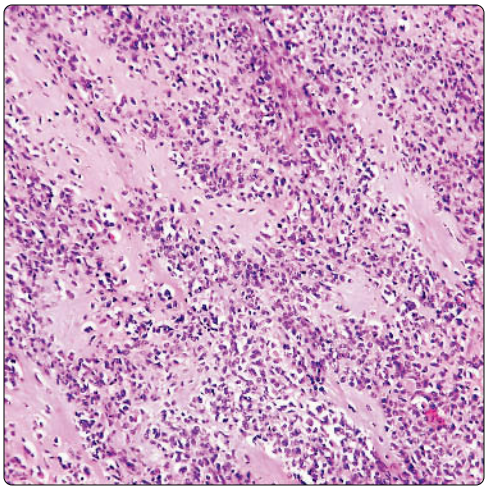

Immature Cartilage: Higher Magnification

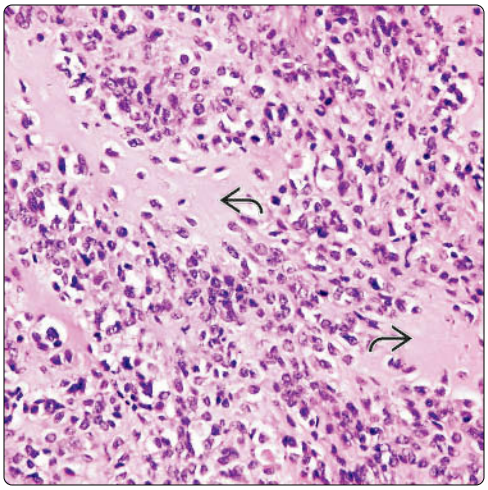

(Left) *Scanning magnification of MC of the mediastinum shows characteristic biphasic appearance with paucicellular areas displaying immature matrix deposition flanked by more cellular areas composed of a small round blue cell population.* **(Right)** *High magnification of an MC of the mediastinum shows a primitive population of small round blue cells circumscribing paucicellular areas with immature hyaline matrix.*

Hemangiopericytic Vascular Pattern

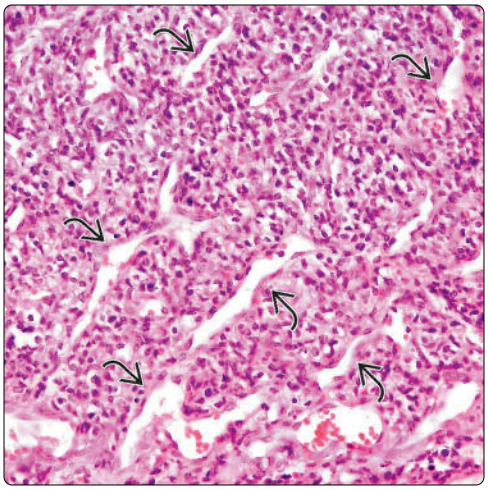

Atypical Spindle Cell Population

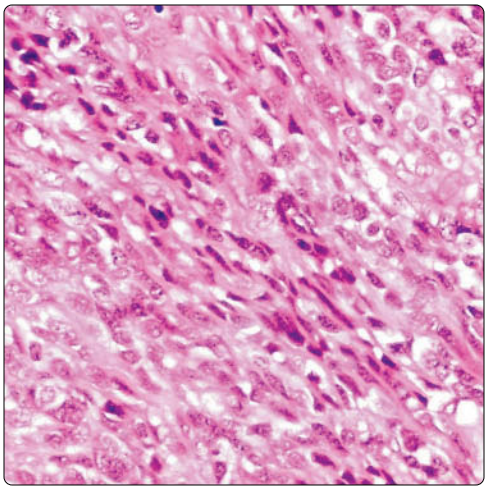

(Left) *MC of the mediastinum shows branching small vessels surrounded by small round blue cell population. This appearance can resemble other soft tissue tumors with a prominent hemangiopericytic growth pattern.* **(Right)** *High magnification of MC of the mediastinum shows an atypical spindle cell population (center) admixed with primitive small round blue cells.*

Metaplastic Bone Formation

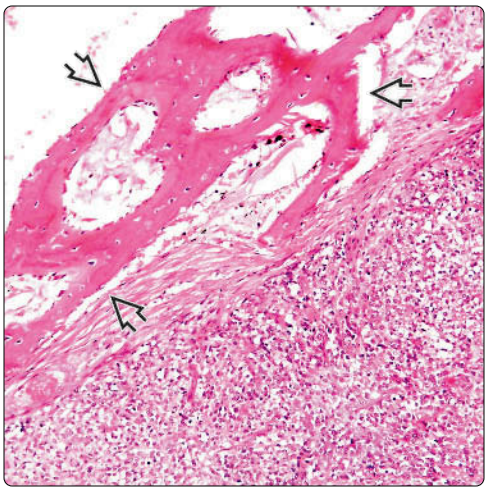

Small Round Blue Cells

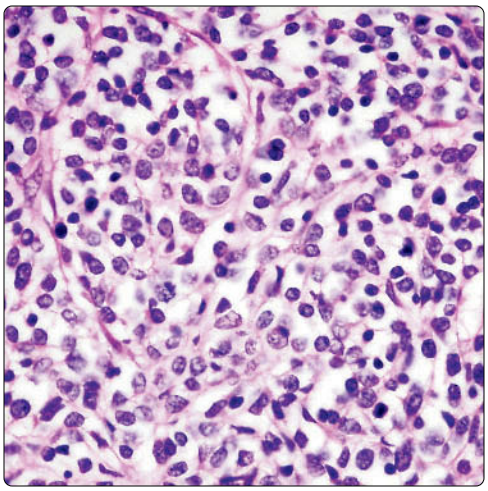

(Left) *MC of the mediastinum shows prominent metaplastic bone formation.* **(Right)** *MC of the mediastinum shows a monotonous population of primitive small round blue cells. The tumor can be mistaken for a number of other small round blue cell tumors in this location, including extraskeletal Ewing sarcoma/PNET, desmoplastic small round blue cell tumor, neuroblastoma, and others.*

Chordoma

KEY FACTS

CLINICAL ISSUES

- Chest pain
- Shortness of breath
- Backache
- Usually slow-growing neoplasms that may often be asymptomatic
- May behave aggressively with frequent recurrences & metastasis and occasional patient deaths from tumor
- Posterior mediastinal location
- Small, well-circumscribed cases amenable to complete excision; may show long-term, disease-free survival

IMAGING

- CT scans show well-circumscribed posterior mediastinal mass without evidence of vertebral involvement or destruction

MICROSCOPIC

- Cords and strands of large tumor cells with abundant cytoplasm
- Abundant myxoid stroma
- Classic chordoma cells are large & epithelioid with abundant cytoplasm & large hyperchromatic nuclei
- Cells may be small and stellate with hyperchromatic nuclei and scant cytoplasm
- Cells can display abundant "bubbly" (vacuolated) cytoplasm (so-called physaliphorous cells)
- "Dedifferentiated" areas show atypical spindle cells with hyperchromatic nuclei and frequent mitoses

ANCILLARY TESTS

- Cells are strongly positive for low molecular weight cytokeratin, EMA, S100
- Cells are negative for CEA, SMA, desmin, and other differentiation markers

Gross Appearance

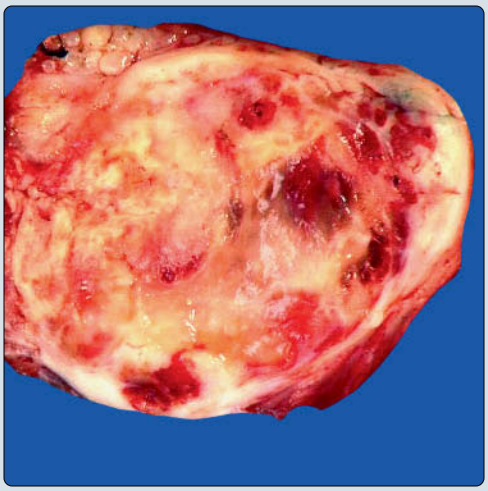

Lobulated Growth

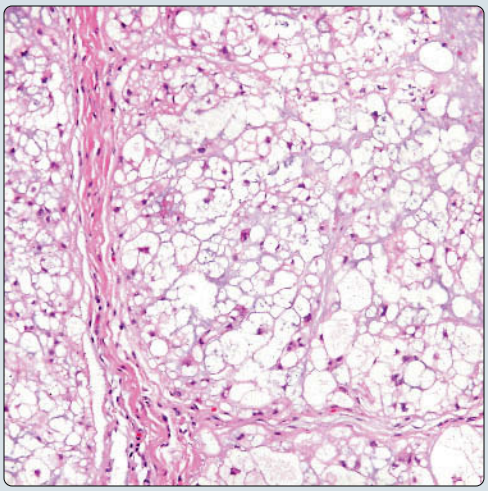

(Left) *Gross photo of posterior mediastinal chordoma shows a well-circumscribed and encapsulated tumor mass with soft, gelatinous areas alternating with more solid, whitish areas.* **(Right)** *Histologic examination on scanning magnification in mediastinal chordoma shows a lobulated mass separated by thin, fibrous septa and containing sheets of large, vacuolated tumor cells.*

Vacuolated Cells

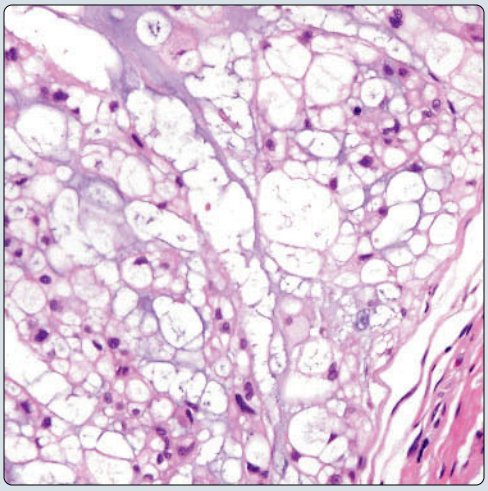

Physaliphorous Cells

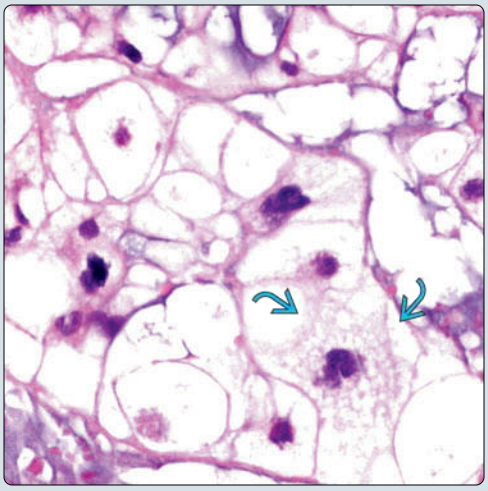

(Left) *Higher magnification in mediastinal chordoma shows sheets of cells with small, hyperchromatic nuclei surrounded by abundant clear cytoplasm. Many of the cells shows multivacuolation of their cytoplasm (so-called physaliphorous cells).* **(Right)** *Higher magnification of chordoma shows large cells with small, dark nuclei and abundant vacuolated and clear cytoplasm. The fine vacuolation of the cytoplasm is reminiscent of soap bubbles.*

TERMINOLOGY

Definitions

- Malignant neoplasm presumed to be derived from remnants of embryonic notochord

CLINICAL ISSUES

Site

- Posterior mediastinum; paravertebral location involving soft tissue without involvement or destruction of bone

Presentation

- Chest pain, shortness of breath, pleural effusion, backache; may be incidental finding
- Usually slow-growing neoplasms, often asymptomatic

Prognosis

- May behave aggressively with frequent recurrences and metastasis; occasional patient deaths due to tumor
- Small, well-circumscribed cases amenable to complete excision; may show long-term, disease-free survival

IMAGING

General Features

- CT shows well-circumscribed posterior mediastinal mass without evidence of vertebral involvement or destruction

MACROSCOPIC

General Features

- Well-circumscribed, encapsulated mass
- Soft, gelatinous, often hemorrhagic cut surface

MICROSCOPIC

Histologic Features

- Striking lobular growth pattern
- Cords & strands of large tumor cells with abundant cytoplasm
- Abundant myxoid stroma
- "Chondroid" chordoma is characterized by areas containing immature chondroid matrix
- "Dedifferentiated" chordoma is characterized by areas containing atypical spindle cell population

Cytologic Features

- Classic chordoma cells are large and epithelioid with abundant cytoplasm and large hyperchromatic nuclei
- Cells may be small and stellate with hyperchromatic nuclei and scant cytoplasm
- Cells can display abundant "bubbly" (vacuolated) cytoplasm (so-called physaliphorous cells)
- "Dedifferentiated" areas show atypical spindle cells with hyperchromatic nuclei and frequent mitoses

ANCILLARY TESTS

Histochemistry

- PAS stain with diastase will demonstrate intracellular glycogen in tumor cells
- Alcian blue at pH 2.5 demonstrates abundant hyaluronic acid in stroma

Immunohistochemistry

- Cells are strongly positive for low molecular weight cytokeratin, EMA, S100
- Cells are negative for CEA, SMA, desmin, and other differentiation markers

Electron Microscopy

- Closely apposed cell membranes joined by frequent desmosomes with small tonofilaments
- May form microglandular lumina lined by short, immature microvilli
- Scant organelles, including ribosomes, Golgi apparati, glycogen granules, and abundant intermediate filaments

DIFFERENTIAL DIAGNOSIS

Metastatic Mucinous Carcinoma

- Usually forms glandular structures rather than displaying cord-like growth pattern
- Cytoplasm is uniformly distended by mucin rather than showing multivacuolation
- Intracytoplasmic mucin can be demonstrated with PAS and mucicarmine stains
- Tumor cells (+) for cytokeratin and EMA but (-) for S100

Extraskeletal Myxoid Chondrosarcoma

- Characteristic cord-like, single file pattern of growth of small tumor cells embedded in abundant myxoid stroma
- Absence of large, multivacuolated physaliphorous cells
- Tumor cells are negative for cytokeratin and EMA

Well-Differentiated Chondrosarcoma

- May be mistaken with chondroid chordoma
- Absence of large, vacuolated chordoma cells embedded in myxoid stroma
- Tumor cells are negative for keratins and EMA

Epithelioid Hemangioendothelioma

- Sheets, cords, and small islands of large epithelioid cells with prominent cytoplasmic vacuoles
- Vacuoles often contain single red blood cells indicating abortive vascular lumen formation
- Tumor cells (+) for FVIIIRAg and CD31 vascular markers

High-Grade Spindle Cell Sarcoma

- May have similar morphologic appearance as "dedifferentiated" chordoma
- Will not show transitions with areas of more conventional chordomatous elements
- Extensive sampling to rule out chordomatous elements

SELECTED REFERENCES

1. Matsubayashi J et al: A case of paravertebral mediastinal chordoma without bone destruction. Skeletal Radiol. 41(12):1641-4, 2012
2. Soudack M et al: Imaging features of posterior mediastinal chordoma in a child. Pediatr Radiol. 37(5):492-7, 2007
3. Horn KD et al: Cytokeratin immunophenotyping of an unusual cervical vertebral chordoma with extensive chondroid foci and perilaryngeal recurrence: a case report with review of the literature. Am J Otolaryngol. 22(6):428-34, 2001
4. Suster S et al: Chordomas of the mediastinum: clinicopathologic, immunohistochemical, and ultrastructural study of six cases presenting as posterior mediastinal masses. Hum Pathol. 26(12):1354-62, 1995

Lobular Architecture

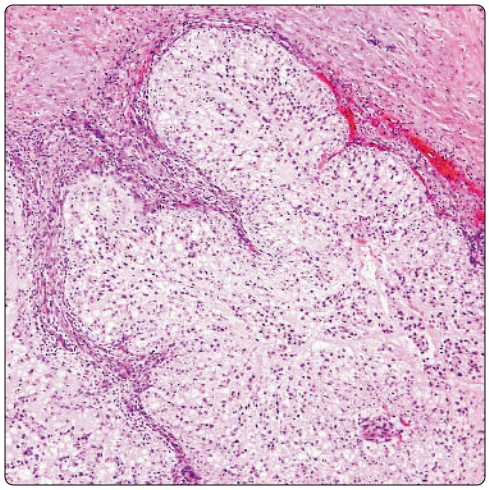

Sheets of Large Clear Cells

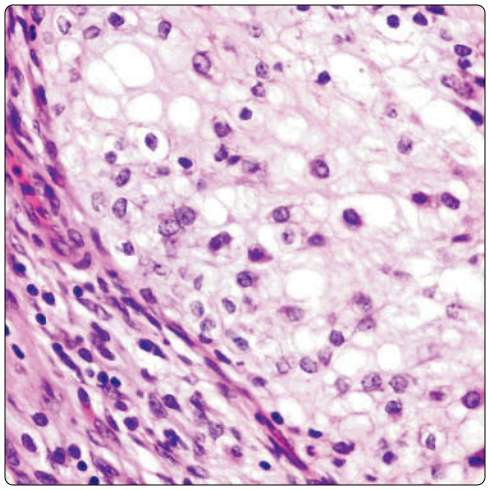

(Left) *Typical scanning magnification of mediastinal chordoma with striking lobular appearance shows irregular lobules of tumor cells with solid architecture surrounded by thick bands of fibrous stroma.* **(Right)** *Higher magnification of mediastinal chordoma shows sheets of large clear cells with small, hyperchromatic nuclei surrounded by abundant clear cytoplasm. The tumors with this pattern can resemble a metastasis from a clear cell carcinoma, such as metastatic renal cell carcinoma.*

Lobule of Tumor Cells

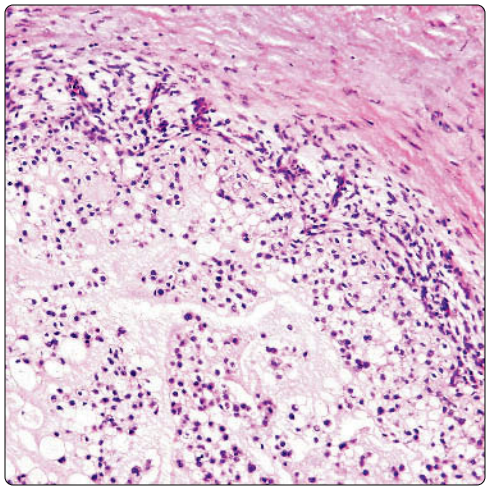

Monotonous Tumor Cell Population

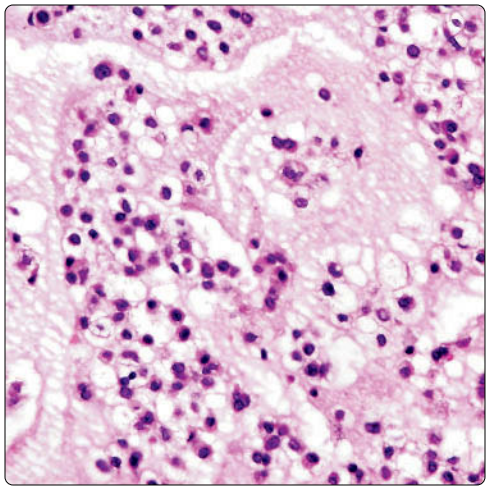

(Left) *Scanning magnification of mediastinal chordoma shows a lobular configuration separated by thick connective tissue bands and a monotonous tumor cell population with abundant background myxoid stroma.* **(Right)** *Higher magnification of mediastinal chordoma shows monotonous tumor cell population composed of round cells with hyperchromatic nuclei surrounded by clear cytoplasmic halos. The tumor cells are embedded in abundant, lightly staining myxoid stroma.*

Cords of Tumor Cells in Myxoid Stroma

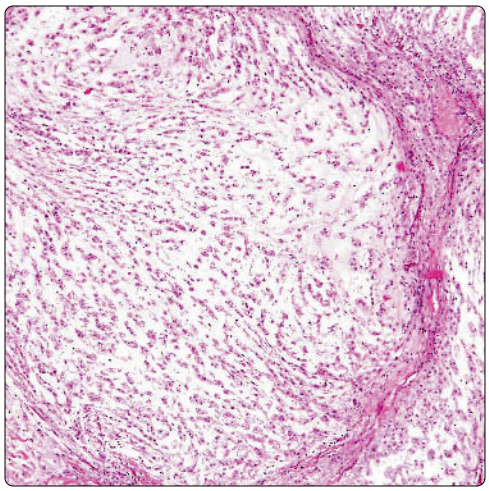

Thin Strands of Tumor Cells

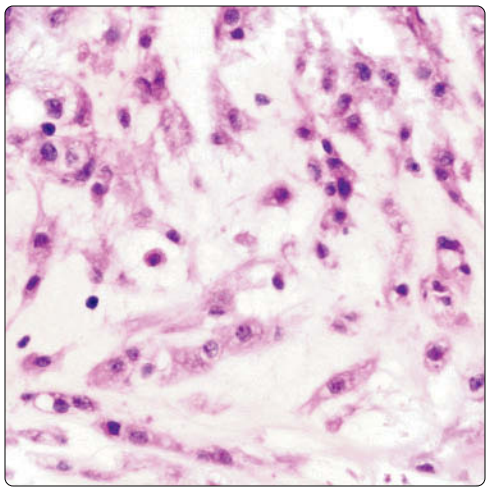

(Left) *Scanning magnification of mediastinal chordoma shows a lobular configuration separated by thin, fibrous bands and containing a uniform small cell population set against a lightly staining myxoid stroma.* **(Right)** *High magnification of mediastinal chordoma shows a monotonous population of small tumor cells with small, round nuclei and a scant rim of eosinophilic cytoplasm suspended in a myxoid stroma. Notice the cording and single-file configuration of the tumor cells.*

Large Epithelioid Cells

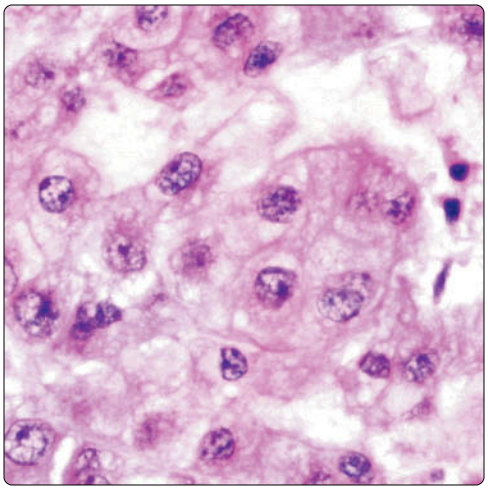

Vacuolated Clear Cells

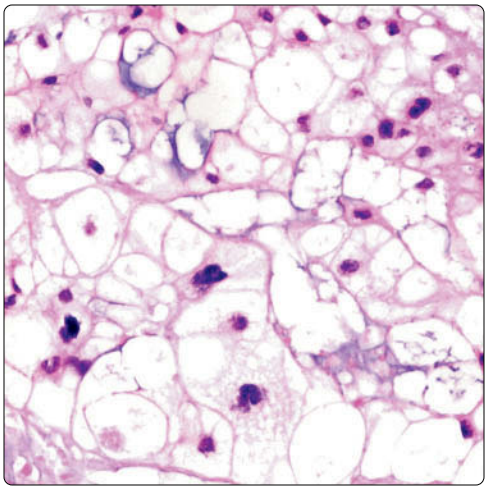

(Left) *Clusters of large, epithelioid cells are seen in the mediastinal chordoma. The cells have large, vesicular nuclei with small nucleoli and are surrounded by abundant, finely granular eosinophilic cytoplasm.* **(Right)** *High magnification of mediastinal chordoma shows cells with small, darkly staining nuclei without significant nuclear atypia, surrounded by abundant clear, amphophilic cytoplasm that is bordered by sharply delineated cell membranes.*

Cytoplasmic Vacuoles

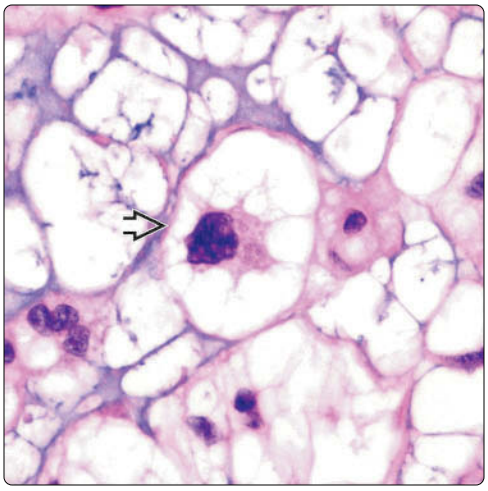

Physaliphorous Cells

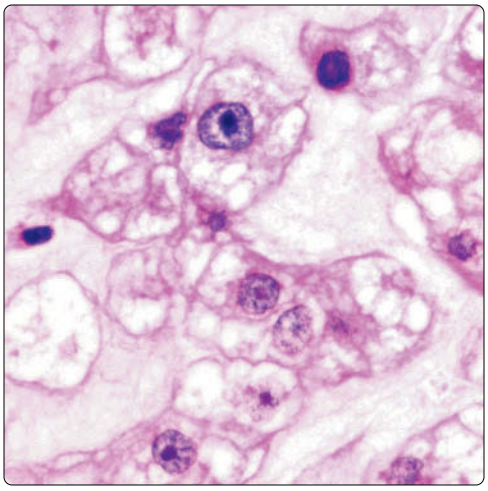

(Left) *Physaliphorous cell in mediastinal chordoma ⇨ shows a centrally placed nucleus with scalloping of the nuclear envelope and multiple clear intracytoplasmic vacuoles.* **(Right)** *Physaliphorous cells in mediastinal chordoma show "bubbly" appearance of the cytoplasm due to multiple cytoplasmic vacuoles. Identification of these cells can be extremely helpful for diagnosis as this represents one of the distinctive morphologic features commonly observed in these tumors.*

Small Tumor Cells

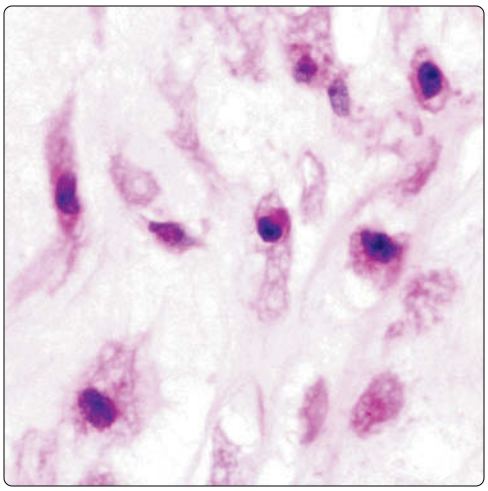

Cord-Like Pattern

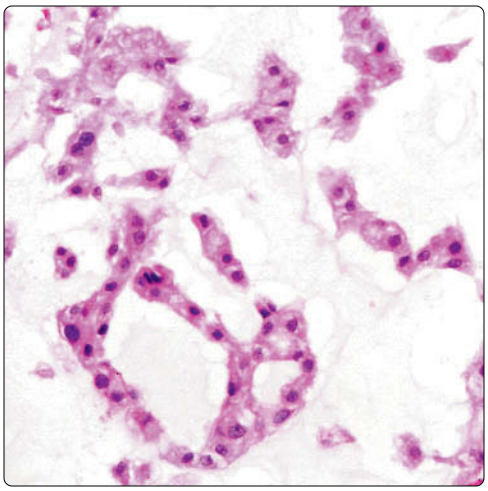

(Left) *Small, stellate cells are seen in this example of mediastinal chordoma. The cells are characterized by small, round nuclei with a dense chromatin pattern and scant nuclear detail, surrounded by a scant rim of eosinophilic cytoplasm.* **(Right)** *Small, dark cells are seen in this example of mediastinal chordoma. Notice the striking "cording" pattern of the tumor cells, which form short cords or trabeculae of tumor cells disposed in single file and embedded in a myxoid stroma.*

Cartilage-Like Appearance

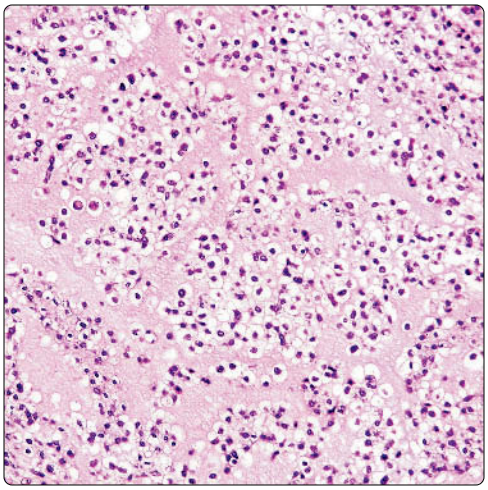

Cells With Clear Cytoplasm

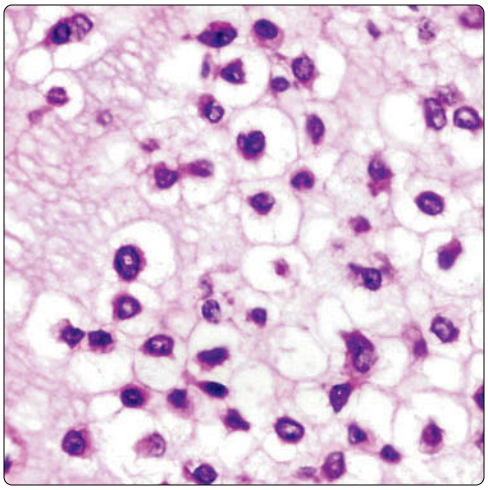

(Left) *Scanning magnification of mediastinal chordoma with a striking cartilaginous appearance shows sheets of tumor cells that appear to be suspended in cartilaginous lacunae closely simulating mature cartilage.* **(Right)** *High magnification of mediastinal chordoma with cartilaginous appearance shows sheets of large tumor cells with round, regular nuclei surrounded by clear cytoplasmic halos. The tumor cell nuclei appear to be suspended in cartilaginous lacunae.*

Cord-Like Arrangement

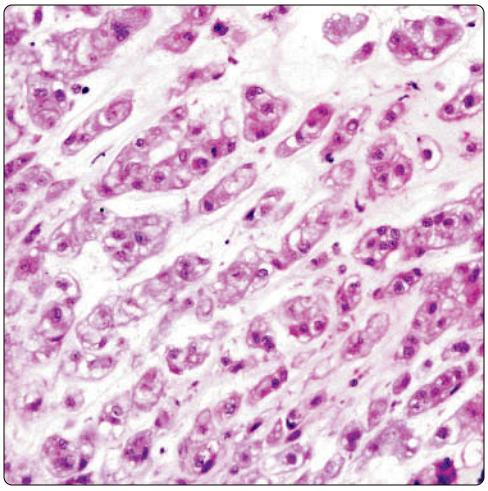

Cord-Like Arrangement

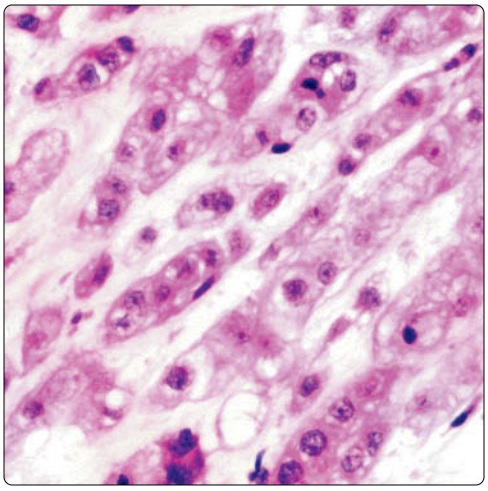

(Left) *Striking cord-like architecture is seen in this example of mediastinal chordoma. This cord-like arrangement of tumor cells is quite distinctive and highly characteristic of these tumors.* **(Right)** *High magnification of mediastinal chordoma with cord-like architecture shows cohesive epithelioid cells with single-file arrangement. The epithelioid cells contain small, round nuclei with small, inconspicuous nucleoli and are surrounded by an ample rim of lightly eosinophilic cytoplasm.*

Dedifferentiation in Chordoma

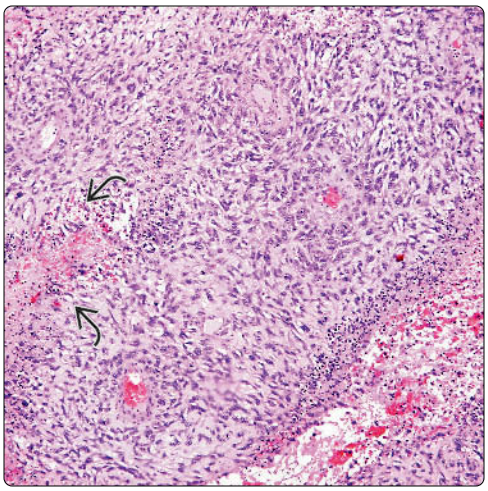

Atypical Spindle Cells

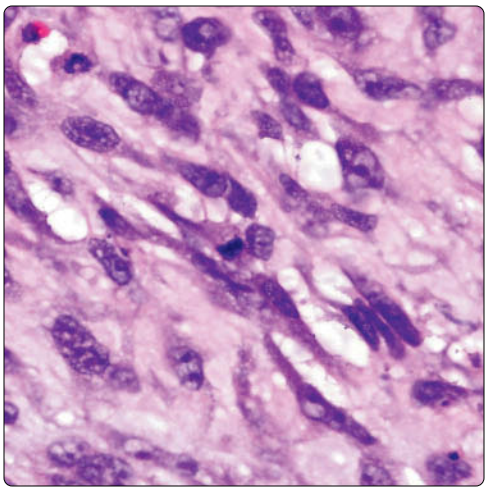

(Left) *"Dedifferentiated" chordoma of the mediastinum shows sheets of atypical tumor cells with perivascular distribution and small foci of necrosis. The morphologic appearance in this area is that of a high-grade spindle cell sarcoma.* **(Right)** *High magnification of "dedifferentiated" chordoma of the mediastinum shows highly atypical and hyperchromatic spindle cells with dark-staining nuclei with prominent nucleoli and scattered mitoses embedded in a myxoid stroma.*

CAM5.2 Immunostaining

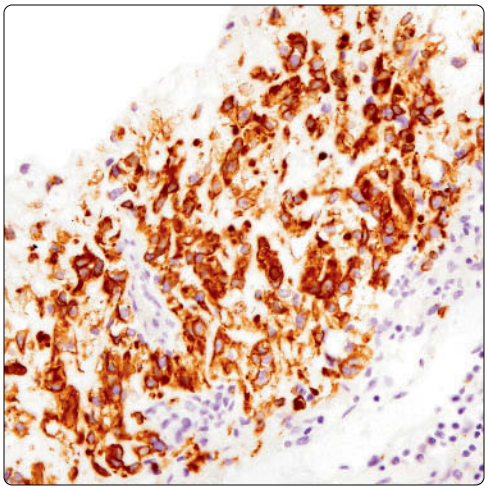

EMA Immunostaining

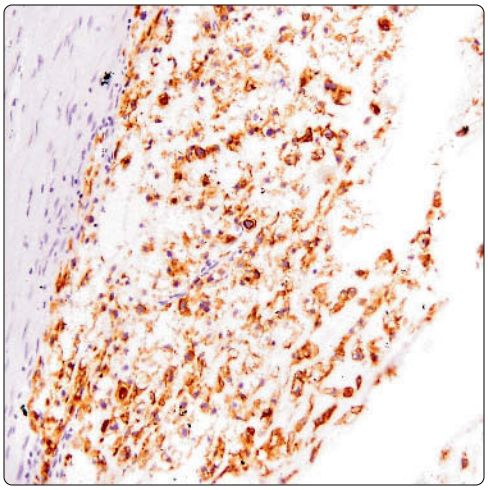

(Left) *Immunohistochemical staining for low molecular weight cytokeratin (CAM5.2) in mediastinal chordoma shows strong cytoplasmic positivity of the tumor cells for this antibody.* **(Right)** *Immunohistochemical staining for EMA in mediastinal chordoma shows strong membrane and cytoplasmic staining in the majority of the tumor cells for this antibody. Staining for EMA, however, can be patchy and focal in some of these tumors.*

S100 Protein Immunostaining

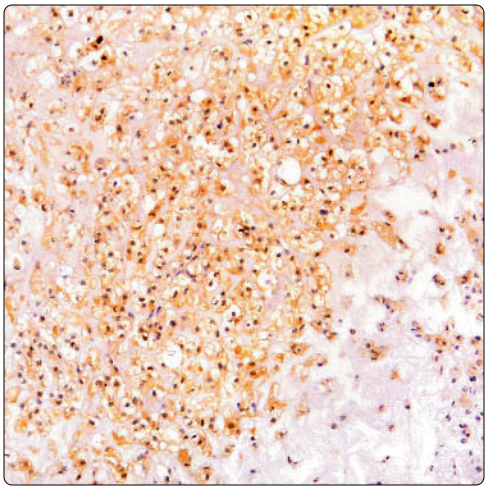

S100 Protein Immunostaining

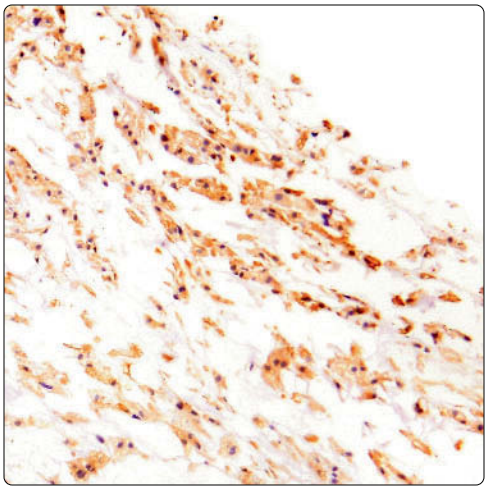

(Left) *Immunohistochemical staining for S100 protein in mediastinal chordoma shows nuclear and cytoplasmic positivity in the majority of the tumor cells in this example with a diffuse growth pattern.* **(Right)** *Immunohistochemical staining for S100 protein in mediastinal chordoma with striking cord-like pattern of growth shows nuclear and cytoplasmic positivity in the small tumor cells comprising the cords. The S100 positivity helps to separate these tumors from metastases of carcinoma.*

Vimentin in Dedifferentiated Chordoma

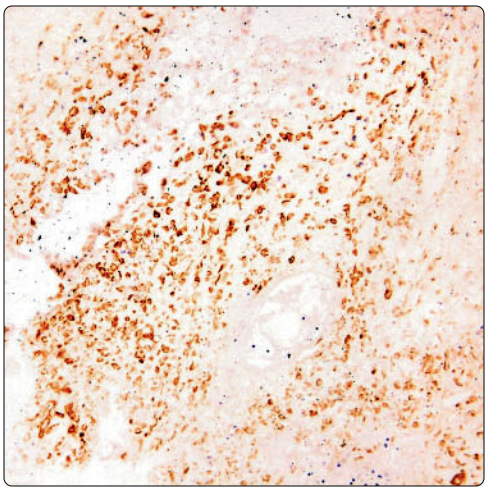

CK-PAN in Dedifferentiated Chordoma

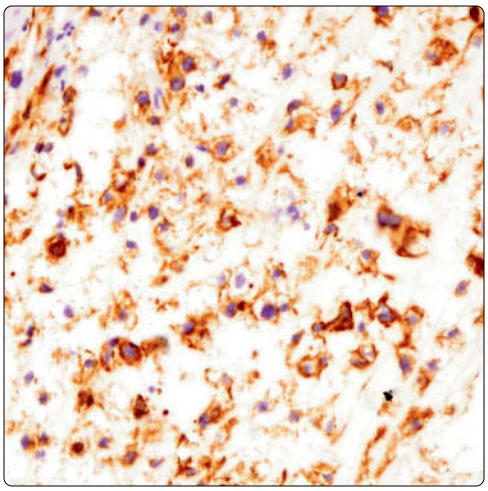

(Left) *Immunohistochemical staining of "dedifferentiated" component in mediastinal chordoma shows strong positivity of the tumor cells for vimentin.* **(Right)** *Immunohistochemical staining of tumor cells for pancytokeratin in "dedifferentiated" component of mediastinal chordoma shows cytoplasmic staining of the tumor cells. The "dedifferentiated" areas are usually negative for S100, and the diagnosis depends on identifying areas of more conventional chordoma.*

Alveolar Soft Part Sarcoma

KEY FACTS

CLINICAL ISSUES

- Incidence
  - Extremely rare tumor in mediastinal compartment
    - It could be in anterior or posterior mediastinum
  - Appears to be more common in young adults in 3rd decade of life
  - More common in soft tissues of extremities &/or head and neck
- Symptoms
  - Chest pain
  - Dyspnea
  - Cough
  - Asymptomatic

TOP DIFFERENTIAL DIAGNOSES

- Rhabdomyosarcoma
  - Positive for muscle markers, including MYOD1, myoglobin, and desmin
- Melanoma
  - Positive for S100, HMB-45, and MART-1
- Paraganglioma
  - Positive for neuroendocrine markers, such as chromogranin-A and synaptophysin
- Thymic carcinoma
  - Carcinomas usually will show positive staining for epithelial markers, such as keratins and EMA/MUC1

DIAGNOSTIC CHECKLIST

- Alveolar growth pattern
- Solid areas may be present
- Focal degenerative changes
- Large cells with ample cytoplasm
- Presence of intracytoplasmic crystals, especially using PAS histochemical stains
- Mitotic figures are rare

Alveolar Pattern

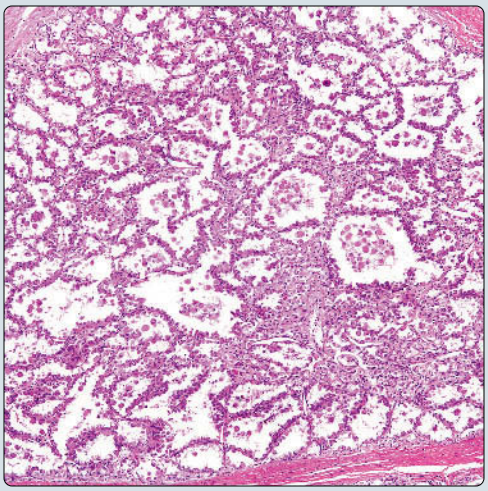

Focal Edema

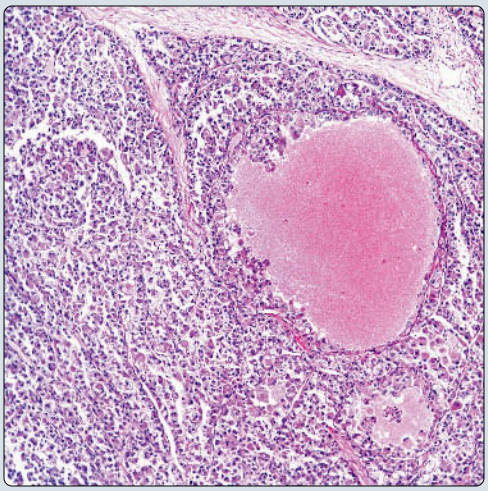

(Left) *Low-power view shows an alveolar soft part sarcoma with a neoplastic cellular proliferation arranged in an alveolar growth pattern, almost mimicking alveolated lung tissue.* **(Right)** *Alveolar soft part sarcoma shows focal areas of edema. The appearance is of a cystic change filled with acellular material. This feature is commonly seen in these tumors.*

Vascular Invasion

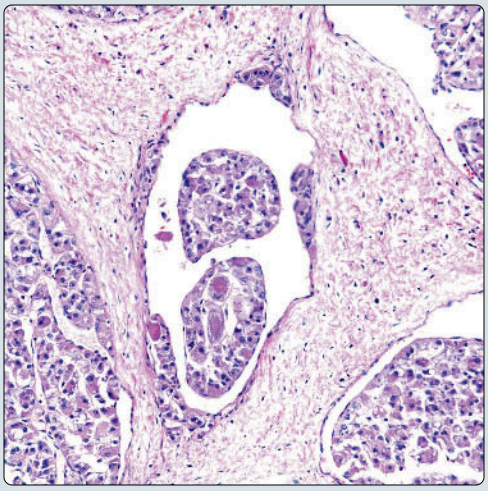

Crystals

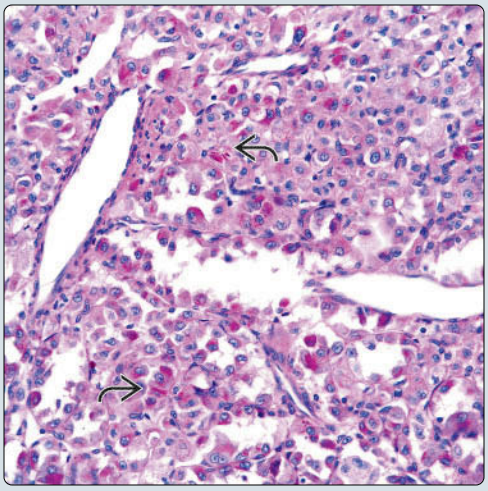

(Left) *Alveolar soft part sarcoma shows lymphatic permeation. Some authors have associated this feature with aggressiveness of the neoplasm.* **(Right)** *Periodic acid-Schiff shows the characteristic intracellular crystals ⇨ typical of alveolar soft part sarcoma. This feature is almost invariably present in all cases.*

TERMINOLOGY

Definitions

- Malignant neoplasm of soft tissues

ETIOLOGY/PATHOGENESIS

Etiology

- Although it has been speculated before as possible neurogenic or myogenic origin, its etiology remains unknown

CLINICAL ISSUES

Epidemiology

- Incidence
  - Extremely rare tumor in mediastinal compartment
- Age
  - Appears to be more common in young adults in 3rd decade of life
- Sex
  - No gender predilection

Site

- More common in soft tissues of extremities &/or head and neck
- Anterior or posterior mediastinum

Presentation

- Chest pain
- Dyspnea
- Cough
- Asymptomatic

Treatment

- Chemotherapy
- Radiation therapy
- Surgical resection

Prognosis

- Variable
- Tumor can metastasize
- Short- and long-term survivals have been reported

IMAGING

General Features

- Mediastinal mass of varying size
- Tumor may be in anterior or posterior mediastinum

MACROSCOPIC

General Features

- Fleshy, soft, and hemorrhagic tumor mass

Size

- Varies in size and can be > 10 cm in diameter

MICROSCOPIC

Histologic Features

- Alveolated growth pattern
- Solid areas may be present
- Degenerative (myxoid) changes be be present
- Large polygonal cells
- Well-defined cell borders
- Ample cytoplasm
- Eccentrically placed nuclei
- Mild to moderate nuclear atypia
- Mitoses are rare
- Intracytoplasmic crystals

DIFFERENTIAL DIAGNOSIS

Rhabdomyosarcoma

- Positive for muscle markers, including MYOD1, myoglobin, and desmin
- Rhabdomyosarcoma is predominantly composed of small blue cells
- PAS will show presence of intracytoplasmic glycogen

Melanoma

- Positive for S100, HMB-45, and MART-1
- Melanoma may show diversity of growth patterns

Paraganglioma

- Positive for neuroendocrine markers, such as chromogranin-A and synaptophysin
- Paraganglioma may sow alveolated growth pattern
- Paraganglioma usually shows areas of sclerosis and ectatic blood vessels
- Paraganglioma usually shows presence of cells with macronuclei

Thymic Carcinoma

- Carcinomas usually will show positive staining for epithelial markers, such as keratins and EMA/MUC1
- Rarely thymic carcinoma will show alveolated growth pattern
- Thymic carcinoma somewhat keeps organotypical features of thymus

DIAGNOSTIC CHECKLIST

Clinically Relevant Pathologic Features

- Cytoplasmic features

Pathologic Interpretation Pearls

- Alveolar growth pattern
- Large cells with ample cytoplasm
- Presence of intracytoplasmic crystals
- Mitotic figures are rare

SELECTED REFERENCES

1. Cheng J et al: [Alveolar soft part sarcoma: a clinicopathologic analysis of 48 cases.] Zhonghua Bing Li Xue Za Zhi. 45(1):16-20, 2016
2. Jaber OI et al: Alveolar Soft Part Sarcoma. Arch Pathol Lab Med. 139(11):1459-62, 2015
3. Pradhan D et al: Validation and utilization of a TFE3 break-apart FISH assay for Xp11.2 translocation renal cell carcinoma and alveolar soft part sarcoma. Diagn Pathol. 10:179, 2015
4. Zhao M et al: Alveolar soft part sarcoma of lung: report of a unique case with emphasis on diagnostic utility of molecular genetic analysis for TFE3 gene rearrangement and immunohistochemistry for TFE3 antigen expression. Diagn Pathol. 10:160, 2015
5. Chamberlain BK et al: Alveolar soft part sarcoma and granular cell tumor: an immunohistochemical comparison study. Hum Pathol. 45(5):1039-44, 2014
6. Setsu N et al: Histological analysis suggests an invasion-independent metastatic mechanism in alveolar soft part sarcoma. Hum Pathol. 45(1):137-42, 2014

Immunohistochemistry

Antibody	Reactivity	Staining Pattern	Comment
Myoglobin	Positive	Cytoplasmic	Focal in some cases
CK-PAN	Negative		Positive in tumors of epithelial origin
CK5/6	Negative		
Desmin	Negative		Mainly positive in tumors of muscle origin
MYOD1	Negative		
Caldesmon	Negative		
S100	Negative		Mainly positive in tumors of neural origin
Mart-1	Negative		
HMB-45	Negative		
HMB-50	Negative		
Actin-HHF-35	Negative		
CK5/6	Negative		
CK8/18/CAM5.2	Negative		
NFP	Negative		
Synaptophysin	Negative		Positive in tumors of neuroendocrine differentiation
Chromogranin-A	Negative		Positive in tumors of neuroendocrine differentiation
CD56	Negative		
CD34	Negative		
GATA3	Negative		
pax-8	Negative		
TFE3	Positive	Cytoplasmic	
Calretinin	Positive	Cytoplasmic	In some cases
CD10	Positive	Cytoplasmic	In few cases
Cathepsin-B	Positive	Cytoplasmic	In some cases
Inhibin	Negative		
SOX10	Negative		

Histochemical Features

Stain	Result
PAS	Highlight presence of cytoplasmic crystals
PAS-D	Negative
Mucicarmine	Negative

Molecular Features

FISH	Result
TFE3-ASPL	Positive
MDM2	Negative
PDGFR	Negative
BRAF	Negative

7. Daigeler A et al: Alveolar soft part sarcoma: clinicopathological findings in a series of 11 cases. World J Surg Oncol. 6:71, 2008
8. Folpe AL et al: Alveolar soft-part sarcoma: a review and update. J Clin Pathol. 59(11):1127-32, 2006
9. Anderson ME et al: Alveolar soft part sarcoma: a rare and enigmatic entity. Clin Orthop Relat Res. 438:144-8, 2005
10. Gupta S et al: Alveolar soft part sarcoma: a rare entity with unique cytomorphological features. Cytopathology. 14(1):40-1, 2003
11. van Ruth S et al: Alveolar soft part sarcoma. a report of 15 cases. Eur J Cancer. 38(10):1324-8, 2002
12. Flieder DB et al: Primary alveolar soft-part sarcoma of the mediastinum: a clinicopathological and immunohistochemical study of two cases. Histopathology. 31(5):469-73, 1997

Fibrous Septa

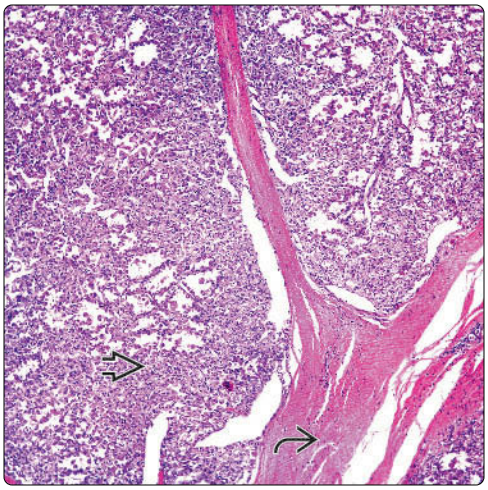

Prominent Vascular Spaces

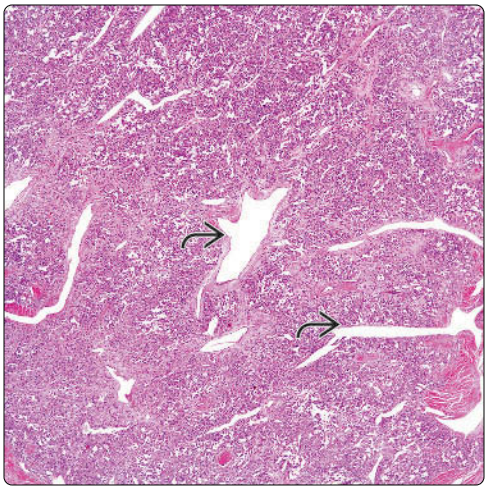

(Left) *Low-power view of alveolar soft part sarcoma shows slight lobulation. The tumor cells ⇨ are separated by thick bands of fibrocollagenous tissue ⇨.* **(Right)** *Alveolar soft part sarcoma displays prominent ectatic vessels ⇨. The presence of these ectatic vessels may mimic hemangiopericytoma; however, the cellular proliferation would be unusual for hemangiopericytoma.*

Focal Solid Areas

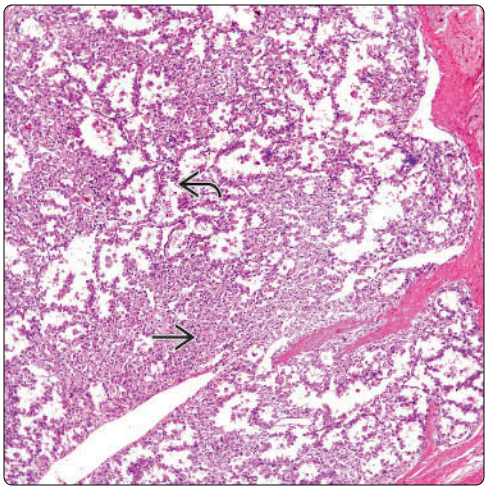

Large Eosinophilic Cells

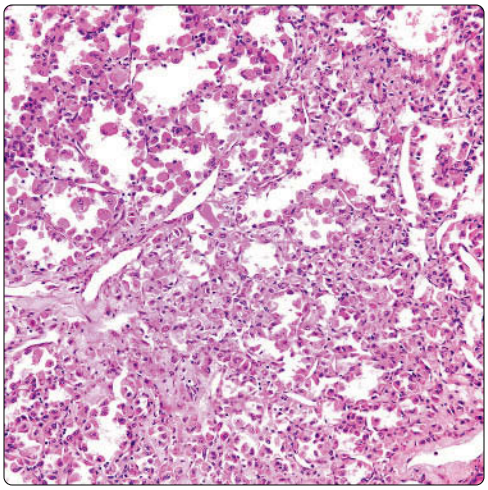

(Left) *Alveolar soft part sarcoma is shown with the characteristic alveolar growth pattern ⇨ and only focal solid areas ⇨.* **(Right)** *Closer view shows the cellular proliferation in alveolar soft part sarcoma. In addition to the alveolar growth pattern, the cells are round to oval with moderate amounts of eosinophilic cytoplasm, round nuclei, and inconspicuous nucleoli. Increased mitotic activity in this tumor is unusual.*

Focal Hemorrhage

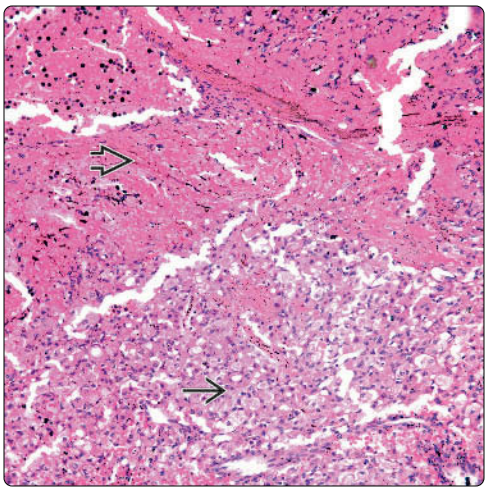

Ectatic Vessels

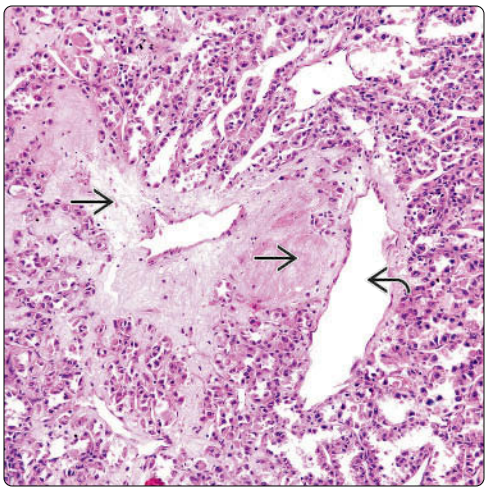

(Left) *Alveolar soft part sarcoma is shown with transition between areas of extensive hemorrhage ⇨ and more viable areas of tumor. Note that the tumor does not show the typical alveolated growth pattern ⇨.* **(Right)** *Another characteristic of alveolar soft part sarcoma is the presence of ectatic vessels ⇨ with perivascular hyalinization ⇨. This pattern may be confused with paragangliomas.*

Extensive Hyalinization

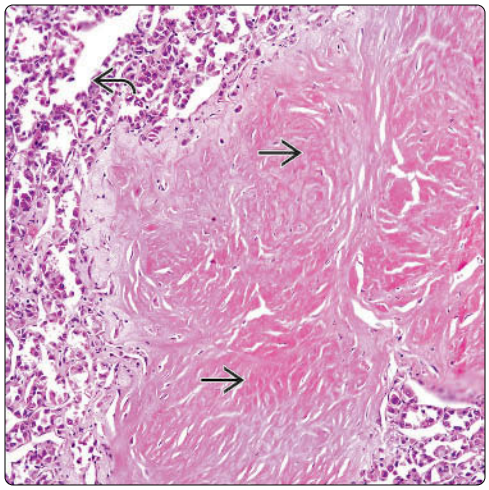

Solid and Minimally Alveolar Pattern

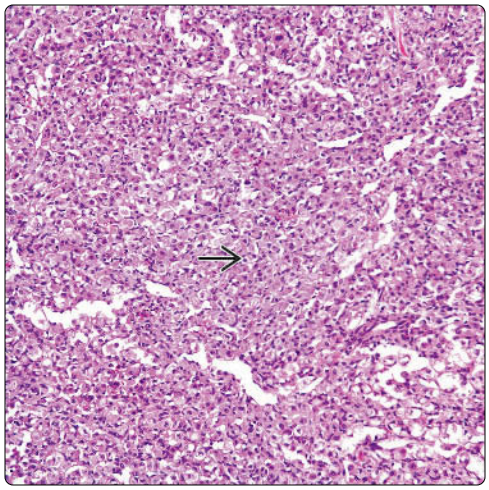

(Left) *Alveolar soft part sarcoma shows extensive stromal hyalinization with only focal areas of viable tumor. Although this feature may also be seen in neuroendocrine tumors, it may be seen focally in alveolar soft part sarcoma.* **(Right)** *Alveolar soft part sarcoma is shown with prominent solid growth pattern. In most of the cases, solid areas of tumor may be seen in association with the more typical alveolar growth pattern.*

Alveolar Pattern

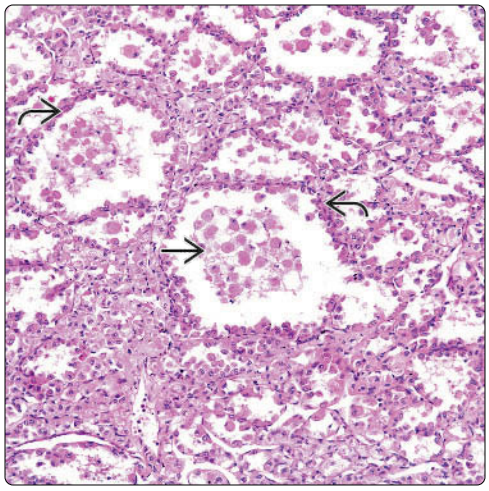

Rhabdoid-Like Cells

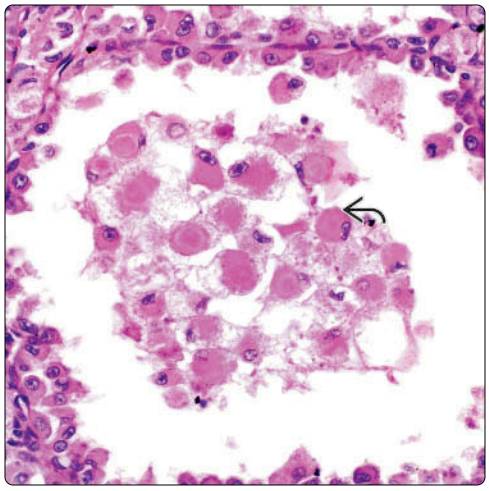

(Left) *Hematoxylin & eosin shows alveolar soft part sarcoma with prominent alveolar-like structures containing malignant cells.* **(Right)** *High-power magnification of neoplastic cells in alveolar soft part sarcoma is shown with a rhabdomyoblastic-like appearance. These cytological features can be easily confused with true rhabdomyoblasts and the tumor interpreted as rhabdomyosarcoma. This cellular proliferation is unusual in alveolar soft part sarcoma.*

Crystals

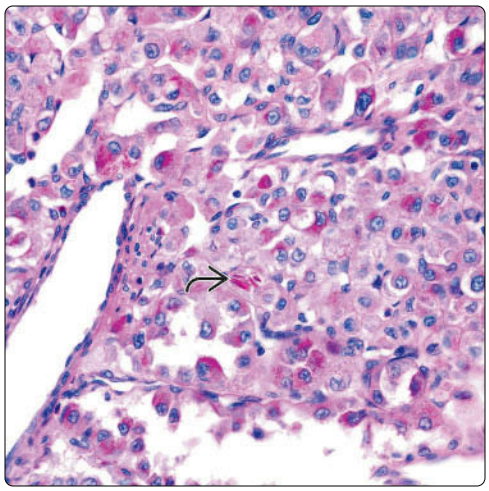

Metastatic Disease

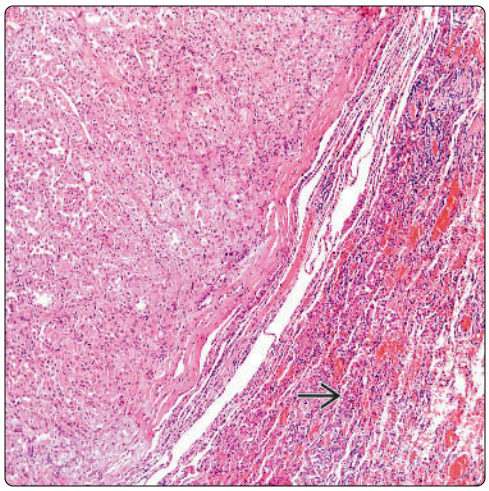

(Left) *Periodic acid-Schiff shows a high-power view of the cytoplasmic crystals that are commonly identified in cases of alveolar soft part sarcoma. The use of PAS histochemical stain facilitates its identification.* **(Right)** *Hematoxylin & eosin shows metastasis from an alveolar soft part sarcoma to the lung. Note the rim of alveolated lung parenchyma. The tumor shows similar features to the original tumor, and lung is a common site of metastasis.*

Degenerative Changes

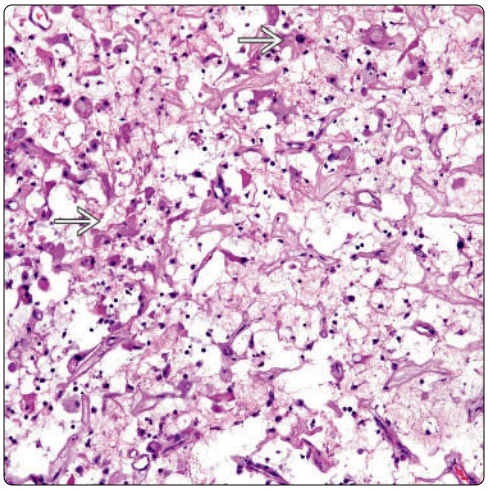

Transitional Areas

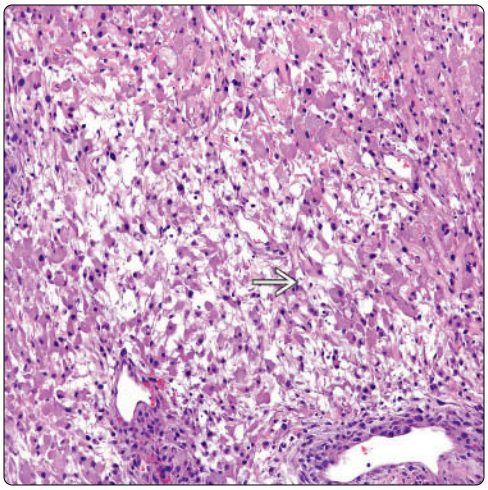

(Left) *Alveolar soft part sarcoma shows degenerative changes. Still one is able to identify single malignant cells ⇒. This degenerative change may obscure the true nature of the neoplasm.* **(Right)** *Alveolar soft part sarcoma shows areas in which degenerative myxoid changes ⇒ merge with more conventional areas of tumor.*

Solid Growth Pattern

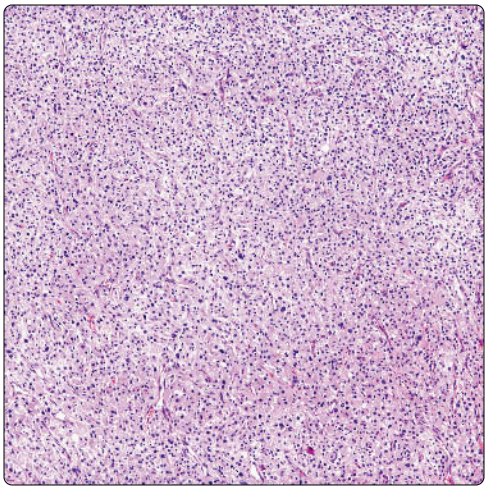

Solid Pattern

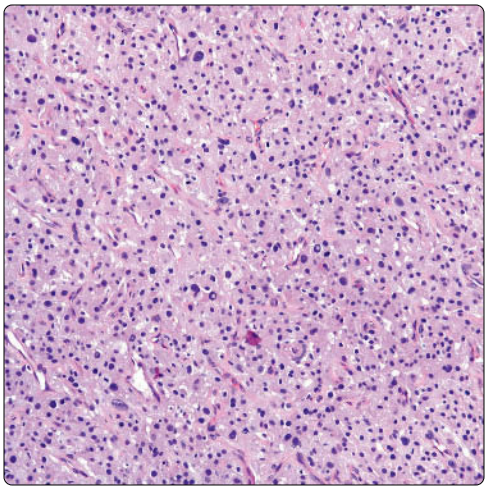

(Left) *Alveolar soft part sarcoma shows a predominantly solid growth pattern. This feature may pose significant problems in interpretation as it does not show the typical conventional growth pattern of this tumor.* **(Right)** *High-power view shows a solid area in an alveolar soft part sarcoma. Note the presence of nuclear atypia with some intranuclear inclusions but not an increase in mitotic activity.*

Prominent Vascular Proliferation

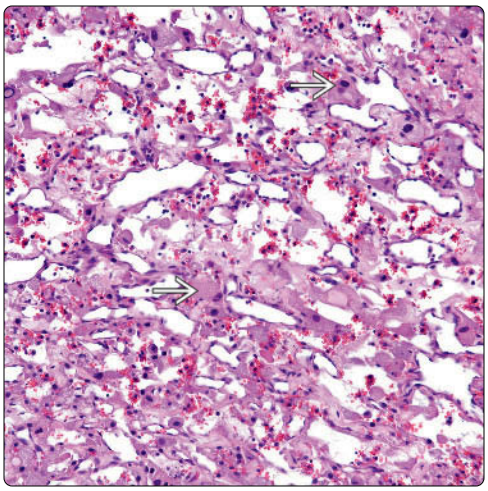

Spindle Cells

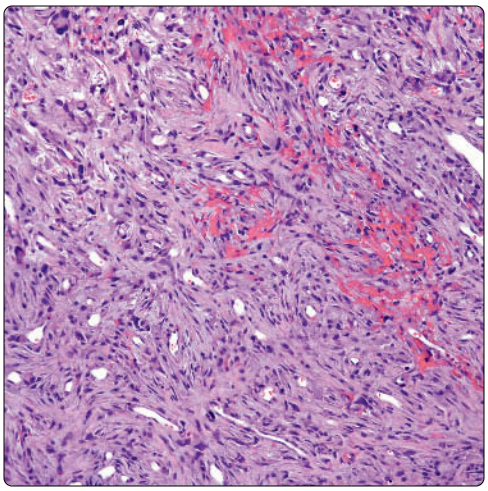

(Left) *Alveolar soft part sarcoma shows a proliferation of vessels, giving the impression of a true vascular neoplasm. However, note the presence of cells that are more in keeping with the diagnosis of alveolar soft part sarcoma ⇒.* **(Right)** *Alveolar soft part sarcoma shows areas composed of spindle cells with small ectatic vessels. Also note the presence of extravasated red cells. These features mimic a vascular neoplasm.*

Rhabdomyosarcoma

KEY FACTS

CLINICAL ISSUES

- Anterior mediastinum
- Cough
- Chest pain
- Dyspnea
- Pleural effusion
- Highly aggressive tumors with short survival

MACROSCOPIC

- Firm, poorly circumscribed, and infiltrative mass
- Homogeneous, tan-gray cut surface
- Areas of hemorrhage and necrosis

MICROSCOPIC

- Sheets of small round blue cells with hyperchromatic nuclei and scant eosinophilic cytoplasm
- Spindle cell variant of embryonal rhabdomyosarcoma (RMS) is composed of fascicular proliferation of atypical spindle cells against myxoid stroma
- Artifactual clefting of nests of small blue cells from periphery results in striking alveolar pattern
- Scattered multinucleated tumor cells with large hyperchromatic nuclei are seen admixed with small blue tumor cells
- Bizarre atypical cells with large, pleomorphic, and irregular nuclei are seen in pleomorphic variant of RMS

ANCILLARY TESTS

- Tumor cells are positive for desmin, MYOD1, and myogenin
- Tumor cells may aberrantly express cytokeratin, NSE, and S100 protein
- Electron microscopy will show thick and thin filaments with Z-bands
- PAX3/FKHR and PAX7/FKHR fusion product can be detected by FISH in alveolar RMS

Alveolar Rhabdomyosarcoma

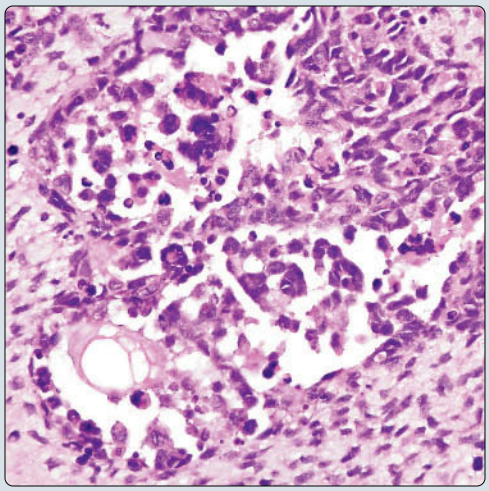

Embryonal Rhabdomyosarcoma

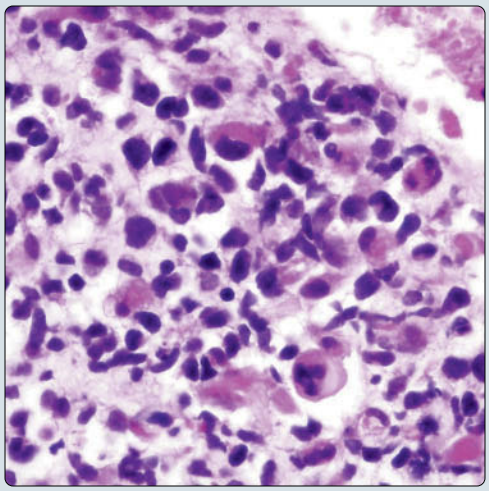

(Left) *Alveolar rhabdomyosarcoma (RMS) of the anterior mediastinum shows sheets of primitive small round blue cells with prominent retraction artifact resulting in an alveolar appearance.* **(Right)** *Embryonal RMS is characterized by sheets of small round blue cells, some of which display eccentric dark nuclei surrounded by a rim of intensely pink, homogeneous cytoplasm.*

Primitive Rhabdomyoblast

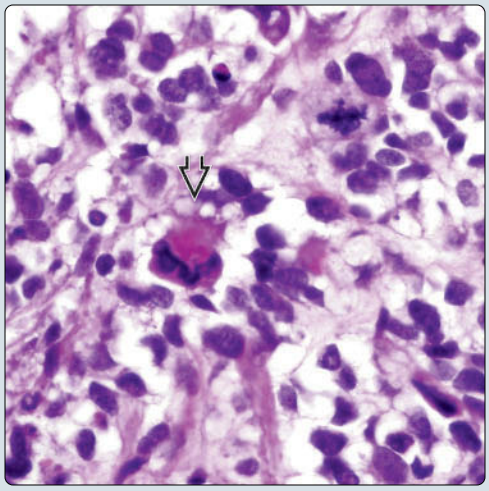

Desmin Immunostaining

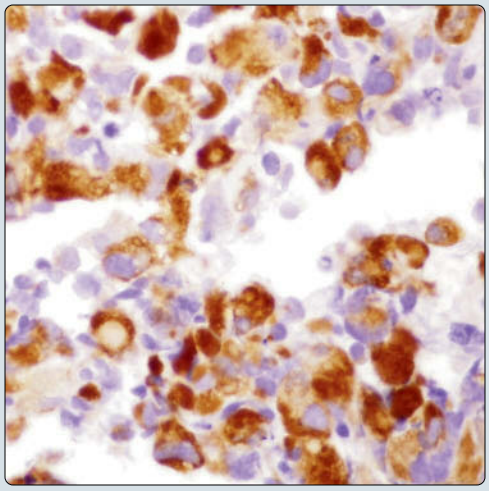

(Left) *High magnification of RMS of the mediastinum shows primitive small round blue cells containing abundant intensely pink cytoplasm. Multinucleated forms are particularly prominent in the solid variant of alveolar RMS.* **(Right)** *The tumor cells in rhabdomyosarcomas show strong cytoplasmic positivity for desmin. This antibody is very sensitive but not specific; follow-up with stains for myogenin and MYOD1 is therefore required for diagnosis.*

TERMINOLOGY

Abbreviations

- Rhabdomyosarcoma (RMS)

Definitions

- Primary malignant neoplasm of mediastinum showing features of striated muscle differentiation

CLINICAL ISSUES

Site

- Anterior mediastinum

Presentation

- Cough, chest pain, dyspnea, pleural effusion
- Mostly affects young adults (mean: 23 years)

Prognosis

- Highly aggressive tumors with short survival time
- Rapid recurrence and metastases generally within first 6 months after diagnosis
- Metastases most often involve lymph nodes but may also involve lung, pleura, bone, and abdominal viscera

IMAGING

General Features

- Solid, unencapsulated expansile lesion with poorly defined, infiltrative borders
- CT scans show large homogeneous mass displacing midline structures with pleural effusion

MICROSCOPIC

Histologic Features

- Tumors may appear de novo in pure form or may be associated with germ cell, teratomatous, or carcinomatous elements
- Pure, de novo tumors may show varied histology
- **Embryonal RMS**
  - Sheets of small round blue cells with hyperchromatic nuclei and scant eosinophilic cytoplasm
  - Scattered immature rhabdomyoblasts characterized by comma-shaped cells with small, dark nuclei and bright pink rim of cytoplasm
  - Spindle cell variant of embryonal RMS is composed of atypical spindle cells set against myxoid stroma
- **Alveolar RMS**
  - Solid sheets of small round blue cells supported by delicate fibrovascular stroma
  - Artifactual clefting of nests of small blue cells from periphery results in striking alveolar pattern
  - Scattered multinucleated tumor cells with large hyperchromatic nuclei are seen admixed with small blue tumor cells
- **Pleomorphic RMS**
  - Bizarre atypical cells with large, pleomorphic, and irregular nuclei surrounded by abundant eosinophilic cytoplasm
  - Cells may show slender, tapering cytoplasmic processes resembling racquet cells
  - Only rarely will cells display cytoplasmic cross striations

Cytologic Features

- Small round blue cells show primitive cytologic appearance with hyperchromatic nuclei devoid of nuclear detail
- High mitotic activity is norm
- Multinucleated tumor cells in alveolar RMS usually assume wreath-like configuration with nuclei in periphery
- Tumor cells in pleomorphic RMS rarely if ever display cross striations in cytoplasm

ANCILLARY TESTS

Immunohistochemistry

- Tumor cells may be focally positive for S100 protein, cytokeratin, NSE, and SMA
- Tumor cells strongly show nuclear expression of skeletal muscle transcription factors, MYOD1, and myogenin
- Tumor cells are positive for desmin and vimentin

Genetic Testing

- Allelic losses in chromosome 11p15 are seen in embryonal RMSs
- Complex structural and numerical chromosomal changes are seen in embryonal RMS, including extra copies of chromosomes 2, 8, and 13
- Specific translocation t(2;13)(q35;q14) is associated with alveolar RMS and gives rise to PAX3/FKHR and PAX7/FKHR fusion proteins

Electron Microscopy

- Parallel arrays of microfilaments and ribosomes (myosin-ribosome complexes) are seen in earliest stages of differentiation
- Bundles of thick and thin filaments with focal condensations (Z-bands) characterize mature tumors

DIFFERENTIAL DIAGNOSIS

Small Round Blue Cell Tumors

- Lymphoblastic lymphoma shows positivity for CD3, CD1a, TdT, and CD99 and is negative for skeletal muscle transcription factors
- Lymphocyte-rich thymoma shows positivity for cytokeratin and p63 and is negative for skeletal muscle transcription factors
- Small cell neuroendocrine carcinoma shows positivity for cytokeratin, chromogranin, and synaptophysin and is negative for skeletal muscle transcription factors
- Primitive neuroectodermal tumor/Ewing sarcoma shows strong positivity for CD99 and is negative for skeletal muscle transcription factors

SELECTED REFERENCES

1. Qi Y et al: Solid alveolar rhabdomyosarcoma with spindle-shaped cells and epithelial differentiation of the mediastinum in a 68-year-old man: a case report and literature review. J Cancer Res Ther. 7(3):353-6, 2011
2. Malagón HD et al: Germ cell tumors with sarcomatous components: a clinicopathologic and immunohistochemical study of 46 cases. Am J Surg Pathol. 31(9):1356-62, 2007
3. Suster S et al: Rhabdomyosarcomas of the anterior mediastinum: report of four cases unassociated with germ cell, teratomatous, or thymic carcinomatous components. Hum Pathol. 25(4):349-56, 1994

Embryonal Rhabdomyosarcoma

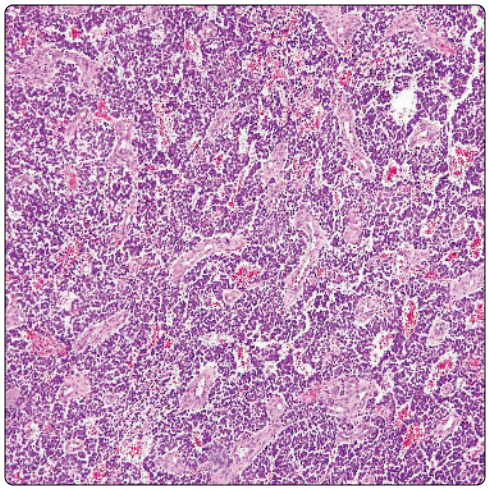

Higher Magnification

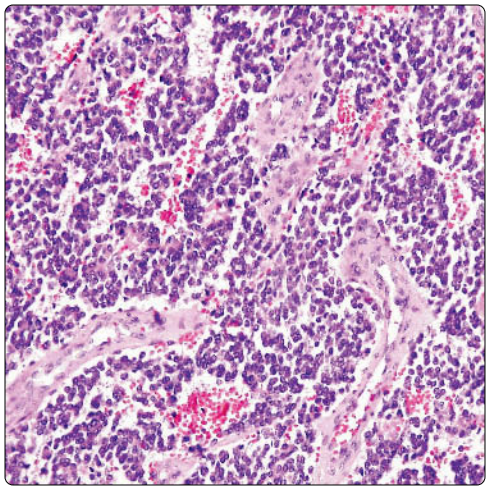

(Left) *Scanning magnification of embryonal RMS of the anterior mediastinum in a 19-year-old man shows sheets of small round blue cells separated by a well-vascularized stroma without any distinctive architectural growth pattern.* **(Right)** *High magnification of embryonal RMS of the anterior mediastinum in a 19-year-old man shows a monotonous population of dyscohesive small round blue cells separated by thin strands of fibrovascular stroma.*

MYOD1 Immunostaining

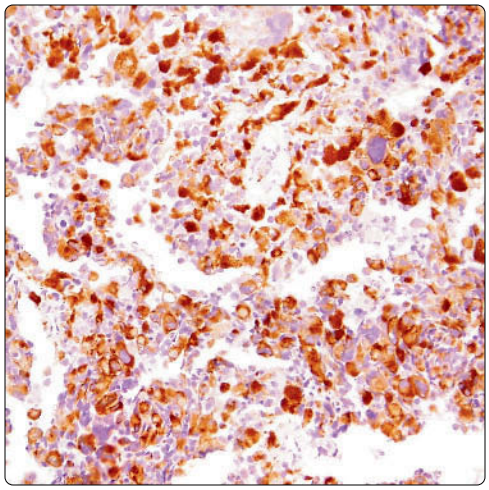

Desmin Immunostaining

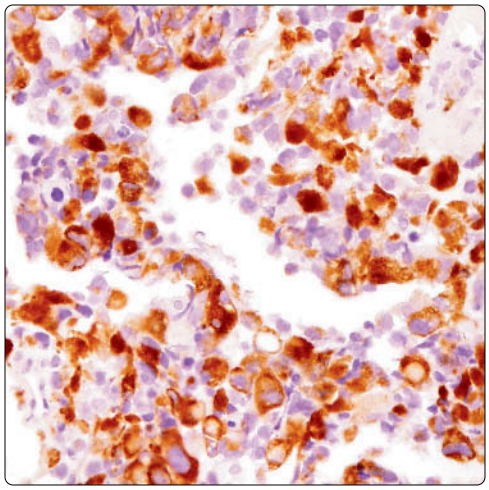

(Left) *Immunohistochemical staining of embryonal RMS of the anterior mediastinum with the striated muscle-specific transcription factor, MYOD1, shows nuclear staining of the tumor cells for this antigen.* **(Right)** *Immunohistochemical staining of embryonal RMS of the anterior mediastinum for desmin shows strong cytoplasmic staining of the tumor cells for this marker, indicative of myogenic differentiation of the tumor cells.*

Small Round Blue Cell Population

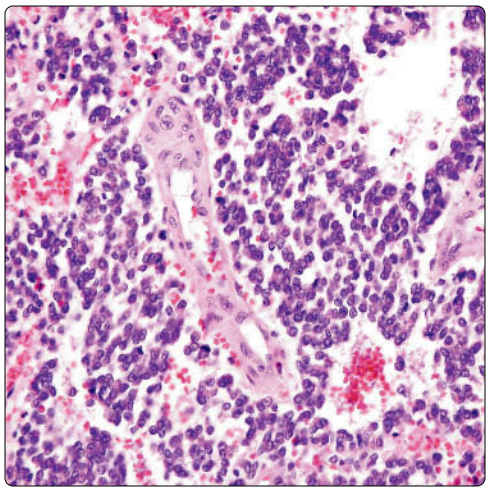

Primitive Rhabdomyoblasts

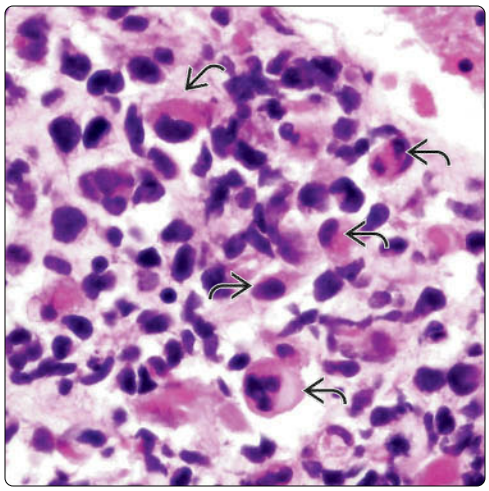

(Left) *Scanning magnification of embryonal RMS shows monotonous proliferation of small round blue cells with scant pink cytoplasm. This tumor can resemble lymphoblastic lymphoma, small cell carcinoma, and Ewing sarcoma/PNET by morphology.* **(Right)** *High magnification of embryonal RMS shows small round blue cells admixed with slightly larger cells containing abundant, eccentric pink cytoplasm, typical of rhabdomyoblasts.*

Areas of Necrosis

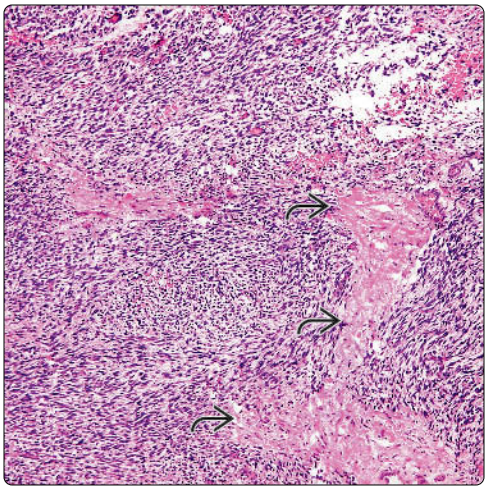

Spindle Cell Rhabdomyosarcoma

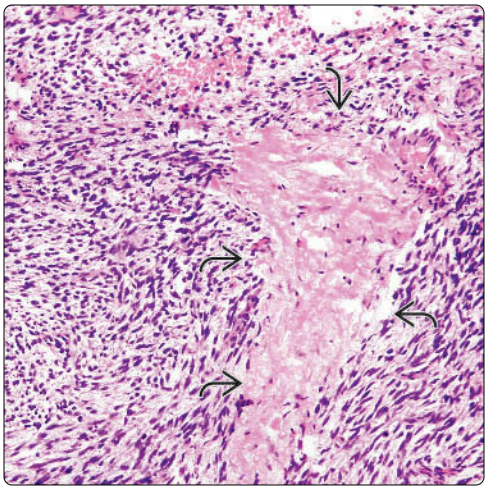

(Left) *Embryonal RMS of the anterior mediastinum in a 21-year-old man is characterized by dense spindle cell proliferation with focal areas of necrosis. The spindle cells show focal whorling and a fascicular pattern of growth.* **(Right)** *Embryonal RMS of the mediastinum (spindle cell type) shows fascicles of atypical spindle cells circumscribing an area of necrosis. This tumor can be confused for a variety of other spindle cell sarcomas.*

Higher Magnification

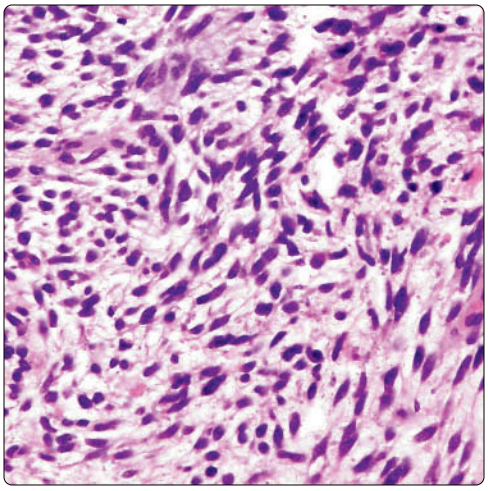

Atypical Spindle Cells

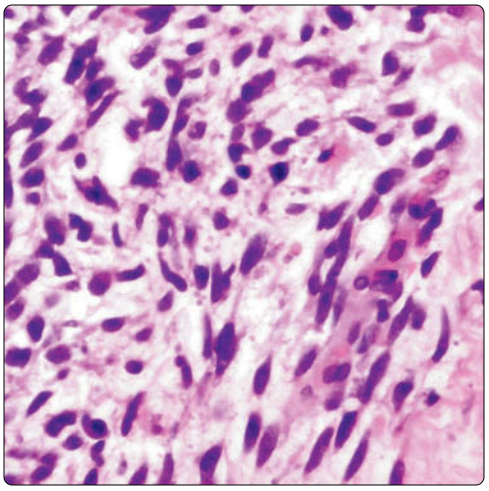

(Left) *High magnification of embryonal RMS of the mediastinum (spindle cell variant) shows haphazardly arranged fascicles of hyperchromatic spindle cells containing a few scattered mitoses and with little intervening stroma.* **(Right)** *High magnification of embryonal RMS of the mediastinum (spindle cell type) shows small spindle cells with dark, hyperchromatic nuclei surrounded by a scant rim of amphophilic cytoplasm.*

Myxoid Stromal Changes

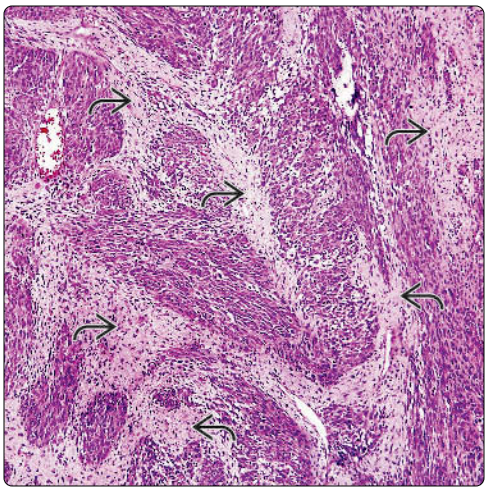

Higher Magnification

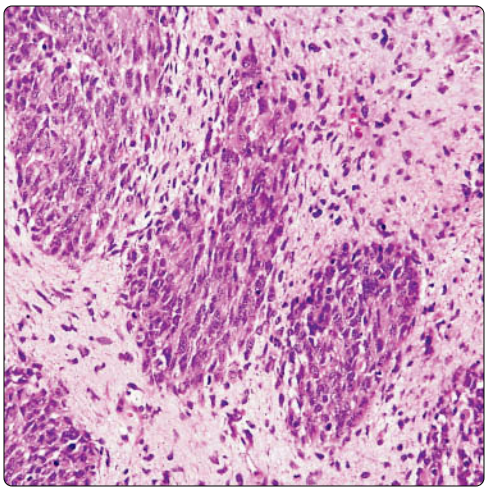

(Left) *Embryonal RMS of the anterior mediastinum (spindle cell type) shows dense fascicles of tightly packed spindle cells separated by strands of myxoid stroma.* **(Right)** *Embryonal RMS of the anterior mediastinum, spindle cell type, shows fascicles of spindle cells separated by abundant myxoid stroma. Notice the spindle cells contain dark nuclei and are surrounded by a scant rim of amphophilic cytoplasm.*

Alveolar Rhabdomyosarcoma

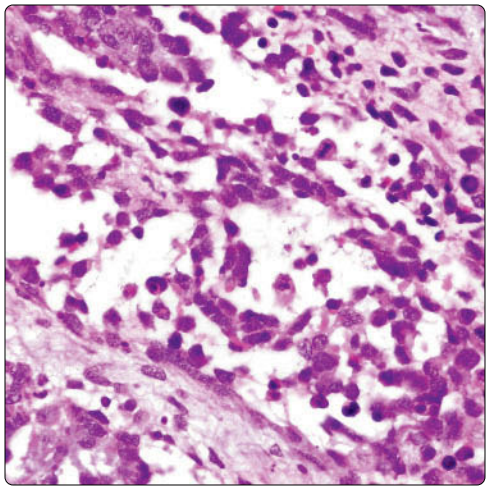

Embryonal Rhabdomyoblast

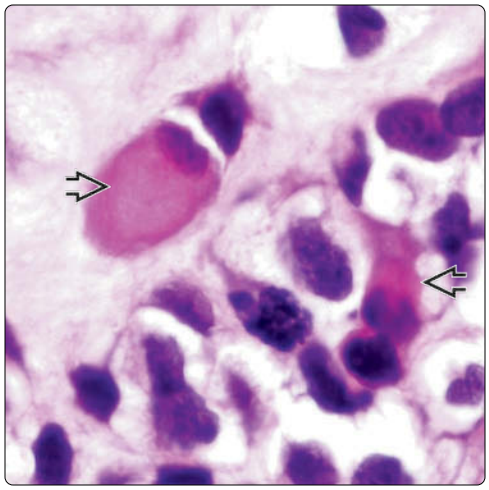

(Left) *Alveolar RMS of the anterior mediastinum shows a population of small round blue cells with characteristic artifactual separation of the tumor cells from the surrounding stroma resembling alveolar lumina.* **(Right)** *High magnification of alveolar RMS of the anterior mediastinum shows primitive cells with abundant globular, eccentric, and deeply staining pink cytoplasm reminiscent of developing embryonal rhabdomyoblasts.*

Alveolar Rhabdomyosarcoma: Solid Variant

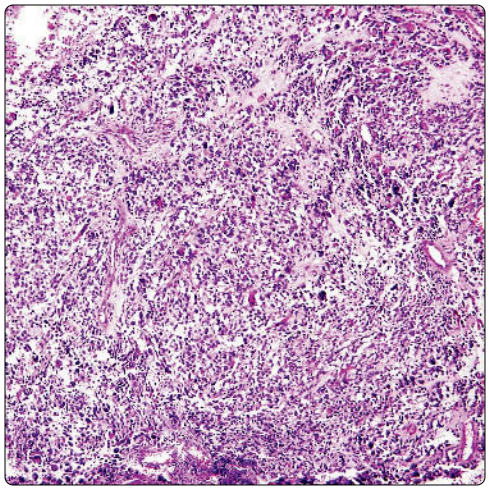

Multinucleated Rhabdomyoblastic Cells

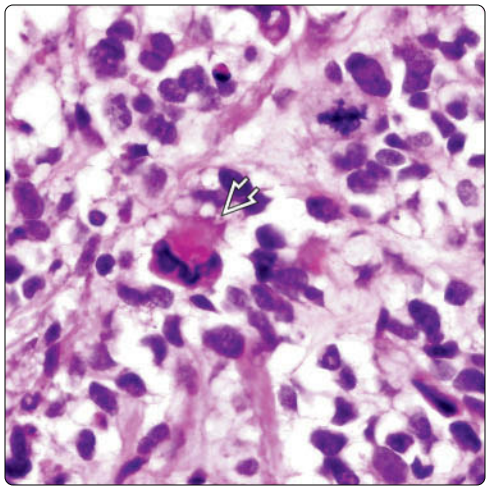

(Left) *Solid variant of alveolar RMS of the mediastinum shows compact sheets of small round blue cells without the characteristic alveolar retraction artifact.* **(Right)** *High magnification of solid variant of alveolar RMS of the mediastinum shows larger cells with marked nuclear pleomorphism and scattered pleomorphic, multinucleated giant cells with abundant pink cytoplasm. The greater variability of the size and shape of the cells characterizes this tumor.*

Desmin Immunostaining

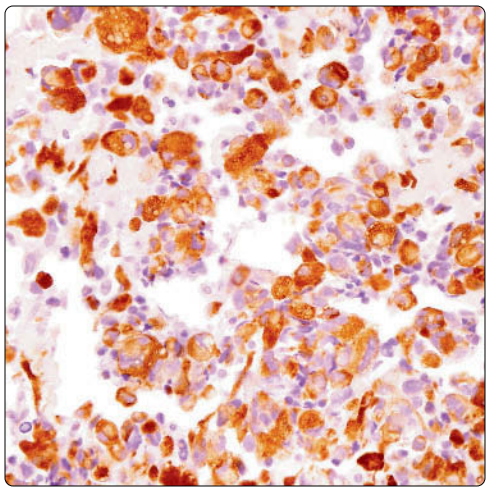

Myogenin Immunostaining

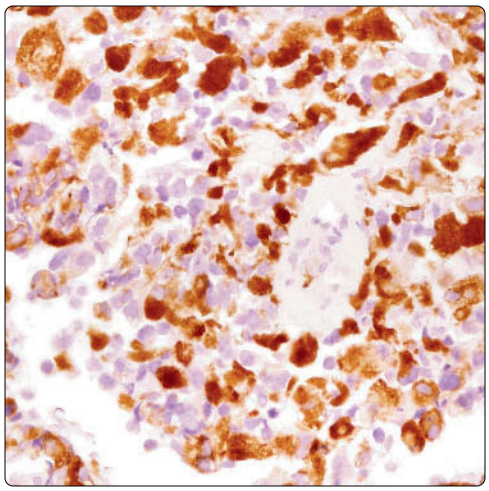

(Left) *Immunohistochemical staining for desmin in alveolar RMS of the mediastinum (solid variant) shows strong cytoplasmic staining of the tumor cells for this antibody.* **(Right)** *Immunohistochemical staining of alveolar RMS of the mediastinum for the skeletal muscle-specific transcription factor, myogenin, shows strong nuclear positivity in the tumor cells. The skeletal muscle transcription factors, myogenin and MYOD1, are highly specific for these tumors.*

Pleomorphic Rhabdomyosarcoma

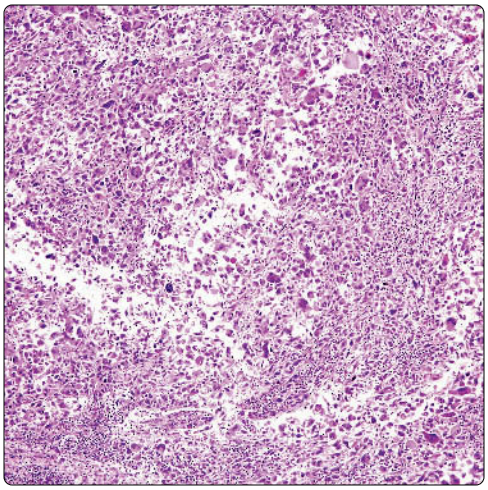

Pleomorphic Tumor Cells

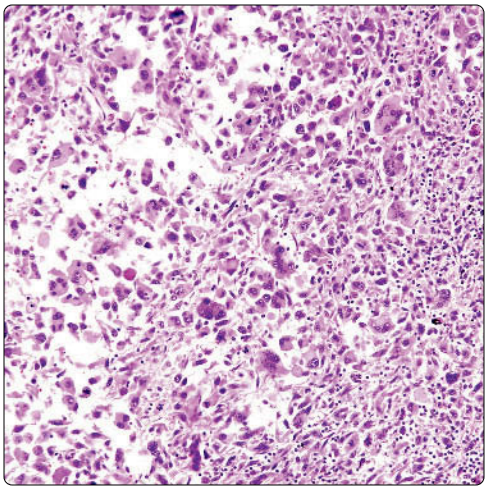

(Left) *Scanning magnification of pleomorphic RMS of the mediastinum shows sheets of large, pleomorphic tumor cells admixed with smaller cells with scant intervening stroma.* **(Right)** *Scanning magnification of pleomorphic RMS of the mediastinum shows sheets of small cells admixed with larger, pleomorphic tumor cells. Tumors with these features may resemble a variety of other neoplasms, including liposarcoma, malignant fibrous histiocytoma, and anaplastic carcinoma.*

Bizarre Cells

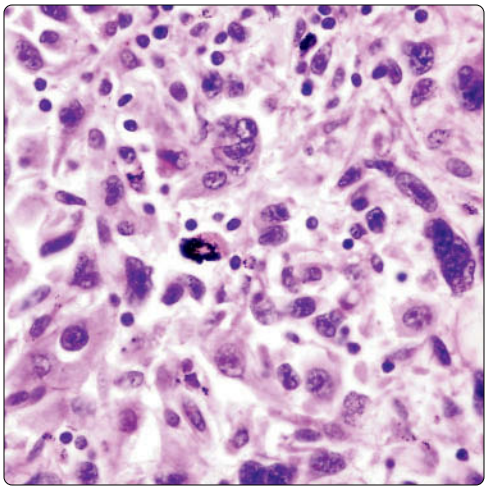

Pleomorphic Tumor Cell Population

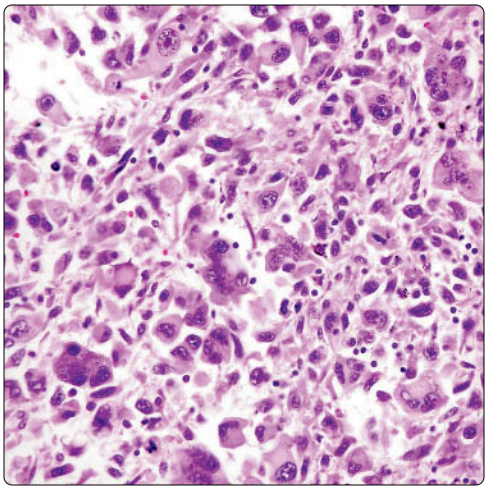

(Left) *High magnification of pleomorphic RMS of the mediastinum shows bizarre, pleomorphic tumor cells admixed with smaller, more primitive tumor cells and a sprinkling of inflammatory cells in the background. Tumors like this can resemble anaplastic carcinomas.* **(Right)** *High magnification of pleomorphic liposarcoma of the mediastinum shows sheets of small atypical cells admixed with scattered larger, pleomorphic cells with bizarre nuclei.*

Multinucleated Tumor Cells

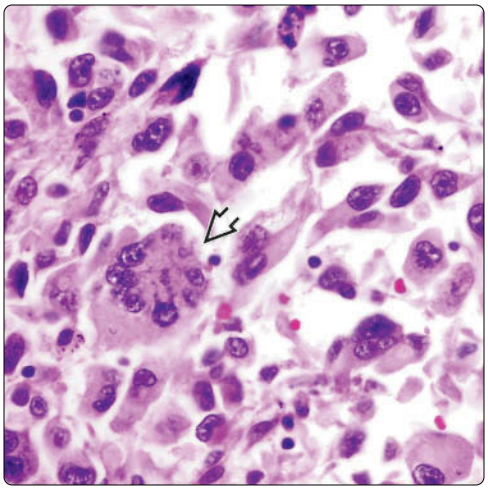

Infiltration of Mediastinal Fat

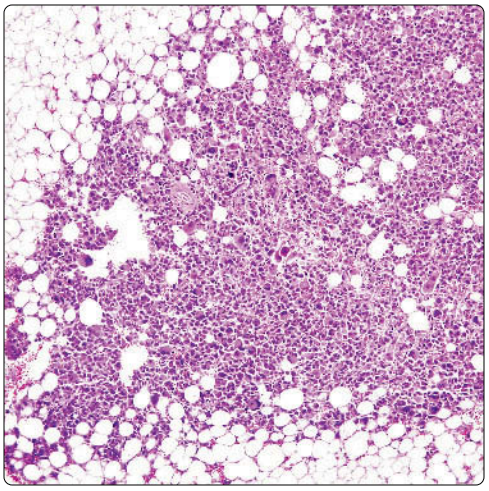

(Left) *High magnification of pleomorphic RMS of the mediastinum shows a dyscohesive population of tumor cells, including spindle cells, "strap" cells, and large multinucleated tumor cells with a Touton-like appearance. Tumors like this can resemble malignant fibrous histiocytoma and pleomorphic liposarcoma.* **(Right)** *Pleomorphic RMS of the mediastinum shows infiltration of mediastinal fat by the tumor cells.*

Ganglioneuroma

KEY FACTS

TERMINOLOGY

- Ganglioneuroma (GN)
- Benign tumor of neural origin

CLINICAL ISSUES

- Incidence
  - Tumor is more common in young patients
- Location
  - More common in posterior mediastinum
- Symptomatology
  - Chest pain
  - Horner syndrome
  - Shortness of breath
  - Neurofibromatosis
- Treatment
  - Surgical resection
- Prognosis
  - Good
- Clinical features
  - Tumor is more common in younger patients
  - More common in posterior mediastinum
- Shortness of breath
- Symptoms
  - Shortness of breath
  - Chest pain
  - Horner syndrome
  - Neurofibromatosis

ANCILLARY TESTS

- S100 protein positive
- NFP positive

TOP DIFFERENTIAL DIAGNOSES

- Schwannoma
- Neurofibroma
- Ganglioneuroblastoma
- Solitary fibrous tumor

Spindle and Oval Cells

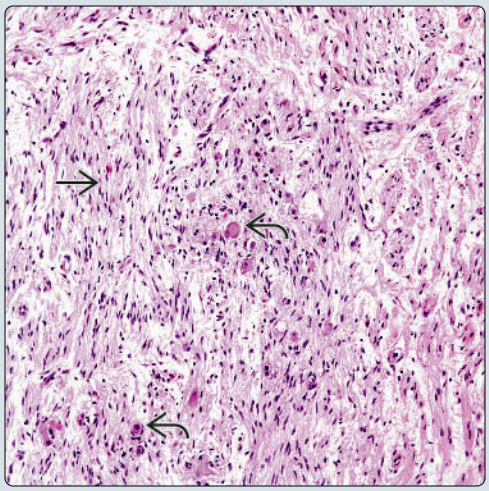

Scattered Larger Cells

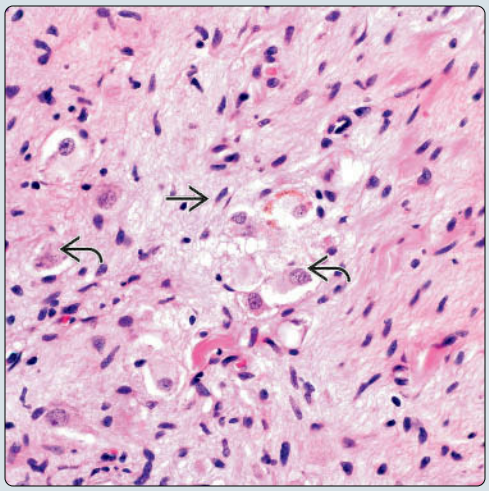

(Left) *Ganglioneuroma shows a bland spindle cellular proliferation with scattered larger cells representing ganglion cells. Both components are essential for the diagnosis.* **(Right)** *Higher-power view of a mediastinal ganglioneuroma displays a spindle cell proliferation admixed with numerous larger cells with prominent nucleoli (ganglion cells).*

Ganglion Cells

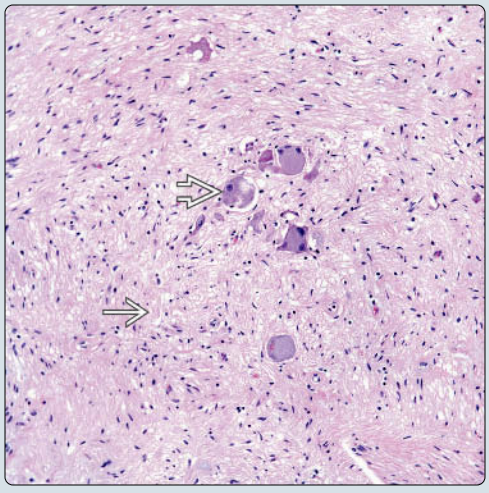

Calcification

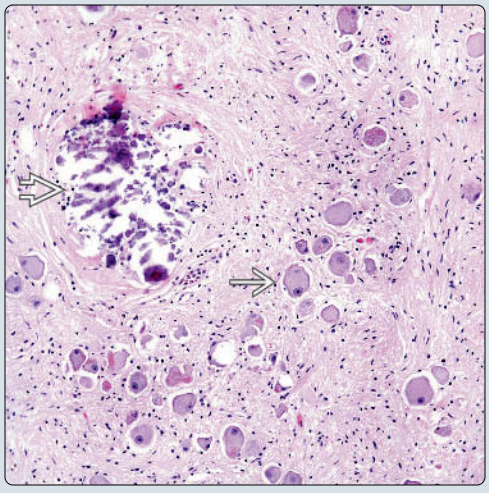

(Left) *Ganglioneuroma shows predominantly fibromatous (spindle cell) component with clusters of larger cells representing ganglion cells.* **(Right)** *Ganglioneuroma shows numerous ganglion cells around an area of calcification. The presence of calcifications in these tumors is often seen.*

TERMINOLOGY

Abbreviations

- Ganglioneuroma (GN)

Definitions

- Benign tumor of neural origin

ETIOLOGY/PATHOGENESIS

Etiology

- No definitive etiology for this neoplasm

CLINICAL ISSUES

Epidemiology

- Incidence: Unusual, representing small percentage of mediastinal tumors
- Age: More common in younger patients
- Site: GN is more common in posterior mediastinum
- Presentation: Shortness of breath, chest pain, Horner syndrome, neurofibromatosis
- Treatment: Complete surgical resection
- Prognosis: Good

MACROSCOPIC

General Features

- Well circumscribed and encapsulated; firm, gray to yellowish
- Cut surface shows whitish smooth or whorled appearance
- Areas of necrosis and hemorrhage are generally absent

Size

- 1 cm to > 10 cm in greatest dimension

MICROSCOPIC

Histologic Features

- Mature ganglion cells embedded in loose fibrocollagenous or subtle spindle cell stroma
- Proliferation of Schwann cells, nerve fibers, ganglion cells
- Nissl granules may be seen in some cases in ganglion cells

Cytologic Features

- Mature ganglion cells

DIFFERENTIAL DIAGNOSIS

Schwannoma

- Classically shows Antoni A and B areas, whereas these would be unusual in GN
- Unusual for schwannoma to show numerous ganglion cells

Neurofibroma

- Spindle cell component of neurofibroma is similar to that of GN
- Neurofibromas lack presence of ganglion cells

Ganglioneuroblastoma

- Shows neuroblastomatous component; absent in GN

Solitary Fibrous Tumor

- May show different growth pattern, including hemangiopericytoma; unusual in GN
- Presence of hypo- and hypercellular areas is commonly seen in soft tissue tumor
- Shows positive staining for CD34 &/or Bcl-2, whereas GN is negative

DIAGNOSTIC CHECKLIST

Clinically Relevant Pathologic Features

- Nuclear features

Pathologic Interpretation Pearls

- Presence of mature ganglion cells embedded in loose fibrocollagenous stroma
- Absence of mitotic activity
- Spindle cell component may be subtle

SELECTED REFERENCES

1. Di Cataldo A et al: Mediastinal ganglioneuroma: a rare and often asymptomatic tumour. A case report. Chir Ital. 57(3):403-5, 2005

Immunohistochemistry

Antibody	Reactivity	Staining Pattern	Comment
S100	Positive	Nuclear & cytoplasmic	May be only focal staining
NFP	Positive	Cytoplasmic	Variable staining intensity
NSE	Positive	Cytoplasmic	Positive in ganglion cells
CD56	Positive	Cytoplasmic	May be focal
CK-LMW-NOS	Negative		May be positive in entrapped epithelial structures
EMA	Negative		May be positive in entrapped epithelial structures
Chromogranin-A	Negative		
Synaptophysin	Negative		
CK-PAN	Negative		May be positive in entrapped epithelial structures
CD34	Negative		
Bcl-2	Negative		

Macroscopic Features

Spindle Cell Proliferation

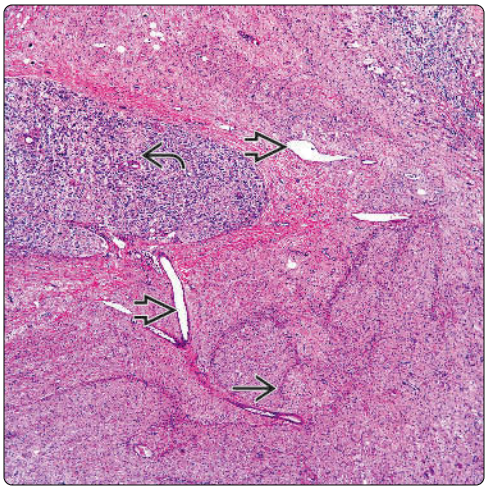

(Left) *A tumor mass with a yellowish color and firm consistency is depicted. The tumor is well circumscribed and slightly lobulated. These features are in keeping with a ganglioneuroma.* **(Right)** *Low power of a mediastinal ganglioneuroma shows a spindle cellular proliferation admixed with ectatic vessels and areas with numerous ganglion cells.*

Ganglion Cells

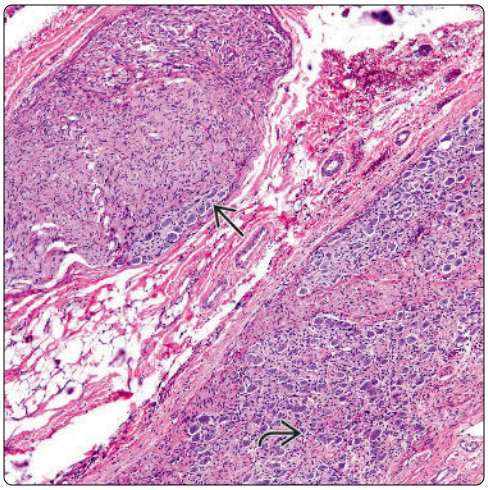

Dystrophic Calcification

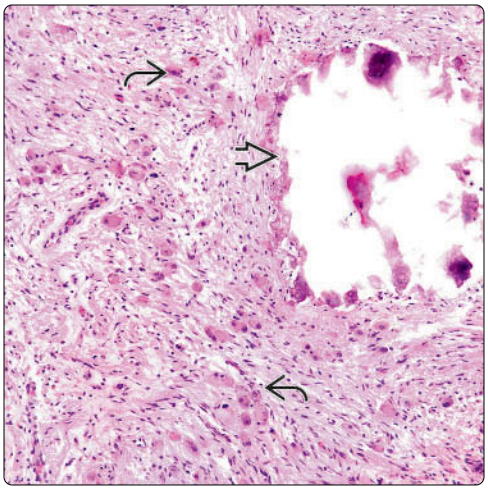

(Left) *Mediastinal ganglioneuroma is shown with prominent ganglion cell component. A 2nd smaller tumor is present with similar histological features.* **(Right)** *Ganglioneuroma shows focal areas of calcification in addition to the common histological features of spindle cells and the presence of ganglion cells.*

Entrapped Nerve

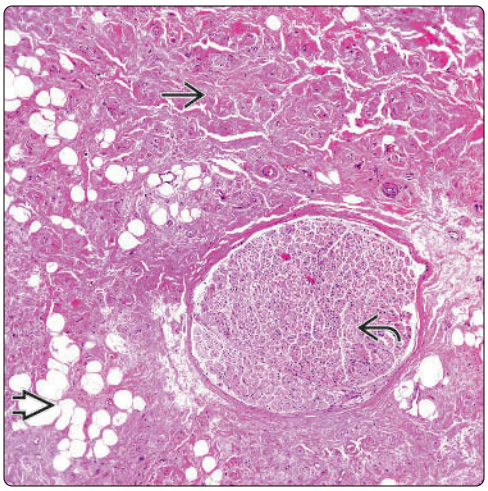

Adipose Tissue Entrapped

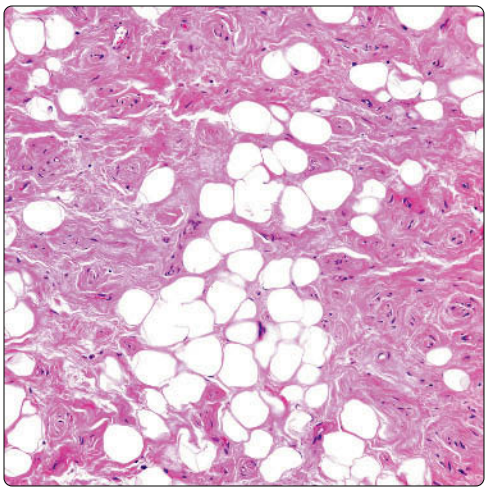

(Left) *In some cases of ganglioneuroma, the diagnosis may not be readily recognized. The tumor may show extensive areas of collagen and adipose tissue with an entrapped nerve.* **(Right)** *High-power view shows ganglioneuroma in which the tumor shows extensive areas of collagen deposition and adipose tissue. These features may be easily encountered in hamartomatous lesions.*

Alveolar-Like Pattern

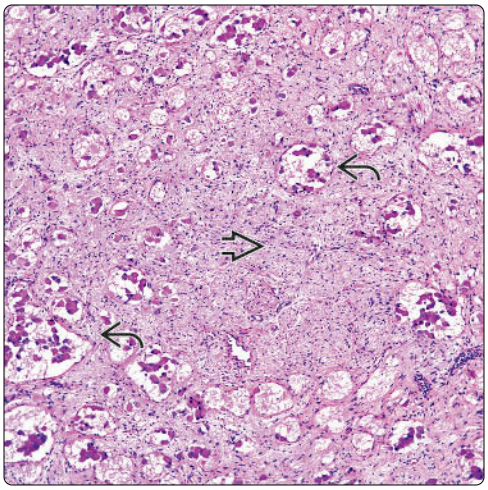

Myxoid Changes

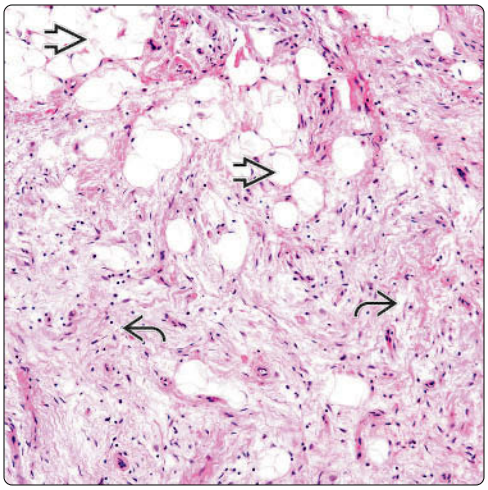

(Left) *Mediastinal ganglioneuroma is shown with a vague alveolar pattern admixed with solid areas. The alveolar-like areas are composed of ganglion cells, whereas the solid areas are composed of spindle cells.* **(Right)** *In some cases of ganglioneuroma, the predominant component may be the neuromatous elements with only scattered ganglion cells and focal myxoid changes admixed with adipose tissue, as is depicted here.*

Scattered Ganglion Cells

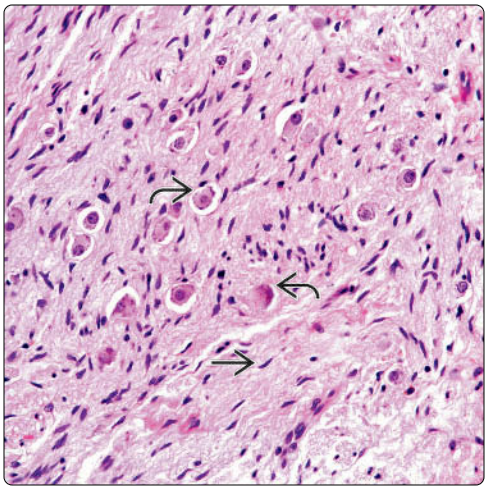

Predominantly Spindle Cell Component

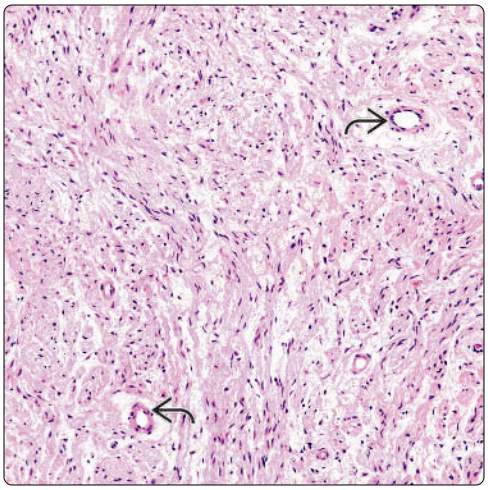

(Left) *Classic histological features of ganglioneuroma are shown in which the tumor shows dual populations of cells. The larger cells represent ganglion cells, whereas the spindle cells represent the neuromatous component.* **(Right)** *Ganglioneuroma shows areas resembling loose fibroconnective tissue or possibly smooth muscle. The predominant cell component is neuromatous with scattered blood vessels.*

Large Ganglion Cells

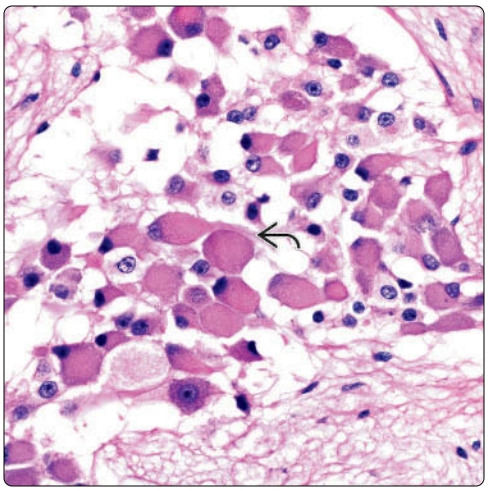

Pigmented Cells

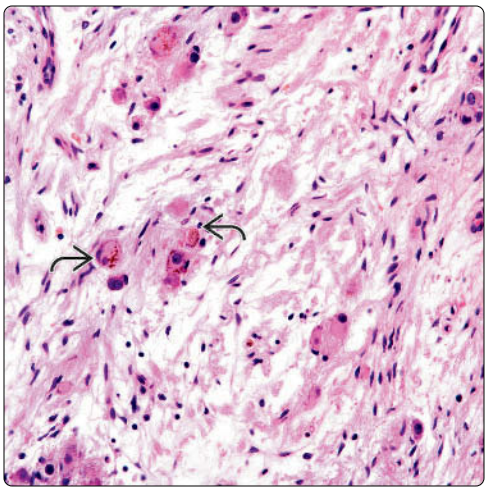

(Left) *High-power view shows the ganglion cells in a ganglioneuroma. This group of ganglion cells can easily be confused with muscle cells like the ones present in tumors with rhabdomyoblastic differentiation.* **(Right)** *High-power view shows a ganglioneuroma in which ganglion cells are embedded in a rather myxoid or loose fibroconnective tissue. Note the presence of pigment in the ganglion cells representing Nissl substance.*

Neuroblastoma/Ganglioneuroblastoma

KEY FACTS

TERMINOLOGY

- Neuroblastoma (NB)
- Ganglioneuroblastoma (GNB)
- Differentiating NB and immature ganglioneuroma both synonyms for GNB
- Malignant neoplasm composed of immature neural elements (NB) that may be admixed with ganglioneuromatous component (GNB)

ETIOLOGY/PATHOGENESIS

- GNB is believed to represent transitional tumor of sympathetic cell origin
- NB is tumor believed to be of neural crest origin

CLINICAL ISSUES

- Tumor is more common in younger individuals
- Usually in patients < 15 years of age
- NB and GNB are usually in posterior mediastinum
- Unusual cases occur in anterior mediastinum
- Prognosis
  - Depends on clinical stage at time of diagnosis
  - Depends on degree of differentiation of tumor
  - Children appear to have more favorable outcome

TOP DIFFERENTIAL DIAGNOSES

- NB
- Ganglioneuroma
- Rhabdomyosarcoma
- Ewing sarcoma/PNET

DIAGNOSTIC CHECKLIST

- Small round blue cell tumor
- Areas of neuropil
- Presence of ganglion cells or precursors
- Homer-Wright rosettes may be present
- Calcifications may be present

Small Neuroblastoma Component

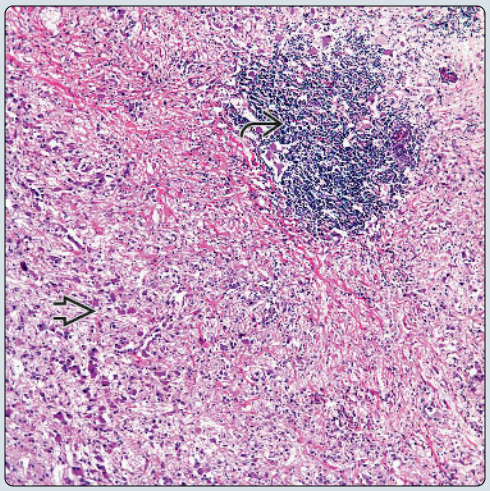

Ganglion Cells

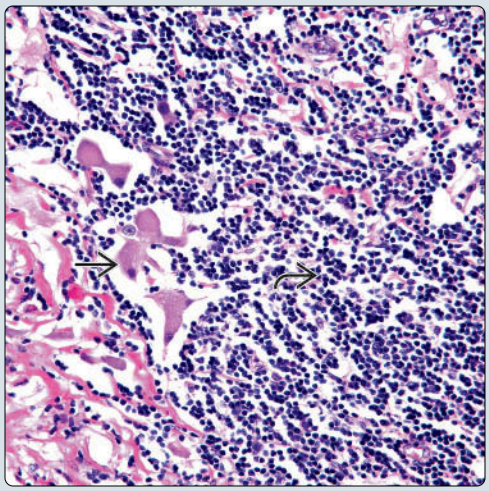

(Left) *Low-power view shows a ganglioneuroblastoma (GNB) a with a predominant ganglioneuromatous component. Note the presence of the small cluster of cells representing the neuroblastomatous component.* **(Right)** *High-power view shows the neuroblastomatous component in a GNB. Note that in the periphery there are still identifiable ganglion cells.*

Large Cells

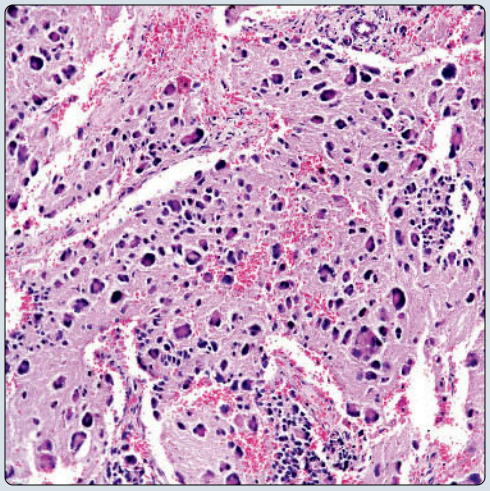

Dual Population

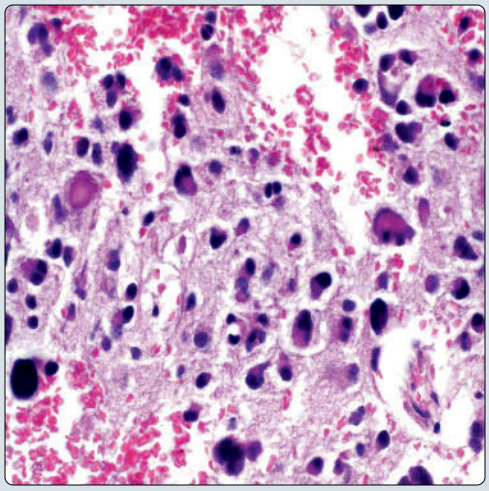

(Left) *Mediastinal GNB shows large cells representing ganglion differentiation of the tumor. Note the presence of a small cell component and the presence of neuropil.* **(Right)** *Mediastinal GNB shows a dual population of larger cells (ganglion differentiation) and small cells representing the neuroblastoma (NB) component. The tumor cells are embedded in neuropil.*

TERMINOLOGY

Abbreviations

- Neuroblastoma (NB)
- Ganglioneuroblastoma (GNB)

Synonyms

- Differentiating NB and immature ganglioneuroma both synonyms for GNB

Definitions

- Malignant neoplasm composed of immature neural elements (NB) that may be admixed with ganglioneuromatous component (GNB)

ETIOLOGY/PATHOGENESIS

Etiology

- GNB is believed to represent transitional tumor of sympathetic cell origin
- NB is tumor believed to be of neural crest origin

CLINICAL ISSUES

Epidemiology

- Incidence
  - Unusual tumors in mediastinal compartment
- Age
  - Tumor more common in younger individuals
  - Usually in patients < 15 years old
- Sex
  - No gender predilection
  - NB may be more commonly seen in male patients

Site

- NB and GNB are usually in posterior mediastinum
- Unusual cases may be in anterior mediastinum

Presentation

- Chest pain
- Paraplegia
- Horner syndrome
- Chronic diarrhea
- Various congenital anomalies
- Asymptomatic

Treatment

- Surgical approaches
  - Complete surgical removal of tumor
- Adjuvant therapy
  - Radiation &/or chemotherapy in advanced cases

Prognosis

- Depends largely on clinical stage of patient at time of diagnosis
- Also depends on degree of differentiation of tumor
- Children appear to have more favorable outcome

IMAGING

General Features

- Mediastinal mass
- Either anterior or posterior mediastinal compartment

MACROSCOPIC

General Features

- Lobulated neoplasm with dumbbell configuration
- Gray to tan in color
- Consistency varies from soft to hard and fleshy
- Focal areas of hemorrhage, necrosis, or calcification may be present

Size

- Tumors may vary in size from 2 cm to > 10 cm in greatest diameter

MICROSCOPIC

Histologic Features

- Small round blue cell proliferation embedded in neuropil
- Variable presence of ganglion cells or precursors in GNB
- Nuclear pleomorphism and increased mitotic activity are not common but vary according to degree of differentiator
- Areas of hemorrhage, necrosis, and calcification may be present
- Neural rosettes of Homer-Wright may be present

DIFFERENTIAL DIAGNOSIS

Neuroblastoma

- Shows similar histological features as those of GNB but lacks presence of ganglion cells

Ganglioneuroma

- Presence of small round blue cell component is characteristic of GNB and is absent in ganglioneuroma

Rhabdomyosarcoma

- GNB shows presence of areas of tumor cells embedded in neuropil, which is not feature of rhabdomyosarcoma
- Positive for muscle markers, while GNB is negative

Ewing Sarcoma/PNET

- Neoplastic cells embedded in neuropil is feature of GNB and is absent in PNET
- Contrary to GNB, PNET has specific translocation by molecular analysis

DIAGNOSTIC CHECKLIST

Pathologic Interpretation Pearls

- Small round blue cell tumor
- Areas of neuropil
- Presence of ganglion cells or precursors

SELECTED REFERENCES

1. Atwal SS: Neuroblastoma of posterior mediastinum: classical imaging findings. J Clin Diagn Res. 8(10):RJ01, 2014
2. Bicakcioglu P et al: Intrathoracic neurogenic tumors. Thorac Cardiovasc Surg. 62(2):147-52, 2014
3. Jrebi NY et al: Review of our experience with neuroblastoma and ganglioneuroblastoma in adults. World J Surg. 38(11):2871-4, 2014
4. Ponsford Tipps AM et al: Fine-needle aspiration of ganglioneuroma, maturing type (a.k.a., "borderline ganglioneuroblastoma") in the mediastinum of a young man: case report and discussion of classification. Diagn Cytopathol. 40(10):906-11, 2012
5. Ueda Y et al: Thymic neuroblastoma within a thymic cyst in an adult. Case Rep Oncol. 5(2):459-63, 2012

Immunohistochemistry

Antibody	Reactivity	Staining Pattern	Comment
NSE	Positive	Cytoplasmic	Strong staining
Synaptophysin	Positive	Cytoplasmic	May be only focal weak staining
Chromogranin-A	Positive	Cytoplasmic	
NB84	Positive	Cytoplasmic	Sensitive marker but not specific
CD99	Negative		Useful for differential diagnosis with other small blue cell tumors
CK-PAN	Negative		
Desmin	Negative		
Myoglobin	Negative		
MYOD1	Negative		
Caldesmon	Negative		
S100	Negative		May show focal positive staining
CD56	Positive	Cytoplasmic	Focal in some cases
CK-PAN	Negative		
CK8/18/CAM5.2	Negative		
NeuN	Positive	Cytoplasmic	In ganglion cells
GFAP	Negative		
PGP9.5	Positive	Cytoplasmic	In some cases
TTF-1	Negative		
NAPSIN-A	Negative		
CEA-M	Negative		
EMA	Negative		

Molecular Features

Study	Result	Comment
MYCN (N-myc) gene	Amplification	Correlates with better prognosis
DNA analysis	Hyperploidy	Correlates with better prognosis
NTRK1 (TRK) gene	High expression	Correlates with better prognosis

Histochemical Features

Stain	Result
PAS	Positive reaction in neuroblastoma (presence of glycogen)
PAS-D	Negative reaction
Mucicarmine	Negative reaction
Grimelius	May show focal positive reaction

6. Ohtaki Y et al: Adult neuroblastoma arising in the superior mediastinum. Interact Cardiovasc Thorac Surg. 13(2):220-2, 2011
7. Demir HA et al: Thoracic neuroblastic tumors in childhood. Pediatr Blood Cancer. 54(7):885-9, 2010
8. Dubashi B et al: Clinicopathological analysis and outcome of primary mediastinal malignancies - a report of 91 cases from a single institute. Ann Thorac Med. 4(3):140-2, 2009
9. Moon SB et al: Neuroblastoma: treatment outcome after incomplete resection of primary tumors. Pediatr Surg Int. 25(9):789-93, 2009
10. Ogawa F et al: Thymic neuroblastoma with the syndrome of inappropriate secretion of antidiuretic hormone. Interact Cardiovasc Thorac Surg. 9(5):903-5, 2009
11. Argani P et al: Thymic neuroblastoma in adults: report of three cases with special emphasis on its association with the syndrome of inappropriate secretion of antidiuretic hormone. Am J Clin Pathol. 108(5):537-43, 1997
12. Nagashima Y et al: Adult ganglioneuroblastoma of the anterior mediastinum. Pathol Res Pract. 193(10):727-32; discussion 733, 1997
13. Grosfeld JL et al: Mediastinal tumors in children: experience with 196 cases. Ann Surg Oncol. 1(2):121-7, 1994
14. Simpson I et al: Mediastinal masses in childhood: a review from a paediatric pathologist's point of view. Prog Pediatr Surg. 27:92-126, 1991
15. Adam A et al: Ganglioneuroblastoma of the posterior mediastinum: a clinicopathologic review of 80 cases. Cancer. 47(2):373-81, 1981

Macroscopic Features

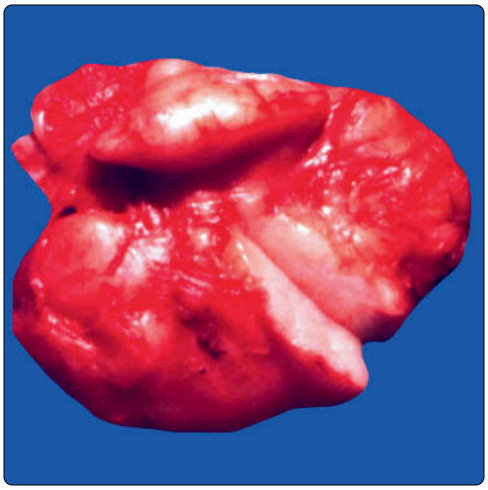

Nodular Pattern

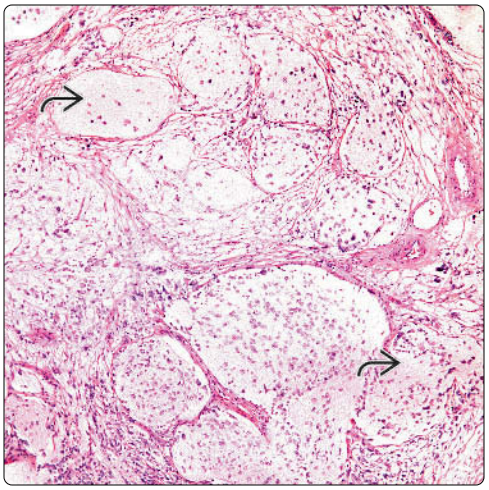

(Left) *In this surgically resected GNB, the tumor shows a slightly lobular appearance surrounded by membranous tissue. The cut surface appears white and smooth. The gross features of GNB and NB may be similar, and histological examination is required to separate these 2 tumors.* **(Right)** *Low-power view of a GNB shows a slightly lobular appearance separated by thin fibroconnective tissue. The tumor appears to be rich in neuropil; such a feature is helpful in the diagnosis.*

Homogeneous Cell Population

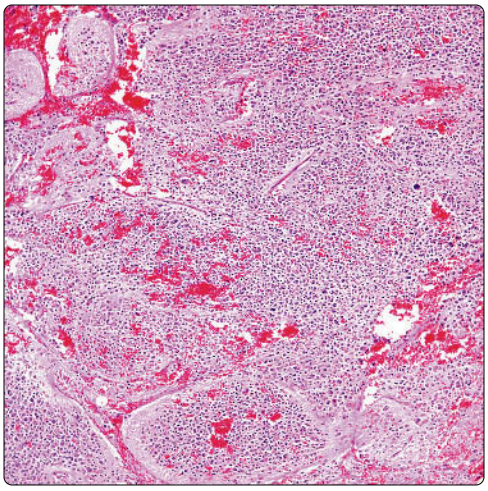

Dual Population

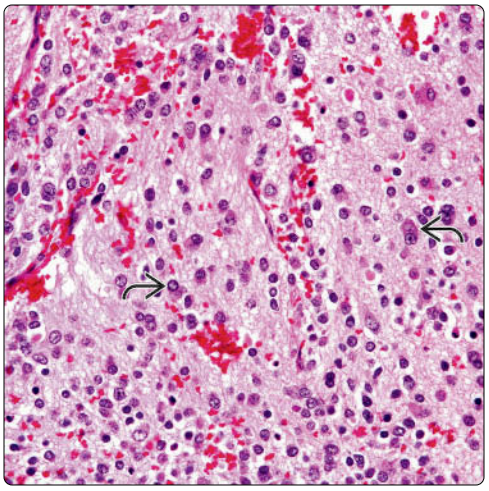

(Left) *Mediastinal GNB is shown with sheets of small round blue cells without any particular growth pattern. There are several ectatic blood vessels containing fresh blood. Note that the presence of neuropil is not marked.* **(Right)** *Mediastinal GNB shows a cellular proliferation composed of small cells and larger cells with eccentrically placed nuclei, which represent ganglion cell precursors. The identification of ganglion cells is essential in the diagnosis of GNB.*

Ganglion Cell Precursors

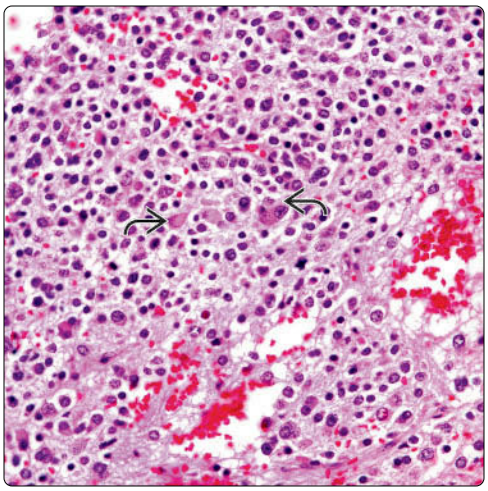

Predominantly Neuroblastoma

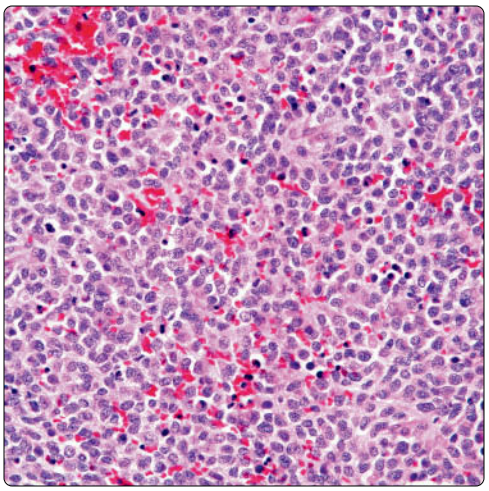

(Left) *Higher magnification shows ganglion cell precursors and more conventional small cells. This image could be mistaken for a mesenchymal neoplasm.* **(Right)** *Mediastinal GNB shows a predominantly neuroblastomatous component. In some cases of GNB, the presence of a ganglion cell or its precursor may be more focal. This particular pattern may be seen in the so-called small round blue cell tumors.*

Cysts and Calcifications

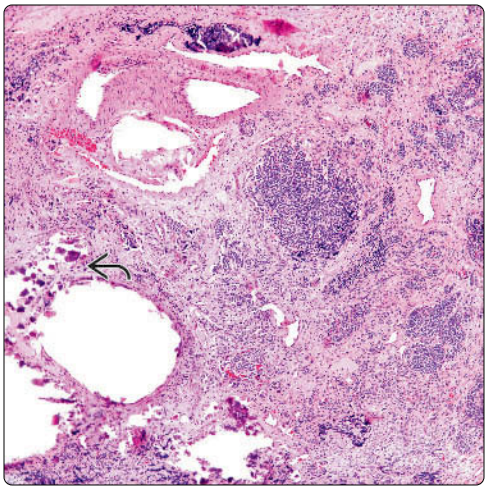

Vascular Involvement

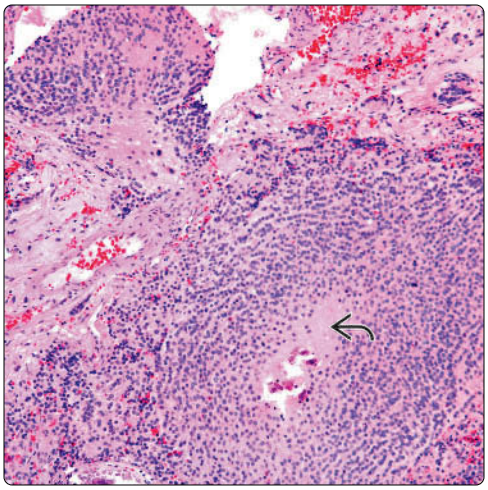

(Left) *Mediastinal NB shows a neoplastic cellular proliferation composed of small round blue cells. The tumor shows 2 uncommon features: Cystic changes and calcifications.* **(Right)** *Higher magnification shows a mediastinal NB with a concentric disposition of the tumor cells around a blood vessel. In the center, one can still see the presence of neuropil.*

Subtle Nested Pattern

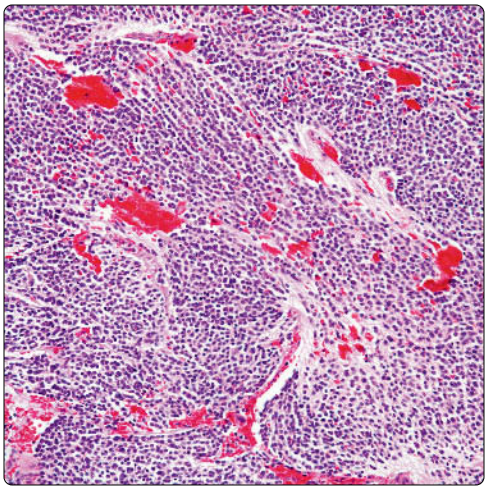

Crush Artifact

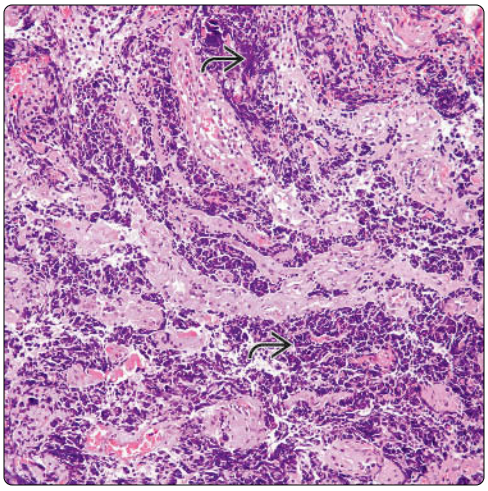

(Left) *Mediastinal NB shows sheets of cells with focal subtle nested areas. In addition, note that the presence of neuropil is not as obvious as it may be in some other cases.* **(Right)** *Mediastinal NB shows a marked crush artifact. The presence of a crush artifact is commonly seen in small cell carcinomas. Therefore, in this setting, the use of immunohistochemical studies is helpful in leading to the correct interpretation.*

Nested Pattern

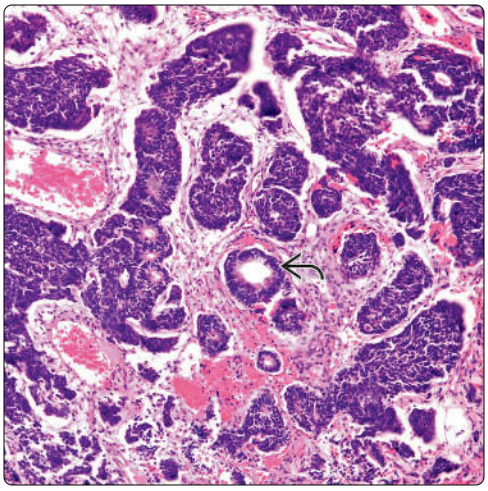

Rosettes

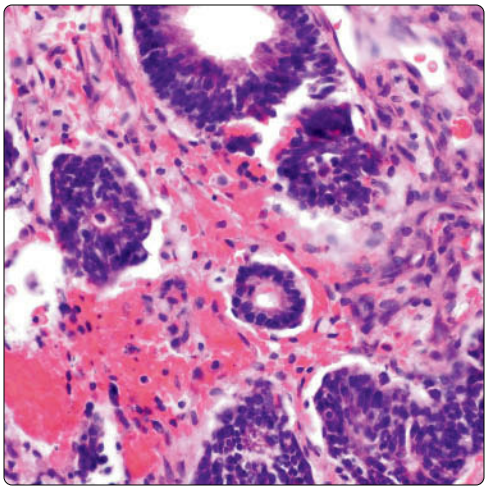

(Left) *Mediastinal NB dissecting fibroconnective tissue in a nested pattern is shown. The presence of rosettes can be identified and is an important feature in the diagnosis of NB. However, this pattern may also be seen in neuroendocrine carcinomas; thus, immunohistochemical studies would be helpful.* **(Right)** *Higher magnification of NB shows rosette-like structures embedded in fibroconnective tissue. This feature may be helpful in the diagnosis of NB.*

Anterior Mediastinal Tumor

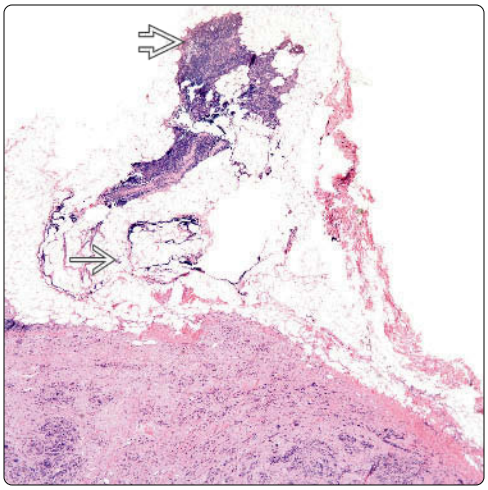

Thymic Tissue

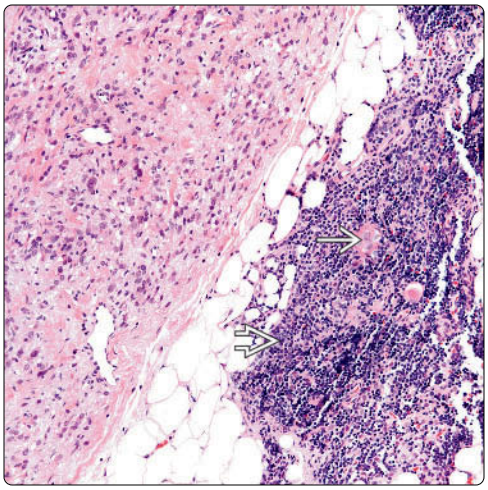

(Left) *Mediastinal GNB involving the thymus is shown. Note the well circumscription of the tumor and the adjacent adipose* ⇨ *and thymic tissue* ⇨. **(Right)** *Mediastinal GNB shows a well-circumscribed tumor in the anterior mediastinum. Note the presence of adjacent thymic tissue* ⇨ *with Hassall corpuscles* ⇨.

Cystic Thymus

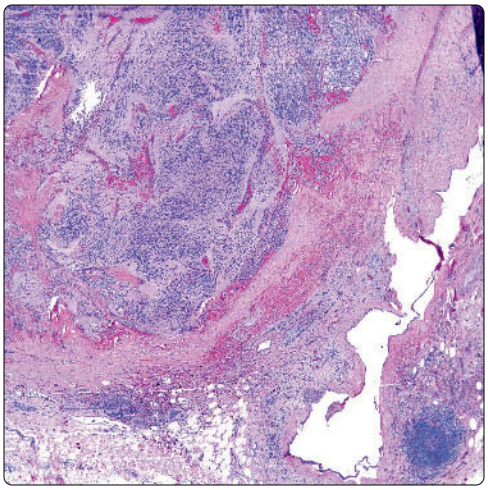

Residual Thymic Epithelium

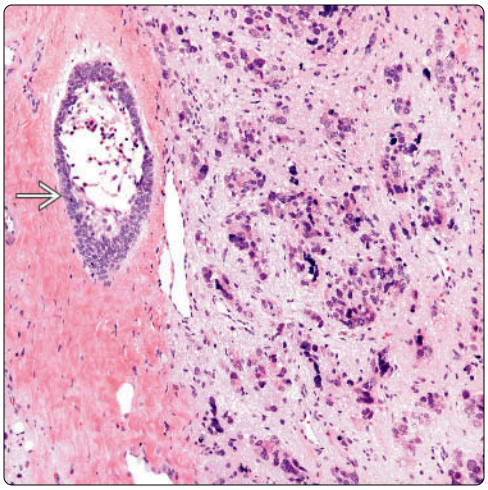

(Left) *Anterior mediastinal GNB shows the typical features of the tumor. Adjacent structures represent cystic changes in the thymic tissue with only a small focus of inflammatory changes.* **(Right)** *Anterior mediastinal GNB shows a small focus of a cystic structure, which represents residual thymic epithelium* ⇨.

Comedo-Like Necrosis

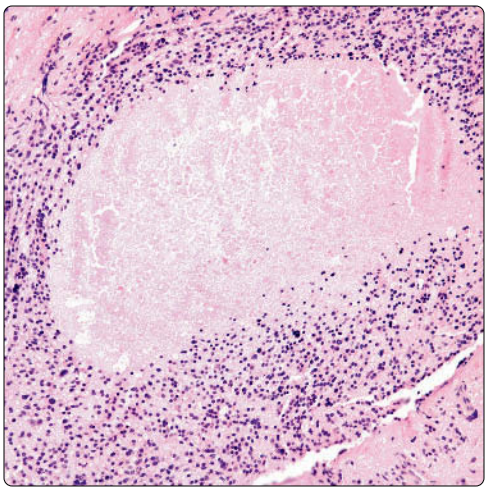

Classic Neuroblastoma

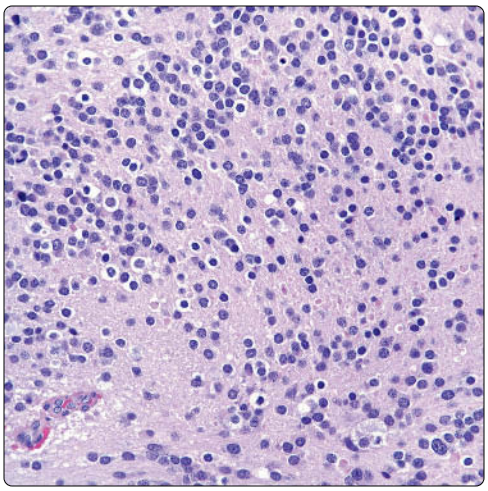

(Left) *Anterior mediastinal GNB shows areas composed only of neuroblastomatous elements with extensive comedo-like necrosis.* **(Right)** *Anterior mediastinal GNB with the classic component of NB in which there is a proliferation of small cells with scattered mitotic activity all embedded in neuropil rich stroma is shown.*

Ependymoma

KEY FACTS

TERMINOLOGY

- Neural neoplasm of possible intermediate malignant potential when in mediastinum

ETIOLOGY/PATHOGENESIS

- Probably derived from paravertebral ependymal rests

CLINICAL ISSUES

- Incidence
  - Ependymomas arising in mediastinum are rare
  - More common in adults with wide range of ages
  - More common in posterior mediastinum
- Symptoms
  - Cough
  - Chest pain
  - Dyspnea
  - Asymptomatic
- Prognosis
  - Mediastinal ependymomas may follow prolonged clinical course
  - Metastasis to lymph nodes may occur

ANCILLARY TESTS

- S100(-)
- GFA(+)
- Epithelial markers (-)

TOP DIFFERENTIAL DIAGNOSES

- Schwannoma
- Neuroendocrine carcinoma
- Metastatic melanoma

DIAGNOSTIC CHECKLIST

- Solid cellular proliferation
- True ependymal rosettes
- Pseudopapillary areas
- Variable mitotic rate
- Necrosis

Solid Areas

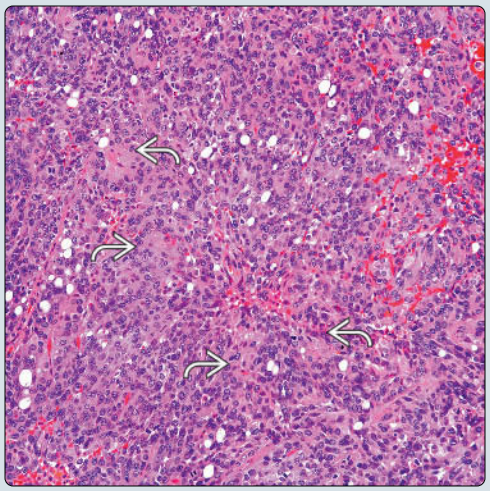

Papillary Areas

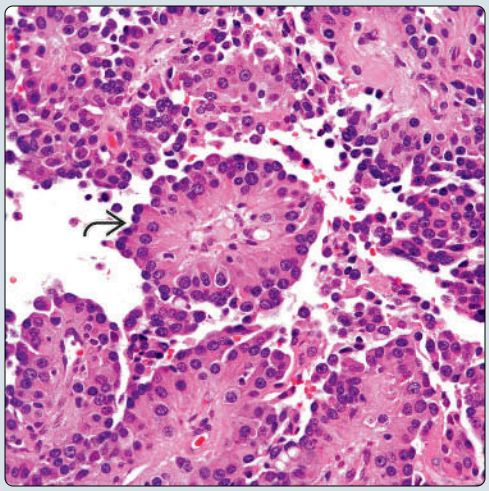

(Left) *Low-power view shows a mediastinal ependymoma with a solid cellular proliferation and the formation of rosettes. Note the presence of a rather homogeneous cellular proliferation.* **(Right)** *Higher magnification of a mediastinal ependymoma shows ependymal rosettes. This feature is important in the diagnosis of ependymoma.*

Neural Pattern

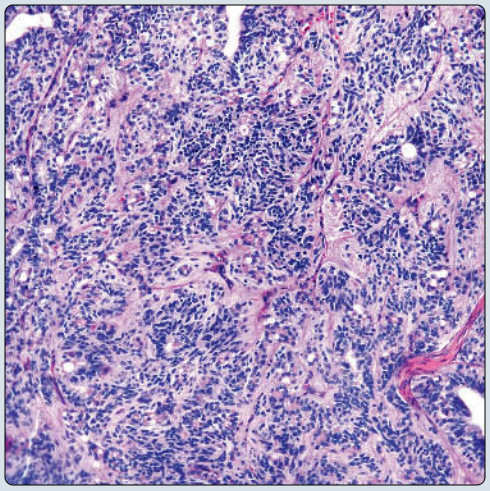

Hyalinization

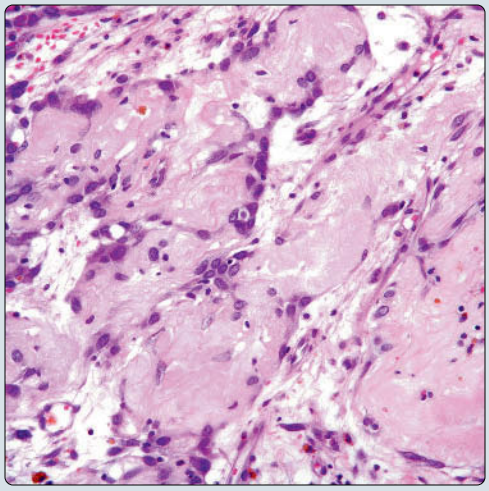

(Left) *Ependymoma shows the conventional classic neural growth pattern with rosette formation and areas of neuropil-like material.* **(Right)** *Ependymoma shows extensive areas of hyalinization. Note the presence of a cellular proliferation around the hyalinized material.*

TERMINOLOGY

Synonyms

- Myxopapillary ependymoma

Definitions

- Neural neoplasm of possible intermediate malignant potential when in mediastinum

ETIOLOGY/PATHOGENESIS

Pathogenesis

- Probably derived from paravertebral ependymal rests

CLINICAL ISSUES

Epidemiology

- Incidence
  - Ependymomas in mediastinum are very rare
- Age
  - More common in adults with wide range of ages
- Sex
  - No sex predilection

Site

- More common in posterior mediastinum

Presentation

- Cough, chest pain, dyspnea; asymptomatic

Treatment

- Surgical approaches
  - Complete surgical resection

Prognosis

- Mediastinal ependymomas may follow prolonged and indolent clinical course
- Metastasis to lymph nodes may occur

MACROSCOPIC

General Features

- Tumors are well circumscribed with glistening surface
- Solid on cut surface, but cystic changes may be seen
- Necrosis and hemorrhage may be seen
- Tan to gray in color

Size

- Variable size; may be > 7 cm in diameter

MICROSCOPIC

Histologic Features

- Solid, fairly uniform cellular proliferation that displays moderate atypia
- Cells with finely stippled to vesicular chromatin
- Perivascular pseudorosettes
- Interanastomosing ependymal tubules
- True ependymal rosettes and canals with ciliated cells
- Pseudopapillary areas
- Occasional psammoma bodies may be seen
- Mitotic activity variable, range from 1 to > 5 per 10 HPF
- Necrosis and hemorrhage may be present also in variable proportions, focal or extensive

DIFFERENTIAL DIAGNOSIS

Schwannoma

- Does not show increased mitotic activity
- Does not show presence of true ependymal rosettes
- Negative for GFAP

Neuroendocrine Carcinoma

- Negative for GFAP and strongly positive for keratin
- Shows positive staining for neuroendocrine markers (chromogranin &/or synaptophysin)
- True ependymal rosettes not seen in neuroendocrine Ca

Metastatic Melanoma

- True ependymal rosettes are not seen in melanomas
- Strong positive staining for S100 protein &/or HMB-45
- Shows negative staining for GFAP

DIAGNOSTIC CHECKLIST

Pathologic Interpretation Pearls

- Solid cellular proliferation, true ependymal rosettes, pseudopapillary areas, variable mitotic rate

GRADING

Anaplastic Ependymoma

- This designation has been given to tumors with increased mitotic activity, necrosis, and cellular atypia

SELECTED REFERENCES

1. Wilson RW et al: Primary ependymoma of the mediastinum: a clinicopathologic study of three cases. Ann Diagn Pathol. 2(5):293-300, 1998

Immunohistochemistry

Antibody	Reactivity	Staining Pattern	Comment
GFAP	Positive	Cytoplasmic	Strong positive staining
S100	Negative		May show focal and weak positivity
CK-PAN	Negative		May be occasionally focally positive
Chromogranin-A	Negative		
Synaptophysin	Negative		
HMB-45	Negative		

Solid Areas

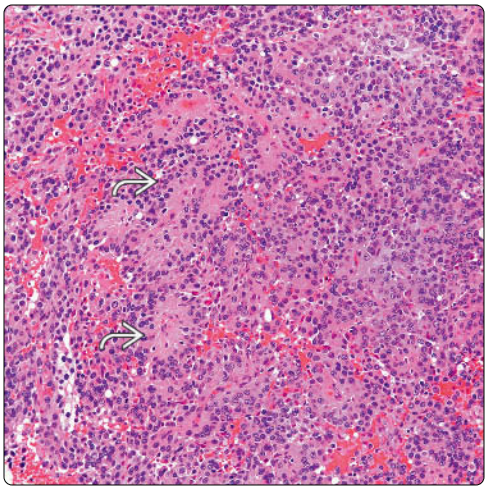

Myxoid Areas

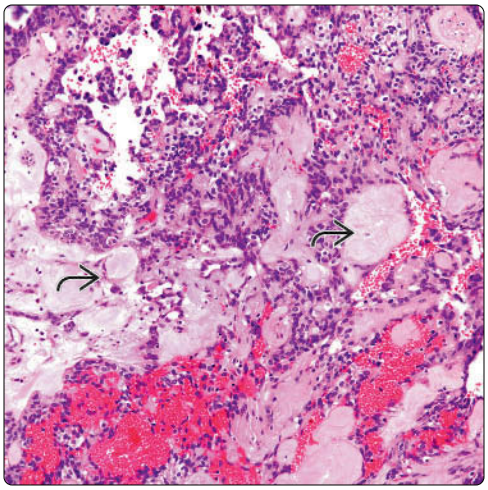

(Left) *Mediastinal ependymoma displays prominent rosettes. This type of differentiation is highly suggestive of a neural neoplasm.* **(Right)** *Mediastinal ependymoma displays extensive areas of hyalinization admixed with a cellular proliferation arranged in a papillary-like growth pattern.*

Papillary Areas

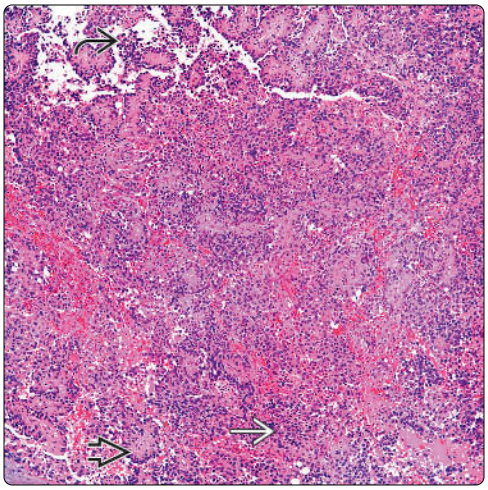

Solid and Papillary Areas

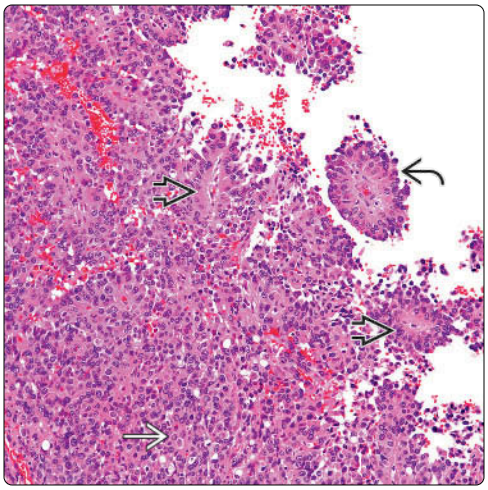

(Left) *Mediastinal ependymoma displays solid areas, rosettes, and papillary-like areas. This constellation of features makes the diagnosis easier.* **(Right)** *Higher magnification of mediastinal ependymoma is shown with solid areas of a homogeneous cellular proliferation, areas of papillary-like structures, and ependymal rosettes.*

Mitotic Activity

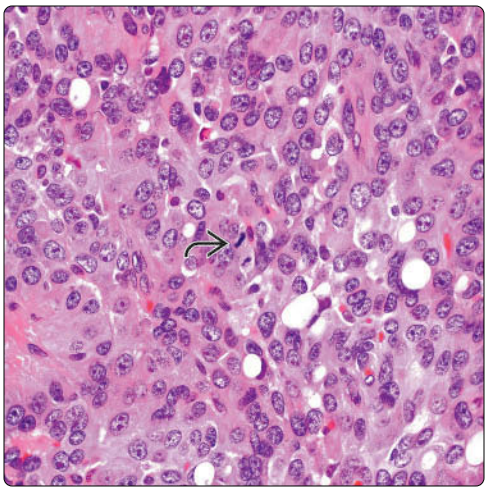

Degenerative Changes

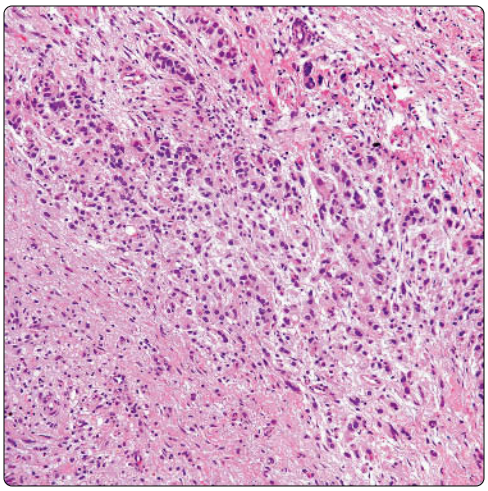

(Left) *High-power view shows a solid area in a mediastinal ependymoma with a rather homogeneous cellular proliferation. There is moderate nuclear pleomorphism and mitotic activity.* **(Right)** *Mediastinal ependymoma is shown with myxoid changes and a cellular proliferation without a particular growth pattern. This feature may also be seen in other more common tumors like carcinomas.*

Extensive Necrosis

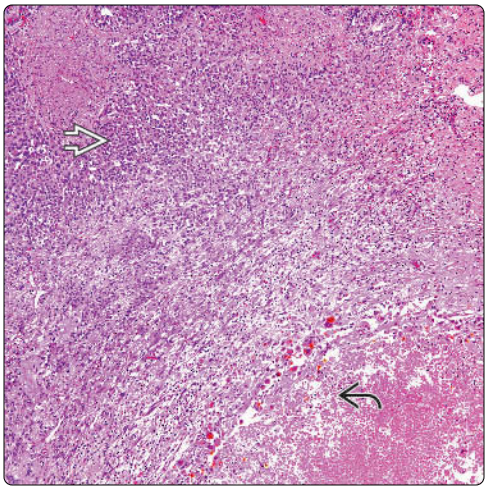

Necrosis and Viable Tumor

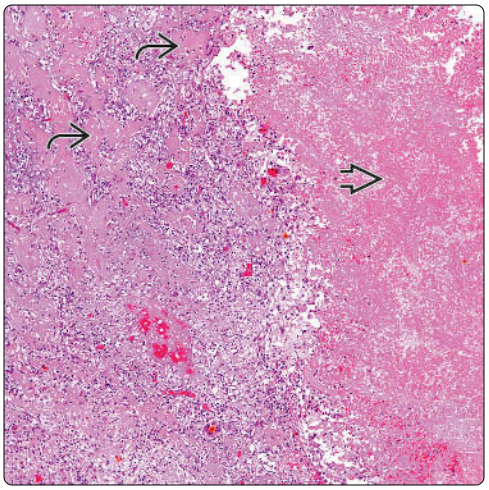

(Left) *Mediastinal ependymoma shows areas of viable tumor embedded in fibroconnective tissue with chronic inflammation. Note the presence of a necrotic area that in some cases may obscure the neoplastic proliferation.* **(Right)** *Mediastinal ependymoma is seen with areas of hemorrhage and adjacent areas of a neoplastic cellular proliferation admixed with fibrinoid material.*

Prominent Papillary Areas

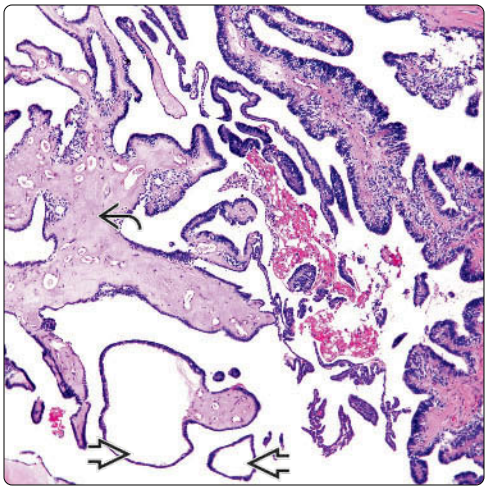

Papillary Areas

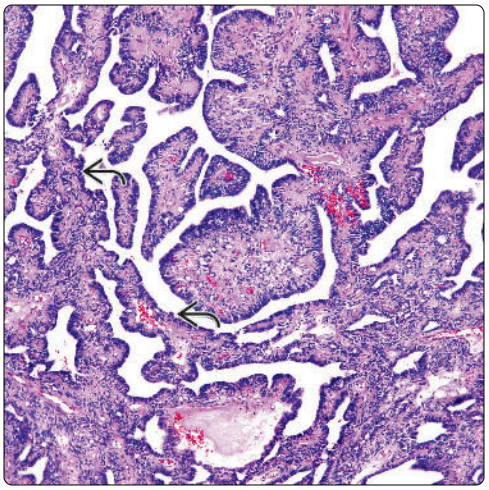

(Left) *Mediastinal ependymoma with prominent papillary-like structures and areas of hyalinization is shown. Some of these papillary-like structures may be devoid of fibrovascular cores.* **(Right)** *Mediastinal ependymoma is shown with papillary features in which there are anastomosing papillary structures with a more complex pattern. Inside these papillary structures there is a homogeneous cellular proliferation.*

Areas of Neuropil

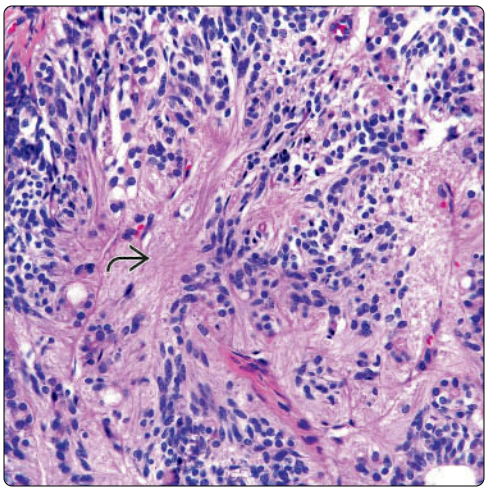

Rosettes

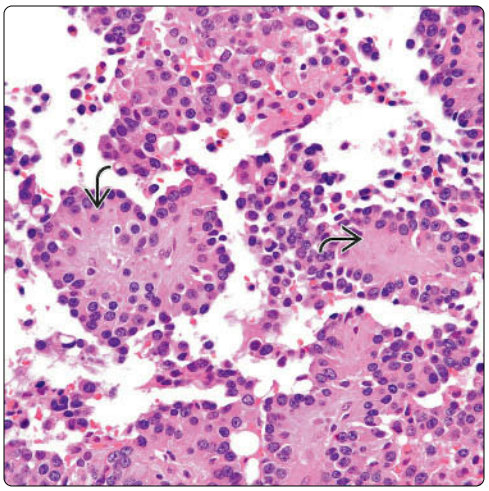

(Left) *Mediastinal ependymoma with prominent neuropil contents is admixed with a small cellular proliferation. These features may also be seen in neuroblastomas.* **(Right)** *Mediastinal ependymoma is shown with prominent ependymal rosettes. This feature is helpful in the diagnosis of ependymoma.*

Ectopic Parathyroid Tumor

KEY FACTS

CLINICAL ISSUES

- Incidence
  - Among the rarest neuroendocrine tumors in mediastinum
  - Usually in adults
- Symptoms
  - Chest pain
  - Cough
  - Dyspnea
  - Hyperparathyroidism
  - Kidney stones

TOP DIFFERENTIAL DIAGNOSES

- Well-differentiated neuroendocrine carcinoma (carcinoid tumor)
  - Neuroendocrine carcinoma and ectopic parathyroid tumors may share similar immunophenotype
  - Parathyroid hormone immunohistochemistry is more commonly seen in ectopic parathyroid tumors
- Paraganglioma
  - Generally negative for keratin stains
- Thymic carcinoma
  - Negative for neuroendocrine markers, including parathyroid hormone

DIAGNOSTIC CHECKLIST

- Symptom complex
- Oncocytic cellular proliferation
- Chief cells
- Mixed oncocytic and chief cells
- In adenomas, lack of mitotic activity
- In carcinomas, presence of mitosis, hemorrhage, &/or necrosis

Thymic Parathyroid Adenoma

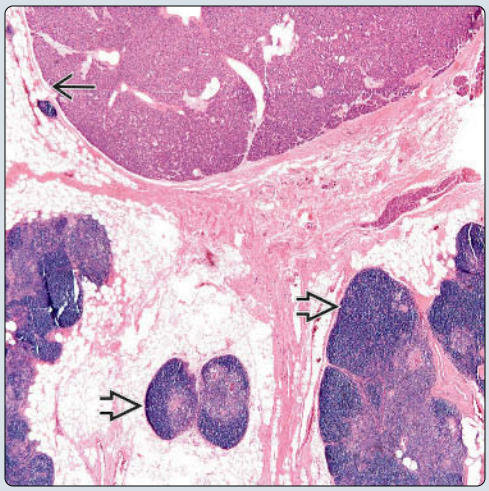

Oncocytic Features

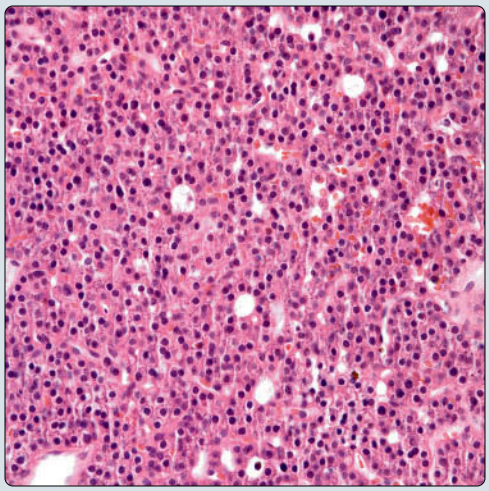

(Left) *Well-circumscribed tumor nodule ⇨ is shown with adjacent areas of adipose and fibroconnective tissue. Note the presence of thymic tissue ⇨.* **(Right)** *Thymic parathyroid adenoma shows prominent oncocytic features. The tumors show a homogeneous cellular proliferation with absence of cellular atypia or mitotic activity.*

Clear Cell Change

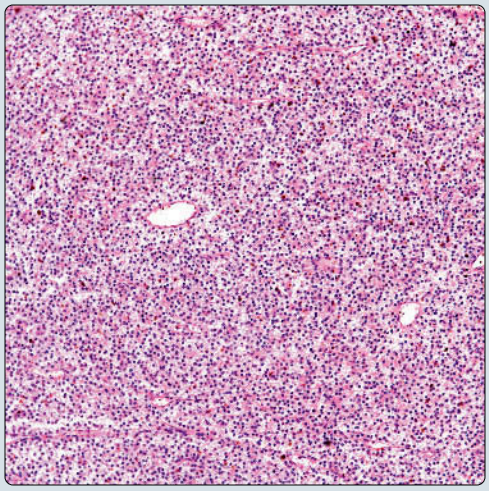

Glycogen Content

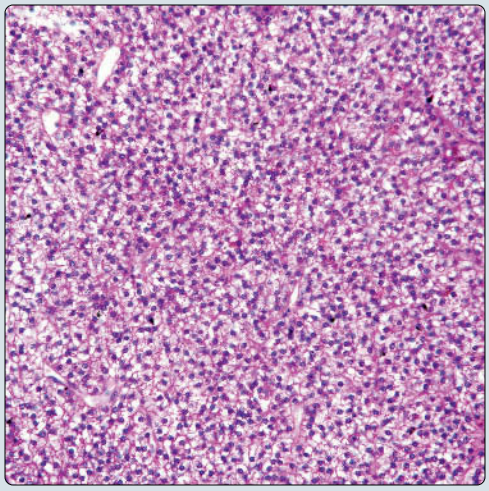

(Left) *Thymic parathyroid adenoma shows sheets of cells with prominent clear cell features. Note the presence of a homogeneous cellular proliferation with scattered ectatic vessels.* **(Right)** *PAS-D stain of thymic parathyroid adenoma shows the presence of glycogen in a predominantly clear cell adenoma.*

TERMINOLOGY

Definitions

- Neuroendocrine tumors of mediastinum

ETIOLOGY/PATHOGENESIS

Developmental Anomaly

- Embryological development of parathyroid glands
- Glands are derived from 3rd and 4th pharyngeal pouches

CLINICAL ISSUES

Epidemiology

- Incidence
  - Among rarest neuroendocrine tumors in mediastinum
- Age
  - Usually in adults
- Sex
  - No sex predilection

Site

- Anterior mediastinum (more common)
- Posterior mediastinum (less common)

Presentation

- Chest pain
- Cough
- Dyspnea
- Hyperparathyroidism
- Kidney stones
- Osteitis cystica

Laboratory Tests

- Calcium, phosphorus

Treatment

- Surgical approaches
  - Complete surgical resection
  - Possible exploration of neck
  - Possible 5th parathyroid
- Adjuvant therapy
  - In cases of ectopic parathyroid carcinoma

Prognosis

- Good in cases of parathyroid adenoma
- Number of mediastinal parathyroid carcinomas is not significant enough to determine outcome

IMAGING

General Features

- Anterior mediastinal tumor
- Posterior mediastinal tumor

MACROSCOPIC

General Features

- Light brown, soft tissue tumor
- Hemorrhage and necrosis may be present

Size

- Variable and can reach > 10 cm in diameter

MICROSCOPIC

Histologic Features

- Oncocytic cellular proliferation
- Chief cells
- Mixed oncocytic and chief cells
- Cystic changes
- Mild nuclear atypia
- Mitotic figures in cases of carcinoma
- Presence of necrosis in carcinoma
- Presence of hemorrhage in carcinoma
- Extensive fibrous bands in carcinoma
- Infiltrative growth pattern in carcinoma
- In unusual cases, parathyroid adenoma may be encountered in association with thymoma

DIFFERENTIAL DIAGNOSIS

Well-Differentiated Neuroendocrine Carcinoma (Carcinoid Tumor)

- Neuroendocrine carcinoma and ectopic parathyroid tumors may share similar immunophenotype
- Parathyroid hormone immunohistochemistry is more commonly seen in ectopic parathyroid tumors
- Clinical presence of disturbances in calcium metabolism is more in keeping with parathyroid tumors
- PAS is more likely to show positive staining in parathyroid tumors

Paraganglioma

- Generally negative for keratin stains
- Show more nuclear pleomorphism
- Mitotic activity is absent or scattered
- Necrosis is unusual in paragangliomas

Thymic Carcinoma

- Negative for neuroendocrine markers, including parathyroid hormone
- Thymic carcinoma is usually keratin 5/6 positive
- Unusual cases of thymic squamous cell carcinoma can secrete PTH

Mediastinal Lymphoma

- Mediastinal lymphomas may show striking clear cell morphology
- Unusual cases of PTH secretion in mediastinal lymphomas have been documented
- Lymphomas will show negative staining for keratin and neuroendocrine markers

Thymoma

- Unusual cases of thymoma may be associated with parathyroid adenoma
- Thymoma will show lobulation
- Thymoma shows negative staining for neuroendocrine markers

DIAGNOSTIC CHECKLIST

Clinically Relevant Pathologic Features

- Symptom complex
- Hyperparathyroidism

Immunohistochemistry

Antibody	Reactivity	Staining Pattern	Comment
CK-PAN	Positive	Cytoplasmic	Not specific
CK8/18/CAM5.2	Positive	Cytoplasmic	Not specific
CK5/6	Negative		
pax-8	Positive	Nuclear	In some cases
Chromogranin-A	Positive	Cytoplasmic	Also positive in other neuroendocrine tumors
Synaptophysin	Positive	Cytoplasmic	Also positive in other neuroendocrine tumors
CD56	Positive	Cytoplasmic	
PTH	Positive	Cytoplasmic	Has been focally positive in other neuroendocrine tumors
TTF-1	Negative		
CEA-M	Negative		
p40	Negative		
p63	Negative		
GATA3	Negative		
S100	Negative		
NAPSIN-A	Negative		
Ki-67	Negative		In cases of adenomas
Ki-67	Positive	Nuclear	High labeling in cases of carcinoma

Histochemical Features

Stain	Result
PAS	Positive
PAS-D	Negative
Mucicarmine	Negative
Grimelius	Negative

Ultrastructural Features

Electron Microscopy
Presence of neurosecretory granules
Presence of glycogen

Pathologic Interpretation Pearls

- Oncocytic cellular proliferation
- Chief cells
- Cystic changes
- Mixed oncocytic and chief cells
- In adenomas, lack of mitotic activity
- In carcinomas, presence of mitosis, hemorrhage, &/or necrosis

SELECTED REFERENCES

1. Hu J et al: Mediastinal parathyroid adenomas and their surgical implications. Ann R Coll Surg Engl. 97(4):259-61, 2015
2. Buderi SI et al: Endobronchial ultrasound-guided biopsy to diagnose large posterior mediastinal parathyroid adenoma prior to video-assisted thoracoscopic resection. BMJ Case Rep. 2014, 2014
3. Cunningham LC et al: Thymoma and parathyroid adenoma: false-positive imaging and intriguing laboratory test results. JAMA Otolaryngol Head Neck Surg. 140(4):369-73, 2014
4. Liman ST et al: Excision of ectopic mediastinal parathyroid adenoma via parasternal videomediastinoscopy. Ann Thorac Cardiovasc Surg. 20(1):67-9, 2014
5. Wang G et al: A case of primary hyperparathyroidism due to ectopic parathyroid adenoma in the thymus, accompanied with vitamin D deficiency. J Clin Endocrinol Metab. 98(6):2218-22, 2013
6. Yoon V et al: Ectopic atypical parathyroid lipoadenoma: a rare cause of severe primary hyperparathyroidism. J Bone Miner Metab. 31(5):595-600, 2013
7. Burger AE et al: Thoracoscopic excision of mediastinal parathyroid adenomas: a report of two cases. Ann R Coll Surg Engl. 90(2):W1-5, 2008
8. Ravipati NB et al: Anterior mediastinotomy for parathyroidectomy. Am J Surg. 195(6):799-802, 2008
9. Righi A et al: Mediastinal parathyroid carcinoma with tumor implants in a child: a unique occurrence. Int J Surg Pathol. 16(4):458-60, 2008
10. Moran CA et al: Primary parathyroid tumors of the mediastinum: a clinicopathologic and immunohistochemical study of 17 cases. Am J Clin Pathol. 124(5):749-54, 2005
11. Moran CA: Primary neuroendocrine carcinomas of the mediastinum: review of current criteria for histopathologic diagnosis and classification. Semin Diagn Pathol. 22(3):223-9, 2005
12. Yoshiike F et al: Thymic squamous cell carcinoma producing parathyroid hormone-related protein and CYFRA 21-1. Intern Med. 43(6):493-5, 2004
13. Hsiao LT et al: Superior vena cava syndrome and hypercalcaemia in a patient with a primary mediastinal B-cell lymphoma secreting parathyroid hormone-related protein. Br J Haematol. 119(1):1, 2002

Remnants of Thymic Tissue

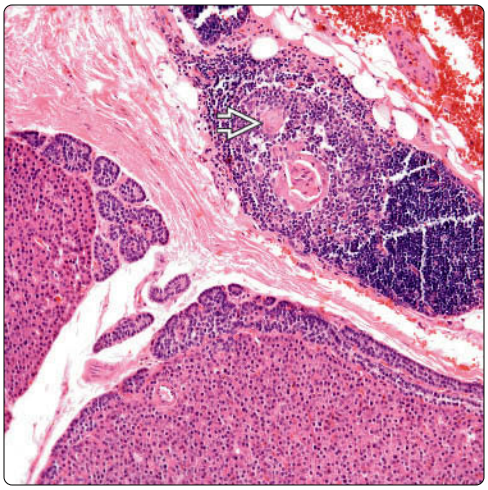

Mixed Cellular Features

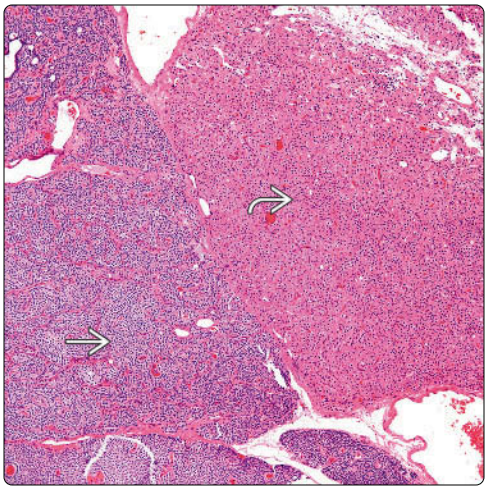

(Left) *Thymic parathyroid adenoma shows the periphery small remnants of thymic tissue. Note the presence of Hassall corpuscles.* **(Right)** *Ectopic parathyroid adenoma shows 2 cell populations composed of chief cells and oncocytic cells. These histological features recapitulate the normal cells of the parathyroid glands.*

Clear Cell Change

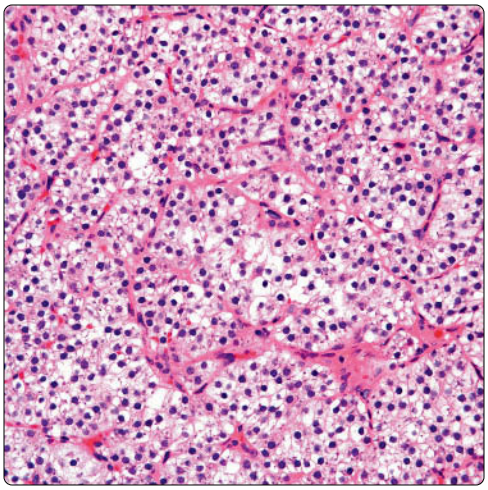

Degenerative Changes

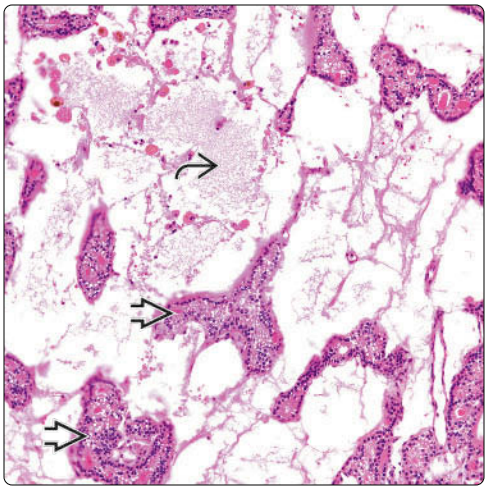

(Left) *Ectopic parathyroid adenoma in the mediastinum shows prominent chief cells composed of round cells with clear cytoplasm, round nuclei, and inconspicuous nucleoli. The cellular proliferation is homogeneous without necrosis or mitotic activity.* **(Right)** *Ectopic parathyroid adenoma of the mediastinum is seen with an edematous component in the background. Note the presence of islands of tumor cells floating in the edematous component.*

Angiectatic Changes

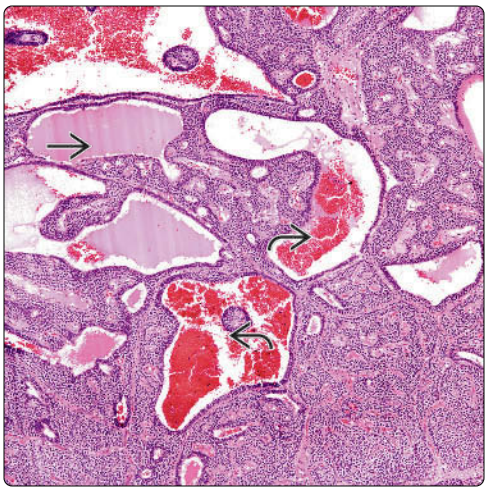

Extensive Hyalinization

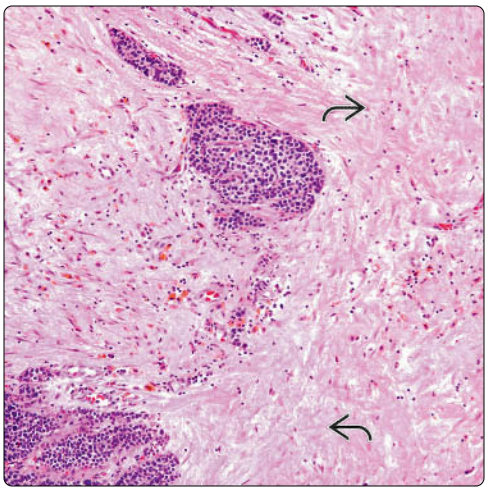

(Left) *Ectopic parathyroid adenoma in the mediastinum with angiectatic-like features is composed of large spaces filled with blood or acellular colloid material. Similar features have been described in neuroendocrine carcinomas of the thymus.* **(Right)** *Ectopic parathyroid adenoma in the mediastinum is shown with extensive hyalinization of the stroma and only small islands of tumor cells. Similar features have been described in paragangliomas.*

Solid and Focal Gland-Like Areas

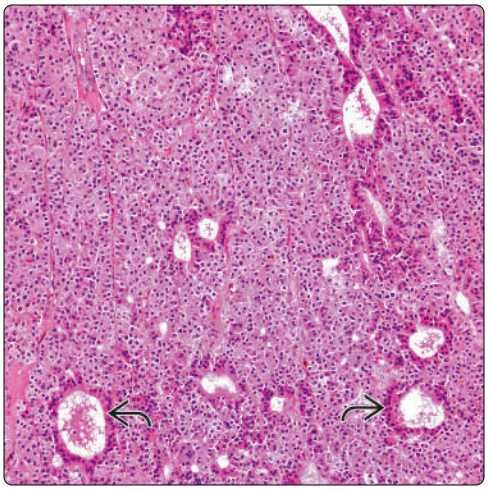

Pseudoglandular Features

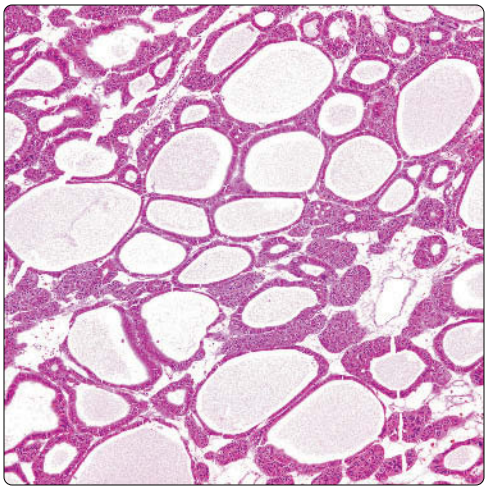

(Left) *Ectopic parathyroid adenoma shows a prominent solid growth pattern with only focal areas of pseudoglandular component. In addition, the cellular proliferation has prominent oncocytic features.* **(Right)** *Ectopic parathyroid adenoma shows a pseudoglandular or alveolar growth pattern. Also note the prominent oncocytic features of the cellular proliferation.*

Solid and Organoid Features

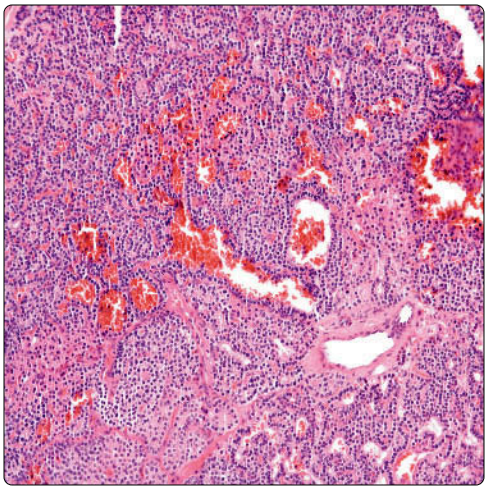

Clear Cells and Hyalinization

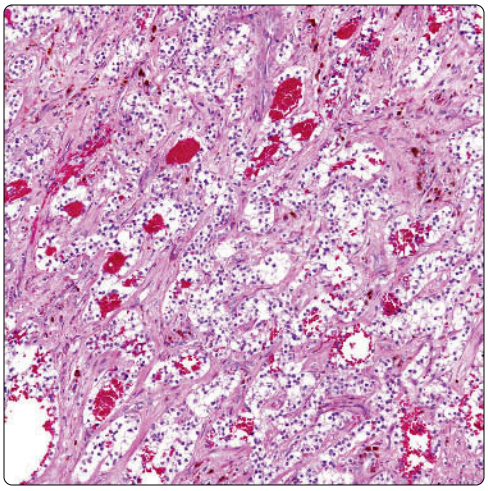

(Left) *Thymic parathyroid adenoma shows a solid and nested proliferation of cells with focal areas of extravasated red cells. The tumor is composed mainly of clear cells.* **(Right)** *Thymic parathyroid adenoma shows nested growth pattern composed of clear cells and separated by thick, fibroconnective tissue.*

Solid and Organoid Features

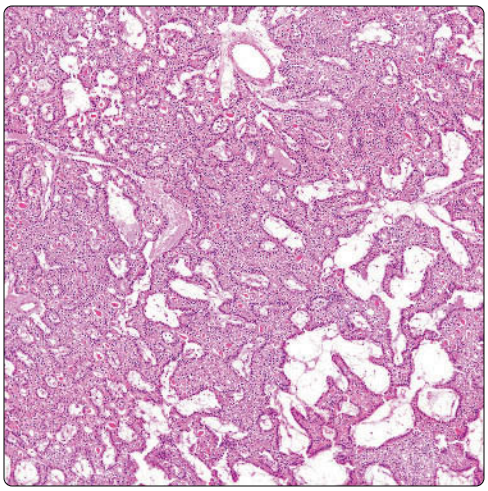

Organoid Features

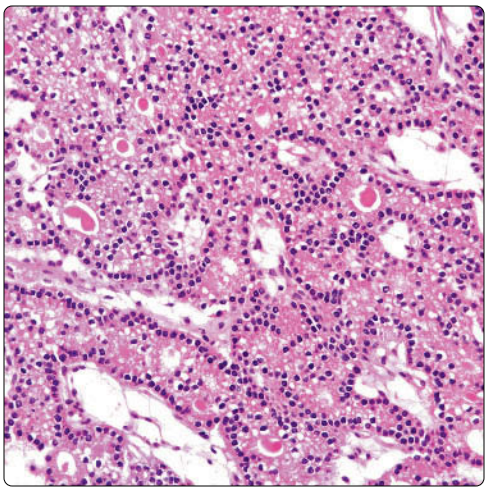

(Left) *Low-power view shows an ectopic parathyroid adenoma of the mediastinum. The histology recapitulates the features of a normal parathyroid tissue.* **(Right)** *High-power view of a parathyroid adenoma of the mediastinum is shown. The tumor shows a striking neuroendocrine morphology with a homogeneous cellular proliferation.*

Thymic Parathyroid Carcinoma

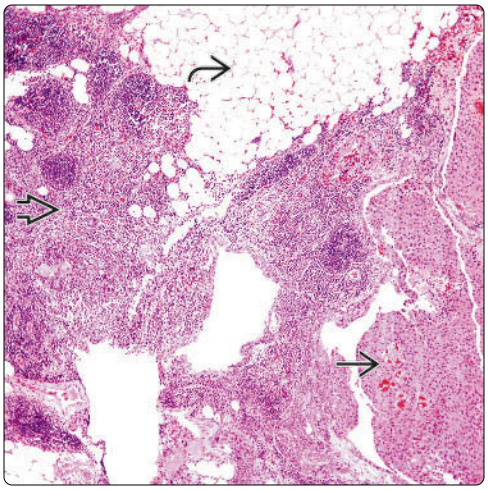

Extensive Necrosis

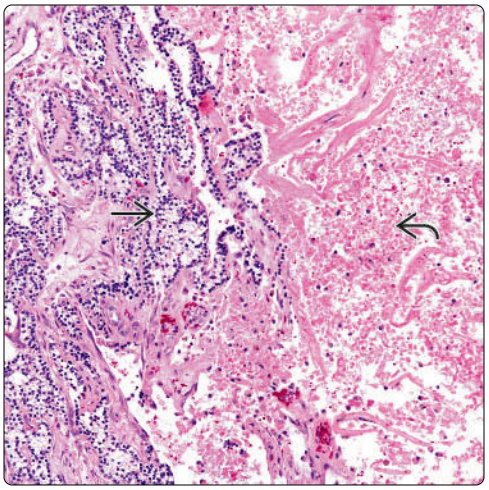

(Left) *Ectopic parathyroid carcinoma of the mediastinum shows areas of residual thymic tissue ⇨, including mature adipose tissue ⇨ and an area of an atypical epithelial cellular proliferation ⇨.* **(Right)** *Ectopic parathyroid carcinoma shows areas of necrosis ⇨ alternating with viable areas of parathyroid ⇨. The presence of necrosis is an important feature in cases of parathyroid carcinoma.*

Homogeneous Cellular Proliferation

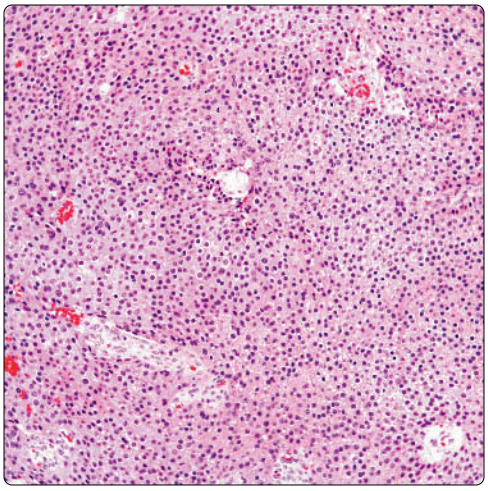

Sheets of Neoplastic Cells

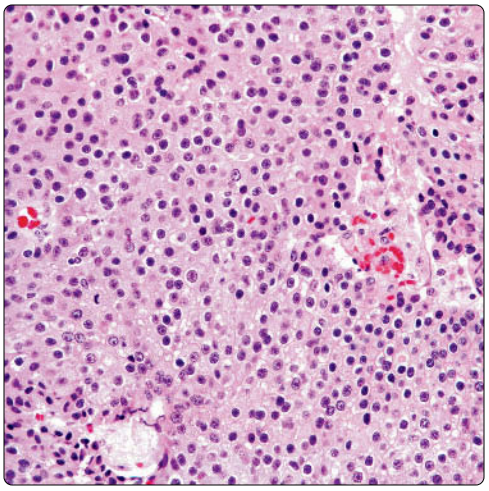

(Left) *High-power view of an ectopic parathyroid carcinoma of the mediastinum shows sheets of epithelial cells with a homogeneous growth pattern. Such cellular proliferation may be seen in other thymic epithelial tumors.* **(Right)** *High-power view of an ectopic parathyroid carcinoma is shown with a cellular proliferation displaying cells with irregular nuclear contours and mitotic activity. Mitoses and necrosis are features of carcinomas.*

Solid Growth Pattern

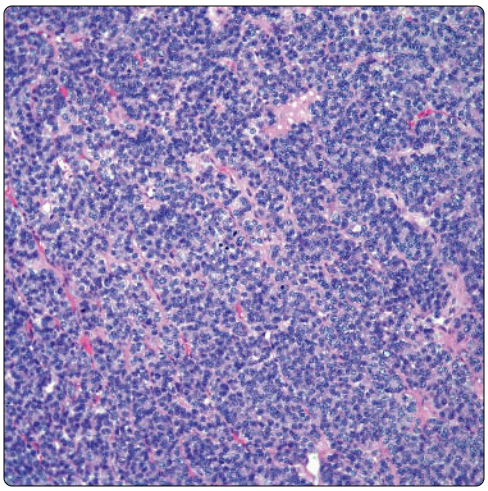

Mitotic Activity

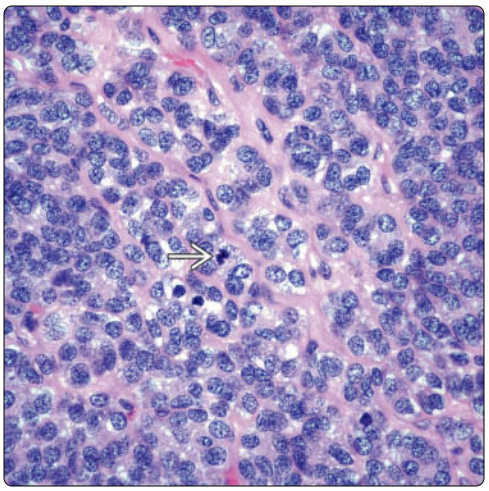

(Left) *Thymic parathyroid carcinoma shows a solid growth pattern with only subtle nested features. Note the presence of nuclear atypia.* **(Right)** *Solid growth pattern of a thymic parathyroid carcinoma shows nuclear atypia and easily identifiable mitotic figures ➡.*

Ectopic Thyroid Tumor

KEY FACTS

CLINICAL ISSUES

- Anterior superior mediastinum; rarely in posterior mediastinum
- Shortness of breath
- Symptoms of hyperparathyroidism
- May be asymptomatic and discovered incidentally on routine chest x-rays
- Majority of lesions are cured by simple excision
- Malignant tumors may recur and metastasize

MACROSCOPIC

- Generally well circumscribed, encapsulated, and multilobulated
- Malignant neoplasms may be poorly circumscribed and infiltrate adjacent structures

MICROSCOPIC

- Hyperplastic thyroid nodules are ill-defined, unencapsulated, and composed of normal follicular structures
- May contain focal papillary structures, calcifications, and intraluminal follicular proliferations (Sanderson polsters)
- Rarely, follicular or papillary carcinoma may arise from ectopic thyroid elements
- Follicular carcinoma shows follicles with invasion of capsule and blood vessels
- Papillary carcinoma is characterized by usual nuclear features of this tumor in thyroid
- Medullary carcinoma, anaplastic carcinoma, and poorly differentiated ("insular") carcinoma can also arise in mediastinum

Multinodular Ectopic Thyroid

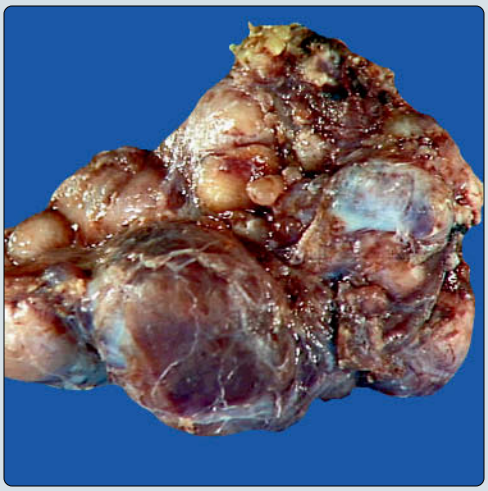

Ectopic Thyroid in Mediastinum

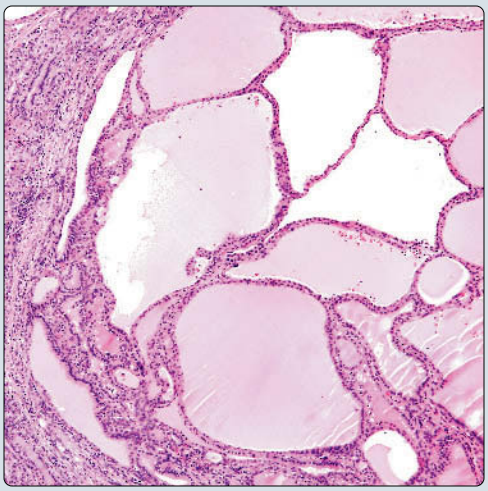

(Left) *Gross appearance of an ectopic mediastinal goiter shows a tan-brown, multinodular mass covered by a thin, shiny capsule with confluence of multiple, soft nodules of varying sizes.* **(Right)** *Histologic appearance of a mediastinal hyperplastic goiter shows distended follicles filled with colloid, forming an ill-defined nodule.*

Degenerative Changes

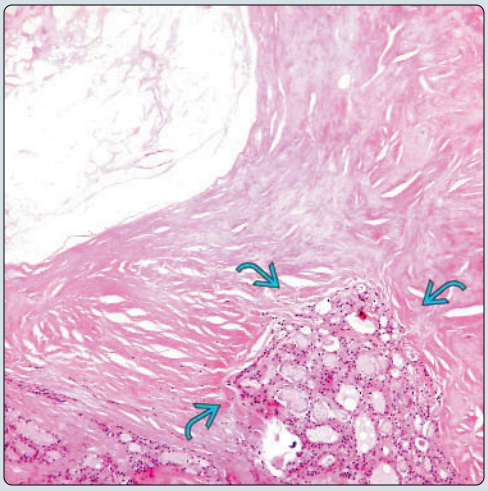

Sanderson Polster

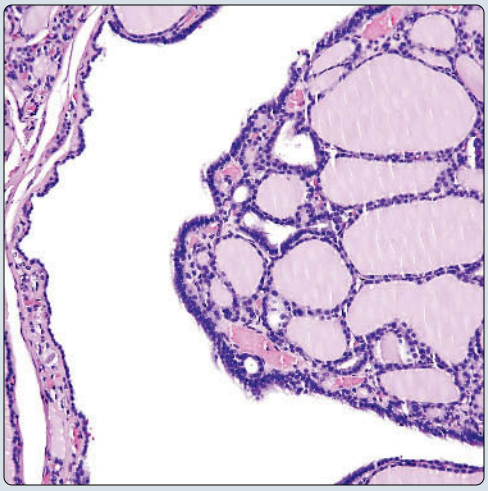

(Left) *Cystic degeneration and extensive stromal sclerosis is seen in an ectopic mediastinal thyroid. Note the residual focus of hyperplastic thyroid entrapped by the fibrosing process.* **(Right)** *Close up of dilated follicle in ectopic thyroid hyperplasia in the mediastinum shows a proliferation of small follicles protruding into the lumen of a dilated thyroid follicle, characteristic of thyroid nodular hyperplasia.*

TERMINOLOGY

Definitions

- Proliferation of thyroid tissue originating from displaced or ectopically located elements in mediastinum

ETIOLOGY/PATHOGENESIS

Developmental Anomaly

- May result from abnormal migration during embryogenesis

CLINICAL ISSUES

Epidemiology

- Age
  - Adults; increases in frequency with advancing age
- Sex
  - More common in females (M:F = 1:3)

Site

- Anterior superior mediastinum; rarely in posterior mediastinum

Presentation

- Shortness of breath
- Cough & dysphagia due to compression of esophagus
- Dyspnea, wheezing, and stridor due to compression of trachea
- Dysphonia may occur due to compression of recurrent laryngeal nerve
- May be asymptomatic and discovered incidentally on routine chest x-rays

Treatment

- Surgical excision

IMAGING

General Features

- Tracheal deviation at level of thoracic outlet
- Involvement of superior mediastinum with extension into neck
- Coarse calcifications in cyst walls in up to 75% of cases
- Best imaging tool is chest x-ray with confirmation by CT scan

MACROSCOPIC

General Features

- Generally well circumscribed, encapsulated, and multilobulated
- Malignant neoplasms may be poorly circumscribed and infiltrate adjacent structures

MICROSCOPIC

Histologic Features

- **Thyroid tumors**
  - Thyroid nodular hyperplasia
    - Ill-defined, unencapsulated nodules composed of normal follicular structures
    - May show abundant regressive changes, including fibrous pseudocapsule, hemorrhage, and cystic degeneration
    - May contain focal papillary structures, calcifications, and intraluminal follicular proliferations (Sanderson polsters)
    - Rare cases may show local recurrence and infiltration of surrounding soft tissues
  - Thyroid carcinoma
    - Rarely, follicular or papillary carcinoma may arise from displaced thyroid elements
    - Medullary carcinoma, anaplastic carcinoma, and poorly differentiated ("insular") carcinoma can also arise in mediastinum
    - Well-differentiated thyroid follicular and papillary neoplasms are positive for thyroglobulin and TTF-1

DIFFERENTIAL DIAGNOSIS

Mediastinal Paraganglioma

- Prominent nesting pattern (zellballen) with fibrovascular septa
- May show nucleomegaly with atypia but no mitotic activity
- Stains positively for neuroendocrine markers (chromogranin, synaptophysin) but is negative for cytokeratins, thyroglobulin, and TTF-1

Neuroendocrine Carcinomas

- Well-differentiated neuroendocrine carcinoma (carcinoid tumor) can show nesting, solid, acinar, or trabecular pattern
- Cells can be very uniform and closely resemble thyroid or parathyroid neoplasms
- Tumor cells are positive for neuroendocrine markers but negative for thyroglobulin or TTF-1

Metastases of Clear Cell Tumors

- Metastatic clear cell carcinomas can in some instances resemble thyroid tumors
- Clinical history is indispensable for adequate interpretation
- Special stains for thyroglobulin or TTF-1 may be of help in identifying correct cell type

Teratomatous Lesions

- Usually contain elements derived from all 3 germ cell layers, including neural, epithelial, and mesenchymal components
- Teratomas only rarely display mature thyroid epithelium

DIAGNOSTIC CHECKLIST

Pathologic Interpretation Pearls

- Residual, normal, involuting thymus is often present in vicinity of tumor
- Ectopic thyroid lesions in mediastinum are more likely to be benign and hyperplastic

SELECTED REFERENCES

1. Hedayati N et al: The clinical presentation and operative management of nodular and diffuse substernal thyroid disease. Am Surg. 68(3):245-51; discussion 251-2, 2002
2. Dominguez-Malagon H et al: Ectopic poorly differentiated (insular) carcinoma of the thyroid. Report of a case presenting as an anterior mediastinal mass. Am J Clin Pathol. 104(4):408-12, 1995
3. Spinner RJ et al: Thoracic intrathymic thyroid. Ann Surg. 220(1):91-6, 1994
4. Kozol RA et al: Management of ectopic thyroid nodules. Surgery. 114(6):1103-6; discussion 1106-7, 1993
5. Wick MR: Mediastinal cysts and intrathoracic thyroid tumors. Semin Diagn Pathol. 7(4):285-94, 1990

Ectopic Mediastinal Thyroid

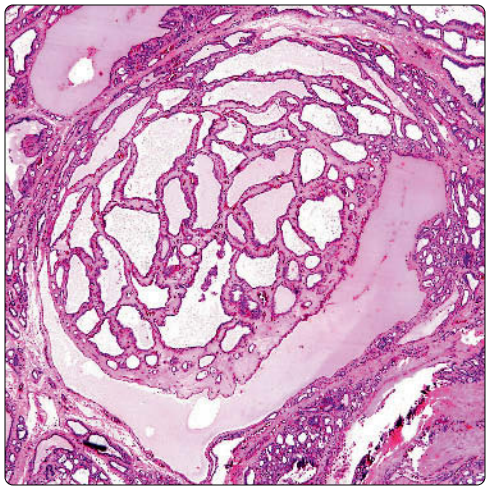

Sanderson Polsters in Ectopic Thyroid

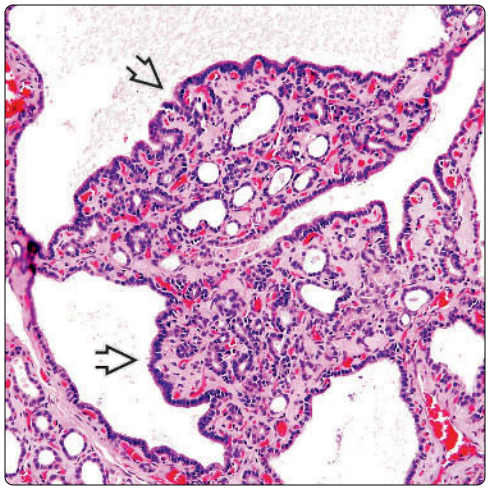

(Left) *Ectopic thyroid tissue in the mediastinum shows features of nodular hyperplasia with well-circumscribed but unencapsulated nodules composed of dilated thyroid follicles of varying sizes.* **(Right)** *High magnification of a dilated follicle in an ectopic mediastinal thyroid shows proliferation of small follicles. These structures (Sanderson polsters) are quite distinctive for nodular hyperplasia of the thyroid.*

Hurthle Cell Changes in Ectopic Thyroid

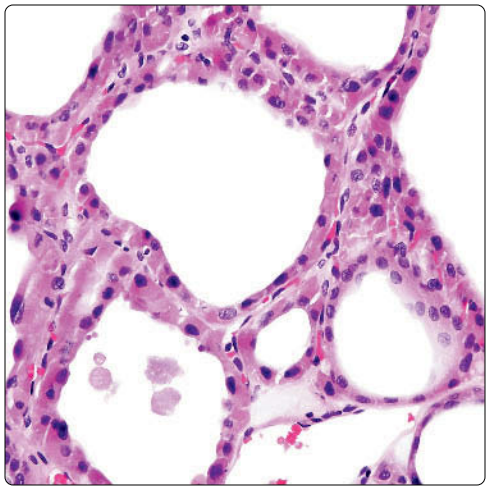

Cholesterol Cleft Granulomas

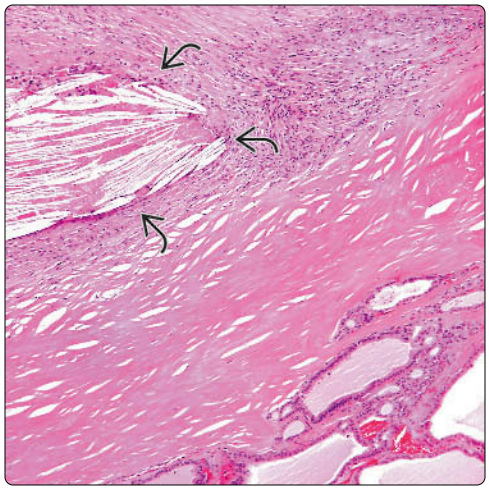

(Left) *Hyperplastic nodule in an ectopic thyroid arising in the mediastinum shows prominent oxyphilic (Hürthle cell) changes of the follicular cells. The ectopic thyroid may give rise to hyperplastic nodules with Hürthle cell changes, Hürthle cell adenoma, or Hürthle cell carcinoma.* **(Right)** *Mediastinal goiter shows extensive degenerative changes, including marked sclerosis and hyalinization, chronic inflammation, and cholesterol cleft granuloma.*

Cystic Degeneration in Ectopic Thyroid

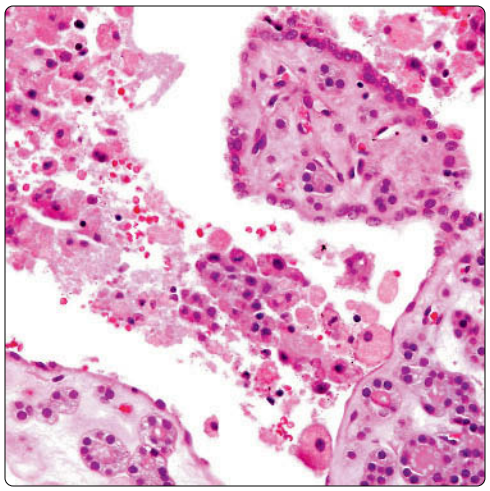

Recurrent Benign Hyperplastic Nodule

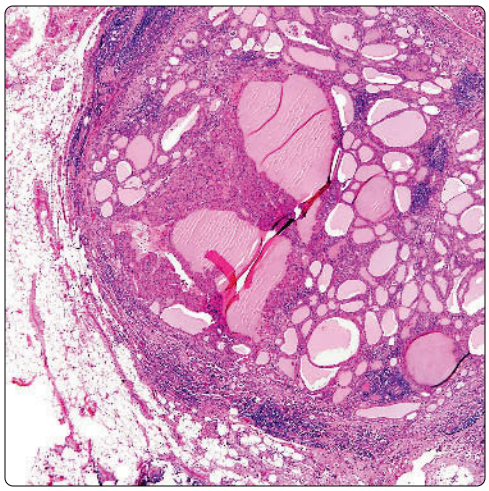

(Left) *Longstanding hyperplastic nodule in a mediastinal goiter shows prominent cystic degeneration within one of the nodules, resulting in a dilated cystic cavity containing scattered follicular structures, chronic inflammation, and hemosiderin-laden macrophages.* **(Right)** *Recurrent benign hyperplastic nodule is seen infiltrating the mediastinal fat in a patient who was previously operated on for nodular hyperplasia of the thyroid originating in the mediastinum.*

Ectopic Follicular Thyroid Carcinoma

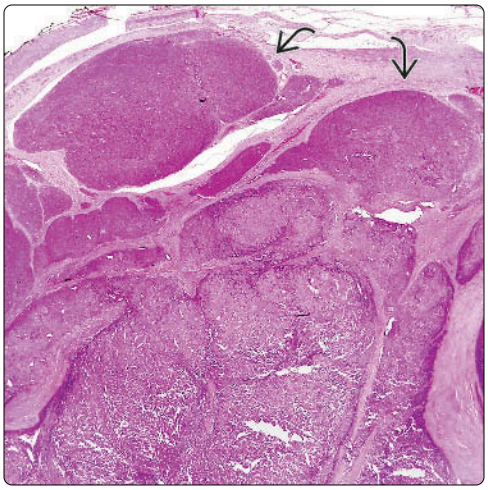

Vascular Invasion

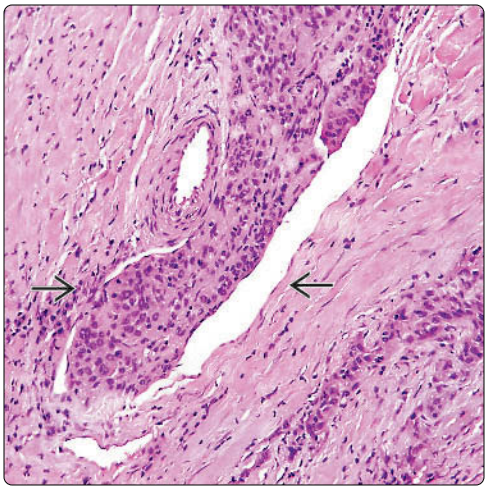

(Left) *Follicular carcinoma of the thyroid arising in an ectopic thyroid in the mediastinum shows infiltration of the capsule and surrounding mediastinum by irregular lobules of thyroid follicular tumor cells.* **(Right)** *High magnification of invasive follicular carcinoma of the thyroid arising in an ectopic mediastinal thyroid shows focus of vascular invasion. These tumors in an ectopic location show identical features as their counterparts in the normal anatomic location.*

Poorly Differentiated Carcinoma

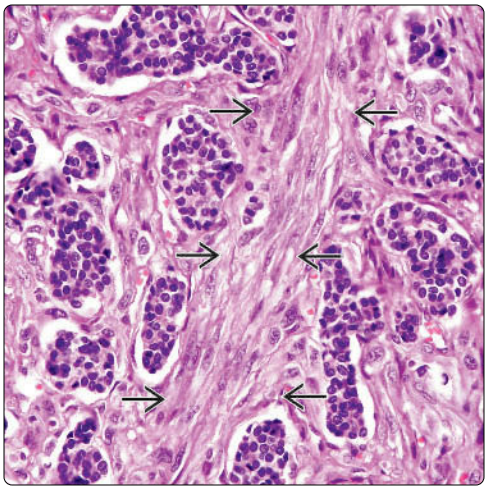

Ectopic Medullary Carcinoma

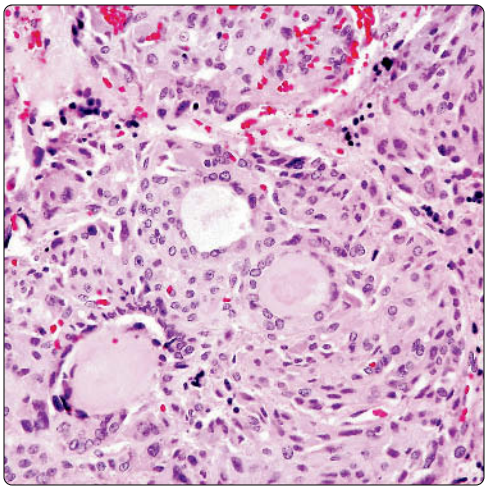

(Left) *Poorly differentiated follicular carcinoma of the thyroid arising in a longstanding mediastinal goiter shows focal anaplastic transformation displaying atypical spindle cell proliferation infiltrating between the follicles.* **(Right)** *Ectopic mediastinal thyroid shows focus of medullary thyroid carcinoma arising from the ectopic thyroid parenchyma. The cells in this tumor reacted positively with antibodies for calcitonin, chromogranin, and CEA.*

Ectopic Poorly Differentiated Carcinoma

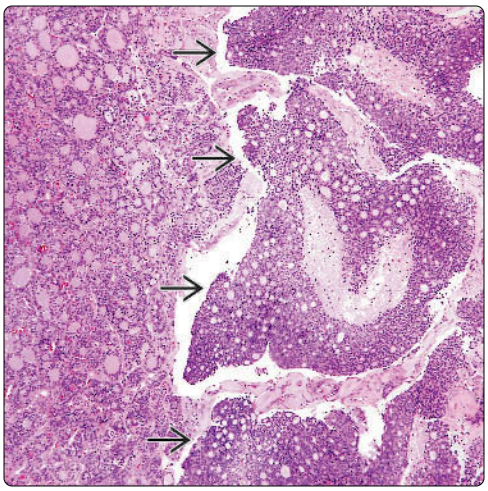

Cribriform Architecture

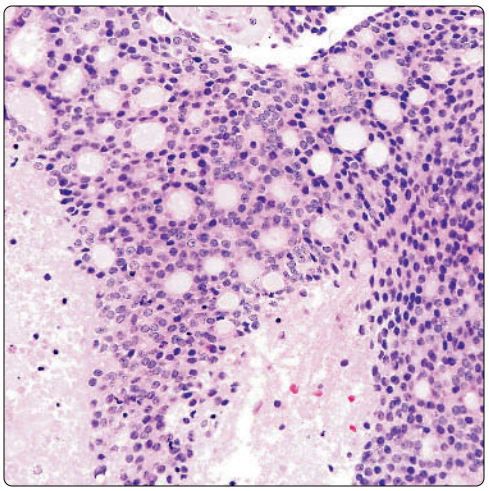

(Left) *Focus of poorly differentiated (so-called insular) carcinoma is seen adjacent to hyperplastic ectopic mediastinal thyroid.* **(Right)** *High magnification of focus of poorly differentiated (so-called insular) carcinoma arising in an ectopic mediastinal thyroid shows a population of primitive follicular cells with a prominent microcystic or cribriform pattern surrounding areas of necrosis.*

This page intentionally left blank

PART III
SECTION 3

Other Benign/Reactive Conditions

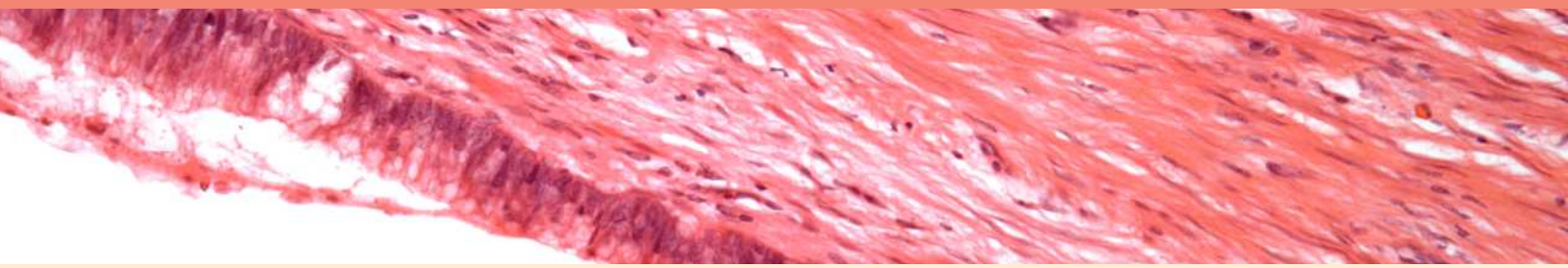

Thymolipoma	**860**
Castleman Disease	**864**
Benign Mediastinal Foregut Cyst	**870**
Acquired Multilocular Thymic Cyst	**876**
Idiopathic Sclerosing Mediastinitis	**884**

Thymolipoma

KEY FACTS

TERMINOLOGY

- Thymic lipoma
- Benign thymic tumor composed of mature adipose tissue

CLINICAL ISSUES

- Incidence
  - Unusual thymic tumor that accounts for < 5% of all thymic tumors
  - Thymolipoma can occur at any age
- Symptoms
  - Cough
  - Dyspnea
  - Tachypnea
  - Myasthenia gravis in some cases
  - Asymptomatic
- Treatment
  - Complete surgical resection

MACROSCOPIC

- Large tumor mass
- Yellowish or light brown in color
- Slightly lobulated
- Variable size from few cm to > 10 cm in diameter

MICROSCOPIC

- Dilatation of Hassall corpuscles
- Remnants of thymic tissue
- Mature adipose tissue

TOP DIFFERENTIAL DIAGNOSES

- Liposarcoma
- Thymic hyperplasia
- Thymoma
- Involuted thymic tissue

CT Scan

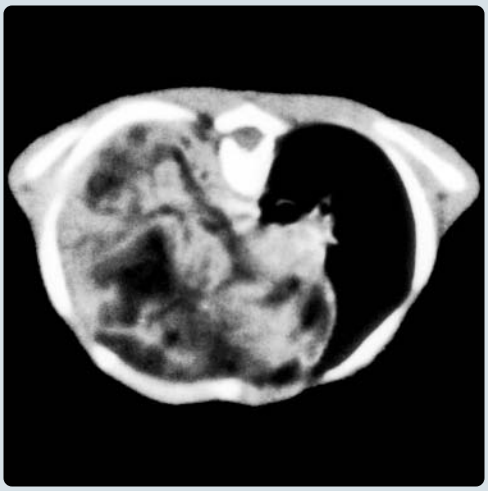

Macroscopic Features

(Left) *CT scan of the thorax shows a large anterior mediastinal mass. The size of thymolipoma varies, and, in some cases, the tumor may reach large proportions.* **(Right)** *Gross photograph of a thymolipoma shows a rather firm consistency. Note the yellowish areas and the presence of whitish areas, most probably representing areas of adipose and possibly fibrous tissue. Intermixed with these areas, residual thymic tissue may be present.*

Thymic and Adipose Tissue

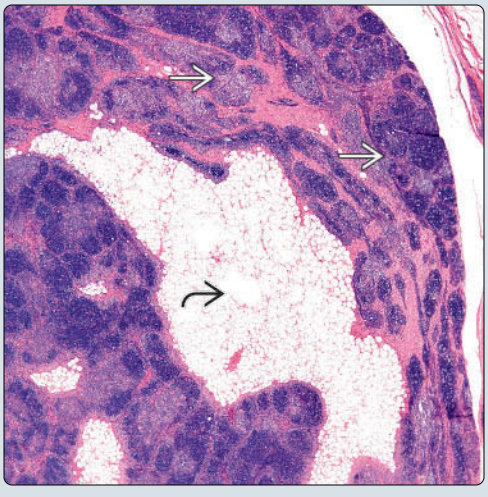

Hassall Corpuscles

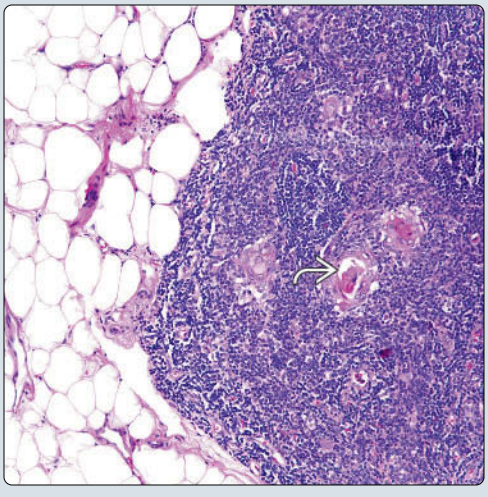

(Left) *Thymolipoma shows areas of thymic tissue and areas of adipose tissue. The presence of these 2 components is essential for the diagnosis.* **(Right)** *Thymolipoma shows the classic mixture of mature adipose tissue admixed with thymic tissue. Note the presence of Hassall corpuscles.*

TERMINOLOGY

Synonyms

- Thymic lipoma

Definitions

- Benign thymic tumor composed of mature adipose tissue

ETIOLOGY/PATHOGENESIS

Etiology

- May represent overgrowth of adipose tissue in hyperplastic gland, closely related to hamartomatous lesion
  - However, definite etiology is not defined

CLINICAL ISSUES

Epidemiology

- Incidence
  - Unusual thymic tumor that accounts for < 5% of all thymic neoplasms
- Age
  - Can occur in any age group
  - More common in young adults
- Sex
  - No gender predisposition

Site

- Anterior mediastinum

Presentation

- Cough
- Chest pain
- Dyspnea
- Tachypnea
- Myasthenia gravis in some cases
- Asymptomatic

Treatment

- Complete surgical resection

Prognosis

- Complete surgical resection is curative

IMAGING

CT Findings

- Fat attenuation is present in most cases

MACROSCOPIC

General Features

- Large tumor mass
- Yellowish or light brown in color
- Slightly lobulated

Size

- Variable size from few cm to > 10 cm in diameter

MICROSCOPIC

Histologic Features

- Mature adipose tissue
- Remnants of thymic tissue
- Dilatation of Hassall corpuscles
- Striated muscle cells may be seen in unusual cases

DIFFERENTIAL DIAGNOSIS

Liposarcoma

- Adipose tissue in liposarcomas shows more atypia
  - Thymolipomas show admixture of thymic tissue and adipose tissue
- Liposarcomas lack presence of dilated Hassall corpuscles

Thymic Hyperplasia

- Thymolipoma always has areas of mature adipose tissue
- Thymic hyperplasia shows abundant thymic tissue with lymphoid hyperplasia and germinal centers

Thymoma

- Would not show presence of extensive areas of mature adipose tissue
- Presence of Hassall corpuscles is unusual in majority of thymomas

Involuted Thymic Tissue

- Thymolipoma presents as mass
- In involutional changes of thymic gland, presence of adipose tissue is not extensive

DIAGNOSTIC CHECKLIST

Clinically Relevant Pathologic Features

- Gross appearance

Pathologic Interpretation Pearls

- Mixture of thymic and mature adipose tissue
- Absence of atypia in adipose tissue
- Presence of Hassall corpuscles

SELECTED REFERENCES

1. Weissferdt A et al: Lipomatous tumors of the anterior mediastinum with muscle differentiation: a clinicopathological and immunohistochemical study of three cases. Virchows Arch. 464(4):489-93, 2014
2. Ajaz B et al: Thymolipoma with sebaceous differentiation: a hitherto unreported variant of thymolipoma. Int J Surg Pathol. 21(5):526-30, 2013
3. Kondo T et al: Thymolipoma, report of a case suggesting an origin from thymic true hyperplasia. Int J Surg Pathol. 18(6):526-9, 2010
4. Hudacko R et al: Thymolipoma: clues to pathogenesis revealed by cytogenetics. Ann Diagn Pathol. 13(3):185-8, 2009
5. Damadoglu E et al: Mediastinal thymolipoma: an analysis of 10 cases. Respirology. 12(6):924-7, 2007
6. Gannon BR et al: Mediastinal thymolipoma: a rare occurrence with striated myoid cells. Tumori. 93(2):198-200, 2007
7. Tsukioka T et al: Thymolipoma associated with myasthenia gravis. Gen Thorac Cardiovasc Surg. 55(1):26-8, 2007
8. Moran CA et al: Thymolipoma: clinicopathologic review of 33 cases. Mod Pathol. 8(7):741-4, 1995
9. Toyama T et al: Pathogenesis of thymolipoma: report of three cases. Surg Today. 25(1):86-8, 1995
10. Rosado-de-Christenson ML et al: Thymolipoma: analysis of 27 cases. Radiology. 193(1):121-6, 1994
11. Iseki M et al: Thymolipoma with striated myoid cells. Histological, immunohistochemical, and ultrastructural study. Am J Surg Pathol. 14(4):395-8, 1990
12. Nishimura O et al: Thymolipoma: a report of three cases. Jpn J Surg. 20(2):234-7, 1990

Solid Areas

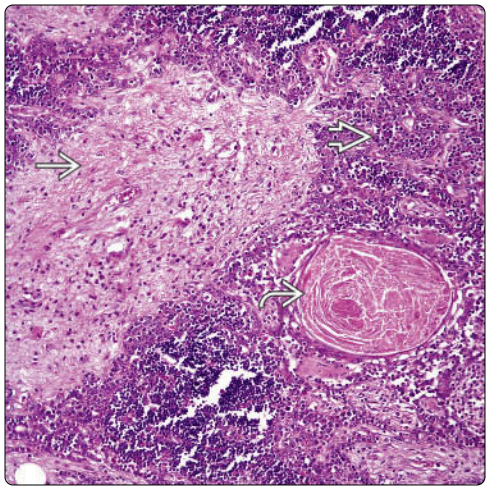

Focal Adipose Tissue

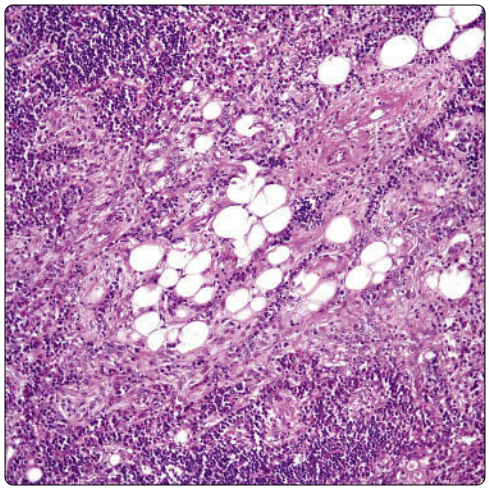

(Left) *Thymolipoma shows solid areas composed of fibrous tissue, lymphoepithelial cells, and dilated Hassall corpuscles. No adipose tissue is present.* **(Right)** *Thymolipoma shows only focal areas of adipose tissue. The remaining is composed of thymic normal elements (lymphocytes and epithelial cells).*

Prominent Adipose Tissue

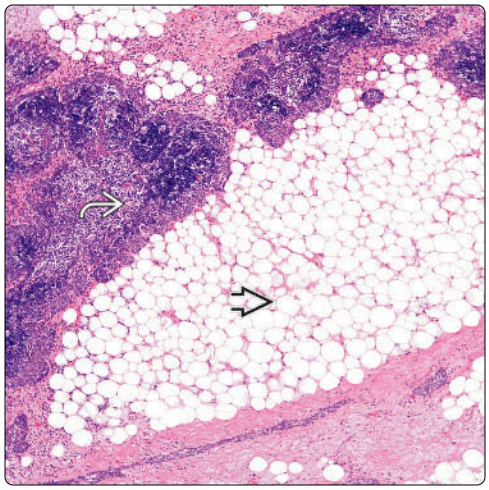

Strands of Thymic Epithelium

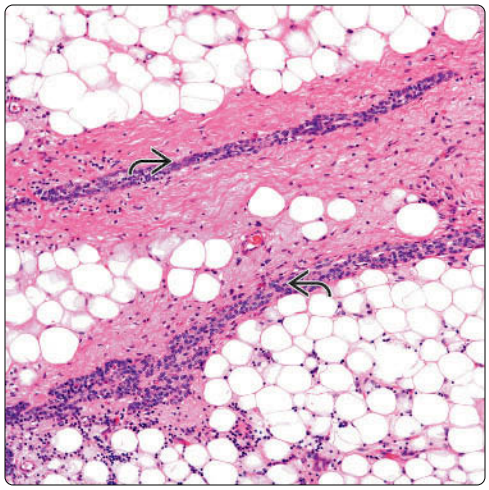

(Left) *Thymolipoma shows extensive areas of mature adipose tissue adjacent to areas of thymic tissue. In some cases, both of these components may be present in almost equal amounts.* **(Right)** *In some cases of thymolipoma, the presence of thymic tissue may be very minimal with only residual strands of thymic epithelium.*

Prominent Fibrous Tissue

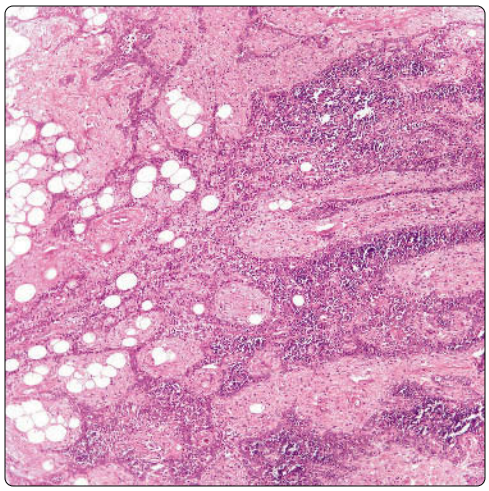

Mixed Fibrous and Thymic Cellularity

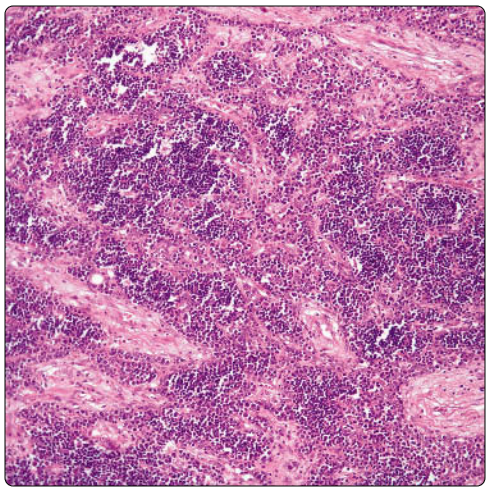

(Left) *Thymolipoma shows extensive areas of fibroconnective tissue admixed with thymic tissue and only a minor component of adipose tissue. Some of these cases have been designated as thymofibrolipoma to describe the components of the tumor.* **(Right)** *Hematoxylin & eosin shows thymic tissue and areas of fibroconnective tissue in which no adipose tissue component is present. These histological changes may be seen in cases of thymic hyperplasia.*

Focal Adipose Tissue

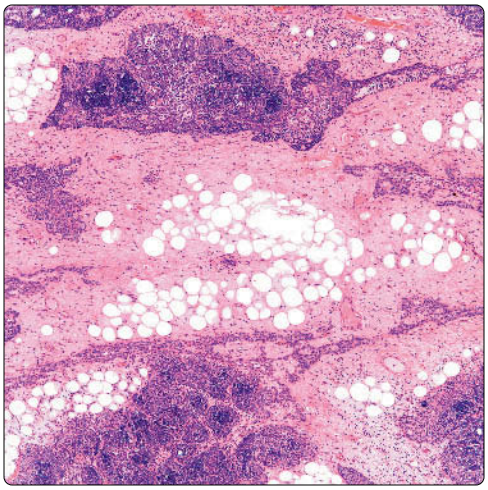

Remnants of Thymic Tissue

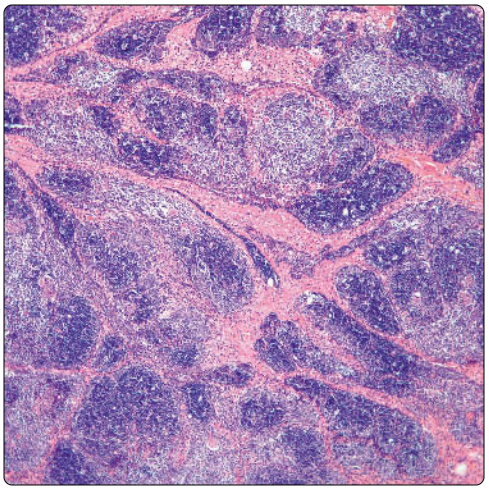

(Left) *Thymolipoma is shown with distinct thymic, adipose, and fibroconnective tissue components. This so-called thymofibrolipoma is due to the marked presence of fibrous component. The designation of thymofibrolipoma does not have any prognostic significance.* **(Right)** *Thymic component in a thymolipoma shows a subtle lobulation. This feature can be easily confused for a thymoma due to the lobulation. Thus, a complete examination of the lesion must be performed.*

Adipose Tissue and Residual Thymus

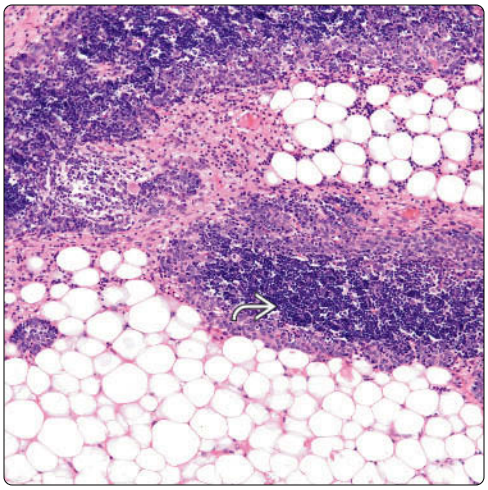

Germinal Centers

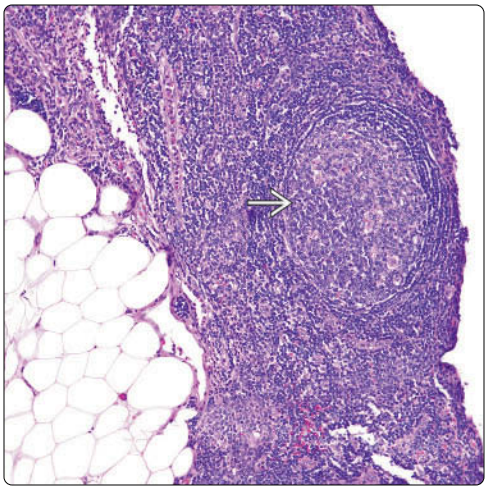

(Left) *Thymolipoma shows areas of residual thymic tissue that, in some areas, almost displays well-demarcated corticomedullary areas. However, there are extensive areas of mature adipose tissue present.* **(Right)** *Thymic component of a thymolipoma shows lymphoid hyperplasia with the presence of germinal centers. Such a feature is commonly associated with cases of myasthenia gravis; however, the presence of germinal centers can be seen without such an association.*

Dilated Hassall Corpuscles

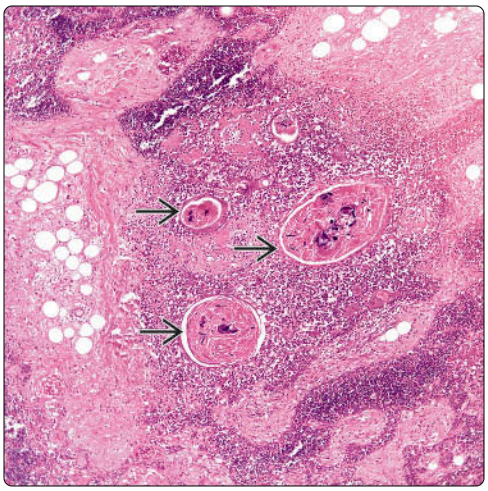

Prominent Dilated Hassall Corpuscle

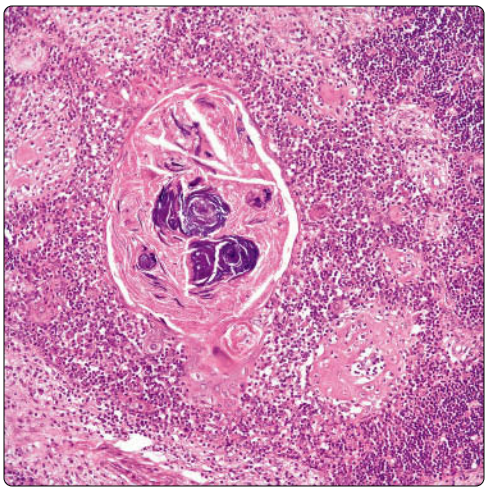

(Left) *Thymolipoma with the characteristic histology shows dilated spaces. At this magnification, they may be suspicious for another type of pathology.* **(Right)** *Higher magnification of the dilated spaces shows keratinization and central calcification. These structures represent dilated and calcified Hassall corpuscles. This is a common occurrence in cases of thymolipoma and has no prognostic significance.*

Castleman Disease

KEY FACTS

CLINICAL ISSUES

- Most common in 3rd decade of life
- Localized type
  - Presents as large mass involving lymph node or lymph node group
  - Many patients are asymptomatic, and mass is discovered incidentally on chest x-rays
- Multicentric type
  - Most often encountered in setting of HIV and HHV-8 infection (Kaposi sarcoma-associated herpesvirus)
  - Multicentric cases are symptomatic and require combination chemotherapy and steroids

MICROSCOPIC

- Hyaline-vascular type is most common type encountered in mediastinum
  - Characterized by follicular abnormalities and interfollicular hypervascularity
  - Enlarged follicles with thickened mantle zones and almost complete obliteration of germinal centers
  - Enlarged follicles containing 2 or more germinal centers
  - Concentric layering of mantle zone lymphocytes around follicles (onion skin appearance)
  - Increased number of vessels in interfollicular spaces admixed with lymphocytes, plasma cells, plasmacytoid monocytes, and immunoblasts
- Plasma cell type is most common type seen in multicentric disease but may also be localized
  - Most characteristic feature is distention of interfollicular spaces by sheets of polyclonal plasma cells
  - Closely associated with HIV and HHV-8 infections
  - Follicles may be normal or show some features seen in hyaline-vascular variant
  - Large, atypical plasmablastic cells are present in mantle zones in HHV8(+) cases

Dysplastic Follicle

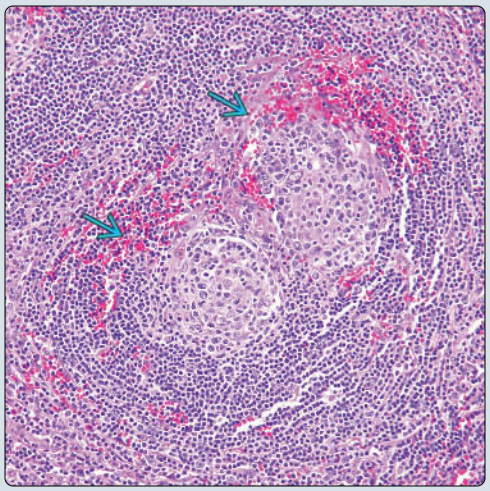

Hyalinized Germinal Center

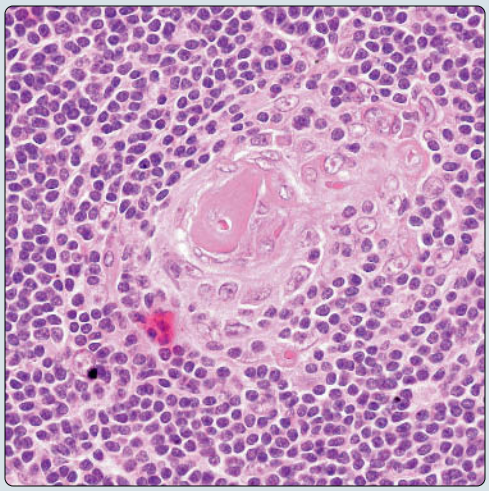

(Left) *An enlarged follicle in mediastinal Castleman disease shows 2 germinal centers within the same follicle. Follicles showing multiple germinal centers within a single enlarged follicle are characteristic for Castleman disease.* **(Right)** *Higher magnification from a hyperplastic lymphoid follicle in mediastinal Castleman disease shows focal hyalinization of a large vessel in the middle of a burned-out germinal center. In the mediastinum, these are often confused for atrophic Hassall corpuscles.*

Hyalinized Vessels in Follicles

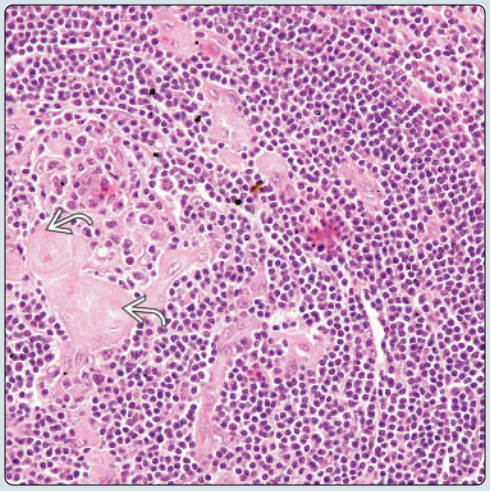

Lollipop Sign

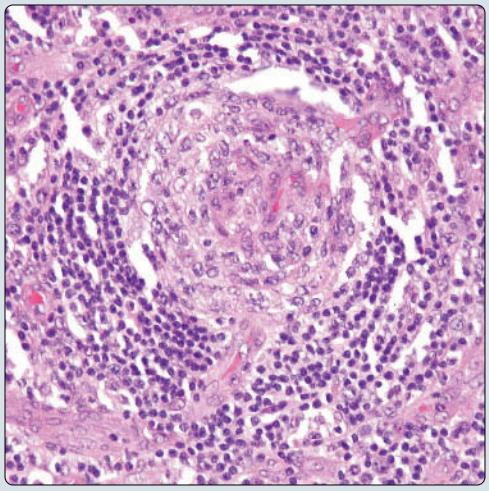

(Left) *Another follicle in mediastinal Castleman disease shows multiple hyalinized vessels coursing through the mantle zone and also involving the germinal center. Notice the concentric, onion skin linear arrangement of the small lymphocytes in the mantle zone.* **(Right)** *Small dysplastic follicle in mediastinal Castleman disease shows a thin vessel traversing the mantle zone and entering the germinal center (bottom) simulating the stick of a lollipop.*

TERMINOLOGY

Synonyms

- Giant lymph node hyperplasia, angiofollicular lymph node hyperplasia, angiomatous lymphoid hamartoma

Definitions

- Heterogeneous group of disorders characterized by lymph nodal enlargement and lymphoid hyperplasia with stromal changes

ETIOLOGY/PATHOGENESIS

Pathogenesis

- Unknown etiology and pathogenesis
- Some cases of plasma cell variant may be related to infection with HHV-8 (Kaposi sarcoma-associated herpesvirus)

CLINICAL ISSUES

Epidemiology

- Incidence
  - Affects males and females equally; most common in 3rd decade of life

Site

- Most common location is anterior mediastinum

Presentation

- Localized type
  - Most common histologic features are those of hyaline-vascular type
  - Presents as large mass involving lymph node or lymph node group
  - Most patients are asymptomatic, and mass is discovered incidentally on routine x-rays
- Multicentric type
  - Most often found in setting of HIV and HHV-8 infection
  - Most cases histologically correspond to plasma cell variant
  - B symptoms (fever, night sweats) occur in 95% of patients
  - Hepatosplenomegaly, body cavity effusions, skin rash can also be seen
  - Elevated erythrocyte sedimentation rate, LDH, IL-6, thrombocytopenia, and polyclonal hypergammaglobulinemia are common

Treatment

- Localized cases are cured with simple surgical excision
- Multicentric cases require combination chemotherapy and steroid treatment

MICROSCOPIC

Histologic Features

- **Hyaline-vascular type**
  - Most common type encountered in mediastinum
  - Characterized by follicular abnormalities and interfollicular hypervascularity
  - Enlarged follicles with thickened mantle zones and almost complete obliteration of germinal centers
  - Enlarged follicles containing 2 or more germinal centers
  - Focal hyalinization of atrophic follicles simulating Hassall corpuscles
  - Concentric layering of mantle zone lymphocytes around follicles (onion skin appearance)
  - Replacement of follicles by pale, epithelioid cells admixed with small vessels with hyalinized walls
  - Tangentially cut vessels seen penetrating germinal center (lollipop sign)
  - Increased number of vessels in interfollicular spaces admixed with lymphocytes, plasma cells, plasmacytoid monocytes, and immunoblasts
  - Hyalinization of interfollicular areas with dense bands of sclerosis
  - Prominence of follicular dendritic cells in follicles
  - Stroma-rich variant is characterized by massive replacement of interfollicular areas by sclerotic vessels and spindle cells
- **Plasma cell type**
  - Most common type seen in multicentric disease but may also be localized
  - Closely associated with HIV and HHV-8 infections
  - Most characteristic feature is distention of interfollicular spaces by sheets of polyclonal plasma cells
  - Follicles may be normal or show some features seen in hyaline-vascular variant
  - Kaposi sarcoma and malignant lymphomas can develop from or coexist in lymph nodes with plasma cell type

ANCILLARY TESTS

Immunohistochemistry

- Plasma cells and B cells in both types are polyclonal
- HHV8(+) staining is seen in mantle zone and interfollicular lymphocytes in most cases of plasma cell type

DIFFERENTIAL DIAGNOSIS

Reactive Follicular Hyperplasia

- Reactive follicles are large with polarization of mantle zones and tingible body macrophages in germinal centers
- No hyalinized small vessels or interfollicular plasmacytosis is seen

Follicular Lymphoma

- Neoplastic follicles are composed of monotonous population of abnormal lymphocytes
- Interfollicular areas are diminished, and there is no evidence of prominent mantle zones
- Neoplastic follicles are monoclonal and stain strongly positive for Bcl-2

SELECTED REFERENCES

1. Nistor C et al: A rare case of unicentric plasma cell type Castleman's disease in the mediastinum. Pneumologia. 59(1):32-5, 2010
2. Erdogan A et al: Posterior mediastinal localization of Castleman's disease: report of a case. Surg Today. 34(9):772-3, 2004
3. Cioffi U et al: Hyaline vascular Castleman's disease of the mediastinum. Int Surg. 84(2):115-7, 1999
4. Keller AR et al: Hyaline-vascular and plasma-cell types of giant lymph node hyperplasia of the mediastinum and other locations. Cancer. 29(3):670-83, 1972

Scanning Magnification

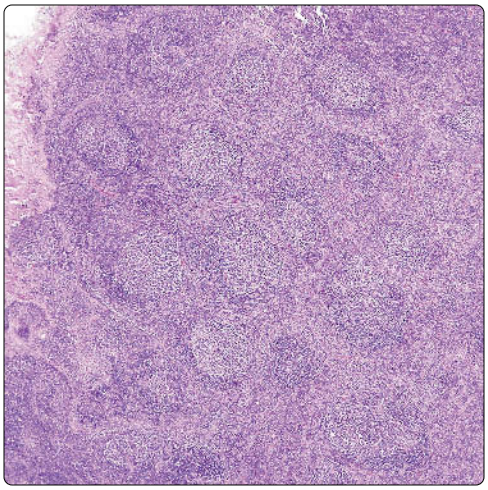

Hyalinized Germinal Center

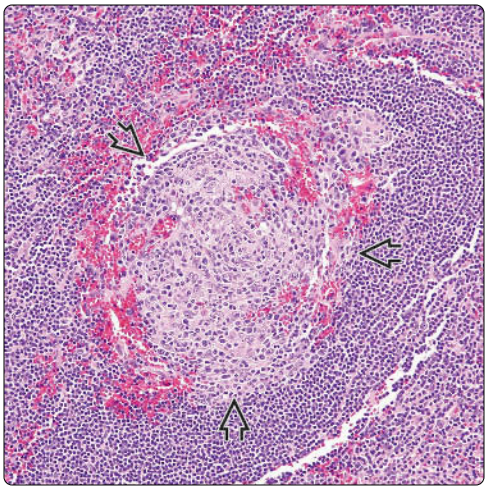

(Left) *Scanning magnification of hyaline-vascular Castleman disease of the mediastinum shows preserved but distorted lymph node architecture with numerous scattered lymphoid follicles, some of which have burned-out germinal centers.* **(Right)** *High magnification of Castleman disease, hyaline-vascular type, shows characteristic abnormal follicle with a hyalinized germinal center replaced by large, epithelioid cells and surrounded by a thick mantle zone of lymphocytes.*

Scanning Magnification

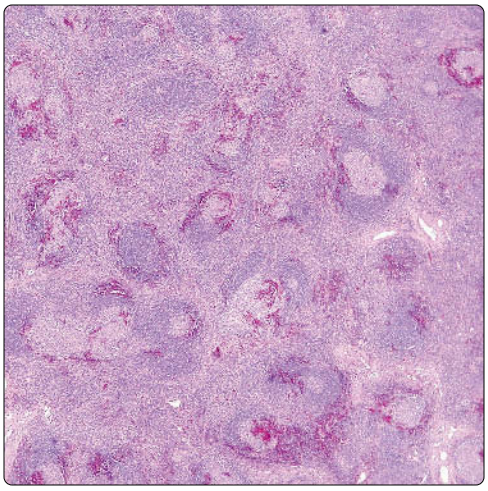

Burned-Out Germinal Center

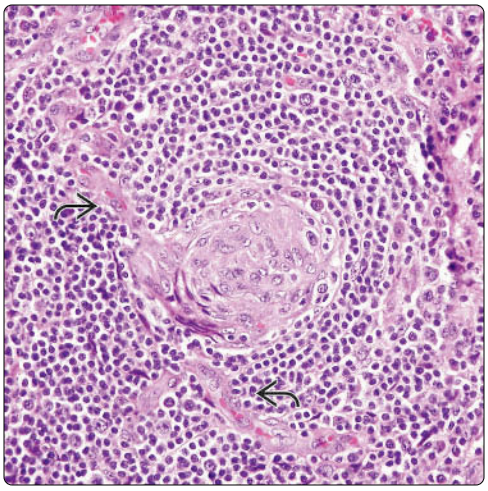

(Left) *Scanning magnification of Castleman disease of the mediastinum, hyaline-vascular type, shows multiple lymphoid follicles of various sizes, some of which contain multiple germinal centers.* **(Right)** *High magnification of abnormal lymphoid follicle in Castleman disease of the mediastinum, hyaline-vascular type, shows a burned-out germinal center with small venules traversing the mantle zone and penetrating into the germinal center.*

Scanning Magnification

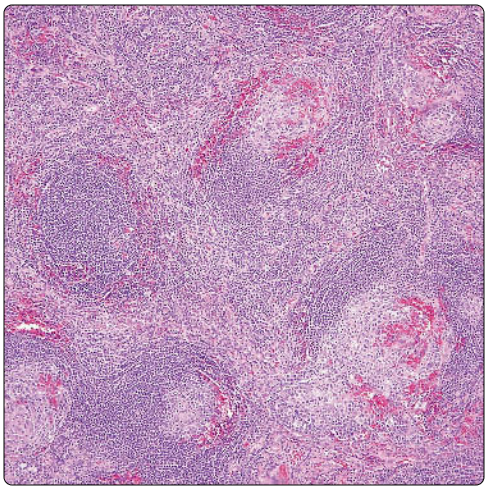

Onion Skinning of Lymphocytes

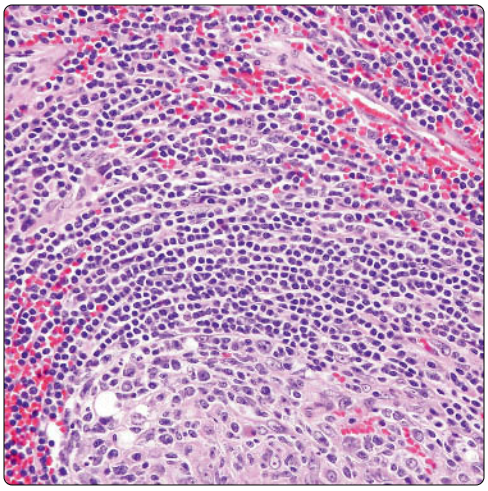

(Left) *Scanning magnification of Castleman disease of the mediastinum, hyaline-vascular type, shows multiple nodules with partially hyalinized germinal centers and prominent vascular proliferation in the interfollicular areas.* **(Right)** *High magnification of an abnormal follicle in Castleman disease of the mediastinum, hyaline-vascular type, shows hyalinization of a germinal center and parallel, concentric arrangement of small lymphocytes in the mantle zone (onion skinning).*

Multiple Germinal Centers

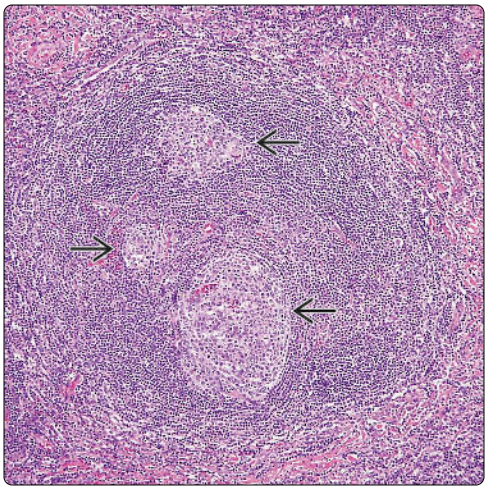

Focus of Sclerosis in Germinal Center

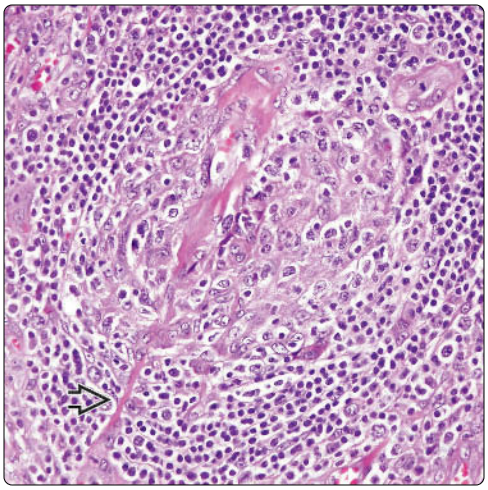

(Left) *Abnormal follicle in Castleman disease of the mediastinum, hyaline-vascular type, shows 3 germinal centers ⇨, all located within the same follicle.* **(Right)** *High magnification of abnormal follicle in Castleman disease of the mediastinum, hyaline-vascular type, shows a burned-out germinal center traversed by a thin capillary with sclerosis of the vessel wall. Notice that part of the vessel ⇨ completely crosses the mantle zone into the interfollicular area.*

Hypervascular Germinal Center

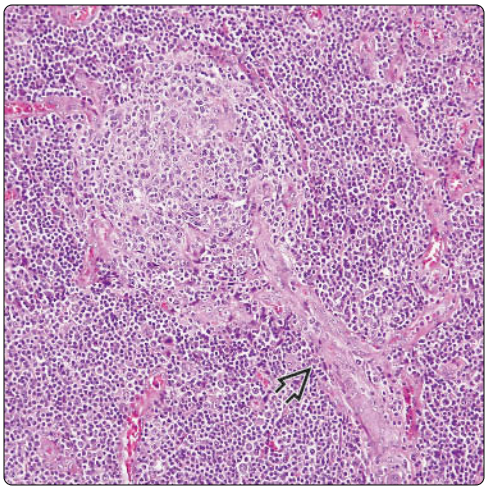

Burned-Out Follicle

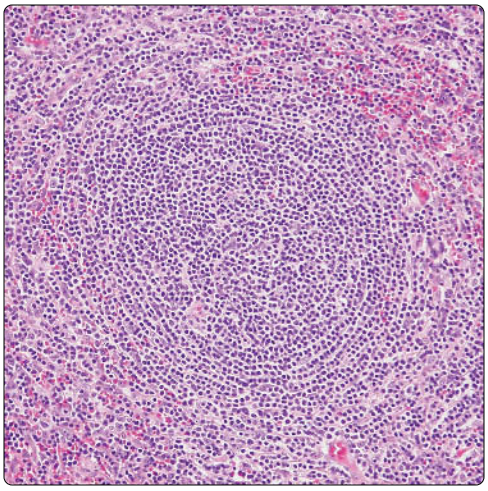

(Left) *High magnification of abnormal lymphoid follicle in Castleman disease of the mediastinum, hyaline-vascular type, shows the lollipop sign characterized by a longitudinally cut vessel with hyalinized walls penetrating into the germinal center, simulating the handle of a lollipop ⇨.* **(Right)** *High magnification of a small, burned-out lymphoid follicle in Castleman disease, hyaline-vascular type, shows a concentric arrangement of lymphocytes with complete absence of the germinal center.*

Hyalinization of Interfollicular Areas

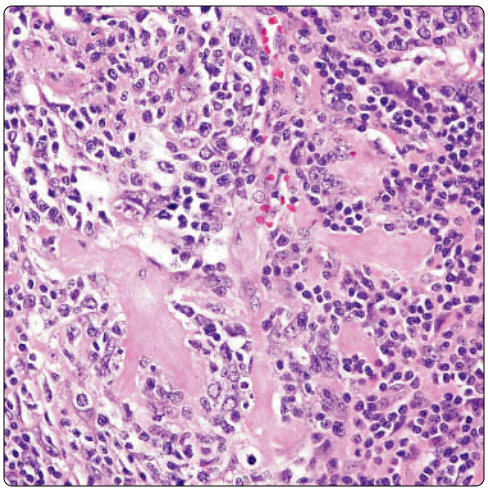

Interfollicular Hypervascularity

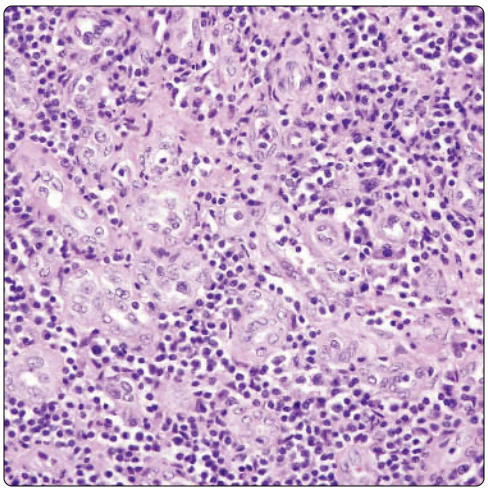

(Left) *High magnification of interfollicular areas in Castleman disease of the mediastinum, hyaline-vascular type, shows stromal sclerosis and hyalinization surrounded by small lymphocytes and occasional immunoblasts.* **(Right)** *High magnification of interfollicular areas in Castleman disease of the mediastinum, hyaline-vascular type, shows characteristic interfollicular hypervascularity with numerous small, postcapillary venules with reactive endothelial cells.*

Abnormal Follicle

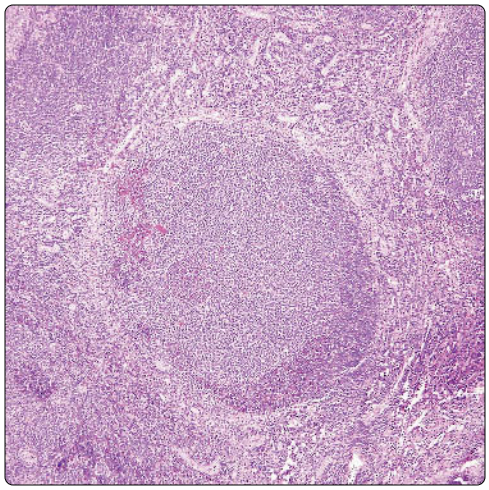

Hyalinization of Follicle

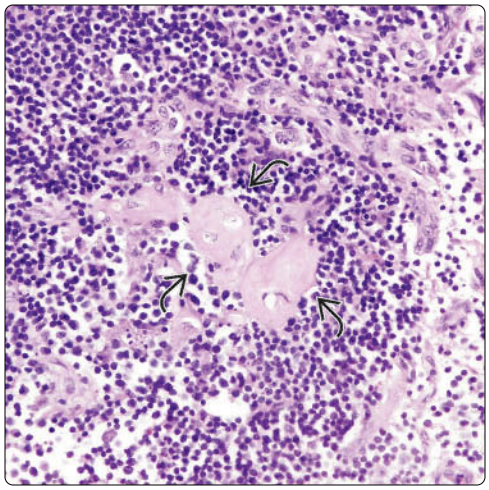

(Left) *This abnormally large follicle is seen in Castleman disease of the mediastinum, hyaline-vascular type. The enlarged follicle shows an indistinct mantle zone and germinal center.* **(Right)** *Burned-out small follicle in Castleman disease of the mediastinum, hyaline-vascular type, shows focal hyalinization in residual follicle. Areas like this have been mistaken in some cases for Hassall corpuscles, leading to an incorrect diagnosis of lymphocyte-rich thymoma.*

Dysplastic Dendritic Cells in Follicle

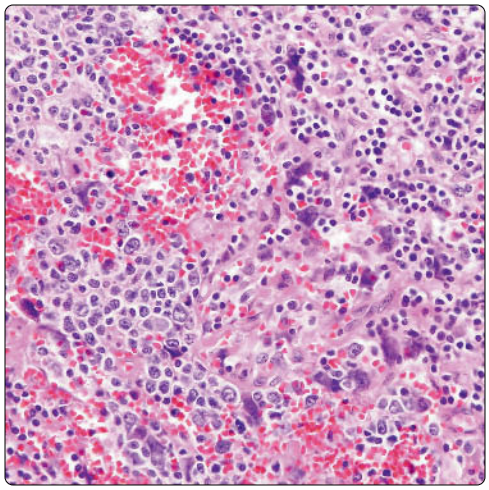

Dendritic Cells: High Power

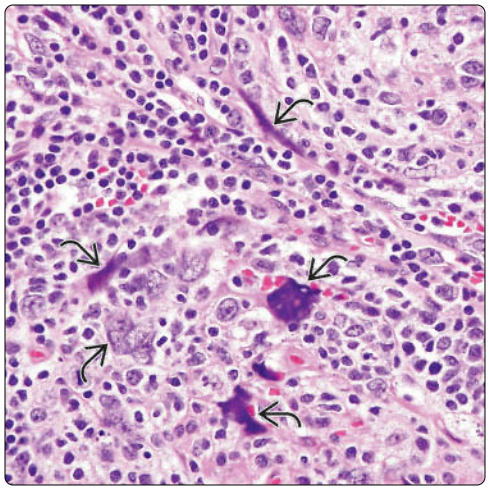

(Left) *Abnormal, dysplastic follicular dendritic cells are seen in a burned-out follicle in Castleman disease of the mediastinum, hyaline-vascular type. Dysplastic or atypical dendritic cells can be found in the follicles or in the interfollicular areas of the nodes and may give rise to dendritic cell sarcomas.* **(Right)** *High magnification of an abnormal follicle in Castleman disease of the mediastinum, hyaline-vascular type, shows large, hyperchromatic dendritic cells.*

Focus of Kaposi Sarcoma

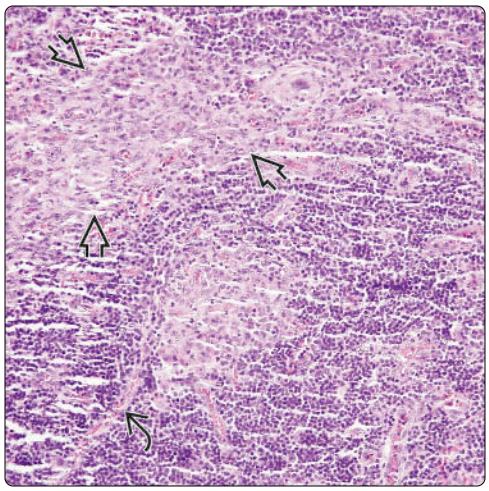

Kaposi Sarcoma: High Power

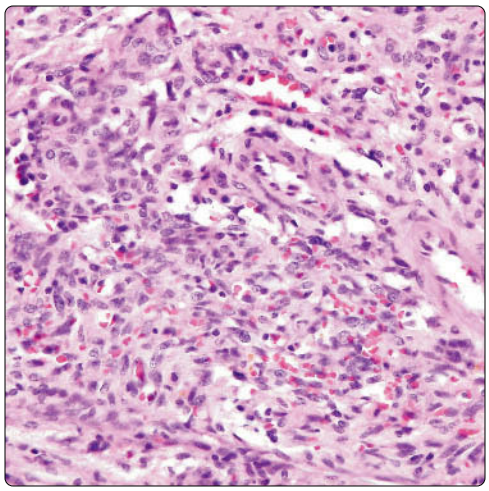

(Left) *Castleman disease of the mediastinum shows a focus of Kaposi sarcoma in the interfollicular areas arising in association with Castleman disease. Notice the abnormal follicle at the bottom with a hyalinized vessel traversing the mantle zone into the germinal center.* **(Right)** *Higher magnification of the focus of Kaposi sarcoma arising in Castleman disease shows spindle cell proliferation with slit-like vascular spaces containing extravasated red blood cells.*

Scanning Magnification

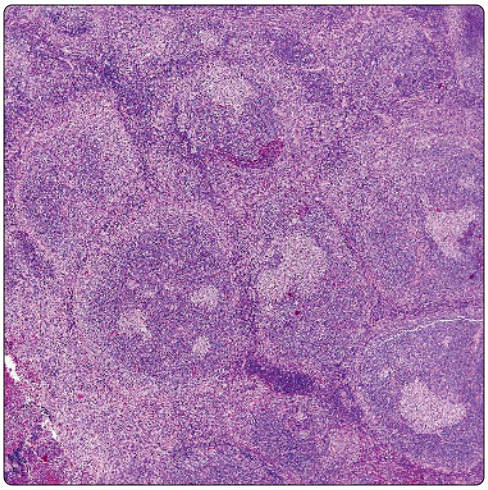

Plasma Cell Type

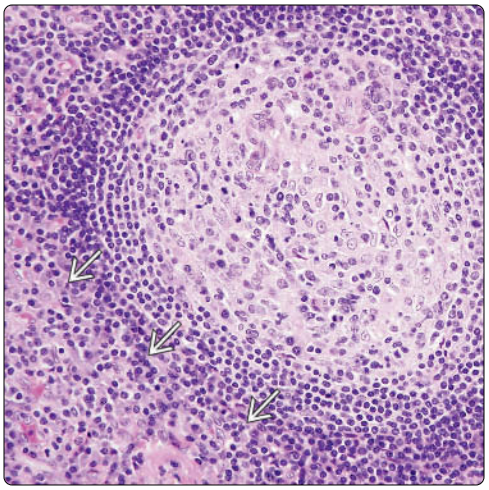

(Left) *Scanning magnification of Castleman disease, plasma cell type, shows numerous, enlarged lymphoid follicles surrounded by a monotonous population of plasma cells in the interfollicular areas.* **(Right)** *Higher magnification of Castleman disease, plasma cell type, shows abnormal follicle with hyalinized germinal center and concentric onion skinning of mantle zone lymphocytes. Notice the interfollicular area is composed of sheets of mature plasma cells.*

Interfollicular Plasmacytosis

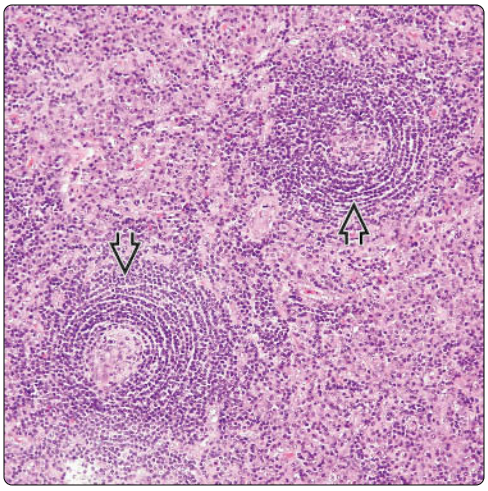

Interfollicular Plasmacytosis: High Power

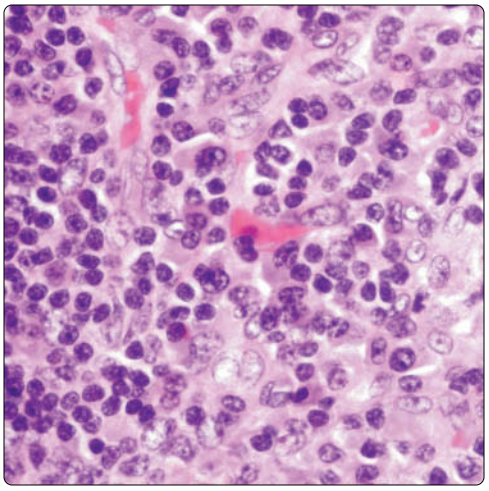

(Left) *Scanning magnification in Castleman disease, plasma cell type, shows 2 small, burned-out follicles with hyalinized germinal centers and onion skin mantle zones surrounded by a dense plasma cell population in the interfollicular areas.* **(Right)** *High magnification of an interfollicular area in Castleman disease, plasma cell type, shows sheets of mature plasma cells. Immunohistochemical studies showed that the plasma cells exhibited polyclonality.*

Plasma Cell Type

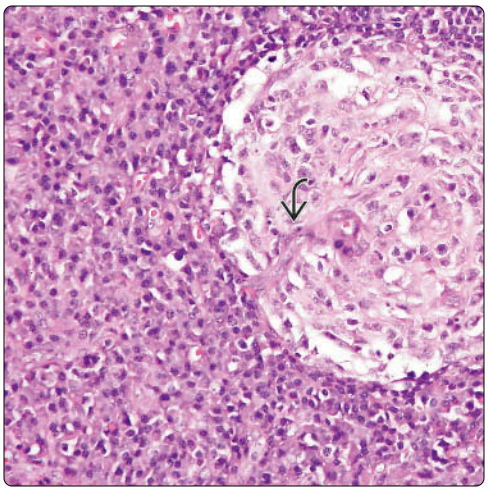

Stroma-Rich Variant

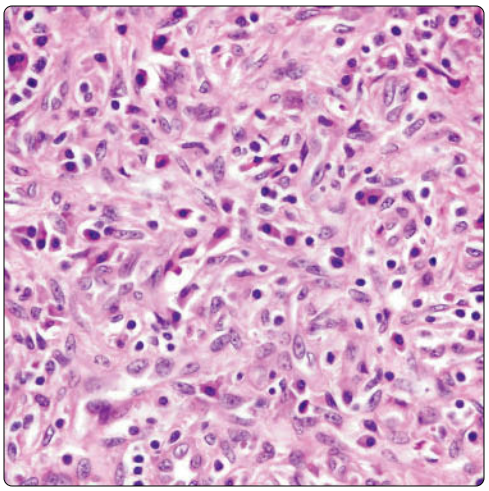

(Left) *Castleman disease, plasma cell type, shows an atrophic, burned-out follicle with a hyalinized germinal center containing a sclerosed vessel. Notice sheets of monotonous mature plasma cells in the interfollicular areas and absence of mantle zone lymphocytes.* **(Right)** *Stroma-rich variant of Castleman disease shows expanded interfollicular areas composed of mature plasma cells admixed with spindle cells. The spindle cells may be of myoid or dendritic cell lineage.*

Benign Mediastinal Foregut Cyst

KEY FACTS

TERMINOLOGY

- Benign cystic tumors that are classified depending on epithelial lining

ETIOLOGY/PATHOGENESIS

- So-called foregut cysts believed to arise due to abnormality during early gestational process in which laryngotracheal groove appears in ventral median aspect of primitive pharynx
  - Eventually develop into trachea and bronchial tree

CLINICAL ISSUES

- Incidence
  - Accounts for ~ 10-20% of all mediastinal tumors
  - More common in children
  - More common in anterior mediastinum
- Symptoms
  - Chest pain
  - Cough
  - Dyspnea
  - Asymptomatic

TOP DIFFERENTIAL DIAGNOSES

- Multilocular thymic cyst
- Cystic thymoma

DIAGNOSTIC CHECKLIST

- Identification of specific type of epithelium
  - Mesothelial
  - Respiratory
  - Columnar

(Left) *Low-power view shows a mediastinal cyst composed of a strip of fibroconnective tissue with an epithelial lining ⇨.* **(Right)** *Bronchogenic cyst shows classic features of a lining of respiratory epithelium ⇨ and the presence of cartilage. These 2 components are important in the diagnosis.*

Cystic Lesion

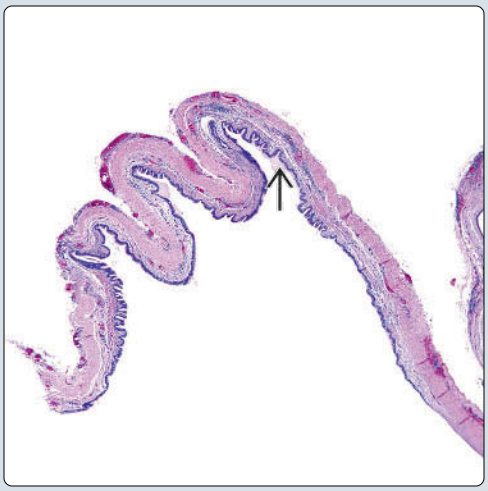

Presence of Cartilage

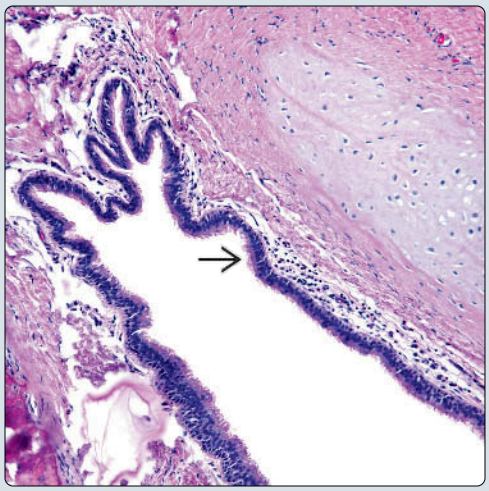

(Left) *Bronchogenic cyst shows respiratory epithelium margin with areas of fibrosis. Note that in the areas of fibrotic change, the epithelium is not easily recognizable.* **(Right)** *Bronchogenic cyst shows the classic respiratory epithelium lining the cystic structure. Note the presence of ciliated epithelium ⇨.*

Attenuated Epithelium

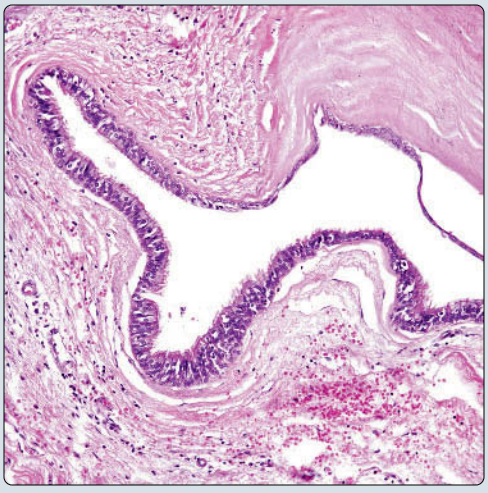

Respiratory Epithelium

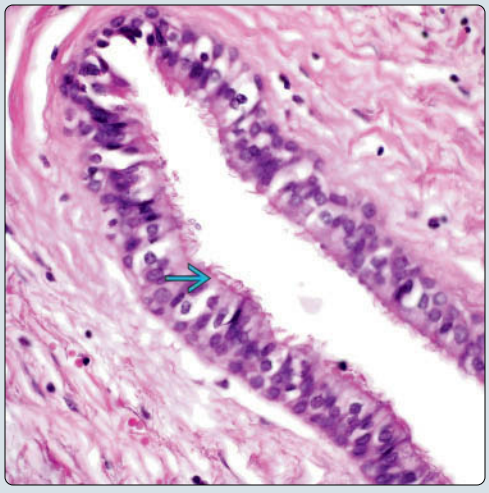

TERMINOLOGY

Definitions

- Benign cystic tumors that are classified depending on epithelial lining

ETIOLOGY/PATHOGENESIS

Developmental Anomaly

- So-called foregut cysts may arise due to abnormality during early gestational process in which laryngotracheal groove appears in ventral median aspect of primitive pharynx
  - Eventually develops into trachea and bronchial tree

CLINICAL ISSUES

Epidemiology

- Incidence
  - Unusual benign tumors that may account for 10-20% of all mediastinal tumors
- Age
  - Unilocular thymic cysts are more common in children
  - Some other cysts may be more common in adults
  - Some cysts may be seen in both children and adults
- Sex
  - No predilection

Site

- More commonly seen in anterior and middle mediastinal compartment

Presentation

- Chest pain
- Cough
- Dyspnea
- Asymptomatic
- May present with another congenital anomaly
- In adults, may present with other concurrent pathology
- Infection may occur in some cases

Treatment

- Surgical approaches
  - Complete surgical resection

Prognosis

- Good

IMAGING

General Features

- Cystic mediastinal mass
- Depending on size, it may display adjacent structures

MACROSCOPIC

General Features

- Unilocular cystic tumors covered by glistening surface

Sections to Be Submitted

- Numerous sections need to be submitted in order to identify specific epithelium to properly classify cyst

Size

- Variable size from few cm to > 10 cm in diameter

MICROSCOPIC

Histologic Features

- Unilocular cyst, which may be lined by different types of epithelium
  - Respiratory epithelium
  - Columnar epithelium
  - Squamous epithelium
  - Mesothelial lining
  - Presence of cartilage
- Inflammatory reaction in wall of cysts may be seen

DIFFERENTIAL DIAGNOSIS

Multilocular Thymic Cyst

- By definition, multilocular thymic cyst is multiloculated cyst in contrast to unilocular aspect of other thymic cyst
- Presence of specific epithelium will lead to correct interpretation

Cystic Thymoma

- Presence of solid areas composed of epithelial cells and lymphocytes will be unusual for unilocular thymic cyst

Other Malignant Neoplasms

- Some germ cell tumors and mucoepidermoid carcinomas have been reported in association with cystic changes
  - Use of immunohistochemical stains in this setting is of utmost importance
- Some lymphoproliferative diseases may present cystic neoplasms
  - Use of immunohistochemical stains in this setting is of utmost importance
- Careful gross evaluation is important
- Histological evaluation of numerous sections with special emphasis toward solid areas associated with cyst

DIAGNOSTIC CHECKLIST

Clinically Relevant Pathologic Features

- Gross appearance
- Tissue distribution
- Age distribution

Pathologic Interpretation Pearls

- Identification of specific type of epithelium
  - Mesothelial
  - Respiratory
  - Columnar

SELECTED REFERENCES

1. Weissferdt A et al: Cystic well-differentiated squamous cell carcinoma of the thymus: a clinicopathological and immunohistochemical study of six cases. Histopathology. 68(3):333-8, 2016
2. Jiang JH et al: Differences in the distribution and presentation of bronchogenic cysts between adults and children. J Pediatr Surg. 50(3):399-401, 2015
3. Li X et al: A case of giant mediastinal cyst initially detected and diagnosed by echocardiography. Echocardiography. 32(7):1193-5, 2015
4. Maturu VN et al: Efficacy and safety of transbronchial needle aspiration in diagnosis and treatment of mediastinal bronchogenic cysts: systematic review of case reports. J Bronchology Interv Pulmonol. 22(3):195-203, 2015
5. Mlika M et al: A unilocular thymic cyst associated with true thymic hyperplasia: a challenging diagnosis especially in a child. Int Med Case Rep J. 8:215-8, 2015

Clinicopathological Features of Mediastinal Cysts

Cyst	Type of Epithelium	Incidence	Origin	Comment
Bronchogenic cyst	Respiratory epithelium	Most common; ~ 40-50% of all cysts	Congenital, unilocular	Occurs at any age
Esophageal cyst	Squamous epithelium	Less common than bronchogenic cyst	Congenital, unilocular	More common in children and young adults; may be more common in males
Enteric cyst	Columnar epithelium	Less common than bronchogenic cyst	Congenital, unilocular	More common in children but can occur in adults; commonly seen in posterior mediastinum; patients with vertebral abnormalities
Thymic cyst	Variable lining that may show low cuboidal and squamous epithelium	Rare	Congenital, unilocular	Occurs mainly in children
Pericardial cyst	Mesothelial lining	Common	Congenital, unilocular, pericardium	More common in adults
Mesothelial cyst	Mesothelial lining	Common	Congenital, unilocular	More common in adults

Histochemical Features

Stain	Result
PAS	May show presence of glycogen in enteric cysts
PAS-D	May show positive reaction in enteric cysts
Mucicarmine	May show positive reaction in enteric cysts

Immunohistochemistry

Antibody	Reactivity	Staining Pattern	Comment
CK-PAN	Positive	Cytoplasmic	In cysts' linings
CK8/18/CAM5.2	Positive	Cytoplasmic	In cysts' linings
Calretinin	Positive	Nuclear	In mesothelial cysts
CK5/6	Positive	Cytoplasmic	In some of these cysts
EMA	Positive	Cell membrane	In cysts' linings
CDX-2	Positive	Nuclear	In enteric cysts
CK20	Positive	Cytoplasmic	In enteric cysts
CK7	Positive	Cytoplasmic	In some of these cysts
TTF-1	Positive	Nuclear	In epithelium of bronchogenic cyst
NAPSIN-A	Positive	Cytoplasmic	In epithelium of brochogenic cyst
Mesothelin	Positive	Cytoplasmic	In mesothelial cyst

6. Oldani A et al: Voluminous oesophageal bronchogenic cyst treated with thoracoscopic approach. Ann Ital Chir. 2015
7. Patel S et al: Common symptoms with rare entity: a giant pericardial cyst. Am J Med. 128(10):e27-8, 2015
8. Bouma W et al: Removal of a giant intrathoracic cyst from the anterior mediastinum. J Cardiothorac Surg. 9:152, 2014
9. Schweigert M et al: Infected mediastinal bronchogenic cyst in a 12 year old girl. Thorac Cardiovasc Surg. 60(3):239-41, 2012
10. Goswamy J et al: Bronchogenic cysts as a cause of infantile stridor: case report and literature review. J Laryngol Otol. 125(10):1094-7, 2011
11. Myung RJ et al: Mediastinal coelomic cyst. Ann Thorac Surg. 91(6):1967-9, 2011
12. Fatimi SH et al: Large mesothelial cyst of the mediastinum causing respiratory distress. Heart Lung Circ. 17(2):141, 2008
13. Scharifker D: True thymic hyperplasia associated with a unilocular thymic cyst: an unusual combination not previously reported. Ann Diagn Pathol. 10(1):32-5, 2006
14. Noyes BE et al: Pericardial cysts in children: surgical or conservative approach? J Pediatr Surg. 38(8):1263-5, 2003
15. McAdams HP et al: Bronchogenic cyst: imaging features with clinical and histopathologic correlation. Radiology. 217(2):441-6, 2000
16. Davis RD Jr et al: Primary cysts and neoplasms of the mediastinum: recent changes in clinical presentation, methods of diagnosis, management, and results. Ann Thorac Surg. 44(3):229-37, 1987
17. Ovrum E et al: Mediastinal tumours and cysts. A review of 91 cases. Scand J Thorac Cardiovasc Surg. 13(2):161-8, 1979
18. Reed JC et al: Morphologic analysis of foregut cysts in the thorax. Am J Roentgenol Radium Ther Nucl Med. 120(4):851-60, 1974

Macroscopic Features

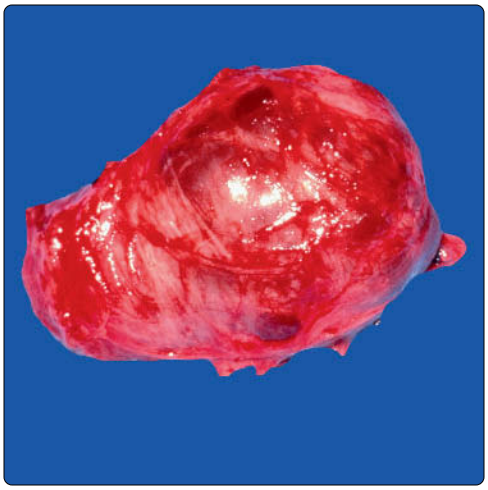

Lymphoid Aggregates

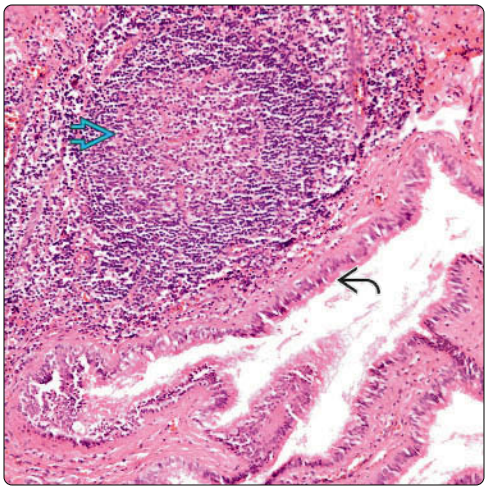

(Left) *Mediastinal foregut cyst is shown surrounded by membranous tissue and hemorrhage. Histopathologic evaluation of the cyst lining is required to establish the correct diagnosis.* **(Right)** *Bronchogenic cyst shows respiratory epithelium and a lymphoid aggregate with germinal center. These features are commonly seen in these cysts.*

Presence of Cartilage

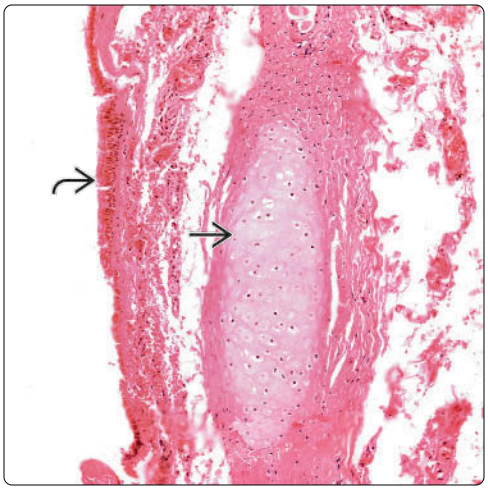

Respiratory Epithelium

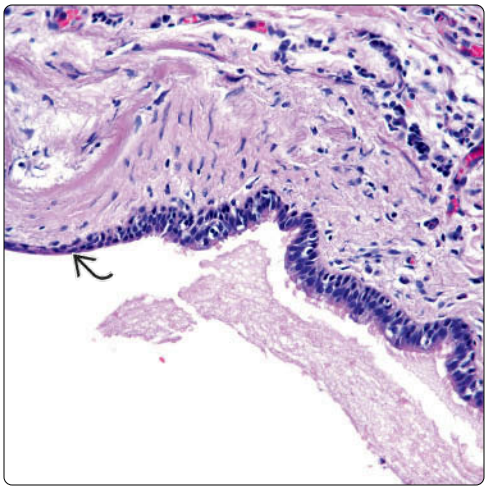

(Left) *Higher magnification of a bronchogenic cyst shows cartilage and a cystic structure lined by a respiratory type of epithelium. Note the presence of cilia in the respiratory epithelium.* **(Right)** *High-power view shows respiratory epithelium in a bronchogenic cyst. The respiratory epithelium does not show any atypical changes but shows a transition toward a flattened attenuated epithelium.*

Bronchial Glands

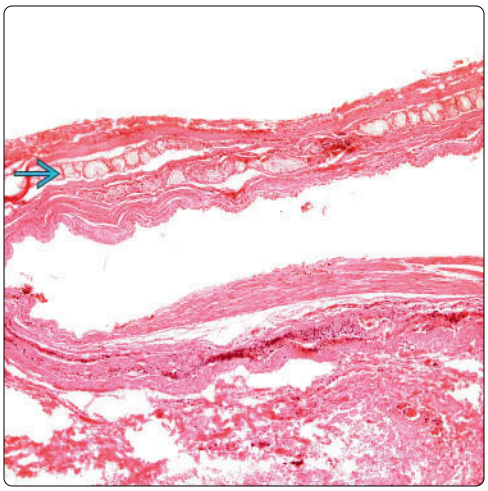

Endobronchial Glands

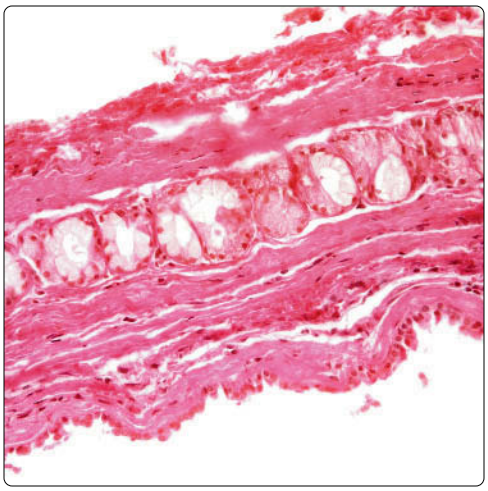

(Left) *Bronchogenic cyst shows normal endobronchial glands in the walls of the cystic structures. At this magnification, it is difficult to determine the type of epithelium.* **(Right)** *Bronchogenic cyst shows a closer view of normal endobronchial glands. Note that the epithelium is attenuated and difficult to specify.*

Cystic Lesion

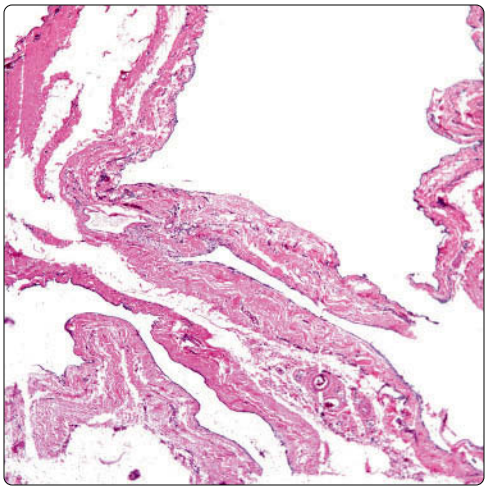

Cuboidal Epithelium

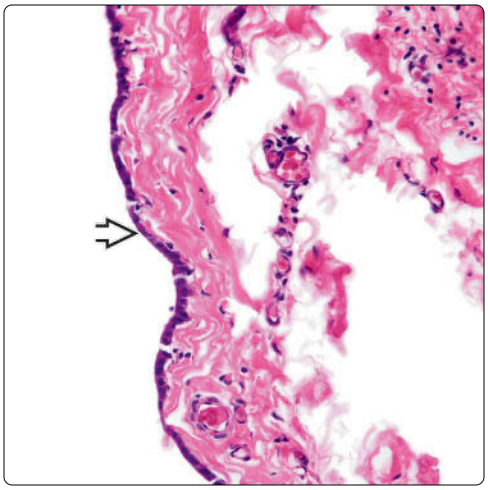

(Left) *Mediastinal cyst is shown composed of several strips of fibroconnective tissue lined by an attenuated epithelium. The cyst wall shows only mild inflammatory changes.* **(Right)** *Higher magnification shows the epithelium of a mediastinal cyst. The lining is a low type of cuboidal epithelium ⇨, and these findings are consistent with a mesothelial cyst.*

Flattened Epithelium

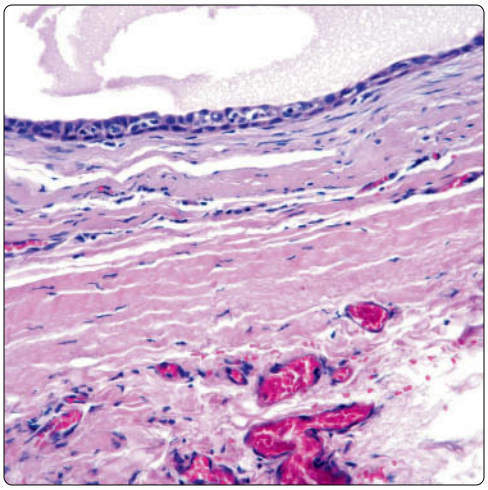

Residual Thymus

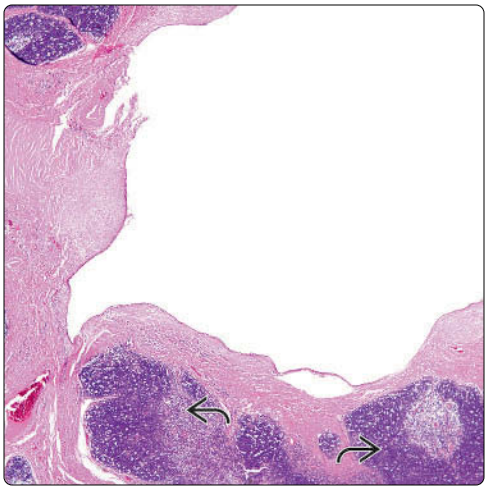

(Left) *This mesothelial cyst is composed of flattened epithelium without atypia and underlying fibroconnective tissue with minimal inflammatory changes.* **(Right)** *H&E of mediastinal cyst shows there is an obvious presence of thymic tissue ⇨. In addition, the cyst appears uniloculated and lined by a flattened type of epithelium.*

Residual Thymus

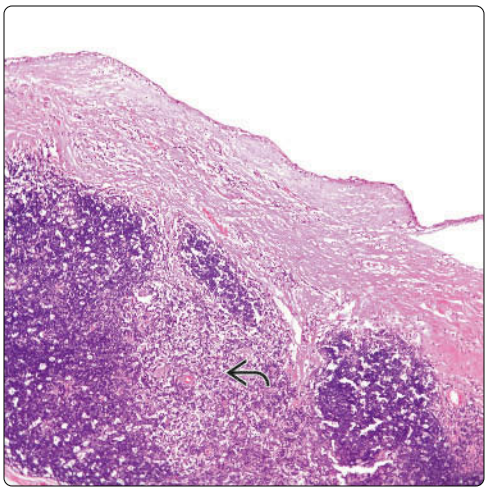

Epithelium With Lack of Atypia

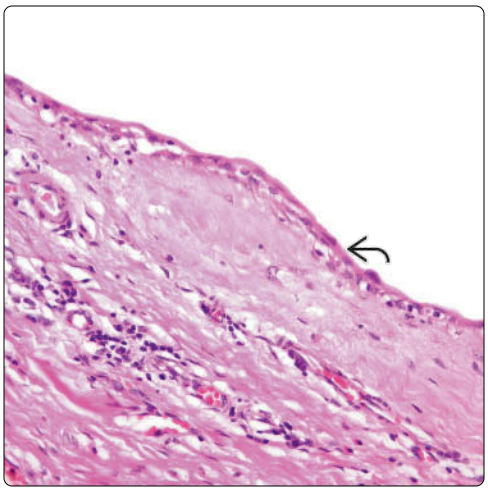

(Left) *High magnification shows a mediastinal cyst with obvious presence of thymic tissue ⇨ and a cystic structure lined by a flattened type of epithelium. These features are consistent with a thymic cyst.* **(Right)** *High magnification shows the epithelium lining a mediastinal cyst, which is composed of a low cuboidal type ⇨ without atypia. Note the presence of mild inflammatory changes in the wall of the cyst.*

Columnar Epithelium

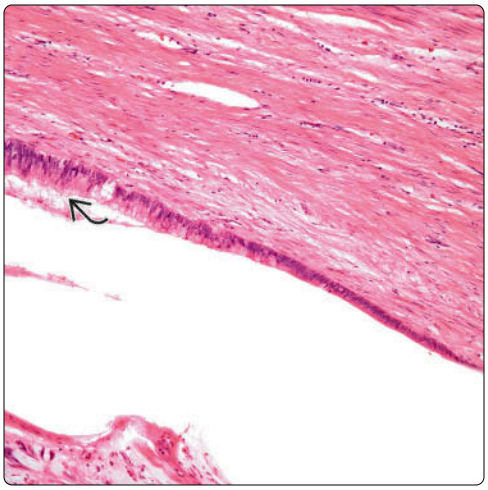

Mucinous Epithelium

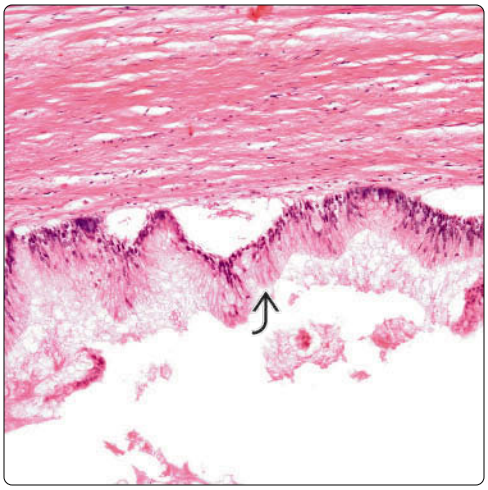

(Left) *Mediastinal cyst composed of dense fibroconnective tissue shows cystic structure lined by an epithelium with tall columnar cells. The cyst wall shows mild inflammatory changes.* **(Right)** *High-power view shows the epithelium lining a mediastinal cyst, which is composed of a mucinous type of epithelium. This finding is diagnostic of an enteric cyst.*

Enteric Epithelium

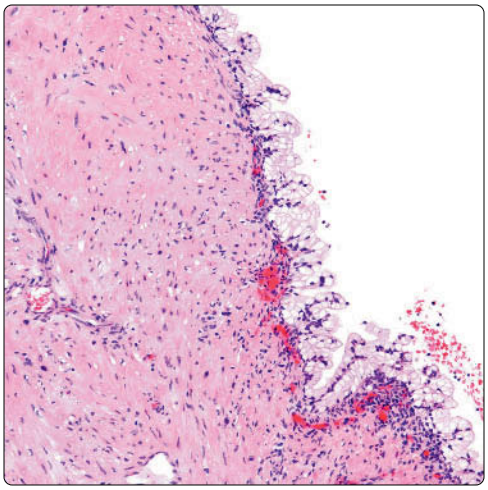

Gastric Type of Epithelium

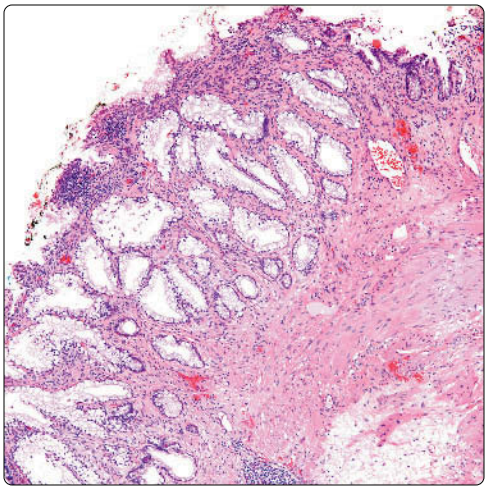

(Left) *Enteric cyst shows the cystic structure lined by enteric, mucinous type of epithelium. Note that the epithelium is overlying the cystic structure.* **(Right)** *Enteric cyst shows prominent enteric (gastric) type of glands lining the cystic structure. In this case, it is easy to identify the type of epithelium.*

Cystic Changes

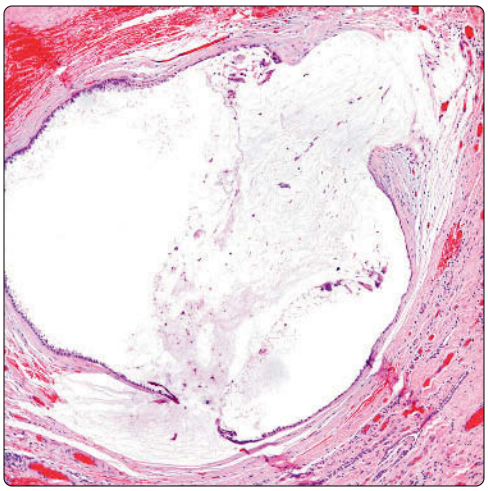

Inflammatory Reaction

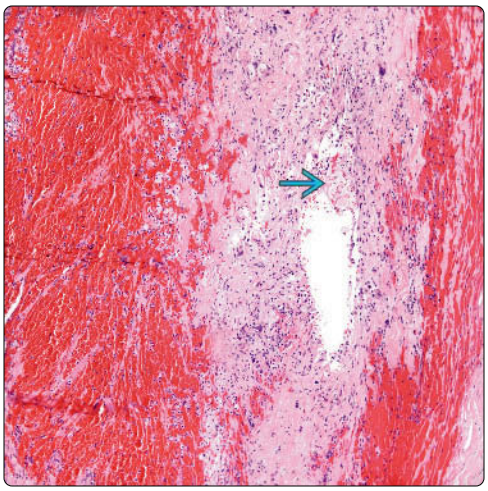

(Left) *Enteric cyst shows cystic changes within the wall of the cyst. Note the presence of mucinous contents in addition to the mucinous epithelium lining the cystic structure.* **(Right)** *Enteric cyst in which the cyst walls show marked hemorrhagic and inflammatory changes with a subtle area of granulomatous reaction is shown. The cyst lining has been completely obliterated.*

Acquired Multilocular Thymic Cyst

KEY FACTS

ETIOLOGY/PATHOGENESIS

- Acquired reactive process resulting from underlying infectious or inflammatory stimulus

CLINICAL ISSUES

- Generally cured by complete surgical excision
  - Rare cases can recur when incompletely excised
- Chest pain and dyspnea
- Often seen in children with AIDS

MACROSCOPIC

- Large, multilocular cystic structure
- May show fibrous adhesions to pleura and pericardium
- 3-25 cm in diameter

MICROSCOPIC

- Cystic spaces lined by flat, cuboidal to squamous epithelium
  - Squamous epithelium may show pseudoepitheliomatous hyperplasia
  - Lining of cysts can be traced to dilated Hassall corpuscles
- Prominent stromal hemorrhage, fibrosis, and chronic inflammation in wall of cysts
- Prominent granulation tissue and cholesterol cleft granulomas in stroma
- Prominent lymphoid follicular hyperplasia
- Residual thymus showing branching, elongated strands of thymic epithelium

DIAGNOSTIC CHECKLIST

- Multiple cysts lined by epithelium that is in continuity with cystically dilated Hassall corpuscles
- Cyst walls show prominent fibrosis and chronic inflammation
- Many cases also show prominent lymphoid follicular hyperplasia (i.e., lymphoepithelial cysts)
- Cases with pseudoepitheliomatous hyperplasia of lining epithelium may be confused for invasive squamous cell carcinoma arising in cyst

Gross Appearance

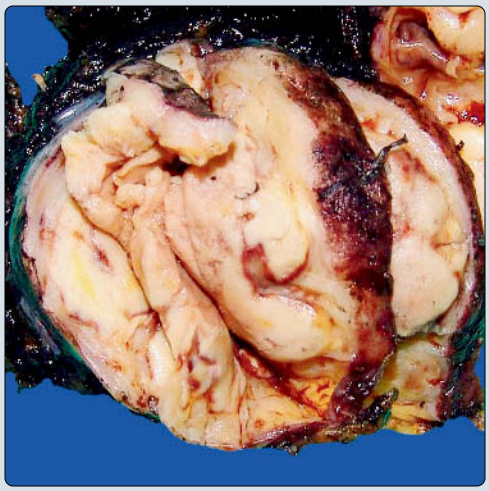

Histologic Appearance

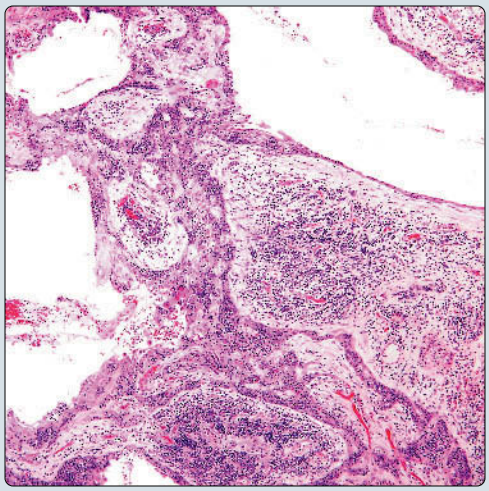

(Left) *Gross appearance of a multilocular thymic cyst shows a well-circumscribed cystic mass with hemorrhage in the walls of the cyst.* **(Right)** *Histologic appearance of a multilocular thymic cyst shows cystic cavities lined by a thin layer of epithelium in continuity with strands of hyperplastic thymic epithelium.*

Cystic Hassall Corpuscles

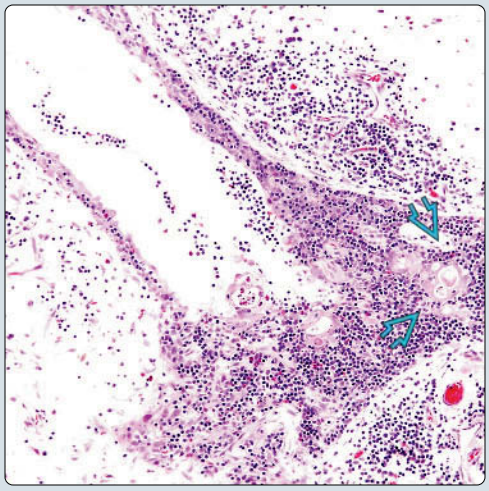

Cholesterol Cleft Granuloma

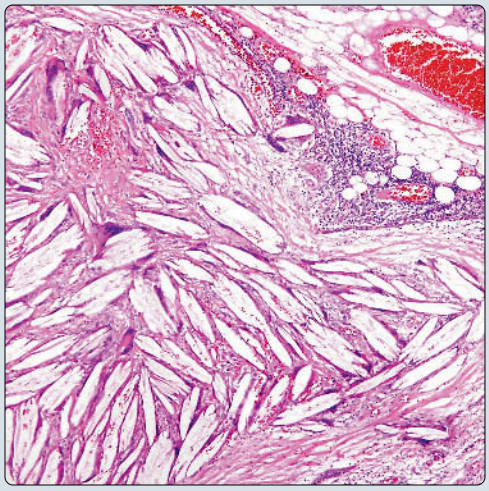

(Left) *Cystic dilatation of Hassall corpuscles is a common feature in acquired multilocular thymic cysts. The lining of the cyst is often seen to be in continuity with residual Hassall corpuscles in the walls of the cysts.* **(Right)** *Cholesterol cleft granulomas are a common finding in acquired multilocular thymic cysts. This is likely due to rupture of the cysts with hemorrhage and extrusion of epithelial cells into the stroma eliciting an inflammatory reaction.*

TERMINOLOGY

Abbreviations

- Acquired multilocular thymic cyst (MTC)

ETIOLOGY/PATHOGENESIS

Acquired Reactive Process

- Resulting from underlying infectious or inflammatory stimulus

CLINICAL ISSUES

Presentation

- Chest pain, dyspnea, chest fullness
- Associated with AIDS in children

Treatment

- Surgical excision

Prognosis

- Excellent prognosis; generally cured by simple excision
- Rare cases can recur when incompletely excised

MACROSCOPIC

General Features

- Large, multilocular cystic structure
- Cysts may contain clear or hemorrhagic fluid
- May show fibrous adhesions to pleura and pericardium

Sections to Be Submitted

- At least 1 section per centimeter of greatest diameter
- Submit all solid areas in walls of cysts

Size

- 3-25 cm in diameter

MICROSCOPIC

Histologic Features

- Cystic spaces lined by flat, cuboidal to squamous epithelium
  - Squamous epithelium may show pseudoepitheliomatous hyperplasia
  - Lining of cysts can be traced in continuity with dilated Hassall corpuscles
- Prominent stromal hemorrhage, fibrosis, and chronic inflammation in wall of cysts
- Prominent granulation tissue and cholesterol-cleft granulomas in stroma
- Prominent lymphoid follicular hyperplasia
- Residual thymus showing branching, elongated strands of thymic epithelium

DIFFERENTIAL DIAGNOSIS

Cystic Hodgkin Lymphoma

- Microscopic islands containing Reed-Sternberg cells should be present
- Positive identification of Reed-Sternberg cells with antibodies to CD30/CD15 required for diagnosis of Hodgkin disease

Cystic Seminoma

- Microscopic islands containing seminoma cells should be present
- Positive identification of seminoma cells using PLAP, OCT4 or C-kit

Cystic Thymoma

- Solid, confluent areas showing features of thymoma should be present in walls of cyst
- Identification of keratin (+) cells amidst immature CD1a/CD3(+) thymocytes required for diagnosis of thymoma

Cystic Teratoma

- Heterologous elements should be identified in walls of cyst (i.e., cartilage, glial tissue, squamous or glandular epithelium, etc.)
- May contain immature neural elements (immature teratoma)

MALT Lymphoma of Thymus

- Cystic spaces in MALT lymphoma show infiltration of small lymphocytes into epithelial lining of cyst
- Monotonous population of monocytoid B cells is present surrounding lymphoid follicles in MALT lymphoma
- Infiltration of Hassall corpuscles by lymphocytes create lymphoepithelial lesions in MALT lymphoma

Thymic Carcinoma

- Cystic mucoepidermoid carcinoma will show solid areas exhibiting epidermoid features and mucocytes in walls of cysts
- Basaloid carcinoma of thymus will show cystic dilatation of tumor cell islands that are lined by atypical, basaloid cells

DIAGNOSTIC CHECKLIST

Clinically Relevant Pathologic Features

- Multiple cysts lined by epithelium that is in continuity with cystically dilated Hassall corpuscles
- Cyst walls show prominent fibrosis and chronic inflammation
- Many cases also show prominent lymphoid follicular hyperplasia (i.e., lymphoepithelial cysts)

Pathologic Interpretation Pearls

- Most important feature is to make sure that malignant thymic neoplasm with secondary cystic changes (such as thymoma, lymphoma, or seminoma) has been ruled out by thorough sampling

SELECTED REFERENCES

1. Izumi H et al: Multilocular thymic cyst associated with follicular hyperplasia: clinicopathologic study of 4 resected cases. Hum Pathol. 36(7):841-4, 2005
2. Kontny HU et al: Multilocular thymic cysts in children with human immunodeficiency virus infection: clinical and pathologic aspects. J Pediatr. 131(2):264-70, 1997
3. Mishalani SH et al: Multilocular thymic cyst. A novel thymic lesion associated with human immunodeficiency virus infection. Arch Pathol Lab Med. 119(5):467-70, 1995
4. Suster S et al: Multilocular thymic cyst: an acquired reactive process. Study of 18 cases. Am J Surg Pathol. 15(4):388-98, 1991
5. Suster S et al: Multilocular thymic cysts with pseudoepitheliomatous hyperplasia. Hum Pathol. 22(5):455-60, 1991

Dilated Cystic Spaces

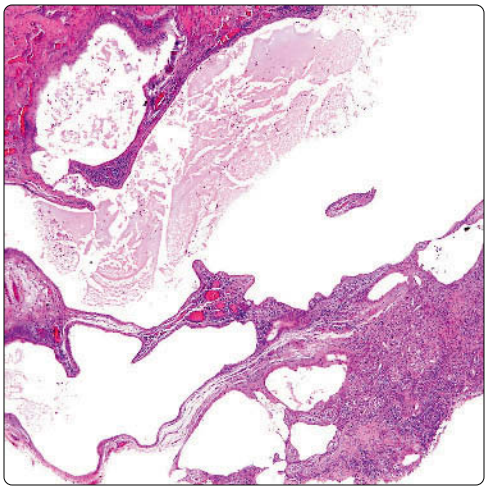

Cystic Spaces With Chronic Inflammation

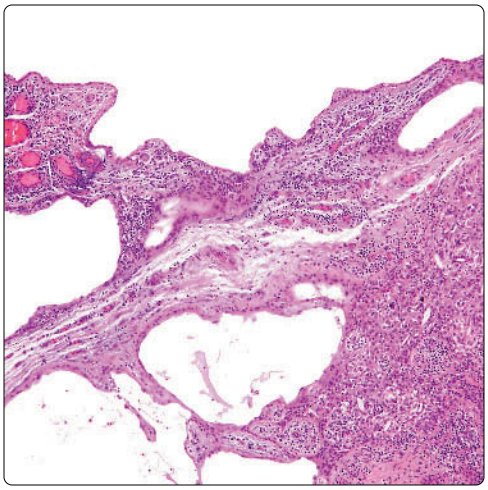

(Left) *Scanning magnification of a multilocular thymic cyst shows large cystic spaces delineating multilocular cavities lined by a single layer of epithelium. The walls of the cysts contain a heavy inflammatory infiltrate.* **(Right)** *Higher magnification of a multilocular thymic cyst shows dense lymphoid infiltrates in the walls of the cysts. The cysts vary in size and shape, and some of the larger cysts appear to result from the confluence of smaller cysts.*

Cystic Space

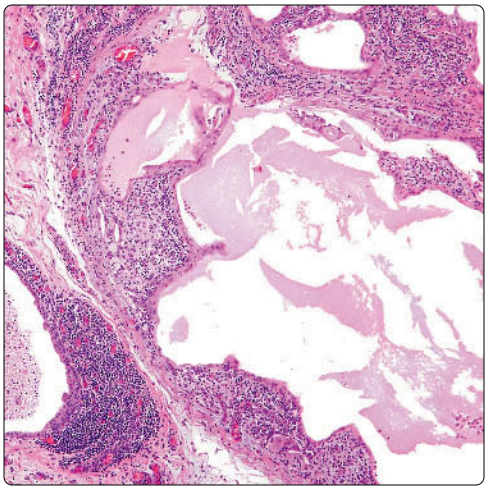

Cyst Wall With Inflammation

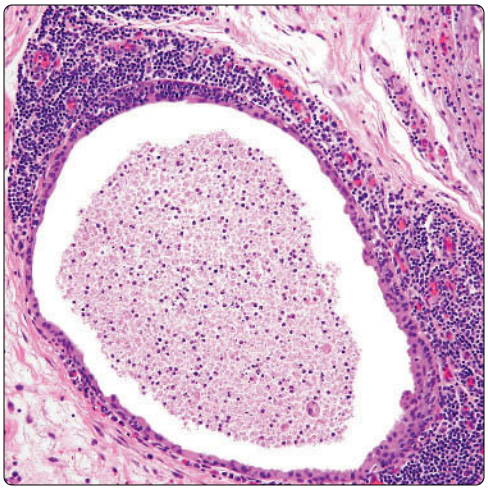

(Left) *A multilocular thymic cyst shows multiple irregular cystic spaces lined by epithelium and containing proteinaceous debris in their lumina.* **(Right)** *High magnification of a multilocular thymic cyst shows a lumen filled with proteinaceous debris admixed with inflammatory cells. The cyst wall is lined by a thin layer of cuboidal epithelium and is surrounded by dense inflammatory infiltrate composed primarily of small lymphocytes and admixed with occasional plasma cells and histiocytes.*

Cyst Wall With Inflammation

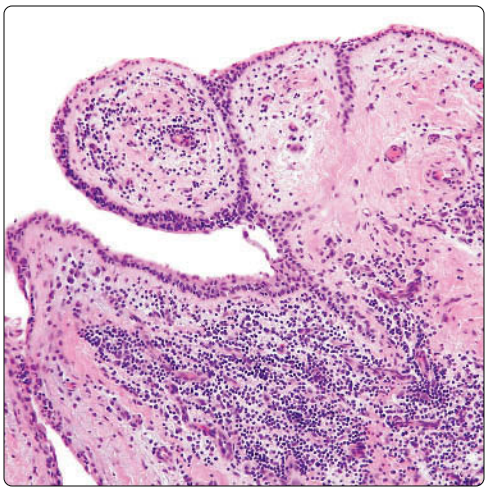

Cyst Lining, Higher Magnification

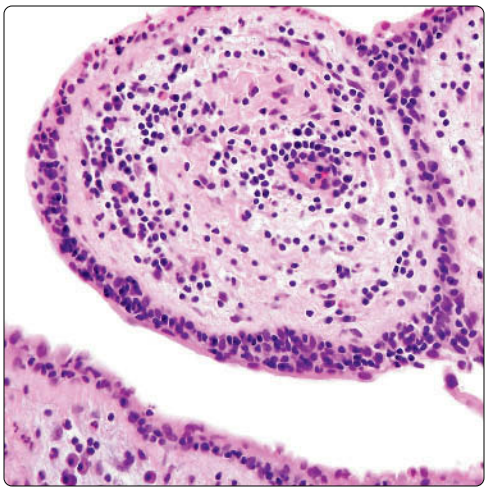

(Left) *Wall of a cyst in a patient with a multilocular thymic cyst shows polypoid protrusion into the lumen by epithelium-lined stroma with features of granulation tissue.* **(Right)** *High magnification of polypoid intraluminal invagination of the cyst wall in a multilocular thymic cyst shows a thin layer of stratified, cuboidal epithelium circumscribing an area of granulation tissue with fibroblastic proliferation, scattered inflammatory cells, and small vessels.*

Residual Thymic Epithelium in Cyst Wall

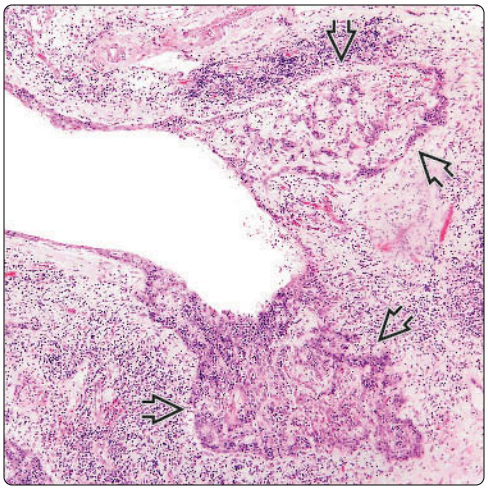

Residual Thymic Epithelium, High Power

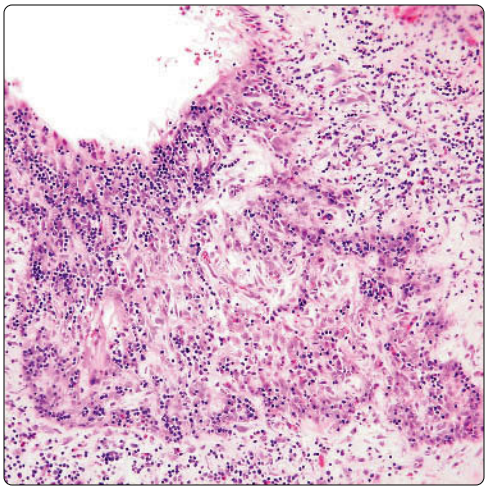

(Left) *Multilocular thymic cyst shows cystic dilatation lined by a thin layer of simple epithelium that can be traced back to residual thymic epithelial elements in the wall of the cyst.* **(Right)** *High magnification of the cyst wall in a multilocular thymic cyst shows the epithelial lining of the cyst in continuity with residual focus of involuting thymic epithelium within the wall of the cyst. Note that the strands of thymic epithelial cells are intimately admixed with small lymphocytes.*

Branching of Thymic Epithelium

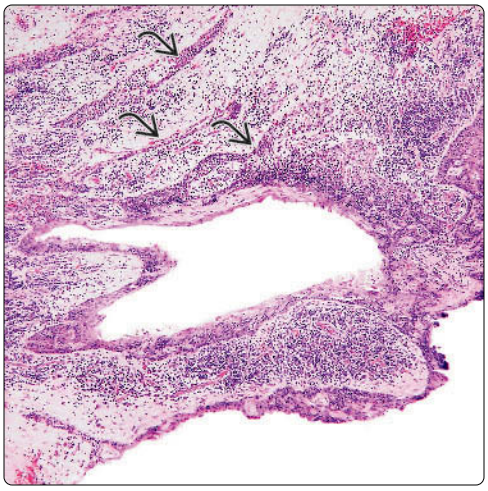

Epithelial Lining of Cyst Wall

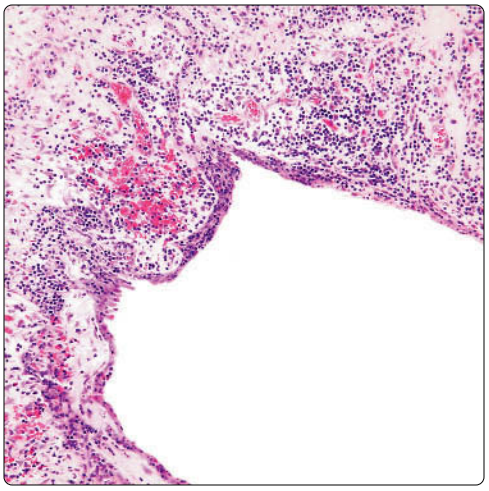

(Left) *Scanning magnification of the cyst wall in a multilocular thymic cyst shows transition between the lining epithelium and strands of residual thymic epithelium. Note that the residual thymic epithelium entrapped in the wall shows a tendency to elongate and branch out into thin strands within the cyst wall.* **(Right)** *High magnification of the cyst wall in a multilocular thymic cyst shows a thin layer of lining epithelium surrounded by abundant inflammatory infiltrate in the wall of the cyst.*

Cyst Wall With Hassall Corpuscles

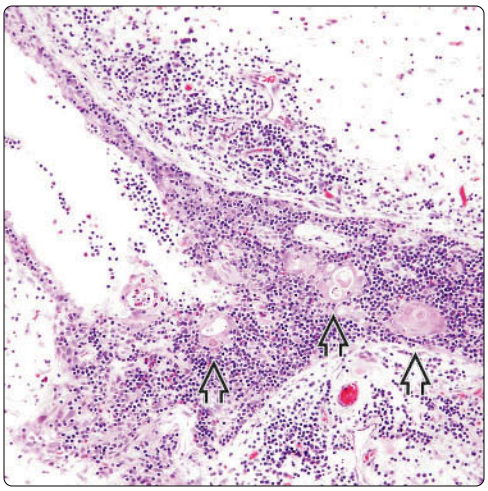

Lining of Cyst Wall

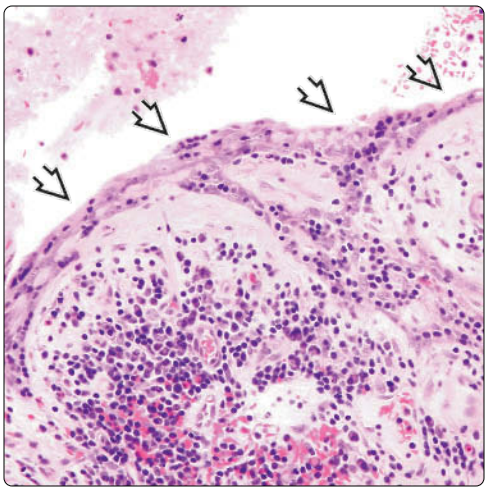

(Left) *High magnification of the cyst wall in a multilocular thymic cyst shows the origin of the cyst lining the epithelium from dilated Hassall corpuscles.* **(Right)** *High magnification of the cyst wall in a multilocular thymic cyst shows simple cuboidal epithelium lining the cyst with focal invaginations into the cyst wall. The wall of the cyst contains dense inflammatory infiltrates mainly composed of small lymphocytes admixed with plasma cells and histiocytes.*

Complex Branching of Thymic Epithelium

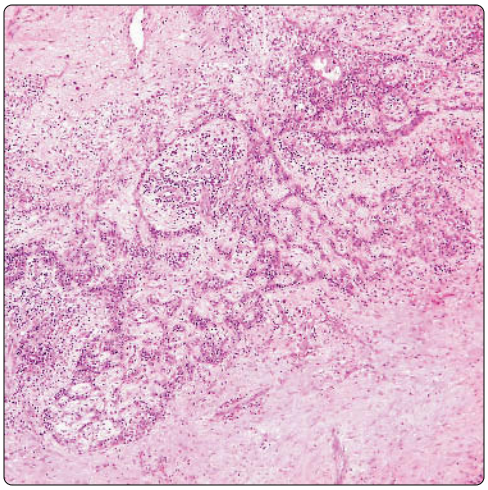

Fibroepitheliomatous Appearance

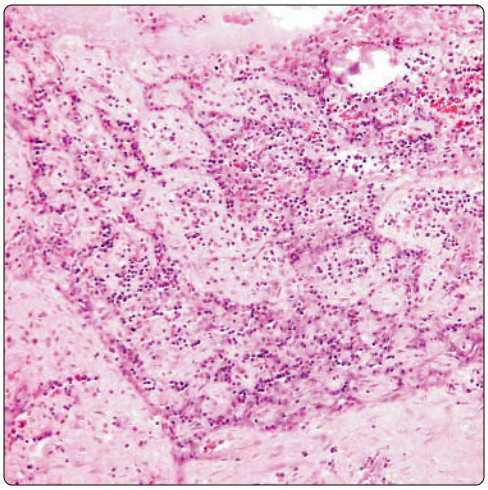

(Left) *Multilocular thymic cyst shows entrapped thymic epithelium within the cyst walls. Note the elongated, branching nature of the strands of thymic epithelium resulting in a complex, fibroepitheliomatous appearance.* **(Right)** *A striking fibroepitheliomatous appearance is shown due to strands of residual thymic epithelium located within the cyst wall of a multilocular thymic cyst. The thin strands of epithelium are surrounded by collagenized stroma with abundant lymphocytes.*

Branching of Thymic Epithelium

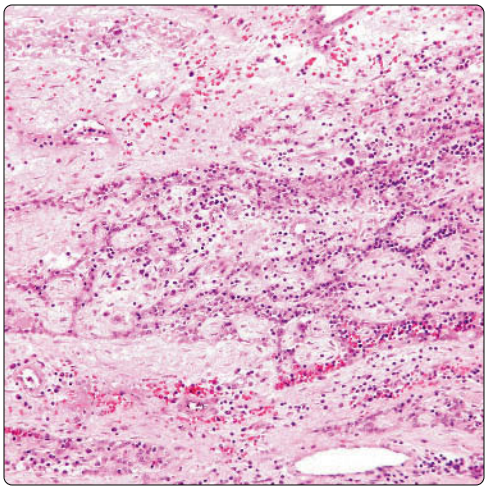

Net-Like Fibroepitheliomatous Appearance

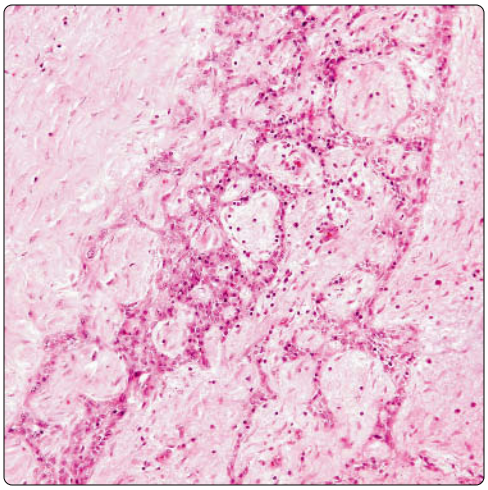

(Left) *Higher magnification of a multilocular thymic cyst shows branching strands of residual thymic epithelium entrapped within the walls of the cyst surrounded by mixed inflammatory infiltrate with abundant small lymphocytes.* **(Right)** *Striking fibroepitheliomatous appearance is seen in the residual thymic epithelium within the wall of a multilocular thymic cyst. This appearance is quite distinctive for this process and represents a reactive response pattern.*

Branching of Thymic Epithelium

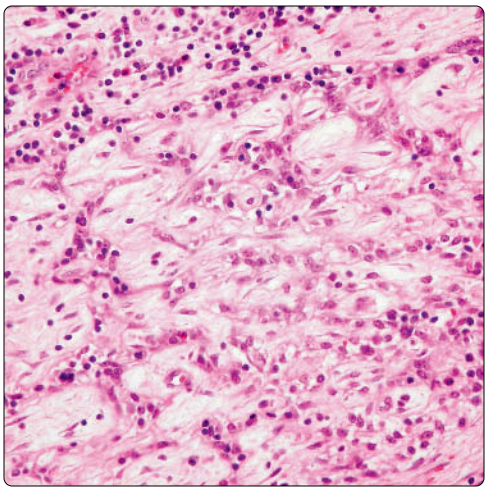

Thymic Epithelium With Inflammation

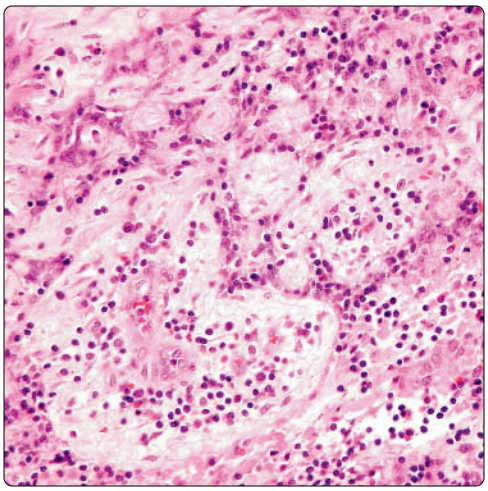

(Left) *High magnification of entrapped thymic epithelial rests within the wall of a multilocular thymic cyst shows a net-like distribution with thin anastomosing strands of epithelial cells circumscribing areas of collagenized stroma.* **(Right)** *High magnification of entrapped thymic epithelium within the wall of a multilocular thymic cyst shows thin, interlacing strands of thymic epithelium surrounded by inflammatory infiltrates, including abundant small lymphocytes, eosinophils, and plasma cells.*

Lymphoepithelial Cyst

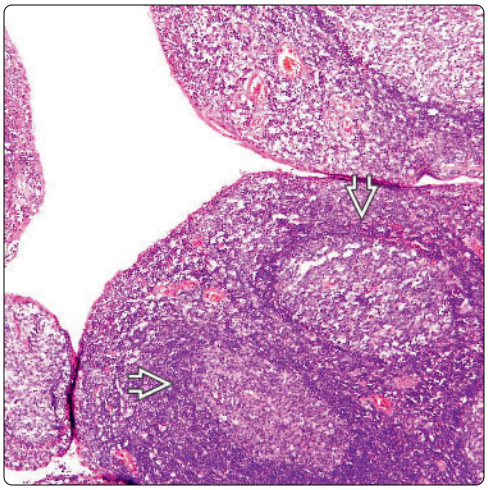

Prominent Lymphoid Hyperplasia

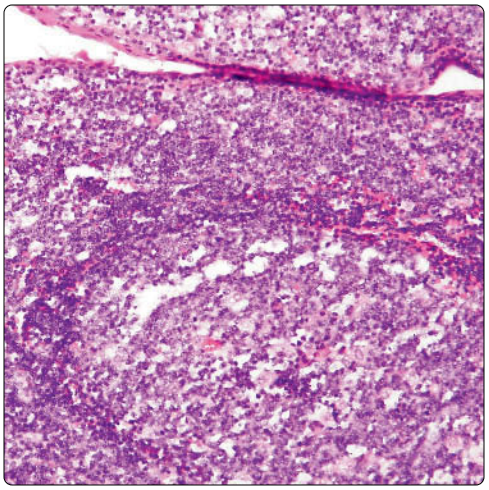

(Left) *Wall of a multilocular thymic cyst shows prominent lymphoid follicular hyperplasia. Lesions with these features are indistinguishable from lymphoepithelial cysts observed in salivary glands, pancreas, and other secretory organs.* **(Right)** *Higher magnification of lymphoid follicle in the wall of a multilocular thymic cyst shows a hyperplastic germinal center with tingible body macrophages. The remainder of the cyst wall also contains a dense lymphoid infiltrate.*

Hyperplastic Lymphoid Follicle

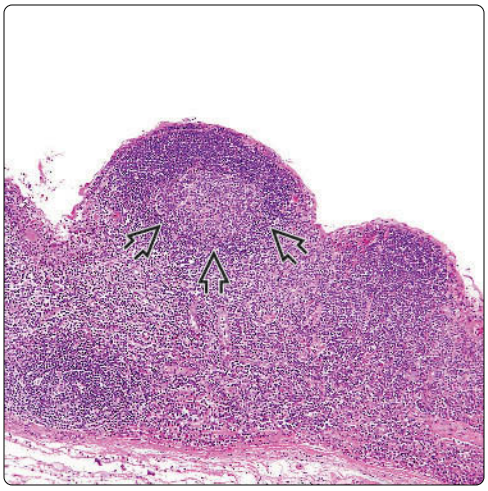

Lymphoid Follicle

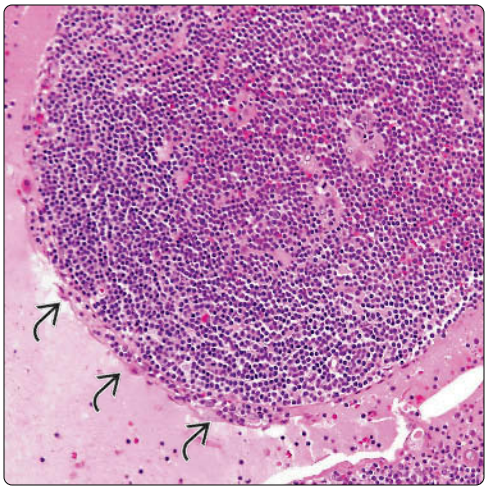

(Left) *Wall of a cyst in a patient with a multilocular thymic cyst shows prominent lymphoid follicular hyperplasia. Some of the lymphoid follicles contain prominent germinal centers.* **(Right)** *High magnification shows a hyperplastic lymphoid follicle within the wall of a cyst in a patient with a multilocular thymic cyst. Note the flattened layer of thymic epithelial cells lining the cyst.*

Cyst Wall With Lymphoid Follicles

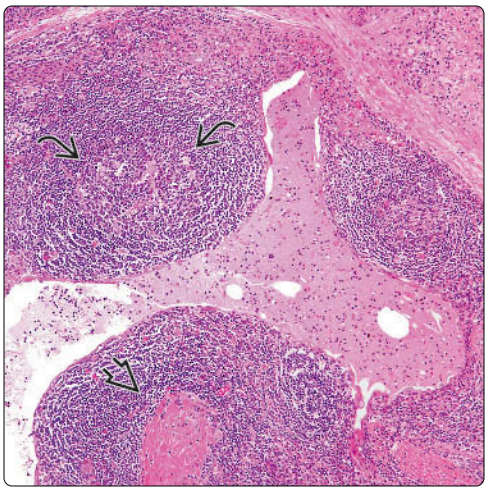

Small Cyst Surrounded by Lymphocytes

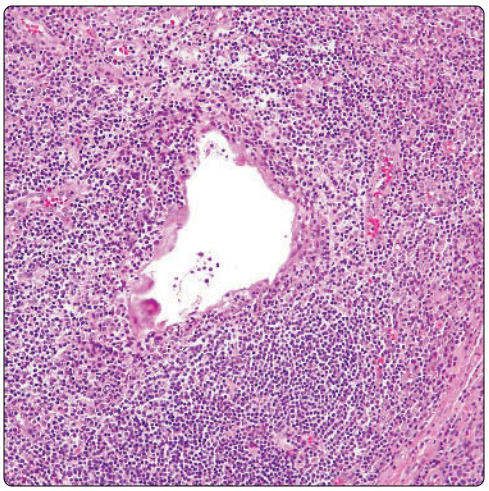

(Left) *Cyst wall in a patient with a multilocular thymic cyst shows dense lymphoid infiltrates with lymphoid follicular hyperplasia with expanded germinal centers; others show prominent hyalinization.* **(Right)** *Higher magnification of a multilocular thymic cyst with prominent lymphoid follicular hyperplasia shows early development of a cyst from dilatation of a small, burned-out Hassall corpuscle. This probably represents the earliest stage of the process.*

Stromal Hemorrhage

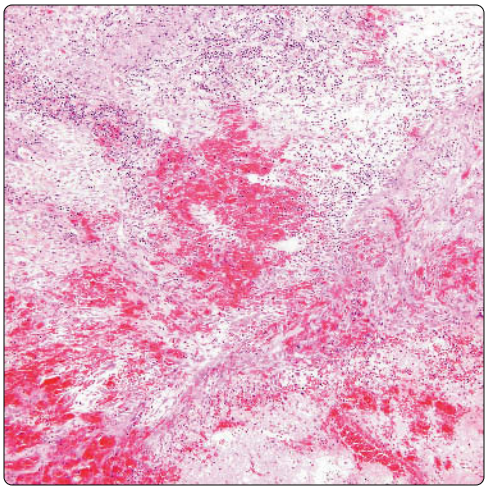

Stromal Hemorrhage, High Power

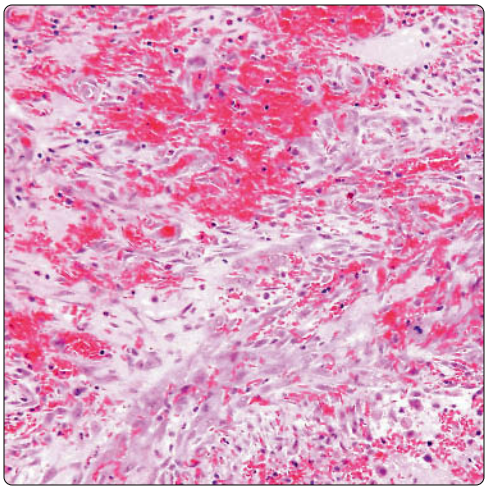

(Left) *Wall of a multilocular thymic cyst shows extensive hemorrhage and fibrosis with striking inflammatory changes.* **(Right)** *Higher magnification of the wall of a multilocular thymic cyst shows fibrosis, inflammation, and stromal hemorrhage. Inflammation and stromal hemorrhage are a prominent component of multilocular thymic cysts. The hemorrhage can sometimes extend into the cystic cavities, filling them with hemorrhagic fluid.*

Cholesterol-Cleft Granuloma

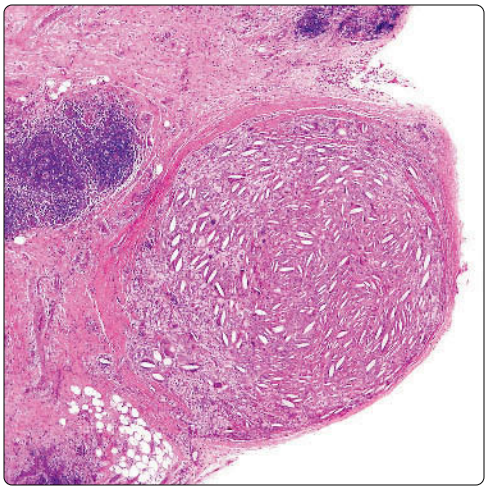

Cholesterol-Cleft Granuloma, High Power

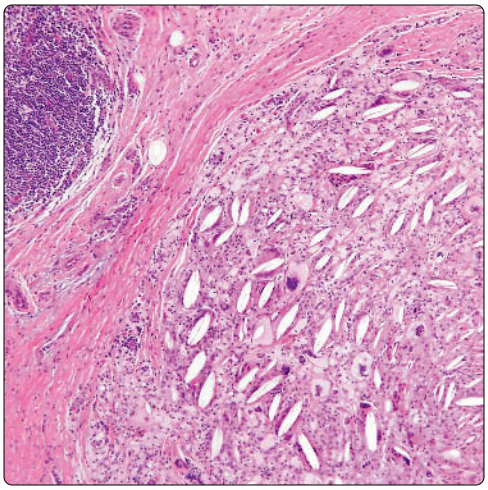

(Left) *Wall of a multilocular thymic cyst shows a polypoid protrusion into the lumen by a well-circumscribed nodule containing cholesterol-cleft granuloma.* **(Right)** *Wall of a cyst in a patient with a multilocular thymic cyst shows cholesterol-cleft granuloma. Cholesterol-cleft granulomas are a frequent feature seen in multilocular thymic cysts and may result from a reaction to extruded keratin squames or keratinous debris from Hassall corpuscles in the cyst walls.*

Cholesterol-Cleft Granuloma

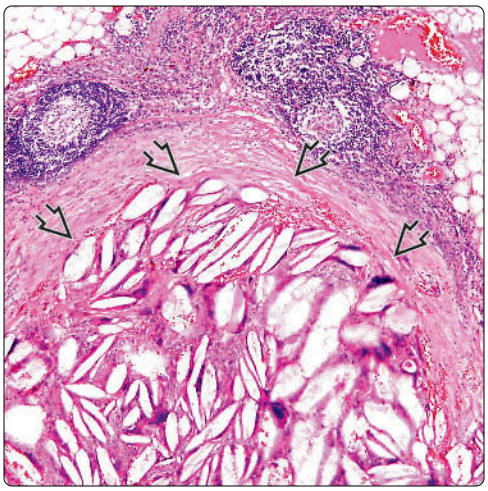

Cholesterol-Cleft Granuloma, High Power

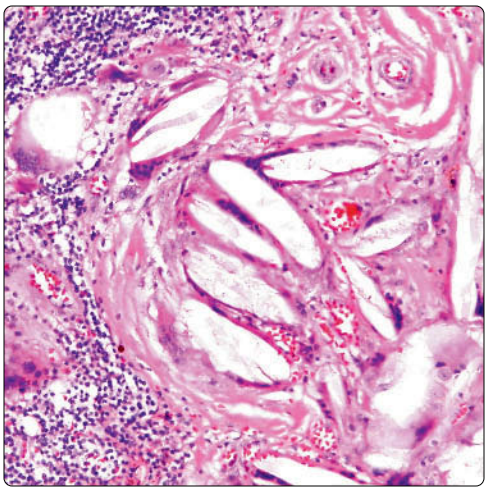

(Left) *Wall of a cyst in a patient with multilocular thymic cyst shows a well-circumscribed area containing cholesterol-cleft granuloma ⇨. Note the well-formed lymphoid follicles surrounding the granuloma at the periphery of the lesion.* **(Right)** *High magnification of cholesterol-cleft granuloma within the wall of a multilocular thymic cyst shows cholesterol clefts surrounded by multinucleated giant cells admixed with abundant fibrous stroma.*

Spindling of Stromal Cells

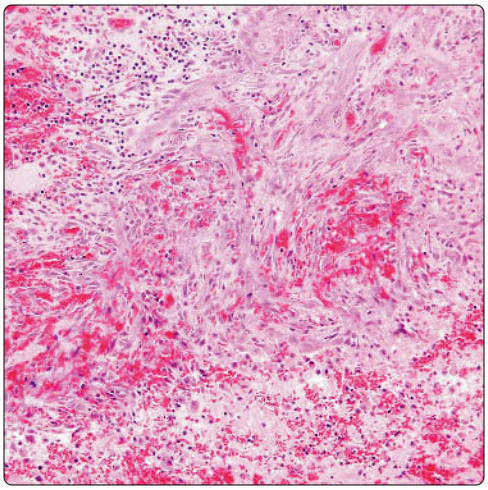

Spindle Cells With Mitosis

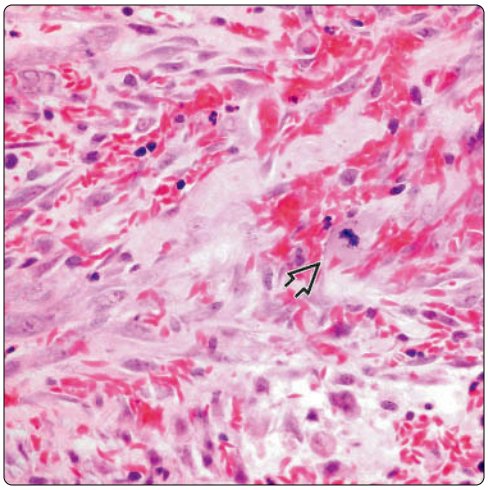

(Left) *Area of cyst wall in a patient with a multilocular thymic cyst shows complex proliferation of squamous epithelium admixed with hemorrhage and inflammation with focal spindling of the epithelial cells suggestive of an invasive malignant process.* **(Right)** *Higher magnification of epithelial proliferation in the wall of a cyst in a patient with a multilocular thymic cyst shows spindling of the epithelial cells and occasional scattered mitoses.*

Pseudoepitheliomatous Hyperplasia

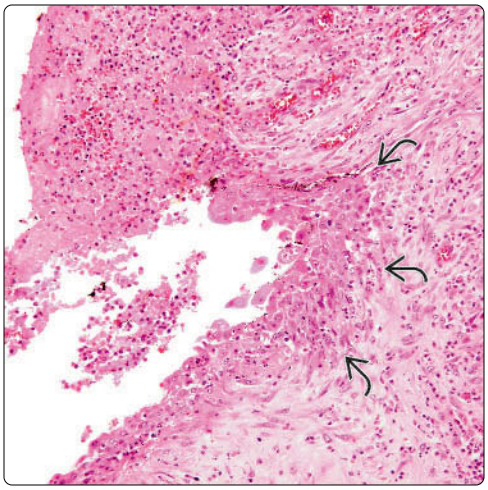

Pseudoepitheliomatous Hyperplasia, High Power

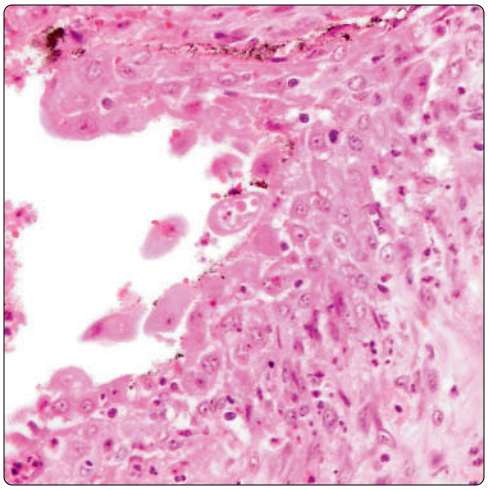

(Left) *Wall of a cyst in a patient with a multilocular thymic cyst shows focus of squamous metaplasia of the lining epithelium with focal invagination of the lining into the wall of the cyst resulting in an appearance of invasion.* **(Right)** *Higher magnification shows a focus of squamous metaplasia of the epithelial lining in the wall of a multilocular thymic cyst. Cases showing features of pseudoepitheliomatous hyperplasia can be confused for squamous cell carcinomas arising from the cyst lining.*

Atypia in Squamous Epithelium

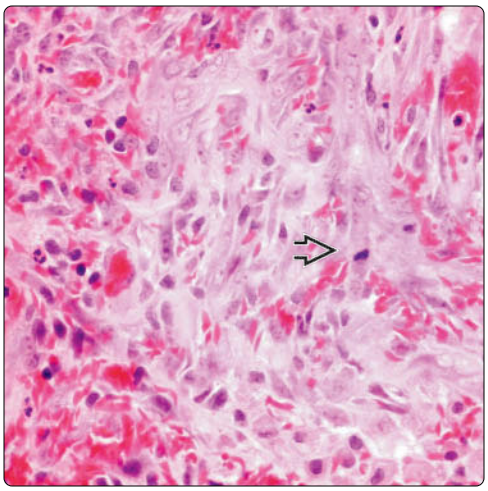

Mitotic Figure

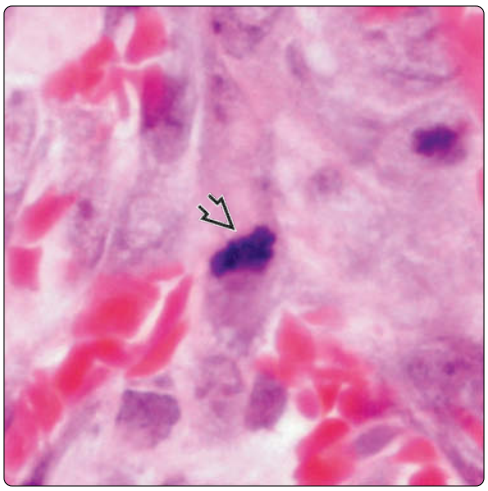

(Left) *Area of pseudoepitheliomatous hyperplasia with cytologic atypia is seen in the wall of a multilocular thymic cyst. The epithelial cells show enlarged, hyperchromatic nuclei and scattered mitoses admixed with granulation tissue.* **(Right)** *High magnification from an area of pseudoepitheliomatous hyperplasia in the wall of a multilocular thymic cyst shows a mitotic figure.*

Idiopathic Sclerosing Mediastinitis

KEY FACTS

ETIOLOGY/PATHOGENESIS

- Most cases are idiopathic
- May be result of healed infection, such as tuberculosis or toxoplasmosis
- May represent end stage of burned-out neoplasms, such as Hodgkin lymphoma or seminoma
- May be secondary to autoimmune disorders, sarcoidosis, rheumatic fever, or drugs (e.g., methysergide)
- Some cases thought to represent abnormal immune response due to delayed hypersensitivity reaction to infectious agents in susceptible individuals

CLINICAL ISSUES

- Mediastinal mass or widening of mediastinum on chest x-ray and CT scan
- Can show calcifications on imaging studies
- Extensive subcarinal involvement most likely to lead to death due to encroachment of vital structures
- Chronic course; may be self-limiting and regress spontaneously or progress to death due to respiratory compromise
- Cough, shortness of breath, fever, and superior vena cava syndrome (in rare instances)
- Mediastinal mass or widening of mediastinum on chest x-ray and CT scan
- Can show calcifications on imaging studies

MICROSCOPIC

- Stage I: Edematous fibromyxoid tissue with fibroblastic spindle cells, eosinophils, mast cells, lymphocytes, plasma cells, and thin-walled blood vessels
- Stage II: Thick bands of dense collagen haphazardly distributed and containing scattered fibroblastic spindle cells, lymphocytes, and plasma cells
- Stage III: Dense acellular collagen with scattered lymphoid follicles and occasional dystrophic calcifications

Histologic Appearance

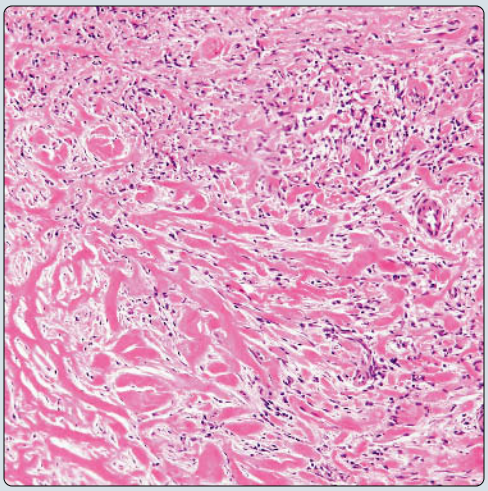

Extensive Sclerosis and Hyalinization

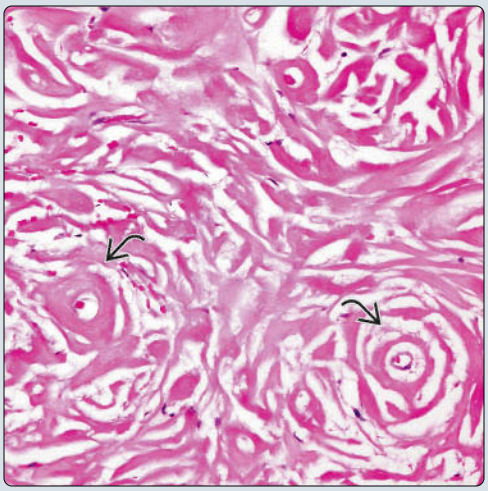

(Left) *Histologic appearance of idiopathic sclerosing mediastinitis shows thick bands of keloidal collagen arranged in haphazard distribution (bottom) admixed with scattered inflammatory cells.* **(Right)** *End stage of idiopathic sclerosing mediastinitis shows complex pattern of hyalinization with thick bands of keloidal collagen in concentric arrangement around residual small vessels.*

Entrapment of Nerve Bundle

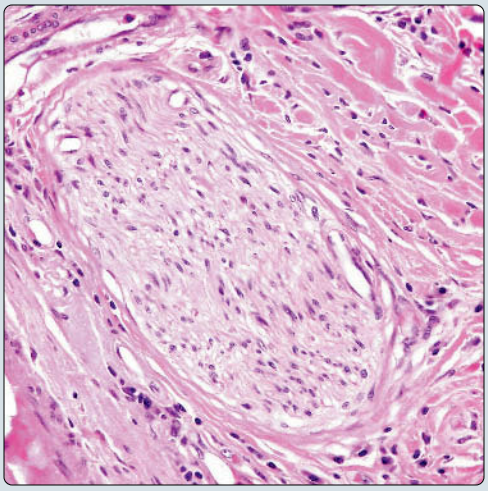

Perivascular Fibrosis

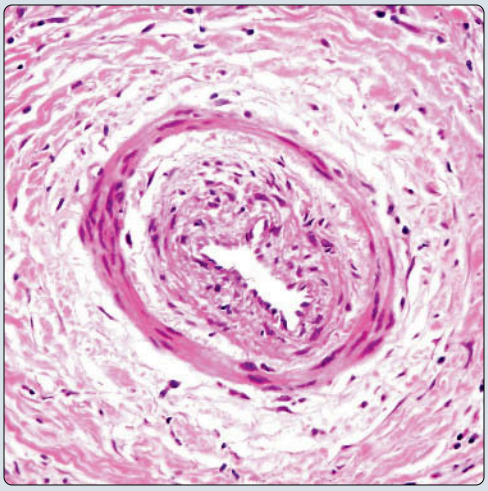

(Left) *Higher magnification shows entrapment of nerve bundles within the sclerosing process in mediastinal idiopathic sclerosing mediastinitis.* **(Right)** *This section shows entrapment of a small-caliber vessel by dense perivascular fibrosis. The fibrosing process may eventually compress the lumen of the vessels and lead to ischemia and degenerative changes.*

TERMINOLOGY

Synonyms

- Idiopathic fibroinflammatory lesion
- Sclerosing mediastinitis
- Inflammatory pseudotumor

Definitions

- Chronic condition characterized by fibrous replacement of soft tissues in mediastinum ± inflammation, of unknown etiology

ETIOLOGY/PATHOGENESIS

Pathogenesis

- Most cases are idiopathic
- May be result of healed infection, such as tuberculosis or toxoplasmosis
- May represent end stage of burned-out neoplasms, such as Hodgkin lymphoma or seminoma
- May be secondary to autoimmune disorders, sarcoidosis, rheumatic fever, or drugs (e.g., methysergide)
- Some cases thought to represent abnormal immune response due to delayed hypersensitivity reaction to infectious agents in susceptible individuals

CLINICAL ISSUES

Epidemiology

- Age
  - Most often involves young individuals between 20-30 years of age
- Sex
  - Slight female predilection
- Ethnicity
  - Slight increase in African Americans

Presentation

- Cough, shortness of breath, fever, and superior vena cava syndrome (in rare instances)
- Mediastinal mass or widening of mediastinum on chest x-ray and CT scan
- Can show calcifications on imaging studies

Treatment

- Steroids
- Surgery difficult and generally of limited benefit
- Favorable response to antifungal agents has been observed in some cases

Prognosis

- Long protracted course with progressive airway compromise
- Extensive subcarinal involvement most likely to lead to death due to encroachment of vital structures

MACROSCOPIC

General Features

- Gray-white, homogeneous rubbery tissue
- Diffusely infiltrative; permeates surrounding structures including great vessels, nerves, pericardium, etc.

MICROSCOPIC

Histologic Features

- Stage I: Edematous fibromyxoid tissue with fibroblastic spindle cells, eosinophils, mast cells, lymphocytes, plasma cells, and thin-walled blood vessels
- Stage II: Thick bands of dense collagen haphazardly distributed and containing scattered fibroblastic spindle cells, lymphocytes, and plasma cells
- Stage III: Dense acellular collagen with scattered lymphoid follicles and occasional dystrophic calcifications
- Other features
  - Entrapment of nerve trunks is common feature
  - Ill-defined or well-formed epithelioid granulomas can also be encountered

ANCILLARY TESTS

Histochemistry

- Special stains for organisms (i.e., GMS, PAS, AFB) should be used to rule out infectious etiology

DIFFERENTIAL DIAGNOSIS

Fibrosis Secondary to Infectious Agents

- Healed or burned-out tuberculosis, histoplasmosis, aspergillosis, mucormycosis, cryptococcosis, atypical mycobacteria, and bacterial infections caused by *Nocardia* and *Actinomyces* species
- Clinical history or serologic evidence of infection may help identify cause in some patients

Fibrosis Secondary to Drugs

- History of methysergide or other drug associated with tissue fibrosis favors this diagnosis

Hodgkin Disease

- Often associated with massive sclerosis in mediastinum
- Extensive sampling and diligent search for residual foci of Reed-Sternberg cells

Seminoma With Secondary Fibrosis

- Extensive sampling and diligent search for residual islands of seminoma cells

DIAGNOSTIC CHECKLIST

Pathologic Interpretation Pearls

- Most important role of pathologist is to rule out infection or burned-out, sclerotic malignant neoplasm

SELECTED REFERENCES

1. Miyata T et al: Sclerosing mediastinitis mimicking anterior mediastinal tumor. Ann Thorac Surg. 88(1):293-5, 2009
2. Kang DW et al: Sclerosing mediastinitis in the differential diagnosis of mediastinal tumors. J Bras Pneumol. 32(1):78-83, 2006
3. Flieder DB et al: Idiopathic fibroinflammatory (fibrosing/sclerosing) lesions of the mediastinum: a study of 30 cases with emphasis on morphologic heterogeneity. Mod Pathol. 12(3):257-64, 1999
4. Dehner LP et al: Idiopathic fibrosclerotic disorders and other inflammatory pseudotumors. Semin Diagn Pathol. 15(2):161-73, 1998

Sclerosing Mediastinitis: Early Stage

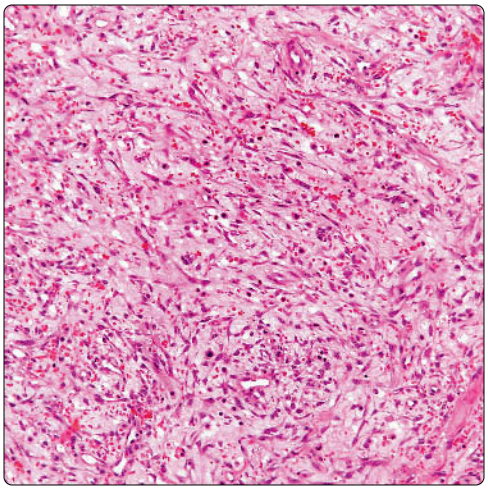

Granulation Tissue-Like Area

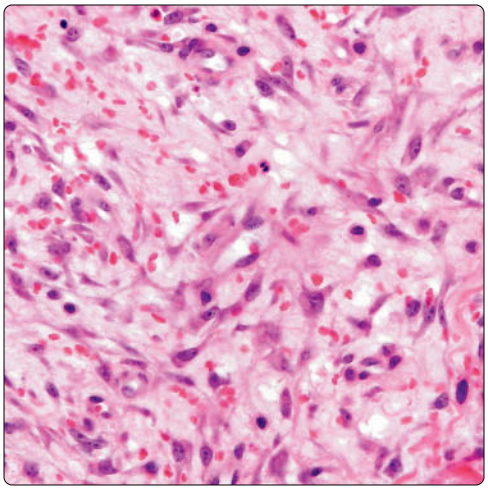

(Left) *Scanning magnification of idiopathic sclerosing mediastinitis, early stage, shows cellular proliferation of spindle cells admixed with scattered inflammatory cells, red blood cells, and small vessels set against a myxoid background.* **(Right)** *Higher magnification of idiopathic sclerosing mediastinitis in early stages shows fibroblastic spindle cells admixed with lymphocytes and small vessels. This appearance is essentially indistinguishable from that of early granulation tissue.*

Mitosis in Sclerosing Mediastinitis

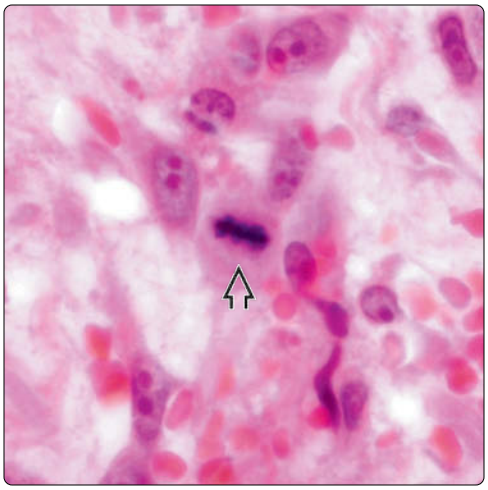

Inflammatory Infiltrates

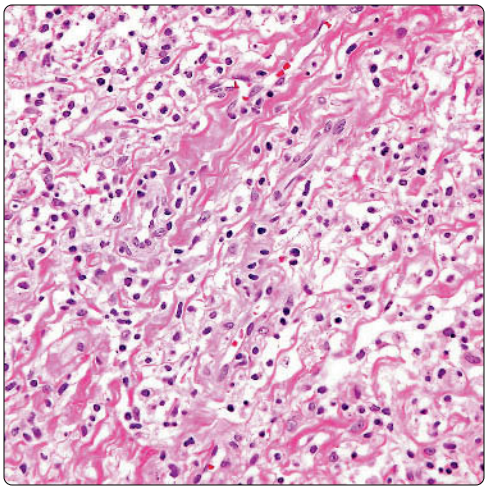

(Left) *Higher magnification of idiopathic sclerosing mediastinitis during the early stages shows plump fibroblastic cells admixed with red blood cells. Notice the mitotic figure in the center ⇨. As in granulation tissue, rare scattered mitoses may be present.* **(Right)** *Idiopathic sclerosing mediastinitis in mid stage shows an equal admixture of inflammatory cells and collagenous stroma. The process becomes more uniform with more evenly distributed fibrosis in this stage of the process.*

Fibrosis and Inflammation

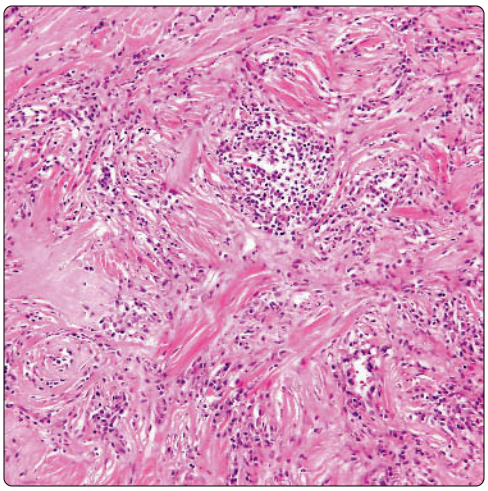

Plasma Cell Infiltrates

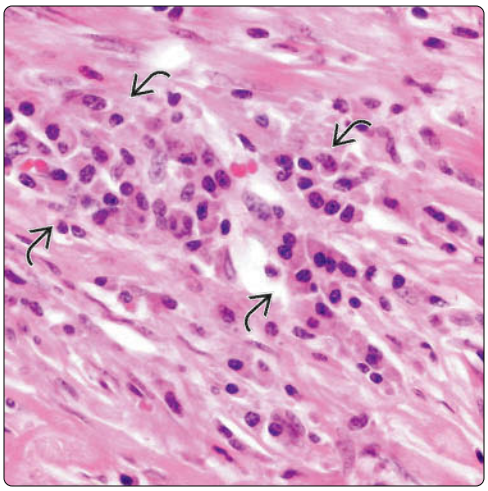

(Left) *Mid stage of idiopathic sclerosing mediastinitis shows progression of the fibrosing process resulting in broad bands of collagen admixed with lymphoid cell aggregates and other inflammatory elements.* **(Right)** *Higher magnification of idiopathic sclerosing mediastinitis shows clusters of mature plasma cells scattered in the stroma ⇨. Lesions with these features can be mistaken for examples of inflammatory myofibroblastic tumors.*

Advanced Stage of Sclerosing Mediastinitis

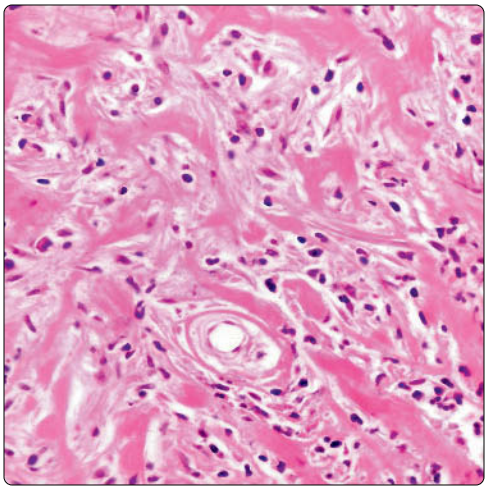

Infiltration of Surrounding Fat

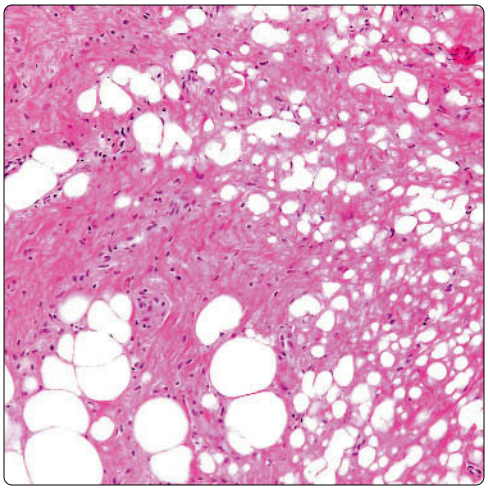

(Left) *More advanced stage of the process in idiopathic sclerosing mediastinitis shows thick bands of keloidal collagen with a few scattered fibroblastic spindle cells admixed with lymphoid cells in the surrounding stroma.* **(Right)** *Infiltration of the fat is seen in this case of idiopathic sclerosing mediastinitis. The infiltrative nature of the process makes it very difficult to surgically resect the lesion and may lead to confusion with a malignant neoplasm.*

Entrapment of Nerves

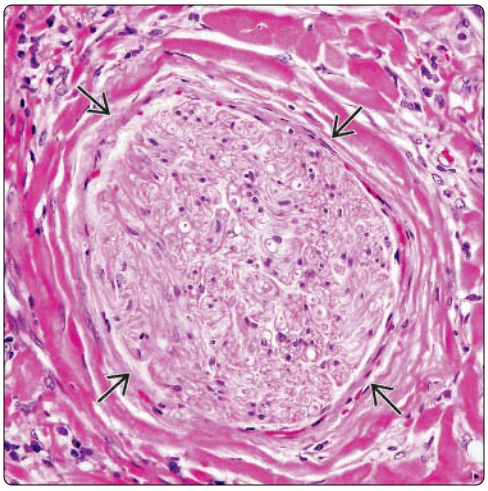

Lymphoid Follicle

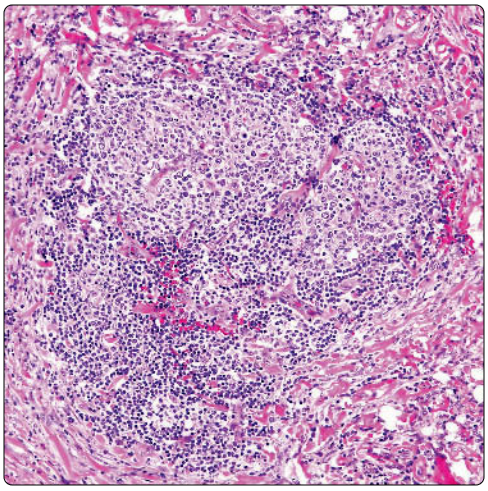

(Left) *Entrapment of large- and medium-sized nerve trunks is commonly seen in the late stages of idiopathic sclerosing mediastinitis. Notice the concentric rings of keloidal collagen surrounding the nerve trunk in this lesion.* **(Right)** *An entrapped, residual lymphoid follicle is seen in this example of idiopathic sclerosing mediastinitis. Notice the enlarged germinal center and progressive disappearance of the mantle zone in the follicle. The surrounding stroma is heavily collagenized.*

Perivascular Fibrosis

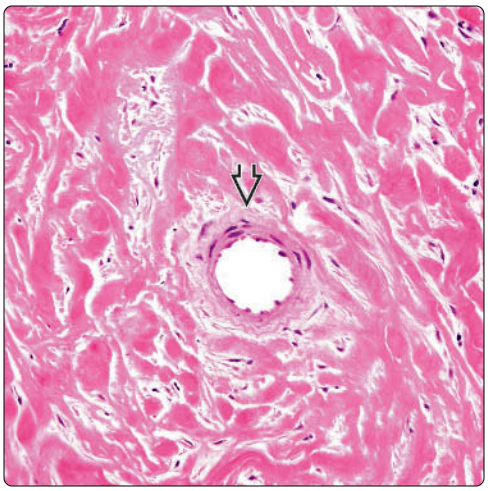

Keloidal Collagen

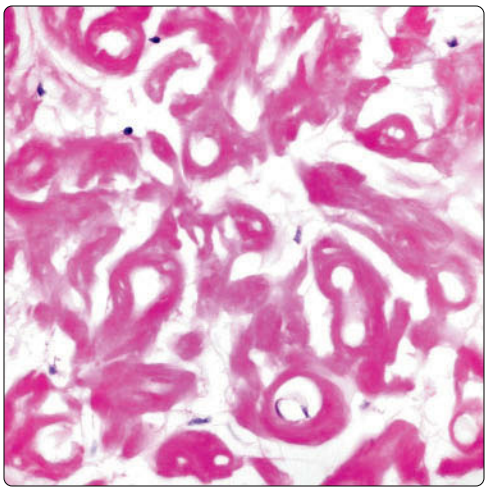

(Left) *Advanced stage of idiopathic sclerosing mediastinitis shows thick bands of keloidal collagen circumscribing a vessel. Lesions with this appearance require extensive sampling to rule out the possibility of a fibrosing neoplasm, such as Hodgkin lymphoma, seminoma, or thymic carcinoma.* **(Right)** *Unusual pattern of stromal sclerosis in idiopathic sclerosing mediastinitis shows concentric sclerosis primarily involving the walls of small-caliber vessels.*

This page intentionally left blank

INDEX

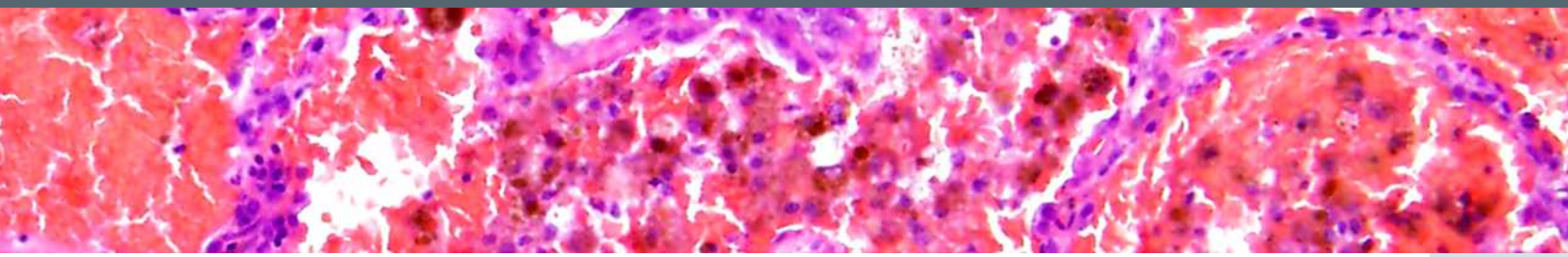

A

Acinic cell carcinoma, **198-205**
- diagnostic checklist, **199**
- differential diagnosis, **199**
- granular cell tumor vs., **57**
- histochemical features, **200**
- immunohistochemistry, **200**
- metastatic, acinic cell carcinoma vs., **199**
- molecular analysis, **200**
- prognosis, **199**
- ultrastructural features, **200**

Acquired immune deficiency syndrome (AIDS)
- lymphomatoid granulomatosis associated, **285**
- pulmonary BALT hyperplasia associated, **259**

Actinomycosis, **538-539**
- botryomycosis vs., **547**
- diagnostic checklist, **539**
- differential diagnosis, **539**
- histochemical features, **539**
- nocardiosis vs., **537**
- prognosis, **539**

Acute histoplasmosis, **507**
Acute invasive aspergillosis, **541**
Acute pulmonary infection, cryptococcosis, **493**
Acute respiratory distress syndrome. *See* Diffuse alveolar damage.
Adenocarcinoma, **76-87**
- acinic cell carcinoma vs., **199**
- adenoid cystic carcinoma vs., **179**
- adenomatoid tumor-like, **78**
- biliary, metastatic carcinoma vs., **358**
- with bronchioloalveolar pattern. *See* Bronchioloalveolar carcinoma.
- carcinosarcoma vs., **167**
- diagnostic checklist, **78**
- differential diagnosis, **78**
- endometrial, metastatic carcinoma vs., **358**
- endometrioid. *See* Endometrioid-like carcinoma.
- epithelial-myoepithelial carcinoma vs., **193**
- from extrathoracic origin, adenocarcinoma vs., **78**
- extrathoracic origin, pseudomesotheliomatous adenocarcinoma vs., **585**
- fetal
  - adenocarcinoma vs., **78**
  - well-differentiated. *See* Pulmonary blastoma.
- grading, **78**
- histochemical features, **79**
- immunohistochemistry, **79**
- intermediate grade, **78**
- with lepidic pattern. *See* Bronchioloalveolar carcinoma.
- low grade, **78**
- metastatic
  - angiosarcoma vs., **597**
  - bronchioloalveolar carcinoma vs., **89**
  - of lung origin, embryonal carcinoma vs., **721**
  - malignant mesothelioma vs., **577**
  - prostatic, endometrioid-like carcinoma vs., **109**
  - pulmonary blastoma vs., **173**
  - synovial sarcoma vs., **776**
- molecular biology, **79**
- mucinous, ciliated muconodular papillary tumor vs., **71**
- mucoepidermoid carcinoma of pleura vs., **591**
- mucoepidermoid carcinoma vs., **187**
- mucous gland adenoma vs., **13**
- pancreatic, metastatic carcinoma vs., **358**
- pleural endometriosis vs., **627**
- prognosis, **77**
- pseudomesotheliomatous, **584-589**
  - diagnostic checklist, **585**
  - differential diagnosis, **585**
  - histochemical features, **586**
  - immunohistochemistry, **586**
  - molecular features, **586**
  - prognosis, **585**
- pulmonary blastoma vs., **173**
- pulmonary invasive, bronchioloalveolar carcinoma vs., **89**
- sclerosing hemangioma (pneumocytoma) vs., **61**
- with signet ring cells. *See* Signet ring cell carcinoma.
- in situ. *See* Bronchioloalveolar carcinoma.
- Warthin-like, **78**
- well-differentiated. *See also* Bronchioloalveolar carcinoma.
  - atypical adenomatous hyperplasia vs., **341**

Adenofibroma/adenomyoma, pulmonary, **22-25**
- differential diagnosis, **23**
- prognosis, **23**

Adenofibromatous hamartoma. *See* Pulmonary adenofibroma/adenomyoma.
Adenoid cystic carcinoma, **178-185**
- adenocarcinoma vs., **78**
- diagnostic checklist, **179-180**
- differential diagnosis, **179**
- epithelial-myoepithelial carcinoma vs., **193**
- histochemical features, **180**
- immunohistochemistry, **180**
- metastatic, adenoid cystic carcinoma vs., **179**
- molecular features, **180**
- myoepithelial carcinoma of lung vs., **213**
- prognosis, **179**
- staging, **180**

INDEX

Adenoma
- alveolar, **8-11**
  - diagnostic checklist, **9**
  - differential diagnosis, **9**
  - immunohistochemistry, **9**
  - prognosis, **9**
- mucous gland, **12-17**
  - diagnostic checklist, **14**
  - differential diagnosis, **13-14**
  - histochemical features, **14**
  - immunohistochemistry, **14**
  - molecular features, **14**
  - mucoepidermoid carcinoma vs., **187**
  - prognosis, **13**
- pleomorphic, **206-211**. *See also* Mixed tumor.
  - benign, **207**
  - cartilaginous hamartoma vs., **5**
  - diagnostic checklist, **207**
  - differential diagnosis, **207**
  - endobronchial lipoma vs., **19**
  - epithelial-myoepithelial carcinoma vs., **193**
  - grading, **207**
  - malignant, **207**
  - mucous gland adenoma vs., **13**
  - myoepithelial carcinoma of lung vs., **213**
  - prognosis, **207**

Adenomatoid tumor-like adenocarcinoma, **78**
Adenomatous hyperplasia, atypical, **340-341**
- adenocarcinoma vs., **78**
- bronchioloalveolar carcinoma vs., **89**
- differential diagnosis, **341**
- prognosis, **341**

Adenomyoepithelioma. *See* Epithelial-myoepithelial carcinoma.
Adenomyomatous hamartoma. *See* Pulmonary adenofibroma/adenomyoma.
Adenosquamous carcinoma
- mucoepidermoid carcinoma vs., **187**
- mucous gland adenoma vs., **13**
- squamous cell carcinoma vs., **115**

Adenovirus, **522-523**
- diagnostic checklist, **523**
- herpes simplex virus vs., **515**
- prognosis, **523**

Adjuvant therapy
- adenocarcinoma, **77**
- pleomorphic carcinoma, **149**
- signet ring cell carcinoma, **103**

Allergic alveolitis, extrinsic, **414-417**. *See also* Alveolitis, extrinsic allergic.
- diagnostic checklist, **415**
- differential diagnosis, **415**
- prognosis, **415**

Allergic angiitis and granulomatosis, **418-421**. *See also* Angiitis and granulomatosis, allergic.
- diagnostic checklist, **419**
- differential diagnosis, **419**
- prognosis, **419**

Allergic bronchopulmonary aspergillosis, **541-542**
Alveolar adenoma, **8-11**
- diagnostic checklist, **9**
- differential diagnosis, **9**
- immunohistochemistry, **9**
- prognosis, **9**

Alveolar damage, diffuse, **386-389**. *See also* Diffuse alveolar damage.
- diagnostic checklist, **387**
- exudative (acute) phase, **387**
- fibrotic (chronic) phase, **387**
- organizing, bronchiolitis obliterans with organizing pneumonia vs., **391**
- prognosis, **387**
- proliferative (organizing) phase, **387**

Alveolar exudate, pneumocystosis, **501**
Alveolar microlithiasis, **464-467**
- diagnostic checklist, **465**
- differential diagnosis, **465**
- histochemical features, **465**
- metastatic/dendriform calcification vs., **321**
- prognosis, **465**

Alveolar proteinosis, **444-447**
- diagnostic checklist, **445**
- differential diagnosis, **445**
- histochemical features, **445**
- immunohistochemistry, **445**
- prognosis, **445**
- pulmonary amyloidosis vs., **449**

Alveolar soft part sarcoma, **822-827**
- diagnostic checklist, **823**
- differential diagnosis, **823**
- histochemical features, **824**
- immunohistochemistry, **824**
- molecular features, **824**
- paraganglioma vs., **641**
- prognosis, **823**

Alveolitis
- cryptogenic fibrosing. *See* Interstitial pneumonia, usual.
- extrinsic allergic, **414-417**
  - diagnostic checklist, **415**
  - differential diagnosis, **415**
  - prognosis, **415**
- necrotizing, **523**

Amelanotic malignant melanoma, metastatic, mediastinal diffuse large cell lymphoma vs., **736**
Amelanotic melanoma, metastatic, angiosarcoma vs., **597**
Amyloid tumor, **316-319**
- associated conditions, **317**
- diagnostic checklist, **317**
- differential diagnosis, **317**
- hyalinizing granuloma vs., **313**
- prognosis, **317**

Amyloidoma. *See* Amyloid tumor; Pulmonary amyloidosis.
Amyloidosis, pulmonary, **448-451**
- diagnostic checklist, **449**
- differential diagnosis, **449**
- prognosis, **449**

Anaplastic carcinoma
- large cell, **140-147**. *See also* Large cell (anaplastic) carcinoma.
  - carcinosarcoma vs., **167**
  - differential diagnosis, **141**
  - lymphoepithelioma-like carcinoma vs., **129**

INDEX

neuroendocrine carcinoma vs., **156**
neuroendocrine differentiation, neuroendocrine carcinoma vs., **156**
neuroendocrine pattern, neuroendocrine carcinoma vs., **156**
prognosis, **141**
rhabdoid features, **141**
undifferentiated. *See* Large cell (anaplastic) carcinoma.
- metastasis, from other organs, large cell (anaplastic) carcinoma vs., **141**
- metastatic poorly differentiated, diffuse large cell lymphoma vs., **269**
- primary, diffuse large cell lymphoma vs., **269**

Anaplastic large cell lymphoma, **269**
- embryonal carcinoma vs., **722**
- Hodgkin lymphoma vs., **277, 728**
- lymphoepithelioma-like carcinoma vs., **129**
- mediastinal diffuse large cell lymphoma vs., **736**

Anaplastic thymoma, **653**
Angiitis and granulomatosis, allergic, **418-421**
- diagnostic checklist, **419**
- differential diagnosis, **419**
- prognosis, **419**

Angiocentric immunoproliferative lesion. *See* Lymphomatoid granulomatosis.
Angiofollicular lymph node hyperplasia. *See* Castleman disease.
Angiolymphoid hyperplasia with eosinophilia, **336-339**
- diagnostic checklist, **337**
- differential diagnosis, **337**
- prognosis, **337**

Angiomatous lymphoid hamartoma. *See* Castleman disease.
Angiomyolipoma
- endobronchial lipoma vs., **19**
- hemangioma vs., **637**

Angiosarcoma, **246-249, 596-601**
- capillary hemangiomatosis vs., **347**
- carcinosarcoma vs., **167**
- diagnostic checklist, **247, 597**
- differential diagnosis, **247, 597**
- epithelioid hemangioendothelioma vs., **241, 807**
- immunohistochemistry, **247**
- metastatic, angiosarcoma vs., **247**
- prognosis, **247, 597**

Asbestos exposure, lung carcinoma, **74**
Asbestosis. *See* Asbestos-related interstitial fibrosis.
Asbestos-related interstitial fibrosis, **438-441**
- diagnostic checklist, **439**
- differential diagnosis, **439**
- prognosis, **439**

Ascariasis, strongyloidiasis vs., **471**
Aspergilloma, **541**
Aspergillosis, **540-545**
- actinomycosis vs., **539**
- allergic bronchopulmonary, **541, 542**
- chronic necrotizing, **541**
- chronic pulmonary, **542**
- differential diagnosis, **542**
- invasive, **541**-**542**
- pulmonary, clinical spectrum, **542**

Atypical adenomatous hyperplasia, **340-341**. *See also* Adenomatous hyperplasia, atypical.
- adenocarcinoma vs., **78**
- bronchioloalveolar carcinoma vs., **89**
- differential diagnosis, **341**
- prognosis, **341**

Atypical carcinoid. *See also* Neuroendocrine carcinoma; Thymus, neuroendocrine carcinoma of.
- poorly differentiated small cell variant squamous carcinoma vs., **135**

Atypical lipomatous tumor. *See* Liposarcoma.
Atypical mycobacterial disease
- nocardiosis vs., **537**
- sporotrichosis vs., **529**

Atypical thymoma, **666-675**. *See also* Thymoma, atypical.
- diagnostic checklist, **667**
- differential diagnosis, **667**
- prognosis, **667**

Autoimmune disorders, usual interstitial pneumonia associated, **399**
Autoimmune process, bronchiolitis obliterans with organizing pneumonia associated, **391**
Autoinfection, strongyloidiasis, **471**
Avian influenza A (H5N1), SARS pneumonia vs., **535**

B

Bacterial bronchopneumonia, echinococcosis (hydatid cyst) vs., **483**
Bacterial infection, bronchiolitis obliterans with organizing pneumonia associated, **391**
Bacterial pneumonia
- *Klebsiella* pneumonia vs., **531**
- nocardiosis vs., **537**
- sporotrichosis vs., **529**

BALT hyperplasia, pulmonary, **258-261**. *See also* Pulmonary BALT hyperplasia.
- differential diagnosis, **259**
- follicular bronchiolitis, **259**
- genetic testing, **259**
- nodular lymphoid hyperplasia, **259**
- prognosis, **259**

BALT lymphoma, pulmonary, **262-267**. *See also* Pulmonary BALT lymphoma.
- differential diagnosis, **263**
- genetic testing, **263**
- prognosis, **263**

Basaloid squamous cell carcinoma, metastasis from head and neck, poorly differentiated small cell variant squamous carcinoma vs., **135**
B-cell chronic lymphocytic leukemia/small lymphocytic lymphoma, lymphoblastic lymphoma vs., **750**
B-cell lymphoma. *See also* MALT lymphoma of thymus.
- amyloid tumor associated with, **317**
- T-cell-rich, lymphomatoid granulomatosis vs., **285**

Benign mediastinal foregut cyst, **870-875**
- diagnostic checklist, **871**

INDEX

- differential diagnosis, **871**
- histochemical features, **872**
- immunohistochemistry, **872**
- prognosis, **871**

Benign metastasizing leiomyoma, **352-355**
- differential diagnosis, **353**
- prognosis, **353**

Berylliosis, sarcoidosis vs., **431**
Bilharziasis. *See* Schistosomiasis.
Biliary adenocarcinoma, metastatic carcinoma vs., **358**
B-immunoblastic lymphoma, **269**
Biphasic malignant mesothelioma, synovial sarcoma vs., **603**
Biphasic mesothelioma, pleural endometriosis vs., **627**
Biphasic pulmonary blastoma
- pleural endometriosis vs., **627**
- pulmonary adenofibroma/adenomyoma vs., **23**

Blastoma
- biphasic pulmonary
  - pleural endometriosis vs., **627**
  - pulmonary adenofibroma/adenomyoma vs., **23**
- pleuropulmonary
  - pleural endometriosis vs., **627**
  - pulmonary blastoma vs., **173**
- pulmonary, **172-177**. *See also* Pulmonary blastoma.
  - biphasic, pleural endometriosis vs., **627**
  - diagnostic checklist, **173-174**
  - differential diagnosis, **173**
  - endometrioid-like carcinoma vs., **109**
  - histochemical features, **174**
  - immunohistochemistry, **174**
  - metastatic sarcoma vs., **368**
  - molecular features, **174**
  - prognosis, **173**
  - synovial sarcoma vs., **776**

Blastomyces dermatitidis, **507**
Blastomycosis, **504-507**
- coccidioidomycosis vs., **497**
- cryptococcosis vs., **493**
- differential diagnosis, **505**
- histoplasmosis vs., **507**
- prognosis, **505**

Blue cell tumors, small round, rhabdomyosarcoma vs., **829**
Bone marrow transplants, pulmonary BALT hyperplasia associated, **259**
Borderline malignancy, mucinous cystic tumor of. *See* Mucinous ("colloid") carcinoma.
Botryomycosis, **546-547**
- differential diagnosis, **547**
- histochemical features, **547**
- prognosis, **547**

Bronchial adenoma. *See* Mucous gland adenoma.
Bronchial chondroma
- cartilaginous hamartoma vs., **5**
- osteosarcoma vs., **233**

Bronchial gland (salivary-type) tumors, **74**
Bronchial lipomas, cartilaginous hamartoma vs., **5**
Bronchial malignant melanoma, **294-297**
- diagnostic checklist, **295**
- differential diagnosis, **295**
- immunohistochemistry, **295**
- prognosis, **295**

Bronchial neuroendocrine carcinoma, granular cell tumor vs., **57**
Bronchiolar metaplasia, ciliated muconodular papillary tumor vs., **71**
Bronchiolitis
- necrotizing, **523**
- respiratory, **394-397**
  - diagnostic checklist, **395**
  - differential diagnosis, **395**
  - prognosis, **395**

Bronchiolitis obliterans. *See* Bronchiolitis obliterans with organizing pneumonia.
Bronchiolitis obliterans with organizing pneumonia, **390-393**
- conditions associated, **391**
- diagnostic checklist, **391**
- differential diagnosis, **391**
- extrinsic allergic alveolitis vs., **415**
- prognosis, **391**

Bronchioloalveolar adenoma. *See* Atypical adenomatous hyperplasia.
Bronchioloalveolar carcinoma, **88-93**
- conventional type, **89**
- diagnostic checklist, **89-90**
- differential diagnosis, **89**
- histochemical features, **90**
- immunohistochemistry, **90**
- molecular findings, **90**
- mucinous type, **89**
- mucinous variant, mucinous ("colloid") carcinoma vs., **95**
- prognosis, **89**

Bronchioloalveolar cell hyperplasia, reactive, atypical adenomatous hyperplasia vs., **341**
Bronchioloalveolar pattern, adenocarcinoma with. *See* Bronchioloalveolar carcinoma.
Bronchioloalveolar tumor, intravascular. *See* Epithelioid hemangioendothelioma.
Bronchitis, necrotizing, **523**
Bronchocentric granulomatosis, **422-425**
- diagnostic checklist, **423**
- differential diagnosis, **423**

Bronchogenic carcinoma, **74**
Bronchogenic cyst, **872**
- lymphangioma vs., **633**

Bronchopneumonia
- bacterial, echinococcosis (hydatid cyst) vs., **483**
- strongyloidiasis vs., **471**

Bronchopulmonary aspergillosis, allergic, **541-542**
Bullous lesion, placentoid. *See* Placental transmogrification.
Burkitt lymphoma, lymphoblastic lymphoma vs., **750**

C

Calcification, metastatic/dendriform, **320-323**
- diagnostic checklist, **321**
- differential diagnosis, **321**
- prognosis, **321**

INDEX

Calcified fibrous pseudotumor, **568-571**
- diagnostic checklist, **569**
- differential diagnosis, **569**
- prognosis, **569**

Candida infection
- actinomycosis vs., **539**
- cryptococcosis vs., **493**

Capillaritis, capillary hemangiomatosis vs., **347**
Capillary hemangioma, **637**
- capillary hemangiomatosis vs., **347**

Capillary hemangiomatosis, **346-349**
- diagnostic checklist, **347**
- differential diagnosis, **347**
- prognosis, **347**

Capillary lymphangioma. *See* Lymphangioma.
Capsule-deficient *Cryptococcus,* histoplasmosis vs., **507**
Carcinoid tumor, **156**. *See also* Neuroendocrine carcinoma; Thymus, neuroendocrine carcinoma of.
- ectopic parathyroid tumor vs., **849**
- ganglioneuroblastoma vs., **291**
- granular cell tumor vs., **57**
- paraganglioma vs., **641**
- pulmonary meningioma vs., **47**
- pulmonary paraganglioma vs., **43**

Carcinoid tumorlet, neuroendocrine carcinoma vs., **155**
Carcinoma
- acinic cell, **198-205**
  - diagnostic checklist, **199**
  - differential diagnosis, **199**
  - granular cell tumor vs., **57**
  - histochemical features, **200**
  - immunohistochemistry, **200**
  - metastatic, acinic cell carcinoma vs., **199**
  - molecular analysis, **200**
  - prognosis, **199**
  - ultrastructural features, **200**
- adenoid cystic. *See* Adenoid cystic carcinoma.
- adenosquamous
  - mucoepidermoid carcinoma vs., **187**
  - mucous gland adenoma vs., **13**
  - squamous cell carcinoma vs., **115**
- angiosarcoma vs., **247**
- bronchial malignant melanoma vs., **295**
- bronchioloalveolar, **88-93**
  - conventional type, **89**
  - diagnostic checklist, **89-90**
  - differential diagnosis, **89**
  - histochemical features, **90**
  - immunohistochemistry, **90**
  - molecular findings, **90**
  - mucinous type, **89**
  - mucinous variant, mucinous ("colloid") carcinoma vs., **95**
  - prognosis, **89**
- carcinosarcoma vs., **167**
- chondrosarcoma vs., **237**
- clear cell, **141**
- embryonal, **720-725**
  - clinical staging of germ cell tumors of mediastinum, **722**
  - diagnostic checklist, **722**
  - differential diagnosis, **721-722**
  - histochemical features, **722**
  - immunohistochemistry, **722**
  - prognosis, **721**
  - yolk sac tumor vs., **709**
- endometrioid-like, **108-113**
  - diagnostic checklist, **109**
  - differential diagnosis, **109**
  - histochemical features, **110**
  - immunohistochemistry, **110**
  - molecular features, **110**
  - prognosis, **109**
- epithelial-myoepithelial, **192-197**
  - adenoid cystic carcinoma vs., **179**
  - diagnostic checklist, **193**
  - differential diagnosis, **193**
  - grading, **193**
  - high-grade, **193**
  - histochemical features, **194**
  - immunohistochemistry, **194**
  - low-grade, **193**
  - molecular features, **194**
  - mucous gland adenoma vs., **14**
  - prognosis, **193**
- giant cell, **141**. *See also* Pleomorphic carcinoma.
- hyalinizing clear cell
  - epithelial-myoepithelial carcinoma vs., **193**
  - mucous gland adenoma vs., **13**
- *Klebsiella* pneumonia vs., **531**
- large cell (anaplastic), **140-147**
  - carcinosarcoma vs., **167**
  - differential diagnosis, **141**
  - lymphoepithelioma-like carcinoma vs., **129**
  - neuroendocrine carcinoma vs., **156**
  - neuroendocrine differentiation, neuroendocrine carcinoma vs., **156**
  - neuroendocrine pattern, neuroendocrine carcinoma vs., **156**
  - prognosis, **141**
  - rhabdoid features, **141**
  - undifferentiated. *See* Large cell (anaplastic) carcinoma.
- lymphoepithelioma-like, **128-133**
  - diagnostic checklist, **129**
  - differential diagnosis, **129**
  - diffuse large cell lymphoma vs., **269**
  - histochemical features, **130**
  - immunohistochemistry, **130**
  - molecular features, **130**
  - mucoepidermoid carcinoma vs., **187**
  - prognosis, **129**
  - in situ hybridization, **130**
- mediastinal teratoma vs., **697**
- metastatic, **356-365**
  - diagnostic checklist, **358**
  - differential diagnosis, **357-358**
  - epithelioid hemangioendothelioma vs., **241**
  - immunohistochemistry, **358**
  - of lung, thymic carcinoma vs., **678**
  - mediastinal diffuse large cell lymphoma vs., **736**
  - metastatic models, **357**

INDEX

metastatic nasopharyngeal, lymphoepithelioma-like carcinoma vs., **129**
metastatic neuroendocrine, neuroendocrine carcinomas of thymus vs., **691**
metastatic papillary, mesothelial hyperplasia vs., **555**
metastatic sarcomatoid renal cell, malignant solitary fibrous tumor vs., **609**
minute pulmonary meningothelial-like nodule vs., **53**
patterns of growth, **357**
prognosis, **357**
thymic carcinoma vs., **678**
yolk sac tumor vs., **709**
- metastatic mucinous
chordoma vs., **817**
extrathoracic origin, mucinous ("colloid") carcinoma vs., **95**
- metastatic mucoepidermoid
mucoepidermoid carcinoma of pleura vs., **591**
mucoepidermoid carcinoma vs., **187**
- metastatic renal cell
metastatic malignant melanoma vs., **377**
sarcomatoid, malignant solitary fibrous tumor vs., **609**
- mucinous
extrathoracic origin, metastatic, mucinous ("colloid") carcinoma vs., **95**
metastatic, chordoma vs., **817**
- mucinous ("colloid"), **94-101**
diagnostic checklist, **95**
differential diagnosis, **95**
grading, **95**
histochemical features, **96**
immunohistochemistry, **96**
molecular features, **96**
prognosis, **95**
- mucoepidermoid, **186-191**
adenoid cystic carcinoma vs., **179**
ciliated muconodular papillary tumor vs., **71**
diagnostic checklist, **187-188**
differential diagnosis, **187**
grading, **188**
histochemical features, **188**
immunohistochemistry, **188**
mixed tumor vs., **207**
molecular features, **188**
mucous gland adenoma vs., **13**
prognosis, **187**
squamous cell carcinoma vs., **115**
- mucoepidermoid of pleura, **590-595**
diagnostic checklist, **591**
differential diagnosis, **591**
histochemical features, **592**
immunohistochemistry, **592**
molecular features, **592**
prognosis, **591**
- multilocular cystic. *See* Mucinous ("colloid") carcinoma.
- myoepithelial, lung, **212-215**
diagnostic checklist, **213**
differential diagnosis, **213**
prognosis, **213**
- neuroendocrine, **154-165**
bronchial, granular cell tumor vs., **57**
bronchial malignant melanoma vs., **295**
diagnostic checklist, **156**
differential diagnosis, **155-156**
ectopic thyroid tumor vs., **855**
ependymoma vs., **845**
ganglioneuroblastoma vs., **291**
grading, **156**
high-grade neuroendocrine carcinoma vs., **155**
immunohistochemistry, **156**
low-grade neuroendocrine carcinoma vs., **155**
moderately differentiated, poorly differentiated small cell variant squamous carcinoma vs., **135**
molecular features, **156**
oncocytic variant, acinic cell carcinoma vs., **199**
prognosis, **155**
pulmonary, well-differentiated, paraganglioma vs., **641**
small cell, poorly differentiated small cell variant squamous carcinoma vs., **135**
thymus, **648**
well-differentiated, ectopic parathyroid tumor vs., **849**
- plasmacytoma vs., **281**
- pleomorphic, **148-153**. *See also* Large cell (anaplastic) carcinoma; Pleomorphic carcinoma.
diagnostic checklist, **149**
differential diagnosis, **149**
histochemical features, **150**
immunohistochemistry, **150**
of lung origin, choriocarcinoma vs., **715**
lymphoepithelioma-like carcinoma vs., **129**
molecular features, **150**
prognosis, **149**
spindle cell (sarcomatoid) carcinoma vs., **123**
- pleural mucoepidermoid. *See* Mucoepidermoid carcinoma, pleural.
- poorly differentiated, osteosarcoma vs., **233**
- poorly differentiated small cell variant squamous cell, **134-139**
diagnostic checklist, **135**
differential diagnosis, **135**
- pseudosarcomatous. *See* Spindle cell (sarcomatoid) carcinoma.
- with pseudosarcomatous component. *See* Spindle cell (sarcomatoid) carcinoma.
- with pseudosarcomatous stroma. *See* Pleomorphic carcinoma.
- rhabdoid, **141**
- sarcomatoid
of lung, inflammatory pseudotumor vs., **299**
smooth muscle tumors of pleura vs., **615**
- signet ring cell, **102-107**
diagnostic checklist, **103**
differential diagnosis, **103**
histochemical features, **104**
immunohistochemistry, **104**
metastatic, signet ring cell carcinoma vs., **103**
molecular features, **104**

INDEX

prognosis, **103**
- small cell. *See also* Neuroendocrine carcinoma.
carcinosarcoma vs., **167**
- soft tissue, primary. *See* Synovial sarcoma.
- spindle cell (sarcomatoid), **122-127**
diagnostic checklist, **123**
differential diagnosis, **123**
histochemical features, **124**
immunohistochemistry, **124**
molecular features, **124**
prognosis, **123**
- squamous cell, **114-121**
basaloid, metastasis from head and neck, poorly differentiated small cell variant squamous carcinoma vs., **135**
carcinosarcoma vs., **167**
diagnostic checklist, **115**
differential diagnosis, **115**
grading, **115**
histochemical features, **116**
immunohistochemistry, **116**
of lung origin, atypical thymoma vs., **667**
moderately differentiated, **115**
molecular features, **116**
mucoepidermoid carcinoma of pleura vs., **591**
mucoepidermoid carcinoma vs., **187**
prognosis, **115**
in situ, **115**
- thymic, **649, 676-689**
acquired multilocular thymic cyst vs., **877**
adenocarcinoma, **678**
adenosquamous, **678**
alveolar soft part sarcoma vs., **823**
anaplastic, **678**
basaloid, **678**
carcinosarcoma, **678**
choriocarcinoma vs., **715**
classification by histologic grade, **679**
clear cell, **678**
diagnostic checklist, **679**
differential diagnosis, **678**
ectopic parathyroid tumor vs., **849**
embryonal carcinoma vs., **722**
epithelioid hemangioendothelioma vs., **807**
genetic testing, **678**
immunohistochemistry, **679**
lymphoepithelioma-like, **677**
mediastinal diffuse large cell lymphoma vs., **736**
mediastinal seminoma vs., **703**
neuroendocrine, **678**
neuroendocrine carcinomas of thymus vs., **691**
papillary, **678**
paraganglioma vs., **641**
prognosis, **677**
rare types, **678**
spindle cell (sarcomatoid), synovial sarcoma vs., **776**

Carcinosarcoma, **166-171**
- chondrosarcoma vs., **237**
- diagnostic checklist, **167**
- differential diagnosis, **167**
- histochemical features, **168**
- immunohistochemistry, **168**
- leiomyosarcoma vs., **223**
- mixed tumor vs., **207**
- molecular features, **168**
- osteosarcoma vs., **233**
- prognosis, **167**
- pulmonary blastoma vs., **173**
- pulmonary, metastatic sarcoma vs., **368**
- thymic, synovial sarcoma vs., **776**

Carotid body tumor. *See* Paraganglioma.

Cartilaginous hamartoma, **4-7**
- diagnostic checklist, **5**
- differential diagnosis, **5**
- immunohistochemistry, **5**
- prognosis, **5**
- pulmonary adenofibroma/adenomyoma vs., **23**

Castleman disease, **864-869**
- differential diagnosis, **865**
- hyaline-vascular type, **865**
- plasma cell type, **865**

Cavernous hemangioma, capillary hemangiomatosis vs., **347**

Cavernous lymphangioma. *See* Lymphangioma.

Cavitary lesions, pneumocystosis, **501**

Cavitation, tuberculosis, **511**

Chemodectoma
- minute pulmonary. *See* Meningothelial-like nodule, minute pulmonary.
- pulmonary. *See* Paraganglioma, pulmonary.

Chester-Erdheim disease. *See* Erdheim-Chester disease.

Cholesterol pneumonia. *See* Lipoid pneumonia (paraffinoma).

Chondroma
- bronchial
cartilaginous hamartoma vs., **5**
osteosarcoma vs., **233**
- pulmonary, metastatic/dendriform calcification vs., **321**

Chondrosarcoma, **236-239**
- carcinosarcoma vs., **167**
- diagnostic checklist, **237**
- differential diagnosis, **237**
- extraskeletal myxoid, chordoma vs., **817**
- mesenchymal, **812-815**
diagnostic checklist, **813**
differential diagnosis, **813**
genetic testing, **813**
prognosis, **813**
- metastatic, chondrosarcoma vs., **237**
- myxoid, epithelioid hemangioendothelioma vs., **807**
- osteosarcoma vs., **233**
- primary or metastatic, cartilaginous hamartoma vs., **5**
- prognosis, **237**
- well-differentiated, mediastinal chordoma vs., **817**

Chordoma, **816-821**
- differential diagnosis, **817**
- epithelioid hemangioendothelioma vs., **807**
- metastatic, epithelioid hemangioendothelioma vs., **241**
- prognosis, **817**

Choriocarcinoma, **714-719**
- clinical staging of mediastinal germ cell tumors, **716**
- diagnostic checklist, **716**

INDEX

- differential diagnosis, **715-716**
- histochemical features, **716**
- immunohistochemistry, **716**
- metastasis, from genital tract
  of gonadal origin, choriocarcinoma vs., **715**
  large cell (anaplastic) carcinoma vs., **141**
  pleomorphic carcinoma vs., **149**
- prognosis, **715**

Chorioepithelioma. *See* Choriocarcinoma.
Chronic histoplasmosis, **507**
Chronic lymphocytic leukemia, B-cell/small lymphocytic lymphoma, lymphoblastic lymphoma vs., **750**
Chronic necrotizing aspergillosis, **541**
Chronic progressive infection, coccidioidomycosis, **497**
Chronic pulmonary aspergillosis, **542**
Chronic tuberculosis, **511**
Churg-Strauss syndrome. *See also* Angiitis and granulomatosis, allergic.
- eosinophilic pneumonia vs., **453**
- Wegener granulomatosis vs., **427**

Ciliated muconodular papillary tumor, **70-71**
- diagnostic checklist, **71**
- differential diagnosis, **71**
- probable benign neoplastic proliferation, **71**
- prognosis, **71**

Classic Hodgkin lymphoma. *See* Hodgkin lymphoma, mediastinal.
Clear cell carcinoma, **141**
- hyalinizing
  epithelial-myoepithelial carcinoma vs., **193**
  mucous gland adenoma vs., **13**
- primary or metastatic, clear cell sugar tumor (PEComa) vs., **67**

Clear cell sugar tumor (PEComa), **66-69**
- diagnostic checklist, **67**
- differential diagnosis, **67**
- histochemical features, **67**
- immunohistochemistry, **67**
- prognosis, **67**

Clear cell tumor. *See also* Clear cell sugar tumor (PEComa).
- metastases, ectopic thyroid tumor vs., **855**

Clonorchis sinensis, paragonimiasis vs., **487**
Cobalt lung disease. *See* Pneumoconiosis pneumonitis, hard metal.
Coccidioidomycosis, **496-499**
- differential diagnosis, **497**
- prognosis, **497**
- sporotrichosis vs., **529**

Cochin China diarrhea. *See* Strongyloidiasis.
Collagen-vascular diseases
- bronchiolitis obliterans with organizing pneumonia associated, **391**
- nonspecific interstitial pneumonia vs., **411**
- pulmonary BALT hyperplasia associated, **259**
- usual interstitial pneumonia associated, **399**

Colloid carcinoma, **95**. *See also* Mucinous ("colloid") carcinoma.
- ciliated muconodular papillary tumor vs., **71**
- of lung, signet ring cell carcinoma vs., **103**

Colorectal carcinoma, metastatic carcinoma vs., **357**
Combined small cell carcinoma, poorly differentiated small cell variant squamous carcinoma vs., **135**
Corpora amylacea, alveolar microlithiasis vs., **465**
Cryptococcosis, **492-495**
- blastomycosis vs., **505**
- capsule-deficient, histoplasmosis vs., **507**
- diagnostic checklist, **493**
- differential diagnosis, **493**
- prognosis, **493**
- sporotrichosis vs., **529**

Cryptococcus neoformans, **493**
Cryptogenic fibrosing alveolitis. *See* Interstitial pneumonia, usual.
Cryptogenic organizing pneumonia. *See* Bronchiolitis obliterans with organizing pneumonia.
Cylindroma. *See* Adenoid cystic carcinoma.
Cyst
- benign mediastinal foregut, **870-875**
  diagnostic checklist, **871**
  differential diagnosis, **871**
  histochemical features, **872**
  immunohistochemistry, **872**
  prognosis, **871**
- bronchogenic, lymphangioma vs., **633**
- hydatid, **482-485**. *See also* Echinococcosis (Hydatid cyst).
  diagnostic checklist, **483**
  differential diagnosis, **483**
  prognosis, **483**
- mediastinal, clinicopathological features, **872**
- multilocular thymic, lymphangioma vs., **633**

Cystadenoma, mucinous. *See* Mucinous ("colloid") carcinoma.
Cystic carcinoma
- adenoid, **178-185**
  adenocarcinoma vs., **78**
  diagnostic checklist, **179-180**
  differential diagnosis, **179**
  epithelial-myoepithelial carcinoma vs., **193**
  histochemical features, **180**
  immunohistochemistry, **180**
  metastatic, adenoid cystic carcinoma vs., **179**
  molecular features, **180**
  myoepithelial carcinoma of lung vs., **213**
  prognosis, **179**
  staging, **180**
- multilocular. *See* Mucinous ("colloid") carcinoma.

Cystic Hodgkin lymphoma, acquired multilocular thymic cyst vs., **877**
Cystic hygroma. *See* Lymphangioma.
Cystic lymphangioma. *See* Lymphangioma.
Cystic seminoma, acquired multilocular thymic cyst vs., **877**
Cystic teratoma
- acquired multilocular thymic cyst vs., **877**
- lymphangioma vs., **633**

Cystic thymoma
- acquired multilocular thymic cyst vs., **877**
- benign mediastinal foregut cyst vs., **871**

Cystic tumor, mucinous. *See* Mucinous ("colloid") carcinoma.

INDEX

Cytomegalovirus, **518-521**
- diagnostic checklist, **519**
- differential diagnosis, **519**
- prognosis, **519**

Cytoplasmic inclusions, cytomegalovirus, **519**

D

Deciduosis. *See* Pleural endometriosis.
Dendriform calcification. *See* Metastatic/dendriform calcification.
Dendritic calcification, alveolar microlithiasis vs., **465**
Dense interstitial lymphoid, pneumocystosis, **501**
Desmoid tumor, smooth muscle tumors of pleura vs., **615**
Desmoplastic small cell tumor with divergent differentiation. *See* Desmoplastic small round cell tumor.
Desmoplastic small round cell tumor, **620-623**
- diagnostic checklist, **621**
- differential diagnosis, **621**
- genetic testing, **621**
- prognosis, **621**

Desquamative interstitial pneumonia, **406-409**. *See also* Interstitial pneumonitis, desquamative.
- diagnostic checklist, **407**
- differential diagnosis, **407**
- prognosis, **407**

Desquamative interstitial pneumonia-like reaction, nonspecific, desquamative interstitial pneumonia vs., **407**
Desquamative interstitial pneumonitis
- asbestos-related interstitial fibrosis vs., **439**
- hard metal pneumoconiosis pneumonitis vs., **435**
- respiratory bronchiolitis vs., **395**

Developmental anomaly
- adenofibroma/adenomyoma, pulmonary, **23**
- benign mediastinal foregut cyst, **871**
- ectopic parathyroid tumor, **849**
- ectopic thyroid tumor, **855**
- lymphangioma, **633**
- meningothelial-like nodule, minute pulmonary, **53**

Differentiating neuroblastoma. *See* Neuroblastoma/ganglioneuroblastoma.
Diffuse alveolar damage, **386-389**
- diagnostic checklist, **387**
- exudative (acute) phase, **387**
- fibrotic (chronic) phase, **387**
- organizing, bronchiolitis obliterans with organizing pneumonia vs., **391**
- prognosis, **387**
- proliferative (organizing) phase, **387**

Diffuse BALT hyperplasia, nonspecific interstitial pneumonia vs., **411**
Diffuse interstitial pneumonia, pulmonary BALT hyperplasia associated, **259**
Diffuse interstitial pneumonitis, cytomegalovirus, **519**
Diffuse large cell lymphoma, **268-275**
- anaplastic large cell lymphoma (ALCL), **269**
- B-immunoblastic lymphoma, **269**
- differential diagnosis, **269**
- genetic testing, **269**
- mediastinal, **734-747**
  - clear cell, **735**
  - diagnostic checklist, **736**
  - differential diagnosis, **736**
  - diffuse large B-cell, with sclerosis, **736**
  - genetic testing, **736**
  - germinotropic, **735**
  - Hodgkin lymphoma vs., **728**
  - immunohistochemistry, **737**
  - large B-cell, with Hodgkin-like or anaplastic large cell lymphoma-like features, **735-736**
  - pleomorphic, **735**
  - prognosis, **735**
  - signet ring cell, **735**
  - spindle cell, **735**
  - unusual histologic features, **736**
- peripheral T-cell lymphoma, **269**

Diffuse large cell lymphoma with sclerosis. *See* Diffuse large cell lymphoma, mediastinal.
Diffuse lymphoid hyperplasia (lymphocytic interstitial pneumonia). *See also* Pulmonary BALT hyperplasia.
- pulmonary BALT lymphoma vs., **263**

Dirofilaria immitis, **475**
- echinococcosis (hydatid cyst) vs., **483**
- strongyloidiasis vs., **471**

Dirofilariasis, **474-477**
- diagnostic checklist, **475**
- differential diagnosis, **475**
- echinococcosis (hydatid cyst) vs., **483**
- eosinophilic pneumonia vs., **453**
- prognosis, **475**

Disseminated histoplasmosis, **507**
Distomiasis, pulmonary. *See* Paragonimiasis.
Drug toxicity, usual interstitial pneumonia associated, **399**
Drugs, fibrosis secondary to, idiopathic sclerosing mediastinitis vs., **885**
Dystrophic calcification, metastatic/dendriform calcification vs., **321**

E

Earth-borne disease. *See* Paragonimiasis.
Echinococcosis (hydatid cyst), **482-485**
- diagnostic checklist, **483**
- differential diagnosis, **483**
- prognosis, **483**

Echinococcus, **483**
Ectopic parathyroid tumor, **848-853**
- diagnostic checklist, **849-850**
- differential diagnosis, **849**
- histochemical features, **850**
- immunohistochemistry, **850**
- neuroendocrine carcinomas of thymus vs., **691**
- paraganglioma vs., **641**
- prognosis, **849**
- ultrastructural features, **850**

Ectopic thyroid tumor, **854-857**
- diagnostic checklist, **855**

- differential diagnosis, **855**
Embryoma, pulmonary. *See* Pulmonary blastoma.
Embryonal carcinoma, **720-725**
- clinical staging of germ cell tumors of mediastinum, **722**
- diagnostic checklist, **722**
- differential diagnosis, **721-722**
- histochemical features, **722**
- immunohistochemistry, **722**
- prognosis, **721**
- yolk sac tumor vs., **709**

Embryonal carcinoma adult type. *See* Embryonal carcinoma.
Emphysema, placental transmogrification vs., **329**
Endobronchial lipoma, **18-21**
- diagnostic checklist, **19**
- differential diagnosis, **19**
- prognosis, **19**

Endodermal sinus tumor. *See* Yolk sac tumor.
Endometrial adenocarcinoma, metastatic carcinoma vs., **358**
Endometrioid adenocarcinoma. *See also* Endometrioid-like carcinoma.
- metastatic, from gynecologic primary, endometrioid-like carcinoma vs., **109**

Endometrioid-like carcinoma, **108-113**
- diagnostic checklist, **109**
- differential diagnosis, **109**
- histochemical features, **110**
- immunohistochemistry, **110**
- molecular features, **110**
- prognosis, **109**

Endometrioma. *See* Pleural endometriosis.
Endometriosis, pleural, **626-629**
- diagnostic checklist, **627**
- differential diagnosis, **627**
- prognosis, **627**

Enteric cyst, **872**
Eosinophilia, angiolymphoid hyperplasia with, **336-339**
- diagnostic checklist, **337**
- differential diagnosis, **337**
- prognosis, **337**

Eosinophilic granuloma. *See* Langerhans cell histiocytosis.
Eosinophilic pneumonia, **452-455**
- allergic angiitis and granulomatosis vs., **419**
- angiolymphoid hyperplasia with eosinophilia vs., **337**
- diagnostic checklist, **453**
- differential diagnosis, **453**
- Langerhans cell histiocytosis vs., **457**
- prognosis, **453**
- respiratory bronchiolitis vs., **395**

Ependymoma, **844-847**
- diagnostic checklist, **845**
- differential diagnosis, **845**
- grading, **845**
- immunohistochemistry, **845**
- myxopapillary. *See* Ependymoma.
- prognosis, **845**

Epidermoid carcinoma. *See* Squamous cell carcinoma.
Epimyoepithelial carcinoma
- mixed tumor vs., **207**
- myoepithelial carcinoma of lung vs., **213**

Epithelial neoplasms, pulmonary. *See* Lung neoplasms, malignant, primary.
Epithelial-myoepithelial carcinoma, **192-197**
- adenoid cystic carcinoma vs., **179**
- diagnostic checklist, **193**
- differential diagnosis, **193**
- grading, **193**
- high-grade, **193**
- histochemical features, **194**
- immunohistochemistry, **194**
- low-grade, **193**
- molecular features, **194**
- mucous gland adenoma vs., **14**
- prognosis, **193**

Epithelial-myoepithelial tumor. *See* Epithelial-myoepithelial carcinoma.
Epithelial-myoepithelial tumor of unknown malignant potential. *See* Epithelial-myoepithelial carcinoma.
Epithelial-rich thymoma. *See also* Atypical thymoma.
- WHO type B3, **39**

Epithelioid cell sarcoma, **367**
- metastatic malignant melanoma vs., **377**

Epithelioid hemangioendothelioma, **240-245, 806-811**
- angiosarcoma vs., **247**
- chordoma vs., **817**
- diagnostic checklist, **241, 807**
- differential diagnosis, **241, 807**
- histochemical features, **242, 808**
- immunohistochemistry, **242, 808**
- mediastinal, hemangioma vs., **637**
- molecular features, **242, 808**
- prognosis, **241, 807**
- ultrastructural features, **242, 808**

Epithelioid hemangioma. *See* Angiolymphoid hyperplasia with eosinophilia.
Epithelioid malignant mesothelioma, angiosarcoma vs., **597**
Epithelioid melanoma, **377**
Epithelioma. *See* Mesothelioma, malignant.
Epstein-Barr virus
- Hodgkin lymphoma, **277**
- pulmonary BALT hyperplasia associated, **259**

Erdheim-Chester disease, **460-463**
- differential diagnosis, **461**
- juvenile xanthogranuloma vs., **309**
- prognosis, **461**
- Rosai-Dorfman disease vs., **333**

Esophageal cyst, **872**
Ewing sarcoma/primitive neuroectodermal tumor (PNET)
- desmoplastic small round cell tumor vs., **621**
- mesenchymal chondrosarcoma vs., **813**
- neuroblastoma/ganglioneuroblastoma vs., **839**
- rhabdomyosarcoma vs., **829**

Exogenous/endogenous lipoid pneumonia. *See* Lipoid pneumonia.
Expleomorphic adenoma, **207**
Extraadrenal paraganglioma. *See* Paraganglioma; Paraganglioma, pulmonary.
Extrapulmonary dissemination, coccidioidomycosis, **497**

Extraskeletal Ewing sarcoma, peripheral nerve sheath tumor vs., **792**
Extraskeletal myxoid chondrosarcoma, chordoma vs., **817**
Extrathoracic origin, adenocarcinoma, pseudomesotheliomatous adenocarcinoma vs., **585**
Extrinsic allergic alveolitis, **414-417**. *See also* Alveolitis, extrinsic allergic.
- diagnostic checklist, **415**
- differential diagnosis, **415**
- prognosis, **415**

F

Familial neuropathy, amyloid tumor associated with, **317**
Fasciola hepatica, paragonimiasis vs., **487**
Fechner tumor. *See* Acinic cell carcinoma.
Fetal adenocarcinoma
- adenocarcinoma vs., **78**
- well-differentiated. *See* Pulmonary blastoma.

Fibrinous pneumonitis, eosinophilic pneumonia vs., **453**
Fibroadenoma, pulmonary. *See* Adenofibroma/adenomyoma, pulmonary.
Fibroinflammatory lesion, idiopathic. *See* Mediastinitis, idiopathic sclerosing.
Fibroleiomyomatous hamartoma. *See* Pulmonary adenofibroma/adenomyoma.
Fibrolipoma. *See* Endobronchial lipoma.
Fibroma
- mediastinal. *See* Solitary fibrous tumor.
- submesothelial. *See* Solitary fibrous tumor.

Fibrosarcoma, **608-613**
- diagnostic checklist, **609**
- differential diagnosis, **609**
- Kaposi sarcoma vs., **251**
- mediastinal. *See* Solitary fibrous tumor.
- prognosis, **609**

Fibrosis
- inflammatory pseudotumor vs., **299**
- interstitial
  - asbestos-related. *See* Asbestos-related interstitial fibrosis.
  - idiopathic. *See* Interstitial pneumonia, usual.
- secondary to drugs, idiopathic sclerosing mediastinitis vs., **885**
- secondary to infectious agents, idiopathic sclerosing mediastinitis vs., **885**

Fibrous histiocytoma, malignant
- pleomorphic carcinoma vs., **149**
- spindle cell (sarcomatoid) carcinoma vs., **123**

Fibrous mesothelioma. *See* Solitary fibrous tumor.
Fibrous plaque, calcified fibrous pseudotumor vs., **569**
Fibrous pseudotumor, calcified, **568-571**
- diagnostic checklist, **569**
- differential diagnosis, **569**
- prognosis, **569**

Fibrous tumor
- intrapulmonary solitary, **26-33**. *See also* Solitary fibrous tumor, intrapulmonary.
  - amyloid tumor vs., **317**
  - diagnostic checklist, **27**
  - differential diagnosis, **27**
  - hyalinizing granuloma vs., **313**
  - inflammatory pseudotumor vs., **299**
  - intrapulmonary synovial sarcoma vs., **217**
  - intrapulmonary thymoma vs., **39**
  - pulmonary adenofibroma/adenomyoma vs., **23**
- localized. *See* Solitary fibrous tumor.
- malignant solitary (fibrosarcoma), **608-613**. *See also* Solitary fibrous tumor.
  - diagnostic checklist, **609**
  - differential diagnosis, **609**
  - prognosis, **609**
  - synovial sarcoma vs., **603**
- solitary, **796-805**
  - alternating hypo- and hypercellular areas, **797**
  - angiofibromatous pattern, **797**
  - benign metastasizing leiomyoma vs., **353**
  - calcified fibrous pseudotumor vs., **569**
  - dense hypercellular pattern, **797**
  - diagnostic checklist, **798**
  - differential diagnosis, **798**
  - epithelioid growth pattern, **797**
  - fascicular pattern, **797**
  - ganglioneuroma vs., **835**
  - hemangiopericytic pattern, **797**
  - herringbone pattern, **797**
  - immunohistochemistry, **798**
  - leiomyosarcoma vs., **223**
  - mesenchymal chondrosarcoma vs., **813**
  - neural-like growth pattern, **797**
  - neurogenic sarcoma vs., **229**
  - patternless pattern, **797**
  - prognosis, **797**
  - storiform pattern, **797**
  - unusual stromal changes, **797**

Follicular bronchiolitis, pulmonary BALT hyperplasia associated, **259**
Follicular hyperplasia, reactive, Castleman disease vs., **865**
Follicular lymphoma
- Castleman disease vs., **865**
- MALT lymphoma of thymus vs., **755**

Foregut cyst, benign mediastinal, **870-875**
- diagnostic checklist, **871**
- differential diagnosis, **871**
- immunohistochemistry, **872**
- prognosis, **871**

Foreign body granulomas, bronchocentric granulomatosis vs., **423**
Friedlander pneumonia. *See Klebsiella* pneumonia.
Fungal granulomatous infection, schistosomiasis vs., **479**
Fungal infections
- aspergillosis, **540-545**
  - actinomycosis vs., **539**
  - allergic bronchopulmonary, **541, 542**
  - chronic necrotizing, **541**
  - chronic pulmonary, **542**
  - differential diagnosis, **542**
  - invasive, **542**
  - pulmonary, clinical spectrum, **542**

- blastomycosis, **504-507**
  - coccidioidomycosis vs., **497**
  - cryptococcosis vs., **493**
  - differential diagnosis, **505**
  - histoplasmosis vs., **507**
  - prognosis, **505**
- bronchiolitis obliterans with organizing pneumonia associated, **391**
- coccidioidomycosis, **496-499**
  - differential diagnosis, **497**
  - prognosis, **497**
  - sporotrichosis vs., **529**
- cryptococcosis vs., **493**
- dirofilariasis vs., **475**
- histoplasmosis, **506-509**
  - actinomycosis vs., **539**
  - acute, **507**
  - chronic, **507**
  - coccidioidomycosis vs., **497**
  - differential diagnosis, **507**
  - disseminated, **507**
  - pneumocystosis vs., **501**
  - sporotrichosis vs., **529**
- nocardiosis vs., **537**
- pneumocystosis, **500-503**
  - differential diagnosis, **501**
  - histoplasmosis vs., **507**
- sarcoidosis vs., **431**
- sporotrichosis, **528-529**
  - diagnostic checklist, **529**
  - differential diagnosis, **529**
  - histochemical features, **529**
  - prognosis, **529**

Fusarium infection, aspergillosis vs., **542**

G

Ganglioneuroblastoma, **290-293**. *See also* Neuroblastoma/ganglioneuroblastoma.
- diagnostic checklist, **291**
- differential diagnosis, **291**
- ganglioneuroma vs., **835**
- prognosis, **291**

Ganglioneuroma, **834-837**
- diagnostic checklist, **835**
- differential diagnosis, **835**
- immunohistochemistry, **835**
- neuroblastoma/ganglioneuroblastoma vs., **839**
- neurofibroma vs., **787**

Gaucher disease
- amyloid tumor associated with, **317**
- malakoplakia vs., **549**

Germ cell tumors
- choriocarcinoma, **714-719**. *See also* Choriocarcinoma.
  - clinical staging of mediastinal germ cell tumors, **716**
  - diagnostic checklist, **716**
  - differential diagnosis, **715-716**
  - histochemical features, **716**
  - immunohistochemistry, **716**
  - metastasis, from genital tract of gonadal origin, choriocarcinoma vs., **715**
  - large cell (anaplastic) carcinoma vs., **141**
  - pleomorphic carcinoma vs., **149**
  - prognosis, **715**
- embryonal carcinoma, **720-725**
  - clinical staging of germ cell tumors of mediastinum, **722**
  - diagnostic checklist, **722**
  - differential diagnosis, **721-722**
  - histochemical features, **722**
  - immunohistochemistry, **722**
  - prognosis, **721**
  - yolk sac tumor vs., **709**
- Hodgkin lymphoma vs., **727-728**
- leiomyosarcoma vs., **769-770**
- mediastinal, clinical staging of, **716**
- mediastinal teratoma vs., **697**
- mixed germ cell tumor
  - choriocarcinoma vs., **716**
  - embryonal carcinoma vs., **721**
  - yolk sac tumor vs., **710**
- seminoma. *See* Seminoma.
- teratoma, mediastinal, **696-701**
  - diagnostic checklist, **697-698**
  - differential diagnosis, **697**
  - histological classification of, **698**
  - immature, **698**
  - immature teratoma, **698**
  - immunohistochemistry, **698**
  - malignant component, **698**
  - mature, **698**
  - prognosis, **697**
- yolk sac tumor, **708-713**
  - diagnostic checklist, **710**
  - differential diagnosis, **709-710**
  - embryonal carcinoma vs., **721**
  - histological growth patterns, **710**
  - immunohistochemistry, **710**
  - prognosis, **709**

Germinoma. *See* Seminoma, mediastinal.
Giant bullous emphysema. *See* Placental transmogrification.
Giant cell carcinoma. *See also* Large cell (anaplastic) carcinoma; Pleomorphic carcinoma.
- choriocarcinoma vs., **715-716**

Giant lymph node hyperplasia. *See* Castleman disease.
Glomangioma. *See* Glomus tumor.
Glomangiosarcoma, glomus tumor vs., **35**
Glomic tumor. *See* Glomus tumor.
Glomus tumor, **34-37**
- alveolar adenoma vs., **9**
- diagnostic checklist, **35**
- differential diagnosis, **35**
- immunohistochemistry, **35**
- prognosis, **35**

Golden pneumonia. *See* Lipoid pneumonia (paraffinoma).
Gonadal origin, metastatic choriocarcinoma of, choriocarcinoma vs., **715**
Goodpasture syndrome, idiopathic pulmonary hemosiderosis vs., **443**

INDEX

Granular cell tumor, **56-59**
- benign, **57**
- diagnostic checklist, **57**
- differential diagnosis, **57**
- immunohistochemistry, **57**
- malignant, **57**

Granulomas
- eosinophilic. *See* Langerhans cell histiocytosis.
- histoplasmosis, **507**
- hyalinizing, **312-315**
  - associated conditions, **313**
  - diagnostic checklist, **313**
  - differential diagnosis, **313**
- of lung, hyalinizing, pulmonary amyloidosis vs., **449**
- necrotizing, coccidioidomycosis, **497**
- nonnecrotizing, dirofilariasis, **475**

Granulomatosis. *See also* Angiitis and granulomatosis, allergic; Bronchocentric granulomatosis; Lymphomatoid granulomatosis.
- bronchocentric, **422-425**
  - diagnostic checklist, **423**
  - differential diagnosis, **423**
- Langerhans cell. *See* Langerhans cell histiocytosis.
- lipoid. *See* Erdheim-Chester disease.
- lymphomatoid, **284-289**
  - diagnostic checklist, **285**
  - differential diagnosis, **285**
  - grading, **285**
  - Hodgkin lymphoma vs., **277**
  - IgG4 sclerosing lung disease vs., **305**
  - Wegener granulomatosis vs., **427**
- with polyangiitis. *See* Wegener granulomatosis.
- Wegener, **426-429**
  - allergic angiitis and granulomatosis vs., **419**
  - bronchocentric granulomatosis vs., **423**
  - diagnostic checklist, **427**
  - differential diagnosis, **427**
  - Granulomatous reaction, **427**
  - lymphomatoid granulomatosis vs., **285**
  - prognosis, **427**

Gregarinosis. *See* Paragonimiasis.

H

Hamartoma
- adenofibromatous. *See* Pulmonary adenofibroma/adenomyoma.
- adenomyomatous. *See* Pulmonary adenofibroma/adenomyoma.
- angiomatous lymphoid. *See* Castleman disease.
- cartilaginous, **4-7**
  - diagnostic checklist, **5**
  - differential diagnosis, **5**
  - immunohistochemistry, **5**
  - prognosis, **5**
  - pulmonary adenofibroma/adenomyoma vs., **23**
- chondrosarcoma vs., **237**
- endobronchial lipoma vs., **19**
- fibroleiomyomatous. *See* Adenofibroma/adenomyoma, pulmonary.
- lipomatous. *See* Endobronchial lipoma.
- osteosarcoma vs., **233**
- pulmonary, mixed tumor vs., **207**

Hard metal lung disease. *See* Hard metal pneumoconiosis pneumonitis.

Hard metal pneumoconiosis pneumonitis, **434-437**
- diagnostic checklist, **435**
- differential diagnosis, **435**
- prognosis, **435**

Hemangioendothelioma, epithelioid, **240-245, 806-811**. *See also* Epithelioid hemangioendothelioma.
- angiosarcoma vs., **247**
- chordoma vs., **817**
- diagnostic checklist, **241, 807**
- differential diagnosis, **241, 807**
- histochemical features, **242, 808**
- immunohistochemistry, **242, 808**
- molecular features, **242, 808**
- prognosis, **241, 807**
- ultrastructural features, **242, 808**

Hemangioma, **636-639**
- capillary, **637**
  - capillary hemangiomatosis vs., **347**
- cavernous, **637**
  - capillary hemangiomatosis vs., **347**
- differential diagnosis, **637**
- lymphangioma vs., **633**
- prognosis, **637**
- sclerosing, **60-65**. *See also* Sclerosing hemangioma (pneumocytoma).
  - diagnostic checklist, **61**
  - differential diagnosis, **61**
  - histochemical features, **62**
  - histogenesis, **61**
  - immunohistochemistry, **62**
  - prognosis, **61**
  - ultrastructural features, **62**

Hemangiomatosis, capillary, **346-349**. *See also* Capillary hemangiomatosis.
- diagnostic checklist, **347**
- differential diagnosis, **347**
- prognosis, **347**

Hemangiopericytoma. *See also* Solitary fibrous tumor.
- intrapulmonary thymoma vs., **39**
- leiomyosarcoma vs., **223**
- mesenchymal chondrosarcoma vs., **813**
- solitary fibrous tumor vs., **798**

Hemangiosarcoma. *See* Angiosarcoma.

Hemoptysis, parasitic. *See* Paragonimiasis.

Hemorrhage, pulmonary, capillary hemangiomatosis vs., **347**

Hemosiderosis, idiopathic pulmonary, **442-443**
- diagnostic checklist, **443**
- differential diagnosis, **443**
- prognosis, **443**

Hepatoid adenocarcinoma, **77-78**

Herpes simplex virus, **514-517**
- differential diagnosis, **515**
- prognosis, **515**

High-grade neuroendocrine carcinoma, **156**
- neuroendocrine carcinoma vs., **155**

High-grade sarcomas, liposarcoma vs., **760**
High-grade spindle cell sarcoma, mediastinal chordoma vs., **817**
High-grade tumors, neuroendocrine carcinoma, **155**
Histiocyte-rich infections, desquamative interstitial pneumonia vs., **407**
Histiocytoma, malignant fibrous
- pleomorphic carcinoma vs., **149**
- spindle cell (sarcomatoid) carcinoma vs., **123**

Histiocytosis
- Langerhans cell, **456-459**
  diagnostic checklist, **457**
  differential diagnosis, **457**
  eosinophilic pneumonia vs., **453**
  Erdheim-Chester disease vs., **461**
  prognosis, **457**
- sinus, with massive lymphadenopathy, Erdheim-Chester disease vs., **461**

Histiocytosis X. *See* Langerhans cell histiocytosis.
Histoplasma, cryptococcosis vs., **493**
Histoplasmosis, **506-509**
- actinomycosis vs., **539**
- acute, **507**
- chronic, **507**
- coccidioidomycosis vs., **497**
- differential diagnosis, **507**
- disseminated, **507**
- pneumocystosis vs., **501**
- sporotrichosis vs., **529**

Hodgkin cells, **277**
Hodgkin disease. *See also* Hodgkin lymphoma, mediastinal.
- idiopathic sclerosing mediastinitis vs., **885**

Hodgkin lymphoma, **276-279**
- angiolymphoid hyperplasia with eosinophilia vs., **337**
- cystic, acquired multilocular thymic cyst vs., **877**
- differential diagnosis, **277**
- genetic testing, **277**
- lymphomatoid granulomatosis vs., **285**
- mediastinal, **726-733**
  diagnostic checklist, **728**
  differential diagnosis, **727-728**
  immunohistochemistry, **728**
  mediastinal diffuse large cell lymphoma vs., **736**
  prognosis, **727**
- prognosis, **277**

Hookworm infections, strongyloidiasis vs., **471**
Human immunodeficiency virus (HIV), pulmonary BALT hyperplasia associated, **259**
Hyaline membrane disease. *See* Diffuse alveolar damage.
Hyalinizing clear cell carcinoma
- epithelial-myoepithelial carcinoma vs., **193**
- mucous gland adenoma vs., **13**

Hyalinizing granuloma, **312-315**
- associated conditions, **313**
- diagnostic checklist, **313**
- differential diagnosis, **313**
- of lung
  amyloid tumor vs., **317**
  pulmonary amyloidosis vs., **449**

Hydatid cyst, **482-485**. *See also* Echinococcosis (Hydatid cyst).
- diagnostic checklist, **483**
- differential diagnosis, **483**
- prognosis, **483**

Hydatidosis. *See* Echinococcosis (Hydatid cyst).
Hyperplasia
- atypical adenomatous, **340-341**. *See also* Adenomatous hyperplasia, atypical.
  adenocarcinoma vs., **78**
  bronchioloalveolar carcinoma vs., **89**
  differential diagnosis, **341**
  prognosis, **341**
- lymphoid
  diffuse, pulmonary BALT lymphoma vs., **263**
  nodular, pulmonary BALT lymphoma vs., **263**
- mesothelial, **554-557**
  diagnostic checklist, **555**
  differential diagnosis, **555**
  prognosis, **555**
- pulmonary BALT, **258-261**
  differential diagnosis, **259**
  follicular bronchiolitis, **259**
  genetic testing, **259**
  nodular lymphoid hyperplasia, **259**
  prognosis, **259**
- thymic, thymolipoma vs., **861**

Hypersensitivity, bronchiolitis obliterans with organizing pneumonia associated, **391**
Hypersensitivity pneumonitis. *See also* Alveolitis, extrinsic allergic.
- nonspecific interstitial pneumonia vs., **411**

Hypertension, pulmonary, schistosomiasis vs., **479**

I

Idiopathic fibroinflammatory lesion. *See* Mediastinitis, idiopathic sclerosing.
Idiopathic interstitial fibrosis. *See* Interstitial pneumonia, usual.
Idiopathic pulmonary fibrosis. *See* Interstitial pneumonia, usual.
Idiopathic pulmonary hemorrhage. *See* Idiopathic pulmonary hemosiderosis.
Idiopathic pulmonary hemosiderosis, **442-443**
- diagnostic checklist, **443**
- differential diagnosis, **443**
- prognosis, **443**

Idiopathic sclerosing mediastinitis, **884-887**
- diagnostic checklist, **885**
- differential diagnosis, **885**
- prognosis, **885**

IgG4 disease
- hyalinizing granuloma vs., **313**
- inflammatory pseudotumor vs., **299**

IgG4 sclerosing lung disease, **304-307**
- bronchovascular pattern of involvement, **305**
- differential diagnosis, **305**
- inflammatory pseudotumor-like, **305**

INDEX

- interstitial fibrosis-like, **305**
- prognosis, **305**

Immature ganglioneuroma. *See* Neuroblastoma/ganglioneuroblastoma.

Immunodeficiency
- cytomegalovirus, **519**
- pulmonary BALT hyperplasia associated, **259**

Immunosuppression, cytomegalovirus, **519**

In situ squamous cell carcinoma, **115**

Infantile-type embryonal carcinoma. *See* Yolk sac tumor.

Infections
- fungal
  - bronchiolitis obliterans with organizing pneumonia associated, **391**
  - cryptococcosis vs., **493**
  - dirofilariasis vs., **475**
  - nocardiosis vs., **537**
  - sarcoidosis vs., **431**
- fungal granulomatous, schistosomiasis vs., **479**
- mycobacterial
  - dirofilariasis vs., **475**
  - lipoid pneumonia vs., **325**
  - sarcoidosis vs., **431**
- parasitic
  - angiolymphoid hyperplasia with eosinophilia vs., **337**
  - echinococcosis (hydatid cyst) vs., **483**
  - strongyloidiasis vs., **471**

Infectious agents, fibrosis, idiopathic sclerosing mediastinitis vs., **885**

Infectious conditions
- allergic angiitis and granulomatosis vs., **419**
- dirofilariasis vs., **475**

Infectious diseases of lung
- actinomycosis, **538-539**
  - botryomycosis vs., **547**
  - diagnostic checklist, **539**
  - differential diagnosis, **539**
  - histochemical features, **539**
  - nocardiosis vs., **537**
  - prognosis, **539**
- adenovirus, **522-523**
  - diagnostic checklist, **523**
  - herpes simplex virus vs., **515**
  - prognosis, **523**
- aspergillosis, **540-545**
  - actinomycosis vs., **539**
  - allergic bronchopulmonary, **541, 542**
  - chronic necrotizing, **541**
  - chronic pulmonary, **542**
  - differential diagnosis, **542**
  - invasive, **542**
  - pulmonary, clinical spectrum, **542**
- blastomycosis, **504-507**
  - coccidioidomycosis vs., **497**
  - cryptococcosis vs., **493**
  - differential diagnosis, **505**
  - histoplasmosis vs., **507**
  - prognosis, **505**
- botryomycosis, **546-547**
  - differential diagnosis, **547**
  - histochemical features, **547**
  - prognosis, **547**
- coccidioidomycosis, **496-499**
  - differential diagnosis, **497**
  - prognosis, **497**
  - sporotrichosis vs., **529**
- cryptococcosis, **492-495**
  - blastomycosis vs., **505**
  - capsule-deficient, histoplasmosis vs., **507**
  - diagnostic checklist, **493**
  - differential diagnosis, **493**
  - prognosis, **493**
  - sporotrichosis vs., **529**
- cytomegalovirus, **518-521**
  - diagnostic checklist, **519**
  - differential diagnosis, **519**
  - prognosis, **519**
- herpes simplex virus, **514-517**
  - differential diagnosis, **515**
  - prognosis, **515**
- histoplasmosis, **506-509**
  - actinomycosis vs., **539**
  - acute, **507**
  - chronic, **507**
  - coccidioidomycosis vs., **497**
  - differential diagnosis, **507**
  - disseminated, **507**
  - pneumocystosis vs., **501**
  - sporotrichosis vs., **529**
- *Klebsiella* pneumonia, **530-533**
  - diagnostic checklist, **531**
  - differential diagnosis, **531**
  - prognosis, **531**
- malakoplakia, **548-551**
  - differential diagnosis, **549**
- measles pneumonia, **524-527**
  - differential diagnosis, **525**
  - prognosis, **525**
- nocardiosis, **536-537**
  - actinomycosis vs., **539**
  - botryomycosis vs., **547**
  - diagnostic checklist, **537**
  - differential diagnosis, **537**
  - histochemical features, **537**
  - prognosis, **537**
- pneumocystosis, **500-503**
  - differential diagnosis, **501**
  - histoplasmosis vs., **507**
- SARS pneumonia, **534-535**
  - diagnostic checklist, **535**
  - differential diagnosis, **535**
  - prognosis, **535**
- sporotrichosis, **528-529**
  - diagnostic checklist, **529**
  - differential diagnosis, **529**
  - histochemical features, **529**
  - prognosis, **529**
- tuberculosis, **510-513**
  - chronic, **511**
  - miliary, **511**
  - primary, **511**
  - prognosis, **511**

pulmonary, *Klebsiella* pneumonia vs., **531**
pulmonary, schistosomiasis vs., **479**
sarcoidosis vs., **431**
secondary, **511**
Infectious pneumonia, hard metal pneumoconiosis pneumonitis vs., **435**
Infectious process
- extrinsic allergic alveolitis vs., **415**
- Wegener granulomatosis vs., **427**
Inflammatory myofibroblastic tumor
- IgG4 sclerosing lung disease vs., **305**
- lymphoepithelioma-like carcinoma vs., **129**
Inflammatory pseudotumor, **298-303**. *See also* Mediastinitis, idiopathic sclerosing.
- bronchiolitis obliterans with organizing pneumonia vs., **391**
- calcified fibrous pseudotumor vs., **569**
- diagnostic checklist, **300**
- differential diagnosis, **299**
- IgG4 sclerosing lung disease vs., **305**
- immunohistochemistry, **300**
- molecular findings, **300**
- plasma cell type
hyalinizing granuloma vs., **313**
plasmacytoma vs., **281**
- prognosis, **299**
- sclerosing hemangioma (pneumocytoma) vs., **61**
Intermediate-grade neuroendocrine carcinoma, **156**
- neuroendocrine carcinoma vs., **155**
Intermediate-grade tumors, neuroendocrine carcinoma, **155**
Interstitial fibrosis
- asbestos-related, **438-441**. *See also* Asbestos-related interstitial fibrosis.
diagnostic checklist, **439**
differential diagnosis, **439**
prognosis, **439**
Interstitial microcalcifications, pneumocystosis, **501**
Interstitial pneumonia
- desquamative, **406-409**
diagnostic checklist, **407**
differential diagnosis, **407**
prognosis, **407**
- lymphocytic, pulmonary BALT lymphoma vs., **263**
- lymphoid, nonspecific interstitial pneumonia vs., **411**
- nonspecific, **410-413**
cellular pattern, **411**
diagnostic checklist, **411**
differential diagnosis, **411**
with fibrosing pattern, **411**
prognosis, **411**
- usual, **398-405**
conditions associated, **399**
desquamative interstitial pneumonia vs., **407**
diagnostic checklist, **399**
nonspecific interstitial pneumonia vs., **411**
prognosis, **399**
Interstitial pneumonitis
- desquamative
asbestos-related interstitial fibrosis vs., **439**
hard metal pneumoconiosis pneumonitis vs., **435**
respiratory bronchiolitis vs., **395**
- diffuse, cytomegalovirus, **519**
- usual
asbestos-related interstitial fibrosis vs., **439**
bronchiolitis obliterans with organizing pneumonia vs., **391**
extrinsic allergic alveolitis vs., **415**
hard metal pneumoconiosis pneumonitis vs., **435**
respiratory bronchiolitis vs., **395**
Intimal sarcoma. *See* Pulmonary artery sarcoma.
Intrapulmonary solitary fibrous tumor, **26-33**. *See also* Solitary fibrous tumor, intrapulmonary.
- amyloid tumor vs., **317**
- diagnostic checklist, **27**
- differential diagnosis, **27**
- hyalinizing granuloma vs., **313**
- inflammatory pseudotumor vs., **299**
- intrapulmonary synovial sarcoma vs., **217**
- intrapulmonary thymoma vs., **39**
- pulmonary adenofibroma/adenomyoma vs., **23**
Intrapulmonary synovial sarcoma, **216-221**. *See also* Synovial sarcoma, intrapulmonary.
- differential diagnosis, **217**
- genetic testing, **217**
- prognosis, **217**
Intrapulmonary thymoma, **38-41**. *See also* Thymoma, intrapulmonary.
- differential diagnosis, **39**
- prognosis, **39**
Intrathoracic pheochromocytoma. *See* Paraganglioma.
Intravascular bronchioloalveolar tumor. *See* Epithelioid hemangioendothelioma.
Invasive adenocarcinoma, pulmonary, bronchioloalveolar carcinoma vs., **89**
Invasive aspergillosis, **541-542**
Involuted thymic tissue, thymolipoma vs., **861**

J

Juvenile xanthogranuloma, **308-311**
- differential diagnosis, **309**
- immunohistochemistry, **309**
- lipoid pneumonia vs., **325**
- prognosis, **309**
- Rosai-Dorfman disease vs., **333**

K

Kaposi sarcoma, **250-253**
- diagnostic checklist, **251**
- differential diagnosis, **251**
- prognosis, **251**
Klebsiella pneumonia, **530-533**
- diagnostic checklist, **531**
- differential diagnosis, **531**
- prognosis, **531**

L

Langerhans cell granulomatosis. *See* Langerhans cell histiocytosis.
Langerhans cell histiocytosis, **456-459**
- diagnostic checklist, **457**
- differential diagnosis, **457**
- eosinophilic pneumonia vs., **453**
- Erdheim-Chester disease vs., **461**
- hard metal pneumoconiosis pneumonitis vs., **435**
- juvenile xanthogranuloma vs., **309**
- lipoid pneumonia vs., **325**
- prognosis, **457**
- respiratory bronchiolitis vs., **395**
- Rosai-Dorfman disease vs., **333**

Large cell (anaplastic) carcinoma, **140-147**
- carcinosarcoma vs., **167**
- differential diagnosis, **141**
- lymphoepithelioma-like carcinoma vs., **129**
- neuroendocrine carcinoma vs., **156**
- neuroendocrine differentiation, neuroendocrine carcinoma vs., **156**
- neuroendocrine pattern, neuroendocrine carcinoma vs., **156**
- prognosis, **141**
- rhabdoid features, **141**
- undifferentiated. *See* Large cell (anaplastic) carcinoma.

Large cell lymphoma
- anaplastic, **269**
  - embryonal carcinoma vs., **722**
  - Hodgkin lymphoma vs., **277, 728**
  - lymphoepithelioma-like carcinoma vs., **129**
  - mediastinal diffuse large cell lymphoma vs., **736**
- diffuse. *See* Diffuse large cell lymphoma.

Large cell neuroendocrine carcinoma, **155**
- poorly differentiated small cell variant squamous carcinoma vs., **135**
- squamous cell carcinoma vs., **115**

Leiomyoma. *See also* Smooth muscle tumors of pleura.
- benign metastasizing, **352-355**
  - differential diagnosis, **353**
  - natural history, **353**
  - prognosis, **353**
- glomus tumor vs., **35**
- lymphangioleiomyomatosis vs., **343**
- mediastinal, leiomyosarcoma vs., **769**
- neurofibroma vs., **787**

Leiomyosarcoma, **222-227, 768-773**. *See also* Smooth muscle tumors of pleura.
- diagnostic checklist, **223, 770**
- differential diagnosis, **223, 769-770**
- grading, **224**
- immunohistochemistry, **224, 770**
- Kaposi sarcoma vs., **251**
- low-grade metastatic, benign metastasizing leiomyoma vs., **353**
- lymphangioleiomyomatosis vs., **343**
- metastatic
  - leiomyosarcoma vs., **769**
  - smooth muscle tumors of pleura vs., **615**
- molecular features, **224, 770**
- peripheral nerve sheath tumor vs., **791**
- prognosis, **223, 769**
- pulmonary ,pleomorphic carcinoma vs., **149**
- spindle cell (sarcomatoid) carcinoma vs., **123**

Lepidic pattern, adenocarcinoma with. *See* Bronchioloalveolar carcinoma.
Lipid storage disorders, malakoplakia vs., **549**
Lipoid granulomatosis. *See* Erdheim-Chester disease.
Lipoid pneumonia (paraffinoma), **324-327**
- diagnostic checklist, **325**
- differential diagnosis, **325**
- histochemical features, **325**

Lipoma
- bronchial, cartilaginous hamartoma vs., **5**
- endobronchial, **18-21**
  - diagnostic checklist, **19**
  - differential diagnosis, **19**
  - prognosis, **19**
- liposarcoma vs., **760**
- thymic. *See* Thymolipoma.

Lipomatosis, pulmonary. *See* Placental transmogrification.
Lipomatous hamartoma. *See* Endobronchial lipoma.
Lipomatous tumor
- atypical. *See* Liposarcoma.
- with muscle differentiation, leiomyosarcoma vs., **770**

Liposarcoma, **758-767**
- dedifferentiated, **759**
- diagnostic checklist, **760**
- differential diagnosis, **760**
- genetic testing, **760**
- metastatic, endobronchial lipoma vs., **19**
- myxoid, **759**
- pleomorphic, **759**
- pleomorphic myxoid, **759**
- prognosis, **759**
- round cell, **759**
- thymolipoma vs., **861**
- well-differentiated, **759**
  - lipoma-like/atypical lipomatous tumor, **759**

Localized fibrous tumor. *See* Solitary fibrous tumor.
Loeffler syndrome. *See* Eosinophilic pneumonia.
Low-grade neuroendocrine carcinoma, **156**
- neuroendocrine carcinoma vs., **155**

Low-grade spindle cell tumors, liposarcoma vs., **760**
Lung
- alveolar adenoma, **8-11**
  - diagnostic checklist, **9**
  - differential diagnosis, **9**
  - immunohistochemistry, **9**
  - prognosis, **9**
- cartilaginous hamartoma, **4-7**
  - diagnostic checklist, **5**
  - differential diagnosis, **5**
  - immunohistochemistry, **5**
  - prognosis, **5**
  - pulmonary adenofibroma/adenomyoma vs., **23**
- ciliated muconodular papillary tumor, **70-71**
  - diagnostic checklist, **71**
  - differential diagnosis, **71**

probable benign neoplastic proliferation, **71**
prognosis, **71**
- clear cell sugar tumor (PEComa), **66-69**
diagnostic checklist, **67**
differential diagnosis, **67**
histochemical features, **67**
immunohistochemistry, **67**
prognosis, **67**
- endobronchial lipoma, **18-21**
diagnostic checklist, **19**
differential diagnosis, **19**
prognosis, **19**
- glomus tumor, **34-37**
alveolar adenoma vs., **9**
diagnostic checklist, **35**
differential diagnosis, **35**
immunohistochemistry, **35**
prognosis, **35**
- granular cell tumor, **56-59**
benign, **57**
diagnostic checklist, **57**
differential diagnosis, **57**
immunohistochemistry, **57**
malignant, **57**
- intrapulmonary solitary fibrous tumor, **26-33**. *See also* Solitary fibrous tumor, intrapulmonary.
amyloid tumor vs., **317**
diagnostic checklist, **27**
differential diagnosis, **27**
hyalinizing granuloma vs., **313**
inflammatory pseudotumor vs., **299**
intrapulmonary synovial sarcoma vs., **217**
intrapulmonary thymoma vs., **39**
pulmonary adenofibroma/adenomyoma vs., **23**
- intrapulmonary thymoma, **38-41**. *See also* Thymoma, intrapulmonary.
differential diagnosis, **39**
prognosis, **39**
- minute pulmonary meningothelial-like nodule, **52-55**
differential diagnosis, **53**
pulmonary meningioma vs., **47**
- mucous gland adenoma, **12-17**
diagnostic checklist, **14**
differential diagnosis, **13-14**
histochemical features, **14**
immunohistochemistry, **14**
molecular features, **14**
mucoepidermoid carcinoma vs., **187**
prognosis, **13**
- pulmonary adenofibroma/adenomyoma, **22-25**
differential diagnosis, **23**
prognosis, **23**
- pulmonary meningioma, **46-51**
diagnostic checklist, **47**
differential diagnosis, **47**
grading, **48**
histochemical features, **48**
immunohistochemistry, **48**
molecular features, **48**
prognosis, **47**
- pulmonary paraganglioma, **42-45**
diagnostic checklist, **43**
differential diagnosis, **43**
neuroendocrine carcinoma vs., **155**
prognosis, **43**
- sclerosing hemangioma (pneumocytoma), **60-65**
diagnostic checklist, **61**
differential diagnosis, **61**
histochemical features, **62**
histogenesis, **61**
immunohistochemistry, **62**
prognosis, **61**
ultrastructural features, **62**

Lung cancer, histopathologic classification, **74**

Lung conditions, nonneoplastic and systemic
- allergic angiitis and granulomatosis (Churg-Strauss), **418-421**
diagnostic checklist, **419**
differential diagnosis, **419**
prognosis, **419**
- alveolar microlithiasis, **464-467**
diagnostic checklist, **465**
differential diagnosis, **465**
histochemical features, **465**
metastatic/dendriform calcification vs., **321**
prognosis, **465**
- alveolar proteinosis, **444-447**
diagnostic checklist, **445**
differential diagnosis, **445**
histochemical features, **445**
immunohistochemistry, **445**
prognosis, **445**
pulmonary amyloidosis vs., **449**
- asbestos-related interstitial fibrosis, **438-441**
diagnostic checklist, **439**
differential diagnosis, **439**
prognosis, **439**
- bronchiolitis obliterans with organizing pneumonia, **390-393**
conditions associated, **391**
diagnostic checklist, **391**
differential diagnosis, **391**
extrinsic allergic alveolitis vs., **415**
prognosis, **391**
- bronchocentric granulomatosis, **422-425**
diagnostic checklist, **423**
differential diagnosis, **423**
- desquamative interstitial pneumonia, **406-409**
diagnostic checklist, **407**
differential diagnosis, **407**
prognosis, **407**
- diffuse alveolar damage, **386-389**
diagnostic checklist, **387**
exudative (acute) phase, **387**
fibrotic (chronic) phase, **387**
organizing, bronchiolitis obliterans with organizing pneumonia vs., **391**
prognosis, **387**
proliferative (organizing) phase, **387**
- eosinophilic pneumonia, **452-455**
allergic angiitis and granulomatosis vs., **419**

angiolymphoid hyperplasia with eosinophilia vs., **337**
diagnostic checklist, **453**
differential diagnosis, **453**
Langerhans cell histiocytosis vs., **457**
prognosis, **453**
respiratory bronchiolitis vs., **395**
- Erdheim-Chester disease, **460-463**
differential diagnosis, **461**
juvenile xanthogranuloma vs., **309**
prognosis, **461**
Rosai-Dorfman disease vs., **333**
- extrinsic allergic alveolitis, **414-417**
diagnostic checklist, **415**
differential diagnosis, **415**
prognosis, **415**
- hard metal pneumoconiosis pneumonitis, **434-437**
diagnostic checklist, **435**
differential diagnosis, **435**
prognosis, **435**
- idiopathic pulmonary hemosiderosis, **442-443**
diagnostic checklist, **443**
differential diagnosis, **443**
prognosis, **443**
- Langerhans cell histiocytosis, **456-459**
diagnostic checklist, **457**
differential diagnosis, **457**
eosinophilic pneumonia vs., **453**
Erdheim-Chester disease vs., **461**
hard metal pneumoconiosis pneumonitis vs., **435**
juvenile xanthogranuloma vs., **309**
lipoid pneumonia vs., **325**
prognosis, **457**
respiratory bronchiolitis vs., **395**
Rosai-Dorfman disease vs., **333**
- nonspecific interstitial pneumonia, **410-413**
cellular pattern, **411**
diagnostic checklist, **411**
differential diagnosis, **411**
with fibrosing pattern, **411**
prognosis, **411**
- pulmonary amyloidosis, **448-451**
diagnostic checklist, **449**
differential diagnosis, **449**
prognosis, **449**
- respiratory bronchiolitis, **394-397**
diagnostic checklist, **395**
differential diagnosis, **395**
prognosis, **395**
- sarcoidosis, **430-433**
bronchocentric granulomatosis vs., **423**
differential diagnosis, **431**
extrinsic allergic alveolitis vs., **415**
genetic predisposition, **431**
- usual interstitial pneumonia, **398-405**
conditions associated, **399**
desquamative interstitial pneumonia vs., **407**
diagnostic checklist, **399**
nonspecific interstitial pneumonia vs., **411**
prognosis, **399**
- Wegener granulomatosis, **426-429**
allergic angiitis and granulomatosis vs., **419**
bronchocentric granulomatosis vs., **423**
diagnostic checklist, **427**
differential diagnosis, **427**
Granulomatous reaction, **427**
lymphomatoid granulomatosis vs., **285**
prognosis, **427**
Lung disease, IgG4 sclerosing, **304-307**
- bronchovascular pattern of involvement, **305**
- differential diagnosis, **305**
- inflammatory pseudotumor-like, **305**
- interstitial fibrosis-like, **305**
- prognosis, **305**
Lung fluke disease. *See* Paragonimiasis.
Lung neoplasms, malignant, primary
- acinic cell carcinoma, **198-205**
diagnostic checklist, **199**
differential diagnosis, **199**
granular cell tumor vs., **57**
histochemical features, **200**
immunohistochemistry, **200**
metastatic, acinic cell carcinoma vs., **199**
molecular analysis, **200**
prognosis, **199**
ultrastructural features, **200**
- adenocarcinoma, **76-87**
acinic cell carcinoma vs., **199**
adenoid cystic carcinoma vs., **179**
adenomatoid tumor-like, **78**
biliary, metastatic carcinoma vs., **358**
with bronchioloalveolar pattern. *See* Bronchioloalveolar carcinoma.
carcinosarcoma vs., **167**
diagnostic checklist, **78**
differential diagnosis, **78**
endometrial, metastatic carcinoma vs., **358**
endometrioid. *See* Endometrioid-like carcinoma.
epithelial-myoepithelial carcinoma vs., **193**
from extrathoracic origin, adenocarcinoma vs., **78**
extrathoracic origin, pseudomesotheliomatous adenocarcinoma vs., **585**
fetal
adenocarcinoma vs., **78**
well-differentiated. *See* Pulmonary blastoma.
grading, **78**
histochemical features, **79**
immunohistochemistry, **79**
intermediate grade, **78**
with lepidic pattern. *See* Bronchioloalveolar carcinoma.
low grade, **78**
metastatic
angiosarcoma vs., **597**
bronchioloalveolar carcinoma vs., **89**
of lung origin, embryonal carcinoma vs., **721**
malignant mesothelioma vs., **577**
prostatic, endometrioid-like carcinoma vs., **109**
pulmonary blastoma vs., **173**
synovial sarcoma vs., **776**
molecular biology, **79**
mucinous, ciliated muconodular papillary tumor vs., **71**

mucoepidermoid carcinoma of pleura vs., **591**
mucoepidermoid carcinoma vs., **187**
mucous gland adenoma vs., **13**
pancreatic, metastatic carcinoma vs., **358**
pleural endometriosis vs., **627**
prognosis, **77**
pseudomesotheliomatous, **584-589**
diagnostic checklist, **585**
differential diagnosis, **585**
histochemical features, **586**
immunohistochemistry, **586**
molecular features, **586**
prognosis, **585**
pulmonary blastoma vs., **173**
pulmonary invasive, bronchioloalveolar carcinoma vs., **89**
sclerosing hemangioma (pneumocytoma) vs., **61**
with signet ring cells. *See* Signet ring cell carcinoma.
in situ. *See* Bronchioloalveolar carcinoma.
Warthin-like, **78**
well-differentiated. *See also* Bronchioloalveolar carcinoma.
atypical adenomatous hyperplasia vs., **341**
- adenoid cystic carcinoma, **178-185**
adenocarcinoma vs., **78**
diagnostic checklist, **179-180**
differential diagnosis, **179**
epithelial-myoepithelial carcinoma vs., **193**
histochemical features, **180**
immunohistochemistry, **180**
metastatic, adenoid cystic carcinoma vs., **179**
molecular features, **180**
myoepithelial carcinoma of lung vs., **213**
prognosis, **179**
staging, **180**
- amyloid tumor, **316-319**
associated conditions, **317**
diagnostic checklist, **317**
differential diagnosis, **317**
hyalinizing granuloma vs., **313**
prognosis, **317**
- angiolymphoid hyperplasia with eosinophilia, **336-339**
diagnostic checklist, **337**
differential diagnosis, **337**
prognosis, **337**
- angiosarcoma, **246-249**
capillary hemangiomatosis vs., **347**
carcinosarcoma vs., **167**
diagnostic checklist, **247**
differential diagnosis, **247**
epithelioid hemangioendothelioma vs., **241**
immunohistochemistry, **247**
metastatic, angiosarcoma vs., **247**
prognosis, **247**
- atypical adenomatous hyperplasia, **340-341**. *See also* Adenomatous hyperplasia, atypical.
adenocarcinoma vs., **78**
bronchioloalveolar carcinoma vs., **89**
differential diagnosis, **341**
prognosis, **341**
- bronchial malignant melanoma, **294-297**
diagnostic checklist, **295**
differential diagnosis, **295**
immunohistochemistry, **295**
prognosis, **295**
- bronchioloalveolar carcinoma, **88-93**
conventional type, **89**
diagnostic checklist, **89-90**
differential diagnosis, **89**
histochemical features, **90**
immunohistochemistry, **90**
molecular findings, **90**
mucinous type, **89**
mucinous variant, mucinous ("colloid") carcinoma vs., **95**
prognosis, **89**
- capillary hemangiomatosis, **346-349**
diagnostic checklist, **347**
differential diagnosis, **347**
prognosis, **347**
- carcinosarcoma, **166-171**
chondrosarcoma vs., **237**
diagnostic checklist, **167**
differential diagnosis, **167**
histochemical features, **168**
immunohistochemistry, **168**
leiomyosarcoma vs., **223**
mixed tumor vs., **207**
molecular features, **168**
osteosarcoma vs., **233**
prognosis, **167**
pulmonary blastoma vs., **173**
pulmonary, metastatic sarcoma vs., **368**
thymic, synovial sarcoma vs., **776**
- chondrosarcoma, **236-239**
carcinosarcoma vs., **167**
diagnostic checklist, **237**
differential diagnosis, **237**
extraskeletal myxoid, chordoma vs., **817**
mesenchymal, **812-815**
diagnostic checklist, **813**
differential diagnosis, **813**
genetic testing, **813**
prognosis, **813**
metastatic, chondrosarcoma vs., **237**
myxoid, epithelioid hemangioendothelioma vs., **807**
osteosarcoma vs., **233**
primary or metastatic, cartilaginous hamartoma vs., **5**
prognosis, **237**
well-differentiated, mediastinal chordoma vs., **817**
- diffuse large cell lymphoma, **268-275**
anaplastic large cell lymphoma (ALCL), **269**
B-immunoblastic lymphoma, **269**
differential diagnosis, **269**
genetic testing, **269**
peripheral T-cell lymphoma, **269**
- endometrioid-like carcinoma, **108-113**
diagnostic checklist, **109**
differential diagnosis, **109**
histochemical features, **110**
immunohistochemistry, **110**

molecular features, **110**
prognosis, **109**
- epithelial, overview, **74-75**
classification, **74**
genetic and molecular alterations, **75**
- epithelial-myoepithelial carcinoma, **192-197**
adenoid cystic carcinoma vs., **179**
diagnostic checklist, **193**
differential diagnosis, **193**
grading, **193**
high-grade, **193**
histochemical features, **194**
immunohistochemistry, **194**
low-grade, **193**
molecular features, **194**
mucous gland adenoma vs., **14**
prognosis, **193**
- epithelioid hemangioendothelioma, **240-245**
angiosarcoma vs., **247**
diagnostic checklist, **241**
differential diagnosis, **241**
histochemical features, **242**
immunohistochemistry, **242**
molecular features, **242**
prognosis, **241**
ultrastructural features, **242**
- ganglioneuroblastoma, **290-293**. *See also* Neuroblastoma/ganglioneuroblastoma.
diagnostic checklist, **291**
differential diagnosis, **291**
ganglioneuroma vs., **835**
prognosis, **291**
- Hodgkin lymphoma, **276-279**
angiolymphoid hyperplasia with eosinophilia vs., **337**
cystic, acquired multilocular thymic cyst vs., **877**
differential diagnosis, **277**
genetic testing, **277**
lymphomatoid granulomatosis vs., **285**
prognosis, **277**
- hyalinizing granuloma, **312-315**
associated conditions, **313**
diagnostic checklist, **313**
differential diagnosis, **313**
of lung
amyloid tumor vs., **317**
pulmonary amyloidosis vs., **449**
- IgG4 sclerosing lung disease, **304-307**
bronchovascular pattern of involvement, **305**
differential diagnosis, **305**
inflammatory pseudotumor-like, **305**
interstitial fibrosis-like, **305**
prognosis, **305**
- inflammatory pseudotumor, **298-303**. *See also* Mediastinitis, idiopathic sclerosing.
bronchiolitis obliterans with organizing pneumonia vs., **391**
calcified fibrous pseudotumor vs., **569**
diagnostic checklist, **300**
differential diagnosis, **299**
IgG4 sclerosing lung disease vs., **305**
immunohistochemistry, **300**
molecular findings, **300**
plasma cell type
hyalinizing granuloma vs., **313**
plasmacytoma vs., **281**
prognosis, **299**
sclerosing hemangioma (pneumocytoma) vs., **61**
- intrapulmonary synovial sarcoma, **216-221**. *See also* Synovial sarcoma, intrapulmonary.
differential diagnosis, **217**
genetic testing, **217**
prognosis, **217**
- juvenile xanthogranuloma, **308-311**
differential diagnosis, **309**
immunohistochemistry, **309**
lipoid pneumonia vs., **325**
prognosis, **309**
Rosai-Dorfman disease vs., **333**
- Kaposi sarcoma, **250-253**
diagnostic checklist, **251**
differential diagnosis, **251**
prognosis, **251**
- large cell (anaplastic) carcinoma, **140-147**
carcinosarcoma vs., **167**
differential diagnosis, **141**
lymphoepithelioma-like carcinoma vs., **129**
neuroendocrine carcinoma vs., **156**
neuroendocrine differentiation, neuroendocrine carcinoma vs., **156**
neuroendocrine pattern, neuroendocrine carcinoma vs., **156**
prognosis, **141**
rhabdoid features, **141**
undifferentiated. *See* Large cell (anaplastic) carcinoma.
- leiomyosarcoma, **222-227**
diagnostic checklist, **223**
differential diagnosis, **223**
grading, **224**
immunohistochemistry, **224**
Kaposi sarcoma vs., **251**
low-grade metastatic, benign metastasizing leiomyoma vs., **353**
lymphangioleiomyomatosis vs., **343**
molecular features, **224**
prognosis, **223**
pulmonary ,pleomorphic carcinoma vs., **149**
spindle cell (sarcomatoid) carcinoma vs., **123**
- lipoid pneumonia (paraffinoma), **324-327**
diagnostic checklist, **325**
differential diagnosis, **325**
histochemical features, **325**
- lymphangioleiomyomatosis, **342-345**
diagnostic checklist, **343**
differential diagnosis, **343**
immunohistochemistry, **343**
minute pulmonary meningothelial-like nodule vs., **53**
molecular biology, **343**
prognosis, **343**
- lymphoepithelioma-like carcinoma, **128-133**
diagnostic checklist, **129**
differential diagnosis, **129**

diffuse large cell lymphoma vs., **269**
histochemical features, **130**
immunohistochemistry, **130**
molecular features, **130**
mucoepidermoid carcinoma vs., **187**
prognosis, **129**
in situ hybridization, **130**
- lymphomatoid granulomatosis, **284-289**
diagnostic checklist, **285**
differential diagnosis, **285**
grading, **285**
Hodgkin lymphoma vs., **277**
IgG4 sclerosing lung disease vs., **305**
Wegener granulomatosis vs., **427**
- metastatic/dendriform calcification, **320-323**
diagnostic checklist, **321**
differential diagnosis, **321**
prognosis, **321**
- mixed tumor (pleomorphic adenoma), **206-211**
benign, **207**
diagnostic checklist, **207**
differential diagnosis, **207**
endobronchial lipoma vs., **19**
epithelial-myoepithelial carcinoma vs., **193**
grading, **207**
malignant, **207**
mucous gland adenoma vs., **13**
myoepithelial carcinoma of lung vs., **213**
prognosis, **207**
- mucinous ("colloid") carcinoma, **94-101**
diagnostic checklist, **95**
differential diagnosis, **95**
grading, **95**
histochemical features, **96**
immunohistochemistry, **96**
molecular features, **96**
prognosis, **95**
- mucoepidermoid carcinoma, **186-191**
adenoid cystic carcinoma vs., **179**
ciliated muconodular papillary tumor vs., **71**
diagnostic checklist, **187-188**
differential diagnosis, **187**
grading, **188**
histochemical features, **188**
immunohistochemistry, **188**
metastatic
mucoepidermoid carcinoma of pleura vs., **591**
mucoepidermoid carcinoma vs., **187**
mixed tumor vs., **207**
molecular features, **188**
mucous gland adenoma vs., **13**
prognosis, **187**
squamous cell carcinoma vs., **115**
- myoepithelial carcinoma of lung, **212-215**
diagnostic checklist, **213**
differential diagnosis, **213**
prognosis, **213**
- neuroendocrine carcinoma, **154-165**
bronchial, granular cell tumor vs., **57**
bronchial malignant melanoma vs., **295**
diagnostic checklist, **156**
differential diagnosis, **155-156**
ectopic thyroid tumor vs., **855**
ependymoma vs., **845**
ganglioneuroblastoma vs., **291**
grading, **156**
high-grade neuroendocrine carcinoma vs., **155**
immunohistochemistry, **156**
intermediate-grade, **156**
neuroendocrine carcinoma vs., **155**
large cell
poorly differentiated small cell variant squamous carcinoma vs., **135**
squamous cell carcinoma vs., **115**
low-grade neuroendocrine carcinoma vs., **155**
mediastinal, thymoma vs., **653**
metastatic
extrathoracic origin, neuroendocrine carcinoma vs., **155**
neuroendocrine carcinomas of thymus vs., **691**
moderately differentiated, poorly differentiated
small cell variant squamous carcinoma vs., **135**
molecular features, **156**
oncocytic variant, acinic cell carcinoma vs., **199**
prognosis, **155**
pulmonary
metastatic, pleural desmoplastic small round cell tumor vs., **621**
well-differentiated, paraganglioma vs., **641**
small cell, poorly differentiated small cell variant
squamous carcinoma vs., **135**
well-differentiated
ectopic parathyroid tumor vs., **849**
pulmonary meningioma vs., **47**
pulmonary paraganglioma vs., **43**
- neurogenic sarcoma (malignant peripheral nerve sheath tumor), **228-231**. *See also* Peripheral nerve sheath tumors.
bronchial malignant melanoma vs., **295**
differential diagnosis, **229**
genetic testing, **229**
prognosis, **229**
- osteosarcoma, **232-235**
carcinosarcoma vs., **167**
diagnostic checklist, **233**
differential diagnosis, **233**
prognosis, **233**
- placental transmogrification, **328-331**
diagnostic checklist, **329**
differential diagnosis, **329**
prognosis, **329**
- plasmacytoma, **280-283**
diagnostic checklist, **281**
differential diagnosis, **281**
immunohistochemistry, **281**
inflammatory pseudotumor vs., **299**
prognosis, **281**
- pleomorphic carcinoma, **148-153**. *See also* Large cell (anaplastic) carcinoma.
diagnostic checklist, **149**
differential diagnosis, **149**

histochemical features, **150**
immunohistochemistry, **150**
leiomyosarcoma vs., **223**
of lung origin, choriocarcinoma vs., **715**
lymphoepithelioma-like carcinoma vs., **129**
molecular features, **150**
prognosis, **149**
spindle cell (sarcomatoid) carcinoma vs., **123**
- poorly differentiated squamous carcinoma, small cell variant, **134-139**
diagnostic checklist, **135**
differential diagnosis, **135**
- pulmonary artery sarcoma, **254-257**
diagnostic checklist, **255**
differential diagnosis, **255**
immunohistochemistry, **255**
prognosis, **255**
- pulmonary BALT hyperplasia, **258-261**
differential diagnosis, **259**
follicular bronchiolitis, **259**
genetic testing, **259**
nodular lymphoid hyperplasia, **259**
prognosis, **259**
- pulmonary BALT lymphoma, **262-267**
differential diagnosis, **263**
genetic testing, **263**
prognosis, **263**
- pulmonary blastoma, **172-177**
biphasic
pleural endometriosis vs., **627**
pulmonary adenofibroma/adenomyoma vs., **23**
diagnostic checklist, **173-174**
differential diagnosis, **173**
endometrioid-like carcinoma vs., **109**
histochemical features, **174**
immunohistochemistry, **174**
metastatic sarcoma vs., **368**
molecular features, **174**
prognosis, **173**
synovial sarcoma vs., **776**
- Rosai-Dorfman disease, **332-335**
diagnostic checklist, **333**
differential diagnosis, **333**
Erdheim-Chester disease vs., **461**
IgG4 sclerosing lung disease vs., **305**
immunohistochemistry, **333**
lipoid pneumonia vs., **325**
of lung, juvenile xanthogranuloma vs., **309**
malakoplakia vs., **549**
prognosis, **333**
- signet ring cell carcinoma, **102-107**
diagnostic checklist, **103**
differential diagnosis, **103**
histochemical features, **104**
immunohistochemistry, **104**
metastatic, signet ring cell carcinoma vs., **103**
molecular features, **104**
prognosis, **103**
- spindle cell (sarcomatoid) carcinoma, **122-127**
diagnostic checklist, **123**
differential diagnosis, **123**
histochemical features, **124**
immunohistochemistry, **124**
molecular features, **124**
prognosis, **123**
- squamous cell carcinoma, **114-121**
basaloid, metastasis from head and neck, poorly differentiated small cell variant squamous carcinoma vs., **135**
carcinosarcoma vs., **167**
diagnostic checklist, **115**
differential diagnosis, **115**
grading, **115**
histochemical features, **116**
immunohistochemistry, **116**
of lung origin, atypical thymoma vs., **667**
moderately differentiated, **115**
molecular features, **116**
mucoepidermoid carcinoma of pleura vs., **591**
mucoepidermoid carcinoma vs., **187**
poorly differentiated small cell variant, **134-139**
diagnostic checklist, **135**
differential diagnosis, **135**
prognosis, **115**
in situ, **115**
well-differentiated, **115**
atypical thymoma vs., **667**
intrapulmonary thymoma vs., **39**

Lung neoplasms, metastatic
- benign metastasizing leiomyoma, **352-355**
differential diagnosis, **353**
prognosis, **353**
- metastatic carcinoma, **356-365**
diagnostic checklist, **358**
differential diagnosis, **357-358**
epithelioid hemangioendothelioma vs., **241**
immunohistochemistry, **358**
of lung, thymic carcinoma vs., **678**
metastatic models, **357**
minute pulmonary meningothelial-like nodule vs., **53**
patterns of growth, **357**
prognosis, **357**
yolk sac tumor vs., **709**
- metastatic malignant melanoma, **376-383**
differential diagnosis, **377**
diffuse large cell lymphoma vs., **269**
epithelioid melanoma, **377**
mediastinal diffuse large cell lymphoma vs., **736**
metastatic malignant solitary fibrous tumor (fibrosarcoma) vs., **609**
metastatic sarcoma vs., **367**
mixed spindle and epithelioid cell melanoma, **377**
pleomorphic melanoma, **377**
prognosis, **377**
rhabdoid melanoma, **377**
signet ring cell melanoma, **377**
small cell melanoma, **377**
spindle cell melanoma, **377**
- metastatic sarcoma, **366-375**
differential diagnosis, **367-368**
epithelioid cell, **367**
immunohistochemistry, **368**

pleomorphic, **367**
prognosis, **367**
pulmonary artery sarcoma vs., **255**
small round blue cell, **367**
spindle cell sarcoma, **367**
Lung parasitic disorders. *See* Parasitic disorders of lung.
Lung parenchyma, normal, capillary hemangiomatosis vs., **347**
Lymph nodes, **653**
Lymphadenopathy, massive, sinus histiocytosis with, Erdheim-Chester disease vs., **461**
Lymphangioleiomyomatosis, **342-345**
- diagnostic checklist, **343**
- differential diagnosis, **343**
- immunohistochemistry, **343**
- minute pulmonary meningothelial-like nodule vs., **53**
- molecular biology, **343**
- prognosis, **343**

Lymphangioma, **632-635**
- alveolar adenoma vs., **9**
- differential diagnosis, **633**
- hemangioma vs., **637**
- prognosis, **633**

Lymphangiomyomatosis. *See* Lymphangioleiomyomatosis.
Lymphoblastic lymphoma, **748-753**
- diagnostic checklist, **750**
- differential diagnosis, **750**
- genetic testing, **749**
- immunohistochemistry, **750**
- intrapulmonary thymoma vs., **39**
- rhabdomyosarcoma vs., **829**
- thymoma vs., **653**

Lymphoblastic lymphoma/leukemia. *See* Lymphoblastic lymphoma.
Lymphocyte-rich thymoma
- lymphoblastic lymphoma vs., **750**
- rhabdomyosarcoma vs., **829**

Lymphocytic interstitial pneumonia, pulmonary BALT lymphoma vs., **263**
Lymphocytic leukemia, chronic, B-cell/small lymphocytic lymphoma, lymphoblastic lymphoma vs., **750**
Lymphoepithelioma-like carcinoma, **128-133**
- diagnostic checklist, **129**
- differential diagnosis, **129**
- diffuse large cell lymphoma vs., **269**
- histochemical features, **130**
- immunohistochemistry, **130**
- molecular features, **130**
- mucoepidermoid carcinoma vs., **187**
- prognosis, **129**
- in situ hybridization, **130**

Lymphoid hamartoma, angiomatous. *See* Castleman disease.
Lymphoid hyperplasia
- diffuse, pulmonary BALT lymphoma vs., **263**
- nodular, pulmonary BALT lymphoma vs., **263**

Lymphoid interstitial pneumonia. *See also* Pulmonary BALT hyperplasia.
- nonspecific interstitial pneumonia vs., **411**

Lymphoma
- anaplastic large cell, **269**
  embryonal carcinoma vs., **722**
  Hodgkin lymphoma vs., **277, 728**
  lymphoepithelioma-like carcinoma vs., **129**
  mediastinal diffuse large cell lymphoma vs., **736**
- Burkitt, lymphoblastic lymphoma vs., **750**
- diffuse large cell, **268-275**. *See also* Diffuse large cell lymphoma.
  anaplastic large cell lymphoma (ALCL), **269**
  B-immunoblastic lymphoma, **269**
  differential diagnosis, **269**
  genetic testing, **269**
  peripheral T-cell lymphoma, **269**
- follicular
  Castleman disease vs., **865**
  MALT lymphoma of thymus vs., **755**
- Hodgkin lymphoma, **276-279**. *See also* Hodgkin lymphoma; Hodgkin lymphoma, mediastinal.
  angiolymphoid hyperplasia with eosinophilia vs., **337**
  cystic, acquired multilocular thymic cyst vs., **877**
  differential diagnosis, **277**
  genetic testing, **277**
  lymphomatoid granulomatosis vs., **285**
  prognosis, **277**
- large cell anaplastic
  embryonal carcinoma vs., **722**
  Hodgkin lymphoma vs., **728**
  mediastinal diffuse large cell lymphoma vs., **736**
- lymphoblastic, **748-753**. *See also* Lymphoblastic lymphoma.
  diagnostic checklist, **750**
  differential diagnosis, **750**
  genetic testing, **749**
  immunohistochemistry, **750**
  intrapulmonary thymoma vs., **39**
  rhabdomyosarcoma vs., **829**
  thymoma vs., **653**
- malignant
  desmoplastic small round cell tumor vs., **621**
  with plasmacytoid features, plasmacytoma vs., **281**
- MALT lymphoma of thymus, **754-757**
  diagnostic checklist, **755**
  differential diagnosis, **755**
  prognosis, **755**
- mediastinal B-cell, mediastinal seminoma vs., **703**
- mediastinal, ectopic parathyroid tumor vs., **849**
- mediastinal Hodgkin lymphoma, **726-733**
  diagnostic checklist, **728**
  differential diagnosis, **727-728**
  immunohistochemistry, **728**
  mediastinal diffuse large cell lymphoma vs., **736**
  prognosis, **727**
- non-Hodgkin lymphoma, angiolymphoid hyperplasia with eosinophilia vs., **337**
- pulmonary BALT, **262-267**
  differential diagnosis, **263**
  genetic testing, **263**
  prognosis, **263**
- T-cell-rich B-cell, lymphomatoid granulomatosis vs., **285**

Lymphomatoid granulomatosis, **284-289**
- diagnostic checklist, **285**
- differential diagnosis, **285**
- grading, **285**
- Hodgkin lymphoma vs., **277**
- IgG4 sclerosing lung disease vs., **305**
- Wegener granulomatosis vs., **427**

M

Malakoplakia, **548-551**
- differential diagnosis, **549**

Malignant fibrous histiocytoma
- pleomorphic carcinoma vs., **149**
- spindle cell (sarcomatoid) carcinoma vs., **123**

Malignant lymphoma
- desmoplastic small round cell tumor vs., **621**
- with plasmacytoid features, plasmacytoma vs., **281**

Malignant melanoma
- bronchial, **294-297**
  - diagnostic checklist, **295**
  - differential diagnosis, **295**
  - immunohistochemistry, **295**
  - prognosis, **295**
- metastatic, **376-383**
  - differential diagnosis, **377**
  - diffuse large cell lymphoma vs., **269**
  - epithelioid melanoma, **377**
  - malignant solitary fibrous tumor (fibrosarcoma) vs., **609**
  - mediastinal diffuse large cell lymphoma vs., **736**
  - metastatic malignant solitary fibrous tumor (fibrosarcoma) vs., **609**
  - metastatic sarcoma vs., **367**
  - mixed spindle and epithelioid cell melanoma, **377**
  - pleomorphic melanoma, **377**
  - prognosis, **377**
  - rhabdoid melanoma, **377**
  - signet ring cell melanoma, **377**
  - small cell melanoma, **377**
  - spindle cell melanoma, **377**

Malignant meningioma, **48**
- pulmonary meningioma vs., **47**

Malignant mesothelioma, **576-583**
- biphasic, synovial sarcoma vs., **603**
- diagnostic checklist, **578**
- differential diagnosis, **577-578**
- early stage, mesothelial hyperplasia vs., **555**
- epithelioid, angiosarcoma vs., **597**
- growth patterns, **577**
- histochemical features, **578**
- immunohistochemistry, **578**
- molecular features, **578**
- prognosis, **577**
- sarcomatoid
  - smooth muscle tumors of pleura vs., **615**
  - synovial sarcoma vs., **603**

Malignant neoplasms, benign mediastinal foregut cyst vs., **871**

Malignant peripheral nerve sheath tumors. *See also* Neurogenic sarcoma; Peripheral nerve sheath tumors, malignant.
- malignant solitary fibrous tumor vs., **609**
- solitary fibrous tumor vs., **217**
- synovial sarcoma vs., **776**

Malignant pleural neoplasms, **574-575**
- molecular genetic alterations, **575**
- primary, **574**
- prognostic factors, **575**
- secondary, **574**
- staging, **575**

Malignant schwannoma. *See* Neurogenic sarcoma; Peripheral nerve sheath tumors.

Malignant smooth muscle tumor. *See* Leiomyosarcoma.

Malignant solitary fibrous tumor (fibrosarcoma), **608-613**. *See also* Solitary fibrous tumor.
- diagnostic checklist, **609**
- differential diagnosis, **609**
- prognosis, **609**
- synovial sarcoma vs., **603**

Malignant thymoma type II. *See* Thymic carcinoma.

MALT lymphoma of thymus, **754-757**
- acquired multilocular thymic cyst vs., **877**
- diagnostic checklist, **755**
- differential diagnosis, **755**
- prognosis, **755**
- pulmonary BALT hyperplasia vs., **259**

Mammary analog secretory carcinoma, acinic cell carcinoma vs., **199**

Marginal zone B-cell lymphoma of mucosa-associated lymphoid tissue (MALT) type. *See* Pulmonary BALT lymphoma.

Marginal zone lymphoma. *See* MALT lymphoma of thymus.

Massive lymphadenopathy, sinus histiocytosis with, Erdheim-Chester disease vs., **461**

Measles, herpes simplex virus vs., **515**

Measles pneumonia, **524-527**
- differential diagnosis, **525**
- prognosis, **525**

Mediastinal B-cell lymphoma, mediastinal seminoma vs., **703**

Mediastinal benign/reactive conditions
- acquired multilocular thymic cyst, **876-883**
  - benign mediastinal foregut cyst vs., **871**
  - diagnostic checklist, **877**
  - differential diagnosis, **877**
  - lymphangioma vs., **633**
  - multilocular yolk sac tumor vs., **710**
  - prognosis, **877**
  - thymoma vs., **653**
- benign mediastinal foregut cyst, **870-875**
  - diagnostic checklist, **871**
  - differential diagnosis, **871**
  - immunohistochemistry, **872**
  - prognosis, **871**
- Castleman disease, **864-869**
  - differential diagnosis, **865**
  - hyaline-vascular type, **865**
  - plasma cell type, **865**

- idiopathic sclerosing mediastinitis, **884-887**
  diagnostic checklist, **885**
  differential diagnosis, **885**
  prognosis, **885**
- thymolipoma, **860-863**
  diagnostic checklist, **861**
  differential diagnosis, **861**
  hemangioma vs., **637**
  liposarcoma vs., **760**
  prognosis, **861**

Mediastinal cyst, clinicopathological features, **872**
Mediastinal diffuse large cell lymphoma, **734-747**. *See also* Diffuse large cell lymphoma, mediastinal.
- clear cell, **735**
- diagnostic checklist, **736**
- differential diagnosis, **736**
- diffuse large B-cell, with sclerosis, **736**
- genetic testing, **736**
- germinotropic, **735**
- Hodgkin lymphoma vs., **728**
- immunohistochemistry, **737**
- large B-cell, with Hodgkin-like or anaplastic large cell lymphoma-like features, **735-736**
- pleomorphic, **735**
- prognosis, **735**
- signet ring cell, **735**
- spindle cell, **735**
- unusual histologic features, **736**

Mediastinal fibroma. *See* Solitary fibrous tumor.
Mediastinal fibrosarcoma. *See* Solitary fibrous tumor.
Mediastinal foregut cyst, benign, **870-875**
- diagnostic checklist, **871**
- differential diagnosis, **871**
- histochemical features, **872**
- immunohistochemistry, **872**
- prognosis, **871**

Mediastinal germ cell tumors, clinical staging, **710, 716**
Mediastinal Hodgkin lymphoma, **726-733**
- diagnostic checklist, **728**
- differential diagnosis, **727-728**
- immunohistochemistry, **728**
- mediastinal diffuse large cell lymphoma vs., **736**
- prognosis, **727**

Mediastinal large B-cell lymphoma. *See* Diffuse large cell lymphoma, mediastinal.
Mediastinal lymphoma, ectopic parathyroid tumor vs., **849**
Mediastinal neoplasms, benign
- hemangioma, **636-639**
  capillary, **637**
    capillary hemangiomatosis vs., **347**
  cavernous, **637**
    capillary hemangiomatosis vs., **347**
  differential diagnosis, **637**
  lymphangioma vs., **633**
  prognosis, **637**
- lymphangioma, **632-635**
  alveolar adenoma vs., **9**
  differential diagnosis, **633**
  hemangioma vs., **637**
  prognosis, **633**
- paraganglioma, **640-645**
  alveolar soft part sarcoma vs., **823**
  diagnostic checklist, **642**
  differential diagnosis, **641**
  ectopic parathyroid tumor vs., **849**
  extraadrenal. *See* Pulmonary paraganglioma.
  histochemical features, **642**
  immunohistochemistry, **642**
  mediastinal, ectopic thyroid tumor vs., **855**
  metastatic to lung, pulmonary paraganglioma vs., **43**
  neuroendocrine carcinomas of thymus vs., **691**
  prognosis, **641**
  ultrastructural features, **642**

Mediastinal neoplasms, malignant, primary
- alveolar soft part sarcoma, **822-827**
  diagnostic checklist, **823**
  differential diagnosis, **823**
  histochemical features, **824**
  immunohistochemistry, **824**
  molecular features, **824**
  paraganglioma vs., **641**
  prognosis, **823**
- atypical thymoma, **666-675**
  diagnostic checklist, **667**
  differential diagnosis, **667**
  prognosis, **667**
- chordoma, **816-821**
  differential diagnosis, **817**
  epithelioid hemangioendothelioma vs., **807**
  metastatic, epithelioid hemangioendothelioma vs., **241**
  prognosis, **817**
- choriocarcinoma, **714-719**
  clinical staging of mediastinal germ cell tumors, **716**
  diagnostic checklist, **716**
  differential diagnosis, **715-716**
  histochemical features, **716**
  immunohistochemistry, **716**
  metastasis, from genital tract
    of gonadal origin, choriocarcinoma vs., **715**
    large cell (anaplastic) carcinoma vs., **141**
    pleomorphic carcinoma vs., **149**
  prognosis, **715**
- diffuse large cell lymphoma of mediastinum, **734-747**
  clear cell, **735**
  diagnostic checklist, **736**
  differential diagnosis, **736**
  diffuse large B-cell, with sclerosis, **736**
  genetic testing, **736**
  germinotropic, **735**
  Hodgkin lymphoma vs., **728**
  immunohistochemistry, **737**
  large B-cell, with Hodgkin-like or anaplastic large cell lymphoma-like features, **735-736**
  pleomorphic, **735**
  prognosis, **735**
  signet ring cell, **735**
  spindle cell, **735**
  unusual histologic features, **736**
- ectopic parathyroid tumor, **848-853**
  diagnostic checklist, **849-850**

differential diagnosis, **849**
histochemical features, **850**
immunohistochemistry, **850**
neuroendocrine carcinomas of thymus vs., **691**
paraganglioma vs., **641**
prognosis, **849**
ultrastructural features, **850**
- ectopic thyroid tumor, **854-857**
diagnostic checklist, **855**
differential diagnosis, **855**
- embryonal carcinoma, **720-725**
clinical staging of germ cell tumors of mediastinum, **722**
diagnostic checklist, **722**
differential diagnosis, **721-722**
histochemical features, **722**
immunohistochemistry, **722**
prognosis, **721**
yolk sac tumor vs., **709**
- ependymoma, **844-847**
diagnostic checklist, **845**
differential diagnosis, **845**
grading, **845**
immunohistochemistry, **845**
myxopapillary. *See* Ependymoma.
prognosis, **845**
- epithelioid hemangioendothelioma, **806-811**
chordoma vs., **817**
diagnostic checklist, **807**
differential diagnosis, **807**
histochemical features, **808**
immunohistochemistry, **808**
molecular features, **808**
prognosis, **807**
ultrastructural features, **808**
- ganglioneuroma, **834-837**
diagnostic checklist, **835**
differential diagnosis, **835**
immunohistochemistry, **835**
neuroblastoma/ganglioneuroblastoma vs., **839**
neurofibroma vs., **787**
- Hodgkin lymphoma of mediastinum, **726-733**
diagnostic checklist, **728**
differential diagnosis, **727-728**
immunohistochemistry, **728**
mediastinal diffuse large cell lymphoma vs., **736**
prognosis, **727**
- leiomyosarcoma, **768-773**
diagnostic checklist, **770**
differential diagnosis, **769-770**
immunohistochemistry, **770**
metastatic leiomyosarcoma vs., **769**
molecular features, **770**
prognosis, **769**
- liposarcoma, **758-767**
dedifferentiated, **759**
diagnostic checklist, **760**
differential diagnosis, **760**
genetic testing, **760**
metastatic, endobronchial lipoma vs., **19**
myxoid, **759**
pleomorphic, **759**
pleomorphic myxoid, **759**
prognosis, **759**
round cell, **759**
thymolipoma vs., **861**
well-differentiated, **759**
lipoma-like/atypical lipomatous tumor, **759**
- lymphoblastic lymphoma, **748-753**
diagnostic checklist, **750**
differential diagnosis, **750**
genetic testing, **749**
immunohistochemistry, **750**
intrapulmonary thymoma vs., **39**
rhabdomyosarcoma vs., **829**
thymoma vs., **653**
- MALT lymphoma of thymus, **754-757**
acquired multilocular thymic cyst vs., **877**
diagnostic checklist, **755**
differential diagnosis, **755**
prognosis, **755**
pulmonary BALT hyperplasia vs., **259**
- mediastinal seminoma, **702-707**
clinical staging of mediastinal germ cell tumors, **704**
diagnostic checklist, **703**
differential diagnosis, **703**
histological, histochemical, and molecular features, **704**
immunohistochemistry, **704**
mediastinal diffuse large cell lymphoma vs., **736**
prognosis, **703**
- mediastinal teratoma, **696-701**
diagnostic checklist, **697-698**
differential diagnosis, **697**
histological classification of, **698**
immature, **698**
immature teratoma, **698**
immunohistochemistry, **698**
malignant component, **698**
mature, **698**
prognosis, **697**
- mesenchymal chondrosarcoma, **812-815**
diagnostic checklist, **813**
differential diagnosis, **813**
genetic testing, **813**
prognosis, **813**
- neuroblastoma/ganglioneuroblastoma, **838-843**
diagnostic checklist, **839**
differential diagnosis, **839**
immunohistochemistry, **840**
molecular features, **840**
prognosis, **839**
- neuroendocrine carcinoma of thymus, **690-695**
diagnostic checklist, **691-692**
differential diagnosis, **691**
immunohistochemistry, **692**
prognosis, **691**
- neurofibroma, **786-789**
diagnostic checklist, **787**
differential diagnosis, **787**
ganglioneuroma vs., **835**

immunohistochemistry, **787**
peripheral nerve sheath tumor vs., **791**
prognosis, **787**
- overview of malignant thymic neoplasms, **648-649**
- peripheral nerve sheath tumors, **790-795**
diagnostic checklist, **792**
differential diagnosis, **791-792**
immunohistochemistry, **792**
molecular features, **792**
prognosis, **791**
solitary fibrous tumor vs., **798**
- rhabdomyosarcoma, **828-833**
alveolar, **829**
alveolar soft part sarcoma vs., **823**
carcinosarcoma vs., **167**
differential diagnosis, **829**
embryonal, **829**
ganglioneuroblastoma vs., **291**
genetic testing, **829**
neuroblastoma/ganglioneuroblastoma vs., **839**
pleomorphic, **829**
prognosis, **829**
- solitary fibrous tumor/fibrosarcoma, **796-805**
alternating hypo- and hypercellular areas, **797**
angiofibromatous pattern, **797**
benign metastasizing leiomyoma vs., **353**
calcified fibrous pseudotumor vs., **569**
dense hypercellular pattern, **797**
diagnostic checklist, **798**
differential diagnosis, **798**
epithelioid growth pattern, **797**
fascicular pattern, **797**
ganglioneuroma vs., **835**
hemangiopericytic pattern, **797**
herringbone pattern, **797**
immunohistochemistry, **798**
leiomyosarcoma vs., **223**
mesenchymal chondrosarcoma vs., **813**
neural-like growth pattern, **797**
neurogenic sarcoma vs., **229**
patternless pattern, **797**
prognosis, **797**
storiform pattern, **797**
unusual stromal changes, **797**
- synovial sarcoma, **774-785**
diagnostic checklist, **776**
differential diagnosis, **776**
mediastinal, monophasic spindle cell type, leiomyosarcoma vs., **769**
mesenchymal chondrosarcoma vs., **813**
prognosis, **775**
solitary fibrous tumor vs., **798**
- thymic carcinoma, **676-689**
- thymoma, **650-665**
- yolk sac tumor, **708-713**
diagnostic checklist, **710**
differential diagnosis, **709-710**
embryonal carcinoma vs., **721**
histological growth patterns, **710**
immunohistochemistry, **710**
prognosis, **709**

Mediastinal paraganglioma, ectopic thyroid tumor vs., **855**
Mediastinal seminoma, **702-707**
- clinical staging of mediastinal germ cell tumors, **704**
- diagnostic checklist, **703**
- differential diagnosis, **703**
- histological, histochemical, and molecular features, **704**
- immunohistochemistry, **704**
- mediastinal diffuse large cell lymphoma vs., **736**
- prognosis, **703**
Mediastinitis, idiopathic sclerosing, **884-887**
- diagnostic checklist, **885**
- differential diagnosis, **885**
- prognosis, **885**
Melanoma
- alveolar soft part sarcoma vs., **823**
- bronchial malignant, **294-297**. *See also* Bronchial malignant melanoma.
diagnostic checklist, **295**
differential diagnosis, **295**
immunohistochemistry, **295**
prognosis, **295**
- ganglioneuroblastoma vs., **291**
- granular cell tumor vs., **57**
- mediastinal seminoma vs., **703**
- metastatic
amelanotic, angiosarcoma vs., **597**
ependymoma vs., **845**
- metastatic malignant, **376-383**
differential diagnosis, **377**
diffuse large cell lymphoma vs., **269**
epithelioid melanoma, **377**
mediastinal diffuse large cell lymphoma vs., **736**
metastatic malignant solitary fibrous tumor (fibrosarcoma) vs., **609**
metastatic sarcoma vs., **367**
mixed spindle and epithelioid cell melanoma, **377**
pleomorphic melanoma, **377**
prognosis, **377**
rhabdoid melanoma, **377**
signet ring cell melanoma, **377**
small cell melanoma, **377**
spindle cell melanoma, **377**
- spindle cell, metastatic, solitary fibrous tumor vs., **560**
Meningioma
- malignant, **48**
pulmonary meningioma vs., **47**
- pulmonary, **46-51**
diagnostic checklist, **47**
differential diagnosis, **47**
grading, **48**
histochemical features, **48**
immunohistochemistry, **48**
molecular features, **48**
prognosis, **47**
Meningothelial-like nodule, minute pulmonary, **52-55**
- differential diagnosis, **53**
- pulmonary meningioma vs., **47**
Meningotheliomatosis, pulmonary meningioma vs., **47**
Mesenchymal chondrosarcoma, **812-815**
- diagnostic checklist, **813**
- differential diagnosis, **813**

- genetic testing, **813**
- prognosis, **813**

Mesenchymoma, benign. *See* Cartilaginous hamartoma.
Mesothelial hyperplasia, **554-557**
- diagnostic checklist, **555**
- differential diagnosis, **555**
- prognosis, **555**

Mesothelioma, malignant, **576-583**
- biphasic
  - pleural endometriosis vs., **627**
  - synovial sarcoma vs., **603, 776**
- diagnostic checklist, **578**
- differential diagnosis, **577-578**
- early stage, mesothelial hyperplasia vs., **555**
- epithelioid type
  - angiosarcoma vs., **597**
  - pseudomesotheliomatous adenocarcinoma vs., **585**
- fibrous. *See* Solitary fibrous tumor.
- histochemical features, **578**
- immunohistochemistry, **578**
- molecular features, **578**
- mucoepidermoid carcinoma of pleura vs., **591**
- prognosis, **577**
- sarcomatoid
  - calcified fibrous pseudotumor vs., **569**
  - malignant solitary fibrous tumor vs., **609**
  - smooth muscle tumors of pleura vs., **615**
  - solitary fibrous tumor vs., **559**
  - synovial sarcoma vs., **603**
- sclerosing hemangioma (pneumocytoma) vs., **61**

Metaplastic carcinoma. *See* Pleomorphic carcinoma.
Metastasizing leiomyoma, benign, **352-355**
- differential diagnosis, **353**
- prognosis, **353**

Metastatic calcification. *See also* Metastatic/dendriform calcification.
- alveolar microlithiasis vs., **465**

Metastatic carcinoma, **356-365**
- diagnostic checklist, **358**
- differential diagnosis, **357-358**
- epithelioid hemangioendothelioma vs., **241**
- immunohistochemistry, **358**
- of lung, thymic carcinoma vs., **678**
- metastatic models, **357**
- minute pulmonary meningothelial-like nodule vs., **53**
- patterns of growth, **357**
- prognosis, **357**
- yolk sac tumor vs., **709**

Metastatic chondrosarcoma, chondrosarcoma vs., **237**
Metastatic chordoma, epithelioid hemangioendothelioma vs., **241**
Metastatic choriocarcinoma, pleomorphic carcinoma vs., **149**
Metastatic leiomyosarcoma
- leiomyosarcoma vs., **769**
- smooth muscle tumors of pleura vs., **615**

Metastatic liposarcoma, endobronchial lipoma vs., **19**
Metastatic low-grade leiomyosarcoma, benign metastasizing leiomyoma vs., **353**
Metastatic malignant melanoma, **376-383**
- differential diagnosis, **377**
- diffuse large cell lymphoma vs., **269**
- epithelioid melanoma, **377**
- malignant solitary fibrous tumor (fibrosarcoma) vs., **609**
- mediastinal diffuse large cell lymphoma vs., **736**
- metastatic malignant solitary fibrous tumor (fibrosarcoma) vs., **609**
- metastatic sarcoma vs., **367**
- mixed spindle and epithelioid cell melanoma, **377**
- pleomorphic melanoma, **377**
- prognosis, **377**
- rhabdoid melanoma, **377**
- signet ring cell melanoma, **377**
- small cell melanoma, **377**
- spindle cell melanoma, **377**

Metastatic melanoma
- amelanotic, angiosarcoma vs., **597**
- ependymoma vs., **845**

Metastatic mucinous carcinoma
- chordoma vs., **817**
- extrathoracic origin, mucinous ("colloid") carcinoma vs., **95**

Metastatic mucoepidermoid carcinoma
- mucoepidermoid carcinoma of pleura vs., **591**
- mucoepidermoid carcinoma vs., **187**

Metastatic nasopharyngeal carcinoma, lymphoepithelioma-like carcinoma vs., **129**
Metastatic neuroendocrine carcinoma
- extrathoracic origin, neuroendocrine carcinoma vs., **155**
- neuroendocrine carcinomas of thymus vs., **691**
- pleural desmoplastic small round cell tumor vs., **621**

Metastatic osteogenic sarcoma, metastatic/dendriform calcification vs., **321**
Metastatic papillary carcinoma
- mesothelial hyperplasia vs., **555**
- of thyroid, sclerosing hemangioma (pneumocytoma) vs., **61**

Metastatic prostatic adenocarcinoma, endometrioid-like carcinoma vs., **109**
Metastatic sarcoma, **366-375**
- differential diagnosis, **367-368**
- epithelioid cell, **367**
- immunohistochemistry, **368**
- pleomorphic, **367**
- prognosis, **367**
- pulmonary artery sarcoma vs., **255**
- small round blue cell, **367**
- spindle cell sarcoma, **367**

Metastatic sarcomatoid renal cell carcinoma, malignant solitary fibrous tumor vs., **609**
Metastatic signet ring cell carcinoma, signet ring cell carcinoma vs., **103**
Metastatic spindle cell melanoma, solitary fibrous tumor vs., **560**
Metastatic spindle cell sarcomas, solitary fibrous tumor vs., **560**
Metastatic/dendriform calcification, **320-323**
- diagnostic checklist, **321**
- differential diagnosis, **321**
- prognosis, **321**

INDEX

Microlithiasis, alveolar, **464-467**. *See also* Alveolar microlithiasis.
- diagnostic checklist, **465**
- differential diagnosis, **465**
- histochemical features, **465**
- metastatic/dendriform calcification vs., **321**
- prognosis, **465**

Minute pulmonary chemodectoma. *See* Meningothelial-like nodule, minute pulmonary.
Minute pulmonary meningothelial-like nodule, **52-55**. *See also* Meningothelial-like nodule, minute pulmonary.
- differential diagnosis, **53**
- pulmonary meningioma vs., **47**

Mixed germ cell tumor
- choriocarcinoma vs., **716**
- embryonal carcinoma vs., **721**
- yolk sac tumor vs., **710**

Mixed tumor (pleomorphic adenoma), **206-211**
- benign, **207**
- diagnostic checklist, **207**
- differential diagnosis, **207**
- endobronchial lipoma vs., **19**
- epithelial-myoepithelial carcinoma vs., **193**
- grading, **207**
- malignant, **207**
- mucous gland adenoma vs., **13**
- myoepithelial carcinoma of lung vs., **213**
- prognosis, **207**

Moderately differentiated neuroendocrine carcinoma. *See* Thymus, neuroendocrine carcinoma of.
Monocytoid B-cell lymphoma. *See* MALT lymphoma of thymus.
Monophasic pulmonary blastoma, adenocarcinoma vs., **78**
Monophasic synovial sarcoma
- leiomyosarcoma vs., **223**
- neurogenic sarcoma vs., **229**
- pleural, solitary fibrous tumor vs., **559-560**

Mucinous carcinoma
- extrathoracic origin, metastatic, mucinous ("colloid") carcinoma vs., **95**
- metastatic, chordoma vs., **817**

Mucinous ("colloid") carcinoma, **94-101**
- diagnostic checklist, **95**
- differential diagnosis, **95**
- grading, **95**
- histochemical features, **96**
- immunohistochemistry, **96**
- molecular features, **96**
- prognosis, **95**

Mucinous cystadenoma. *See* Mucinous ("colloid") carcinoma.
Mucinous cystic tumor. *See* Mucinous ("colloid") carcinoma.
Mucinous type, bronchioloalveolar carcinoma, **89**
Mucoepidermoid carcinoma, **186-191**
- adenoid cystic carcinoma vs., **179**
- ciliated muconodular papillary tumor vs., **71**
- diagnostic checklist, **187-188**
- differential diagnosis, **187**
- grading, **188**
- histochemical features, **188**
- immunohistochemistry, **188**
- metastatic
  - mucoepidermoid carcinoma of pleura vs., **591**
  - mucoepidermoid carcinoma vs., **187**
- mixed tumor vs., **207**
- molecular features, **188**
- mucous gland adenoma vs., **13**
- pleural, **590-595**
  - diagnostic checklist, **591**
  - differential diagnosis, **591**
  - histochemical features, **592**
  - immunohistochemistry, **592**
  - molecular features, **592**
  - prognosis, **591**
- prognosis, **187**
- squamous cell carcinoma vs., **115**

Mucoepidermoid tumor. *See* Mucoepidermoid carcinoma.
Mucosa-associated lymphoid tissue (MALT) lymphoma. *See* MALT lymphoma of thymus.
Mucous gland adenoma, **12-17**
- diagnostic checklist, **14**
- differential diagnosis, **13-14**
- histochemical features, **14**
- immunohistochemistry, **14**
- molecular features, **14**
- mucoepidermoid carcinoma vs., **187**
- prognosis, **13**

Müllerian rests and proliferations, mesothelial hyperplasia vs., **555**
Multilocular cystic carcinoma. *See* Mucinous ("colloid") carcinoma.
Multilocular thymic cyst, acquired. *See* Thymic cyst, multilocular, acquired.
Muscle differentiation, lipomatous tumor with, leiomyosarcoma vs., **770**
Mycobacterial disease, atypical
- nocardiosis vs., **537**
- sporotrichosis vs., **529**

Mycobacterial infections
- dirofilariasis vs., **475**
- lipoid pneumonia vs., **325**
- sarcoidosis vs., **431**

Mycobacterial pneumonia, malakoplakia vs., **549**
Mycobacterium avium intracellulare (MAI) infection, malakoplakia vs., **549**
Myoblastoma. *See* Granular cell tumor.
Myoepithelial carcinoma of lung, **212-215**
- diagnostic checklist, **213**
- differential diagnosis, **213**
- prognosis, **213**

Myofibroblastic tumor. *See also* Inflammatory pseudotumor.
- inflammatory
  - IgG4 sclerosing lung disease vs., **305**
  - lymphoepithelioma-like carcinoma vs., **129**

Myxoid chondrosarcoma, epithelioid hemangioendothelioma vs., **807**
Myxopapillary ependymoma. *See* Ependymoma.

N

Nasopharyngeal carcinoma, metastatic, lymphoepithelioma-like carcinoma vs., **129**
Neuroblastoma, neuroblastoma/ganglioneuroblastoma vs., **839**
Neuroblastoma/ganglioneuroblastoma, **838-843**
- diagnostic checklist, **839**
- differential diagnosis, **839**
- immunohistochemistry, **840**
- molecular features, **840**
- prognosis, **839**

Neuroendocrine carcinoma, **154-165**
- bronchial, granular cell tumor vs., **57**
- bronchial malignant melanoma vs., **295**
- diagnostic checklist, **156**
- differential diagnosis, **155-156**
- ectopic thyroid tumor vs., **855**
- ependymoma vs., **845**
- ganglioneuroblastoma vs., **291**
- grading, **156**
- high-grade neuroendocrine carcinoma vs., **155**
- immunohistochemistry, **156**
- intermediate-grade, **156**
  - neuroendocrine carcinoma vs., **155**
- large cell, **155**
  - poorly differentiated small cell variant squamous carcinoma vs., **135**
  - squamous cell carcinoma vs., **115**
- low-grade neuroendocrine carcinoma vs., **155**
- mediastinal, thymoma vs., **653**
- metastatic
  - extrathoracic origin, neuroendocrine carcinoma vs., **155**
  - neuroendocrine carcinomas of thymus vs., **691**
- moderately differentiated, poorly differentiated small cell variant squamous carcinoma vs., **135**
- molecular features, **156**
- oncocytic variant, acinic cell carcinoma vs., **199**
- prognosis, **155**
- pulmonary
  - metastatic, pleural desmoplastic small round cell tumor vs., **621**
  - well-differentiated, paraganglioma vs., **641**
- small cell, poorly differentiated small cell variant squamous carcinoma vs., **135**
- of thymus, **690-695**
  - diagnostic checklist, **691-692**
  - differential diagnosis, **691**
  - immunohistochemistry, **692**
  - prognosis, **691**
  - thymic neuroendocrine carcinomas
    - classification of, **692**
    - histological classification, **692**
- well-differentiated
  - ectopic parathyroid tumor vs., **849**
  - pulmonary meningioma vs., **47**
  - pulmonary paraganglioma vs., **43**

Neuroendocrine pulmonary "tumorlet," minute pulmonary meningothelial-like nodule vs., **53**
Neurofibroma, **786-789**
- diagnostic checklist, **787**
- differential diagnosis, **787**
- ganglioneuroma vs., **835**
- immunohistochemistry, **787**
- peripheral nerve sheath tumor vs., **791**
- prognosis, **787**

Neurofibrosarcoma. *See also* Peripheral nerve sheath tumors.
- neurofibroma vs., **787**

Neurogenic sarcoma, **228-231**. *See also* Peripheral nerve sheath tumors.
- bronchial malignant melanoma vs., **295**
- differential diagnosis, **229**
- genetic testing, **229**
- prognosis, **229**

Niemann-Pick disease, malakoplakia vs., **549**
Nocardiosis, **536-537**
- actinomycosis vs., **539**
- botryomycosis vs., **547**
- diagnostic checklist, **537**
- differential diagnosis, **537**
- histochemical features, **537**
- prognosis, **537**

Nodular lymphoid hyperplasia. *See* Pulmonary BALT hyperplasia.
Non-Hodgkin lymphoma, angiolymphoid hyperplasia with eosinophilia vs., **337**
Non-small cell carcinoma, mixed tumor vs., **207**
Nonspecific interstitial pneumonia. *See* Interstitial pneumonia, nonspecific.
North American blastomycosis. *See* Blastomycosis.

O

Oncocytic carcinoma, extrathoracic origin, adenocarcinoma vs., **78**
Organizing diffuse alveolar damage, bronchiolitis obliterans with organizing pneumonia vs., **391**
Osteogenic sarcoma. *See also* Osteosarcoma.
- metastatic, metastatic/dendriform calcification vs., **321**

Osteosarcoma, **232-235**
- carcinosarcoma vs., **167**
- diagnostic checklist, **233**
- differential diagnosis, **233**
- prognosis, **233**

P

Papillary carcinoma
- metastatic
  - mesothelial hyperplasia vs., **555**
  - of thyroid, sclerosing hemangioma (pneumocytoma) vs., **61**
- placental transmogrification vs., **329**
- of thyroid origin, adenocarcinoma vs., **78**

Papillary tumor, ciliated muconodular, **70-71**
- diagnostic checklist, **71**
- differential diagnosis, **71**
- probable benign neoplastic proliferation, **71**
- prognosis, **71**

Paraffinoma, **324-327**. *See also* Lipoid pneumonia (paraffinoma).
- diagnostic checklist, **325**
- differential diagnosis, **325**
- histochemical features, **325**

Parafollicular B-cell lymphoma. *See* MALT lymphoma of thymus.

Paraganglioma, **640-645**
- alveolar soft part sarcoma vs., **823**
- diagnostic checklist, **642**
- differential diagnosis, **641**
- ectopic parathyroid tumor vs., **849**
- extraadrenal. *See* Pulmonary paraganglioma.
- histochemical features, **642**
- immunohistochemistry, **642**
- mediastinal, ectopic thyroid tumor vs., **855**
- metastatic to lung, pulmonary paraganglioma vs., **43**
- neuroendocrine carcinomas of thymus vs., **691**
- prognosis, **641**
- pulmonary, **42-45**
  - diagnostic checklist, **43**
  - differential diagnosis, **43**
  - neuroendocrine carcinoma vs., **155**
  - prognosis, **43**
- ultrastructural features, **642**

Paragonimiasis, **486-489**
- diagnostic checklist, **487**
- differential diagnosis, **487**
- prognosis, **487**

Parainfluenza virus infection, measles pneumonia vs., **525**

Parasitic disorders of lung
- dirofilariasis, **474-477**
  - diagnostic checklist, **475**
  - differential diagnosis, **475**
  - echinococcosis (hydatid cyst) vs., **483**
  - eosinophilic pneumonia vs., **453**
  - prognosis, **475**
- echinococcosis (hydatid cyst), **482-485**
  - diagnostic checklist, **483**
  - differential diagnosis, **483**
  - prognosis, **483**
- paragonimiasis, **486-489**
  - diagnostic checklist, **487**
  - differential diagnosis, **487**
  - prognosis, **487**
- schistosomiasis, **478-481**
  - diagnostic aids, **479**
  - diagnostic checklist, **479**
  - differential diagnosis, **479**
  - echinococcosis (hydatid cyst) vs., **483**
  - paragonimiasis vs., **487**
  - prognosis, **479**
- strongyloidiasis, **470-473**
  - differential diagnosis, **471**
  - dirofilariasis vs., **475**
  - echinococcosis (hydatid cyst) vs., **483**
  - histochemical features, **471**
  - identification, diagnostic methods, **471**
  - indirect infection, **471**

Parasitic hemoptysis. *See* Paragonimiasis.

Parasitic infections
- angiolymphoid hyperplasia with eosinophilia vs., **337**
- echinococcosis (hydatid cyst) vs., **483**
- strongyloidiasis vs., **471**

Parathyroid tumor, ectopic, **848-853**
- diagnostic checklist, **849-850**
- differential diagnosis, **849**
- histochemical features, **850**
- immunohistochemistry, **850**
- neuroendocrine carcinomas of thymus vs., **691**
- paraganglioma vs., **641**
- ultrastructural features, **850**

PEComa. *See* Clear cell sugar tumor (PEComa).

Peripheral nerve sheath tumors, **790-795**
- diagnostic checklist, **792**
- differential diagnosis, **791-792**
- immunohistochemistry, **792**
- malignant
  - malignant solitary fibrous tumor vs., **609**
  - solitary fibrous tumor vs., **217**
  - synovial sarcoma vs., **776**
- molecular features, **792**
- prognosis, **791**
- smooth muscle tumors of pleura vs., **615**
- solitary fibrous tumor vs., **798**

Peripheral neuroectodermal tumor, desmoplastic small round cell tumor vs., **621**

Placental transmogrification, **328-331**
- diagnostic checklist, **329**
- differential diagnosis, **329**
- prognosis, **329**

Plasmacytoma, **280-283**
- diagnostic checklist, **281**
- differential diagnosis, **281**
- immunohistochemistry, **281**
- inflammatory pseudotumor vs., **299**
- prognosis, **281**

Pleomorphic adenoma. *See also* Mixed tumor (pleomorphic adenoma).
- cartilaginous hamartoma vs., **5**
- endobronchial lipoma vs., **19**
- epithelial-myoepithelial carcinoma vs., **193**
- mucous gland adenoma vs., **13**

Pleomorphic carcinoma, **148-153**. *See also* Large cell (anaplastic) carcinoma.
- diagnostic checklist, **149**
- differential diagnosis, **149**
- histochemical features, **150**
- immunohistochemistry, **150**
- leiomyosarcoma vs., **223**
- of lung origin, choriocarcinoma vs., **715**
- lymphoepithelioma-like carcinoma vs., **129**
- molecular features, **150**
- prognosis, **149**
- spindle cell (sarcomatoid) carcinoma vs., **123**

Pleomorphic sarcoma
- high-grade
  metastatic malignant melanoma vs., **377**
  solitary fibrous tumor vs., **798**
- undifferentiated, large cell (anaplastic) carcinoma vs., **141**

Pleura, smooth muscle tumors, **614-619**
- diagnostic checklist, **615**
- differential diagnosis, **615**
- grading, **616**
- immunohistochemistry, **616**
- molecular features, **616**
- prognosis, **615**

Pleural endometriosis, **626-629**
- diagnostic checklist, **627**
- differential diagnosis, **627**
- mesothelial hyperplasia vs., **555**
- prognosis, **627**

Pleural fibrosarcoma. *See* Solitary fibrous tumor.

Pleural monophasic synovial sarcoma, solitary fibrous tumor vs., **559-560**

Pleural mucoepidermoid carcinoma. *See* Mucoepidermoid carcinoma, pleural.

Pleural neoplasms, benign
- calcified fibrous pseudotumor, **568-571**
  diagnostic checklist, **569**
  differential diagnosis, **569**
  prognosis, **569**
- mesothelial hyperplasia, **554-557**
  diagnostic checklist, **555**
  differential diagnosis, **555**
  prognosis, **555**
- solitary fibrous tumor, **558-567**
  diagnostic checklist, **560**
  differential diagnosis, **559-560**
  genetic testing, **559**
  histologic growth patterns, **560**
  immunohistochemistry, **560**
  prognosis, **559**

Pleural neoplasms, malignant, **574-575**
- molecular genetic alterations, **575**
- primary, **574**
- prognostic factors, **575**
- secondary, **574**
- staging, **575**

Pleural neoplasms, malignant, primary
- angiosarcoma, **596-601**
  diagnostic checklist, **597**
  differential diagnosis, **597**
  prognosis, **597**
- desmoplastic small round cell tumor, **620-623**
  diagnostic checklist, **621**
  differential diagnosis, **621**
  genetic testing, **621**
  prognosis, **621**
- malignant mesothelioma, **576-583**
  biphasic, synovial sarcoma vs., **603**
  diagnostic checklist, **578**
  differential diagnosis, **577-578**
  early stage, mesothelial hyperplasia vs., **555**
  epithelioid, angiosarcoma vs., **597**
  growth patterns, **577**
  histochemical features, **578**
  immunohistochemistry, **578**
  molecular features, **578**
  prognosis, **577**
  sarcomatoid
    smooth muscle tumors of pleura vs., **615**
    synovial sarcoma vs., **603**
- malignant pleural neoplasms, **574-575**
  molecular genetic alterations, **575**
  primary, **574**
  prognostic factors, **575**
  secondary, **574**
  staging, **575**
- malignant solitary fibrous tumor (fibrosarcoma), **608-613**
  diagnostic checklist, **609**
  differential diagnosis, **609**
  prognosis, **609**
  synovial sarcoma vs., **603**
- mucoepidermoid carcinoma of pleura, **590-595**
  diagnostic checklist, **591**
  differential diagnosis, **591**
  histochemical features, **592**
  immunohistochemistry, **592**
  molecular features, **592**
  prognosis, **591**
- pseudomesotheliomatous adenocarcinoma, **584-589**
  diagnostic checklist, **585**
  differential diagnosis, **585**
  histochemical features, **586**
  immunohistochemistry, **586**
  molecular features, **586**
  prognosis, **585**
- smooth muscle tumors of pleura, **614-619**
  diagnostic checklist, **615**
  differential diagnosis, **615**
  grading, **616**
  immunohistochemistry, **616**
  molecular features, **616**
  prognosis, **615**
- synovial sarcoma, **602-607**

Pleuropulmonary blastoma
- pleural endometriosis vs., **627**
- pulmonary blastoma vs., **173**

Pneumoconiosis pneumonitis, hard metal, **434-437**
- diagnostic checklist, **435**
- differential diagnosis, **435**
- prognosis, **435**

Pneumocystic pneumonia
- alveolar proteinosis vs., **445**
- amyloid tumor vs., **317**

Pneumocystosis, **500-503**
- differential diagnosis, **501**
- histoplasmosis vs., **507**

Pneumocystosis pneumonia. *See* Pneumocystosis.

Pneumocytic adenomyoepithelioma. *See* Epithelial-myoepithelial carcinoma.

Pneumocytoma, **60-65**. *See also* Sclerosing hemangioma (pneumocytoma).
- diagnostic checklist, **61**

- differential diagnosis, **61**
- histochemical features, **62**
- histogenesis, **61**
- immunohistochemistry, **62**
- prognosis, **61**
- ultrastructural features, **62**

Pneumonia
- bacterial
  Klebsiella pneumonia vs., **531**
  nocardiosis vs., **537**
  sporotrichosis vs., **529**
- cryptogenic organizing. *See* Bronchiolitis obliterans with organizing pneumonia.
- infectious, hard metal pneumoconiosis pneumonitis vs., **435**
- *Klebsiella* pneumonia, **530-533**. *See also Klebsiella* pneumonia.
  diagnostic checklist, **531**
  differential diagnosis, **531**
  prognosis, **531**
- lipoid, **324-327**
  diagnostic checklist, **325**
  differential diagnosis, **325**
  histochemical features, **325**
- measles pneumonia, **524-527**. *See also* Measles pneumonia.
  differential diagnosis, **525**
  prognosis, **525**
- mycobacterial, malakoplakia vs., **549**
- placental transmogrification vs., **329**
- plasmacytoma vs., **281**
- pneumocystic, amyloid tumor vs., **317**
- pneumocystis. *See* Pneumocystosis.
- pneumocystosis. *See* Pneumocystosis.
- respiratory bronchiolitis vs., **395**
- SARS, **534-535**
  diagnostic checklist, **535**
  differential diagnosis, **535**
  prognosis, **535**
- viral, cytomegalovirus vs., **519**

Pneumonia, eosinophilic, **452-455**
- allergic angiitis and granulomatosis vs., **419**
- angiolymphoid hyperplasia with eosinophilia vs., **337**
- diagnostic checklist, **453**
- differential diagnosis, **453**
- Langerhans cell histiocytosis vs., **457**
- prognosis, **453**
- respiratory bronchiolitis vs., **395**

Pneumonia, interstitial, desquamative, **406-409**
- diagnostic checklist, **407**
- differential diagnosis, **407**
- prognosis, **407**

Pneumonia, interstitial, lymphoid, nonspecific interstitial pneumonia vs., **411**

Pneumonia, interstitial, nonspecific, **410-413**
- cellular pattern, **411**
- diagnostic checklist, **411**
- differential diagnosis, **411**
- fibrosing pattern, **411**
- prognosis, **411**

Pneumonia, interstitial, usual, **398-405**
- conditions associated, **399**
- desquamative interstitial pneumonia vs., **407**
- diagnostic checklist, **399**
- nonspecific interstitial pneumonia vs., **411**
- prognosis, **399**

Pneumonitis
- fibrous, eosinophilic pneumonia vs., **453**
- interstitial desquamative
  asbestos-related interstitial fibrosis vs., **439**
  hard metal pneumoconiosis pneumonitis vs., **435**
  respiratory bronchiolitis vs., **395**
- interstitial usual
  asbestos-related interstitial fibrosis vs., **439**
  bronchiolitis obliterans with organizing pneumonia vs., **391**

Polygonal cell thymoma. *See* Atypical thymoma.

Polyphenotypic small round cell tumor. *See* Desmoplastic small round cell tumor.

Poorly differentiated carcinomas, osteosarcoma vs., **233**

Poorly differentiated neuroendocrine carcinoma. *See* Thymus, neuroendocrine carcinoma of.

Poorly differentiated squamous carcinoma, small cell variant, **134-139**
- diagnostic checklist, **135**
- differential diagnosis, **135**

Poorly differentiated (high-grade) thymic epithelial neoplasm. *See* Thymic carcinoma.

Postperfusion lung. *See* Diffuse alveolar damage.

Precursor lymphocytes, lymphoma of. *See* Lymphoblastic lymphoma.

Primary carcinoma of soft tissue. *See* Synovial sarcoma.

Primary intrapulmonary sarcoma, pulmonary artery sarcoma vs., **255**

Primary lung sarcoma, metastatic sarcoma vs., **367**

Primary pulmonary marginal zone lymphoma, pulmonary BALT hyperplasia vs., **259**

Primary thymic epithelial neoplasm. *See* Thymoma.

Primitive neuroectodermal tumor (PNET). *See* Ewing sarcoma/primitive neuroectodermal tumor (PNET).

Proteinosis, alveolar, **444-447**
- diagnostic checklist, **445**
- differential diagnosis, **445**
- histochemical features, **445**
- immunohistochemistry, **445**
- prognosis, **445**
- pulmonary amyloidosis vs., **449**

Pseudallescheria boydii infection, aspergillosis vs., **542**

Pseudolymphoma. *See* Pulmonary BALT hyperplasia.

Pseudomesotheliomatous adenocarcinoma, **584-589**
- diagnostic checklist, **585**
- differential diagnosis, **585**
- histochemical features, **586**
- immunohistochemistry, **586**
- molecular features, **586**
- prognosis, **585**

Pseudosarcomatous carcinoma. *See* Pleomorphic carcinoma; Spindle cell (sarcomatoid) carcinoma.

Pseudotumor
- calcified fibrous, **568-571**
  diagnostic checklist, **569**
  differential diagnosis, **569**
  prognosis, **569**
- inflammatory, **298-303**. *See also* Mediastinitis, idiopathic sclerosing.
  bronchiolitis obliterans with organizing pneumonia vs., **391**
  calcified fibrous pseudotumor vs., **569**
  diagnostic checklist, **300**
  differential diagnosis, **299**
  hyalinizing granuloma vs., plasma cell type, **313**
  IgG4 sclerosing lung disease vs., **305**
  immunohistochemistry, **300**
  molecular findings, **300**
  plasmacytoma vs., plasma cell type, **281**
  prognosis, **299**
  sclerosing hemangioma (pneumocytoma) vs., **61**

Pulmonary adenofibroma/adenomyoma, **22-25**
- differential diagnosis, **23**
- prognosis, **23**

Pulmonary alveolar proteinosis. *See* Alveolar proteinosis.

Pulmonary amyloidosis, **448-451**
- diagnostic checklist, **449**
- differential diagnosis, **449**
- prognosis, **449**

Pulmonary artery sarcoma, **254-257**
- diagnostic checklist, **255**
- differential diagnosis, **255**
- immunohistochemistry, **255**
- prognosis, **255**

Pulmonary BALT hyperplasia, **258-261**
- differential diagnosis, **259**
- follicular bronchiolitis, **259**
- genetic testing, **259**
- nodular lymphoid hyperplasia, **259**
- prognosis, **259**

Pulmonary BALT lymphoma, **262-267**
- differential diagnosis, **263**
- genetic testing, **263**
- prognosis, **263**

Pulmonary blastoma, **172-177**
- biphasic
  pleural endometriosis vs., **627**
  pulmonary adenofibroma/adenomyoma vs., **23**
- diagnostic checklist, **173-174**
- differential diagnosis, **173**
- endometrioid-like carcinoma vs., **109**
- histochemical features, **174**
- immunohistochemistry, **174**
- metastatic sarcoma vs., **368**
- molecular features, **174**
- prognosis, **173**
- synovial sarcoma vs., **776**

Pulmonary carcinosarcoma
- metastatic sarcoma vs., **368**
- pulmonary adenofibroma/adenomyoma vs., **23**

Pulmonary chemodectoma. *See* Pulmonary paraganglioma.

Pulmonary chondroma, metastatic/dendriform calcification vs., **321**

Pulmonary distomiasis. *See* Paragonimiasis.

Pulmonary embryoma. *See* Pulmonary blastoma.

Pulmonary fibroadenoma. *See* Pulmonary adenofibroma/adenomyoma.

Pulmonary fibrosis, idiopathic. *See* Interstitial pneumonia, usual.

Pulmonary ganglioneuroblastoma. *See* Ganglioneuroblastoma.

Pulmonary hamartoma, mixed tumor vs., **207**

Pulmonary hemorrhage, capillary hemangiomatosis vs., **347**

Pulmonary hemosiderosis, idiopathic, **442-443**
- diagnostic checklist, **443**
- differential diagnosis, **443**
- prognosis, **443**

Pulmonary hyalinizing granuloma. *See* Hyalinizing granuloma.

Pulmonary hypertension, schistosomiasis vs., **479**

Pulmonary invasive adenocarcinoma, bronchioloalveolar carcinoma vs., **89**

Pulmonary juvenile xanthogranuloma. *See* Juvenile xanthogranuloma.

Pulmonary leiomyosarcoma. *See also* Leiomyosarcoma.
- pleomorphic carcinoma vs., **149**

Pulmonary lipomatosis. *See* Placental transmogrification.

Pulmonary malignant melanoma. *See* Bronchial malignant melanoma.

Pulmonary meningioma, **46-51**
- diagnostic checklist, **47**
- differential diagnosis, **47**
- grading, **48**
- histochemical features, **48**
- immunohistochemistry, **48**
- molecular features, **48**
- prognosis, **47**

Pulmonary microlithiasis. *See* Alveolar microlithiasis.

Pulmonary paraganglioma, **42-45**
- diagnostic checklist, **43**
- differential diagnosis, **43**
- neuroendocrine carcinoma vs., **155**
- prognosis, **43**

Pulmonary scar, amyloid tumor vs., **317**

Pulmonary tuberculosis
- *Klebsiella* pneumonia vs., **531**
- schistosomiasis vs., **479**

R

Reactive bronchioloalveolar cell hyperplasia, atypical adenomatous hyperplasia vs., **341**

Reactive follicular hyperplasia, Castleman disease vs., **865**

Renal cell carcinoma
- clear cell sugar tumor (PEComa) vs., **67**
- metastatic
  metastatic malignant melanoma vs., **377**
  sarcomatoid, malignant solitary fibrous tumor vs., **609**

- metastatic carcinoma vs., **357-358**
Respiratory bronchiolitis, **394-397**
- diagnostic checklist, **395**
- differential diagnosis, **395**
- prognosis, **395**
Respiratory bronchiolitis-interstitial lung disease. *See* Respiratory bronchiolitis.
Respiratory distress syndrome, acute. *See* Diffuse alveolar damage.
Respiratory syncytial virus infection, measles pneumonia vs., **525**
Rhabdoid carcinoma. *See* Large cell (anaplastic) carcinoma.
Rhabdomyosarcoma, **828-833**
- alveolar, **829**
- alveolar soft part sarcoma vs., **823**
- carcinosarcoma vs., **167**
- differential diagnosis, **829**
- embryonal, **829**
- ganglioneuroblastoma vs., **291**
- genetic testing, **829**
- neuroblastoma/ganglioneuroblastoma vs., **839**
- pleomorphic, **829**
- prognosis, **829**
Rosai-Dorfman disease, **332-335**
- diagnostic checklist, **333**
- differential diagnosis, **333**
- Erdheim-Chester disease vs., **461**
- IgG4 sclerosing lung disease vs., **305**
- immunohistochemistry, **333**
- lipoid pneumonia vs., **325**
- of lung, juvenile xanthogranuloma vs., **309**
- malakoplakia vs., **549**
- prognosis, **333**

S

Salivary gland-type tumors
- adenoid cystic carcinoma, epithelial-myoepithelial carcinoma vs., **193**
- late metastases, myoepithelial carcinoma of lung vs., **213**
- of lung, myoepithelial carcinoma of lung vs., **213**
San Joaquin Valley fever. *See* Coccidioidomycosis.
Sarcoidosis, **430-433**
- bronchocentric granulomatosis vs., **423**
- differential diagnosis, **431**
- extrinsic allergic alveolitis vs., **415**
- genetic predisposition, **431**
Sarcoma
- alveolar soft part, **822-827**
  diagnostic checklist, **823**
  differential diagnosis, **823**
  histochemical features, **824**
  immunohistochemistry, **824**
  molecular features, **824**
  paraganglioma vs., **641**
  prognosis, **823**
- angiosarcoma, **246-249, 596-601**
  capillary hemangiomatosis vs., **347**
  carcinosarcoma vs., **167**
  diagnostic checklist, **247, 597**
  differential diagnosis, **247, 597**
  epithelioid hemangioendothelioma vs., **241, 807**
  immunohistochemistry, **247**
  metastatic, angiosarcoma vs., **247**
  prognosis, **247, 597**
- carcinosarcoma vs., **167**
  chondrosarcoma vs., **237**
  diagnostic checklist, **167**
  differential diagnosis, **167**
  histochemical features, **168**
  immunohistochemistry, **168**
  leiomyosarcoma vs., **223**
  mixed tumor vs., **207**
  molecular features, **168**
  osteosarcoma vs., **233**
  prognosis, **167**
  pulmonary blastoma vs., **173**
  pulmonary, metastatic sarcoma vs., **368**
  thymic, synovial sarcoma vs., **776**
- chondrosarcoma, **236-239**
  carcinosarcoma vs., **167**
  diagnostic checklist, **237**
  differential diagnosis, **237**
  extraskeletal myxoid, chordoma vs., **817**
  metastatic, chondrosarcoma vs., **237**
  myxoid, epithelioid hemangioendothelioma vs., **807**
  osteosarcoma vs., **233**
  primary or metastatic, cartilaginous hamartoma vs., **5**
  prognosis, **237**
  well-differentiated, mediastinal chordoma vs., **817**
- epithelioid cell, metastatic malignant melanoma vs., **377**
- Ewing sarcoma/primitive neuroectodermal tumor
  desmoplastic small round cell tumor vs., **621**
  mesenchymal chondrosarcoma vs., **813**
  rhabdomyosarcoma vs., **829**
- extraskeletal Ewing, peripheral nerve sheath tumor vs., **792**
- fibrosarcoma, **608-613**
  diagnostic checklist, **609**
  differential diagnosis, **609**
  Kaposi sarcoma vs., **251**
  mediastinal. *See* Solitary fibrous tumor.
  prognosis, **609**
- glomangiosarcoma, glomus tumor vs., **35**
- hemangiosarcoma. *See* Angiosarcoma.
- high-grade
  liposarcoma vs., **760**
  pleomorphic, metastatic malignant melanoma vs., **377**
- inflammatory pseudotumor vs., **299**
- Kaposi sarcoma, **250-253**
  diagnostic checklist, **251**
  differential diagnosis, **251**
  prognosis, **251**
- leiomyosarcoma, **222-227, 768-773**. *See also* Smooth muscle tumors of pleura.
  diagnostic checklist, **223, 770**
  differential diagnosis, **223, 769-770**
  grading, **224**
  immunohistochemistry, **224, 770**

Kaposi sarcoma vs., **251**
low-grade metastatic, benign metastasizing leiomyoma vs., **353**
lymphangioleiomyomatosis vs., **343**
molecular features, **224, 770**
peripheral nerve sheath tumor vs., **791**
prognosis, **223, 769**
pulmonary ,pleomorphic carcinoma vs., **149**
spindle cell (sarcomatoid) carcinoma vs., **123**
- liposarcoma. *See* Liposarcoma.
- malignant mesothelioma vs., **577-578**
- mediastinal diffuse large cell lymphoma vs., **736**
- mediastinal teratoma vs., **697**
- mesenchymal chondrosarcoma, **812-815**
diagnostic checklist, **813**
differential diagnosis, **813**
genetic testing, **813**
prognosis, **813**
- metastatic, **366-375**
differential diagnosis, **367-368**
epithelioid cell, **367**
immunohistochemistry, **368**
to lung, pulmonary adenofibroma/adenomyoma vs., **23**
pleomorphic, **367**
prognosis, **367**
pulmonary artery sarcoma vs., **255**
small round blue cell, **367**
spindle cell sarcoma, **367**
- neurofibrosarcoma. *See* Peripheral nerve sheath tumors.
- neurogenic sarcoma, **228-231**. *See also* Peripheral nerve sheath tumors.
bronchial malignant melanoma vs., **295**
differential diagnosis, **229**
genetic testing, **229**
prognosis, **229**
- osteosarcoma, **232-235**
carcinosarcoma vs., **167**
diagnostic checklist, **233**
differential diagnosis, **233**
prognosis, **233**
- pleomorphic
high-grade
metastatic malignant melanoma vs., **377**
solitary fibrous tumor vs., **798**
undifferentiated, large cell (anaplastic) carcinoma vs., **141**
- pleural monophasic synovial, solitary fibrous tumor vs., **559-560**
- pleural synovial, malignant solitary fibrous tumor vs., **609**
- primary intrapulmonary, pulmonary artery sarcoma vs., **255**
- primary, of lung, metastatic sarcoma vs., **367**
- pseudosarcomatous carcinoma. *See* Spindle cell (sarcomatoid) carcinoma.
- pulmonary artery sarcoma, **254-257**
diagnostic checklist, **255**
differential diagnosis, **255**
immunohistochemistry, **255**
prognosis, **255**
- pulmonary blastoma vs., **173**
- rhabdomyosarcoma, **828-833**
alveolar, **829**
alveolar soft part sarcoma vs., **823**
carcinosarcoma vs., **167**
differential diagnosis, **829**
embryonal, **829**
ganglioneuroblastoma vs., **291**
genetic testing, **829**
neuroblastoma/ganglioneuroblastoma vs., **839**
pleomorphic, **829**
prognosis, **829**
- sarcomatoid, metastatic malignant melanoma vs., **377**
- spindle cell
high grade, mediastinal chordoma vs., **817**
metastatic malignant melanoma vs., **377**
metastatic, solitary fibrous tumor vs., **560**
of soft tissue, metastatic, malignant solitary fibrous tumor (fibrosarcoma) vs., **609**
- spindle cell (sarcomatoid) carcinoma, **122-127**
diagnostic checklist, **123**
differential diagnosis, **123**
histochemical features, **124**
immunohistochemistry, **124**
molecular features, **124**
prognosis, **123**
- squamous cell carcinoma vs., **115**
- synovial, **602-607, 774-785**
diagnostic checklist, **603, 776**
differential diagnosis, **603, 776**
genetic testing, **603, 776**
intrapulmonary, **216-221**
differential diagnosis, **217**
genetic testing, **217**
intrapulmonary solitary fibrous tumor vs., **27**
metastasis from, peripheral soft tissues vs., **217**
prognosis, **217**
intrapulmonary solitary fibrous tumor vs., **27**
mesenchymal chondrosarcoma vs., **813**
monophasic type, smooth muscle tumors of pleura vs., **615**
mucoepidermoid carcinoma of pleura vs., **591**
prognosis, **603, 775**
of soft tissue, metastatic to mediastinum, synovial sarcoma vs., **776**
- thymic carcinosarcoma, mediastinal synovial sarcoma vs., **776**
- yolk sac tumor vs., **709-710**

Sarcomatoid (spindle cell) carcinoma. *See also* Spindle cell (sarcomatoid) carcinoma.
- intrapulmonary thymoma vs., **39**
- leiomyosarcoma vs., **223**
- of lung
inflammatory pseudotumor vs., **299**
metastatic sarcoma vs., **367-368**
- metastatic malignant melanoma vs., **377**
- pleomorphic carcinoma vs., **149**
- smooth muscle tumors of pleura vs., **615**

Sarcomatoid malignant mesothelioma
- solitary fibrous tumor vs., **798**
- synovial sarcoma vs., **603**

Sarcomatoid mesothelioma
- calcified fibrous pseudotumor vs., **569**
- malignant solitary fibrous tumor vs., **609**
- solitary fibrous tumor vs., **559**

SARS pneumonia, **534-535**
- diagnostic checklist, **535**
- differential diagnosis, **535**
- prognosis, **535**

Schistosomiasis, **478-481**
- diagnostic aids, **479**
- diagnostic checklist, **479**
- differential diagnosis, **479**
- echinococcosis (hydatid cyst) vs., **483**
- paragonimiasis vs., **487**
- prognosis, **479**

Schwannoma
- benign metastasizing leiomyoma vs., **353**
- ependymoma vs., **845**
- ganglioneuroma vs., **835**
- malignant. *See* Neurogenic sarcoma; Peripheral nerve sheath tumors.
- neurofibroma vs., **787**
- peripheral nerve sheath tumor vs., **791**

Sclerosing hemangioma (pneumocytoma), **60-65**
- diagnostic checklist, **61**
- differential diagnosis, **61**
- histochemical features, **62**
- histogenesis, **61**
- immunohistochemistry, **62**
- prognosis, **61**
- ultrastructural features, **62**

Sclerosing lung disease, IgG4, **304-307**
- bronchovascular pattern of involvement, **305**
- differential diagnosis, **305**
- inflammatory pseudotumor-like, **305**
- interstitial fibrosis-like, **305**
- prognosis, **305**

Sclerosing mediastinitis, idiopathic, **884-887**
- diagnostic checklist, **885**
- differential diagnosis, **885**
- hyalinizing granuloma vs., **313**
- prognosis, **885**

Secondary fibrosis, seminoma, idiopathic sclerosing mediastinitis vs., **885**

Secretory carcinoma, mammary analog, acinic cell carcinoma vs., **199**

Seminoma
- cystic, acquired multilocular thymic cyst vs., **877**
- embryonal carcinoma vs., **721**
- epithelioid hemangioendothelioma vs., **807**
- mediastinal, **702-707**
  - clinical staging of mediastinal germ cell tumors, **704**
  - diagnostic checklist, **703**
  - differential diagnosis, **703**
  - histological, histochemical, and molecular features, **704**
  - immunohistochemistry, **704**
  - mediastinal diffuse large cell lymphoma vs., **736**
  - prognosis, **703**
- metastatic from testicular origin, mediastinal seminoma vs., **703**
- secondary fibrosis, idiopathic sclerosing mediastinitis vs., **885**

Severe acute respiratory syndrome. *See* SARS pneumonia.

Shock lung. *See* Diffuse alveolar damage.

Signet ring cell carcinoma, **102-107**
- diagnostic checklist, **103**
- differential diagnosis, **103**
- histochemical features, **104**
- immunohistochemistry, **104**
- metastatic, signet ring cell carcinoma vs., **103**
- molecular features, **104**
- prognosis, **103**

Sinus histiocytosis with massive lymphadenopathy. *See* Rosai-Dorfman disease.

Small airway disease. *See* Bronchiolitis, respiratory.

Small cell carcinoma. *See also* Neuroendocrine carcinoma; Thymus, neuroendocrine carcinoma of.
- carcinosarcoma vs., **167**
- combined, poorly differentiated small cell variant squamous carcinoma vs., **135**
- ganglioneuroblastoma vs., **291**
- squamous cell carcinoma vs., **115**

Small cell neuroendocrine carcinoma
- poorly differentiated small cell variant squamous carcinoma vs., **135**
- rhabdomyosarcoma vs., **829**

Small lymphocytic lymphoma, lymphoblastic lymphoma vs., **750**

Small lymphocytic lymphoma/chronic lymphocytic leukemia, MALT lymphoma of thymus vs., **755**

Small round blue cell tumors
- liposarcoma vs., **760**
- rhabdomyosarcoma vs., **829**

Small round cell tumor, desmoplastic, **620-623**. *See also* Desmoplastic small round cell tumor.
- diagnostic checklist, **621**
- differential diagnosis, **621**
- genetic testing, **621**
- prognosis, **621**

Smoker bronchiolitis. *See* Bronchiolitis, respiratory.

Smooth muscle tumors of pleura, **614-619**
- diagnostic checklist, **615**
- differential diagnosis, **615**
- grading, **616**
- immunohistochemistry, **616**
- molecular features, **616**
- prognosis, **615**

Soft part sarcoma, alveolar, **822-827**
- diagnostic checklist, **823**
- differential diagnosis, **823**
- histochemical features, **824**
- immunohistochemistry, **824**
- molecular features, **824**
- prognosis, **823**

Solitary fibrous tumor, **558-567, 796-805**
- alternating hypo-and hypercellular areas, **797**
- angiofibromatous pattern, **797**

- benign, **27**
- benign metastasizing leiomyoma vs., **353**
- calcified fibrous pseudotumor vs., **569**
- dense hypercellular pattern, **797**
- diagnostic checklist, **560, 798**
- differential diagnosis, **559-560, 798**
- epithelioid growth pattern, **797**
- fascicular pattern, **797**
- ganglioneuroma vs., **835**
- genetic testing, **559**
- hemangiopericytic pattern, **797**
- herringbone pattern, **797**
- histologic growth patterns, **560**
- immunohistochemistry, **560, 798**
- intrapulmonary, **26-33**
  - amyloid tumor vs., **317**
  - diagnostic checklist, **27**
  - differential diagnosis, **27**
  - hyalinizing granuloma vs., **313**
  - intrapulmonary synovial sarcoma vs., **217**
  - intrapulmonary thymoma vs., **39**
  - prognosis, **27**
  - pulmonary adenofibroma/adenomyoma vs., **23**
- leiomyosarcoma vs., **223, 769**
- malignant, synovial sarcoma vs., **603**
- mediastinal
  - synovial sarcoma vs., **776**
  - thymoma vs., **653**
- mesenchymal chondrosarcoma vs., **813**
- neural-like growth pattern, **797**
- neurofibroma vs., **787**
- neurogenic sarcoma vs., **229**
- patternless pattern, **797**
- peripheral nerve sheath tumor vs., **791**
- pleural, malignant, **608-613**
  - diagnostic checklist, **609**
  - differential diagnosis, **609**
  - prognosis, **609**
- pleural, smooth muscle tumors of pleura vs., **615**
- prognosis, **559, 797**
- pulmonary meningioma vs., **47**
- storiform pattern, **797**
- synovial sarcoma vs., **603**
- unusual stromal changes, **797**

Spindle cell (sarcomatoid) carcinoma, **122-127**
- diagnostic checklist, **123**
- differential diagnosis, **123**
- histochemical features, **124**
- immunohistochemistry, **124**
- molecular features, **124**
- prognosis, **123**

Spindle cell melanoma, metastatic, solitary fibrous tumor vs., **560**

Spindle cell sarcoma
- high grade, mediastinal chordoma vs., **817**
- metastatic malignant melanoma vs., **377**
- metastatic, solitary fibrous tumor vs., **560**
- of soft tissue, metastatic, malignant solitary fibrous tumor (fibrosarcoma) vs., **609**

Spindle cell thymic carcinoma, synovial sarcoma vs., **776**

Spindle cell thymoma. *See also* Thymoma, spindle cell.
- pulmonary meningioma vs., **47**
- solitary fibrous tumor vs., **798**

Spindle cell tumors, low-grade, liposarcoma vs., **760**

Sporotrichosis, **528-529**
- diagnostic checklist, **529**
- differential diagnosis, **529**
- histochemical features, **529**
- prognosis, **529**

Squamous cell carcinoma, **114-121**
- basaloid, metastasis from head and neck, poorly differentiated small cell variant squamous carcinoma vs., **135**
- carcinosarcoma vs., **167**
- diagnostic checklist, **115**
- differential diagnosis, **115**
- grading, **115**
- histochemical features, **116**
- immunohistochemistry, **116**
- of lung origin, atypical thymoma vs., **667**
- moderately differentiated, **115**
- molecular features, **116**
- mucoepidermoid carcinoma of pleura vs., **591**
- mucoepidermoid carcinoma vs., **187**
- poorly differentiated small cell variant, **134-139**
  - diagnostic checklist, **135**
  - differential diagnosis, **135**
- prognosis, **115**
- in situ, **115**
- well-differentiated, **115**
  - atypical thymoma vs., **667**
  - intrapulmonary thymoma vs., **39**

Strongyloidiasis, **470-473**
- differential diagnosis, **471**
- dirofilariasis vs., **475**
- echinococcosis (hydatid cyst) vs., **483**
- histochemical features, **471**
- identification, diagnostic methods, **471**
- indirect infection, **471**

Submesothelial fibroma. *See* Solitary fibrous tumor.

Sugar tumor. *See* Clear cell sugar tumor (PEComa).

Synovial sarcoma, **602-607, 774-785**
- diagnostic checklist, **776**
- differential diagnosis, **776**
- intrapulmonary, **216-221**
  - differential diagnosis, **217**
  - genetic testing, **217**
  - intrapulmonary solitary fibrous tumor vs., **27**
  - metastasis from, peripheral soft tissues vs., **217**
  - prognosis, **217**
- Kaposi sarcoma vs., **251**
- malignant mesothelioma vs., **578**
- mediastinal, monophasic spindle cell type, leiomyosarcoma vs., **769**
- mesenchymal chondrosarcoma vs., **813**
- monophasic
  - leiomyosarcoma vs., **223**
  - neurogenic sarcoma vs., **229**
  - smooth muscle tumors of pleura vs., **615**
- mucoepidermoid carcinoma of pleura vs., **591**

- pleural, malignant solitary fibrous tumor (fibrosarcoma) vs., **609**
- pleural monophasic, solitary fibrous tumor vs., **559-560**
- prognosis, **775**
- solitary fibrous tumor vs., **798**

Synovial sarcoma of soft tissue, metastatic to mediastinum, mediastinal synovial sarcoma vs., **776**

T

T-cell-rich B-cell lymphoma, lymphomatoid granulomatosis vs., **285**

Teratoma
- cystic
  - acquired multilocular thymic cyst vs., **877**
  - lymphangioma vs., **633**
- mediastinal, **696-701**
  - diagnostic checklist, **697-698**
  - differential diagnosis, **697**
  - histological classification of, **698**
  - immature, **698**
  - immature teratoma, **698**
  - immunohistochemistry, **698**
  - malignant component, **698**
  - mature, **698**
  - prognosis, **697**

Teratomatous lesions, ectopic thyroid tumor vs., **855**

Testicular origin, metastatic seminoma of, mediastinal seminoma vs., **703**

Thread worm infection. *See* Strongyloidiasis.

Thymic carcinoma, **676-689**
- acquired multilocular thymic cyst vs., **877**
- adenocarcinoma, **678**
- adenosquamous, **678**
- alveolar soft part sarcoma vs., **823**
- anaplastic, **678**
- basaloid, **678**
- carcinosarcoma, **678**
- choriocarcinoma vs., **715**
- classification by histologic grade, **679**
- clear cell, **678**
- diagnostic checklist, **679**
- differential diagnosis, **678**
- ectopic parathyroid tumor vs., **849**
- embryonal carcinoma vs., **722**
- epithelioid hemangioendothelioma vs., **807**
- genetic testing, **678**
- immunohistochemistry, **679**
- lymphoepithelioma-like, **677**
- mediastinal diffuse large cell lymphoma vs., **736**
- mediastinal seminoma vs., **703**
- mucoepidermoid, **677**
  - poorly differentiated, **677, 679**
  - well-differentiated, **679**
- neuroendocrine, **678**
- neuroendocrine carcinomas of thymus vs., **691**
- papillary, **678**
- paraganglioma vs., **641**
- prognosis, **677**
- rare types, **678**
- spindle cell (sarcomatoid), **678**
  - synovial sarcoma vs., **776**
- squamous cell, well-differentiated, **677**

Thymic carcinosarcoma, synovial sarcoma vs., **776**

Thymic cyst, multilocular, acquired, **876-883**
- benign mediastinal foregut cyst vs., **871**
- diagnostic checklist, **877**
- differential diagnosis, **877**
- lymphangioma vs., **633**
- multilocular yolk sac tumor vs., **710**
- prognosis, **877**
- thymoma vs., **653**

Thymic hyperplasia, thymolipoma vs., **861**

Thymic lipoma. *See* Thymolipoma.

Thymic lymphoid hyperplasia, MALT lymphoma of thymus vs., **755**

Thymic lymphoproliferative disorders, **648**

Thymic neoplasms, malignant, overview, **648-649**

Thymic neuroendocrine carcinomas
- classification, **692**
- histological classification, **692**

Thymic seminoma. *See* Seminoma, mediastinal.

Thymic tissue, involuted, thymolipoma vs., **861**

Thymolipoma, **860-863**
- diagnostic checklist, **861**
- differential diagnosis, **861**
- hemangioma vs., **637**
- liposarcoma vs., **760**
- prognosis, **861**

Thymoma, **650-665**
- anaplastic, **653**
- atypical, **666-675**
  - diagnostic checklist, **667**
  - differential diagnosis, **667**
  - prognosis, **667**
  - thymic carcinoma vs., **678**
- cell types, **652**
- classification, according to grades of differentiation, **654**
- cystic
  - acquired multilocular thymic cyst vs., **877**
  - benign mediastinal foregut cyst vs., **871**
- diagnostic checklist, **653**
- differential diagnosis, **653**
- ectopic parathyroid tumor vs., **849**
- histologic classification systems for, **654**
- Hodgkin lymphoma vs., **728**
- immunohistochemistry, **654**
- intrapulmonary, **38-41**
  - differential diagnosis, **39**
  - epithelial-rich (WHO type B3), **39**
  - lymphocyte-rich (WHO types B1-B2), **39**
  - prognosis, **39**
  - spindle cell (WHO types A and AB), **39**
- lymph nodes, **653**
- lymphatic/vascular invasion, **653**
- lymphocyte-rich
  - lymphoblastic lymphoma vs., **750**
  - rhabdomyosarcoma vs., **829**
- malignant mesothelioma vs., **578**
- margins, **653**

- mediastinal seminoma vs., **703**
- micronodular, **653**
- mixed, **652**
- mixed lymphoepithelial (WHO Type B2), atypical thymoma vs., **667**
- modified Masaoka staging, **649**
- neuroendocrine carcinomas of thymus vs., **691**
- prognosis, **651**
- spindle cell
  - leiomyosarcoma vs., **769**
  - pulmonary meningioma vs., **47**
  - synovial sarcoma vs., **776**
- thymolipoma vs., **861**
- type A, **652**
- type AB, **652**
- type B1, **652**
- type B2, **652**
- type B3, **652**
- unusual types, **653**

Thymus
- MALT lymphoma of, **754-757**
  - acquired multilocular thymic cyst vs., **877**
  - diagnostic checklist, **755**
  - differential diagnosis, **755**
  - prognosis, **755**
  - pulmonary BALT hyperplasia vs., **259**
- neuroendocrine carcinoma of, **690-695**
  - diagnostic checklist, **691-692**
  - differential diagnosis, **691**
  - immunohistochemistry, **692**
  - prognosis, **691**

Thyroid tumor, ectopic, **854-857**
- diagnostic checklist, **855**
- differential diagnosis, **855**

Tojil (earth-borne disease). *See* Paragonimiasis.
Triton tumor, peripheral nerve sheath tumor vs., **791-792**
Tuberculosis, **510-513**
- chronic, **511**
- miliary, **511**
- primary, **511**
- prognosis, **511**
- pulmonary, *Klebsiella* pneumonia vs., **531**
- pulmonary, schistosomiasis vs., **479**
- sarcoidosis vs., **431**
- secondary, **511**

Tuberous sclerosis, lymphangioleiomyomatosis vs., **343**
Tumor
- amyloid, **316-319**
  - associated conditions, **317**
  - diagnostic checklist, **317**
  - differential diagnosis, **317**
  - hyalinizing granuloma vs., **313**
  - prognosis, **317**
- carcinoid, **156**. *See also* Neuroendocrine carcinoma; Thymus, neuroendocrine carcinoma of.
  - ectopic parathyroid tumor vs., **849**
  - ganglioneuroblastoma vs., **291**
  - granular cell tumor vs., **57**
  - paraganglioma vs., **641**
  - pulmonary meningioma vs., **47**
  - pulmonary paraganglioma vs., **43**
- ciliated muconodular papillary, **70-71**
  - diagnostic checklist, **71**
  - differential diagnosis, **71**
  - probable benign neoplastic proliferation, **71**
  - prognosis, **71**
- desmoid, smooth muscle tumors of pleura vs., **615**
- ectopic parathyroid, **848-853**
  - diagnostic checklist, **849-850**
  - differential diagnosis, **849**
  - histochemical features, **850**
  - immunohistochemistry, **850**
  - neuroendocrine carcinomas of thymus vs., **691**
  - paraganglioma vs., **641**
  - prognosis, **849**
  - ultrastructural features, **850**
- ectopic thyroid, **854-857**
  - diagnostic checklist, **855**
  - differential diagnosis, **855**
- Ewing sarcoma/primitive neuroectodermal, mesenchymal chondrosarcoma vs., **813**
- glomus, **34-37**
  - alveolar adenoma vs., **9**
  - diagnostic checklist, **35**
  - differential diagnosis, **35**
  - immunohistochemistry, **35**
  - prognosis, **35**
- granular cell, **56-59**
  - benign, **57**
  - diagnostic checklist, **57**
  - differential diagnosis, **57**
  - immunohistochemistry, **57**
  - malignant, **57**
- intrapulmonary solitary fibrous, **26-33**. *See also* Solitary fibrous tumor, intrapulmonary.
  - amyloid tumor vs., **317**
  - diagnostic checklist, **27**
  - differential diagnosis, **27**
  - hyalinizing granuloma vs., **313**
  - inflammatory pseudotumor vs., **299**
  - intrapulmonary synovial sarcoma vs., **217**
  - intrapulmonary thymoma vs., **39**
  - pulmonary adenofibroma/adenomyoma vs., **23**
- lipomatous
  - atypical. *See* Liposarcoma.
  - with muscle differentiation, leiomyosarcoma vs., **770**
- malignant solitary fibrous, synovial sarcoma vs., **603**
- metastatic clear cell, ectopic thyroid tumor vs., **855**
- mixed (pleomorphic adenoma), **206-211**
  - benign, **207**
  - diagnostic checklist, **207**
  - differential diagnosis, **207**
  - endobronchial lipoma vs., **19**
  - epithelial-myoepithelial carcinoma vs., **193**
  - grading, **207**
  - malignant, **207**
  - mucous gland adenoma vs., **13**
  - myoepithelial carcinoma of lung vs., **213**
  - prognosis, **207**
- mixed germ cell
  - choriocarcinoma vs., **716**
  - embryonal carcinoma vs., **721**

yolk sac tumor vs., **710**
- neuroectodermal, peripheral, desmoplastic small round cell tumor vs., **621**
- parathyroid, ectopic, neuroendocrine carcinomas of thymus vs., **691**
- peripheral nerve sheath, **790-795**
  diagnostic checklist, **792**
  differential diagnosis, **791-792**
  immunohistochemistry, **792**
  molecular features, **792**
- primitive neuroectodermal, rhabdomyosarcoma vs., **829**
- salivary gland-type
  adenoid cystic carcinoma, epithelial-myoepithelial carcinoma vs., **193**
  late metastases, myoepithelial carcinoma of lung vs., **213**
  of lung, myoepithelial carcinoma of lung vs., **213**
- small round blue cell
  liposarcoma vs., **760**
  rhabdomyosarcoma vs., **829**
- small round cell, desmoplastic, **620-623**
  diagnostic checklist, **621**
  differential diagnosis, **621**
  genetic testing, **621**
  prognosis, **621**
- smooth muscle, of pleura, **614-619**
  diagnostic checklist, **615**
  differential diagnosis, **615**
  grading, **616**
  immunohistochemistry, **616**
  molecular features, **616**
  prognosis, **615**
- solitary fibrous, **796-805**
  alternating hypo-and hypercellular areas, **797**
  angiofibromatous pattern, **797**
  dense hypercellular pattern, **797**
  diagnostic checklist, **798**
  differential diagnosis, **798**
  epithelioid growth pattern, **797**
  fascicular pattern, **797**
  ganglioneuroma vs., **835**
  hemangiopericytic pattern, **797**
  herringbone pattern, **797**
  immunohistochemistry, **798**
  neural-like growth pattern, **797**
  patternless pattern, **797**
  peripheral nerve sheath tumor vs., **791**
  prognosis, **797**
  storiform pattern, **797**
  synovial sarcoma vs., **603**
  unusual stromal changes, **797**
- spindle cell, low-grade, liposarcoma vs., **760**
- Triton, peripheral nerve sheath tumor vs., **791-792**
- yolk sac, **708-713**
  diagnostic checklist, **710**
  differential diagnosis, **709-710**
  embryonal carcinoma vs., **721**
  histological growth patterns, **710**
  immunohistochemistry, **710**
  prognosis, **709**

U

Undifferentiated carcinoma, large cell. *See* Large cell (anaplastic) carcinoma.
Usual interstitial pneumonia, **398-405**. *See also* Interstitial pneumonia, usual.
- conditions associated, **399**
- desquamative interstitial pneumonia vs., **407**
- diagnostic checklist, **399**
- nonspecific interstitial pneumonia vs., **411**
- prognosis, **399**

Usual interstitial pneumonitis
- asbestos-related interstitial fibrosis vs., **439**
- bronchiolitis obliterans with organizing pneumonia vs., **391**
- extrinsic allergic alveolitis vs., **415**
- hard metal pneumoconiosis pneumonitis vs., **435**
- respiratory bronchiolitis vs., **395**

V

Varicella-zoster virus infection
- herpes simplex virus vs., **515**
- measles pneumonia vs., **525**

Viral pneumonias, cytomegalovirus vs., **519**

W

Wegener granulomatosis, **426-429**
- allergic angiitis and granulomatosis vs., **419**
- bronchocentric granulomatosis vs., **423**
- diagnostic checklist, **427**
- differential diagnosis, **427**
- Granulomatous reaction, **427**
- lymphomatoid granulomatosis vs., **285**
- prognosis, **427**

Well-differentiated adenocarcinoma. *See also* Bronchioloalveolar carcinoma.
- atypical adenomatous hyperplasia vs., **341**

Well-differentiated fetal adenocarcinoma. *See* Pulmonary blastoma.
Well-differentiated neuroendocrine carcinoma. *See also* Thymus, neuroendocrine carcinoma of.
- pulmonary meningioma vs., **47**
- pulmonary paraganglioma vs., **43**

Well-differentiated squamous cell carcinoma, intrapulmonary thymoma vs., **39**
WHO type B3. *See* Atypical thymoma.
WHO type C thymoma. *See* Thymic carcinoma.

X

Xanthogranuloma, juvenile, **308-311**
- differential diagnosis, **309**
- immunohistochemistry, **309**
- lipoid pneumonia vs., **325**

- prognosis, **309**
- Rosai-Dorfman disease vs., **333**

Y

Yolk sac tumor, **708-713**
- diagnostic checklist, **710**
- differential diagnosis, **709-710**
- embryonal carcinoma vs., **721**
- histological growth patterns, **710**
- immunohistochemistry, **710**
- prognosis, **709**

Z

Zygomycetes infection, aspergillosis vs., **542**

Expert CONSULT Built with inkling | E books

Any screen. Any time. Anywhere.

Activate the eBook version
of this title at no additional charge.

Expert Consult eBooks give you the power to browse and find content, view enhanced images, share notes and highlights—both online and offline.

Unlock your eBook today.

1. Visit **expertconsult.inkling.com/redeem**
2. Scratch off your code
3. Type code into "Enter Code" box
4. Click "Redeem"
5. Log in or Sign up
6. Go to "My Library"

It's that easy!

Scan this QR code to redeem your eBook through your mobile device:

Place Peel Off Sticker Here

For technical assistance:
email expertconsult.help@elsevier.com
call 1-800-401-9962 (inside the US)
call +1-314-447-8200 (outside the US)

ELSEVIER

Use of the current edition of the electronic version of this book (eBook) is subject to the terms of the nontransferable, limited license granted on expertconsult.inkling.com. Access to the eBook is limited to the first individual who redeems the PIN, located on the inside cover of this book, at expertconsult.inkling.com and may not be transferred to another party by resale, lending, or other means.

2015v1.0