

# Essentials of Avian Medicine and Surgery

---

Third edition

**Brian H. Coles BVSc, Dip. ECAMS,  
Hon. FRCVS**

With contributions from

Professor Dr Maria Krautwald-Junghanns,  
Dr med vet, Dr met vet habil, Dip. ECAMS  
Universitat Leipzig  
Institute for Avian Diseases  
Leipzig, Germany

Dr Susan E. Orosz, DVM, PhD, Dip. ABVP (avian), Dip. ECAMS  
Bird and Exotic Pet Wellness Center  
Toledo, Ohio, USA

Professor Thomas N. Tully, DVM, MSc, Dip. ABVP (avian), Dip. ECAMS  
Louisiana State University  
Department of Veterinary Clinical Sciences  
Baton Rouge, USA



# **Essentials of Avian Medicine and Surgery**

---



# Essentials of Avian Medicine and Surgery

---

Third edition

**Brian H. Coles BVSc, Dip. ECAMS,  
Hon. FRCVS**

With contributions from

Professor Dr Maria Krautwald-Junghanns,  
Dr med vet, Dr met vet habil, Dip. ECAMS  
Universitat Leipzig  
Institute for Avian Diseases  
Leipzig, Germany

Dr Susan E. Orosz, DVM, PhD, Dip. ABVP (avian), Dip. ECAMS  
Bird and Exotic Pet Wellness Center  
Toledo, Ohio, USA

Professor Thomas N. Tully, DVM, MSc, Dip. ABVP (avian), Dip. ECAMS  
Louisiana State University  
Department of Veterinary Clinical Sciences  
Baton Rouge, USA

© 1985, 1997 by Blackwell Science Ltd, a Blackwell Publishing company  
© 2007 by Blackwell Publishing Ltd

Blackwell Publishing editorial offices:  
Blackwell Publishing Ltd, 9600 Garsington Road, Oxford OX4 2DQ, UK  
Tel: +44 (0)1865 776868  
Blackwell Publishing Professional, 2121 State Avenue, Ames, Iowa 50014-8300, USA  
Tel: +1 515 292 0140  
Blackwell Publishing Asia Pty Ltd, 550 Swanston Street, Carlton, Victoria 3053, Australia  
Tel: +61 (0)3 8359 1011

The right of the Author to be identified as the Author of this Work has been asserted in accordance with the Copyright, Designs and Patents Act 1988.

All rights reserved. No part of this publication may be reproduced, stored in a retrieval system, or transmitted, in any form or by any means, electronic, mechanical, photocopying, recording or otherwise, except as permitted by the UK Copyright, Designs and Patents Act 1988, without the prior permission of the publisher.

Designations used by companies to distinguish their products are often claimed as trademarks. All brand names and product names used in this book are trade names, service marks, trademarks or registered trademarks of their respective owners. The publisher is not associated with any product or vendor mentioned in this book.

This publication is designed to provide accurate and authoritative information in regard to the subject matter covered. It is sold on the understanding that the Publisher is not engaged in rendering professional services. If professional advice or other expert assistance is required, the services of a competent professional should be sought.

First edition published 1985 by Blackwell Science Ltd  
Second edition published 1997 by Blackwell Science Ltd, reprinted 2005  
Third edition published 2007 by Blackwell Publishing Ltd

ISBN: 978-1-4051-5755-1

Library of Congress Cataloging-in-Publication Data  
Essentials of avian medicine and surgery / B.H. Coles with contributions from Maria Krautwald-  
Junghanns, Susan E. Orosz, Thomas N. Tully. – 3rd ed.

p. ; cm.

Rev. ed. of: Avian medicine and surgery / B.H. Coles. 2nd ed. 1997.

Includes bibliographical references and index.

ISBN: 978-1-4051-5755-1 (pbk. : alk. paper)

1. Avian medicine. 2. Birds–Diseases. 3. Birds–Surgery. I. Coles, B. H. (Brian H.) II. Coles, B. H. (Brian H.) Avian medicine and surgery.

[DNLM: 1. Bird Diseases–therapy. 2. Birds–surgery. 3. Veterinary Medicine–methods. SF 994 E78 2007]

SF994.E87 2007  
636.5'098–dc22  
2007018855

A catalogue record for this title is available from the British Library

Set in 9.5 on 11.5 pt Sabon  
by SNP Best-set Typesetter Ltd., Hong Kong  
Printed and bound in Singapore  
by Markono Print Media Pte Ltd

The publisher's policy is to use permanent paper from mills that operate a sustainable forestry policy, and which has been manufactured from pulp processed using acid-free and elementary chlorine-free practices. Furthermore, the publisher ensures that the text paper and cover board used have met acceptable environmental accreditation standards.

For further information on Blackwell Publishing, visit our website:  
[www.blackwellpublishing.com](http://www.blackwellpublishing.com)

# Contents

---

<i>Preface</i>	vii
1 Diversity in Anatomy and Physiology: Clinical Significance	1
2 The Special Senses of Birds – Dr Susan E. Orosz	22
3 Clinical Examination	40
4 Aids to Diagnosis – Professor Dr Maria Krautwald-Junghanns	56
5 Post-mortem Examination	103
6 Medication and Administration of Drugs	115
7 Anaesthesia	124
8 Surgery	142
9 Nursing and After Care	183
10 Breeding Problems	196
11 Release of Casualty Wild Birds	208
Appendices	219
1 An avian formulary – Professor Thomas N. Tully	219
2 Bacterial diseases of birds	266
3 Viral diseases of birds	279
4 Mycotic diseases of birds	308
5 Parasitic diseases of birds	313
6 Poisons likely to affect birds	334

---

7	Some suggested diagnostic schedules	339
8	Weights of birds most likely to be seen in general practice	352
9	Incubation and fledging periods of selected birds	355
10	Glossary	357
11	Some useful websites	361
	<i>Further reading</i>	363
	<i>References</i>	364
	<i>Index</i>	380

*Colour plates appear between pages 184 and 185*



# Preface

---

This *Essentials of Avian Medicine and Surgery* is the third edition of the work originally published as *Avian Medicine and Surgery* more than twenty years ago. Since that time the subject has expanded beyond what was then envisaged. Many large, superbly illustrated multi-author volumes on the subject have been published. However it was felt that there was still a need for a small book that would enable the busy practitioner to have a quick reference or for the student just starting out to get a basic understanding of the subject.

The use of molecular biology in diagnostics and the variety of imaging techniques have advanced considerably, even since the second edition was produced. Because of the need for up-to-date information on this aspect, Professor Maria Krautwald-Junghanns kindly agreed to update the chapters on Aids to Diagnosis and Post-Mortem Examination.

Therapeutics is an important part of clinical practice, and so one of the forerunners in this field, Professor Tom Tully, generously agreed to look at and update the 'Avian Formulary'.

A third expert in her field, Dr Susan Orosz, very kindly agreed to write a chapter on The Special Senses of Birds. The original author requested this because it was felt that although the veterinarian has always considered animal welfare to be of primary importance, there is now an increasing interest on the part of the general public and an increase in well-intentioned but sometimes ill-informed *focus groups* looking into this matter. It is therefore imperative that the veterinarian should have the most up-to-date objective, scientific and unemotional information on the subject when advising their clients and the decision makers.

With the recent emergence of the importance of the viruses of avian flu and of West Nile virus, together with the general public's desire to visit 'exotic' habitats around the globe and to come in contact with unfamiliar habitats together with the indigenous animals, avian zoonotic diseases have been highlighted in the sections on infectious diseases.

I am very grateful to all those colleagues who have discussed their cases with me and contributed to my knowledge and to those friends who have given permission to use their photographs. I am indebted to my colleague Peter McElroy for bringing to my notice the long ago (1917) published work of Dr Casey Woods. I am grateful to veterinary nurse Cathy Smith for her observations on the chapter on nursing, to Adam Burbage and others at Blackwell Publishing for their help and patience. Also my thanks go to my copy editor, Judith Glushanok, for her many helpful suggestions.

My thanks goes to Ms Anne Meller who provided the main cover photograph of an Atlantic Puffin. This photograph has important conservation implications for this species. The quality of the fish held in the beak is of poor nutritive value. The sand eels are small and low in fat, moreover the pipe fish has a tough indigestible skin. A species reduced to feeding its young on such items is threatened with the combined effects of commercial over fishing and climate change.

Again my grateful thanks to the co-authors, all of whom are very busy clinicians, for their contributions, which have helped to make this third edition more comprehensive. Lastly grateful thanks to my colleague Nicola Miller for agreeing to proofread the finished book and to my ever patient and always forbearing wife, Daphne.

Brian H. Coles  
2006

# Diversity in Anatomy and Physiology: Clinical Significance

---



There are approximately 8900 species of living birds compared with only about 4200 species of mammals. In this chapter it is not possible to consider all aspects of anatomy and physiology. Only those variations in the more clinically important parts of avian anatomy and physiology will be considered, because knowledge of these is important when carrying out surgery and autopsies or interpreting radiographs.

To the casual observer there are many obvious differences in size, ranging from the hummingbird to the ostrich (*Struthio camelus*), in the varying forms of the bill and in the colour and profusion of the plumage occurring in different species of birds. However beneath this great variety of body form there is a greater degree of uniformity in the basic anatomy and some aspects of the physiology of the class Aves than there is in many single orders of other types of vertebrate. Even in the case of the large flightless birds, all present-day living birds have originally evolved from a flying ancestor and the capacity to be able to become airborne imposed quite severe restrictions on the basic anatomy and some aspects of the physiology which have been retained by their descendants. It is because of their ability to fly that birds have been able quickly (i.e. in evolutionary time) to reach and exploit a wide variety of habitats. This, in turn, resulted in the evolution of many different anatomical forms, all with the same overall basic pattern.

The field observations of Charles Darwin on the variations in body size and bill shape which adapted the bird to different habitats and sources of food, exhibited by otherwise apparently closely related finches in the Galapagos Islands, helped him formulate his theory of the origin of species. However Darwin was primarily concerned with the process of divergent evolution, while we now know that convergent evolution also takes place. Apparent externally recognised similarities are not always an infallible guide. For instance the martins, swallows and swifts all look quite similar and all behave similarly and occupy similar habitats. However while martins and swallows are taxonomically placed in the order Passeriformes, or perching birds, the swifts are more closely related to the hummingbirds, both being placed in the superorder Apodimorphae. Unlike most other birds, the skeleton is not well pneumonised in Apodimorphae, a condition only seen in the egg-laying female of other species. The Victorian biologists were great anatomists and much of today's taxonomy is based on their observations, such as those of T.H. Huxley (1867). Consequently we know quite a lot about the detailed anatomical variations between species. We still do not know a lot about the physiological differences.

Some Victorian-based taxonomy has been and is being overturned by present-day laboratory investigation using DNA analytical techniques (Sibley & Ahlquist, 1990). New World vultures, for example, are now considered to be more closely related to the storks than to the Old World vultures. Most of our knowledge of physiology has been derived from experimental work on domestic poultry (ducks and chickens) and particularly on the

domestic fowl that originated from the red jungle fowl (*Gallus gallus*). This particular species is not really typical of birds as a whole.

Since the underlying skeleton of the bird largely influences the external appearance and anatomy, these two topics will be considered together.

## THE SKELETAL SYSTEM AND EXTERNAL ANATOMY

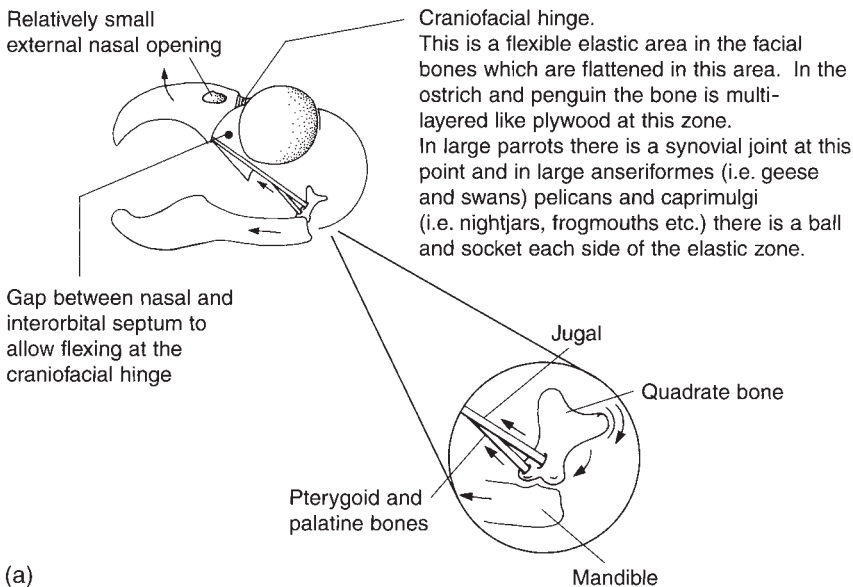
*When carrying out radiography or any imaging diagnostic technique, it is important to know what is normal for a particular species so that an inaccurate diagnosis is not made.*

### The skull

In all birds the cranial part of the skull is remarkably uniform. However that part of the skull associated with the mouthparts, as might be expected, does show considerable variation. In fact one aid in classifying birds used by the Victorian anatomists was to use the relative size and presence or absence of the vomer, the pterygoids and the palatine bones.

In hornbills (Bucerotidae) and cassowaries (Casuariidae) the frontal and nasal bones contribute to the horn-covered casque. In the cassowary this is used to push the bird's way through the thick undergrowth of tropical rainforest. In most hornbills the casque is very light and cellular in texture but in the helmeted hornbill (*Rhinoplax vigil*) it is solid and ivory like.

The many different types of articulation of the maxilla, premaxilla and mandible with the skull are illustrated in Figures 1.1(a) and 1.1(b). When considering the surgical repair



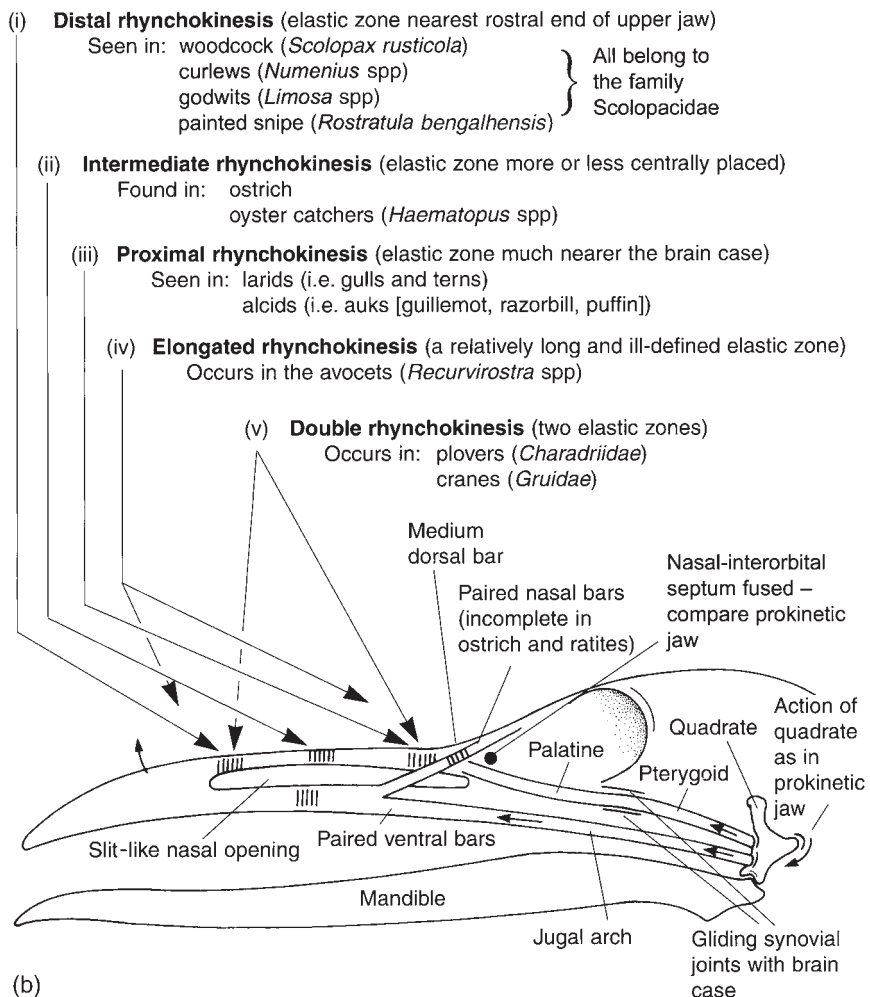
**Fig. 1.1(a)** Kinesis of the avian jaw (simplified and diagrammatic) – the prokinetic (hinged) lower jaw (adapted from an illustration by King & McLelland, 1984). This type of jaw articulation is found in most species of birds including the parrots.

As the quadrato bone rotates clockwise, horizontal forces are transmitted via the jugal arch (laterally) and the pterygopalatine arch (medially) to the caudal end of the ventral aspect of the upper jaw, causing this to rotate dorsally pivoting on the craniofacial hinge.

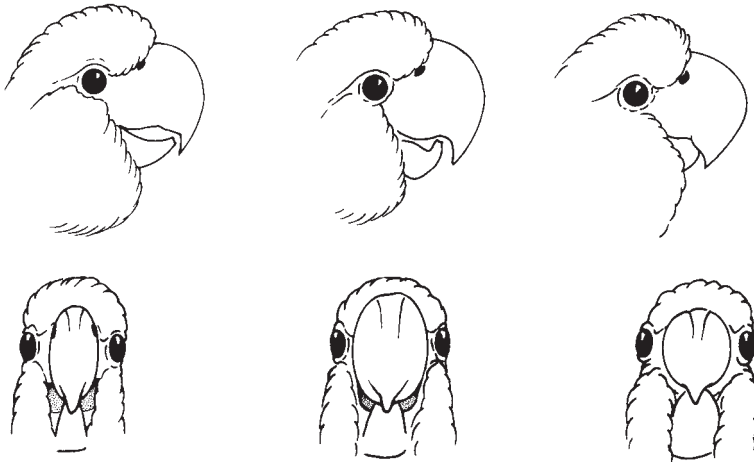
Injury to the cere is common in many birds and may involve the underlying craniofacial hinge. Fractures of the jugal, pterygoid and palatine bones occasionally occur and need good quality radiographs for diagnosis. All the injuries affect prehension of food.

of a traumatised or fractured beak it is important to take into account these interspecific variations.

The sheath of keratin overlying the skeleton of the bill also varies in thickness, composition and sensitivity. In ducks and geese (Anatidae) only the tip is hard, while in waders (Charadriidae) the bill tends to be soft, leathery and flexible, extending distally well beyond the underlying bone. Different races of the redshank (*Tringa totanus*) have developed different lengths of beak dependent on their preferred diet. In most species of parrot and most raptors the beak is hard and tough. Hardness depends on the content of orientated hydroxyapatite crystals. The hard tip of the bill of the Anatidae contains a tactile sensory structure – the bill-tip organ – while Herbst corpuscles, sensitive mechanoreceptors, are well distributed over the whole of the beak of waders. The beak of toucans is also a very



**Fig. 1.1(b)** The rhynchokinetic jaw. Most of the movement of the jaw occurs rostral to the junction of the upper jaw and the brain case within the area of the 'nose'. Among the many forms of rhynchokinetic articulation, proximal rhynchokinesis (iii) most nearly resembles prokinetic articulation, giving these birds (gulls, terns and auks) a wide gape so that they can more easily swallow their prey. Rhynchokinetic articulation overall is found mostly in the order Charadriiformes (i.e. waders and shore birds) which mostly feed on invertebrates and other aquatic organisms. Many species of these birds probe for their food in sand or soft earth.



*C. funereus*

The upper beak is comparatively long and narrow with a rather prominent tip. Adapted for digging into timber to extract wood-boring larvae.

*C. magnificus*

A rather broad blunt upper beak adapted for crushing seeds, hard nuts and rotting timber.

*C. lathami*

Has a rather bulbous beak with a comparatively broad lower beak adapted for tearing apart the cones of the casuarina tree.

**Fig. 1.2** Variations in the form of the beak among members of the genus *Calyptorhynchus*, the black cockatoos (after W.T. Cooper in Forshaw, 1978). Although *C. funereus* and *C. magnificus* inhabit parts of south-western Australia, all three species co-exist in parts of south-eastern Australia where, because of their different feeding habits, they are ecologically isolated.

sensitive structure, being well supplied by branches of the Vth cranial nerve (see p. 23). Figure 1.2 shows the variation in beak form of a closely related group of cockatoos.

### The axial skeleton

#### The cervical vertebrae

In all species the atlas articulates with the skull via a single occipital condyle, but in some hornbills (Bucerotidae) the atlas and axis have fused, possibly to support the very large skull. Most birds, even small Passeriformes, which have an apparently quite short neck, have 14–15 cervical vertebrae compared with a total of seven in all mammals. The swans (genus *Cygnus*), most of the large herons in the family Ardeidae, most of the storks (Ciconiidae) and the ostrich have an obviously long and flexible neck and, as would be expected, an increased number of cervical vertebrae (in swans 25). Usually long necks go with long legs since the bird needs to use its bill to perform many tasks (e.g. manipulating food, grooming and nest building or burrowing) all of which are often carried out by the pectoral (or fore-) limb in mammals. In darters (genus *Anhinga*) there is a normal 'kink' in the neck between the 7th, 8th and 9th cervical vertebrae. This, when suddenly straightened, enables the bird to thrust the beak forward at the prey in a stabbing action.

#### The thoracic vertebrae

In many birds the first few thoracic vertebrae (2–5) are fused to form a notarium. This is present in Galliformes (pheasants, turkeys, guinea fowl, grouse and quails, etc.), Colum-

biformes (pigeons and doves), Ciconiidae (herons, egrets, bitterns, storks, ibises, spoon-bills) and Phoenicopteridae (flamingos).

The notarium may not be very apparent on all radiographs. In all birds some of the posterior thoracic vertebrae together with all of the lumbar vertebrae, the sacral vertebrae and some of the caudal vertebrae are fused to form the synsacrum, which is also fused with the ilium, ischium and pubis. The exact numbers of fused vertebrae derived from the various regions of the spine is not possible to define accurately.

### The caudal vertebrae and pelvis

The pygostyle (4–10 fused caudal vertebrae) gives support, together with the retrical bulb (a fibro-adipose pad), to the rectrices (the tail feathers). The pygostyle is well developed in most flying birds in which the tail is important to give added lift during hovering (e.g. the kestrel *Falco tinnunculus*) or soaring or for accurate steering, as in the goshawk (*Accipiter gentilis*) and other woodland species. This area in the flying birds and those which use the tail for display purposes (e.g. the peacocks and the Argus pheasant) is well supplied with muscles, many of which are inserted into the inter-retrical elastic ligament.

The pygostyle and the free caudal vertebrae are well developed in woodpeckers, in which, together with specially stiffened tail feathers, they help to support the bird when it is clinging on to a vertical surface. The tail feathers may also help support such species as the Emperor penguin when standing or pygmy parrots, woodpeckers and tree creepers when climbing. In these many different types of birds damage to this area of the anatomy could have an effect on feeding, breeding, flying or roosting behaviour.

The *rigid synsacrum*, unlike the pelvis in mammals, in most birds is open on the ventral surface to allow passage of the often quite large shelled egg. However in the Ratides, the large flightless birds, it is fused either at the pubic symphysis (in the ostrich) or at the ischial symphysis. This may help to prevent compression of the viscera when the bird is sitting.

In all birds there is an antitrochanter situated dorsal to the acetabular fossa, but even these two anatomical structures vary between quite apparently similar species such as the peregrine falcon (*Falco peregrinus*) and the goshawk (*Accipiter gentilis*) (Harcourt-Brown, 1995). The pelvis tends to be comparatively wide in the running birds compared with the narrower and longer pelvis of the foot-propelled diving birds, e.g. loons (Gaviidae) and grebes (Podicipedidae) which closely resemble each other in body form and behaviour but are taxonomically unrelated. This is probably an instance of convergent evolution.

### The thoracic girdle

In most birds the scapula is long and narrow, but in the ostrich it is short and fused to the coracoid. The clavicles are usually fused at the furcula to form a 'wishbone' and they function as bracing struts to hold the two shoulder joints apart during contraction of the supracoracoideus. They also act as a major attachment for the pectoral muscle; they are well developed and widely spaced in the strongly flying birds. As would be expected, the supracoracoid muscle and the pectorals, as well as the other wing muscles, are reduced in some non-flying birds. In the penguins, which literally 'fly' through the water, the supracoracoid muscle is greatly developed whilst many of the other wing muscles are tendinous.

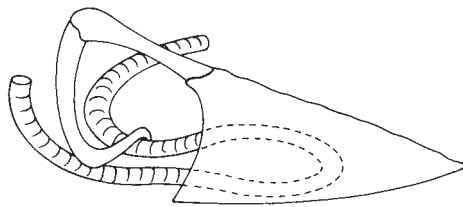
In some birds pelicans, frigate birds and the secretary bird (*Sagittarius serpentarius*) the furcula is fused to the sternum. In the ostrich the scapulocoracoid bone is not quite fused but has a fairly rigid attachment to the sternum. In the albatrosses and fulmars (Procellariidae) the furcula forms a synovial joint with the sternum. However in some parrots the clavicles and the furcula are absent, being represented by a band of fibrous tissue. The coracoid is well developed in most species but the 'triosseal canal' normally formed between coracoid, scapula and clavicle, is completely enclosed within the coracoid

in the hoopoe (*Upupa epops*) and also in hornbills (Bucerotidae). Both these species belong to the order Coraciiformes and it is possible that other members of this order may have this anatomical variation although this has not been documented.

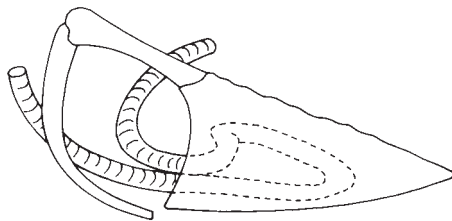
### The ribs and sternum

The uncinat processes are unusually long in the guillemots or murre (Alcinae) and the divers or loons (Gaviidae). This may help to resist the pressure of water on the thorax when the bird is diving. Guillemots and razorbills have been recorded at a depth of 150 metres, the emperor penguin at 350 metres. Water pressure increases at the rate of 1 atm/10 m, which is approximately 1 kg/sqcm.

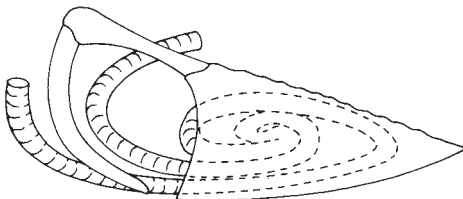
As is the case in the pelvic girdle, the thorax in these birds is long and comparatively thin; consequently the sternum is long thus reducing the space between its caudal margin and the pubic bones and so making surgical access to the abdomen more difficult. The keel of the sternum is well developed in the flying birds particularly the swifts and the hummingbirds (Apodiformes). However it is absent or reduced in the ratites (i.e. with a raft-like sternum). It is reduced in many flightless island species in which other members of the same family are flying birds, e.g. the kakapo or the owl parrot of New Zealand (*Strigops habroptilus*) which can only glide downhill, or again some of the flightless island rails (e.g. *Atlantisia rogersi*). The sternal keel is well developed in penguins and in these birds the supracoracoid muscle is greatly increased in size compared with the pectoral. In some cranes (Gruidae) and the swans this part of the sternum has been excavated to accommodate coils of an elongated trachea as is illustrated in Figure 1.3.



Whooper swan (*Cygnus cygnus*)  
Also occurs in some other species of swan but not all species of *Cygnus* (e.g. only short bends occur in *Cygnus melanocoryphus* – the black-necked swan and in *Cygnus atratus* – the black swan).



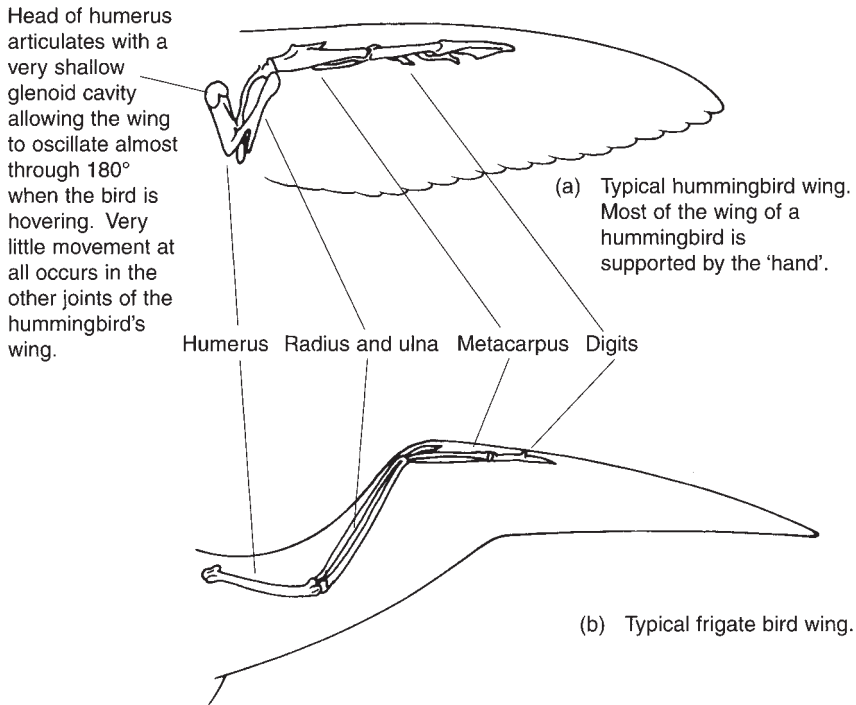
Common crane (*Grus grus*)  
Also like this in *Anthropoides* spp (i.e. demoiselle and stanley cranes).



Whooper crane (*Grus americana*)

**Fig. 1.3** Various types of looped trachea partly enclosed in the excavated sternum (redrawn after King & McLelland, 1989, by permission of Academic Press Limited, London). Knowledge of these variations is important in the interpretation of radiographs.





**Fig. 1.4** The relative comparable sizes of the wing bones in two different types of bird (not drawn to the scale of the two species).

### The pectoral limb – the wing

The overall layout of the skeletomuscular system of the wing is similar in all birds. However the relative lengths of the individual bones do vary (Fig. 1.4) (see also p. 209). In most specialised soaring birds, e.g. the gulls (*Laridae*), the humerus is short compared with the relatively longer radius and ulna. In contrast in the albatross, which spends most of its life soaring over very great distances, the humerus is longer than the radius and ulna. In the penguins, auks and diving petrels the humerus and the other bones of the wing have become flattened. The alula is a digit corresponding to the human thumb. It is usually well developed in most flying birds and when abducted from the wing it acts as a slot, as in an aircraft wing, to smooth the airflow over the aerofoil section of the wing at low air-speeds and when the wing is canted as the airborne bird comes in to land (see p. 168). During these conditions the airflow tends to break away from the surface of the wing and the bird or aircraft loses lift and begins to stall. As would be expected this structure is reduced or absent in some non-flying birds (e.g. kiwis and cassowaries). In the young hoatzin (*Opisthocomus hoatzin*) there are claws on the alula and the major digit which the bird uses for climbing around the nest site. Adult cassowaries, kiwis, emus, rheas and the ostrich also have vestigial non-functional claws on these digits. The varying types of avian wing are illustrated in Figure 1.5.


### The legs

Again the basic layout of the hind limb is the same in all species with most of the evolutionary changes having taken place in the foot. In the long-legged birds the tibiotarsus and the tarsometatarsus are of approximately the same length. This is essential if the centre of

### Type I The elliptical wing

Has fairly low wing loading and a low aspect ratio. Enables bird to take off rapidly and manoeuvre through narrow spaces.

- (a) Typical small finch or bunting  
This type has a large alula and additional slots in the wing to prevent stalling at slow speed.

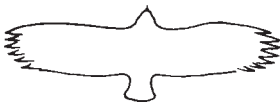


- (b) Pheasant type  
Typical of many galliforms. Adapted for rapid take off often in dense cover.

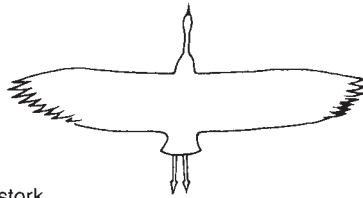
### Type II Long wide wing

Enables bird to glide and soar at *relatively low speed*. Has a moderate wing loading and medium type aspect ratio. The alula and wing slots are well developed and obvious, giving bird reasonable manoeuvrability.

- (c) Typical large eagle



- (d) Typical stork

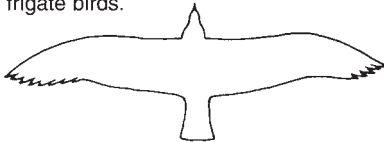

This type also seen in condors, vultures and pelicans.

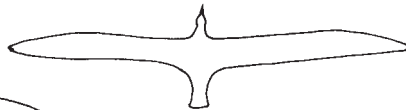### Type III Long, relatively slim wing

With no wing slots and a tapered end to the wing. Sometimes the alula is large. These birds glide at *high speed* in strong wind. High wing loading, high aspect ratio.

- (e) Typical gull  
Type of wing also seen in gannets and frigate birds.



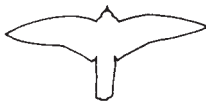- (f) Albatross



### Type IV High speed wing

Long and relatively narrow with no wing slots. Tip of wing pointed and may be swept back. High wing loading, moderate-high aspect ratio enables bird to fly at high speed to chase prey.

- (g) Typical falcon



- (h) Swift



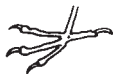**Fig. 1.5** Varying types of avian wing (definitely not to scale).

- Any loss of wing extension through fracture, trauma or damage to the propatagial membrane is most serious prognostically in birds with a high wing loading. Of course, if the damage is extensive enough it is significant in all species of birds. However, see p. 209.
- Trauma to the carpo-metacarpal region resulting in fibrosis or possible ankylosis is most grave in birds with a Type I or Type II wing plan. The author has seen a number of kestrels (*Falco tinnunculus*, type IV wing plan) and gulls (*Larus* sp., Type III wing plan) fly effectively with slight damage to the carpo-metacarpal area.

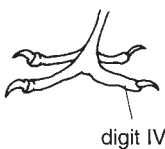
**Clinical importance:** assessment for release of wildlife casualties.

gravity of the bird's body is to remain above the feet when the bird is crouched and the limb is flexed, otherwise the bird would overbalance. In flamingos there are no menisci in the intertarsal joints. In the grebes (Podicipedidae) and divers or loons (Gaviidae), which are foot-propelled diving birds, the tibiotarsus lies almost parallel to the vertebral column and the limb is bound to the body by a fold of skin. The cnemial crest in these divers is well developed, projecting beyond the stifle joint. In grebes it is fused to the patella thus increasing the area of attachment for the crural muscles. In divers and grebes the gastrocnemius is greatly developed providing the main power stroke of the foot. Quite obviously all the leg muscles are powerful and well developed in the ostrich which can run at 40 mph (64kph) and can produce a lethal strike forward with its foot. All the major types of avian foot are illustrated in Figure 1.6.

#### Feet with four toes



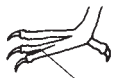*Anisodactyl* i.e. three forward toes and one backward pointing toe. This type of foot is adapted for perching or grasping and is seen in songbirds and birds of prey. This is the pattern seen in most birds. The gannets have four webbed toes, so do cormorants.



*Zygodactyl* i.e. two forwardly directed toes (digits II & III) and digits I & IV are backwardly directed toes. This foot is seen mostly in birds which climb but also grasp with the foot, e.g. parrots, toucans, cuckoos, woodpeckers. In owls, touracos and the osprey the foot is basically of this type but digit IV can easily be moved forwards.



*Pamprodactyl* i.e. all four toes are directed forward. This type of foot is found in the swift. Unable to perch on the ground but clings to a vertical nesting site.



*Syndactyl* i.e. two digits are partially united, e.g. kingfishers.

digits III & IV

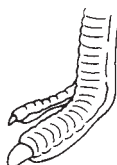
#### Feet with only three toes, i.e. *tridactyl* feet



This type of foot is seen in running birds (e.g. plovers), wading birds, some climbing birds, some woodpeckers, the emu, diving petrels and auks, cassowaries, kiwis, tinamous and pheasants.



Many birds with webbed feet are like this with a vestigial first digit, e.g. gulls, penguins, loons, albatross, swans and ducks.



#### Feet with two toes

This is found only in the ostrich. Digits I & II are absent and digit III is much larger than digit IV. The foot is rather like that of the horse where one digit is greatly developed and adapted to running and walking over open country and grassland.

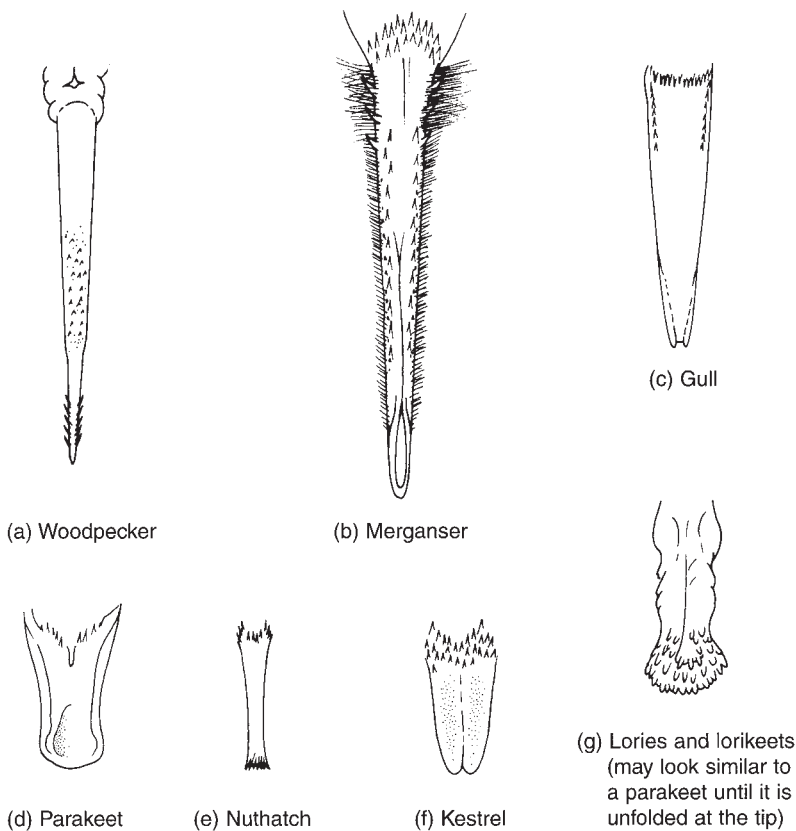
**Fig. 1.6** Varying types of avian foot.

**Clinical importance:** Foot problems in birds are common. As well as obvious trauma, digits are sometimes congenitally maldirected so knowledge of what is normal is important.

## THE ALIMENTARY OR DIGESTIVE SYSTEM

### The beak and mouth

Brief reference has already been made to the varying types of beak. Within the oral cavity itself there are differences in the anatomy, which are not quite so obvious to the casual observer. The palate is often ridged and the pattern of ridges is usually related to the diet. In the Fringillidae group of finches, e.g. the chaffinch (*Fringilla coelebs*) and canary (*Serinus canarius*), most of which feed on dicotyledonous seeds (i.e. those of trees, shrubs and most herbaceous plants), there is a lateral palatine ridge between which and the edge of the upper beak the seed is lodged while it is cut by the sharp-edged lower bill. Even among the Fringillidae there is considerable variation in bill size and shape. In two other groups of small seed eating birds, the Emberizinae (e.g. the cardinal, *Pyrrhuloxia cardinalis* and the snow bunting, *Plectrophenax nivalis*) and the Ploceidae, the typical weaver birds (e.g. quelea and house sparrow, *Passer domesticus*), which feed on monocotyledonous seeds (i.e. the grasses and cereal crops), there is a prominence rostral to the choanal gap against which the seed is wedged transversely while it is crushed by the blunt-edged lower beak. Many parrots also use the transverse ridge on the rostral part of the palate to hold the seed while it is cracked and manipulated into position by the muscular tongue (the only avian order with intrinsic tongue muscles). The tongues of birds show a lot of variation in relation to the diet and some of these differences are illustrated in Figure 1.7.



**Fig. 1.7** Variations in the types of avian tongue.

**Clinical importance:** A completely normal tongue is more important in some species than in others (redrawn after King & McLelland, 1979, by permission of Academic Press Limited, London).

Abscessation of the choanal gap and the tongue is common in caged parrots, and neoplastic lesions occasionally occur in all species. Partial amputation of the tongue or beak owing to a ligature of nylon fishing line is seen in waterfowl. All these lesions affect prehension of food.

The salivary glands, which mainly secrete mucus, are best developed in birds that swallow dry foods. They are least developed in birds swallowing slippery foods such as fish. In the woodpeckers the mandibular glands below the tongue secrete a sticky fluid for mopping up invertebrates. Swifts secrete an adhesive glycoprotein which after secretion hardens into a nest-building material.

Taste buds are variously developed in birds and these are associated with the salivary glands. In most birds there are a few taste buds at the caudal end of the tongue, but in some ducks, e.g. the mallard (*Anas platyrhynchos*), there are none in this position. Instead they are located near the tip of the upper and lower bill and on the roof of the oropharynx. Parrots have taste buds either side of the choanal opening and just rostral to the laryngeal mound (see p. 36). The acuity of the taste varies between species. Bitter and salt tasting substances are generally rejected, this is important when administering therapeutic drugs by mouth or in drinking water (see p. 117).

Some species of bird, such as the male of most bustards (Otididae) have inflatable oral sacs on the floor of the mouth which are used for sexual display. In the great bustard (*Otis tarda*) this sac is an oesophageal structure. Those structures also occur in frigate birds, sage grouse (*Centrocercus urophasianus*) and prairie chicken (*Tympanuchus cupido*). In the pelican, the sac on the floor of the mouth is large and together with the flexible mandible forms a hoop like a fishing net to catch food.

### **The oesophagus and crop**

The oesophagus is folded longitudinally and is very distensible in hawks, owls and cor-morants but in swifts and some finches feeding on much less bulky food it is quite narrow, a factor to consider if these species have to be gavaged. Just cranial to the thoracic inlet is a storage region, the crop. *Not all birds have a crop.* It is absent in gulls and penguins, which store the food along the whole length of the oesophagus. It is also absent in the toucans (Ramphastidae). In many species such as ducks and geese (Anatidae) and also in some species of songbirds the oesophagus is only slightly increased in diameter at its caudal end. Swellings at the thoracic inlet that may be occasionally seen in any of these species are not due to an impacted crop.

#### **Crop milk**

Crop milk is produced by pigeons and doves (Columbidae) to feed their young. Its composition is similar to mammalian milk but lacks calcium and carbohydrates. Both sexes of the flamingos and the male emperor penguin also produce a nutritive fluid which is regurgitated to feed the young. However in the Columbidae and emperor penguin the crop milk is produced by desquamation of epithelium, whereas that from the flamingos is a secretion from the merocrine glands of the oesophagus.

### **The stomach (i.e. the proventriculus together with the ventriculus or gizzard)**

There are two basic forms of avian stomach: (1) that of the carnivorous birds in which the food requires less trituration and alternatively (2) the more complex avian stomach found in those birds feeding on much less digestible food, which requires to be physically broken up before enzymatic digestion. Such types of bird are granivorous, herbivorous, frugivorous and insectivorous. There are many intermediate forms between these two basic types.

1. In the simpler stomach the division between proventriculus (fore stomach) and ventriculus (true stomach) is not always easy to discern on external appearance. This type of organ acts largely as a storage zone giving time for the digestive secretions of the stomach to penetrate and act on the food.
2. In the more complex avian stomach the division between the thin-walled proventriculus and the well-developed muscular gizzard is easily recognised. Although the distribution of the digestive secreting glands varies between species, the glands themselves and composition of digestive secretion containing hydrochloric acid and pepsin does not vary. The foul-smelling 'stomach oil' ejected by petrels including the fulmar (*Fulmarus glacialis*) as a means of defence is of dietary origin and not a secretion.
3. In the ostrich the greatly enlarged proventriculus lies caudal to the ventriculus acting as a storage and fermentation chamber as in ruminants. Ostriches graze rather like cattle.

The gizzard itself is lined by a tough cuticle or koilin layer. Koilin is a material secreted by glands and hardened by hydrochloric acid. This can be stained brown, yellow or quite intense green due to the regurgitation of bile pigment. The intensity of this colour and the extent of staining should be noted during autopsy. Sometimes pathological bile staining extends into the proventriculus. Some species, e.g. magpies (*Pica pica*) and starlings (Sturnidae), normally periodically shed the cuticle. In those species in which the gizzard is less well defined the cuticle is thinner and relatively soft. Erosion and necrosis of the koilin layer can be a sign of gizzard worms in ducks and geese and also a sign of megabacteriosis in budgerigars.

In the carnivorous species particularly, the contractions of the stomach form a regurgitated pellet (called by falconers the *casting*) from the indigestible parts of the food, such as pieces of skeleton, claws and teeth. A healthy hawk should regularly produce these pellets. They should be firm in consistency and not smell offensive. It is not generally known that many other species of bird besides hawks and owls also sometimes produce pellets, e.g. thrushes (Turdinae), crows (Corvidae) and herons (Ardeidae).

It is generally thought that parrots are vegetarians but some parrots will take small pieces of meat, and the remains of invertebrates have been found in the stomachs of wild parrots.

### Grit

Grit is taken in by many species with a well-muscled gizzard that, together with the tough koilin layer, helps to grind up food. Although grit is mainly quartz, the size and coarseness of the particles is related not only to the size of the bird but also to the diet. The lesser flamingo (*Phoenicopterus minor*) feeds mainly on algae and diatoms filtered from the water in which it stands so that it ingests a fine sandy grit. The ostrich, which feeds on coarse vegetation, uses pebbles, although captive ostriches have a habit of swallowing unfamiliar objects. The dippers (genus *Cinclus*), some of the diving birds and some species of duck all feeding on molluscs and crustaceans use grit derived from molluscan shells. Even when available not all caged birds will take grit into their gizzard and apparently do not suffer any adverse effect.

### The pylorus, the duodenum and the intestines

All show quite a lot of variation among different species. In fact the number and the way in which the coils of the intestine are arranged was one method used by the Victorian anatomists to classify birds.

In general, as would be expected, the intestines are relatively shorter in carnivores, insectivores and frugivores, in which the food requires much less digestion. The alimentary transit time in some frugivores is relatively short, e.g. in the hill mynah (*Gracula religiosa*)

it is 1½ hours, in the common buzzard (*Buteo buteo*) 3 hours. In the granivorous and herbivorous birds the digestive tract is much longer, being longest of all in birds feeding on a fibrous diet, e.g. the red grouse (*Lagopus lagopus*) which feeds principally on heather (*Calluna vulgaris*). In fact a seasonal change may occur in the length of the intestine in some species, e.g. the bearded reedling (*Panurus biarmicus*), in relation to seasonal changes in the diet.

### The caeca

Left and right caeca are usually present at the junction of the ileum and the rectum but their shape and size varies considerably as is illustrated in Figure 1.8. These normal variations should be familiar to the pathologist.

In some species, such as the parrots, the swifts, the pigeons and toucans, the caeca are either rudimentary or absent. At one time it was thought that the major function of the caeca was the breakdown of cellulose by the action of symbiotic bacteria. However this theory is now in some doubt and the size of the caeca apparently has little relation to the type of avian diet. However the autochthonous flora of the alimentary canal of those birds with well-developed caeca does apparently vary from those birds in which the caeca are absent.

### The gallbladder

A gallbladder is usually present in many species except for most parrots, pigeons and the ostrich. In the cockatiel (*Nymphicus hollandicus*), in rheas, the hoatzin and penguins, its presence is variable. In woodpeckers (Picidae), toucans (Ramphastidae) and barbets (Capitonidae) the gallbladder is exceptionally long in some individuals extending as far as the cloaca.

### The liver

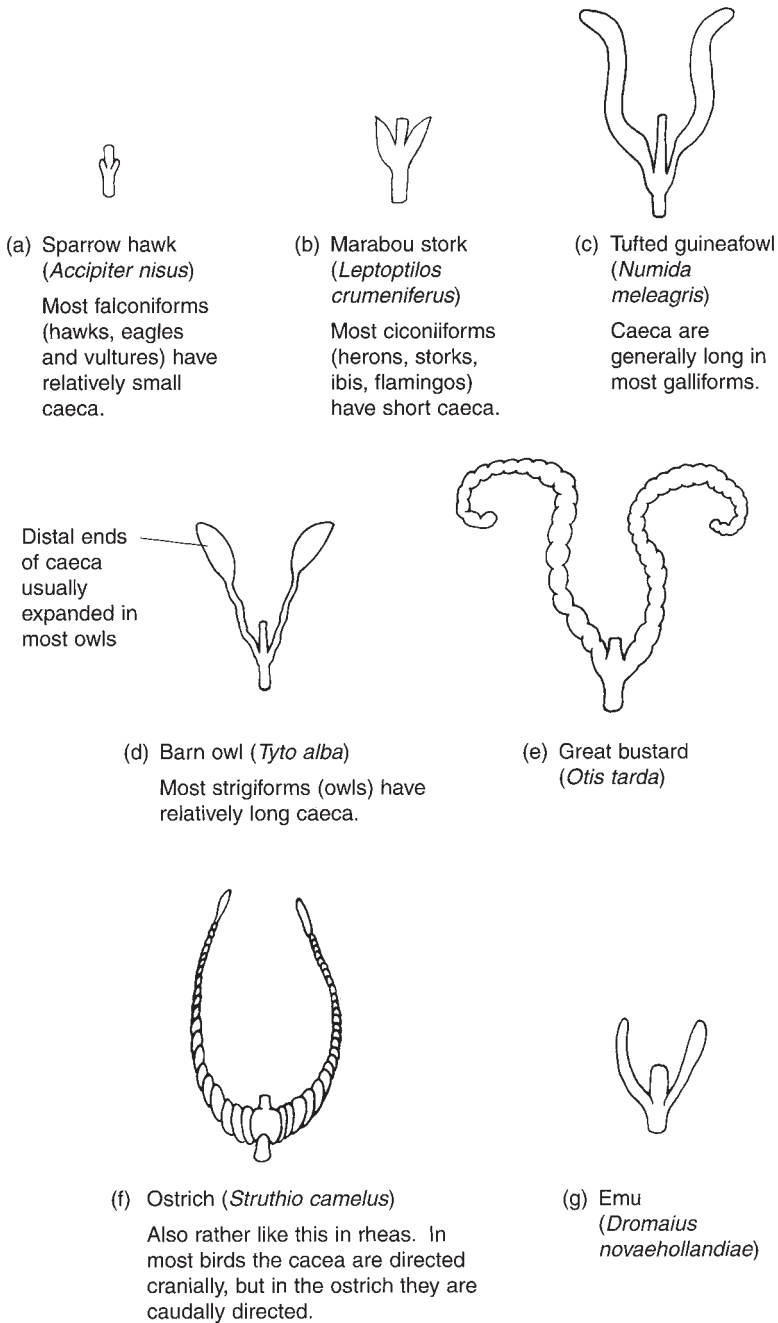
The liver varies slightly in the number of lobes present but there is quite a lot of variation in the normal level of liver enzymes even in apparently fairly closely related genera of birds such as the parrots, see Table 1.1. Knowledge about liver enzymes in birds is very patchy but is slowly accumulating. Awareness of these normal variations is important when using this data to make a diagnosis of hepatopathy (see p. 70). Good references on normal values are in some BSAVA manuals (Benyon 1996; Harcourt-Brown & Chitty 2005).

## THE RESPIRATORY SYSTEM

### The nares

There is a lot of interspecific variation in the size and position of the external nares, knowledge of which is useful when masking birds for the administration of a gaseous anaesthetic. In toucans the nares are oval slits placed transversely at the caudal end of the large bill and partially covered by feathers. In the Procellariidae, i.e. the tubenoses or petrels and the fulmar, they are at the rostral end of a small tube along the dorsal aspect of the upper bill. In parrots the external nares are circular holes in the cere. In gulls and cranes the external nares are placed approximately half way along the upper bill *and pierce this structure*. The gannets and boobies (Sulidae), which are plunge divers, do not have any external nares but breathe through an opening and closing gap at the corner of the mouth. In kiwis the nostril is on the tip of the long probing beak. The bird uses this, together with an increased surface of the caudal conchal cartilage, to smell out its food. Moreover there are extensively developed olfactory bulbs in the brain.

The sense of smell is also well developed in storm petrels (members of the Procellariidae or tubenoses), which navigate by smell back to their nesting burrow in darkness. The South American turkey vulture (*Carthartes aura*) also uses smell to locate carrion hidden



**Fig. 1.8** The different forms of caeca found in birds (after King & McLelland, 1979). In many species the right and left caeca may not be of equal size with one side being almost vestigial (e.g. Ardeidae – herons), also there are many intraspecific differences in length.

No caeca occur in Psittaciformes (parrots), Apodimorphae (hummingbirds and swifts), some Piciformes (woodpeckers, toucans, barbets, honeyguides, etc.), some Columbidae (pigeons and doves) and kingfishers (Alcedinidae) (redrawn after King & McLelland, 1979, by permission of Academic Press Limited, London).



**Table 1.1** Differences in the range of normal blood chemistry values of liver enzymes in apparently healthy parrots.

Species	Number of individual birds data based on	Blood chemistry values						
		ASAT (aspartate aminotransferase) (IU/l)	ALAT (alanine aminotransferase) (IU/l)	GGT (gamma glutamyl transferase) (IU/l)	LDH (lactate dehydrogenase) (IU/l)	CPK (creatinine phosphokinase) (IU/l)	Bile acids ( $\mu\text{mol/l}$ )	
African grey ( <i>Psittacus erithacus</i> )	103	54–155	12–59	1–3.8	147–384	123–875	18–71	
Amazon ( <i>Amazona</i> sp.)	99	57–194	19–98	1–10	46–208	45–565	19–144	
Cockatoo ( <i>Cacatua</i> sp.)	27	52–203	12–37	2–5	203–442	34–204	23–70	
Macaw ( <i>Ara</i> sp.)	16	58–206	22–105	<1–5	66–166	61–531	25–71	

Because of the variation in the maximum and minimum values of the different enzymes in different genera, within this apparently fairly uniform group of parrots, there is an indication of varying liver physiology.

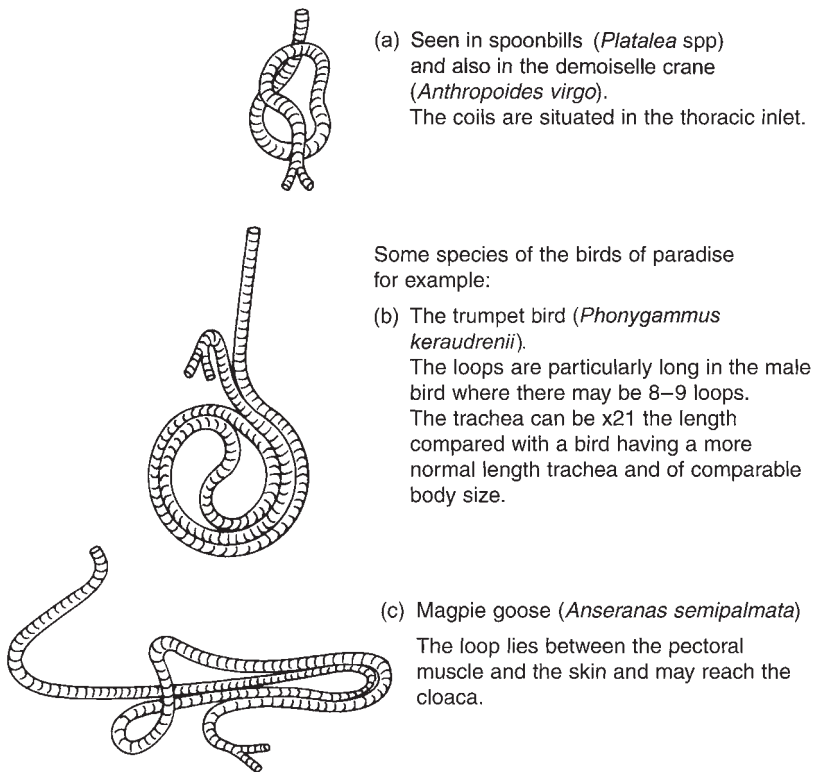
*Clinical significance:* Blood chemistry values of liver enzymes should not be relied upon as the only diagnostic indication of a hepatopathy particularly if the data has not been recorded for a particular genus or species. This information is based on the work of Lumeij and Overduin (1990).

below the tree canopy of the tropical rain forest. In contrast, the African vultures searching the open savannah depend mainly on sight to locate their food. In swifts the caudal conchal cartilage is absent as it is in some Falconides and the olfactory bulb of the brain is small.

The nasal cavity of birds in general tends to be rather long and narrow and of the three nasal conchae the middle cartilage is the largest and acts primarily as a heat exchanger and water conservation organ.

## The trachea

The trachea of birds show quite a lot of variation, as already indicated in the notes on the sternum. In some species it is coiled and elongated (Figs. 1.3 and 1.9). Increased length increases the resistance to airflow and increases the dead space. To compensate for this disadvantage, birds overall have a proportionately greater tracheal diameter when compared with that found in mammals of comparable size ( $\times 1.3$ ), which reduces resistance to air flow, and the tidal volume is also greatly increased ( $\times 4$ ). Moreover the rate of respiration is slower than in mammals ( $\times 1/3$ ). Very few detailed interspecific physiological measurements have been made but some of those that have been determined are shown in Table 1.2.



**Fig. 1.9** The extraordinary shapes of the looped trachea which occur in some species of bird (redrawn after King & McLelland, 1979, by permission of Academic Press Limited, London).

In species where the trachea is looped this may be seen in male birds or, if in both male and female, it is often more marked in the male. It doesn't develop until adulthood and probably has an acoustic function to lower the pitch of the sound of the voice. An elongated trachea may provide an increased area for respiratory evaporative loss.

**Table 1.2** Diversity in some data on the respiratory system in three different types of bird.

	<b>Starling (<i>Sturnus vulgaris</i>)</b>		<b>Pigeon (<i>Columba livia</i>)</b>		<b>Black duck (<i>Anas rubripes</i>)</b>	
	<b>Rest</b>	<b>Flight</b>	<b>Rest</b>	<b>Flight</b>	<b>Rest</b>	<b>Flight</b>
Body mass (g)		78		380		1,026
Respiratory frequency (min <sup>-1</sup> )	92	180	26	487	27	158
Tidal volume (ml)	0.67	2.80	7.2	6.0	30.2	71.0
Dead space volume (ml)		0.22		2.2		6.4
Minute volumes (ml)	61.64	504	187.2	2,922.0	815.4	11,218

Note: The respiratory frequency at rest is not related to body mass. In small passerines depression of the respiratory frequency, which is often caused by anaesthetic drugs, may be of more concern than in the larger species.

The above information is extracted from King and McLelland, 1989, by permission of Academic Press Limited London. This reference contains a mass of information on respiratory physiology of birds but unfortunately only on a very limited number of species.

In penguins the trachea is divided into left and right segments by a medial cartilaginous septum which also occurs in some Procellariiformes. This is important to note if introducing an endotracheal tube. In hummingbirds the trachea divides into the two primary bronchi in the mid-cervical region and in the roseate spoonbill (*Ajaja ajaja*) this division occurs in the caudal two-thirds of the neck. In the male ruddy duck (*Oxyura jamaicensis*) and in both male and female emu (*Dromaius novaehollandiae*) there is an inflatable tracheal diverticulum. All these facts may be important in correctly interpreting radiographs.

### The syrinx

Amongst birds as a whole the syrinx shows considerable diversity. Few anatomical structures can have received so much study, primarily as an aid to taxonomy and because of the interest in vocalisation and bird song. However an attempt at a logical analysis of this structure's function has often only resulted in greater confusion. Many male ducks (sub-family Anatidae) exhibit an ossified dilation on the side of the syrinx called the *syringual bulba*. Again among this group of birds there is some interspecies variation in this structure. This structure can often be seen on radiographs.

### The lungs

In most species the lungs extend from the rib carried on the last cervical vertebra to the cranial border of the ilium. However in the storks, geese and hoatzin it reaches almost to the level of the hip. This results more from the relative increased size of parts of the skeleton rather than from an actual increase in the size of the lung.

The lung is divided into paleopulmo and neopulmo – this part forms 20–25% of the lungs of the more evolutionarily advanced birds. The paleopulmo, which allows a continuous unidirectional flow of air through its parabronchi (see p. 127), is considered to be phylogenetically the most primitive area of the avian lung, and is present in all species. The neopulmo is progressively developed in the more 'evolutionarily advanced birds' and gradually expands over the dorsal and cranial aspects of the paleopulmo starting on the ventrolateral area of this primordial lung. In penguins the neopulmo is entirely absent, so that the whole lung is more triangular in outline than in other species. The neopulmo is minimally developed in the storks and in the emu. It is poorly developed in buzzards, ducks, owls, gulls, cormorants, auks and cranes. In most other orders of bird, including

Galliformes, pigeons and Passeriformes, it is quite well developed. Quite how the neopulmo differs in physiological function from the paleopulmo is not clear except that the parabronchi appear to be arranged more in a network than in strict lineal order as in the paleopulmo so that the airflow may not be entirely unidirectional.

### The air sacs

The air sacs vary considerably in number and size in different orders of birds. Storks have the largest number, with each caudal thoracic air sac subdivided into two parts. In songbirds the cranial thoracic air sacs are fused into a single large median clavicular air sac. In hummingbirds the caudal thoracic air sac is proportionately larger than in all other species of bird. The cervical air sac extends up the neck via the tubular extensions running one on each side of the cervical vertebrae, with one diverticulum inside the neural canal and another externally running through the transverse foraminae formed by the head and tubercle of the vestigial rib. In parrots there is a clinical condition in which there is hyperinflation of this cervicocephalic air sac. This has not been seen in other birds. Possibly this structure is more developed in the parrots as it extends round the caudal part of the cranium and connects with the postorbital diverticulum of the infraorbital sinus.

The medullary cavity of some bones of the skeleton (the sternum, the scapula, humerus, femur, pelvis and cervical and thoracic vertebrae) is pneumonised by diverticula from the air sacs. However in swallows, swifts and some other small birds pneumonisation is minimal. In hummingbirds it is absent. In some aquatic and diving birds, including diving ducks, cormorants, loons, rails and penguins, pneumonisation of the skeleton is also poor or absent. This may be related to reducing the buoyancy of the bird when diving.

## THE FEMALE REPRODUCTIVE SYSTEM

Basic anatomy and physiology is the same for all species. Most species have only a left ovary and a left oviduct. However in some species covering some 16 orders of bird among which are the Falconides (i.e. eagles, hawks, buzzards, falcons and the Old World vultures) and also the Cathartidae (the New World vultures) there are both right and left ovaries and also two oviducts. Nevertheless the right oviduct may be vestigial and non-functional, occasionally becoming pathologically cyst-like. These normal anatomical differences are important to note when carrying out autopsies. Technicians artificially inseminating birds only recognise the left oviduct but fertility rates do not seem to be affected. In kiwis there are right and left ovaries but only one oviduct with a very large infundibulum extending across the whole body which collects ova from both ovaries.

### Breeding maturity in birds

Japanese quail (*Coturnix japonica*) are mature and capable of breeding at 6 weeks. Most seasonal breeders are mature at 11 months and breed in their second year of life. Most medium sized parrots (e.g. Amazon parrots) do not breed until 3–4 years of age (some slightly younger). Macaws are usually at least five years old before they breed, while the albatrosses (Diomedidae) are eight years of age before reaching maturity.

### Eggs

#### Number of eggs, clutches and hatching

In general the larger birds lay one egg (e.g. bustards, petrels, gannets and albatrosses). However some ostriches may lay up to 48 eggs in a clutch. In general tropical birds tend to lay fewer eggs because when the eggs hatch the birds have fewer daylight hours in which to feed the chicks (approximately 12 hours of daylight only). Birds in the more northern or southern temperate seasonal climates lay more eggs and in fact the higher the latitude

the longer the daylight hours and the more eggs are laid even among the same species, e.g. European robin (*Erithacus rubecula*).

Some species, for example the red jungle fowl, *Gallus gallus*, from which domestic poultry are derived) are *indeterminate layers*, i.e. they go on laying eggs particularly if the eggs are removed from the nest. One domestic hen is recorded to have laid 352 eggs in a year. However some hens do become 'broody' and stop laying long before this occurs. The yellow shafted flicker (*Colaptes auratus*) has been recorded to have laid 71 eggs and the wryneck (*Jynx torquilla*) has laid 62 eggs.

Captive cockatiels (*Nymphicus hollandicus*) sometimes lay large numbers of eggs (up to 80) but this is pathological because they are *determinate layers*. Determinate layers lay clutches of a fixed number of eggs, usually four. Such birds are budgerigars (*Melopsittacus undulatus*), the common crow (*Corvus corone corone*), the (common) magpie (*Pica pica*) and the Barn swallow (*Hirundo rustica*).

Most birds lay one clutch of eggs a year but some species such as some of the albatrosses and penguins lay in alternate years. Some birds such as captive barn owls (*Tyto alba*) will lay more than one clutch if being well fed. The interval between individual eggs laid in a clutch varies. Usually it is one egg every 24 hours but the eggs will all hatch at the same time. In raptors, e.g. the goshawk (*Accipiter gentilis*), the eggs are laid at 48 hour intervals and the chicks are also 48 hours apart in age (i.e. the time when they hatch). In the Andean condor (*Vultur gryphus*) the eggs (1–3) are laid 4–5 days apart. In the brown kiwi (*Apteryx australis*) this interval can be in the range 11–57 days.

With the exception of the raptors, where the age and size of chicks in a clutch are noticeably different, in most clutches of eggs the chicks all hatch at the same time, because they are able to communicate with each other while still in the shell and so synchronise pipping times. Pipping, or the initial breaking of the shell, is usually accomplished by the egg tooth on the dorsal surface of the upper bill, but in the ostrich the thick shell (up to 2 mm) is broken by the arching of the powerful complexus muscle which overlies the base of the skull and cranial end of the neck.

### Superficial appearance of eggs

The size, colour and shape of the eggs vary considerably between species. What is not generally appreciated is that the texture of the shell surface also varies. Because of this the porosity of the shell varies and this influences the rate at which water is lost during incubation. In cormorants the egg shell surface is chalky, in flamingos it is powdery, both surfaces being relatively porous and allowing high rates of water vapour exchange in the microclimate of relatively high humidity in which the eggs hatch. Eggs from the same species (e.g. ostrich) laid at the same time but by different individual birds may need to be sorted into batches according to their egg shell appearance before being artificially incubated. The relative humidity of the incubator will need adjusting to suit the egg shell texture of a particular batch. Variation in egg shell texture among farmed ostrich is due to this 'domesticated' bird being derived from a number of original sub-species.

## THE MALE REPRODUCTIVE SYSTEM

The most important variations are in the presence or absence of a phallus. Two main types occur:

1. The intromittent (or protruding) form found in ratites, tinamous, kiwis and Anseriformes (ducks, geese and swans)
2. The non-intromittent type seen in the domestic fowl and turkey and in some Passeriformes (the Emberizinae)

In the intromittent phallus, in the resting position, the phallus lies on the floor of the cloaca and becomes erect by lymphatic engorgement from left and right lymphatic bodies. Semen is conveyed in an external channel, the phallic sulcus. In the emu, cassowaries, rheas and Anseriformes, but not the ostrich, the phallus is filled with a blind-ended long hollow tube which, when at rest, is inverted like the finger of a glove. During erection, also by lymphatic engorgement, the tip of this inversion is protruded. Since the left lymphatic body is much larger than the right, the erected phallus has a spiral twist.

In the non-intromittent phallus, there are two lateral folds (the lymphatic phallic bodies) on the ventral lip of the vent. Between these lateral bodies lies a smaller median body. During ejaculation, which occurs very rapidly, the lymphatic bodies become momentarily engorged with lymph causing the ventral lip of the vent to protrude. This is then rapidly applied to the protruding oviduct of the female. Semen is channelled in the groove formed between the two lateral lymphatic bodies.

A third type of phallus, somewhat intermediate, occurs in the vasa parrots (*Coracopsis vasa* and *C. nigra*). In this type the everted and swollen fleshy bag-like protrusion from the male's cloaca is inserted into the relatively large opening of the female's stretched and expanded cloaca. Male and female may remain locked in copulation for up to 100 minutes (Wilkinson & Birkhead, 1995) (see Plate 15). The cloacal protrusion in the male greater vasa parrot (*C. vasa*) was estimated to be 50–55 mm long by 40–45 mm wide and was freely everted or withdrawn during the breeding season, whether the male was about to mount the female or not. In these circumstances this structure should not be mistaken by the clinician for a pathological prolapse (see Plate 15).

Although not documented because insufficient research has been carried out, it is possible that phalluses of the second two types may occur in other species, although tumescence and detumescence may occur so rapidly as to be not practically observable. In all cases if surgery such as partial wedged-shaped cloacoplasty (see p. 161), for the resolution of persistent cloacal prolapse, is carried out on the ventral area of the male (or female) cloaca this may result in the bird becoming infertile.

### IMPORTANT ASPECTS OF THE EXCRETORY SYSTEM IN BIRDS

- The kidneys in birds are relatively larger than in mammals of the same body mass. In general 26% of avian body mass is kidney, whilst in most mammals this figure is only 0.5%
- The smaller the bird the larger, relatively, is the kidney
- Some species of bird, e.g. marine and desert living, have well-developed salt glands and these birds also tend to have relatively larger kidneys

There are two types of nephron, the *reptilian* (situated in the kidney cortex) and the *mammalian* (located in the medulla). The reptilian type is smaller with a simpler glomerulus. The tubules are straight and folded on themselves but *there are no loops of Henle*. In the mammalian type the tubules are much more convoluted and *loops of Henle are present*.

### Water conservation in birds

Many marine birds but particularly albatrosses and petrels (Procellariiformes), which spend much of their life airborne at sea a long way from land, have well-developed supraorbital salt or nasal glands. They can cope with drinking seawater (3% salt solution). Such glands can secrete salt solution at a concentration of 5%. Even the herring gull (*Larus ridibundus*) can secrete salt solution at the rate of 0.3–0.4 ml/min/g of gland, the concentration of the

sodium chloride solution being 800 mEq/l, whilst that of mammalian urine is only about 30 mEq/l. The supraorbital salt glands are also important in desert-living species of birds which, apart from the lack of fresh water, may be eating a diet containing high levels of sodium chloride.

Not all birds inhabiting arid areas are relatively independent of water. Budgerigars (*Melopsittacus undulus*), which live in the arid central area of Australia, can go for quite long periods without water. However zebra finches (*Poephila guttata*), although found in much the same area, are always near water and are very water dependent.

### The significance of the loops of Henle

Their presence or absence is important because it is here that re-absorption of water and solutes takes place via a counter-current system as in mammals. Moreover the proportion of reptilian to mammalian (with loops of Henle) nephrons varies in different species e.g. Gambel's quail (*Lophortyx californicus*), a desert type, has 90% reptilian and the European starling (*Sturnus vulgaris*) has 70%.

### Re-absorption of water from the alimentary canal

In some birds urine is carried by reflux anti-peristaltic action up as far as the small intestine where water re-absorption takes place. This is best exhibited in xerophilic species. In Gambel's quail the caecal epithelium is modified for this purpose, with a thin epithelium and an extensive microvillous surface.

### The renal portal system

It should be noted that *only* the reptilian nephrons are drained by the renal portal vein. There is a plexus of arterioles and anastomosing venules around the tubules draining the simple glomerulus which then leads into the renal portal vein. The venules from the mammalian nephrons flow directly into the portal vein. Moreover blood flow through the kidney is controlled by the renal portal valve and a complex system of shunts (King & McLelland, 1979). The clinical implication of this is that drugs injected into the legs are not necessarily 'washed out' via the renal portal system before reaching the systemic circulation.

The clinical significance of the interspecific variations of the excretory system amongst birds is important when considering the pharmacokinetics of different drugs and also in some husbandry situations.

# 2

## The Special Senses of Birds

---

**Susan E. Orosz, PhD, DVM, Dipl ABVP (Avian), Dipl ECAMS**

Bird and Exotic Pet Wellness Center Toledo, Ohio, USA

### INTRODUCTION

Birds are unique and wonderful creatures and their senses are an integral part of their makeup. *A greater understanding of their senses can help the avian clinician in his or her daily care of their patients.* There are a number of features that are unique and should be understood when working with them. Since all birds are not created equally, different species have different solutions to acquiring information concerning the external environment in which they live.

There are a number of receptors located on the body surface for perceiving and translating that information for the brain to understand. Neurologically, the somatosensory system is classified based on the location of the dendritic zone for the head, thoracic and pelvic limbs and the body surface. Cutaneous receptors represent the peripheral or dendritic endings of the spinal or cranial ganglion cells. These receptors are excited by mechanical, thermal or noxious stimuli. Stimulation of them is then transmitted to the brain where the quality of these modalities and their location of origin are perceived. The somatosensory system is divided into two parts: the trigeminal system and the spinal system. The trigeminal system innervates the head and the spinal system transmits information concerning the body surface and extremities. In addition to the somatosensory system, there are the “special senses”. Neurologically, these “special senses” are divided into the special somatic afferents and the special visceral afferents.

The somatic afferents consist of the general somatic afferents (GSA) representing cranial nerve V and the spinal nerves to the body. The information processed by the receptors in these locations sends information to the brain stem and the telencephalon. The special somatic afferents (SSA) collect information concerning “wave” function from the external environment for processing in the brain. The SSA includes the visual system and the auditory system. The visual system is involved with processing wavelengths of light and this information travels by cranial nerve II, or optic nerve, to the optic relay area, or optic cortex. The auditory system processes waves of sound using the cochlear division of cranial nerve VIII, or auditory nerve.

In addition to the somatic afferents, there are visceral afferents. The visceral afferents include those that send sensory information from the viscera of the body and the special visceral afferents that translate and send information concerning “chemical” information from the environment. Special visceral afferents include the chemical sense of taste from cranial nerves VII, IX and X and smell from cranial nerve I.



## PROPRIOCEPTION

The brain of any animal requires information concerning the external environment and it needs to know where the body and the head are in three-dimensional space to react and move appropriately. Proprioception, or the understanding of where each joint is at that moment in time, is sent to the brain by the spinal system, in the case of the body, and is termed general proprioception. Conscious proprioception allows the brain to bring to a conscious or knowing level where the body is in three-dimensional space. Unconscious proprioception allows the brain, and more specifically the cerebellum, to know (unconsciously) where the body is in three-dimensional space.

Information concerning conscious proprioception travels from the soma or body wall through the spinal nerves into the dorsal column of the spinal cord called the fasciculus gracilis or cuneatus, depending on where the information originates. From here, it synapses in the caudal medulla and then proceeds as the medial meniscus to the thalamus on to the hyperstriatum and neostriatum. In addition to carrying information about conscious proprioception or kinesthesia, this tract also carries information from the body relating to touch and pressure. This allows the bird to know consciously the precise location where they have been touched and the quality of that touch. The information travels somatotopically so that information from the distal half of the body is arranged medially to the more proximal portion, which ascends laterally in the dorsal columns of white matter in the spinal cord.

In addition to conscious proprioception of the body wall, there is conscious proprioception of the head. Information concerning touch, pressure, and general kinesthesia of the head travels via cranial nerve V, or trigeminal nerve, to the brainstem (pons and medulla), where it synapses in the trigeminal nucleus. Then, like its counterpart from the body, that information moves to the thalamus where it synapses, then proceeds to the neostriatum and hyperstriatum where conscious understanding of these modalities occurs.

As the name suggests, if there is conscious proprioception, there must be unconscious proprioception. This system of unconscious proprioception takes information concerning kinesthesia from the body wall and head using a separate set of white matter tracts to the cerebellum. The information from the body wall travels via the dorsal and ventral spinocerebellar tracts. The dorsal spinocerebellar tract takes information concerning kinesthesia of predominantly the wing or thoracic limb and girdle, while the ventral spinocerebellar tract takes information from the pelvic limb and girdle to the cerebellum for processing. Special proprioception is defined as proprioception of the head. That information travels via the vestibular portion of cranial nerve VIII or the vestibulocochlear nerve to the cerebellum to process unconsciously where the head is in three-dimensional space. Simplistically, the cerebellum understands where the body and head are at any moment. It can, where the cortex makes a willful decision to move, provide the game plan to execute the desired movement in an orderly and smooth fashion when all tracts and receptors are working normally or when “all systems are go”.

## SOMATIC AFFERENTS OF THE SOMATOSENSORY SYSTEM

The skin of birds in most locations is relatively thin compared with mammals. However, the nerve endings are similar in character. Like mammals, they have both free nerve endings and encapsulated nerve endings. The free nerve endings are often supplied by unmyelinated or thinly myelinated axons that include the C-fibers and the A $\alpha$ -fibers. These nerve endings transmit thermal information or nociception. The encapsulated nerve endings

are mechanoreceptors. They are supplied with thickly myelinated fibers of the group II, group I or A $\alpha$  or A $\beta$  type. These different fiber types belie the fact that these fibers transmit their electrical signals at different velocities. For example, the C-fibers have small fiber diameters of approximately 1  $\mu$ m with conduction velocities of less than 2 m/sec. That is slow compared with the large myelinated fibers that approach up to 4–7  $\mu$ m and have speeds up to 15–35 m/sec.

Herbst corpuscles are widely distributed in the deep portion of the dermis of the skin. These multilamellar sensory receptors are similar in structure and function to the Pacinian corpuscles of mammals. The lamellar structure, when displaced, alters the centrally located axonal endings, thereby transducing the mechanical changes into an electrical stimulus.

Herbst corpuscles are found in the feathered skin, in the beak, legs and feet. Many birds have a collection of these corpuscles in an interosseous membrane of the leg and/or feet that is often described as a strand or “Herbstscher Strang” (Schildmacher, 1931). This strand is able to detect vibrations of the ground (Schwartzkopff, 1949) and may even detect earthquakes. Most likely, they pick up the vibrations of a Dremel grinding tool when the avian patient is groomed.

Herbst corpuscles are also found in the beak and in shorebirds, chickens, and psittacine birds. They are congregated near the tip of the beak as a bill-tip organ. Raptors and psittacine birds, both Orders that use the feet and bill like the human hand for food handling, have a large sensory receptor area resulting in a larger representation in the brain. This can be likened to the “homunculus” on the lateral cortex in humans. It is a topographic representation of the human body in the precentral gyrus, the primary motor area.

The mechanoreceptors of the skin detect changes in the feathers of the skin, including turbulence and alterations of the plumage. These changes from normal can stimulate preening or alter flight patterns. It is presumed that feather damage from self-induced trauma is perceived by the brain of the bird.

In addition to Herbst corpuscles, there are Merkel cells and Grandry corpuscles that function as mechanoreceptors. Unlike the epidermally located Merkel cells of mammals, birds have dermally located Merkel cells. These cells may occur singly or in groups and have been found in a variety of locations including the beak and tongue (Toyoshima & Shimamura, 1991), toes (Ide & Munger, 1978) and the feathered skin (Andres & von Doring, 1990). Grandry cells are typically stacked with axons sandwiched between them. They are found in the dermal layer of the bill in ducks and geese and may form part or all of the bill-tip organ.

Thermal receptors appear as free nerve endings that alter their regular spontaneous discharge rate when the temperature of the skin warms (warm receptors) or cools (cool receptors) from normal. Often, when there are rapid temperature changes, there is a corresponding excitatory overshoot.

Nociceptors respond to those stimuli that threaten to damage the skin. This may include mechanical stimuli as well as thermal stimuli. Varying types of nociceptor have been described with a number of them in the feathered skin and beak. They seem to have little spontaneous activity (Necker, 2000).

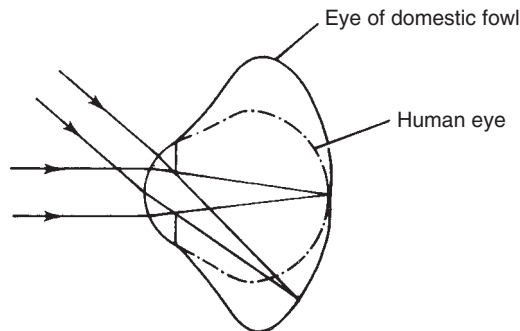
A number of techniques have been used to study the response of birds to pain. In birds studied, there appear to be two types of response to pain: a reflex escape response (or flight or fight response) and the immobility response (conservation/withdrawal). Pain response was evaluated over time using debeaking experiments in chickens, and it was observed that birds have an initial pain-free period of approximately one day followed by a longer-lasting guarding period. *These studies demonstrate that birds experience chronic pain* (Gentle, 1992), something that avian clinicians experientially deal with in their patients.

## VISUAL SYSTEM

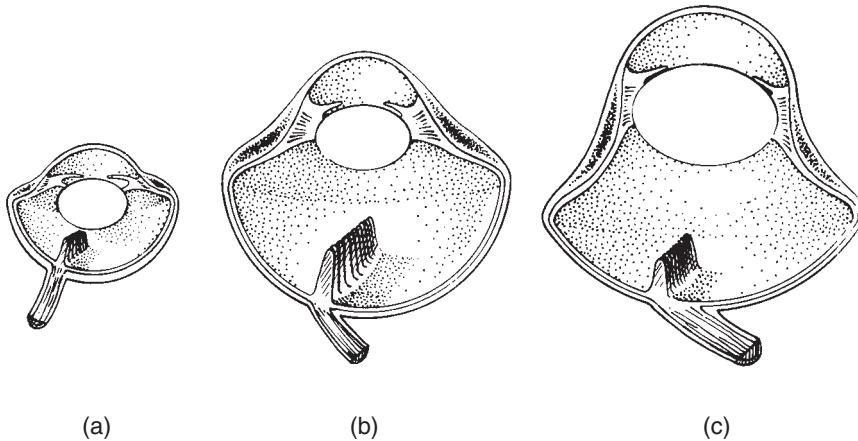
Of all the senses of birds, vision is by far their most important sense. Birds are exquisitely visual animals. This is evidenced by the fact that the cross-sectional diameter of their optic nerves is larger than the diameter of their cervical spinal cord (Portman & Stingelin, 1961; King & McLelland, 1984; Breazile & Kvenzel, 1993). It indicates that, for birds, there is far greater information about the visual world that is transmitted to the brain than for any other animal. The optic nerve represents the large collection of myelinated axons from the ganglion cell layer of the retina. In comparison, humans are highly visual primates but have only 40% of the numbers of retinal axons per optic nerve when compared to pigeons or chicks (Binggeli & Paule, 1969; Rager & Rager, 1978). Raptors have even larger numbers of neurons per optic nerve as their acuity surpasses that of other living beings (Fox, Lehmkuhle & Westendorf, 1976). Studies in pigeons show that they are better than humans in their ability to discriminate luminances (Hodos *et al.*, 1985) and discern subtle color differences (Emmertson & Delius, 1980).

The eyes of birds represent a considerable volume of the head and are very large in relation to brain size. The basic components of the eye are similar to mammals except for the scleral ossicles that help maintain the shape of the globe. Light has to pass through the cornea, anterior chamber, lens and the vitreous body before it reaches the retina. It is in the retina where light energy is converted to electrical impulses by “bleaching” of the photoreceptors. These components of the globe or optic media are very transparent and are able to transmit light down into the near ultraviolet spectrum (at least 310nm) (Emmertson & Delius, 1980). This ability to see into the near ultraviolet allows them to discern ripeness of food items, identify birds within their own species as individuals and to determine the sex within a species that, to us, appears visually as sexually monomorphic (Korbel & Gropp, 1999). *These factors need to be taken into account clinically as humans, for example, determine ripeness by taste not by sight.*

The shape of the globe of a particular species of bird is the result of its ecological requirements (Güntürkün, 2000). Acuity is maximized by increasing the anterior focal length of the eye, thereby allowing the optic image to be spread out over a larger retinal surface (Fig. 2.1). The eye of the ostrich has an axial length of 50 mm, which is the largest of any land vertebrate and twice that of a human (Walls, 1942). Another technique that achieves the same goal is represented in the eyes of raptors particularly noticeable in the owls (Fig. 2.2). Their tubular-shaped globes result in high visual acuity. Part of this is the



**Fig. 2.1** Diagram of the eye of a bird and a man superimposed, the scales being adjusted so that the polar diameters are equal. The avian retina lies near the position of focus for all directions of incident light, but the retina of the human eye lies anterior to the focal surface, except at the bulbar axis. (Reprinted from *Birds: Their Structure and Function*, A.S. King & J. McLelland, p. 286. Copyright 1984, with permission from Elsevier.)



**Fig. 2.2** The ventral half of the left eyeball of (a) a 'flat' eye as in swans, (b) a 'globular' eye as in eagles and (c) a 'tubular' eye as in owls. In all three forms the eyeball consists of a relatively small corneal region, a variable intermediate region supported by the scleral ossicles (dark shading) and a more or less hemispherical 'posterior' region. In all birds the eyeball is somewhat asymmetrical, in that the bulbar axis begins slightly towards the nasal side of the midline (to the right in these diagrams). (Reprinted from *Birds: Their Structure and Function*, A.S. King & J. McLelland, p. 285. Copyright 1984, with permission from Elsevier.)

tubular shape and the remainder is from the high ganglion-cell-to-receptor hookup ratio to increase visual resolution. However, this non-pooled system requires high light intensity to function adequately. Consequently, these daylight raptors have reduced resolution at dusk (Raymond, 1985). *Clinically, this may make it difficult for the bird in a low light hospital cage to locate its food but it may be calmer than at higher light levels.*

Information from the retina is sent to the area which is represented as the superior colliculus in mammals. This is a relay station for visual information. This area is so large in birds that it is described as the optic lobe. It sits dorsally over the midbrain. This reflex pathway is thought to relay information concerning moving objects as occurs in mammals (Rogers & Miles, 1972). It is also involved in enhancing contrast under dim light conditions (Hellmann *et al.*, 1995). This area may also be involved in pecking and food selection.

The position of the eye in the skull varies with the species. Birds with narrow heads, in general, have their eyes laterally placed in their skulls. Birds with broader heads tend to have their eyes directly more frontally. Binocular vision is possible with frontally placed eyes, and reaches its highest representation in the owls. Those birds with laterally directed eyes have bulbar axes oriented from a large angle of  $145^\circ$  (as in pigeons) to a smaller angle of  $90^\circ$  (as with kestrels). The angle formed by the intersection of the line that passes through the center of each cornea and lens to the retina represents the bulbar axis. Monocular vision is when only one eye is focused on the object at a time. This is commonly observed clinically in parrots when they want to fix their gaze on an object. They cock their heads so that the object is parallel to the horizontal axis of the globe so that they can clearly visualize the object. Their highest acuity is in this horizontal line as that axis has the highest density of cone cells in most birds.

Binocular vision occurs when both eyes are fixed on an object and the two eyes act in concert. Birds with a wide bulbar axis have reduced binocular vision, while those with broad heads have increased binocular vision. Binocular viewing doubles visual acuity, while monocular vision of frontally placed objects results in much reduced acuity. Birds tend to use their lateral visual fields (superiotemporal) for detailed inspection of distant objects. The lateral monocular field of vision is at the area centralis of the globe.

Checking for visual field impairment clinically is very difficult due to the stoic nature of avian patients. *Dropping cotton balls from various locations to demonstrate response to lateral monocular and more centrally directed binocular vision can be helpful.*

Blindness may be determined by placing objects in the path of the patient when it is placed on a flat, unfamiliar surface and letting it maneuver. However, this provides just a gross clinical observation as some birds can perceive light in a darkened room but bump into objects – suggesting partial loss of visual fields or possibly “cortical” blindness. Cortical blindness occurs when the informational pathway to the brain is intact but the higher centers scramble the image so that the bird acts blind.

### **Visual acuity**

Birds have remarkable visual acuity stemming from several anatomical features, including the relative size of the eye and the focusing accuracy on the retina (King & McLelland, 1984). Birds may possess one or more foveas, depressed areas of the retina, which may magnify the image. Further gains in acuity occur because there are no blood vessels in the avian retina.

Visual acuity is also enhanced in birds by the makeup of the ganglion cell hookup in the retina. Diurnal birds have a preponderance of cones over rods over the entire retina. Cones are responsible for visual acuity and color vision. (Humans have an even greater cone density than birds.) The retina of *diurnal birds has a one-to-one hookup between the cone cells that synapse with a single bipolar cell, which in turn synapses with a single ganglion cell* (Fig. 2.3). This one-to-one relationship results in added “pixel” information to the optic lobe of the brain in birds. In the diurnal hawk, the fovea has about 300,000 cones/mm<sup>2</sup>, compared to a human’s 147,000 cones/mm<sup>2</sup> (King & McLelland, 1984).

Rods on the other hand are sensitive to the intensity of light, with *nocturnal birds having some cones, but mostly rods. It appears that several rods synapse with a single bipolar cell and several bipolar cells synapse with a single ganglion cell. This convergence enhances visual sensitivity to limited levels of light.*

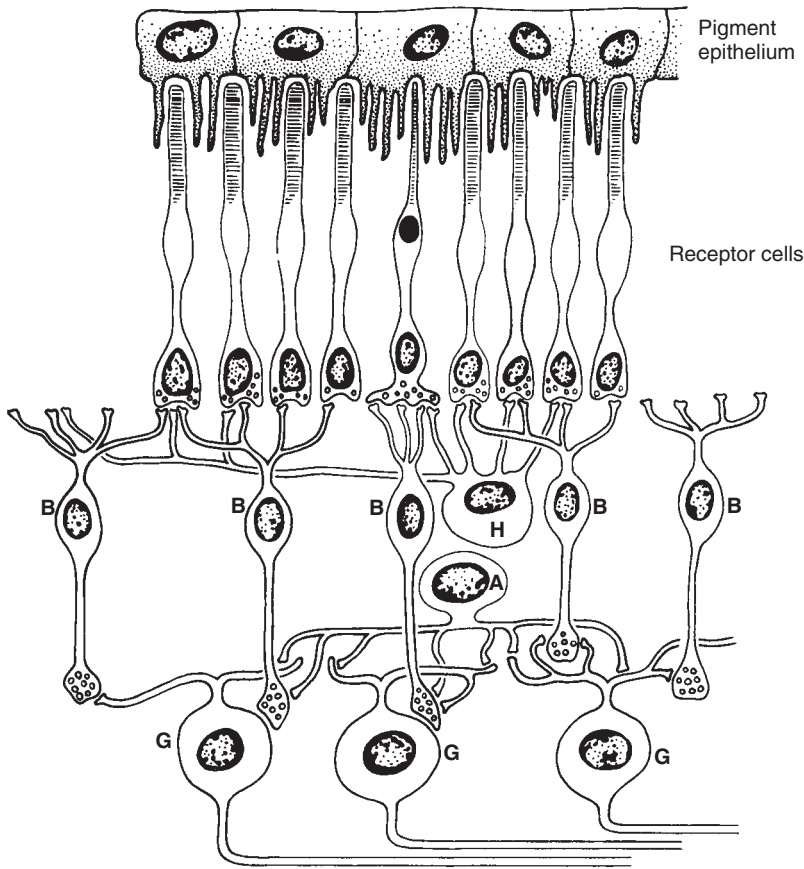
Birds also benefit from the presence of oil droplets in the avian cone cells that, among other things, increase the contrast between an object and its background.

The result of all these visual factors is that birds, especially diurnal birds, can see a panorama as a focused whole, allowing them to identify small features across the landscape with a glance. For example, the acuity threshold of the American kestrel would enable it to discriminate 2 mm insects from 18 meters when light was bright. However, birds’ visual acuity drops rapidly as light is dimmed. The visual acuity of humans, in contrast, is best around the fovea, a very small part of their visual field.

Birds’ ability to see and follow fast stimuli at a distance may present problems in the clinic or household. Glass windows may present too much of a view to a companion bird, if hawks or other predators may be visible. To minimize this potential and the stress created by this problem, the cage of companion birds should be placed partially away from the window and with a visual escape that acts as a hide behind a partial barrier.

### **Ultraviolet vision**

The combination of cone pigments and oil droplets increases the spectral sensitivity of the avian cone, expanding the range. In addition, pigeons have been shown to see (Remy & Emmerton, 1989) and discriminate between objects in the ultraviolet range (Emmertson, 1983). Pigeons and other species may use the UV spectrum to discriminate other birds and the ripeness of fruit reflecting UV light (Burkhardt, 1989).



**Fig. 2.3** Simplified 'wiring' diagram of the retina. The four rods on the left converge onto one bipolar neuron (B). So also do the four rods on the right. The ganglion cells (G) on the right and left receive synapses from two or more rod bipolar cells. Thus many rods converge on one ganglion cell. In contrast the single cone in the middle (identified by its oil droplet) may project onto a single bipolar cell, which in turn may project onto one ganglion cell, thus creating a 'private line' for the cone. The horizontal cell (H) and the amacrine cell (A) cause divergence of neural activity from side to side. (Reprinted from *Birds: Their Structure and Function*, A.S. King & J. McLelland, p. 292. Copyright 1984, with permission from Elsevier.)

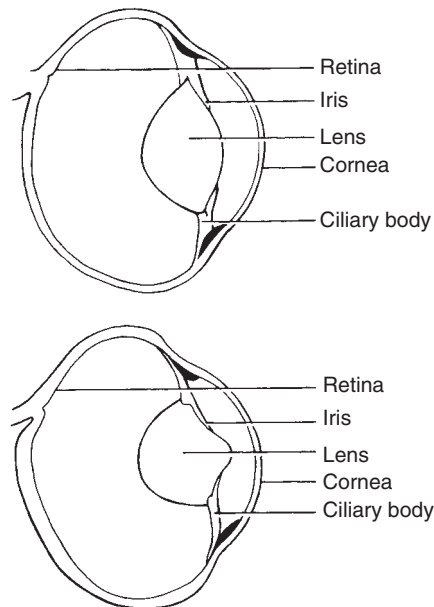
### Flicker frequency

Diurnal birds are able to discern a much faster flicker of light than the ultraviolet spectrum, with pigeons able to discern between individual flashes at a rate of 140/sec, or 140Hz (King & McLelland, 1984). Budgerigars can distinguish between 115Hz light and steady light (Ginsburg & Nilsson, 1971) and some raptors can distinguish as high as 160Hz, depending on light intensity and contrast (Korbel & Szoelgyenyi, 2001). This is in contrast to the maximal rate in man of 70/sec (King & McLelland, 1984). Fluorescent lighting (including low energy light bulbs), in comparison, cycles as high as 100Hz in Europe or 120Hz in the United States, perceivable to many birds, including chickens (Korbel & Szoelgyenyi, 2001). *To avoid this flicker, an increased flicker frequency of fluorescent lighting should be used in hospitals housing avian patients (see Table 9.1). Alternatively, incandescent lighting may be used.* Birds then are also better able to detect and follow movement.

Accommodation occurs when the eye is able to focus on objects at various distances. Birds are able to accomplish accommodation using a number of intriguing techniques that are species-dependent and, in part, based on the visual medium and/or water. In general, accommodation is achieved by changes in the corneal curvature and by changes in the shape of the lens. Additionally, the asymmetry of the globe allows some birds to keep objects on the ground in focus irrespective of their distance. This results in lower visual field myopia in some species like the Ciconiiformes; in these species, myopia can be overcome by adjusting the attitude or plane of the head in relation to the ground. However, this adaptation does not occur in a raptor, which requires a fast-paced attack.

Birds have skeletal ciliary muscles that act on the cornea and lens instead of smooth muscle, as occurs in mammals. Although these muscles are skeletal, they are still innervated by cranial nerve III, the same nerve used in mammals. Unfortunately, willful control of pupillary constriction makes assessment of cranial nerve III (afferent) and cranial nerve VIII (efferent) impossible using the direct and consensual light response of mammals. Dilating the pupil for retinal examination is also technically difficult without the use of skeletal muscle blocking agents (d-tubocurarine) (see also p. 47). Since this is technically difficult and may have serious consequences, *dilation can be achieved by placing birds in darkened rooms for visual examination.*

Many of the diurnal birds compress the entire lens using the posterior sclerocorneal muscle for accommodation. This forces the ciliary body against the lens, thereby increasing its curvature and sharpening the image when it gets closer. Another technique used by hawks and nocturnal birds to change the corneal curvature is compression of the front of the lens; this alters the refraction of light. The center of the cornea is most affected (Fig. 2.4).



**Fig. 2.4** Diagrammatic sagittal sections of the eyes of the hooded merganser with accommodation relaxed (top) and with accommodation induced (bottom). Coordinated action of the sclerocorneal muscles and the sphincter muscle of the iris have forced the lens against the iris so that the central part of the lens bulges through the pupil. (Reprinted from *Birds: Their Structure and Function*, A.S. King & J. McLelland, p. 287. Copyright 1984, with permission from Elsevier.)

Diving alters accommodation as the change to a water/corneal interface from an air/corneal interface requires an additional 20 diopters of refraction due to the loss of corneal refraction. Birds that dive handle this problem in three different ways. One method is to keep sight suited for the air/cornea interface: Terns appear to be unable to accommodate underwater and are therefore long-sighted or hypermetropic. However, they employ a successful strategy of detecting fish from above and then plunge diving. Penguins, on the other hand, are myopic or short-sighted on land, but see accurately when underwater. A third strategy is used by many diving birds including cormorants, diving ducks (e.g. hooded merganser) and dippers. These birds are able to see well both in the air and underwater by having a very soft lens and well-developed sclerocorneal muscles. In these birds, the lens literally bulges into the pupillary space, thereby increasing the curvature to enhance visual acuity underwater (Fig. 2.4).

### **Oil droplets and the perception of ultraviolet light**

The lens of birds does not have the yellow filter as in mammals, a fact that allows ultraviolet (UV) radiation to pass through the avian globe. However, many birds have oil droplets in the cone cells of the retinas. The oil droplets have been shown to act as cut off filters to the UV light, thus providing a protective shield like the yellow lenses of mammals (Emmerton, 1983). The oil droplets are found in the distal inner segment of the cones. Additionally, there are at least five colored types of oil droplets and their color range is based on the presence and the concentration of carotenoids including red, orange, greenish-yellow, pale and transparent (Varela, 1993). These oil droplets can be mixed in a variety of ways along with the numbers of cone pigments to increase their spectral sensitivity, with a maxima of 370–580nm (Chen & Goldsmith, 1986).

Another unique feature of birds is that these oil droplets have a differential distribution throughout the retina. In pigeons, there is a dorsotemporal accumulation of red and yellow droplets or “red field” with the remainder consisting of greenish-yellow droplets or “yellow field” (Galifred, 1968). Data suggests that this difference results in altered behavior depending on the part of the retina (i.e. red field or yellow field) that is used. It also appears that the yellow field has enhanced UV sensitivity (Remy & Emmerton, 1989). Pigeons have been shown to be able to discriminate between objects in the ultraviolet range (Emmerton, 1983). This is important for discriminating the plumage between birds to allow them to distinguish sex as well as individuals. It is also important for determining ripeness of their food items as ripe foods reflect UV light differently than unripe fruit (Burkhardt, 1989).

The eye blink used in the clinical neurologic exam has a sensory and a motor component. The sensory component is from the optic nerve, or cranial nerve II. The axons of the ganglion cell layer of the retina become the optic nerve when they emerge from the globe. This nerve in birds almost entirely decussates at the optic chiasm before traveling to several locations. Many of the fibers travel to areas that are involved with interpretation of the optic stimulus. Other fibers travel to an area that is called the superior colliculus in mammals. In birds, this area is often so large that it has been termed the optic lobe. This large collection of nerve fibers and cells lies dorsal to the midbrain just rostral to the cerebellum. This system associated with the optic lobe represents the centrifugal pathway and contains two cell groups: the isthmo-optic nucleus (ION) and the ectopic isthmo-optic neurons (EION). In seed and fruit eaters, the ION appears large, well differentiated and laminated and is arranged somatotopically. In raptors, these cell bodies are small suggesting that this system is associated with pecking and visual food selection of static stimuli. However, other studies demonstrated profound deficits in the detection of suddenly occurring moving stimuli and grain on a checker-board pattern. These data suggest that, as in mammals, this centrifugal system plays an important role in detecting moving objects and enhancing contrast under dim lighting conditions.



The tectofugal pathway transmits axons from the retina to the optic tectum. The optic tectum projects to the thalamus which then sends fibers to the ectostriatum, homologous to optic cortex of mammals. From here, fibers project to forebrain nuclei for interpretation. Birds have excellent visual memory as some use this for caching food while others use this ability for homing. Clarke's nutcrackers have been found to cache up to 6,600 food items and are able to remember where they are stored. Pigeons are capable of concept discrimination with great flexibility regardless of whether the target concept is biologically significant or not. This information demonstrates the amazing ability of birds, particularly of their optic system. For a long time humans were considered superior due to their cerebral cortex with its gyri and sulci compared with the smooth lissencephalic brain of birds. *These recent data suggest that birds have the ability to interpret and store complex visual information for periods of time.*

## AUDITORY SYSTEM

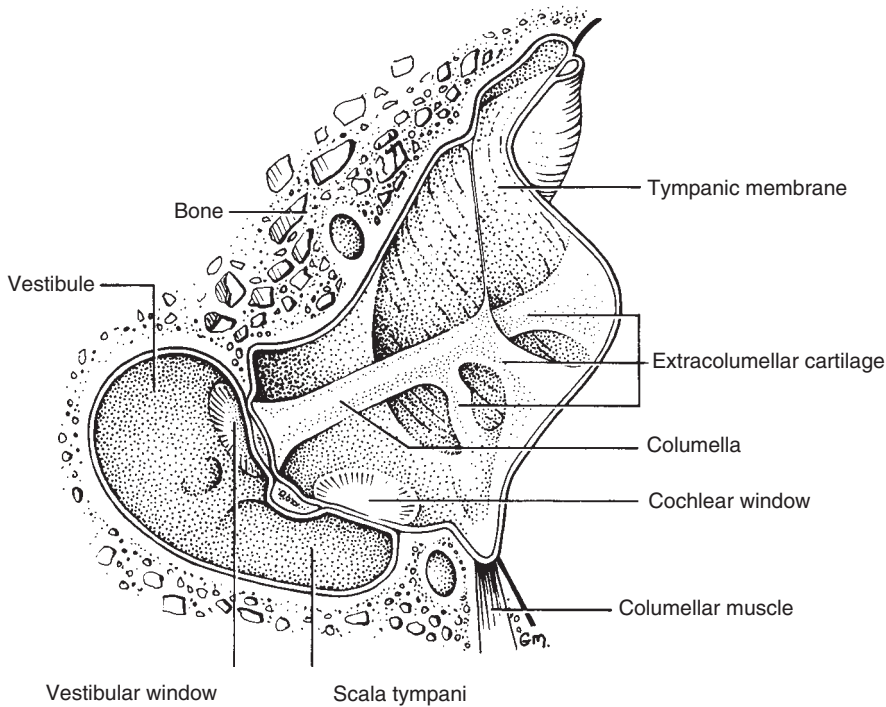
The auditory system of birds is the most highly evolved among non-mammals. Birds are endowed with sensitive hearing and are masters of vocal communication. The mammalian ear is considered to be more specialized than birds but that does not mean it is inferior in acoustic performance. The upper limit appears to be around 20 kHz but birds tend to hear best between 3–10 kHz. There are a few birds that are able to hear infrasound, as can elephants.

The process of hearing depends on the anatomy and physiology of the ear and its processing in the central nervous system. In general, the airborne sound waves enter the external acoustic meatus causing movement of the tympanic membrane. The oscillations of this membrane set up a wave motion of endolymph by movement of its single ossicle, the columella. This wave of fluid that is produced at the vestibular window causes movement of the membrane suspended within the labyrinth (Fig. 2.5). The suspended basilar membrane has on its surface sensory papillae or hair cells that are neuroepithelial receptors (Fig. 2.6). Excitation of the hair cells results in stimulation of the cochlear nerve, part of cranial nerve VIII, the vestibulocochlear nerve. Cranial nerve VIII transmits this wave information from air to components of the brain for auditory interpretation with vocal communication and appropriate behavioral responses.

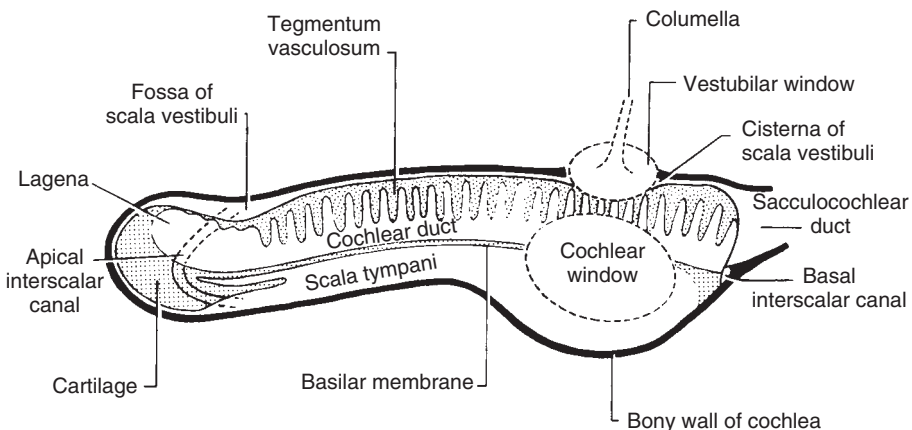
### External acoustic meatus

The external acoustic meatus opens on the side of the head caudal and distal to the eye. Its relatively small opening is often circular and covered by specialized covert feathers that appear "different" to the others of the head. This is because these feathers often do not have barbules. The lack of barbules reduces turbulence by reducing drag when the bird is flying. Turbulence could cause sound distortion thereby reducing sound perception. Clinically, the meatus should be inspected visually, particularly with concern for infection and for accumulation of blood post head injury.

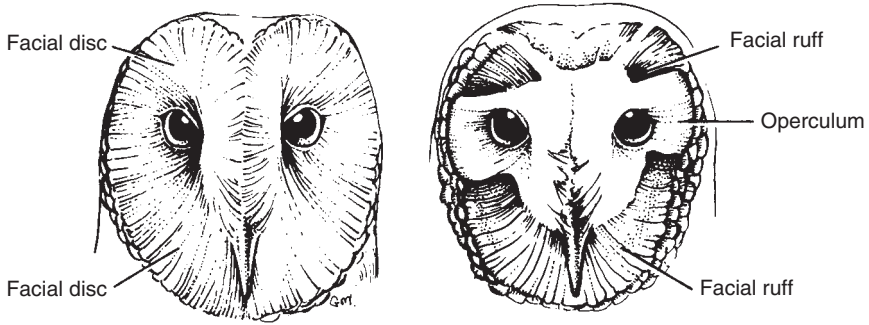
In addition to the reduction in turbulence, these coverts are often shaped to form a funnel to direct sound into the acoustic canal. Additionally, owls have an operculum which is a moveable flap of skin covered with feathers. This produces a cupping effect to help direct the sound into the external ear canal. Some species, including barn owls, have a facial ruff that helps direct sound into the meatus (Fig. 2.7). This ruff consists of small, stiff curved feathers that channel the sound peripherally to a localized area around the head. Owls and other birds have their ear canals located asymmetrically to each other to enhance acoustic location. There may also be asymmetry of both the middle and inner ear cavities within the skull as well. Diving ducks have feathers that are tightly applied to the external acoustic meatus to keep water out while diving. Some divers are able to close their external acoustic meatus completely when diving.



**Fig. 2.5** Diagrammatic transverse section through the right middle ear of the domestic fowl. In the diagram, dorsal is upwards and lateral is to the right. Ossicular conduction from the tympanic membrane to the vestibular window is achieved by the columellar complex, consisting of the extracolumellar cartilage laterally and the bony columella medially. The columellar muscle attaches to the tympanic membrane rather than to the columella, but is innervated by the facial nerve. The vestibular and cochlear windows have both been partly transacted by the plane of the section. (Reprinted from *Birds: Their Structure and Function*, A.S. King & J. McLelland, p. 304. Copyright 1984, with permission from Elsevier.)



**Fig. 2.6** The cochlea of a songbird. The cochlear duct is bounded on one side by the basilar membrane, which carries the sensory acoustic epithelium of the papilla basilaris, and on the other side by the thick-folded tegmentum vasculosum. The scala vestibuli is vestigial, but remnants of it persist apically as the fossa of the scala vestibuli and basally as the cistern of the scala vestibuli. The scala tympani and the remnants of the scala vestibuli connect with each other via the apical interscalar canal and the basal interscalar canal. (Reprinted from *Birds: Their Structure and Function*, A.S. King & J. McLelland, p. 306. Copyright 1984, with permission from Elsevier.)



**Fig. 2.7** Facial disc, facial ruff and operculum of the barn owl. In the drawing on the left the facial disc is intact. In the drawing on the right the facial disc has been removed to show the facial ruff and the operculum on each side. The left and right opercula are asymmetrical. The external acoustic meatus lies between the operculum and the facial ruff. (Reprinted from *Birds: Their Structure and Function*, A.S. King & J. McLelland, p. 302. Copyright 1984, with permission from Elsevier.)

### The middle ear

The function of the middle ear is to transduce sound waves to fluid waves. The cavity of the middle ear is air-filled. It sits between the tympanic membrane and the inner ear and is partially surrounded by bone. The tympanic membrane, forming its outer boundary, is connected by a single bone, the columella to the vestibular window (Fig. 2.5). The columella is homologous to the mammalian stapes. The incus and malleus of mammals are comparable to the quadrate and articular bones (see p. ●●), respectively, of birds. However these bones are not involved in the transformation of sound.

Like mammals, birds have a muscle that can alter the tension of the tympanic membrane, the columellar muscle. Although this muscle is homologous to the stapedius muscle of mammals, it functions like the mammalian tensor tympani muscle. The columellar muscle is innervated by the facial nerve, CN VII, the cranial nerve to the second pharyngeal arch. The tensor mainly acts to attenuate sound at the upper and lower ends of its range. This may allow the bird to select a frequency range for hearing in the most sensitive portion of their range (i.e. for song, a range for vocal communication in songbirds).

The sound wave vibrates the tympanic membrane which results in movement of its attached extracolumellar cartilage. This cartilage is attached to the columellar bone that ends at the vestibular window. Vibrations of the tympanic membrane cause movement of the vestibular window which in turn sets up fluid waves within the perilymph. Compression by the columella into the perilymphatic space causes an outward movement at the oval window, which is found near the vestibular window. The middle ear has to transform large amplitude sound waves to smaller amplitudes with greater force at the cochlear or vestibular window. The physics of this action helps define the range that the bird is able to hear. Most birds hear best above 2kHz and below 10kHz. It appears that the decrease in amplitude results from the energy lost in the flexing motion of the extracolumellar cartilage.

### The inner ear

The inner ear of birds is basically similar to that of mammals. It consists of a bony labyrinth that encloses a membranous labyrinth. The bony labyrinth includes the vestibule, semicircular canals and the cochlea. The space between the bony and the membranous labyrinths is filled with perilymph while the fluid contained within the membranous

labyrinth is endolymph. Part of the membranous labyrinth includes components of the vestibular system which provides sensory information as to the location of the head in three-dimensional space. These components consist of the utricle, saccule and the semicircular canals. The cochlear duct transforms the fluid wave to electrical signals concerned with hearing only – it is not involved with the position and the movement of the head.

The avian cochlea differs from that of mammals in that it is not spiral but short and only slightly curved. However, the cochlea of owls is longer than that of other birds. Within the cochlea is the cochlear duct. It is separated from the vestigial scala vestibuli by the thickly folded vascular tegmentum vasculosum and separated from the scala tympani by the basilar membrane, containing the neuroepithelial cells or hair cells. Each hair cell contains a single kinocilium with up to 100 stereocilia and their tips are embedded in the tectorial membrane. This membrane is more massive than that of mammals. When shearing stresses are produced by the movement of the tectorial membrane in relation to the hair cells, these negatively charged receptor cells are then electrically stimulated. The hair cells are morphologically distinct and hence have different functions as they relate to hearing.

It is interesting that birds have comparable acoustic acuity to mammals but have a cochlear duct that is significantly reduced in length. The bird is able to make up this difference in a number of ways. Even though the duct is shorter, the basilar membrane is considerably wider, allowing more hair cells per unit length. The hair cells form a continuous ridge along the basilar membrane in birds and contains up to ten times the number of hair cells in cross section. Therefore, the total number of hair cells may be similar between birds and mammals.

### **Auditory performance**

The auditory performance of birds differs from mammals in several aspects. The discrimination of pitch is about the same between birds such as songbirds and parrots, and humans. It appears that humans can hear tones slightly higher or lower than birds, but birds have much greater temporal resolution (up to ten times greater) than humans. That means that in songbirds in particular, their song would need to be slowed down by a factor of ten for the human ear to hear all of the details in the song burst.

Directional analysis by the auditory system of the sound's origin depends on the species of bird. Localization of sound appears to be similar in diurnal birds compared with humans. When the song is repeated or contains a full range of transients, it helps improve localization. The barn owl has the ability to localize sound better than any other terrestrial animal and is the source for study in sound localization. Locating the sound source uses binaural hearing, defined as information derived from the convergence of neurons from both ears to the auditory brainstem. The main binaural cue is the interaural time difference (ITD) detected between the two ears by the brainstem. These differences are used to create a topographic map of ITD for spatial position in the horizontal plane using the relative timing of the sound source from the two ears.

Owls have the ability to discriminate changes in the location of sound sources that are as small as 3° apart and can aim their heads within 2° of the source. They have a spatial map in their midbrains that is much larger than their behavioral perception. For example, a typical neuron has a spatial receptive field that spans 40° – many times wider than the behavioral threshold (Bala *et al.*, 2003).

### **Sound production and vocal learning**

Hearing represents the sensory component of the motor response, vocalization. Studies of vocalization and vocal learning are providing further information about the avian brain and its processing. For example, the mammalian basal ganglia and its connections with the thalamus and cortex are important for motor control and cognitive function. It appears

that the avian brain has a closed loop for vocal learning that is similar to that of mammals (Luo *et al.*, 2001). *This suggests that birds have an ability comparable to that of mammals to learn and should not be relegated to second class citizen status in the animal world.* This has important implications from a lab animal perspective and a humane one as well. Studies in Amazon parrots of contact calls demonstrate that there are vocal dialects. Studies show that related species in a geographic area have similar dialects. This suggests that it is not genetics and culture but regional diversity that promotes social learning.

## AVIAN INTELLIGENCE

Social learning is thought to increase brain size regardless of species. When the brain of corvids is compared with that of chimpanzees, its size is similar when body size is taken into account. The forebrain of corvids and parrots is larger than that of other species of bird with less complex social interactions. The areas that are larger are analogous to the prefrontal cortex and this suggests that this results in an increase in intelligence. Parrots, corvids and other birds are capable of tool use and manufacture. Tool use can be defined as the use of an external object that acts as an extension of the mouth, beak, hand or claw for the attainment of an immediate goal (Emery & Clayton, 2004). Birds are capable of complex cognition in the use of tools as they can take novel materials to solve their problems for retrieving food.

Birds are able to understand time and space. This is often shown in their ability to cache foods that are stored either seasonally or for shorter periods (see p. 316). The seasonal foods are acknowledged to withstand caching for long periods while the composition of the perishable items are understood and retrieved at appropriate times for that particular item. This requires different cognitive abilities for caching, understanding the item and environmental temperatures over time and retrieval. Birds are also able to understand cache protection and pilfering. These studies suggest that certain species use causal reasoning and have flexibility in their strategies for learning to be successful as a species and as an individual.

Studies have shown that birds such as the Clarke's nutcracker have visual memory for over 6,600 caches of stores containing 33,000 seeds (Van der Wall & Balda, 1977). The lowly pigeon has not been considered the smartest bird but they have been found to understand visual concepts of "animals" (Roberts & Mazmanian, 1988) as well as "same" versus "different" (Wright *et al.*, 1988). They are also able to rank optic patterns by using transitive inference logic (Gütürkün, 2000; von Fersen *et al.*, 1992). Clinical observations by the author show that parrots know the difference between individual dogs, as they love to call them by name, and they know humans as individuals as well.

Memory of visual images and working memory are also observed in birds. It was supposed that working memory – the ability to temporarily store and manipulate currently relevant information – was the consequence of a prefrontal cortex and a neocortex containing grey matter. However, birds are able to handle working memory without a laminated neocortex. Instead, they appear to use their neostriatum caudolaterale. Data demonstrates that even though they do not possess the same anatomic components as mammals, they evolved neuronal mechanisms to master equivalent cognitive demands (Diekamp *et al.*, 2002).

## GUSTATION OR TASTE

Birds have relatively few taste buds when compared to other vertebrates, yet taste is important in determining food acceptance and avoidance for birds (Koutsos *et al.*, 2001). Taste buds are distributed throughout the oropharynx, often in close association with

salivary gland openings (Berkhoudt, 1985). Parrots have been reported to have 350 taste receptors, compared with 9,000–10,000 in humans (Berkhoudt, 1985). In parrots, taste buds are located on the roof of the oropharynx on either side of the choanal opening, and on the floor of the oropharynx at the rostral end of the laryngeal mound (see p. 11). Birds are presumed to have low acuity to taste, but pigeons may have relatively high acuity (King & McLelland, 1984).

The avian taste bud does not open directly onto the epithelial surface. This suggests that saliva would be important to the transference of the chemical sense to a mechanical nerve ending associated with the taste bud. While birds do not have large organized salivary glands, they have small glands sprinkled throughout their oropharynx. These glands produce the necessary saliva for the mechanical deliverance of the chemicals from food to the taste bud. Interestingly in chicks with a vitamin A deficiency, they did not exhibit customary avoidance of foods they would normally reject.

Information from the taste buds is transmitted to the brain via cranial nerves VII and IX, with about 20–30 axons entering a typical taste bud (King & McLelland, 1984). Although most of the chemical sense of birds is toward avoidance of a noxious compound, their taste preferences are not well documented. Studies suggest that some species may have keener abilities of nutrient detection, whereas others have sharper toxin avoidance capacities (Koutsos *et al.*, 2001). While we humans may enjoy something and project that a bird may like it, our taste preferences may serve the bird poorly.

Many species including parrots, budgerigars and nectar feeders have a preference for sweetness using natural sugars mixed with drinking water (Kare & Rogers, 1976; Stromberg & Johnsen, 1990). Yet, cockatiels favor ordinary water over sugar water. Finches in the family of Carduelidae have a great preference for salt (Mason & Espailat, 1990). Birds without a nasal salt gland tend to refuse foods with a concentration that is hypertonic to their body fluids (Bartholomew & MacMillan, 1960). Birds may be tolerant of sour but this tolerance is species dependent. Cockatiels are more sensitive in detecting organic acids than inorganic acids (Matson *et al.*, 2001). In general, birds tend to avoid inorganic acids. Finally, studies suggest that cockatiels are more sensitive to those “ecologically relevant” compounds (i.e. toxic secondary compounds in the case of a granivore, sugars for nectarivores, etc.) and less sensitive to those compounds that are unlikely to be encountered (Koutsos *et al.*, 2001). These data suggest that food preferences are individualized to species. *Clinicians may benefit from learning preferred foods for a species and for individual patients; this can be especially valuable when a bird is cachexic and is being reintroduced to food. Their avoidance of inorganic acids most likely reflects the bird avoiding medications and drugs which are predominantly inorganic acids.*

## CHEMICALLY INDUCED PAIN – CHEMESTHESIS

The chemical senses of birds include their ability to taste and their ability to smell. Chemesthesis is the perception of chemically induced pain. Sensitivity to chemical irritants is adaptive so that they avoid actual physical damage by avoiding noxious stimuli. The sensory input for this chemical avoidance sense in birds appears to be components of the trigeminal nerve (CN V). It seems that birds rarely avoid mammalian irritants even though the trigeminal nerve is responsive to the chemical stimuli (Mason *et al.*, 1989; Mason & Otis, 1990).

Many aromatic chemicals are aversive to birds on a purely chemical basis. This aversive quality is unlearned, it appears on the initial contact, and there is no evidence that aversion is altered by gastrointestinal (GI) feedback. Further, birds do not seem to associate aversion of the stimulus with other chemosensory cues, suggesting that conditioned flavor avoidance learning does not occur (Clark, 1995). It has also been determined that birds do not habituate to the stimulus so that the avoidance persists without reinforcement

(Clark & Shah, 1994). *As a result, oral medications may continue to be refused despite frequent attempts to habituate a bird to their taste.*

Behavioral studies confirm that birds can distinguish certain tastes, but in general the acuity of taste is less than that of mammals. However, pigeons have relatively high acuity (King & McLelland, 1984).

## OLFACTION

While birds rely on their sense of sight for survival, it is not the only sense used in food identification or for navigation. While the optic lobe was enlarged during evolution at the expense of the olfactory lobe, olfactory stimuli do play a significant role in physiology and behavior. The full role is still being explored.

The olfactory region of the nasal cavity is located within the dome of the caudal nasal concha. The nasal surface of the concha is lined by an olfactory epithelium, where odors diffuse across the mucous membrane to receptor cells. The axonal processes of the receptor cells form the olfactory nerve (CN I) and end in the olfactory bulb of the brain. The size of the olfactory bulb relative to the brain varies greatly: the smallest occurs in parrots, passerines and woodpeckers and the largest in Anseriformes such as loons and in oceanic birds such as petrels and storm petrels. The relative size of the bulb in comparison with the rest of the brain is an indicator of olfactory performance: a lower detection olfactory threshold is possible for those orders of birds with larger olfactory bulbs (Clark & Shah, 1993). In other words, a larger bulb suggests a greater ability to detect odor stimuli. A Leach's storm petrel (with one of the largest olfactory bulbs in comparison with the size of its brain) is estimated to be able to detect and home in on an odor target 1–12 km away (Clark & Shah, 1992). Black-footed albatrosses (*Diomedea nigripes*) were reported to be attracted to bacon drippings from as far away as 20 miles (Miller, 1942). Petrels, albatrosses, and shearwaters recognize krill-related odors and odors related to phytoplankton, and may use their olfactory capabilities to build olfactory maps of their ocean range, reflecting areas where those prey items reliably occur, including seamounts and upwelling zones (Nevitt, 2000). Oceanic procellariiforms such as the Leach's storm petrel have been found to navigate, at least partly, by olfaction (King & McLelland, 1984).

Variations of the concha occur, depending on the species. The usual arrangement is domelike, but the surface area is greatly increased by scroll-formation in a few species, such as vultures, or by transverse folds, as in kiwis. A small septal concha is also present in petrels, and it is also covered with olfactory epithelium. In swifts, there are no caudal nasal conchae; instead, the olfactory epithelium covers the roof and lateral walls of the nasal cavity, as well as the dorsal part of the nasal septum. The degree of scrolling of the caudal nasal conchae in birds is correlated with the relative size of the olfactory bulb (Bang & Wenzel, 1986), and hence with a greater ability to identify odors.

As a result of these anatomical features, olfaction is possible for some birds, and of greater or lesser importance in others. Studies suggest that most birds tested have comparable olfactory capabilities to mammals (Davis, 1973). Passerines, which have the least developed olfactory system, demonstrate behavioral responsiveness to odors.

### Role of olfaction in foraging

Studies suggest that olfaction plays a fundamental role in foraging behavior (Bang, 1965 & 1966). For example, turkey vultures are attracted to ethyl mercaptan fumes associated with carrion (Stager, 1964 & 1967) and are able to locate decomposed remains without visual cues (Houston, 1987). As described earlier, Procellariiformes use odor cues to locate food sources, while ravens, hummingbirds and kiwis have all been shown to be capable of using olfactory cues to identify and discriminate between foods (Mason & Clark, 2000).

## Role of olfaction in navigation

Studies with homing pigeons have confirmed that pigeons derive directional information from atmospheric odors. In particular, they rely on local odors for homeward orientation, and then integrate olfactory cues perceived during passive transportation with those picked up at the release site. Some telencephalic areas of the brain have been identified as having roles in processing olfactory information for orientation (Papi, 1991).

## Reproductive behavior

Olfaction also plays a role in the reproductive behavior of a variety of species. In breeding studies with mallards, males whose olfactory nerves were sectioned had a significant decrease in their social displays and sexual responses for intact hens. Parental care with ring doves was decreased or lost when the young squabs were re-scented with unfamiliar odors. Pigeons also use olfaction in localization and in identifying individual nests. Starlings have been shown to recognize nesting materials by olfactory cues as they tend to select materials used to fumigate their nests for ectoparasites and pathogens.

## Other uses of the olfactory sense

Studies of chickens suggest that the sense of smell may also play a role in the formation of attachments to familiar objects or environments. Alarm and predator-related odors may elicit fear responses, and odors may also control aspects of feeding and drinking (Jones & Roper, 1997).

## MIGRATORY SENSES

In the spring, many species of bird migrate hundreds or even thousands of miles, driven by instinct to find sources of food, to breed and to raise their young. In the fall, they reverse direction, completing the circuit to avoid the increasing scarcity of food and open water. But what drives birds to leave, how do they know where to go, and how do they know where they are in relation to the goal?

Long-distance migratory birds have an internal circadian rhythm that controls the onset of migration and the behavior prior to migration. Environmental factors such as the amount of daylight stimulate hormonal changes that change both the behavior and physiology of the bird in preparation for migration. Temperature also plays a role: several long-distance migratory birds have advanced their spring migration to Scandinavia in response to earlier springs in Europe (Jonzen *et al.*, 2006). Barometric pressure also influences the onset of migration.

## Navigational senses

An endogenous time and direction program may be used to help determine where a bird is to migrate (Wallraff, 1991). This program is instinctive and species specific and provides the species with a general road map. With this sense of destination in mind, birds use a variety of senses to guide them on their journey, which allow them to take advantage of celestial cues from star patterns, the geomagnetic field, the location of the sun, polarization patterns of the sun at sunrise and sunset, olfaction, geographic features, very low-frequency sound waves and other cues. Navigational cues are likely used in combination to help determine the bird's location, rather than any single cue. Some cues may be used more by some birds and less or not at all by others, but it appears that a range of cues provides feedback and corrective signposts to keep each species of bird on course for its migration.

Many birds orient to star patterns to identify the rotational point of the starlit sky (north) and employ this star compass (Mouritsen & Larsen, 2001). While this confirma-



tion of night-time north is visual, it provides an important tool and check of flight for night-time migratory flyers.

Many birds show evidence of two magnetodetection senses, one based on magnetite near the beak and one based on light-dependent radical-pair processes in the bird's eye(s). Cryptochromes in the eyes of migratory birds may represent the magnetosensory organs in the eye (Mouritsen & Ritz, 2005). There is a complex relationship between the wavelength of light and magnetoreception, which suggests the presence of more than one receptor (Wiltschko & Wiltschko, 2002). Extracellular recordings from the nucleus of the basal optic root and the tectum opticum revealed units that responded to changes in magnetic north, each peaking in distinctive spatial directions. Collective processing and integration could possibly be used by the bird to indicate compass directions. The magnetic vector may provide a compass, whereas magnetic intensity or characteristics may provide a map or even elicit specific responses.

Current evidence suggests that the radical pair mechanism provides directional information and the beak's magnetite-based mechanism provides information about the bird's position relative to its internal "map" (Wiltschko & Wiltschko, 2005). It appears that polarized light at sunset (and possibly also sunrise for many birds) (Muheim *et al.*, 2006) allows birds to calibrate the magnetic compass to their geographic location, including when they cross the magnetic equator (Wiltschko & Wiltschko, 2005). Cue conflict experiments have delved into what happens when conflicting information about "north" is provided. In one experiment, *Catharus* thrushes were exposed to eastward-turned magnetic fields during the twilight period before takeoff and then followed. Instead of flying north, experimental birds flew westward. Yet, on subsequent nights, the same individuals migrated northward. It was surmised that the magnetic compass was calibrated daily from twilight cues (Cochran *et al.*, 2004). A similar recalibration to the magnetic compass using polarized light at sunrise and sunset was demonstrated for Savannah sparrows (Muheim *et al.*, 2006).

Many questions remain about birds' geomagnetic sense and the means by which this information is processed. One piece of the puzzle may be found in the hippocampal formation of birds, which mediates spatial orientation behaviors. This is consistent with a map-like representation, and this formation appears to underpin long-distance navigation across unfamiliar terrain (Jacobs, 2003).

Olfaction may play a role for some birds when migrating. Ocean procellariiforms such as storm petrels navigate in part by olfaction, and olfactory navigation close to the final destination may play a role for some birds in identifying specific burrows, nests or rookeries.

Hearing may be used by some avian species such as pigeons to identify very low-frequency sounds generated by waves lapping upon the shore. By identifying the presence of coastline, hearing may cue birds to their position relative to aural landmarks.

Some navigational cues are instinctive and inherent, yet others must be developed or learned. This appears to be the case for the detection of and correction for wind drift. Adult raptors were found in one study to exhibit significantly less wind drift (29% that of juveniles), suggesting that the adults had learned a more sophisticated orientation system, permitting detection of and compensation for wind drift (Thorup *et al.*, 2003).

# 3

## Clinical Examination

---

### CLINICAL HISTORY

Before starting to examine the bird in detail it is important to obtain from the owner as much information as possible. Particular attention should be paid to the following questions:

- What has the owner noticed wrong with the bird? Falconers will often notice a change in a hawk's performance which may be an early sign of disease.
- Are there any other birds kept by the owner and have any of them been ill or died?
- Has the owner bought in any other birds recently?
- How long has the patient been in the owner's possession?
- Has the bird been ill before and has it had any treatment?
- Have there been any changes in the environment which may have put it under stress? Some individuals within a species are more highly strung and therefore more easily distressed than others.
- Has the owner changed the food or bought in a new supply?
- In the case of raptors, was the food fresh? If the food was stored in a deep freeze was it properly defrosted? Falconers feed their hawks with meat from a canvas bag. This should have a separate, easily cleaned plastic lining. Some falconers become careless and the meat becomes contaminated from a dirty bag. Ask if the droppings (called mutes by falconers) have changed in character.

Other relevant questions will occur to the experienced clinician and the answers should be sought from the client. However, owners vary greatly in their powers of observation and the practitioner may find it rewarding to hospitalise the avian patient so that more accurate observations can be made.

### EXAMINATION OF THE CAGE OR SURROUNDINGS

#### The character of the droppings

Always try to examine some fresh droppings. When the client makes the initial inquiry on the telephone tell them not to clean the cage out before coming to the surgery.

The cloacal excreta usually consist of a dark-coloured central part (from the rectum) and an off-white surrounding portion consisting mainly of urate crystals and also a variable amount of clear fluid from the kidneys. This clear fluid can be collected and tested

for specific gravity and the presence of glucose. A *tentative* diagnosis of diabetes mellitus should be confirmed by blood glucose estimation. For other causes of polydipsia/polyuria see Appendix 7.

The consistency and to some extent the colour of the droppings vary with the species and the diet of the bird. Fruit eaters, such as mynahs and starlings, have rather fluid droppings. Even parrots, which normally feed on a seed diet resulting in a more compact faecal mass, will develop more fluid droppings if fed with more fruit. Parrots on a proprietary pelleted diet produce brownish pellet-like faeces. On the other hand, geese have a more bulky and rather more formed stool. It is therefore important that the practitioner is familiar with what is normal for each species and the particular diet.

As to be expected in birds with enteritis, the dark, central part of the droppings becomes more fluid; the reverse is true in constipation. An absence of the faecal fraction may be the result in the egg-bound female, which is usually dull and anorexic. In gross worm infestation (usually ascarids) resulting in impaction (see Plate 1) the bird is thin but often quite bright and eating well whereas, in contrast, in the anorexic bird or one with reduced appetite due to disease other than an enteropathy, the central (faecal) part of the droppings tends to be of a more fluid greenish nature.

Birds with pancreatic disease show excessive droppings that are buff grey in colour and waxy in texture (e.g. paramyxovirus in *Neophema* parakeets, see Plate 2). Test these for starch with Lugol's iodine. Excessive or decreased urate crystals indicate a renal problem. Suspicious coloured urates which are orange or yellow in colour indicate a biliverdinuria due to hepatopathy (be suspicious of *Chlamydophila* infection, see Appendix 3) (see p. 277).

Undigested seed or grit in the droppings is always abnormal and indicates a malfunction of the gizzard. Blood in the droppings may come from the rectum, the cloaca, the oviduct or the ureters. The clinician should try to decide if this blood is with the faecal or urate fraction of the droppings. This may indicate ulceration, possibly involving a neoplasm. Sharp foreign bodies, such as pieces of metal, can be ingested and can reach the rectum in some birds such as ducks.

### **Blood in the cage**

Blood spattered round the cage may have come from the cloacal orifice or it may be from an injury to the wings, feet, beak or body. If the blood is widely spread, it is probably from wing trauma, possibly a damaged growing feather.

### **Regurgitation and vomiting**

With small birds, examine the cage bars, perches, mirrors and other cage furniture for any evidence of adherent small flecks of white material. This may be evidence of regurgitation. Regurgitation is normal courtship behaviour in the male budgerigar. The young are also fed in this manner. However, this normal behaviour can develop into a pathological neurosis and the bird will sometimes even attempt to feed its owner.

Vomiting undigested seed in parrots may be a sign of proventricular dilatation disease (PDD) (see p. 307). This is often accompanied by undigested seed in the droppings.

Raptors daily produce pellets or castings formed in the gizzard composed of the undigested parts of the diet (skeletal tissues, feathers, fur, etc.). The colour of the castings will depend on the diet but they should be of a crumbly, almost dry texture and have no offensive smell. Liquid or putty-like castings or those with blood or excessive mucus are abnormal. Many other species of bird such as thrushes (Turdidae), crows (Corvidae) and herons (Ardeidae) sometimes produce pellets. Although doubted by some authorities, from the author's clinical observations true vomiting occurs in many species of birds and is always a sign of disease.

### **Other observations to be made on the cage**

In the case of seed-eating birds, note whether the seed is being dehusked or simply being scooped out of the feeding dish and on to the floor. In the case of psittacines, note whether the perches or any of the toys (splintered hard plastic can cause trauma) are being chewed. The clinician should also observe if there is any sign of rust on the cage structure or if the cage has been galvanised with zinc. With a magnifying lens it may be possible to see signs of parasitic mites on the cage fittings. These appear as minute black, red, orange or greyish-white specks, which are seen to move. Some mites hide in cracks and crevices and emerge to feed on the bird at night, so they are best seen with a torch in a dark room or when the electric light is switched on suddenly.

## **OBSERVATION OF THE PATIENT**

If an experienced aviculturist or falconer brings you a bird and says that it is ill, even if you cannot see anything abnormal, the chances are that the bird has something wrong with it. The changes that take place in a bird from one that is completely healthy to one in the early stages of illness are so subtle that it takes an experienced observer to notice them. The problem with most sick birds is that usually by the time someone realises that they are ill, they are very ill. The bird should have a full-rounded, bright eye, with no sign of the membrana nictitans. An eye which is slightly oval means that the bird is not fully alert. Any bird that spends all its time huddled in the bottom of the cage, taking no notice of an observer, is near death. The plumage of the bird should be sleek and lie flat over the body. If all the body feathers are ruffled, the bird is trying to conserve heat.

### **Breathing**

A bird that is obviously dyspnoeic, with its mouth open and gasping, may not necessarily have a respiratory condition, but is certainly very ill. Mouth breathing in birds is seen in parrots with blocked nares. These birds may also sneeze. However, geese in flight normally mouth breathe. Tail bobbing in small birds is also a sign of an impaired respiratory system. In both these types of abnormal breathing, a space-occupying lesion of the abdomen may prevent the full expansion and contraction of the posterior air sacs, so that air flow through the lungs is considerably reduced.

Cyanosis is sometimes indicated by a blue coloration of the beak and legs. If the part of the neck in the region of the crop slightly inflates with each expiration but breathing is otherwise normal, this may indicate some obstruction of the outlet ostia of the anterior air sacs where these connect with the secondary bronchi. On post-mortem examination a bird may show gross abscessation of the coelom and yet in life not show any respiratory signs, which indicates the importance of radiography in the initial general examination.

A change in the voice, which becomes harsher, or a change in pitch in the sound from a raptor or parrot could indicate a problem with the syrinx. Hypovitaminosis A with or without secondary bacterial infection and abscessation involving the tissue of the syrinx could be responsible for these signs. A partial blockage of the main airway, particularly the syrinx, with a plug of inspissated pus is often an acute and desperate condition, particularly in the African grey parrot. Immediate relief by cannulation of the abdominal air sac is imperative (see p. 140).

Falconers talk of 'kecks' and 'snits' (sneezing) in their birds. An incessant and often irritating high-pitched squeak in the budgerigar is sometimes due to pressure of the enlarged thyroid on the syrinx. This is initiated by an iodine deficiency and a consequent hypothyroidism. Hypothyroidism may also be brought about by suppression of the thyroid gland after prolonged use of thyroid extract subsequent to a misdiagnosis. Clicking or asthmatic noises, which may be almost imperceptible unless carefully listened for, can be

caused by viral, bacterial, fungal or yeast infection of the respiratory tract or by the nematode, *Syngamus trachea*, which affects many species of bird. In the latter case, obstruction of the airflow in the trachea is enough to cause gaping typical of the disease.

A change of voice in a bird always indicates a pathological condition of the syrinx and therefore prognosis is much more serious. This contrasts with the situation in the mammal where a change in voice indicates an upper respiratory condition and the outlook is more favourable.

### Central nervous system signs

Birds may show any of the following signs: torticollis, opisthotonos, ataxia, circling, paralysis and clonic spasms or fits (see Plate 3). All these may be caused by deficiency of B or E vitamins, infectious disease, poisoning, concussion, cerebral vascular disturbances and tumours (see p. 349). A falconer may decide to change the diet, e.g. from dead hatchery chicks to quail. The bird may refuse to eat, which in a thin bird (kept near its so-called 'flying weight') may lead to the acute onset of hypoglycaemia. Such birds may appear 'drunk' or may appear asleep or even dead. Tube feeding these birds with glucose or administration i.v. often leads to a dramatic recovery.

Hypocalcaemia is a well-recognised condition in African grey parrots (Roskopf & Woerpel, 1984). This sometimes starts with a bird which is anorexic and lethargic and progresses to violent seizures. However, some of these birds appear perfectly normal between fits. Confirmation of diagnosis in both hypoglycaemia and hypocalcaemia can be obtained by blood analysis. For the differential diagnosis of fits see pp. 348–9.

It is not uncommon for a budgerigar to be presented with an acute onset of a variety of the above signs. Making a specific diagnosis is difficult and the prognosis is always grave. Thrombosis is said by Hasholt (1969) to be uncommon in birds, but atheromata are recorded from a range of species. Hasholt (1969) records the cases of arteriosclerosis of the carotid arteries in three old Amazon parrots. The birds were presented because they kept falling off their perches, and were believed to have suffered from cerebral ischaemia – the result of arteriosclerosis. Pituitary neoplasia, resulting in CNS signs, is recorded in a number of species.

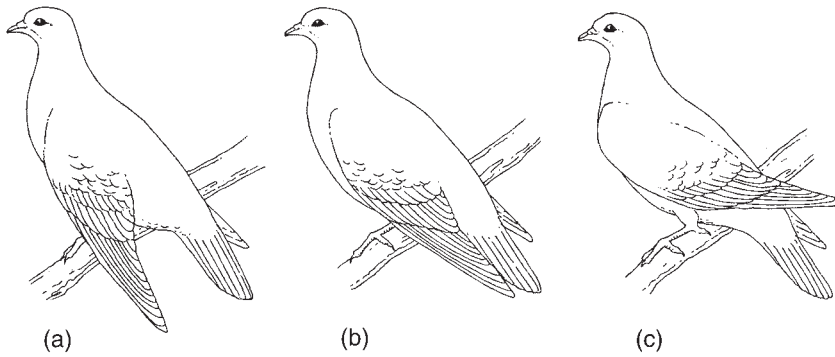
In diurnal raptors hypocalcaemia and hypoglycaemia are both common causes of fits. Most important among the infectious diseases causing nervous signs is Newcastle disease (PMV), affecting all species. The variant of this organism, paramyxovirus (PMV-1), causes nervous signs in pigeons both domestic and feral and some psittacine species (see p. 289).

A rhythmic swinging of the head from side to side, particularly in owls, is indicative of vestibular disease and is equivalent to nystagmus in mammals. A flaccid paralysis with an inability to hold the neck up ('limber neck') is seen in botulism (p. 274) and lead poisoning (p. 336), particularly in swans but also in other birds (Borland *et al.*, 1977). Folic acid deficiency can also cause paralysis of the neck in turkey poults. Bilateral or unilateral paralysis or paresis of the legs may be caused by nephropathy resulting in compression of the lumbosacral plexus, or by Marek's disease (p. 283) or sarcoma/leucosis virus.

The clinician should always bear in mind that although it is very difficult to carry out a clinical examination of the cardiovascular system, what appears to be a breathing difficulty or some indication of a problem with the nervous system may well be due to a cardiovascular problem. Krautwald-Junghanns *et al.* (2004) found that 99% of caged psittacine birds have some pathological signs of a cardiovascular problem (p. 351).

### Wing injuries

A dropped wing may be due to a neuropathy but is most likely to be due to injury to the bones or muscles. Some idea of the part of the wing that is damaged can be gained by observing exactly how the wing is held. If the injury lies between the digits and the middle of the radius and ulna, the primary feathers are usually trailing on the ground (Fig. 3.1a).



**Fig. 3.1** How the wing is held after injury to different parts of the skeleton: (a) between the digits and the radius and ulna; (b) the elbow or humerus; (c) the coracoid or shoulder.

Injury to the elbow or the humerus very often results in the wing being held lower than that on the normal side but the primary feathers are held up off the floor (Fig. 3.1b). Injury to the coracoid or shoulder joint causes the wing to be rotated so that, although the whole wing is lower, the primaries are above the level of those on the opposing side (Fig. 3.1c).

Since there is considerable interspecies variation in the relative lengths of the different sections of the wing (see p. 7) and, consequently, variation in the weight of these parts, the signs will not only depend on the nature of the injury (bone, muscle or nerve) but on the species of bird involved. Small birds in particular may sustain quite serious fractures of the wing bones and still look quite normal. An accurate diagnosis can only be made by a detailed inspection and by radiography.

## HANDLING BIRDS

Before attempting to handle a small and obviously sick bird, it is wise to warn the owner that there is a risk that the bird may suddenly die of heart failure when an attempt is made to catch it. This can occur with apparently healthy birds not used to being handled.

To reduce this risk, the task can be carried out in a dark room using the light from a torch covered with a red filter or in even more cases using blue filtered light. Two or three layers of coloured Vetrap bandage over a small torch will suffice. In many species of bird vision is severely restricted at the blue end of the spectrum. In many cases it is then possible to pick the bird straight from its perch. However, some birds see better in subdued light than others. To catch a small bird use a clean soft cloth (handkerchief) or towel draped over the hand. Preferably use a paper towel to be discarded after use to reduce cross-infection.

When handling the larger birds care should be taken to control the feet of raptors, which have a powerful grip, also to watch the beaks of the larger parrots which can cause a severe injury. Small raptors can strike out rapidly with their feet. A hawk which is hooded is often easier to handle, although some falconers are reluctant to use a hood. Hooding any bird of prey (trained or wild) usually has a sedating effect and the use of a towel or even the cut corner of a large brown paper envelope placed over the head is quite effective.

Birds such as herons (Ardeidae), storks (Ciconiidae), rails (Rallidae), gulls (Laridae) and gannets (Sulidae) can use their beaks as stabbing weapons. Cormorants (Phalacrocoracidae) can attack with the hooked end of the beak.

In all these cases a strong pair of welders or industrial gloves is invaluable. Tamed raptors and parrots used to being handled can often be handled without gloves but the clinician would be well advised not to take any chances.

For catching and handling parrots (but not macaws or large cockatoos) a hand towel draped over the outstretched hand is useful. A padded net with a short handle can sometimes be very useful for catching escapees in a room. For catching swans and other large waterfowl a long-handled crook is sometimes used and when captured a wrap-round cloth of nylon or other tough material with quick fastening Velcro is very useful for controlling these birds. All the large birds are best cast on a cushion or soft surface before examination. The wings need to be held gently but firmly to the body with no undue pressure placed on the thorax.

## PHYSICAL EXAMINATION OF THE RESTRAINED BIRD

In a bird that is not too ill, the clinician might find it easier to carry out a more thorough examination if the bird is under moderately deep sedation or light anaesthesia (see Chapter 7).

### Feathers and plumage

The plumage should be of a good, even, dense colour. Barbules should lock together so that the feathering gives a uniform outline to the body form. In the normal bird only the axillae are sparsely covered in feathers. If the areas of skin covering the lumbosacral and sternal regions are thinly covered or are covered in an abnormal greyish fluff instead of the usual contour feathers, the cause may be of nutritional or endocrine origin, e.g. thyroid. Progressive feather loss with a typical white, flaky, but thickened skin may be due to ringworm (*Trichophyton* spp) (see p. 311), particularly if this is seen around the head and neck. In poultry a zinc deficiency has caused dermatitis and failure of feather growth.

Sometimes, particularly in parrots, there may be evidence of self-trauma. In this case, apart from skin wounds, the vane of the flight feathers may be chewed or the shaft may be crushed (as distinct from snapped or broken off). Some of the growing feathers may have been plucked leaving bleeding follicles. Plucked feathers are usually replaced quickly and new feathers can be seen emerging. In some cases the lesion may be localised suggesting a subcutaneous or deeper painful lesion. Examine these new feathers to see if they are short and club-shaped. See if they have a circumferential constriction or are curled or deformed. Any of these signs may indicate a viral infection causing psittacine beak and feather dystrophy (Pbfd) (see p. 299) or a nutrient deficiency.

Self-mutilation may have a large number of causes and exact diagnosis is sometimes difficult. It may be initiated by frustration or boredom or stress brought on by isolation from a busy owner (parrots are birds which normally live in flocks) or any change in household routine. A cardinal sign of the self-plucking bird is usually that, while any of the other plumage is damaged, that on the head is normal. Sometimes trauma may be self-inflicted and have been initiated by the handler savagely cutting growing flight feathers to stop the bird flying.

Rarely, self-plucking may be initiated by mite infestation which may lead to invasion of the feather follicle, with damage and loss of the feather. Both mites and lice cause irritation. A careful search of the plumage will show any lice situated along the feather shaft or on the skin surface. Healthy birds groom themselves to keep infestation in check, sick birds do not. Examination of the skin or of the powdery remains of a feather shaft with a magnifying lens will be necessary to identify any mites present. The initiating cause of self-feather-damage may have been eliminated but the habit becomes established and it is

difficult to break. Use may have to be made of Elizabethan collars or psychotropic drugs combined with behavioural modification programmes (see p. 264). Excessive allopreening leading to feather picking or even severe injury by an incompatible or dominant cage mate is not uncommon. This may become worse during the breeding season.

Malformed and curled flight feathers or those without proper vane formation are usually the result of faulty nutrition (inadequate essential amino acids or vitamin deficiency), but may also be the result of chewing by lice or other infection. In parrots the yellowing of green feathers may be due to a deficiency of the amino acid lysine. Feathers that are frayed or have the shaft cleanly broken or snapped off can result from careless handling or inadequate sized caging.

In the budgerigar and some other psittacines the condition called French moult, in which fledglings lose some of their primary wing and tail feathers, has been shown to be due principally to two viral infections. Some original work by Pass and Perry (1984) on wild Australian cockatoos and by others more recently indicates this may be one of a number of viral infections affecting many species of psittacines. The condition described by Pass and Perry was originally called cockatoo beak and feather syndrome but is now known to infect many species and so is renamed psittacine beak and feather syndrome (PBFS) (see p. 299). In these cases the emerging feather does not open up properly and remains club-shaped. Feathers are not moulted normally and the bird's whole plumage, including the head, is very unkempt. Large areas become devoid of feathers. The beak looks abnormally shiny in cockatoos, due to lack of powder down, and has a tendency to accelerated growth. In cockatoos skin pigmentation is subtly increased, but in lovebirds (*Agapornis*) the skin coloration remains normal (see Plate 4). In all cases there is pruritus. In the black Vasa parrots (*Coracopsis* sp.) the normal black feathers progressively become white (see Plate 5). In all cases the condition is immunosuppressive and usually fatal (see Appendix 3).

The minute structure of feathers may be permanently damaged after contamination with mineral oil, even after this has been completely removed. The barbules may not hook together properly. In aquatic birds where integrity of the feather covering is incomplete due to barbule damage, inability to preen due to beak damage or with disease of the preen gland, the bird may not be able to float properly in water. A well-recognised condition known as 'wet feather' of ducks has the same effect. The aetiology is obscure.

Lines of decreased density and weakness across the vane of the feather, known variously as 'fret', 'hunger' or 'stress' marks, are recognised by falconers but are also seen in birds other than raptors. These are believed to be caused by a check in growth of the proliferating cells of the epidermal papilla during the formation of the feather in its follicle and may be accompanied by other feather defects. Moulting or feather replacement takes place in many birds from temperate climates that have well-defined seasons at definite spaced intervals – once, twice or three times a year. In a few species, such as cranes and eagles, moulting may be every two years. However, in parrots (mostly tropical in origin) the process tends to be continuous, with increased feather growth during breeding activity. Nutritional or infectious conditions that cause feather abnormalities often have similar effects on the germinative cells of the beak and claws.

Occasionally a developing feather will fail to emerge properly from the feather sheath. The follicle continues to enlarge pushing its way below the surface of the skin and a feather cyst is formed – a condition most commonly seen in canaries and probably genetic in origin (see p. 146) but also seen in other breeds. The cyst is often associated with an inflammatory condition of the skin and causes marked irritation to the bird, so that the bird picks at the cyst and may rupture it.

Tick bites (see Plate 6) can sometimes be responsible for subcutaneous oedema and haemorrhage and result in acute death (Forbes & Simpson 1993). For more in-depth investigation of plumage problems see p. 344.



## The head region

After detailed examination of the plumage it is best to continue with an examination of the head region, starting with the eye.

### The eye

The observer may first see a variety of conditions. Keratitis, oedema of the eyelids and blepharospasm due to a foreign body are relatively common. Matting of the feathers around the eye can be evidence of epiphora which may be unilateral or bilateral. If bilateral, this could be due to lesions blocking the common opening of the nasolacrimal ducts, situated together in the posterior part of the choanal opening. Swellings just above or below the eye may be evidence of sinusitis of the supraorbital and infraorbital sinuses, which may have progressed to abscessation (see p. 145). These are often initiated by hypovitaminosis A. Brown, crusty eruptions around the eyelids and commissures of the beak may be due to avian pox (see p. 392 and Plate 7).

In budgerigars the powdery white encrustations of cnemidocoptic mange mite infestation may extend from the cere to the areas around the eye and the commissures of the beak. This may also be seen in other species (see p. 332).

Retrobulbar neoplasms of the orbit and tumours of the nictitating membrane have been recorded. Examination of the anterior chamber of the eye may reveal evidence of hypopyon (see Plate 8), or hyphaema, or damage of the iris. Fluorescein should be instilled on to the surface of the cornea to detect any scars or ulcers. All these lesions are not uncommon, particularly in owls, and may be due to fighting or to road traffic accidents (see Plate 8). Also they may be a sign of systemic infection, e.g. with picornavirus (see p. 294, V41).

Examination of the eye reflexes is generally difficult but is somewhat easier in raptors, because of the proportionately larger-sized eyes. The pupillary light response is difficult to elicit, because the muscle of the iris is striated and partially under voluntary control. It is also affected by emotional disturbance of the bird. A rapid pupillary light reflex indicates central blindness because conscious control may have been removed due to brain trauma. The pupils may be widely dilated after an accident resulting in concussion (see p. 27).

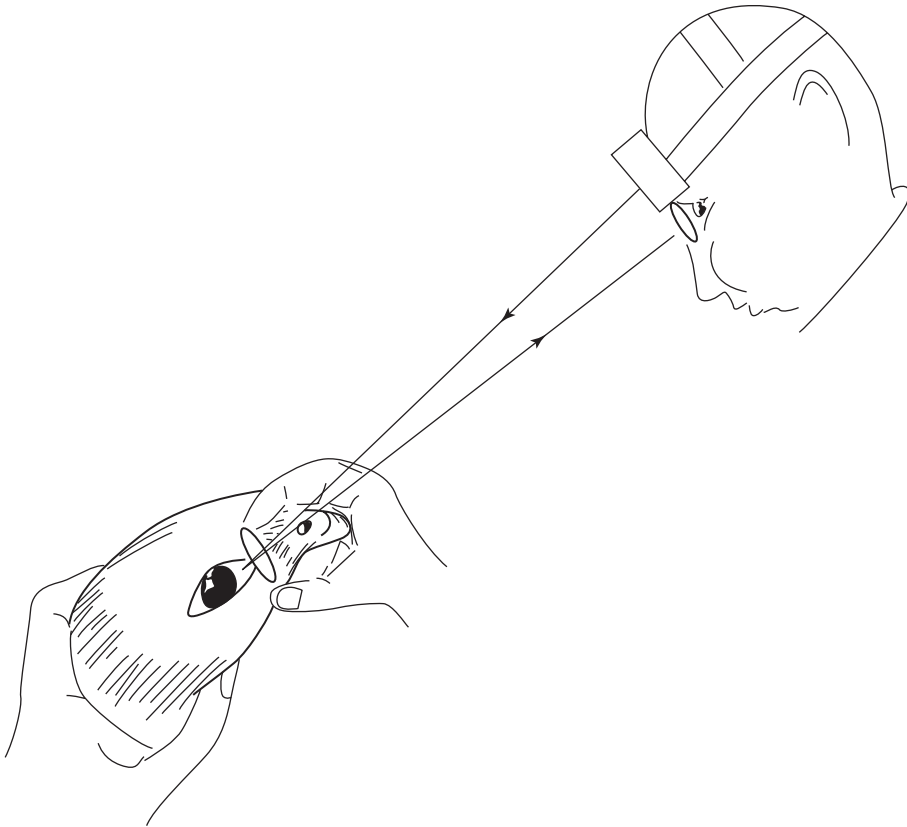
Consensual pupillary light reflexes do not take place in birds because all optic nerve fibres completely cross over at the optic chiasma and representation on the cortex of the optic tectum is contralateral. Touching the cornea produces a pupillary response and a consensual response is shown in the other eye. If a bird is not too frightened, it will sometimes show a fixation reflex towards an interesting object. This can be shown by using food (for a raptor) or a glittering object (for a corvid) moved from side to side in front of the eyes (see p. 27).

A blink reflex of the eyelids or nictitating membrane reflex may be stimulated by a threatening gesture of the hand, preferably carried out from behind a transparent screen.

Cataracts are not uncommon and can be seen with or sometimes without an ophthalmoscope. They are occasionally reported in wild birds.

**Examination of the posterior chamber** with the ophthalmoscope is more difficult than in mammals but using the *indirect method* enables a greater area of the fundus to be seen. A 30D lens is used for the larger birds whilst an 80D or 90D lens is needed for the smaller species. Use vecuronium reconstituted powder (in 10mg ampoule) as eye drops (see p. 259). This dilates the pupil, which in birds is controlled by skeletal muscle. Use *one drop* only (see formulary for further details) (Fig. 3.2).

The retina appears as a uniform granular tissue usually grey or brownish-red in colour. There is *no reflective tapetum* in birds. The optic disc is obscured by the large vascular projection of the choroid, known as the pecten. *The shape and size of this structure varies considerably* in the different species and this was first documented in 1917 by Casey Wood MD (Fig. 3.3).

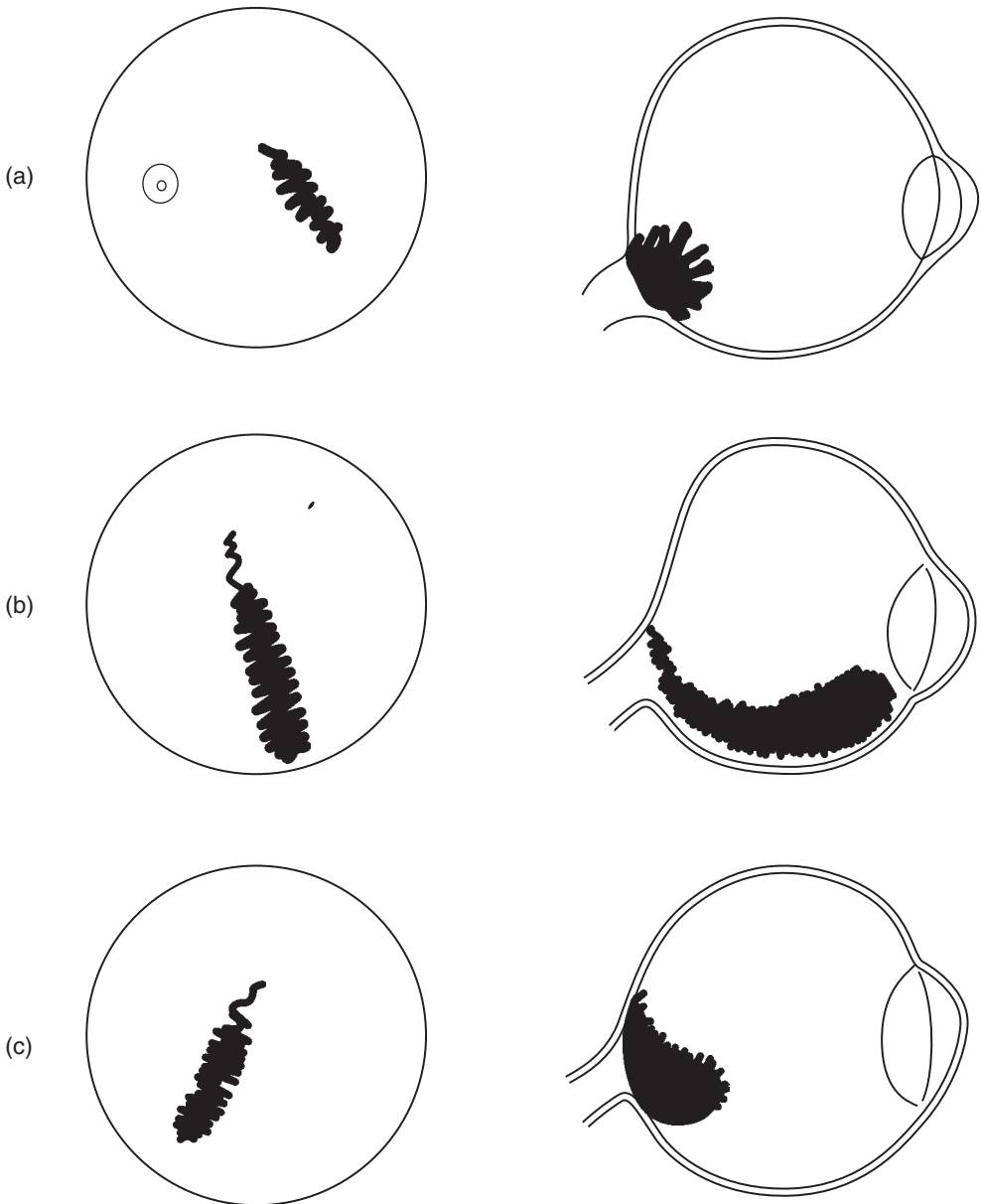


**Fig. 3.2** Examining the posterior chamber (fundus oculi) of a bird by indirect ophthalmoscopy. Vecuronium drops are used to dilate the pupil. The bird's head is held steadily with the left hand, whilst the right hand holds a suitable condensing lens (30D–90D) just in front of the eye being examined. Light from a focused light beam from a source mounted on a head band is directed through the lens into the posterior chamber of the bird's eye, which is at the same time examined by a binocular lens system (one lens for each eye) also mounted on the head band. With this method a much greater area of the fundus can be seen than when using straightforward direct ophthalmoscopy. If a binocular system is not available, a focused light source can be mounted separately beside the examiner's head and a hand-held monocular ophthalmoscope can be used to examine the eye.

Post-traumatic intravitreal haemorrhage from the pecten oculi is common (40% of cases) particularly after road traffic accidents. This can result in the deposition of pigment, adhesions and other retinopathies, greatly influencing the prognosis. Luxation of the lens is also a not uncommon injury.

A very useful reference with excellent coloured photographs is Korbel (2000); and Coles & Krautwald-Junghanns (1998) has a number of coloured photographs of eye conditions.

Many systemic infectious diseases, for instance chlamydophilosis (psittacosis) (see p. 277), salmonellosis (see p. 267), mycobacteriosis (see p. 273) and a variety of viral infections, including the paramyxoviruses (see p. 288) are manifested by ocular lesions. These may include epiphora, conjunctivitis, keratitis and iridocyclitis. Conjunctival oedema has been reported as a sign of *Plasmodium* infection (see p. 321) in over 40 species of birds. Any of these signs alert the clinician to carry out further investigation for evidence of systemic infectious disease.



**Fig. 3.3** Three illustrations with abbreviated descriptions, after Dr Casey Woods, to indicate the many varied forms of the pecten oculi seen in various avian species.

- (a) The fundus oculi of the tawny owl (*Strix aluco*). The underlying background colour is a dull yellow covered with closely packed, irregularly radiating choroidal blood capillaries, producing an overall impression of dark orange-red. The distinct macula can be seen situated at about '15 minutes to the hour' and is surrounded by a bluish grey haze.
- (b) The fundus oculi of the (common) raven (*Corvus corax*). The overall background colour is light buff/fawn sprinkled with slightly darker dots. The macula is a small dark dot situated in the middle of an almost colourless area at about 2 o'clock. In the lower part of the fundus, around the base and sides of the pecten, orange-red choroidal blood capillaries can be seen.
- (c) The fundus oculi of the sulphur crested cockatoo (*Cacatua galerita*). The background colour is a uniform greyish-blue. The macula is situated at about 10–11 o'clock and is an irregularly round brownish area merging into the background.

### The ear

The ear is not obvious in birds since there is no pinna. In most birds the external orifice is covered by modified contour feathers (see p. 31). In owls the ears are large and placed asymmetrically, a condition which improves directional sensitivity. Because of its nearness to the eye, the ear may be involved in trauma affecting the eye. Attention is drawn to otitis externa by the feathers being matted around the external ear. Small (1969) reports the protrusion of the tympanic membrane through the external orifice but this is a rare condition, as are neoplasms. Swelling of the infraorbital sinus may occasionally cause swelling of the ear.

### The skin of the head


The skin should be examined for any sign of subcutaneous haemorrhage due to accidents or wounds, such as those caused by fighting or attack from cage mates.

### The cere and external nares

Look for any discharges, which may vary from catarrhal to dried exudate. Nasal exudate is often due to hypovitaminosis A together with microbial infection, which may be an indication of upper respiratory disease. Swabs should be obtained for microbiology and antibiotic sensitivity testing. A more representative specimen can be obtained from the choanal slit where there are often associated abscesses. Staining of the feathers, which may be blood stained, above the cere is evidence of nasal discharge. Excess growth of the cornified tissue of the cere, a condition often seen in budgerigars and called brown hypertrophy, is of no clinical significance unless the nares become blocked (Fig. 3.4) (see p. 149).

In the male pigeon there may be a similar exuberant growth of the cere. In the budgerigar, the cere is pink in the immature bird, blue in the male and brown or buff-coloured in the female. Birds that show some blue and brown colouring may be intersexes with both one ovary and one testis present in the abdomen. Reversal of colour may indicate chronic illness. Intersexes may also be seen in the ostrich, in which the plumage is not the dense black of the male bird but more brownish like that in the female. In these birds the phallus isn't like that of the male or the female bird.

Cnemidocoptic mange infection (see p. 382) is not uncommon in budgerigars and can affect other species. It is shown by a greyish, scabby, crumbling texture of the cere often accompanied by excrescences around the commissures of the beak and the eye. Using a lens, the burrowing tracts of the mite can sometimes be seen in the horn of the beak. Associated lesions are sometimes found on the scaly part of the leg. The debris shed from these lesions contributes to the dust of breeders' bird rooms and helps in the maintenance of a high incidence of this condition. Diagnosis can be confirmed by scraping the lesion. After clearing the scrapings with 10% potassium hydroxide, examine under a microscope.



**Fig. 3.4** Brown hypertrophy of the cere.

Trauma to the cere can be the result of a collision during flight or from a caged bird flying at the meshwork of its cage. Damage to this area may involve the cranial facial hinge situated between the premaxilla, nasal and frontal bones (see p. 2). Occasionally, a neoplasm may involve this region (see Fig. 1.1a,b).

### The beak

Examine the beak for any evidence of cracking or splitting, which may be a sign of underlying fractures of the premaxilla or mandible. Care should be taken when examining some birds, such as gannets and some ducks, in which the edges of the beaks are quite sharp. Toucans (Ramphastidae) and mergansers (*Mergus* spp) have a serrated edge to the beak. Cracking of the horny beak may be traumatic or a sign of vitamin A deficiency or infection. Overgrowth or distortion of the beak may be due to a neoplasm (e.g. osteosarcoma) or trauma to the proliferating epidermal cells or due to cnemidocoptic mite infection.

Deficiency of vitamin D, calcium, biotin and B vitamins are all said to cause abnormal beak formation (Altman, 1982). Raptors fed on an artificial diet that does not need very much tearing of the food before swallowing can develop a marked overgrowth of the upper beak. Parrots can develop beak abnormalities brought about by wear on their cage bars by constant climbing. The beak is a constantly growing and changing structure. Some wild birds, e.g. oystercatchers (Haematopodidae) have a comparatively rapid growing beak which can develop a different shape adapting the beak to different feeding habitats. Those feeding on cockles develop a spatulate beak, whilst those feeding on earthworms develop a more pointed beak.

### The mouth and oropharynx

In aquatic birds a piece of fishing line protruding from the pharynx may be attached to a fish hook embedded lower down the alimentary canal. Diagnosis can be confirmed by radiography or by endoscopy. Fish hooks may damage other birds and the author has even seen one case in a blackbird (*Turdus merula*).

To examine the mouth of a conscious powerful bird some sort of speculum may be necessary. A pair of artery forceps can be placed between the two beaks and then opened, or the speculum of a canine auroscope can be utilised.

Abscesses are seen sometimes on the surface of the tongue and small pin-point lesions of candidiasis may be observed also. Both these conditions may be brought on by vitamin A deficiency. This leads to a hyperkeratosis of the epithelium of the mucus-secreting glands (Gordon & Jordan, 1977; Jones, 1979). Abscesses may also be seen anywhere on the mucous membranes of the mouth, particularly around the choanae where they may block the single central nasolacrimal opening. Closer inspection of the nasal mucous membrane can be carried out by endoscopic examination through the choanal space.

Abscesses in the mouth may be bacterial in origin or they may be the early signs of trichomoniasis (see p. 319). This is seen more usually as an extensive, cheese-like, diphtheritic membrane covering the oropharynx and sides of the mouth. This disease occurs in a number of species but is particularly common in pigeons (Columbidae) when it is called 'canker' by pigeon owners, and has also been known for many years by falconers to occur in raptors, when it is known as 'frounce'. Again, hypovitaminosis A may predispose to this condition. The lesions of both trichomoniasis and candidiasis look similar and may occasionally be confused with capillaria infection (see Plate 9) (see p. 325).

Avian pox lesions (see p. 392) may be seen at the commissures of the beak, in all species particularly in Passeriformes, Columbiformes, raptors and psittacines. However, they are not seen in Anseriformes.

The glottis is a slit-like opening into the larynx and trachea, lying on the floor of the mouth usually just posterior to the root of the tongue. In some species such as herons (Ardeidae) it lies farther back. Neoplasms and exudative lesions can affect this area,

resulting in partial obstruction of the airways. Sinusitis of the infraorbital sinuses can lead to gross swelling, filled with catarrhal exudate, on both sides of the oropharynx (see p. 276). This condition can be caused by mycoplasma and has been seen in a number of species including parrots (Psittacidae), gulls (Laridae), mynah birds (*Gracula* spp) and raptors. Cooper (1978) advocates digital examination of the mouth and oropharynx and laboratory examination of any exudate obtained.

### The neck

The neck should be palpated for any swelling which may indicate a foreign body impacted in the oesophagus (e.g. a bone wedge in a raptor's throat) or an impaction of the crop (see p. 153), which can occur in most species. A fluid swelling may be due to the condition of 'sour crop', when there may also be excessive gas present. The crop in the budgerigar may also swell due to thyroid enlargement obstructing the organ. This is sometimes accompanied by regurgitation. Neoplasia of the thyroid, although rare, may be responsible for similar symptoms (Blackmore, 1982; see also p. 42 and Plate 10).

Many seed eating birds temporarily store seed in the crop but this should not feel hard to the touch. Gulls (Laridae), penguins (Spheniscidae) and cormorants (Phalacrocoracidae) store food in the oesophagus and can easily regurgitate this food.

### Examination of the body

After the thoracic inlet at the base of the neck has been examined, the clavicle and coracoid bones should be palpated for evidence of fractures. In the latter case, observe how the wing is held when the bird is free standing (Fig. 3.1c). Skin wounds around the thoracic inlet are commonly seen in pigeons (Columbidae) as a result of collision with telegraph wires during flight. They sometimes involve the crop and associated air sacs. Subcutaneous emphysema around the thorax may indicate a ruptured air sac, particularly rupture of the cervical or interclavicular air sacs. Ruptured air sacs often resolve spontaneously.

The condition of the pectoral muscles should be assessed by palpation. They should be symmetrical but one side may be found to have undergone atrophy, in which case the bird's flying ability will be affected. The condition of the pectoral muscles is an important guide to the overall nutritional state of the bird. The carina of the sternum can be felt but should not be very prominent. Decubitus of this region is common in heavy birds such as geese and swans that are unable to walk. Accumulation of fat and lipomas are common over this region of the pet budgerigar.

The ribs and scapulae should be carefully palpated for fractures. Auscultation of the lateral and dorsal thorax or at the thoracic inlet may reveal abnormal sounds, though it may be difficult to pinpoint these. A stethoscope incorporating battery amplification is most useful. Heart murmurs are very occasionally detectable in the larger birds, although undoubtedly diagnosis of avian cardiac disease is much undiagnosed. There is little doubt that many birds spending their life in a cage develop a cardiomyopathy (Krautwald-Junghanns *et al.*, 2004). Cooper (1978) describes some cardiovascular conditions encountered in raptors at post-mortem. The use of electrocardiography in birds has been described by a number of authors among whom Lumeij *et al.* (1993 and 1994) and Lawrie (2005) are most useful for the practitioner.

### The body from the thoracic vertebrae to the synsacrum

These areas should be carefully examined for wounds caused by predators or fighting among cage mates. The preen (or uropygial) gland (see p. 143) should be palpated and the tip touched with the finger for evidence of secretion. The gland may be impacted or show neoplastic changes.

## The abdomen

In the larger birds it may just be possible to palpate the tip of the liver beyond the edge of the sternum. Should the liver be easily felt it is probably enlarged. This can be confirmed by radiography or the use of ultrasound.

The ease with which the abdominal contents can be palpated will obviously depend on the size of the bird. In birds smaller than a budgerigar this is almost impossible to do safely without putting too much pressure on the air sacs. In some species, e.g. auks (*Alcinae*), there is very little room between the sternum and the pelvic bones. However, even in budgerigars it is possible to distinguish a fairly large, rather irregular neoplasm from a regular, smooth and rounded retained egg in the female. The female often has a history of laying several eggs, and then has suddenly stopped and the bird is often noticeably unwell. Occasionally a solitary egg may form and cause obstruction.

In slightly larger birds, e.g. pigeons, the thick-walled gizzard is easily palpated as firm and globular with angular margins and its retained grit can be felt to grate between the fingers. In raptors, the full or impacted stomach can be distinguished as a rather fusiform softer-walled structure.

Softer and more fluid enlargements of the abdomen which can become quite pendulant in the perching bird, sometimes without apparent ill effect, may be due to either ascites or rupture of the abdominal muscles. Ascites can be confirmed by very careful paracentesis. This is carried out in the midline at the most pendulant part of the swelling. The ascites is often due to neoplasia of the liver or gonads. In female birds, a soft abdominal swelling may be due to an enlarged oviduct caused by salpingitis, or an impacted soft-shelled egg, both of which may result in an egg peritonitis. Contrast radiography or the use of ultrasound can help in the differential diagnosis.

Large cyst-like swellings over the abdomen can be differentiated from true ruptures by radiography. The cloaca should be palpated. It may contain a calculus of impacted urate crystals or show a prolapse. Cooper (1978) recommends digital exploration of the cloaca in the larger bird, with a well-lubricated, gloved finger and microscopical examination of the evacuations. An auroscope speculum or endoscope inserted into the emptied cloaca can sometimes be helpful to examine the mucosa. Matting of the feathers around the cloaca together with excoriation of the surrounding skin can indicate either an alimentary or urinary problem. If the adherent mass is mainly composed of faecal material and the surrounding feathering is stained green, then the problem is probably due to diarrhoea. If the concretions are white, and especially if accompanied by an impacted cloaca, then the bird most probably has a kidney problem (see p. 342).

Since the urodeum is the posterior part of the cloaca in which the urates from the kidney and ureters collect, any impaction in this region due to a urate calculus will necessarily hold up the evacuation of faecal matter in the anterior part of the cloaca or coprodeum and the bird will become constipated. Paralysis and prolapse of the penis (see p. 163) may occur in some ducks when two or more male ducks kept together results in bullying and damage to the nerve supply (P.N. Humphreys, 1984, personal communication). However, see duck plague caused by a herpes virus (Plate 11) (see p. 283).

The body temperature of a bird can be taken via the cloaca, but since there is such a great interspecific variation as well as a normal diurnal variation in individuals, this is not especially helpful in clinical examination. The body temperature of most birds falls within the range 40–42°C.

## The wings

Examine each wing bone separately for any evidence of fractures or luxations of the joints. Excessive mobility of the shoulder joint compared with the other side, together with a wing that is slightly dropped at the shoulder, could indicate a rupture of the tendon of

the supracoracoid muscle (deep pectoral), which can be only confirmed by surgical exploration. Swellings of the bones may be due to old fractures or to tumours or infections. In pigeons (Columbidae) swellings and suppuration of the joints may be due to *Salmonella* spp causing a chronic arthrosynovitis (see p. 267) (Gordon & Jordan, 1977). In raptors, injury to the carpal joints may result in a bursitis (called 'blain' by falconers). Wing-tip oedema and dry gangrene in raptors has been described by a number of authors (Forbes, 1991; Forbes & Harcourt-Brown, 1991; Lewis, Storm & Greenwood, 1993). In the opinion of Forbes, the condition is most likely caused by tethering a raptor within a metre of the ground in sub-zero temperatures at night. Forbes also suggests an unidentified virus or toxic factor may be involved.

In young birds, deformation of the bones may indicate metabolic bone disease due to calcium/phosphorus imbalance in the diet. Waterfowl fed on a diet too high in protein (over 18%) can develop an outward rotation of the carpal joint (valgus or 'slipped wing') – the primary feathers are relatively too heavy, because they grow faster than minerals can be laid down in the bone (see p. 179).

The mobility of all joints should be checked and compared in the two wings. Comparison should be made of the swelling and development of the muscles for signs of atrophy. Examine the propatagial membranes, which stretch between the shoulder and carpal joints and form the leading edge of the wing when this is fully extended. These are often damaged in flight and may show evidence of scar tissue formation. This results in the wing not being fully extensible or the proximal attachment of the membrane being displaced more posteriorly. In both cases the bird's flying capability may be affected. However, some birds can still fly, but they veer off to the normal side (see Figs 1.5 and 11.1).

Feather cysts and neoplasms are commonly found in the carpal areas. They are not always easy to differentiate except by biopsy and/or surgical incision. Tumours in this area are easily damaged and may bleed profusely.

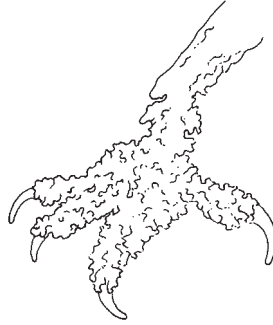## The legs and feet

Each of the bones of the leg should be examined for any evidence of fractures or luxations. This may be difficult with the femur in small birds or in such birds as auks (Alcinae) where this bone is well covered by muscle and dense feathering.

In fledgling raptors the tarsometatarsal bones are inwardly rotated in a 'hand-holding' position. As the bird grows and begins to take weight on its legs, the feet rotate outward to the normal position. In some young birds with metabolic bone disease this does not happen and the gastrocnemius tendon becomes permanently displaced medially. The bird becomes a cripple. In some artificially reared waterfowl fed on a ration too high in protein (i.e. over 18%) the tibial cartilage can become displaced. The bird grows too fast and becomes too heavy for the rate at which calcium and phosphorus can be incorporated into the bone of the leg. A similar condition, called perosis, occurs in poultry and has been seen in parrots (Smith, 1979). This is caused by manganese deficiency. This mineral activates several enzymes required for the formation of chondroitin sulphate concerned in bone growth (Butler & Laursen-Jones, 1977).

The scales of the legs should be examined for any evidence of swelling, ulceration or scars caused by excoriation of identification rings. In the budgerigar, captive raptors and parrots, swelling due to a tight ring can become suddenly an acute problem (see Plate 12) – restriction of the blood supply to the foot can lead to ischaemic necrosis or gangrene. The feet should be examined for any evidence of abscesses. This condition, known as 'bumblefoot', is seen in cranes, penguins, waterfowl, domestic fowl and especially in raptors; the heavier birds are at greater risk. Bumblefoot abscesses may extend as far as the hock and may erode the bones of the foot (see p. 181). This can be confirmed by a radiograph. Smaller birds such as budgerigars or cockatiels may show abscesses on the





**Fig. 3.5** 'Tassle foot' as seen typically in canaries.

feet that may be difficult to distinguish from the tophi of gout which are due to accumulations of urate crystals.

If the suspected tophi are opened and the contents placed on a slide, confirmation that urates are present can be attained from the following test: the crystals are mixed with a drop of concentrated nitric acid and carefully evaporated to dryness over a Bunsen burner. A drop of ammonia is then added. If urates are present a mauve colour will develop.

Cnemidocoptic mange mite infestation can occur on the legs of many Passeriformes, particularly crossbills (*Loxia curvirostra*) and also in other species of bird causing the nails to slough. In canaries the condition has long been called 'tassle foot' (Fig. 3.5). Although the infection is common on the head of budgerigars it is not often seen on their feet. In Passeriformes the lesions on the legs can be confused with avian pox lesions and papillomas (see p. 301). Claws that are overgrown through 'tassle foot' and other causes can easily become broken and bleed. Frostbite has been reported in a number of raptor species and in some aviary birds (e.g. parrots) through clinging to frost-covered wire mesh.

# 4

## Aids to Diagnosis

---

### Professor Dr Maria Krautwald-Junghanns

Universität Leipzig  
Institute for Avian Diseases, Leipzig, Germany

#### HAEMATOLOGY, BLOOD CHEMISTRY AND SEROLOGY EXAMINATION

The examination of blood samples is an important aid in the routine diagnosis of avian disease. The veterinary clinician, having already taken into account the value of a particular case to the owner and offset this against the potential cost of the anticipated laboratory procedures, should note that one laboratory test by itself is usually of little diagnostic or prognostic value. Serial blood samples taken over a period of time offer a greater degree of diagnostic precision. Some suggested diagnostic routines (incorporating haematology) for the investigation of particular avian syndromes are given in Appendix 7.

#### The collection of blood samples

##### Anticoagulant and equipment

A variety of suitable paediatric tubes and micro-containers are available and can often be obtained free of charge from the laboratory which is to carry out the tests. In the opinion of most haematologists, to get the best staining results for the examination of blood cells EDTA is the most suitable anticoagulant. Heparin can sometimes affect the staining of the leucocytes. However, in some species (Corvidae, curassows, crowned cranes, hornbills and the eagle owl) EDTA can cause haemolysis of the erythrocytes so that heparin is preferred. If the bird is large enough and 1.5–2 ml of blood can be harvested, half the blood can be placed in a tube with anticoagulant whilst the other half is immediately centrifuged and the plasma used for blood chemistry examination.

Usually in the smaller birds a 23–25 G  $\times$   $\frac{5}{8}$ " (0.65–0.5  $\times$  16 mm) hypodermic needle bent at a slight angle (approximately 10°) and attached to a 2 ml syringe is found to be satisfactory. The bevel of the needle point is kept uppermost. The walls of avian veins are fragile and haematoma formation easily occurs so that digital pressure should be immediately applied over the puncture site when withdrawing the needle. If too much negative pressure is applied to the syringe plunger when withdrawing blood the vein will collapse onto the orifice needle and blood flow stops.

##### The volume of blood which can be collected safely

In birds generally the circulating blood volume is usually 6–20 ml/100 g body weight. In a 40 g budgerigar the total blood volume may be 2.5–3.0 ml. Consequently in a healthy bird, if a state of shock is not to ensue, 0.5 ml is the maximum volume which can safely be withdrawn from a bird of this size. In the Amazon parrot or an African grey parrot

weighing 250–400g, 2 ml of blood can safely be obtained. Overall birds can tolerate a greater degree of blood loss in relation to size than can mammals because they are able to rapidly draw upon extra-vascular reserves. However, splenic contraction in response to blood loss does not occur in birds.

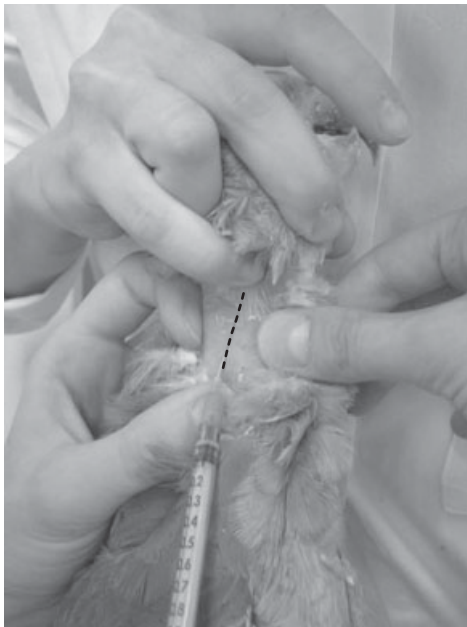
#### Suitable sites for blood collection

##### *The right jugular vein (Fig. 4.1a)*

The right jugular vein is often more prominent than the left, so it is usually the easiest place from which to collect blood in most birds including budgerigars, raptors, penguins, flamingos and the ostrich (however, in this case the operator should take great care not to get injured). This site is not suitable in pigeons due to the fat deposits in the neck. Unlike in mammals the jugular vein in birds is much more mobile and can be found subcutaneously anywhere over the right side of the neck without its lying in a definite furrow. The jugular vein is often covered by a featherless tract of skin and can be made more visible by wetting the area with antiseptic (quaternary ammonium compound) or alcohol. If a finger is placed under the neck with the bird's head extended the skin can be tensed over the site and the thumb can be placed in the thoracic inlet to raise the vein.

##### *The subcutaneous ulnar (brachial) vein*

To visualise this vein it is often necessary to first pluck a few feathers and then to wet the site with antiseptic (Fig. 3.1b). This vein can be utilised in most birds including the ostrich.



(a)



(b)

**Fig. 4.1** (a) The position of the right jugular vein used for venipuncture. (b) The position of the right ulnar vein used for venipuncture.

Again, the operator must take great care not to get injured when working with this bird or any of the larger ratites. In small birds particularly this vein is very liable to haematoma formation, which may be a particular problem for racing pigeons.

#### *The medial metatarsal (caudal tibial) vein*

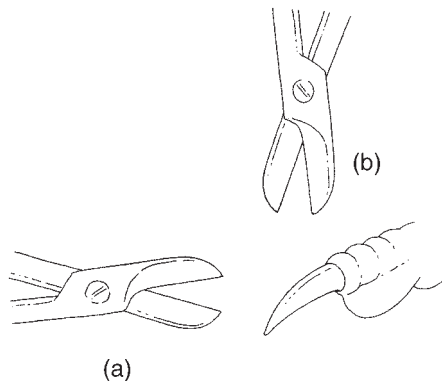
Although perhaps not the most easily visualised of subcutaneous veins the medial metatarsal vein can be utilised in a variety of species. It has been used in ducks, raptors and pigeons and is particularly useful in the conscious swan (*Cygnus olor*). Digital pressure over the caudal part of the medial surface of the tibial tarsal bone, wetting and rubbing the area with alcohol or diethyl ether usually enables the operator to raise the vein coursing beneath the scaly skin. Because this vein is well supported by surrounding tissue, haematoma formation is uncommon and repeated sampling can be carried out from this blood vessel.

#### *Cutting a claw (Fig. 4.2)*

This method may be used for very small birds (i.e. small finches of 10g or less). The claw and foot is first thoroughly cleansed with a suitable antiseptic (e.g. quaternary ammonium compound) since blood samples taken from this area are quite easily contaminated with a bird's droppings, soil, etc. The blood from the cut claw should be allowed to drip or be drawn into a capillary tube (i.e. a microhaematocrit tube). It should on no account be squeezed out of the foot, since this alters the characteristics of the sample. Blood samples obtained from this site are from capillary blood and may contain cellular artefacts. Bleeding can be staunched after blood collection by the application of a silver nitrate pencil or ferrous subsulphate.

#### *Other sites for blood collection*

Nicking of the external thoracic vein (i.e. running dorsal to the shoulder joint), direct needle puncture of the heart and from the occipital venous sinus have all been used for blood collection mainly in research establishments (Campbell, 1995).



**Fig. 4.2** Clipping the claw for collection of a blood sample: (a) the correct way to clip the claw for collection of a blood sample; (b) this tends to compress the blood vessel.

## Haematology

The definition of some terms used by haematologists

<i>Anisocytosis:</i>	An abnormal variation in the size of RBCs.
<i>Aplastic anaemia:</i>	Total failure of RBC formation.
<i>Crenation:</i>	Collapse of the normal cell resulting in an irregular outline.
<i>Smudge cell:</i>	Cytoplasmic rupture of the cell membrane usually the result of a faulty method in making the blood smear.
<i>Howell-Jolly bodies:</i>	Small round densely staining particles in the cytoplasm thought to be the remnants of the nucleus. Large numbers are the result of malfunction of the erythropoietic tissues.
<i>Hypoplastic anaemia:</i>	Reduction of all the normal blood cell types, i.e. RBCs, heterophils and lymphocytes, etc.
<i>Poikilocyte:</i>	An abnormally shaped RBC.
<i>Polychromasia, polychromatic, polychromatophia:</i>	The cytoplasm of the RBCs, shows a variable bluish colour.
<i>Reticulocyte (rubricyte):</i>	Immature RBC rather more rounded in shape than the ovoid shape of the mature RBC. The cytoplasm shows a darker staining reticular pattern.
<i>Erythroplastids:</i>	Abnormal avian RBCs without a nucleus.

### Haematocrit or packed cell volume (PCV)

By using microhaematocrit heparinised centrifuge capillary tubes, determination of PCV is quick and easy. The result provides valuable information. In most birds normal values for PCV can be 40–55%. In the adult ostrich the PCV is 32–47% whilst in ostrich chicks it is 25–45%. More precise details are given in standard texts such as those edited by Petrak (1996), Fowler and Miller (2003), Samour (2006), Campbell (1994, 1995) and Hernandez (1991). After determination of the PCV the serum can be drawn off with a micro-pipette and used for obtaining biochemical information.

### Blood smears

Only one drop of blood is needed for a smear that can provide information on blood parasites, cell morphology and differential white cell count. Slides can be stained with Leishman's, Wright's or Giemsa stain. However, avian blood does need a somewhat longer staining period than mammalian blood, at least five minutes, and the buffered water used for washing the slide after staining needs to be more acid, pH5 instead of pH7, and should be left on the slide for at least five minutes.

Avian white cells can be more difficult to find than the corresponding mammalian cells. Apart from the fact that the avian red cell is nucleated, the leucocytes in the blood smear are scattered throughout the slide and not aggregated at the edges of the smear as in the case of mammals. There is also much more variation in the appearance of leucocytes in avian blood. Unless a practitioner is carrying out a lot of avian work, it is probably better to fix the slide with methanol and send it to a specialist laboratory for examination. The overall interpretation of the haemogram will depend on the laboratory and the expertise of the technician examining the sample. Notwithstanding this, the fact is that the fresher the blood sample is at the time of examination, the more consistent and reliable the results.

Useful illustrated references for avian haematology are Campbell (1994, 1995) and Samour (2006).

### Clinically significant numerical and morphological changes in the erythrocytes

The reader should note that the avian RBC is nucleated, in contrast with the non-nucleated mammalian erythrocyte. Erythrocyte counts can be obtained by using standard blood cell counting techniques. The figures for a range of species are given in standard texts edited by Fowler and Miller (2003), Harrison and Lightfoot (2006) and Ritchie *et al.* (1994). As a general rule, although the normal erythrocyte count varies between species, the values for PCV (40–55%), haemoglobin (12.2–20.00 g/dl) and mean corpuscular haemoglobin concentration (28–38 g/dl) are constant within fairly narrow limits across the taxonomic range. Also as a general rule, immature birds, particularly those not fully fledged, tend to have lower values for PCV, total erythrocyte count and MCHC than adult birds (Garcia del Campo *et al.*, 1991; Hernandez, 1991). They may also show large numbers of fairly mature RBC precursor cells in the circulating blood. Blood values in wild birds also vary with seasonal activity and depending on whether they migrate and fly at high altitudes and low oxygen tension. As a guide, the range of values for total red cell count is  $2.1\text{--}5.5 \times 10^{12}/\text{l}$  with a mean value of  $3.9 \times 10^{12}/\text{l}$ .

### Mean corpuscular erythrocyte indices

#### *Mean corpuscular volume (MCV)*

Erythrocyte indices can be calculated from PCV, Hb and total RBC count and when used together with the erythrocyte morphology and the total serum protein can give an indication as to the type of an anaemia and may also suggest the aetiology of the disease process.

$$\text{Mean corpuscular volume (MCV)} = \frac{\text{PCV} \times 10}{\text{Total RBC count (millions } \mu\text{l or } 10^6/\text{mm}^3\text{)}} \\ \text{(in femtolitres [fl])}$$

For most birds the MCV lies between 121–200 fl but for small psittacines it can be as low as 99 fl and in the cassowary it can be as high as 286 fl. *An increase in this value is most useful for indicating a regenerative (i.e. macrocytic or increased cell volume) anaemia.* In a non-regenerative anaemia (i.e. normocytic or microcytic) the cells are either normal or reduced in size.

#### *Mean corpuscular haemoglobin concentration (MCHC)*

$$\text{Mean corpuscular haemoglobin concentration (MCHC)} = \frac{\text{Hb (g/100 ml)} \times 100}{\text{PCV (\%)}} \\ \text{(expressed as a percentage)}$$

*A reduced value (i.e. a hypochromic anaemia) usually indicates a deficiency anaemia resulting in an insufficiency of haemopoietic factors.* An increase in this value does not occur since RBCs do not become supersaturated with haemoglobin.

#### *Mean corpuscular haemoglobin*

$$\text{Mean corpuscular haemoglobin (MCH)} = \frac{\text{Hb (g/100 ml)} \times 10}{\text{Total RBC count (millions } \mu\text{l or } 10^6/\text{mm}^3\text{)}} \\ \text{(in picograms [pg])}$$

This is not such a useful index as the MCHC.

### Polychromatic index (PI)

$$\text{The polychromatic index (PI)} = \frac{\text{polychromatic RBCs} \times 100}{\text{mature RBCs}}$$

The polychromatic index (PI) is the ratio of polychromatic or immature erythrocytes to fully mature RBCs and is expressed as a percentage. *This index gives some indication of the rate of turnover of the RBCs and is a useful parameter together with the MCV for indicating if an anaemia is regenerative or non-regenerative and how well the bone marrow is responding.* Hernandez (1991) indicated that in various raptors in a regenerative anaemia the values are all above 3.5%.

### Anaemias

It should be stressed that anaemia as such is only a sign of underlying disease. Anaemias can be classified as follows:

- Haemorrhagic (both acute and chronic)
- Haemolytic (both acute and chronic)
- Depression anaemia (i.e. non-regenerative)
- Regenerative

#### Regenerative

Regenerative anaemias are so named because the body's haemopoetic tissues are endeavouring to replace depleted numbers of normal RBCs. These anaemias are indicated by changes in the morphology of circulating erythrocytes. There may be an increased polychromasia (with new methylene blue stain A, reticulocytosis) together with an increase in size of the RBCs (i.e. macrocytic anaemia) or there may be an excessive variation in the size of the RBCs (i.e. anisocytosis). Reticulocytes, the precursors of mature RBCs, stain with new methylene blue, which stains RNA, and are equivalent to polychromatic cells produced by Wright's stain. Polychromatic cells, the precursors of mature RBCs, occur normally in the blood in small numbers (1–5%). They are slightly larger more rounded cells (Campbell, 1994) than the mature ovoid RBC and have a more basophilic cytoplasm containing a more rounded and less condensed nucleus. These cells are often more evident in the normal blood of the large raptor species (Hernandez, 1991). Birds tend to develop anaemia more rapidly than mammals because of their shorter life span.

#### Acute, subacute, haemorrhagic and haemolytic anaemia

This type of anaemia is usually indicated by normal cell morphology (i.e. normocytic with normal MCV) but the PCV and Hb are reduced (i.e. it is hypochromic) if the blood sample has been taken immediately after the acute incident. When, however, the sample is taken some hours later, which in practice is usually the case, the haemopoetic tissue will have had time to respond and the RBC morphology will become macrocytic (i.e. increased MCV). Possible causes of these anaemias are:

1. Road traffic accidents or other violent trauma such as a gunshot wound, an attack from a predator, a cage mate or even severe self trauma
2. Ulceration or rupture of an internal organ (e.g. rupture of a friable neoplasm of liver)
3. Bacterial and viral infection, e.g. salmonellosis, colibacillosis, conure haemorrhagic syndrome, yersiniosis, *Macrorhabdus*-infection with proventricular ulceration (seen in small birds and also diagnosed in ostriches), trichomoniasis in budgerigars occasionally

results in ulceration, campylobacteriosis in juvenile ostriches, Pacheco's virus in parrots and some other avian herpes virus infections

4. Acute toxaeemias (mycotoxins, lead)

### Chronic haemorrhagic and haemolytic regenerative anaemias

Both the PCV and the haemoglobin levels are decreased but the MCV is increased and there is a reticulocytosis (indicating the haemopoetic tissues are responding). The causes of this type of anaemia can be:

1. Blood parasitism, e.g. microfilaria, *Plasmodium*, *Lankesterella*, *Aegyptianella*, *Haemaphysalis* and *Leucocytozoon*. There may be some interspecies variation since the latter two parasites are often found in Spanish raptors without causing anaemia (Hernandez, 1991).
2. Gastrointestinal (GI) parasitism, e.g. *Capillaria*, ascarids, caecal worms, coccidiosis, histomoniasis, giardiasis, *Hexamita*. Often GI parasitism is associated with a nutritional deficiency or actual starvation which results in a chronic non-regenerative anaemia.
3. External parasites, e.g. red mite – *Dermanyssus* sp., northern fowl mite – *Ornithonyssus* sp., hippoboscids (louse flies) and ticks.
4. Some bacterial infections.

### Chronic non-regenerative or depression anaemias

In this form of anaemia usually the MCHC index is reduced. The cell morphology can be either normocytic or microcytic (i.e. the MCV value may be normal or depressed). The number of reticulocytes is reduced or absent. Possible causes include:

1. Chronic infectious disease, e.g. *Mycobacterium avium*, often leading to a chronic debilitating disease. Other possible chronic infectious diseases are chlamydophilosis, toxoplasmosis, aspergillosis, salmonellosis, yersiniosis, colibacteriosis, campylobacteriosis in juvenile ostriches (this is usually acute or subacute) and chronic forms of viral diseases such as polyoma disease, duck plague, Marek's disease, papillomatosis and avian sarcoma/leucosis complex.
2. Toxaeemias, e.g. lead, copper, zinc, rat poisons (warfarin), chloramphenicol, pesticides (DDT, carbamates), aflatoxins, oak leaves and some other toxic plants.
3. Nutritional deficiencies of haemopoetic factors, e.g. iron, copper, vitamin B<sub>12</sub>, folic acid; overall malnutrition and starvation, secondary nutritional hypoparathyroidism, hypothyroidism (iodine deficiency).
4. Hepatopathies and coagulopathies.
5. Debilitating malignant neoplasms.

## Leucocytes

In birds the mammalian neutrophil is replaced by the heterophil. The cytoplasmic granules of the heterophil are eosinophilic and fusiform in shape. The heterophil has a partially lobed and usually eccentrically situated nucleus.

### Interpretation of the avian leucocyte count

Identification and differentiation of the avian white cells can be difficult for the inexperienced observer. The primary purpose of this handbook is not only to aid the field worker in the interpretation of laboratory reports but also to help that person to make any necessary requests for a more detailed further examination of the sample. Those persons wishing to carry out their own haematological examinations are advised to refer to a more detailed text, with coloured illustrations, e.g. Campbell (1994, 1995) and Samour (2006).



There is some interspecies variation in the morphology of the avian leucocyte and also quite a wide diversity in the normal numerical value not only between species but also within a particular species. Consequently it is often more helpful to the clinician, if it is practical and economic, when using leucocyte counts, to assess a particular case to compare the changes taking place in serial blood samples spaced out over several days. Also this routine is helpful if the range of normal numerical values for a particular species is unavailable.

As a very general guide, values for the total white cell count range from  $1.0\text{--}32.00 \times 10^9/\text{l}$  with percentages for heterophils 20–75%, lymphocytes 20–65%, monocytes 2–5%, basophils 2.5–6% and eosinophils 1–4%.

### Changes in the leucocyte picture indicative of certain disease processes

- *Leucopenias*: i.e. an overall decrease in the number of all types of circulating leucocytes. This usually occurs with severe toxæmia by itself or associated with an overwhelming infection. Toxic drugs or chemical poisons can also have this effect.
- *Leucocytosis*: i.e. an overall increase in the number of circulating white blood cells which is usually well in excess of  $10^9/\text{l}$ . This can be caused by:
  - Infection with bacteria, fungi or parasites.
  - Trauma resulting in massive tissue necrosis.
  - Neoplasia with extensive tissue necrosis.
  - Lymphoid *leucosis* complex. In the opinion of Gerlach (1994), differential leucocyte counts are rarely of any help in diagnosis. The lymphocytes are usually mature and there can be an overall leucocytosis.
  - A marked *leucocytosis* with a relative heterophilia (i.e. a bias towards the heterophils) often indicates a recent infection, as with *Chlamydothyla*, *Mycobacterium avium* or aspergillosis. In contrast, a heterophilia without an overall leucocytosis is possibly indicative of a very early or a poor response to infection. Leucocytosis may result from the use of glucocorticosteroids or as the result of a stress response. However, in this case the leucocytosis is usually only slight to moderate. However, if the heterophilia is dominated by large numbers of very immature heterophils, this could indicate a severe infection which has destroyed large numbers of the mature heterophil population resulting in the rapid mobilisation of immature cells from the haemopoetic tissues in the medullary cavities of the bones. A true shift to the left is not often recognised because the heterophils are already lobulated before leaving the bone marrow so that normally immature forms are difficult to recognise.

The presence of toxic leucocytes (i.e. loss of granulation, vacuolization and a change in cytoplasmic staining) which are graded by Campbell (1994, 1995) as stages 1–4 also indicates a severe systemic illness and a poor prognosis.

- *Heteropenia*: This may occur as a very early reaction to a viral infection.
- *Lymphocytosis*: This usually indicates a chronic antigenic response to immune-mediated disease which is often viral in origin. However it could possibly indicate a lymphoid leukaemia with neoplastic cells and their precursors. Gerlach (1994) is of the opinion that this does not often occur although there may be an overall leucocytosis exhibiting mature lymphocytes. The presence of reactive lymphocytes (identified as medium to large circular WBCs with a large round nucleus in which both cytoplasm and nucleus are deeply staining) indicates an active immune response and these cells are often referred to as immunocytes.
- *Lymphopenia*: This usually indicates a chronic viral infection but could be caused by continuous stress or the use of corticosteroids.

- *The avian thrombocyte*: Small, ovoid, nucleated cells about the size of small lymphocytes but with a colourless cytoplasm. Like mammalian platelets they tend to clump in blood films and they are involved in blood coagulation. They are also phagocytic and the normal count for most birds is  $20\text{--}30 \times 10^9/l$ .
- *Thrombocytosis*: This is possibly a response to a bacterial infection or as a result of excessive haemorrhage. Campbell (1994) describes early and late immature thrombocytes and also reactive forms.
- *Thrombocytopenia*: This is usually the result of a severe septicaemia or poor blood collection techniques.
- *The avian monocyte*: These are the largest of the leucocytes and are macrophages. They are chemically attracted to such infections as *Chlamydophila* and mycobacteria.
- *Monocytosis*: This indicates a successful host response to a chronic bacterial infection or to tissue necrosis. However a monocytosis takes 4–5 days to develop. Monocytes are relatively long lived cells and can survive 45 days. *Chlamydophila* (and some other pathogens) which may have been phagocytosed by these cells remain viable within them for the whole 45 day period and this necessitates *at least a 45 day treatment* for birds infected with *Chlamydophila* or other intra cellular pathogens.
- *The avian eosinophil*: An increase in eosinophils in avian blood samples may not necessarily indicate a parasitic infection, since the function of these cells may be different from that in mammals. It is thought that an eosinophilia may indicate a delayed hypersensitivity reaction.
- *The avian basophil*: This leucocyte is believed to carry out the same function in birds as in mammals, being involved in the early acute inflammatory reaction and in reaction to neoplasms with significant tissue necrosis.

### The selection of biochemical data as an aid to diagnosis

Only those enzymes, metabolites and electrolytes which are of most value to the avian diagnostician are mentioned in this text. However, additional information on the usefulness of other blood chemistry constituents may become available.

#### The advised routine for the collection of blood chemistry samples

If a clinician is going to take the trouble to collect a blood sample from a bird and is to obtain meaningful information then it is imperative that the collection procedure and the subsequent handling of the sample should be faultless.

1. The venipuncture site, the needle and the syringe must all be clean and the equipment should be new and unused. Water droplets in a re-sterilised syringe invalidate the result.
2. The correct type of microcontainer containing either no or an appropriate anticoagulant should be selected.
3. Preferably use plasma obtained after immediate centrifugation of freshly drawn unclotted blood. This should be placed in a microcontainer with a neutrally reactive gelatine serum separator. The sooner the cellular element of the blood is separated from the plasma the better, since nucleated RBCs continue to metabolise intracellular enzymes until all the oxygen within the cell is used, after which the integrity of the cell wall is vitiated and enzymes start to leach into the plasma, so affecting the assay of plasma enzymes.
4. If an anticoagulant is used, lithium heparin (not the potassium or sodium salts) should be used for most biochemical estimations but it should not be used for estimations of glucose or calcium.

5. To mix the sample with the anticoagulant, the container should be rolled along the work surface. It should not be shaken violently which may result in haemolysis so invalidating some results.
6. Serum can be used after the blood has clotted and the clot has been allowed to contract, which will take a minimum of 20 minutes. Speeding the clotting process by placing the sample above a radiator only produces erroneous data.
7. Whether serum or plasma is obtained, the sample should preferably be tested immediately. If this not practical and it has to be posted to a laboratory, it is better to first freeze the sample and then pack in insulation.

### How much reliance can be placed on the results?

It is important for the avian practitioner to appreciate that the biochemical data obtained from a particular bird can only be a *rough guide* to a final diagnosis. It is a mistake to base a definitive diagnosis solely on the information obtained about one or two biochemical constituents after checking these against the values on the data base taken from so-called 'normal' healthy birds. This is because there is a wide variation in both the physiological (i.e. age, gender, moulting, egg laying, possible migratory behaviour and circadian rhythm) and environmental conditions (i.e. whether the bird is wild or captive, husbandry, nutrition, varying weather conditions, also possible exposure to undiagnosed subclinical viral infection), imposed on these so-called 'normal' birds.

Another important factor affecting the validity of the result will be the laboratory. Different commercial laboratories will use variously different methodologies when assaying for the same enzyme. All the methods used have been developed for use and comparison on humans and domestic mammals. The net result is that the final figure obtained from the same sample from a particular case may vary slightly from one laboratory to another.

During the last decade an abundance of data has been collected on those elements of biochemistry mentioned in this text. Nevertheless often the information published by different groups of workers in this field differs to a greater or lesser degree. Consequently, here only a broad guide to the 'normal' levels of blood biochemical elements is given together with an indication of when these values for a particular species are known to be outside the normal pattern. All values are expressed in SI units (Système International d'Unites, 1977) (conversion factors to SI units are given).

All biochemical data can only indicate a trend towards a particular clinical condition and to be of any significant value most results (particularly in the case of the enzymes) should show a result of at least a two-fold increase above the 'normal' data base. All diagnosis is a matter of obtaining as much available evidence from as many varied sources as possible (i.e. haematology, biochemistry, imaging and all the other different aids mentioned in this chapter) after which using one's clinical acumen to assess the balance of probabilities in favour of a specific diagnosis. In addition to this the practitioner will have to consider the economic cost of the various tests in terms of the time and cost of laboratory fees, etc., in direct relation to the value of a particular case to the client.

## The plasma proteins

These can provide important information on the overall state of health of the bird.

### Total serum protein

Assessment of total protein values are probably of most use when used in conjunction with protein electrophoresis.

For most species the value for total serum protein will be 3–5 g/dl. Note that the level of plasma protein will be approximately 0.15 g/dl above the value for serum protein because the fibrinogen will have been removed during coagulation. However, normal levels

of fibrinogen do vary, e.g. cockatoos 0.09–0.33 g/dl, macaws 0.1–0.32 g/dl. In the past many avian clinicians have used a hand-held refractometer, a method which was quick and convenient. Unfortunately the results so obtained have been shown to be unreliable. Both haemolysis and lipaemia are only two of a number of factors affecting the result.

### *Hypoproteinaemia*

Since most of the serum proteins are produced by the liver a reduction in total serum protein is one indicator of the severity and progression of hepatopathy. Other possible causes of reduced serum protein level are any disease associated with anaemia, malnutrition, starvation, malabsorption consequent upon gastrointestinal disease, gastrointestinal parasitism, glomerulonephritis, severe trauma, prolonged stress, acute lead poisoning, chronic infectious disease and Pacheco's disease, etc.

### *Hyperproteinaemia*

This may be due to dehydration (PCV is also elevated), shock or acute infection. There is also a rise in the total serum protein just prior to egg laying due to the transport of the globulin yolk precursors to the ovary (Lumeij, 1987). Serum protein tends to be higher in older birds. Very high levels of serum protein may be encountered with the leucosis complex.

### *Albumin*

Albumin is usually 1.0–2.2 g/dl for most species of bird. This is the major protein produced by the liver and forms most of the plasma protein, so that a hypoalbuminaemia is usually responsible for a drop in the total serum protein. Since albumin is important in the transport of anions, cations, fatty acids and thyroid hormone, a drop in the serum level of albumin has overall serious consequences.

### *Globulins*

This fraction of the serum protein comprises the  $\alpha$ -,  $\beta$ - and  $\gamma$ -immunoglobulins together with the globulin precursors of the yolk proteins. As Hochleithner (1994) has indicated,  $\alpha$ - and  $\beta$ -globulins (one of which is fibrinogen) are acute-phase proteins and tend to rise with acute nephritis, with a severe hepatitis and with trauma including surgery. The  $\gamma$ -globulins are the immunoglobulins which increase with both acute and chronic infection. Their increase should be compared with any simultaneous lymphocytosis, which may not be present.

*Hyperglobulinaemia* is usually the result of subacute or chronic infectious disease; alternatively it can occur as a result of trauma including surgery.

### *Fibrinogen*

For psittacines, levels greater than 0.3–0.5 g/dl are significant. This is one of the significant  $\beta$ -globulins and since it is concerned with the blood coagulation mechanism it has to be determined in plasma. EDTA must be used as the anticoagulant not heparin. This plasma protein is an important guide to an acute inflammatory response.

### *The albumen/globulin ratio*

For many birds the normal values are 1.4–4.9. As Lumeij (1987) has indicated, *serial determinations of the A/G ratio is a valuable guide* to the progress of a disease process. The ratio tends to decrease (the globulins rise and the albumin falls) during both acute and chronic infections (e.g. *Chlamydophila*, aspergillosis, mycobacteriosis and egg peritonitis). As recovery proceeds, the globulins tend to fall whilst the albumin level rises and the ratio returns to normal. A persistent low A/G ratio together with an overall reduction in total protein indicates liver failure.

## The metabolite fraction of the plasma biochemical elements

These substances tend to provide more organ specific information regarding the functional condition of some of the body's tissues.

### Glucose

For most birds, serum glucose lies in the range 200–500 mg/dl. To convert mg/dl to mmol/l multiply by 0.05551. In the emu, the normal level can be as low as 158 mg/dl.

When collecting avian blood samples for glucose estimation it is not necessary to use fluoride as an anticoagulant provided the plasma sample has had the red cells immediately removed. In any case, fluoride can have an inhibitory effect on some enzyme test samples.

In general, avian serum glucose levels are much higher than in mammals but as with many other biochemical constituents of avian blood the level does tend to vary with age, diet, breeding season, stress and also diurnally. For most birds the level falls during daylight hours and rises at night. The reverse may be true in the nocturnally active birds. In the moulting mallard duck the normal level of serum glucose is rather on the low side at 185 mg/dl.

Depending on the laboratory technique used lipaemia may invalidate the result.

### Hyperglycaemia

This state can occur during stress, including hyperthermia. It has been recorded in Amazon parrots with lead toxicosis. Also it may be seen in some cases of peritonitis where there is an associated pancreatitis.

A transient hyperglycaemia occurs for the first 72 hours after the withdrawal of food in pigeons (Lumeij, 1987) in consequence of which, except in the case of the very small (i.e. below 100 gm) birds, pre-surgical fasting has a positive advantage, especially when gastrointestinal surgery is anticipated.

### Diabetes mellitus

*Diabetes mellitus* has been recorded in some granivorous birds, budgerigars, cockatoos, Amazon parrots, macaws and cockatiels, also in toco toucans (which are not granivorous) (Hochleithner, 1994). In these cases the serum glucose levels can be above 750 mg/dl and can reach 1000–2000 mg/dl. However, this hyperglycaemia may not be due to an insufficiency of insulin (in granivorous birds) since the hormone glucagon is more important in the regulation of blood glucose levels. In carnivorous birds insulin may be a more important regulator of blood glucose as is the situation in mammals. However this subject in birds has not been well researched.

### Hypoglycaemia

Glucose levels below 100 mg/dl indicate a grave prognosis. Hypoglycaemia occurs in cases of starvation and particularly in immature raptors and can result in hypoglycaemic convulsions after only a few days of anorexia. How long this state of affairs takes to develop will depend on the size of the bird and on the species. Some inexperienced falconers in an attempt to reduce a bird's weight to its so-called flying weight will take the reduction of food intake too far and produce relative starvation.

Hypoglycaemia may be induced by malnutrition, possibly by hypovitaminosis-A, by toxaeemias resulting from neoplasia and infectious diseases developing septicaemia.

### Uric acid

For most birds, the normal value for uric acid is in the range 2–15 mg/dl (to convert mg/dl to  $\mu\text{mol/l}$  multiply by 59.48). Levels of uric acid vary with age and species and they are generally 50% lower in granivorous birds when compared with carnivorous birds.

Birds excrete 60–80% of their nitrogenous waste as uric acid (synthesized in the liver but excreted through the kidney) in a form which is almost independent of the rate of flow of fluid urine through the kidney. Of this uric acid, 90% is excreted dynamically via active cellular secretion from proximal renal tubules and glomeruli. A much smaller amount is derived from actual glomerular filtration. The avian kidney has at least 50% reserve capacity so that extensive nephrosis must have occurred before the amount of uric acid in the plasma exceeds normal, providing of course other factors affecting the level of uric acid remain normal. Abnormally high amounts of uric acid in plasma occur in starvation (due to catabolism of the body's tissues), in extensive trauma, in gout (often uric acid rises before clinical gout is seen), in toxicosis of the kidney with aminoglycosides (particularly gentamycin), nephrocalcinosis caused by excessive vitamin D<sub>3</sub> and some other medications, such as occasionally sulphonamides or the azole antifungals.

Uric acid can rise after the use of corticosteroids, in dehydration, toxæmia from some bacterial and viral infections and with gastrointestinal haemorrhage, also, possibly, due to chronic hypovitaminosis A resulting in damage to the epithelium of the kidney tubules. To keep the uric acid and urate crystals in colloidal suspension large amounts of mucus have to be secreted by the healthy cells of the renal collecting tubules.

Because of the multiplicity of causes which can result in a rise of the uric acid level, plasma uric acid is not a very useful single indicator of kidney disease.

## Urea

Normal levels of urea for most birds are 2.4–4.2 mg/dl (to convert mg/dl to mmol/l multiply by 0.3510). In the ostrich the normal is 1.8–3.00 mg/dl and in the cassowary it is 8.7–9.9 mg/dl.

Urea, which forms 20–40% (the actual amount varies between species – see p. 21) of avian nitrogenous waste is excreted by glomerular filtration. In normally hydrated birds a little is reabsorbed in the distal renal tubules but in dehydrated birds nearly all of the urea is reabsorbed. The urea is in aqueous solution so that its excretion, unlike that of uric acid, is entirely dependent on the rate of flow of fluid through the kidney. Consequently any factor which impairs this flow, such as dehydration, cardiopathy, or post-renal obstruction (e.g. cloacal impaction, a neoplasm or blocking of the oviducts with an egg which may cause pressure on the ureters) or possibly the careless surgical placement of a purse string suture around the vent to reduce a prolapse (see p. 161), or impaction of the renal tubules with urate crystals as happens in cases of salt poisoning, can all cause a rapid rise in 2–3 days of the urea in the plasma. This rise can be as much as 15-fold particularly if there is a concurrent increase in the level of nitrogenous waste production.

## The urea/uric acid ratio

For pigeons the normal is  $1.8 \pm 1.8$ . Experimental work by Lumeij (1987) on the pigeon has shown that this ratio is not only an indicator of the state of dehydration (as also demonstrated by PCV) but may also be an indicator of urinary fluid flow so that in cases of renal failure accompanied by a reduced urinary flow, the urea/uric acid level rises significantly. After four days' starvation (i.e. resulting in tissue catabolism and increased nitrogenous waste production) accompanied by four days' water deprivation, the ratio rose to  $12.0 \pm 2.0$ .

$$\text{Urea/uric acid} = \frac{\text{urea (mmol/l)} \times 1000}{\text{uric acid } (\mu\text{mol/l})}$$

To convert uric acid in mg/dl to  $\mu\text{mol/l}$  multiply by 59.48.

### Creatinine

Normal values of creatinine in most birds are 0.2–0.5 mg/dl (to convert mg/dl to  $\mu\text{mol/l}$  multiply by 88.4).

In the present state of knowledge about avian blood biochemistry, estimations of this constituent are not a lot of value to the avian clinician.

### Cholesterol

Normal values for cholesterol are in the range 108–330 mg/dl (to convert mg/dl to mmol/l multiply by 0.02586). In ostriches the range is 58.05–162.57 mg/dl.

This substance is the precursor of all steroid hormones (i.e. sex hormones and corticoid hormones) as well as the bile acids. Some cholesterol is obtained from the protein in the diet, its level being higher in carnivores. The remainder of the cholesterol is produced in the liver. Plasma levels of cholesterol are increased in cases of fatty liver and kidney syndrome. Very high levels of plasma cholesterol accompanied by a lipaemia indicate fatty degeneration of the liver. Hochleithner (1994) has indicated that the plasma cholesterol may increase together with xanthomatosis in the budgerigar; and the author has seen this in an African grey parrot (*Psittacus erithacus*).

### Lipaemia

Lipaemia may occur together with a rise in plasma cholesterol and sometimes there is a post-prandial increase in chylomicrons in the blood, particularly with a high fat diet. Diets containing seeds such as sunflower, hemp, rape and safflower can produce this effect. Lipaemia also occurs with hepatopathies (not only fatty liver), in hypothyroidism and sometimes with egg peritonitis (egg yolk absorbed from the coelomic/peritoneal cavity).

Lipaemia can be recognised by the naked eye in plasma and serum samples. Very often immediately the blood sample is collected it is noticed to be milky in colour. The presence of lipaemia may invalidate or may make the carrying out of some blood biochemical tests impossible.

### Bile acids

For psittacines the range for bile acids is 18–144  $\mu\text{mol/l}$ . Bile acids are produced by the liver and excreted in the bile. After acting on the ingesta they are reabsorbed and recycled through the liver. A small amount continues to circulate in the blood stream. There is normally a post-prandial rise in plasma bile acids. Anything which interferes with the normal recycling process leads to a rise in plasma levels. In hepatopathy there may be an imbalance between the quantity manufactured in the liver and the amounts being re-used by the liver (which may drop) so that an inevitable rise in the blood level occurs. Conversely a reduction in liver size resulting from chronic liver disease and fibrosis leads to a gradual wastage and fall off in the amount circulating in the blood stream. Bile acids are therefore a good indicator of liver disease and these substances have the great advantage that they are stable compounds unaffected by the handling of the blood sample.

Since birds produce mostly biliverdin rather than bilirubin true icterus does not usually occur in birds, although it can occasionally be detected on the face of macaws if the level of bilirubin exceeds 2.36 mg/dl (Hochleithner, 1994).

### Serum enzymes

The enzymes found in serum function normally within the confines of the individual cells of specific organs. Anything which disrupts the integrity of the cell can lead to an increase in the release of enzymes into the blood stream, but in some cases of hepatic fibrosis may result in normal plasma levels or even a fall in the normal level. In consequence their presence and the quantity present give the clinician some indication of the degree of organ or tissue damage.

### The amino transferases

This group of enzymes controls the transfer of amino groups in amino acids. None of these enzymes is organ specific. Besides the liver, these enzymes are found in the heart muscle, skeletal muscle, the gastrointestinal cells, the kidney and brain. Of this group of enzymes the most useful to the avian clinician are:

#### *Aspartate amino transferase (AST, SGOT)*

Normal plasma values for AST in most birds should normally be below 230 IU/l but can be in the range of 52–270 IU/l. In the ostrich, the normal value is 100–160 IU/l. As with the biochemistry of many of the blood constituents, the level varies with the age and seasonal activity. Although, as already indicated, AST has a wide distribution in the body's tissues and although it is not liver specific it is possibly the single most useful enzyme for indicating liver disease. However, any soft tissue damage including intramuscular injection, particularly with irritant drugs (e.g. doxycycline and occasionally potentiated sulphonamides), can result in an elevation of the plasma AST. Because of this the level of AST should always be compared with that of CPK which is much more specific for soft tissue trauma (particularly muscle) and is unaffected by liver damage. Increases of AST occur with any kind of hepatopathy, including Pacheco's disease and chlamydophilosis, also toxic chemicals (e.g. some pesticides and carbon tetrachloride) and the use of some drugs (e.g. doxycycline injection), besides causing a rise in CPK also can result in a rise in AST. The use of many of the azole antifungal drugs (ketoconazole, fluconazole and itraconazole) can also increase AST levels.

#### *Alanine amino transferase (ALT, SGPT)*

Normal levels of ALT in birds vary considerably from 6.5–263 IU/l. Changes in the plasma level of this enzyme are not a reliable index of hepatopathy in birds.

#### *Lactate dehydrogenase (LD, LDH)*

For most birds normal levels of LDH are 46–442 IU/l. In the ostrich they can be 1000.0–2000.0 IU/l and in canary finches they are approximately 1582.63 IU/l.

This enzyme is not organ specific; in fact it is found in many tissues of the body. However, increased blood plasma quantities are commonly noticed with hepatopathy and myopathy. Levels of this particular enzyme tend to rise and fall much more rapidly with acute hepatopathy so that in this respect LDH has some value in indicating acute liver disease. Nevertheless the value of LDH should always be compared with that of CPK.

#### *Alkaline phosphatase (ALP, AP)*

Levels of ALP for psittacines are 42–479 IU/l. In the ostrich they are 330–820 IU/l.

This is another non-organ-specific enzyme which is found mostly in the duodenum and kidney (Lumeij, 1987). Some authors consider this enzyme to be a good indicator of osteoblastic activity (i.e. osteomyelitis, bone neoplasms, fractures, rickets and hyperparathyroidism). Its level is also increased in growing birds and in egg laying birds when calcium metabolism is increased in the medullary bone. It is suggested that ALP blood levels may also be increased in some cases of liver disease, such as aflatoxin poisoning. However one should also look for concurrent rises in AST and bile acids. Low levels of ALP may be seen in zinc dietary deficiency.

#### *Creatine phosphokinase (CPK, CK)*

Normal values for CPK in birds lie between 110–480 IU/l. In the ostrich they can be 400–900 IU/l.

This enzyme is a specific indicator of muscle trauma. It is therefore a very useful guide for the differentiation of muscle and liver damage when levels of AST and LDH may also



be raised. It should be noted that intramuscular injections given prior to blood sampling may help to increase CPK values. Also CPK values are said to rise with neuropathies associated with convulsions, with lead toxicity, with chlamyophilosis, with bacterial septicaemias and vitamin E deficiency.

### **The blood electrolytes**

Maintenance levels of these in the blood plasma are essential for many living processes.

#### **Calcium**

Normal calcium levels in most birds are within the range 8–12 mg/dl (to convert mg/dl to mmol/l multiply by 0.25). In the ostrich they are 6.8–10 mg/dl, in budgerigars they are 6.4–11.2 mg/dl and in the chicken 13.2–23.7 mg/dl.

Blood samples for calcium analysis must be collected in heparinised tubes, since all other normal anticoagulants (i.e. EDTA, citrate and oxalate) bind calcium ions in the blood. Because some calcium ions in the blood are bound to protein (principally albumin), the total blood calcium level should always be considered together with the level of albumin. A hypoalbuminaemia can result in a drop in total blood calcium. However, the calcium bound to protein is not necessarily in an ionized biochemically active form.

Total blood calcium levels tend to be higher during ovulation (corresponding with increased ALP) and coincident with the transport of protein-bound calcium to the shell gland, but the level of calcium ions in the blood remains constant. Immature birds tend to have lower blood calcium levels.

#### *Hypercalcaemia*

Serum calcium levels may be raised after use of excessive dosage with vitamin D<sub>3</sub> and also in conjunction with some osteolytic bone tumours. Also, possibly dehydration may result in an increase in total blood calcium.

#### *Hypocalcaemia*

Normal blood calcium levels of ionized calcium falling below 6.0 mg/dl in most birds leads to loss of muscular condition, muscle twitching and eventually to clonic and tonic muscle spasms. In some species (e.g. African grey parrots and some raptors) the bird becomes hypersensitive so that when suddenly startled it develops a seizure. A hypoalbuminaemia can lead to a depression of protein-bound calcium and eventually to a hypocalcaemia. Glucocorticoid therapy can also result in a decrease in the total blood calcium.

#### **Chloride, sodium and potassium determinations**

Chloride, sodium and potassium determinations are of questionable value in the diagnosis of avian disease except for the confirmation of hypernatraemia which may occur in cases of suspected salt poisoning in wild birds after draught conditions or in parrots fed on large amounts of salted peanuts or potato crisps. Normal values for plasma sodium for most birds are 127–170 mEq/l but for the ostrich they are 113–181 mEq/l.

## **MICROBIOLOGICAL INVESTIGATIONS**

Since bacteria and fungi play an important part in the development of avian disease, the clinician should try to establish what potential pathogens are present. However, it is very easy to make a hurried decision and conclude that some innocent micro-organism is the sole cause of the disease process.

Birds pick up a variety of micro-organisms from their contacts such as wild birds, rodents, human handlers and the environment. Birds newly introduced into an aviary can

bring in diseases such as chlamydophilosis (psittacosis), salmonellosis, avian tuberculosis, Newcastle disease or Pacheco's parrot disease, etc. Also, cage and aviary hygiene can sometimes leave much to be desired, and perches, food and water containers become contaminated.

Bacteriological swabs can be taken from a variety of sites, such as bumblefoot abscesses, suspected cysts, wounds and natural orifices including the trachea and the crop. They can also be taken after paracentesis of abdominal fluid. In the first instance they should be cultured on blood agar plates and on enterobacteriaceae differential agar plates (e.g. MacConkey's agar) at 38–40°C and the organism checked for antibiotic sensitivity.

Faecal swabs are best obtained direct from the cloaca, the vent having first been cleaned and sterilised with a quaternary ammonium antiseptic. If this is not possible the swab can be taken from fresh faecal droppings on a clean surface. When a bird is first handled it will often eject fresh faecal matter from the proctodeum and this can be utilised. A useful method of collecting uncontaminated faeces from small cage birds is to substitute a piece of X-ray film or aluminium foil for the sand sheet in the bottom of the cage. Faecal swabs should be routinely cultured on blood agar and enterobacteriaceae differential agar plates.

When *Chlamydophila psittaci* is suspected, collecting *one combined swab of conjunctiva, choana and cloaca is advisable*. The swab has to be dry and not wet as for other bacteria. *Chlamydophila* spp live intracytoplasmically and therefore cells are needed for their detection e.g. using the Clearview™ (unipath) test. The use of dry swabs is also necessary for detection of *Mycoplasma*.

When *Salmonella* spp are suspected, a bulk sample of droppings collected over a period of three days should be examined, using enriched culture media and special agar plates for the culture of *Salmonella* spp. *Salmonella* spp are found in most species of pigeon and wild birds and are easily spread to aviary birds by faecal contamination. However, *Salmonella* spp do not appear to be common in the faeces of raptors. *Salmonella typhimurium* is by far the most common specific organism in this group of bacteria isolated from birds.

It should be noted that a wide variety of bacteria are normal commensals in the gut of many birds and these may be pathogenic only if the bird becomes subjected to stress. A careful assessment of the patient is necessary before one can be reasonably certain that the organism isolated is causing the disease. *To some extent the spectrum of avian gut flora is influenced by the diet of the bird*. *Escherichia coli* is a normal inhabitant of the gut of most raptors and pigeons living in outdoor aviaries. Gram- bacteria are not normally present in large numbers in the alimentary tract of grain and fruit eating birds but may become more evident when the bird starts eating insects during the breeding season.

Tracheal swabs can be taken in the conscious bird or, if necessary, in the sedated bird, and a human nasopharyngeal swab is very useful for this purpose.

When *Aspergillus* spp are suspected in the respiratory tract, samples from the air sacs may also be taken endoscopically (see p. 85) in some instances and cultured on Sabouraud's dextrose agar at 37°C for 36–48 hours.

Swabs should be taken from any eggs that have failed to hatch. The surface of the egg should be first sterilised with alcohol before a small hole is made in the shell and the swab used to sample the contents. Swabs should be cultured on blood agar and enterobacteriaceae differential agar plates.

When taking swabs from post-mortem specimens, one should take into account that cultures obtained from birds that have been dead more than 24 hours may not be representative. Some organisms, such as *Proteus* spp, that are normally present in the gut of some birds (e.g. raptors) may rapidly invade other organs after death and overgrow other pathogens on a culture plate.

## Examination of stained smears

This is quick, and although not conclusive, it is a useful guide to examine stained smears of pus, faeces and exudate. These can be stained with modified Romanowsky stain (e.g. DiffQuik®, Hemacolor®), Gram stain, methylene blue (for bipolar staining of *Pasteurella*) or, where avian tuberculosis is suspected, with Ziehl-Neelsen stain. Liver impression smears can also be stained for acid-fast organisms.

Where *Chlamydophila* (psittacosis) infection is suspected these smears can be stained by a modified Ziehl-Neelsen (STAMP) technique to show up the intracytoplasmic inclusion bodies. This technique is carried out as follows: the slide is flooded with dilute carbolfuchsin stain for ten minutes, but is not heated as in normal Ziehl-Neelsen staining. The slide is then washed and decolourised with 0.5% acetic acid – not acid alcohol which is normally used. Decolourisation is carried out only for 20–30 seconds until the slide is very faintly pink. Counterstain with methylene blue in the normal manner. The tissue cells may then be seen to contain clusters of very small red intracytoplasmic inclusion bodies. However, because of the risk of zoonotic infection, investigation of this disease is best left to specialised laboratories that have the necessary air extraction safety cabinets.

It is generally considered that the presence of Gram– bacteria is abnormal in caged birds, however Phalen (2006) states that in healthy birds Gram– bacteria may not always be pathogenic. *To decide whether detected bacteria are pathogenic or not one should consider the relative amount of bacteria isolated and whether a pure or mixed bacterial culture is present.* Additionally, the result of the investigation should be compared with the clinical symptoms. Routine staining of a sample by Gram's method can help in the interpretation of antibiotic sensitivity testing. The stain will indicate the relative numbers and the morphology of Gram– and Gram+ bacteria and also if yeasts are present. This technique may show anaerobic bacteria to be present when there is little or no growth on a routine blood agar culture.

If *Aspergillus* spp are suspected in a post-mortem preparation, a portion of the lesion can be teased out onto a slide and treated with 20% KOH. The alkali clears the other tissues and renders the fungal hyphae more easily seen. If necessary the slide can subsequently be gently washed, fixed with heat and stained with lactophenol cotton blue stain.

## Serology, DNA probes and viral culture

The laboratory examination of serum samples can be a valuable aid in assessing if a bird has already been exposed to infection by a specific micro-organism, which, particularly in the case of some viruses, may remain latent for years. Alternatively, by using paired serum samples taken two weeks apart the bird can be shown to be actively responding to the infection immunologically by a rising titre. Serology is particularly valuable in making a definitive diagnosis of viral infection where there are often no or few pathognomonic signs and viral culture may be difficult and take weeks.

Viruses can be cultured in living cells from a variety of tissues from both ante- and post-mortem cases providing the autopsy specimen is *very* fresh. However, if viral culture is to be attempted special transport media containing antibiotic (to prevent bacterial overgrowth) is needed and the swab or specimen needs to be frozen (–4°C). When intending to use this aid to diagnosis the clinician is advised to first consult with the laboratory which is to carry out the culture.

There are a variety of serological tests available, e.g. complement fixation, virus neutralisation, ELISA, haemagglutination inhibition, immunofluorescence and others. Some of these serological tests are much more sensitive and specific than others. Which test is to be used for a particular case is best left to the judgement of the laboratory, but before a choice can be made the laboratory will need a good anamnesis and an indication of what is the clinician's tentative diagnosis.

### Polymerase chain reaction (PCR)

The polymerase chain reaction (PCR) is a method for detection of specific DNA or RNA of micro-organisms in any samples (for example blood, faeces, exudates, different tissues). DNA polymerase is used to produce copies of DNA template molecules with the use of specific primers by repeated heating and cooling. RNA must first be converted into DNA. Using this method viral DNA can be amplified to detectable amounts. Advantages of this method are high sensitivity and automation. Disadvantages are high risk of contamination and high costs. Furthermore the DNA or RNA of the virus must already have been sequenced. Specific PCRs which are extremely sensitive have been developed for the detection of the presence of some micro-organisms such as polyoma- and circoviruses and *Chlamydoiphila*. In the detection of *Chlamydoiphila* infection faeces or, better, swabs from conjunctiva, choana and cloaca are used. *Nevertheless all these PCRs will only indicate the presence of DNA or RNA of a potentially infective micro-organism; they do not give any indication of the activity of the infection.* Table 4.1 lists various pathological micro-organisms together with the different molecular biological tests which can be used for the detection of that particular infection.

For more detailed information on the detection of micro-organisms consult standard texts edited by Fudge (2000), Harrison and Lightfoot (2006) and Ritchie *et al.* (1994, 1995) and for more information on particular laboratory tests available in the UK contact the Central Veterinary Laboratory. Also for information on PCR consult: Vetgen Europe, PO Box 60, Winchester SO23 9XN; telephone 01962 880376, fax 01962 881790.

## DIAGNOSTIC CYTOLOGY

The microscopical examination of cell morphology in samples harvested from abnormal tissue is a quick and relatively inexpensive method of making a tentative and sometimes a definitive diagnosis. The technique has almost infinite possibilities. Specimens for examination can easily be obtained and examined immediately by the experienced clinician, so that the result is available much more rapidly than when biopsy samples are sent away for histopathology. However, *cytology will only indicate changes in individual cell morphology* and will not show any structural changes in diseased tissue.

### Collection of samples

Hyperplastic tissue, swellings and suspected malignancies

The surface of the tissue is first cleaned with alcohol and allowed to dry. Using a hypodermic needle (e.g. 14–22g × 1") attached to a 10ml syringe, the needle is then inserted into the tissue and a sample aspirated into the syringe. A quantity of tissue is obtained so that it just appears above the hub of the needle in the bottom of the syringe. If too much aspirate fills the syringe then it is difficult to expel. Whilst aspirating the sample it is best to partially withdraw the needle and reinsert it several times in different directions to get a representative sample. The sample is then expressed onto a slide, spread into a thin smear, fixed and stained. When making the smear the aim is to achieve a single layer of cells. This can sometimes best be carried out by squashing the specimen between two glass slides and then sliding these carefully apart so that two smears are obtained, one on each of the opposing faces of the two glass slides. Each can then be stained differently.

### Bone marrow samples

Examination of bone marrow samples is helpful when the haematology of a blood sample reveals a grossly reduced or absence of one or other of the normal cellular constituents. Alternatively such samples may be helpful in cases of non-regenerative anaemia or suspected leukaemias.

**Table 4.1** Tests for specific pathogenic micro-organisms.

<b>Micro-organism</b>	<b>Possible Laboratory Tests</b>
<i>Salmonella</i>	ELISA, culture
Avian <i>Mycobacterium</i>	Ziehl-Neelsen stain, PCR, ELISA, slide agglutination, culture
<i>Chlamydophila</i>	ELISA, DNA probe, PCR, immunofluorescence
<i>Mycoplasma</i>	ELISA, PCR
Avian encephalomyelitis virus	Immunodiffusion or ELISA
Avian influenza virus	Immunodiffusion or ELISA, PCR
Avian reticuloendotheliosis virus	Histological examination only
Avian sarcoma leukosis virus	Histological examination, immunohistochemistry, possibly ELISA
Equine encephalomyelitis virus Eastern and Western strains	Haemagglutination, ELISA, haemagglutination inhibition
Avian paramyxoviruses	Haemagglutination inhibition, viral culture (including Newcastle disease and PMV 1 pigeon)
Parvovirus infection of geese	Virus neutralisation, ELISA or immunofluorescence, electron microscopy
Psittacine circovirus; Columbidae circovirus; Canary circovirus	Haemagglutination inhibition, PCR
Polyoma virus	Virus neutralisation
Avian pox viruses	Viral culture; virus can be cultured from the faeces of carrier birds; virus neutralisation or immunodiffusion; histopathology is best for confirming clinical cases
<i>Avian herpes viral infections</i>	
a) Infectious laryngotracheitis	Virus neutralisation, immunofluorescence, ELISA, PCR
b) Duck plague virus (duck virus enteritis)	Virus neutralisation, PCR
c) Pacheco's parrot disease	Virus neutralisation, ELISA or immuno-fluorescence, immunodiffusion, PCR
d) Budgerigar herpes virus	Virus neutralisation or immunodiffusion, PCR
e) Pigeon herpes virus (inclusion body hepatitis)	Virus neutralisation, ELISA or immunodiffusion, PCR
f) Pigeon encephalomyelitis (contagious pigeon paralysis)	Serological tests are not at present available. Confirmation of diagnosis will depend on histopathology, often using electron microscopy
g) Marek's disease	Histological examination, PCR
<i>Adenoviruses</i>	
There are a multiplicity of adenoviruses, not all of which may be pathogenic. Some adenoviruses may act as triggers.	Although <i>group-specific</i> antibodies are detectable by ELISA and immunodiffusion tests and there are also specific DNA probes for other pathogenic adenoviruses, diagnosis of some adenoviruses mostly depends on virus neutralisation together with histopathology with a search for inclusion bodies and also on electron microscopy

Bone marrow samples can be obtained from the keel of the sternum or more easily from the proximal tibiotarsal bone when approached from the medial aspect just distal to the stifle joint. The skin over the sampling area is first cleaned and sterilised with alcohol and a small incision made with a scalpel. A hypodermic needle containing an in-dwelling stylet is best used (e.g. a paediatric bone biopsy needle or a 23 G spinal needle). Sometimes a normal hypodermic needle can be used with a length of sterile stainless steel suture wire inserted in the lumen or, as a last resort, a tunnel can be pre-bored in the bone with a suitable diameter Steinman intramedullary pin, and the hypodermic needle inserted through this prepared entrance hole.

### Abdominocentesis

Samples of abnormally present abdominal fluid can be carefully aspirated for examination. The sampling needle is carefully inserted in the mid-point of the abdomen and directed towards the right hand side of the bird (e.g. the operator's left hand if the bird is in dorsal recumbency) so as to avoid the gizzard (ventriculus). If the needle is inserted too far anteriorly it is liable to puncture the liver and if too far posteriorly it will enter the distended cloaca. Samples for cytology from the abdomen can also be obtained using the laparoscope.

### Crop washings

A blunt ended catheter or gavage tube can be used to instil normal warm saline into the crop (20 ml/kg). A part of the fluid is then immediately aspirated but care must be taken not to apply too much negative pressure to the syringe otherwise the mucous membrane is liable to be sucked into and block the catheter.

Washings of the proventriculus can be obtained in the same way. However this is best carried out under a general anaesthetic with an endotracheal tube in place. The procedure can be carried out blind but it is safer if an endoscope is used.

### Air-sac washings

A sterile flexible catheter, attached to a syringe, is inserted into the last intercostal space of the bird, and 3 ml of sterile saline (in a large bird 3 kg and above) are injected and this fluid is withdrawn immediately for culture.

### Tracheal washings

A small diameter (16G or 1mm, e.g. a canine i.v. catheter) length of nylon tube, long enough to reach the syrinx, which lies just caudal to the thoracic inlet, is passed through the glottis with the neck extended and 0.5–2 ml/kg of normal saline is flushed into the lumen of the trachea and immediately withdrawn for examination. This procedure is probably best carried out in the lightly anaesthetised or deeply sedated bird.

### Aspiration of infraorbital or paraorbital sinuses

The needle is inserted into the point of greatest distension or through the skin at the commissure of the mouth, passing either above or below the zygomatic arch (which can be palpated just below the skin). Great care needs to be taken in directing the needle so that it does not puncture the eyeball or any of the adjacent musculature and so induce profuse bleeding.

### Impression imprints from autopsy specimens

After incision through a representative area (e.g. liver, neoplasm) the cut surface is blotted gently with paper towel to remove excess blood or fluid. A glass slide is then firmly placed on the surface and then removed. Sometimes indurated tissue is best scraped with a scalpel and the scrapings placed on the slide for examination.

### Direct smear of the droppings

A wet swab is taken from fresh faeces and smeared onto a slide with cover slip.

### Blood smear

A blood sample is taken as described above; only a small drop of blood is required. The blood smear is stained with modified Romanowsky stain (e.g. DiffQuik®).

## Processing samples

### Fluid samples

After collection into the aspirating syringe and before processing, exudates are best first transferred to an EDTA blood collection vial to prevent any tendency to clotting which sometimes occurs. If the fluid is relatively clear and possibly has little suspended cellular content it can be centrifuged at slow speed (1500 rpm) for ten minutes to concentrate the cellular content. *High speed centrifugation can damage some cells.* Alternatively, the sample can be placed in a vertically supported tube and allowed to precipitate by gravitation. Another method is to place a piece of filter paper with a suitable size hole (8–10 mm) on top of a glass slide and then hold paper and inverted tube in place with a rubber washer placed over the hole and clamped to the slide. The fluid for examination having been placed in a glass tube placed over the centre of the hole is gradually absorbed by the filter paper leaving the solid cellular content on the glass slide for examination.

Fluid samples should be assessed for their colour (haemolysis, milkiness – indicating fat droplets, etc.), clarity, specific gravity and protein content (using a dipstick). Also, the cellular content of the sample should be analysed for the presence of heterophils, macrophages (containing phagocytosed bacteria), extracellular micro-organisms, normal epithelial cells and cells with signs of malignancy.

### Solid samples

If the tissue from which the sample was obtained looks fatty, the smear should be stained with Sudan III or IV together with new methylene blue stain (a water soluble stain). Otherwise the smear can be stained with a Romanowsky stain (Wright's or Giemsa). It is often useful to stain a second companion slide with new methylene blue since some features of cell morphology are seen more clearly with this stain whilst other aspects of the cell are seen best with the Romanowsky stain. In some cases, use of a bacterial stain (Gram or acid fast, etc.) may be appropriate.

## Interpretation of samples

### Hyperplastic tissue, inflammatory swellings and malignancies

An attempt should be made to identify the various types of cell present in the sample and also their relative proportions.

- Does the smear contain a high proportion of leucocytes, indicating an inflammatory reaction?
- Are these cells mainly heterophils, monocytes or lymphocytes, indicating an acute or chronic inflammatory response?
- Do any of the heterophils look toxic? Cell toxicity is indicated by a degranulated and degenerative rather indistinct staining nucleus. The cytoplasm of the cell tends to stain more basophilic (but compare this with the general background staining of the slide). Also there may be variable granulation and vacuolation in the cytoplasm.
- Do some of the monocytes (macrophages) contain phagocytosed bacteria?
- If a sample has been obtained from the surface of a mucous membrane or from fluid adjacent to such (e.g. alimentary canal, trachea) and has been stained with a bacterial stain which indicates a mixed selection of extra cellular organisms, then these are most likely representative of normal flora. If the stained smear is dominated by one particular organism this is most likely pathogenic.

Neoplastic cells not only show an increase in the proportion of cells with mitotic figures in their nuclei (the presence of which is normal in a few bone marrow and liver cells) but also the *overall size of the nuclei in relation to the cytoplasm is greater than in normal mature cells*. Also the cytoplasm tends to stain more basophilic, i.e. bluish. Neoplastic

cells overall and their nuclei in particular tend to be much more pleomorphic (i.e. they vary considerably in size and shape).

### Bone marrow

On a sample from a normal bird it should be possible to identify the normal maturing stages of erythroblast.

#### *Rubriblasts*

The early, very immature cells, the rubriblasts, like all immature cells, are large round cells containing a nucleus which occupies most of the cell. Although both cytoplasm and nucleus are intensely stained, at this stage the cytoplasm is the more densely stained of the two. As maturation proceeds, the overall size of the cell reduces and the nucleus becomes much smaller in proportion to the cytoplasm. Also the intense colour of the cytoplasm gradually fades, passing through a polychromatic phase with varying depths of blue staining, and ultimately acquiring the pale pink of the mature erythrocyte. At the same time, the nucleus shrinks and its chromatin becomes condensed and more intensively stained.

In normal bone marrow all stages of this developing process should be recognisable and not dominated by one type.

#### *Myeloblasts*

The precursor cells of avian granulocytes (myeloblasts) are at first similar to the rubricyte although the cytoplasm is less deeply staining and gradually it will develop the cytoplasmic granules typical of heterophils (fusiform light red eosinophilic), basophils (deeply staining basophilic dark blue spherical granules) or eosinophils (round deeply staining eosinophilic red granules).

#### *Thrombocytes*

Round cells (approximately the same size as erythrocytes) which have a large nucleus and in which the whole cell is very intensely stained are the precursor cells of thrombocytes. These cells gradually reduce in size and take on the shape and characteristics of small erythrocytes, except that their cytoplasm is colourless or very faintly blue in colour.

#### *Other cells*

Also normally found in bone marrow samples are small numbers of lymphocytes, monocytes, osteoclasts and osteoblasts. Some mitotic figures are normal in some of the cells of a bone marrow sample.

For those clinicians wishing to pursue this subject the best references with colour illustrations are given by Campbell (1994, 1995).

### Crop washings

- Check the pH of the aspirate, which should be around 6.5–7. A decreased pH may indicate sour crop.
- The normal sample of crop washings should show squamous epithelial cells, a mixture of normal symbiotic bacteria and a lot of background debris.
- If the squamous epithelial cells are excessively cornified (use the same stain as when examining canine vaginal mucosa for signs of oestrus, for example DiffQuik) this may suggest hypovitaminosis A.
- In the case of a *Candida* infection, one may see budding yeast cells together with short length hyphae, both of which stain with methylene blue or the Romanowsky stains.
- In direct smears, trichomonads will *only be seen in freshly examined wet-mounted samples preferably placed on a slightly warmed slide*. When present the flagellated



protozoa can be seen to be moving vigorously. However they can also be detected in stained smears, where their flagella are visible.

#### Proventricular washings

The normal PH of the proventriculus in psittacids is 0.7–2.7. Washings can be used to check for the presence of *Macrorhabdus ornithogaster* (*Megabacteria*) which can be seen in unstained smears or by Gram stain

#### Tracheal and air sac washings

- The observer should look for signs of bacterial phagocytosis.
- Also, look for signs of aspergillosis. The hyphae are long, septate and branch at 45°. Occasionally a conidiophore may be seen. Again, these fungi stain with methylene blue or the Romanowsky stains.

#### Direct smears of faeces

Especially in budgerigars and other psittacines, as well as in passerines, which are losing weight, faecal samples should be examined directly using 40× magnification for detection of *Macrorhabdus ornithogaster*. This should also be carried out in other species, especially parrots, raptors or pigeons; all gastrointestinal parasites are detectable using this method.

#### Blood smears

The stained blood smear is examined for blood parasites, such as *Haemoproteus*, *Plasmodium*, *Trypanosoma* and *Aegyptianella*.

For those who wish to look for further information on the technique of avian cytology the most useful texts are those from Campbell (1994, 1995).

## HISTOPATHOLOGY

Biopsy specimens can be most easily taken from surface neoplasms. They may also help in the diagnosis of skin lesions, such as those caused by avian pox virus, when the typical inclusion bodies may be found. Biopsies may also be taken from internal organs under direct vision via a laparoscope. Detailed explanations are given by Taylor (1994). Histology of post-mortem tissues may be necessary to help to confirm a diagnosis of such diseases as Pacheco's parrot disease. This often shows few signs except slight mottling of the liver and the typical eosinophilic intranuclear inclusion bodies in the liver cells and sometimes the kidney cells.

Histopathology may be the only method of confirming a diagnosis in some diseases such as proventricular dilatation disease of psittacines or viral induced papillomatosis of Amazon parrots. Liver biopsy samples may be obtained using direct vision via an endoscope or by making a small incision in the abdomen just posterior to the sternum.

## FAECAL EXAMINATION FOR HELMINTHS

Birds carry a variety of helminth parasites. Many birds kept in outside aviaries will easily become infected from the faeces of wild birds, which may shed large numbers of parasite eggs. Imported birds may be carrying unfamiliar parasites from their countries of origin. Faecal samples should therefore be examined on a routine basis. *If the first sample is negative, subsequent samples on alternate days* should be examined, as some species of helminth parasite shed eggs intermittently. Also, if the owner has recently but inconclusively wormed his birds, then samples are best not examined for several days, as some

drugs, especially if used at sub-optimal doses, merely suppress egg-laying rather than completely kill the parasites. Faecal samples can be examined by the standard flotation and centrifugation concentrating techniques.

## LAPAROSCOPY

Laparoscopy in one form or another has been used in man and animals since the early part of the twentieth century. This technique was first used in birds to determine the sex of those species that do not show sexual dimorphism – the so-called technique of surgical sexing. Other methods of sexing birds are discussed in Chapter 10. However, apart from direct visual inspection of the avian gonads, it is also possible to evaluate the state of many of the other organs. It is possible to see much of the kidneys, the adrenal glands, the posterior surface of the lungs, the heart, the liver, the proventriculus, the gizzard and the intestines. It is also easy to see parts of the air sac system. Laparoscopy is therefore a useful tool to aid in the diagnosis of many conditions.

### The equipment

The endoscopes used for this operation have been designed for the inspection of human joint spaces and range in diameter from 1.7–2.7 mm. A larger 5 mm instrument can be used in larger birds or sometimes birds down to 200 g in body weight, when it is necessary to carry out photography. The apparatus consists of a light source, a flexible light guide and the arthroscope, together with a trocar and cannula. The latest systems now use a fluid-filled light guide.

The endoscope is made up of an outer bundle of glass fibres, transmitting light into the organ being viewed, which are wrapped around an inner core of lenses forming the viewing telescope. The whole is encased in a stainless-steel sheath. The angle of vision varies with different instruments from direct-forward to retrograde. The direct-forward viewing lens is the simplest to use for avian laparoscopy (Fig. 4.3).



**Fig. 4.3** Equipment for laparoscopy: monitor, working channel with second access, rigid endoscope and simple working channel.

## Operative methods

### Sites of entry

Various entry sites to the bird's body are favoured by different authorities for viewing the gonads and other organs. One possibility is placing the anaesthetised bird in right lateral recumbency with the left side uppermost. The left leg is then drawn forward and held in this position by an assistant or by a restraining tape. In birds below 400g in body weight it is often easier if the operator holds the left leg and left wing out of the way of the incision site. The area of the incision is found in the angle formed just posterior to the proximal end of the femur and anterior to the pubic bones (Fig. 4.4a).

An alternative method is to pull the left leg posteriorly and to make the incision midway into the space between the anterior edge of the femur and the last rib (Fig. 4.4b). Other possibilities are using the sternal notch, a landmark in the angle formed between the sternum and where this is joined by the last rib (Fig. 4.4b) or an incision between the last two ribs just above the angulation (Fig. 4.4c). Whichever point of entry is used, it is very important, particularly in small birds, to get the bird correctly positioned and to be certain of the anatomical landmarks.

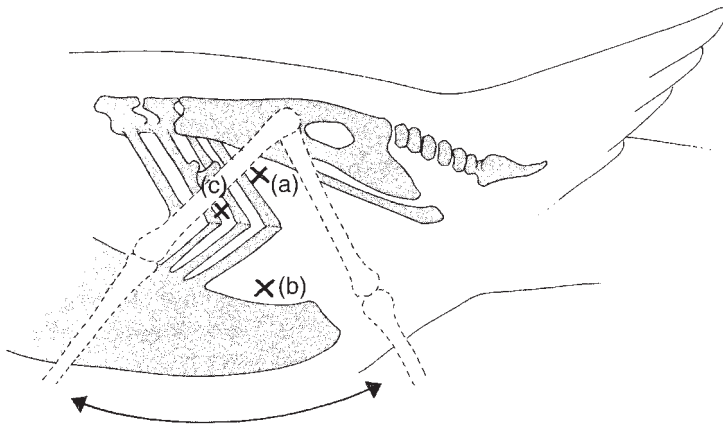
### Sterilisation

Before use, the instrument is sterilised using either ethylene oxide gas or by cold sterilisation with benzalkonium chloride (1:2500). The latter is more convenient when a number of consecutive surgical sexings have to be carried out. After cold sterilisation the endoscope is rinsed in sterile water and dried with a sterile towel.

### Surgical technique

Together with the endoscope it is necessary to have a scalpel fitted with a number 11 blade and useful to have a selection of sterile ophthalmic instruments available. The operation can be carried out using a general anaesthetic. This allows easy and safe control of the patient, with only little risk of damage to the internal organs by the endoscope. In addition there is enough time to carry out a thorough inspection of all the viscera.

Having correctly positioned the anaesthetised bird, the operation site is plucked free of feathers. Only the minimum number of feathers necessary to clear the area should be removed. The region is then cleaned and sterilised with a quaternary ammonium antiseptic,



**Fig. 4.4** Entry points (a), (b), (c) for laparoscopy in relation to skeleton.

taking care not to get the bird too wet. An alcohol or iodine preparation can be used to complete the process. The operation site is then draped with a transparent plastic or paper drape. Both of these are lighter in weight than cloth drapes and a transparent drape enables the bird's respiratory rate to be monitored during the operation. Either type should contain a small central opening.

A small incision, 4–7 mm in length, is made and any bleeding from the skin vessels is controlled because this is liable to cloud the distal end of the endoscope during insertion and obstruct the view. Also, any subsequent leak of air from the air sacs during expiration will cause blood on the surface of the skin to foam and obscure the incision. The cannula, fitted with the trocar, is next inserted through the underlying muscle using controlled pressure and at the same time slightly rotating the trocar backwards and forwards. To minimise trauma and reach the desired area it is most important to aim the trocar and cannula in the right direction. If the site using the angle between the femur and pubic bone is used, the instrument is directed downwards and forwards at a slight angle to the vertical away from the vertebrae so that it is travelling more or less towards the centre of the abdominal cavity. In the other methods the trocar and cannula are directed vertically in a direction parallel to the plane of the thoracic and lumbar vertebrae.

If the procedure is carried out correctly, the operator can feel the slight pressure on the trocar suddenly give as it pops through the muscle layer into the abdominal cavity. The trocar is then withdrawn leaving the cannula in position so that the arthroscope can then be inserted. Should there be any blood on the pointed tip of the trocar when it is withdrawn, the whole operation is stopped immediately.

During manipulation of these instruments it is best to be seated and to have the elbows resting on the table. The left hand supports the cannula near the point of entry and the right hand controls and directs the trocar and laparoscope. This position of the operator allows delicate and careful control of the instruments. In small birds below 60 g and down to 20 g in body weight, the arthroscope can be inserted after the initial incision has been made in the muscle, by pushing a pair of mosquito artery forceps into the incision and opening these to expand the incision. Care must be taken not to bend or break the arthroscope when applying this method.

### **Problems associated with the technique**

No method is without hazard. The first site of entry described has the slight risk that the ischiatic nerve and femoral blood vessels may be damaged. In all methods, if care is not taken and the instrument is pushed in with too much force or is wrongly directed the viscera could be damaged. Obviously, rupture of the heart or of a main blood vessel will prove rapidly fatal. However, slight puncture of the liver or kidney results in haematoma formation which usually resolves within a few days. Penetration of the gizzard is unlikely in the herbivorous birds because of its thick-walled nature, but in carnivorous birds the gizzard has a much thinner wall and is much more likely to rupture, particularly if the bird has not been starved for 12 hours before laparoscopy. However, before starving the bird the clinician should take account of the bird's nutritional state because of the danger of hypoglycaemia. If the gizzard is punctured this will necessitate a laparotomy and suturing the organ, as well as appropriate antibiotic cover. In the case of all sites of entry there is a slight risk of subcutaneous emphysema through air leaking from the air sac system but this usually resolves spontaneously.

Apart from these hazards the technique is not as easy as it might at first appear and much practice is required to develop the necessary skill, particularly in the smaller birds. The practitioner would therefore be wise to learn this art on several freshly killed cadavers before proceeding to the live bird.

One of the first difficulties of the unskilled operator is failure to obtain a clear sighting of the internal organs when first looking down the endoscope. One may see nothing more than an opaque pale-pink haze. This usually means that the tip of the endoscope is lying against one of the viscera or its view is obscured by air sac or peritoneal membrane or it has not properly penetrated the abdominal muscles. Very slight and slow retraction of the endoscope and cannula, or slight withdrawal of the endoscope into the cannula, often results in the view clearing. If nothing happens the instrument should be pulled further back and if there is no improvement then it is likely that the abdominal muscle has not been penetrated. The endoscope should be removed, the trocar reinserted and the direction of the penetration reassessed.

If the internal organs can be dimly seen but they are not clear then the operator is looking through an air sac membrane. Air sacs vary in their clarity and it may be possible for the experienced clinician to identify an ovary or testis without proceeding any further. However, to obtain a clearer view, the posterior abdominal air sac will have to be penetrated. It may be possible to do this by simply advancing the endoscope and cannula and at the same time giving a slight twist. However, it might also be necessary to reinsert the trocar.

If the view down the endoscope is obscured by a blood red haze, then a blood vessel has been ruptured or the liver or kidney has been penetrated. It is safer to cease the operation for a short period until the situation can be evaluated. If the endoscope is only partially obscured by blood this can often be wiped free against a suitable internal organ such as the gizzard.

Another problem is excess abdominal fat. This is not uncommonly found in captive, inactive raptors. Also the abdomen may be partly filled with exudate as in the case of an egg peritonitis.

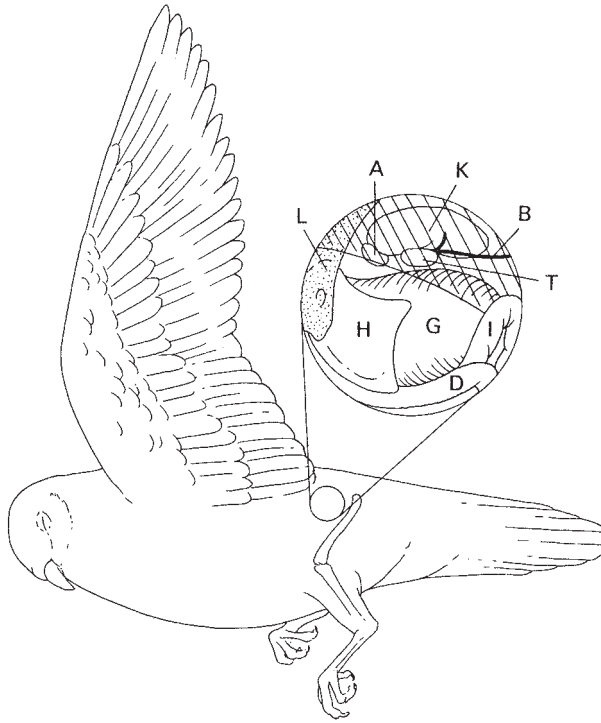
Having penetrated the abdomen and obtained a clear view, the next problem experienced by the unskilled operator is orientation of the various organs in relation to each other. The operator must learn to appreciate that slightly advancing or withdrawing the endoscope makes a relatively rapid change in the magnification of the object being viewed.

At the end of laparoscopy the skin and the underlying muscle are brought together with a single suture. Some operators consider this unnecessary.

### **Examination of the internal organs**

After examination of the air sacs, the first organs usually to be seen and which are unlikely to be mistaken by anyone who has carried out a number of avian post-mortems are the lungs. The caudal ventral surface of these structures can be examined and the ostia of the secondary bronchi, where these enter the caudal thoracic air sac, can be seen. Depending on which site of entry is used, the endoscope may have entered the caudal thoracic or the abdominal air sac. It may be necessary to puncture the division between these two air sacs to see other organs clearly.

Lying ventral to the lungs (to the left in the recumbent bird) the pulsating heart can easily be recognised. Moving the tip of the endoscope further to the operator's left, the lobes of the liver can be seen as they approach the heart and partially envelop the gizzard. If the endoscope is then carefully moved to find the medial caudal edge of the left lung, the large rounded dark brownish-red colour of the left cranial division of the kidney can be recognised. This lies posterior but very close to the lung. Immediately ventral and slightly anterior to the kidney is situated the pink-coloured adrenal gland. The gonads lie adjacent but caudal to the adrenal gland, so that the kidney, adrenal and gonads form the three points of a triangle (Fig. 4.5).



**Fig. 4.5** Organs that can be identified by laparoscopy. The striped area indicates the extent of the abdominal air sac. A, adrenal gland; B, main blood vessels; D, duodenum; G, gizzard; H, liver; I, intestine; K, kidney; L, lung; T, testis.

## Surgical sexing

### *The testis*

In the immature male the testis is a rounded, slightly oval structure very little bigger than the adrenal gland but a little more yellow in colour. In some species the testes may be wholly or partly pigmented dark green or black in colour. In the immature bird it may be possible to see both testes lying one on each side of the dorsal aorta and vena cava. As the testis matures, it increases in size and blood vessels become obvious on the surface. The blood vessels become more tortuous with age. In the active testes during the breeding season the organ may become very large and more difficult to recognise. In the aged testis the gonad is more angular in shape.

### *The ovary*

In the immature female the ovary tends to be L-shaped and about the same length as the cranial division of the left kidney. The colour is a buff yellow; the surface is flat and the texture slightly granular in appearance. Sometimes the ovary is pigmented. As the ovary matures, follicles become more apparent and these will vary in size. Gradually, as the ovary increases in size, it begins to obscure the kidney and adrenal gland. In the active ovary during the breeding season some of the individual follicles can become very large, taking up a large part of the abdominal cavity. In the old female bird the ovary has contracted again and while follicles can be recognised much of the ovary is occupied by scar tissue.

Also important is the detection of the suspensory ligament of the ovary: it crosses the cranial pole of the kidney. In juvenile birds, only the suspensory ligament characterizes

the female bird, because the ovary is very small and without follicles and may be not easy to detect. Apart from sexing, evaluation of the ligament allows the judgement of the possible breeding performance of the bird (Lierz, 2006).

### **Biopsy**

Another possibility is taking of biopsy specimens under direct vision, using a secondary cannula containing biopsy forceps or using a biopsy needle, to aid in the early diagnosis of tuberculosis of the liver. Samples can also be taken from other organs for culture and histopathology. Fluids can be aspirated from an air sac under direct vision or small quantities (up to 3 ml in a large bird) of fluid can be instilled into the air sacs to obtain sample washings. For further information about avian endoscopy consult Murray *et al.* (2002).

### **Other uses for the endoscope**

The instrument can also be used to examine the posterior part of the nasal cavity through the choanal opening. The trachea, the syrinx and bronchi may also be inspected. Before the latter is examined the posterior air sacs are cannulated to allow the partially obstructed respiration to proceed. The ease with which all these cavities can be viewed will obviously depend on the size of the bird. It is also possible to visualise the oesophagus, crop and proventriculus of a bird as small as 40 g in body weight.

### **Laparoscopic photography**

Special cameras can be used for clinical documentation of the organs viewed through the endoscope. Adaptors and stepping rings can also be obtained so that the telescope eyepiece can be coupled to the standard lens of any single lens reflex or digital camera. The best results are obtained if a xenon flash tube is incorporated in the light source, but this increases the initial cost of the equipment. For photography it is better to use a 5 mm diameter endoscope which transmits more light than the smaller diameter instruments – less exposure of the film being necessary. Nevertheless, it is possible to obtain reasonably good results with a 2.7 mm diameter endoscope, using traditional film (ISO 64), with exposures of the order of 0.25–0.50 seconds. Film with higher ISO will produce even better results.

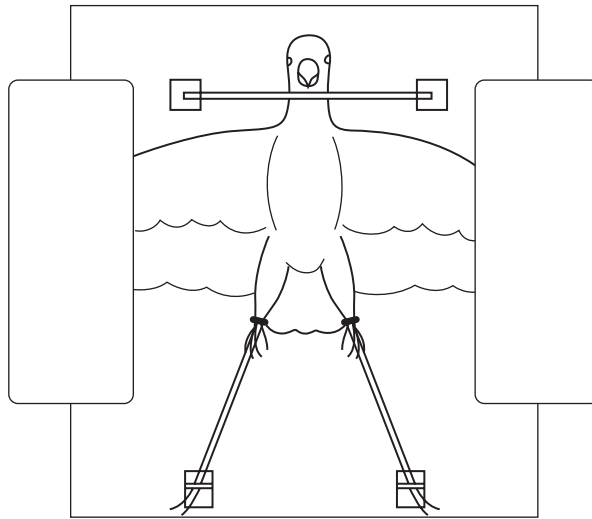
Digital cameras should theoretically make the task much easier as they can operate at much lower light levels without the need for a xenon flash incorporated into the endoscope but obviously the camera's built in flash needs to be turned off, which may not be possible with all digital cameras. One needs a steady hand, good anaesthesia and an assistant to operate the shutter of the camera with a cable release. The camera lens is focused at infinity and set to the maximum aperture before coupling to the endoscope. If the camera has interchangeable viewing screens a clear screen is best. All these problems can be overcome if using the latest apparatus (Fig. 4.3), which has a built in monitor from which photographs can be obtained.

## **RADIOGRAPHY**

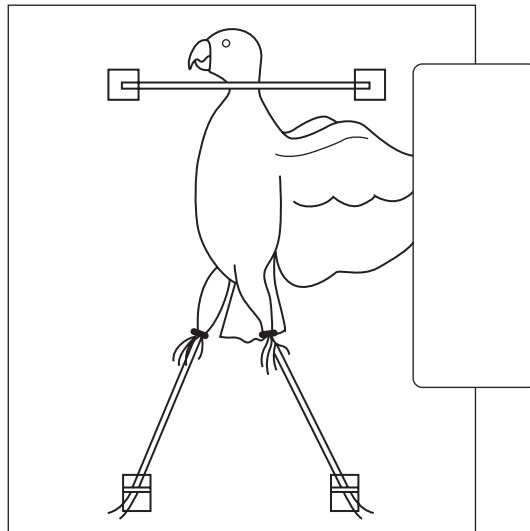
As birds tend to show hardly any specific clinical symptoms and as the number of diagnostic methods is limited in most pet birds, radiography in avian medicine is even more important than in mammalian medicine. It is a fast and useful, routinely performed aid to diagnose abnormalities of the skeleton, but also of the inner organs.

### **Restraint**

Although often performed under isoflurane anaesthesia, radiography may be routinely carried out without anaesthesia without problems in most birds, having the conscious bird



(a)



(b)

**Fig. 4.6** (a) Restraint for ventro-dorsal position with a Perspex<sup>®</sup> plate. (b) Restraint for latero-lateral position with a Perspex<sup>®</sup> plate.

restrained on a custom-made radiolucent Perspex<sup>®</sup> plate (Figs 4.6a and 4.6b). The head is fixed with a special head clamp positioned over the bird's neck; the feet are fixed by foot straps; the wings are restrained with tapes or weights.

Sedation or general anaesthesia may be necessary in very excited birds, for example wild birds, however, this is not required for routine radiography in birds accustomed to human contact. The advantage of not resorting to anaesthesia is getting through the radiography procedure more rapidly than when employing anaesthesia and in avoiding the possible side effects for the human operators and the birds by using inhalation anaesthesia. The advantage of restraint using a Perspex<sup>®</sup> plate is radiation



protection of the examiner. The stress produced for the birds is only for seconds and probably not even higher than for inducing anaesthesia. The Perspex® plate enables the radiographer to position the bird carefully with correct centring and collimation of the X-ray beam.

If, in exceptional circumstances, it is necessary to use manual restraint, the person involved should have regard to the current Health and Safety regulations in force in their country. Manual restraint is required in very sick birds likely to suffer from shock and in large birds weighing more than 2 kg. With this method the operator's hands should never be within the primary beam, additionally they are protected from scatter radiation by use of lead gloves. Proper correct restraint with adhesive tapes placed over the limbs and neck and stuck to a radiotranslucent Perspex® sheet can only be achieved in anaesthetised birds.

### Positioning

Radiographs, to be of maximum diagnostic value, should be obtained only after care has been exercised to obtain a true ventro-dorsal and exact latero-lateral position of the patient. *This is tedious and needs meticulous assessment by the operator to judge by sight and touch that in the ventro-dorsal position the sternum overlies the vertebral column.* Furthermore, in order to avoid superimposition, the legs should be stretched as far as possible caudally and the wings stretched outwards away from the body. If correct positioning is not achieved, the two sides of the body cannot be accurately compared, which is especially important in the ventro-dorsal view as the symmetry between the left and right sides and any alterations may only be judged in this plane. Apparent distortion of various structures and body cavities, which has no clinical significance, may be seen. The air sacs on one side may look smaller than those on the other side of the body. The shadow of the liver and the position of the gizzard may become distorted.

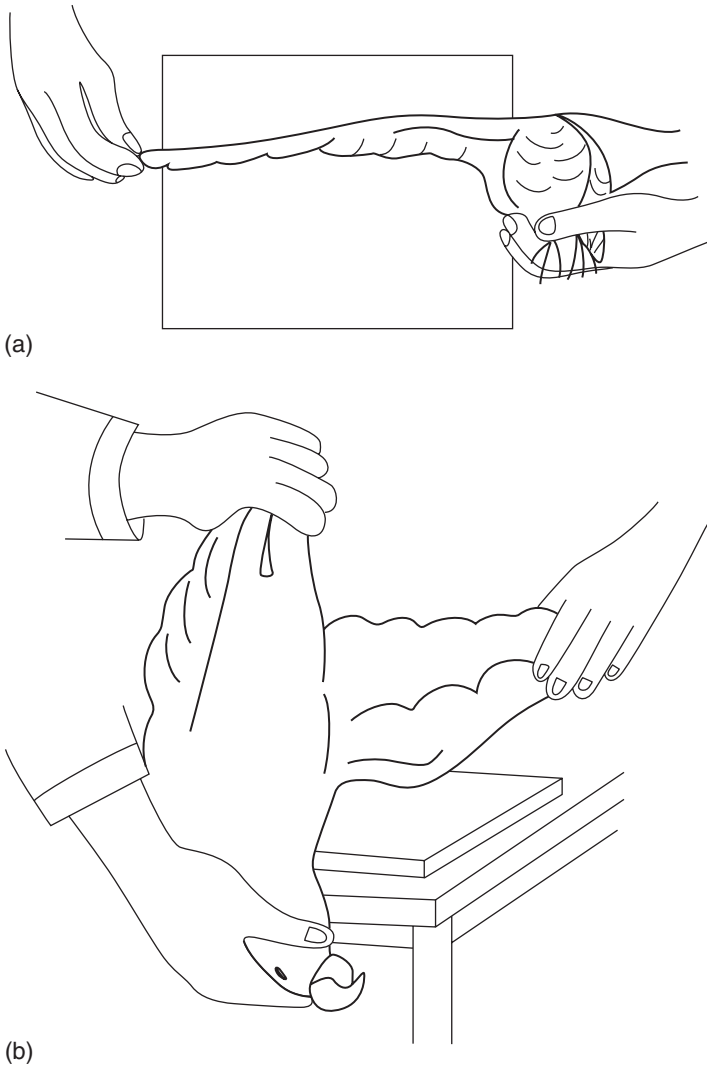
In the true latero-lateral position the two hip joints and the two shoulder joints should overlap. The wings must be held dorsally above the body using tapes or weights. Again the legs need to be stretched caudally as far as possible so that their radiographic image does not obstruct any part of the body which is of radiographic interest (e.g. the spleen, the reproductive tract, the intestine).

When radiographing the wings in a ventro-dorsal positioned bird (medio-lateral projection of the wing) care should be taken not only to have both wings in a flat position and as close to the X-ray film as possible but also to make sure that both wings are extended to the same degree. It is very helpful in making a diagnosis to be able to compare the radiographic image of the two wings.

The second plane necessary for proper diagnosis of wing alterations is the caudo-cranial projection (as in latero-lateral recumbency of the body the wings would be shown in the same medio-lateral projection). For the caudo-cranial projection the patient has to do a 'headstand' (Figs 4.7a and 4.7b), so that it is turned with the head upside down on one edge of the table/cassette. The wing is then extended laterally as far as possible and placed onto the cassette so that its cranial border comes to lie parallel to the edge of the cassette.

### Films and exposure factors

One of the greatest problems in the radiological examination of birds is the loss of sharpness due to movement and high respiratory rates. Therefore the maximum exposure times should be 0.015–0.05 seconds or less. This requires a modern high frequency apparatus or a radiographic apparatus with a minimum performance of 200–300 mA (two- or multi-phase generator). Digital radiography does not automatically solve this problem – in fact the resolution power of digitals is lower than that of film/screen combinations commonly used in avian medicine.



**Fig. 4.7** (a) Caudo-cranial projection of the right wing viewed from above. (b) Caudo-cranial projection of the right wing viewed obliquely from a horizontal perspective.

Exposure factors (kV, mAs) are dependent on the thickness and density of the object, the type of apparatus, the focus/film distance, the film, the screen types and the processing of the film. In radiography of most pet birds the kV values should not be higher than 45–55 kV in order to obtain pictures of high contrast with many shades of grey. The general distance between film and focus should be about 1 m. A possibility for lowering the radiation dose is to reduce this distance, but the picture quality may be affected because of enlargement and poor definition of those parts of the object more distant from the film. Therefore only a high definition film/screen combination should be used, with a maximum reduction of distance to 60–70 cm. Those intensifying screens permit also a reduction of the radiation dose and therefore of the exposure time. Compared with conventional screens (calcium tungstate), rare-earth screens provide a greater intensification at similar definition. Non-screen films may hardly be used to obtain greater detail, because they require a much

higher radiation dose or increased exposure times. Mammography films may be used, especially for the skeletal system, however again they require higher exposure times. The use of grids is not necessary in pet birds due to their small size.

## Interpretation

The radiographer should be aware that there is only a difference in size in the air sacs between the inspiratory and expiratory phases of the respiratory cycle – no differences may be noted in the lung tissue. However due to the very rapid respiratory rates of the relatively small avian patient, it is commonly not possible to trigger or complete the whole exposure at the end of the inspiratory phase (when the air sacs are at maximum dilation so that optimal use is made of the natural contrast in the avian body).

Many diseases are multisystemic, so that it is a good policy to get into the habit of examining whole body radiographs in a systematic manner. One should start with the external outline and work inwards, so that each organ system can thus be considered in detail. A common fault is to fix attention on an obvious lesion and to miss less apparent abnormalities.

## Radiography of the musculoskeletal system

### Bone

Radiography is an aid to avian orthopaedic surgery, and is helpful in assessing the degree of distortion and prognosis in metabolic bone disease.

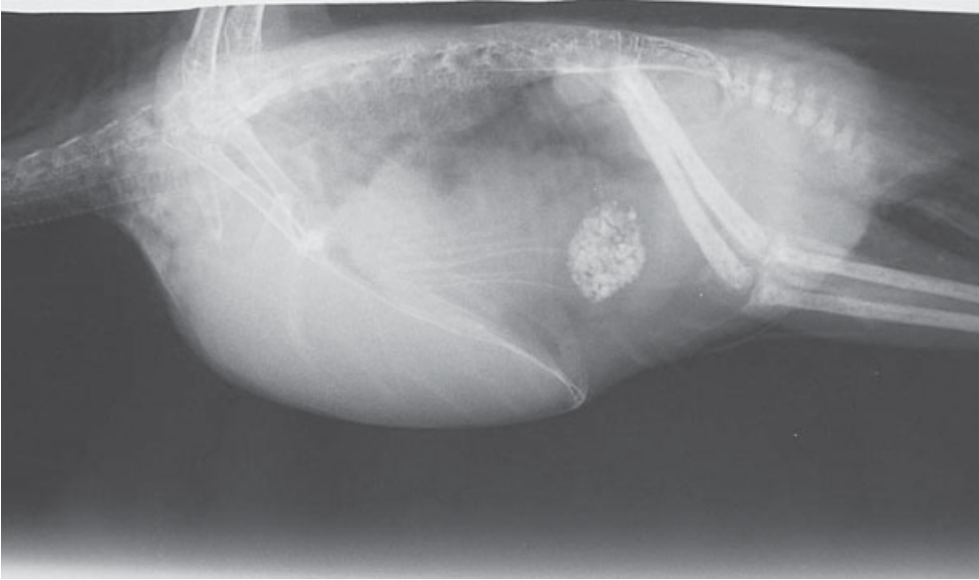Most fractures of long bones can be seen easily in radiographs, but the diagnosis of fractures of the bones of the shoulder girdle is more difficult because of the muscle mass found in this area. The bird should be positioned asymmetrically for the radiographic interpretation of those bones, otherwise the coracoid and the scapula are superimposed. Fractures of the vertebral column usually involve the last thoracic vertebra before the synsacrum.

Apart from diagnosing the type, extent, age (fresh fracture: sharp edges; older: rounded edges etc.) and dislocation of a fracture, radiography helps to follow fracture healing. Physiological endosteal callus is hardly seen radiographically in birds. When an osteomyelitis is present in a long bone, new bone tends to be formed by the cortex of the bone and by the endosteum rather than by the periosteum as is the case in mammals. Osteomyelitis may be recognized radiographically after 10–14 days.

Metabolic bone disease is most often but not only seen in raptors. It occurs in fledglings (as rickets) which have not received a balanced calcium/phosphorous intake, which should be about 1.5:1.0. This results in folding distortion of the thin and weak cortex of the long bones. Gross distortion and pathological fractures occur first in the legs (as these are the first parts that have to carry the weight of the growing body), later the vertebral column (kyphosis) and the wings, which often results in a bird becoming a permanent cripple. The disease is most likely to occur in the case of artificially-reared birds of prey fed entirely on a diet of meat, which contains little if any calcium. Also it is not uncommon in fledgling parrots, particularly when hand reared. One of a clutch of chicks will sometimes develop the condition while its siblings are normal. The condition also occurs in wild birds.

Other conditions that can be recognised by radiography include osteoporosis (radiographic picture similar to rickets), neoplasia, arthritis and tuberculosis. Neoplasia tends to be predominantly osteolytic in birds. Arthritis is sometimes seen in pigeons with *Salmonella* infection. Radiography of all the limb joints in the bird is easy except in the case of the hip joint where the shape of the ilium makes outlining of the joint difficult.

In mycobacteriosis there is often localised osteolysis together with surrounding sclerosis accompanied by focal densities in the long bones (Pieper *et al.*, 1991). These signs in the skeletal tissues are often seen together with soft tissue changes in the lungs (focal densities) together with hepatomegaly and splenomegaly.



**Fig. 4.8** Latero-lateral projection. Female cockatiel (*Nymphicus hollandicus*). Formation of physiological medullary bone (femur and tibiotarsus).

A physiological condition, often found incidentally during radiography, is the formation of the so-called medullary bone. The condition normally occurs in female birds with a high oestrogen level before egg laying (calcium storage for the egg shell). It is recognised by the medullary cavities of the long bones – normally filled with air – becoming calcified. In this condition the bone appears much denser on the radiograph and also sometimes involves the bones of the skull. In case of pathological alterations of the genital tract that go along with increased oestrogen level (e.g. egg binding with laminated eggs, ovarian cysts, tumours), formation of this medullary bone may be a hint that the examiner is dealing with a genital tract disease.

Another pathological condition is polyostotic hyperostosis (Fig. 4.8). In this condition, medullary bone formation develops excessive periosteal and endosteal hyperostosis, especially in the region of the joints. This is not uncommon in the budgerigar and is occasionally seen in other psittacines. The disease was believed to be due to excessive oestrogen imbalances but newer studies from the University of Zurich/Switzerland could not prove increased oestrogen levels in the diseased birds. So the cause of this condition remains unknown, however it is seen often in combination with abdominal hernia and genital tract disease.

### *Muscle*

When viewing radiographs of the skeleton in the diagnosis of orthopaedic problems, one should try and get as much information as possible about the muscular system. A reduction in size of one of the pectoralis muscles due to muscle atrophy can often be seen on a radiograph though it may not be so obvious on palpation. It may be possible to detect slight contraction and swelling of the muscle mass of the supracoracoideus after rupture of the tendon that passes through the foramen triosseum.

In the forelimb, the shadows of the biceps and triceps muscles can be identified. A large part of the latter muscle originates from the surface of the humerus and is liable to sustain

trauma in fracture of the adjacent bone. The tensor muscles and tendon of the propatagial membrane are often damaged. This may result from collision with such objects as telephone wires. The flexors and extensors of the carpus and digits should also be examined.

Signs of injury to muscles are shown by a subtle increase in their density when compared with the other wing. Some idea of how recent an injury to the skeleton is can be gauged by the condition of the neighbouring muscles. In a very recent injury there is a noticeable increase in the size and density of the radiographic shadow. This usually decreases considerably almost returning to normal during the course of the next few days, providing the fracture is not compound and there is no superimposed infection.

### Interpretation of soft tissue radiographs

Since the radiograph is a two dimensional shadow of a three dimensional structure, it is essential to take both ventro-dorsal and latero-lateral views when radiographing the internal organs (Figs 4.9a,b and 4.10a,b). The ventro-dorsal view is especially valuable to judge the symmetry of alterations e.g. of the lungs/airsacs etc. The latero-lateral view on the other hand allows better differentiation and shape/size verification of the individual organs.

One of the most obvious features to be seen when first looking at the avian ventro-dorsal view is the 'waist' between the shadow of the heart and that of the liver in granivorous species. In carnivorous species generally the outline is less distinct due to the more distensible proventriculus. If the hour-glass shape in corn eaters becomes indistinct and merges into one uniform outline, this usually indicates an enlargement of the liver or the GI-tract or some other soft tissue structure in this region – the latero-lateral view is necessary for verification.

### *The heart*

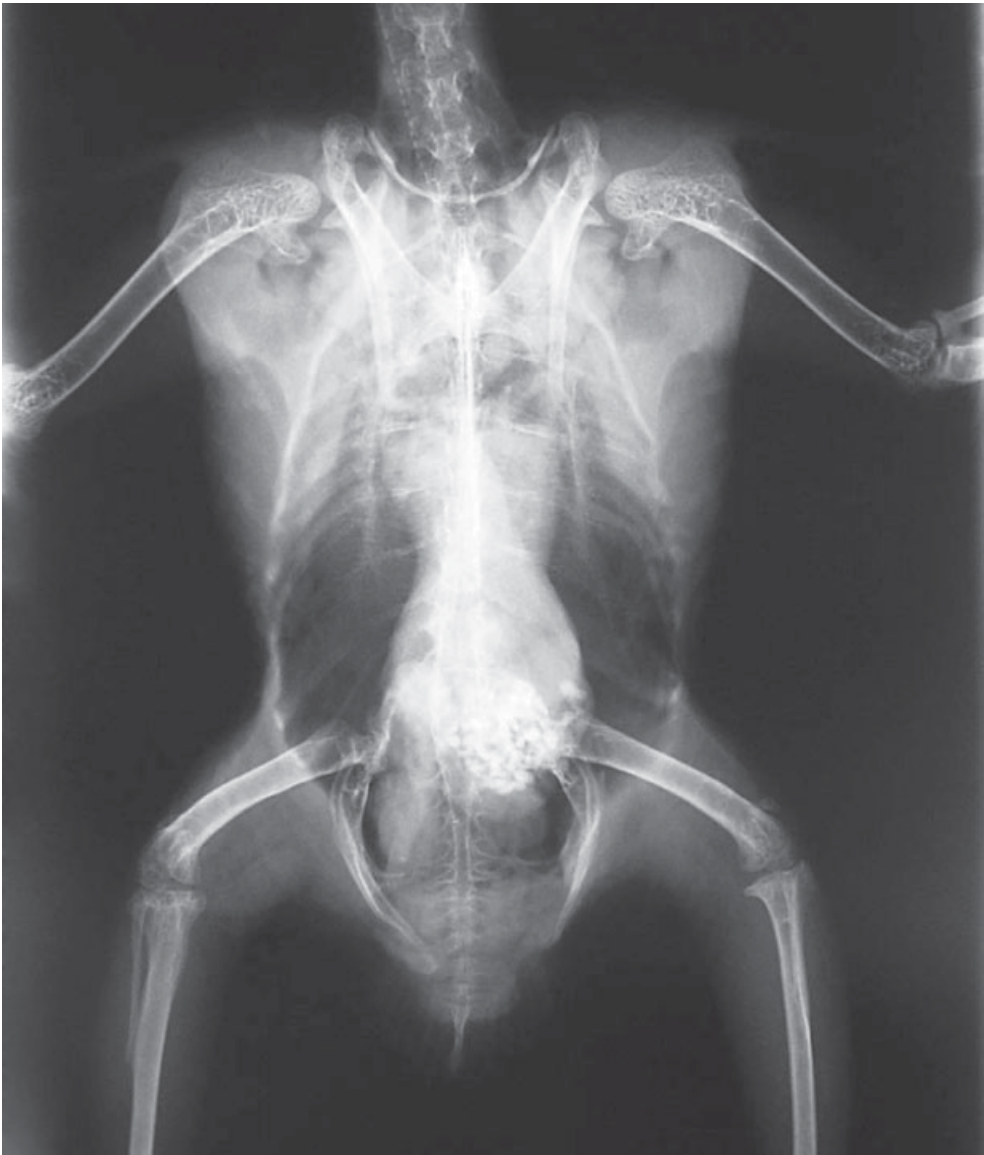Concerning the shadow of the heart, the examiner may judge size, shape and radiodensity as well as the visualisation of the great heart vessels; however the radiographic signs are non-specific and may give first hints only to an existing cardiac disease. A more firm diagnosis has to be made by other diagnostic methods, e.g. echocardiography. An enlarged heart shadow may indicate any heart disease, such as hydropericard or a dilatation of a heart chamber. Increased radiodensity is usually a sign of inflammation or congestion. Furthermore, alterations in the cardiac shape may be suggestive of dilation of the heart chambers or granulomatous lesions (e.g. of mycotic/mycobacterial origin). Increased radiodensity of any of the great vessels of the heart, particularly in very old parrots, indicates calcification, possibly arteriosclerosis.

### *The liver*

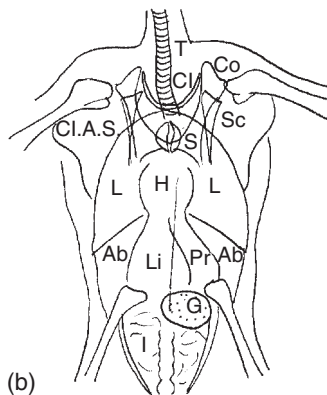
The radiographic shadow of the liver is in the ventro-dorsal view part of the hour-glass silhouette in granivorous species. An increase in the hepatic size may alter the hour-glass and lead to a displacement of the proventriculus in the latero-lateral view (best seen with barium sulphate contrast). Hepatomegaly is seen in cases of intoxication, fatty liver degeneration, neoplasia as well as infections (of mostly viral and bacterial origin). In mynah birds, some other Passeriformes and toucans a degenerative iron storage hepatopathy is often responsible for ascites. The latter leads to nearly no differentiation of the inner organs in the radiograph. These birds are often in respiratory distress, consequently good radiographs of this condition are not easy to obtain.

### *Gastrointestinal (GI) tract*

From the GI tract the crop is seen just anterior to the thoracic inlet, partly filled with food. An apparent increase in size on the left side of the hepatic shadow may be caused by an

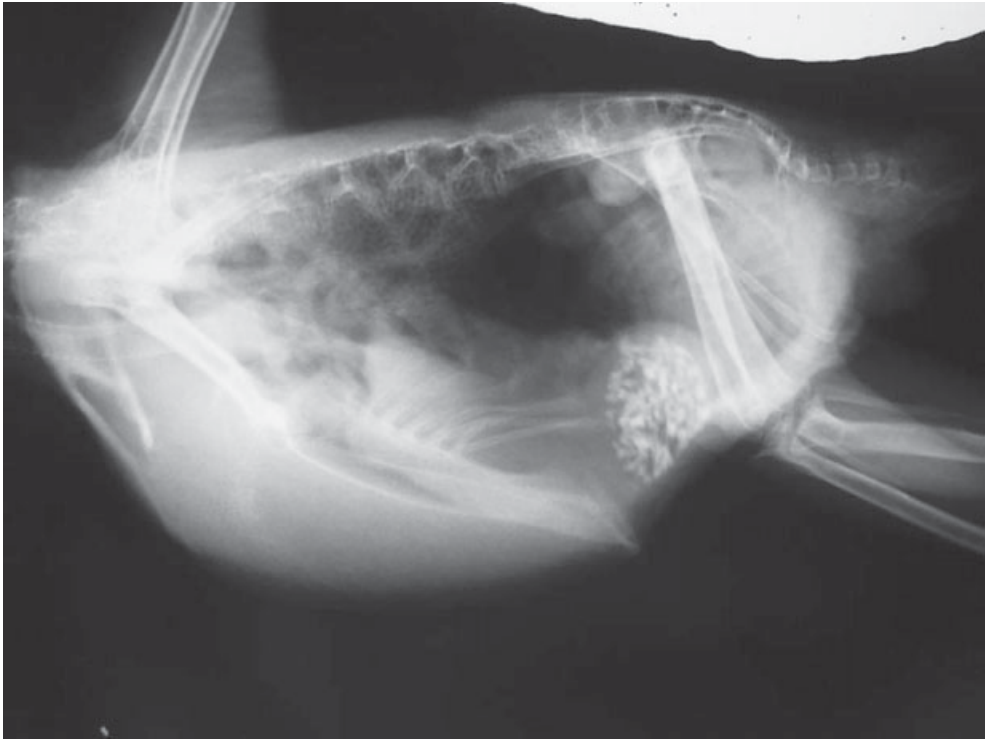

(a)

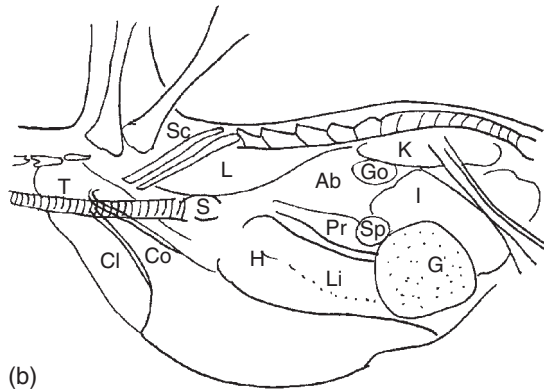


(b)

**Fig. 4.9** (a) Vento-dorsal projection. African grey parrot (*Psittacus erithacus*). (b) Key to Fig. 4.9a: T, trachea; S, syrinx; Cl, clavicula; Co, coracoid; Sc, scapula, Cl.A.S, clavicular air sacs; L, lungs; H, heart; Li, liver; Pr, proventriculus; G, gizzard; I, intestine; Ab, abdominal air sacs.



(a)



(b)

**Fig. 4.10** (a) Latero-lateral projection. African grey parrot (*Psittacus erithacus*). (b) Key to Fig. 4.10a: T, trachea; S, syrinx; Cl, clavicle; Co, coracoid; Sc, scapula; L, lungs; H, heart; Li, liver; Pr, proventriculus; G, gizzard; I, intestines; Sp, spleen; Ab, abdominal air sacs; Go, gonads; K, kidneys.

increase in size of the proventriculus. A thickening of the wall together with an increased density of the crop/oesophagus/proventriculus, seen best in lateral projections, may indicate hypovitaminosis A or chronic infections (e.g. *Candida*). A definite enlargement with the organ occupying much of the thoraco-abdominal cavity is best seen using barium contrast and usually indicates psittacine proventricular dilatation syndrome. *Macrorhabdus ornithogaster* (mostly seen in budgerigars, formerly called 'Megabacteria' or

‘going-light syndrome’) as well as tapeworm infestation and/or *Candida* infection may occasionally cause an enlarged proventricular shadow as well.

The gizzard is easily recognisable in granivorous birds because of the retained grit and normally occupies a position just to the left of the midline and just below an imaginary line joining the two hips. Space-occupying lesions may be responsible for displacing the normal position of the gizzard shadow. In raptors the non-grit-filled ventriculus (or gizzard) is usually just cranial to this level and not so distinct. If a granivorous bird has been given only soluble oyster shell grit, then the gizzard may not be identified by this method. Also, a bird may have been deprived of grit. If the amount of grit in the gizzard is excessive, this tends to indicate malfunction of the gastrointestinal tract.

Foreign bodies such as fish hooks, lead shot and nails are not uncommonly seen lodged in the oesophagus, the proventriculus or gizzard of water fowl, psittacines and ratites and are sometimes also seen in other species. They may occasionally pass further along the alimentary canal.

Other signs of gastrointestinal disease are an increased density, leading to greater visualisation of the intestinal loops. This is sometimes accompanied by gas filling and distension. These signs may also be indicative of microbiological or parasitic infection. However, gas filling is normal in some waterfowl and in game birds. Foreign body obstruction of the intestine in birds is not usually accompanied by a build-up of gas as is the case in mammals. There may, however, be enlargement and greater visualisation of the intestine. Gastrointestinal disease is also indicated by grit and, when using barium contrast, undigested seed in the intestine.

### *Respiratory tract*

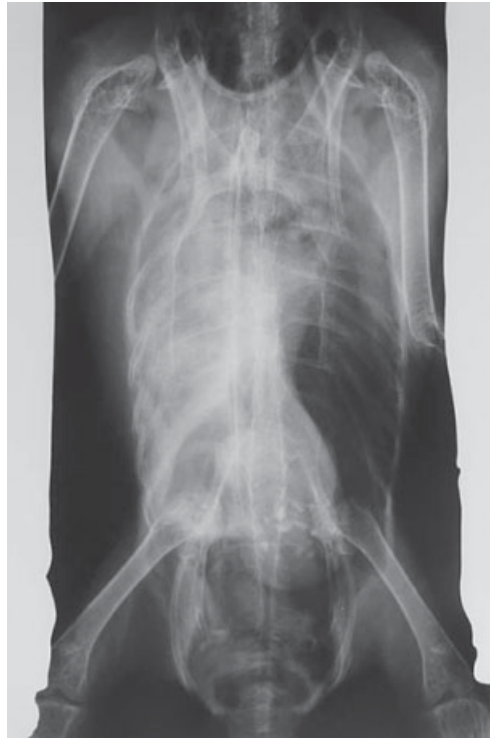There are a few interspecies peculiarities of the respiratory tract of which the avian radiologist should be aware. In some species the cervical air sac extends subcutaneously along the ventral side of the neck. Overall there is a considerable interspecific and sometimes intraspecific variation in the anatomy of the air sacs and also in the pneumatization of the bones. In the Anatidae (ducks and geese) there is a normal, balloon-like, irregular distension of the syrinx. This increases in size with age. In swans, cranes, spoonbills and birds of paradise, the trachea is elongated into coils which lie between the skin and the pectoral muscles or within a tunnel in the sternum. In penguins the trachea is bifurcated for most of its length (see Figs 1.3 and 1.9).

In good quality radiographs the two lungs can be identified by their slight honeycomb appearance in the latero-lateral view. The diagnostician should look for any slight increase in density or patches where there is loss of the normal reticular pattern. Such localised densities may be discrete and nodular when caused by mycosis. When bacterial infection is the cause, sometimes the patches of abnormality are more diffuse and very occasionally are accompanied by calcification if the infection has been prolonged. However, no differentiation between fungus and bacteria as causative agents can be made definitively by radiography.

The air sacs should be carefully examined. The extrathoracic diverticula of the clavicular sacs can be seen in the pectoral muscle mass around the proximal end of the humerus. There is considerable interspecific variation in these diverticula. In case of overdistension of these air sacs, this hints at a stenosis in the lower part of the respiratory tract. When looking at the caudal air sacs, absence of their outline may be due to a space-occupying lesion, or, more likely, due to adhesions or gross air sacculitis (Fig. 4.11). Less severe air sacculitis is recognised by a general haziness of part or all of the air sac spaces in the ventro-dorsal view.

In the lateral view, striated dense lines on the radiograph represent the end-on view of thickened air sacs. Overdistension of the caudal air sacs, so-called ‘air-trapping’ is again due to a stenosis – this time in the upper respiratory tract (e.g. due to mycotic granuloma





**Fig. 4.11** Ventro-dorsal projection. African grey parrot (*Psittacus erithacus*). Absence of the outline of the right caudal air sacs (mycosis). Gas-filled cloaca.

formation in the syrinx). In the ventro-dorsal view the left and right thoracic and abdominal air sacs should always be compared for any signs of localised increase in density due to mycotic or bacterial infection. In pigeons the abdominal air sacs are often considerably reduced in size due to excessive fat. An overall homogeneous 'ground glass' increase in density, of both thoracic and abdominal cavities accompanied by obvious distension of the caudal abdomen is usually due to peritonitis or ascites.

### *The kidneys*

The latero-lateral projection provides information about the size and radiopacity of the kidneys, since the surrounding air sacs provide a good negative contrast. Active gonads must not be confused with kidney tumours.

In the ventro-dorsal projection, the kidneys are superimposed upon by the gastrointestinal tract, therefore only high-grade alterations can be diagnosed. Enlargement of the renal shadow is interpreted as a non-specific sign of many generalised infections, as well as non-infectious causes like vitamin A deficiency, kidney cysts and neoplasia. In cases of massive enlargement of the kidneys it may be necessary to have recourse to contrast radiography in order to define the kidneys against the surrounding organs. This could involve GI contrast or renal contrast. In severe dehydration, gout and vitamin A deficiency, there tends to be an increased density of the kidney shadow, but this is difficult to evaluate. The presence of radiodense deposits in the kidney is readily demonstrated in both of the standard planes. Such crystals are evenly distributed throughout the organ and are due to the precipitation of uric acid and/or renal calcinosis. They occur in chronic kidney infections,

indicating renal insufficiency, often in association with a high blood uric acid level, but *they are not specific for gout*. They are also seen after prolonged fluid deprivation.

### *Reproductive tract*

Considering the gonads, one must differentiate between pathological enlargement and physiological activity, but the clinical findings give the necessary indications. Budgerigars are particularly prone to gonadal neoplasia which causes massive enlargement of the organ resulting in pressure on the air sacs and ventro-caudal displacement of the gastrointestinal tract (seen with barium-sulphate contrast studies). Alterations in the size and shape of the gonads, as they occur, for instance, in cystic ovaries, are often associated with other radiographic features such as polyostotic hyperostosis and abdominal hernia.

In some cases of salpingitis the oviduct's shadow is enlarged and more dense than normal. In birds with egg retention the egg can often be palpated, provided it is calcified. A radiograph is not only necessary to provide information about the form, size, number and position of eggs, it can also help to decide between their surgical and non-surgical removal. Unfortunately, it is not possible to differentiate radiographically between eggs without a calcified shell or with a very thin shell and other soft tissue masses (for example tumours or cysts) in the thoraco-abdominal cavity.

Laminated or thin-shelled eggs may be the cause of egg-binding in birds, with or without radiographically diagnosed medullary bone. Also in birds with ovarian cysts and gonadal tumours, medullary bones are often seen in radiographic examination. Medullary bone is therefore a helpful finding in radiographs with otherwise unclear findings. However, it is also found in other disease processes, and no definite conclusion on the existence of a pathological process can be made on this basis. On the radiograph, the laminated eggs produce a distinct soft tissue shadow, but there may also be evidence of an abdominal hernia and displacement of the gastrointestinal tract.

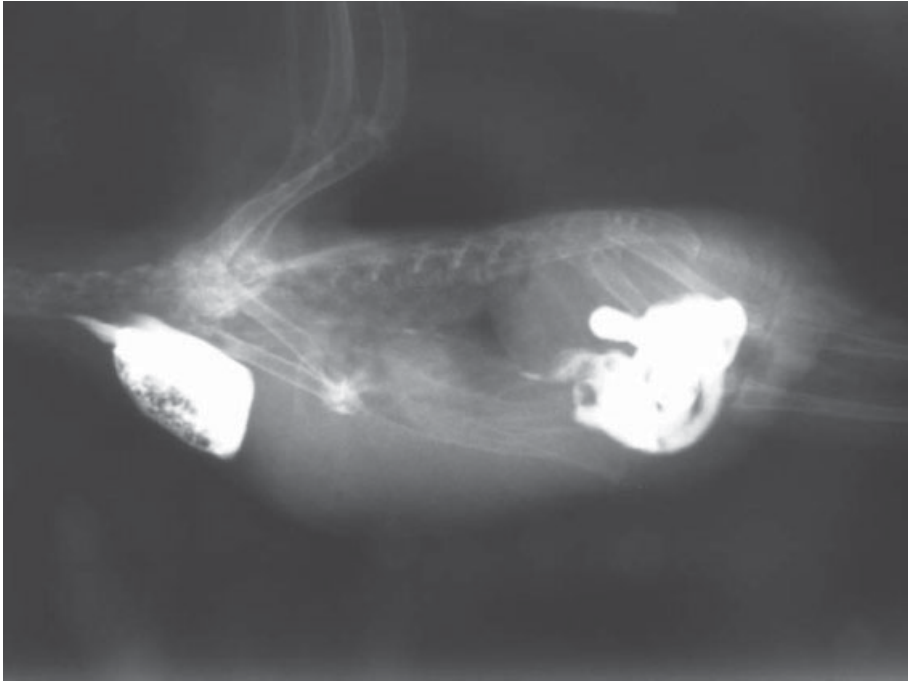### *The spleen*

The spleen is seen sometimes on the lateral projection. It shows as a relatively small round or oval (raptors) shadow situated between the angle of the proventriculus and the gizzard. Although in normal birds the spleen may not always be recognisable, when it is enlarged due to neoplasia or infection it is easily seen. In psittacines a great increase in size accompanied by hepatomegaly is very suggestive of *Chlamydophila* or mycobacteria.

## **The use of contrast media**

There are positive (barium or iodine compounds) and negative (air) contrast media. The most common contrast media are barium compounds for demonstration of the gastrointestinal tract. Indications for this method are, for example, diseases of the gastrointestinal tract with retarded or accelerated passage times, suspected abnormal content of the gastrointestinal tract, diseases with alteration of the gastrointestinal walls, diseases of the gastrointestinal and neighbouring organs that are associated with changes in size, shape and position. In the latter case contrast media can help by showing the outlines of the alimentary organs and the border between the gastrointestinal tract and anatomically related organs.

The bird should have a more or less empty GI tract in order to judge transit time. No anaesthesia should be used, because this may cause almost complete cessation of gastrointestinal motility. When perforations are suspected, non-absorbable barium compounds should not be used. Organic non-ionic iodine compounds (10 mg/kg body weight of a 250 mg iodine/ml solution) may be administered in these cases, transit time being much faster in this instance. Barium sulphate suspension is infused into the crop by an oesophageal tube made from any suitable diameter plastic or rubber tubing fitted to the nozzle of a hypodermic syringe. A rigid metal catheter, smooth at the distal end, can also be utilised



**Fig. 4.12** Latero-lateral projection. Budgerigar (*Melopsittacus undulatus*). Contrast radiograph with barium sulphate, 45 minutes after the installation; soft tissue mass displacing the GI tract caudo-ventrally (renal tumour).

for birds such as psittacines which are liable to nip off a softer tube. When using a rigid tube, it should be well lubricated. The dose is 20ml/kg body weight of a 25–45% suspension.

After the administration, the bird should be held in an upright position for a few minutes in order to avoid regurgitation of the suspension. The time taken for the suspension to reach the various parts of the alimentary canal will depend on any drugs used for premedication and anaesthesia and also on any pathological condition that may be present. On average the barium will have reached the proventriculus and gizzard within 5 minutes and be in the small intestine within 30 minutes. It should have reached the cloaca in about 3 hours at the longest in granivorous species. In raptors and particularly in frugivores, e.g. mynah birds, the passage time may be considerably shorter.

Barium sulphate suspension or one of the iodine contrast agents such as iohexol or iopamidol can also be used retrograde to outline the cloaca and rectum. Furthermore the double contrast technique (10ml/kg air, followed by 10ml/kg positive contrast medium orally or cloacally) is useful for the examination of the wall of the GI tract (Figure 4.12).

## ULTRASONOGRAPHY

Ultrasound is an additional non-invasive diagnostic imaging technique which is especially useful in complementing imaging information gained by radiography. Whereas a radiograph provides a series of superimposed shadows of the external outlines of various

internal organs, ultrasonography gives information about the internal structural changes occurring within soft tissue organs.

In the present state of knowledge, unlike radiography, ultrasound is thought to be completely biologically safe for both the operator and the patient. It is painless, quick and can normally be used on the hand held conscious bird without anaesthesia or sedation. The capital investment in apparatus is expensive but once acquired the running costs are minimal. Because of this the apparatus is unlikely to be acquired solely for use in avian practice although a practitioner may have access to the equipment if it has been purchased for use in other species.

Despite limiting factors for the use of ultrasonography in birds (small size, limited coupling possibilities), it has become a valuable and important diagnostic tool in avian medicine. Main indications are the examination of the cardiovascular system and the urogenital tract, as well as liver alterations. For some disease processes, e.g. pericardial effusion, it is even the only definite possibility for *intra vitam* diagnosis.

Whereas the ultrasonographic presentation of the inner organs in healthy birds may sometimes be difficult to interpret, the situation in diseased birds is often characterised by organomegaly, displacement of the air sacs and fluid accumulations which improve the image quality considerably.

### **Technical equipment and examination procedure**

The ultrasonographic examination of birds requires electronic probes with small coupling surfaces (microcurved or phased array probes) with examination frequencies of at least 7.5 MHz. Best results are obtained using scanners developed for human paediatric medicine as well as for operative or gynaecological use.

For echocardiographic examinations a high frame rate is necessary to get images from defined cardiac stages such as systole and diastole.

Since the content of the gastrointestinal tract may disturb the ultrasound beam, birds should have a more or less empty GI tract. Anaesthesia is commonly not necessary for routine examination. The patient may be held manually in dorsal or lateral recumbency or – better – in an upright position. There are two main approaches:

1. The ventro-median approach is the main approach. The transducer is coupled in the median directly behind the caudal end of the sternum.
2. The parasternal approach may be used in birds with sufficient space between the last rib and the pelvic bones, e.g. pigeons and some raptor species.

The scanner is coupled on the right side of the bird, because on the left side the gizzard might disturb the penetration of the ultrasound waves. The leg is pulled either backwards or forwards and the probe has to be pressed slightly to the body wall to compress the underlying air sacs.

Feathers in these areas have either to be plucked or parted only. In most psittacines, for example, separating the feathers is sufficient in most cases. A commercially available water-soluble acoustic gel should then be applied to ensure a good contact between transducer and skin. These gels are well tolerated and can be removed from feathers and skin easily after the examination.

### **Pathological alterations**

#### **The heart**

The great advantage of ultrasound in examining the avian heart is the presentation of the inner structures and therefore the morphological and the functional status may be assessed. However, due to anatomical peculiarities of the avian heart, the protocol (standardized views) recommended for echocardiography in mammals cannot be used. M-Mode, a

valuable tool for assessment of wall thickness and contractility in mammals, is not useful in birds, since the avian heart is only visualized in longitudinal and semi-transversal views.

To date, B-Mode (2-D echocardiography) in birds is an established examination technique and reference values have been reported for several species. By that the inner structures of the heart, e.g. the size of the ventricles, the wall thickness of the interventricular septum and the contractility of the ventricles are important parameters to evaluate the cardiac morphology and function, as well as the left atrioventricular (AV) valves, the aortic valves and the right muscular AV valve. The most frequent pathological findings are hydropericardium and hypertrophy/dilatation of the right ventricle, which are often caused by right-sided congestive heart failure.

### The liver

The use of ultrasonography has led to a great deal of progress in the *intra vitam* diagnosis of the internal structure of parenchymatous organs. The normal liver parenchyma is finely granulated and of homogeneous echogenicity. It is spotted with small to medium-sized anechoic areas which, depending on the section, appear round, oval or long, have a hyper-echoic wall and are clearly differentiated from the parenchymal structure. These areas represent the liver vessels, but a differentiation in branches of the portal vein and hepatic veins (which is possible in humans because of the differences in the structures of their walls) is not possible. Dilated vessels are routinely diagnosed, e.g. in liver congestion.

Concerning the liver parenchyma, in most cases it is possible by ultrasound to differentiate between inflammation, neoplasia, calcification, granuloma, cyst, fatty liver degeneration, etc. However it is not possible to predict the histological nature of a lesion from its ultrasonographic appearance. Ultrasound-guided biopsies may be taken easily from defined regions of the liver parenchyma according to the procedure as used in mammals.

### Reproductive system

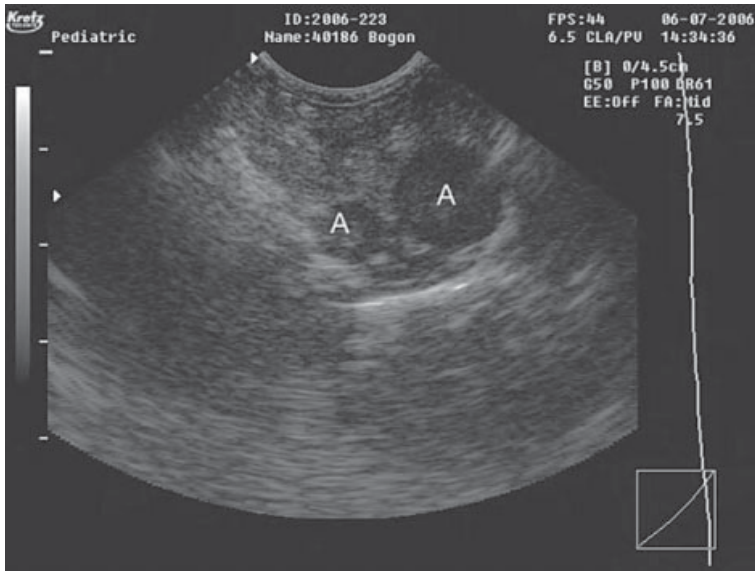
Ultrasonographic demonstration of the gonads is only successful in sexually active birds. The picture of active ovaries is characterised by the presence of follicles in different sizes representing various stages of development (differentiable in the ultrasound picture) (Fig. 4.13). The active oviduct can be distinguished due to the presence of eggs and the lack of contractility (in comparison to the intestines). Again cysts and neoplasia, as well as salpingitis and laminated eggs, are recognized routinely in the examination. Advanced inflammatory processes of the oviduct are also recognizable by increased thickness of the oviduct wall.

### The kidneys

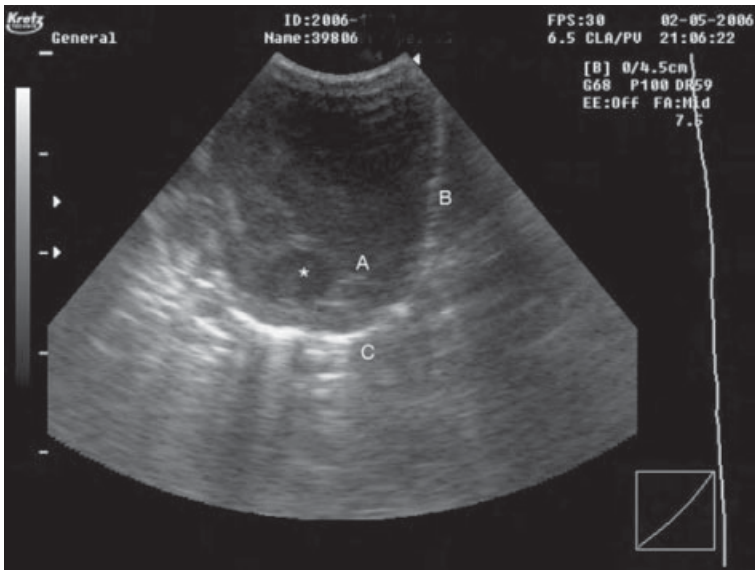
The ultrasonographic demonstration of *normal* kidneys is not possible due to their position along the vertebral column and the surrounding abdominal air sacs. However, in cases of kidney enlargement, the size and the parenchyma can be assessed not only in large birds but also in smaller ones without problems. Again, as in the diagnosis of hepatic parenchymal alterations, differentiation of renal inflammation, neoplasia, cysts, etc. can be done sonographically (Fig. 4.14). Uric acid deposits and/or calcification cause reflections (increased echogenicity), the renal tissue appears more inhomogeneous. However, diagnosis of renal gout by means of ultrasound is difficult; other techniques (radiology, endoscopy, blood chemistry, biopsy) should be taken into account.

### Gastrointestinal tract

Since studies of the use of ultrasound for the examination of the gastrointestinal tract in diseased birds have not yet been documented, the value of ultrasound for the examination of the GI tract in birds is limited in comparison to radiography. Identification of the normal



**Fig. 4.13** Ultrasound examination. Ventro-median approach. Scarlet-chested parrot (*Neophema splendida*). Follicles in the ovary (A).



**Fig. 4.14** Ultrasound examination. Ventro-median approach. Budgerigar (*Melopsittacus undulatus*). Enlargement of the kidney (A) with inhomogeneous echogenicity (\*), tumour; B, body wall; C, total reflection of spinal column bone.

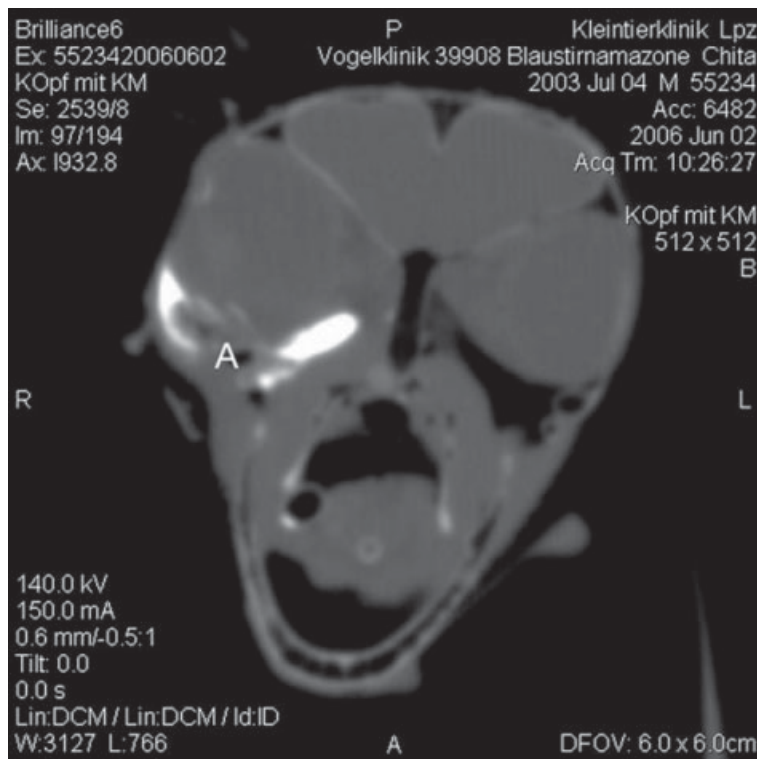
appearance of the GI tract in the sonogram however is easy in case of the gizzard and the intestinal loops. The gizzard is easily seen due to its large muscles and its large content of grit in granivorous birds as is the peristalsis of the intestinal loops. A retrograde filling of the cloaca with fluid may help to assess the mucosa, e.g. in cases of papillomatosis.

Other organs in which there may be an indication for ultrasonography are spleen and eye. Further information about avian ultrasonography is given by Krautwald-Junghanns *et al.* (1991, 1995, 1997).

### COMPUTED TOMOGRAPHY

Computed tomography (CT) is a method of using X-rays for diagnosis by producing cross-sectional images of a body. It is a quick method for the examination of the avian skeleton, particularly spine and skull, but also of soft tissues and the lungs. In contrast to conventional radiographs there are no superimpositions of tissues, and the computer can produce three-dimensional images of organs. With the help of CT, radiodensity measurements can be taken to define a pathological process. A CT examination may be indicated in patients with CNS symptoms, respiratory diseases or with swellings of tissues of unclear aetiology. Figure 4.15 shows an example of a CT image of the head with contrast.

Urography, sinography and angiocardiology using iodine contrast media are also possible. Disadvantages include relatively high costs. For further information about computed tomography also consult Souza *et al.* (2006), Gumpenberger and Henninger (2001), Krautwald-Junghanns *et al.* (1993, 2005, 2006) and Helmer (2006).



**Fig. 4.15** Computed tomography, contrast study (intrasinusoidal injection). Axial view. Blue-fronted Amazon (*Amazona aestiva*). Solid mass (A), granuloma.

## **MAGNETIC RESONANCE IMAGING**

Magnetic resonance imaging (MRI) creates three-dimensional images of the patient using an external magnetic field. MRI is best used for the visualisation of different structures of the CNS, abnormalities in soft tissues and tumours. It needs anaesthesia in every case, because of the noise of the apparatus and the relatively long examination time. Very sick patients may be at especially high risk, therefore – due to the fast examination time – CT may be superior for examining birds. No magnetic objects, for instance foreign bodies or microchips, which may move, should be in or near the bird's body.

Helmer (2006) can give more details about MRI as an aid to diagnosis.



# 5

## Post-mortem Examination

---

**Amended by Professor Dr Maria Krautwald-Junghans**

Universität Leipzig  
Institute for Avian Diseases, Leipzig, Germany

There is probably no other way in which a clinician's acumen is increased than by post-mortem examination. The post-mortem of patients subsequent to an ante-mortem diagnosis will help increase the practitioner's diagnostic ability and indicate ways in which the diagnostic routine can be improved.

The owner of a single bird, be it a pet cage bird or a falconer's hawk, is often interested in the cause of death and if there was anything he/she could have done to prevent death. The client who has a flock of wild fowl or an aviary of birds that are chronically sick is often willing to sacrifice one or a few birds to establish the cause of the problem.

To be of maximum value, post-mortem specimens should be as fresh as possible. Owing to the high initial body temperature of 40°C and to good body insulation of the feathers, autolysis occurs rapidly in birds. However, sometimes a client will produce a carcass of a bird which died 24–36 hours previously. In this case the carcass should be thoroughly soaked with cold soapy water and placed in a plastic bag with any excess air expressed. The sealed bag should then be put in a refrigerator so that the body is kept at a temperature just above freezing but not frozen. The feathering helps to retain body heat, so cooling the body as quickly as possible will help to reduce autolytic changes. If the carcass is deep-frozen the fine cellular structures are ruptured by ice crystals. Such tissues are useless for histopathology. However, in those specimens that are up to three days old and in which no precautions have been taken to prevent autolysis, some useful information may often still be obtained.

A post-mortem should always be carried out in a systematic and routine order so that nothing is overlooked or forgotten. Having a check-list to hand is invaluable.

The practitioner should realise that the gross lesions seen during post-mortem can only provide a tentative diagnosis. Further laboratory tests will be needed for confirmation in most cases. Therefore it is wise to have certain equipment ready before starting the autopsy.

### **EQUIPMENT AND LABORATORY TECHNIQUES**

- A check-list of all body organs to be examined
- Scalpel and blades
- Rat-toothed forceps
- Sharp-pointed dissecting scissors
- Spirit lamp or Bunsen burner
- Bacteriological culture plates, blood agar and MacConkey agar

- Bacteriological swabs in transport medium. However, do not use transport medium if a swab is taken for a PCR test to detect *Chlamydophila* spp. The use of the transport medium may give a false positive result. All living specimens have a better chance of survival if placed in transport medium.
- Screw-top containers with 10% formaldehyde that should preferably be neutral buffered. Use of buffered formaldehyde makes histological examination easier. When harvesting solid organs, specimens should not be more than 0.5 cm thick, otherwise the formalin will not fully penetrate the tissue. At least ten times the volume of the specimen is required as preservative.
- Screw-top sterile containers to contain tissues for bacteriological culture
- Slides. These can be used for:
  - Bacteriological staining; if the slide is sterilised by heating in the flame, the bacteriological swab will remain uncontaminated after the smear has been made on the sterile slide.
  - Slides can be used to make impression smears from liver, spleen, lung, gut, air sacs and all organs with pathological findings using Romanowsky stains. Liver smears can be stained with modified Ziehl-Neelsen (STAMP) or Macchiavello's stain for *Chlamydophila* inclusion bodies. Furthermore Ziehl-Neelsen stain can be used for the detection of mycobacteria.
  - If the bacteriological swab is rolled along the sterile slide instead of being smeared across it, it can be stained with Wright's or Leishman's stain and then used for cytological examination.
  - Slides can be used for simple smears of crop, proventriculus and gut content especially in cases of *Macrorhabdus ornithogaster* mycosis or fresh dead birds.
- Strong scissors or even bone forceps for large birds
- Some sterile gauze swabs are sometimes useful if a blood vessel is inadvertently punctured
- Sterile syringes and needles for the sterile collection of heart, blood and intestinal contents for culture. If the ingesta are too viscid, a little sterile normal saline injected into the lumen of the gut will make them more fluid. To collect sterile samples from the interior of unopened hollow organs, first sterilise the surface by searing with a hot spatula before inserting the needle.
- At least one pair of sterile Petri dishes to collect tissues for virus isolation, as suggested by Harrison and Herron (1984)
- Plastic tubes to collect and preserve organ samples for virological examination
- Good lighting, possibly combined with a magnifying lens
- A suitable board and dissecting needles for pinning out small birds.

Always wear gloves and a mask. Apart from the risks of *Chlamydophila* spp infection, which is not confined to parrots and is not uncommon in ducks and pigeons, there are many other avian zoonoses.

## EXTERNAL EXAMINATION

Before starting the post-mortem it may be helpful to X-ray the carcass, if, for instance, it was suspected the bird was shot or suffering from metabolic bone disease or was involved in some sort of an accident or was ill because of heavy-metal poisoning (e.g. fisherman's lead weights, lead chewed from leaded light windows, etc.). X-rays will also show if a bird has been microchipped.

Before opening the body a thorough examination should be carried out looking for any of the external signs described in Chapter 3. External parasites are often a lot more obvious

on the dead body as they move away from the cooling surface of the skin. The specimen should next be saturated with a quaternary ammonium antiseptic. This reduces the amount of airborne feather debris. Feather dust can carry *Chlamydothrips* spp and other organisms and also contaminates the viscera when the carcass is opened.

The body is next pinned out on a board. In large birds the medial adductor leg muscles can be cut and the hip joints disarticulated. Simpson (1996) suggests pinning the legs over the flexed wing tips to keep the wing feathers out of the way. Plucking the whole body is unnecessary, however the removal of feathers along the midline in densely feathered species, such as ducks and gannets, does help to make it easier to incise the skin cleanly without damaging the underlying viscera.

## INTERNAL EXAMINATION

The initial incision is made through the skin from the cranial end of the sternum to just in front of the vent. The cut is then extended on each side just along the caudal edge of the sternal plate. By blunt dissection the skin is then eased away from the underlying pectoralis muscle and at the same time the condition of the muscle is observed.

### The pectoralis muscle

Both sides of the pectoralis muscle should be similar and well-rounded. If the two muscles are not symmetrical it may indicate an old injury or an inspissated and contracted abscess. The muscle should be of normal red colour showing no sign of anaemia, hyperaemia or bruising. The latter may be anything from bluish-black to green (within 24 hours) in colour depending on how long previously the trauma occurred. Discoloration of abdominal muscles may occur if they have had prolonged contact after death with the gut or gallbladder (if this was displaced caudally). Bacterial invasion from the gut into the surrounding tissue can be relatively rapid in the uncooled carcass.

Incise the pectoralis muscles and look for any evidence of petechial haemorrhages in the muscles which could indicate warfarin poisoning (Reece, 1982) (see 335) or vitamin K deficiency. Note the observations of Fiennes (1969) mentioned in the section dealing with disease of the lower alimentary canal. Also look for evidence of pale streaks in the direction of the muscle fibres which may indicate sarcocytosis (see p. 317) or so-called leucocytozoon infection (Simpson, 1991) (see p. 322): if suspected submit a specimen for histopathology.

### Exposing the viscera

The skin incisions are now deepened through the muscle and the lateral incisions are now extended to the level of the costochondral junctions, which are either cut with scissors or shears if very large birds, or, in small birds, dislocated by pressure from the handle of a scalpel. Do not cut through the coracoids or clavicles at this stage, as this may damage the large blood vessels leaving the heart.

The sternum now can be lifted upwards away from the underlying viscera. As this is done examine the underside (anatomically the dorsal aspect) of the sternum together with the general appearance of the organs. If the body cavity is filled with exudate, take swabs for culture. There should be very little fluid in the normal coelomic cavity. Decide if the colour of the tissues looks a normal pink or is hyperaemic, indicating a possible septicaemia. Discoloration on one side only, due to hypostatic congestion, would indicate the bird had been left for some time lying on that side after death. The carcass may look anaemic. Even if heavy infestation with blood-sucking parasites had been noticed initially, there may also be other less obvious contributing factors. The muscle may look dry indicating dehydration or shrunken indicating cachexia.

## Examination of the viscera before removal from the body

In egg peritonitis large quantities of yellow inspissated yolk material may cover the intestines. Occasionally at this stage of the post-mortem the organs can be seen to be covered with a scintillating sheen of urate crystals, indicating visceral gout.

### Air sacs

The signs of air sacculitis may be seen and will become more evident as the post-mortem proceeds. During the initial stages of air sacculitis the crystal-like clarity of these delicate sheets of tissue is lost. They become increasingly opaque and thickened as exudate begins to collect between their two layers of cells. At first this cloudiness is patchy but later extends through the whole system of air sacs. Yellow caseous material becomes more evident. There may be a varying distribution of discrete, 'suede-like', greenish-yellow, disc-like plaques which show a necrotic centre. These may indicate *Aspergillus* infection (see p. 304) and diagnosis should be confirmed by taking a swab for culture and microscopical examination.

*Aspergillus* lesions vary in colour from cream to bluish-grey, etc. Mixed infections of *Aspergillus* and *Mycobacterium avium* (see p. 273) can occur. An impression smear can also be taken and stained with Gram stain or lactophenol blue, when mycelia and the club-shaped fruiting heads can be seen, particularly at the edge of the specimen. In air sacculitis due to *Escherichia coli* (see p. 268), the thickened parts of air sac and caseation tend to be more generalised and irregular in shape.

The minute black mites of the genus *Sternostoma* (see p. 332) may be seen in the air sacs, particularly of finches. Occasionally in falcons nematodes of the genus *Serratospiculum* (see p. 327) may be seen in the air sacs (Cooper, 1978). These have also been seen by the author in an immature herring gull (*Larus argentatus*).

### The liver

If the liver is ruptured and is accompanied by a large blood clot this could be due to a blow over the sternum. In this case there will usually be signs of bruising of the overlying muscle and skin. The liver may be bile-stained (in those species which have a gallbladder – it is absent in many pigeons and parrots) due to bile diffusion from the gallbladder through the dead tissue of the bladder wall – a process which takes place within a few hours of death.

The patency of the bile duct should be checked by gently squeezing the gallbladder, particularly in Amazon parrots in which there is a high incidence of bile duct carcinoma. These birds may also show papillomata of the cloaca and/or oral cavity and oesophagus. The liver may be enlarged, and in fatty livers rupture will occur easily without any external trauma. Enlargement of the liver is indicated by loss of the normal sharp edges, which become rounded. If this is accompanied by faint areas of necrosis, which are seen at the same time as a fibrinous or serous pericarditis and air sacculitis, death may have been due to *Chlamydophila psittaci* (psittacosis) infection (see p. 277). An impression smear of the liver, stained with either a modified Ziehl-Neelsen stain or Macchiavello's stain, may show the pink intracytoplasmic inclusion bodies. Also in *Chlamydophyla* spp infection the spleen will usually be enlarged or distorted in shape. In fledgling parrots up to 14 weeks of age hepatosplenomegaly accompanied by subepicardial and subserosal haemorrhage may be due to avian polyoma virus (see p. 300).

Pacheco's parrot disease (see p. 280) may cause liver lesions that mimic *Chlamydophila* spp infection. These lesions tend to be more saucer-shaped and cause a faint yellow discoloration which stands out against the mahogany-coloured liver. Other herpes viruses (see pp. 280–5) affect other groups of birds and can cause necrotic foci in the liver. Principal among these is the disease in falcons, storks and cranes. Pigeons can also be affected by a herpes virus but this attacks mainly the young birds. In owls, herpes virus liver lesions

look more like avian tuberculosis, with small white or yellowish pustules up to the size of a pea and possibly not raised above the surrounding surface. Some of the other organs may be covered by these lesions.

Avian tuberculosis or even bovine or human TB in birds should not be confused with the pin-head white or yellow necrotic foci of *Salmonella*, *E. coli* or *Yersinia pseudotuberculosis*. A swab stained with Ziehl-Neelsen and Gram stain may identify the organism. Fiennes (1969) describes the liver as being a rich golden colour and somewhat swollen and fatty in the case of septicaemic *Salmonella* infection.

In neonates the liver is normally a pale yellow colour due to lipidosis caused by the metabolism of egg yolk from the yolk sac which is absorbed after several days.

In turkeys and gamebirds the black, circular lesions of blackhead due to histomoniasis infection (see p. 320) may be found. If the liver is mottled with irregular, lighter-coloured areas this may be neoplasia.

In fresh specimens it is possible to carry out a vitamin A analysis. A minimum of 1 g of liver is required and it should be stored and transported to the laboratory frozen.

### Heart blood

If at this initial examination of the viscera there are signs of septicaemia, and the carcass is fresh, a sterile specimen of heart blood should be taken. The surface of the organ is first sterilised by searing with the blade of a hot spatula. A sterile needle attached to a syringe is then inserted into the heart for the withdrawal of blood. If the bird has not long been dead it may be possible to make a smear and look for blood parasites. The blood obtained should also be cultured and stained with Gram stain.

## REMOVAL AND EXAMINATION OF THE ALIMENTARY CANAL, SPLEEN AND LIVER

Removal of the digestive tract, spleen and liver should be carried out by cutting the lower oesophagus and incising the skin around the vent. The cloaca and the attached bursa of Fabricius should be removed intact and care should be taken not to contaminate the rest of the carcass. The spleen should be attached to the underside of the caudal end of the proventriculus (anatomically the dorsal side), lying behind the gizzard.

### The spleen

The spleen is globular in most species but may be triangular in ducks and geese and is usually about one-quarter to one-third the size of the heart. Never ignore an enlarged or angular-shaped spleen or one that may have ruptured. It may indicate *Chlamydophila* spp (see p. 277) infection. However an enlarged spleen is not always present with *Chlamydophila* spp infection. If other signs are present, and the clinician is suspicious of the presence of *Chlamydophila* spp, the spleen should be checked by using an impression smear stained with the modified Ziehl-Neelsen technique (see p. 73). If this is positive it is wiser for the practitioner to proceed no further.

The spleen may be slightly enlarged and hyperaemic due to a septicaemic infection or, as in the case of the liver, mottled with the foci of neoplasia. The signs of tuberculosis (see p. 273), pasteurellosis (see p. 271), *E. coli* septicaemia and aspergillosis are similar to those seen on the liver.

### The lower alimentary canal

Before dissecting out the gut, examine the pancreas, which is enclosed within the duodenal loop and which can usually be seen before the alimentary canal is removed from the abdomen. The pancreas should be examined for evidence of atrophy or neoplasia, neither

of which is common in birds. If paramyxovirus (see p. 290) is suspected (particularly in the *Neophema* parakeets) specimens of pancreas and also brain and lung should be placed in separate pots, cooled to 48°C and dispatched to a laboratory for histopathology.

The accompanying duodenum may look congested or distended with gas, which often occurs if the bird has been dead some time before post-mortem. Take a sterile sample of the contents, in the same way as harvesting a sterile sample of heart blood. *Clostridia* spp (see p. 274) may be cultured.

If the ingesta are too viscid, dilute by injecting a little sterile saline. Examine the sample for *Coccidia*, by simple smear, Gram stain and culture. The Gram stain will enable assessment of the relative numbers of Gram+ and Gram- organisms. The latter should not be predominant in most healthy birds.

### Haemorrhage

Look for signs of intestinal haemorrhage, which could be generalised or patchy throughout the intestine. If this is accompanied by pathological signs in other parts of the body it may be an indication of Newcastle disease. However, the pathological signs of Newcastle disease (see p. 288) vary greatly among different species and lesions may not be present in any of the viscera. Always look at the pattern of pathological change in the intestine together with other changes in the rest of the viscera. A single intestinal haemorrhage may not be due to bacterial enteritis but rather caused by terminal venous congestion brought on by right-sided heart failure as a result of toxæmia. A condition of stress enteropathy has been described by J.R. Baker (personal communication). It is characterised by a seepage of large quantities of blood into the lumen of the intestine resulting in rapid death. The stress can have occurred hours or days previously and the condition has often been noted by the author.

Fiennes (1969) has pointed out that sporadic haemorrhage occurring anywhere in the body, both internally and externally and un-associated with any other signs, may be due to vitamin K deficiency. Vitamin K is partially synthesised by normal gut flora. This may have been disrupted by disease of the bowel or indiscriminate use of antibiotics. Haemorrhage may be due to warfarin poisoning as mentioned previously when discussing examination of the pectoralis muscle.

### Caeca

Examine the caeca; these vary considerably in shape and size in different species (see Fig. 1.8). They are large and obvious in poultry, in passerines they are small and in pigeons and parrots they are rudimentary. They have lobate ends in the barn owl. In turkeys, chickens and game birds, the lesions of blackhead (see p. 320) may be seen. The caeca are swollen, the mucosa extensively ulcerated and the lumen contains a lot of necrotic material. In *Salmonella* infection, the caecal wall may have a white, glistening appearance.

### Lumen

After an external examination of the bowel the whole alimentary canal should be opened to expose the lumen. The interior may be filled only with a green fluid without any ingesta, indicating anorexia. The lower intestine may contain grit or undigested seed from the gizzard, indicating increased peristalsis. The mucosa of the bowel may be congested and swollen or flaccid and dilated. If the lumen is filled with catarrhal exudate this could be caused by a parasitic infection.

The contents of the bowel and scrapings of the mucosa should be examined for *Coccidia* or *Capillaria* (up to 1 cm long) or helminth eggs or even *Cryptosporidia* (see p. 315). In freshly dead birds a simple smear could be helpful to look for parasites e.g. *Spiroucleus* spp or worm eggs. The scraping should be stained with Giemsa to confirm

diagnosis, when numerous minute spherical organisms will be seen adherent to the mucous membrane. For parasites the specimen is best stained with Lugol's iodine. The gut may contain ascarid worms which may be so numerous as to cause impaction and rupture of the bowel. Signs of *Aspergillus* infection are occasionally found in the lumen of the bowel.

In the case of *Salmonella* infection the mucosa may show small nodules of necrosis. Even if the gut looks normal it is always wiser to take a swab for *Salmonella*.

Foreign bodies such as fish hooks and small nails are sometimes found in the lumen of the gut and occasionally penetrate the bowel wall.

#### *Proventriculus and ventriculus (gizzard)*

The proventriculus and ventriculus (or gizzard) should be examined for evidence of the cheesy exudate of trichomoniasis, which is more commonly found higher up in the alimentary canal. If the interior of the proventriculus is filled with mucous content, blood or an ulceration of the mucosa then a straightforward smear should be examined for the detection of *Macrorhabdus ornithogaster* (see p. 312). The proventriculus may be enlarged and filled with grit and undigested food. This may be an indication of psittacine neuropathic gastric dilatation (originally known as macaw wasting disease) (see p. 307), which occurs in all species of psittacines.

Striations seen in the muscle of the wall of the gizzard may be due to vitamin E deficiency. The koilin layer of the gizzard of granivorous and herbivorous birds may be stained with bile. If staining is intense or extends into the proventriculus this may indicate antiperistalsis.

#### Cloaca and bursa of Fabricius

Lastly the cloaca together with the bursa of Fabricius should be examined. The latter should be small and involuted in the adult bird. It is only easily recognisable in the young growing bird, when it looks like a large lymph node. A prominent bursa of Fabricius indicates persistent B-cell production to boost humoral antibody as a response to chronic antigen stimulation from chronic infection such as paramyxovirus (see p. 288). The cloaca may be impacted, with urate crystals forming a crumbling calculus, or it may be filled with blood clot as the result of damage during artificial insemination.

The mucosa of the cloaca can show signs of inflammation or neoplastic change (papillomata) sometimes seen in New World psittacines such as Amazon parrots and macaws.

### **EXAMINATION OF THE HEART AND ASSOCIATED MAJOR BLOOD VESSELS**

The exterior of the heart together with the pericardium will already have received some attention when the carcass was first opened, but must now be examined in greater detail. The normal heart of a bird is roughly triangular in shape; any tendency to a spherical shape is abnormal. The pericardial sac should be examined for any increase in fluid content, the amount of which is normally imperceptible. If the pericardium is unusually opaque this may be caused by infiltration with urate crystals. Examine the myocardium, endocardium and coronary blood vessels for any sign of petechial haemorrhages, which may be a sign of septicaemia or alternatively of violent struggling just before death. Occasionally the right atrium may be found to be ruptured as a consequence of massive dilation during circulatory failure brought on by an overwhelming disease.

The major blood vessels leaving the heart should be examined. At the same time look for any signs of air sacculitis in the cervical and interclavicular air sacs. If this is present, it may be productive to cut through the head of the humerus and take a swab from the medullary cavity since this is connected to the anterior air sacs.

When examining the brachiocephalic trunk and the carotid arteries leading away from it, the crop must not be damaged. The interior of the major blood vessels, as well as those of the abdominal aorta and renal arteries, may show atheromatous plaques and these may be so extensive as to apparently occlude the lumen of the vessel. They may also make the blood vessels less flexible. These lesions are not uncommon in Anseriformes, Falciformes and ostriches. They are occasionally found in many other species such as Psittaciformes. Young turkeys commonly suffer from dissecting aneurysms of the arteries, which can lead to sudden death.

### EXAMINATION OF THE CROP

Normally the crop wall is quite thin – in small birds as delicate as tissue paper. However, where there is infection, as with *Candida* or *Trichomonas* (see p. 319), the mucosa of the crop can become hypertrophied and noticeably thick. If the white, caseous exudate of *Candida* is scraped from the mucosa, the surface will look rather like velvet.

Physiological regurgitation of seed is normal in the budgerigar when feeding nestlings but there is no accompanying hypertrophy of the crop (J.R. Baker, 1984, personal communication). Occasionally the crop will become impacted, a condition affecting all species. The trapped food will ferment, with superimposed bacterial infection and inflammation of the crop. The layman's term of 'sour crop' can cover any of the above conditions. Brooks (1982) reports necrosis of the crop wall in a sparrow-hawk leading to a fistula probably caused by a penetrating spicule of bone. Fistulas may also result from external wounds or from scalding in hand reared psittacines. In cases of unexplained death, examine the crop contents for signs of poisonous plant material.

### THE OESOPHAGUS AND OROPHARYNX

The whole of the oesophagus should be opened by making a parallel cut with scissors along each side. If a pair of strong scissors or a pair of bone forceps (in large birds) is inserted with one blade in the mouth, the quadrate bone can be cut and the lower jaw disarticulated. The whole of the upper alimentary tract can now be examined.

A caseous exudate could indicate trichomoniasis or candidiasis (see p. 310), or there may be signs of an *Aspergillus* mycosis. The signs of all these infections can be confused and diagnosis should be confirmed by laboratory examination. Trichomonads are sometimes difficult to find under the microscope. In a newly dead bird the mucosal scrapings should be examined using a hanging drop method after mixing with a little normal saline. Use a 620 objective and rack the condenser down. However, if the exudate is incubated overnight in a trichomonad culture medium, there is no difficulty (A.S. Wallis, 1984; personal communication). The clinician should be aware that signs of trichomoniasis may be superimposed on an underlying *Chlamydophila* infection (de Gruchy, 1983) or indeed on other infections such as avipox together with hypovitaminosis A.

Excessive mucus in this region may be indicative of capillaria infection, and the worms are sometimes easily seen in the mucus by naked eye although microscopical examination may be necessary. Abscesses in the mouths of birds, particularly parrots, are not uncommon and may be due to an underlying vitamin A deficiency. However, the small white specks sometimes seen on the roof of the mouth in pigeons (A.S. Wallis, 1984; personal communication) are not considered to be of any clinical significance; the lesions of avipox are much larger. For differentiation of pathological signs the use of impression smears could be helpful.

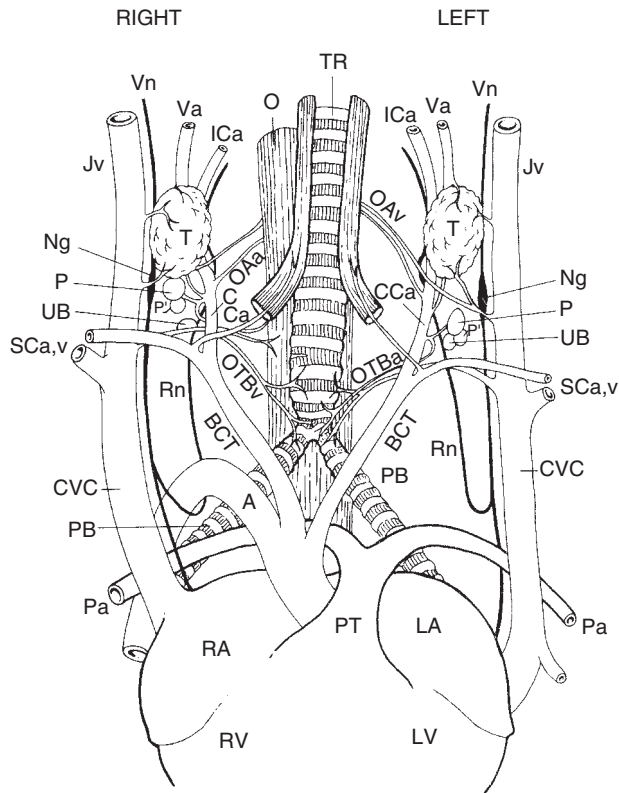
Haemorrhage into the choanal space or into the oral cavity may be noticed when the mouth is first opened. This may be as a result of trauma. Both wild and pet birds will fly



into window panes. Sparrow-hawks, in their enthusiastic pursuit of prey, may collide with the same window pane as their prey and both be found dead together.

### THYROID AND PARATHYROID GLANDS

After the crop has been carefully dissected to one side in order to examine the carotid arteries, the thyroid and parathyroid glands should be examined (Fig. 5.1). Neoplasia of the thyroid is not common in birds but a number of clinicians have reported seeing occasional cases in which the signs exhibited before death are similar to those of thyroid dysplasia. Secondary hyperparathyroidism occurs in birds that have been fed almost entirely on seed that contains very little calcium but excess phosphorus. If these birds have been deprived of soluble grit, metabolic osteodystrophy or secondary nutritional hyperparathyroidism may follow. In these cases the parathyroid glands (Fig. 5.1) are somewhat enlarged and white in colour. In the normal bird they are often difficult to find.



**Fig. 5.1** Ventral view of the blood vessels, nerves and glands at the thoracic inlet of the domestic fowl. The carotid bodies are on the medial surfaces of the parathyroid glands. A, aorta; BCT, brachiocephalic trunk; CCa, common carotid artery; CVC, cranial vena cava; Ica, internal carotid artery; Jv, jugular vein; LA, left atrium; LV, left ventricle; Ng, nodose (distal vagal) ganglion; O, oesophagus; OAa, ascending oesophageal artery; OAv, ascending oesophageal vein; OTBa, oesophagotracheobronchial artery; OTBv, oesophagotracheobronchial vein; P, cranial parathyroid gland; P', caudal parathyroid gland; Pa, pulmonary artery; PB, primary bronchus; PT, pulmonary trunk; RA, right atrium; Rn, recurrent nerve; RV, right ventricle; SCa, subclavian artery; SCv, subclavian vein; T, thyroid gland; TR, trachea; UB, ultimobranchial body or gland; Va, vertebral artery; Vn, vagus nerve. After Abel-Magied & King (1978), with kind permission of the editor of the *Journal of Anatomy*.

## THE RESPIRATORY SYSTEM

### The palatine choanal opening

Mites may sometimes be found inhabiting this area. Look for any sign of infection in this region. The upper beak should be cut across just in front of the cere and the sinuses examined. They may contain catarrhal or caseous exudate or there may be a blood clot.

### The glottis and trachea

There may be signs of inflammatory change along the edges. Open the trachea by making two parallel cuts. The mucosa may be congested or there may be signs of fungal infection. In those birds that feed on invertebrates, and *this includes a wide range of species*, the nematode *Syngamus trachea* (see p. 326) is commonly found, particularly in young birds. Occasionally a foreign body such as a seed is found obstructing the trachea. Caseous plaques are not uncommon in the region of the syrinx and may partially occlude the airway. These lesions should be crushed on a slide and stained with lactophenol cotton blue (methylene blue stain also works reasonably well). Look for signs of mycotic infection.

### The lungs

The air sac system has already received attention when first opening the carcass. The lungs should be examined *in situ* and then carefully eased away from the adjoining ribs using the handle of a scalpel. Look for any evidence of abscessation (sometimes only found on the dorsal surface of the lung) or look for haemorrhage. If this is present examine the adjacent rib. There may be signs of a recent or old fracture. Lungs that are dark in colour and exude moisture when compressed are oedematous. This can be due to the inhalation of toxic fumes, such as carbon monoxide from a faulty gas heater, polytetrafluoroethylene (Teflon®) from a chip pan fire or from the fumes of an industrial waste plant upwind from an aviary. Section the lung and look for smoke particles.

Haemorrhage into the lung substance may be agonal (unorganised clot) and occur as the result of right-sided heart failure. It may also be the result of inflammatory change. If the lung looks solid, try and float a piece in water. If there is pneumonic change the piece of lung will sink. Also, if the lung is solid, sear the surface with a hot blade and take a bacteriological swab through a cut *into the sterilised area*. Also send samples for histopathology.

## THE GONADS, THE ADRENALS AND KIDNEYS

First look at these organs *in situ*. It may then be possible to strip them out in one piece from their 'bed' ventral to the *synsacrum*. This is attempted by gripping the fascia just cranial to this group of organs, peeling back gently and easing the organs out with closed scissors. However the sacral plexus transverse the kidney and so makes complete removal difficult. In small birds the kidney *and the synsacrum* may have to be removed in one piece.

### Ovaries and testes

Both ovaries and testes vary considerably in size according to the maturity of the bird and the breeding season. In both cases there may be a total or partial pigmentation (black or dark green) of the gonads – which is normal in some species (e.g. cockatoos, gulls and others). In the ovary affected with *Salmonella pullorum* disease, the follicles may become misshapen and angular instead of being globular. *The disease has been diagnosed in many species.*

Both male and female gonads can undergo neoplastic change. If there are cysts present in the ovary, examine the bones (ribs, vertebrae, sternum, humerus and skull) to see if there is any distortion or increase in solidity. The condition of polyostotic hyperostosis is not uncommon in budgerigars and may occasionally be seen in other birds. It is most often first noticed during radiography (see p. 90) and may be associated with an increased level of oestrogens seen in females with neoplastic change in the ovary and in male birds with sertoli tumours.

### **Adrenal gland**

The adrenal gland, closely associated with the cranial end of the gonad, is normally a pale pink or orange colour but it may become hyperaemic during the course of an infection or it may look almost white in colour. The adrenals may be enlarged in the chronically stressed bird.

### **The kidney**

The kidney may be hyperaemic, together with the rest of the viscera in septicaemic conditions. Alternatively it may be grey in colour, due to cloudy swelling. The kidneys may show any of the signs seen in the liver due to infectious disease mentioned above. The kidney may be pale in colour, the tubules and the ureters may be prominent when impacted with urate crystals. Small quantities of urate crystals in the ureters may be normal.

Salt poisoning results in marked deposition of urates. This condition is sometimes seen in aquatic birds in time of drought or in pet parrots fed salted peanuts or crisps.

Occasionally neoplasms or aspergillosis granulomas are seen in the avian kidney. These may result in pressure on the sacral plexus. In geese and some other Anseriformes swollen kidneys covered in white patches may be caused by *Eimeria truncata*.

## **THE NERVOUS SYSTEM**

### **The peripheral nerves**

After the kidney, examine the nerves of the sciatic plexus where these leave the spinal cord and emerge beneath the synsacrum. These nerves together with those of the axillae and the intercostal nerves should be examined for signs of irregular thickening typical of Marek's disease (see p. 283), seen in poultry and occasionally in falcons, owls and pigeons, and possibly other species. The thickening of the nerves is caused by lymphocytic infiltration resulting in tumours as in the viscera. Take a length of nerve from either the sciatic or brachial plexus, stretch it out on filter paper, leave to dry then fix in 10% formaldehyde for histopathology.

### **Neoplasia of the hypophysis, or pituitary gland**

In any bird but particularly budgerigars exhibiting polydipsia/polyuria and CNS signs ante mortem this gland should be examined. It lies in a fossa dorsal to the basisphenoid bone, which forms the cranial part of the brain case. The organ is immediately caudal to the optic chiasma. It is roughly a 2 mm globe in the budgerigar.

### **The brain**

During removal of the skin covering the head, evidence of subcutaneous haemorrhage may be seen. This is only significant if there has been a lot of bleeding. Next find the foramen magnum and in small birds insert the blade of a scalpel; in larger birds a pair of strong scissors or bone forceps will be needed. Cut around the cranium on each side and raise the calvaria to expose the brain. Signs of haemorrhage within the substance of the bone, sometimes quite extensive, are of no significance and are caused by blood extravasated

from blood vessels very soon after death. However, an organised blood clot, either over or under the meninges or in the substance of the brain, is important. This is so, even if the blood is not clotted, and may be evidence of concussion, particularly if there is also a matching bruising of the skin, or haemorrhage into the nasal cavities.

## THE SKELETON

Before finishing the post-mortem, examine those parts of the skeleton that were not examined when looking for Marek's disease. Open and look particularly at the joints. Greenish discoloration in the muscles around the joints is evidence of bruising. Signs of a septic arthritis of the joints with discharge of exudate may be signs of *Salmonella* infection in pigeons and poultry. The articular cartilage may also show petechiae.

Urate crystals as well as subcutaneous tophi may be seen in the joints of those birds affected with visceral gout. For the murexide test to confirm the presence of urate crystals see Chapter 3.

Cut off the head of the femur and sample the medullary cavity for blood-borne bacteria and examine the blood corpuscles for signs of any cellular disorder.

# Medication and Administration of Drugs

---



A problem for the busy practitioner in his consulting room is being presented with an obviously sick bird brought in by an anxious and sometimes demanding owner. He is required to reach an instant diagnosis and to initiate appropriate and immediate treatment. Yielding to these pressures, it is all too common among practitioners to assume that the bird is suffering from a bacterial infection and to dispense a soluble antibiotic. Whereas the original oxytetracycline powder was commonly used in the past, nowadays it may be doxycycline (Ornicure) or one of the fluoroquinolones (enrofloxacin or marbofloxacin). The owner is told to put some of this in the drinking water each day.

This routine is not only ineffective, it may in fact decrease the chances of the bird's recovery by disturbing the normal bacterial flora of the alimentary canal. In addition, it increases the chances of the emergent antibiotic resistant strains of bacteria, some of which may be pathogenic for humans. Gerlach (1994) has shown that tetracyclines can cause a transient rise in corticosteroids and suppress the immune system by inhibiting the activity of macrophages.

If the practitioner cannot persuade the client to let him/her hospitalise the bird so that a more accurate diagnosis can be made, it would be more logical to assume the sick bird is vitamin deficient. The metabolic turnover of the B vitamins is rapid, many birds in captivity are maintained on a restricted diet and some are chronically short of vitamin A. These vitamins can be given safely in the drinking water or by injection and will give the practitioner a little more time in which to make a more considered diagnosis, aided by taking samples for laboratory investigation.

## ASSESSING THE WEIGHT OF A BIRD

To administer adequate and safe medication, the bird must first be weighed. Today small, inexpensive, digital scales are readily available for weighing even small birds (see Vetark in list of websites in Appendix 11). Larger birds, particularly falcons and some parrots, will sit on a perch attached to the scales. Falconers often weigh their birds regularly to maintain them in flying condition (i.e. at optimum flying weight) and may be able to tell you the weight of the bird. Ducks, geese and similar birds may be put in a sack, with the head out and the sack tied around the bird's neck or may be placed in a box or other suitable container for weighing.

If for some reason it is not practical to weigh the bird then reference may be made to a table of bird weights (see Appendix 8). *However, the clinician should be aware that weights in normal birds can vary at least 25% on either side of the mean weight for the species. In sick or starved birds the deviation from the mean weight could be greater.*

## CALCULATING THE DOSE OF DRUGS

Few medicines are marketed specifically for use in birds. Doses are therefore based on anecdotal reports or have to be extrapolated from the doses advised by the manufacturer for use in dogs, cats and small mammals. However, birds have a higher metabolic rate than mammals and the rate increases as the size of the creature decreases. There are also differences in metabolic rate between the passerine and non-passerine groups of birds. In addition, other factors, such as the density of feather covering, are involved.

In general, the higher the metabolic rate the faster are drugs absorbed, metabolised and cleared from the body. Nevertheless, Bush *et al.* (1979) have pointed out that there are anomalies to this pattern, resulting from the many metabolic and subtle anatomical differences even between closely related species such as the psittacine birds. The pharmacokinetics of drugs in most species of bird need much more investigation, as has recently been highlighted by Donita *et al.* (1995).

If there is not a recommended or proven dose for a particular circumstance then it is best to calculate the dose from the bird's metabolic/effective weight using a method of allometric scaling. In general, this is derived as an exponential of the body weight raised to the power of 0.75. For example, if the recommended dose of a drug for a cat is 2 mg/kg the dose for a budgerigar weighing 40 g will not be:

$$\frac{40}{1000} \times 2 = 0.08 \text{ mg}$$

But will be

$$\frac{(40)^{0.75}}{(1000)} \times 2 = (0.040)^{0.75} \times 2 = 0.178$$

which is well over three times as much as the original dose calculated on a weight for weight basis. This of course is the total quantity to be given in 24 hours and will need to be divided into a larger number of fractions to be administered more frequently than is recommended for the cat. *Doses given in this book are those used by other clinicians and the author. They are not necessarily based on the metabolic effective weight and may need to be adjusted in the light of future experience.* Always be aware of any possible toxicity, particularly in the case of a rare, valuable or unusual species in which the drug has not been used before.

## THE ADMINISTRATION OF DRUGS

As in the case with mammals, medicines may be given to birds by a variety of routes, some of which are more effective and more appropriate to certain disease conditions.

### Medication of the drinking water

This is a convenient method when large numbers of birds have to be treated, such as those in a zoological collection or at a quarantine station or in a poultry flock. A number of drugs are formulated for use in poultry by this method. The daily dose has been calculated on the mean water intake of an average bird during 24 hours. At a *very rough approximation*, 150 ml of water is consumed per kilogram of avian body weight daily. However, there may be at least a 50% increase or decrease on either side of this figure.

The water consumption of healthy birds varies considerably depending on bodily condition, ambient temperatures, diet and species. Fruit eaters such as mynah birds and toucans get much of their water from their food. Raptors may not drink very much. Some birds whose normal habitat is desert (e.g. budgerigars) are able to rely almost entirely on metabolic water (Johnson, 1979) (also see p. 21).

In the diseased bird, water consumption will vary even more; not only will this depend on the normal function of the alimentary canal and kidneys but also on the health of the upper respiratory tract. The nasal cavities in the bird are important organs of water conservation. Consequently drugs given in the drinking water must have a wide margin of safety. A bird that is polydipsic could take in much greater amounts of medicament. At best, blood levels of the drug are liable to be irregular. Antibiotics given by this method are *least likely* to reach minimal inhibitory concentrations within the lumen of the alimentary canal, providing the bird is drinking some water.

Nevertheless, birds are creatures of habit and sensitive to changes in their feeding and watering routine. If the medication colours the water or adds a taste to it the bird is quite likely to refuse to drink and its illness is made worse. There is little doubt that birds have colour vision. The more brightly coloured the plumage of the species the more acute is their perception of colour likely to be (see p. 30).

It was once thought that birds have little sense of taste. Certainly the number of taste buds per unit area is much fewer in birds than in mammals. Work quoted by King and McLelland (1984) has shown that, dependent on the species, birds do have a definite sense of taste (see p. 36). Pigeons are apparently more sensitive than the domestic fowl. Bitter and salt-tasting substances tend to be rejected. Therefore a drug such as levamisole, with a bitter taste, may not be readily taken by a species with a well-developed sense of taste. Sweet substances such as sugars (but not saccharin) produce variable responses in individual birds. Therefore adding these to medicines to make them more palatable will have varying results.

One advantage to medicating the drinking water of a group of birds with an antibiotic is that it reduces the number of bacterial organisms that may have contaminated the water supply and so helps to limit the spread of infection. Another point in favour of the method is that it is much less stressful for the bird than having to be caught up for medication. However, many drugs quickly lose their potency when in solution.

If drugs for water medication are to be dispensed on a regular basis, it is more convenient to have ready-weighed small quantities. These can be *added daily* to a known quantity of water. Drinking containers for cage birds vary in volume so that it is simpler if the quantities dispensed are sufficient to be added to a common household utensil, such as a kitchen measuring jug (500 ml). This is used as a stock solution to keep the drinking container filled. The remainder of the stock solution is discarded when the next quantity of drinking water is medicated. The method is wasteful but the quantities of drugs dispensed for birds are small and the method is simple for the client. Alternatively, smaller weighed amounts can be dispensed, for example, sufficient to be dissolved in 50 ml of water and at the same time a 10 ml syringe is dispensed so that the client can accurately measure the volume of water to be used.

### **Medication by mouth**

The same drugs used for medicating the drinking water can be given orally. Also there are a number of human paediatric preparations suitable for oral administration in birds (e.g. Abidec paediatric drops). Galenicals such as liquid paraffin and formulations containing kaolin and bismuth may also be used.

Although it is possible to administer liquid preparations using a syringe or a dropper (not glass for parrots), or even to let the fluid drip into the mouth from the end of a cocktail stick, it is not very satisfactory. There is a danger of inhalation of the medication

**Table 6.1** Suitable volumes (in ml) for oral medication.

Type of Bird	Suitable Volume for Oral Dosing (ml)
Canary	0.25
Budgerigar	0.5–1.0
Lovebird	1.0–3.0
Cockatiel	2.0–4.0
Amazon Parrot	5.0–10.0
African Grey Parrot	5.0–10.0
Macaw	10.0–15.0

and it can be wasteful and messy. It is more sensible to give the preparation using an oesophageal or gavage tube.

For many species a piece of soft plastic (used drip tubing) or rubber tubing attached to a hypodermic syringe works well. The length of the tube should be measured against the bird's neck so that when the neck is extended the tube will reach well down to the level of the crop or the thoracic inlet. The diameter of the tube and capacity of the syringe will depend on the size of the bird. Birds the size of small finches (zebra) to swans can be dosed by this method. In the swan a canine stomach tube and a 60ml plastic syringe are suitable.

In some birds, particularly the parrots, it is imperative to use either a gag or speculum of some kind or a rigid metal catheter (see p. 197). The author prefers the latter since the procedure can then sometimes be accomplished by one person. During this procedure the bird may need to be restrained by gently wrapping in a towel. Protective gloves may be necessary but can often be dispensed with once the head is controlled. While holding the beak open, the neck is extended in a vertical direction to straighten out the typical avian S-shape curve of the cervical vertebrae. Having placed the lubricated (use liquid paraffin or K-Y jelly), rigid tube in the mouth, it is then advanced beyond the glottis and *allowed to slide down the oesophagus under its own weight*. *No stomach tube should ever be forced down* – the avian oesophagus is thin and easily ruptured.

Using this method birds can be accurately dosed and fed if nutrients are added to the medication. Experienced nursing staff and intelligent owners can be instructed to dose birds in this way. *However, strict hygiene of the tube, syringe and utensils is necessary*. Suitable volumes that can be given by this method are given in Table 6.1.

When giving medication orally or in the drinking water it should always be noted that the absorption of drugs from the gut can be adversely affected by parasitism, a diseased mucosa and nutritional deficiencies, particularly hypovitaminosis A. The absorption of some antibiotics, such as penicillin, ampicillin and lincomycin, is reduced in the presence of food. Oxytetracycline has a reduced absorption in the presence of calcium and magnesium and so will be affected if a bird is receiving soluble grit in the diet or the antibiotic is given with antacids.

### Medicating the food

If the practitioner is dealing with a situation where a large number of birds will need medicating on a regular basis, then it *may* be possible to get a feed manufacturer to incorporate the desired drug in the pelleted feed (see p. 193). Most psittacine birds, will accept pelleted food, providing it is *introduced into the diet gradually* over 2–3 days. For a useful guide on how to introduce an unfamiliar food see Harrison's Foods in the list of websites in Appendix 11.



Parrots will sometimes eat powdered tablets or the powder contents of capsules if these are spread on sweet biscuits or on bread with peanut butter or honey. It may be possible to inject some drugs into fruits such as grapes. Toucans swallow grapes whole without crushing them. Seeds can be coated with a powdered drug by moistening the seed or adding a little corn oil. However, *if given too much oil* the bird may become coated in it. Nevertheless, because most seed is dehusked by the bird before being swallowed, this method of giving drugs is unreliable.

For the prophylactic administration of chlortetracycline to psittacines exposed to *Chlamydophila* infection, Ashton and Smith (1984) recommend the following mash:

- two parts maize
- two parts rice
- three parts water

The above should be cooked to a soft, but not mushy consistency. The drug is added at the rate of 5 mg/g of cooked feed.

The food is prepared daily and a little brown sugar and seed is added for palatability (see p. 36). At a rough approximation, most birds eat about one quarter of their weight in food daily but small Passeriforme birds may consume up to 30% of their body weight daily.

## Medication by injection

### Intramuscular injection

Undoubtedly, this is the most accurate and reasonably safe route for parenteral administration of drugs. The pectoralis, the iliotibialis lateralis or biceps femoris muscles of the leg can be used. Injection should go into the middle of the muscle mass. All sites have advantages and disadvantages.

### *Pectoralis*

If injection is made into the pectoralis this must be carried out at the caudal end of the muscles. The veins are better developed at the rostral end of the muscle and there is a much greater chance of accidental intravenous injection. Quite severe inflammatory reaction can occur in the muscle after injection (Cooper, 1983), but this is only likely to be of any consequence with repeated injections at exactly the same site. Some falconers and racing pigeon owners do not like the pectoral muscle used, since they believe the flight muscles will be damaged. If the injection is made slightly to one side of the carina or keel of the sternum then the needle is unlikely to go beyond the lateral edge of this bone and penetrate the underlying viscera. Take great care in fledglings in which the bone may not have been fully calcified and is still cartilaginous. It is easy to penetrate this soft bone and give the injection directly into the underlying liver.

### *Leg muscles*

Injections into the leg muscles have the same disadvantages regarding bruising. In addition, the large ischiadic nerve may be damaged where it courses down the posterior aspect of the femur. Also, injections into the legs may pass through the renal portal system before entering the systemic circulation (however, see p. 21). This is particularly important with drugs that are excreted through the kidney in an un-metabolised state. Some part of the dose may be partly lost before it has a chance to reach therapeutic blood levels (Coles, 1984b).

Both 1 ml tuberculin syringes divided into 0.01 amounts with a permanently attached 27 G  $\times$  1/2" needle and insulin syringes with a total capacity of 0.5 ml or 0.3 ml also with a permanently attached 29 G  $\times$  1/2" needle are useful. Many drugs in aqueous solution can be diluted in such syringes to measure very small quantities.

### Subcutaneous injection

This method can be used, but only one or two sites are suitable because the avian skin is not very elastic and fluids tend to leak out through the point of needle puncture. If the area covering the pectoralis muscle is used there is little danger of damage to vital structures, but the needle must be advanced well under the skin and only a little fluid can be injected at this site. A much better region is the precrucial fold. Greater volumes (2 ml into an African grey parrot) can be injected here and, provided the skin is picked up with forceps before making the injection and the needle is not inserted too far, there is little chance of damaging the subcutaneous nerves and blood vessels. Movement of the bird's leg helps disperse the injection. Dispersion can also be aided by adding hyaluronidase (half an ampoule or 750 IU) to the injection. Another useful site is the skin on the dorsal base of the neck. Care must be taken to hold the loose skin of this area away from the underlying vertebrae and muscles and to make the injection in the midline.

The administration of volumes of liquid suitable for fluid therapy in birds is quite practical using these sites.

### Intravenous injection

This is most easily given into the brachial vein, but the superficial metatarsal vein on the medial surface of the leg can be used in some birds as can the right jugular vein (Fig. 4.1). The medial tarsal vein is particularly useful for blood sampling or injecting large waterfowl such as conscious swans. The jugular is useful in small birds. Both the right jugular and the brachial vein can be used in the ostrich. Intravenous injection is not always easy not only because of the small diameter of the vein but also because of the fragility of the vein wall. Haematoma formation after intravenous injection is a common occurrence. However, intravenous injection is an effective and important method of treatment in an emergency where a bird's life is threatened by disease.

### Intraosseous injection

This route provides a stable access port into the vascular system. The cannula (20–22 G needle with an indwelling stylet – e.g. a spinal needle) can be left strapped in with Vetrap self-adhesive bandage and used for several days.

An approach is made to the intramedullary cavity of the distal extremity of the ulna with the carpal/metacarpal and carpal/ulnar joints held in a flexed position (see Fig. 9.2). The proximal tibiotarsal bone can also be used for this purpose, using a craniomedial approach through the plateau of the cnemial crest (see p. 191).

### Intracoelomic injection

This method has been used by some clinicians but is not without the hazard of entering one of the air sacs. A small volume of fluid is probably of no great consequence, and in fact the method is suggested by Clubb (1984) as a method of treating disease of the air sacs.

If the injection is only to reach the coelomic cavity, the skin and underlying muscle must be picked up by forceps to form a 'tent' slightly to the right of the midline. The injection is made into this area, with the needle directed almost horizontally thus keeping away from the underlying viscera. If a 16 G × 0.5 mm needle is used, the injection should go into the ventral hepatic peritoneal cavity (see Fig. 8.5 and the accompanying text in Chapter 8). This procedure is carried out most easily in the sedated or lightly anaesthetised bird and is most useful for euthanasia.

### Intratracheal injection

Intratracheal injection has been used to treat disease of the respiratory system. Amphotericin B can be administered by this route. In small birds this is most easily carried out

by using a mammalian intravenous catheter, cut short and attached to the syringe. The drug is then introduced *very slowly* into the trachea through the glottis, easily seen on the floor of the oral cavity. The bird's neck needs to be held vertically and slightly extended and the tongue needs to be gently restrained on the floor of the mouth. The *method is not practical in the unanaesthetised parrot* unless the bird is deeply sedated. There will be some coughing but this is usually only temporary. Obviously the volume of fluid must be kept to a minimum, though up to 1 ml has been given to pigeons and parrots (400–500 g) by this method.

### Topical applications

The local application of ointments and creams can be used but these should only be applied *sparingly using a cotton wool bud*. If too much is used the plumage becomes damaged. If larger quantities of ointment have to be used then an Elizabethan collar will be necessary to stop the bird becoming grossly contaminated. Topical applications that are absorbed or dry quickly, such as tinctures, are more suitable. Dimethylsulfoxide (DMSO) is a useful preparation applied to the legs and feet of birds. It is rapidly absorbed and may be used as a carrier for other drugs.

### Ophthalmic preparations

Ophthalmic ointments can be used but have the same disadvantages as other ointments. Ophthalmic drops are much better but their effect is very short and their use needs constant handling of the bird which is a disadvantage. Subconjunctival injection of slowly absorbed drugs is more effective and less stressful for the bird. The instillation of ophthalmic drops into the nasal cavities for the treatment of sinusitis can be used, but direct injection into the infra-orbital sinus is more effective. Also, misting the eye with a fine spray of sterile water with the dissolved drug has been used effectively.

### Subconjunctival injections

Very small amounts (0.01–0.05 ml) of drugs can be placed under the conjunctiva of the upper eyelid. These are usually antibiotics and *short-acting* steroids and can be very effective when a specific diagnosis has been made. The author has also used the NSAID carprofen. Since the technique requires the bird to be absolutely still, general anaesthesia or deep narcosis is essential.

### Injections into the infraorbital sinus

This technique is described in the chapter on surgery (Fig. 8.2). The method has been used for many years for treating poultry and is quite applicable to many other types of birds.

### Inhalation therapy

A major problem in the treatment of disease of the respiratory system is infection of the air sacs. These thin-walled extensions of the lungs hold about 80% of the volumetric capacity of the respiratory system. The walls are no more than two cells thick and have no blood vessels. There is therefore a large dead space within the bird filled with warm, moist air that is not very accessible to the bird's cellular and humoral defence mechanisms. This area is subject to infection, particularly by *Aspergillus* fungi and coliform bacteria. The lungs, which have a good blood supply, are much less liable to be infected unless challenged by massive infection. Unfortunately, air sacculitis can be present for some time and can become fairly extensive, before outward signs are evident.

Inhalation therapy aims to saturate the air in this dead space and reach the internal surface of the air sacs. To be effective the droplet size of the medication must be below 5 mm in diameter otherwise the droplet does not remain suspended in the air stream long enough to reach the target area. Vaporising the medication does not work because most

**Table 6.2** Suitable doses (in mg) for inhalation therapy, to be diluted in 15 ml of saline and administered over a 30-minute period, 3–4 times a day.

Drug	Suitable Dose (mg)
Amphotericin	25–100
Tylosin	150
Chloramphenicol	200
Spectinomycin	200
Gentamicin	50–200
Dexamethasone	3

of the droplets are too big and condense in the upper respiratory tract. To be effective the drug needs to be administered by a nebuliser into a chamber in which the bird is housed during therapy. The drug is mixed with a suitable volume of saline, or, better, with a vehicle such as tyloxapol which aids better dispersion of the medicament. Suitable doses are listed in Table 6.2. Some custom-made hospitalisation cages for birds incorporate a nebuliser. Alternatively, a number of companies marketing veterinary equipment now supply nebulisers, e.g. F10biocare (see website).

## THE LOGICAL USE OF ANTIBIOTICS

*No antibiotic should be used unless the clinician is reasonably certain that the bird is suffering from a bacterial infection.* However, there is sometimes a rapid deterioration in the condition of a young or small bird challenged by an overwhelming infection. In these circumstances the practitioner may decide to start antibiotic therapy before the results of laboratory tests to confirm his diagnosis become available.

### Selection of antibiotics

If the antibiotic is required for systemic use it must be of low toxicity. It should penetrate all the bird's tissues easily and the minimal inhibitory concentration of the drug should be as low as possible. A swab should be taken from the choanal space, the oropharynx or the cloaca, stained by the Gram method and examined under the microscope. This will at least indicate if the organisms present are mainly Gram– or Gram+ and show their relative numbers.

*The autochthonous gut flora of most birds consists mostly of Gram– organisms; clinical infection is usually dominated by one organism.* This may indicate whether it is safe to use an antibiotic that is principally active against the one or the other group of bacteria. However, in the first instance, until subsequent laboratory tests are completed, a broad-spectrum antibiotic will usually be chosen. Ampicillin, amoxicillin combined with clavulanic acid, trimethoprim combined with a sulphonamide and the quinolones (e.g. Baytril) are all reasonable choices. If given by injection the quinolones, amoxicillin and trimethoprim combination are bactericidal but *the tetracyclines (including doxycycline) are only bacteriostatic and rely on the host's immune response to be effective.* The results of more extensive laboratory investigation, such as antibiotic-sensitivity testing from swabs *taken before and after starting antibiotic therapy* may show that it is necessary to change the antibiotic being used.

Bactericidal antibiotics are probably better in the first instance. These drugs work only on bacteria that are dividing. There is a school of thought that considers intermittent exposure or less frequent dosage to be a more effective way of using the antibiotic.

Bacteriostatic antibiotics inhibit bacterial multiplication and give time for the mobilisation of the body's defences. However, the maintenance of a plasma concentration for several days, well above the minimum inhibitory concentration, is essential.

The use of broad-spectrum antibiotics inevitably has some adverse effect on the host's normal bacterial flora, particularly that inhabiting the gut. Because of this, once the pathogenic organism causing the illness is identified, together with its sensitivity to antibiotics, it is wiser to select an antibiotic that has a narrow range of activity.

If the bacterial flora of the gut is disturbed, then the administration of a probiotic may help to restore the balance. This can be given by oesophageal tube at the rate of 2 ml/mg. It is more logical to use a custom-made probiotic, such as Avipro-plus, which contains a combination of microbial strains specific to birds. This is soluble and can be given in the drinking water simultaneously with the administration of antibiotic.

In some cases of chronic infection the rate of maturation of the T-lymphocytes may be depressed and cell-mediated immunity may be impaired. In these cases it has been demonstrated in birds and mammals that levamisole, used intermittently, at a lower dose than the normal anthelmintic dose, may have a beneficial and sometimes quite marked effect on the progress of the disease.

### **THE USE OF UNLICENSED DRUGS**

Although some drugs are listed in this book for use in a particular species, genus or class of birds this should not be interpreted as meaning that the drug is officially or otherwise approved or licensed for use in a particular species, genus or class of bird, but only that it indicates that, to the best of the author's knowledge, the particular drug has been used as described. Under the present day law in the United Kingdom, preparations licensed for use in other species, including humans, may be administered under the responsibility of a qualified veterinary surgeon who has the birds under his/her direct care and when no other suitable drug is licensed for use in that particular species, genus or class of birds. For further information in the UK the reader is referred to the *R.C.V.S. Guide to Professional Conduct*.

# 7

## Anaesthesia

---

### GENERAL CONSIDERATIONS

Before selecting an anaesthetic the practitioner should take into account the reasons for its use.

#### **Hypnosis and restraint**

Perhaps the main indication for using an anaesthetic drug is to produce chemical restraint while radiography, endoscopy or some other non-painful procedure is carried out. There are several inhalation anaesthetics or combinations of injectable agents suitable for the purpose but which may have little analgesic effect.

#### **Analgesia**

The abolition of painful stimuli may be the prime consideration. If this is to produce analgesia of a limited surface area then local anaesthetics can be used. These have not been very popular with many clinicians in the past, particularly the drugs of the procaine-based group, which have a reputation for toxicity. This is most probably because many small birds were grossly overdosed. Local anaesthetics are safe in birds if the dose is carefully calculated.

Some surgical procedures on poultry, such as the relief of an impacted crop or an ovariectomy have in the past been carried out without any anaesthetic and with little apparent distress to the bird. Although the level of sensory perception appears to be low in many parts of the avian skin and subcutaneous tissues, in the present state of knowledge we really do not know how birds 'in general' perceive pain (see p. 24). Cutting the integument seems to provoke much less response than stretching or undermining the skin. However, the plucking out of two feathers in a lightly anaesthetised bird may stimulate violent wing flapping. Those parts of the bird's anatomy that are most sensitive are the cere, the comb, the wattles (in Galliformes), the cloaca together with the surrounding skin, the scaled parts of the legs and the pads of the feet. However, there is some individual and interspecies variation in the tenderness of the feet, particularly in raptors. Some general anaesthetic agents such as isoflurane and medetomidine are better analgesics than others, such as ketamine.

#### **Butorphanol**

Butorphanol is an opioid, which is a kappa ( $\kappa$ ) agonist, the  $\kappa$  opioid receptors being more important in birds than in mammals in which the  $\mu$  receptors are more important. Dose: 0.3–2 mg/kg q 6–12 h; the higher doses produce marked sedation and even recumbency in

some raptors. It produces good post-surgical analgesia and reduces the dose of inhalation anaesthetics needed, Curro *et al.* (1994).

Some non-steroidal anti-inflammatory drugs such as carprofen (2–4 mg/kg i.m. q 24 h) or meloxicam (200 µg/kg q 24 h) provide good post-operative analgesia. The author has in the past used butorphanol at 2 mg daily for a month in an African grey parrot without marked sedation and without ill effect. However, for long-term use the non-steroidals are better.

### Acetylsalicylic acid

The dose for acetylsalicylic acid (aspirin) in its soluble form is 325 mg per 250 ml drinking water (Paul-Murphy, 1998).

### Muscle relaxation

This may be required during surgery, particularly orthopaedic surgery when there is often contracture of muscle groups around a fracture site. Some anaesthetic agents, although good hypnotics, do not provide good muscle relaxation.

### The relief of fear and anxiety

Although placed last on this list, it is by no means the least important consideration. Anxiety and fear in the bird *considerably increase stress and reduce the chances of survival* after an operation. It is for this reason that an anaesthetic technique should be chosen which goes some way in combining all the above-mentioned requirements of anaesthesia and often this can only be achieved by using a balanced combination of drugs.

## ASSESSMENT OF THE AVIAN PATIENT FOR ANAESTHESIA

The clinician should be aware that there is not only an interspecies disparity in the response of birds to a particular anaesthetic agent but there is also some individual variation. This is probably due to differences in liver and plasma enzyme systems and the rate of detoxication and excretion of the anaesthetic. This is more evident in birds than is the case in related mammalian species. The bird that panics when handled or is difficult to catch will have an increased adrenaline outflow which will increase anxiety during induction of anaesthesia. Conversely, the bird that is too easily caught and is just picked off its perch is also a worry – it may be more ill than suspected. Wild birds are normally frightened or aggressive; if they are not, they are ill. It is better to delay anaesthesia in this group of patients for 48 hours so that they *have a chance to feed* and reach a better nutritional status. A falcon in flying condition or a racing pigeon is usually athletically fit. However, many falconers keep their birds hungry (to so-called flying weight) to make them keen hunters. If the bird becomes sick it may be very near hypoglycaemia with depleted liver glycogen reserves.

An aged parrot (it is not uncommon to see one that is 35–40 years old) may have spent most of its life in a cage and may be obese or have an undetected impaired cardiovascular system. Krautwald-Junghanns *et al.* (2004) evaluated 107 caged psittacine birds and found 99% had evidence of a cardiopathy. Small birds kept in aviaries are more likely to be fit than their caged fellows. A bird that is chronically ill or suffering from a low-grade toxæmia will have a depressed rate of detoxication of drugs. Because of all these factors, *the anaesthetist should always carry out a thorough clinical assessment of the patient before giving the anaesthetic.*

Measure the haematocrit. If the PCV is over 55% the bird needs rehydrating with fluid therapy, as described in Chapter 9, *before anaesthesia is attempted.* If the PCV is below

20%, then, theoretically, the bird needs blood. If a donor pigeon is available blood from this bird can be given on a once-only basis to any species. Subsequent transfusions will produce a reaction (see p. 144). If there is any doubt about the health status of the avian patient and time is available it is wiser to take a blood sample and carry out a full clinical profile to include the minimum of AST, bile acids, LDH, urea, uric acid, full haematology and clotting time.

### **Some physiological considerations**

#### Gas flow rates and the control of respiration

The avian lung compared with that of a mammal of comparable size is small and non-expandable. The evolution of the fixed-volume avian lung has taken place along with the development of a rigid meshwork of blood and air capillaries. The largest diameter of the air capillaries of birds is less than one-third the size of the smallest mammalian alveolus. The very small diameter of the non-collapsible terminal airway produces a high pressure gradient for the diffusion of blood gases (King & McLelland, 1984c). The system provides a greatly increased gaseous exchange surface, about ten times that of a mammal of comparable body weight.

Blood flow in the lung in relation to the air flow is principally cross-current. In the mammal the blood and gas flows are more linear. This again increases the efficiency of gas exchange in the avian lung. The air sacs take no part in gaseous exchange and act merely as bellows, driving the air in a one way flow through the respiratory tract, as illustrated in Figure 7.1. The air sacs do however greatly increase the dead space (approximately 34% in the chicken) (however, see p. 18).

Because of the unidirectional air flow in the avian lung, approximately 50% of inhaled anaesthetic gases go first to the posterior air sacs before any gas exchange has taken place, and are thus unabsorbed. The remaining anaesthetic gas passes through the lung again before being exhaled via the anterior air sacs. The other 50% of initially inhaled gas passes directly through the lung on inspiration but also in the same one-way direction as the other secondly absorbed 50%. If apnoea should take place because too much anaesthetic gas has been administered, and artificial respiration has to be started, then further absorption of anaesthetic gas will take place (on the initially unabsorbed 50% portion) as it passes back through the lung exchange surface from that temporarily stored in the posterior air sacs.

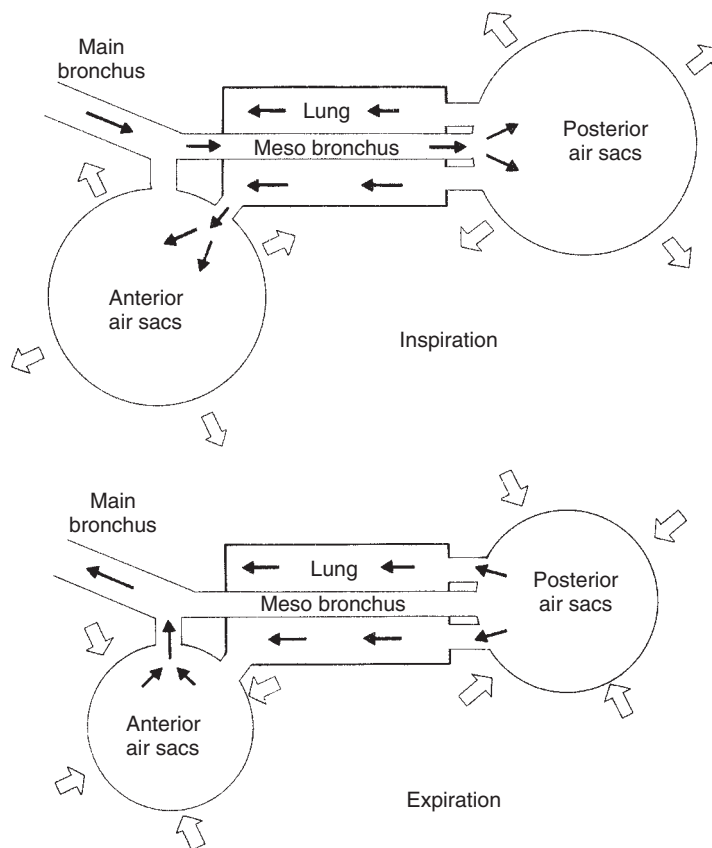
The net effect of the anatomy and physiology of the avian respiratory system results in gaseous exchange being much more rapid and efficient than in the mammal. *Volatile anaesthetics can reach dangerous plasma concentrations very quickly.*

Another physiological aspect of the rigid lung is that the chemoreceptors monitoring PaCO<sub>2</sub> are much more important than the mechanoreceptors monitoring pressure changes (Fedde and Kuhlman, 1977). The PaCO<sub>2</sub> of the domestic fowl is normally about 30% lower than in mammals because of the more efficient 'washout' in the avian lung. Birds are thus much more sensitive to hypercapnoea. It is therefore important to *maintain high gas flow rates of oxygen during avian anaesthesia*. These should be at least three times the normal minute volume. Klide (1973) gives the following normal minute volumes:

- Domestic fowl weighing 2.5 kg, the minute volume is 770 ml/min
- Racing pigeon weighing about 300 g, the minute volume is 250 ml/min
- A small cage bird weighing 30 g, the minute volume is 25 ml/min

In practice, the author uses flow rates of not less than 1 l/min for the small birds and 3 l/min for birds the size of domestic fowl. Flow rates higher than this are unnecessary and even wasteful of volatile anaesthetic. However, see Table 1.2. Marley and Payne (1964)





**Fig. 7.1** Diagrammatic representation of the function of the avian respiratory system, illustrating the uniflow of gas through the exchange surface of the lung.

demonstrated, when using halothane anaesthesia, that the  $\text{PaCO}_2$  gradually increased during prolonged anaesthesia *even in those birds where respiration appeared to be normal*. In birds where respiration was depressed, the  $\text{PaCO}_2$  increased much more rapidly (from 18–27 mmHg to 50–75 mmHg within 10 minutes). If the  $\text{PaCO}_2$  rose to 80 mmHg the bird died.

Some volatile anaesthetics may have a depressive effect on the  $\text{PaCO}_2$  chemoreceptors. King and Payne (1964) showed that in the chicken, when the bird was placed in dorsal recumbency, the minute volume could be reduced by a factor of 10–60%. This was brought about by the pressure on the air sacs by the viscera. These workers showed that the effect was greater in the female than in the male and was less if the bird was in lateral recumbency. Also, if a bird is in ventral recumbency, there is the pressure of the viscera on the sternum restricting its normal movement during respiration.

### Hypoxia

The effects of hypoxia vary in different groups of birds. Nevertheless the oxygen uptake is higher in all birds than in mammals of comparable size. High-flying birds and diving ducks can withstand the effects of oxygen withdrawal better than surface-feeding ducks and birds that are mainly terrestrial (Dawson, 1975). The gentoo and chinstrap penguins, which remain submerged for long periods, withstand hypoxia better than the Adelle penguin which is a short-term diver.

Many agents used in general anaesthesia are also respiratory depressants. All these factors make the *maintenance of an adequate rate of respiration together with relatively high flow rates of oxygen very important*, whatever type of anaesthetic technique is being used.

### Hypercapnoea

*If adequate oxygenation of the patient is not maintained, the PaCO<sub>2</sub> can build up rapidly and without warning.* Even if there is a high flow rate of oxygen, the elimination of carbon dioxide may be inefficient. *If the bird's respiratory rate is allowed to drop to a level where it is just perceptible the hypercapnoea may become irreversible.* A condition of respiratory acidosis quickly supervenes, the myocardium is depressed and blood pressure drops. A raised PaCO<sub>2</sub> predisposes to atrial and ventricular fibrillation and to cardiac failure.

### Hypothermia

Hypothermia affects all birds under anaesthesia, particularly the small ones (higher ratio of surface area to body mass), and also helps to depress the myocardium. If the core body temperature drops more than 6°C the bird may not recover at all. Preferably use a flexible thermistor inserted into the oesophagus or a continually recording cloacal thermometer.

### Dehydration

Because of the large internal surface area of the air sacs, there may be a high fluid loss during prolonged anaesthesia. In an already dehydrated bird this could be critical and lead to a reduced circulating blood volume with a fall in cardiac output, reduced tissue perfusion and to anaerobic respiration. This in turn leads to a fall in plasma pH and a condition of metabolic acidosis ensues. Many anaesthetics also depress blood pressure.

*Cardiac failure during anaesthesia of birds is most likely to be caused by hypercapnoea, but hypoxia, the anaesthetic agent, dehydration, hypothermia and the positioning of the patient are all contributing factors.*

## SUGGESTED PRECAUTIONARY MEASURES

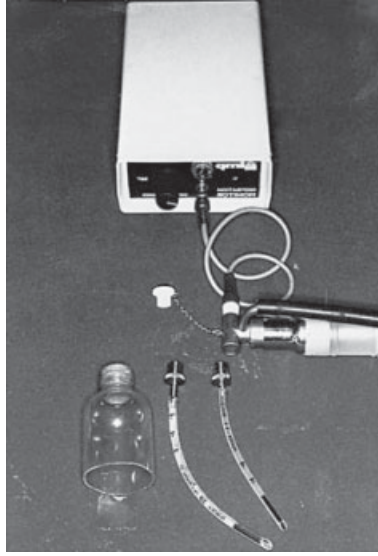
1. Whether employing an injectable or volatile anaesthetic agent *always administer oxygen*. If possible have an endotracheal tube in place rather than a mask, to maintain a clear airway and to enable artificial ventilation, should this prove necessary. If there is a suspicion of food in the crop or distal oesophagus, pack the proximal oesophagus with wet cotton wool.
2. It is safer to have too high a rate of flow of oxygen than one that is too low (see legend to Figure 1.9 and Table 1.2).
3. Make sure the respiratory rate is not reduced too much and maintain as light a plane of anaesthesia as is possible.
4. It is safer to use intermittent positive pressure ventilation (IPPV), either manually, by intermittently compressing the rebreathing bag, or, better still, using a mechanical ventilator (airway pressures should not exceed 15–20 cm H<sub>2</sub>O and the end tidal pressure of CO<sub>2</sub> should not go above 30–45 mmHg (Edling *et al.*, 2001).
5. If possible use lateral recumbency.
6. Use some means of maintaining body temperature such as a heat pad (if this is electrical it may take time to warm up) or, better still, a radiant heat lamp (poultry brooder lamp) directed towards the body of the patient (Phalen *et al.*, 1997). However constantly monitor body temperature *and don't let the body over heat*.

7. Do not make the bird too wet during pre-operation preparation. Keep the operating table top dry. Maintain a comfortable high operating room ambient temperature. If there is a forced-air ventilation system, reduce any air currents to a minimum.
8. Green (1979) suggests leaving a long piece of capillary tubing, with the tip in the oropharynx of a very small bird, to aspirate any excess mucus by capillary action. It is useful to have a syringe with an attached piece of catheter ready, in case it is necessary to aspirate any mucus blocking the airway.
9. The author has now ceased using atropine for premedication because:
  - a) It has a tendency to increase the viscosity of mucus
  - b) It may inhibit the PaCO<sub>2</sub> chemoreceptors
  - c) It may lead to respiratory depression
10. Do not stretch the wings out too tightly. This may cause damage and stimulation to the nerves of the brachial plexus.
11. In addition, if the bird is in light anaesthesia and the anaesthetic agent does not give complete muscle relaxation of the pectoralis muscles, movement of the thorax may be restricted.
12. Use fluid therapy if the bird is anaesthetised for any period longer than ten minutes. This is particularly important if the anaesthetic drug is excreted through the kidneys. Use 0.1 ml of lactated Ringer's i.m. for a 30 g budgerigar, every ten minutes or, for larger birds, 1 ml/kg per hour given i.v. or intraosseously (Fig. 9.1).
13. For birds weighing more than 1 kg withhold food for 12 hours before anaesthesia. For those between 300 g and 1 kg withhold food for 6 hours, 100–300 g withhold food for 3–4 hours. For birds below 100 g do not withhold food at all.

### Monitoring anaesthesia

Whenever possible and when practical the anaesthetised bird should be monitored and the operator should not rely entirely on human senses, which may not detect subtle changes in the patient's physiological state rapidly enough.

1. An oesophageal stethoscope is easy to use, is not expensive and can be used along with the oesophageal thermometer.
2. Since many companion animal practitioners may already possess an ECG machine, recording the ECG of a bird under anaesthesia gives a good indication of cardiac activity. However, the equipment should have a paper speed of 100 mm/sec with 1 cm = 1 mV and be able to record a heart beat of up to 500 beats/minute. The standard leads are used connected directly to the metal of 25 G needles placed through the skin: lead I (propratal fold of right wing), lead II (similarly to left wing), lead III to the left hind limb (medial thigh). The right hind limb is connected to the ground plate. Edling (2005) describes a recent and simpler technique using an oesophageal probe without using the usual limb leads and which is attached to the standard ECG leads via an adaptor.
3. If IPPV is not being used, an Imp respiratory monitor (IMP Electronics (Fig. 7.2) or an ApAlert apnoea monitor and alarm (MBM Enterprises, Australia) may provide a warning of apnoea. Nevertheless it is wiser to use IPPV.
4. A pulse oximeter positioned on the foot can be used to indicate the arterial oxygen saturation level, which should be well above 85%. Below 80% can be dangerous. However Schmitt *et al.* (1998) indicated this was not a very reliable method when used in birds and could give a false impression of safety.
5. An electronic continuously recording intraoal or, better, intra-oesophageal, thermometer is also a useful piece of equipment. *The temperature of a small bird can drop alarmingly during prolonged surgery even if it is on a heat pad.*



**Fig. 7.2** The Imp respiratory monitor, which can be used with all species of bird weighing 100g or more. Also, Bethune T-piece and Portex endotracheal tubes.

6. Capnography. The measurement and continuous recording of the regularly varying wave form (either on a video display unit or on a paper trace) of the level of end tidal  $\text{CO}_2$  in birds was initially investigated by J.I. Cruz and the author in 1995. Cruz *et al.* (1997) has since continued to research this subject. Also Edling *et al.* (2001) have since recorded their experiences with this technique. When using this instrument, an 18G hypodermic needle is inserted into the side of the endotracheal tube adaptor with the bevel of the needle directed towards the bird's body. This is then connected to the capnograph recorder. Since the level of  $\text{PaCO}_2$  is one of the most important factors controlling avian respiration and the level of end expired  $\text{CO}_2$  is probably very similar to  $\text{PaCO}_2$  this method of monitoring avian anaesthesia has become more important than pulse oximetry. Capnography can provide simultaneous information on the respiratory rate and the state of the bird's respiratory system including the efficiency of the blood gas exchange barrier. It can also give information on the level of oxygenation and the effectiveness of the anaesthetic circuit. Also capnography can give early warning of a failing heart and of a developing cardiovascular hypotension.

## LOCAL ANAESTHESIA

Indications for the use of local anaesthesia as a local nerve block, together with a sedative, are most often likely to be used in the field for treating the larger birds where general anaesthesia may not be very practical. When combined with low dose butorphanol (0.5 mg/kg) it is even more effective.

### Lignocaine hydrochloride 2%

Lignocaine hydrochloride 2% is quite safe in all but very small birds, which are easily over-dosed. For a 30g bird 0.3ml would be fatal. It is always safer to dilute the 2% solution to produce a 0.5% solution and the injection should always include adrenaline to limit the rate of absorption. In birds over 2kg, 1–3ml can safely be used and in a

pigeon-sized bird (400 g) up to 1 ml can be used. Maximum dosage rates are 1.0–4.0 mg/kg administered s.c. or i.m. Lignocaine ointment may be *used sparingly* around the vent after a cloacal prolapse.

### **Procaine hydrochloride 2%**

This has been used in the larger birds (e.g. swans and flamingos) without difficulty but care needs to be exercised with the dosage because of the drug's narrow safety margin. Again the 2% preparation is best diluted to produce a 0.2% solution when 1–2 ml/kg can safely be used.

## **GENERAL ANAESTHESIA**

### **Pre-anaesthetic medication and tranquillisation**

In most cases, butorphanol (1 mg/kg) is a useful pre-anaesthetic. It reduces the dose of anaesthetic used and provides good post-operative pain relief. Some of the injectable general anaesthetic agents mentioned below, which are not in themselves entirely satisfactory anaesthetics, make very good hypnotic or induction anaesthetics. These can then be supplemented with volatile anaesthetics so that the desired depth of anaesthesia can be achieved.

### **Assessing the depth of general anaesthesia**

This can be difficult and although it is convenient to classify general anaesthesia into light, medium and deep planes, the response of the individual bird to the stimulation of various reflexes shows considerable variation. Sometimes a bird that is apparently deeply asleep will be awoken suddenly by the stimulation of a particularly sensitive area. The skilful clinician relies on his or her experience and knowledge of a particular anaesthetic technique together with the response of the species on which it is being used.

The anaesthetist should diligently observe the depth, rate and pattern of respiration, noting any sudden changes. The aim should be to maintain the patient in light-to-medium-depth anaesthesia in which the response to stimulation of the cere, possibly the wattles or the comb (in Galliformes) and the cloaca together with the surrounding skin is just abolished or is sluggish.

Pinching the interdigital web of the foot or the under surface of the foot produces a variable and unreliable response, particularly in raptors. The eyelids may be closed but the corneal reflex, indicated by the nictitating membrane sliding obliquely across the eye, should be sluggish but never entirely lost. *If there is no corneal reflex the bird is too deep.* Obviously, if righting reflexes are not completely abolished the plane of anaesthesia is too light. Respiration should be regular, deep, not too slow (not much less than half the normal resting respiratory rate), with the bird not stressed and at ease with its environment, all of which should have been noted before starting. A rapid, shallow or intermittent respiration indicates the depth of anaesthesia is too great.

### **Injectable general anaesthetics**

When using any injectable anaesthetic agent it is *mandatory* that the bird must first be weighed accurately to enable precise computation of the dose.

#### **Alphaxolone/alphadolone**

This drug has been used widely both by intravenous and intramuscular injection – also intraperitoneally. When given intravenously induction is rapid and anaesthesia lasts for about ten minutes, with good muscle relaxation. When first given there is a fall in blood pressure and there is some respiratory depression. The drug is safe for most raptors when

given at the rate of 10 mg/kg i.v. (Cooper, 1978) and has been used in dosages as high as 36 mg/kg i.v. (Harcourt-Brown, 1978). However, Cooper and Redig (1975) reported cardiac irregularities and deaths when using it on red-tailed hawks and Cribb and Haigh (1977) demonstrated serious cardiac irregularities in red-tailed hawks and waterfowl. Haigh (1980) also showed that there was a temporary apnoea lasting approximately 46 seconds after intravenous injection. Samour *et al.* (1984) considered it to be the injectable drug of choice for cranes, flamingos, storks, touracos, vultures and hornbills. With the possible exception of the above species mentioned by Samour, *the author considers that this drug has no advantages over ketamine and its various combinations. There is also the increased risk of heart failure if the heart is not healthy.*

### Propofol

Use of this injectable anaesthetic has been investigated by Fitzgerald and Cooper (1990). It is non-irritant to tissue but is so rapidly metabolised that it gives a very short period of anaesthesia. Because of this, and because of its narrow safety margin (Machin & Caulkert, 1996), in the opinion of the author *its use in birds even as an induction agent is not very practical.*

### Ketamine (a cyclohexamine)

This dissociative anaesthetic produces a *cataleptic state* and has been widely used in birds both by itself and in combination with synergistic drugs. *It has no analgesic effect.* It is both a cardiac and respiratory depressant. In almost all species when given intramuscularly it produces anaesthesia in approximately 3–5 minutes. Incoordination, opisthotony and relaxation are evident within 1–3 minutes of the injection and anaesthesia lasts about 10–35 minutes. The eyes may or may not remain open. A palpebral reflex is present and muscle relaxation is not very good. There may be some excitement during recovery. The blood pressure and heart rate are slightly lowered and there is some respiratory depression.

Mandelker (1972, 1973) used it in budgerigars and other birds at doses of 50–100 mg/kg. The author has used it in the budgerigar at a dose of 50 mg/kg for anaesthesia on three consecutive days without ill effect. Green (1979) used it at 15 mg/kg for induction of anaesthesia which he maintained on 0.5–1.0% halothane in 50% nitrous oxide. Altman (1980) suggested it had an adverse effect on the thermoregulatory centre in some species. For raptors it has been used in doses of 2.5–170 mg/kg. Ketamine is broken down by the liver and excreted by the kidney so that *it is important that fluid therapy is used if there is any doubt about the bird being dehydrated or having a hepatopathy or nephropathy.* It is now rarely used as the sole anaesthetic agent.

### Ketamine and acepromazine

Both Stunkard and Miller (1974) and Steiner and Davis (1981) have used this drug combination, stating that there is a smoother recovery, with less wing flapping than with ketamine alone. These workers use 1 ml of acepromazine containing 10 mg added to a 10 ml vial of ketamine containing 100 mg/ml. The dose of ketamine is then calculated at 25–50 mg/kg without taking into account the acepromazine in the vial. The bird is therefore receiving a dose of acepromazine of 0.5–1.0 mg/kg. *However like ketamine acepromazine induces bradycardia* and is not recommended by this author.

### Ketamine and diazepam (or midazolam, the aqueous equivalent)

Redig and Duke (1976) used 20–40 mg/kg of ketamine together with 1.0–2 mg/kg of diazepam. Forbes (1984) and Lawton (1984) also report using this combination at the same dose rate given intramuscularly. The combined drugs have been used on psittacines, Galliformes, Anseriformes, Passeriformes and raptors and the results were generally good

with deep sedation or anaesthesia and good muscle relaxation. However, Forbes reported that recovery was prolonged in raptors. Both drugs have some depressant effect on respiration. This combination of drugs has been used in the ostrich: ketamine (2–5 mg/kg i.v.) with diazepam (0.2–0.3 mg/kg i.v.).

### Ketamine and xylazine

This combination produces relatively safe hypnosis or anaesthesia in a wide range of species. Muscle relaxation is fairly good and respiration is only slightly depressed. The eyes are sometimes closed and the palpebral reflex is sluggish or absent. The depth and duration of anaesthesia and length of recovery time to some degree depend on the dose of ketamine used.

The combination has been used in various ratios of the two drugs. Increasing the amount of xylazine in relation to the ketamine has very little beneficial effect since the main effect of the xylazine appears to be to reduce the rate of breakdown of the ketamine. Redig (1983) has two routines when using this combination of raptors:

1. Three-quarters of the computed dose is given rapidly intravenously; 1 min is allowed to assess the effect; then the rest of the dose is given slowly
2. Alternatively, three-quarters of the dose may be given intramuscularly then if necessary the rest of the dose is given intravenously, but to effect. If this does not produce sufficient relaxation, and there is still some wing flapping, a further one-half the original computed dose is given.

Redig (1983) and also Haigh (1980) found that when this drug combination was given intravenously there were some cardiac irregularities and disturbance of the respiratory pattern. This does not happen if the combination is used intramuscularly. Haigh at first used an intravenous dose of 30–40 mg/kg of ketamine together with 0.5–1.0 mg/kg of xylazine. This worker now uses a dose of 2.5–5.0 mg/kg for the ketamine and 0.25–0.5 mg/kg for the xylazine and finds there is no adverse effect on the heart. Anaesthesia lasts 4–15 minutes and the bird is perching in about 30–40 minutes.

There is some individual species response to this drug combination and Redig (1983) has worked out the optimum dose for a number of species of raptor. In general, he advises a sliding scale of doses which is approximately 30 mg/kg of the ketamine for birds in the 100–150 g range, 20 mg/kg for those near to 400 g in weight and 10 mg/kg for larger birds weighing 1 kg or slightly more. In eagles weighing 4–5 kg Redig uses 4.5 mg/kg. Haigh considers, and it is also the author's experience, that the nocturnal raptors metabolise the drugs more rapidly than diurnal raptors.

The author has also recorded (Coles, 1984a) that the genus *Buteo* seems unusually sensitive to this drug combination when used intramuscularly – going into deep anaesthesia, sometimes with apnoea – and that recovery times were prolonged. Redig (1983) also found that the goshawk and Cooper's hawk needed higher doses and that recovery time was prolonged. Steiner and Davis gave 50 mg/kg of ketamine together with 10 mg/kg xylazine intramuscularly in the budgerigar. These workers consider that induction and recovery are somewhat rough.

The author has used this drug combination on a wide range of species and found it to be safe and effective. The dose used is 20 mg/kg of ketamine and 4 mg/kg of xylazine given intramuscularly. *The bird is weighed accurately* and the dose of ketamine computed. An equal volume of xylazine is then added. Signs of sedation occur within a few minutes and induction is complete in 5–7 minutes. Using this dose, anaesthesia lasts 10–20 minutes and birds are usually standing and able to perch in 1–2 hours. There is incoordination and sometimes a little excitement during recovery so that it is best to roll the bird loosely in a sheet of paper towel.

The combination is not satisfactory or safe in the pigeons or doves and several authors, Forbes (1984), Green and Simpkin (1984), Samour *et al.* (1984) and Coles (1984a), have all recorded that it is not satisfactory in the Gallinules. Ludders *et al.* (1989) have recorded their experiences when using it in Pekin ducks. Also it is unsafe in the long-legged birds which are liable to damage themselves during recovery. In penguins there is a prolonged recovery period. It is also not safe in some pheasants, touracos, vultures and the large owls.

### Alpha 2-adrenoceptor stimulants

Alpha 2-adrenoceptor stimulants cause a dose dependent reduction in the release and turnover of noradrenaline at the synapses in the central nervous system. In this way it results in sedation, muscle relaxation, analgesia, bradycardia and peripheral vasoconstriction which in turn results in some rise in blood pressure.

#### Xylazine

When used by itself in doses of 10mg/kg i.m. xylazine produces narcosis but not true anaesthesia. However, by itself it is not a very satisfactory anaesthetic or hypnotic agent. Not only is recovery time prolonged but there is nearly always excitement and even severe convulsions during induction in some species. *It can cause bradycardia and partial atrio-ventricular heart block*, and there is decreased respiration and often muscle tremors. Although the fatal dose is approximately ten times the therapeutic dose it is *not a particularly safe drug to use by itself*. It is not satisfactory at all in the domestic fowl even in doses as high as 100 mg/kg (Green & Simpkin, 1984). Its effects can be reversed by yohimbine or atipamezole.

#### Medetomidine

Like xylazine this is also an alpha 2-adrenoceptor stimulant. It is more potent. but it has a wider margin of safety. Like xylazine *it is best used in combination with ketamine* and is given intramuscularly. The author has found this combination particularly useful in swans and other waterfowl. Its use has also been reported in a variety of species of birds by Jalanka (1991), Reither (1993), Scrollavezza *et al.* (1995) and Lawton (1996). *Because of its potency the dosages of medetomidine are much less than for xylazine*. A range of doses have been used but for practical purposes the author suggests the doses shown in Table 7.1.

Lumeij and Deenik (2003) did not consider that this combination of drugs used as the sole anaesthetic gave satisfactory anaesthesia in pigeons. However, adding midazolam (2 mg/kg) to the combination of medetomidine (0.05 mg/kg) and ketamine (10 mg/kg) makes it even more effective. The best results, however, are obtained if all drugs are given

**Table 7.1** Doses of medetomidine and ketamine.

Bird	Medetomidine (µg/kg, i.m.)	Ketamine (mg/kg, i.m.)
Diurnal raptors	100	5
Owls	100–150	10
Geese, swans and other water fowl	200	10
Psittacines (because the health status of many captive psittacine species is often suspect, minimum doses are best)	75	5



by *slow* intravenous injection (Machin & Caulkett, 1998). After induction of anaesthesia with the above combination (which takes approximately 3–5 minutes), anaesthesia can be maintained with very low doses (0.5–1%) of isoflurane.

### Atipamezole

This is a selective alpha 2-adrenergic receptor antagonist, which reverses all the sedative, analgesic, cardiovascular and respiratory effects of both medetomidine and xylazine. It should be given at the same dose as the previously administered medetomidine. If given too soon after induction with the medetomidine and ketamine combination (i.e. within 10–15 minutes), when the full effect of the ketamine has not yet had time to be reduced by metabolism, some violent wing flapping may occur. Also atipamezole is metabolised more rapidly than medetomidine so re-sedation can occur, and for this reason higher doses of atipamezole than medetomidine are sometimes used.

## General anaesthesia using volatile anaesthetics

### Administration and anaesthetic circuits

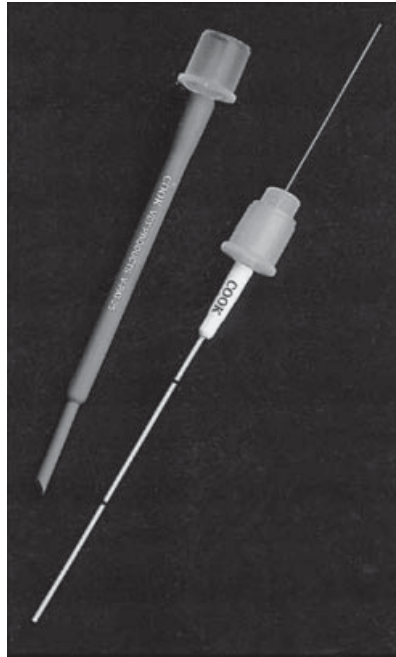
Volatile anaesthesia can be induced using an anaesthetic chamber or directly from a mask, with the gas flow delivered from an anaesthetic machine. A custom-made glass box is best used as an anaesthetic chamber for very small birds. However, adequate monitoring of the patient when using this method is difficult. Whichever method is used for induction, the bird is maintained on the volatile anaesthetic preferably by connecting it to the anaesthetic gas flow via an endotracheal tube, certainly for all birds above about 300 g in body weight. In smaller birds a mask may have to be used.

It is safer to use a non rebreathing semi-open circuit, such as an Ayre's T-piece, modified Rees or a mini-Bain, since in only the very large birds is the tidal volume sufficient to move anaesthetic gas through a closed circuit. The author has in the distant past used a Waters' to-and-fro system in the adult swan. Using the mini-Bain co-axial circuit helps to warm the inhaled anaesthetic gas mixture. This may be particularly important if cylinders of oxygen are stored outside in the cold, with the gas piped to the operating theatre. Also, if possible the oxygen should be humidified since the air sacs are regions of high water loss. The Rees modification of the Ayre's T-piece, using an open-ended rebreathing bag attached to the exhaust limb of the T-piece, enables manual intermittent positive pressure ventilation (IPPV) to be applied if necessary. The Bain circuit can also be fitted with an open-ended bag. The most useful T-piece is the Bethune T which has minimum dead space and can be connected to a respiratory monitor.

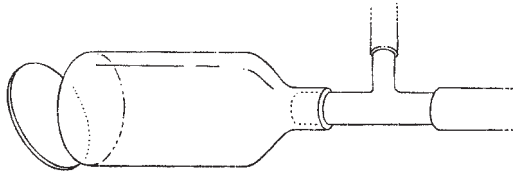
### Endotracheal tubes and face masks

Plastic endotracheal tubes oral/nasal sizes 2.5 mm and 3.0 mm suitable for birds down to the size of a pigeon are manufactured by Portex and Cook (Fig. 7.3). Rubber, uncuffed endotracheal tubes sizes 3 or 4 can be used for slightly larger birds, such as some Amazon parrots or macaws. A canine urinary catheter can be adapted by cutting the end obliquely and smoothing the end in a flame. These catheters can be fitted to an 8 mm endotracheal tube adaptor using the cut off nozzle end of a 2 ml plastic syringe. The length of all tubes should be reduced as far as is practical to reduce the dead space. The tube should loosely fit in the glottis to allow the escape of gas around it so that there is no danger of over inflating the air sacs or trauma to the trachea which in birds has complete non expandible rings of cartilage. If the bird is in light anaesthesia, particularly when using ketamine, there may be some temporary apnoea after the tube is passed.

The glottis can be seen just behind the root of the tongue. In some birds (e.g. cockerel and heron) the glottis is further back in the oropharynx and in the parrots the bulbous tongue hides the glottis, so if the finger is placed over the skin in the intermandibular space this helps to bring the base of the tongue and glottis into view. In all cases, intubation of



**Fig. 7.3** Endotracheal tube and stylet (Cook Ltd). Can be reduced in length if necessary by cutting the proximal end.



**Fig. 7.4** A small anaesthetic face mask made from a plastic bottle with the base removed.

the trachea is made easier if the tongue is pulled forward. The tube should be *slightly* lubricated (too much lubricant may block the airway) and good spot lighting is advantageous.

The use of a mask may be the only practical way of maintaining small birds on volatile anaesthesia. Suitable masks can be made by cutting the base off a small plastic bottle (Fig. 7.4) or by adapting various sizes (10–60 ml) of plastic syringe case. Tall plastic bottles or plastic drinking cups can be used to make masks for birds with long beaks (e.g. sandpipers, herons and toucans). If the plastic is transparent then the bird's eye can be seen during anaesthesia. To make a better fit the open end of the face mask can be covered with a latex surgical glove held in place by an elastic band and this can then be pierced for insertion of the bird's head. A number of gaseous anaesthetics have been successfully used in birds.

### Halothane

This anaesthetic has been used by many workers, among whom are Marley and Payne (1964), and Graham-Jones, 1966. The author used the anaesthetic for over 25 years, often as the sole anaesthetic. Many of these anaesthetic sessions lasted over an hour and Marley and Payne used it for up to three hours. However, with introduction of isoflurane and other volatile anaesthetics halothane is not now considered to be a safe anaesthetic for birds.

### Nitrous oxide

By itself, nitrous oxide does not produce anaesthesia in birds. Nitrous oxide, at a concentration of 50%, has been used in the past to lower the level of halothane and other inhalation anaesthetics required, but respiration is still depressed. Levels of PaCO<sub>2</sub> rise, and consequently the overall risk is not decreased. Nitrous oxide is therefore better not used as part of the anaesthetic combination for anaesthesia in birds.

### Isoflurane

Isoflurane is a fluorinated ether and it is by far the safest anaesthetic to use in avian practice. Its advantages are:

- It is relatively insoluble in plasma so that the induction and recovery from anaesthesia is smooth and rapid; stress for the bird is consequently reduced to the minimum. On recovery the bird is rapidly perching without any apparent hangover effect.
- The depth of anaesthesia can be altered quickly by increasing or decreasing the percentage of isoflurane in the gas mixture.
- It has much less effect on the myocardium and the decrease in blood pressure is largely due to a reduction in peripheral vascular resistance.
- *Cardiac arrest does not occur until several minutes after apnoea* so that, unlike the case with halothane, the anaesthetist has plenty of time to 'wash out' the respiratory system and so reduce the level of inhaled anaesthetic gas.
- Only 0.3% of isoflurane is metabolised by the liver so that it is much less hepatotoxic and safer with patients with a possible undiagnosed hepatopathy. It is also less toxic to theatre staff if a scavenging system does not happen to be in operation.
- Because of its safety and the ease with which it can be given it can be administered if necessary two or three times daily for the routine taking of blood samples, the changing of dressings or the administration of parenteral fluids, etc. The author has used it for the last 28 years for several thousand birds of a variety of species with very few anaesthetic fatalities.

The method generally used for most birds is to induce with 5% isoflurane in a flow of oxygen of just over 2l. When light anaesthesia is achieved (usually in 2–3 minutes or less) the level of isoflurane is maintained at 1.5–3%. Anaesthesia may take longer to induce in waterfowl and the maintenance setting may be somewhat higher. With these species, induction with an injectable combination of medetomidine and ketamine and then maintenance with isoflurane is easier. The author has used isoflurane as the sole anaesthetic for an adult rhea (*Rhea americana*). A flow rate of 4l of oxygen containing 5% isoflurane was used. Induction using a mask took approximately 7 minutes.

The vapour pressure of isoflurane is similar to that of halothane so that *it is possible* to use the same vaporiser. However, this is not recommended because the vaporiser needs to be thoroughly soaked and flushed out with ether after using halothane to rid it of preservatives in the liquid halothane. The only real disadvantage for the practitioner when using isoflurane is the initial capital cost of a dedicated vaporiser and the greater cost of isoflurane compared with halothane. However, if used sensibly without using unnecessarily

high gas flow rates, which waste a lot of anaesthetic, the significant advantages far outweigh the increased cost.

### Desflurane

Desflurane is another fluorinated ether with a very low blood solubility. It is less potent than isoflurane and requires a specialised vaporiser. In humans it causes irritation of the respiratory tract. It has no advantages over isoflurane and is seldom used in avian anaesthesia.

### Sevoflurane

Sevoflurane is another gaseous anaesthetic in the same class as isoflurane, but it is somewhat less soluble in plasma with consequently a lower blood gas partition coefficient (0.69 compared with 1.41 for isoflurane). Because of this, induction and recovery times are much more rapid. Moreover, unlike isoflurane, it is not irritant to the respiratory tract so the stress of mask induction is reduced (Klaphake *et al.*, 2006). Its main disadvantages are that it is considerably more expensive and, because of the more rapid induction, *great care* must be taken to watch respiratory movement *constantly*.

## ANAESTHETIC EMERGENCIES

### Apnoea

The most likely causes of apnoea are too much anaesthetic, the toxicity of the anaesthetic and hypercapnoea. Apnoea will obviously also occur after primary cardiac arrest.

In cases of apnoea, switch off any volatile anaesthetic and nitrous oxide. Increase the flow rate of oxygen and start gentle manual (if not using a mechanical ventilator) ventilation immediately, by intermittently occluding the exhaust arm of the Ayer's T-piece or other non-rebreathing circuit with the finger or by using the rebreathing bag. Do not over inflate the bag and the air sacs. Quite satisfactory ventilation can be obtained in all but the larger birds by this method. In small birds even if an endotracheal tube is not in place, providing the oxygen flow rate is relatively high (e.g. 2 l per minute) and the escape of gas between the bird's head and the mask is prevented by a latex surgical glove, cotton wool or tissue, adequate ventilation can be carried out.

*Do not over-ventilate – the aim is to get a moderate excursion of the abdominal (coelomic) wall (so alternatively inflating and deflating the 'abdominal' air sacs) together with slight movement of the thorax. Over-ventilation washes out carbon dioxide and inhibits the chemoreceptors stimulating respiration. If too forceful, it may rupture the air sacs or even damage the air capillaries.*

Even if a volatile anaesthetic is *not* in use it is still important to have an endotracheal tube in place so that artificial respiration can be carried out. Trying to ventilate a bird artificially by rhythmically compressing the sternum is not likely to be very effective and may well cause damage to the ribs, the liver or other organs. *It is a mistake to take the bird off the oxygen immediately at the end of the operative procedure.*

If spontaneous respiration does not start within 1–2 minutes of artificial respiration give doxapram at the rate of 7 mg/kg (0.3 ml/kg). This can be diluted 1:3 and given to a large bird by slow i.v. injection or i.m. injection. In small- or medium-sized birds it can be dropped into the mouth so that it is absorbed through the mucous membrane. *Have the syringe already loaded before starting anaesthesia in case an emergency occurs.*

### Depression of the respiratory rate during a long period of anaesthesia

Stop the operative procedure. There may be a build up of PaCO<sub>2</sub>. Increase the oxygen flow rate and gently artificially ventilate to wash out anaesthetic from the air sacs.

## **A blocked endotracheal tube**

A blocked endotracheal tube may be indicated by more forceful and exaggerated respiratory movement and is more likely to occur with small birds and when using fine endotracheal tubes. Clicking, gurgling or high-pitched squeaking sounds that could be mistaken for the bird awakening all indicate some obstruction to the airway. Cyanosis is not usually seen, except perhaps in chickens, and by the time it is recognised it is usually too late to rectify the situation. Immediately insert an air sac catheter as described below and administer oxygen via this route. Remove the tube, blow it out, or preferably replace it with another tube. If there still appears to be some mucus present in either the trachea or the only endotracheal tube available, aspirate using a syringe and catheter. *Have a syringe with an attached catheter ready before starting anaesthesia.*

## **Cardiac arrest**

Cardiac arrest usually occurs sometime after respiratory arrest. Marley and Payne (1964), using halothane anaesthesia in chickens, noted there was a lag of about ten minutes between respiratory and cardiac arrest. *This is not typical of birds in general, in which, with halothane, cardiac and respiratory arrest are simultaneous. Unless some method of monitoring the heart is in use it will not be appreciated that cardiac arrest has actually occurred.* The practitioner can try intermittent digital pressure on the sternum but this is not usually very successful, neither are intracardiac injections of adrenaline (0.1 mg/kg) or adrenaline given i.v. or intraosseously. In birds above 350–400 g (e.g. African grey or Amazon parrot) direct cardiac massage using the finger through an abdominal incision or using a moist cotton wool bud may be tried but is not usually successful.

## **SUGGESTED ANAESTHETIC ROUTINES**

### **Short procedures lasting no more than ten minutes, where a quick recovery is required**

There is little doubt that isoflurane (without any other supportive drugs) administered in a gas flow of 100% oxygen is the best anaesthetic for all species for quick procedures requiring general anaesthesia. However it must be administered carefully from an accurate dedicated vaporiser. If available, sevoflurane could be used. In large birds always consider whether local anaesthesia plus sedation (low dose ketamine + midazolam + xylazine or medetomidine) may be more applicable. If there is liable to be post-operative pain, give butorphanol (1 mg/kg) before administering the anaesthetic (see p. ●●).

### **For prolonged anaesthesia for a period of up to an hour or more**

The following routine is satisfactory for most species: before induction give butorphanol (1 mg/kg). Anaesthesia is then induced with a mixture of ketamine and medetomidine (or midazolam) given intramuscularly and the bird is maintained on 0.5–1% isoflurane given in 100% oxygen. If practical, weigh the bird and compute the dose of ketamine and medetomidine or diazepam accurately. If it is not practical to weigh the bird, estimate its weight from the tables given in Appendix 8. Give 75% of the computed dose intramuscularly. Wait 5 minutes, and if narcosis is sufficient proceed with the volatile anaesthetic. If the bird is not sufficiently sedated give a further 50% of the computed dose. Wait a further 5 minutes before giving any gaseous anaesthetic. Always use an endotracheal tube wherever possible. *Always flush out the anaesthetic circuit with oxygen every 5 minutes.*

It is a good idea to have a drip line inserted into a vein or, better, intraosseously once anaesthesia has been induced and before the operation is started. In this way fluids (Hartmann's or lactated Ringer's solution given at the rate of 10 ml/kg/hr) can be given to maintain the fluid balance and also serve as a route for the emergency administration of drugs.


## Air sac anaesthesia

This method is used after induction of anaesthesia by another method or as an emergency procedure. A plastic cannula either fashioned from a cut-off endotracheal tube or commercially available from Cook Instrumentation (Fig. 7.5) is inserted into the left side of the bird's abdomen, just posterior to the dorsal part of the last rib and above the level of the junction of the vertebral and sternal parts of the rib cage. The purpose is to insert the cannula into the caudal thoracic air sac and not into the abdominal air sac, which is deeper in the abdomen. In larger birds (above 1 kg) it may be possible to insert the cannula between the last two ribs.

After surgical preparation of the selected site the skin is picked up with rat-toothed forceps to form a 'tent'. A snick is made with scissors and their points used to spread and enlarge the hole to reveal the underlying muscle and ribs. The point of a closed pair of straight mosquito forceps or round pointed scissors is quickly thrust through the muscle and into the abdominal cavity. The points of the instrument are then opened sufficiently to enable insertion of the plastic cannula which can then be sutured in place. The surgeon can check if air is moving freely through the tube by holding a wisp of cotton wool or fine suture material near the opening and watching for fluctuation during each respiration. The anaesthetic circuit can be connected to the tube and gaseous anaesthesia or just oxygenation maintained via this route.

The method is useful for surgery of the head or used as an emergency procedure to relieve partial obstruction of the airway. Although Korbelt *et al.* (1993) have demonstrated in both pigeons and buzzards that  $PO_2$  and  $PaCO_2$  levels, oxygen saturation and blood pressure are within reasonably normal limits, nevertheless considerable disruption of the normal pattern of air flow occurs and the percentage of anaesthetic gas often has to be increased to maintain anaesthesia.

The altered air flow is necessarily confined to the left side of the respiratory system. The right side will continue to function much as it did before the introduction of the cannula unless the normal main airway (i.e. the trachea) is blocked. This disadvantage can be overcome by inserting the tube into the interclavicular air sac, but this is more difficult to do and maintain the tube in position together with the added risk of damage to the heart and its major blood vessels. Total gas flows need to be higher than normal to make sure fresh gas is always entering the caudal thoracic air sac and reaching the exchange barrier in the lung. The air sac tube can be left in place and it will be found most parrots will leave it alone.



**Fig. 7.5** 'Coles' design avian air sac cannula (Cook Ltd).

## RECOVERY

Do not disconnect the bird from the oxygen supply before there are signs of recovery with slight jaw movement. Soon movement of the wings and legs can be detected. Remove the endotracheal tube when movement of the beak takes place otherwise, particularly in parrots, it is liable to get chopped off. During the whole recovery period it is best if the bird is gently held upright, wrapped in a towel, by a competent nurse regardless of how busy is the clinic.

**There is no completely safe anaesthetic method for birds, only careful anaesthetists. There is always a risk whatever the species of bird. Always get an anaesthetic consent form signed. (Yaakov *et al.*, 2006)**

## GENERAL CONSIDERATIONS

### The assessment of avian patients for surgery

Before carrying out any sort of operation on a bird it is wise to carry out a thorough clinical examination and if necessary a complete clinical profile on sampled blood (see Chapter 4). Obviously, birds that are in a state of shock due to trauma are bad surgical risks. The obese budgerigar which has been confined to its cage throughout life is also a bad risk. However, the author has been surprised on a number of occasions by birds that have been abnormally thin and in poor condition which have survived anaesthesia and surgery. If possible, it is better to try to improve the nutritional state of these patients first. Probably the bird at greatest risk is the one with an obvious respiratory problem. Any bird that is dyspnoeic or one that becomes dyspnoeic with the minimum of handling is a bad surgical risk (see Chapter 7). A bird that has ascites or a large abdominal space-occupying lesion is a bad risk.

### Positioning of the patient during surgery

As discussed in Chapter 7, birds placed in dorsal recumbency will have a reduced air sac volume, consequently in birds with space-occupying lesions of the abdomen this condition is exacerbated. Although the vast majority of surgical patients can be placed on their backs and are less liable to be moved in this position, it is better to have them in ventral or lateral recumbency. When in lateral recumbency care should be taken not to forcibly fold the wings too far back above the body, as this may restrict respiratory movement.

### Essential equipment

#### Surgical instruments

A selection of small instruments, such as those used in ophthalmic or microsurgery, should be used. The following list is the most useful and the minimum that should be available:

1. 114mm enucleation or strabismus scissors
2. Tissue forceps with 1 × 2 teeth, such as Lister's conjunctival forceps; better still are atraumatic grasping forceps, such as Harris ring tips
3. Straight Halsted mosquito forceps
4. Curved Halsted mosquito forceps
5. A blunt-ended probe; sterile cotton wool buds will serve this purpose and will also act as swabs for clearing blood or exudates
6. Fine needle holders



7. A Spreull needle attached to a sterile 10 ml syringe is useful for suction or irrigation
8. Suitable retractors: for very small birds, ophthalmic eyelid retractors or an Alm; in many other cases the Lone Star retractor is useful for keeping the operation site open
9. Haemoclips plus applicators are very useful when working deep in the abdomen
10. Suitable surgical drapes; the best are clear plastic used with an aerosol spray adhesive
11. Suitable suturing materials, sizes 3/0 to 6/0, e.g. pseudo-monofilament polyamide, polyglactin 910 (absorbed by hydrolysis in about 6 weeks) or polydioxanone (PDS:Ethicon), swaged on to round-bodied, taper-cut, pointed needles. If absorbable sutures are used in the skin the bird will not need handling again for suture removal
12. Chromic cat gut (3/0) is not generally advised, although the author has used it many times in the past. It causes a lot of local granulocytic inflammatory reaction because the heterophils and avian macrophages, unlike the case in mammals, lack myeloperoxidase with which to break the foreign protein down and, in most cases should be avoided.

### Lighting and magnification

When using instruments for delicate surgery the hands are under better control if the surgeon is seated and the elbows are placed on the table. Also some form of magnification combined with good illumination is advisable. An operating microscope is the ultimate choice but this is costly. Binocular loupes or magnifying spectacles are also useful. The least expensive system is a combined lens and circular fluorescent light. These are marketed by several surgical instrument companies and a number of different designs are used in industry by persons carrying out delicate work, however the degree of magnification may not be sufficient for the most delicate surgery. Harrison (1984) suggested mounting a rigid fibre optic laparoscope on a flexible arm, such as that used for some table lamps, and using this for magnification and lighting. This gives excellent lighting and magnification but the field of vision is somewhat restricted.

### Radiowave surgery

Although not essential, it is desirable to have the use of a radio surgical instrument for both incision and coagulation. The equipment should preferably have a frequency range up to 5 MHz, such as has the Ellman Surgitron ([www.ellman.com/vet/](http://www.ellman.com/vet/)). Most other equipment of this type operates through a monopolar active electrode using an indifferent plate placed under the bird. Bipolar forceps with both active and indifferent electrodes incorporated into the same hand-held instrument are better, since the current does not have to pass through the whole body of the patient.

The advantages of this equipment are:

- There is little co-lateral tissue damage
- There is good haemostasis
- Because of minimal tissue damage there is much less post-operative pain
- Accurate incision at the operative site
- Can be used with both local and general anaesthesia

### LASER (Light Amplification by Stimulated Emission of Radiation)

The CO<sub>2</sub> laser is the most useful equipment for delicate avian surgery and is probably even better than radiowave surgery. At the present time the cost of the equipment is becoming affordable. Bartels (2002) has reviewed its use. Using a focused beam there is very accurate non-contact (so absolutely sterile) cutting. The collateral damage is no more

than 0.05–0.2 mm and the thermal penetration is superficial (50–100 µm in depth). There is minimal pain during its use, which the author can vouch for having tried it on the back of his own hand.

During cutting the instrument coagulates blood vessels up to 0.6 mm in diameter.

## Haemorrhage

There is little doubt that many avian surgical patients die of blood loss. Systemic blood pressures in birds are high compared with mammals. Blood loss from severed vessels is therefore rapid and the control of bleeding is of paramount importance, particularly in small birds. However, Kovách *et al.* (1968, 1969) have demonstrated that several species of bird are able to tolerate blood loss better than mammals. Circulating blood volume is usually little more than 10% of body weight, yet Kovách has shown that pigeons can survive blood loss of 8% of body weight during prolonged haemorrhage. Although the blood pressure and heart rate dropped, these returned to normal within 30 minutes to 4 hours.

This effect is apparently due to the greatly increased capillary surface area (3–5 times that found in the domestic cat) that is available for the absorption of the reserve of extravascular tissue fluid and to a very pronounced vasoconstriction in the skeletal muscles. From the practical point of view the author has often noticed that birds presented at the surgery because of trauma have suffered considerable blood loss, as shown by their surroundings, and yet they have survived.

The arterial capillaries in the muscles are more influenced by autonomic nervous control than by the level of local metabolites ( $H^+$  ions,  $CO_2$ , and lactic acid) than is the case in mammals. Although the resting heart rate of many birds is lower than that in mammals of comparable size, stress or excitement very soon leads to a much more rapid heart rate. Struggling due to an inadequate depth of anaesthesia can result in considerable haemorrhage.

## Transfusion and plasma expanders

Both Harrison (1984) and the author have used blood transfusions in birds. It has been shown that blood from heterogeneous species can safely be used for a first transfusion. However, blood for transfusion is unlikely to be readily available, and in view of the above mentioned observations of Kovách *et al.* the discrete use of blood volume expanders, the artificial colloidal plasma substitutes, which also contain electrolytes, may be helpful.

Products available include *gelatine*, *dextrans* and *hexastarch* (hydroxyethyl starch): 5–10 ml/kg i.v. every 8 hours, used up to four times. Also, the haemoglobin glutamer Oxyglobin®, given at a dose rate of 20 ml/kg/h i.v. *used once*, may be useful if there is any pre-operative anaemia.

If there is any suspicion of a hepatopathy a pre-operative vitamin K injection should be given.

## Cleaning and antiseptics of the operation site

To obtain a clear operating area every feather has to be meticulously plucked. If cut, the feather does not grow until the bird's next moult. Plucking can be tedious and it is sometimes easier using forceps. The shaft of the feather must be firmly gripped and pulled out cleanly so that the germinal layer of the feather papilla is not damaged and the feather will regenerate. Regeneration will occur in most cases within a few weeks of plucking. If the feather is fully grown, it is a dead structure which will not bleed when plucked. If the feather is plucked before growth is completed and the feather has not completely emerged from its sheath haemorrhage is likely to occur.

Only the minimum number of feathers consistent with clearing the operation site should be plucked to avoid excessive heat loss, particularly in small birds. For the same reason

the surgical site should be cleansed with minimal antiseptic solution. Cleaning and sterilisation can be carried out using a quaternary ammonium solution, chlorhexidine, benzalkonium chloride or one of the iodine antiseptics such as povidone-iodine.

To limit heat loss the patient should be placed on an electrically heated pad, on a rigid hot water bottle covered in sterile cloths or a water-circulating heat pad.

## **SURGERY OF THE SKIN AND ASSOCIATED STRUCTURES**

Overall the skin of birds is much thinner than that of mammals of comparable size. In the feathered area the thickness and strength varies between the feather tracts (pterylae) and the featherless areas between these tracts (apteria). In the apteria the dermis has a stronger mesh of collagen fibres (Stettenheim, 1972). Surgical incisions are best made in the apteria, parallel and midway between the adjacent feather tracts and the subsequent sutures placed in the apteria.

The subcutis and dermis contain only a few horizontal sheets of elastic fibres so that avian skin is not very elastic. The skin is not firmly attached to the underlying muscle, but in some areas (the skull, the carpus, the digits and the pelvis) the skin is firmly and extensively attached to bone. Avian skin is therefore not very mobile and tears easily, particularly where it is attached to the bone.

The skin is best sutured using suture material swaged on to atraumatic, taper-pointed needles. There are numerous blood vessels, both capillary and larger vessels, within the skin and haemorrhage can be a problem.

When possible, incisions should be made with a radio or laser surgical instrument. The scalpel should not be used at all for most types of avian surgery. If the above instruments are not available an incision can be made by slightly tenting the skin then nicking with scissors and then blunt dissection with the scissors, after first crushing the skin with artery forceps along the line of the intended incision.

### **Lacerated wounds**

Lacerations are sometimes caused by attacks from aviary mates or by flying into sharp objects, particularly during stormy and gusting weather. Racing pigeons not uncommonly return home having been blown into telephone or barbed wire. If these wounds involve the anterior sternum, as they often do, there may be damage to the clavicular air sac, with resulting subcutaneous emphysema. This usually resolves spontaneously, but, if necessary, can be deflated with a hypodermic needle and syringe. Providing the wound is fresh and haemorrhage has been controlled it can be treated on a routine basis and usually heals by first intention without secondary infection. If skin has been lost and the wound has started to granulate, debride the wound and then cover with a hydrocolloid dressing. Some types of this dressing, e.g. Granuflex, are rigid enough to be lightly sutured in position and will help epithelialisation of quite large areas.

Several workers have described the use of skin flaps and skin grafts. Where skin has been lost over the top of the skull it is not too difficult to mobilise a pedicle from the back of the neck and advance this over the wound. Because of tension on the wound, skin closure should be with horizontal mattress sutures. Hernandez-Divers and Hernandez-Divers (2003) published a useful article reviewing the subject and describing the use of xenogeneic grafts using commercially available porcine small intestinal submucosa to repair skin defects in a number of birds.

### **Subcutaneous abscesses**

Subcutaneous abscesses are not uncommon around the head, particularly in parrots. They often involve the paranasal sinuses around the eye but also occur in the submandibular

region. These abscesses are usually filled with inspissated, caseous pus. The abscess should be opened with a scalpel fitted with a No. 11 blade, by inserting the point first and directing the cutting edge away from the bird. The pus is then scooped out and the cavity curetted. A Volkmann's spoon can be used, but a useful instrument for a small bird is a canine tooth scaler with a rounded spatulate end. When opening a submandibular abscess care should be taken to avoid the large subcutaneous blood vessels in this region.

Before suturing the skin, a bacteriological swab should be taken for culture and antibiotic-sensitivity testing. An injection of ampicillin may be given at the time of opening the abscess although this antibiotic may need to be changed later in the light of the results of bacteriological culture. In the case of very small birds of 15–20 g, it may not be practical to suture an abscess after opening. In this case the cavity can be cauterised with a silver nitrate pencil or, better, fulgurated with the radio surgical instrument and then left to heal by granulation.

Abscesses sometimes occur around and in the ear. The surrounding skin can become thickened and the ear canal filled with exudate. These abscesses need great care because of the risk of haemorrhage and damage to the tympanum which is relatively near the surface. It may be wiser to try and first reduce the swelling using a small amount of carprofen s.c. into the local area. Non-steroidal anti-inflammatory drugs (NSAIDs) are more commonly mentioned in the context of the relief of pain, but they act primarily by reducing the inflammatory reaction.

### **Feather cysts**

Feather cysts are usually seen in the region of the carpus but can occur in other parts of the body. The author has never seen them in the many thousands of wild birds he has examined. They are most often seen in some breeds of canary (Norwich and hybrids of this breed) but do occur in other captive birds. Peer Zwart (2003) has demonstrated that these are benign tumours, which he proposes to call plumafolliculomas. These have been reported in the chick (*Gallus gallus*) and are analogous to mammalian trichofolliculomas. They are usually dry and contain the remains of the undeveloped feather which has been unable to emerge in a normal manner from the follicle. Some other neoplasms may look like feather cysts and bleed profusely when opened.

Since the feather cysts are neoplasms they will recur if they are simply opened. The whole section of skin, including the 'cyst', should be carefully dissected out using fine instruments, good magnification and good illumination. Dissection is not easy without damaging the neighbouring follicles and the skin is adherent to the underlying bone in the area of the carpus.

### **Subcutaneous tumours and cysts**

Subcutaneous tumours and cysts are seen in all species but are most common in the psittacine birds, particularly the budgerigar. They are not usually invasive but can become ulcerated. They are usually easily dissected free of surrounding tissue by using a closed pair of mosquito haemostats or preferably radio-surgery. Great care should be taken to search out, clamp and coagulate any blood vessels supplying the neoplasm. This is particularly the case with the common lipomatous tumours found over the thorax of the budgerigar, which often have a large blood vessel beneath them and which can bleed profusely. Meticulous attention should be given to any haemorrhage into the wound after surgery. For this reason any loose skin left after removing a large tumour should be trimmed and dead space diminished.

### **Lipomas**

In budgerigars, lipomas are best reduced before surgery by strict dietary and medical routines. De Voe *et al.* (2003) advise the addition of L-carnitine to the diet. This is given at

the rate of 1000 mg/kg of food, which is changed to a pelleted diet such as that formulated by Harrison's diets. This also improves the general physical condition of the bird. Diluted Lugol's iodine can be added to the drinking water. If the condition has been accurately diagnosed as a thyroid problem the use of levothyroxine may be indicated. As the tumour could be a liposarcoma or a lipomyosarcoma all tumours after removal should be sent for histopathology.

### **Tumours of the uropygial or preen gland**

Tumours of the uropygial gland may be benign adenomas or malignant adenocarcinomas that can become adherent to the underlying bone. They must be differentiated from abscesses. Haemorrhage is not usually a problem but if the tumour has been allowed to reach an appreciable size some difficulty may be experienced in repair. Removal of the preen gland does not seem to have any adverse effects. It does not seem to be essential to the maintenance of budgerigar plumage and it may not be essential to other species of bird, since it is absent in some species, such as many pigeons, some parrots (green wing and hyacinth macaw), emus, cassowaries and bustards (King & McLelland, 1975). It is also absent in woodpeckers, cormorants and the anhinga, a bird in which the plumage actually absorbs water to become completely saturated so that the bird can easily submerge and swim like a snake (it is called the snake bird) under water.

The composition of the uropygial secretion varies in different species but usually contains a complex of water-repellent waxes, lipids and proteins. It may also contain a precursor of vitamin D (Stettenheim, 1972). The vitamin D precursor may only be important in growing birds.

When removing the gland, dissection should be commenced at the caudal end proceeding towards the cranial section, where there is most attachment to underlying muscle.

## **THE HEAD REGION**

### **Accidental wounds**

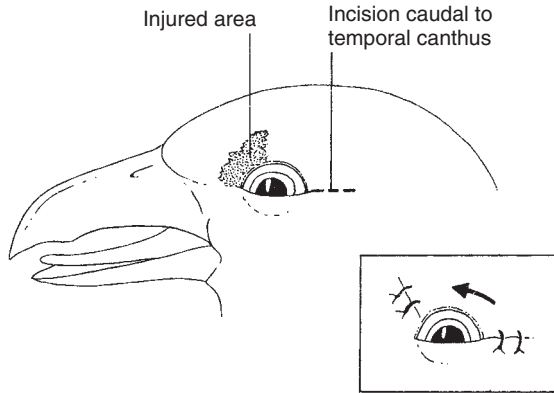
Apart from the fractures of the beak dealt with below, cranial fractures are liable to result in instant death. However, non-fatal injury may traumatise the skin, including the eyelids. The skin over the whole of the skull in most species is not very elastic and is adherent to the bone. Any wound more than a few days old will have contracted, with resultant fibrosis and it will be difficult to suture the skin edges together. If the upper eyelid is damaged at the nasal canthus it may be possible to slide the remaining part of the eyelid forward, by making a lateral *canthotomy*, as shown in Figure 8.1. Do not remove a wedge of skin below this incision, as is sometimes done in the mammals for this type of plastic surgery (also see Plate 13). In the bird this only results in too much tension across the lower eyelid. In birds it is the lower eyelid that carries out most of the movement in covering the eyeball.

### **The eye**

#### **Corneal ulcers**

Corneal ulcers can be the result of trauma or a variety of infections, including avipox virus and *Chlamydophila*. Fluorescein can aid diagnosis. Surgery for indolent ulcers can be performed using good magnification and standard ophthalmic techniques. If suturing the nictitating membrane over the cornea, the direction this travels across the cornea is from the ventral nasal canthus to the dorsal temporal canthus in a somewhat different direction than is the case with mammals.

Using good magnification it may be possible to suture a lacerated cornea with 8/0 polydioxanone (PDS:Ethicon).



**Fig. 8.1** Position of incisions for suturing damaged upper eyelid.

### Enucleation

Before enucleation is undertaken the following factors should be taken into account. The eye in birds is relatively much larger than in mammals of comparable size, particularly in raptors. In fact, avian eyes are much larger than they appear to the casual observer and occupy more space in the skull than the brain. The extra-ocular muscles have been greatly reduced in size and the resulting loss of movement in the eyeball is compensated for by an increased movement of the whole head supported by the very flexible neck.

Reduction in the eye muscles has resulted in much less space for the surgeon to work in between the eyeball and its socket. The globe of the eyeball is much more rigid than in the mammal. Not only is the sclera cartilaginous, but there is a ring of bony plates around the circumference near the corneal scleral junction. There is only a thin interorbital septum between the two eyes, which is particularly evident in the owls. In removing one eye the optic nerve of the other eye can easily be damaged. At the back of the eye in some species there is a U-shaped bone in the sclera surrounding the optic nerve.

The simplest method of enucleation is by lateral canthotomy, then an incision of the cornea to remove the aqueous, the lens and the vitreous. The sclera and choroid should then be carefully collapsed into the resulting free space using scissors and forceps. It may be wiser to leave the back of the sclera with the attached tissues intact and to plug the socket with an absorbent fibrin or gelatine sponge. The eyelids are then sutured together after removing the margin of each lid.

### Removal of the nictitating membrane

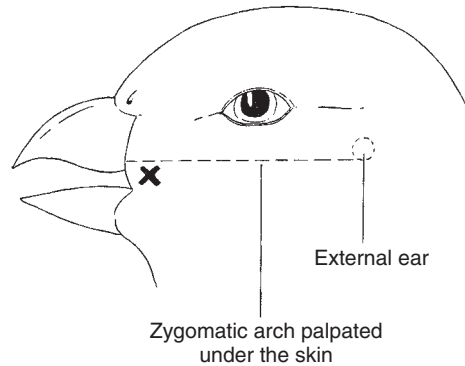
Tumours of the nictitating membrane are occasionally seen in birds. Apart from the cosmetic aspect, which worries the owner, the surgeon should always consider whether the removal of this membrane is absolutely necessary. As in mammals, but probably more so in birds, the nictitating membrane has a very important protective function to the eye. Removal of the membrane can lead to a keratitis.

### Cataract surgery

Cataracts are not uncommon in birds. If bilateral surgery is justified, it should be carried out by an ophthalmic veterinary surgeon using phacoemulsification techniques.

### Cannulation of the infra-orbital sinuses

Cannulation of the infra-orbital sinuses is a simple procedure that can be carried out in a quiet bird without anaesthetic. It may be required in any bird with chronic sinusitis (see section on clinical examination of the head, Chapter 3).



**Fig. 8.2** The X shows the point of entry for cannulation of the infra-orbital sinus. This is just dorsal to the commissure of the mouth, where the distal end of the zygomatic arch can be felt to impinge on the premaxilla (i.e. the skeletal element of the upper beak) (see Fig. 1.1).

The point of entry is illustrated in Figure 8.2. A 20–22 G hypodermic needle is held almost parallel to the skin surface with the needle pointed to a position halfway between the orbital globe and the external nares. Care must be taken not to pierce the globe of the eye. In bad cases the sinus is well distended and entry can be made without any difficulty into the area of greatest distension. In the budgerigar the hypodermic needle needs only to be advanced horizontally to a depth of approximately 2 mm. A suitable volume of fluid for injection is 0.1–0.3 ml. Excess fluid should exit through the nares and may also flow into the pharynx so care must be taken that none flows down the glottis. During this procedure it is best to have an endotracheal tube in place and to pack the oropharynx with gauze.

### **Cannulation of the supraorbital sinuses**

A more difficult and hazardous procedure for the inexperienced is to trephine and cannulate the supraorbital sinuses, which might well be involved in infection of this region.

The sites of entry are dorsal and slightly towards the beak each side of the midline. Incision is made through the skin, when the bone of the os frontalis will be seen. Very carefully two holes are made in this first layer of bone with a rotary drill. It should then be possible to see the cavity of the supraorbital sinus and the underlying cortical bone overlying the orbit. If fluid is then flushed into the sinus it should exit into the oral cavity if the supraorbital sinus has been entered. When carrying out this procedure for the first time the surgeon is advised to study the latero-lateral radiographs.

### **Hyperkeratinisation of the cere and nares**

In budgerigars, a horn-like projection sometimes develops from the cere and occasionally may obstruct the nares (see Fig. 3.4). This is purely excessive keratin that has not desquamated from the basal tissues. It is dry and bloodless and can be cut with scissors or nail clippers, care being taken not to go too close to the sensitive cere.

The larger psittacines may also develop rhinolyths, or collections of dry exudate, within the nares, which can act like ball valves. They may partially obstruct breathing and cause annoyance. It is a simple matter to scoop these out with a dental scaler. Some underlying infection may be present (swabs should be taken) and the area should be cleaned with povidone-iodine, chlorhexidine or F10.

## Abscesses in the oral cavity

Abscesses can occur anywhere in the mouth. They may be seen around and partly blocking the choanal opening from the nasal cavity or on the tongue, particularly in parrots. They should be opened and thoroughly curetted. It is not practical to suture those over the choanal opening so they should be cauterised.

## Beak problems

### Deformities and overgrowth

Budgerigars are often seen with overgrown or distorted beaks. Often by the time the owner presents the bird there is very little that can be done surgically to correct these defects. Regular careful clipping with nail clippers, finishing with a hand-held hobby (Dremel) rotary stone or carborundum burr (but note Analgesia, p. 24), is the best routine.

Other psittacines also get overgrown beaks, sometimes through lack of proper wear, or they may become distorted through excessive wear caused by climbing the metal bars of their cage. Other species of bird also occasionally suffer distortion of the beak through trauma to the germinal layer.

Metabolic bone disease not only affects the other parts of the skeleton but also affects growth of the premaxilla and mandible so that the overlying beak becomes distorted. The rhamphotheca, or heavily cornified covering of the beak, is a constantly growing structure. The cornified surface of the tissue obliquely slides towards the tip of the beak (Stettenheim, 1972), the edges and surface of which are continually worn away during use. Falconers regularly 'cope' or cut the upper beaks of their birds to counteract overgrowth.

In all cases the beak should be trimmed to shape (not just cut off square) with nail clippers and then smoothed off with fine sandpaper. An emery board is very suitable. Sometimes the beak can be ground into shape with a modeller's cordless Dremel drill fitted with a small carborundum stone. A diamond chip dental cutting disc is also a useful attachment. If bleeding occurs, often the heat generated when using the rotary instrument cauterises the blood vessels. If bleeding doesn't stop, the beak can be cauterised with a silver nitrate pencil or solution of ferric chloride after which it is neutralised with sodium chloride. *Because painful, these procedures are best carried out under general anaesthesia.*

Occasionally a beak is seen that has either developed abnormally from hatching or has been fractured and allowed to heal in an uncorrected position. The lower beak may extend out at an angle to the upper beak. The owner might think this is due to dislocation, but because of the double articulation of the avian lower jaw (Fig. 1.1), dislocation is unlikely. There are two joints of the quadrate bone, dorsally with the temporal bone and ventrally with the articular bone, that distribute any disrupting force applied to the mandible. Also in young growing birds the tip of the upper beak may lie behind the lower beak resulting in prognathism. Another deformity is 'scissor beak', in which growth on the two sides of the rhinotheca or upper beak is unequal, so that this is deviated to one side of the lower beak.

All these malformations result in difficulties in prehension and with soft food tending to lodge at the side of the beak. There are two methods of dealing with this problem in birds other than parrots, both of which require osteotomy.

First, the difference in the lengths of the two sides is measured carefully. The first procedure is to remove a section of bone from the longer of the two mandibles and then wire the bone back in position with one or two stainless steel wire sutures.

### *Sliding osteotomy*

The second technique is to use a sliding osteotomy. This is carried out just anterior to the commissure of the integument covering the upper and lower beaks. In this area the bone is fairly accessible and there are no large blood vessels overlying the bone. The pseudo-



temporalis muscle closing the beak (but not in parrots, in which the ethmomandibularis is the main closing muscle) overlies the posterior part of the section to be made in the bone. The size of this muscle depends on the species and the power of closing the beak, which depends on the bird's feeding habits. Fortunately, most of those birds where the operation is required have weak pseudotemporalis muscles and relatively long, straight mandibles.

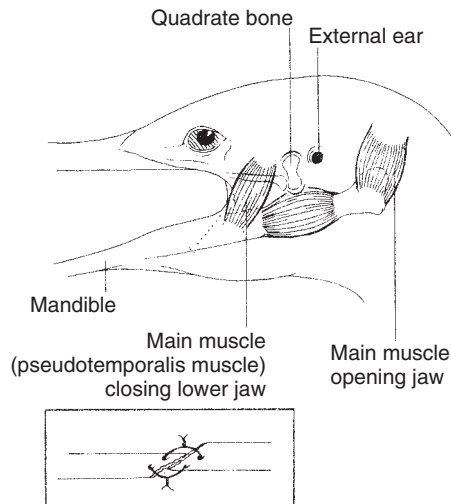
The part of the muscle which may overlie that part of the bone to be sectioned is partly freed from its insertion onto the bone. Having decided on the direction of the oblique section through the bone, a line of fine holes is drilled along this position. The bone is then cut with a saw. The anterior part of the mandible can then be slid cranially in relation to its posterior half and again wired in position with stainless steel wire sutures. If the upper pair of holes drilled for the wire are large enough, they will take a catgut, or, better, polyglactin suture as well as the stainless steel suture. This absorbable suture can be used to hold the pseudotemporalis muscles back in place (Fig. 8.3).

In carrying out both these methods, the integument covering the bone needs to be carefully stripped for a little way down on each side of the section through the bone. As far as is practical, it is better to try and suture the integument so that the suture line does not overlie the union in the bone but is more to one side.

For sectioning the bone a sterile junior hacksaw blade can be used. This is sometimes easier if the blade is first snapped in half. The wire sutures should be tight enough only to bring the bone together; over-tightening usually results in the wire cutting its way through the fine trabecular structure of the bone.

Birds show little discomfort after both these procedures and are surprisingly rough with their beaks. They usually start to feed straight away. Because of this, some external support is recommended. A splint made of hexcelite thermoplastic splinting material can be moulded to form a cradle for the mandible. This can then be wired into position with the wire going through the skin and over the bone.

The success of these operations will depend not only on the skill of the surgeon but also on the correct selection of cases. The temperament of the bird is important. Ducks usually make good subjects. Success also depends on the size and shape of the lower beak.



**Fig. 8.3** Diagrammatic representation of the articulation of the mandible in a typical bird, showing one method of osteotomy. The dotted line indicates where the bone is sectioned.

One needs a relatively long and straight area on which to operate. One disadvantage of these operations is that the mandibular branch of the fifth cranial nerve runs through a canal in the mandible and is quite likely to be destroyed when the bone is sectioned. When using the second method on a reasonably large bird it may be possible to cut carefully round the circumference of the bone providing the pre-drilling has not already damaged the nerve. However, the nerve distal to this area is only sensory and the bird is not apparently affected by anaesthesia of this area, although subsequent searching for food *may* be affected (first read p. 36).

### Parrots

*The techniques described above are not suitable for parrots, in which other techniques should be used.*

1. In the case of scissor beak, after appropriate trimming a prosthetic ramp of acrylic is built up on the lower beak so that as the tip of the upper beak bears onto the lower beak it tends to be pushed into the correct position. The ramp is fashioned from dental acrylic or Technovit and anchored to the lower beak with a transverse Kirschner Ehmer (KE) wire, and possibly stainless steel mesh, after the surface of the beak has been scarified with a dental burr.
2. A Kirschner-Ehmer (K) wire is passed transversely through the frontal bone just above the eyes and hooks formed on each side. A second K wire with a hook is passed through the central area on the upper beak. Acrylic or Technovit is used to help hold this in position. Elastic bands (or orthodonture rubber bands) are placed across the hooks to pull the beak into position.

Both methods work best in birds that are not fully grown. For more information on these methods see Martin and Ritchie (1994) or Gelis (2006).

### Splints or fractures of the beak

If the damage is a simple crack in the bone, particularly if only one side is affected, then a stainless steel wire suture will suffice. If only the cornified integument is damaged it can often simply be glued back into position using an epoxy resin glue or one of the 'super glues' or, better still, bone cement (cyanomethylacrylate).

If the beak is more seriously damaged, and is hanging by the intact integument, something more robust than simple wire suturing will be needed. Various methods have been used by different workers. These methods nearly always involve the use of Steinmann's pins or Kirschner wires placed in a cruciate pattern. These are further braced with figure-of-eight stainless steel wire sutures placed around the ends of the pins. The ends of the pins are best protected by an epoxy resin glue or similar substance. Some sort of cradling device as described above, to give external support, can be used.

### Partial loss of the beak

Partial loss of the beak can happen in any species, but is commonest in those birds with rather large or long beaks such as the hornbill, the toucan, parrots, ducks and, occasionally, wading birds. In this last group, because of the long, thin beak, the problem can be insoluble. In those birds with a wider base to the beak it may be possible to fit a prosthesis. If only the tip of the beak is broken off, particularly if this does not involve the underlying premaxilla, the beak can be filed and shaped with sandpaper. Eventually the beak will return to normal (see Fig. 1.1).

If a small part of the premaxilla is missing, the open end needs to be first plugged before shaping. Surgical glue, such as a self-curing acrylic, is preferable but if this is not available epoxy resin glues, such as those used for car body repair kits, can be used and do not appear to be toxic when used externally.

There are few papers in the scientific literature that record the fitting of a prosthesis. Von Becker (1974) reports a problem in two hornbill ravens, damaged in transit, that were repaired by fitting steel plating to cover the ends of the remaining stumps. Most other reports have used a beak moulded from fibreglass or dental acrylic. The material marketed under the name of Technovit 609 is suitable. The author has on two occasions used high-density polyethylene for a prosthesis fitted to two parrots and has also used polypropamide to replace a duck's partly-missing upper beak. In the latter case the polypropamide upper beak was fashioned from the barrel of a 10 ml plastic syringe. Approximately one-third of the circumference of the plastic tube was used and was found to have about the right curvature. This was then overlapped on the remaining proximal half of the beak and kept in position with stainless steel wire sutures. The bird started to feed as soon as it recovered from the anaesthetic (see Plate 14).

In the psittacine cases the prostheses were carved from a block of high-density polyethylene, the material used for making human artificial hips.

The problem in both cases is the satisfactory and permanent fixation of the prosthesis to the remainder of the beak. A surgical glue can be used, or wire sutures or Kirschner wires used in a cruciate pattern. In all cases the attachment eventually works loose due to the birds' constant rough usage and to pressure erosion of the bone. The bone, in any case, is not very solid in the region of the nares, being composed of a mesh of interlocking trabeculae enclosed in a thin, outer shell. Nature has provided a very strong and light-weight structure admirably adapted to the function of prehension for the particular species but quite useless as a firm anchorage in orthopaedic surgery. The parrots used the prosthesis quite readily to climb both vertically and across the top of the cage. They did not use the beak to crack nuts. This may have been due to the fact that the natural beak has a number of transverse ridges across the internal surface. They are used in lodging a nut with the tongue in order to crack it with the force of the lower beak. The bird has subsequently to be maintained on soft foods such as seed, ground down in a food blender and mixed with peanut butter or mashed potato (see p. 192). These birds readily eat a variety of fruit. Oesophagostomy tubes may be required (see below).

It is questionable whether the use of a prosthesis is always justified in parrots. Although the device is well tolerated, apart from the improved cosmetic effect, there may be little advantage to the bird. The birds soon learn to climb and to feed quite effectively on soft foods without an upper beak and appear to be quite happy once the original lesion has healed. A Tasmanian green rosella (*Platycercus caledonicus*) is reported to have fed and reared its chicks normally. A prosthesis is, however, essential if the mandible is lost.

## **Surgery of the neck**

Sometimes a foreign body will lodge in the oesophagus. This could be a long bone from the prey of a raptor or a fish hook in a water bird. The oesophagus in most birds is wide and easily dilated, but the muscular wall is thin. It may be possible to extract the object via the oropharynx in the unanaesthetised subject. In other cases an incision will have to be made in the neck. There are no particular problems but it is as well to make the incision on the left side since the jugular vein is better developed on the right side. The external carotid artery does not form until near the base of the skull and the internal carotids are tucked under the cervical vertebrae.

## **Surgery of the crop**

### **Impaction of the crop**

This can occur through a variety of causes: foreign bodies (newspaper, hay, any nest material) all of which may become infected, the sudden ingestion of food too high in fibrous content. The aetiology of crop stasis in hand-reared nestlings can be similar to impaction in adult birds but is more often caused by food given either too frequently or in too great

a quantity or at the wrong temperature. In chicks the condition can usually be relieved by gentle flushing and aspiration with warm saline. The impaction can be felt usually as a plastic mass, but which could be more solid, situated at the thoracic inlet.

First put in place two stay sutures. Then, providing an incision is made over the area of greatest distension, there is little danger of damage to other structures. Both crop and skin should be sutured separately using a single inversion pattern.

### Fistula of the crop

Fistula of the crop is also seen in hand-reared nestlings and results from scalding by food given at too high a temperature. Surgical repair is feasible but defer surgery as long as possible so that the chick first reaches maximum weight. Also necrotic debris needs to be cleared so that the edges of the wound are easily defined and the adherent crop wall and skin can be easily defined. Have a crop tube in place during suturing to facilitate visual differentiation of the crop mucosa and skin. If there has been extensive loss of skin it may be possible to mobilise skin from higher up the neck. The most dangerous situation is food trapped between the skin and the crop resulting in subcutaneous necrosis. After operation a pharyngostomy tube needs to be put in place.

### Use of a pharyngostomy tube

A pharyngostomy tube is sometimes useful after beak, neck or crop surgery, is simple to insert and can be left in place for a number of weeks. An incision is made through the skin of the right side of the neck just caudal to the mandible. If possible place a finger in the oesophagus and dissect down onto it.

## SURGERY OF THE RESPIRATORY SYSTEM

### Devoicing birds

Devoicing might be requested by an owner and although carried out in the past, principally on the domestic cockerel or a peacock, it is not an ethical procedure for a veterinarian to perform. In any case the long-term end result was often not satisfactory.

### Acute respiratory obstruction

In psittacines, including cockatiels, and occasionally in other birds, respiratory obstruction is not uncommonly encountered and is an emergency situation. There is usually pronounced acute onset of dyspnoea accompanied by abnormal expiratory wheezing sounds. This condition is distinct from the more slowly developing syndrome seen in the budgerigar due to hypertrophy of the thyroid gland. In other birds it is often due to inspissated pus and occasionally seed husks or chewed carpet material. In parrots often there is a history of increasing respiratory disease.

In desperate cases, insertion of an air sac cannula as auxiliary airway is essential (as described in Chapter 7) after which diagnosis can be confirmed by endoscopy. If possible it is better to stop the foreign body passing further down the airway by transfixing the trachea with a suitable-sized hypodermic needle passed transversely just caudal to the obstruction. The obstruction may be removed in an African grey parrot by aspiration using a modified canine urinary catheter (e.g. 6 Fr, 2 mm diameter) attached to a 60 ml syringe. This combination, if the plunger is rapidly withdrawn, produces a good negative pressure. Sometimes two or three attempts are required.

### Tracheotomy

If aspiration doesn't work, then tracheotomy may be required. Before operation the bird's head should be elevated 45° to the length of the body. The exact location of the foreign

body having been located by endoscopy or possibly radiography, a transverse incision no more than 50% of the diameter is made in the trachea. Incision only half way through the diameter helps maintain alignment of this structure. Fine (6/0) stay sutures on either side of the incision can be used for manipulation. When suturing after operation place the sutures around two or three tracheal rings. Leave the air sac cannula in place for two or three days.

Always culture any aspirate, purulent or foreign material.

### Trachectomy

Trachectomy may be required for neoplasm or severe stricture. It is said that most species of bird can tolerate a loss of up to five tracheal rings. Before surgery insert pre-placed stay sutures in position.

## COELIOTOMY (ABDOMINAL SURGERY)

The usual clinical indications for entering the avian abdomen are:

1. Diagnostic – biopsy of liver, kidney, pancreas, gonads or possibly lung
2. The removal of foreign bodies from the proventriculus or gizzard
3. The relief of an impacted gizzard or ventriculus
4. The removal of tumours
5. The relief of an impacted oviduct
6. Colopexy
7. Salpingohysterectomy

Some of these problems may be solved using the endoscope together with endoscopic surgical intervention.

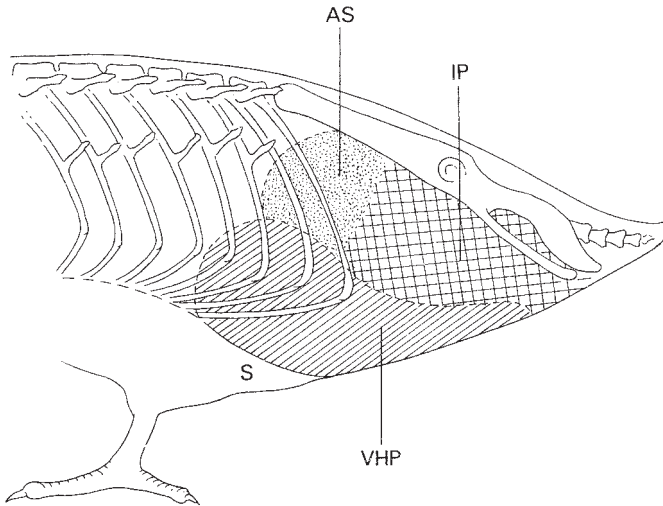
### Midline, ventral approach

If the endoscope is not to be used, then the approach to the abdomen can be through a midline ventral incision, but if a neoplasm of the gonads or adrenal gland is definitely diagnosed, a flank incision gives better access to these organs and their associated blood supply. If using the ventral approach, take into account the possible problems with a bird in dorsal recumbency already mentioned in Chapter 7.

The ventral incision is best made slightly to the (surgeon's) left of the midline. The abdominal muscles are the same as those in the mammal but the extent of the linea alba and the thickness of the muscles vary according to the species of bird. It is best developed in strong flying birds, since the body wall is the site of the elastic and active movement governing the bellows action of the air sacs driving air through the avian respiratory system. Harrison (1984) suggests extending the midline incision by incisions at right angles, parallel to the caudal edge of the sternum, so as to form two flaps. This produces better exposure. But if these parasternal incisions are extended more than a third of the distance from the midline to the ribs in some species, the intestinal peritoneal cavity may be entered, which may not be necessary.

Just below these outer areas lie the left and right posterior thoracic air sacs. Also depending on the species, the midline incision, if extended too far caudally, will enter the intestinal peritoneal cavity. This cavity contains the two abdominal air sacs. Taking the above anatomical facts into consideration it is not desirable to incise and deflate all four posterior air sacs (see Fig. 8.4).

If a careful incision is made through the linea alba, with blunt-pointed scissors, while picking it up with rat-toothed forceps to form a tent and hold it away from the underlying



**Fig. 8.4** Diagram showing the relative positions of the coelomic cavities: AS, left and right caudal thoracic air sacs; IP, left and right intestinal peritoneal cavities. The two cavities are divided by the dorsal mesentery, in which are suspended the intestinal and reproductive tracts. Intimately connected with the intestine are the left and right abdominal air sacs; VHP, left and right ventral hepatic cavities. These are divided by the ventral mesentery. The cavities only contain the two lobes of the liver; S, sternum. After Dunker (1978).

viscera, entry is made into the right ventral hepatic cavity. This initial incision is preferably carried out with a radio-surgical instrument.

On the floor of this cavity (anatomically the dorsal aspect of the cavity) is a membrane (right post-hepatic septum) that resembles an air sac but is one of the peritoneal membranes. Contained within this first cavity are the organs shown in Fig. 8.5. The ventriculus is attached by the central mesentery to the abdominal wall at the midline.

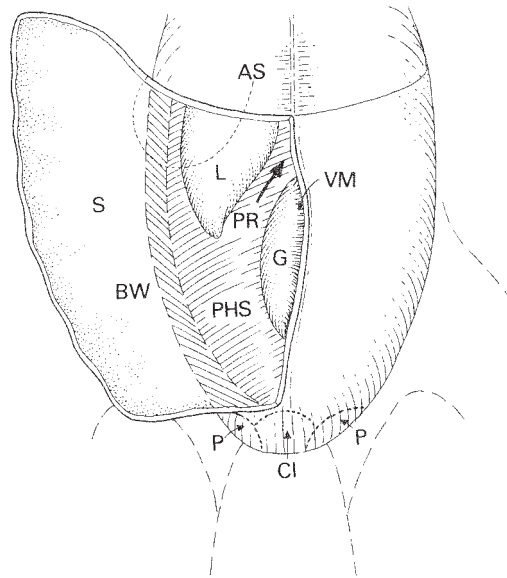
Distal to the ventral mesentery lies the left ventral hepatic cavity containing the left lobe of the liver. The ventral hepatic cavities contain no air sacs. The thickness and translucency of the post-hepatic septal membranes vary with the size of the bird (also if there is any degree of air-sacculitis or peritonitis with adhesions). In small birds the post-hepatic septum acts as a fat depot, obscuring the intestine beneath. The air sacs are mostly adherent to and supported by the surrounding tissues and so will not collapse if punctured. Providing entry into and destruction of the integrity of the air sacs *is not extensive*, it has no more effect on the respiratory system than tracheotomy does in mammals.

### **Gastrotomy: proventriculotomy/ventriculotomy**

Access to the proventriculus and ventriculus may be required for the removal of foreign bodies. These can sometimes be flushed out, with the bird's body tilted on the table to 45° with the head downwards or, if of ferrous metal, removed by miniature magnets glued inside a plastic tube. Sharp objects can even penetrate the ventriculus to become walled off in the coelomic cavity.

#### **Ventriculus**

The muscular stomach, or ventriculus, is easily visible through the initial abdominal incision. Its muscular wall varies in thickness. In the gizzard of some granivorous birds it is very thick. In these species haemorrhage from the muscle can be a problem if a radio-



**Fig. 8.5** Incision through the linea alba into the right ventral hepatic cavity: AS, dotted line shows the position of the right caudal thoracic air sac below the level of the ventral hepatic cavity containing the liver; L, right lobe of liver; PR, the approach to the proventriculus; G, gizzard attached to linea alba by the ventral mesentery; PHS, right post-hepatic septum, distal to which lie the duodenum and pancreas in the intestinal peritoneal cavity, which is surrounded by the abdominal air sac; CL, cloaca – an incision in this area will enter the intestinal peritoneal cavity; P, pubis; BW, body wall; S, skin flap; VM, ventral mesentery.

surgical knife is not used. In this type of bird surgical access is better attempted via the proventriculus and through the isthmus into the ventriculus. In the fish- and meat-eating birds it is much less thick and sometimes almost indistinguishable from the proventriculus.

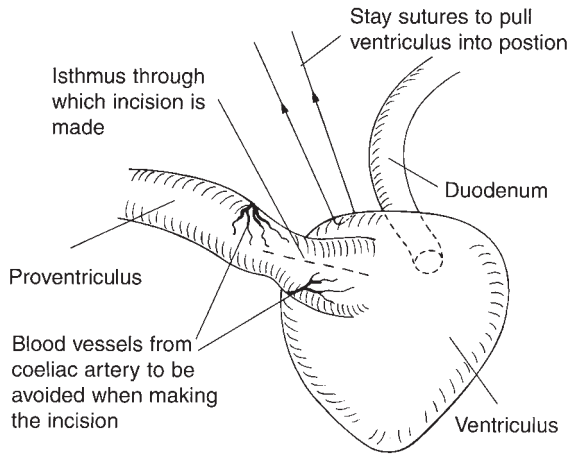
### Proventriculus

The glandular part of the stomach, or proventriculus, is not quite so visible (being partly covered by the liver) but gentle traction on the ventriculus will bring the posterior part of this organ into view (Fig. 8.6). In the ostrich, proventriculotomy for the relief of impaction may be required and the surgical approach is somewhat different (Fig. 8.7).

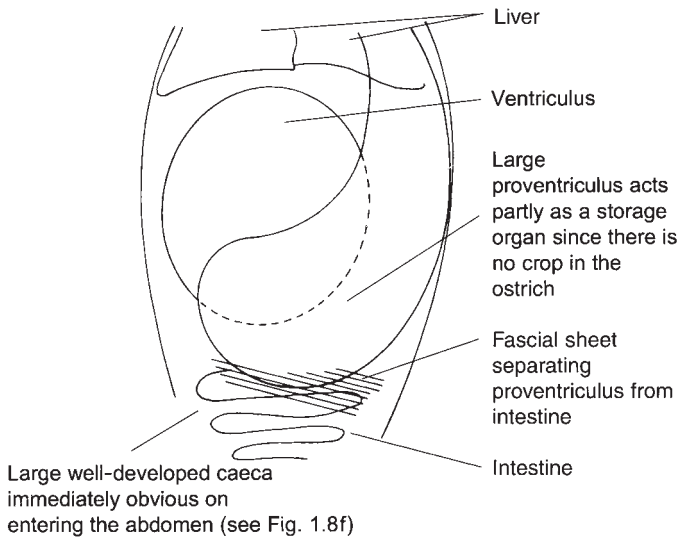
### Surgical access to the rest of the alimentary canal

If it is necessary, an approach can be made via the route used by Durant (1926, 1930) and Schlotthauer *et al.* (1933) for ablation of the caeca. Make an incision medial and parallel to the left pubis. There is a large artery in this area that must be avoided. This approach gives access not only to the caeca but also the rectum and the distal part of the ileum, the duodenum, the proventriculus, the ventriculus and the gonads (Fig. 8.8).

The duodenum and pancreas, however, are best approached via a ventral abdominal incision. This is made through the midline into the right ventral hepatic cavity and then through the right post-hepatic septum (described above) on the floor of this coelomic cavity. The duodenum is found directly underneath. This surgical approach also gives access to the supraduodenal loop of the ileum and some other parts of the small intestine. However, the intestine in birds is not as mobile as in mammals, being suspended in the mesentery attached *both dorsally and ventrally*, also this mesentery is intimately surrounded by the abdominal air sacs. Any traction on the intestine is liable to lead to a



**Fig. 8.6** Surgical approach to the proventriculus.



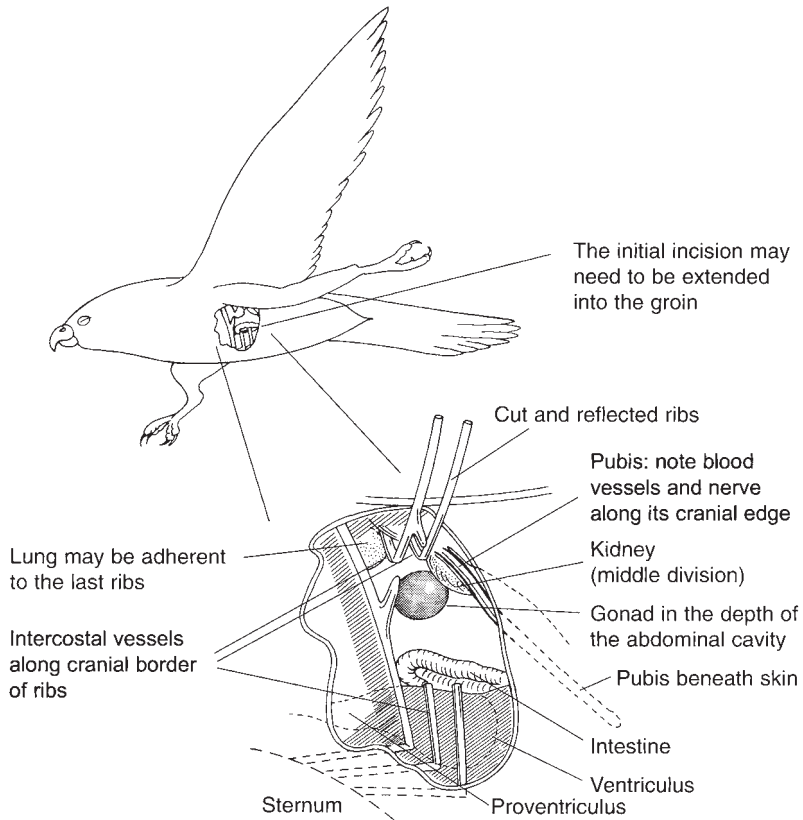
**Fig. 8.7** The ostrich abdomen.

tearing of these membranes and possible rupture of the associated blood vessels, together with traction on and stimulation of the nerve of Remak, containing the autonomic nerves.

#### Intussusception of the ileum

Intussusception of the ileum is usually indicated by prolapse of the bowel. It is not common, although the author has seen three cases (two Harris's hawks and a lovebird). In the opinion of Gelis (2006) it is more common in gallinaceous birds. Greenwood and Storm (1994) reported the successful reduction of intestinal intussusception in two red-tailed hawks (*Buteo jamaicensis*) and give a useful discussion on possible aetiology in this species.





**Fig. 8.8** Surgical approach to the abdomen via a left lateral coeliotomy.

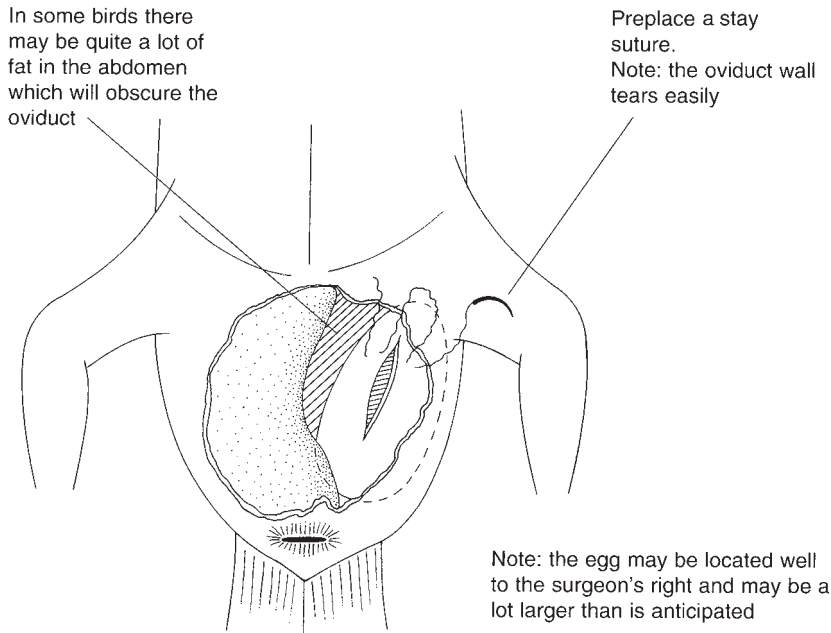
All these cases are emergencies and need immediate surgery. They nearly always need resection of the bowel, which is a difficult and delicate operation. When carrying out an end-to-end anastomosis, the operation is made easier if a length of plastic tubing is inserted into the cloaca, then through into the colon and so on up into the site of resection. This tube can then be used as a framework around which sutures of 6/0 to 10/0 material in a continuous suture pattern can be used. Two sutures, at 12 o'clock and 6 o'clock should first be inserted.

### The reproductive tract

#### Egg retention and egg peritonitis

Egg binding can be due to a number of causes, commonly hypocalcaemia, plus other nutritional deficiencies, both of which with infection may result in malformed eggs. Also, an old or very young bird or a persistent egg layer may develop impaction. Neoplasms, obesity and torsion of the oviduct (Harcourt-Brown, 1996) may also result in impaction.

Any lesion causing enlargement of the reproductive tract is likely to displace the stomach towards the right. An incision in the midline is therefore quite likely to pierce the ventral mesentery, by which the ventriculus is attached to the ventral abdominal wall, and to enter the left ventral hepatic cavity. On the floor of this cavity, and probably displaced upwards by the enlarged oviduct, will be the left post-hepatic septum, incision of which will expose the oviduct. If an egg is to be removed by hysterotomy it is best to put in one



**Fig. 8.9** Hysterotomy to remove an impacted egg.

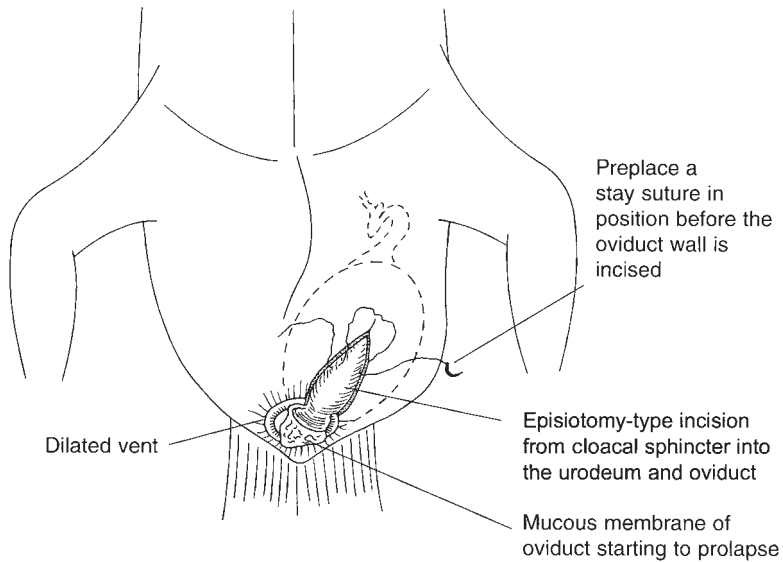
or two preplaced sutures before making the incision into the oviduct (Fig. 8.9). Once this is opened the wall of the oviduct contracts and, being very thin, is difficult to find and suture.

If there is any fluid in the abdomen, as in egg peritonitis, Harrison (1984) suggests draining with a Penrose drain and flushing with antibiotics. This is carried out 2–3 days before hysterotomy in the case of an egg impacted in the oviduct.

Instead of carrying out a laparotomy, Rosskopf and Woerpel (1982) describe paracentesis of the egg contents by using a hypodermic needle pushed through the abdominal wall and through the egg shell. However, the point of the needle easily slides off the surface of the shell (particularly with thick-shelled waterfowl eggs) unless thrust in with controlled force. When yolk and albumen have been aspirated, the egg shell collapses. Romagnano (2005) then recommends that the bird has a prostaglandin E2 gel (Prostin E2 Vaginal Gel/Pharmacia) applied to the opening of the cloacal oviduct (0.1 ml/100 g body weight) rather than use an injection of oxytocin. Oxytocin is not produced by birds and is said to have profound effects on the cardiovascular system together with very painful and ineffective smooth muscle contraction. The remains of the egg should then be expelled within two days. Whatever other therapy is used the bird's calcium reserves need to be boosted.

If part of the impacted egg can be seen through the cloacal opening, the needle can be inserted into the egg through this exposed section of shell. Alternatively an episiotomy type of incision can be employed to extract the egg (Fig. 8.10).

An impacted egg sometimes leads to prolapse of the oviduct, with the contained egg, through the cloaca. If this is not dealt with quickly the tissues become congested, they can dry and eventually become necrotic. It is essential to moisten the prolapsed parts with normal saline. Use a lubricant such as KY jelly or liquid paraffin together with moist heat (i.e. just above body heat) to relax the cloacal sphincter to ease the egg out through the



**Fig. 8.10** Episiotomy-type incision for removal of an impacted egg.

opening in the prolapsed oviduct. The blunt end of a sterile thermometer is very useful for this purpose, being slowly rotated around the circumference of the egg, between it and the wall of the oviduct.

### Cloacal prolapse

After the egg has been removed the cloaca may remain prolapsed. This may also occur after normal egg laying in a weakened oviduct. Rosskopf *et al.* (1983) described the use of No. 0 stainless steel wire sutures around the vent to retain the cloaca in a greater sulphur-crested cockatoo.

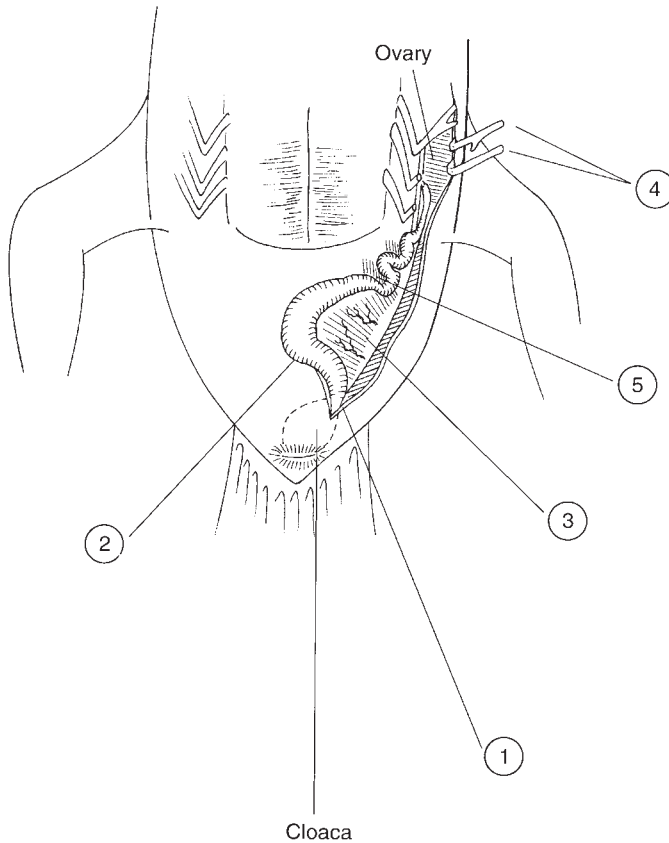
These authors also describe cloacopexy, for persistent prolapse, by suturing the cloaca to the abdominal wall. Push this into position using a cotton bud or, if the bird is large enough, the finger. The cloaca is readily accessible through a midline incision between the two pubic bones. The cloaca may also be kept in place by sutures round the last two ribs after carrying out a coeliotomy. Great care must be taken not to trap a loop of colon between the cloaca and the body wall, as noted by Radlinsky *et al.* (2004).

It should be noted that there is a *grave danger that any prolapse may contain intestine, oviduct, or ureter* and may lead to obstruction of these organs. Also, persistent cloacal prolapse may be due to a tumour (see viral papillomas, p. 301) or to a cloacitis.

As a short-term measure a purse-string suture around the vent will suffice, but *be very careful* that this is placed *exactly* at the mucocutaneous junction, otherwise the ureters may be trapped and the nerve supply permanently damaged. Alternatively, use two mattress sutures on either side of the vent. Another solution is to remove a wedge of vent to reduce its circumference, but do this in the male bird in the dorsal aspect (Lumeij & Westerhof, personal communication).

### Salpingohysterectomy

Removal of the oviduct but not the ovary may be required to stop persistent egg laying, particularly in cockatiels. The procedure can be hazardous for the inexperienced and is best carried out using radio-surgery. However, it can be accomplished without this aid if



**Fig. 8.11** Salpingohysterectomy. Although the vasculature is better developed when the bird is in the egg-laying condition, and some surgeons may decide to delay the operation because of this, the organ is much more easily identified in this state.

the surgeon is careful and has good anaesthesia (see Fig. 8.11). Greenwood (1992) reported salpingectomy in a 4-year-old hybrid flamingo using two small laparoscopy incisions and the use of a 2.7 mm diameter endoscope and Shae's aural forceps. Scott Echols (2002) has reviewed this subject.

### *Surgical procedure*

1. The primary incision is made well to the left side of the abdomen, and extended from the cloaca to past the last two ribs. It starts just in front of the pubic prominence. Note that only the uterus (i.e. the oviduct) is to be removed, not the ovary. Carefully puncture the abdominal air sac with the pointed end of a pair of closed straight mosquito forceps, and then open the forceps still in the incision. Two layers of air sac need to be opened before the ovary can be seen lying in the dark in the depth of the abdomen.
2. The oviduct and uterus are a whitish-pink, slightly corrugated organ, which may be much longer than anticipated. In breeding condition the oviduct may grow to four times its size in the quiescent state.
3. The dorsal suspensory ligament of the oviduct (mesovarian ligament) has branches of the ovarian artery running through it. Clamp these with artery forceps, or coagulate with radio-surgical equipment, then carefully tear the ligament by *slow* steady traction.

4. Cut and reflect the last two ribs. There is no real need to carefully dissect the fimbria – use gentle careful traction on the uterus.
5. Finally, ligate the distal end of the oviduct and amputate.

### Neoplasia

Access to the ovary or adrenal gland, necessary because of a neoplasm, may be achieved via a flank incision. Arañez and Sanguin (1955) give an excellent description of this approach for poulardisation (removal of the ovary) in the domestic fowl. The incision is made over the last two left-hand ribs (sixth and seventh). The skin is incised, the sartorius muscle is pushed posteriorly and the incision deepened between the two ribs. The aim is to keep close to the anterior border of the seventh rib to avoid the intercostal artery. The ribs are kept apart with a retractor.

Below the ribs the left abdominal air sac is penetrated revealing the intestines, which are pushed aside with a blunt probe. The ovary and adrenal gland should then be visible. In the normal immature organ the blood supply at the base can be clamped with haemoclips then very carefully the organ can be grasped with forceps and twisted off. The same technique can be applied to the testes (see Fig. 8.8). *In both cases the operation is hazardous.*

In a bird smaller than the domestic fowl, or one where the gonad is enlarged and neoplastic, the situation can be very much more difficult. The same approach as is used for a salpingohysterectomy can be used. Unfortunately, by the time many of these cases are finally correctly diagnosed they are too large for successful surgery.

The blood vessels supplying the gonads are short and not extensible, unlike the case in the dog or cat. They are close to the dorsal aorta and vena cava, which can easily be ruptured. Very good illumination, magnification and meticulous surgical technique are required for success.

### Retained yolk sac in neonates

If the yolk sac is not absorbed during the normal post-hatching period it is liable to become infected. It is possible to remove it surgically. Indications for removal are abdominal distension, anorexia, lethargy, inability to stand and inflamed umbilicus. An encircling incision is made around the umbilicus and this is extended by two incisions transversely or longitudinally. Then, carefully rolling the chick over, the yolk sac is encouraged to fall out of the abdomen. The stalk to the intestine must be ligated. Delicate surgery is required. *Do not attempt to aspirate the yolk or inject antibiotics into the yolk sac.*

### The penis

An occasional problem seen in male ducks is prolapse of the enlarged penis [see Plate 11]. This can be 5–7 cm long and drags on the ground. It can become dry and excoriated and necrotic. The cause is usually injury brought about by bullying from another drake. However, if several cases occur simultaneously and the ducks look rather ill, then this may be due to duck virus enteritis (see p. 283). In the duck the penis is an extension of the mucous membrane lining the cloaca. There is no vascular corpus spongiosum as in the mammal. The only solution to the traumatic problem is amputation, which seems to have little deleterious clinical effect, except to make the duck ineffective for breeding purposes. In Vasa parrots (*Coracopsis* spp) there is a normal intromittent phallus which may remain protuberant for some time after copulation, as mentioned in Chapter 1 (see p. 20 and Plate 15).

### Repair of the ruptured abdominal wall

Rupture of the abdominal wall is a difficult problem, which is not uncommon in the obese female budgerigar. The muscle is weakened by egg laying and infiltration of fat so muscle fibres separate. Gradually the whole abdominal musculature is stretched apart along the linea alba. The weight of the abdominal viscera causes marked enlargement and descent

of all the structures, so that the swelling becomes pendulant. The results are potentially serious, with impaired respiratory and cardiac function. The liver may be enlarged and infiltrated with fat.

These cases are bad surgical risks. Since quite large haematomas and lipoma-like neoplasms can occur in the same region, diagnosis should be confirmed with radiography or possibly ultrasound. Some of the less serious cases may not be true hernias, but just an extended body wall and may be due to malnutrition, lack of exercise, chronic masturbation, etc. All cases need thorough investigation before undertaking surgery.

If successful anaesthesia can be achieved, with the bird in dorsal recumbency, it is best not to completely incise the body wall since in these cases the underlying air sacs and contained viscera are easily damaged. The body wall should be picked up so that the underlying viscera falls away back into position. Afterwards, alternative mattress sutures of 4/0 chromic catgut together with non-absorbable pseudo-monofilament polyamide are placed through skin and the muscle remaining at the edges of the hernia. The object is not to pull the body wall tightly together but for the catgut to induce some fibrosis via induced granulocytic inflammatory reaction. If possible, it is better to incorporate a supporting, fine, non-absorbable surgical mesh attached to the eighth ribs and sternum. It is hoped this will produce a renewed and stronger linea alba. Providing the suture needle is placed just below the skin it will not damage the underlying viscera, which are often covered in fat.

## ORTHOPAEDIC SURGERY

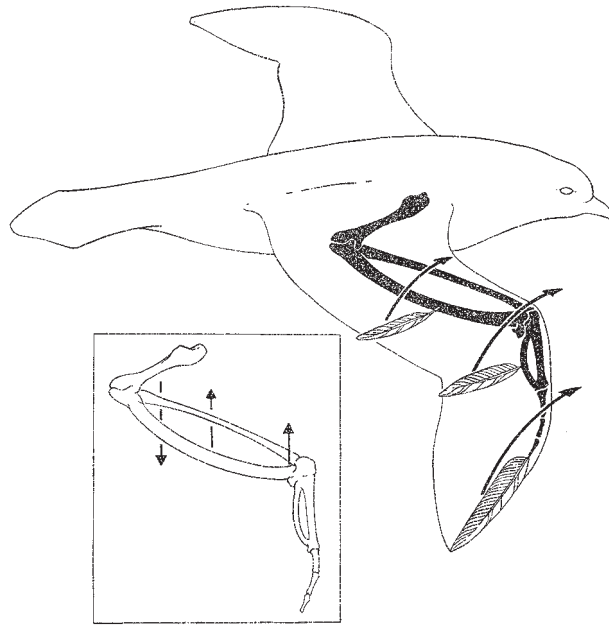
### General considerations

Before attempting any surgery on the bones of birds it is as well to take into account some general considerations. During evolution the avian skeleton has undergone structural adaptations to the biological engineering problems of support and movement imposed on a flying vertebrate. Although the elemental structure of the bone, which is a lattice of hydroxyapatite crystals intimately associated with a mesh of collagen fibrils, is basically the same as in mammals, the gross anatomy of the bone has changed.

The bulk of an avian long bone is concentrated in a thin, porcelain-like shell which shows little or no organisation into Haversian systems. The interior of the bone contains a network of struts, or trabeculae, each one of which is orientated to counteract the external forces imposed on the bone at that particular point. The maximum stress on the bone is at the two ends, so that it is here the bone is expanded with the greatest concentration of trabeculae. The thin outer shell is the most efficient structure to resist the forces of torque imposed on the bone when it is under twisting and torsional loading, which is exactly what is occurring during flight (see Fig. 8.12). In this situation, a thin hollow cylinder is the most efficient. All these engineering principles are used in the design of modern jet aircraft.

In consequence of the porcelain-like shell, avian bones shatter much more easily during surgery. Except perhaps in very large birds, the cortex of avian bones does not form a very sound bed for bone screws. Intramedullary pinning, which in the mammal displaces haemopoietic tissue, in the bird destroys part of the integral strength of the bones.

Avian fractures heal in the same manner as those in mammals. This has been demonstrated by Bush *et al.* (1976), who showed that fibrous followed by cartilaginous callus develops from both the periosteal and endosteal membranes. The rate at which the bone heals is probably a little faster than in mammals. It is most rapid in the smaller birds and one can detect signs of healing on X-ray plates within eight days. As in mammals, excessive displacement of the fractured ends, movement and infection all retard healing. The so-called very rapid healing of the avian bones reported by a number of workers may be



**Fig. 8.12** The mechanical forces imposed on the bones of the avian wing during flight. The curved arrows show the torsional stress placed on the bones as the wing descends during flapping flight. The straight arrows illustrate the bending moments applied to the bone at the same time as the torsional stress.

due to the swift mobilisation of fibroblasts and the formation of collagen fibres binding the bones together, rather than to complete resolution of the fracture with newly formed bone. *Under optimum conditions* the gap between the fractured ends is filled with fibrous tissue within five days and cancellous bone within nine days. True bony union takes 22 days and complete remodelling takes six weeks.

Apart from the healing of bone, *there is little doubt that the maintenance of maximum joint mobility is of far more importance in birds than the attainment of perfect bone alignment.* This is not denying that perfectly-aligned bones heal more rapidly.

In all cases of fracture, after the initial diagnosis it is important to first stabilise the fracture site to prevent contraction of the soft tissue before any more intricate orthopaedic procedure is carried out. With compound fractures take swabs then clean and disinfect with chlorhexidine, F10, etc. Do not irrigate any exposed medullary cavities. Remove any protruding bone. Bandage but leave the wound open for daily wound treatment, together with the systemic treatment of antibiotics and analgesics. When the wound is clean the surgeon can proceed with the necessary orthopaedic surgery. After the orthopaedic surgery has been performed, polymethylmethacrylate (PMMA) antibiotic beads can be used around the operation site.

### **Preparation of the antibiotic-impregnated beads**

A good description of the method of preparation of PMMA beads is given by Remple and Forbes (2000). Essentially, a selected antibiotic powder is ground in a mortar and pestle with polymethylmethacrylate powder (one part of antibiotic to five parts of PMMA powder). Enough liquid monomer is added to the mixture to make a dough. This is then packed into a 20 ml syringe, squeezed out into a flexible rod and cut into sections before it hardens.

## The pectoral limb

### The clavicle

In a survey of 6212 specimens, Tiemeier (1941) found 3.41% of wild Passeriformes had fractures of the clavicle. These are not often diagnosed by veterinarians and when they are, they are best left alone with cage rest only. It is not practical to splint these bones in any way. Note that not all species have a clavicle.

### The coracoid

The coracoid is a massive bone counteracting the compressive forces of the pectoralis muscle. In birds below 500 g fracture of this bone is best treated with cage rest and a figure of eight bandage round the wing on the affected side. In small birds the bone will heal by itself and the bird may be able to fly again, but this could take up to one year. If the fracture is near the junction of the coracoid with the sternum and is well displaced then the two bones will have to be wired together.

In a bird of 500 g or more this particular fracture is best dealt with using an intramedullary Steinmann pin. The bone is difficult to access, lying deep below the supracoracoideus (superficial pectoral) muscle. Since this muscle is the main elevator of the wing it must not be damaged and needs to be carefully dissected away from the clavicle, or its fibrous equivalent, the edge of which can be felt subcutaneously at the thoracic inlet (Fig. 8.13). If one half of the fractured coracoid has been displaced inwardly, great care must be taken in manipulating the bone back into position, because the great vessels from the heart lie just below this region. Unfortunately, some of these cases are associated with avulsion of the brachial plexus, in which case surgery would not be justified and the prognosis is guarded.

### Luxation of the shoulder

The shoulder joint is well-supported by muscle and ligament, particularly the coracohumeral ligament. However, the tendon of the supracoracoideus muscle is sometimes stripped from the muscle belly. Rupture of the tendon leads to upward subluxation of the head of the humerus.

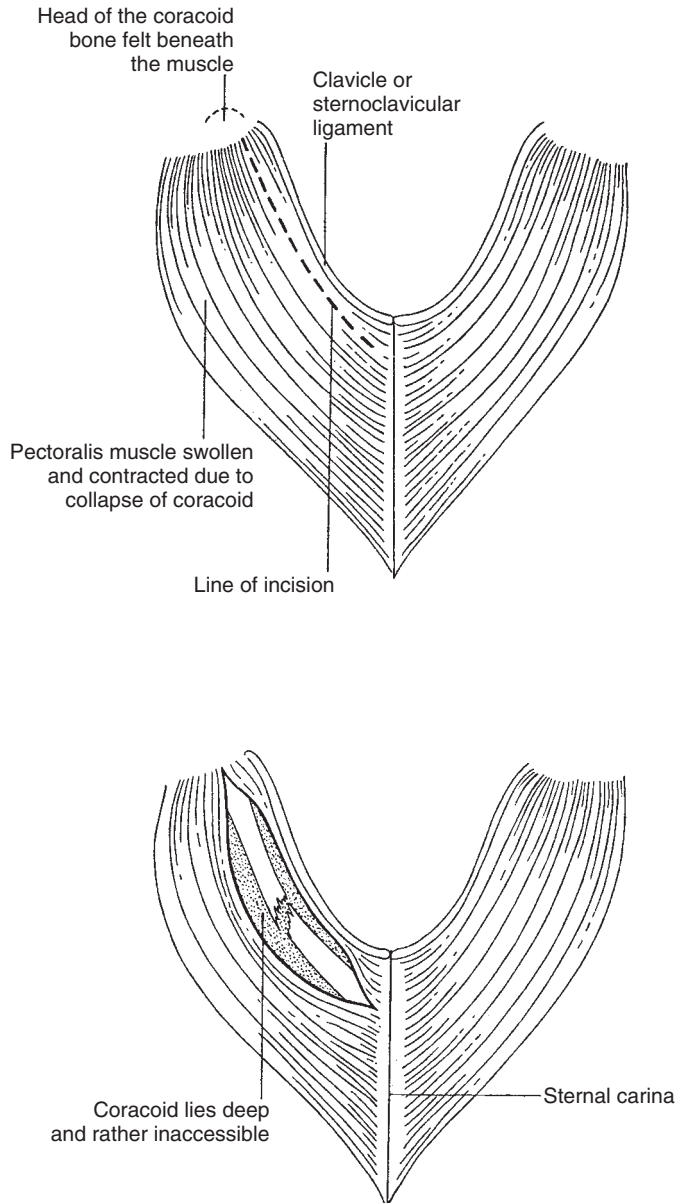
The supracoracoideus muscle and tendon are best developed in birds with a slow flapping flight, in those which hover and in birds which have a rapid jump take off, such as pheasants. In fact, rupture of this tendon has only been seen by the author in pigeons and one crow, both of which have fast-forward flight, and in gulls which are mainly gliders.

The surgical approach to the shoulder joint is not difficult. The fibres of the overlying dermatensor muscle are split longitudinally in the direction of their fibres and the shoulder joint lies underneath. However, locating and suturing the ruptured tendon back in position is very difficult and an almost impossible task. The retention of complete mobility in the shoulder joint, if the bird is to fly again, is very important, more so than in any other joint in the wing. All the mechanical forces and differential movements of the wing are concentrated on this joint.

### The humerus

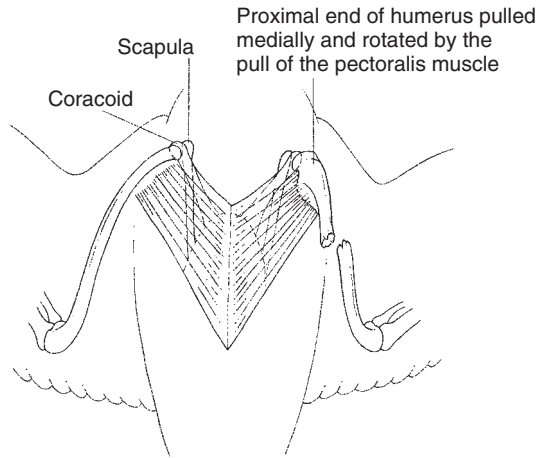
The majority of fractures of the humerus occur midshaft or at the junction of the middle and lower thirds of the bone. These are the areas where the bone is least protected by surrounding muscle. In most cases the fractured ends of the bone are well separated and the proximal part is often rotated along its longitudinal axis, due to the tension caused by spasm of the contused pectoralis muscle (Fig. 8.14). Although there is an extension of the clavicular air sac into the medullary cavity of the humerus and damage to this structure can sometimes be seen on X-ray in the region of the pectoralis muscle, it is usually sealed off by blood clot. Emphysema of the tissues is not usually a problem.



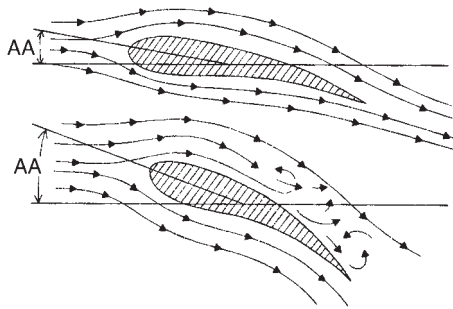


**Fig. 8.13** The surgical approach to the coracoid.

Since most of the mechanical forces imposed on the wing during flight are transmitted to the humerus it is important to get accurate alignment and as near perfect apposition of the bone as is possible. A slight error in rotational alignment could lead to a change in the angle of attack of the aerofoil surface and the aerodynamic properties of the wing (Fig. 8.15) (see pp. 8 and 209). The bird may well learn to adjust to this situation in time but this only increases its problems of rehabilitation. In spite of all this there are a number of recorded instances in wild birds where the humerus has healed in a grossly distorted position with non alignment of the shaft and where the bird has been found flying again (Olney, 1958/9; Tiemeier, 1941).



**Fig. 8.14** Diagram showing the traction exerted on the proximal end of the fractured humerus by the pectoralis muscle.

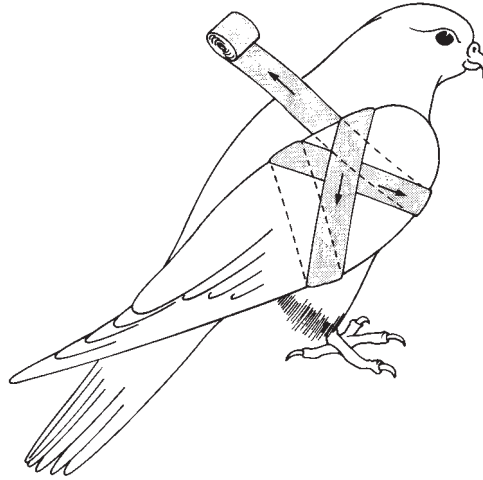


**Fig. 8.15** Diagram illustrating how permanent rotation of the humerus through a badly aligned fracture can affect the angle of attack of the aerofoil section of the wing. The angle of attack (AA) affects the airflow across the wing and its lifting qualities.

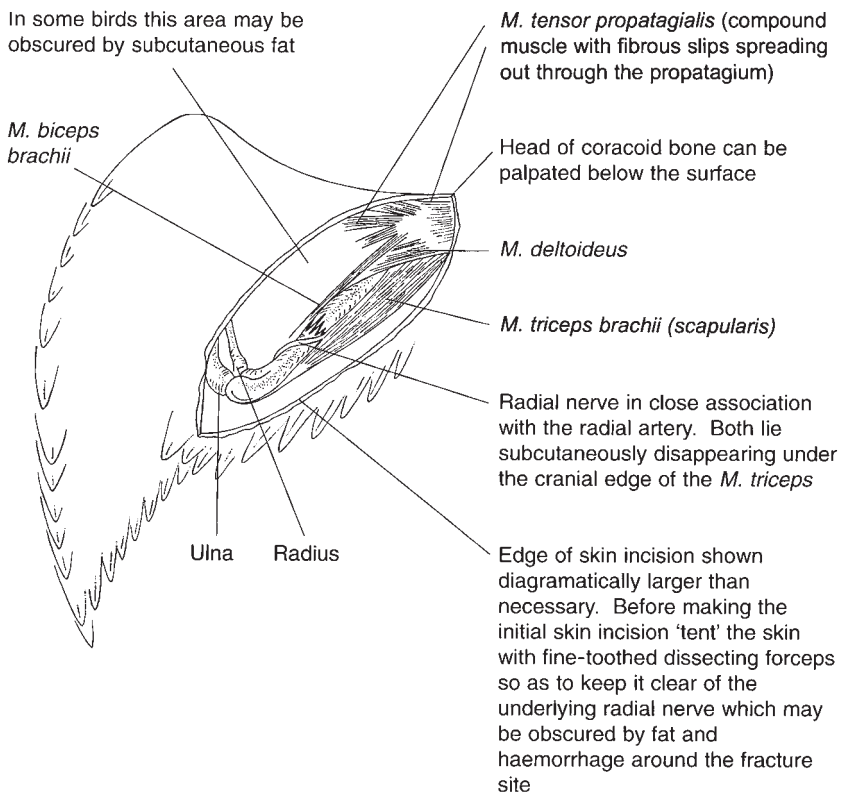
In a fractured humerus more than three days post-trauma, and notwithstanding other considerations such as secondary infection, there is always organisation in the tissue in response to the trauma. The smaller the bird the more rapid is the process. If extensive dissection is needed to find and free the bone, there is grave risk that the nerves and blood vessels traversing the injured area will be damaged. It is difficult to identify the medullary cavity of a long bone of a small bird in a mass of granulating tissue. If the subject is below 100g in weight (cockatiel size) and a captive bird, it may be wiser to leave the fractured wing alone, except to support it with a figure of eight bandage for 2–3 days only (Fig. 8.16). *Bandaging only needs to be done if the wing is badly dropped and the wing should not be supported for a longer period, since this only leads to excessive fibrosis with resultant stiffening of muscles and joints.*

On the other hand, if the bird is a falcon and is to fly again, some attempt at perfect reduction will have to be made. The avian humerus is well supplied with blood vessels. This has been studied by Joji and Popovic (1969) who have shown that there is a separate blood supply to the proximal, middle and distal parts of the humeral shaft. The surgical approach to the bone can be made from either the ventral or dorsal aspect. The latter is probably the easier of the two (Fig. 8.17).

A number of techniques have been devised to repair humeral fractures.



**Fig. 8.16** Figure-of-eight bandage using Vetrap or similar semi-elastic co-adhesive bandage cut into suitable width strips according to the size of the bird. In some cases it may be necessary to bandage the wing to the body. With the wing bandaged in the flexed position the quills of the primary feathers act as a strong, light-weight splint.



**Fig. 8.17** The surgical approach to the humerus from the dorsal aspect, after plucking the covert feathers and wetting the area with alcohol. The diagram is not drawn to scale, the humerus being relatively larger for the clarity of the illustration. (After Coles, 1996, BSAVA *Manual of Psittacine Birds*.)

### *Intramedullary pinning*

Intramedullary pinning can be carried out using the standard Steinmann pin and is the simplest method. In some species such, as the goshawk (*Accipiter gentilis*), the humerus is shaped like an extended 'S' so that it is possible for the ends of the pin to emerge from the bone away from the shoulder and elbow joints (Fig. 8.18). This is important because any trauma to soft tissues near an avian joint usually leads to excessive fibrosis and reduction in mobility of the joint.

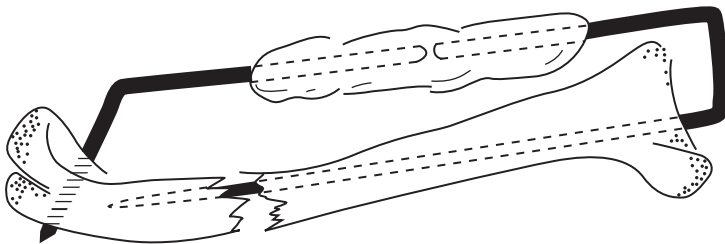
Intramedullary pinning also has the disadvantage that it destroys the trabecular structure of the bone. This will be regenerated when the pin is removed but it does take time. The intramedullary pin used by itself does not guard against rotation and, because of the proportionately larger diameter of the avian medullary cavity, a larger and heavier pin has to be used than in a mammal of comparable size. The intramedullary pin also does not allow endosteal bone regeneration.

### *Professor Redig's 'tie in' technique*

A modification of simple intramedullary pinning is to use the Redig 'tie in' technique (Fig. 8.19). The intramedullary pin can be smaller in diameter and lighter in weight since it only needs to fill 50% of the medullary cavity. At the pin's exit it is bent at 180°. To do this slightly retract the pin after full insertion and grip the shaft of the pin with strong forceps or locking surgical pliers so that when bending the pin the force of bending is not transmitted though the pin onto the easily split humeral diaphysis. One or two further pins are inserted transversely through the two 'solid ends' of the bone. These should be threaded to provide a firm anchorage in the bone. Positive threaded pins are best but negatively threaded pins are often satisfactory. When inserting these transverse pins great



**Fig. 8.18** Intramedullary pinning through cortex of curved humerus to avoid the shoulder and elbow joints.



**Fig. 8.19** Fractures of the long bones can be stabilised using the principles of Redig's tie-in method. For illustrative purposes the diagram shows the method used on a fractured humerus.

care needs to be exercised as the bone easily shatters. Pre-drilling with a smaller diameter drill bit may help to prevent this happening.

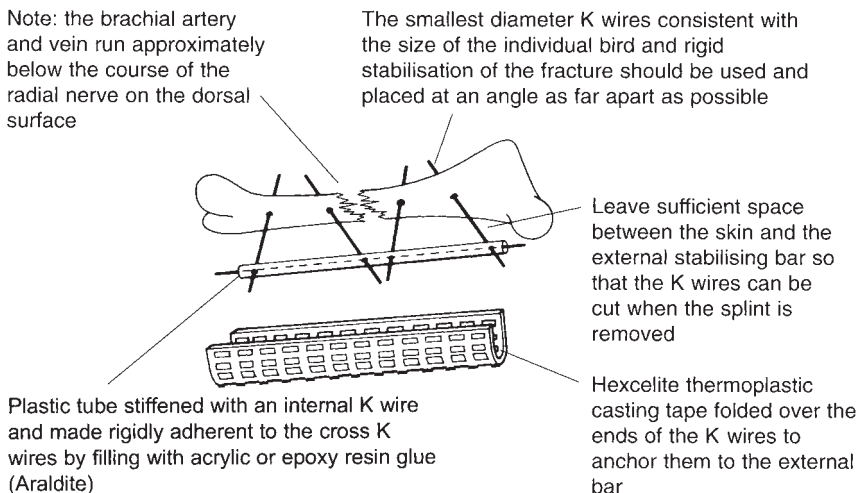
The intramedullary pin which has been bent through 180° and the one or two transverse pins are *rigidly* connected using any suitable epoxy resin fixative such as Aradite, car body repair material or Technovite (horse hoof repair material) etc. After mixing the powder and liquid components of the epoxy to form a putty like mixture this is then squeezed around the pins as illustrated in Fig. 8.19 to so form a rigid external bar after the plastic mixture has set rigidly in a few minutes. Alternatively, Redig (2000) uses thermoplastic casting tape squeezed around the connections but the ends of the transverse pins are first bent at 90° with bent ends lying parallel to the diaphysis of the bone. The tie-in method achieves both longitudinal and rotational stability and is relatively light in weight.

### *Kirschner splints or external skeletal fixators (ESF)*

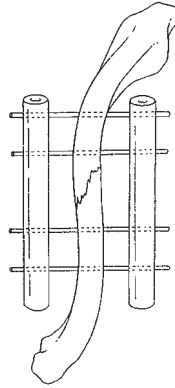
External fixation has been used successfully in large birds by Bush (1981). The pins pass perpendicularly or, better (if using unthreaded pins), at an angle of 30–45° through the skin and then through the cortex of the bone from one side to the other. Four pins are used, two in the proximal half of the bone and two in the distal half. The four pins traversing the bone are then clamped to a rod running parallel to the longitudinal axis of the bone. This is the so-called half-pin method (Fig. 8.20). If the external clamping rod can be placed on the dorsal surface of the wing this causes less discomfort to the bird.

If the pins are pushed further through the bone they can be clamped to another pin or bar on the other side of the bone, the full-pin technique (Fig. 8.21). In this case the pins must be inserted perpendicularly to the longitudinal axis of the bone. The disadvantages of this method are increased weight, the need to insert four transverse pins, so increasing the likelihood of splitting the bone and also the more cumbersome nature of the device when compared with the tie-in method described above.

However, very lightweight Kirschner splints are being developed for finger surgery in humans and may be adaptable for birds. The technique is relatively rapid and it does allow endosteal regeneration of the bone. This method is described by Hatt, Christen and Sandmeier (2005) and is illustrated in Figures 8.22a,b,c.



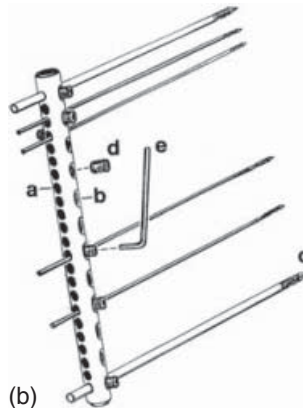
**Fig. 8.20** The half-pin method of fracture stabilisation, using Kirschner (K) wires. (After Coles, 1996, *BSAVA Manual of Psittacine Birds*.)



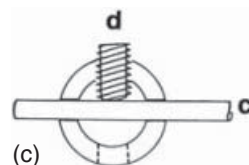
**Fig. 8.21** The full-pin method of internal splinting a fractured bone, using the Kirschner-type splint made from Kirschner (K) wire and the barrels of 1 ml hypodermic plastic syringes filled with glue. Leave enough space to enable the pins to be cut when the splint is removed.



(a)



(b)



(c)

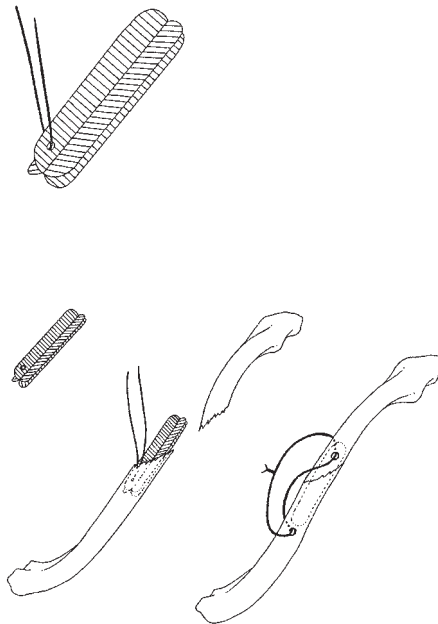
**Fig. 8.22** (a) A parrot with its femur stabilised according to the method developed by the Swiss army for fingers, and modified by Hatt *et al.* (2005). (b) Diagram showing the equipment used in the Swiss technique for external stabilisation: gliding (a) and threaded (b) holes; Kirschner pins (c); screws (d); Allen key (e). Pins may be placed perpendicular (Fig. 8.22c) or at a 30° angle. (c) Fixation of pin at 90°.

A modification of this method that is applicable to smaller birds (down to 200 g in size) is to use Kirschner wires and to anchor these to a piece of plastic (not rubber) tubing filled with methyl-methacrylate-based plastic or an epoxy resin glue or dental acrylic which then sets and holds the pins firmly. The diameter of the plastic tubing can be adapted to the size of the bird. When the pins need to be removed they are cut through and withdrawn. The surgeon must make sure there is enough space between the skin and the external bar for this to be carried out. The advantage of this method is that the weight of the device is reduced.

When placing the pins, the pins farthest apart are first put in position, and then joined by the external rod or plastic tube. The bone is aligned and the other pins are placed in position. If using a tube filled with plastic epoxy, it is sometimes helpful to *temporarily* anchor the transverse pins to another temporary external bar, placed parallel to the plastic tube by using wire twisted round the junctions. When the whole splint is finished the ends of the transverse pins must be protected with tape, otherwise the bird may be further injured (Fig. 8.18).

The author has successfully used short intramedullary pegs made of several materials. These were then held in place by a figure-of-eight stainless steel wire suture. This method keeps the bone in alignment and helps to put some compression on the fracture site to aid healing (Fig. 8.23). The materials used for the intramedullary pegs have ranged from short lengths of a Steinmann pin or hypodermic needles and polypropamide rods. The latter were obtained by using the plunger stem of a plastic hypodermic syringe.

The plunger stem is cut to approximate size and then cut down and filed to shape during the operation, using a sterile file. The material snaps if too long a length is used, but only a short peg is needed to hold the bone in alignment. If the fracture is more than a few days old, new endosteal bone will have to be reamed out of the medullary cavity. The peg is pushed into the longer fragment first and then reversed into the shorter piece of the bone. The reversal is accomplished by pulling on a piece of suture material threaded through a hole drilled at the end of the peg. Holes for the tension band sutures are then drilled with a fine drill bit or a straight triangular needle. This can be held in a mini bone chuck or an instrument maker's chuck and rotated between the fingers. One hole may go through the intramedullary peg but the other hole must be beyond the end of the peg, otherwise the bone cannot be pulled together. Too much tension must not be put on the wire suture; the fragments must be carefully brought together to avoid splitting. When passing the wire suture through the drill holes it is sometimes useful to use a hypodermic needle as a wire guide.



**Fig. 8.23** Using a peg made of cruciate section plastic and a figure-of-eight wire suture to reduce a fractured humerus.

This method is only really applicable in birds larger than about 600 g in weight. It can be tedious, but it does allow some endosteal bone formation, as the peg has a cruciate cross-section. It is also light in weight and the polypropamide is well-tolerated.

Unfortunately, many humeral fractures are compound and grossly contaminated. Osteomyelitis does not affect birds systemically as much as mammals, but it prevents healing. Bacteriological culture for antibiotic sensitivity should always be carried out. A variety of organisms have been isolated but coliform organisms are common and anaerobes are sometimes cultured.

The whole area should be cleaned and debrided. If the bone is discoloured and necrotic it is best removed, even if this means a reduction in the length of the bone. Provided not more than 25% of the length of the bone is lost some birds will learn to adapt and may even fly again (Olney, 1958/9; Scott, 1968).

### *Post-operative care*

After operating on the humerus the wing is best strapped to the body in a folded position for 2–3 days. *This short period of bandaging should not be extended because the circulation is restricted. Low oxygen tension in traumatised tissue probably predisposes the tissue to excessive fibrosis.* A suitable perch should be provided to stop the primary feathers trailing on the floor. Also these can be wrapped in a protective bandage.

Atrophy of muscle through disuse can be rapid in birds. The white muscle fibres (the glycogen users) as distinct from the red muscle fibres (the fat users) are more susceptible to atrophy when subject to disuse (George & Berger, 1966). There is always a mixture of the two types of fibres in the pectoralis muscle of all birds but the proportion varies with the species. Birds that have a rapid jump take off, such as pheasants, have a higher proportion of white fibres so the chances of disuse atrophy in the pectoralis of these species is higher.

### Luxation of the elbow joint

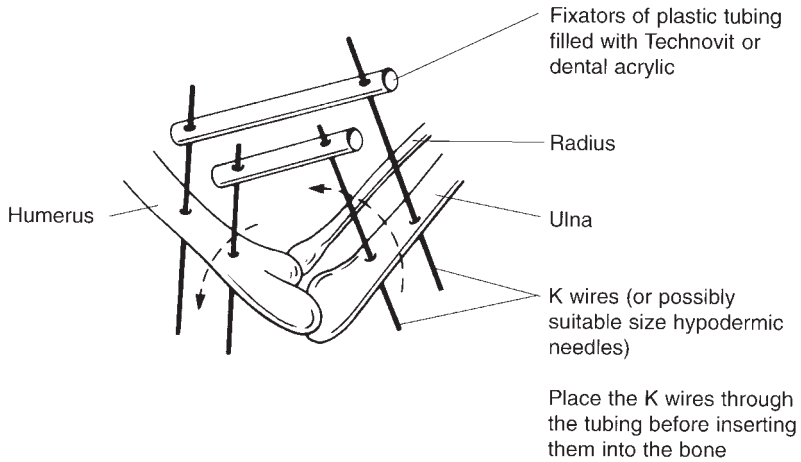
Elbow luxation is not uncommon and can be difficult to resolve. The joint is covered by a weak joint capsule, which also encloses the ends of the humerus, radius and ulna. There is little surrounding muscle to give protection. Any attempt to stabilise the joint with wire sutures is very likely to end in fibrosis and even eventual ankylosis. J.L. Rodger (1981, personal communication) used a hinged splint successfully on a buzzard. Martin *et al.* (1993) devised a method of stabilising the joint, and this has subsequently been modified by Forbes (1995, personal communication) as shown in Fig. 8.24. When attempting to relocate the displaced bones, the covert feathers should be plucked and the whole area wetted so that the anatomy of the parts can be more easily seen.

### Fractures of the radius and ulna

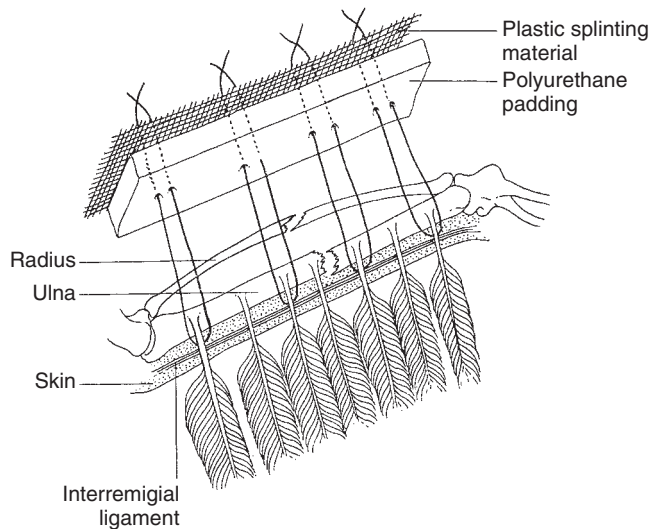
In about 50% of cases either the radius or the ulna is fractured, but not both. When only one bone is fractured it is wiser to leave the fractured bone alone. The normal one will help to splint it. Even if there is not perfect alignment of the healed fractured bone this does not matter, the bird will manage quite adequately and fly again. Strapping of the wing *for 2–3 days only* is required. However, if both radius and ulna are fractured some method of splinting will be required.

Occasionally, when both radius and ulna have been fractured, during healing a synostosis is formed and both bones become locked in the same callus. For the wing to function normally these two bones should be able to slide longitudinally in relation to each other. The synostosis can be overcome if an ostectomy is carried out on part of the radius *or* ulna (Rupiper, 1993; Tanzella, 1993).





**Fig. 8.24** A method of stabilising the repositioned luxated elbow joint. To get the parts in apposition, it may be found easiest to *slightly* flex and at the same time rotate the radius and ulna as indicated, then press firmly on a flat surface. (After Coles, 1996, *BSAVA Manual of Psittacine Birds*.)

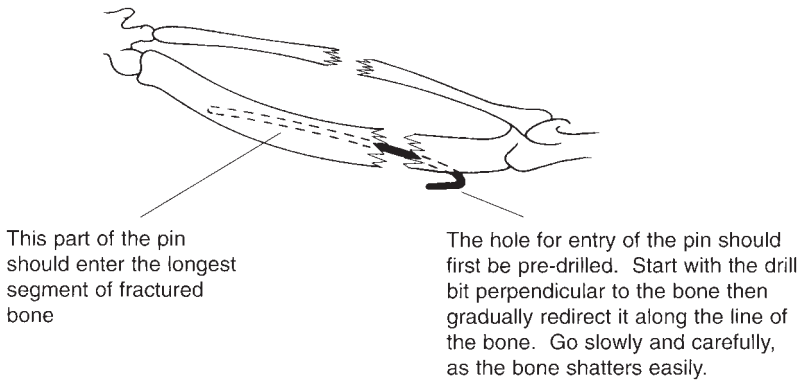


**Fig. 8.25** Method of external splinting of a fractured ulna, using a mesh of plastic splinting material.

### External splinting

External splinting is more applicable to the smaller birds, in which the bones may not be thick enough to support some method of internal fixation. The simplest method is to use a figure-of-eight bandage combined with cage rest. However, remove the bandage every 3–4 days and very gently flex and extend the wing to encourage the circulation, after which replace the bandage for another 3–4 days.

Another method of external splinting is to suture a piece of lightweight plastic material, such as a length of Hexcelite or Vetcast casting tape, padded with polyurethane foam, over the fracture site. The sutures pass through the mesh of the splinting material through the skin and between the shafts of the secondary feathers (Fig. 8.25). It is best to remove most of the covert feathers and to wet the area so that the anatomy of the parts can be



**Fig. 8.26** Rush pinning of a fractured ulna using a suitable K wire bent into shape. (After Coles, 1996, *BSAVA Manual of Psittacine Birds*.)

distinguished through the semi-transparent skin. The sutures should be placed well behind the ulna so that the main blood vessels are avoided. However, if possible, the posterior sutures should be placed in front of the interremigial ligament. All the sutures should be preplaced before being tied so that they can be accurately positioned. This splint is light in weight, is comfortable, and, providing it is properly positioned, does allow some movement of the joints during healing.

A similar, but simpler, splint, using X-ray film, is applicable to birds the size of a canary (20 g) and is described under fractures of the carpus.

#### *Internal splinting of the radius and ulna*

The Kirschner splint as described for use in fractures of the humerus, is quite applicable to fractures of radius and ulna. The author also once used the barrel of a 1 ml plastic tuberculin syringe cut to size and smoothed off at the ends. This was used as a sleeve to push over the outside of the fractured ulna of a barn owl. A cut was made along the posterior side of this cylinder so that it would slide past the shafts of the adjacent secondary feathers, which are directly attached to the bone. This prosthetic sleeve was sufficiently firm when in position so that no further anchorage was necessary. This provided excellent alignment and the bird was able to fly perfectly with the sleeve permanently in position (Plate 20). The author has also used a rush pin made from a suitable Kirschner (K) wire bent into shape. This needs to be very carefully inserted into the ulna (Fig. 8.26).

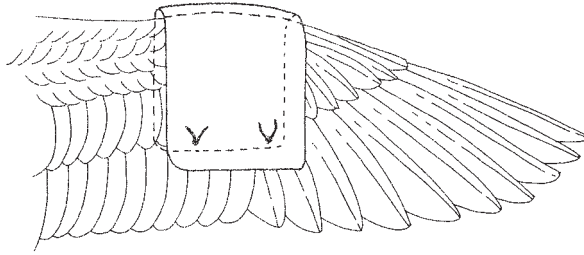
#### Fractures of the carpus, metacarpus and digits

In very large birds it is possible to use a Kirschner-Ehmer splint for fractures of the carpus metacarpus and digits, but in birds below 200 g in weight the metacarpal bone is so thin the method is not practical.

A method of external splinting that the author has found to work quite well is to use a piece of disused X-ray film or clear acetate sheet (thermoplastic casting tape could also be used). This is bent over the leading edge of the wing and held in position by sutures. The sutures pass through the skin covering the primary feathers. Just posterior to the carpus and metacarpus is the ulnocarporemigial aponeurosis (King & McLelland, 1984). This triangular sheet gives very good anchorage for the sutures (Fig. 8.27).

This splint is light in weight and allows some movement of the carpal joint. Many medium sized birds (200–1000 g) on which this splint has been used have been able to fly again.

In very small birds suturing the shafts of the adjacent primary feathers together on each side of the fracture may work – as the shafts are directly attached to the bone.



**Fig. 8.27** External splinting of the carpus and metacarpus using acetate film.

### Prevention of flight

The practitioner is sometimes asked to carry out these procedures on free-ranging birds to stop them flying. Amputation of the tip of the wing may be required in those birds that sometimes suffer from a so-called 'slipped wing' or 'angel wing', a condition common in waterfowl (Sanderson, 2006; personal communication), in a northern goshawk, (Zvivanovits, 2006) and the author has seen it in budgerigars (see Chapter 3, p. 54). Resolution of this condition may be possible in large birds by osteotomy and intramedullary pinning of the large metacarpal bone. A bandage is applied for 4–6 weeks (Yeisey, 1993).

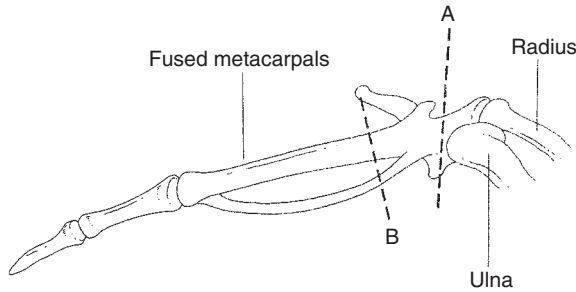
### Pinioning

Pinioning can be carried out by simply cutting short some of the primary and most of the secondary feathers to prevent flight. A sharp pair of strong scissors is sufficient for the operation, and, providing the shaft is cut while the feather is not growing (i.e. not in their 'pins'), it does not bleed. It is best to leave the outer one or two primaries, which will cover the defect in the wing when it is folded and lead to a better cosmetic appearance. Only one wing is treated, since the principle is to unbalance the bird's flight. If both wings are operated on, many birds are able to achieve short-distance flight, certainly over an enclosure fence. Some parrot owners like to walk round with the bird perched on their shoulder. It is wise to warn owners of pet parrots that even after clipping the wings the bird may still be able to get over the garden fence or high into the nearest tree. Some parrots will persistently fall heavily onto their sternum, resulting in a chronically bruised and ulcerated area.

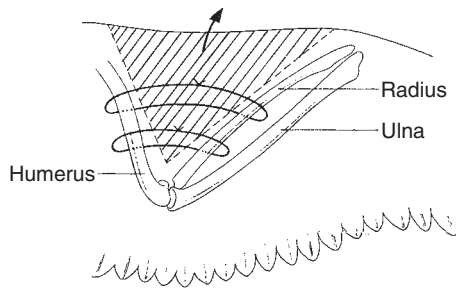
### Wing-tip amputation

Amputation of the wing tip for pinioning is usually carried out in fledglings through the third and fourth metacarpal bones, just distal to the carpus. The blood supply to this area, particularly when the feathers are growing, can be well developed. It is therefore wise to place a tourniquet around the carpal area just proximal to the attachment of the second metacarpal or alula digit (attachment of bastard wing) before making any incision. If the covert feathers are well plucked from the area and the operation site is wet, the underlying structures can more easily be seen.

An encircling incision is made through the skin at least half way along the length of the third and fourth metacarpal bones, *so that there is plenty of skin left to cover the ends of the bone*. The skin, tendons and any muscle are then dissected back to the proximal end of the third and fourth metacarpal bones. These are cut at this level with bone forceps or strong scissors (Fig. 8.28). If the temporary ligature is effective, bleeding is minimal; otherwise there can be a lot of haemorrhage which is difficult to control. The skin and other soft tissue is then sutured so that the remaining muscle will cover the ends of the bone.



**Fig. 8.28** Amputation of the wing tip: (A), position of tourniquet; (B) site of amputation.



**Fig. 8.29** Patagiotomy. The shaded area of the prepatagium is removed, after each side is clamped with artery forceps, and the area is closed by sutures placed around the humerus and radius. The edges of the skin on the dorsal and ventral surfaces are sutured.

#### *Prevention of flight by patagiotomy*

Patagiotomy, devised by Mangilgi (1971) and later used by Robinson (1975) is to render large birds flightless. It can also be used in some cases where a wing is so badly injured that amputation is considered necessary. The end result is not only cosmetically more acceptable than amputation but may well enable the bird to maintain better balance. The technique is illustrated in Figure 8.29.

#### *Tendonectomy*

Tendonectomy of the extensor tendons on the cranial edge of the metacarpal bone has been used to deflight birds. About 8–10 mm of tendon needs to be removed. Also, wiring the metacarpus and ulna together in permanent flexion using two or three wire sutures is effective.

### **The pelvic limb**

#### Fractures of the femur and the tibiotarsal bone

Fractures of the femur and tibiotarsal bone can all be dealt with by one of the methods described for internal fixation of the fractured humerus. Harcourt-Brown (1996) has described a tension band technique for proximal fractures of the femur. The surgical approach to the femur is from the lateral aspect and is not difficult so long as the muscles are carefully dissected apart and split in the direction of their muscle fibres. The major blood vessels and nerves lie towards the caudal aspect. The tibiotarsal bone is best approached from the cranio-medial aspect to avoid the nerves and blood vessels in this part of the leg.

In the case of the tibiotarsal bone with a transverse midshaft fracture, there is a definite tendency for the distal end of the bone to rotate outwardly. While this may not be a problem to the bird, which often manages quite well, it is usually not acceptable to the owner. The rotation is probably caused by the tension of the digital flexor muscles involved in the perching mechanism. This is one reason why intramedullary pinning of the tibiotarsal bone by itself is often not entirely satisfactory without the support of an exterior splint.

Because of the conical shape of the muscles surrounding the tibiotarsal bone, external splinting by itself is not well adapted to this area. However, a combination of intramedullary pinning and external splinting often works reasonably well, providing the fracture site is well clear (proximal) to the distal part of the bone and the intertarsal joint. Otherwise developing callus may entrap the free movement of the tendons of the cranial tibial muscle and the extensor digitorum longus.

To overcome these problems, Harcourt-Brown (1996) suggests using a cross pinning technique with two K wires or pins passed through the lateral surfaces of the epicondyles of the tibiotarsal bone to enter the medullary cavity, and then 'bounced off' the opposing cortex to cross each other approximately midshaft. The distal ends of the pins are hooked around the epicondyles.

Redig (2000) suggests using a type of tie-in technique. First, a polypropylene shuttle as illustrated in Figure 8.19 is inserted in the medullary cavity, to bring the two fractured halves of the diaphysis into alignment. Next, up to four transverse pins are inserted, as illustrated, and the ends of the pins having been bent at right angles are held in position with casting tape.

### Fractures of the bones below the hock joint

Except in the case of the larger birds, where Kirschner-Ehmer (K-E) splinting is quite suitable, external splinting often produces reasonably good results. In birds over 100 g (cockatiel) in weight a plastic casting material, such as Hexcelite or Vetcast tape, padded with a 5–6 mm thick piece of expanded polyurethane, works very well. The polyurethane pad is cut generously so that it overlaps the area to be splinted. When the softened Hexcelite is placed in position it is moulded to the part by binding snugly with an elastic bandage such as Vetrap. The excess polyurethane padding and any sharp projections of Hexcelite can be trimmed with scissors.

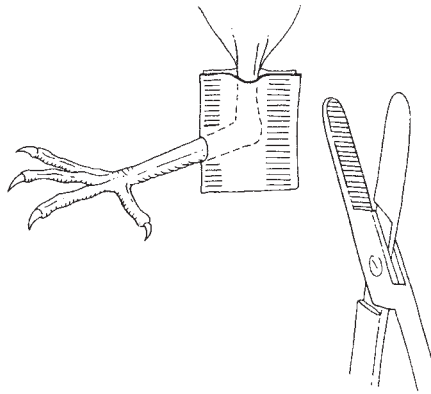
In small birds, like budgerigars and canaries – up to cockatiel size, the use of an Altman splint made of a strip of sticking plaster has been described by a number of authors and is very effective. Any tape material that sticks to itself is effective, but zinc oxide plaster is probably the best. The application of the splint is illustrated in Figure 8.30 and it can be reinforced by incorporating matchsticks, cocktail sticks, nylon catheter tubing, etc., within the layers of the splint. When applying these external splints, they can always be placed much more effectively if the bird is under light anaesthesia. This allows muscle relaxation and better alignment. Trying to fit a splint on a struggling, conscious bird may result in further trauma. At the proximal end of the splint, if this does not adhere very well because of feathering, two sutures through the tape will overcome this problem.

A few birds will not tolerate the splint and will remove it in a few days. Even if the splint is only in place for about four days it has often been found to be sufficient time in these very small birds.

When the time comes for removal of the splint, soaking the zinc oxide splint in ether or other suitable solvent (Zoff, available from pharmacists) will dissolve the adhesive. Again, it is safer to do this if the bird is under light anaesthesia.

### Valgus deformity

Valgus deformity can be seen as bending of any of the long bones as a result of a calcium: phosphorus imbalance or vitamin D<sub>3</sub> deficiency during the critical period of ossification



**Fig. 8.30** Splint for small birds, using adhesive tape crimped together with artery forceps.

of the bones in the growing bird. Some of these deformities can be corrected, when growth has ceased and the diet has been corrected, using a wedge or dome osteotomy technique and subsequently stabilising the area with a K-E splint. The condition is common in hand-reared parrots and raptors.

#### Ring removal

In budgerigars particularly, but also in other birds it is often necessary to remove a metal identification ring. The ring may have excoriated the underlying scales, or worse, the underlying tissue may have begun to swell, so that the ring acts as a ligature causing swelling of the whole foot. If this is not promptly relieved the blood supply can be cut off and the foot becomes gangrenous. Very often the ring has become buried in the inflamed and swollen tissues by the time veterinary advice is sought.

It is most important to have the bird held firmly on a table by another person. General anaesthesia may be necessary. The surgeon can then hold the ring firmly with artery forceps while the ring is cut with the points of a pair of nail clippers. There is a risk that the ring will slip out of the grip of the artery forceps and rotate while being cut. Great care must be taken to avoid this, otherwise the tibiotarsus may be fractured. Specially designed cutters are available for this purpose. Also, fine hairs from bedding and nest materials can become embedded round the ring and good lighting and magnification is needed to find them. A fine cutting suture needle may be used for this purpose (see Plate 12).

#### Hip luxation

Luxation of the hip joint usually results in fracture of the femoral head, because of the strong round ligament. After this injury the leg becomes fixed in extension and the only solution is a femoral head arthrotomy. Most birds accept this surgery with little disablement. A cranial approach to the joint is made and after excision a slip of iliofibularis muscle (i.e. a large muscle originating on the caudo-lateral aspect of the pelvis) is transposed cranially over the proximal end of the femur (i.e. the trochanter) and anchored in through the acetabulum and under the ischiatic nerve.

#### Achilles tendon luxation

The Achilles tendon (hallucis longus tendon), the long flexor of the foot, tends to slip medially away from the trochlea of the tarsometatarsal bone in cases of perosis causing marked angular deformity of the leg and severe disablement. Before surgery the diet must be corrected.

On examination, the joint is noticeably swollen and sometimes the tendon can be pushed back into position. One or both legs may be affected and not all chicks in a clutch are necessarily affected. The author's method of resolving this condition is to make a caudo-lateral skin incision over the joint and then, by careful blunt dissection, define the tendon and trochlea. The tendon is then held in position, using a suture of polydioxanone through half the tendon thickness, through a tunnel made in the lateral epicondyle of the trochlea with a hypodermic needle (used as a guide for the suture).

Since there is some force on the tendon causing it to pull through the suture and to relaxate, another method used by the author is, once the tendon is pushed back into its normal position, to insert a K wire transversely into the tibiotarsal bone to the lateral side of the tendon, and bend this into a hook to hold it in position. It is important to insert the pin above (proximal) to the epiphysis at the junction of the tibia and proximal tarsal bones. Whichever method is used, apply external splinting with Vetrap self-adhesive bandage for three weeks, but watch for swelling of the foot.

For splayed legs in fledglings, see p. 206.

## Bumblefoot

Bumblefoot is a septic condition of the foot leading to abscessation. It has been recognised in poultry for many years and is not uncommon among falconers' birds. It is also seen in water birds and occasionally in psittacine birds, even in budgerigars. It is a serious condition and can ruin a bird for falconry. It is rarely, if ever, seen in wild birds.

The infection penetrates the foot from the plantar surface because the integrity of the integument has been impaired. This can take place in water birds if the feet become excessively dry or the skin is abraded. Falcons and heavy, inactive birds, constantly standing on the same diameter perches so that their feet get little exercise, are predisposed to bumblefoot. Cooper (1978) discusses the subject thoroughly in his book and points out that puncture of the metatarsal pad or sole by an overgrown claw of the first or hind digit may cause this condition in some falcons.

Birds' feet are covered with scales, which are modified areas of the epidermis. The scales are formed by areas of hyperkeratinisation. Between them are sulci or clefts. Some areas of the foot are raised in papillae which increases the grip of the foot. There is constant growth and shedding of the skin surface through normal wear. Sometimes the scales are shed during the moult of the feathers. Anything that interferes with this normal pattern of skin change, such as excessive abrasion, will allow micro-organisms to reach the sub-dermal tissues.

Any bird kept in dirty, unhygienic conditions is subject to bumblefoot. The skin is tight and in places adherent to the underlying bone. Any swelling in this region due to an inflammatory response is restricted and tends to track along tendon sheaths and other planes of least resistance. Within a few days of the initial infection, fibroplasia sets in, possibly exacerbated by a low oxygen tension through swelling of the tissues and inactivity of the sessile, tethered falcon. The increased fibrous tissue retards any penetration of antibodies to the focus of infection. The whole process is a vicious circle.

The abscess may be filled with caseous or serosanguinous pus and may contain a variety of micro-organisms. These commonly include *Staphylococcus aureus*, *Escherichia coli* and *Proteus* spp. The infection may track as far as the intertarsal or hock joint. When first presented for veterinary examination the lesion may be 3–4 months old or even older. The obvious swelling is usually covered by a scab caused by hyperkeratinisation. The foot should be X-rayed in the lateral and ventro-dorsal positions, because osteoarthritis is a common sequel to a long-standing infection. The scab should be removed and a bacteriological culture taken for antibiotic sensitivity. Swelling of the tendon sheaths and tenosynovitis can sometimes be detected, because even when the digits are moved under general anaesthesia small ratchet-like projections on the inside of the tendon sheaths catch with

those on the tendons, making the movement feel jerky. This ratchet mechanism is normally brought into play when the bird is perching and there is tension on the flexor tendons. In the relaxed anaesthetised bird there should be no tension on these tendons and the digits can be moved freely.

### *Treatment of bumblefoot*

If the swelling on the foot is very small and there is no sign of the infection tracking, it may be treated with the appropriate systemic and local antibiotics. The local antibiotics may be mixed with dimethyl sulphoxide (DMSO) to help penetration of the drugs. Vitamin A given systematically may help improve the health of the integument.

In the vast majority of cases surgery will be necessary. This consists of opening the abscess and carefully removing all caseous and necrotic material, taking care to avoid nerves, tendons and blood vessels. All sinuses should be investigated with a blunt probe and the whole area should be vigorously irrigated, preferably with chymotrypsin solution. Before starting, it is a wise precaution to place a tourniquet around the lower part of the tibiotarsal bone because the granulating tissue within the swelling can bleed profusely. The tourniquet should be released periodically.

After thorough curettage the skin is accurately sutured with mattress sutures using non-absorbable suture material, preferably placed across the line of flexion of the skin. Use of antibiotic-impregnated beads may be indicated, see p. 165. The foot is bandaged and the bandage may be left in place 2–3 weeks until healing is completed. A non-adhesive dressing such as fucidin intertulle should be placed under the bandage.

As suggested by Remple (1993), better results can be achieved by using a foot cast. After the foot has been covered with a thin sheet of polyurethane foam (obtainable from DIY upholsterers), a cast is made of Hexcelite, dental acrylic, plastic padding or Technovit, and while this is still plastic it is moulded to the plantar surface of the foot and kept in position with strips of Vetrap self-adhesive elastic bandage. When the cast is set hard the bandage is unwound and the cast is removed. A large hole is cut in the centre of the cast and the edges smoothed off so that when re-applied the pressure is taken off the central metatarsal pad and the surgical incision. The same principle can be applied using human orthopaedic felt pads or the foam-covered material used for the flexible insoles of shoes. Obviously, these materials are not so rigid or robust.

The surgeon or the owner must regularly inspect the foot to ensure it does not become swollen and the surgical wound should be inspected every 2–3 days without removing the cast. The bird should be allowed on to a perch padded with foam rubber or plastic foam. The patient should be encouraged to use a variety of different sized and shaped perches so that the foot is not constantly held in the same position and so becomes cramped. The perches may need to be permanently padded and *very strict attention to hygiene must be the rule. The owner should be constantly aware of the problem and routinely examine the feet for early signs of trouble.*

The use of AstroTurf to cover block perches, or in the concrete enclosures of captive waterfowl, also helps to prevent this condition. Use of an apparently unstable but slightly moveable perch (as in the branch of a swaying tree), such as one mounted on a short piece of metal spring, may encourage the perched bird to constantly shift its weight, helping venous return and encouraging blood supply to the foot.



## Nursing and After Care

---

This chapter is based on a paper by the author published in the *Journal of Small Animal Practice* (1984b). Sections of it are reprinted here by permission of the editor and publishers.

Few practices routinely hospitalise birds which is regrettable because, apart from wild bird casualties for which the public expects immediate expert veterinary attention, diagnosis in individual sick birds is difficult. A practice routine for hospitalising avian patients gives the veterinarian time to observe and evaluate the patient, leading to a more accurate diagnosis and a higher standard of treatment. Hospitalising birds is also advantageous to nursing staff. The clinical state of avian patients can change hourly, often with little obvious signs. In developing their ability to recognise these slight changes, nurses enhance their powers of observation of all types of patients, and because of the delicate nature of many sick birds, proficiency acquired in nursing these creatures leads to a general upgrading of all nursing skills.

The essential attributes that are common in all branches of nursing are:

1. A *diligent* attention to hygiene
2. A genuine concern for the well-being of the patient
3. *Accurate recording* of the clinical changes
4. A methodical approach to the task in hand

Many of the techniques and skills used by the veterinary clinician and the animal nurse have been developed and adapted from those used in human nursing. However, there are dangers in the extrapolation of knowledge from one branch of science to another. Successful avian nursing depends on the realisation that there are fundamental differences between the biology of birds and that of mammals, including humans.

### ASPECTS OF BIRD BEHAVIOUR

#### **Stress**

When hospitalised, birds are generally more liable to psychological stress than mammals. Bird behaviour is largely instinctive. A routine behavioural response is triggered by a specific stimulus or releaser present in the environment. If there are none of the *normal* releasers in the bird's hospital environment the creature becomes stressed. Similarly, a bird will make certain ritualistic movements that act as greetings, threats, etc. to a member of its own species. If the bird makes these to an unfamiliar handler and there is no response, it becomes stressed.

Stress is also related to birds' high metabolic rates and to the fact that most birds are creatures of the air and less used to confined surroundings. Stress, caused by fright or frustration of confinement, will vary among species and be influenced by their degree of habituation to man. Even within species there is considerable variation. Some wild barn owls (*Tyto alba*), for example, willingly eat dead hatchery chicks while others have to be persuaded to do so – this being quite unrelated to the severity of their injuries. Most hospitalised parrots will feed readily, but occasionally one will feed only on one part of a presented seed diet (e.g. hemp) for which it has a particular liking. Always accept some of the parrot's normal (usual) food if this is offered by the owner. Aviculturists recognise that some birds will feed out of, for example, a red dish, a colour with which they are familiar, but will not touch a blue dish of exactly the same type.

Some kestrels (*Falco tinnunculus*) are more aggressive than others. Individuals within a species all have different 'personalities' and some species of bird are more easily handled than others. Amongst raptors, buzzards (*Buteo buteo*) are generally much less aggressive and nervous than goshawks (*Accipiter gentilis*) or sparrow-hawks (*Accipiter nisus*).

However, there are some aspects of avian behaviour that are common to all birds, with relatively few exceptions. With the exclusion of the ground-living species, such as fowls (Galliformes) and waterfowl (Anseriformes), most birds spend a great deal of their time above human eye level, either in flight or perching. Consequently, when hospitalised, birds are less stressed if they are kept at as high a level as is practical in a room. Their cages, if portable, can be kept on a high shelf. In contrast to this, if one is feeding altricial nestlings, these creatures inherently expect a parent bird bringing food to approach from above. If the nurse is to simulate this pattern of behaviour the chick must be approached from above not from a horizontal direction.

Although all birds have good hearing, abnormal sounds, such as a nearby human voice or barking of a hospitalised dog, seem to disturb them much less than the sight of, or quick movement of, other creatures. This is particularly so with wild birds that are not accustomed to human contact. The nurse must learn to move slowly and deliberately when in the bird's vicinity. Ideally, hospitalised birds are less stressed if kept in a separate room out of sight and sound of creatures other than birds, where the light intensity can be suitably reduced (see p. 27) and where higher ambient temperatures can be maintained.

Quite apart from a reduction in light level it is not generally recognised that birds are stressed by the flickering of fluorescent strip lights. Korbel (2005) indicated that birds can resolve motion pictures at a flicker frequency of 180 frames/sec compared with humans (except for some autistics and other neurologically impaired humans) with a flicker frequency of 15–80 frames a minute. Consequently most conventional fluorescent tubes (including low energy bulbs) are not flicker free and are potentially stressful to birds (see p. 28 and Table 9.1).

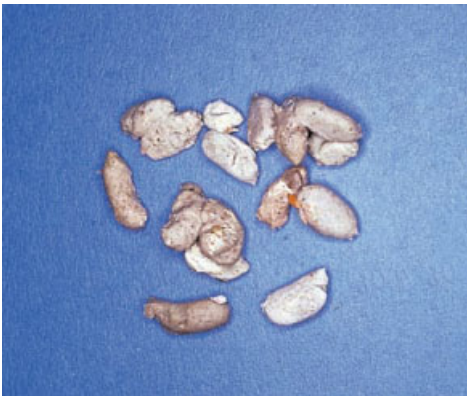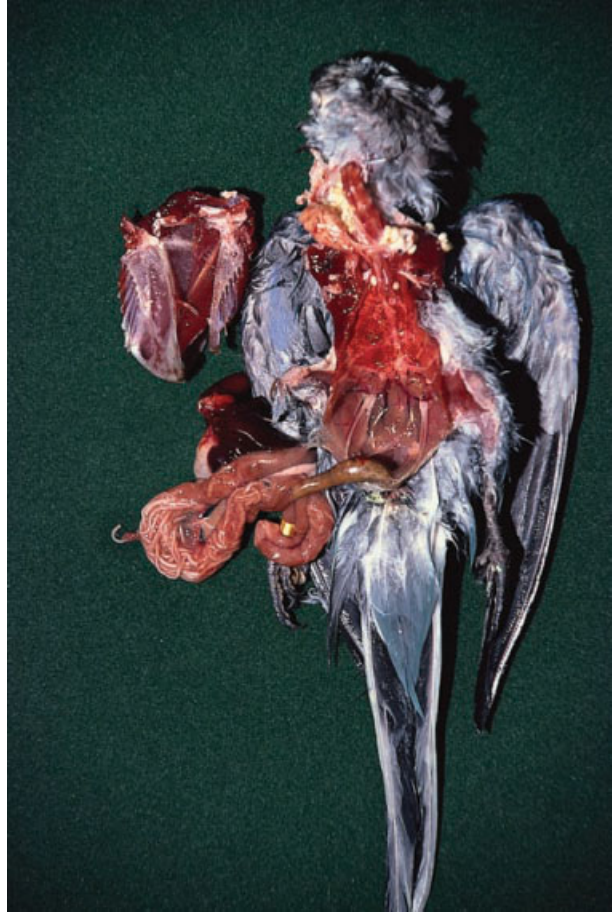Moreover, ideally birds should be hospitalised in cages which are individually and separately ventilated so that possible carriers of latent pathogens are effectively isolated (see Plate 16).

If a cloth is placed inside across the bars of a cage to prevent self injury by the bird continually bouncing or batting against the bars of its cage, this should not restrict the nurses' constant observation of the patient.

If birds are frequently hospitalised, a thin board, covered in easily-cleaned plastic laminate, can be made to hang across the front of the cage, as a holder for case records and can also be used when cleaning out the cage so as to confine the bird to one corner without actually handling it. There is less disturbance to the bird if the cage has a removable tray.

When hospitalising birds it may be better to let the birds see each other, particularly in the case of social species. Birds often live in flocks of the same or allied species. Some birds, such as hospitalised psittacines, may have led a long, solitary caged existence and

**Plate 1** Bourke's parrot (*Neophema bourkii*). This bird died of emaciation due to a small intestine grossly impacted with nematode worms.

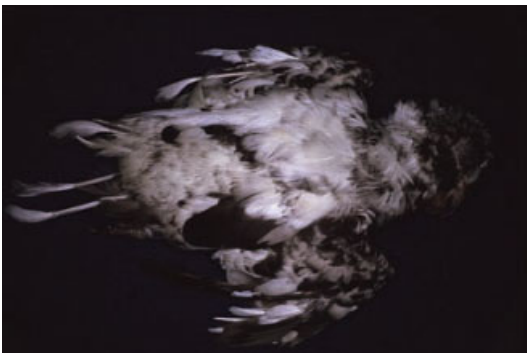

**Plate 2** Bulky droppings containing little associated urate content passed by a splendid/scarlet-chested parrot (*Neophema splendida*). These droppings had a high undigested starch content due to a pancreatitis secondary to paramyxovirus-(PMV-3) infection.



**Plate 3** This peregrine falcon (*Falco peregrinus*) exhibits torticollis and 'star gazing'. The bird was in good condition and showed no external signs of trauma, but radiography revealed a crack in the cranium and some increased density of adjacent soft tissue.

**Plate 4** This lovebird (*Agapornis* spp hybrid) is infected with psittacine beak and feather disease caused by a circovirus (presence of the virus confirmed by DNA PCR). Note that unlike this disease in some other species the body feathers and the beak appear normal. It is only some of the plumage on the head which is obviously abnormal.



**Plate 5** Lesser vasa parrot (*Coracopsis nigra*). Dorsum and wings show marked loss of normal black pigmentation due to psittacine beak and feather disease viral infection.

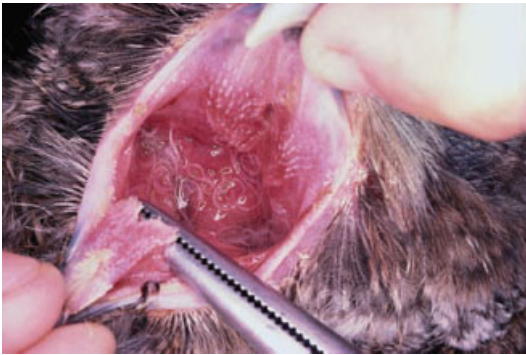

**Plate 6** This escaped and stray budgerigar with several ticks on its head was found in a forest area in the Netherlands. It was very debilitated and died shortly after being found. In this particular case, because of the light colour of the plumage and the size and maturity of the ticks, their presence is obvious. In other cases, where the plumage may be darker in colour and the ticks immature nymphs and much smaller in size, their presence may not be so easily noticed. The ticks in this photograph are almost certainly, although not confirmed to be, *Ixodes ricinus*, which can transmit louping ill, to humans. (Photo by courtesy of Dr. Jan Hooimeijer.)



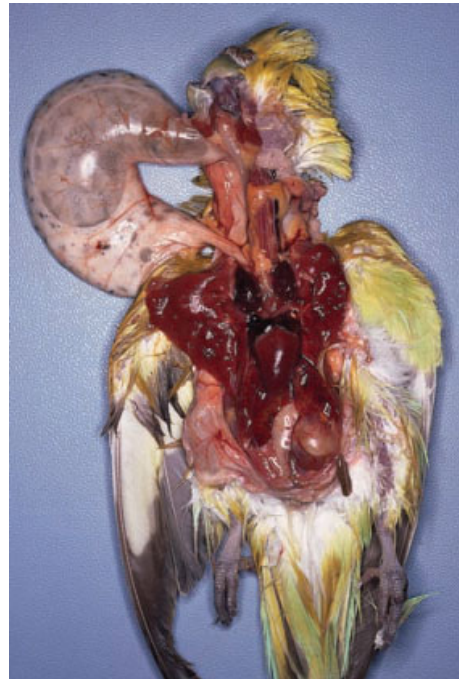
**Plate 7** Kestrel (*Falco tinnunculus*) with avipox viral infection.

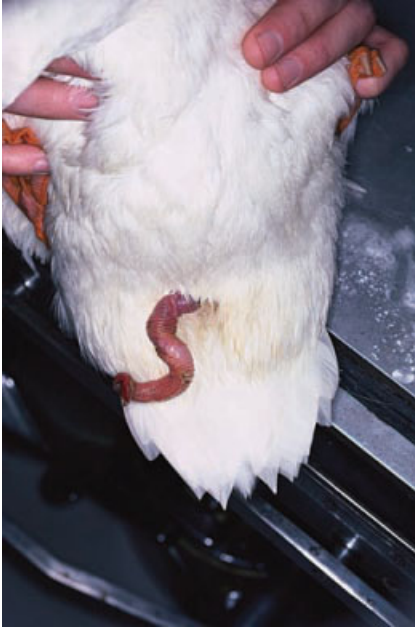**Plate 8** Little owl (*Athene noctua*) showing coloboma and hypopyon almost certainly caused by interspecies aggression to which this species is prone. There were no signs of intraocular haemorrhage from a traumatised pecten. Providing infection is treated, the hypopyon will resolve and, although the coloboma will remain, vision is not so affected that the bird will not be able to hunt and be rehabilitated into the wild.



**Plate 9** Tawny owl (*Strix aluco*) showing *Capillaria* spp helminths in the oropharynx.

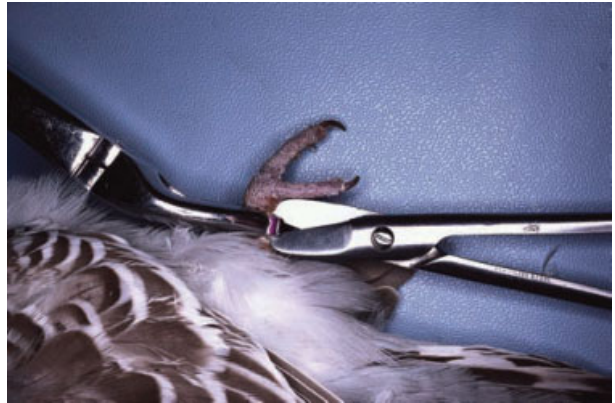**Plate 10** This budgerigar (*Melopsittacus undulatus*) exhibits grossly enlarged thyroid glands due to hypothyroidism caused by a lack of iodine. The swollen thyroid glands partially obstruct the oesophagus and may also cause pressure on the adjacent syrinx, so altering the voice.





**Plate 11** This domestic duck shows a pathologically prolapsed phallus. This is often the result of bullying by dominant male ducks when kept intensively. If several cases occur simultaneously this could be due to duck viral enteritis, a herpes virus.

**Plate 12** The correct method of cutting a breeder's ring from the tarsometatarsus of a small bird. Specially designed cutters with a nick on each blade near the point are used, and the ring is held firmly with a pair of forceps – in this case tooth forceps. If this is not done there is a tendency for the ring to twist forcibly whilst being cut, with the danger of the bone being broken.



**Plate 13** Red-tailed hawk (*Buteo jamaicensis*). On first examination this looks like a neoplasm, which could be either a papilloma, fibrosarcoma, squamous cell carcinoma or a basal cell carcinoma. However, the pathology report stated no evidence of any neoplasia but only pseudoepitheliomatous hyperplasia. In removing the lesion great care must be taken not to cause fibrosis and contraction of the lower lid.



**Plate 14** Loss of the distal half of the upper beak in a female teal (*Anas crecca*), possibly caused by being ripped off in a struggle with a predator or by a constricting ligature of a fisherman's nylon line. This duck has survived in the wild but will do much better with support feeding.

**Plate 15** Greater vasa parrot (*Coracopsis vasa*) of Madagascar, showing prominent swollen phallus. This normal protuberant phallus should not be mistaken for a pathological prolapse. (Photo by courtesy of Dr R. Wilkinson.)



**Plate 16** Hospital cages for birds used at the University of Leipzig in Germany. Depending on size, the birds are retained in their own cages, with which they are familiar. The cage and bird are then enclosed in a *separate*, glass-fronted air space with an inlet air grill near the bottom of each cage. The pipe work of the filtered air extraction system can be seen at the top. Infrared lamps over each cage provide individually required supplementary heating for each bird. The individual case notes are attached to the front of the cage in transparent plastic bags so that they do not collect dust and do not become contaminated when the cage is washed.



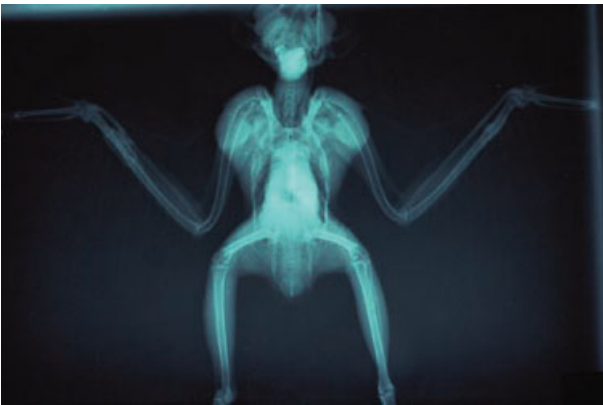**Plate 17** Young fledgling song thrush (*Turdus philomelos*) being fed using a 2 mm syringe. It has been filled with a soft food and squeezed out by the nurse so that to the bird it looks like a worm.



**Plate 18** Fledgling tawny owl (*Strix aluco*). When they first leave the nest, these young birds often fall to the ground. They are sometimes picked up by well-meaning walkers who wrongly assume they are lost and bring them into veterinarian's clinics. These fledglings are quite capable of looking after themselves and, if left alone, will crawl up to the nesting site and be fed by the parent birds.



**Plate 19** Barn owl (*Tyto alba*) being test flown in a farmer's barn before being released back to the wild. Note both wings are held fully extended and quite straight. As can be seen in the radiograph shown in Plate 20, the bird originally had fractured both ulnas. On the right side, since the radius was intact, nothing surgically was done except to temporarily strap the wing for three days. However, on the left side, since the radius was also fractured, the ulna was splinted with a polypropylene tube.



**Plate 20** Radiograph of the bird shown in Plate 19. As shown, the wings, which are the important area of this photograph, are a little under exposed, ie, they are too dark.



**Plate 21** Feather duster syndrome in a British show budgerigar (*Melopsittacus undulatus*). Probably genetic in origin but may be associated with a herpes virus. (Photograph courtesy of Dr J.R. Baker.)

**Table 9.1** Light sources according to their suitability for birds.

Light Source	Brand Name	Spectral Range	Flicker-free?*	UVA Portion
<b>Incandescent</b>	Conventional	400–1100 nm, max at 950 nm	Yes	None
	ESU Birdlife Brightlight Spot Incandescent Lamp®	Full-spectrum	Yes	Not described <sup>1</sup>
<b>Fluorescent+CF</b>	Conventional	3-band-spectrum	According to ballast <sup>2</sup>	None
	True-light SoLux®	Full-spectrum	According to ballast	Described
	Vita-Lite (Duro-Test)	Full-spectrum	According to ballast	Described
	Activa (Sylvania/Osram)	Full-5-bands-spectrum	According to ballast	Described
	Arcadia Birdlamp	Full-spectrum	According to ballast	12% UVA, 2.4% UVB
<b>Halogen</b>	ESU Avian Birdlamp	Full-spectrum	According to ballast	10% UVA, 3% UVB
	Conventional	80% in infrared	Yes	None
	DECOSTAR IRC cold-light reflector lamp (Osram)	Full-spectrum	Yes	None (absorbs radiation below 390 nm)
	Conventional	Near UV to infrared	According to ballast	According to filter
<b>HID</b>	SoLux®	Natural daylight spectrum	According to ballast	Practically none (filter)
	Conventional	Narrow-band spectrum	Yes (DC <sup>3</sup> )	None
<b>LED</b>	Golden Dragon (Osram)	380–700 nm, peak at 410 nm	Yes (DC)	None

\* Flicker frequency over 180 Hz.

<sup>1</sup> No UVA according to Thrush 2000.<sup>2</sup> CCG: operates at twice the mains supply current: 100–120 Hz; ECG: operates at 30–50 megahertz frequencies.<sup>3</sup> DC: operates under direct current.

After Professor Ruediger Korbel, Prof. Dr med vet, Dr med vet habil, Cert. Vet. Ophthalmol, Dip. ECAMS, Ludwig-Maximilians-University, Munich.

sometimes seem to derive benefit from seeing or being near another similar bird. In the budgerigar this is particularly noticeable. A bird that was relatively inactive will suddenly become more alert and interested in its environment. Some parrots have been noticed to reduce or cease self-plucking of their feathers.

The one type of bird that all species instinctively recognise is the predator. If hospitalised, this type of bird must be kept out of sight of other birds. Even parrots such as Amazon parrots will recognise and fluff up their plumage if they see a peregrine falcon, which does not normally occur in their country of origin. Hospitalised raptors are usually silent so that other birds do not know they are in the same room unless they see them (see p. 27).

## Perches

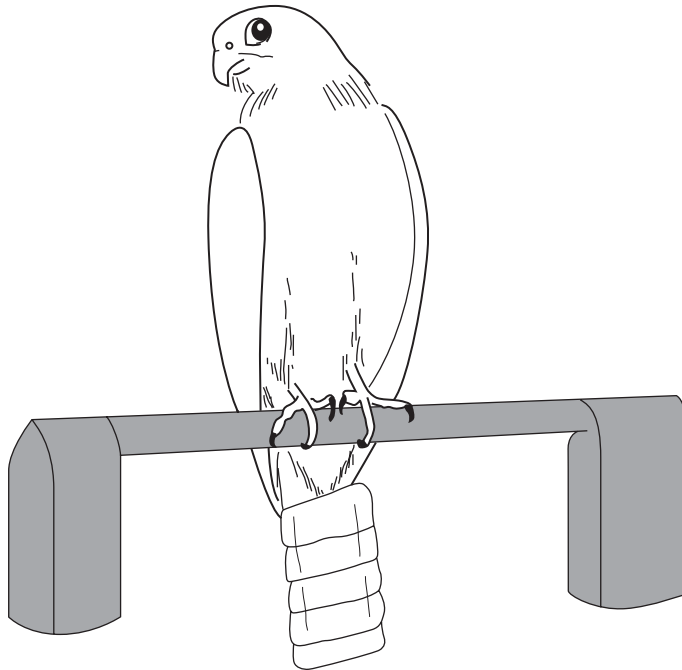
Many of the birds that veterinarians treat use perches. There is little doubt this type of bird, confined to a cage, is much happier and less stressed if it has somewhere to perch. This instinct in some birds is so strong that even those born with feet so deformed that they are unable to grip will still attempt to perch using the sides of their feet. Ideally there should be more than one perch and these should be of varying size and surface texture so that the muscles of the feet are constantly exercised and do not become cramped. The standard perch used by aviculturists is made of a round wooden dowel and, although easy to keep clean, it is not really ideal because of its uniform diameter and smooth surface. Natural twigs or branches are better and can be replaced when dirty and worn. Branches from most deciduous trees (except oak) can be used, but those from rhododendron and yew must be avoided when used for psittacines, which like to gnaw.

For medium to large birds, weighing 200–1500 g, a robust, temporary block perch can be made from a brick or an earthenware flowerpot turned upside down. This can be covered with a piece of cloth. A block of wood covered with soft leather makes an even better perch. These coverings need frequent replacement or cleaning (see p. 181). They provide a good grip and protection from abrasion to the scales of the feet, which predisposes to infection leading to bumblefoot. Another alternative emergency perch is illustrated in Figure 9.1.

Falcons and other raptors are best kept tethered on block perches covered with Astro-Turf. All perches should be high enough to prevent soiling or fraying of the plumage trailing on the floor. Tail feathers can be bound with Vetrap self-adhesive bandage or suitable paper tape. Wooden perches can be placed across the corner of the cages since some birds, such as owls, like to lean against the side of the cage when roosting. Perches should be so placed that the droppings do not contaminate food or water containers – remember that the faeces of some falcons are ejected horizontally (i.e. sliced) instead of dropping vertically.

## Bathing

Most birds bathe more frequently than most mammals, and many raptors, including owls, will bathe if given the opportunity. Some parrot species come from tropical rainforests, where during most afternoons there is a tropical rainstorm lasting usually no more than a few minutes. The birds will take advantage of this to have a thorough bath. Aviculturists recognise this, and many of them regularly spray their show birds with a fine mist of water from a spray. Aviary birds can be sprayed with a fine jet from a garden hose or the aviary can be fitted with an automatically timed sprinkler system. The birds will then purposefully fly into the spray, just as aviary birds will deliberately go out into rain. Falconers tether their birds to a perch, to weather (see p. 360) and may place a dish of water near at hand to bathe. Consequently, whenever it is not inconsistent with other veterinary treatment, hospitalised birds will benefit if given a bath or sprayed with a fine mist from a household spray.



**Fig. 9.1** An emergency perch can be easily constructed of two full food tins over which is strapped, with Vetrap elastic bandage, a length of suitable-diameter rod. The weight of the food tins gives stability to the perch, while the Vetrap bandage provides the bird with a reasonably soft grip. Note that the tail of the bird is bound with paper tape to protect the remiges from fraying through contact with the floor.

The depth of water in a bird bath should not be more than half an inch for small birds and not more than one inch for a bird the size of a tawny owl (*Strix aluco*), otherwise there is a risk of drowning. Chicks should not be bathed, since in many species the down does not give them sufficient protection. Because of the desire of most caged birds to bathe, their drinking water containers should not be too large and should be kept above ground level.

The temperature of the water used for bathing should be about 40°C. Bathing keeps the plumage clean and also encourages active preening. This is a normal activity of the healthy bird, since the maintenance of the plumage is not only essential for flight but also for the conservation of body temperature. In waterfowl (Anseriformes), in gulls and waders (Charadriiformes), the skin of the feet needs constant contact with water to remain healthy, otherwise ulceration and infection may develop. In the Anseriformes, putting the bird into the water of a bath may act as the releaser to encourage preening.

### **The advantages and disadvantages of constant handling**

Tender loving care by the nurse is of particular benefit to nestlings before their eyes open and will also benefit all ages of birds used to human contact. McKeever (1979) suggests that with single baby owls, a piece of dark cloth hung over the top of their box, or a soft toy to nestle up to will be beneficial and simulate physical contact with the adult bird or with the young bird's siblings. Too much handling and attention can be disadvantageous to an adult wild bird because the creature becomes tame – which may be disadvantageous if release is intended. However, if the bird is to be regularly handled for medical treatment then the sooner it gets conditioned to human contact the better.

## PHYSIOLOGICAL CONSIDERATIONS

### The implications of a high metabolic rate

#### Energy requirements

Birds have a higher basal metabolic rate than mammalian companion animals. This is related to the ratio of body surface area to body volume which increases with decreasing body weight. All birds tend to look larger than they really are, due to the depth of plumage which holds a layer of insulating static air in contact with the skin. However, Kendeigh (1970) has indicated that there are other factors, such as the weight of feathers per unit of surface area, their microscopic anatomy and also the rate of metabolism. Moreover, basal metabolic rate is higher in Passeriformes compared with non-passerine birds (Lasiewski & Dawson, 1967).

High rates of metabolism result in rapid heat loss and rapid utilisation of the body's energy reserves of glycogen and fat. This is so marked in birds, that they will regularly and normally lose weight overnight while they are not feeding (Perrins, 1979). This is particularly marked if the ambient temperature is low, e.g. 18°C. Consequently, healthy birds of the order of 10 g bodyweight, e.g. blue tits (*Parus caeruleus*), kept under optimum conditions of minimal stress, minimal activity and an ambient temperature of 15°C probably cannot survive more than 48–72 hours without food. As size increases, survival from inanition will be longer.

*Most hospitalised birds often need frequent support feeding by gavage even when they appear to be taking some food themselves. If the bird is not seen to be feeding itself, nourishment needs to be given at least every hour. Feeding two or three times daily as for small hospitalised mammals is just not sufficient.*

Small healthy birds need of the order of 1 kcal of energy per gram of body weight (Perrins, 1979). One gram of fat yields about 9 kcal and 1 g of carbohydrate yields about 4 kcal. A 20 g canary therefore needs to take in about 5 g of utilisable carbohydrate a day, or approximately half this quantity of lipids. Perrins (1979) pointed out that great tits (*Parus major*) feed nestlings 58–78 times daily. Very small birds of 20 g and below this weight which have lost condition through illness need the maximum number of daylight hours in which to feed. *It is a wise precaution with these small birds to leave the animal room lights on throughout the night, particularly during the winter months.*

In larger birds, particularly raptors, the feeding requirements are not quite so stringent. It is reasonable to feed these birds once or twice daily and, provided the food intake is regular, they can with advantage go without food one day a week. The work of Kirkwood (1981) has done much to clarify the rate at which weight is lost in raptors during starvation.

#### Effect of the inflammatory response

The basal metabolic rate of all homoiotherms increases as part of the body's inflammatory response to disease. This leads to even greater energy demands and a more rapid loss of weight, mediated by a complex neuroendocrine response (Richards, 1980). The nurse should be constantly monitoring the condition of a sick bird by palpation of its pectoral muscles. *All hospitalised birds should be weighed daily and their weight plotted on a graph.* Suitable digital scales accurate to 1 g are available (see Chapter 6). Variation in weight is one of the most reliable and easily measurable parameters in a bird's daily progress.

The nurse will need to use discretion regarding how much stress is caused to the individual bird by weighing and should not carry this out if the bird gets too excited. The least stressful methods of handling birds are mentioned in Chapter 3.

As a consequence of an increased metabolic rate, tissues probably heal more quickly. Such changes as fibrosis and the formation of scar tissue in traumatised muscle also occur more rapidly in small birds than in mammals.

### Ambient temperature

The maintenance of a high metabolic rate results in a bird's normal body temperature of about 40°C and in very small birds, particularly Passeriformes, it may reach 41°C. There may be a diurnal variation of 2–3°C. All sick and severely injured birds, which are rapidly depleting their limited energy reserves, will be less stressed if their ambient temperature is raised to at least 26°C. Sometimes this can, with benefit, be increased to 38°C for a period of 24–48 hours, after which it is gradually reduced. In many veterinary premises warmth can be provided by an infrared lamp (possibly combined with a UV lamp). It will be better if this is controlled by an ordinary household dimmer switch; alternatively, the lamp can be gradually moved further away or the lamp can be positioned in a corner so that there is a heat gradient for the bird to move into and out of. Always check the temperature at the level of the bird. A hot water bottle wrapped in newspaper and placed together with the patient in a cardboard box with ventilation holes in the top of the box will provide warmth in an emergency situation.

It should be remembered that contaminated oiled birds lose their normal insulation and need emergency protection from heat loss. Special bird hospital cages are available commercially in which the temperature of the cage can be controlled thermostatically. Some of these cages are fitted with means for a supplementary oxygen supply and a nebuliser. However, the thermostats in the less expensive and simpler units may not be very sensitive. Also, many cages do not have any means of controlling humidity and, because the volume of the cage is relatively small, they need to be well ventilated without actually creating a draught. One method of achieving a high degree of control over temperature and humidity is the use of a hospital surplus premature baby incubator, but these have the disadvantage of being internally low in height and are not very suitable for larger birds. These incubators have a facility for enriching the air supply with oxygen and controlling humidity. Alternatively, plastic plant propagators sold in many garden centres can be adapted for the purpose.

### Disinfection and cleaning

Although the importance of cleanliness and disinfection in all hospital premises have been appreciated from at least the time of Florence Nightingale, it is now becoming increasingly apparent that many apparently healthy creatures carry latent pathogens which may only be shed at times of stress. This is particularly the case with birds, in which, over the last two decades, ever more latent viruses have been discovered. In consequence, not only do sick birds need to be isolated in biosecure hospital cages (see Plate 16) but the premises themselves and all items of equipment must be scrupulously clean and thoroughly disinfected.

In addition to normal cleansing and disinfection of horizontal surfaces, including those above eye level, use of a fogging apparatus has great advantages for getting into hidden corners and cracks. A good review of this subject is by Forbes (2005) who mentions the use of the disinfectant F10 as being very effective and safe for this purpose in birds. For the supply of foggers see [www.f10biocare.co.uk](http://www.f10biocare.co.uk) and [info@f10biocare.co.uk](mailto:info@f10biocare.co.uk). Incubators or hospital cages for sick birds are a potent source of infection not only for birds but also for staff and need to be *frequently* and scrupulously cleaned.

### The physiological consequences of the avian air sac system

As mentioned in Chapter 6, the air sacs are prone to infection. This is exacerbated in the resting bird because during flying activity the action of the main flight muscles alternatively contracting and relaxing, helps to pump air through the air sacs and at the same time cooling hard working muscle. The continual forceful flushing of air through the air sac system reduces the chances of pathogenic organisms contained in this warm, moist, internal atmosphere of establishing themselves on the surface of the air sac.

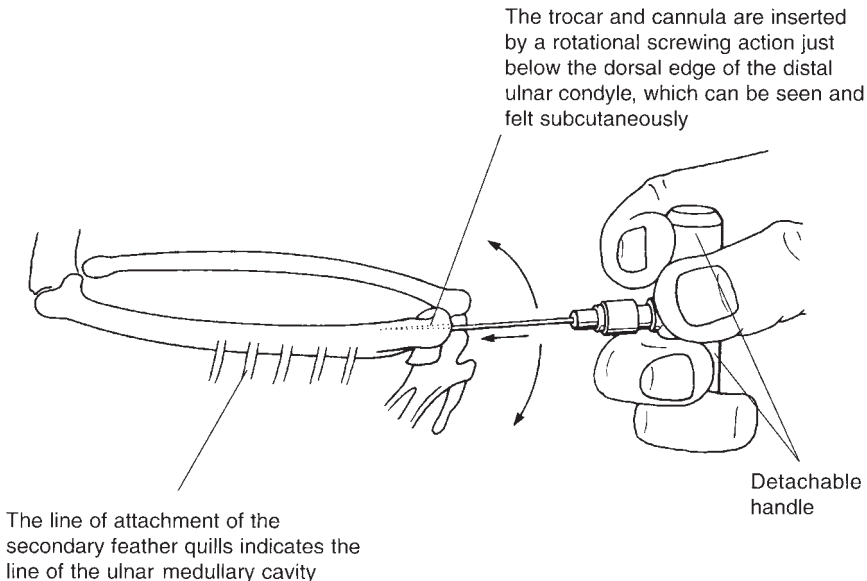
Because of the large internal surface area of their air sacs and high body temperature, small birds have an inherently high water loss from the pulmonary system. Many birds obtain a lot of their water requirements from metabolised food and body fat stores. Therefore all sick or injured birds that have not been feeding can be assumed to be dehydrated even though this may not be obvious. Many birds normally require less water than mammals to excrete the waste products of the gastrointestinal and urinary tracts. Consequently anorexic birds with diarrhoea very rapidly become dehydrated.

### Dehydration in birds

Dehydrated birds should be given fluid by mouth, by subcutaneous injection or, preferably, by intravenous or intraosseous injection (Figs 9.2 and 9.3). The subcutaneous injection of fluid can be made over the pectoral muscles, in the propatagial skin fold of the wing, inside the thigh or at the base of the neck. Normal saline can be given at the rate of 20.5 ml/kg body weight four or five times daily. This volume needs to be halved for small birds, and Steiner and Davis (1981) recommend using 0.1 ml of Hartmann's solution, which helps to counteract metabolic acidosis, given every 10–15 minutes in the budgerigar, using alternate sides of the body. The rate of absorption is increased if hyaluronidase is added to the fluid. All fluids should be given at 39°C.


Extreme care must be taken when giving subcutaneous injections to birds, since avian skin is not as elastic as mammalian skin and aqueous injections tend to ooze out through the needle puncture if too much is given at one site (see p. 120). Given by slow i.v. injection the volume for the budgerigar is 1.0 ml, for a cockatiel 2.0 ml, for an Amazon parrot 8.0 ml and for a large macaw or large cockatoo 12 ml.

As a consequence of the common dehydration in sick and injured birds, constipation easily occurs. Johnson (1979) states that the rectum and coprodeum are areas of active



**Fig. 9.2** The dorsal aspect of the carpal joint, showing the method of insertion of the author's modification of the Cook Instrumentation intraosseous cannula, fitted with a detachable corkscrew-type handle. The joint should be flexed and, after plucking the covert feathers, should be wetted with alcohol or antiseptic to make the anatomy more easily definable.





**Fig. 9.3** 'Coles' modified avian intraosseous cannula (Cook Ltd).

water absorption, and reflux passage of fluid contents (urine and faeces) occurs from these areas as far as, and into, the caeca. Other considerations apart, dehydration will lead to the cessation of these physiological activities and devitalisation of the associated tissues, resulting in constipation. McKeever (1979) suggests relieving this condition by manual evacuation; the use of a warm saline enema is sometimes useful.

For continuous drip via an intraosseous catheter use a 20–22 G spinal needle with an indwelling stylet. The catheter is inserted into the distal medullary cavity of the ulna or into the proximal tibia (Fig. 9.2). The needle is kept in place with self-adhesive bandage, such as Vetrap. An Arnold's pressure drip feed is a useful aid. Instead of a spinal needle, Cook Instrumentation makes a useful custom-made catheter with a detachable handle for easy insertion (Fig. 9.3).

### FEEDING HOSPITALISED BIRDS

As Redig (1996) has stated, 'the correct use of fluid therapy and nutritional supplementation will save the lives of more birds than any other form of therapy'.


There is little problem with birds that are eating. The owner of an exotic cage or aviary bird or the owner of a falcon will be pleased to advise on what the bird is normally fed and will often supply a sample. However, if a falconer's sick bird is received into the hospital, the nurse should be made aware that these birds are sometimes kept short of food by their owners to make them keen hunters (i.e. kept at flying weight), and sick or injured raptors under stress may be near starvation. Casualty wild birds may not have been feeding for some time before being found.

The main problems for the nurse arise with the nutrition of the emergency case which cannot, or will not, feed readily, or, in the case of the wild bird, for which there is none of the normal diet readily to hand. As a rule a 10% solution of glucose or glucose saline given by mouth at the rate of 10 ml/kg body weight will help. It should be given at least once every half hour for at least six hours, but even then it will not meet the daily maintenance requirements of metabolisable energy. Preparations containing amino-acids and essential vitamins (e.g. Duphalyte 75 ml/kg) are better, since they provide a more comprehensive range of nutrients. These can be given subcutaneously in quantities similar to those given for fluid therapy.

Artificial feeds made for human infants are useful. They contain fairly high levels of energy-yielding constituents, mainly in the form of carbohydrates with some vegetable fats. The several varieties of Milupa brand baby food contain 422 kcal/100 g and are relatively low in protein. The Milupa fruit salad or tropical fruit varieties are most suitable for parrots, which will often take them voluntarily. The digestibility of these foods is improved if the contents of a Pancrex-V or Trypsin capsule is mixed with the food before administration. Emerald Critical Care, marketed by Lafeber Company, USA, is a product suitable for the nutritional support of sick birds. Vetark Ltd UK also market a critical care 'formula', specifically for sick birds. Vetark's probiotic Avipro Plus can be added with advantage to all these foods.

All these support foods can be given easily via the large diameter avian oropharynx and oesophagus in a liquid form with the aid of a stomach (gavage) tube (Fig. 9.4) The stomach tube must be placed well down into the oesophagus or crop. Stomach tubes can be devised from suitable diameter pieces of rubber or plastic tubing fitted to the nozzle of a plastic syringe. A rigid metal stomach catheter can be used if this is well-lubricated and allowed to slip into the oesophagus under its own weight. If the bird's head and neck are extended in a vertical direction, there is little danger of trauma. However the tube must not be forced down the oesophagus. When passing a stomach tube the progress of this tube can often be seen, particularly in a long-necked bird like a swan, as it passes down the dorsal aspect of the neck. It passes under the trachea just before the thoracic inlet.

Other types of preparation that can be used for the general feeding of sick birds are Convalescent Diet or Hill's Prescription Diet Canine/Feline a/d which are specially formulated for invalid dogs and cats. These foods are of animal origin and are formulated for carnivores. Except for some very specialised feeders, such as nectar feeders (e.g. hummingbirds and sunbirds), all species of bird are *probably* capable of digesting this type of food. These foods are soft and can be forced into the barrel of a 2 ml plastic syringe so that when the plunger is depressed the food is extruded from the nozzle as a small worm-like thread which some birds will readily peck at (see Plate 17).



**Fig. 9.4** Gavage tubes for the feeding and medication of birds (Cook Ltd).

Another method of administering semi-solid foods is to cut off the nozzle of the 2 ml syringe to enlarge the orifice and then place a plug of the food into the bird's oropharynx. Care must be taken to place the food well *beyond* the glottis, which in most birds is on the floor of the mouth just behind the root of the tongue. In some birds such as the heron (*Ardea cinerea*) it may be farther back.

A food that is suitable for most species of orphan bird, as well as invalid birds, is mashed, hard boiled, or scrambled eggs mixed with an equal quantity of sweet biscuit meal, or bread crumbs, with a little glucose powder added. This mixture should be slightly moistened and can be given by one of the above methods. If given too dry, the food is not easily swallowed. This mixture can also be offered to small nestlings on the tip of an artist's brush. Some aviculturists feeding parrot nestlings use a small spoon bent up at the tip to form a sort of scoop, shaped like the mandible of a parent bird. It is always better to feed a little and often and make sure the crop is emptying properly.

A technique for feeding orphaned house martins (*Delichon urbica*), a particularly difficult species to get started, is to offer a drop of water held between tweezers. This is usually readily taken. Follow with moistened Beta Puppy pellets, which have a high protein content (Penny Rudd, personal communication).

All these foods require less mechanical work by the bird's alimentary canal and so a more rapid and economical utilisation is possible.

Once the initial emergency period of convalescence has passed, the nurse should consider providing food for the patient which is as near to its normal diet as possible. If one is dealing with a convalescent parrot always enquire what the bird has been fed on in the past. This food may not be what you think is the right diet but nevertheless start with the food the bird is used to and then *gradually change* to a more suitable diet. Birds will often refuse to eat unless they are familiar with the food offered.

Start by adding 5% glucose to the bird's normal diet and liquidising this in a food blender – this aids digestion. Birds are very specialised feeders with varied adaptations of their anatomy for this function (see pp. 10–12). The more obvious differences in beak form are also supplemented by variations in the internal anatomy, the function of the oral cavity and alimentary canal. Although many species are quite adaptable, failure to appreciate a bird's normal feeding methods could lead to difficulties in prehension and an inadequate food intake. Parrots, for example, vary considerably in size and need seed which is applicable to their size. Lorikeets, although belonging to the Psittaciformes and looking like small parrots, are adapted to eating fruit and taking nectar.

For most granivorous species the local pet shop can usually supply suitable seed foods and they may also be able to supply more specialised foods such as Sluis Universal which is suitable for feeding insectivorous birds. Granivorous birds also require grit, which needs to be the right size for a particular species. A choice of limestone grit, oyster shell and quartz-based gravel should be offered. However, there is scientific evidence that some birds may be able to manage without grit.

Most raptors can be maintained for quite long periods on the dead male chicks obtained from hatcheries. However there is a danger that these chicks may carry latent viruses not dangerous to poultry but damaging to raptors. Moreover, these dead chicks are low in calcium which could in time result in hypocalcaemia. Also they are high in cholesterol contained in the unabsorbed yolk sac. Captive raptors are best maintained on minced hare, rabbit or quail with an added vitamin and mineral supplement, such as SA 37 or Vionate, and a probiotic preparation. Pieces of meat can be offered with the fingers or, in the case of the more powerful bird of prey, with forceps. The tips of these are best covered with tape to protect the points from damaging the oropharynx, and they must also be kept scrupulously clean.

When feeding by mouth, if the sensitive vibrissae at the sides of the mouth, present in some species, are touched the bird will often grab at the food. If the mouth has to be

opened by hand the upper beak or premaxilla can easily be raised, and this has the effect, through the rod-like articulations of the palatopterygoid and jugal bones connected to the quadrate bone, of depressing the lower beak or mandible (see Fig. 1.1).

Hatchery chicks can be used for, and may be taken quite readily by, herons (Ardeidae), cormorants (Phalacrocoracidae), birds of the crow family (Corvidae) and rails. If hatchery chicks are not readily available, small pieces of meat supplemented with vitamins and minerals and mixed with fur and feathers to provide roughage can be given. Always moisten these morsels of food before feeding. Combing of hair from any cat or dog will suffice as roughage in an emergency.

As already mentioned, all raptors and many other species of birds, regularly produce oral pellets. However, some parts of the skeleton of the prey are digested and are essential, particularly in young, growing raptors if metabolic bone disease is to be avoided. If hospitalised birds of prey do not regularly produce pellets this usually means there is something wrong with the alimentary canal. Nevertheless, if there is insufficient roughage there is no scientific evidence that the production of pellets is essential to the normal function of the alimentary canal.

If feeding casualty young growing birds, *meal worms and maggots are not very suitable*. Their chitinous exoskeleton is relatively indigestible. Also if the mealworms have been kept in bran the phytic acid may also be harmful.

In the piscivorous species, the provision of a fish diet is probably not essential to health. However, these birds will often not feed voluntarily unless the food offered looks like fish, and even in some cases unless it is thrown into a bath of water and appears to move like a fish. Many types of bird only recognise food presented in a familiar form. Once over this difficulty they often thrive on an artificial diet.

Most of the gulls will feed readily on tinned pet food, but force-feeding of this group of birds is difficult since food is stored in the lower oesophagus and easily regurgitated. Fulmars can eject an evil-smelling oil from the oesophagus a distance of up to a metre; vomiting in other species of birds is usually an indication of upper alimentary disease. When feeding gannets, care should be taken with the sharp edge of their beaks.

*Always weigh the bird regularly and do not rely on what it looks like.*

## PHYSIOTHERAPY

Many injured birds received into a veterinary practice will have trauma to muscle and tendons and to the nerve supply to these tissues. They may also be suffering from concussion. Although all fractures must first be treated, much can be done by intelligent nursing to restore the function of damaged soft tissue. The nurse must always be aware that hospitalised birds are like human athletes who are out of regular training. The longer they are hospitalised the greater will be the deterioration in the cardiovascular and muscular systems due to disuse atrophy.

Faradism has been used to restore the function in a barn owl's leg (L. Randall, 1980, personal communication), but this is unlikely to be available in most veterinary practices. Immersion of an injured limb in hot water at 45°C and gentle flexion and extension of the joint as advised by J. Ratcliffe (1982, personal communication) is simple and can often restore function. Use of an infrared 'A' lamp is beneficial to healing tissue.

McKeever (1979) recommends the use of a sling and neck brace supports for birds with neurological injuries when the bird cannot support its own weight or the head cannot be held up. The writer has successfully suspended a pigeon in a plastic bag for a total of three weeks whilst both fractured legs were allowed to heal, and has used also this support on a Harris's hawk (*Parabuteo unicinctus*) requiring simultaneous operations on both legs. Once function has been restored to the muscles and other soft tissues of the legs these

need to be strengthened and built up again. A bird will often do this if it is kept in a large cage or aviary but this can also be encouraged by daily exercising the patient. The bird can at first be held by the legs by hand (gloved if a raptor) and gently raised and lowered to stimulate wing flapping. Later exercise on a leash or creance (see p. 212) can be helpful. The leash can be attached to all types of bird by small soft leather straps or jesses as used by falconers, providing of course the legs of the species are stout enough for this purpose.

Increasing demand and monetary value together with increased conservation legislation reducing the supply of wild-caught birds will result in more bird owners attempting to breed from stock. Veterinary advice will be sought if these ambitions are not fulfilled.

British birds and those from temperate climates breed during a few months of the summer when there is a maximum food supply and favourable weather. Some of the cage birds kept by aviculturists have evolved in tropical conditions but they have been bred in captivity for so long as to be almost domesticated. They are capable of breeding throughout the year and, even if kept in outside aviaries, sometimes during unsuitable weather. This may be the case for parrots, exotic doves and small finches e.g. zebra and Bengalese species.

Successful bird breeding needs luck, good management and some understanding of the natural history of the species. The breeder should have an empathy with the birds and anticipate their needs. The zebra finch (*Poephila guttata*) breeds so easily that the veterinarian may be asked how to *halt* this process. Possible solutions are either to:

1. Remove the nest boxes and nesting materials
2. Separate the sexes
3. Remove the eggs laid and replace with artificial eggs
4. In some species, pierce the eggs

### FAILURE TO BREED

Failure to breed may be due to many causes. These can be catalogued under the following four headings:

1. Failure to mate
2. Inability to produce a normal fertile egg
3. Failure of the fertile egg to hatch
4. Failure to rear the young

Some reasons for failure to breed have a single cause, but many are multi-factorial.

#### **Failure to mate**

A not uncommon reason for failure to mate is having a pair of monomorphic birds of the same sex. Homosexuality sometimes occurs in birds. Two isolated male lovebirds may copulate and appear to mate normally. The only solution is to sex the birds. The author has seen four Cloncurry parrots (*Barnardius* spp), all the same age, split into two breeding

pairs. When surgically sexed, one pair was male and female while the other pair was two males. The behaviour of both pairs was similar, but in one male of the homosexual pair the testicles were much smaller than in the other two males of similar age.

### Sexing birds

Sexing birds can be carried out by several methods:

1. Direct visual inspection of the cloacal anatomy, as used in poultry (in other Galliformes), ratites, penguins and vasa parrots
2. Surgical sexing – the technique has the added advantage that the condition of the gonads can also be inspected at the same time (see Laparoscopy, Chapter 4)
3. Most parrot species can now be sexed using DNA techniques on the cells attached to a newly-plucked feather (dead moulted feathers are no good) or from a small amount of blood (e.g. tip of clipped claw)

### Stress and aggression

Two birds of opposite sexes may not be compatible and, depending on the species, either sex can dominate the other. At worst this can lead to death of the submissive partner or at least infertility due to stress. A female merlin or northern goshawk may kill her partner if both are confined to an aviary and she is not ready to mate. The male will have to have an escape route into an adjoining aviary. In *Psittacula* spp of parrot the female is usually dominant to the male, except during breeding when their roles are reversed. Sometimes a change of partner, a larger aviary or more feeding points or nest boxes may solve the problem. The latter is particularly important with falcons, weaver birds and whydahs.

Persecution by other species in a mixed aviary will stop breeding. Some species are incompatible and in some cases, such as the small tropical doves or blue waxbills, will not tolerate another breeding pair of their own kind.

Birds breeding in a colony in an aviary may fight for the highest nest box; consequently these boxes should all be placed at the same height. However, aviaries with mixed species may have nest boxes at varying heights to suit different species. The colonial aviary and the mixed aviary should be well established long before the breeding season. Occasionally a neurotic and aggressive bird will be encountered among a normal breeding group of budgerigars. This one bird can upset the whole flock.

Birds need to be reasonably tame and used to their keeper. Wild birds are reluctant to breed in captivity. It was demonstrated by Burnham *et al.* (1983) that peregrine falcons taken from the wild breed less readily than those bred in captivity. Stress can be induced by excessive noise or any change in the birds' routine management. Observations of shy breeding pairs, such as falcons, can be carried out by a one-way glass window. Prowling predators, such as foxes, domestic cats and rodents around the aviary can disturb birds and prevent mating. Rats, mice, stoats and weasels will get into an aviary causing havoc. Transportation can cause stress. After capture, foreign species are held by the dealer abroad, and then transported by air. Legally they usually have to undergo a period of quarantine before being sold to their final owners having possibly passed through a chain of traders. Consequently these birds may take a long time to become adjusted to their final place of captivity before being ready to breed.

The breeder must realise that all birds are individuals in their behaviour during copulation, courtship, etc. and allowances for this will have to be made. Budgerigars, and particularly the larger psittacine birds, as well as waterfowl, tend to form permanent pair bonds for life, so that if one of a pair dies it may be difficult for the survivor to accept another partner. It may take one or two years for a breeding pair to become properly adjusted so that they copulate and produce fertile eggs. It is wise to pair up birds well before a breeding season.

### Age and breeding condition

One of a breeding pair may not be sexually mature. Also the two sexes of a pair of parrots may not come into breeding condition at the same time, so that there is frustration on the part of the bird ready to breed. Many birds are mature in one year but some of the very large birds of prey may take several years. Macaws take four years and the *Psittacula* parakeets, such as the Alexandrine (*Psittacula eupatria*) and plum-headed (*Psittacula cyanocephala*) take three years to reach maturity. Nevertheless, in most cases if a pair of birds have not bred after three years they are unlikely to do so.

Breeding birds should be in good physical condition, in good health and be good examples of their species. However permanent loss of one leg will not always prevent a male bird from copulating. They should not be obese. This can be a common problem with captive and disabled raptors, which are often overfed and under exercised. However, to breed the bird must receive food in excess of its metabolic maintenance requirement.

### Weather and photoperiod

The cold weather of a late spring in temperate climates delays breeding in wild birds because they need more food for maintenance (Elkins, 1983). Weather conditions in 2006 severely depleted the breeding of wild barn owls (*Tyto alba*) (A. S. Duckells, personal communication). A sudden spell of mild weather stimulates song, courtship and pairing in wild birds and influences captive specimens as well.

The increasing number of daylight hours has a major influence on sexual activity. Canary breeders gradually extend the length of daylight hours over 2–3 months, from 8–10 hours to a maximum of 15 hours to stimulate breeding. However, the irregular use of artificial lighting can have an adverse effect and therefore the process is best controlled by a dimmer and time switch. Note the stress-inducing effect of the stroboscopic effect of fluorescent strip lights (see Chapter 9).

Many parrot species, including budgerigars, cockatiels and lovebirds, continue to breed throughout the year, but these species are not normal inhabitants of the European climate. An increase in food supply, particularly animal protein, may trigger a breeding cycle.

### Disease

Only after all the aforementioned factors have been taken into account should the clinician consider disease. Systemic infectious disease is likely to exhibit other signs long before breeding is affected. However, particularly note pathogens such as *Salmonella* spp, *Escherichia* spp, *Klebsiella* spp, *Enterobacter* spp, *Pseudomonas* spp, and *Candida* spp. Also budgerigar herpes virus (see p. 284), all adenoviruses, particularly adenovirus group 111 (see p. 304) and corona viruses (see p. 305) and, in young chicks, the viruses of polyoma (see p. 300), proventricular dilatation disease (see p. 307), psittacine beak and feather disease (see p. 299) and, lastly, avipox virus (see pp. 335–8).

### Toxic chemicals (see pp. 335–8)

Other less common influences on breeding are toxic chemicals, such as the chlorinated hydrocarbons used in insecticides and the polychlorinated biphenyls widely used as industrial plasticisers and released when plastic materials are burned. It was thought initially that these compounds only caused thinning of the eggshell but it has been shown that they depress breeding by their influence on oestrogen levels (Peakall, 1970). Wood preservatives may be detrimental to parrots. Some parrots become particularly destructive at nesting time and will destroy wooden nesting boxes.



## INABILITY TO PRODUCE A NORMAL FERTILE EGG

### Feeding

Breeding birds should be chosen from those individuals that will take a wide variety of foods and are not restricted in their feeding habits. In this way a deficiency of an essential element is less likely to occur. Some parrots, for instance, will eat sunflower seed and nothing else. Where possible, home-grown foods are better than those harvested abroad. Bird seeds grown in places like Morocco or parts of Australia are more likely to be cultivated on soils deficient in some mineral elements. If the viability of seed is in doubt, sow some in a pot and let it sprout. If the green shoots look normal the seed is probably all right. To be successful, breeders need to feed an adequate and *balanced* diet. Most commercially available seed mixes have multiple deficiencies.

As well as adequate calcium (soluble grit or cuttlefish bone) and vitamin D<sub>3</sub> for healthy egg shell production, it is essential to provide *increased* protein in the diet, particularly animal protein (e.g. egg food in lieu of insect food for seed eating passerines) containing essential amino acids (particularly lysine and methionine). When not breeding the increased protein diet only needs to be fed twice weekly.

In addition, a lack of adequate fresh drinking water will stop breeding. The whole problem of inadequate diet for breeding passerine birds has been reviewed by Stockdale (2005).

### Nesting sites

Birds seen to have mated may not have produced a fertile union because copulation took place on an insecure perch or one or both partners was inexperienced. Birds may not lay eggs in an aviary if there is not a suitably secure or sheltered nesting site or nesting material available. Many breeders of raptor species use enclosed breeding aviaries open only to the sky. It has been shown by Perrins (1979) that great tits (*Parus major*) and blue tits (*Parus caeruleus*) lay earlier in the season if they have warmer nesting boxes. Nest boxes for aviary birds are warmer if they are as small as is practicable. As well as warmth, some 'hole nesters', such as parrots, need a sufficiently dark box to stimulate the hen to lay. This will not be achieved if there is a crack or warped joint in a wooden nest box. For these birds hollow logs make good nesting sites.

Some species need to have a supply of nesting materials, such as dried grass (but not hay which may contain *Aspergillus* spores), leaves, shredded paper, coconut fibre or moss.

### Egg laying

In all birds it is normal for the hen to look rather sick and suffer egg lethargy as egg laying becomes imminent. If the bird is disturbed while laying, she may drop the eggs anywhere in the aviary or may crack the shell. Egg eating is a habit formed by some birds which can turn into a vice copied by other birds in the aviary. This can be detected by noticing egg yolk on the bird's face. For egg-eating budgerigars make a hole in the centre of the nesting concavity in the base of the nest box. The laid egg can then drop through on to sawdust beneath and be hatched under a foster parent.

Infertile eggs are more liable to be laid by an old bird or one which has been allowed to raise too many broods in a season or a bird on an inadequate diet.

### Candling

If access to the clutch can be gained without disturbing the hen, the eggs should be candled six or seven days after being laid. This enables one to decide if the egg is infertile or 'clear' and to assess the condition of the egg shell, the air cell and the position of the embryo in

the fertile egg. Candling can be carried out on thin-shelled eggs, such as those from parrots, using natural light or a pen torch. For others an artificial light source such as a 40 watt bulb can be used. For very thick-shelled eggs such as those laid by turkeys, some waterfowl and large raptors, an ultraviolet source is necessary. To avoid harm, eggs should not be exposed to the candling light for more than a few seconds. For those inexperienced in candling a useful web site with good images, The 'Easy Chicken', is given in Appendix 11 (p. 362). Although produced for poultry breeders, this web site has some useful pictures of candled good and bad eggs: [www.homestead.com/shilala/candling](http://www.homestead.com/shilala/candling).

### **Artificial insemination**

Artificial insemination has for many years been used routinely in poultry, and during the last three decades been successfully developed for breeding raptors. The procedure is described by Berry (1972), Grier *et al.* (1972), Temple (1972), Grier (1973), Boyd (1978), Weaver (1983) and Wilkinson (1984). The techniques of collection of semen in poultry and in raptors are essentially the same. The lower part of the lumbosacral and abdominal regions are massaged in a rhythmic manner until a drop of semen is produced at the papilla in the cloaca. The papilla is gently held between thumb and forefinger so that the semen is expressed into a syringe. There is no technical reason why this technique could not be developed in other species of bird. Samour *et al.* (1986) collected semen samples from budgerigars and Brock (1991) has carried out artificial insemination in parrots.

Boyd and Schwartz (1983) review the technique of semen collection used by a number of workers using a peregrine falcon imprinted on to its handler. An artificial pair bond is slowly formed between the handler and the gradually maturing young bird. This occurs after a long and intensive period of falconry training, including greeting the bird with a vocalisation appropriate to its species and by food transfers. After this long period of socialisation, during which time a close physical and psychological bond has been developed between bird and handler, the tiercel (see p. 360) will eventually copulate voluntarily with a specially designed hat worn by the handler. The hat carries a neoprene gutter around the brim which catches the semen. Using this technique semen can be collected several times a day over a period of a number of weeks.

To be successful, the handler needs to understand and interpret correctly the courting displays made by the bird to its artificial 'mate'. The whole process requires a lot of patience and complete dedication from the handler. For an excellent description of the technique the reader is referred to the publication by Boyd and Schwartz (1983).

Once collected the semen can be microscopically examined, or diluted with 50% Ringer's solution before being used for inseminating the female. Avian semen is less liable to temperature shock than mammalian semen. Also, in those species so far examined it is found to be less dense, but the spermatozoa should all be the same size with no abnormalities of the head or tail and mobile. Semen should be collected early in the day before the birds are fed and after defecation. It is then less likely to be contaminated with faeces and urates.

Insemination must be carried out at the correct time in the egg laying cycle. Weaver (1983) states this to be within six hours after the last egg was laid and favours insemination after each egg. However, in commercial poultry practice the birds are inseminated at 7–10 day intervals. Gilbert (1979) states that in those birds that have been examined (mainly fowl-like birds and waterfowl) the sperm is stored in the sperm host glands situated at the distal end of the oviduct. Fertilisation, which takes place in the infundibulum at the proximal end of the oviduct, can occur several weeks after a single insemination. Gilbert thinks this is probably the case in all birds.

## FAILURE OF THE FERTILE EGG TO HATCH

Dead-in-shell is probably the most common problem of all breeders and often caused by a fault during incubation. However Stockdale (2005) has indicated that with small passerines a major cause of dead-in-shell eggs is overall inadequate nutrition, particularly of the essential amino acids lysine and methionine. Only approximately 30% of all raptor eggs laid in private breeding aviaries in the UK hatch and produce surviving young, i.e. for the peregrine, northern goshawk and merlin.

### Development of the egg

During the first few days of incubation the respiratory needs of the developing embryo are supplied by simple diffusion of oxygen and carbon dioxide through the shell and its membranes. As the oxygen demands from the embryo increase, a network of capillary blood vessels forms in the chorio-allantoic membrane. Halfway through incubation this network lies under the whole of the inner shell membrane and can be seen during candling. Respiration is then taking place across the surface of the shell and oxygen is pumped round by the embryonic heart.

Dunker (1977) states that, at the end of incubation, the embryo absorbs the amniotic fluid and the remainder of the albumen (the so-called breakfast of the chicken). The amniotic cavity becomes aerated and air may penetrate the inner shell membrane. Respiratory movements become regular and serve to ventilate the lungs and air sac system *before* hatching. Unlike the respiratory system of the mammalian foetus, which undergoes further development after birth, the avian respiratory system is virtually complete and functioning at hatching.

The evolution of this method of development has enabled birds to create a constant-volume lung containing extremely thin-walled air capillaries. The minimum thickness barrier between the twin circulations of air and blood, together with a one-way flow of air, has made the avian lung the most efficient among the vertebrates. The developing egg with its delicate embryo and associated blood vessels is a fragile structure. Jerky movements, or vibration caused by nearby machinery, heavy trucks or children at play can all damage incubating eggs, particularly if held in an incubator.

The two most important environmental factors influencing incubation are temperature and relative humidity.

### The influence of temperature

There is a narrow range of optimal temperatures for incubating eggs, which for poultry is 36–38°C and this has been found to be the same for falcons (Heck & Konke, 1983). The psittacine species range is similar at 37.2–37.0°C. The experienced bird will maintain the clutch within these limits. Incubating eggs can withstand some cooling, but not rises in temperature that exceed those of the adult bird. In fact, on large commercial ostrich breeding farms eggs are collected twice daily and stored in cooled conditions for up to a week so that they can be incubated in batches so that hatching can be synchronised.

Persistent low temperatures due to cold weather prolong incubation and lead to small, weakly chicks with developmental abnormalities and un-retracted yolk sacs. In wild birds, such as swifts and sea birds, where incubating eggs may have to be left for a period to enable the parent to forage, the eggs have adapted to chilling without adverse effect (Elkins, 1983). Chilling of the eggs with other birds can occur with a careless or inexperienced hen or from extreme weather with strong winds and rain. Draughty and damp nest boxes can lead to chilling. If birds are being bred inside, the optimum ambient temperature is about 15°C. Overheating of eggs, which could occur if they were in a faulty incubator or if they were exposed to the direct rays of the sun coming through a glass window, is lethal. If the embryo survives it is likely to be deformed.

### The influence of humidity

Equally important to the survival of the embryo is the humidity around the egg. Most of the energy needs of embryonic development are supplied by fat stored in the yolk. For every gram of fat metabolised an almost equal quantity of water is generated. If this water is not eliminated the embryonic tissues become waterlogged. Rahn *et al.* (1979) have pointed out that all eggs of whatever species need to lose as water about 15% (some authorities say 11–16%) of their initial weight at lay. This water loss needs to be evenly spread throughout the incubation period and leads to a gradual increase in size of the air cell at the blunt end of the egg. Failure of the egg to lose the correct amount of water leads to a tissue fluid imbalance. Insufficient loss of water vapour molecules through the shell is exactly paralleled by the low exchange rate of oxygen and carbon dioxide. The embryo becomes weak and may develop deformities.

If the correct amount of water has been lost from the egg at the end of incubation, the shell is free to rotate around the embryo at hatching. If the egg is waterlogged, resulting in a 'wet chick', the whole contents are too tight within the shell and this normal process cannot take place. For this reason dead-in-shell chicks are often found to be oedematous. Conversely, if the egg loses too much water the tissue becomes dehydrated and the air-cell is bigger than normal. In all cases of tissue fluid imbalance the chick lacks muscle tone and is unable to force its way out of the shell. In healthy and undisturbed female birds the desire to brood her clutch is very strong and she not only will make considerable efforts to maintain the eggs at both the correct temperature and humidity but will turn them regularly. Most species of birds develop a vascular brood patch over the breast, which transfers heat from the parent to the egg (King & McLelland, 1975). Frith (1959) has demonstrated that the incubator birds, the Megapodiidae are able to use the beak as a thermometer.

In an attempt to increase the humidity, some breeders will provide the nesting birds with damp nesting material. Fortunately this usually dries out before the eggs are laid so has little effect. Rotten wood provided as a nesting material for parrots may contain fungal spores. Also some breeders will spray the eggs of a sitting hen with water to increase humidity. This is of doubtful benefit and may be harmful. The bird is best left to control the situation instinctively. Rahn *et al.* (1979) has shown that the relative humidity of the nest of most wild birds is kept at about 45%, which is about right for the eggs to lose the requisite amount of water.

### Incubators

If eggs are incubated artificially correct hatching conditions will have to be duplicated. Management of the incubator, even to the room in which it is kept, will have to be meticulous. Temperature and relative humidity must be strictly controlled. Incubators are best kept in a room at a temperature of 21–24°C and the relative humidity should be kept low, no more than 50%. If kept in such a room the conditions within the incubator are less liable to fluctuate. Incubator temperatures for most species are 37.2°C. For safety, incubators should be controlled by double thermostats and any draughts or hot spots within the incubator should be identified. Forced air incubators are better than still air incubators since temperature control is more accurate. The eggs will need to be rotated eight times a day through 45° in alternate directions. This can be carried out by hand or mechanically by automatically timed rollers. Hygiene must be faultless and fumigation using a mixture of potassium permanganate (0.4g) and formalin (0.8 ml of 37.5%) or fogging with F10 must be carried out at the end of the hatching season (see Chapter 9). The eggs must be weighed regularly to make sure the weight loss is correct. The weight can be checked against a graph indicating predicted weight loss. Considering that so few breeders follow these guidelines it is surprising that any normal chicks are ever hatched.

### Influence of the egg shell

Apart from the relative humidity of the microclimate around the egg, the most important factor controlling water loss is the egg shell. The exchange of water vapour, oxygen and carbon dioxide takes place through well-defined shell pores. The pattern and complexity of these channels varies with species. They are more complex in the larger species with thicker shells. Ar and Rahn (1977) have shown that in eggs that are of comparable weight and egg shell thickness the pore size is inversely proportional to the incubation period. Any factor that affects shell quality and shell thickness will have an effect on porosity of the shell. This will affect gaseous exchange and egg weight loss during incubation.

In a commercial ostrich hatchery in Israel the eggs are sorted into batches according to the texture of the egg shell, which can vary from rough to smooth. This is because farmed ostriches originate from a variety of sub-species.

Abnormal shell may be caused by a variety of factors. There may be disease of the shell gland due to micro-organisms such as *Escherichia coli* and *Mycoplasma* spp, etc. A salpingitis can result in soft-shelled eggs. Some waterfowl and some Galliformes may get trematode infestations of the oviduct. Also an abnormal shell may be genetic in origin or due to the age of the hen. A dietary calcium/phosphorous imbalance (which should be calcium: phosphorus 1:5) may result in soft-shelled eggs or a cessation of egg laying. Soluble grit must always be available for herbivorous birds. There may be a deficiency of zinc, manganese or vitamin D3. Unlike mammals, birds are unable to metabolise vitamin D2. One breeder improved egg production in macaws by feeding chicken carcasses and also using a good mixed diet of fruit and vegetables.

Use of sulphonamides and excessive use of antibiotics can affect shell quality. The chlorinated hydrocarbon DDT, its metabolite DDE and dieldrin, as well as the polychlorinated biphenyls have been a notorious cause of thin-shelled eggs, not only in wild raptors but in many other birds at the top of the food chain, such as pelicans and cormorants (Peakall, 1970). This cause is unlikely in captive birds unless insecticides have been used in an aviary to control insects, but must always be taken into account.

Shell quality can also be affected if the bird is stressed during formation of the egg shell. Some birds such as parrots normally lay thin-shelled eggs which may be related to the more humid environment of a hole-nesting species. Some parrots can damage the thin shelled egg with overgrown claws.

Thin-shelled eggs tend to be laid in very hot weather. Hyperventilation by the bird to overcome hyperthermia leads to respiratory alkalosis. This results in a lowering of the partial pressure of carbon dioxide in the blood with the result that fewer calcium ions are available to the cells of the shell gland.

The cause of 50% of dead-in-shell embryos takes place in the last few days of incubation and is due to adverse temperature and humidity during incubation together with malnutrition. Persistent laying of soft-shelled eggs may be an indication of hormonal imbalance, i.e. the rate of passage of the egg along the oviduct. Cracked or damaged shells will obviously affect water loss and can sometimes be repaired using clear nail varnish.

### Hatching

At the end of incubation, which varies with species, the egg hatches. Incubation times are given in Appendix 9. A few hours (36–48) prior to hatching, the embryo, using its egg tooth (a small projection on the upper beak), pierces the internal shell membrane and starts to inhale from the enlarged air cell – a process known as internal pipping. In some species chicks may start calling to each other at this time. Next a small crack indicating external pipping appears in the shell. The time between internal and external pipping ranges from 3–72 hours in parrots (Romagno 2005). The area around the crack starts to break up and eventually a flap with a sizeable hole develops. In ostrich chicks pipping is

carried out primarily by using the powerful complexus muscle running from the base of the skull along the back of the neck. The chick arches the neck and heaves a crack in the thick shell.

The whole process is gradual, leading to the progressive functioning of the chick's respiratory and cardiovascular systems. Simultaneously, the yolk sac starts to retract into the chick and the blood vessels of the chorio-allantois begin shutting down. From the start of external pipping to the emergence of the chick may take up to 24 hours. A weak chick will take longer.

If the chick is taking too long to hatch there is a great temptation on the part of the anxious breeder to help it out of the shell – this is a mistake. There is a grave danger that the respiratory system may not be ready, the yolk sac may not be retracted and the chorio-allantoic vessels may not be completely shut down. These vessels easily tear and a fatal haemorrhage can result. It is better to leave the chick at least 48 hours from the first sign of pipping or hearing the chick chirp *and only then*, if necessary, carefully extract it. Using blunt ended forceps very carefully prise away bits of shell. Bluntly dissect the shell membranes and tear rather than cut, to reduce haemorrhage. The yolk sac may require ligating (see p. 163). Once the shell is open, fluid is lost more rapidly and prolonged hatching may lead to a dehydrated chick which will benefit from a little subcutaneous sterile saline.

### **Infection of the egg**

The chick embryo has long been the laboratory tool of the microbiologist. The avian embryo has no effective immunological defence mechanism, although passive immunity is acquired from the hen via the yolk. However, the antibodies probably do not pass into the embryonic circulation until about half-way through incubation. Before this, the egg is at greatest risk. Approximately 25% of dead-in-shell chicks die in the early stages of incubation due to infection.

Infertile eggs can become infected and act as a focus for pathogenic organisms. Some breeders are in the habit of leaving unhatched eggs in the nest to give support to the chicks. It should not be forgotten that in some species, such as parrots, owls and other raptors, the eggs do not all hatch out on the same day. There may be several days' age between each chick. In passerines and many other birds, although the eggs do not hatch simultaneously there is very little interval between hatching. The egg can become infected any time from the start of its formation in the oviduct. However, the most common cause of infection is from dirty nest boxes or unhygienic incubators or from excessive handling and contamination by the owner who can transfer staphylococci on the hands to the egg shell.

The hands should be washed in antiseptic and disposable surgical gloves worn. All dead-in-shell eggs should be cultured for bacteria and fungi. Cultures should be taken from the yolk sac, the albumen and the embryo's liver. The results of these cultures and a post-mortem examination on the embryo may give some indication as to how and when the egg was infected. The dead chick should be examined for any developmental abnormalities and its age should be estimated from the size relative to the egg. If pathogenic organisms are isolated, then an assessment of the whole nesting area and incubator together with bacteriological sampling of these needs to be made.

In summary, the veterinarian investigating the failure of the eggs to hatch needs to differentiate between the following common problems:

1. Eggs that are infertile
2. Waterlogged eggs
3. Dehydrated eggs with contained dead-in-shell chicks
4. Eggs which are infected or affected by toxins

The investigation will also need to take into account other less common causes such as the age, nutrition and disease status of the female and if the eggs have been handled and stored carelessly before incubation.

### **FAILURE TO REAR THE YOUNG**

As well as deserting eggs, birds will sometimes abandon the chicks and cease to feed them at any stage of brooding. This may be caused by stress or it may be genetic or neurotic in origin. If a bird rears one year but not the next then stress is the most likely cause. Similar to the situation in mammals, some birds will attack the chicks as will happen with over-defensive cockatoos or goshawks, both species of which can be quite dangerous to human contacts when breeding.

### **Fostering**

If the survivors are rescued they will have to be reared artificially or by foster parents. These can readily be found from among such birds as zebra or Bengalese finches, redrump parrots, budgerigars, or, in the case of raptors, other falcons. Perrins (1979) found that wild blue tits (*Parus caeruleus*) will feed the young of blackbirds (*Turdus merula*) or treecreepers (*Certhia familiaris*), and wrens (*Troglodytes troglodytes*) will feed coal tits (*Parus ater*). Cross fostering, e.g. of the galah (*Eolophus roseicapillus*) with Leadbeater's or Major Mitchell's cockatoo (*Cacatua leadbeateri*), has been successfully carried out by breeders. Fostering may result in the young bird becoming imprinted on to the species of the foster parents and may result in pairing difficulties when the birds reach sexual maturity and come to breed. This has not been demonstrated in wild birds. There is an increasing tendency for aviculturists to take the first clutch of eggs in an effort to encourage further laying by the hen. The first group of eggs is then incubated artificially. Double clutching may increase productivity but it is not a practice to be encouraged unless performed by trained biologists.

### **The needs of birds feeding young**

All breeding birds should have access to a shallow pan of water. This enables them not only to bathe but to carry water, held in the breast feathers, to the chicks or eggs if necessary. Also, birds feeding young may have increased fluid requirements. Pigeons produce crop milk during the early part of brooding and there is increased flow of saliva in parrots rearing young. Smith (1982) suggests that this may have an effect on the activity of plant enzymes when the seed is held for some hours in the crop of the adult bird. This may increase the nutritive value of the food. Smith has shown that such regurgitated seed has a higher nutritive value than that fed to the adult bird. This worker also observes that the primitive bird, the hoatzin, may carry out fermentation in its crop similar to that taking place in the large proventriculus of an ostrich. J.R. Baker (1981, personal communication) notes that protozoa are normal inhabitants of the crop in the budgerigar.

Birds feeding young need a good quality protein diet. Merlins rearing young and fed a diet of hatchery chicks failed. The fledglings were pale and weak. If the diet was changed to dead (trapped) sparrows the chicks thrived.

Most of the seed-eating birds need to feed their young on animal protein, such as caterpillars and larvae of other insects. Live insects should be provided by the aviculturist during this period, although the use of mealworms is contentious because some chicks may not be able to digest thick chitin. If birds such as parrots are fed too much green food or fruit, their droppings become very moist. This can lead to a damp, unhygienic nest with flies and maggots that will attack the chicks. Many wild birds go to considerable trouble to keep the nest clean, either carrying away debris or trampling it into the dry material at

the bottom of the nest. Passerines remove faecal sacs from the young and, often, egg shells and dead chicks are removed from the nest by many species of birds. Young raptors instinctively defecate over the side of the nest or, if ground nesters, wander away from the nest to defecate. If the birds are used to the handler it is sometimes advantageous to clear out nests daily if the birds are 'wet' feeders. Droppings glued around chicks' claws can cause necrosis.

### **The progress of growing chicks**

Properly fed young should gain in weight regularly. A competent bird breeder, whose birds are adjusted to him, should be able to examine and weigh the chicks regularly. Some aviculturists do examine the chicks but few seem to weigh and record their progress. If the weather is cold there may be some temporary loss of weight.

By far the commonest problem in growing chicks, particularly hand-reared chicks, is metabolic bone disease caused by an imbalance of calcium and phosphorus and insufficient vitamin D3. Occasionally, a chick may develop splayed legs, a condition seen in both raptors and psittacines. This usually is due to a chick being reared on an unsuitable, slippery surface during growth. If left untreated this can rapidly result in permanent damage. The condition can be treated using a figure-of-eight suture round the legs for about a week or better still by splinting the legs in slots (i.e. splits) made in a suitable block of expanded polystyrene foam or by putting the chick in a cup or small bowl which tends to push the legs under the body.

Harcourt-Brown (2003) has also pointed out that artificially reared parrot chicks (particularly grey parrots) may be encouraged, by premature ambulation or by stretching up to be fed, to place too much mechanical stress on the main weight-bearing bone, the tibiotarsus, before this is fully mineralized. This could result in deformity. Other congenital abnormalities seen in neonate chicks are opisthotonus, various other joint deviations, scoliosis, hydrocephalus and beak abnormalities. Unabsorbed yolk sacs can occasionally be a problem since these become infected. The yolk sac usually disappears within a few days although it may persist in the ostrich for up to eight days (see Chapter 8 on surgery for this condition).

### **Feathers**

During the first ten days of brooding, the chicks are poikilothermic and gradually become homoiothermic (Elkins, 1983). The adult birds will brood them continuously. During this period the feathers of altricial chicks begin to grow. The rate of growth varies among individual chicks, the larger and stronger chicks growing feathers fastest. At the end of this period, when the adults begin to spend less time keeping their brood warm, the least-feathered chicks are at greatest risk.

The initial feather cover is not a very efficient heat insulator. Many young chicks die of chilling at this time. The chilled youngster becomes torpid, fails to beg for food and dies of starvation. Nest boxes that are too large, poorly insulated, damp or with only one or two chicks can become quite cold. The larger the number of fledglings in a nest, the greater the body mass and the smaller the ratio of surface area to body volume. Even the totally feathered and active precocial chicks of waterfowl sustain considerable losses if there are adverse weather conditions during the first weeks of life.

### **Artificial rearing**

If chicks are reared artificially in a hatcher, the temperature will need to be reduced progressively during the growing period. As the feathers grow the breeder should take note from their behaviour if the chicks are too hot or too cold and adjust the temperature accordingly. A hot chick will lie with wings and legs stretched out and will keep away from other chicks. The chick will pant and the skin will look red. However redness of the



skin could also indicate infection. Cold chicks huddle together or, if by themselves, wander around their enclosure. In both cases they tend to make a lot of noise because they are stressed.

In chicks being hand reared the breeder should try to assess if a chick's crop and stomach are being filled or emptied properly. This may either be felt or seen through the semi-transparent skin of the neck and abdomen. Slow crop emptying may be due to the humidity of the brooder being too low or if the temperature of the food is too low. However food given too hot can cause scalding and crop burns (see p. 154). Be wary of food heated in a microwave in which hot spots may occur. Crops should be full but not over distended which may lead to impaction. Sour crop may be caused by either fungal or bacterial infection. Aspirate the contents and examine the sample bacteriologically. Nystatin suspension (see p. 242) and Avipro paediatric are suitable treatments.

In conclusion it should be stressed that the three most common causes of death in nestlings are hypothermia, starvation and infection. Infanticide is not uncommon and such factors as vitamin and mineral deficiencies and chemical toxins occasionally increase mortality. Also, young chicks are very susceptible to many infections such as:

- The viruses of polyoma, psittacine beak and feather disease, avipox, serositis, infectious bronchitis (see p. 305), reovirus (see p. 306), adenoviruses (see p. 301) and duck virus hepatitis (see p. 294)
- Trichomoniasis, coccidiosis (see p. 319), *Giardia* (see p. 320), toxoplasmosis (canaries) (see p. 317) and various bacteria

All of these conditions are covered in more detail in the relevant Appendices. Prophylactic measures should include meticulous hygiene, quarantine for up to 12 weeks of all newly acquired birds, together with diagnostic testing and avoidance of bird shows and auctions, etc. Keep visitors, particularly those from other bird collections, away from hatching and rearing areas.

# Release of Casualty Wild Birds



## FACTORS THAT AFFECT SURVIVAL

Considerable interest has been shown and much has been written during the last two decades about the rehabilitation of injured wild raptors. This knowledge has been developed particularly in the United States with the foundation of such organisations as the Raptor Research and Rehabilitation Program, based at the University of Minnesota. Concern about raptors is important, since this group of birds is at the greatest risk of extinction. Raptors are often in direct conflict with man, and being at the top of the food chain they are most liable to the cumulative effects of the toxic agricultural chemicals. However, the veterinarian in practice is often presented with other groups of sick and injured wild birds, some of which he or she will want to release.

The factors that must be taken into account when birds other than raptors are released vary tremendously. Comparatively little has been written about this aspect of the problem and this chapter is an attempt to examine the task as it affects all species of birds.

As will be seen in the following pages, the release of wild birds is something that should not be undertaken lightly. It not only requires skill as an avian clinician but also knowledge of the bird's natural history. Cooper (1979) has pointed out that in the UK, under the Abandonment of Animals Act 1960, 'the indiscriminate release of wild bird casualties without careful consideration of their chances of survival in the wild could amount to an offence.' On the other hand, any person who keeps any wild bird that could be released is guilty of an offence under the UK's Wildlife and Countryside Act 1981 (see Plate 18). The factors that affect survival can be broadly divided into two areas, which are to some extent interrelated:

1. The bird's physical and mental fitness to cope with its environment
2. The habitat into which it is to be released

The habitat is constantly changing, and unless a bird is to be released where it was found within a few days of injury, there are many aspects that must be considered. A bird that is in the wrong environment and not completely fit will not only be unable to feed itself properly but will soon be spotted by a predator, even if that bird looks normal to the casual observer. If the bird is a predator and unable to hunt efficiently it will not be able to maintain itself.

## ASSESSMENT OF HEALTH

One of the first questions the veterinarian examining a wildlife casualty must ask him/herself is why and how has this bird become a casualty? Is this a genuine accident casualty

such as a road accident or the bird having been blown or inadvertently flown into a high voltage electric cable or electricity-generating windmill? Has it become poisoned by some toxic substance? Or, more importantly, is this a chronically sick bird suffering from some infectious disease such as avian flu or West Nile virus (see p. 297)? Of course, if so there are likely to be other birds around with similar signs but not always – this could be the first of many such birds.

Apart from the zoonosis aspect, placing a chronically sick bird with an infectious disease in a rehabilitation centre is a considerable risk to the other invalidated inmates (see p. 184). Infection by the pathogen and incubation may take place, and then the pathogen, possibly increased in virulence, is reintroduced back into the wild if an apparently healthy individual rehabilitated bird is subsequently released. Rehabilitators don't always appreciate the risks involved in the long-term rehabilitation of chronically sick birds. The ethical aspects of this problem have been reviewed by Harris (2005).

So what should the examining veterinarian be on the look-out for?

- If the bird has frayed tail feathers it has probably been on the ground for some time; this is also indicated by blunted frayed talons.
- Overgrown or blunted beaks in birds of prey indicate the bird has not been feeding properly. The author remembers seeing a rook (*Corvus frugilegus*) unable to fly properly but wandering around a motorway service area feeding on scraps left by the public.
- Unkempt, tatty, dull plumage indicates the bird has not been preening properly.
- Loss of bodily condition and a prominent *carina* or sternal keel.
- Is the bird grossly infested with ectoparasites? Healthy birds keep their ectoparasite load in check by constant preening.
- If a radiograph shows a previously healed fracture, does this mean the bird is accident prone and not 100% fit?

If there is any suspicion that the bird is chronically ill, further health checks may need to be carried out and, if considered necessary, euthanasia performed. As Harris (2005) has aptly asked: 'If an individual cannot be released because of some infirmity is it appropriate to keep it confined in captivity for the 'term of its natural life'?' There is really no justification whatsoever for keeping a collection of invalid birds just to keep them alive. The author once saw a mixed flock of gulls (*Larus* spp), none of which could or were ever going to fly again, kept by a well-meaning 'rehabilitator' on a small muddy paddock, in the belief that they were enjoying their existence in being with their fellows.

## PHYSICAL FITNESS

While it is generally true that a bird needs to be anatomically perfect and 100% fit before release, it is not entirely necessary. How much disability a bird can adapt to will depend a great deal on its normal patterns of behaviour.

### Skeletal damage

A healed fracture of the humerus or the ulna may not be in perfect alignment and there may have been some shortening of the bone, but many birds will still be able to fly (however, see p. 174). There are a number of recorded instances where birds have been found surviving with misaligned, healed fractures (Olney, 1958/9; Tiemeier, 1941; Hurrell, 1968). The author has seen several cases in raptors where the fracture had not healed perfectly but where the bird had mated and successfully reared young. This indicates that the bird was hunting effectively enough not only to survive but also to catch enough food to feed its young. Quite obviously these birds had learned to compensate for the disparity between the normal and abnormal wing.

What is much more important for the bird to be able to fly efficiently is movement in its wing joints. Even here some slight loss in the range of movement may be tolerable and a bird may learn to adapt. A short-winged hawk, such as a sparrow-hawk or goshawk, may be able to cope with the loss of 10% range of movement in its carpal joints. These creatures are birds of fast forward flight with a high wing loading and a high tail-surface: wing-surface ratio. Once airborne the momentum of the bird helps to keep it in the air. Steering and braking depend on the tail. Ducks and pigeons are also birds with short, broad wings and fast forward flight (see Fig. 1.5).

On the other hand, a bird such as a barn owl or harrier has quite a different mode of flight. The wing loading is lower, particularly in the owl, and full mobility of the carpal joints is essential for the bird's manoeuvrability. These birds need the maximum lift on their wings to hunt – slowly quartering the ground and, in the case of the owl, pivoting in the air. A barn owl with an ankylosed elbow joint was seen to be able to ascend and to glide, but once it tried to turn it collapsed completely.

Large, soaring birds of prey slowly rising in thermals need complete mobility in the digital and carpal joints. The muscles of this area are well developed. The large emarginated primary feathers are splayed out and act like slots in an aeroplane wing to reduce turbulence and increase lift. The distance between the slots is constantly being adjusted by the bird. In the soaring gull, in which the method of flight is somewhat different, mobility of the carpal joint is not so important so long as the bird can extend the wing completely (see Fig. 1.5).

The hovering kestrel, searching for its prey, probably needs complete mobility in all the wing joints, as does the hovering flycatcher. Hovering requires more energy than fast forward flight so that it is possible that the kestrel needs to be a more efficient predator than the sparrow-hawk. However if the casualty kestrel cannot hover but can fly it may learn to hunt from a 'pole perch'. Kingfishers normally hunt from a perch but can hover. Terns (*Sterna* spp) also hover when hunting but do not have the option of a pole perch if partially disabled.

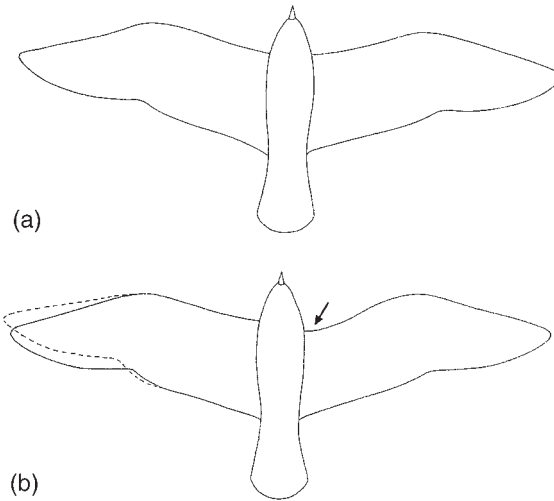
Some colleagues are of the opinion that all raptors that lose a leg should be euthanised. The author would agree with this view in the case of the larger birds, which will inevitably develop bumblefoot on the normal side; but in the smaller species (e.g. kestrel, merlin or even small passerines) this is not the case.

### **Soft tissue damage to the locomotor system**

Some muscles may have been so badly damaged as to be permanently atrophied. The propatagial membrane is often injured in collisions, and if scar tissue results extension of the wing may be severely affected. The author has seen cases where the leading edge of the wing is placed more than one inch further back on the body than that on the normal side. In these cases flight is affected. In a less severely disabled case the bird may be able to fly but lift on the affected side is reduced because of a reduction in effective wing area. The bird may compensate by trimming (slightly flexing) the normal wing so that both wings are equal in area and also by flying a bit faster (Fig. 11.1).

Lift on an aerofoil, be it a bird's wing or an aeroplane, is not only proportional to the effective wing area but is proportional to the square of the relative wind speed. The author has seen a case of damage to the propatagial membrane in a Harris's hawk where the bird was able to fly but constantly veered off to the left. Quite obviously this bird would not have survived in the wild.

Small birds, such as wrens, blackbirds and tits, which live in dense woodland cover and do not normally fly great distances (providing it is a species that does not migrate annually), may survive with wings which are not quite normal. Providing the distance between perching positions is not too great these birds will adapt. However, if they are released in a more open habitat, where the distance between trees and bushes is greater,



**Fig. 11.1** (a) The position of the wings in a normal bird; (b) shows how the bird trims the wing on the uninjured (L in the diagram) side, by slight flexion to balance the abnormal wing. The arrow indicates the position of the scarred and displaced propectagial membrane. To get the same amount of lift, (b) flies slightly faster than (a).

they will be at a disadvantage. They are unable to glide properly like the short-winged hawk and ducks mentioned earlier – although they have short broad wings, the frontal body surface area in relation to their body mass is high (i.e. the profile drag is high) and they do not have sufficient momentum to carry them forward.

Small birds, such as the wren, the robin and the starling, need to be able to manoeuvre accurately to be able to get into and out of their hole nesting sites. However, small birds do have an advantage over the large birds. They can sustain a proportionately larger amount of permanent damage to their main flight muscles than can large birds. This is because the power margin (the energy available from the muscles required to lift the bird into the air and keep it airborne, beyond the minimum power required for this activity) is much greater in small birds. In a bird the size of a swan or large vulture, which cannot jump into the air but has to have some distance or a strong head wind to get up relative air speed, the power margin is low. The bird, in fact, only just makes it. Very little damage needs to occur to the soft tissue of these large birds and they will not fly again.

No two species of bird have the same flight pattern and probably no two individual birds fly in exactly the same manner, just as no two people walk exactly the same. How a partially disabled bird learns to fly again will depend on the particular disability and on behaviour pattern of that species. So that a considered judgement can be made on these matters it is important that the clinician carries out a thorough physical examination of the patient before release is considered. This should include radiography and the examination of the mobility of all wing joints together with the extensibility of the wings. The examination should be carried out systematically even if no fractures of the wings have occurred. Investigation of these problems can only be carried out properly if the bird is relaxed under anaesthesia. One cannot properly compare the mobility of the joints in each wing in the conscious bird and it is easy to miss a slightly damaged propectagial membrane.

A bird may look normal when it is alert and perching under observation. Once the observer has disappeared the bird relaxes and both wings may not be held symmetrically.

A bird may feel round and in good condition, its weight may be normal for the species and time of year, but the weight may just be fat. If a bird has been in captivity for some time the ratio of fat to muscle may be too high. Nevertheless some fat must be present as an energy reserve.

### Testing flying ability

Having considered all the above factors there is only really one way to assess a bird's flying ability and that is to see it fly. To a limited extent this may be possible in a large aviary. The larger the aviary in relation to the size of the bird the better. Much information can be gained by watching the bird fly in a large garage or barn (see Plates 19 and 20). It may be possible to give the bird daily exercise with these facilities to build up the bird's fitness. Ideally the enclosure needs to be as high and as long as possible, the bird can then practise gaining in height as well as propelling itself forward.

Falconers have developed methods of flying birds on a leash or creance (see p. 257). This is light in weight and the bird is allowed to trail up to 100 m, which enables it to be controlled. A large open space is essential although, for instance, on heather moorland the leash tends to snag on the heather. There should be no obstructions and no distractions for the bird. Obviously the total weight of the leash must not be heavy. If possible it is best to fly the bird uphill and with the wind behind it. This makes flying much harder work and gives a better assessment of how well the bird can fly.

This technique is applicable to other types of bird than raptors. Such birds as pigeons, ducks and gulls, with strong legs, are suitable but the method cannot be used in those species with long legs, such as herons or waders, or any bird with delicate legs. The method only tests the ability to fly in a straight line, it does not show if the bird can gain height or show how it can manoeuvre. These skills really can be tested only in a large, confined space. If, after allowing the bird to fly for a short distance, it is dyspnoeic for more than a few seconds it is not fit to release. A normal bird should be able to fly long distances without getting into respiratory distress.

Holz, Naisbitt and Mansel (2006) working with peregrine falcons (*Falco peregrinus*) and brown goshawks (*Accipiter fasciatus*) have found that falconry based pre-release exercise training programmes increased the chances of the bird's successful survival after release.

### Loss of feathers and damage to plumage

Before release, the plumage must be in good order. Not only must most of the main flight feathers be present, but the thermal insulating properties of the covert feathers must be effective. Many birds can fly with a few feathers missing – they often do so when moulting and can look rather ragged, but the loss of these flight feathers must not form large gaps in the aerofoil section of the wing. Large birds have an irregular pattern of moulting because they cannot afford to lose too many feathers at once to remain airborne. Waterfowl become flightless during moulting.

Lorenz (1965) cut off different sections of the remiges in pigeons to see what effect this had on flight. When most of the primary flight feathers had been removed the bird could still fly in level flight but could not ascend. If the secondary flight feathers were progressively removed level flight was affected, although height could be gained.

A new feather can be stimulated to grow by gently pulling out the stump of the old feather. However, growth of the new feather takes time. The loss of tail feathers is more important in some birds than others (see p. 5). Many birds can fly without the tail but birds such as sparrow-hawks, hen harriers, magpies, gulls and kites cannot steer properly. The kestrel, the buzzard and the tern cannot hover. The large eagles and the owls can probably manage better than most but the precision of flying will be affected.

### Imping

Falconers use the technique of imping to replace a damaged feather with one that has been moulted or one that has been obtained from a casualty bird. The feather does not have to be from the same species, although it must not only be of approximately the right size but must be of the same texture. The flight feathers of chickens and pheasants are harder than those of other birds. The shape must be right. In many large birds, particularly the raptors, the outer primaries are emarginated, and the vane on one side of the shaft is very much narrower for part of its length.

The technique of imping is applicable to birds other than raptors. The shaft of the broken feather is cut below the damaged area and the shaft of the new feather is cut so that the upper part replaces the faulty section. The two halves are joined together with a peg made of bamboo, a needle, or the quill of another feather of suitable diameter. Any substance can be used so long as it is the right diameter to be inserted into the ends of the two cut shafts and is strong enough. The whole is held in place with glue.

### Damage to the legs

The full functioning of both legs is probably not as important as that of the wings. Fishing line trapped around the legs can eventually lead to necrosis and loss of part of the leg in birds such as gulls or rails. Some birds lose toes through frost bite. All these birds can and do survive. Some rotation of the tibiotarsus after healing is also quite tolerable. The legs are more important to a raptor, but there are reports of these birds hunting and surviving with only one leg functional. Nevertheless the chances of a heavy bird such as a buzzard developing a bumblefoot infection are greatly increased if it is constantly standing on one foot. Species such as herons, storks and waders are severely handicapped in their methods of hunting with one leg and should be euthanased.

### Damage to the eyes

Fifty percent of wildlife casualties have intraocular trauma (often haemorrhage from the pecten – see p. 48). The loss of an eye might be thought to be a severe handicap that would affect the judgment of distance but this is not always so. Birds can manage with one eye and are able to judge distance sufficiently accurately to be able to land with precision on a branch. Dr Leslie Brown (an ornithologist in Kenya) in a personal communication (1978) records such a case in a female crowned eagle (*Stephanoaetus coronatus*). This bird survived at least two years with what appeared to be a cataract in one eye. However, Brown notes that the breeding success of this bird was reduced after it developed disease of the eye. It was then probably not a completely efficient predator.

In the peregrine falcon two perfect eyes are thought to be essential. These birds may start their attack on a victim anything from 500 m to 4.5 km away from the target (Brown, 1976). However, the author has heard of at least one peregrine that survived in the wild with only one functional eye. The author has also known of two owls and a buzzard in which loss of an eye occurred and the birds were able to survive. In the prey species the bird may survive but its chances of eluding a predator would be reduced (see p. 26).

### The importance of good hearing

In birds such as owls or harriers, that have sustained damage to the head, the clinician should consider if the hearing of the bird is likely to be affected. Both these groups quarter the ground they are hunting with a slow methodical flight, using their facial discs to pick up the slightest sound (see p. 34). Hearing in these birds is more important than sight.

Hearing may be important to some invertebrate feeders. Certainly the thrushes locate earthworms by listening. Also woodpeckers, nuthatches and treecreepers may locate grubs below tree bark by hearing.

## MENTAL HEALTH

When considering if a bird's behaviour pattern will enable survival in a given environment, casualties can be divided into two fundamentally different groups. First there are those birds that were mature when first caught. These birds have learned to find food for themselves. Provided they still retain their natural fear of man and his domestic animals they pose little problem. If this group are not kept in captivity for more than about 14 days they soon settle back in their old habitats. If they are released into the exact location where they were found then they know the local geography and where the likely food sources are situated. This group usually survives very well.

If a bird has been captive for several months before it is released it may take a little time to get back to its normal routine. Apart from being out of the habit of continually having to search for food, the bird's food supply will have changed. Summer has changed to autumn or winter. Abundant supplies of insects and vegetable food have changed. Many small birds have migrated and the countryside which yielded a plentiful supply of easily caught young animals for the predator has disappeared. The released casualty will need support feeding from a familiar source while it is learning to adapt to the changed situation.

Hooimeijer (2006) records that white storks (*Ciconia ciconia*) kept in captivity for three years as part of a conservation breeding program lost their normal migratory behaviour.

The group of birds that pose the greatest problem for release are the young which may have been captured at some stage of their development. These birds, which have never lived freely, not only may have to be taught to search for food but may develop undesirable mental attitudes during their nursing period.

The altricial nestlings, which include the raptors, are fed by the parents not only during the time they are in the nest but also for a period after they have left the nest. During this post-fledgling period the young bird is not only developing the skills of flying but also, in the case of predators, is learning to hunt and catch prey successfully. Foraging for food in the prey species may also be partly learned by watching parents and also by natural curiosity and investigating a range of potential food items. C.S. Jones (1984, personal communication) has noted that the rate at which young tawny owls learn to fly and pounce accurately on a moving prey, varies between individuals. Some birds may never become quite as good as others and may under natural conditions not survive. Mortality in young wild raptors through inefficient hunting is quite high.

Young raptors can be taught to hunt by traditional falconry methods using feeding from the fist, feeding to the lure and 'waiting on', etc. (see p. 360). The reader is referred to standard texts on falconry such as Mavrogordato's *A Hawk for the Bush* (1960) and Woodford's *A Manual of Falconry* (1960). A raptor will learn to hunt if it is confined to a barn where there are live mice or rats or if it is in an aviary where small mammals and birds can get through the mesh of the netting but through which the predator cannot escape. To feed live animals to a bird of prey is illegal in the UK under the Protection of Animals Act 1911–1964.

In the precocial species, such as pheasants, plovers and waterfowl, where the young hatch fully feathered, feeding behaviour is almost entirely instinctive, but these birds do need to be exposed to their normal habitat during the developing period so that they will learn to investigate all types of potential food items, such as invertebrates.

### Imprinting

This phenomenon, first demonstrated by Lorenz in geese (1935 and 1937) is seen in all species and has far reaching implications. As the young bird matures, its mental awareness of its environment becomes more acute. The bird recognises not only its parents, which feed it, but also its siblings, nest site and food. These images become fixed



in that part of the brain (the hippocampus) controlling behaviour. Alter any of these normal contacts in the developing bird's environment and problems of behaviour occur. The bird fails to recognise or has difficulty in recognising its own species when it reaches maturity. If raptors are not presented with a variety of their normal prey species they may never learn to hunt properly. All birds have great difficulty recognising food items with which they are not familiar even though these may be quite suitable as food. Feed a developing raptor entirely on hatchery chicks and it becomes imprinted on them. Birds often return to the same nest site, possibly because the surrounding environment is imprinted on them.

Young fledglings reared and hand fed by humans become imprinted on the handler. They continue to beg for food and can become totally dependent on their human benefactor. These birds may never pair and mate with their own species because they do not recognise them (see p. 205). They may in fact form a sexual pair bond with their human rescuer. When such birds are released they may attack unsuspecting humans in the belief that these persons are a natural food source or that they are a natural mate. McKeever (1979) thought that human imprinted owls released into the wild could be dangerous. In the more rapacious species injury to humans could be severe. Each year newspaper reports appear, usually towards the end of the summer or in the autumn, of a demented owl which has attacked someone. These may be imprinted birds released by well-meaning but ignorant do-gooders.

The critical period of socialisation takes place in different groups at different stages of development. In the altricial nestling it is generally later and longer than in the precocial chick. The rigidity of imprinting probably also varies with the species. Some authorities believe that imprinting can never be reversed, although there is some evidence that some types of imprinting may be negated. Certainly it is difficult and may take years. For the biologist intent on the captive breeding of the rare species of raptor this may be practical. For the veterinarian who wants to release a wild bird after treatment, imprinting can produce insuperable problems.

Reversion to juvenile behaviour by an injured bird can sometimes occur (Lack, 1975) and the author has noticed this in an injured parrot which had lost its upper beak. Reverted mature birds open their mouths and at the same time carry out slight fluttering movements of the wings begging for food.

If a young bird is reared, by a well-meaning person, in complete isolation in an attempt to stop imprinting on to its human contact, it becomes completely neurotic. It is hypersensitive, frightened of its own shadow and fears all living things – a mental state not confined to birds. These birds are excessively aggressive and frightened of their surroundings. The worst effects of imprinting can be avoided by rearing a young bird with its siblings. A good discussion of abnormal and maladaptive behaviour which is important to the releaser of wild birds is given by Jones (1980).

## THE RELEASE ENVIRONMENT

Taking the potential release environment into account is an equally important part of the problem of releasing wild birds. The summer period in temperate climates is a time of plentiful food supply. Birds that are physically and mentally fit should have no difficulty in finding sufficient food. However, at the beginning of the summer period, there is often intense competition among conspecifics for breeding territory. This biological phenomenon is an attempt on the part of the breeding birds to map out and familiarise themselves with a secure food supply on which to rear their young. An outsider of the same species or even a competitive species released into this territory comes under considerable stress through constant attack and harassment. This is bad for a bird that is trying to rehabilitate

itself into the environment. It would be wiser to pick a release area where the food supply is plentiful and where the number of suitable nesting sites is restricted (Newton, 1979).

As the summer period advances, the ground cover in a wood increases and makes it harder for the tawny owl to hunt for its food. But this is an easier time for the prey species, including many small birds, as food is abundant and it is easier to hide from the predator. As autumn turns to winter, the ground cover is much less dense giving fewer refuges for the prey and the balance shifts in favour of the owl. These constantly changing circumstances favouring first one group of birds, then another, take place to some extent in all types of habitat. They should always be considered before releasing the bird.

Many birds are migratory, being only in the UK or North America or northern Europe for a relatively short period during the summer to breed. This is a time of plentiful food supply in such regions. By the time they are fit for release the food supply of insectivores such as swifts, swallows and warblers may have gone. The short-eared owl and the hen harrier breed on the upland moor during the summer but migrate locally to the estuaries and lowlands during the winter.

Before any bird is released into a habitat it is essential that the releaser makes sure that an adequate food supply is available. The habitat may look right – it does not necessarily mean that the food, for instance the prey species, is present. It is therefore important that to be successful in releasing casualty birds, the veterinarian should either be a competent naturalist or have the cooperation of such a person. The County Naturalists Trusts or the RSPB local groups (in the UK) or similar organisations can be found throughout these areas and can be contacted for help. The correct assessment of the complex interactions of the bird and the environment requires a wealth of knowledge of natural history and some practical skill as a field naturalist.

## **The weather**

The weather is another important and complicated consideration. Prolonged heavy rain can severely restrict the feeding of many species – from the aerial insectivores to the hovering species such as the kestrel. For the barn owl and harrier, rain reduces the acuity of hearing. Sea shore waders, and small birds feeding in dense foliage, such as the wren, are less affected. Just after heavy rain there are often many invertebrates, particularly earthworms, near the surface. In dry weather, particularly if prolonged, the invertebrates migrate deeper into the soil. In wetland areas during the drought, soil increases in salinity so that fewer invertebrates are available.

Cold weather is important, especially if the ground is frozen. Under these conditions the balance between the energy intake of the bird and its energy losses in searching for food and maintaining body temperature may be critical. It is therefore important that the bird has adequate fat reserves before release. Even the barn owl probably only stores sufficient fat reserves to last three days, and has been observed to cache food (Anthony Duckels, 2005, personal communication). In small birds the energy reserve is much less.

Unless the cold weather is very severe the sea shore and estuarine mud is unlikely to freeze as it is periodically warmed by the tide. However, the invertebrates travel deeper in cold weather so that the species feeding near the surface with short beaks are disadvantaged. The wind chill factor, with high wind in low temperature, can lead to the loss of a lot of body heat. Prolonged frost can have disastrous effects on woodland birds feeding on the pupae and eggs of insects secreted in the tree bark. Wind and cold have less effect near the ground and on the leeward side of a wood but are important in the woodland clearings.

High wind churns up large expanses of water, including the sea. This stirs up bottom mud making feeding for diving species difficult. A rough sea constantly pounding a rocky shore disturbs the purple sandpiper and the turnstone so that they can spend less time feeding. The subject of weather and bird behaviour is very well covered by Elkins (1983).

Because of all these factors it is wise to consider the weather forecast for the next few days before releasing a bird.

### **Other factors to be considered before releasing casualty birds**

Birds should be released at first light or as early in the day as possible. This gives them the maximum feeding period before darkness and gives them as much time as possible to orientate themselves. A prey species, such as a small tit, a plover or a starling, may stand a better chance of survival if it is released near a flock of the same or similar species. Even here there is often a pecking order and the bird will be under some stress until it is accepted.

It is unwise to release birds near a busy main road. Many owls and other species such as crows are attracted to the small vertebrate casualties killed on the road and then themselves become injured or killed. Even small birds, such as wrens, robins and thrushes, tend to fly low over road-ways and become casualties. Some birds of prey, such as the buzzard, the little owl and the short-eared owl, use telegraph poles or fence posts alongside the road as perches to watch for prey.

When releasing raptors onto farmland or near large estates it is better to have the permission and cooperation of the occupier of the land and his staff. Releasing a sparrowhawk near an industrial estate or where there is a large complex of buildings would be unwise. These birds often chase prey into a building and then become trapped. The netting of a fruit farm is a similar hazard. Barbed wire fences across open farmland are a particular hazard to barn owls. Swans need a large expanse of water with no overhead wires.

## **THE TECHNIQUES OF RELEASE**

As stated earlier, when a bird is building up its strength and initially learning to fly, or convalescing after injury, it can be kept in an aviary or other suitable enclosure. If this is situated in a suitable area for release, when the time comes to let the bird go, the netting on top of the aviary can be rolled back quietly. This method has several advantages. The bird can see and has become familiar with the surrounding countryside. It can go back to the aviary as a temporary refuge and this can also be a source of support food while the bird learns to forage for itself.

A method that has been used successfully to release falcons is to use a 'hack box'. This is basically the same principle as the aviary method except that it is portable. The box is really a small cage, the size dependent on the species. For falcons it should be about 1.8 m × 1.2 m × 1.2 m. The box is transported to the site chosen for release and left containing the bird on site for 7–10 days. The box needs to be well protected from predators. During this time the bird is fed from behind a screen or using a chute so that the handler cannot be seen. The principle is to try and break the feeding bond and give the bird time to familiarise itself with the surrounding area. At the end of the habituation period the cage is opened but feeding continues for long enough to make sure the bird is foraging for itself. Support feeding may need to be gradually reduced to encourage normal hunting.

Both of the above methods are suitable for most types of bird but may need some modification. Raptors can be released after using standard hacking back techniques. After training they can be tethered to a 'hack board'. This is a wooden platform which acts like an artificial nest site. The bird is tethered for several days, during which time it is fed and gets to know the neighbouring territory, and then is released. Some falconers suggest carrying the bird on the fist around the area surrounding the hack board for several days before release. This helps familiarise the bird with its territory. Regular feeding on the hack board continues and is gradually reduced to encourage hunting. Survival of all species depends not only on the physical and mental well-being of the bird but also on it having an intimate knowledge of its local environment so that it can find food and shelter.

## CONCLUSION

It can be appreciated that the problem of releasing the casualty after treatment is complex. The work can be time consuming and frustrating, because a bird may die at any stage in the rehabilitation process. However, it is important that veterinary surgeons should be involved in this work and in co-operation with other natural scientists should record their experiences and observations so that others can make use of these records and build on them. The veterinarians' expertise and skill used in this way can help to make some positive contribution to conservation. A good review of the subject was carried out by Brown and Luebbert (2003).

The techniques worked out on common species can be used on the rarer birds. Today's common bird may become tomorrow's rarity or even become extinct, like the passenger pigeon, which was so numerous in North America during the early part of the 19th century. During that period, migration flocks containing two billion birds would darken the sky. As HRH Prince Philip has stated:

It is absolutely inevitable that a very large number of species are going to become extinct in spite of our best efforts.

The Prince warned that in not protecting wildlife our own days would be numbered:

. . . for we simply cannot survive without the other living species that co-exist with us on this planet.

# Appendices

---

## APPENDIX 1 AN AVIAN FORMULARY

### **Professor Thomas N. Tully**

Louisiana State University

School of Veterinary Medicine

Department of Veterinary Clinical Sciences, Baton Rouge, USA

### **Antibacterial drugs for use in birds**

Owners commonly request the prescription and administration of antibiotics for their birds. This request is often made without any thought as to the real need for antimicrobial treatment in relation to the patient's presentation. There is generally an assumption that 'antibiotics' are the drugs of choice for any sick bird and response to the therapy will be rapid. It is incumbent upon the veterinarian to explain both the benefits and side effects of antimicrobial therapy to owners. This information will often help with owner compliance, thereby applying the therapeutic benefits that are needed to successfully treat the presenting disease condition.

Antibiotic therapy should only be initiated when the therapeutic benefits outweigh the negative side effects associated with the drug. With close to 9000 different avian species, developing a plan for administration of therapeutic agents, including antibiotics, is often difficult and imprecise. There is a paucity of information regarding actual pharmacokinetic studies involving the many bird species, therefore extrapolation from research performed on other bird species or experience is often used to determine a dose regimen. This method of dose determination may or may not be effective. Fortunately there has been an increased amount of information published on various drug dosages within the last few years that contribute to a better understanding of determining a proper drug dose for each individual avian patient or group of patients.

Veterinarians that are most successful in treating birds suffering from bacterial infections understand the common bacterial organisms isolated from this group of animals and the therapeutic agents used to treat these diseases. Birds presented with a bacterial infection will recover more rapidly when the appropriate antibiotic is used and conversely they will deteriorate rapidly if the incorrect antibiotic is used. Knowledge of the common bacterial infections and their presenting signs will aid the clinician in selecting the initial antibiotic therapy while waiting for a culture and sensitivity result of a diagnostic sample collected from the affected area. **One cannot underestimate the importance of bacterial culture and sensitivity when diagnosing avian bacterial infections.** Often the antibiotics that may appear to be most effective provide no clinical benefit to the patient.

Selection of the antibiotic also includes the capacity of the dosage administered to penetrate the patient's body. A veterinarian may be limited in the choice of an antibiotic drug because of the method of manufacture or the ability of the owner to give the medication. For most birds, an oral liquid, injection or therapeutically impregnated food or water are the methods by which an avian patient receives medication. Not only will the form in which the drug is manufactured determine selection, but also the ability of the animal to accept that form of drug. If an owner finds giving a drug stressful then compliance will be compromised regarding management of the treatment therapy. Ultimately the patient will not respond to the treatment and remain ill because the antibiotic therapy is not being provided. *Owners must be informed of the importance of compliance* and if they are unable to meet the demands of treatment then either the bird needs to be hospitalised for medication or an alternative method of antibiotic presentation needs to be considered.

A recent trend in formulation of antibiotics for avian acceptance has been the compounding of tablets and capsules into flavoured suspensions. Unfortunately, there have also been problems with regulation and quality control of these compounded medications. The main message regarding compounded medication is buyer beware. There is also little if any information regarding the shelf life of compounded medications.

For successful avian antibiotic therapy *communication and information* to the client is essential. The veterinarian's knowledge of avian physiology, antibiotic references, bacterial infections and antibiotic methods of action will contribute to a successful treatment outcome in many bird cases.

Unless specifically acknowledged, the drug dosages that are new to this edition are to be found in Carpenter (2005).

### **The $\beta$ -lactam antibacterials (i.e. the penicillins and the related cephalosporins)**

The  $\beta$ -lactam (Appendix Table 1.1) antibacterials are mostly ionised in the plasma and are widely distributed in the body (except for the CNS – they are not very lipid soluble). They are rapidly excreted, unmetabolised, primarily through the kidneys although in birds when compared to mammals a greater proportion is excreted through the bile. Depot preparations have been developed to prolong their activity in the body. They have a high therapeutic index and consequently are usually relatively safe when used in birds. There are some 74 penicillins licensed for veterinary use, of which only about five are useful for birds. Resistance is developed by those bacteria which produce  $\beta$ -lactamase – for example *Staphylococcus* spp, *E. coli*, *Klebsiella* spp, *Pasteurella* spp, *Pseudomonas* spp and *Salmonella* spp.

There are at least 13 cephalosporins (Appendix Table 1.2) licensed for veterinary use, but only two of these have been used in birds. Cephalosporins penetrate most tissue (except the CNS), including bone, and their prophylactic use before orthopaedic surgery is recommended. Excretion of this class of antibiotics is through the kidney. The earlier generations of cephalosporins are more effective against Gram+ organisms while the later, more complex generation, products have a broader range of activity, including against Gram– bacteria. The third generation cephalosporins have been used synergistically with aminoglycosides (e.g. amikacin) in very severe bacterial infections.

### **The tetracyclines**

The tetracycline antibiotics (Appendix Table 1.3) are one of the most widely used groups in avian medicine for treating bacterial infections. The tetracycline class of antibiotics has a generalised and effective tissue distribution except in the CNS. Tetracycline products are metabolised in the liver and excreted both in the bile and through the kidneys. Injectable preparations often cause irritation and the injection sites are often subject to tissue necrosis. As with other antibiotic administration, this group of drugs often depresses gut flora and causes GI disturbances.

(Continued on p. 230)

**Appendix Table 1.1** The penicillins.

Generic and Trade Names	Formulation	Route of Administration	Dosage	Activity	Comment
<i>Benzyl penicillin</i> or <i>penicillin G</i> , e.g. Crystapen (Mallinckrodt Veterinary)	3 g phial of powder for reconstitution	s.c. i.m. i.v.	60 mg/kg q 6–8 hr	Bactericidal – active against most Gram+ and some Gram–	Safe in birds but rarely used because of the necessity of frequent handling and frequent injection
<i>Procaine penicillin</i> many trade names					
<i>Ampicillin sodium</i> (Omnipen-N, Wyeth-Ayerst; Polycillin-N, Apothecon)	50 mg and 125 mg tablets	p.o.	150–200 mg/kg q 8–12 hr, pigeons, Amazon parrots, except blue front Amazon parrots 100 mg/l drinking water	As above but more broad spectrum – active against some Gram–, e.g. <i>Pasteurella</i> spp Not effective against <i>Haemophilus</i> spp, <i>E. coli</i> , <i>Klebsiella</i> spp, <i>Proteus</i> spp, <i>Pseudomonas</i> spp, <i>Chlamydophila psittaci</i>	Absorption from the gastro-intestinal tract is poor and erratic. These antibacterials should be used for a minimum of 5 days.
	150 mg/ml injection	i.m. s.c.	15–20 mg/kg i.m. emus and cranes 100 mg/kg q 12 hr		

(Continued)

Appendix Table 1.1 Continued.

Generic and Trade Names	Formulation	Route of Administration	Dosage	Activity	Comment
Ampicillin trihydrate (Omnipen, Wyeth-Ayerst; Polycillin Apothecon)	250 mg and 500 mg capsules 125 mg/5 ml and 250 mg/5 ml oral suspension	p.o.	11–15 mg q 8 hr – ratites 25–100 mg/kg q 12–24 hr – pigeons 100–200 mg/kg q 6–8 hr – psittacines 170 mg/l drinking water – gamebirds 1000–2000 mg/l drinking water – canaries/aviary use 2000–3000 mg/kg soft food – canaries/aviary use 1000 mg/l drinking water – Galliformes flock 15 mg/kg q 12 hr – raptors 100 mg/kg q 4 hr – psittacines and most species	Broad spectrum, poor GI absorption and Gram- activity of common bacterial isolates of birds; may be effective when organism is sensitive	
	125 mg, 250 mg, 500 mg, 1 g, 2 g, and 10 g phials	i.m.	155 mg/kg q 12–24 hr – pigeons 100 mg/kg q 12 hr – cranes		Amoxicillin favoured over ampicillin for i.m. use in pigeons
			4–7 mg/kg q 8 hr – ratites (except emus)		Also s.c.
			15–20 mg/kg q 12 hr – emus		Also s.c.
Amoxicillin/clavulanate (Clavamox, Pfizer; Synulox, SmithKline Beecham (Augmentin is the human form))	140 mg amoxicillin and 35 mg clavulanic acid/ml 40 and 100 ml phials Tablets 40 mg amoxicillin and 10 mg clavulanic acid	i.m.	60–120 mg/kg q 8–12 hr – collared doves 7–14 mg/kg q 24 hr – ostriches 10–15 mg/kg q 12 hr – ratites 125 mg/kg q 12 hr – most species, q 8 hr in blue-fronted Amazon parrots	Broad spectrum bactericidal antibiotic, poor activity against common Gram- organisms isolated from avian infections. Effective against resistant <i>Staphylococcus</i> spp, some anaerobes and some Gram- including <i>E. coli</i> , <i>Klebsiella</i> spp Clavulanic acid is a $\beta$ -lactamase inhibitor but by itself has no direct antimicrobial action	Amoxicillin is better absorbed from the GI tract than ampicillin, but amoxicillin GI absorption is still considered unpredictable $\beta$ -lactamase inhibitor
	Drops 40 mg amoxicillin and 10 ml clavulanic acid/ml 15 ml dropper bottle	p.o.	125–250 mg/kg q 8–12 hr – collared doves 500 mg/l drinking water – chickens		



<p><i>Amoxicillin sodium</i> (Shandong Reyoung Pharm)</p>	<p>250 mg, 500 mg, 1 g phials</p>	<p>i.m.  i.m. i.v.</p>	<p>150 mg/kg q 8hr – passerines 250 mg/kg q 12–24hr – pigeons Gram+ bacteria</p> <p>100 mg/kg q 4–8hr – bustards to maintain blood levels &gt;2 µg/ml</p>	<p>Gram+ and Gram– bacteria 50 mg/kg q 12–24hr for Gram+ bacteria</p>
<p><i>Amoxicillin trihydrate</i> (Amoxicil, GlaxoSmithKline; Amoxidrops, Pfizer)</p>	<p>125 mg and 250 mg powder for reconstitution.</p>	<p>p.o.</p>	<p>100–200 mg/kg q 12hr – pigeons 55–110 mg/kg q 12hr – poultry 100 mg/kg q 8hr – most species 100–150 mg/kg q 12hr – raptors 150–175 mg/kg q 12hr – passerines and psittacines 15–22 mg/kg q 8hr – ratites 300–500 mg/kg soft feed – canaries 600 mg/kg soft feed – psittacines 500–800 mg/l drinking water – pigeons 200–400 mg/l drinking water – canaries/aviary use 65 mg/l drinking water – ratites</p>	<p>Duration of most courses of treatment is five days</p>
<p><i>Carbenicillin Pyopen</i> (Link)</p>	<p>1 g and 5 g phials of powder for reconstitution</p>	<p>i.m.  p.o.  i.v. i.t.</p>	<p>100–200 mg/kg q 6–12 hr – most species 250 mg/kg q 12 hr – raptors 1058 mg/l drinking water – most species 11–15 mg/kg q 8 hr – ratites 100 mg/kg q 24 hr – most species</p>	<p>Active against some Gram–, particularly <i>Pseudomonas</i> spp and <i>Proteus</i> spp</p>

Intratracheal use targets  
*Pseudomonas* spp  
infections within that  
anatomic structure

(Continued)

Appendix Table 1.1 Continued.

Generic and Trade Names	Formulation	Route of Administration	Dosage	Activity	Comment
Ticaracillin Ticar (Link)	1 g and 5g phials of powder for reconstitution	i.m.	75–100 mg/kg q 4–6 hr – Amazon parrots (for blue-fronted Amazon parrots give q 2–4 hr)	More active against <i>Proteus</i> spp than carbenicillin	Ticaracillin is broken down by $\beta$ -lactamase produced by some strains of <i>Pseudomonas</i> , it has therefore been combined with clavulanic acid (see below)
Piperacillin Pipril (Lederle)	1 g and 2g phials of powder for reconstitution	i.m. s.c.	200 mg/kg q 6–12 hr – most species 75–100 mg/kg q 8–4 hr – Amazon parrots, most species 25 mg/kg q 12 hr – ratiites < 6 months of age 100–200 mg/kg q 6–12 hr – psittacines 200 mg/kg q 8 hr – budgerigars, raptors, passerines	Less active against most Gram+ than amoxicillin but more active against Gram– organisms and anaerobes; may be difficult to find or a discontinued product in many countries	For passerine species, drug may need to be administered every 4hr
Piperacillin sodium/tazobactam sodium Zosyn (Lederle) (Nementz, Lennox, 2004)	2.25 g, 3.375 g, 4.5 g phials	i.m.	100 mg/kg q 12 hr – most species	Tazobactam sodium is an antibiotic potentiator to increase the drug's effectiveness against <i>Staphylococcus</i> spp and <i>Streptococcus</i> spp	For severe or polymicrobial bacterial infections, preoperative orthopaedic or coelomic surgery
Ticaracillin and clavulanic acid i.e. Timentin (SmithKline Beecham)	Powder for reconstitution Ticaracillin 1.5g clavulanic acid 100mg 1.6 g phials	i.m. i.v.	100–200 mg/kg q 12 hr – most species	Effective against many Gram–, particularly against resistant strains of <i>Pseudomonas</i>	

**Appendix Table 1.2** The cephalosporins.

Generic and Trade Names	Formulation	Route of Administration	Dosage	Activity	Comment
<i>Cephalexin</i> Ceporex (Malinckrodt Veterinary)	50 mg and 250 mg tablets	p.o.	35–50 mg/kg q 6 hr or q 2–3 hr – small species, quail, ducks	Some Gram+, some anaerobes and most Gram–, including <i>E. coli</i> , <i>Proteus</i> spp and <i>Pseudomonas</i> spp	Cephalosporins have a wide margin of safety in birds and are resistant to β-lactamase enzymes
A first generation cephalosporin	Oral suspension for reconstitution 100 mg/ml 10 ml phial	p.o.	100 mg/kg q 8–12 hr – most species: 14–21 day therapy may be needed for deep pyodermas 1.5–2.2 mg/kg q 8 hr – ratite		Well absorbed from GI tract Can be nephrotoxic if given with some diuretics, e.g. furosemide Can be stored after making up in bulk and used for up to 6 months
<i>Cefazolin</i> Ancef (SmithKline Beecham)	180 mg/ml 30 ml and 100 ml phials injectable suspension (oily)	i.m.	35–50 mg/kg q 6 hr or q 2–3 hr in small species, quail, ducks		
A first generation cephalosporin	500 mg, 1 g, 10 g phials	i.m.	25–75 mg/kg q 8–12 hr – most species 50–100 mg/kg q 12 hr – raptors		Administration p.o. is also an acceptable means of treating raptors
<i>Cefadroxil</i> Cefa-Tabs (Fort Dodge)	50 mg, 100 mg, 200 mg, 1 g tablets	p.o.	20 mg/kg q 12 hr – ratites		
A first generation cephalosporin	50 mg/ml oral suspension		100 mg/kg q 12 hr for 7 days – most species, including pigeons		
<i>Cephalothin</i> Keftol (Lilly)	1 g phials	i.m.	100 mg/kg q 6–8 hr – most species, emus 30–40 mg/kg q 6 hr – ratites 100 mg/kg q 2–3 hr – quail, ducks 100 mg/kg q 2–6 hr – passerines		

(Continued)

Appendix Table 1.2 Continued

Generic and Trade Names	Formulation	Route of Administration	Dosage	Activity	Comment
<i>Cephadrine</i> Cephadrine (Biocraft)	125 mg/5 ml oral suspension	p.o.	35–50 mg/kg q 4–6 hr – most species		
A first generation cephalosporin	250 mg and 500 mg capsules		100 mg/kg q 4–6 hr – pigeons, emus, cranes		
<i>Cefoxitin</i> Mefoxin (Merck)	1 g phial	i.m.	50–100 mg/kg q 6–12 hr – most species	Broad spectrum activity against Gram– and Gram+ organisms	
A second generation cephalosporin					
<i>Cefotaxime</i> Claforan (Rossel)	Powder for reconstitution 500 mg, 1 g, 2 g phials	i.m.	75–100 mg/kg q 4–8 hr – most species	Active against a wide range of Gram–, particularly	Penetrates CSF and CNS
A third generation cephalosporin			25 mg/kg q 8 hr – ratites/young birds	<i>Pseudomonas</i> spp	
<i>Ceftazidime</i> Ceptaz, Fortaz (GlaxoSmithKline)	Powder for reconstitution 1 g and 2 g phials	i.m.	50–100 mg/kg q 4–8 hr – most species		Penetrates CSF and CNS
A third generation cephalosporin					
<i>Ceftiofur</i> Naxcel (Pharmacia)	5 mg/ml injectable solution	i.m.	50–100 mg/kg q 4–8 hr – most species	Broad spectrum activity against Gram– and Gram+ organisms	
A third generation cephalosporin			10 mg/kg q 8–12 hr – orange-winged Amazon parrots		
			10 mg/kg q 4 hr – cockatiels		
<i>Ceftriaxone</i> Rocephin (Roche)	250 mg, 500 mg, 1 g phials powder for reconstitution	i.m.	75–100 mg/kg q 4–8 hr – most species		
A third generation cephalosporin			100 mg/kg q 4 hr – chickens		

Appendix Table 1.3 The tetracyclines.

Generic and Trade Names	Formulation	Route of Administration	Dosage	Activity	Comment
Oxytetracycline Liquamycin LA-200, Tetramycin soluble powder (Pfizer), many other trade preparations	Oral powder for addition to drinking water or for mixing in food 225g and 2 kg packs	p.o.   i.m.	4–12 mg/l drinking water 5g/kg food 25–50 mg/kg q 8 hr for 5–7 days – raptors  80 mg/kg q 48 hr – pigeons <400 g 50–200 mg/kg q 3–5 days – raptors 50–100 mg/kg q 2–3 days – cockatoos, passerines 50 mg/kg q 24 hr for 5– 7 days – psittacines 10 mg/kg q 3 days – ratites 200 mg/kg q 24 hr – most species, waterfowl	Only bacteriostatic Broad spectrum Effective against many Gram+ and Gram- (but not <i>E. coli</i> , <i>Salmonella</i> spp, <i>Proteus</i> spp or <i>Pseudomonas</i> spp Also active against some protozoa and flagellates	Oral absorption is erratic and in graniferous birds the dose should be increased to maintain the minimal inhibitory concentration in the plasma Intramuscular injection may cause muscle irritation or necrosis Outdated tetracycline has been found to be nephrotoxic (Carpenter, 2005)
Engemycin (Mycofarm), Oxytetrin (Mallinckrodt Veterinary)	As the hydrochloride for injection 5% i.e. 50 mg/ml, 50 ml and 100 ml phials	i.m.	58 mg/kg q 24 hr for birds over 400 g 100 mg for birds below 400 g		Do not be tempted to use the higher concentrations available for large farm animals (e.g. 100 mg/ml instead of 50 mg/ ml) in an attempt to reduce the bulk of the injection as this only results in tissue necrosis (Continued)

Appendix Table 1.3 Continued.

Generic and Trade Names	Formulation	Route of Administration	Dosage	Activity	Comment
Doxycycline (Pfizer)	Long-acting depot preparation	i. m.	75–100 mg/kg every 5–7 days for 5–7 treatments for <i>Chlamydomytila psittaci</i> cockatiels 0.5 ml budgerigars 0.25 ml	Antimicrobial activity as for other tetracyclines but because of its pharmacokinetic properties much more effective	Vibravenos is only available for medical use on the continent of Europe but can be obtained by special order from Pfizer. It has a very prolonged half-life. It is more lipid soluble than other tetracyclines and so better penetrates intracellular tissue, however its half life is much shorter in Amazon parrots and cockatoos than other species of parrot. Doxycycline has fewer side effects, both hepatic and renal, than the other tetracyclines but the side effects of Vibravenos can be: <ul style="list-style-type: none"> <li>• Blood clotting time increased</li> <li>• Haemorrhages</li> <li>• Possible hepatotoxicity (AST and ALT↑)</li> </ul> To counteract, add vitamin K to injection
Doxycycline hyclate Vibramycin (Pfizer)	100 mg/5 ml phials	i. v.	25–50 mg/kg q 24hr for 3 days – psittacines		Has been associated with cardiovascular collapse after rapid i. v. injection
		i. m.	75–100 mg/kg q 5–7 days		

Ronaxan (Rhône-Mérieux)	20 mg and 100 mg tablets	p.o.	<p>40–50 mg/kg, i.e. 0.16 tablet per Amazon parrot and cockatoos                  25–30 mg/kg i.e. 0.1 tablet per African grey parrot                  0.3 tablet per macaw</p>	<p>Is much less effected by cations than other tetracyclines so that absorption from the GI tract is almost 100% and, in contrast to the water soluble tetracyclines, only 30% is excreted via the kidneys.                  If regurgitation occurs, reduce the dose by 25%.                  70% of doxycycline is excreted in the bile and some undergoes enterohepatic recirculation, which helps maintain plasma levels.                  The tablets are really too large except for the larger birds.</p>
<p><i>Chlortetracycline</i>                  Aureomycin Soluble Powder (Willows Francis and others)</p>	<p>Soluble powder for solution in drinking water or incorporation in food                  225 g pack</p>	p.o.	<p>0.25–0.5% in food i.e. 2.5 g/kg food or 6–12 level teaspoons/pound of cooked food or 2.5–5 g/l i.e. one level teaspoon/1–2 l of drinking water                  15–20 mg/kg q 8 hr–ratites                  40–50 mg/kg q 8 hr (with grit) or q 12 hr (without grit) – pigeons                  100 mg/kg q 6 hr–psittacines                  250 mg/kg q 24 hr–raptors                  6–10 mg/kg q 24 hr–raptors</p>	<p>Needs to be used for at least 45 days continuous treatment against <i>Chlamydophila psittaci</i> since it is only bacteriostatic                  Retest birds for infection at the end of this period and continue treatment if necessary                  Has a bitter taste, therefore food may be refused leading to partial starvation and failure of treatment – add sugar, etc. to make food more palatable.                  Using the lower levels of chlortetracycline in the food often leads to an increased palatability and an overall increased intake of the drug.                  When using chlortetracycline-laced pellets for treatment of <i>C. psittaci</i> infected passerine and psittacine species the calcium content should be reduced to 0.7%.</p>

Oral absorption is very variable. An important clinical consideration is that *tetracycline antibiotics are chelated by calcium and magnesium salts* (particularly important if administered orally to graniferous birds, which take in calcium and magnesium-containing grit into the ventriculus). If administered intravenously, chelation of blood calcium ions can occur, resulting in cardiovascular collapse. The tetracyclines can be immunosuppressive and cause photosensitivity. Their toxicity is variable and dependent on the species, the product being used and the duration of treatment. Doxycycline, a fifth generation tetracycline product, is the drug of choice to treat *Chlamydophila psittaci* infections. The efficacy of this *bacteriostatic* group of antibiotics is enhanced by its lipophilic characteristics, allowing easy access through cell membranes.

### The aminoglycosides

*All these antibacterials have a narrow therapeutic margin and are all relatively toxic. If possible, their systemic use in birds is best avoided, particularly in dehydrated birds or birds with raised urea or raised uric acid or polyuria/polydipsia. This group of antibacterials includes streptomycin, dihydrostreptomycin, neomycin, kanamycin, framamycin, gentamycin, apramycin, spectinomycin, tobramycin and amikacin. They are often the most effective antibiotics against many Gram- bacteria.*

They are all *bactericidal*, except spectinomycin, but enteric bacteria rapidly acquire resistance to them. *None is absorbed from the GI tract so when used p.o. they are relatively safe.* They are poorly distributed in the body and toxic to kidney and CNS (ototoxicity). Extrapolating doses for birds from those used for mammals is very hazardous. Only those of real use in birds are listed below (Appendix Table 1.4).

### Macrolides and lincosamides

The macrolides and lincosamides (Appendix Table 1.5) include tylosin, tiamulin, erythromycin, tilmicosin, spiramycin, carbomycin, leucomycin, oleandomycin, clindamycin and lincomycin. They are variably absorbed from the GI tract and well distributed in the body. They are primarily eliminated via metabolism in the liver. Toxicity is low and is confined to the GI tract. In some mammals some of these drugs have caused a fatal enterocolitis, but this has not been reported in birds, in which they are generally considered to be safe antibacterials with a high therapeutic index.

### Chloramphenicol

Chloramphenicol (Appendix Table 1.6) is lipid soluble so it is widely distributed in the body, including the CNS and eyes. It is metabolised in the liver and is potentially toxic for several liver functions (neonates are particularly susceptible to toxicity). Also potentially toxic for the bone marrow it is excreted via the kidneys. There is known to be a wide variation in the pharmacokinetics amongst different species of bird. Oral absorption is erratic. *Its use in birds is probably best avoided.*

**NB:** A small percentage of humans can develop a *non-dose-related irreversible aplastic anaemia even with mild cutaneous contact.* Therefore *always wear surgical gloves when handling.*

### The potentiated sulphonamides

The sulphonamides, when combined synergistically with the dihydrofolate reductase inhibitors baquiloprim and trimethoprim, are active against a wide range of bacteria and some protozoa (Appendix Table 1.7). They are well distributed in the body's tissues. Excretion is primarily via the kidneys but there is also some degree of hepatic metabolism which varies with the species. Usually five parts of sulphonamide are combined with one part of trimethoprim or baquiloprim. They have few toxic side effects but, like all sulphonamides, will crystalize in the kidney if used in dehydrated birds. *Occasionally* cause irritation and

(Continued on p. 237)



**Appendix Table 1.4** The aminoglycosides.

Generic and Trade Names	Formulation	Route of Administration	Dosage	Activity	Comment
<i>Spectinomycin</i> Spectam soluble (Agri Labs)	A soluble powder for solution in drinking water 1 g sachets licensed for use in pigeons	p.o.	1 g/2l drinking water, 3–5 days 165–275 mg/l drinking water – pigeons 200–400 mg/l drinking water – canaries 400 mg/kg soft food – canaries	Bacteriostatic only Active against a wide range of Gram–, including <i>E. coli</i> and <i>Salmonella</i> spp, also <i>Mycoplasma</i> spp Some Gram+ but not <i>Streptococcus</i> spp	
<i>Amikacin</i> Amikin (Bristol-Myers)	Injection as the sulphate 50 mg/ml and 25 mg/ml 2 ml phials	i.m.	10–20 mg/kg q 8–12 hr – psittacines, raptors 7.6 mg/kg q 8 hr – ostriches	Very effective against Gram–, particularly <i>Pseudomonas</i> spp In Amazon parrots probably only has a half-life of 1.5 hr, less than in some other species of parrot	This is the parenteral aminoglycoside of choice in birds, since it is much less toxic than the other antibacterials of this group although it is approximately four times less active. Nevertheless, when combined with the β-lactams, it is very effective. This combination may slightly increase its nephrotoxicity.
<i>Gentamycin</i> Garamycin (Schering)	40 mg/ml multidose vial	i.m.	1–2 mg/kg q 8 hr – ratites, except emus 2.5 mg/kg q 8 hr – raptors 3–10 mg/kg q 6–12 hr – passerines 5 mg/kg q 8 hr – pheasants, emus, cranes 5–10 mg/kg q 4 hr – pigeons		Not recommended for use in most avian cases. Extremely nephrotoxic. Hydration of patient is essential with constant monitoring of treatment response renal blood values.
		intranasal	2–3 drops ophthalmic solution intranasal q 8 hr – most species		

(Continued)

Appendix Table 1.4 Continued.

Generic and Trade Names	Formulation	Route of Administration	Dosage	Activity	Comment
Kanamycin Kantrim (Fort Dodge)	50 mg/ml injectable solution	i.m.	10–20 mg/kg q 12 hr – most species 13–65 mg/l drinking water for 3–5 days made fresh daily – most species		Primary use in enteric infections
Lincomycin	100 mg, 200 mg, 500 mg tablets	p.o.	25–30 mg/kg q 12 hr – raptors	Gram+ spectrum	
Lincocin (Upjohn)	50 mg/ml suspension		35–50 mg/kg q 12–24 hr – passerines 50–75 mg/kg q 12 hr for 7–10 days – psittacines, raptors 100 mg/kg q 24 hr – raptors 100–200 mg/l drinking water – canaries 2 g/l drinking water for 5–7 days – waterfowl 100 mg/kg q 12 hr – psittacines		
Lincomycin/Spectinomycin LS-50 Water Soluble, Lincospectin 100 Soluble Powder (Upjohn)	Oral powder for addition to drinking water 33.3 g lincomycin 66.7 g spectinomycin per pack	p.o.	50 mg/kg q 24 hr – most species 750 mg/l drinking water for 5–7 days – waterfowl 175 mg/kg q 12 hr – raptors (Forbes, 1995, personal communication) 150 g/120–180 l – poultry	Gram+ spectrum, <i>Mycoplasma</i> spp	Licensed for poultry Toxic in ostriches
Tobramycin Tobramycin (Elkins-Sinn), Nebcin Injection (Lilly), Tobralax (Alcan)	Sulphate for injection 10 mg/ml 2 ml phial	i.m.	2–5 mg/kg q 12 hr – most species 10 mg/kg q 12 hr for 5–7 days – raptors	Similar to amikacin	Recommended for use only in cases of severe infection in which very resistant organisms have been isolated (e.g. <i>Pseudomonas</i> spp) Has been associated with neuro- and nephrotoxicity.
Apramycin i.e. Apram (Elanco)	Soluble powder 1 g and 50 g packs	p.o.	25–50 g/100 l	Primarily of use against <i>Salmonella</i> spp	Licensed for poultry

**Appendices Table 1.5** Macrolides and lincosamides.

Generic and Trade Names	Formulation	Route of Administration	Dosage	Activity	Comment
<i>Tylosin</i> Tylan, Tylan Soluble Powder (Elanco)	Injection 50mg/ml 50ml phial	i.m.	10–40 mg/kg q 6–8 hr – poultry, passerines 15–30 mg/kg q 12 hr for 3 days – raptors 20–40 mg/kg q 8 hr – psittacines 2.5 mg/kg q 8 hr – emus	Macrolides and lincosamides are only bacteriostatic Active against Gram+, <i>Mycoplasma</i> spp, a few Gram– and <i>Campylobacter</i>	In cranes the i.m. injection is reported to have caused tissue necrosis Do not add the oral solution to galvanised drinkers with a zinc coating – toxic effects have been reported
	Oral powder (as the tartrate) 100g pack	p.o.	2.5 mg/kg q 6 hr – pigeons 50 mg/l drinking water – most species 250 – 400 mg/l drinking water – canaries 800 mg/l drinking water – pigeons 300 mg/l drinking water – house finches (mycoplasmosis) 200 mg/kg feed – Galliformes		
<i>Azithromycin</i> Zithromax (Pfizer)	Powder for reconstitution 100 mg/5 ml and 200 mg/5 ml oral suspension	p.o.	45 mg/kg q 24 hr – most species 10–20 mg/kg q 48 hr for 5 treatments – blue/yellow macaws non-intracellular infections 40 mg/kg q 24 hr for 30 treatments – blue/yellow macaws intracellular infections	Recommended for intracellular infections (e.g. <i>Toxoplasma</i> spp, <i>Plasmodium</i> spp, <i>Chlamydomydia psittaci</i> , <i>Cryptosporidium</i> spp)	
<i>Tiamulin fumarate</i> Denegard (Fermental), Tiamulin (Novartis)	Oral solution for addition to drinking water 125 mg/ml 20 ml phial	p.o.	2.5–50 mg/kg q 24 hr – most species 300–400 mg/kg feed for 7 days 225–250 mg/l drinking water for 3–7 days – poultry, pigeons	Bacteriostatic Broader spectrum than tylosin Active against <i>Haemophilus</i> spp, <i>Bordetella</i> spp, <i>Pasteurella</i> spp, <i>Mycoplasma</i> spp, <i>Streptococcus</i> spp and <i>Staphylococcus aureus</i> and some anaerobes, some spirochetes and protozoa (e.g. <i>Toxoplasma</i> spp)	

(Continued)

Appendices Table 1.5 Continued.

Generic and Trade Names	Formulation	Route of Administration	Dosage	Activity	Comment
<i>Clindamycin</i> Antirobe (Upjohn),	25 mg, 75 mg, 150 mg capsules	p.o.	5.5 mg/kg q 8 hr – ostriches 100 mg/kg q 24 hr for 3–5 days – most species 150 mg/kg q 24 hr – pigeons, raptors (osteomyelitis) 200 mg/l drinking water – pigeons	Particularly useful for Gram+ anaerobes, bactericidal for <i>Streptococcus</i>	Has been used by the author to treat anaerobes in raptors with no noticeable side effects. A very useful prophylactic for orthopaedic surgery. 2–10 times more active than lincomycin.
Dalacin (Upjohn)	150 mg/ml 2 ml and 4 ml injectable	i.m.	100 mg/kg q 12 hr for 7 days – psittacines		
<i>Erythromycin</i> Erythrocin (Abbott), Erymycin 100 (Bimedja)	250 mg and 500 mg tablet	p.o.	60 mg/kg q 12 hr – most species 10–20 mg/kg q 12 hr – psittacines 50–100 mg/kg q 8–12 hr – passerines 125 mg/kg q 8 hr – pigeons 5–10 mg/kg q 8 hr – ratites 125 mg/l drinking water – canaries 132 mg/l drinking water (10 days treat, 5 days off medication, 10 days treat) – most species 525–800 mg/l drinking water – psittacines 200 mg/kg soft food – most species	Gram+ spectrum	
<i>Oleandomycin</i> Amimycin, Matromycin, Romcil (Pfizer)		i.m.	10–20 mg/kg q 24 hr – passerines		Intramuscular injection has been associated with muscle necrosis
		p.o. i.m.	50 mg/kg q 24 hr – passerines 2.5 mg/kg q 24 hr – passerines		

**Appendix Table 1.6** Chloramphenicol.

Generic and Trade Names	Formulation	Route of Administration	Dosage	Activity	Comment
Chloramphenicol Chloromycetin Succinate (Parke-Davis)	300 mg and 1.2 g Powder for reconstitution	i.m.	50 mg/kg q 6–12 hr – most species, may be given i.v. 22 mg/kg q 3 hr – ducks, raptors, may be given i.v. 30 mg/kg q 8 hr for 3 days – raptors 35–50 mg/kg q 8 hr for 3 days – ratites, may be given s.c. or i.v. 60–100 mg/kg q 8 hr – pigeons	Only bacteriostatic Fairly broad spectrum Active against Gram+, <i>Chlamydophila psittaci</i> , <i>Pasteurella</i> spp, <i>Haemophilus</i> spp, <i>E. coli</i> and <i>Salmonella</i> spp, but not <i>Pseudomonas</i> spp	Its use in birds is only justified when penetration of the CNS or eyes is required, against <i>Salmonella</i> spp or where no other antibacterial is suitable. It is antagonistic to the β- lactams and quinolones The analogue florfenicol is less hazardous and may become useful in avian medicine.

**Appendix Table 1.7** The potentiated sulphonamides.

Generic and Trade Names	Formulation	Route of Administration	Dosage	Activity	Comment
Trimethoprim+ sulphamide Borgal (Hoechst)	Sulphadoxine 62.5 mg and trimethoprim 2.5 mg and 1 mg lignocaine in 50ml	i.m. s.c. p.o.	20mg/kg q 12 hr 16–24 mg/kg q 4 hr or q 6 hr	Broad spectrum Often bactericidal, sometimes only bacteriostatic, against many Gram+ and Gram– (but not <i>Pseudomonas</i> spp) and <i>Chlamydothila psittaci</i> Generally not effective against anaerobes or <i>Mycoplasma</i> spp	Do not use if dehydration is suspected. Occasional/ toxic side effects after more than 7 days use.; granulocytosis, haemolytic anaemia, haemorrhagic diathesis, due to avitaminosis K. Sometimes vomiting after administration p.o. therefore best given in small frequent doses in food. Macaws may regurgitate, often several hours after p.o. administration, but not after parental administration.
Cosumix Plus (Ciba), many other preparations	Sulphachloropyridazine 100g and trimethoprim 20 g Oral powder	p.o.	2.4 mg/kg for addition to drinking water or food 400 mg/kg feed – geese	Reported to be effective against <i>Mycoplasma gallisepticum</i> and <i>E. coli</i>	
Duphatrim (Solvay-Duphar)	Sulphaquinoxaline 500 mg/g and trimethoprim 165 mg/g 500g pack Oral granules for addition to drinking water or food	p.o.	30mg/kg for broiler chickens and turkeys more than 21 days of age		
Scoprin (Willows) Di-Trim (Fort Dodge)	Sulphadiazine 50mg and trimethoprim 10mg per dose of 1.1 ml Suspension	p.o.	0.5 ml of 1.1 ml dose per pigeon 30mg/kg q 8–12 hr – most species 60mg/kg q 12 hr for 3 days treat, 2 days off medication, 3 days treat – raptors, waterfowl ( <i>Cocciida</i> )		Raptors with <i>Sarcocystis</i> spp infection treat for at least 6 weeks.
Devoprim (Mycopharm) Duphatrim (Solvay-Duphar)	Sulphadiazine 100mg, trimethoprim 20 mg per tablet	p.o.	½ tablet per pigeon		
Bacitrim (Roche), Septra (Burroughs Welcome)	Trimethoprim and sulphamethoxazole	p.o.	25 mg/kg q 24 hr – toucans, mynaths ( <i>Cocciida</i> ) 320–525 mg/l drinking water – poultry ( <i>Cocciida</i> )		

Many other formulations of co-trimoxazole are available; those listed above are the most applicable to avian medicine.

necrosis at the site of injection. To be effective both parts of the combination are at optimal levels in the tissues. *Since their pharmacokinetics differ it is essential not to use sub-therapeutic doses.*

The baquiloprim preparations have not yet been used much or assessed in birds, but may be more effective since the baquiloprim takes longer to be broken down and inactivated in the body than trimethoprim – so frequency of dosing is likely to be less.

### The fluoroquinolones

This fluoroquinolone group (Appendix Table 1.8) includes norfloxacin, ofloxacin, pefloxacin, enrofloxacin, ciprofloxacin and marbofloxacin. They are widely distributed in body tissues, including intracellular tissue. They undergo some hepatic metabolism and are excreted via the kidneys. They have low toxicity but can cause occasional GI disturbance due to reduction in GI flora. An additional clinical sign associated with GI side effects is anorexia. *They have potential neurological side effects so do not administer to birds with CNS signs.* They are known to cause articular defects in joint cartilage and feather development problems in growing pigeons. They are antagonistic to tetracyclines, macrolides and chloramphenicol. They are bactericidal, acting by blocking bacterial DNA synthesis.

### Anti-mycobacterial drugs

*Treatment of tuberculosis in birds is not recommended* because of the serious zoonotic hazard and the increasingly frequent resistance of mycobacteria to available drugs. However, in the case of a particularly valuable bird or an insistent owner who appreciates the hazards, treatment may be justified but does require skilled management with constant monitoring. The dosage range is based on the treatment combination used. There are currently at least ten different drug combinations to treat avian mycobacteriosis (Appendix Table 1.9). *Always verify the drug dosage within the specific treatment combination selected.*

### Antifungal drugs

Antifungal drugs are used for the treatment of aspergillosis, yeast infections, candidiasis, cryptococcosis, sporotrichosis, blastomycosis and histoplasmosis.

Compared with antibacterials, it is difficult and time-consuming to carry out antifungal sensitivity testing. In addition:

- Many tests are not standardised
- They are expensive
- They take a long time before results are known
- Many antifungals look good when tested in vitro but turn out to be poor when used in vivo

Therefore antifungal drug use is largely empirical. There are hundreds of strains of *Aspergillus* spp with varying pathogenicity. Many antifungal agents often work best in synergistic combination with other drugs in this classification, i.e. either an 'azole' drug combined with amphotericin or flucytosine (this second combination is best if CNS involvement is suspected).

*Most of the antifungal drugs listed here (Appendix Tables 1.10 and 1.11.) are only fungostatic and therefore fungal infections require much longer treatment periods than those prescribed for antibacterials.* *Aspergillus* spp infections are often systemic, but fungal hyphae may be identified in locally concentrated granulomas, where the ability of the drug to penetrate the lesion is important for therapeutic effectiveness.

Appendix Table 1.8 The fluoroquinolones.

Generic and Trade Names	Formulation	Route of Administration	Dosage	Activity	Comment
<i>Enrofloxacin</i> Baytril (Bayer)	15 mg, 50 mg, 150 mg tablets	p. o.	7.5–20 mg/kg q 24 hr – passerines, psittacines, pigeons 15 mg/kg q 12 hr – most species, may be given s.c. 1.5–2.5 mg/kg q 12 hr – raities mg/kg q 8 hr × 3 days – raities 50–100 mg/l drinking water – chickens, turkeys, gamebirds 200 mg/l drinking water – canaries 500 mg/l drinking water – psittacines	Bactericidal broad spectrum active against wide range of Gram+, Gram– and <i>Mycoplasma</i> spp (but not <i>Pseudomonas</i> spp) Not effective treating <i>Chlamydophila psittaci</i> Not active against anaerobes	Eliminated more rapidly in African grey parrots than Amazon parrots and cockatoos. <i>Injection may cause some irritation and pain.</i> Material within the gastrointestinal tract containing Ca, Al, Fe, mg and Zn will interfere with gastrointestinal absorption of enrofloxacin.
<i>Ciproxin</i> (the primary metabolite of <i>Enrofloxacin</i> ) (Bayer)	500 mg tablet (human preparations only)	p. o.	380 mg/l drinking water 10–20 mg/kg q 12 hr – most species 50 mg/kg q 12 hr – raptors 3–6 mg/kg q 12 hr – raities 250 mg/l drinking water × 5–10 days – pigeons		Slightly better activity against Gram–, has a bitter taste. A 50 mg/ml suspension can be compounded by crushing a 500 mg tablet and mixing with sterile water or flavoured compounding solution.
<i>Marbofloxacin</i> Marbocyl (Univet)	5 mg, 20 mg, 80 mg tablets	p. o.	5 mg/kg q 24 hr – most species 10–15 mg/kg q 12 hr × 5–7 days – raptors, bustards		Longer half-life period in dogs and cats, possibly also in birds.
<i>Norfloxacin</i> Noroxin (Merck), Veriflox 20% oral solution (Lavet Ltd.)	400 mg tablets	p. o.	10 mg/kg q 24 hr – chickens, geese 10 mg/kg q 6–8 hr – turkeys 3–5 mg/kg q 12 hr – raities 175 mg/l drinking water × 5 days – chickens		
<i>Sarafloxacin</i> SaraFloX (Abbott)	50 mg/ml aqueous formulation	p. o.	10 mg/kg q 8 hr – chickens 20–40 mg/l drinking water × 5 days – chickens (colibacillosis) 30–50 mg/l drinking water × 5 days – turkeys (colibacillosis)		



**Appendix Table 1.9** Anti-mycobacterial drugs and drug combinations.

Generic and Trade Names	Formulation	Route of Administration	Dosage	Comment
<i>Azithromycin</i> Zithromax (Pfizer)	100mg/5 ml, 200 mg/5 ml oral suspension	p.o.	43–45 mg/kg q 24 hr	Use with ethambutol and rifabutin
<i>Ciprofloxacin</i> Cipro (Bayer)	500mg tablets	p.o.	80 mg/kg q 24 hr 15 mg/kg q 12 hr	
<i>Clarithromycin</i> Biaxin (Abbott)	250mg, 500 mg tablets 250 mg/5 ml granules for reconstitution	p.o.	55–85 mg/kg q 24 hr	
<i>Clofazimine</i> Lamprene (Geigy)	100mg capsules	p.o.	1.5–4 mg/kg q 24 hr	Human drug. May produce gastrointestinal side effects. Originally produced for the treatment of leprosy.
<i>Cycloserine</i> Seromycin (Lilly)	250mg capsules	p.o.	5 mg/kg q 12 hr	
<i>Enrofloxacin</i> Baytril (Bayer)	15 mg, 50mg, 150 mg tablets	p.o.	6–30 mg/kg q 24 hr 10–15 mg/kg q 12 hr	
<i>Ethambutol hydrochloride</i> Myambutol (Lederle)	150mg, 400 mg tablets	p.o.	15–30 mg/kg q 24 hr	Human anti-tuberculosis drug. Visual side-effects in humans, not documented in birds.
<i>Isoniazid</i> Niazid (Duramed)	300mg tablets 50mg/5 ml elixir 25 mg/ml injection	p.o. i.m.	30 mg/kg q 24 hr	Human anti-tuberculosis drug. May be hepatotoxic and may cause gastrointestinal disturbance.
<i>Rifabutin</i> Mycobutin (Pharmacia)	150mg capsules	p.o.	15–45 mg/kg q 24 hr	
<i>Rifampin</i> Rifadin (Hoechst)	150–300mg capsules 100mg/5 ml syrup	p.o.	15–20 mg/kg q 12 hr	Human anti-tuberculosis drug. May be hepatotoxic and may cause gastrointestinal disturbance.
<i>Streptomycin</i> Spectam (AgriLabs)	100mg/ml injectable	i.m.	30 mg/kg q 12 hr	See toxicity of the aminoglycosides (Appendices Table 1.4)

## The imidazoles

The imidazoles are listed here (Appendix Table 1.10) in order of their discovery and also in order of decreasing toxicity and increasing effectiveness. Only those of current importance in avian therapeutics are discussed in detail: miconazole, enilconazole, econazole, clotrimazole, ketoconazole, fluconazole and itraconazole. All are absorbed with varying degrees of effectiveness from the GI tract.

**Appendix Table 1.10** Imidazoles.

Generic and Trade Names	Formulation	Route of Administration	Dosage	Activity	Comment
Ketoconazole Nizoral (Janssen)	200 mg tablets soluble in a slightly acid media	p.o.	10–30 mg/kg q 12 hr × 30–60 days – most species 40 mg/kg q 12 hr × 15–60 days – pigeons 50 mg/kg/day – toucans	Broad spectrum, active against fungi, yeasts and some Gram+.	Some strains of <i>Aspergillus</i> spp (of which there are many hundreds) are resistant, therefore always combine with other antifungals. Readily absorbed p.o. and widely distributed in the body's tissues, but not CNS. Eliminated by hepatic metabolism and can cause hepatocellular necrosis – jaundice, vomiting and anorexia – therefore usually only used for 2–3 weeks. Also possibly teratogenic. More toxic than later imidazoles. The crushed tablets can be mixed in food or fruit juice or dissolved – one tablet/4 ml (0.8 ml of a one molar HCl solution diluted with 3.2 ml water). <u>Take care if used with potentially hepatotoxic drugs.</u>
Fluconazole Diflucan (Roerig)	200 mg tablets	p.o.	2–5 mg/kg q 24 hr × 7–10 days – most species (candidiasis) 5–15 mg/kg q 12 hr × 14–60 days – most species (aspergillosis) 100 mg/kg soft food – Gouldian finches (candidiasis) 150 mg/l drinking water – Gouldian finches (candidiasis)	In vitro × 100 more potent than ketoconazole. Excellent against yeasts but variable activity against <i>Aspergillus</i> spp	Very soluble, readily absorbed p.o. Widely distributed in the body including CNS. Eliminated via the kidneys. Toxicity low with mild GI upset and CNS signs (but only reported in humans). Since liver enzymes are sometimes elevated it would be wiser to monitor these during treatment. <u>Take care if used with potentially nephrotoxic drugs.</u>

<p><b>Itraconazole</b> Sporanox (Janssen)</p>	<p>100 mg capsules Also oral liquid (peppermint or cherry flavoured)</p>	<p>p.o.</p>	<p>10 mg/kg q 12 hr × 35 days – macaws 17 mg/kg q 24 hr × 29 days – king penguins 10 mg/kg q 24 hr – other penguins 5–10 mg/kg q 24 hr – Amazon parrots 5–10 mg/kg q 12–24 hr × 10–14 days, then q 48 hr – raptors (aspergillosis prophylaxis) 15 mg/kg q 12 hr, up to 4–6 weeks – raptors 6–10 mg/kg q 12–24 hr–pigeons 6–10 mg/kg – raptors</p>	<p>5–10 × more potent than ketoconazole</p>	<p>Well absorbed if taken with food. Widely distributed (but not CNS or eye). Degraded in liver, excreted in bile. Can cause hepatitis in mammals. Mostly used in birds at 10 mg/kg q 24 hr × 30 days +. Anorexia and depression relating to itraconazole therapy affects African grey parrots, requiring intensive treatment, therefore <u>other antifungal options should be considered when treating African grey parrots.</u></p>
<p><b>Enilconazole</b> Imaverol (Janssen), Clinafarm (Sterwin)</p>	<p>100 mg/ml</p>	<p>p.o.  i.t. (intratracheal)</p>	<p>6 mg/kg q 12 hr – psittacines 200 mg/l drinking water – canaries (cutaneous dermatophytosis) 1 mg (0.5 ml)/kg of a 1 : 10 dilution q 24 h × 7–14 days – falcons (aspergillosis) 1 : 10–1 : 100 dilution – psittacines (aspergillosis, candidiasis)</p>	<p>Active against <i>Penicillium</i> spp and dermatophytes</p>	<p>For aspergillosis it has been used for nebulisation at 1 : 10 dilution with sterile water, using a fogging machine to produce a mist with a particle size of 5–10µ. Given for 5 consecutive days × one hour, then twice weekly for 5 weeks. Patient needs strict supervision throughout.</p>
<p><b>Clotrimazole</b> Mycelex solution (Schering-Plough)</p>	<p>50 mg, 200 mg tablets</p>	<p>i.t.</p>	<p>2 mg/kg q 24 hr × 5 days – psittacines (tracheal granulomas)</p>	<p>Antifungal agent with broad spectrum activity</p>	<p>May be nebulised or administered topically on lesions in air sac.</p>
<p><b>Voriconazole</b> Vfend (Pfizer)</p>	<p>50 mg, 200 mg tablets</p>	<p>p.o.</p>	<p>10 mg/kg q 12 hr – psittacines 12.5 mg/kg q 12 hr – raptors</p>		

## The polyene antifungals

**Appendix Table 1.11** The polyene antifungals.

Drug and Trade Names	Formulation	Route of Administration	Dosage	Activity	Comment
Nystatin Nystatin (Bristol-Myers Squibb)	500,000 IU tablets 100,000 IU/ml suspension, 300 ml phial	p.o.	300,000–600,000 IU/kg q 8–12 hr × 7–14 days – psittacines 1,000,000 IU/kg q 12 hr– raptors, pigeons 250,000–500,000 IU/kg q 12 hr – ratites 300,000 IU/kg q 12 hr × 7–14 days – most species, waterfowl 100,000 IU/l drinking water – canaries, finches 200,000 IU/kg soft food – canaries, finches	Effective against most strains of <i>Candida</i> spp and some other yeasts, but not aspergillosis	Not absorbed from GI tract. To be effective must come into direct contact with yeast cell, therefore best not mixed with food or other media. Causes occasionally GI upset with vomiting but generally not toxic and not expensive
Amphotericin-B Fungizome (Squibb)	5 mg/ml injection	Slow i.v.  i.t. (intratracheal), nebulisation direct into air sac	1.5 mg/kg q 8 hr × 3–7 days – most species 1 mg/kg q 8–12 hr – raptors, psittacines (tracheal granulomas)	Broad spectrum, active against fungi, yeasts, some strains of <i>Aspergillus</i> spp resistance	Not well absorbed p.o., irritant if injected i.m. or s.c., therefore must be given i.v. but slowly otherwise cardiac arrhythmia occurs and, in some species, mild convulsions. Widely distributed in the body. Metabolised and excreted by the liver. Not thought to be nephrotoxic in birds in contrast to mammals, nevertheless monitor kidney function. Turkeys and raptors excrete the drug more rapidly.
		p.o.	0.2 ml q 12 hr × 10 days – budgerigars (megabacterial), use i.v. formulation. (5 mg/ml) 1000 mg/l drinking water × 10 days – budgerigars (megabacteria)	Active against megabacteria ( <i>Macrorhabdus ornithogaster</i> )	Because the pH of the proventriculus in megabacteriosis is changed from a normal of 0.7–2.7 to approximately 7.0, this drug is best administered in a slightly acid solution, i.e. 1 ml of 10% (approximately 1 normal HCl) diluted in 30 ml water. Give 0.5 ml p.o. of this diluted acid solution (J.R. Baker, 1995, personal communication).

<p><i>Flucytosine 5</i> – Fluorcytosine, Alcobon (Roche)</p>	<p>500 mg tablets</p>	<p>p.o. (gavage) or in feed</p>	<p>75–100 mg/kg q 6 hr – most species 120 mg/kg q 6 hr – raptors (aspergillosis) 250 mg/kg q 12 hr – raptors (candidiasis) 75 mg/kg q 12 hr × 5–7 days, then q 24 hr × 14 days – raptors and waterfowl (prophylaxis) 65 mg/kg body weight q 24 hr – cockatoos 50–250 mg/kg of feed – psittacines, mynahs</p>	<p>Broad spectrum but resistant strains rapidly develop. Effective for yeast but not systemic fungi except in combination with other antifungals.</p>	<p>Well absorbed from GI tract and widely distributed in the body's tissues including CNS, excreted almost unchanged. Since may have an adverse effect on the bone marrow, best to monitor haematology. May cause slight GI upset otherwise not thought to be toxic in birds.</p>
<p><i>Chlorhexidine</i> Hibiclens (Astra Zeneca)</p>	<p>Hibitane concentrate solution contains 25% chlorhexidine, marketed as an antiseptic</p>	<p>Drinking water</p>	<p>0.05% (0.5 ml or 500 mg/l drinking water) – most species 2.6 ml/l drinking water – finches 2.6–6.6 ml/l drinking water – psittacines</p>	<p>Consult manufacturer before use. Has been used in the USA for flock treatment of candidiasis. Also slows the spread of some viral infections (e.g. psittacine herpes virus). May be virucidal. Not absorbed from the gut (Clubb, 1984). Used by the author in budgerigars and not found to be toxic at 3x this dose.</p>	<p>Well absorbed from GI tract and widely distributed in the body's tissues including CNS, excreted almost unchanged. Since may have an adverse effect on the bone marrow, best to monitor haematology. May cause slight GI upset otherwise not thought to be toxic in birds.</p>

**Anti-parasitic drugs**

A large number of parasites infect birds: nematodes, cestodes, trematodes, protozoa and arthropods. Parasitic infection varies geographically and also depends on the bird's origin, e.g. tapeworms are sometimes seen in imported parrots, but not in parrots bred in the UK because the intermediate host is absent. However nematodes, e.g. *Ascaridia* spp, *Syngamus trachea*, are common and found in many species of bird, particularly those kept in outside aviaries.

**Drugs for the treatment of metazoan endoparasites  
The benzimidazoles**

Many benzimidazoles (Appendix Table 1.12) are licensed in the UK for veterinary use. These include albendazole, fenbendazole, flubendazole, mebendazole, oxfendazole, oxiabendazole and thiabendazole. Only those that are relatively safe to use are listed below.

**Appendix Table 1.12** The benzimidazoles.

Generic and Trade Name	Formulation	Route of Administration	Dosage	Activity	Comment
Fenbendazole (Hoechst) Panacur	2.5% (25 mg/ml) oral suspension	p.o.	20–100 mg/kg once – most species 1.5–3.9 mg/kg q 24 hr × 3 days – chickens 15–45 mg/kg – ostriches 5–15 mg/kg q 24 hr × 5 days – waterfowl 10–12 mg/kg q 24 hr × 3 days – pigeons 10–50 mg/kg repeat in 14 days – raptors 1.5 mg/kg q 24 hr × 5 days – psittacines 30 mg/kg once – bustards 33 mg/kg q 24 hr × 3 days – psittacines, passerines, raptors (microfilaria, trematodes)	Broad spectrum. Active against adult and larval nematodes. Ovicidal. Also active against tapeworms and some flukes.	A tasteless and odourless drug. The suspension has been used for finches in the drinking water at a dose of 10 mg/l although quite how it remains in suspension has not been stated. <u>Even at this low dose it can be toxic for finches.</u> <u>Also reported to be toxic in marabou storks and some species of vulture.</u> Should not be used when birds are actively growing feathers. Shown to be teratogenic in sheep, otherwise when used at the recommended dose a relatively safe drug. <u>Resistant strains of nematode can develop.</u>

Wormex (Hoechst)	<p>4% oral powder (40 mg/ml) for incorporation in food</p> <p>capsules containing 8 mg (licensed for pigeons) 2% (20 mg/ml) oral suspension for incorporation in feed</p> <p>300 ml pack licensed in UK for gamebirds</p>	<p>50 mg/kg q 24 hr × 5 days – most species (capillaria)</p> <p>40 mg/g of dry food used for grouse, formulated in grit-like pellets (trematodes)</p> <p>one capsule per pigeon over 2 months of age</p> <p>7–10 mg/kg body weight q 24 hr</p>	<p>GI roundworms, gapeworms and tapeworms in poultry and gamebirds.</p>	<p>Contraindicated in psittacines. <u>Has been reported to have caused death in pigeons, cormorants, pelicans, raptors and finches; also toxic for ostriches.</u> Use best restricted to those species for which it is licensed where there are resistant strains of nematode, i.e. poultry and gamebirds.</p>
<p>Mebendazole</p> <p>Mebenvet (Janssen), Telmin Suspension, Telminic Powder (Pitman-Moore)</p>	<p>Oral powder 1.2% (12 mg/g) 250 g pack, 5% (50 mg/g) 2.4 kg pack</p>	<p>25 mg/kg q 12 hr × 5 days repeat q 30 days – raptors (intestinal nematodiasis)</p> <p>20 mg/kg q 24 hr × 14 days – raptors (filariids)</p> <p>25 mg/kg q 12 hr × 5 days – psittacines, ramphastids (nematodes)</p> <p>5–6 mg/kg q 24 hr × 3–5 days repeat in 21 days – pigeons</p> <p>5–7 mg/kg body weight – ostriches</p> <p>5–15 mg/kg q 24 hr × 2 days – waterfowl (nematodes)</p> <p>10–21 mg/l drinking water × 3–5 days – pigeons</p>	<p>GI roundworms, gapeworms and tapeworms in poultry and gamebirds.</p>	<p>Contraindicated in psittacines. <u>Has been reported to have caused death in pigeons, cormorants, pelicans, raptors and finches; also toxic for ostriches.</u> Use best restricted to those species for which it is licensed where there are resistant strains of nematode, i.e. poultry and gamebirds.</p>
<p>Flubendazole</p> <p>Flutelimium 7.5% (Janssen – Cilag)</p>	<p>25 mg/g oral powder</p>	<p>30 mg/kg feed × 7 days – poultry</p> <p>60 mg/kg feed × 7–14 days – partridges, pheasants</p>	<p>Roundworms, gapeworm and some flukes</p>	<p>The use of this agent in species other than those for which it is licensed is not documented.</p>
<p>Thiabendazole</p> <p>Thilbenzole (Merck)</p>	<p>176 mg/ml oral suspension</p>	<p>40–100 mg/kg q 24 hr × 7 days – most species</p> <p>100 mg/kg q once, repeat in 10–14 days – ratites</p> <p>100–500 mg/kg once – most species</p> <p>425 mg/kg feed × 14 days – pheasants, cranes</p>	<p>Roundworms, gapeworm and some flukes</p>	<p>Not a very safe drug for birds, although it has been used in the past</p> <p>Toxic to ratites, ducks and cranes</p>

## Other metazoan antiparasitics

**Appendix Table 1.13** Other metazoan antiparasitics.

Generic and Trade Name	Formulation	Route of Administration	Dosage	Activity	Comment
Levamisole Nilverm (Pitman-Moore), Tramisol (Mallinckrodt)	7.5% (75 mg/ml) for injection for farm animals, 500 ml pack 1.5%, 3.2%, 3.0%, 7.5% solution for oral administration, 100 ml pack Note the injectable preparations are all 7.5% but the oral preparations vary	p.o.	20 mg/kg once – most species 20–50 mg/kg once – waterfowl 30 mg/kg q 10 days – ratites 80 mg/l drinking water × 3 days – finches 100–200 mg/l drinking water × 3 days – psittacines, passerines, raptors 264–396 mg/l drinking water × 1–3 days – most species, pigeons One tablet of 20 mg per pigeon	Effective against intestinal nematodes, adult and larval forms.	<u>Has a low therapeutic index – toxicity has occurred when the drug has been injected (i.m. or s.c.) at doses above 20 mg/kg. Bitter tasting, so reasonably safe when administered in drinking water because tends to be self-regulating. Deaths have occurred in macaws, budgerigars, lovebirds, pigeons and ibis.</u> Causes vomiting, CNS signs, death. Leave birds without water or fruit for 24 hr before dosing. Dose for 6–8 hr only. Has been used as an immunostimulant at a dose of 2 mg/kg q 24 hr i.m. every 14 days × 3 doses – this only works if T-cell function is depressed below normal. It does not elevate normal functional T-cell levels.
Ivermectin Ivomec (Merial)	10 mg/ml injection for cattle (1% solution) 50 ml, 200 ml and 500 ml phials	s.c.	0.2 mg/kg repeat in 14 days – most species dilute 1% solution 1 ml 0.4 mg/kg once – raptors 0.5–1.0 mg/kg once – pigeons 1 mg/kg repeat in 7–14 days – falcons ( <i>Serratospiculum</i> ) 0.8–1.0 mg/l drinking water – canaries	Broad spectrum antiparasitic Effective against invertebrate parasites, intestinal roundworm, gapeworm, microfilaria, <i>Cnemidocoptes</i> spp, air sac mite, lice, ectoparasitic mites. Not ovicidal. Not active against tapeworms or flukes. May be effective against some coccidia.	Generally a safe drug in birds, however it persists in body tissues for long periods, therefore, <u>frequent dosing can lead to toxicity, i.e. ataxia, depression, CNS signs. Toxic dose in budgerigars, some finches, kingfishers and woodpeckers may be as low as 0.02 ml, therefore best used in small birds by dripping directly onto the skin – one drop onto the skin between the scapulae on a Gouldian finch is effective against air sac mite. Is rapidly absorbed, even percutaneously, and spreads throughout the body. If the injection is diluted with water, tends to settle out unless used immediately, therefore best diluted with propylene glycol.</u>



<p><b>Praziquantel</b> Droncit (Bayer)</p>	<p>50 mg tablets 56.8 mg/ml 10 ml phial</p>	<p>p.o., i.m., s.c.  p.o., i.m.  p.o.</p>	<p>10–20 mg/kg, repeat after 10–14 days – most species  30–50 mg/kg, repeat in 14 days – raptors  6 mg/kg repeat in 10–14 days – cranes 7.5 mg/kg – ostriches</p>	<p>Tapeworms. May stop passage of eggs, but not get rid of adult tapeworm.</p>	<p>A fairly safe drug but can be toxic if the dose is exceeded, particularly by injection and in finches. Tablets are insoluble but can be crushed, mixed in vegetable oil and then mixed in food.</p>
<p><b>Niclosamide</b> Yomesan (Bayer)</p>	<p>Tablet containing 0.5 g of niclosamide</p>	<p>p.o. crop tube in feed</p>	<p>220 mg/kg repeat in 10– 14 days – most species 50–100 mg/kg repeat in 10–14 days – ostriches 250 mg/kg q 14 days as needed – cranes 500 mg/kg q 7 days × 4 weeks – finches</p>	<p>Active against tapeworms.</p>	<p>Tablets are not soluble, must be suspended in water or mixed in mash. <u>Death has occurred in pigeons and some Anseriformes at recommended doses.</u></p>
<p><b>Piperazine Biozine</b> (Vetark), Wazine (Fleming Laboratories)</p>	<p>Piperazine dihydrochloride 55% 10 g sachet</p>	<p>p.o.</p>	<p>100 mg/kg repeat in 14 days – raptors 35 mg/kg q 24 hr × 2 days – pigeons (ascariids) 50–100 mg/kg once – emus, ostriches, chickens 45–200 mg/kg once – waterfowl (<i>Tetrameres</i> spp, <i>Capillaria</i> spp) 100–500 mg/kg once, repeat in 10–14 days – gamebirds 250 mg/kg once – pigeons, psittacines 1–2 g/l drinking water for 1–3 days – pigeons, gamebirds</p>	<p>For use in Galliformes and Anseriformes, but <u>do not use in parrots.</u></p>	

## Drugs for use against protozoal endoparasites

**Appendix Table 1.14** Drugs for use against protozoal endoparasites.

<b>Drug and Trade Name</b>	<b>Formulation</b>	<b>Route of Administration</b>	<b>Dosage</b>	<b>Activity</b>	<b>Comments</b>
Amprolium Amprol Plus (M.S.D.), Corid (Merck)	Water miscible solution with 7.68% w/v amprolium hydrochloride BP 0.49% w/v ethopabate BP and aqueous propylene glycol vehicle to 100%	p.o.	25 mg/kg/day – pigeons 30 mg/kg q 24 hr × 5 days – raptors 50–100 mg/l drinking water × 5–7 days – most species	<i>Eimeria</i> spp of coccidia	Licensed for use in poultry and in pigeons. Chemically related to thiamine and competitively inhibits its uptake by parasites, but may also destroy some autochthonous micro-organisms in the GI tract and so produce a thiamine deficiency in the host. <i>Toxic to falcons at 22 mg/kg q 24 hr</i> (Forbes 1995). Efficacy of this agent is reduced by thiamine exposure. Resistant strains can develop after repeated use.
	Amprolium hydrochloride 38.4 mg/ml 112 ml and 500 ml (112 ml enough to treat 30 pigeons)	p.o. by addition to drinking water	200 mg/l drinking water – pigeons 60 mg/l drinking water – cranes		
Clazuril Appertex (Janssen)	2.5 mg tablets	p.o.	7 mg/kg, treat 3 days, off 2 days, treat 3 days – psittacines 6.25 mg/kg once – pigeons 5–10 mg/kg q 72 hr × 3 treatments – waterfowl, raptors 5–10 mg/kg q 24 hr, treat 3 days, off 2 days, treat 3 days – poultry, pigeons 1.1 mg/kg feed × 5 days – cranes	Coccidiosis in pigeons. Coccidiostatic.	Not very effective in cranes and Galliformes. May cause vomiting in cranes and Galliformes.

## Nitroimidazoles

**Appendix Table 1.15** Nitroimidazoles.

Generic and Trade Names	Formulation	Route of Administration	Dosage	Activity	Comment
<i>Metronidazole</i> Torgyl (Rhône-Mérieux), Flagyl (Searle)	0.5% solution (5 mg/ml) 50 ml phial 200 mg tablets	i. m. p. o.	10–20 mg/kg q 12–24 hr × 2 days – pigeons, psittacines 25–50 mg/kg q 12–24 hr × 5–10 days – psittacines 30 mg/kg q 12 hr × 5–7 days – raptors 50 mg/kg body weight – waterfowl 50 mg/kg q 24 hr × 5 days – raptors (trichomoniasis) 50 mg/kg q 12 hr × 5 days – pigeons 30 mg/kg once by gavage – finches ( <i>Cochlosoma</i> spp) 30 mg/kg q 12 hr × 6 days – Gouldian finches (trichomoniasis) 40 mg/kg q 24 hr – rheas 20–25 mg/kg q 12 hr – ratites 100 mg/l drinking water – canaries 40 mg/l drinking water – finches ( <i>Cochlosoma</i> spp) 1057 mg/l drinking water – pigeons 1250 mg/l drinking water × 7–10 days – ratites 100 mg/kg soft food – canaries	Active against <i>Trichomonas</i> spp, <i>Giardia</i> spp, <i>Hexamita</i> spp, and anaerobic bacteria	A relatively safe drug, but <u>may be toxic for finches</u> . May cause necrosis at site of injection. Well absorbed orally and penetrates all body tissues, including CNS. May reduce water intake, and therefore dose taken.
<i>Dimetridazole</i> Emtryl soluble (Rhône-Mérieux)	400 g/kg oral powder for addition to drinking water Licensed for use in poultry and game birds 500 g pack	p. o.	650 mg/l drinking water × 7–12 days – pigeons 800 mg/l drinking water – poultry, gamebirds 100 mg/l drinking water – canaries, finches 200–400 mg/l drinking water × 5 days – psittacines, gamebirds 300 mg/l drinking water × 10 days – bustards (trichomoniasis prophylaxis) 900 mg/l drinking water × 10 days, followed by 7 g/10 l drinking water × 10 days – bustards (treatment for trichomoniasis)	Effective against trichomoniasis, hexamitiasis, giardiasis, histomoniasis and some anaerobes	Not as safe a drug as metronidazole. Has a low therapeutic index. <u>Toxic for many species of finch</u> . Extended therapy or overdosing easily causes toxic CNS signs and death. <u>In lories and mynahs use ½ normal dose.</u>

### Anti-malarial drugs licensed for human use

Anti-malarial drugs used in man (Appendix Table 1.16) may be effective against the blood protozoan parasites sometimes found in birds, e.g. *Plasmodium*, which occurs in wild birds in the UK and is transmitted to captive birds by biting arthropods: *Leucocytozoon* spp – probably specific; *Haemoproteus* spp – may not be pathogenic; trypanosomes – possible in imported birds.

**Appendix Table 1.16** Anti-malarial drugs licensed for human use.

Generic and Trade Names	Formulation	Route of Administration	Dosage	Activity	Comment
Chloroquine phosphate Aralen (Sanofi)	68 mg/ml syrup 40 mg/ml injection, 5 ml ampoule	p.o.	10 mg/kg once then 5 mg/kg at 6, 18 and 24 hr – penguins 25 mg/kg body weight, then 15 mg/kg at 12, 24, and 48 hr – most species, raptors, use in conjunction with 0.75–1.0 mg/kg primaquine at 0 hr	Active against <i>Plasmodium</i> spp	Bitter taste, so crush tablet and dissolve in fruit juice or with honey. Low therapeutic index, <u>overdose fatal</u> . Rapidly absorbed from GI tract. May cause mucous membranes to turn yellow. Best used in combination with primaquine. Used in penguins, raptors and psittacines.
Primaquine Phosphate (Sanofi)	7.5 mg tablets		0.03 mg/kg q 24 hr × 3 days – gamebirds, penguins 1.25 mg/kg q 24 hr – penguin prophylaxis therapy ( <i>Plasmodium</i> spp)	Active against <i>Plasmodium</i> spp	Used in penguins. Used in conjunction with chloroquine.
Pyrimethamine Daraprim Wellcome Fansidar (Roche) Maloprim Wellcome	25 mg, 12.5 mg tablets	p.o.	0.25–0.5 mg/kg q 12 hr × 30 days – raptors, waterfowl 0.5 mg/kg q 12 hr × 14–28 days – most species 1 mg/kg feed – gamebirds 100 mg/kg feed – most species	Active against <i>Plasmodium</i> spp, <i>Toxoplasma</i> spp, <i>Sarcocystis</i> spp	Folic acid antagonist, therefore effects potentiated by the simultaneous administration of sulphonamides. Patients being treated should be supplemented with folic or folinic acid.
Quinacrin HCl Atabrine (Sanofi)	100 mg tablets	p.o.	7.5 mg/kg q 24 hr × 7–10 days – most species (atoxoplasmosis) 5–10 mg/kg q 24 hr × 7–10 days – most species 26–79 mg/l drinking water × 10–21 days – pigeons	Active against <i>Plasmodium</i> spp, <i>Atoxoplasma</i> spp	Hepatotoxicity a concern with overdose.

Drugs for use against ectoparasites

**Appendix Table 1.17** Ectoparasitics.

<b>Drug and Trade Names</b>	<b>Formulation</b>	<b>Route of Administration</b>	<b>Dosage</b>	<b>Activity</b>	<b>Comments</b>
<i>Piperonyl butoxide</i> Fleacare (Animal Care)	Powder with piperonyl butoxide 0.8%, pyrethrins 0.113% w/v	External application	Dust onto feathers	Active against all ectoparasites	Safe and effective. Brush out excess from hand-held bird.
<i>Derris powder</i> Derris 2% (Vet Drug)	Powder containing 2% w/v derris	External application	Dust onto feathers	Active against all ectoparasites	Safe and effective. Brush out excess from hand-held bird.
<i>Coumaphos</i> Negasunt (Bayer)	Powder containing 3% w/v coumaphos 2% w/v propoxur 5% w/v sulphanimide	External application	Dust onto feathers	Active against all external parasites	Contains carbamate propoxur. Useful for fly-blown wounds.
<i>Fipronil</i> Frontline (Merial UK)	0.25% solution in alcoholic spray	External application	Lightly wipe feathers with cotton wool moistened with spray	Blocks GABA neurotransmitters in all ectoparasites	<u>Do not use the spot-on preparation.</u> Best not to spray directly onto the feathers as the alcoholic preparation may damage plumage.

## Viruses

### Prophylactic protection against viruses

**Appendix Table 1.18** Prophylaxis against viruses.

<b>Virus</b>	<b>Formulation</b>	<b>Effectiveness and Comment</b>
<i>Pox viruses</i>		Very few species-specific vaccines for the many pox viruses.
Fowl Pox	Vaccine Freeze-dried live virus powder for reconstitution Poxine (Solway)	Licensed in the UK for use in poultry. Effective against turkey pox, quail pox, falcon pox. Does not protect peacocks against peacock pox virus.
Pigeon Pox	Living vaccine Nobilus (Intervet) Freeze-dried for reconstitution Acti/vaccPP (Maine Biological Lab)	Licensed in the UK for use in pigeons. If used in raptors may increase mortality. Booster if exposed. Immunity usually develops within 4–6 weeks post administration.
Canary Pox	Poximmune-C (Biomune) Homologous vaccine (Maine Biological Lab)	A scab at the injection site in the wing web indicates an effective vaccination. May be used in birds that have no overt clinical signs in an aviary in which positive cases have been identified.
Psittacine Pox	Homologous vaccine (Maine Biological Lab)	Associated with granuloma formation at injection site.
<i>Herpes viruses</i>	Only very few taxon-specific vaccines available for the many herpes virus diseases	Herpes viruses are intranuclear and so protected by the cytoplasm of the cell from the body's humoral defences.
Duck virus hepatitis enteritis	Duck virus hepatitis (Animal Health Trust) Duck plague virus (Intervet)	Animal Health Trust vaccine only available to members of Duck Producers Association. Intervet vaccine – Anseriformes/MLV may be used during outbreak.
Infectious laryngotracheitis	Freeze-dried live vaccine ILT Vaccine (Solway)	Licensed for use in UK in poultry, not pheasants. May be effective against Amazon tracheitis but there is a risk of an undesirable reaction.
Marek's disease virus	Freeze-dried live vaccines: Delvax (Mycofarm) Marixin (Intervet) Md-Yac (Solway) Also cell-associated live vaccines available.	Licensed for use in UK in poultry. Before use consult manufacturers and DEFRA.
Pacheco's virus of parrots	Psittimune PDV (Biomune)	Granuloma formation associated with vaccine at injection site. Unsubstantiated deaths reported with vaccine use in some psittacine species, especially cockatoos.

<p><i>Corona viruses</i></p>	<p>Avian infectious bronchitis</p>	<p>Live virus vaccines for addition to drinking water                      IBMM (Solvay)                      IB Nobilis H-52 and H-120 and Strain MA5 (Intervet)                      Poulvac H52 and H120 (Solvay)</p>	<p>Licensed for use in UK in poultry but may be effective in pheasants, guinea fowl, psittacines, pigeons, ostrich and Japanese quail, providing an exact diagnosis has been made. Consult manufacturer and DEFRA before use.</p>
<p><i>Arbo viruses</i></p>	<p>Avian encephalomyelitis</p>	<p>Live virus vaccine for addition to drinking water                      AE-Vac (Solvay)                      AE-Nobilis (Intervet)</p>	<p>Licensed for use in UK in poultry but may be effective in other species providing a specific diagnosis has been made. Consult manufacturer and DEFRA before use.</p>
<p>Louping ill virus</p>	<p>Inactivated + oil adjuvant louping ill vaccine                      (Pitman-Moore)</p>	<p>Licensed for use in UK in cattle, sheep and goats but may be effective in susceptible avian species, i.e. grouse, capercaillie and pheasant. Consult manufacturer and DEFRA before use.</p>	<p>Emus, eclectus parrots and palm cockatoos should be vaccinated and boosted annually in endemic areas.</p>
<p>Eastern and western equine encephalitis</p>	<p>Triple-E (Solvay)                      EEE vaccine (Fort Dodge)</p>	<p>Full equine dose recommended if at all possible. Inconsistent and unsubstantiated immunity from available equine vaccine in avian species. Not licensed for avian use.</p>	<p>West Nile – Innovator (Fort Dodge)</p>
<p><i>Paramyxo viruses</i></p>	<p>Newcastle disease virus</p>	<p>Live freeze-dried vaccines                      Hitchner Bi (Solvay)                      Hitchner Bi Nobilis (Intervet)                      Inactivated vaccines                      Newcavac Nobilis (Intervet)</p>	<p>A <i>notifiable disease in UK</i>.                      Licensed for use in the UK in poultry. Do not use live vaccines in species other than those for which licensed. The inactivated vaccine may be effective in other avian species after a specific diagnosis has been made. Consult the manufacturer and DEFRA before use.</p>
<p>Pigeon paramyxovirus</p>	<p>Inactivated virus:                      Colum Boval (Solvay)                      Nobivac (Intervet)                      Paramyx (Harkers)                      Inacti/vac PMV1 (Maine Biological Lab)                      Columbovac (Solvay Duphar)</p>	<p>A <i>notifiable disease in UK</i>.                      Licensed in the UK for use in pigeons.</p>	<p>Thickened skin may be noted at vaccination site.</p>
<p><i>Papova viruses</i></p>	<p>Polyomavirus</p>	<p>Avian Polyoma Vaccine (Biomune)</p>	<p>Thickened skin may be noted at vaccination site.</p>

### Suggested routines for dealing with virus infections

1. *For herpes virus infections only*, use acyclovir tablets or suspension, e.g. Zovirax (Wellcome Medical) at the rate of 80 mg/kg 8 hr (gavage) or 240 mg/kg of feed.
  - a) This drug blocks herpes virus DNA polymerase in infected cells.
  - b) Most effective in aviary outbreaks before clinical signs are recognised.
  - c) May be nephrotoxic so do not use in dehydrated birds or with other potentially nephrotoxic drugs, such as the aminoglycosides or sulphonamides.
  - d) Do not use the injectable formulation.
  - e) Acyclovir may help in some pox virus cases.
2. Use *ascorbic acid* (non proprietary) at dose rate of 20–40 mg/kg q 24 h up to 7 days. This, together with zinc, has a salutary effect on the immune response.
3. *Ensure the diet is adequate*, particularly in essential amino acids, vitamins A, E and B and also zinc, e.g. use Ace-High (Vetark).
4. *Treat secondary invaders* and any concomitant parasitic infection.
5. *Practice strict aviary hygiene*, noting the modes of transmission and possible latent carriers.
  - a) Use a fogging machine with F10 in closed aviaries.
6. *Idoxuridine* blocks the replication of some DNA viruses.
  - a) Use Idoxuridine, Idoxene (Spodefell), 0.5% eye ointment.
  - b) A *little* applied to the eye of herpes virus infected birds may help to improve the condition of the eyes and encourage the bird to feed.
  - c) May also help in some pox virus cases.
7. Use chlorhexidine (Hibiclens/Astra Zeneca; see Polyene antifungals, p. 242) or F10 (Biocare) antiseptic, diluted 1:250 in drinking water.



**Hormones**

**Appendix Table 1.19** Hormones for use in birds.

Generic and Trade Names	Formulation	Route of Administration	Dosage	Comment
<i>Testosterone</i> Androject (Intervet)	An oily solution for injection containing 10 mg testosterone phenylpropionate/ml	i.m. s.c.	2–8 mg/kg once – most species 8.0–8.5 mg/kg q 7 days as needed – most species 10–15 ml stock solution/1 drinking water × 5 days for 2 months	For stimulation of sexual behaviour in the male. Has been used to treat baldness, finch moult, and/or regain singing in canaries. Should not be used in birds with liver or renal disease.
Durateston (Intervet)	50 mg total esters/ml oily solution for injection containing four esters of testosterone	i.m., s.c.	2–8 mg/kg once	Prolonged activity over 2 weeks.
<i>Nandrolone phenylpropionate</i> Nandrolin (Intervet)	A sterile oily injection containing 25 mg/50 mg/ml	i.m.	0.4 mg/kg once or q 3 weeks – psittacines, raptors, bustards 0.02–2.0 mg/kg once – most species	For chronic and debilitating disease. Should not be used if there is liver disease.
<i>Dexamethasone</i> Dexadron (Intervet) Azium (Schering-Plough)	10 mg/ml clear aqueous suspension	i.m., i.v.	0.2–1.0 mg/kg once or q 12–24 hr × 2–7 days, then q 48 hr × 5 days – most species (anti-inflammatory) 2–4 mg/kg q 12–24 hr – most species, raptors (shock, trauma) 2–8 mg/kg q 12–24 hr – cranes Mixed in 50% solution with DMSO	<i>The action of corticosteroids is subtly different in birds compared with mammals (Westerhof 1995). Birds are much more sensitive to their action. To reduce the inflammatory response and combat shock. Preferably given with appropriate antibiotics. If possible always use NSAIDs</i>
<i>Dexamethasone sodium phosphate</i> Dexaject SP (Vetus)	4 mg/ml injectable vial	s.c., i.m., i.v.	2–4 mg/kg q 6–24 hr – most species	Faster acting dexamethasone product for head trauma, shock.
<i>Dinoprost tromethamine</i> Lutalyse (Upjohn)	5 mg/ml contains naturally occurring prostaglandin	i.m. intraoalcal	0.02–0.1 mg/kg body weight, used once only	For egg binding – relaxes vent and increases tone in oviduct. Also useful in treating salpingitis. Recommended when the uterovaginal sphincter is dilated.

(Continued)

Appendix Table 1.19 Continued.

Generic and Trade Names	Formulation	Route of Administration	Dosage	Comment
<i>Delmadinone</i> Tardak (Syntex)	10 mg/ml aqueous suspension	i.m.	1 mg/kg (0.02 ml/30 g) once	An anti-androgen. Sometimes effective for neurotic regurgitation in budgerigars. Well tolerated. Used successfully for excessively aggressive swans.
<i>Medroxyprogesterone</i> Depo-Provera, Promone- E (Upjohn) Perlutex (Leo)	25 mg/ml, 50 mg/ml aqueous suspension	i.m., s.c.	5–25 mg/kg repeat q 4–6 weeks as needed – psittacines	Because of adverse health consequences associated with the use of the drug it is not a recommended therapeutic agent.
		s.c.	30 mg/kg repeat in 90 days as needed – most species	Side effects: obesity, polyuria, diabetes. Cockatoos are the most sensitive to this drug. Neurotic regurgitation in budgerigars. Also some feather conditions involving excessive preening. Has been used for persistent egg laying in budgerigars and in other species of psittacine bird.
<i>Oxytocin</i> Oxytocin-S (Intervet) Oxytocin (Butler)	10 IU/ml clear aqueous solution	i.m.	3–5 IU/kg may repeat q 30 minutes – most species 0.5–2 IU/kg (lower dose may be repeated in 60 minutes) – psittacines 20–30 IU/bird q 24 hr × 2 treatments – raptors	Used in conjunction with calcium borogluconate for egg impaction of the oviduct. Uterovaginal sphincter should be well dilated prior to the use of oxytocin.
<i>Atropine</i> Atropine Sulfate (Animalcare) [C-Vet VP] (Bimedaj) (Abbott)	600 µg/ml, 0.6 mg/ml sterile solution for injection 10 mg/ml solution	i.m. s.c.	0.05–0.1 mg/kg, 0.1–0.6 ml/kg (use higher doses for small birds only)	For premedication 10 minutes prior to anaesthesia. As a partial antidote to organophosphorous poisoning.
<i>Dinoprostone</i> (prostaglandin E <sub>2α</sub> ) Prepidil Gel (Upjohn)	0.5 mg gel	topical	0.02–0.1 mg/kg applied to the uterovaginal sphincter – most species	Relaxes uterovaginal sphincter. <u>User must wear gloves for application – transdermal exposure may have adverse hormonal effects in humans.</u>

<p><b>Thyroxine</b> Elitroxin (Evans) Soloxine (Daniels Vet-2-Vet) <i>Liothyronine sodium</i> Tertroxin (Link)</p>	0.05 mg, 100 µg tablets  20 µg tablet	in drinking water oral, crushed and mixed in feed  oral	50 µg ( $\frac{1}{2}$ – $\frac{3}{4}$ tablet)/100 ml for 4 weeks Up to 100 µg/kg q 24 h every 3 days  20 µg/kg q 24 hr	For treatment of hypothyroidism. Double the dose for birds that drink little. The tablets are not very soluble. May induce moulting in some species – use only for 7 days. Toxic effects: vomiting, loss of weight, convulsions and ultimately death
<p><b>Thyroid stimulating hormone (TSH)</b> Thyrogen (Genzyme Corp.), Dermathycin (Coopers), Thyrotropar (Armour)</p>		i.m.	0.1 IU – cockatiels 0.2 IU/kg – macaws 1 IU/kg – Amazon parrots, African grey parrots, pigeons 1–2 IU/kg – psittacines	Available in USA but not in UK. The related thyroid releasing hormone (TRH) can be obtained in the UK and functions for diagnostic purposes as well, providing the pituitary gland is normal.
<p><b>Thyroid releasing hormone (TRH)</b> (Non proprietary)</p>		i.m.	15 µg/kg once – most species	

## Analgesics

**Appendix Table 1.20** Analgesics.

<b>Drug and Trade Name</b>	<b>Formulation</b>	<b>Route of Administration</b>	<b>Dosage</b>	<b>Comments</b>
<p><b>Carprofen</b> Zenocarp (C-Vet)</p>	50 mg/ml injection 20 ml phial	i.m.	2 mg/kg q 24 hr	An NSAID which is a weaker inhibitor of cyclo-oxygenase than either ketoprofen or flunixin and therefore safer. A potent analgesic and a useful anti-inflammatory even systemically. Has a marked euphorbic effect. A better choice than using corticosteroids.
<p><b>Meloxicam</b> Metacam Boehringer Ingelheim UK <i>Acetylsalicylic acid</i> (Aspirin)</p>	5 mg/ml solution for injection 1.5% oral solution 75 mg and 300 mg dispersible tablets	i.m  oral  oral	200 µg/kg once  200 µg/kg orally q 24 hr  5 mg/kg q 8 hr 325 mg/250 ml drinking water 300 mg/230 ml drinking water	An NSAID. Using the oral formulation, one drop of the 1.5 mg suspension is sufficient for an African grey parrot. A relatively safe drug.
<p><b>Butorphanol</b></p>				An opioid analgesic (see Chapter 7)
<p><b>Acetyl salicylic acid/Aspirin</b></p>	Dispersible tablets 75 mg & 300 mg	oral	5 mg/Kg q 8 hr 325 mg/250 ml drinking water 300 mg/230 ml drinking water	

## Miscellaneous drugs

Appendix Table 1.21 Miscellaneous drugs for use in birds.

Drug and Trade Name	Formulation	Route of Administration	Dosage	Comment
Iodine Lugol's iodine	Lugol's iodine BP	in drinking water	Dilute by adding 2 parts to 28 parts of water, add 3 drops of this solution to 100 ml drinking water – use for 3 weeks	For treatment of secondary thyroid hyperplasia due to iodine deficiency. Commonly seen in budgerigars. Often an overall general improvement in activity and plumage is seen in budgerigars and other psittacines after 3–4 months' treatment.
Sodium iodide	20% sterile solution for injection (200 mg/ml)	i.m.	0.01–0.03 ml (2 mg–6 mg)/30 g bird 0.33–1.0 ml (66–133 mg)/kg body weight	Secondary thyroid hyperplasia due to iodine deficiency. Considerable improvement to respiratory obstruction seen within 3 days in budgerigars.
Potassium iodide		in drinking water	100–200 mg/100 ml	As a palliative in the treatment of chronic respiratory disease. Should not be given for periods longer than a week.
Bromhexine hydrochloride Bisolvon (Boehringer)	3 mg/ml solution for injection 8 mg tablet (human medical product) 10 mg/g oral powder for addition to drinking water	i.m.	3–6 mg/(1–2 ml)/kg, 0.1 ml/30 g divided into 2 or 3 doses daily	Mucolytic. May help better penetration of antibiotics and gamma globulins into respiratory tract. Well tolerated. The injection is water-based so can be given orally or in daily water intake (Ahlers, 1970).
Calcium borogluconate	10% (100 mg/ml)	i.v. s.c.	0.5–2 ml (50–250 mg)/kg by slow intravenous injection to effect	Treatment of impaction of the oviduct and egg binding used together with oxytetrin. Treatment of raptors with 'fits' due to hypocalcaemia. Advisable to give dextrose injection at the same time.
Dimethylsulphoxide (non-proprietary) DMSO (Univet), DOMOSO (Syntex)	50% w/w	Topical to affected area	1 mg/kg q 4–7 days	Solvent dissolving many drugs and transporting these through the skin through which it easily penetrates. Is itself an anti-inflammatory agent, helping in the dissolution of collagen. May be toxic in some species and to humans.

<i>Ferric chloride solution BP also powder (non proprietary)</i>		Apply topically to bleeding areas	To arrest minor haemorrhage.
<i>Silver nitrate</i>	Stick or pencil	Apply to points of minor haemorrhage	To arrest localised bleeding by chemical cautery. Flush the area with saline solution to form silver chloride when bleeding has ceased, to neutralise the cauterising action.
<i>Hyaluronidase BP</i>	Ampoule with 1,500IU for reconstitution	500IU per injection site	Breaks down the polysaccharide hyaluronic acid which is part of intracellular connective tissue. Disperses fluids.
<i>Glibenclamide BP (non proprietary)</i>	2.5 mg tablets	Oral in drinking water	For non-insulin-dependent diabetes mellitus in psittacines, particularly budgerigars.
<i>Propentofylline Vivitonin (Hoechst)</i>	50 mg tablets (small)	Oral in food	Peripheral vasodilator used for idiopathic dullness, lethargy in old senile parrots possibly with cardiopathy. Also for treatment of wing tip oedema (Forbes, 1995).
<i>Isoxsuprine Navilox (Univet)</i>	30 mg/g oral powder	5–10 mg/kg q 24hr	Arterioliator working predominantly on skeletal muscle. Appears to work better than the above drug in the treatment of wing tip oedema (Lewis, 1993).
<i>Vecuronium bromide Norcuron (Organon-Teknika)</i>	10 mg ampoule powder for reconstitution	Topical Reconstitute in 2.5 ml water Use one drop only, every 5 minutes for 15 minutes until pupil dilates	Used as an alternative to tubocurarine as a non-depolarising muscle relaxant to cause dilation of the pupil (mydriasis), since in birds this is under CNS and <i>not</i> parasympathetic control (as in mammals).
<i>Aminophylline Roxane (Watson)</i>	105 mg/5 ml oral solution	p.o. 4–5 mg/kg q 6–12 hr – most species, psittacines 8–10 mg/kg q 6–8 hr – raptors, ratiies	Bronchodilator.
<i>Cimetidine Tagamet (SmithKline Beecham)</i>	300 mg/2 ml injectable solution	i.m. 5 mg/kg q 8–12 hr – psittacines 5–10 mg/kg q 12 hr – ratiies	Used for ingluvial inflammation and gastric ulceration.

(Continued)

Appendix Table 1.21 Continued.

Drug and Trade Name	Formulation	Route of Administration	Dosage	Comment
Diphenhydramine Benadryl (Pfizer)	Multiple oral formulations (tablets, liquid medication)	p.o.	1–4 mg/kg q 8 hr – macaws, Amazon parrots 20–40 mg/l drinking water – most species 2–4 mg/kg q 12 hr – most species	Inflammatory skin and respiratory reactions.
Diphenhydramine injectable (Elkins-Sinn)	50 mg/ml injectable solution	i.v., i.m.		
Enalapril Enacard (Merck)	1 mg, 2.5 mg, 5 mg, 10 mg, 20 mg tablets	p.o.	0.25–0.5 mg/kg q 24–48 hr – psittacines	Treatment for cardiomyopathy. Not recommended if patient has renal disease.
Furosemide Furosemide (Roxane), Injectable solution (Baxter)	20 mg, 40 mg, 80 mg tablets 10 mg/ml and 40 mg/5 ml oral solution 10 mg/ml injectable solution	p.o., s.c., i.m., i.v.	0.1–2.0 mg/kg q 6–24 hr – most species	Diuretic. Toxicity associated with neurological signs and death.
Hyaluronidase Wydase (Wyeth-Ayerst)	150 USP/ml hyaluronidase once reconstituted	Add to fluids	75–150 IU/l fluids	Absorption rate of fluids significantly improved.
Hydroxyzine Atarax (Roerig)	10 mg, 25 mg, 50 mg, 100 mg tablets 10 mg/5 ml syrup	p.o.	2.0–2.2 mg/kg q 8 hr – Amazon parrots 34–40 mg/l drinking water – most species	Used for feather picking and self-mutilation in psittacine patients.
Lactulose Lactulose Solution (Roxane)	10 g/15 ml oral solution	p.o.	150–650 mg/kg q 8–12 hr – most species	Decreases blood ammonia levels. Used in cases of liver compromise. Adverse side effects include diarrhoea.
Nortriptyline Nortriptyline HCl (Pharmaceutical Associates)	10 mg/5 ml oral solution	p.o.	16 mg/l drinking water	A tricyclic antidepressant used to treat feather picking birds. Has anti- inflammatory properties.

## Vitamins, minerals and nutritional supplements

Appendix Table 1.22 Food supplements.

Drug	Formulation	Route of Administration	Dosage	Comment
Avipro (Vetark)	Water soluble probiotic containing lactobacillus (2 species), <i>Streptococcus faecium</i> ; yeasts; enzymes: lipase, amylase, protease and cellulose; electrolytes and vitamins	Orally in drink or food	One scoop (provided with pack), i.e. 4g/100 ml drinking water	A probiotic specifically adapted for use in birds under stress. Can be used simultaneously with antibiotics, particularly if autochthonous flora is liable to be affected.
Avipro Paediatric (Vetark)	Enzymes and electrolytes as above, but less lactobacillus and contains glucose	As above	Follow suggested routine on pack	Designed to mimic the effects of the parent bird's crop to aid in support of the hand reared chick.
Ace-High (Vetark)	Powdered vitamin supplement with high levels of vitamins A, C and E, plus B vitamins and minerals including zinc.	Orally in food	Follow directions on pack	As an aid in the treatment of stress or infectious disease, particularly viral infections. <i>Do not use with other vitamin supplements.</i>
Nutrobal (Vetark)	Powdered vitamin/mineral supplement with calcium:phosphorus ratio of 40–50 : 1	Orally in food	Follow directions on pack	Designed to balance diets low in calcium; also contains 150IU vitamin D <sub>3</sub> /g. Valuable supplement for fast growing young birds and laying hen birds. <i>Do not use with other vitamin supplements.</i>
Critical Care Formula (CCF) (Vetark) also Emerald Critical Care (Lafeber Co., USA)	Each 5g contains 0.72g protein, 18 Kcal of energy	Orally	Make up 1 : 2 with water Do not make up more concentrated and give orally by gavage	To stop weight loss in severely ill birds. Provides easily digestible calorific support as mixture of short chain maltodextrin plus concentrated protein and amino acids.
Multivitamin and mineral preparations SA 37 (Intervet) Vionate (Squibb)	See makers' data and information sheets	Oral	500 mg/kg body weight	May be wasteful when mixed with seed. Needs to be given in a mash.
Multivitamin injections (C-Vet) (Norbrook) (Arnolds)	See makers' data and information sheets	i.m.	0.5 ml/kg supplying 7,500IU vitamin A and other vitamins	<u>Vitamin A overdose is toxic</u> and can produce skeletal abnormalities and damage to membranes. <u>Use with caution in macaws and African grey parrots.</u>

(Continued)

Appendix Table 1.22 Continued.

Drug	Formulation	Route of Administration	Dosage	Comment
<i>Multivitamin oral drops</i> Abidec (W-L, human preparation) vitamins A, B group, C and D Duphalyte (Duphar)	See maker's data and information sheets Vitamin A approximately 6,500 IU/ml	in drinking water	5 drops/0.3 ml/30 g bird, every third day	
<i>Vitamin E</i> Vitesel (Norbrook)	An injectable solution of electrolytes, vitamins, amino acids and dextrose	s.c., very slowly i.v.	10 ml/kg q 12 hr	Given in the groin or at base of neck with hyaluronidase.
<i>Vitamin C</i> (non-proprietary)	68 mg $\alpha$ -tocopheryl acetate, 1.5 mg/ml selenium injection	i.m., s.c.	0.5–0.1 mg/kg q 24 hr $\times$ 14 days	Cockatiel paralysis/paralysis syndrome and similar neuropathies in other psittacine species.
<i>Vitamin K</i> <i>Phytomenadione</i> (synthetic vitamin K) Konaktion (Roche)	Ascorbic acid 100 mg/ml	i.m.	20–40 mg/kg q 24 hr	Nutrition support for infectious disease.
<i>Vitamin K</i> <i>Phytomenadione</i> (synthetic vitamin K) Konaktion (Roche)	2 mg/ml injection	i.m.	0.2–2.5 mg/kg q 24 hr up to 70 days	May help in cases of haemorrhage. Can be used together with sulpha drugs.
<i>Vitamin A</i> Ro-A-Vet (Roche)	50,000 IU/ml 2 ml ampoule	i.m.	5,000 IU/kg q 24 hr $\times$ 2–4 weeks	Supportive treatment for many infectious diseases but be careful not to overdose.
<i>Lactulose</i> Duphalac (Duphar)	Liquid containing 3.35 g/5 ml lactulose 300 ml	Orally	0.3 ml/kg q 24 hr	Slows GI transit of ingesta. Helps to absorb enterotoxins. Mild laxative. Useful in cases of autochthonous GI flora dysfunction.
Natural yogurt	Contains <i>Lactobacillus acidophilus</i>	Oral	2 ml/kg body weight	May help to restore gut flora after antibiotic therapy. Controversial but will do no harm.
<i>Human invalid foods</i> Farlene Complan (Farley Health Foods) Build Up (Carnation Foods) Vita Food (Boots Ltd) Milupa	Human invalid foods that contain approximately 400 Kcal/100 g of food	by crop tube	100 g/kg daily 7.5 g/30 g daily	Best results obtained in the severely debilitated bird by dividing daily dose and giving at hourly intervals. Add a probiotic, e.g. Avipro. Useful in an emergency if no specific avian product readily available.



**Drugs acting on the alimentary canal**

**Appendix Table 1.23** Drugs acting on the alimentary canal.

Drug	Formulation	Route of Administration	Dosage	Comment
Liquid paraffin mineral oil		Oral per cloacum	4 ml/kg q 24 hr	For impaction of the cloaca and egg binding.
Glycerine		Oral per cloacum	5 ml/kg q 24 hr	For impaction of the cloaca and egg binding.
Sucrose in water	30% solution	Oral	up to 10 ml/kg q 12 hr	Mild purgative

Antidiarrhoeals without antibiotic

**Appendix Table 1.24** Antidiarrhoeals without antibiotics. (NB: Many birds that are anorexic or have recently arrived in the clinic have watery droppings but do not have diarrhoea.)

Drug	Formulation	Route of Administration	Dosage	Comment
BPC (Vet Drug)	Light kaolin BP 20% w/v Light magnesium carbonate 5% w/v Sodium bicarbonate BP 5% w/v	Oral		
Stat (Interveil)	100 ml contains: Light kaolin 10.8g Aluminium hydroxide gel 1.93 g Sodium acetate 1.98g Sodium chloride 1.81g Potassium acetate 330mg Magnesium chloride 100 mg Calcium chloride 100 mg	Oral	3 ml/kg q 12hr or q 8 hr	
Kaogel (Parke Davis)	15 ml contains: Light kaolin 200 mg/ml Pectin 4.3 mg/ml			
Meioclopramide Reglan (Robins)	Meioclopramide hydrochloride BP injection 5 mg/ml 2 ml phial	i.m., i.v.	0.5 mg/kg 8–12 hr – most species 2 mg/kg q 8–12 hr – raptors, waterfowl 12.5 mg/kg – ratites	Increases motility of upper GI tract and reduces vomiting. Indicated in sour crop to empty crop. Do not use if GI obstruction suspected. Can cause restlessness and excitement in some birds
		p.o.		

## Sedatives, stimulant drugs and drugs for behavioural modification

Appendix Table 1.25 Sedatives, stimulants and behavioural modifiers.

Drug	Formulation	Route of Administration	Dosage	Comment
Diazepam Valium (Roche)	10 mg/2 ml ampoules	i. m.	0.5–0.6 mg/kg – most species 0.5–1.0 mg/kg q 8–12 hr – most species (seizure control)	To control feather picking and seizures. Also used as an appetite stimulant.
		p. o.	2.5–4.05 mg/kg q 6–8 hr – psittacines (sedation) 10–20 mg/l drinking water – most species	
Ketamine Vetalar (Upjohn) Dodge (Aveco) Ketalar (Parke-Davis)	Sterile solution for injection containing 100 mg/ml	i. m.	5–30 mg/kg – raptors (sedation) 11.1 mg/kg – ostriches 15–30 mg/kg – waterfowl 20–50 mg/kg – psittacines, pigeon	Poor muscle relaxation. Often used in combination to reduce violent prolonged recovery.
Xylazine Rompun (Bayer)	Sterile aqueous solution for injection 20 mg/ml	i. m.	1.0–2.2 mg/kg – raptors, psittacines, ratites (heavy sedation) 1–20 mg/kg – waterfowl, raptors (sedation)	For anaesthetic doses see Chapter 7
Primidone Mysoline	250 mg tablets 250 mg/5 ml suspension	Oral	56 mg/kg q 24 hr	Treatment of idiopathic epilepsy in parrots.
Potassium bromide BP	Crystals to be dissolved in water at the rate of 250 mg/ml	Oral	25 mg/kg q 24 hr	Clear, tasteless, odourless fluid for the treatment of idiopathic epilepsy in parrots.
Doxepin Sinequan (Pfizer)	10 mg, 25 mg, 50 mg and 75 mg capsules 10 mg/ml suspension	Oral	0.5–1 mg/kg q 12 hr – most species	Tricyclic human antidepressant. May be effective in some cases of feather plucking.

<p><i>Haloperidol BP</i> Haldol (McNeil)</p>	<p>2 mg/ml clear colourless and odourless liquid 100 ml</p>	<p>Oral</p>	<p>0.1–0.15 mg/kg q 12–24 hr – birds weighing &gt; 1 kg 0.2 mg/kg q 12 hr – most species weighing &lt; 1 kg 0.1–0.4 mg/kg q 24 hr – psittacines (dose increased in 0.01 mg/kg increments if no response in noted in 5–7 days) 6.4 mg/l drinking water × 7 months – African grey parrots (feather picking)</p>	<p>Sedative effects variable. Small birds will sometimes take high doses with little sedation. Sometimes effective in cases of feather picking with prolonged treatment, but will also sometimes regress if the drug is stopped. <u>Associated with anorexia, severe depression, and macaw deaths. Also not recommended for use in cockatoos.</u></p>
<p><i>Doxapram hydrochloride</i> Dopram-V (Willows Francis)</p>	<p>Oral drops and injection Multidose phials containing 20 mg/ml doxapram hydrochloride</p>	<p>oral i.m., i.v.</p>	<p>One drop in a small bird's mouth 20 mg/kg – most species (respiratory depression) 5–10 mg/kg – raptors (respiratory depression)</p>	<p>Respiratory stimulant when apnoea occurs. To stimulate breathing in newly hatched chicks. Use once. Neurotoxic with excessive dosage.</p>
<p><i>Sodium calcium edetate BVC</i> (Vet Drug) Ledclair (Sinclair)</p>	<p>A sterile solution containing 25% w/v 250 mg/ml Contains 200 mg/ml</p>	<p>i.v., i.m., s.c.</p>	<p>62.5 mg (0.25 ml)/kg for swans q 24 hr (Cooke 1984) Also 20–40 mg/kg q 8 hr May be able to increase dose to 80–100 mg/kg for smaller birds</p>	<p>For lead and other heavy metal poisonings. <i>If given i.v. must give slowly.</i> Injection s.c. may cause some slight reaction. Can be nephrotoxic if bird is dehydrated or there are signs of polydipsia/polyuria. May need to give for prolonged periods of up to 6 weeks.</p>
<p><i>Dimercaprol BP</i> (non-proprietary) Bal (British Anti Lewisite)</p>	<p>2 ml ampoules 50 mg/ml in arachis oil</p>	<p>oral i.m.</p>	<p>25–35 mg/kg q 12 hr × 5 days per week, rest 2 days and recommence for 3–5 weeks</p>	<p>May be more effective as a chelating agent than EDTA, also less toxic. Can be used together with EDTA.</p>

## APPENDIX 2 BACTERIAL DISEASES OF BIRDS

It is important to note that a number of these diseases are **zoonotic** and that the symptoms of many of them in humans are identical to those of flu and may not appear until several weeks after exposure. These diseases have been marked as zoonoses in the tables that follow. Anyone who has contact with birds and subsequently becomes ill should consider zoonotic infection as a possibility.

NB: In Appendices 2–7 all infectious diseases are numbered and prefixed by a letter, B for Bacterial, M for Mycological, P for Parasitic, V for Viral, etc. This is to make cross-reference easier.

A useful website for general information covering all aspects of infectious disease is <http://pathmicro.med.sc.edu/mayer>.

Table 2.1 does not necessarily include all the diseases affecting poultry.

### Enterobacteriaceae

These bacteria are mostly Gram– rods. Pathological strains all produce endotoxins and most can cause septicaemia.

In many infectious diseases of birds, both bacterial and viral, the clinical signs are not pathognomonic and the disease can only be diagnosed on post-mortem and subsequent laboratory examination. In the case of viruses, infection may have occurred some considerable time previously (months) although damaged cells and immune responses may remain impaired after this primary infection so that the bird is open to secondary infection, however the initiating virus may have disappeared from the body systems before other pathogens such as *Staphylococcus*, *Streptococcus*, *Proteus*, *Pseudomonas* and *Corynebacterium* spp act as secondary invaders *but are not always the prime cause of disease*. When making a diagnosis please refer to the relevant organ system in Chapter 5.

### Mycoplasmas

These organisms are now considered to be bacteria that lack a typical cell wall and which also have small genomes. It is believed that they are phylogenetic descendents of the *Lactobacillus–Clostridium* type bacteria which lost their cell walls. They may be saprophytic, commensals or pathogenic parasites of the mucus membranes of respiratory and genital tract of many vertebrates but also infect insect and plant species. Approximately half the genus *Mycoplasma* is limited to a specific host with some animal hosts harbouring both commensal and parasitic forms. In most cases, cholesterol is required from their animal host for the growth and stability of their cytoplasmic membranes. These organisms are not stable in the environment and are susceptible to most antiseptics, but are not affected by those antibiotics which disrupt cell wall development of normal bacteria. There are over 100 species of *Mycoplasma*, only a few of which are listed as causing disease. No doubt in time many more pathogenic species will be discovered.

### Rickettsial infections

Because these organisms are small, obligate, intracytoplasmic parasites they were once classed with the viruses, but all are now known to be true bacteria that stain like Gram– bacteria. Also, these life forms are able to make the metabolites necessary for growth and have an ATP transport system (except *Chlamydomphila*) which can therefore make use of the host's ATP, so starving the host cell.

**Appendix Table 2.1** Bacterial causes of disease.

Disease	No.	Cause	Susceptible Species	Relative Occurrence	Principal Clinical Signs	Confirmation of Diagnosis	Differential Diagnosis
<b>Salmonellosis</b> An important carrier companion and wild birds A notifiable disease in the UK. Public health hazard.	B1	Over 2000 species of <i>Salmonella</i> Most common <i>S. typhimurium</i> . Carried by rodents, insects, water, wild birds. Most strains motile under right conditions. Propagate outside host. Egg transmission from day old infected chicks.	All avian species often infected and act as carriers, particularly when in winter flocks. Species without caeca apparently more susceptible.	Common except in raptors. Human carriers can infect companion birds. Imported parrots held in quarantine stations may carry unusual strains.	Non-specific signs of illness and diarrhoea. Sudden death or subacute septicæmic disease with enteritis. Also chronic disease. Post-mortem (PM) signs depend on stage of death at which death occurred. White focal necrosis, caseous impaction of caeca, localised necrosis of the intestine. In pigeons and some parrots often localises in the joints, producing arthrosynovitis. Also localised dermatitis in some parrots.	Isolation and culture of the organism. Serology. Agglutination on tests.	<i>E. coli</i> (B3) and other enteric pathogens: <i>Chlamylophila</i> (B26), <i>Pasteurella</i> spp (B12, B13), <i>Pseudomonas</i> spp (B4), <i>Campylobacter</i> (B6).
<b>Avian typhoid</b> ( <i>Pullorum</i> disease)	B2	<i>Salmonella gallinarum</i> , <i>Salmonella pullorum</i> Carrier birds.	Mainly diseases of poultry but can affect gamebirds and sometimes other birds, including wild birds.	Common in unsanitary conditions.	General malaise, anorexia enteritis. In chronic form drop in egg production. At PM in <i>S. pullorum</i> infection disease localised in the ovary with misshapen ova. PM of <i>S. gallinarum</i> cases shows septicaemic signs with enlarged liver and spleen.	Rapid slide agglutination test for <i>S. pullorum</i> . Otherwise as for other <i>Salmonella</i> spp.	

(Continued)

Appendix Table 2.1 Continued.

Disease	No.	Cause	Susceptible Species	Relative Occurrence	Principal Clinical Signs	Confirmation of Diagnosis	Differential Diagnosis
<b>Colibacillosis</b> <b>Serious zoonotic</b> disease caused by some toxic strains, e.g. 0157	B3	<i>Escherichia coli</i> Genus contains many species some motile, some non- motile. Primary or secondary invader.	All species	Very common. Hjarré's disease, or coligranulomatosis, is most common in Galliformes.	Often an acute septicaemic disease with no premonitory signs. In subacute or chronic form, dullness, anorexia, stunted growth, brownish diarrhoea. PM shows air- sacculitis, fibrinous pericarditis with ecchymosis and perihepatitis with enlarged liver. There may be hepatic granulomas. Enlarged necrotic spleen, caseous peritonitis. Organism often found in salpingitis and bumblefoot infections.	Isolation of the organism by culture from infected tissue. Serotyping is academic. Histology indicates serofibrinous inflammation with plasma cells in liver and kidney.	<i>Mycobacterium avium</i> infection (B17).
<b>Pseudomonas</b> <b>aeruginosa</b> and <b>Aeromonas</b> <b>hydrophila</b>	B4	Both common avian pathogens, also both types of organism can propagate in cool water, particularly if contaminated by organic waste. Also contaminated food.	All species of bird but particularly aquatic birds, free-ranging waterfowl.	Widespread. These organisms are usually pathogens producing potent extracellular toxins.	Although <i>Pseudomonas</i> and <i>Aeromonas</i> are unrelated, infection with either can produce similar signs: (1) Localised upper respiratory tract infection, dyspnoea, diarrhoea. (2) Septicaemia → death. PM: widespread haemorrhages, necrosis of the liver, spleen and kidney together with enteritis, either catarrhal or haemorrhagic.	Both Gram- rods. Cultural isolation from diseased tissue and possibly contaminated food or water supply.	Other pathogens causing enteritis with respiratory signs. Possibly <i>Salmonella</i> (B1) Avian cholera (B12).

<p><b><i>Alcaligenes faecalis</i>,</b> <b><i>Bordetella avium</i></b> and <b><i>B. bronchiseptica</i></b></p>	<p>B5 Both organisms are shed in faeces. Infection in both cases by ingestion of these organisms.</p>	<p>Many species of bird susceptible, particularly psittacines, turkeys and many species of finch.</p>	<p>Both widespread in the environment, <i>Alcaligenes</i> particularly in water.</p>	<p>Both organisms cause upper respiratory tract infection, often as secondary invaders after other primary bacterial or viral infections. <i>Alcaligenes</i> may also produce necrotic lesions in the liver.</p>	<p>Isolation and culture of the causative specific organism.</p>	<p>Other pathogens causing similar ante- and post-mortem signs plus necrotic liver lesions. <i>Pasteurella</i> (B12).</p>
<p><b><i>Campylobacter</i> spp</b> Several species and many serovars of varying pathogenicity (Note: <i>C. jejuni</i> often confused with <i>Vibrio</i> spp). An important <b>Zoonosis</b></p>	<p>B6 Pathogenic strains of <i>C. jejuni</i> in faeces. Dogs may act as carriers and possibly also other mammals. Both domesticated and also wild birds. Birds may be the natural reservoir for these pathogens. Ingestion of animal and human sewage. Contaminated food (milk in bottles with pecked tops) or water.</p>	<p>Probably all species, but particularly Galliformes, gulls, crows, waders, waterfowl, some tropical finches and canaries and ostriches.</p>	<p>Fairly widespread. Not very stable in the environment. Can be a serious problem in young ostriches which pass typical green urine.</p>	<p>May act as a secondary invader to other enteric pathogens. Lethargy, marked weight loss, anorexia, diarrhoea (often yellow faeces), subacute → chronic hepatitis → death (mortality high in nesting canaries. PM often enlarged focal necrotic liver with prominent liver lobules, mucoid haemorrhagic enteritis. Many birds die of chronic liver damage.</p>	<p>Culture from affected tissues and faeces. Must use transport medium for swabs.</p>	<p>Other organisms causing hepatitis together with enteritis. Consider <i>Salmonella</i> (B1).</p>
<p><b><i>Klebsiella pneumoniae</i></b> and <b><i>K. oxytoca</i></b></p>	<p>B7 Non-motile Enterobacteriaceae often encapsulated so survives well in the environment and resistant to many older types of disinfectants.</p>	<p>Pigeon, finches, waterfowl, raptors, parrots. May be transmitted to humans. <i>K. oxytoca</i> possibly carried by herbivores.</p>	<p>Often primary pathogens particularly in some finches. Often isolated as a local infection of upper respiratory and alimentary tracts.</p>	<p>Non-specific sick bird → septicæmia. Polydipsia/polyuria due to renal failure. Chronic respiratory signs.</p>	<p>Isolation and culture of the causal organism.</p>	<p>Other pathogens causing respiratory signs with polydipsia/polyuria. See DD for <i>Salmonella</i> (B1).</p>

(Continued)

Appendix Table 2.1 Continued.

Disease	No.	Cause	Susceptible Species	Relative Occurrence	Principal Clinical Signs	Confirmation of Diagnosis	Differential Diagnosis
<b>Enterococcus faecalis</b> (formerly <i>Streptococcus faecalis</i> )	B8	<i>Enterococcus faecalis</i> Opportunistic pathogen triggered by immunosuppression and other debilitating factors. <i>Citrobacter</i> spp can cause secondary infection in some birds.	Probably most species.	Thought to be part of the autochthonous flora of avian skin, and all mucous membranes.	(1) Acute posthatching septicaemia as a result of infection through the yolk sac. (2) <i>Respiratory infection</i> of all species, especially Passeriformes, and particularly canaries. Dyspnoea, rales (due to chronic tracheitis which sounds like a catch in the throat), loss of normal voice.	Culture and isolation. Although not strictly belonging to the Enterobacteriaceae, since they are Gram+, they grow on selective culture media for Enterobacteriaceae.	Air sac mites (P45) and tracheal mites which often cause the same signs in Gouldian finches; Borreliosis (B9), <i>Haemophilus</i> (B22), Cryptosporidiosis (P6).
<b>Spirochaetaceae</b> <b>Borreliosis</b> Non-classified spirochaetes	B9	Biting arthropods, principally ticks, act as vectors for: <i>Borrelia anserinae</i> , <i>Spirochaeta gallinarum</i>	Waterfowl, Galliformes, pigeons, Corvidae, sparrows and starlings, African grey parrots, raptors.	May be fairly common where the incidence of ticks is high. Tick bites can cause subcutaneous haemorrhage and oedema for 2–3 cm which may easily be missed at PM. Tick saliva may be toxic. Not common.	Young chicks particularly susceptible. Signs 4–8 days post infection. Acute bacteraemia → fever, anorexia, depression, cyan-blue congested heads. Yellow diarrhoea, ataxia → paralysis. High morbidity. Mortality up to 100%. Chronic anaemia, dyspnoea, paralysis. PM: Hepatomegaly with haemorrhage and necrotic foci.	Culture of the organism difficult. Stain blood smears with Giemsa. Gram-helical organism. Agglutination, immunofluorescence can be used.	<i>E. faecalis</i> (B8), spiral bacteria (B10).
<b>Motile spiral bacteria</b> Can be an important Zoonosis in immunodeficient persons (Wade <i>et al.</i> , 2003)	B10	<i>Helicobacter cinaedi</i> and <i>Flexispira rappini</i>	Only documented so far in cockatiels and lovebirds. Occurs in wild birds and poultry.	Very common in young. Occurs in the upper respiratory tract. Found in intestines.	Signs of upper respiratory disease. Head shaking, oral pain, peri-orbital oedema, depression, anorexia, fluffed up, dry skin.	Examine wet smear. Use Diff-Quik stain. Responds to doxycycline.	<i>Alcaligenes</i> and <i>Bordetella</i> (B5), <i>Enterococcus</i> (B8), <i>Borreliosis</i> (B9), <i>Haemophilus</i> (B22).



<b>Pseudotuberculosis</b>	B11	<p><i>Yersinia pseudotuberculosis</i> Formerly called <i>Pasteurella pseudotuberculosis</i>. Can replicate outside host at very low temperatures if organic nitrogen available. Motile at high temperatures. Organism carried by rodents and wild birds which contaminate food supplies. Soil invertebrates including molluscs act as mechanical vectors.</p>	<p>All species. Wild birds, particularly those forming large flocks in winter. Birds that inhabit sewage farms. Captive birds in open-topped aviaries. Falcoliformes of rare occurrence. Toucans, barbets, toucacos all very susceptible.</p>	<p>Not uncommon, particularly at the end of a severe winter.</p>	<p>Non-specific clinical signs in the live bird. Can be peracute in all ages of bird. At PM in the acute case the liver and spleen are enlarged. In the chronic condition there are yellowish white miliary necrotic foci on the liver, spleen and pectoral muscles. There may be severe enteritis.</p>	<p>Bacterial isolation by culture. May take up to 2 weeks to grow. May need to store culture in fridge first. Negative acid fast organisms on Ziehl-Neelsen stained smear to differentiate from tuberculosis.</p>	<p>Tuberculosis (B17), subacute avian cholera (B12), <i>E. coli</i> (B3). All 3 diseases can produce similar miliary abscesses in the liver.</p>
---------------------------	-----	---	---	--	---	---	--

<b>Avian cholera</b>	B12	<p><i>Pasteurella multocida</i>, <i>Pasteurella gallinarum</i> Organisms can survive and propagate in the environment in suitable conditions, e.g. large volumes of water. Large numbers excreted in droppings and nasal discharge. Infection from blood-sucking arthropods acting as mechanical vectors. Birds bitten by cats often develop <i>Pasteurella</i> infection and die in 12–24 hours.</p>	<p>Most species: wild passerines, owls, diurnal raptors, Anseriformes. Large flocks of wild ducks normally on large areas of water may be concentrated by agricultural developments onto small ponds or lakes and may suffer high losses.</p>	<p>Can cause epidemics in aviaries.  Sporadic epidemics. Occasional.</p>	<p>A highly infectious and virulent disease, often causing sudden death. Dyspnoea, mucoid oral and nasal discharge, diarrhoea.  PM: septicæmic changes with multiple petechiae. In chronic cases, white serositis and necrotic foci in viscera. In raptors and pigeons – granulomatous dermatitis.</p>	<p>Stained smear of liver imprints, Giemsa, Leishman's or methylene blue show bipolar stained rounded end rods.  Culture and animal inoculation. Serological tests.</p>	<p><i>E. coli</i>, septicæmia (B3), Pseudotuberculosis (Yersiniosis) (B11), <i>Erysipelas</i> (B15). Also other pathogens causing respiratory or septicæmic signs.</p>
----------------------	-----	---	---	--	--	---	--

(Continued)

Appendix Table 2.1 Continued.

Disease	No.	Cause	Susceptible Species	Relative Occurrence	Principal Clinical Signs	Confirmation of Diagnosis	Differential Diagnosis
<b>New duck disease</b>	B13	<i>Cytophaga anatispestifer</i> (formerly <i>Pasteurella anatispestifer</i> ) Probably from the egg and via respiratory route.	A specific infection of ducklings. Other species of poultry, waterfowl and parrots.	Not uncommon Rarely	Ocular discharge, diarrhoea. CNS signs. Often just found dead. 75% mortality. Survivors stunted. PM: congestion of lungs, enlarged liver and spleen. Fibrinous membranes on the viscera. Pericarditis and perihepatitis. Inspissated caseation in the air sacs.	Stained smear from lesions shows Gram-pleomorphic rods, often in long filaments. Bacterial culture and isolation of the organism. ELISA.	Duck plague, viral enteritis, duck viral hepatitis (V39), coccidiosis and as above for <i>P. multocida</i> (B12).
<b>Actinobacillosis</b>	B14	<i>Actinobacillus</i> Transmission by the egg.	Many species.	Not uncommon.	Acute death → chronic cases with joint lesions. PM: necrotic liver, salpingitis, peritonitis and fibrinous arthritis.	Isolation by culture. Stained smear shows polymorphic rods with bipolar staining as for <i>Pasteurella</i> .	<i>E. coli</i> (B3), New duck disease (B13), other bacterial infections.
<b>Erysipelas</b>	B15	<i>Erysipelothrix rhusiopathiae</i> Can propagate outside host in environment even in sea water and reservoirs. Carried by rodents, pigs.	All species, but most common in waterfowl and fish-eating birds. Pigeons. Occasionally parrots.	Only occasionally seen, but can cause epidemics in avaries, particularly in winter.	Usually acute death. Dullness inappetence. Loose droppings. Septicaemic in a subacute form. Conjunctivitis may be seen in budgerigars. May see bruising of non-pigmented skin. PM: widespread petechiae.	Stained smear shows a Gram+ pleomorphic, slender, rod-like bacterium, which is sometimes beaded. Culture liver and spleen or bone marrow if carcass is autolytic.	As for avian cholera (B12).
<b>Zoonosis</b>							

<b>Listeriosis Zoonosis</b>	B16	<i>Listeria monocytogenes</i> Can survive in environment and propagate outside host. Non-pathogenic species of <i>Listeria</i> do occur.	Many species. Canaries may be most susceptible.	Rare, tends to be localised.	Often a peracute septicaemia, occasionally there are opisthotonos and other CNS signs. Sometimes produces a wasting disease. Often sporadic deaths in a group of birds. PM: there may be no gross lesions even in brain.	CNS signs may be caused by a variety of bacterial infections, e.g. <i>E. coli</i> (B3), <i>Salmonella</i> (B1), secondary <i>Staphylococcus</i> infection, <i>Klebsiella</i> (B7). Trauma.
<b>Avian tuberculosis Potential zoonotic disease</b> , particularly for immunosuppressed humans. Treatment of avian patients not recommended.	B17	<i>Mycobacterium avium</i> A number of subspecies and serovars. Shed in faeces and urine. Remains in soil and water. Very resistant. Can remain up to 7 years in environment. Usual route of infection is oral.	All species. Wild birds, particularly starlings, sparrows, woodpigeons. Ostriches, Raptors, Anseriformes. White winged wood duck ( <i>Cairina scutulata</i> ) much more susceptible – has little natural immunity. Parrots have contracted disease from human contacts.	Chronic problem in farms Not uncommon Common in all birds living in aquatic environments.  Not common nowadays.	Adults often maintain appetite. Debility, emaciation and diarrhoea. Anaemia. PM: tubercles can be found on and in any of the viscera, particularly the liver, which may be studded with foci. Raptors may show persistent ulcerated and thickened skin on thigh or shank and arthritis. Suspect any persistent ulceration or granuloma of the head. Not all species of birds form tuberculous granulomas.	Pseudotuberculosis (yersiniosis) (B11). Possibly confused with salmonellosis (B1) or <i>E. coli</i> (B3) at PM.
<b>Anthrax Zoonosis</b>	B18	<i>Bacillus anthracis</i> Vultures and scavenging raptors may act as mechanical vectors.	Probably all species susceptible except carrion feeders, e.g. vultures, also possibly some kites and the large corvids.	In most species very rare. Usually in zoos, possibly from mammalian contacts. Occurs in ostriches.	No clinical signs. Sudden death. Enlarged liver, spleen and kidneys. Haemorrhages throughout carcass.	Stained smear with methylene blue shows typical rod-shaped bacilli.

(Continued)

Appendix Table 2.1 Continued.

Disease	No.	Cause	Susceptible Species	Relative Occurrence	Principal Clinical Signs	Confirmation of Diagnosis	Differential Diagnosis
<b>Botulism</b> ( <i>Limberneck</i> , <i>Western duck</i> <i>sickness</i> )	B19	<i>Clostridium botulinum</i> C toxin found in rotting carcasses and rotting vegetable and invertebrate matter. Maggots act as mechanical vectors.	Particularly Anseriformes. Also gulls and raptors feeding on carrion. Vultures are resistant to the toxin.	Not uncommon in hot, humid weather of late summer in Europe. Not uncommon in gulls in times of drought → shallow water.	A progressive flaccid paralysis of the neck, tongue, legs and wings. Greenish diarrhoea due to anaemia. No PM signs. Death due to respiratory failure or drowning.	Mouse protection inoculation test using specific antitoxin. Sample liver and kidney, also food or water or mud/sewage. <i>Deep freeze all samples.</i>	Lead poisoning. Poisoning with chlorinated hydrocarbons. Newcastle disease (V25). In raptors, hypocalcaemia. Listeriosis (B16). Also during hot, dry, late summer, blue-green or red algal toxin. Also <i>Pseudomonas</i> (B4), <i>Aeromonas hydrophila</i> (B4).
<b>Clostridial enterotoxaemia</b> (other than that caused by <i>Clostridium botulinum</i> )	B20	<i>C. perfringens</i> An opportunistic pathogen. Ingestion of organism from contaminated food together with: (1) Reduced gut motility (2) Change of diet (3) Food items inhibiting trypsin production, e.g. peas, cereals, lentils, some beans (4) Diets with high sugar levels.	Gamebirds (grouse, quail), Galliformes, both captive and free-ranging, pigeons, lorikeets, ostriches.	Widespread. A not uncommon disease in ostriches of all ages.	Acute form in young birds. Diarrhoea possibly sanguineous. Polydipsia → death in a few hours. Chronic in older birds. Weight loss → death. Ulcerative necrotic enteritis of upper intestine. May be swelling and necrosis of liver and spleen. Often ulcerative gastritis in ostriches.	Gram smears from necrotic mucosa – short Gram+ rod. Spores if present central or subterminal, large and oval producing a 'safety-pin-like' image. Anaerobic culture. ELISA for alpha, beta and epsilon toxins. Culture and demonstration of toxin.	Newcastle disease virus (V25), <i>E. coli</i> (B2), <i>Salmonella</i> (B1) and other Enterobacteriaceae. Enteritis due to coccidiosis.

<b>Clostridial gangrenous dermatitis</b>	B21	<p><i>C. perfringens</i>, <i>C. septicum</i>, <i>C. novyi</i></p> <p>Triggering factors: damaged skin secondary to pox virus, trauma, <i>Staphylococci</i>, Immunosuppression.</p>	Probably all species but particularly birds attacked by cage mates or rivals.	Uncommon. Birds tend to be relatively resistant to wound infection.	Localised loss of feathers together with dark pigmentation of skin. May be oedematous. Death within 24 hours. PM: emphysema, oedema, haemorrhage beneath skin and in muscle including heart muscle.	Culture lesions.	Viral dermatitis of macaws and cockatoos (V18).
<b>Haemophilus</b>	B22	<p><i>H. paragallinarum</i>, <i>H. avium</i>, <i>H. paravia</i></p> <p>Contagious coryza.</p>	Chickens, pigeons, some parrot species, some Anseriformes, some Galliformes.	Not uncommon.	Mainly an upper respiratory disease causing coryza, rhinitis (serous), mucoid → fibrinous exudate. Conjunctivitis and sinusitis. Occasional pneumonic signs. Often a secondary invader after other pathogens (? viral infections).	Culture of organism, but positive culture often not the definitive cause.	Other pathogens causing respiratory signs: <i>Chlamydoiphila</i> (B26), <i>Pasteurella</i> (B12, B13), Enterobacteriaceae, <i>Pseudomonas</i> (B4), <i>Mycoplasma</i> (B25).
<b>Tularaemia (Lemming disease of Russia)</b> <b>Zoonotic</b> (producing a long feverish illness with possible ulceration of skin)	B23	<p><i>Francisella tularensis</i></p> <p>Rodents (lagomorphs and hares) act as a reservoir. Carried by ticks, fleas and mosquitoes.</p>	25 species of bird have been infected. Pheasants, diurnal and nocturnal raptors, ravens and other large corvids. Also cats, dogs, cattle and sheep.	Birds inhabiting northern and subarctic regions.	Birds usually found dead. PM signs as for <i>Pasteurella</i> or <i>Yersinia</i> .	Short, Gram- rod. Culture.	Anthrax (B18), actinobacillosis (B14).

Appendix Table 2.2 Mycoplasmas.

Disease	No.	Cause	Species Susceptible	Relative Occurrence	Principal Clinical Signs	Confirmation of Diagnosis	Differential Diagnosis
<b>Mycoplasmosis</b> No specific named disease of birds as in the case of cattle [bovine pleuropneumonia] or man [primary atypical pneumonia]	B25	<i>M. gallisepticum</i> A parasite of mucous membrane which may be a primary pathogen or a secondary invader. Vertical transmission is possible but unusual. Possibly as with all <i>Mycoplasma</i> species they are contained in excessive mucous secretions.	Apart from poultry (in which it can cause serious problems) many other Galliformes, such as pheasants and quail. Also house finches (Hartup and Kollias 1999). Waterfowl. Possibly many psittacines although these may be infected with more host-specific <i>Mycoplasma</i> spp	Almost certainly worldwide where birds are kept intensively crowded together. May be a commensal organism found on the tracheal mucosa of many wild birds.	These are not pathognomonic since infection often associated with other pathogens. Serous/serofibrinous conjunctivitis, blepharitis, rhinitis, coryza (swollen infraorbital sinuses), tracheitis, air sacculitis and focal bronchopneumonia. In poultry may affect joints causing lameness.	Histopathology on PM and endoscopic samples of air sacs, lungs and spleen. Lab tests include, primarily, PCR, immunobinding assay (IBA), ELISA supplemented with other tests carried out by a specialist laboratory for species identification. Other laboratory tests may be used but serological techniques are not very helpful.	<i>Chlamydophila</i> (B26). Other upper respiratory infections. Possibly Trichomoniasis (P14) and <i>Haemophilus</i> (B22).
		<i>M. gallinarum</i> , <i>M. pullorum</i> <i>M. gallinaceum</i> <i>M. iowa</i> <i>M. meleagridis</i>	All these species primarily infect poultry and other Galliformes.	As above	As above	As above	As above
		<i>M. lipofaciens</i>	Turkeys, falcons (Lierz <i>et al.</i> 2002) Chickens, turkeys, ducks, raptors, and probably other avian species. A high percentage of nestlings of free ranging raptorial species normally infected with these and other <i>Mycoplasma</i> spp. (Lierz 2005)	As above	As above	As above	As above
		<i>M. falconis</i> <i>M. gypis</i> (Eurasian griffon vulture) <i>M. buteonis</i> (Eurasian buzzard) <i>M. columbinasale</i> <i>M. columborale</i>	Falconidae (Lierz <i>et al.</i> 2000a, 2002) Pigeons	As above	As above	As above	As above

**Appendix Table 2.3** Rickettsias.

Disease	No.	Cause	Species Susceptible	Relative Occurrence	Principal Clinical Signs	Confirmation of Diagnosis	Differential Diagnosis
<b>Ornithosis, psittacosis, chlamydophilosis</b> Important zoonotic disease	B26	Various strains of <i>Chlamydophila</i> Rickettsia-like DNA/RNA analysis shows they are not true Rickettsial organisms since they are unable to make their own ATP and so are energy parasites.	All species, particularly psittacines. Anseriformes, Columbiformes. Also in owls and raptors. Besides humans infect a wide range of mammals, reptiles and amphibians. Because of rigid outer cell membrane very environmentally resistant.	Not uncommon  Common	Unthriftiness. Ocular and nasal discharge, dyspnoea, enteritis. These signs are not pathognomonic. PM: hepatomegaly, patchy faint necrosis. Mottled enlarged spleen, air-sacculitis, pericarditis, sometimes serosal haemorrhage. One cause 'one-eyed cold' in pigeons.	Impression smears from liver. Stain modified Ziehl-Neelsen or Macchiavello stain. Isolation by culture of the organism from faeces and tissues. Organism can be isolated from faeces of apparently healthy birds. PCR for <i>Chlamydophila</i> DNA carried out by Central Veterinary Laboratories.	Pacheco parrot virus (V2), Herpes virus of other species (V2-V20), Pox infection (V37), mycoplasmosis, trichomoniasis, often together with ornithosis. <i>Salmonellosis</i> (B1) Avian influenza (V38).
<b>Q-Fever Zoonosis</b>	B27	<i>Coxiella burnetii</i> Spores are very stable in the environment and persist in soil. Resist many disinfectants. Ticks main source of infection for animals but not humans (mainly oral route).	Over 50 species identified as being susceptible. Also infects many species of mammal.	Worldwide. Not uncommon in urban pigeons in Europe.	Infected chickens (which are the most susceptible species of bird) may shed the organism in faeces 7-40 days post infection.	Serology. Examine macrophages in stained blood smear.	

(Continued)

Appendix Table 2.3 Continued.

Disease	No.	Cause	Species Susceptible	Relative Occurrence	Principal Clinical Signs	Confirmation of Diagnosis	Differential Diagnosis
<b>Rocky Mountain Spotted Fever Zoonosis</b>	B28	<i>Rickettsia Rickettsii</i> , <i>Dermacentor</i> spp. Tick bites.	Chickens, pheasants, pigeons, Falconiformes and magpie documented but probably other species could be susceptible.		Clinical signs not recorded.		
<b><i>Aegyptianella</i></b>	B29	<i>A. pullorum</i> Tick ( <i>Argus</i> ) Bites.	Primarily Passeriformes, chickens. Also most other species of bird including ostrich.	Tropical and subtropical regions including Mediterranean.	Young birds: anaemia, anorexia, weakness, weight loss, diarrhoea → death. Older birds: chronic infection, possibly jaundiced. PM: anaemia and enlarged liver and spleen.	Small endocyttoplasmic inclusions in erythrocytes. Stain with Giemsa.	<i>Chlamydoiphila</i> (B26), Macrorhabdus ornithogaster, or <i>Megabacteria</i> (B24).
		Other unclassified rickettsias		Others seen in tracheal epithelium of Gouldian finches and probably more rickettsias yet to be discovered.			



### APPENDIX 3 VIRAL DISEASES OF BIRDS

It is important to note that a number of these diseases are **zoonotic** and that the symptoms of many of them in humans are identical to those of flu and may not appear until several weeks after exposure. These diseases have been marked as zoonoses in the tables that follow. Anyone who has contact with birds and subsequently becomes ill should consider zoonotic infection as a possibility.

Only the more important viruses found in avian tissues are listed and not those just found only in poultry. As PCR techniques are constantly and rapidly improving, many more viral pathogens are likely to be documented and existing viral species will be subdivided. For a more comprehensive description of avian viruses see Gerlach (1994) and Ritchie (1995). See also list of Further Reading.

#### **Herpesviridae**

The Herpesviridae are thought to be a well-established old group of viruses that often produce latent and persistent infections. They are enveloped, intranuclear, double-stranded DNA viruses and replicate in the nuclei of epithelial cells, nerve tissue and B- and T-lymphocytes. They are therefore probably partially immunosuppressive.

Appendix Table 3.1 The Herpesviridae.

Disease	No.	Cause	Species Susceptible	Relative Occurrence	Principal Clinical Signs	Confirmation of Diagnosis	Differential Diagnosis
<b>Psittacine herpes viruses</b> <i>Pacheco's parrot disease</i> 4 genotypes of psittacine herpes virus are now recognised: psittacine herpes 1 and 4 have similar serotypes and can give rise to papillomas of the bile duct → carcinoma; psittacine herpes 2 is newly discovered in African grey parrots.	V1	Herpes virus. Asymptomatic latent carriers. Disease probably flares up when bird stressed/in captivity.	All Psittacines, but Old World parrots seem to be more resistant. Conures may be asymptomatic carriers. In one isolated case, psittacine herpes was isolated from a Passeriforme species (Phalen <i>et al.</i> 2004).	Worldwide distribution. Very often not diagnosed. May be much more common than generally realised. Be aware of latent carrier birds newly introduced into a collection.	Often peracute; may be just found dead with no premonitory signs. Acute → infection, lethargy, anorexia, diarrhoea, bright-green biliverdin stained faeces and urates. Occasionally conjunctivitis and tremors → convulsions. PM: faintly mottled, swollen liver with saucer-shaped necrotic areas. Sometimes necrotic foci in swollen kidney and spleen. Some cases papilloma of bile duct.	Isolation of causal organism by culture in embryonated eggs. Antibody titres may produce false negatives. Virus identification with VN, ELISA and immunofluorescence.	<i>Chlamydoiphila</i> (B26) infection, bacterial hepatitis <i>Salmonella</i> (B1), paramyxoviruses (V25–V28), <i>Yersinia</i> (B11), <i>Campylobacter</i> (B6).
<b>Falcon inclusion body hepatitis</b>	V2	Herpes virus. Contaminated food or water or from infected pigeons.	The virus is specific for diurnal raptors, but experimentally can infect some owls, some pigeons and immature budgerigars.	Widespread in northern hemisphere.	Usually acute with severe depression and anorexia. A non-specific generalised disease. But the incubation period of 7–10 days is longer than for other herpes viruses. PM: focal diffuse necrosis of the enlarged liver and spleen. May show signs on the lungs and kidneys and lymph follicles of intestine.	Haematology shows leucopenia in all cases. The falcon, owl and pigeon herpes viruses are closely related serologically. The viruses can be isolated after cultivation in embryonated eggs.	It is possible there may be some cross infection between falcon, owl and pigeon herpes viruses. Avian tuberculosis (B17), Newcastle disease (V25), Trichomoniasis (P14), Candidiasis (M2), <i>Salmonella</i> (B1), <i>Listeria</i> (B16), Avipox (V37).

<p><b>Owl herpes virus</b> (<i>infectious hepatosplenitis</i>) (a separate hepatosplenitis virus may occur in falcons)</p>	<p>V3 Herpes virus. Contaminated food or water or infected pigeons.</p>	<p>Believed to occur only in the strigid owls (i.e. most owls). Not in tyonid owls (barn, bay and grass owls), which are in a separate taxonomic family, the Tytonidae.</p>	<p>May be more common than generally realised.</p>	<p>May be peracute with sudden death. Necrotic foci in the oropharynx may look like trichomoniasis, which can also be a secondary invader. Necrotic foci in liver, spleen, intestine and lungs.</p>	<p>Secondary infection with <i>Staphylococcus</i> spp., <i>Streptococcus</i> spp., <i>E. coli</i> (B3), <i>Pasteurella</i> (B12), <i>Mycoplasma</i> (B25).</p>
<p><b>Pigeon herpes virus (PHV 1)</b> <i>Infectious oesophagitis</i></p>	<p>V4 Herpes virus. Contaminated feed or water.</p>	<p>Specific for pigeons, but falcons might be susceptible by contact with infected pigeons. <i>Budgerigars</i> are also susceptible.</p>	<p>Periodic epizootics in some lofts. Squabs most at risk.</p>	<p>Up to 15% mortality. Mainly respiratory – dyspnoea, rhinitis, conjunctivitis. Sometimes CNS signs with tremors and ataxia → paralysis. PM: may show faint necrotic foci in liver and other viscera. Focal diphtheroid membrane in pharynx and larynx.</p>	<p>Histopathology shows intranuclear inclusion bodies from the areas of necrotic foci of liver and spleen.</p> <p>As for falcon and owl herpes viruses together with pigeon paramyxovirus PMV-1 (V26), Newcastle disease (V25).</p>

<p><b>Pigeon herpes virus (PHV 2)</b> <i>encephalomyelitis</i> <i>Contagious paralysis of pigeons</i></p>	<p>V5 Another pigeon herpes virus.</p>	<p>Pigeons</p>	<p>Progressive CNS signs. Circling, torticollis. Ataxia → paralysis. PM: signs similar to those for paramyxovirus.</p>	<p>A third pigeon herpes virus (PHV 3) may cause an inclusion body hepatitis similar to (V4) above.</p>	<p>(Continued)</p>
---	--	----------------	--	---	--------------------

Appendix Table 3.1 Continued.

Disease	No.	Cause	Species Susceptible	Relative Occurrence	Principal Clinical Signs	Confirmation of Diagnosis	Differential Diagnosis
<b>Crane herpes</b> <b>Ciconiidae herpes</b> <i>Stork herpes virus</i>	V6 V7	Two distinct, unrelated viruses. Latent viruses in captive birds.	Cranes (Gruidae). Storks (Ciconiidae), both black and white.	Worldwide	Usually acute. Apathy and diarrhoea. Both viruses cause swelling and lesions in the liver, spleen, kidney and intestine, i.e. military necrotic foci. Diphtheroid membranes in upper GI tract and throughout gut in cranes.		As above for the other herpes virus infections together with visceral coccidiosis in cranes (P1).
<b>Infectious laryngotracheitis (ILT)</b>	V8	Herpes virus of Galliformes.	Chickens, pheasants, peafowl. May also be another separate herpes viral strain affecting canaries.	Worldwide, but not common where routine vaccination is carried out.	<b>Acute:</b> respiratory signs with death in 2–3 days. <b>PM:</b> haemorrhagic tracheitis. <b>Subacute:</b> respiratory signs less severe, conjunctivitis, sinusitis. <b>Chronic:</b> cough only if stressed. <b>PM:</b> mucoid diphtheritic membranes on the upper respiratory tract with a cheesy necrosis.	Eosinophilic intranuclear inclusion bodies found in diseased tissue in the early stages. Growth of virus in chick embryo. Virus neutralization, immunofluorescence and ELISA tests.	Chronic Avipox (V35), avitaminosis A, Newcastle disease (V25), mycoplasmosis → infraorbital sinusitis, infectious coryza (B25), <i>Syngamus</i> (P31).

<b>Amazon tracheitis</b>	V8a	<p>Herpes virus, possible a mutant strain of ILT. Probably aerial transmission. May be latent carrier birds, with the infection becoming active through stress.</p>	<p>Amazon parrots. Possibly Bourkes's parrot.</p>	<p>Found to be more common in newly-imported birds.</p>	<p><i>Peracute:</i> death. <i>Chronic:</i> up to 9 months' duration. Pseudomembranous tracheitis with ocular, nasal and/or oral exudate. Chronic dyspnoea with râles and coughing. Death due to blocked trachea.</p>	<p>Swabs from oropharynx in transport medium. Isolation of causal organism in chicken embryo chorioallantois.</p>	<p>Avian influenza (V38), avitaminosis A, avipox (V37), Newcastle disease (V25), <i>Candida</i> (M2), trichomoniasis (P14)</p>
<b>Duck herpes</b> (Duck viral enteritis)	V9	<p>Herpes virus survives in pond water. Vertical transmission through the egg. Adverse climate acts as a trigger.</p>	<p>Ducks, geese, swans. Mallard fairly resistant. <i>Carriers shed virus for up to 5 years.</i></p>	<p>Worldwide. Sporadic outbreaks. Epizootics result in high concentrations of virus in the local environment.</p>	<p><i>Peracute:</i> often just found dead. Blood from orifices. <i>Acute:</i> polydipsia, photophobia, ocular and nasal exudate, paralysis of the phallus, inability to fly, neck extended, may drown. <i>PM:</i> haemorrhagic eruptive lesions of the GI mucosa. Diphtheritic oesophagitis, which is diagnostic.</p>	<p>Growth of the virus in chick embryo. VN test.</p>	<p>Bacterial septicaemia. Avian cholera (B12), erysipelas (B15), duck picorna virus. Virus hepatitis (V39), (V40). Influenza virus (V38), botulism (B19).</p>
<b>Marek's disease</b>	V10	<p>Herpes virus living in cells of feather follicle. Remains in feather debris for a long time. Direct and indirect transmission.</p>	<p>Common in gallinaceous birds also in swans and ducks. Occurs in domestic fowl in birds as young as 6 weeks. Pigeons, possibly canaries, toucans. Has been reported in some wild birds. Not confirmed in raptors.</p>	<p>Worldwide. Prior to vaccination, very common in domestic poultry. Rare and sporadic in other birds.</p>	<p>Progressive paresis and paralysis leading to emaciation. <i>PM:</i> lymphoid infiltration → tumours of viscera, thickening of the peripheral nerves. Tumours in skin, eyes and muscle.</p>	<p>Clinical signs combined with PM picture.</p>	<p>Avian leucosis (V21). Riboflavin deficiency (causes thickening of the nerves in young chicks). Rare in raptors but consider 'Goshawk cramps' (Cooper 1978).</p>

Appendix Table 3.2 Other less important and well-known herpes viruses.

Disease	No.	Cause	Species Susceptible	Relative Occurrence	Principal Clinical Signs	Confirmation of Diagnosis	Differential Diagnosis
<b>Budgerigar herpes virus</b>	V11	Herpes virus transmitted in feathers, shed in droppings.	Budgerigars, double yellow headed Amazons, pigeons.		Acute in some flocks, 3–5 days after initial case. Reduced hatchability. Often associated with <i>feather duster syndrome</i> , which is a genetic problem (see Plate 21).	Isolation of virus in cell culture from feathers, blood, faeces, viscera. VN or ID tests.	
<b>Lovebird herpes virus</b>	V12	Herpes virus	Lovebirds (Agapornis spp)				
<b>American bald eagle herpes virus</b>	V13	Herpes virus	Bald eagle ( <i>Haliaeetus leucocephalus</i> ), possibly other eagles particularly same genus.	Only two cases recorded.			
<b>Lake Victoria cormorant virus</b>	V14	Herpes virus	Little pied cormorant ( <i>Phalacrocorax melanoleucos</i> )	One isolate.			
<b>Bob white quail herpes virus</b>	V15	<i>Colinus</i> herpes virus	Bob white quail	Probably only occurs in North America.	Necrotic hepatitis.		
<b>Turkey herpes virus</b>	V16	Herpes virus	Turkeys, chickens.		Asymptomatic in turkeys.		

<p><b>Gouldian finch herpes virus</b></p>	<p>V17</p>	<p>Herpes virus</p> <p>Some other finches and some small Passeriformes.</p>	<p>Apathy → dyspnoea. Eyelids swollen and sealed with exudate → death. PM: fibrinous thickening of air sacs. Apparently has a predilection for epithelial tissue.</p>
<p><b>Cytomegalovirus</b> <b>Zoonosis</b> particularly important in immunosuppressed humans, in which it is a common cause of morbidity and mortality.</p>	<p>V18</p>	<p>Herpes virus</p> <p>A common latent infection in non-human primates. Immunosuppressive virus cytotoxic to T-lymphocytes.</p>	<p>Possibly more widespread than recognised to date.</p> <p>Mostly seen in Australian and African finches. Can severely affect Gouldian finches.</p> <p>Acute illness – 100% mortality. Both adults and nestlings. Dyspnoea. Severe conjunctivitis with crusty closed eyes. Birds can't see food and water and die of starvation (P. Coutteel, personal communication).</p> <p>Basophilic intranuclear inclusions in conjunctiva. PCR test.</p> <p><i>Chlamydoiphila</i> (B26).</p>
<p><b>Localised dermal viral disease</b></p>	<p>V19</p>	<p>Herpes virus plus possible immunosuppression</p> <p>Cockatoos, macaws.</p>	<p>Causes wart-like lesions on the feet, but birds otherwise normal.</p> <p>Electron microscopy.</p> <p>Clostridial dermatitis (B21).</p>
<p><b>Conure papilloma virus</b></p>	<p>V20</p>	<p>Herpes virus</p> <p>Conures</p>	<p>Causes wart-like lesions on the feet, but birds otherwise normal.</p> <p>Cloacal papilloma.</p> <p>One case demonstrated.</p> <p>Benign papilloma virus (V60).</p>

### Retroviridae

These are non-enveloped, single-stranded RNA viruses.

Appendix Table 3.3 Retroviridae.

Disease	No.	Cause	Species Susceptible	Relative Occurrence	Principal Clinical Signs	Confirmation of Diagnosis	Differential Diagnosis
<b>Avian sarcoma/leucosis complex</b>	V21	A number of RNA viruses of the leucosis/sarcoma group which may be species specific. Vertical and horizontal transmission occur.	All species, but mostly domestic poultry and other Galliformes. Birds over 14 weeks old.	Rare, sporadic. Incubation period may be months.	Viruses can induce a whole range of neoplasms, including leucosis. Tumours particularly of the liver ( <i>Big liver disease</i> ) but also of the kidney, spleen, skin and other organs as well as long bones.	PM: macroscopic lesions. Usually multiple. Isolation of virus. Samples should be frozen.	Marek's disease (V10) Marek's usually in birds 6–24 weeks old. With other types of neoplasm the tumours are usually single.
<b>Haemorrhagic conure syndrome</b>	V22	Ill-defined viral cause, possibly a retrovirus that may be related to sarcoma/leucosis virus	Many species of conure (Genus <i>Aratinga</i> ).		Periodic bleeding from nasal passages, dyspnoea, weakness, diarrhoea. PCV ↓ 50%. Marked heterophilia, polychromasia and anisocytosis. Rubricytes in blood. Erythraemic myelosis of bone marrow. Hypocalcaemia may trigger disease. PM: multiple haemorrhages, particularly in lungs.		



<p><b>Reticuloendotheliosis virus</b></p>	<p>V23 These viruses are oncogenic. Virus shed in faeces. Transmitted by biting insects. Immunosuppressive, both B- and T-lymphocytes affected.</p>	<p>Turkeys</p>	<p>Mostly young birds.</p>	<p>Relatively long incubation. Diarrhoea, dilated liver, lameness. Mortality up to 60%. PM: grossly enlarged liver and multiple small tumours in parenchymatous organs, cloacal bursa, thymus and bone marrow.</p>	<p>Heparinised blood for virus isolation. Homogenate of tumour tissue. Consult laboratory on transport media, storage and package of sample. EUSA, IF or ID tests.</p>
		<p>Japanese quail</p>	<p>Young birds that have just reached sexual maturity.</p>	<p>Depression, anorexia, dyspnoea. Mortality up to 100%. Multiple small tumours, particularly along GI tract.</p>	
		<p>Pheasants and guinea fowl</p>		<p>Compact nodules in skin of head and oral mucosa. Caseous infra-orbital sinusitis. PM: small tumours in many viscera and skeletal muscle.</p>	
		<p>Ducks, both domestic and free ranging. Domestic geese</p>	<p>Disease in ducks in Australia</p>	<p>Non-specific signs. PM: similar to that in pheasants except no skin or head lesions. Mortality 40%.</p>	
<p><b>Infectious anaemia of ducks</b></p>	<p>V24 Reticuloendotheliosis virus. Transmitted by <i>Plasmodium</i> (avian malaria).</p>	<p>Ducks</p>	<p>Very rare.</p>		

## Paramyxoviridae

The Paramyxoviridae are enveloped, single-stranded RNA viruses found as both intranuclear and intracellular inclusions.

**Appendix Table 3.4** Paramyxoviridae.

Disease	No.	Cause	Species Susceptible	Relative Occurrence	Principal Clinical Signs	Confirmation of Diagnosis	Differential Diagnosis
<b>Newcastle disease</b> <i>A notifiable disease in the UK and many other countries</i>	V25	Paramyxovirus serotype group 1. Other serotypes 1–9. Infection orally, via respiratory tract.	All species – variable susceptibility; Galliformes – very susceptible.	Worldwide  Not uncommon	Respiratory signs with rhinitis and conjunctivitis; GI signs with greenish, watery diarrhoea. CNS signs → torticollis, opisthotonus, drooping of a wing, paralysis. PM: sometimes petechiae on viscera and green staining around the vent. Sometimes haemorrhagic necrotic enteritis.	Virus isolation and haemagglutination-inhibition test. Swabs from faeces, respiratory tract, in special transport medium and ice. PM: specimens for lab, trachea, lung, spleen, liver, brain.	Avian pox (V37), Laryngotracheitis (V8), falcon, crane, pigeon, owl, Ciconiidae herpes virus infections (V2–V7): B vitamin deficiencies. Listeriosis (B16), Paramyxovirus disease of pigeons (V26). <i>Chlamydoiphila</i> (B26), <i>Salmonella</i> (B1). Lead toxicity. Other infectious diseases of GI and respiratory tract.
A relatively mild <b>zoonotic</b> disease		Shed in faeces. Mechanical vectors. Reservoirs in many wild birds, which may carry a latent infection.	Anseriformes – not very susceptible. Raptors – not very susceptible.	Often latent infection  Rare. Often only show mild signs but can be severe			
		Passeriformes, Psittaciformes – variable susceptibility; Columbiformes – fairly resistant to serotype Group 1 Ostrich – moderately susceptible, 30% mortality.	Not very common  Typical Newcastle disease is rare.	Clinical signs vary with species of bird and virulence of different strains of virus. Severe conjunctivitis in humans.			

<p><b>Pigeon paramyxovirus (PPMV-1)</b> Notifiable disease in the UK</p>	<p>V26</p>	<p>A mutant strain of Newcastle disease (V25). Originated in Middle East c. 1980s. Carried by house sparrows, blackbirds, feral pigeons.</p>	<p>Mainly in pigeons, but also chickens, raptors, parrots, pheasants, peafowl and turacos.</p>	<p>Worldwide. Common if birds not vaccinated. Very common in wild/feral pigeons. Has infected kestrels (Harcourt-Brown, 1995).</p>	<p>Rather vague clinical signs which, when seen, are similar to those of Newcastle disease, with CNS signs (flaccid wings, torticollis, lameness and paralysis) often being seen before diarrhoea. However some cases have been seen with just loose droppings and loss of weight. Adults may recover in 3–4 weeks.</p>	<p>Haemagglutination inhibition test and virus isolation. Histopathology of brain but this may be negative.</p>	<p>Pigeon herpes virus (V4, V5), Newcastle disease (V25), Ornithosis/<i>Chlamydothila</i> (B26).</p>
<p><b>Paramyxovirus (PMV-2)</b></p>	<p>V27</p>	<p>Possibly carried by free ranging wild birds, especially Passeriformes, many of which are migratory.</p>	<p>Some Passeriformes (endemic). Galliformes, ducks, rails, homing pigeons.</p>	<p>Worldwide</p>	<p>Mostly a latent infection, sometimes a mild upper respiratory infection. These birds may just exhibit loose droppings with no CNS signs. PM: young birds may have persistently enlarged bursa. Quite a severe infection with signs of weakness, loss of weight and respiratory disease, death.</p>	<p>As for PMV-1</p>	<p>See above</p>
<p><b>Paramyxovirus (PMV-2)</b></p>		<p>Some birds of prey.</p>	<p>Especially African grey parrots.</p>				<p>(Continued)</p>

Appendix Table 3.4 Continued.

Disease	No.	Cause	Species Susceptible	Relative Occurrence	Principal Clinical Signs	Confirmation of Diagnosis	Differential Diagnosis
<b>Paramyxovirus (PMV-3)</b>	V28	Probably occurs normally in free ranging wild birds.	Galliformes, Australian finches.	Northern hemisphere	Conjunctivitis in finches, yellow diarrhoea, dyspnoea. Some die, some recover. CNS signs not usually seen in finches.	Histopathology of liver, kidneys. Haemorrhagic enteritis. Pancreatitis in parrots. Check for starch in droppings with iodine.	<i>Salmonella</i> (B1, B2), <i>Chlamydia</i> (B26). Mycotoxins from spoiled food. <i>E. coli</i> (B3). Avitaminosis E (van der Hege <i>et al.</i> , 1987). Psittacine adenovirus (V68). <i>Listeriosis</i> (B16).
			Psittaciformes, particularly <i>Neophema</i> spp, <i>Platycercus</i> spp.	Not uncommon	Parrots develop CNS signs like Newcastle disease, eye lesions and bloody nasal exudate, particularly. Torticollis.		
			Domestic pigeons		Yellow/white chalky stool containing a lot of starch and with increased appetite (Plate 2). Some birds emaciated → die. Mortality 30%.		

<p><b>Paramyxovirus (PMV-5)</b></p>	<p>V29</p>	<p>Kunitachi virus</p>	<p>Carried by free-ranging budgerigars and rainbow lorries.</p>	<p>Localised area of Australia.</p>	<p>Acute diarrhoea, dyspnoea, CNS signs → death. Mortality 50%. PM: congestion of parenchymatous organs, necrotic ulceration of mucosa of GI tract.</p>
<p><b>Paramyxovirus (PMV-7)</b></p>	<p>V30</p>		<p>Pigeons and doves.</p>	<p>USA and Japan.</p>	<p>No clinical signs.</p>
<p><b>Paramyxoviruses (PMV-4, -6, -8 and -9)</b></p>	<p>V31–V34</p>		<p>Waterfowl.</p>	<p>USA and Asia.</p>	<p>No clinical signs.</p>
<p><b>Twirling syndrome</b></p>	<p>V35</p>	<p>Suspected PMV virus.</p>	<p>Some imported old world finches.</p>	<p>Some torticollis and circling. Emaciation. Mortality 20%. Some birds remain disabled, others recover completely.</p>	

## Avipox viruses

The avipox viruses are enveloped, double-stranded DNA viruses, both intranuclear and intracytoplasmic. They are, unusually, very stable outside the host.

Appendix Table 3.5 Avian pox.

Disease	No.	Cause	Species Susceptible	Relative Occurrence	Principal Clinical Signs	Confirmation of Diagnosis	Differential Diagnosis
Avian pox	V37	Avian pox viruses. At least 17 distinct viruses identified. Mostly adapted to different families of bird so that some viruses are species specific. Crosta <i>et al.</i> (1995) recorded an outbreak confined to <i>Neophema</i> parakeets in a mixed collection. These viruses often transmitted by biting arthropod vectors such as mites, ticks, mosquitoes, which can retain viruses for up to 8 weeks. Virus excreted in saliva so can contaminate drinkers and human clothing.	Most species susceptible to a species-specific virus. Including ostrich, mortality 10–15% in young birds. The pigeon pox virus is more virulent for chickens than is the specific fowl pox virus for chickens.	Common in Passeriformes. More common in S. American parrots than Australian parrots. Uncommon in raptors and generally mild. Localised when mosquitoes about in late summer. Geographically important in the Middle East (see Plate 7).	<i>Acute:</i> septicaemia, sudden death. Usually in canaries. Due to pneumonia. <i>Subacute to chronic:</i> yellowish papules changing to brown appear on the skin of head and legs. <i>Dry:</i> usually in Passeriformes and raptors. Conjunctivitis, erythraemia, oedema, lachrymation, dysphagia because diphtheritic lesions appear in oropharynx. Bleeding if diphtheritic membranes removed. This often seen in parrots, pheasants, pigeons and starlings. Some pigeons and Passeriformes, which survive, subsequently develop wart-like neoplasms.	Histopathology. Bollinger bodies – intracytoplasmic inclusions seen in the epithelium of the skin, respiratory tract, oral cavity. Viral culture from faecal samples, ID or VN tests. Serology often not a lot of help.	Avitaminosis A. Pigeon herpes (infectious oesophagitis) (V4, V5), Newcastle disease (V25), laryngotracheitis (ILT) (V8), Amazon tracheitis (V8a). Trauma. <i>Trichophyton</i> (M5), <i>Cnemidocoptes</i> (P46), trichomoniasis (P47), candidiasis (M2), aspergillosis (M1).

**Orthomyxoviridae**

The orthomyxoviridae are enveloped, single-stranded RNA viruses. There are no intranuclear or intracytoplasmic inclusions. The virus can change its characteristics both by resortment of the genome and by antigenetic shift (simultaneous infection in a 'mixing' vector, e.g. pigs by two different influenza viruses).

**Appendix Table 3.6** Orthomyxoviridae.

Disease	No.	Cause	Species Susceptible	Relative Occurrence	Principal Clinical Signs	Confirmation of Diagnosis	Differential Diagnosis
<b>Avian influenza</b> ( <i>Fowl plague</i> , <i>Fowl pest</i> ) This is a <b>serious zoonotic</b> disease which may cause human pandemics.	V38	Avian influenza 'A' virus ('B' and 'C' viruses are usually human strains). A large number of serotypes (H1-16 combined with N1-9). Free living waterfowl (9.5% of wild ducks seropositive) are main reservoir of the virus. H1 N1 serotype caused 1918 Spanish flu pandemic (50 million human deaths). In 2006, the most serious threat is from the H5 N1 variant.	Potentially all species of bird, of which the young are more at risk than adults. Birds mainly. Domestic poultry, including chickens turkeys, ducks and geese. Also not uncommon in other water birds particularly gulls and rails. Many other species can be experimentally infected with H5 N1 variant. Virus also recovered from predatory and scavenging birds. Also infects cats (both domestic and wild), foxes, probably dogs, mustelids, civets, seal, horses and pigs.	Worldwide. Flares up from time to time, usually starting in eastern Asia. H5 N1 endemic in south China (Li <i>et al.</i> , 2004). Possibly spread by migratory birds. The evidence is equivocal, however many wild birds proven infected in the absence of poultry.	Highly variable. In the <i>low pathogenic form</i> : Mild respiratory signs, ↓ egg production and lassitude... In the <i>highly pathogenic form</i> : sudden death → massive die offs, CNS signs, severe decrease in egg production. PM signs variable: <i>low pathogenicity</i> → inflammation of respiratory and GI tracts; <i>High pathogenicity</i> → oedema and haemorrhages, skin, viscera and brain.	PM signs and sampling of selected tissues for cell culture and serology.	For poultry Newcastle disease, fowl cholera. For other birds ornithosis/ <i>Chlamydophila</i> B26) and <i>Mycoplasma</i> (B25)

## Picornaviridae

The Picornaviridae are non-enveloped, single-stranded RNA viruses. Intracytoplasmic inclusions are seen in cockatoos.

Appendix Table 3.7 Picornaviridae.

Disease	No.	Cause	Species Susceptible	Relative Occurrence	Principal Clinical Signs	Confirmation of Diagnosis	Differential Diagnosis
<b>Duck virus hepatitis Type I</b>	V39	A picorna virus spread in faeces. Rats may act as a mechanical vector.	Ducklings from 2 weeks of age. Mallards may be infected but are not susceptible to the disease. May attack exotic duck species in zoos.	Not uncommon. Worldwide.	<i>Peracute</i> : sudden death within hours. Maybe first sluggishness followed by CNS signs, e.g. opisthotonos. PM: liver enlarged and shows signs of petechial haemorrhages. Mortality may be 100%.	Inoculation of embryonated chicken eggs and serology.	Often secondary to infection with <i>Salmonella</i> (B1), <i>Chlamydia</i> (B2b), duck virus enteritis (V9), bacterial septicaemia, coccidiosis (P1) or mycotoxicosis.
<b>Duck virus hepatitis Type III</b> (for Type II see V43 below)	V40	A picorna virus as above for V39	Only mallards and domestic ducks.	Only seen in USA.	Mortality up to 30%.	As above for V39.	As above for V39. Note that duck virus hepatitis Type II (V43) is caused by an astrovirus.
<b>Specific avian encephalomyelitis</b>	V41	A picorna virus. Vertical transmission. Latent carriers.	Mainly a poultry disease but can also affect pigeons, Anseriformes, pheasants, partridge, quail, black grouse and capercaillie.	Worldwide. Affects young chicks 1–6 weeks.	CNS signs: → epidemic tremors, paralysis, incoordination. Egg production ↓ 5–10%. Survivors develop eye lesions.	Inoculation of embryonated eggs plus serology. ID and ELISA tests. Histopathology of brain, proventriculus, pancreas and heart.	Newcastle disease (V25), Marek's disease (V10), vitamin E and selenium deficiency. Lead poisoning.



<b>Cockatoo viral enteritis</b>	V42	A picorna virus which is not transmitted vertically.	Free ranging rose-breasted cockatoos, sulphur-crested cockatoos and galahs.	Australian birds affected just after they have left the nest at 8–12 weeks.	Profuse yellow-green faeces, anorexia, weight loss → death. Mortality 10–20%.	Histopathology of intestine.
---------------------------------	-----	--	---	---	--	------------------------------

**Astroviridae**

The Astroviridae are non-enveloped, single-stranded RNA viruses.

**Appendix Table 3.8** Astroviridae.

Disease	No.	Cause	Species Susceptible	Relative Occurrence	Principal Clinical Signs
Duck virus hepatitis Type II	V43	Astrovirus	Ducks.	Locally identified only in East Anglia UK.	Mortality 10–50%.

**Parvoviridae**

The Parvoviridae are non-enveloped, single-stranded DNA viruses exhibiting intranuclear inclusions.

**Appendix Table 3.9** Parvoviridae.

Disease	No.	Cause	Species Susceptible	Relative Occurrence	Principal Clinical Signs	Confirmation of Diagnosis	Differential Diagnosis
Goose virus hepatitis ( <i>Derzsy's disease</i> , <i>Goose influenza</i> , <i>Goose plague</i> )	V44	A parvovirus laterally transmitted via oral and nasal exudates.	Goslings of domestic geese, Canada geese and Muscovy ducks.	Europe and Asia. Not uncommon.	Anorexia, polydipsia, coryza, diarrhoea, ataxia. PM: fibrinous exudates of viscera, enlarged liver, petechiae, haemorrhages. Up to 100% mortality.	Virus identification, VN and ELISA tests.	Reovirus (V76), which is mainly a respiratory infection. Adenovirus of waterfowl (V69).

## Togaviridae and Flaviridae (the arboviruses)

Both the Toga- and Flaviridae are enveloped, single-stranded RNA viruses. They are all transmitted by invertebrate arthropod vectors.

There are probably at least seven other arboviruses in various parts of the world, which are transmitted by mosquitoes, ticks and other biting insects and which are spread by migrating birds (Jericová, 1993) and guillemots. They all have a *zoonotic* potential, causing CNS signs in humans, although they may be asymptomatic in infected birds. Although not yet documented as occurring in ostriches they may yet be found to be so.

**Appendix Table 3.10** Togaviridae and Flaviridae.

Disease	No.	Cause	Species Susceptible	Relative Occurrence	Principal Clinical Signs	Confirmation of Diagnosis	Differential Diagnosis
<b>Eastern and western equine encephalitis</b> (Venezuelan equine encephalitis, <i>Everglades viral encephalitis</i> ) <b>Zoonosis</b> , producing flu-like symptoms often weeks after infection.	V45, V46	Togaviruses transmitted by biting insects, e.g. mosquitoes.	Birds may act as important latent hosts. All species of bird are susceptible, including raptors, Galliformes, passerines (house sparrows). Anseriformes are most susceptible.	Mainly found in the Americas but also in other parts of the world.	May cause CNS signs in birds: paralysis, incoordination, torticollis. Mortality up to 80%. Sometimes haemorrhagic enteritis.	Virus isolation from brain homogenate. HI, ELISA tests.	
<b>Avian serositis</b>	V47	A togavirus possibly related to the virus of Psittacine proventricular dilatation.	Macaws and rose-ringed parakeets. Possibly other species of parrot.	Only documented in USA.	Sudden death or weight loss, distended abdomen with ascites. PM: hepatomegaly, oedema and congestion of lungs, intestinal and hepatic serosa.	Histopathology of proventriculus, gizzard, spleen, brain, heart and skeletal muscle.	
<b>Louping ill virus</b> <b>Zoonotic infection</b> , rather like V45 and V46 above, and may produce signs some weeks after infection.	V48	A flavivirus transmitted by biting ticks. Virus also carried by and affects sheep, deer, blue mountain hare, and domestic dogs.	Grouse species (Duncan <i>et al.</i> , 1978) and pheasants.	Northern hemisphere. Caused considerable reduction of black grouse on Welsh moors in UK. Birds most at risk are moorland species.	CNS signs.	As above for V43 and V44	

Murray Valley fever	V49	→ Australia	With viruses V49–V54 Most species of bird if native to an area usually resistant but introduced bird species tend to be susceptible, e.g. house sparrows not native to St. Louis died. Poultry, both chickens and ducks. Many wild birds, including marine species, act as reservoirs. Crows, swallows and swifts.	One or other of these viral fevers occur worldwide.	Usually most of these viruses V49–V54 are asymptomatic in birds, but <b>in humans</b> flu-like symptoms occur with severe headache, vomiting → coma → death. Symptoms may not appear until several weeks after infection.	Histopathology, other laboratory tests.	Toxicosis from environmental contaminants.
St. Louis fever	V50	→ USA					
Japanese summer fever	V51						
Yellow fever	V52	→ African and American tropics					
Russian spring and summer fever	V53	→ Russia, Siberia and continental northern hemisphere.					
West Nile fever	V54	→ Originated in Africa carried by migrating birds and now occurs over most of northern hemisphere. A notifiable disease in France.	Also horses.				Possibly avian influenza (V38) in the case of West Nile virus.
All these viruses are <b>serious Zoonotic diseases</b> (see Clinical Signs)							
			All of these viruses are transmitted by mosquitoes or similar biting flies.				

### Rhabdoviridae

The Rhabdoviridae are enveloped, single-stranded RNA viruses with intracytoplasmic inclusions.

Appendix Table 3.11 Rhabdoviridae.

Disease	No.	Cause	Species Susceptible	Relative Occurrence	Principal Clinical Signs	Confirmation of Diagnosis
<b>Rabies</b> This is a <b>zoonotic infection</b> but humans are not usually infected by birds.	V55	Many species of bird, particularly raptors and scavengers are documented as carrying the virus and act as reservoirs of infection, as well as the common reservoir, the fox.	Birds do not usually develop an active infection because of their rapid production of antibodies.	Worldwide except in the UK.	Very occasionally birds may show a change in behaviour towards humans → after which they develop epileptiform fits as well as other CNS signs → die.	VN antibodies can be detected in nerve tissue.

### Circoviridae

These are non-enveloped, single-stranded DNA viruses with both intranuclear and intracytoplasmic inclusions. Most of them propagate in dividing cells, e.g. epidermis, and so cause defective feather growth, also in the precursors of T-cells so are immunosuppressive. The exception is chicken anaemia virus, which also propagates in haemocyto blasts of the bone marrow.

Appendix Table 3.12 Circoviridae.

Disease	No.	Cause	Species Susceptible	Relative Occurrence	Principle Clinical Signs	Confirmation of Diagnosis	Differential Diagnosis
<b>Black spot canary disease</b> (Goldsmith, 1995)	V56	Circovirus Unrelated to the psittacine beak and feather disease	Canary chicks up to 7–20 days old.	Not uncommon.	Abdominal enlargement due to a swollen gall bladder seen through the thin skin. Mortality 90%.	Necrosis of bursa of Fabricius. Yellow fluid in air sacs.	Plasmodia (P18), atoxoplasmosis (also called 'black spot') (P12).

<p><b>Psittacine beak and feather disease</b></p>	<p>V57</p>	<p>A circovirus favouring rapidly dividing cells, i.e. in the immune system, epidermis, upper GI tract. Persists in environment in feather dust and faeces. Vertical transmission by adults feeding chicks.</p>	<p>All species of parrot, but there are probably species specific strains. Young birds most susceptible. A few adults may be latent carriers.</p>	<p>Endemic in wild cockatoos in Australia and Southeast Asia. Now worldwide in captive parrots.</p>	<p>Loss of normal contour feathers → short, club-like feathers, fret-lines, blood-filled sheath. Shiny, elongated, fragile-tipped beak. Vasa parrots: black feathers turn white. Grey parrots may show red feathers. Immunosuppressive so usually die within 12 months. Some species, e.g. lovebirds, clinical picture slightly different, just look rather scruffy with patchy feather loss.</p>	<p>Lesions usually bilaterally symmetrical. Take blood or feathers for DNA probe. Consult lab before sampling. Histopathology of feather biopsy and surrounding skin shows inclusions.</p>	<p>Apart from self-inflicted feather pecking, when head feathers are normal, polyoma virus (V59). May cause 'French moult' in budgerigars. Adenovirus, fungal and bacterial skin infections (B21). Dermatomycosis (M5). Suspect all feather abnormalities in young birds.</p>
<p><b>Pigeon circovirus</b></p>	<p>V58</p>	<p>Circovirus of pigeons.</p>	<p>Young birds 2–3 months old.</p>	<p>Unknown</p>	<p>Diarrhoea and loss of condition.</p>	<p>Green GI tract contents. Histopathology shows intranuclear inclusions in bursa and spleen.</p>	<p></p>
<p><b>Chicken anaemia virus</b></p>	<p>V58a</p>	<p>Circovirus Oral infection by virus. Vertical transmission. Virus infection becomes more prevalent under stress. Propagates in T-cell precursors and haemocyto blasts of bone marrow.</p>	<p>Chickens less than 3 weeks. Older birds immunologically depressed.</p>	<p>Anaemia</p>	<p></p>	<p>Histopathology of spleen and other lymphoid tissues, also of feathers. PCR tests, electron microscopy.</p>	<p></p>

(Continued)

Appendix Table 3.12 Continued.

Disease	No.	Cause	Species Susceptible	Relative Occurrence	Principal Clinical Signs	Confirmation of Diagnosis	Differential Diagnosis
Dove circovirus	V58b	Circovirus		Probably a lot more common than hitherto recognised. Found in Senegal	Feather abnormalities	Histopathology of spleen and other lymphoid tissues, also of feathers. PCR tests, electron microscopy.	
Finch circovirus		Oral infection by virus. Vertical transmission.					
Black backed gulls (both southern and northern)		Virus infection becomes more prevalent under stress.					
Black casqued wattled hornbill							

## Papovaviridae

The Papovaviridae are non-enveloped, double-stranded DNA viruses with intranuclear inclusions.

Appendix Table 3.13 Papovaviridae.

Disease	No.	Cause	Species Susceptible	Relative Occurrence	Principal Clinical Signs	Confirmation of Diagnosis	Differential Diagnosis
Polyoma virus infection (including <i>Budgerigar fledgling disease</i> )	V59	Polyoma virus carried by latently infected adult birds. Both vertical and horizontal transmission. Virus environmentally persistent. Shed in feather dust and faeces.	Apart from budgerigars, in which the disease has been seen but the cause undiagnosed for many years, also probably infects most other parrot species but particularly macaws, <i>Eclactus</i> and lovebirds. Also canaries and other finches.	Worldwide. May be much more common than realised. Fledglings most at risk but latently infected adults may show signs if stressed by show, sale or change of environment.	Young budgerigars about to leave nest just found dead. Slightly older birds, abdominal distension, no down feathers, enlarged heart and liver, ascites. 30–100% die. Survivors become 'runners'. Canary nestlings die in 24–48 hours, older birds stunted, growth abnormalities.	DNA probe on blood or cloacal swab or cut surface of liver. Intranuclear inclusions in epidermis and feather follicles. Use fluorescent antibody.	Most important is psittacine beak and feather disease, but GI signs more evident in polyoma. Any cause of sudden death, even in adult birds, e.g. toxicosis.

<b>Benign papilloma virus</b>	V60	Papilloma virus Possibly carried by wild chaffinch, but this could be a distinct strain.	All parrot species, but particularly Amazon parrots and macaws. Some finches (Fringillidae), canaries (Dom <i>et al.</i> , 1993).	Not uncommon.	Wart-like growths first noticed in cloaca but also in upper GI tract and bile duct. Owner may see blood in droppings. Also growths (warts) on unfeathered skin of parrots and on legs and feet of finches.	Histopathology. Note many Amazons and other birds also have malignant bile and pancreatic duct carcinomas so need scans, endoscopy etc.	Dermatomycosis (M5), conure papilloma virus (V20), psittacine herpes virus (V1).
-------------------------------	-----	---	---	---------------	--	---	--

**Adenoviridae**

The Adenoviridae are non-enveloped, double-stranded DNA viruses with intranuclear (contain virus) and intracytoplasmic (do not contain virus) inclusions. All adenoviruses are environmentally persistent. They are found worldwide and often act as a trigger for other infectious diseases. Parvoviruses require their presence to complete their replication.

Many birds are latent carriers and shed virus in faeces. Many species are known to be susceptible and many more viruses are likely to be identified in the future. Vertical transmission can occur.

**Group I fowl adenovirus**

There are 12 serotypes and a number of subgroups of varying pathogenicity in Group I.

Appendix Table 3.14 Group I fowl adenovirus.

Disease	No.	Cause	Species Susceptible	Relative Occurrence	Principal Clinical Signs	Confirmation of Diagnosis	Differential Diagnosis
<b>Guinea fowl adenovirus</b>	V61	Adenovirus	Guinea fowl	Young chicks are very susceptible.	Main clinical sign is a necrotic pancreatitis.	Histopathology of liver, kidney, pancreas. Intranuclear inclusions. Upper respiratory tract. Viral culture. DNA probes, ELISA.	
<b>Japanese quail virus</b>	V62	Adenovirus	Japanese quail	Isolated from chicks.	Exhibited CNS signs.	As above for (V61)	Polyoma virus (V59), possibly Marek's disease (V10), ILT (V8).
<b>Chicken adenovirus</b> ( <i>Chicken inclusion body hepatitis, Chicken splenomegaly, Egg drop syndrome</i> )	V63	Adenovirus Both vertical and horizontal transmission.	Chickens	Chicks 5–7 weeks Adult birds in lay	Anorexia, white pasty faeces → death.	As above for (V61)	
<b>Quail bronchitis</b>	V64		Bob white quail	Young birds up to 6 weeks. Game farms in USA.	Sudden death and severe respiratory distress. Sometimes CNS signs.	PM: respiratory system, excess mucus in airways, cloudy air-sac membranes. Hepatic necrosis. Also as above for (V61).	
<b>Pigeon inclusion body enteritis</b>	V65	Adenovirus of pigeons type I. Latent carriers. Oral infection from droppings whilst in trucks in racing baskets.	Young pigeons under one year during their first racing season during May–August.	At present only documented in Europe, but probably worldwide.	Dull. Watery mucoid green diarrhoea, weight loss. Sometimes apparent recovery then a week later condition flares up exhibiting more severe signs → death.	Histopathology: extensive pinpoint necrotic areas in liver and quite large intranuclear inclusions in liver and intestinal epithelium. Virus isolation.	Newcastle disease (V25), salmonellosis (B1), hexamitiasis (P16).



<b>Pigeon inclusion body hepatitis</b>	V66	Adenovirus of pigeons type II.	Pigeons of all ages.	Probably worldwide.	Sometimes vomiting with yellow liquid faeces. Usually sudden death within 24–48 hours. 30–100% mortality, but some young birds quite unaffected.	PM: pale, yellow, swollen liver with both focal and extensive areas of necrosis. Histopathology: less numerous and smaller intranuclear inclusions than above in type I.	As above
<b>Falcon adenovirus disease</b> (Wetterer <i>et al.</i> , 2005)	V67	Wild peregrine falcons may act as a reservoir of the virus. Virus may be carried in dead hatchery chicks of chicken, turkey or quail. Best to use mammalian source of food.	Goshawk, American kestrel, merlin, Mauritius kestrel, Bengalese eagle owl, white bellied sea eagle, Taito falcon, gyrfalcon, peregrine falcon.	Probably global.	Signs rather non specific. Depression, anorexia 4–5 days → death. Sometimes slight hepatosplenomegaly and enlarged kidney and congestion of lungs. Haemorrhagic enteritis.	Histopathology: multifocal hepatocellular necrosis and basophilic intranuclear inclusions. PCR, electron microscopy.	Raptor adenovirus (V73)
<b>Psittacine adenovirus disease</b>	V68	Psittacine adenovirus Carrier state may flare up when birds are stressed in captivity.	All parrot species. One documented epizootic in budgerigars (Cassman <i>et al.</i> , 1981).	Probably worldwide.	Occasional sudden death. Dullness, possibly diarrhoea together with blepharitis. 30% mortality. CNS signs, hepatitis, enteritis, pancreatitis.	PM: pancreatitis, nephritis, distended proventriculus and duodenum. Viral culture. DNA probes, ELISA.	Neuropathic psittacine proventricular disease. Paramyxo disease in <i>Neophema</i> parakeets (V27), polyoma (V59), herpes (V1), circovirus (V57), <i>Chlamydomphila</i> (B26).
<b>Adenovirus disease of waterfowl</b>	V69	Adenovirus	Muscovy ducks, goslings, free ranging herring gulls.	Lameness and emaciation. Mortality about 10–15%. Some have bronchitis and pneumonia.			
<b>Ostrich fading chick syndrome</b> (Raines <i>et al.</i> , 1995)	V70	Un-typed adenovirus	Ostriches	Weight loss, anorexia, chalky faeces, ascites, death in 2–3 weeks.			

## Group II adenoviruses

Appendix Table 3.15 Group II adenoviruses.

Disease	No.	Cause	Species Susceptible	Relative Occurrence	Principal Clinical Signs	Confirmation of Diagnosis
<b>Galliform marble spleen disease</b>	V71	Group II adenovirus Faeces from latently infected birds.	Pheasants, guinea fowl and chickens. Possibly blue grouse.	Global	Acute: death. PM: grossly enlarged, mottled, grey spleen. Subacute: anorexia, dyspnoea and diarrhoea.	DNA probe and virus isolation.
<b>Turkey haemorrhagic enteritis</b>	72	Group II adenovirus Shed in faeces from infected birds.	Turkeys, chickens, pheasants.	Global	Rapid spread through flock. Chicks 4–12 weeks. 60% mortality.	EIISA

## Group III adenoviruses

Appendix Table 3.16 Group III adenoviruses.

Disease	No.	Cause	Species Susceptible	Relative Occurrence	Principal Clinical Signs	Confirmation of Diagnosis	Differential Diagnosis
<b>Raptor adenovirus disease</b> [Zsivanovits <i>et al.</i> , 2005]	V73	Adenovirus Possible source dead hatchery chicks [chicken, quail and turkey chicks].	Harris hawk, European eagle owl, Bengal eagle owl, Verreaux's eagle owl.	Two isolated epizootics.	CNS signs → clonic fits → death in 48 hours; or anorexia and depression → death.	As for falcon adenovirus (V67).	Falcon adenovirus (V67).
<b>Turkey soft-shell egg disease</b>	V74	Group III adenovirus Latently infected carrier birds.	Turkeys, geese, Muscovy ducks, chickens, cattle egrets and guinea fowl. All are asymptomatic carriers.	Probably worldwide.	Only clinical signs are soft-shelled eggs.	Virus isolation.	

**Coronaviridae**

The Coronaviridae are enveloped, single-stranded RNA viruses.

**Appendix Table 3.17** Coronaviridae.

<b>Disease</b>	<b>No.</b>	<b>Cause</b>	<b>Species Susceptible</b>	<b>Relative Occurrence</b>	<b>Principal Clinical Signs</b>	<b>Confirmation of Diagnosis</b>
<b>Infectious bronchitis</b>	V75	Coronavirus Carried by chickens and possibly wild birds: owls and Passeriformes.	Pheasants and Guinea fowl.	Worldwide, but common in UK. Chicks most susceptible.	Moderate respiratory signs. Reduced egg production. 40% mortality in chicks. PM: swollen kidney and signs of visceral gout plus egg peritonitis. Guinea fowl may also show enteritis and pancreatitis.	Virus isolation but submit specimens to lab in 50% glycerol and deep freeze
		Psittaciformes, including budgerigars. Pigeons.		Only two recorded instances of natural infection. One documented case.	Necrotic hepatosplenitis. Respiratory signs with mucopharyngitis plus ulcerated crop and oesophagus.	
		Ostrich chicks and rhea (Kennedy and Brenneman, 1995).			Anorexia, loss of weight, enteritis. PM: proventriculus (main food storage and digestive organ in these species) thin-walled, enlarged and filled with food. Low mortality.	
		Japanese quail.		One documented case.	Respiratory signs.	

## Reoviridae

These are non-enveloped, double-stranded RNA viruses with intracytoplasmic inclusions.

**Appendix Table 3.18** Reoviridae.

Disease	No.	Cause	Species Susceptible	Relative Occurrence	Principal Clinical Signs	Confirmation Of Diagnosis	Differential Diagnosis
<b>Reovirus disease subgroup I</b> ( <i>Orbiviruses</i> )	V76	Reovirus ( <i>Orbivirus</i> ) These viruses are probably immunosuppressive.	Galliformes (including pheasants) and raptors are probably main carriers.	Worldwide	Since immunosuppressive, virus complicated by secondary infections.	Cloacal swabs or PM: swabs from Liver, spleen, kidney and other viscera for virus isolation.	Adenovirus disease of water fowl (V69), goose parvovirus (V42).
		Latent carriers shed virus in faeces. Not all strains of virus are pathogenic. May be spread by biting insects.	Psittaciformes, probably the Old World parrots, are more susceptible than those of the Americas.		Often non-pathogenic but eyes may be swollen. Enteritis → emaciation and incoordination. PM: swollen liver, kidney and spleen with necrotic areas. Fluid in lungs. Mortality 70–100%.		
			Pigeons →	Approximately 10% of all pigeons in Europe may carry the virus.	Diarrhoea and dyspnoea, mucoid enteritis.		
		Muscovy ducks and their hybrids. →		Affects ducklings in France	Stunted growth and feather dystrophy. Mortality up to 90%. PM: inflammation of the pericardium and air sacs.		
		Geese		Goslings	Sudden death or dullness, anorexia, mild respiratory signs grey/white diarrhoea, weakness and tremor. PM: grey, dilated heart, respiratory and liver lesions.		
		Budgerigars and cockatiels.			Sudden death. PM: myocarditis, hepatosplenomegaly, enteritis.		

## Other diseases that may well be viral in origin

Appendix Table 3.19 Other diseases that may well have a viral origin.

Disease	No.	Cause	Species Susceptible	Relative Occurrence	Principal Clinical Signs	Confirmation of Diagnosis	Differential Diagnosis
<b>Neuropathic proventricular dilatation of psittacine birds</b> (Macaw wasting disease, <i>Psittacine myoentericganglioneuritis</i> , <i>Encephalomyelitis of parrots</i> )	V77	Suspect viral particles seen in spinal cord and coeliac ganglion by electron microscopy. Destruction of intramural ganglia (Auerbach's plexus), of proventriculus and first part of duodenum. Also affects autonomic ganglia of heart, brain and spinal cord. Possibly carried by free ranging birds. Possible virus may be shed in faeces. Stress and change of husbandry may precipitate condition.	Only documented in many species of parrot <i>not just macaws</i> .	Probably worldwide. An increasingly common problem in North and South America. Has been epidemic in some aviaries. Not uncommon in Europe.	A chronic wasting disease with an incubation period of up to two years. Usually only seen in young birds. Depression. Undigested food in vomit and in faeces. Anorexia, weakness, possible lameness (CNS involved). Marked leucocytosis (both heterophilia and monocytosis). Death after prolonged disease. PM: emaciation, distended and impacted proventriculus and crop. Muscle layers of gizzard white and atrophied → may ulcerate and rupture.	Barium contrast radiograph. Very reduced proventricular emptying time. Biopsy of crop or, better, proventriculus. Surgically difficult and risky in debilitated bird. May produce false negative.	Vitamin E, selenium deficiency. Neoplasia of upper GA tract. Foreign body in proventriculus. Pyloric obstruction → gastric impaction. Megdacteria infection (M7), nematode infestation/visceral larva migrans (P22).
<b>Similar disease in Canada geese</b>	V77						
<b>Runting and stunting syndrome</b>	V78	May have a similar cause to V76	Seen in broiler chickens and in Goshawks (Forbes and Simpson)	One suspected case in a 4-week-old bird.			

**APPENDIX 4 MYCOTIC DISEASES OF BIRDS**

It is important to note that a number of these diseases are **zoonotic** and that the symptoms of many of them in humans are identical to those of flu and may not appear until several weeks after exposure. These diseases have been marked as zoonoses in the tables that follow. Anyone who has contact with birds and subsequently becomes ill should consider zoonotic infection as a possibility.

All mycotic diseases in this table are numbered and prefixed M.

Other rare mycotic infections of birds are caused by *Microsporidia*, *Penicillium*, *Nocardia*, *Rhinosporidia* (from sprouted seed) and *Mucor* spp hyphae in vascular endothelium of finches.

**Appendix Table 4.1** Mycotic diseases.

<b>Disease</b>	<b>No.</b>	<b>Cause</b>	<b>Species Susceptible</b>	<b>Relative Occurrence</b>	<b>Principal Clinical Signs</b>	<b>Confirmation of Diagnosis</b>	<b>Differential Diagnosis</b>
<b>Aspergillosis</b> Can be a primary or a secondary infection A potential <b>zoonotic disease</b> . Can cause bronchopneumonia, asthma and occasional generalised infection in humans.	M1	Aspergillus spp, e.g. <i>A. fumigatus</i> , <i>A. flavus</i> , <i>A. niger</i> , <i>A. terreus</i> At least 200 species, all of which are normally saprophytic and found in damp and warm, mouldy straw, hay, wood chips, etc. The spores are ubiquitous.	All species both captive and wild including ostrich chicks. More common in diving birds, possibly because of air recirculation during diving. Also not uncommon in captive parrots and raptors which are overfed and inactive.	Common predisposing causes include: hypovitaminosis A, stress, challenge by massive dose of spores, age i.e. esp. young birds, injudicious use of antibiotics, steroids, etc., ammoniacal fumes in poorly ventilated and unhygienic aviaries.	Can be sudden death, particularly in young, if organism is spread haematogenously. More usually debility and emaciation, respiratory signs (10% of acute respiratory obstruction cases caused by aspergillosis), post paralysis, lesion in spine. Also not uncommon in captive parrots and raptors which are overfed and inactive.	Often heterophilia, monocytois and non-regenerative anaemia. Examine lesions for signs of hyphae and fruiting bodies. Look for typical 'foot' cell and septate branches. Use 20% KOH and stain with lactophenol cotton blue or new methylene blue. Radiography, laparoscopy, tracheal swab, abdominal swabs for culture and cytology. ELISA or agar gel diffusion not very reliable.	Tuberculosis (B17), <i>Yersinia</i> (B11), Avipox (V35), trichomoniasis (P14), <i>Candida</i> (M2), ggapeworm (P31), <i>E. coli</i> (B3). Hypovitaminosis A in parrots. <i>Salmonella</i> can produce granulomatous plaques.

(Continued)

Appendix Table 4.1 Continued.

Disease	No.	Cause	Species Susceptible	Relative Occurrence	Principal Clinical Signs	Confirmation of Diagnosis	Differential Diagnosis
<b>Candidiasis</b> ( <i>Moniliasis</i> ) A primary or secondary infection	M2	<i>Candida albicans</i> ( <i>Monilia</i> ) May occur in normal gut flora and overgrow after indiscriminate use of antibiotic and faulty hygiene practices or stress. Even hand feeding can precipitate this condition.	Probably all species but particularly pigeons, turkeys, partridges, grouse, budgerigars, psittacines, Passeriformes. When kept in captivity.	Not uncommon, particularly in young birds. Said to be common in nectar-feeding birds.	Vomiting, delayed crop emptying, loss of condition, anorexia, sporadic deaths. PM: mucosa of crop and oesophagus thickened and covered in a soft, whitish, cheesy material under which the mucosa is velvet towel-like. Occasionally in proventriculus. Also seen in mucosa of cloaca, respiratory tract and skin.	It is possible to examine the crop in a live bird with a laparoscope. Wet mount smears stained with lactophenol blue, Gram stain, methylene blue or Giemsa show budding, yeast-like organisms. Occasionally hyphae or mycelia are seen. Histopathology.	Trichomoniasis (P14) (macroscopically <i>Candida</i> lesions are indistinguishable from this disease, which causes 'Sour crop' with a bacterial necrosis). <i>Salmonella typhimurium</i> (B1) in passerines can infect the crop. In psittacines neuropathic gastric dilation (macaw wasting disease) (N77). Other mycotic diseases. Hypovitaminosis A. Foreign bodies.
<b>Cryptococcosis</b> ( <i>Torulosis</i> ) ( <i>Blastomycosis</i> ) A serious and potentially fatal zoonotic disease particularly from sick birds kept in unsanitary conditions in old wooden aviaries. Infection by inhalation of dust containing spores.	M3	<i>Cryptococcus neoformans</i> Common saprophytic yeast found on plant and organic material often excreted and found on faeces.	Potentially all avian species but least likely in raptors.	Ubiquitous but particularly in faeces of Passeriformes, Galliformes and pigeons.	In birds can cause dyspnoea, debility, emaciation, non-regenerative anaemia and generalised, necrotising, myxomatous, gelatinous granulomata in viscera, lung, air sacs and liver.	Impression smears. Stain typically with Gram stain or use Indian ink. Look for thickly encapsulated yeast-like organisms.	Other fungal infections, particularly M1, M3, M4.



<p><b>Histoplasmosis</b> As above, another potentially serious zoonotic disease with the same causes as Cryptococcosis.</p>	<p>M4 <i>Histoplasma</i> spp. Another soil saprophyte found in bird faeces. Can build up in aviaries with earthen floors.</p>	<p>As above for <i>Cryptococcus</i>.</p>	<p>Ubiquitous</p>	<p>As above for Cryptococcus. Can cause acute influenza-like symptoms in humans which can progress to pericarditis and endocarditis, lung and liver lesions and meningitis.</p>	<p>As above</p>
<p><b>Dermatophytosis (Ringworm) (Favus) Zoonosis</b></p>	<p>M5 <i>Trichophyton</i> spp, <i>Cladosporium</i> spp</p>	<p>Probably occurs in all species but particularly Passeriformes.</p>	<p>Uncommon</p>	<p>Loss of feathers. Skin thickened, greyish-white, lifeless. Skin has tendency to be corrugated and encrusted. White crust on comb or wattles causing 'Fowl favus'.</p>	<p>Mange mite infection (P46), avian pox (V35). Malnutrition, feather picking.</p>

<p><b>Actinomyces</b></p>	<p>M6 <i>Actinomyces</i> spp</p>	<p>Reported by Coffin in parrots. One case seen by the author in a Moluccan cockatoo, which formed a granuloma caudal to the vent.</p>			
---------------------------	----------------------------------	--	--	--	--

(Continued)

Appendix Table 4.1 Continued.

Disease	No.	Cause	Species Susceptible	Relative Occurrence	Principal Clinical Signs	Confirmation of Diagnosis	Differential Diagnosis
<b>Macrorhabdus ornithogaster</b> (Formerly called <i>Megabacteria</i> )	M7	An anamorphic Ascomycetous yeast Probably asymptomatic carrier birds. Organism may be an opportunistic pathogen of stressed, immunosuppressed or debilitated birds.	Primarily budgerigars, but also canaries, finches (particularly European goldfinches and green finches in Australia 60%), cockatiels, lovebirds, other parrot species. Less serious in chickens, turkeys, quail, guinea fowl, chucker partridge, toucan, pigeons and rhea ostriches.	Worldwide not uncommon and in British exhibition budgerigars the incidence is increasing. Probably can infect all grain eating and herbivorous birds.	Breeders describe bird as dull and 'going light'. Bird may show 'sham' feeding, vomit undigested food and occasional blood in faeces. Sometimes sudden death but older birds may linger. PM: white, slim, ulceration and haemorrhage in proventriculus and gizzard. Latter bile stained with degenerated smooth koilin pads. X-ray may show dilatation and filling defects of proventriculus.	Gram+ rod. Can easily be seen with microscope. 85% of cases can be diagnosed on repeated exam of faecal smears. Well dilute to thin slush, maximize contrast, examine under X100, with maximum contrast. Also stain with Gram or Lugol's iodine. Take impression smears from liver and spleen. Like all fungi, culture of organism difficult.	See the differential diagnosis of Pseudotuberculosis (B11).

## APPENDIX 5 PARASITIC DISEASES OF BIRDS

It is important to note that a number of these diseases are **zoonotic** and that the symptoms of many of them in humans are identical to those of flu and may not appear until several weeks after exposure. These diseases have been marked as zoonoses in the tables that follow. Anyone who has contact with birds and subsequently becomes ill should consider zoonotic infection as a possibility.

All diseases in this section are numbered and prefixed P.

### **Protozoal parasites**

#### Coccidiosis and related parasitic diseases (Family Eimeriidae)

The *Coccidia* comprise an extremely variable and large group of protozoan parasites, all of which are in the family Eimeriidae. Many species of this family are host specific. Reproduction within the host results in the production of an environmentally resistant oocyst formed within the mucosal cell of the host, from which it is discharged. After maturation in the faeces (called *sporulation*), the oocyst produces infectious sporozoites. Specific diagnosis in most cases is confirmed by examination of faecal smears.

Severe disease does not always result from infection. Instead, a state in which the organism exists as a commensal may result, with the host exhibiting little or no signs of disease while the parasite still carries on its life-cycle. It is only when the host becomes stressed or is otherwise immunocompromised that full-blown disease occurs.

*All parasites within the group thrive in batches of stressed and overcrowded birds kept under unsanitary conditions. The young are particularly vulnerable with the adult birds often acting as latent carriers.*

**Appendix Table 5.1** Coccidian parasites with *direct life cycles*. The following coccidian parasites all have *indirect life cycles* with both definitive and secondary hosts. Predators act as the main host whilst prey species are the secondary hosts in which asexual reproduction of the parasite takes place.

Disease	No.	Cause	Species Susceptible	Relative Occurrence	Principal Clinical Signs	Confirmation of Diagnosis	Differential Diagnosis
<i>Eimeria</i> spp ( <i>classical coccidiosis</i> )	P1	<i>Eimeria</i> spp Cyst forming protozoan parasites. At least 160 species of these host-specific parasites infect birds.	Poultry, pigeons, gamebirds, toucans.	Common	Can vary from being an asymptomatic condition to vague signs of mucoid to sanguineous diarrhoea. Sometimes acute death.	Faecal exam of unstained smears shows oocysts characteristic for each genus. In passerine birds more oocysts may be shed midday.	Salmonellosis (B1), <i>Chlamydothila</i> (B26), <i>Campylobacter</i> (B6).
			Budgerigars	Common in Australia, but elsewhere rarer.	PM: may be dilation of coelom and haemorrhage into bowel. <i>Eimeria truncata</i> infects the kidneys of geese and some other Anseriformes. The kidneys are swollen and covered in white patches.	Sporulation in faeces may take several days. Identification of individual <i>Eimeria</i> species important to indicate range of susceptible hosts. In kidney check impression smears.	
<i>Isospora</i> spp	P2	<i>Isospora</i> spp Not so host specific as <i>Eimeria</i> and often not so pathogenic.	Parrots (except lories) Anseriformes Raptors	Uncommon Not uncommon Occasional			
			Infects many avian species including rarities, canaries, finches and other passerines.	Common	Clinical signs as for <i>Eimeria</i> .	Oocyst contains 2 sporocysts, each with 4 sporozoites, as distinct from <i>Eimeria</i> with 4 sporocysts each with 2 sporozoites.	

<b>Dorisiella spp</b>	P3	<i>Dorisiella</i> spp	Passeriformes	Common	Clinical signs as for <i>Eimeria</i> but not usually very pathogenic.	Oocyst has 2 sporocysts, each with 8 sporozoites.
<b>Tyzzeria spp</b>	P4	<i>Tyzzeria</i> spp	Ducks		Quite pathogenic. Haemorrhagic white lesions in caudal intestine.	<i>Tyzzeria</i> has no sporocyst, only 8 freely separated sporozoites.
<b>Wenyonella spp</b>	P5	<i>Wenyonella</i> spp	Ducks and passerines			The <i>Wenyonella</i> oocyst contains 4 sporocysts each with 4 sporozoites.
<b>Cryptosporidium spp</b> An increasingly important zoonotic infection particularly in immunosuppressed persons.	P6	<i>Cryptosporidium</i> spp Not so host specific as <i>Eimeria</i> and may be an opportunistic pathogen infecting immunosuppressed birds. Endogenous sporulation. Low rate of shedding. Can be auto infection. Large numbers of infected cysts in particularly moist environments.	Infects a wide range of avian and mammalian hosts, including Galliformes, waterfowl, Psittaciformes, raptors, finches (urinary tract) and ostriches.	Worldwide	As well as GI tract parasite, invades whole body, particularly Bursa of Fabricius, kidney, upper respiratory tract. Replicates on mucosal surfaces causing excess mucus. Marked respiratory and GI signs, with PM signs in both respiratory and GI tracts. <i>In humans</i> , persistent diarrhoea, vomiting and sometimes abdominal pain 2–12 days post infection.	Avian cholera (B12), <i>Pseudomonas</i> (B4), <i>Haemophilus</i> (B22), <i>Alcaligenes</i> (B22), Enterococcosis (B8). Faecal exam but very small intermittently shed oocyst difficult to find. Stain with Gram. Oocyst similar to <i>Isoospora</i> but is already sporulated when shed, often releasing sporozoites directly into faeces.

Appendix Table 5.2 Coccidians with *indirect* life cycles.

Disease	No.	Cause	Species Susceptible	Relative Occurrence	Principal Clinical Signs	Confirmation of Diagnosis	Differential Diagnosis
<b><i>Caryospora</i> spp</b>	P7	<i>Caryospora</i> spp Over 100 species, some of which may be host specific.	Raptors including owls. Rodents are the intermediate host.	May be much more common than so far documented.	Dependent on the host species, parasite may or may not be pathogenic. Pathogenesis results in listlessness, anorexia, mucoid, haemorrhagic diarrhoea, muscle cramp or sudden death.	Faecal exam shows large oocyst containing 8 non-encysted, stubby sporozoites.	
<b><i>Frenkelia</i> spp</b>	P8	<i>Frenkelia</i> spp Only two species so far recorded.	Both species occur in the buzzards, including the red-tailed hawk.	N. America	Non-pathogenic in the definitive host but causes a severe and fatal illness in the secondary host, making them more susceptible to predation.	Sporulated oocyst contains 2 sporocysts, each with 2 sporozoites.	

Other cyst forming parasites which are not in the family Eimeriidae (Family Sarcocystidae)

Appendix Table 5.3 Other cyst forming parasites.

Disease	No.	Cause	Species Susceptible	Relative Occurrence	Principal Clinical Signs	Confirmation of Diagnosis	Differential Diagnosis
<b>Sarcocystis spp</b> Potential zoonotic infection, but rare through little consumption of uncooked flesh in the West.	P9	<i>Sarcocystis</i> spp Very many species. Encysted parasite in muscle of prey eaten by predator. Vectors: flies, cockroaches. Intermediate hosts: skunks and raccoons.	Documented in a broad range of vertebrate species, including many birds. Raptors (including owls) may act as both definitive and intermediate hosts. Recorded in many captive parrots. USA particularly at risk as native opossum is the definitive host. Encephalitis in <i>Cacatua alba</i> (Siegal-Willmot <i>et al.</i> 2005).	Worldwide although some species of <i>Sarcocystis</i> have restricted range. Carried by many raptors and their prey, e.g. passerines, rodents, deer, etc.	Dependent on the host, the parasite may or may not be pathogenic and even fatal. Encysted parasite may be found incidentally in muscle when death is due to another cause. In parrots, dullness, weakness, respiratory signs, sudden death. PM: hepatosplenomegaly, histology of lung, muscle, liver, spleen, heart and CNS.	Sporulated oocyst contains 2 sporocysts each containing 4 sporozoites. Although schizogony occurs throughout the body, sarcocyst formation takes place primarily in muscle and lungs → acute respiratory distress, sometimes severe tissue reaction. <b>Ante-mortem diagnosis:</b> Protein electrophoresis - β and γ globulins ↑, immunofluorescence, serology, WBC ↑.	
<b>Hammondia and Besnoitia spp</b>	P10	<i>Hammondia</i> spp. <i>Besnoitia</i> spp. Similar to <i>Sarcocystis</i>			Schizonts documented in the muscle of parakeets.		
<b>Toxoplasmosis</b> A potentially serious zoonotic disease, particularly in pregnant women and immunocompromised persons. Estimated 65% of world human population is infected, with 22% in UK.	P11	<i>Toxoplasma gondii</i> The primary host are cats (all Felidae) but intermediate host is a wide range of vertebrates. Birds infected from food contaminated by cat faeces or in predator birds from infected carcass.	Potentially all species of bird. Pathogenic and recorded in many species of Parrot. Anseriformes Passeriformes	Worldwide ubiquitous in the environment where Felidae occur. Not common Quite common Only occasionally	In birds the parasite may or may not be pathogenic. Pathogenesis is caused by asexual reproduction within the host tissues (blood-borne throughout body), causing focal tissue necrosis → anorexia, weight loss, diarrhoea, respiratory and CNS signs (behavioural changes). Can be fatal in parrots and cause disease in Anseriformes.	The oocyst is only found in cat faeces. Diagnosis in birds is by histopathology, serology.  Paramyxoviruses (V24-Y32), <i>Listeria</i> (B16).	

(Continued)

Appendix Table 5.3 Continued.

Disease	No.	Cause	Species Susceptible	Relative Occurrence	Principal Clinical Signs	Confirmation of Diagnosis	Differential Diagnosis
<b>Atoxoplasmosis (formerly Lankesterellosis)</b> (Big liver disease of finches)	P12	<i>Atoxoplasma</i> spp ( <i>Lankesterella</i> ) Infection by ingestion of oocyst in faeces. Direct life cycle. Red mite ingests sporozoites, acting only as mechanical vector. Oocyst resistant to infection.	Probably all species of Passeriformes. In canaries can cause disease in hatchlings. One cause of so called 'black spot' due to enlarged liver seen through skin. May be cause of 'going light' in green finch.	Global distribution and may be more common than realised.	Often non-pathogenic, but heavy infection may be fatal in nestlings. Depression, anorexia, diarrhoea due to gross enteritis. Occasional CNS signs in canaries.	Blood, impression smears from liver, spleen, bone marrow, heart and lung. Stain with Giemsa. Intracytoplasmic parasite in mononuclear cells. Causes indentation of nucleus. Use buffy coat of heamatocrit. Oocyst may be found in faeces. PM: marbled hepatosplenomegaly, dilated loops of bowel. Histopathology: necrotic enteritis, lesions in kidney.	<i>Circovirus</i> infection of canaries (V56), <i>Plasmodium</i> (P18).
<b>Microsporidiosis</b> <b>Zoonotic</b> hazard for immunocompromised humans. Note many asymptomatic cage birds may be shedding spores.	P13	<i>Microsporidium</i> spp Opportunistic pathogens. At least 14 species. Resistant spore build-up in unsanitary conditions.	Documented in lovebirds (25% of asymptomatic lovebirds shed spores), also fledgling budgerigars, but probably all captive birds kept intensively.	Probably global	Intracellular development within intestinal cells → each producing many spores. Unifrifiness in nestlings. Yellow pasty droppings. Mortality 75%. PM: distended alimentary canal and necrotic liver.	Histopathology	Polyoma virus (V59), Reoviruses (V75).



Motile protozoal parasites

**Appendix Table 5.4** Motile protozoan parasites.

Disease	No.	Cause	Species Susceptible	Relative Occurrence	Principal Clinical Signs	Confirmation of Diagnosis	Differential Diagnosis
<b>Trichomoniasis</b>	P14	<i>Trichomonas gallinae</i> Motile, flagellated parasite. Probably many healthy carriers. Direct transmission by (1) Adults feeding young (2) Contaminated food (can survive in moist unsanitary conditions for short period) (3) Raptors feeding on prey.	Probably all species. Pigeons, parrots, budgerigars, cockatiels, Ostrich chicks. Particularly raptors feeding on pigeons.	Probably global because carried by many apparently healthy nidicolous birds. 63% of captive falcons in Saudi Arabia (Samour 2003).	Occasionally acute death. Failure to thrive, dyspnoea, diarrhoea. PM: thick, cheesy exudates in upper GI tract and respiratory system. Initially lesions may be quite small but become gross.	Microscopic examination of lesions for motile parasites, with typical 4 anterior flagellae. (1) Use wet cotton bud squeeze out onto warm slide (2) Crop wash (3) Impression smear of lung, stain with Giemsa. If in doubt culture overnight in special liquid medium and examine, on warm slide.	Candidiasis, gross lesions of <i>Trichomonas</i> , <i>Candida</i> , M1, M2 are indistinguishable. Hypovitaminosis A, Aviropox (V35), pigeon herpes (V4), 'sour crop'. Scalds in gavaged chicks. <i>Capillaria</i> (P27).
<b>Cochlosoma spp</b>	P14a	<i>Cochlosoma</i> spp Flagellated protozoan parasites taxonomically related to the Trichomonads. Parasite in colorectum and cloaca of adult finches, which act as carriers infecting young.	Infects a number of species of finch, e.g. Bengalese (often used as cross-foster parents for other species), zebra, Gouldian, redheaded parrot finch, etc. Also infects some mammals. Often high mortality in juveniles.	Not uncommon amongst breeders of Australian finches.	Young birds 10 days – 12 weeks: shivering, respiratory signs, vomiting and diarrhoea, sometimes seed in droppings → dehydration. PM: bowel full of yellow ingesta and seed.	Examine: warm saline swab from crop; fresh warm droppings. Look for motile flagellated parasite with undulating membrane.	Trichomoniasis (P14)

(Continued)

Appendix Table 5.4 Continued.

Disease	No.	Cause	Species Susceptible	Relative Occurrence	Principal Clinical Signs	Confirmation of Diagnosis	Differential Diagnosis
<b>Giardiasis</b> zoonotic cause of non-bacterial enteritis and flatulence. In USA known as 'beaver fever'.	P15	<i>Giardia</i> spp Motile flagellated parasite. Can become encysted inside host and remain viable several weeks in faeces. Chlorination most effective disinfection.	Infects a wide range of vertebrates, including many species of bird. Once thought not to be zoonotic but this is equivocal. Although first observed in 1681, biology still not well understood.	Global, probably much more common than generally recognised.	Chronic diarrhoea and unthriftiness due to malabsorption. Can result in high mortality in young. Feeds on mucus on surface of mucosal membrane, therefore few PM signs.	Identification of motile parasites difficult. Thick-walled cysts may be seen using flotation. Use IF and ELISA. Histopathology may show crypts of Lieberkühn between villi packed with cysts and trophozoites. Stain faeces with Lugol's iodine.	May be associated with <i>E. coli</i> (B3), <i>Coccidiosis</i> (P1), <i>Hexamita</i> (P16).
<b>Hexamitiasis</b>	P16	<i>Hexamita</i> spp A motile parasite, related to <i>Giardia</i> , with a similar life history. May encyst outside the host. Wild pigeons may be latent carriers. Infection by ingestion of infected cysts.	Pigeons Galliformes Documented in some parrot species, particularly lorries.	Probably worldwide and often undiagnosed. Important; 50% of young pigeons can be carriers and can cause 10% of clinical cases of diarrhoea; More common in summer. Not very common.	Bright green diarrhoea with an unpleasant odour. Unthriftiness. PM: catarrhal inflammation of intestine and dilatation of small intestine.	Histopathology as above. May see quick-moving parasites in deep scrapings of mucosa in fresh PM specimens or cloacal swab fresh wet mount. Examine at body temperature or stain with Giemsa.	Trichomoniasis (P14), Giardiasis (P15), Coccidiosis (P1), <i>Salmonella</i> (B1), <i>E. coli</i> (B3), paramyxoviruses (V24-V32), herpes viruses (V1, V6) Helminths (P22, P27, P28).
<b>Histomoniasis</b> (Black head of turkeys)	P17	<i>Histomonas meleagridis</i> Parasite carried by the ova of the worm <i>Heterakis gallinae</i> which acts as a vector for the parasite.	Turkeys and other Gallinaceous birds, e.g. chickens, pheasants, quail, peafowl and grouse.	Common, particularly if associated with the domestic fowl, which carry the vector.	Dullness, diarrhoea, yellowish droppings. PM: caeca enlarged, filled with caseous necrotic material. Characteristic cream-coloured circular lesions on liver. Centre of lesion haemorrhagic.	Characteristic gross PM signs and histopathology.	All diarrhoeas, particularly those due to <i>Salmonella</i> (B1), <i>Campylobacter</i> (B6), <i>Chlamydothila</i> (B26).

**Haematozoan protozoal parasites**

Those protozoan parasites inhabiting the host's blood vascular system are, in birds, mostly benign or latent infections. However, any form of increased stress, such as migration, moulting, breeding, transportation or a change in the husbandry of captive birds can cause these parasites to cause clinical problems. Moreover, a concurrent infection with another, non-related, pathogen may precipitate a clinical parasitaemia. Simultaneous infection with more than one haematozoan is not uncommon. Wild birds act as reservoirs of infection for captive or domesticated birds. A good review of this subject is by Remple (2004).

Other haematozoan parasites occur in birds: *Babesia* and *Aegyptianella* (causing Piroplasmosis), are both found in the RBCs, as is *Hepatoozoon*, a tick-transmitted Rickettsia occurring in passerines, lovebirds, raptors, pigeons, Anseriformes and Galliformes.

**Appendix Table 5.5** Haematozoan protozoal parasites.

Disease	No.	Cause	Species Susceptible	Relative Occurrence	Principal Clinical Signs	Confirmation of Diagnosis	Differential Diagnosis
Avian malaria	P18	<i>Plasmodium</i> spp At least 25 species. Invade RBCs. Transmitted by various species of mosquito. Wild Passeriformes may act as latent carriers and act as a reservoir.	Probably most species of bird. Parasite is not always host specific. Documented in canaries, penguins, waterfowl, raptors, pigeons and parrots.	Almost certainly much more common than realised and not confined to the tropics. Distribution will be influenced by the occurrence of mosquitoes.	Swelling of eyelids reported in some species. Depression, fluffed up, haemolytic anaemia: Dyspnoea, vomiting, bright green faeces due to increased biliverdin. Death within a few hours. PM: subcutaneous haemorrhage, hepatosplenomegaly.	Examine stained blood smear for pigmented parasites within both RBCs and leucocytes, the nuclei of which are often displaced.	<i>Haemoproteus</i> , <i>Leucotoxozoon</i> , Ornithosis (B26), <i>Atoxoplasma</i> (P12).

(Continued)

Appendix Table 5.5 Continued.

Disease	No.	Cause	Species Susceptible	Relative Occurrence	Principal Clinical Signs	Confirmation of Diagnosis	Differential Diagnosis
<b>Leucocytozoonosis</b>	P19	<i>Leucocytozoon</i> spp Transmitted by biting flies ( <i>Simulium</i> spp) and midges ( <i>Culicoides</i> ).	Very pathogenic in the young of Galliformes, Anseriformes (important disease of ducks and geese in N. America due to black flies), Passeriformes. Parrot species	Where and when the right weather conditions occur for build-up of flies. Common	Anorexia, anaemia and possible deaths. Take into account prevailing climatic conditions.	Examine stained blood smear. A large intracellular parasite usually in leucocytes but may be in RBCs. PM: hepatosplenomegaly. Schizonts in impression smears of viscera.	Avian malaria (P18), <i>Haemoproteus</i> (P20) (this parasite also large but pigmented and does not distort host cell as does <i>Leucocytozoon</i> .
			Rare but can be fatal.				
			Owls	Common but not pathogenic.			
			Raptors – may be serious in young	Common			
<b>Haemoproteus spp</b>	P20	<i>Haemoproteus</i> spp Probably has a more restricted range of host species than <i>Leucocytozoon</i> . Transmitted by Hippoboscid flies, midges ( <i>Culicoides</i> which also transmits the sub-genus <i>Parahaemoproteus</i> ).	Probably potentially all species. Documented in many passerine and parrot species as well as Galliformes, Columbiformes, owls and diurnal raptors. Many wild birds act as latent carriers.	Global and quite common.	Not usually pathogenic; except in case of heavy infection or stressed birds. Haemolytic anaemia → weakness. PM: schizonts cause white streaks in cardiac and skeletal muscle. Occasionally Hepatosplenomegaly.	Stained blood smear shows large pigmented parasites in RBCs. Schizonts found in imprints of liver and spleen.	<i>Plasmodium</i> (P18), <i>Haemoproteus</i> may occupy 2/3 of cell but does not distort shape of cell like <i>Leucocytozoon</i> (P19).
<b>Trypanosomiasis</b>	P21	<i>Trypanosoma</i> spp Transmitted by biting arthropods, including Hippoboscids and red mite.	Documented in a wide variety of species, including parrots and probably potentially occurs in all species.	Probably not uncommon.	In most cases non-pathogenic.	Examine stained blood smear or smear from bone marrow. Parasite found in the plasma.	

## Helminth parasites

- During faecal examination of birds of prey for helminth parasites, the eggs of parasites of the prey species, which have not hatched in the alimentary canal of the predator, may be found. This is termed *pseudoparasitism*.
- Imported species of bird may have been infected in their country of origin long before they were imported and remain undetected for years.

**Appendix Table 5.6** Helminth parasites.

Disease	No.	Cause	Species Susceptible	Relative Occurrence	Principal Clinical Signs	Confirmation of Diagnosis	Differential Diagnosis
<b>Ascariidiasis</b>	P22	<i>Ascaridia</i> spp Eggs resistant to disinfection. Coprophagia in budgerigars. In other species, picked up from contaminated environment.	Probably all species, although the parasite may have species-specific forms.	Global. Found in many species but not particularly common.	Loss of condition. Sudden death or paralysis of legs due to impaction of intestine. Visceral larva <i>migrans</i> documented. In USA, contact with racoon faeces. Racoons are definitive host of <i>Bayliascaris procyonis</i> .	Examination of droppings by usual flotation methods to identify eggs.	Salmonellosis (B1), chronic colibacillosis.

<b>Gizzard worms</b>	P23	<i>Porrocaecum</i> spp	Documented in many Passeriformes. Also in ducks and raptors (rare).	Global	Unthriftiness. PM: Large intestinal worm larvae found under horny lining of gizzard. Larvae may cause tumours in the serosal surface of intestine.	Eggs in faeces look rather like ascarid eggs. Thick-walled, oval egg 1.5 size of ascarid egg.	Avian tuberculosis (B17).
----------------------	-----	------------------------	---	--------	--	---	---------------------------

(Continued)

Appendix Table 5.6 Continued.

Disease	No.	Cause	Species Susceptible	Relative Occurrence	Principal Clinical Signs	Confirmation of Diagnosis	Differential Diagnosis
<b>Proventricular and gizzard worms</b>	P24	<i>Microtreimeres</i> spp, <i>Dispharynx</i> spp, <i>Spiroptera</i> spp ( <i>Habronema incertum</i> ). Intermediate hosts groundliving arthropods; cockroach and some 'bugs' <i>Sireptocar</i> spp intermediate hosts are crustaceans.	Galliformes, Passeriformes, Psittaciformes, raptors including owls.	May be more common than recognised. Not always pathogenic.	Parasite burrows beneath horny lining of gizzard and into mucosa of oesophagus and intestine. Unthriftiness and sudden death. Causes nodules and ulceration in intestine.	Faecal exam. Embryonated egg, oval, thick-walled and half the size of Ascarid egg.	Avian tuberculosis (B17), chronic colibacillosis.
<b>Eyeworms</b>	P25	<i>Thelazia</i> spp Has invertebrate intermediate host, possibly a species of fly.  <i>Ceratospira</i> spp, <i>Annulospira</i> spp, <i>Oxyspirura</i> spp, cockroach is intermediate host.	All found in Psittaciformes, some pigeons and also in raptors.  →found in tropical areas of new world	Not uncommon	Mucosa of upper GI tract may be ulcerated → possible haemorrhage.  Occurs under nictitating membrane and associated structures → irritation, chemosis and ulceration.		Mycoplasmosis (B25)

<p><b>Gizzard worms specific to ducks and geese</b></p>	<p>P26</p>	<p><i>Amidostomum anseris</i> Adult birds act as carriers. Direct life cycle, but earthworms can act as transport vectors. Eggs hatch in water and larvae ingested.</p>	<p>All Anseriformes.</p> <p>Probably global and very common.</p>	<p>Anorexia, emaciation in young growing birds → death. PM: erosion and necrosis of lining of gizzard. Larvae found beneath kailin. May be found in proventriculus and oesophagus.</p>	<p>Faecal examination, oval eggs, thin-walled, usually embryonated, slightly larger than Ascarid egg.</p> <p>Avian tuberculosis (B17).</p>
<p><b>Capillaria spp</b> (thread worms or hair worms)</p>	<p>P27</p>	<p><i>Capillaria</i> spp Sometimes pass through a transport host, e.g. earthworm. Embryonation of egg takes 3 weeks.</p>	<p>Galliformes, Passeriformes, all raptors, Psittaciformes. Probably all species.</p> <p>Probably global and not uncommon.</p>	<p>Dysphagia. Worms sometimes seen in oropharynx (Plate 9). Loss of condition. Mucoïd diarrhoea, sometimes with blood → death. PM: heavy infection → anaemia. Worms found throughout GI tract or produce white plaques in pharynx.</p>	<p>Faecal exam shows eggs with typical bi-polar plugs. Eggs shed sporadically, therefore must examine serial samples.</p> <p>In raptors, Trichomoniasis (P14) can produce similar white necrotic lesions. Examine scrapings of mucosa in oropharynx for eggs. Cryptosporidiosis (P6)</p>

<p><b>Caecal worms</b> (carriers of the protozoan parasite <i>Histomonas</i>)</p>	<p>P28</p>	<p><i>Heterakis gallinarum</i> Earthworms act as transport hosts.</p>	<p>Domestic fowl and all Gallinaceous birds. Anseriformes.</p> <p>Common</p>	<p>The worm itself is probably not pathogenic unless there is a heavy infestation leading to unthriftiness and diarrhoea. PM: pin haemorrhages and nodules in mucosa of caeca.</p>	<p>Examine faeces for ova which are like <i>Ascaridia galli</i> but egg wall thinner and egg smaller.</p>
---	------------	---	--	--	---

(Continued)

Appendix Table 5.6 Continued.

Disease	No.	Cause	Species Susceptible	Relative Occurrence	Principal Clinical Signs	Confirmation of Diagnosis	Differential Diagnosis
<b>Proventricular worms</b>	P29	<i>Acuaria (Echinuria)</i> spp Intermediate host water flea ( <i>Daphnia</i> spp)	Anseriformes	Very high mortality in cygnets during a hot summer with warm shallow water.	Parasites cause nodules in proventriculus and gizzard resulting in partial obstruction → weight loss and diarrhoea. PM: excess mucus in proventriculus.	Faecal examination: small, elliptical, embryonated egg containing a single larva.	Gizzard worms (P26, P23).
<b><i>Trichostrongylus</i> spp</b>	P30	<i>Trichostrongylus tenuis</i>	Galliformes particularly. Grouse on the moor. Waterfowl.	On grouse moors. Cyclical variation results in epizootics.	Large numbers of worms in caeca cause a typhlitis → haemorrhage → death.	Elliptical embryonated eggs in faeces.	
<b><i>Angiostrongylus</i> spp Zoonotic</b>	P30A	<i>Angiostrongylus cantonensis</i> The 'rat' lung worm, found in variety of mammalian species including humans. Eggs in faeces → slugs or snails → paratenic host (fresh water prawns, crabs, planarians → final host.	Reported in yellow tailed cockatoo and tawny frogmouths (Monks <i>et al.</i> 2005).	Southeast Asia and Pacific basin, but spreading even to Caribbean.	Lethargy, weakness, possible CNS signs. Leucocytosis, heterophilia, lymphopaenia, monocytosis, AST↑, CK↑. Often death.	PM and histopathology of brain, liver and GI tract.	Paramyxoviruses (V24–V33).
<b><i>Syngamus</i> spp</b> (Gapes in poultry)	P31	<i>Syngamus</i> spp Direct transmission or may pass through a transport host, e.g. earthworms, molluscs and beetles.	Probably can infect all species and many Passeriformes act as reservoirs.	Very common. Can be a continuing problem in aviaries with earthen floors and uncovered roofs.	Dyspnoea → gaping, cough, head shaking, anorexia, unthriftiness → death. PM: parasites found in trachea, bronchitis, pneumonia.	Faecal examination: operculum at each end like egg of <i>Capillaria</i> but larger. Endoscopy of trachea.	In raptors <i>Capillaria</i> (P27), Trichomoniasis (P14), Candidiasis (M2), Aspergillosis (M1) (particularly parrots), avian pox (V35).



<p><b>Cyathostoma</b> By genus closely related to <i>Syngamus</i></p>	<p>P32 <i>Cyathostoma lari</i> Possible predator-prey transmission or via an intermediate host – earthworm. <i>Cyathostoma</i> spp Probably species specific forms for many species of bird.</p>	<p>Raptors (Simpson and Harris 1992). Also gulls waders, herons, crows, geese, cockatoos.</p>	<p>May be much more common than documented.</p>	<p>Parasite found in the orbit and nasal cavities → localised inflammation. Occasional anaemia. Found in lungs of cockatoos → consolidation → necrosis → death.</p>	<p>PM: remove eye and examine orbit. Faecal examination or use flotation technique.</p>
<p><b>Filariasis</b></p>	<p>P33 Larvae of <i>Serratospiculum</i> spp found as microfilaria in blood stream. Biting arthropods act as vectors. Weather conditions may favour increase in vector e.g. gnats.</p>	<p>Falcons  Documented in Passeriformes, Psittaciformes and ostrich chicks.</p>	<p>Commonly found in tropical and subtropical regions.  Not uncommon.</p>	<p>During visceral migration, larvae can cause severe reaction in lungs and air sacs. In parrots both adult worms and larvae can be found in fluid swellings around metatarsals. Microfilariae have been removed from anterior chamber of eye by author. In ostrich may cause CNS signs.</p>	<p>PM: adult worm in body cavities in alimentary canal and beneath serosa. Examine stained blood smear or wet mount of unstained blood. Most easily removed from buffy coat. Exhibits periodicity, so examine serial samples. Adult worm accidentally seen during endoscopy. Oval, thin-walled, embryonated egg in faeces.</p>
<p><b>Thorny headed worms</b></p>	<p>P34 Various species of Acanthocephalia (<i>Polymorphus</i>, <i>Prosthorhynchus</i>, <i>Centrotrichynchus</i> and <i>Fillicollis</i>) All have specific intermediate invertebrate hosts which may be either aquatic or terrestrial</p>	<p>Documented in waterfowl, Passeriformes, raptors (including owls), pigeons and lorikeets.</p>	<p>Geographically localised. Can be a serious problem in Cygnets and captive sea ducks where fresh-water shrimp (<i>Gammarus</i> spp) are present)</p>	<p>PM: found in intestinal mucosa causing enteritis and unthriftiness if present in large numbers.</p>	<p>Faecal examination: spindle-shaped, embryonated egg. Embryo contains cirlet of hooks on head. Avian tuberculosis (B17).</p>

(Continued)

Appendix Table 5.6 Continued.

Disease	No.	Cause	Species Susceptible	Relative Occurrence	Principal Clinical Signs	Confirmation of Diagnosis	Differential Diagnosis
<b>Tapeworms</b>	P35	A very large number of the class Cestoda, or tapeworms, occur in birds. All require an intermediate host, usually an arthropod but sometimes a fish. Often only found in the country of origin.	Probably all species. Less common in seed and fruit eating birds except for nestlings being fed on insects. Raptors and owls. Occasionally seen in imported birds.	Occurrence variable.	Often not pathogenic. General debility, diarrhoea, anorexia.	PM: varying degree of enteritis and presence of worms. If a lot of mucus present scrape and examine mucus microscopically – embryonated eggs show larvae with hooks. May find proglottids in faeces. Examine more than one sample.	<i>Railiellina</i> spp can produce nodules in gut wall which may look like avian tuberculosis (B17).
<b>Flukes</b>	P36	Numerous trematode species in birds. Not particularly host specific. Infection depends on feeding habits of bird and secondary host. Their complex life cycles always require a secondary host. Maybe insect or a mollusc which is usually but not always aquatic. Sometimes involves water snail eaten by fish then predated by bird.	Passeriformes  Waterfowl and aquatic birds, including Penguins  Columbiformes Falconiformes  Psittaciformes	Global. Not very common, except if near water.  Not uncommon  Not common Most common in local tropical regions  Seen in imported birds. 30% in tropical and subtropical areas.	General unthriftiness, anaemia. Signs may be related to where flukes are situated in body. PM: flukes may be found in almost any location, even in vascular system, and influence secondary PM signs.	Examine faeces for fluke eggs.	

**Arthropod ectoparasites**

Wild birds migrating from tropical climates may pick up parasites (e.g. *Amblyomma* spp), that do not normally occur in temperate climates. Ectoparasites may also act as the transport or the intermediate host of other avian parasites (haematoprotozoa) and other infectious pathogens.

The parasite load of birds tends to increase during the breeding season when the birds are under increased stress and may also be more closely associated in breeding colonies. This can affect egg production and chick mortality.

Mosquitoes, gnats, midges and black flies all bite and suck blood and often transmit the haematoprotozoa. All can cause anaemia, particularly in hatchlings.

**Appendix Table 5.7** Ectoparasites.

Parasite	No.	Contributing Factors	Species Susceptible	Relative Occurrence	Principal Clinical Signs	Confirmation of Diagnosis	Differential Diagnosis
Lice	P36	All bird lice are biting or chewing lice (Order: Mallophaga) The sucking lice (Order: Siphunculata) are found in mammals.	Almost certainly all bird lice are host specific but more than one species of louse may be found on a bird, at different sites.	Very common, particularly on debilitated birds. Often seen leaving a dying bird.	Most lice feed on feather debris and not on blood but some may feed on the growing feathers 'in the blood'. May cause irritation and restlessness. Loss of condition. Healthy birds keep lice in check by preening or 'anting'	Very often easy to find even on marine birds such as the gannet (Boobies). With small birds during visual exam hold feather up to the light. Since entire life cycle is carried out on the bird, look for lice eggs (nits) attached in clusters around shaft of feather.	Other causes of irritation, possibly hippoboscids and certainly red mite, etc.
Hippoboscids (flat flies or louse flies)	P37	Arthropods, often wingless related to the sheep ked. Some species complete life cycle on host others lay eggs in environment (bird's nest).	Probably all species and not particularly host specific. Seen particularly on raptors, pigeons, swifts, martins, swallows.	Very common on many wild birds.	Can cause pruritus and suck blood. Transmit <i>Haemoproteus</i> and trypanosomes. Often jump onto human handler, get into clothing and hair and difficult to remove. Can be a problem for nestling pigeons.	Recognition of dorsoventrally flattened, stout, dark-coloured flies.	Because of shape and size (slightly bigger than house fly) unlikely to be confused with any other ectoparasite. Can transport parasitic mites.

(Continued)

Appendix Table 5.7 Continued.

Parasite	No.	Contributing Factors	Species Susceptible	Relative Occurrence	Principal Clinical Signs	Confirmation of Diagnosis	Differential Diagnosis
<b>Fleas</b>	P38	Many species of insects of the order Siphonaptera. Although wingless, able to leap a long way. Eggs laid in dust, dirt, debris. Can long survive in dry conditions.	All species of bird. Parasite not as host specific as lice.	Global. Not so often seen but can build up in nesting areas and nest boxes.	Irritation → restlessness. Although they suck blood they are of doubtful pathogenicity. As they are not very host specific, birds can become infected with fleas from domestic pets and humans can get fleas from birds. Fleas from nestling starlings can build up in the roof space of a house.	Identification of adult eggs and larvae. Adult fleas may not remain on the bird for a long time. Because of cross species infestation it is important to get expert identification of adult fleas to ascertain the probable source of the infestation.	
<b>Sticktight fleas</b>	P39	<i>Echidnophaga gallinacea</i>	Mainly on poultry but also on gamebirds, pigeons, Passeriformes and raptors if near poultry.	Common in the tropics and subtropics but may be seen on imported birds.	Adult fleas do not jump but remain attached in clusters around the head and eyes → hyperkeratinisation, anaemia → death in young birds.	Examine specimens removed from head.	
<b>Mites</b>	P40	Red mite ( <i>Dermanyssus</i> spp) Breeds off host in woodwork, cracks and crevices, etc. Feeds on bird at night. Multiplies rapidly in summer months. Northern fowl mite (also red or dark colour) ( <i>Ornithonyssus</i> spp). Life cycle completed on host, therefore more pathogenic.	Documented on large range of species both wild and captive, common in many aviaries.	Both types of mite probably global and probably more common in the wild than realised.	Can cause intense irritation, restlessness and feather damage often caused by bird itself. Tends to leave hospitalised sick birds and get onto nurses, etc. Sucks blood and probably transmits Trypanosomes, <i>Lankasterella</i> and both eastern and western equine encephalitis. Sitting hens and nestlings most at risk. Can be lethal to small nestlings → just found dead.	When looking for mites wear gloves and observe gloved surface or place bird in glass cage. For <i>Ornithonyssus</i> examine perches by torch at night or use a white sheet under perches.	Other types of ectoparasite, but not usually the cause of feather picking in captive parrots.

<p><b>Harvest mites</b></p>	<p>P41 Larvae of <i>Trombicula</i> spp Adults free living in scrub and old pasture during spring and autumn, feeding on invertebrates and plants.</p>	<p>Not host specific and found on most ground living birds.</p>	<p>Widespread but clinical infection uncommon and localised.</p>	<p>Irritation and vesicles where mite has bitten and feather loss.</p>	<p>Identification of larvae on skin.</p>	<p>Red mites</p>
<p><b>Feather and feather quill mites</b></p>	<p>P42 Various species inhabit different parts of the feather and are found on different parts of the body</p>	<p>Documented in quite a wide range of species and probably most species are infected at some time or other.</p>	<p>Probably global.</p>	<p>Usually not pathogenic unless there is a heavy infestation → pruritus and feather loss with occasional thickening of the skin. May be found in powdery material of feather stumps.</p>	<p>Examine with a hand lens or, better still, pluck a growing feather 'in the blood' and gently squeeze the contents onto a slide and examine microscopically.</p>	<p>Circovirus, feather and quill mites (P42).</p>
<p><b>Epidermoptic mites</b></p>	<p>P43 <i>Myialges</i> spp and other species Cause a 'depluming itch' or 'mange'. Burrow into the stratum corneum of the skin. Transported by hippoboscids (P37)</p>	<p>Documented in passerines, psittacines and owls. Probably occurs in most species.</p>	<p>May be a lot more common than recognised.</p>	<p>Heavy infestation may cause pruritus, scaly dermatitis with brown scabs and desquamation of the skin. Mostly affects the covert feathers of the head, neck and body. May look rather like sarcoptic mange</p>	<p>Skin scrapings and possibly biopsy.</p>	<p>Circovirus, feather and quill mites (P42).</p>
<p><b>Forage mites</b></p>	<p>P44 Many free living species. Found on foodstuffs, usually grain or seeds, but also cheese and dried fruit. Transported on insects and by wind. Scavenge in birds' nests.</p>	<p>Mainly granivorous species.</p>	<p>Can be found anywhere where food is badly stored in humid conditions.</p>	<p>Not pathogenic but may be confused with pathogenic species. Causes considerable spoiling of seed foods. May cause an allergic reaction and very occasionally → death after eating the spoiled food. Author has seen the floor heaving with the mites on grain fed to over 100 quail without any deaths.</p>	<p>Very small and off-white in colour. Need expert identification.</p>	<p>Red mites (P40), <i>Trombicula</i> (P41).</p>

(Continued)

Appendix Table 5.7 Continued.

Parasite	No.	Contributing Factors	Species Susceptible	Relative Occurrence	Principal Clinical Signs	Confirmation of Diagnosis	Differential Diagnosis
<b>Air sac mites</b>	P45	<i>Sternostoma</i> spp Complete life cycle carried out on the host. Mostly adult birds infect the young during feeding but eggs in faeces may contaminate food and infect birds.	Mostly reported in many Passeriformes, particularly Gouldian finches. Occasionally in Psittaciformes.	Global, possibly more common than realised.	Loss of condition, dyspnoea, loss of voice, sneezing, gasping, head shaking, rhinitis → death, but low mortality. PM: mites coloured black in trachea and upper airways also in air sacs with mucus and pneumonia.	In live bird may be seen in air sacs by endoscopy and occasionally by transillumination of the trachea in small birds. Eggs may be found in the faeces.	Avipox (V35) Enterocolitis (B8).
<b>Scaly face and scaly leg mites</b> 'Depluming itch' or 'Feather rot' in pigeons	P46	<i>Cnemidocoptes</i> spp	Budgerigars Crossbills, other Passeriformes Psittaciformes, canaries, Galliformes, many free living birds.	Very very common. Common, particularly on legs. Occasional.	Grey-white encrustations around the cere, the beak, the commissures of upper and lower beak. Often results in gross distortion of the beak. Prolonged infection can cause gross hyperkeratosis and necrosis. Also <i>tassie foot</i> lesions on canaries and other Passeriformes. May also cause lesions around cloaca.	Gently scrape lesions onto a slide with 10% KOH. Mites very easily found.	Neoplasms of the beak, avipox (V35), papillomas of the legs, brown hypertrachy of the cere, malnutrition.

<p><b>Bugs</b> Bedbugs Parasitic on both mammals and birds.</p>	<p>P47 Members of the Order Hemiptera, e.g. <i>Cimex</i> spp, <i>Oeciacus</i> spp Adults can survive off the host for some time. Eggs laid in the environment – birds' nests. Adults can survive in the environment a long time.</p>	<p>Pigeons, Galliformes, swallows.</p>	<p>Mostly in temperate and subtropical climates.</p>	<p>Sucks blood. Heavy infestation → anaemia → death in young.</p>	<p>Tends to feed on the host at night.</p>	<p>Body size larger than mites.</p>
<p><b>Ticks</b></p>	<p>P48 Hard ticks, e.g. <i>Ixodes</i> spp</p>	<p>Probably all species, including ostriches. Seen on migrating birds at ringing stations.</p>	<p>Probably global but localised. Attacks grouse on moors. Carried by sheep, small mammals, and humans. Seen on falcons tethered near sheep or poultry.</p>	<p>Irritation, loss of condition, anaemia and death if infestation is severe. Small birds do not need many ticks to lose quite a lot of blood. Transmit haematoprotozoa, arboviruses (e.g. louping ill → grouse on British uplands). May also transmit <i>Borrelia</i> spp. Tick bites can cause oedema and haemorrhage (Plate 6).</p>	<p>Sometimes easily seen but also close and detailed bodily examination of the bird.</p>	
<p><b>Dipterous flies</b></p>	<p>P49 <i>Calliphora</i>, <i>Lucilia</i> and <i>Phormia</i> spp All these genera can cause blow fly strike</p>	<p>Potentially all species, particularly if the bird has an open wound.</p>	<p>Blow fly strike is not all that common in birds but can affect chicks in a dirty nest.</p>	<p>Larvae or maggots are easily seen and must be removed from the affected area. Meticulous care is needed to make sure all the maggots are removed.</p>		

## **APPENDIX 6 POISONS LIKELY TO AFFECT BIRDS**

This list is not comprehensive and is only a guide. A specific diagnosis of poisoning is not always possible – much depends on the species, even the individual on circumstantial evidence.

The analysis of samples can be expensive and the analyst must be given a good idea of what to look for. One should collect samples of liver, kidney and the contents of proventriculus and gizzard. Collect pancreas if zinc is suspected or brain for organophosphates. Wrap all samples in aluminium foil and freeze. Contact the laboratory to ascertain if analysis is possible. Many poisons do not cause acute death, but in sub-lethal doses may be responsible for lowered fertility, reduced resistance to infection and non-specific symptoms such as sporadic nervous tremors. Few cases of poisoning are malicious; most are due to carelessness or thoughtlessness.

For a fuller discussion of the subject of poisoning in birds the reader is referred to: Labonde (2006), Arnall and Keymer (1975), Cooper (1978) and Cooper and Eley (1979). In the UK: Veterinary Poisons Information Service (VPIS), London Tel. 0207 635 9195, Leeds 0113 245 0530. In case of wildlife poisoning, contact the Wildlife Officer of the local DEFRA Agricultural Development and Advisory Service or use DEFRA's website, [www.defra.gov.uk/portal/site/defraweb/index](http://www.defra.gov.uk/portal/site/defraweb/index).



**Appendix Table 6.1** Poisonous substances.

Type of Poison	Comments
<p>Agricultural and gardening chemicals. Seed dressings and storage preservatives. Organomercury compounds. Lead arsenate. Sodium chlorate used as a weed killer. Paraquat and diquat – herbicides.</p>	<p>Many substances are used to control infection of the seed and growing plants by micro-organisms. They may also be used to control weevils in stored grain. The chemicals may be used at the wrong dose or the treated seed inadvertently fed to birds. Supplies of many seeds come from countries where the control of these chemicals is not strict enough.</p>
<p>Insecticidal and herbicidal sprays. Agricultural fertilisers. Agricultural diesel. Ammonium sulphate, phenoxyacid herbicides, carbamates. Phosphorothionates and malathion. Many of these substances are under strict government control.</p>	<p>Most notorious of the insecticides in the past has been DDT, the other organochlorines, lindane (BHC) and dieldrin, and the polychlorinated biphenyls (PCBs). Many organophosphates are used to spray growing crops including fruit crops. The cloud of spray may be blown by wind. The insects killed and contaminated with the insecticide may be eaten by birds. Nitrogenous fertilisers may leach into water supplies. Roadside and garden herbage may be contaminated by many chemicals. Water supplies of birds may become contaminated. Diesel fuel leaking from a farm into a waterway killed many ducks.</p>
<p>Insecticides used to control pests in domestic animals. Organophosphates (OPs) are inhibitors of the cholinesterase enzymes of the nervous system, and birds are 10–20 times more sensitive to these chemicals than humans.</p>	<p>Sheep dips and preparations to control fly strike in sheep may be misused. Many OPs used on domestic pets as sprays and baths are toxic if misused on birds. Such substances are carbaryl, dursban, malathion, etc. Dichlorvos organophosphate strips <i>if misused</i>. Birds must not have direct contact with them. Must be used in a well-ventilated room. Minimum air space 30 cubic metres per strip. Use for three days only. Avoid use in high temperatures. Clinical signs are usually CNS – twitching, weakness, sometimes paralysis – together with GI signs.</p>
<p>Rodenticides</p>	<p>In the past, strychnine, arsenic, thallium, zinc phosphide and phosphorus were widely used and are still used in some countries. Warfarin (see p. 105) and related compounds together with the OPs are now commonly used and birds may gain access to treated bait. Sodium fluoroacetate and fluoroacetamide are also widely used in many parts of the world and are very poisonous. Strychnine can still be used under licence in the UK for killing moles and rodents.</p>
<p>Tea, coffee, cocoa (drinking chocolate), eating chocolate.</p>	<p>All contain theobromine which can cause hyperexcitability, cardiopathy and death. Few documented cases in birds but see Cole and Murray (2005).</p>
<p>Crude oil</p>	<p>Ingested by birds after oil spillage at sea. Also some wild birds nest in and around oil refineries.</p>
<p>Molluscicides</p>	<p>These are used to control garden and agricultural pests (slugs and snails) and the vectors of many helminth infections. Metaldehyde and copper sulphate are both toxic to birds.</p>
<p>Alphachloralose</p>	<p>These are used to control pigeons in urban areas. Affected pigeons are narcotised and may be eaten by raptors. Also used as a rodenticide.</p>

(Continued)

Appendix Table 6.1 Continued.

Type of Poison	Comments
Disinfectants (including pine disinfectants)	Phenols and cresols and hyperchlorites are often used far more concentrated than the manufacturers' recommendations. Can lie in pools in the bottom of aviaries and dry on perches, etc. The quaternary ammonium antiseptics are relatively non-toxic.
Lead In <i>waterfowl</i> the differential diagnosis is botulism.	Cage or aviary birds may be exposed to old lead paint, window leaded lights, linoleum, lead toys, curtain weights, discarded lead pipes, solder, golf balls. <i>Waterfowl</i> and gamebirds may pick up lead from ground which has been heavily shot over. <i>Waterfowl</i> , particularly swans, may gradually accumulate lead from discarded fishermen's lead weights lying in the bottom mud of watercourses. Lead poisoning has also been seen in <i>waterfowl</i> near a rubbish tip containing lead car batteries. Old lead mining areas, lead smelting and industrial areas may be heavily contaminated. Plants and insects become contaminated and may be eaten by birds.
Raptors	Raptors may pick up sub-clinical lead levels from the tissues of prey species and also intact lead shot from their gizzards (Reiser and Temple, 1980). The latter may or may not be voided in the casting of the raptor. Also, possible chronic exposure to automobile exhaust fumes. Radiographs of affected birds may be negative but plasma levels raised.
Parrots	Out of their natural environment, parrots tend to chew a great variety of household goods containing lead: linoleum, metal strips wrapped round champagne and wine bottles, lead curtain weights, bell clappers, leaded strips on glass windows, solder, costume jewellery, old woodwork covered in lead paint and the galvanized wire on cages etc. The cardinal signs of poisoning in all species are CNS and also in Parrots haematuria.
Other heavy metal poisoning (zinc, copper, manganese, titanium)	Sources of zinc are galvanized dishes and mesh, galvanized roofing nails, staples, zinc oxide ointment, etc. Parrots particularly may have access to these objects and may chew galvanized cage bars or be given 'toys' containing these metals (Kersing, 2006). Signs of acute zinc poisoning are as for lead except no haematuria. Pathologically there are marked signs of degeneration in the pancreas, liver and kidney. Sources of copper are wire, particularly electrical, copper boat nails, copper piping and pennies. Sources of manganese are industrial waste ash from manufacturing.
Fumes from Teflon non-stick cooking utensils, chip pans, saucepans. Polytetrafluoroethylene (PTFE), a common airborne toxin. Besides cooking utensils, PTFE may come from electric irons, ironing board covers, heat-lamp covers (see p. 189).	If these cook dry and overhear, toxic fumes can be produced.

In the industrial process of coating plastic onto metal sheets, faulty setting of electrical controls resulted in the discharge of toxic airborne effluent downwind of the plant, resulting in many bird deaths. Because the avian respiratory system is more efficient and 'sensitive' than that of humans, humans in the same area showed only moderate upper respiratory distress. PM (see p. 112) of affected birds showed intense red coloration of all tissues, particularly the lungs. A similar picture is seen in carbon monoxide poisoning.

These fumes can come from a car left running in a garage or from a gas central heating boiler or gas water heater which is not functioning properly. Birds may be transported in the boot/trunk of a vehicle with faulty exhaust system.

*Botulism:* mentioned under infectious diseases. Blow flies often attack meat infected with *Clostridium botulinum*, the maggots take in the toxin and they may then be eaten by birds. Another cause is dead aquatic invertebrates in rotting vegetation. Sometimes associated with poisoning by blue-green algae (*Cyanophyceae*) and other algal blooms occurring in static shallow water in hot weather. Also in these weather conditions consider salt poisoning (see p. 338). Many plants or parts of plants are poisonous to birds, but many plants poisonous to one species are not necessarily poisonous to another species of bird, e.g. parsley (*Petroselinum* spp) is toxic to ostriches but not parrots. Insects that eat poisonous plants may contain the toxins that, if they are themselves eaten by birds, poison the bird. For example, the milkweeds (*Asclepias* spp) of the western hemisphere are eaten by monarch butterflies (*Danaus plexippus*) and these contain cardiac glycosides produced by the plant. If the insect is eaten by a bird it is poisoned.

Other plastics if burnt can produce toxic fumes (dioxin).

Garden incinerators, industrial manufacturers of fertilisers.

Carbon monoxide

Naturally occurring toxins

**Garden and House Plants**

Listed are a few plants found in the garden and sold as house plants some of which may be toxic for some species of bird

- Amaryllis (*Amaryllidaceae*)
- Lily of the valley (*Convallaria majalis*)
- Oleander (*Nerium oleander*)
- Virginia creeper (*Parthenocissus quinquefolia*)
- Dumb cane (*Dieffenbachia* spp)
- Swiss cheese plant (*Monstera* spp)
- Philodendron* spp
- Poinsettia (*Euphorbia* spp)
- Clematis (*Clematis* spp)
- Foxglove (*Digitalis* spp)
- Lupin (*Lupinus* spp)
- Croton (*Codiaeum* spp)
- Castor oil plant (*Ricinus communis*)
- Cherry laurel (evergreen, *Prunus laurocerasus*) (clippings of laurel trees if stored in a plastic bag overnight in a warm atmosphere can accumulate toxic cyanide fumes)
- Rhododendron species, including azaleas
- Bird of paradise *Poinciana gilliesii*
- Bay tree (*Laurus nobilis*)
- Avocado (*Persea* spp) (toxicity of different species is variable)
- Tobacco plant (*Nicotiana affinis*) – ingestion of tobacco products (e.g. cigarette ends), direct contact or indirect contact through tobacco stains on a smoker's hands can be toxic to household pets

(Continued)

Appendix Table 6.1 Continued.

Type of Poison	Comments
	<p>Hemlock (<i>Conium sp.</i>) – seeds eaten by pigeons have caused fatalities            Yew (<i>Taxus spp</i>) – eaten by game or aviary birds. All parts of the plant are very poisonous            Ivy (<i>Hedera helix</i>) – berries eaten by some wild species of bird with impunity            Boxwood (<i>Buxus sempervirens</i>)            Caladium (<i>Caladium spp</i>)            House plant ferns (<i>Pteris spp</i>)            Hydrangea (<i>Hydrangea spp</i>)            Hyacinth (<i>Hyacinth orientalis</i>)            Iris (<i>Iris reticulata</i>)            Narcissus (<i>Narcissus spp</i>, including daffodil)</p>
Aflatoxins and other mycotoxins	<p>First discovered in groundnuts affecting turkeys. The toxin is a metabolite of an <i>Aspergillus</i> fungus which can grow in badly-stored grain or seed. Toxicity of aflatoxins is variable. Aflatoxin B1 is an hepatotoxin.</p>
Ergot infected grain ( <i>Claviceps purpurea</i> ) Salt poisoning	<p>If eaten in large amounts causes necrosis of the extremities            Brackish water consumed in drought. Peanuts (salted) and potato crisps fed to parrots. Some birds are able to excrete salt through nasal salt gland (see Chapter 1) (see p. 113).</p>
Plant tannins and alkaloids	<p>The leaves and twigs of rhododendron, azalea, laburnum and many other plants are toxic to herbivorous mammals, and the bark may be toxic for birds. The leaves and bark of many trees contain low-grade toxins such as tannins. These are bitter tasting and are part of the plants' natural defence systems against insects and vertebrates feeding on them. Perrins (1979) has shown that blue tit nestlings fed on mealworms containing tannins grow more slowly than nestlings fed on mealworms which do not contain tannins. This phenomenon could occur with many other plant substances taken directly or indirectly by birds.</p>
A few household toxins	<p>Chlorine – used in garden swimming pools and contain bleach            Alcohol – one pub budgerigar became addicted and in sampling the pint glasses fell in one day            Various household furniture and cleaning sprays            Paint remover            Soaps and shampoos            Nail varnish            Ammonia</p>
iatrogenic toxins	<p>The 14th century physician Paracelsus said 'All things are poison; nothing is without poison, only the dose permits something not to be poisonous' (Wikipedia, 2006).            All drugs used in veterinary treatment are potential poisons, particularly in the case of those species of bird in which they have not been documented as having been safely used.            A steep decline in the population of vultures in India occurred because they were susceptible to the toxic effects of diclofenac, secondarily acquired through feeding on carcasses of cattle in which this NSAID drug had widely been used.</p>

## APPENDIX 7 SOME SUGGESTED DIAGNOSTIC SCHEDULES

Not all the procedures listed may be necessary to reach a definitive diagnosis.

### **Schedule 1: Basic investigation of the sick bird**

A basic investigation will be carried out as a sequel to the initial clinical examination and anamnesis, after which there is still no clear indication of the cause of the problem. If some more definite clinical signs are present to indicate which body system or systems are involved then it might be more appropriate to commence with one of the other schedules listed. If a number of birds are affected, euthanasia of the worst and subsequent post-mortem examination may enable a more rapid diagnosis to be made.

#### Full haematological examination

A haematological examination may indicate an inflammatory reaction, however, two examinations 24–48 hours apart of total white cell count (TWCC) and red cell count (RCC) are more useful than one single sample alone. For quick results, carry out in clinic. If two consecutive counts are low in a young bird suspect *circovirus*.

A differential white cell count (WCC) may not be very helpful in making a diagnosis in birds. Take into account any previously administered steroids.

Haematology may also indicate haemoparasite infection, anaemia and its type.

#### Basic biochemical profile

##### *Total protein, albumin:globulin ratio, fibrinogen*

In most cases, this data will only provide a rough guide to the problem. For in-depth interpretation of the results see the relevant sections in Chapter 4. These parameters provide some information on the overall state of health and the presence or absence of an inflammatory response.

##### *AST, CPK, bile acids*

These parameters *may* indicate a hepatopathy or only just tissue trauma (blood samples should not be taken after i.m. injection).

##### *If the sample is lipaemic*

Cholesterol estimation will indicate possible hypothyroidism, which will also be indicated by hypoglycaemia. Alternatively, hypercholesterolaemia may be associated with *fatty liver and kidney syndrome*.

##### *Calcium*

Latent hypocalcaemia can be an important cause of debilitation in some parrots (particularly African grey parrots – *Psittacus erithacus*) and also in raptors.

##### *Uric acid*

Increased levels of uric acid do not necessarily indicate nephropathy. Uric acid should be considered in conjunction with the plasma levels of albumin, glucose and CPK, together with the haematology. Changes in these parameters may indicate starvation (also indicated by loss of pectoral muscle), or extensive trauma accompanied by haemorrhage. These conditions may also result in an increase of plasma uric acid.

#### Whole body radiography

Both ventro-dorsal and latero-lateral views should be taken, and may be supplemented with ultrasonography. It may indicate neoplasia, respiratory disease (e.g. air sacculitis), skeletal disease, tuberculosis, aspergillosis, splenomegaly, which, with haematology and

biochemistry, may indicate an increased immune response (e.g. to *Chlamydophila*), changes or displacement of the GI tract (e.g. neuropathic proventricular dilatation of psittacine birds) or a possible cardiopathy.

## **Schedule 2: For the investigation of respiratory signs**

To carry out some of the following procedures, light isoflurane anaesthesia may be required. If respiratory disease is severe an air sac cannula will be needed. The clinician should try to decide if upper or lower systemic disease is present.

Don't forget hypovitaminosis A or iodine deficiency (particularly in budgerigars) can cause respiratory signs. Also, respiratory disease may be the most obvious sign of an overall systemic infection particularly viral in origin.

### Whole body radiography

Both ventro-dorsal and latero-lateral views should be taken. Apart from indications of disease in the respiratory tract (air sacculitis, granulomata of the lungs, air trapping etc.), space-occupying lesions (neoplasms, egg peritonitis, etc.) may be responsible for respiratory signs.

### Full haematological and biochemical profiles – including cholesterol

This should be done for the same reasons as outlined in Schedule 1. Hypercholesterolaemia may indicate hypothyroidism, with associated hypertrophy of the gland and pressure on the syrinx.

### Endoscopy and laparoscopy

Endoscopy should be performed on the trachea, syrinx, choanal aperture and posterior nares. A laparoscopic examination of the coelomic air sacs, caudal surface of the lung and, in larger birds, the mesobronchus, should also be carried out.

Together with these procedures, collect *cytological* and *bacteriological* samples. Apart from overt air sacculitis and aspergillosis, etc., parasites such as *Serratospiculum* (this should also show microfilaria), *Syngamus* and *Sternostoma* may be seen. Air sac mites in small finches are more easily seen by transillumination of the trachea via the skin of the neck.

### Microbiology

Carry out microbiological examination of all exudates and solid lesions including the examination of stained smears as well as culture. A variety of organisms may be isolated, some of which will be secondary viral infection, or lesions of hypovitaminosis A may be found. Lesions of trichomoniasis may be confused with *owl herpes virus* infection. *Mycobacteria* may be isolated as well as *Aspergillus* spp, *Candida* spp and *Cryptococcus* spp. They may all take time to culture, so cytology is important.

### Serological examination

Serological examination may confirm the presence of *Chlamydophila*, *Aspergillus*, *Mycobacteria*, *Salmonella* (sometimes a systemic infection), *Borrelia*, *Mycoplasma* and a variety of viral infections. Among the latter are paramyxovirus (including Newcastle disease virus), avian influenza, laryngotracheitis and goose parvovirus. Which test is used will depend on the particular circumstances.

### Virus isolation

Some viruses can be isolated and identified by cell culture. However, special transport media must be used. Check with the laboratory first. These viruses include Amazon tracheitis, infectious bronchitis and pigeon herpes.

### Cytology

Cytology can be carried out by either the clinician or the laboratory. Sample exudates, washings or solid material from the paraorbital sinuses, the choanal space, tracheal washings, etc., as well as specimens obtained by endoscopy or laparoscopy. Don't forget the use of Indian ink if searching for *Cryptococcus*.

### Faecal examination

When investigating respiratory signs perhaps faecal examination may not be such an obvious part of the search. However, some parasites (e.g. *Syngamus*, *Capillaria*, *Sarcocystis* and *Cryptosporidia*) produce ova or encrusted larvae that are shed in the faeces. These may not be released regularly so that more than one sample should be examined. Don't forget use of Giemsa stain for *Cryptosporidia*.

### Toxins

Industrial effluent, crop and forestry sprays, tobacco smoke, Teflon, carbon monoxide, creosote and other timber treatments, ammonia from unsanitary aviaries or cages and aerosols may all be responsible for respiratory signs.

## **Schedule 3: Investigation of gastrointestinal problems, including hepatopathy**

### Faecal examination

It is necessary to carry out a complete faecal examination for parasites and bacterial culture.

Not all birds with loose droppings have diarrhoea or a GI problem. They may be just anorexic. Take note of any abnormal colour for that particular species. Bright green, caused by excessive biliverdin, usually indicates hepatitis, often viral but may be caused by *Chlamydophila* or even *Plasmodium*. Clay-coloured faeces may be due to maldigestion or paramyxovirus III in *Neophema* parakeets. Chalky faeces in ostrich chicks may be caused by adenovirus.

Overt blood may be due to neoplasms, tuberculosis, bacterial enteritis (often with mucus), lead or faecoliths. Take into account what the bird may have eaten (e.g. elder or blackberries). Some drugs (e.g. B vitamins) may colour droppings. Absence of or reduced faeces may be due to mechanical obstruction, parasites, cloacal impaction, intussusception or just water deprivation.

### Microscopic examination

- Stain faeces sample with Giemsa
  - To detect *Cryptosporidia* or *Giardia*
- Stain sample with iodine
  - Detection of excessive starch
- Stain sample with Sudan III
  - Detection of fat
- Stain with Gram stain
  - Differential assessment of Gram- and Gram+
- Stain with acid-fast stain
  - Detection of *Mycobacteria*
- Examine fresh (within 10 minutes of being voided) faecal sample on warm slide
  - Detection of *Giardia* or *Hexamita* – often difficult to confirm

### Microbiological and cytological examination of crop and proventricular washings

This is particularly important for the detection of trichomonads, yeasts and fungi. Use Gram stain and lactophenol cotton blue and examine unstained fresh sample on warm slide to detect moving trichomonads.

### Microbiological examination of fresh castings from raptors

Note that some other species may also produce regurgitated castings or pellets.

### Radiography

Use ventro-dorsal and lateral projections, plain and contrast media techniques (possibly via enema). Radiography may be supplemented by ultrasonography. Imaging techniques may indicate foreign bodies, neoplasia, ulceration, proventricular dilatation, undigested seed in the intestine and occasionally parasitic nematodes.

### Endoscopy

Endoscopy of the upper alimentary tract should be carried out as far as the proventriculus and also of the cloaca and rectum. If necessary, inflate with air or water.

### Haematology

Complete haematology profile for the same reasons as in Schedule 1.

### Biochemical profile

A blood biochemistry profile as for Schedule 1 should be obtained, but in addition to include lactate dehydrogenase (LDH), glucose and alkaline phosphate (AP). This should give an indication of hepatopathy (this may need to be associated with radiographic and/or ultrasonographic interpretation, liver biopsy, haematology and microbiological examination (via laparoscopy) to confirm the aetiology). There may be a need to investigate toxins. Hyperglycaemia may indicate a pancreatitis, diabetes mellitus or lead toxicosis. Increased AP may be a sign of aflatoxicosis.

### Laparoscopy/laparotomy for biopsy of liver or proventriculus

If a hepatopathy is suspected and a liver biopsy is contemplated, give a prior injection of vitamin K. Biopsy of proventriculus may confirm neuropathic proventricular dilatation.

### Plasma T4 estimation

Reduced thyroid hormone may indicate thyroid dysplasia in an enlarged thyroid. This may cause possible retching, change in vocalisation. Also note any increased cholesterol.

## **Schedule 4: The investigation of renal disorders**

It is important to appreciate that renal disease in birds is not usually suspected during the initial examination. Nephropathy is much more likely to be revealed during the subsequent laboratory examination or during the investigation of other body systems. It may be indicated by other apparently unrelated signs, such as unilateral or bilateral lameness or paresis of the legs or by gross abdominal changes resulting in dyspnoea.

The classical early signs of nephropathy in mammals (polydipsia, polyuria, oliguria) are not usually notable signs of avian renal disease. The avian kidney is proportionately larger than in mammals so that most of it will have to have become diseased before plasma uric acid levels rise significantly or gout is seen. Also uric acid is much less toxic than urea. The physiology of avian kidneys varies considerably between species and also quite differently from that in mammals and is not well documented.



### Complete haematology

Complete haematology should be performed for the same reasons in Schedule 1. The kidneys are involved in approximately 50% of all cases of multisystemic diseases and also many renal disease cases are anaemic.

### Biochemical profile

A biochemical profile should be performed as in Schedule 1, but with the addition of plasma urea. Although not hitherto considered an important parameter in the diagnosis of nephropathy, Lumeij (1987) has demonstrated that a rise in plasma urea is the single most important factor for diagnosis of pre-renal failure (see Chapter 4).

Note the normally high levels of postprandial uric acid in peregrine falcons and red tailed hawks which may also occur in other raptors. Also note a hypoalbuminuria may be the result of protein loss due to glomerulonephritis.

### Urine analysis

Urine for analysis may be carried out on a sample aspirated by syringe and needle from waxed paper or directly from the bird. Birds, especially parrots, when stressed in a clinic often pass fluid excreta, the urinary fraction of which can be harvested. In ostriches the urine is voided first and separately from faecal matter.

Use Multistix dip stick tests (the test for protein is unreliable). Examine the urine sample for castes and/or cell types which may give an indication of renal disease. Check the specific gravity. This should be 1.005–1.020. Check the pH. This should be between 4.7–8.0.

It is most important to be careful to collect only urine uncontaminated by faeces – this may not be easy. Persistent proteinuria together with hypoalbuminaemia and glycosuria with hyperglycaemia may indicate a glomerulonephritis, also often with ascites or pedal oedema. Red pigmentation of the urine may be due to haemoglobinuria or haematuria or porphyrinuria (an indication of lead toxicity). Urine positive for porphyrins fluoresces red under ultraviolet light but blue if negative. Haematuria may be from the reproductive tract or caused by Amazon or conure bleeding syndromes. Haemoglobinuria may be the result of a coagulopathy, *Plasmodium*, bacterial or chemical toxins.

In birds laying eggs, the pH becomes acid (4.7). Calcium deposited in the shell results in a plasma excess of hydrogen ions. Bicarbonate is reabsorbed from the urine to buffer this, so that the urine becomes acid.

### Endoscopy of the cloaca and laparoscopy

Endoscopy and/or laparoscopy may reveal a cloacal impaction not always seen at the initial examination. Alternatively, a cloacal neoplasm may be seen.

Laparoscopy and examination of the surface of the kidney may show any of the following: the pale waxy appearance of amyloidosis, the irregular surface texture of glomerulonephritis, neoplastic change, uric acid deposits in the parenchyma or on the surface together with signs of gout on the surface of heart or liver.

### Faecal examination

Some parasites, evidence of which may be found in the faeces, notably *Eimeria truncata* of geese, *Cryptosporidia* and occasionally trematodes, infect the kidneys.

In addition, any bird exhibiting signs of hypovitaminosis A, i.e. pustules in the oropharynx (particularly African grey parrots), hyperkeratosis of the feet, paraorbital sinusitis or bilateral epiphora, should be suspected of having an underlying nephropathy caused by metaplasia of the epithelium of the kidney tubules. This may reduce active excretion of uric acid or affect urea excretion. Other renal toxins not already mentioned are aflatoxin, other mycotoxins, ethylene glycol and carbon tetrachloride.

### **Schedule 5: Signs of polydipsia/polyuria**

Polydipsia and polyuria are generally not indications of nephropathy in birds. These signs are most likely to indicate a hormonal problem, hepatopathy or the use of corticosteroids or they may be psychogenic. Also, excessive fruit or high protein or toxic drugs or the use of progesterones may all precipitate this condition. Some infections, particularly paramyxovirus in pigeons, chronic chlamydophilosis or *Klebsiella* infection may all be responsible for a marked and prolonged polydipsia and polyuria. Always take into account any concurrent and primary alimentary tract disease which may account for substantial fluid loss.

#### Urinary glucose

See Schedule 4 for method of sampling.

Dipstick testing for glucose should be negative, but if the sample is slightly contaminated with faeces there may be a false positive. *Only if there is a hyperglycaemia should a diagnosis of diabetes mellitus be made* otherwise the cause may be glomerulonephritis if other signs are present.

#### Water deprivation test

Collect urine samples as described in Schedule 4.

*This test must only be carried out on normally hydrated birds (first check the PCV) and those in good bodily condition.* Starve the bird 12 hours if a small bird or up to 20 hours for pigeon-sized birds, to reduce the risk of faecal contamination. Measure the urinary specific gravity at the start and after 24 hours without water. Specific gravity should increase to above 1.025 in the normal bird which if polydipsic/polyuric may be psychogenic in origin. If no increase occurs and the specific gravity of the sample remains between 1.008 and 1.012, this could indicate nephropathy, rectal disease (an important region of water conservation) or central diabetes insipidus. Psychogenic polydipsia may be related to stressors and increased secretion of corticosteroids. It is not uncommon in recently weaned parrots, cockatoos and African grey parrots.

#### The use of antidiuretic hormone

Arginine vasotocin is the principle hormone regulating water balance in birds. Mammalian vasopressin does have some effect but is not so potent. Using a dose of 0.5 units/kg body weight of vasopressin, the urinary specific gravity should increase with the water deprivation test. If this occurs, a diagnosis of central diabetes insipidus involving the pituitary gland can be made. There may be other signs such as exophthalmos or episodic seizures if a neoplasm is involved.

#### Radiography

Barium enema with air contrast of the coprodaeum and rectum may indicate pathology of these areas which are important in water conservation

### **Schedule 6: The investigation of dermatological problems including skin, feathers, beak, claws, feet, wattles and comb**

As in mammals, the diagnosis of some of these problems can sometimes be very difficult and they are often complex and multifactorial.

Before considering the use of any ancillary aids or laboratory tests, it is essential to obtain a thorough clinical history, which should include enquiry about the duration of the condition and the relation of this to the breeding history and breeding cycle of the bird. Information should also be sought on any previous illness and any relevant vaccine status.

Husbandry practices should be considered, including the type and size of caging, since this affects physical fitness and behaviour. The humidity of the ambient atmosphere if too dry leads to brittle feathering. How much natural and artificial light the bird is subjected to is important, since prolonged periods beyond what is normal for the species or decreasing or increasing periods of light affect the pineal/hypothalamus/pituitary complex which has an important influence on moulting. Diet received by the bird is most important and many pet and captive birds are deficient in one or more fractions of their diet. Hypovitaminosis A is easy to recognise by its other signs.

In sexually dimorphic species any abnormal changes in secondary sexual characteristics or behaviour may indicate an underlying sex hormone problem. Other abnormalities of behaviour, particularly in household parrots, may be stress-related resulting from changes in the routine or life style of the owner.

Next, a thorough visual examination of the affected part or parts, if necessary using magnification and good lighting, should be carried out and much of what to look for has been described in Chapter 3. However, when examining feathers, note further if they look worn and frayed (i.e. not just chewed as with some parrots). Are new feathers emerging and do they look normal? Some parrots which have been self-plucking for months or years may have so damaged the epidermis of the follicles that they will never regenerate. A simple but good routine is to carefully pluck a damaged feather, use it for testing, *note the exact position from which it was taken*, then during the next 2–4 weeks watch the new feather gradually emerge. If the epidermis and dermis have not been damaged, regrowth of a new normal feather should occur.

The observer should look to see if the uropygial gland is functional in those species that have one. It is absent in ratites, rudimentary or absent in most pigeons and many parrots. However, it is present in the African grey parrot and the budgerigar. When examining the beak, note if there is any lesion of the germinative layer and note if the claws look normal.

#### Full health check (see Schedule 1)

Feather plucking, particularly in African grey parrots, can be due to chronic chlamydophilosis. *These birds may look just like psychogenic feather pluckers*. Also, chronic hypocalcaemia can cause self-trauma in these birds. *Giardia* may cause self-plucking in cockatiels. Underlying neoplasms and traumatic arthritis may also initiate localised self-trauma. Hepatopathy may result in changes to the colour of plumage from green to yellow or black or dark brown to black. Particularly dark-coloured or black feral pigeons often have an underlying health problem.

#### Cytology and microscopy

Cytology of the pulp of affected feathers together with scrapings of cere and skin lesions may reveal some ectoparasitic infections. Other ectoparasites may need special techniques (see Appendix 7). Excessive dirt and debris may be seen trapped between the barbules indicating the bird is not preening or able to bathe.

#### Biopsy

Skin biopsies should be preserved in buffered normal saline as for other biopsies. Always include at least one feather follicle. A biopsy punch or scalpel can be used. Biopsy may be necessary to confirm a suspicion of Avipox virus infection.

#### Microbiology and antibiotic sensitivity

Samples for microbiology and antibiotic sensitivity testing may be dry or moist. If the sample is dry, small pieces harvested aseptically can be placed in the transport medium of a swab tube. Squeeze feather pulp into a swab tube with sterile forceps.

Microbiological pathogens may be either primary or secondary causes of skin problems, so always search for an underlying cause. A great variety of pathogens, bacterial, yeast and fungi, have been documented as having been isolated from avian skin and feathers. Clostridial dermatitis is documented as causing a localised loss of feathers together with a dark pigmentation of the skin (see Appendix 2).

### Virology

Viruses, other than avipox, causing skin lesions for which histopathology may be appropriate are *papilloma virus* of the feet of some Passeriformes, *localised dermal virus* of the feet of cockatoos, macaws and mallard ducks and *herpes virus* of lovebirds. The feather duster syndrome of budgerigars is probably not caused by a virus but is genetic in origin (Plate 21).

If the facility is available, use electronmicroscopy to examine newly emerging and growing pin feathers. This has been used (courtesy of J.E. Cooper) to identify PBFV virus in vasa parrots (*Coracopsis vasa*) (see Plate 5).

### Test treat with haloperidol

If all the above tests are negative, a presumptive diagnosis of psychogenic self-feather-plucking may be made. Some species of parrot are particularly prone to this condition, e.g. African greys, occasionally cockatoos and macaws, rarely budgerigars or cockatiels. The latter is more prone to self-trauma of the prepatagium. All psychogenic cases need nutritional support, spraying or bathing facilities, attention to light levels and other husbandry improvements. Overall, complete resolution can only be expected in 20% of cases and 30% show no improvement at all (see also other behavioural modifying drugs pp. 260 and 264).

## Schedule 7: For the investigation of neurological signs

Many infectious diseases, toxins and traumas are responsible for neurological signs. In many cases, because of the species affected and the circumstances, the experienced clinician will have a fair idea of the cause. Tests will then be needed to confirm the tentative diagnosis. Of course, in all cases, it is necessary to obtain a thorough clinical history, including the duration of the problem, whether the bird has been recently purchased or received by the owner, whether the signs are constantly present or occur sporadically. It is important to obtain in-depth information on the husbandry and whether any medicaments have been recently administered.

Listed below are those conditions commonly responsible for neurological signs.

If none of those causes listed above could be the reason for any of the neurological signs, or these have not been confirmed with subsequent tests, then a systemic examination commencing with a thorough health check including those tests detailed in Schedule 1 will need to be carried out. A systematic assessment of the nervous system may also have to be implemented. The bird's alertness, signs of hyperactivity, signs of sleepiness or any abnormal behaviour will give an indication of the general state of the central nervous system.

### Cerebrospinal fluid

Although CFS is present, its collection from the subarachnoid space is not very practical because of the considerable haemorrhage from the venous sinuses in this area.

**Appendix Table 7.1** Possible causes of neurological signs.

<b>Disease/disorder</b>	<b>Comment</b>
<b>Viruses</b> (see Appendix 3)	
Newcastle disease (paramyxovirus serotype I)	All species can be affected and can exhibit a variety of neurological signs.
Also PMV-1 mutant strain, PMV-3	Common in feral pigeons. Not uncommonly seen in <i>Neophema</i> spp grass parakeets.
A suspected PMV virus	Twirling syndrome in some finches
Polyomavirus (one cause of budgerigar bleeding disease)	Occasional CNS signs can sometimes affect finches
Duck virus hepatitis (picorna virus)	May have extended necks and drown
Duck virus enteritis (duck plague) a herpes virus	Paralysis of the phallus
Marek's disease	Mainly Galliformes but also waterfowl and occasionally in some other species
Pigeon herpes virus (infectious oesophagitis)	
Pigeon herpes virus (contagious paralysis)	Mainly Galliformes but can affect waterfowl and pigeons
Avian encephalomyelitis (epidemic tremor)	Grouse spp and pheasants
Louping ill (an arbo virus)	Rare in birds but can occur in many avian species
Rabies	Recorded as occurring in ostrich chicks
Borna disease	Quail, raptors, Psittaciformes and waterfowl
Adenoviruses	Psittaciformes and geese
Reovirus (orthovirus)	Young turkeys – may cause lameness
Reticuloendotheliosis virus	
<b>Other infectious diseases</b> (see Appendices 2 and 5)	
Mycobacteriosis	All species
Aspergillosis	Both pathogens can cause granulomata which may start in the vertebral column, causing paralysis
Listeriosis	Rare, geographically localised, all species but mostly canaries
<i>Chlamydophila</i>	Occasional CNS signs
Filariasis	Raptors, Passeriformes, Psittaciformes and ostrich chicks
Toxoplasmosis	All species but particularly waterfowl
Sarcocystis and the related <i>Hammondia</i> and <i>Besnoitia</i> spp	In the case of a very heavy infection, the encysted parasites may cause muscle damage and atrophy, weakness and paresis
<i>Giardia</i>	May be associated with hypovitaminosis in cockatiels resulting in weakness, paresis and paralysis
Caryospora spp	Occasionally in other psittacines May be the cause of muscle cramps in raptors

(Continued)

Appendix Table 7.1 Continued.

Disease/disorder	Comment
<b>Metabolic and nutritional causes</b>	
Hypocalcaemia	Particularly common in the African grey parrot due to nutritional secondary hyperparathyroidism
Seizures in African grey parrots	Precipitated by oxytetracycline
Ataxia in conures	Can also occur in conures with conure haemorrhagic syndrome
Hypoglycaemia	Raptors kept by falconers on a reduced diet Weakness, dullness and fits
Hepatopathies	Also possible in parrots secondary to hepatopathy and starvation
Hypovitaminosis B	May result in hepatic encephalopathy due to raised plasma ammonia
Hypovitaminosis E	Reduced dietary vitamins B1, B2, B6 and B12 may all cause neuropathy
Hypovitaminosis D3, calcium deficiency	So-called 'star gazing' or opisthotonos due to hypovitaminosis B1 Particularly in cockatiels but also documented in other psittacines and possible in other species As for hypocalcaemia (above)
<b>Toxins (see Appendix 8)</b>	
Lead and other heavy metals, such as zinc	Common in swans, due to bottom feeding of fishermen's weights Also other water birds
Agricultural sprays drifting into aviaries from poorly controlled manufacturing processes	Differentiate botulism
Leakage into waterways of badly stored agricultural chemicals	Also household and aviary parrots
Household pet aerosol sprays	All species
Botulism	All species
	Particularly water birds but also raptors
	Most common in hot weather but can occur at any time where there is decaying animal waste.

<p>Household plants and aviary pot plants Iatrogenic medical drug overdose</p> <p>Aflatoxins</p> <p>Algal toxins</p>	<p>Usually pet parrots but any aviary kept birds</p> <p>Some drugs which might be implicated include aminoglycosides, fluoroquinolones, some 'azole' antifungals, levamisole, ivermectin, metronidazole, dimepridazole, xylazine and medetomidine</p> <p>All species feeding on grains, seeds or peanuts</p> <p>Warm, shallow, static water</p> <p>Most water birds but any other birds drinking the water</p>
<p>Hypothalamic/pituitary tumours in budgerigars</p>	<p>Usually occurs in birds under 4 years. A well recognised and not uncommon syndrome results in a variety of CNS signs including episodic seizure. Often with polydipsia/polyuria, sometimes obesity or small size, cere may change colour</p>
<p>Neoplasia of the gonads in budgerigars</p> <p>Idiopathic epilepsy</p>	<p>These may squeeze the sacral plexus between synsacrum and tumour affecting nerves to the legs so bird becomes lame</p> <p>A tentative diagnosis can be assumed after ruling out other causes</p> <p>Documented in parrots (particularly Amazon parrots) and Mynah birds</p> <p>Can be petit mal or grand mal in type</p> <p>Response to phenobarbitone at 0.5–6.0 mg/kg p.o. every 12 hours</p>
<p>Cerebrovascular episode, strokes</p> <p>Nephropathy, gonadal tumours and egg impaction</p>	<p>May result from fat embolism during egg laying</p> <p>All of these can cause pressure on the sacral plexus causing lameness, paresis or paralysis</p>
<p>Trauma</p>	<p>Gunshot wounds, not always obvious</p> <p>Aggression from cage mates, wild conspecifics during breeding, predators</p> <p>Road traffic or railway injuries</p> <p>Healed fractures but still paralysis due to avulsion of peripheral nerves</p>

**Miscellaneous causes**

## Cranial nerves

## Appendix Table 7.2 Assessment of cranial nerve function.

Cranial Nerve (CN)	Comment
<b>Olfactory (I)</b>	Olfaction varies considerably between species and checking this nerve's function is difficult and often not very practical. Note noxious odours used for testing could be toxic. See the section dealing with <i>Olfaction</i> in Chapter 2.
<b>Optic (II)</b>	<p>Checking this nerve is not difficult, but make sure the bird does not have a cataract or intraocular haemorrhage from the pecten.</p> <p>If a bird persists in keeping one particular eye on the observer be suspicious of defective vision in the other eye.</p> <p>In birds, there is almost complete decussation of the optic fibres so a defect on one side indicates a brain lesion on the contralateral side.</p> <p>Total blindness may indicate a lesion in the region of the optic chiasma, e.g. budgerigar pituitary neoplasm.</p> <p>Decussation of the optic fibres also results in there being no consensual pupillary light reflex. In any case, this reflex is difficult to assess in birds because the iris muscles are striated and partially under voluntary control, so a bright light directed at the eye may not evoke a response because of voluntary inhibition.</p> <p>There is a great deal of information on the visual system in Chapter 2, so if investigating CN II it would be better to read this first.</p>
<b>Oculomotor (III) and Trochlear (IV)</b>	In most birds, except for the toucans and hornbills, the extraocular eye muscles are considerably reduced and eye movement is minimal (compensated for by the highly mobile neck). Consequently, assessment of the function of CNs III and IV is often not very practical. However, ptosis or paralysis of the upper eyelid indicates a lesion of the dorsal branch of CN III.
<b>Trigeminal (V)</b>	<p>Function of this nerve is easy to assess since it is sensory to all the structures of the head and motor to both the lower and upper jaws.</p> <p>There is some discussion of the trigeminal nerve in Chapter 2 under the heading <i>Proprioception</i>.</p>
<b>Abducent (VI)</b>	Along with the lateral rectus muscle of the eyeball, CN VI innervates the nictitating membrane. Although this is controlled by two striated muscles and is to some extent under voluntary control, touching the cornea with a moist cotton bud usually produces a marked response, providing of course the afferent nerve in cranial nerve V is intact.
<b>Facial (VII)</b>	Separate assessment of this cranial nerve is difficult and not always practical.
<b>Vestibulocochlear (VIII)</b>	<p>Hearing may be difficult to check but head tilt, ataxia and spontaneous nystagmus may all indicate dysfunction of this nerve.</p> <p>Check for signs of exterior auditory disease. These signs may be more common in the night hunting owls due to increased size of external ear, to their dependency on hunting by sound rather than sight and the complexity of the many auditory nuclei in the brain.</p> <p>First read the section dealing with the <i>Auditory system</i> in Chapter 2.</p>
<b>Glossopharyngeal (IX)</b>	Paralysis of the tongue and lack of sensation indicate dysfunction.
<b>Vagus, Accessory and Hypoglossal (X, XI, XII)</b>	Independent assessment of these nerves is not easy.



### The peripheral nervous system

The withdrawal reflexes in both wings and legs are segmental reflexes but should elicit a conscious response if the spinal cord is intact. Similarly, the cloacal reflex is segmental. Lesions of the thoracolumbar vertebrae are not uncommon and are indicated by conscious appreciation of intact wing withdrawal reflex but no response by the bird to an intact leg withdrawal reflex together with a cloacal reflex. Check by radiography.

Knuckling of the legs or an inability to grip the perch may be either an upper or lower motor lesion.

### **Schedule 8: Cardiac disease**

Although avian cardiac disease is probably a lot more common than is generally realised, particularly in cage birds, there are few well-documented case history investigations of cardiac disease in birds. This is because of the relatively small size of the patient and the high heart rates, leading to difficulties in the interpretation of auscultation. Signs of cardiac disease may be complicated by other accompanying disease problems such as such as respiratory disease, obesity and neoplasia.

The following signs in the absence of any other disease may lead the clinician to a tentative diagnosis of cardiac disease:

- Chronic exercise intolerance
- General weakness and reluctance of the bird to hold itself erect on the perch
- Overall lethargy

An investigation can be carried out using radiography, ultrasonography and the electrocardiography, preferably without using general anaesthesia.

### Radiography

Measurements of the dimensions of the cardiac shadow can be made on a good radiograph. Pees *et al.* (2006) have indicated the following parameters: in most medium-sized psittacine birds, African greys and Amazons (200–500g), the maximum transverse width of the heart should be 36–41% of the length of the sternum and 51–61% of the width of the thorax.

These workers have also detailed measurements for a limited number of other species.

### Ultrasound

Echocardiography may be useful to supplement radiography of the heart. Details are given in Chapter 4.

### Electrocardiography (ECG)

Electrocardiography is used regularly for monitoring anaesthesia in birds. However, except for pigeons, Amazon and African grey parrots and some Macaw species, little has been documented for the normal reference values for most avian species. Nevertheless the ECG can be useful in indicating cardiac arrhythmias and conduction disorders. Detailed information has been published by Lumeij and Ritchie (1994).

**APPENDIX 8 WEIGHTS OF BIRDS MOST LIKELY TO BE SEEN IN GENERAL PRACTICE**

This list should be used as a general guide only. In all clinical situations birds should preferably be weighed accurately.

**Appendix Table 8.1** Weights of birds.

Order	Common Name	Scientific Name	Weight Range (g)
<b>Psittaciformes</b>	Lesser sulphur-crested cockatoo	<i>Cacatua sulphurea</i>	228–315
	Greater sulphur-crested cockatoo	<i>Cacatua galerita galerita</i>	670–800
	Moluccan cockatoo	<i>Cacatua moluccensis</i>	670–800
	Roseate cockatoo	<i>Eolophus roseicapillus</i>	340–480
	Umbrella cockatoo or great white cockatoo	<i>Cacatua alba</i>	530–610
	Blue and gold macaw	<i>Ara ararauna</i>	850–2000
	Scarlet macaw	<i>Ara macao</i>	810–1100
	Hahn's macaw (noble macaw)	<i>Ara nobilis</i>	150–180
	Orange-winged Amazon	<i>Amazona amazonica</i>	440–470
	Blue-fronted Amazon	<i>Amazona aestiva</i>	275–510
	Yellow-fronted Amazon	<i>Amazona ochrocephala</i>	260–460
	Double yellow-headed Amazon (Levaillant's)	<i>Amazona ochrocephala oratrix</i>	545
	Mealy Amazon	<i>Amazona farinose</i>	600–685
	Yellow-billed Amazon	<i>Amazona collaria</i>	215–270
	Festive Amazon	<i>Amazona festiva</i>	358–500
	Hispaniolan Amazon	<i>Amazona ventralis</i>	268
	African grey parrot (three main varieties with different average weights)	<i>Psittacus erithacus</i>	310–460
	Orange-bellied Senegal parrot	<i>Poicephalus senegalus</i>	125–150
	Dusky-headed conure	<i>Aratinga acuticaudata</i>	155–185
	Red-masked conure	<i>Aratinga erythrogenys</i>	158–168
	Jendaya conure	<i>Aratinga jandaya</i>	118–128
	Yellow rosella parakeet	<i>Platycercus flaveolus</i>	100–120
	Pale-headed rosella parakeet	<i>Platycercus adscitus palliceps</i>	100–120
	Blue bonnet	<i>Psephotus haematogaster</i>	100–120
	Port Lincoln	<i>Barnardius zonarius</i>	170–180
	Blue-headed parrot/Pionus parrot	<i>Pionus menstruus</i>	238–278
	Cockatiel	<i>Nymphicus hollandicus</i>	70–108
	Budgerigar	<i>Melopsittacus undulatus</i>	35–85
	Bourke's parakeet	<i>Neophema bourkii</i>	50
	Turquoise parakeet	<i>Neophema pulchella</i>	50
	Blue-winged grass parakeet		
	Fisher's lovebird	<i>Neophema chrysostoma</i>	50
		<i>Agapornis fischeri</i>	40–50

<b>Columbiformes</b>	Racing/feral pigeon Wood Pigeon Collared Dove Diamond dove	<i>Columba livia</i> <i>Columba palumbus</i> <i>Streptopelia decacoto</i> <i>Geopelia cuneata</i>	230-540 454-680 150-220 40
<b>Gruiformes</b>	Moorhen Coot	<i>Gallinula chloropus</i> <i>Fulica atra</i>	278 520
<b>Charadriides (Infraorder)</b>	Lapwing plover Common sandpiper Herring gull Lesser black-backed gull Great black-backed gull Common/arctic tern Heron	<i>Vanellus vanellus</i> <i>Tringa hypoleucos</i> <i>Larus argentatus</i> <i>Larus fuscus</i> <i>Larus marinus</i> <i>Sterna hirundo/paradisaea</i> <i>Ardea cinerea</i>	200-235 50 690-1495 620-1000 1000-2000 90-100 1362
<b>Ciconiides (Infraorder)</b>	(Northern) gannet Shag (Great) cormorant Fulmar petrel	<i>Sula bassana</i> <i>Phalacrocorax aristotelis</i> <i>Phalacrocorax carbo</i> <i>Fulmaris glacialis</i>	2750 1700-2200 2000-2500 800
<b>Anseriformes</b>	Mute swan Canada goose Domestic/greylag goose Bean Goose Muscovy Duck Domestic/mallard duck	<i>Cygnus olor</i> <i>Branta canadensis</i> <i>Anser anser</i> <i>Anser fabalis</i> <i>Cairina moschata</i> <i>Anas platyrhynchos</i>	8000-13,000 4540 3100-4090 2700-3600 3500-5000 975-3500
<b>Falconides</b>	(Eurasian) sparrow hawk (Northern) goshawk Common buzzard Red-tailed hawk Harris's hawk Peregrine falcon Kestrel Saker falcon Lanner Falcon Laggar Falcon Merlin Gyrffalcon	<i>Accipiter nisus</i> <i>Accipiter gentilis gentilis</i> <i>Buteo buteo</i> <i>Buteo jamaicensis</i> <i>Parabuteo unicinctus</i> <i>Falco peregrinus</i> <i>Falco tinnunculus</i> <i>Falco cherrug</i> <i>Falco biarmicus</i> <i>Falco jugger</i> <i>Falco columbarius</i> <i>Falco rusticolus</i>	Males 150-210, Females 190-300 Males 634-880, Females 980-1200 680-1100 Males 698-1147, Females 1000-1350 574-1000 Males 560-850, Females 1100-1500 Males 145-167, Females 193-282 Males 680-990, Females 970-1300 Males 500-600, Females 700-900 515 Males 160-170, Females 220-250 Males 805-1300 Females 1400-2100

(Continued)

Appendix Table 8.1 Continued.

Order	Common Name	Scientific Name	Weight Range (g)
<b>Galliformes</b>	(Common) pheasant	<i>Phasianus colchicus</i>	Males 1300–1600, Females 500–1135
	Domestic chicken	<i>Gallus gallus</i>	1000–4000
<b>Strigiformes</b>	Tawny owl	<i>Strix aluco</i>	330–465
	Short-eared owl	<i>Asio flammeus</i>	325–440
	Long-eared owl	<i>Asio otus</i>	210–325
	Little owl	<i>Athene noctua</i>	150–175
	(Eurasian) eagle owl	<i>Bubo bubo</i>	1600–2500
	Barn owl	<i>Tyto alba</i>	262–600
<b>Passeriformes</b>	Carion crow	<i>Corvus corone corone</i>	358–650
	Rook	<i>Corvus frugilegus</i>	335–460
	(Western) jackdaw	<i>Corvus monedula</i>	145–210
	Song thrush	<i>Turdus philomelos</i>	80
	(Common) blackbird	<i>Turdus merula</i>	57
	American robin	<i>Turdus migratorius</i>	64.8–84.2
	(European) robin	<i>Erithacus rubecula</i>	20–30
	Pekin robin	<i>Leiothrix lutea</i>	26
	(Common) starling	<i>Sturnus vulgaris</i>	64
	Purple glossy starling	<i>Lamprolornis purpureus</i>	74–82
	Great Indian Hill mynah	<i>Gracula religiosa intermedia</i>	180–260
	House sparrow	<i>Passer domesticus</i>	25–30
	Zebra finch	<i>Poephila guttata</i>	10–16
	Java sparrow	<i>Padda oryzivora</i>	24–30
	(European) goldfinch	<i>Carduelis carduelis</i>	15–20
	(American) goldfinch	<i>Carduelis tristis</i>	15–20
	Common/red crossbill	<i>Loxia curvirostra</i>	41
	Great tit	<i>Parus major</i>	17.5–20.72
	Blue tit	<i>Parus caeruleus</i>	10–13.75
	Canary	<i>Serinus canaria</i>	12–29
	Green singing finch	<i>Serinus mozambicus</i>	10

**APPENDIX 9 INCUBATION AND FLEDGING PERIODS OF SELECTED BIRDS**

**Appendix Table 9.1** Incubation and fledging periods.

Order	Common Name	Scientific Name	Incubation Period (days)	Fledging Period (days)
<b>Psittaciformes</b>	Budgerigar	<i>Melopsittacus undulatus</i>	16–18	22–26
	Australian parakeets in general	Genera: <i>Neophema</i> , <i>Platyercus</i> , <i>Psephotus</i>	18–19	30–45
	Cockatiel	<i>Nymphicus hollandicus</i>	About 18	28
	Ringneck parakeet	<i>Psittacula krameri</i>	23–24	55–65
	Lorikeys	<i>Trichoglossus</i> spp	25–26	62–70
	Lovebirds	<i>Agapornis</i> spp	About 18	30–35
	Amazon parrots	<i>Amazona</i> spp	23–24	45–60
<b>Columbiformes</b>	Domestic pigeon	<i>Columba livia</i>	17–19	35–37
	Wood pigeon	<i>Columba palumbus</i>	17–19	16–38
	Collared dove	<i>Streptopelia decaocto</i>	14	18–21
<b>Charadriides (Infraorder)</b>	Herring gull	<i>Larus argentatus</i>	20–34	42
	Common gull	<i>Larus canus</i>	24–27	35
	Black-headed gull	<i>Larus ridibundus</i>	22–24	35–42
<b>Anseriformes</b>	Mute swan	<i>Cygnus olor</i>	34–40	Leave nest in 24–48 hours Dependent on parents for 100–120 days
	Greylag/domestic goose	<i>Anser anser</i>	24–30	Post fledging with parents 53–57 days
<b>Falconides (Infraorder)</b>				45
	Shelduck	<i>Tadorna tadorna</i>	28	52
	Mallard	<i>Anas platyrhynchos</i>	28	49–56
	Pochard	<i>Aythya ferina</i>	23–29	
	(Eurasian) sparrow-hawk	<i>Accipiter nisus</i>	32–35	24–30
	(Northern) goshawk	<i>Accipiter gentilis gentilis</i>	36–38	41–43
	Buzzard	<i>Buteo buteo</i>	34–38	42–49
	Red-tailed hawk	<i>Buteo jamaicensis</i>	32–35	43–48
	Harris's hawk	<i>Parabuteo unicinctus</i>	32	40
	Peregrine falcon	<i>Falco peregrinus</i>	29–32	35–42
	(Eurasian) Kestrel	<i>Falco tinnunculus</i>	28–31	27–30
	American kestrel (formerly called sparrow-hawk)	<i>Falco sparverius</i>	28–31	27–30
Lanner falcon	<i>Falco biarmicus</i>	32–34	44–46	
Golden eagle	<i>Aquila chrysaetos</i>	41–49	about 77	

(Continued)

Appendix Table 9.1 Continued.

Order	Common Name	Scientific Name	Incubation Period (days)	Fledging Period (days)
<b>Galliformes</b>	Pheasant	<i>Phasianus colchicus</i>	21–28	Fly at 12–14 days
	Domestic chicken	<i>Gallus gallus</i>	21	Precocial
<b>Strigiformes</b>	Tawny owl	<i>Sirix aluco</i>	28–30	30–37
	Short-eared owl	<i>Asio flammeus</i>	24–28	24–27
	Long-eared owl	<i>Asio otus</i>	27–28	about 23
	Little owl	<i>Athene noctua</i>	28–29	35–40
	(Common) barn owl	<i>Tyto alba</i>	32–34	64–86
	Snowy owl	<i>Nyctea scandiaca</i>	32–34	51–57
<b>Passeriformes</b>	Carrion crow	<i>Corvus corone corone</i>	16–20	26–38
	Rook	<i>Corvus frugilegus</i>	16–18	28–30
	(Eurasian) jackdaw	<i>Corvus monedula</i>	17–18	30–35
	Black-billed magpie	<i>Pica pica</i>	17–18	22–27
	(Common) blackbird	<i>Turdus merula</i>	13–14	13–14
	Song thrush	<i>Turdus philomelos</i>	13–14	13–14
	(European) robin	<i>Erithacus rubecula</i>	13–14	12–14
	European starling	<i>Sturnus vulgaris</i>	12–16	20–22
	House sparrow	<i>Passer domesticus</i>	12–14	About 15
	Zebra finch	<i>Poephila guttata</i>	12	14–21
	Common/red crossbill	<i>Loxia curvirostra</i>	12–13	17–25
	(European) goldfinch	<i>Carduelis carduelis</i>	12–13	13–14
	Chaffinch	<i>Fringilla coelebs</i>	11–13	13–14
	Great tit	<i>Parus major</i>	13–14	18–20
	Blue tit	<i>Parus caeruleus</i>	17–18	About 16
	Canary	<i>Serinus canaria</i>	13–14	Fed by parents for 28 days

**APPENDIX 10 GLOSSARY**

**Alcinae** A taxonomic family of short-winged marine diving birds, the auks, included in the taxonomic infraorder the Charadriides.

**Altricial nestlings** Newly hatched birds born blind, helpless and without true feathers, although they are covered in down. These chicks are nidicolous, or nest attached, and are entirely parent dependent.

**Anseriformes** The taxonomic order of birds containing four families, amongst which are the Anatidae (ducks, geese, swans).

**Adeidae** The taxonomic family of birds containing the herons, egrets and bitterns.

**Ayrie** See eyrie.

**Bate, bating** A falconer's term; fluttering or flying off the fist or an object.

**Bewits** Short strips of leather by which bells are fastened to the legs.

**Block** A cylindrical piece of wood to which the hawk is attached by a leash, and upon which it can perch.

**Calling off** Luring a hawk from an assistant at a distance.

**Casting** Fur, feathers and bone being the indigestible part of a raptor's diet which are periodically ejected in the form of a pellet.

**Charadriiformes** A taxonomic infraorder of birds containing fourteen taxonomic families and subfamilies of aquatic bird, prominent amongst which are Haematopodidae (oyster catchers), Charadriidae (plovers and lapwings), Scolopacidae (sandpipers) and Laridae (gulls and terns).

**Cockatiel** The smallest member of the sub-family Cacatuinae (cockatoos) group of parrots and a popular pet bird.

**Ciconiidae** A taxonomic superfamily of birds including the storks and the New World vultures.

**Columbidae** A large taxonomic family of birds including the pigeons and doves.

**Columbiformes** The taxonomic order of birds containing the Columbidae and the extinct dodos.

**Conspecific** Of the same species.

**Coping** A falconer's term meaning to cut off the sharp points of beak and talons.

**Covert feathers** The smaller feathers which cover the base of the shaft of the main flight feathers.

**Corvidae** The taxonomic family of birds included in the order of Passeriformes, which contains the crows, magpies and jays.

**Creance** A falconer's term referring to a long line attached to the swivel and used when 'calling off' (q.v.).

**DEFRA, UK** Department of Environment, Food and Rural Affairs. As from 1 April 2007 this department is known as the Animal Health Agency.

**Eyess or eyas** A nestling hawk taken from the eyrie or nest.

- Eyrie (ayrie)** Nest of a bird of prey perched high up.
- Falcon** A female hawk.
- Feake** When a hawk wipes its beak on a perch after feeding.
- Fledgling** The growing period of a young bird until it is able to fly or 'fledge'.
- Frounce** Trichomoniasis of the oropharynx of a raptor.
- Galliformes** A taxonomic order of fowl-like birds including grouse, ptarmigan, pheasants, peacocks, partridges, quails, domestic fowl, turkeys and guinea fowl.
- Gallinaceous** Pertaining to the taxonomic order Galliformes.
- Graminivorous** Grass and cereal eating.
- Granivorous** Feeding on grain and seeds.
- Hack, flying at** Young falcons recently taken from the nest are allowed to fly freely, only coming back to the falconer to be fed on a hack board.
- Hack back** To train a captive hawk to hunt and be able to sustain itself in the wild.
- Haematopodidae** A taxonomic family of seashore wading birds, the oystercatchers.
- Haggard** A hawk which has been caught in the wild, after it has undergone its first moult and has got its adult plumage.
- Hardbill** Bird that feeds by cracking open seeds.
- Hood** A leather hat placed over the head of a hawk to blindfold it and to make it more easily handled.
- Hornbill** Medium to large old world tropical bird with brightly coloured and large bill that is often surmounted by a large decorative casque. Its plumage is usually black and white.
- Imping** A falconer's method of repairing a broken flight or tail feather.
- Interremigial ligament** An elastic ligament lying within the skin fold caudal to radius and ulna and carpus, metacarpus and digits of the wing. It unites the shafts of the primary and secondary feathers, the remiges (q.v.).
- Jack** The male merlin (*Falco columbarius*).
- Jesses** The short, narrow straps of leather fastened round the legs of a hawk so that the falconer can control the bird.
- Laridae** The taxonomic family of birds containing the gulls and terns.
- Leash** A long, narrow strip of leather attached via the swivel to the jesses (q.v.).
- Long-winged hawks** The true falcons; 39 species of diurnal birds of prey in the single genus *Falco*, including peregrine, saker, lanner, laggar, merlin, kestrel, etc.
- Lure** A falconer's apparatus for recalling a hawk. Often a bunch of feathers wrapped around a piece of meat and weighted. Sometimes two wings tied together. It is swung by a cord in a large arc around the falconer to attract the bird.
- Lutino** A yellow bird (often a psittacine bird) with no other markings and red eyes.
- Macaws** A group of South American parrots. These are mostly, *but not all*, fairly large, long-tailed birds with a patch of bare skin on each side of the face.



**Manning** Taming a hawk.

**Megapodiidae** The taxonomic family of robust ground dwelling birds resembling pheasants found in Southeast Asia and Australia. Also known as incubator birds.

**Mergus** A genus of seaducks.

**Mews** A place where hawks are kept to moult (from the verb 'mew', to moult).

**Mules** Hybrid canaries produced by crossing the canary with other finches, such as goldfinches and greenfinches, crossbills.

**Musket** The male sparrow-hawk.

**Mutes** The faeces of a hawk (from the verb 'mute', to void faeces). Short-winged hawks (e.g. sparrow-hawk, goshawk) are said to 'slice', i.e. eject the mutes horizontally.

**Ostringer (austringer)** A falconer who flies short-winged hawks (e.g. goshawk).

**Pannel** A falconer's term meaning the stomach of a hawk.

**Parakeet** A small parrot. In the USA usually refers to the budgerigar (*Melopsittacus undulates*).

**Passeriformes** The taxonomic order of birds containing the largest number of species, grouped into 55 families. It contains all the birds that have three forward toes and one well-developed hind toe – an adaptation to perching (Fig.1.6).

**Passerines** Pertaining to the taxonomic order Passeriformes.

**Phalacrocoracidae** The taxonomic family of birds containing the cormorants and shags.

**Picidae** The family of birds containing the woodpeckers.

**Pin feathers** First sign of a developing feather, still retained within its sheath.

**Precocial chicks** Newly hatched birds born covered in downy feathers, active and able to find their own food as soon as leaving the egg. These chicks are *nidifugous* or nest leaving.

**Prepatagial (propatagial)** Referring to the prepatagium, a membranous fold of skin between the shoulder and carpal joints forming the leading edge of the wing.

**Primary feathers** The main flight feathers attached to the metacarpal bones and digits.

**Psittaciformes** The taxonomic order of birds containing one family – the Psittacidae or parrots.

**Psittacine birds** Parrots and related species.

**Psittacula parakeets** A large genus of medium-sized, mostly Asiatic parakeets, including the popular Plum-headed and Ring-necked species.

**Rallidae** The family of birds known as rails, including the coots, gallinules and moorhens.

**Ramphastidae** The toucans – South American tropical birds with large brightly coloured bills.

**Rangle** A term commonly used in Europe since the Middle Ages and in the Middle East for small rounded stones given to a raptor and sometimes taken voluntarily by both captive and wild birds. These are usually cast within 24 hours and may help to aid digestion.

**Raptor** A bird with a hooked beak and sharp talons – a bird of prey.

**Red-rump parakeet** A species of small Australian parrot with red feathers over the base of the tail or rump.

**Remiges** The main flight feathers of the wings (i.e. the primaries and secondaries).

**Seeling** a term used by falconers in the Middle East and in the past in Europe when threads are passed through the lower eyelids of a recently captured hawk and are tied behind the head to make the bird more easily tamed and handled. The same purpose is achieved by using a hood.

**Short-winged hawks** Usually taken to mean the *Accipiters* or bird hawks, which include the goshawks, sparrow-hawk and Cooper's hawk. Also refers to the broad-winged birds – the buzzards.

**Softbills** Birds that feed on fruit or insects.

**Spheniscidae** The taxonomic family of birds containing the penguins.

**Split** A heterozygous bird carrying a recessive colour.

**Stoop** The swift descent of a falcon onto its quarry from a height.

**Sulidae** The taxonomic family of birds containing the gannets and boobies.

**Swivel** A metal attachment to join the jesses to a leash (q.v.) and which prevents these from becoming twisted when the hawk is tethered to its perch.

**Tiercel** The male of any species of hawk. The female is known as the falcon, especially in the case of the peregrine.

**Tiring** A tough piece of meat or tendon given to a hawk to help exercise the muscles of the back and neck and keep the beak in trim.

**Turdinae** The taxonomic subfamily of birds containing the thrushes and including such birds as the European blackbird, both American and European robins and also the nightingale.

**Ulnocarporemigial aponeurosis** A triangular aponeurosis, lying on the ventral side of the wing, just caudal to the metacarpus and joining the bases of the shafts of the metacarpal primary feathers.

**Wait on** When a hawk soars above the falconer waiting for the game to be flushed.

**Weather** To place a hawk on a perch out in the open. Usually an area shielded from extreme weather is chosen.

**Weaver birds** Small- to medium-sized passerine birds. Many species are gregarious and include the common house sparrow. Some species are popular aviary birds.

**Whydahs (widow birds)** A group of brood parasitic passerines (like cuckoos) allied to the weaver birds. The males usually have long tail feathers.

## APPENDIX 11 SOME USEFUL WEBSITES

These are some of the websites that the author has used when researching this edition and which may be found helpful to readers.

### **Birds Databases**

This is an excellent site for all ornithological information, with links to searchable data bases

<http://ecams-online.org/public/links.asp>

### **American Association of Wildlife Veterinarians**

For all areas of wildlife health and the environment

[www.aawv.net](http://www.aawv.net)

### **European College of Avian Medicine and Surgery (ECAMS)**

[www.ecams-online.org](http://www.ecams-online.org)

### **The European Association of Avian Veterinarians**

[www.eaav.org](http://www.eaav.org)

### **Harrison's Bird Foods**

Bird food and feeding and information for avian practitioners

[www.harrisonsbirdfoods.com](http://www.harrisonsbirdfoods.com)

### **Karl Storz Endoscopy**

Information on endoscopy equipment

[www.karlstorz.com](http://www.karlstorz.com)

### **Endoscopy Support Services**

Useful for the purchase of new and used endoscopy equipment, including video

[www.endoscopy.com](http://www.endoscopy.com)

### **Dremel Electric Hand-Held Tool**

[www.dremel.com](http://www.dremel.com)

### **University of Miami Department of Pathology**

Comparative pathology laboratory and avian and wildlife laboratory for assistance in the conversion of biochemical values. May also have data bases for reference values.

<http://pathology.med.miami.edu/cpl/about.asp>

### **Lafeber Company**

Has a number of links, mainly on feeding pet parrots

[www.lafeber.com](http://www.lafeber.com).

### **Vetark**

[www.vetark.co.uk](http://www.vetark.co.uk) → Sponsored link [www.24parrot.com/vetark](http://www.24parrot.com/vetark)

For supply of Avian electronic scales with fitted perch.

### **F10Biocare**

For disinfectants, cleansing agents, foggers and nebulisers

[www.f10biocare.co.uk](http://www.f10biocare.co.uk)

**The Easy Chicken for Beginners**

Useful images of candled eggs and common pathological problems  
[www.homestead.com/shilala/candling.html](http://www.homestead.com/shilala/candling.html)

**Public Library of Science**

Open access online to freely available range of scientific publications  
<http://www.plos.org/index.php>

**International Journal of Systemic and Evolutionary Microbiology**

<http://ijs.sgmjournals.org/>

**Oxford Journals/Life Sciences/Toxicological Sciences**

<http://toxsci.oxfordjournals.org>

**A UK university-backed website providing a free online service and access to the best web resources**

<http://www.vts.intute.ac.uk/he/tutorial/vet/>

**Wikipedia, the Free Encyclopedia Online**

<http://en.wikipedia.org>

## Further Reading

---

- Cooper, J.E. & Eley, J.T. (1979) *First Aid and Care of Wild Birds*. David & Charles, London.
- Elkins, N. (1983) *Weather and Bird Behaviour*. T.A.D. Poyser Ltd., Carlton.
- Krautwald-Junghanns, M.E., Tellhelm, B., Hummel, G., Kostka, V. & Kaleta, E.F. (1992) *Atlas of Radiographic Anatomy and Diagnosis in Cage Birds*. Verlag Paul Parey, Berlin.
- Mavrogordato, J.G. (1973) *A Hawk for the Bush*, 2nd edn. Neville Spearman, London.
- Nigel Harcourt-Brown & John Chitty (eds) (2005) *BSAVA Manual of Psittacine Birds*, 2nd edn. British Small Animal Veterinary Association, Quedgeley, Glos.
- Ritchie, B.W. (1995) *Avian Viruses*. Wingers Publishing, Lake Worth, Florida.
- Roskopf, W. & Woerpel, R. (eds) (1996) *Diseases of Cage and Aviary Birds*, 3rd edn. Williams & Wilkins, A Waverly Company, Baltimore, London, Munich.
- Wallack, J.D. & Boever, W.J. (1983) *Diseases of Exotic Animals; Medical and Surgical Management*. W.B. Saunders, Philadelphia/London.
- Woodford, M.H. (1960) *A Manual of Falconry*. A. & C. Black, London.

In addition the reading list of the European College of Avian Medicine and Surgery (ECAMS) is a useful resource. It is accessible on the web as Appendix A of the ECAMS Constitution at <http://www.ecams-online.org>. This is a very comprehensive list of:

- Refereed journals published in previous years
- Proceedings
- Monographs
- Suggested additional reading

## References

---

- Ahlers, W. (1970) Report on the use of Bisolvon in small animal practice. *Kleintier-Praxis*, 15, 50–3.
- Allwright, D.M. and van Rensburg, W.J.J. (1994) Botulism in ostriches (*Struthio camelus*) *Avian Pathology*, 23, 183–6.
- Altman, R.B. (1980) Avian anaesthesia. *The Compendium on Continuing Veterinary Education*, 2, 8–42.
- Altman, R.B. (1982) In: *Diseases of Cage and Aviary Birds*, 2nd edn (ed. M.L. Petrak), p. 369. Lea and Fibiger, Philadelphia.
- Altman, R.B. and Miller, M.S. (1979) The effect of halothane and ketamine anaesthesia on body temperature and electro-cardiographic changes of birds. *Proceedings of the American Association of Zoo Veterinarians*, Denver, Colorado, 61–62A.
- Andres, K.H. and von Düring, M. (1990) Comparative and functional aspects of the histological organization of cutaneous receptors in vertebrates. In: *The Primary Afferent Neuron – A Survey of Recent Morpho-Functional Aspects* (eds W. Zenker and W. Neuhuber), pp 1–16. Plenum, New York.
- Ar, A. and Rahn, H. (1977) Interdependence of gas conductance, incubation, length and weight of the avian egg. In: *Respiratory Function in Birds, Adult and Embryonic*, a satellite symposium of the 27th *International Congress of Physiological Sciences, Paris, 1977* (ed. J. Piper), pp 227–36. Springer-Verlag, Berlin, Heidelberg, New York.
- Arañez, J.B. and Sanguin, C.S. (1955) Poulardization of native ducks. *Journal of the American Veterinary Medicine Association*, 127, 314–17.
- Arnall, L. and Keymer, I.F. (1975) *Bird Diseases*. Baillière Tindall, London.
- Ashash, E., Weisman, Y., Malkinson, M., Perl, S. and Mechany, S. (1995) Borna disease in ostriches. *Proceedings 3rd Conference of European Committee of the Association of Avian Veterinarians*, Jerusalem, pp 44–7.
- Ashton, G. and Smith, H.G. (1984) *Psittacosis in Birds and Man*. The Unit for Veterinary Continuing Education, Vet 31, The Royal Veterinary College, London.
- Bala, A.D., Spitzer, M.W. and Takahashi, T.T. (2003) Prediction of auditory spatial acuity from neural images on the owl's auditory space map. *Nature*, 424, 771–4.
- Bang, B.G. (1965) Anatomical adaptations for olfaction in the snow petrel. *Nature*, 205, 513–15.
- Bang, B.G. (1966) The olfactory apparatus of tube-nosed birds (Procellariiformes) *Acta Anat.*, 65, 391–415.
- Bang, B. and Wenzel, B.M. (1986) Nasal cavity and olfactory system. In: *Form and Function in Birds* (eds A.S. King and J. McLelland), pp 195–225. Academic Press, London.
- Bartels, K.E. (ed.) (2002) Lasers in medicine and surgery. *The Veterinary Clinics of North America*, 32, 3.
- Bartholomew, G.A. and MacMillan, R.E. (1960) The water requirements of mourning doves and their use of sea water and NaCl solutions. *Physiol. Zool.*, 33, 171.

- Benyon, P. (ed.) (1996) Haematology and biochemistry values. *Manual of Raptors, Pigeons and Waterfowl*. British Small Animal Veterinary Association, Cheltenham.
- Berkhoudt, H. (1985a) Special sense organs: structure and function of the avian taste receptors. In: *Birds, Their Structure and Function* (eds A.S. King and J. McLelland) Academic Press, New York, NY.
- Berkhoudt, H. (1985b) Structure and function of avian taste receptors. In: *Form and Function in Birds* (eds A.S. King and J. McLelland) Academic Press, New York, NY.
- Bernier, G., Morin, M. and Marsolais, G. (1981) A generalised inclusion body disease in the budgerigar (*Melopsittacus undulatus*) caused by Papova-like agent. *Avian Diseases*, 23, 1083–93.
- Berry, R.B. (1972) Reproduction by artificial insemination in captive American goshawks. *Journal of Wildlife Management*, 36, 1283–8.
- Binggeli, R.L. and Paule, W.J. (1969) The pigeon retina: Quantitative aspects of the optic nerve and ganglion cell layer. *J. Comp. Neurol.* 137, 1–18.
- Bird, D.M., Lague, P.C. and Buckland, R.B. (1976) Artificial insemination versus natural mating in captive American kestrels. *Canadian Journal of Zoology*, 54, 1183–91.
- Blackmore, D.K. (1982) In: *Diseases of Cage and Aviary Birds*, 2nd edn, (ed. M.L. Petrak), p. 484. Lea and Fibiger, Philadelphia.
- Borland, E.D., Morgan, C.T. and Smith, G.R. (1977) Avian botulism and the high prevalence of *Clostridium botulinum* in the Norfolk broads. *Veterinary Record*, 100, 106–9.
- Bortch, A. and Vroege, C. (1972) Amputation of the wing under Rompun sedation and experimental sedation of the homing pigeon with Rompun. *Veterinary Review*, (3/4), 275.
- Böttcher, M. (1980) Endoscopy of birds of prey in clinical veterinary practice. *Recent Advances in the Study of Raptor Diseases* (eds J.E. Cooper and A.G. Greenwood), pp 101–4. Chiron Publications Ltd, Keighley, Yorks.
- Bourne, W.R.P. (1989) The role of birds in the long-distance dispersal of disease. In: *Disease and Threatened Birds*, 121. *International Council for Bird Preservation Tech. Pub. No. 10* (ed. J.E. Cooper), pp 121–8. ICBP, Cambridge.
- Boyd, L.L. (1978) Artificial insemination of falcons. *A Symposium of the Zoological Society of London*, 43, 73–80.
- Boyd, L.L. and Schwartz, C.H. (1983) Training imprinted semen donors. In: *Falcon Propagation, a Manual on Captive Breeding* (eds J.D. Weaver and T.J. Cade), p. 10. The Peregrine Fund, Inc. Ithaca, New York.
- Breazile, J.E. and Kvenzel, W.J. (1993) Systema nervosum central. In: *Handbook of Avian Anatomy: Nomina Anatomica Avium* (ed. J.J. Baumel). Nuttall Ornithological Club No. 23, Cambridge, Mass.
- Brock, M.S. (1991) Semen collection and artificial insemination in Hispaniolan parrot (*Amazonia ventralis*). *Journal of Zoo and Wildlife Medicine*, 22(1), 107–14.
- Brooks, N.G. (1982) Crop wall necrosis in a sparrowhawk. *Veterinary Record*, 3(22), 513.
- Brown C.S and Luebbert, J. (2003) *Proceedings of the Conference of the Association of Avian Veterinarians*, pp 207–19.
- Brown, L. (1976) *Birds of Prey: Their Biology and Ecology*, p. 117. Hamlyn, London.
- Burkhardt, D. (1989) UV vision: A bird's eye view of feathers. *J. Comp. Physiol. A*. 164, 787–96.
- Burnham, W., Walton, B.J. and Weaver, J.D. (1983) Management and maintenance. In: *Falcon Propagation, a Manual on Captive Breeding* (eds J.D. Weaver and T.J. Cade), p. 11. The Peregrine Fund, Inc. Ithaca, New York.
- Bush, M. (1980) *Animal Laparoscopy* (eds R.M. Harrison and D.E. Wildt), pp 183–93. Williams and Wilkins, Baltimore/London.
- Bush, M. (1981) Avian fracture repair using external fixation. In: *Recent Advances in the Study of Raptor Diseases* (eds J.E. Cooper and A.G. Greenwood), pp 83–93. Chiron Publishers Ltd, Keighley, Yorks.

- Bush, M., Locke, D., Neal, L.A. and Carpenter, J.W. (1980) Pharmacokinetics of cephalin and cephalexin in selected avian species. *American Journal of Veterinary Research*, **42**(6), 1014–17.
- Bush, M., Montali, R.I., Novak, R.G. and James, F.A. (1976) The healing of avian fractures. A histological xeroradiographic study. *American Animal Hospital Association Journal*, **12**(6), pp 768–73.
- Bush, M., Neal, L.A. and Custer, R.S. (1979) Preliminary pharmacokinetic studies of selected antibiotics in birds. *Proceedings of the American Association of Zoo Veterinarians*, 45–7.
- Butler, E.J. and Laursen-Jones, A.P. (1977) Nutritional disorders. In: *Poultry Diseases* (ed. R.F. Gordon), p. 158. Baillière Tindall, London.
- Campbell, T.W. (1994) Cytology. In: *Avian Medicine: Principles and Application* (eds B.W. Ritchie, G.J. Harrison and L.R. Harrison). Wingers Publishing, Inc., Lake Worth, Florida, pp. 199–222.
- Campbell, T.W. (1994) Hematology. In: *Avian Medicine: Principles and Application* (eds B.W. Ritchie, G.J. Harrison and L.R. Harrison). Wingers Publishing, Inc., Lake Worth, Florida, pp. 176–98.
- Campbell, T.W. (1995) *Avian Haematology and Cytology*, 2nd edn. Iowa State University Press, Ames, Iowa.
- Chen, D.M. and Goldsmith, T.H. (1986) Four spectral classes of cone in the retinas of birds. *J. Comp. Physiol. A.*, **159**, 473–9.
- Carpenter, J.W. (2005) *Exotic Animal Formulary*, 3rd edn. Elsevier/Saunders, St Louis, MO.
- Clark, L. (1995) Modulation of avian responsiveness to chemical irritants: effects of prostaglandin E1 and analgesics. *J. Exp. Zool.*, **271**, 432–40.
- Clark, L. and Shah, P.S. (1992) Information content of prey odor plumes: What do foraging Leach's storm petrels know? In: *Chemical Signals in Vertebrates* (eds R.L. Doty and D. Muller-Schwarze), pp 421–8. Plenum Press, New York, NY.
- Clark, L. and Shah, P.S. (1993) Chemical bird repellents: Possible use in cyanide ponds. *J. Wild. Manage.*, **57**, 657–64.
- Clark, L. and Shah, P.S. (1994) Tests and refinements of a general structure-activity model for avian repellents. *J. Chem. Ecol.*, **20**, 321–39.
- Clubb, S.L. (1984) Therapeutics in avian medicine – flock vs. individual bird treatment regimens. *The Veterinary Clinics of North America* (ed. G.J. Harrison), **14**(2), 345–61.
- Cochran, W.W., Mouritsen, H. and Wikelski, M. (2004) Migrating songbirds recalibrate their magnetic compass daily from twilight cues. *Science*, **304**(5669):373.
- Coffin, D.L. (1969) In: *Diseases of Parrots and Parrot-like Birds* (ed. the Duke of Bedford), p. 35. T.F.H. Publications, Inc., Hong Kong.
- Cole, G. and Murray, M. (2005) Suspected case of chocolate toxicosis in an African grey parrot (*Psittacus erithacus*). *Proceedings of the Association of Avian Veterinarians*, pp. 339–40.
- Coles, B.H. (1984a) Avian anaesthesia. *Veterinary Record*, **115**(12), 307
- Coles, B.H. (1984b) Some considerations when nursing birds in veterinary premises. *Journal of Small Animal Practice*, **25**(5), 275–88.
- Coles, B.H. and Krautwald-Junghanns, M.E. with Herman J. Thomas (1998), *Avian Medicine Self-Assessment Picture Tests*, pp 52,53,57,62,85,99,102. Mosby Inc, St Louis, MO.
- Cooke, S.W. (1984) Lead poisoning in cygnets. *Veterinary Record*, **114**(8), 203.
- Cooper, J.E. (1978) *Veterinary Aspects of Captive birds of Prey*. Stanford Press, Gloucester.
- Cooper, J.E. (1983) In: *Sonderdruck aus Verhandlungsbericht des 25 internationalen Symposiums über die Erkrankungen der Zootiere*, pp 61–5. Wien Akademie Verlag, Berlin.
- Cooper, J.T. and Eley, J.E. (1979) *First Aid and Care of Wild Birds*. David and Charles, Ltd, London.
- Cooper, J.E. and Redig, P.T. (1975) Unexpected reactions to the use of C.T. 1341 by red-tailed hawks. *Veterinary Record*, **97**, 352.
- Cooper, M.E. (1979) *Wild bird hospitals and the law in first aid and care of wild birds* (eds J.E. Cooper and J.T. Eley), pp 15–20. David and Charles Ltd, London.
- Cribb, P.H. and Haigh, J.C. (1977) Anaesthesia for avian species. *Veterinary Record*, **100**, 472–3.



- Crosta, L., Sironi, G. and Rampin, T. (1995) An outbreak of avian pox in *Neophema* parakeets. *Proceedings 3rd Conference of European Committee of Association of European Veterinarians*, Jerusalem, 1995, pp 23–5.
- Curro, T.G., Brunson, D.B. and Paul-Murphy, J. (1994) Determination of the ED50 of isoflurane and the evaluation of the isoflurane sparing effect of butorphanol in cockatoos (*Cacatua* spp). *Veterinary Surgery*, 23, 429–33.
- Davis, R.G. (1973) Olfactory psychophysical parameters in man, rat, dog and pigeon. *J. Comp. Physiol. Psychol.*, 85, 221–32.
- Dawson, R.W. (1975) Avian physiology. *Annual Review of Physiology*, 37, 441–65.
- De Gruchy, P.H. (1983) Chlamydiosis in collared doves. *Veterinary Record*, 113(14), 327.
- Diekamp, B., Kalt, T. and Güntürkün, O. (2002) Working memory neurons in pigeons. *J. Neurosci.*, 22(4), RC210.
- Donita, L.F., Jones, M.P. and Orosz, S.E. (1995) Pharmacokinetic considerations of the renal system in birds: anatomic and physiologic principles of allometric scaling, Part II. Review of drugs excreted by renal pathways. *Journal of Avian Medicine and Surgery*, 9(2), 92–104.
- Dorrestein, G.M. (1996) Cytology and haemocytology. In: *The Manual of Psittacine Birds*, pp 38–48. British Small Animal Veterinary Association, Cheltenham, Glos.
- Ducateile, R., Charlier, G. and de Herdt, P. (1993) Papilloma-like virus infections in canaries (*Serinus canarius*). *Proceedings of 1993 European Conference on Avian Medicine and Surgery*. The Association of Avian Veterinarians and the Dutch Association of Avian Veterinarians. Utrecht, the Netherlands, pp 224–31.
- Duncan, J.S., Reid, H.W., Moss, R., Phillips, J.D.P. and Watson, A. (1978) Ticks, louping ill and red grouse in Speyside, Scotland. *Journal of Wildlife Management*, 42, 500–5.
- Dunker, H.R. (1977) Development of the avian respiratory and circulatory systems; respiratory function in birds, adult and embryonic. *Satellite Symposium of the 27th International Congress of Physiological Sciences*, Paris, 1977, p. 267. Springer-Verlag, Berlin.
- Dunker, H.R. (1978) Coelom-Gliederung der Wirbeltiere-Funktionelle Aspekte. *Verhandlungen der Anatomischen Gesellschaft*, 72, 91–112.
- Durant, A.J. (1926) Caecal ablation in fowls. *Veterinary Medicine*, 21, 14–17.
- Durant, A.J. (1930) Blackhead in turkeys, surgical control by caecal ablation. *Research Bulletin University of Missouri College of Agriculture*, 133.
- Durant, A.J. (1953) Removal of vocal cords of the fowl. *Journal of the American Veterinary Medical Association*, 122, 14–17.
- Edling, T.M. (2005) Anaesthesia and analgesia. In: *Manual of Psittacine Birds*, p. 94. British Small Animal Veterinary Association, Cheltenham, Glos.
- Edling, T.M., Degernes, L., Flammer, K. and Horne, W.B. (2001) Capnographic monitoring of African grey parrots during positive pressure ventilation. *Journal of the American Veterinary Medical Association*, 219, 1714–17.
- Elkins, N. (1983) *Weather and Bird Behaviour*, pp 86–90. T.A.D. Poyser Ltd., Carlton.
- Emery, N.J. and Clayton, N.S. (2004) The mentality of crows: convergent evolution of intelligence in Corvids and Apes. *Science*, 306, 1903–07.
- Emmerton, J. (1983a) Pattern discrimination in the near-ultraviolet by pigeons. *Percept. Psychophys.*, 34, 555–59.
- Emmerton, J. (1983b) Vision. In 'Physiology and Behaviour of the Pigeon' (M. Abs, ed.), pp 245–66. Academic Press, London.
- Emmerton, J. and Delius, J.D. (1980) Wavelength discrimination in the 'visible' and ultraviolet spectrum by pigeons. *J. Comp Physiol.*, 141, 47–52.
- Fedde, M.R. and Kuhlman, W.D. (1977) Intrapulmonary carbon-dioxide sensitive receptors: Amphibians to mammals. Respiratory function in birds, adult and embryonic. *Symposium of the 27th International Congress of Physiological Sciences, Paris* (ed. J. Piper), pp 30–50. Springer-Verlag, Berlin.
- Fiennes, T-W., R.N. (1969) Infectious diseases of bacterial origin. In: *Diseases of Cage and Aviary Birds* (ed. M.L. Petrak), pp 361–9. Lea and Febiger, Philadelphia.

- Fitzgerald, G. and Cooper, J.E. (1990) Preliminary studies on the use of propofol in the domestic pigeon (*Columba livia*). *Veterinary Science*, 49, 334–8.
- Forbes, N.A. (1984) Avian anaesthesia. *Veterinary Record*, 115(6), 134.
- Forbes, N.A. (1991) Wing tip oedema and dry gangrene of birds. *Veterinary Record*, 129(3), 58.
- Forbes, N.A. and Harcourt-Brown, N.H. (1991) Wing tip oedema and dry gangrene of raptors. *Veterinary Record*, 128(24), 576.
- Forbes, N.A. and Simpson, G.N. (1993) Pathogenicity of ticks on aviary birds. *Veterinary Record*, 133, 21.
- Forbes, N.A. and Simpson, G.N. (in press in 1997) A review and update of viruses affecting raptors in the United Kingdom. *Veterinary Record*, 141(5), 123–6.
- Forbes, N.A., Simpson, G.N., Higgins, R.J. and Gough, R.F. (1997) Adenovirus infection in Mauritius kestrels (*Falco punctatus*). *Journal of Avian Medicine and Surgery*, 11(1), 31.
- Forshaw, J.M. (1978) *Parrots of the World*. David and Charles, Newton Abbot.
- Fowler, M.E. (1978) *Zoo and Wild Animal Medicine*. W.B. Saunders, Philadelphia, London, Toronto.
- Fowler, M.E. and Miller, R.E. (2003) *Zoo and Wild Animal Medicine*, 5th edn. W.B. Saunders, Philadelphia, London, Toronto.
- Fox, R., Lehmkuhle, S.W. and Westendorf, D.H. (1976) Falcon visual acuity. *Science*, 192, 263–5.
- Franchetti, D.R. and Klide, A.M. (1978) *Restraint and Anaesthesia in Zoo and Wild Animal Medicine* (ed. M.E. Fowler), p. 303. W.B. Saunders, Philadelphia.
- Frith, H.J. (1959) Incubator birds. In: *Scientific American: Birds* (ed. B.W. Wilson), pp 142–8. W.H. Freeman, San Francisco.
- Fudge, A.M. (2000) Laboratory medicine. *Avian and Exotic Pets*. W.B. Saunders Company, Philadelphia.
- Galifred, Y. (1968) Les diverses aires fonctionnelles de la retine di pigeon. *Z. Zellforsch. Mikrosk. Anat.*, 86, 535–45.
- Galvin, C.E. (1978) Cage bird medicine. *Veterinary Clinics of North America*, 14(2), 285.
- Garcia del Campo, A.L., Puerta, M.L., Abelenda, M., et al. (1991) Haematology of free-living chicks of the Greater Flamingo. *Proceedings of First Conference of European Committee of Association of Avian Veterinarians*, Vienna, pp 434–6.
- Gassman, R. et al. (1981) Isolierung von Adenoviren bei Wellensittichen mit Zentralnervösen Ausfallsercheinungen II D.V.G.-Tagung, Vogelkrankht, 1981, München, pp 44–7.
- Gelis, S. (2006) Evaluating and treating the gastrointestinal system. In: *Clinical Avian Medicine*, vol I (eds G.J. Harrison and T. Lightfoot), 417–23. Spix, FL.
- Gentle, M.J. (1992) Pain in birds. *Animal Welfare*, 1, 235–47.
- George, J.C. and Berger, A.J. (1966) *Avian Myology*. Academic Press, New York.
- Gerlach, H. (1994) Viruses. In: *Avian Medicine: Principles and Application* (eds B.W. Ritchie, G.J. Harrison and L.R. Harrison). Wingers Publishing, Lake Worth, FL.
- Gerlach, S. (1991) Macaw wasting disease. *Proceedings of First Conference of Association of Avian Veterinarians*, Vienna, p. 273.
- Gilbert, A.B. (1979) Female genital organs. In: *Form and Function in Birds* (eds A.S. King and J. McLelland), p. 331. Academic Press Inc. (London) Ltd.
- Ginsburg, N. and Nilsson, V. (1971) Measuring flicker thresholds in the budgerigar. *J. Exper. Anal. Behav.* 15, 189–92.
- Goldsmith, T.L. (1995) Documentation of passerine circoviral infection. *Proceedings Main Conference Association of Avian Veterinarians*, p. 349–50.
- Gordon, R.F. and Jordan, F.T.W. (1977) *Poultry Diseases*. Ballière Tindall, London.
- Gough, R.E., Cox, W.J. and Devoy, J. (1992) Isolation and identification of rotavirus from racing pigeons. *Veterinary Record*, 130, 273.
- Green, C.J. (1979) Animal anaesthesia. In: *Laboratory Animal Handbooks* 8, pp 126–8. Laboratory Animals Ltd., London.

- Green, C. and Simpkin, S. (1984) Avian anaesthesia. *Veterinary Record*, **115**(7), 159.
- Greenwood, A.G. (1992) Laparoscopic salpingectomy in a hybrid flamingo. *Veterinary Record*, **131**(15), 349.
- Greenwood, A.G. and Storm, J. (1994) Intestinal intussusception in two red-tailed hawks (*Buteo jamaicensis*). *Veterinary Record*, **134**(22), 578–9.
- Grier, J.W. (1973) Techniques and results of artificial insemination with golden eagles. *Raptor Research*, **7**, 1–12.
- Grier, J.W., Berry, R.B. and Temple, S.A. (1972) Artificial insemination with imprinted raptors. *Journal of the American Falconers Association*, **11**, 45–55.
- Gumpenberger, M. and Henninger, W. (2001) The use of computed tomography in avian and reptile medicine. *Seminars in Avian and Exotic Pets Medicine*, **10**(4), 174–80. WB Saunders, Philadelphia, London, Toronto.
- Gumpenberger, M. and Korbel, R.T. (2001) Comparative aspects of diagnostic imaging in avian ophthalmology using ultrasonography and computed tomography. *Proceedings, European Association of Avian Veterinarians*, pp 99–102.
- Güntürkün, O. (2000) Sensory physiology: Vision. In: *Sturkie's Avian Physiology*, 5th edn (ed. G.C. Whittow). Academic Press, San Diego, CA.
- Hagner, D., Prehn, H. and Krautwald-Junghanns, M.E. (1995) Ultrasonography of the avian urogenital tract. Physiology and pathological conditions. *Proceedings of 3rd Conference European Association of Avian Veterinarians*, Jerusalem, pp 195–9.
- Haigh, J.C. (1980) Anaesthesia of raptorial birds. In: *Recent Advances in the Study of Raptor Diseases* (eds J.E. Cooper and A.G. Greenwood), 61–6. Chiron Publications Ltd, Keighley, Yorks.
- Harcourt-Brown, N.H. (1978) Avian anaesthesia in general practice. *Journal of Small Animal Practice*, **19**, 573–82.
- Harcourt-Brown, N.H. (1995) Diseases of the pelvic limb of birds of prey. *FRCVS Thesis*, Wellcome Library, Royal College of Veterinary Surgeons, London.
- Harcourt-Brown, N.H. (1996a) Pelvic limb problems. In: *Manual of Psittacine Birds* (eds P. Beynon, N.A. Forbes and M. Lawton), pp 126–7. British Small Animal Veterinary Association, Cheltenham, Glos.
- Harcourt-Brown, N.H. (1996b) Torsion and displacement of the oviduct as a cause of egg-binding in four Psittacine birds. *Journal of Avian Medicine and Surgery*, **10**(4), 262–7.
- Harcourt-Brown, N.H. (2003) Physical development of parrots, related to social development. *Proceedings of 5<sup>th</sup> European College of Avian Medicine and Surgery Scientific Meeting*, p. 29.
- Harcourt-Brown, N.H. and Chitty, J. (2005) Chapter 7. In: *Manual of Psittacine Birds* (eds P. Beynon, N.A. Forbes and M. Lawton), pp 126–7. British Small Animal Veterinary Association, Cheltenham, Glos.
- Harcourt-Brown, N.H. and Gough, R.E. (1997) Isolation of a virus-like agent with proventricular dilatation syndrome in macaws. *Proceedings of the 4<sup>th</sup> Conference of the European Committee of The Association of Avian Veterinarians*, pp 111–14.
- Harris, J.M. (2005) *Proceedings of the Conference of Avian Veterinarians*, pp 303–5.
- Harrison, G.J. (1984) New aspects of avian surgery. *Veterinary Clinics of North America*, **14**(2), 363–80.
- Harrison, G.H. and Harrison, L.R. (1986) *Clinical Avian Medicine and Surgery*. W.B. Saunders, Philadelphia, London, Toronto.
- Harrison, G.J. and Lightfoot, T.L. (2006) *Clinical Avian Medicine*. Spix Publishing, Inc., Palm Beach, Florida.
- Harrison, L.R. and Herron, A.J. (1984) Submission of diagnostic samples to a laboratory. *Veterinary Clinics of North America*, **14**(2), 165–72.
- Hartup, B.K. and Kollias, G.V. (1999) Field investigation of *Mycoplasma gallisepticum* infection in house finch (*Carpodacus mexicanus*) eggs and nestlings. *Avian Diseases* **43**(3), 572–6.

- Hasholt, J. (1969) Diseases of the nervous system. In: *Diseases of Cage and Aviary Birds* (ed. M.L. Petrak). Lea and Febiger, Philadelphia.
- Heck, R.W. and Konke, D. (1983) Incubation and rearing. In: *Falcon Propagation, a Manual on Captive Breeding* (eds J.D. Weaver and T.J. Cade), p. 49. The Peregrine Fund, Inc., Ithaca, New York.
- Hellmann, B., Waldmann, C. and Güntürkün, O. (1995) Cytochrome oxidase activity reveals percolations of the pigeon's ectostriatum. *Neuroreport*, 6, 881–5.
- Helmer, P. (2006) Advances in diagnostic imaging. In: *Clinical Avian Medicine* (eds Harrison, G.J. and Lightfoot, T.L.), pp 653–9. Spix Publishing, Inc., Palm Beach, FL.
- Hernandez, M. (1991) Raptor clinical haematology. *Proceedings of First Conference of European Committee of Association of Avian Veterinarians*, Vienna, pp 420–33.
- Hernandez-Divers, S.J. and Hernandez-Divers, S.M. (2003) Xenogeneic grafts using porcine small intestinal submucosa in the repair of skin defects in 4 birds. *Journal of Avian Medicine and Surgery*, 17(4), 224–34.
- Hochleithner, M. (1994) Biochemistries. In: *Avian Medicine: Principles and Application* (eds B.W. Ritchie, G.J. Harrison and L.R. Harrison). Wingers Publishing, Lake Worth, FL.
- Hodos, W., Bessette, B.B., Macko, K.A. and Weiss, S.R.B. (1985) Normative data for pigeon vision. *Vision Res.*, 25, 1525–7.
- Holz, P.H., Naisbitt, R. and Mansell, P. (2006) Fitness level as determining factor in the survival of rehabilitated peregrine falcons (*Falco peregrinus*) and brown goshawks (*Accipiter fasciatus*) released back into the wild. *Journal of Avian Medicine and Surgery*, 20(1), 15–20.
- Hooimeijer, J. (2006) Twenty-five years of white stork (*Cinconia cinconia*) reintroduction in the Netherlands. *Proceedings of the Conference of the Association of Avian Veterinarians*, pp 333–9.
- Hoop, R.K., Ossent, P. and Pfyffer, G. (1995) *Mycobacterium genavense*, a new cause of mycobacteriosis in pet birds. *Proceedings 3rd Conference of European Committee of Association of Avian Veterinarians*. Jerusalem, pp 1–3.
- Houston, D.C. (1987) Scavenging efficiency of turkey vultures in tropical forests. *Condor*, 88, 318–23.
- Hurrell, L.H. (1968) Wild raptor casualties. *Journal of Devon Trust*, 19, 806–7.
- Ide, C. and Munger, B.L. (1978) A cytologic study of Grandy corpuscle development in chicken toe skin. *J. Comp. Neurol.*, 179, 301–24.
- Ivins, G.K. (1975) Sex determination in raptorial birds – a study of chromatic bodies. *Journal of Zoo Animal Medicine*, 6, 9–11.
- Jacobs, L.F. (2003) The evolution of the cognitive map. *Brain Behav Evol.* 62(2), 128–39.
- Jalanka, H. (1991) Medetomidine-Ketamine and Atipamezole, a reversible method of chemical restraint of birds. *Proceedings First Conference of European Committee of Avian Veterinarians*, Vienna, 102–4.
- Jericová, Z. and Hublek, Z. (1993) Arboviral examination of free-living birds in the Czech Republic. *Proceedings of 1993 European Conference on Avian Medicine and Surgery*. Utrecht, The Netherlands, pp 507–21.
- Johnson, O.W. (1979) Urinary organs. In: *Form and Function in Birds, Vol. I* (eds A.S. King and J. McLelland). Academic Press, London.
- Joji, D. and Popovi, S. (1969) Artery vascularization of certain aerated bones of domestic hen and pigeon wings. *Acta Veterinaria* (Belgrade), 29, 87–95.
- Jones, C.G. (1980) Abnormal and maladaptive behaviour in captive raptors. In: *Recent Advances in the Study of Raptor Diseases* (eds J.E. Cooper and A.G. Greenwood). Chiron Publications Ltd., Keighley, Yorks.
- Jones, D.M. (1979) The nutrition of parrots: the husbandry and medicine of the parrot family. *Proceedings of B.V.Z.S./Parrot Society Meeting* (eds J.E. Cooper and A.G. Greenwood), p. 31. Regent's Park, London.
- Jones, R.B. and Roper, T.J. (1997) Olfaction in the domestic fowl: a critical review. *Physiol Behav.*, 62(5), 1009–18.

- Jonzen, N., Linden, A., Ergon, T., *et al.* (2006) Rapid advance of spring arrival dates in long-distance migratory birds. *Science*, **312**(5782):1959–61.
- Kare, M.R. and Rogers, J.G. (1976) Sense organs: taste. In: *Avian Physiology* (ed. P.E. Sturkie). Berlin, Springer Verlag.
- Kendeigh, S.C. (1970) Energy requirements for the existence in relation to size of birds. *Condor*, **72**, 60.
- Kennedy, M.A. and Brenneman, K.A. (1995) Enteritis associated with a coronavirus-like agent in a Rhea chick (*Rhea americana*). *Journal of Avian Medicine and Surgery*, **9**(2), 138–40.
- Kersing, D. (2006) A clinical case of zinc toxicosis and potential copper toxicity from toothbrushes. *Proceedings of Association of Avian Veterinarians*, pp 349–51.
- Keymer, I.F. (1969) *Diseases of Cage and Aviary Birds*, 1st edn (ed. M.L. Petrak), p. 434. Lea and Febiger, Philadelphia.
- King, A.S. and McLelland, J. (1975) *Outlines of Avian Anatomy*. Baillière Tindall, London.
- King, A.S. and McLelland, J. (1979) *Form and Function in Birds, Vol. 1*. Baillière, Tindall, London.
- King, A.S. and McLelland, J. (1984a) *Birds: Their Structure and Function*. Baillière Tindall, London.
- King A.S. and McLelland, J. (1984b) Special sense organs. In: *Birds, Their Structure and Function*, 2nd edn, pp 311–12. Baillière Tindall, Bath, United Kingdom.
- King, A.S. and McLelland, J. (1984c) *Birds, Their Structure and Function*, pp 140–2. Baillière Tindall, London.
- King, A.S. and McLelland, J. (1989) *Form and Function in Birds, Vol. 4*, pp 211–16. Academic Press, London.
- King, A.S. and Payne, D.C. (1964) Normal breathing and the effects of posture in *Gallus domesticus*. *Journal of Physiology*, **174**, 340–7.
- Kirkwood, J.F. (1981) Recent advances in the study of raptor diseases. *Proceedings of the International Symposium on Diseases of Birds of Prey* (eds J.E. Cooper and A.G. Greenwood), pp 153–7. Chiron Publications Ltd, Keighley, Yorks.
- Klaphake, E., Schuemaker, J., Greenacre, C., Jones, M.P. and Zagaya, N. (2006) Comparative anesthetic and cardiopulmonary effects of pre- versus post-operative butorphanol administration in Hispaniolan Amazon parrots (*Amazona ventralis*) anesthetized with sevoflurane. *Journal of Avian Medicine and Surgery*, **20**(1), 2–7.
- Klide, A.M. (1973) Avian anaesthesia. *Veterinary Clinics of North America*, **3**(2), 175–86.
- Kock, M. (1983) Sexing birds. *Veterinary Record*, **112**(19), 463.
- Korbel, R. (2000) Disorders of the posterior eye segment in raptors – examination procedures and findings. *Raptor Biomedicine III*. Zoological Education Network Inc., Lake Worth, FL.
- Korbel, R., Mlovanovic, A., Erhardt, W., Burike, S. and Hemke, J. (1993) Aerosaccular perfusion with isoflurane – an anaesthetic procedure for head surgery in birds. *Proceedings European Conference Association of Avian Veterinarians*, Utrecht, Netherlands. AAV, Lake Worth, FL.
- Korbel, R. and Sturm, K. (2005) Review of light sources for bird housing under artificial light circumstances. *Proceedings 6th Scientific Meeting of European College of Avian Medicine and Surgery*. Arles, France.
- Korbel, R.T. and Gropp, U. (1999) Ultraviolet perception in birds. *Proc. Annu. Conf. Assoc. Avian. Vet.*, 77–81.
- Korbel, R.T. and Szoelgyenyi, W. (2001) Vision related aspects of animal welfare in aviculture. *Proceedings 6th European AAV–DVG Conference, 4th Scientific ECAMS Meeting, Avian Medicine and Surgery*, Munich, Germany, March 7, 2001, pp 12–13.
- Koutsos, E.A., Matson, K.D. and Klasing, K.C. (2001) Nutrition of birds in the Order Psittaciformes: a review. *J. Avian Med. Surg.*, **15**(4), 257–75.
- Kovach, A.G.B. and Szász, E. (1968) Survival of pigeons after graded haemorrhage. *Acta Physiologica*, **34**(301).

- Kovach, A.G.B., Szász, E. and Pilmayer, N. (1969) The mortality of various avian and mammalian species following blood loss. *Acta. P.N. Acad. Sci.*, 35–109.
- Krautwald, M.E., Reidel, V. and Neumann, W. (1991) Diagnostic use of ultrasonography in birds. In: *Proceedings Association of Avian Veterinarians Conference*, Chicago, pp 269–75.
- Krautwald, M.E., Schumacher, F. and Tellhelm, B. (1993) Evaluation of the lower respiratory tract in psittacines using radiology and computed tomography. In: *Veterinary Radiology and Ultrasound*, 34(3), 382–90.
- Krautwald, M.E., Tellhelm, B., Hummel, G., Kostka, V. and Kaleta, E.F. (1992) *Atlas of Radiographic Anatomy and Diagnosis of Cage Birds*. Paul Parey Scientific Publishers, Berlin and Hamburg.
- Krautwald-Junghanns, M.E., Bartels, T. and Pees, M. (2006) The use of iodinated contrast media in avian medicine. In: *Proceedings of 27<sup>th</sup> Annual Conference of the Association of Avian Veterinarians*, San Antonio, Texas, pp 69–72.
- Krautwald-Junghanns, M.E., Braun, S., Pees, M., Straub, J. and Valerius, Hans-P. (2004), Research on the anatomy and pathology of the psittacine heart. *Journal of Avian Medicine and Surgery*, 18(1), 2–11.
- Krautwald-Junghanns, M.E. and Enders, F. (1997) Ultrasonography. In: *Avian Medicine and Surgery* (eds R.B. Altman, S.L. Clubb, G.M. Dorrestein and K. Quesenberry), pp 200–9. W.B. Saunders Company, Philadelphia, London, Toronto.
- Krautwald-Junghanns, M.E. and Pees, M. (2005) Radiographic diagnosis of the head. In: *Proceedings of 26<sup>th</sup> Annual Conference of the Association of Avian Veterinarians*, Monterey, California, pp 51–6.
- Krautwald-Junghanns, M.E., Schulz, M., Hagner, D., Failing, K. and Redman, T. (1995) Transcoelomic two-dimensional echocardiography in the avian patient. *Proceedings 3rd Conference European Committee of the Association of Avian Veterinarians (Incorporating 1st ECAMS Scientific Meeting)*, Jerusalem, p. 10.
- Krautwald-Junghanns, M.E., Stahl, A., Pees, M., Enders, F. and Bartels, T. (2002) Sonographic investigations of the gastrointestinal tract of granivorous birds. *Veterinary Radiology and Ultrasound*, 43(6), 576–8.
- Labonde, J. (2006) *Avian Toxicology*. A paper presented to the Congress of the Association of Avian Veterinarians, pp 191–201.
- Lack, D. (1975) *The Life of the Robin*, 4th edn. H.F. and G. Wetherby, London.
- Lasiewski, R.C. and Dawson, L.R. (1967) A re-examination of the relation between standard metabolic rate and bodyweight of birds. *Condor*, 69, 13–23.
- Lawrie, A. (2005) Systemic non-infectious disease. *Manual of Psittacine Birds* (eds N.H. Harcourt-Brown and J. Chitty). British Small Animal Veterinary Association, Cheltenham, Gloucester.
- Lawton, P.C. (1984) Avian anaesthesia. *Veterinary Record*, 115(3), 71.
- Lawton, M.P.C. (1996) Anaesthesia. In: *Manual of Psittacine Birds* (eds P.H. Beynon, N.A. Forbes and M.P.C. Lawton). British Small Animal Veterinary Association, Cheltenham, Glos.
- Levinger, I.M., Kedem, J. and Abram, M. (1973) A new anaesthetic-sedative preparation for birds. *British Veterinary Journal*, 129, 296–300.
- Lennox, A.M. (2002) Successful treatment of mycobacteriosis in three psittacine birds. *Proc. Association of Avian Veterinarians Conference*, p. 111.
- Lewis, J.C.M., Storm, J. and Greenwood, A.G. (1993) Treatment of wing tip oedema and dry gangrene of raptors. *Veterinary Record*, 128(24), 578.
- Lierz, M., Schmidt, R., Goebel, T., Ehrlein, J. and Runge, M. (2000) Detection of *Mycoplasma* spp in raptorial birds in Germany. In: *Raptor Biomedicine III* (eds J.T. Lumeij, J.D. Remple, P.T. Redig, M. Lierz and J.E. Cooper), pp 25–33. Zoological Education Network Inc., Lake Worth, FL.
- Lierz, M. (2006) Diagnostic value of endoscopy and biopsy. In: *Clinical Avian Medicine* (eds G.J. Harrison and T.L. Lightfoot), pp 631–52. Spix Publishing, Inc., Palm Beach, FL.

- Lierz, M. (2005) *Mycoplasma* spp in healthy free-ranging raptor nestlings. *RCVS Thesis for Diploma in Zoological Medicine (Avian)*, Library of Royal College of Veterinary Surgeons, London.
- Lorenz, K. (1935) Companions as factors in the bird's environment. In: *Studies in Animal and Human Behaviour*, Vol. 1 (1970 edn, trans. R. Martin). Methuen, London.
- Lorenz, K. (1937) The companions in the bird's world. *Auk*, 54, 245–73.
- Lorenz, K. (1965) Die 'Erfindung' von Flugmasken in der *Evolution der Wirbeltiere*. In: *Darwin hat recht gesehen*. Neske Verlag.
- Ludders, J.W., Rode, J.A. and Mitchell, G.S. (1989) Effects of ketamine, xylazine and a combination of ketamine and xylazine in Pekin ducks. *American Journal of Veterinary Research*, 50, 245–9.
- Lumeij, J.T. (1987) A contribution to clinical investigative methods for birds, with special reference to the racing pigeon (*Columba livia domestica*). *PhD thesis*. Rijksuniversiteit, Utrecht.
- Lumeij, J.T. and Deenik, J.W. (2003) medetomidine-ketamine-ketamine anaesthesia in racing pigeons (*Columba livia domestica*): a comparative study. *Journal of Avian Medicine and Surgery*, 17(94), 191–6.
- Lumeij, J.T. and Overduin, L.M. (1990) Plasma chemistry references in Psittaciformes. *Avian Pathology*, 19, 235–4.
- Lumeij, J.T., Ritchie, B.W. and Blanco, J.M. (1993) Avian electrocardiography: a contribution for the practitioner. *Proceedings European Association of Avian Veterinarians*, Utrecht, pp 137–54.
- Lumeij, J.T., Ritchie, B.W. and Branson, W. (1994) Cardiology. In: *Avian Medicine: Principles and Application* (eds B.W. Ritchie, G.J. Harrison and L.R. Harrison), pp 695–722. Wingers Publishing, Lake Worth, FL.
- Luo, M., Ding, L. and Perkel, D.J. (2001) An avian basal ganglia pathway essential for vocal learning forms a closed topographic loop. *J Neurosci.*, 21(17), 6836–45.
- Machin, K.L. and Caulkett, N.A. (1996) The cardiopulmonary effects of propofol in mallard ducks. *Proceedings of the American Association of Zoo Veterinarians* pp 149–54.
- Machin, K.L. and Caulkett, N.A. (1998) Investigation of injectable anaesthetic agents in Mallard ducks (*Anas platyrhynchos*): A descriptive study. *Journal of Avian Medicine and Surgery*, 12(4), 255–62.
- Mandelker, L. (1972) Ketamine hydrochloride as an anaesthetic for parakeets. *Veterinary Medicine/Small Animal Clinician*, 67, 55–6.
- Mandelker, L. (1973) A toxicity study of ketamine HCl in parakeets. *Veterinary Medicine/Small Animal Clinician*, 68, 487–9.
- Mangilgi, G. (1971) Unilateral petagiectomy: A new method of preventing flight in captive birds. In: *International Zoo Year Book XI*, pp 252–4.
- Marley, E. and Payne, J.P. (1964) Halothane anaesthesia in the fowl. In: *Small Animal Anaesthesia. Proceedings of a British Small Animals Veterinary Association/ Universities Federation for Animal Welfare Symposium* (ed. O. Graham-Jones), p. 127. Pergamon, Oxford.
- Martin, H.D., Bruecker, K.A., Herrick, D.D. and Scherpelz, J. (1993) Elbow luxations in raptors: a review of eight cases. In: *Raptor Biomedicine* (eds P.J. Redig, J.E. Cooper, J.D. Remple and D.B. Hunter), pp 199–206. University of Minnesota Press, Minneapolis.
- Martin, H.D. and Ritchie, W.B. (1994) Orthopaedic surgical technique. In: *Avian Medicine: Principles and Application* (eds W.B. Ritchie, G.J. Harrison and L.R. Harrison), pp 1166–8. Winger Publishing, Lake Worth, FL.
- Mason, J.R., Adams, M.A. and Clark, L. (1989) Anthranilate repellency to starlings: chemical correlates and sensory perception. *J. Wildl. Manage.*, 53, 55–64.
- Mason, J.R. and Clark, L. (2000) The chemical senses in birds. In: *Sturkie's Avian Physiology*, 5th edn (ed. G.C. Whittow). Academic Press, San Diego, CA.
- Mason, J.R. and Espallat, J.E. (1990) Differences in taste preference between red-winged blackbirds and European starlings. *Wilson Bull.* 102, 292–9.

- Mason, J.R. and Otis, D.L. (1990) Aversiveness of six potential irritants on consumption by red-winged blackbirds (*Agelaius phoeniceus*) and European starlings (*Sturnus vulgaris*). *Wilson Bull.* 102, 292–9.
- Matson, K.D., Millam, J.R. and Klasing, K.C. (2001) Thresholds for sweet, salt, and sour taste stimuli in cockatiels (*Nymphicus hollandicus*). *Zoo Biol.*, 20, 1–13.
- Mavrogordato, J.G. (1960) *A Hawk for the Bush*, 2nd edn. Neville Spearman, London.
- Miller, L. (1942) Some tagging experiments with black-footed albatrosses. *Condor*, 44, 3–9.
- McKeever, K. (1979) *Care and Rehabilitation of Injured Owls*. W.F. Rannie, Lincoln, Ontario, Canada.
- McLelland, J. (1989) Anatomy of the air sacs. In: *Birds, Form and Function* (eds A.S. King and J. McLelland), pp 258–73. Academic Press, London
- McMillan, M.C. (1982) *Diseases of Cage and Aviary Birds*, 2nd edn (ed. M.L. Petrak). Lea and Febiger, Philadelphia.
- McMillan, M.C. (1996) Avian radiology. In: *Diseases of Cage and Aviary Birds*, 3rd edn (ed. M.L. Petrak), pp 329–59. Lea and Febiger, Philadelphia, PA.
- Monks, D.J., Carlisle, M.S., Carrigan, M., *et al.* (2005) *Angiostrongylus cantonensis* as a cause of cerebrospinal disease in a yellow-tailed black cockatoo (*Calyptorhynchus funereus*) and two tawny frogmouths (*Podargus strigoides*). *Journal of Avian Medicine and Surgery*, 9(4).
- Mouritsen, H. and Larsen, O.N. (2001) Migrating songbirds tested in computer-controlled Emlen funnels use stellar cues for a time-independent compass. *J Exp. Biol.*, 204(22), 3855–65.
- Mouritsen, H. and Ritz, T. (2005) Magnetoreception and its use in bird navigation. *Curr. Opin. Neurobiol.*, 15(4), 406–14.
- Muheim, R., Phillips, J.B. and Akesson, S. (2006) Polarized light cues underlie compass calibration in migratory songbirds. *Science*, 313(5788), 837–9.
- Murdock, H.R. and Lewis, J.O.D. (1964) A simple method for obtaining blood from ducks. *Proceedings of the Society for Experimental Biology and Medicine*, 116, 51–2.
- Murray, M.J., Schildger, B. and Taylor, M. (2002) *Endoscopy in birds, reptiles, amphibians and fish*. Endo-Press, Tuttingen.
- Murrell, L.R. (1975–76) A practical method of determining bird sex by chromosome analysis. *Annual Proceedings of the American Association of Zoological Parks and Aquariums*, 87–90.
- Necker, R. (2000) The somatosensory system. In: *Sturkie's Avian Physiology*, 5th edn (ed. G.C. Whittow). Academic Press, London.
- Needham, J.R. (1981) Bacterial flora of birds of prey. In: *Recent Advances in the Study of Raptor Diseases* (eds J.E. Cooper and A.G. Greenwood), pp 3–9. Chiron Publishers Ltd., Keighley, Yorks.
- Nevitt, G.A. (2000) Olfactory foraging by Antarctic Procellariiform seabirds: Life at high Reynolds numbers. *Biol. Bull.*, 198, 245–53.
- Newton, I. (1979) *Population Ecology of Raptors*, pp 81–94. T.A.D. Poyser Ltd.
- Olney, P.J.S. (1958/9) *Wild Fowl Trust Report 11*, p. 154. Slimbridge, Glos.
- Papi, F. (1991) Orientation in birds. Olfactory navigation. *EXS*, 60, 52–85.
- Pass, Paul-Murphy (1998) Pain management in clinical practice. *Journal of Avian Medicine and Surgery*, 12(4), 277.
- Pass, D.A. and Perry, R.A. (1984) The pathology of psittacine beak and feather disease. *Australian Veterinary Journal*, 61(3), 69–74.
- Peakall, D.B. (1970) Pesticides and reproduction of birds. In: *Scientific American: Birds* (ed. B.W. Wilson), pp 255–61. W.H. Freeman, San Francisco, CA.
- Pees, M., Straub, J. and Krautwald-Junghanns, M.E. (2004) Echocardiographic examinations of 60 African grey parrots and 30 other psittacine birds. *Veterinary Record*, 155, pp 73–6.
- Pees, M., Krautwald-Junghanns, M.E. and Straub, J. (2006). In: *Clinical Avian Medicine*, ol I (eds G.J. Harrison and T. Lightfoot), p. 380. Spix, FL.



- Peiper, K. and Krautwald-Junghanns, M.E. (1991) Diagnosis of tuberculosis in pet birds with the help of radiology. *Proceedings of First Conference of European Committee of Association of Avian Veterinarians*, Vienna, p. 186.
- Perman, V., Alsaker, R.D. and Riis, R.C. (1979) *Cytology of the Dog and Cat*. American Animal Hospital Association, Indiana.
- Perrins, C.M. (1979) *British Tits*. Collins, London.
- Petrak, M.L. (1982) *Diseases of Cage and Aviary Birds*, 2nd edn. Lea and Febiger, Philadelphia.
- Phalen, D.N. (2006) Preventive medicine and screening. In: *Clinical Avian Medicine* (eds G.J. Harrison and T.L. Lightfoot), pp 573–85. Spix Publishing, Inc., Palm Beach, FL.
- Phalen, D.N., Lau, M.T. and Filippich, L.J. (1997) Considerations for the safety of maintaining the avian patient under prolonged anaesthesia. *Proceedings of the Annual Conference and Expo of the Association of Avian Veterinarians*, pp 111–16.
- Phalen, D.N., Tomaszewski, E.K. and Styles, D.K. (2004) Epizootiology, diversity and pathogenicity of psittacoid herpes viruses. *Proceedings of Association of Avian Veterinarians*.
- Philip, H.R.H. Prince (1984) *Address to General Assembly of the International Union for Conservation of Nature and Natural Resources, Madrid*.
- Pieper, K. and Krautwald-Junghanns, M.E. (1991) Diagnosis of tuberculosis in pet birds with the help of radiology. In: *Proceedings of First Conference of European Committee of Association of Avian Veterinarians*, Vienna, p.186.
- Portman, A. and Stingelin, W. (1961) The central nervous system. In: *Biology and Comparative Physiology of Birds* (ed. A.J. Marshal), pp 1–36.
- Radlinsky, M.A., Carpenter, J.W., Mison, M.B. and Armbrust, L.J. (2004) Colonic entrapment after cloacopexy in two psittacine birds. *Journal of Avian Medicine and Surgery*, 18(3), 175–82.
- Rager, G. and Rager, U. (1978) Systems-matching by degeneration. I. A quantitative electron microscopic study of the generation and degeneration of retinal ganglion cells in the chicken. *Exp. Brain. Res.*, 33, 65–8.
- Rahn, H., Ar, A. and Pagenelli, C.V. (1979) How bird eggs breathe. In: *Scientific American: Birds* (ed B.W. Wilson), pp 208–17. W.H. Freeman and Company, San Francisco, CA.
- Raines, A.M., Kocan, A. and Schmidt, R. (1995) Pathogenicity of adenovirus in the ostrich (*Struthio camelus*). *Main Proceedings of Conference of Association of Avian Veterinarians*, pp 241–5. Association of Avian Veterinarians, Boca Raton, FL.
- Raymond, L. (1985) Spatial visual acuity of the eagle *Aquila audax*: A behavioral, optical and anatomical investigation. *Vision Res.*, 27, 1859–74.
- Redig, P.T. (1978) Raptor rehabilitation: diagnosis, prognosis and moral issues. *Conference on Bird of Prey Management Techniques, Oxford* (ed T.A. Greer).
- Redig, P.T. (1979) *First Aid and Care of Wild Birds* (eds J.E. Cooper and J.T. Eley). David and Charles, Newton Abbot.
- Redig, P.T. (1981) Aspergillosis in raptors. In: *Recent Advances in the Study of Raptor Diseases* (eds J.E. Cooper and A.G. Greenwood), pp 117–22. Chiron Publications Ltd., Keighley, Yorks.
- Redig, P.T. (1983) Anaesthesia for raptors. *Raptor Research and Rehabilitation Program*, Newsletter 4, 9–10.
- Redig, P.T. (1996) *Nursing Avian Patients*. In: *Manual of Raptors, Pigeons and Waterfowl*, p. 46. British Small Animal Veterinary Association, Cheltenham, Glos.
- Redig, P.T. and Duke, G.E. (1976) Intravenously administered ketamine and diazepam for anaesthesia of raptors. *Journal of the American Veterinary Medical Association*, 169, 886–8.
- Reece, R.L. (1982) Observations on the accidental poisoning of birds by organophosphate insecticides and other toxic substances. *Veterinary Record*, 111(20), 453.
- Reiser, M.H. and Temple, S.A. (1980) Effects of chronic lead ingestion on birds of prey. In: *Recent Advances in the Study of Raptor Diseases* (eds J.E. Cooper and A.G. Greenwood), pp 21–5. Chiron Publications Ltd, Keighley, Yorks.

- Reither, N.D. (1993) Medetomidine and atipamezole in avian practice. *Proceedings European Conference Avian Medicine and Surgery*, Utrecht, pp 43–8.
- Remple, J.D. (1993) Raptor bumblefoot: a new treatment technique. In: *Raptor Biomedicine* (eds P.T. Redig, J.E. Cooper, J.D. Remple and D.B. Hunter). Chiron Publications, Keighley, W. Yorks.
- Remple, J.D. (2004) Intracellular hematozoa of raptors: a review and update. *Journal of Avian Medicine and Surgery*, 18(2), 75–88.
- Remple, J.D. and Forbes, N.A. (2000) Antibiotic-impregnated polymethyl methacrylate beads in the treatment of bumblefoot in raptors. *Raptor Biomedicine III Zoological Education Network*, FL.
- Remy, M. and Emmerton, J. (1989) Behavioral spectral sensitivities of different retinal areas in pigeons. *Behav. Neurosci.*, 103, 170–7.
- Richards, J.R. (1980) Current concepts in the metabolic responses to injury, infection and starvation. *Proceedings of the Nutrition Society*, 39, 113.
- Richardson, J.D. (1984) Avian anaesthesia. *Veterinary Record*, 115(7), 154.
- Riedel, V. (1991) Ultrasonography in birds. *Proceedings First European Conference of Avian Veterinarians*, Vienna, pp 190–98.
- Ritchie, B.W. (1995) *Avian Viruses*. Wingers Publishing, Inc., Lake Worth, FL.
- Ritchie, B.W., Harrison, G.J. and Harrison, L.R. (1994) *Avian Medicine, Principles and Application*. Wingers Publishing, Lake Worth, FL.
- Roberts, W.A. and Mazmanian, D.S. (1988) Concept learning at different levels of abstraction by pigeons, monkeys, and people. *J. Exp. Psychol. Anim. Behav. Process.* 14, 247–60.
- Robinson, P. (1975) Unilateral patagiectomy. A technique for deflighting large birds. *Veterinary Medicine/Small Animal Clinician*, 70(2), 143.
- Rogers, J.J. and Miles, F.A. (1972) Centrifugal control of the avian retina. V. Effects of lesions of the isthmo-optic nucleus on visual behaviour. *Brain Res.*, 48, 147–56.
- Romagno, A. (2005) Reproduction and paediatrics. In: *Manual of Psittacine Birds*, 2nd edn, p. 204. British Small Animal Veterinary Association, Cheltenham, Glos.
- Roskopf, W.J. and Woerpel, R.W. (1982) Abdominal surgery in pet birds. *Modern Veterinary Practice*, 63(2), 889–90.
- Roskopf, W.J., Woerpel, R.W. and Pitts, B.J. (1983) Surgical repair of a chronic cloacal prolapse in a greater sulphur crested cockatoo (*Cacatua galerita*). *Veterinary Medicine Small Animal Clinician*, 78(5), 719–24.
- Roskopf, W.J. and Woerpel, R.W. (1984) Clinical experiences with avian laboratory diagnostics. *Veterinary Clinics of North America*, 14(2), 261.
- Rupiper, D.J. (1993) Radial ostectomy in a barn owl. *Journal of the Association of Avian Veterinarians*, 7(3), 160.
- Samour, J. (2006) Diagnostic value of hematology. In: *Clinical Avian Medicine* (eds G.J. Harrison and T.L. Lightfoot), pp 587–610. Spix Publishing, Inc., Palm Beach, FL.
- Samour, J.H., Baggott, G.K., Williams, G., Bailey, I.T. and Watson, P.F. (1986) Seminal plasma concentration in budgerigars (*Melopsittacus undulatus*). *Comparative Biochemistry and Physiology*, 84(4), 735.
- Samour, J.H., Jones, D.M., Knight, J.A. and Howlett, J.C. (1984) Comparative studies of the use of some injectable anaesthetic agents in birds. *Veterinary Record*, 115(1), 6–11.
- Samour J.H. and Naldo J.L. (2003) Diagnosis and therapeutic management of trichomoniasis in falcons in Saudi Arabia. *Journal of Avian Medicine and Surgery*, 136–43.
- Schildmacher, H. (1931) Untersuchungen über die Funktion der Kerbstöchen Körperchen. *J. Ornithol.*, 79, 374–415.
- Schlotthauer, C.F., Essex, H.E. and Mann, F.C. (1933) Caecal occlusion in the prevention of blackhead (enterohepatitis) in turkeys. *Journal of the American Veterinary Medical Association*, 83, 218.
- Schmitt, P.M., Gobel, T. and Trautvetter, E. (1998) Evaluation of pulse oximetry as a monitoring method in avian anaesthesia. *Journal of Avian Medicine and Surgery*, 12, 91–9.

- Schöpf, A. and Vasicek, L. (1991) Blood chemistry in canary finches (*Serinus canaria*). *Proceedings of First Conference European Committee of Association Avian Veterinarians*, Vienna, p. 933.
- Schwartzkopff, J. (1949) Über Sitz und Leistung von Gehör und Vibrationssinn bei Vögeln. *Z. Vergl. Physiol.* 31, 527–608.
- Scott, D.C. (1968) Intramedullary fixation of a fractured humerus in a wild owl. *Canadian Veterinary Journal*, 9, 98–9.
- Scott Echols, M. (1998) Surgery of the avian reproductive tract. In: *Seminars in Avian and Exotic Pet Medicine*, 11(4), 177–95.
- Scrollavezza, P., Zanichelli, S., Palestra, L., Stella, G. and Arus, A. (1995) Medetomidine-ketamine association and atipamezole in the anaesthesia of birds of prey. *Proceedings 3rd Conference of European Committee of the Association of Avian Veterinarians*, Jerusalem, p. 211.
- Secord, A.C. (1958) Fractures in birds repaired with the Jonas splint. *Veterinary Medicine*, 53, 655–6.
- Sibley, C.G. and Ahlquist, J.E. (1990) *Phylogeny and Classification of Birds. A Study of Molecular Evolution*. Yale University Press, New Haven, CT.
- Siegal-Willmot, J.L., Pollock, C.G., Carpenter, J.W. and Nietfeld, J. (2005) *Journal of Avian Medicine and Surgery*, 19(1), 19.
- Simpson, V.R. (1991) Leucocytozoon-like infection in parakeets, budgerigars and a common buzzard. *Veterinary Record*, 129, 30.
- Simpson, V.R. (1996) Post-mortem examination. In: *Manual of Psittacine Birds* (eds P.H. Benyon, N.A. Forbes and M.P.C. Lawton), p. 70. British Small Animal Veterinary Association, Cheltenham, Glos.
- Simpson, V.R. and Harris, E.A. (1992) *Cyathostoma lari* (Nematoda) infection of birds of prey. *Journal of Zoology* (London), 227, 655–9.
- Small, E. (1969) *Diseases of Cage and Aviary Birds*, 1st edn (ed M.L. Petrak), p. 354. Lea and Febiger, Philadelphia.
- Smith, G.A. (1979) Parrot disease as encountered in a veterinary practice. In: *The Husbandry and Medicine of the Parrot Family – The Proceedings of a British Veterinary Zoological Society/Parrot Society meeting*, Regent's Park, London (eds A.G. Greenwood and J.E. Cooper).
- Smith, G.A. (1982) *Magazine of the Parrot Society*, 16(11), 340.
- Souza, M.J., Greenacre, C.B., Jones, M.P., *et al.* (2006) Clinical use of MicroPET and CT imaging in birds. In: *Proceedings of 27th Annual Conference of the Association of Avian Veterinarians*, San Antonio, Texas, pp 13–16.
- Stager, K.E. (1964) The role of olfaction in food location by the turkey vulture (*Cathartes aura*). *Los Ang. Cty. Mus. Contrib. Sci.*, 81, 1–3.
- Stager, K.E. (1967) Avian olfaction. *Am. Zoo.*, 7, 415–20.
- Stauber, E., Papegeorges, M., Sande, R. and Ward, L. (1990) Polyostotic hyperostosis associated with oviductal tumour in a cockatiel. *Journal of American Veterinary Medical Association*, 196(6), 939–40.
- Steiner, C.V. and Davis, R.B. (1981) *Caged Bird Medicine*. Iowa State University Press, Ames, Iowa.
- Stettenheim, P. (1972) The integument of birds. In: *Avian Biology*, Vol. II (eds D.S. Farmer, J.R. King and K.C. Parkes), p. 7. Academic Press, New York/London.
- Stockdale, B.C. (2005) The nutritional implications of producing the 'optimal egg' in captive birds. *Proceedings of the European Association of Avian Veterinarians*, p. 340.
- Stromberg, M.R. and Johnsen, P.B. (1990) Hummingbird sweetness preferences: taste or viscosity. *Condor*, 32, 606–12.
- Stunkard, J.A. and Miller, J.C. (1974) An outline guide to general anaesthesia in exotic species. *Veterinary Medicine/Small Animal Clinician*, 69, 1181–6.
- Tanzella, D.T. (1993) Ulna ostectomy in a pale-headed rosella (*Platyercus adscitus*) with multiple injuries. *Journal of the Association of Avian Veterinarians*, 7(3), 153.

- Taylor, M. (1994) Biopsy techniques. In: *Avian Medicine Principles and Application* (eds R.W. Ritchie, G.J. Harrison and L.R. Harrison). Wingers Publishing, Lake Worth, FL.
- Taylor, M. (1994) Endoscopic examination and biopsy techniques. In: *Avian Medicine: Principles and Application* (eds B.W. Ritchie, G.J. Harrison and L.R. Harrison), pp 327–54. Wingers Publishing, Inc., Lake Worth, FL.
- Temple, S.A. (1972) Artificial insemination with imprinted birds of prey. *Nature*, 237, 287–8.
- Thorup, K., Alerstam, T., Hake, M. and Kjellen, N. (2003) Bird orientation: compensation for wind drift in migrating raptors is age dependent. *Proc. Biol. Sci.*, 270(Suppl 1), S8–11.
- Tiemeier, O.W. (1941) Repairing bone injuries. *Auk*, 58, 350–9.
- Toyoshima, K. and Shimamura, A. (1991) Ultrastructure of Merkel corpuscles in the tongue of the finch *Lonchura striata*. *Cell Tiss. Res.*, 264, 427–36.
- Van der Hage, M.H. and Dorrestein, G.M. (1991) Flagellates in the crop of canary bird. *Proceedings of First Conference of European Committee of Association of Avian Veterinarians*, Utrecht, Netherlands, pp 303–7.
- Van der Hage, M.H., Dorrestein, G.M. and Zwart, P. (1984) Pancreatitis is associated with paramyxovirus III in some aviary birds (*Neophema* and Passeriformes). *Proceedings Meeting of Veterinary Pathologists*, Utrecht, p. 28.
- Van der Hage, M.H., Dorrestein, G.M. and Zwart, P. (1987) Paramyxovirus infections in Psittaciformes and Passeriformes. *European Symposium over Vogelziekten*, Beerse, Belgique. Netherlands Association of Avian Veterinarians.
- Van Wettere, A.J., Wünschmann A, Latimer K.S., Redig T.P. (2005) Adenovirus Infection in taita falcons (*Falco fasciinucha*) and hybrid falcons (*Falco rusticolus* × *Falco peregrinus*). *Journal of Avian Medicine and Surgery*, 19(4), 280–5.
- Varela, F.J., Pacacios, A.G. and Goldsmith, T.H. (1993) Color vision of birds. In: *Vision, Brain and Behavior in Birds* (eds H.P. Zeigler and H.-J. Bischof), pp 77–98. MIT Press, Cambridge.
- Von Becker, E. (1974) Schnabelschienung bei Afrikanischen Hornrabben. *Praktische Tierärztl.*, 55(9), 492–4.
- Von Fersen, L., Wynne, C.D.L., Delius, J.D. and Staddon, J.E.R. (1992) Transitive inference formation in pigeons. *J. Exp. Psychol. Anim. Behav. Process*, 17, 334–41.
- Wade, L.L. et al. (2003) Identification of oral spiral bacteria in cockatiels (*Nymphicus hollandicus*). *Proceedings Association of Avian Veterinarians*, pp 23–4.
- van der Wall, S.B. and Balda, R.P. (1977) Coadaptation of the Clark's nutcracker and the pinyon pine for efficient seed harvest and dispersal. *Ecol. Mon.*, 47, 89–111.
- Wallack, J.D. and Boever, W.J. (1983) *Diseases of Exotic Animals: Medical and Surgical Management*. W.B. Saunders Co., Philadelphia.
- Wallraff, H.G. (1991) Conceptual approaches to avian navigation systems. *EXS*, 60, 128–65.
- Walls, G.L. (1942) *The Vertebrate Eye and Its Adaptive Radiations*. Cranbrook Institute of Science, Bloomfield Hills, MI.
- Weaver, J.D. (1983) Artificial insemination. In: *Falcon Propagation, a Manual on Captive Breeding* (eds J.D. Weaver and T.J. Cade), pp 19–23. The Peregrine Fund, Ithaca, New York.
- Westerhof, I.N.A. (1996) Pituitary-adrenocortical function and glucocorticoid administration in pigeons (*Columba livia domestica*). *PhD thesis*. University of Utrecht.
- Wilgus, H.S. (1960) Reserpine for tranquillising geese. *The 2nd Conference on the Use of Reserpine in Poultry Production*, 54–6. The Institute of Agriculture, Minnesota, St. Paul, Minnesota.
- Wilkinson, J.S. (1984) A.I. Work in France. *Journal of the Welsh Hawking Club*, 9–13.
- Wilkinson, R. and Birkhead, T.R. (1995) Copulation behaviour in vasa parrots, *Coracopsis vasa* and *C. nigra*. *Ibis*, 37(1), 117–19.
- Wiltshcko, W. and Wiltshcko, R. (2002) Magnetic compass orientation in birds and its physiological basis. *Naturwissenschaften*, 89(10), 445–52.

- Wiltshcko, W. and Wiltshcko, R. (2005) Magnetic orientation and magnetoreception in birds and other animals. *J. Comp. Physiol. A. Neuroethol. Sens. Neural. Behav. Physiol.*, **191**(8), 675–93.
- Woerpel, R.W. and Rosskopf, W.J. (1984) Clinical experience with avian laboratory diagnostics. In: *Symposium on Caged Bird Medicine. The Veterinary Clinics of North America*, **14**(2), 249–86.
- Wood, C.A. (1917) *The Fundus Oculi Of Birds, Especially As Viewed By The Ophthalmoscope*. Lakeside Press, Chicago.
- Woodford, M. (1977) *A Manual of Falconry*, 3<sup>rd</sup> edn. Adam & Charles Black, London.
- Wright, A.A., Cook, R.G., Rivera, J.J., Sands, S.F. and Delius, J.E.D. (1988) Concept learning by pigeons: matching-to-sample with trial-unique video picture stimuli. *Anim. Learn. Behav.*, **16**, 436–44.
- Yaakov, D.R., Rosenthal, K.L. and Shofer, F.S. (2006a) *Proceedings of the Conference of the Association of Avian Veterinarians*, p. 369.
- Yaakov, D.R., Rosenthal K.L. and Shofer, F.S. (2006b) *Proceedings of the Conference of the Association of Avian Veterinarians*, p. 810.
- Yeisey, C.L. (1993) Surgical correction of valgus carpal deformities in water-fowl. In: *Proceedings of the Association of Avian Veterinarians Annual Conference*. Lake Worth, FL.
- Zwart, P. (2003) Plumafolliculoma (feather cyst) in canaries (*Serinus canaria*), a benign tumour. *Proceedings 7th Meeting of Association of Avian Veterinarians, Loro Parque, Tenerife, Spain, April 22–26, 2003*, pp 241–7.
- Zwart, P. and Grimm, F. (2000) Plumafolliculoma, feather cysts, in canary birds, a tumourous growth. *Proceedings 18th meeting of the European Society of Veterinary Pathology, Amsterdam*, p. 126.

# Index

---

- Abandonment of Animals Act 1960, 208
- abdomen  
  coelomic cavities, 156  
  palpation, 53
- abdominocentesis diagnostic samples, 76
- abdominal muscles, 155  
  incision, 155  
  rupture/hernia, 163
- Abscesses  
  infra-orbital, 145  
  mouth, 51, 110, 150  
  subcutaneous, 145
- Acanthocephalid spp.*, 327
- accommodation of the avian eye, 29  
  and post-sclerocorneal muscle, 29  
  and diving birds, 30  
  and Terns, 30
- Acepromazine, 132
- Acetyl salicylic acid (Aspirin), 125, 257
- Achilles tendon luxation, 54, 180
- Actinobacillosis, 272
- Actinomyces spp.* infection, 311
- Acuaria sp.*, 326
- acuity sight, 27  
  and cones, 27  
  taste, 11, 35  
  of smell, 13, 16, 37
- acoustic acuity, 34
- Acylovir, 254
- adaptation to skeletal/muscle injury, 209–211
- adenoviruses, 301  
  lab tests, 75
- Adrenal gland, 83  
  signs/autopsy, 113
- Aegyptianella pullorum* (Piroplasmosis), 278, 321
- aerodynamics, wings, 8, 168, 229
- Aeromonas, 268
- Aflatoxin, 338  
  and chronic anaemia, 62
- aggression, *see* stress
- and breeding, 197, 215
- bullying/ducks, 53, 163
- towards humans, 205, 215
- agricultural chemicals, toxic, 335
- air flow/lung, 17, 127
- Air sac anaesthesia, 140
- Air sacculitis, 94, 106, 122
- Air sacs, 18, 126, 156 189  
  canulation, 76, 83, 140  
  mites, 332  
  swabs, 72  
  washings, 76, 79
- ‘air trapping’, airsacs, 95
- Albatross  
  breeding maturity, 18
- Albumen/Globulin ratio, 66
- Alcaligenes sp.*, 269
- Alcobon, 243
- Alimentary canal  
  and drug absorption, 117  
  content transit time, 12–13  
  drugs acting on alimentary canal, 263  
  radiography, 91  
  signs, autopsy, 107–109  
  surgery, 157  
  ultrasonography, 99
- allometric scaling, 116
- allopreening, 46
- ALP (Alanine Amino Transferase), 70
- Alphachoralose poisoning, 335
- Alphaxalone – alphadolone (Saffan) anaesthetic, 131
- ALT (Alanine Amino Transferase), 70
- altman tape splint, 179
- alula digit, 7
- Amazon tracheitis (Herpes virus), 283
- ambient temperature  
  when nursing, 189  
  during anaesthesia, 128
- Amyloma spp.*, 333
- Amidostomum anseris*, 325
- American bald eagle herpes virus*, 284
- Amikacin, 231
- aminoglycoside antibiotics, 230–232
- Aminophylline (Roxane), 259
- Amoxycillin, 222–223
- Amphotericin-B (Fungizone), 242
- Ampicillin, 221–222
- amyloidosis of the kidney, 343
- anabolic steroids/  
  Nandrolone, 255
- anaemias, 61  
  aplastic, 59  
  diagnostic bone marrow samples, 74
- anaesthesia  
  Air sac anaesthesia, 140  
  cardiac failure during, 128  
  emergencies, 138  
  general anaesthesia  
    Atropine, 129

- inhalation, 135–138  
 injection, 131  
 cardiac arrest, 139  
 cardiac failure causes, 128  
 circuits, 135  
 depth assessment, 131  
 endotracheal tubes, 135  
 fluid therapy, 129  
 heat pads, 128  
 hypercapnia, 128  
 hypoxia, 127  
 hypothermia, 128  
 intermittent positive pressure ventilation, 138  
 masks, 135  
 mechanical ventilation during, 135  
 monitoring, 129  
 oxygen flow rates, 126  
 PaCO<sub>2</sub>, 126–128, 130  
 precautions during, 128–129  
 premedication and tranquillisation, 131  
 respiratory rate, critical, 128, 138  
 volatile anaesthetics, 135  
 importance pre-clinical assessment, 125  
 local anaesthesia safety, 124  
 physiological considerations, 125  
 suggested anaesthetic routines, 138  
 analgesia and Analgesics, 124, 257  
 Anamnesis (clinical history), 40  
*Anatipestifer* infection, 272  
 Aneurysms, turkeys, 110  
 Angel wing, valgus deformity, 54, 179  
*Angiostrongylus cantonensis*, 326  
 Anisocytosis, 59  
*Annulospira spp.*, 324  
 anorexia post-mortem/autopsy indications of, 108  
 droppings, 41  
 Anthrax, 273  
 Antibiotics, 219–239  
 eggshell quality, 203  
 impregnated beads, 165  
 selection and logical use, 122, 219  
 anticoagulants, blood, 56, 64  
 anti-diarrhoeals, 263  
 Antidiuretic hormone test, 344  
 anti-fungal drugs, 237  
   polyene antifungals, 242  
 anti-Malarial drugs, 250  
 anti-mycobacterial drugs, 237, 239  
 anti-parasitic drugs  
   ectoparasites, 251  
   endoparasites, 244  
   protozoal endoparasites, 248–250  
 Antirobe, 234  
 AP (Alkaline phosphatase), 70  
 apnoea during anaesthesia, 126, 138  
   stimulant (Doxapram-V), 138, 265  
 Appertex (clazuril), 248  
 Apramycin, 232  
*Arboviruses*, 296  
 Ardeidae (Hérons) feeding, 194  
*Argus spp.*, (soft ticks), 333  
 aromatic chemicals avoidance, 36  
 arthropod ectoparasites, 329–333  
   treatment, 251  
 Arthrosynovitis/Salmonella in pigeons, 54, 89  
 artificial insemination, 200  
 artificial respiration, 138  
 Ascarid worms, 323  
 ascites, 53  
   investigation, 76  
 Ascorbic acid, 254  
 Aspirin (Acetyl salicylic acid), 125, 257  
*Aspergillus sp.*, 106, 309  
   culture, 72  
   chronic anaemia, 62  
   clinical signs Humans, 309  
   microscopical staining, 73, 309  
   treatment, 237, 240–243  
 AST, SGOT (Aspartate Amino Transferase), 70  
 ataxia, 43  
 Atheromata, 43, 110  
 Atipamezole, 135  
*Atoxoplasma sp.*, 318  
   treatment, 250  
 Atropine, 129, 256  
*Astroviridae*, 295  
 attacks on humans, 205, 215  
 auditory system, 31  
   external auditory meatus, 31–32  
   importance/casualty birds, 213  
 auscultation of the thorax, 52  
 autopsy, 52  
   colour changes in muscles, viscera, 105  
 Avian cholera (Pasteurella), 271  
*Avian encephalomyelitis*, specific/epidemic tremor, 294  
   lab test, 75  
   vaccine, 253  
*Avian influenza*, 209, 293  
   lab test, 75  
*Avian malaria*, 321  
   effective drugs, 250  
 Avipox viruses, 47, 110, 292, 392, Plate 7  
   vaccines, 252  
*Avian reticuloenteliosis*, lab test, 75  
*Avian sarcoma leucosis*, lab test, 75  
*Avian serositis*, 296  
 Avian TB, 273  
   lab test, 75  
   drugs effective against, 237, 239  
 Avian typhoid (Pulorum disease), 267  
 aviary birds  
   Helminth parasites, 79  
   frostbite, 55  
 Avipro, 261, 192  
 Avocet beak anatomy, 3  
 Azithromycin, 233, 239  
  
*Babesia*, 321  
*Bacillus anthracis*, 273  
 Bacteria  
   antibacterial drugs, use, 219  
   diseases, 266–278  
   infection eggs, 204  
   microbiological investigations, 71  
   stained smears, 73

- Bactrim, 236  
 baldness, 255  
 bandaging wings, 168  
 banding rings, removal, 180,  
 Plate 12  
 Barn owl – flight, 210, Plate  
 19  
 and facial ruff, 33  
 assymetrical location ear  
 canals, 33  
 localizing sound, 34  
 Basophil, 64  
*Bayliascaris procyonis*, 323  
 bathing or spraying, 186  
 benefit, water birds, 187  
 Beak, *see* bill  
 anatomical variation, 2–4,  
 10  
 Beak and Feather disease  
 virus, 46, 299  
 Bill Tip Sensitive Organ,  
 3, 24  
 change, colour, 50  
 deformity, surgery, 51,  
 150  
 examination, 51  
 hardness, 3  
 magnetite in beak, 39  
 mite infestation,  
 /Knemidocoptic  
 mange  
 Osteosarcoma, 51  
 partial loss, 153  
 splits, fractures, 152  
 sensitivity, 24  
 Beaver fever, 320  
 behaviour, *see* aggression  
 brooding/fostering, 205  
 mental health birds, 214  
 hot/cold chicks, 206–207  
*Besnoitia sp.*, 317  
 bile acids, 69  
 Bile Duct Carcinoma, 106,  
 280  
 Biliverdin/Bilirubin, 69  
 biochemical data  
 selection, 64  
 collection blood samples,  
 64  
 results reliance, 65  
 binocular vision, 26  
 biopsy specimens, 79  
 obtaining with endoscope,  
 85  
 ultrasound directed liver,  
 99  
 Birds/Paradise, trachea, 16  
 Bisolvon, 258  
 biting flies, 333  
*Blackhead* (Histomoniasis),  
 320  
*Black Spot diseases/canaries*,  
 298  
 Blain, 54  
*Blastomycosis*, 310  
 treatment, 237  
 bleeding, *see also*  
 haemorrhage  
 during pinioning, 177  
 from feathers, 41, 144,  
 177  
 blepharospasm, 47  
 blindness, 27, 47, 350  
 blood  
 cell counts and  
 haemoglobin, 60–62  
 chemistry reliability, 65  
 chemistry samples, 64  
 circulating volume, 56  
 glucose, 67  
 haematocrit (PCV), 59  
 in droppings, 41  
 mean RBC corpuscular  
 indices, 60  
 parasites treatment, 250  
 plasma collection, 65  
 sample collection,  
 anticoagulants, 56  
 serum chemistries, 64–71  
 smears, staining methods,  
 59  
 transfusions, 144  
 values immature and wild  
 birds, 60  
 volume, 144  
 Blow Fly Strike (Myiasis), 333  
 Blue Green Algae, 337  
 Bob White Quail  
*Herpesvirus*, 284  
 bones  
 autopsy examination, 114  
 elemental structure, 164  
 secondary  
 Hyperparathyroidism,  
 111  
 flight stresses, 165  
 healing, rate, 164–165  
 marrow examination, 74,  
 78  
 Osteoporosis, 89  
 Perosis, 54  
 Polyostotic hyperostosis,  
 90  
 pneumonisation  
 interspecific variation,  
 18  
 signs/injury, wing bones,  
 44  
 surgery, 166–176,  
 178–180  
*Bordetella spp.*, 269  
 boredom, 45, 346  
 Borreliosis, 270  
 Botulism (limberneck), 274,  
 337  
 brachial plexus, avulsion,  
 166  
 brachial vein/injection, 45,  
 46, 119  
 brain investigation, 346  
 autopsy examination, 113  
 clinical signs/disease, 43  
 stem, 22  
 pons and medulla, 23  
 “breakfast of the chicken”,  
 201  
 breathing, abnormal signs,  
 42  
 breeding  
 age and breeding  
 condition, 198  
 artificial insemination,  
 200  
 and disease, 198  
 colony breeding, mixed  
 species, 197  
 dead in shell eggs,  
 201–203  
 diet, 198, 199  
 incompatibility of  
 breeding pairs, 197  
 toxic chemicals, 198  
 failure, 196  
 failure rearing young  
 chicks, 205  
 fostering chicks, 205  
 maturity, 18, 198  
 nesting sites, 199  
 weather and photo period,  
 198  
 Bromhexidene (Bisolvon),  
 258  
 Bromide, potassium, 264  
 bronchodilator/  
 Aminophylline, 259  
 brood patch, 202  
 brown hypertrophy/cere, 50,  
 149  
 Budgerigars  
 anaesthetics, 132  
 conditions  
 Budgerigar Herpes  
 virus, 284  
 diagnostic lab test, 75  
*Cnemidocoptes* mites,  
 332  
 Coccidiosis, 314



- eggs
  - number layed, 18
  - retained, 53
  - French Moulting (Psittacine Circo virus), 299
  - Fledgling Disease*, 300
  - gonadal tumours/radiographs, 96
  - Hypothyroidism, 42
  - Infectious Oesophagitis* (PHV1), 281
  - intersexes, 50
  - lipomas, 146
  - Microsporidium spp.*, 318
  - Paramyxovirus (PMV) – 5, 291
  - tight ring removal, Plate 12
  - regurgitation, normal and pathological, 41, 52
  - taste, 36
  - water dependency, 20–21
- Bugs (*Hemiptera spp.*), 333
- Bumblefoot abscesses, 181–182
  - species affected, 54
- Bursa of Fabricius, signs at autopsy, 109
- Bursitis, *see* blain
- Bustards, oesophageal sac, 11
- Butorphanol, 124
- Buzzards, *see* raptors
  - Frenkelia* infection, 316
- Caeca, 13, 14, 108
  - signs/autopsy, 108
- Caecal worms, 325
- cachexic birds, feeding, 36
- caching food, 31, 35
- cages/hospitalisation, 184
- calcium
  - Calcium boroglucomate, 258
  - total/protein bound/ions/blood, 71
  - hypocalcaemia, 71
- Campylobacter spp.*, 269
  - in juvenile ostriches, 62
- canaries
  - canary pox vaccine, 252
  - conditions
    - Atoxoplasma*, 318
    - Avipox infection, 292
    - beak anatomy/feeding, 2–4
    - Black spot diseases, 298, 318
    - breeding stimulation, 198
    - Budgerigar Fledgling disease*, 300
    - Circo virus*, 298
    - feather cysts, 46, 146
    - susceptibility/ILT, 282
    - Tassle foot, 55, 332
    - Polyoma virus*, 300
  - incubation and fledging periods, 356
  - weight range, 354
- Candida*, 93, 110, 310
  - candling of eggs, 199
  - chorio-allantoic membrane blood vessels, 201
- Canine a/d Feline diet, 192
- canker, 51
- canthotomy, 147
- Capercaillie, trachea of, 16
- Capillaria spp.*, 325
- capnography, 130
- Carbenicillin, 223
- Carbon monoxide 337
  - signs/autopsy, 112
- cardiac failure/anaesthesia, 139
- cardiopathy
  - diagnosis, 91, 98, 351
  - treatment, 259, 260
- Carotenoids and oil droplets in cone cells, 30
- Carprofen, 125, 146, 257
- Caryospora sp.*, 316
  - treatment, Appertex, 248
- cascade system, use of unlicensed drugs, 123
- Castings (pellets), 12, 41, 194
  - see also* regurgitation
- casualty birds
  - assessment of health and reasons why found, 209
  - factors affecting survival, 208
  - Hack boxes, 217
  - importance of good hearing, 34, 213
  - release
    - additional factors, 217
    - and the environment, 215, 217
    - and weather, 216
    - Skeletal/muscle injury and adaption, 209–211
    - techniques for release, 217
  - testing flying ability/falconry techniques, 212
- Cataracts, 47
  - surgery on, 148
- cat bites (and *Pasteurella*), 271
- catching birds, 44
- caudal medulla, 23
- Central Nervous System signs
  - illness, 43, Plate 3
  - investigation, 346–351
- Centrorhynchus sp.*, 327
- Cephalexin, 225
- Cephalothin, 225
- Cephalosporins, 225–226
- Cefoxitaxime, 226
- Cephadrine, 226
- Ceratospira spp.*, 324
- Cere, 50
  - colours
    - hyperkeratinisation, Budgerigars, 50, 149
- Cerebellum, 23
  - body's unconscious awareness in space, 23
- cerebral ischaemia, 43
- Cervical vertebrae in Darters (Anhinga), 4
- Cestoda, 328
  - treatment, 247
- checking sight/visual impairment, 27
- Chelating agents, 265
- chemicals, toxic, *see* poisoning
- chemesthesis, 36
- Chicken Adenovirus (inclusion body hepatitis)*, 302
- Chicken anaemia virus*, 299
- Chicks
  - artificial rearing, 205
  - chilling, 206
  - congenital abnormalities, 206
  - crop impaction, 153, 207
  - dead in shell, 201–203
  - fostering, 205
  - hatchery dead, feeding dangers, 193
  - hatching, 19, 203
    - artificial assistance, 204
  - infanticide, 205
  - Metabolic bone disease, 206

- overheated/too cold, 206–207
- progress of growing chicks, 206
- rearing failures, 205
- rehydration, hatchlings, 204
- splayed legs, 206
- Vitamin A deficiency chicks, 36
- wet chick in egg, 202
- Chlamydophila*, 62, 277
- signs at autopsy, 106, 107
- dry swabs for culture, 72, 104
- effective drugs, 228, 229, 233, 235, 236
- Ornithosis, 277
- PCR DNA test, 275
- Psittacosis, 277
- staining of smears, 73
- lab tests for, 75
- Chloramphenicol, 230, 235
- Chlortetracycline, 229
- Chlorhexidine, 243
- Chloromycetin, 235
- Chocolate toxicity, 335
- cholesterol, 69
- Chorio-Allantoic membrane blood vessels, 201
- Chromic cat gut, 143
- Ciconidae
- Herpes virus*, 282
- lower visual field myopia, 29
- Circoviridae*, 298
- ciliary muscles, 29
- Clometine (Tagamet), 259
- Cimex spp.*, 333
- Ciproxin, 238–239
- Circoviridae*, 298
- Circo viruses*, lab tests for, 75
- Doves, Finches, Gulls, Hornbills, 300
- CK (CPK), 70
- Cladosporium sp.*, 311
- Clavamox/clavulanate, 222
- clavicular injury, 166
- Clavicle anatomical presence, 5
- claws, sloughing, 55
- Cleaview (unipath) test, 72
- Clindamycin, 234
- cloaca
- autopsy signs, 109
- conditions, 53
- prolapse, 161
- papillomata, 106
- Clostridial spp.*, 274–275
- Cl. perfringens* (enterotoxaemia), 274
- Clostridial dermatitis*, 275
- Clotrimazole, 241
- Cnemidocoptic/  
Knemidocoptic mange, 332
- CNS, sedatives/stimulants/  
behavioural modification drugs, 264–265
- Coccidiosis, 314
- Cockatiel
- persistent egg laying, 19, 161–163
- Reovirus/acute enteritis, 306
- taste, 36
- Trichomoniasis, 319
- Cochlostoma spp.*, 319
- Cockatoo
- Beak and Feather syndrome, 24, 45, 46, 299
- Viral enteritis, 295
- weights, 352
- Coclea nerve, 22, 31
- Avian cocklea, 34
- coeliotomy (laparotomy), 155
- Coelomic cavities, 156
- Coffee, toxicity, 335
- Coli bacillosis, 268
- Colinus herpes virus, 284
- colour vision, 27, 30
- Columella, 31–33
- muscle, 32–33
- Computed tomography (CT), 101
- of head, 101
- concussion
- signs/autopsy, 114
- and pupillary dilatation, 47
- nervous signs, 43
- conduction rates of various myelinated fibres, 24
- cone cells/retina and hookup, 27, 28
- oil droplets, cones, 30
- constipation
- see also cloacal impaction, 53
- drugs for relief, 263
- Contagious coryza, 275
- Contagious paralysis of pigeons, 281
- Conures, haemorrhagic syndrome virus, 286
- Conure papilloma herpes virus, 285
- Coots
- Coracoid bone, 5, 166
- Corona viruses, 305
- cortical blindness, 27
- Copper deficiency/poisoning, 62, 336
- Cormorants feeding hospitalised, 194
- herpes virus, 284
- regurgitation, 39
- Cornea, 47
- ulcers, 147
- curvature changes for accommodation, 29
- corneal reflex, 131
- Coronaviridae*, 305
- Corticosteroids, 255
- Corvidae (Crows)
- feeding, 194
- Cosumix, 236
- Coumaphos (Negasunt), 251
- courtship and regurgitation, 41
- simulating courtship behaviour, 200
- Coxiella burnetti*, 277
- CPK, (Creatine phosphokinase), 70
- Cranes beak, 3
- Herpes virus*, 282
- Cranial nerves examination of, 350
- V, 23, 36;
- VII, 33, 36;
- IX, 36
- Craniofacial hinge2, 2
- Creance, 257
- Creatinine phosphokinase, see CPK, 70
- creatinine, 69
- Critical Care formula, 261, 192
- Crop
- autopsy, 110
- burns/fistula, 154
- infections, 110
- impaction, 11, 153
- Milk, 11, 205
- presence/absence, food storage, 11
- slow emptying, 207
- Sour, Crop, 52, 110, 207
- swelling of, 52

- washings, examination, 76, 78
- cross fostering chicks, 205
- crows  
 feeding hospitalised, 194  
 incubation, fledging periods, 355  
 weight ranges, 354
- cyanosis, 42
- Cyrophaga antipestifer*, 272
- Cryptococcus*, 310  
 treatment, 237  
 zoonotic potential, 310
- Cryptosporidium sp.*, 108, 315  
 signs in humans, 315  
 treatment of, 233
- Curlews, beak, 3
- Curassows, trachea, 16
- cutaneous receptors, 22
- Cyanthostoma sp.*, 327
- cypermethrin, 261
- cysts feather, 46, 146  
 subcutaneous, 146
- cytology diagnostic, 74  
 interpretation, 77
- Cytomegalo virus*, 285
- Cytophaga anatipestifer*, 271
- Dalacin, 234
- damping nest materials, 202
- Daphnia spp.*, 326
- Darters (Anhinga), cervical vertebrae in, 4
- DDT and DDE, toxæmia, 335  
 chronic anaemia, 61
- deafness, casualty birds, 213
- dehydration, 190  
 due/not eating, 190  
 chicks, 212
- Delmadinone, 256
- Depluming itch (P43, P46), 331, 332
- Dermal viral (Herpes) disease, 285
- Dermanyssus sp.*, 330
- dermatological problems, 344
- Dermatomycosis (Ringworm), 311
- Dermis and sub cutis, 145
- Derris Powder, 251
- Desflurane, 138
- devoicing birds, 154
- Devoprim, 236
- Dexamethosone, 255
- Dextrans, 149
- diabetes mellitus (non insulin dependant), 259
- diarrhoea, 40, 341
- Diazepam (Valium), 264
- Diclofenac, 338
- Dichlorvos strips, 335
- digestive tract, seasonal change in length, 13
- Dieldrin, 335
- diet changing, 193  
 breeding birds, 199, 205  
 parent birds, 205
- dilation of pupil (mydriasis), 259
- Dimercaprol (British Anti Lewisite), 265
- Dimethyl suboxide (DMSO), 258
- Dimetriadazole, 249
- Dinoprost, 255
- Dinoprostone, 256
- Dioxins, toxicity, 337
- Diphenhydramine (Benadryl), 260
- Dipterous flies/Myiasis, 333
- disinfection, cleaning hospital cages, 189
- disinfectants  
 F10, 189, 361  
 Chlorhexidene, 243, 254  
 poisoning, 336
- Dispharynx spp.*, 324
- Diving birds and ext. auditory meatus, 31
- DNA probes, 73, 197
- Dopram-V, 265
- Dorisiella sp.*, 315
- double clutching, 205
- Dove circo virus*, 300
- Doves incubation and fledging periods, 355  
 weights, 353
- Doxapram, 138, 265
- Doxepin (Sinequan), 264
- Doxycycline, 228  
 drills, Dremel, 150, 361
- drinking water, medication of, 116
- Droncit, 247
- droppings  
 blood, in, 41  
 change in character, 40
- drugs administration, 115–123  
 calculating dose, 116  
 inhalation therapy, 121  
 relative absorption from gut, 118
- dispensing, 117  
 unlicensed use/birds, 123
- DSMO, 258
- Duck plague (Herpes enteritis) virus, 62, 283  
 lab tests for, 75  
 vaccine, 252
- Duck viral hepatitis, (Picorna) types I and III, 294
- Duck virus hepatitis* (Astro) type II, 295
- Ducks  
 Gizzard worms, 325  
 Infectious anaemia, 287  
 mode/flight, 210  
 Muscovy  
 Adenoviruses, 303  
 Reovirus, 306  
 Penis, prolapse, 19, 163, Plate 11  
*Porrocaecum* infection, 323  
 Proventricular worms, 324  
 Reovirus stunting, 306  
 Syringeal distension, 17  
 taste buds, 36  
*Tyzzeria infection*, 315  
 wet feather, 46
- Duphalyte, 262, 191
- Duphatrim, 236
- Duratestone, 255
- dyspnoea and gasping, 42, 340
- Eagles, *see also* raptors  
 American Bald Eagle  
 Herpes virus, 284  
 mode/flight, 8, 210  
 moulting intervals, 46
- ear, conditions, 31, 50
- ECG/anaesthesia, 129
- Echinophaga gallinacean*, 330
- Echinuria sp.*, 326
- ectoparasitic diseases, 329  
 treatment, 251
- EDTA, use, 265
- eggs  
 autopsy examination, 204  
 candling, 199  
 chilling, 201  
 dead in shell, 201–203  
 development, 201  
 double clutching, 205  
 eating, 199  
*Egg drop syndrome*, 302  
 episiotomy/egg removal, 160

- excess temperature, 201  
 failure to hatch, 201  
 fertility/Raptors/Passerines, 201  
 hatching, 19, 203  
 humidity, 202  
 impaction/binding, 96, 159, 168  
 inability to produce normal, 199  
 incubation, 24, environmental factors, 201–203  
 indeterminate/determinate layers, 19  
 infection, causes, 204 swabs from, 72  
 laying, 199  
 lethargy, 199  
 interval between laying, 19  
 malformed, 159  
 number laid, 19  
 nutritional deficiency, 203  
 paracentesis, 160  
 peritonitis, 69, 160  
 persistent egg laying, 19, 161–163, 256  
 pipping external, 19, 203 internal, 203  
 respiration, 19, 201  
 retention surgery for relief, 159–161 medical treatment, Prostaglandin, Calcium, 256, 258  
 rotation during incubation, 202  
 shell texture/quality variation, 19, 203  
 tooth/egg, 203, 19  
 toxins effect, 203  
 water logging, 202  
 water loss during incubation, 202  
 weighing during incubation, 202  
 wet chick in egg, 202  
*Eimeriidae*, 314  
*Eimeria sp.*, 314 treatment, 248 *truncata/geese*, 314  
 elbow joint luxation, 174  
 electro surgery  
 electrocardiography, 351  
 Embryo, respiratory system, 201  
 Emerald Critical Care, 192, 261  
 Emphysema subcutaneous, 52  
 Emtryl, 249  
 Emu, vestigial wing claws, 7  
 Enalapril (Enacard), 260  
 encephalomyelitis, Avian specific/epidemic tremor, 294 lab tests, 75 vaccine, 253  
 Encephalomyelitis Equine (Tago virus), 296 lab tests, 75 vaccine, 253  
 Endolymph, 31, 34  
 endoscopy, 80  
 Endotracheal tubes, 135  
 energy requirements, 188  
 Engemycin, 227  
 Enilconazole (Imaverol), 241  
 Enrofloxacin, 238–9  
 Enterobacteriaceae, 266  
*Enterococcus faecalis*, 270  
 Eosinophils, 64  
 Epidemic tremor, 294  
 Epidermoptic mites, 331  
 Epilepsy, idiopathic treatment, 264  
 Epiphora, 47  
 episiotomy, egg removal, 160  
 Ergot poisoning, 338  
*Erysipelas*, 272  
 Erythromycin, 234  
*Escherichia coli*, 106, 268 strains toxic/humans, 268  
*Everglades Equine Viral Encephalitis*, 296  
 Eye anterior chamber conditions, 47 blink reflex, 30 canthotomy, 147  
 Cataracts, 47 surgery, 148 conjunctival oedema, 48  
 Cornea, 47  
 drugs/treatment, 121  
 enucleation, 148  
 examination, 47  
 injury/casualties, 213  
 lens, luxation, 48  
 loss/survival, 213  
 Nictating membrane, 148  
 Pecten oculi, 48–49  
 posterior chamber, 47–49  
 reflexes, 47  
 surgical anatomy, 147–14  
 Eyelids, 147  
 subconjunctival injection, 121  
 Eyeworms, 324  
*Cyanthostoma sp.*, 327  
*Thelazia sp.*, 324  
 F10, 189  
 faecal examination, 79–80  
 faeces, character of, 40  
 Falconers expressions used, 357 techniques used for feather replacement, 213  
*Falcon inclusion body hepatitis*, 280  
 falcons, *see also* raptors conditions of *Adeno virus*, 303 eyesight, 213 *Infectious hepatosplenitisvirus*, 280 *Serratospiculum sp.* infection, 327 *Trichomoniasis*, 319 mode/flying, 8 semen collection, 200  
 faradism, 194  
 fatty liver and kidney syndrome, 69  
 Favus (Ringworm), 311  
 faeces, blood in, 41 direct smears, and Helminth eggs, 79  
 fear, anxiety, relief, anaesthesia, 125  
 Feathers Apterium, 145 and quill mites, 331 dermatological problems, 344 duster syndrome, 284, Plate 21 feather rot (mites), 332  
 Feathers and sexing by DNA, 197  
 Beak and Feather virus disease, 45, 299  
 chicks, growth, 206 conditions, 45–46  
 cyst (Plumafolliculomas), 46, 146  
 damaged in casualties, 212

- Feather dust and  
 pathogens, 50, 105, 283
- Fret/hunger/stress marks, 46
- imping, 213
- loss and flight, 212
- malformed primary, flight, 46
- moulting, 46
- plucking, self, 45  
 awareness of self  
 induced damage, 24
- plucking prior to surgery, 144, 286
- plumage and colour  
 vision, 30
- preening, 186
- protection of tail feathers  
 during nursing, 187
- Tail feathers during flight, 24
- Tail feathers, importance, 5, 212
- Wet Feather*/ducks, 46
- feeding behaviour  
 captive raptors, 193  
 during nursing, 188, 191
- hatchery chicks, dangers  
 of feeding, 193
- Insectivorous birds, 193
- Meal worms/Maggots, 194
- wild birds, and weather, 216
- feet conditions, 54–55, 181–182  
 rotation in fledgling  
 Raptors, 54  
 types, 9
- Fenbendazole (Panacure), 244
- Ferric chloride, 259
- fertilisation of ova, 200
- Fibrinogen, 66
- Fibronyl, 251
- Filiariasis*, 327
- Fillicollis sp.*, 327
- Finches  
 Air sac mites, 332
- Australian and PMV3, 290
- Big liver disease, 318
- breeding, 196
- and *Budgerigar Fledgling Disease*, 300
- Circo virus*, 300
- Cochlosoma spp.*, 319
- Fringillidae* finches, beaks, 10
- 'Going Light' syndrome, 318
- Gouldian (*Chloebia gouldiae*)  
*Herpes virus*, 285  
 susceptibility to  
 Cytomegalovirus, 285
- Isospora spp.*, 314
- Macrorhabdus ornithogaster* (Megabacteria)  
 infection, 312
- oesophagus and crop, 11
- Polyoma virus*, 300
- taste, 35
- Twirling syndrome, 291
- Zebra (*Poephila guttata*)  
 water dependency, 21  
 breeding, 196
- Fish eating birds, behaviour, 194
- fish hooks in birds, 51
- fits, 43, 348, 349
- Flagellates, antibiotics active  
 against, 227
- Flamingoes  
 Crop milk, 11  
 Intertarsal joint, 9
- Flat flies, 329
- Flaviviridae, 296
- Fleas, 330  
 sticktight, 330
- Flexispira rappini*, 270
- flies, dipterous, 333
- flicker frequency, 28, 184
- flight  
 injuries affecting, 209–211  
 lift on aerofoil, 210  
 mechanics, 164–165  
 modes of, 8, 209–212  
 prevention by surgery, 177–178  
 testing fitness for, 212
- Flubendazole, 245
- Fluconazole, 240
- fluid therapy, 129  
 and nursing, 190
- Flukes (trematodes), 328
- Flucytosine, 243
- Fluorescent strip lights  
 flicker frequency, 28, 184, 198
- Fluoroquinolones, 237–238
- flying weight, 191
- fogging/fumigation, 189
- Folic acid deficiency, 6243
- Food  
 and energy requirements, 188
- feeding during  
 hospitalisation and  
 convalescence, 188, 191–194
- medicating food, 118
- preferences in species, 36
- Forage mites, 331  
 in G.I. tract/radiography, 94
- fostering chicks, 205
- Foveas, 27
- Fowl  
 Adenoviruses, 302  
*Favus*, 311  
 Fowl plague (Influenza), 293
- fractures  
 basic initial treatment, 165
- Beak, 152
- bones below hock, 179
- Carpus, Metacarpus and  
 Digits, 176
- Clavicle and Coracoid, 166
- ESF, Kirschner splints, 171
- Femur, 178
- grossly contaminated/  
 infected, treatment, 174
- healing, 164
- Humerus, 166–171
- intramedullary pegs, 173
- intramedullary pins, 170
- Radius and Ulna, 176
- shortened and  
 misaligned, 174, 209
- tension band sutures, 173
- Tibiotarsal, 178
- Redig's Tie-in technique, 170
- Vertebral column, 89
- Wing, 166–172
- Francisella tularensis*, 275
- French moult, 46  
*see also* Beak and Feather  
 disease, Polyoma  
 virus
- Frenkelia spp.*, 316
- Fret/Stress marks, 46
- Frigate birds, Furcula of, 7
- frostbite, 55
- Frounce, 51, 319
- Fulmar petrel weight, 535
- fulmars, oil regurgitation, 12, 194

- fumes  
toxic, 336  
Cherry laurel (*Prunus laurocerasus* sp.), 337
- fumigation *see* fogging  
by birds, 38
- Fungizone, 242
- Furcula, 5
- Furosemide, 260
- Gall bladder, 13
- Galliformes*  
Marble Spleen Disease, 304  
*Reovirus*, 306  
presence of notarium, 4
- Gannets  
absence of nares, 13
- Gapes, *see* *Syngamiasis*, 43, 112, 326
- gardening chemicals, 335
- Gastrocnemius tendon  
displacement, 54
- gastro-intestinal problems,  
investigation, 341
- gastrotomy/  
proventriculotomy/  
ventriculotomy, 156
- gavaging, 118, 192
- Geese*  
*Canada*, Wasting Syndrome, 307  
droppings, 41  
Gizzard worms specific, 325  
Proventricular worms, 325  
reovirus infection, 306
- Gentamicin, 231
- Giardiasis*, 320  
treatment, 249
- Gizzard (Ventriculus)  
erosion and necrosis, 12  
gizzard palpation, 53  
Koilin layer, 12  
radiography of, 94  
staining, 12  
striations on the wall of, 109  
surgical access, 156–158  
worms, 323
- Gladosporium* sp.  
(Ringworm), 311
- Glass windows hazard, 27
- Glibenclamide, 259
- Globulins, 66
- Glottis  
position, 135  
Neoplasms, 51
- Glucocorticoids adverse  
effect, 71
- Glycerine, 263
- Godwits, beak, 3
- Going Light Syndrome*, *see*  
*Megabacteria*, 94, 312
- Gonads  
autopsy examination, 112  
neoplasia, 163  
radiography, 96
- Geese, Influenza/Plague/  
Derzsy's/viral  
hepatitis, 295
- Gout, 55  
visceral signs at autopsy, 106
- Grandry corpuscles in  
beak, tongue, toes  
and skin, 24
- Granivorous birds and grit,  
193  
regurgitated seed nutritive  
value/nestlings, 205
- Granuloflex, 145
- Grit, 12  
amount in gizzard, 94  
type and need for, 12, 193
- Goose virus hepatitis (Goose  
influenza/Plague), 295
- Gouldian finches air sac  
mites, 332
- Gouldian finches/  
*Cytomegalovirus*, 285
- Grouse  
*Louping ill* infection, 296  
*Trichostrongylus*, 326
- Granuloflex, 145
- Guillemot beak, anatomy, 3  
diving depth, 6
- Guinea fowl adenoviruses,  
302  
*Infectious bronchitis*, 305  
*Marble spleen disease*, 304  
Trachea, anatomy, 16, 94
- Gulls  
*Waterfowl Adeno virus*, 303  
Beak anatomy of, 3  
Black backed, *Circo virus*, 300  
feeding, 194  
feet, keeping moist, 187  
Humerus, 7  
regurgitation, 12, 194  
flight, 8
- Habronema incertum*, 324
- Hack box, hack board,  
hacking back, 217, 358
- Haemoglobin glutamer, 144
- haemoglobin value, 60
- Haematocrit (PCV), 59
- Haematologists, terms used, 59
- Haemophilus* spp., 275
- Haemoproteus* infection, 322
- haemorrhage, 144  
agonal, 112  
intraocular, 213  
choanal space, 110  
*see* bleeding during  
surgery, 144  
sporadic/autopsy, 108
- Haemorrhagic conure*  
*syndrome*, 286
- Haemorrhagic enteritis*/  
Turkeys, 304
- Hair worms, 325
- Haloperidol (Hadol), 265
- Halothane anaesthesia, 137
- Hammondia* sp., 317
- handling/catching birds, 44
- Harrier  
hearing, 213  
flight, 210
- Harvest mites, 331
- hatching/eggs, 203–204
- hearing, 184, 213
- head swinging, 43
- hearing range/birds, 34, 184  
importance/casualty birds, 31–34, 213
- Heart  
autopsy examination, 109  
cardiopathy  
diagnosis, 351  
electrocardiography, 351  
ultrasonography, 98
- Heavy metal poisoning, 336
- Helicobacter cinaedi*, 270
- Helminth parasites, 323  
treatment, 244–247
- Hemiptera*, 333
- Hepatomegaly and  
radiography, 91
- Hepatozoon*, 321
- Herbst corpuscles, 24  
in beak, 24
- Herbstscher Strang  
vibrations, 24
- Hernia, abdominal, 163

- Herons feeding hospitalised, 194  
*Herpesviridae*, 279  
*Heterakis gallinae*, 325  
 heteropenia, 63  
 heterophil, 62  
*Hexamitiasis*, 320  
   treatment, 249  
 Hexastarch, 144  
 Hibitane, 243  
 Hip, luxation, 180  
*Hippoboscids*, 329  
 Hippocampus in spatial orientation, 39  
*Histomoniasis* (Blackhead), 107, 108, 320  
*Histoplasmosis*, 311  
   potential zoonosis, 311  
   signs/humans, 311  
   treatment, 237  
 Hjarré's disease, 268  
 Hock, luxation, 54, 180  
 homosexuality, 196  
 Hoopoe, coracoid anatomy, 6  
 Hormone treatment, 255  
 Hornbills coracoid anatomy, 6  
   Extra ocular muscles, 350  
   Occipital condyle, 4  
 Hospital cages, 184, Plate 12  
 Household toxins, 338  
 House martins, feeding, 193  
 Howell-Jolly bodies, 59  
 Humerus  
   injury and repair, 166–174  
   surgical anatomy, 169  
 humidity relative and egg incubation, 202  
 Humming birds, 6  
 Hunger marks, 46  
 Hyaluronidase use with injectables, 120, 190, 259–260  
 Hydrocolloid dressings, 145  
 Hydroxyzine, 260  
 Hypercalcaemia, 71  
 Hyperglobulinaemia, 66  
 Hyperglycaemia, 67  
 Hyperkeratinisation/cere, 50, 149  
 Hyperparathyroidism, 111  
 Hyperproteinaemia, 66  
 Hyperstriatum, 23  
 hyperthermia/  
   hyperventilation, chicks, 206–207  
 Hypoalbuminaemia, 66  
 Hypocalcaemia, 43, 71, 348  
 Hypoglycaemia, 43, 67  
 Hypoparathyroidism, 62  
 Hypoproteinaemia, 66  
 Hypophysis  
   neoplasia, 349  
 Hypopyon, 47, Plate 8  
 Hypothyroidism, 42, 62  
 Hypovitaminosis A, 47, 93, 95  
 hysterotomy, 160  
 Iatrogenic poisoning, 338  
 icterus, 69  
 Identification rings, 180, Plate 12  
 idiopathic dullness, Propentophylline, 259  
 Idoxuridene, 254  
 Imidazoles, 240  
 immunity/Levamisole stimulant, 246  
 Immunocytes, 63  
 imping feathers, 213  
 importance of support feeding, 188  
 impression imprints, autopsy, 76  
 imprinting, 205, 214–215  
 Incubator birds, 202  
 Incubators, 202  
 infanticide of chicks, 205  
 infection of the egg, 204  
*Infectious anaemia* of ducks, 287  
*Infectious bronchitis*, 305  
   vaccine for, 253  
*Infectious laryngotracheitis* (ILT), 282  
   lab test, 75  
   vaccine for, 252  
*Infectious oesophagitis*/ pigeons, 281  
 Influenza, avian, lab tests, 75  
 infra-orbital sinus injection, 148  
   aspiration, 76  
 Infrared lamps, 194  
 inhalation therapy, 121  
 injections, various methods, 119–121  
 Inner ear, 33  
 Insectivores, feeding, 193  
 insemination, 200  
 intelligence, avian, 35  
   tool use, 35  
   caching foods, 35  
   mental health, 214–215  
 Intersexes, 50  
 Intestine blood in lumen, 108  
   examination during autopsy, 107–109  
 intussusception/intestine, 158  
 intramedullary pinning, 170  
 intraosseus injection, 120, 190  
 intratracheal injection, 120  
 Iodine, 62, 258  
 Iron deficiency and chronic Anaemia, 62  
 Isoflurane, 137  
*Isospora sp.*, 314  
 Isoxsuprine, 259  
 Itraconazole, 241  
 Ivermectin, 246  
  
*Japanese Quail Adeno virus*, 302  
*Japanese Summer Fever*, 297  
 Jaw articulation, 2, 3  
 joints  
   autopsy, 114  
   affected by Salmonella, 54  
   Bursitis (Blain), 54  
   luxations, 166, 174, 180  
  
 Kakopo (Owl parrot), 6  
 Kanamycin, 232  
 Koagel, 263  
 Kaolin mixtures, 263  
 'Kecks', 42  
   *Paramyo virus PMV-1*, 288  
 Ketamine, 132, 264  
   plus, Acepromaxine, Diazepam, Xylazine, 132–133  
 Ketoconazole, 240  
 Kidneys  
   autopsy, 113  
   comparative anatomy, 20–21  
   investigation of disease, 242  
 Kirschner splints, 179–182  
 Kiwis  
   external nares, 13  
   ovaries, 18  
*Klebsiella sp.*, 282  
 Knemidocoptic mange mite, 47, 50, 55, 332  
   treatment, 246  
 Koilin of gizzard, 12  
 Kyphosis, 89

- Lactulose (Duphalac), 260, 262
- Lake Victoria Cormorant  
*Herpes virus*, 284
- Lankesterellosis*/  
*Atoxoplasma*, 318
- laparoscopy, 80  
  photography with, 85  
  problems with technique, 82
- Laryngo tacheitis*, lab tests for, 75
- Laser surgery, 143
- Laxatives, 263
- L-carnitine use of, 147
- LD, LDH (Lactate dehydrogenase), 70
- Lead poisoning, 43, 62, 336  
  and CPK, 70  
  and Porphyrinuria, 323
- learning, vocal, 34–35
- Ledclair (Sodium Calcium Edetate), 265
- legs  
  bone fractures, *see*  
  orthopaedic surgery  
  differential anatomy, 7, 9  
  injured legs/survival, 213  
  Paresis of, 43  
  physiotherapy, 194  
  splayed in chicks, 206  
  tight identification rings, 180, Plate 12
- Lemming Disease of Russia*, 275
- Lens/avian eye  
  changes in shape, 29  
  luxation, 48
- Leucocytes, 62  
  toxic, 63
- Leucocytosis, 63
- Leucocytozoonosis*, 105, 322  
  treatment, 250
- Leucopenia, 63
- Leucosis/sarcoma Complex Viruses*, 286
- Levamisole, 246  
  immunostimulation, 123
- Lice, 329
- light, influence on breeding activity, 198  
  flicker frequency, 28, 184–185  
  Lignocaine anaesthetic, 130  
  ointment, 131
- Limber neck (Western duck sickness)*, 274
- Lincomycin, 232
- Lincomycin/Spectinomycin, 232
- Liothyronine sodium (Tertroxine), 257
- Lipaemia, 69
- Lipomas, 146
- Liquid paraffin (Mineral oil), 263
- Listeriosis*, 273
- Liver  
  conditions/autopsy, 106–107  
  fatty degeneration of, 69
- Louping ill virus*, 296  
  vaccine, 253
- Louse flies, 329
- Lovebird Herpes Virus*, 284
- Low energy bulbs/fluorescent strip lights, 184
- Lugol's iodine, 258
- Lungs  
  autopsy examination, 112  
  Chemoreceptors, 126  
  evolution of avian, 201  
  extent, 17–18  
  focal densities in radiographs, 89  
  Mechanoreceptors, 126  
  Neopulmo/Paleopulmo, 17  
  Physiology/gaseous exchange, 126  
  Radiography, 94
- luxation  
  Joints, 166, 174, 180  
  Achilles tendon, 180
- Lyme disease, 270
- Lymphocytes, reactive, 63
- Lymphocytosis, 63
- Lymphopenia, 63
- Lysine deficiency, 46
- Macaws  
  maturity, 198  
  Wasting disease/Psittacine proventricular dilatation (PDD), 109, 307
- Macrolides and Lincosamides, 230, 233–234
- Macrorhabdus ornithogaster* (Megabacteria), 79, 93, 109, 312  
  drug effective against, 242
- Maggots, blow fly strike, 333
- Magnetic Resonance Imaging (MRI), 102
- magnetodetection in migration, 39
- Mallophaga*, 329
- mandible articulation, 2, 3
- Manganese deficiency, 54, 203  
  poisoning, 336
- Marble spleen disease, 304
- Marek's disease, 62, 283  
  autopsy, 113  
  vaccine, 252
- Marbofloxacin, (Marbocyl), 238
- martins house, orphaned, feeding, 193
- mating failure, 196  
  *see* fostering, 205
- Mean corpuscular erythrocyte indices, 60
- Mechanoreceptors  
  skin, 23–24  
  detection of air turbulence with plumage, 24
- Mebendazole, 245
- Medetomidine and Ketamine anaesthesia, 134
- Medication  
  administration of drugs, 115–123  
  oral, 117  
  persistent refusal/oral medication, 37  
  relative absorption from gut, 118  
  suitable volumes/oral medication, 118  
  topical, ointments/creams, 121  
  via drinking water, 116  
  via food, 118
- Medicines, law relating to use of unlicensed drugs, 123
- Medroxy-progesterone, 256
- medullary bone, 90, 96
- “Megabacteria”,  
  *Macrorhabdus ornithogaster*, 79, 93, 109, 312  
  treatment, 242
- Meloxicam (Metacam), 125, 257
- memory, 35
- mental health of birds, 214  
  imprinting, 200, 214–215
- Merkel cells, 24



- Metabolic bone disease, 89, 150, 206  
 metabolic/effective weight, 116  
 metabolic rate high, energy requirements, 188  
 Medoxyprogesterone, 256  
 Metoclopramide (Reglan), 263  
 Metomidate, 135  
 Metronidazole (Torgyl), 249  
 Miconazole, 240  
 microbiological smears, examination of, 73  
*Microsporidium* sp., 316  
*Microtetrameres* spp., 324  
 migratory senses, navigation, 38  
 Milkweeds, toxicity appendix, 337  
 Milupa, 192, 262  
 Mineral oil, *see* liquid paraffin  
 minute volumes/respiration, 17, 126  
 Mites (red and northern fowl), 330  
 and forage, 331  
 depluming itch or mange, 331  
 harvest mites (*Trombicula* spp.), 331  
 plumage, (feather and quill), 331  
 mange mite (*Cnemidocoptes*), 332  
*Sternostoma*, (air sac mites), 331  
 treatment, 246  
 molluscicide poisons, 335  
*Monilia*, 310  
 monocytosis, 64  
 Motile spiral bacteria, 270  
 moulting, 46  
 Mouth  
 oropharynx conditions of, 51  
 and *trichomoniasis*, 51  
 multivitamin and mineral supplements, 261–262  
*Murray valley fever*, 297  
 Muscles  
 abdominal, 155  
 atrophy, 52, 174  
 Ethmomandibularis, 151  
 conditions/radiography, 90, 91  
 conditions of, at autopsy, 105  
 Pseudotemporalis, 150  
 red muscle fibres, 174  
 ruptured abdominal, 163  
 Sarcocystis, 317  
 Supracoroideus muscle (deep pectoral)  
 rupture/tenon, 53–54, 90, 166  
 muscle, well developed, 166  
 white muscle fibres, 174  
 white streaks/muscle/haemoproteus, 322  
*mites*, 40  
*Mycobacteria* sp., 106, 107, 273  
 and anaemia, 62  
 Mycobacteriosis and radiography, 89  
 Lab tests, 75  
 Mycoplasmas, 266, 276  
 antibiotics against, 229, 231–233, 239  
 collection/dry swabs for culture, 72  
 lab tests, 75  
 Mycotic diseases/fungal diseases  
 Mycosis/radiographs/lungs, 94–95, 95  
 Mydriatics, 259  
*Myialages* spp., 331  
 Myiasis (Blow fly strike), 333  
 Mynah birds  
 droppings, 41  
 Mysoline (Primadone), 264  
 Nandrolone, 255  
 Nares, 13  
 hyperkeratinisation, 149  
 Nasal cavity, 16  
 Nasal salt glands, 20–21, 36  
 Nasolachrymal ducts, 47  
 navigational senses, 38  
 Nebcin, 232  
 nebulisers for inhalation therapy, 122  
 Neck  
 brace use, 194  
 parrots/air sacs, 18  
 inflation time/breathing, 42  
 Negasunt, 251  
 Nematodes, 323–327  
 treatment, 244–247  
 Neostriatum, 23  
 caudolaterale, working memory, 35  
*Neophema* sp., PMV (3), 290  
 Neoplasia  
 abdominal, 163  
 bile duct carcinoma, 106, (herpes), 280  
 bones, 89  
 glottis, 51  
 lipomas, 146  
 nictating membrane, 148  
 pituitary, 43  
 preen gland, 147  
 retrobulbar, 47  
 nephropathy diagnosis, 346–351  
 nerve endings/skin, 23  
 unmyelinated and thinly myelinated axons of, 23  
 nerves peripheral autopsy, 113  
 nervous signs of illness, 43, 346–351  
 nest boxes, 197, 199  
 and hygiene, 205–206  
 nesting materials, choice of, 199, 202  
 nestlings  
 causes of death, 207  
 some signs/autopsy, 113–114  
 neurosis, 197, 215  
*Newcastle disease*, 108, 288, 315  
 vaccine, 253  
*New duck disease* (*Anatipestifer*), 272  
 Niclosamide (Yomesan), 247  
 Nictating membrane, tumours, 148  
 Nilverm, 246  
 Nitrous oxide, 137  
 Nizoral, 240  
 Nociceptors, 24  
 Norcuron, 259  
 Norfloxacin, 238  
*Northern fowl mite*, 330  
 Nortriptyline, 260  
 Notarium, 5  
 NSAID drugs, 257  
 nursing birds, 183  
 physiological aspects, 188  
 nutrition, severely ill birds, 191  
 deficiencies, 62  
 nystagmus, 350  
 Nystatin, 242

- oak leaves, toxicity and chronic anaemia, 62  
*Oeciacus spp.*, 333  
 Oesophagitis infectious (Pigeon Herpes Virus), 281  
 oesophagostomy/  
 pharyngostomy tubes, 154  
 oil droplets, distribution/  
 retina, UV light, 30  
 Ointments/creams, 121  
 Oleandomycin, 234  
 Olfaction, 37  
 in petrels, albatrosses and shearwaters, 37  
 and foraging, 37  
 olfaction/navigation, 38  
 olfaction/reproduction, 38  
 Olfactory bulb/brain size, 37  
 Operculum/owls ear, 33  
 ophthalmic treatments, 121  
 opisthotonus, 43  
 Optic cortex/lobe (optic relay area), 22, 26–27, 30–31  
 optic nerve, 25, 30  
 Oral sacs, inflatable, 11  
*Orbiviruses*, 306  
 organophosphates, 335  
*Ornithonyssus spp.*, 330  
 Ornithosis  
 see Chlamydiophylia, 277  
 Orthomyxoviridae, 293  
 ostectomy/radius or ulna, 174  
 osteoarthritis, 193  
 osteodystrophy, metabolic, 89, 150, 206  
 osteomyelitis/osteoporosis, 89  
 osteosarcoma/neoplasia, 89  
 Ostriches  
*Aegyptianella*, 278  
*Anthrax*, 273  
*Aspergillosis*, 309  
 Avian pox, 292  
 Campylobacteriosis/  
 juveniles, 62, 269  
 chicks  
 pipping (hatching) eggs, 203  
 Clostridial  
 enterotoxaemia, 274  
 eggs, artificial incubation, 201  
 eyes, 25–31, 47–49  
 Chick fading syndrome, adenovirus, 303  
*Infectious bronchitis*, 305  
 intersexes, 50  
 “Megabacteria”, *M. ornithogaster sp.*, 61, 93, 312  
 Newcastle disease, 288  
 parsley, toxicity, 33  
 proventriculus, 11–12  
 proventriculotomy, 157, 158  
 tuberculosis, 273  
 toxicity of Thiabendazole, 245  
 yolk sacs (unabsorbed), 163, 206  
 Ovaries  
 left and right, 18  
 cystic seen in radiographs, 90, 96  
 neoplasia, 163  
 Oviduct  
 impaction, 159  
 prolapse, 160–161  
 salpingohysterectomy, 161–162  
 torsion, 159  
 Owls  
 attacks on humans, 215  
 head swinging, 43  
 localizing sound, 34  
*Owl herpes virus (Infectious hepatosplenitis)*, 281  
 eyes/tubular shape, 25–26  
 Oxyglobin, 149  
*Oxyspirura spp.*, 324  
 Oxytetracycline, 227  
 Oxytocin, 160, 256  
 Oystercatcher  
 beaks, 3, 51  
*Pacheco’s parrot disease*, 280  
 lab tests, 75  
 autopsy signs, 106  
 vaccine for, 252  
 Pain  
 chronic pain, 24  
 chemically induced, 36  
 initial pain free period, 24  
 perception, 124  
 response birds, 24  
 sensitive areas, 124  
 pair bonding for life, 197  
 Panacure, 244  
 Pancreas, autopsy  
 examination, 107  
 pancreatitis droppings, Plate 2  
*Papilloma virus*, 301  
 chronic and anaemia, 62  
*Papovoviridae*, 300  
 paraffin, liquid, 263  
*Paraheamproteus*, 322  
*Paramyxo viruses*, 288–291  
 and bursa of fabricus at autopsy, 109  
 lab tests for, 75  
 vaccines, 253  
 parathyroids, 62  
 parrots  
 acuity of vision, 26  
 Amazon, breeding  
 maturity, 18  
 Amazon tracheitis (Herpes virus), 283  
*Aspergillosis*, 309  
 beak surgery, 152  
 caeca, 104  
 coccidiosis, 314  
 Cockatoo viral enteritis, 295  
 beak abnormalities, head  
 and beak, 147–153  
 eating invertebrates, 12  
 enlarged spleen in  
 radiographs, 96  
 feather colour changes, 46  
 feather plucking, 45, 186, 346  
 intelligence, 35  
 lead poisoning, 336  
*Papilloma virus*, 301  
 proventricular dilatation (PDD), (macaw  
 wasting disease), 109, 307  
*Reovirus*, 306  
 medicating food, 118  
 Metabolic bone disease, 89  
 Macaws, breeding  
 maturity, 18  
 moulting, 46  
*Neophema spp.* and  
 PMV3, 290  
*Platycercus spp.* and  
 PMV3, 290  
*Polyoma virus*, 300  
 self trauma, 45, 186, 346  
 taste, 35  
*Vasa (Coracopsis sp.)*  
 copulation, 20, Plate 15

- Parvo virus of geese*, 295  
lab tests, 75
- Pasteurella sp.*, 271
- patagiotomy, 178
- pathogens latent danger, 189
- pathogens, micro, specific tests for, 75
- PCBs (polychlorinated biphenyls), 335
- PCR (Polymerase chain reaction)  
For detection DNA/RNA, 74
- PCV (haematocrit), 59
- PDD, (psittacine proventricular dilatation), 109, 307
- Peafowl, histomonas infection, 320
- Pellets/castings, regurgitated, 12, 41, 194
- Penguins avian malaria, 321  
crop milk, 11  
Emperor, diving depth, 6  
hypoxia, 127  
lungs extent, 17  
Ketamine and Zylazine, 133–134  
short sighted/myopic, 30  
trachea, 17  
wing muscles, 5  
wing bones, 7
- penicillins, 220–224
- Penis (Thallus), 19  
prolapse, 163, Plate 11
- perches, 186
- peritonitis, 95
- perosis, 54
- Petrels sense smell, 13, 39
- pharyngostomy tube, 154
- Pheasants  
*Histomonas* infection, 320  
*Infectious bronchitis*, 305  
*Marble spleen disease*, 304
- physiotherapy, 194
- Picornoviridae*, 294
- Pigeons  
discrimination  
luminescences and colour, 30, 31  
*adenovirus* infection, 302  
air sacs/radiography, 95  
canker, 51, 319  
*Circo virus*, 299  
*Contagious paralysis*, (*Encephalomyelitis*), 281  
diagnostic lab tests, 75  
feather rot, 332  
*Herpes viruses*, 281  
diagnostic lab test, 75  
*Hexamita* infection, 320  
hippoboscids in nestlings, 329  
*Inclusion Body enteritis* (V65), 302  
*Inclusion Body hepatitis* (V66), 303  
*Infectious eosophagitis*, 281  
intelligence, 35  
olfaction in reproduction and navigation, 38  
*Paramyxo virus* (PPMV-1), 289  
vaccine, 253  
*Reovirus enteritis*, 306  
salmonella/joints, 54  
*Trichomoniasis*, 319  
pinioning/prevention of flight, 177
- Piperacillin, 224
- Piperazine, 247
- Piperonyl butoxide, 251
- piscivorous birds, feeding, 194
- pituitary gland/autopsy, neoplasia, 113
- plants  
poisonous, 337–338  
*Platyercus spp.* PMV-3, 290  
plasma T 4, 342  
plasma proteins, 65
- Plasmodium infection, 321  
treatment, 250  
transmission, Infectious anaemia, ducks, 287
- Plumafolliculomas, 146
- post mortem specimens  
storage, 103
- Poikilocyte, 52
- Poisoning, 335  
collection of samples, 334  
agricultural and garden chemicals, 335  
Diesel, 335  
heavy metals, 335  
insecticides, 335
- Polychlorinated biphenols (PCBs), 335
- polychromatic index, 61
- polydipsia/polyurea, 344
- Polyomorphus sp.*, 327
- Polyoma virus*, 62, 300, 304  
lab tests for, 75  
P.M. signs, 106  
vaccine, 253
- polyostotic hyperostosis, 90, 96, 113
- Porrocaecum sp.*, 323
- Post mortem, colour changes in muscles, viscera, 105
- Potassium bromide, 264
- Potassium iodide, 258
- potentiated sulphonamides, 230, 236
- Polyene antifungals
- Pox, avian, 47, 110, 292, 392, Plate 7  
lab tests, 75  
vaccines various, 252
- Praziquantel (Droncit), 247
- Preen gland (Uropygial), 147
- prescription diet (Hills), 192
- premedication/GA, 131
- presurgical fasting, 67
- Primaquine, 250
- Primidone (Mysoline), 264
- Probiotics, 123
- Procaine hydrochloride, 131
- Procellariformes*, navigation/smell, 39
- prognathism, 150
- prolapse  
Cloaca, 161  
Oviduct, 160  
Penis, 163
- Propatagial membranes, 54, 91, 210–211
- Propentofylline (Vivitonin), 259
- proprioception, 23
- Propofol, 132
- Prostaglandin E2 (Dinoprostone), 160, 256
- Prosthorhynchus spp.*, 327
- Protection of Animals Acts 1911 and 1964, 214
- protozoa/gut  
treatment, 227, 230, 236, 248
- Proventriculus  
autopsy signs, 109  
neuropathic dilatation, PDD, 109, 307  
proventriculotomy, 156, 158  
washings, 79  
worms, 324, 326
- Pseudomonas spp.*, 268
- pseudoparasitism, 323
- Pseudotuberculosis spp.*, 271

- psittacine  
 Beak and Feather disease  
*Circo virus*, 24, 45, 46, 299  
*Adenovirus*, 303  
*Herpes viruses*, 280  
 proventricular dilatation (PDD), (Macaw Wasting disease), 109, 307
- Psittacosis  
*see* Chlamydophyllia infection, 277
- PTFE poisoning, 336  
 Puffins, beak, 3  
*Pullorum disease*, 267  
 Pulseoximeter, 129  
 pupil, dilation of (mydriasis), 259  
 and concussion, cortical blindness, 27
- Pygostyle, 5  
 Pyopen (Carbencillin), 223  
 Pyrimethamine, 250
- Quadrat bone, 2  
 Q-fever, 277
- Quail  
*Adenovirus*, 302  
 bronchitis, 302  
*Coronavirus*, 305  
*Herpes virus*, 284  
*Histomoniasis* infection, 320  
 Japanese  
 breeding maturity, 18
- Quinacrin, 250
- Rabies virus*, 298
- Radiography, 86  
 contrast media, 96  
 gut transit time, 97  
 Digital, 87  
 Film and exposure factors, 87  
 gizzard, 94  
 G.I. tract, 91–94  
 use of grids, 89  
 gonads, 96  
 Heart, 91  
 intensifying screens, 88  
 interpretation, soft tissue radiography, 91  
 interpretation, muscle/skeletal system, 89  
 Kidneys, 95  
 Liver, 91  
 mammography films, 89  
 non-screen film, 88
- Respiratory tract, 94  
 Spleen, 96  
 restraint manual or anaesthetic, 85  
 tracheal, variations, 16  
 positioning, 87  
 wings, caudal-cranial projection, 88  
 radio wave surgery, 143  
 Radius and Ulna fractures, 174
- Rainbow lorries, Paramyxovirus, 291
- Raptors  
 Adenovirus infection, 304  
*Aspergillosis*, 309  
 blain, 54  
*Caryospora spp.*, 316  
*Runting and Stunting syndrome*, 307  
 Trichomoniasis (Frounce), 51, 319
- Razorbill  
 beak, 3  
 diving depth, 6
- Red mites, 330
- Red-tailed hawk  
 Frenkelia infection, 316
- Reglan, 263  
 regurgitation, 41, 52  
 renal disease/investigation, 342
- Renal portal system, drugs washed out, 21
- Reoviruses*, 306
- Reproductive system  
 female, 18  
 male, 19
- respiratory disease  
 investigation, 340
- Respiratory system, 13  
 acute obstruction, 154  
 signs/autopsy, 112  
 Reticulocyte, 74, 78  
*Reticulo endotheliosis virus*, 287  
 lab tests, 75
- Retinal examination, 29, 47–49
- Retroviridae*, 286
- Rhamphotheca, 150
- Rhombicephalus spp.*, 333
- Rhinolyths, 149
- Ricketts/flegglings, 89
- Rickettsial infections, 266  
*Rickettsia dermatocentor*, 278
- Rings identity/constriction, 180, Plate 12
- Ringworm, 311
- ripeness/fruit and UV light, 27
- Rocky Mountain Spotted fever, 278
- rodenticide poisoning, 335
- Rodentiosis, 271
- Rods retina/vision, 27
- Rompun (Xylaxine), 264
- Ronoxan, 229
- Rotavirus*, 322  
*Russian spring and summer fever*, 297
- SA-37, 261
- Saffan, (Alphaxalone/Alphadolone) anaesthetic, 131
- Sage grouse  
 Oesophageal sac, 11  
*Saint Louis Fever*, 297  
 salivary glands, 11, 36  
*Salmonella*, 62, 267  
 affecting joints, 54  
 autopsy signs/gut, 108, 109  
 Lab tests, 75  
 ovary/autopsy, 112
- Salpingitis/radiography, 96  
 salpingo-hysterectomy, 161–163
- salt poisoning, 71, 113, 338
- Sarafloxacin, 238
- Sarcocystidae*, 317
- Sarcocystis spp.*, 105, 317  
 effective drugs, 250
- Sarcoma/leucosis complex  
 Retrovirus, 286  
 chronic anaemia, 62  
 lab tests, 75
- Scaly face/scaly leg, 332
- Scissor beak, 150
- Scoprin, 236
- sedatives/stimulants/  
 behavioural  
 modification drugs, 264
- seed, toxins, 338  
 coated/agricultural chemicals, 335
- semen, collection, 200
- sensory receptor area/brain  
 like “Homunculus”, 24
- Serratospiculum*, 106, 327
- Serositis, avian viral*, 296
- Serum  
 enzymes, 13, 69  
 protein/plasma, 65  
 biochemistry, 65

- Sevoflurane, 138  
sexing birds  
  DNA techniques, 197  
  surgical, 81–82  
SGOT, *see* AST, (Aspartate Amino transferase), 70  
SGPT (ACT), 70  
Shell gland, disease, 203  
Shoulder joint, luxation, 166  
sight in low light conditions, 26–27  
Silver nitrate/cautery, 259  
Sinequan, 264  
sinuses/intraorbital/  
  paraorbital/aspiration/  
  injection, 76, 146  
sinusitis, infra-orbital, 35  
*Siphonaptera*, 330  
skin  
  investigation/  
  dermatological  
  problems, 344  
  structure, 145  
skeletal injury/casualties, 209–212  
skeleton, signs/autopsy, 114  
slipped wing, 42  
smears microbiological,  
  examination of, 73  
smell  
  sense of, 37  
  swifts and falconides, 16  
sneezing, 42  
'snits', 42  
Sodium Calcium Edetate  
  (Ledclair), 265  
Sodium iodide injection, 258  
Sodium chlorate poisoning, 335  
Sodium/Potassium, plasma  
  levels, 71  
Soloxine, 257  
somatosensory system, 23–24  
Sour crop, 52, 110, 207  
Spectinomycin, 231  
Sperm  
  fertilization/ova, 200  
  Host glands, 200  
Spinal cord, afferent spinal  
  tracts, 23  
*Spirochaetacea*, 270  
*Spiroptera spp.*, 324  
splayed legs/chicks, 206  
Spleen signs/autopsy, 107  
splenomegaly in TB, 89  
splinting  
  external, 174, 177,  
  179–180  
  internal, 170–171, 176  
*Sporotrichosis*  
  treatment, 237  
squeaking in budgerigars, 42  
Stat, 263  
*Sternostoma sp.*, 106, 327  
Sternum, differential  
  anatomy, 6  
Stick tight fleas, 330  
stomach/oesophageal tubes,  
  118, 192  
*Stork herpes virus*, 282  
Streptomycin, 239  
*Streptocar spp.*, 330  
*Streptococcus faecalis*, 270  
stress  
  breeding problems, 197  
  enteropathy, 108  
  reduction during nursing,  
  183  
*Streptococcus faecalis*, 270  
*Stunting syndrome/reovirus*,  
  306  
Sucrose solution, as laxative,  
  263  
Sulphonamide drugs,  
  potentiated, 236  
Surgery  
  abscesses/tumours/cysts,  
  subcut, 146  
  abdominal (coeliotomy),  
  155  
  alimentary canal, 157  
  canthotomy, 147  
  chromic cat gut, 143  
  cloacal proplapse,  
  161–162  
  cloacoplexy, 161  
  crop  
  impaction, 153  
  fistula, 154  
  electro/radio surgery, 143  
  endoscopic  
  instrumentation, 155  
  enucleation of eye, 148  
  episiotomy, for egg  
  removal, 160  
  essential equipment, 142  
  Feather cysts,  
  (Plumafolliculomas),  
  46, 146  
  gastrotomy/  
  proventriculotomy/  
  ventriculotomy, 156  
  haemorrhage during, 144  
  head and beak, 147–153  
  hysterotomy, 159–160  
  intussusception/gut, 158  
  laser surgery, 143  
  Nictating membrane,  
  147–148  
  Oesophagus, 153  
  orthopaedic, 164–181  
  positioning/patient, 142  
  Preen gland (Uropygial),  
  147  
  preparation/op'site, 144  
  Reproductive tract, 159  
  use of a radio-wave  
  instrument, 143  
  use of heat pad, 145  
  skin, 145  
  skin graphs/flaps, 145  
  suturing materials, 143  
  torsion/oviduct, 159  
  yolk sac retention, 163  
  surgical sexing, 84  
  survival/casualty birds, 208  
*Syngamus trachea*, 43, 112,  
  326  
Synsacrum, 5  
Synulox, 222  
Synringeal bulba, 17  
Syrinx, 17  
  devoicing, 152  
  autopsy examination,  
  112  
*Tagoviridae/Flaviridea*, 296  
Tannins, toxicity, 338  
Tail  
  bobbing, 42  
  feathers (Retrices), 5  
  supporting body, 5  
tape worms, 328  
Tardak, 256  
Tassle foot, 55, 332  
taste/gustation, 36  
  and medication, 117  
  buds, 35  
Tea, toxicity, 335  
Teflon poisoning, 336  
  signs at autopsy, 112  
temperature  
  ambient/hospitalized birds,  
  189  
  body, 53, 189  
tendonectomy preventing  
  flight, 178  
terns, long sighted/  
  hypermetropic, 30  
Terramycin, 227  
Tertroxin, 257  
Testes, 163  
Testosterone, 255

- tetracycline antibiotics, 220, 227–230
- T 4 estimation plasma, 342
- Thallus (penis) prolapse, 20, 163
- Thelazia* sp., 324
- Thermal receptors/skin, 24
- Thibendazole, 245
- thoracic inlet, inflation, 42
- Thorny headed intestinal worms, 327
- threadworms, 325
- Thrombocytopenia, 64
- Thrombosis, 43
- Thrombocytosis, 64
- Thyroid
- autopsy, 111
  - see hypothyroidism
  - neoplasia, 111
  - Releasing hormone, 257
  - Stimulating hormone, 257
  - treatments, 257
- Thyroxine, 257
- Tibial cartilage displacement, 54
- Tiamulin, (Tiamutin), 233
- Tibiotarsal bone, fractures, 178
- Ticarcillin, 224
- ticks, 333
- tick bites, 270, 333
- Timentin, 224
- Tobramycin, 232
- Tongue
- abscessation/trauma, 11, 51
- Torulosis, 310
- toxic household plants, 337–338
- Toxoplasmosis, 62, 317
- effective drugs, 248, 264
- trachea variations, 16, 94
- swabs, 72
  - washings, 76, 79
- tracheotomy, 155
- tracheotomy, 154
- tree bark poisoning, 338
- Trematodes* sp., (Flukes), 328
- Trichomonads*, demonstration, 110
- Trichomonas gallinae*, 319
- treatment, 249
- Trichostrongylus* sp., (Ring Worm), 45, 311
- Trichostrongylus* infection, 326
- Trigeminal nerve (cranial n. V), 23
- Triosseal canal, 5
- Trombicula* spp., 331
- Trypanosoma* spp., 322
- Tuberculosis avian, 273
- autopsy signs, 107
  - anti-tuberculosis drugs, 239
- Tularaemia*, 275
- turkeys
- adenoviruses, 304
  - Blackhead* (histomoniasis), 320
  - Herpes virus*, 284
  - Haemorrhagic enteritis*, 304
  - Soft shell egg disease*, 304
- Twirling syndrome*, old world finches, 291
- Tylosin, 233
- Tympanic membrane, 31–32
- Tyzzeria* sp., 315
- ultrasonography, 97
- Equipment required, 98
  - Examination/heart, 98
  - Kidneys, 99, 100
  - Gonads, 99, 100
  - G.I. tract, 99
  - Liver, 99
  - ventromedian approach, 98
  - parasternal approach, 98
- Ultra violet light
- vision, 27, 30
  - oil droplets/types, 30
- unlicensed drugs, 123
- urate crystals
- colour change in faeces, 41
  - kidneys/radiographs, 95
  - lab test, 43
- urea levels, 68
- urea/uric acid ratio, 68
- uric acid, 67
- Uropygial/preen gland
- function and surgery, 147
- vaccines, viruses, 252–253
- valgus deformity
- metacarpus (angel/slipped wing), 54, 179
  - leg bones, 179
- Vasa parrots, copulation, 20
- Vecuronium Bromide (Norcuron), 259
- Venezuelan equine viral encephalitis*, 296
- Vestibular disease, CNS, 350
- see inner ear, 33
- Vertebral column, Kyphosis, 89
- fractures, 89
- Vionate, 261
- viral diseases, 279–307
- tests, 73–75
  - prophylactic protection (vaccines), 252
- Viral Papillomas, 280, 301
- Visceral afferent nerves, 22
- visual system, 25
- perception of colour, 30
  - use of polarized light in navigation, 39
- visual memory, 31
- vitamin (also mineral and nutritional supplements), 261–262
- Vitamin:-
- A
    - deficiency, 36(chicks)95, 345
    - see Carotenoids and vision, 30
    - injection, 261, 262
    - supplement, Nutrobal, 272  - B
    - Folic acid deficiency, CNS, 43
    - chronic anaemia, 62
    - multivitamin inj, 261
    - B<sub>12</sub>/chronic anaemia, 62  - C
    - injection, 262  - D
    - preparations, 262  - E
    - deficiency CNS signs, 43, 71
    - autopsy signs, 109
    - injection, 262  - K
    - deficiency, heamorrhage/autopsy, 108
    - prior to surgery, 144
    - injection, 262
- Vivitonin (Propentofyline), 259
- vocal learning, 34
- voice
- change, 42
  - devoicing birds, 152
- vomiting/regurgitation, 41, 194
- Voriconazole, 241

- vultures  
Diclofenac, 338  
turkey, smell sense, 13, 37
- Warfarin poisoning, 105, 335
- water conservation/birds  
Conchal cartilage, 16  
Salt glands, 20–21  
kidney/alimentary canal, 20–21, 190–191  
average daily consumption, 116
- water deprivation test, 344
- water drinking, medication, 116
- Waterfowl  
adenovirus, 303
- weight/flying/*see* glossary, 191
- Wenyonella sp.*, 315
- West Nile virus Fever, 209, 297  
vaccine, 253
- Western duck disease (*Limber neck*), 274
- Wet feather, 46
- White winged wood ducks/  
TB, 273
- Wildlife and Countryside Act 1981, 208
- wings  
*Angel*, 177  
bandaging, 169  
injuries/treatment, 43, 53–54  
pinioning/feather cutting, 177
- Wing tip oedema, 54, 259
- wood  
toxic species, 338  
head, 147
- Xylazine (Rompun), 134, 264
- xanthromatosis, 69
- Yellow Fever, 297
- Yersinia pseudotuberculosis*, 62, 271  
*entero-colitica*, 271
- Yoghurt, 262
- Yolk sac, problems, 163, 204, 206
- Yomesan, 247
- Zebra finches, stopping breeding, 196
- Zenecarp, 257
- Ziehl – Neelson (Modified STAMP), 73
- zinc deficiency, 45, 70
- Zinc poisoning, 336  
and anaemia, 62
- Zovirax (Acyclovir), 254