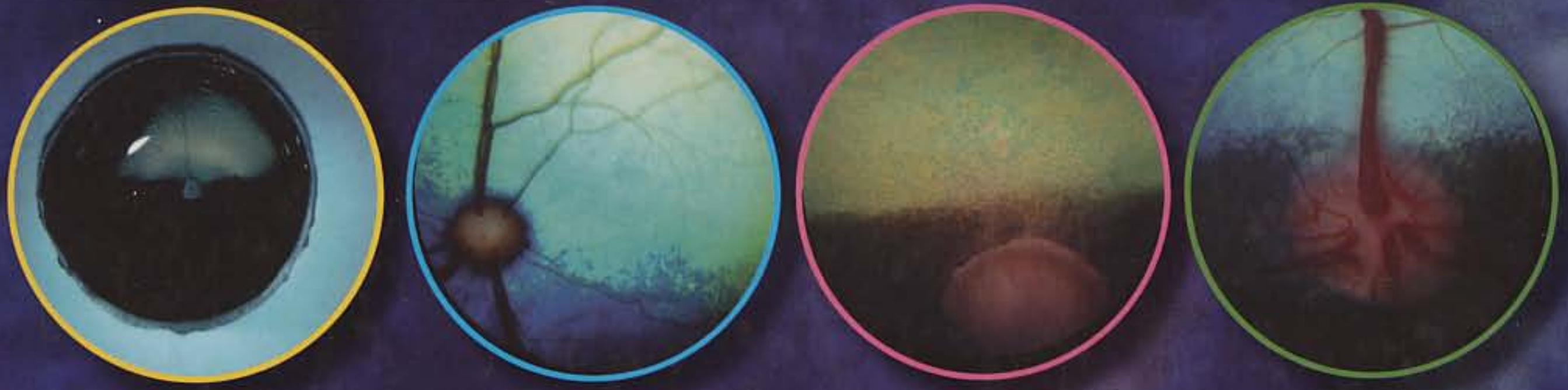




# Diagnostic Atlas of Veterinary Ophthalmology

**Dr Keith Barnett**



# Diagnostic Atlas of Veterinary Ophthalmology

Second Edition

Dr Keith Barnett

Consultant Ophthalmologist, Centre for Small Animal Studies, Animal Health Trust, OBE, MA, PhD,  
DVOphthal, FRCVS, DipECVO

**MOSBY**



ELSEVIER

**MOSBY**  
ELSEVIER

© KC Barnett 1990

© 2006, Elsevier Limited. All rights reserved.

No part of this publication may be reproduced, stored in a retrieval system, or transmitted in any form or by any means, electronic, mechanical, photocopying, recording or otherwise, without either the prior permission of the publishers or a licence permitting restricted copying in the United Kingdom issued by the Copyright Licensing Agency, 90 Tottenham Court Road, London W1T 4LP. Permissions may be sought directly from Elsevier's Health Sciences Rights Department in Philadelphia, USA: phone: (+1) 215 238 7869, fax: (+1) 215 238 2239, e-mail: [healthpermissions@elsevier.com](mailto:healthpermissions@elsevier.com). You may also complete your request on-line via the Elsevier homepage (<http://www.elsevier.com>), by selecting 'Customer Support' and then 'Obtaining Permissions'.

First Edition 1990

Second Edition 2006

ISBN 0 7234 3280 5

British Library Cataloguing in Publication Data

A catalogue record for this book is available from the British Library

Library of Congress Cataloging in Publication Data

A catalog record for this book is available from the Library of Congress

**NOTE**

Knowledge and best practice in this field are constantly changing. As new research and experience broaden our knowledge, changes in practice, treatment and drug therapy may become necessary or appropriate. Readers are advised to check the most current information provided (i) on procedures featured or (ii) by the manufacturer of each product to be administered, to verify the recommended dose or formula, the method and duration of administration, and contraindications. It is the responsibility of the practitioner, relying on their own experience and knowledge of the patient, to make diagnoses, to determine dosages and the best treatment for each individual patient, and to take all appropriate safety precautions. To the fullest extent of the law, neither the publisher nor the author assumes any liability for any injury and/or damage.

The Publisher

Printed in Spain

**ELSEVIER  
SCIENCE** your source for books,  
journals and multimedia  
in the health sciences  
[www.elsevierhealth.com](http://www.elsevierhealth.com)

The  
Publisher's  
policy is to use  
paper manufactured  
from sustainable forests

Working together to grow  
libraries in developing countries

[www.elsevier.com](http://www.elsevier.com) | [www.bookaid.org](http://www.bookaid.org) | [www.sabre.org](http://www.sabre.org)

**ELSEVIER**

**BOOK AID**  
International

**Sabre Foundation**

# Contents

- Acknowledgements **vii**
- Preface **viii**
- Chapter 1 Globe and Orbit **1**  
Introduction **1**  
Enophthalmos **2**  
Exophthalmos **2**  
Prolapse **4**  
Microphthalmos **4**  
Buphthalmos **6**  
Hydrophthalmos **6**  
Phthisis bulbi **7**  
Strabismus **7**  
Nystagmus **8**
- Chapter 2 Upper and Lower Eyelids **9**  
Introduction **9**  
Entropion **10**  
Ectropion **13**  
Distichiasis **14**  
Ectopic cilia **14**  
Trichiasis **16**  
Blepharitis **16**  
Meibomianitis **18**  
Hordeolum **18**  
Meibomian cyst **18**  
Eyelid neoplasia **18**  
Congenital anomalies **21**
- Chapter 3 Nictitating Membrane **23**  
Introduction **23**  
Prominence of the nictitating membrane **23**  
Trauma and foreign bodies **23**  
Inflammation **23**  
Prolapse of the nictitans gland **26**  
Deformity of the cartilage **26**  
Neoplasia **27**
- Chapter 4 Lacrimal System **29**  
Introduction **29**  
Punctal abnormalities **30**
- Chapter 5 Conjunctiva, Limbus, Sclera **35**  
Introduction **35**  
Conjunctivitis **35**  
Chemosis **37**  
Conjunctival haemorrhages **37**  
Subconjunctival masses **38**  
Symblepharon **38**  
Foreign bodies **41**  
Conjunctival dermoid **41**  
Conjunctival cyst **41**  
Neoplasia **42**  
Scleritis and episcleritis **42**
- Chapter 6 Cornea **47**  
Introduction **47**  
Keratitis **48**  
Corneal ulcers **52**  
Keratoconjunctivitis sicca (KCS) **53**  
Corneal oedema **60**  
Lipid keratopathies **63**  
Corneal sequestrum **65**  
Trauma and foreign bodies **66**  
Neoplasia **68**  
Congenital anomalies **68**
- Chapter 7 Uveal Tract **69**  
Introduction **69**  
Clinical signs of anterior uveitis **70**

	Sequelae <b>70</b>		Other types of cataract <b>113</b>
	Cysts <b>78</b>		False cataracts <b>113</b>
	Neoplasia <b>78</b>		Lens luxation <b>120</b>
	Congenital anomalies <b>78</b>		
Chapter 8	<b>Glaucoma and Aqueous 89</b>	Chapter 10	<b>Vitreous 129</b>
	Introduction <b>89</b>		Introduction <b>129</b>
	Clinical signs <b>90</b>		Congenital <b>129</b>
	Primary hereditary glaucoma in the UK <b>93</b>		Acquired <b>131</b>
	Secondary glaucoma <b>93</b>	Chapter 11	<b>Fundus 135</b>
	Gonioscopy <b>94</b>		Introduction <b>135</b>
	Aqueous <b>96</b>		The normal canine fundus <b>135</b>
Chapter 9	<b>Lens 97</b>		The normal feline fundus <b>150</b>
	Introduction <b>97</b>		The normal equine fundus <b>153</b>
	Primary hereditary non-congenital cataracts <b>98</b>		The normal bovine and ovine fundus <b>157</b>
	Congenital cataracts and associated anomalies <b>106</b>		The fundus of other species <b>160</b>
	Cataracts secondary to another eye disease or condition <b>110</b>		Diseases of the retina – the retinopathies <b>160</b>
	Metabolic, toxic and nutritional cataracts <b>113</b>	Chapter 12	<b>The Optic Nerve 203</b>
			Introduction <b>203</b>
			Conditions of the optic nerve <b>203</b>

# Acknowledgements

All the illustrations in this book are taken from the collection at the Comparative Ophthalmology Unit of the Animal Health Trust. Several were taken by colleagues and residents I greatly enjoyed working with over a number of years. These now well-recognised veterinary ophthalmologists include Roger Curtis, Arnold Leon, Nick Millichamp, Jane Sansom, Tony Read, Beverly Cottrell, David Williams, Lorraine

Fleming, Sally Turner, Christine Heinrich and Heidi Featherstone. I also acknowledge the referring veterinary surgeons, the owners and breeders and, most particularly, the animals themselves whose patience enabled us to photograph their eyes. I should also like to thank the staff who were involved in the production of this book at Mosby Elsevier for their interest and expertise.

## Preface

In my preface to the first edition, *A Colour Atlas of Veterinary Ophthalmology* published by Wolfe in 1990, I stated that the book was intended for both the practicing veterinary surgeon and also for the veterinary student with interests in eye disease. This edition was little more than a collection of favourite photographs and although the great majority have been reproduced in this second edition, together with several further illustrations, I have also included some text and tables which I believe may

help, together with the illustrations, in a more accurate diagnosis of the many eye conditions, including many hereditary eye diseases in the dog, that have now been described. However, this book is still intended as an atlas, and I hope will provide a valuable pictorial resource for clinicians and compliment the increasing number of textbooks on veterinary ophthalmology.

K C Barnett

# Globe and Orbit

## Introduction

This first chapter covers the globe as a whole – and the orbit – the following chapters dealing with specific parts of the eye, e.g. eyelids, cornea, lens, fundus, etc. Therefore, some overlap is inevitable between this chapter and those that follow and certain figures depicted here could appear in subsequent chapters.

A naked-eye examination of the globe, perhaps aided by a pen torch, should note the position of the globe within the orbit and the size of the globe, together with ocular movements and the presence or absence of an ocular discharge or lacrimation. The globe should be examined from both directly in front and above, which will greatly assist the differential diagnosis between increased size of the globe and abnormal position of the globe.

Retropulsion, through the upper eyelid, will also be of help and the two eyes should be compared. A detailed examination of all the other parts of the eye should follow and must include examination of the contralateral eye, even if this appears normal on naked-eye examination (Table 1.2).

All three companion animals (horse, dog and cat) have large globes, very large and prominent in the horse. Both the dog and the cat have an open or incomplete orbit, whereas the horse has a complete bony orbital rim and an enclosed orbit.

Conditions affecting the globe and orbit can be divided into two groups:

1. Position of the globe in relation to the orbit, e.g. exophthalmos (proptosis) and enophthalmos (Tables 1.1 and 1.2).
2. Size of the globe, e.g. microphthalmos, medical buphthalmos, hydrophthalmos, phthisis. Also note strabismus and nystagmus.

The differential diagnosis is not always obvious and the position, prominence or retraction of the nictitating membrane may help or confuse. Radiography and CT or preferably MRI scans can be of considerable assistance.

Table 1.1 – Position of globe: differential diagnosis

### Enophthalmos (+ nictitating membrane prominence)

1. Normal variant – breed-related, e.g. Flat-Coated Retriever
2. Unilateral or bilateral
3. Pain
4. Microphthalmos, phthisis
5. Orbital neoplasia (uncommon)
6. Atrophy of orbital tissue
7. Horner's syndrome (+ miosis, ptosis)

### Exophthalmos (+ nictitating membrane prominence usual)

1. Normal variant – breed-related, e.g. Pekingese
2. Unilateral or bilateral
3. Retrobulbar space-occupying lesion
  - Acute – Pain
  - Abscess
  - Haemorrhage
  - Cellulitis
  - Chronic – No pain
  - Neoplasia
4. Prolapse
  - Exophthalmos may also be confused with an enlarged eye (hydrophthalmos and buphthalmos)

Table 1.2 – The painful eye

### Signs

Lacrimation, blepharospasm, photophobia, enophthalmos (globe retraction) in some cases.

1. Orbital disease (abscess, cellulitis)
2. Endophthalmitis – uncommon
3. Supernumerary eyelashes
4. Eyelid abnormalities and blepharitis
5. Keratoconjunctivitis sicca
6. Conjunctivitis – mild
7. Corneal ulcers
8. Uveitis (acute)
9. Glaucoma (acute)



## Enophthalmos (Figs 1.2–1.3)

Enophthalmos is sinking or recession of the globe into the orbit and has a variety of causes. Degrees of enophthalmos are a normal variant in a number of dog breeds, such as the Rough Collie and Flat-Coated Retriever, with deep-set eyes and often mucus accumulation at the inner canthus. A painful eye can be withdrawn into the orbit by the retractor bulbi muscle and, in Horner's syndrome, enoph-

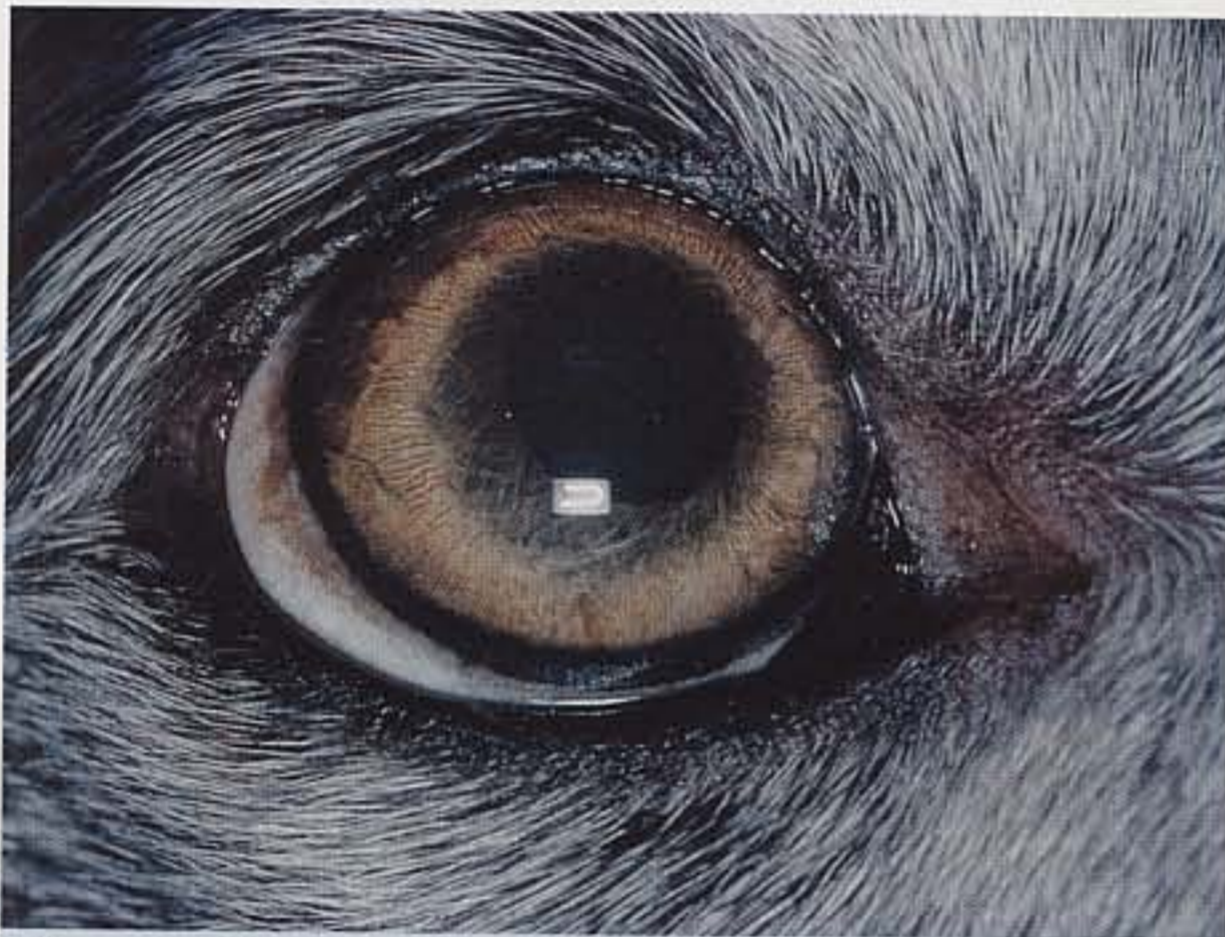

Fig. 1.1 The normal eye (Greyhound, young adult) Note the shape and perfect apposition of the eyelids to the globe, the absence of any discharge and the regular corneal reflection.



Fig. 1.3 Enophthalmos Orbital adenocarcinoma pushing the globe backwards into the orbit. Note that in this case, due to the position of the tumour, protrusion of the nictitating membrane is not evident.

thalmos, together with ptosis and miosis, are the classical presenting signs. Enophthalmos also accompanies a small globe in cases of microphthalmos and phthisis and is an uncommon sign in cases of orbital neoplasia with extension of the tumour into the orbit pushing the globe more deeply into the orbit (exophthalmos is a much more common sign with retrobulbar tumours). Atrophy of orbital tissue also leads to degrees of enophthalmos. In all these cases, the enophthalmos is accompanied by prominence of the nictitating membrane.

## Exophthalmos (Figs 1.4–1.8)

Exophthalmos, or proptosis, is the prominence of a normal-sized globe and associated with a retrobulbar space-occupying lesion. It is usually unilateral and often, but not invariably (see later), accompanied by prominence of the nictitating membrane. The degree of natural exophthalmos, and enophthalmos, is related to breed differences, e.g. the Pekingese and the Pug. Obviously prolapse (dislocation of the globe to a position in front of the eyelids) occurs much more readily in the brachycephalic breeds with their prominent eyes and shallow orbits. With a space-occupying retrobulbar lesion protrusion of the nictitating membrane is usual. Other clinical signs include strabismus, periorbital swelling, conjunctival congestion and chemosis, ocular discharge and pain, together with difficulty in opening the mouth. Causes include retrobulbar abscess and haemorrhage and orbital

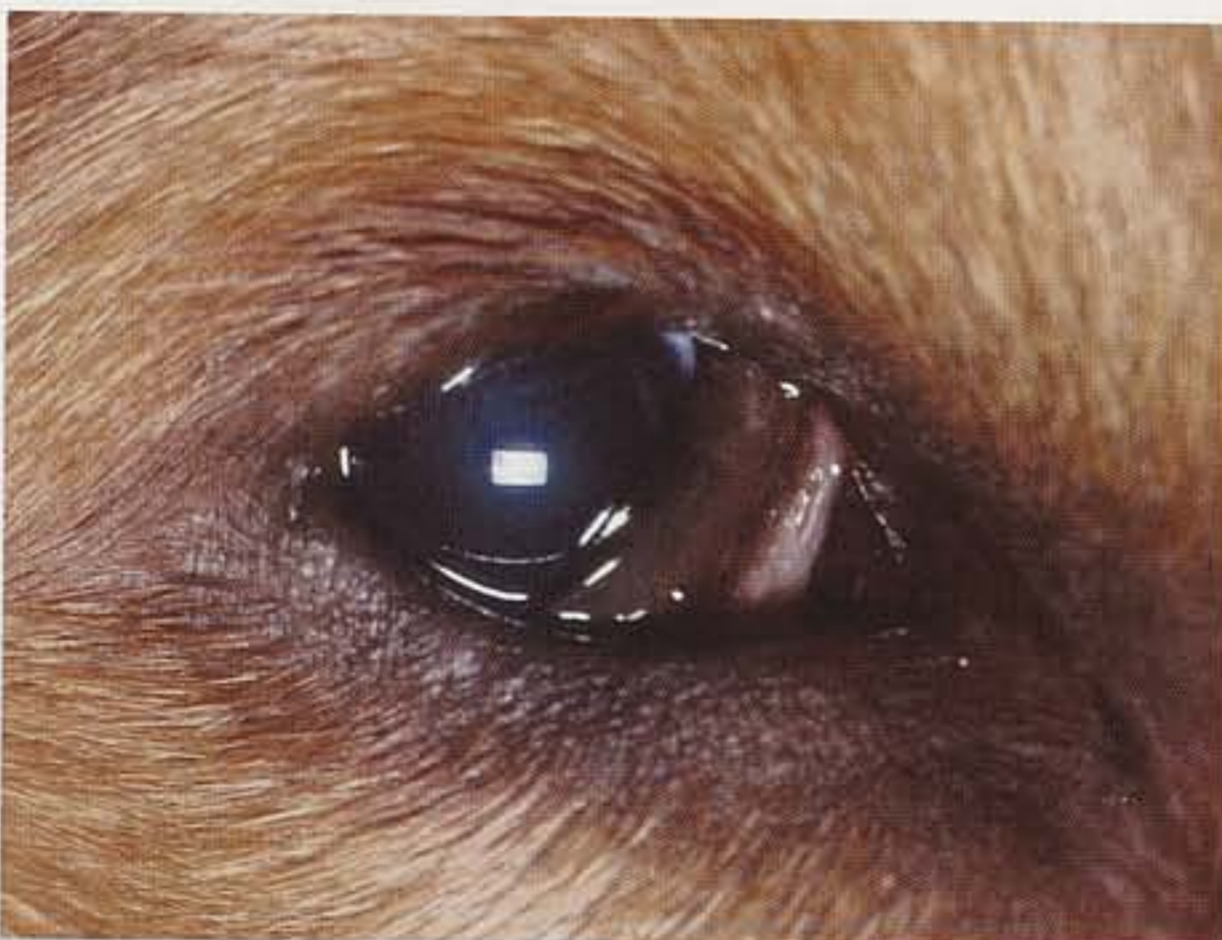

Fig. 1.2 Enophthalmos (Rough Collie, young adult) The small eye normal in certain breeds. Note the small sunken globe with prominence of the nictitating membrane.



Fig. 1.4 Exophthalmos (Labrador Retriever, 8 years old) Note the prominence of both the globe, with changed shape of the palpebral orifice, and the nictitating membrane, together with mild lacrimation on the right side. This tumour proved to be a glioma of the optic nerve which was closely applied to the back of the globe and the cause of a small retinal detachment.

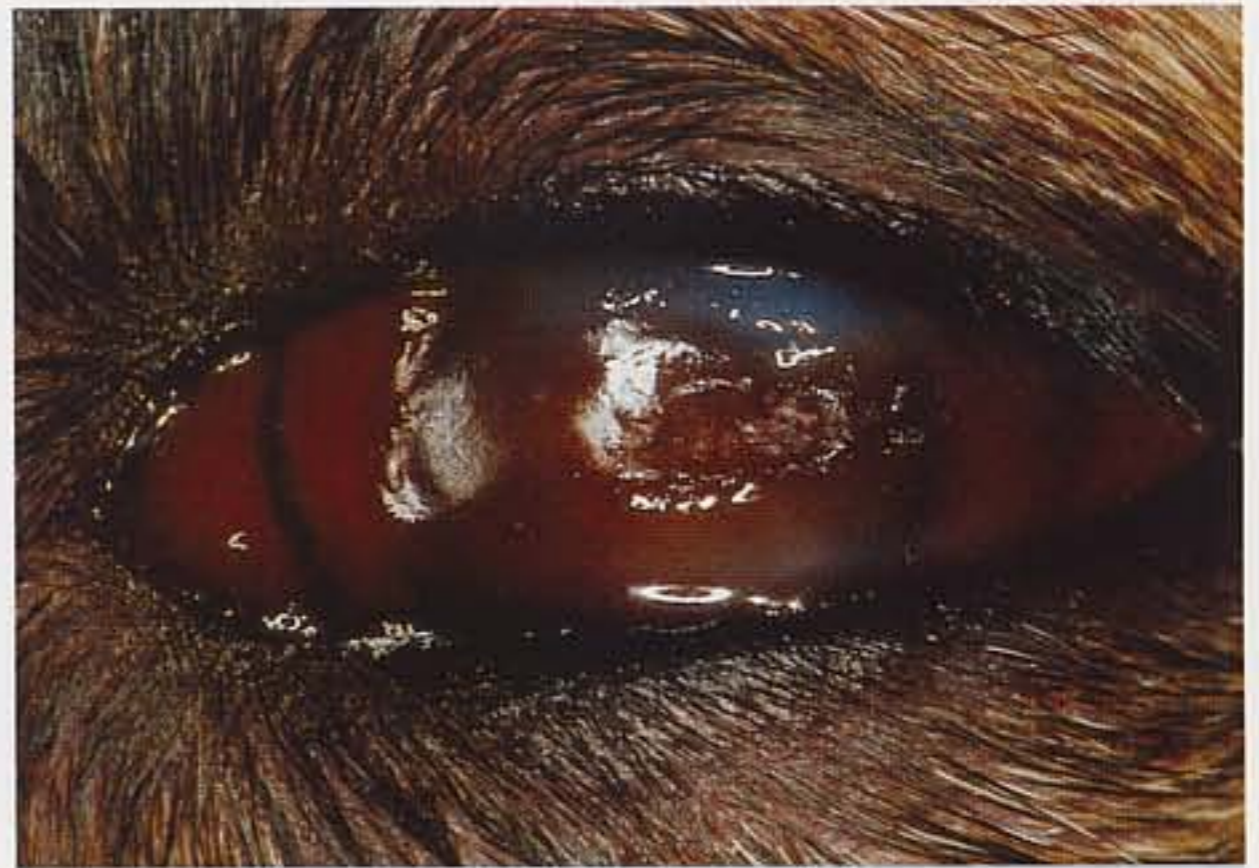

Fig. 1.6 Exophthalmos Prominence of the globe and third eyelid with central exposure keratitis and ocular discharge. This acute case was accompanied by pain and was due to a retrobulbar abscess.

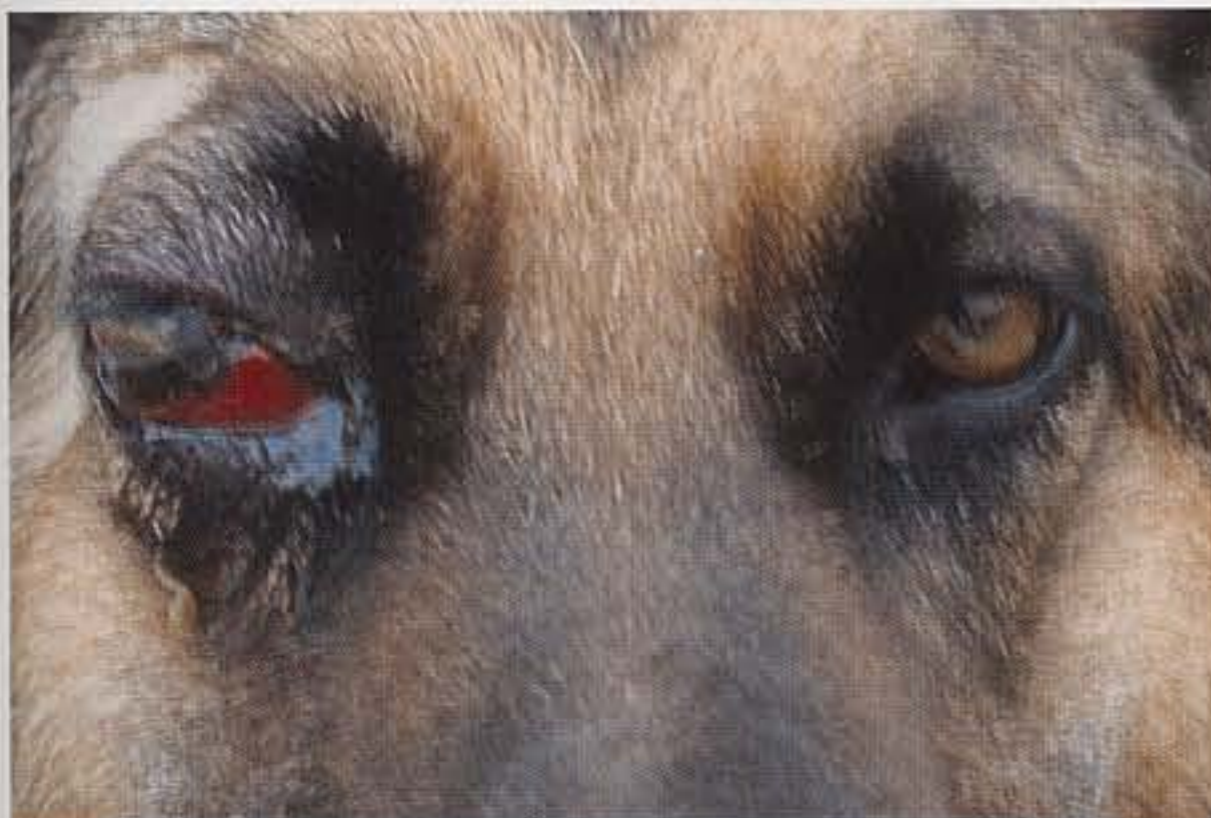

Fig. 1.5 Exophthalmos (German Shepherd Dog, 3 years old) Obvious prominence of both globe and third eyelid, together with periorbital swelling and ocular discharge. The retrobulbar mass proved to be a spindle cell sarcoma.

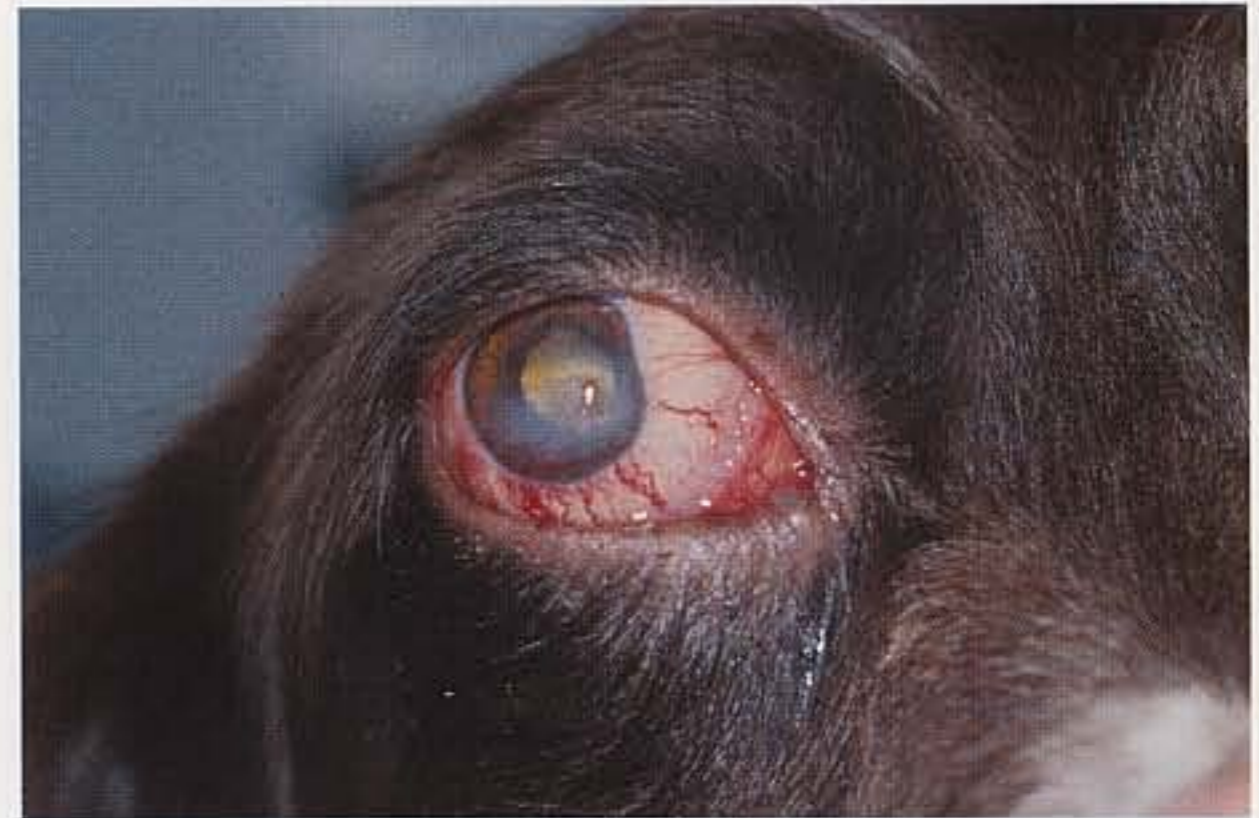

Fig. 1.7 Exophthalmos (English Springer Spaniel, aged) Chronic case with considerable prominence of the globe, together with conjunctival congestion and exposure keratitis due to inability to close the lids over the globe. The cause was a retrobulbar tumour.

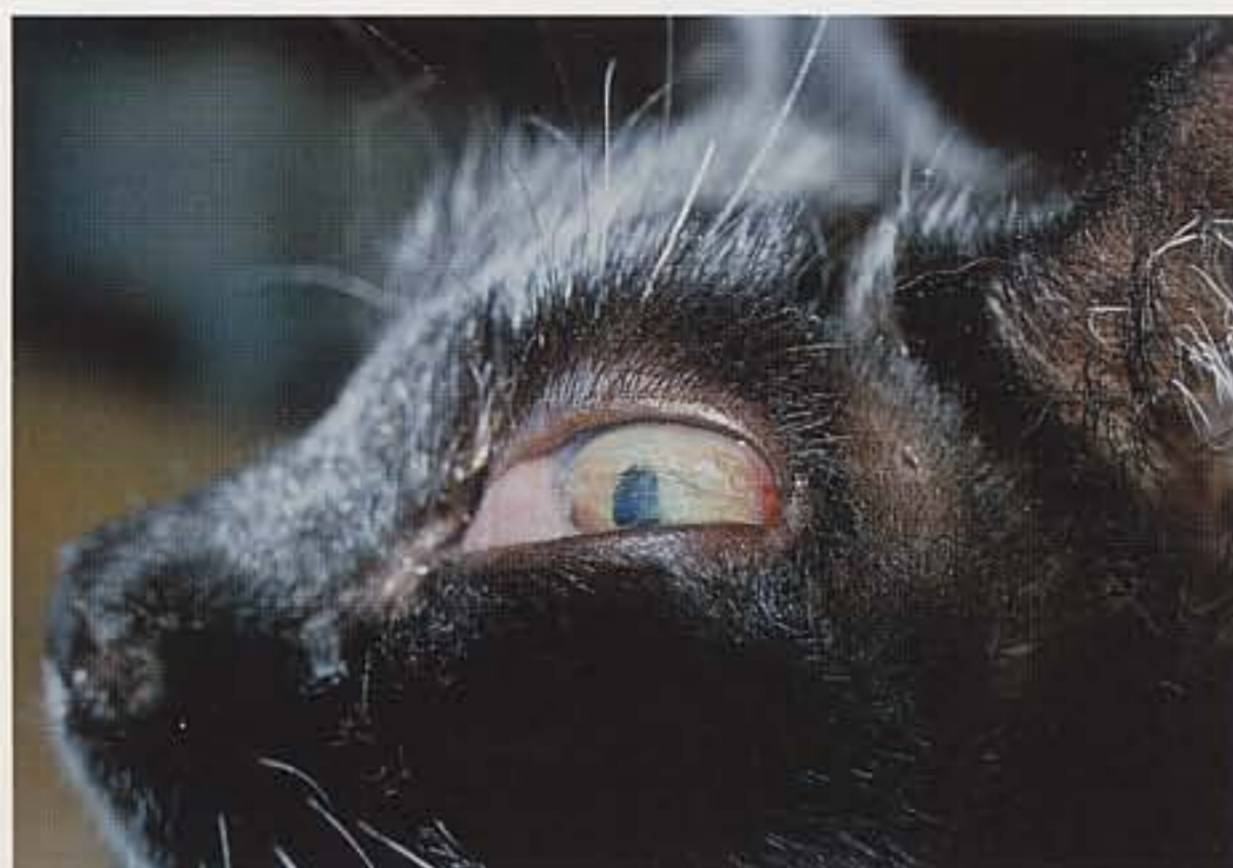

Fig. 1.8 Exophthalmos (Domestic Shorthaired (DSH) cat, 9 years old) Prominence of the globe and nictitating membrane with periorbital swelling and change in the shape of the palpebral aperture. The cause is a retrobulbar lymphosarcoma.

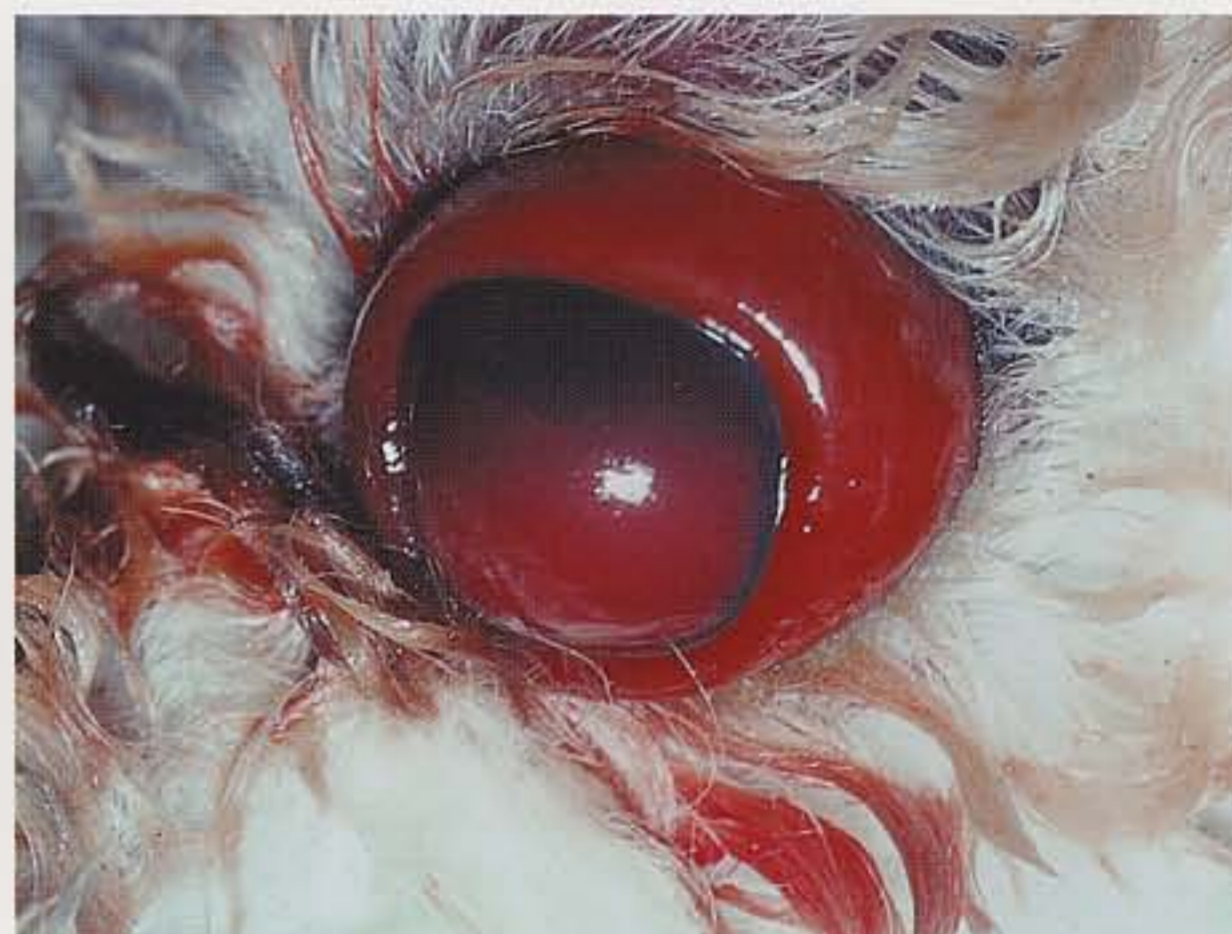

Fig. 1.9 Eyeball prolapse (Miniature Poodle, young adult) Following trauma, the globe is trapped in front of the eyelids and prevented from returning to the orbit. Note the intraocular and subconjunctival haemorrhage.

cellulitis; all carrying an acute history. Other causes include neoplasia, particularly in the dog, and have a chronic, slowly progressive, and usually non-painful, history.

### **Prolapse** (Figs 1.9–1.10)

Prolapse, sometimes referred to as proptosis, is the forward displacement of the globe which becomes trapped between the eyelids so preventing its return to the orbit. It always follows trauma, is rare in the cat and horse, and is particularly seen in the brachycephalic breeds on account of their shallow orbits. It is always a dire emergency; is often accompanied by optic nerve damage; and, following replacement, the eye often exhibits a divergent strabismus.

### **Microphthalmos** (Figs 1.11–1.15)

Microphthalmos is an abnormally small globe; is congenital, and in the dog, some cases are inherited; is unilateral or bilateral in which case the two eyes may be similar or show differing degrees. It is common in the dog, also occurs in the horse, but is rare in the cat. Microphthalmos is often accompanied by other ocular defects, particularly cataract which

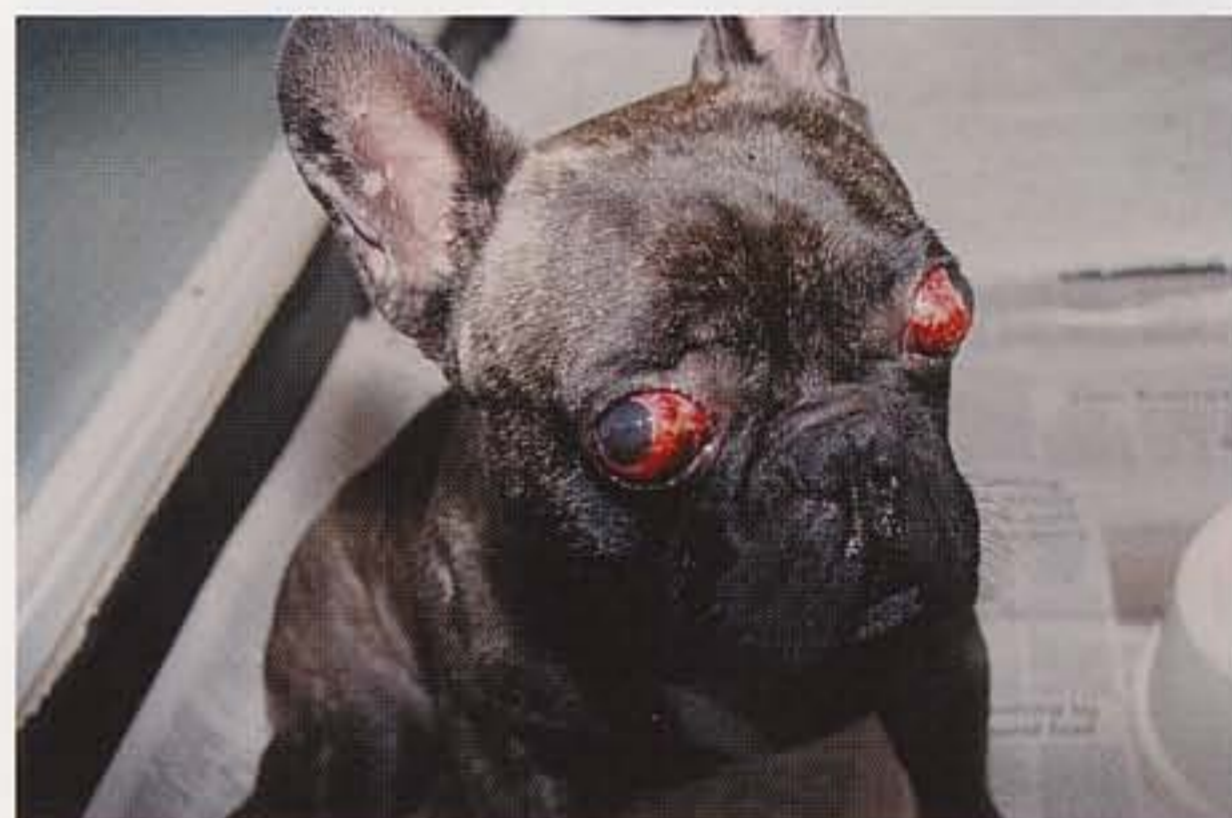

Fig. 1.10 Eyeball prolapse (French Bulldog) Prolapse of both globes in this brachycephalic breed, following a road traffic accident. Note the absence of the haemorrhage present in the previous figure and the divergence of both globes following the prolapse.

may well be the presenting sign. Microphthalmos varies in the degree of severity from a small but otherwise normal eye (nanophthalmos) to cases with multiple ocular defects (MOD). The microphthalmic eye usually shows degrees of enophthalmos accompanied by prominence of the nictitating membrane.



Fig. 1.11 Microphthalmos (Collie puppy) Severe bilateral microphthalmos in a deaf and blind white puppy resulting from a blue merle × blue merle mating.

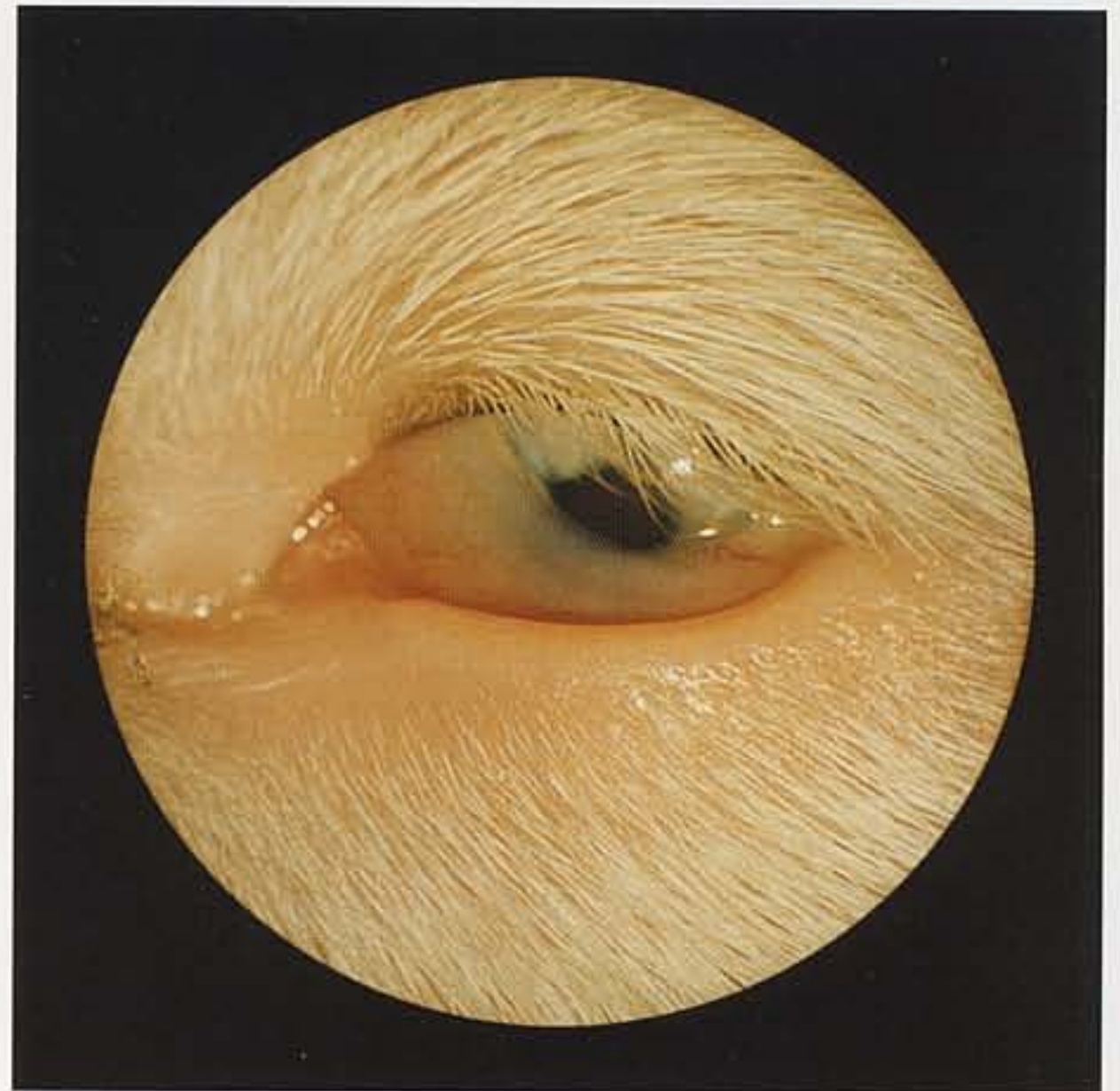

Fig. 1.13 Microphthalmos (Shetland Sheepdog, puppy) Note the prominence of the third eyelid and enophthalmos in this Shetland Sheepdog puppy.



Fig. 1.12 Microphthalmos (Thoroughbred, foal) 'Button eye' occurs congenitally in all breeds of horse and is often, as in this case, accompanied by other ocular defects. This figure shows differing degrees in the two eyes of the same foal; other cases may show only one apparently affected.

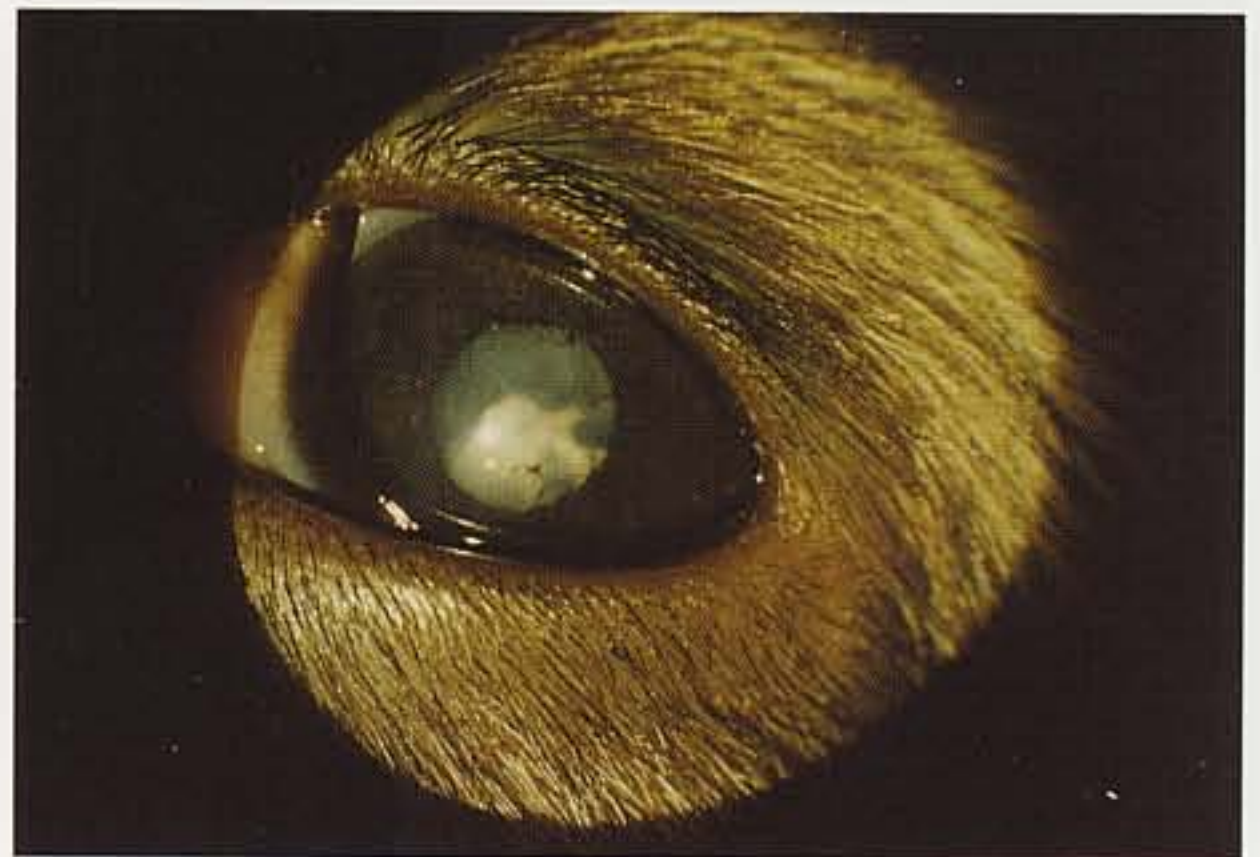

Fig. 1.14 Microphthalmos with MOD (German Shepherd Dog, puppy) Note the dense white partial non-progressive cataract, together with fine persistent pupillary membranes.

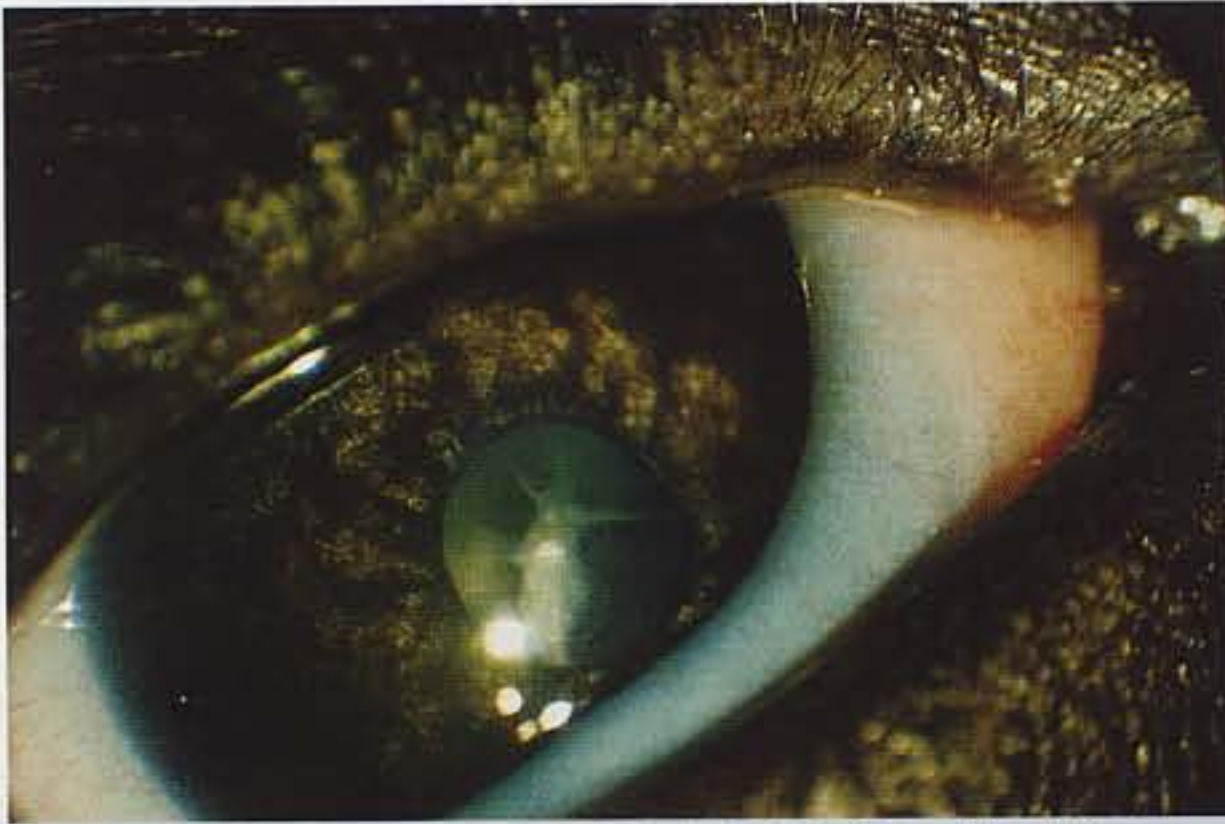

Fig. 1.15 Microphthalmos with MOD (Cavalier King Charles Spaniel, puppy) Note the iris hypoplasia and anterior cataract.

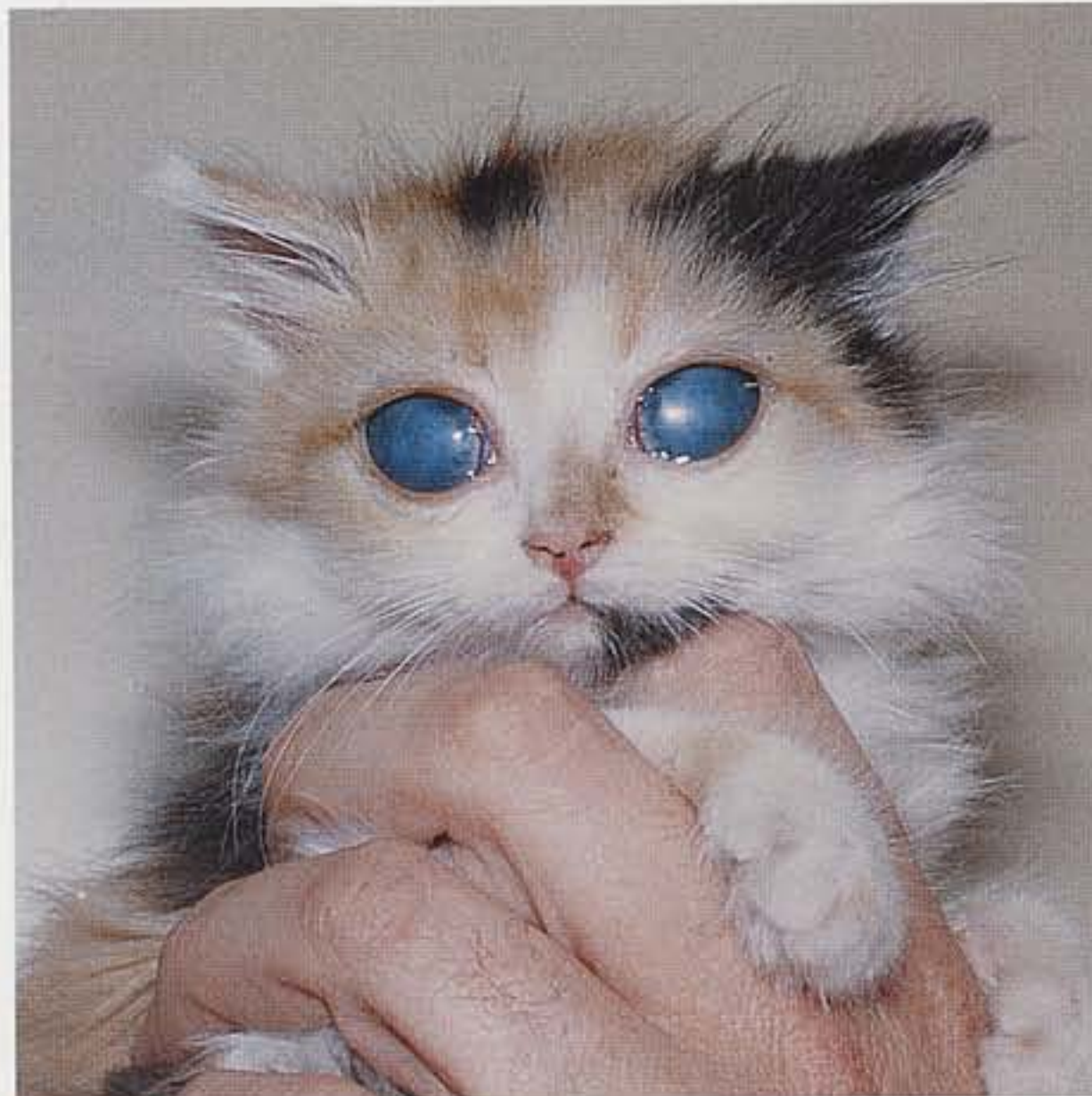

Fig. 1.16 Buphthalmos (DSH cat, 9 weeks old) Bilateral congenital glaucoma.

### Buphthalmos (Fig 1.16)

Buphthalmos is an enlarged globe due to congenital glaucoma; it is congenital but not inherited; it is unilateral or bilateral and is seen more regularly in the kitten than the other species. The eye is prominent due to its increased size and the cornea is usually opaque and may be vascularized. The nictitating membrane is often retracted and there is little evidence of pain, in spite of the increase in eyeball size.

### Hydrophthalmos (Figs 1.17–1.19)

Hydrophthalmos is also an enlarged globe due to glaucoma, primary or secondary, but is not congenital. The increased intraocular pressure occurs usually in adult life. Corneal changes are usually

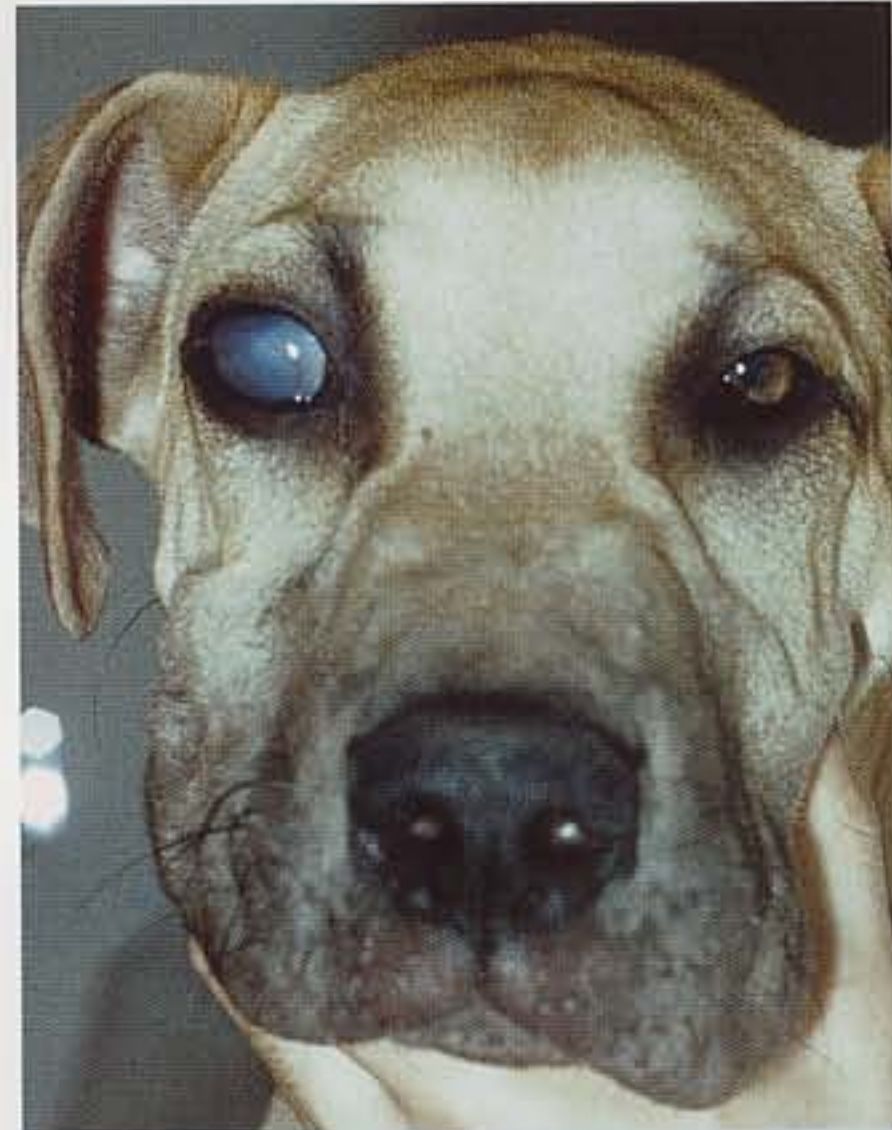

Fig. 1.17 Hydrophthalmos (Great Dane, 7 months old) Unilateral case following primary glaucoma.

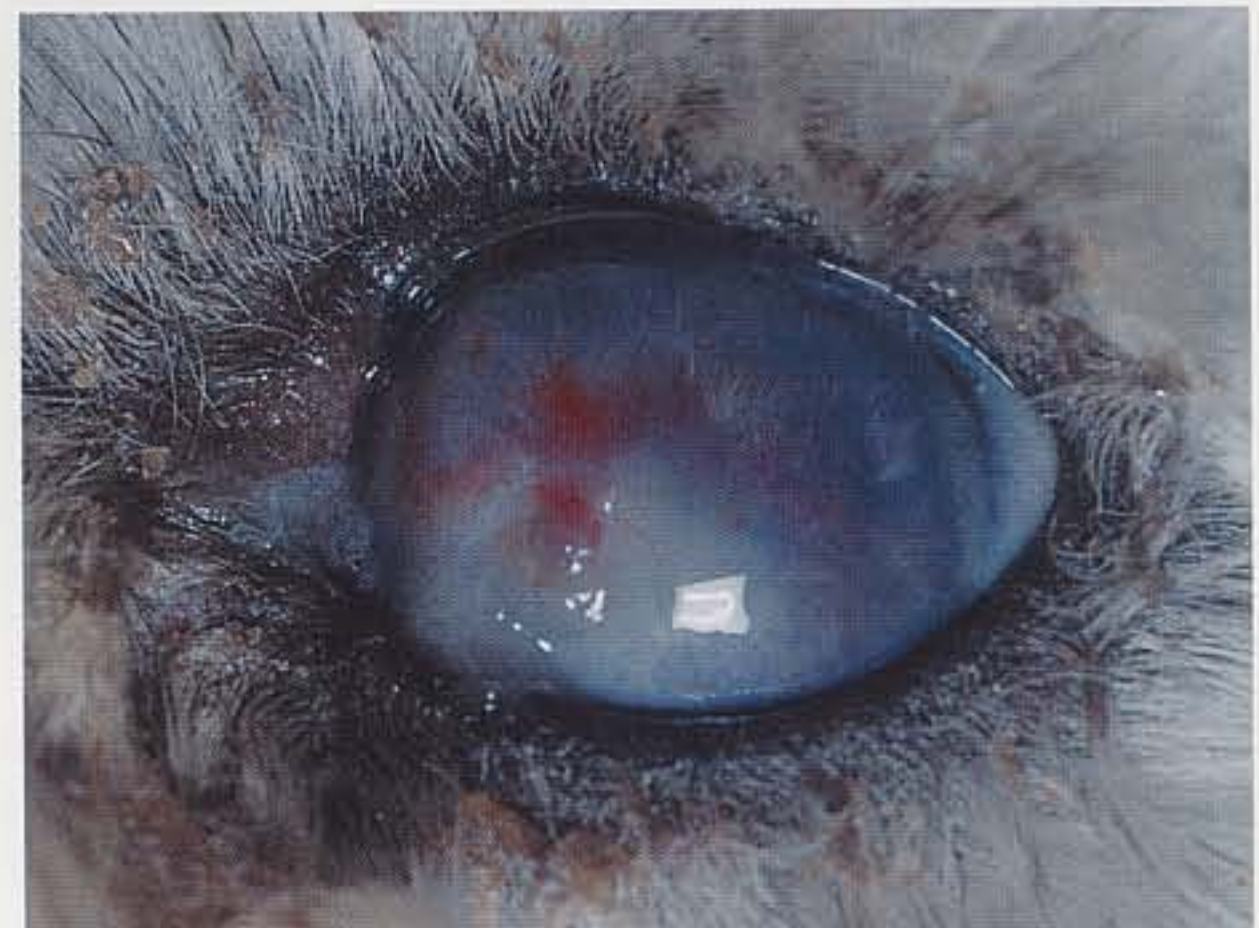

Fig. 1.18 Hydrophthalmos (Sealyham Terrier, 6 years old) Due to secondary glaucoma following lens luxation. Note the retraction of the nictitating membrane in both this and the previous two figures with relative increased size of globe in comparison to the cases of exophthalmos in which the globe is of normal size.

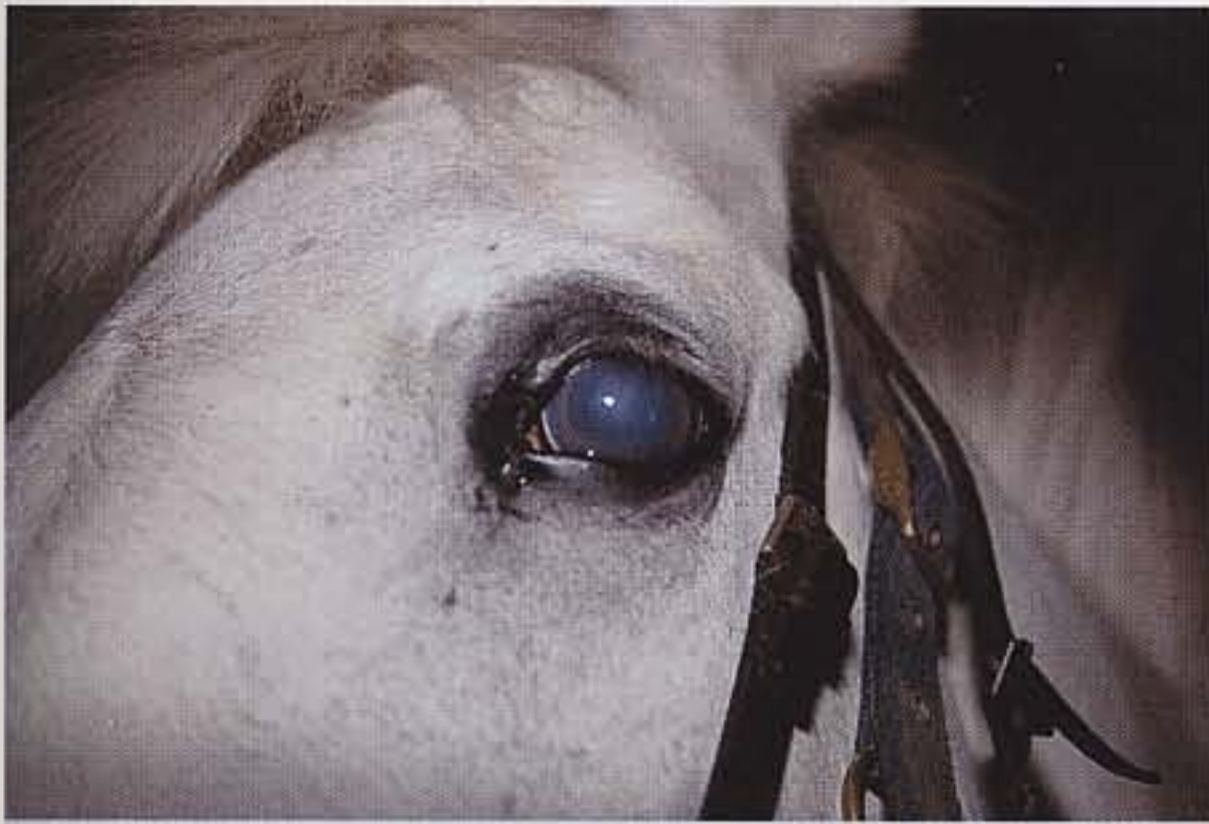

Fig. 1.19 Hydrophthalmos (horse, grey) The cause of this secondary glaucoma was a ciliary body melanoma.

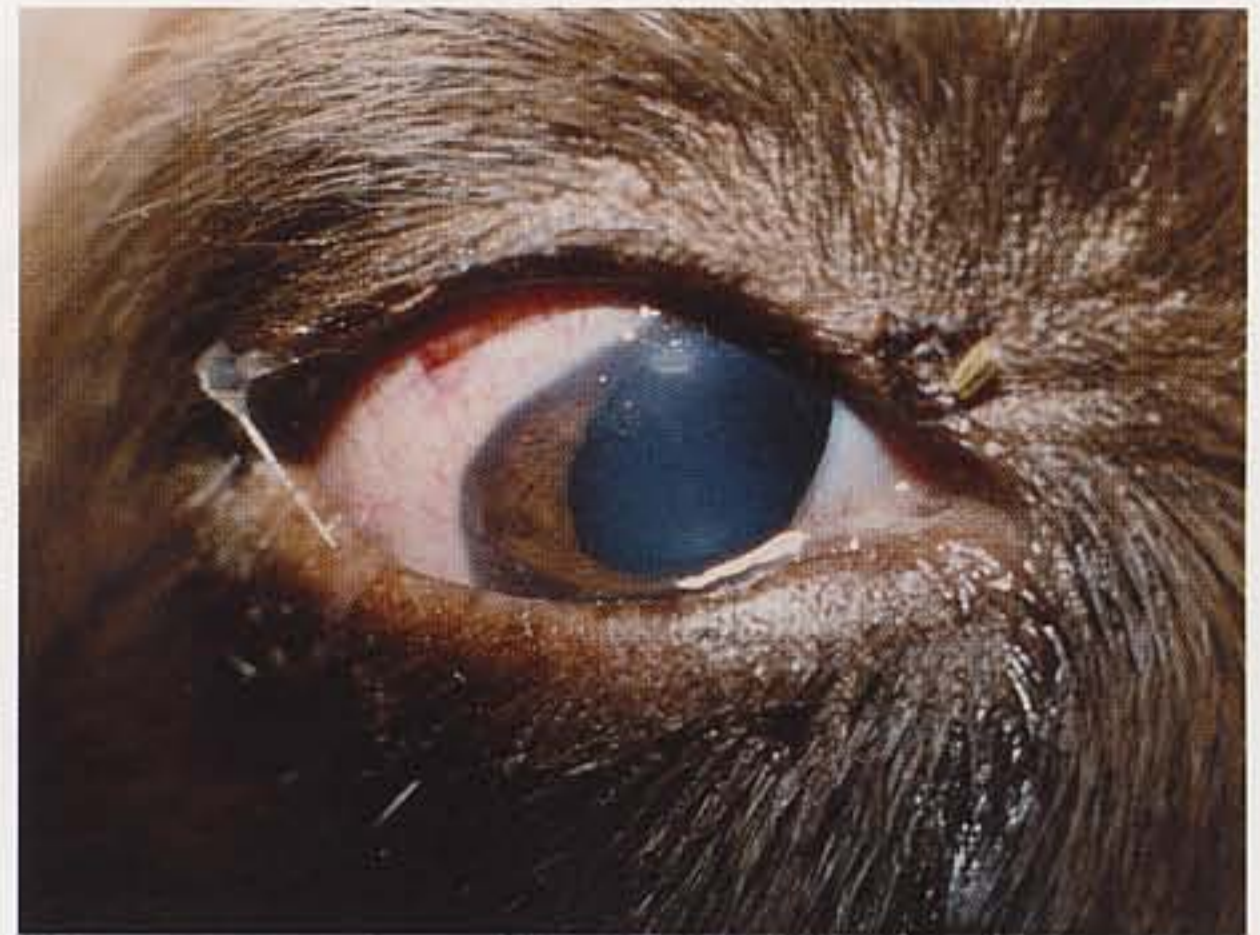

Fig. 1.21 Strabismus (English Springer Spaniel, 2 years old) Convergent squint due to a retrobulbar adenocarcinoma.

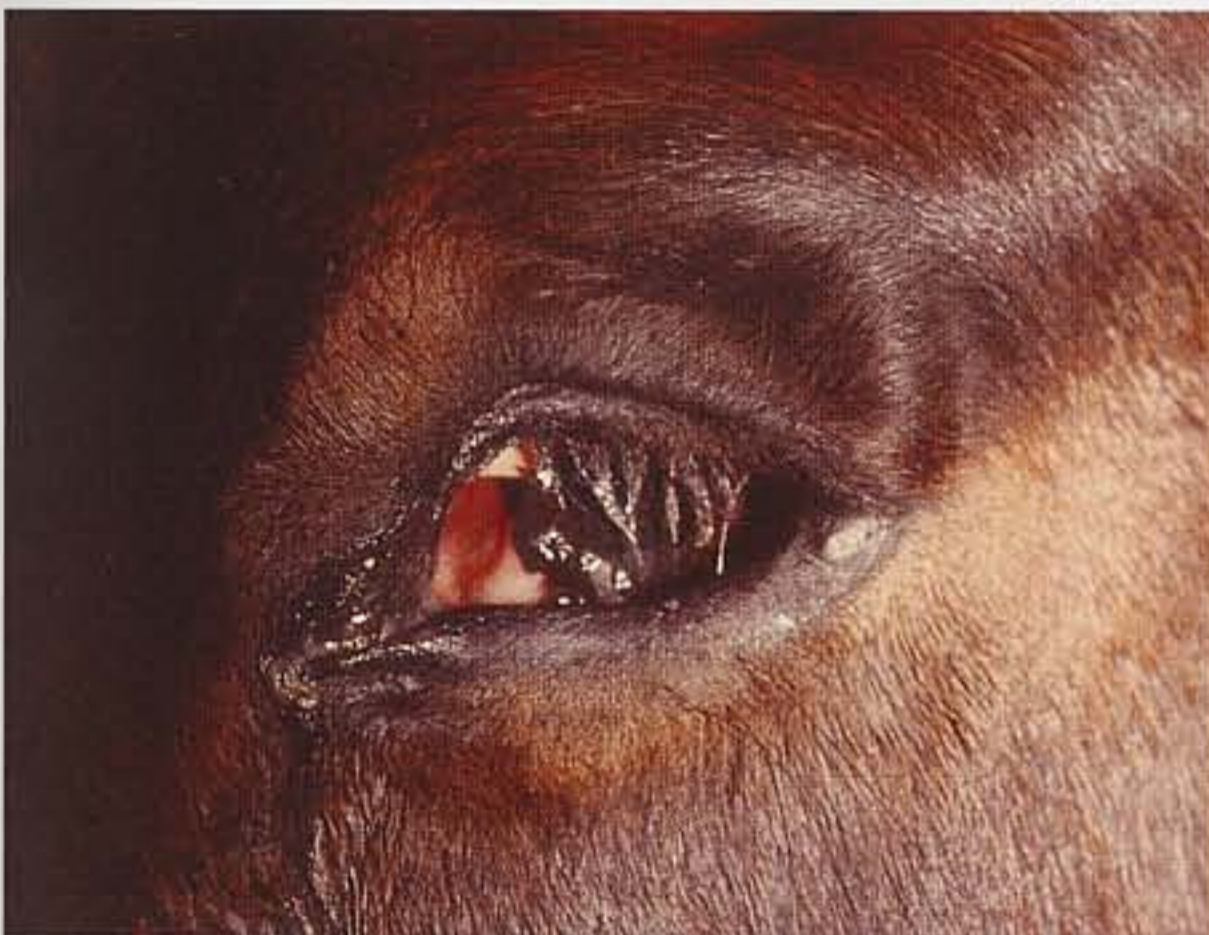

Fig. 1.20 Phthisis bulbi (polo pony) Shrivelled and sunken enophthalmic globe, again with prominence of the third eyelid, following severe trauma. Note the ocular discharge.

evident, in particular fractures in Descemet's membrane seen as grey branching lines in a more diffuse corneal oedema, sometimes with corneal vascularization. The condition is painful and the eye is irreparably blind.

### Phthisis bulbi (Fig 1.20)

Phthisis is a shrunken and enophthalmic globe following some severe insult, trauma, inflammation or glaucoma. Again the eye is irreparably blind, the nictitating membrane prominent and the condition may be accompanied by an ocular discharge due to the small eye in a normal-sized orbit.

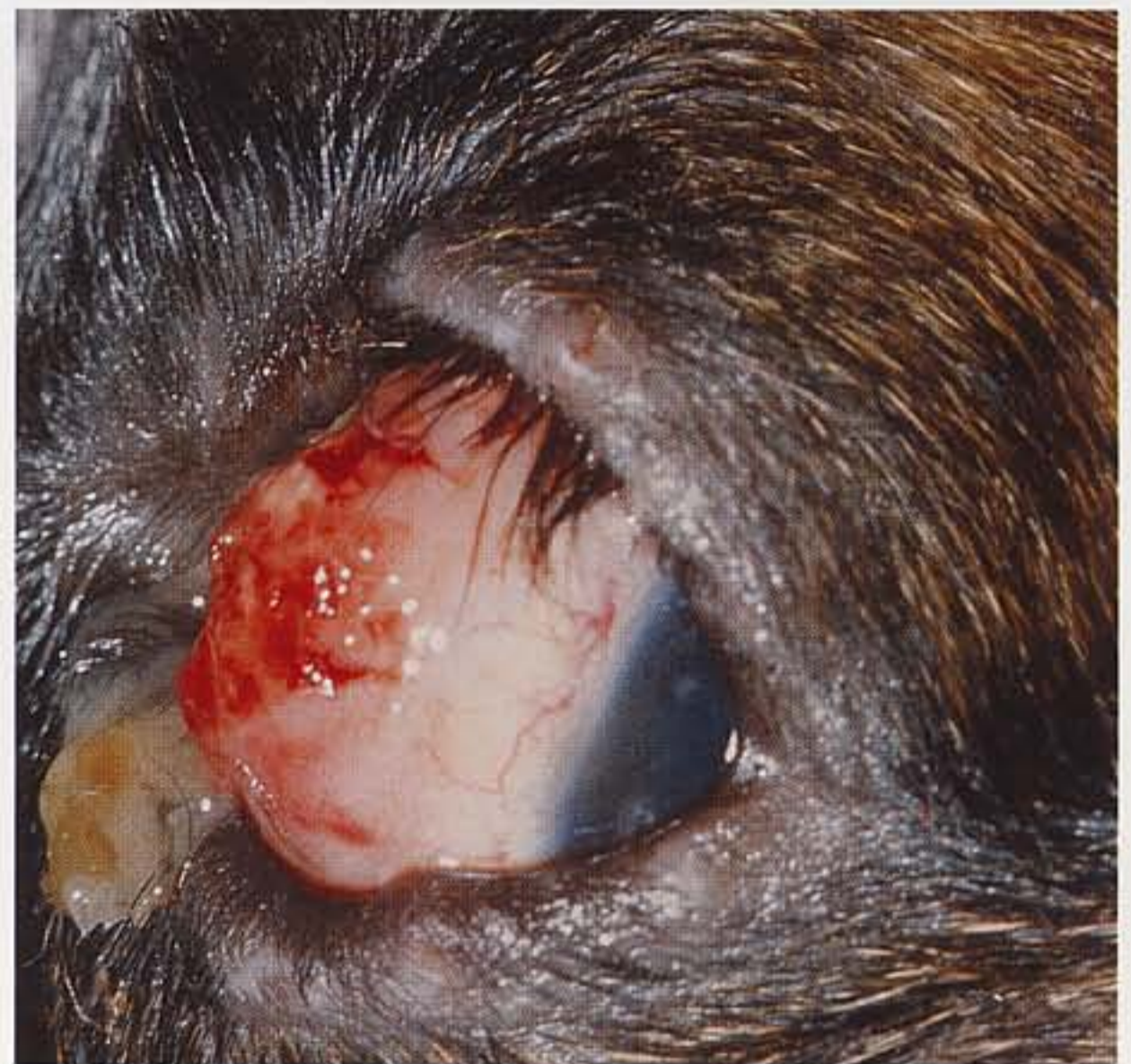

Fig. 1.22 Strabismus (Boxer puppy, 9 weeks old) Divergent squint following trauma and prolapse of the globe.

### Strabismus (Figs 1.21–1.23)

Convergent bilateral strabismus is said to be inherited in the Siamese breed and odd cases are seen in both the dog and horse and are sometimes congenital. Divergent strabismus of a previously prolapsed globe is common.

## Nystagmus

Ocular nystagmus, intermittent and oscillatory, is inherited in the Siamese breed with or without strabismus. Ocular nystagmus also often accompanies cases of microphthalmos with MOD.



Fig. 1.23 Strabismus (Shetland Sheepdog, puppy)  
Unilateral congenital strabismus.

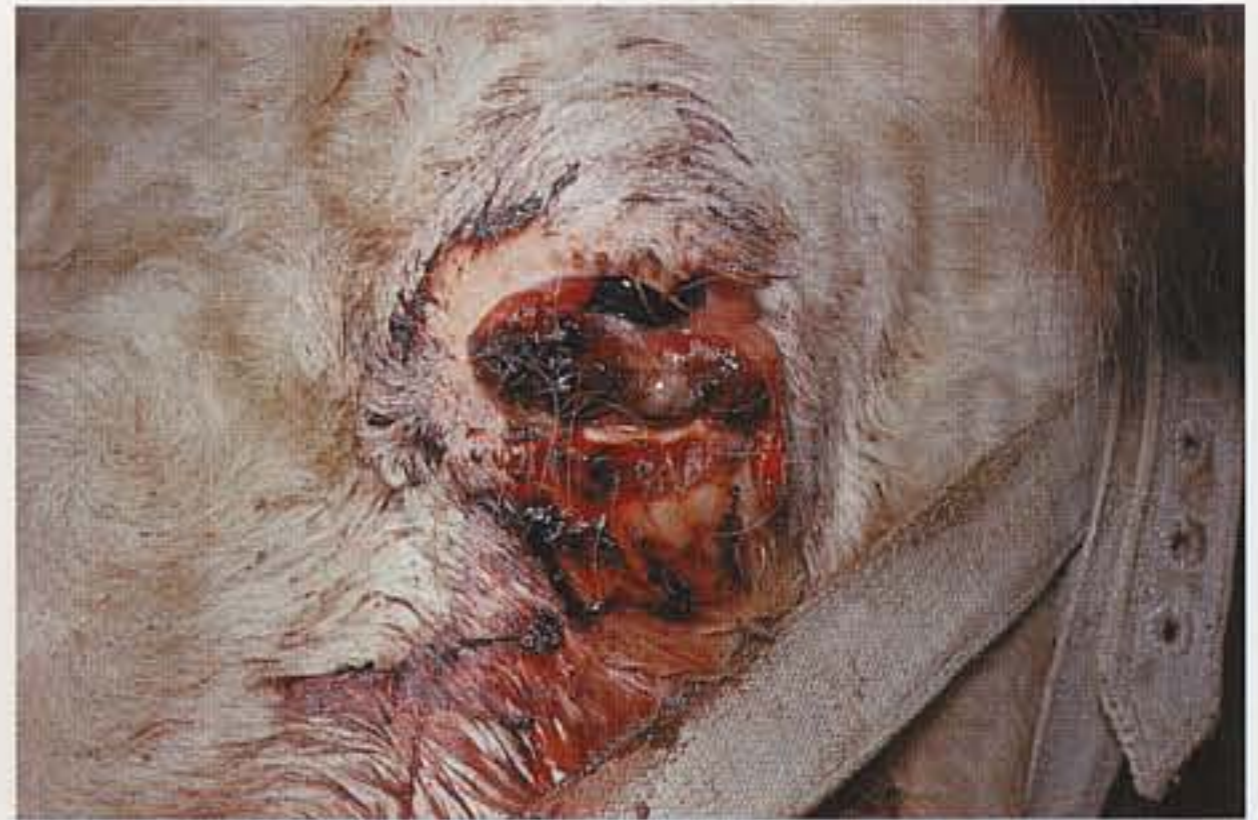

Fig. 1.24 Neoplasia (Hereford cow, adult) Squamous cell carcinoma of the globe.

## Chapter 2

# Upper and Lower Eyelids

### Introduction

Eyelid disease is common in the dog, cat and horse, particularly the former which exhibits several inherited anomalies, basically entropion and ectropion. Supernumerary eyelashes (distichiasis, ectopic cilia and trichiasis) also account for much eyelid disease and, in the dog, are due to an inherited factor.

Inflammation of the eyelid (blepharitis) is uncommon, as are other localized infections such as meibomianitis and cyst, chalazion and hordeolum or sty. The periorbital region carries a thin skin with a good blood supply and is sometimes involved with parasitic skin diseases such as sarcoptic and demodectic mange, ringworm infection and also atopic dermatitis.

Injuries, often full thickness, occur frequently in all species, usually due to fight wounds, barbed wire and other accidents. Suturing is often required, particularly for vertical wounds as opposed to horizontal wounds, and the excellent blood supply is an important factor in healing. A further eyelid condition in this category is ptosis or

drooping of the upper lid, commonly seen as part of Horner's syndrome, together with miosis and enophthalmos, usually presenting as prominence of the nictitating membrane; there is a remarkably high incidence of Horner's syndrome in the UK in the Golden Retriever. Ptosis is usually idiopathic.

Neoplasia affecting the eyelids is important in all the species, particularly the aged animal. The tumour may be malignant or, more usually, benign and tumour types include papilloma, adenoma, melanoma, adenocarcinoma, histiocytoma, lymphoma, mast cell, squamous cell carcinoma and sarcoïd in the horse.

Congenital anomalies include colobomas, which may affect any part of the lid (centre or lateral), and one or both lids and eyes. Colobomas are more common in the cat than the dog or horse and may well be associated with colobomas affecting other parts of the eye. The other congenital anomaly of the eyelid is the dermoid which may extend from the eyelid onto the conjunctiva and possibly beyond. Dermoids are considered to be inherited in the Birman cat.



## Entropion (Figs 2.1–2.12)

Entropion, in-turning of the eyelid margin, is common, particularly in the dog and is breed, and to some extent age, related. It may affect upper or lower or both lids and one or both eyes. Entropion is

affected by facial conformation, in particular the desired eye shape, the amount of skin, usually excessive, and wrinkles or folds in the periorbital region. In the dog entropion occurs at different ages, usually up to 1 year, in different breeds; occasional

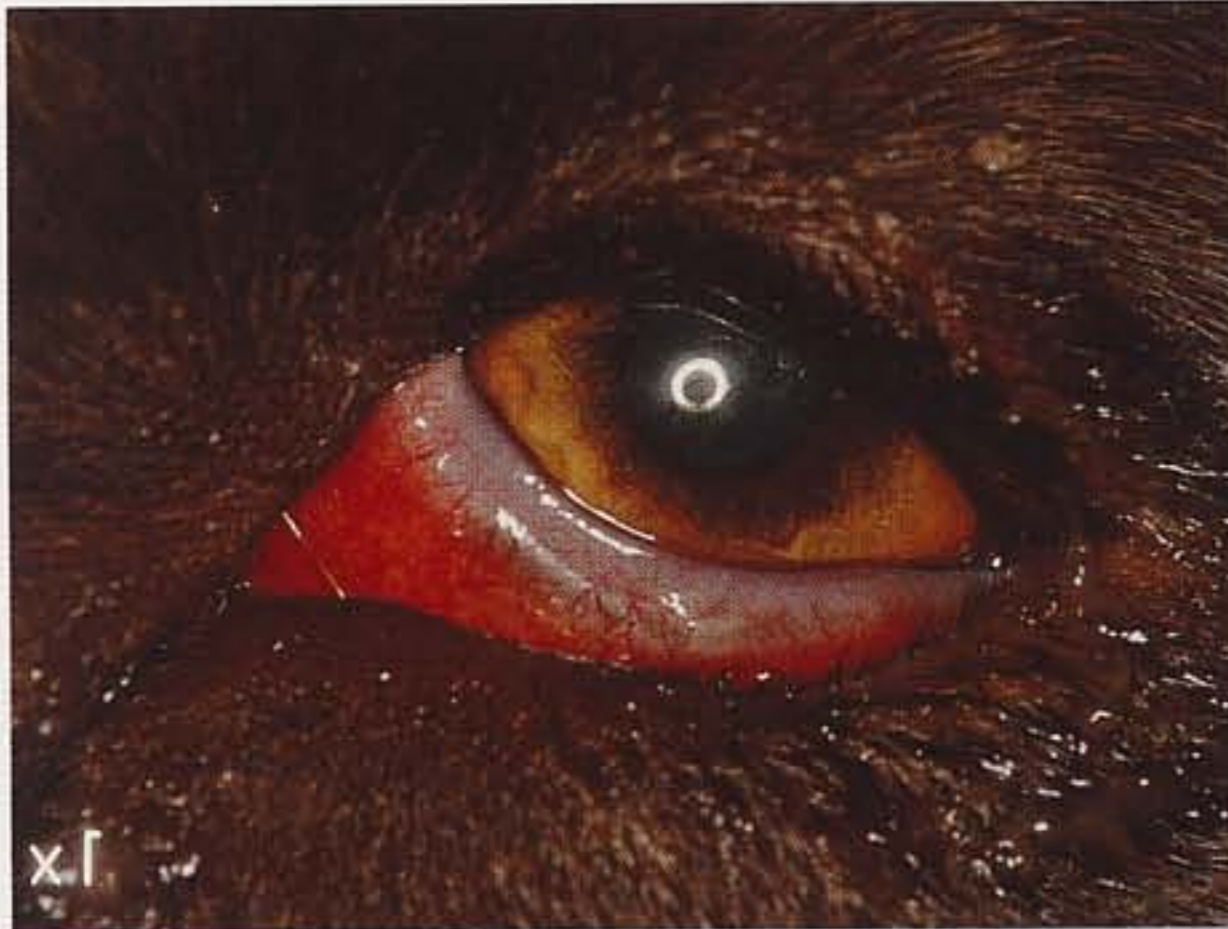

Fig. 2.1 Entropion (German Shorthaired Pointer, 14 weeks old) Simple lower lid entropion. Note the signs of irritation caused by the eyelid in-turning with consequent enophthalmos and prominence of the nictitating membrane and lacrimation, but no corneal changes.

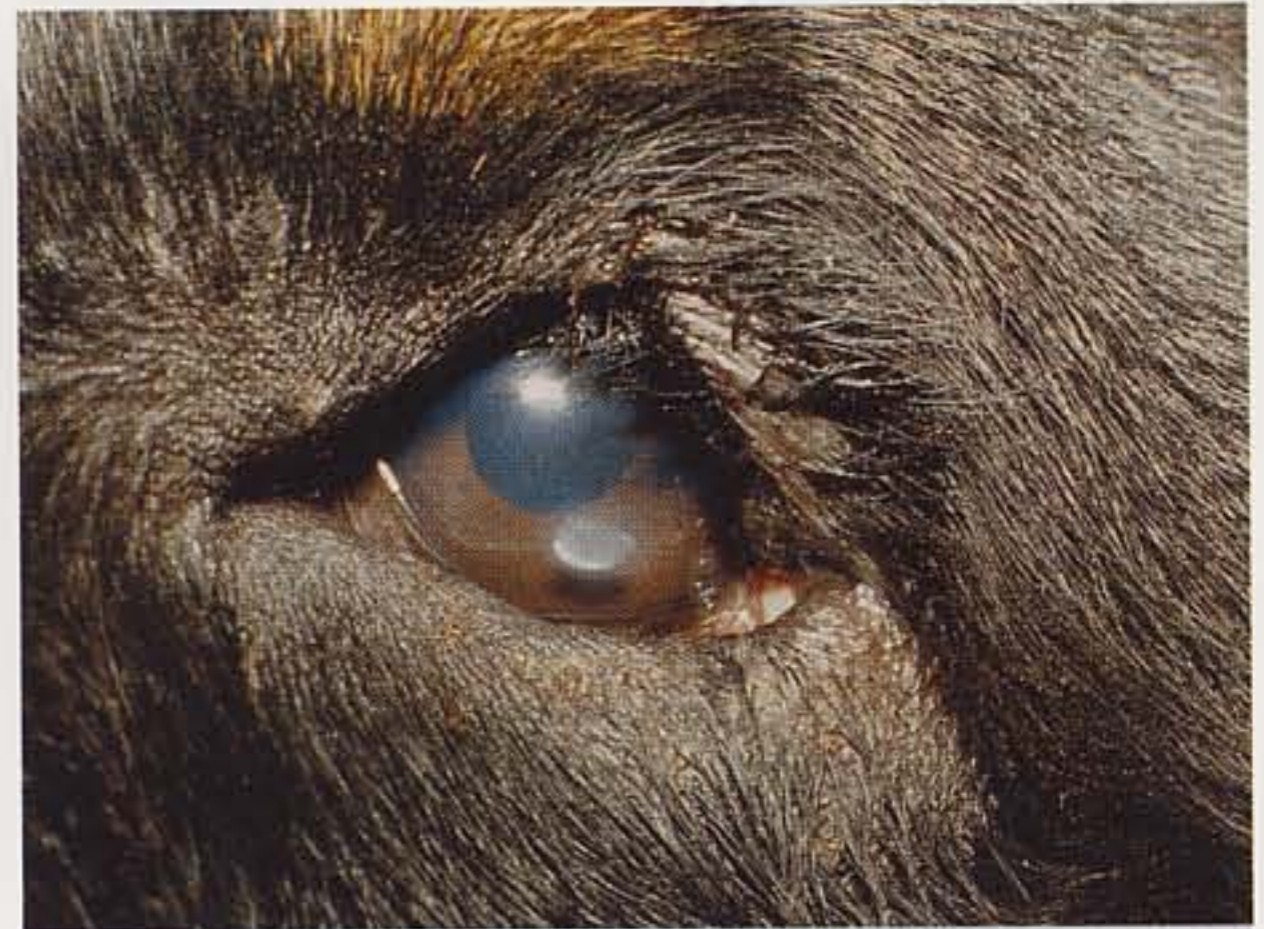

Fig. 2.3 Entropion (Rottweiler, 4 years old) Upper and lower lid entropion. Note the age in this breed and compare with the ages in the previous two figures and following two figures. Also note the small corneal opacity and ulcer.

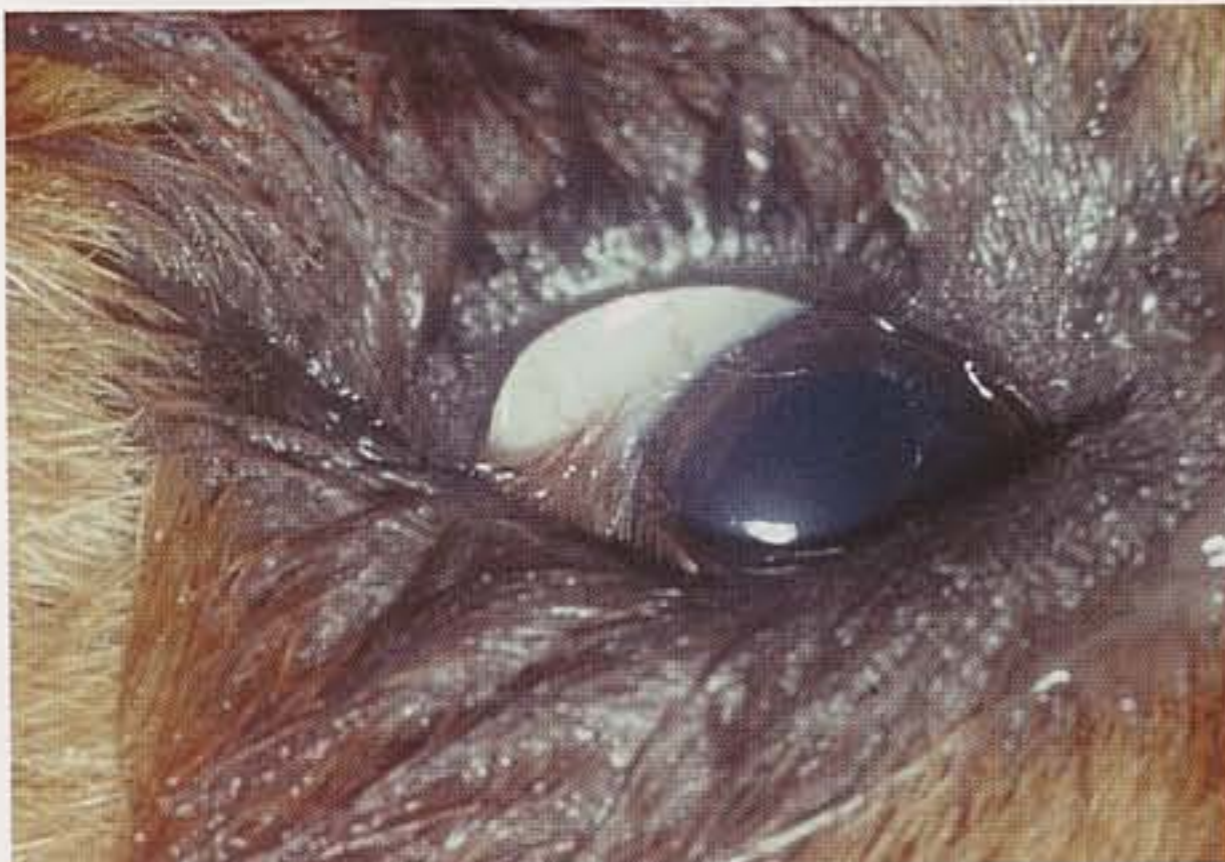


Fig. 2.2 Entropion (Chow, 8 months old) Classical upper and lower lid entropion with profuse lacrimation.

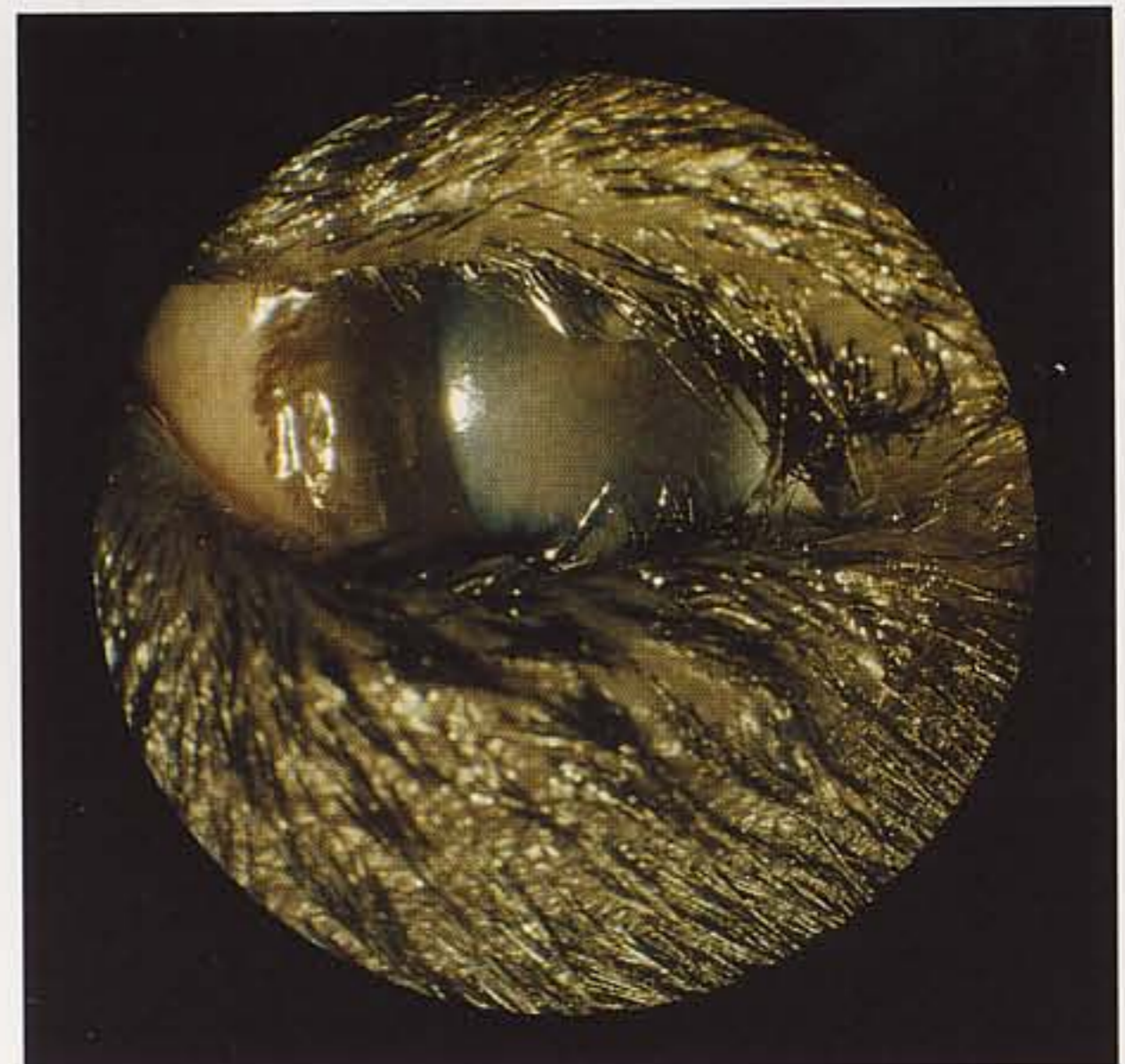

Fig. 2.4 Entropion (Great Dane, 7 weeks old) Upper and lower lid entropion with corneal changes including vascularization.

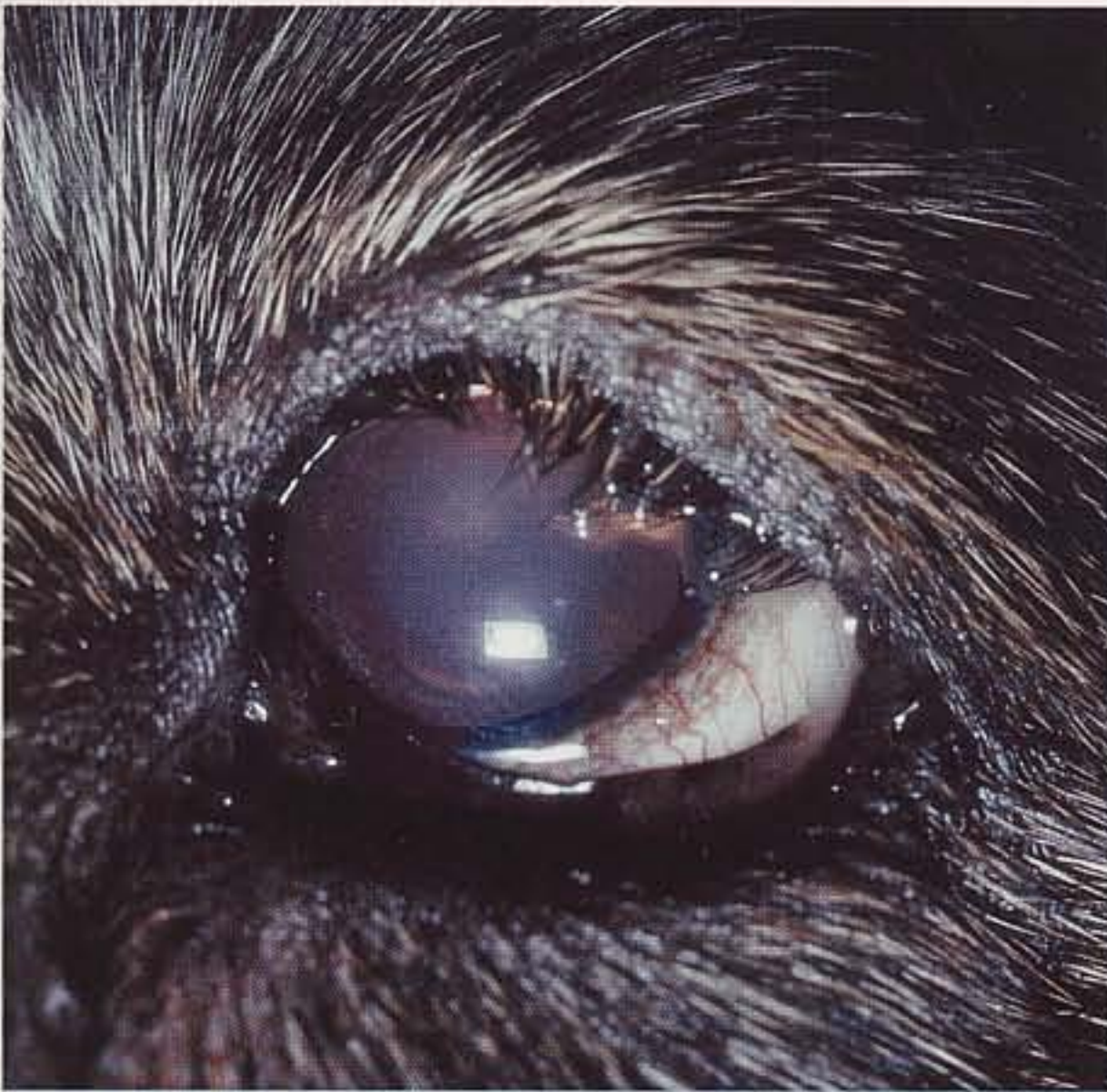

Fig. 2.5 Entropion (Cocker Spaniel, 10 years old) Senile upper lid entropion. See also Fig 2.14.

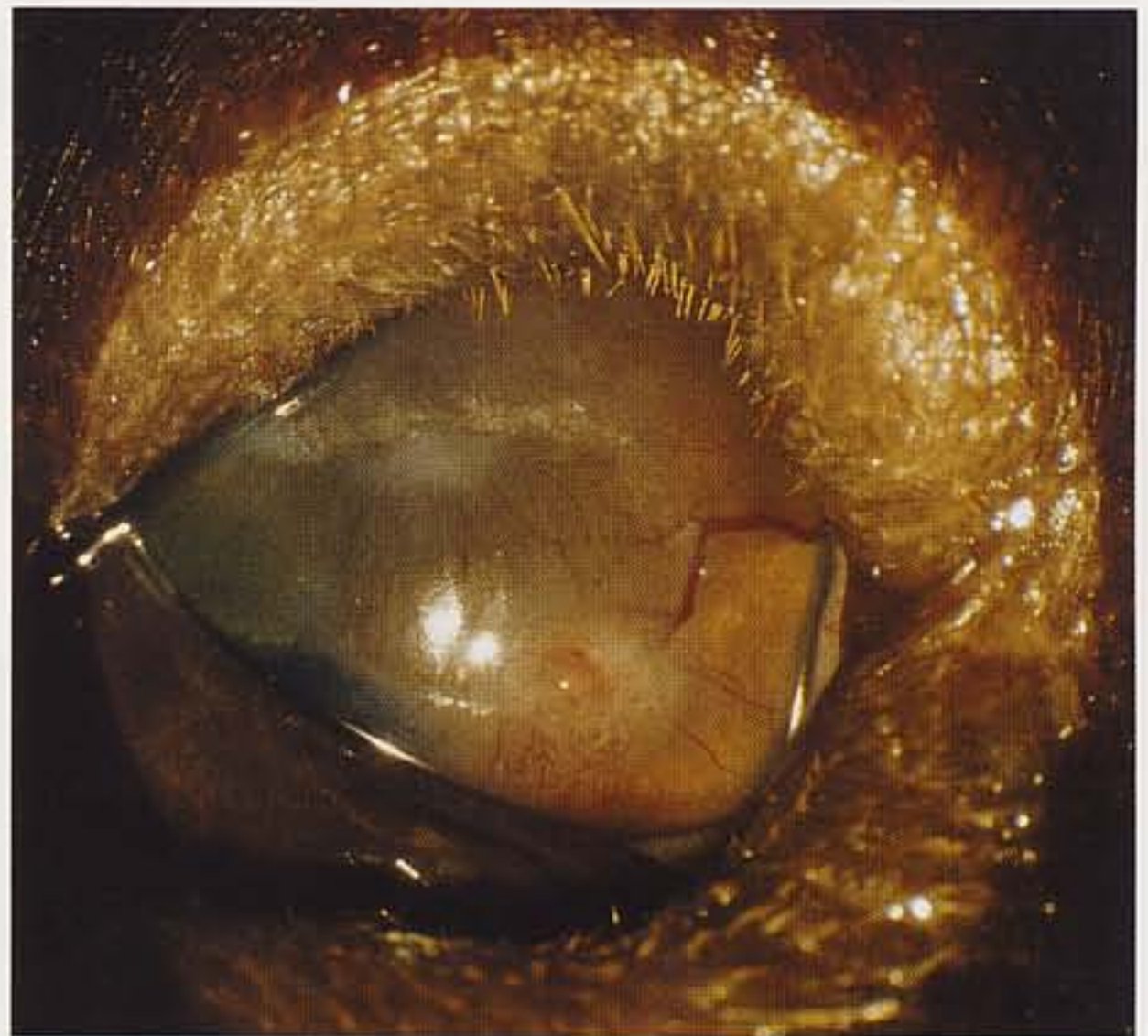

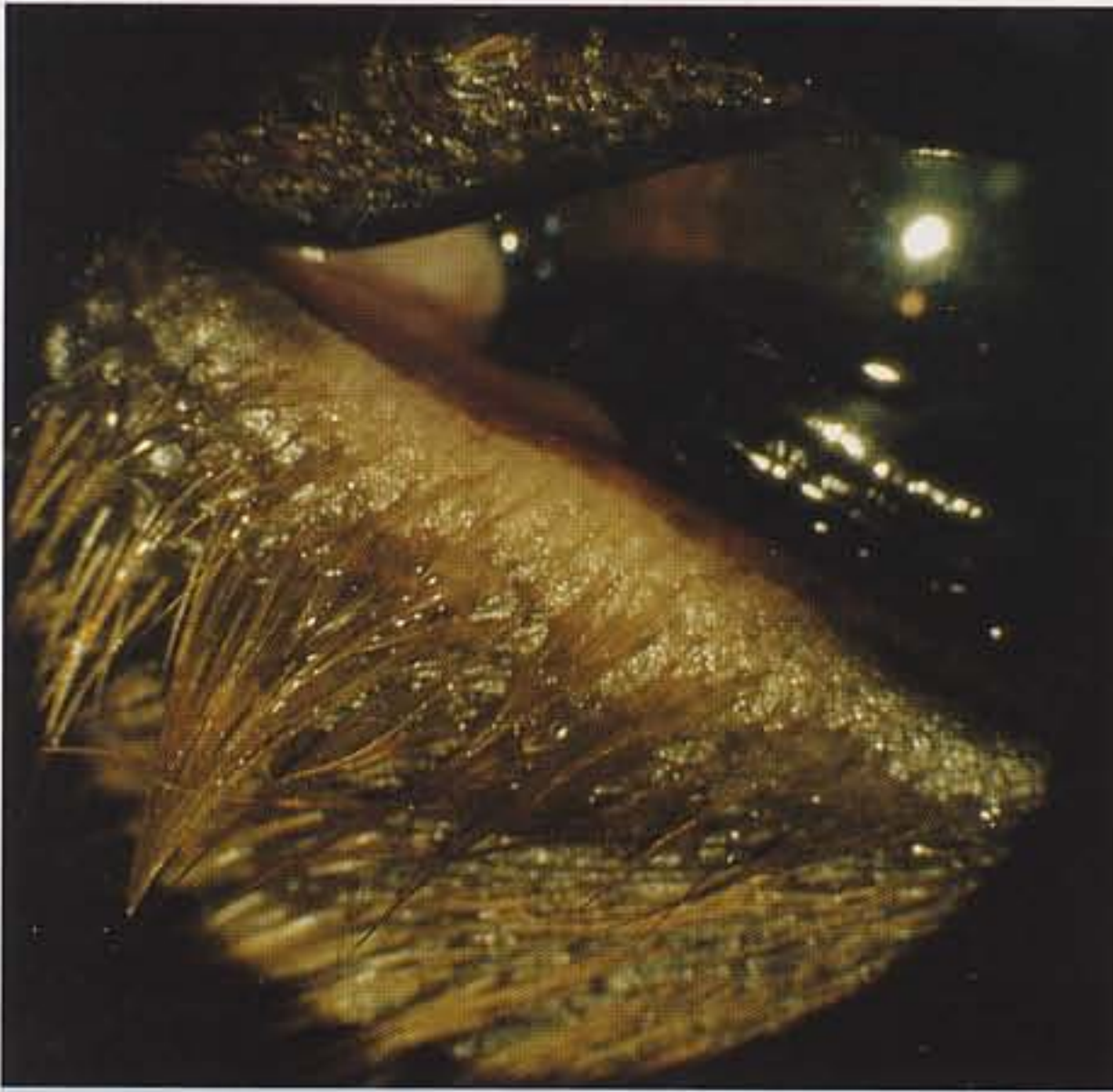
Fig. 2.7 Entropion (same dog as in previous figure) Note the marked enophthalmos, prominent nictitating membrane and severe corneal changes.

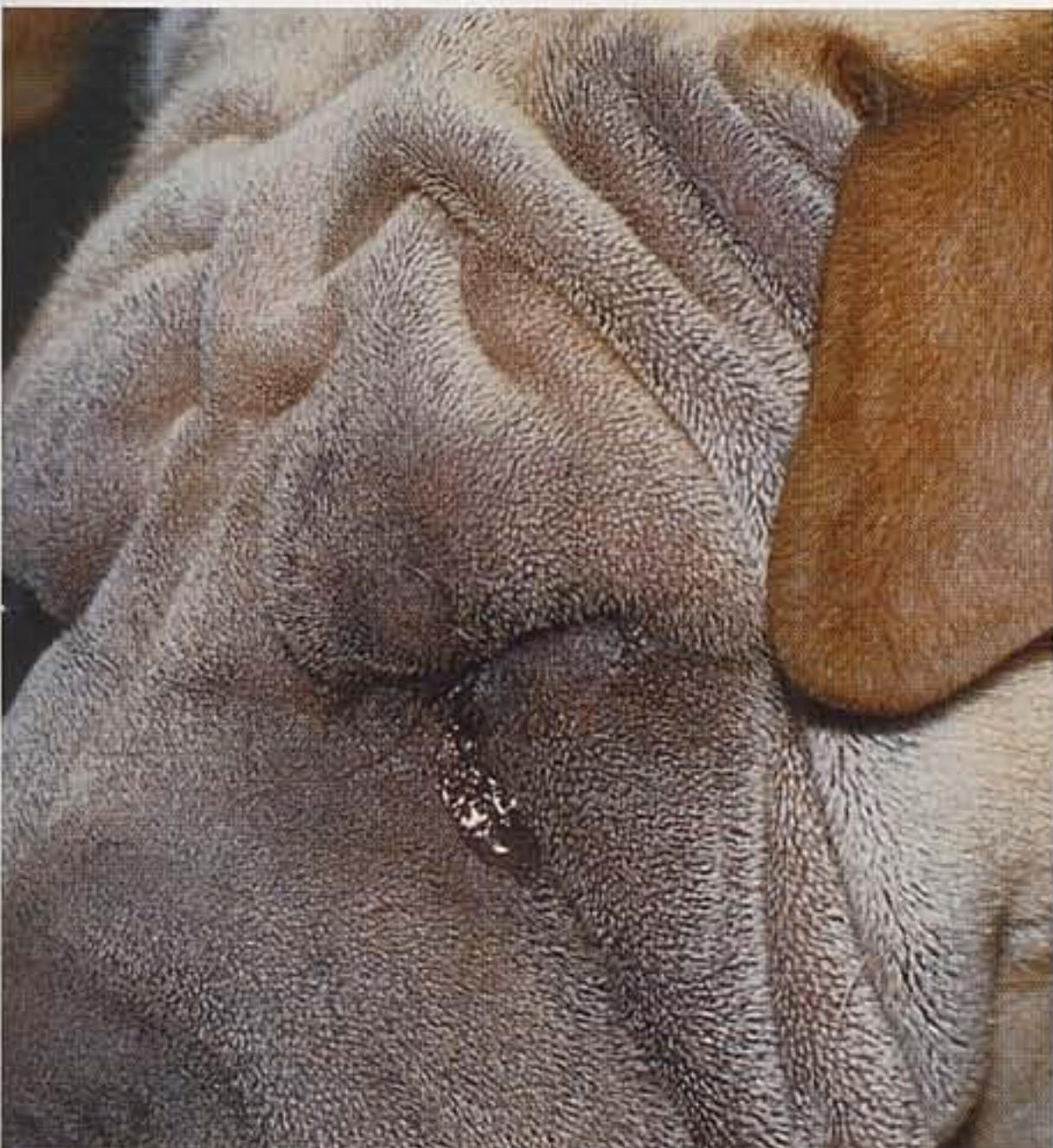

Fig. 2.6 Entropion (Shar Pei, 12 months old) Entropion associated with multiple facial folds. Note the closed eye and lacrimation.

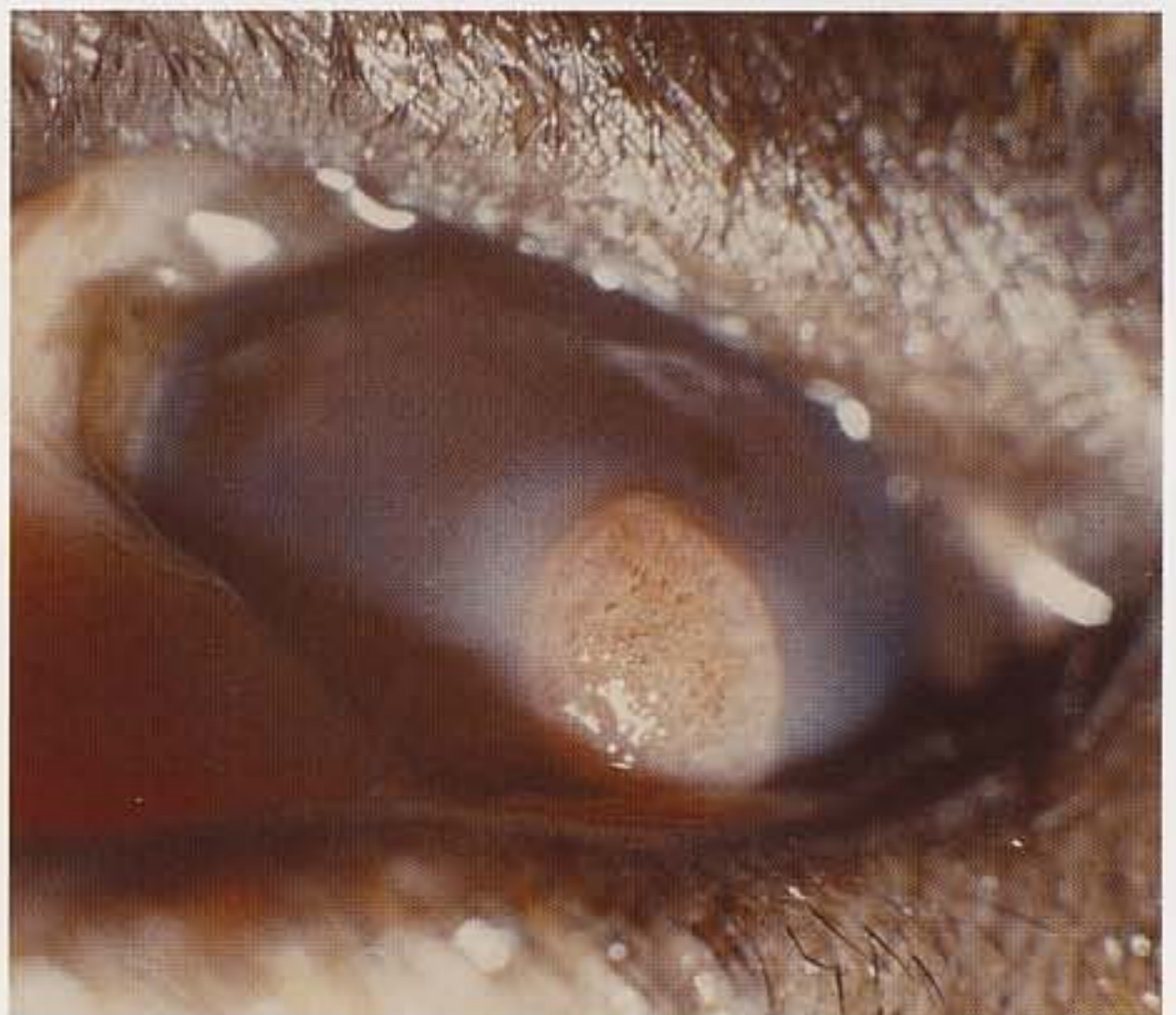

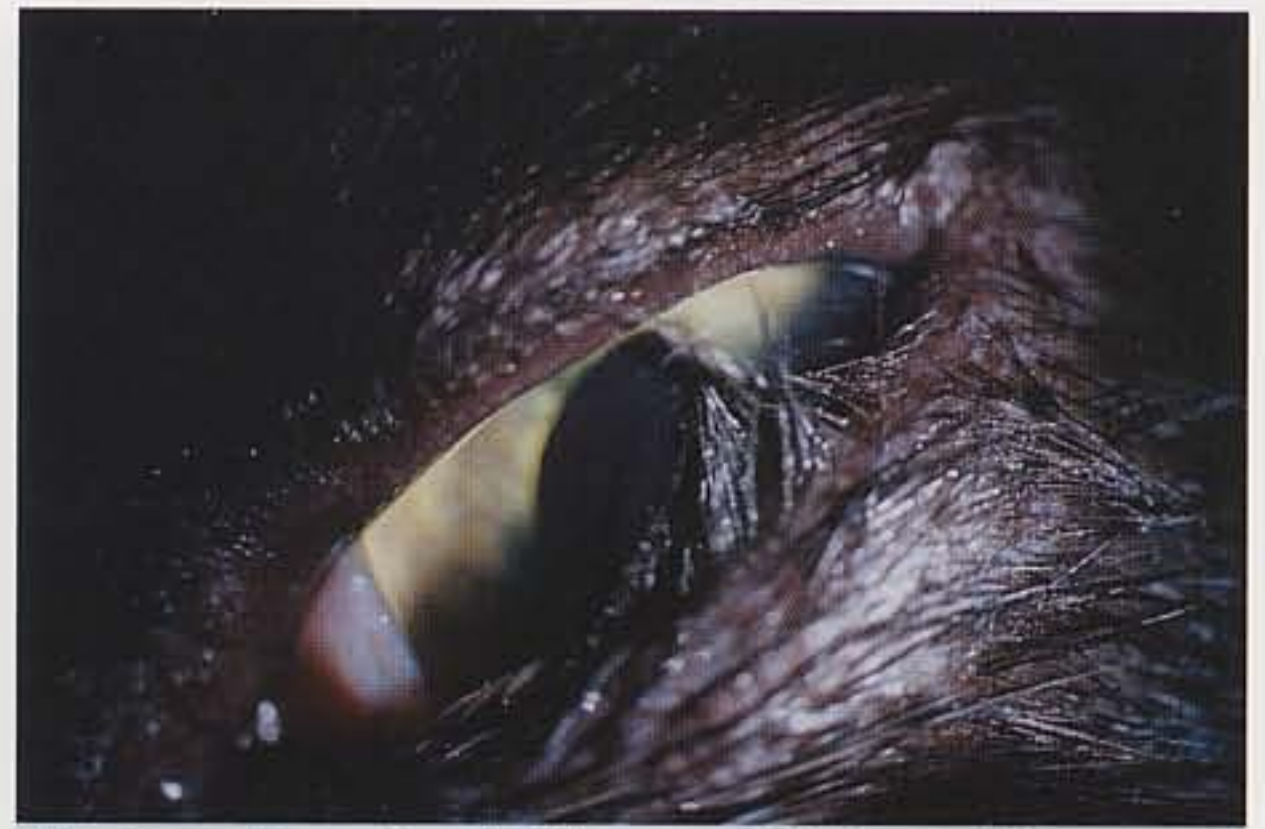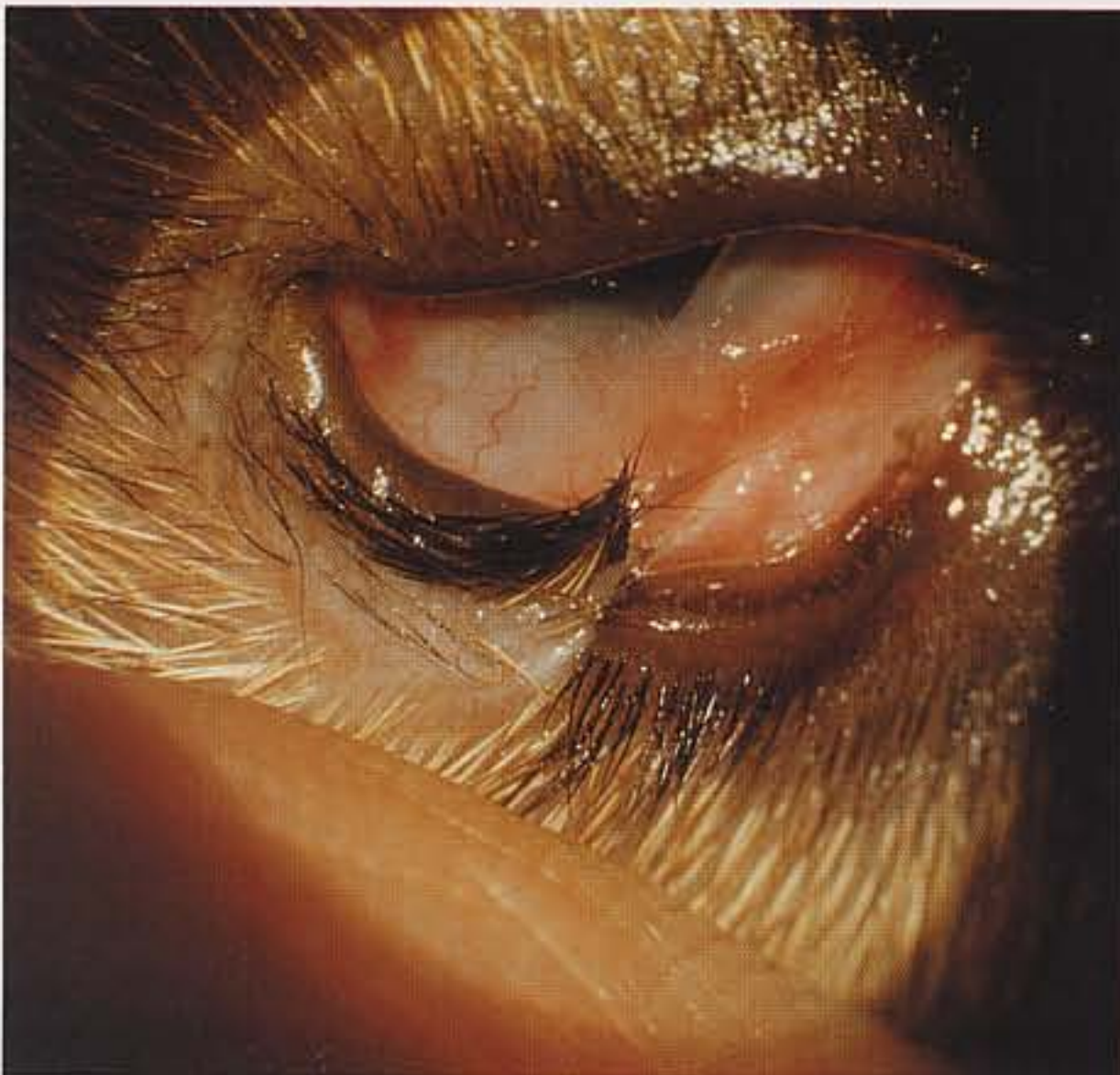Fig. 2.8 Entropion (Chow, 13 months old) Corneal granulation tissue resulting from the chronic irritation due to entropion.



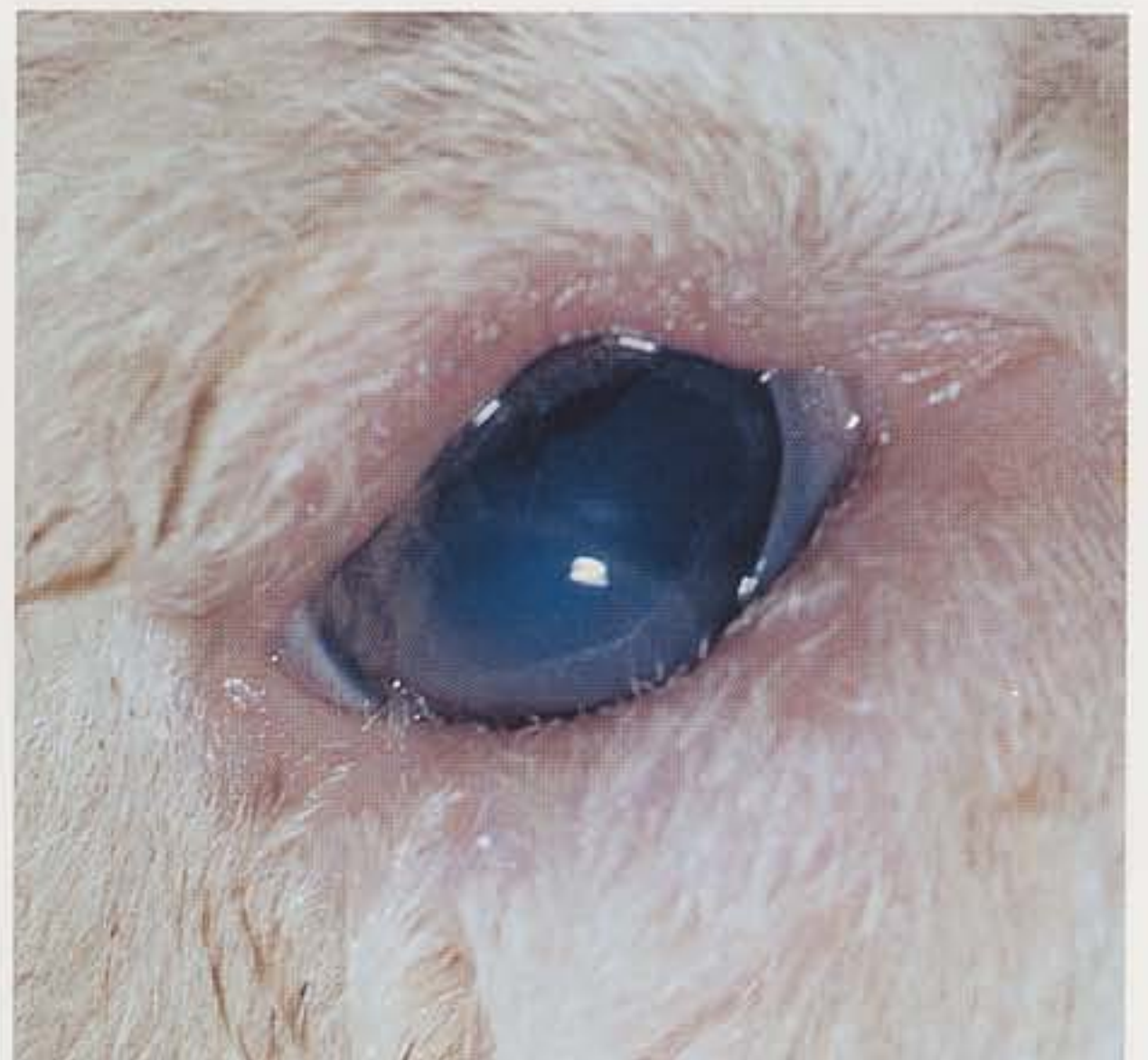**Fig. 2.9 Entropion (Golden Retriever, 8 months old)**  
Typical sign of depigmentation of the lower eyelid which has been rolled inwards and in contact with the tear film for some time.



**Fig. 2.11 Entropion (DSH cat, adult) Lower lid entropion.**



**Fig. 2.10 Entropion (Pembroke Corgi, 6 weeks old)**  
Traumatic entropion following a split eyelid.



**Fig. 2.12 Entropion (Dorset Horn lamb, 3 days old)**  
Lower lid entropion. Congenital and hereditary.

cases are not inherited and usually due to trauma (Fig 2.10). The mode of inheritance is not known but is likely to be complex because of the related factors. In the horse and sheep (Fig 2.12) it is usually congenital. Entropion due to irritation caused by the hairs of the lid margin on the cornea leads to pain and often profuse lacrimation (Fig 2.2), corneal oedema and vascularization (Fig 2.7) and even

granulation tissue (Fig 2.8), ulceration and possible globe penetration. Entropion is rare in the cat.

### Ectropion (Figs 2.13–2.17)

Ectropion, out-turning of the eyelid margin, is uncommon but again breed and age related. It affects the lower lids and is usually due to too long a lid.

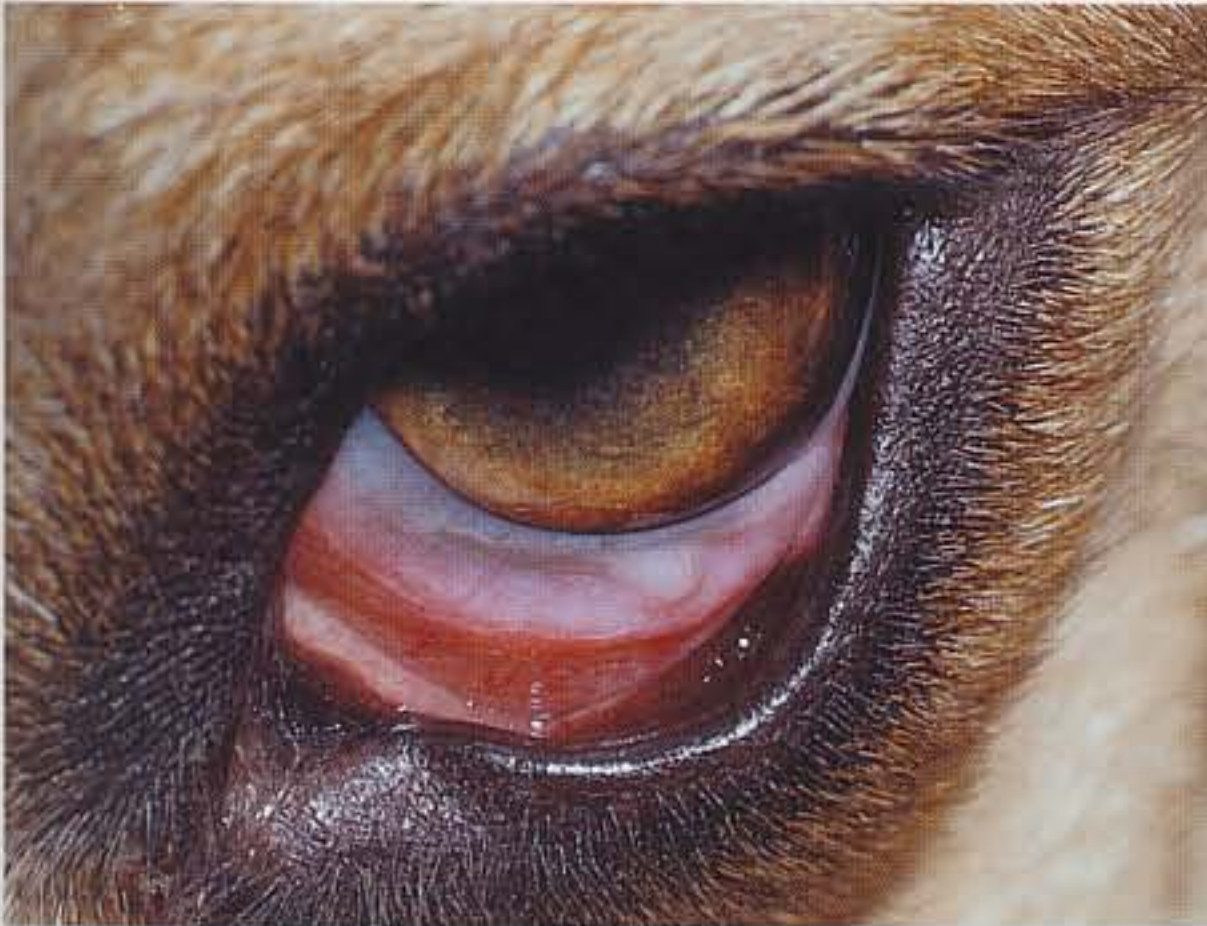

Fig. 2.13 Ectropion (Beagle, young adult) Simple lower lid ectropion due to too long a lid.



Fig. 2.15 Ectropion (Cavalier King Charles Spaniel, puppy) Ectropion of both upper and lower lids with eyelid swelling due to juvenile pyoderma. Note also the affected muzzle.

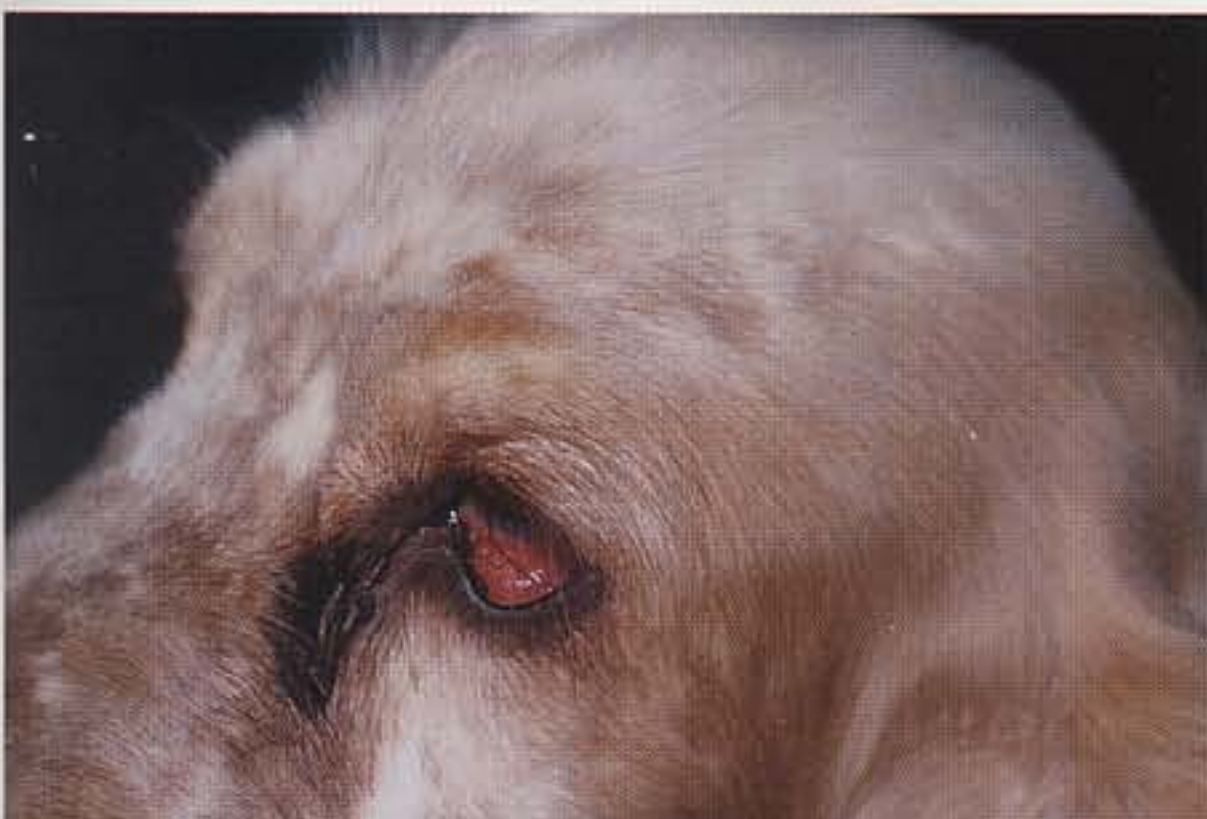

Fig. 2.14 Ectropion (Cocker Spaniel, aged) Senile ectropion of the lower lid. Note the low ear carriage and excess skin on the head and face. This situation is typically seen in the English Cocker Spaniel and note also the senile entropion of the upper lid in Fig 2.5.

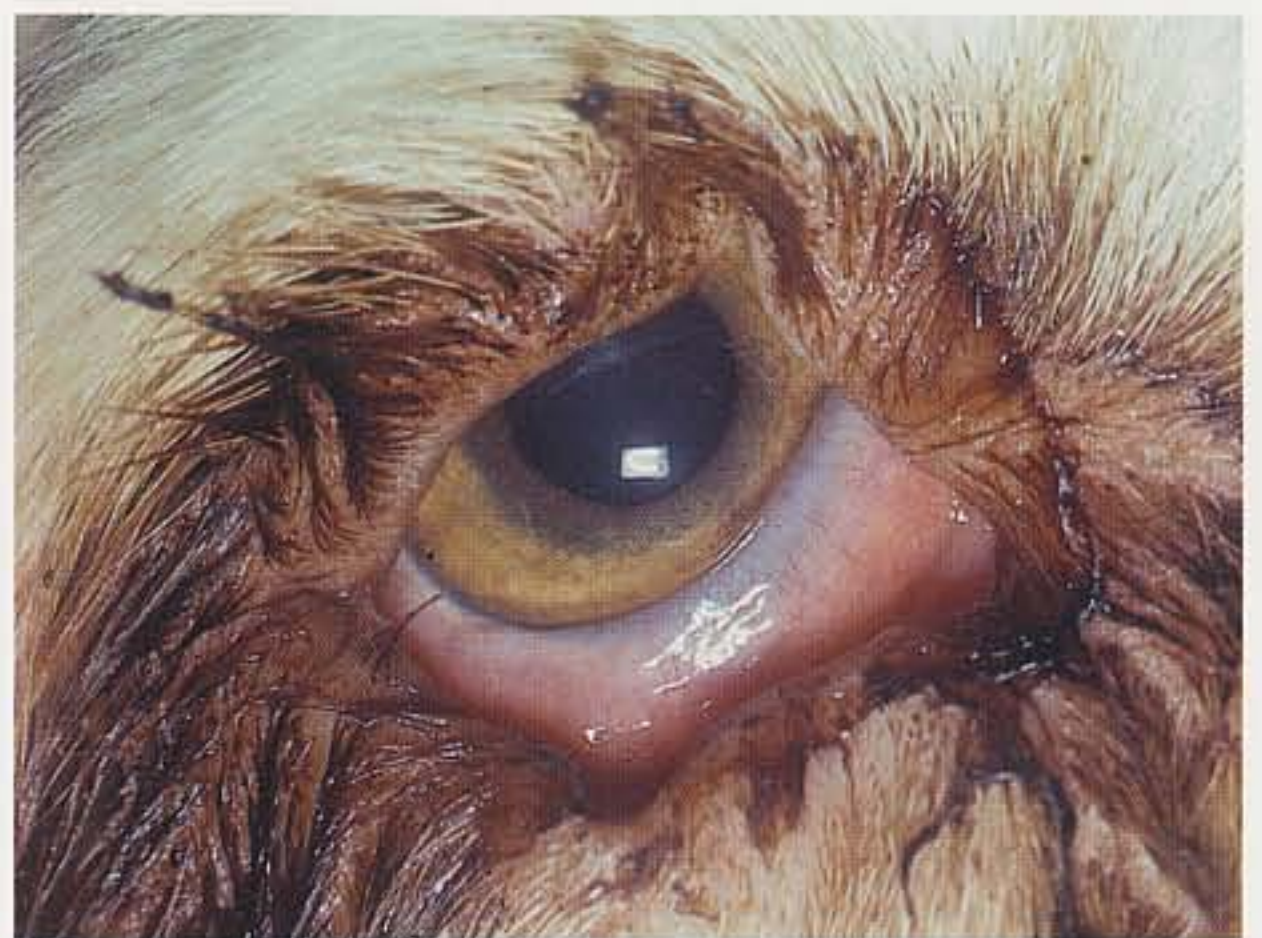

Fig. 2.16 Ectropion (Clumber Spaniel, young adult) Diamond eye with ectropion at the kink in the centre of both upper and lower lids complicated by entropion on either side. This situation is also seen typically in the St Bernard, Bloodhound and Basset Hound.

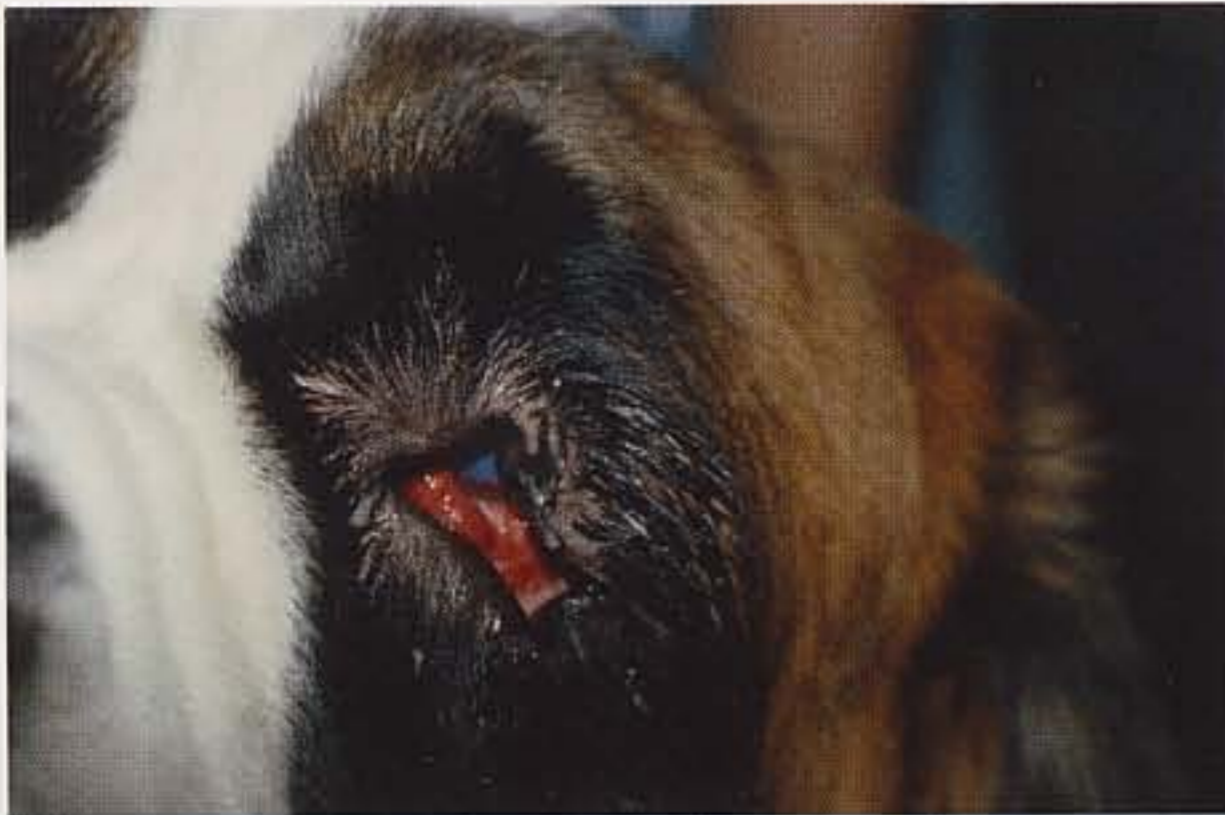

Fig. 2.17 Ectropion/entropion (St Bernard) Grossly abnormal diamond eye. Note also corneal changes and prolapsed nictitans gland.

Ectropion does not cause the irritation of entropion but exposure of conjunctiva leads to some inflammation and normal tear drainage may be affected, leading to a degree of epiphora.

### Distichiasis (Figs 2.18–2.25)

Distichiasis, extra or supernumerary eyelashes arising from or near the meibomian gland orifices, is common in the dog and inherited, usually occurring at a few months of age, sometimes younger. It is rare in other species. Distichiasis may or may not cause a clinical problem, depending upon the length, direction and number of the supernumerary eyelashes. It may be accompanied by lacrimation, blepharospasm and sometimes corneal ulceration (Fig 2.20).

### Ectopic cilia (Figs 2.23–2.26)

Ectopic cilia are extra lashes emerging from the palpebral conjunctiva and usually impinging directly onto the cornea, often causing acute blepharospasm and lacrimation, and sometimes corneal ulceration. The ectopic cilia may be single or in groups and the condition is usually associated with degrees of distichiasis. Again, there is a strong breed incidence.

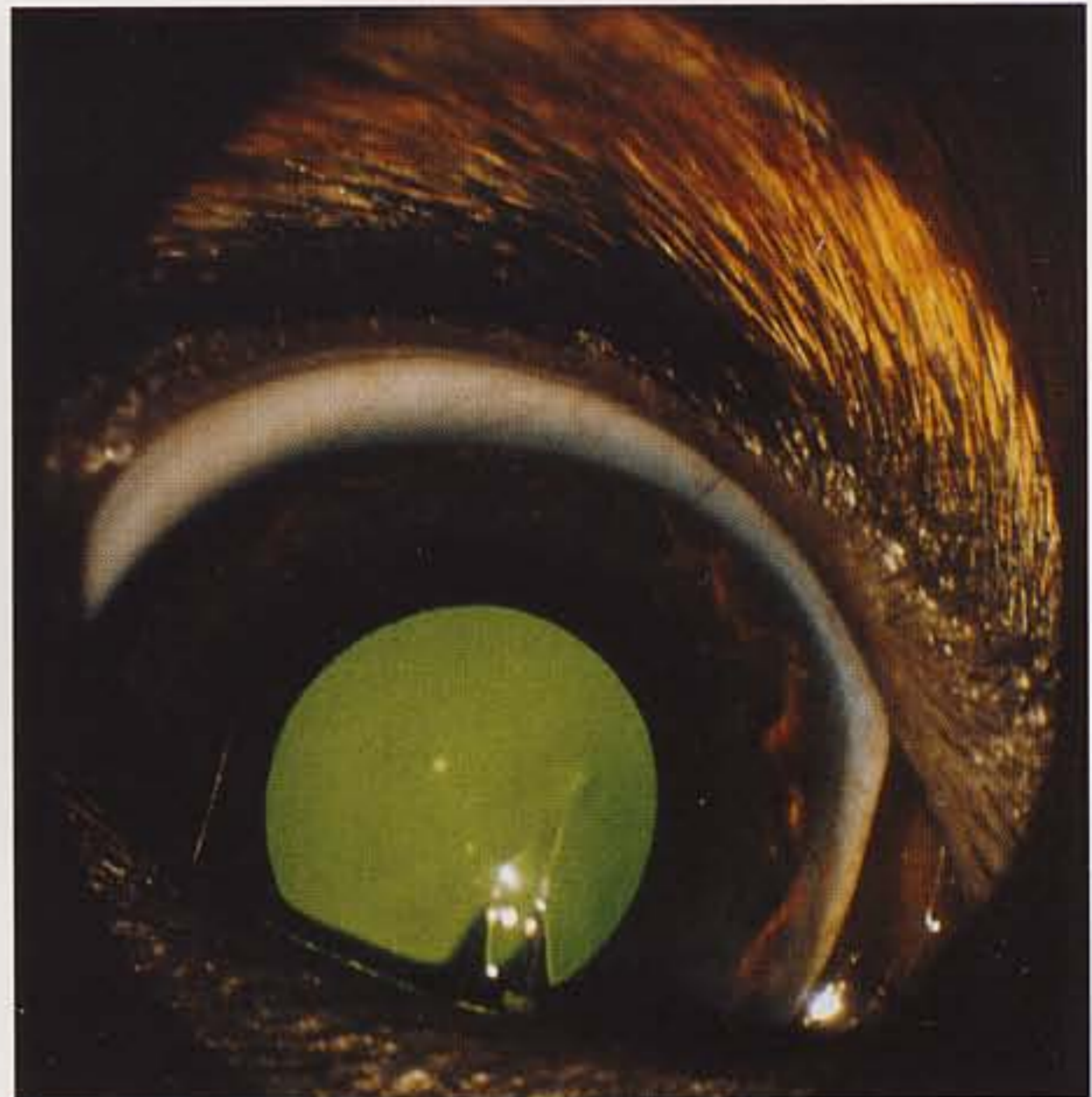


Fig. 2.18 Distichiasis (Miniature Longhaired Dachshund, young adult) Note the long supernumerary cilia in the lower lid producing a slight increase in the tear film but no other clinical signs and no corneal damage.

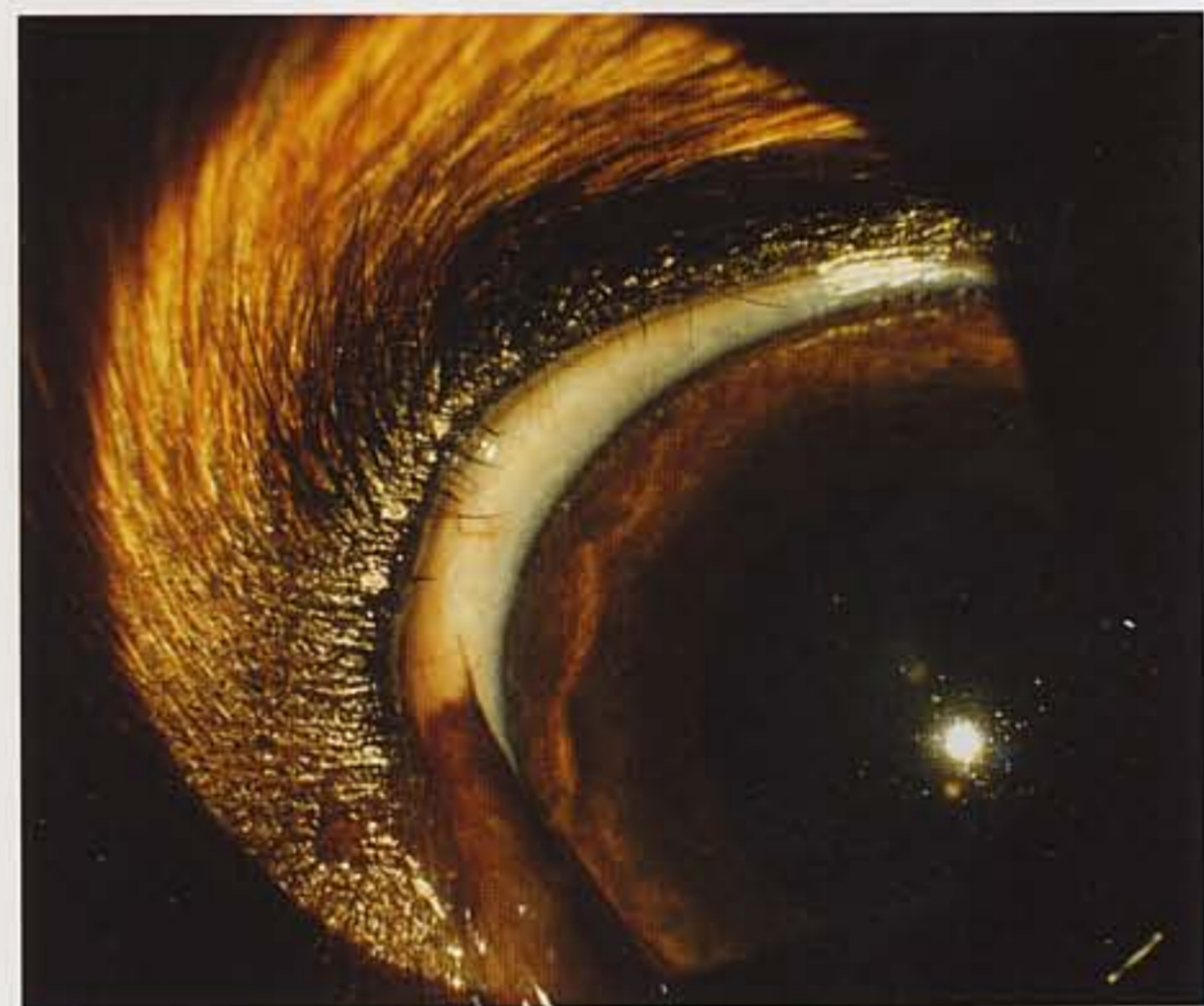


Fig. 2.19 Distichiasis (Miniature Longhaired Dachshund, 1 year old) Several shorter cilia in the upper lid and of different lengths, but still not causing corneal damage or any other clinical sign. Distichiasis is particularly common in this breed.

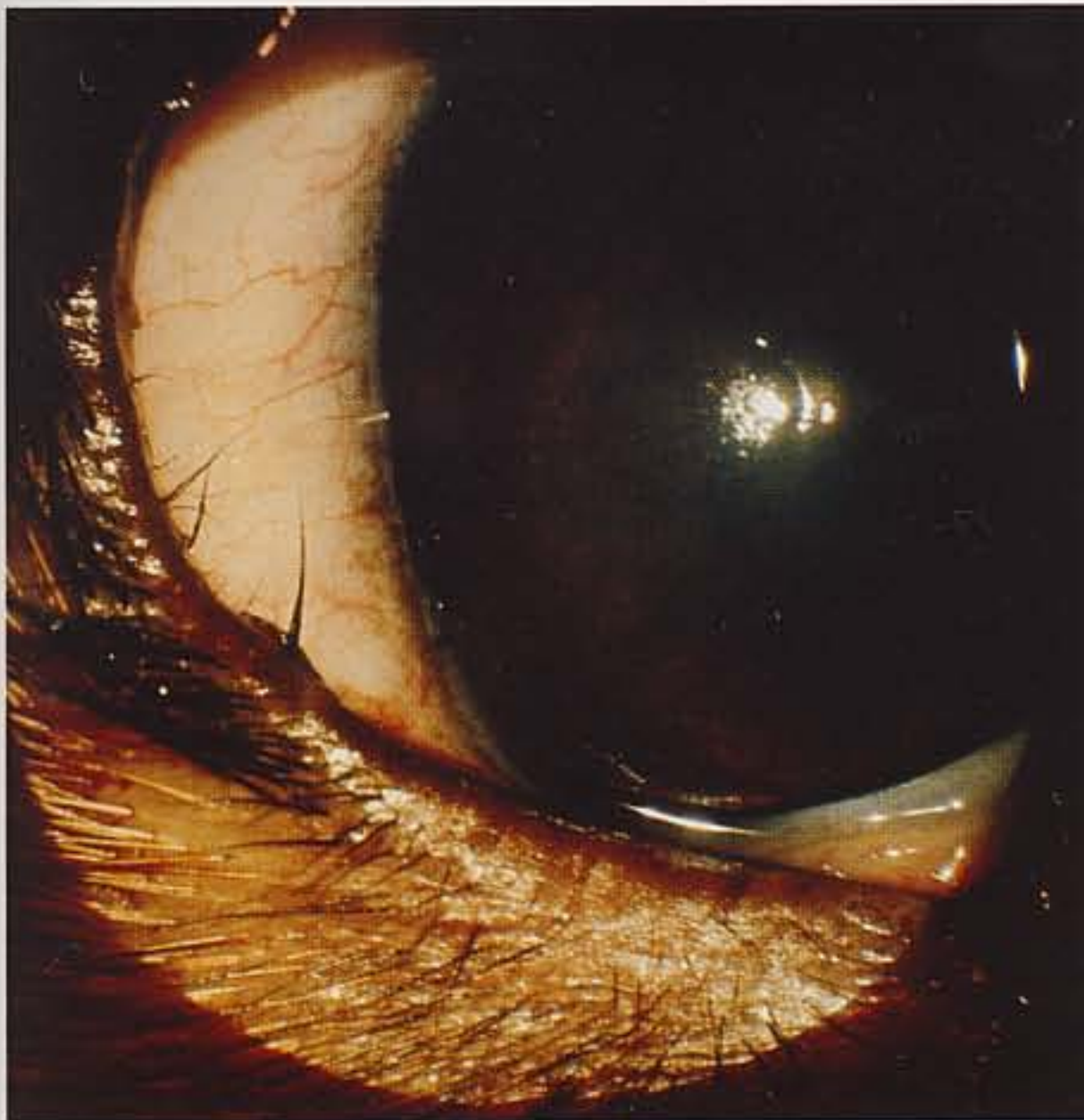

Fig. 2.20 Distichiasis (Pekingese, young adult) Short supernumerary lashes causing a corneal ulcer.

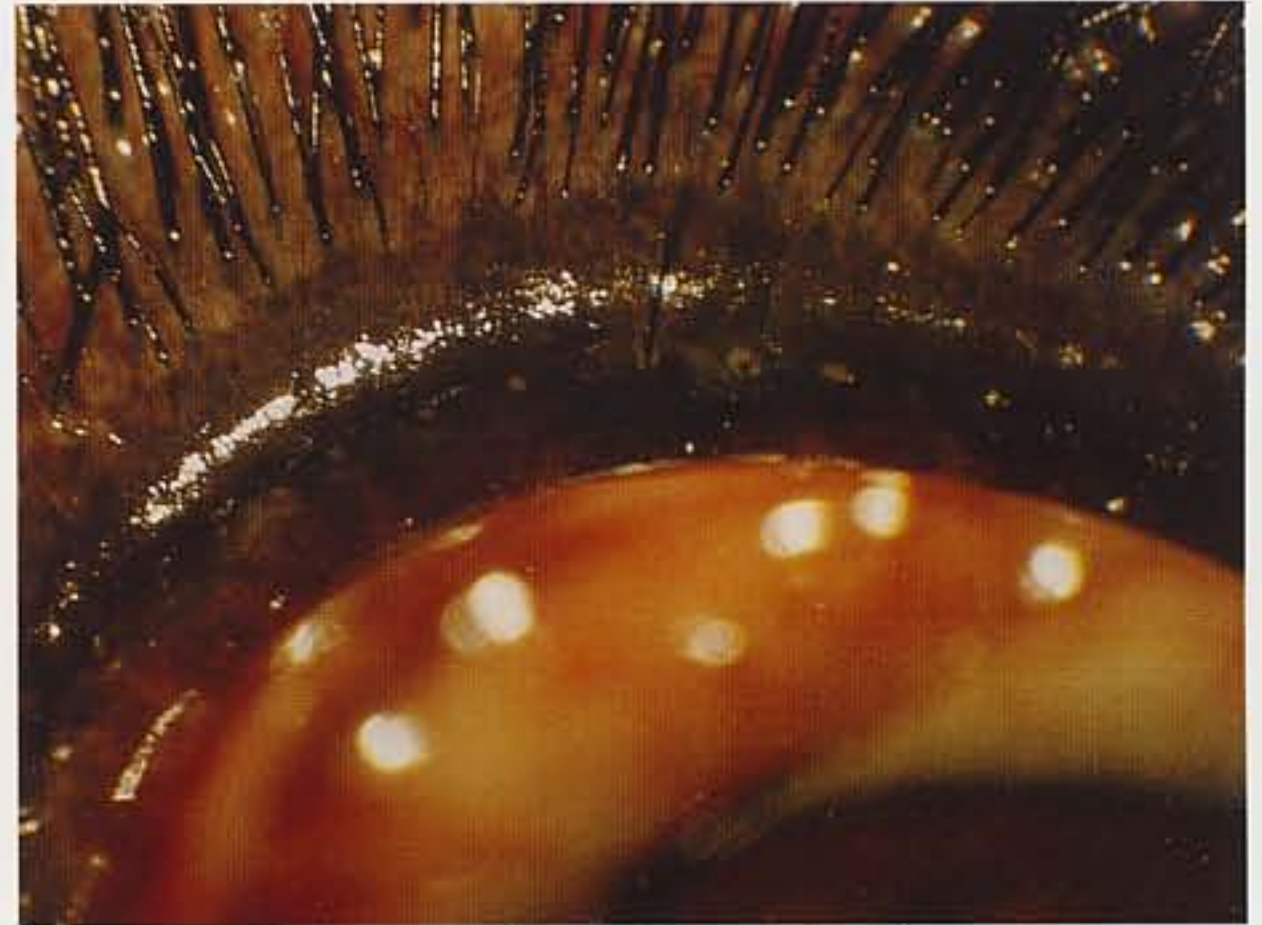

Fig. 2.22 Distichiasis (Flat-Coated Retriever, 2 years old) Two supernumerary cilia arising from the meibomian gland openings.

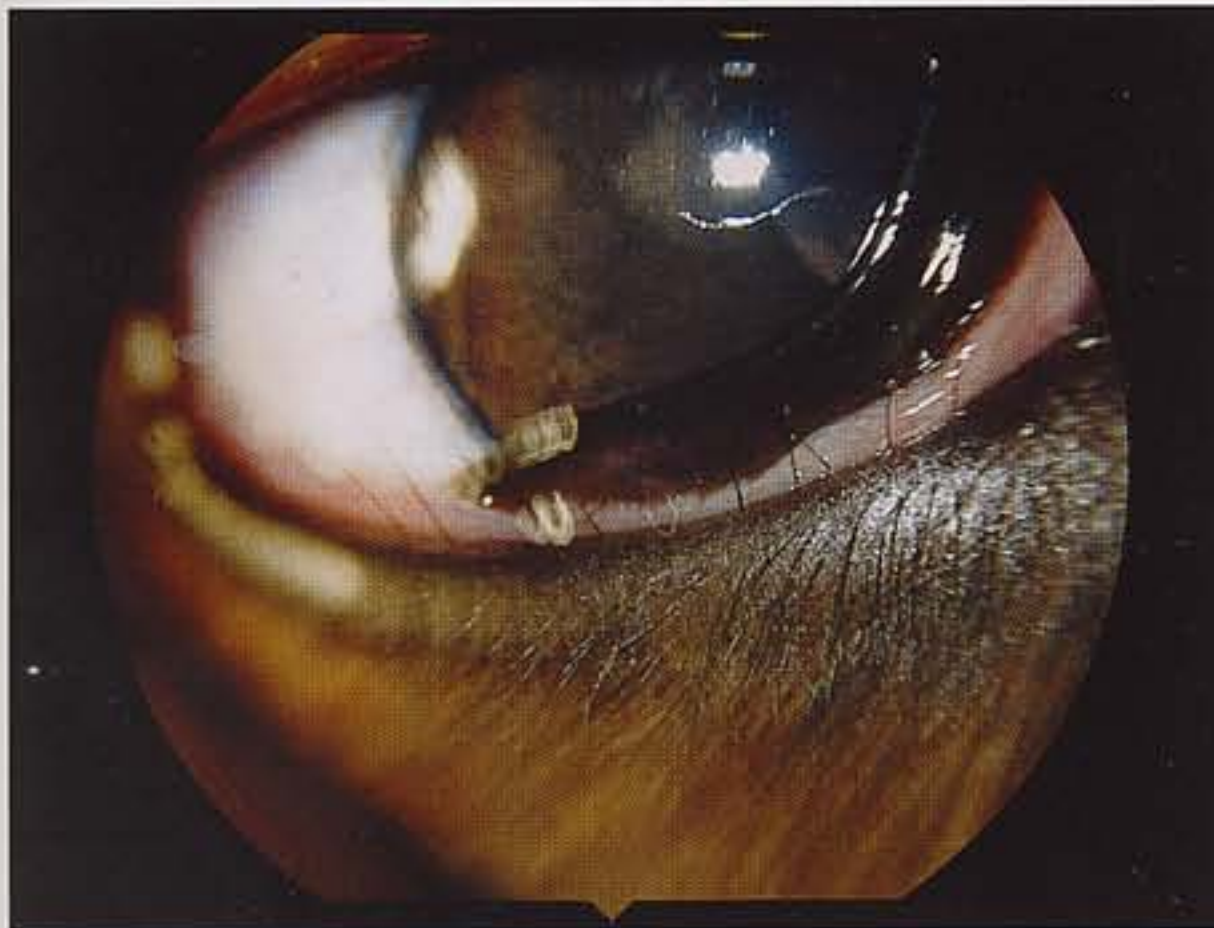

Fig. 2.21 Distichiasis (Shetland Sheepdog, young adult) Several lashes causing irritation. Note the enophthalmos and prominence of the nictitating membrane. Another breed often involved with this condition.



Fig. 2.23 Distichiasis and ectopic cilia (Flat-Coated Retriever, young adult) Note marked blepharospasm and increased lacrimation. Another breed often exhibiting this problem.

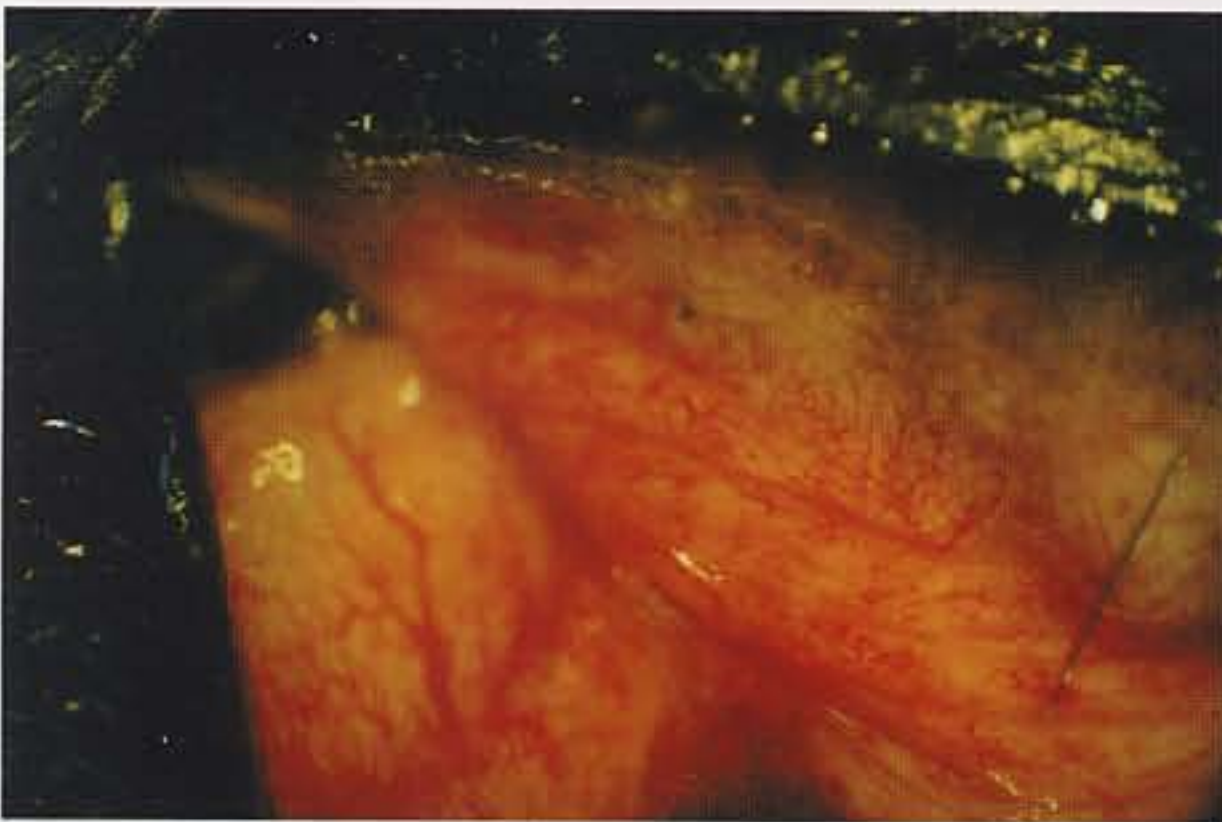


Fig. 2.24 Ectopic cilia (Flat-Coated Retriever, 7 months old) Note the origin of the aberrant cilia well inside the upper eyelid margin.

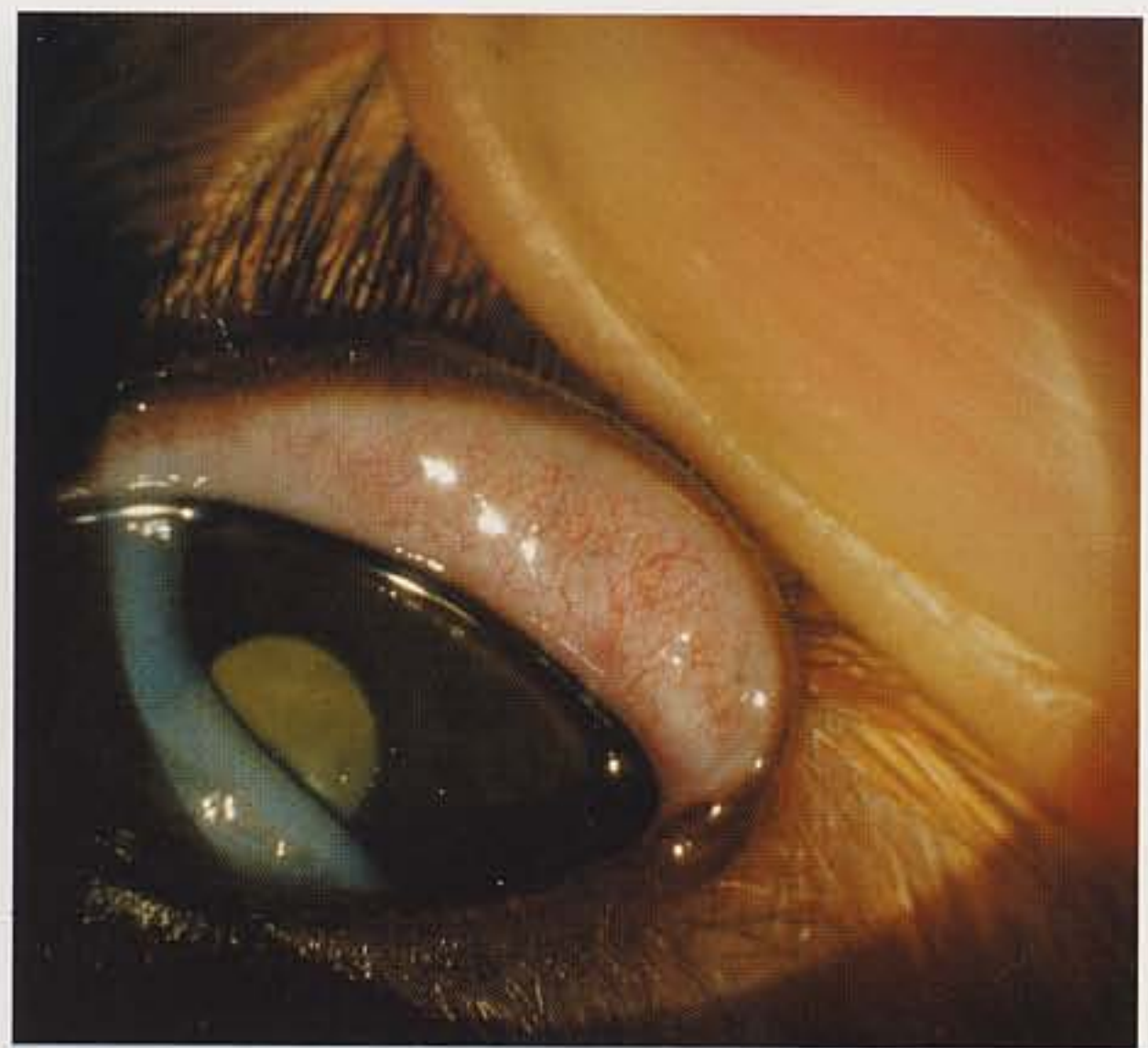

Fig. 2.26 Ectopic cilia (Shetland Sheepdog, 4 months old) Several potential ectopic cilia lying beneath the palpebral conjunctiva.

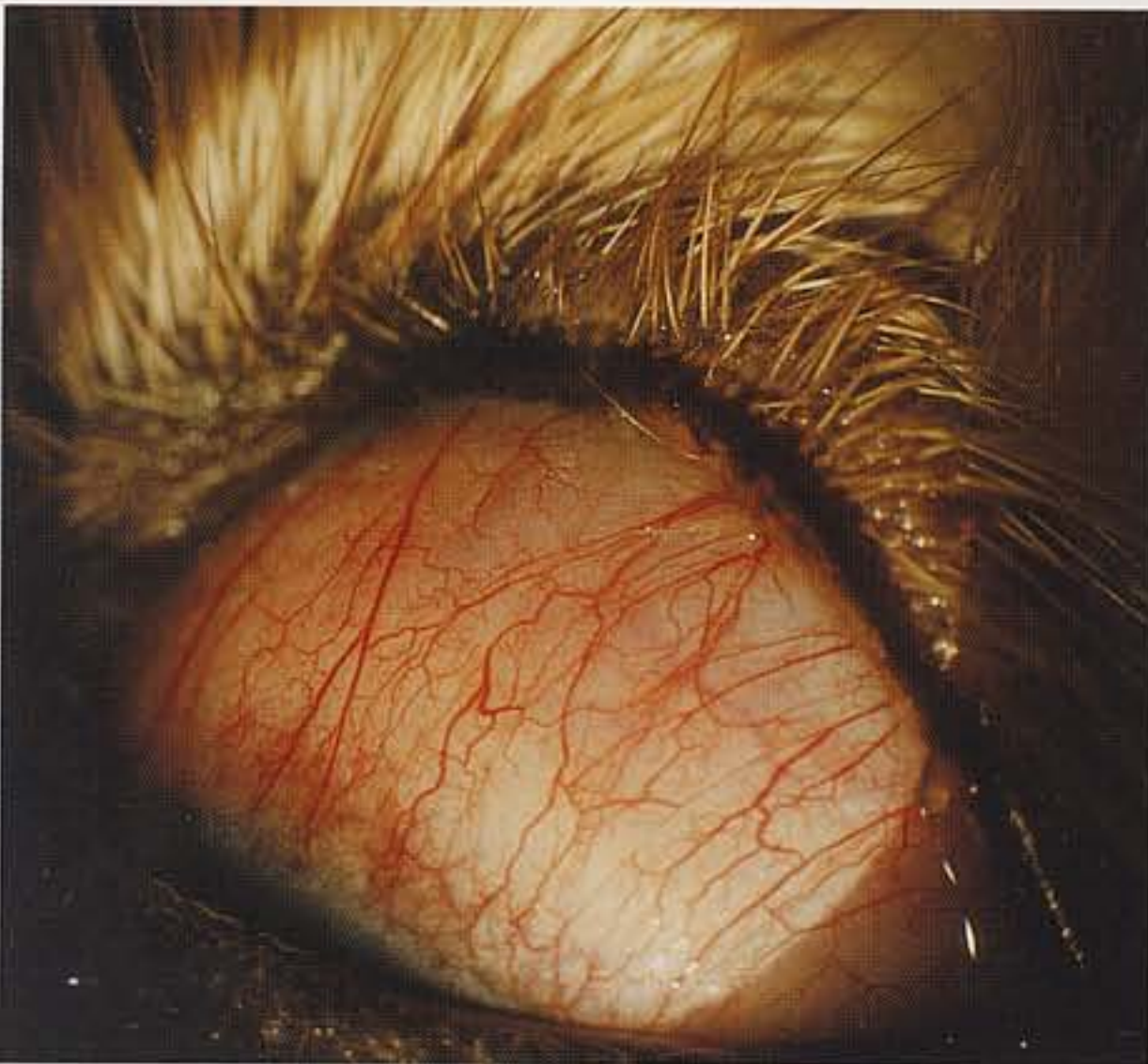

Fig. 2.25 Distichiasis and ectopic cilia (Pekingese, 1 year old) These two conditions are frequently found in the same eye.

### Trichiasis (Figs 2.27–2.28)

Trichiasis is normal facial hair in contact with the cornea and/or conjunctiva from nasal folds; it is occasionally traumatic in origin.

### Blepharitis (Fig 2.29–2.30)

Blepharitis, eyelid inflammation, is usually associated with a primary dermatological problem and with secondary conjunctival involvement. Clinical signs depend upon the primary condition and the degree of severity and include ocular discharges sticking to the lashes and periorbital region, irritation and hair loss.

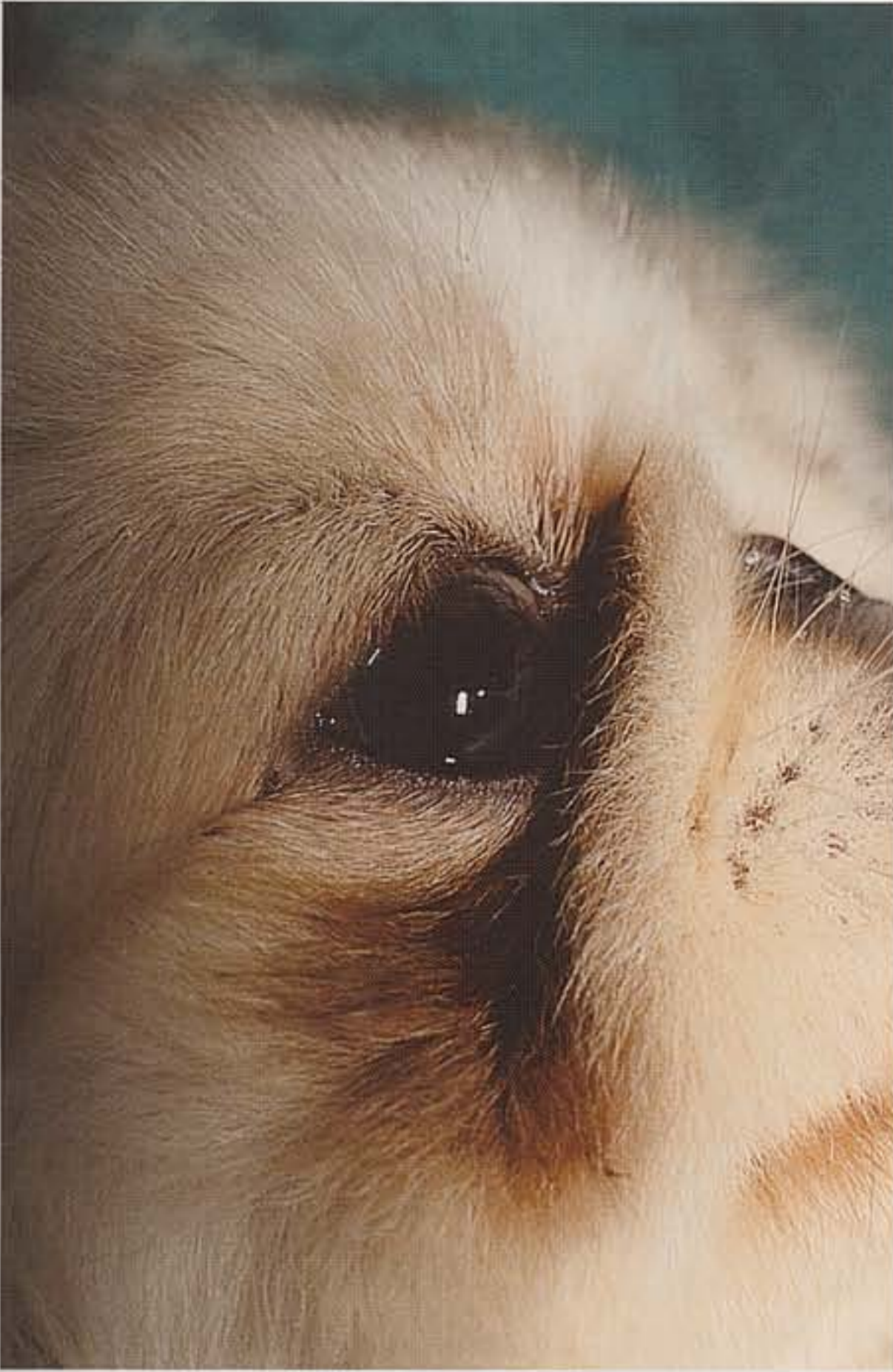

Fig. 2.27 Trichiasis (Pekingese, puppy) Pronounced nasal fold. Note the tear streak.

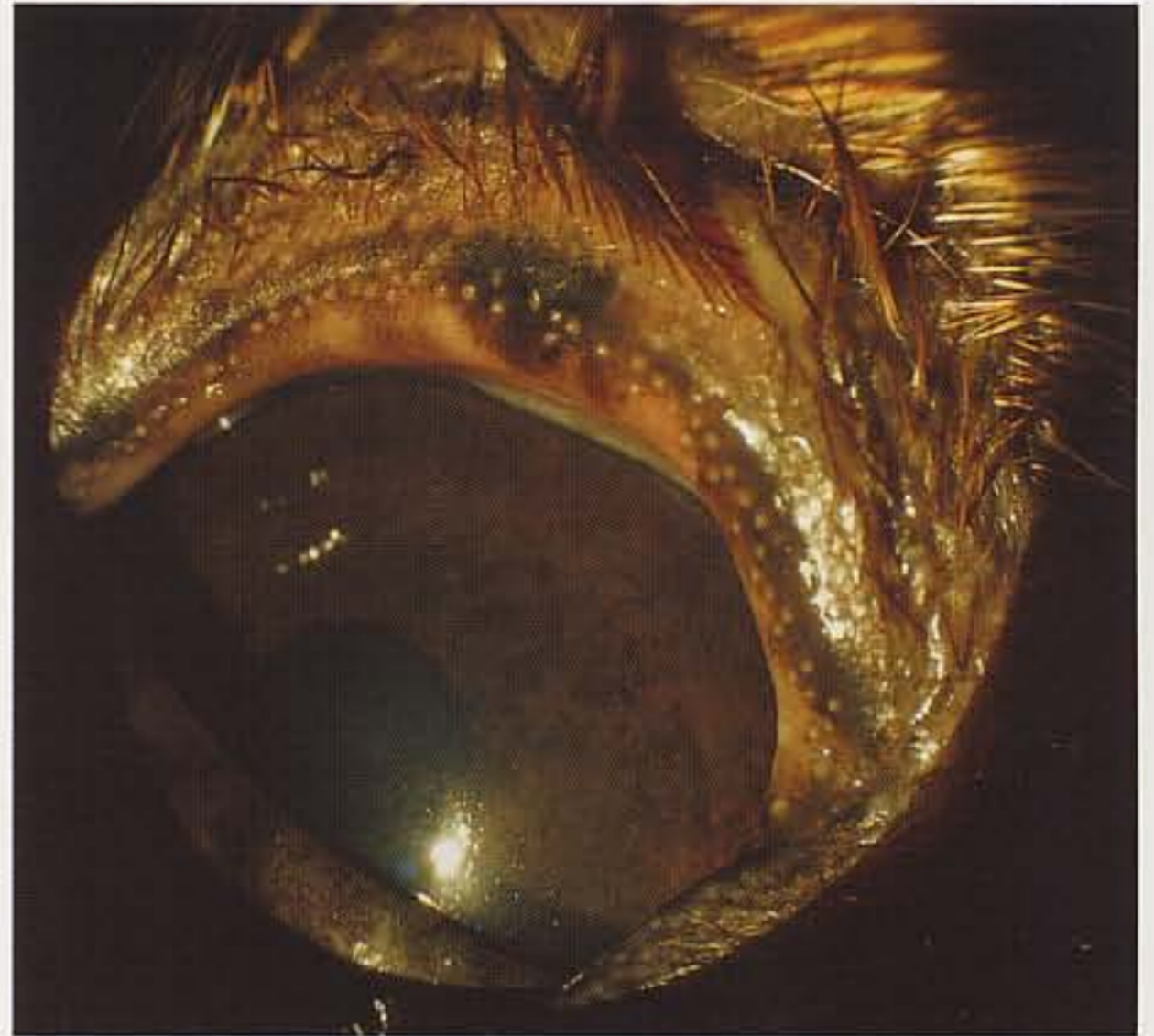


Fig. 2.29 Blepharitis (Cocker Spaniel, 6 years old) Note the discharge sticking the eyelashes together, the associated early vascular keratitis and the prominence of the meibomian gland openings.



Fig. 2.28 Trichiasis (Pekingese, 4 years old) Irritation and corneal ulcer due to a nasal fold.

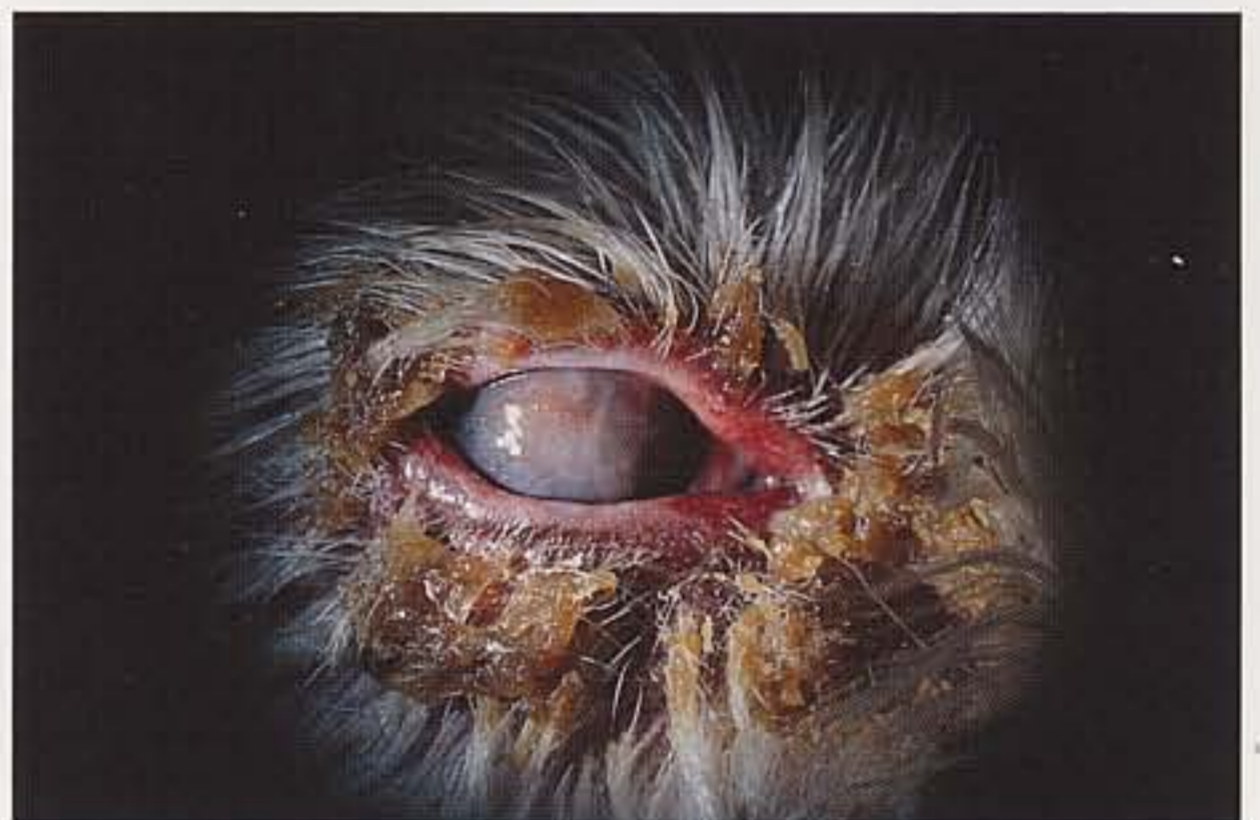

Fig. 2.30 Blepharitis Secondary to keratoconjunctivitis sicca.



**Meibomianitis** (Fig 2.31)

Meibomianitis, inflammation of the meibomian glands, may be acute or chronic and may accompany blepharitis or conjunctivitis.

**Hordeolum – external (stye)** (Fig 2.32)

Infection of one or more of the meibomian glands.

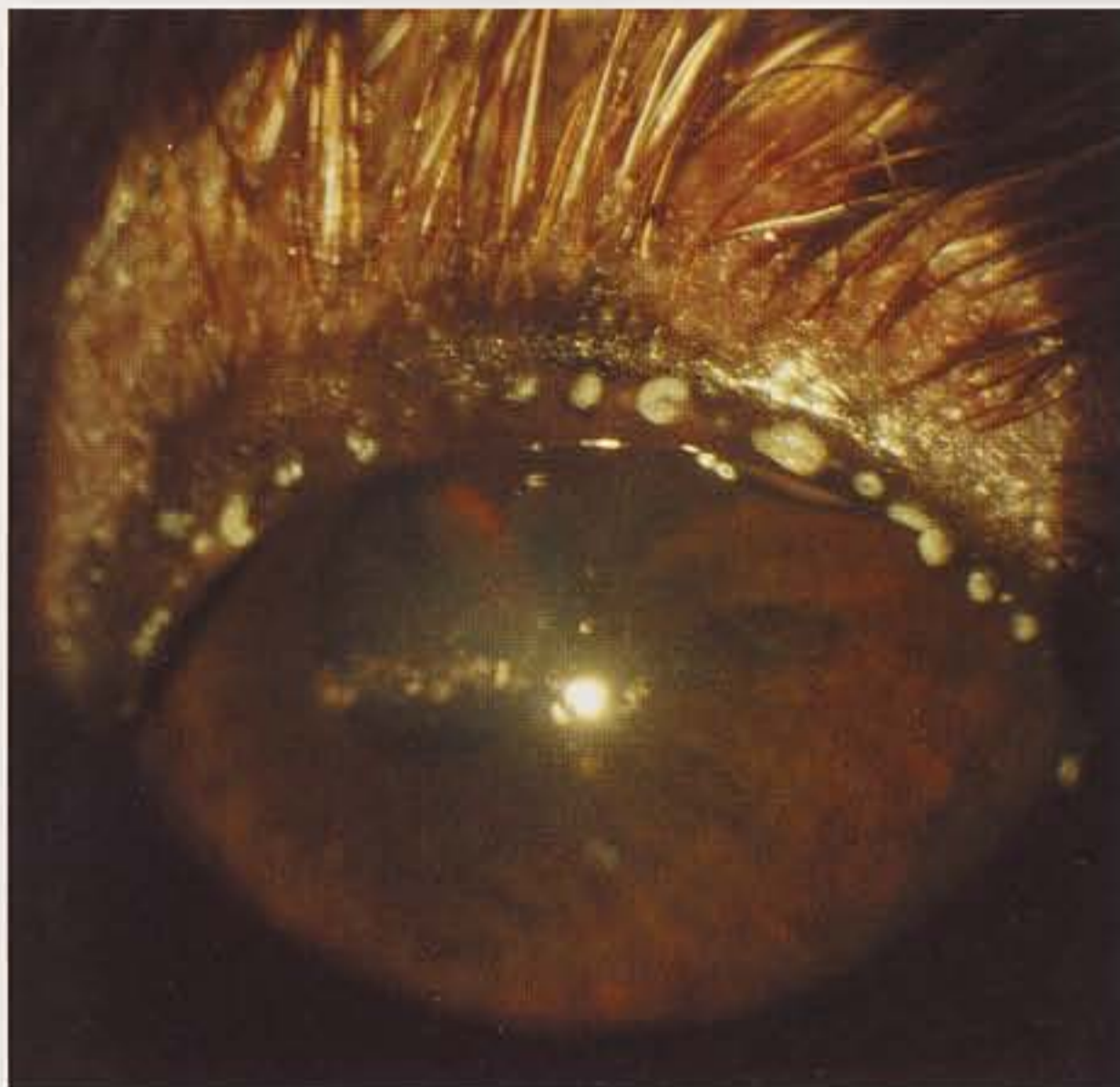


Fig. 2.31 Meibomianitis (Cavalier King Charles Spaniel, 4 years old) Note the secretion from the meibomian glands.

**Meibomian cyst** (Fig 2.33)

Meibomian cyst is the cystic distension of the gland and is mainly visible on the conjunctival side of the lid.

**Eyelid neoplasia** (Figs 2.34–2.44)

Eyelid neoplasia is common, particularly in the older

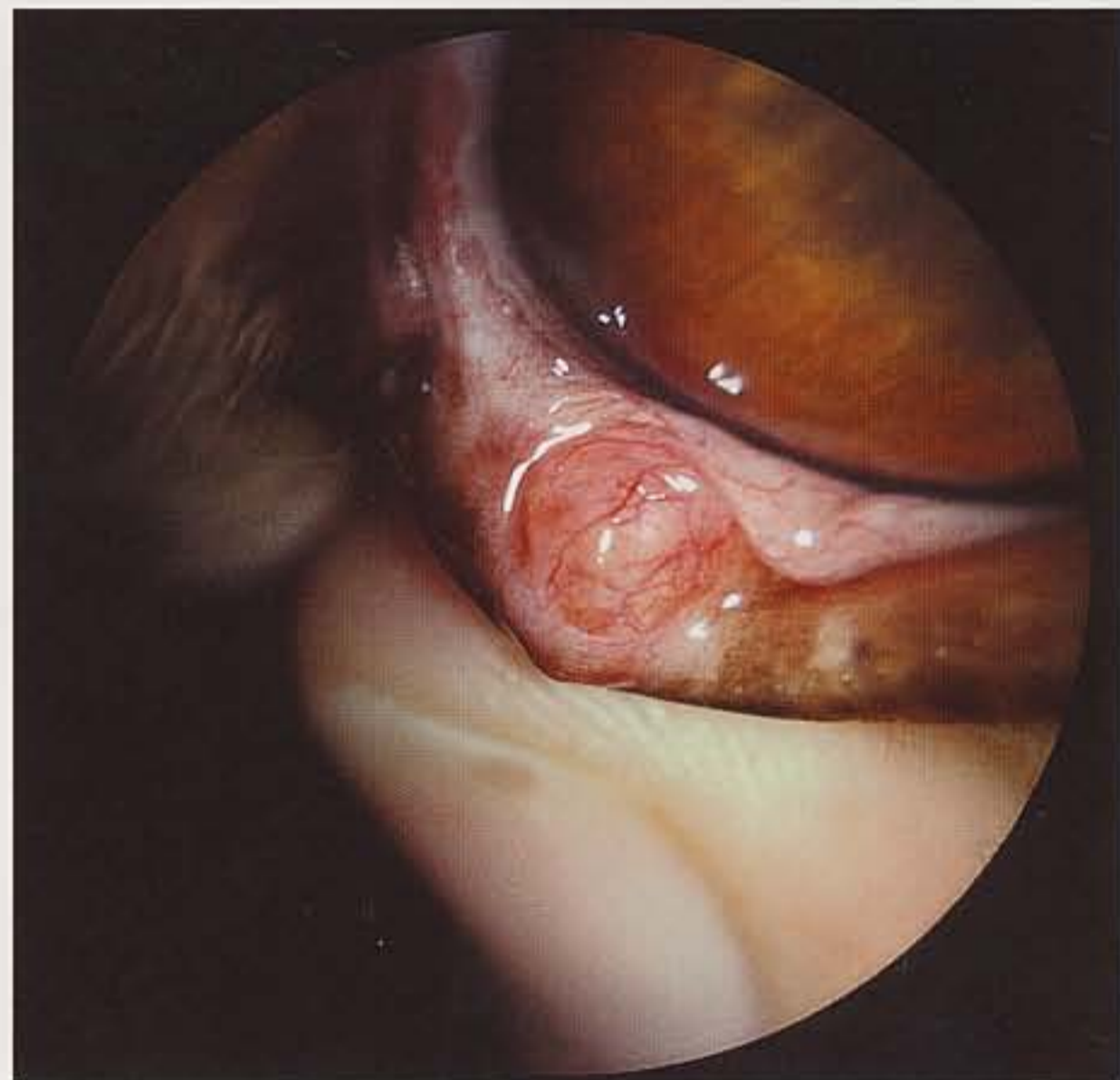

Fig. 2.33 Meibomian cyst (Beagle, young adult) Cystic distension of meibomian gland visible on the conjunctival side of the lid.

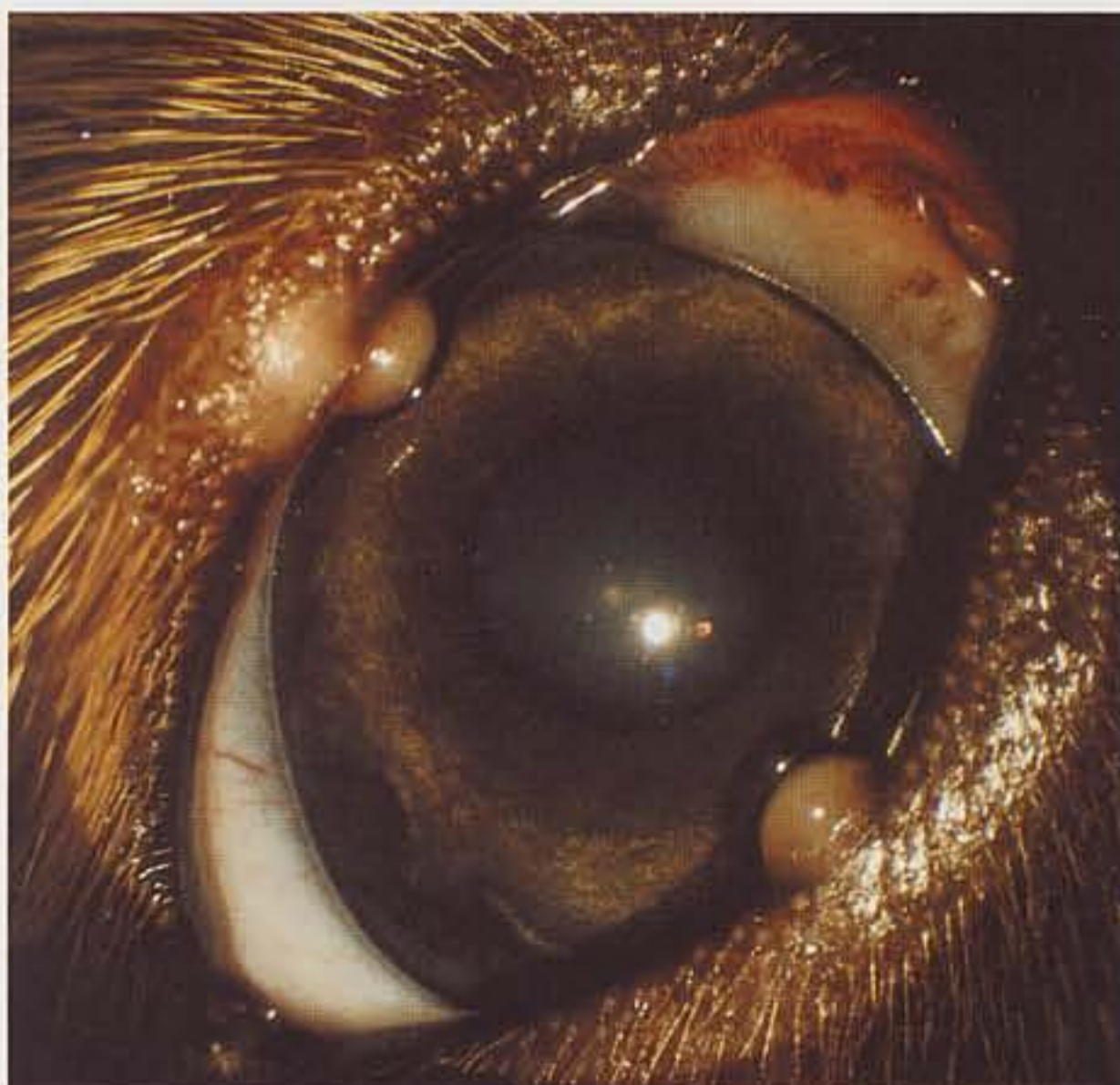


Fig. 2.32 Hordeolum or stye (Labrador Retriever, 8 weeks old) Infected and distended meibomian glands.

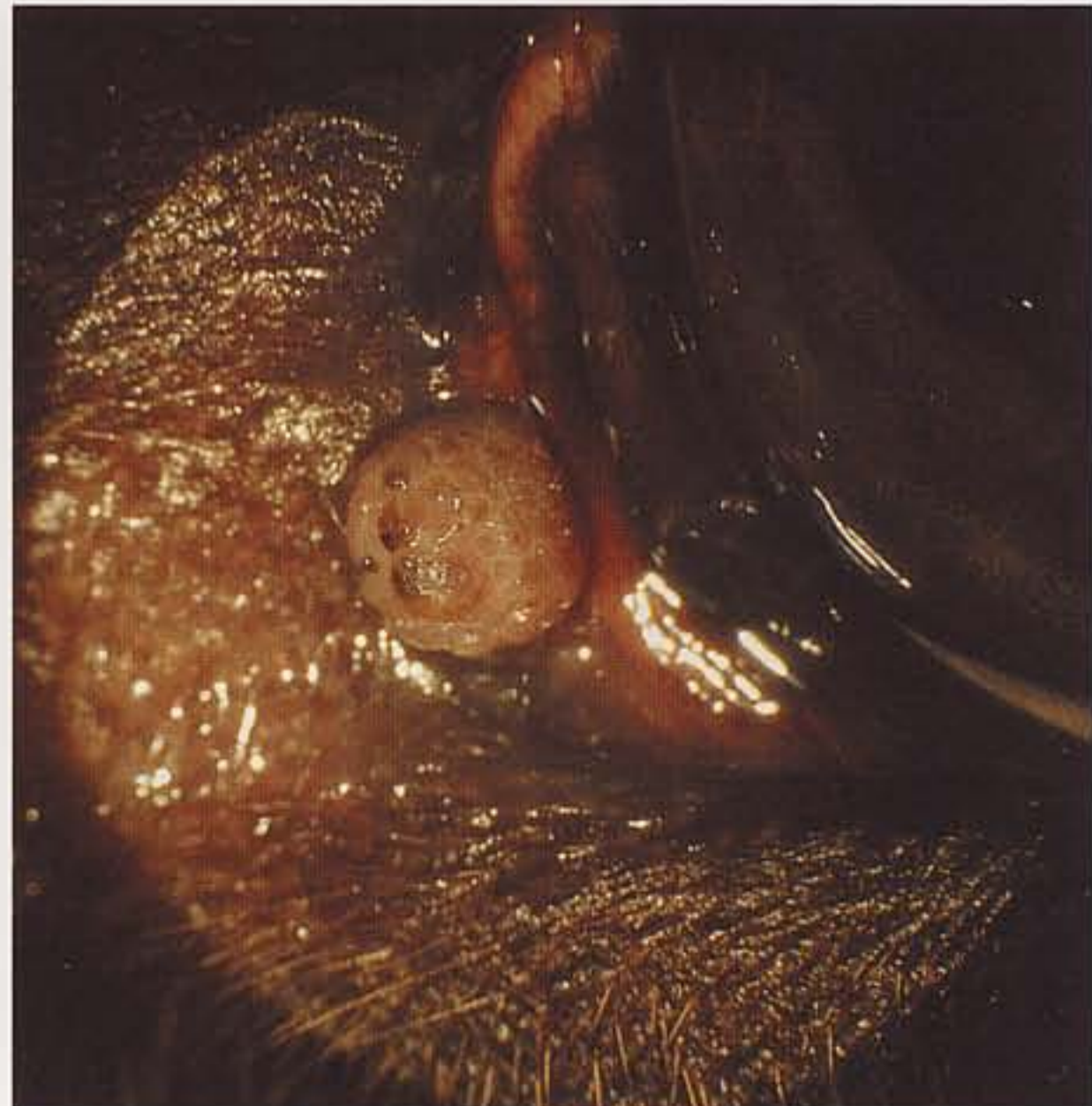

Fig. 2.34 Eyelid tumour (Golden Retriever, 1 year old) Viral papilloma.

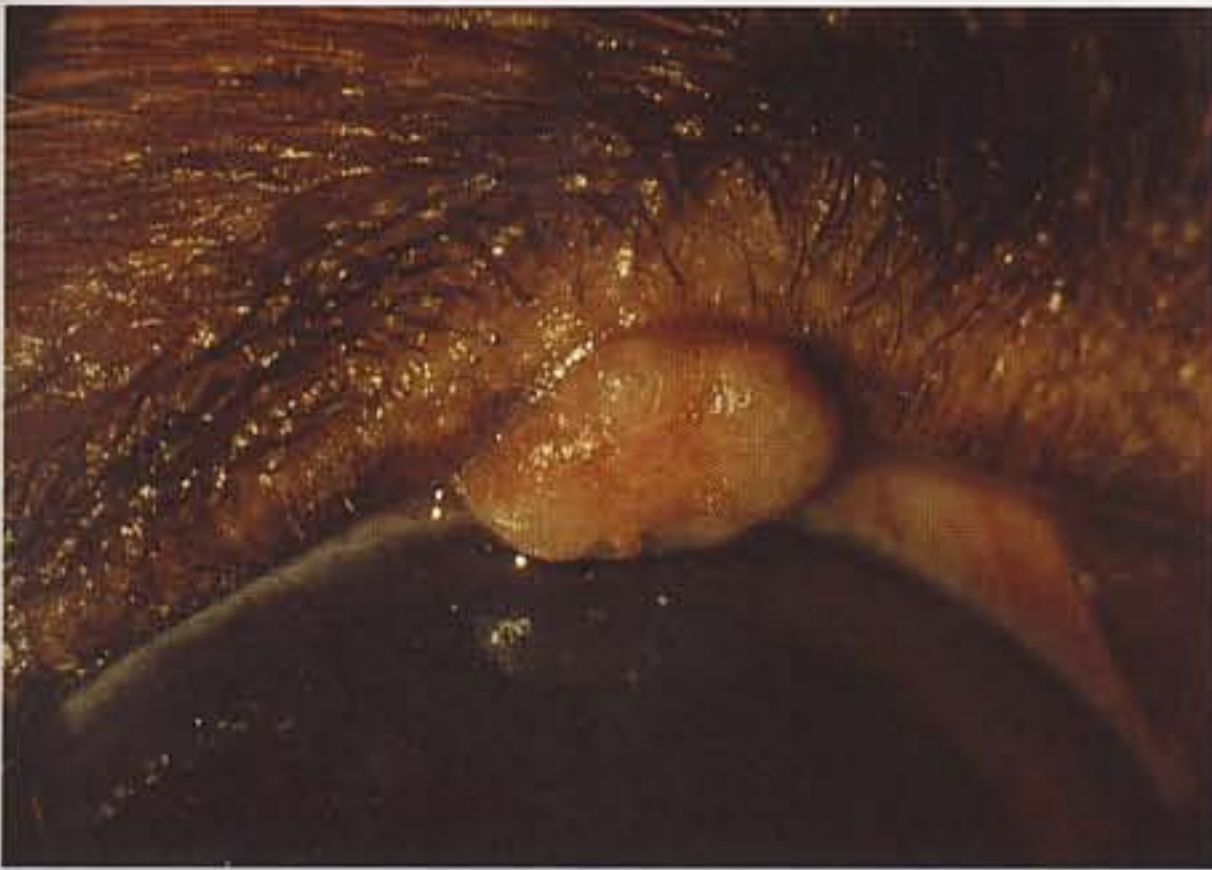

Fig. 2.35 Eyelid tumour (Irish Setter, 7 years old) Papilloma.

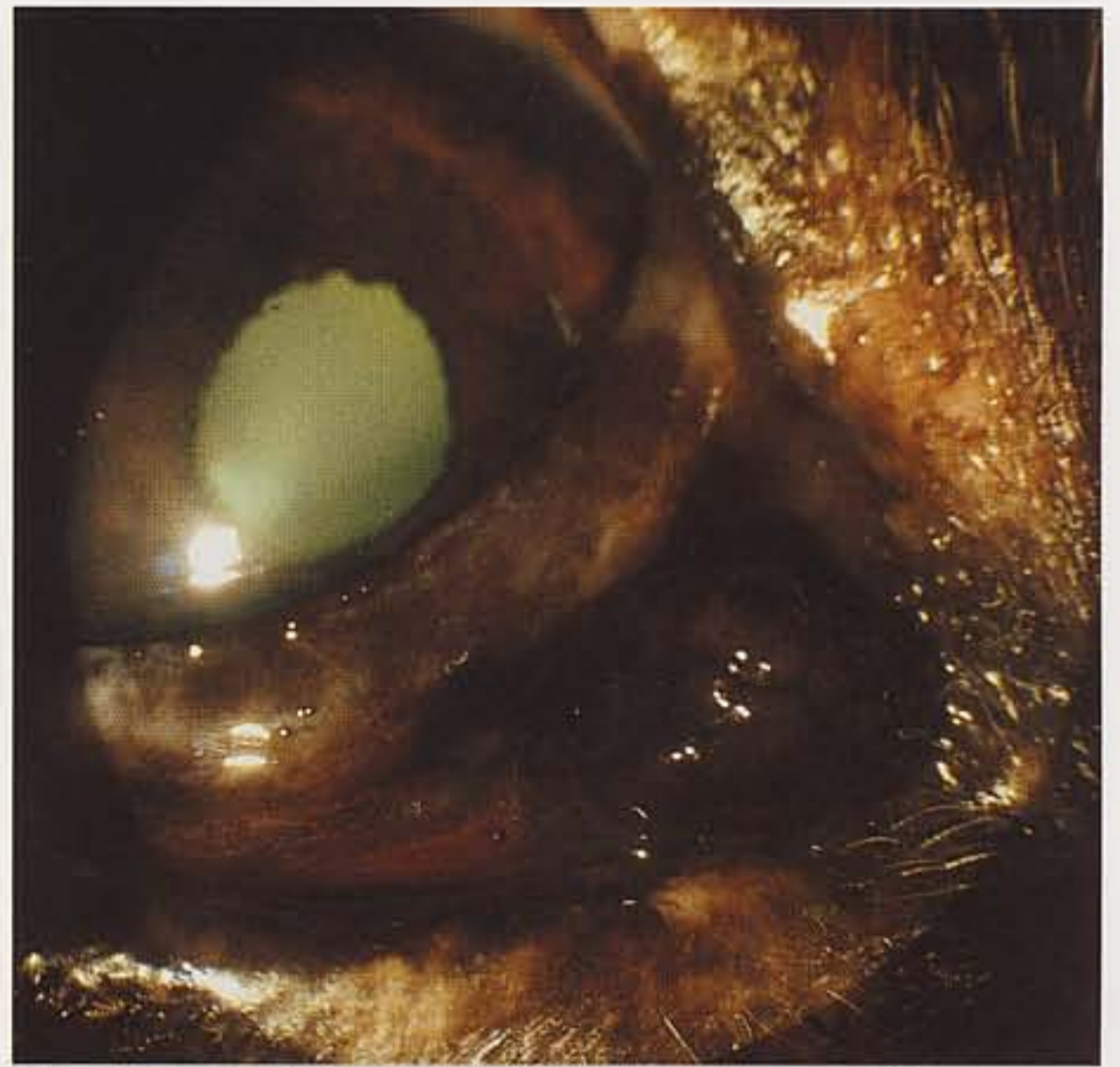

Fig. 2.38 Eyelid tumour (Beagle, 10 years old) Melanoma.

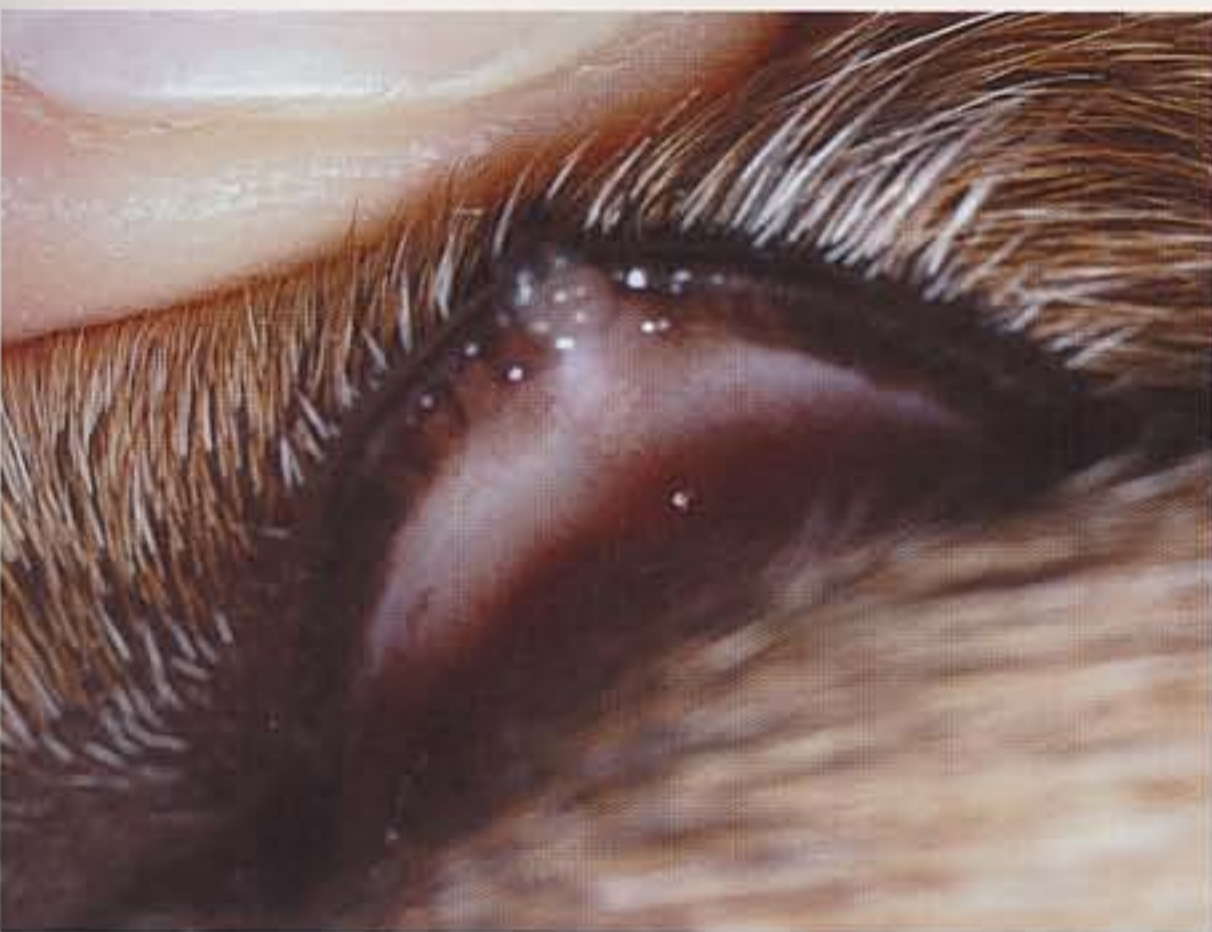

Fig. 2.36 Eyelid tumour (Pembroke Corgi, 9 years old) Papilloma. Note the extension of the tumour into the substance of the lid visible only on the palpebral surface.

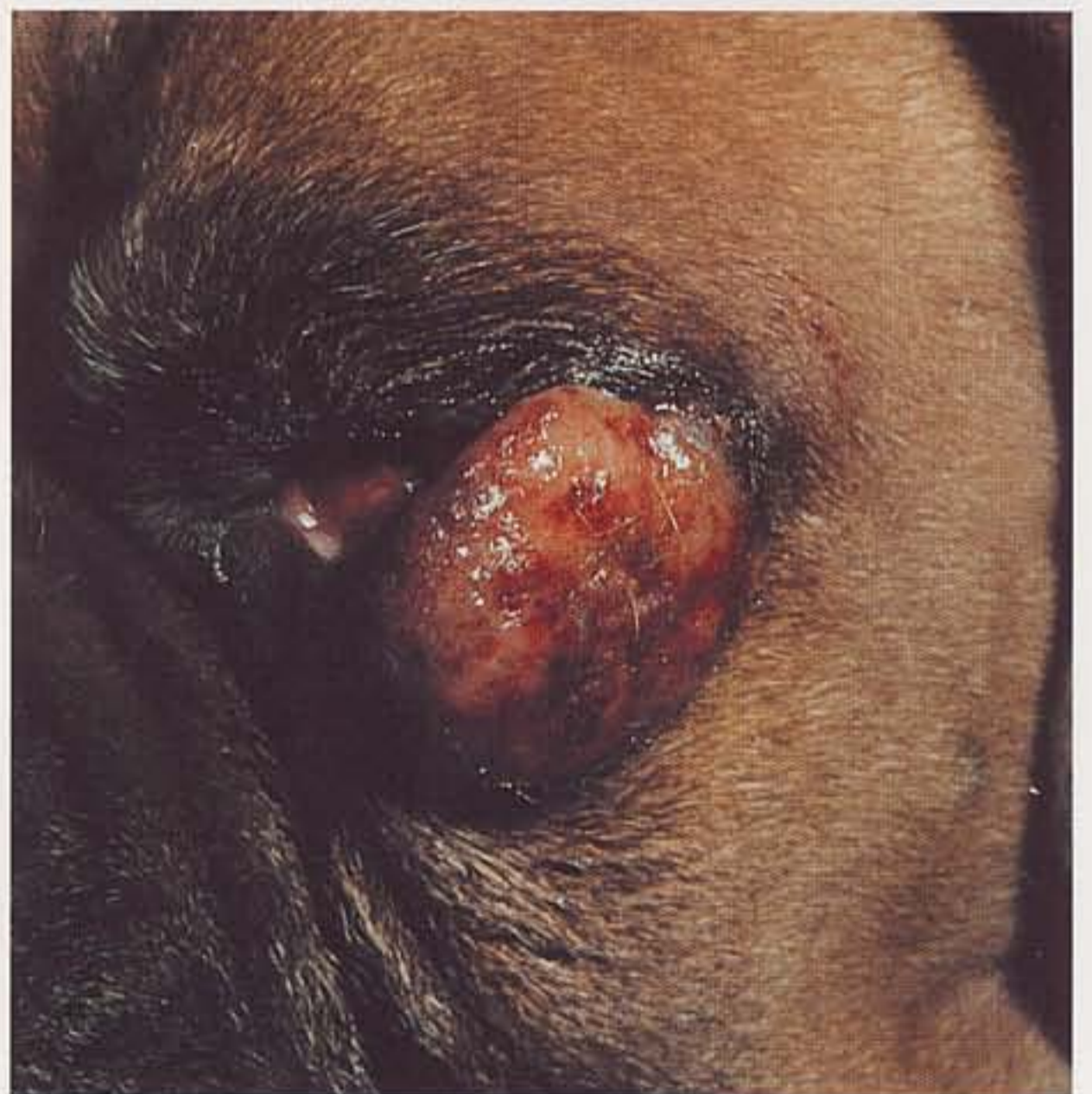

Fig. 2.39 Eyelid tumour (Boxer, 9 years old) Mast cell tumour.

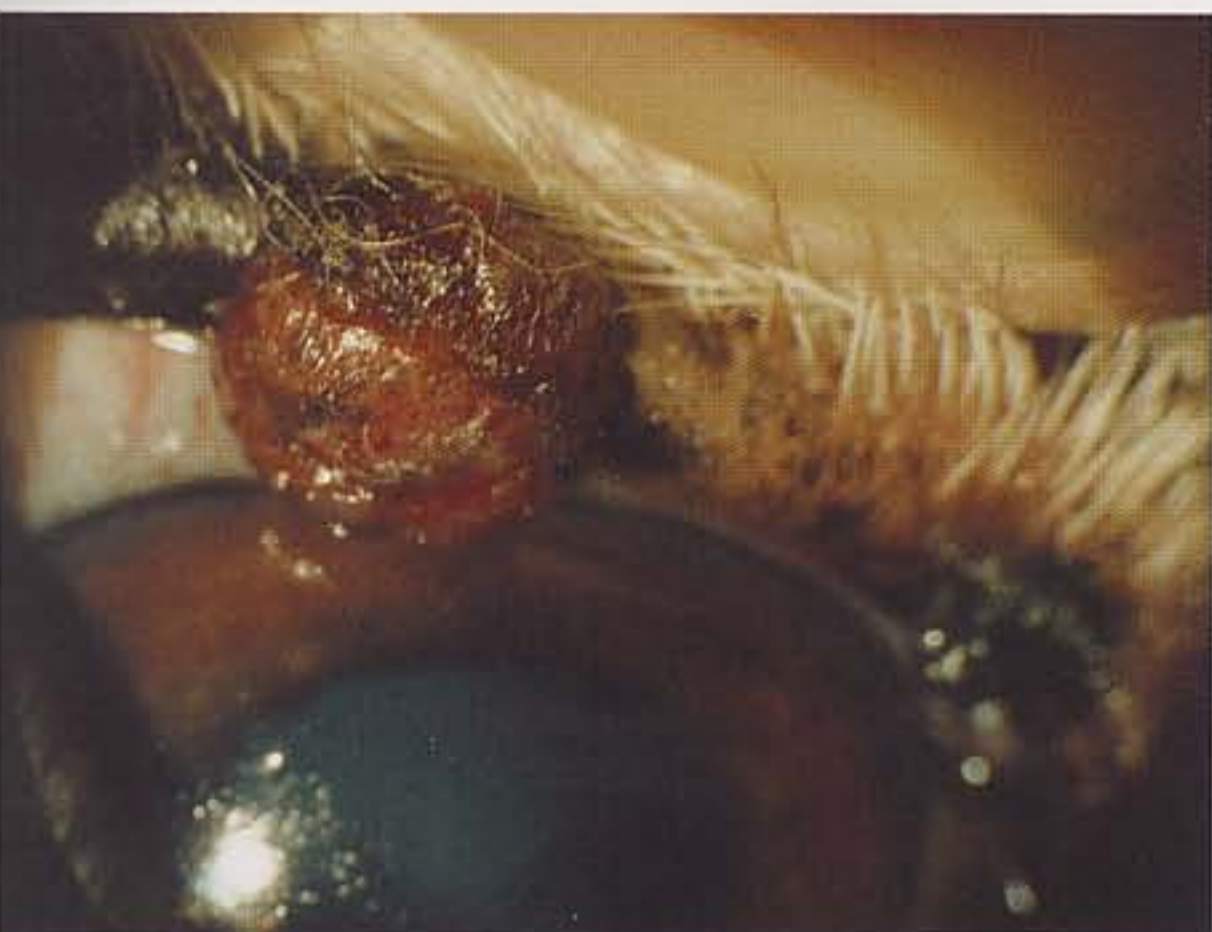

Fig. 2.37 Eyelid tumour (Labrador Retriever, 9 years old) Squamous papilloma.

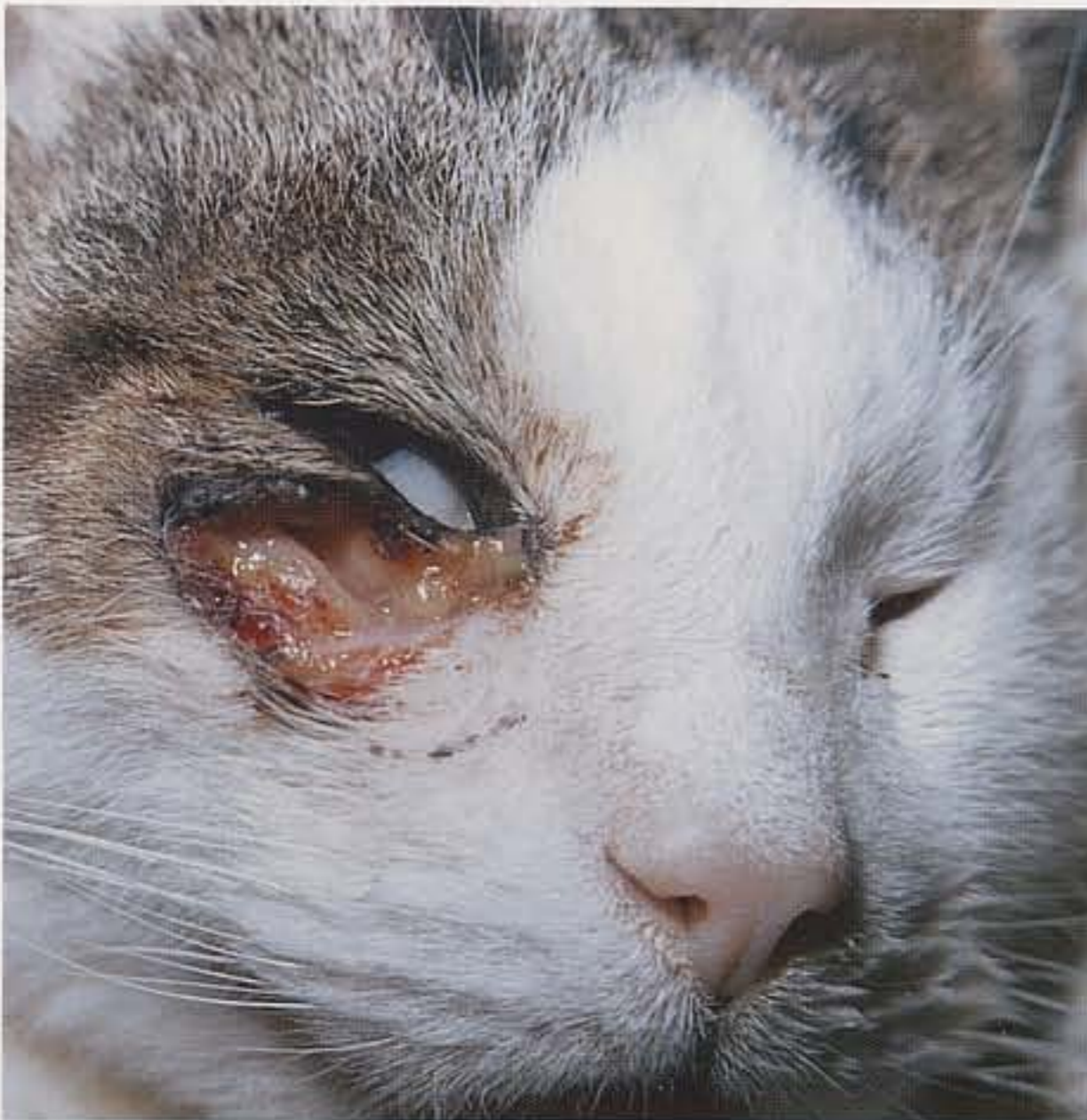

Fig. 2.40 Eyelid tumour (DSH cat, 14 years old, tabby and white) Squamous cell carcinoma in the unpigmented skin of the lower lid. Note the affected area is in unpigmented skin and the age of the animal.

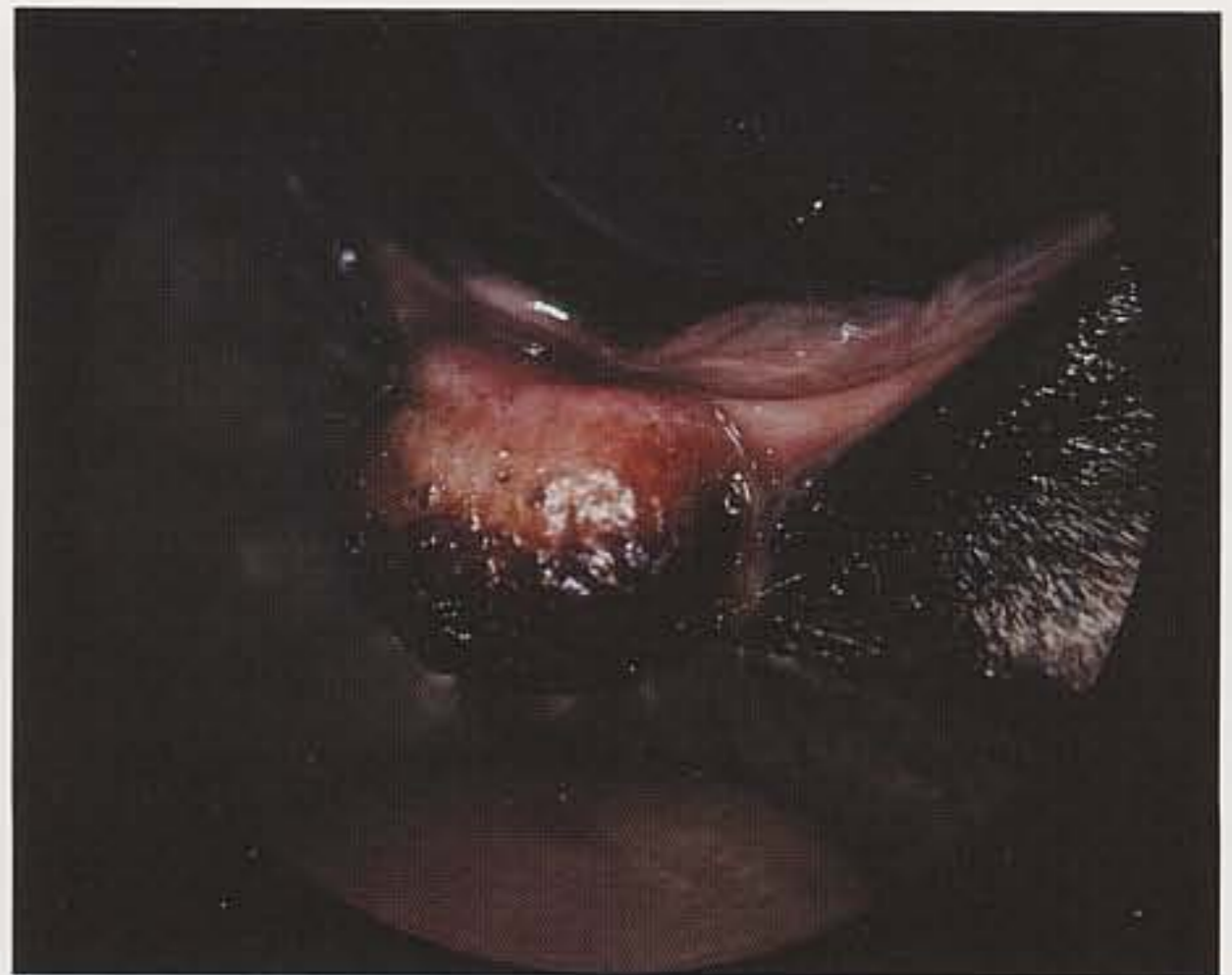

Fig. 2.42 Eyelid tumour (New Forest mare, 13 years old) Sarcoid.

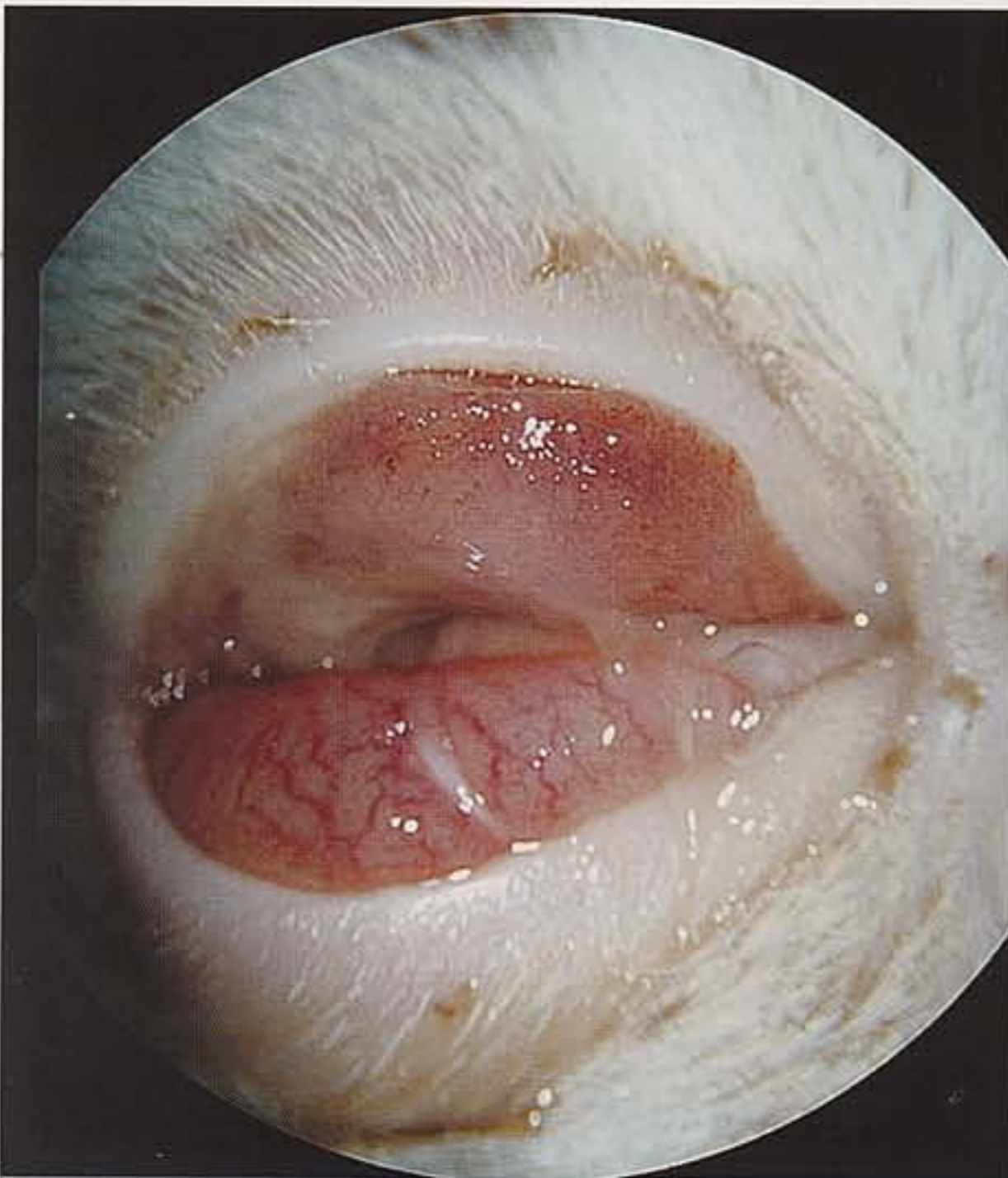

Fig. 2.41 Eyelid tumour (DSH cat, 10 years old, white) Lymphosarcoma of the upper lid. Note the chemosis affecting the lower lid.

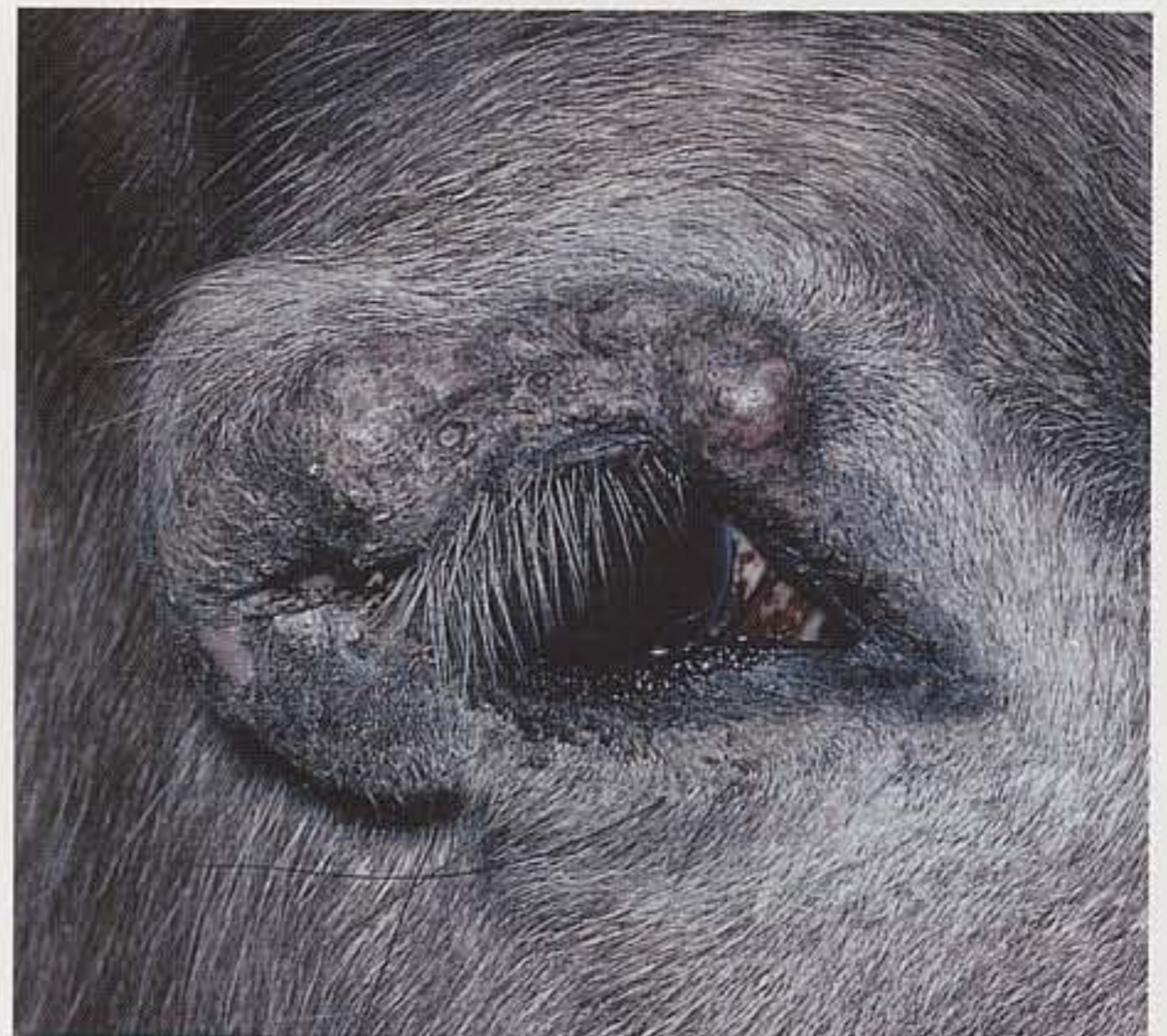

Fig. 2.43 Eyelid tumour (Welsh pony gelding, 8 years old) Sarcoid.

dog, although occasionally tumours occur in younger animals, even puppies (Fig 2.34). The type of tumour is often related to the age of the animal. Tumours, depending upon their size and position, may cause irritation, blepharospasm, lachrimation and corneal ulceration.

### Congenital anomalies (Figs 2.45–2.50) Colobomas and dermoids.

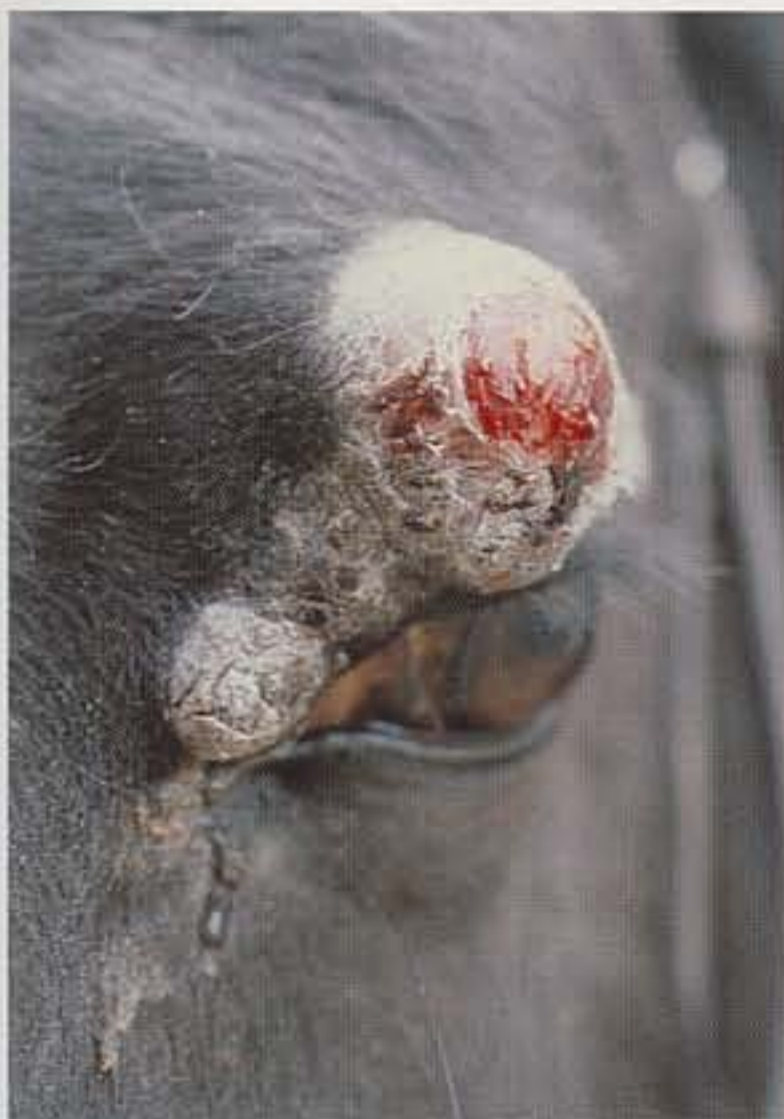

Fig. 2.44 Eyelid tumour (Welsh Cob stallion, 5 years old) Sarcoid. Note the ulcerated surface of part of the tumour.

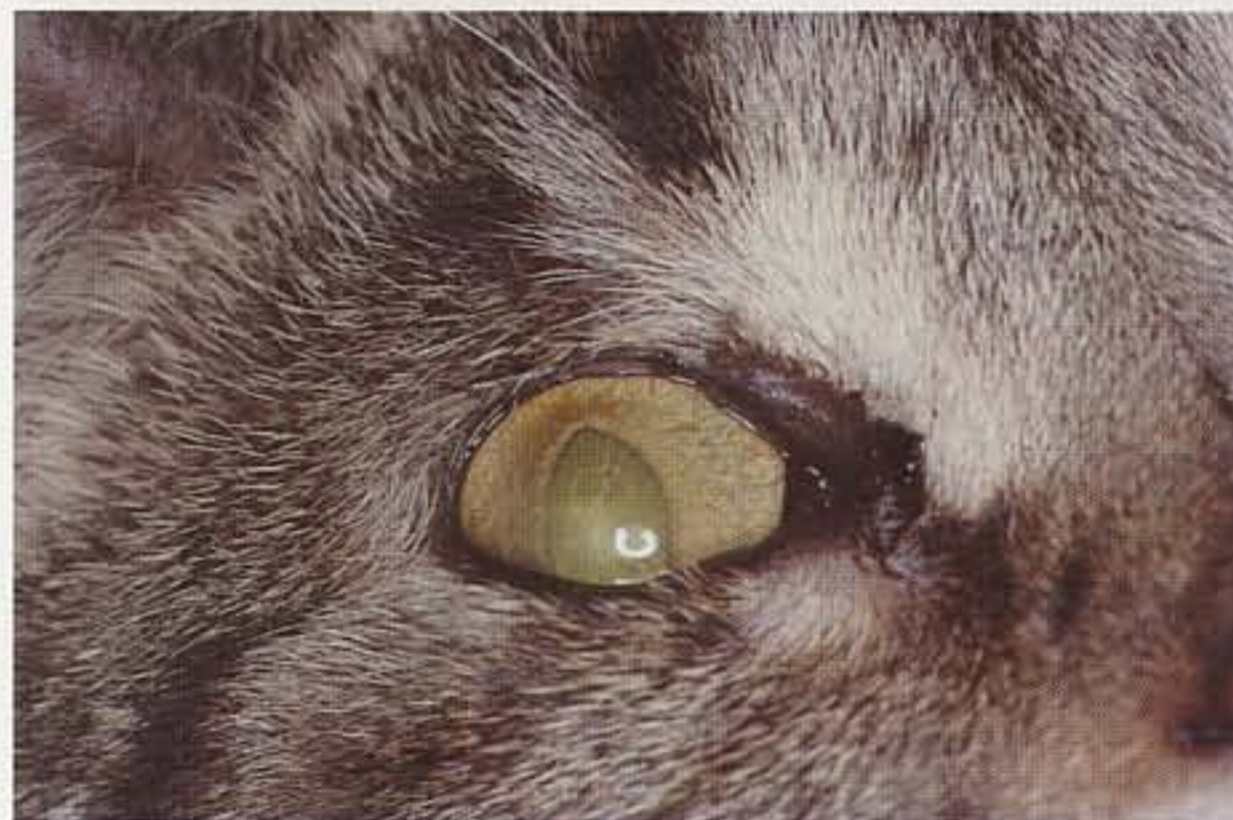

Fig. 2.46 Coloboma or agenesis (DSH cat, 13 months old) Upper eyelid absence with consequent trichiasis causing a mild vascular keratitis.

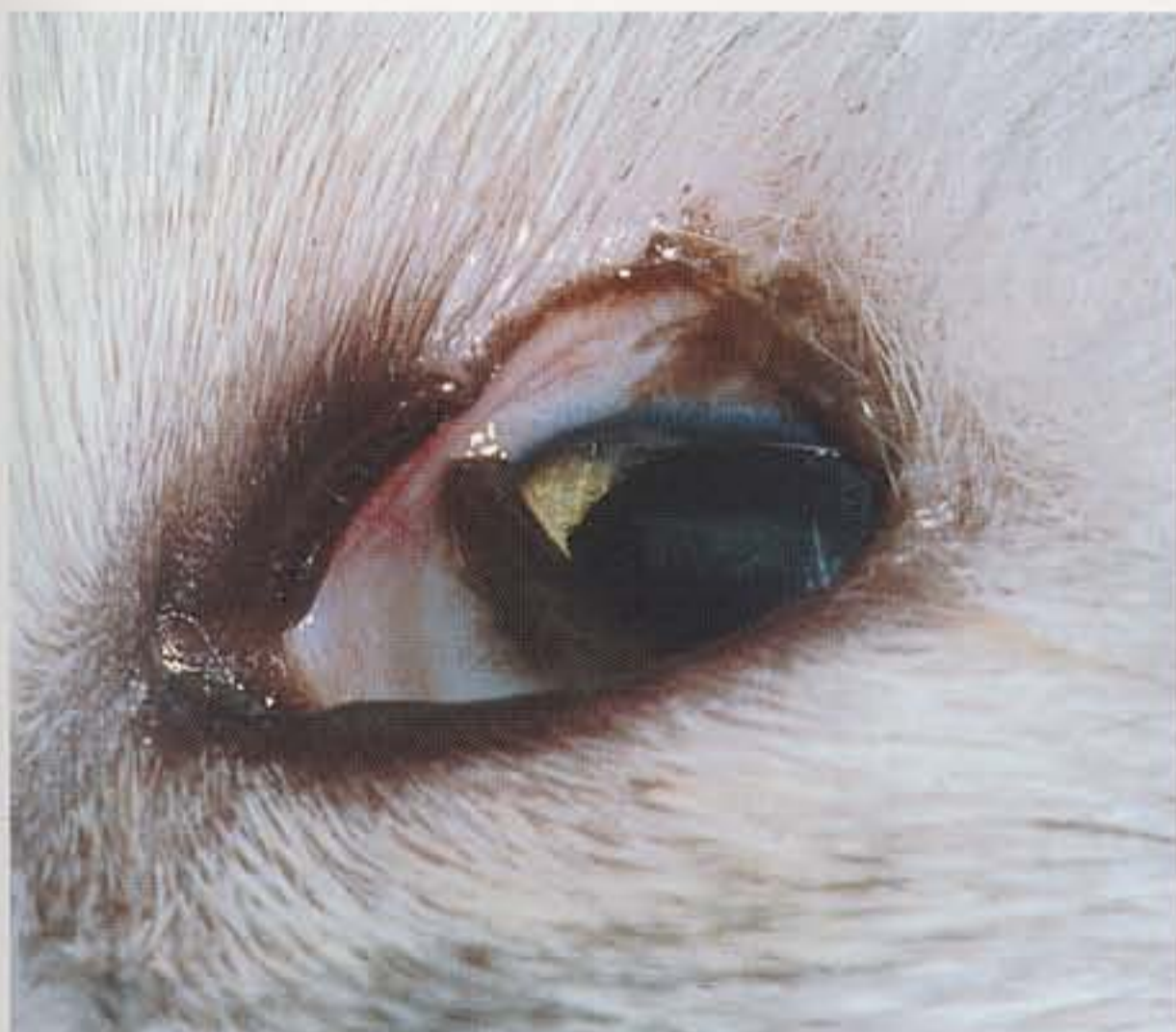

Fig. 2.45 Coloboma or agenesis (DSH cat, 1 year old) Congenital absence of the outer half of both upper eyelids.

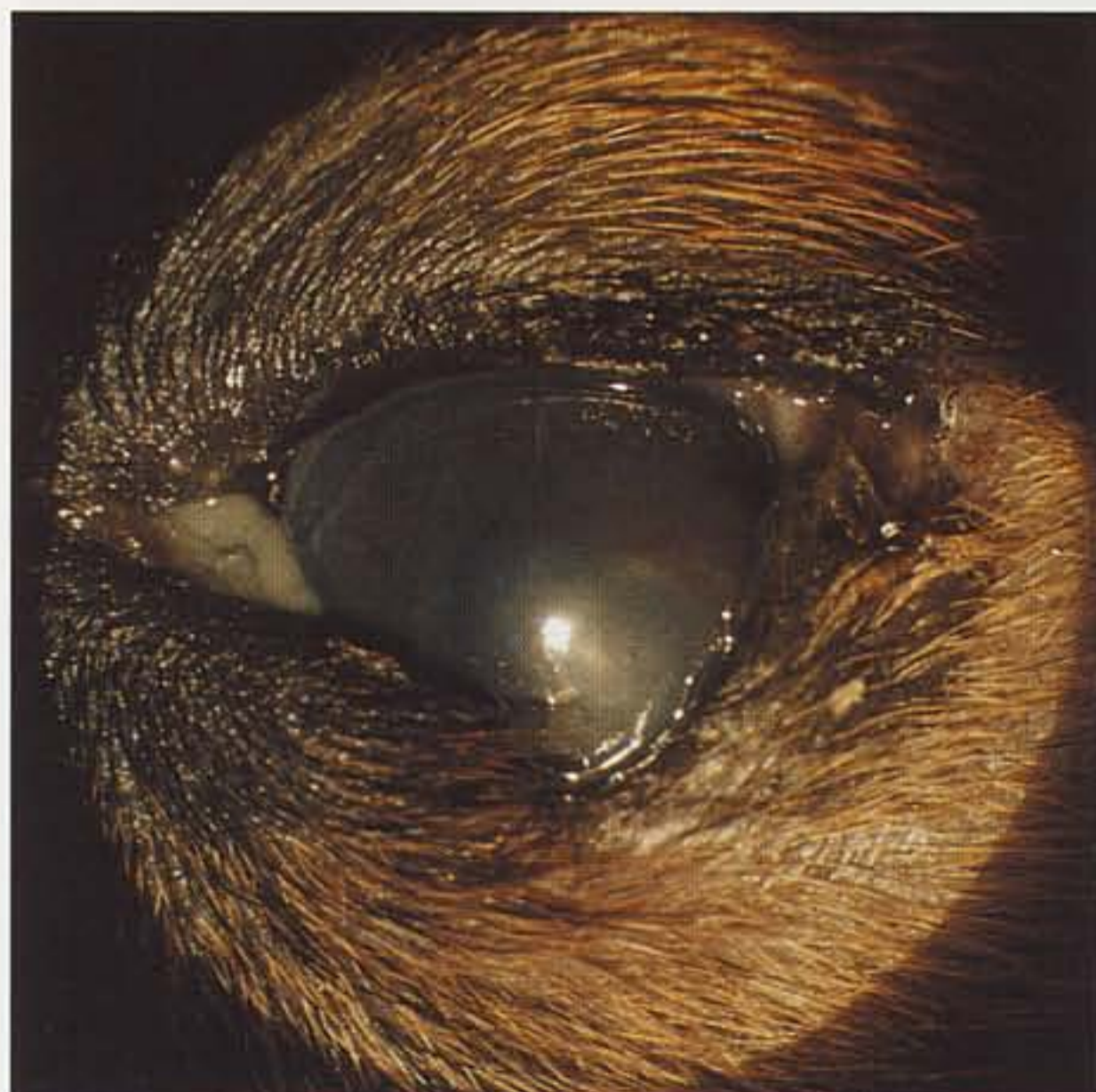

Fig. 2.47 Coloboma (Staffordshire Bull Terrier, 2 weeks old) Congenital absence of part of the lower lid. Rare in this species.

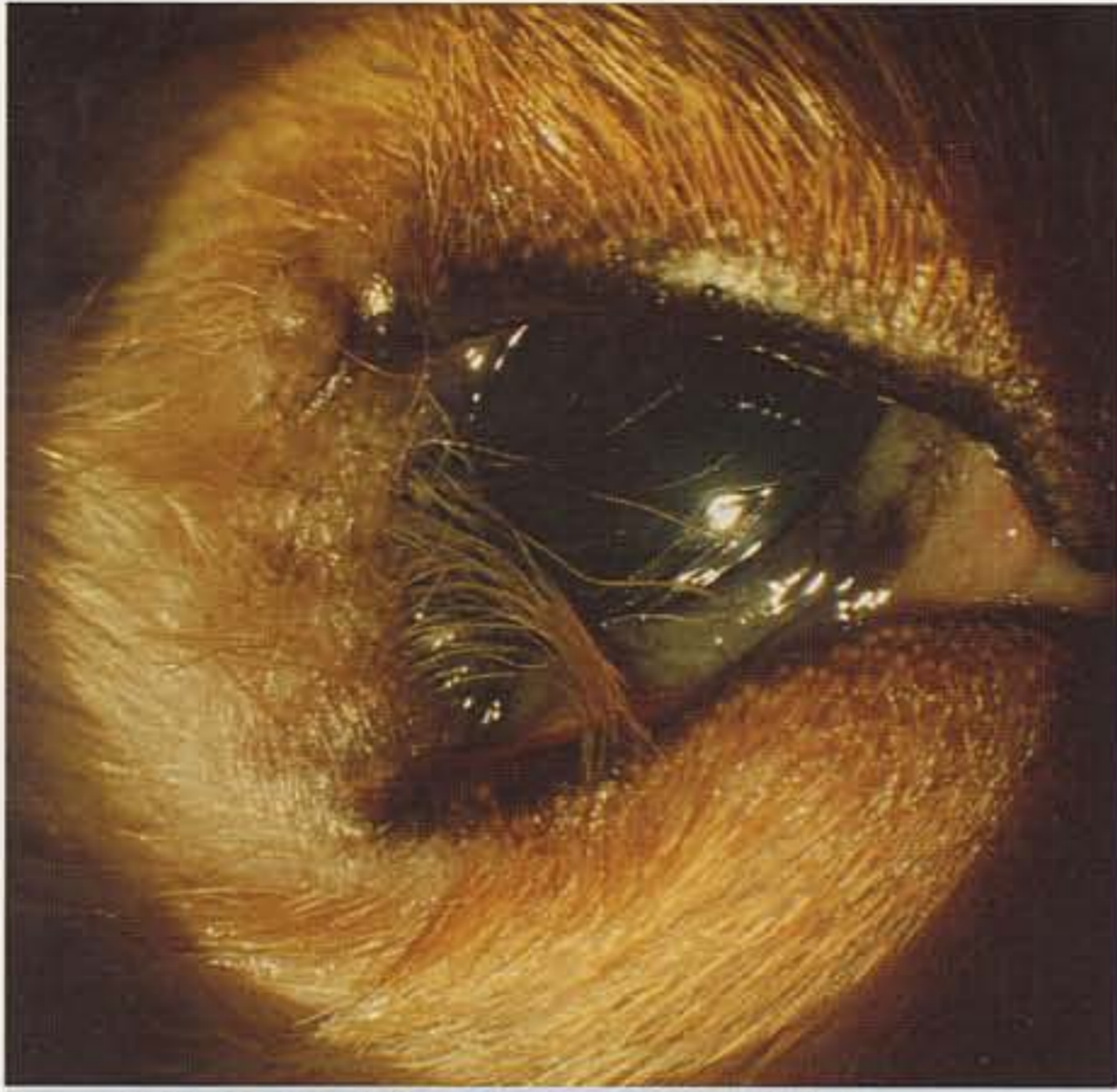

Fig. 2.48 Eyelid deformity (Labrador Retriever, 6 weeks old) Gross congenital deformity of the eyelids.

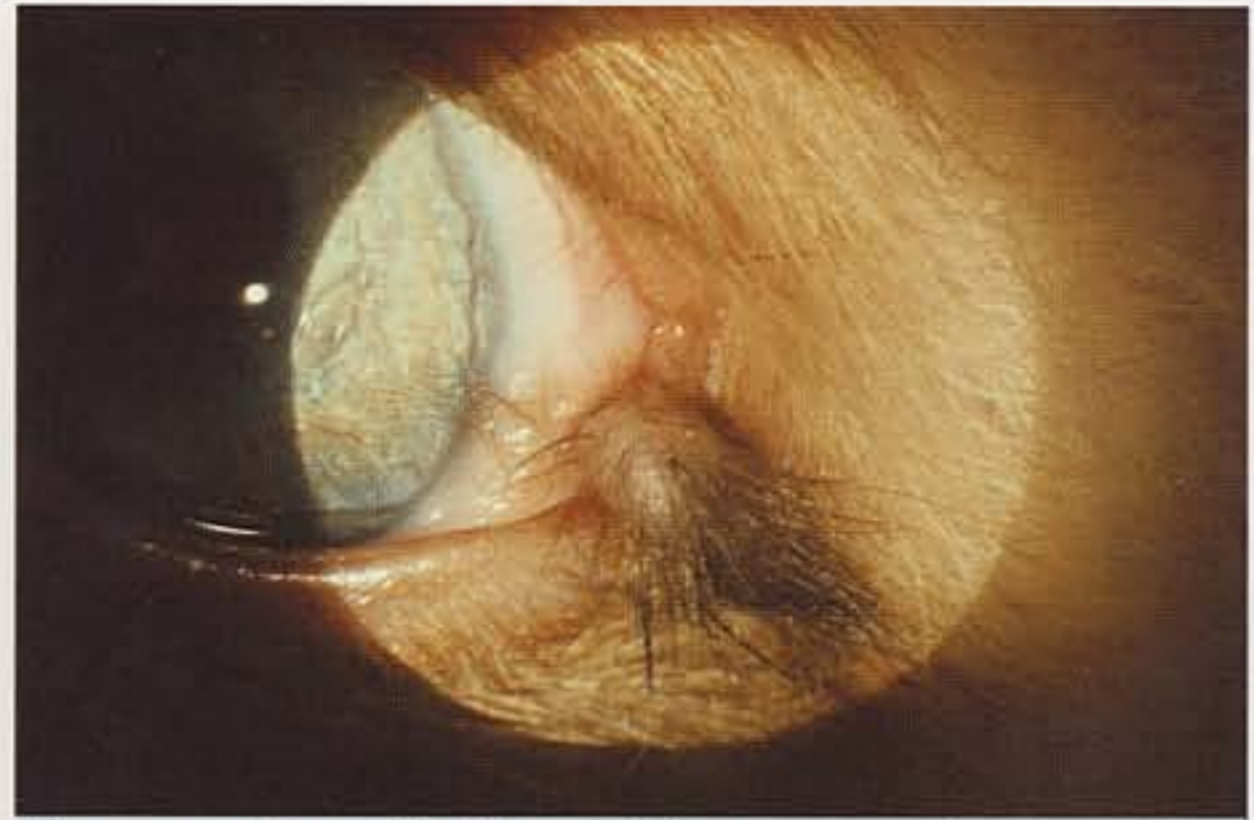


Fig. 2.50 Dermoid (Birman kitten, 10 weeks old) The condition is inherited in this breed.

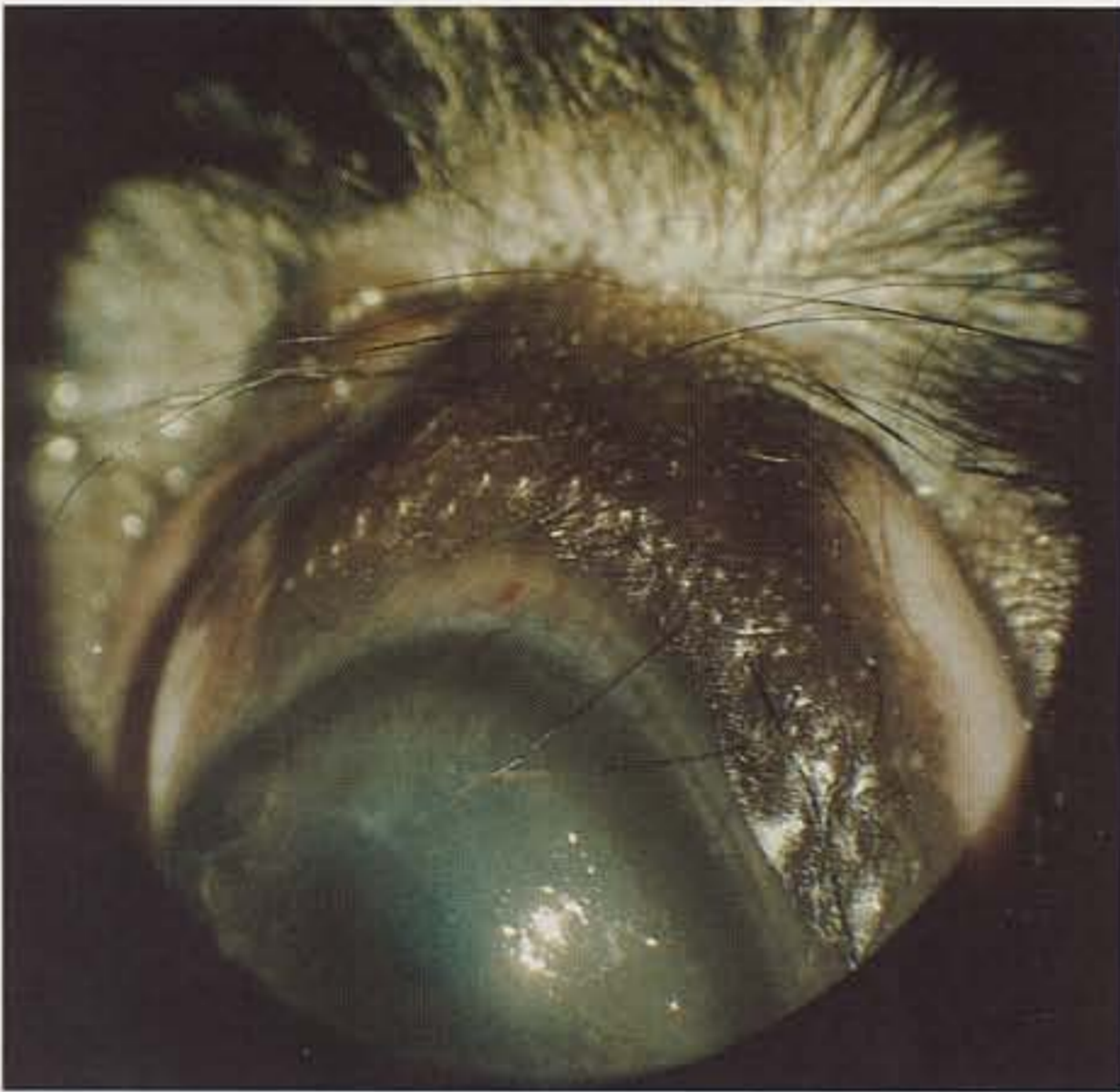

Fig. 2.49 Dermoid (Labrador Retriever, 6 weeks old) Pigmented and hairy dermoid of lid and conjunctiva.

# Chapter 3

## Nictitating Membrane

### Introduction

The appearance of the nictitating membrane (third eyelid or haw) is often a presenting sign in veterinary ophthalmology and prominence, or protrusion, is the commonest clinical condition and is due to a variety of causes.

### Prominence of the nictitating membrane (Table 3.1)

Prominence, unilateral or bilateral, may be accompanied by lacrimation and blepharospasm indicating pain, usually anterior segment, e.g. glaucoma (see also Chapter 1).

Prominence also accompanies several conditions affecting the globe, including some cases of enophthalmos (Fig 1.2), also exophthalmos (Figs 1.4–1.8), microphthalmos (Fig 1.13) and phthisis (Fig 1.20).

Prominence may also indicate tetanus (bilateral and intermittent in the horse); Horner's syndrome

(almost invariably unilateral); dysautonomia in the cat (bilateral) and also, in some cases, chronic diarrhoea in this species.

A non-pigmented third eyelid will look more prominent than a pigmented third eyelid and is a common cause of concern, particularly when affecting one eye only (Fig 3.1).

### Trauma and foreign bodies

(Figs 3.2–3.3)

The third eyelid is prone to injury (Fig 3.2), both in cats and by cats! Also the pocket at the inner canthus behind the third eyelid is a favourite site for foreign bodies, in particular grass awns (Fig 3.3).

### Inflammation (Figs 3.4–3.10)

Both surfaces of the nictitating membrane are covered by conjunctiva (palpebral) and may therefore exhibit forms of conjunctivitis (see also Chapter 5). These include follicular conjunctivitis (Figs 3.4–3.5), chemosis (Fig 3.6) and conjunctival cysts (Fig 3.7).

Table 3.1 - Prominence of nictitating membrane

1. Unilateral or bilateral
2. Pain – anterior segment with globe retraction; lacrimation and blepharospasm
3. Enophthalmos
4. Exophthalmos
5. Microphthalmos
6. Phthisis
7. Tetanus (bilateral)
8. Horner's syndrome (unilateral) + miosis, ptosis
9. Dysautonomia
10. Chronic diarrhoea (cat) (bilateral)
11. Cartilage deformity (scrolled) (dog)

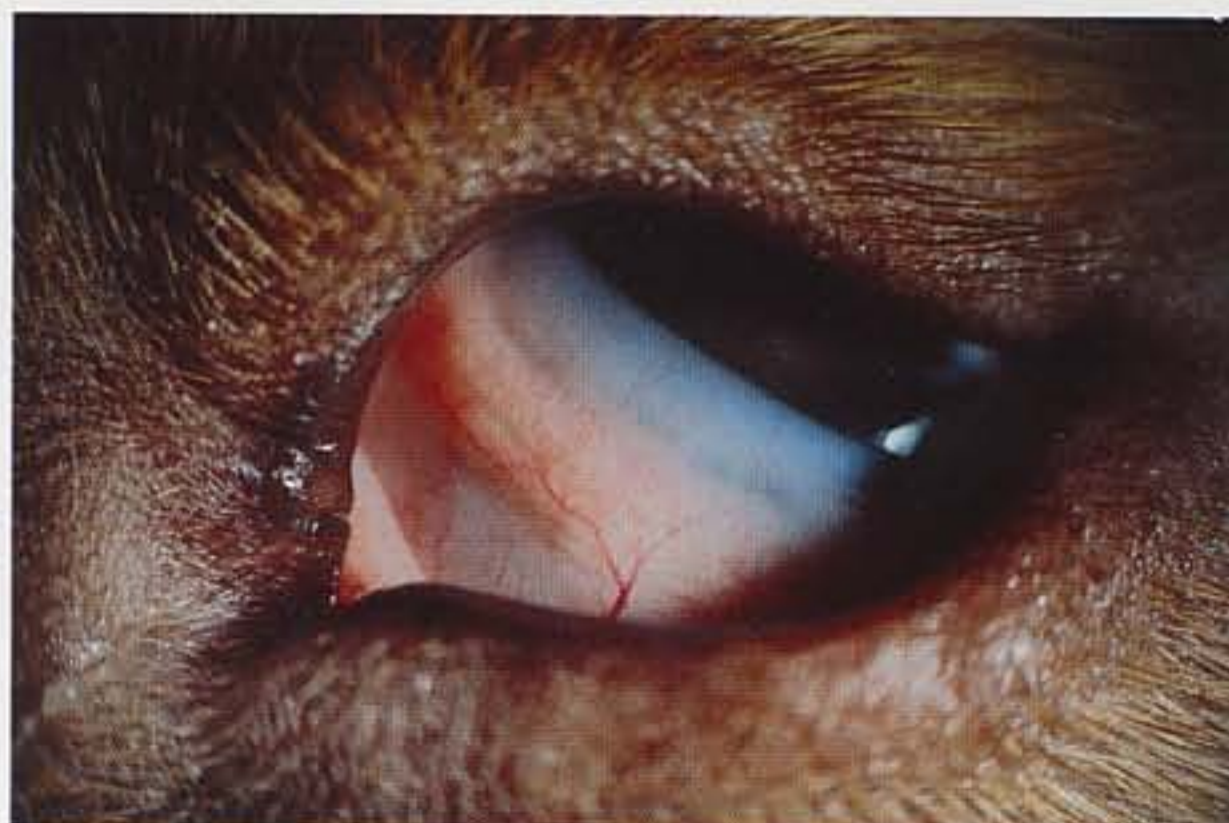

Fig. 3.1 Prominence of a normal non-pigmented third eyelid.

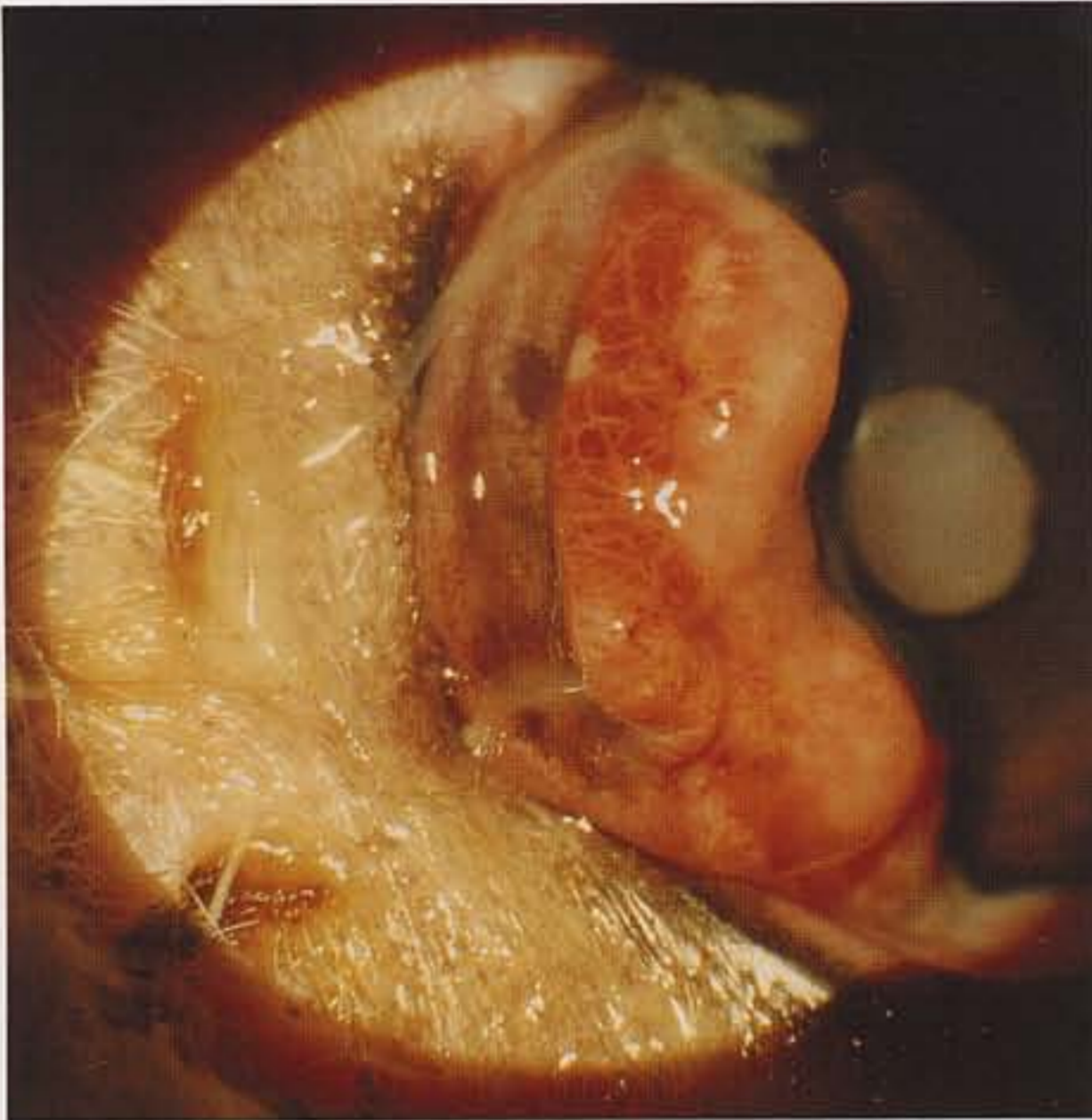

Fig. 3.2 Torn and prolapsed nictitans gland and nictitating membrane following trauma.

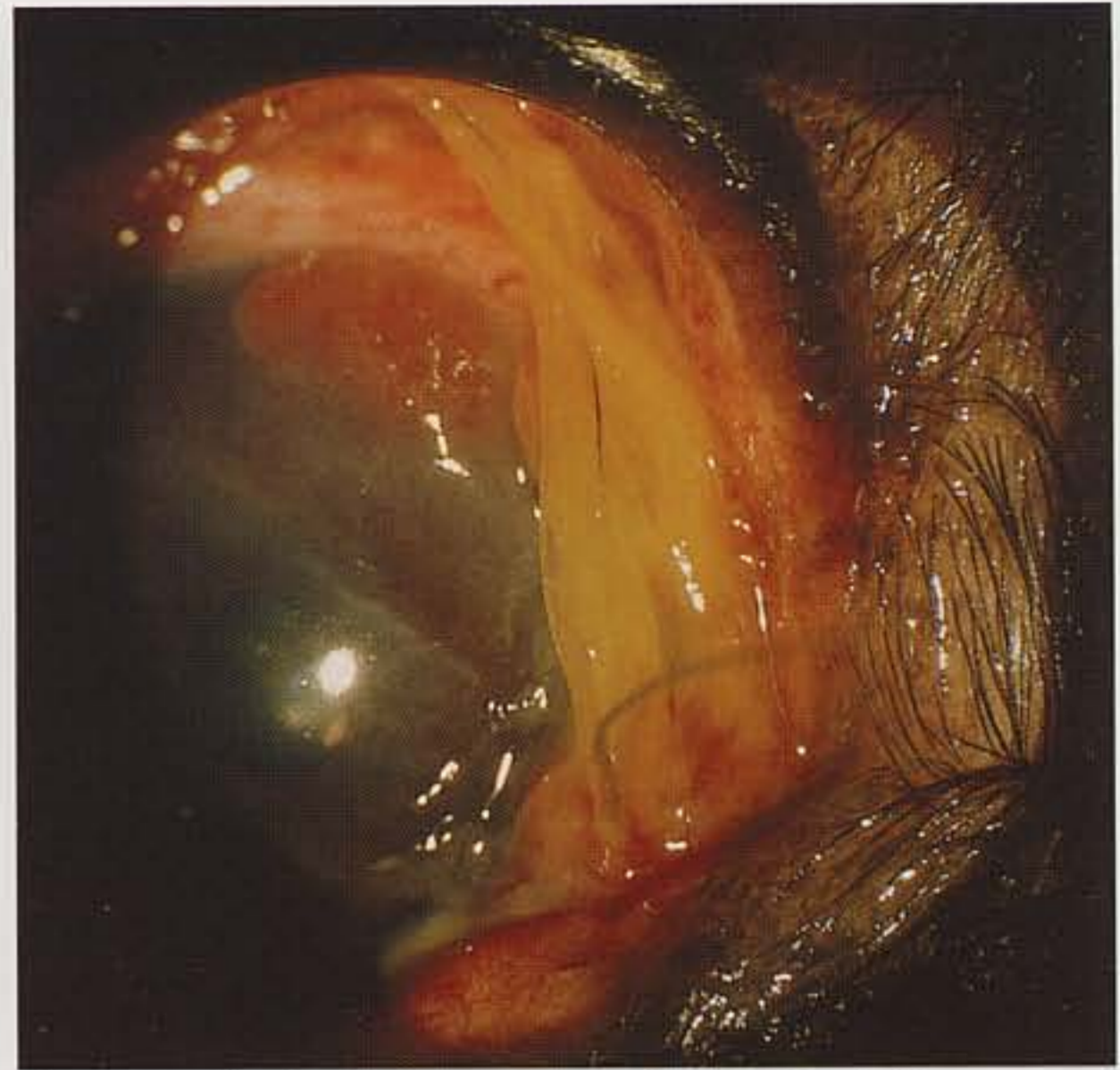

Fig. 3.3 Nictitating membrane foreign body Grass awn behind the third eyelid. Note the corneal granulation tissue.

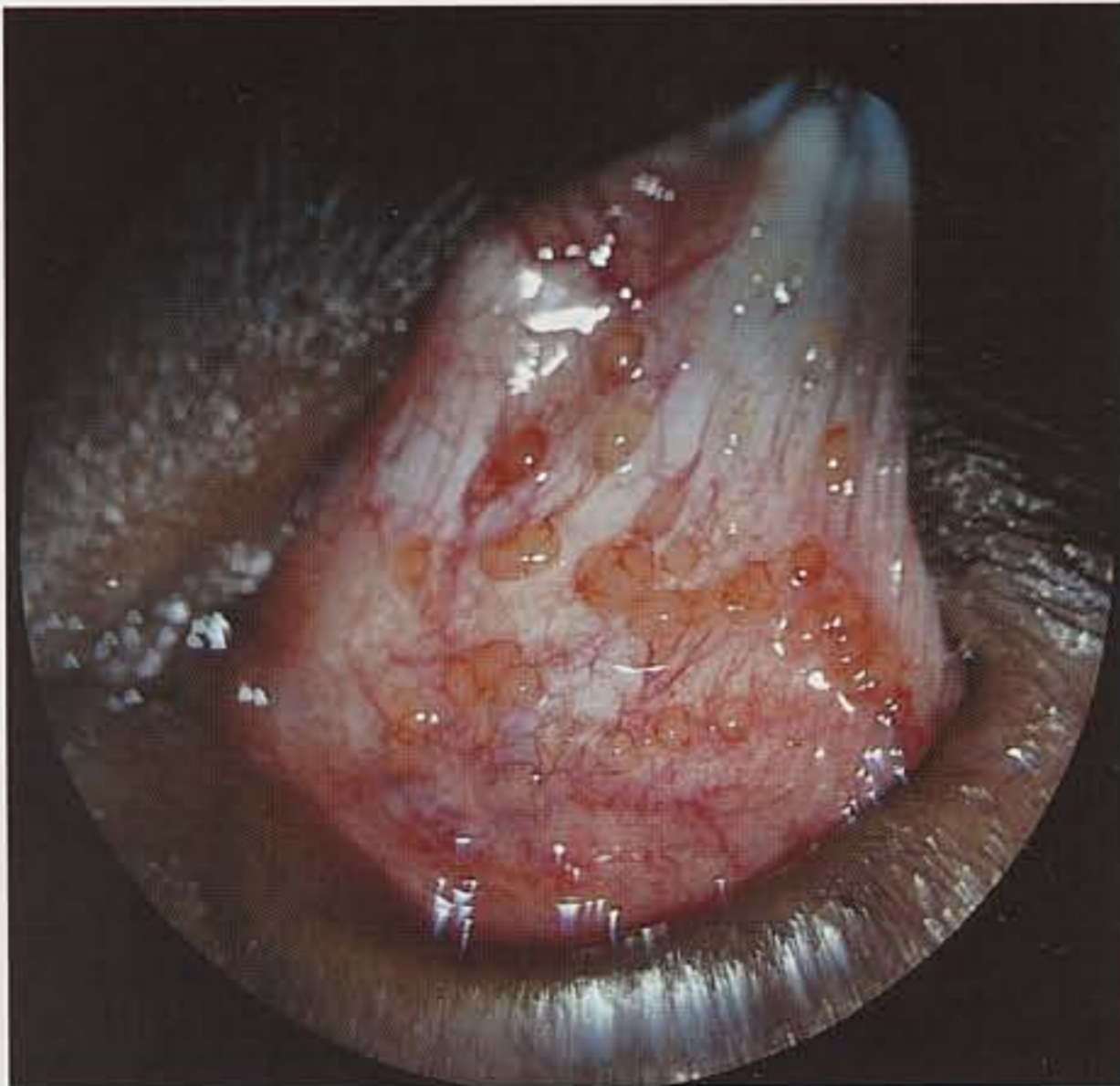

Fig. 3.4 Follicular conjunctivitis Usually affecting both aspects of the nictitating membrane and other palpebral conjunctiva and a not uncommon cause of lacrimation due to the irritation.

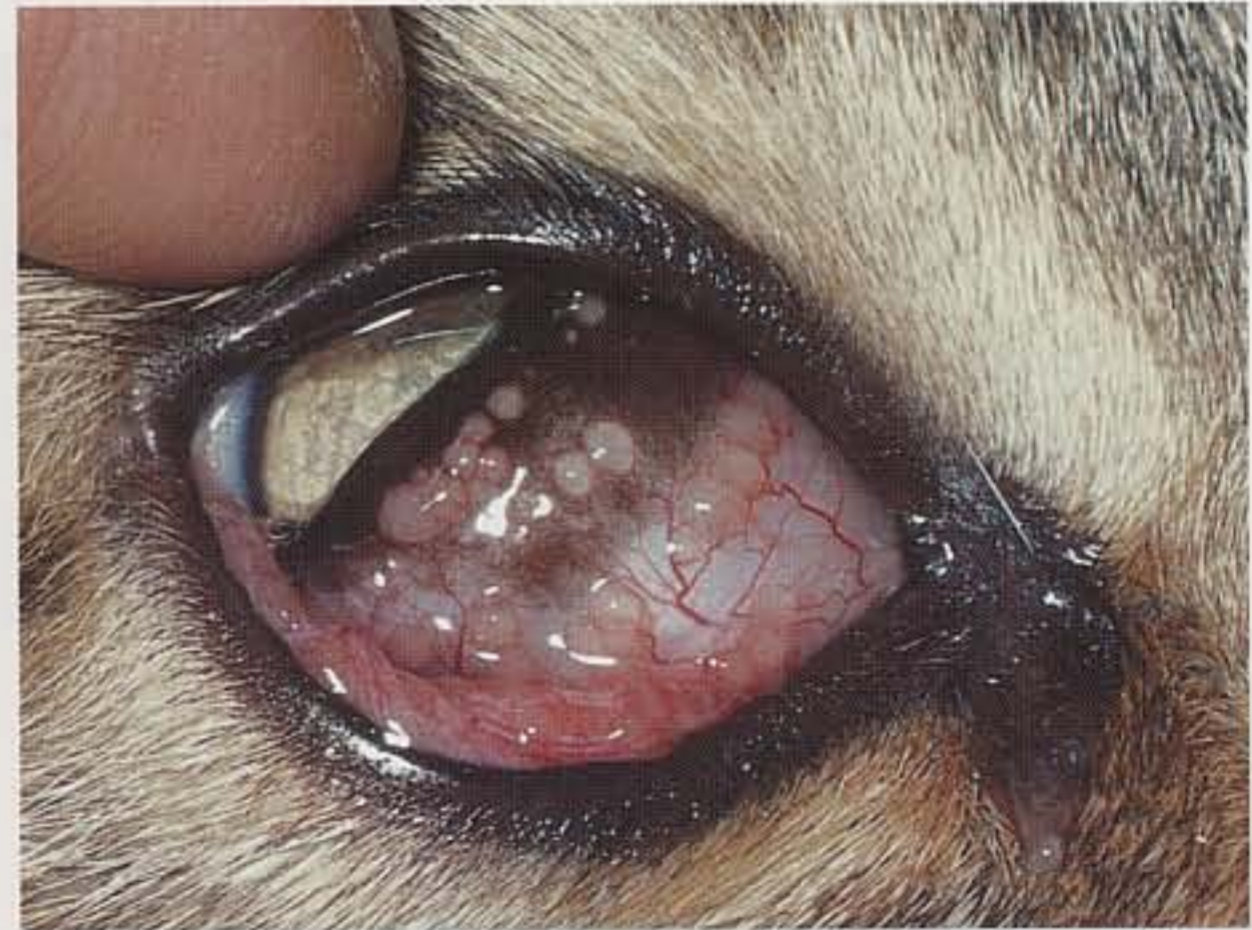

Fig. 3.5 Follicular conjunctivitis (DSH cat, 1 year old) Note the depigmentation in the region of the follicles and the serous ocular discharge.

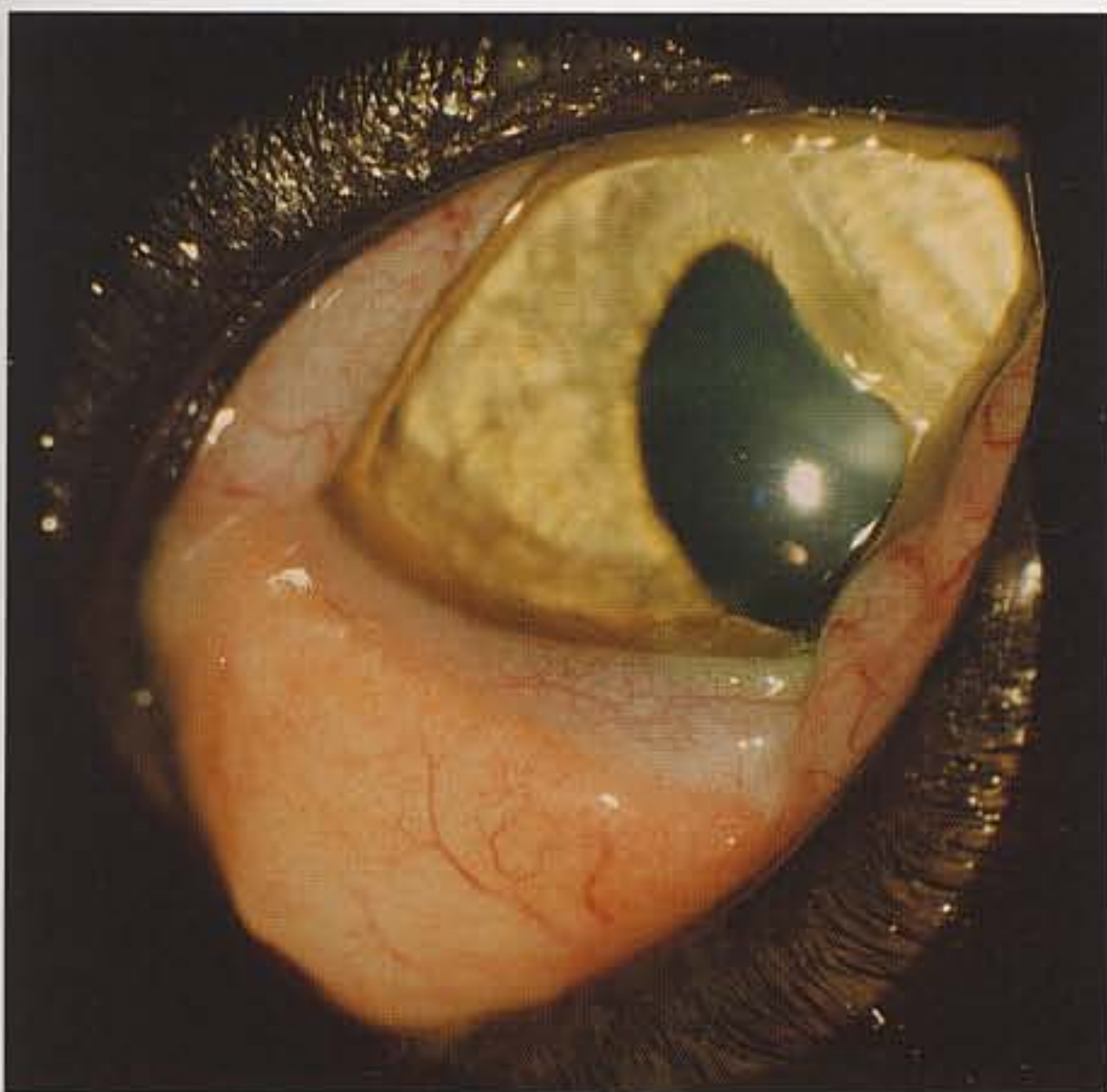


Fig. 3.6 Chemosis (DSH cat, 11 years old) Bulbar and palpebral conjunctiva are affected. Unknown aetiology.

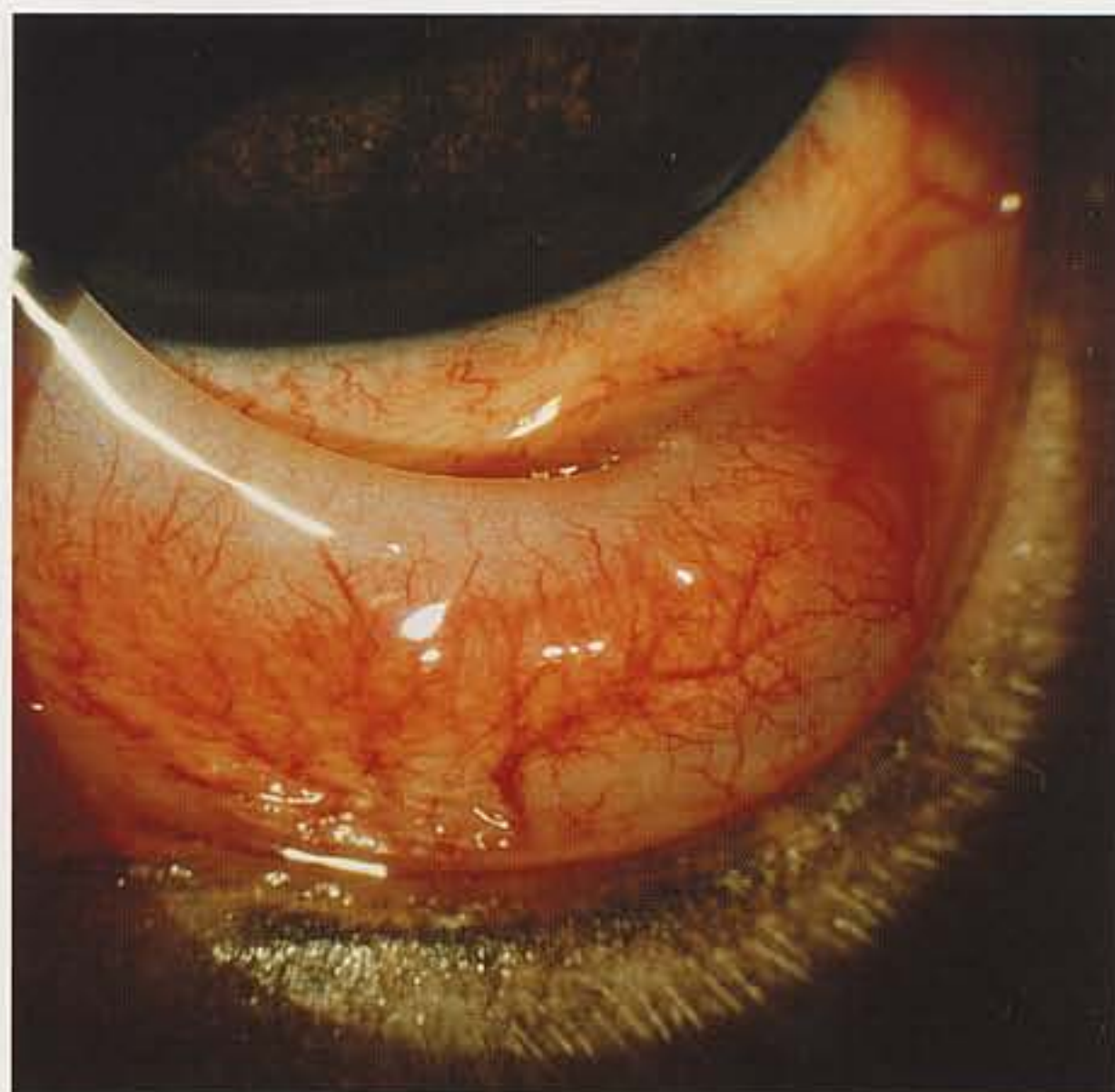


Fig. 3.7 Conjunctival cyst (English Setter, 8 months old) Subconjunctival cyst at the base of the third eyelid resulting in mild prominence of the third eyelid.

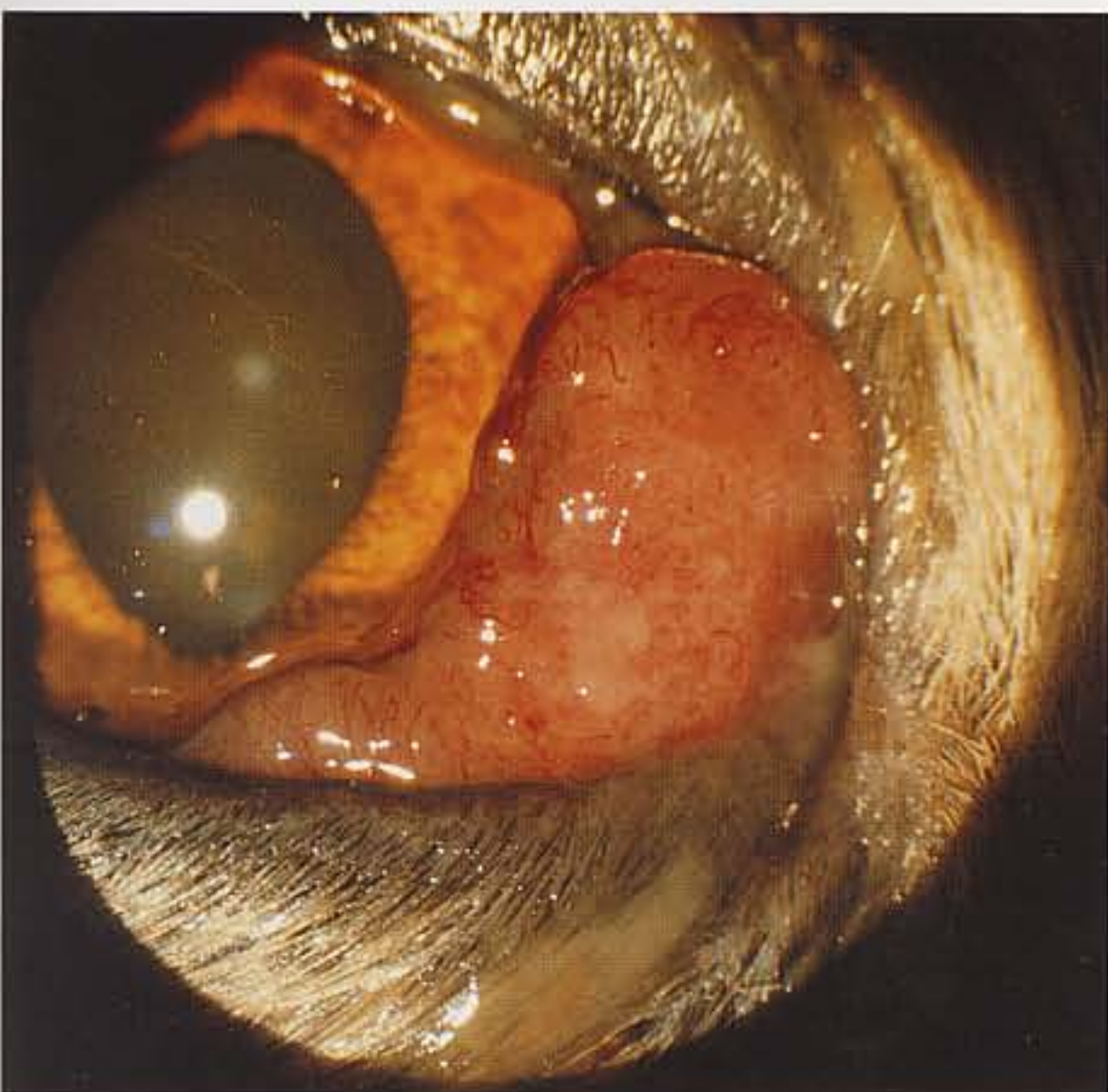

Fig. 3.8 Granuloma of the nictitating membrane (Persian cat, 18 months old) Bilateral, unknown aetiology.

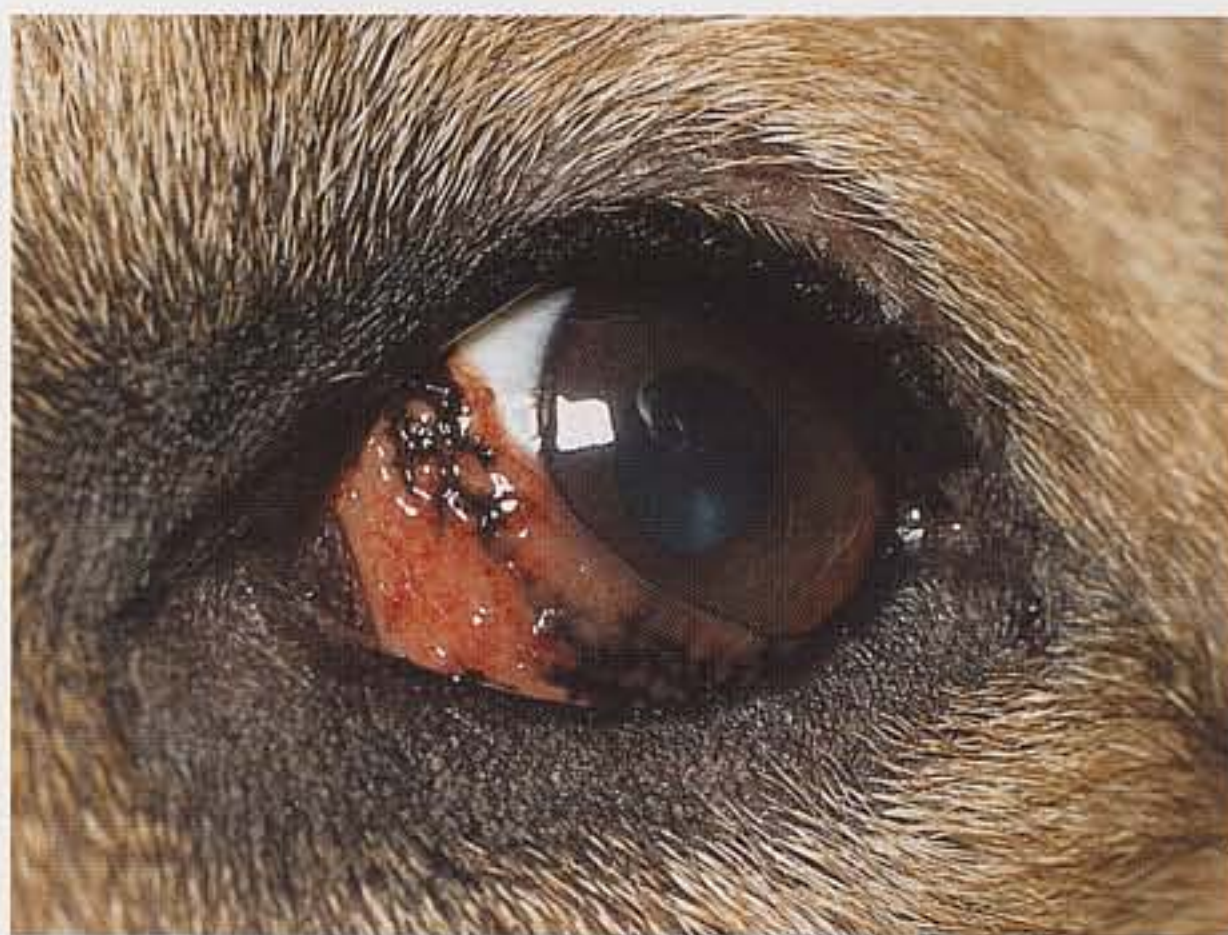

Fig. 3.9 Plasma cell infiltration (German Shepherd Dog, 7 years old) Note depigmentation of the affected area. This condition frequently accompanies pannus.



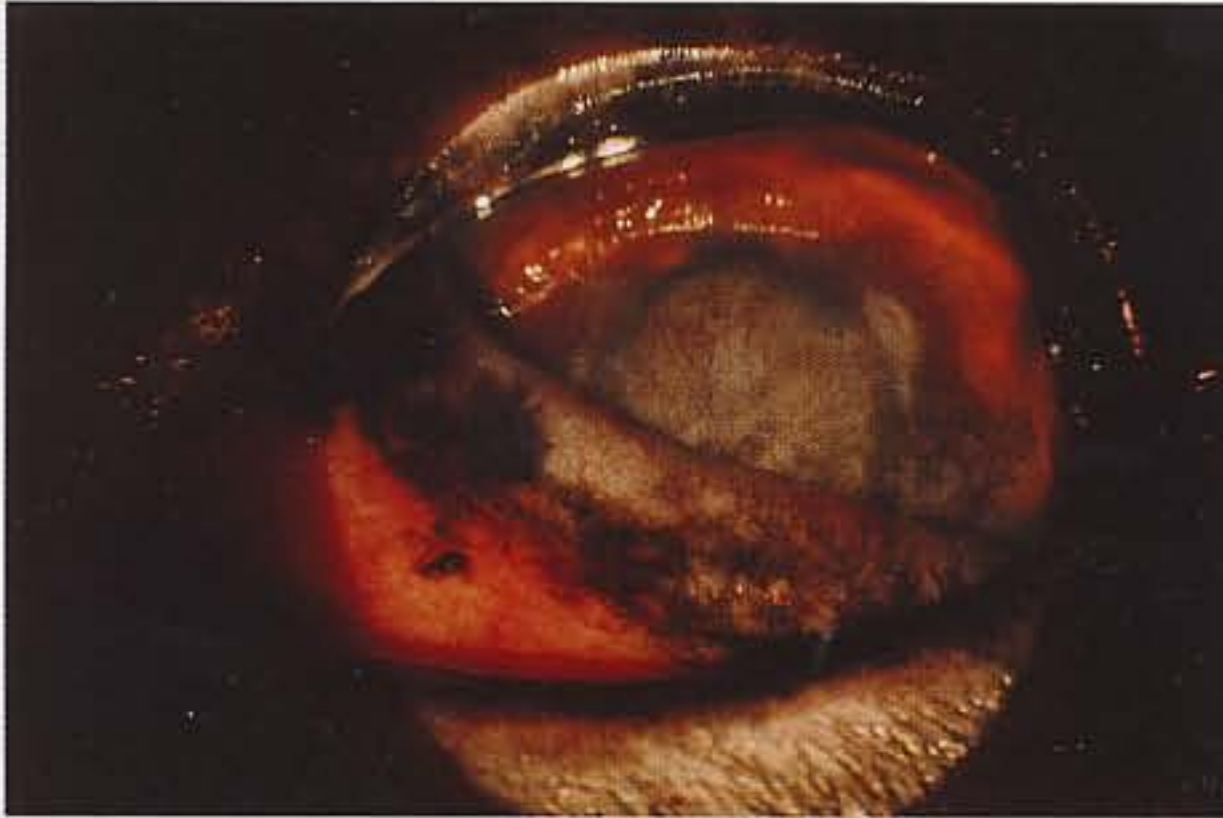


Fig. 3.10 Plasma cell infiltration (German Shepherd Dog, 8 years old) Again note depigmentation and the accompanying pannus.

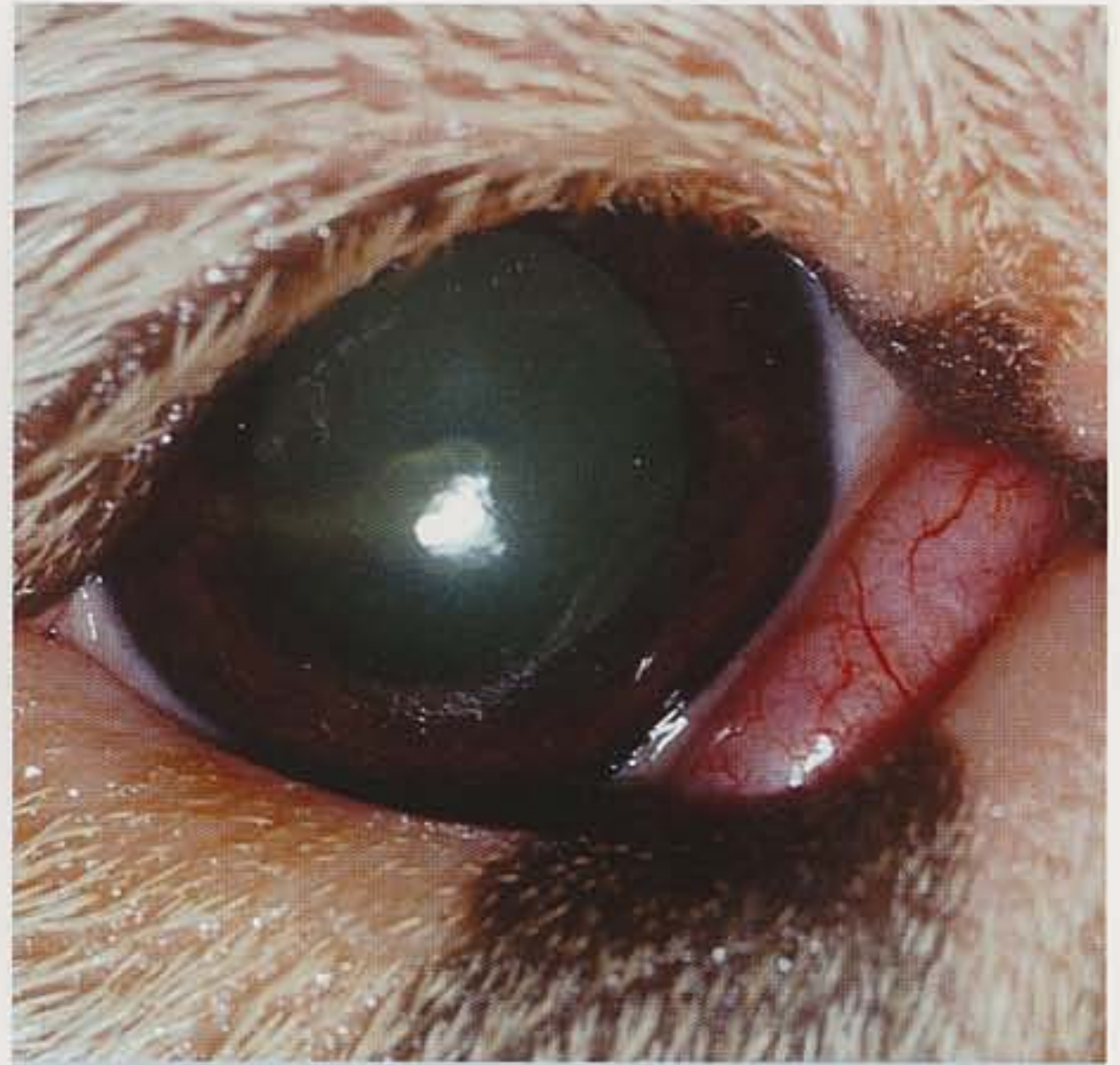

Fig. 3.11 Prolapse of the nictitans gland (Bulldog, 2 years old) Note the visible free border of the nictitating membrane.

A specific, immune-mediated, bilateral but not necessarily symmetrical conjunctivitis is plasma cell infiltration (Figs 3.9–3.10) which frequently accompanies pannus in the German Shepherd Dog and others. Another important cause of inflammation is habronemiasis in the horse.

### Prolapse of the nictitans gland

(Figs 3.11–3.12)

A condition mainly seen in the dog, unilateral or more frequently bilateral, and usually one eye following the other; often in young dogs including puppies, and known as 'cherry eye'.

### Deformity of the cartilage

(Figs 3.13–3.15)

Sometimes referred to as scrolling of the cartilage; an unusual but not uncommon condition, particularly in the larger breeds of dog, but rare in other species. Bilateral or unilateral; the cartilage deformity usually

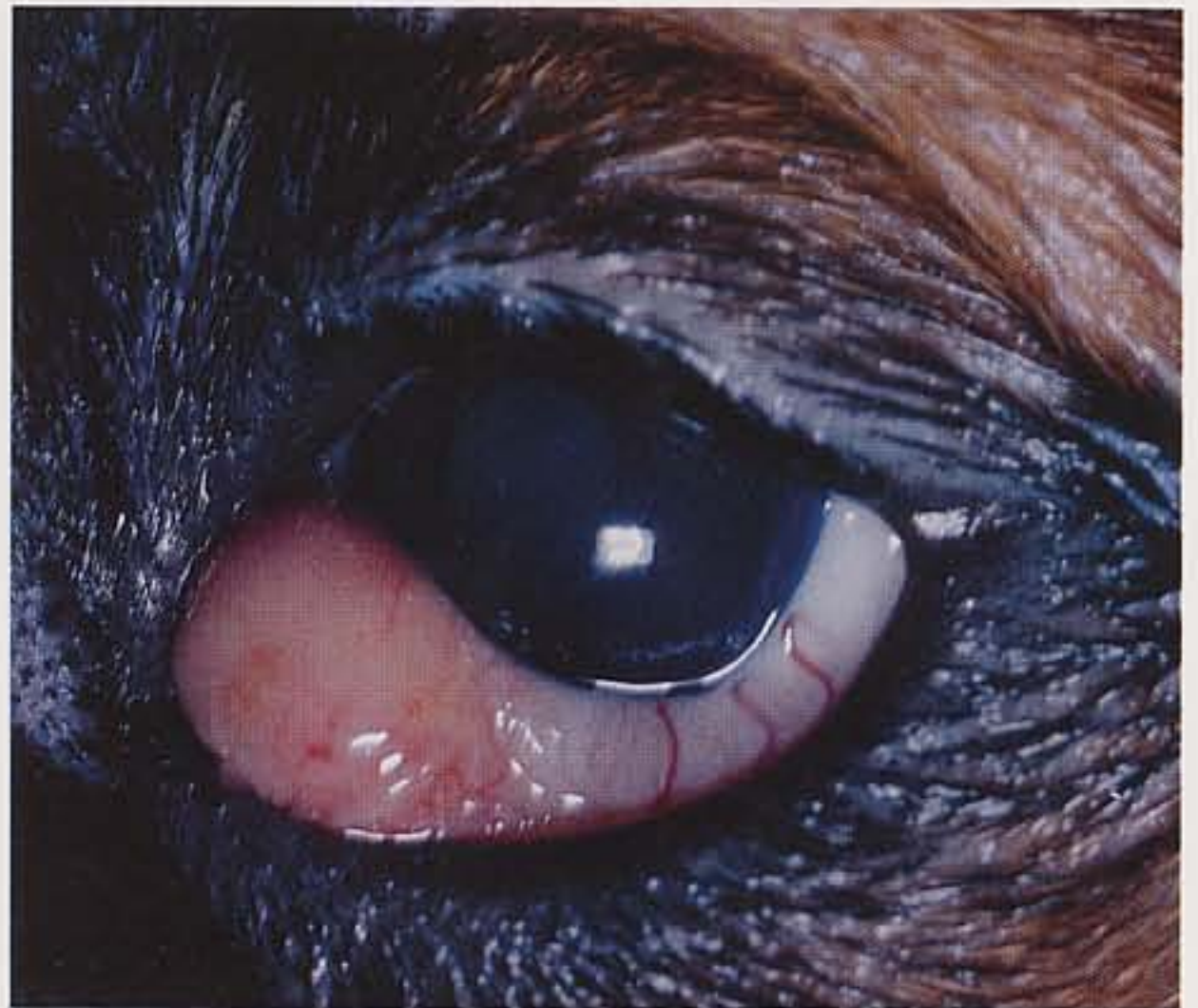

Fig. 3.12 Prolapse of the nictitans gland (Bulldog, 10 weeks old) Note age and breed in this case.

results in the free border of the third eyelid rolling outwards (Fig 3.13), and more rarely inwards (Fig 3.14). It is another cause of prominence of the nictitating membrane and may be accompanied by mild epiphora and mucoid discharge.

### Neoplasia (Figs 3.16–3.18)

Various neoplasms may be involved but are comparatively rare in the dog and cat, although the nictitating membrane is a common site for squamous cell carcinoma in the horse (Fig 3.18), often presenting as a case of persistent ocular discharge.

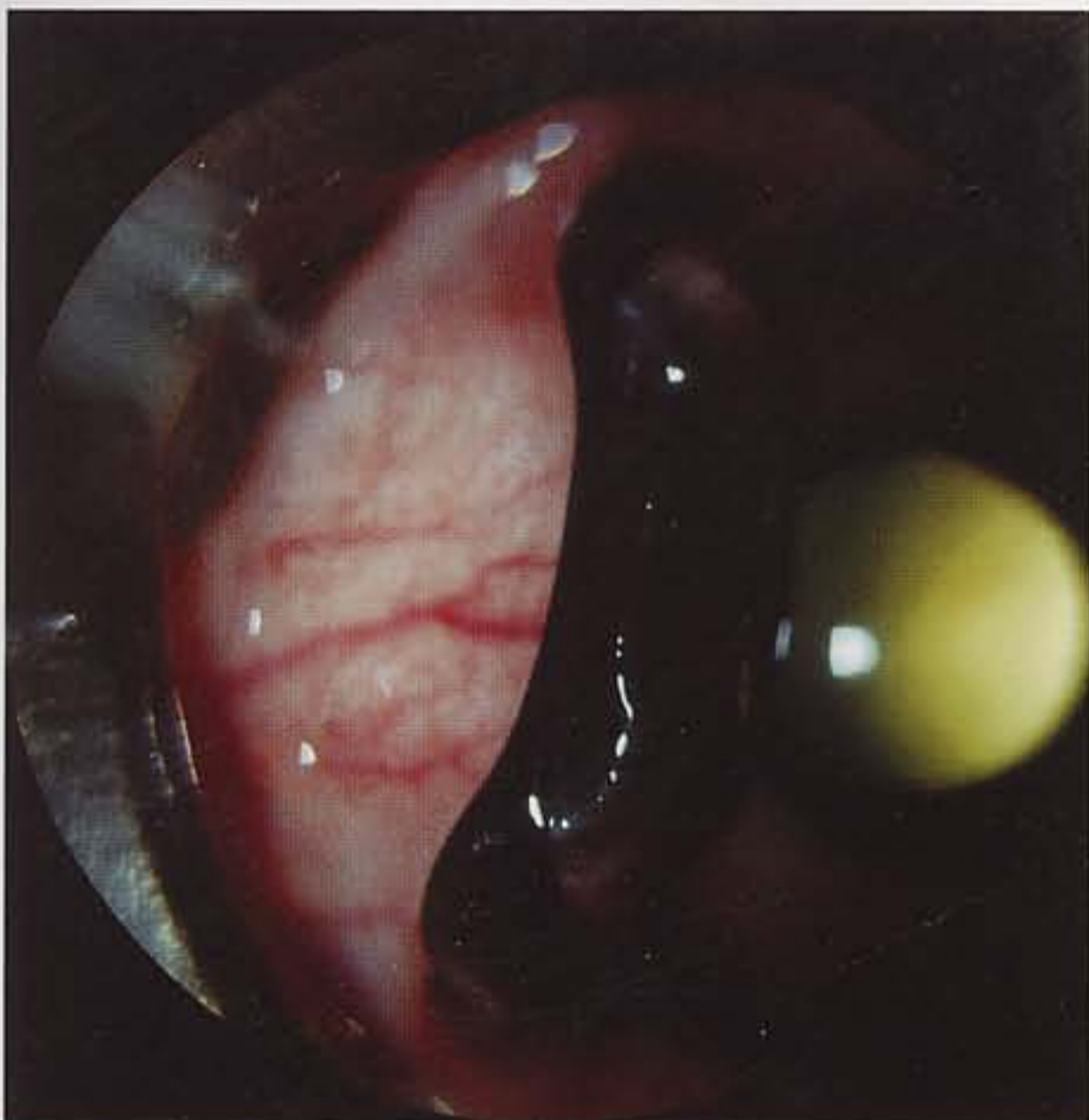

Fig. 3.13 Cartilage deformity (German Shepherd Dog, 7 months old) Free border of the third eyelid rolled outwards.

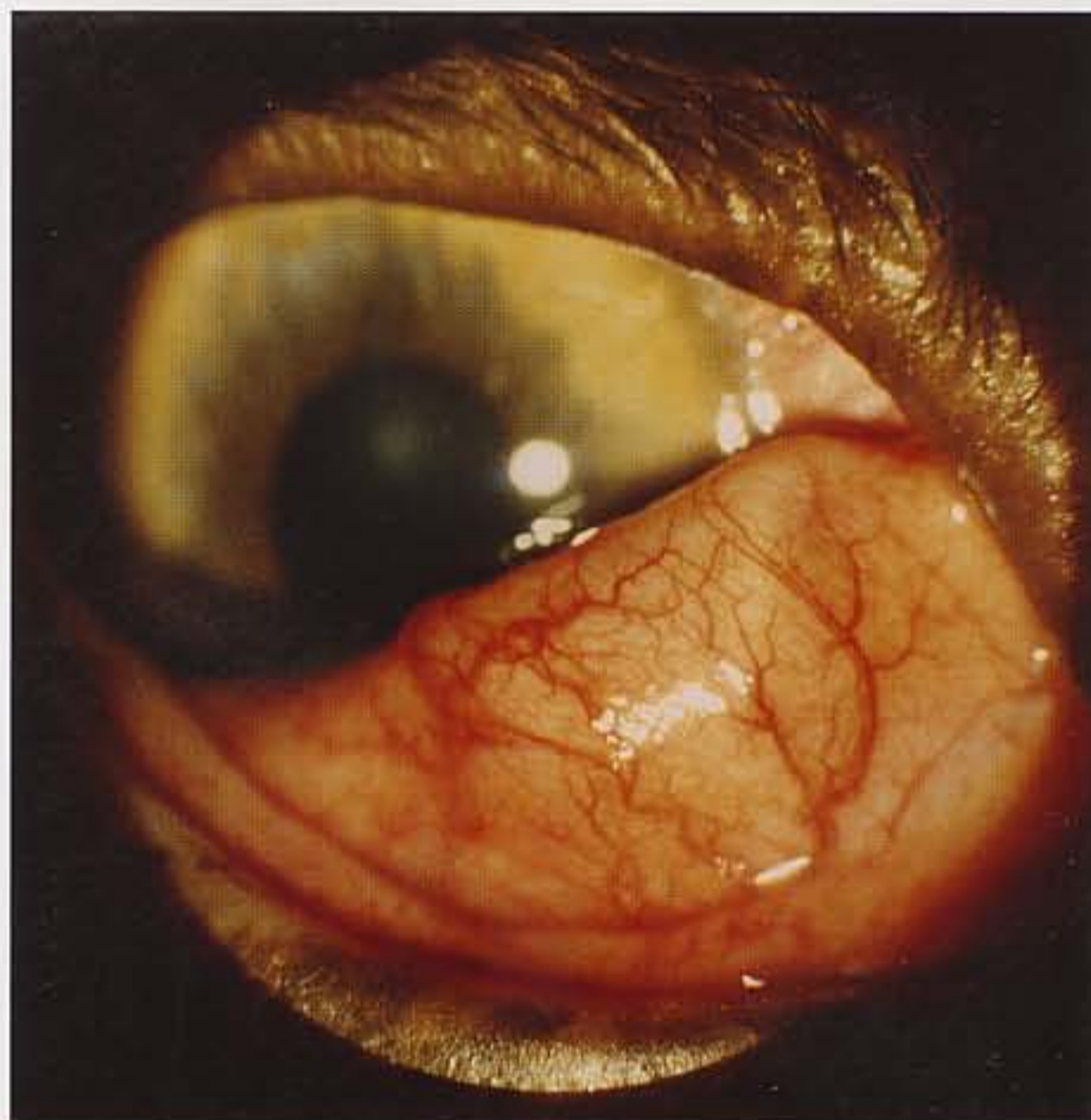

Fig. 3.14 Cartilage deformity (Weimaraner, 5 years old) Free border of the third eyelid rolled inwards.

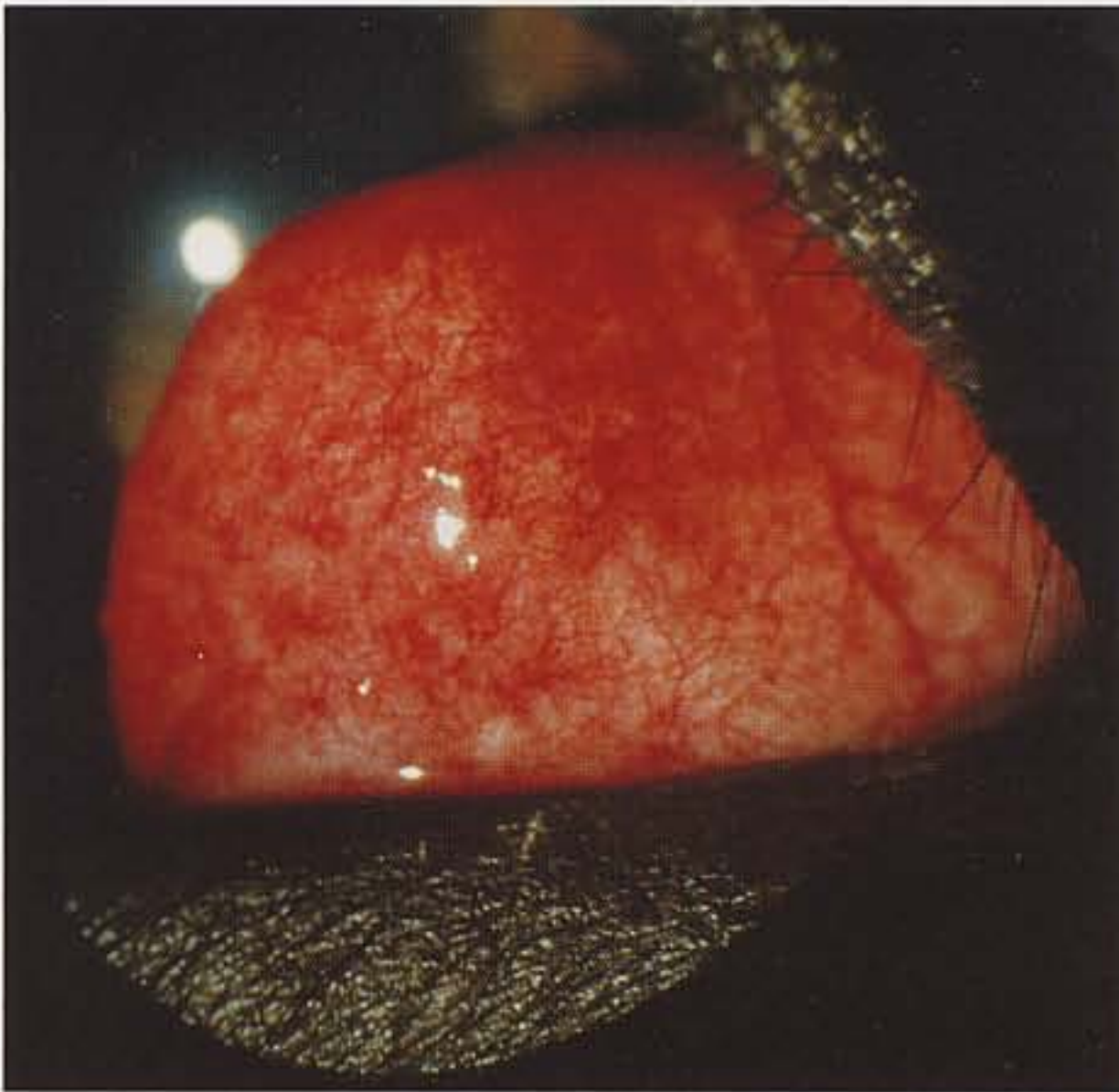

Fig. 3.15 Cartilage deformity (Great Dane, 8 months old) Similar to Figure 3.13, but note similarity to prolapse of the nictitans gland (Figs 3.10–3.11) and tumour (Fig 3.15).

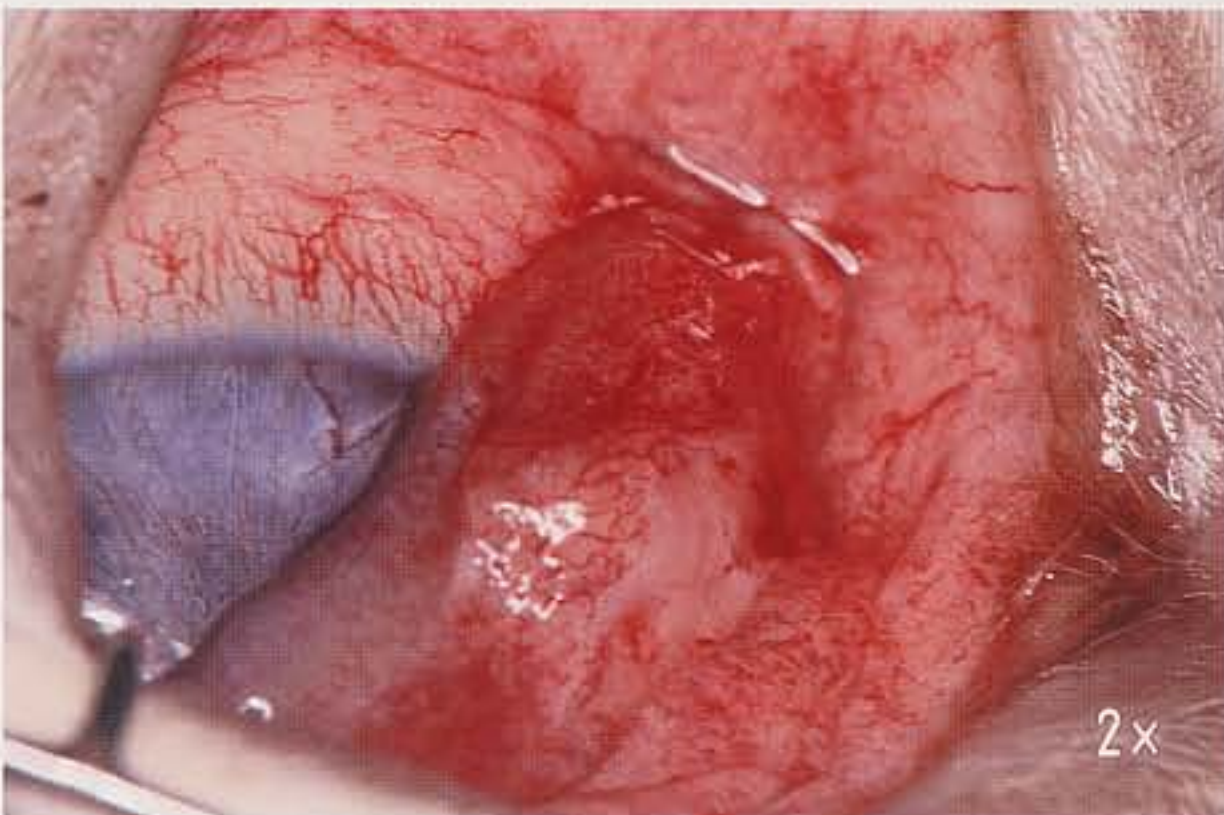


Fig. 3.17 Nictitating membrane tumour (Siamese cat) Adenocarcinoma.

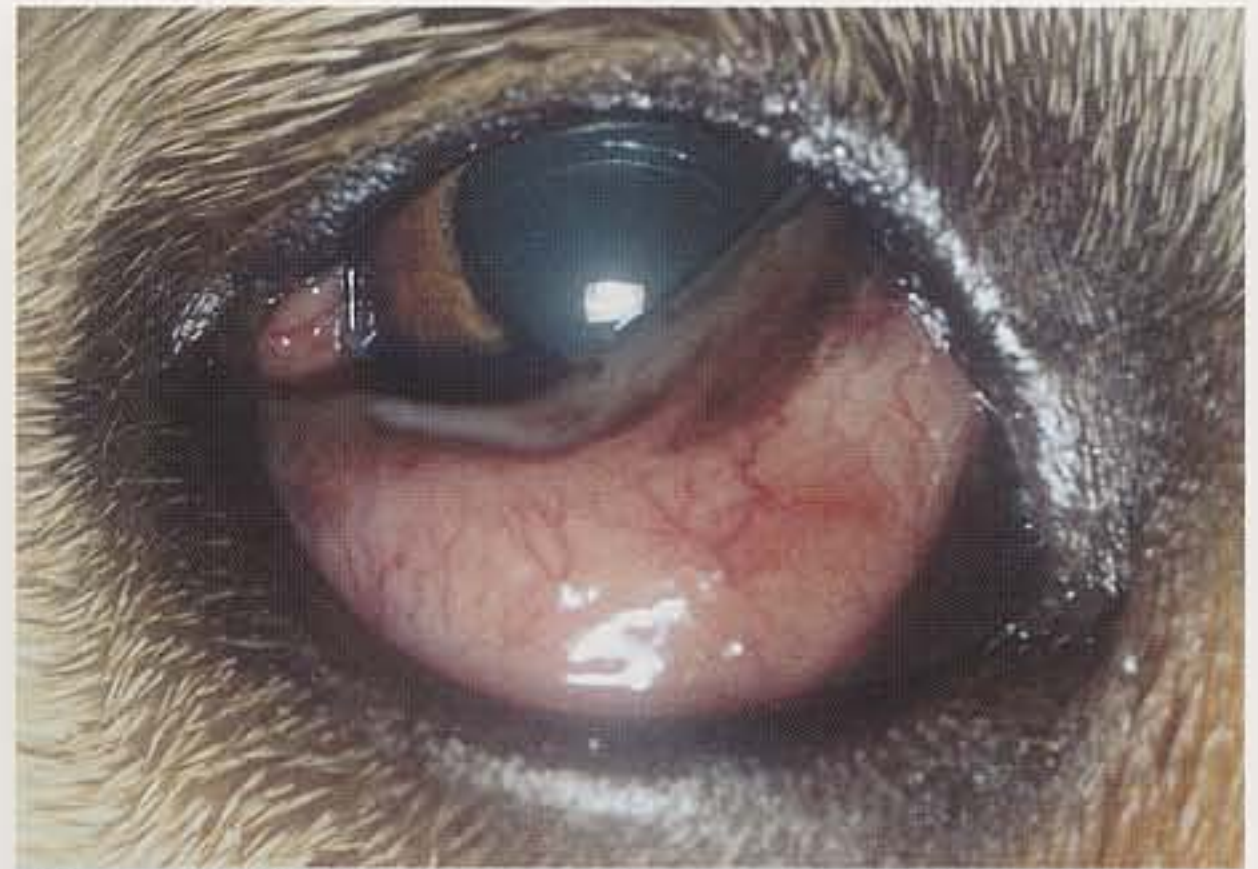

Fig. 3.16 Nictitating membrane tumour (Labrador Retriever, 3 years old) Lymphosarcoma.

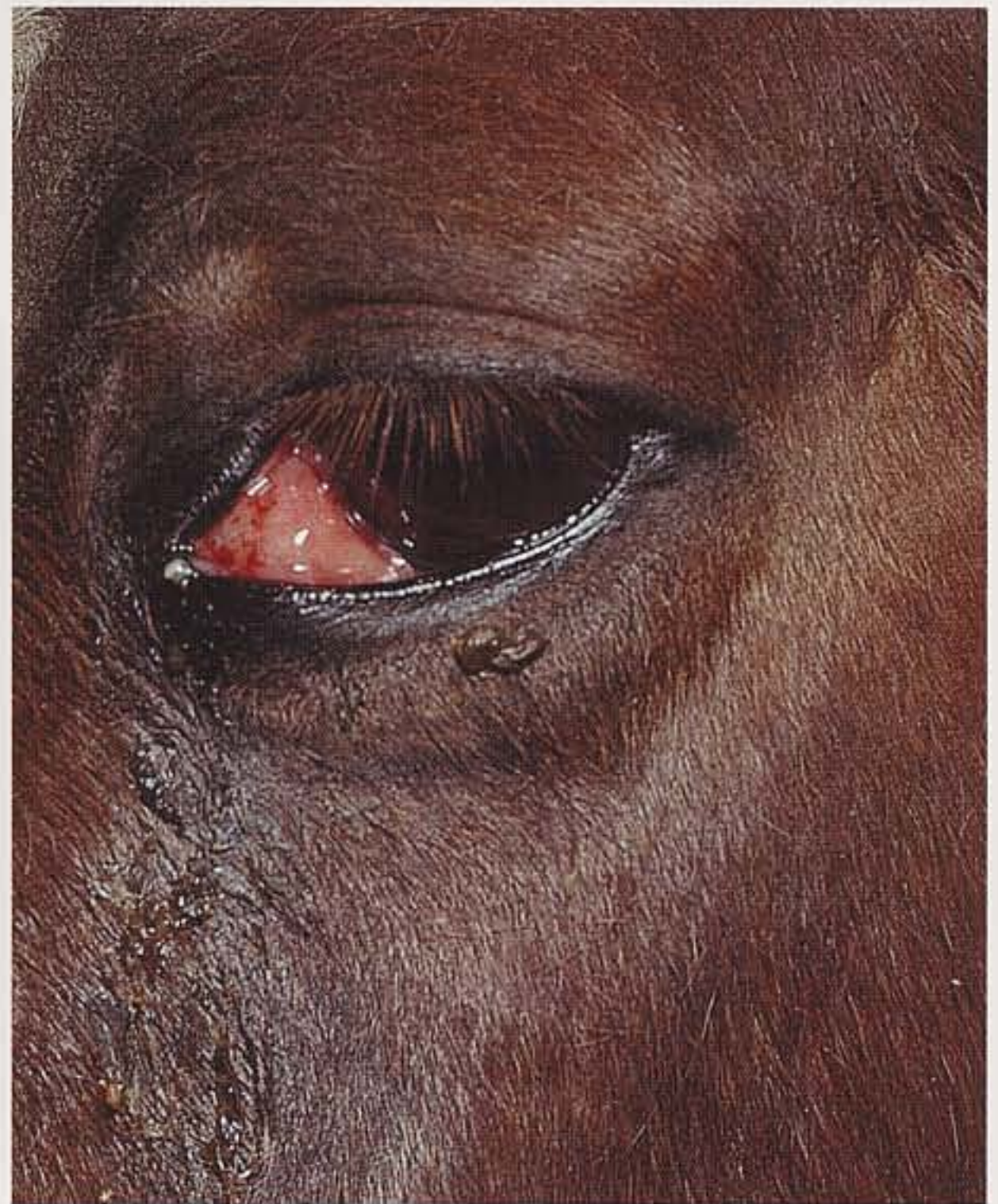

Fig. 3.18 Nictitating membrane tumour (Thoroughbred, 8 years old) Squamous cell carcinoma. Note the ocular discharge in this case. The third eyelid is a common site for this tumour in the horse.

## Chapter 4

# Lacrimal System

### Introduction

The lacrimal system is responsible for two important, and often presenting, clinical signs of 'wet eye' and 'dry eye'. The lacrimal system has two functions: secretory (tear production) to produce the important pre-corneal tear film (ptf) and excretory (lacrimal drainage) via the puncta, canaliculi, sac, nasolacrimal duct and its opening. The dry eye, or keratoconjunctivitis sicca (KCS), is described in Chapter 6 (Figs 6.35–6.44), as it usually presents as a keratitis with a considerable ocular discharge. KCS is a relatively common eye disease in the dog but seldom diagnosed in the cat or horse.

There are two important aids to diagnosis for the lacrimal system:

1. The Schirmer tear test 1 – one minute with no use of topical anaesthesia (Fig 4.1).

2. The fluorescein test – fluorescein into the conjunctival sac and the appearance, or otherwise, of a green stain after a few minutes at the ipsilateral nostril (Fig 4.2) (when stain appears it proves that the nasolacrimal duct system is patent but when no stain appears it does not prove that the system is blocked – resort then to irrigation, usually via the upper punctum).

The wet eye has two components (Table 4.1):

1. Lacrimation, or overproduction of tears, a common clinical condition denoting pain and/or inflammation and often accompanied by blepharospasm (Fig 4.3).
2. Epiphora, abnormal or impaired drainage.

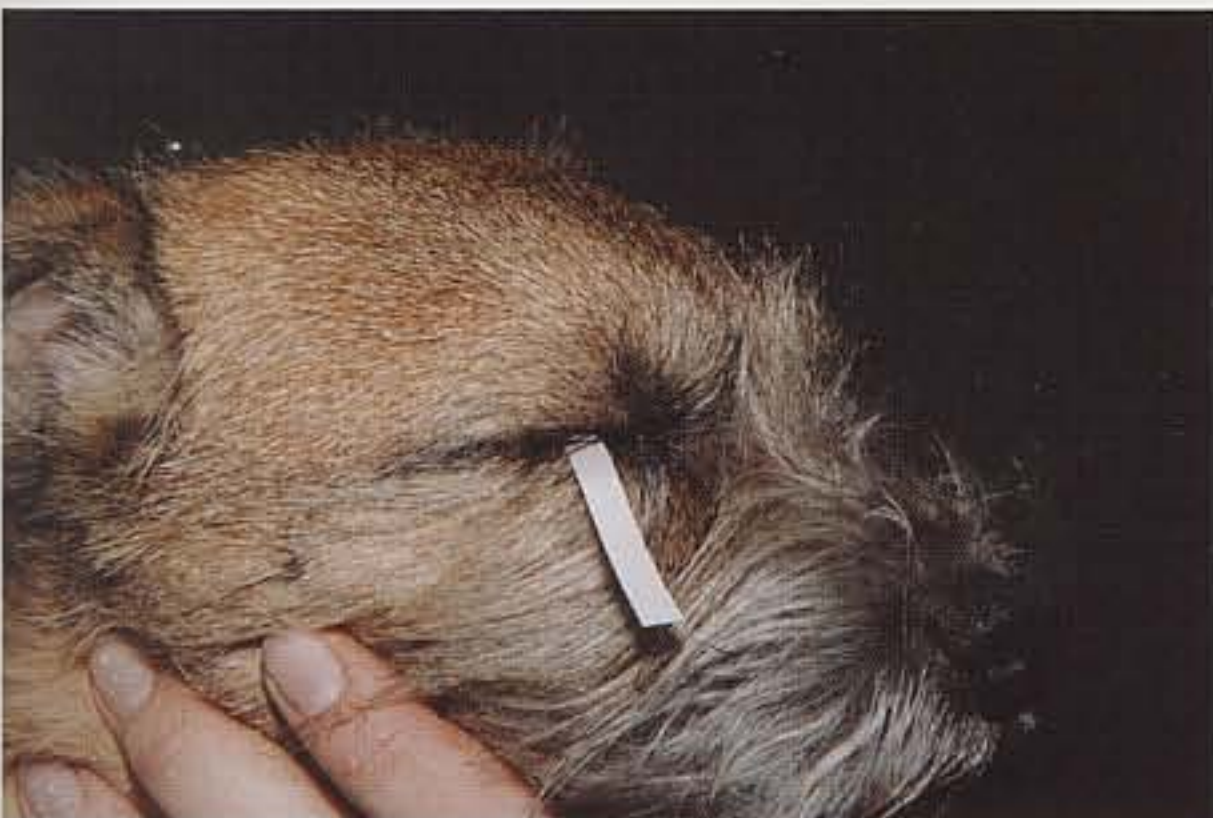

Fig. 4.1 Schirmer tear test Paper strip folded under the lower lid and left for 1 minute.



Fig. 4.2 Fluorescein patency test Fluorescein put into the conjunctival sac and appearing at the nostril (proving patency of the nasolacrimal duct system).

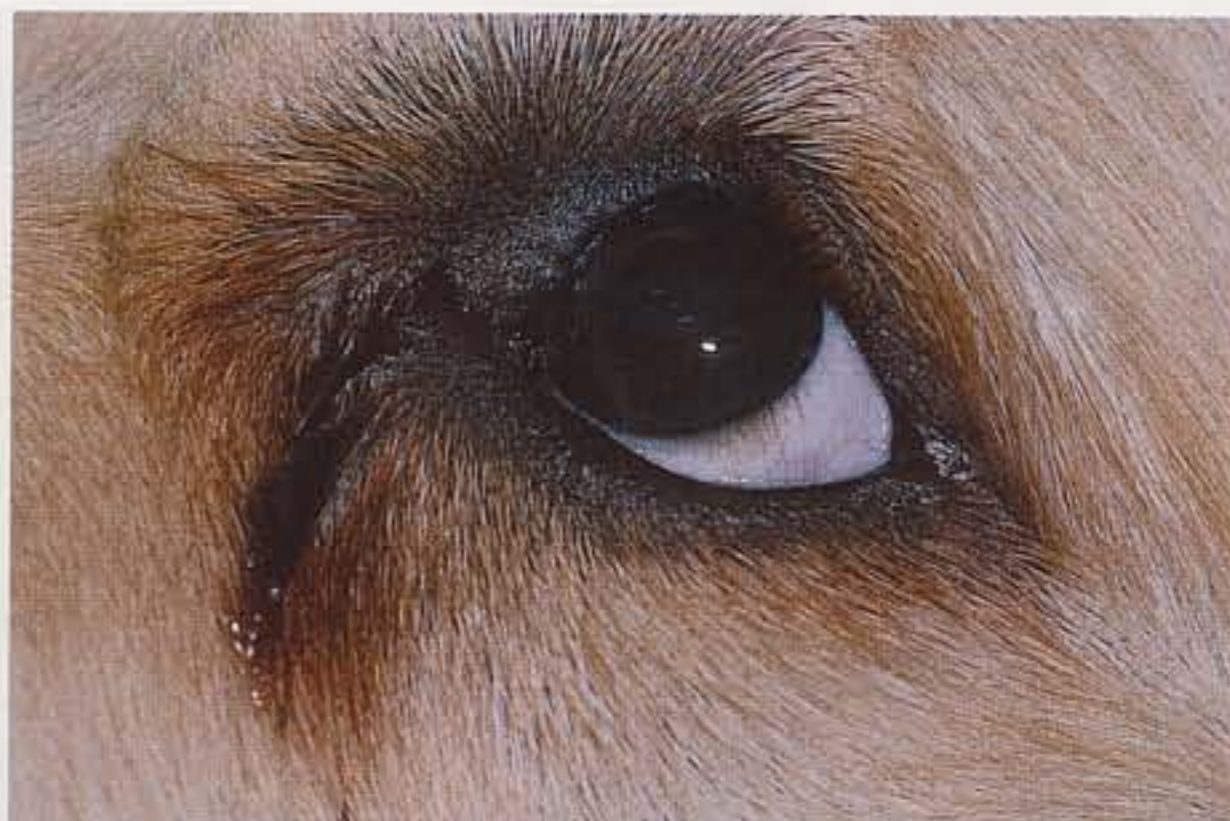**Table 4.1 – The wet eye**

## Lacrimation (unilateral or bilateral)

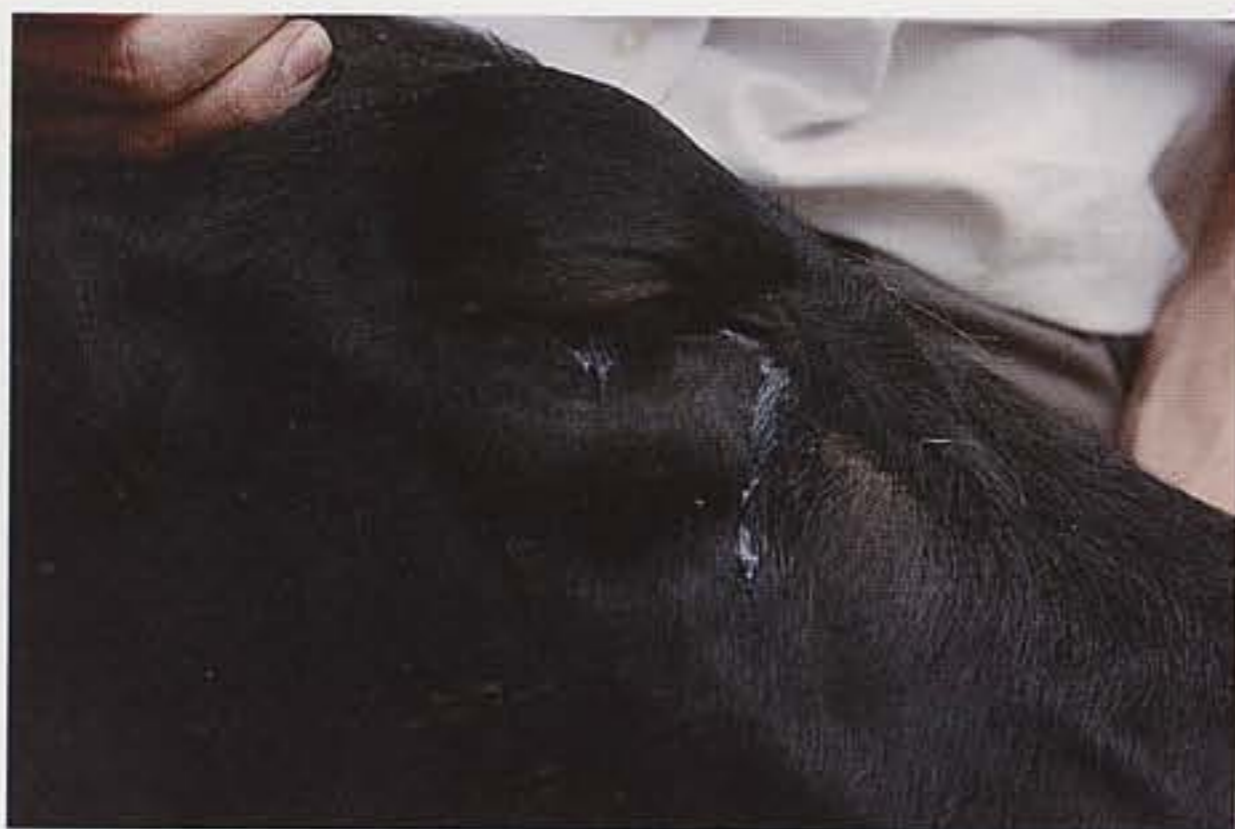1. Anterior segment pain with globe retraction
2. Entropion
3. Ectropion
4. Distichiasis
5. Ectopic cilia
6. Trichiasis
7. Foreign body
8. Eyelid tumour

## Epiphora (unilateral or bilateral)

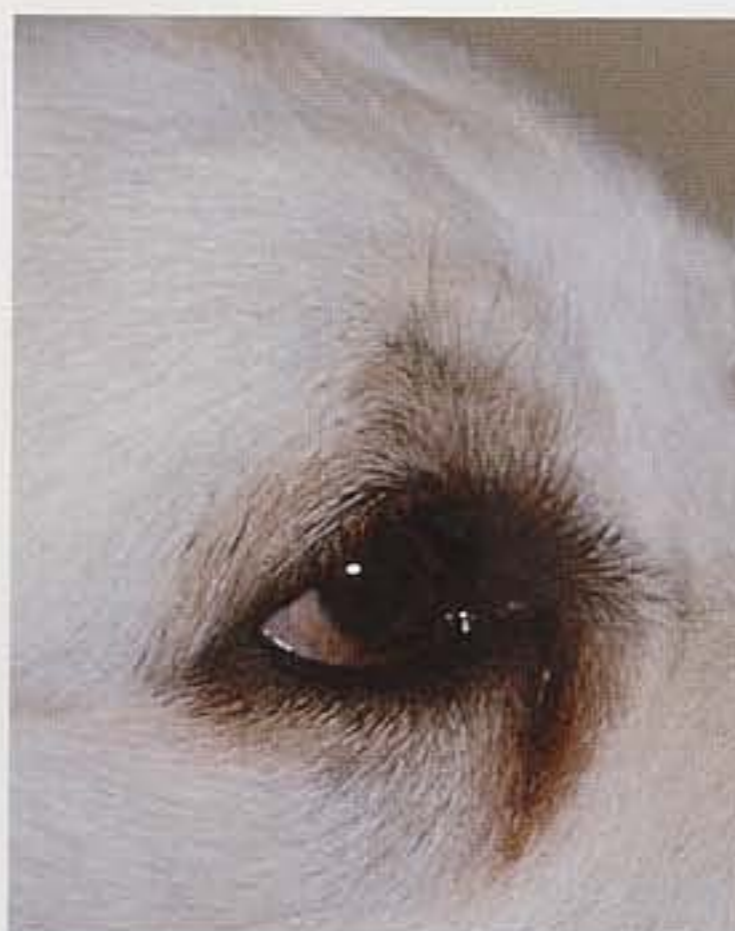1. Imperforate or micropuncta
2. Trauma
3. Foreign body
4. Infection
5. Nasal neoplasia
6. Symblepharon (cat)



**Fig. 4.4 Epiphora (Golden Retriever, 6 months old)**  
Imperforate lower punctum.



**Fig. 4.3 Lacrimation** An early sign of bovine keratoconjunctivitis.



**Fig. 4.5 Tear streak (Golden Retriever, 6 months old)**  
Typical brown staining due to imperforate punctum causing epiphora. See also Fig 5.5 and note the similarity in the case of lacrimation associated with atopy.

## Punctal abnormalities

Congenital imperforate and micropuncta may present, depending upon whether both upper and lower puncta are involved, as a wet eye (Fig 4.4) with a typical tear streak or stain (Fig 4.5) or more commonly as a purulent discharge in the horse (Figs 4.6–4.7). One or both eyes may be involved, in addition to one or both puncta which may be either imperforate or micro. In the dog there is almost certainly a hereditary component with a definite breed incidence in the Golden Retriever and the English Cocker Spaniel. In the dog it is usually the lower punctum that is involved but if it were the

upper punctum, with a normal lower punctum, the presenting sign would be unlikely to occur as the lower punctum drains the greater part of the tear film under normal conditions, i.e. no increased lacrimation. In the horse it is usually the nasal opening of the nasolacrimal duct that is involved and often with a variable distal portion of the nasolacrimal duct. In the cat the condition is rare but, when present, is often accompanied by absence of the canaliculi or part of the duct.

Other causes of punctal occlusion include trauma (Fig 4.12), foreign body (Fig 4.13) and infection of some part of the nasolacrimal duct system (Figs

4.14–4.15), sometimes due originally to a foreign body, or neoplasia affecting adjacent structures or teeth. Perhaps the commonest cause of punctal occlusion in the cat is symblepharon (Fig 4.16; see also Figs 5.13–5.18).

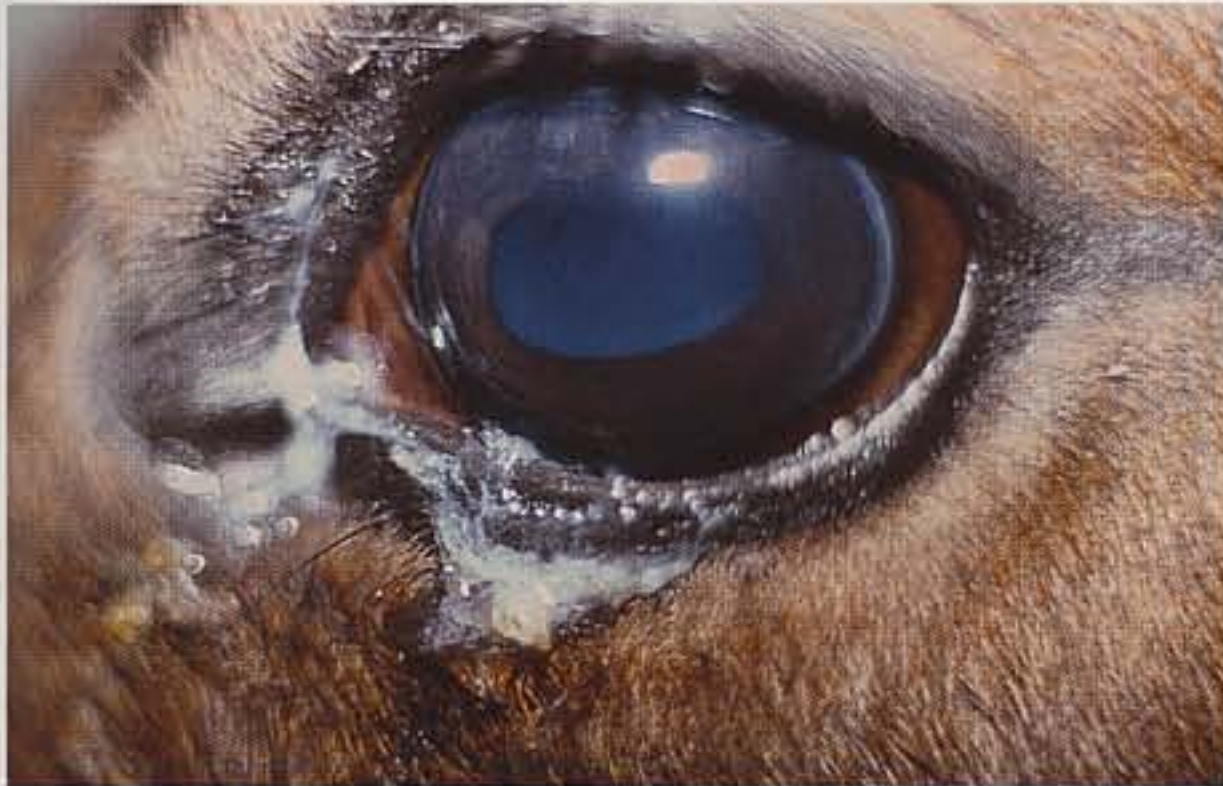

Fig. 4.6 Imperforate punctum (Thoroughbred foal, 8 months old) Purulent ocular discharge with atresia of the nasal opening of the nasolacrimal duct – the usual situation in the horse.

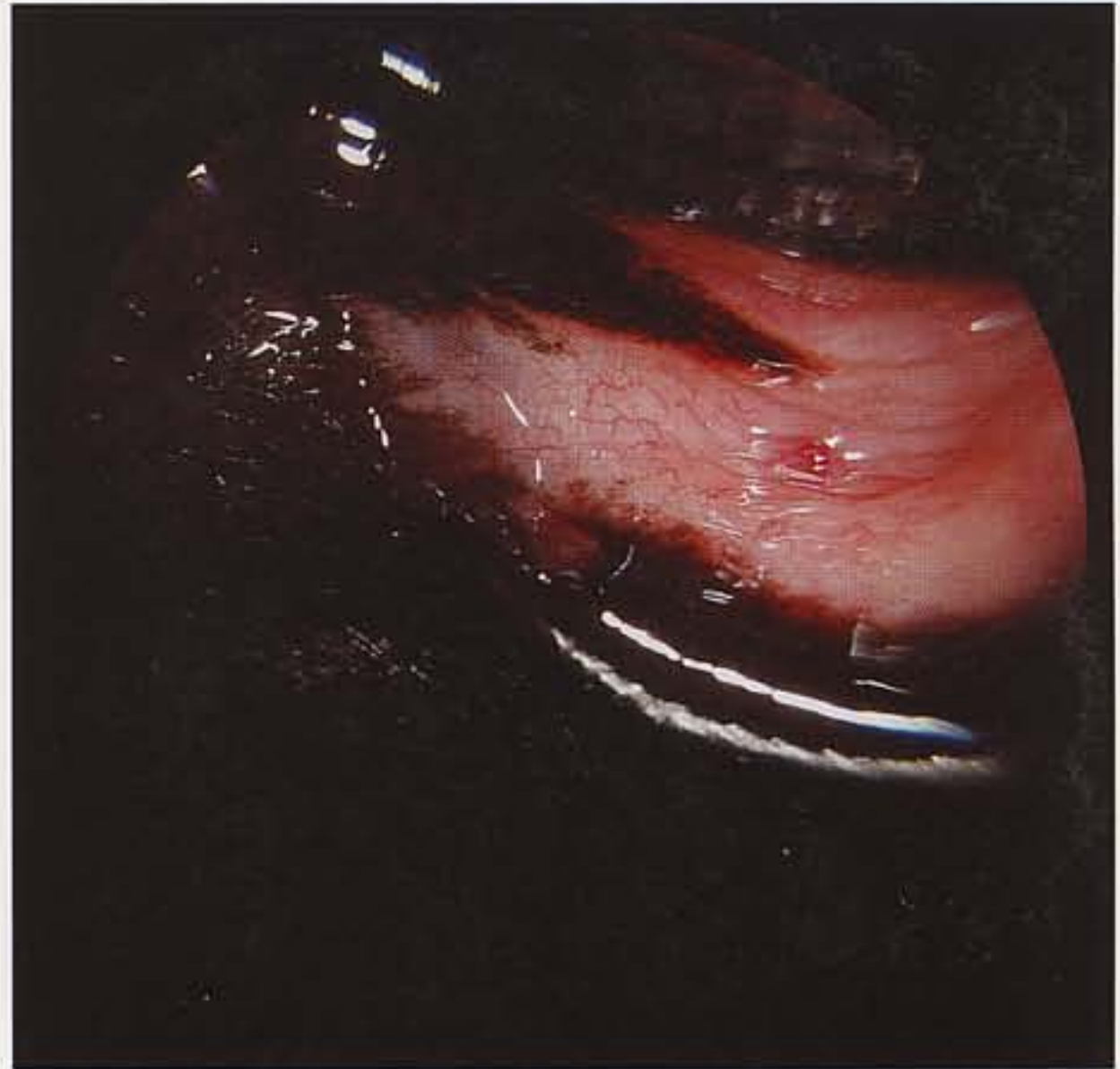

Fig. 4.8 The normal punctum in the lower eyelid of a dog

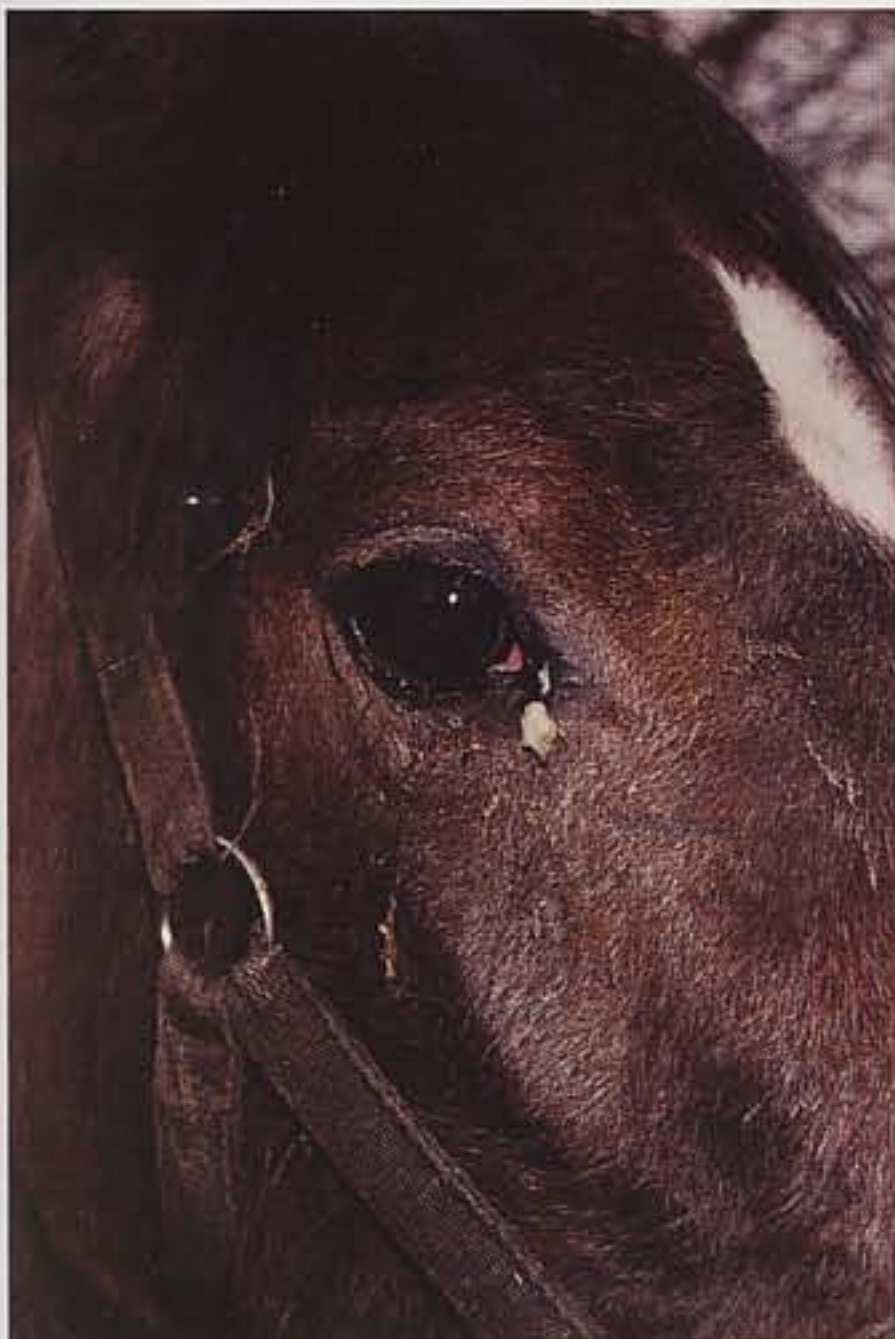

Fig. 4.7 Ocular discharge (horse) Mild purulent ocular discharge, the presenting sign of another case of absence of the nasal opening of the nasolacrimal duct.

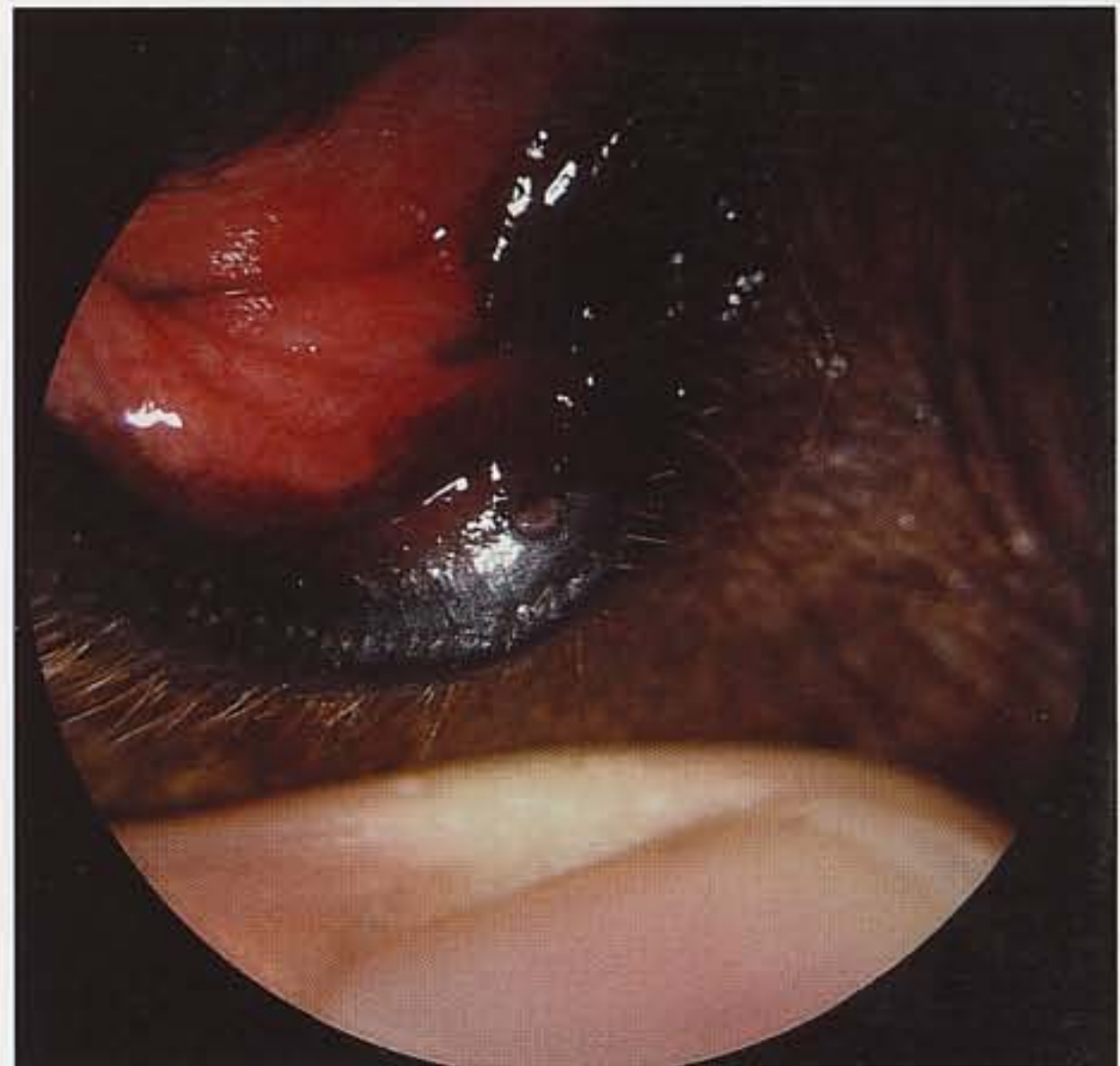

Fig. 4.9 Micropunctum (Cocker Spaniel, 8 months old) Note the thickened edge of the small opening.

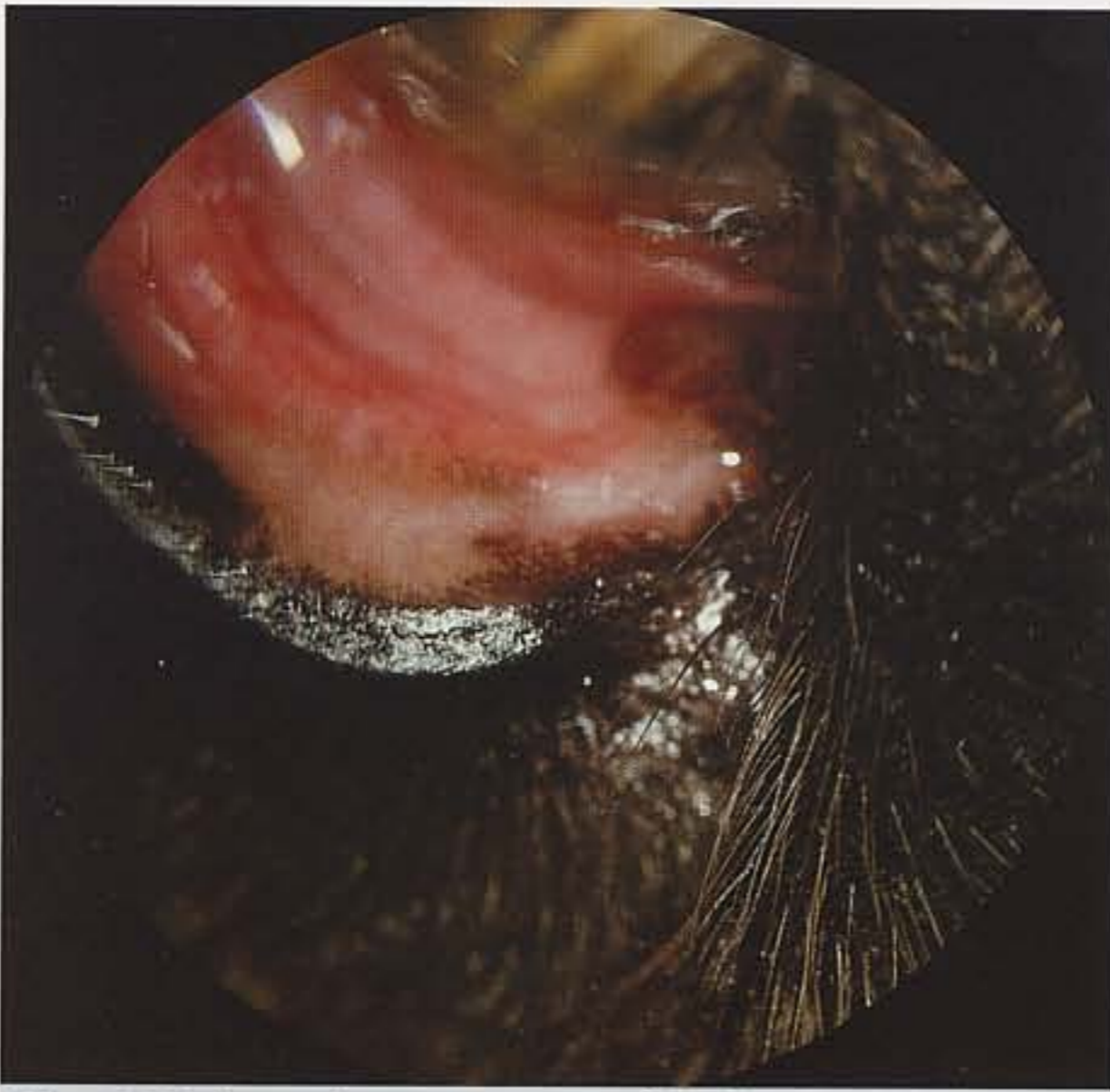

Fig. 4.10 Imperforate punctum (Golden Retriever, 6 months old) Note absence of any opening.

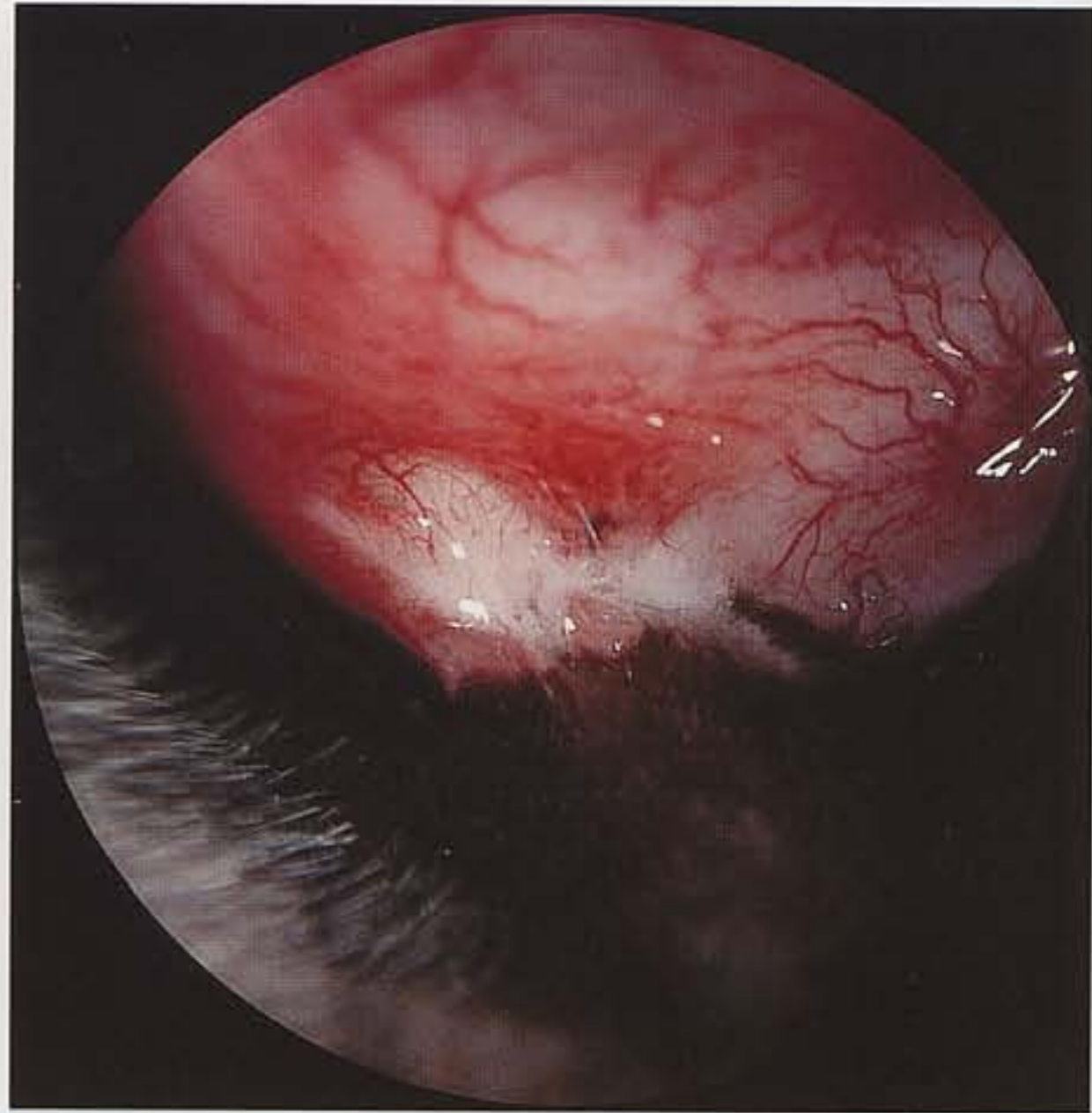

Fig. 4.12 Occluded punctum (Crossbred terrier, 6 months old) Scar tissue following trauma.

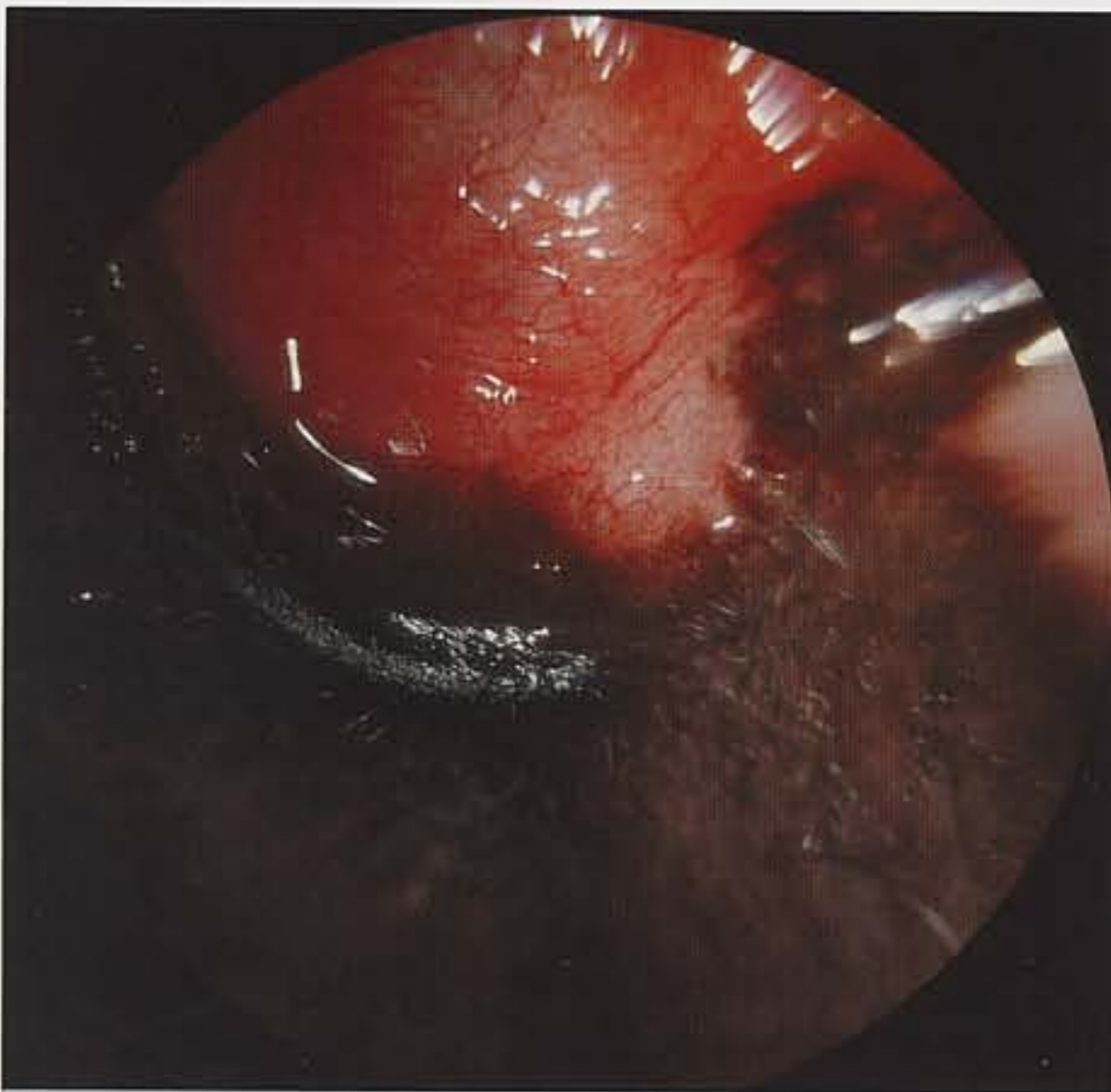


Fig. 4.11 Imperforate punctum (Basset Hound, 14 months old) Note the depression in the conjunctiva covering the opening of the lower punctum.

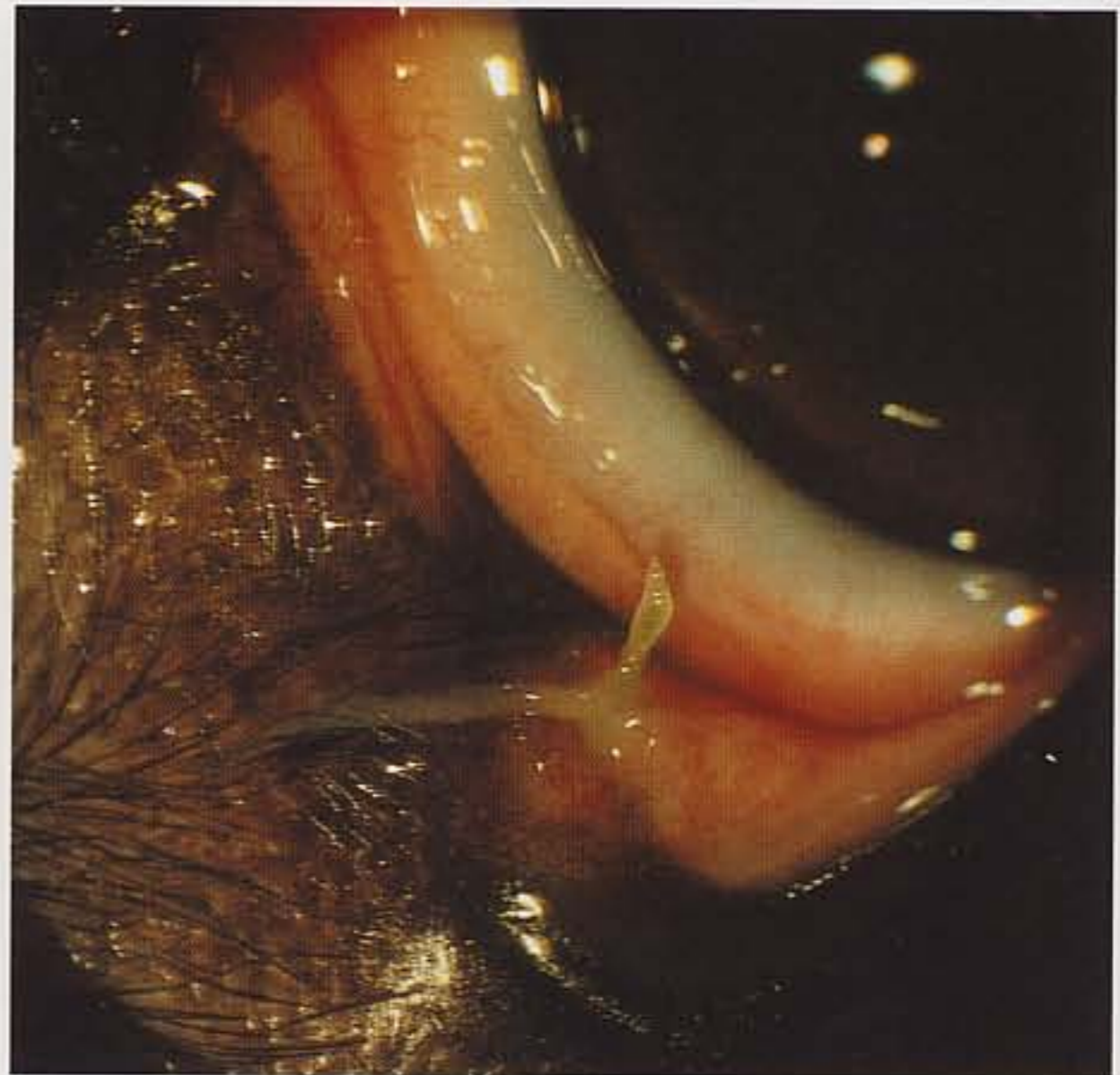

Fig. 4.13 Nasolacrimal duct foreign body (Old English Sheepdog, 14 months old) Grass awn protruding from the lower punctum following irrigation via the upper punctum.

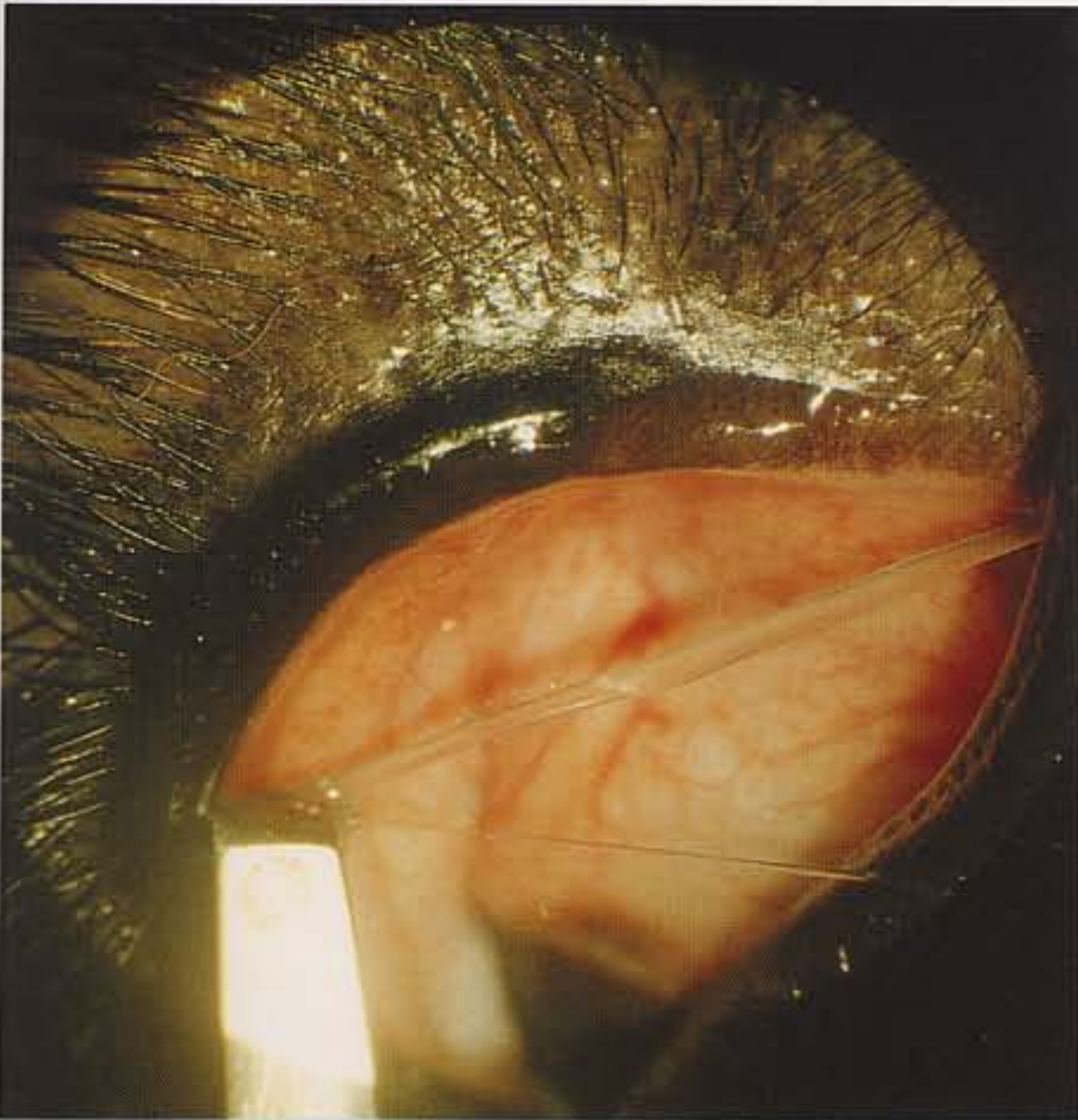
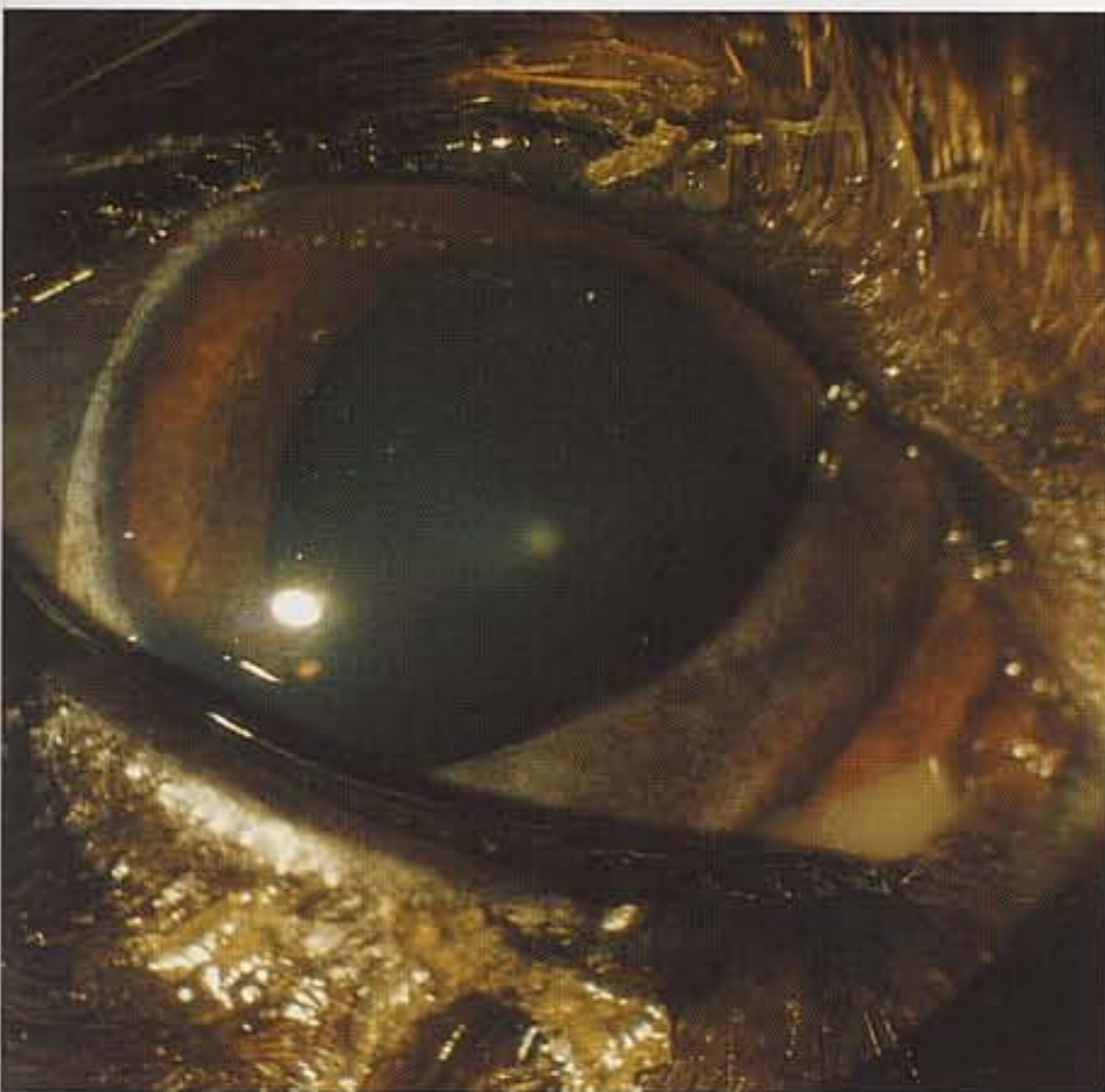


Fig. 4.14 Nasolacrimal duct infection Mucus strand from the lower punctum following irrigation of the lacrimal system via the upper punctum.

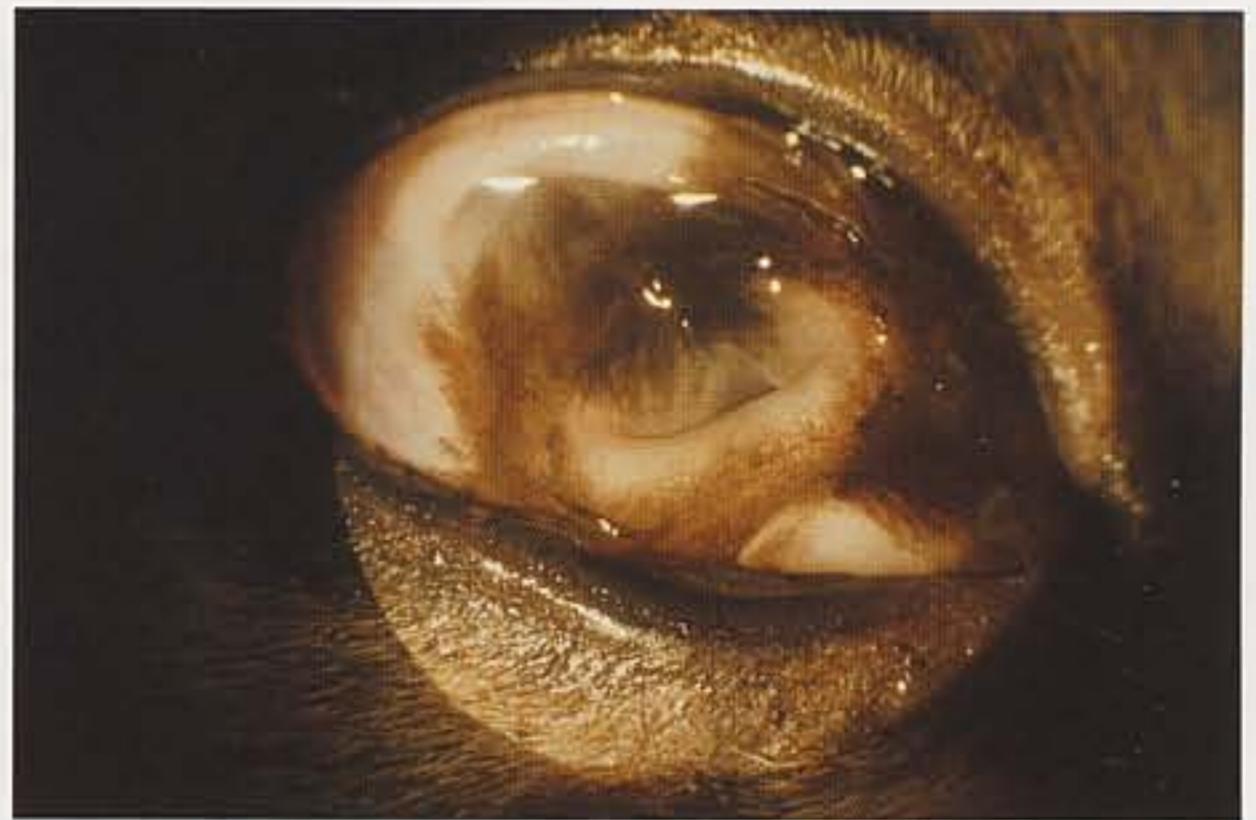

Fig. 4.16 Occluded nasolacrimal puncta (cat, young adult) Due to severe symblepharon. The nictitating membrane is fused to the cornea and the conjunctival fornices obliterated, together with the nasolacrimal duct puncta.



4.15 Nasolacrimal duct infection (Rough Collie, 6 years old) Note the persistent and purulent ocular discharge and bead of pus from the lower punctum at the inner canthus.



# Conjunctiva, Limbus, Sclera

## Introduction

The conjunctiva (bulbar, palpebral and nictitating parts) is frequently influenced by diseases of the eyelids (Chapter 2), nictitating membrane (Chapter 3), lacrimal system (Chapter 4) and cornea (Chapter 6). Inflammation, or conjunctivitis, is probably the commonest eye condition in veterinary ophthalmology, occurring in all species but with a difficult classification as the exact cause is often unknown (Table 5.1).

The conjunctiva may indicate systemic disease in all animals, the changes being bilateral. Examples are canine distemper, respiratory tract viruses in both the cat and the horse, blood dyscrasias, jaundice and anaemia (Fig 5.6). Primary conjunctivitis has a varied aetiology – often bacterial but also viral, trauma, etc.

Table 5.1 - The red eye

Unilateral or bilateral
Acute or chronic
Local ocular disease or systemic with pyrexia (bilateral)
1. Conjunctivitis
Primary or, more commonly, secondary (ocular or systemic)
Traumatic (subconjunctival haemorrhage)
2. Glaucoma
Breed-specific for primary, some secondary cases
Unilateral at first presentation
3. Uveitis
Photophobia
4. Episcleritis/scleritis
Uncommon, usually no pain
5. Keratitis
Including corneal ulcer (pain)
6. Orbital disease
Endophthalmitis
Panophthalmitis
Retrobulbar (inflammation, neoplasia)
Prolapse

## Conjunctivitis (Figs 5.1–5.5)

Conjunctivitis may be unilateral or bilateral; affect any age including the neonate; and may be primary or secondary to another eye disease and it may be difficult to decide which is the primary condition, e.g. keratoconjunctivitis. Conjunctivitis is not normally a painful condition but does cause a degree of irritation and therefore may be accompanied by lacrimation and blepharospasm (Table 5.2).

Conjunctivitis may be acute (Fig 5.1) with clinical signs of hyperaemia, chemosis, lacrimation and a variable discharge, or chronic (Fig 5.2) with a dull redness, thickening and less and drier discharge. Follicular conjunctivitis (Fig 5.3) mainly affects the palpebral conjunctiva and carries a non-specific aetiology. Atopic conjunctivitis also mainly affects the palpebral conjunctiva (Fig 5.4) and accompanies atopic dermatitis, often in the periorbital region and with an increased lacrimation (Fig 5.5).

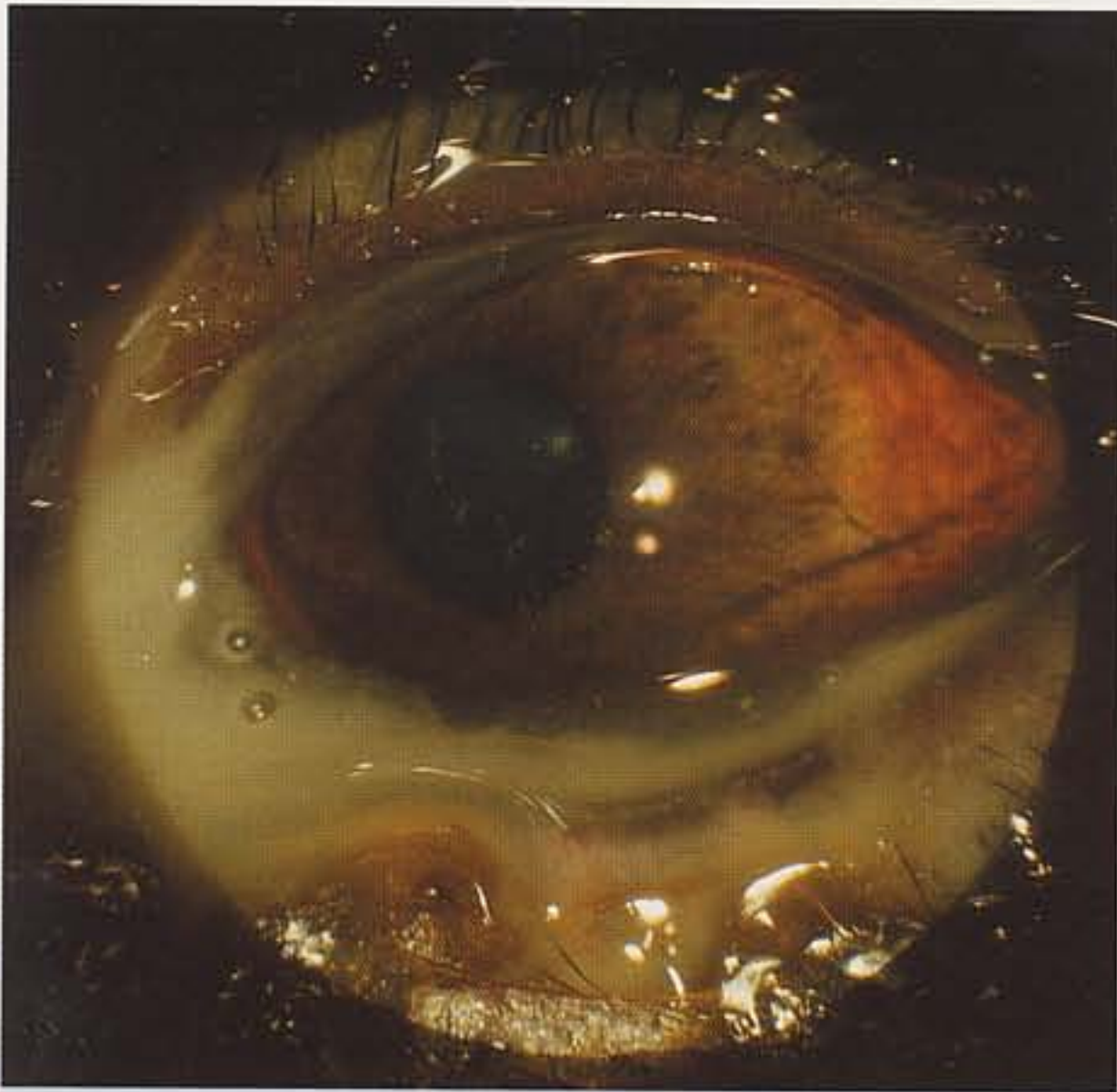

Fig. 5.1 Acute purulent conjunctivitis (young dog)  
Note that the discharge is not adherent to the cornea and is washed away onto the eyelid margins by the increased lacrimation.

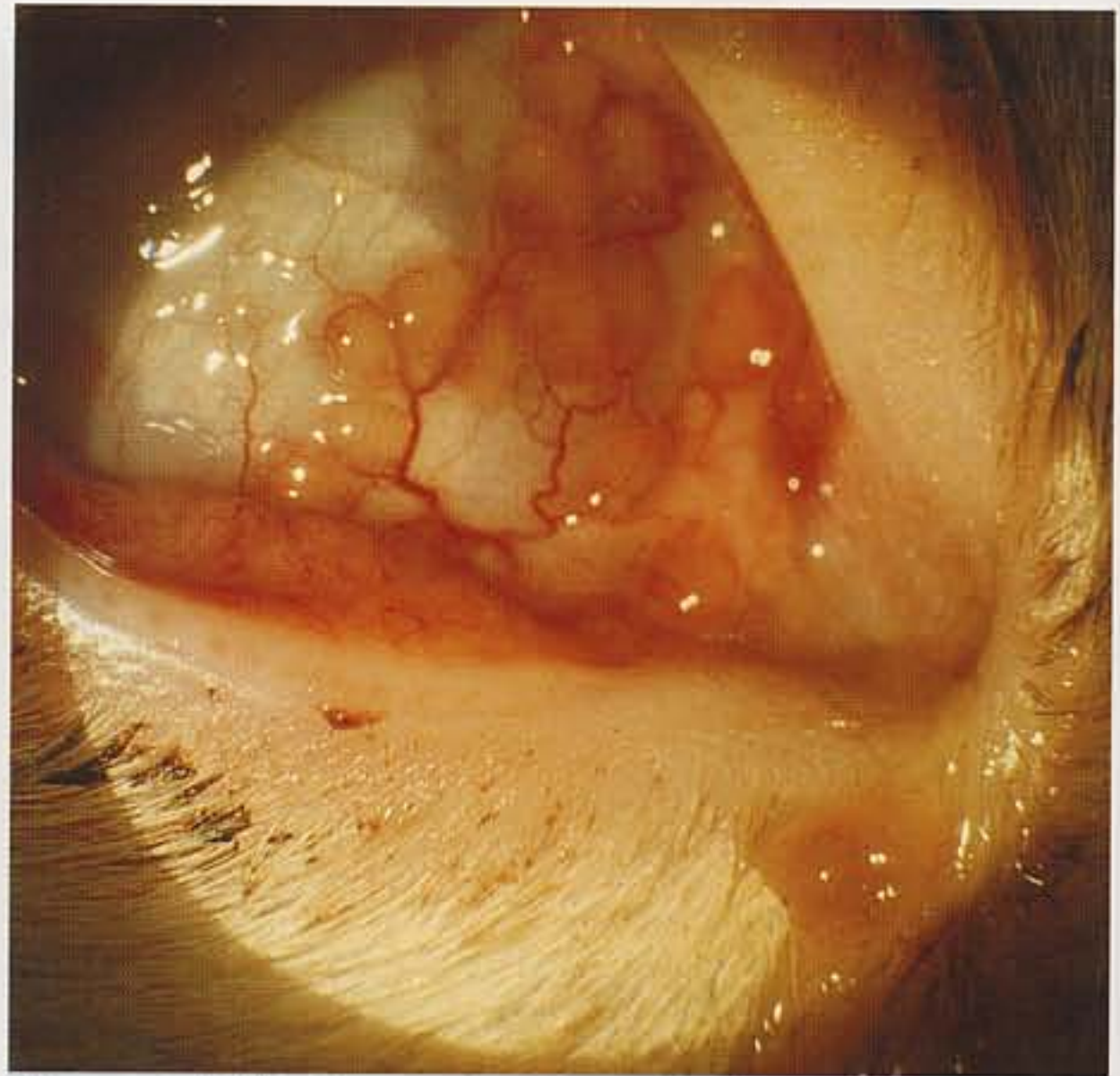


Fig. 5.3 Follicular conjunctivitis (cat) Note some chemosis and ocular discharge.

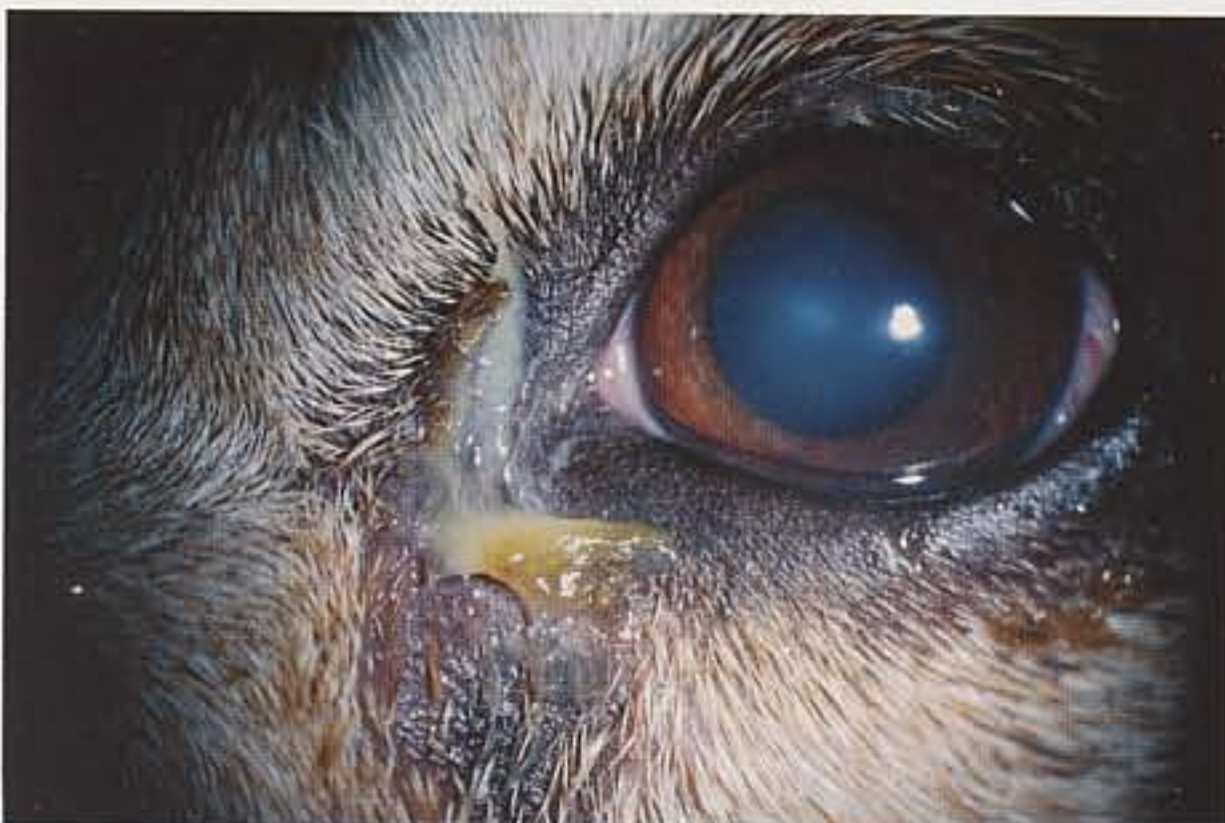

Fig. 5.2 Chronic conjunctivitis Note the dryer nature of the discharge and its position and the clear cornea.

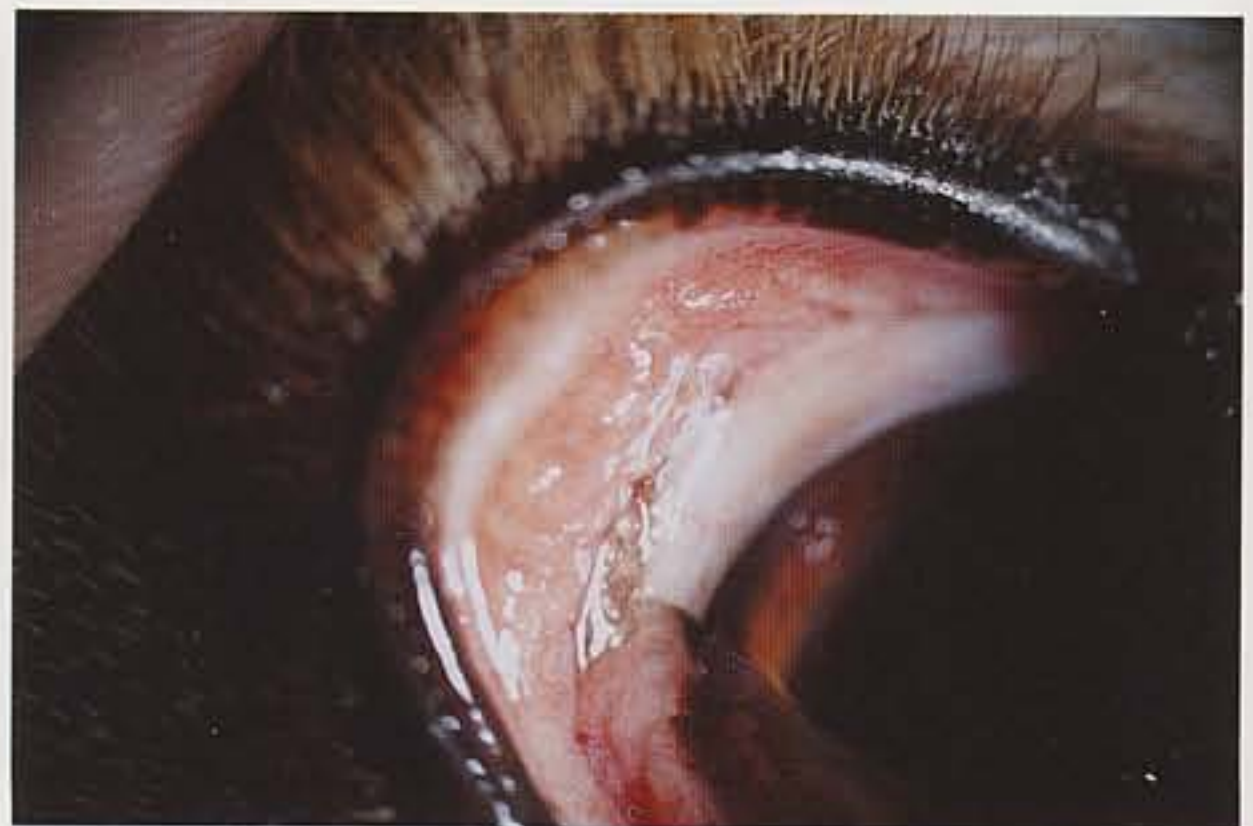

Fig. 5.4 Atopic conjunctivitis (Labrador Retriever, adult) Note the involvement of the palpebral conjunctiva only visible when the lid is everted.

Table 5.2 - Conjunctivitis: differential diagnosis

	Pupil	Intraocular pressure	Pain	Vision	Discharge
Conjunctivitis	No change	No change	+	No change	Serous-purulent
Glaucoma	Dilates	↑	+++	Blind	Lacrimation
Uveitis	Constricts	↓	++	Minor effect	Lacrimation



Fig. 5.5 Atopic conjunctivitis Note the excessive lacrimation causing a typical tear streak and compare with the tear streak due to epiphora in Fig 4.5.

### Chemosis (Figs 5.6–5.7)

Chemosis, or conjunctival oedema, usually accompanies acute conjunctivitis or trauma and occurs particularly in the cat (Fig 5.6) and horse (Fig 5.7).

### Conjunctival haemorrhages

(Figs 5.8–5.10)

Trauma is probably the commonest cause of conjunctival and subconjunctival haemorrhages and may be quite spectacular (Fig 5.8). However, there are a number of other causes of haemorrhage to mucous membranes that may aid diagnosis of a more serious condition (Fig 5.9).

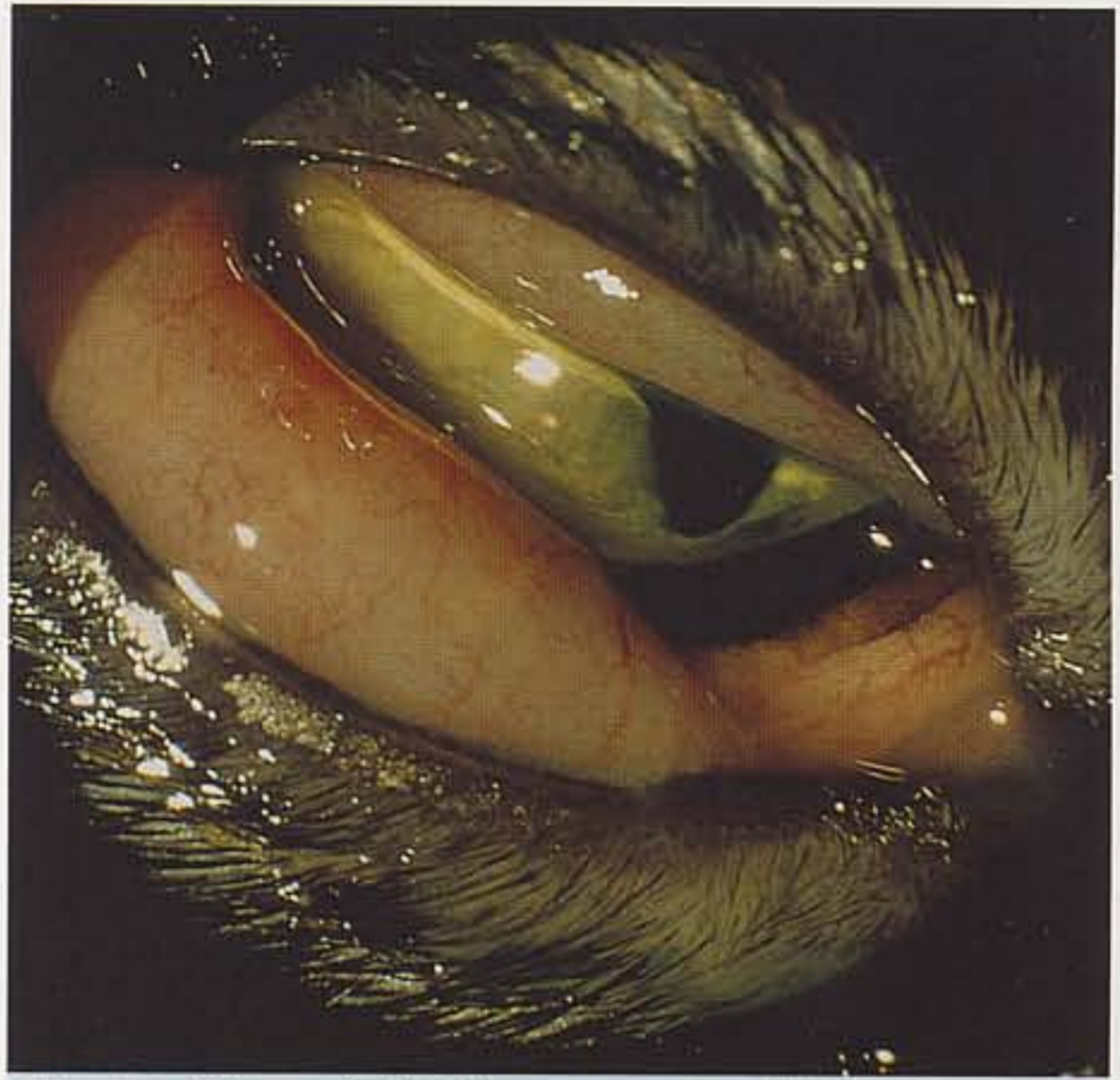


Fig. 5.6 Chemosis (DSH cat, 3 years old) Conjunctival oedema in a cat positive for *Chlamydia*.

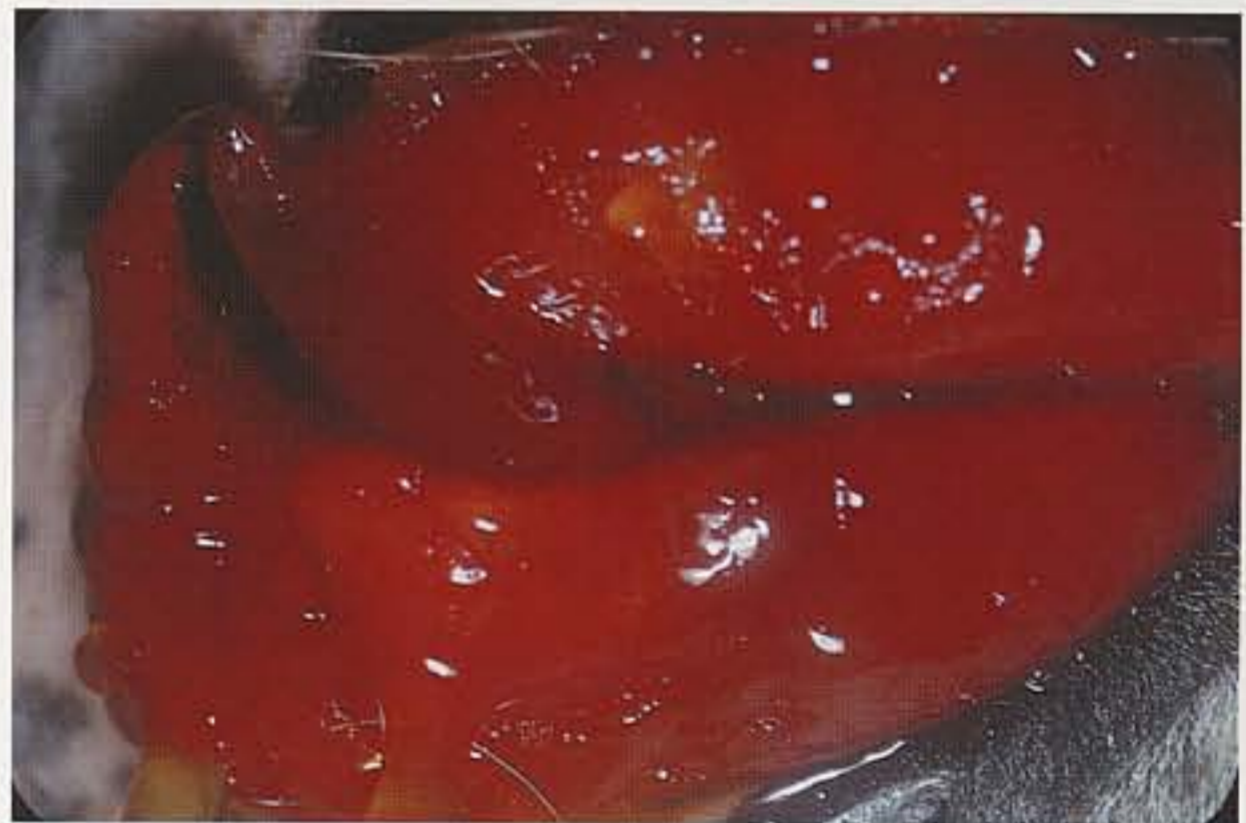

Fig. 5.7 Chemosis (Pony) Severe case obscuring the globe and due to trauma.

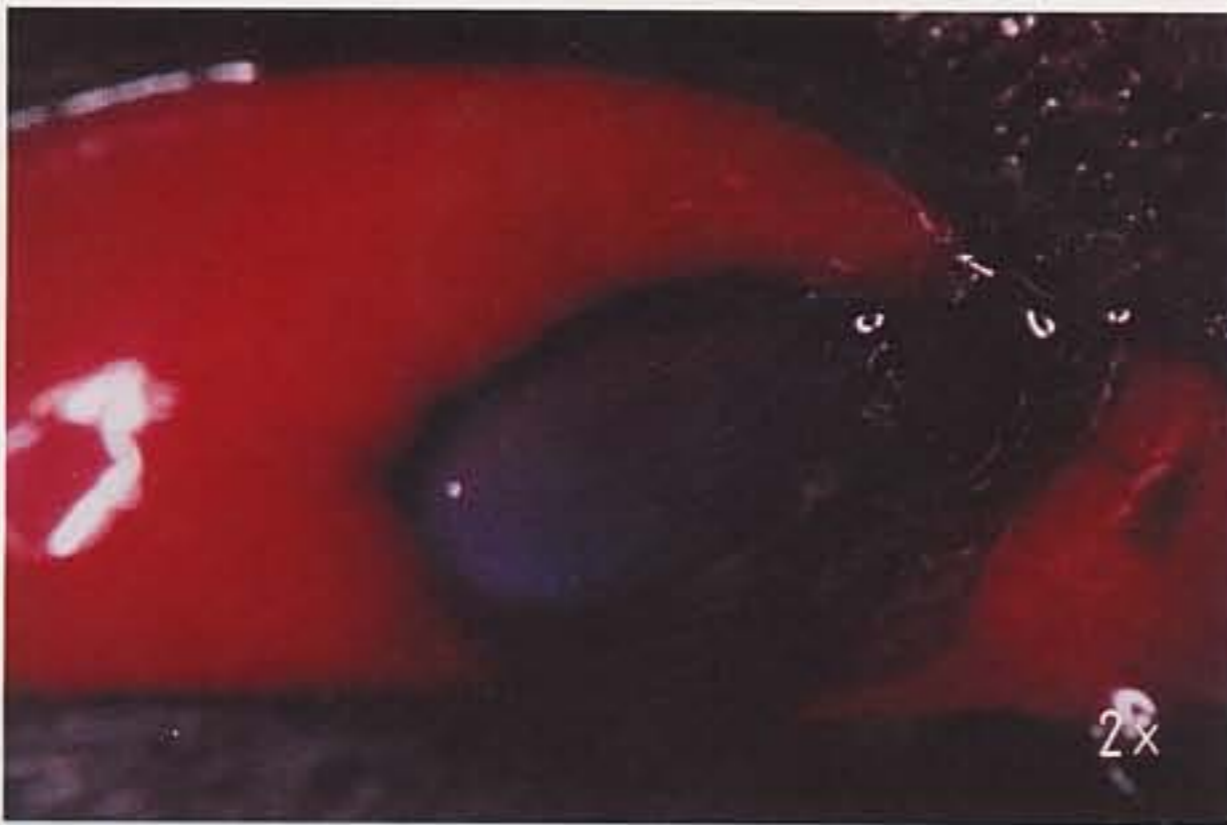

Fig. 5.8 Subconjunctival haemorrhage (Spaniel)  
Haemorrhage following a golf club injury.

## Subconjunctival masses

(Figs 5.11–5.12)

Occasionally retrobulbar fat may appear subconjunctivally and has been reported in the horse in association with the nictitating membrane. Fig 5.12 shows a rare case of conjunctival calcinosis in the dog causing a vascular keratitis and corneal ulcer.

## Symblepharon (Figs 5.13–5.18; see also Fig 4.16)

Symblepharon is a conjunctival adhesion to the conjunctiva or cornea. It is common in the cat but rare in the dog and may be congenital or more

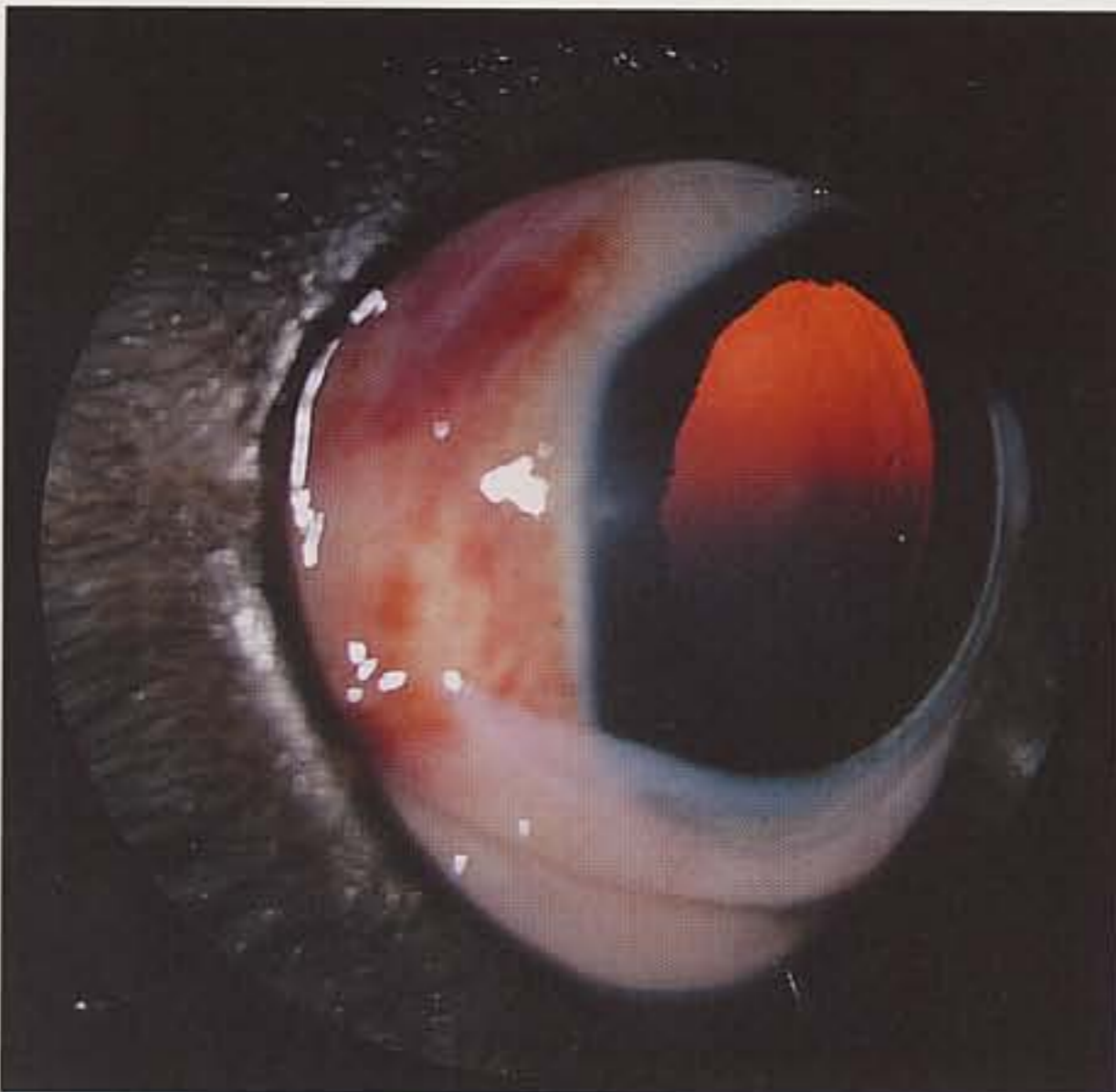


Fig. 5.9 Subconjunctival haemorrhage (Cocker Spaniel)  
Haemorrhage due to Warfarin poisoning (see also Fig 11.206).

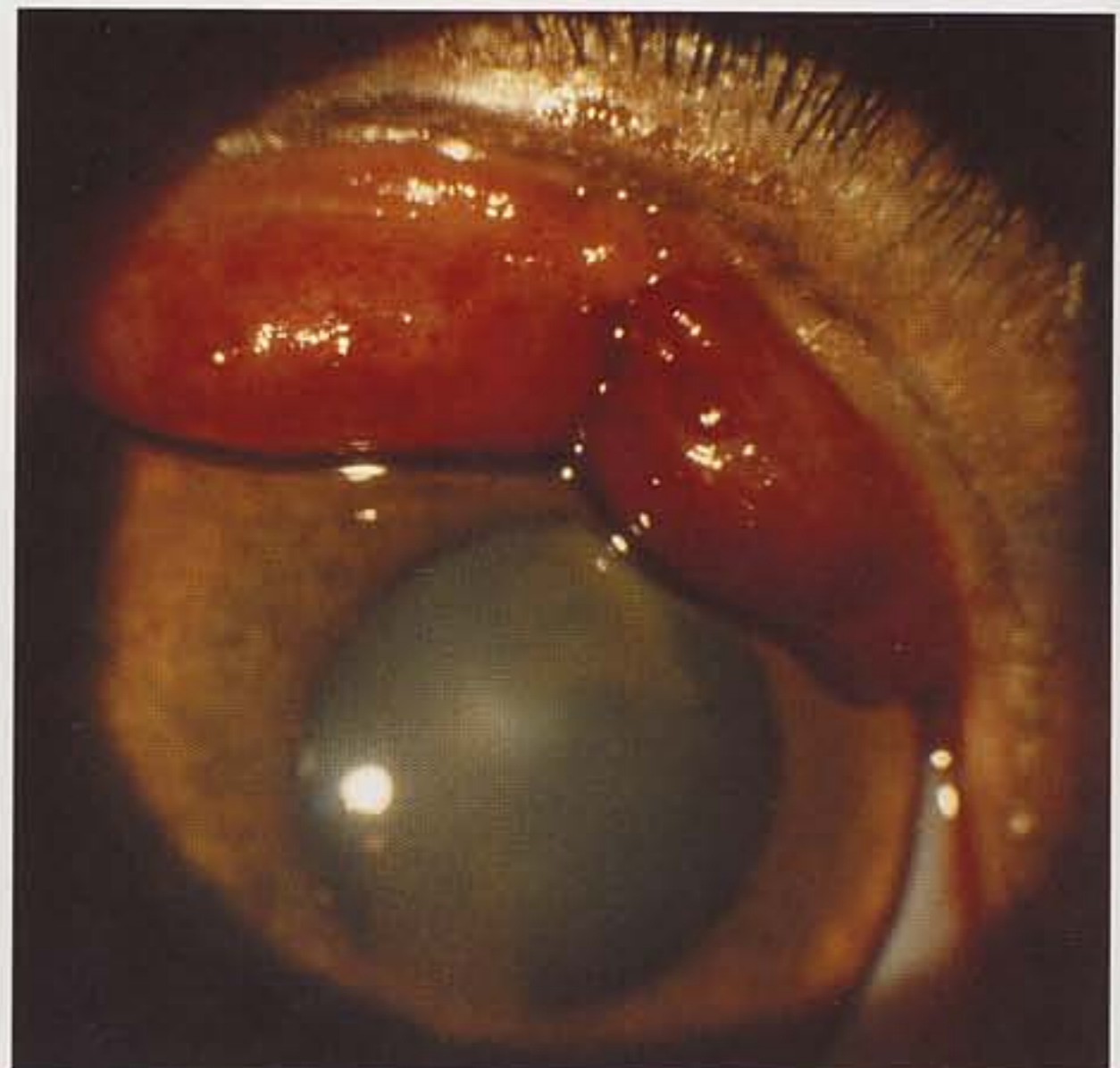


Fig. 5.10 Subconjunctival haemorrhage This particular case was reaction to a paint stripper.

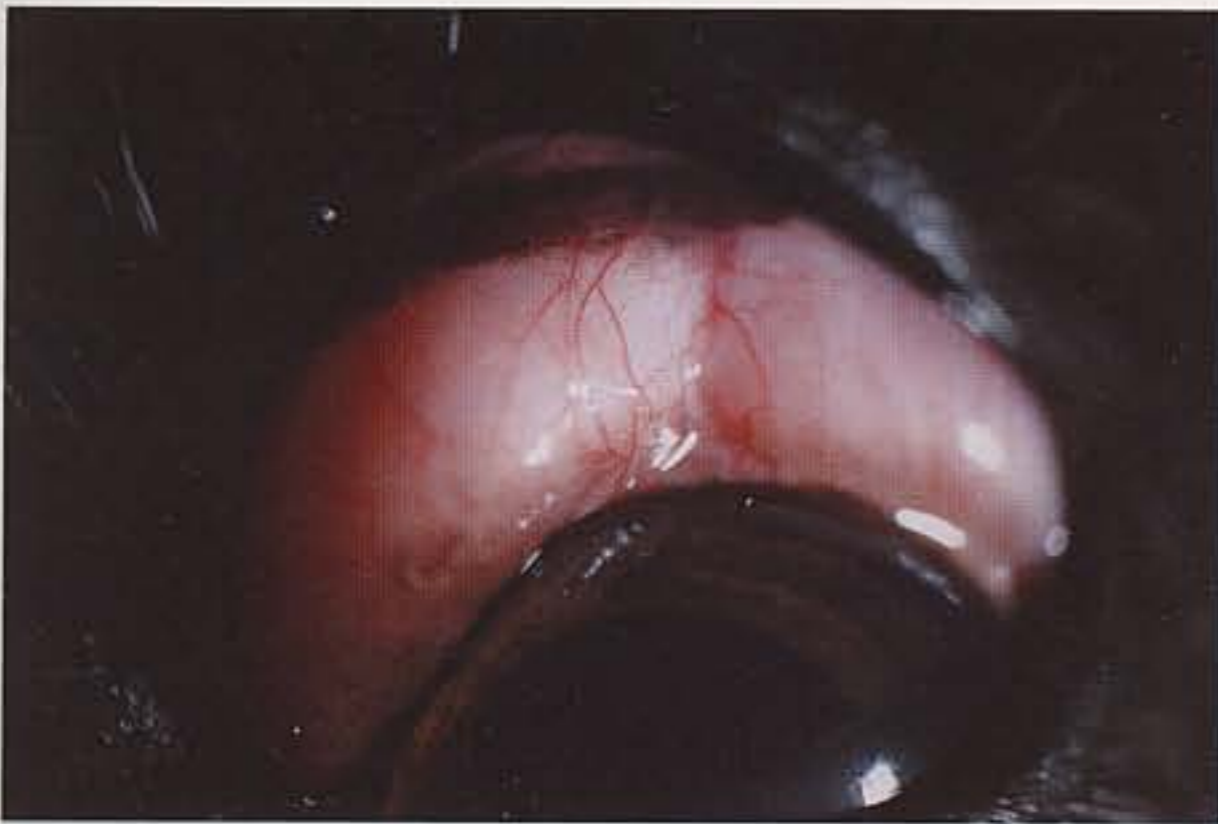

Fig. 5.11 Subconjunctival fat prolapse (Cairn Terrier, 8 years old)

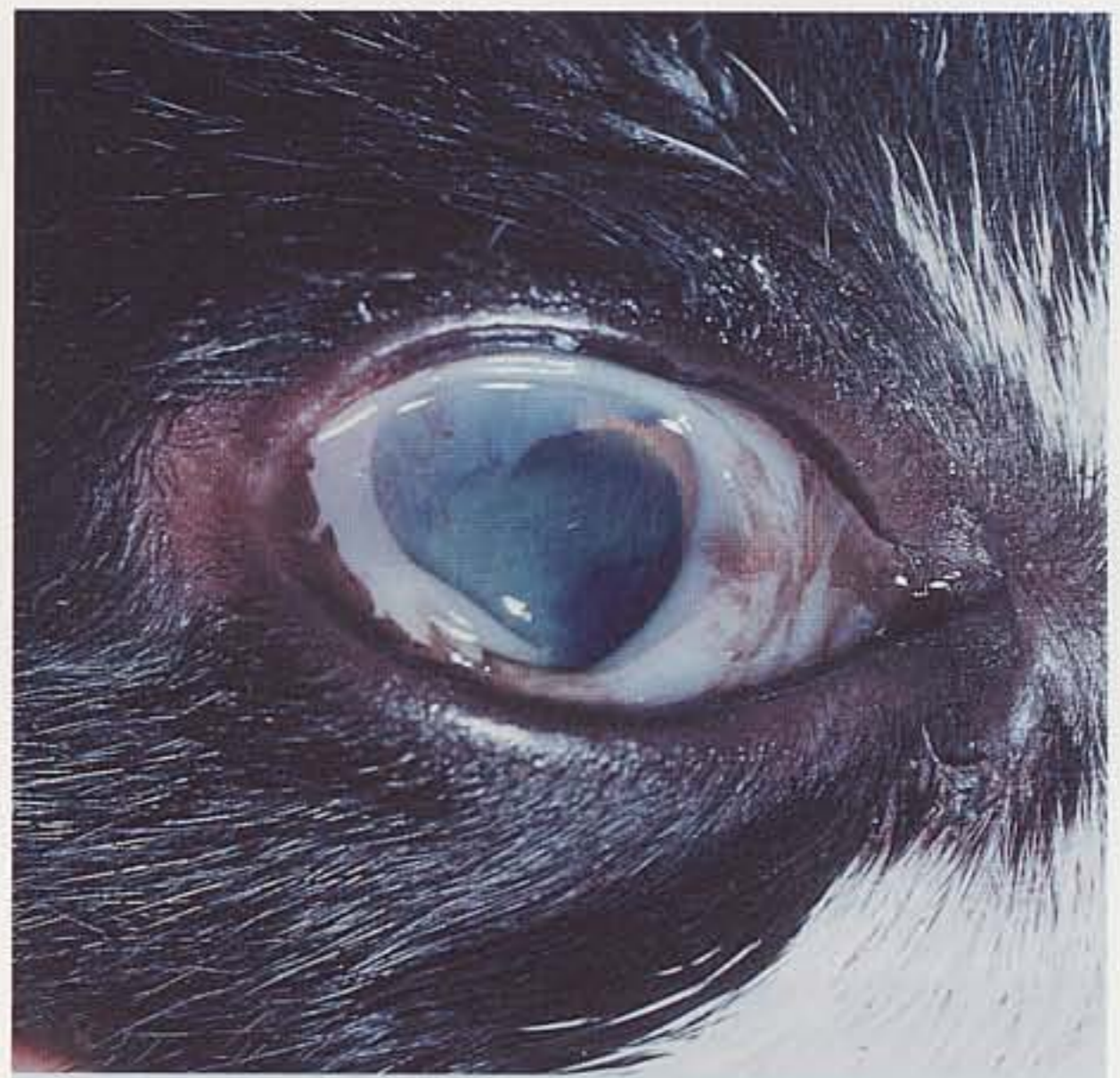


Fig. 5.13 Symblepharon (DSH cat, 2 years old)  
Adhesion of palpebral conjunctiva to the cornea  
obliterating the conjunctival fornices.

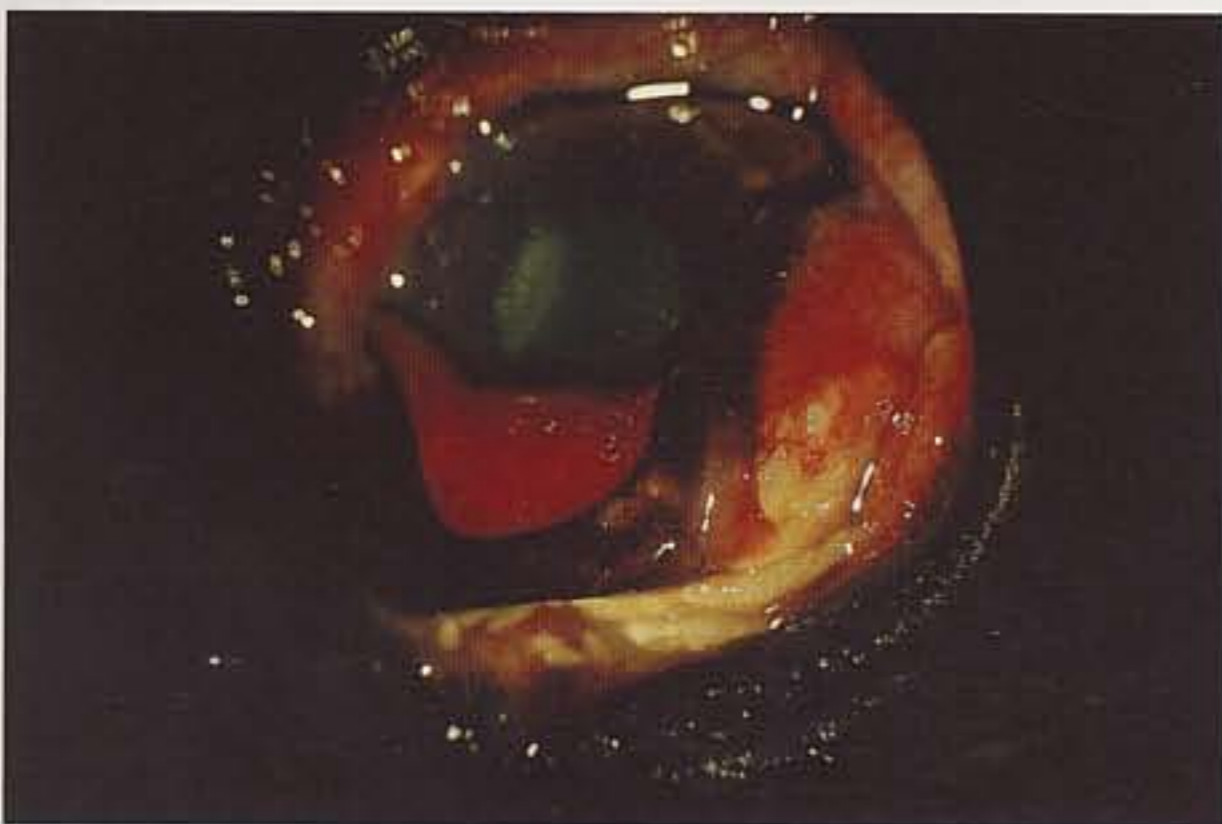

Fig. 5.12 Conjunctival calcinosis (Munsterlander, 5 months old)  
Calcinosis with bulbar conjunctiva and outer aspect of the nictitating membrane affected and causing a vascular keratitis and corneal ulcer. A rare case of unknown aetiology.

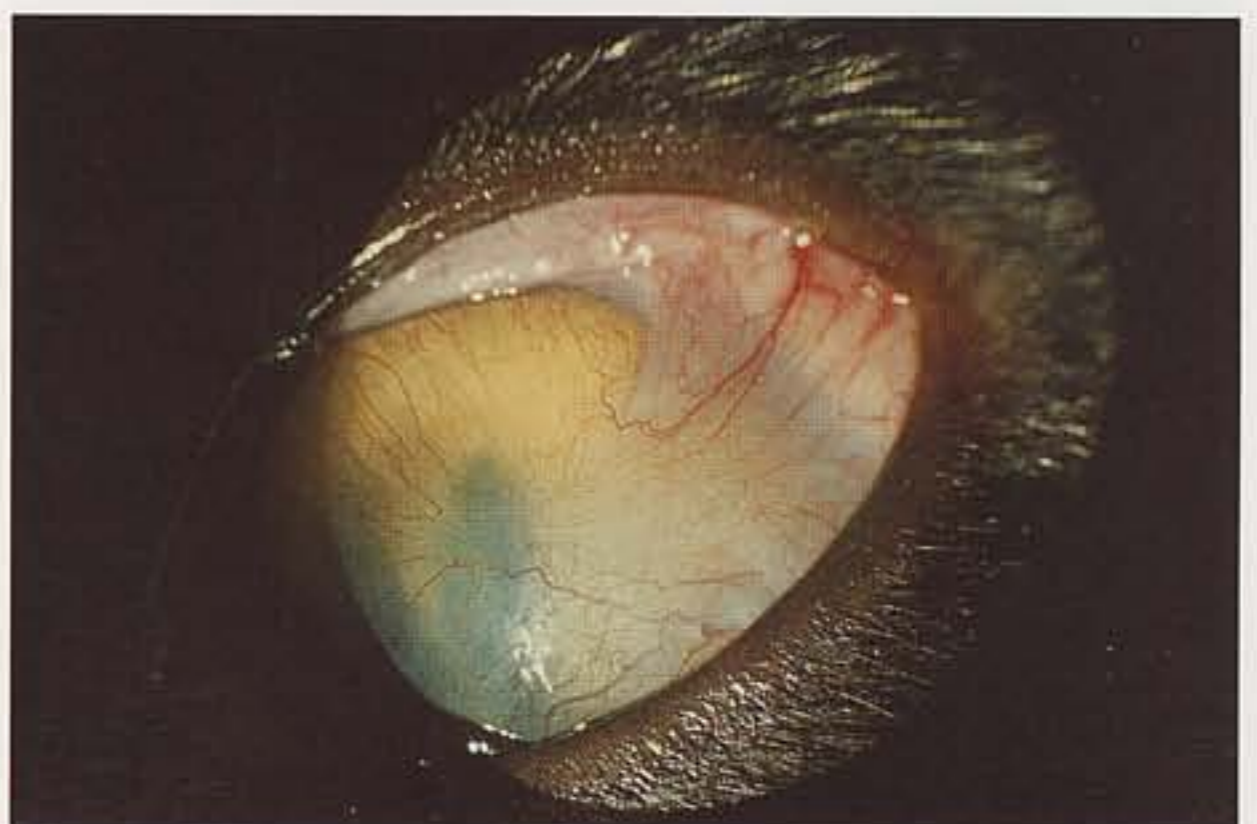

Fig. 5.14 Symblepharon (DSH cat, 6 months old)  
A mild case not affecting vision.

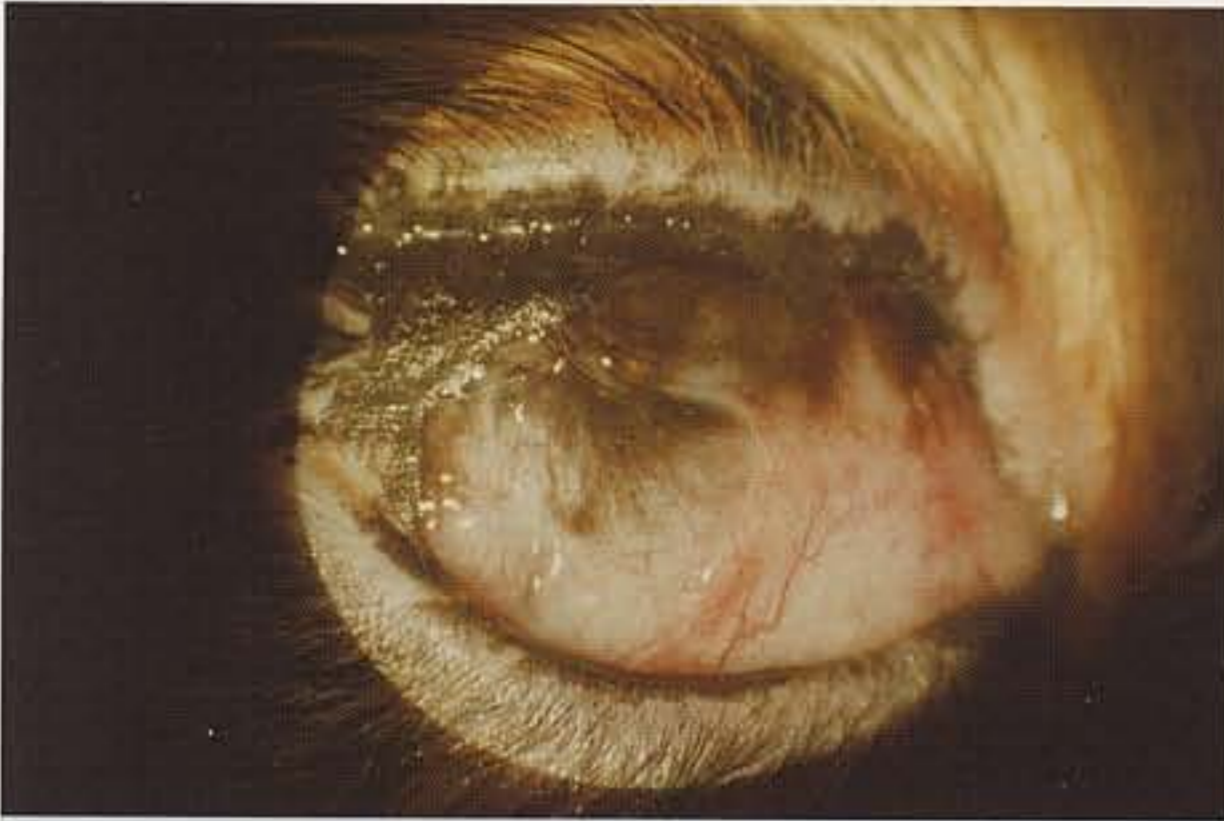

Fig. 5.15 Symblepharon (cat, young adult) Severe case causing blindness.



Fig. 5.17 Symblepharon (cat, young adult) Unilateral case causing a narrowed palpebral aperture.

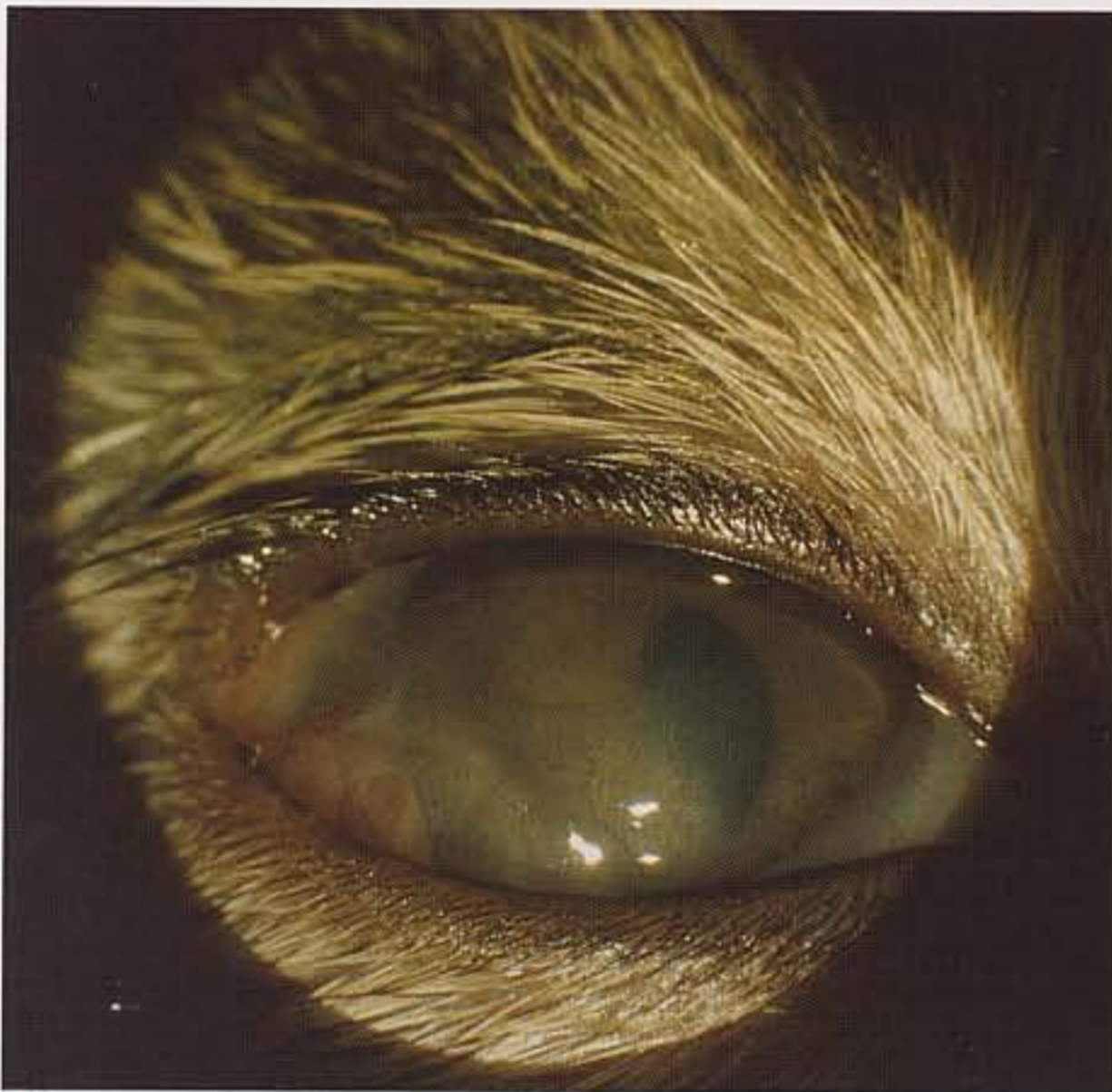

Fig. 5.16 Symblepharon (DSH kitten, 5 weeks old)

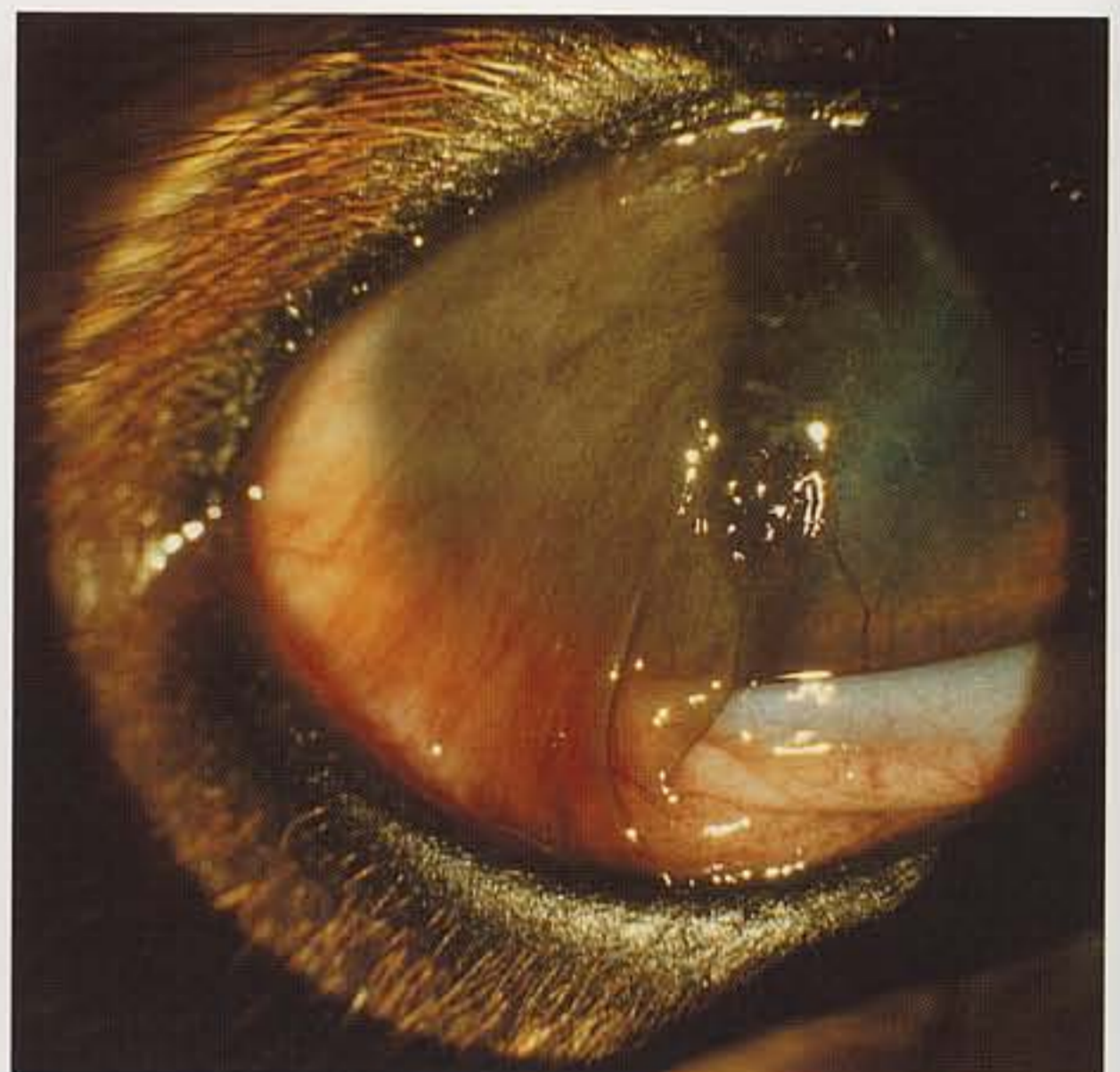

Fig. 5.18 Symblepharon (Cavalier King Charles Spaniel, 15 weeks old) Congenital adhesion of conjunctiva to cornea. This condition is rare in this species.

particularly due to neonatal infection with FEHV-1; burns are another factor in aetiology. The condition is painless but may be accompanied by discharge due to drainage problems; the degree is very variable, mechanically causing blindness in severe cases.

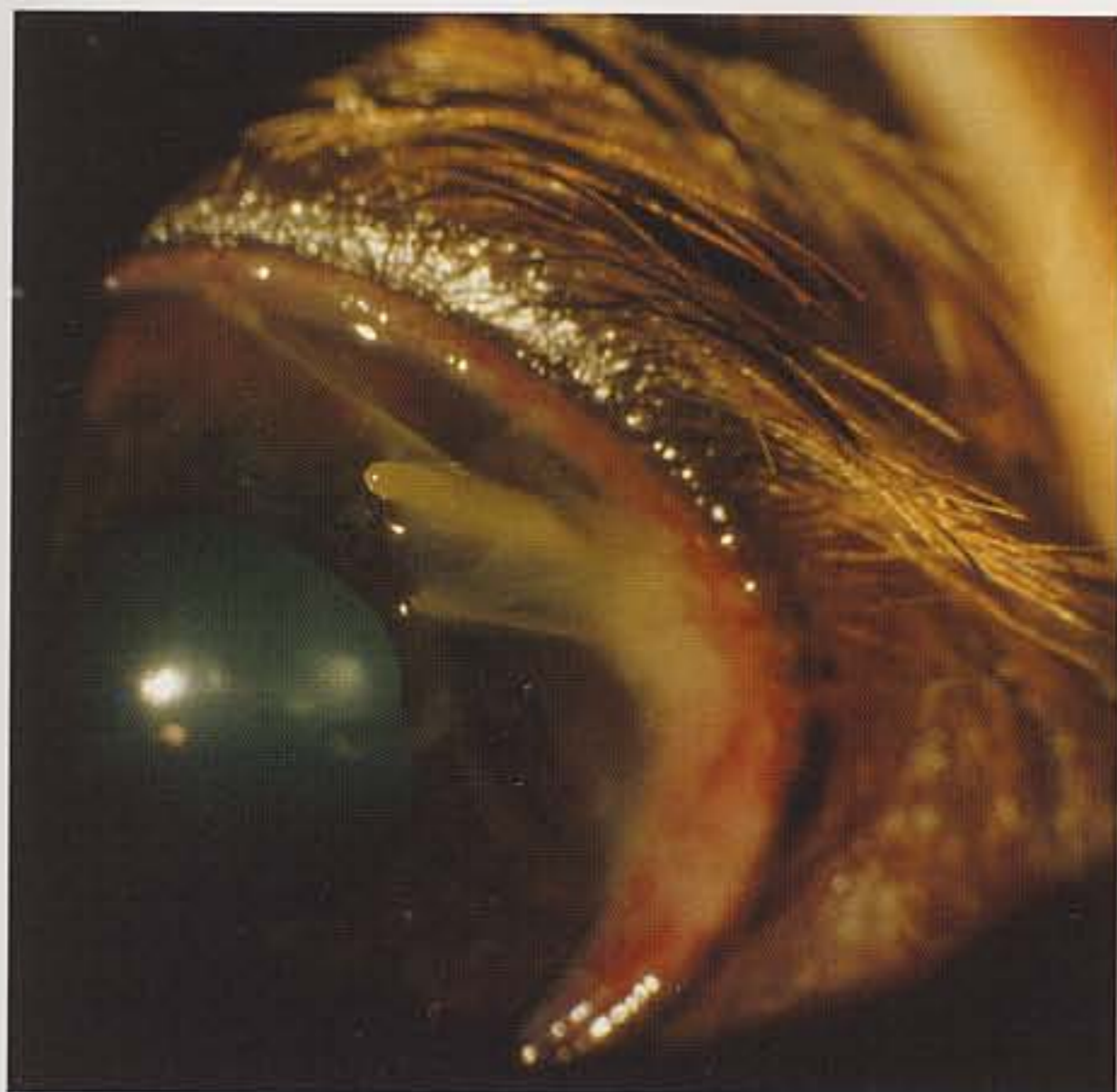


Fig. 5.19 Conjunctival foreign body (Yorkshire Terrier, adult) Grass awn in the left upper conjunctival fornix.

### Foreign bodies (Fig 5.19)

The conjunctival fornices are favourite sites for foreign bodies, particularly of organic origin, and should always be searched under local anaesthesia in cases of acute unioocular conjunctivitis often with a purulent discharge.

### Conjunctival dermoid (Figs 5.20–5.22)

Epibulbar dermoids occur on the conjunctiva in all the species and three examples are shown.

### Conjunctival cyst (Figs 5.23–5.24)

Two examples are shown; the first in a puppy and the second, in a cat, associated with symblepharon.

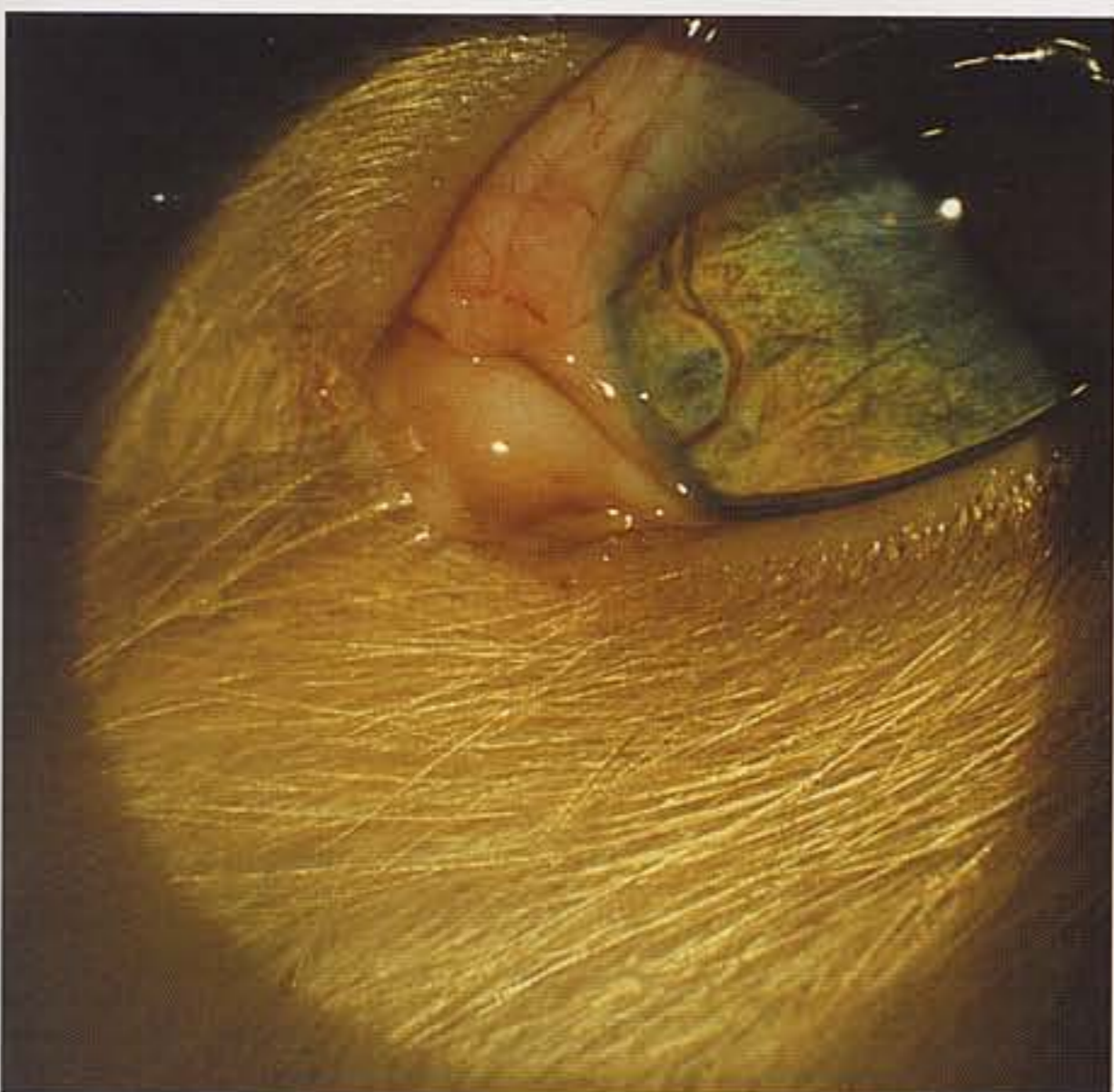


Fig. 5.20 Conjunctival dermoid (Birman kitten, 12 weeks old) The condition is hereditary in this breed.

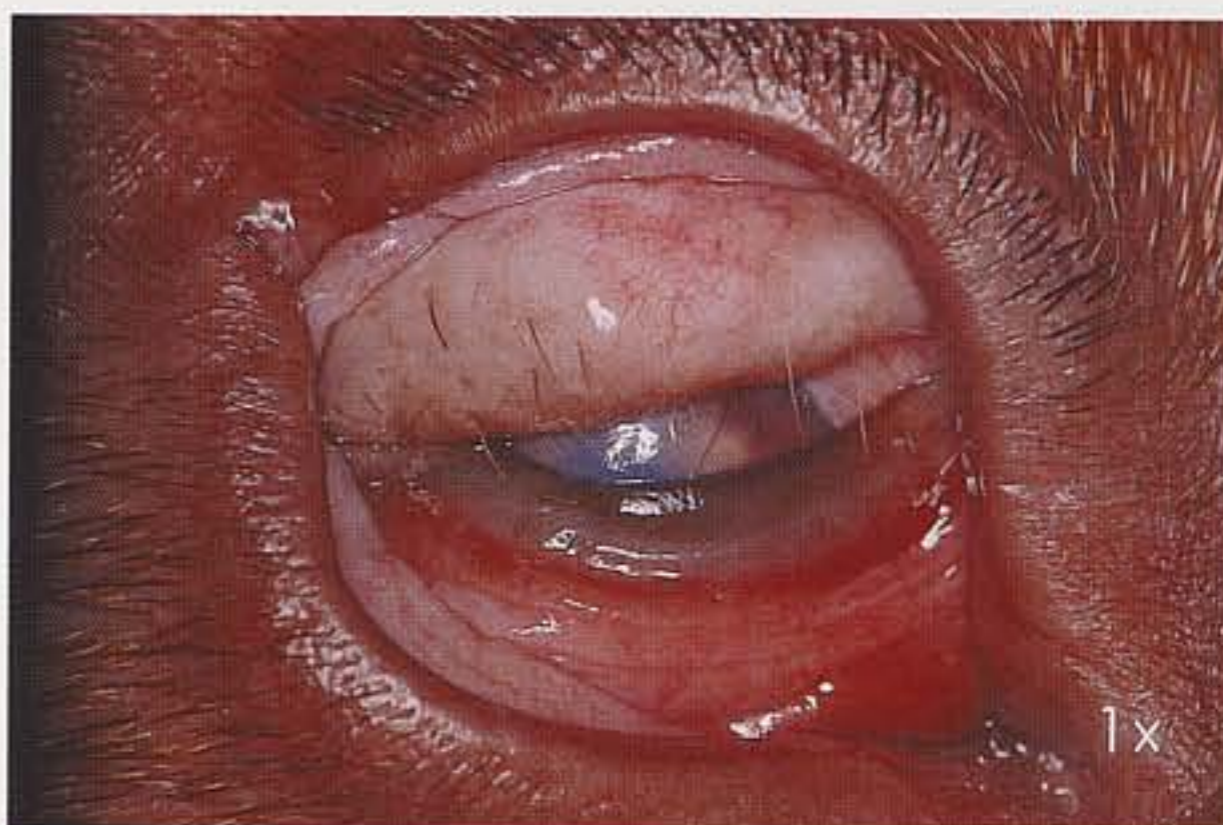

Fig. 5.21 Conjunctival dermoid (Dogue de Bordeaux, 1 year old) Unusual case causing a corneal ulcer.

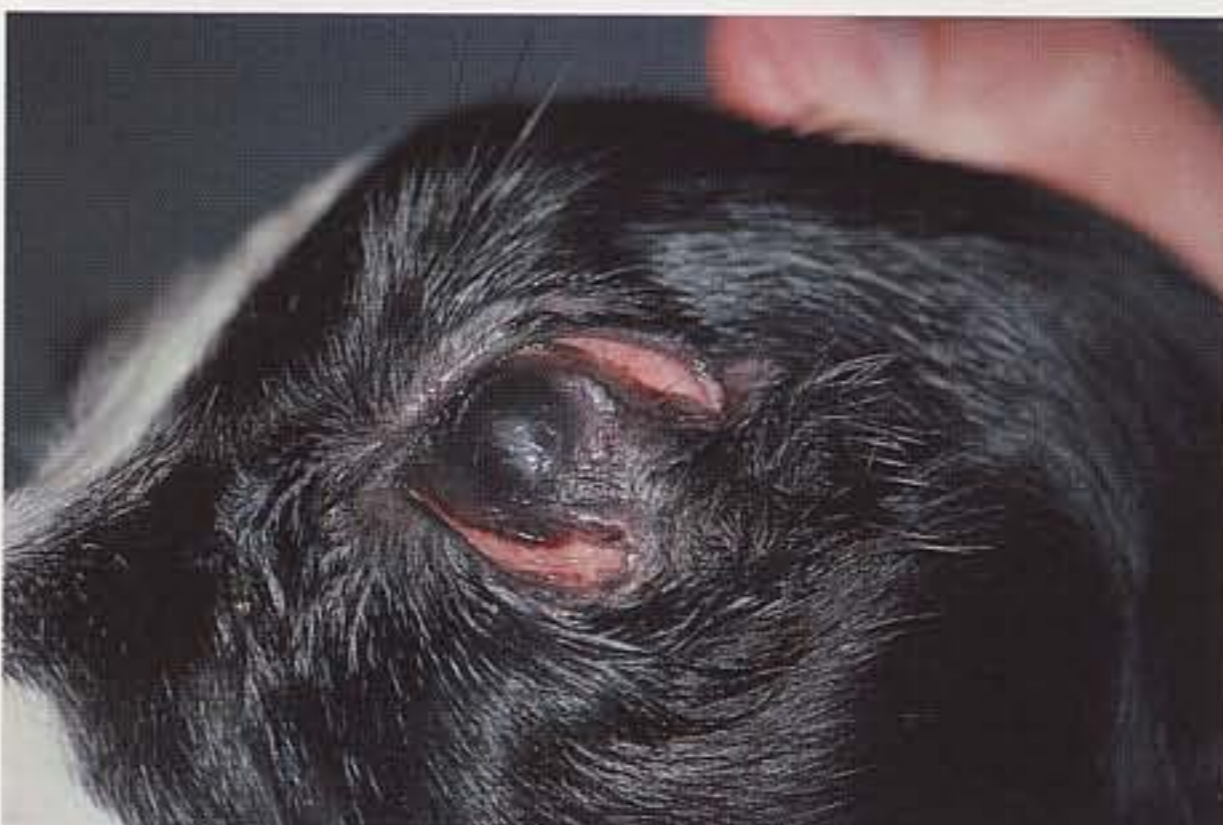

Fig. 5.22 Conjunctival dermoid (Crossbred puppy) Involvement of conjunctiva, limbus and lateral canthus.

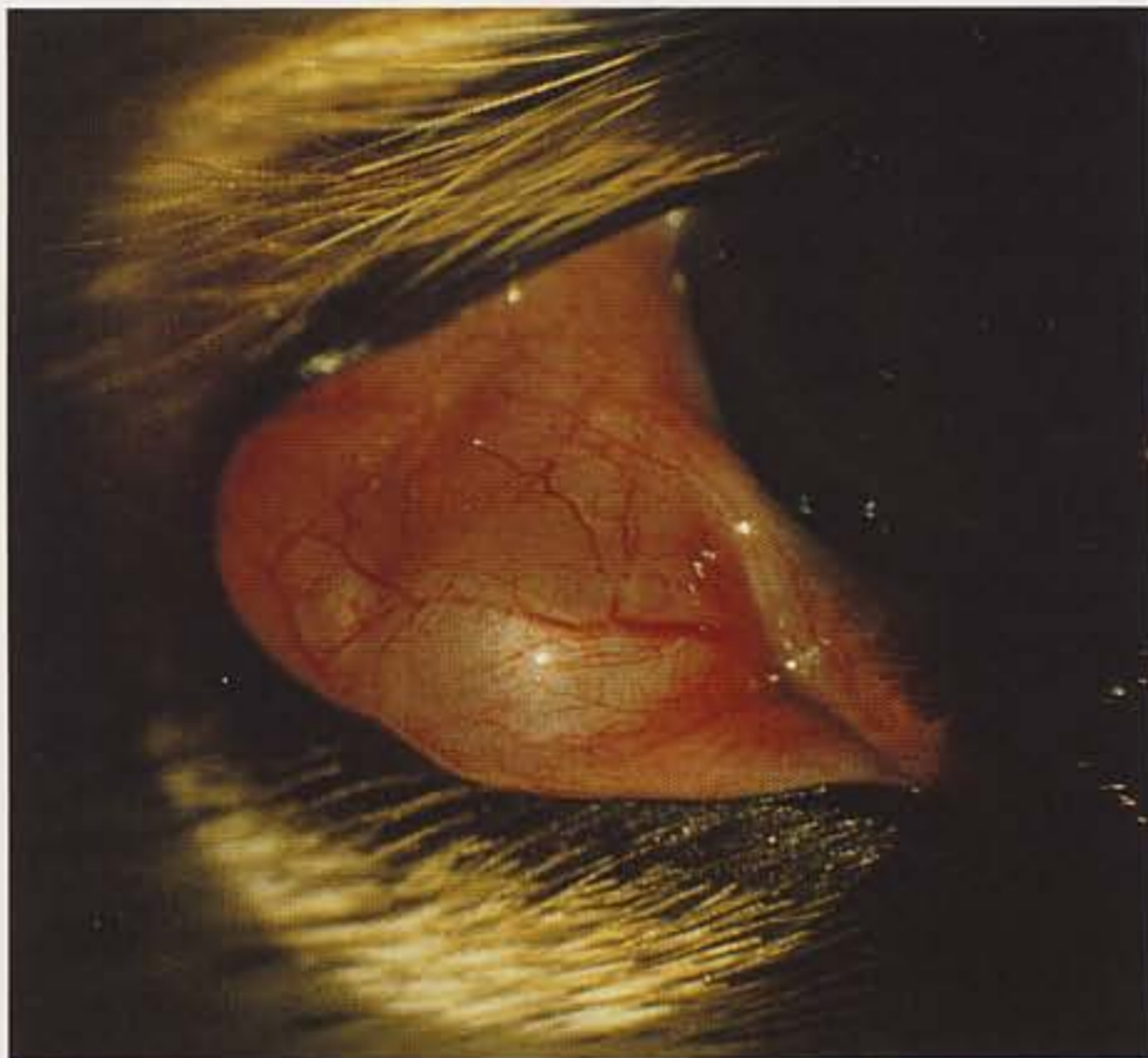

Fig. 5.23 Conjunctival cyst (Golden Retriever, 6 months old)

### Neoplasia (Figs 5.25–5.32)

The conjunctiva, particularly palpebral, and limbus are favoured sites for squamous cell carcinoma in the horse, a relatively common tumour in this species. Examples are also shown of a haemangioma of the conjunctiva in a dog and a lymphosarcoma of the conjunctiva in a cat. In addition limbal melanoma in the dog is shown, a benign tumour to be distinguished from iris and ciliary body tumours in this and other species (see Chapter 7).

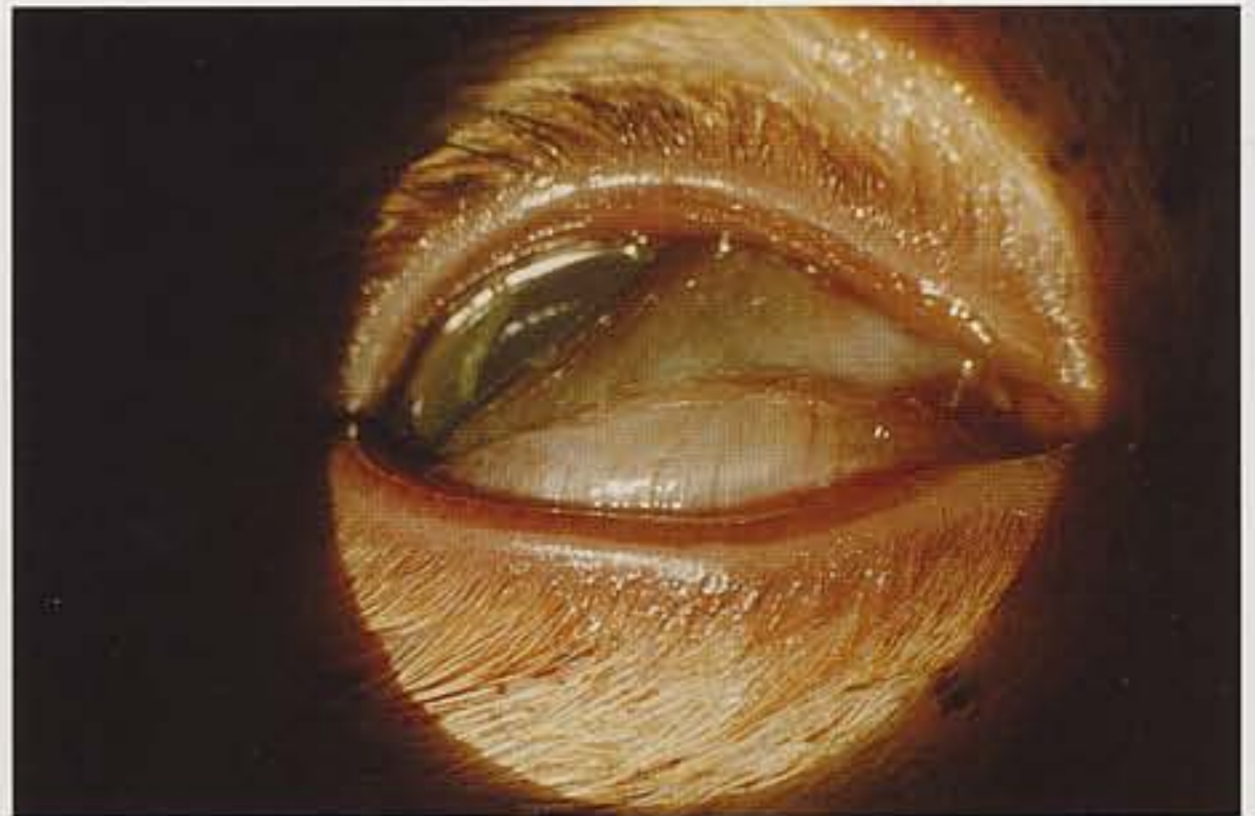

Fig. 5.24 Conjunctival cyst together with symblepharon (DSH cat)

### Scleritis and episcleritis

(Figs 5.33–5.35)

Classification and nomenclature is confused and variable but these are inflammatory and usually non-painful conditions and are not neoplastic in spite of their appearance. Episcleritis may be nodular or simple (diffuse), occurring near to the limbus with hyperaemia of conjunctiva and oedema of adjacent cornea. The condition may be unilateral or bilateral and there is a predilection in the Golden Retriever. Nodular episclerokeratitis is usually bilateral, involving more of the cornea and particularly occurs in the Rough Collie and Shetland Sheepdog.



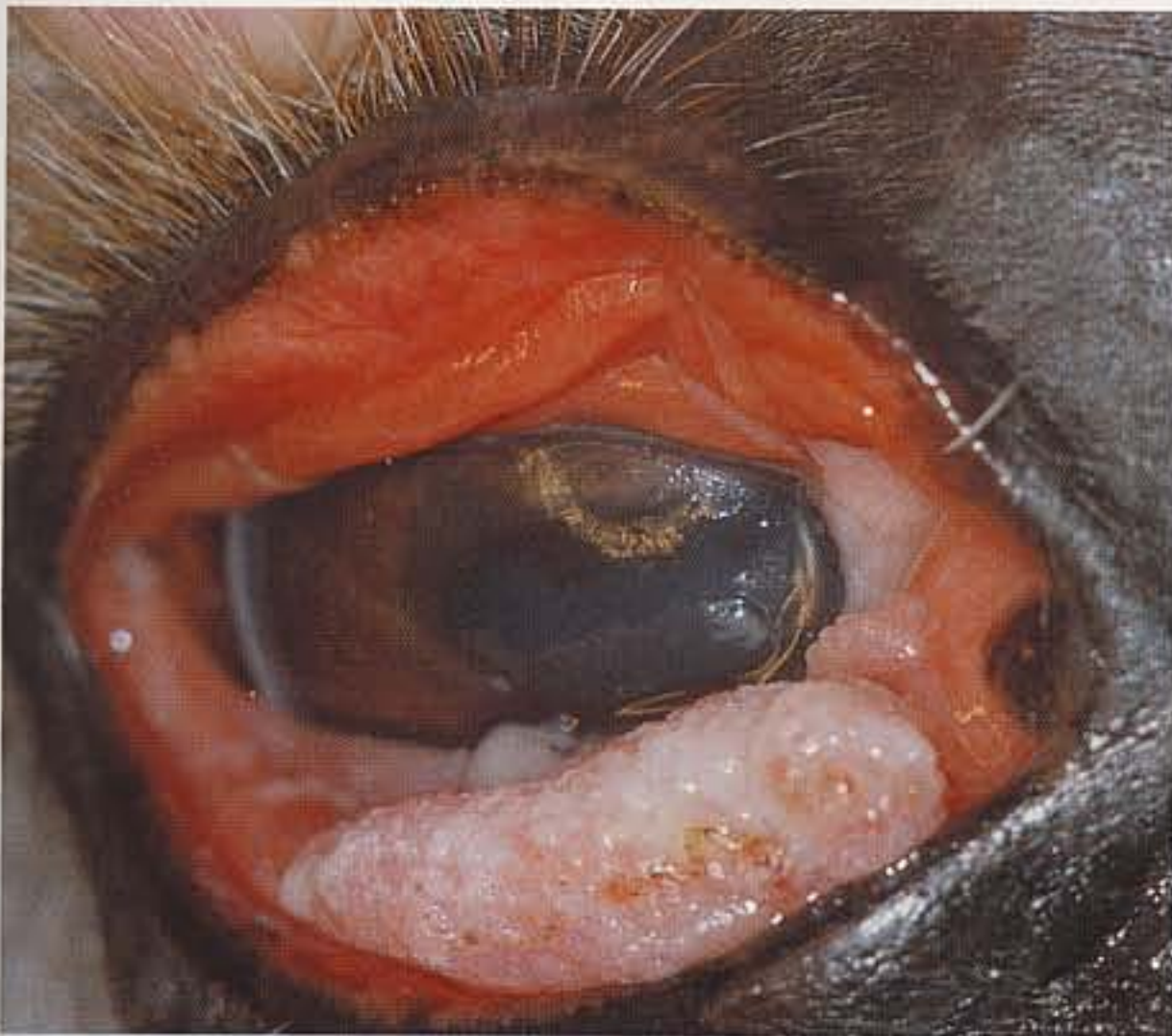

Fig. 5.25 Conjunctival tumour (Hunter-type, 13 years old, palomino) Squamous cell carcinoma of lower palpebral conjunctiva and nictitating membrane.

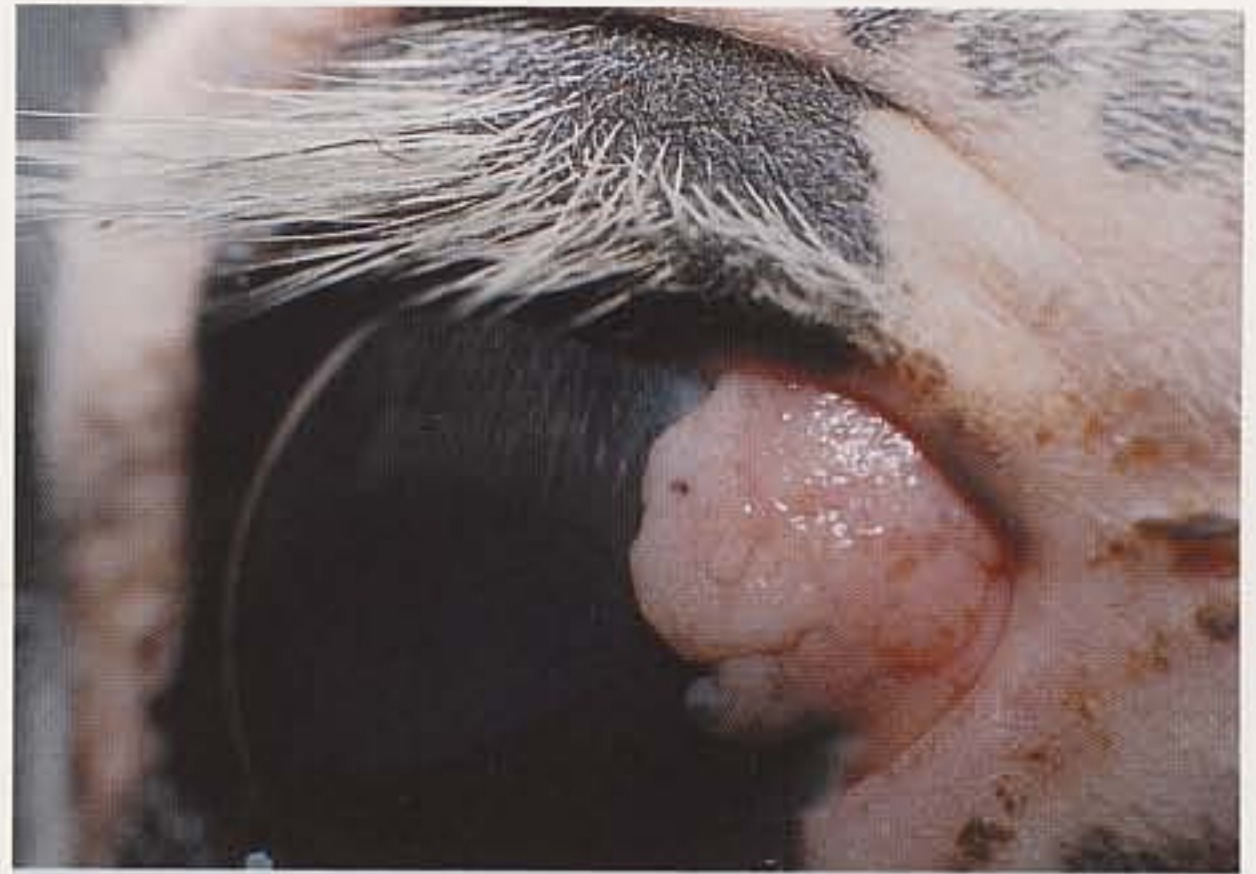

Fig. 5.27 Conjunctival tumour (Hunter-type, 17 years old) Squamous cell carcinoma in a similar position to previous figure.

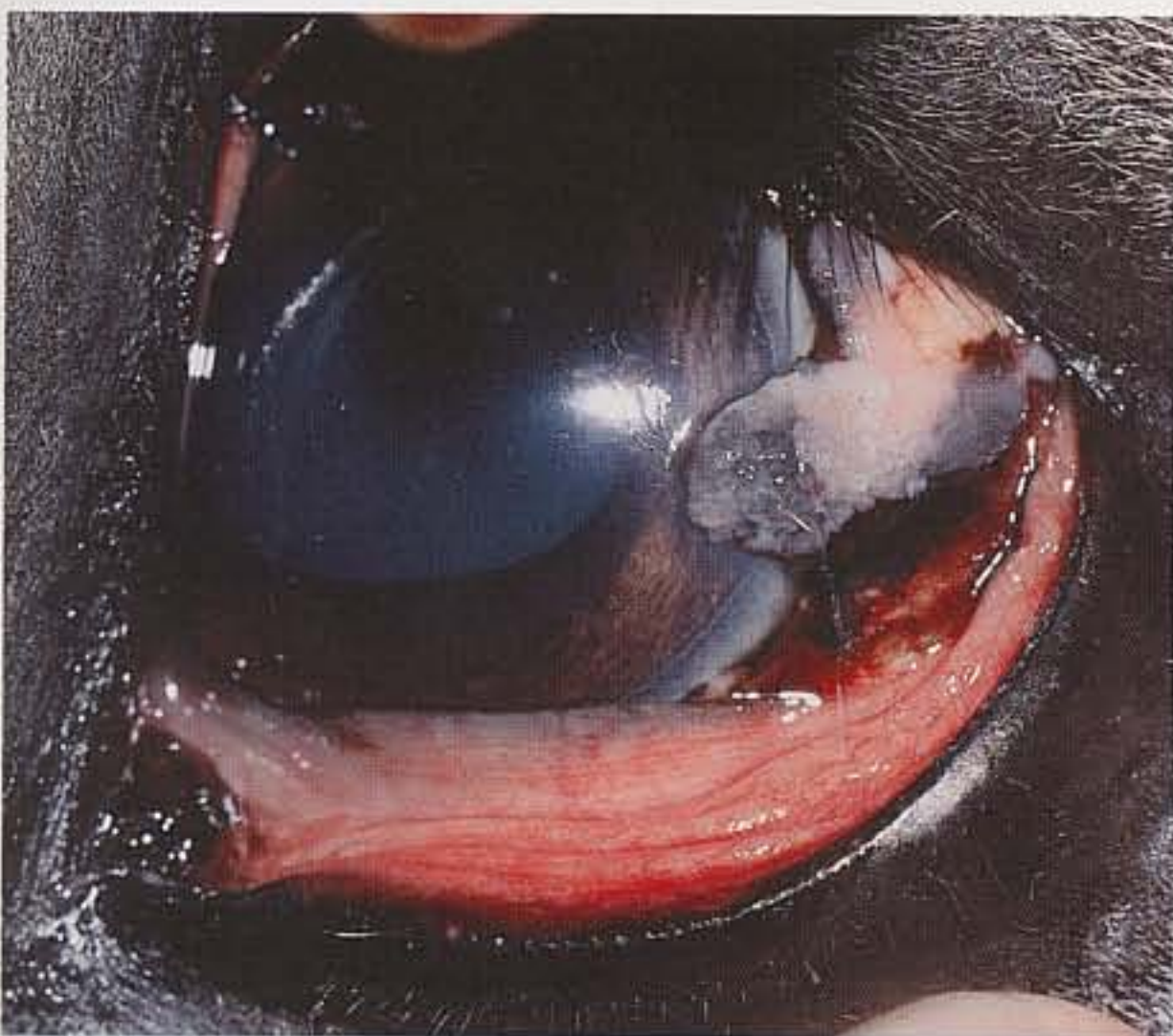

Fig. 5.26 Conjunctival tumour (Connemara pony, 8 years old) Squamous cell carcinoma at the limbus and bulbar conjunctiva.

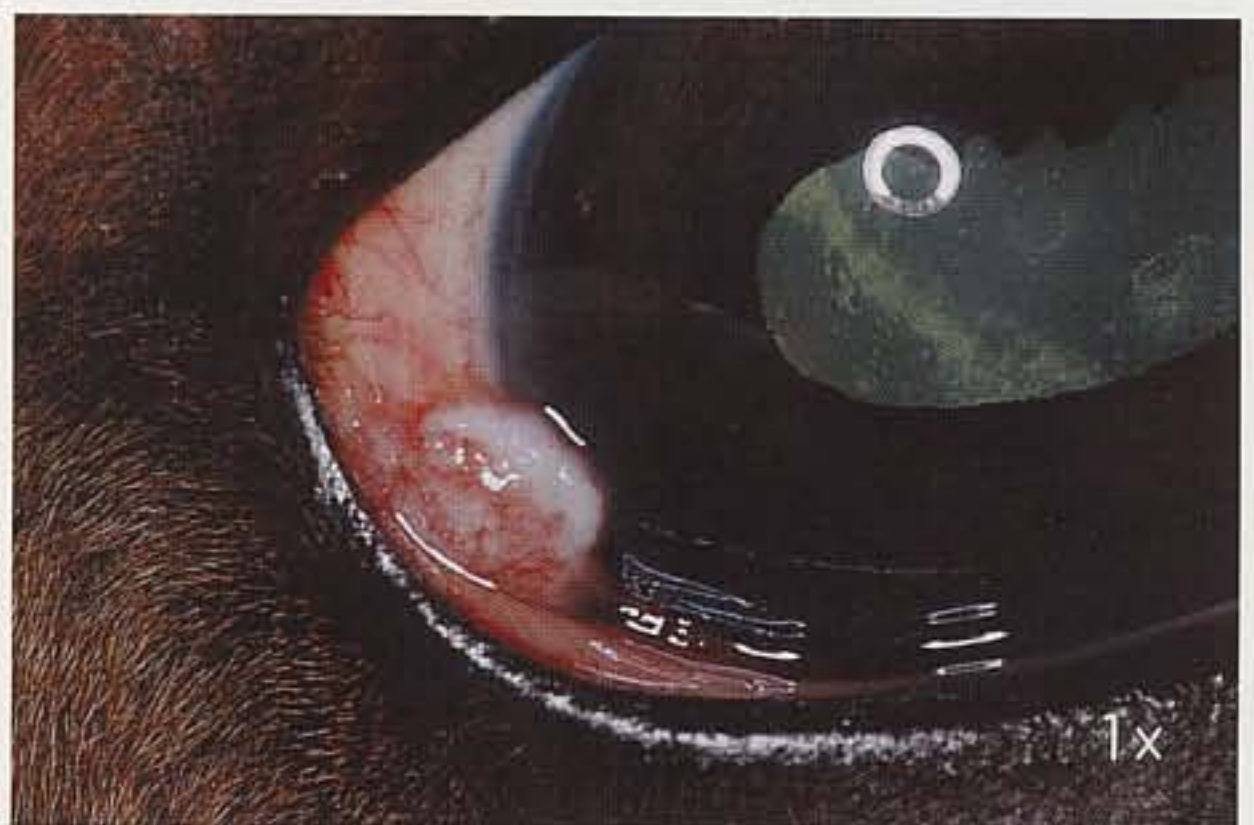

Fig. 5.28 Conjunctival tumour (Horse) Squamous cell carcinoma at the limbus. Note the typical pale grey appearance in this case. The horse was affected in both eyes.

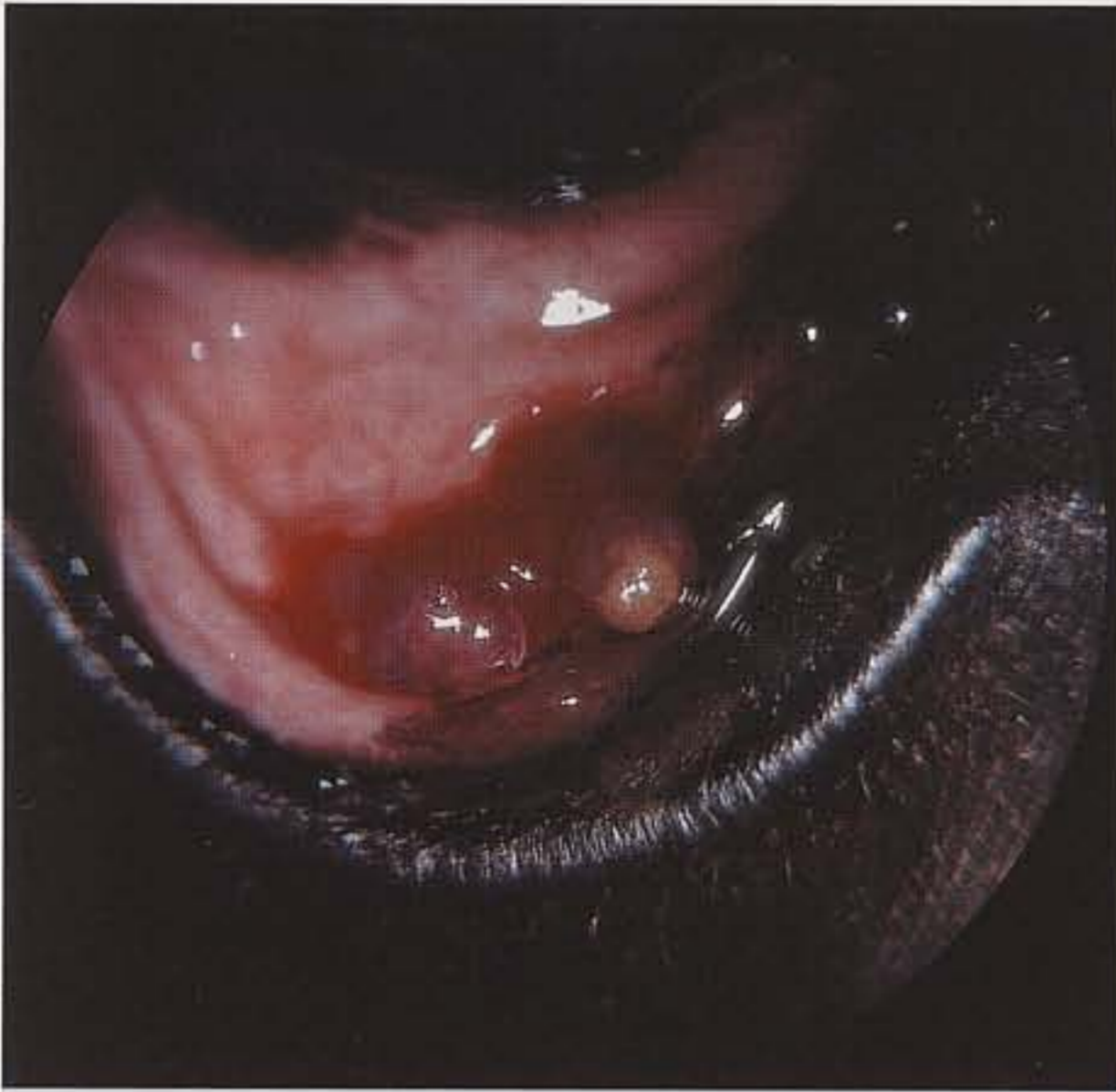

Fig. 5.29 Conjunctival tumour (Gordon Setter, 11 years old) Benign haemangioma. Lower conjunctival fornix.

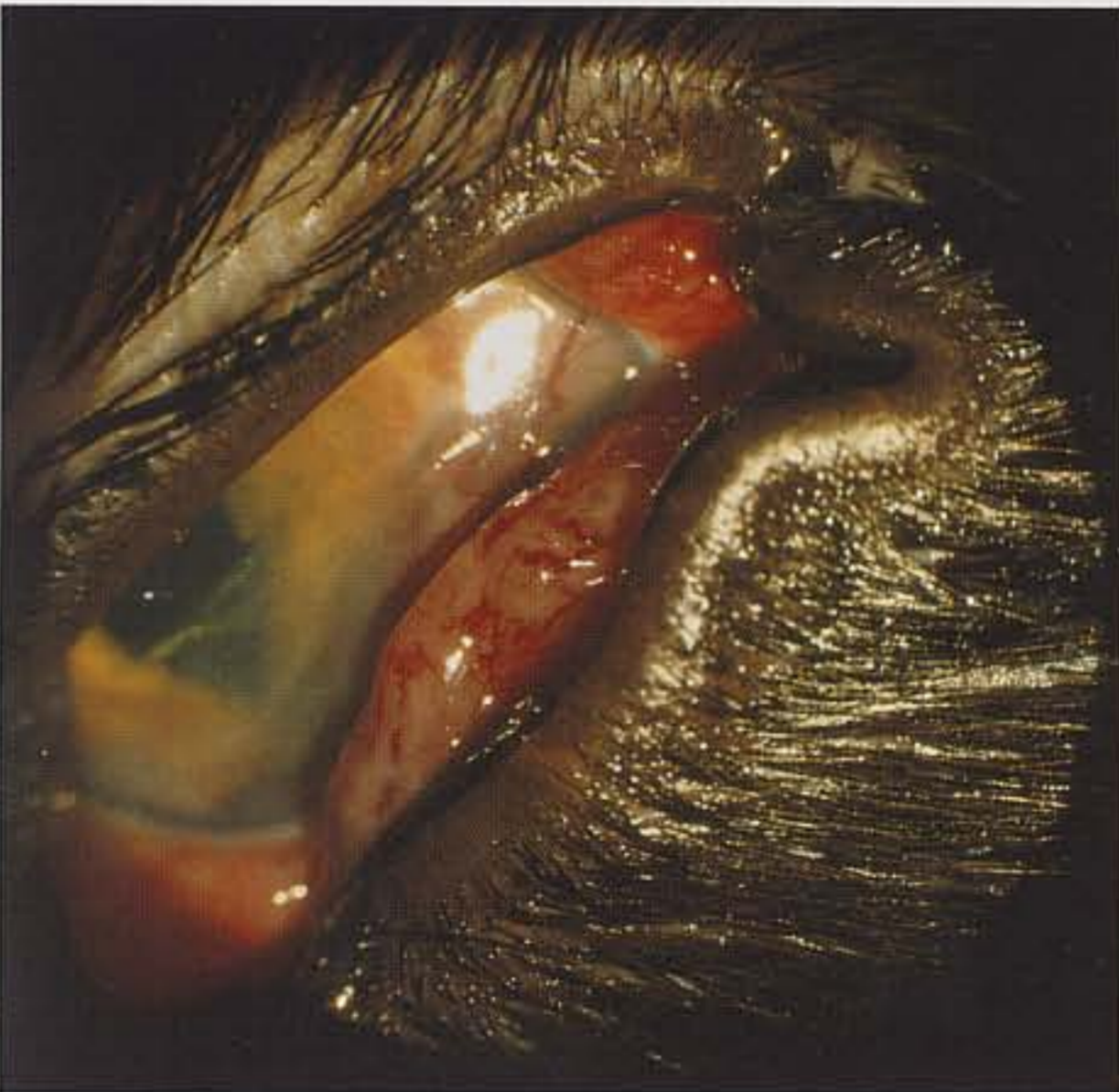

Fig. 5.30 Conjunctival tumour (DSH cat 11 year old) Lymphosarcoma affecting palpebral conjunctiva and nictitating membrane.

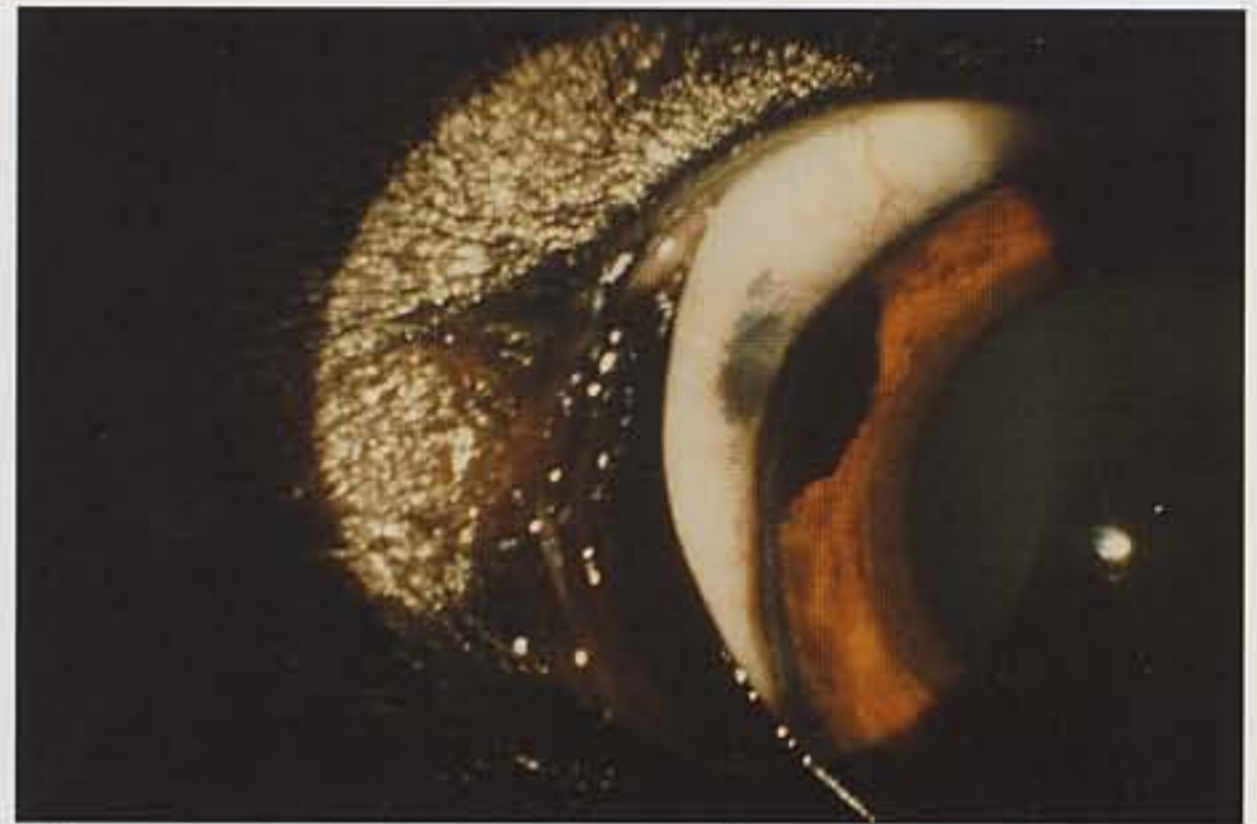


Fig. 5.31 Conjunctival tumour (Labrador Retriever, adult) Limbal melanoma. Note the appearance at the limbus and adjacent sclera and particularly the lack of involvement of iris and pupil. Compare with Fig 7.41.

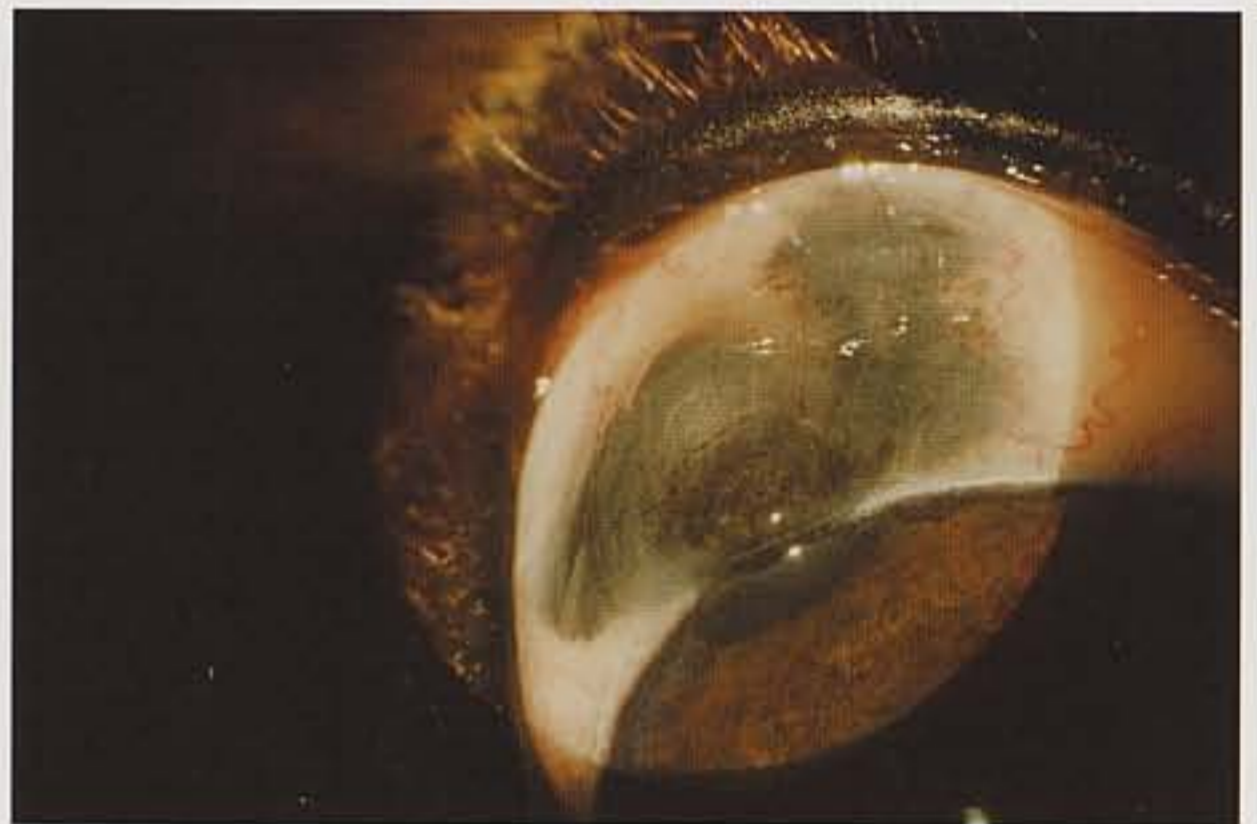

Fig. 5.32 Conjunctival tumour (Golden Retriever, adult) Limbal melanoma. Again note the appearance with no evidence of iris involvement. This tumour occurs particularly in this breed as well as the Labrador Retriever (previous figure).

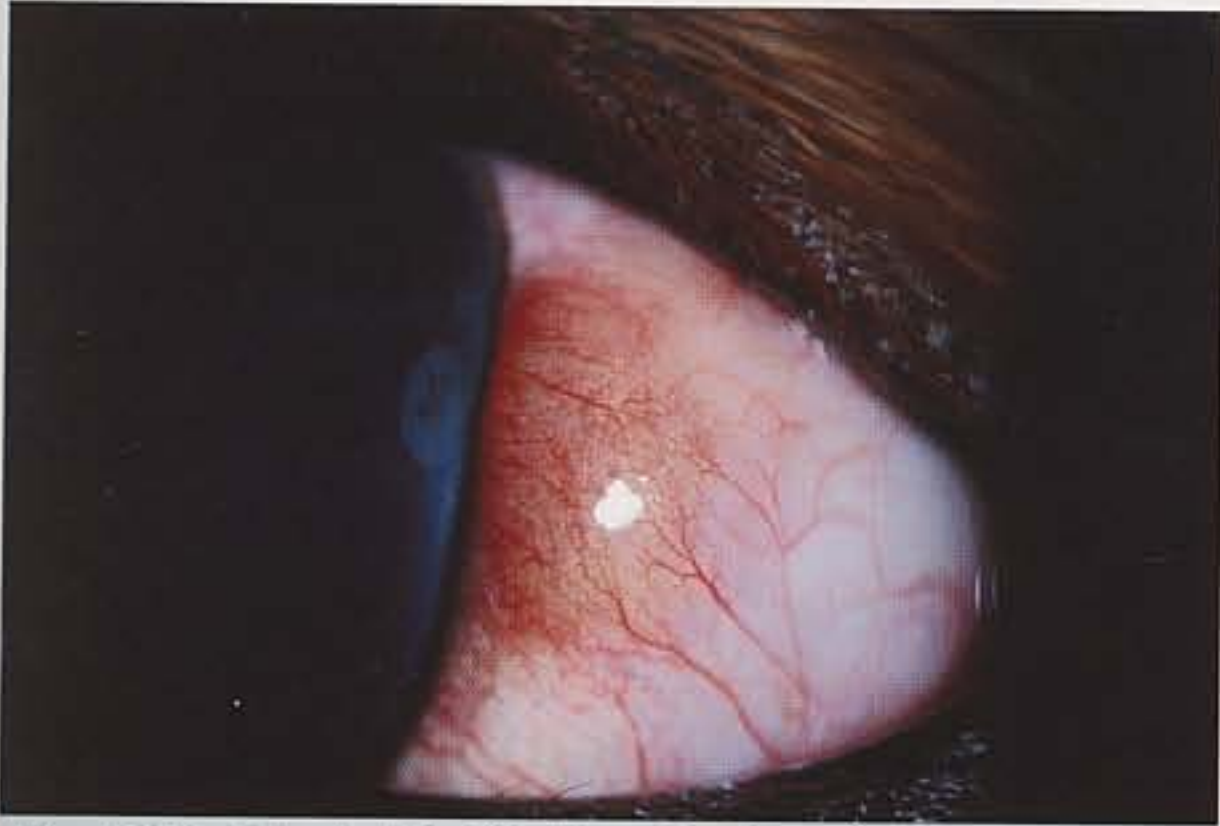

Fig. 5.33 Episcleritis (Golden Retriever) Nodular episcleritis. Note the corneal oedema adjacent to the tumour.

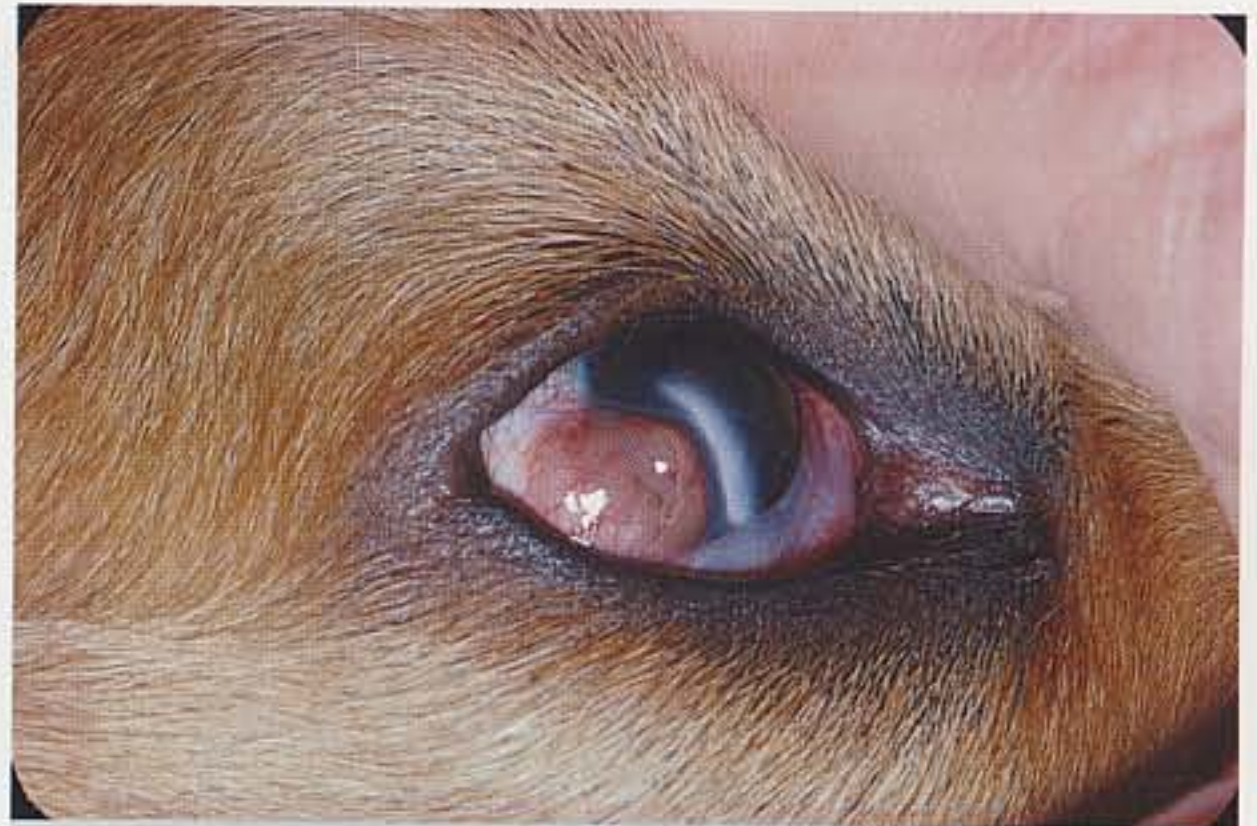

Fig. 5.35 Episcleritis (Rough Collie, young adult) Nodular episclerokeratitis, bilateral case. Note the adjacent corneal arcus.

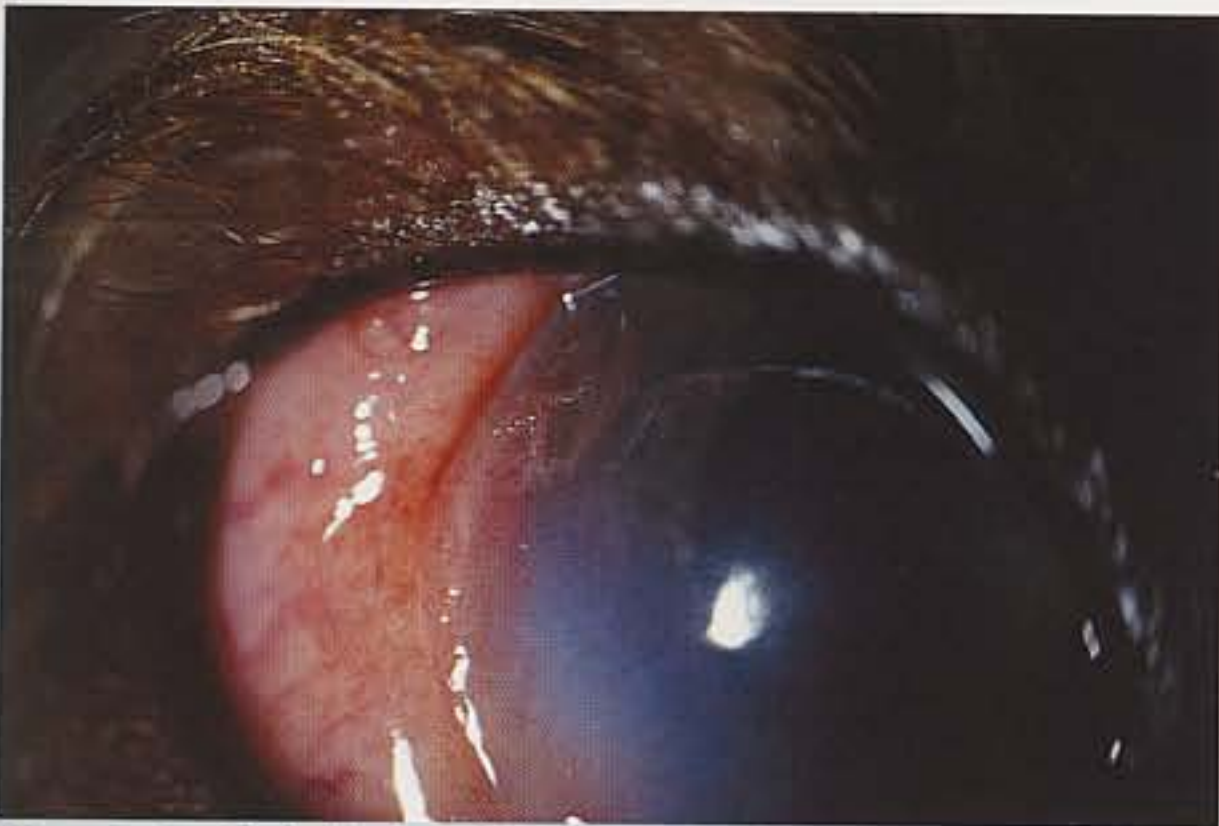

Fig. 5.34 Episcleritis (Airedale Terrier, 5 years old) Diffuse episcleritis. Note hyperaemia of overlying conjunctiva.

## Chapter 6

# Cornea

### Introduction

Corneal disease and keratitis are among the most common eye diseases in all the domestic animals and with a wide variety of causes and appearances.

The presenting signs of corneal disease vary considerably between case, severity and cause and in a number, particularly in the dog, the aetiology remains unknown. Pain is an important sign and will accompany most forms of keratitis, whatever the cause, with the classical triad of blepharospasm, photophobia and lacrimation. However, the degree of pain in corneal disease is again variable, from severe in cases of corneal ulceration and trauma, to non-existent in cases of corneal oedema and most other forms of opacity. The presence or absence of ocular discharge, in addition to lacrimation, should be noted, as should the presence of pigment in the cornea which is more common in the dog than the other species. Corneal opacity is another variable and important presenting sign (Table 6.1), involving the whole cornea, for example in cases of corneal oedema, or only part of the cornea in cases of lipid infiltration, abscess or scar formation. The lipid keratopathies are a complex but an important group with different appearances, often familial in the dog and usually with little or no effect on vision. In fact, vision loss is an uncommon sign of corneal disease generally in spite of the history from the owner who imagines the animal cannot see because of the appearance of the eye(s). The presence or absence of corneal ulceration should also be checked by suitable staining, both at the initial clinical examination and subsequently, if considered necessary. The corneal reflection to a light source can be most useful in deciding the depth of the lesion within the cornea; for example

the reflection may be broken or irregular (Fig 6.1) indicating a superficial lesion with interference of the corneal epithelium, or regular (Fig 1.1) indicating no interference with the epithelium, the lesion being within the corneal stroma or endothelium.

Keratitis may be accompanied by conjunctivitis (keratoconjunctivitis) and also, if severe or chronic, by uveitis which may well require additional treatment. Forms of keratitis may occasionally indicate systemic involvement.

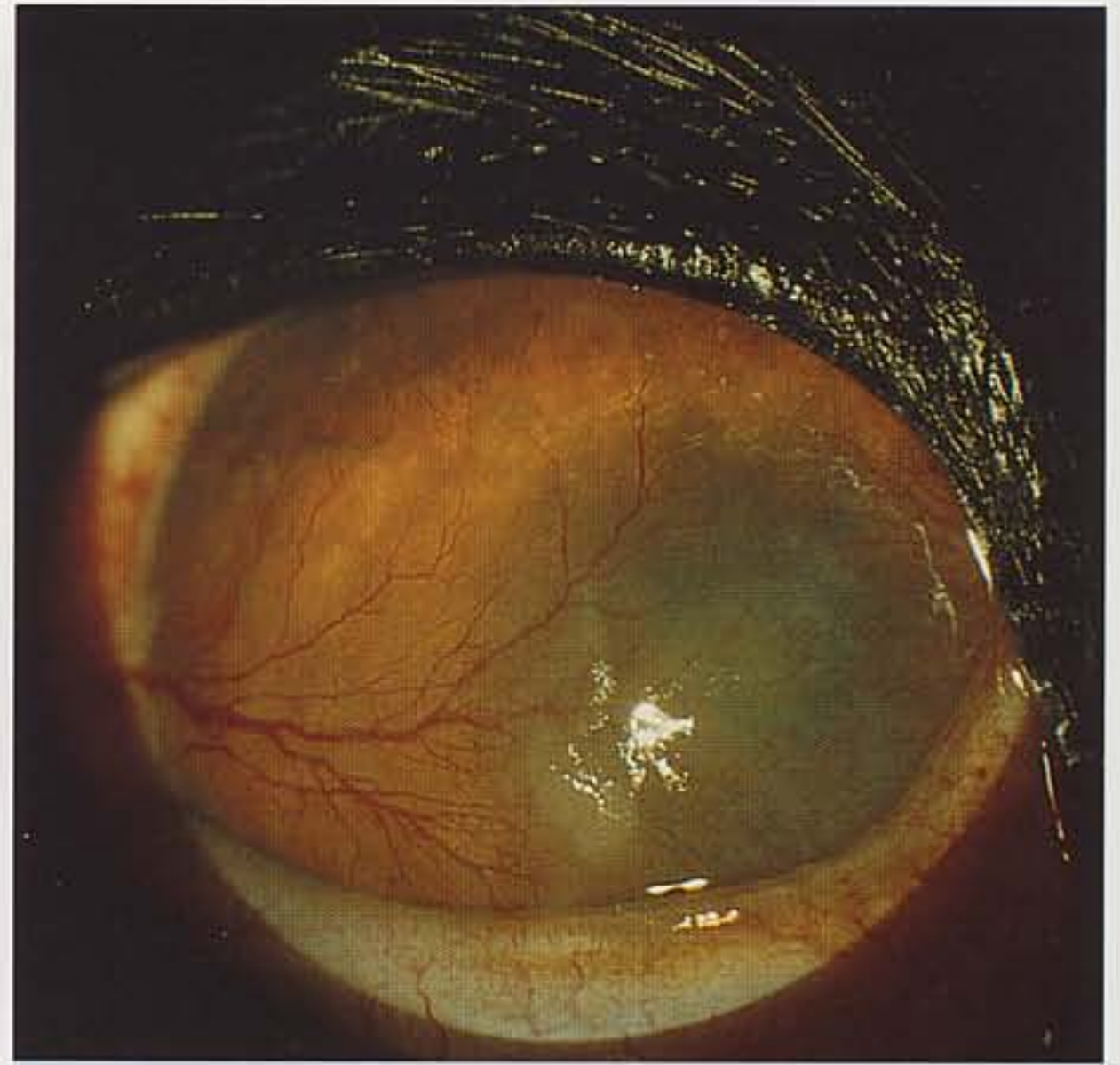
Congenital and hereditary abnormalities affecting the cornea are uncommon – the epibulbar dermoid and microcornea being the most important of the congenital anomalies. However, certain specific corneal conditions have an interesting and significant breed susceptibility in the dog, for example keratoconjunctivitis sicca in the West Highland White Terrier, pannus in the German Shepherd Dog, corneal lipidosis in the Shetland Sheepdog and others. Corneal tumours are also relatively rare, although squamous cell carcinoma, particularly in the horse, is important. Corneal cysts are very rare.

The main responses to corneal insult are (1) oedema, (2) vascularization and (3) pigmentation and any or all of these may act as presenting signs but are not, in themselves, specific diseases.

The classification of corneal disease is complex; it is perhaps best categorized by aetiology but the cause of a number of conditions is still not known. Corneal disease will be described here and illustrated under several headings, although it must be realized that certain specific conditions can be included in more than one section.

**Table 6.1 - Corneal opacity: differential diagnosis**

Unilateral or bilateral
Partial or complete
Diffuse or dense
Temporary or permanent
1. Corneal oedema
Neonate puppy
Endothelial degeneration, e.g. Chihuahua
Corneal ulcer with loss of epithelium
Corneal wound or burn
Uveitis ('blue eye')
Glaucoma (+ conjunctival oedema)
Descemet's membrane tears
Anterior lens luxation - subcentral, oval
Anterior segment neoplasia (uveal melanoma)
2. Lipid keratopathies (infiltrations and degenerations)
3. Corneal abscess
4. Corneal scar
5. Congenital anterior synechia (persistent pupillary membrane)
6. Conjunctival adhesion (symblepharon)
7. Epibulbar (corneal) dermoid



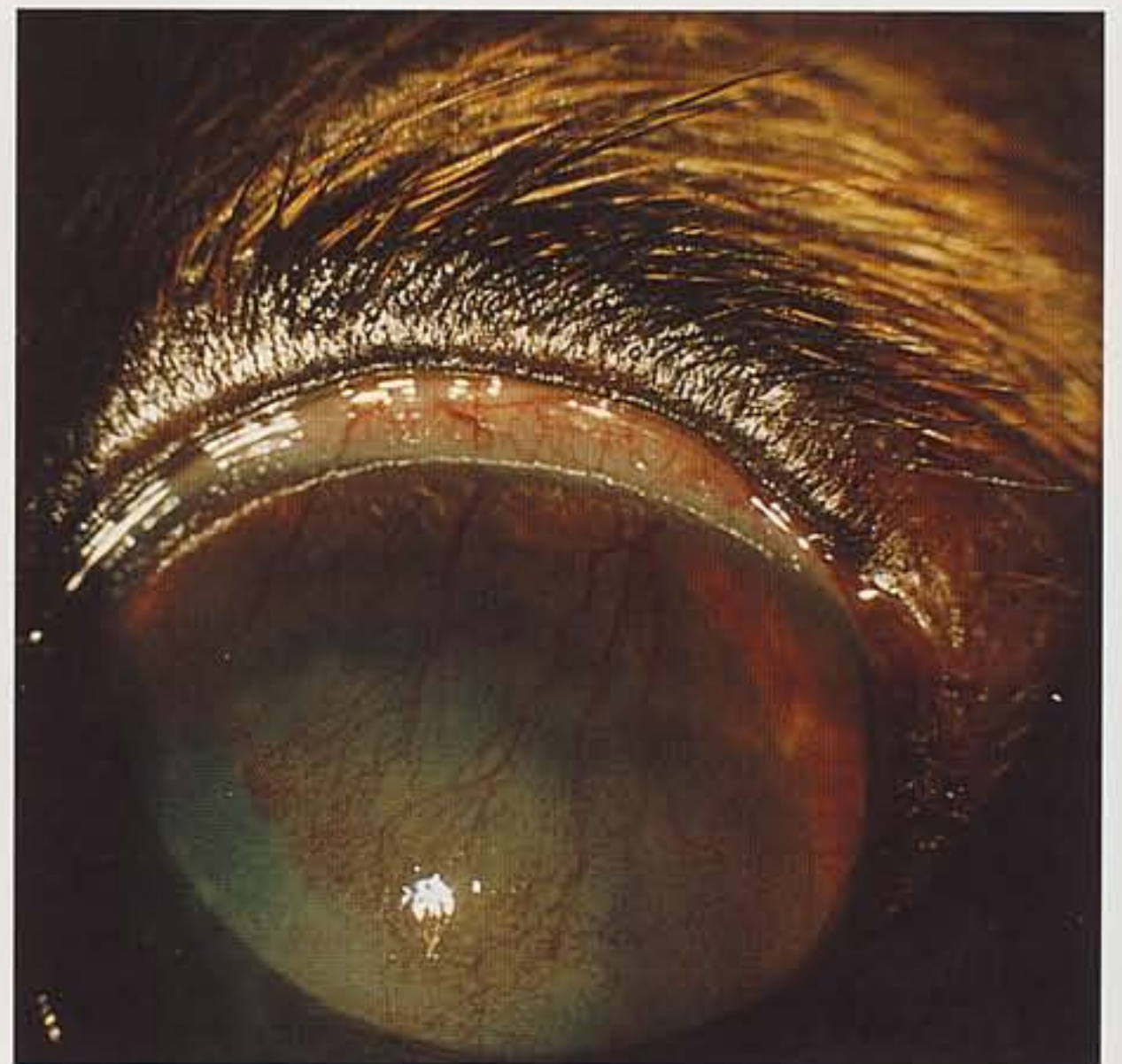
**Fig. 6.1** Superficial keratitis Note the blood vessel crossing the limbus and the irregular branching; also the uneven corneal surface with break up of the corneal reflection.

## Keratitis (Figs 6.1–6.5)

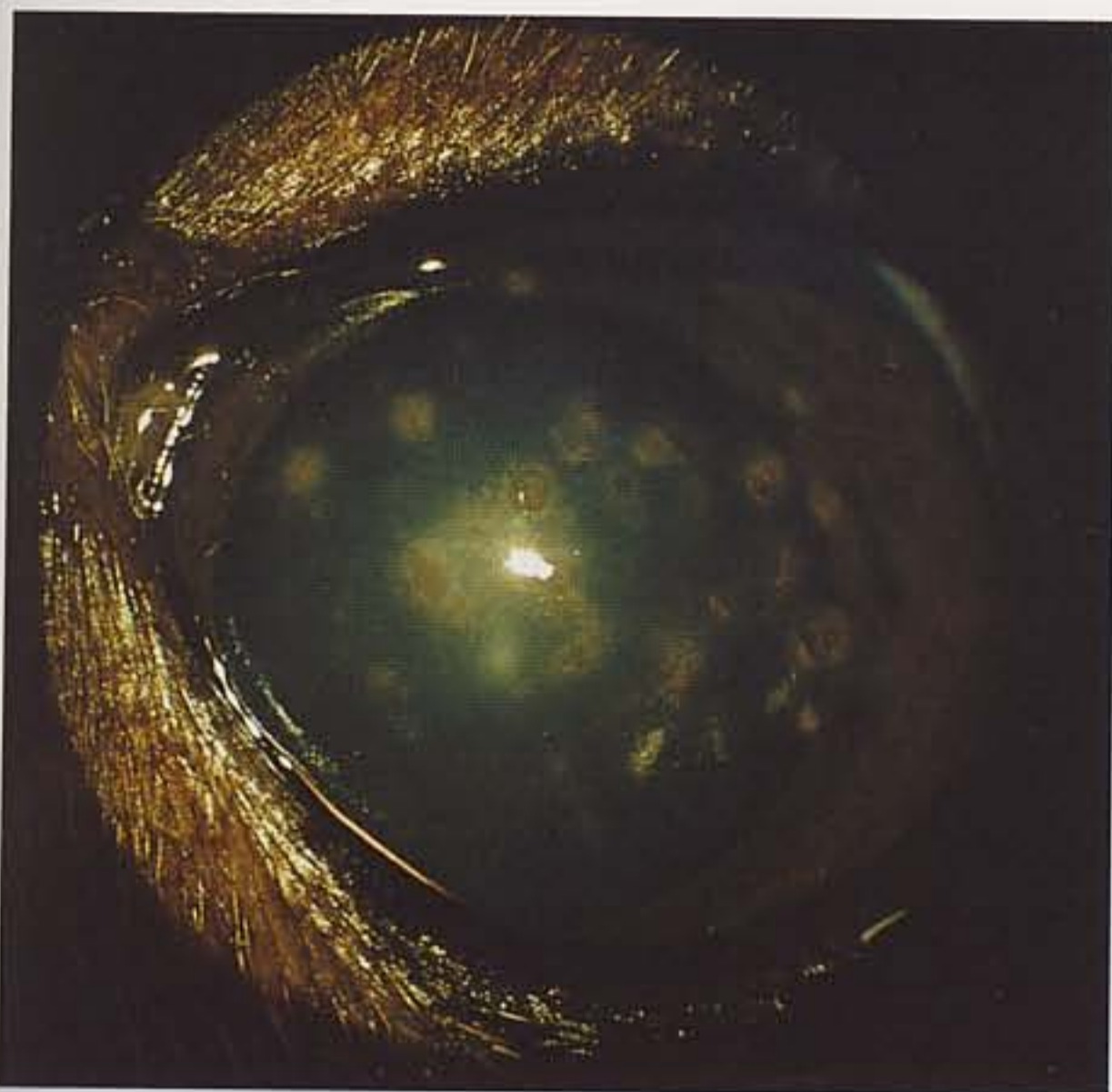
- Superficial
- Interstitial (stromal)
- Punctate
- Pigmentary
- Exposure
- Chronic superficial (pannus)
- Eosinophilic keratitis (cat)
- Fungal keratitis (horse)
- Infectious bovine keratoconjunctivitis (cattle).

### *Chronic superficial keratitis (pannus)* (Figs 6.6–6.12)

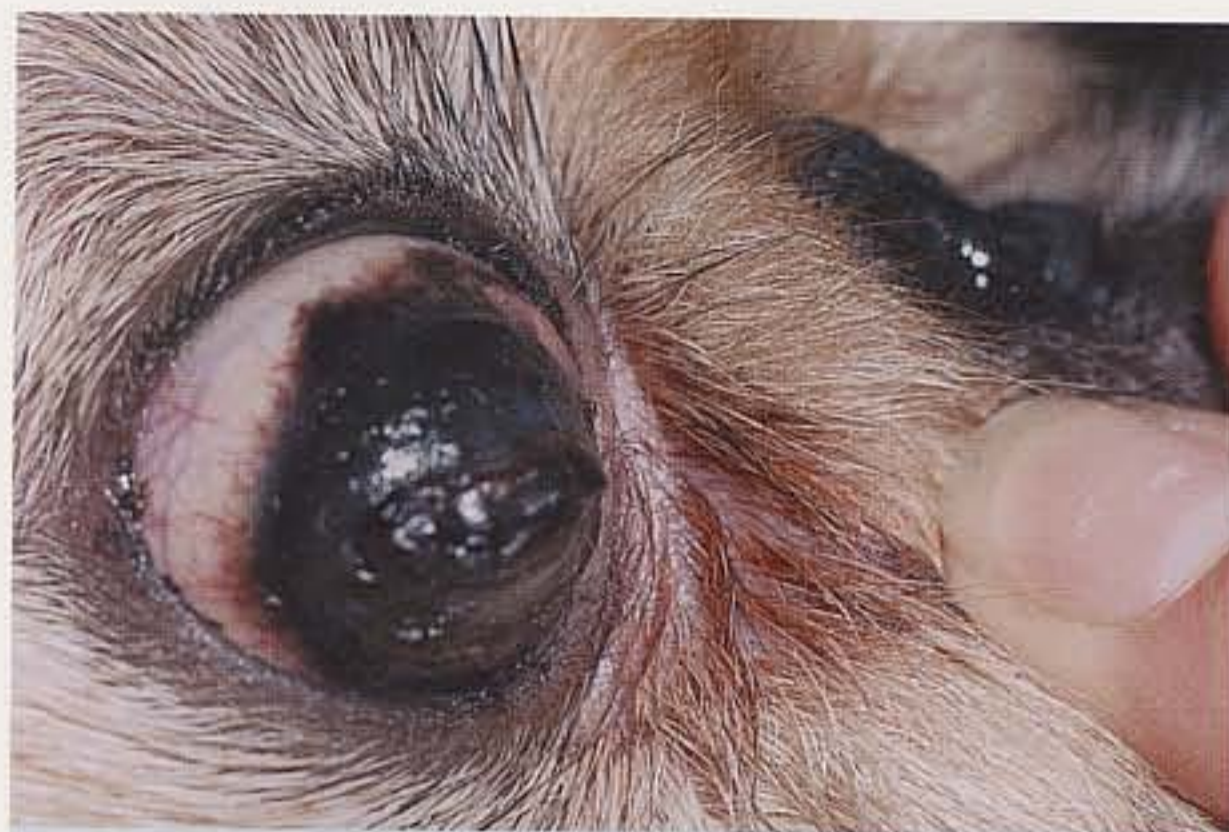Pannus is a type of superficial vascular keratitis often with later pigmentation. It is usually bilateral but not necessarily symmetrical; often one eye is more severely affected than the other. Pain and discharge are moderate and blepharospasm is usually present. The disease is immune-mediated with a strong tendency to recur with cessation of treatment. A conjunctival component is invariably present and frequently the nictitating membrane is involved with a plasma cell infiltration (Fig 3.10). The German



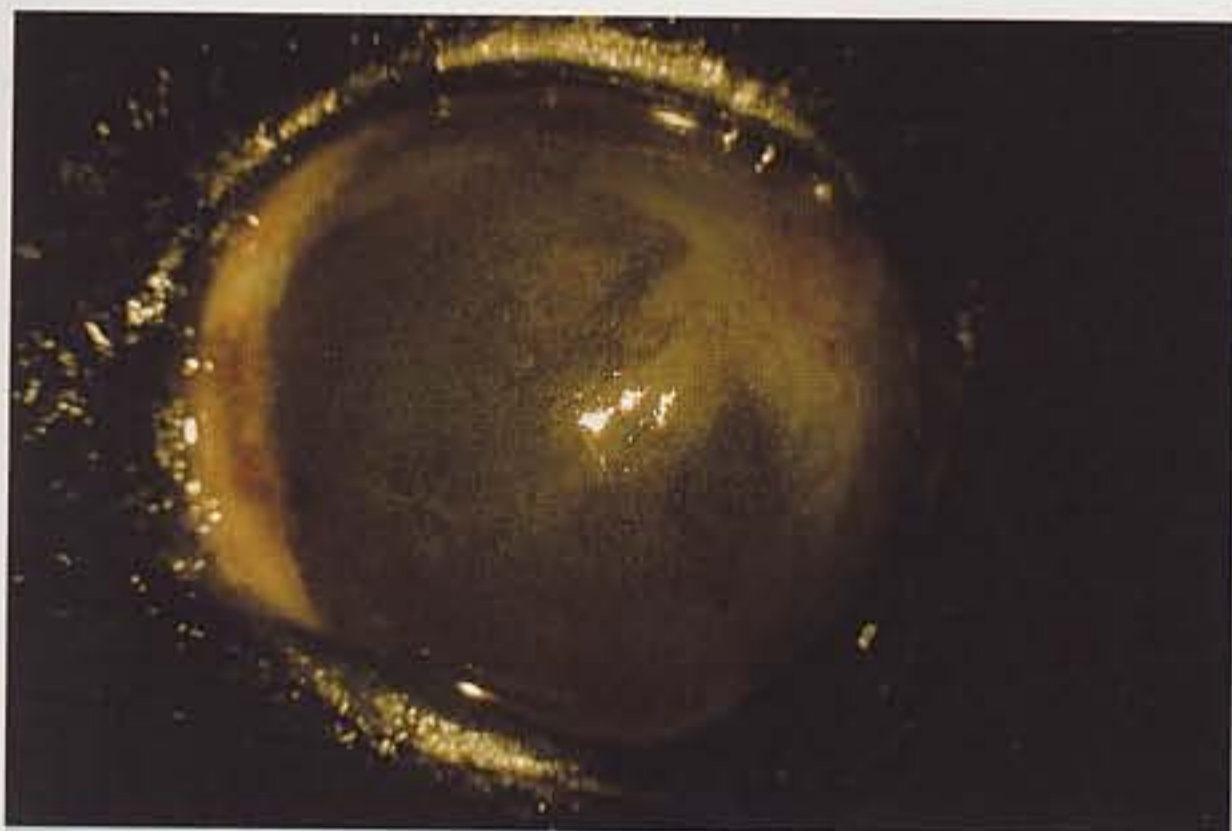
**Fig. 6.2** Interstitial keratitis Note the appearance of blood vessels on the corneal side of the limbus, unlike Figure 6.1, and the typical more regular vascular branching.



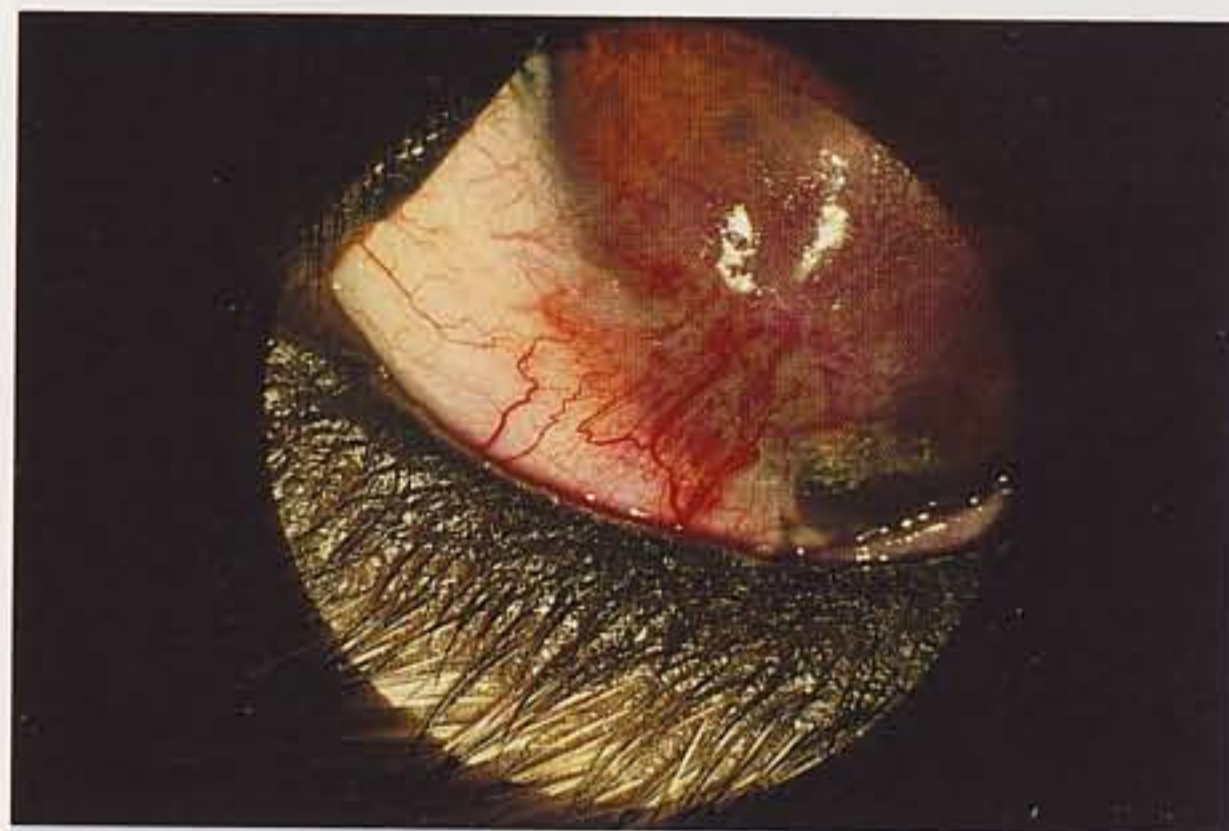
**Fig. 6.3 Punctate keratitis (Shetland Sheepdog)**  
Aetiology unknown but usually bilateral and the small grey areas may take fluorescein stain. Has been described as an epithelial dystrophy and the Shetland Sheepdog, as in this case, is mainly involved.



**Fig. 6.5 Exposure keratitis (Pekingese)** Due to inability to spread the tear film across the whole cornea in cases of globe prominence, as depicted here; also with lid paralysis (Fig 6.24) and keratoconjunctivitis sicca.



**Fig. 6.4 Pigmentary keratitis** Often accompanied by vascularization, as in this case, and also fibrosis. Pigmentation is a classical sign of keratitis, particularly in the dog, and may accompany other forms of keratitis, especially chronic cases, e.g. pannus (Fig 6.9), keratoconjunctivitis sicca (Fig 6.42) or corneal oedema (Fig 6.48).



**Fig. 6.6 Chronic superficial keratitis (pannus) (German Shepherd Dog, 3 years old)** Early case with superficial vascularization typically affecting the lower lateral quadrant.

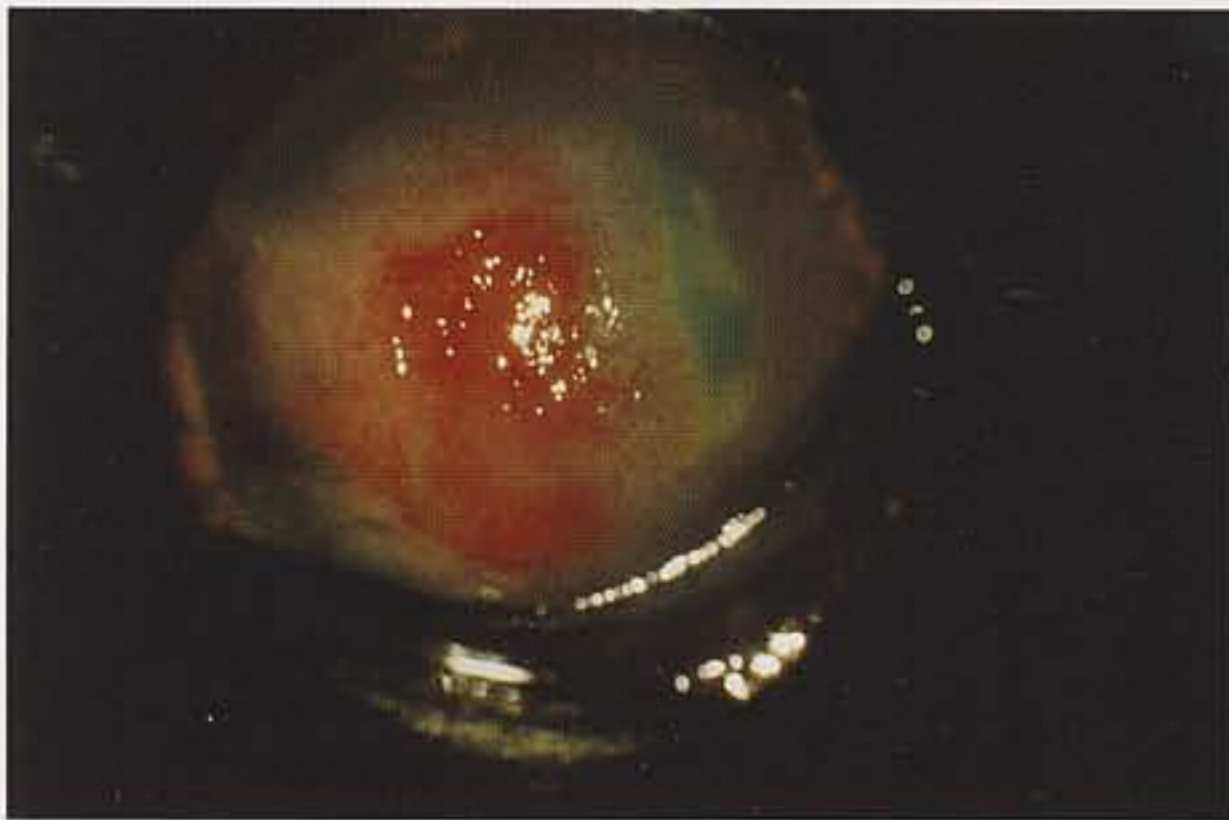

Fig. 6.7 Chronic superficial keratitis (pannus) (German Shepherd Dog, 4 years old) More severe than previous case with granulation tissue. Note break-up of corneal reflection and early pigmentation from the lateral limbus.

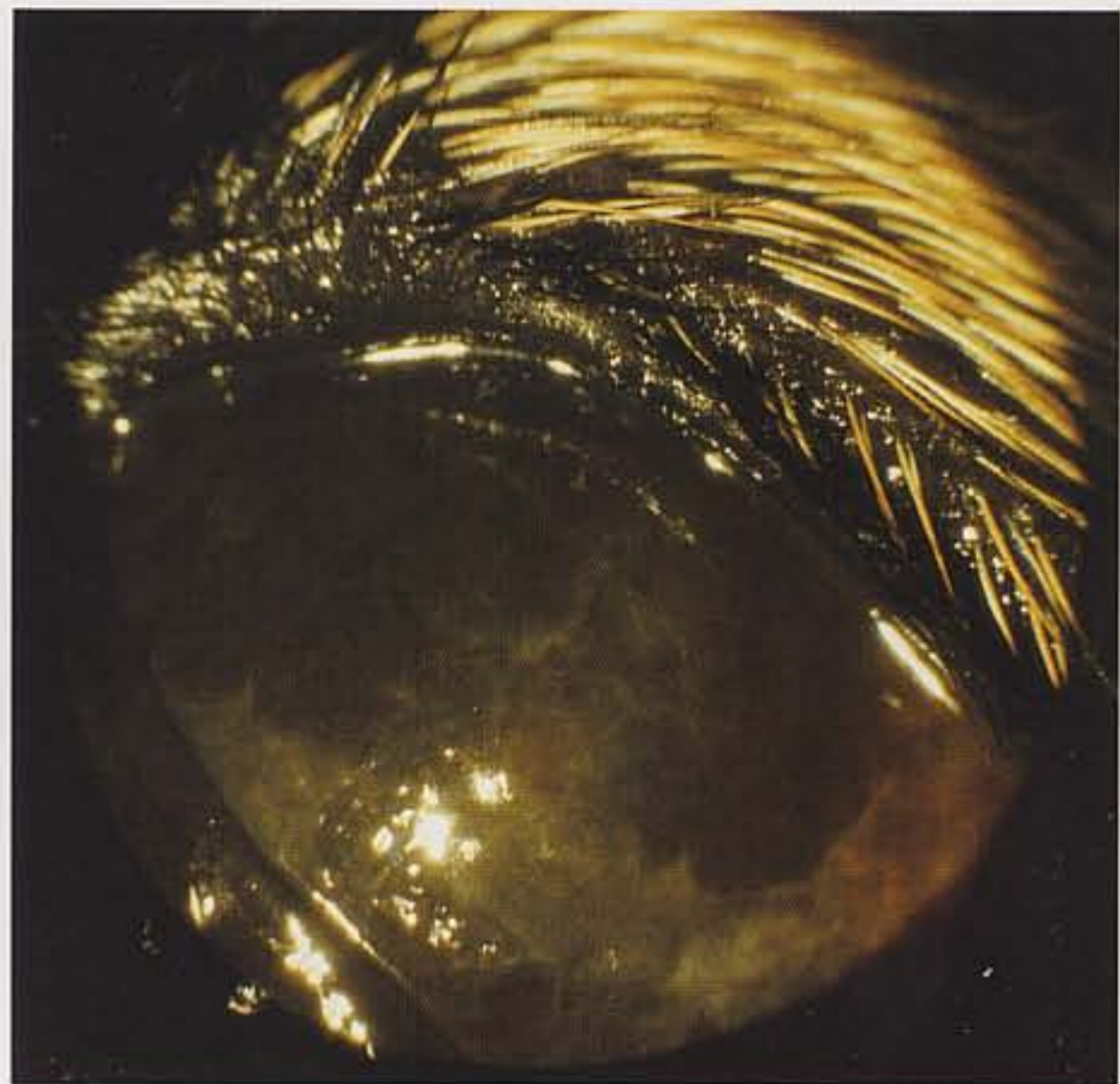


Fig. 6.9 Chronic superficial keratitis (pannus) (German Shepherd Dog, 9 years old) Chronic case with pigmentation.

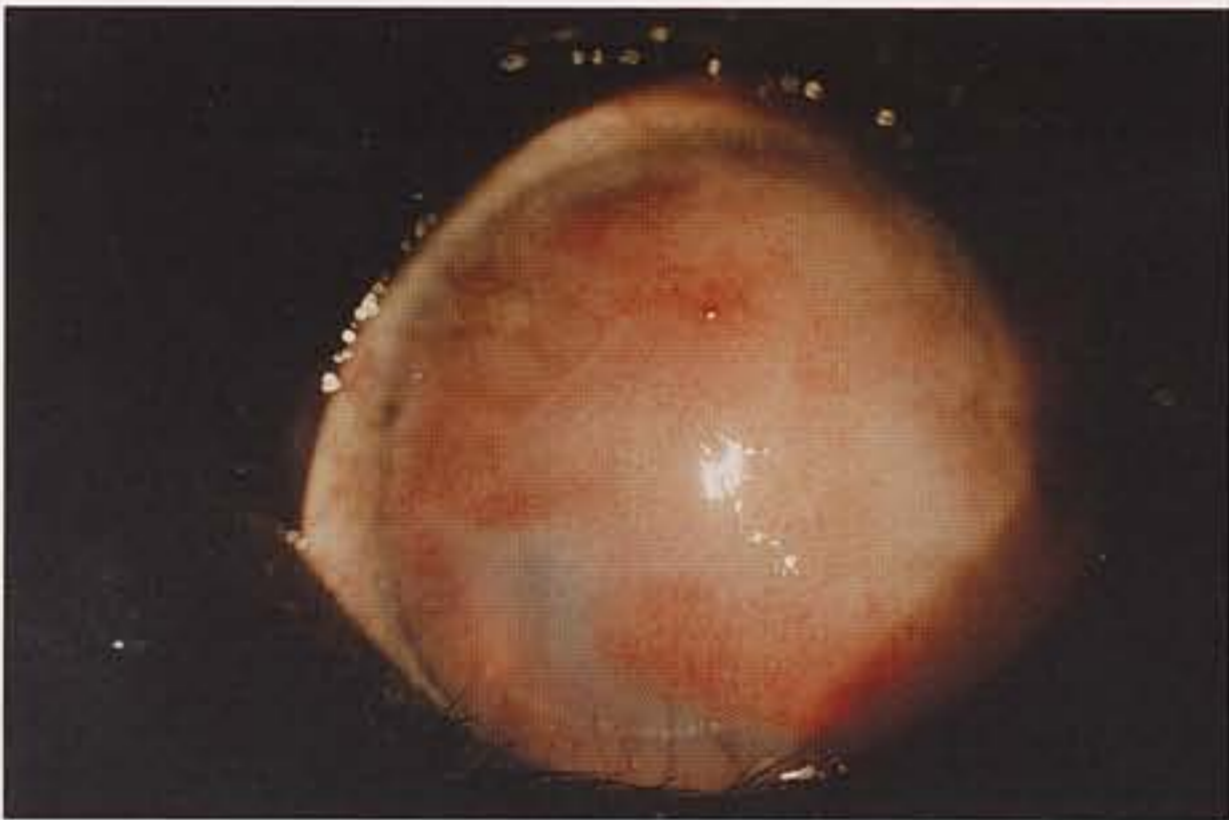

Fig. 6.8 Chronic superficial keratitis (pannus) (German Shepherd Dog, 6 years old) Note involvement of the whole cornea and early scarring.

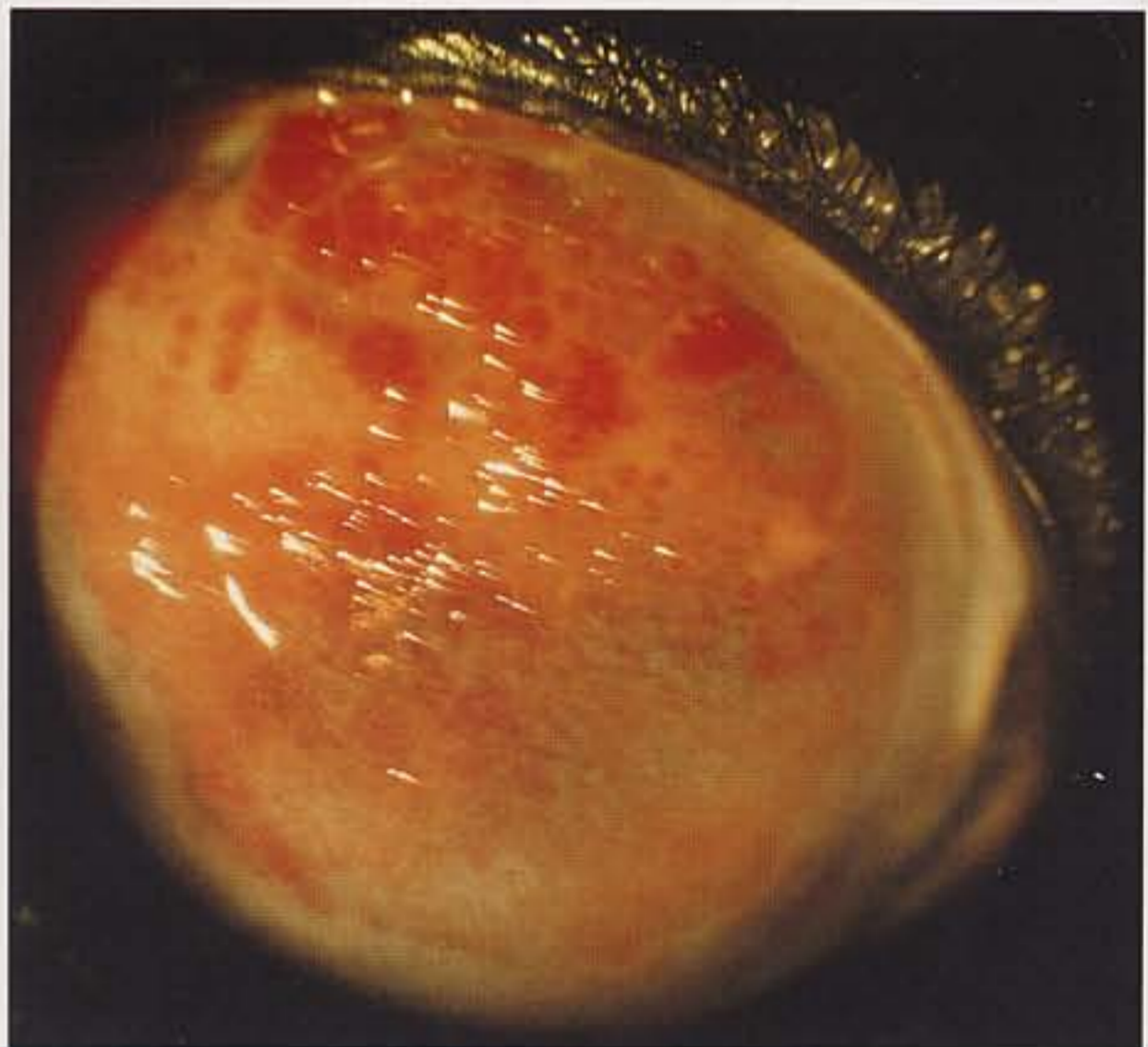


Fig. 6.10 Corneal granulation tissue (Crossbred, 6 years old) Superficial keratitis following a chemical burn.

Shepherd Dog is the breed usually affected but also Belgian Shepherd Dogs and Lurchers. Age incidence is the young adult (3–5 years) and pannus commonly, but not invariably, starts in the lower lateral quadrant, just occasionally medially.

Figures 6.10–6.12 show other forms of chronic superficial keratitis for differential diagnosis.

### *Eosinophilic keratitis (Figs 6.13–6.16)*

Typically seen in the cat; the cause is unknown and recurrence following treatment is usual, as is the case with pannus. Initially eosinophilic keratitis is unilateral, later becoming bilateral if left untreated. Diagnosis is aided by the appearance of a number

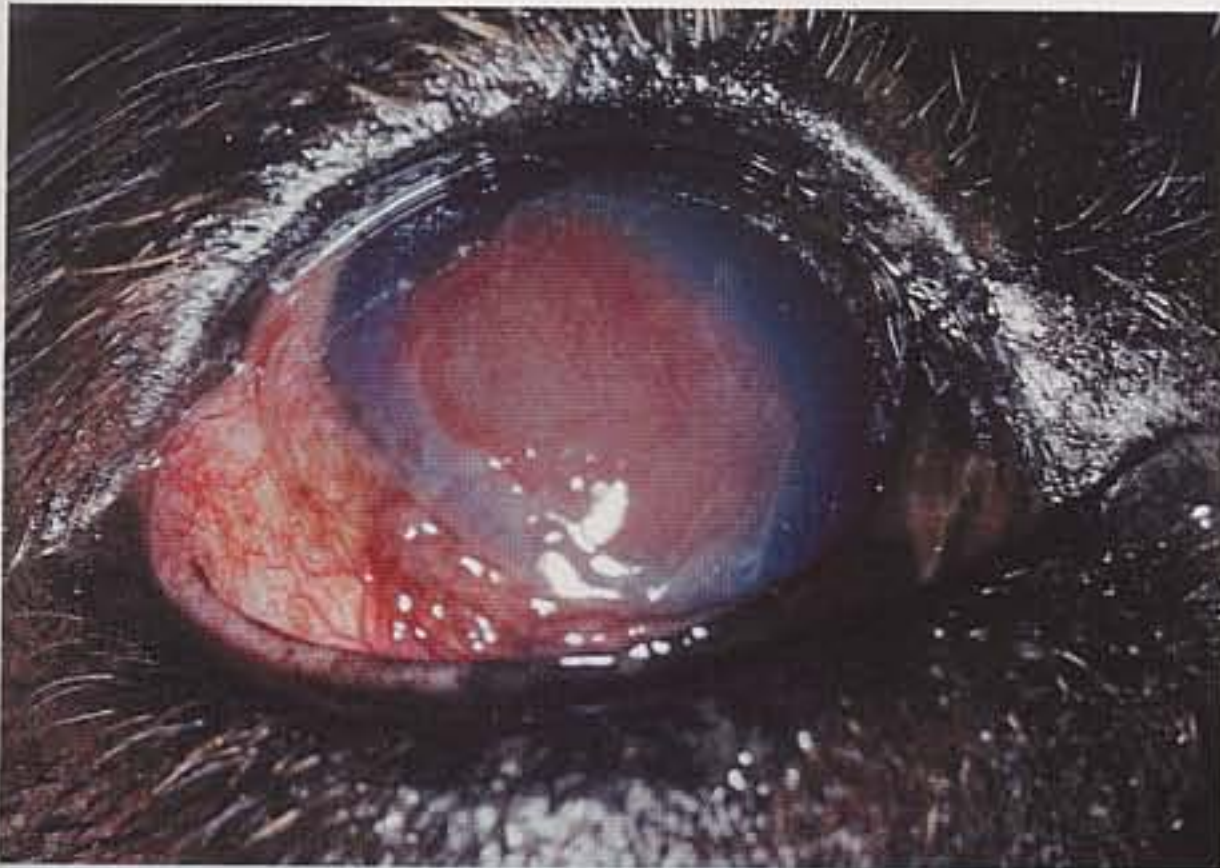

Fig. 6.11 Corneal granulation tissue (Boxer, 7 years old) Following recurrent corneal erosion (see also Figs 6.20–6.22).

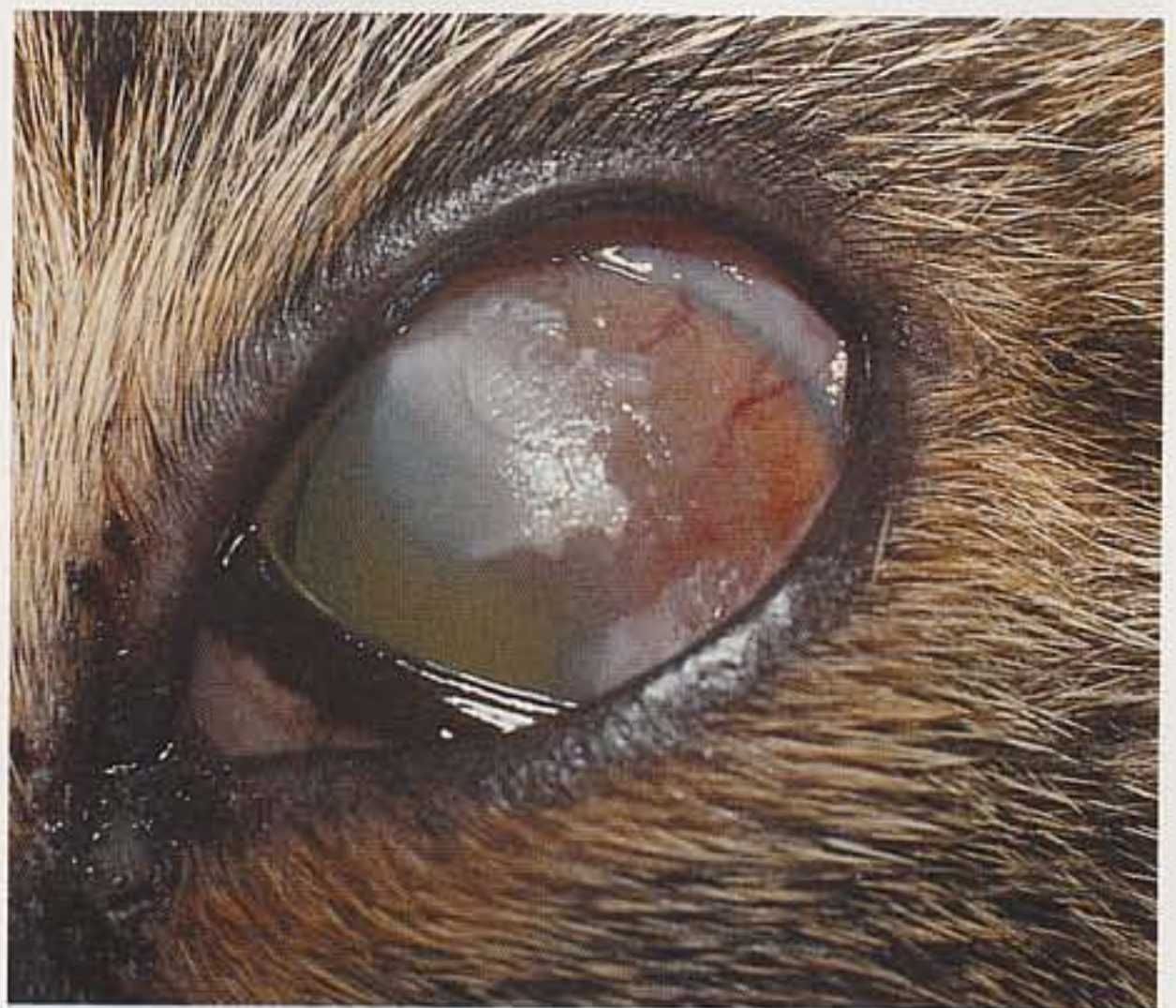

Fig. 6.13 Eosinophilic keratitis (DSH cat, 1 year old) Note vascular keratitis and grey plaque-like lesion. Unilateral case and note slight prominence of nictitating membrane due to retraction of the globe due to pain, and mild ocular discharge.

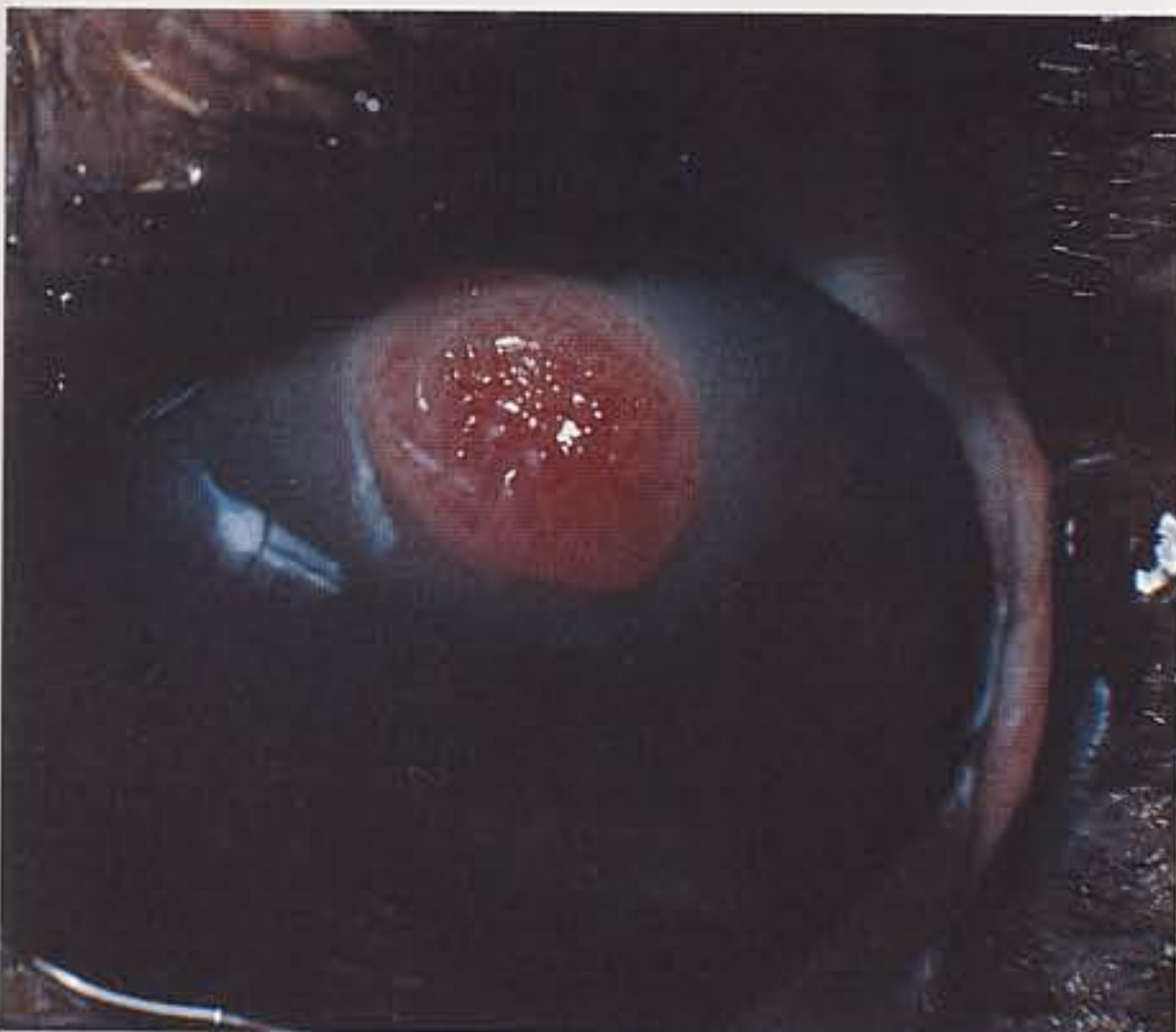


Fig. 6.12 Corneal granulation tissue (Chow, 8 months old) Associated with long-standing case of entropion.

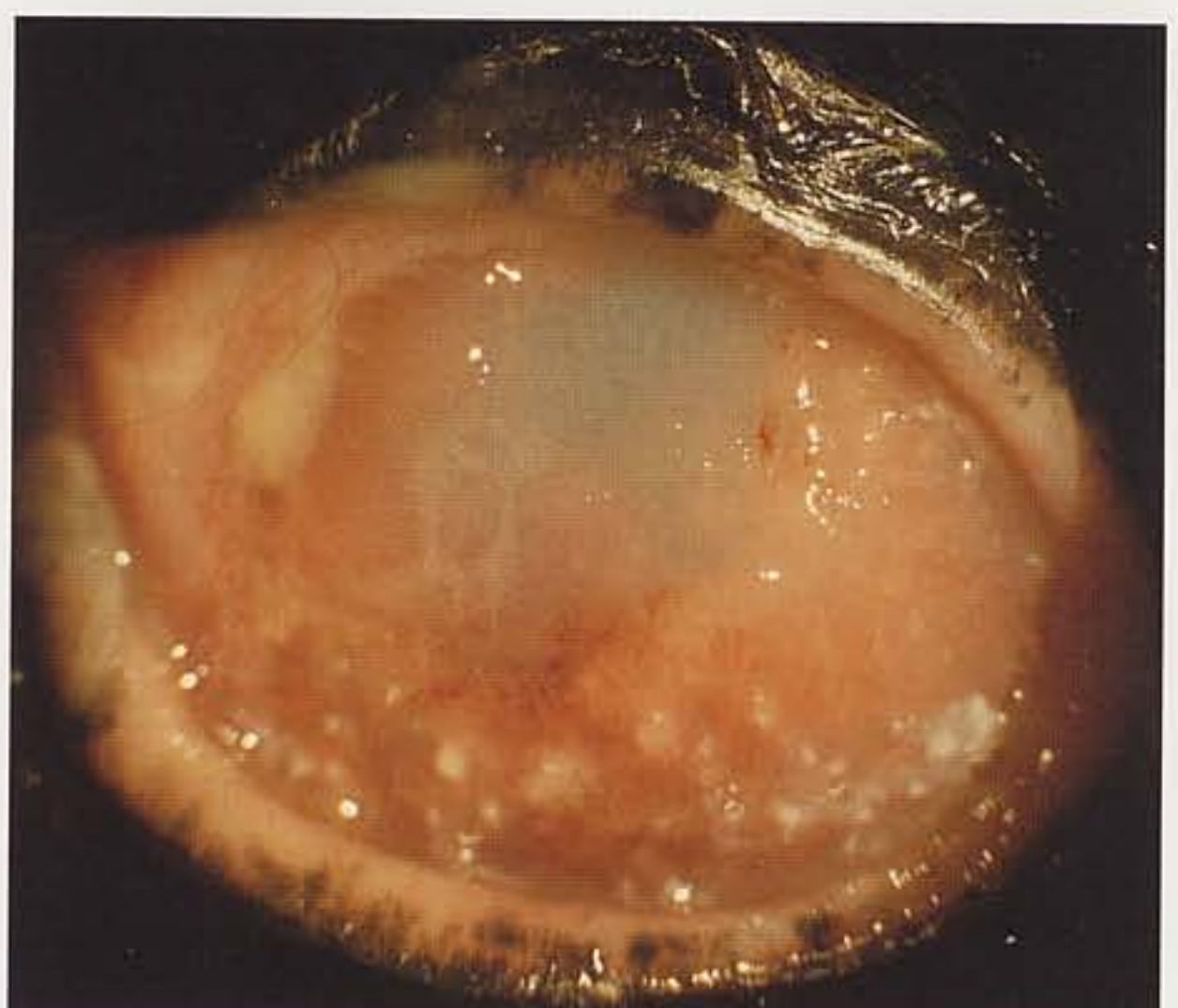

Fig. 6.14 Eosinophilic keratitis (DSH cat, 3 years old) Bilateral case and note typical white spots.



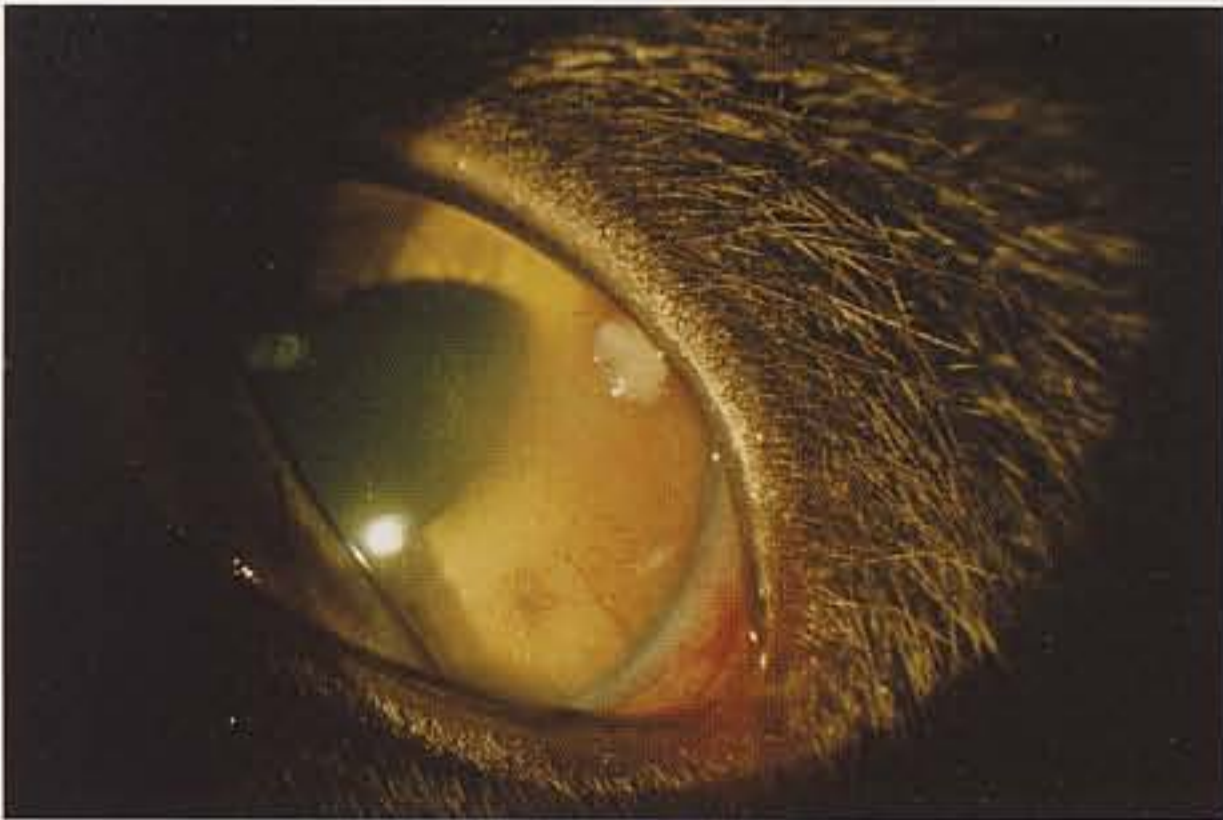

Fig. 6.15 Eosinophilic keratitis (DSH cat, 4 years old)  
An early case with fine vascularization and raised irregular white spots.

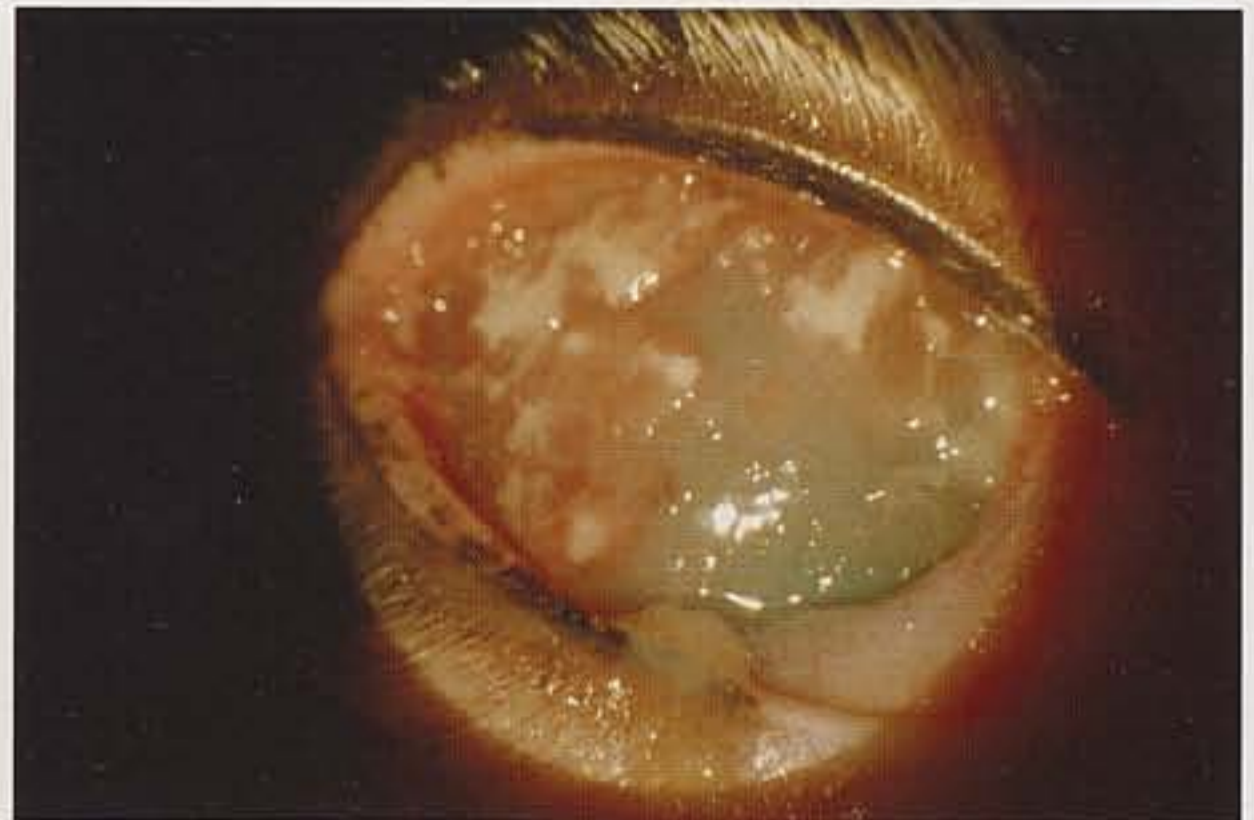

Fig. 6.16 Eosinophilic keratitis (DSH cat, 3 years old)  
Severe case. Note ocular discharge.

of superficial white round raised spots of different sizes and superficial vascularization; a conjunctival component is present. Pain is mild with a slight ocular discharge.

### *Fungal keratitis (Fig 6.17)*

Keratomycosis in the horse has been well recognized in the USA for a number of years but only recently has been diagnosed with certainty in the UK. There are a number of different clinical presentations of ulceration with furrowing, ulceration with 'cake frosting' appearance and stromal abscessation. The condition is unilateral with moderate to severe pain and associated uveitis, corneal vascularization and chemosis.

### *Infectious bovine keratoconjunctivitis (IBK) (Figs 6.18–6.19)*

IBK or New Forest disease in cattle is usually unilateral with a central opacity, leading to ulceration, surrounded by an opaque cornea, due to oedema, and circumcorneal hyperaemia. Pain can be severe and there is an associated iritis. Ocular discharge becomes mucopurulent, originally being clear profuse lacrimation. Superficial vascularization toward the primary lesion occurs and the cornea clears from the periphery.

### **Corneal ulcers (Figs 6.20–6.34)**

The corneal ulcer is common, usually unilateral, the appearance varying considerably according to the cause and stage of the ulcer. It is invariably painful and accompanied by blepharospasm and lacrimation. Diagnosis can be confirmed by staining with fluorescein to show areas of denuded epithelium (Fig 6.20) and Rose Bengal to show areas of devitalized epithelium (Fig 6.21). Causes include trauma, including self-inflicted and that due to eyelid abnormalities (supernumerary eyelashes, neoplasia, entropion), thermal and chemical burns, immune-mediated, facial paralysis and forms of exposure keratitis and absence of the protective tear film; also infections with bacteria, viruses and fungal elements. The appearance of the corneal ulcer is dependent upon size, depth and time, varying from a faint opacity (oedema) to a clear, central, usually circular, deep and non-staining keratocoele. Vascularization is usual, except in the indolent ulcer (recurrent epithelial erosion, Fig 6.22). If severe or of some standing, an associated uveitis, with hypopyon (Figs 6.27–6.28) and hyphaema (Fig 6.29) will be present. Pain is variable, from mild to severe, particularly when uveitis is present.

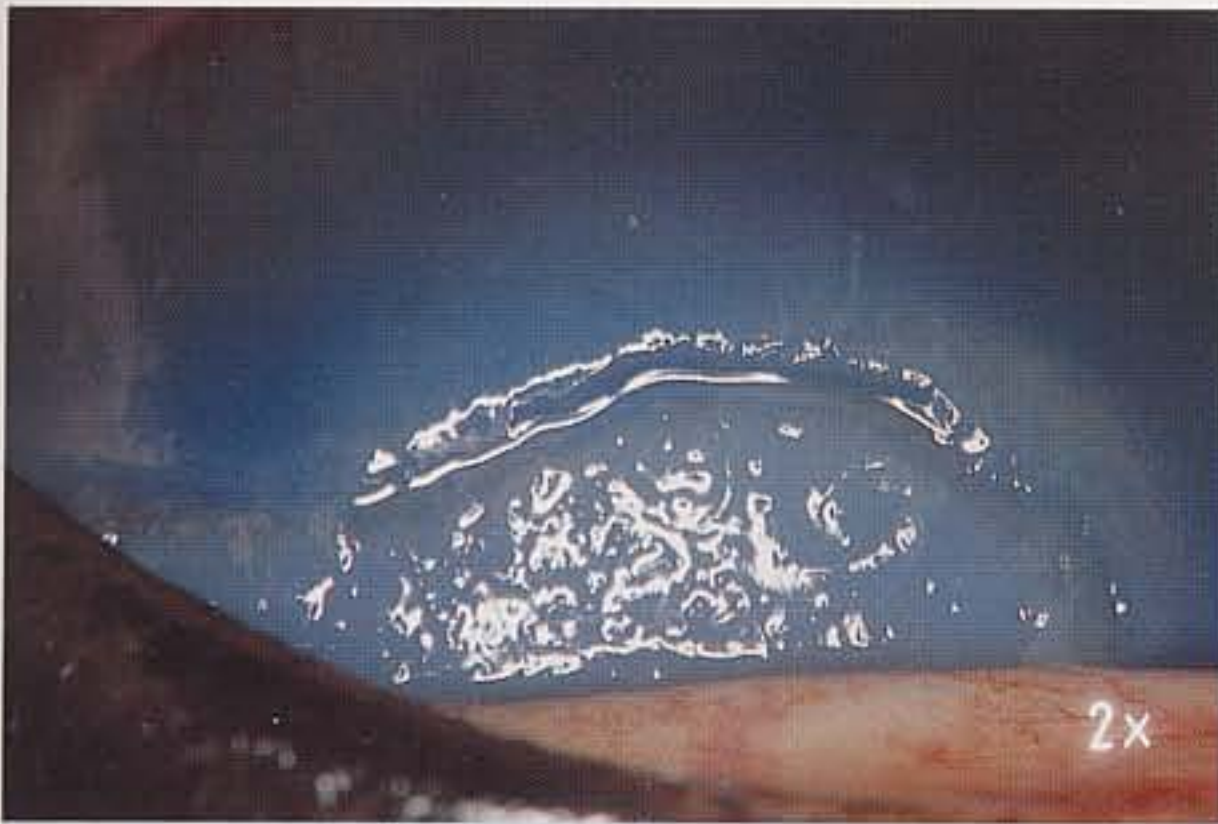

Fig. 6.17 Fungal keratitis (Arab-cross mare, 12 years old) Large central deep area of ulceration with furrowing.

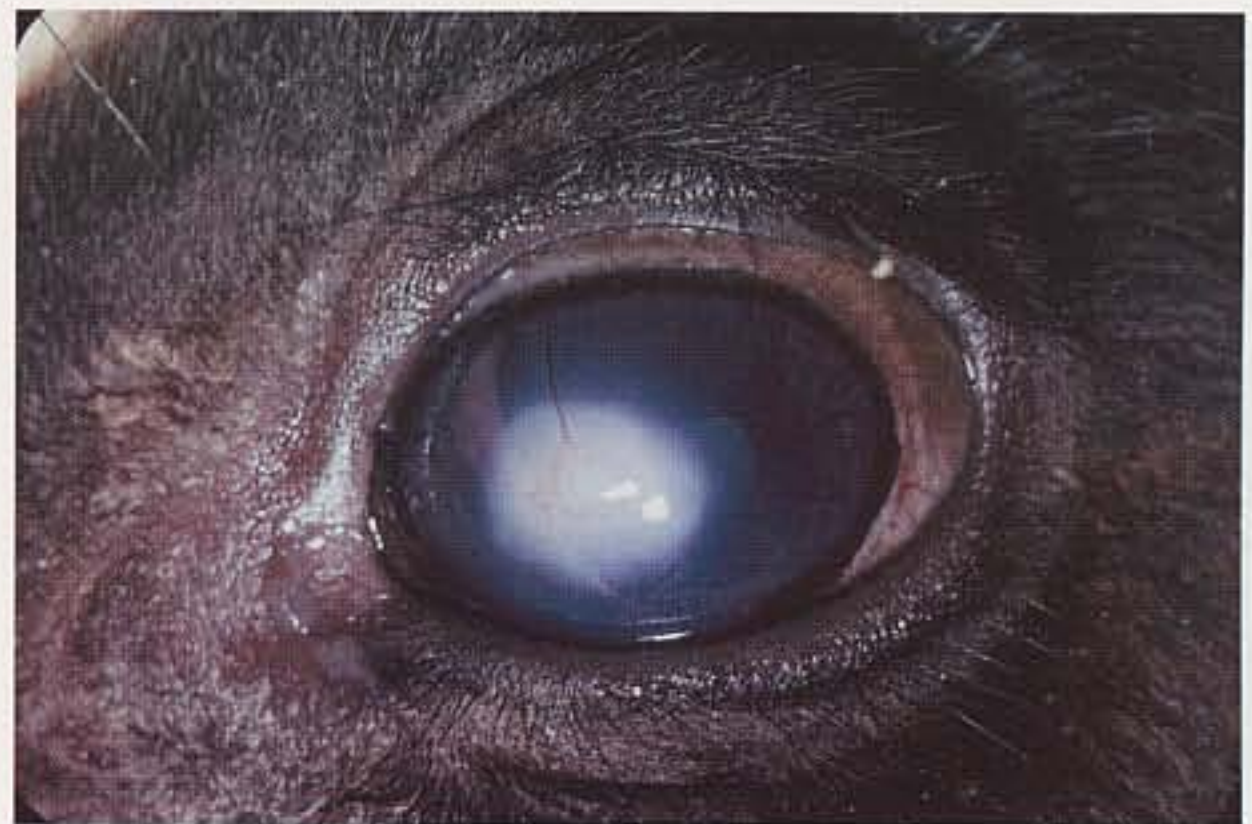

Fig. 6.19 Infectious bovine keratoconjunctivitis (Friesian calf) Note central opaque area with vascularization following a previous ulcer in this position. Peripheral cornea now clear.

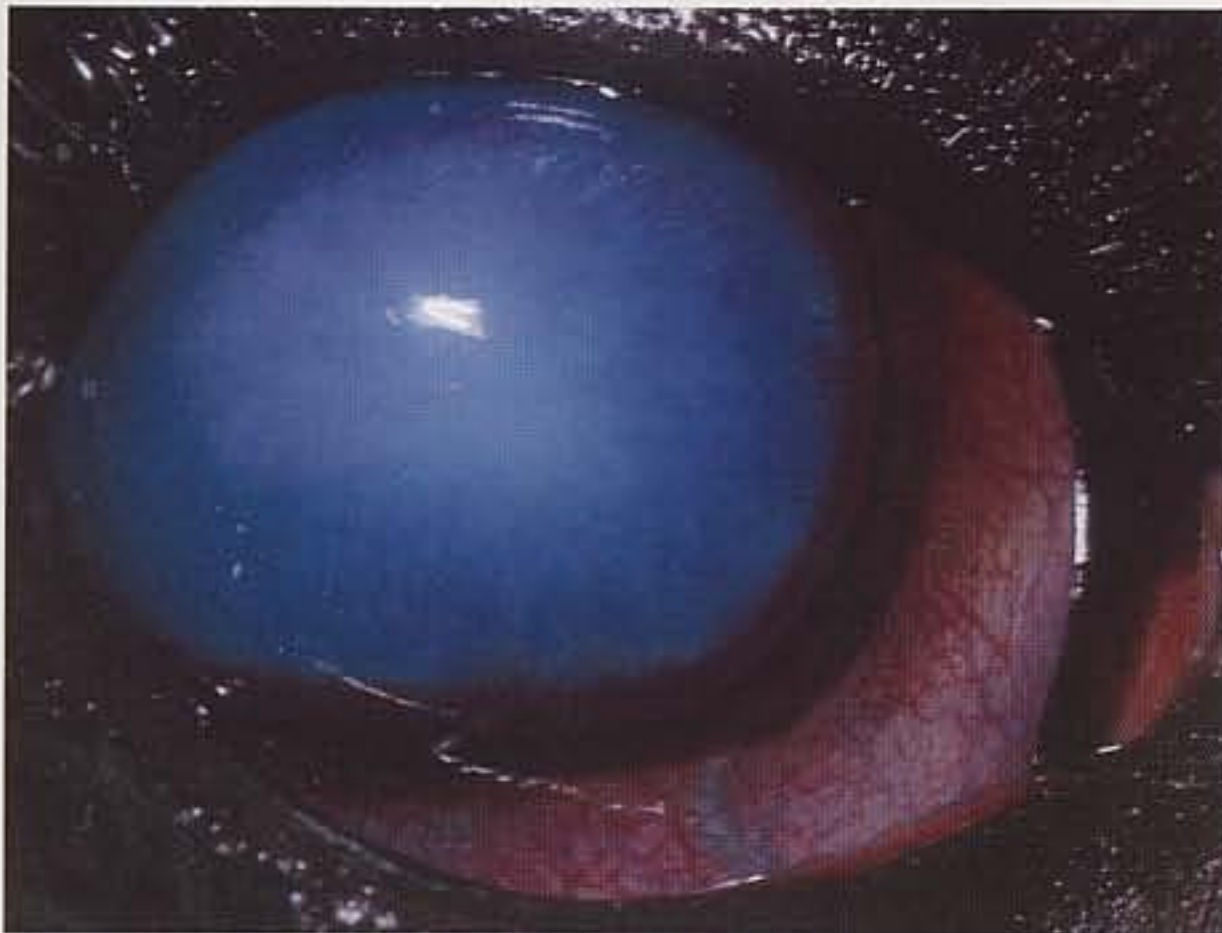


Fig. 6.18 Infectious bovine keratoconjunctivitis (Friesian calf) Note corneal opacity due to oedema, vascular fringe and mild conjunctival congestion.

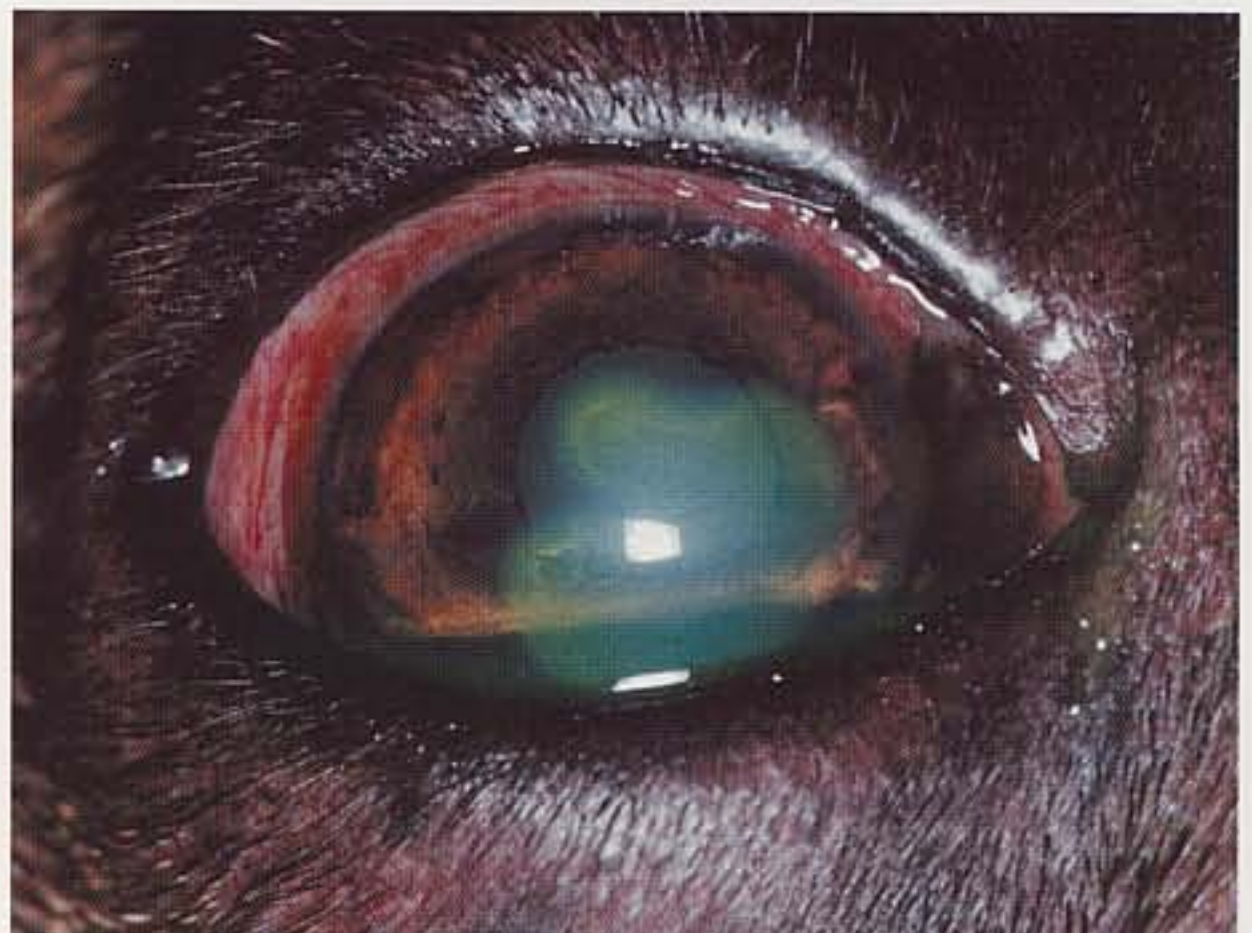

Fig. 6.20 Corneal ulcer Case of recurrent corneal erosion showing area of denuded epithelium stained with fluorescein.

## Keratoconjunctivitis sicca (KCS)

(Figs 6.35–6.44)

KCS is not primarily a keratitis but a deficiency of the pre-ocular tear film (aqueous portion), although it usually presents as a keratitis with a copious, tacky (Fig 6.37), purulent-like, discharge adherent to the cornea (Fig 6.38) and often present in the conjunctival fornices (Fig 6.39). Severity varies from mild (Fig 6.35) to severe (Fig 6.36). Ulceration is unusual but when present is often deep and circular and with vascularization (Fig 6.41). Pigmentation is

common in chronic cases (Fig 6.42) and a conjunctival component is always present. KCS of various causes is a common eye condition in the dog; most cases are immune-mediated and classically occurring in the UK in the middle-aged, often female, West Highland White Terrier. Other causes are systemic disease (canine distemper), metabolic disease (hyperthyroidism), surgical, traumatic, neurogenic (often unilateral and accompanied by a dry nose) and idiopathic. An important group are due to lacrimotoxic drugs e.g. sulphasalazine (Fig 6.43) and recently a congenital form of KCS (Fig 6.44), together

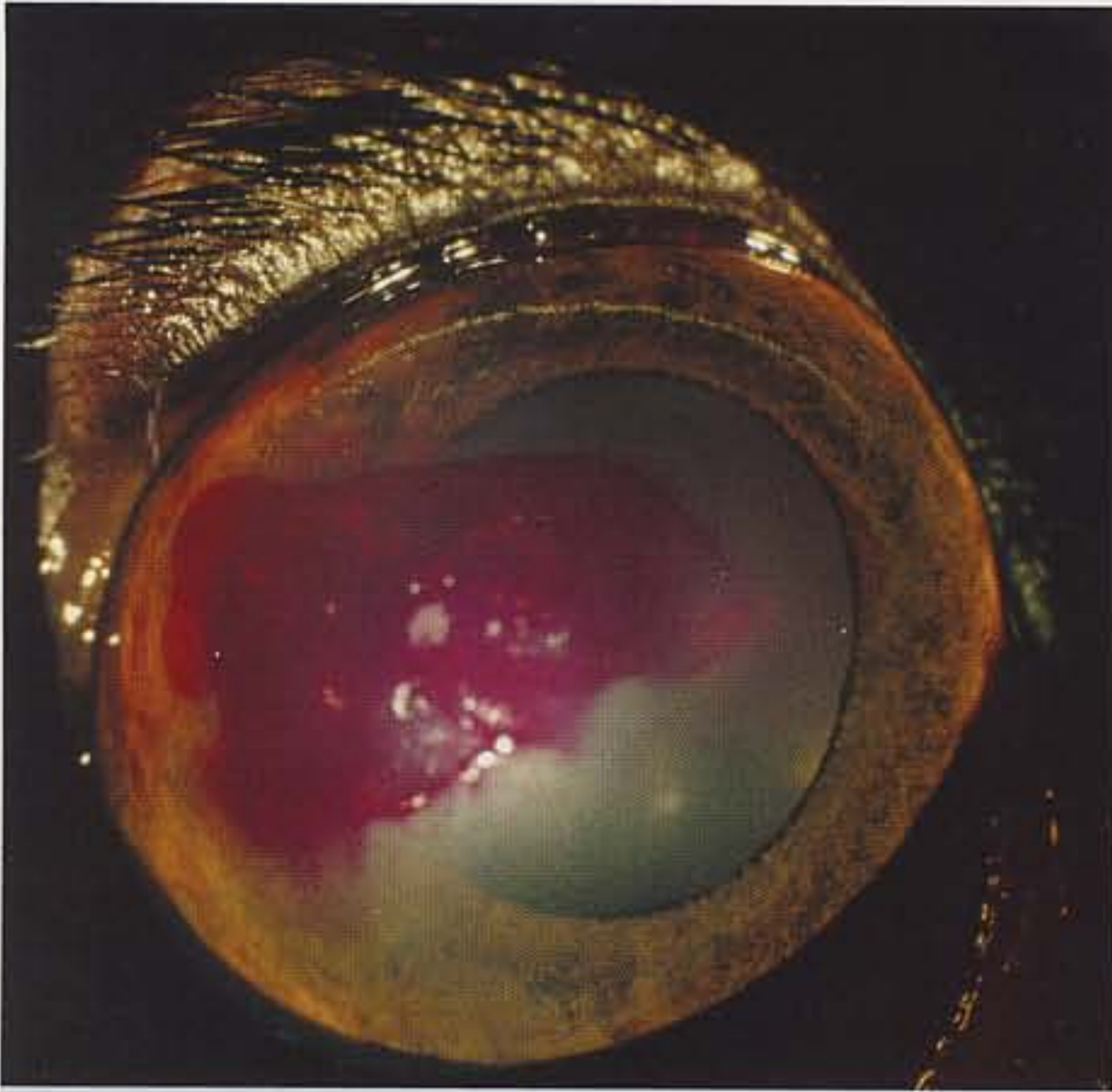


Fig. 6.21 Corneal ulcer (Pembroke Corgi) Case of recurrent corneal erosion stained with Rose Bengal to show large area of devitalized epithelium surrounding the actual ulcer.

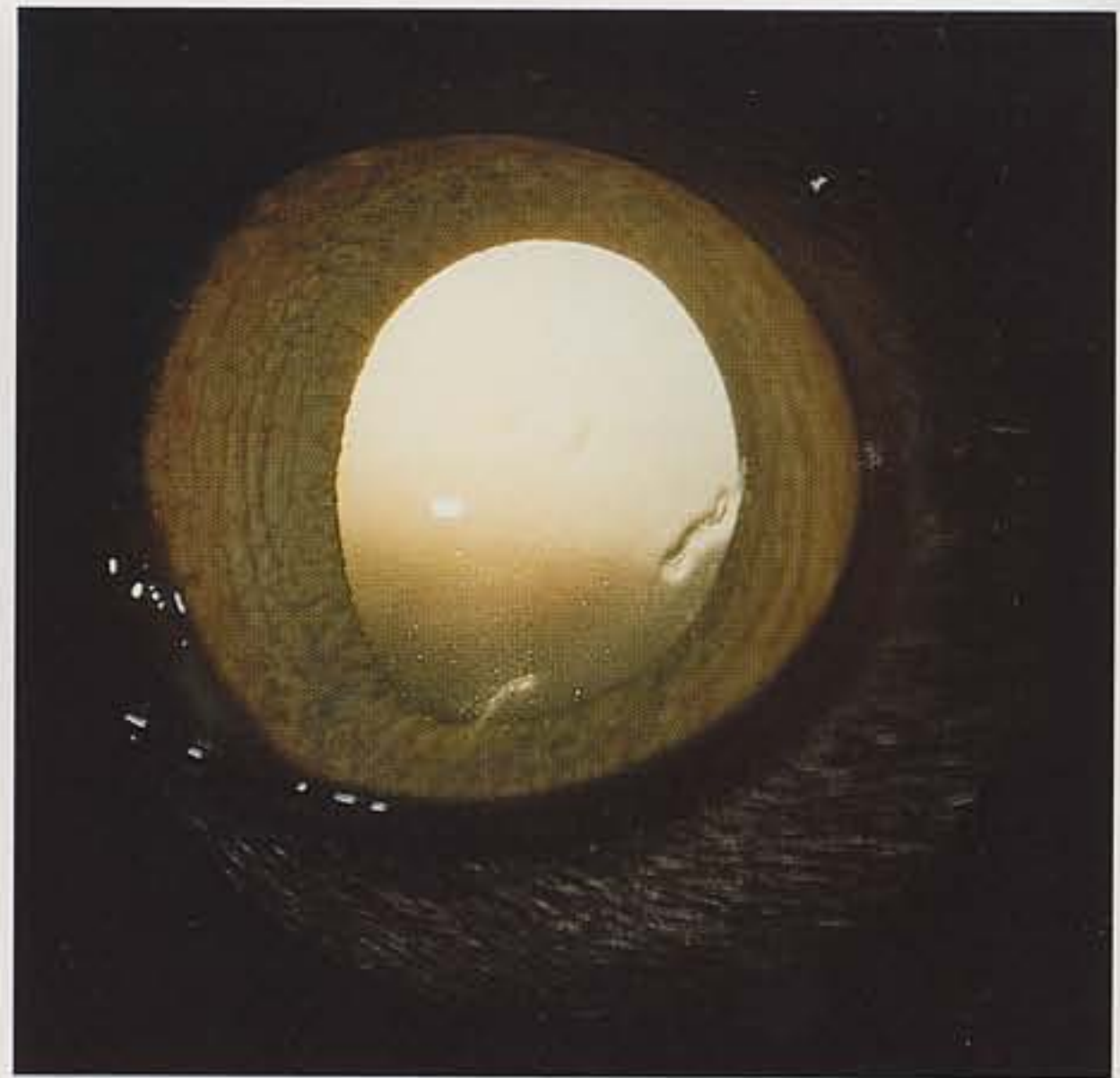

Fig. 6.23 Corneal ulcer (DSH cat, young adult) Superficial dendritic ulcers in acute feline herpesvirus-1 infection.

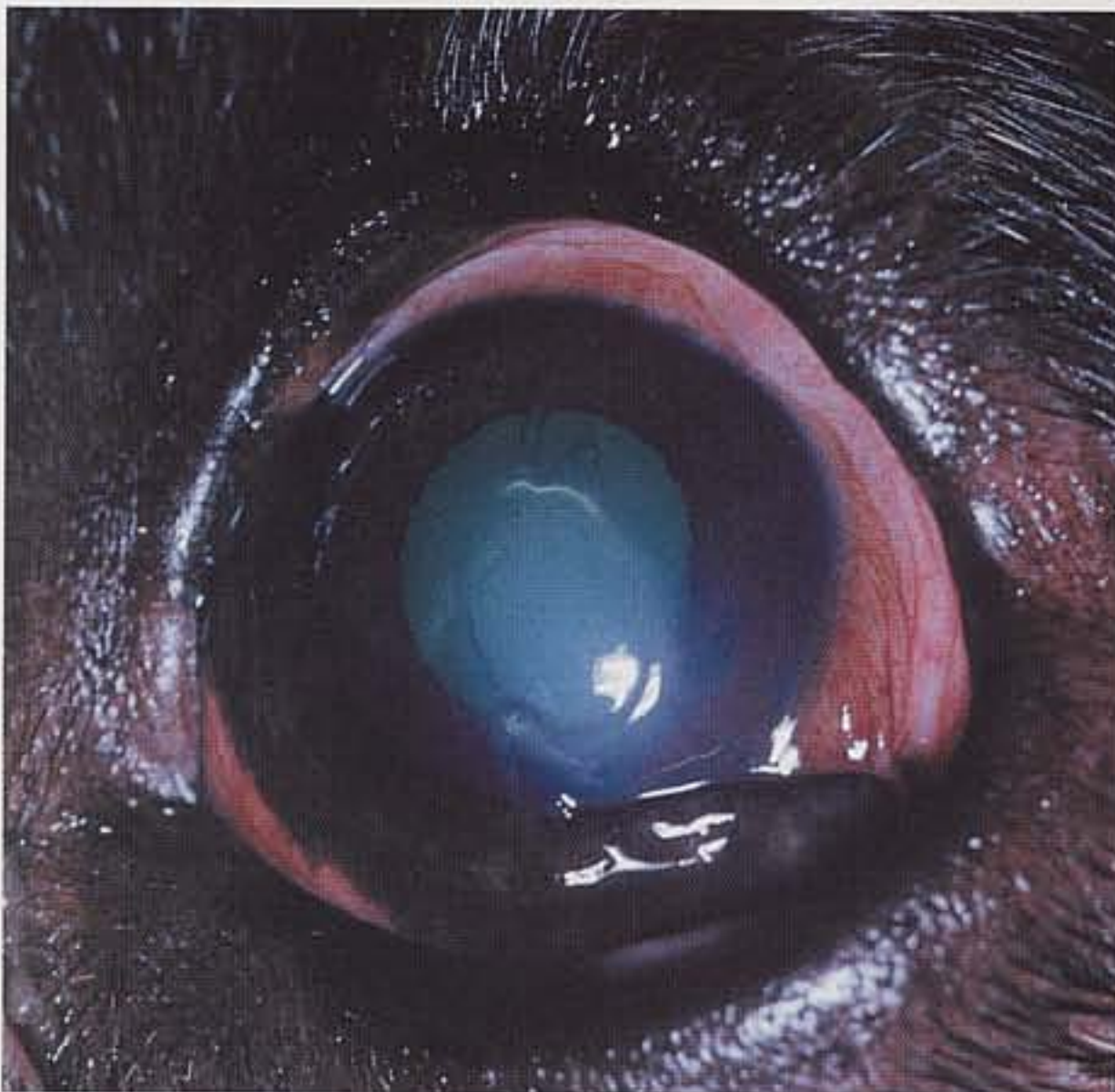

Fig. 6.22 Corneal ulcer (Boxer, 7 years old) Recurrent corneal erosion case. Note mild corneal oedema of the ulcerated area and the epithelium at the edge of the ulcer. An early case, but see also Fig. 6.11.

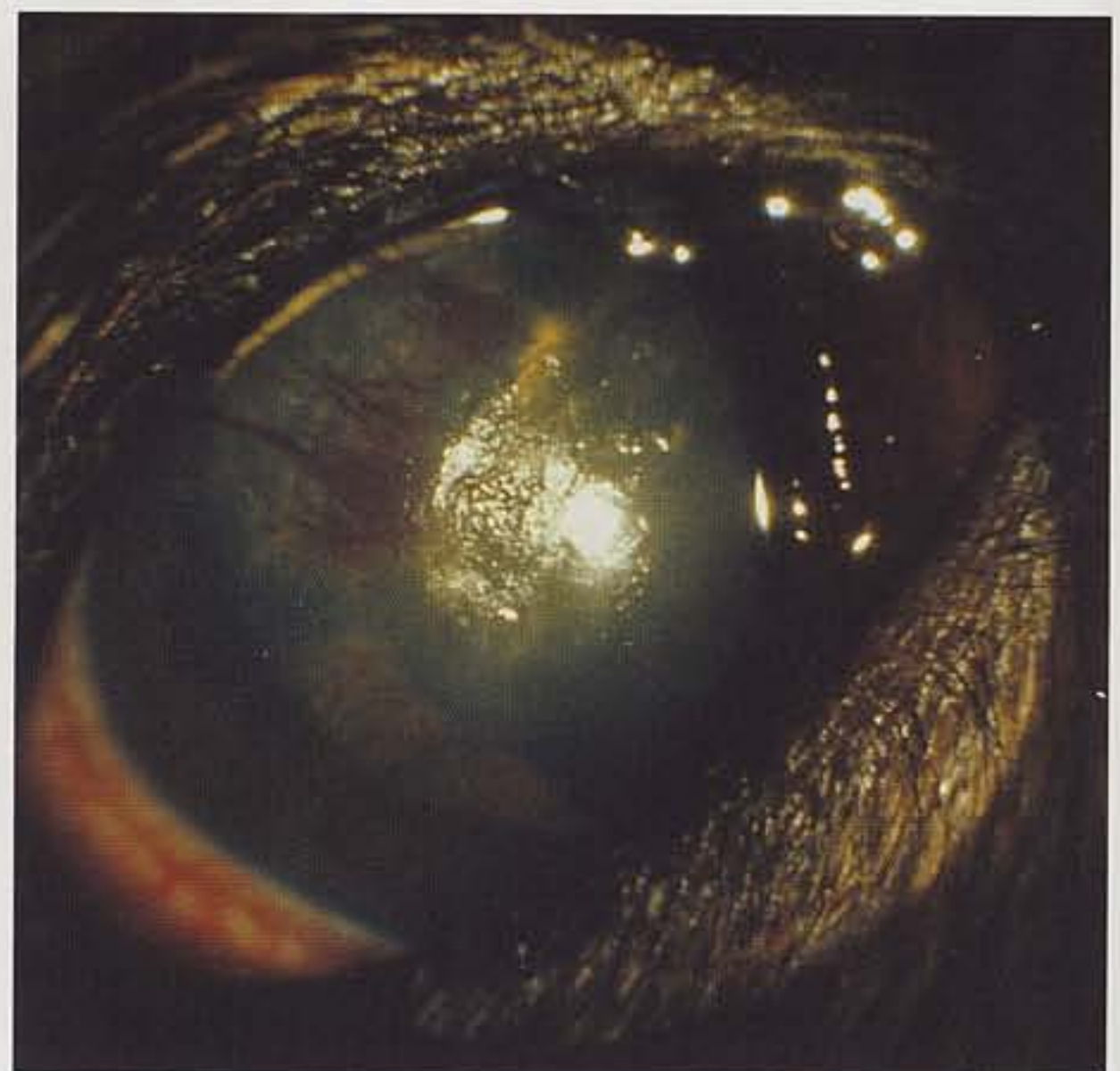

Fig. 6.24 Corneal ulcer Ulceration and subsequent vascularization in a case of facial paralysis.

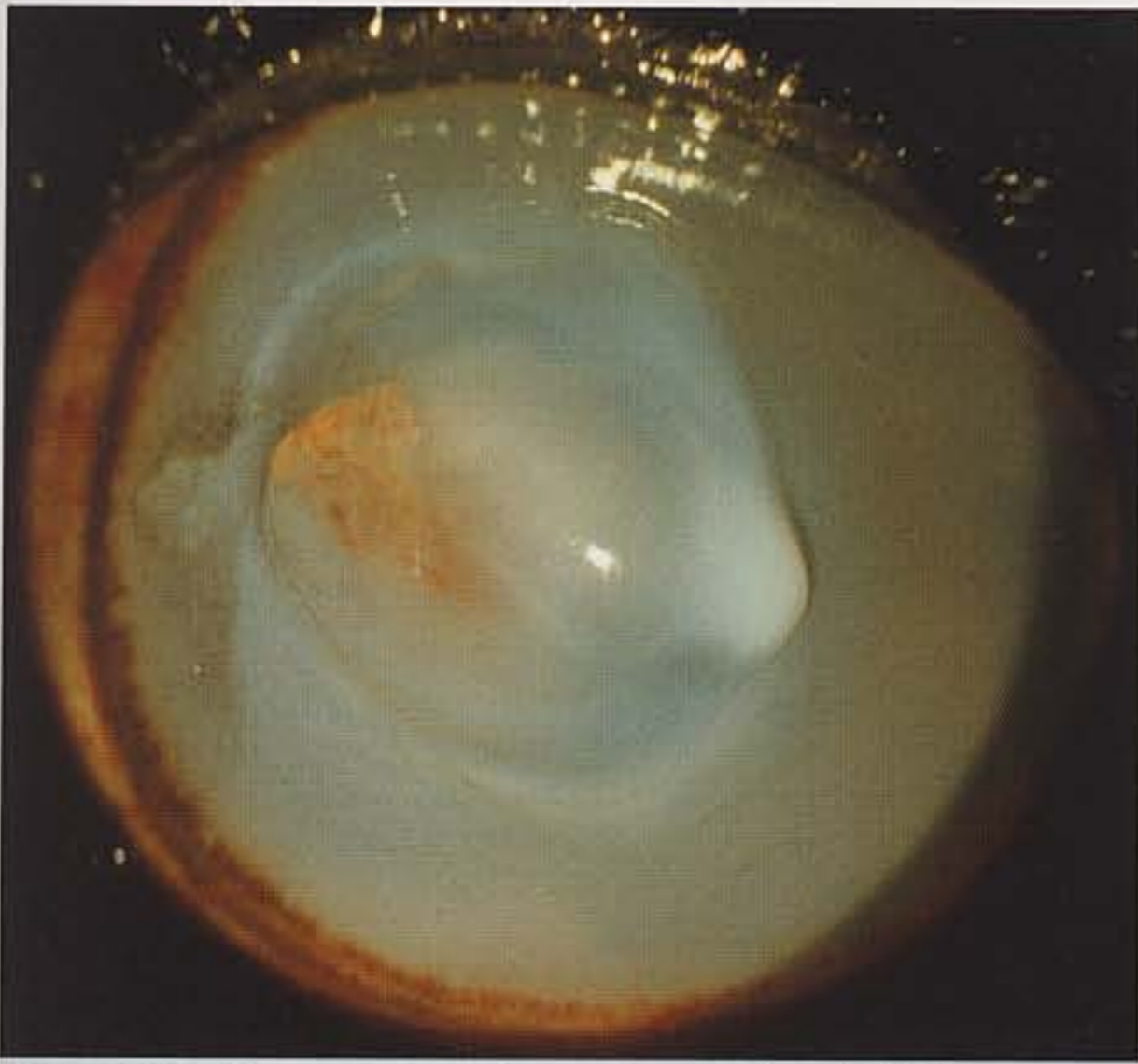


Fig. 6.25 Corneal ulcer (Pug, 8 months old) The coagulase or melting ulcer. Note the stromal involvement and clearer central portion indicating very thin remaining cornea, together with marked corneal oedema of the remaining non-ulcerated cornea.

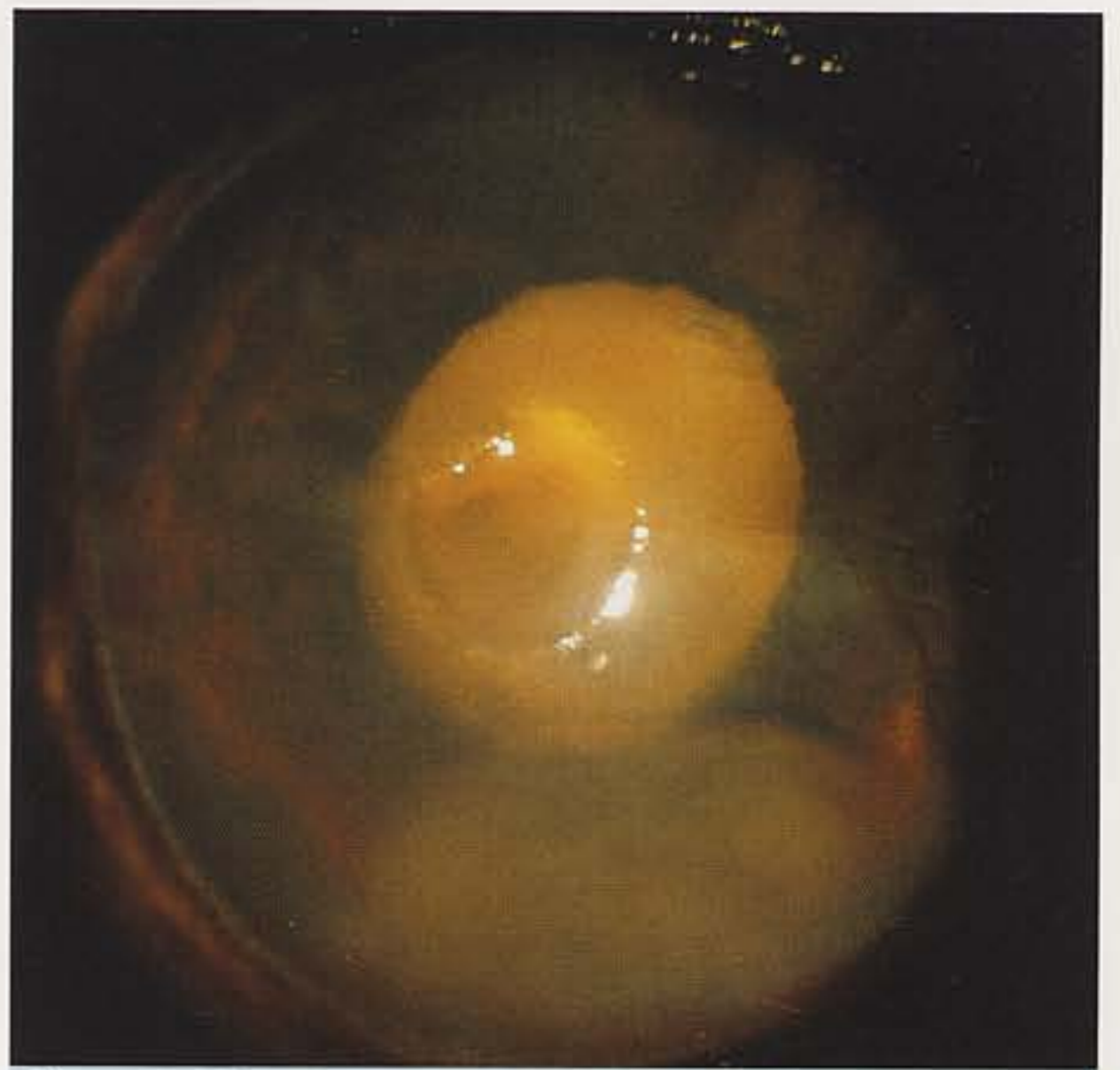


Fig. 6.27 Corneal ulcer Deep ulcer and iritis. Note the hypopyon and the mild miosis.

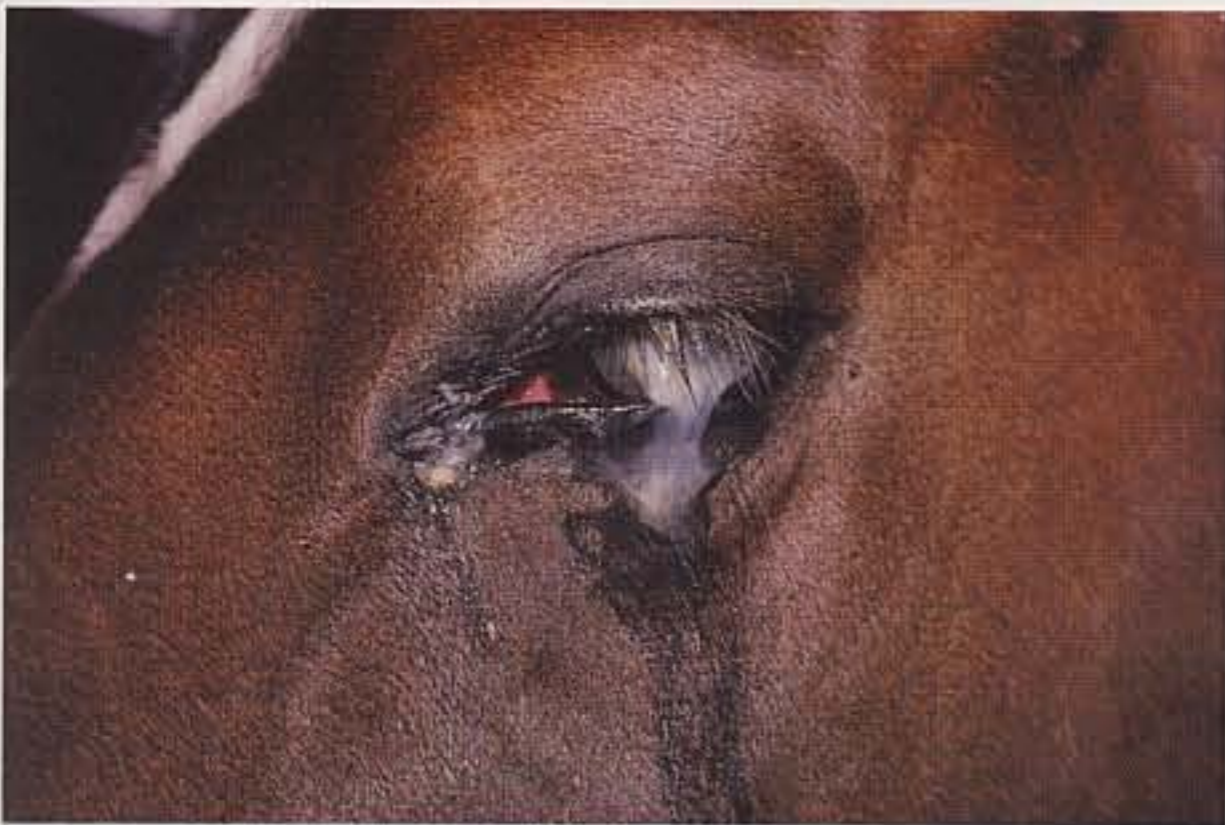

Fig. 6.26 Corneal ulcer (Hunter-type, 7 years old) Coagulase or melting ulcer. Note the gelatinous discharge over the lower lid and adherent to the eyelashes; considerable pain.

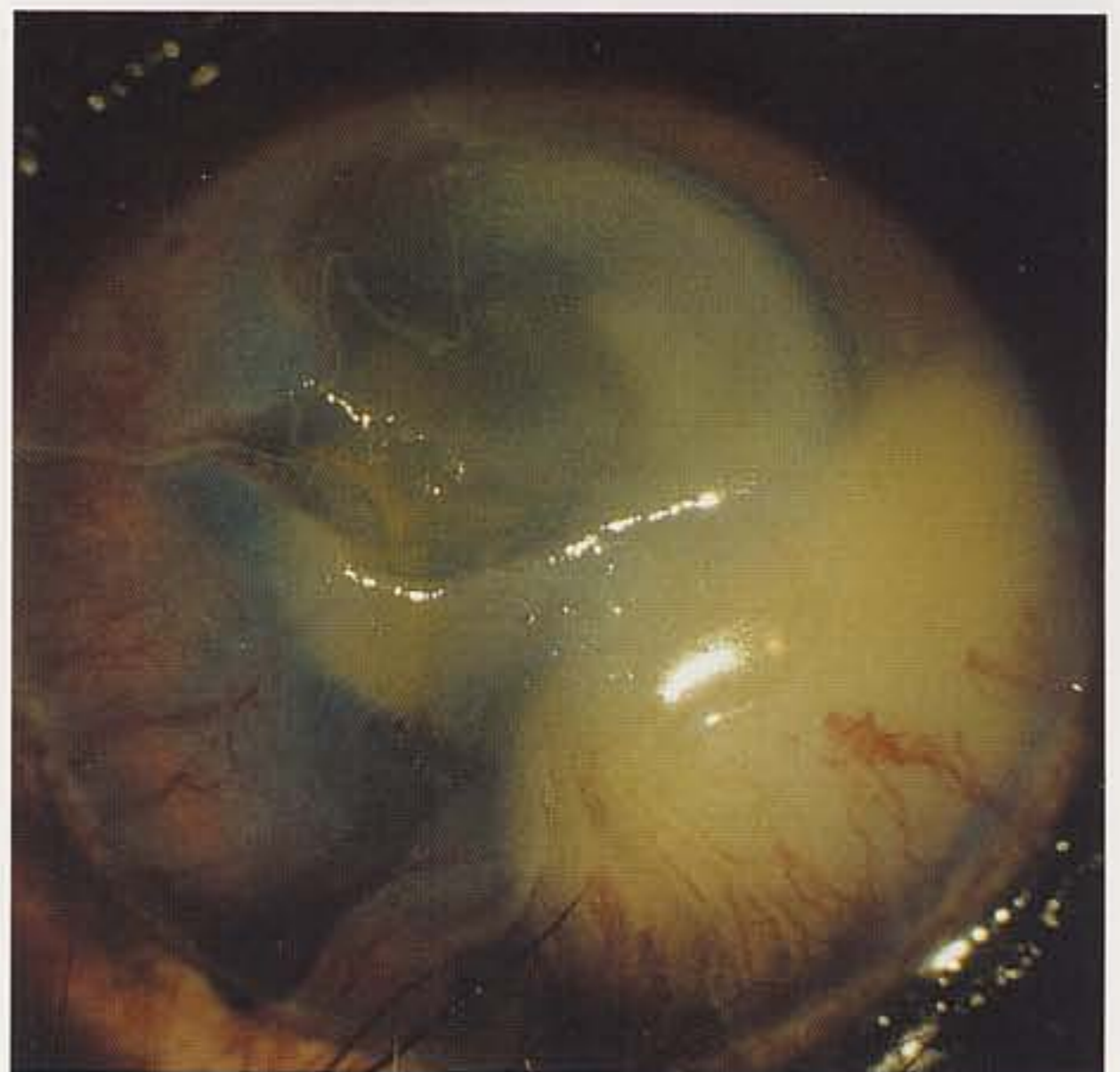


Fig. 6.28 Corneal ulcer Deep ulcer and note the dense hypopyon and corneal vascularization.

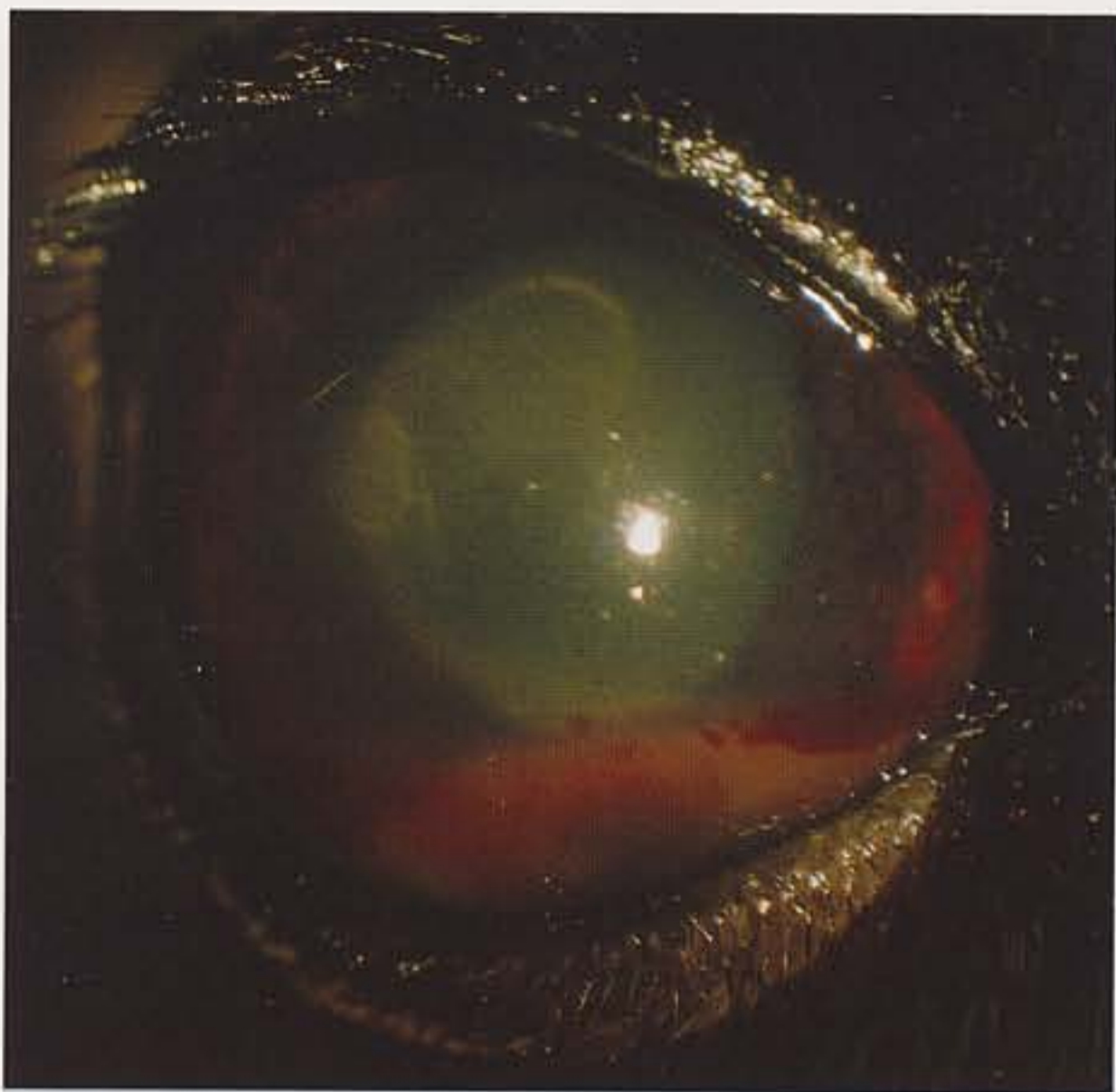


Fig. 6.29 Corneal ulcer Note the hypopyon and hyphaema in this case.

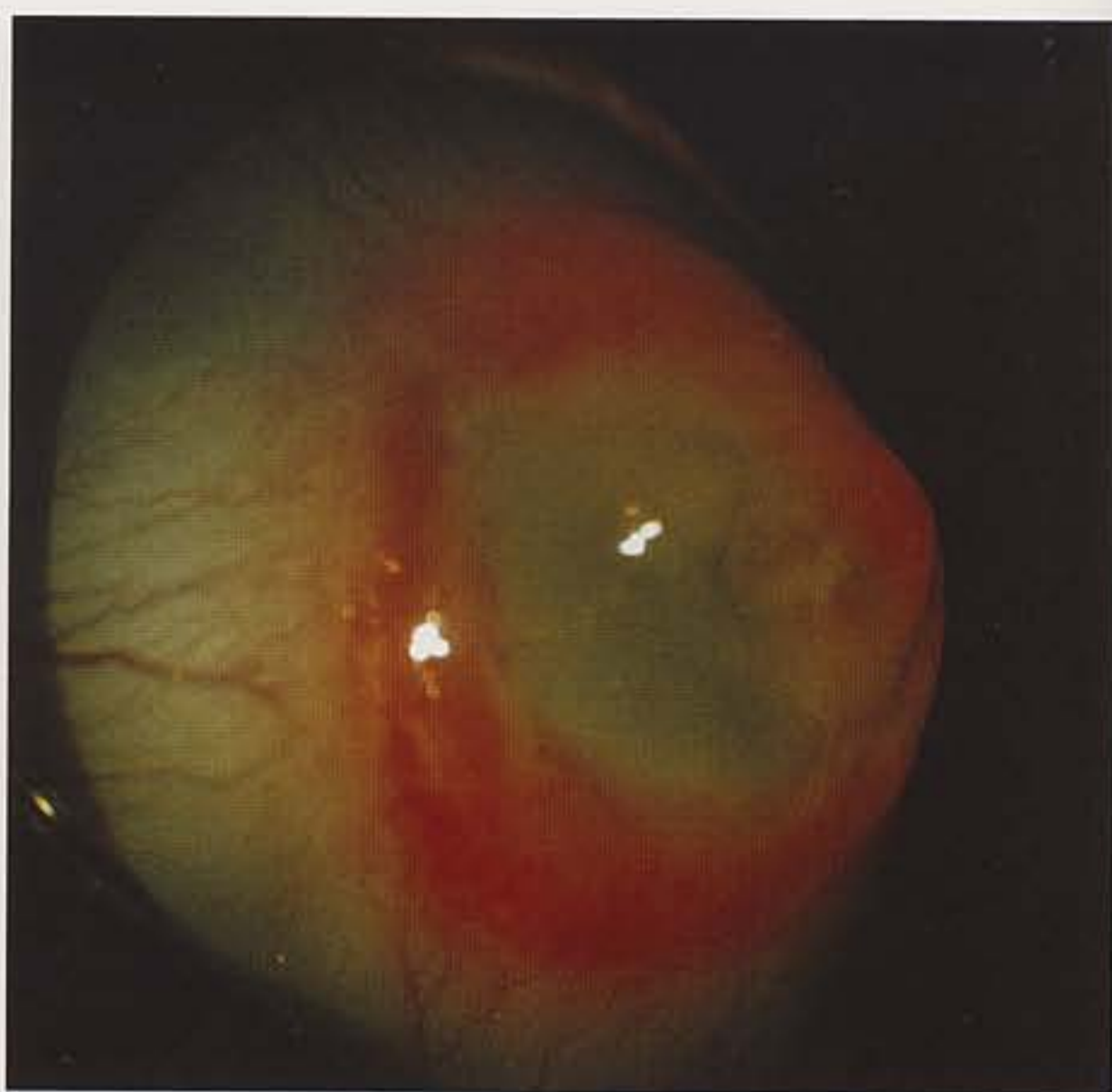


Fig. 6.31 Corneal ulcer Large keratocoele with surrounding granulation tissue and vascularization.

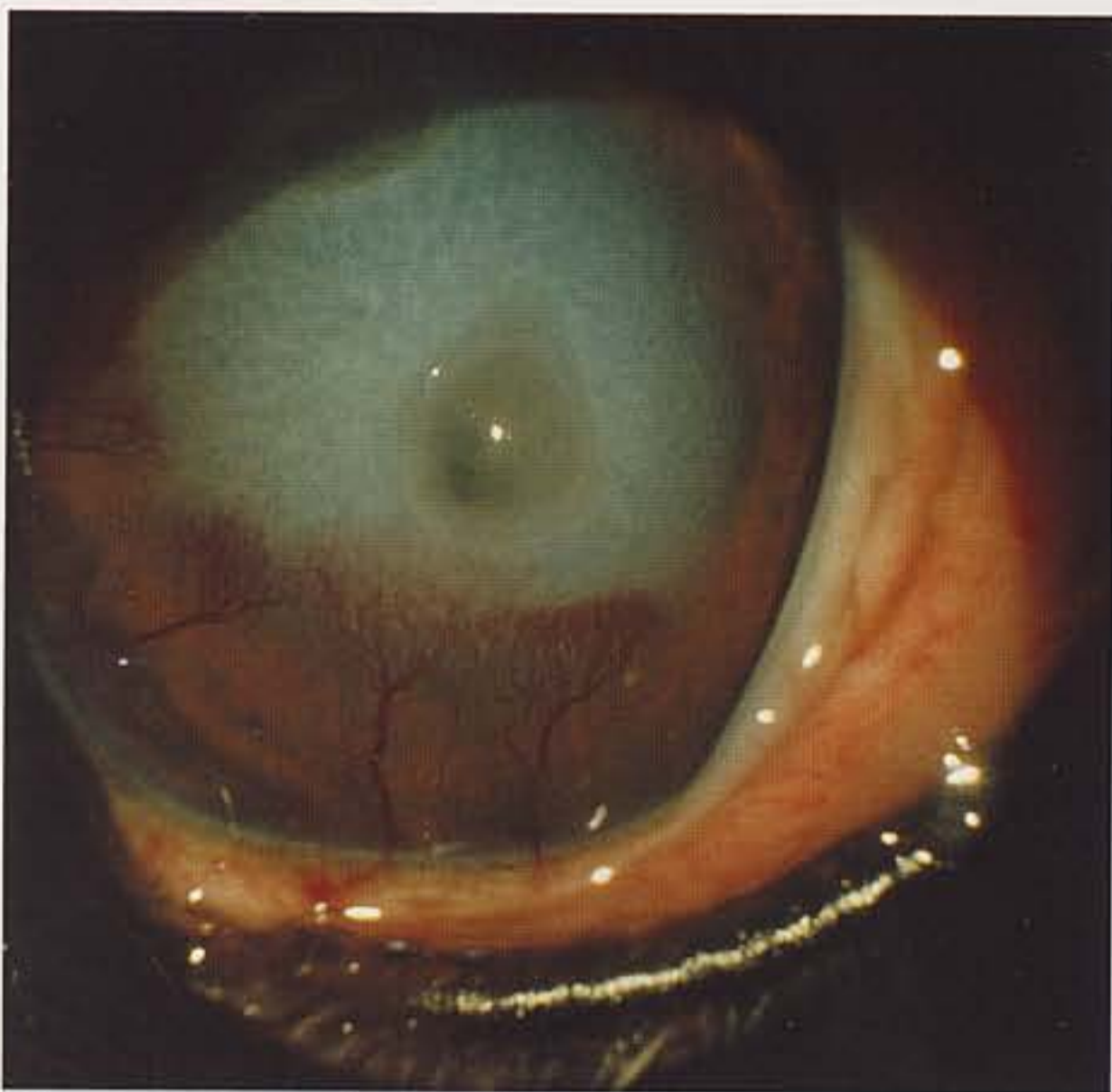


Fig. 6.30 Corneal ulcer Note the corneal oedema, small clear circular keratocoele and vascularization in the lower clear cornea.



Fig. 6.32 Corneal ulcer Small deep ulcer with clear keratocoele; in this region the epithelium and stroma have been lost leaving only Descemet's membrane and endothelium. Note also the vascular fringe and oedema of the surrounding stromal region.

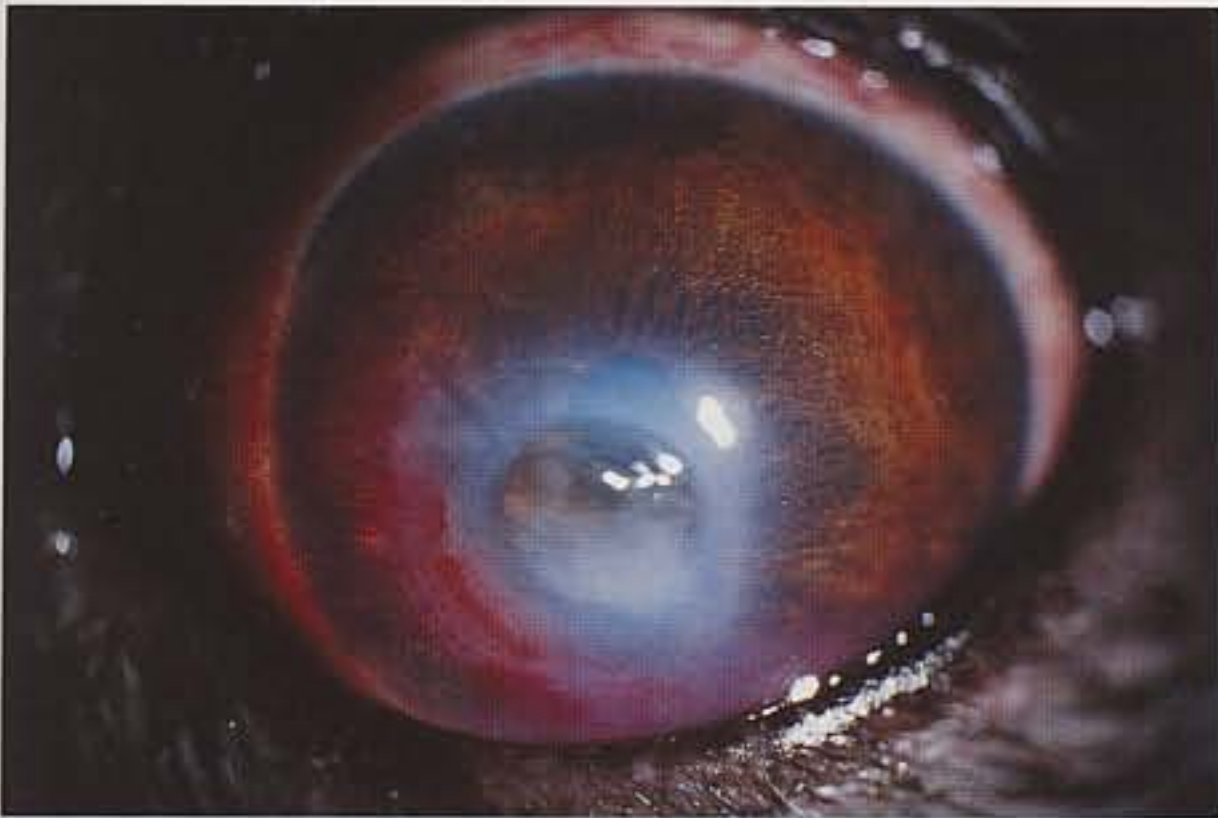

Fig. 6.33 Corneal ulcer Ruptured keratocoele with clearer central area and surrounding corneal oedema and vascular fringe. Note the shallow anterior chamber due to early anterior synechiae and loss of aqueous.

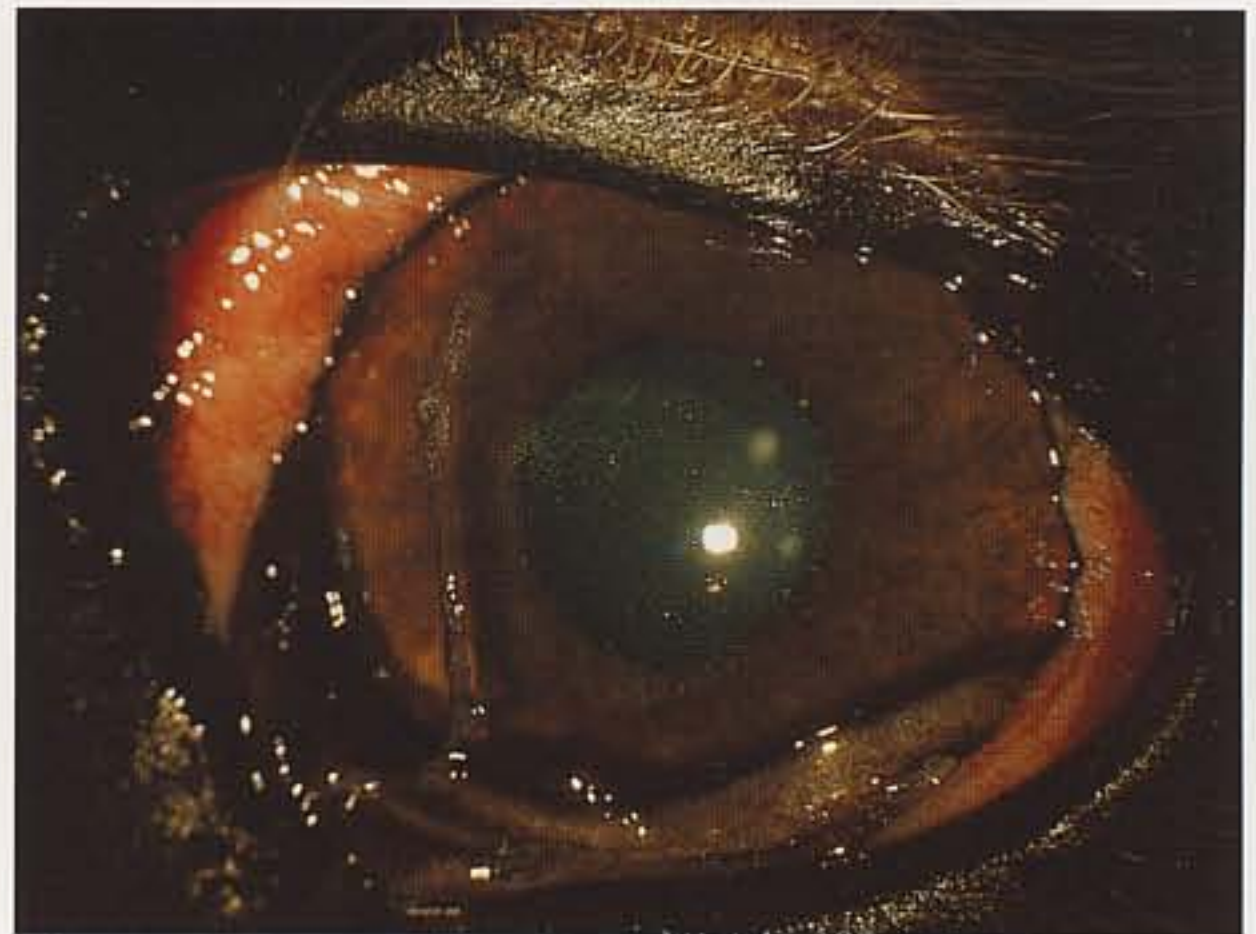


Fig. 6.35 Keratoconjunctivitis sicca (West Highland White Terrier, male, 3 years old) Early case with mucoid filaments on the cornea but no corneal pathology. The Schirmer tear test result was zero.

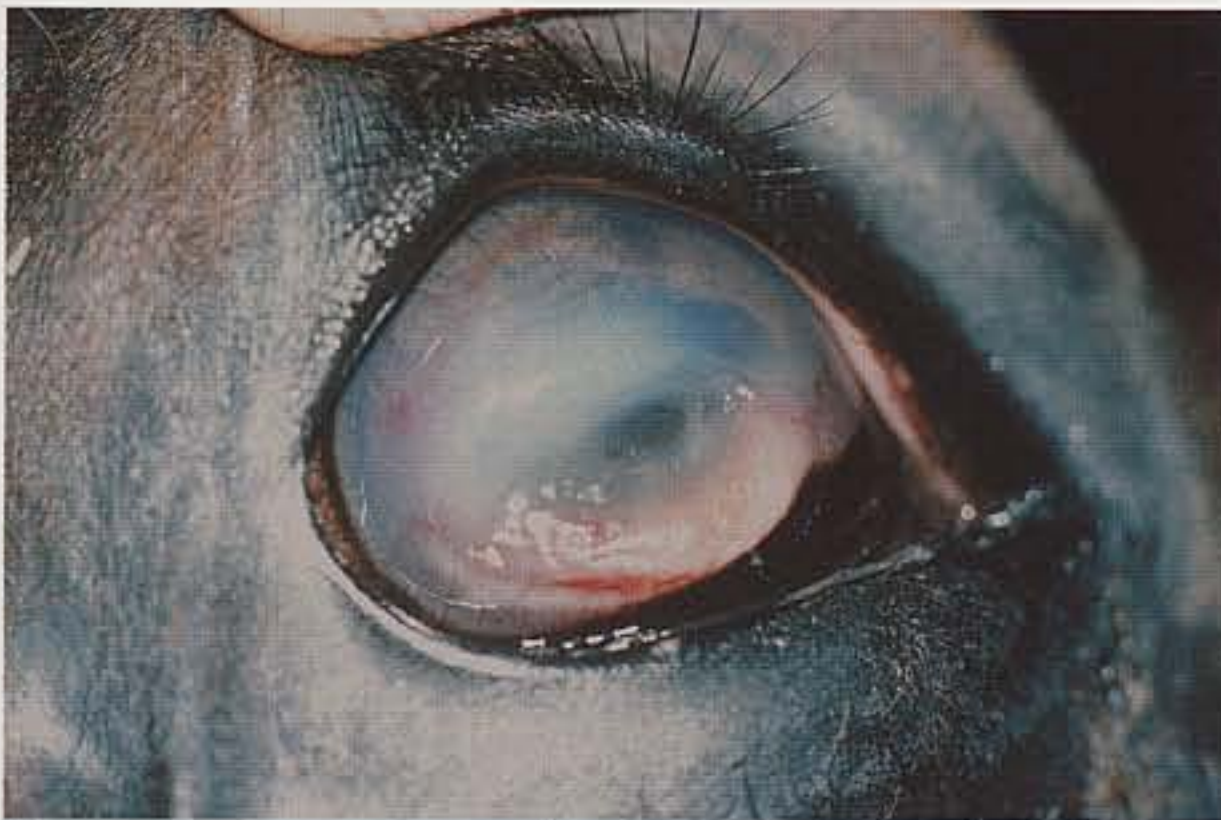

Fig. 6.34 Corneal ulcer (Thoroughbred mare) Deep ulceration with surrounding granulation tissue, oedema and vascularization.

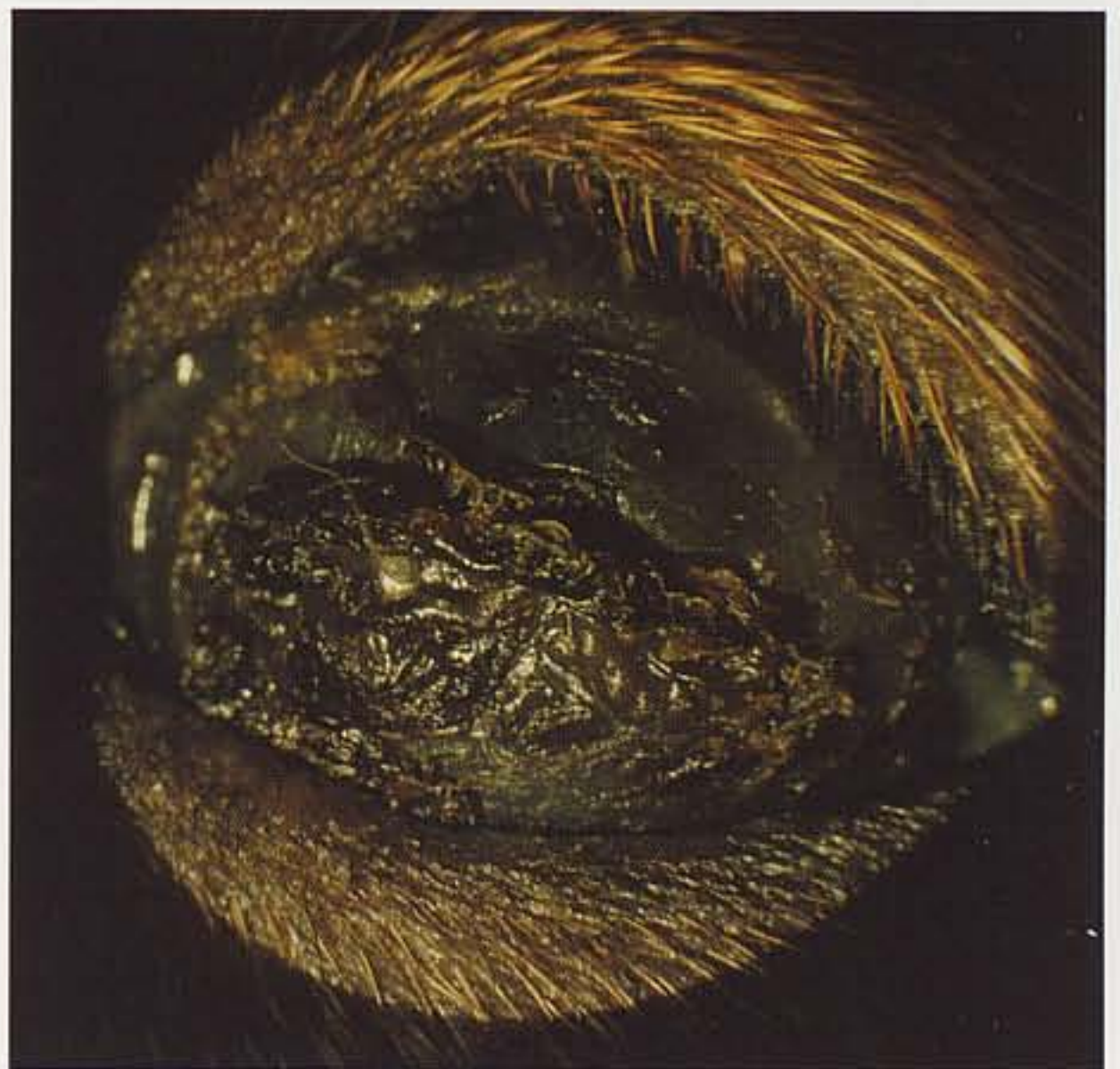


Fig. 6.36 Keratoconjunctivitis sicca (Jack Russell Terrier, female, 4 years old) Advanced case of xerosis.

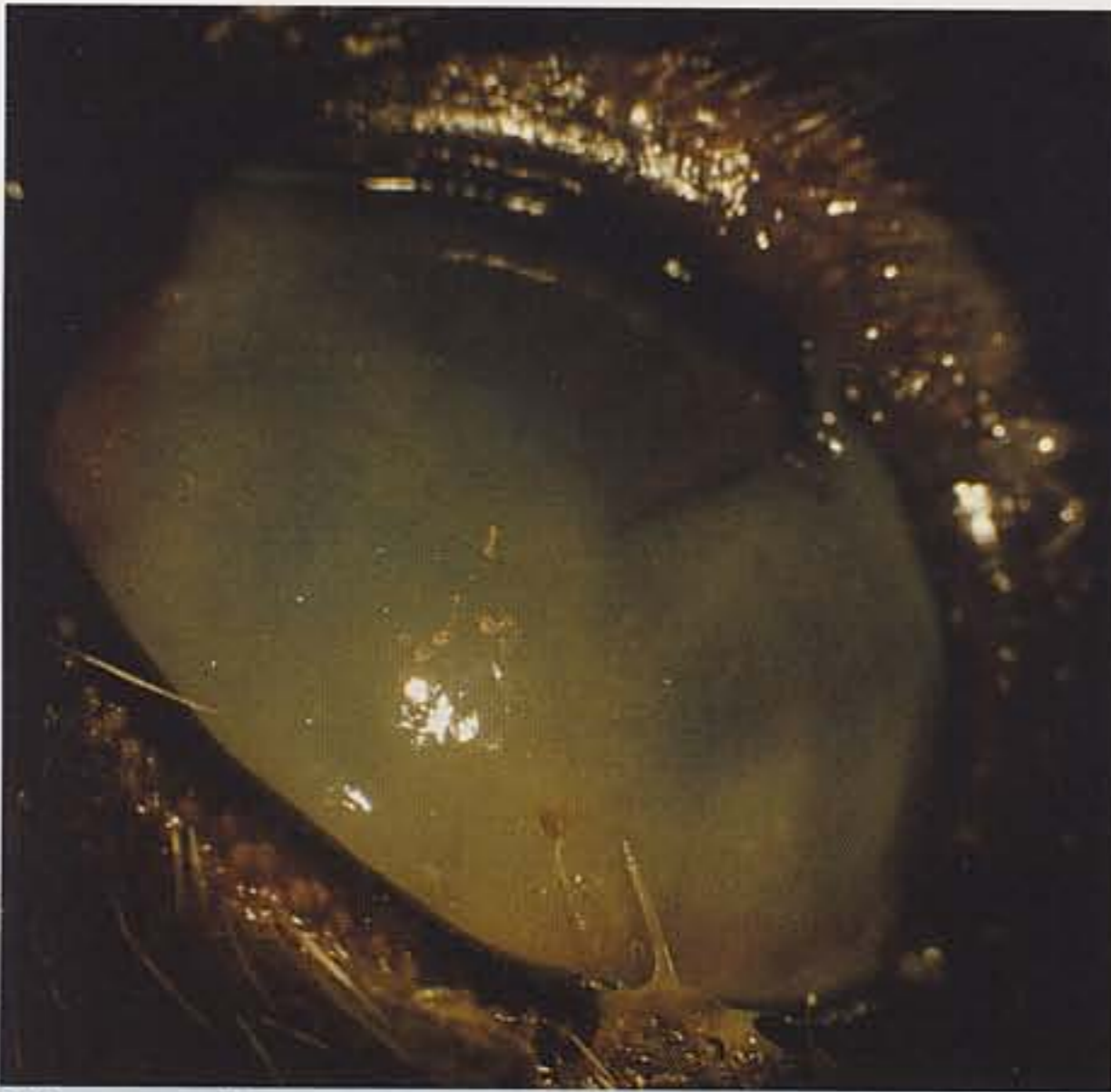

Fig. 6.37 Keratoconjunctivitis sicca (West Highland White Terrier, male, 8 years old) Moderately severe case with typical discharge.

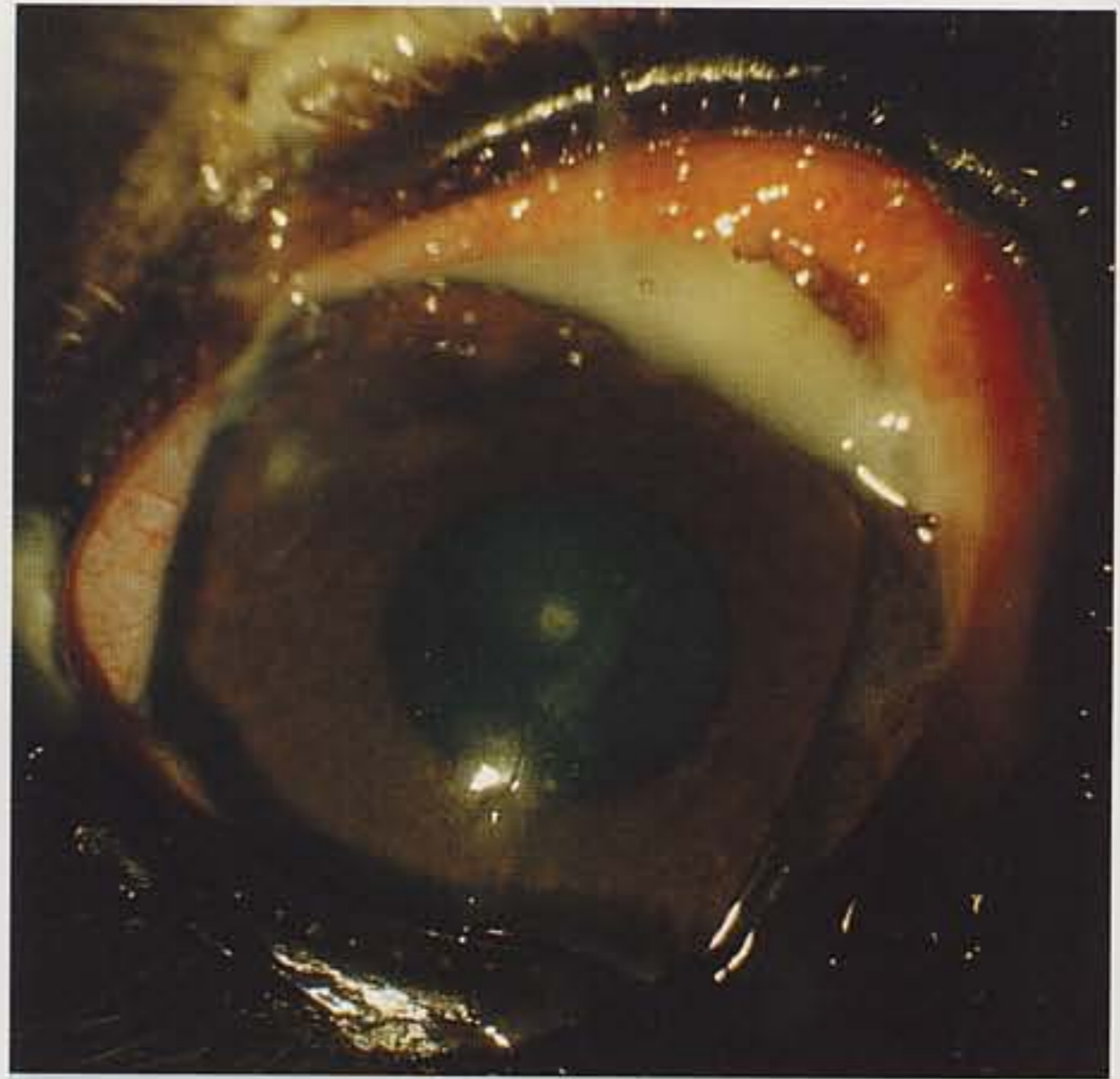


Fig. 6.39 Keratoconjunctivitis sicca (West Highland White Terrier, female, 2 years old) Note ocular discharge in the conjunctival fornix.

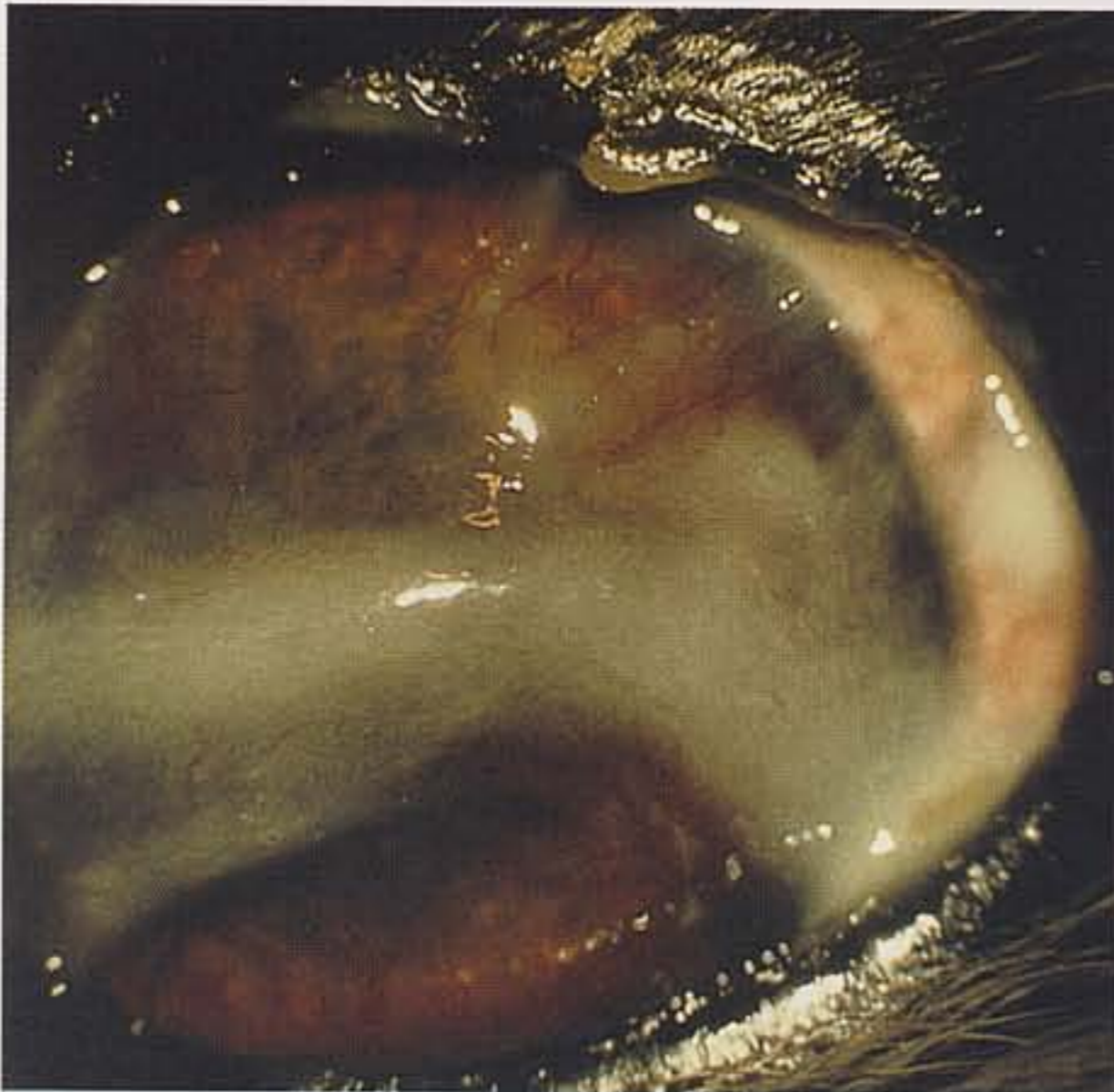


Fig. 6.38 Keratoconjunctivitis sicca (Samoyed, female, 6 years old) Typical discharge stuck on cornea and eyelid edge. Compare with Fig 5.1 of purulent conjunctivitis in which the ocular discharge is washed off the cornea by the associated lacrimation.

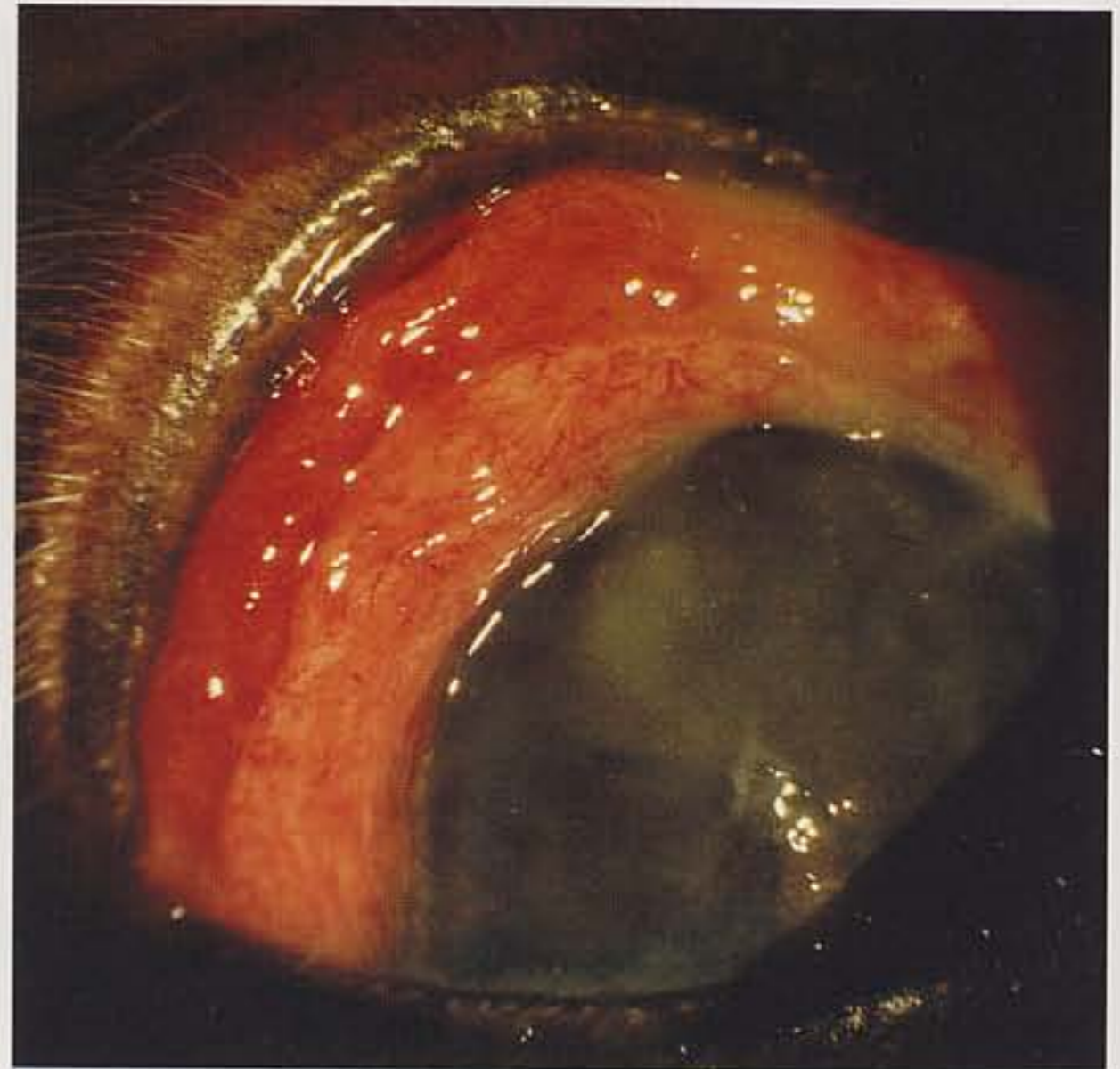


Fig. 6.40 Keratoconjunctivitis sicca (Bichon Frise, male, 3 years old) Note typical conjunctival hyperplasia.

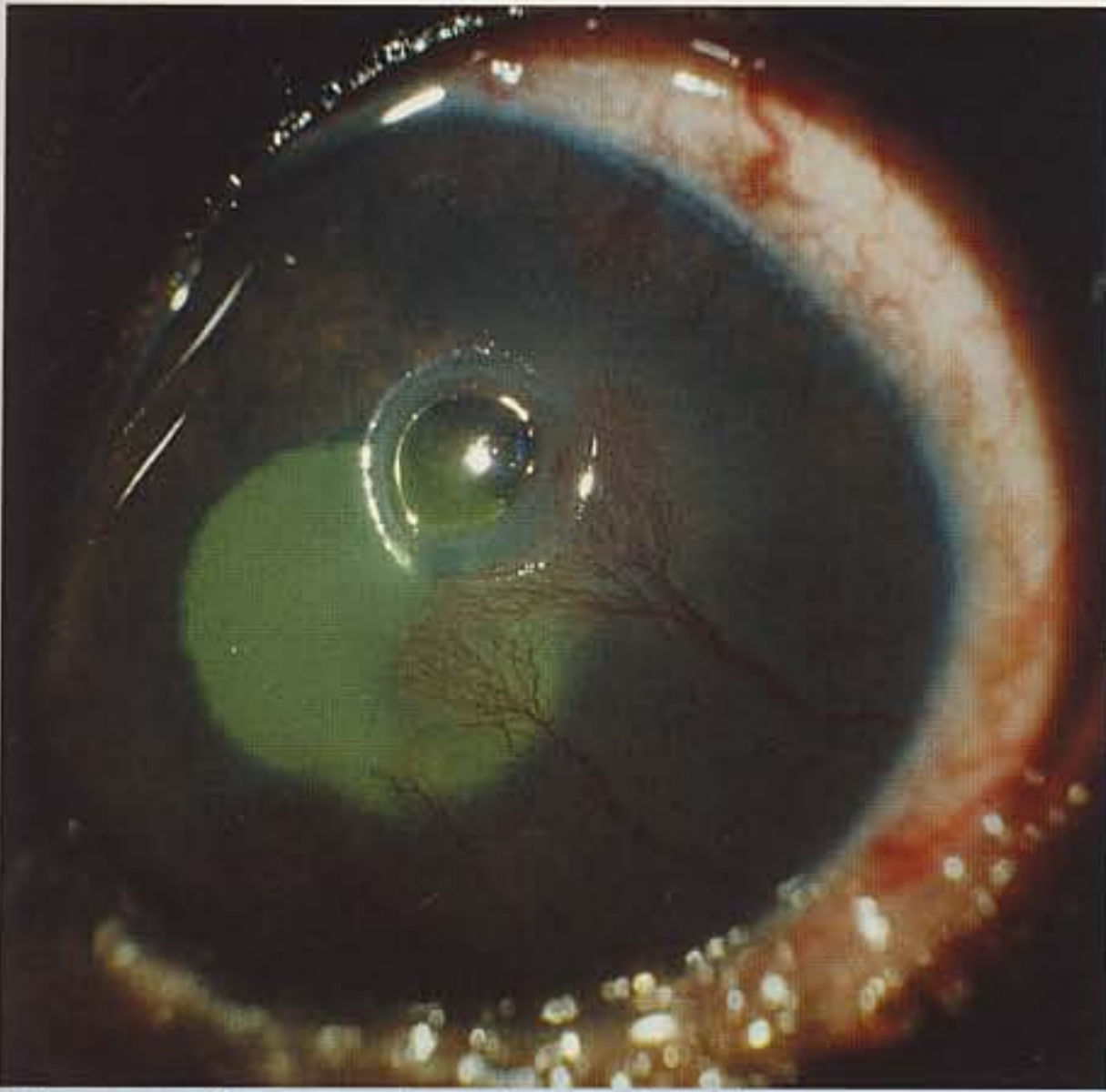


Fig. 6.41 Keratoconjunctivitis sicca (West Highland White Terrier, female, 7 years old) Typical deep circular ulcer and keratocoele.

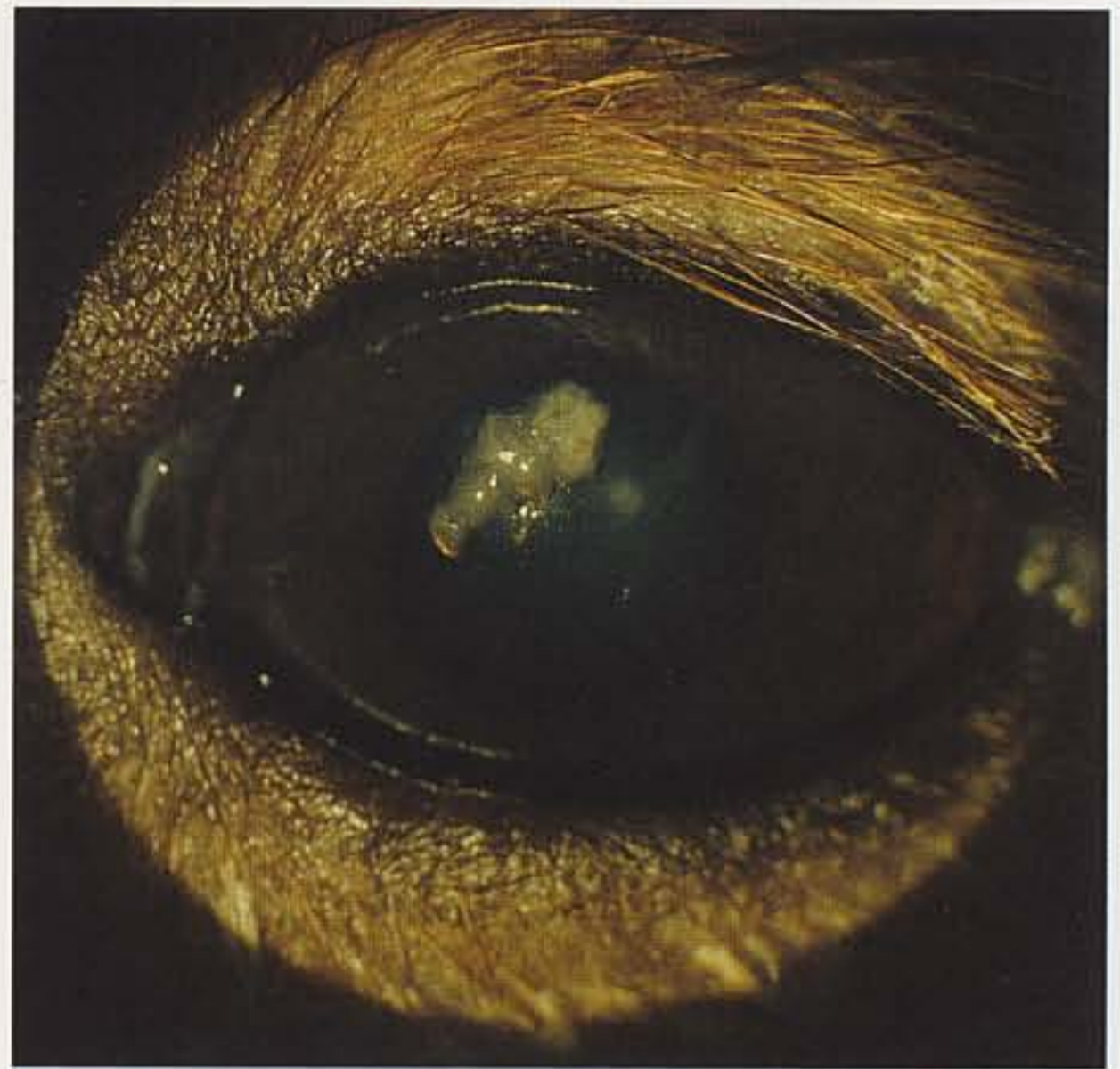


Fig. 6.43 Keratoconjunctivitis sicca (Yorkshire Terrier, female, 2 years old) Iatrogenic case following sulphasalazine therapy for colitis.

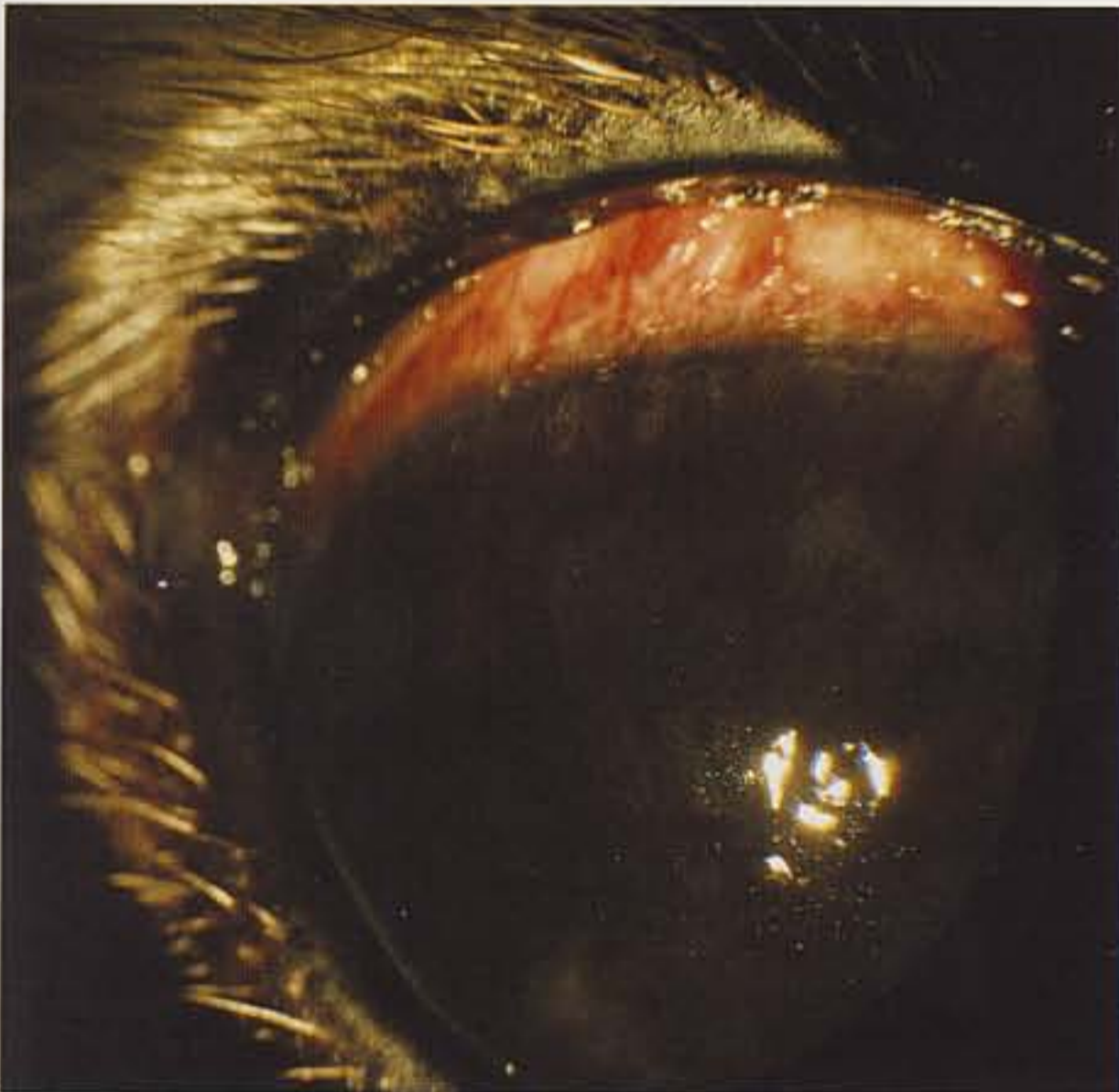

Fig. 6.42 Keratoconjunctivitis sicca (West Highland White Terrier, male, 5 years old) Long-standing case with secondary pigmentary keratitis.

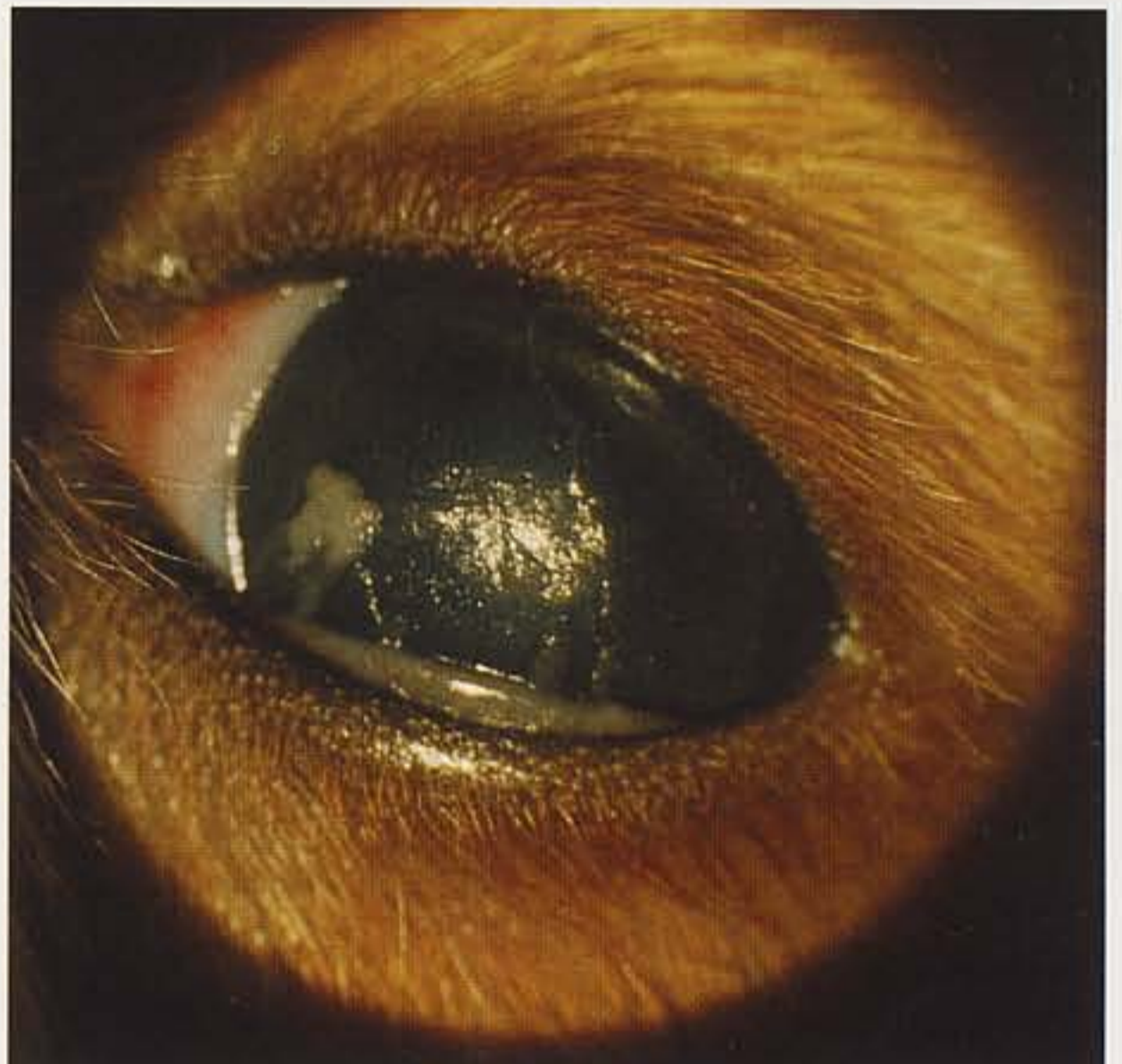

Fig. 6.44 Keratoconjunctivitis sicca (Cavalier King Charles Spaniel, female, 16 weeks old) Congenital case associated with skin condition.



with a skin disease (ichthyosis), has been described. KCS is usually bilateral but the two eyes may differ in the degree of severity and the condition is more uncomfortable than painful. Diagnosis is based on the clinical signs, together with a Schirmer tear test 1 to measure tear secretion.

### Corneal oedema (Figs 6.45–6.55)

Corneal oedema is not a specific disease but results from a failure of the corneal pump mechanism, usually damage to the corneal epithelium or, more commonly, the endothelium. Corneal oedema is an opacity, and presents as such, varying in density and is either focal or diffuse. There are a number of known causes, including trauma and inheritance,

but many cases are idiopathic. It is, together with vascularization and pigmentation, one of the classic responses of the cornea to insult.

Corneal oedema may affect one or both eyes and to the same or differing degrees. Although the eye may appear 'blind', there is little or no effect on vision. Other parts of the eye may well be involved with corneal oedema, including uveitis (Fig 6.45), lens luxation (Fig 6.53) and glaucoma (Fig 6.54). Corneal oedema is not painful, but in severe cases may develop into a bullous keratopathy in which disruption of the bullae does cause pain (Figs 6.46–6.47). Corneal oedema leads to a thickened cornea and sometimes to an obvious keratoconus (Fig 6.49).

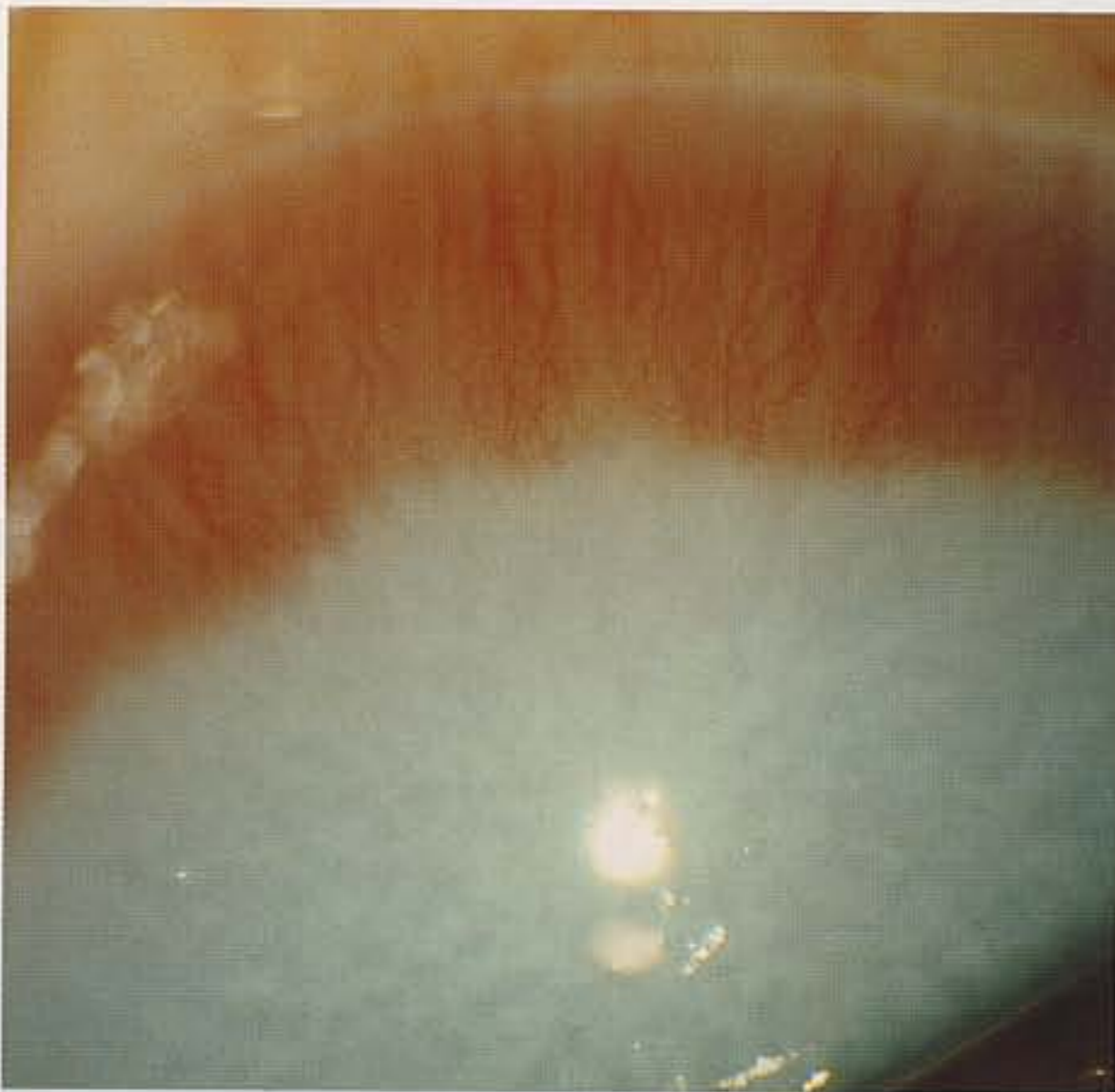


Fig. 6.45 Corneal oedema (Airedale Terrier, 4 months old) Dense corneal oedema and vascular fringe occurring 12 days after vaccination with live attenuated canine adenovirus-type-1 vaccine; referred to as 'blue eye'.

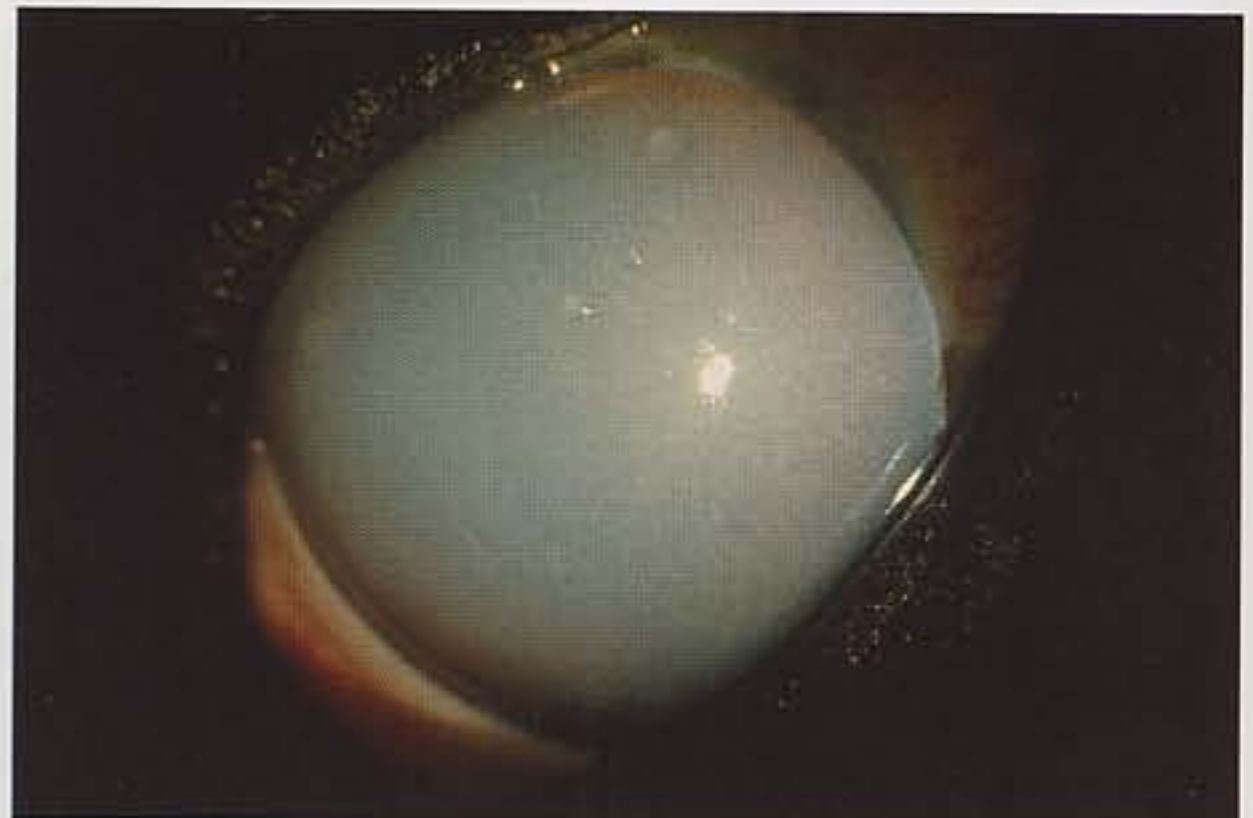

Fig. 6.46 Corneal oedema Dense oedema, together with a few clear bullae.

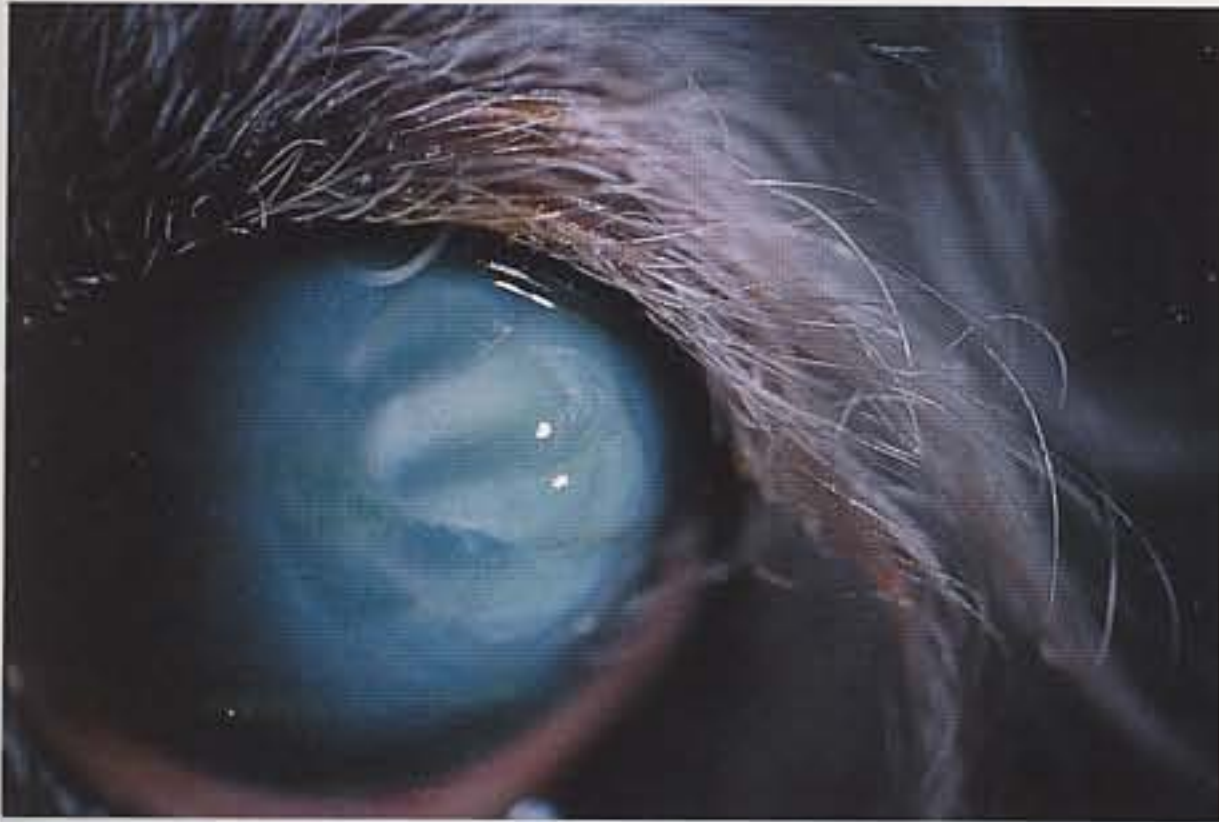

Fig. 6.47 Corneal oedema Severe bullous keratopathy.

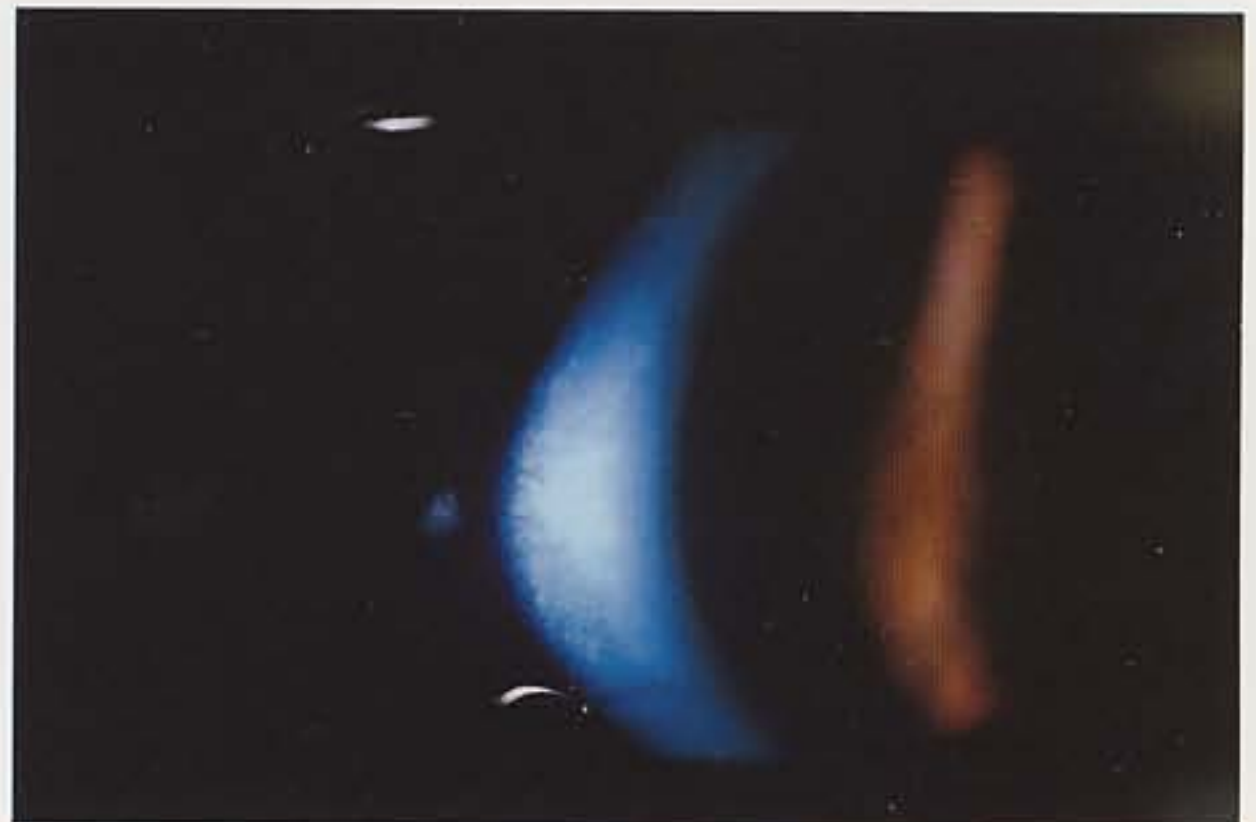

Fig. 6.49 Corneal oedema Slit-lamp photograph showing thickening of the central cornea due to the oedema and keratoconus.

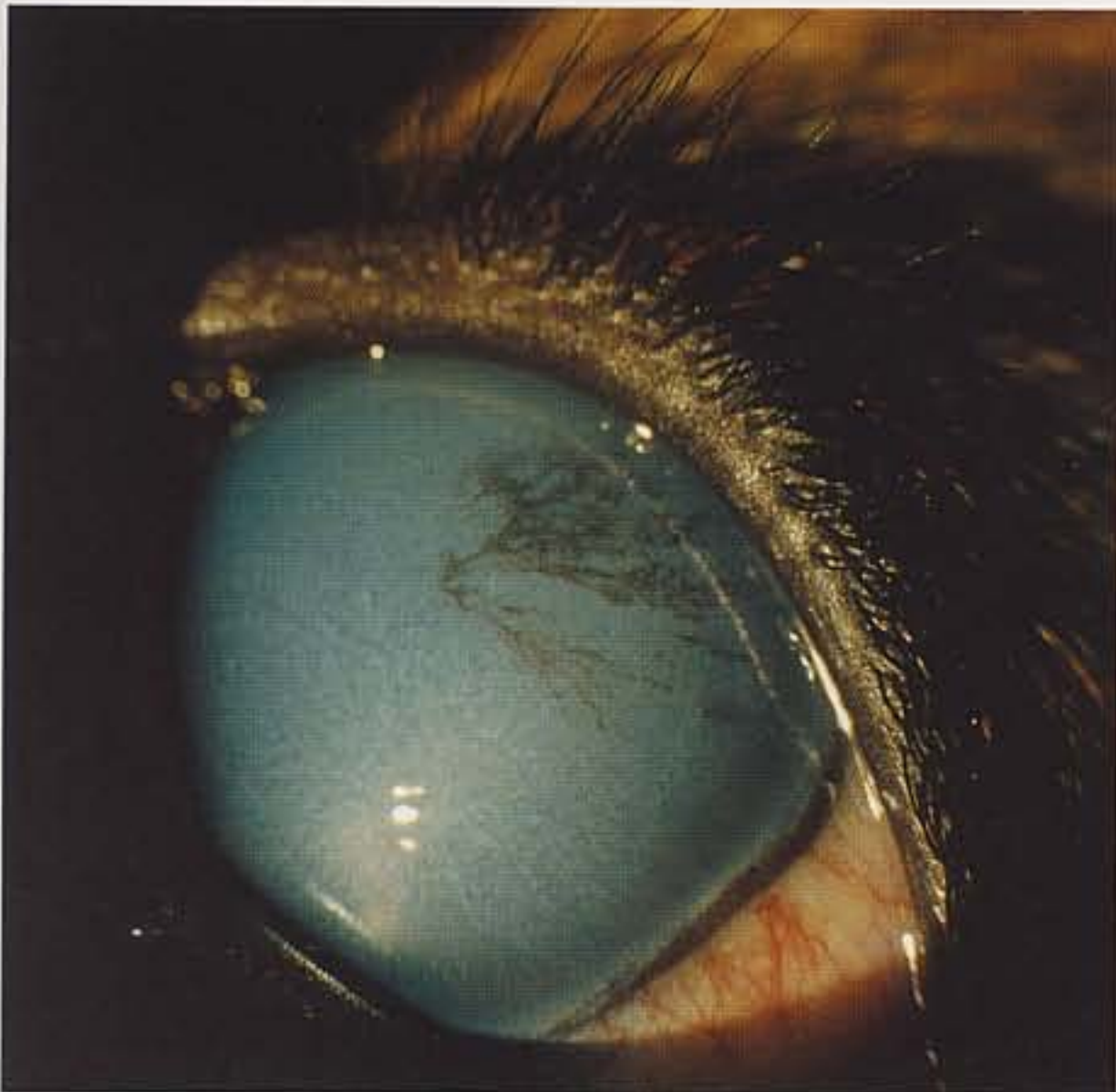

Fig. 6.48 Corneal oedema (Longhaired Dachshund, 6 months old) Long-standing case with corneal pigmentation. Another post-vaccination case (see Fig. 6.45).

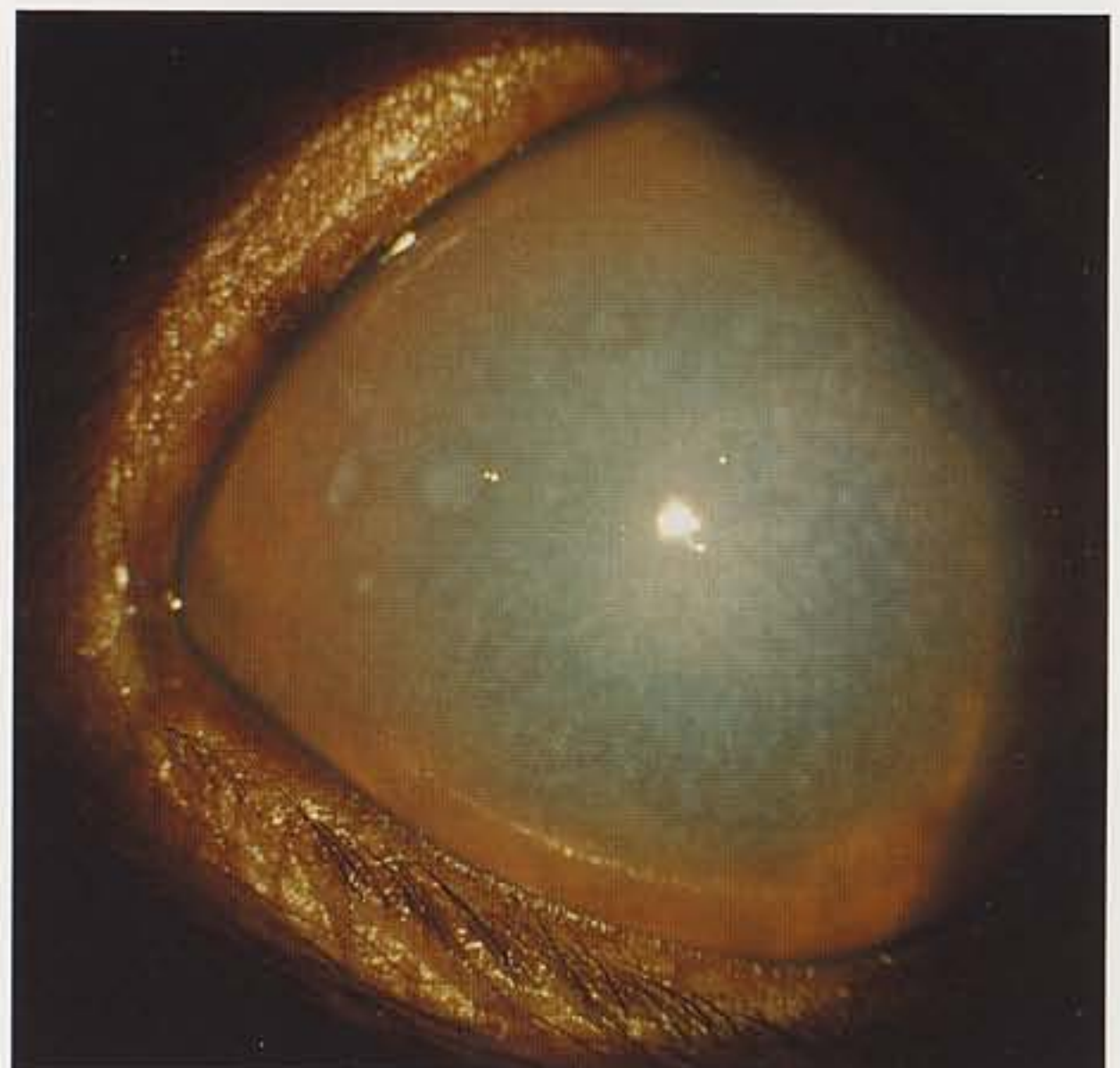

Fig. 6.50 Corneal oedema (English Springer Spaniel, 9 years old) Note the typical mottled appearance of the oedema in the central region, together with one or two small bullae. This is a case of endothelial dystrophy presenting as corneal oedema in this breed.

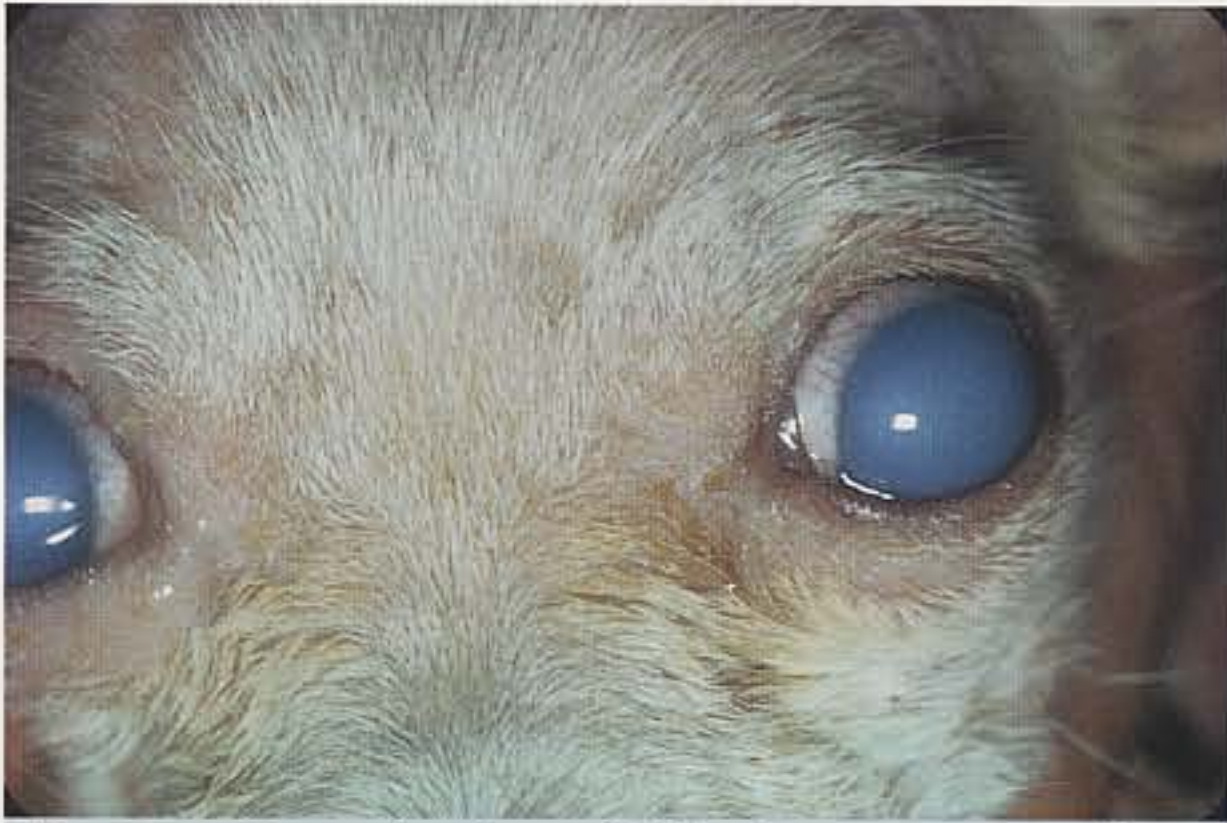

Fig. 6.51 Corneal oedema (Chihuahua, 5 years old) A bilateral case with severe oedema again due to an inherited corneal endothelial dystrophy.

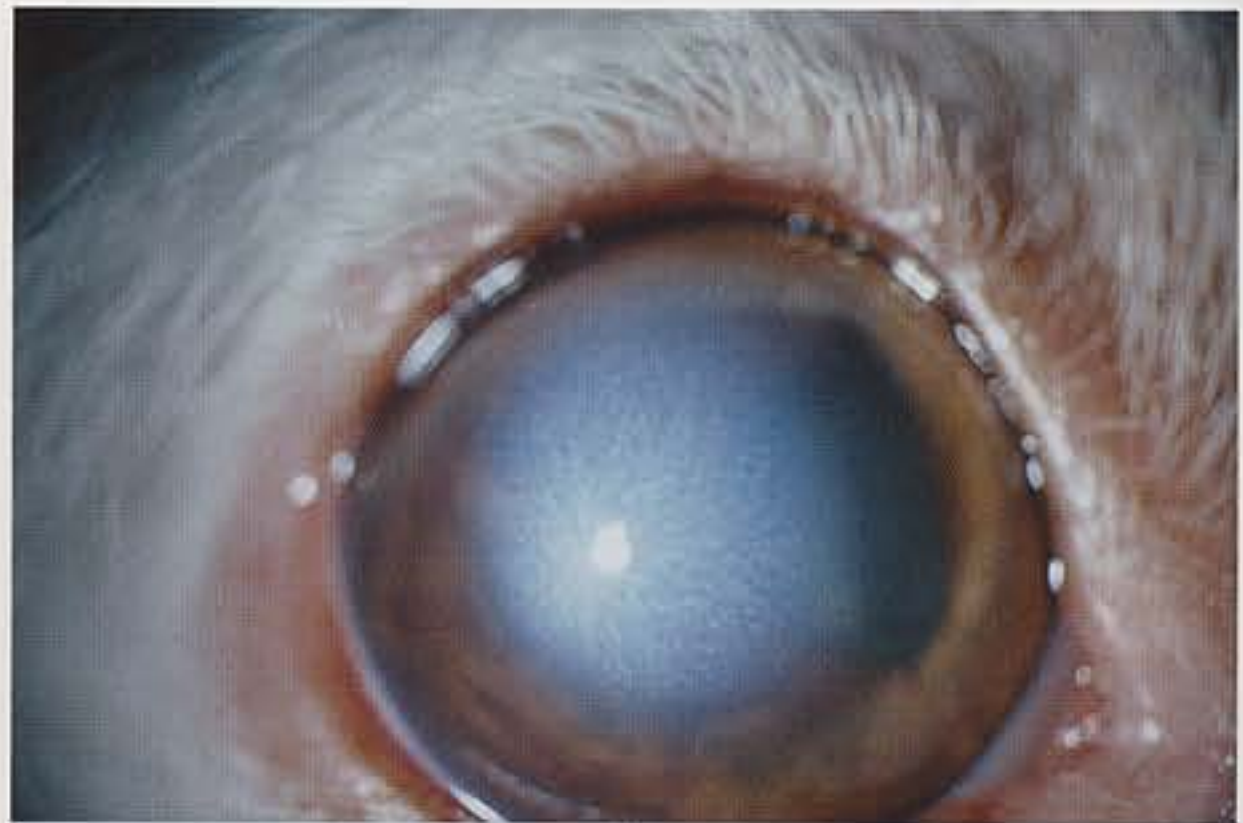

Fig. 6.53 Corneal oedema (Jack Russell Terrier, 5 years old) Central or subcentral corneal opacity associated with primary lens luxation. The anteriorly dislocated lens is pushed against the corneal endothelium causing the oedema. If the lens later becomes dislocated into the posterior segment, this corneal opacity will persist.

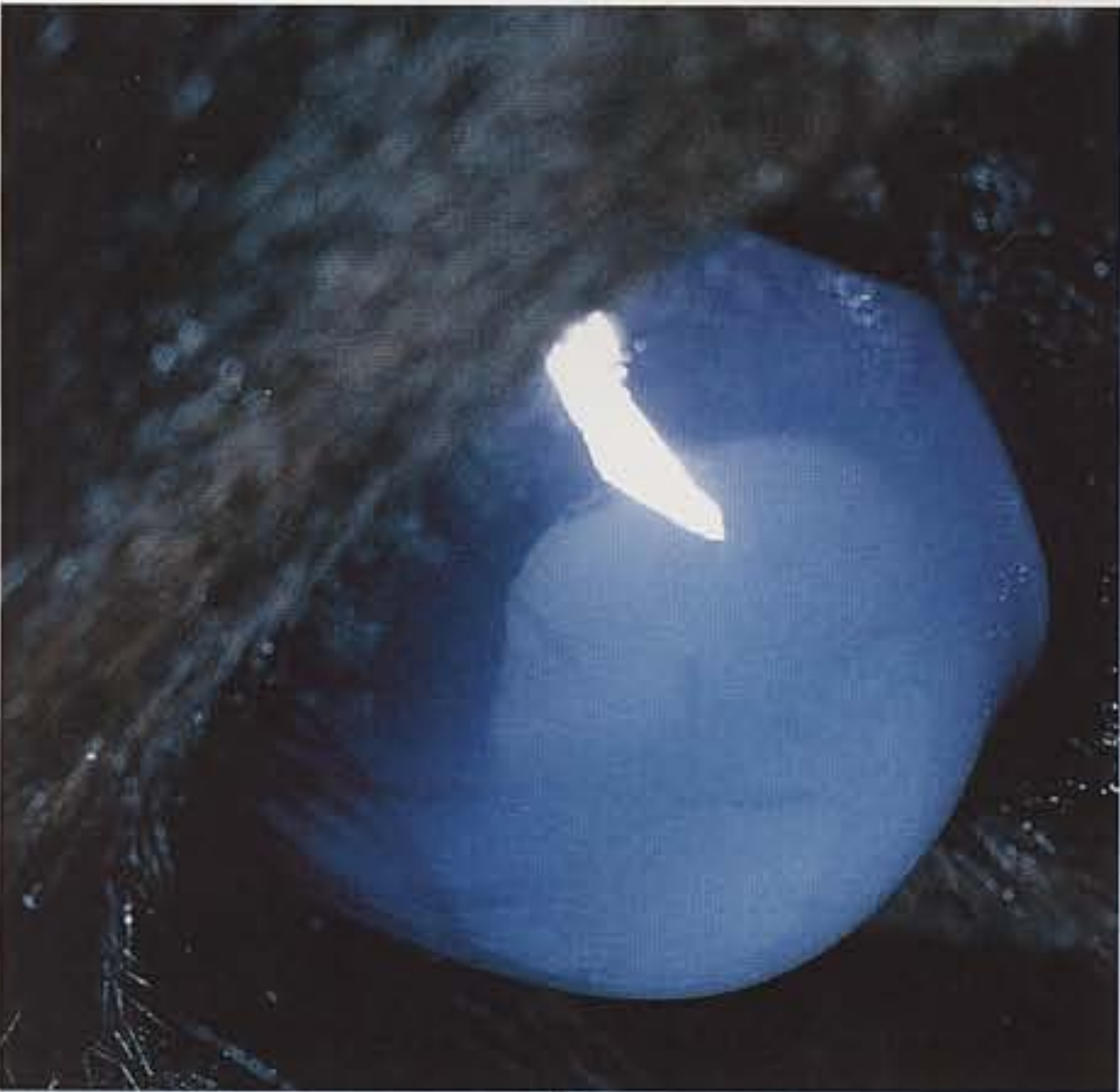

Fig. 6.52 Corneal oedema (Friesian calf) Bilateral condition inherited in this breed. Again, note an associated keratoconus.

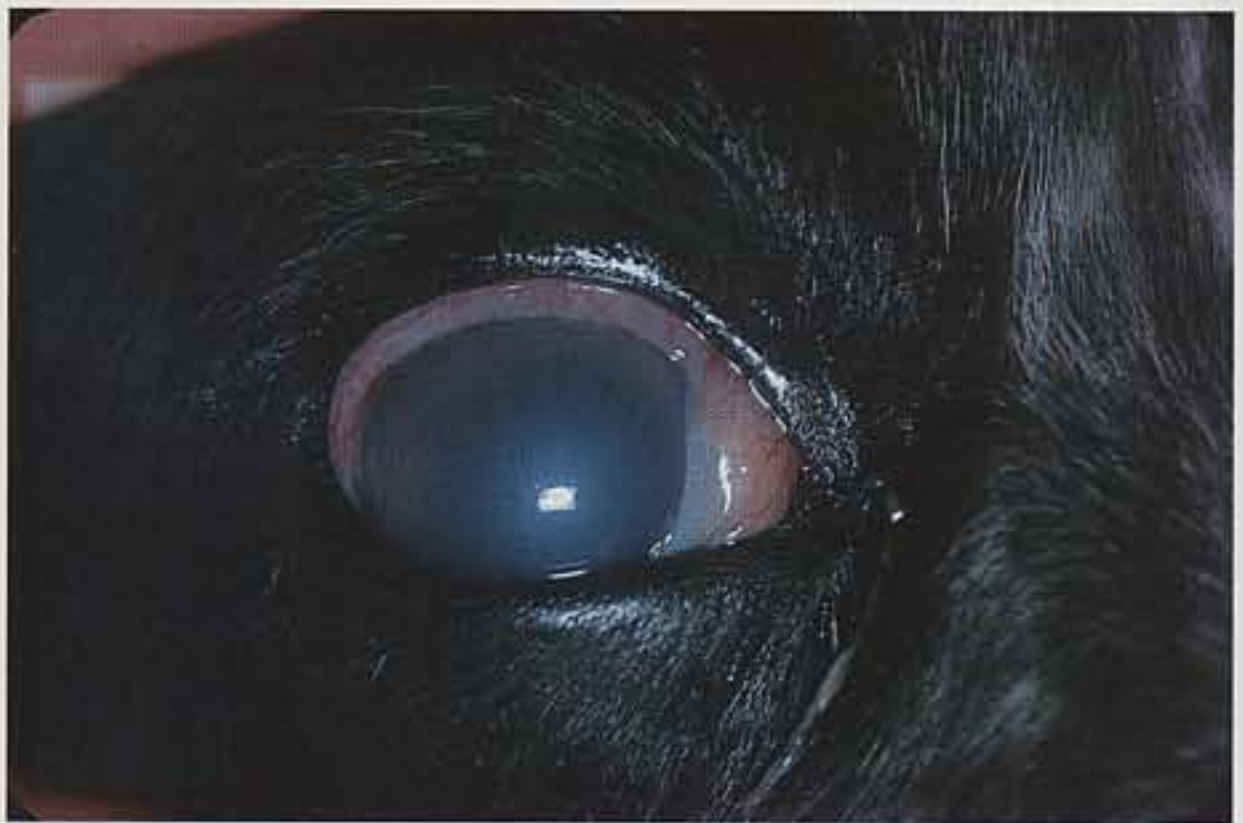

Fig. 6.54 Corneal oedema (American Cocker Spaniel, 5 years old) Diffuse oedema associated with primary glaucoma. Note also the slight conjunctival oedema (chemosis).

### Lipid keratopathies (Figs 6.56–6.62)

Lipid deposition in the cornea, sometimes incorrectly referred to as a corneal dystrophy (correctly dystrophy is a primary inherited bilateral condition affecting any part of the cornea and not associated with inflammation), occurs in a number of not fully understood conditions which present as a corneal opacity.

The commonest form of lipid keratopathy, often referred to as corneal lipidosis (Figs 6.56–6.59), is a usually bilateral, not always symmetrical and sometimes starting in only one eye, central or paracentral, subepithelial (non-staining with fluorescein), silver-grey metallic oval opacity. It is progressive to a stage but not further and sometimes regressive, and not associated with any inflammation or pain. It usually occurs in young adults and with a definite breed incidence (Rough Collie, Shetland Sheepdog, Cavalier King Charles Spaniel, Afghan and Siberian Husky) and is sometimes related to the oestral cycle, although it also occurs in the male.

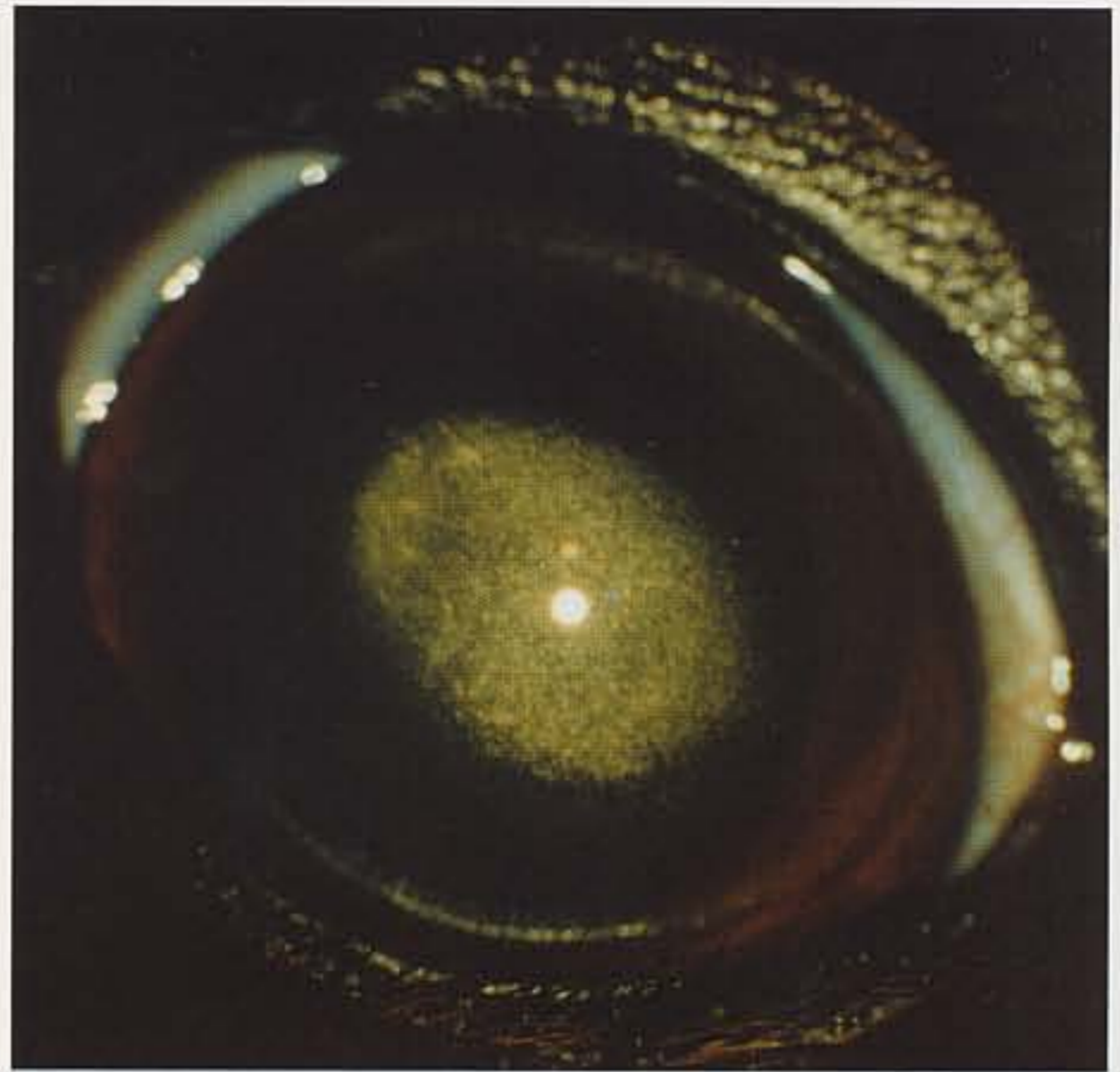


Fig. 6.56 Lipid keratopathy (corneal lipidosis) (Rough Collie, 3 years old) Typical appearance, bilateral condition, approximately symmetrical, central cornea. Note the perfect corneal reflection indicating normal overlying epithelium.

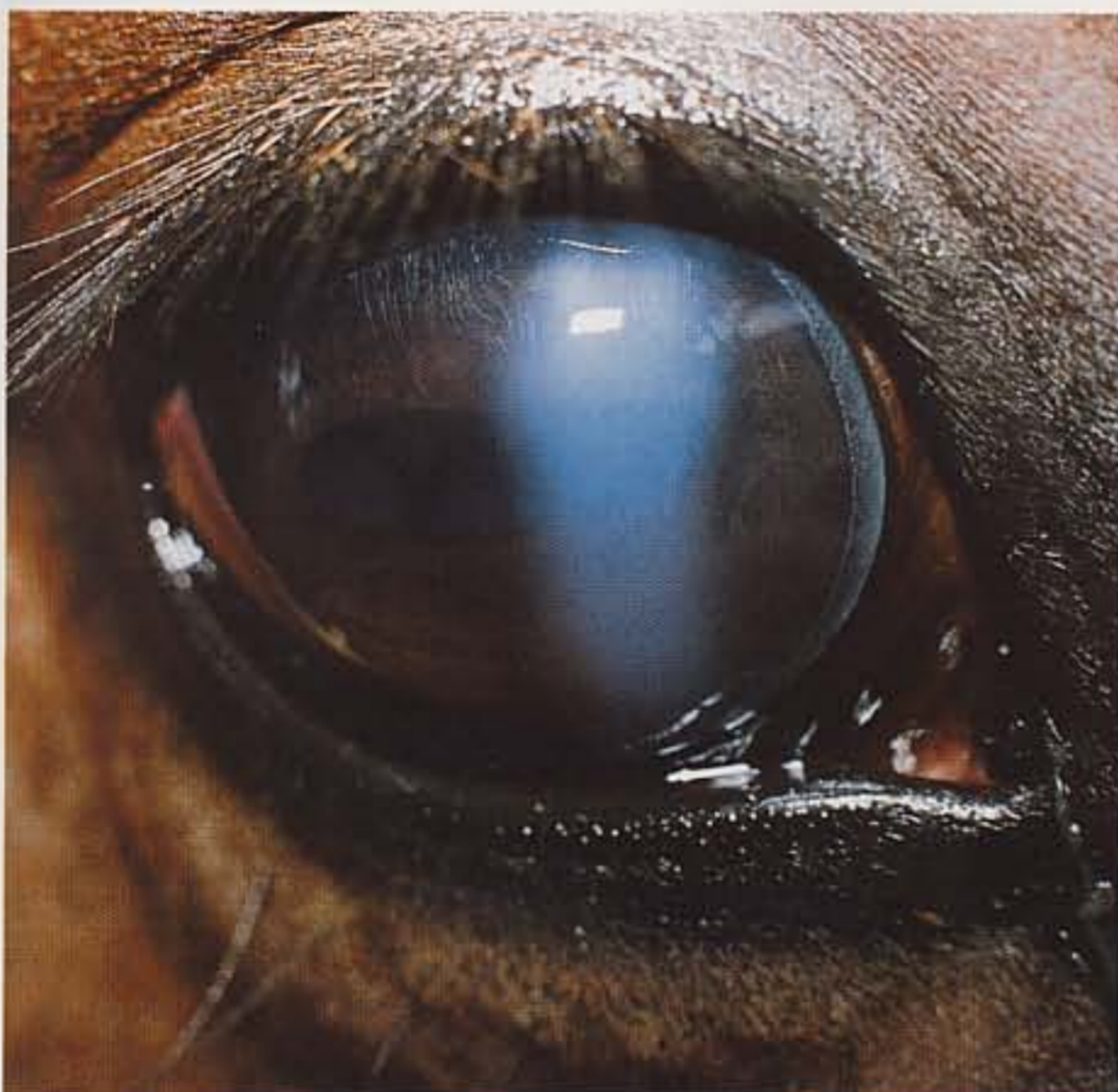

Fig. 6.55 Corneal oedema (Half-bred mare, 7 years old) Bilateral and asymmetrical, partial oedema in a vertical stripe and of unknown aetiology. This distribution of oedema has only been seen in the horse.

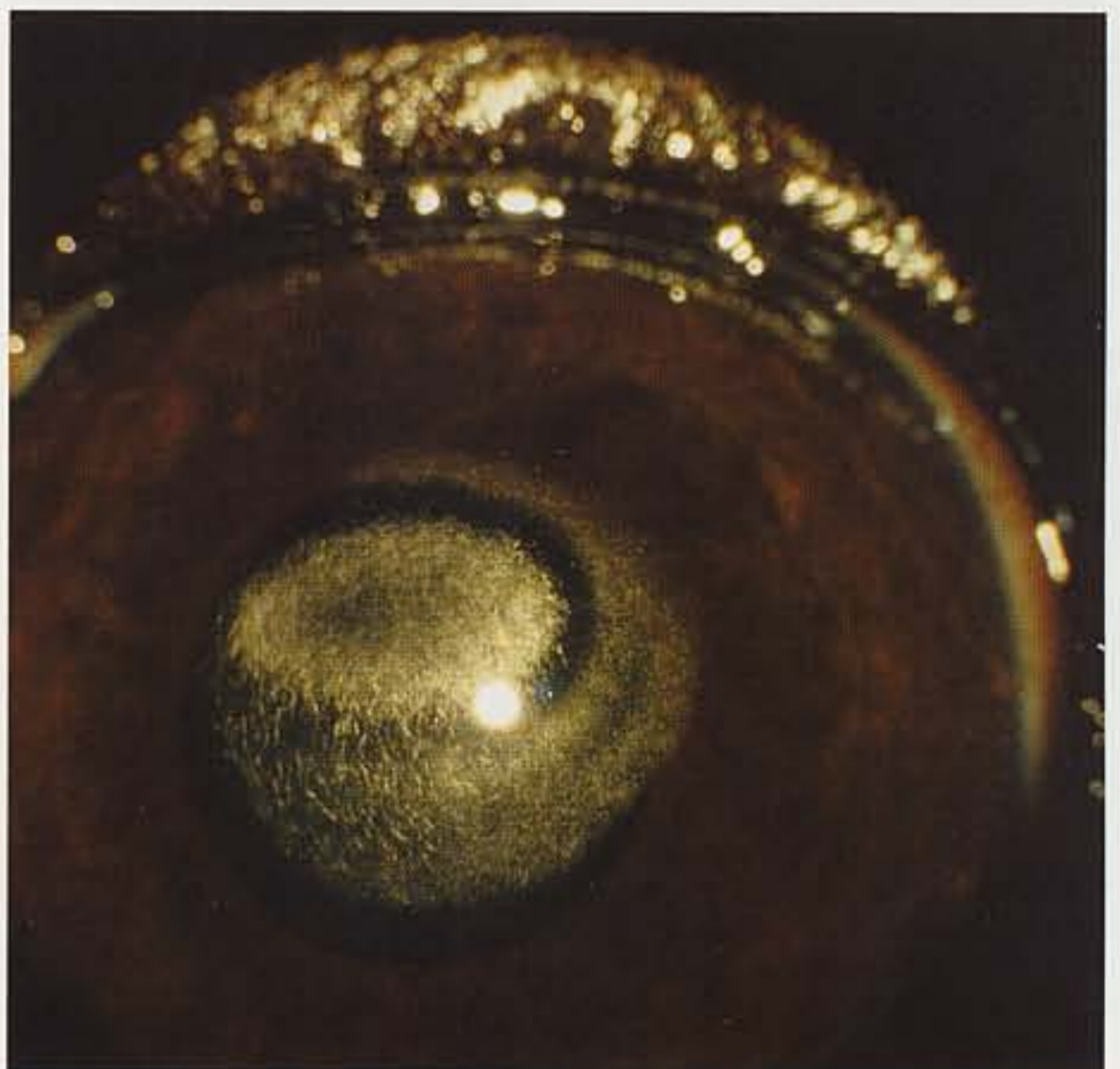


Fig. 6.57 Lipid keratopathy (corneal lipidosis) (Cavalier King Charles Spaniel, female, 3 years old) Typical age, breed and sex. Note the crystalline appearance of the lesion.

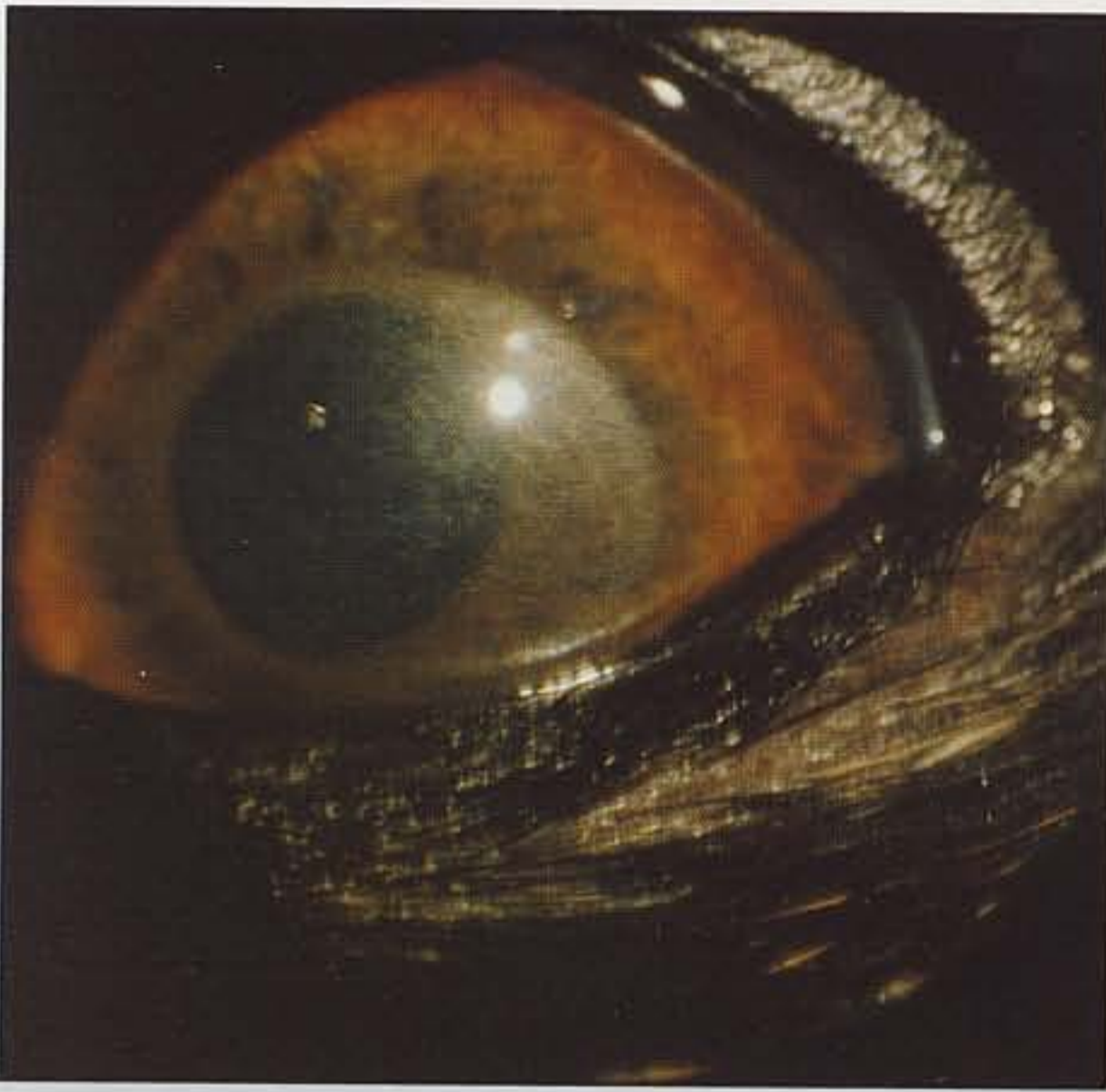

Fig. 6.58 Lipid keratopathy (corneal lipidosis) (Cavalier King Charles Spaniel, female, 3 years old) Larger and less dense lesion than that shown in the previous figure.

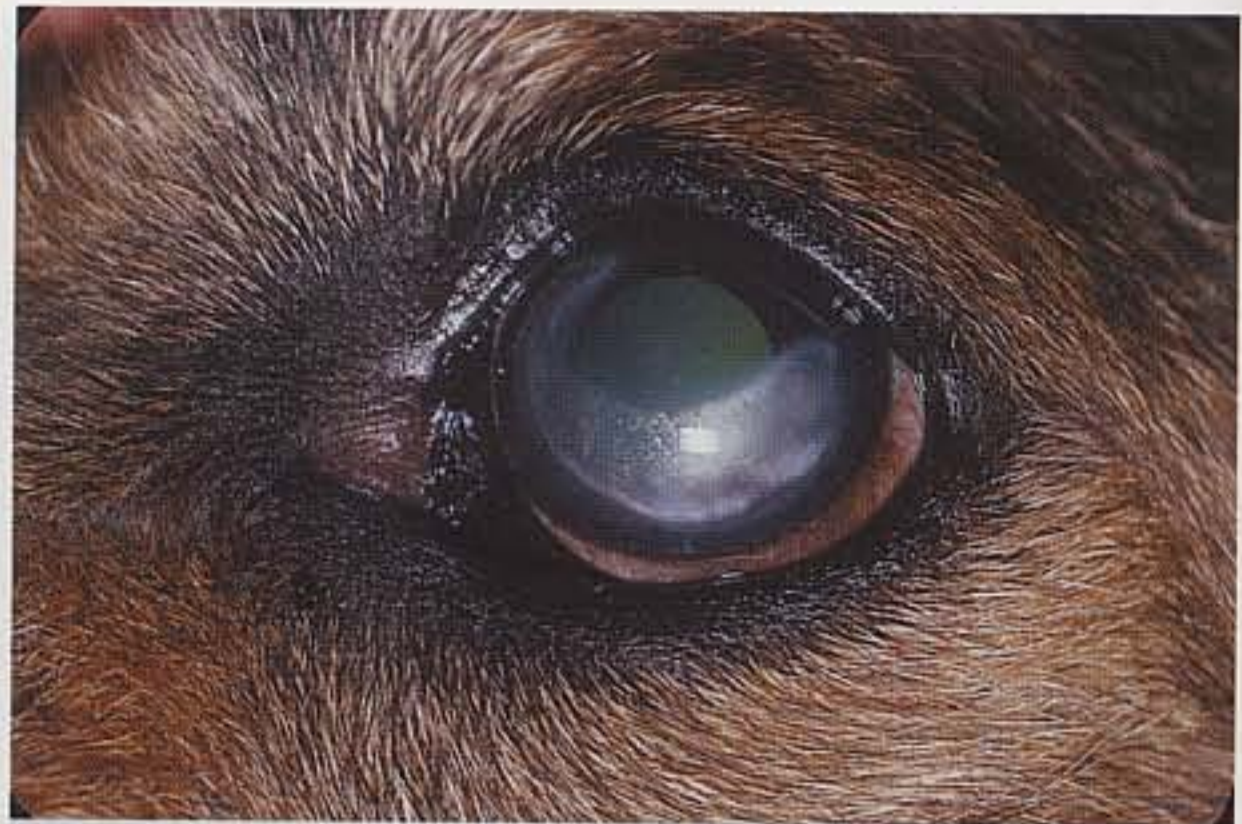

Fig. 6.60 Lipid keratopathy (corneal lipidosis) (German Shepherd Dog) A case of primary hypothyroidism. Note the perfect corneal reflection, the incomplete arcus superiorly and a clear band of cornea immediately inside the limbus.

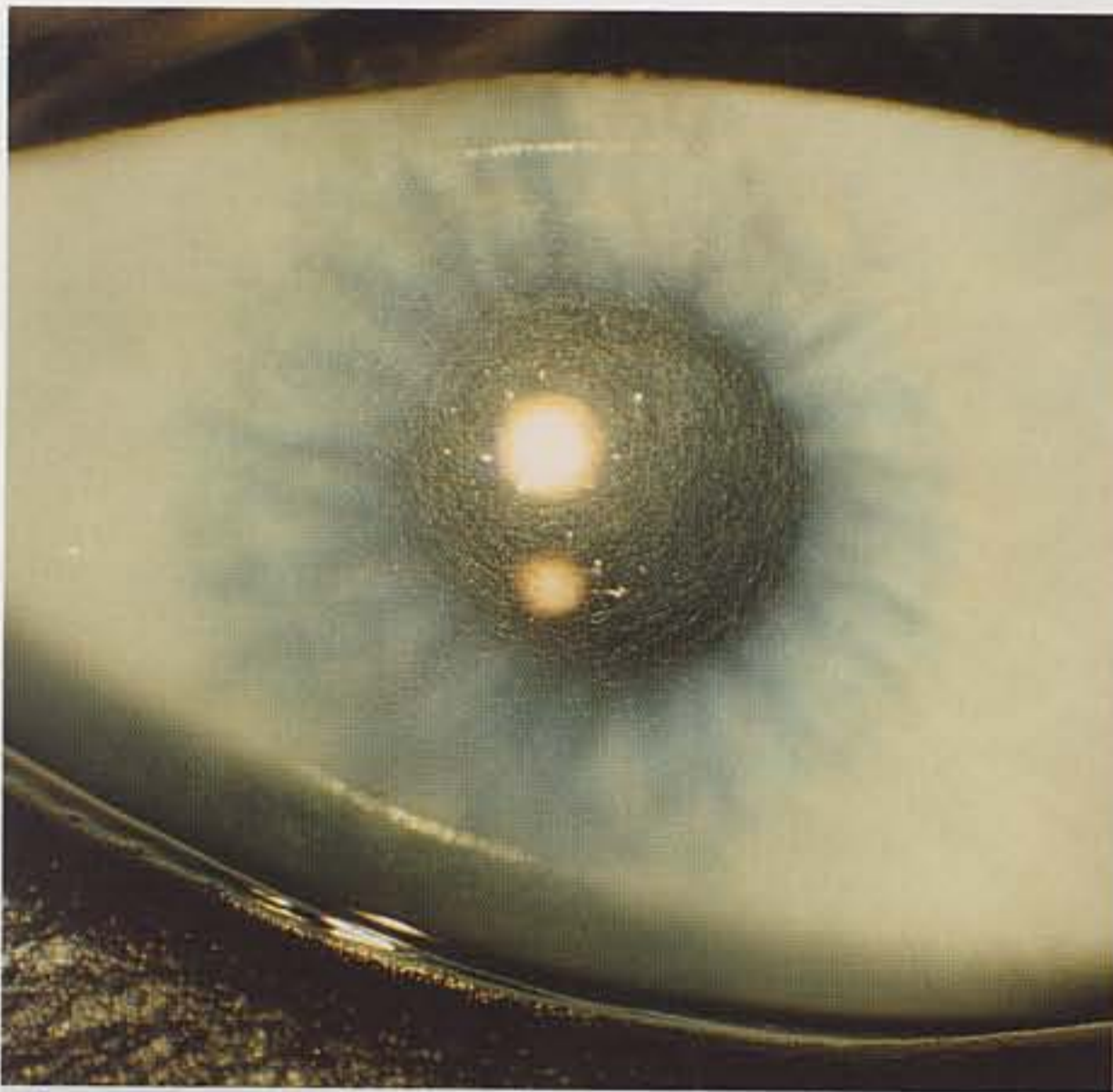


Fig. 6.59 Lipid keratopathy (corneal lipidosis) (Siberian Husky, 3 years old) Another typical breed.

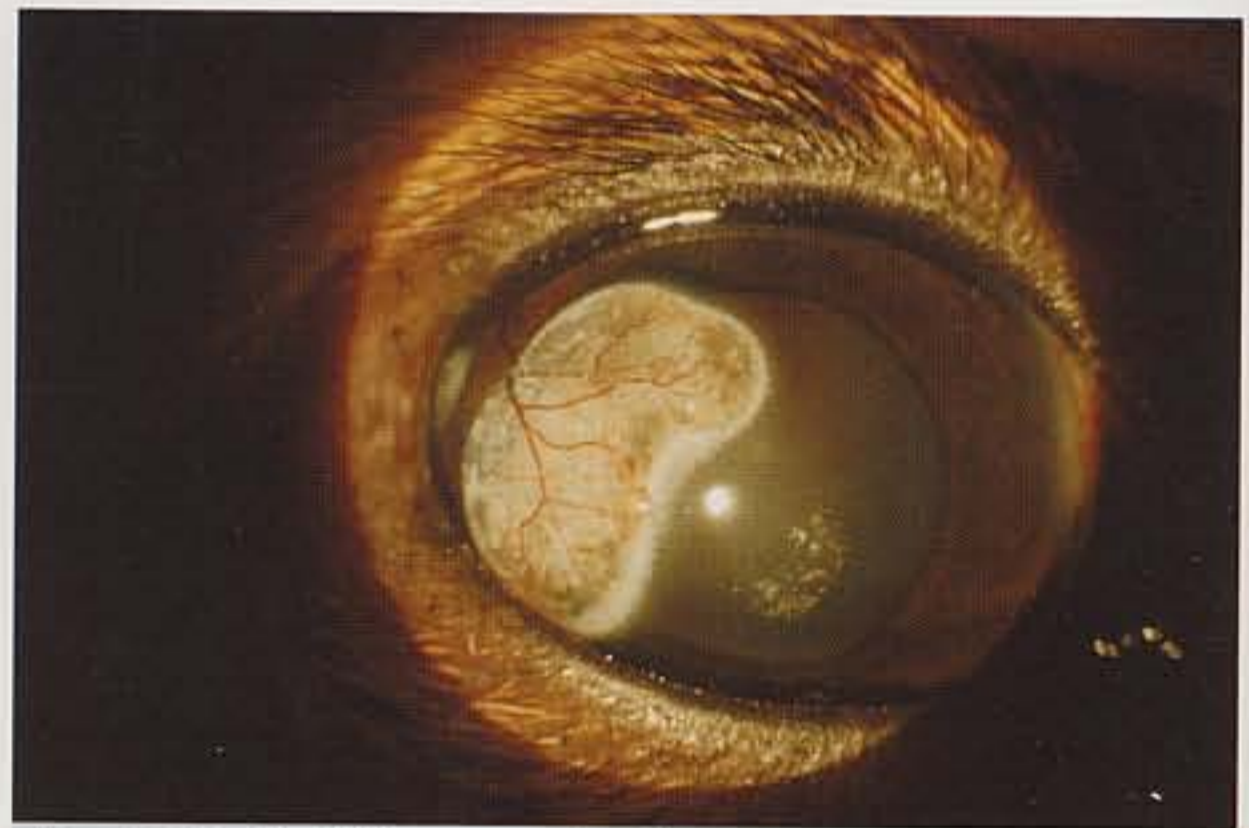

Fig. 6.61 Lipid keratopathy (lipid and calcareous degeneration) (Golden Retriever, 3 years old) Perilimbal lesion with epithelial involvement and vascularization.

Arcus lipoides (Fig 6.60) is another bilateral, but not necessarily symmetrical, accumulation of lipid in the peripheral cornea adjacent to the limbus, in dogs with hypothyroidism and secondary hyperlipoproteinaemia. It occurs particularly in the German Shepherd Dog but has been reported in other breeds.

Lipid and calcareous degeneration (Fig 6.61) occurs in young adult Golden Retrievers presenting as opaque white sausage-shaped lesions, again in the peripheral cornea inside the limbus. They are stromal in position and the overlying epithelium is missing. They are often vascularized and may give discomfort and consequent blepharospasm.

A further lipid keratopathy, unilateral or bilateral and also with vascularization present (Fig 6.62), occurs with a variety of other anterior segment abnormalities, including foreign body, focal keratitis, keratoconjunctivitis sicca, tumour, etc.

There is confusion over the terminology of this group of 'lipid keratopathies', as well as the corneal dystrophies, in the dog, partially due to lack of knowledge on aetiology and inheritance. However, there is an interesting familial pattern with an

obvious breed incidence with several of the corneal conditions described above; for example, recurrent epithelial erosion or indolent ulcer of the Boxer and Pembroke Corgi has also been called epithelial basement membrane dystrophy; corneal lipidosis or crystalline stromal dystrophy in several breeds; and endothelial dystrophy presenting as corneal oedema in the Chihuahua and English Springer Spaniel, as well as others.

## Corneal sequestrum (cat)

(Figs 6.63–6.65)

This can be unilateral or bilateral in predisposed breeds such as the colourpoint and other Persian breeds. It has a striking, but variable, appearance with a clearly defined dark brown/black plaque-like lesion often raised above the corneal surface, which is central or paracentral, stromal and of varying shapes, and often vascularized. There is some discomfort and often a slight black-stained ocular discharge.

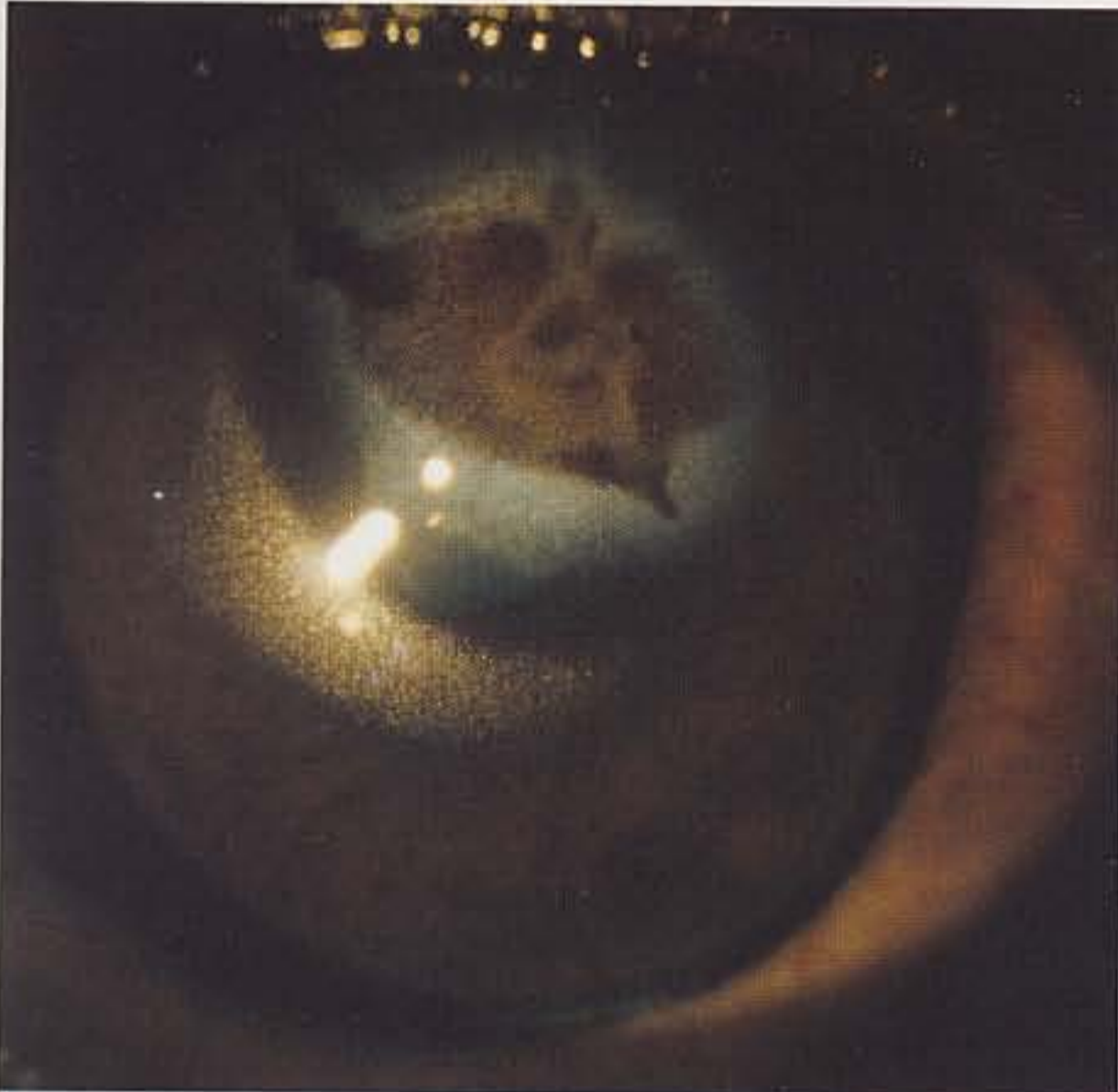

Fig. 6.62 Lipid keratopathy (Pug, 13 months old) Unilateral, subepithelial and associated in this case with a corneal scar, pigment and anterior synechiae.

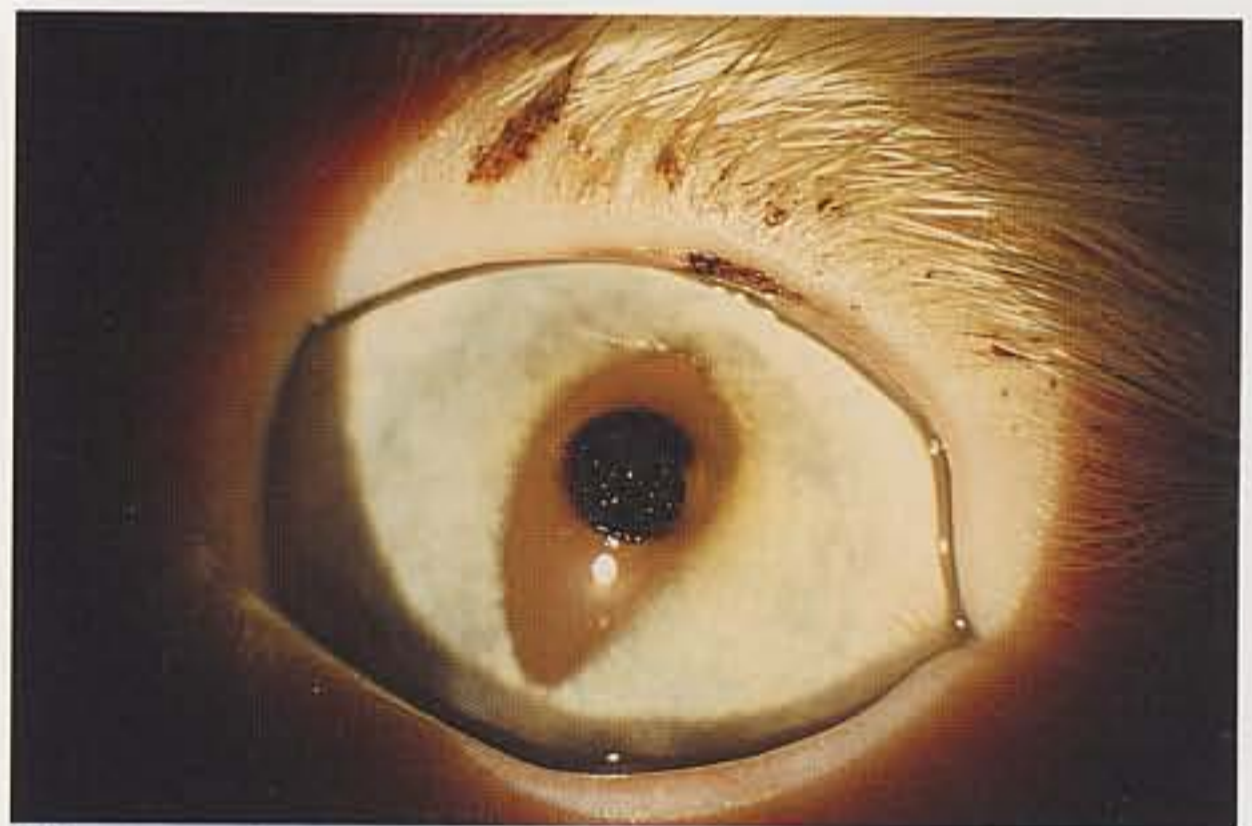

Fig. 6.63 Corneal sequestrum (Colourpoint cat, 4 years old) Small-medium sized, central and no vascularization. Note the slight pigmented ocular discharge on the upper lid immediately above the sequestrum.

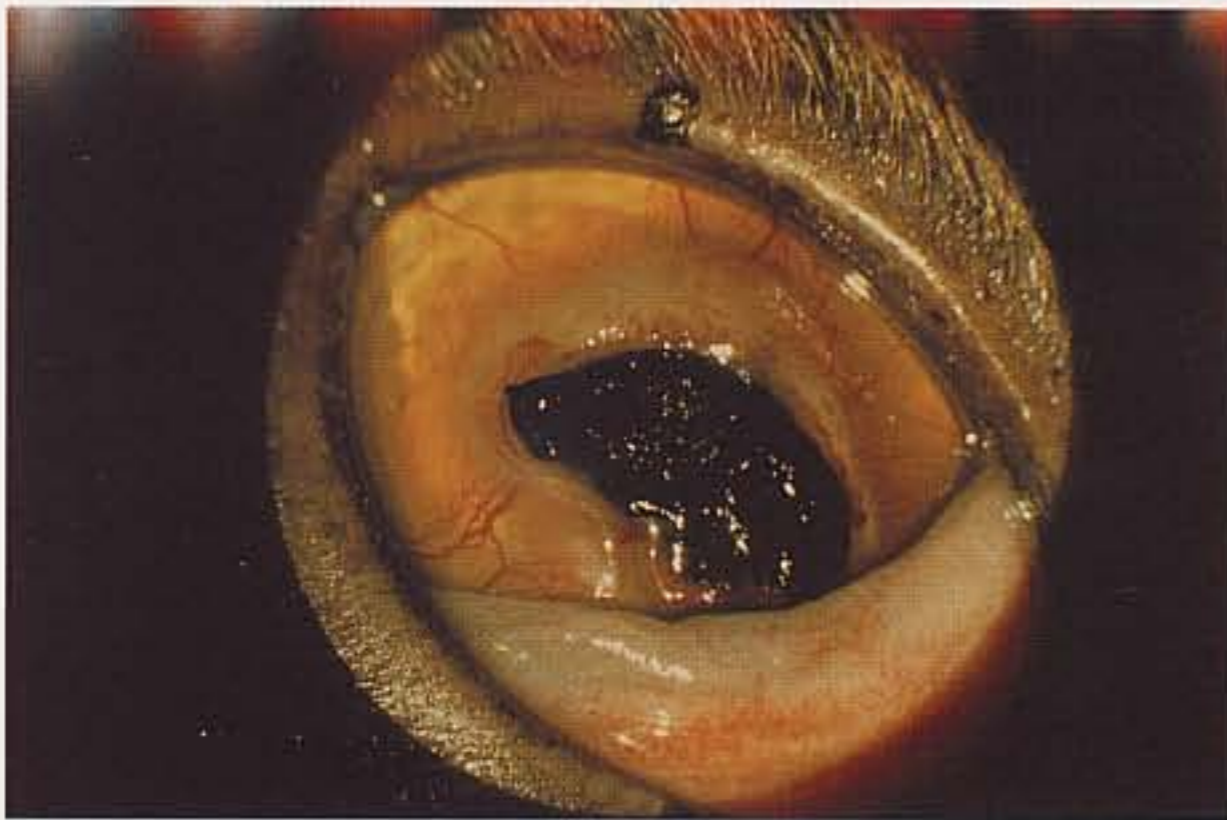

Fig. 6.64 Corneal sequestrum Large well-defined sequestrum surrounded by granulation tissue and much corneal vascularization. Note also the prominence of the nictitating membrane due to globe retraction due to pain and again the black discharge on the upper lid.

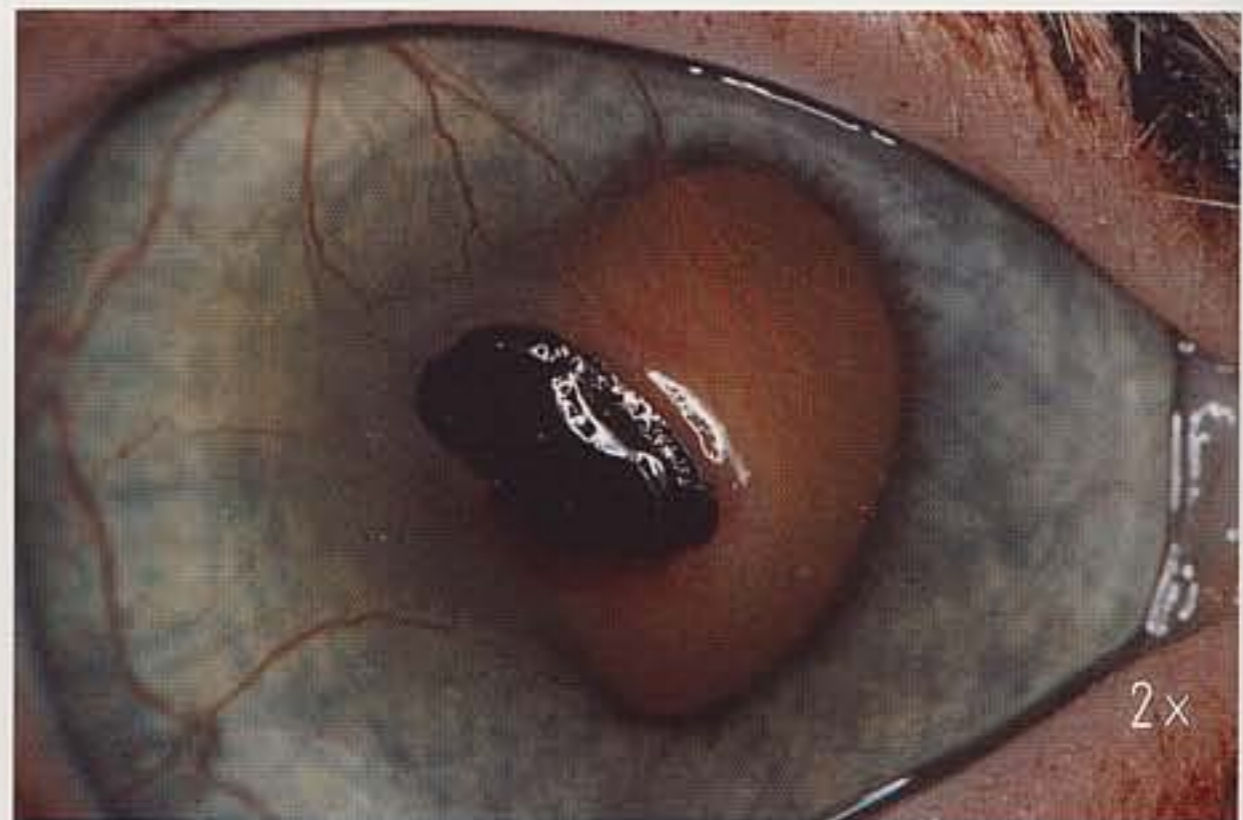


Fig. 6.65 Corneal sequestrum (Persian cat, 4 years old) Medium-sized sequestrum with vascularization. Both eyes of this cat were involved.

## Trauma and foreign bodies

(Figs 6.66–6.70)

Corneal foreign bodies are common in all the domestic species and vary considerably in their nature. Corneal reaction, usually following a sudden onset, varies according to the size, depth and nature of the foreign body: pain, blepharospasm or a closed eye. The ocular discharge varies from clear lacrimation to purulent.

Corneal trauma is also common in the horse, dog and cat, particularly in the former with its large prominent eyes. Trauma varies from blunt trauma with corneal oedema to a penetrating injury with loss of aqueous, haemorrhage which may be profuse, loss of anterior chamber and prolapse of iris. Pain may be severe.

Corneal abscess (Fig 6.70) appears as a small focal non-painful raised swelling, associated with vascularization, and usually adjacent to the limbus.

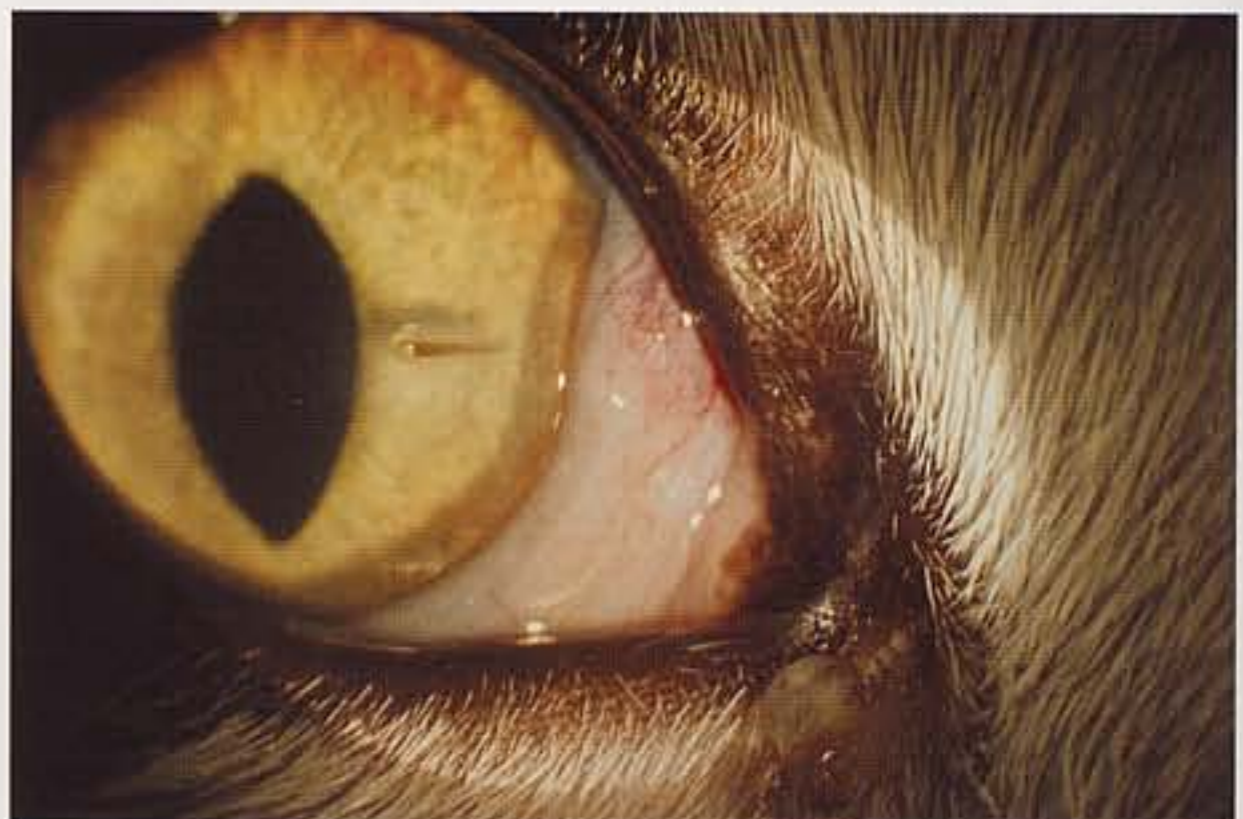

Fig. 6.66 Corneal foreign body (DSH cat, 2 years old) Small thorn foreign body, recent case. This cat presented with acute blepharospasm.

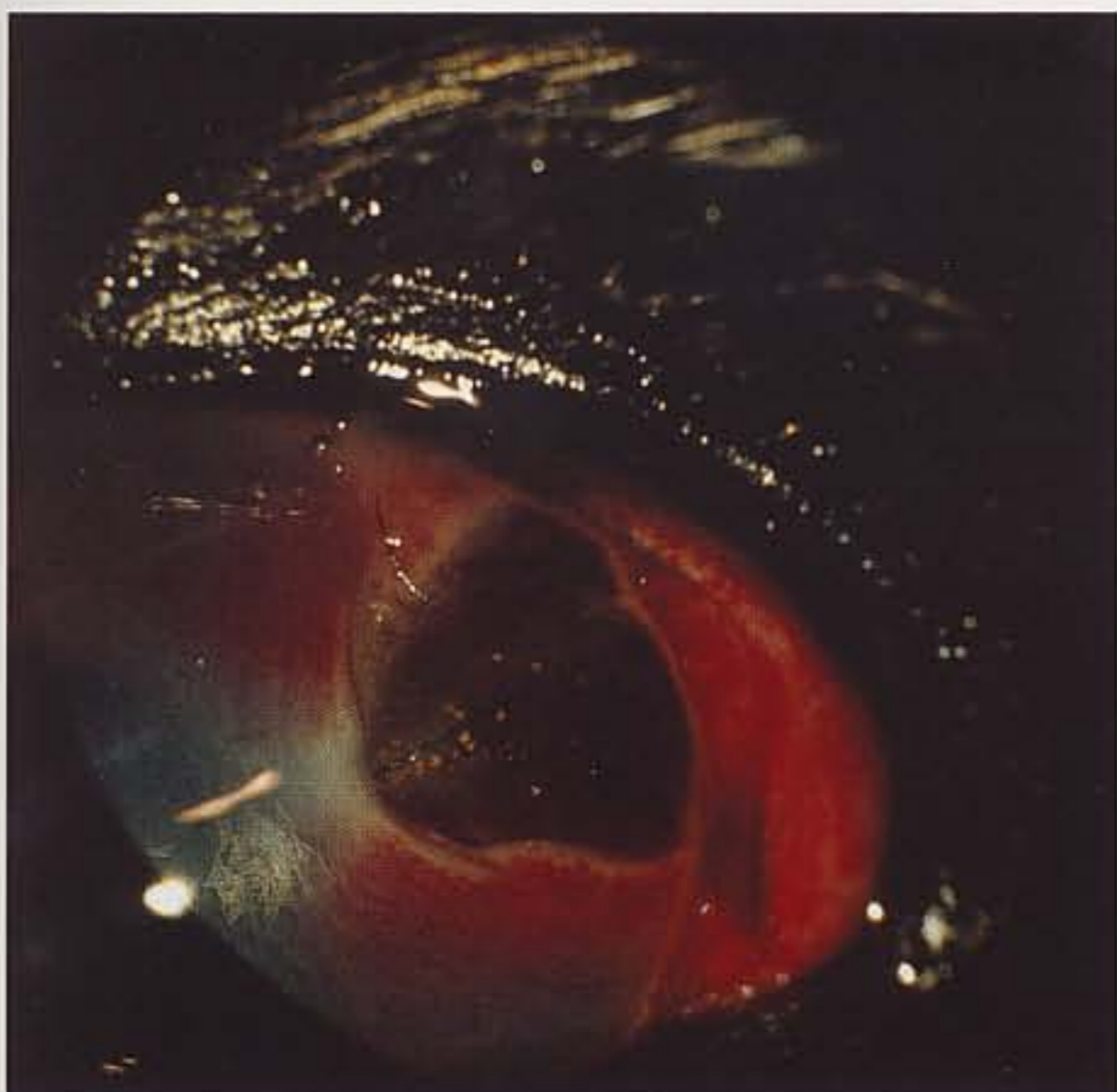


Fig. 6.67 Corneal foreign body (Border Terrier, 7 years old) Leaf foreign body of 3 weeks' duration. Note the profound corneal reaction to this foreign body of organic material.

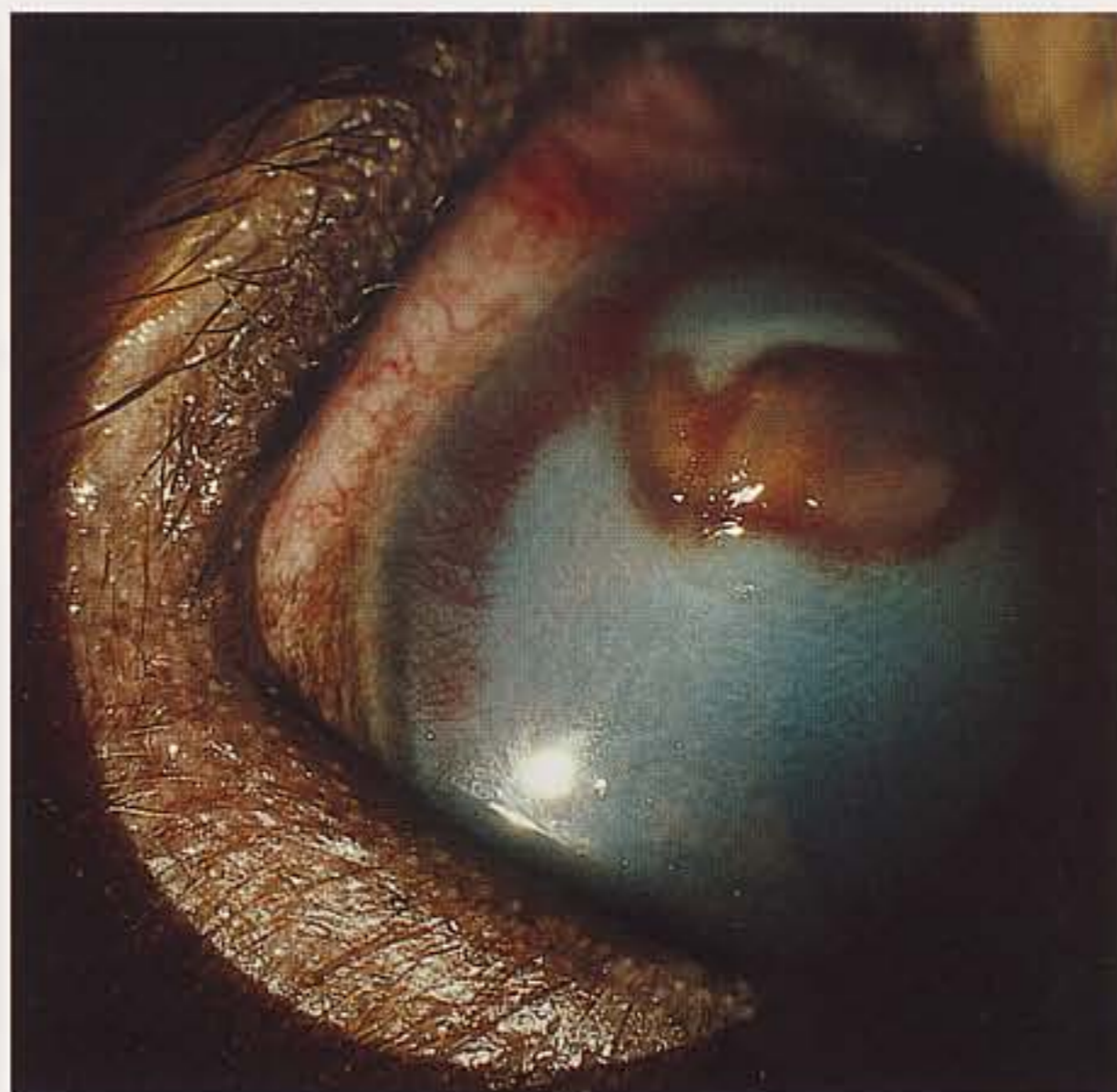

Fig. 6.69 Corneal trauma (Cavalier King Charles Spaniel, 3 years old) Corneal rupture with iris prolapse plugging the wound. Note the surrounding corneal oedema and vascular fringe.

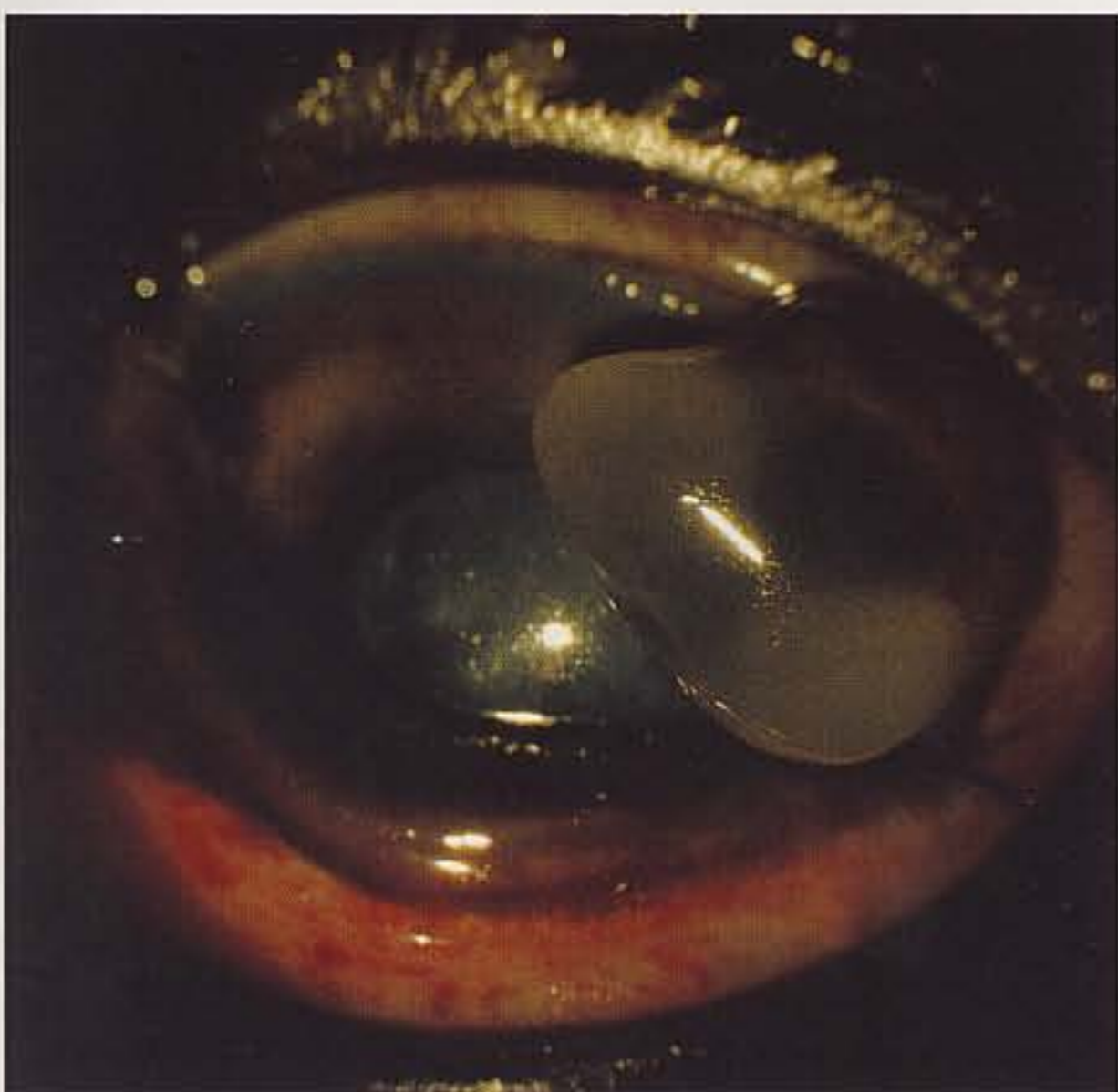

Fig. 6.68 Corneal trauma (German Shepherd Dog, 10 weeks old) Penetrating corneal wound with coagulated aqueous and prolapse of iris tissue but no haemorrhage in this case. Of recent origin. This injury was due to a cat scratch – a typical history.

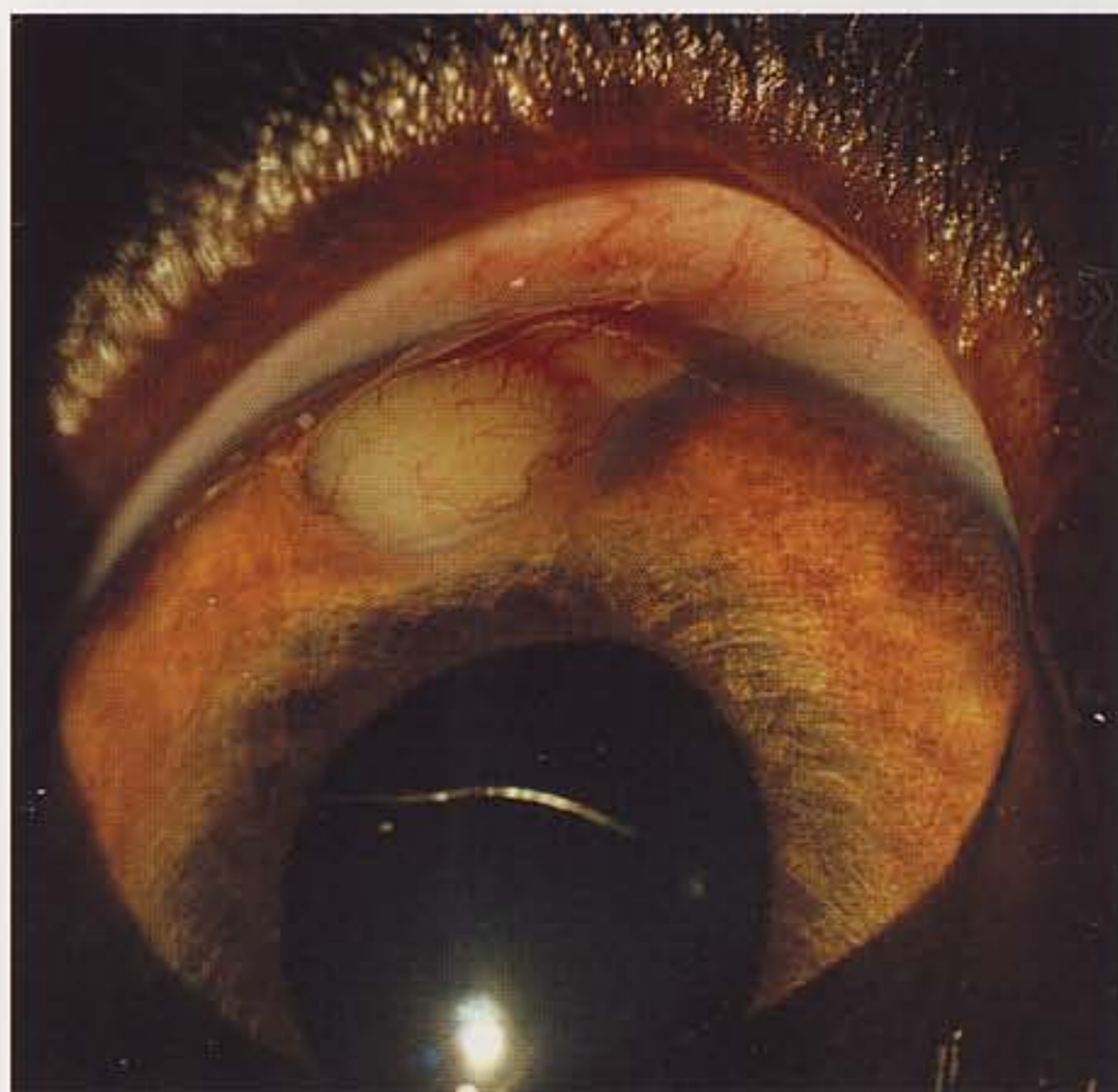

Fig. 6.70 Corneal abscess (English Springer Spaniel, 3 years old) Note the raised appearance of the lesion which is subepithelial and the vascularization. In this case the lesion was non-painful, the dog presenting with a focal area of corneal opacity.



## Neoplasia (Figs 6.71–6.72)

Corneal neoplasia in the dog and cat is rare but squamous cell carcinoma in the horse is an important condition. The appearance is of a pinkish grey granular tumour spreading across the eye and usually associated with a slight ocular discharge and a degree of blepharospasm.

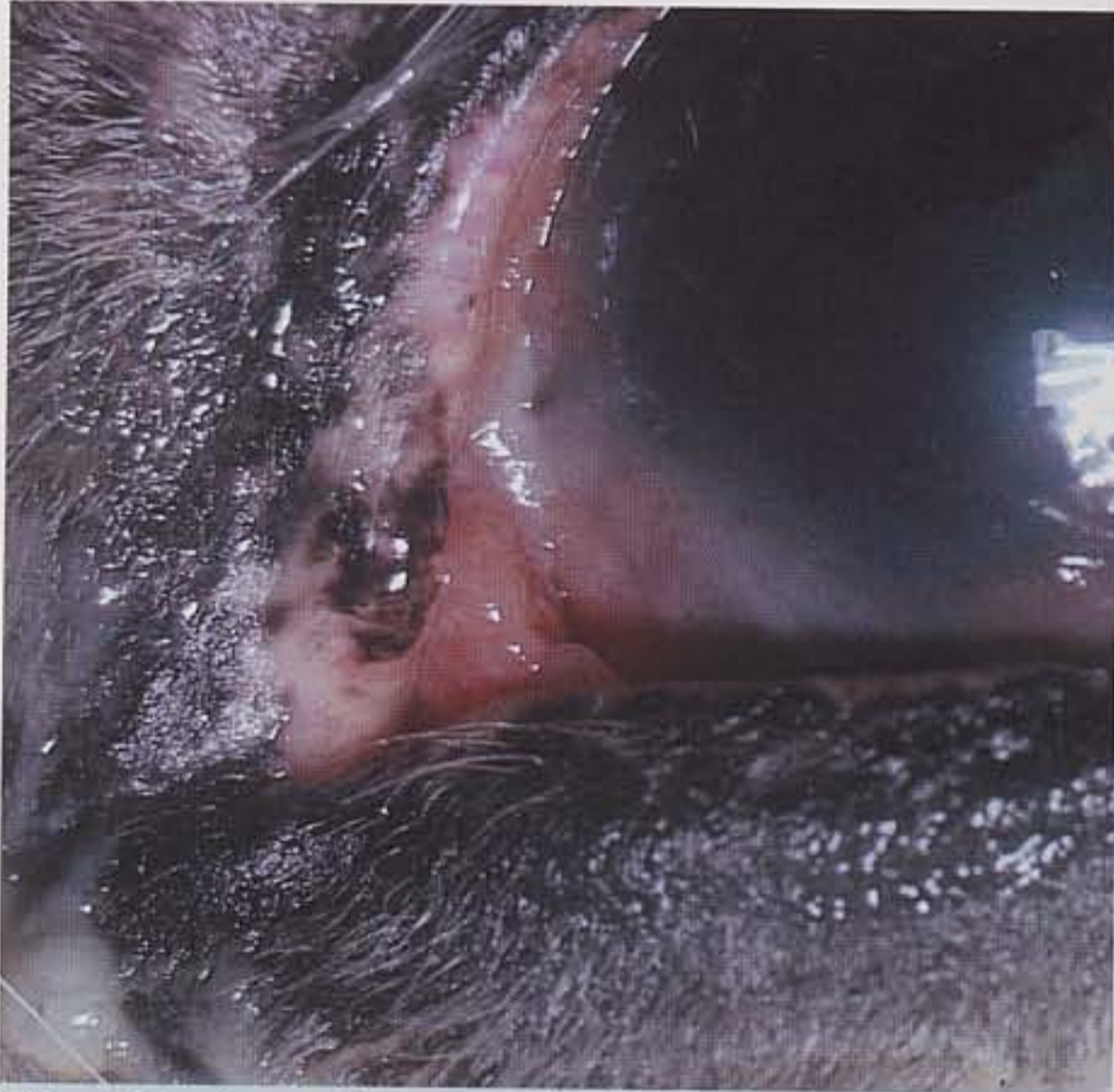

Fig. 6.71 Corneal tumour (Hunter-type, 10 years old) Squamous cell carcinoma of cornea and limbus. The nictitating membrane of this horse had been removed, probably also due to a squamous cell carcinoma.

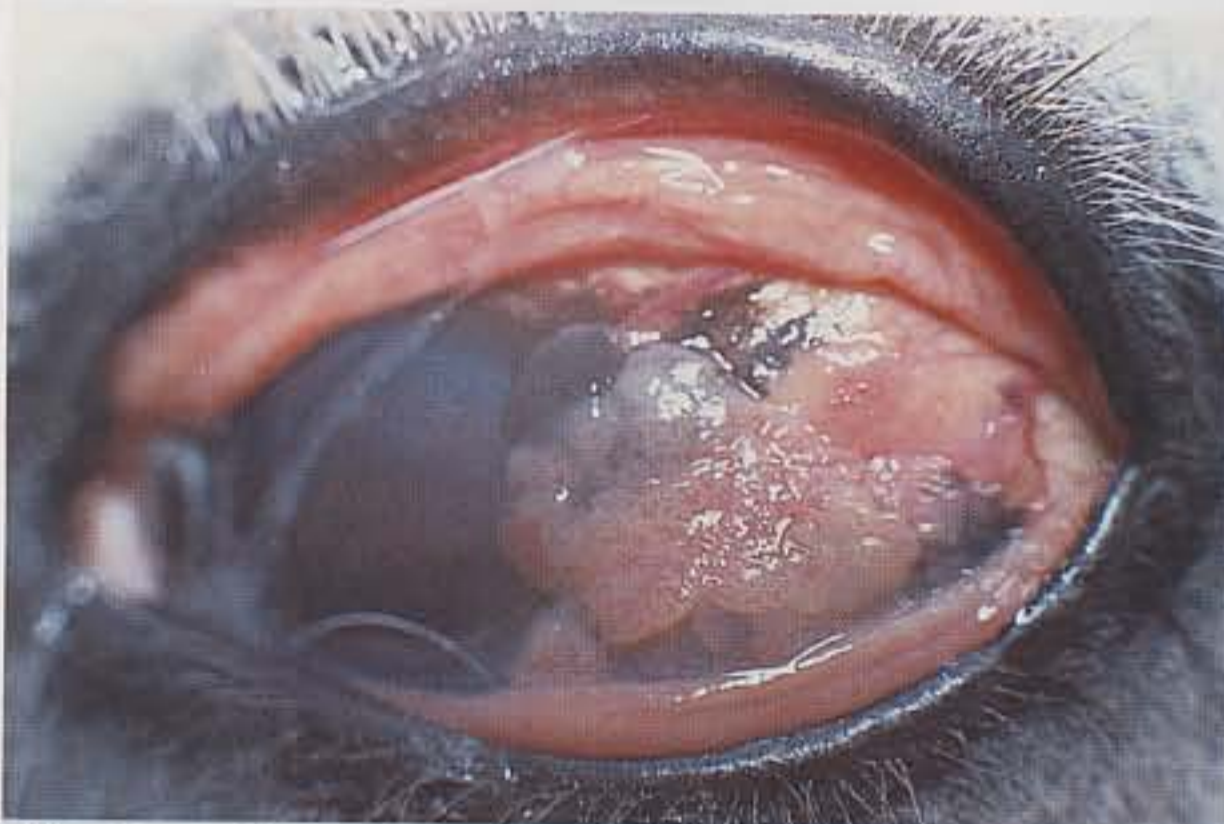

Fig. 6.72 Corneal tumour (Pony, 9 years old) Squamous cell carcinoma. Note the typical greyish appearance of the tumour.

## Congenital anomalies (Figs 6.73–6.74)

Microcornea is usually associated with microphthalmos and multiple congenital anomalies (Fig 1.12.)

Epibulbar dermoids (Figs 6.73–6.74) occur on the cornea, particularly in the dog. They are usually pigmented and contain hair and cause surprisingly little discomfort.

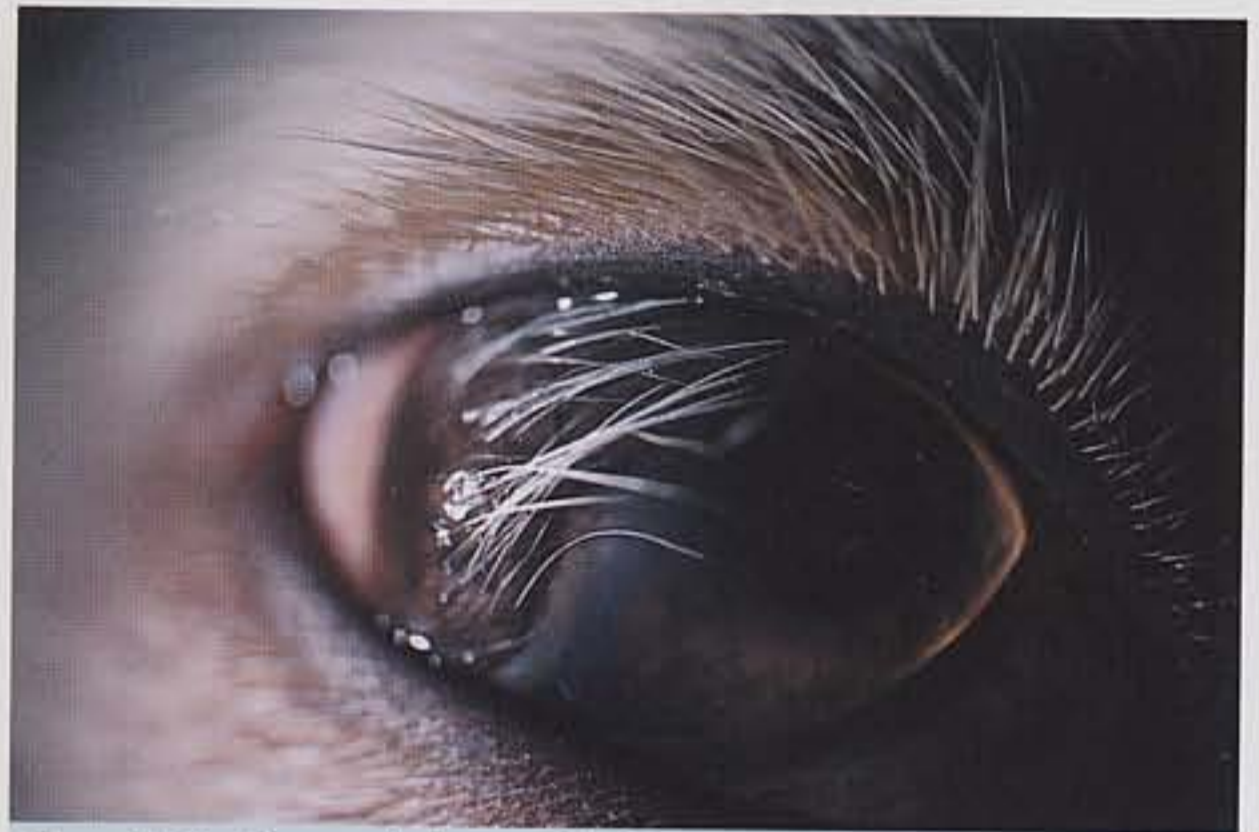

Fig. 6.73 Corneal dermoid (German Shepherd Dog, 3 months old) Pigmented epibulbar dermoid containing hair but apparently causing little discomfort.

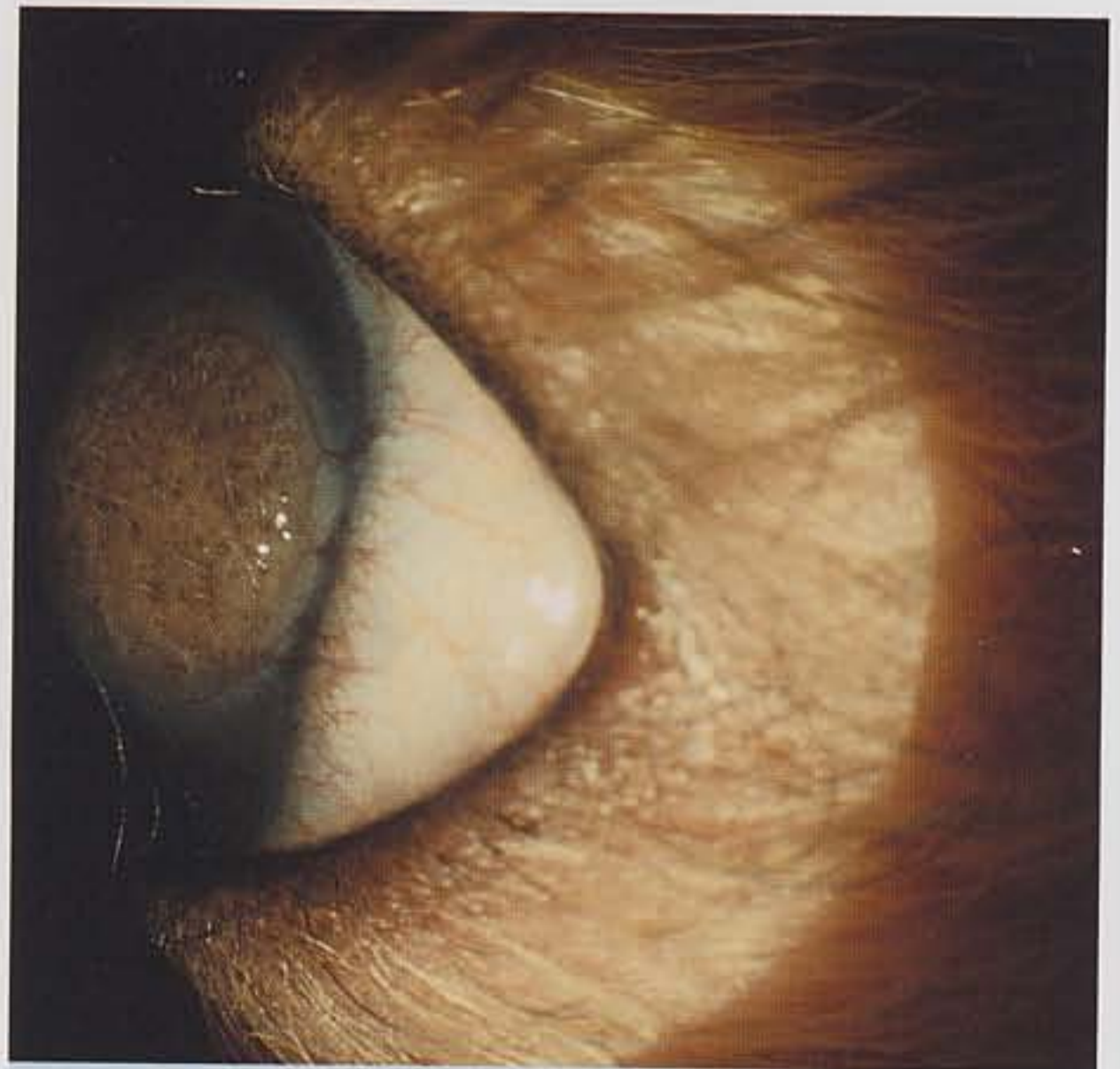

Fig. 6.74 Corneal dermoid (German Shepherd Dog, 3 months old) Fleshy and hair containing. Epibulbar dermoids are typically seen in this breed (see also Figs 2.49–2.50 and 5.20–5.22).

# Chapter 7

## Uveal Tract

### Introduction

The uveal tract consists of iris and ciliary body, together with the choroid which is best included in the fundus (Chapter 11). The uveal tract is important in veterinary ophthalmology in dog, cat and horse; it may present as a unioocular or binocular eye disease or condition and may indicate local (ocular) or systemic disease (Table 7.1). Diagnosis can be difficult and aetiology is often obscure (Table 7.2). The uveal tract is prone to trauma and also exhibits several congenital, some hereditary, conditions in addition to cysts and tumours.

The colour of the iris varies considerably and is associated with coat colour. Most irides in the dog and horse are shades of brown and in the cat yellow or gold and often metallic. However, pale blue irides, either partial or total, are not uncommon in all three species and usually are accompanied by areas of subalbinism in the fundus. Furthermore, a change in iris colour may denote disease. The pupil shape also differs considerably in the three species and may change with disease.

Table 7.1 - The red eye

Unilateral or bilateral
Acute or chronic
Local ocular disease or systemic with pyrexia (bilateral)
1. Uveitis
Photophobia
2. Glaucoma
Breed-specific for primary, some secondary cases
Unilateral at first presentation
3. Conjunctivitis
Primary or, more commonly, secondary (ocular or systemic)
Traumatic (subconjunctival haemorrhage)
4. Episcleritis/scleritis
Uncommon, usually no pain
5. Keratitis
Including corneal ulcer (pain)
6. Orbital disease
Enophthalmitis
Panophthalmitis
Retrobulbar (inflammation, neoplasia)
Prolapse

Table 7.2 - Uveitis: differential diagnosis

	Pupil	Intraocular pressure	Pain	Vision	Discharge
Uveitis	Constricts	↓	++	Minor effect	Lacrimation
Glaucoma	Dilates	↑	+++	Blind	Lacrimation
Conjunctivitis	No change	No change	+	No change	Serous-purulent

## Clinical signs of anterior uveitis (iritis or iridocyclitis)

The clinical signs vary with the cause, severity and species but are not specific to the aetiology:

- Pain – may be considerable and presenting with the usual triad of lacrimation, blepharospasm and photophobia.
- Miosis (Figs 7.1–7.3, 7.5).
- Intraocular pressure low.
- Iris colour – in the brown iris the colour is duller and darker, particularly evident in the chronic case (Fig 7.2) and a useful clinical sign to indicate a previous iritis; in the yellow (cat) or blue iris the congested blood vessels are obvious (Figs 7.11 and 7.13), known as rubeosis iridis.
- Flare (Figs 7.7, 7.11, 7.29), hypopyon (Fig 7.10), hyphaema (Figs 7.9, 7.12–7.13) – cells (white and red blood cells) in the anterior chamber.
- Conjunctival and episcleral hyperaemia – particularly in the ciliary region (ciliary flush) (Fig 7.1).
- Synechia formation – commonly posterior with adhesion to anterior lens capsule producing irregular pupil shapes (Figs 7.15–7.19); occasionally anterior (Fig 7.28) leading to secondary glaucoma.
- Chemosia and corneal oedema (Figs 7.5–7.6 and 7.24–7.25).
- Vascularization – usually as a fringe in the peripheral cornea (Figs 7.5–7.6); occasionally blood vessels extending onto the anterior lens capsule.
- Vitreous – cloudy and turbid.
- Chorioretinitis – see Chapter 11.

## Sequelae

- Cataract (Figs 7.23, 7.26) – by far the most common, usually anterior capsular, cortical, sometimes total. May or may not be associated with posterior synechiae.

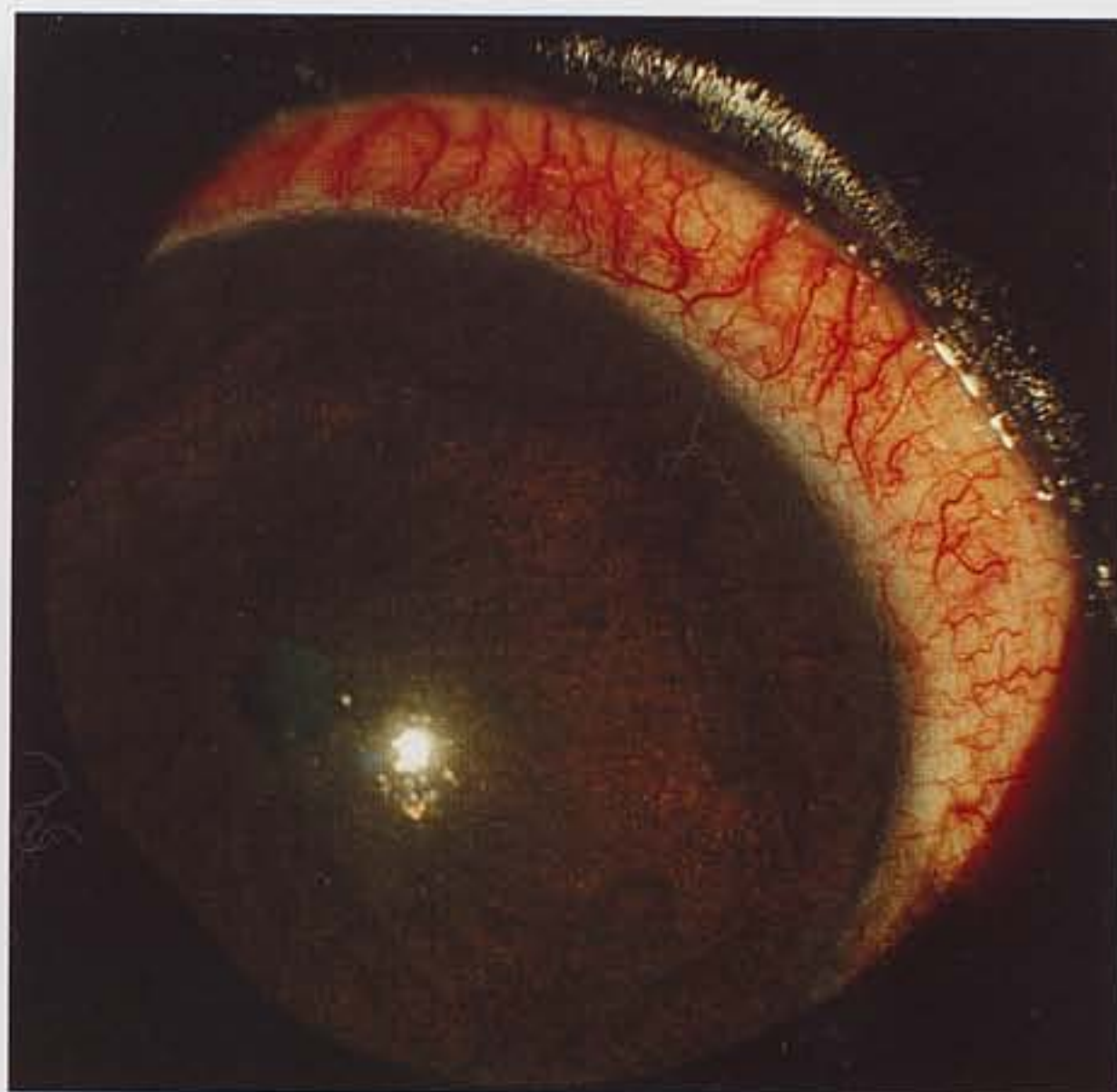


Fig. 7.1 Iritis (Cavalier King Charles Spaniel, 10 years old) Acute traumatic iritis. Note the marked miosis and the conjunctival injection.

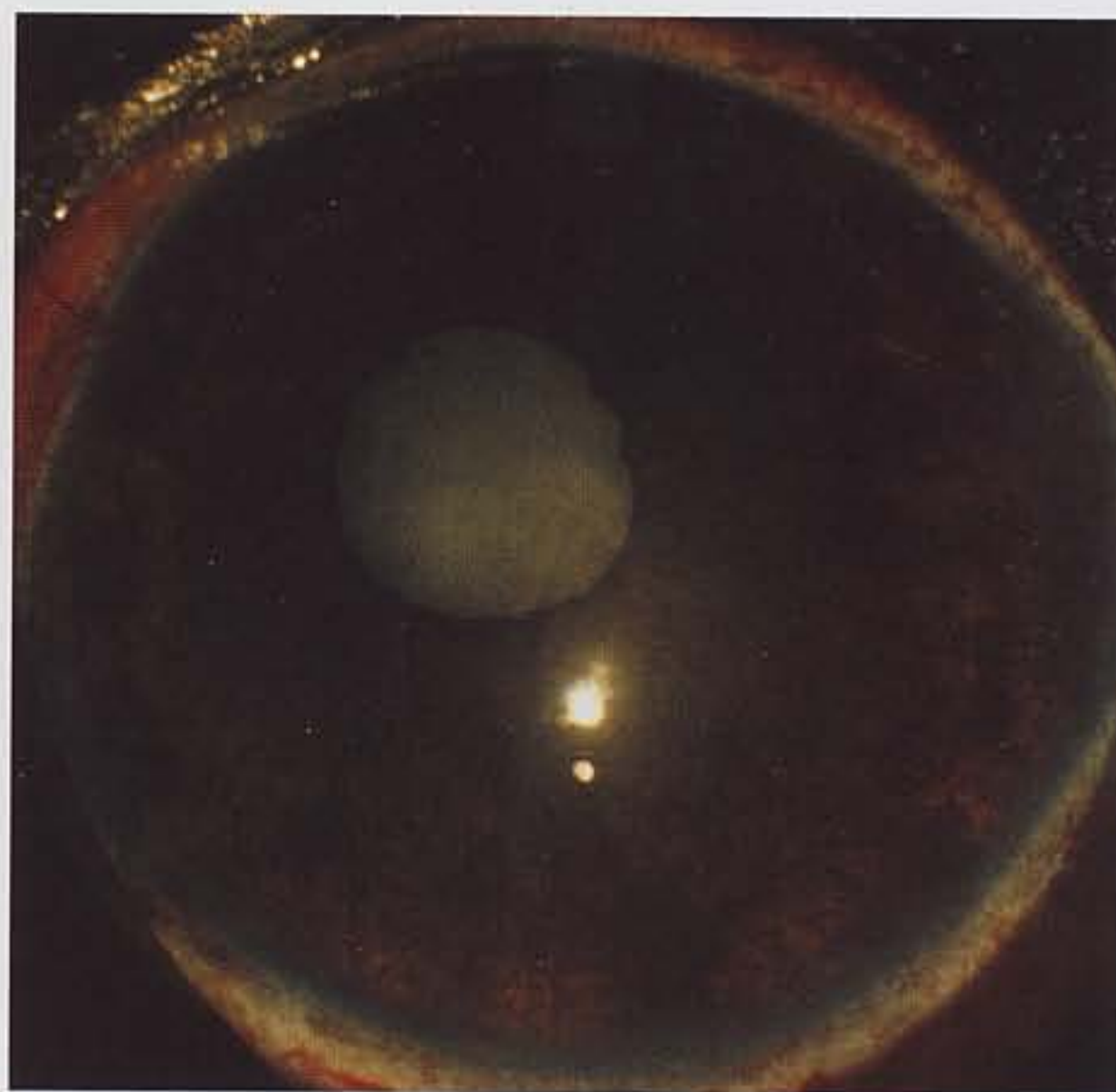


Fig. 7.2 Iritis (Miniature Poodle, 10 years old) Chronic iritis. Note the darkened iris, pigment on anterior lens capsule together with small posterior synechiae, and miosis.



Fig. 7.3 Iritis (Thoroughbred, 6 years old) Equine recurrent uveitis. Note occlusion of pupil due to miosis and posterior synechiae and dull dark iris.

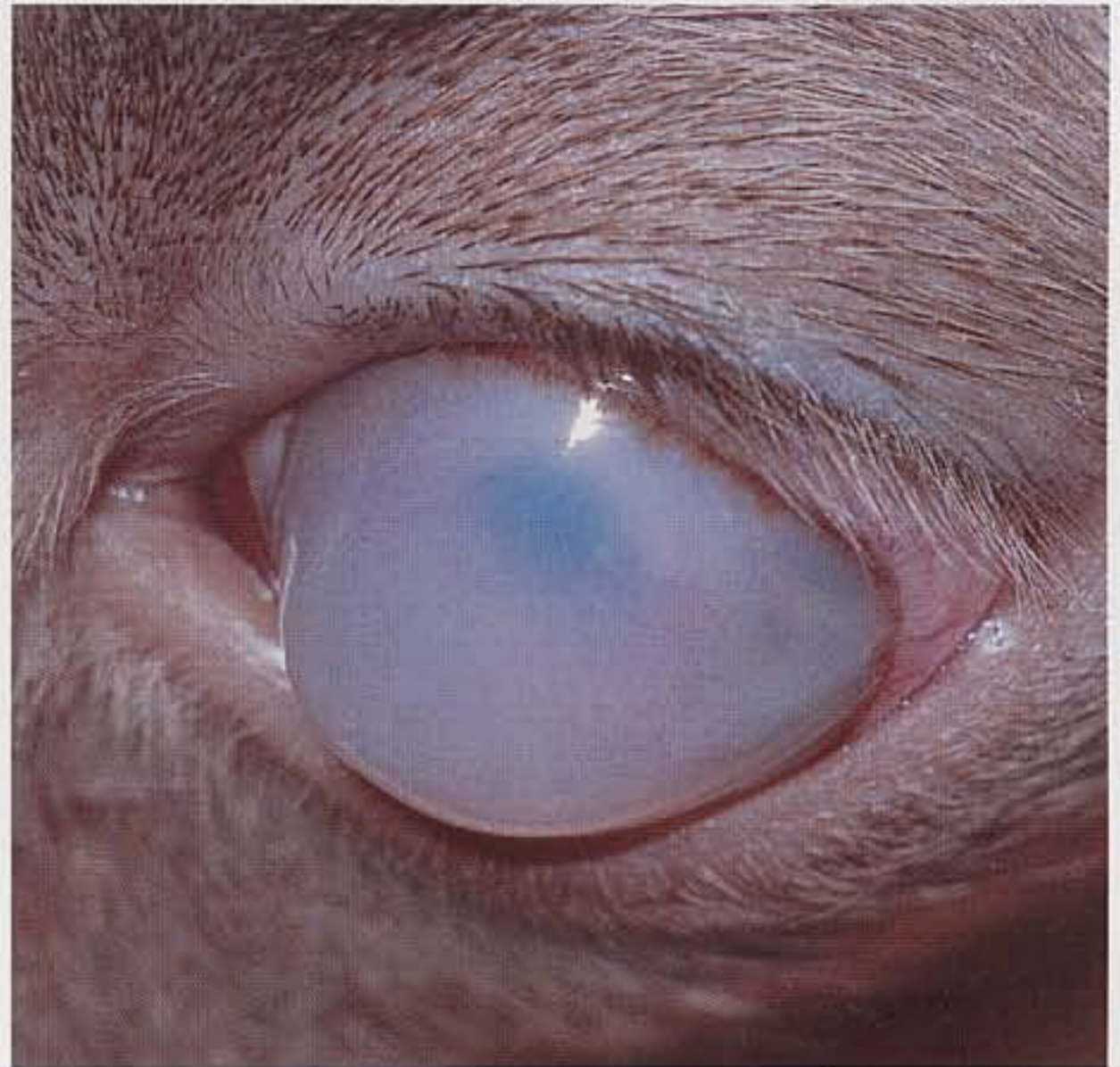

Fig. 7.5 Iritis (Weimaraner, 3 months old) Note miosis, fine vascular fringe from superior limbus, marked corneal oedema and keratoconus. See also Figs 6.45–6.48 of corneal oedema and uveitis associated with canine viral hepatitis and vaccination.

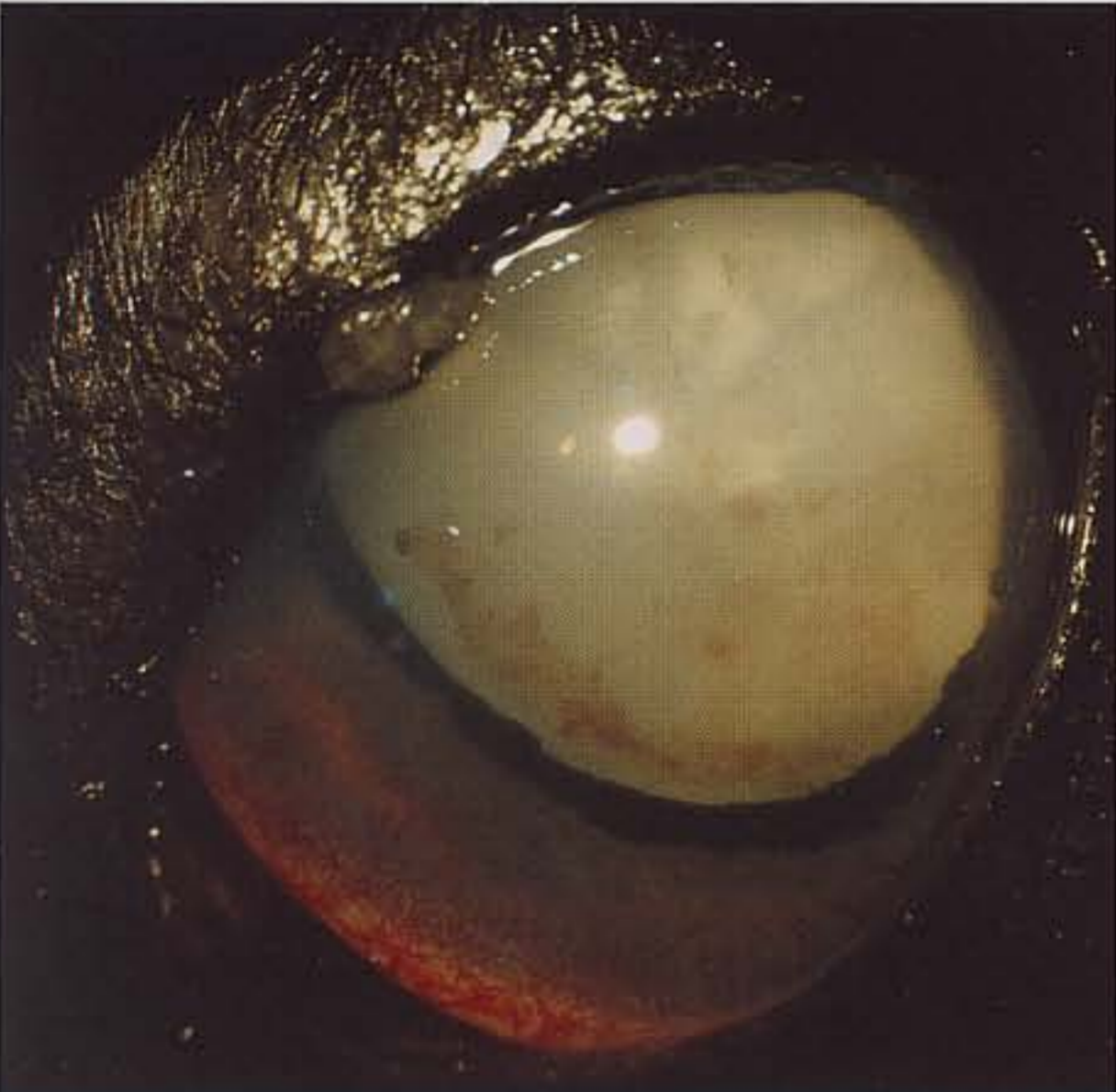

Fig. 7.4 Iritis (Miniature Poodle, 6 years old) Vascular corneal fringe, together with haemorrhage on the lens and cataract. Note the herniated uveal pigment around the pupil edge.

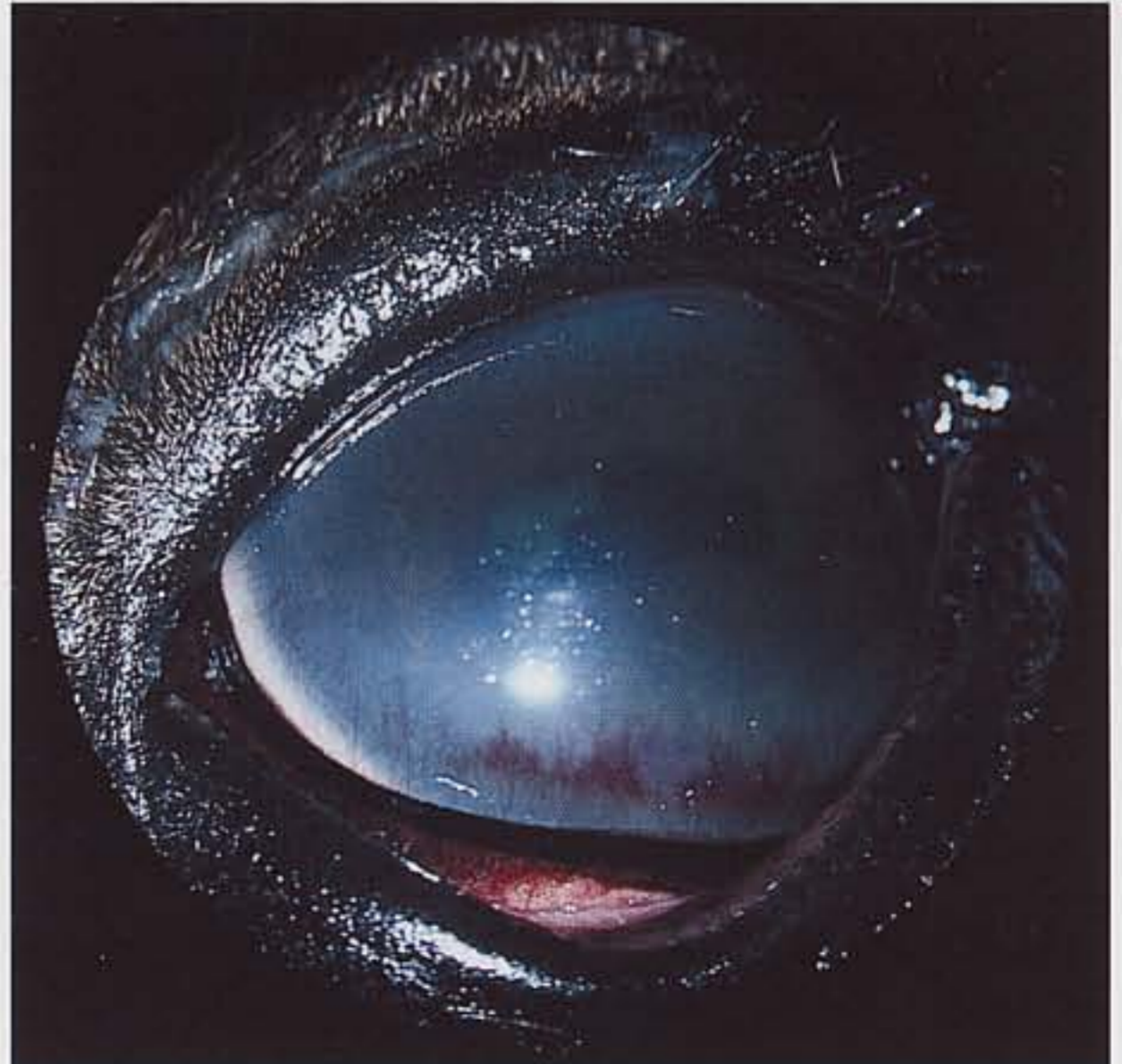

Fig. 7.6 Iritis Equine recurrent uveitis. Note corneal vascularization from the superior limbus and mild corneal oedema.

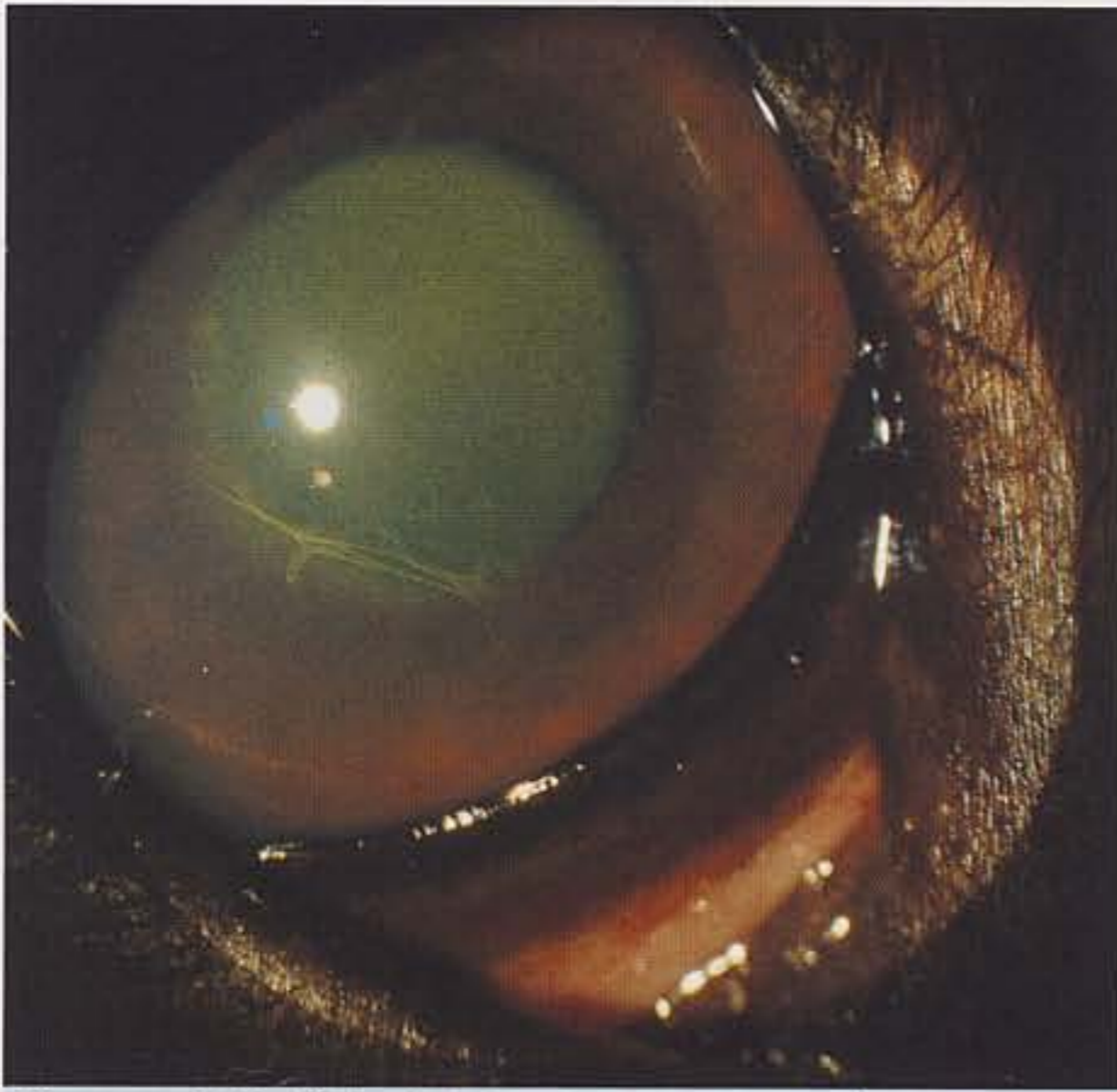


Fig. 7.7 Iritis (Airedale Terrier, 2 years old) Acute iritis, showing plastic endothelial deposit and flare. Idiopathic case.

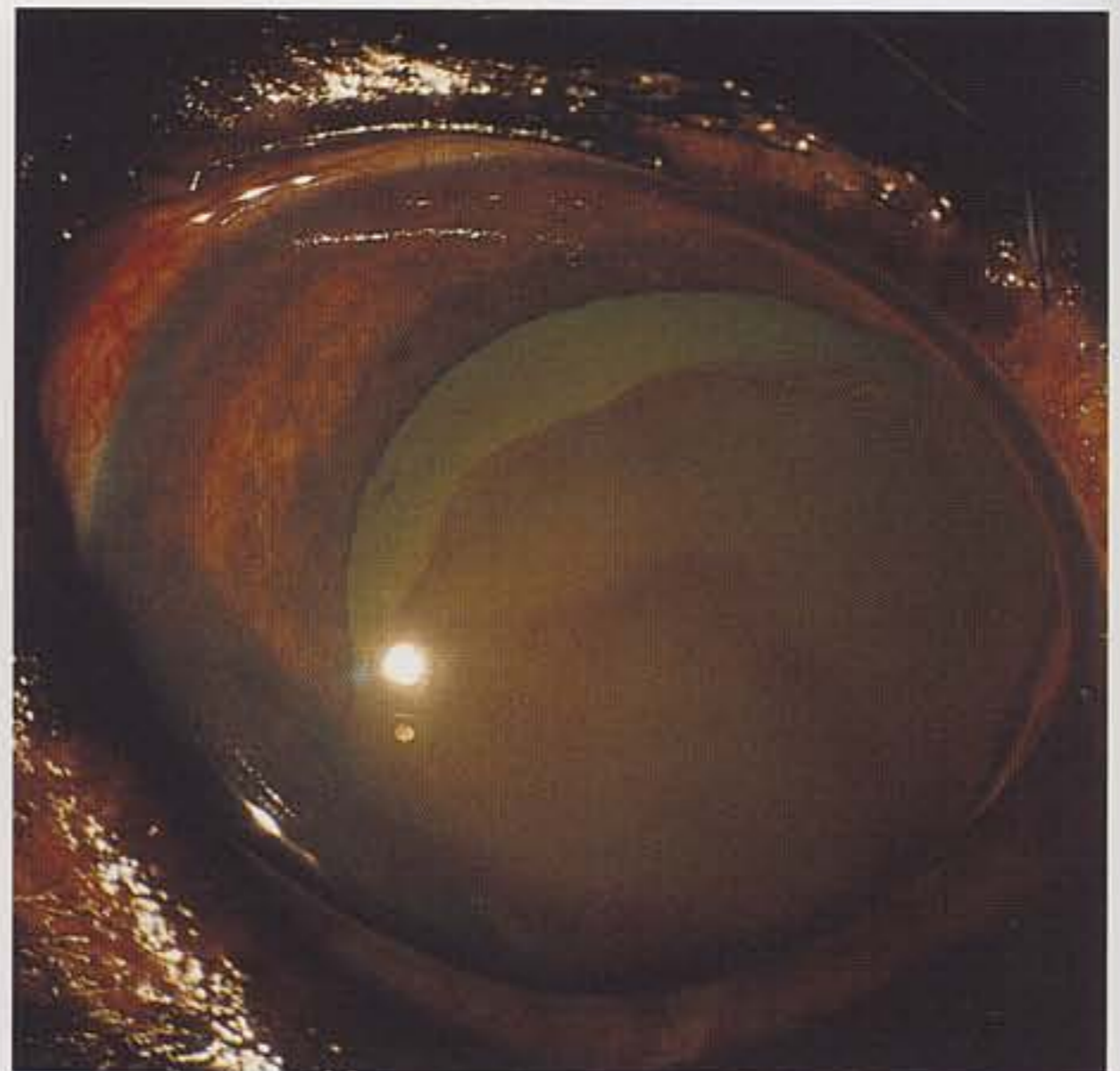


Fig. 7.9 Iritis (Crossbred dog, 14 years old) Note diffuse cloud of haemorrhage and dull iris. Idiopathic case.

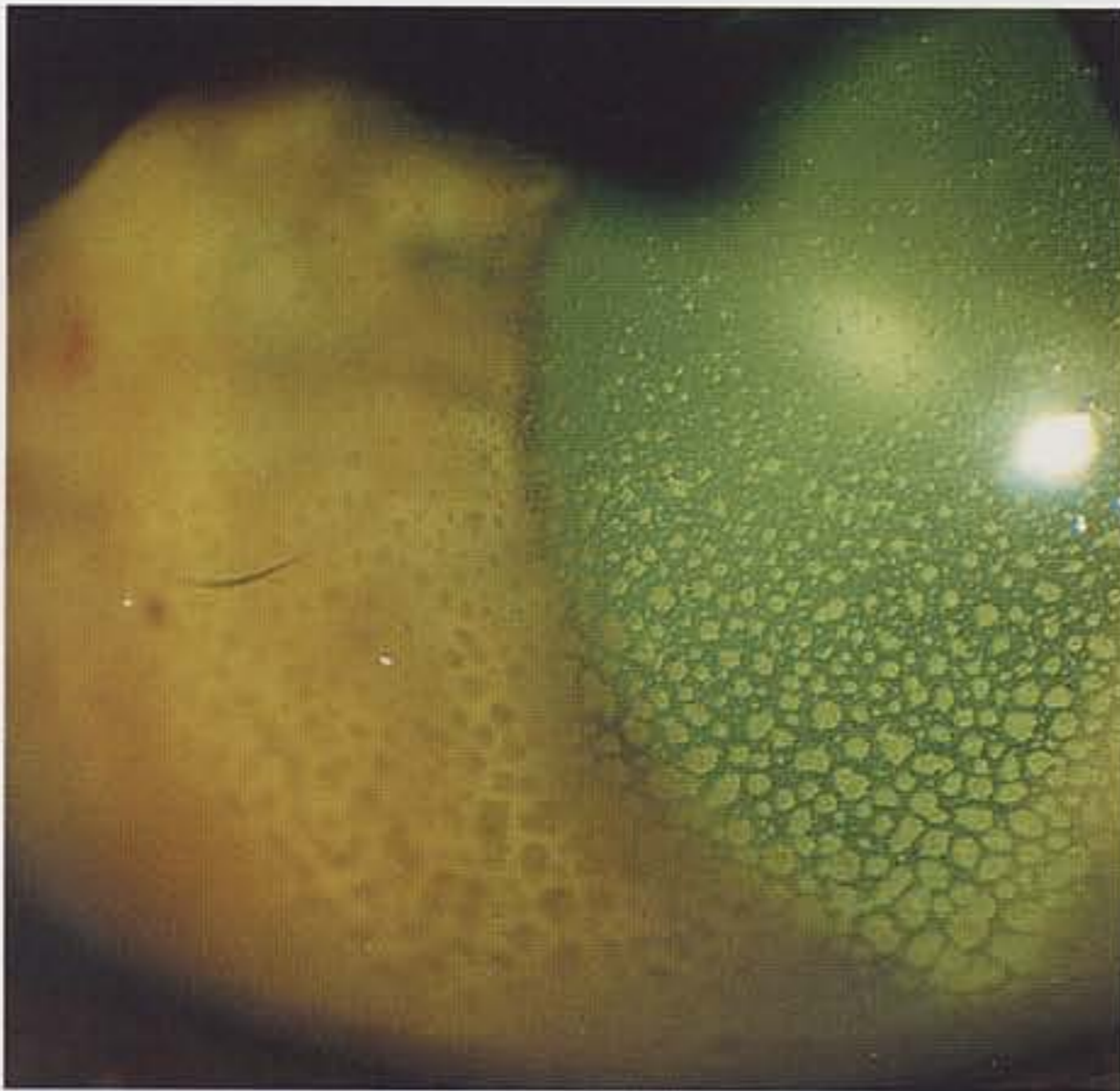


Fig. 7.8 Iritis (DSH cat, 15 years old) A case of toxoplasmosis showing keratitis precipitata (KP).

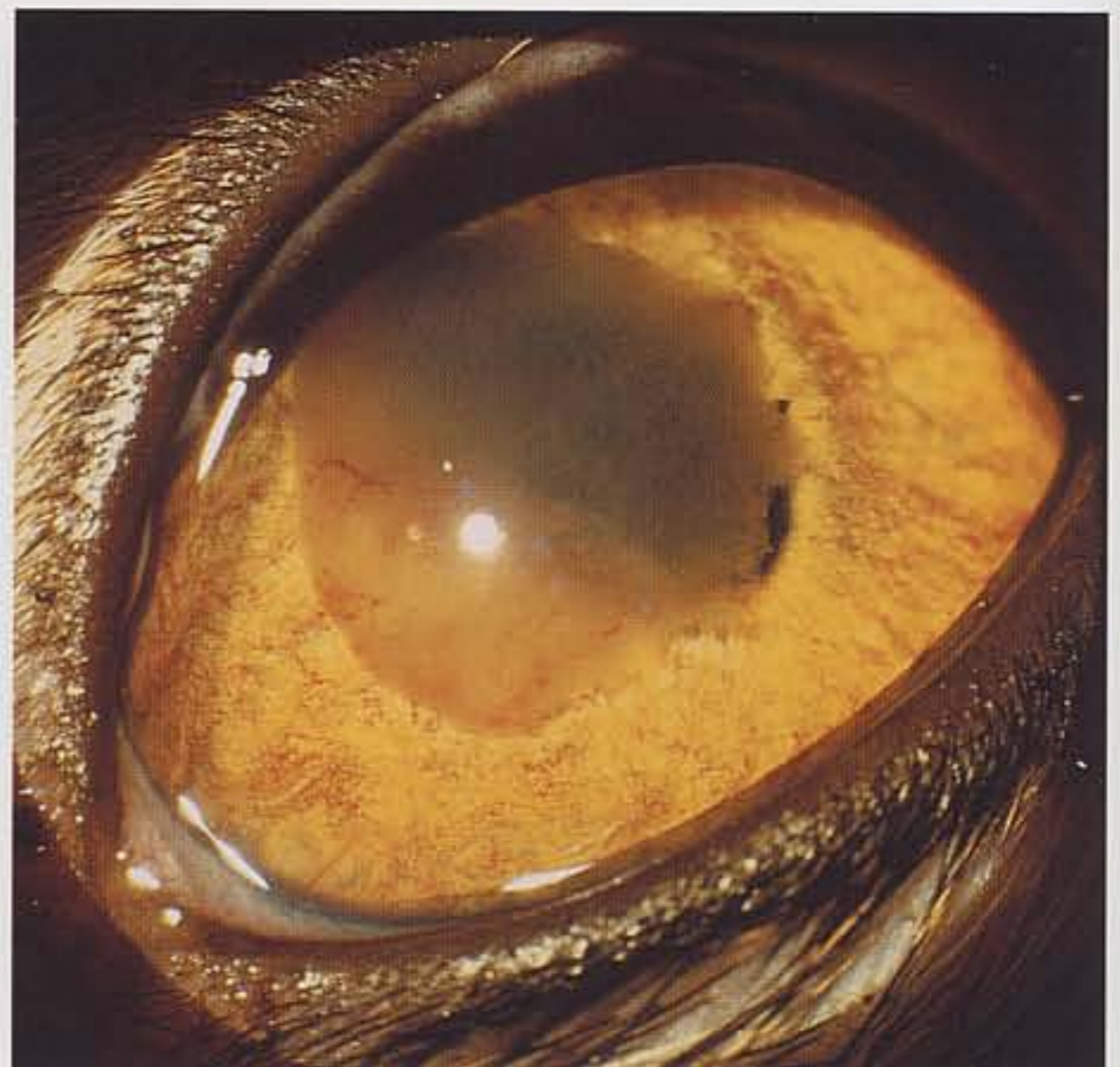


Fig. 7.10 Iritis (DSH cat, 10 months old) Note cloud of white cells obscuring the pupil. Another toxoplasmosis case.

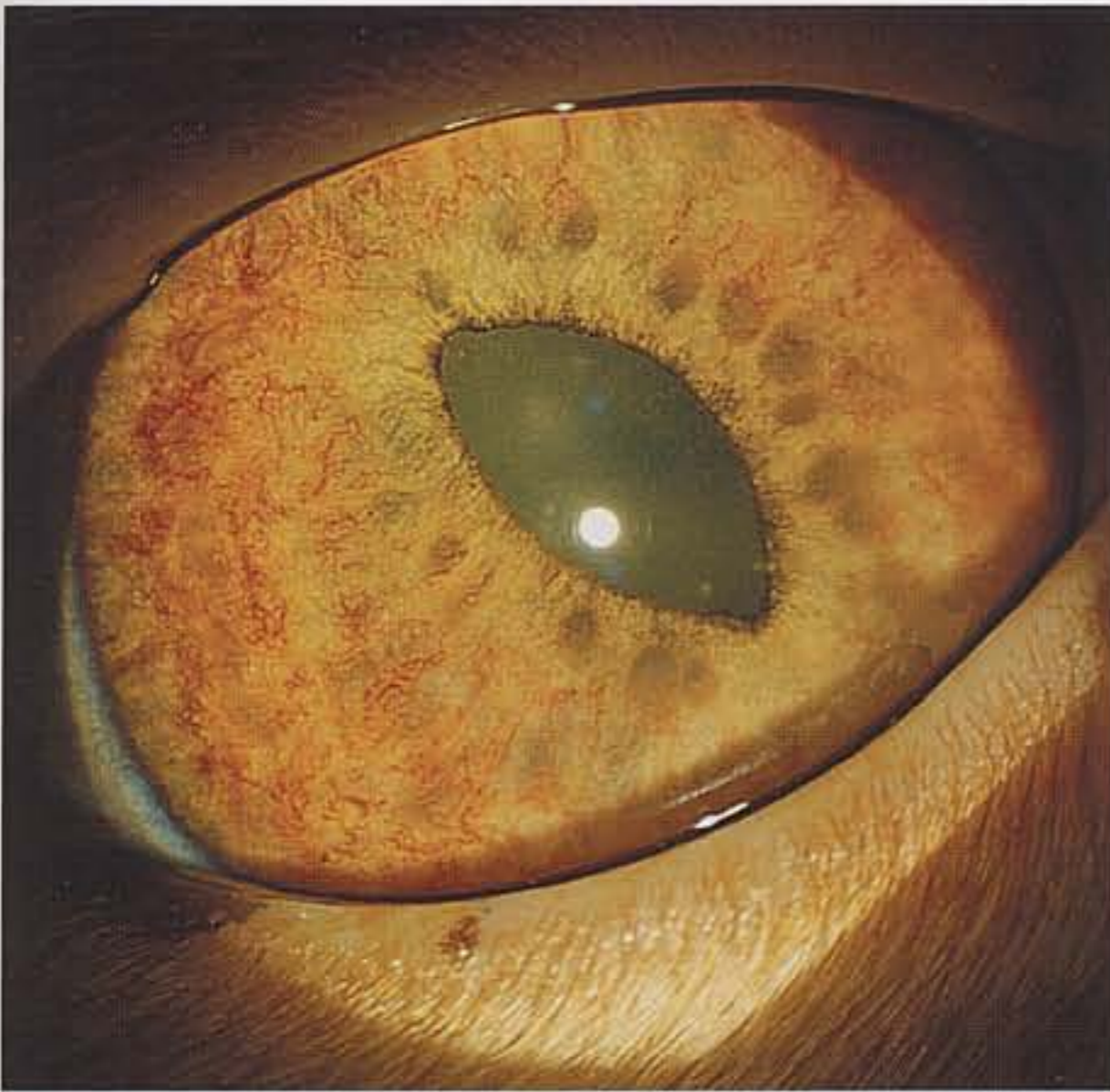


Fig. 7.11 Iritis Rubeosis iridis and flare (visible in the pupillary area).

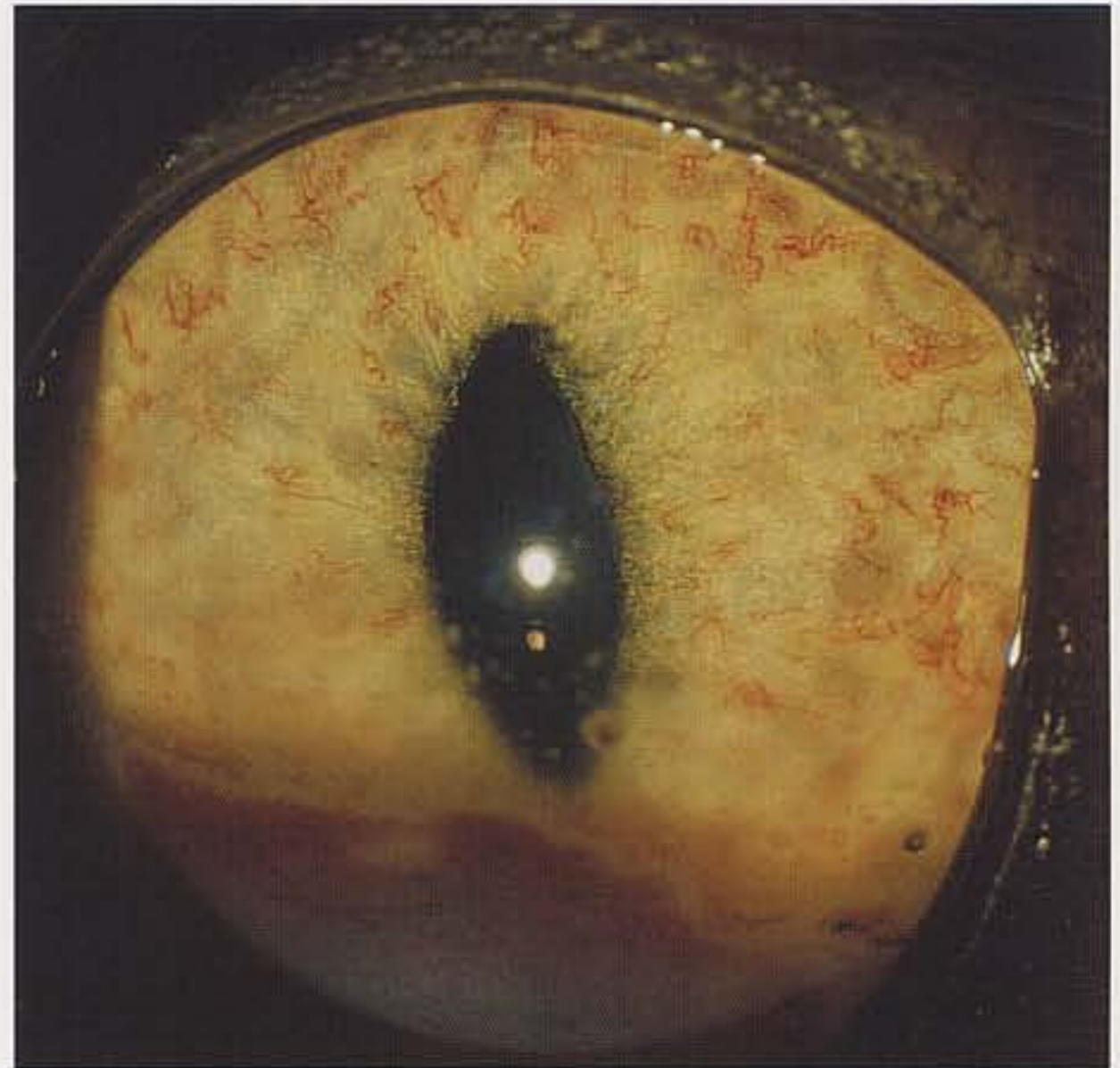


Fig. 7.13 Iritis (DSH cat, 8 years old) Hyphaema and rubeosis iridis. A further case of toxoplasmosis and note the difference in presenting signs between Figs 7.8, 7.10 and 7.13.

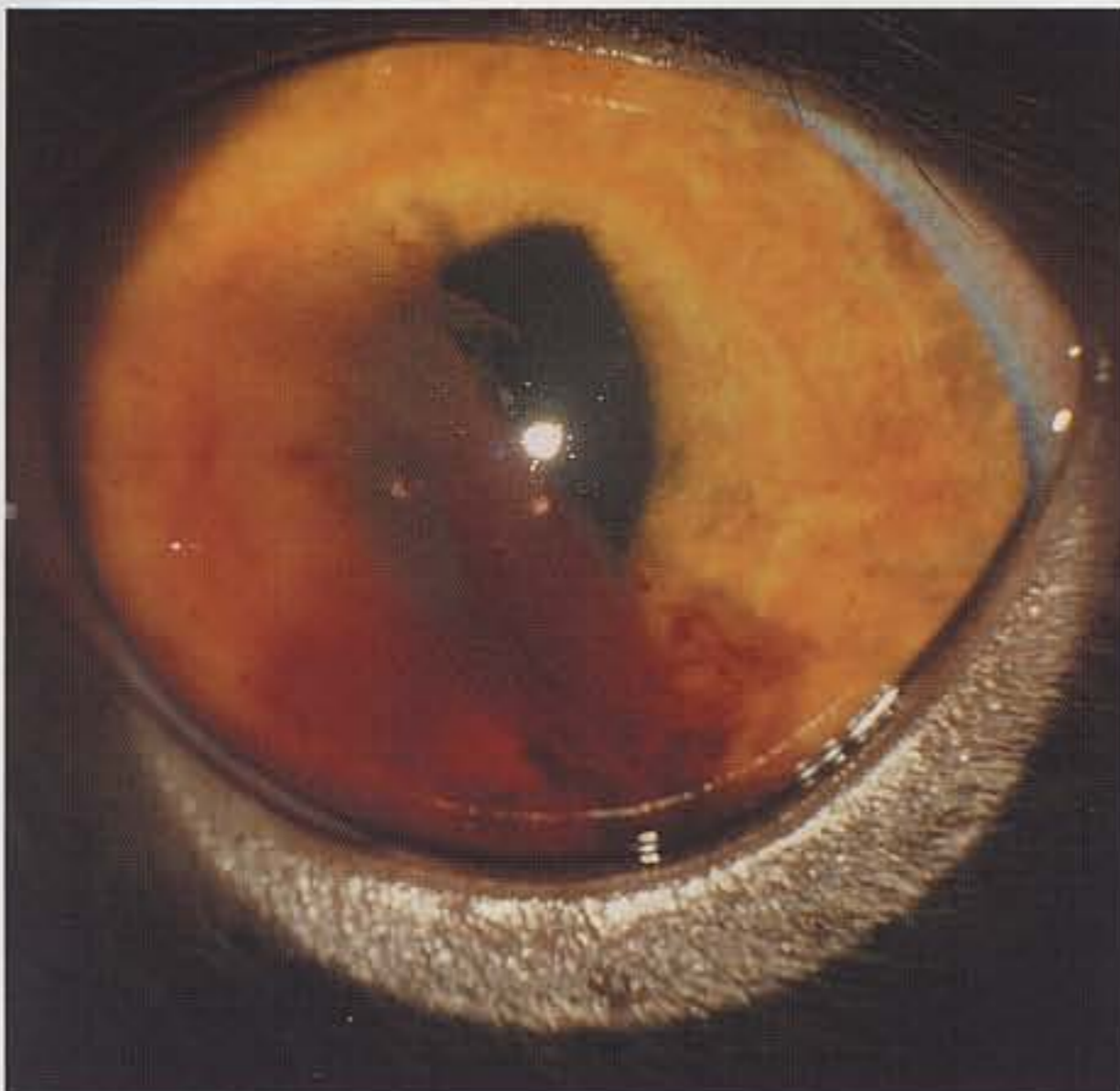


Fig. 7.12 Iritis (DSH cat, 1 year old) Hyphaema in a cat with feline infectious peritonitis.

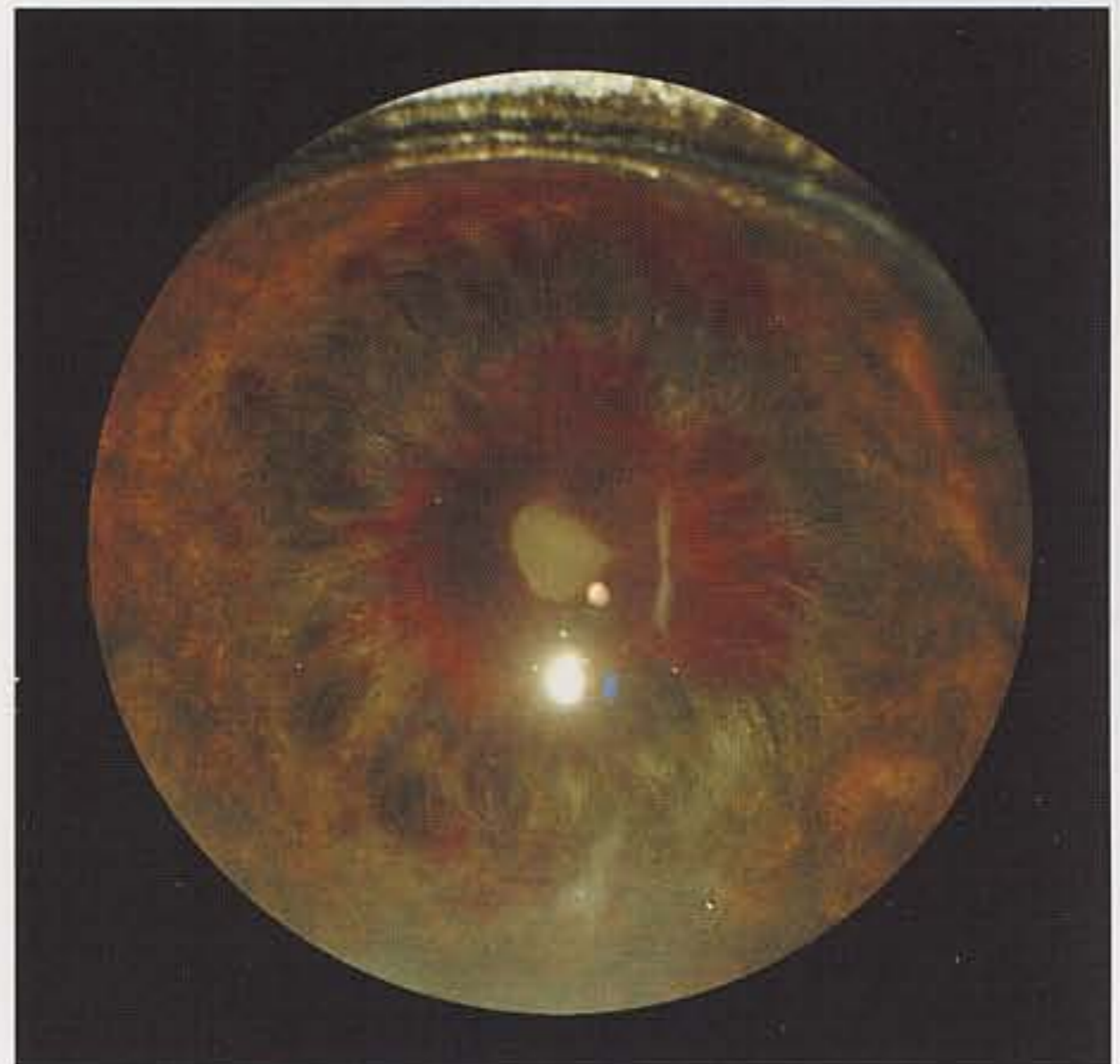


Fig. 7.14 Iritis (Crossbred dog, 4 years old) Case due to trauma showing swollen iris, miosis and haemorrhage.

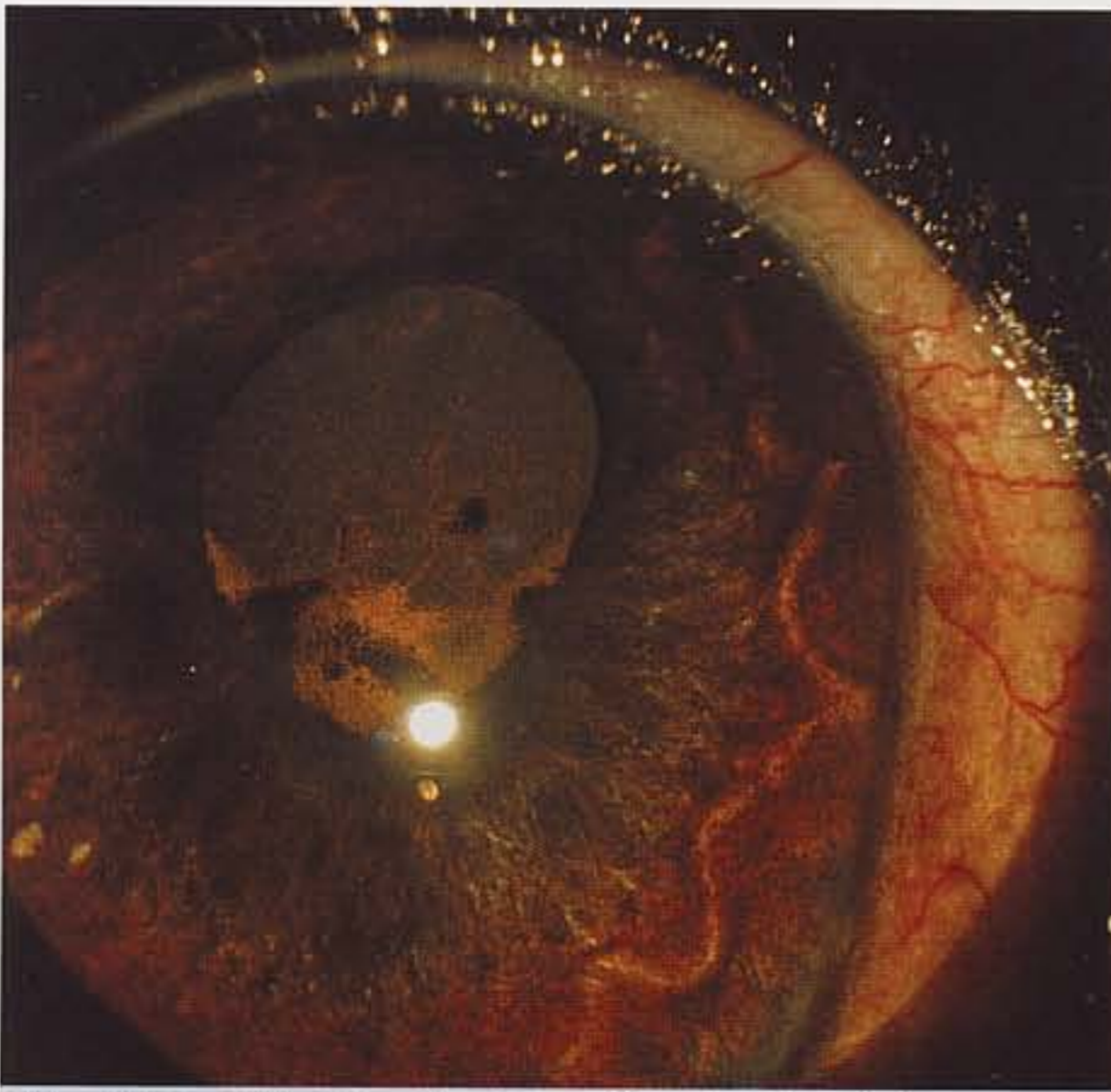


Fig. 7.15 Iritis (Cavalier King Charles Spaniel, 4 years old) Posterior synechiae and eccentric pupil.

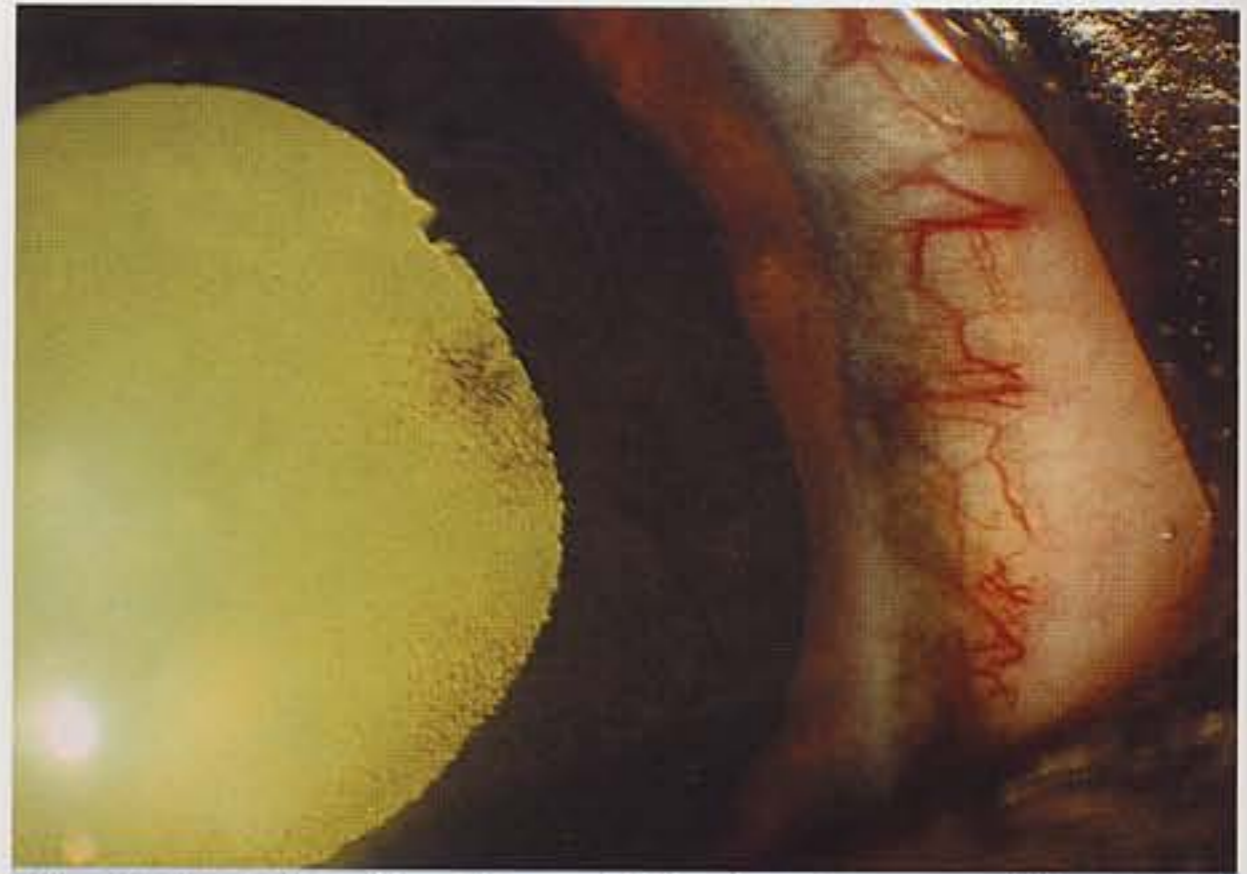


Fig. 7.17 Iritis (Jack Russell Terrier, 6 years old) Posterior synechiae and secondary glaucoma.

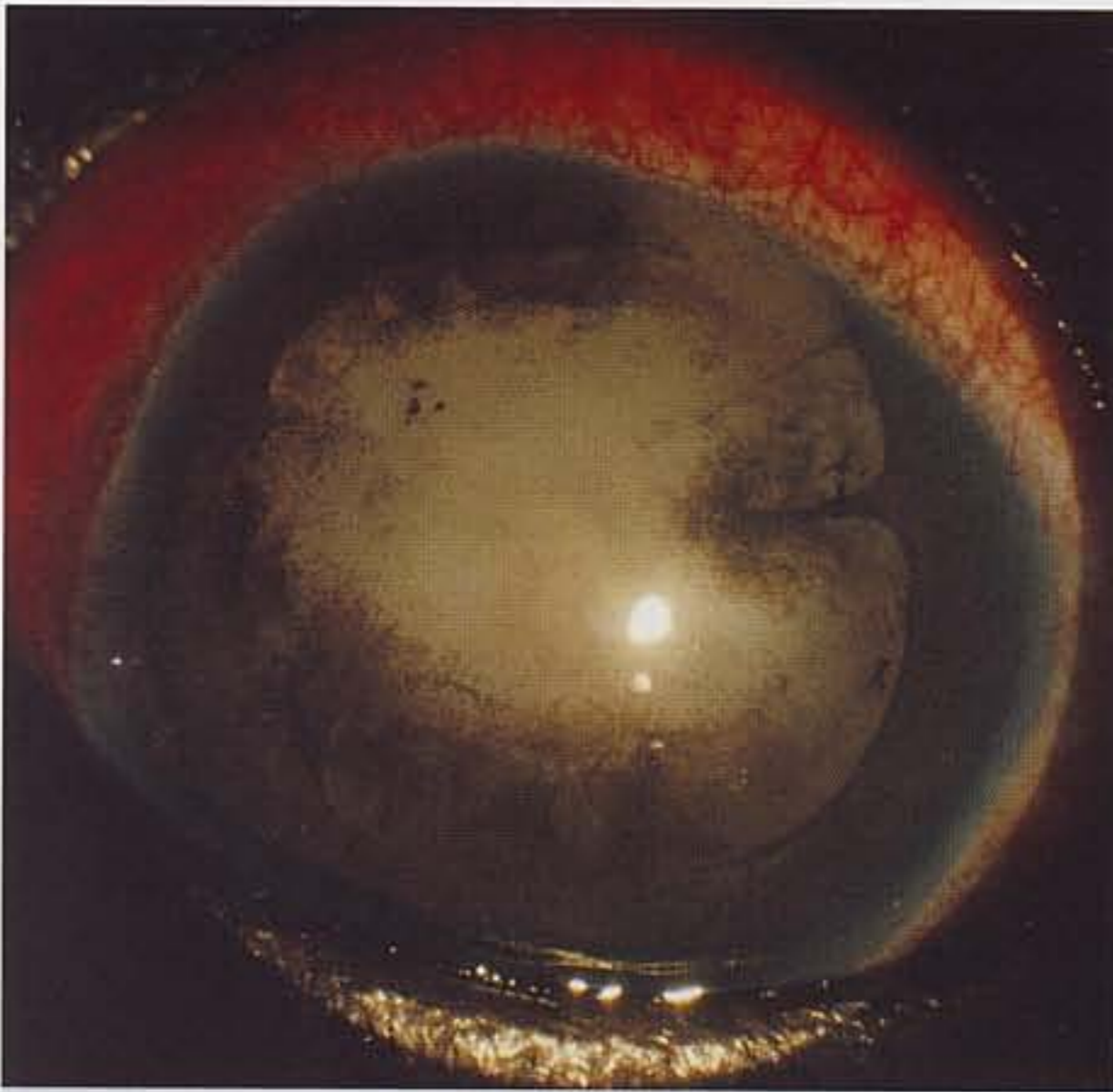


Fig. 7.16 Iritis (Miniature Poodle, 10 years old) Posterior synechiae and cataract.

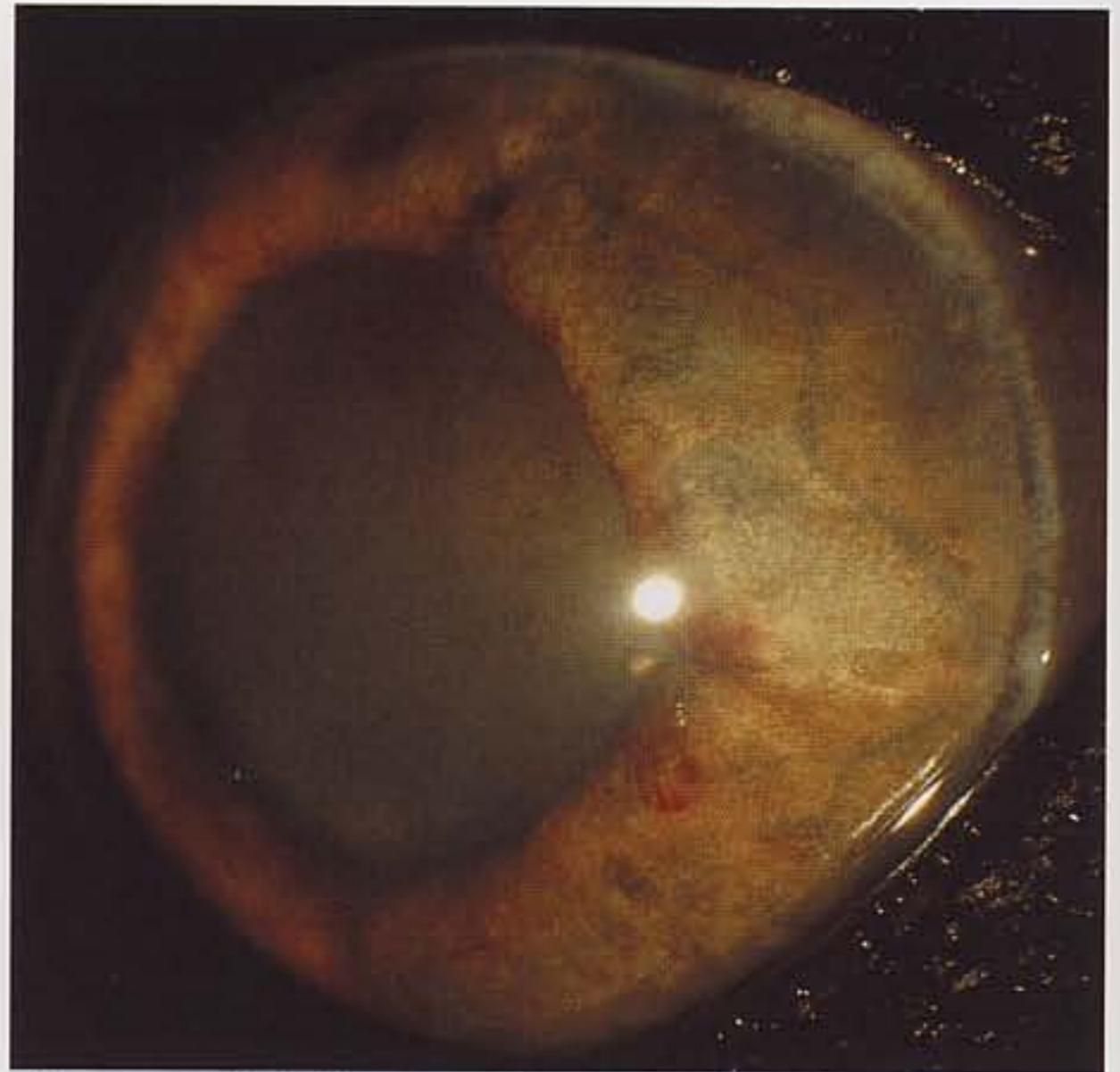


Fig. 7.18 Iritis (Border Collie, 9 years old) Iris bombé due to posterior synechiae and secondary glaucoma.

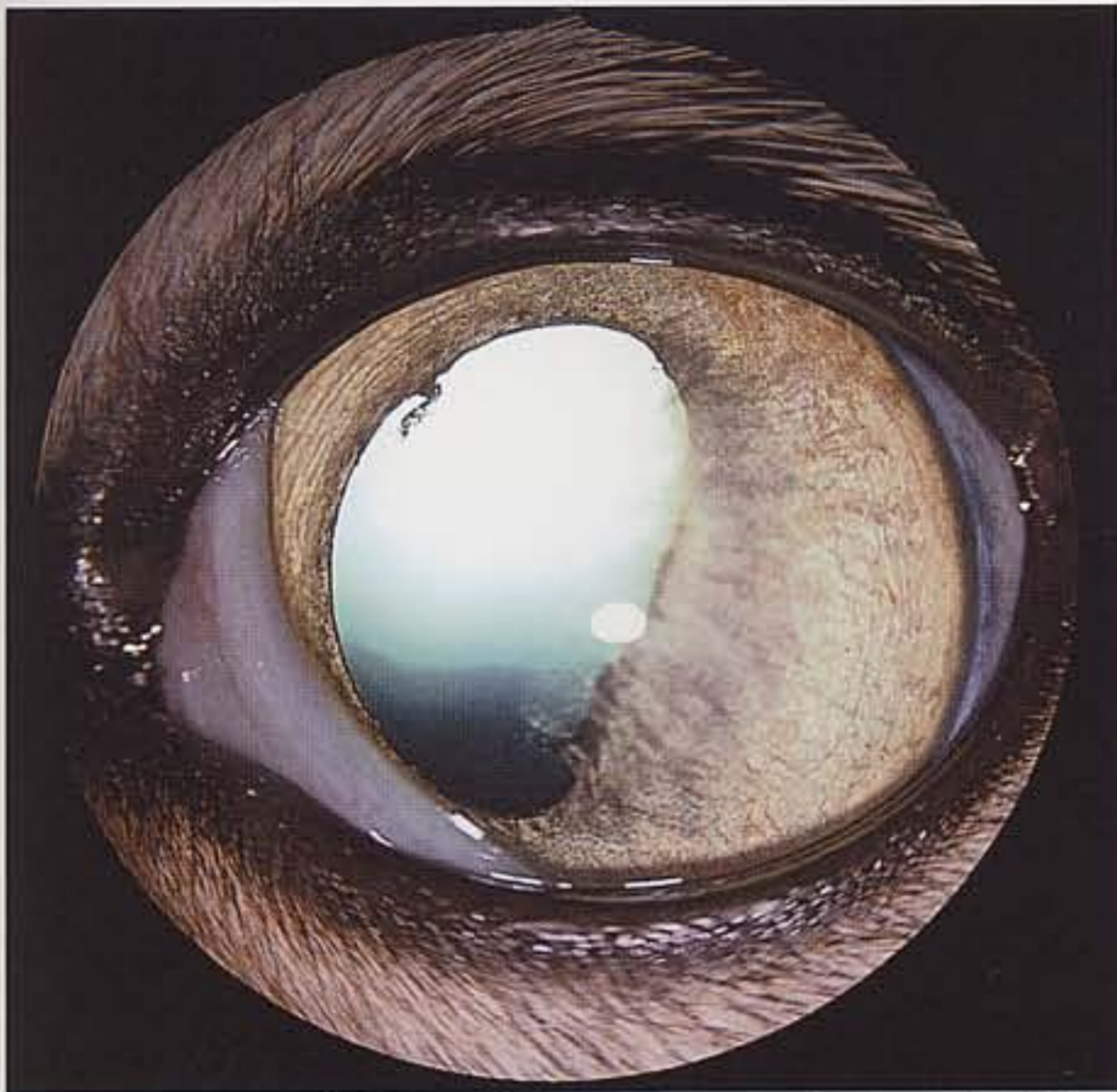

Fig. 7.19 Iritis (DSH cat) Posterior synechiae and mild irregularity of pupil. Idiopathic case.

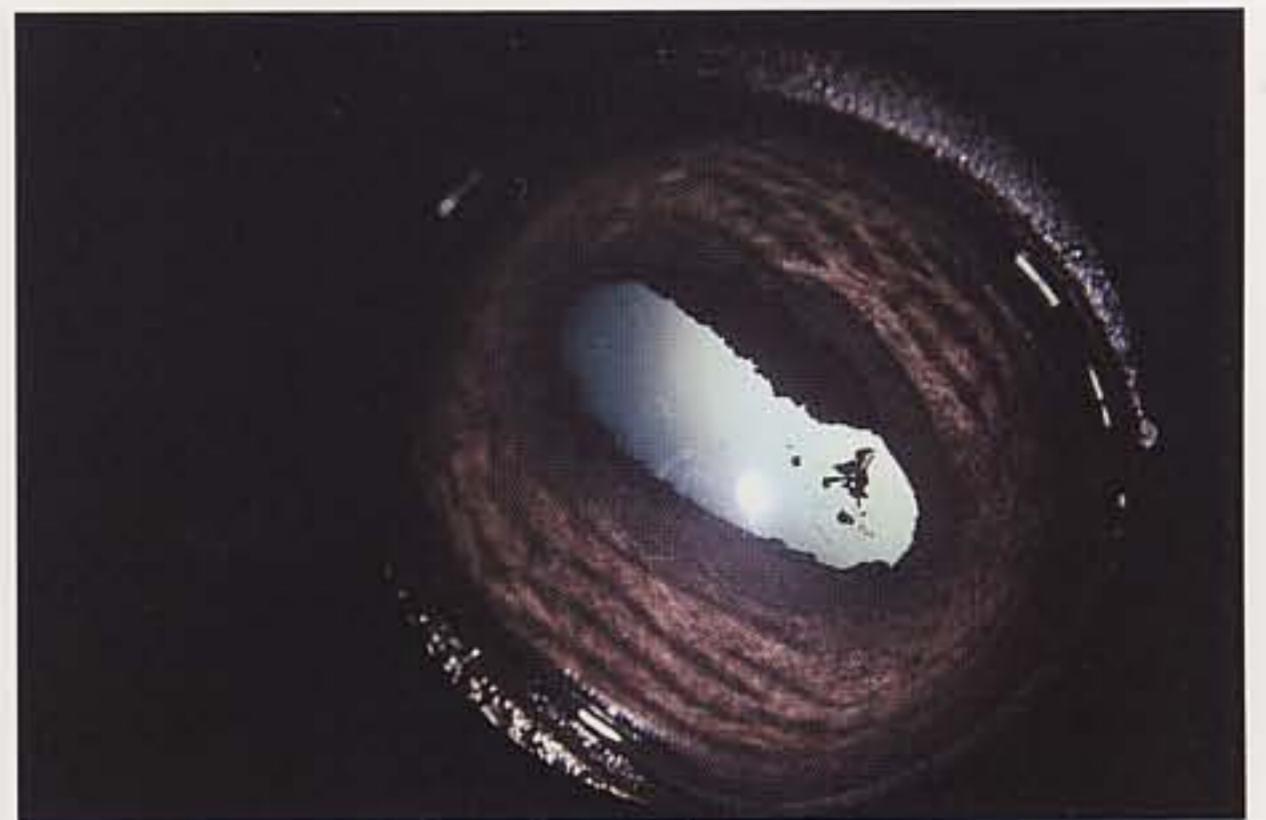

Fig. 7.21 Iritis (Thoroughbred) Iris rests. Idiopathic case.

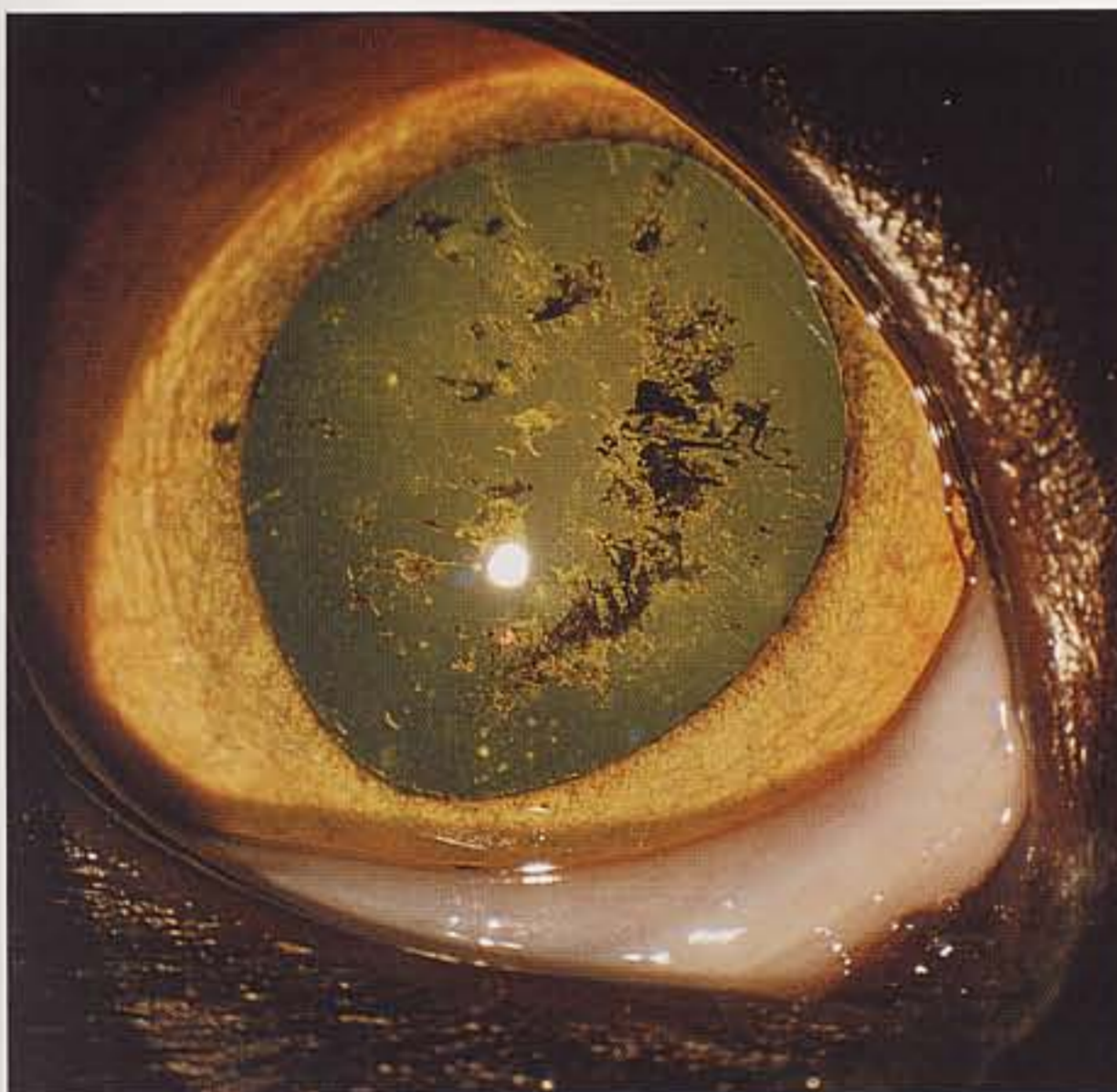

Fig. 7.20 Iritis (DSH cat, 18 months old) Iris rests (posterior synechiae).

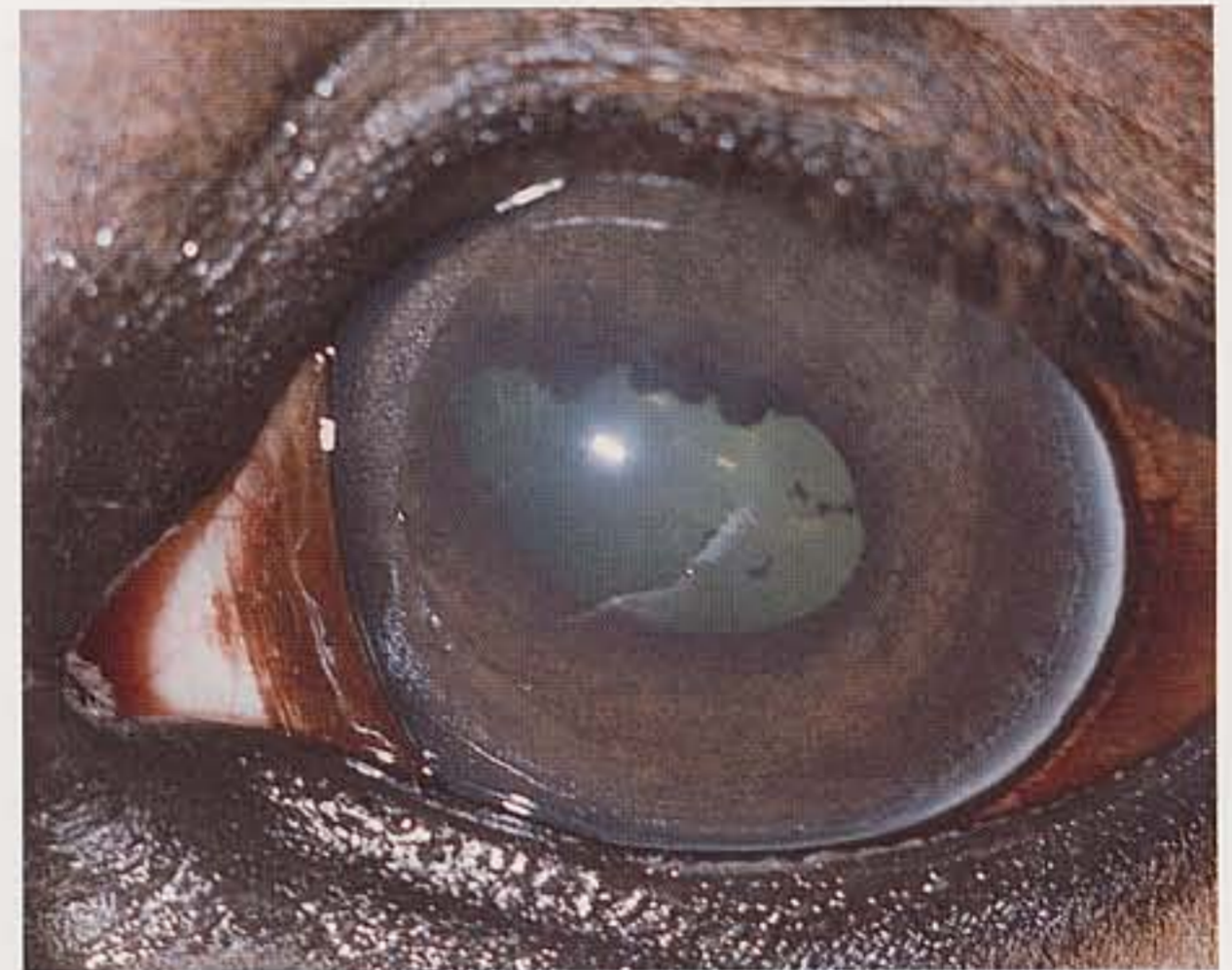

Fig. 7.22 Iritis Equine recurrent uveitis. Posterior synechiae producing irregularity of the pupil.





Fig. 7.23 Iritis (Thoroughbred, 12 years old) Equine recurrent uveitis. Posterior synechiae and cataract.

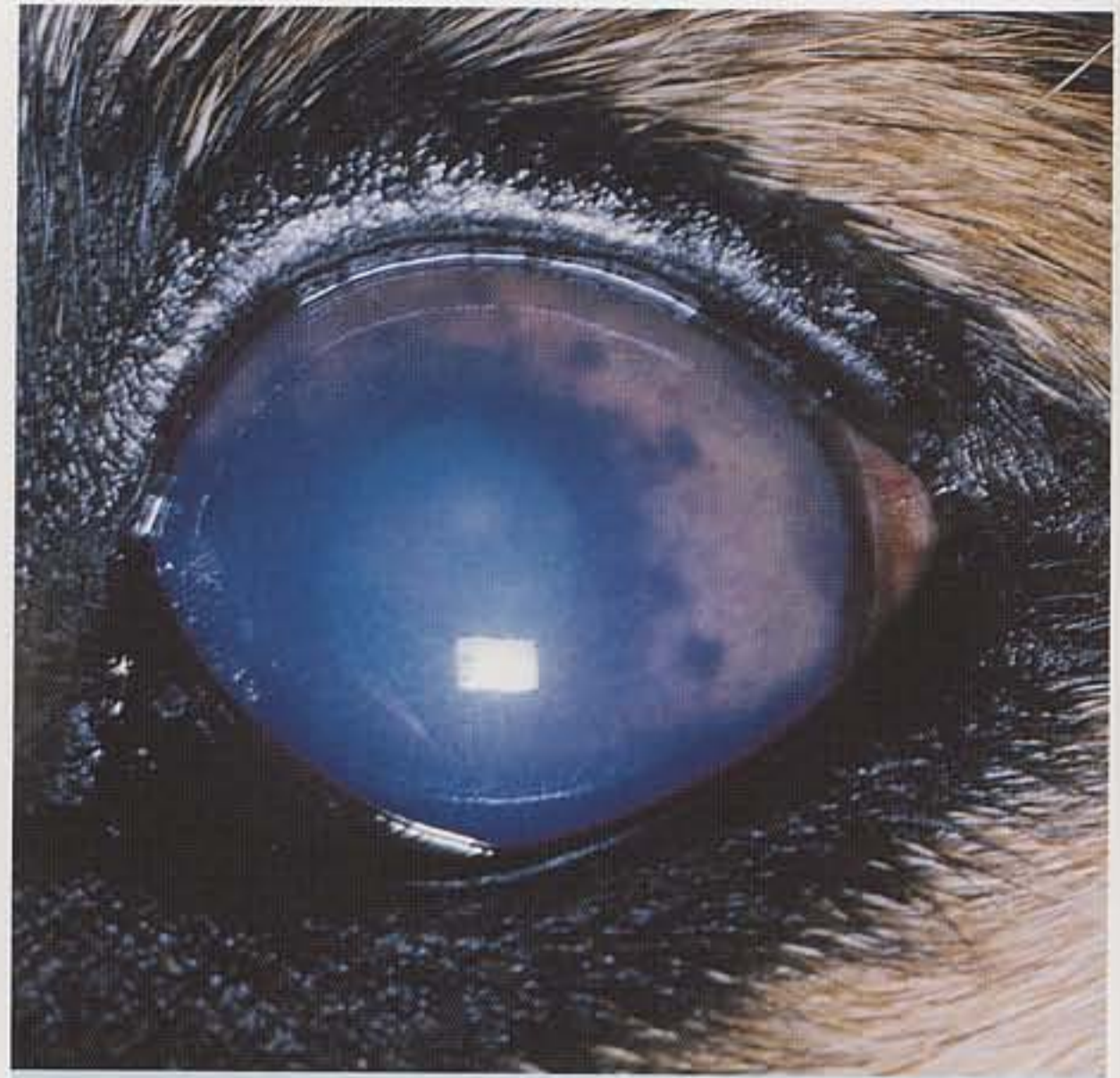

Fig. 7.25 Iritis (German Shepherd Dog, 3 years old) Ehrlichiosis. Note the multiple haemorrhages on the iris and the corneal oedema.

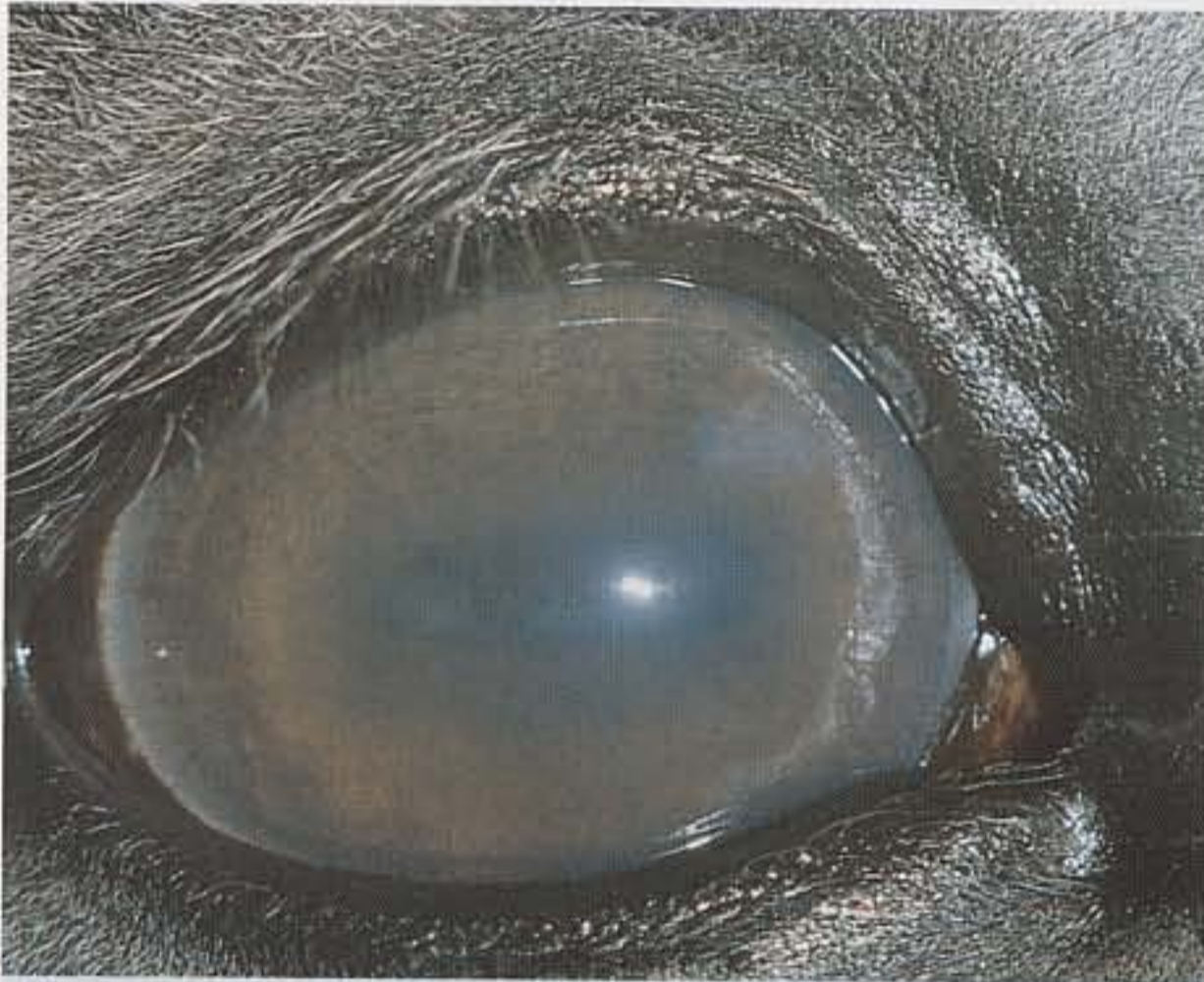


Fig. 7.24 Iritis (Connemara pony, 3 years old) Equine recurrent uveitis. Dull and faintly opaque cornea with miosis.

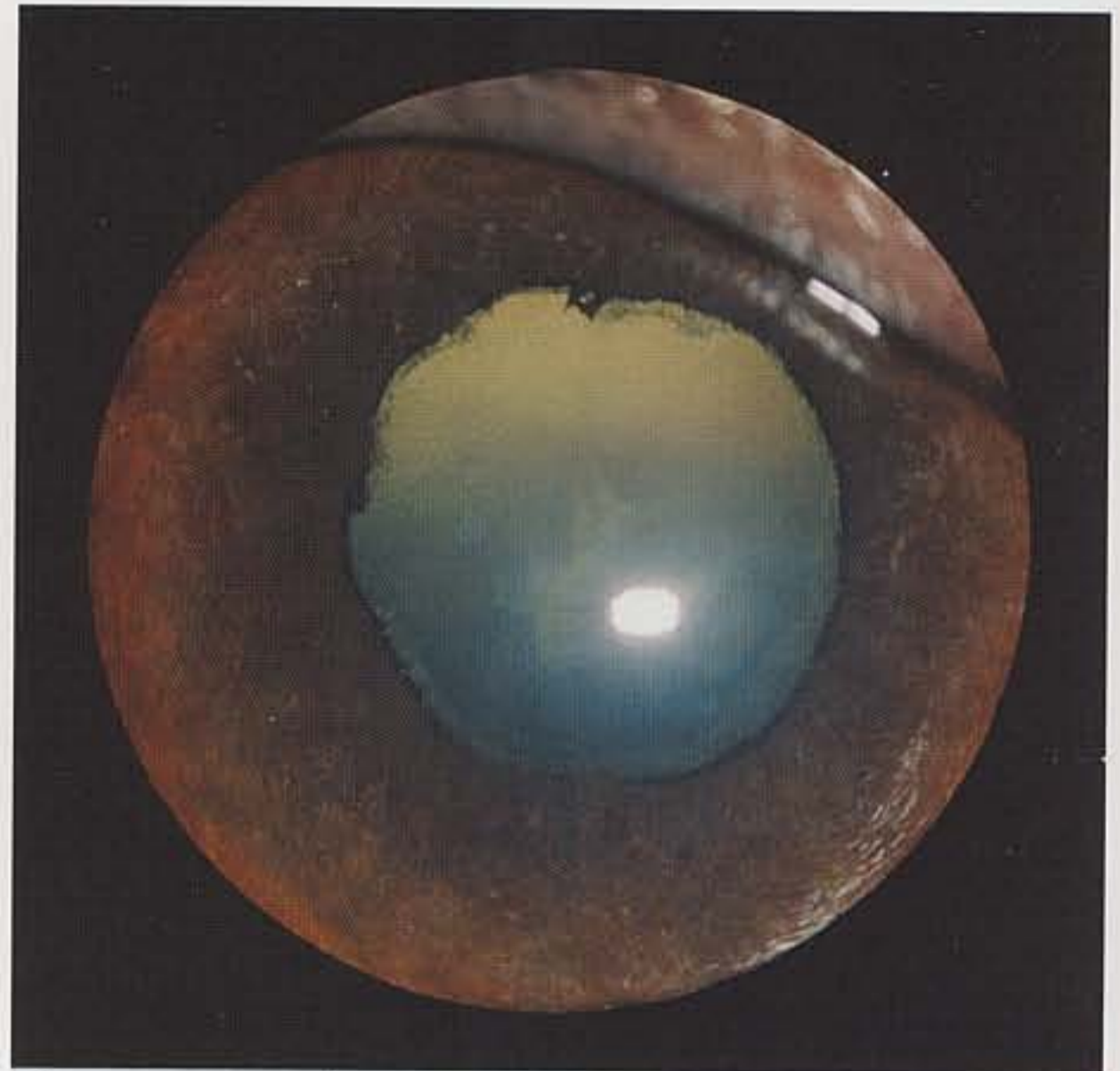


Fig. 7.26 Iritis (Akita, young adult) A case of Harada's disease, or Voght-Kayanaga-Harada (VKH). Note posterior synechiae and cataract.

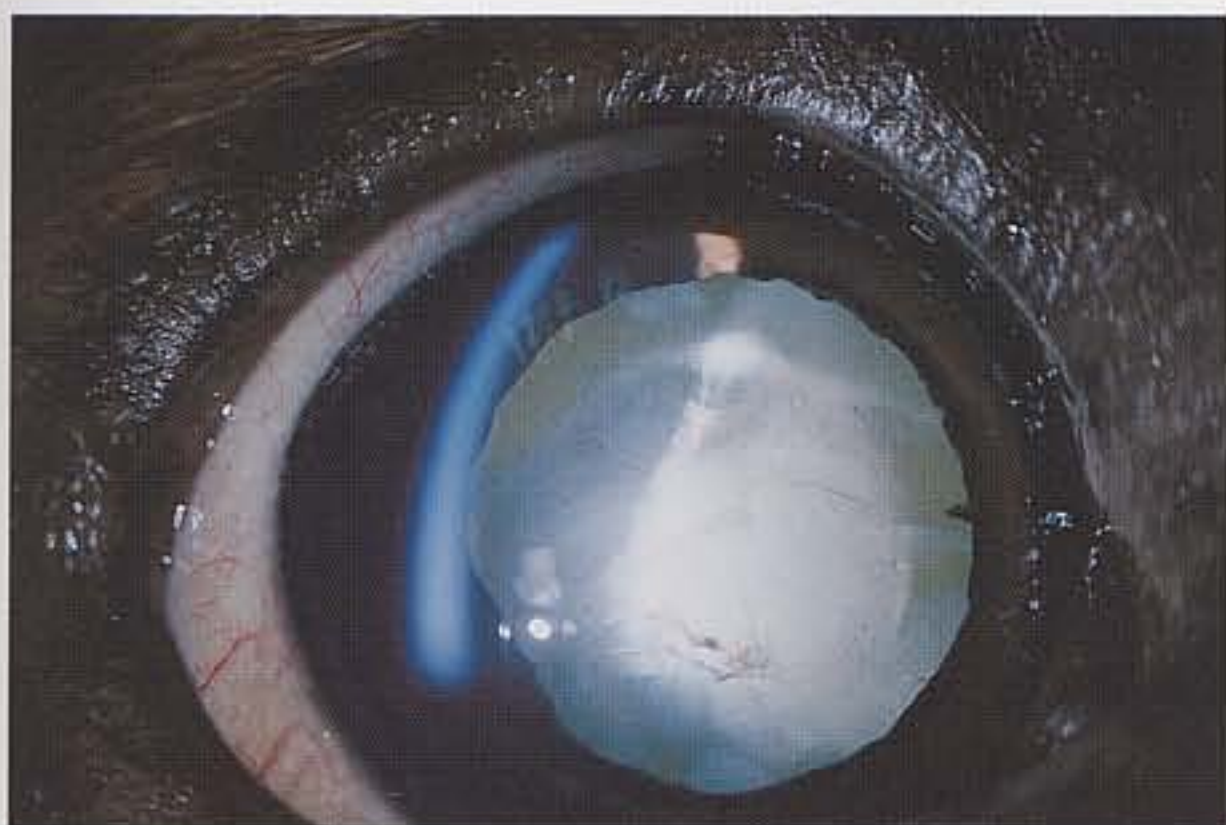

Fig. 7.27 Iritis Lens-induced uveitis in a diabetic dog. Note the irregularity of the anterior lens capsule, the darkened iris and posterior synechiae. See also Fig 9.24.

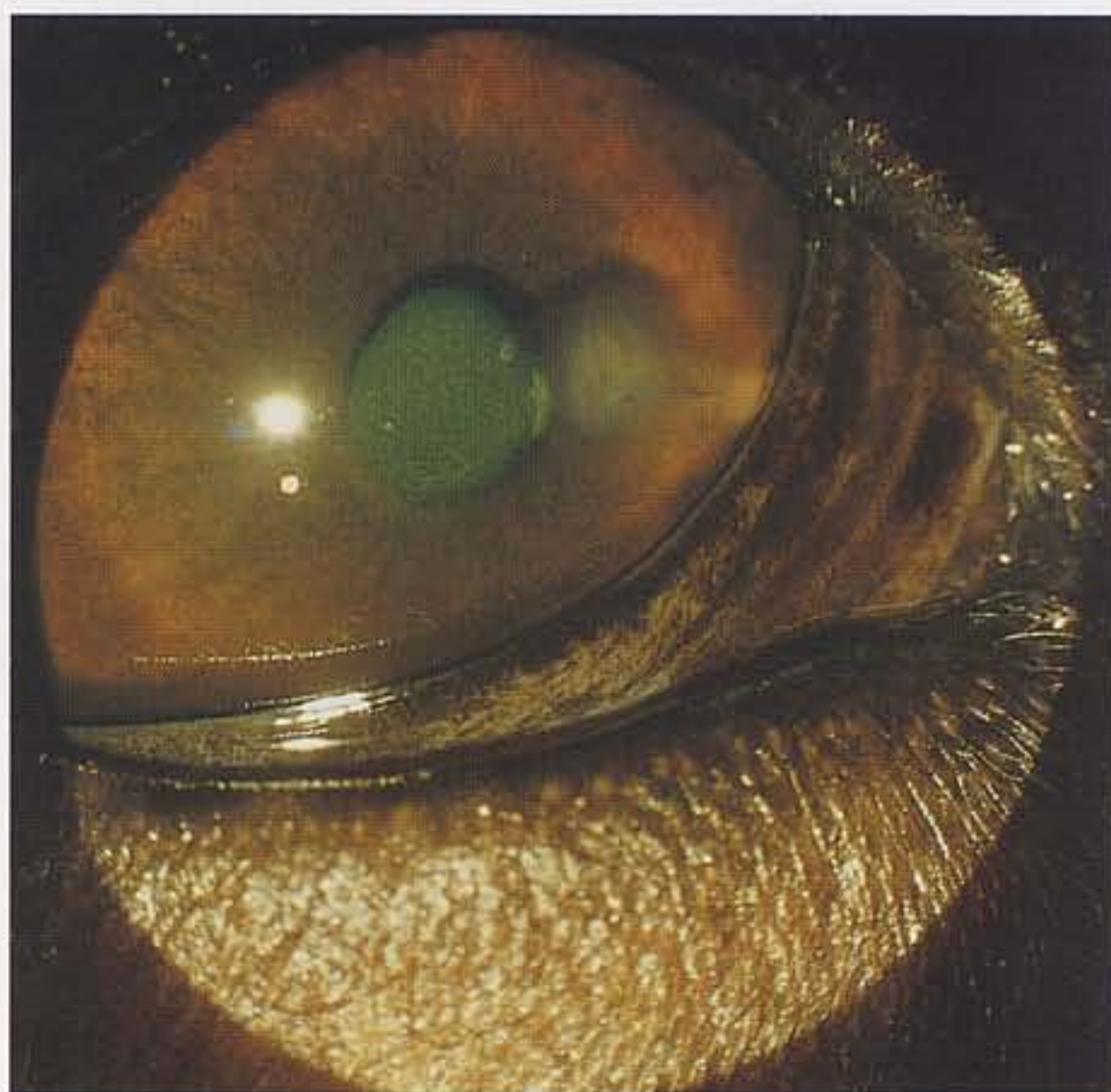

Fig. 7.29 Trauma Penetrating corneal injury. Note the foreign body, flare particularly evident in the pupil, miosis and herniation of posterior uveal pigment in the superior part of the pupil.

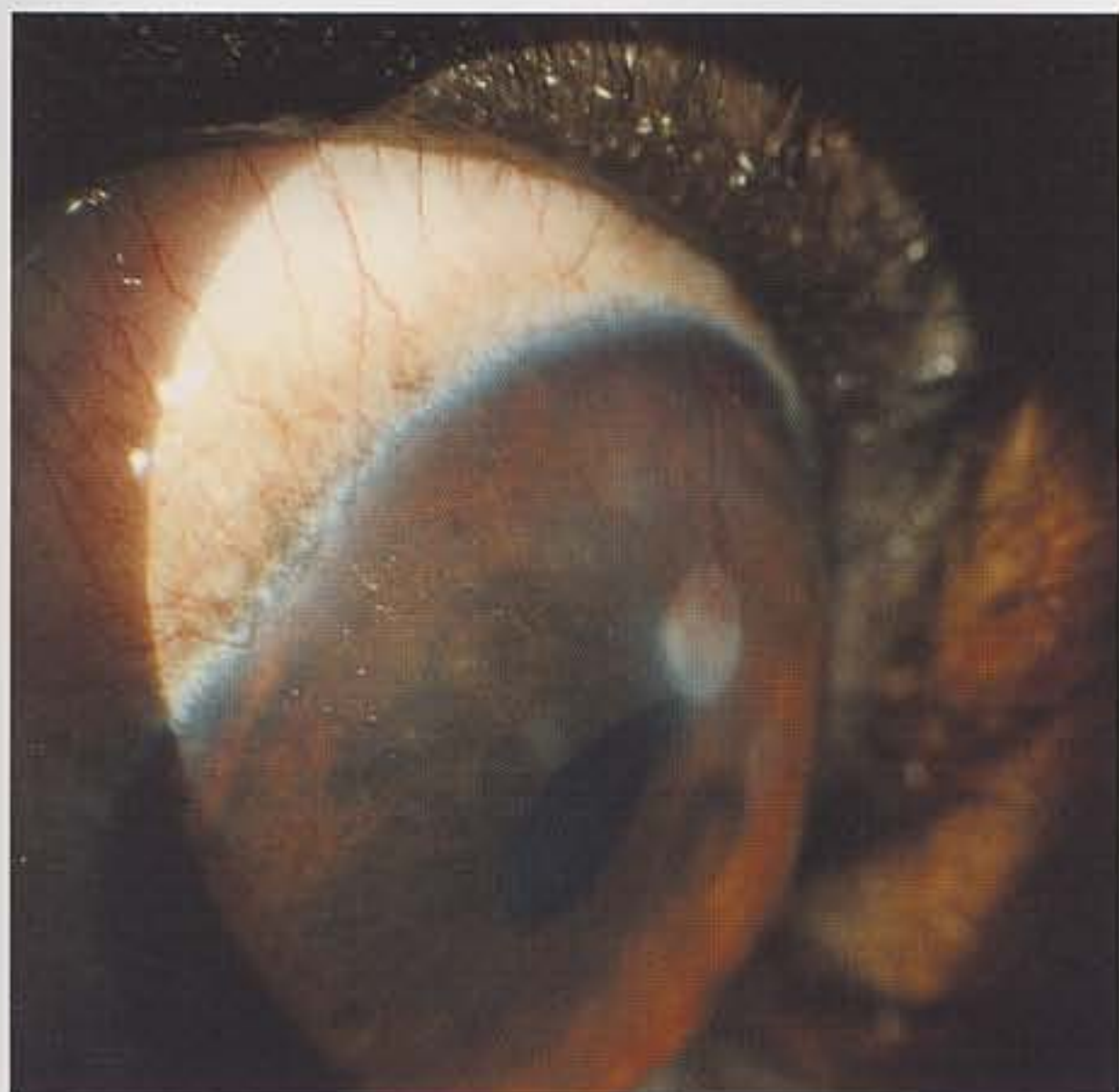


Fig. 7.28 Trauma Penetrating corneal injury with anterior synechiae and healed corneal scar with fine vascularization.

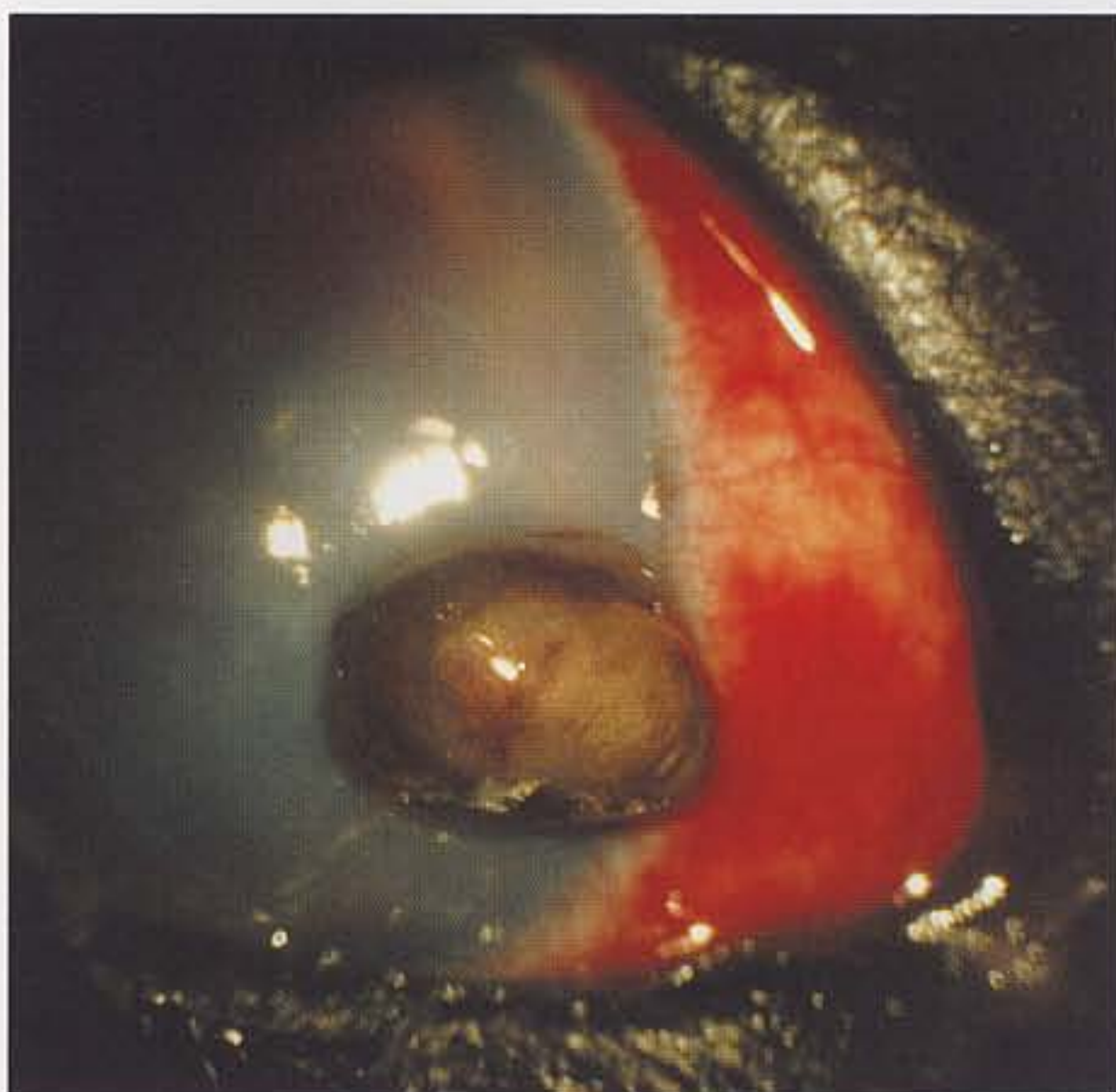


Fig. 7.30 Trauma (English Springer Spaniel, 3 years old) Iris prolapse following a shot injury. Note the subconjunctival haemorrhage.

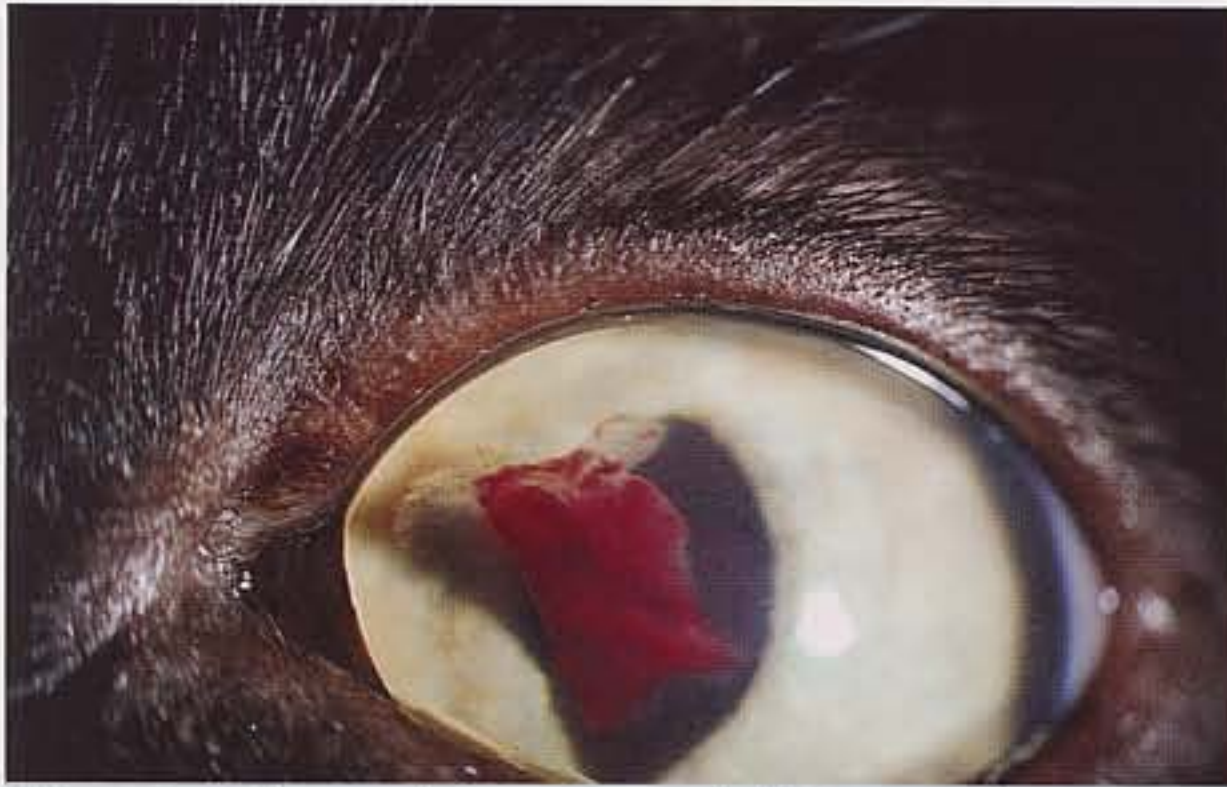

Fig. 7.31 Trauma (cat, young adult) Penetrating corneal injury with iris haemorrhage.

### Sequelae (continued from p. 70)

- Lens luxation.
- Glaucoma (secondary) – uveitis commonly precedes cases of glaucoma in the horse.
- Phthisis – the result of severe inflammation, again usually in the horse.

The causes of uveitis are many and varied, and include trauma (Fig 7.14), reflex (corneal ulcer), immune-mediated, lens-induced, viral, Rickettsial, bacterial, fungal and parasitic. Uveitis may be unocular or binocular and accompanies several systemic diseases in the three species (Figs 7.8, 7.10, 7.12–7.13, 7.25–7.26). Many cases remain idiopathic.

### Cysts (Figs 7.32–7.38)

Not uncommon in all three species.

### Neoplasia (Figs 7.41–7.54)

Melanoma is the most common (particularly in grey horses), but also adenoma, adenocarcinoma, medulloepithelioma and multicentric lymphosarcoma.

### Congenital anomalies (Figs 7.55–7.67)

Persistent pupillary membranes (Figs 7.59–7.67). Not uncommon in all three species and may cross part of the iris or the pupil or be attached to anterior lens capsule or posterior cornea and present as opacities in these positions.

Colobomas (Figs 7.55–7.58) Occur in all species but are rare in the cat.

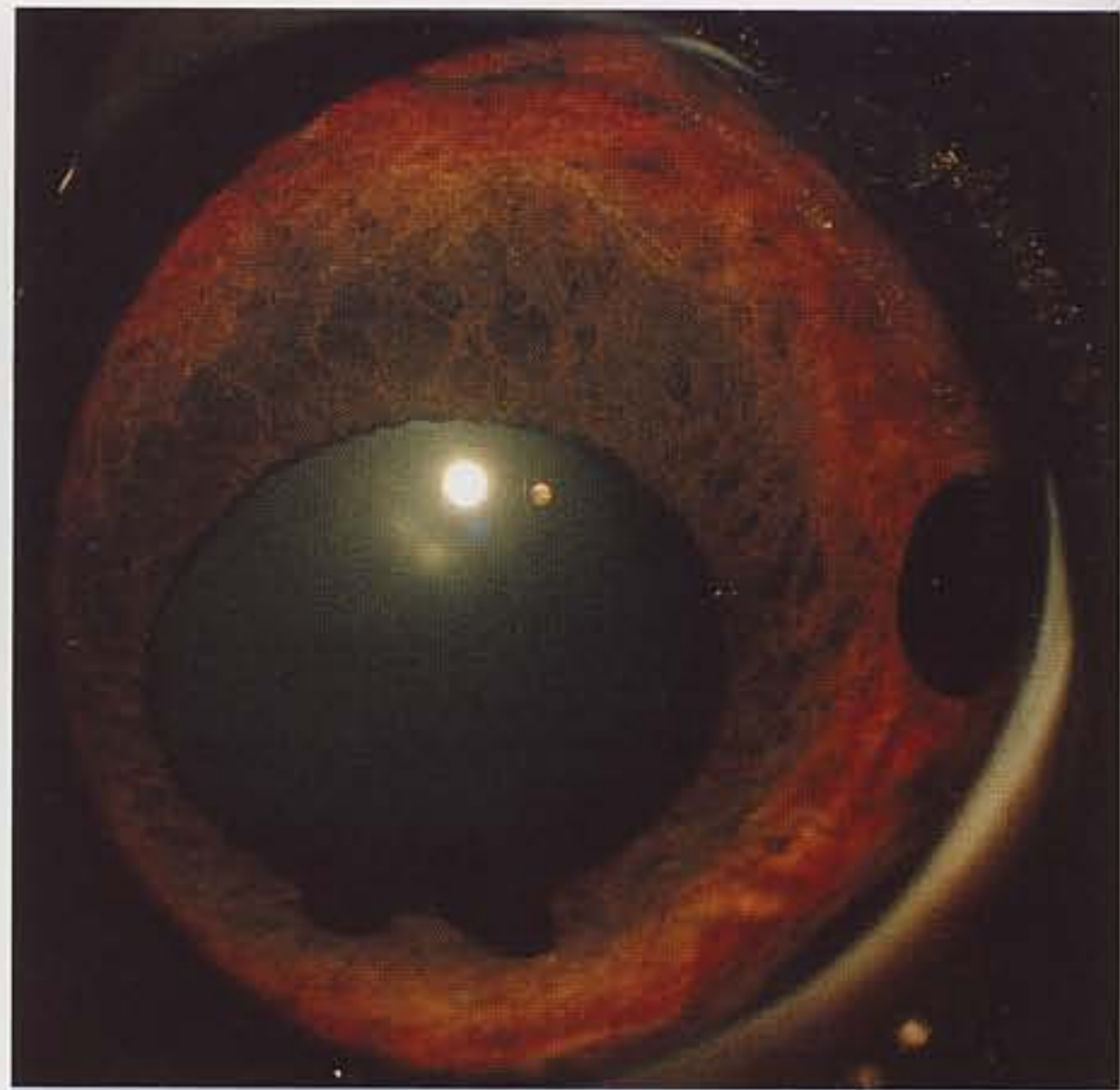

Fig. 7.32 Uveal cysts (Crossbred dog, 7 years old) Two attached at pupillary margin and one free in anterior chamber. Dense cysts.

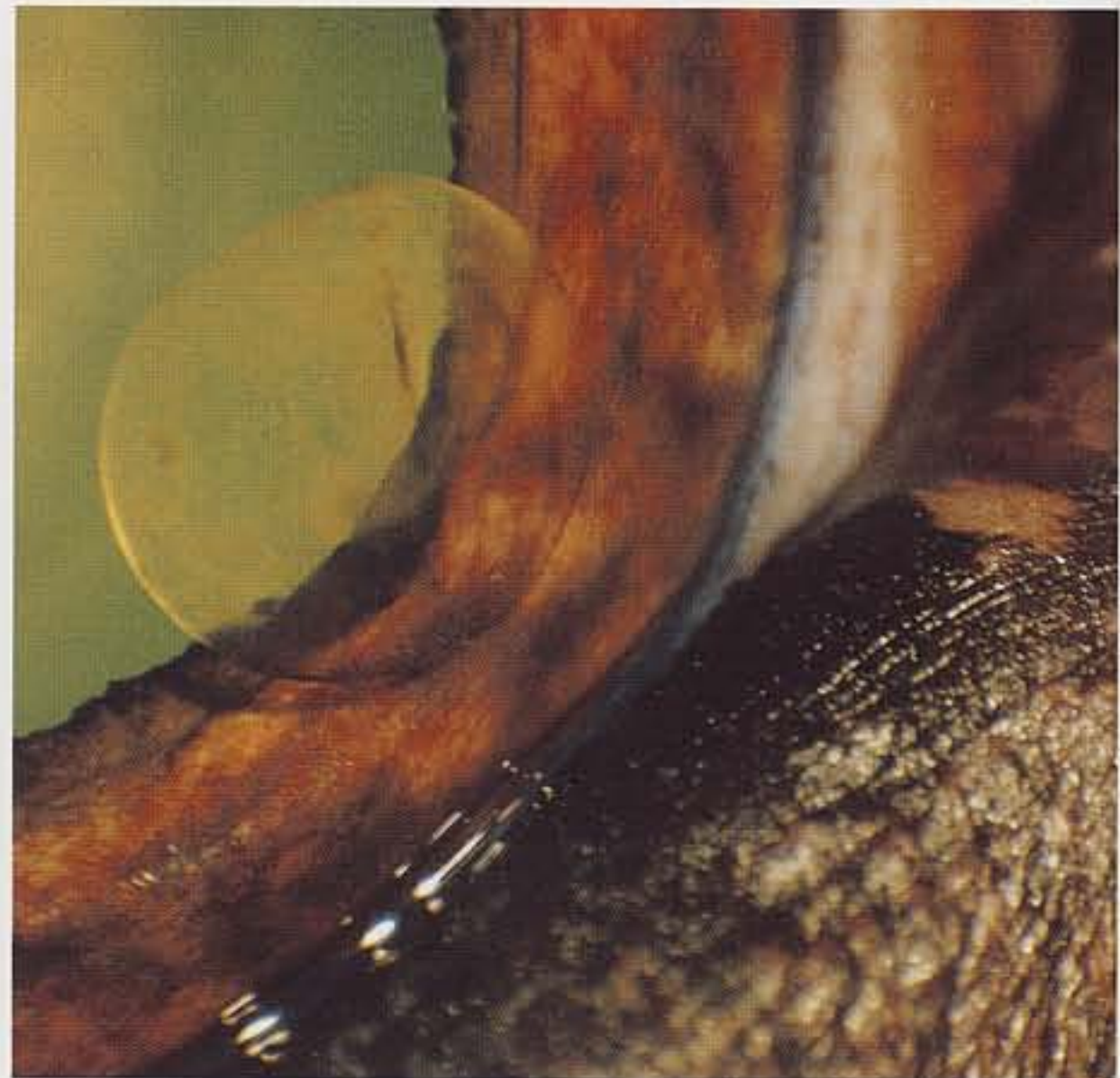

Fig. 7.33 Uveal cyst (Labrador Retriever) Single thin-walled cyst.

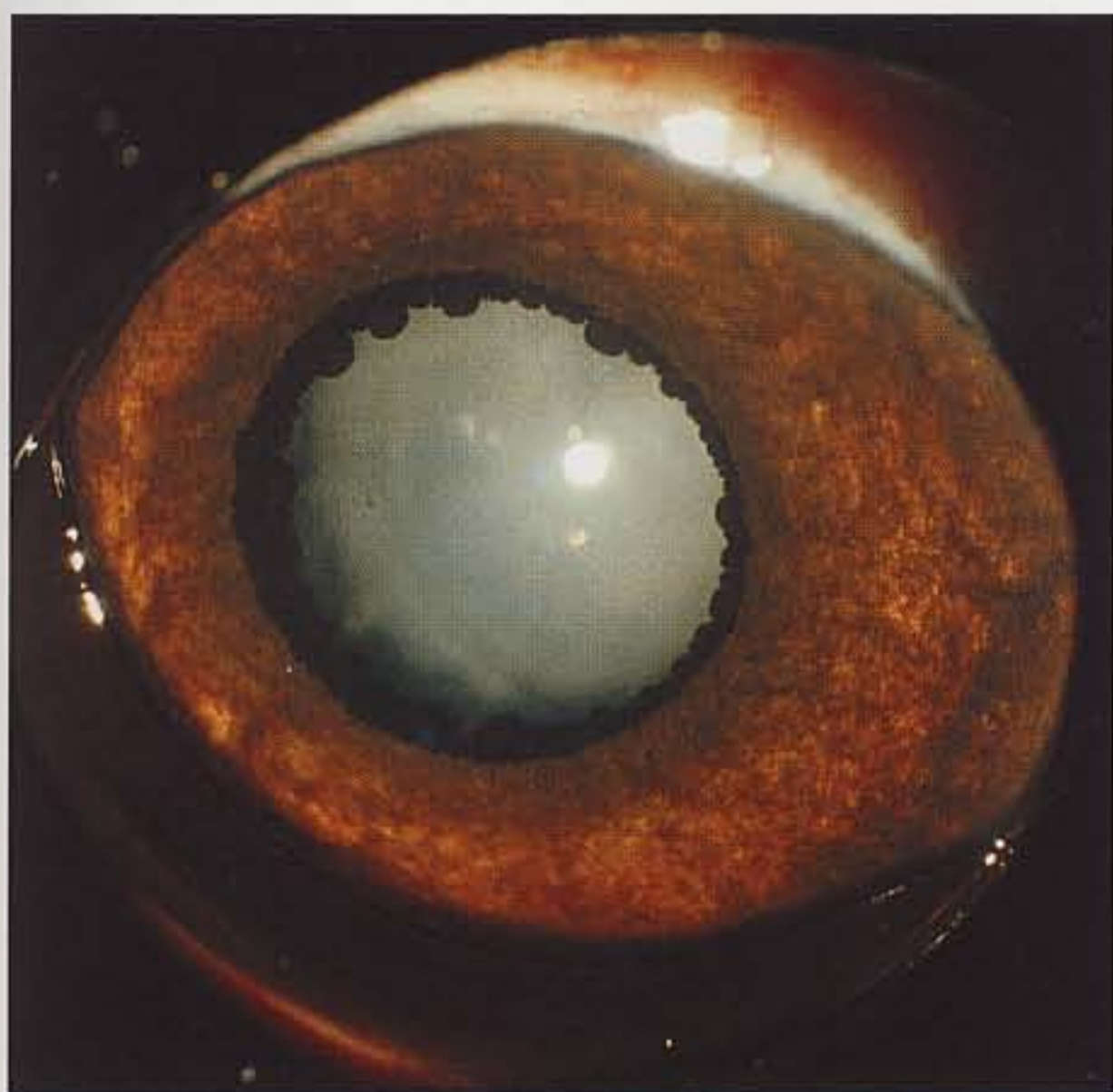

Fig. 7.34 Uveal cysts (Labrador Retriever, 9 months old) Cataract and associated cysts around the pupillary border following uveitis.

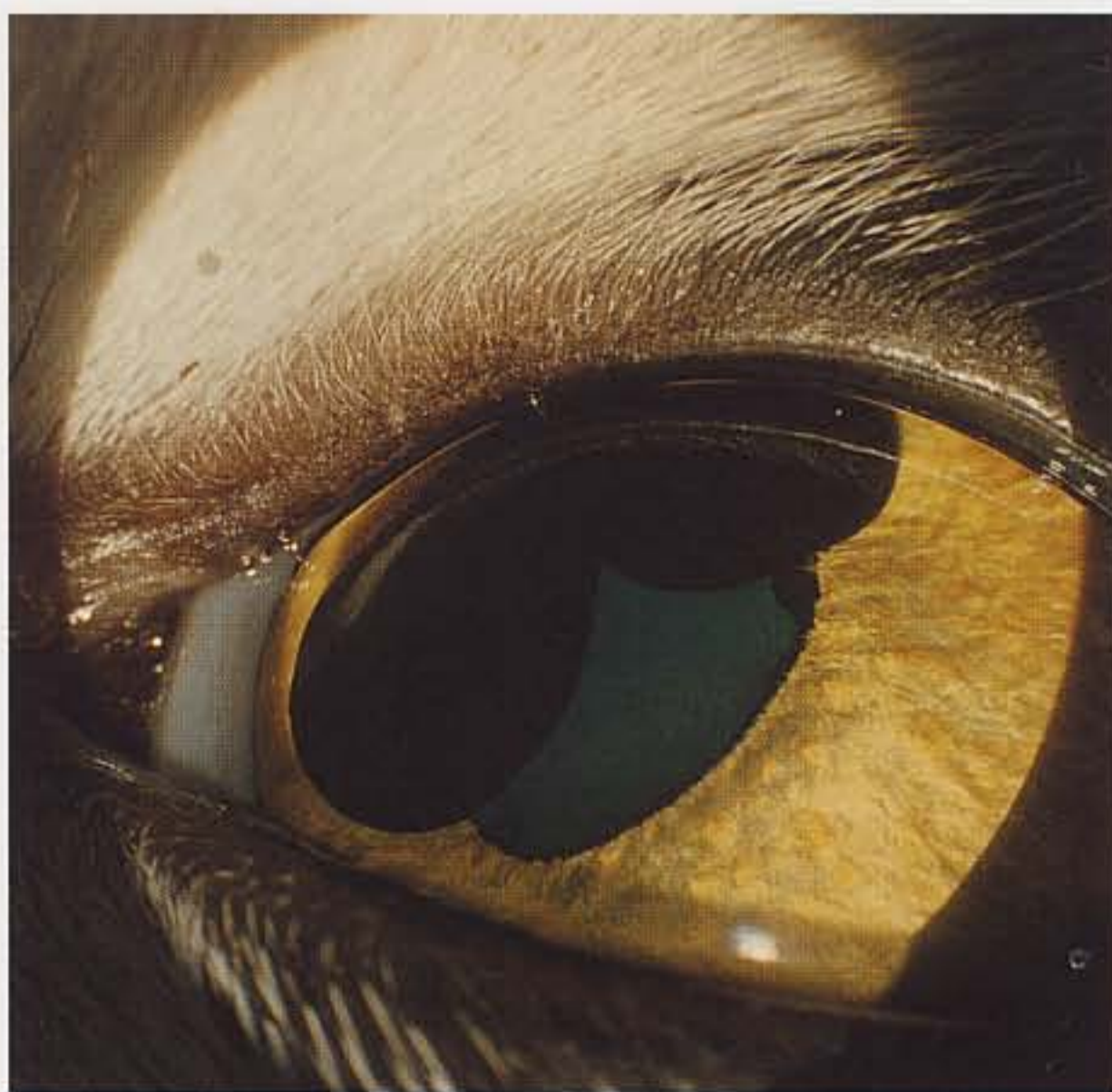

Fig. 7.36 Uveal cysts (DSH cat, 5 years old) Several free cysts in the anterior chamber.

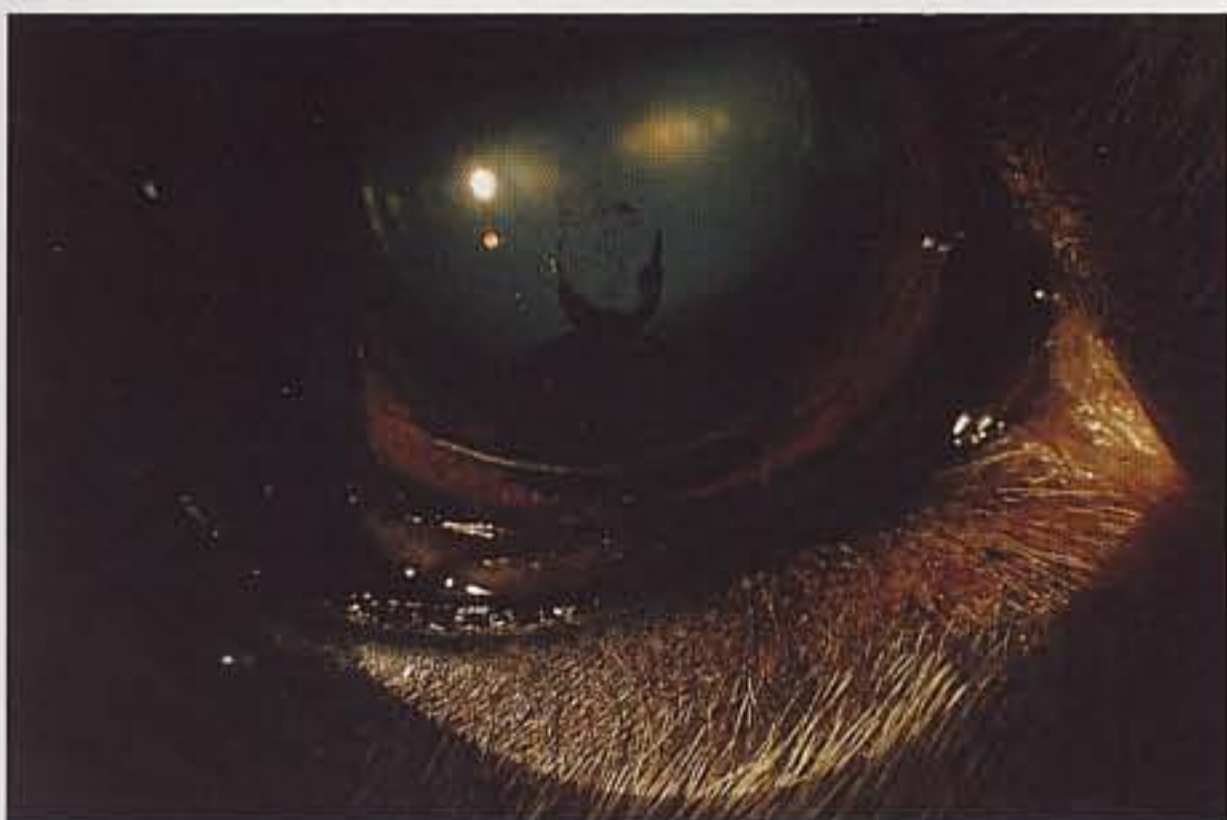

Fig. 7.35 Uveal cyst (Labrador Retriever, adult) Ruptured cyst adherent to the posterior cornea.

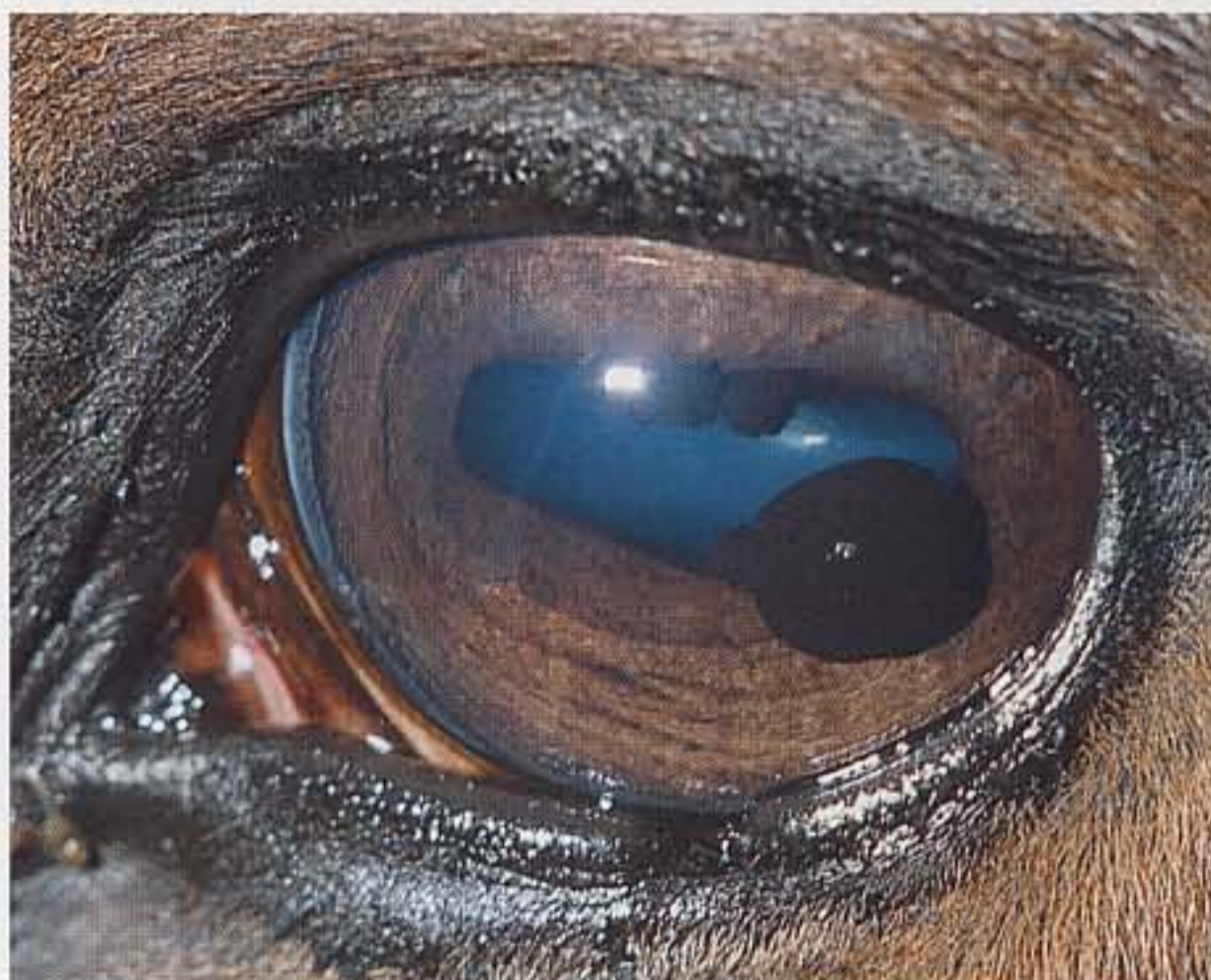

Fig. 7.37 Uveal cysts (Hunter-type, 9 years old) Cysts attached to pupillary margin.

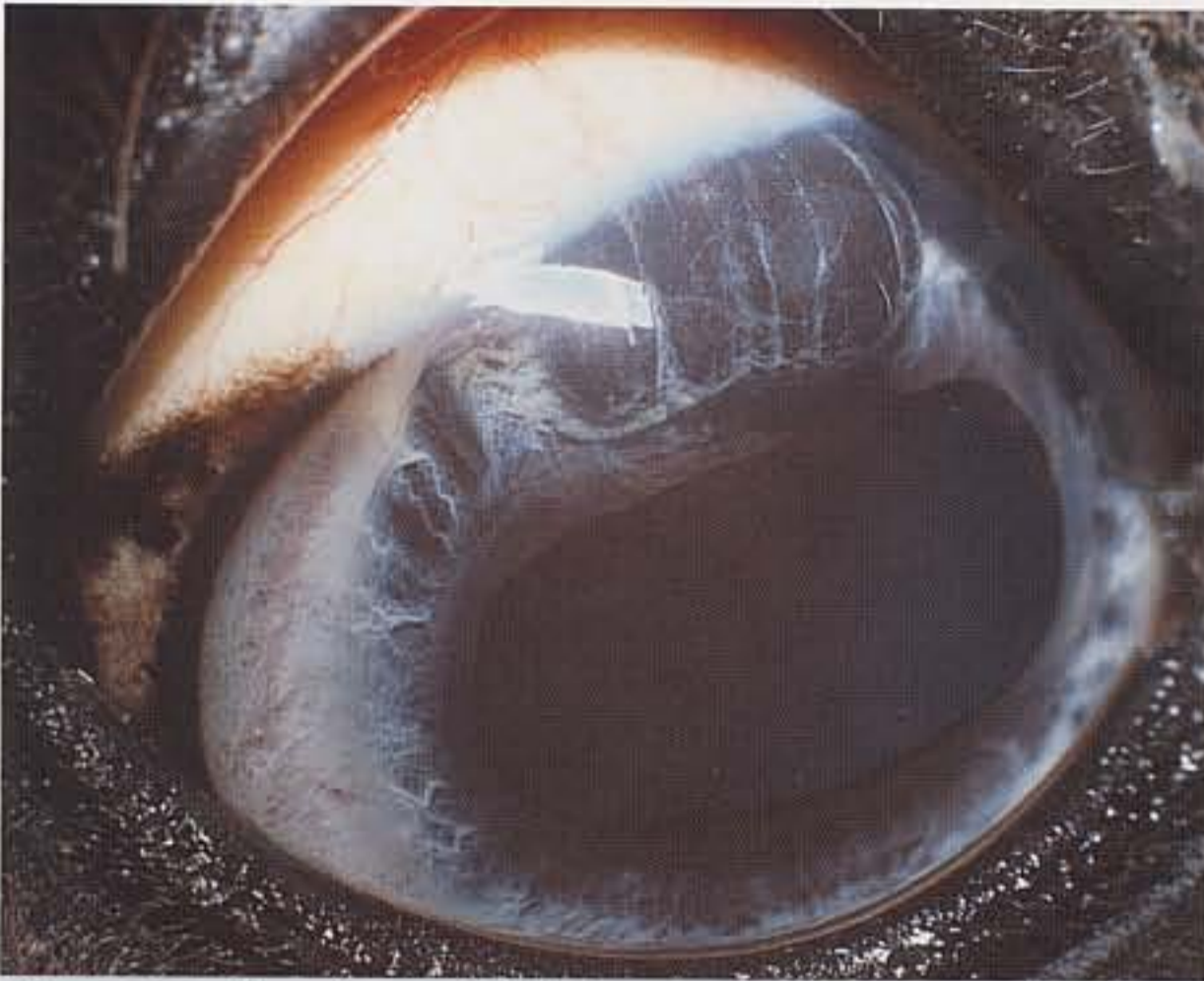


Fig. 7.38 Uveal cyst (Welsh pony, 7 years old, grey) Stromal cyst or iris hypoplasia. Typically occurs in the superior mid iris region in a heterochromic iris.

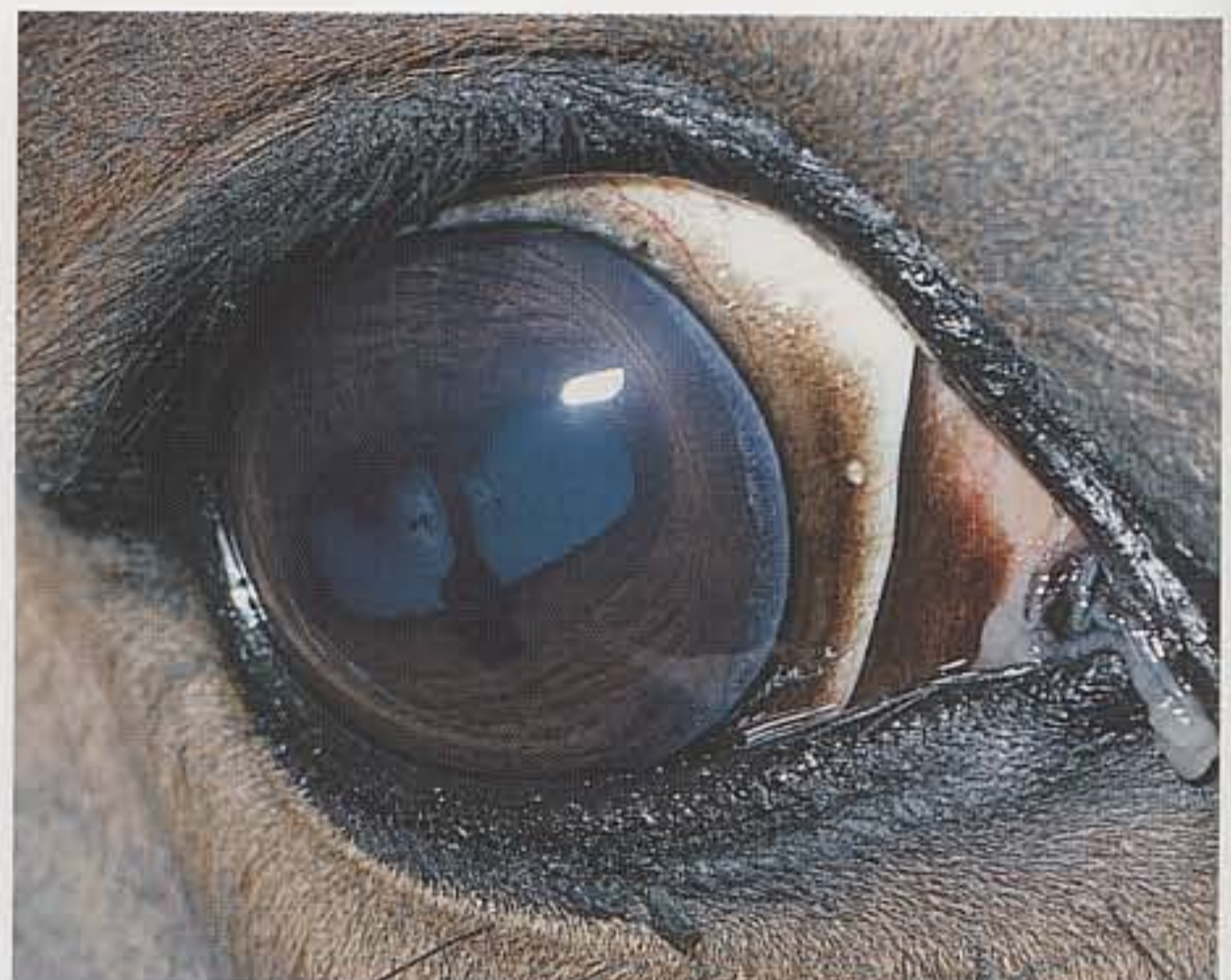

Fig. 7.40 Corpora nigra trauma (Thoroughbred, 4 years old) Whiplash type injury resulting in tearing of the corpora nigra.

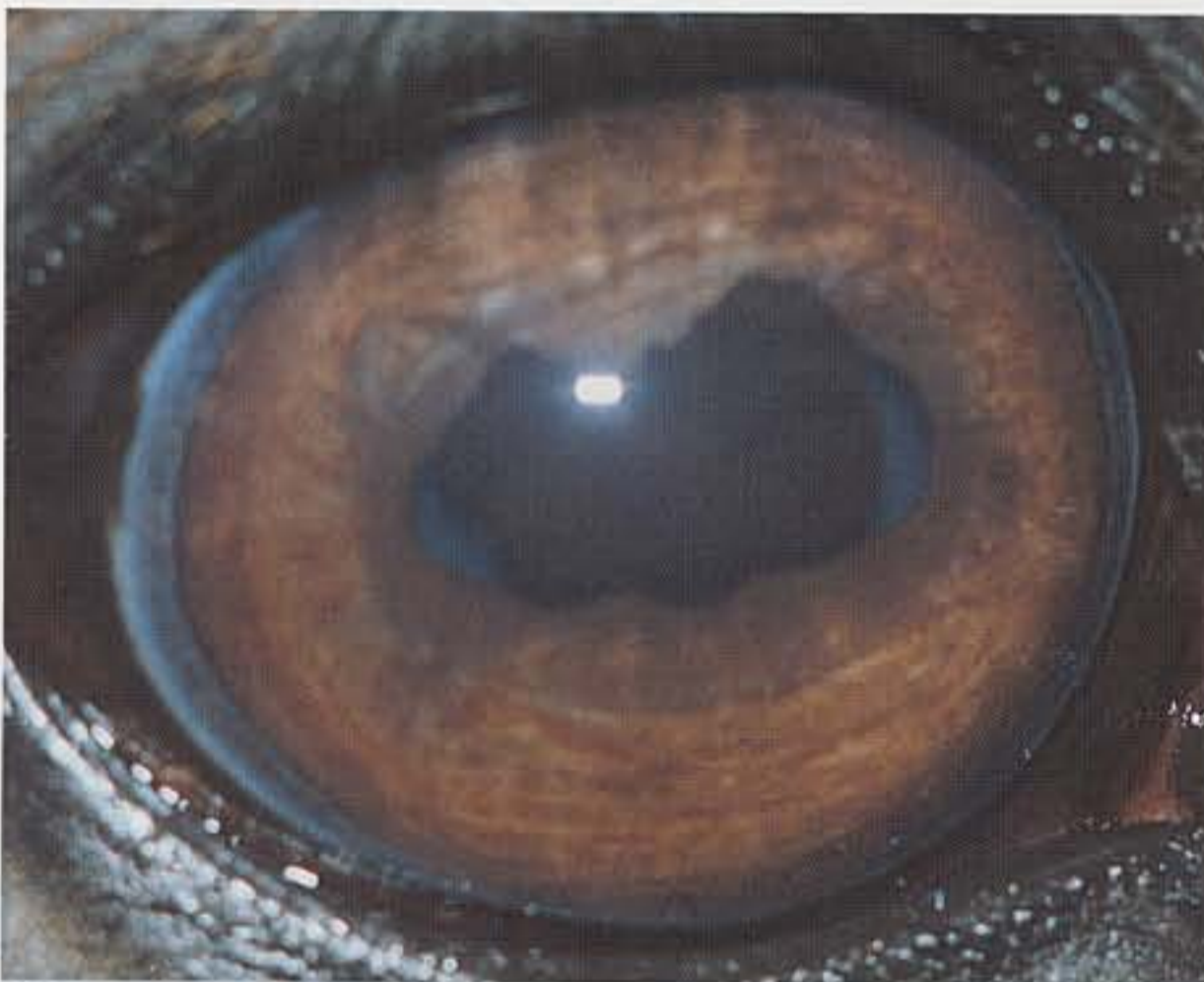

Fig. 7.39 Corpora nigra hyperplasia (Hunter-type, 13 years old) Note the complete obliteration of the centre part of the pupil. The other eye showed no abnormality and there was no further progression.

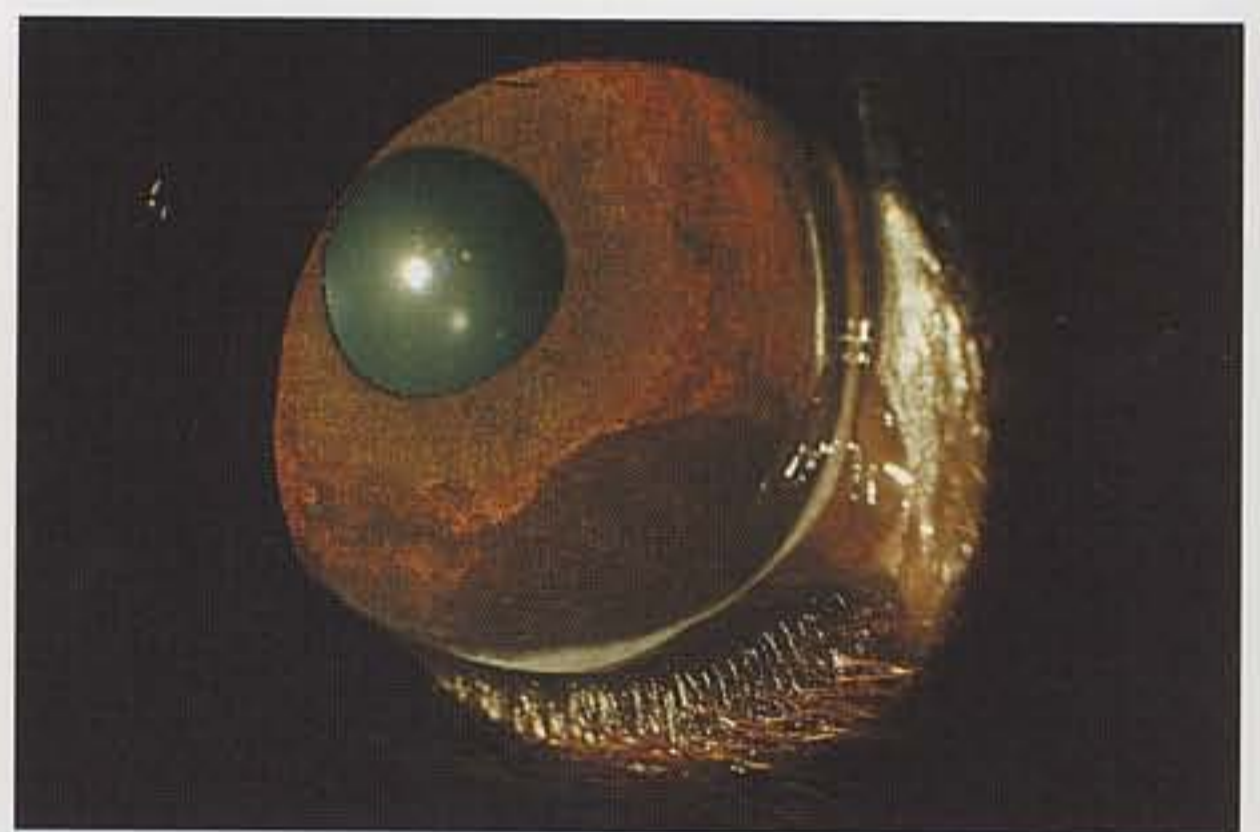


Fig. 7.41 Tumour (English Springer Spaniel) Iris and ciliary body melanoma. Note the early distortion of the pupil and compare with the limbal melanoma (Figs 5.31–5.32).

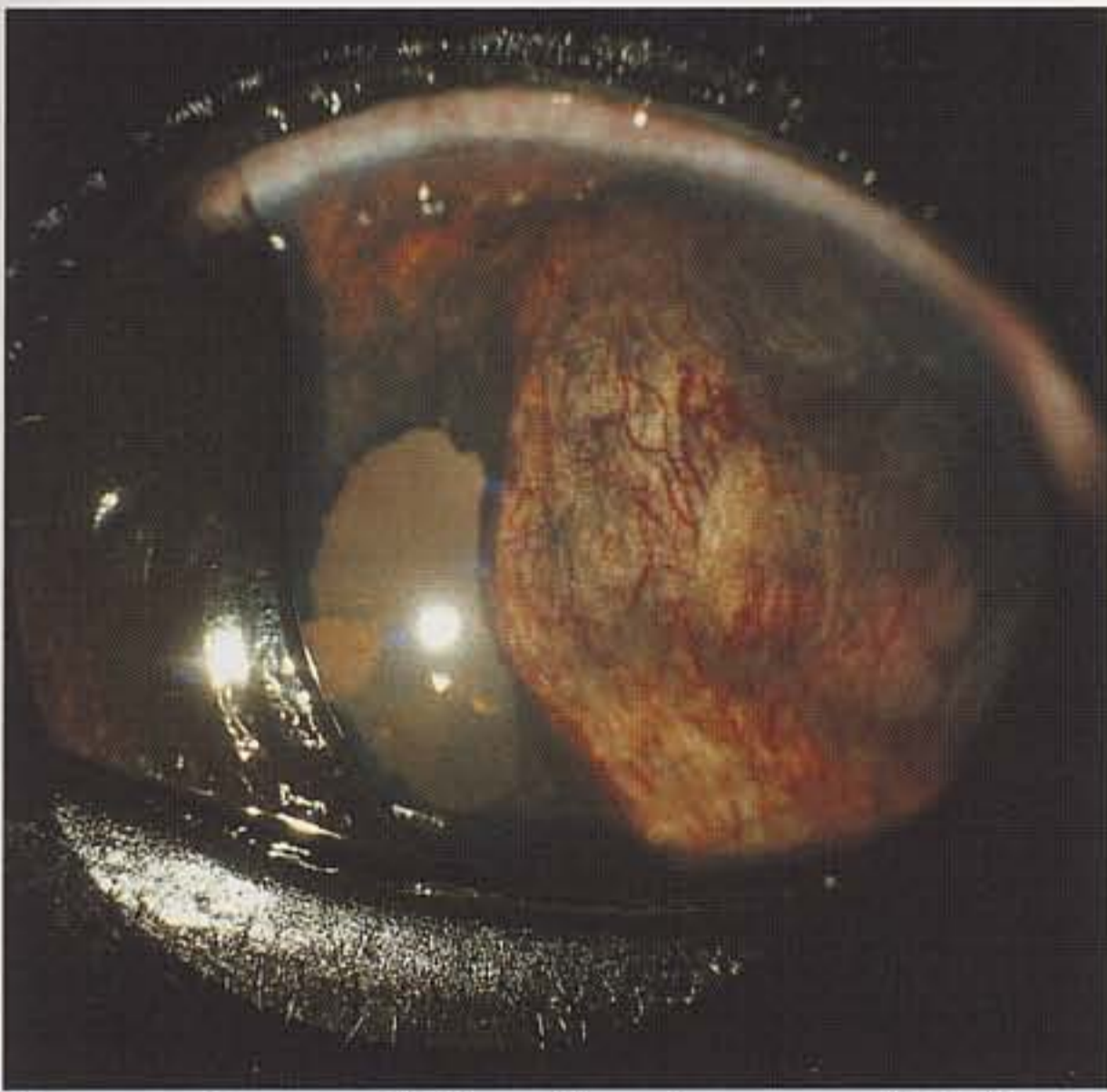

Fig. 7.42 Tumour (Afghan Hound, 7 years old) Ciliary body melanoma. Note the large swelling with gross distortion of the pupil.

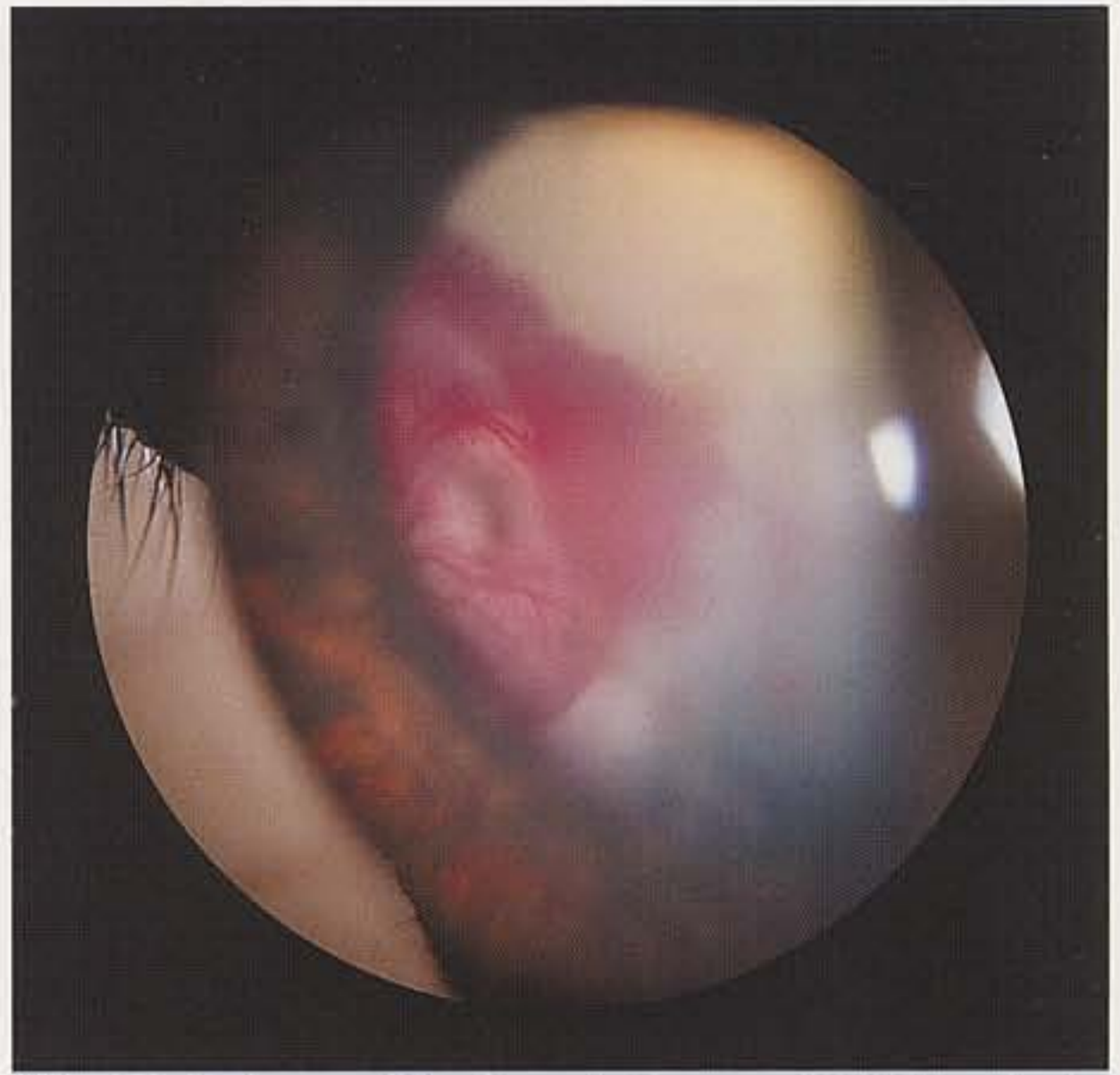

Fig. 7.44 Tumour (Greyhound, 7 years old) Ciliary body adenocarcinoma. Note the appearance of the tumour through the pupil.

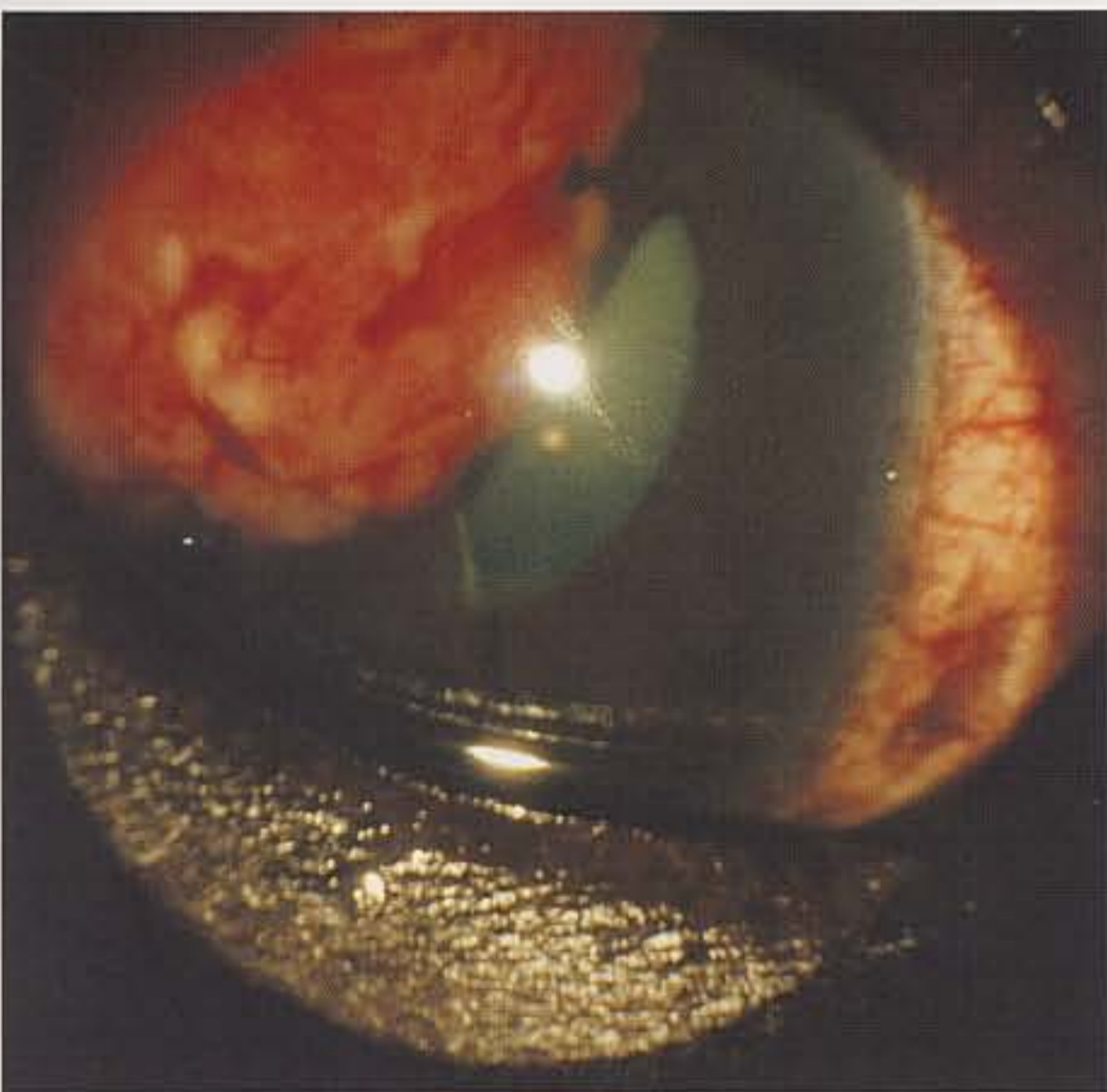


Fig. 7.43 Tumour (Staffordshire Bull Terrier, 6 years old) Ciliary body adenocarcinoma. Note the unpigmented pink mass in the anterior chamber with distortion of the pupil.

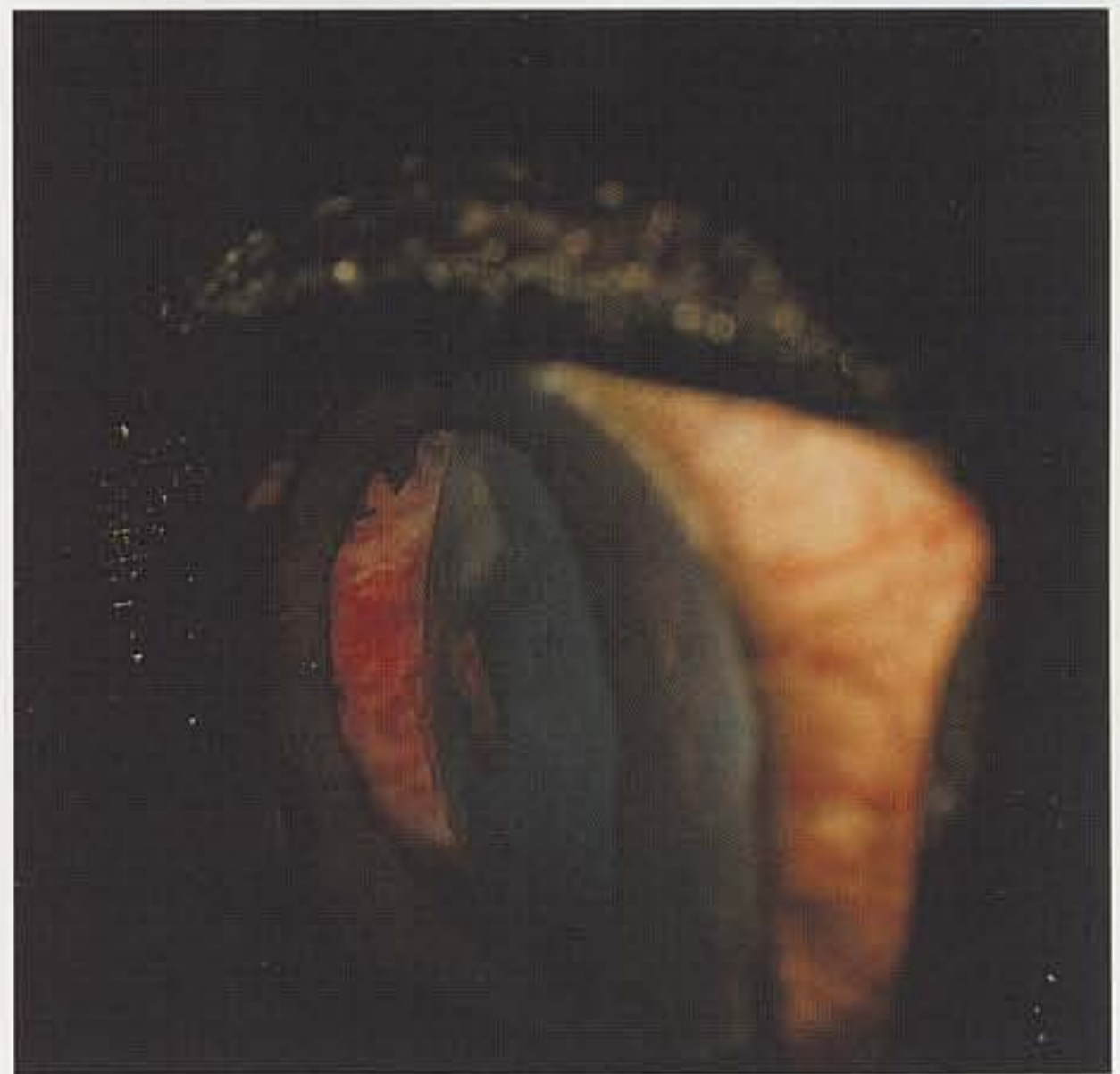


Fig. 7.45 Tumour (Labrador Retriever, 9 years old) Ciliary body adenoma. Note the small haemorrhage on the anterior lens capsule and the appearance of the tumour through the pupil.

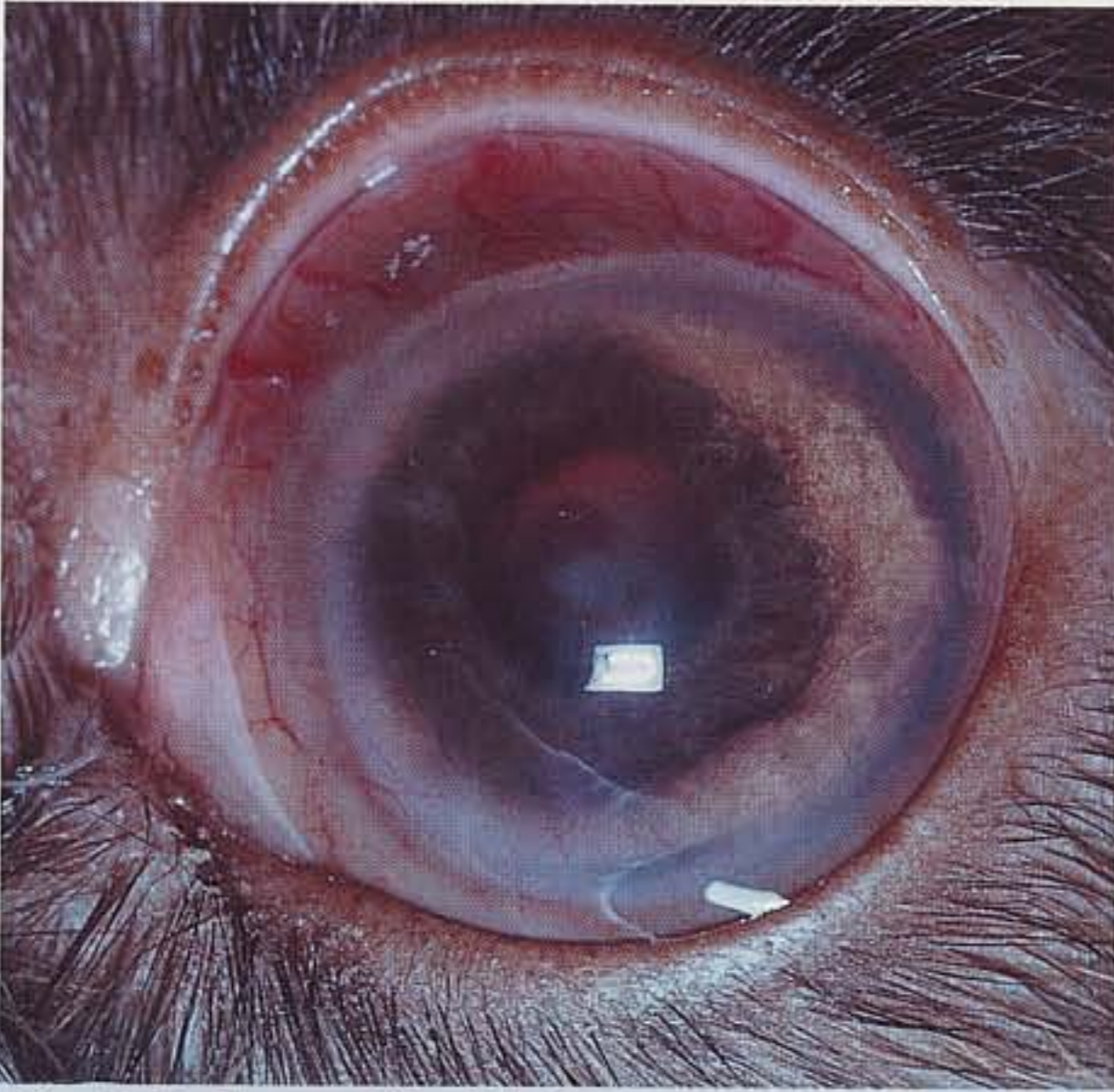

Fig. 7.46 Tumour (English Springer Spaniel, 5 years old) Multicentric lymphosarcoma. Note the secondary glaucoma due to obliteration of the angle of filtration.

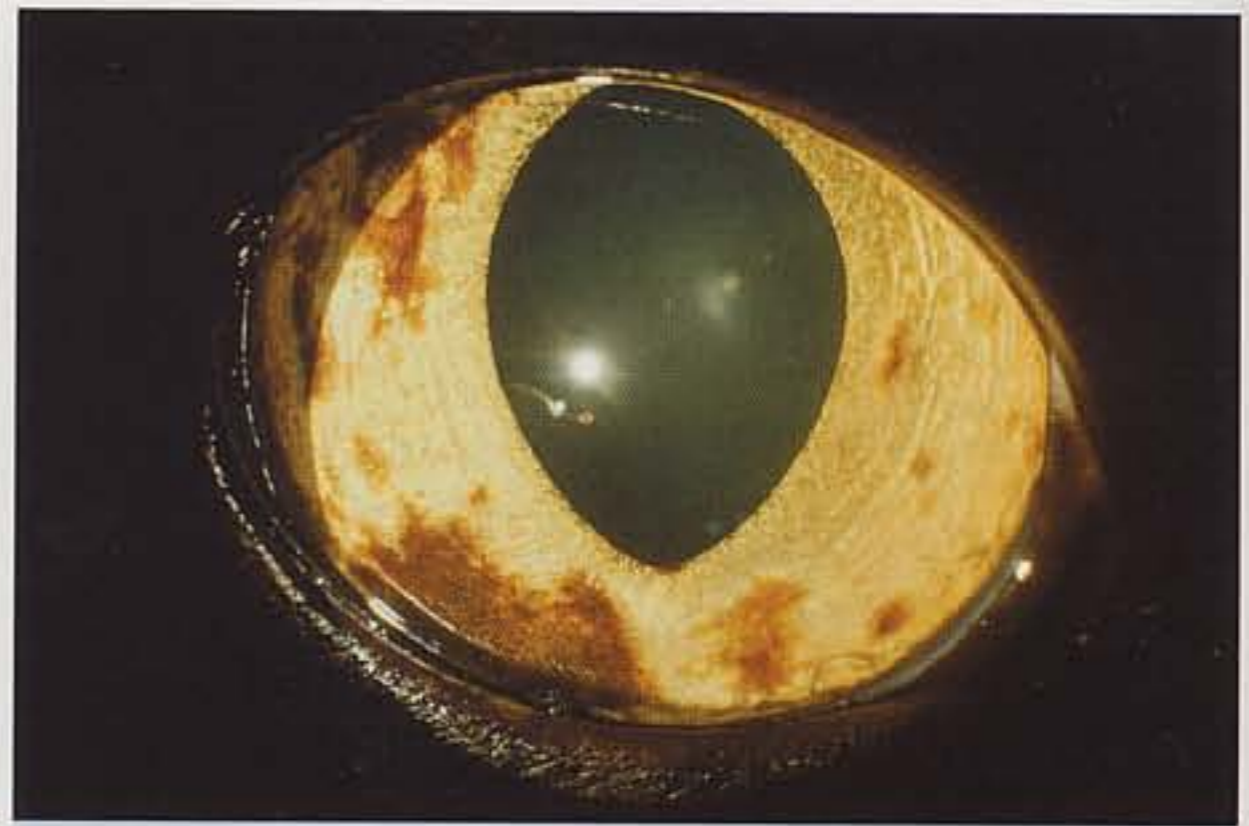

Fig. 7.48 Tumour (DSH cat, 9 years old) Diffuse iris melanoma with pigmentary deposits on the posterior cornea.

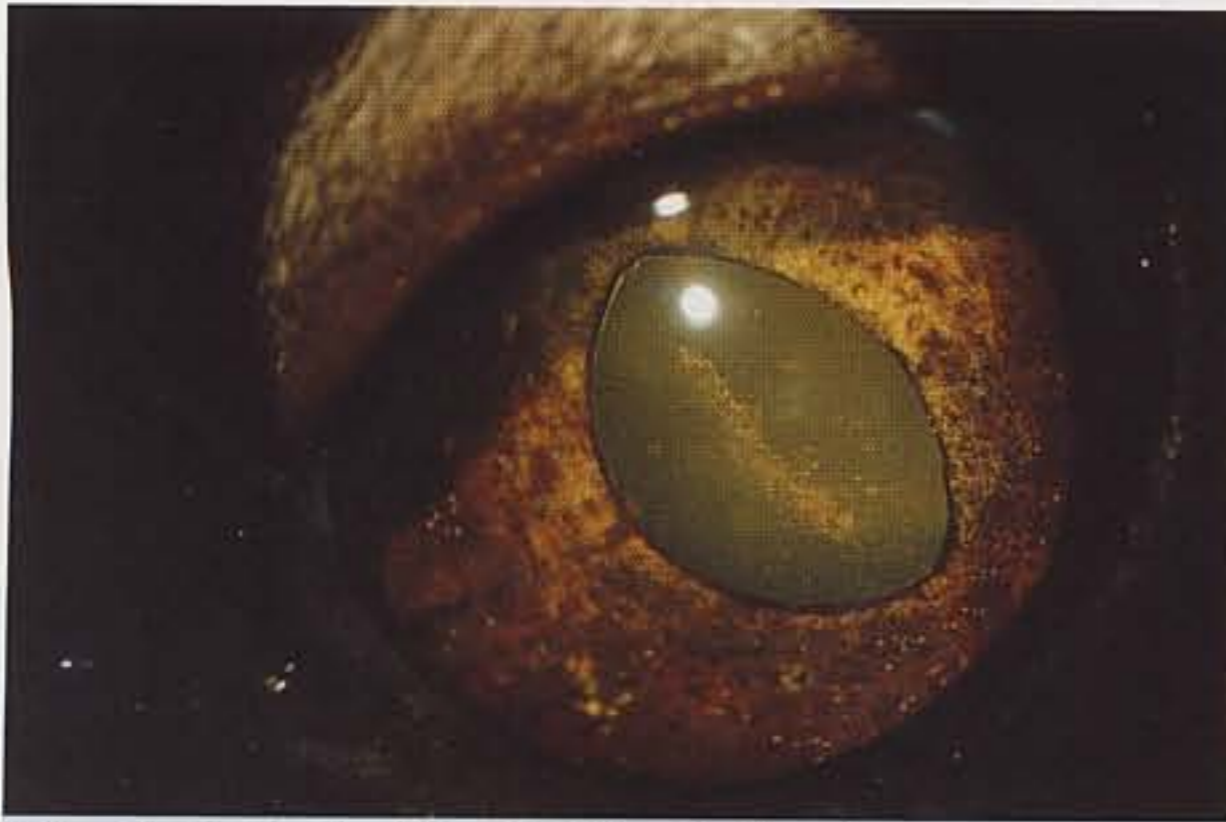

Fig. 7.47 Iris freckles (DSH cat) Flat pigmentary change of the anterior iris surface with no distortion of the pupil.

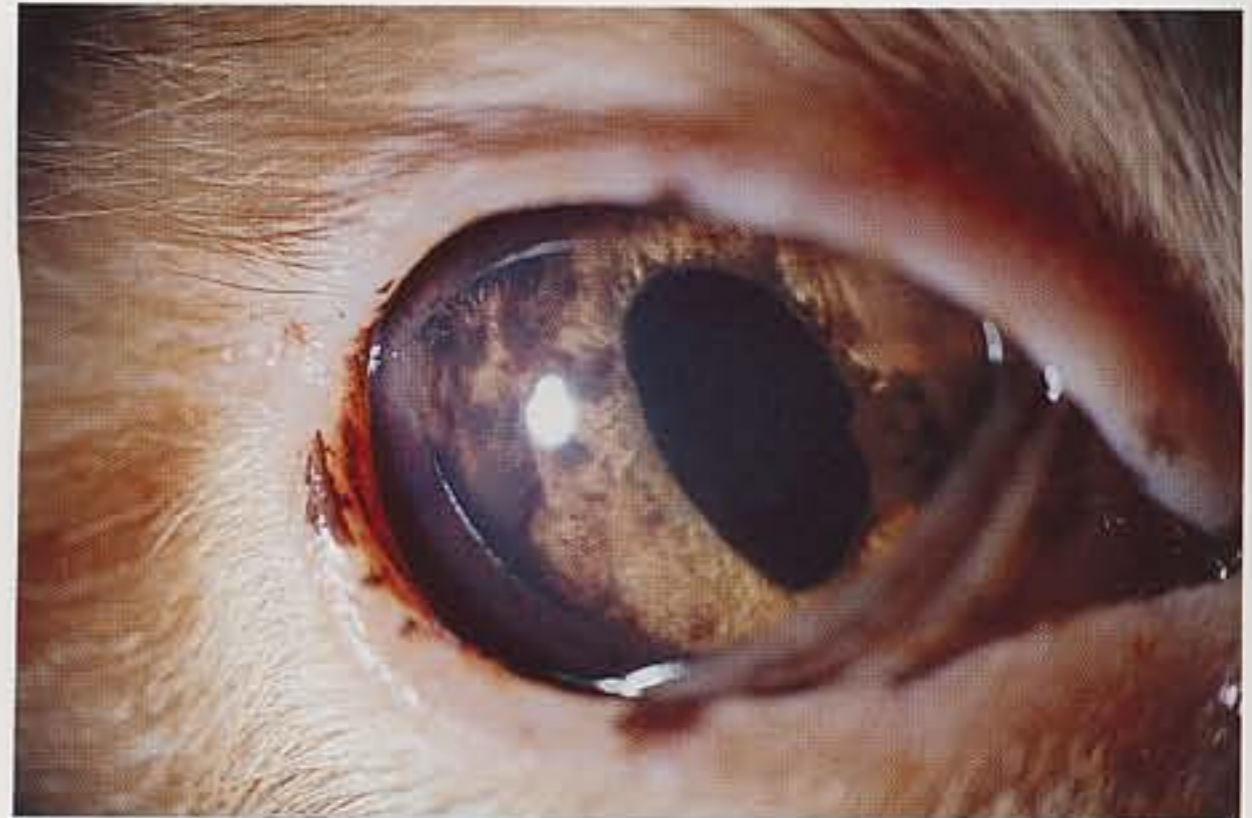

Fig. 7.49 Tumour (DSH cat) Iris melanoma. Note the raised areas of iris and pupil distortion.

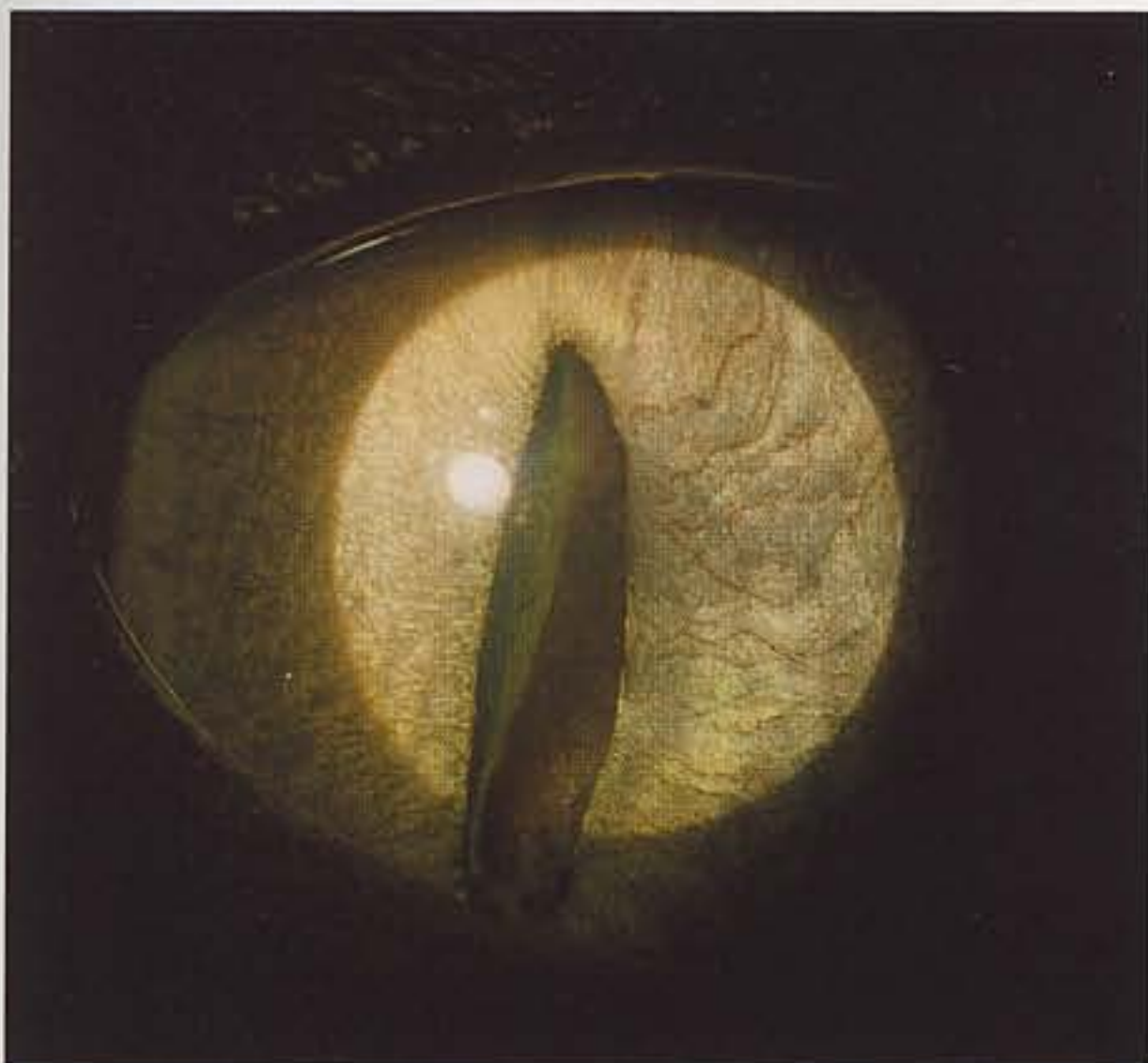

Fig. 7.50 Tumour (DSH cat, 7 years old) Iris melanoma. Note the pigmented mass appearing in the pupil and the increased vascularization of the iris on that side.

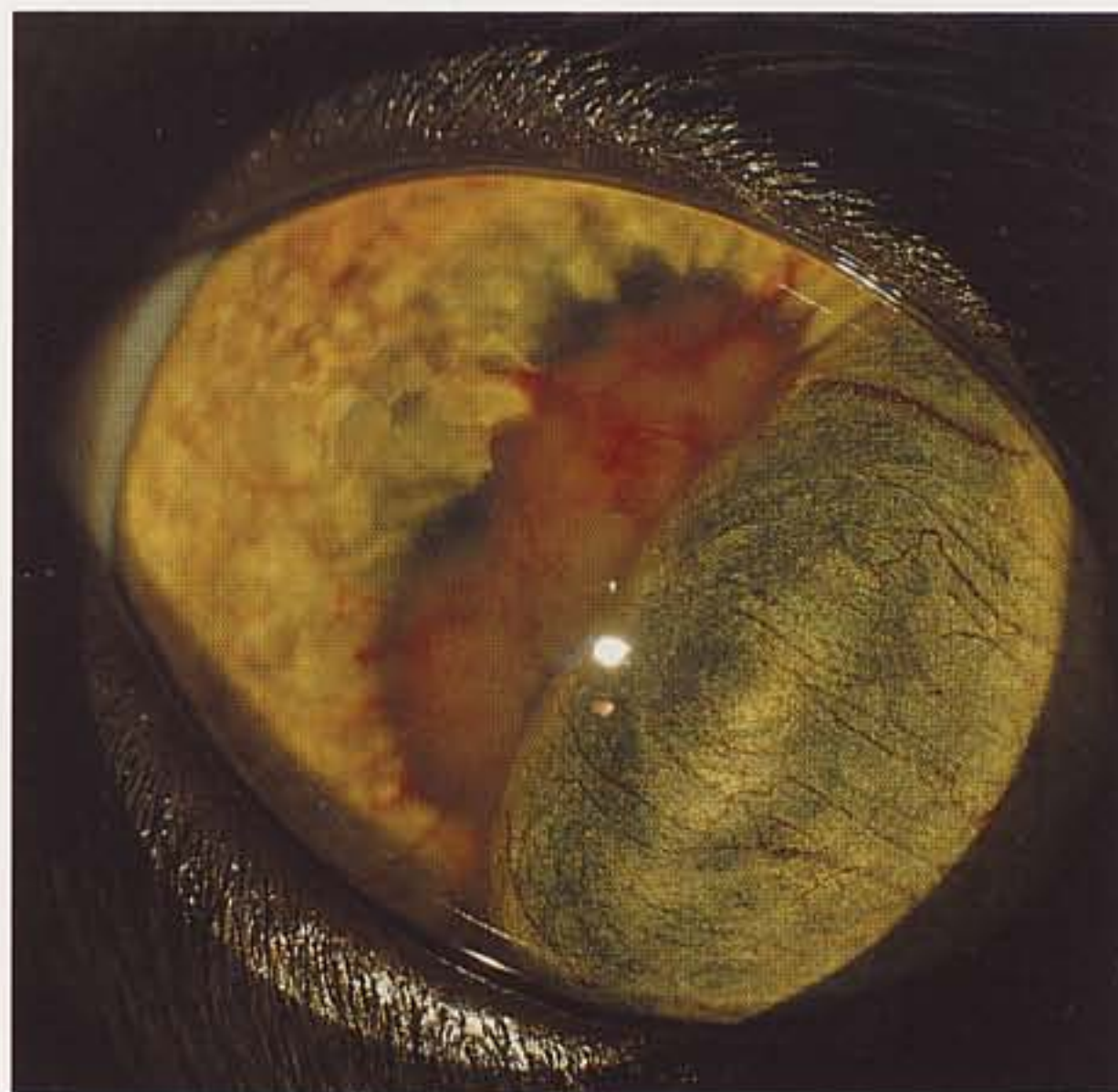

Fig. 7.52 Tumour (DSH cat, 3 years old) Multicentric lymphosarcoma.

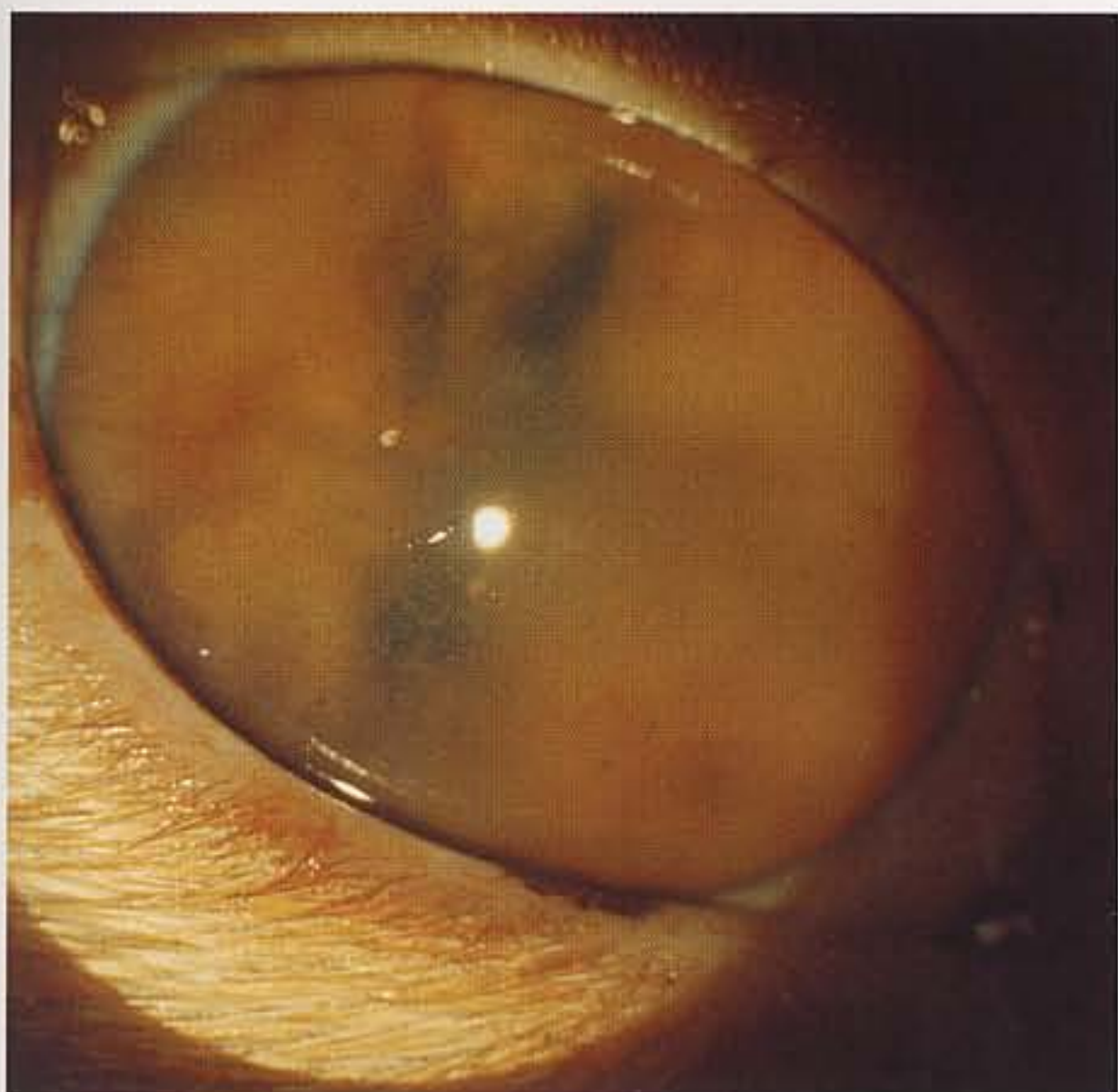


Fig. 7.51 Tumour (DSH cat, 16 years old) Multicentric lymphosarcoma. The kidneys were also involved.

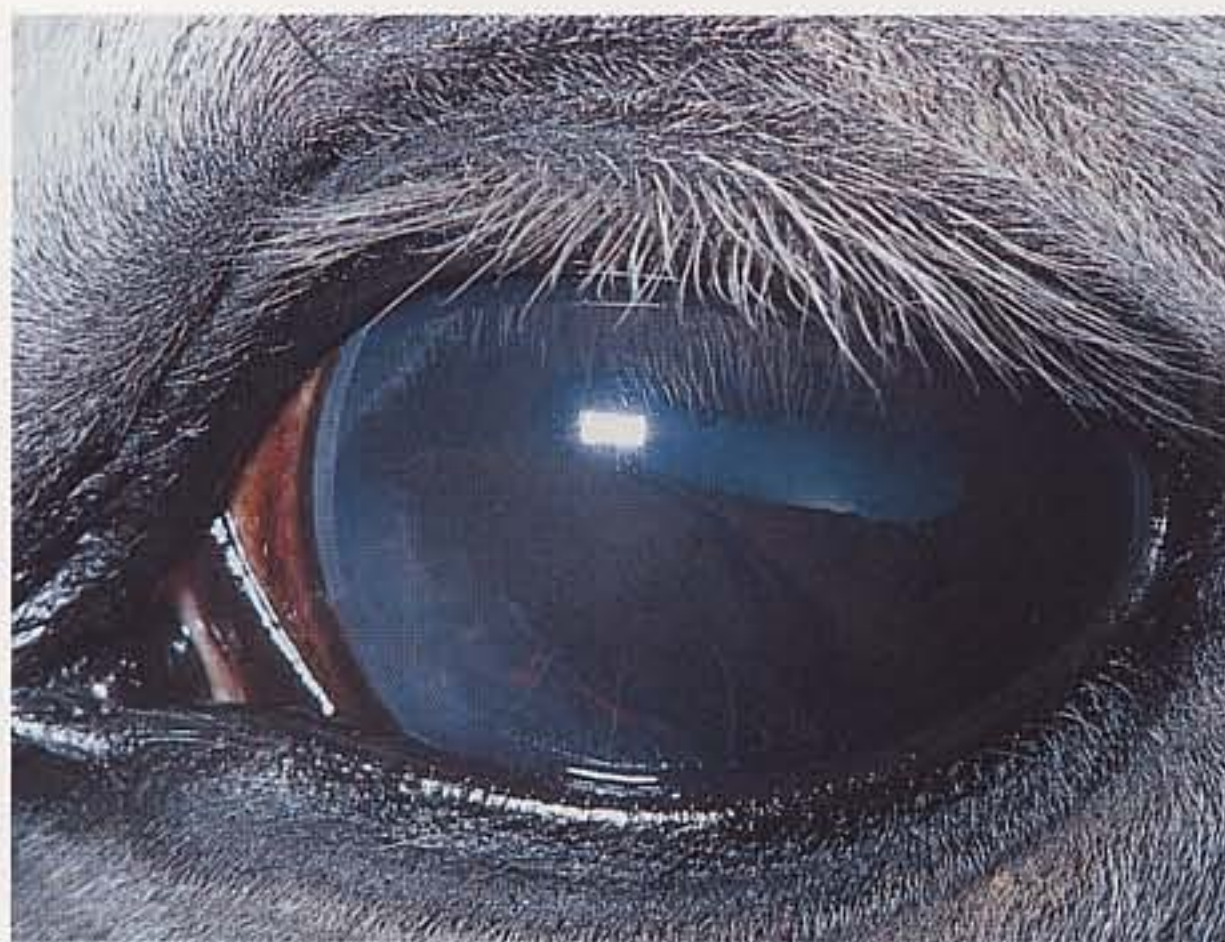

Fig. 7.53 Tumour (Pony, 13 years old, grey) Iris melanoma. The tumour is touching the posterior cornea and producing an area of corneal oedema.



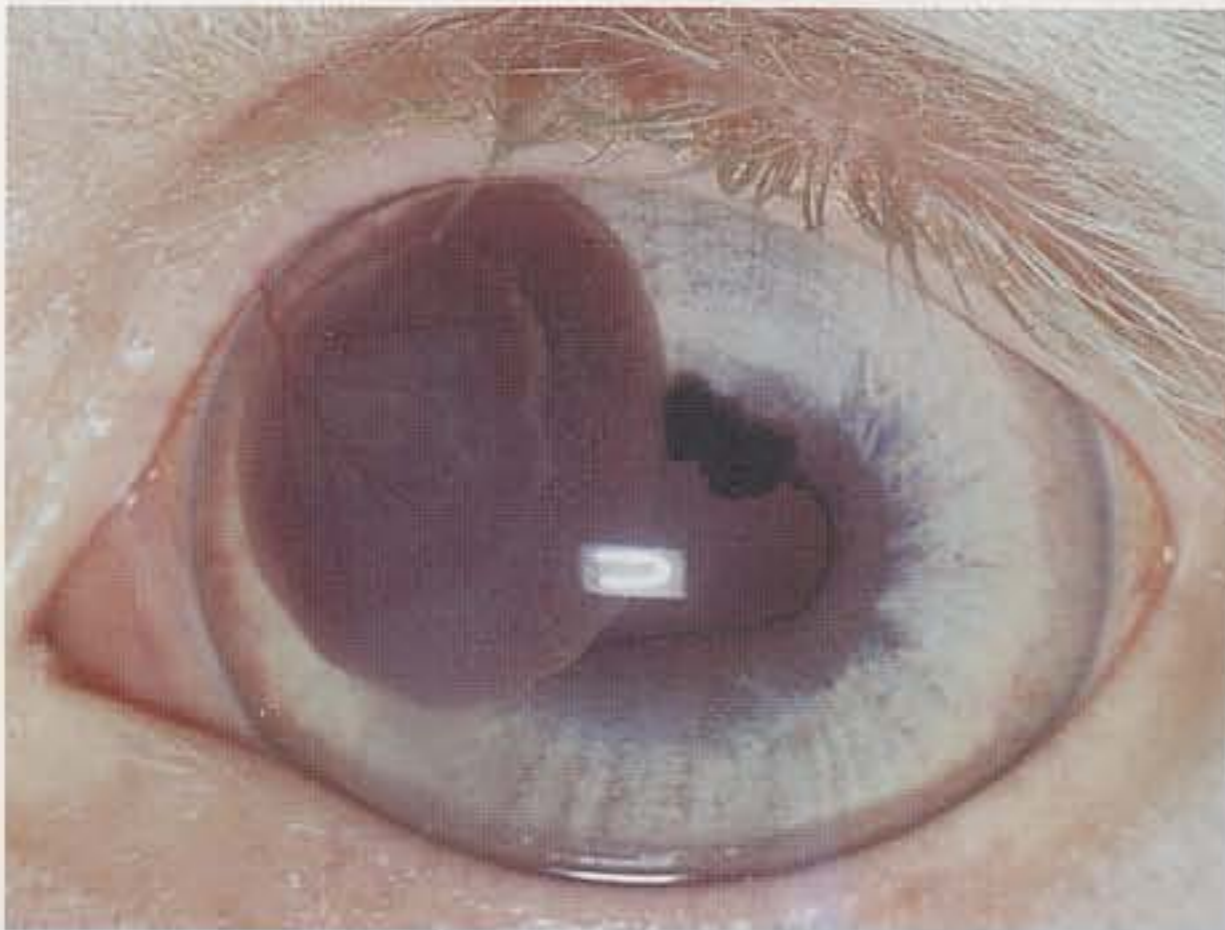

Fig. 7.54 Tumour (Pony, 7 years old, blue-eyed cream)  
Amelanotic melanoma.

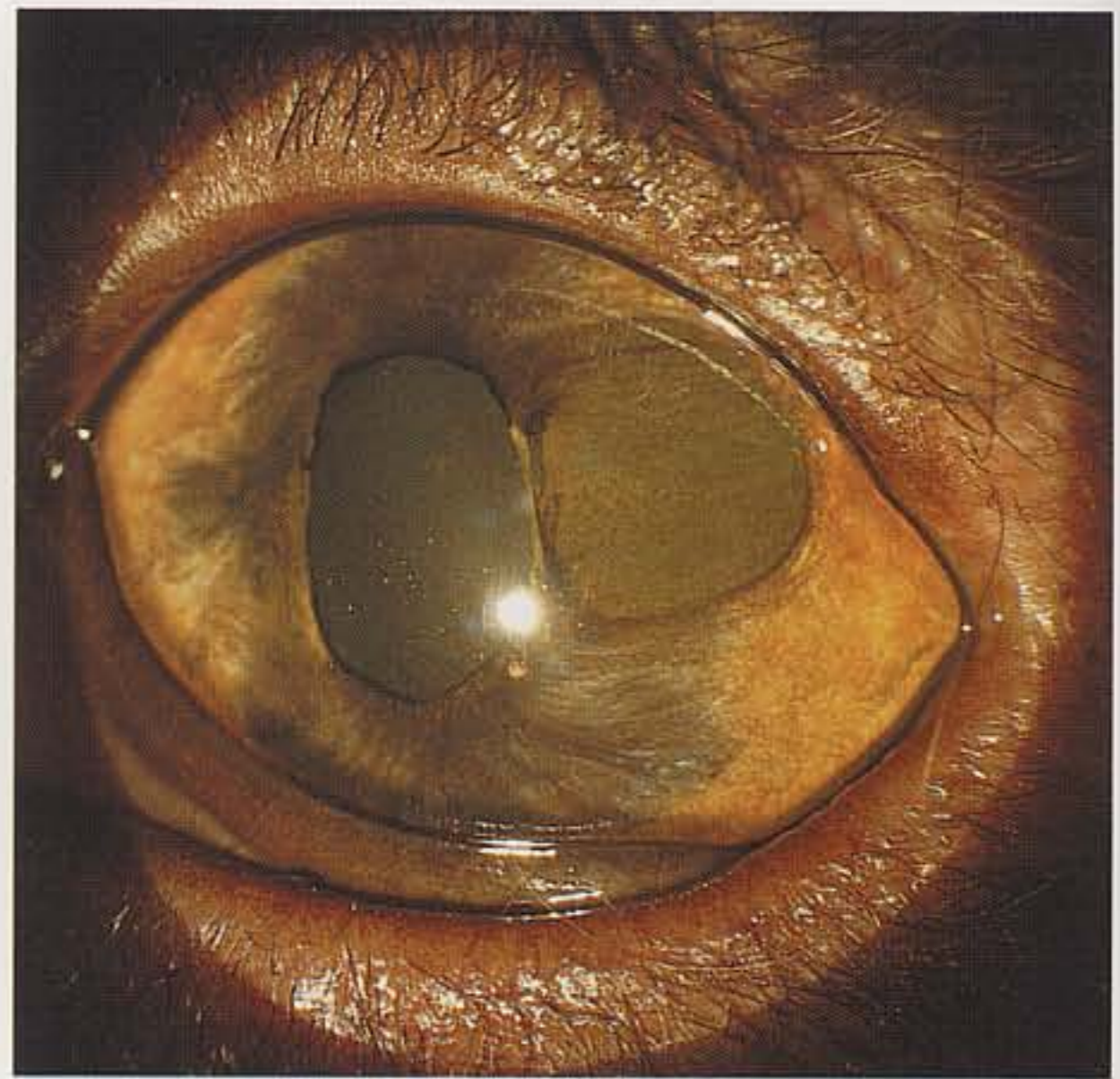


Fig. 7.56 Coloboma (Miniature Poodle, 3 years old)  
Partial thickness iris coloboma at 2 o'clock. Note  
distortion of the pupil shape.

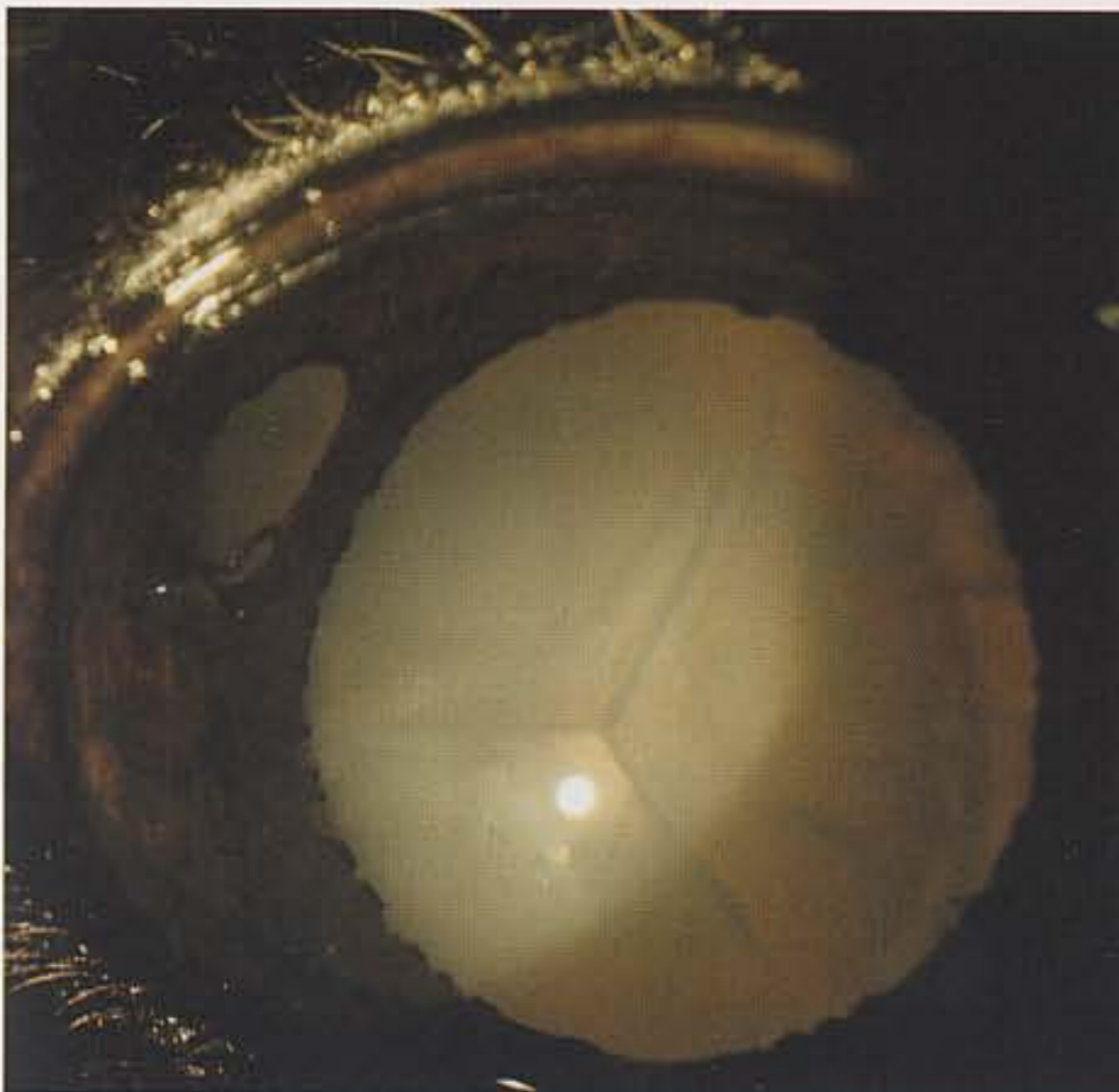


Fig. 7.55 Coloboma (Miniature Poodle, 5 years old)  
Mid-iris full thickness coloboma at 10 o'clock. The  
cataract is unrelated.

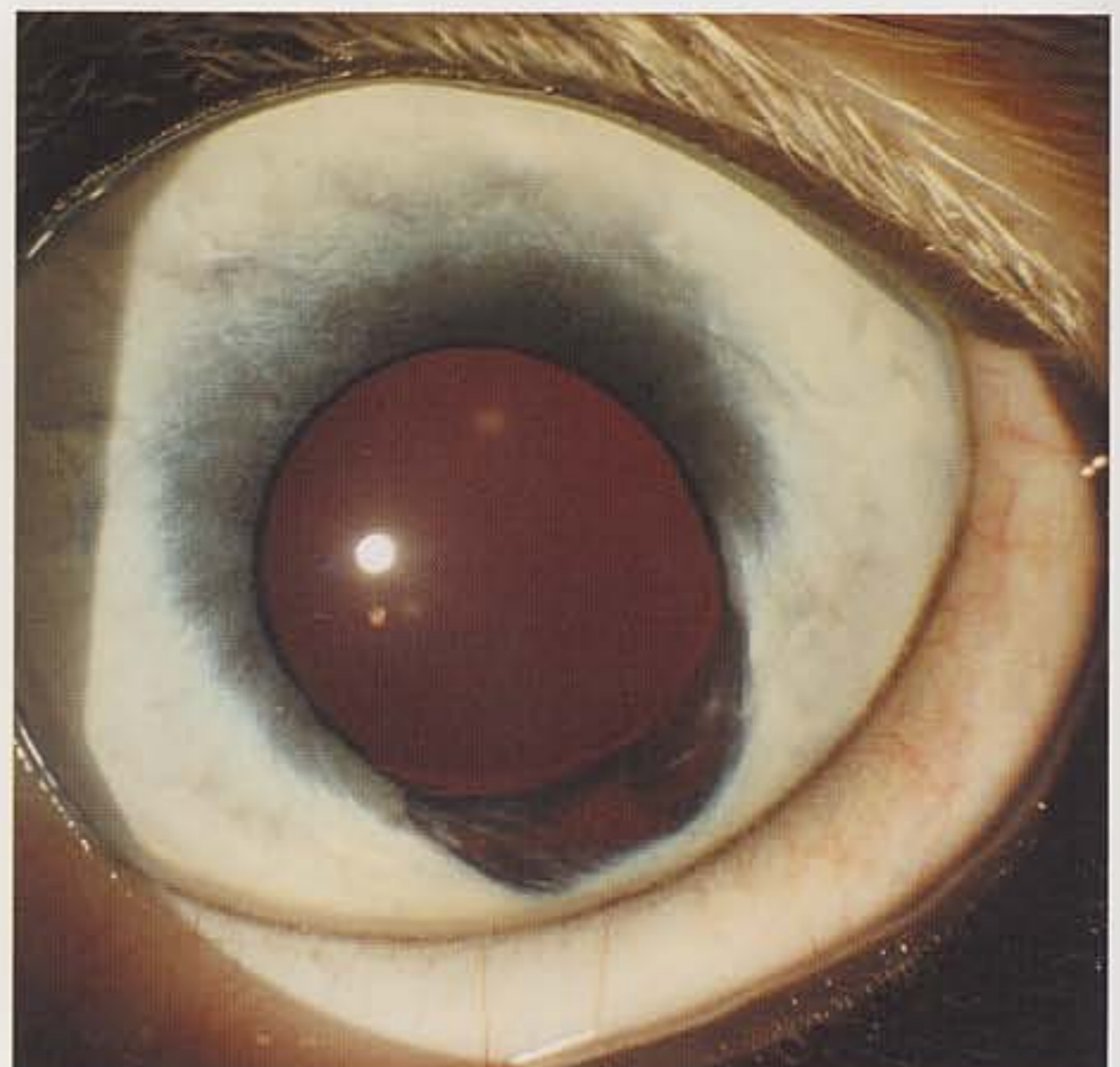


Fig. 7.57 Coloboma (Great Dane, 3 months old, blue  
merle) Partial thickness coloboma at the typical position  
of 6 o'clock in the pale blue iris. Note the red fundus  
reflex.

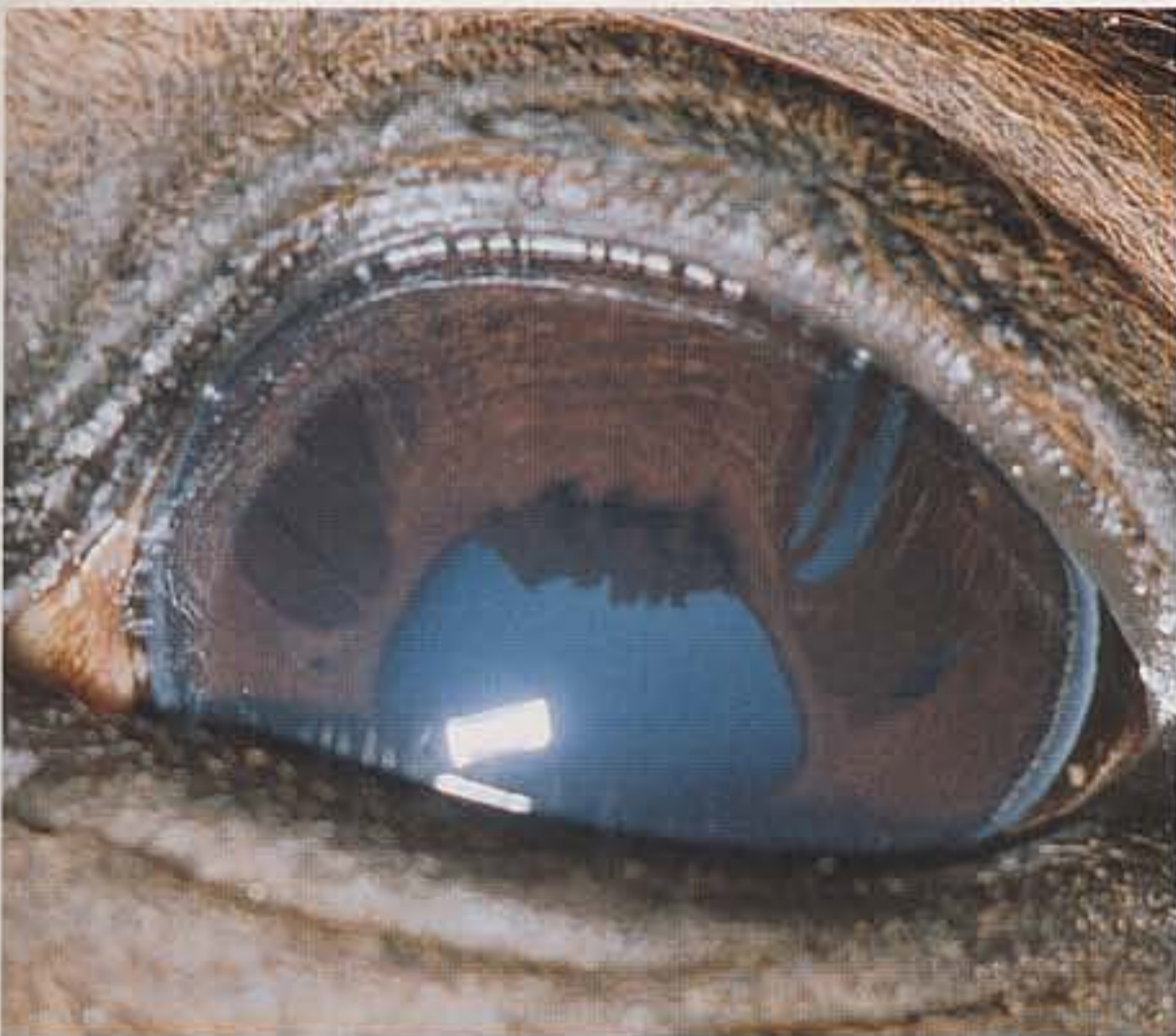

Fig. 7.58 Coloboma (Pony, 5 years old) Complete (1 o'clock) and partial (10 o'clock) colobomas. Both eyes of this animal were affected but asymmetrically.

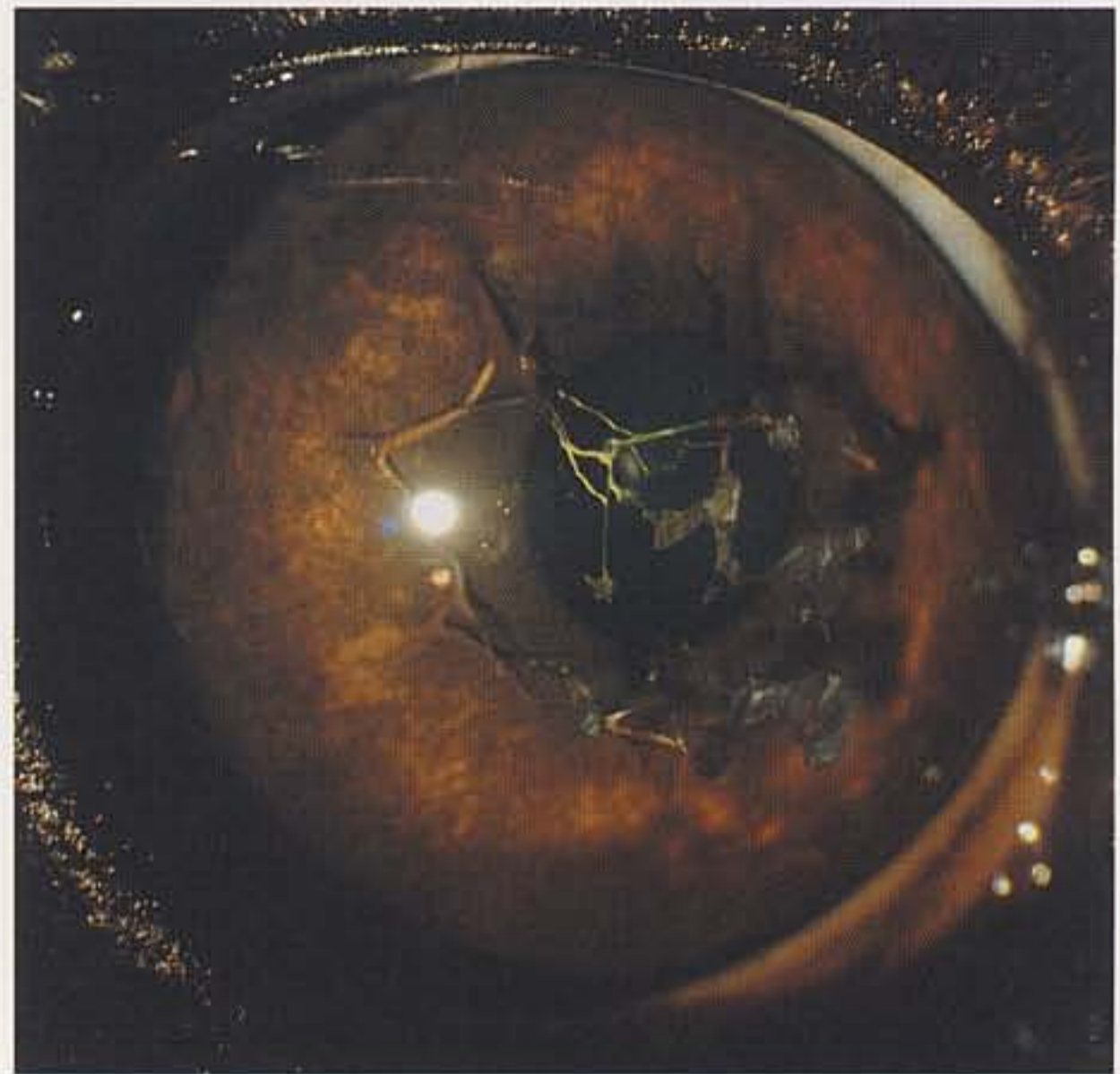


Fig. 7.60 PPM (Labrador Retriever, 6 months old) Multiple PPMs, or congenital anterior synechiae, with focal corneal opacities.

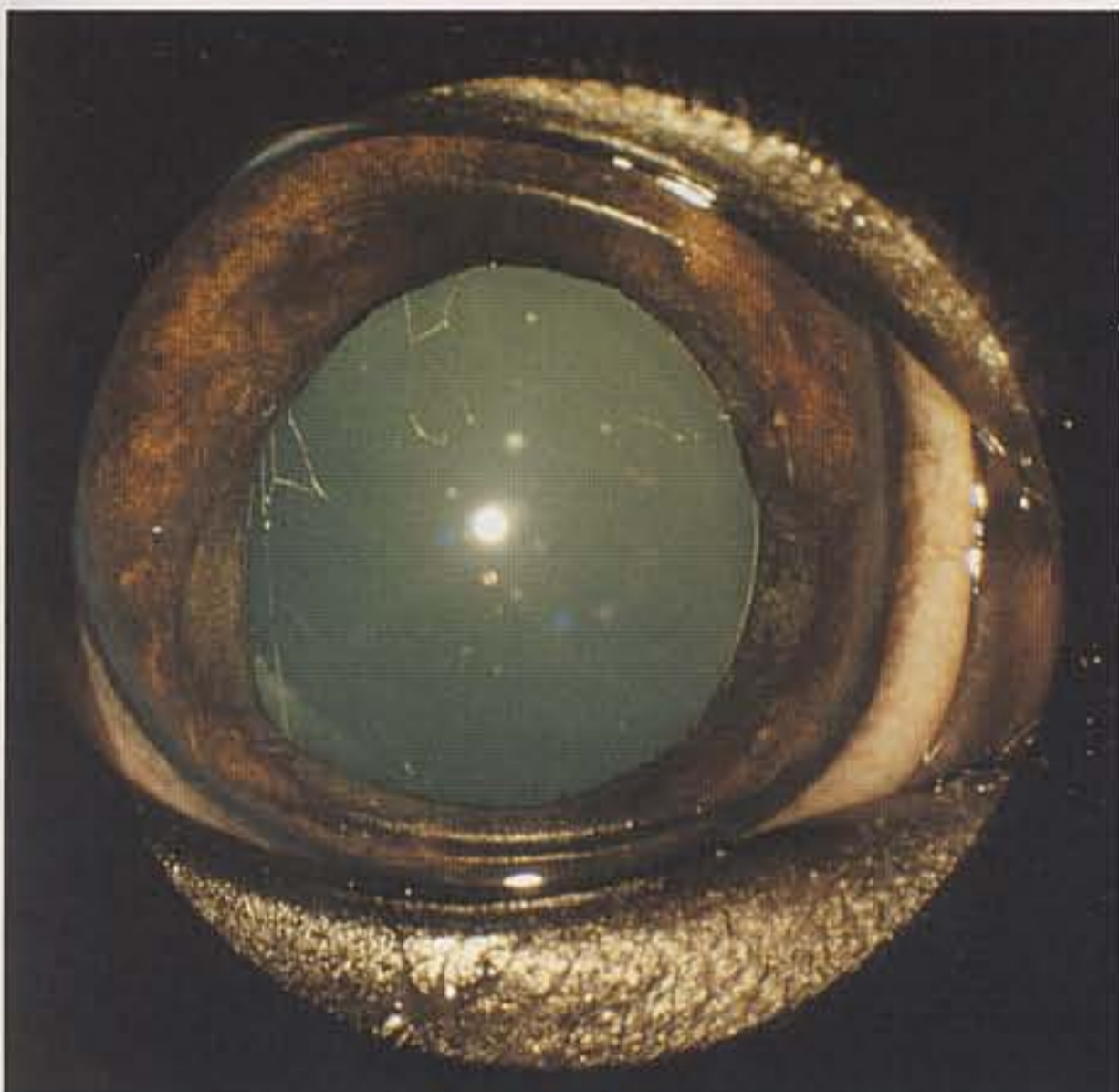

Fig. 7.59 Persistent pupillary membranes (PPM) (Rottweiler, 11 weeks old) Fine PPMs crossing the pupil. Note the irregular pupil due to iris hypoplasia in addition to the pupillary membranes.

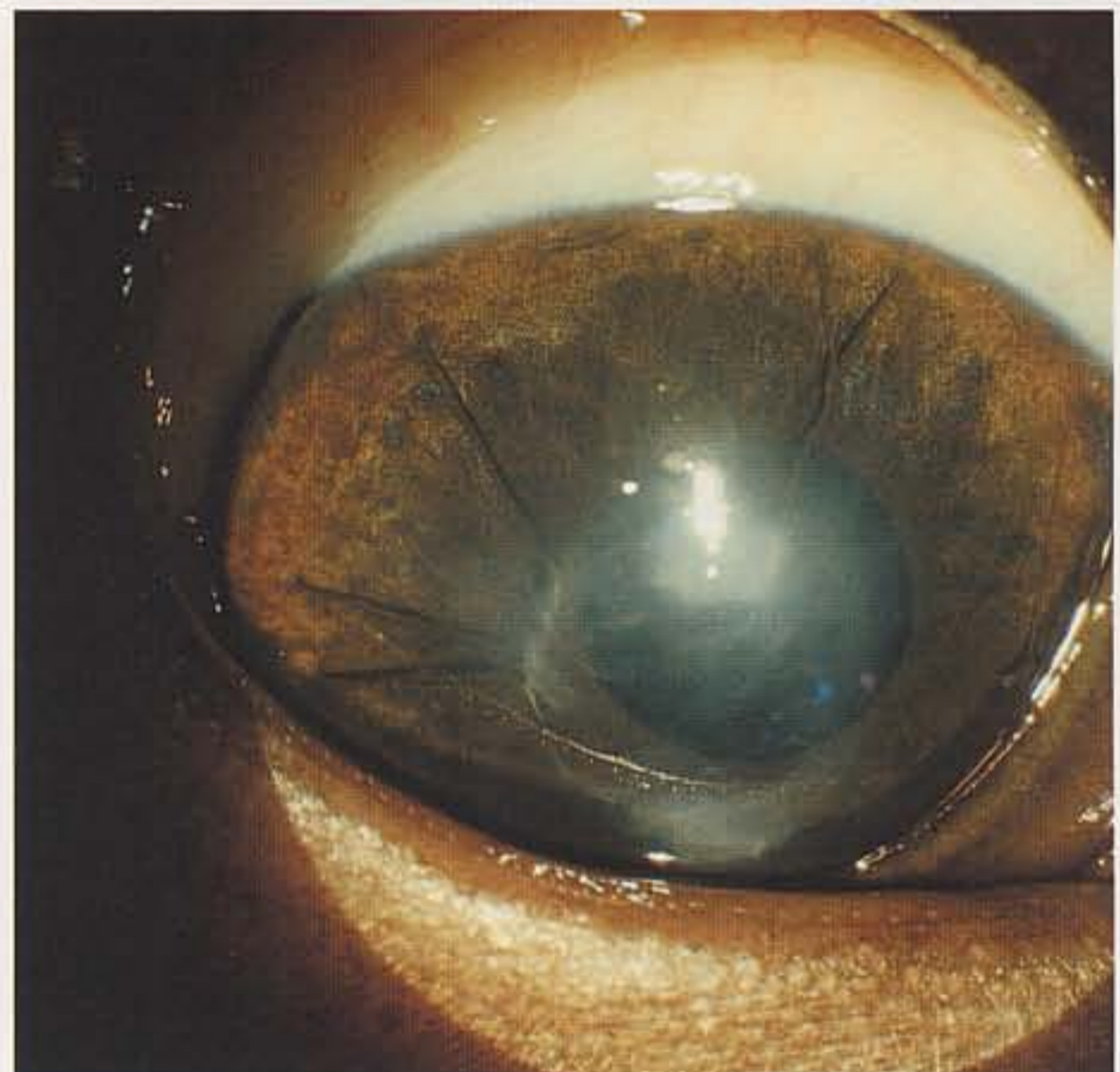


Fig. 7.61 PPM (Beagle, 3 months old) Similar to the previous figures but less severe and with a larger diffuse corneal opacity.

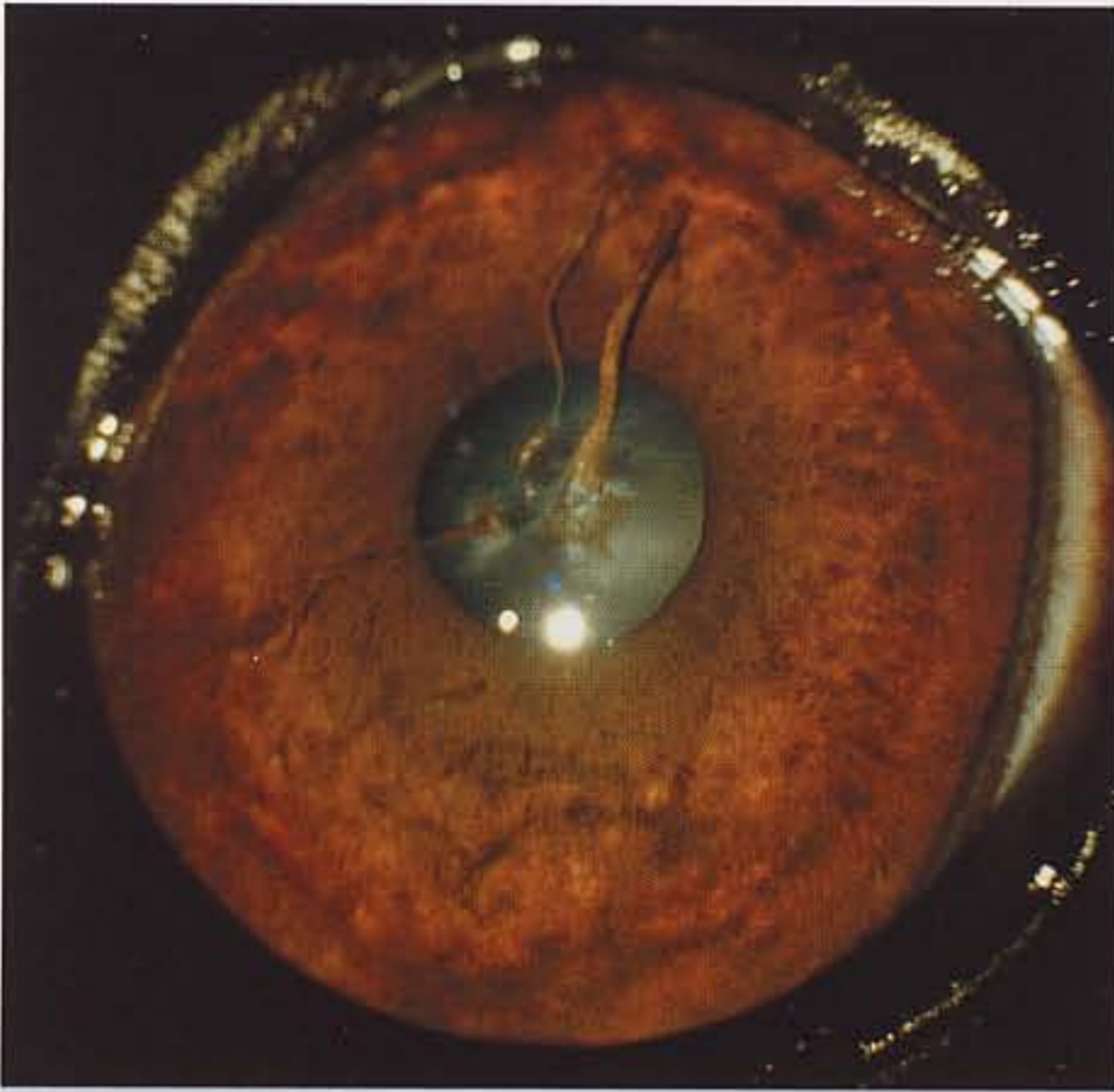


Fig. 7.62 PPM (Cairn Terrier, 6 years old) Pupillary membrane attached to the anterior lens capsule with associated focal cataract.

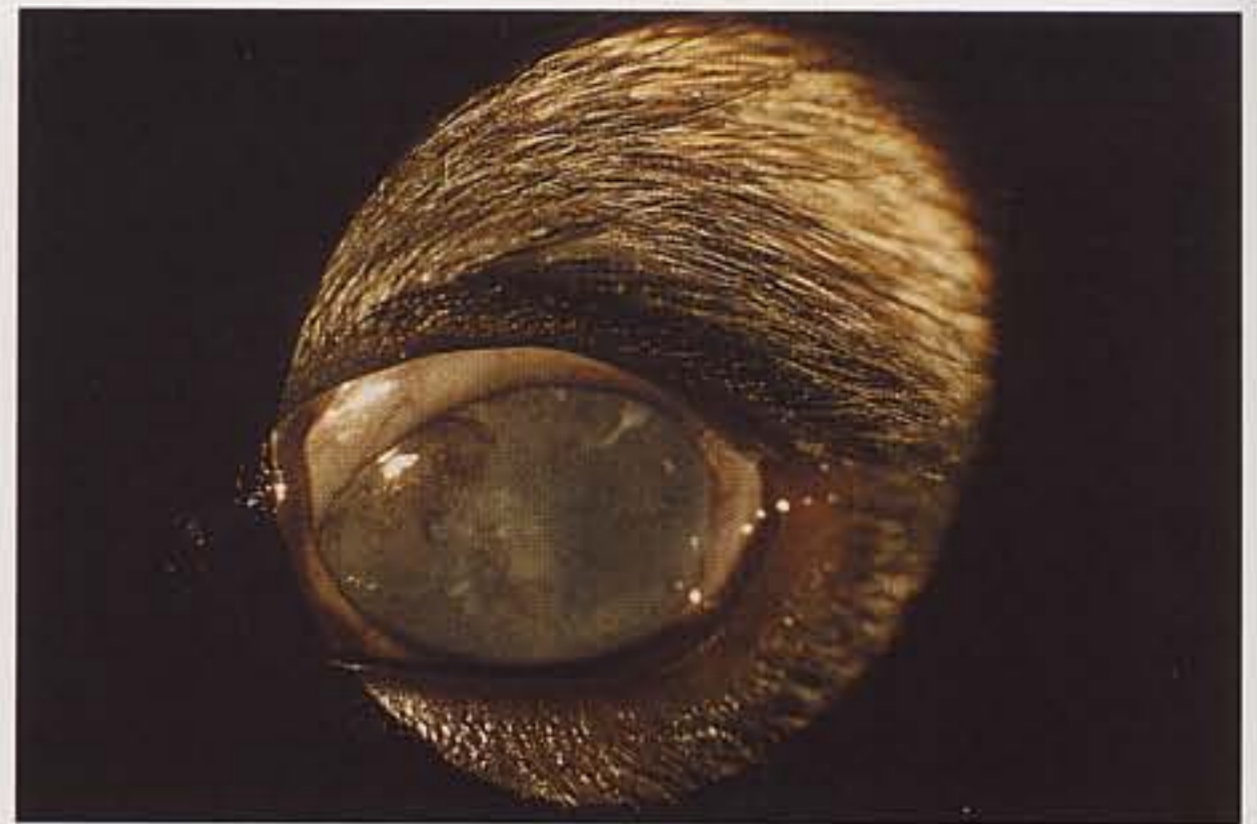

Fig. 7.64 PPM (Bull Mastiff, 5 weeks old) Persistent pupillary membranes together with corneal opacity. PPMs are known to be inherited in this breed, as well as some other breeds including the Basenji.

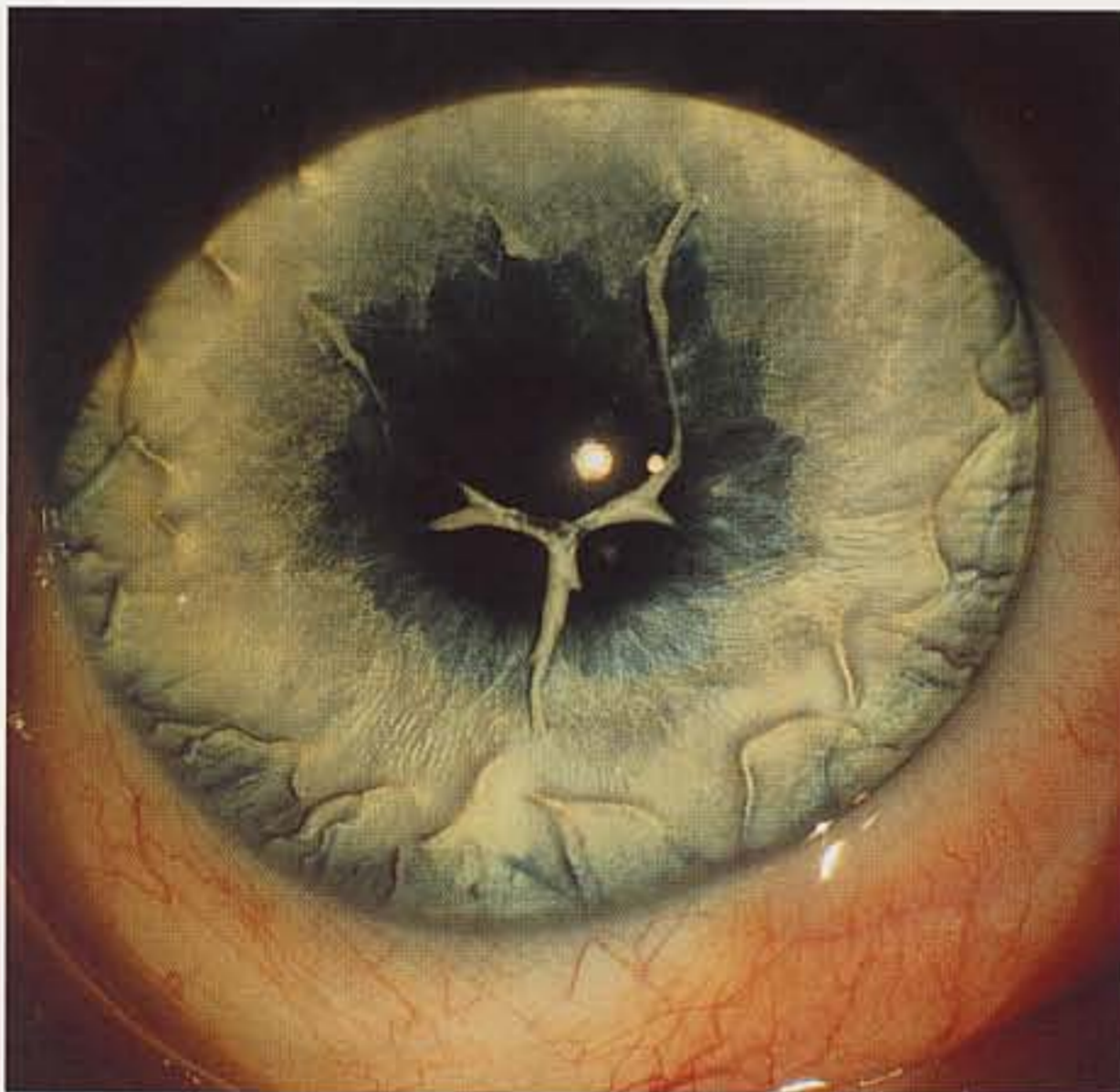


Fig. 7.63 PPM (Old English Sheepdog, 3 months old) Pupillary membranes in a pale blue iris.

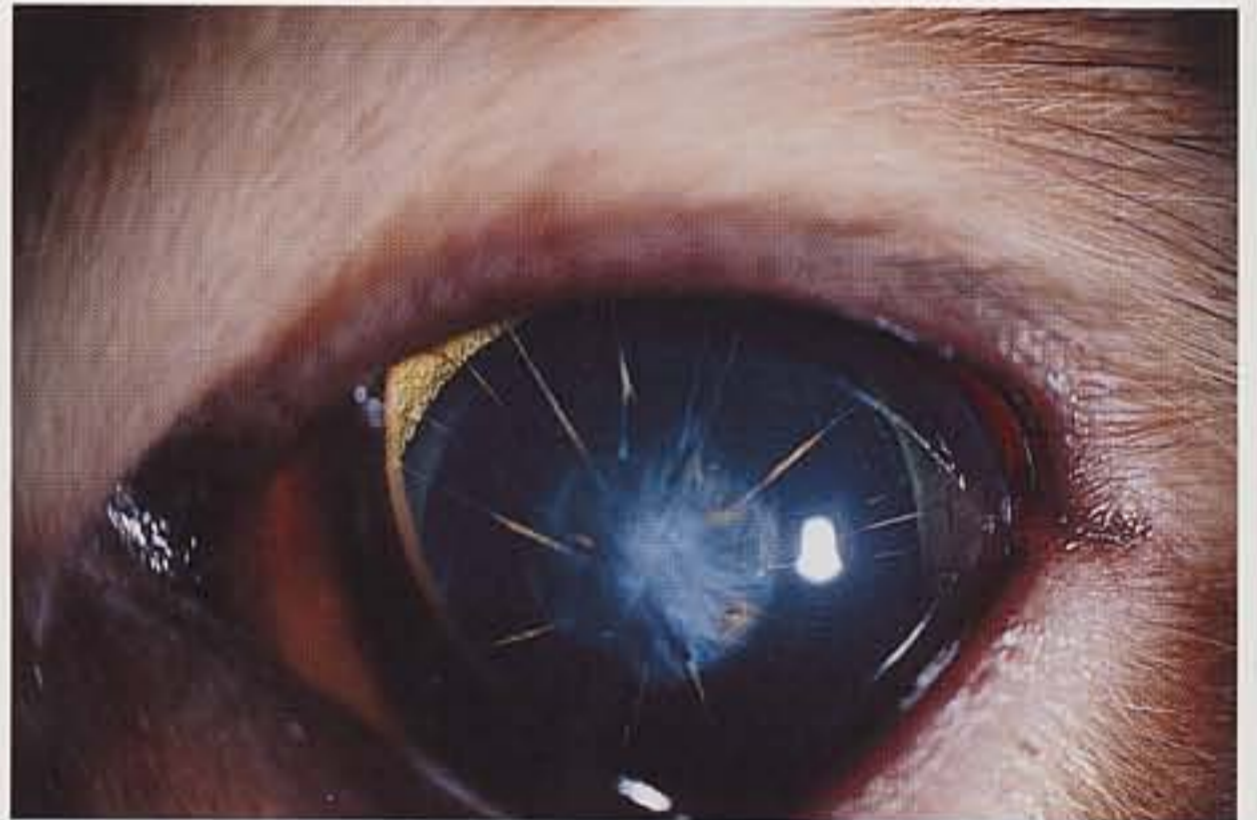

Fig. 7.65 PPM (Bengal cat, 9 months old) PPM and cataract.

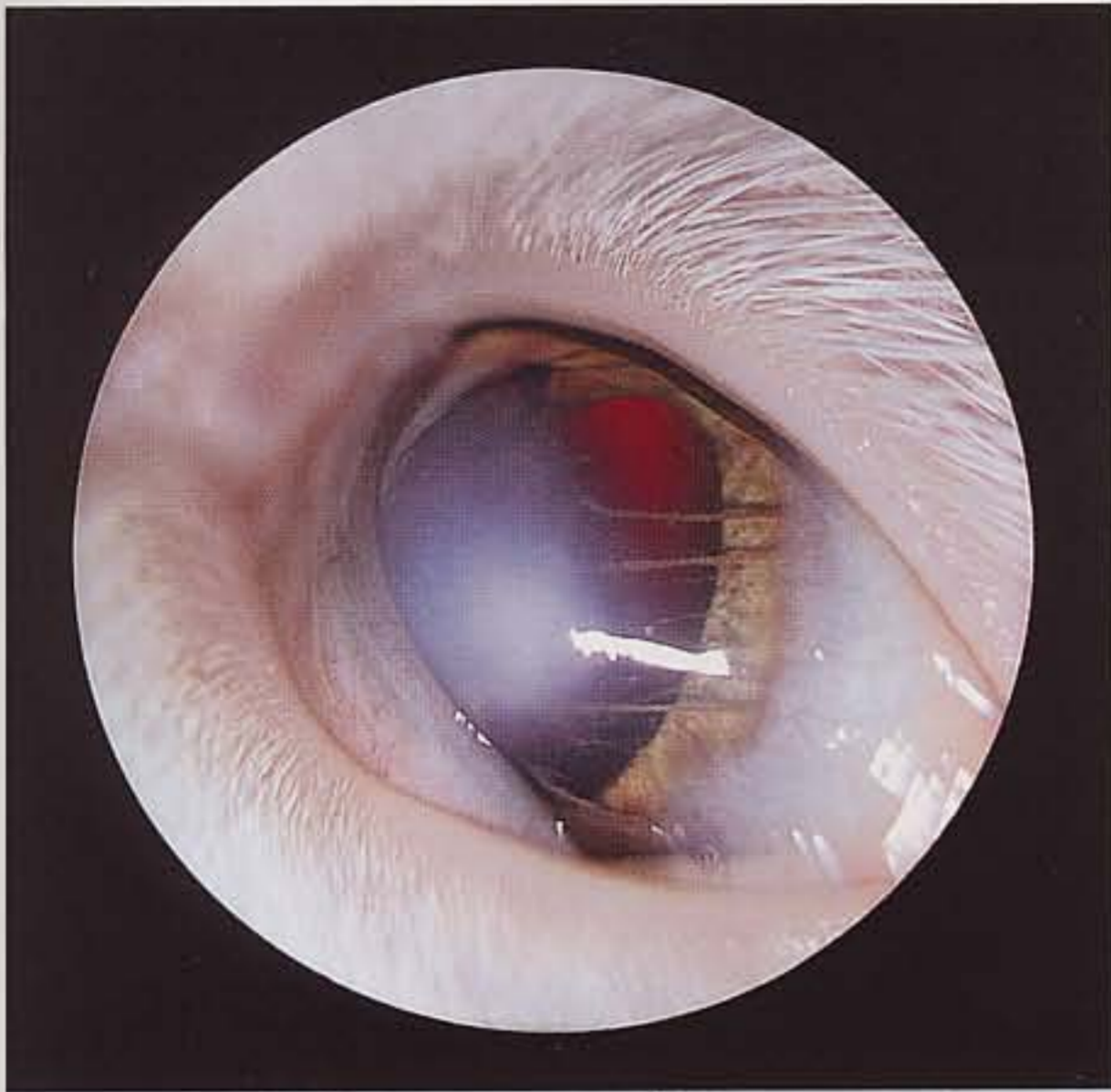

Fig. 7.66 PPM (Cat, adult, white) PPM and obvious corneal opacity.

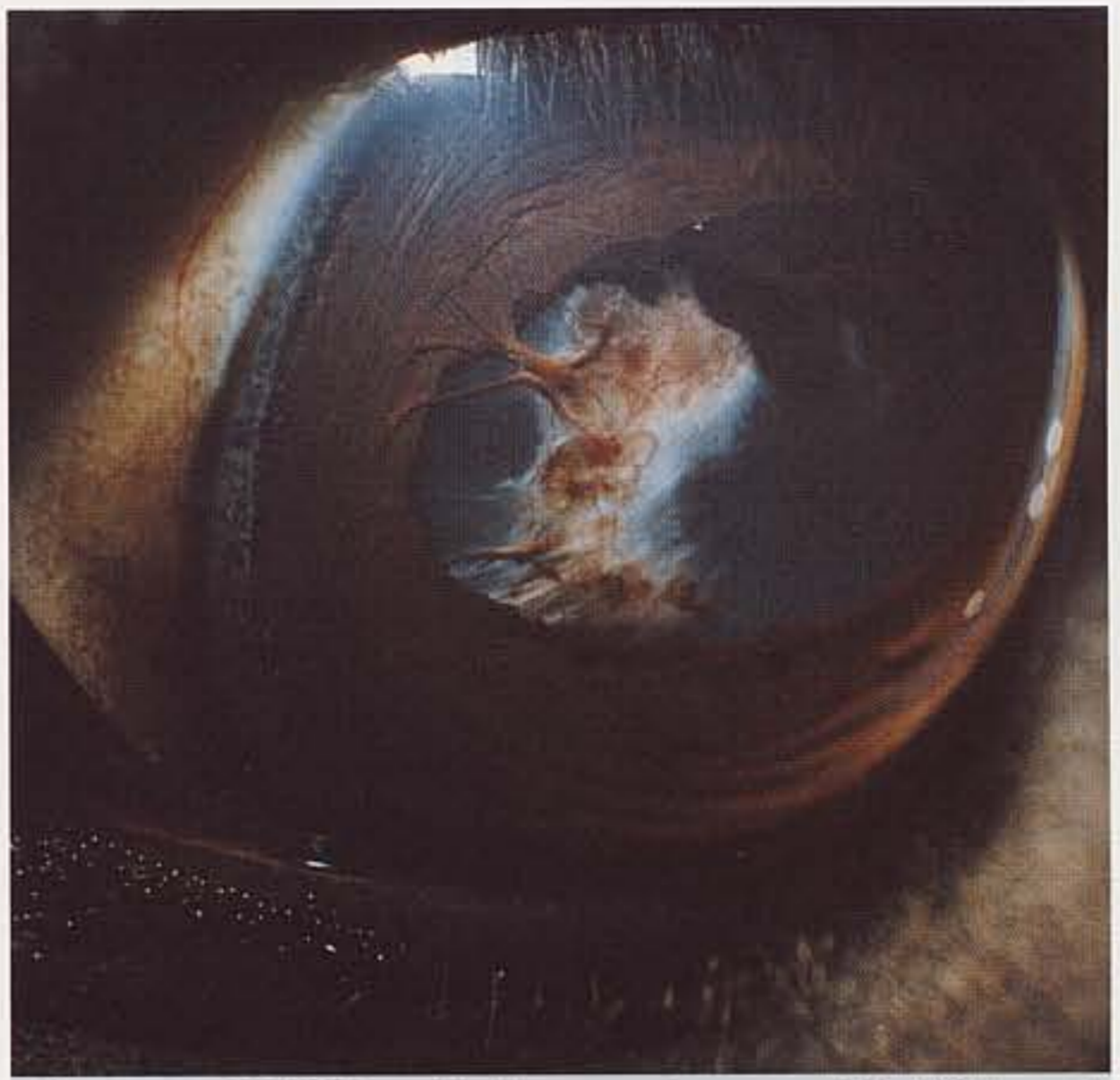


Fig. 7.67 PPM (Part-Arab mare, 8 years old) PPMs and associated pigmented capsular cataract. (See also Figs 9.43–9.44 and 9.46–9.47)

Chapter **8**

# Glaucoma and Aqueous

## Introduction

The glaucomas are a complex group of diseases with an increased intraocular pressure (IOP) which damages the optic nerve head and retinal ganglion cells leading to irreversible blindness. In animals the raised IOP is due to a decrease in drainage (not an over-production of aqueous).

Glaucoma is an important disease in veterinary ophthalmology. It is a painful disease; acute glaucoma in the dog can be extremely painful, causing inappetance, depression and even vomiting. Glaucoma can be a difficult diagnosis as several of the clinical signs may be found in other eye diseases (Tables 8.1 and 8.2) and a reliable diagnosis requires tonometry; subjective symptoms are absent. Gonioscopy is particularly helpful for diagnosis of the canine primary glaucomas. Furthermore, treatment, both medical and surgical, is difficult and too often ends with a blind, swollen and painful eye.

The glaucomas are usually classified as:

- Congenital (buphthalmos) (Fig 1.16) – rare in the dog and horse.
- Primary – rare in the cat and horse.
- Secondary – the most common glaucoma in the dog.

Table 8.1 - The red eye

Unilateral or bilateral
Acute or chronic
Local ocular disease or systemic with pyrexia (bilateral)
1. Glaucoma
Breed-specific for primary, some secondary cases
Unilateral at first presentation
2. Conjunctivitis
Primary or, more commonly, secondary (ocular or systemic)
Traumatic (subconjunctival haemorrhage)
3. Uveitis
Photophobia
4. Episcleritis/scleritis
Uncommon, usually no pain
5. Keratitis
Including corneal ulcer (pain)
6. Orbital disease
Endophthalmitis
Panophthalmitis
Retrobulbar (inflammation, neoplasia)
Prolapse

Table 8.2 - Glaucoma: differential diagnosis

	Pupil	Intraocular pressure	Pain	Vision	Discharge
Glaucoma	Dilates	↑	+++	Blind	Lacrimation
Conjunctivitis	No change	No change	+	No change	Serous-purulent
Uveitis	Constricts	↓	++	Minor effect	Lacrimation

## Clinical signs

- The presenting signs vary according to the speed of onset of the disease, the severity of the rise in IOP, the duration, the cause and the age of the animal. Both primary and secondary glaucoma almost invariably present as a unioocular disease, later becoming binocular, particularly in the primary (hereditary) cases.

The signs are:

- Pain, evidenced by lacrimation and blepharospasm and also degrees of enophthalmos with prominence of the nictitating membrane.
- Head-shyness and resentment to handling may occur in severe cases.
- Corneal oedema (Figs 8.1–8.2, 8.7–8.8).
- Conjunctival chemosis (Fig 8.2).
- Conjunctival and episcleral congestion (Figs 8.3, 8.5).
- Deep corneal vascularization as a 'brush border' advancing from the limbus through 360° (Figs 8.4–8.8).
- Superficial corneal vascularization with branching vessels which can be seen crossing the limbus, unlike the deep vessels of the brush border (Fig 8.9).
- Mydriasis (Figs 8.9–8.12) – not always present, particularly in glaucoma secondary to a uveitis.
- Hydrophthalmos (Figs 1.17–1.19 and 8.12).
- Fractures in Descemet's membrane (Figs 8.10–8.11).
- Lens subluxation with an aphakic crescent (often in an inferior position) (Figs 8.10, 8.13).
- Cataract (Fig 8.8).
- Phthisis bulbi.
- Optic disc cupping with retinal changes of blood vessel attenuation and tapetal hyper-reflectivity (Figs 12.8–12.9).
- Vision loss due to the above fundus changes.

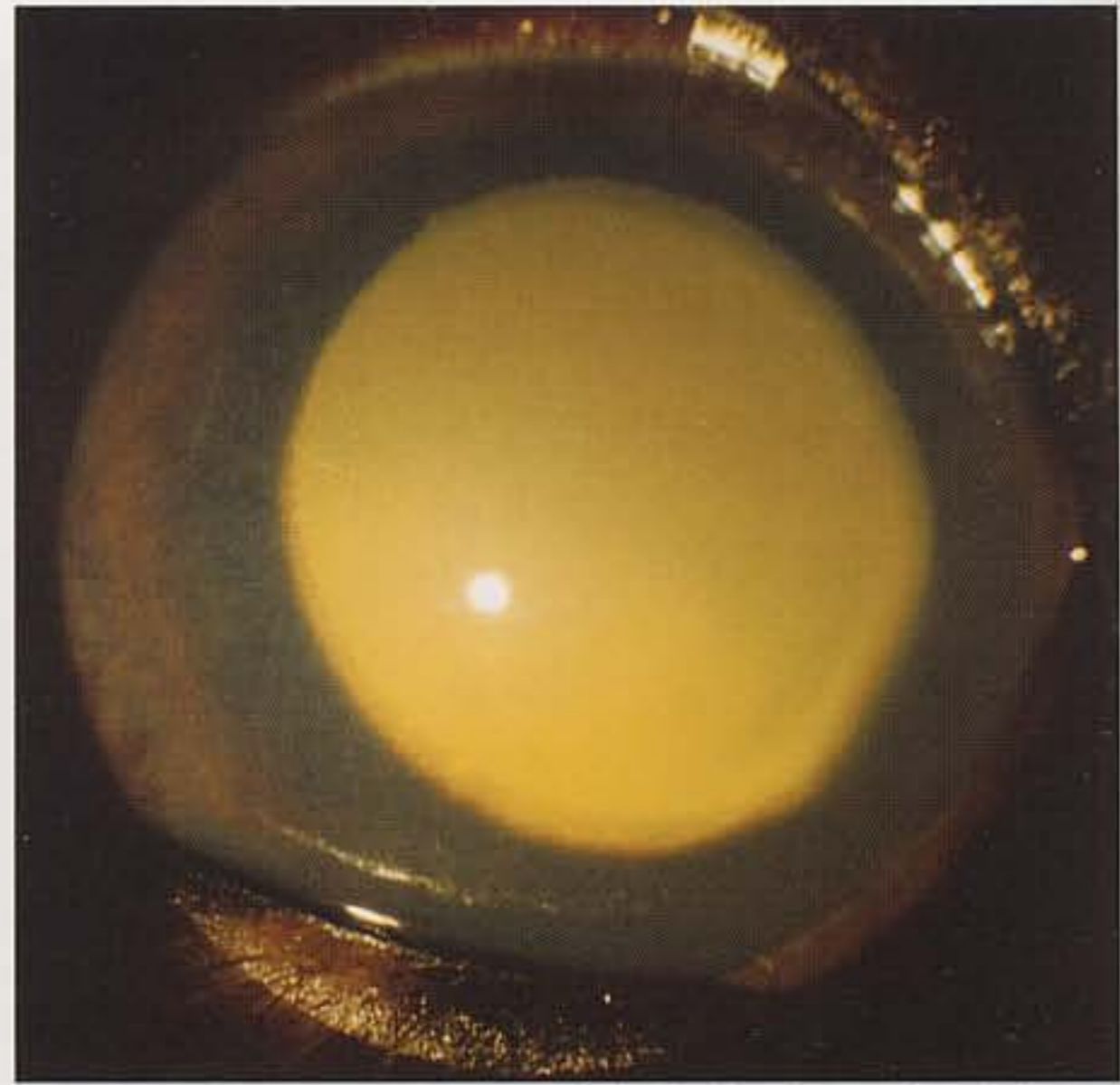


Fig. 8.1 Primary glaucoma (Welsh Springer Spaniel, 5 years old) Note dilated pupil and 'steamy' cornea due to mild oedema.

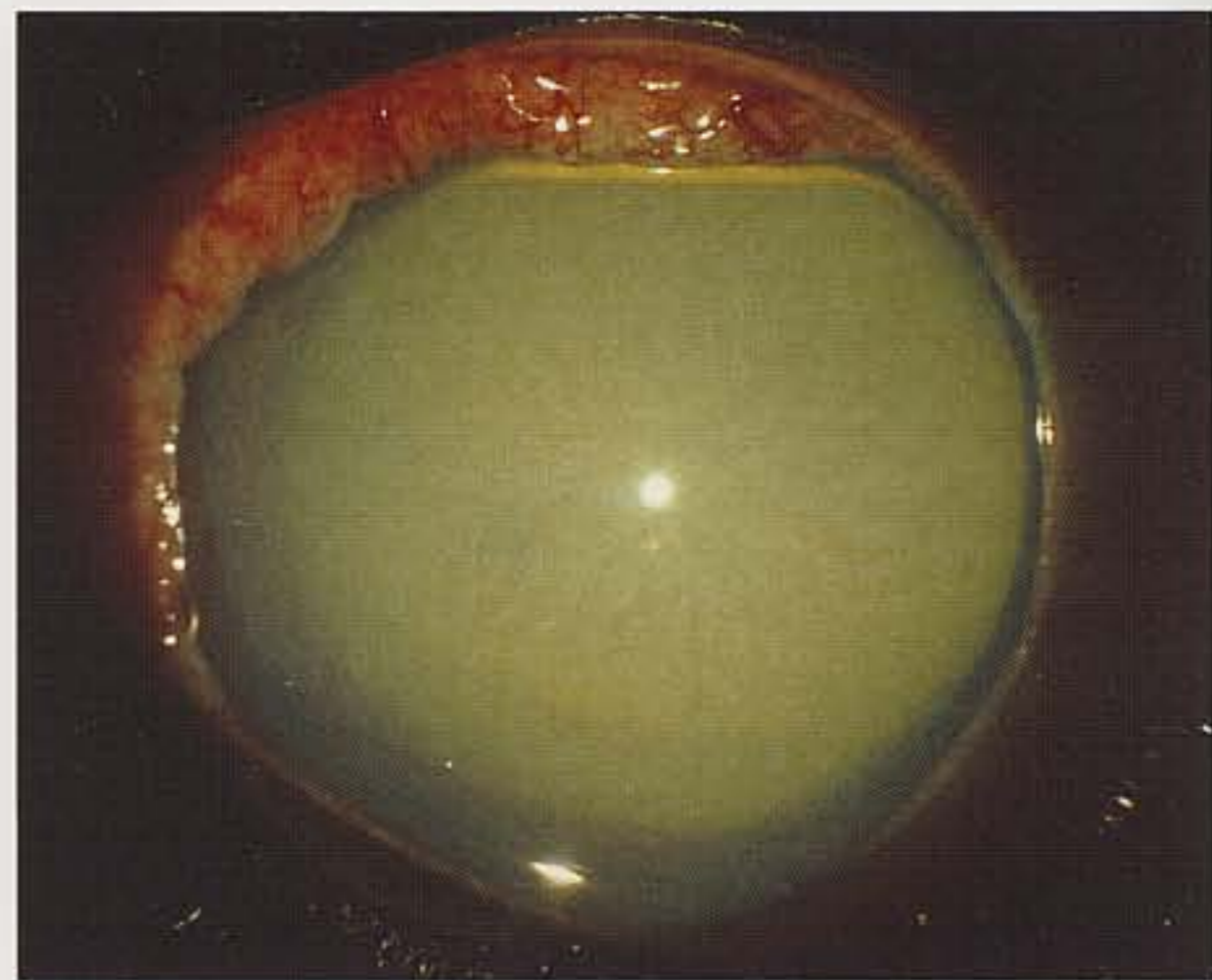

Fig. 8.2 Primary glaucoma (Welsh Springer Spaniel, 18 months old) Note conjunctival chemosis, mild corneal oedema and dilated pupil.

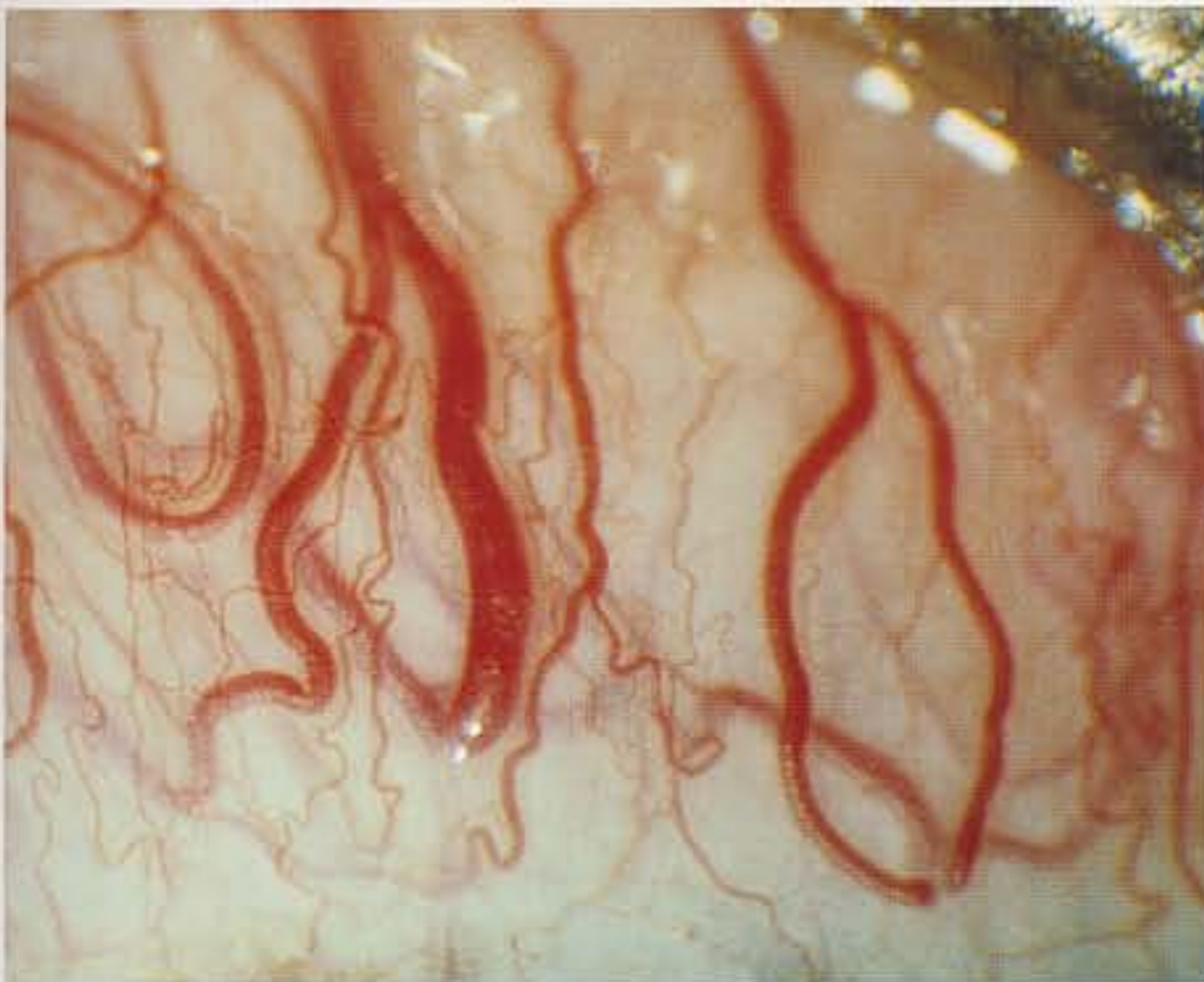

Fig. 8.3 Glaucoma (Beagle, 9 years old) Note conjunctival and episcleral congestion.

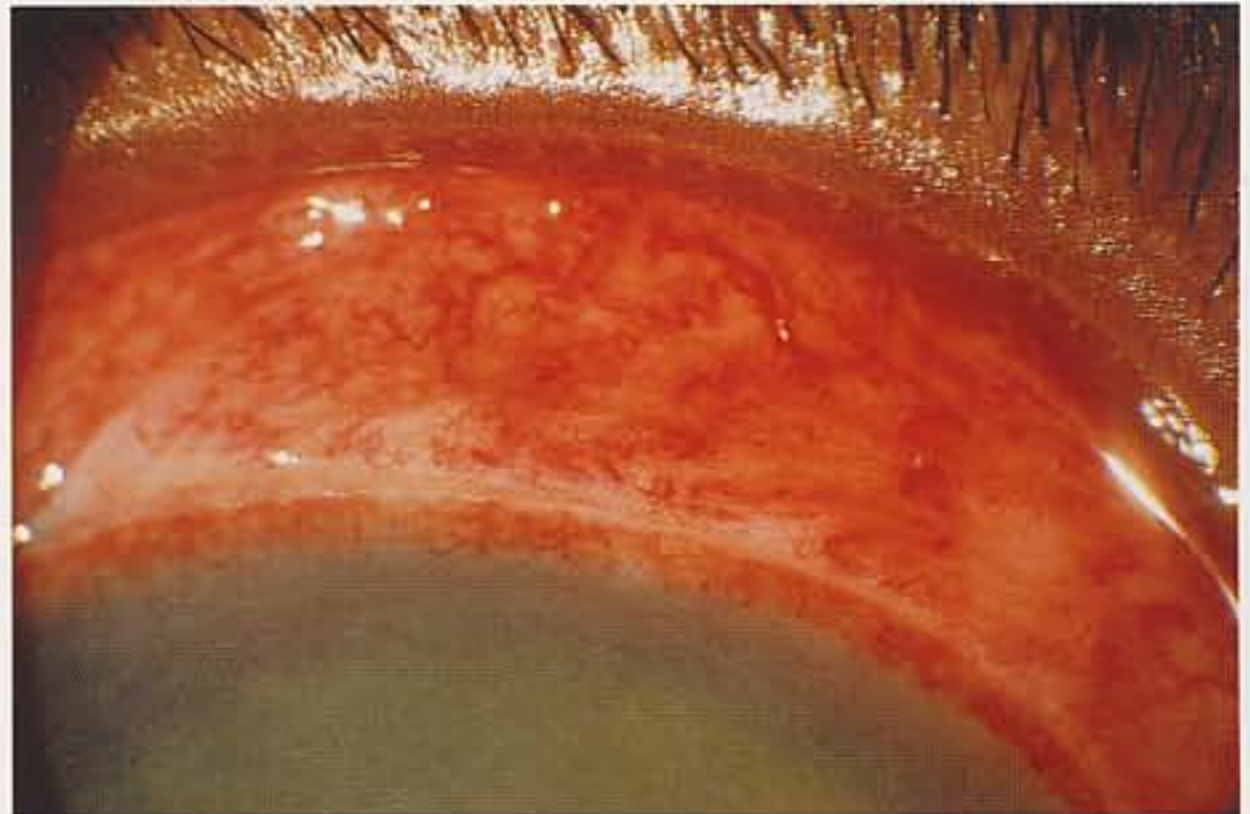


Fig. 8.5 Glaucoma Note early vascular fringe plus conjunctival congestion and corneal oedema.

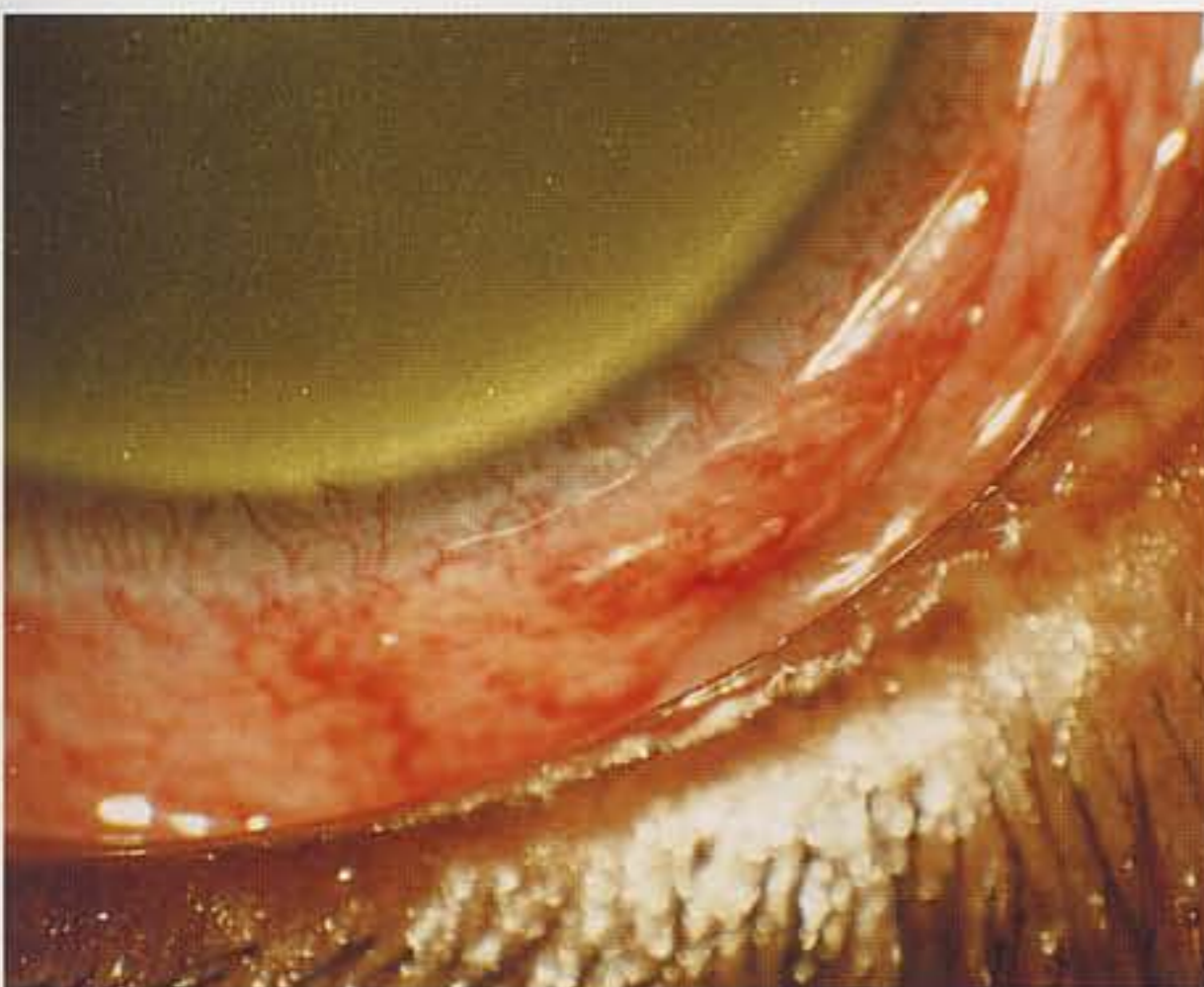


Fig. 8.4 Primary glaucoma (English Springer Spaniel, 11 years old) Note early vascular fringe advancing from the limbus.

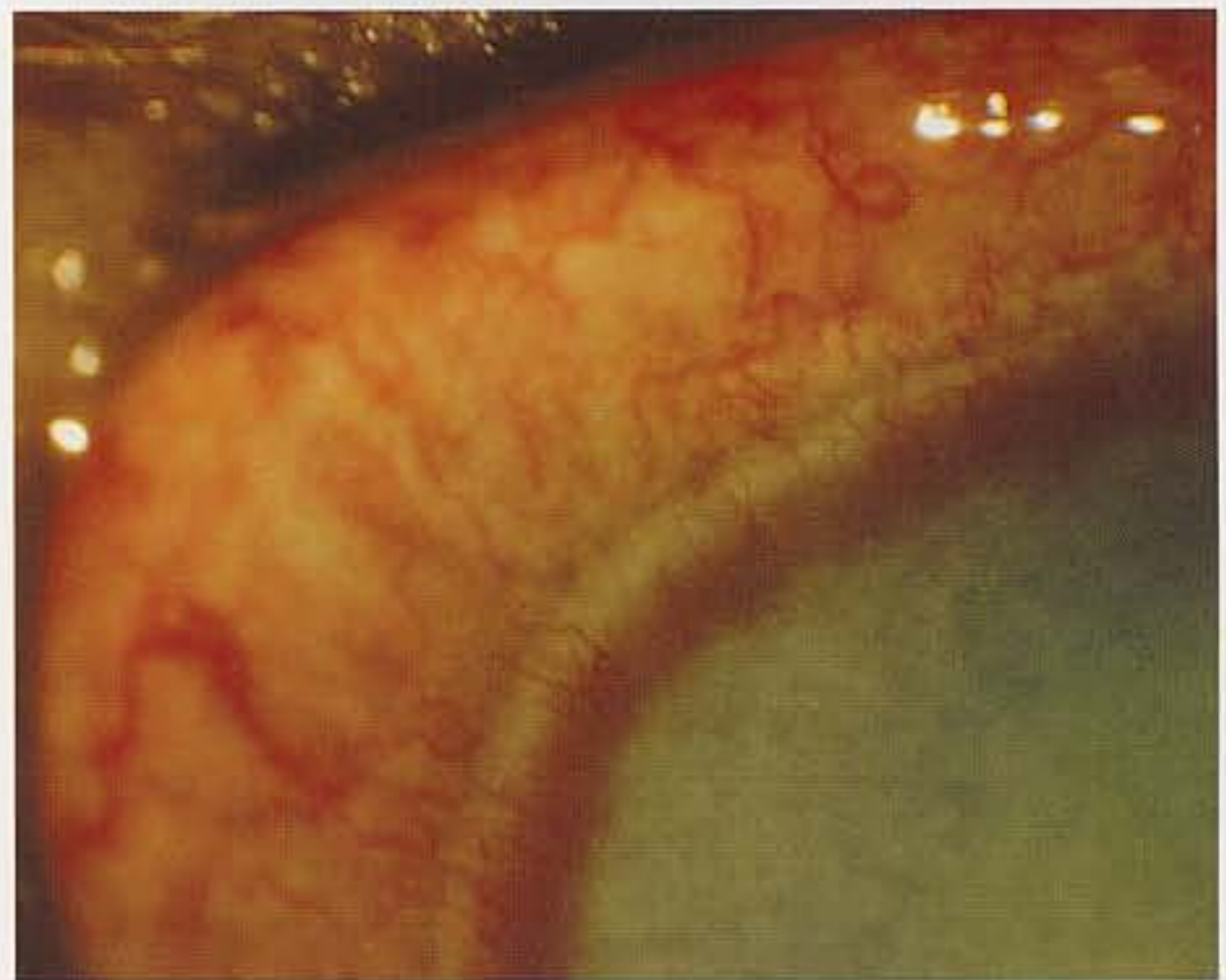


Fig. 8.6 Primary glaucoma (Welsh Springer Spaniel, 9 months old) Later vascular fringe.

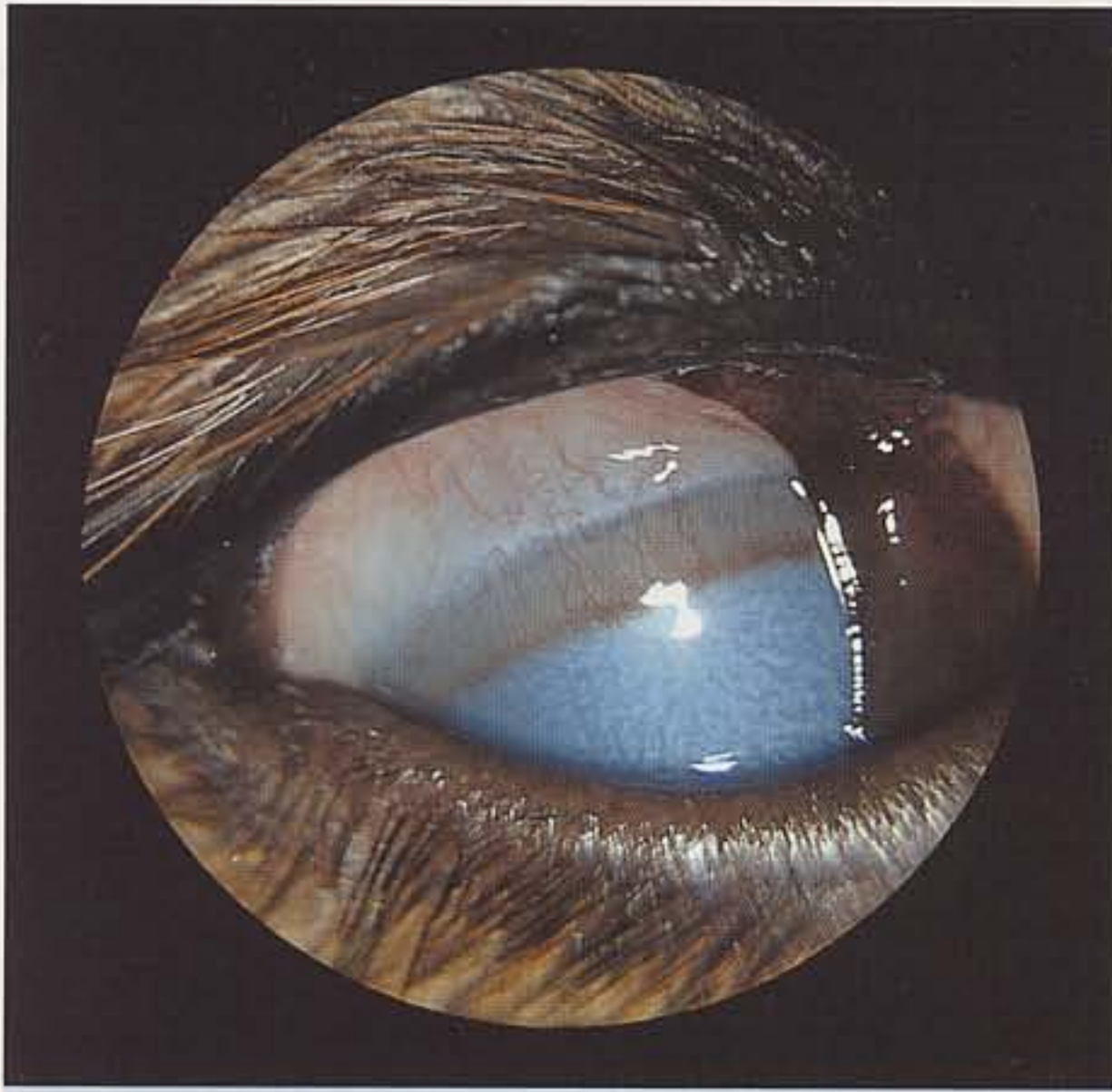


Fig. 8.7 Primary glaucoma Typical vascular fringe and corneal oedema.

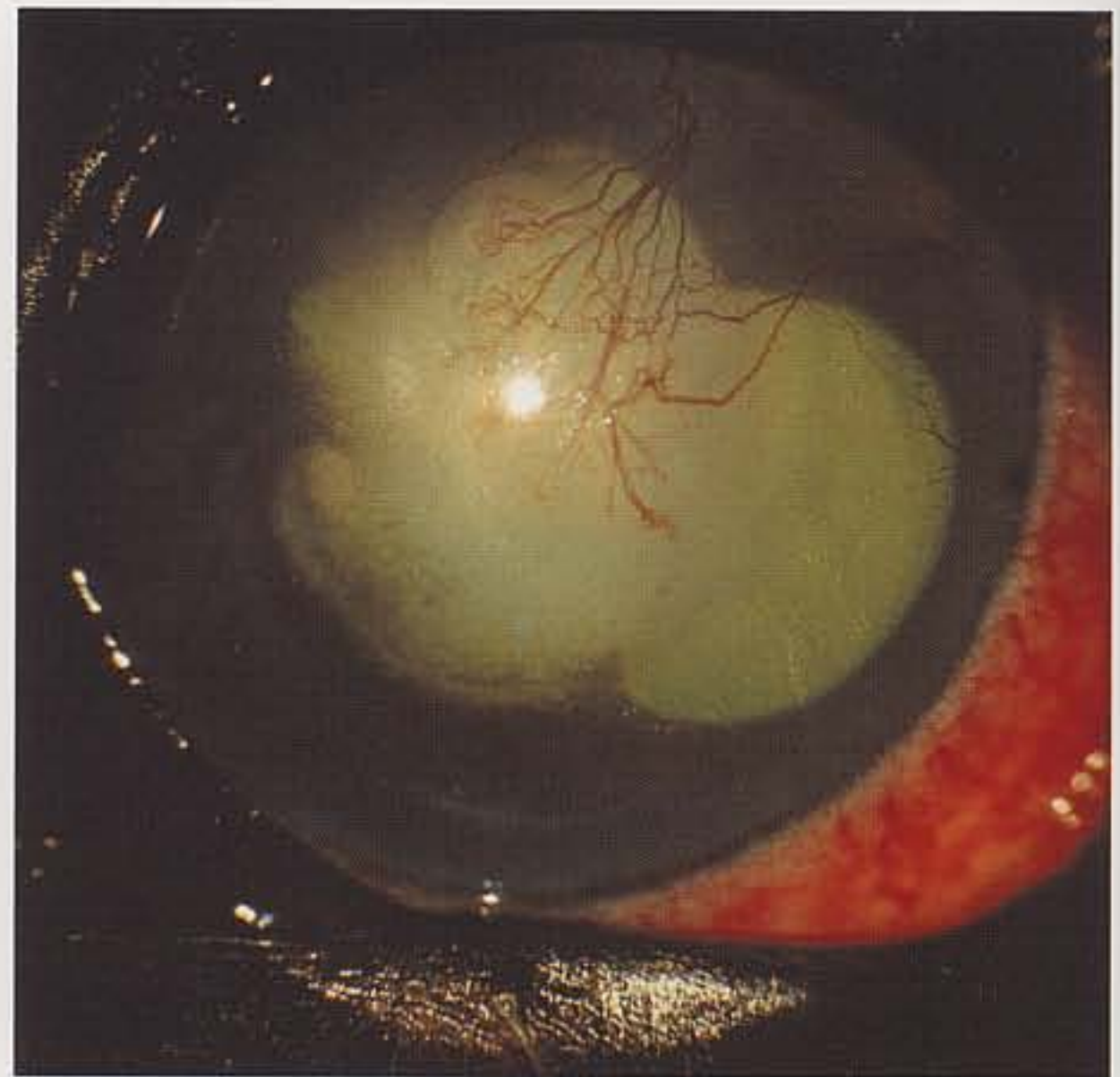


Fig. 8.9 Secondary glaucoma (post-iritis) (Standard Schnauzer, 14 years old) Note posterior synechiae resulting in eccentric and dilated pupil. Also the superficial vascularization with branching vessels crossing the limbus.

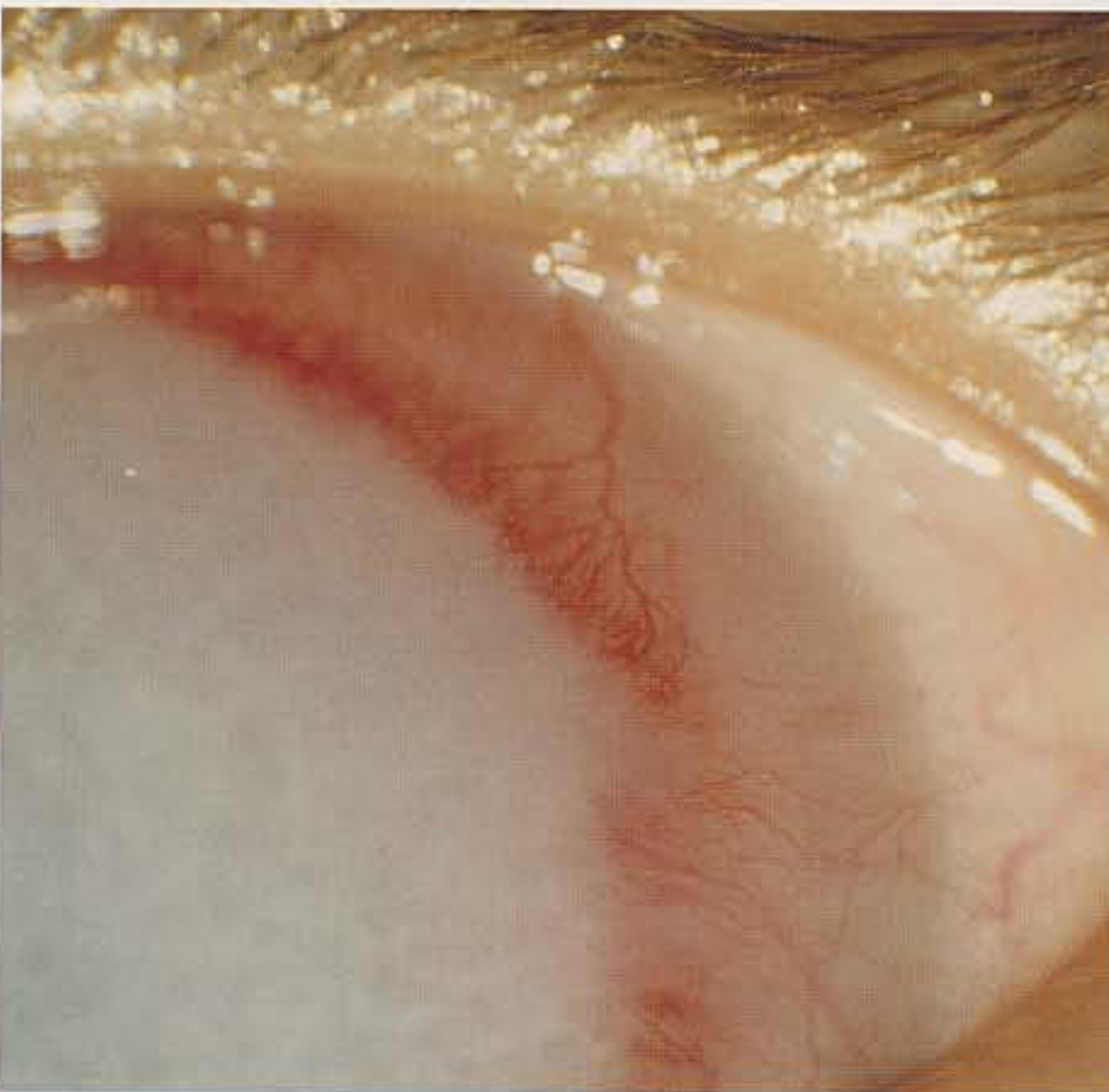


Fig. 8.8 Glaucoma (Miniature Poodle, 11 years old) Late fringe and marked corneal oedema.

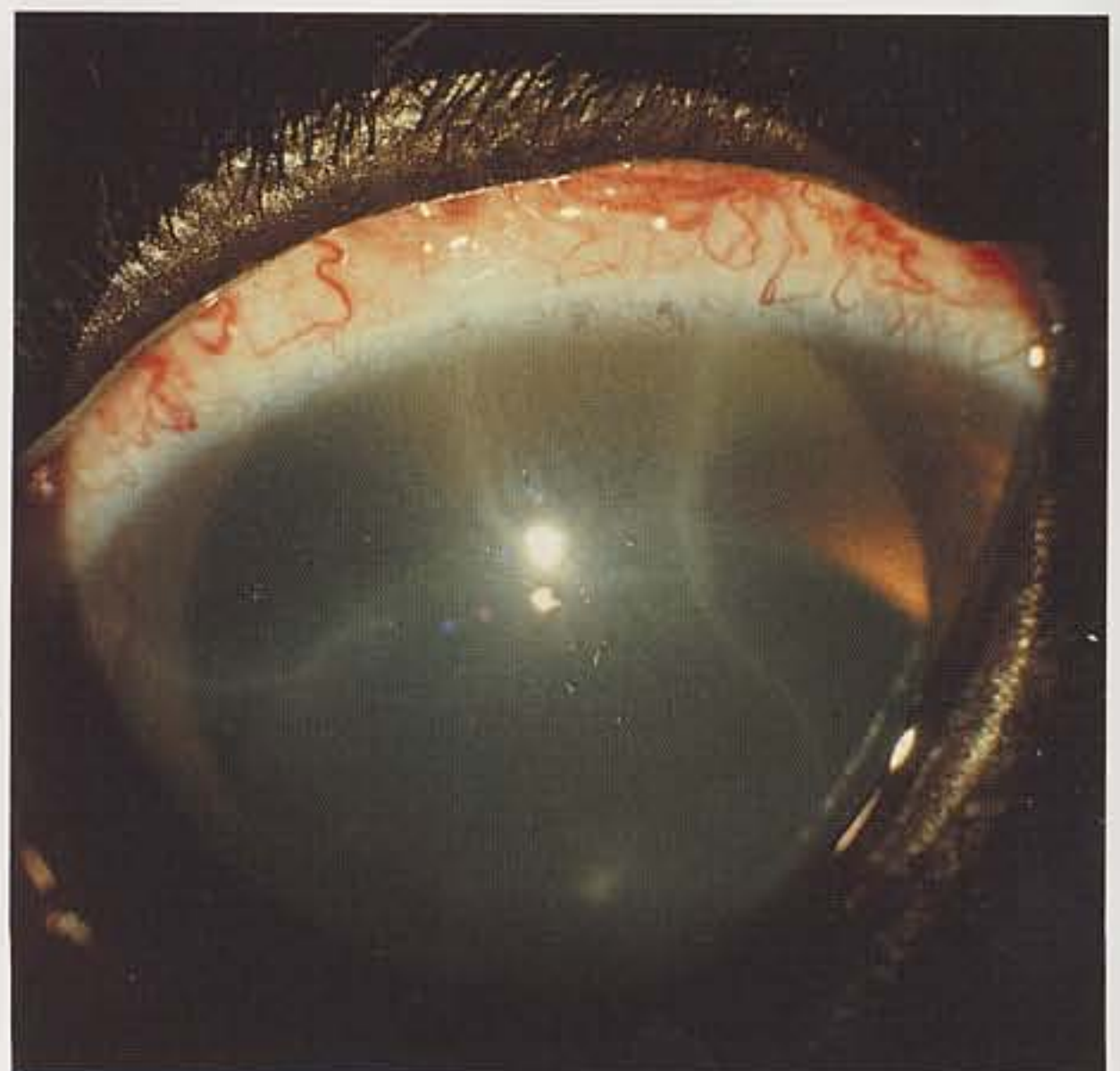

Fig. 8.10 Primary glaucoma (Basset Hound, 7 years old) Fractures in Descemet's membrane and dislocated lens (secondary).



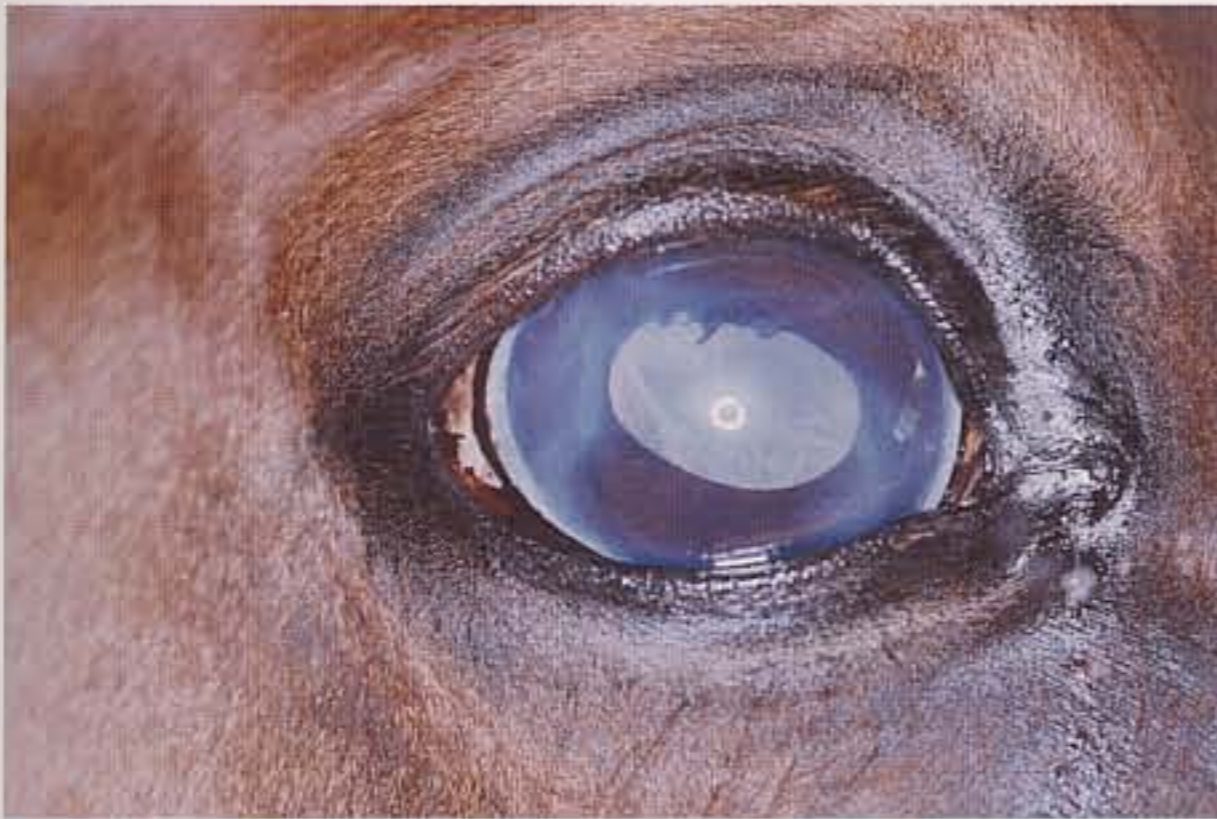

Fig. 8.11 Glaucoma (Thoroughbred, aged) Fractures in Descemet's membrane and early hydrophthalmos.

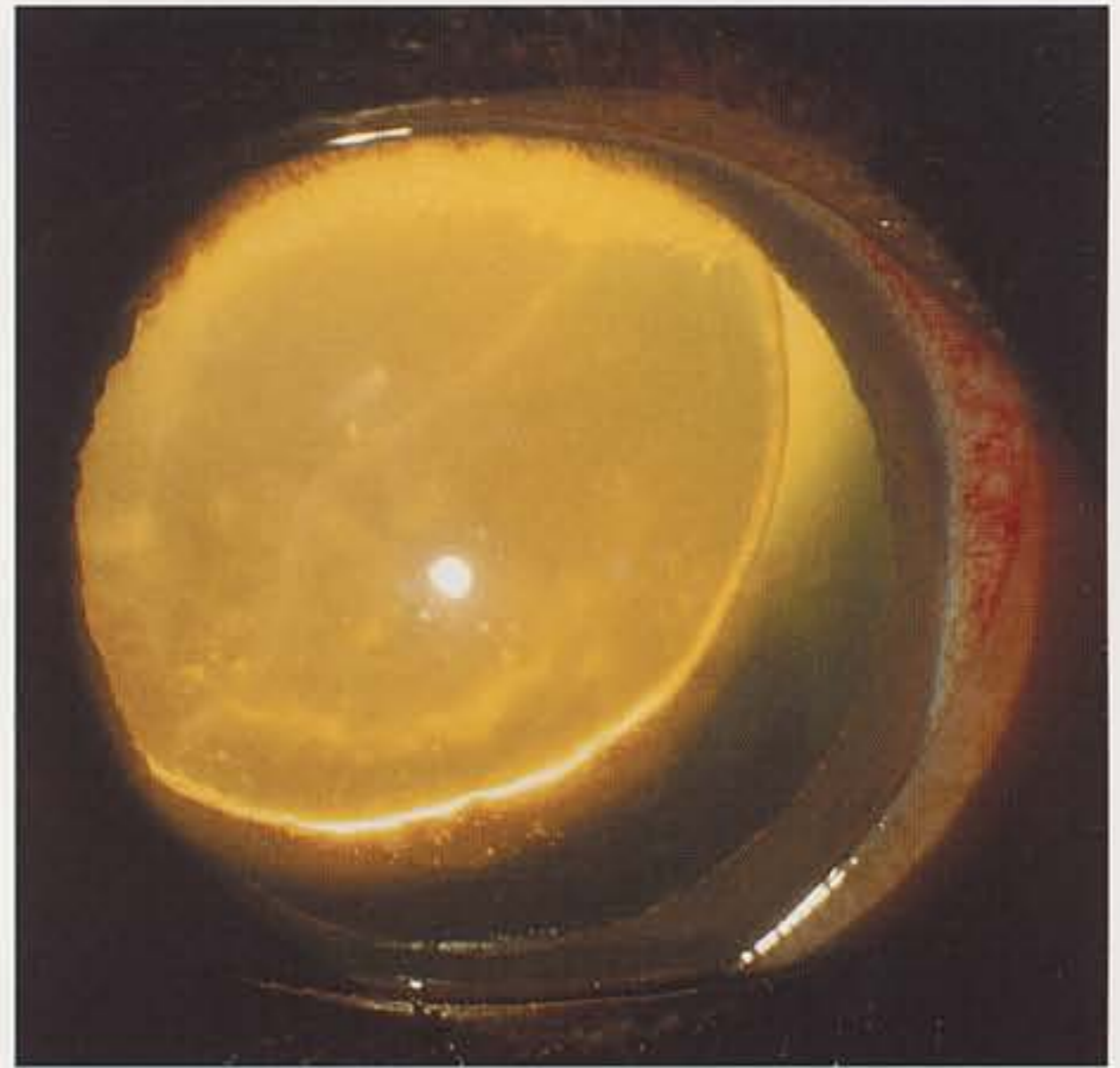


Fig. 8.13 Primary glaucoma (Welsh Springer Spaniel, 4 years old) Secondary lens dislocation – note the direction of the dislocation in this case.

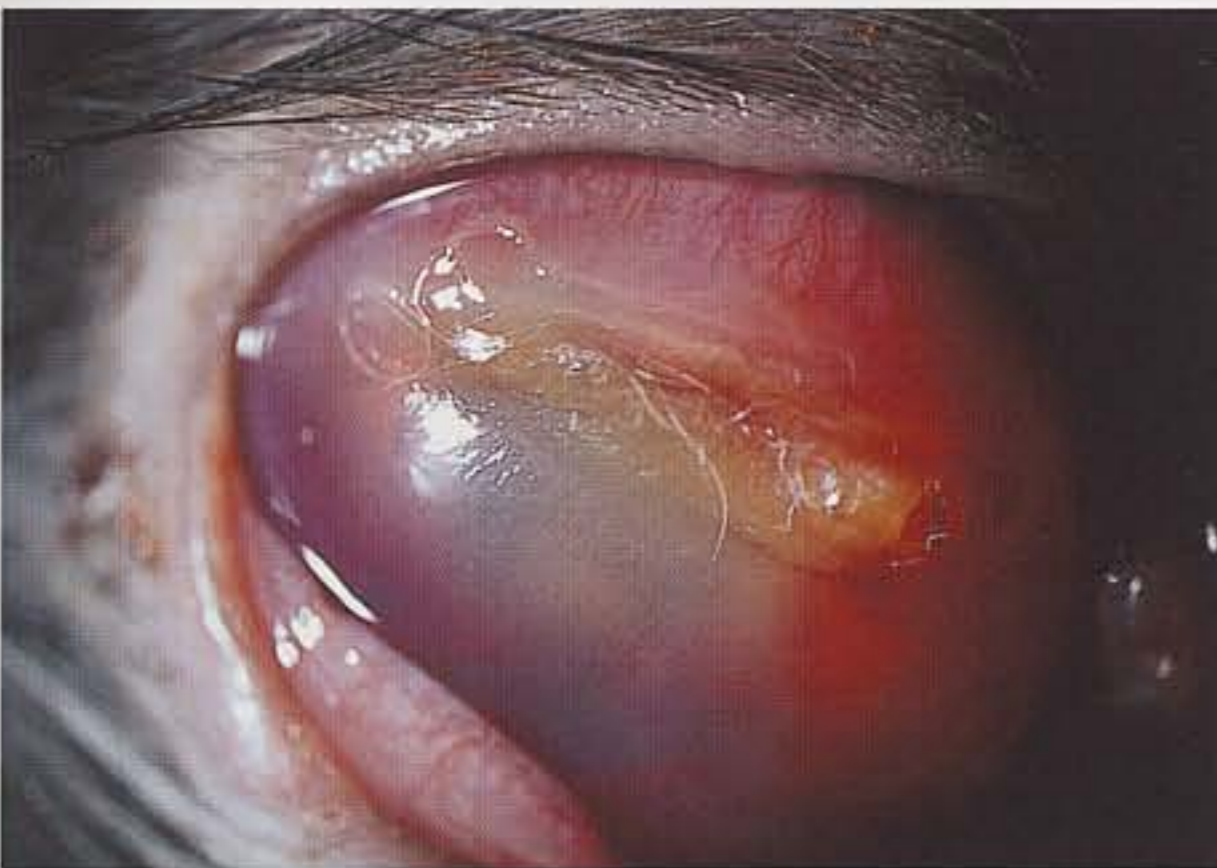

Fig. 8.12 Hydrophthalmos and exposure keratitis (DSH cat).

### Primary hereditary glaucoma in the UK – breeds affected

#### *Closed angle or goniodysgenesis (acute)*

- Spaniels (English Cocker, American Cocker, English Springer, Welsh Springer)
- Retrievers (Labrador, Golden, Flat-Coated)
- Basset Hound
- Siberian Husky
- Great Dane
- Samoyed
- Dandie Dinmont Terrier
- Others, particularly in other countries.

#### *Open angle glaucoma (chronic)*

- Norwegian Elkhound.

The breed and age are important factors in diagnosis.

### Secondary glaucoma – causes

- Primary lens luxation
- Uveitis
- Intraocular haemorrhage
- Intumescent cataract
- Neoplasia
- Pigmentary glaucoma or ocular melanosis in the Cairn Terrier (Fig 8.14).

### Gonioscopy

Examination of the angle of filtration using a goniolens and topical anaesthesia, and of particular value in distinguishing primary glaucoma in the dog, as in cases of primary glaucoma the second, probably normotensive, eye will reveal evidence of goniodysgenesis (abnormal or closed angle) (Figs 8.15–8.21).

## Aqueous

- Hypopyon (white cells in the anterior chamber) (Fig 8.22).
- Hyphaema (red cells in the anterior chamber) (Fig 8.23).

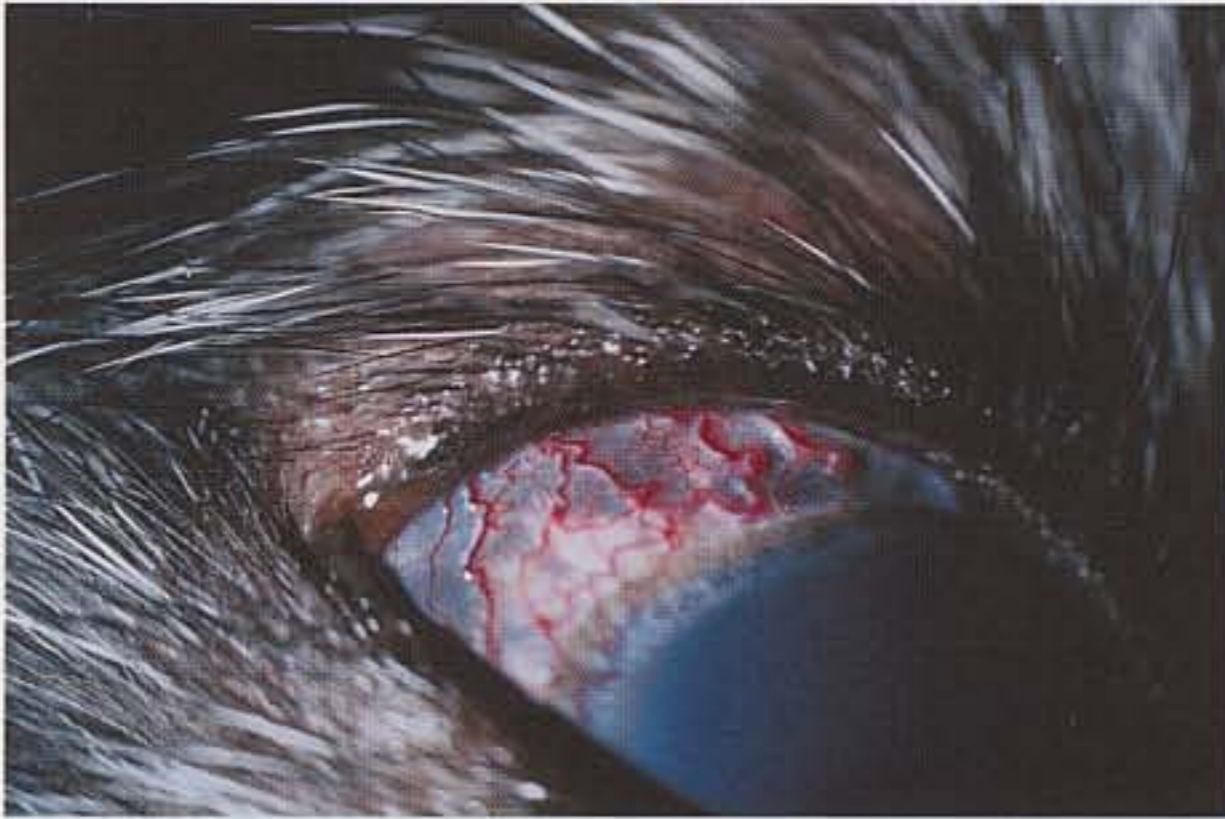

Fig. 8.14 Pigmentary glaucoma (Cairn Terrier).



Fig. 8.16 Goniophotograph (Crossbred, 3 years old) Open angle.



Fig. 8.15 Goniophotograph (Irish Setter, 1 year old) Open angle.

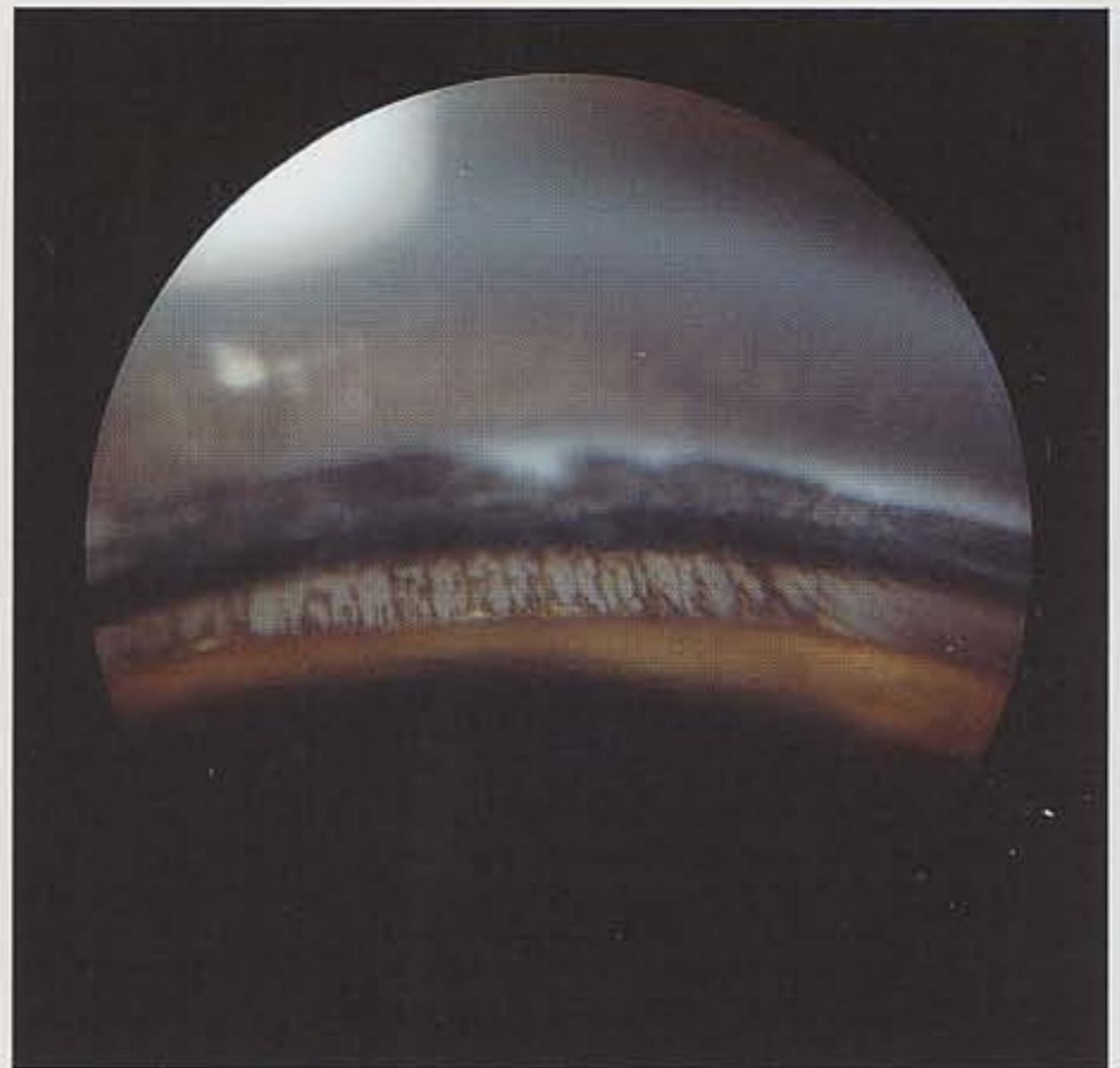


Fig. 8.17 Goniophotograph (Welsh Springer Spaniel, 2 years old) Open angle.

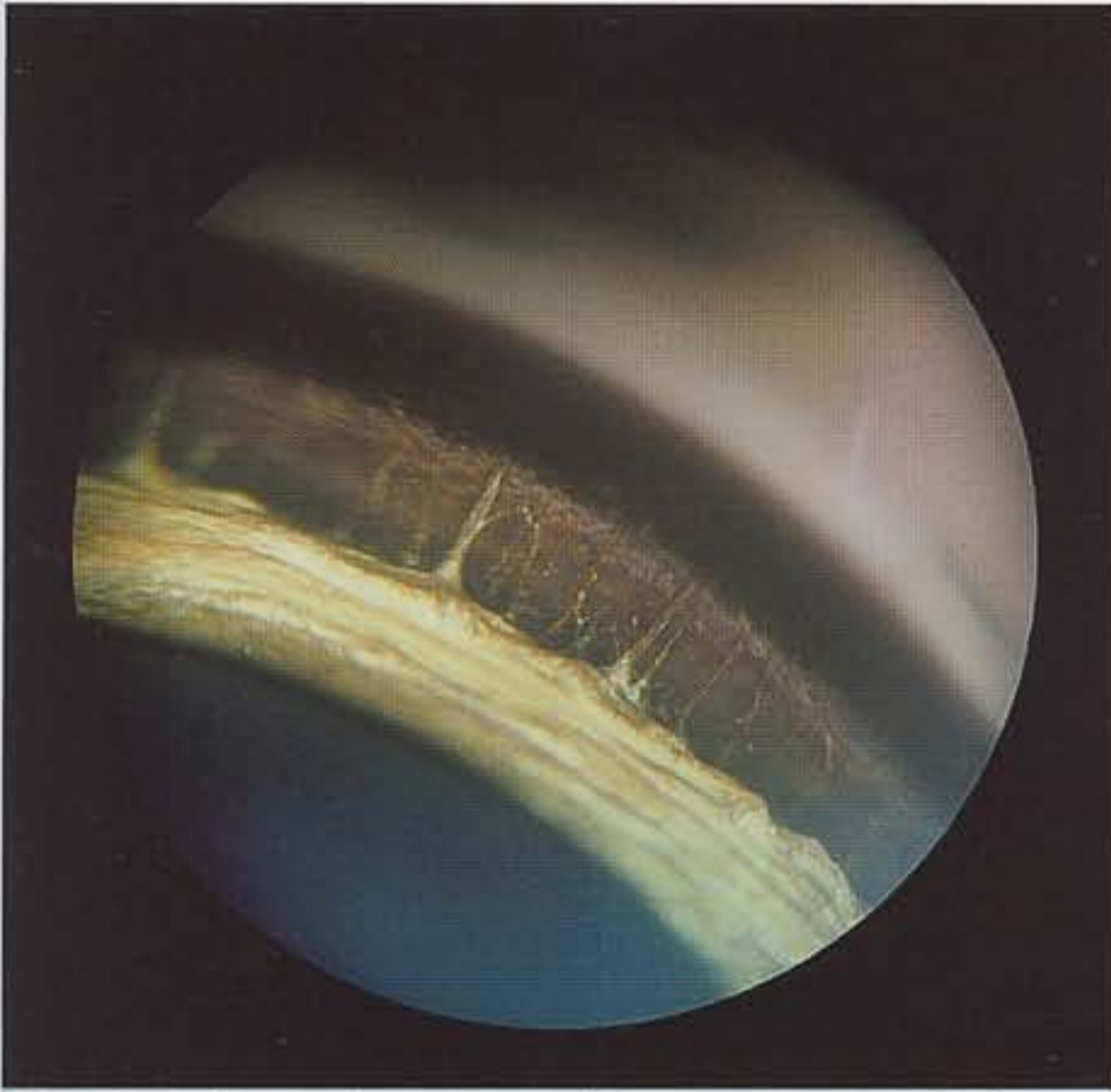

Fig. 8.18 Goniophotograph (DSH cat, 6 years old) Open angle.

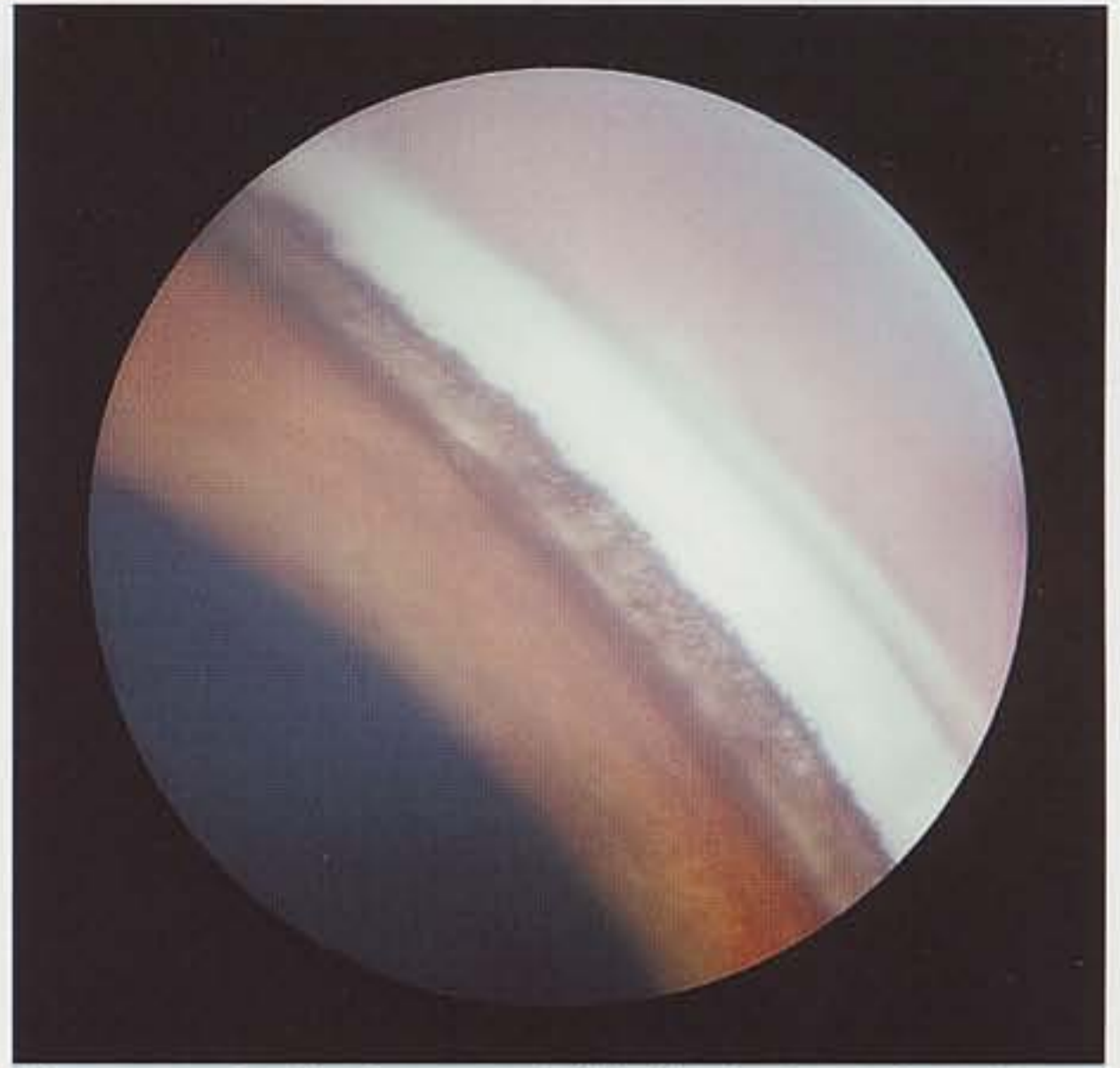


Fig. 8.20 Goniophotograph (Welsh Springer Spaniel, 2 years old) Closed angle.

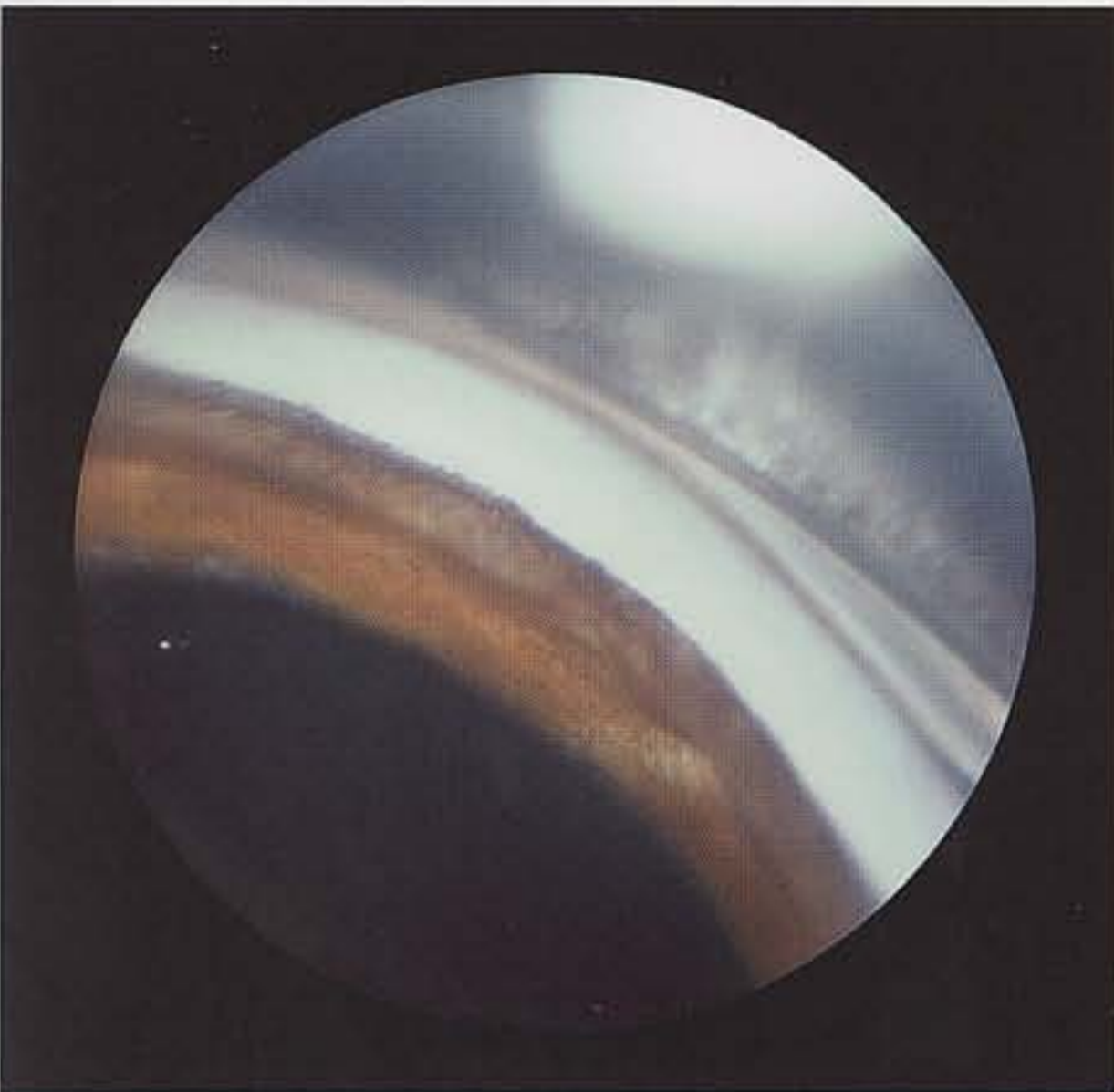


Fig. 8.19 Goniophotograph (Welsh Springer Spaniel, 4 years old) Closed angle.

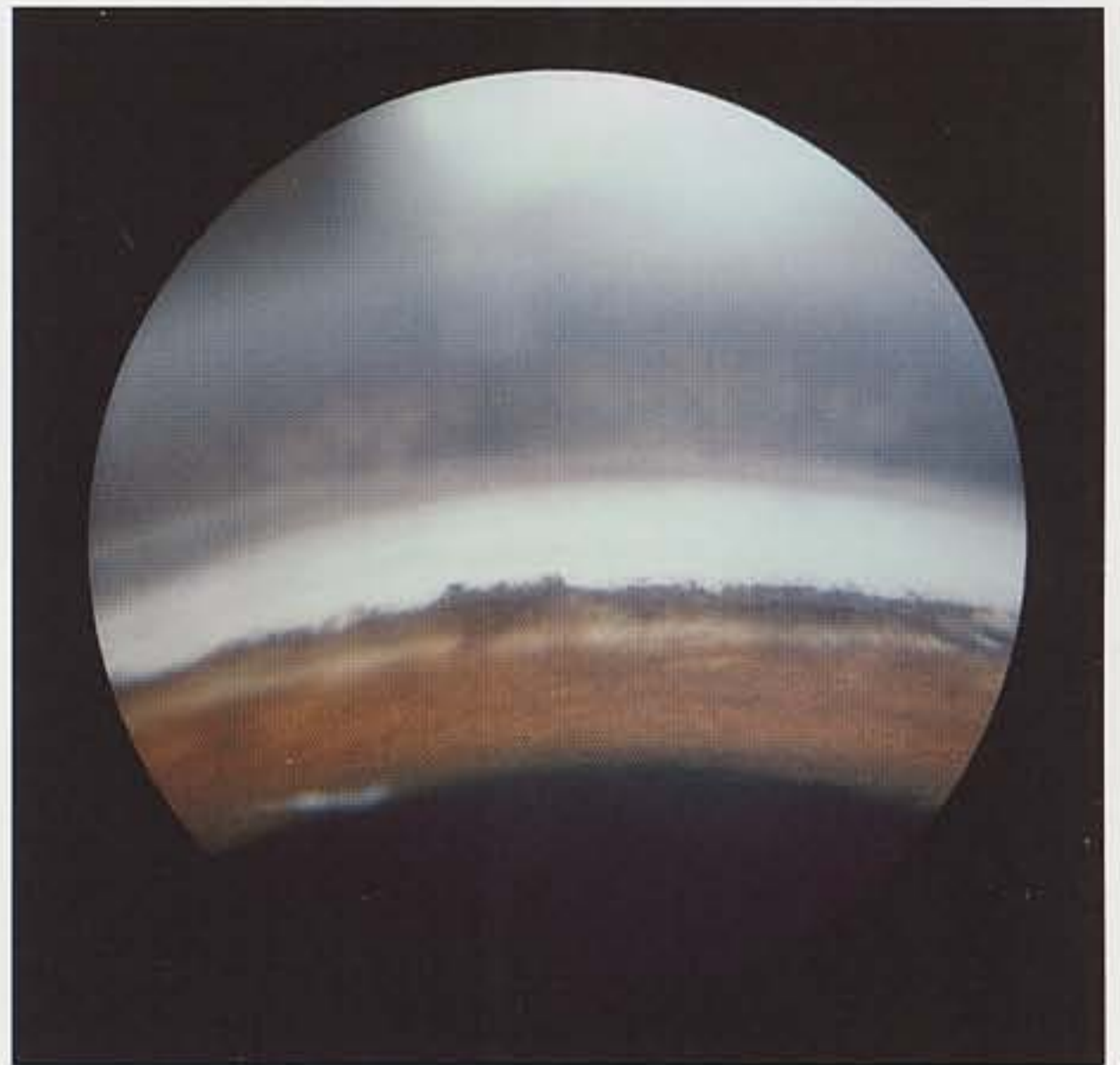

Fig. 8.21 Goniophotograph (Welsh Springer Spaniel, 4 years old) Closed angle.

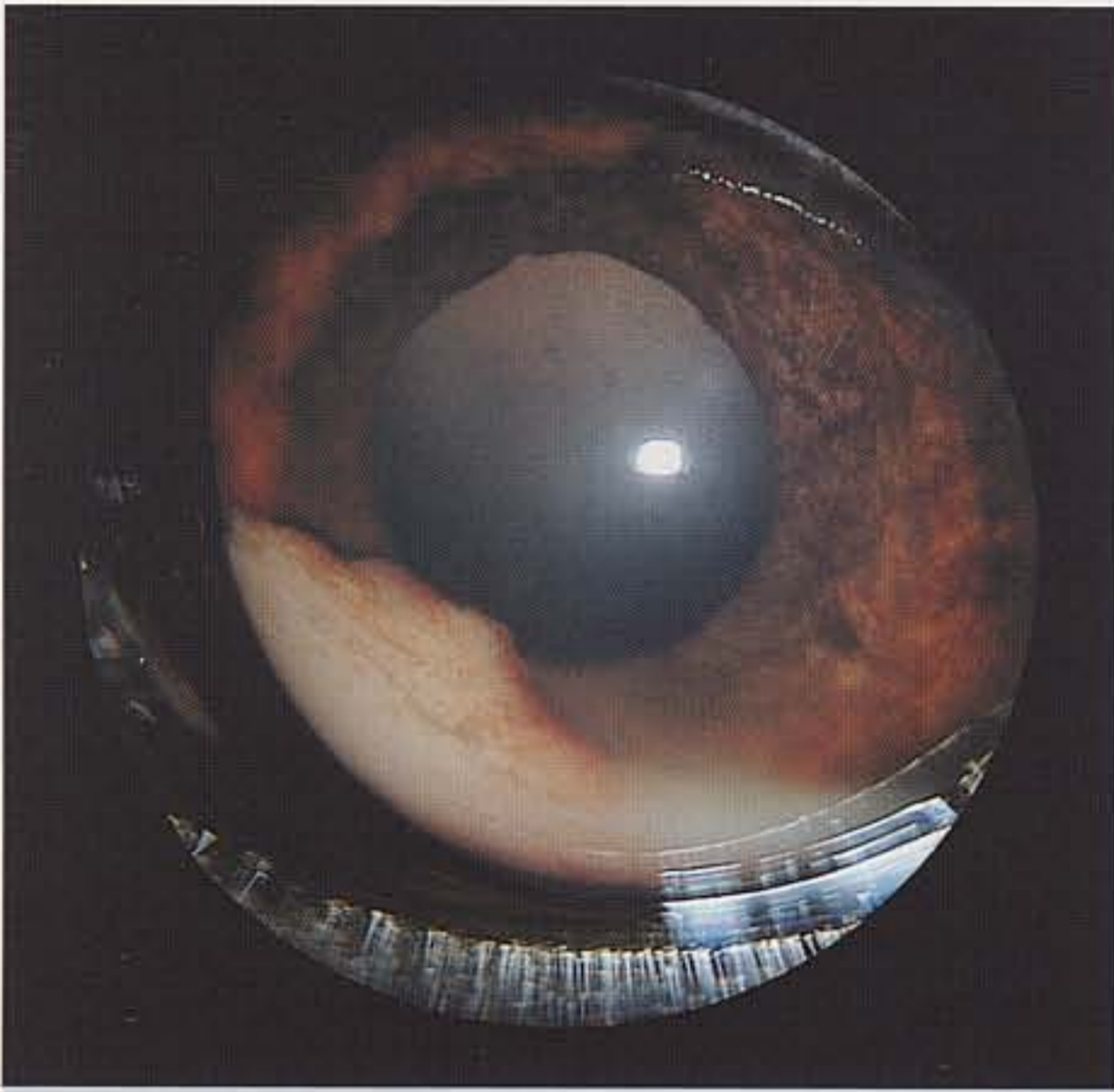


Fig. 8.22 Hypopyon.

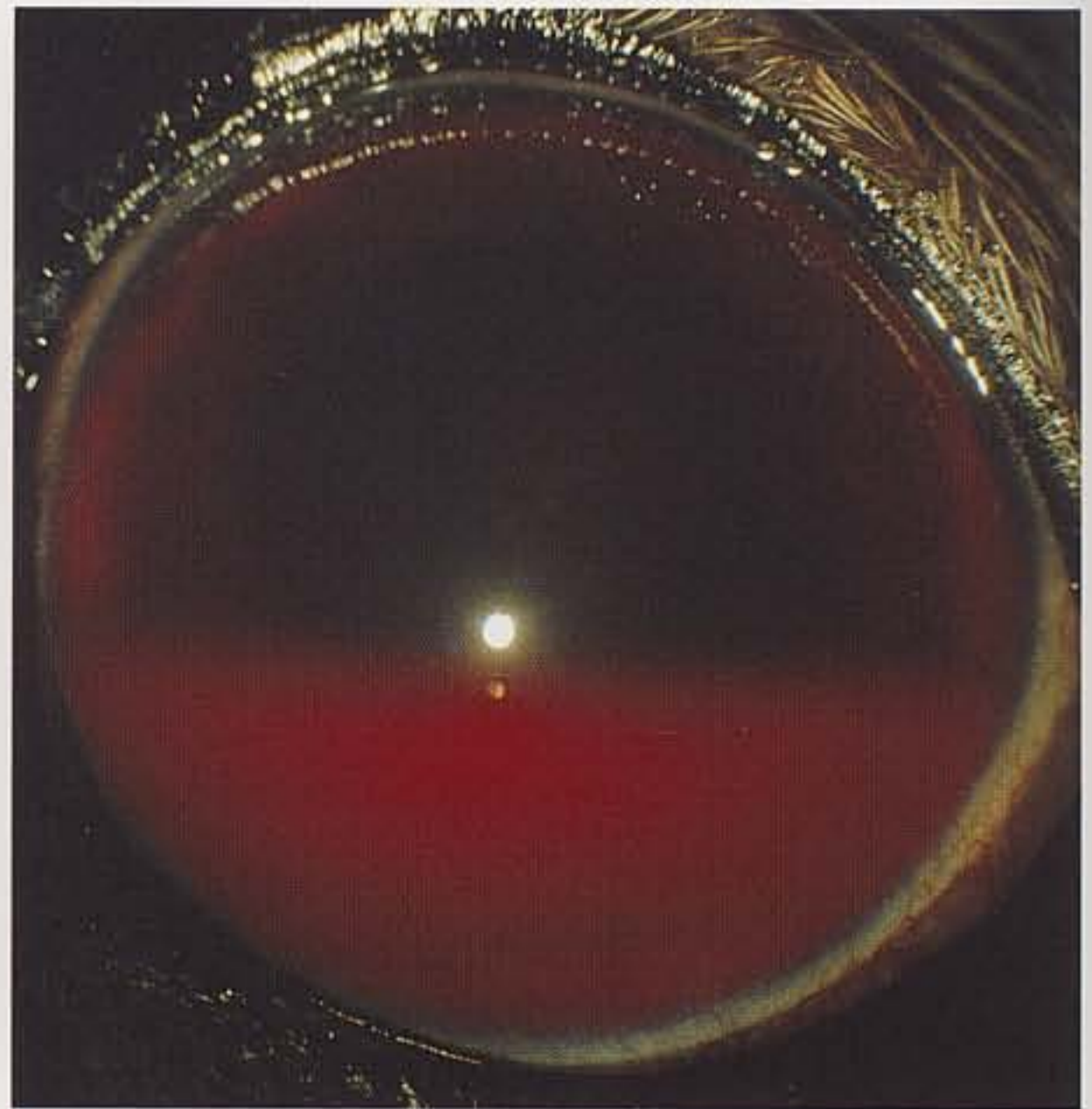


Fig. 8.23 Hyphaema.

## Introduction

There are two main conditions that affect the lens: cataract and luxation. Congenital anomalies (coloboma, microphakia), except for cataract which is usually associated with another abnormality e.g. microphthalmos, are rare in all species.

Cataract is simply defined as an opacity of the lens and/or its capsule and with suitable equipment (ophthalmoscope, slit lamp biomicroscope) should not present any problem in diagnosis. However, senile nuclear sclerosis, a normal ageing change in all animals, and not a true cataract as it is not an opacity, is often confused with cataract and wrongly diagnosed as cataract due to the opalescent bluish-grey appearance of the centre of the lens in direct light (Figs 9.80–9.81). Distant direct ophthalmoscopy should immediately distinguish it from cataract.

Cataract and lens luxation are common in the dog but relatively rare in the cat and the horse. This

is, in part, due to the considerable number of primary (hereditary) cataracts which occur in many breeds of dog but which, apart from cataract in the Morgan horse, are not, to date, proven to be inherited in the other species. Primary lens luxation is also inherited in several breeds of dog but not in the other species where it is secondary to some other eye condition, in particular uveitis and glaucoma.

Cataract may be partial or complete; unilateral or bilateral; the two eyes similar in degree or not; progressive or stationary or temporary or undergoing resorption. There are a number of known causes of cataract (heredity, trauma, other ocular disease, metabolic) but a significant number, to date, are of unknown aetiology. Other classifications may rely on the age at onset (congenital, juvenile, senile) and the stage of development (incipient, immature, mature, intumescent, hypermature, Morgagnian).

## Primary hereditary non-congenital cataracts (Figs 9.1–9.31)

These are cataracts that are not present at birth but develop later in life with a variable age onset according to breed. Their appearance is breed-

specific (see Table 9.1) and this, together with the age of onset, are important factors for accurate diagnosis and therefore prognosis. As the title suggests, these cataracts are not associated with any other eye disease and are inherited with an important breed incidence. The cataracts are usually, but not

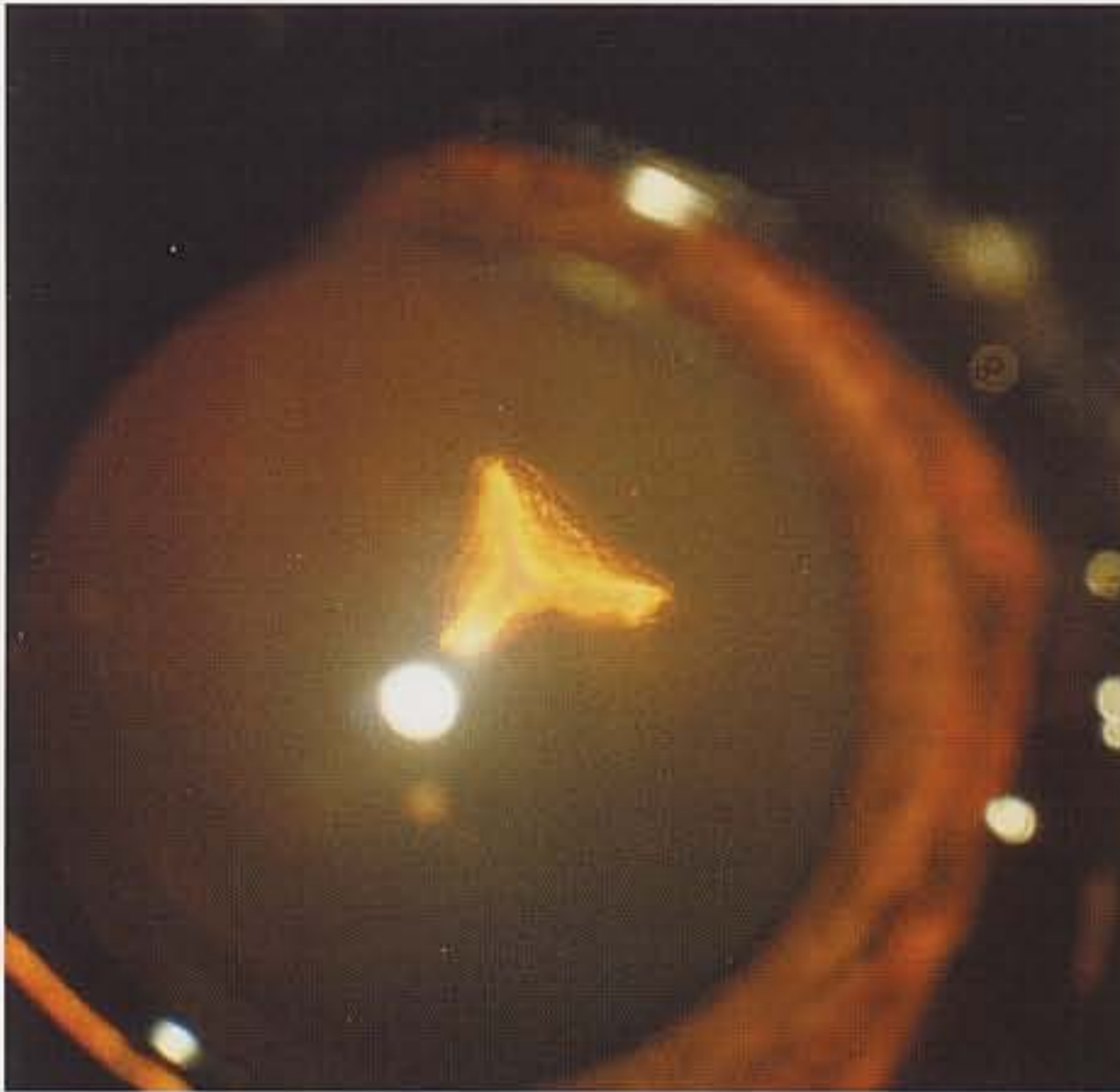


Fig. 9.1 Posterior polar cataract (Golden Retriever, 1 year old) Subcapsular, dense focal opacity.

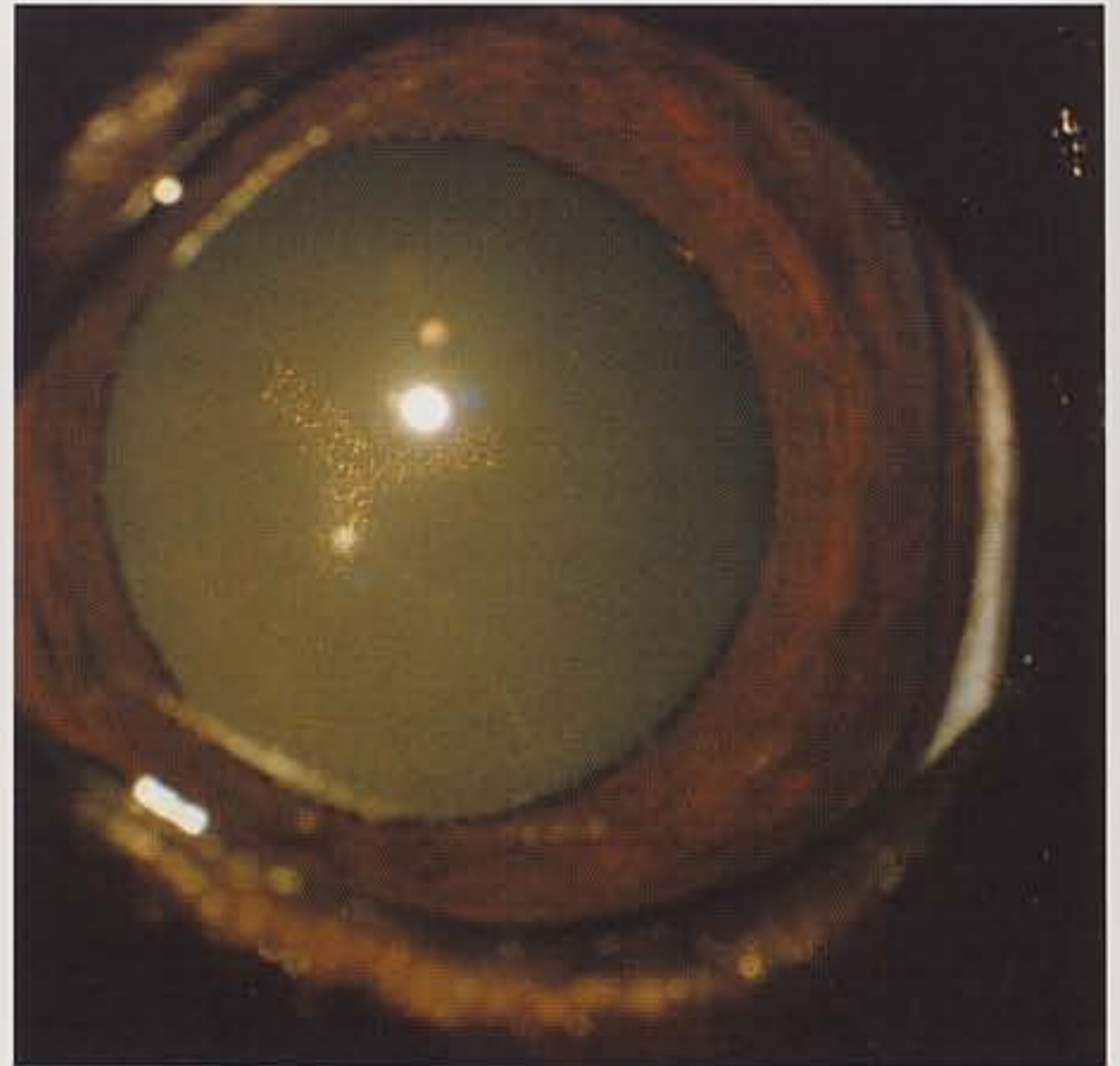


Fig. 9.3 Posterior polar cataract (Golden Retriever, 4 years old) Subcapsular, faint inverted-Y opacity.

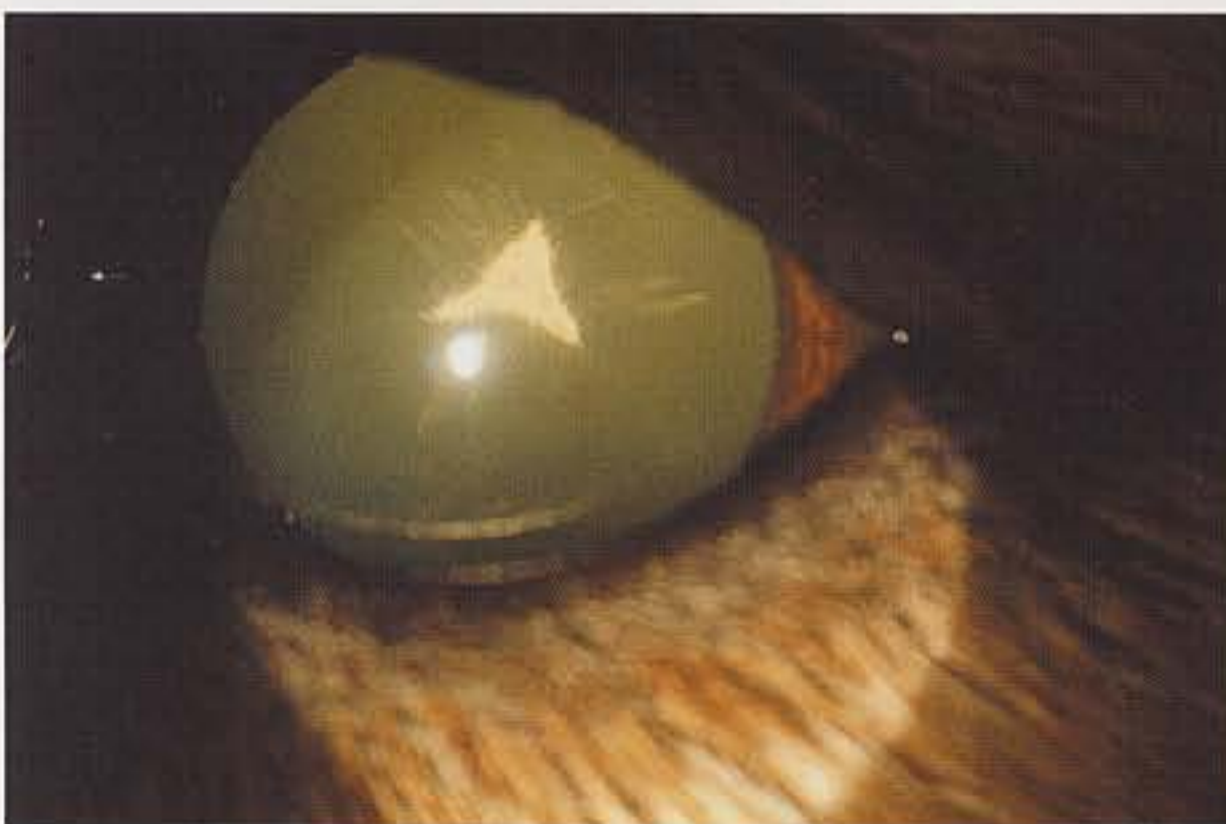

Fig. 9.2 Posterior polar cataract (Golden Retriever, 4 years old) Similar cataract to previous figure, but with few fine extensions.

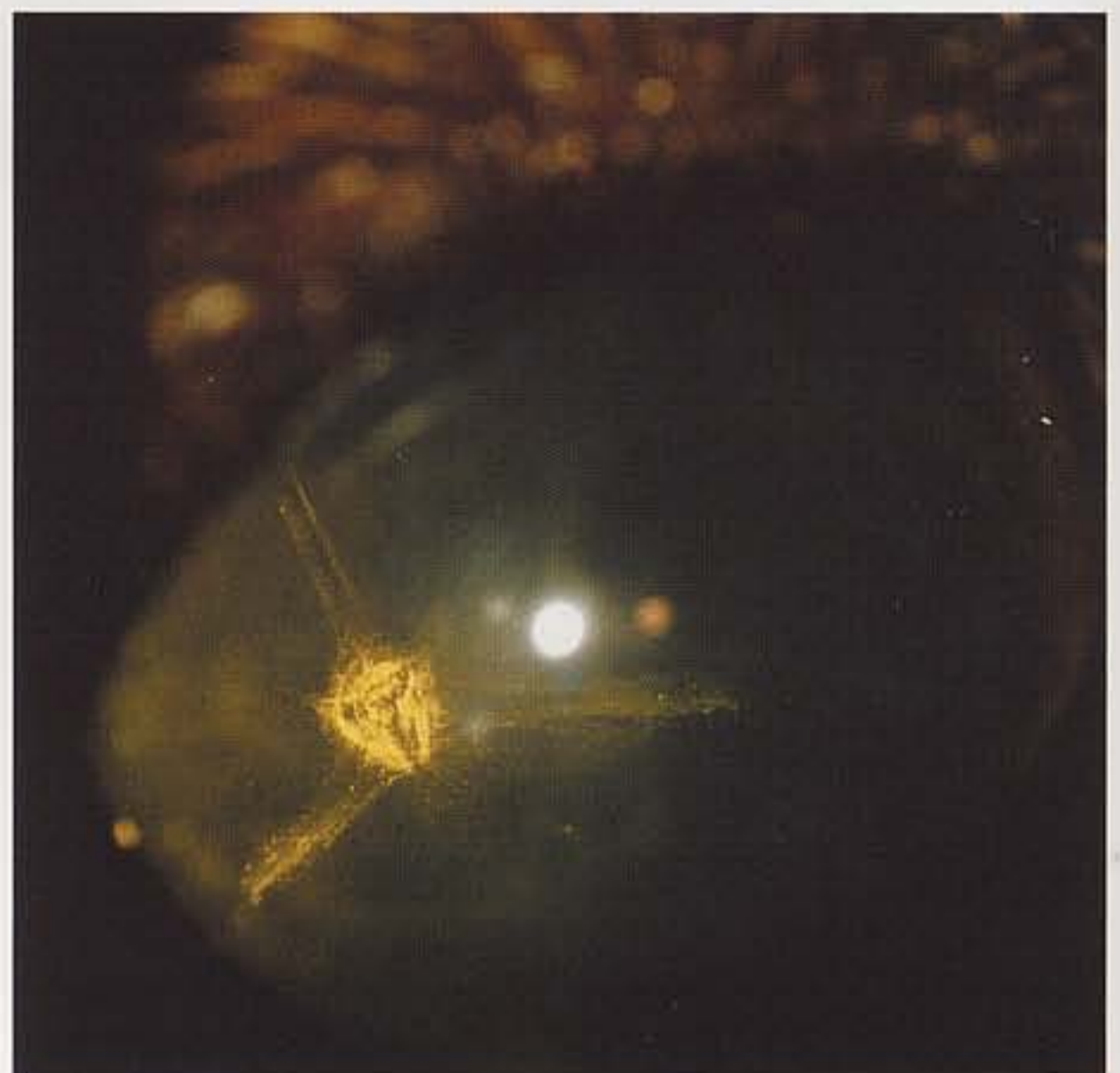


Fig. 9.4 Posterior polar cataract (Golden Retriever, 18 months old) Subcapsular, dense triangle with extensions along the suture lines.

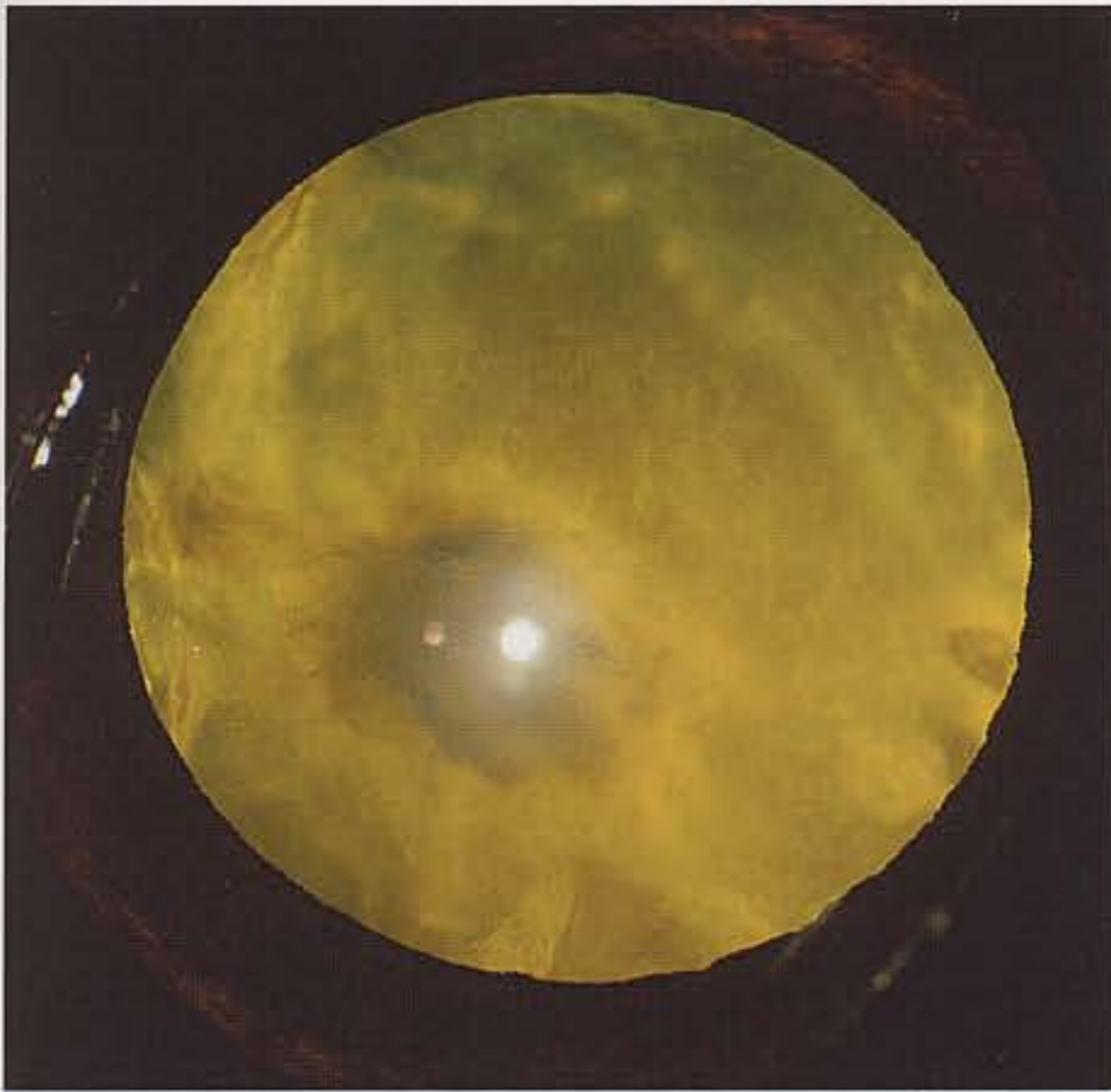

Fig. 9.5 Posterior polar and cortical cataract (Golden Retriever, 4 years old) Cortical and progressive opacities and dense posterior polar cataract.

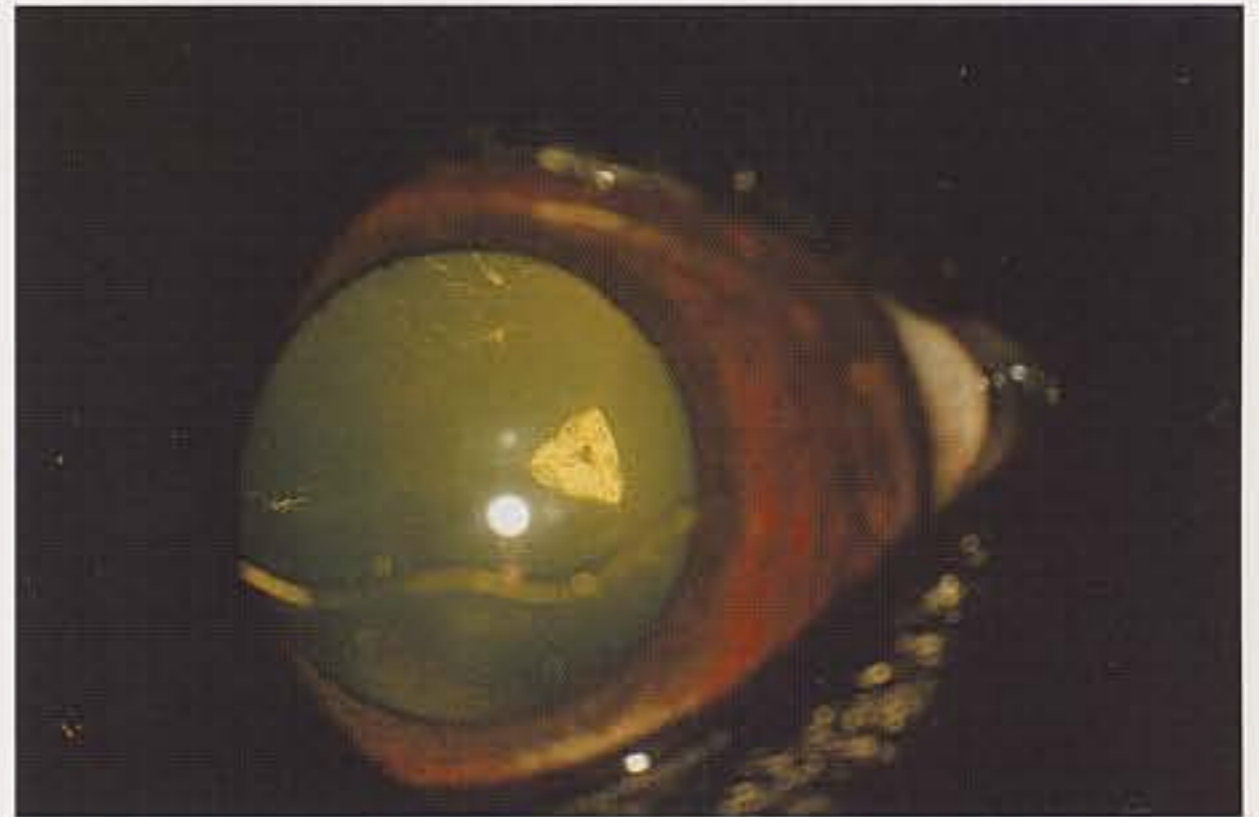


Fig. 9.7 Posterior polar cataract (Labrador Retriever, 3 years old) Subcapsular, dense focal opacity.

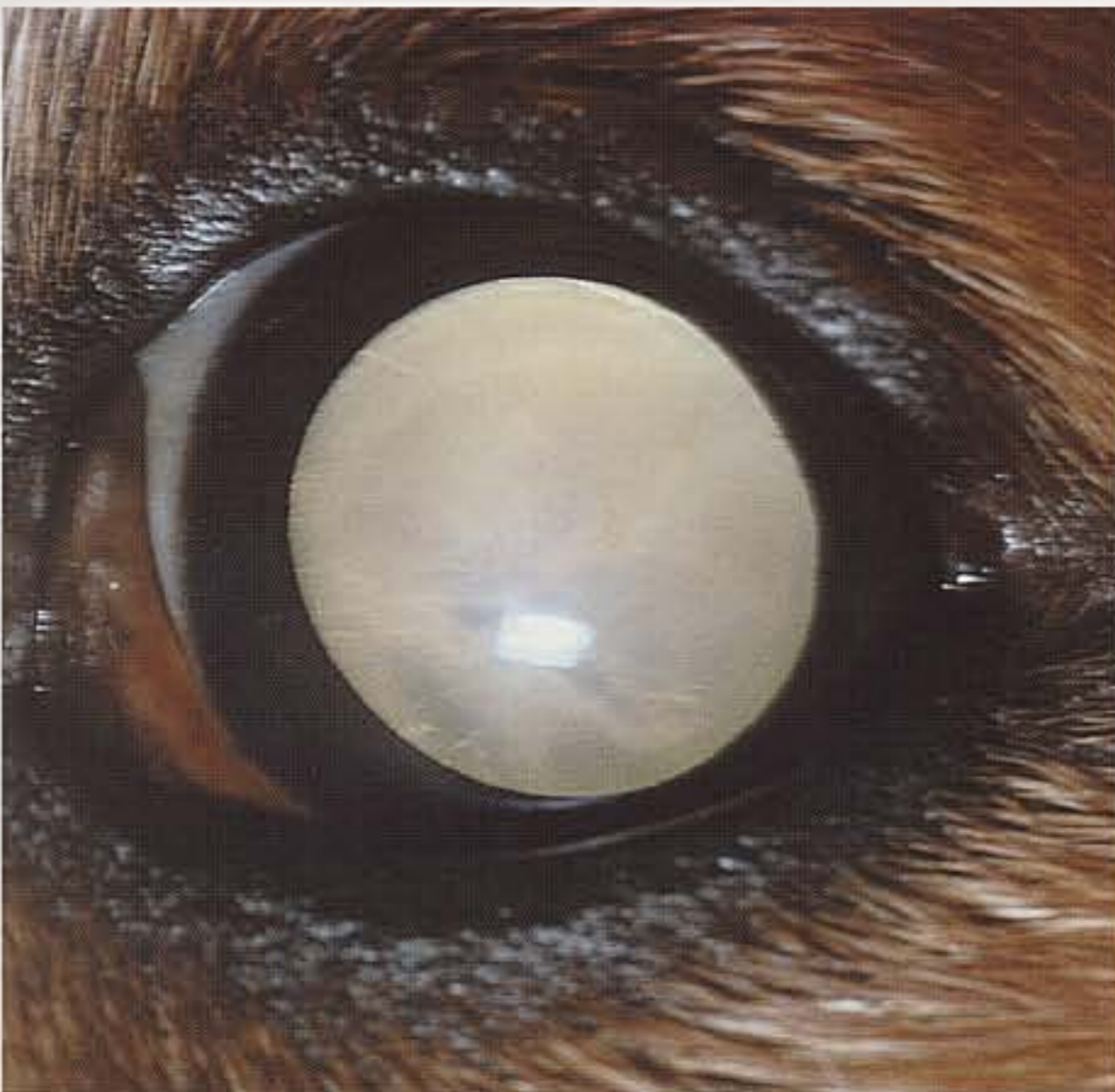

Fig. 9.6 Total cataract (Golden Retriever, 2 years old).

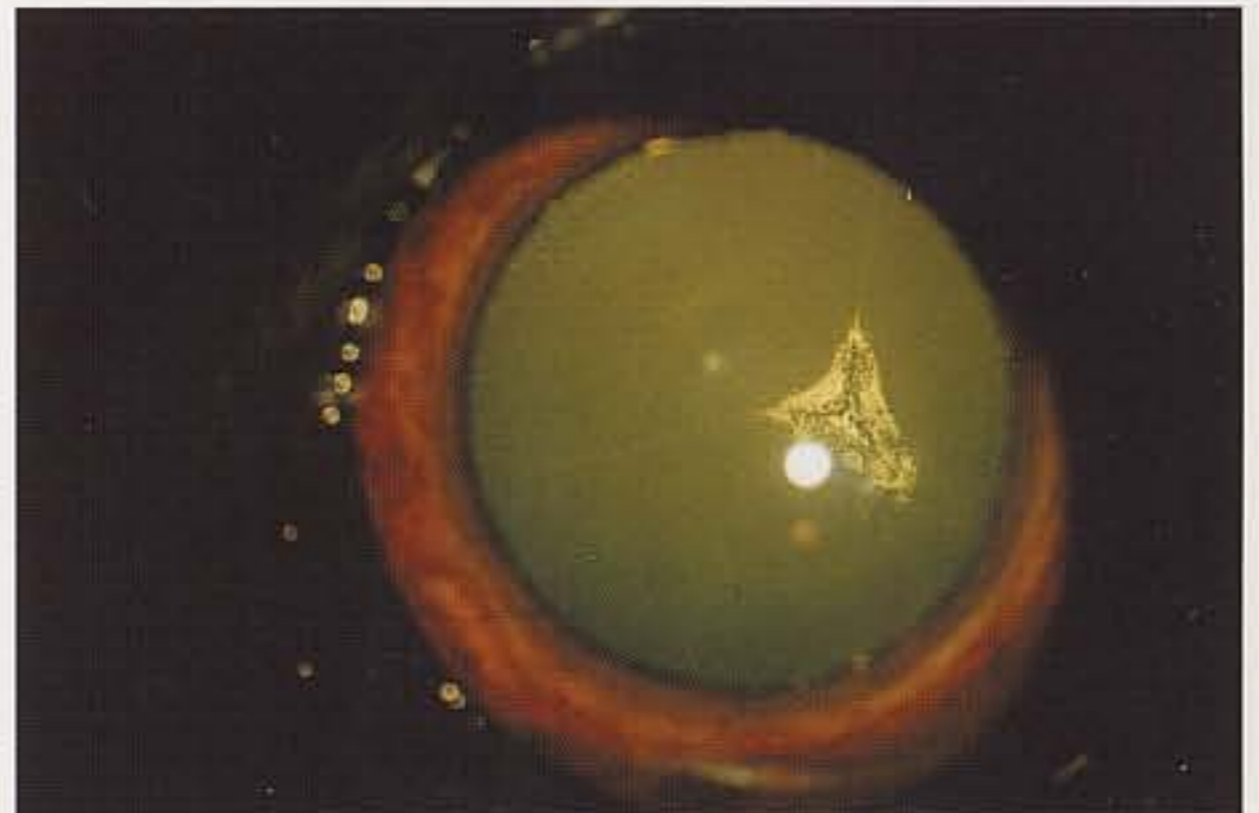

Fig. 9.8 Posterior polar cataract (Labrador Retriever, 4 years old) Typical example of subcapsular opacity.

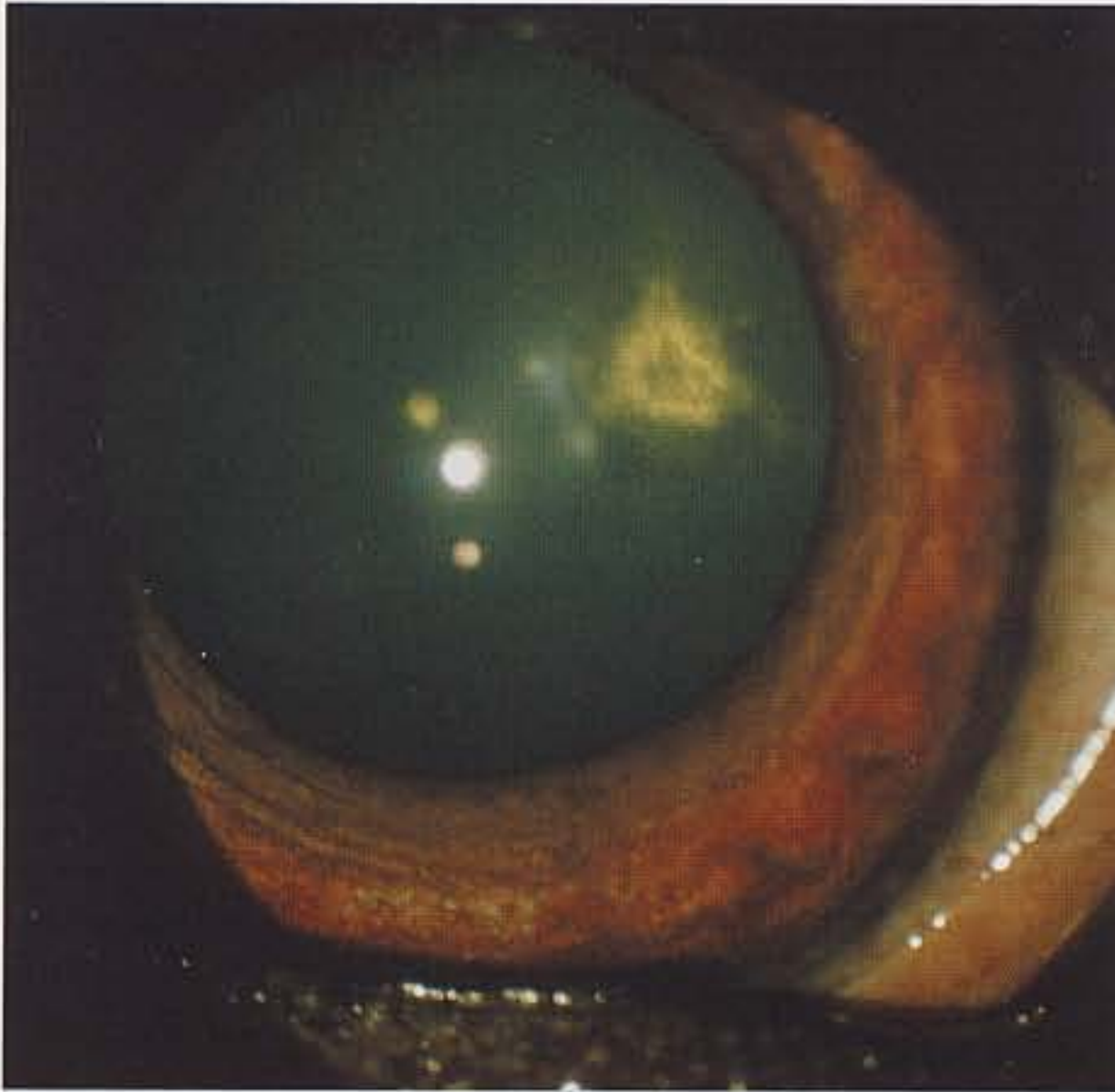


Fig. 9.9 Posterior polar cataract (Labrador Retriever, 3 years old) Subcapsular opacity.

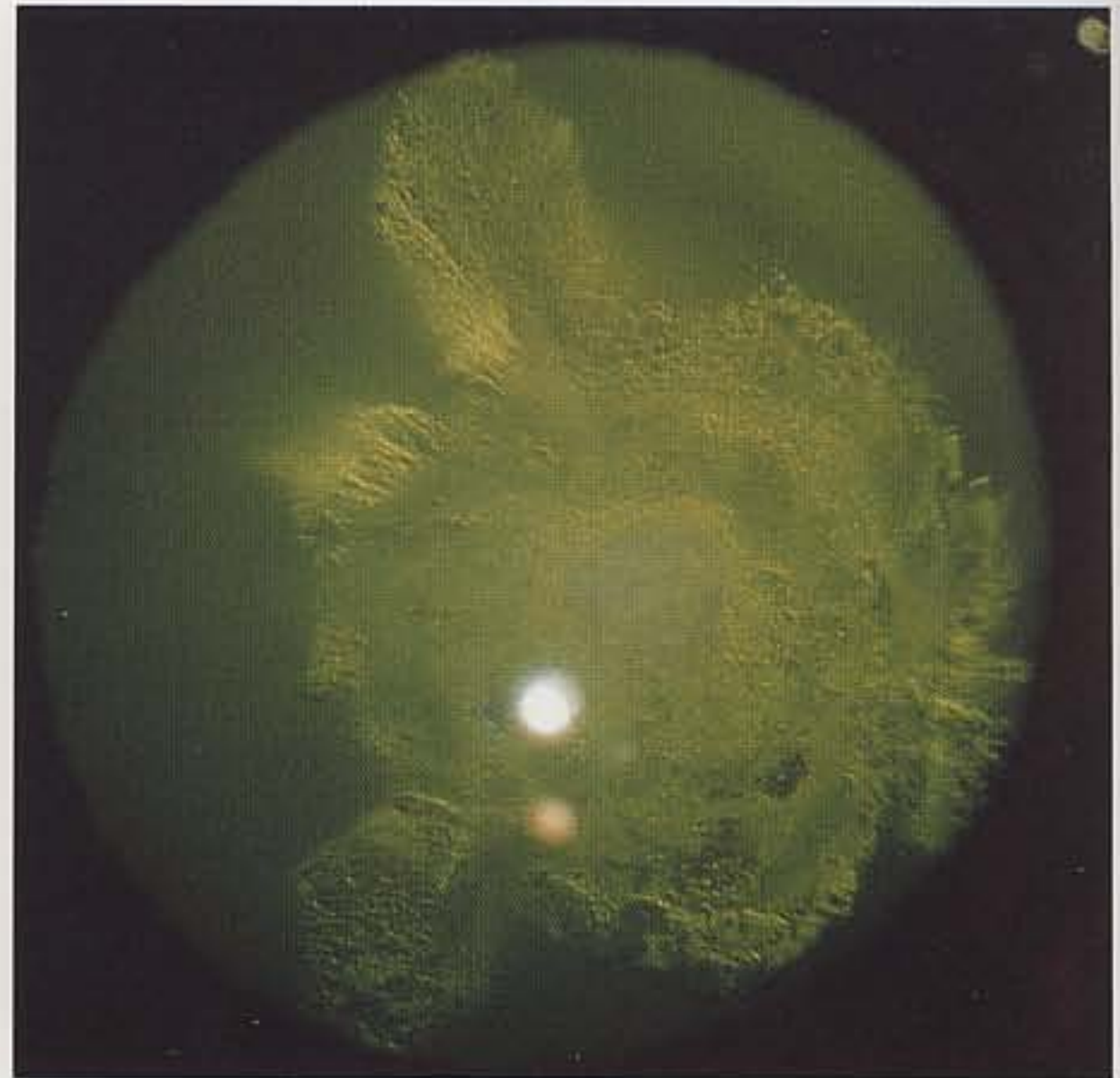

Fig. 9.11 Posterior polar cataract (Labrador Retriever, 9 years old) Large cataract with extensions. This dog retained good vision.

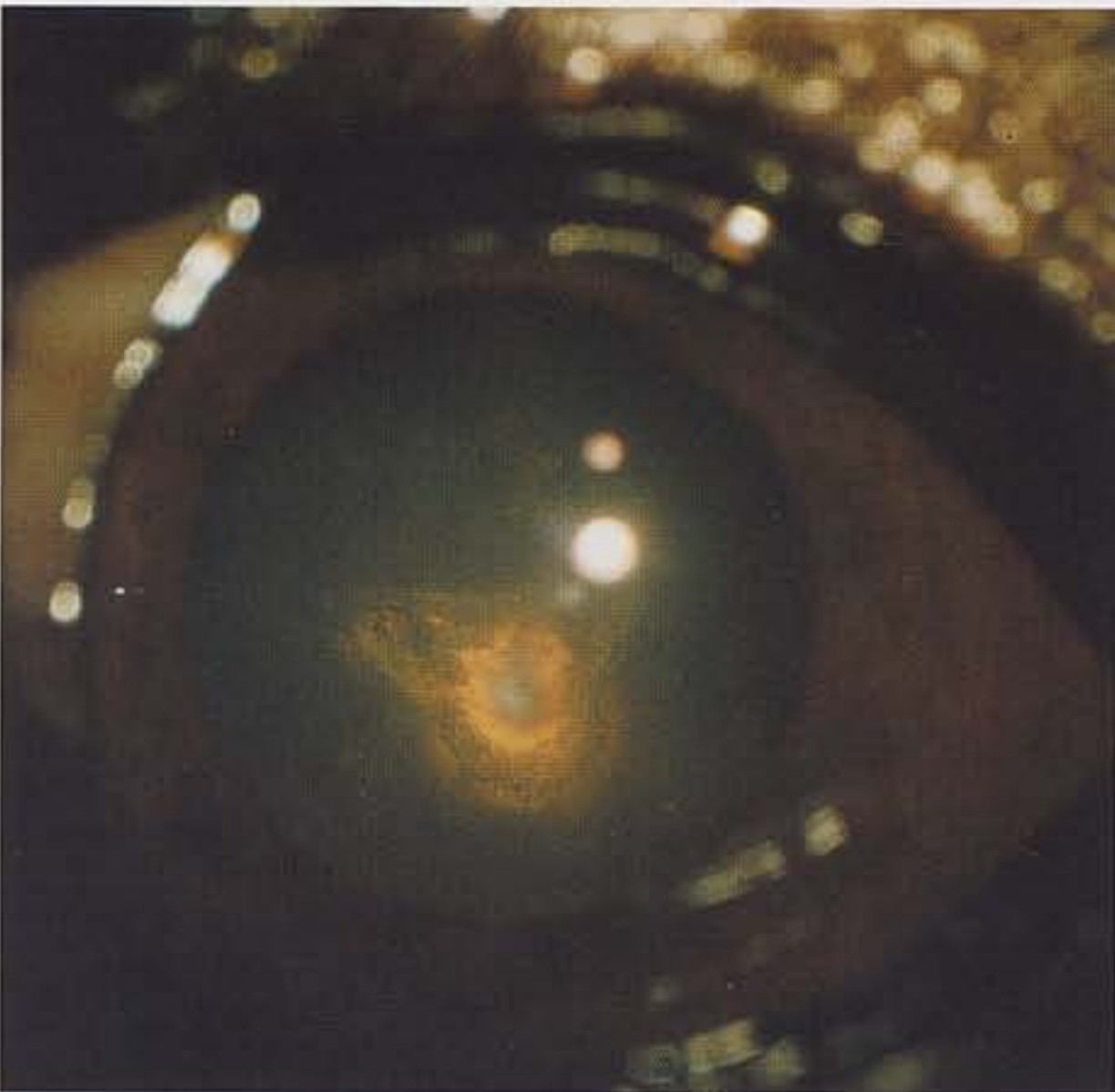


Fig. 9.10 Posterior polar cataract (Labrador Retriever, 6 years old) Dam of the dog shown in the previous figure.

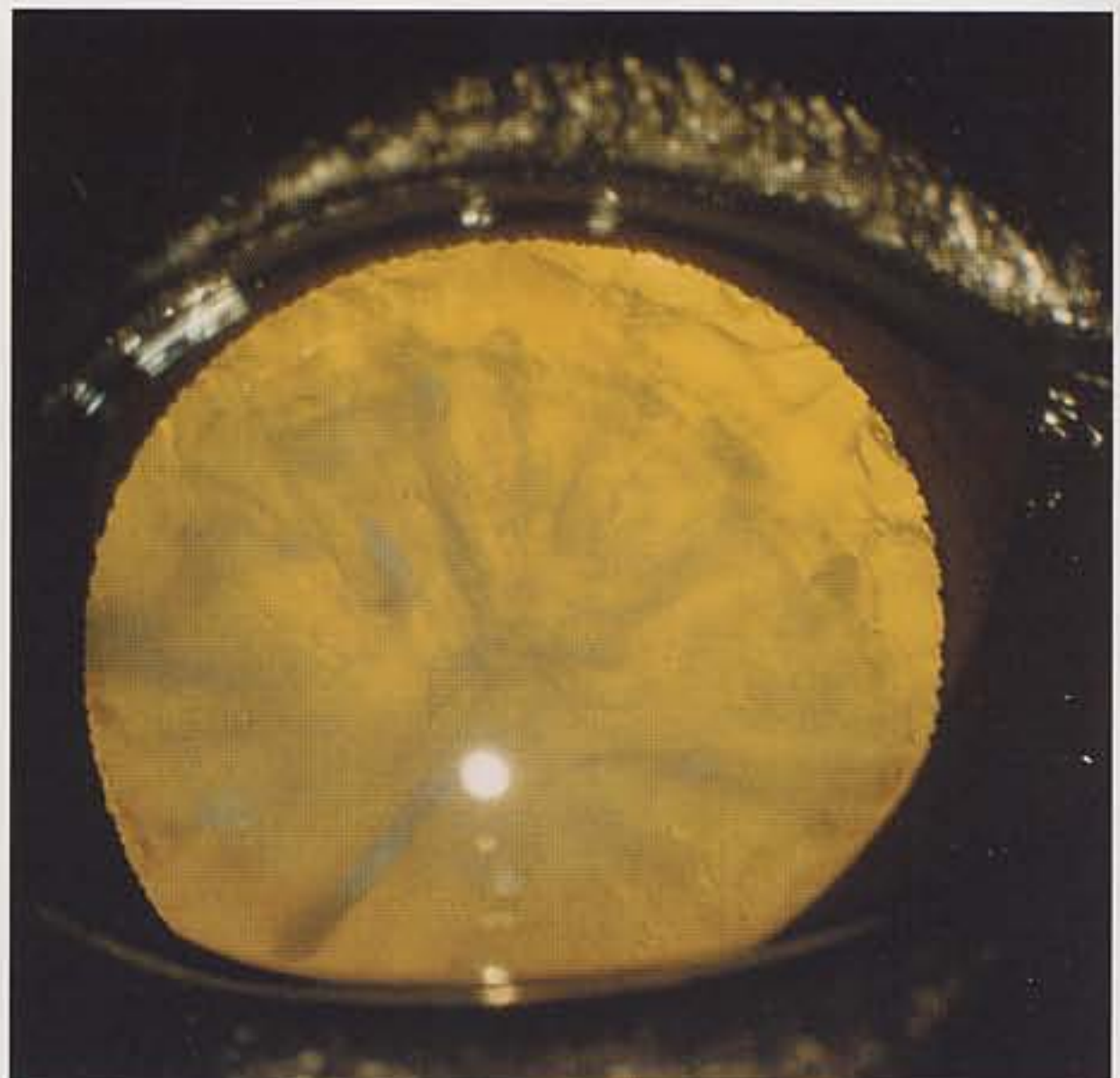


Fig. 9.12 Total cataract (Labrador Retriever, 4 years old) Note the density of the inverted-Y posterior suture lines. Tapetal reflex still visible and dog retains reasonable vision.



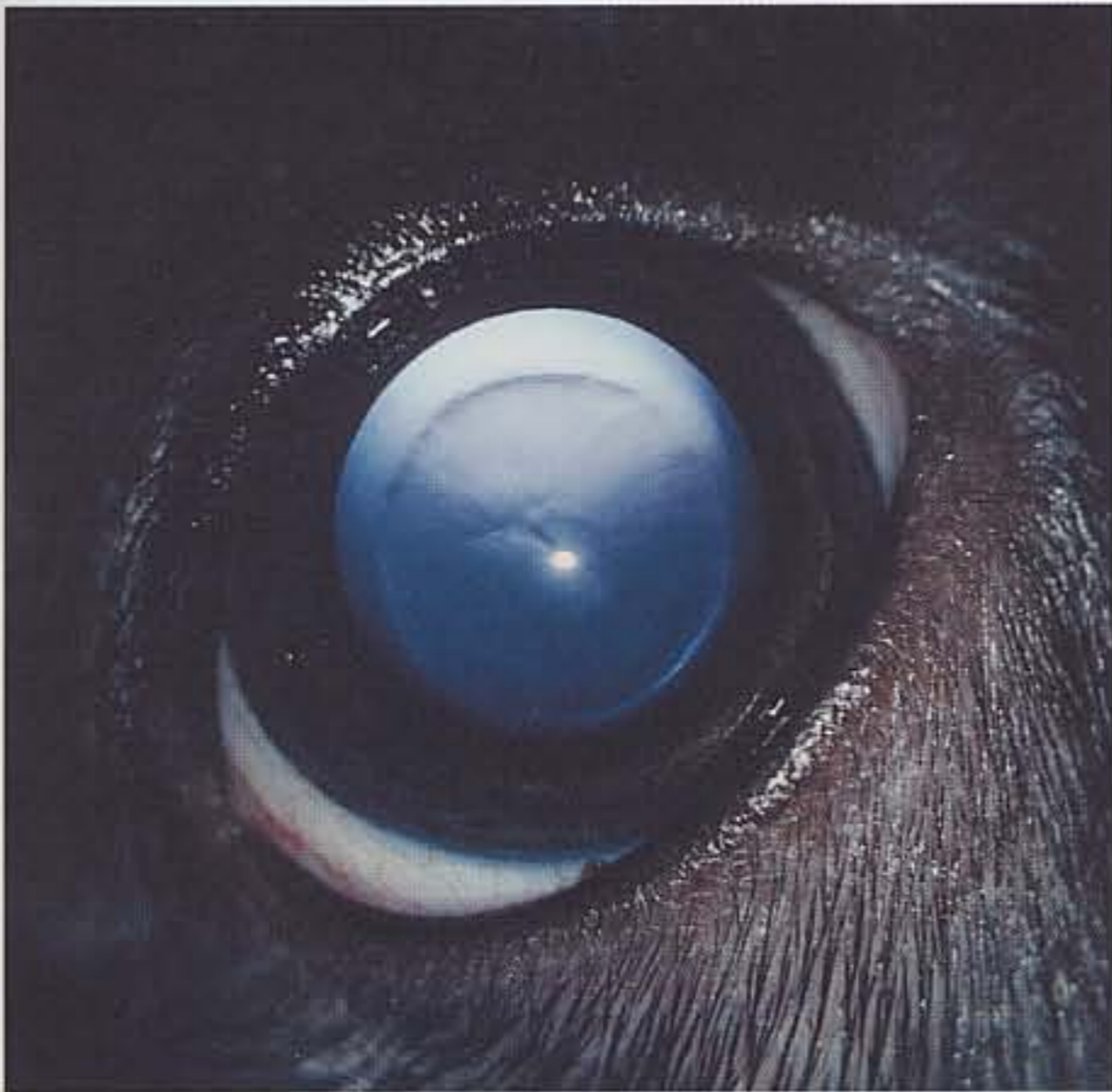

Fig. 9.13 Early cataract (Boston Terrier, 8 weeks old)  
Central opacity, bilaterally symmetrical cataract.

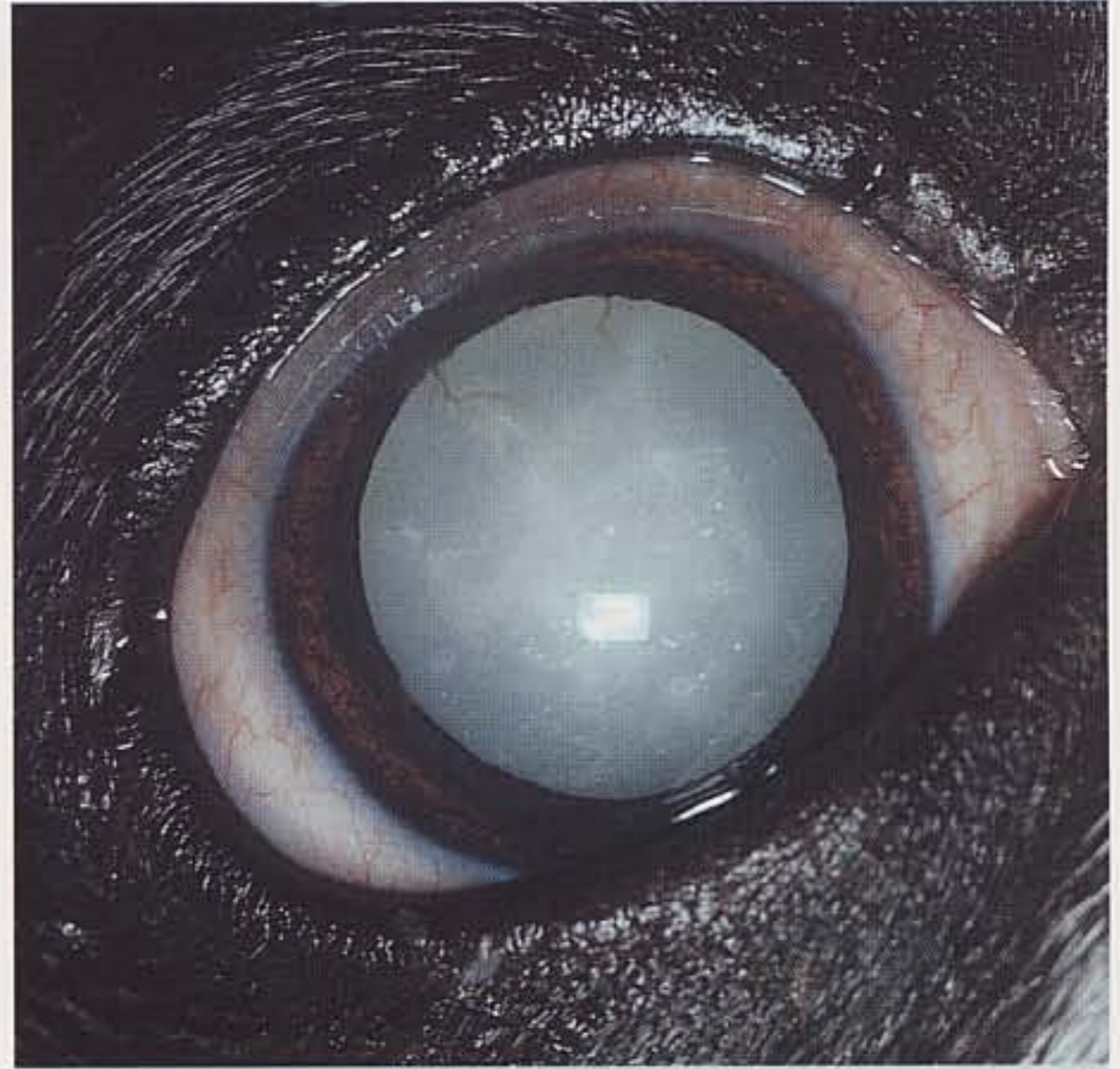

Fig. 9.15 Total cataract (Boston Terrier, 3 years old)  
Mature cataract.

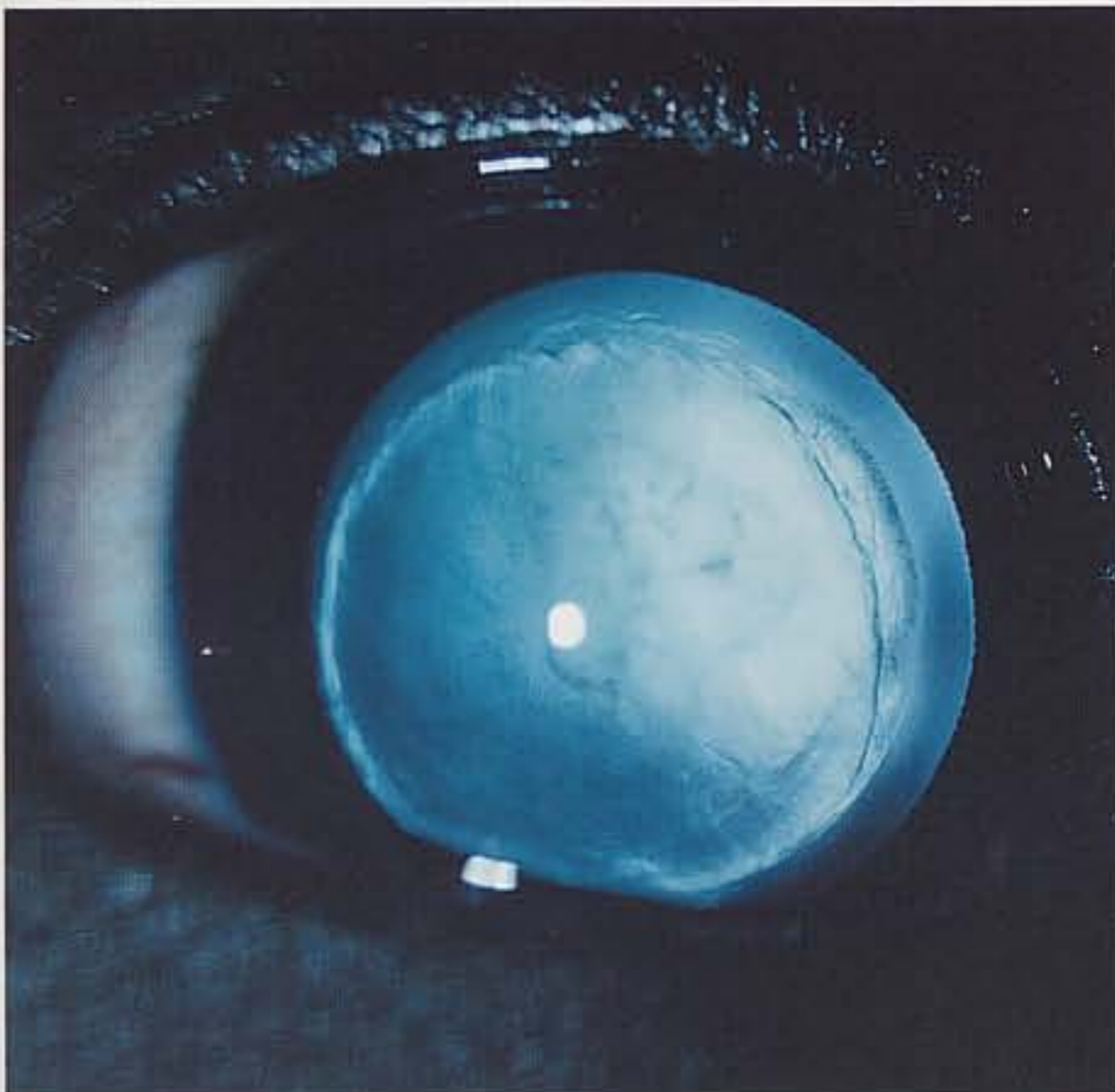


Fig. 9.14 Early cataract (Boston Terrier, 4 months old)  
Progression of central opacity.

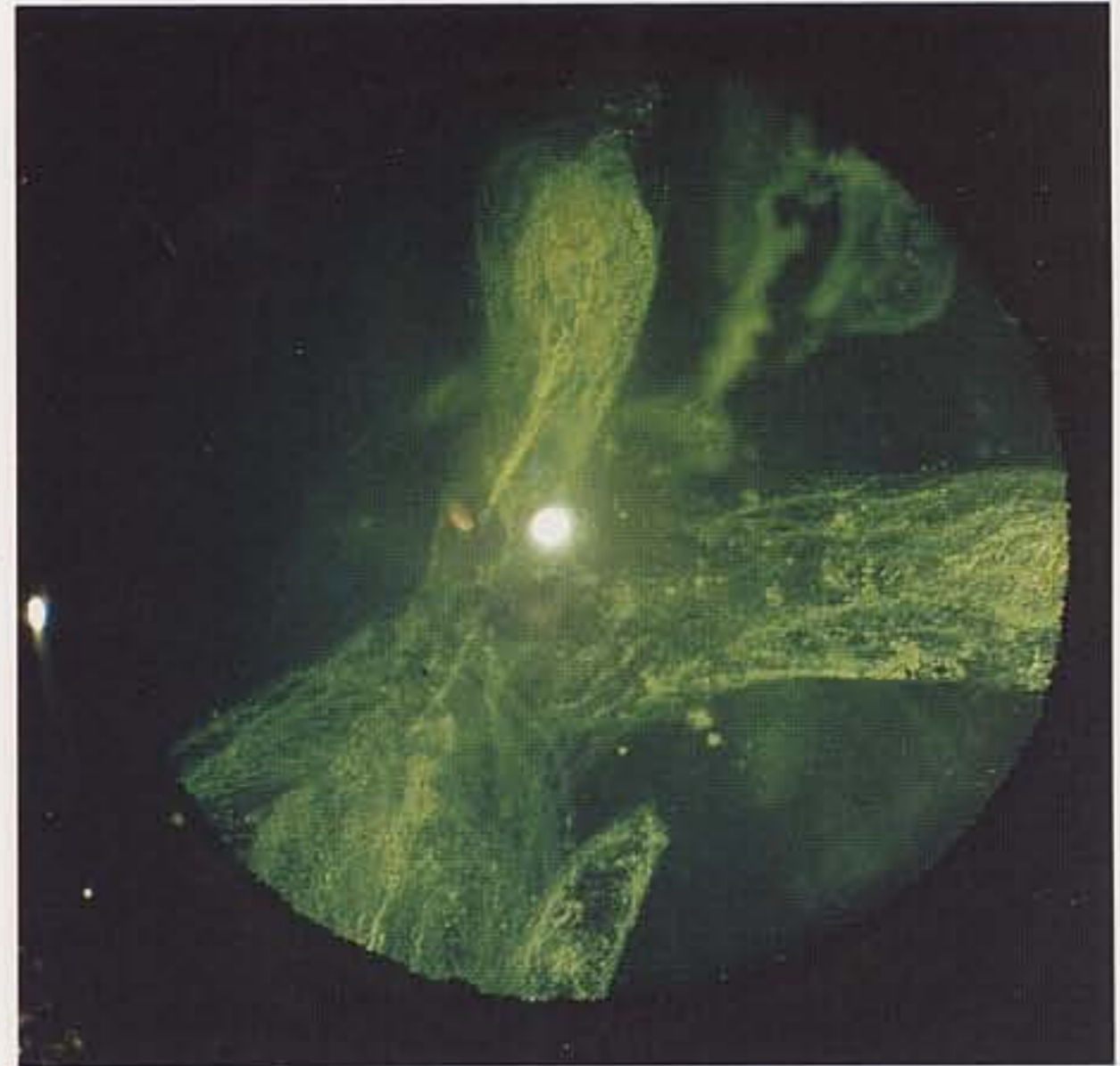


Fig. 9.16 Cataract (Boston Terrier, 6 years old) Late-onset type cataract.

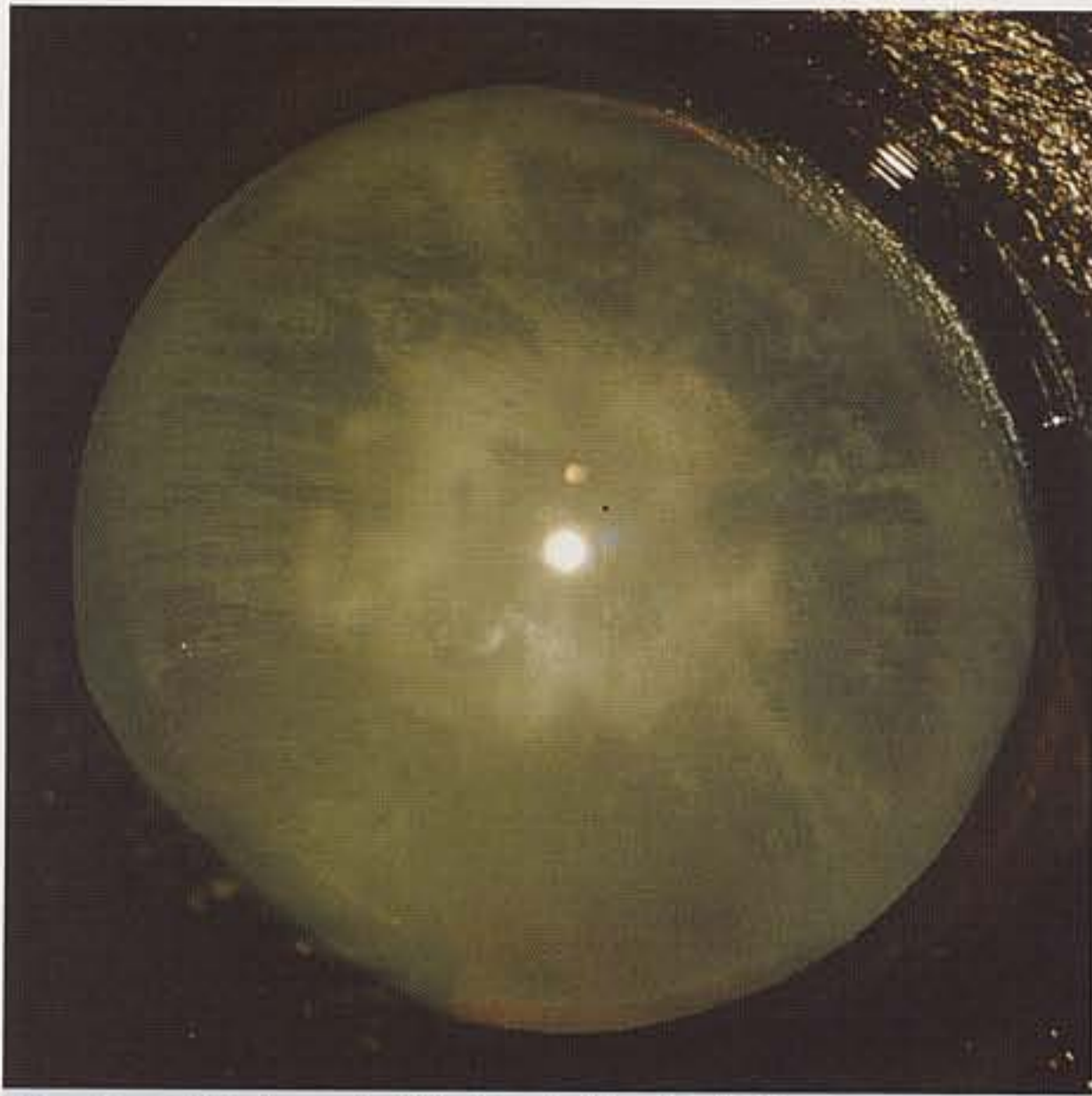

Fig. 9.17 Cataract (Staffordshire Bull Terrier, 2 years old) Progressive bilaterally symmetrical cataract, similar in appearance to the first type in the Boston Terrier (Figs 9.13–9.15). Note also the cataract associated with persistent hyperplastic primary vitreous (PHPV) in this breed (Figs 10.4–10.5).

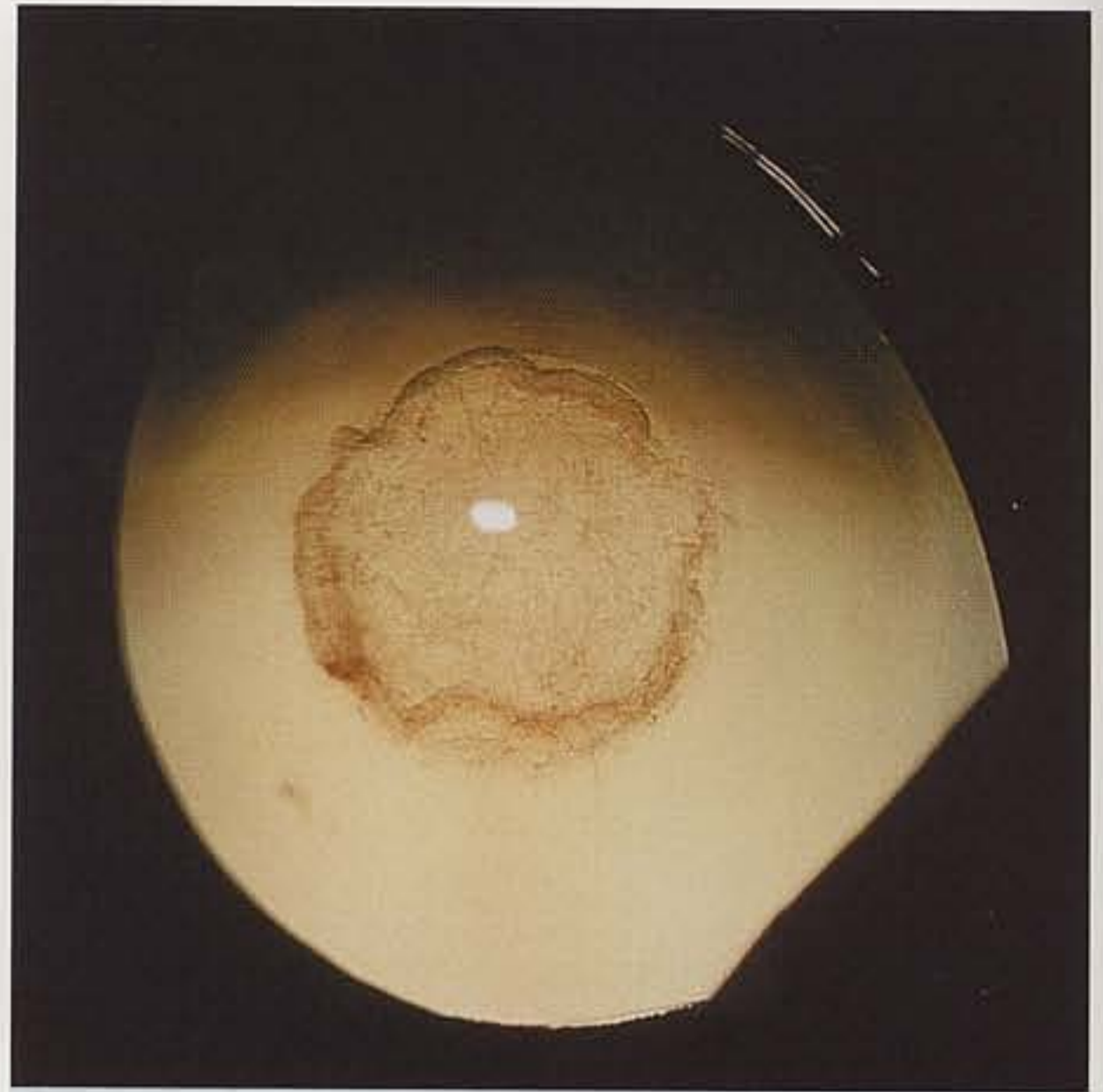


Fig. 9.19 Central cataract (Leonberger, 2 years old) Some variation of the opacity occurs in this breed but is usually central and bilateral.

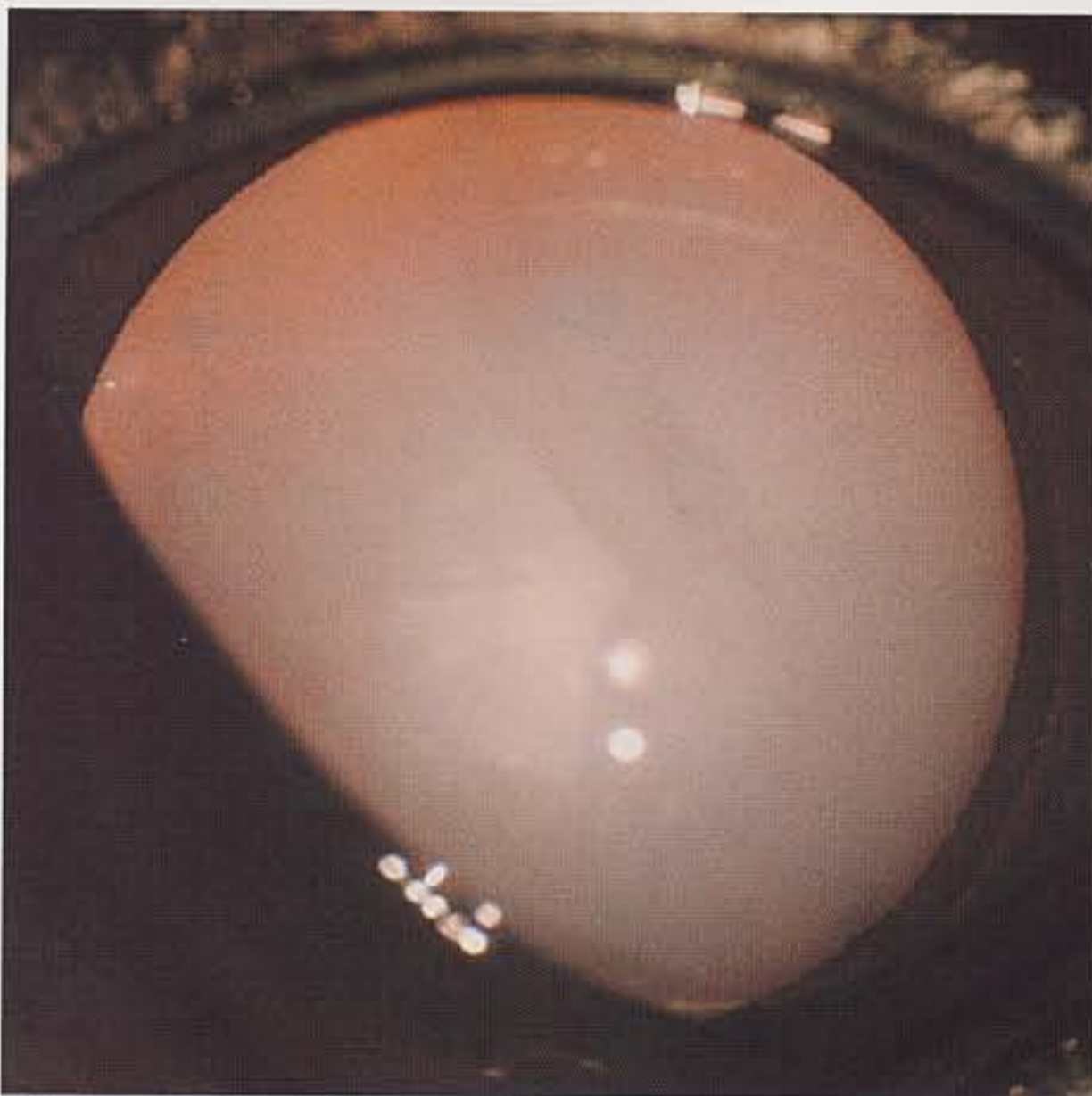


Fig. 9.18 Total cataract (Afghan Hound, 2 years old) Bilaterally symmetrical cataracts.

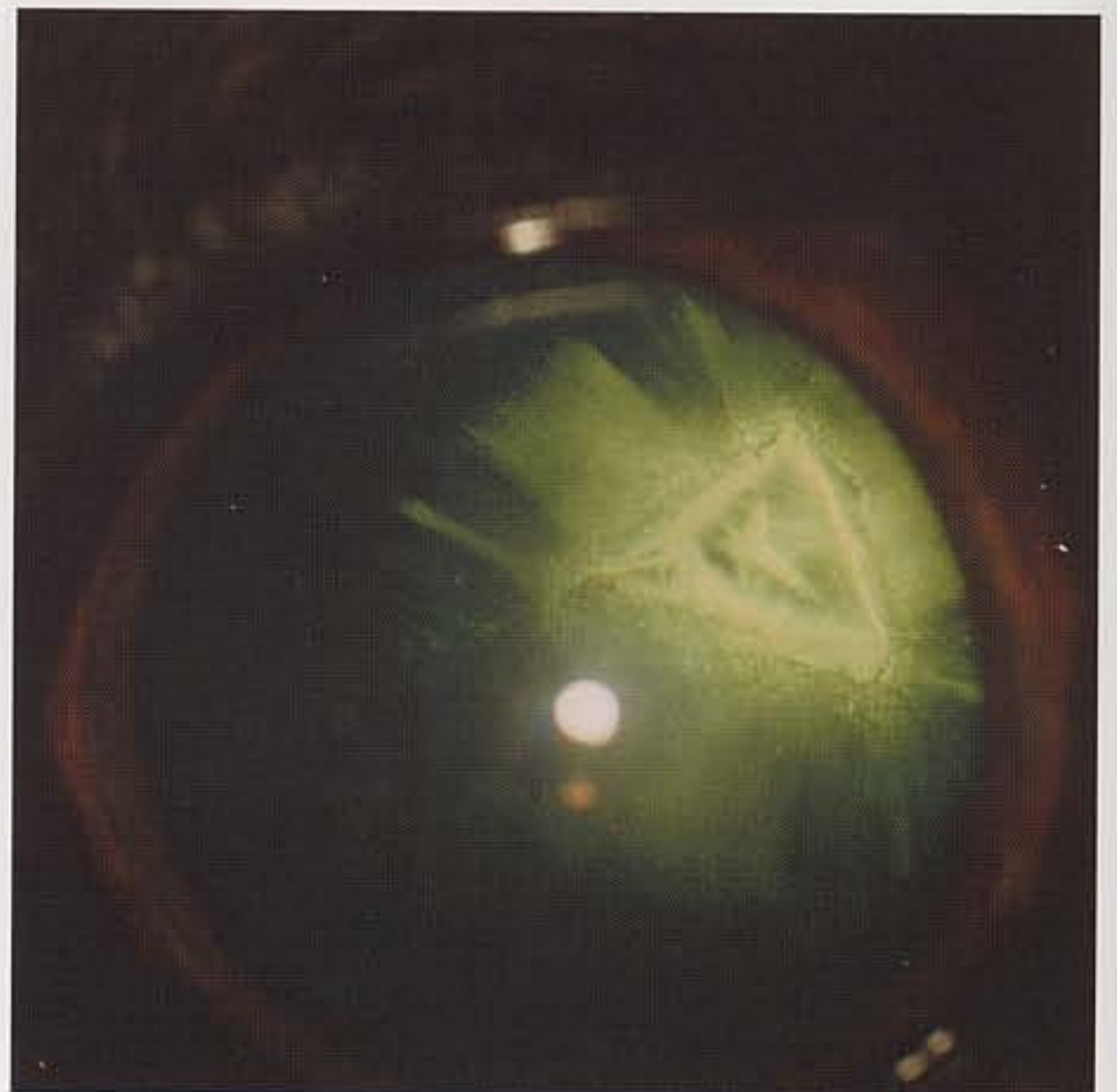

Fig. 9.20 Posterior polar cataract (Norwegian Buhund, 10 months old) With extensions.

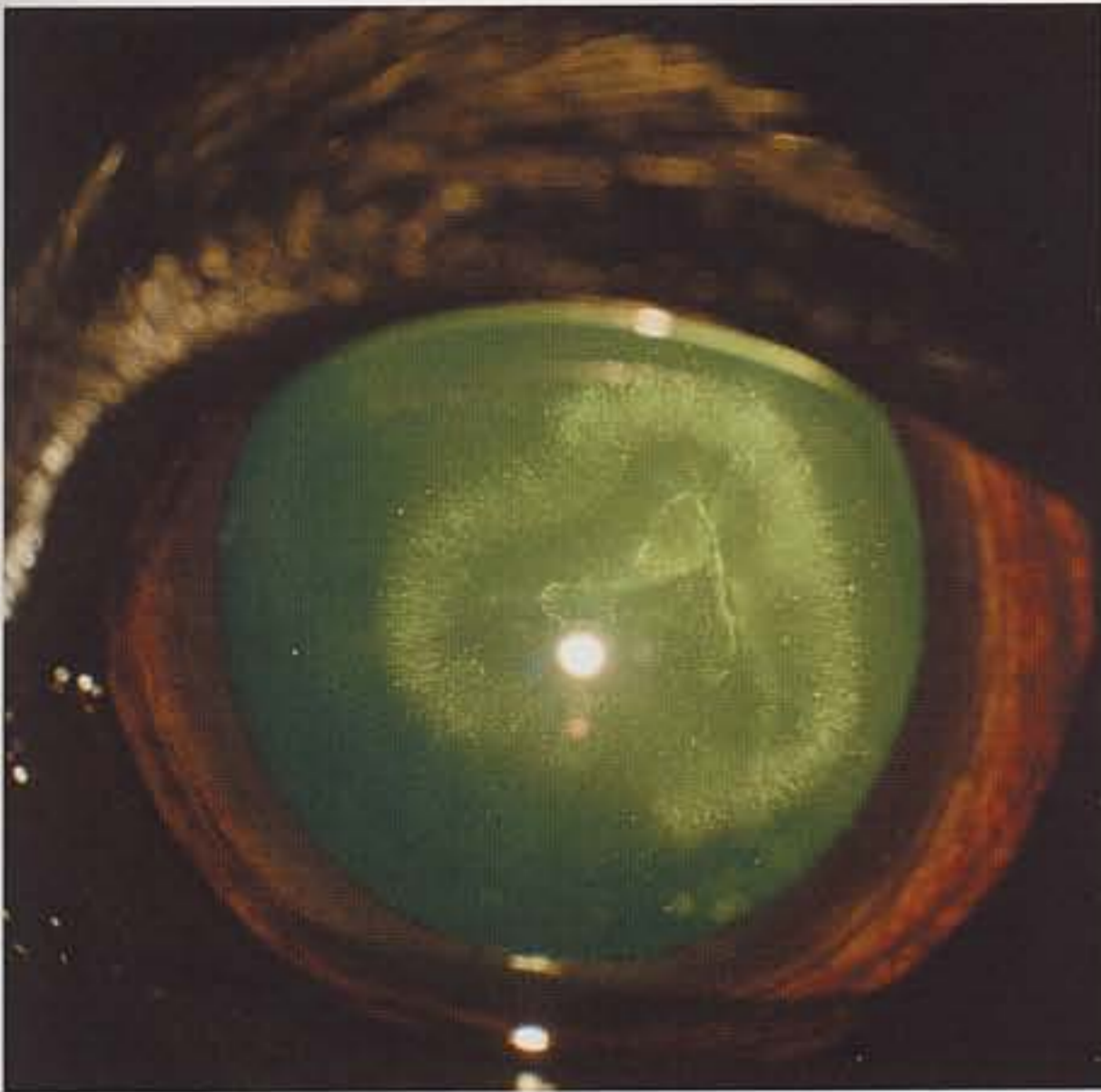

Fig. 9.21 Posterior polar cataract (Norwegian Buhund, 6 months old) Large posterior polar opacity.

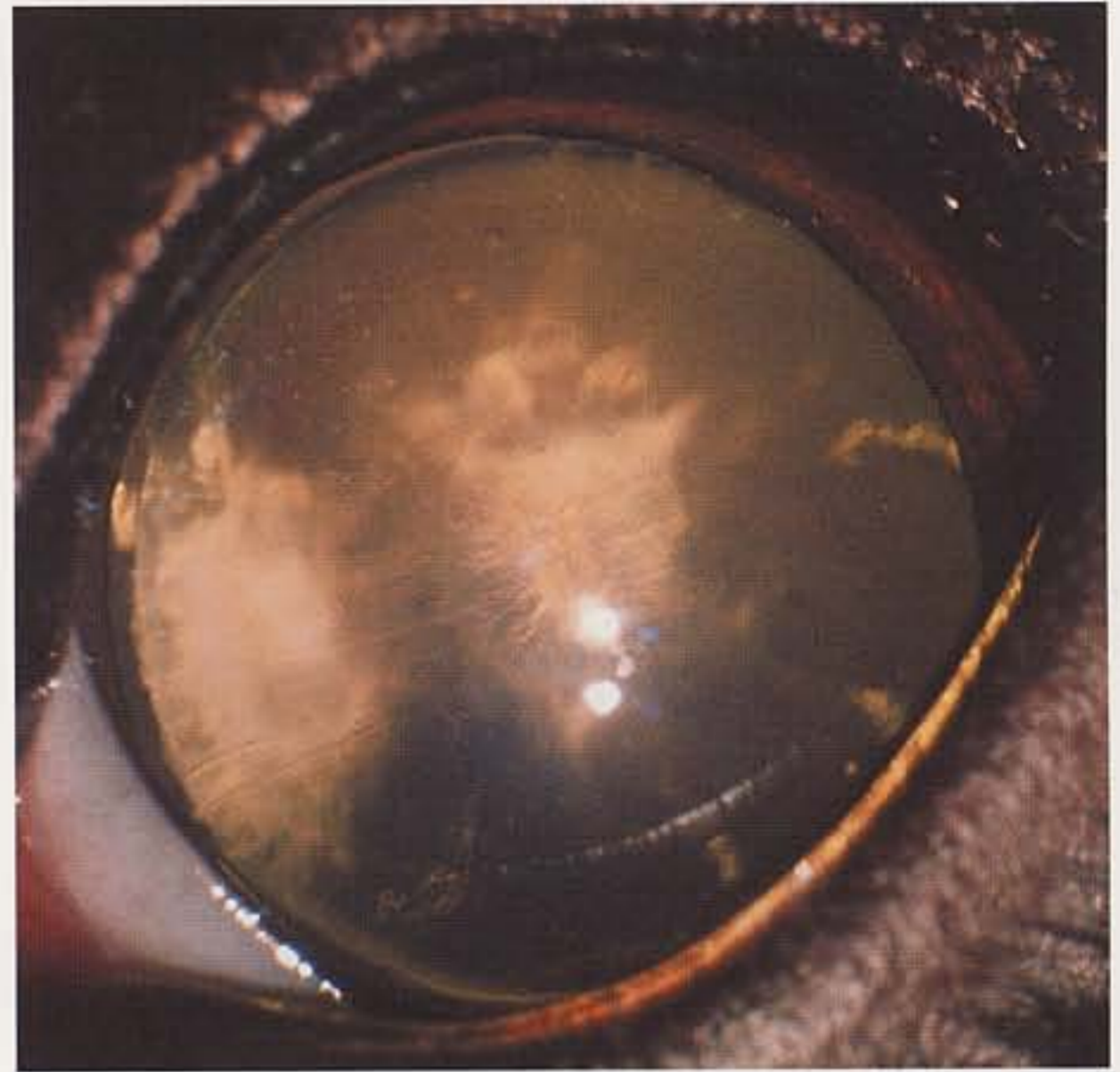


Fig. 9.23 Two foci of cataract (American Cocker Spaniel, 3 years old) Cataract in this breed is markedly pleomorphic and often asymmetrical but usually bilateral.

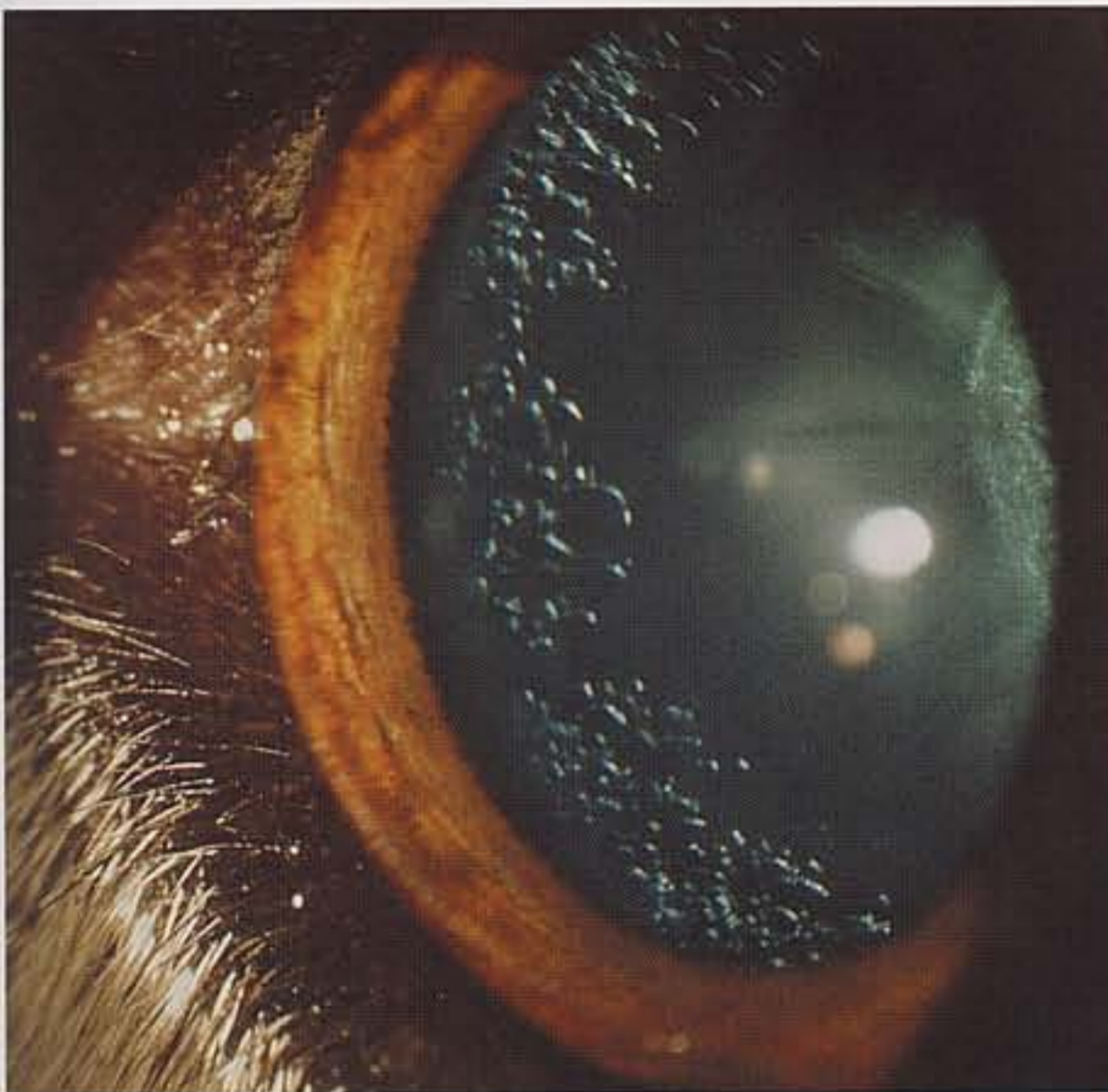

Fig. 9.22 Cortical cataract (Norwegian Buhund, 21 months old) Progressive, peripheral, cortical cataract plus posterior polar opacity.

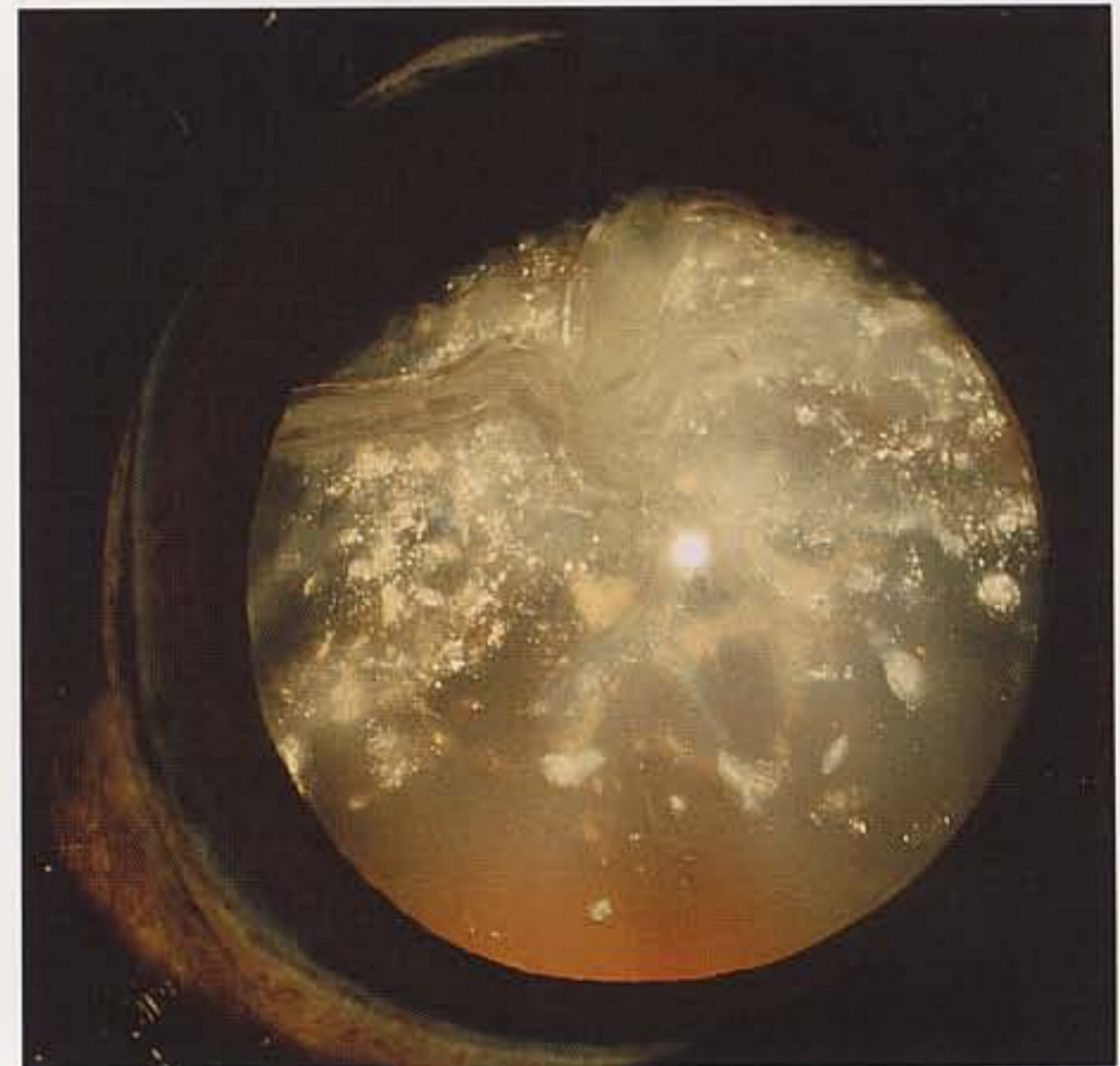

Fig. 9.24 Total cataract (American Cocker Spaniel, 5 years old) Lens resorption with folding of the lens capsule visible from 10 o'clock.

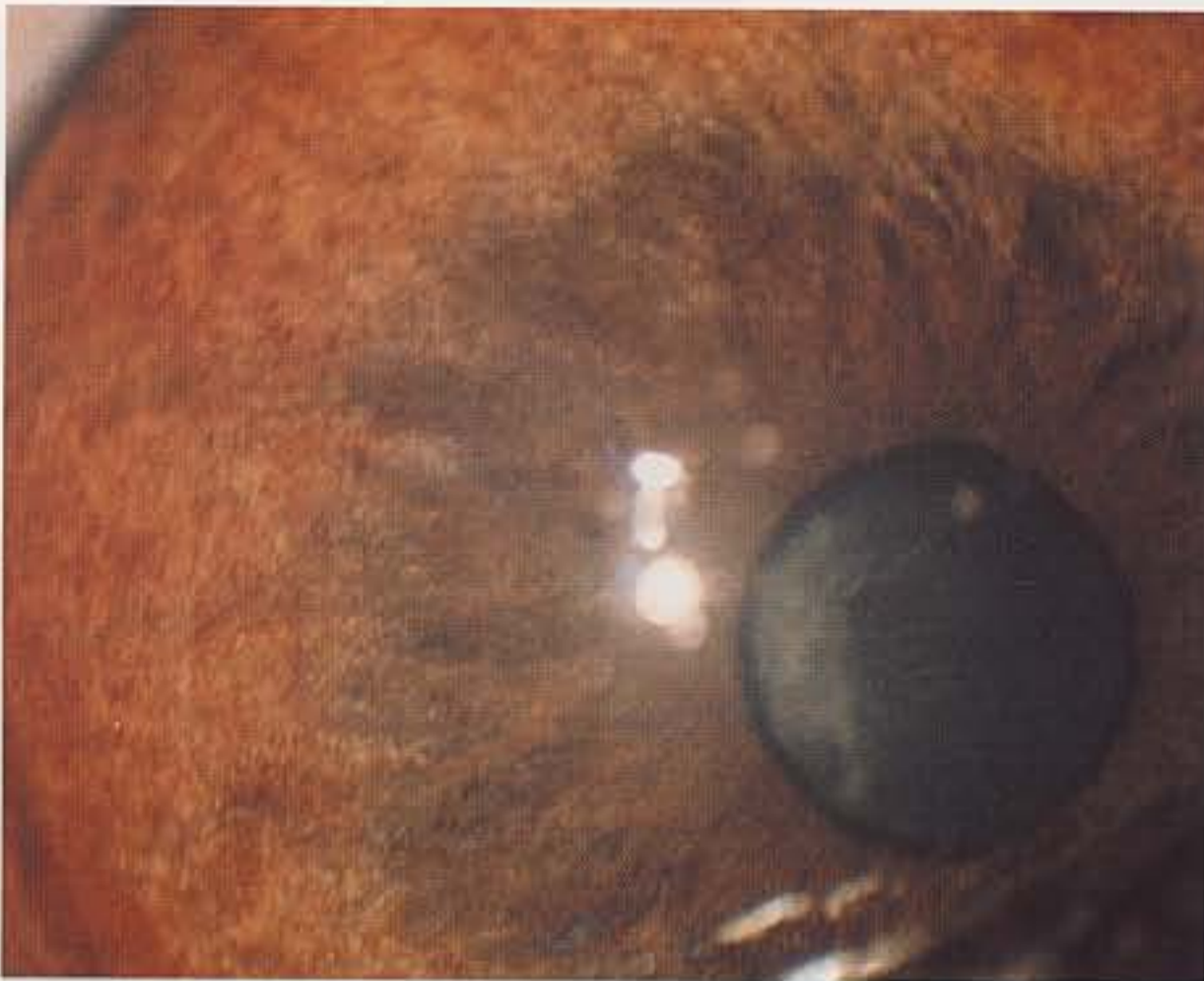


Fig. 9.25 Partial cataract (American Cocker Spaniel, 3 years old) Note the normal iris colour.

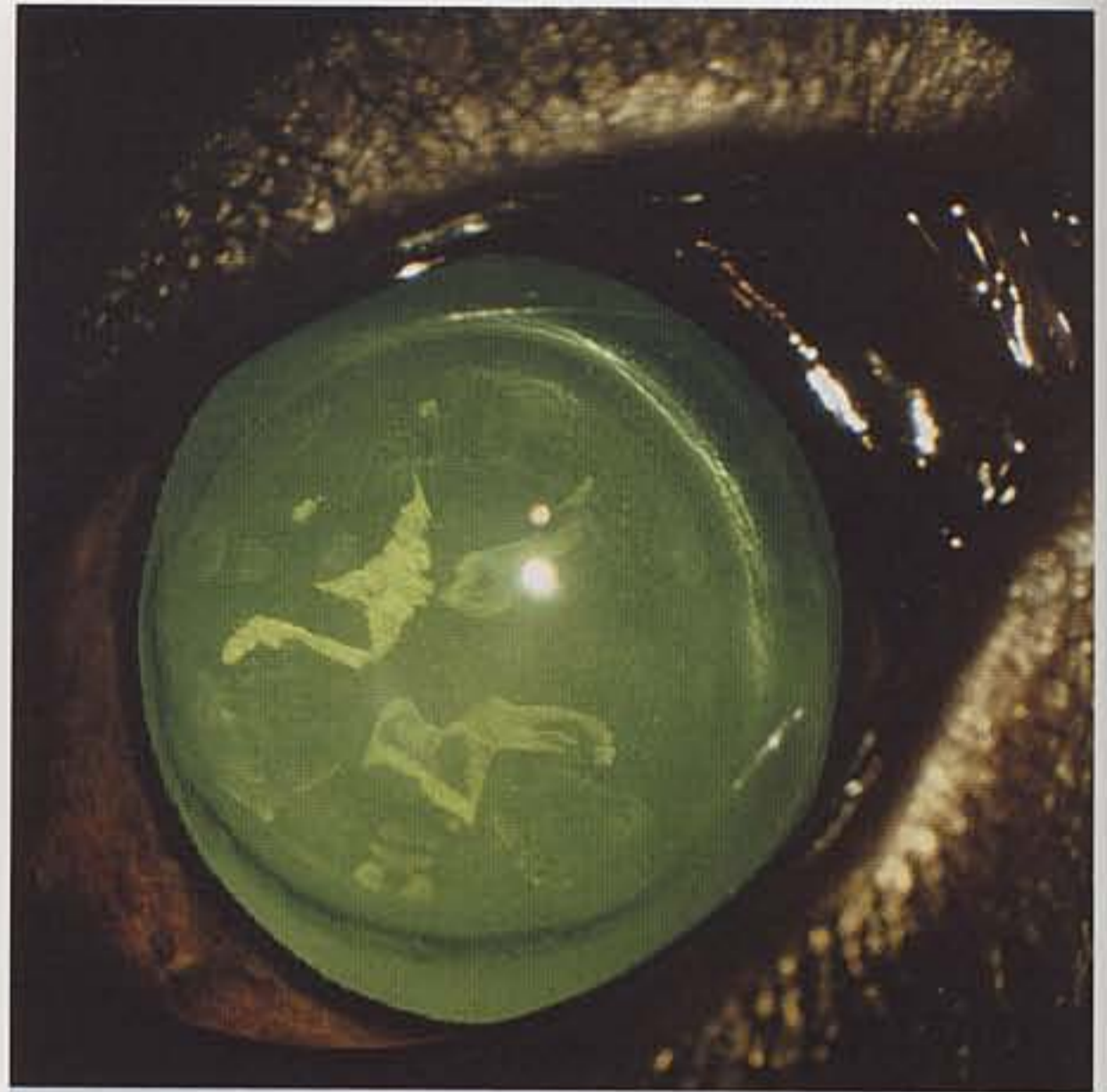

Fig. 9.27 Cataract (German Shepherd Dog, 4 months old) Bilateral and progressive.

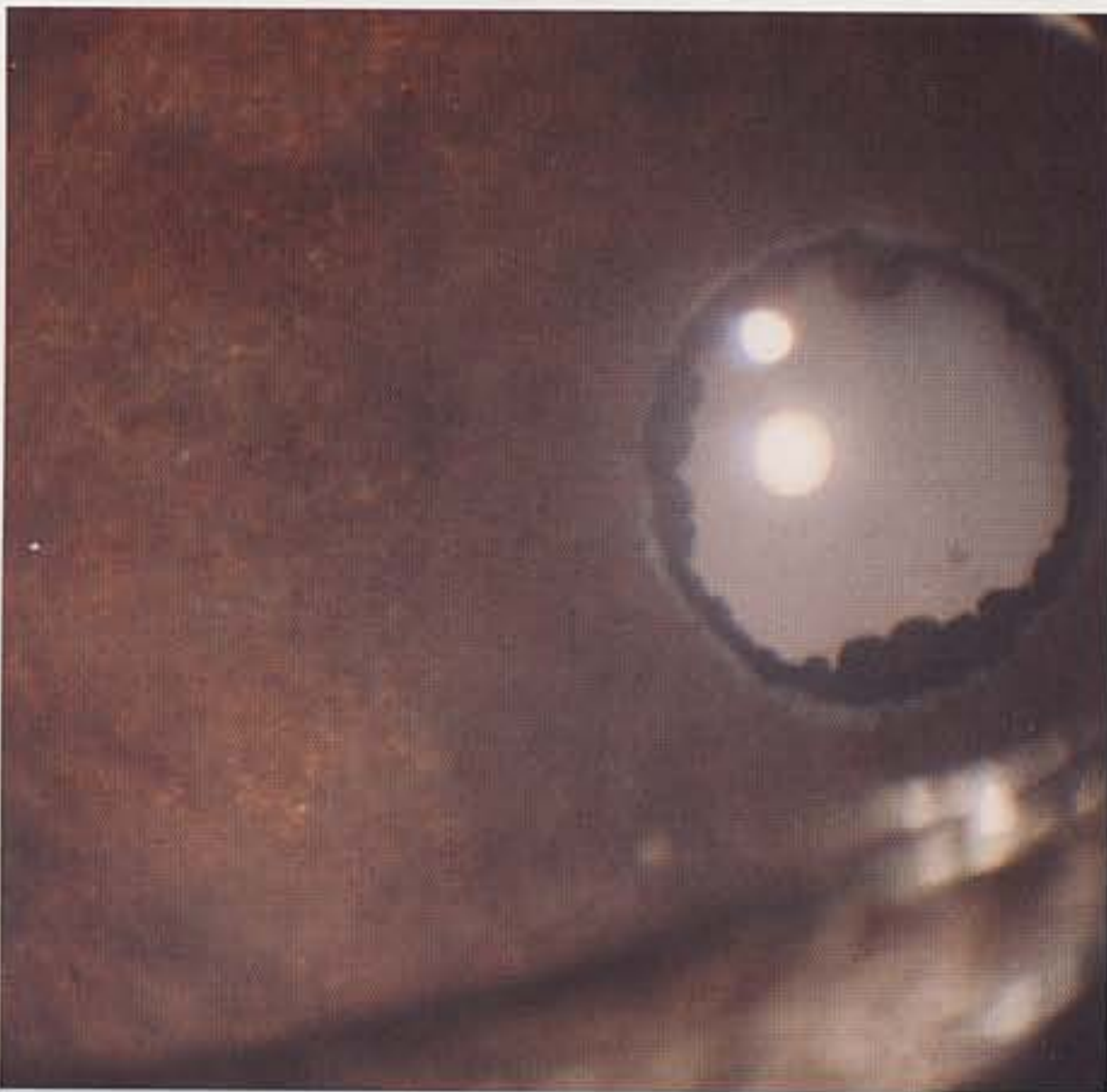

Fig. 9.26 Total cataract with associated uveitis (American Cocker Spaniel, 4 years old) Note the iris colour in comparison to the previous figure and the presence of multiple pupillary cysts.



Fig. 9.28 Cataract (German Shepherd Dog, 9 months old) Bilateral; the two eyes are not always identical.

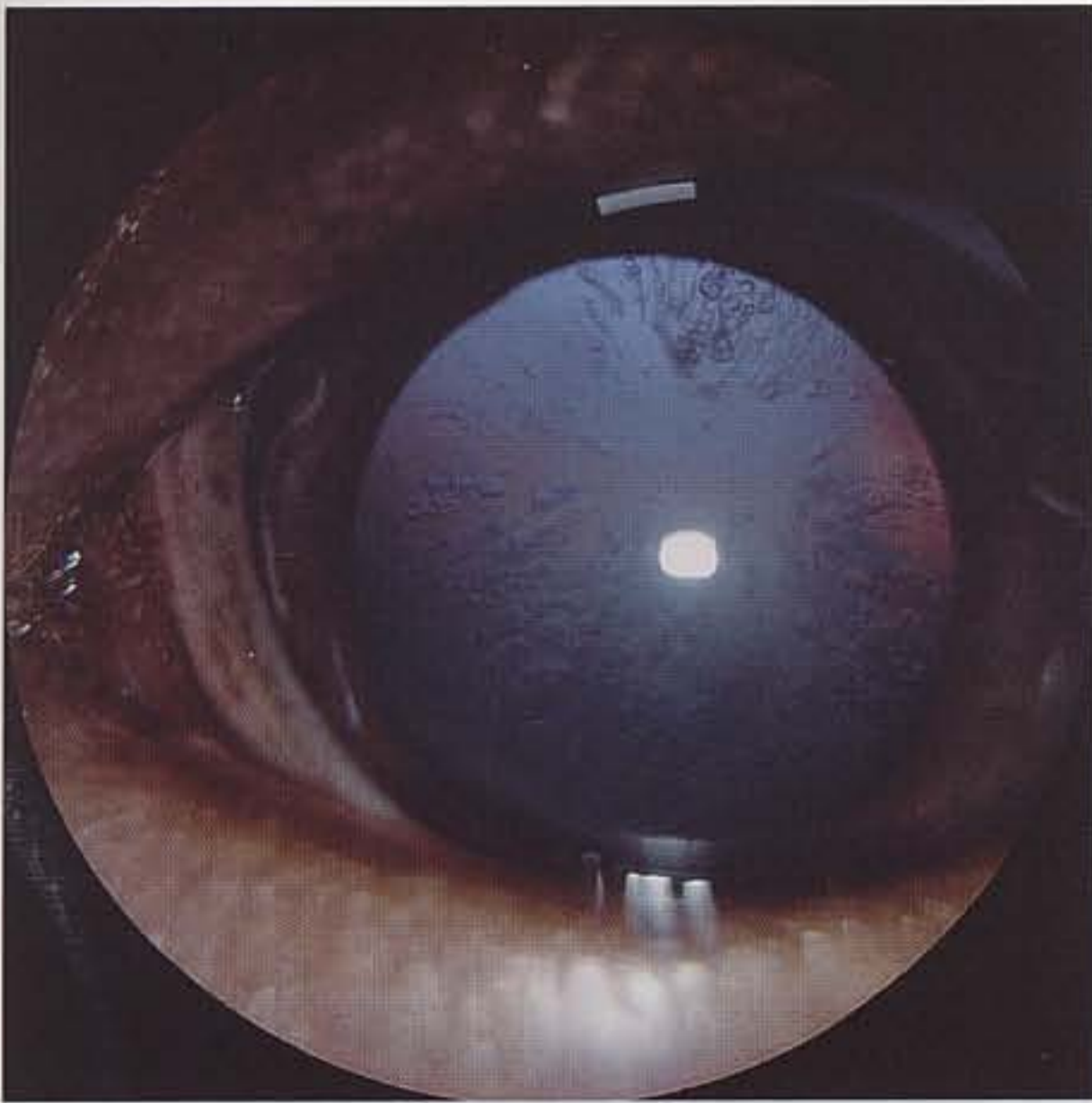


Fig. 9.29 Cataract (Welsh Springer Spaniel, 8 weeks old) Bilateral, symmetrical and progressive.

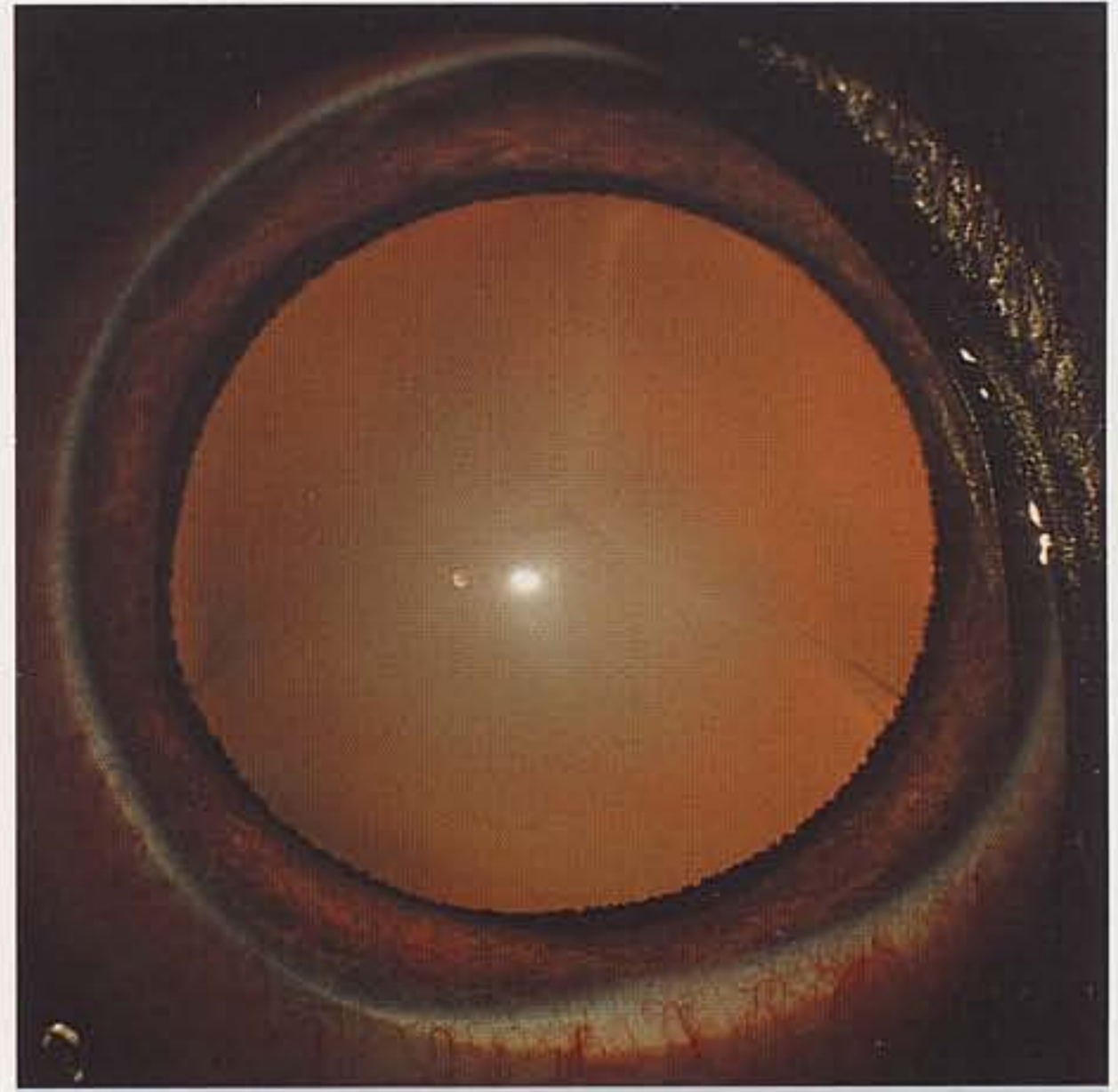


Fig. 9.31 Cataract (Cavalier King Charles Spaniel, 18 months old) Bilateral, total and progressive. This cataract is not congenital. See also Figs 9.35–9.38.

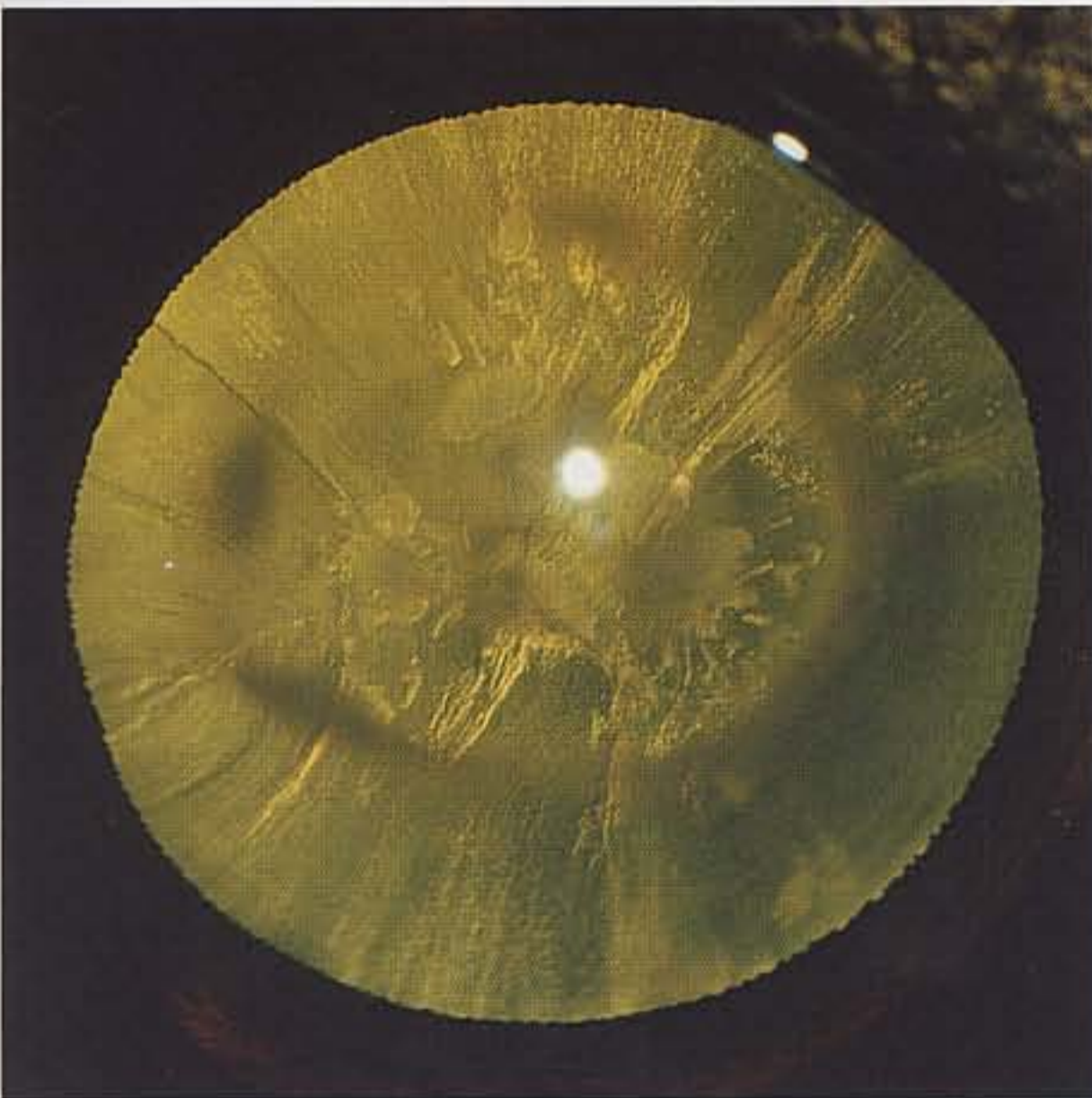

Fig. 9.30 Cataract (Standard Poodle, 12 months old) Bilateral and progressive. The two eyes are similar.

Table 9.1 - Primary hereditary cataracts

Congenital (with mild microphthalmos)

- Cavalier King Charles Spaniel
- Schnauzer, Miniature

Non-congenital (usually bilateral, equal and progressive)

- Belgian Shepherd Dog
- Boston Terrier (two forms)
- Cavalier King Charles Spaniel (two forms - see also congenital)
- German Shepherd Dog
- Leonberger
- Munsterlander, Large
- Norwegian Buhund
- Poodle, Standard
- Retriever, Chesapeake Bay
- Retriever, Golden
- Retriever, Labrador
- Setter, Irish Red and White
- Siberian Husky
- Spaniel, American Cocker
- Spaniel, Welsh Springer
- Staffordshire Bull Terrier

invariably, bilaterally symmetrical and are commonly progressive producing defective vision and often blindness, the exception being posterior polar cataract in the retriever breeds which often only progresses to a certain point and does not interfere with vision.

### Congenital cataracts and associated anomalies (Figs 9.32–9.49)

These cataracts are present at birth and are almost, if not always, associated with some other ocular anomaly, in particular microphthalmos, which may

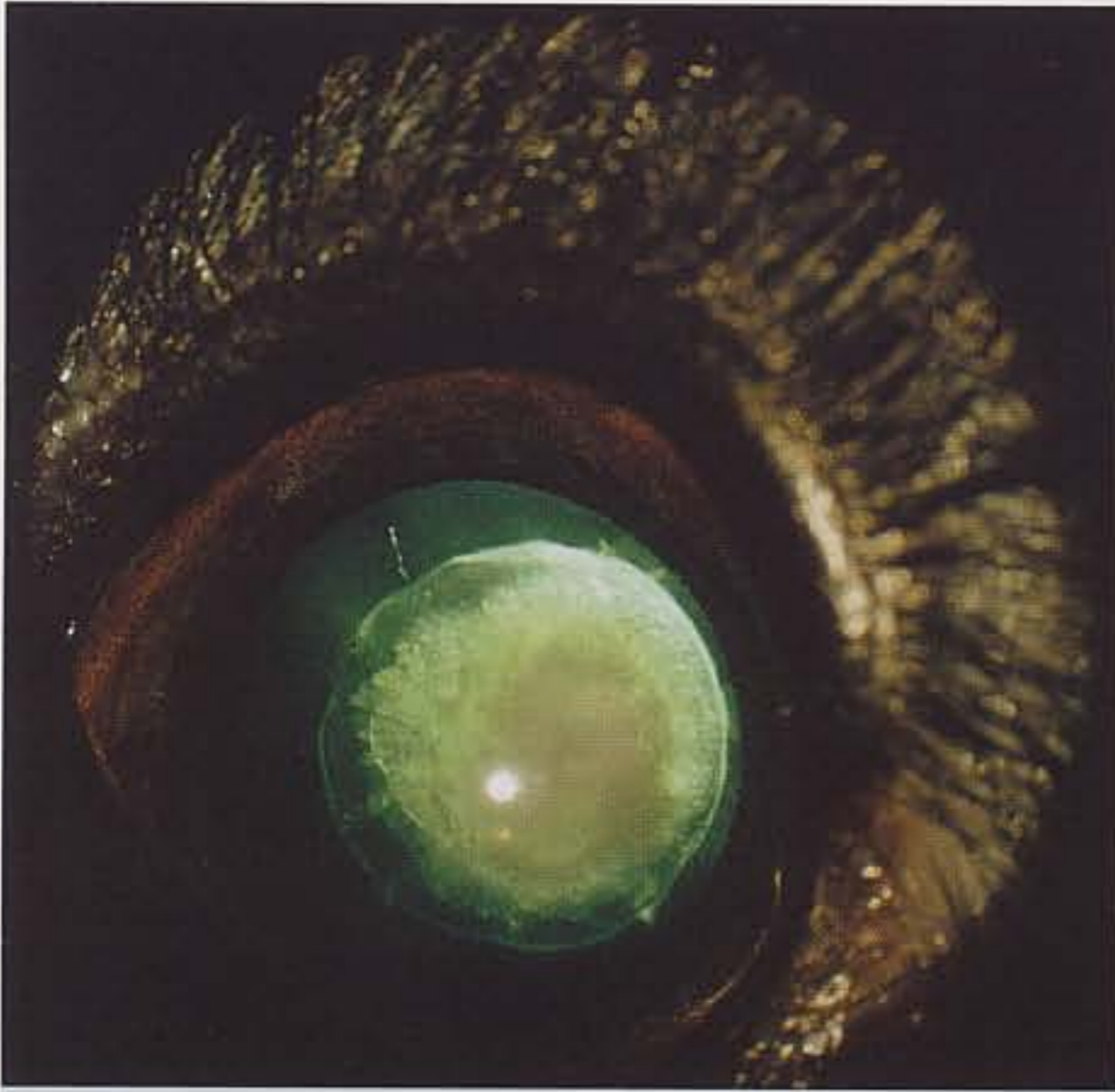


Fig. 9.32 Nuclear cataract (Miniature Schnauzer, 6 months old) Bilateral and associated microphthalmos.

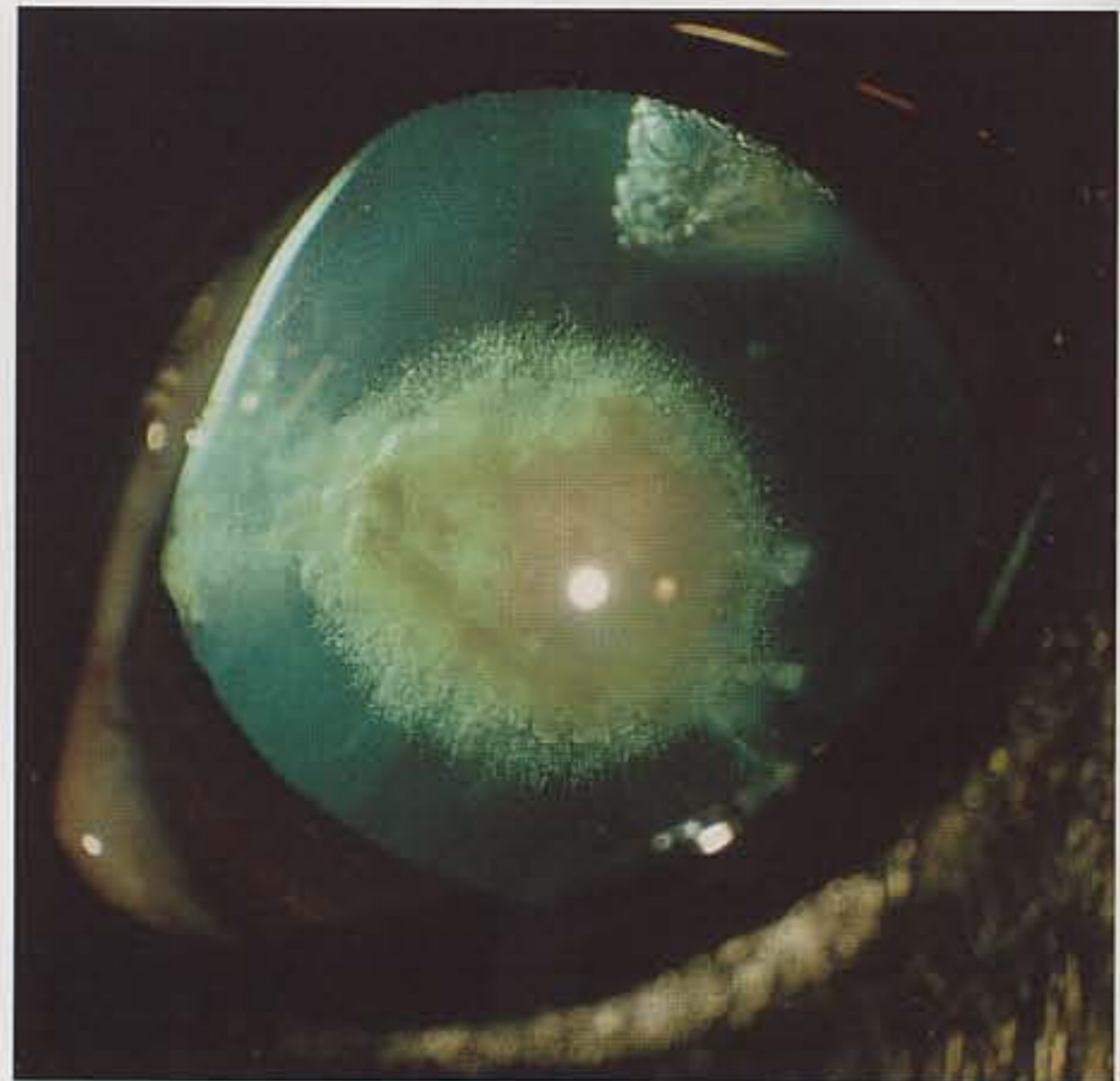


Fig. 9.34 Nuclear cataract (Miniature Schnauzer, 14 months old) Cataract plus cortical wedge.

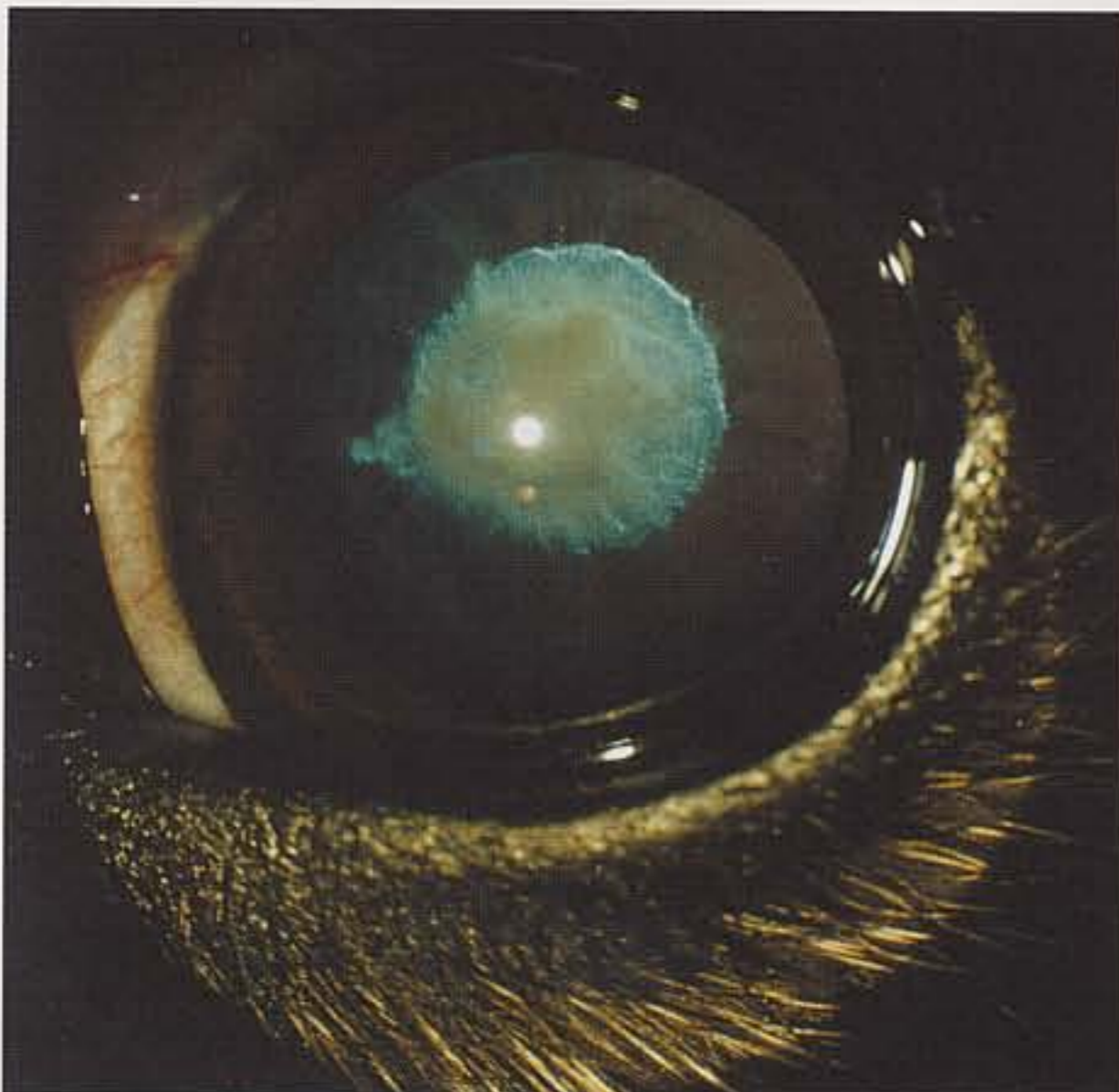


Fig. 9.33 Nuclear cataract (Miniature Schnauzer, 6 months old) Note extension at 9 o'clock.

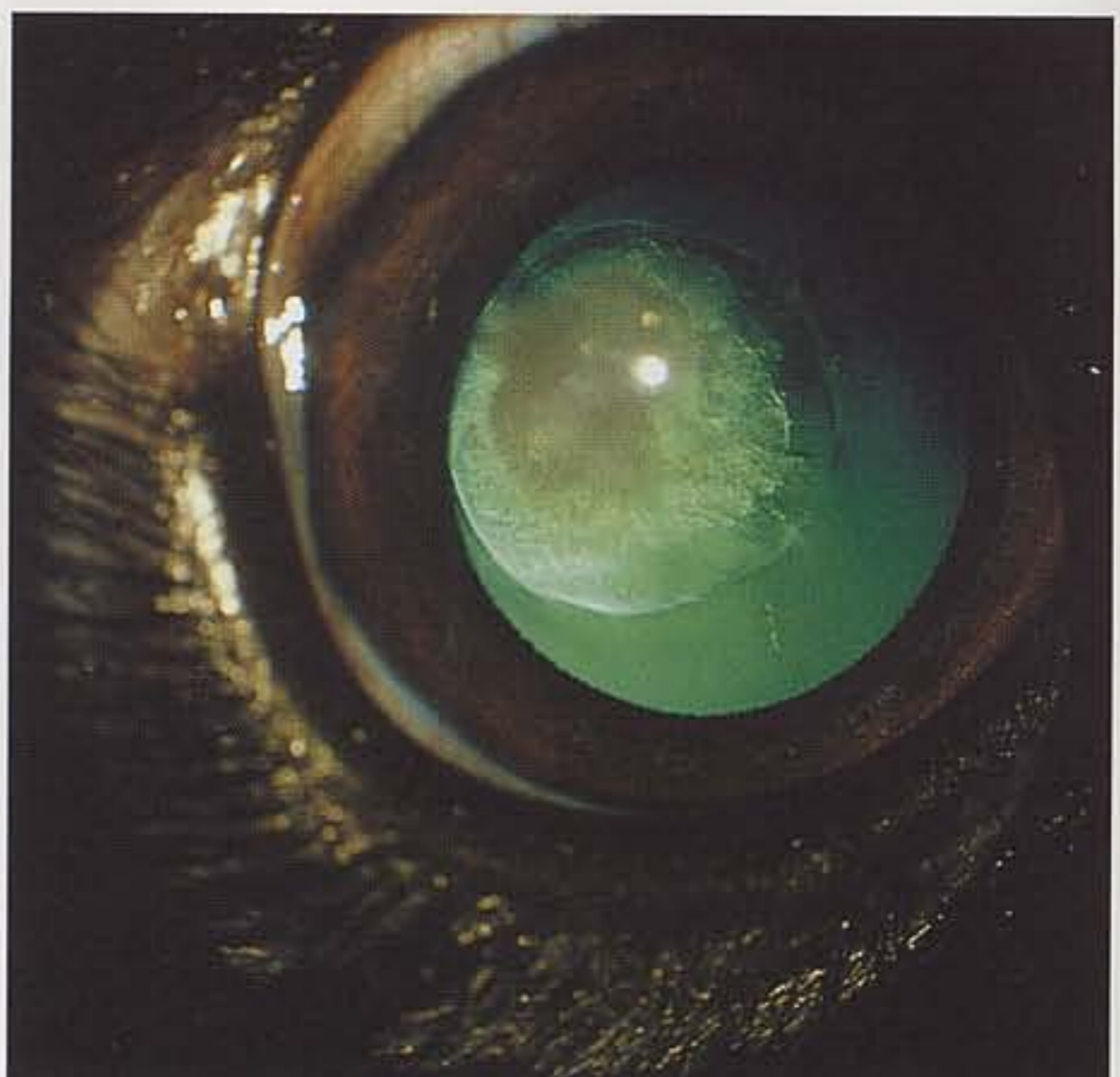

Fig. 9.35 Nuclear cataract (Miniature Schnauzer, 6 months old) This type is usually non-progressive. Note the wide clear peripheral lens.

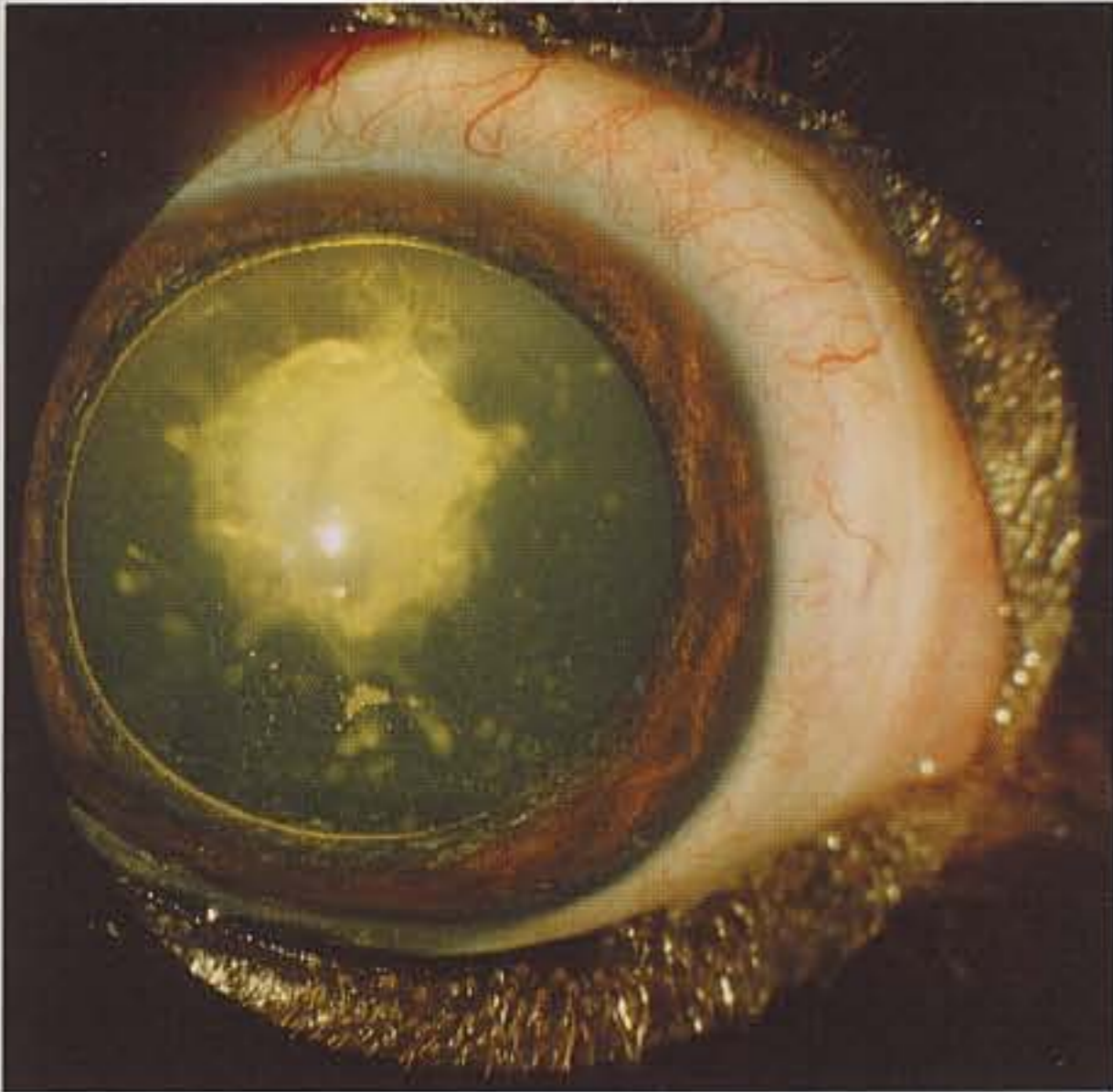


Fig. 9.36 Nuclear cataract (Cavalier King Charles Spaniel, 6 months old) Microphthalmos and note also the anterior capsular involvement.

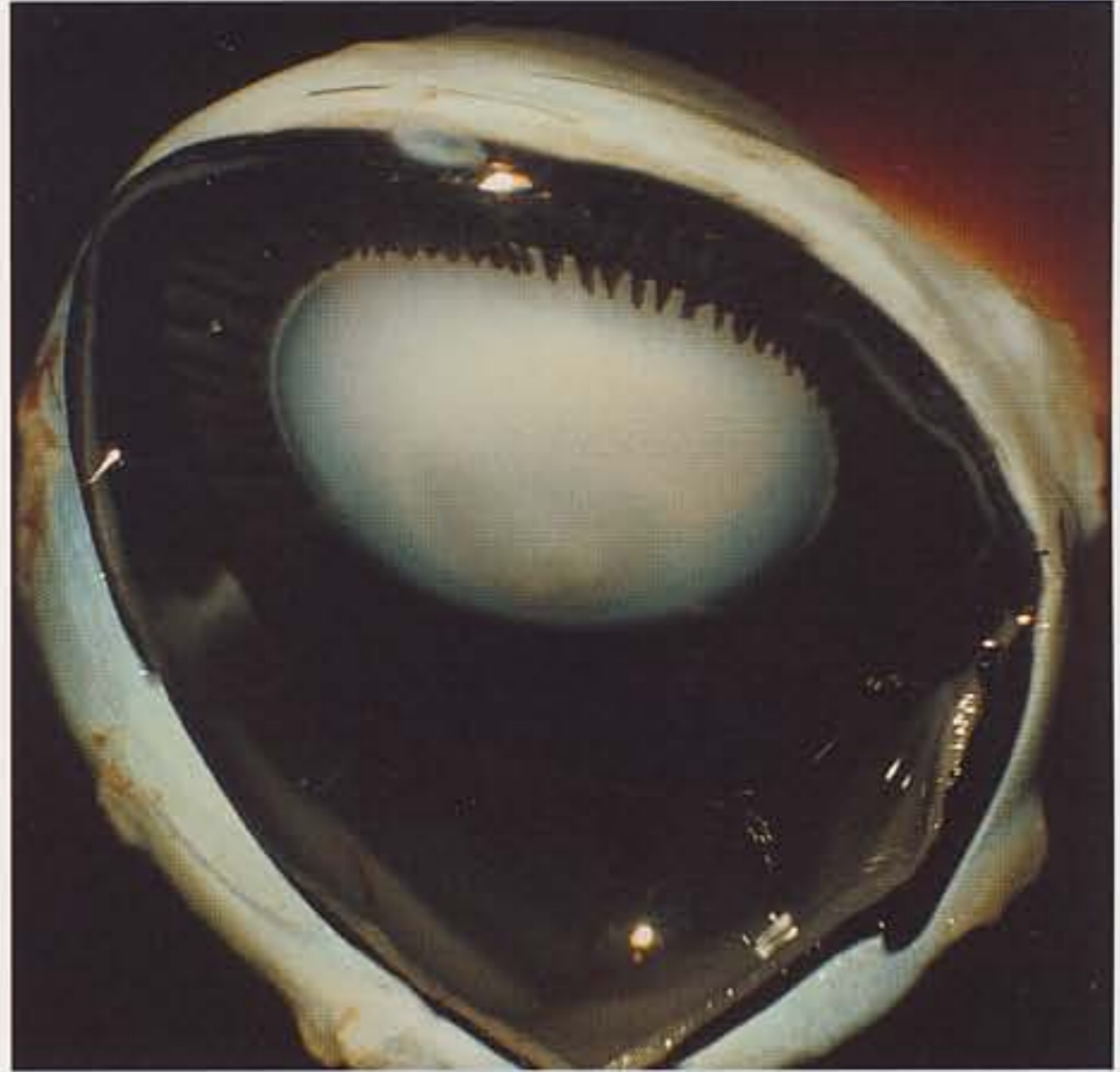


Fig. 9.38 Cataract and posterior lenticonus (Cavalier King Charles Spaniel, 7 weeks old) Post mortem specimen showing mild posterior lenticonus. The same eye as shown in the previous figure.

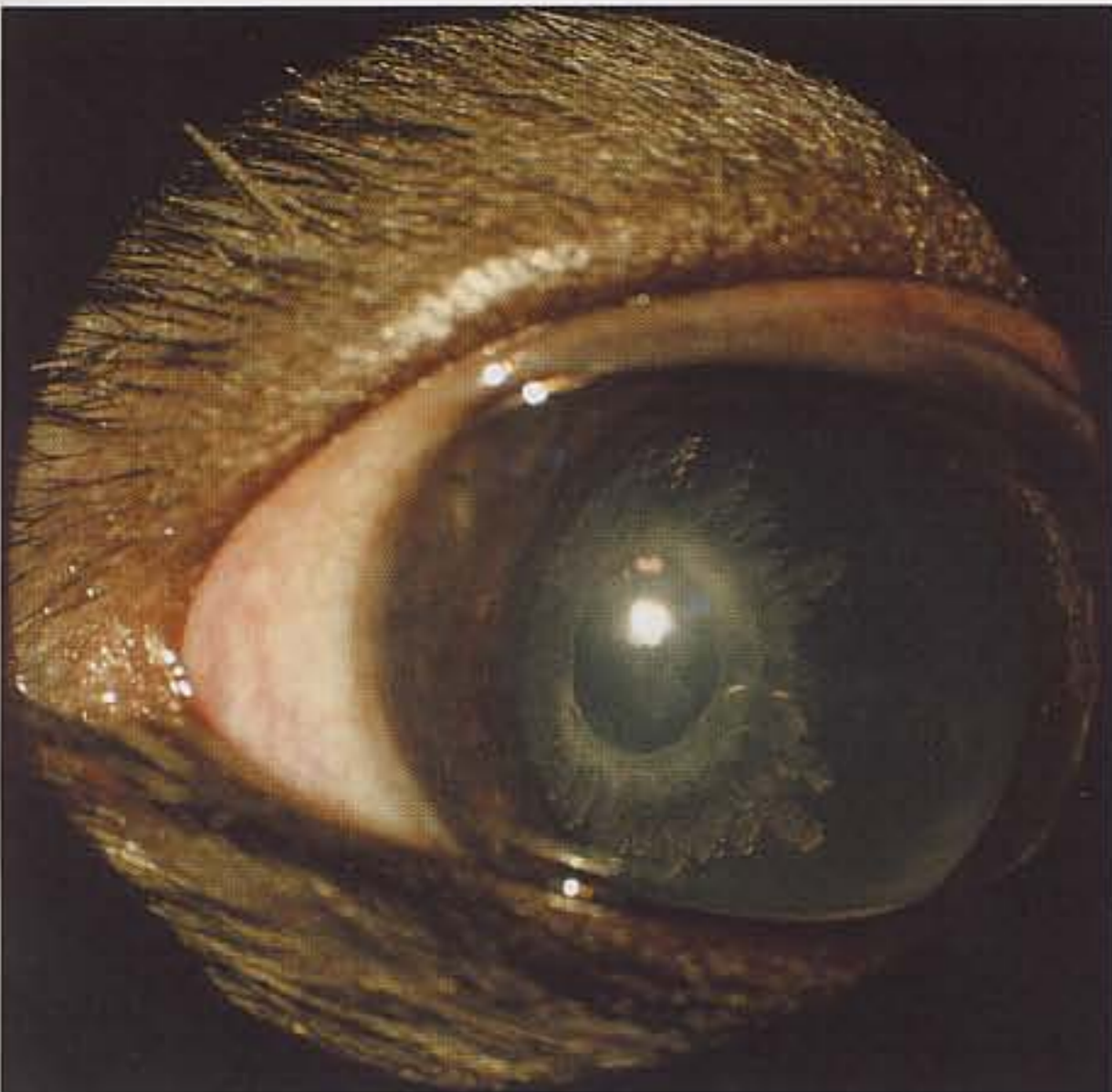


Fig. 9.37 Cataract and posterior lenticonus (Cavalier King Charles Spaniel, 7 weeks old)

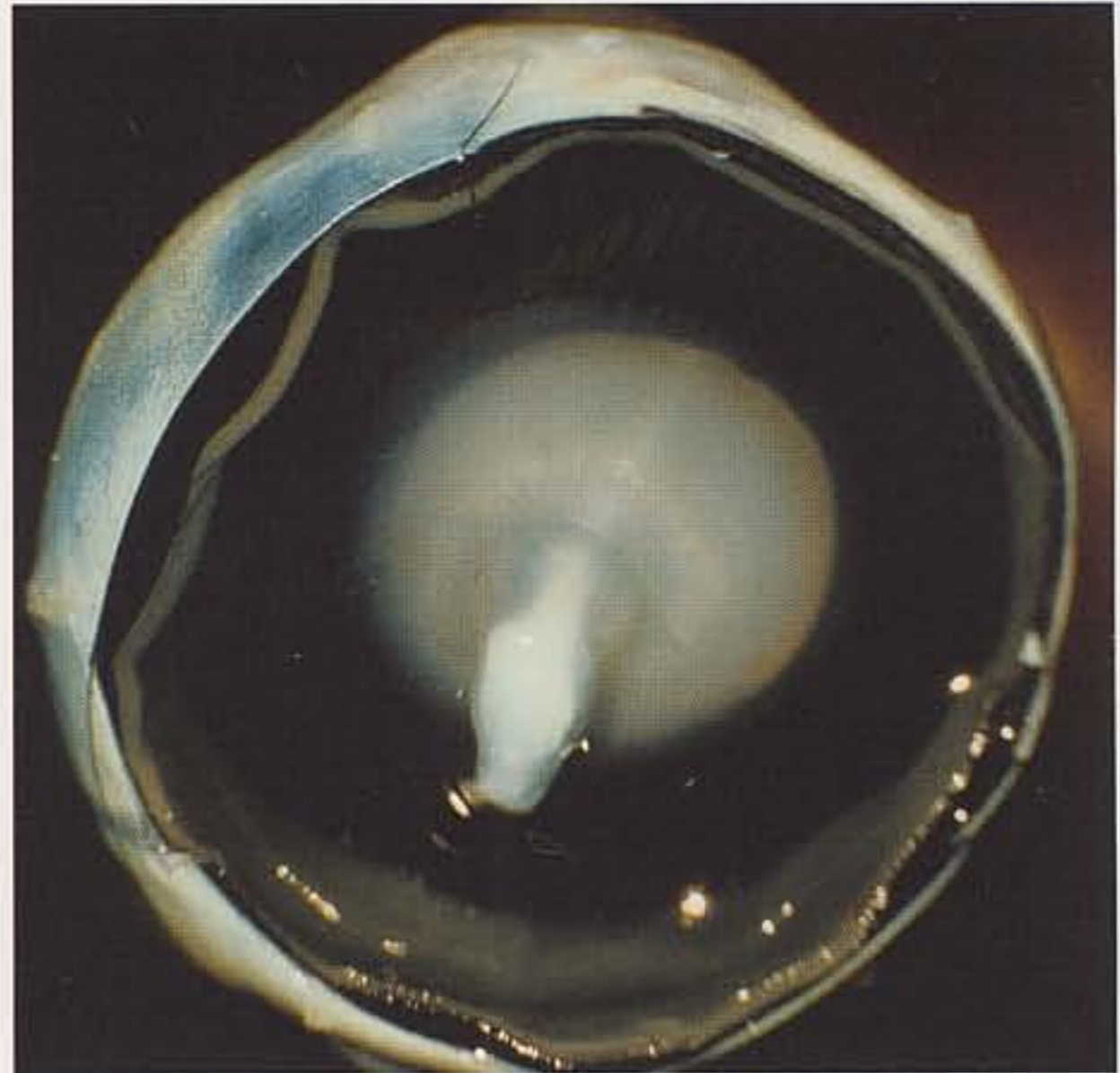


Fig. 9.39 Cataract and posterior lentiglobus (Cavalier King Charles Spaniel, 7 weeks old) The other eye of the same dog as shown in the previous figures.

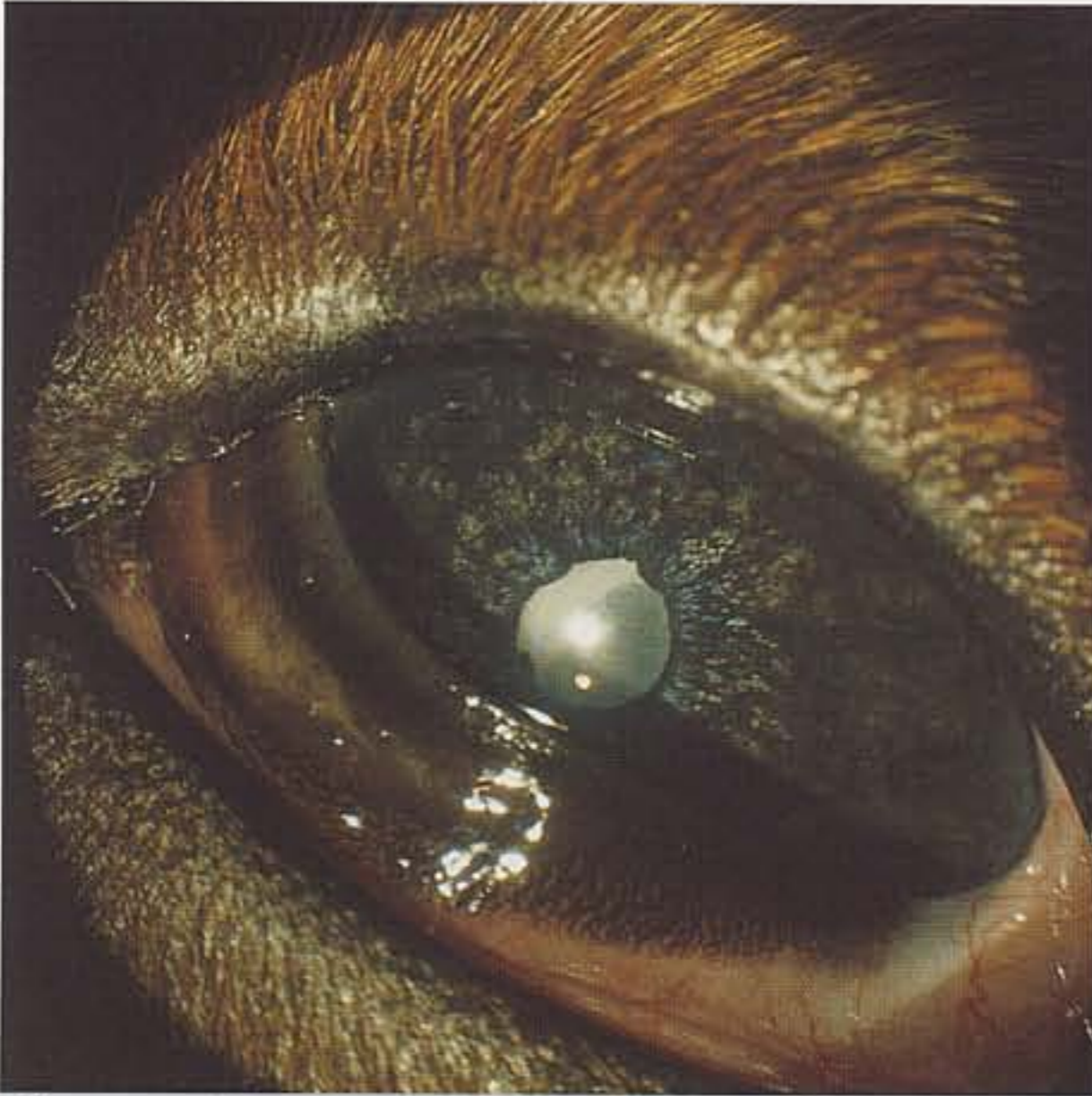

Fig. 9.40 Cataract and microphthalmos (Cocker Spaniel, 14 weeks old) Bilateral and note the prominence of the nictitating membrane, together with iris hypoplasia.

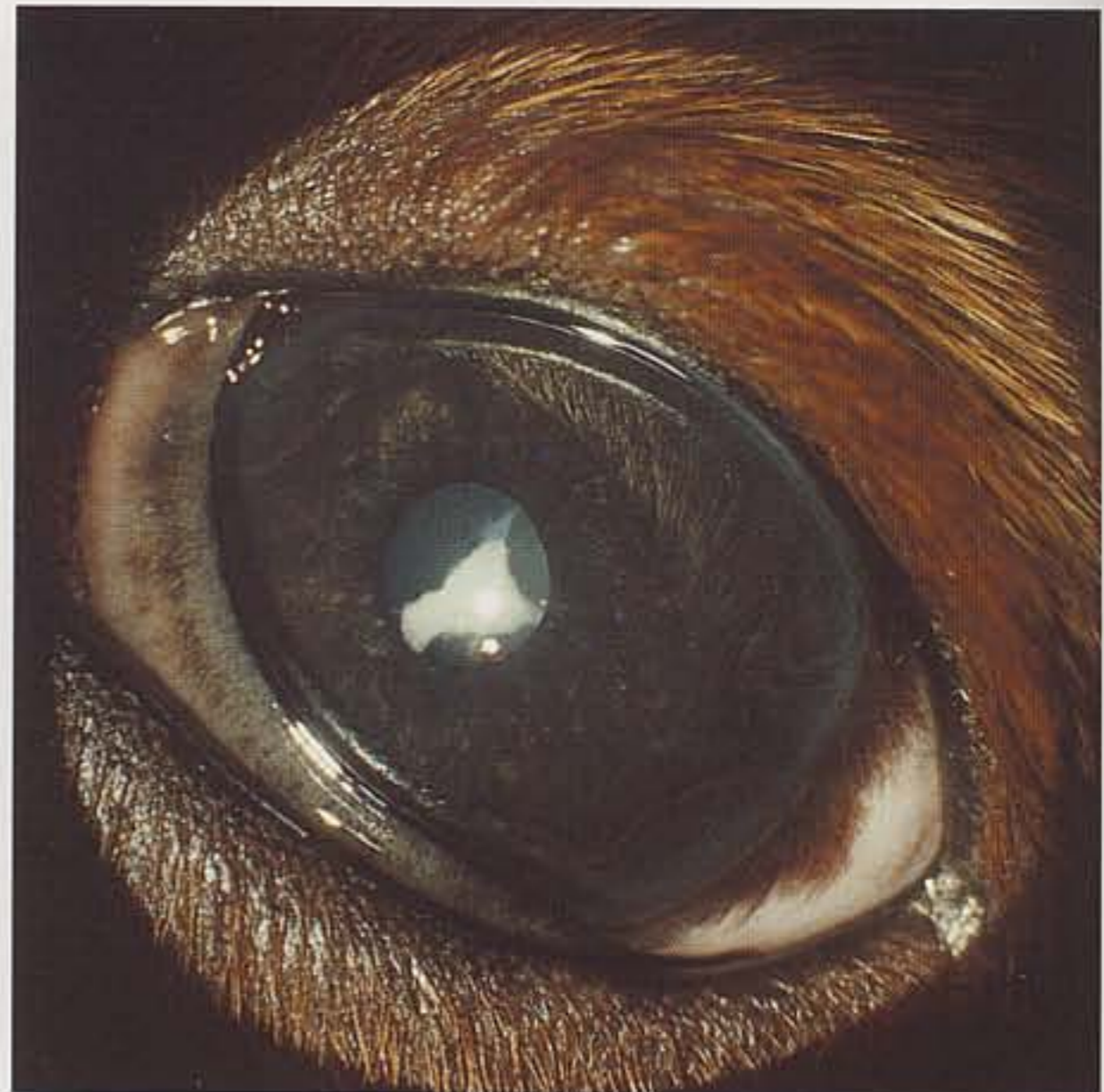

Fig. 9.42 Cataract and microphthalmos (Cocker Spaniel, 10 weeks old) Dense white anterior capsular, sometimes pyramidal, cataract.

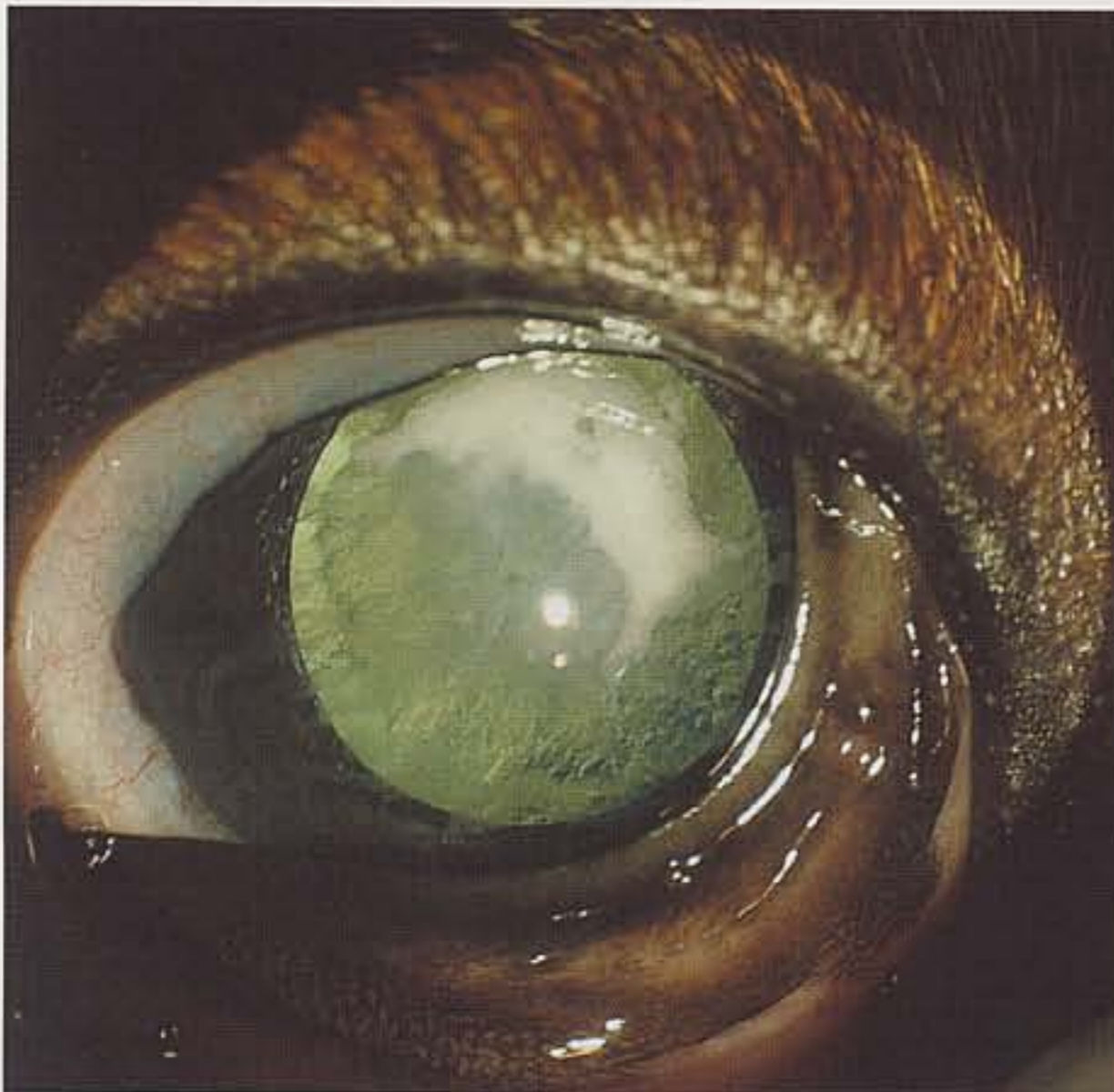

Fig. 9.41 Cataract and microphthalmos (Cocker Spaniel, 14 weeks old) Littermate to the animal shown in Fig. 9.40 following mydriasis to demonstrate the extent of the cataract.

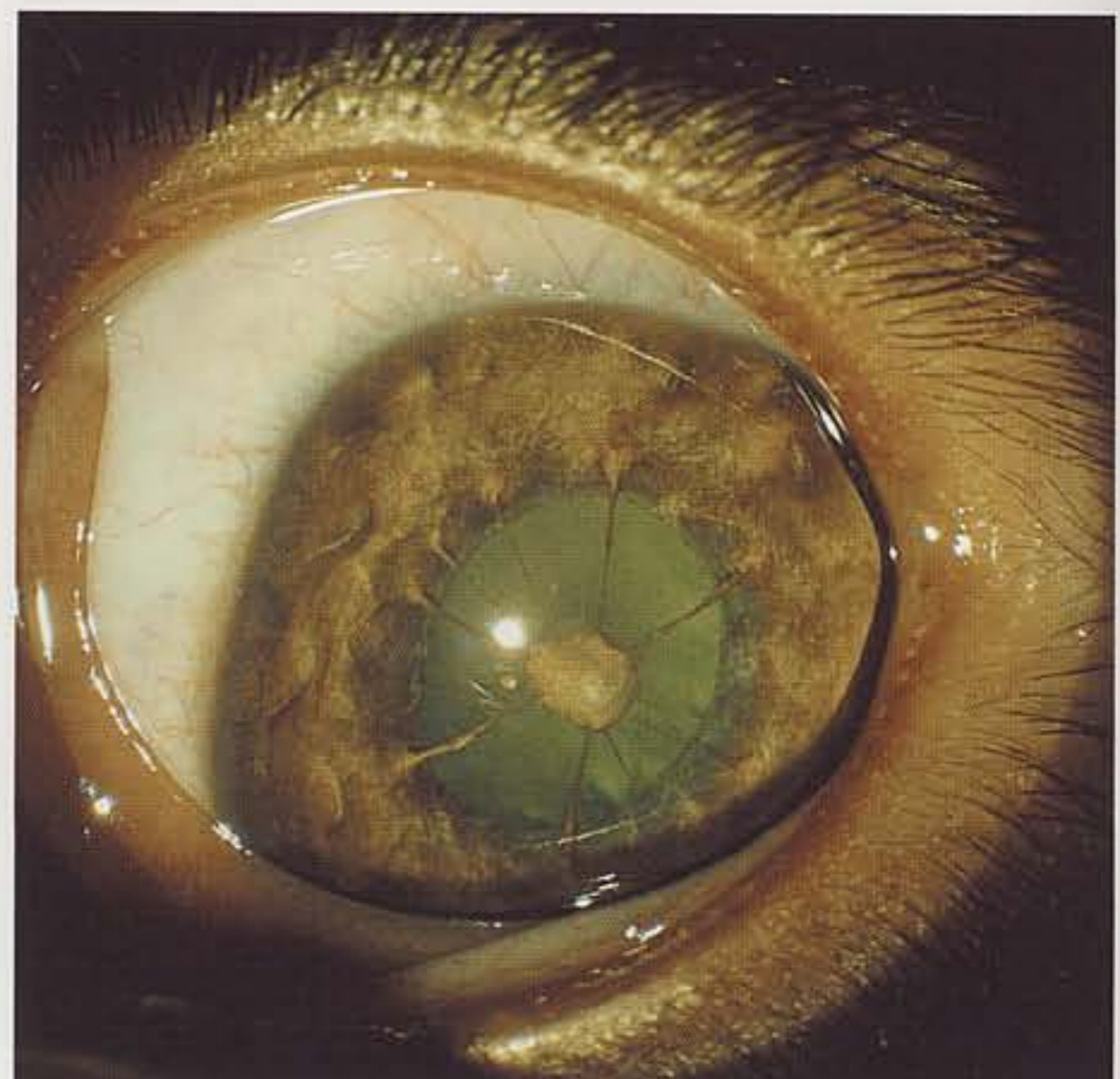


Fig. 9.43 Cataract and microphthalmos (English Springer Spaniel, 13 weeks old) Microphthalmos, congenital cataract and persistent pupillary membranes.



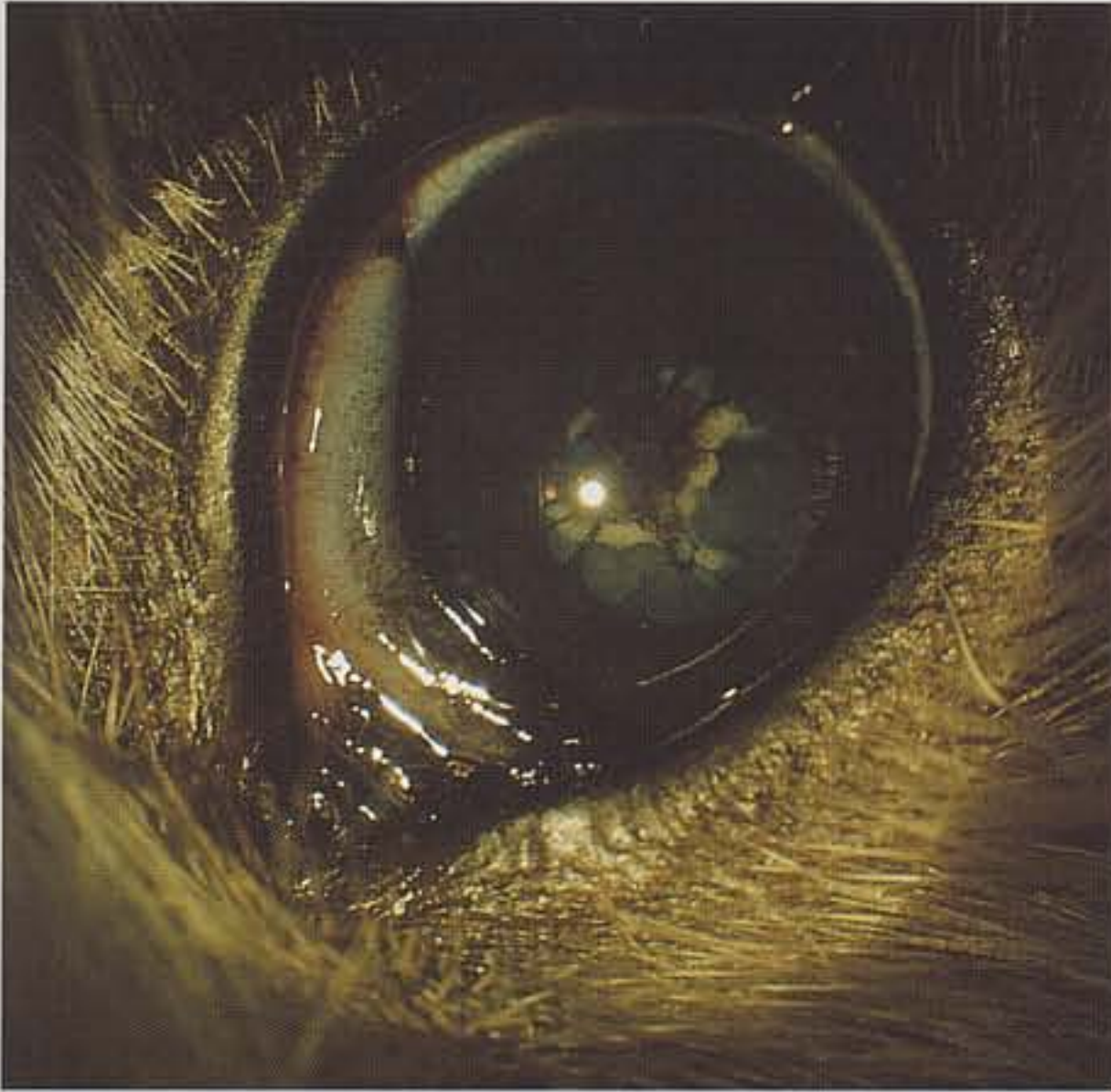

Fig. 9.44 Cataract and microphthalmos (West Highland White Terrier, 11 weeks old) Microphthalmos, congenital cataract and persistent pupillary membranes.

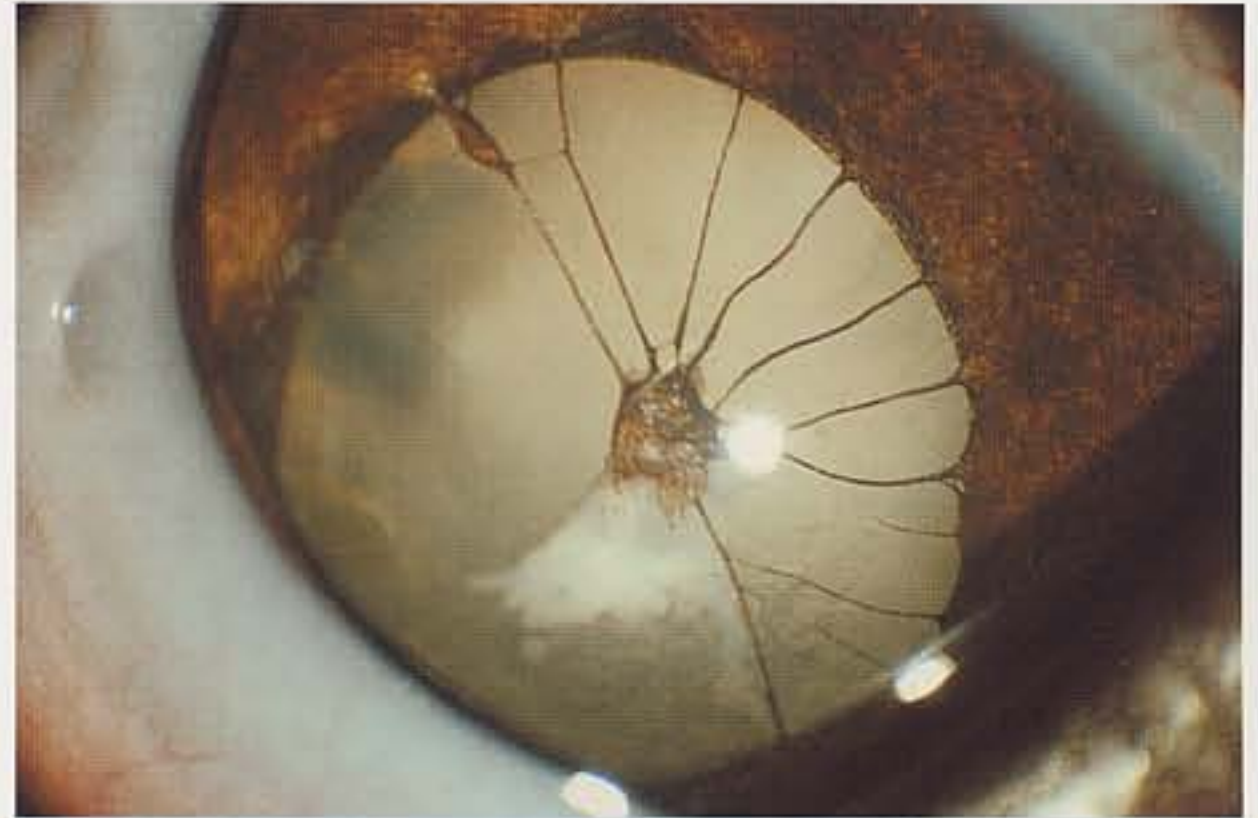


Fig. 9.46 Cataract and microphthalmos (Old English Sheepdog, 6 months old) Microphthalmos, congenital cataract and persistent pupillary membranes.

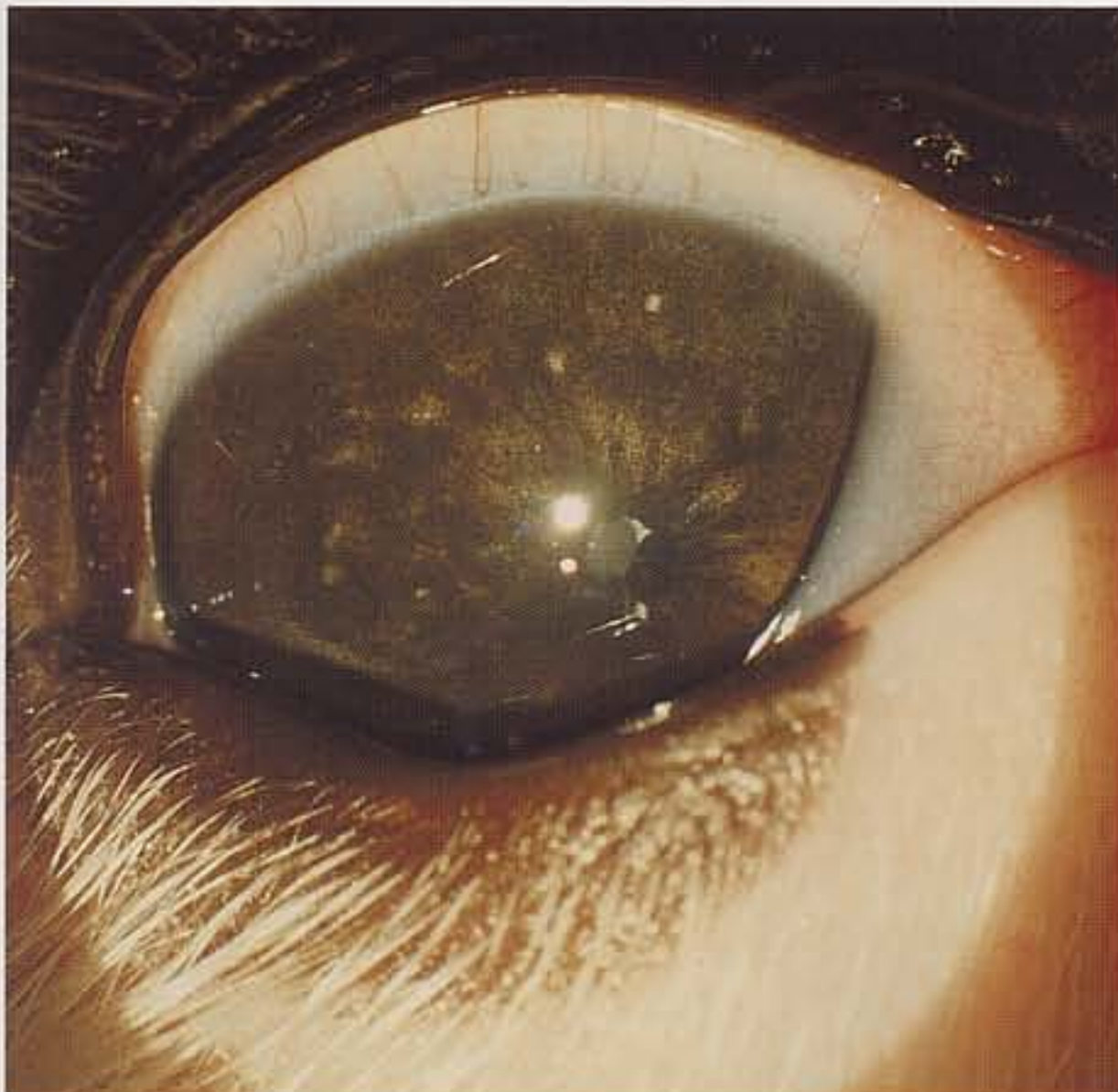

Fig. 9.45 Cataract and microphthalmos (Old English Sheepdog, 9 months old) Note the marked miosis and few small uveal cysts around the pupil, but no current evidence of uveitis.

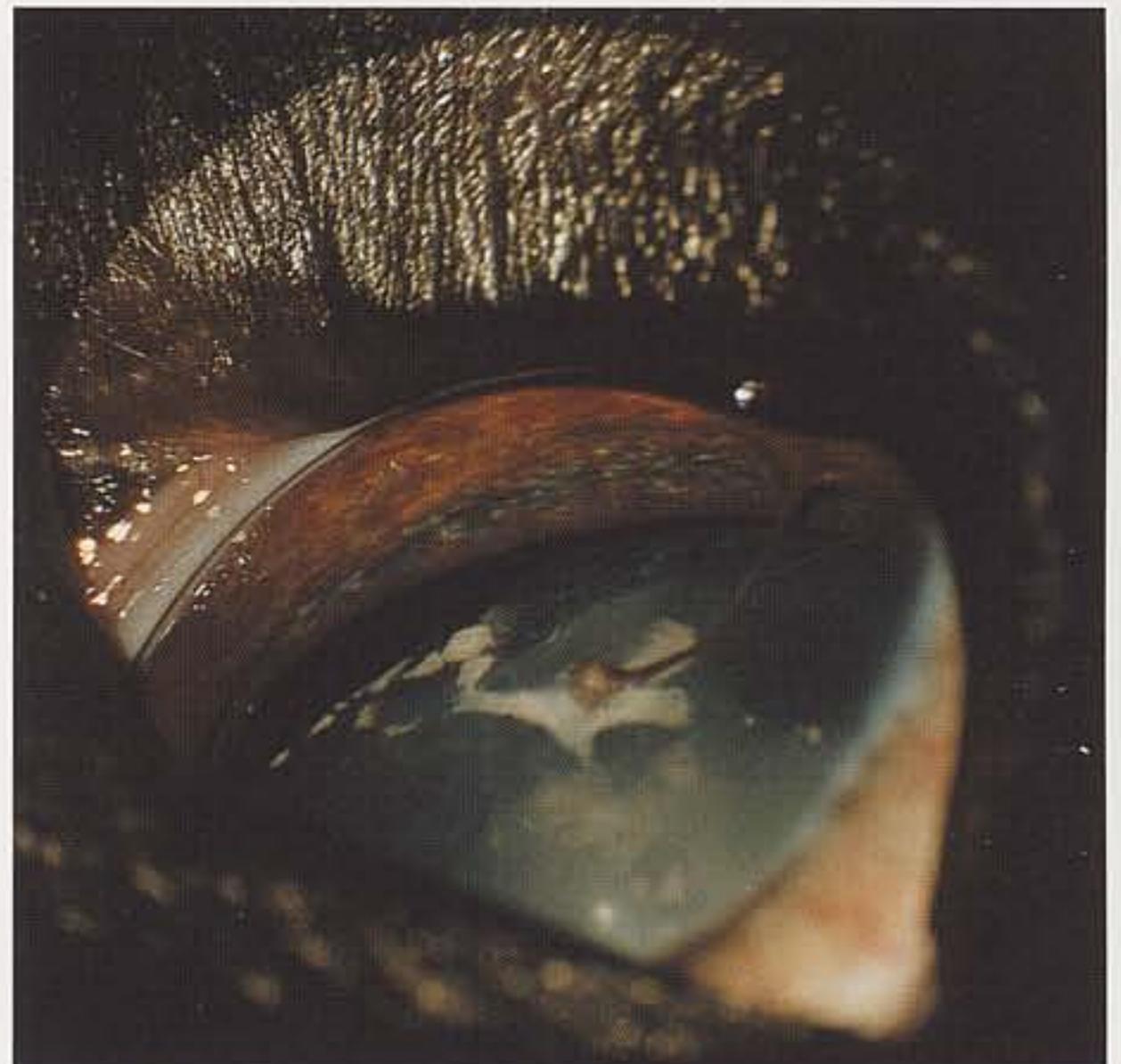
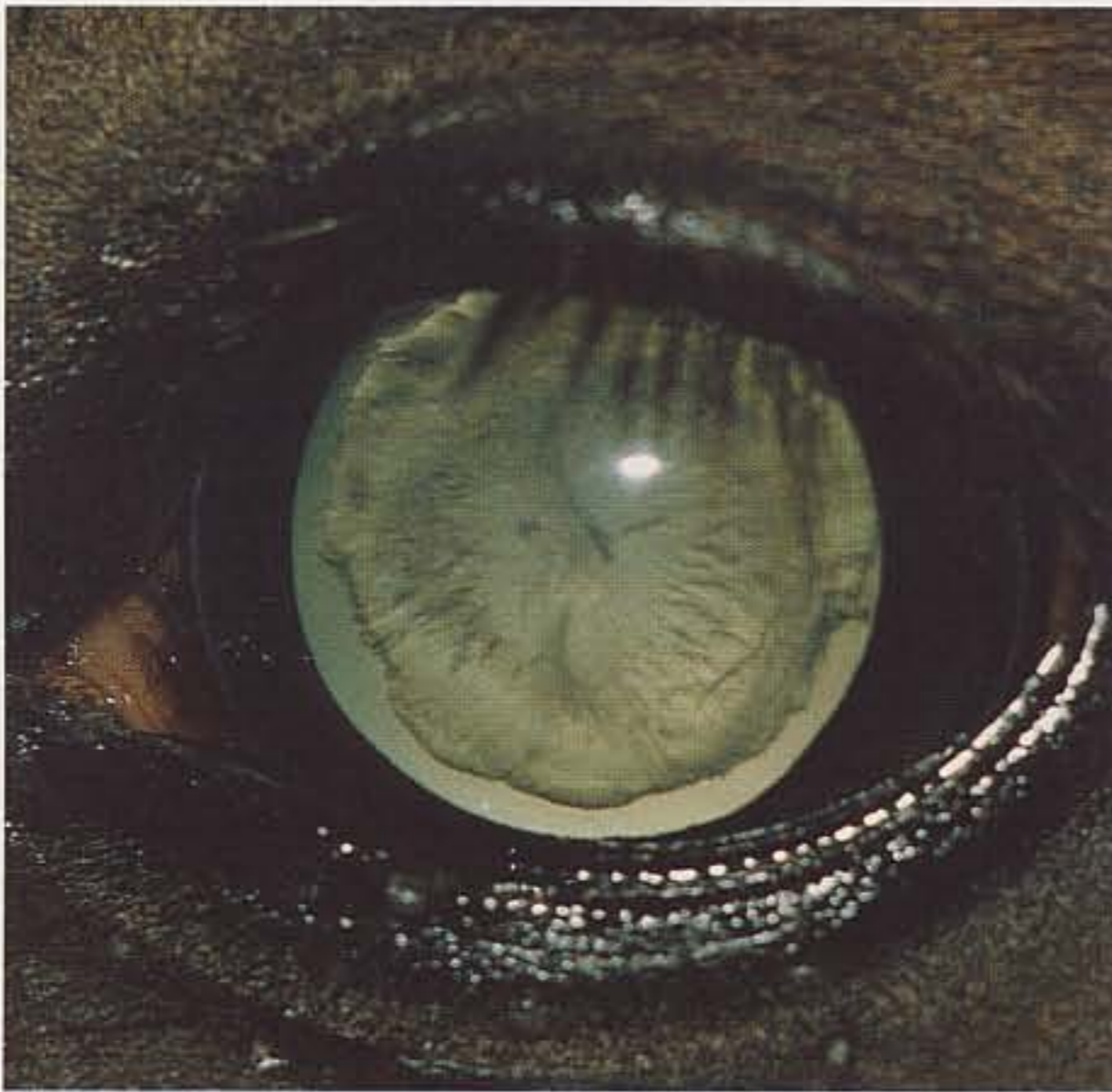
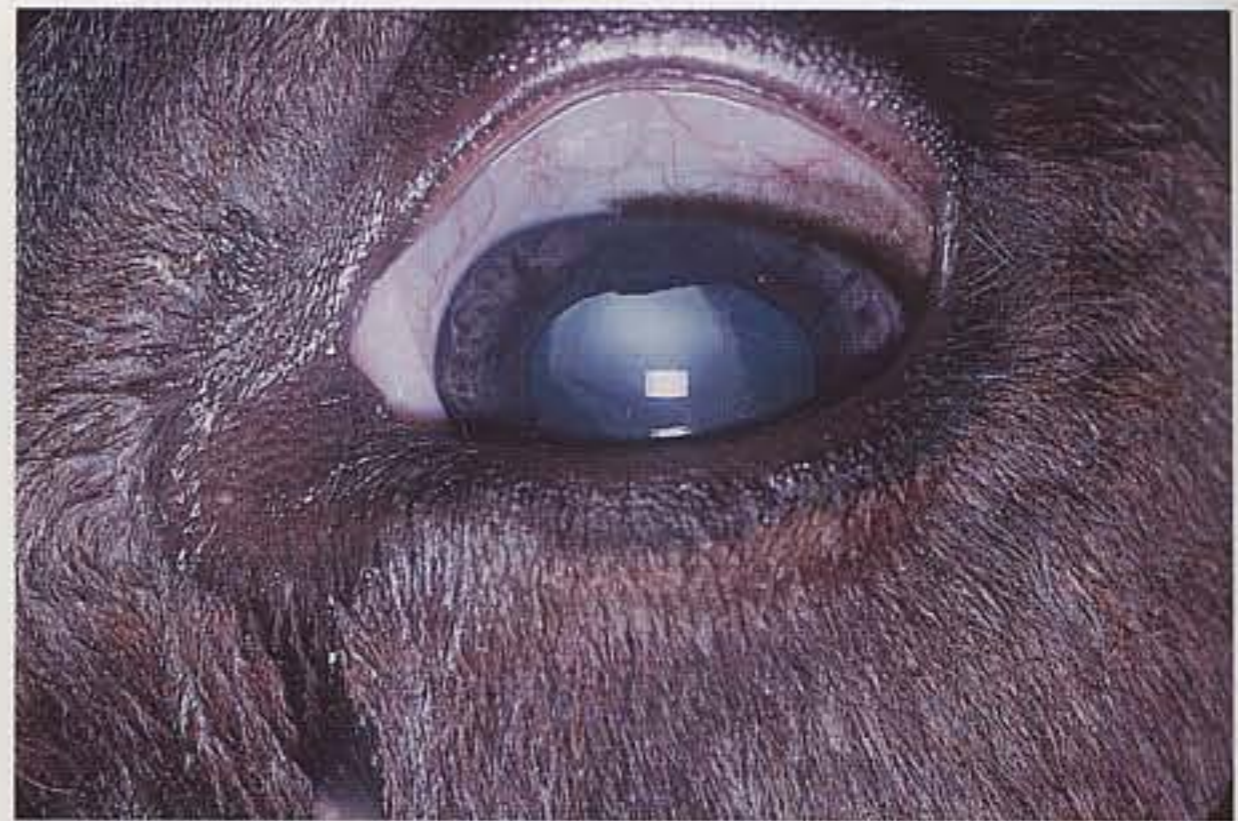
Fig. 9.47 Cataract and microphthalmos (Crossbred, 11 months old) Microphthalmos, congenital cataract, persistent pupillary membranes, lens coloboma and poor limbal differentiation. Multiocular defects (MOD), as with all the above examples of congenital cataract.



**Fig. 9.48 Nuclear cataract (Arab foal)** Congenital central cataract in the Arabian horse is more common than in the Thoroughbred and is usually bilateral. In this animal the cataract is central but it may take other forms. No direct evidence of inheritance.



**Fig. 9.49 Nuclear cataract (Friesian calf)** Bilateral and congenital, of unknown aetiology. Non-progressive and often affects several calves in a herd.

well be the primary condition. They are sometimes included as multiocular defects but cataract is common to all. Some of these congenital cataracts have been proven to be inherited, e.g. Miniature Schnauzer, others are suspected of being inherited as they show a strong breed predisposition (Cavalier King Charles Spaniel and English Cocker Spaniel); whereas others would seem to be isolated examples of a congenital non-inherited anomaly, sometimes occurring in crossbreds. Congenital cataracts may be bilateral and symmetrical or not; are usually non-progressive; and have a limited effect on vision, puppies not normally presenting with blindness. Cataracts associated with other congenital lens anomalies, e.g. persistent hyaloid artery (Fig 9.59), coloboma (Fig 9.58) and lenticonus (Fig 9.57), are further examples.

Other congenital cataracts that may be included in this category are capsular cataracts associated with persistent pupillary membranes (Figs 7.62, 7.65 and 7.67) and persistent hyperplastic primary vitreous (Figs 10.4–10.5 and 10.7–10.8).

### **Cataracts secondary to another eye disease or condition (Figs 9.50–9.59)**

This is a varied group, the commonest being cataracts associated with uveitis, the cataract being either the result or the cause of the uveitis (see also Figs 7.23 and 7.26). Included in this group are cataracts in which the lens is undergoing resorption (Figs 9.73–9.76), a phenomenon that occurs particularly in young animals and which may present as a uveitis which always accompanies the lens resorption. Cataracts secondary to uveitis are the commonest in the cat and horse. Traumatic cataracts are also invariably associated with uveitis (Figs 9.71 and 9.77–9.79) and may be due to penetrating corneal injuries and rupture of the anterior lens capsule; they often result from cat scratches and occur frequently in cats and puppies. Cataract may also develop from blunt injury. Traumatic cataracts are almost always unilateral and the uveitis may become quite severe following damage to the lens capsule and subsequent escape of lens material.

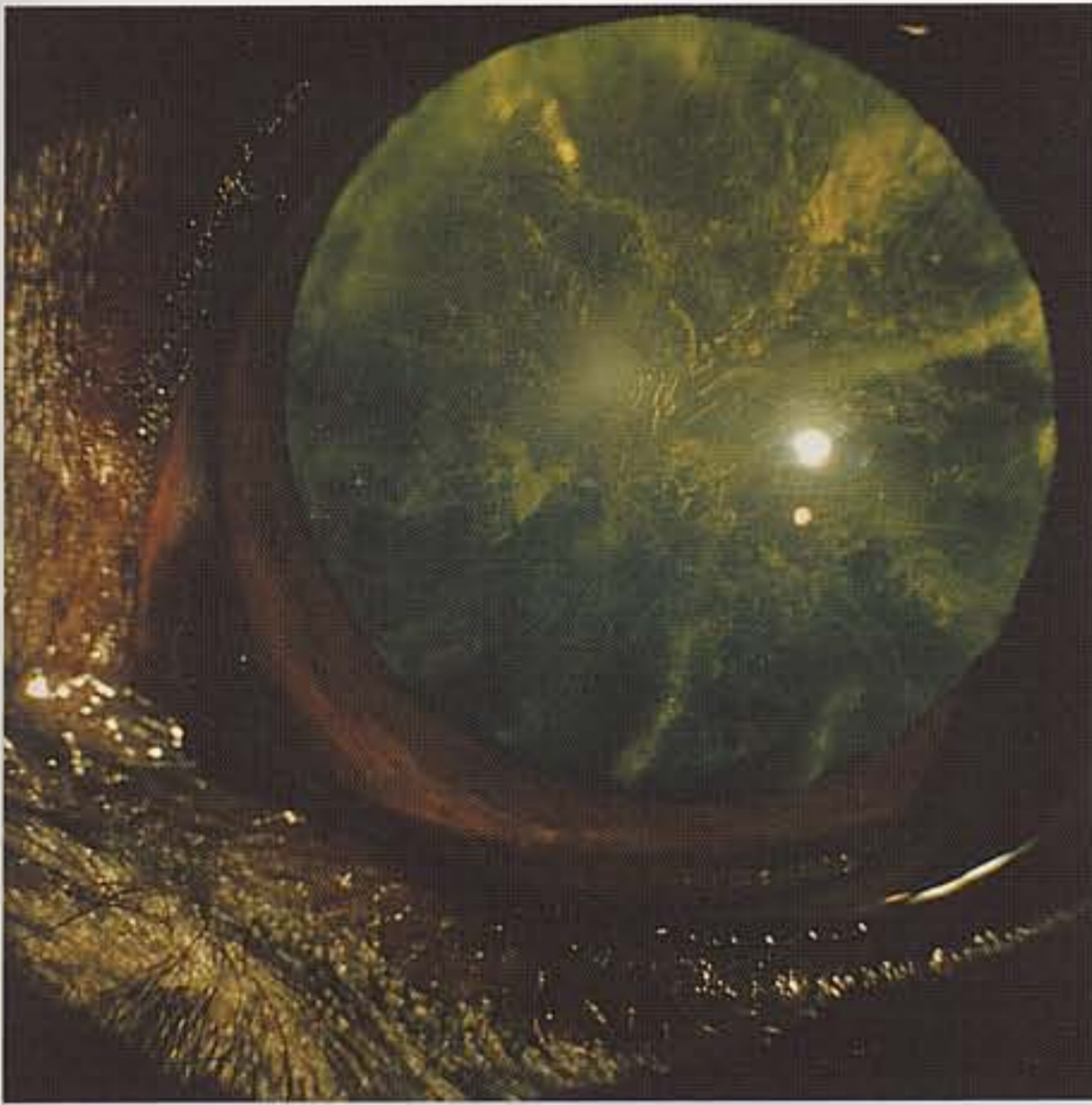


Fig. 9.50 Cataract secondary to retinal disease – generalized progressive retinal atrophy (Miniature Poodle, 7 years old) Typical appearance of anterior and posterior cortical and progressive cataract.

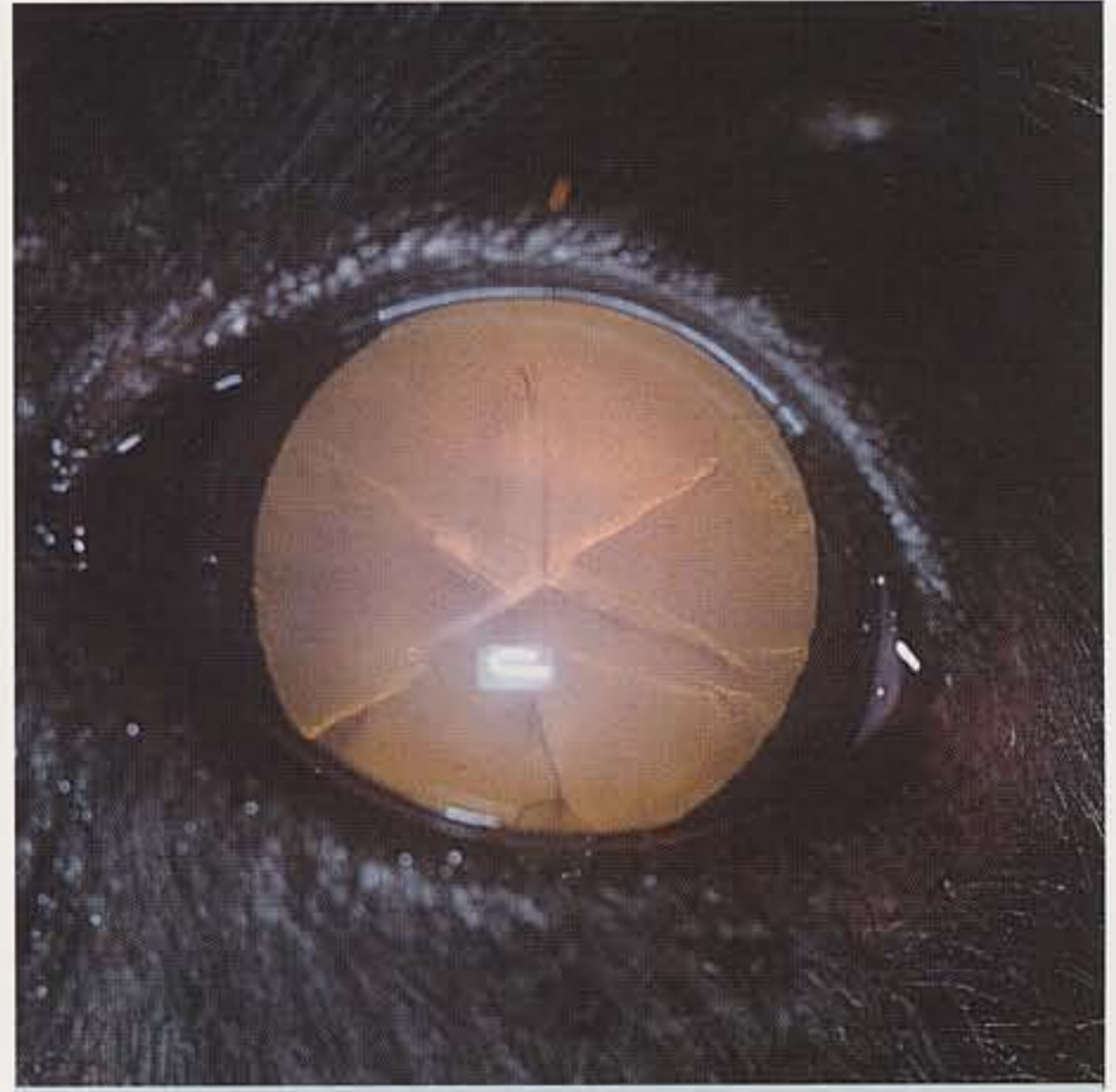

Fig. 9.52 Cataract secondary to retinal disease – generalized progressive retinal atrophy (Miniature Poodle, 5 years old) Total cataract but note the tapetal glow visible through the lens.

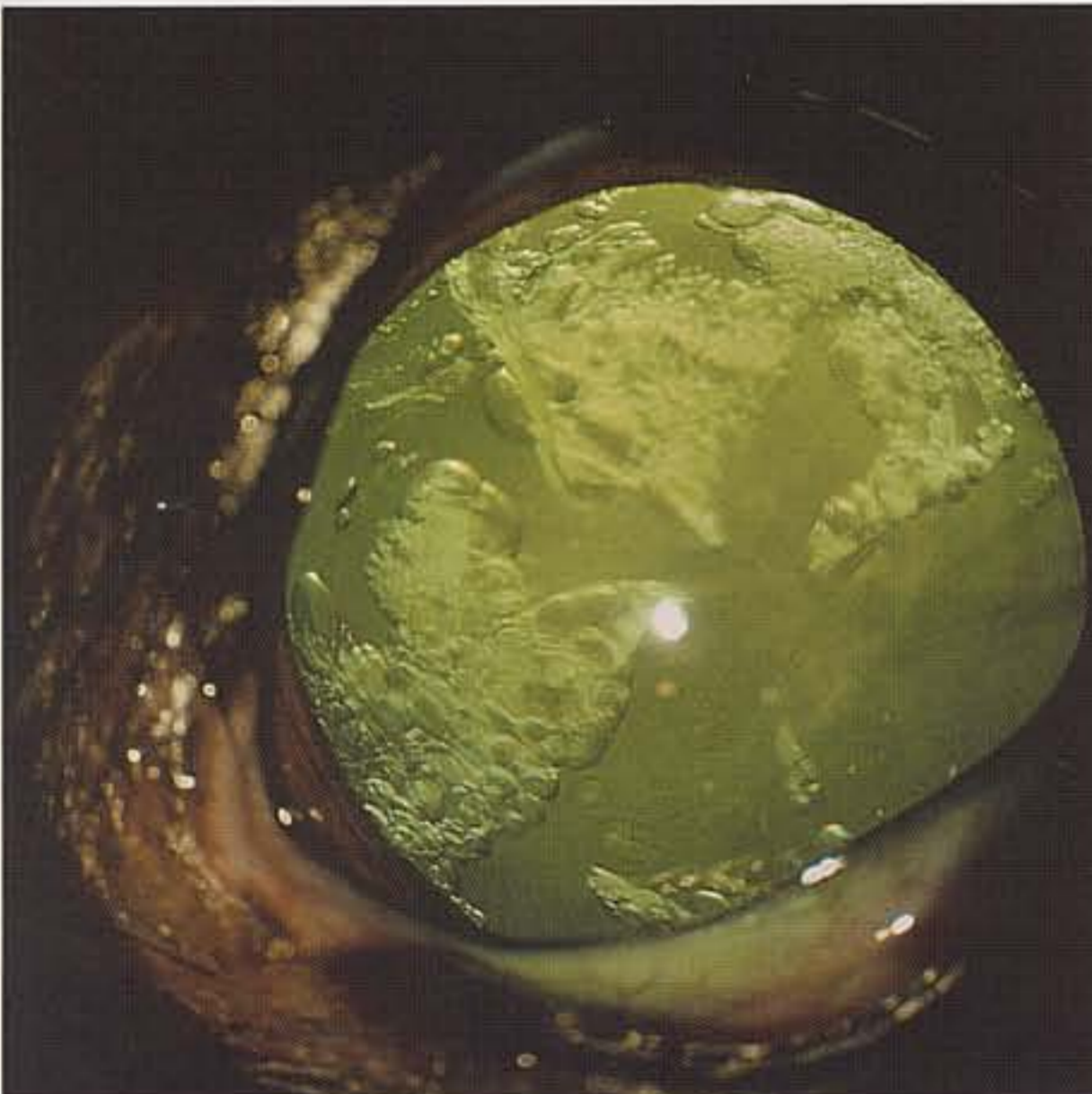


Fig. 9.51 Cataract secondary to retinal disease – generalized progressive retinal atrophy (Tibetan Terrier, 5 years old) Typical wedges of cortical vacuoles.

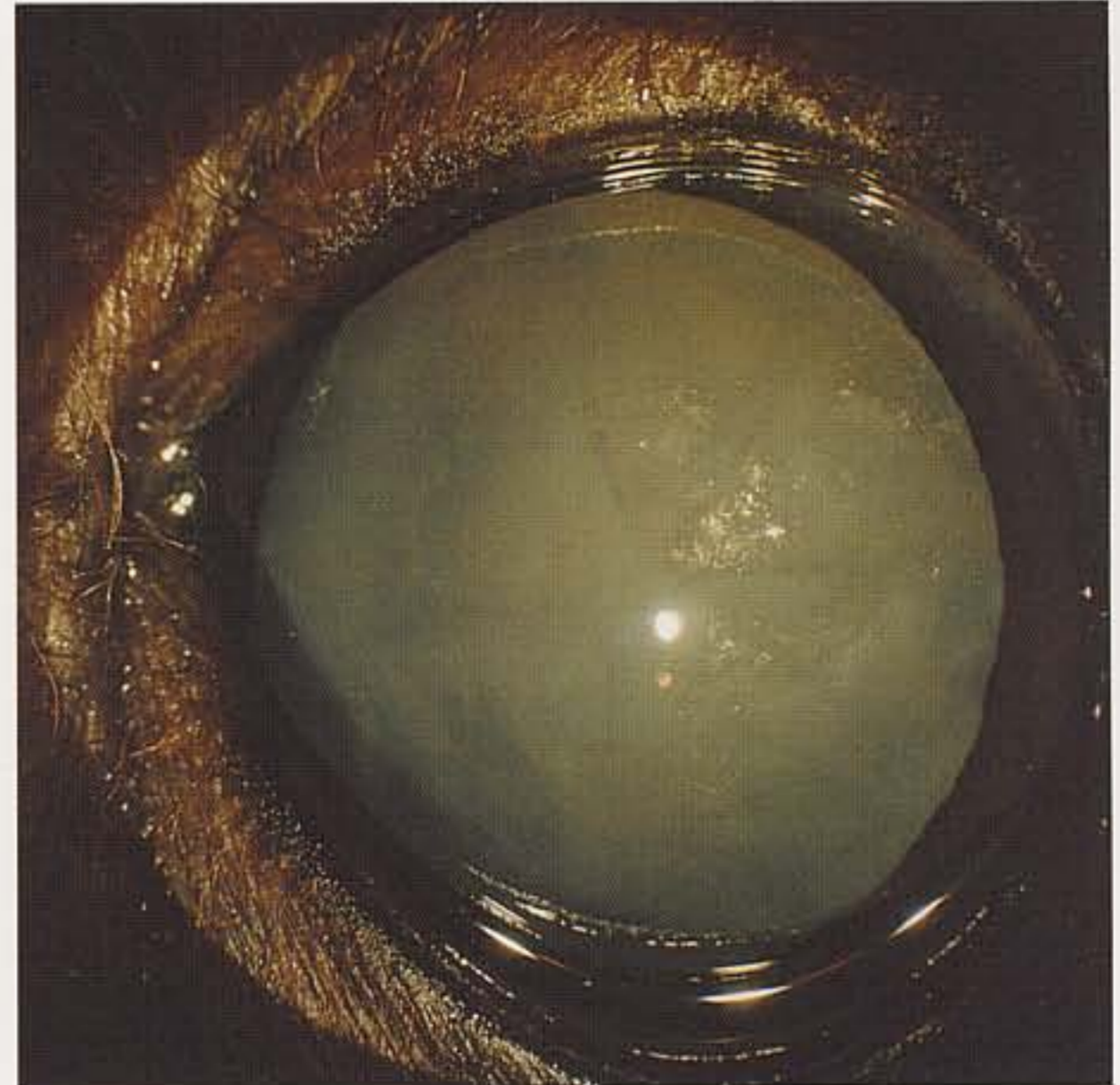

Fig. 9.53 Cataract secondary to retinal disease – generalized progressive retinal atrophy (Miniature Poodle, 5 years old) Total dense and mature cataract.

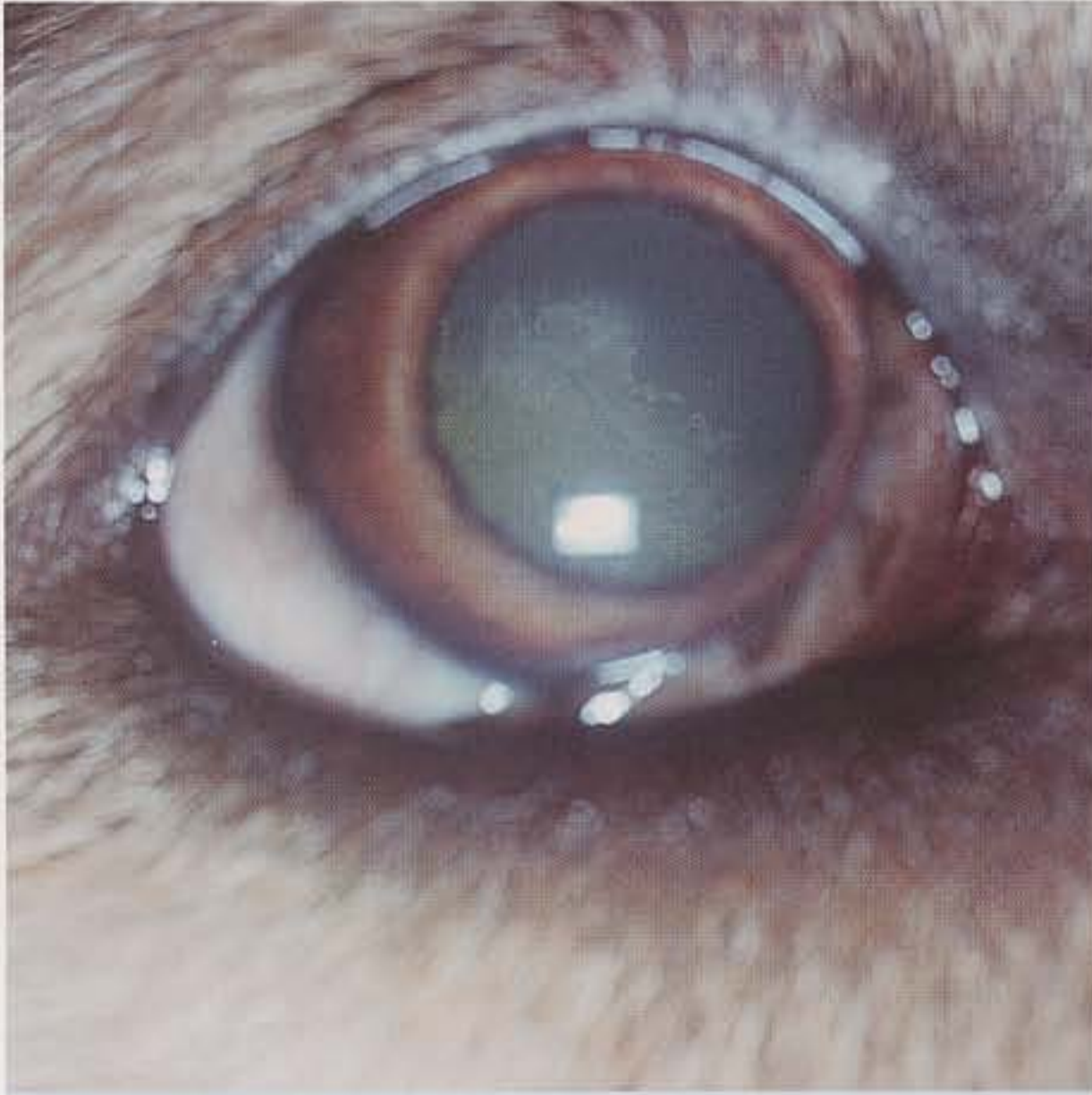

Fig. 9.54 Cataract secondary to retinal disease – central progressive retinal atrophy or pigment epithelial dystrophy (Labrador Retriever, 10 years old) An occasional finding.

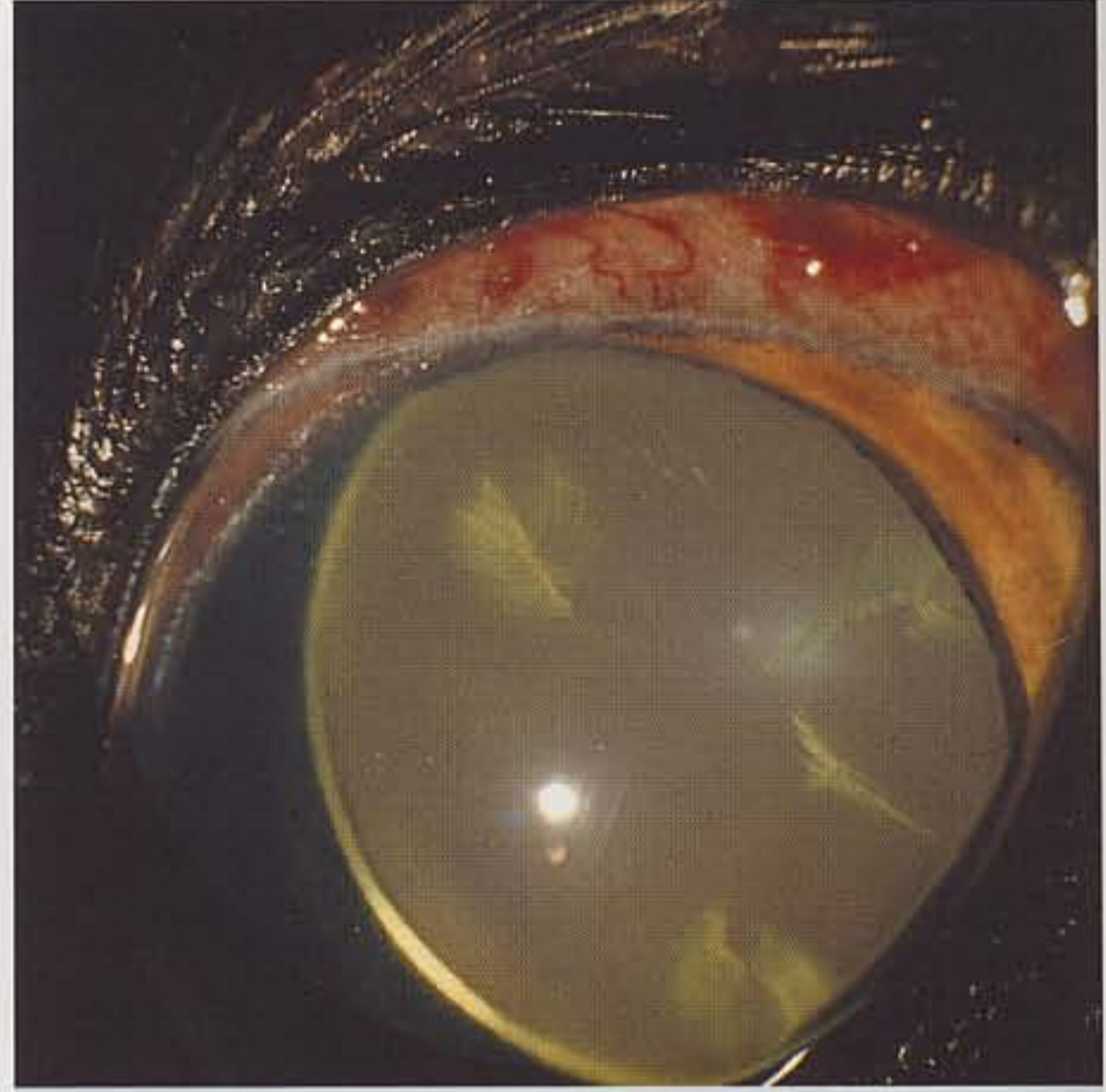


Fig. 9.56 Cataract secondary to glaucoma (Border Collie, 5 years old) Note the congested blood vessels and dilated pupil.

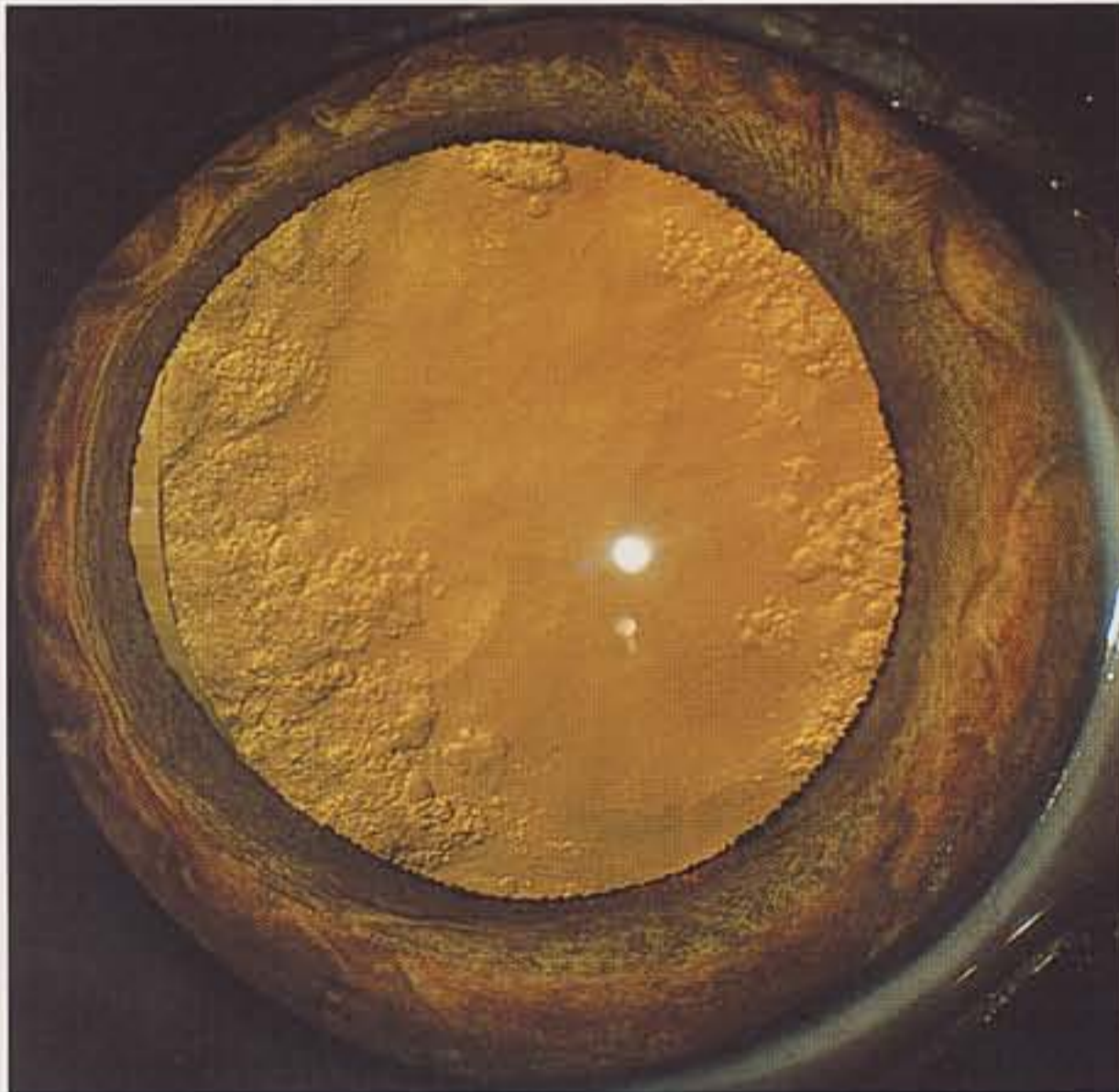

Fig. 9.55 Cataract secondary to retinal disease – multifocal retinal dysplasia (English Springer Spaniel, 8 months old) Again an occasional finding.

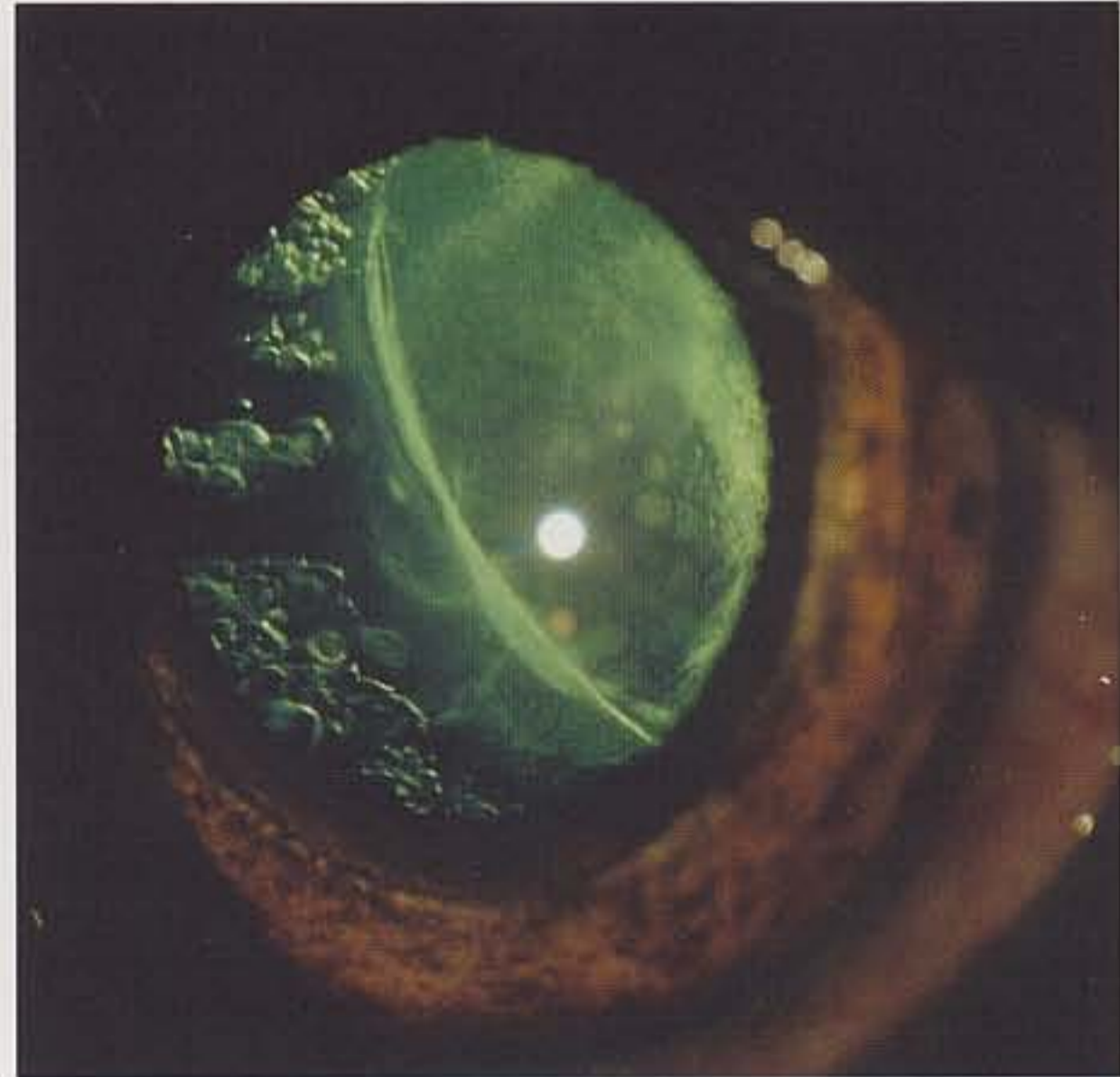

Fig. 9.57 Cataract and posterior lenticonus (Labrador Retriever, 18 months old) A unilateral case.

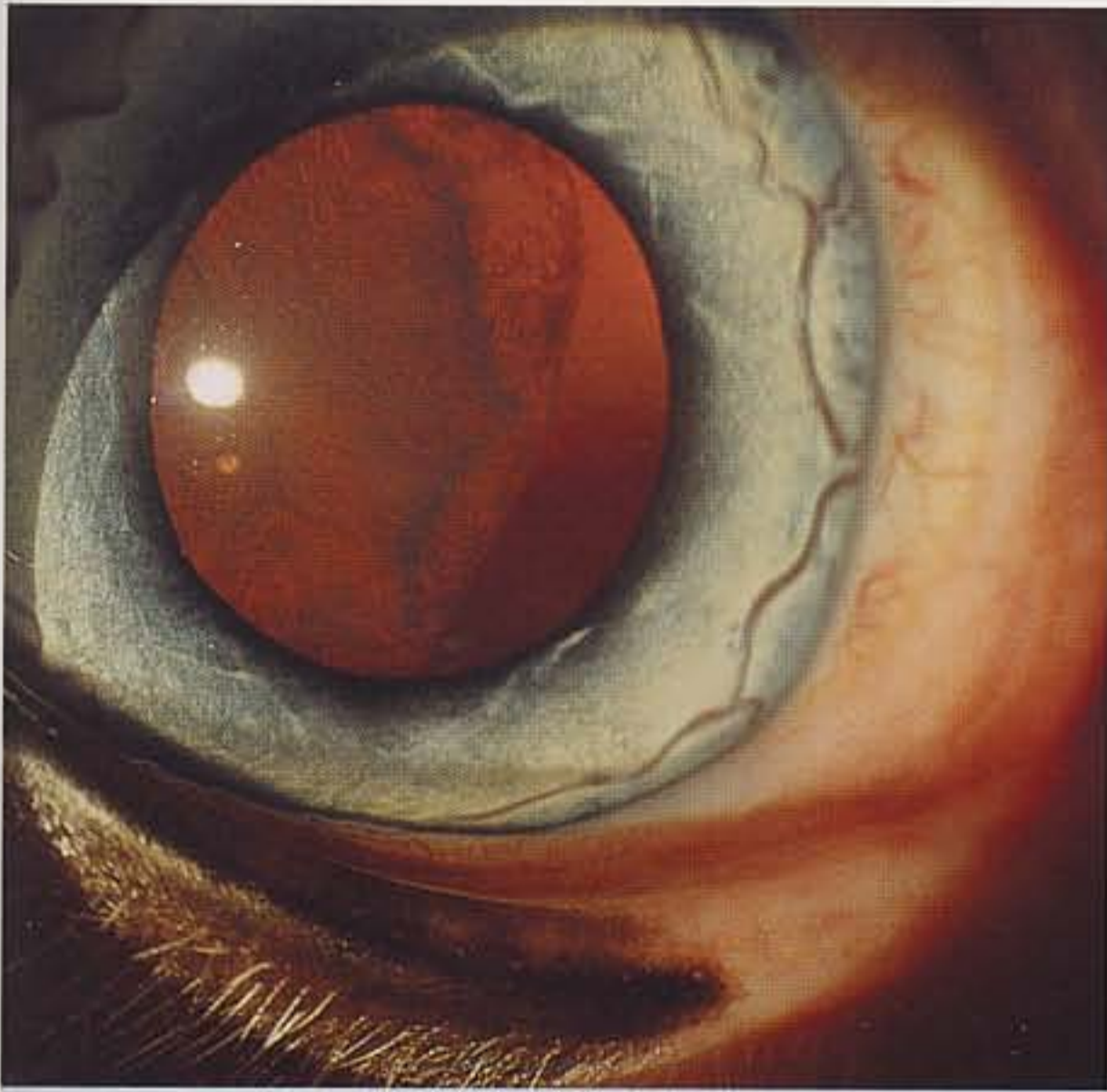


Fig. 9.58 Cataract and coloboma (Old English Sheepdog, 3 months old) This case had multiple congenital ocular abnormalities.

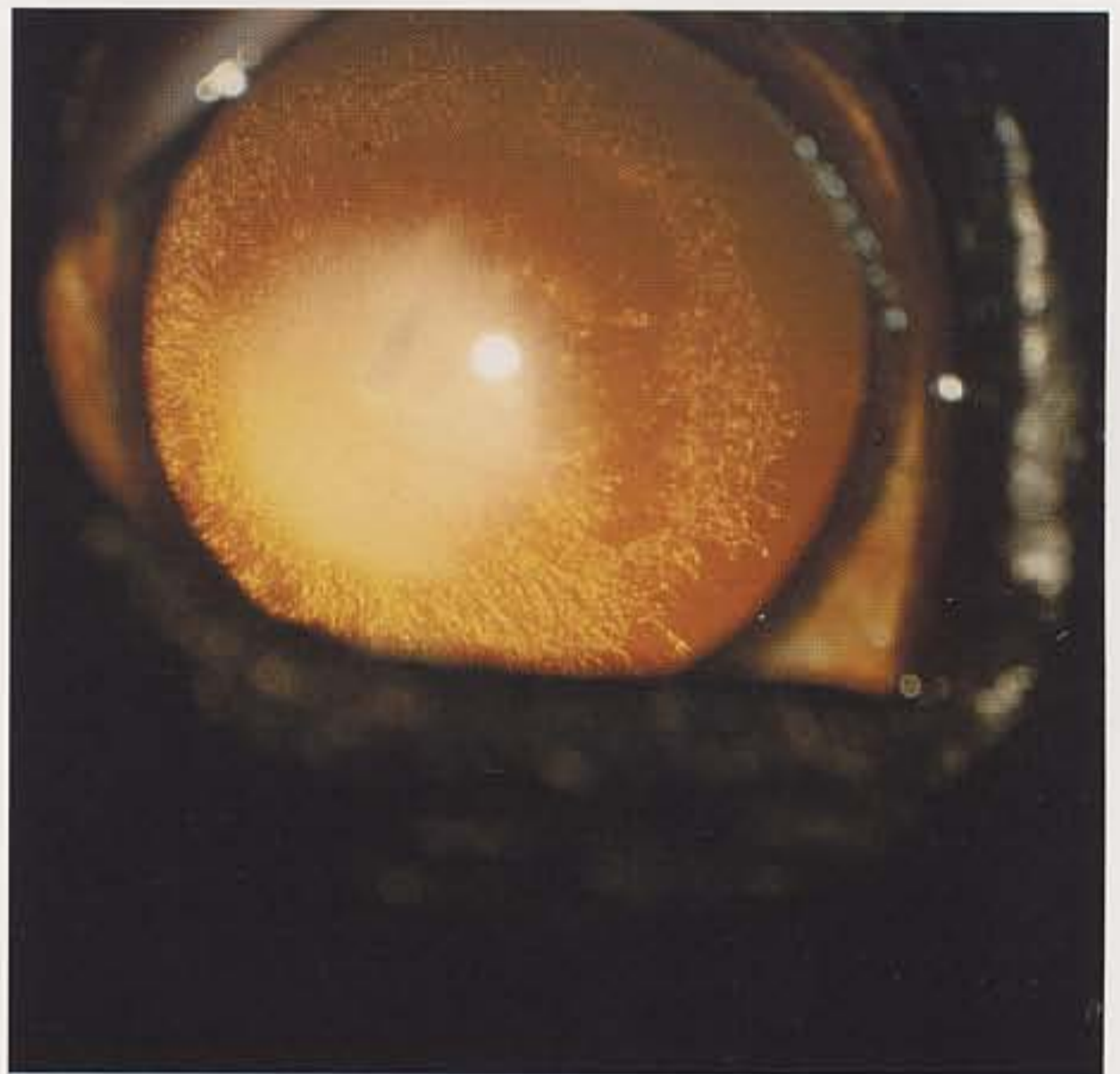

Fig. 9.59 Cataract and persistent hyaloid artery (Border Collie, young adult) Another unilateral case. See also Figs 10.1–10.3.

Secondary cataracts also occur with a number of retinal diseases (Figs 9.50–9.55) including the progressive retinal atrophies, retinal dysplasia and retinal detachment. Glaucoma is another eye disease in which cataract may occur (Fig 9.56) and cataract also accompanies such congenital lens abnormalities as lenticonus, coloboma and persistent hyaloid artery (Figs 9.57–9.59).

### Metabolic, toxic and nutritional cataracts (Figs 9.60–9.67)

These cataracts are also secondary but to a systemic disease or condition. Diabetic cataract in the dog is relatively common and may be the presenting sign of the diabetes (Figs 9.60–9.62). It is always bilateral and usually symmetrical and often sudden in onset, although there is also a pre-senile type which is

much slower in onset. Diabetic cataract in the cat does occur but is much less common.

There are a few reports of nutritional cataract (Figs 9.63–9.64) and several reports of toxic cataracts due to a variety of substances (Figs 9.65–9.67).

### Other types of cataract (Figs 9.68–9.72)

Cataract may be classified according to the position of the opacity in the lens. Figs 9.68–9.72 show five examples.

### False cataracts (Figs 9.80–9.86)

The final group of lens opacities are not true cataracts but are often confused with cataract or are only temporary opacities.

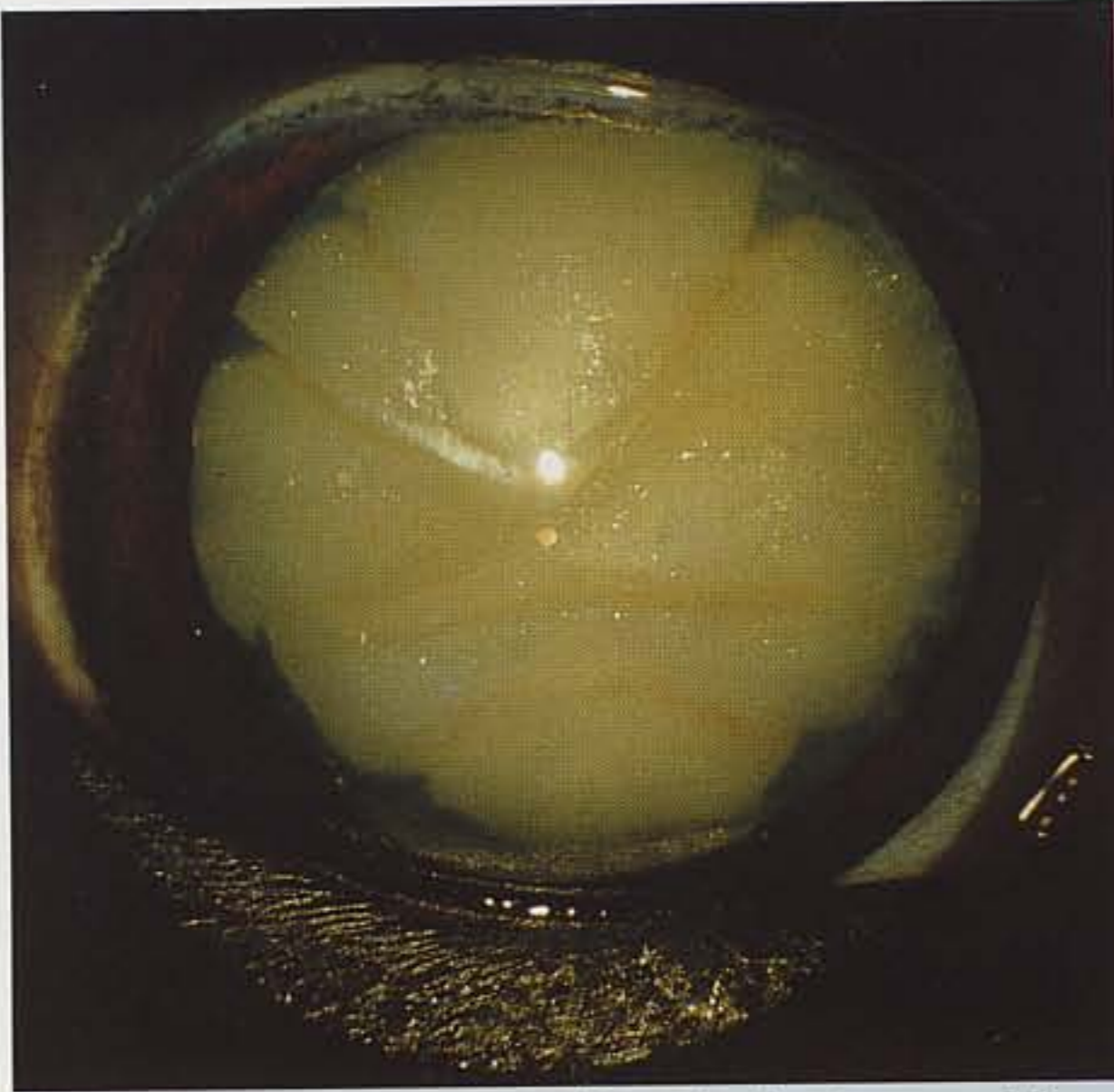

Fig. 9.60 Diabetic cataract (Crossbred, 12 years old) Bilateral, symmetrical and frequently sudden in onset. Note the water clefts.

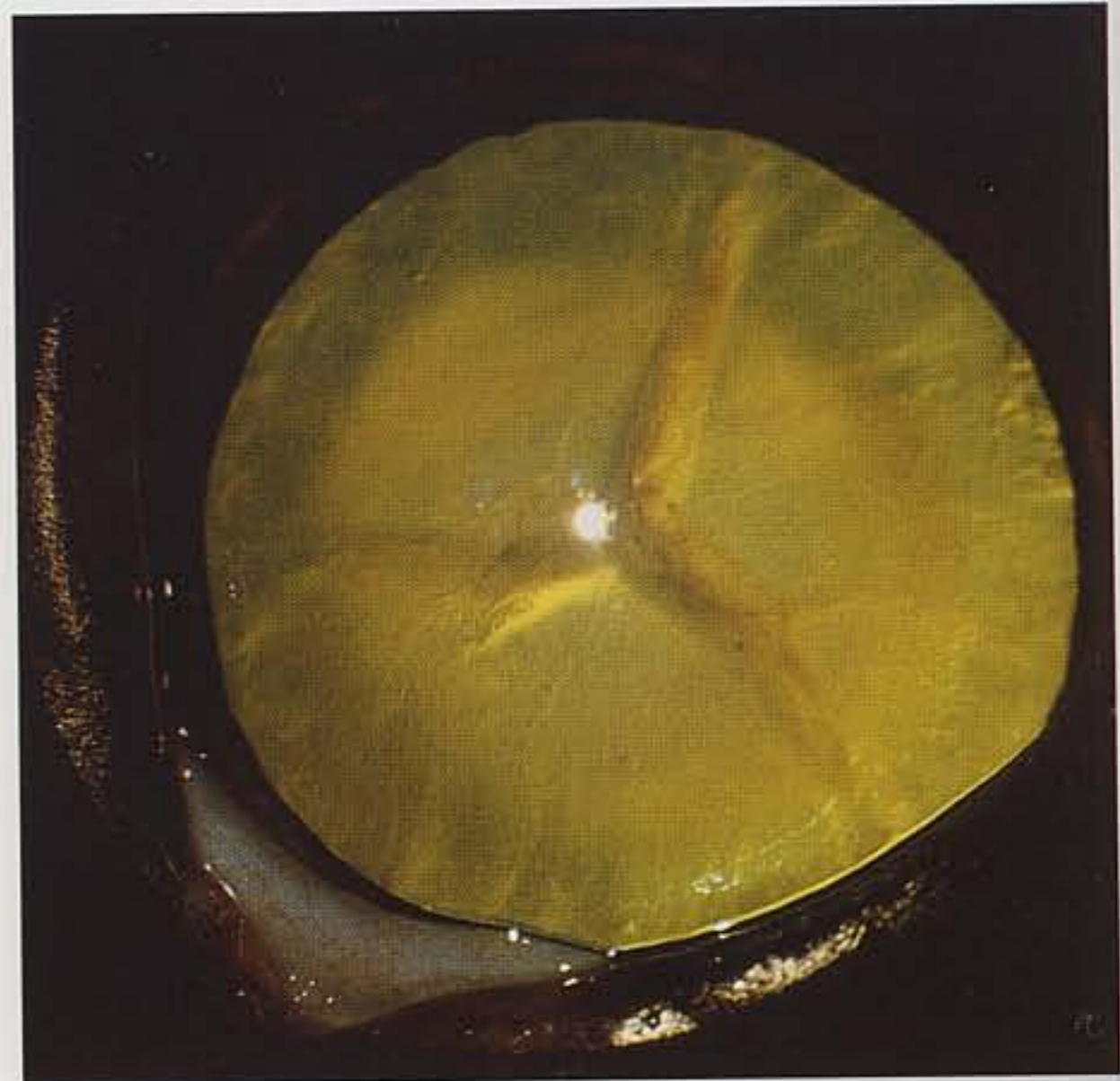

Fig. 9.62 Diabetic cataract (Pembroke Corgi, 9 years old) Pre-senile type – slower in onset than the previous diabetic cataracts.

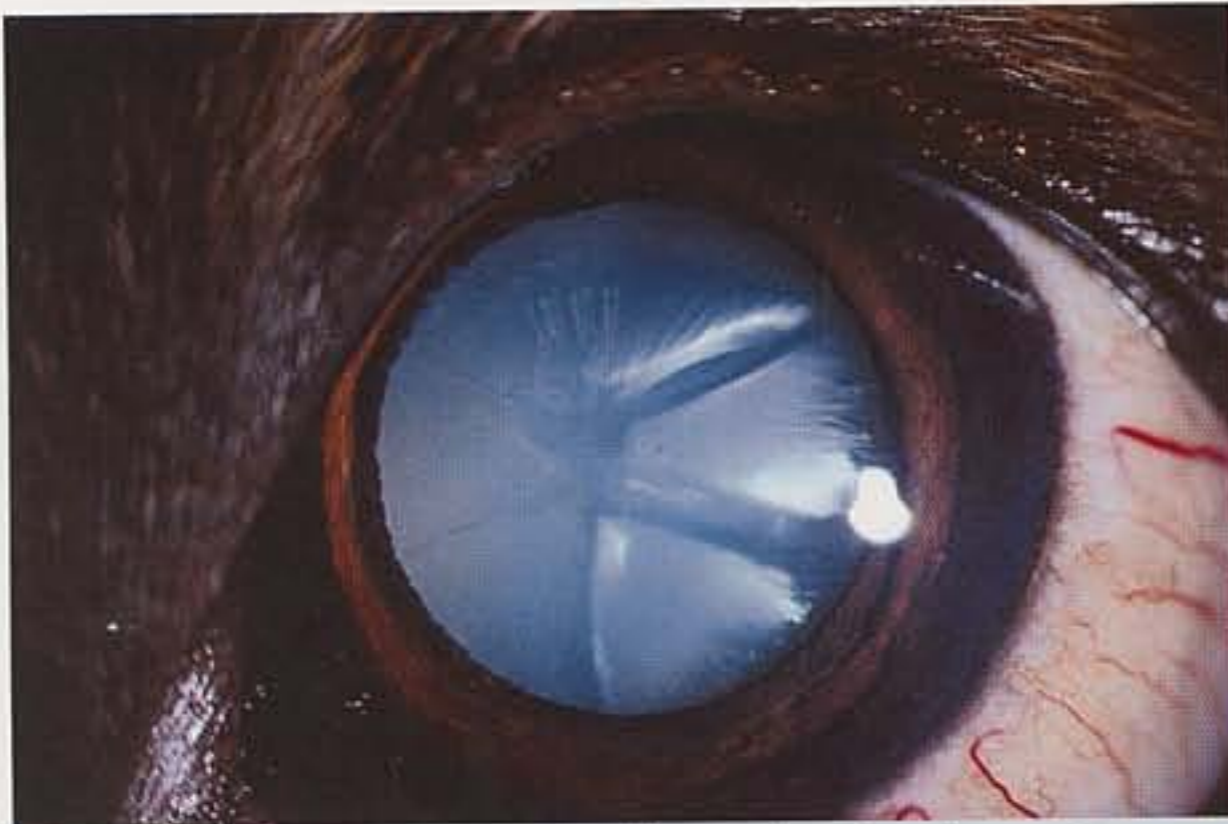

Fig. 9.61 Diabetic cataract (Labrador Retriever, 6 years old) Again, note the obvious water clefts.

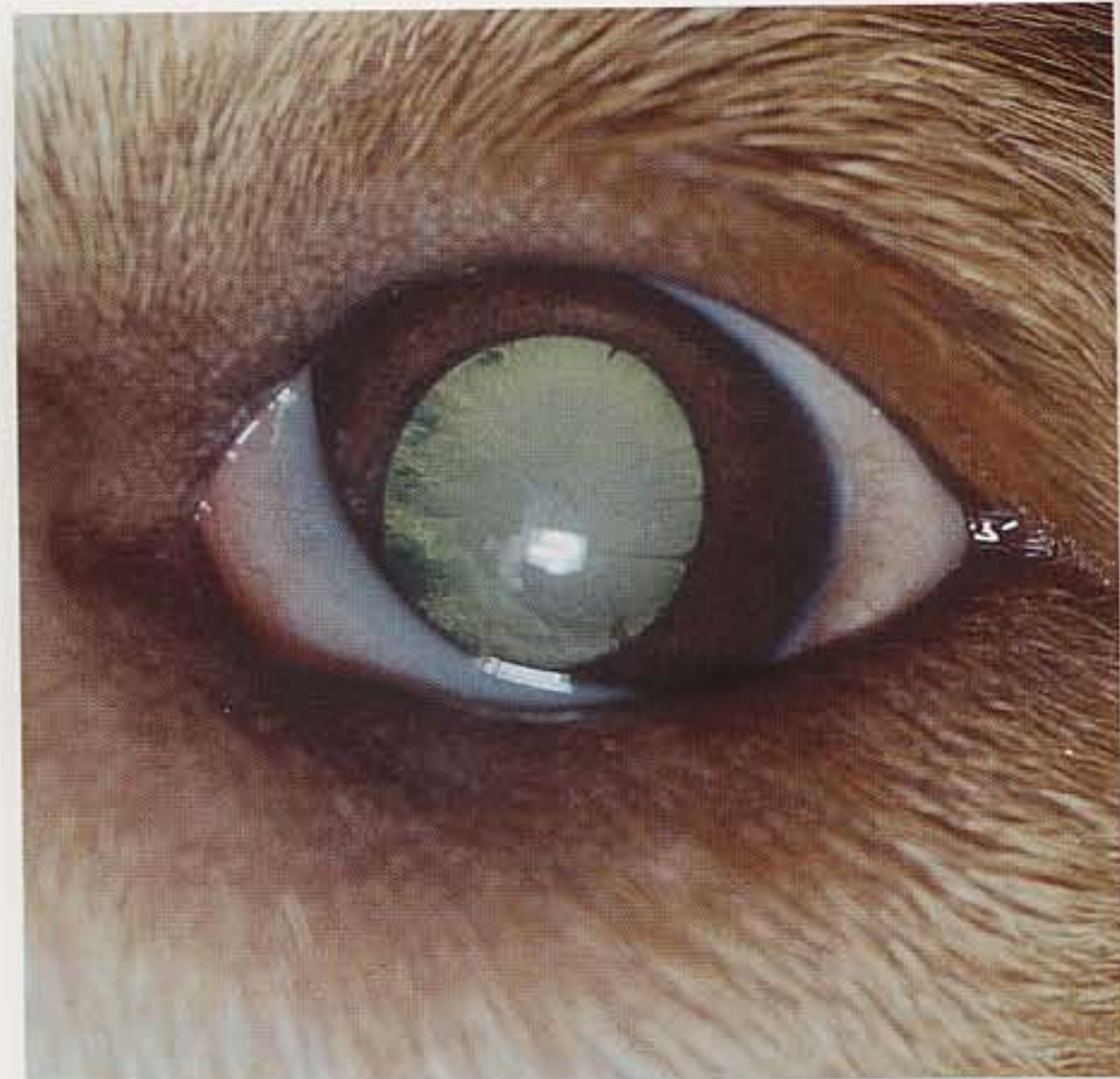

Fig. 9.63 Nutritional cataract (Foxhound puppy) Probably due to a deficiency of the vitamin B complex. Several puppies in the pack were affected. Congenital.



Fig. 9.64 Nutritional cataract (Tiger cub) Bilateral cataract in a hand-reared animal. Cataracts of this type have been examined in several, always hand-reared, big cats.

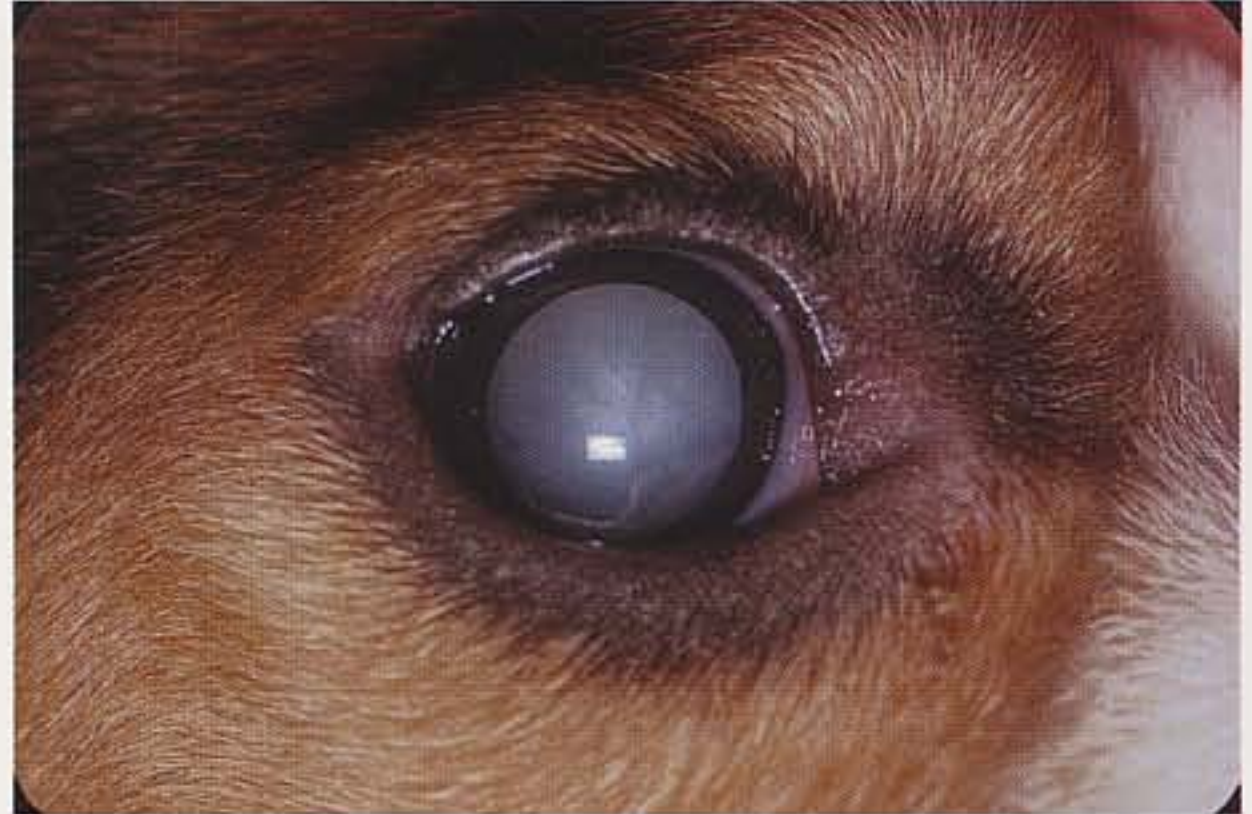

Fig. 9.66 Toxic cataract (Beagle) Total bilateral cataract.

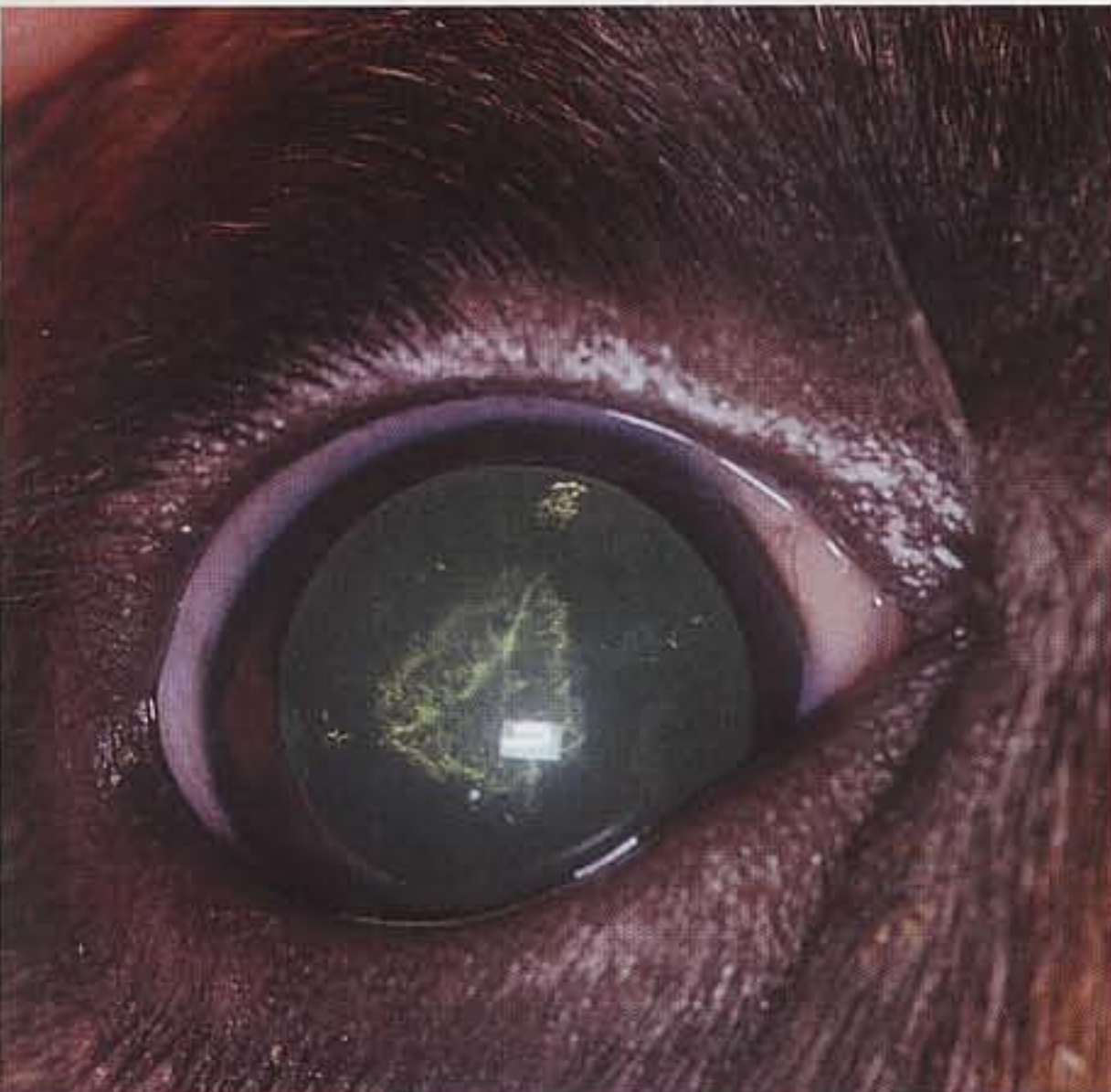

Fig. 9.65 Toxic cataract (Beagle) Partial cataract affecting the posterior cortex and the ends of the suture lines. Cataracts of various forms are a common finding in toxicity trials and can be caused by many compounds.

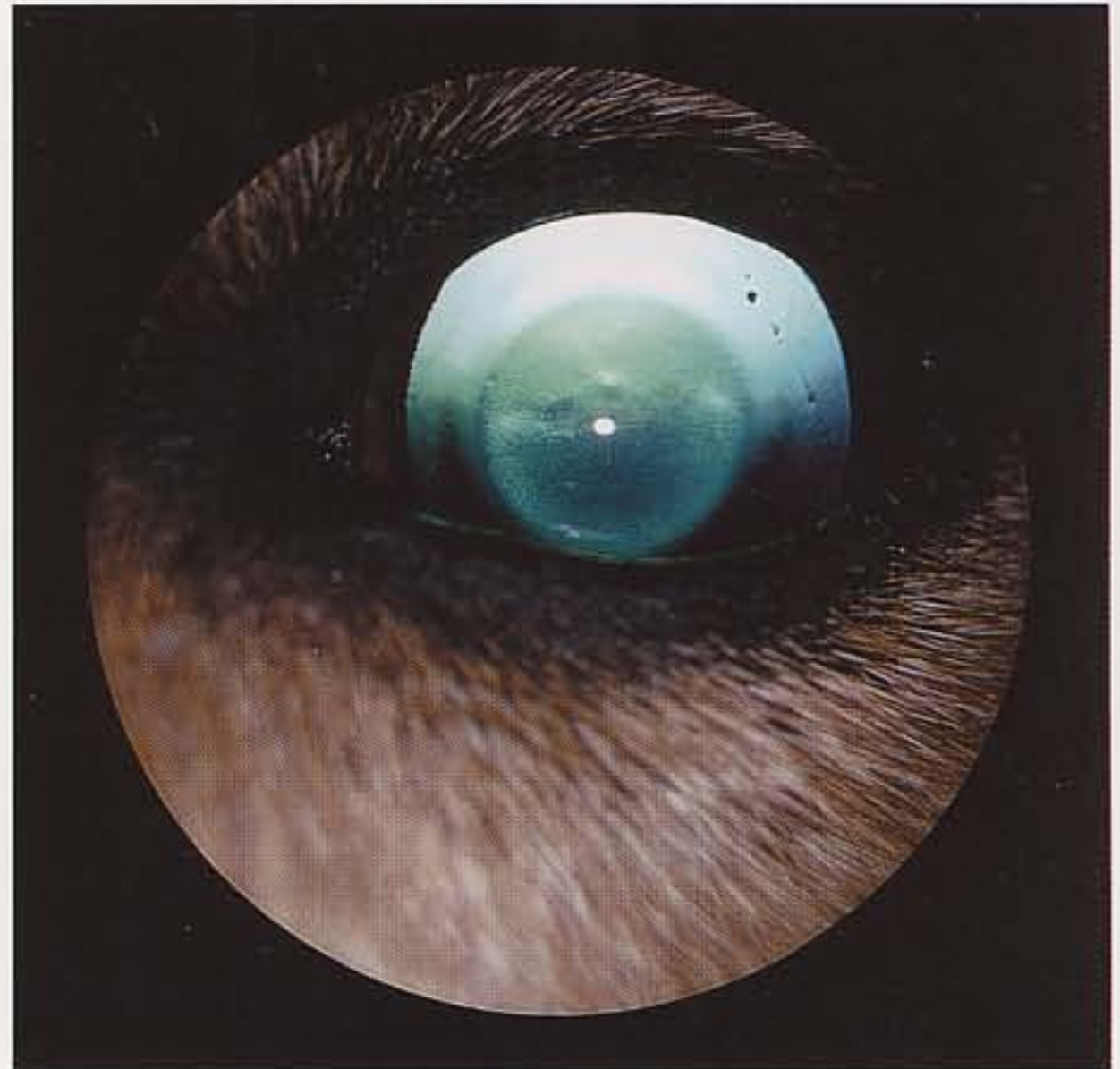


Fig. 9.67 Toxic cataract (Beagle) Unusual appearance of the lens nucleus due to dimethyl sulphoxide toxicity.

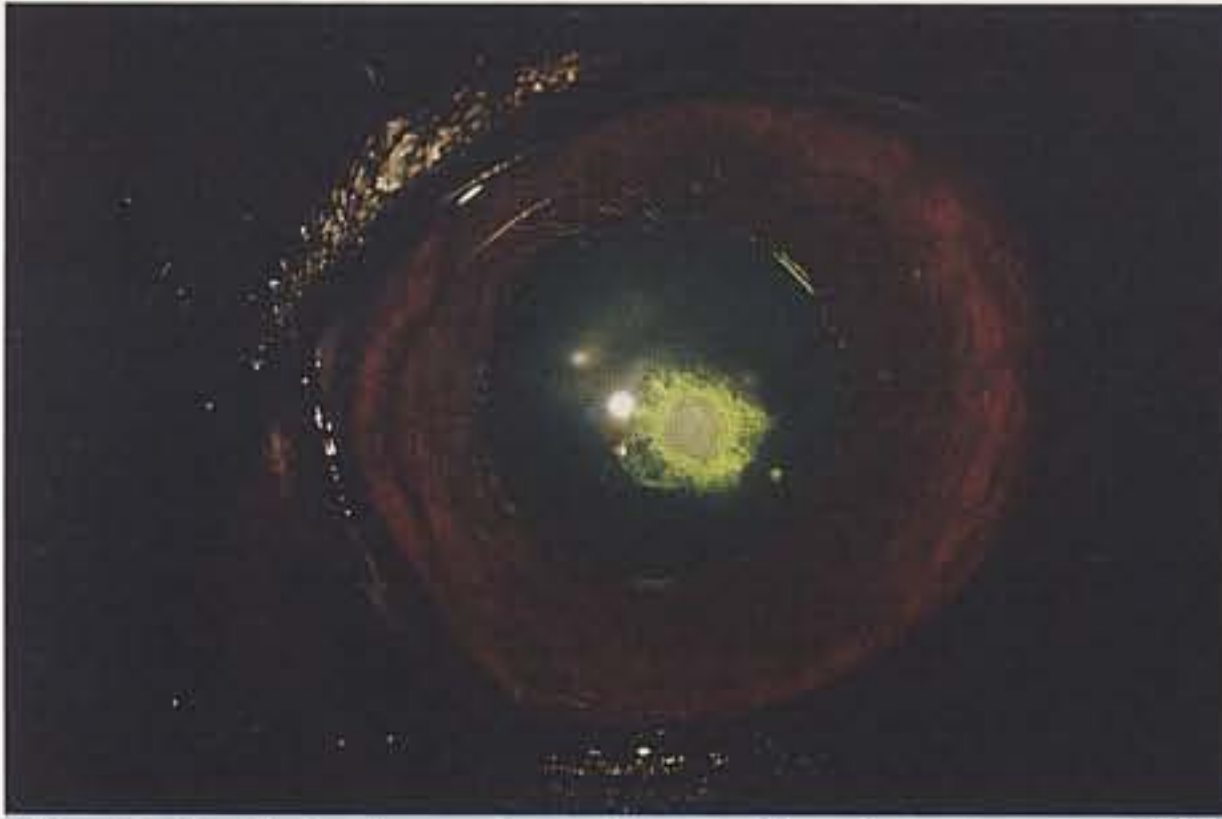


Fig. 9.68 Anterior polar cataract (Lurcher, 6 years old)  
Bilateral in this case.

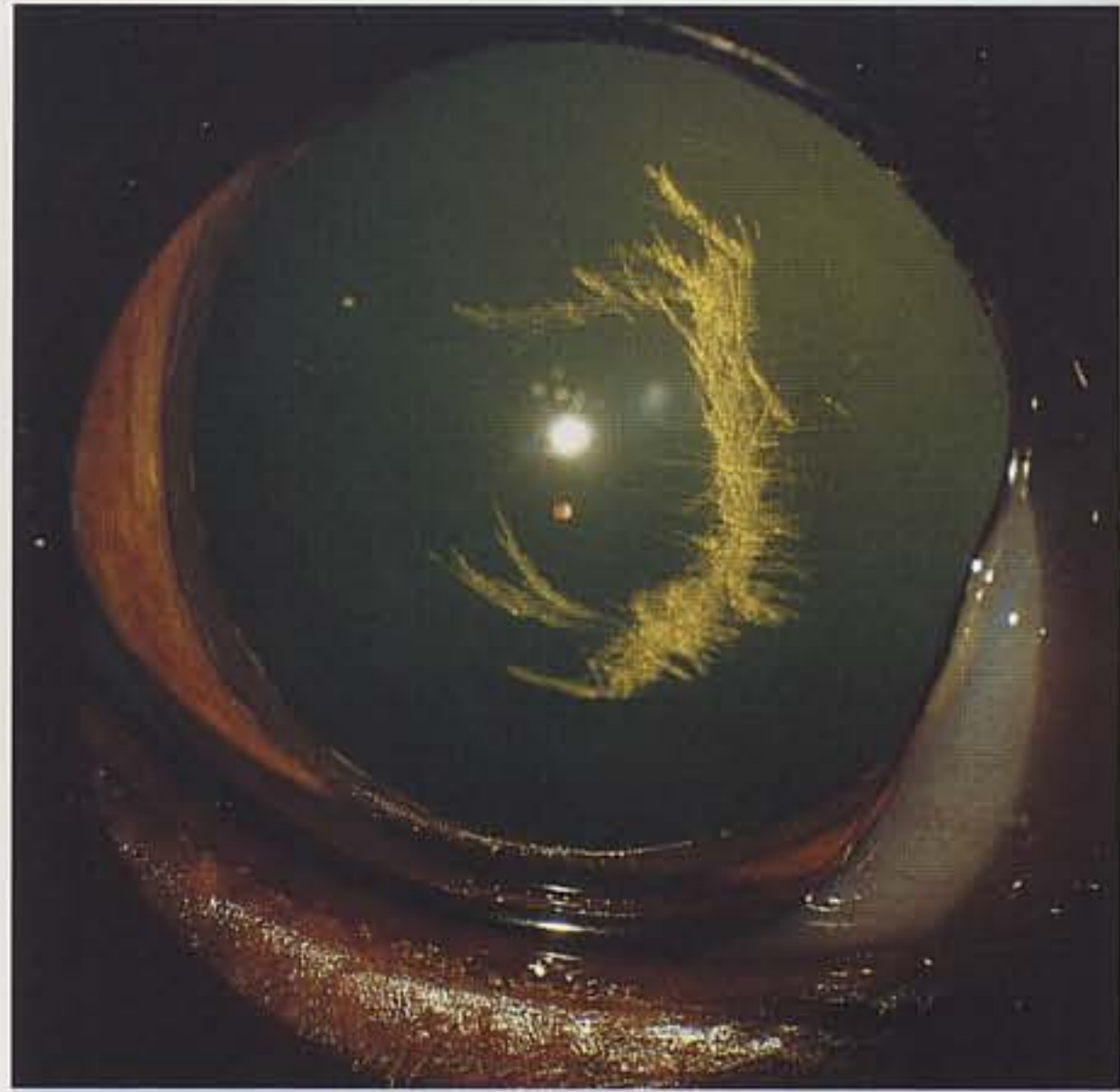

Fig. 9.69 Lamellar cataract (English Springer Spaniel,  
6 years old) Feather-like opacity around part of the  
edge of the nucleus.

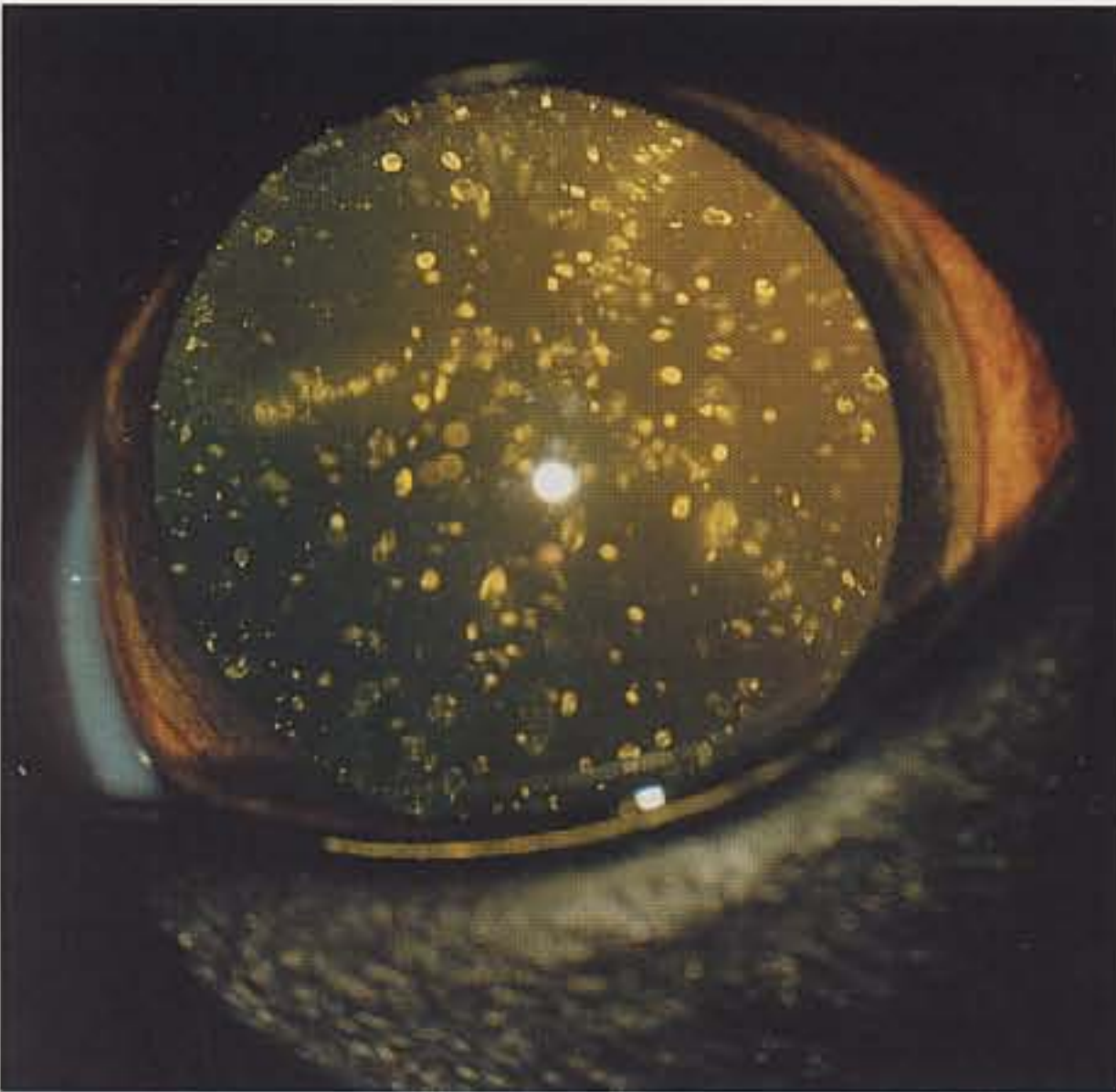


Fig. 9.70 Subcapsular cataract (Border Collie,  
18 months old) Multiple focal dots, particularly  
involving the suture lines; bilateral.

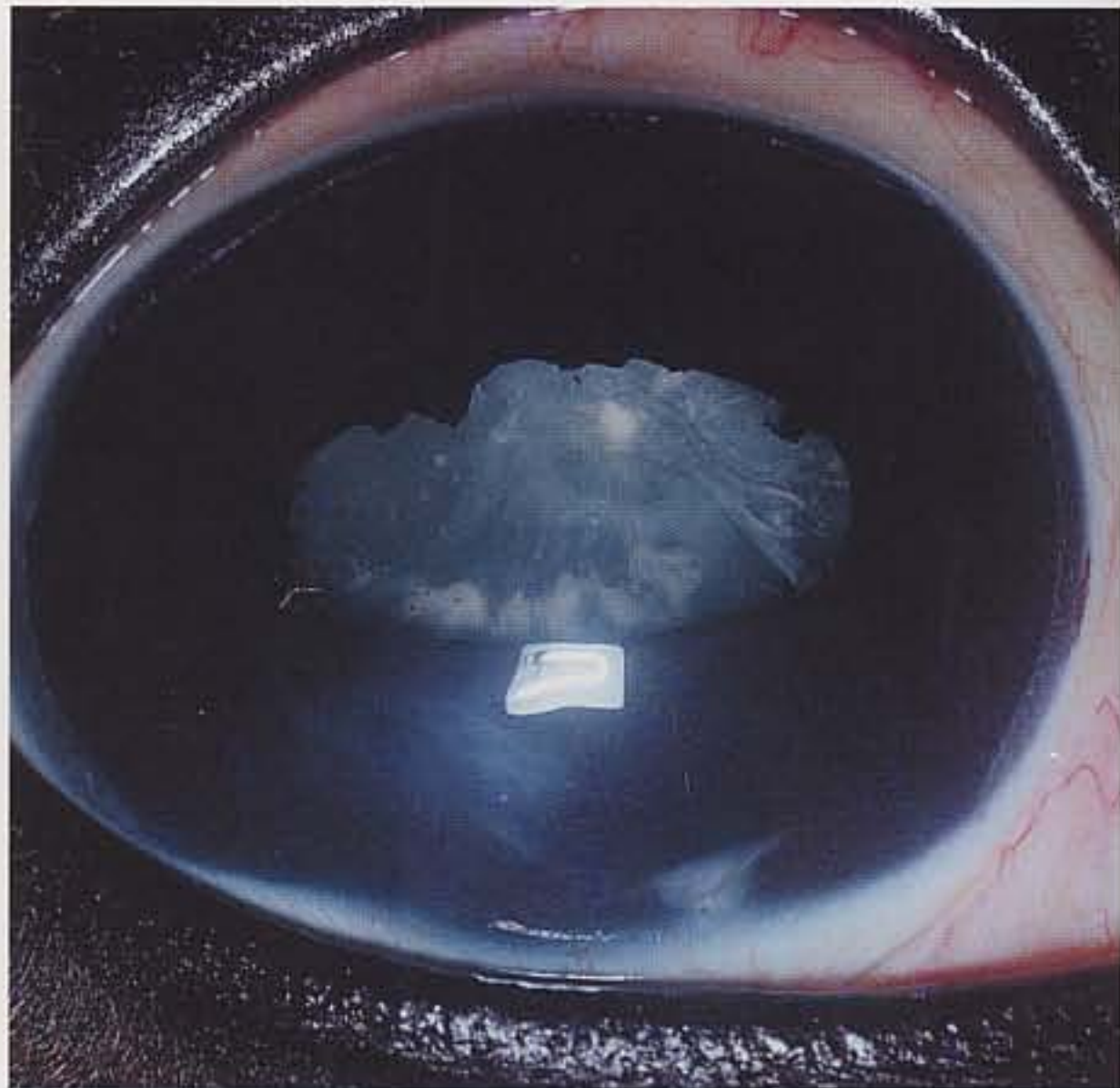


Fig. 9.71 Partial cataract (Hunter-type, 7 years old)  
Traumatic cataract and note the corneal scar at 5 o'clock  
near the limbus.



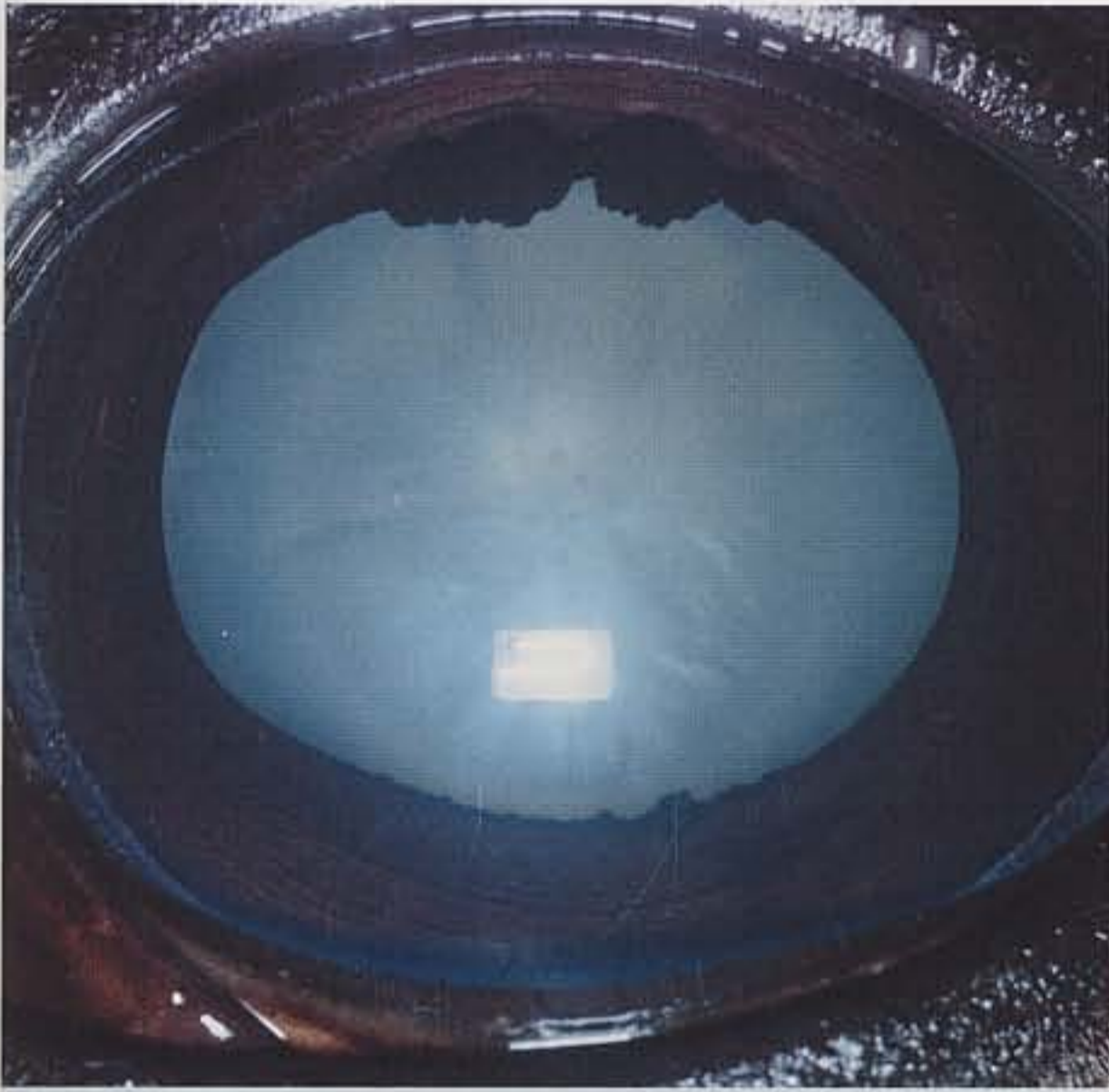


Fig. 9.72 Total cataract (Thoroughbred, 5 years old) Mature cataract of unknown aetiology (pupil dilated).

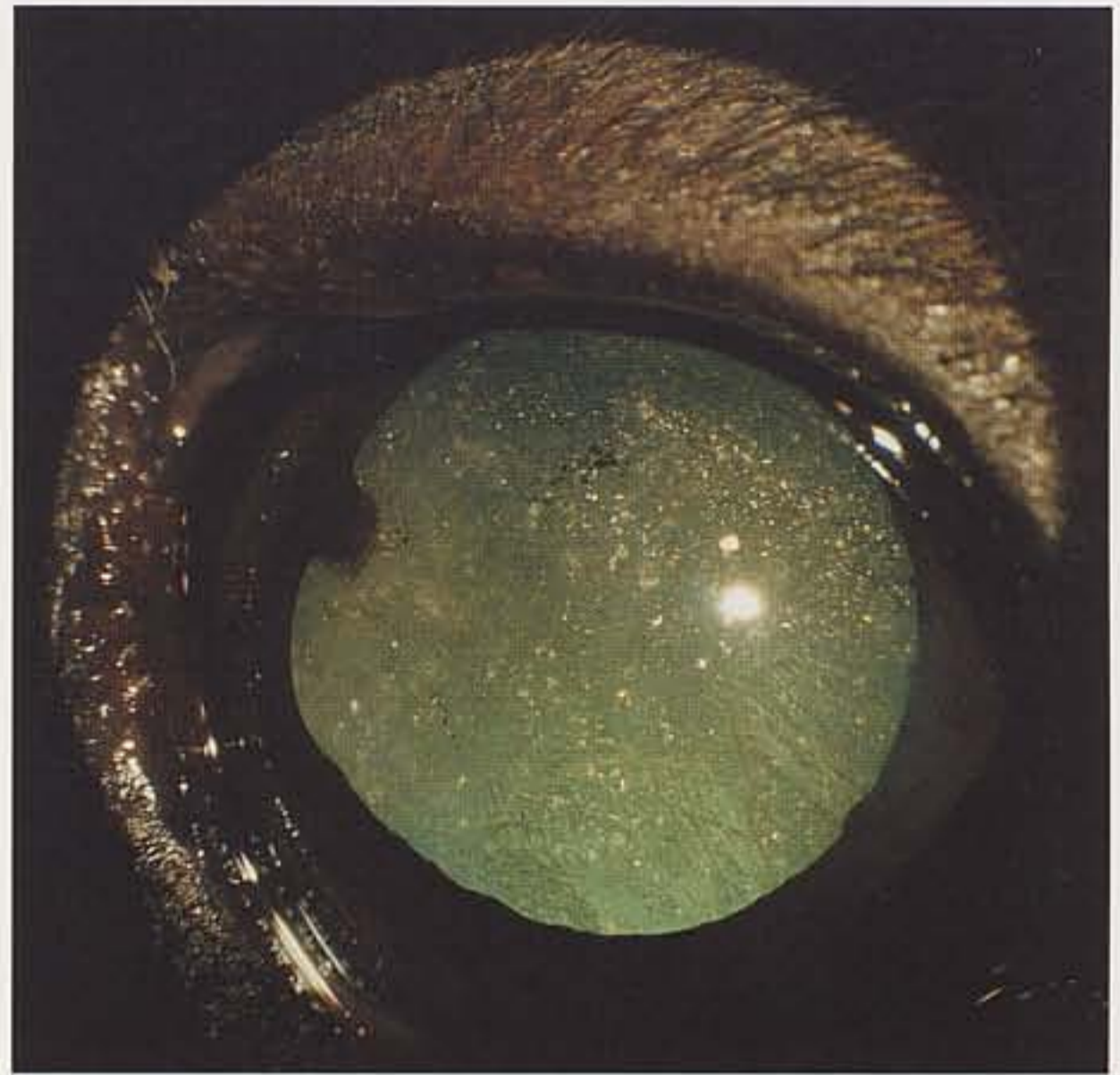


Fig. 9.74 Cataract resorption (Lakeland Terrier) Green tapetal reflex now visible. Note uveitis and posterior synechia at 9 o'clock.

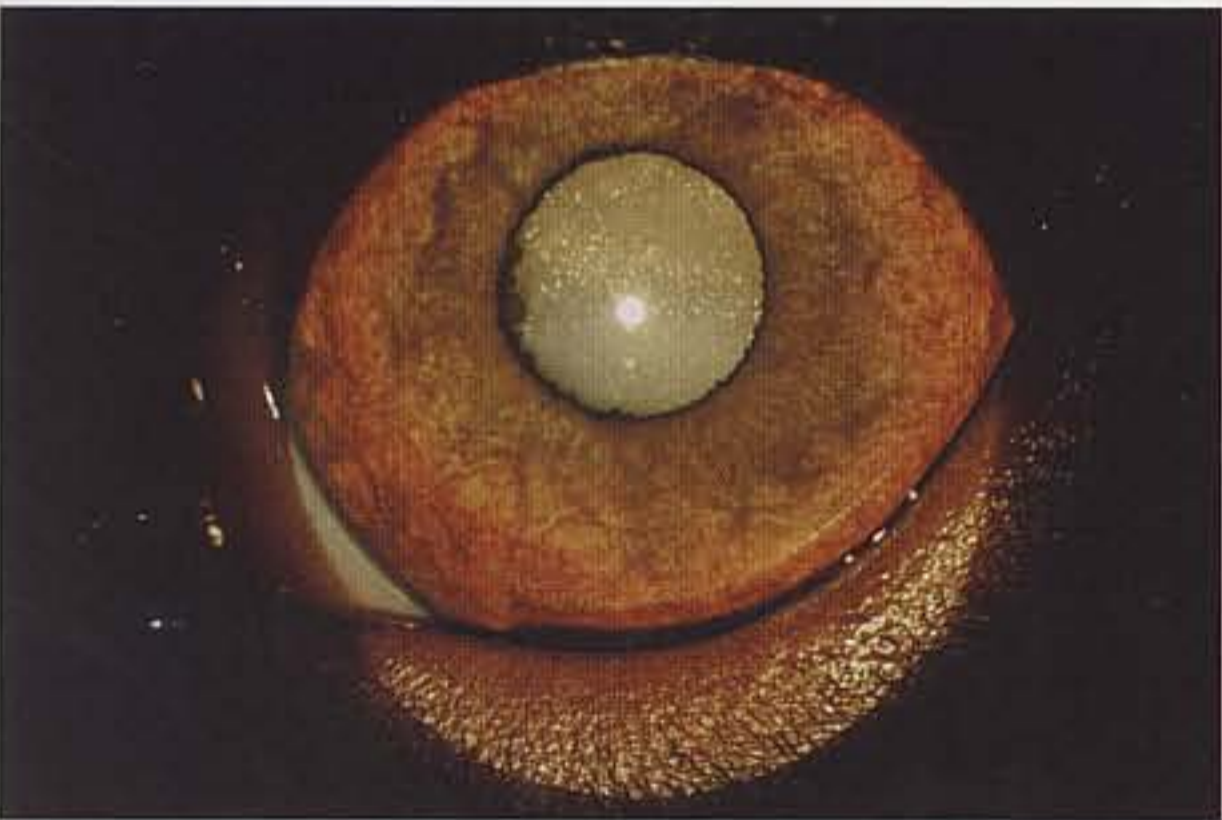

Fig. 9.73 Cataract resorption (English Springer Spaniel, 18 months old) Note the metallic appearance of the lens and the pupillary cysts.

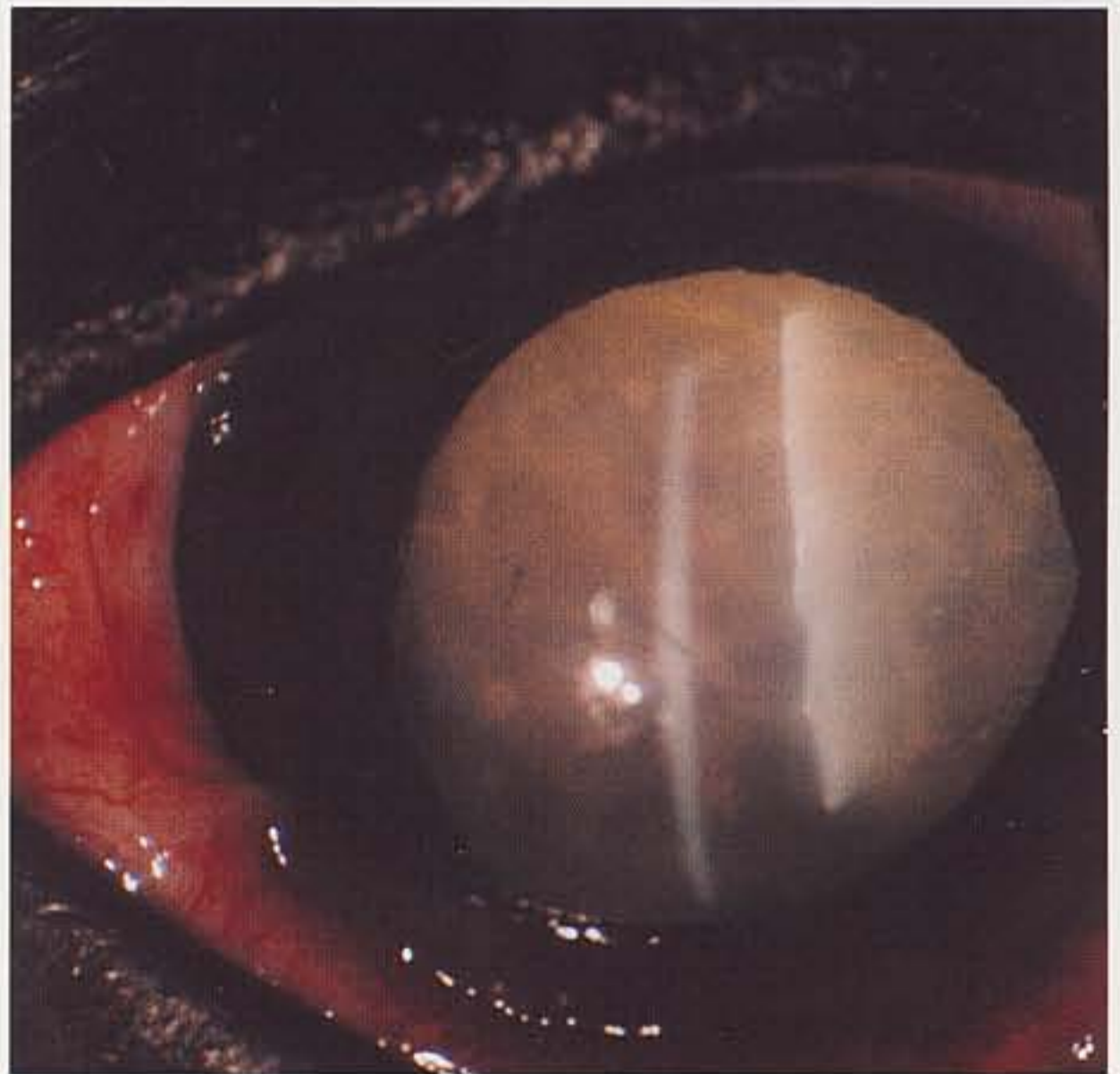


Fig. 9.75 Cataract resorption (American Cocker Spaniel, 18 months old) Note the slit beam on the anterior lens capsule showing it to be flat and uneven with a deep anterior chamber.

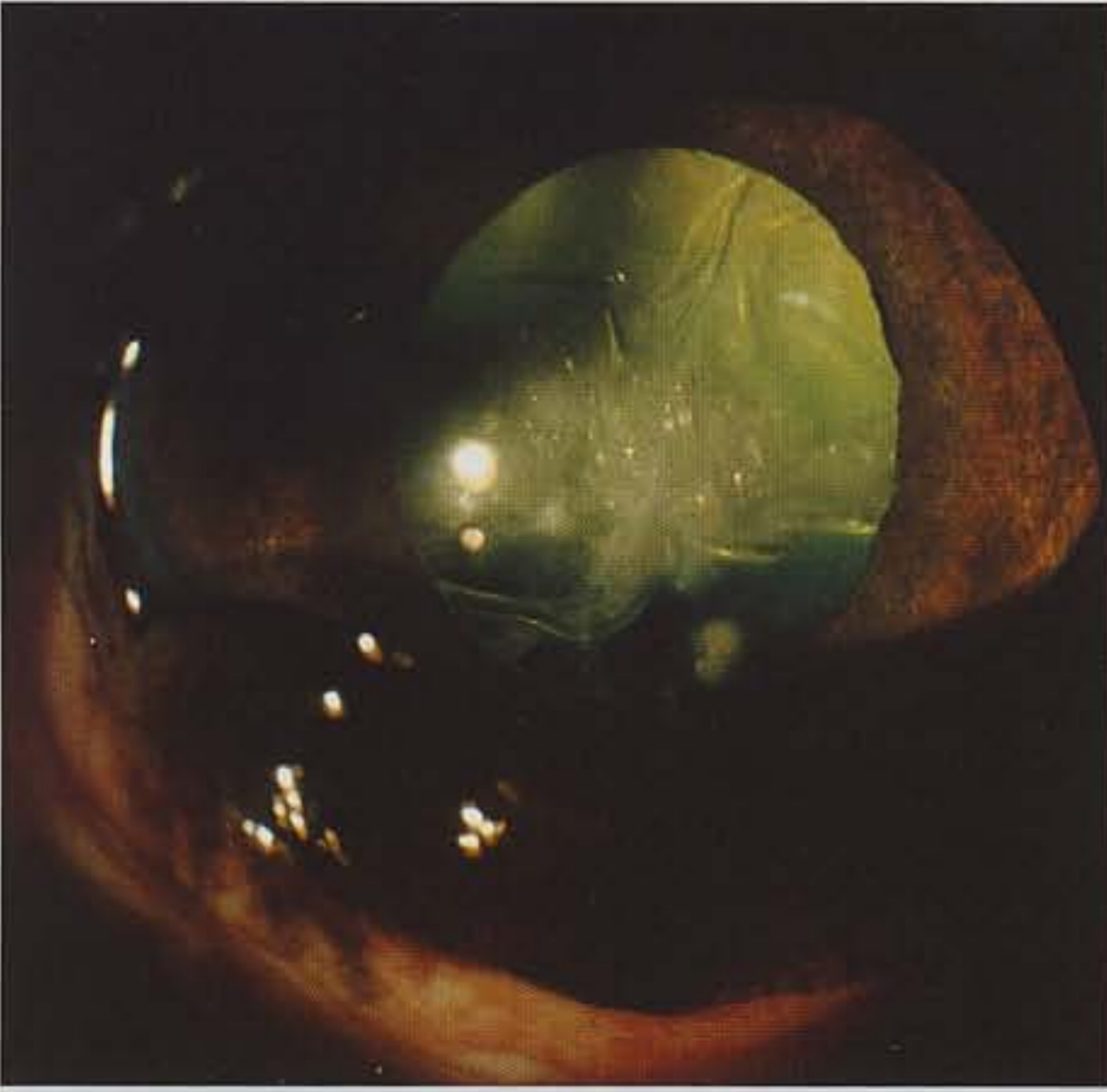

Fig. 9.76 Cataract resorption (Great Dane, 4 years old) Note the wrinkled anterior capsule and visible green tapetal reflex. This eye was visual, although it had been blind prior to the cataract resorption.

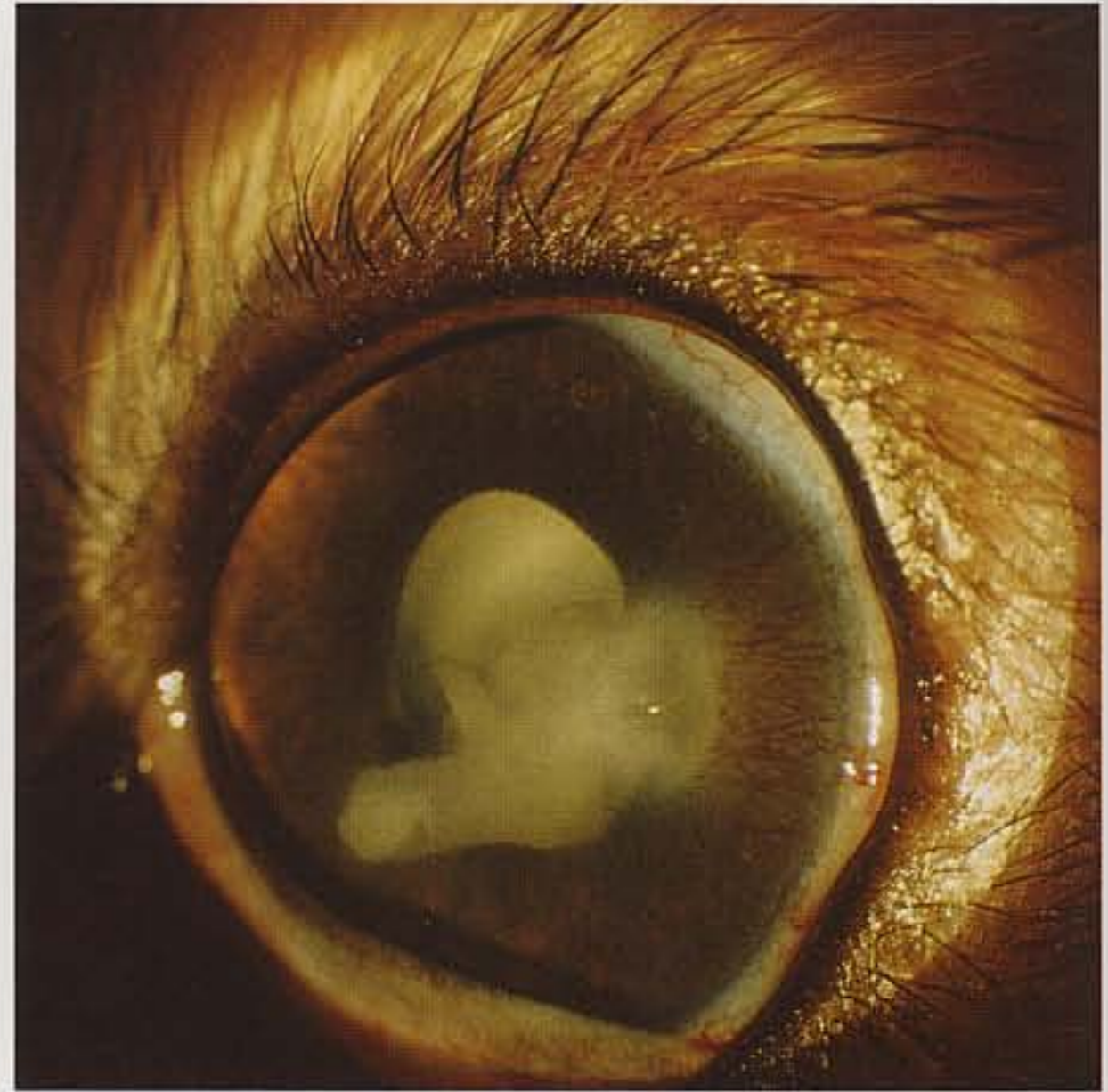

Fig. 9.78 Traumatic cataract (Jack Russell Terrier, 4 months old) Note corneal puncture wound at 6 o'clock with blood vessels from the limbus and lens material in the anterior chamber. The result of a cat scratch.

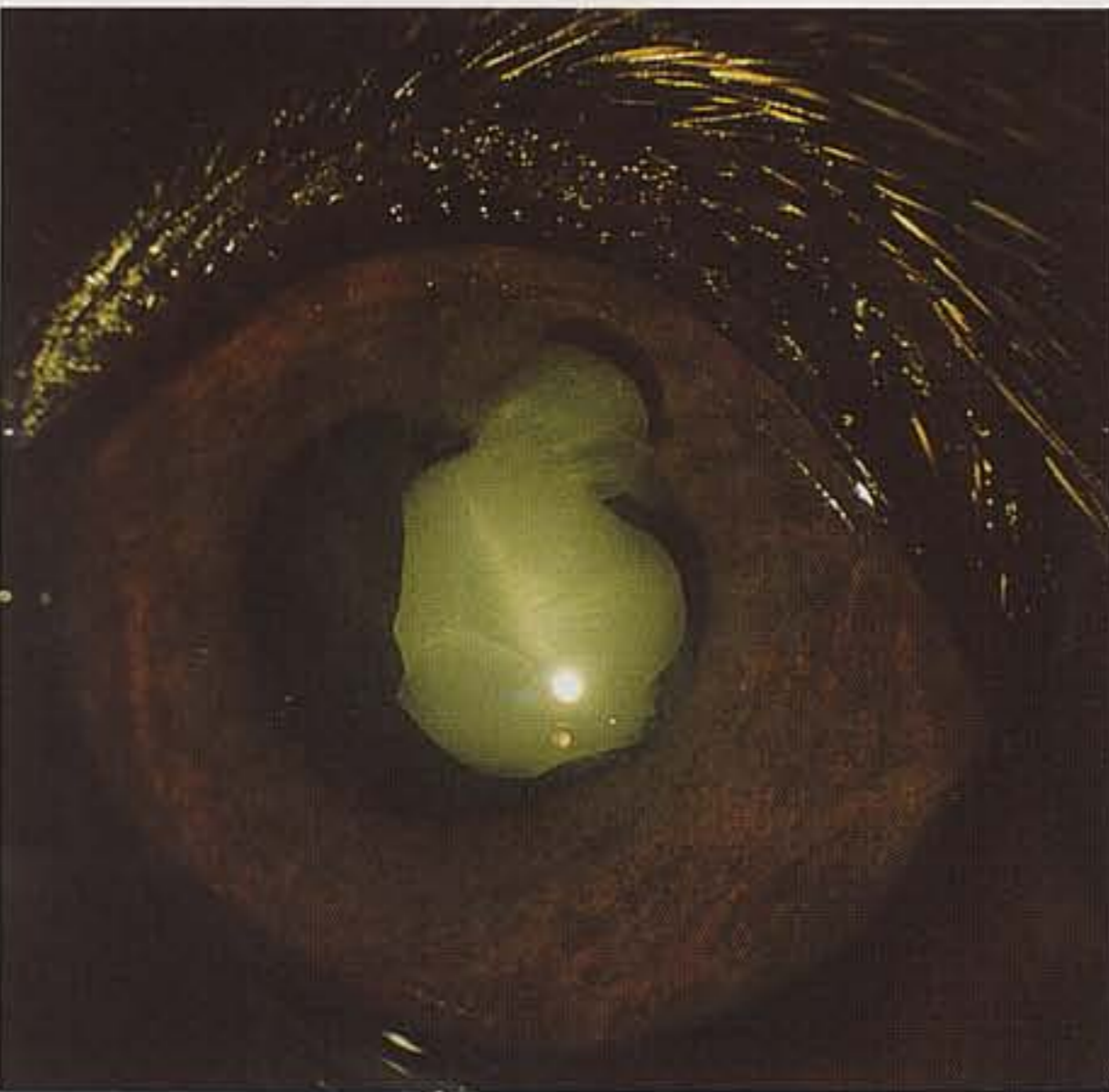


Fig. 9.77 Traumatic cataract (Jack Russell Terrier, 2 years old) Note also the uveitis and irregular pupil.

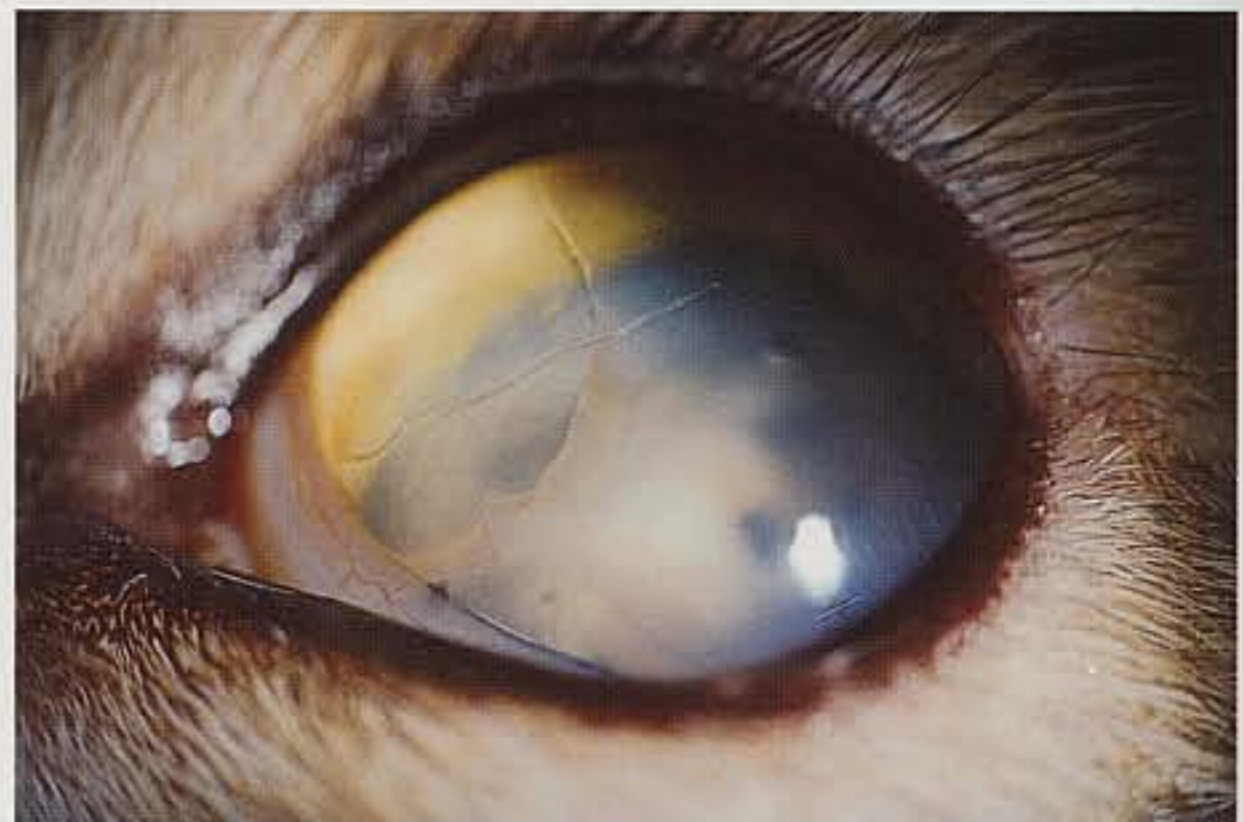

Fig. 9.79 Traumatic cataract (DSH cat, 9 years old) Corneal wound and cataractous lens material in the anterior chamber which will promote a sometimes severe uveitis.

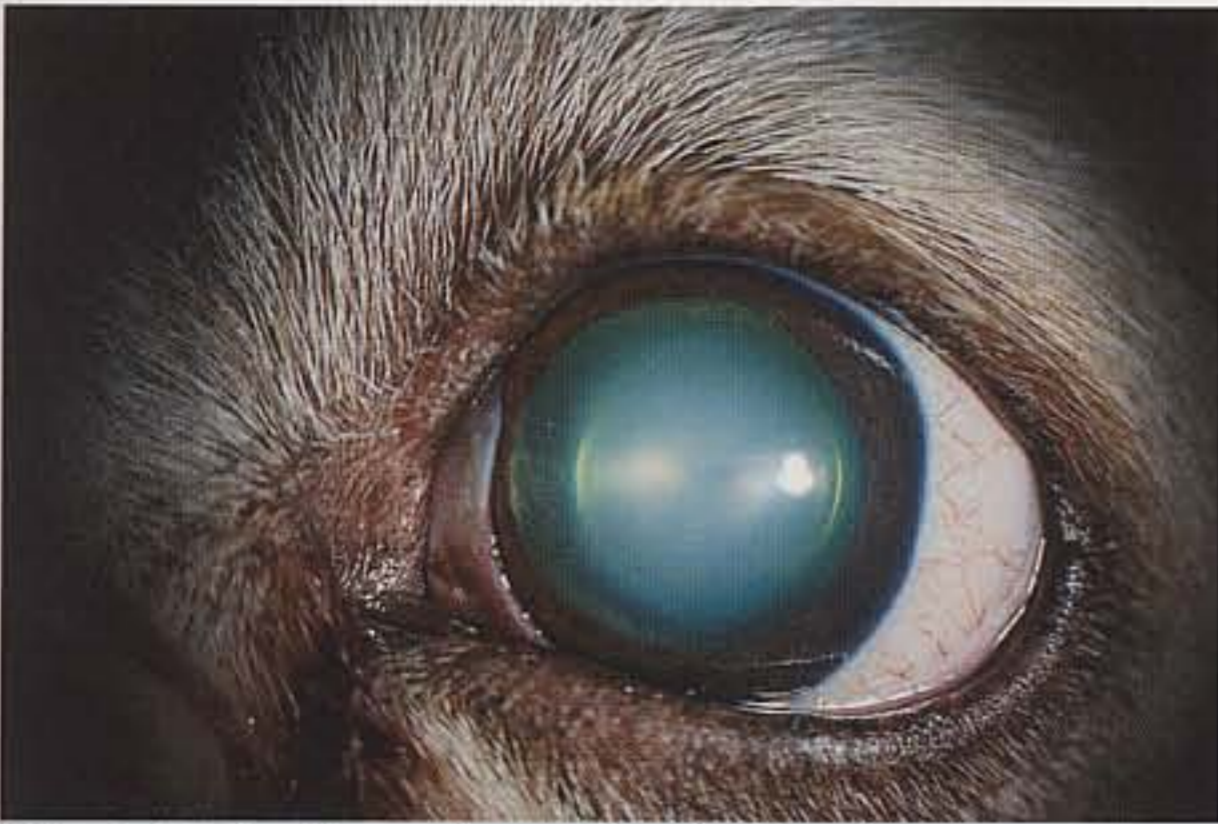

Fig. 9.80 Senile nuclear sclerosis (Beagle, 13 years old) Lens appears opalescent in direct light but there is no opacity on distant direct ophthalmoscopy. A normal age change.

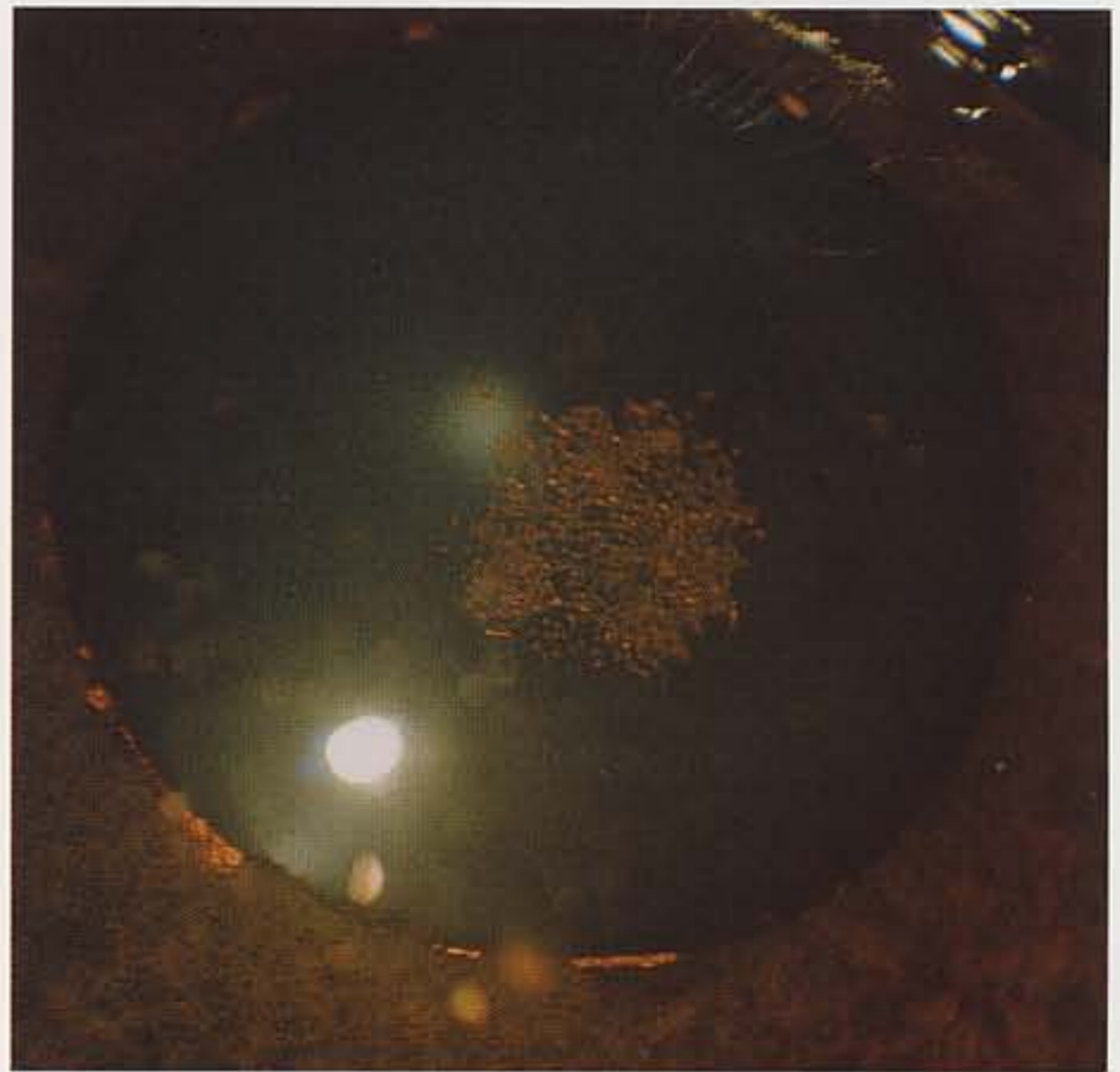


Fig. 9.82 Pigment on anterior lens capsule (Cocker Spaniel, 5 years old) Particularly common in this breed. It appears as a lens opacity with distant direct ophthalmoscopy but is actually a remnant of the pupillary membrane.

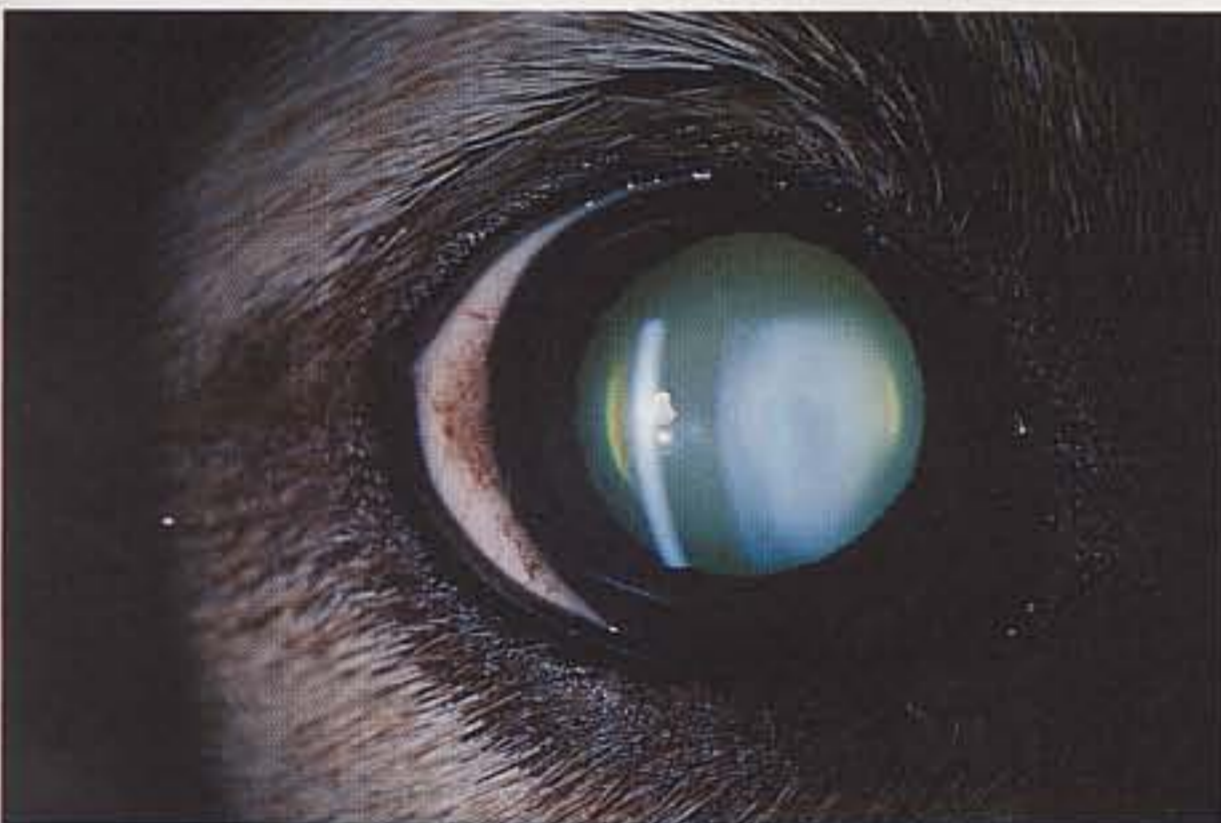

Fig. 9.81 Senile nuclear sclerosis (Labrador Retriever, 14 years old) The appearance with a slit beam.

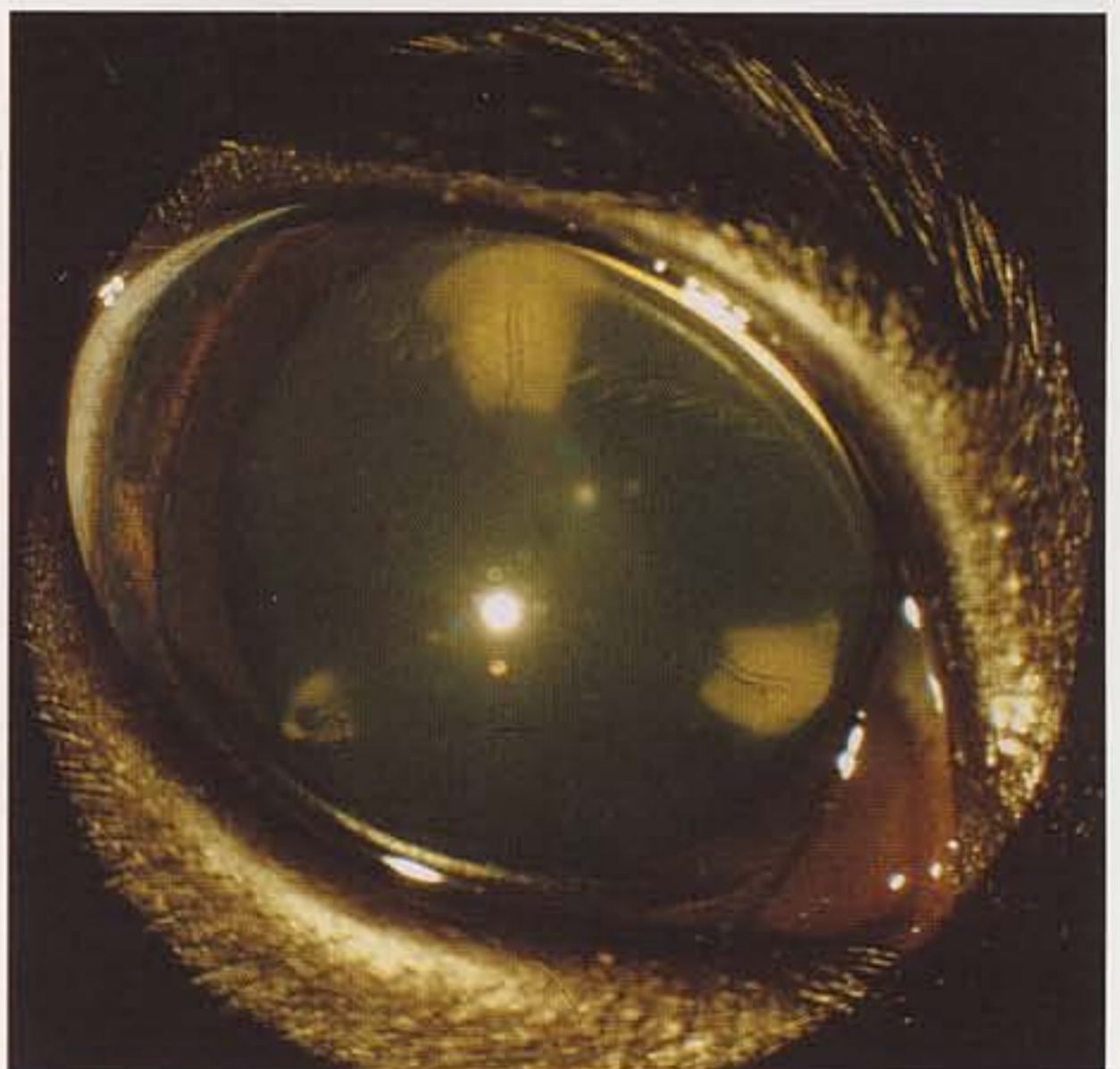


Fig. 9.83 Temporary opacity (Miniature Longhaired Dachshund, 13 weeks old) Opacities (cataracts) at the ends of the anterior suture lines.

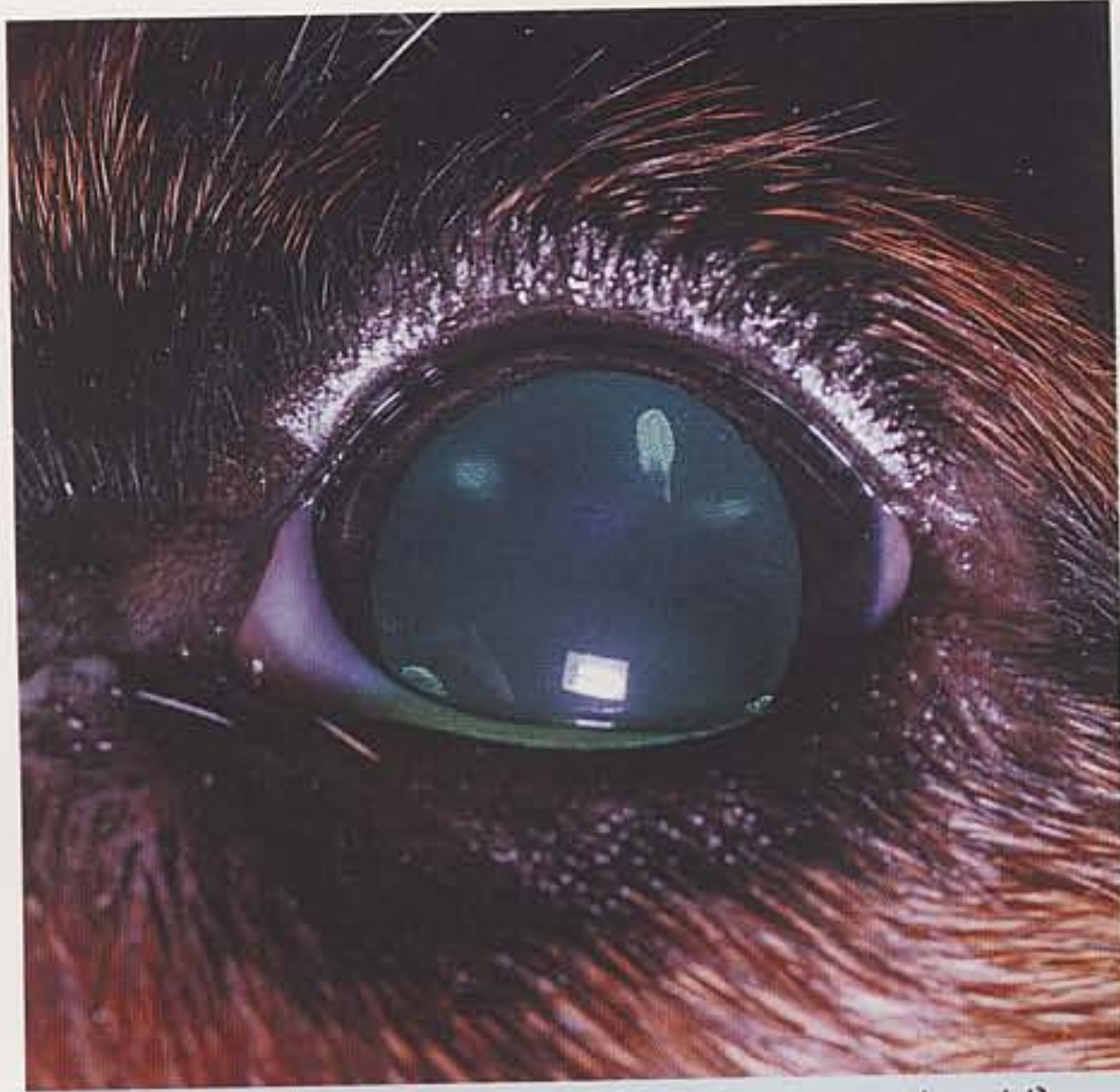

Fig. 9.84 Temporary opacity (Beagle, 6 months old) Small focal cataracts on both anterior and posterior suture lines.

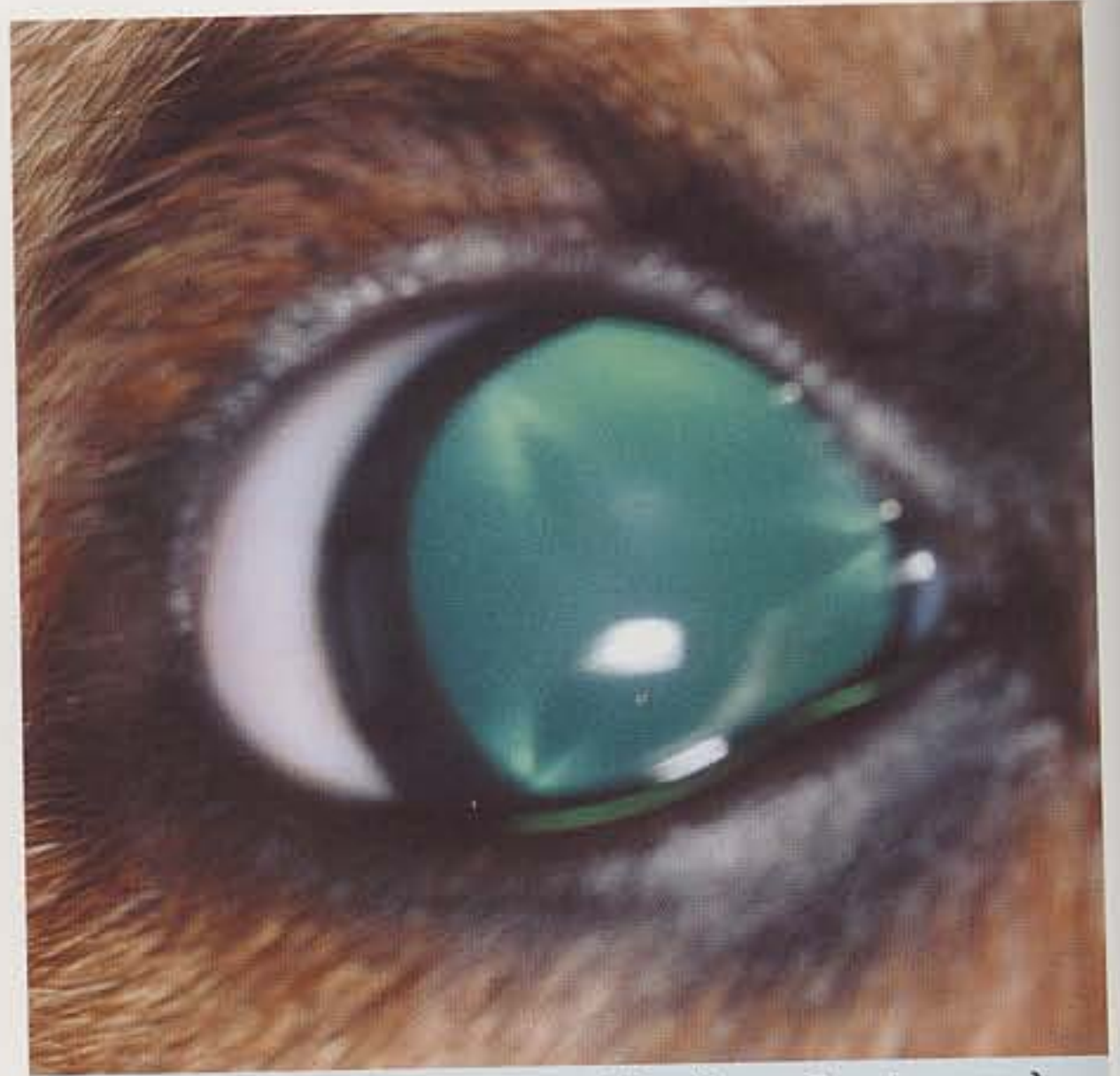

Fig. 9.85 Temporary opacity (Cardigan Corgi puppy) Similar to the previous two figures.

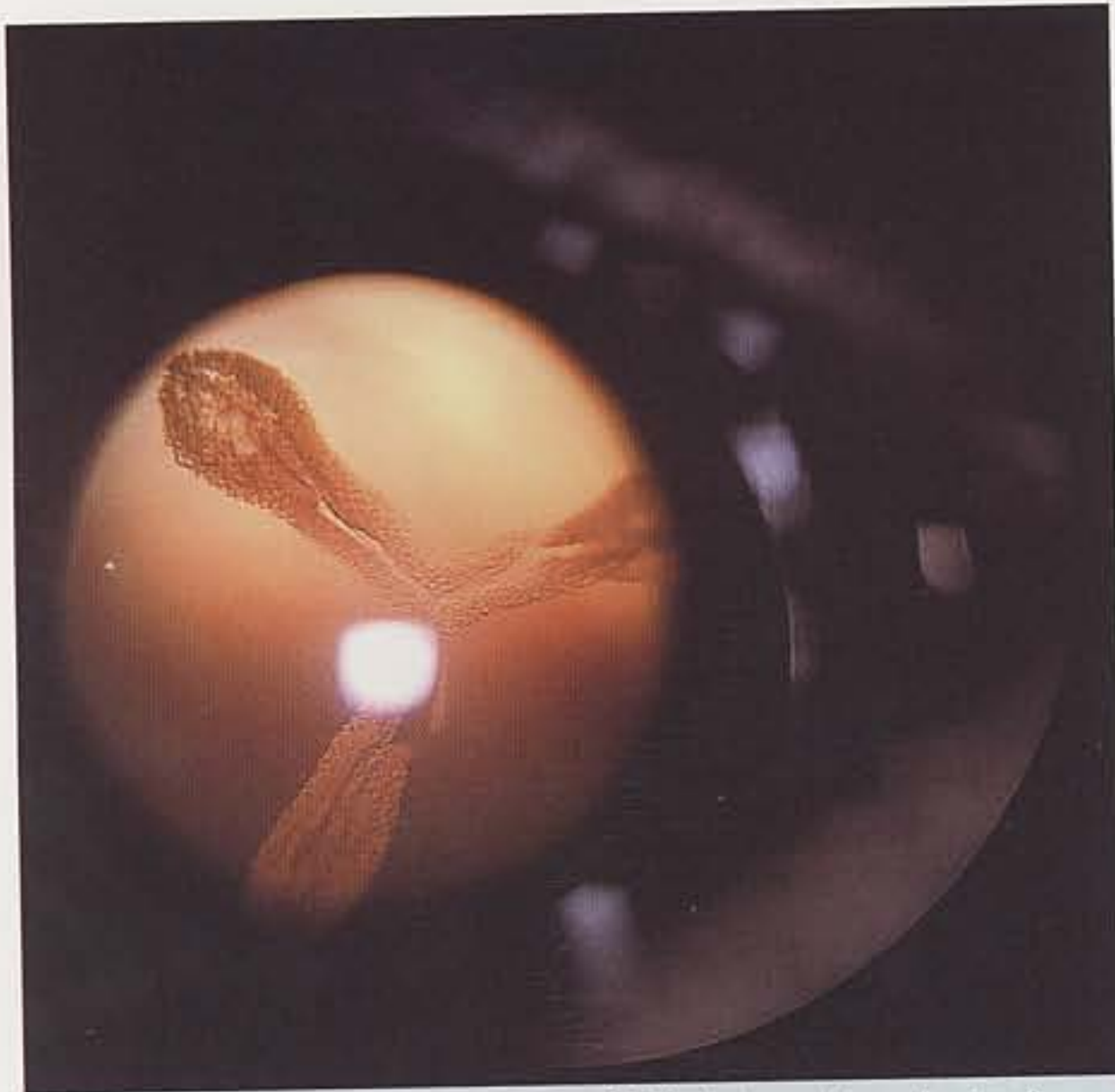


Fig. 9.86 Temporary opacity (Miniature Longhaired Dachshund, 4 months old) Extensive opacities affecting the suture lines and viewed against the tapetal reflex. There was no sign of these opacities a few weeks later.

### Lens luxation (Figs 9.87–9.112, Table 9.2)

Lens luxation, or dislocation, occurs in the dog, cat and horse but primary or hereditary lens luxation has only been reported in the dog and it is therefore much more common in this species. Table 9.2 lists the breeds in which hereditary lens luxation is known to occur in the UK. Although a simple recessive inheritance has been shown in the Tibetan Terrier, it is also seen, not uncommonly, in crossbred terriers.

Table 9.2 - Primary lens luxation – breeds

Border Collie
Bull Terrier (Miniature)
Fox Terrier (Smooth)
Fox Terrier (Wire)
Lancashire Heeler
Parson Jack Russell Terrier
Sealyham Terrier
Tibetan Terrier
Webster Terrier

The clinical signs of lens luxation are illustrated in Figures 9.87–9.112, with the exception of iridodonesis, a trembling of the iris with eye movement due to the lack of support of the iris from the lens following its change of position. The clinical signs can be divided into two groups: those which are associated with the luxation of the lens (change in position of the lens), in themselves of little consequence, and those which are associated with the secondary glaucoma following the lens luxation and which are the cause of pain, often considerable, and, if uncontrolled, eventual swelling of the globe and irreparable blindness. The first group, in addition to iridodonesis, include: the appearance of vitreal strands appearing in front of the lens at the pupil margin; the aphakic crescent appearing in the pupil between its margin and the edge of subluxated lens; the totally luxated lens, either in the anterior chamber of the eye between the iris and the cornea, or the posteriorly luxated lens in the vitreous; finally a classical subcentral corneal opacity where the lens has been, or still is, in contact with the posterior cornea resulting in an area of corneal oedema – this

opacity is permanent even when the lens has passed into the posterior segment of the eye. The clinical signs associated with the secondary glaucoma include pain, which can be severe, conjunctival congestion, hydrophthalmos and eventual phthisis (see also Chapter 8).

Secondary lens luxation also occurs in the dog and the cat and horse. The causes are trauma, uveitis, glaucoma and cataract. Dislocated lenses of some standing also become cataractous and cataractous lenses are more likely to dislocate than non-cataractous lenses. The distinction between primary glaucoma and lens luxation (secondary) and the secondary glaucoma due to hereditary (primary) lens luxation can be difficult, particularly when it occurs in breeds in which primary lens luxation occurs, e.g. terriers.

Primary lens luxation is essentially a bilateral condition, although the lens luxation usually presents as a unioocular condition, the second eye becoming involved some time (days to months) later. The age incidence of primary lens luxation is usually 3–6 years.

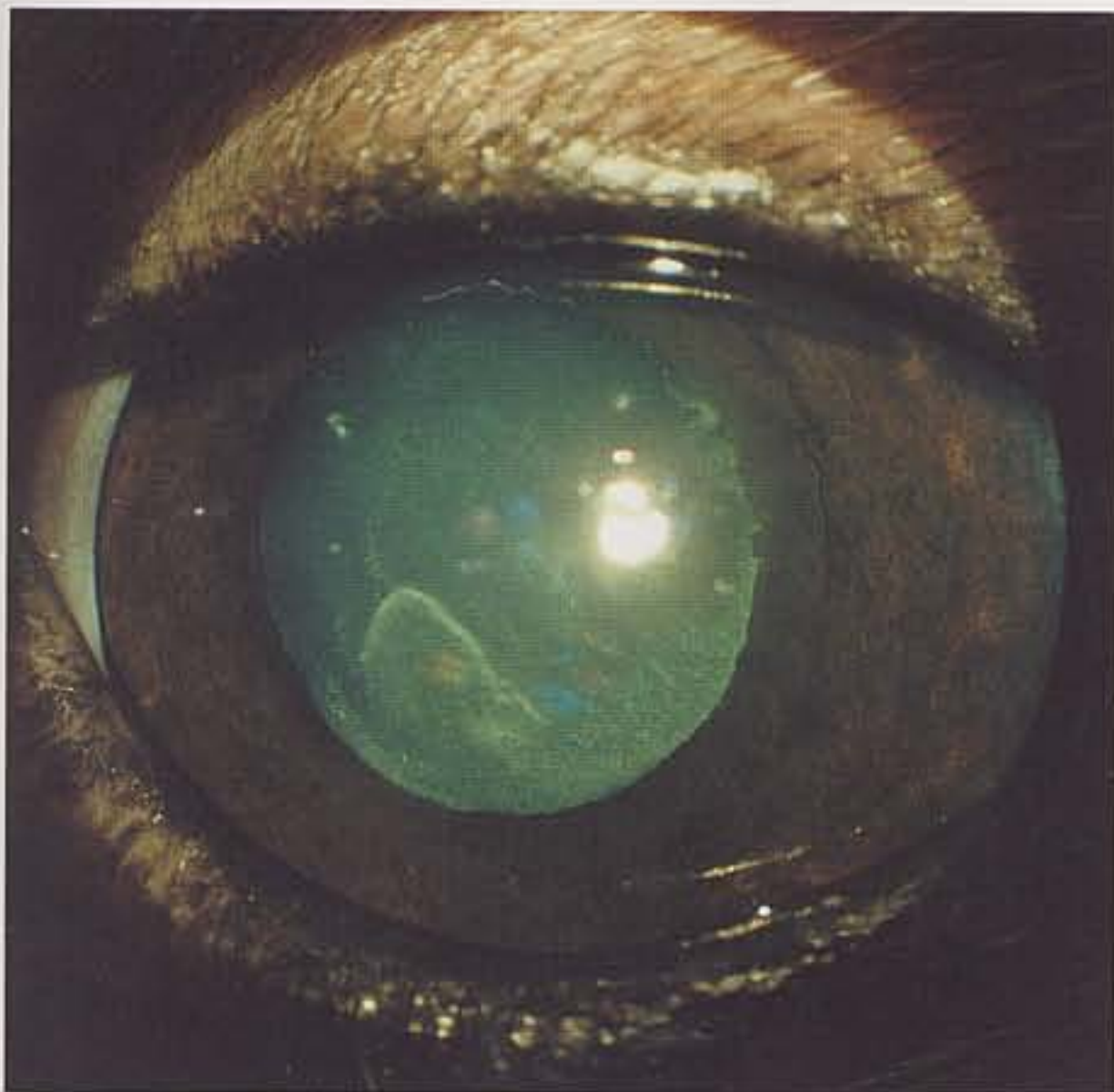


Fig. 9.87 Vitreous in the pupil (Jack Russell Terrier, 4 years old) Note the appearance of vitreous on the right side of the pupil. Iridodonesis was also present.




Fig. 9.88 Vitreous in the pupil (Jack Russell Terrier, 5 years old) Note the swirling vitreous in front of the lens from the edge of the pupil.

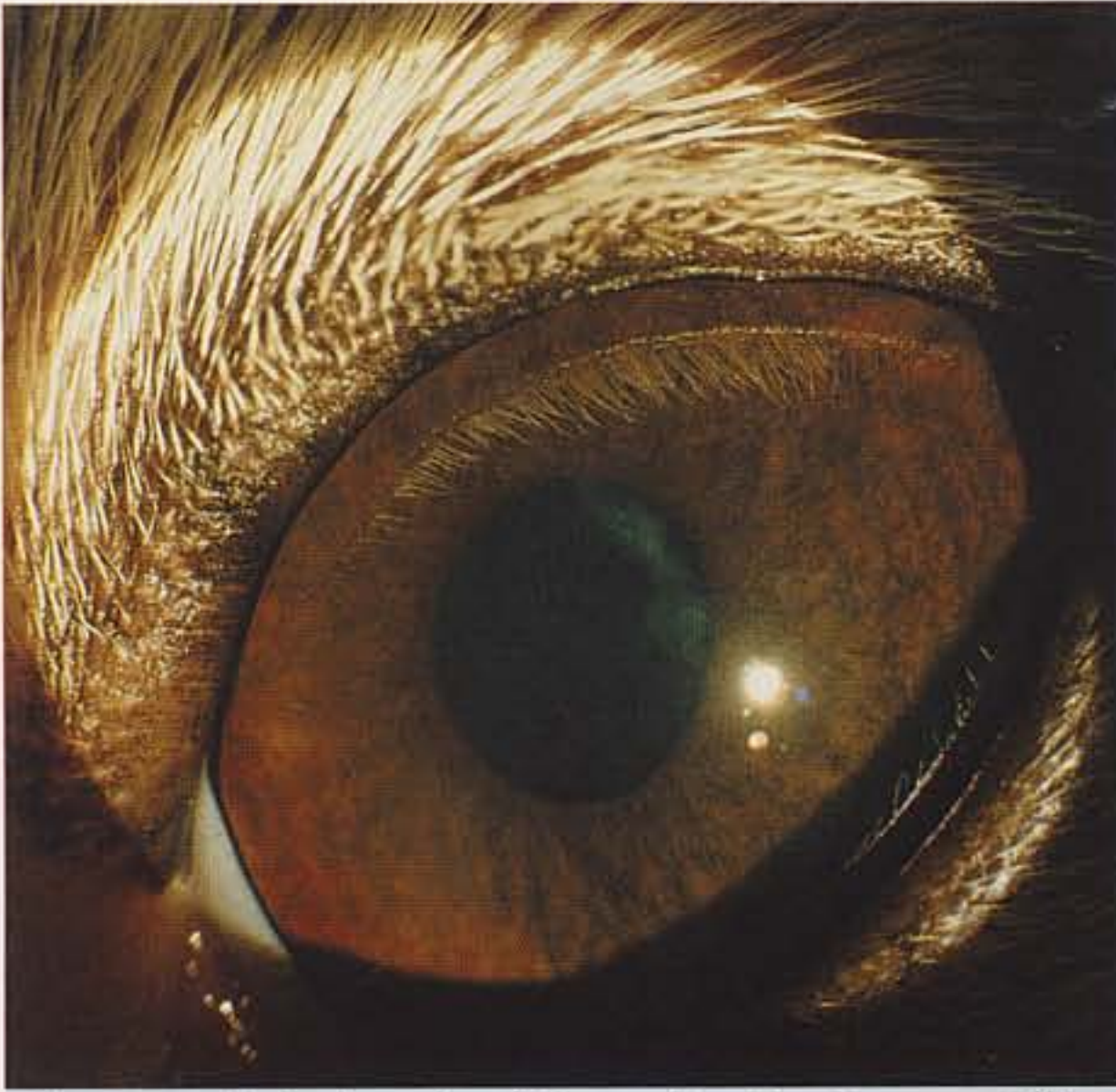

Fig. 9.89 Early luxation (Tibetan Terrier, 3 years old) Fine aphakic crescent superiorly and early breakdown of some of the zonular fibres. Pupil dilated with mydriatic.




Fig. 9.91 Anterior luxation (Border Collie) Lens dislocating through a dilated pupil. Again, note the swirling vitreous superiorly.

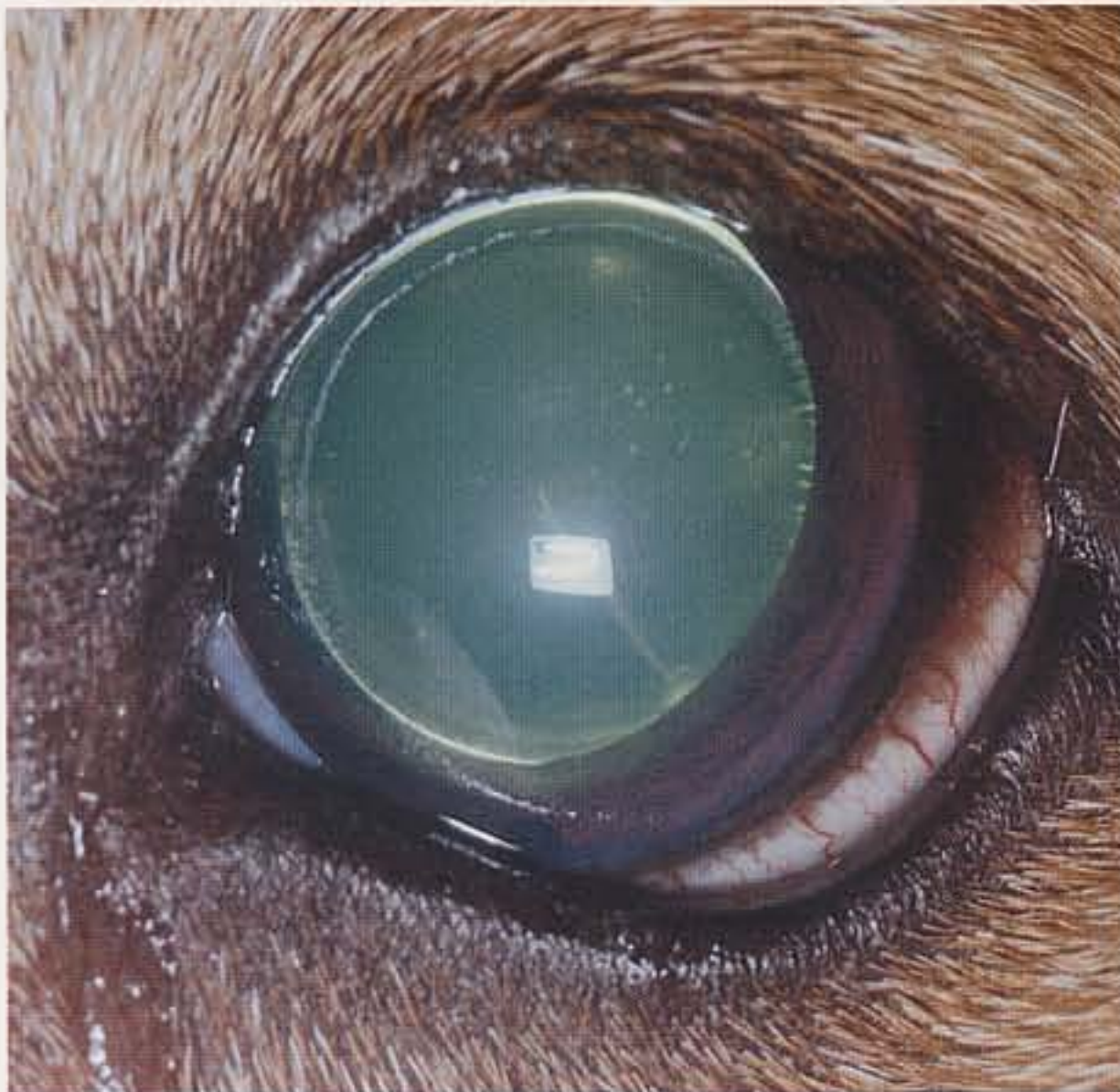

Fig. 9.90 Anterior luxation (Crossbred terrier, 5 years old) Note the light on the edge of the lens as it passes through the pupil.

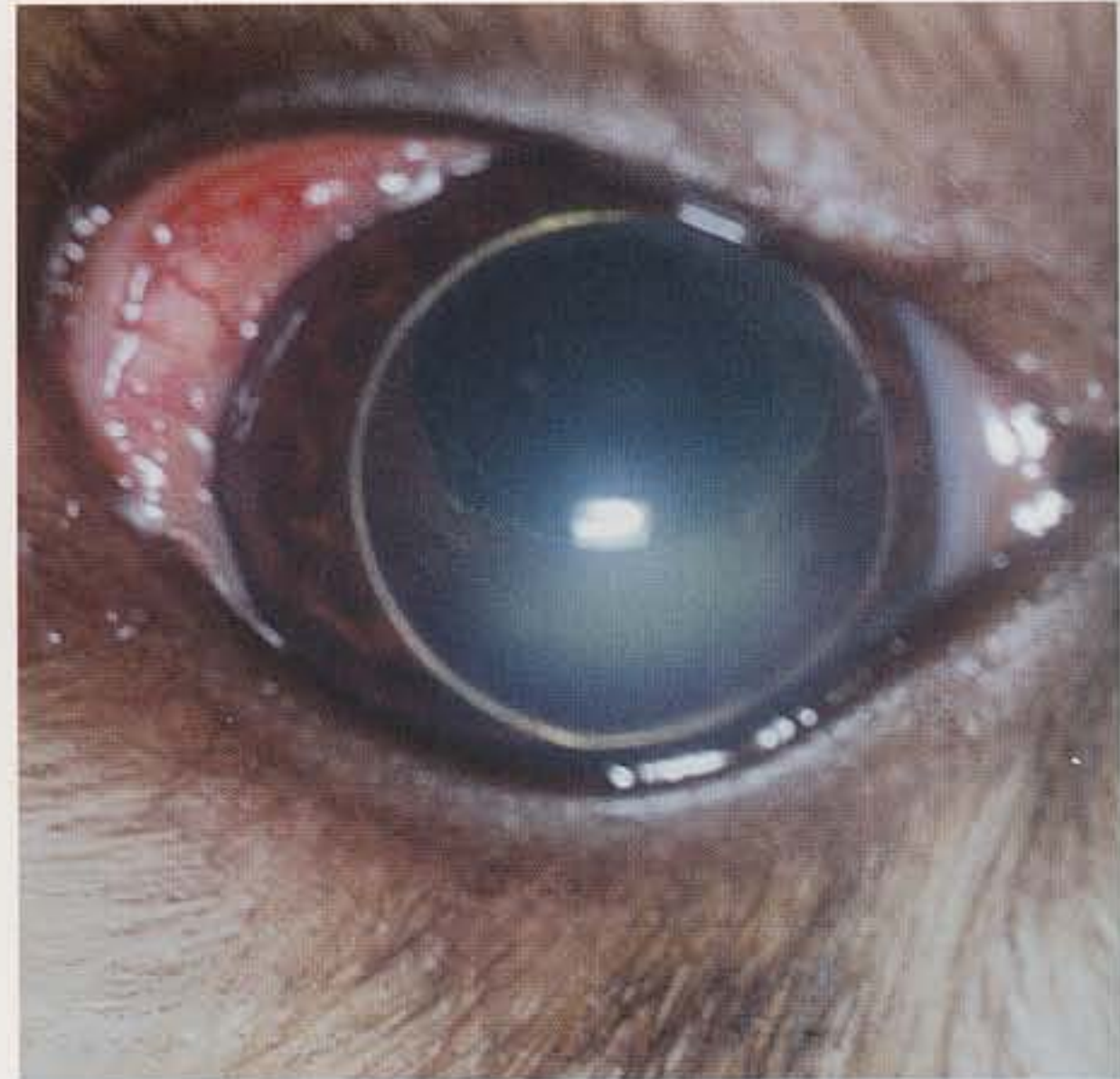

Fig. 9.92 Anterior luxation (Sealyham, 4 years old) Lens completely through the pupil. Note the corneal opacity just below the centre of the cornea due to pressure of the lens on the corneal endothelium and subsequent area of corneal oedema.

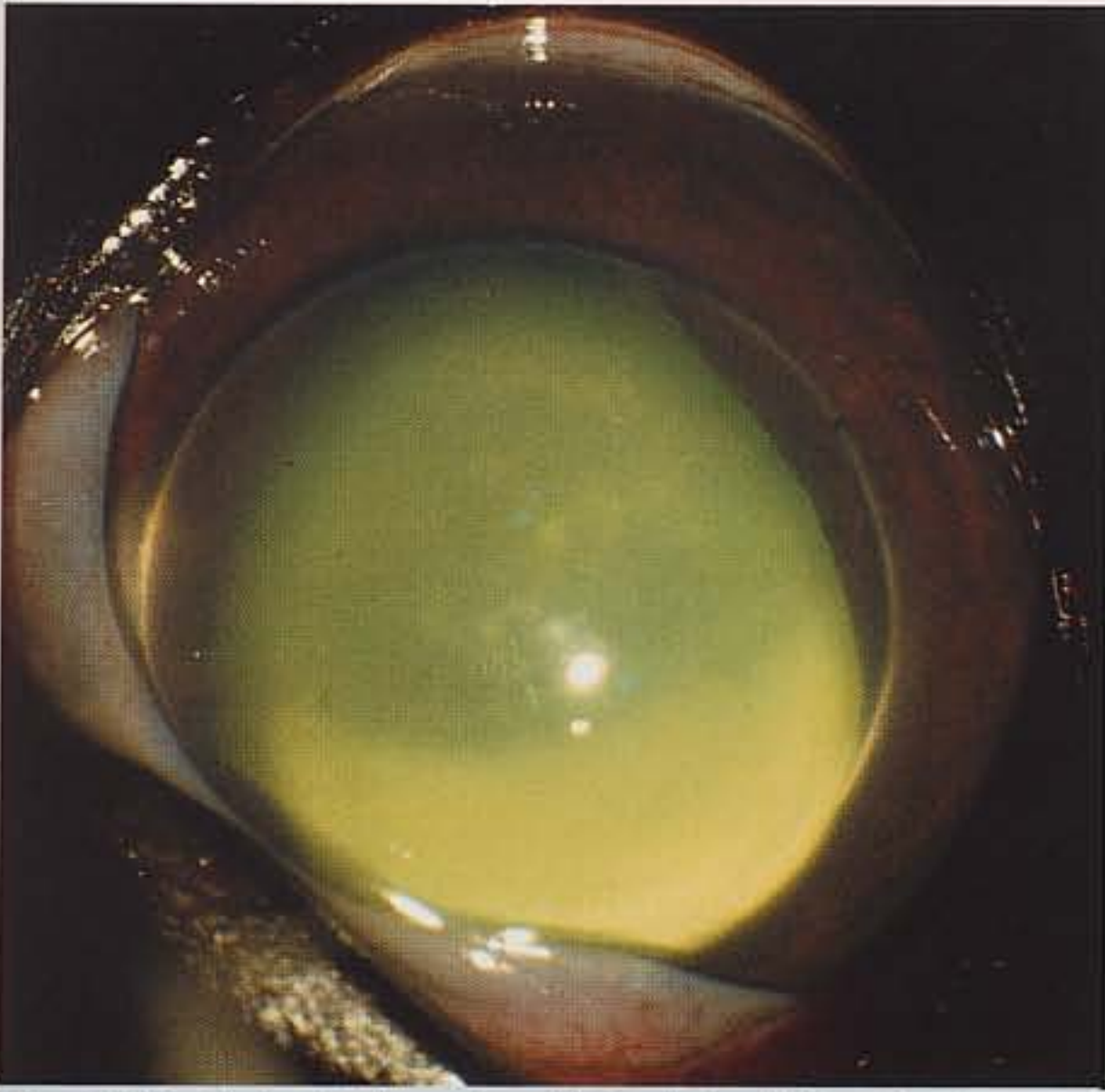


Fig. 9.93 Anterior luxation (Wirehaired Fox Terrier, 4 years old) Note the distortion of the pupil due to the position of the lens and the edge of the pupil visible through the lens.

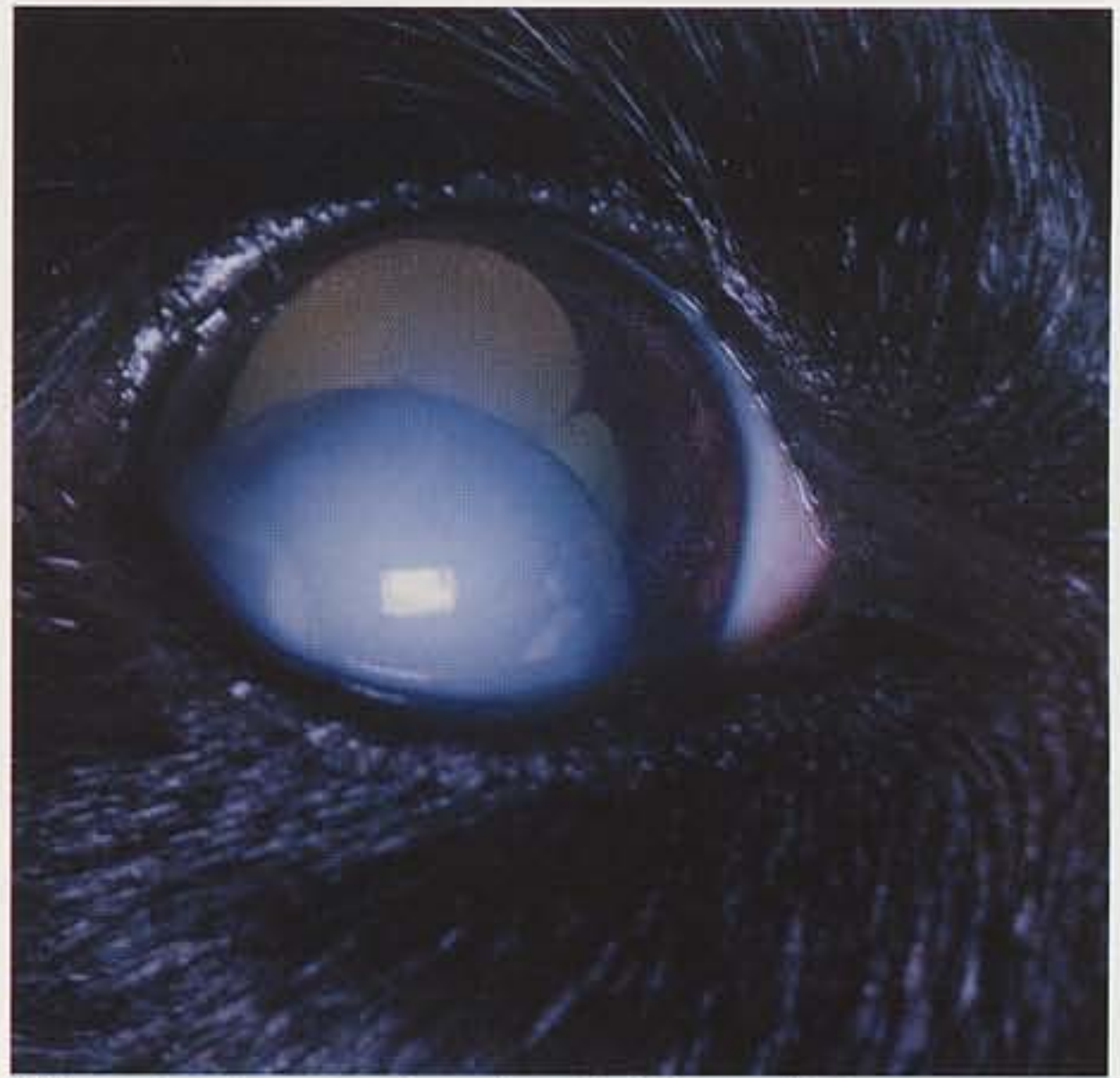

Fig. 9.95 Anterior luxation (Jack Russell Terrier, 4 years old) Anteriorly dislocated lens becoming cataractous. Note the adhesion from the pupil edge to the lens capsule at 2 o'clock.

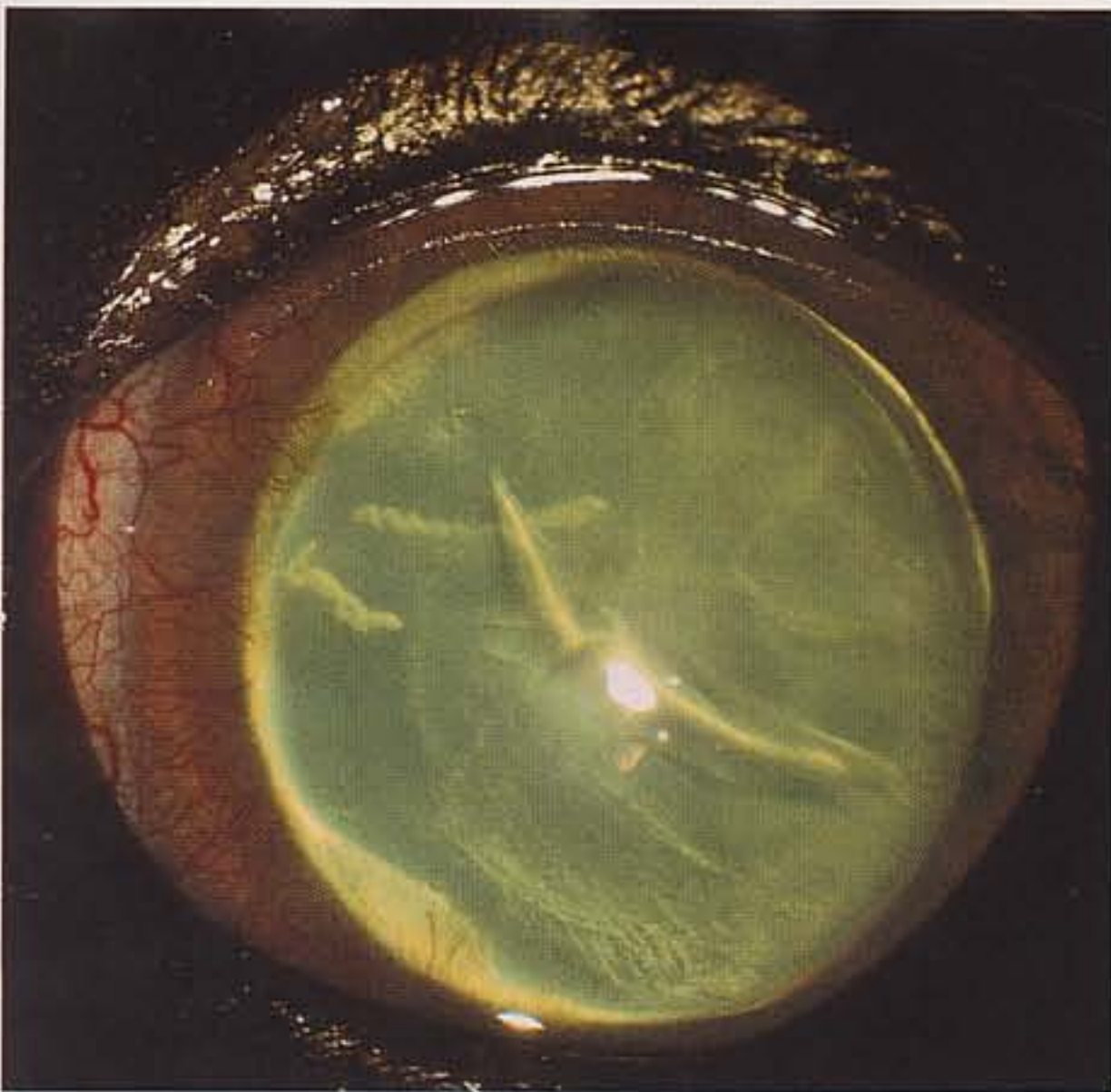

Fig. 9.94 Anterior luxation (Jack Russell Terrier, 4 years old) Pupil block and secondary glaucoma with corneal vascularization.

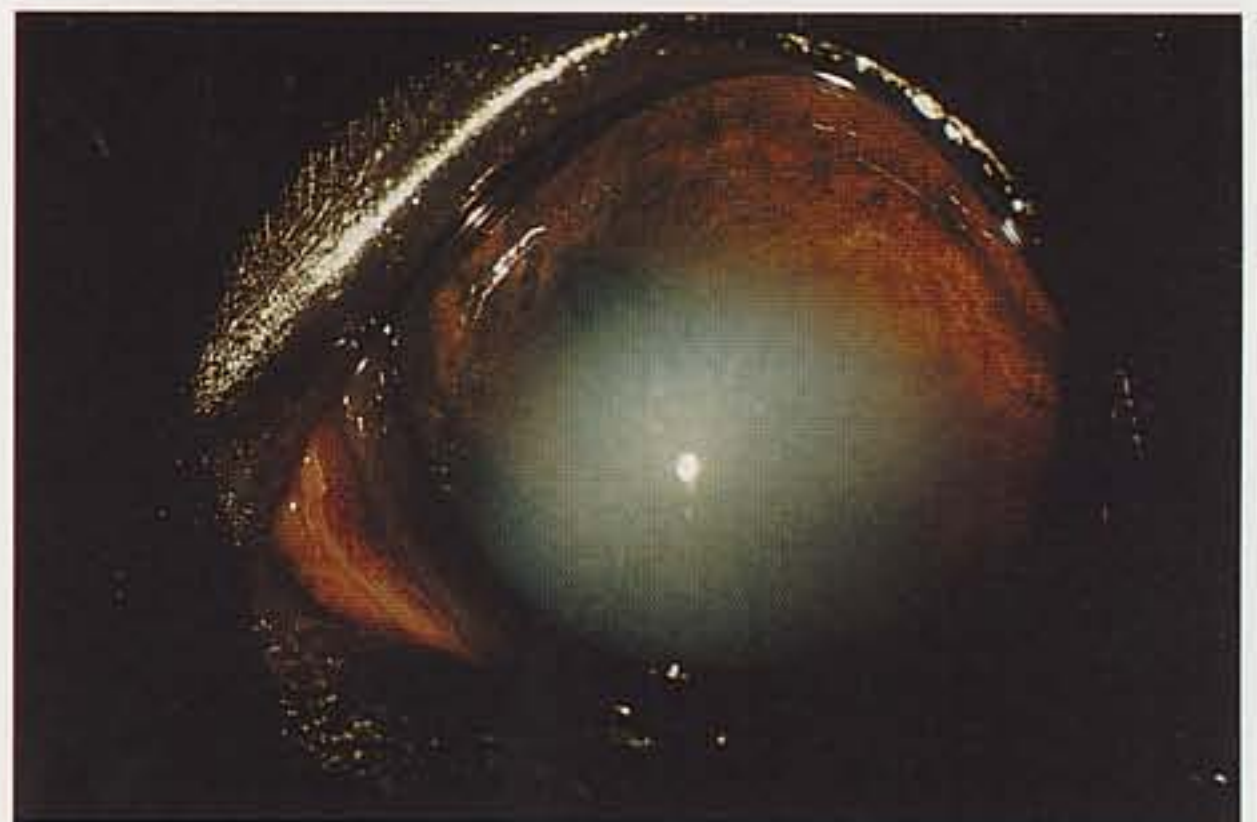


Fig. 9.96 Subcentral corneal opacity (Tibetan Terrier, 3 years old) Area of corneal oedema remaining where the lens has been in contact with the cornea.

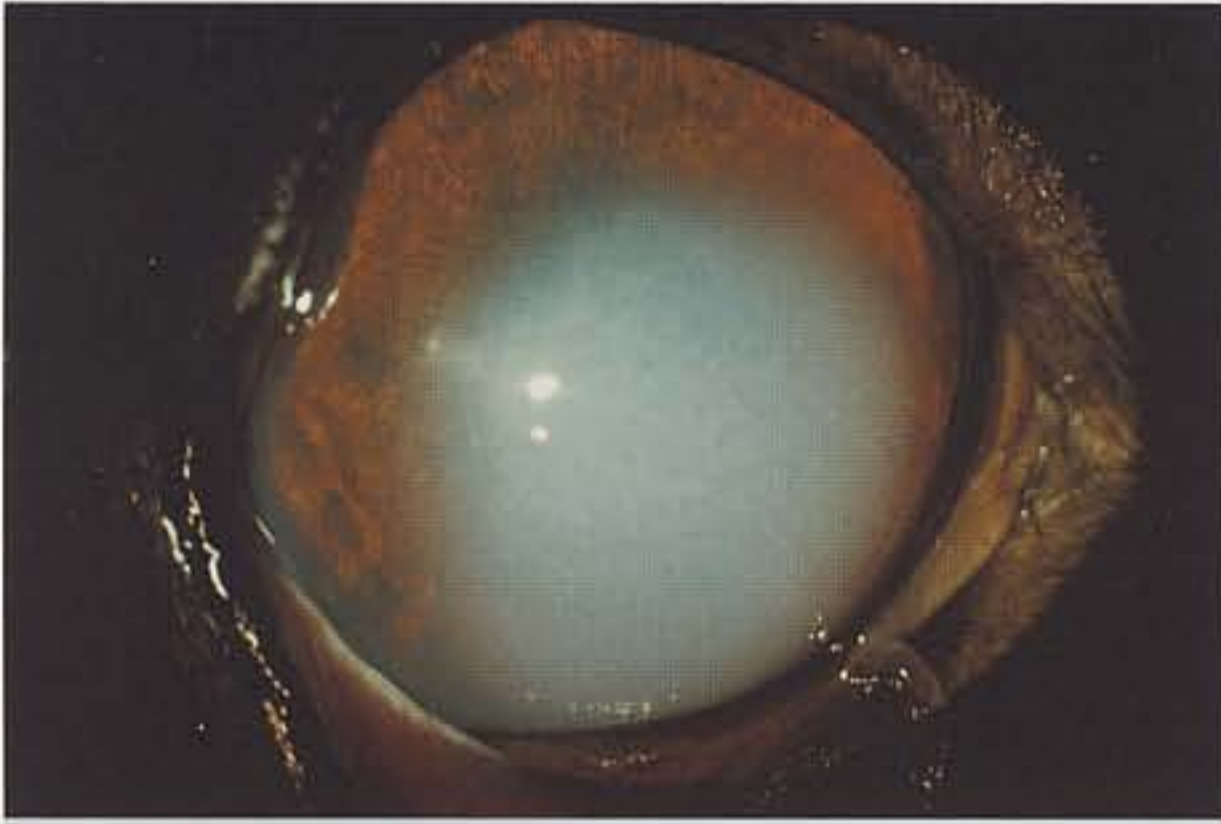


Fig. 9.97 Subcentral corneal opacity (Smooth-haired Fox Terrier, 4 years old) Extensive area of corneal oedema remains, although the lens is now dislocated posteriorly.

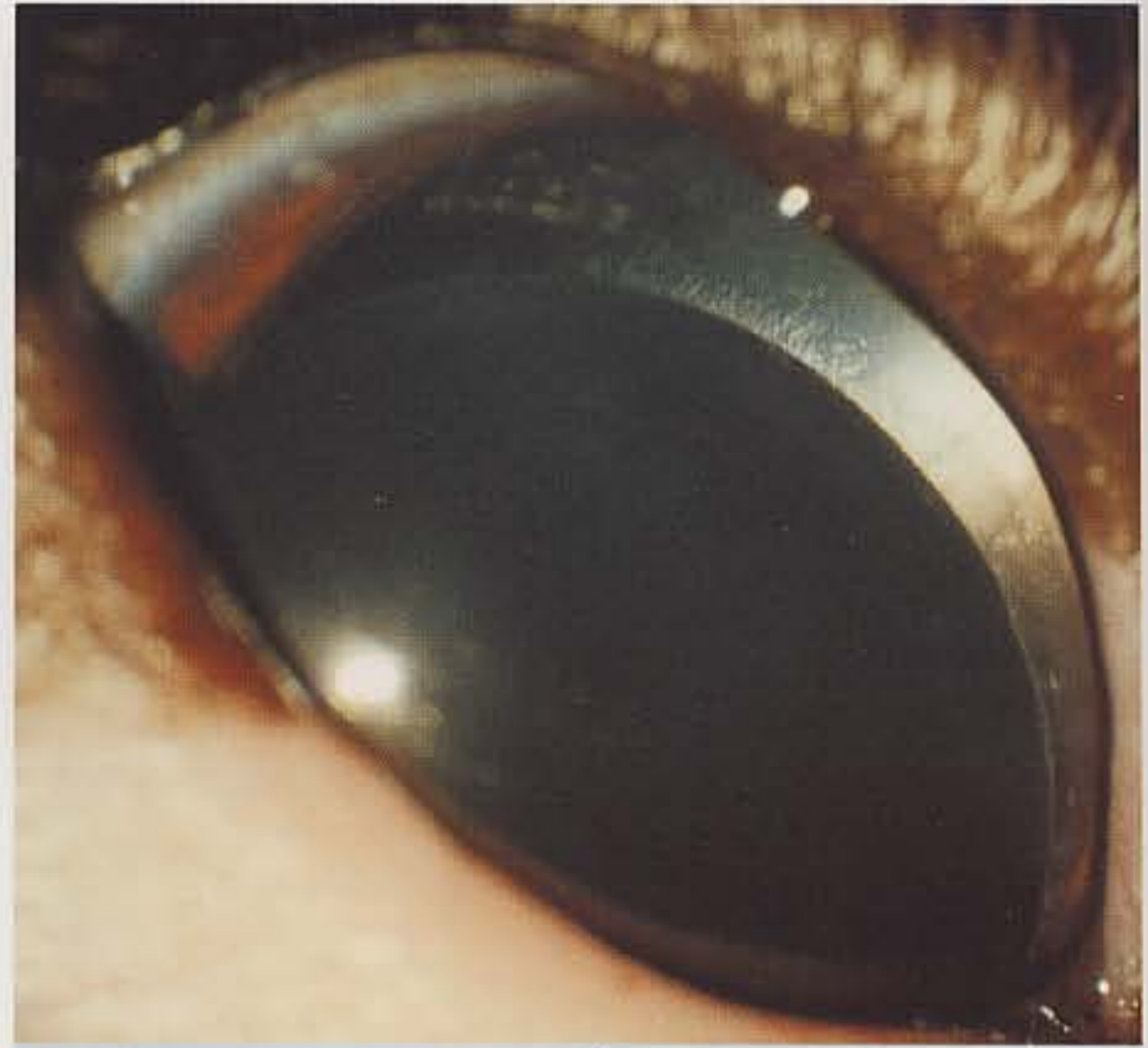

Fig. 9.99 Aphakic crescent (Jack Russell Terrier, 5 years old) Note the ruptured zonular fibres visible on the lens periphery.



Fig. 9.98 Aphakic crescent (Jack Russell Terrier, 4 years old) Tapetal reflex visible over the upper border of the lens.

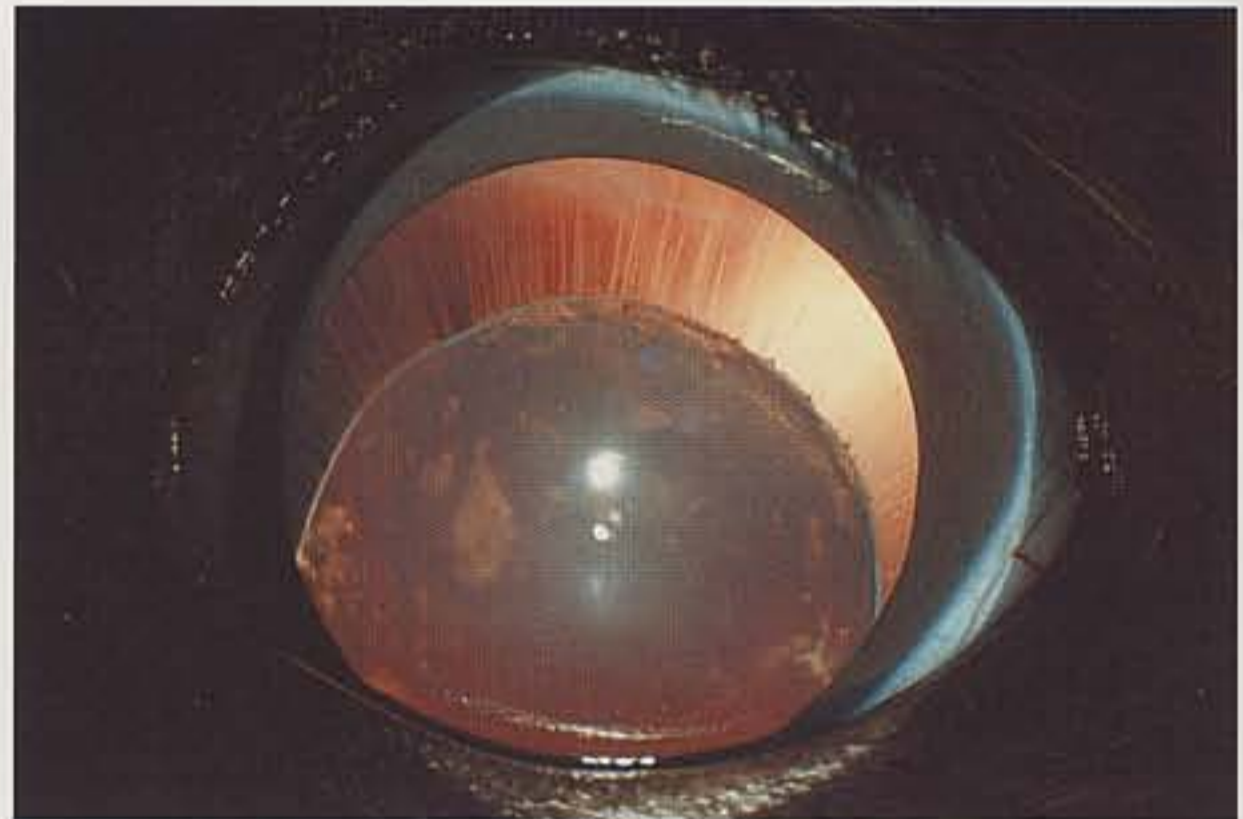


Fig. 9.100 Aphakic crescent (Shetland Sheepdog, 17 months old) Partial dislocation with stretching of the zonular fibres.



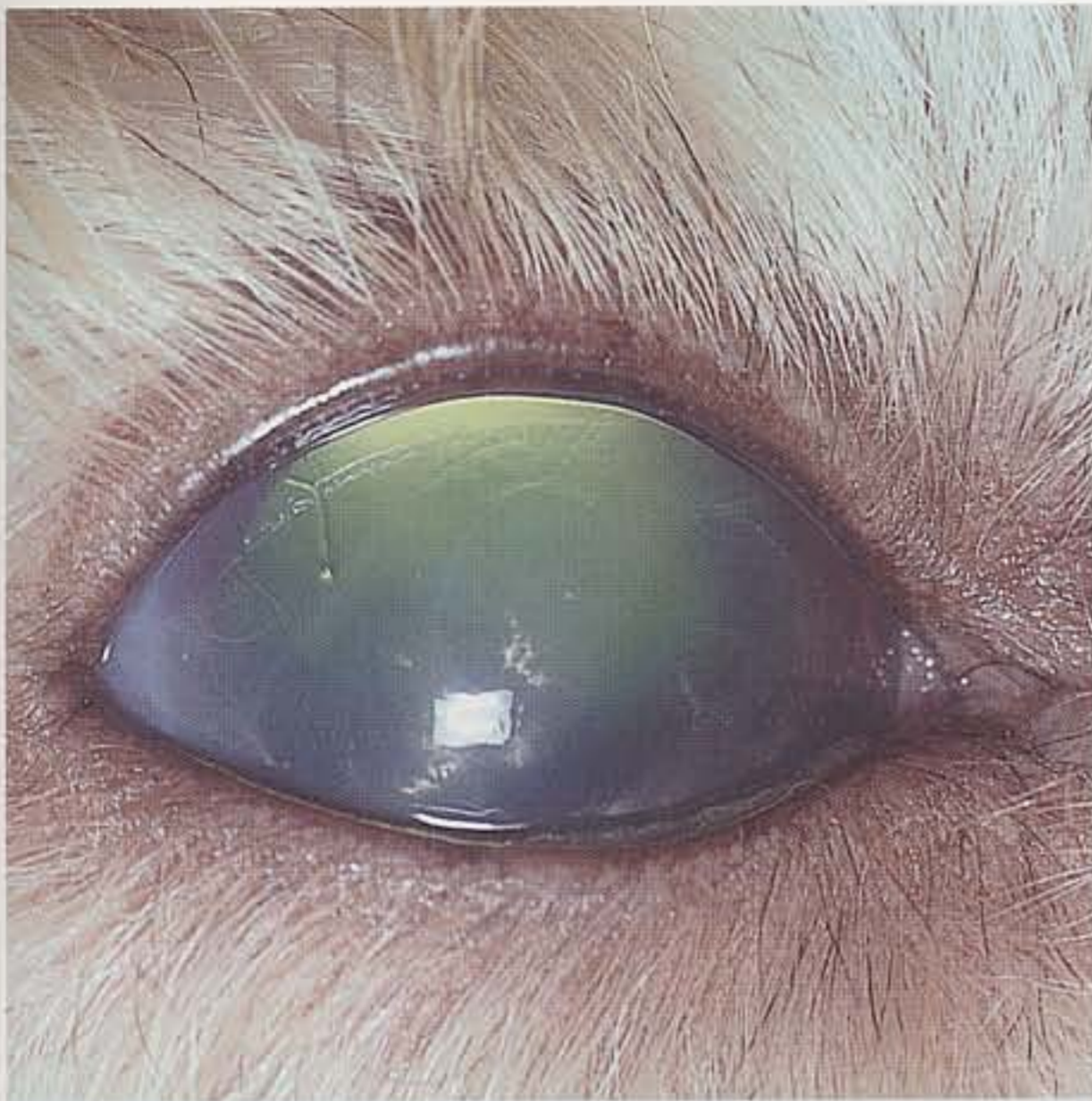

Fig. 9.101 Posterior dislocation (Sealyham Terrier, 6 years old) Aphakic dilated pupil with lens in the vitreous.

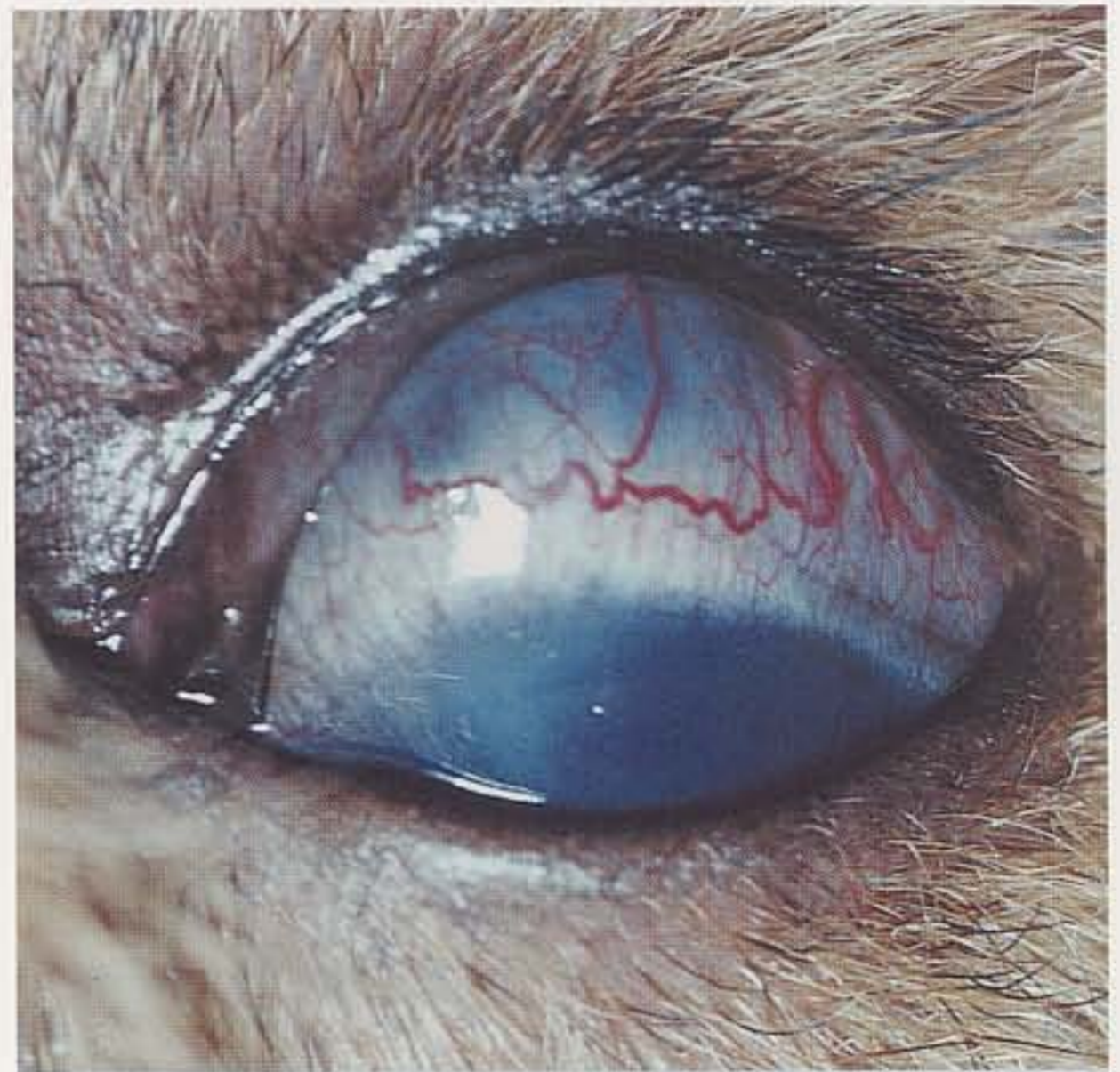

Fig. 9.103 Secondary glaucoma (Welsh Terrier, 4 years old) Hydrophthalmos with scleral ectasia in the ciliary region.

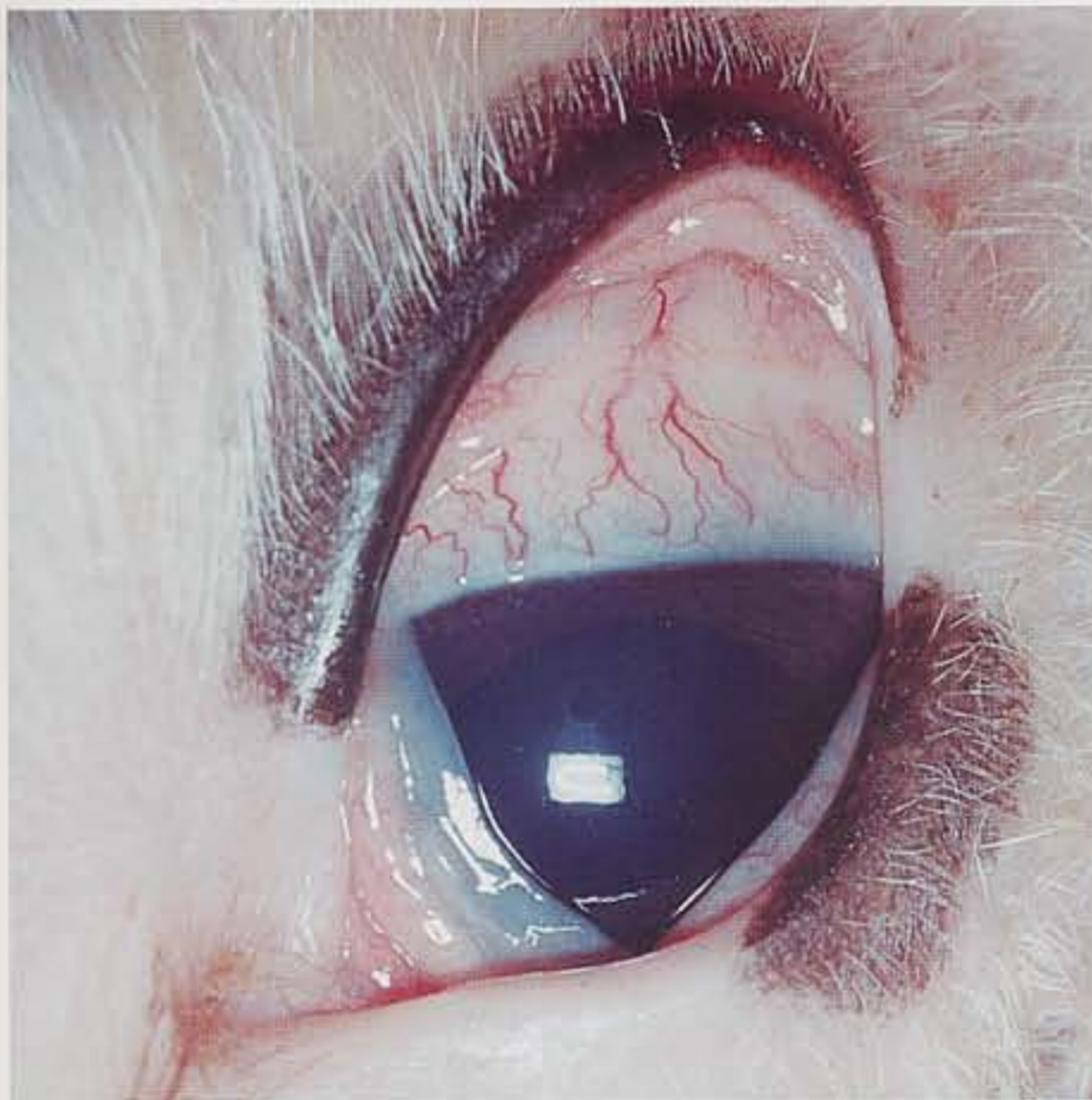

Fig. 9.102 Secondary glaucoma (Sealyham Terrier, 5 years old) Note early conjunctival congestion and 'steamy' cornea.

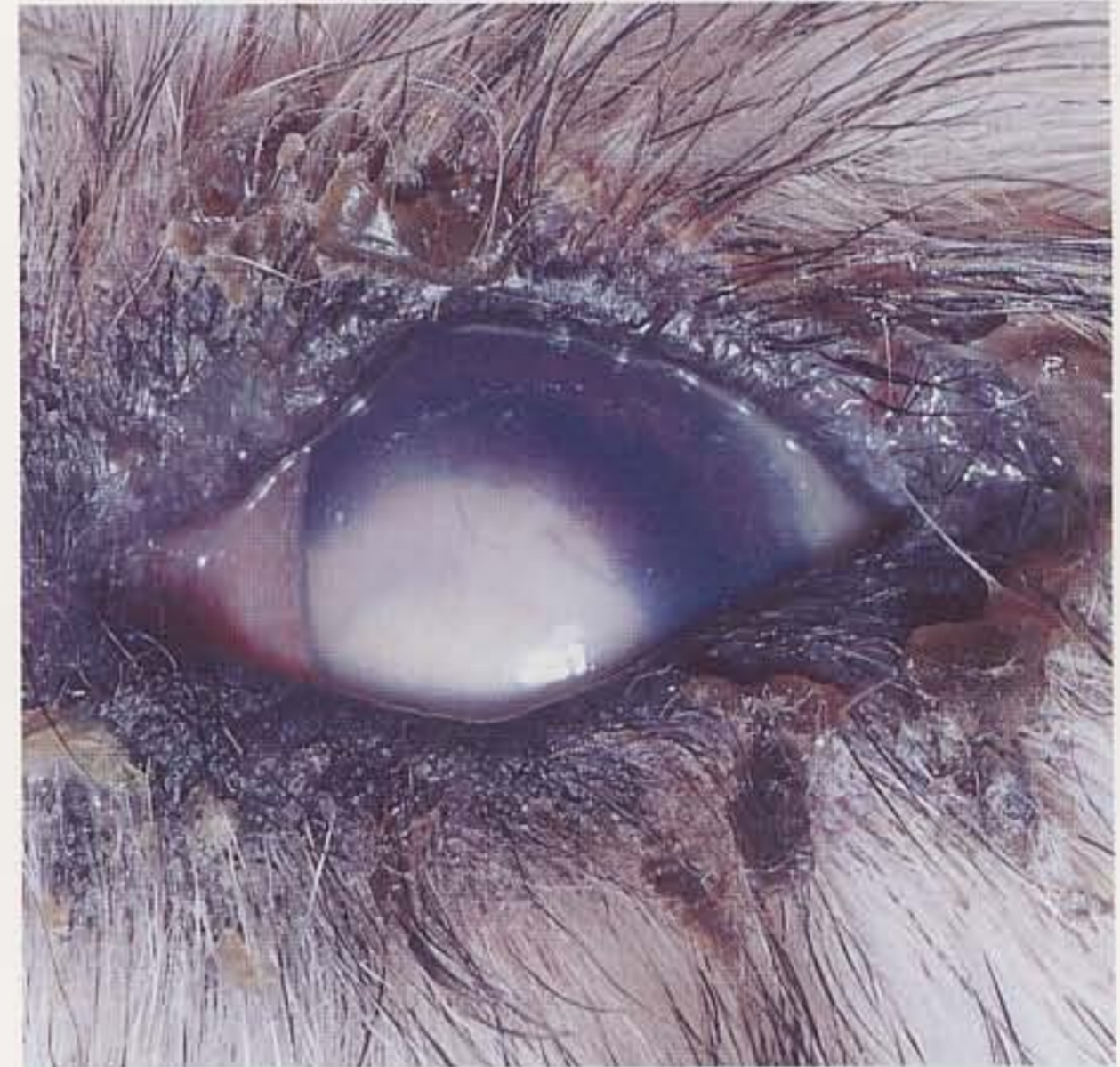

Fig. 9.104 Secondary glaucoma (Sealyham Terrier, 7 years old) Phthisis bulbi following hydrophthalmos, the primary condition being lens luxation.

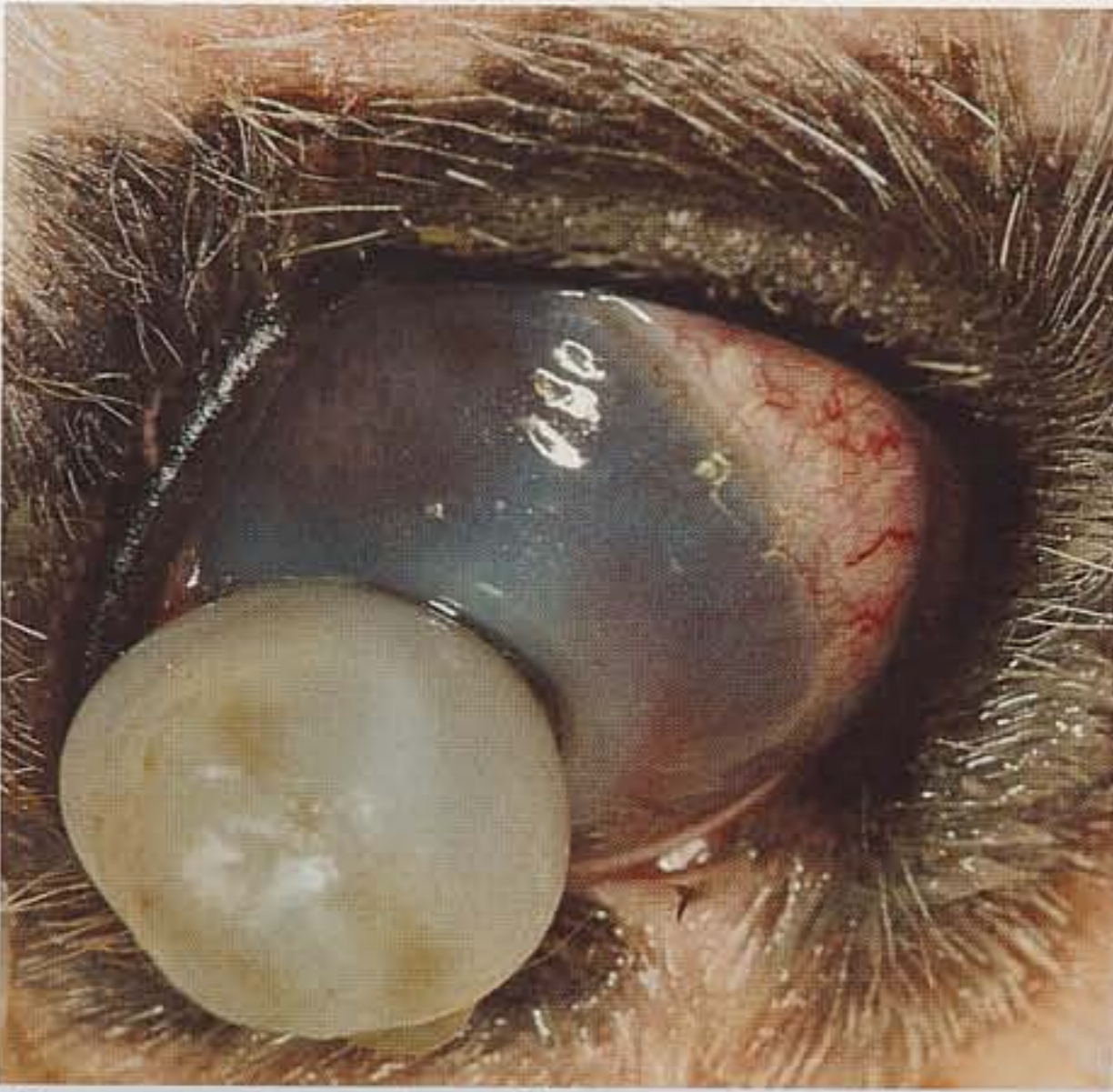


Fig. 9.105 Extruded lens (Sealyham Terrier, 5 years old) Lens dislocated anteriorly and forced out through the cornea. An unusual case.

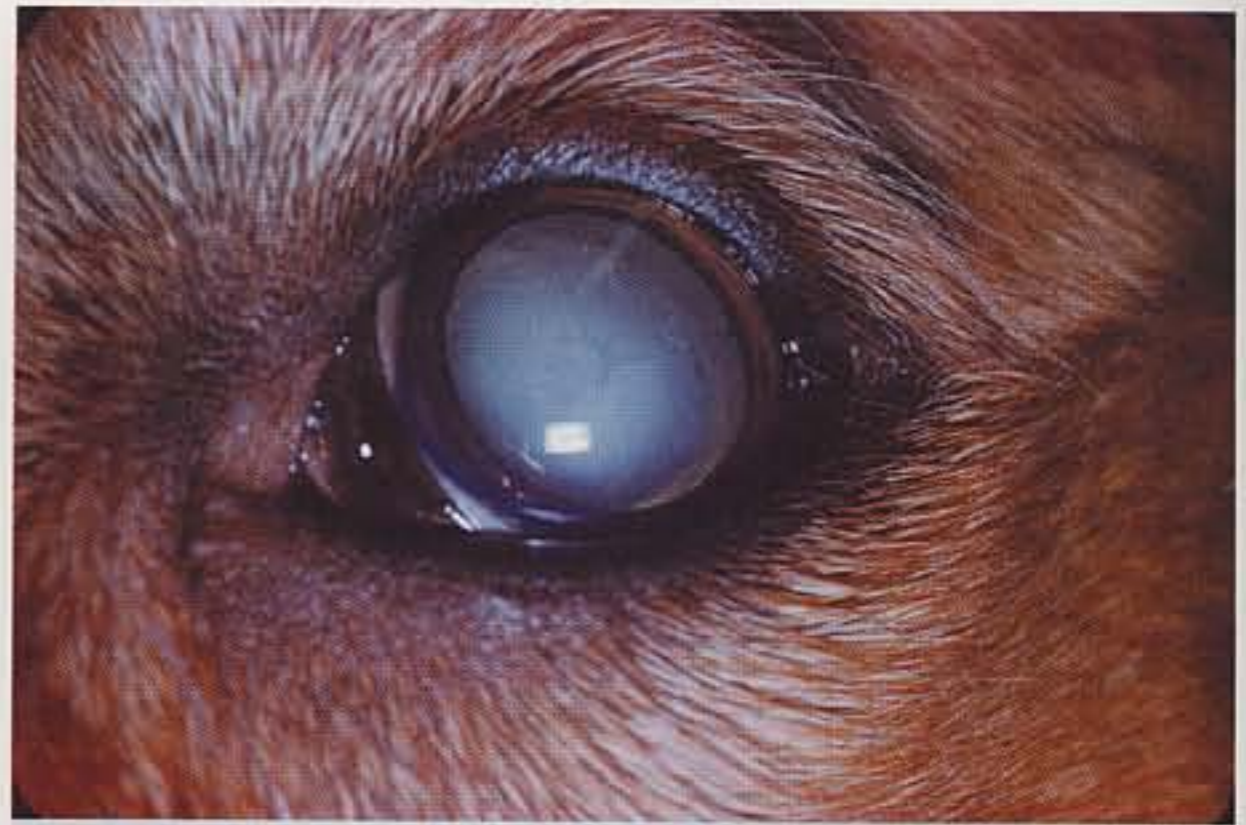

Fig. 9.107 Lens luxation (Jack Russell Terrier, 5 years old) Primary lens luxation with secondary cataract formation.

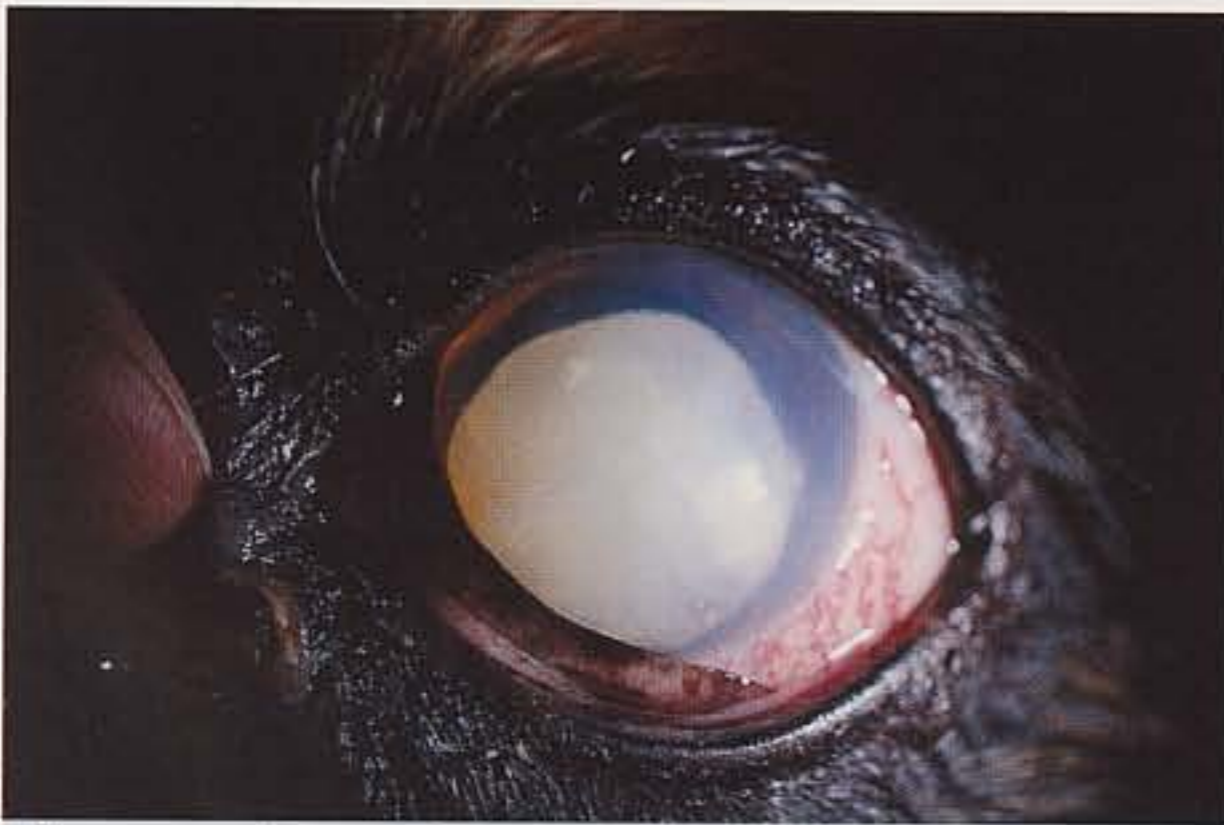

Fig. 9.106 Luxated cataract (Cavalier King Charles Spaniel, 6 years old) The primary condition in this case is cataract, with luxation followed by glaucoma.

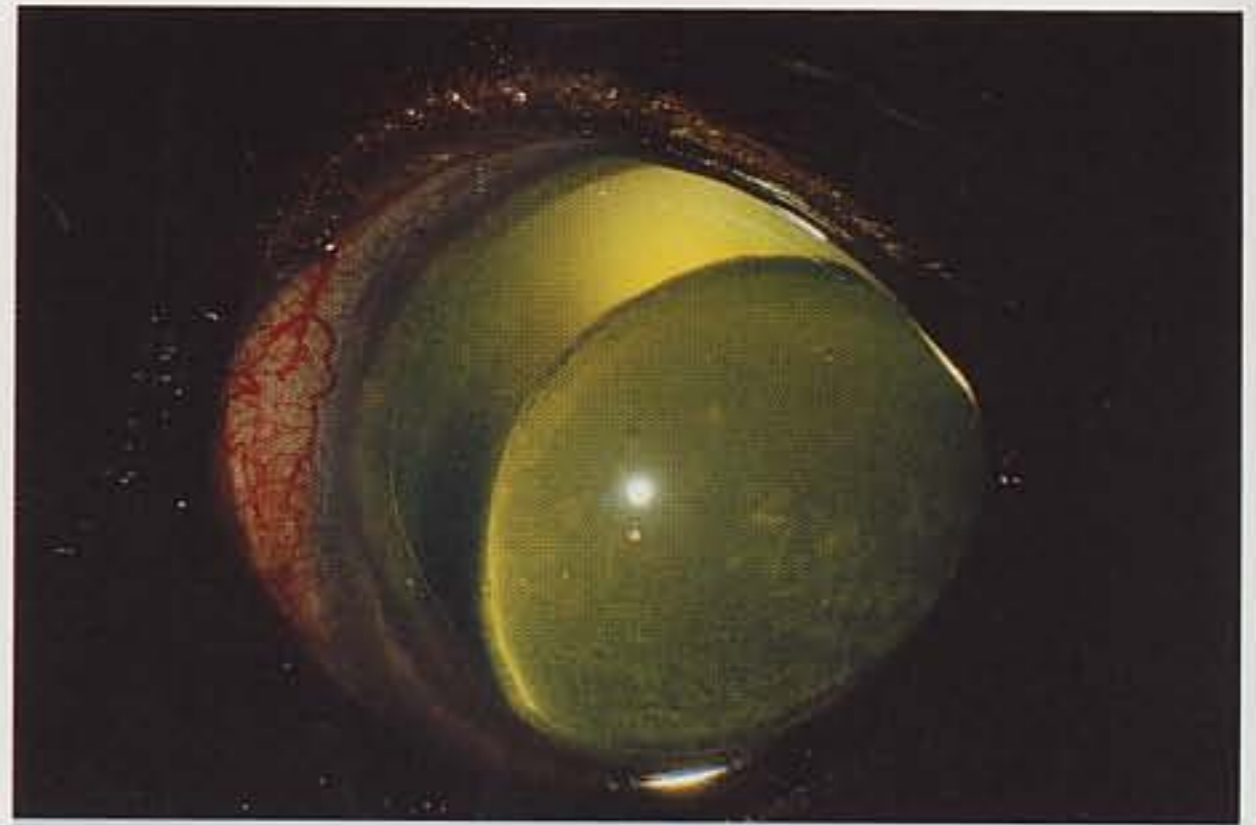


Fig. 9.108 Lens luxation secondary to primary glaucoma Note the dilated pupil and conjunctival congestion.

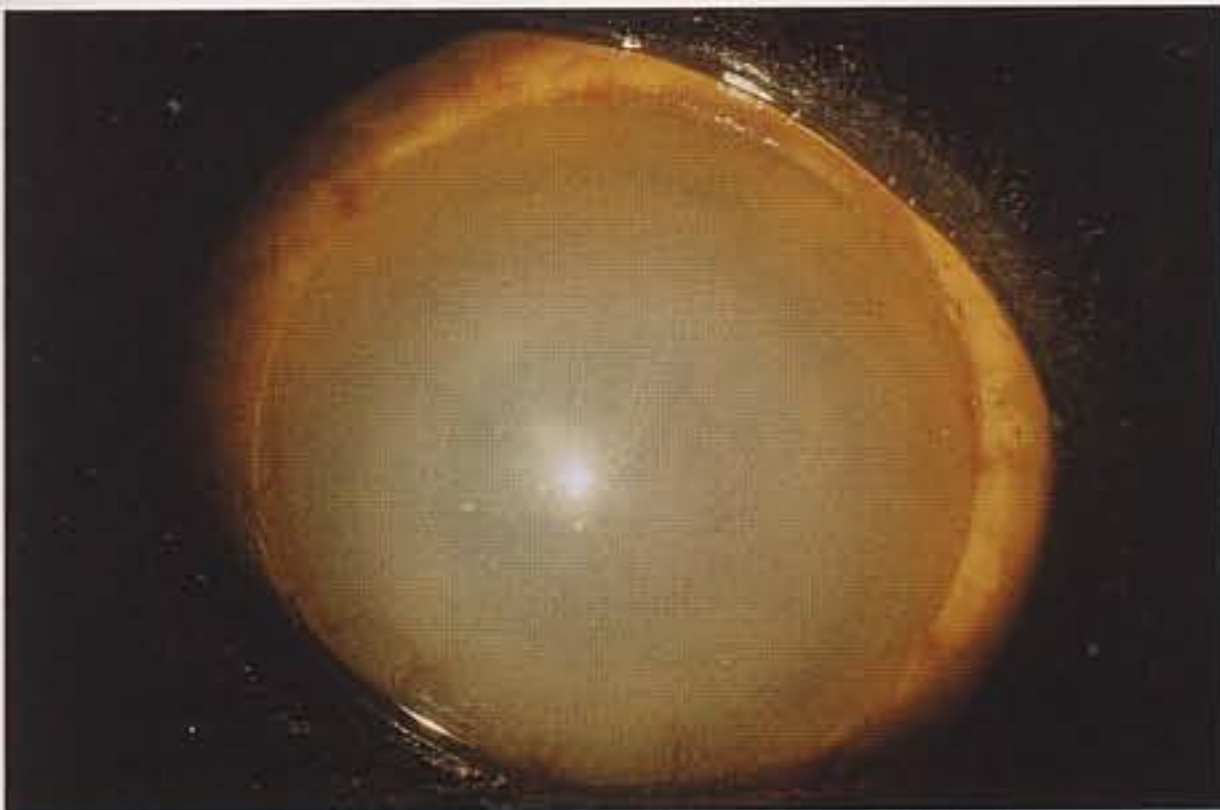

Fig. 9.109 Anterior luxation (Persian cat) Early cataractous changes.

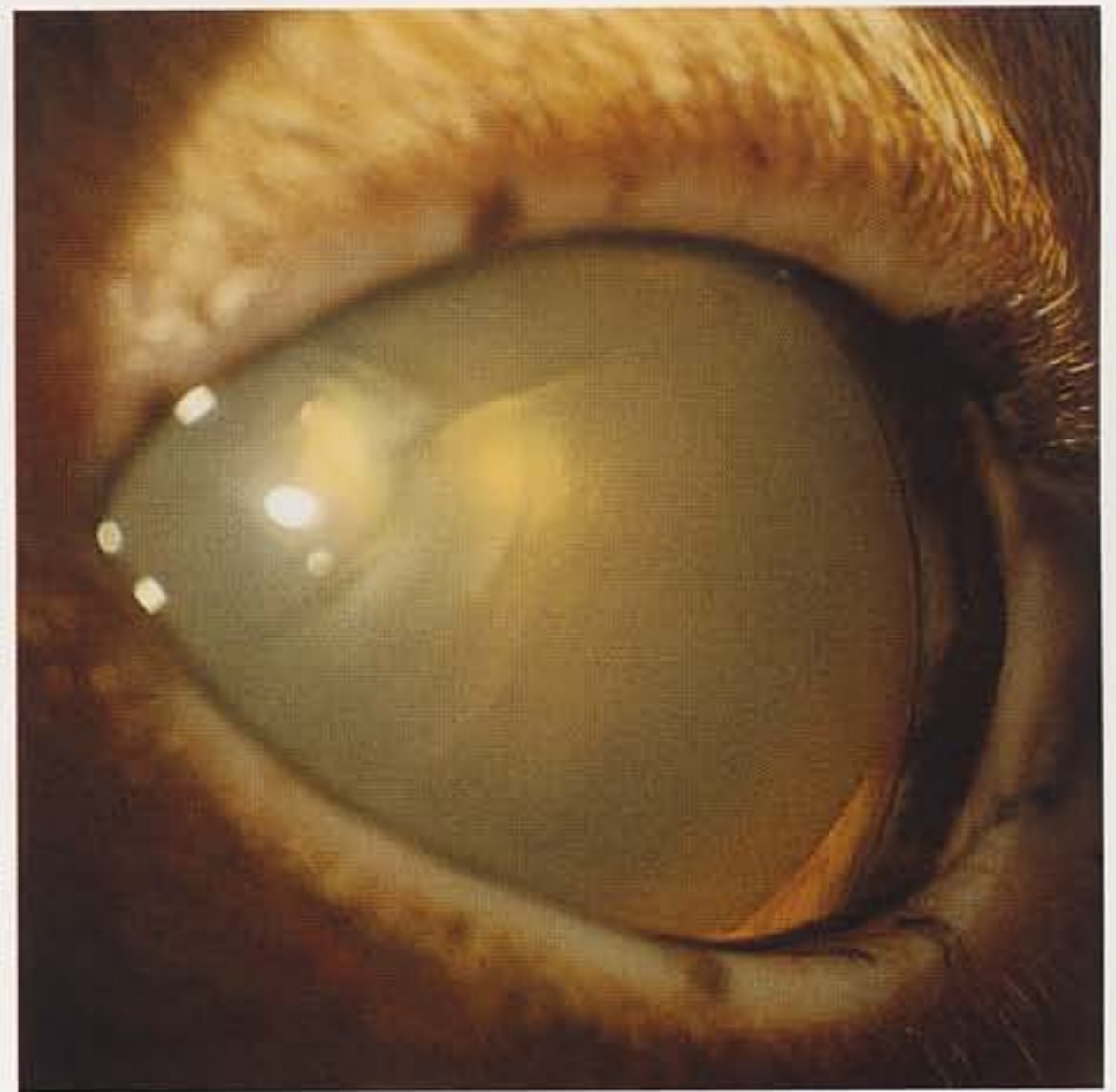


Fig. 9.111 Dislocated cataract (DSH cat, 10 years old)

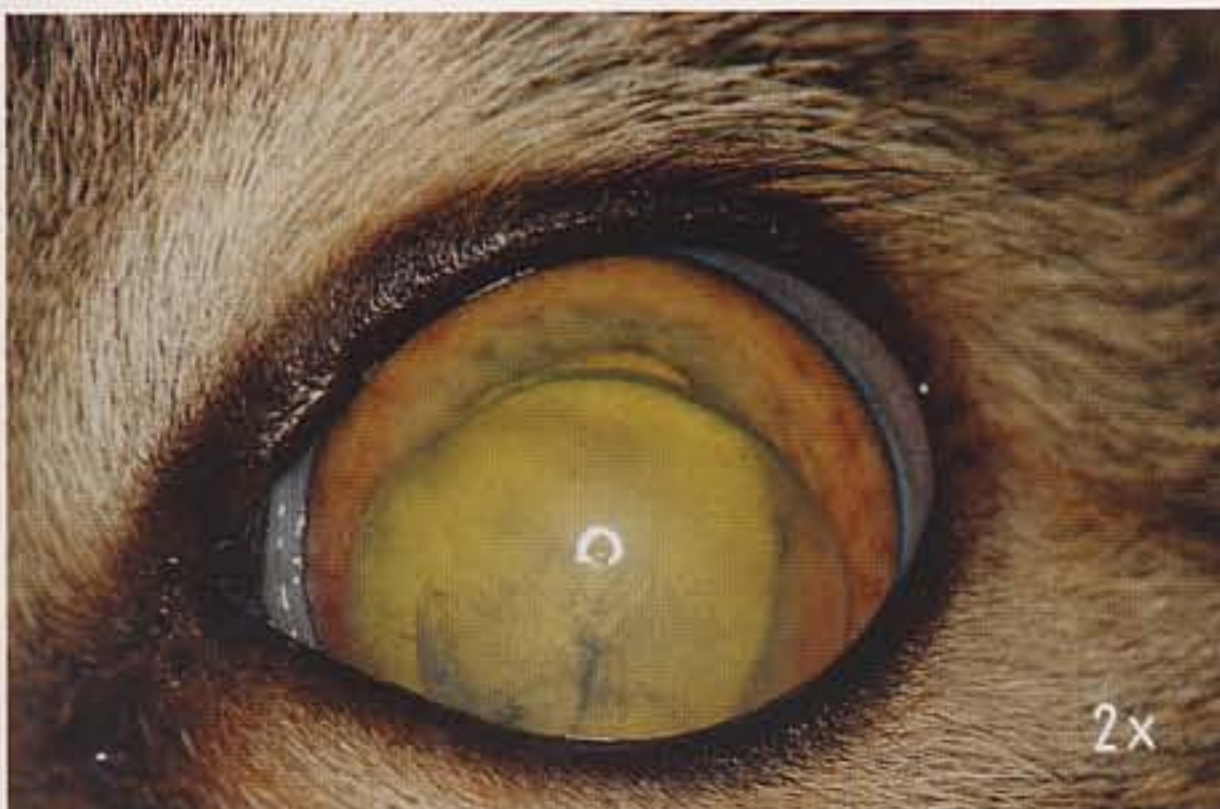

Fig. 9.110 Anterior luxation (DSH cat, 5 years old) Note the evidence of a uveitis; probably the primary condition.

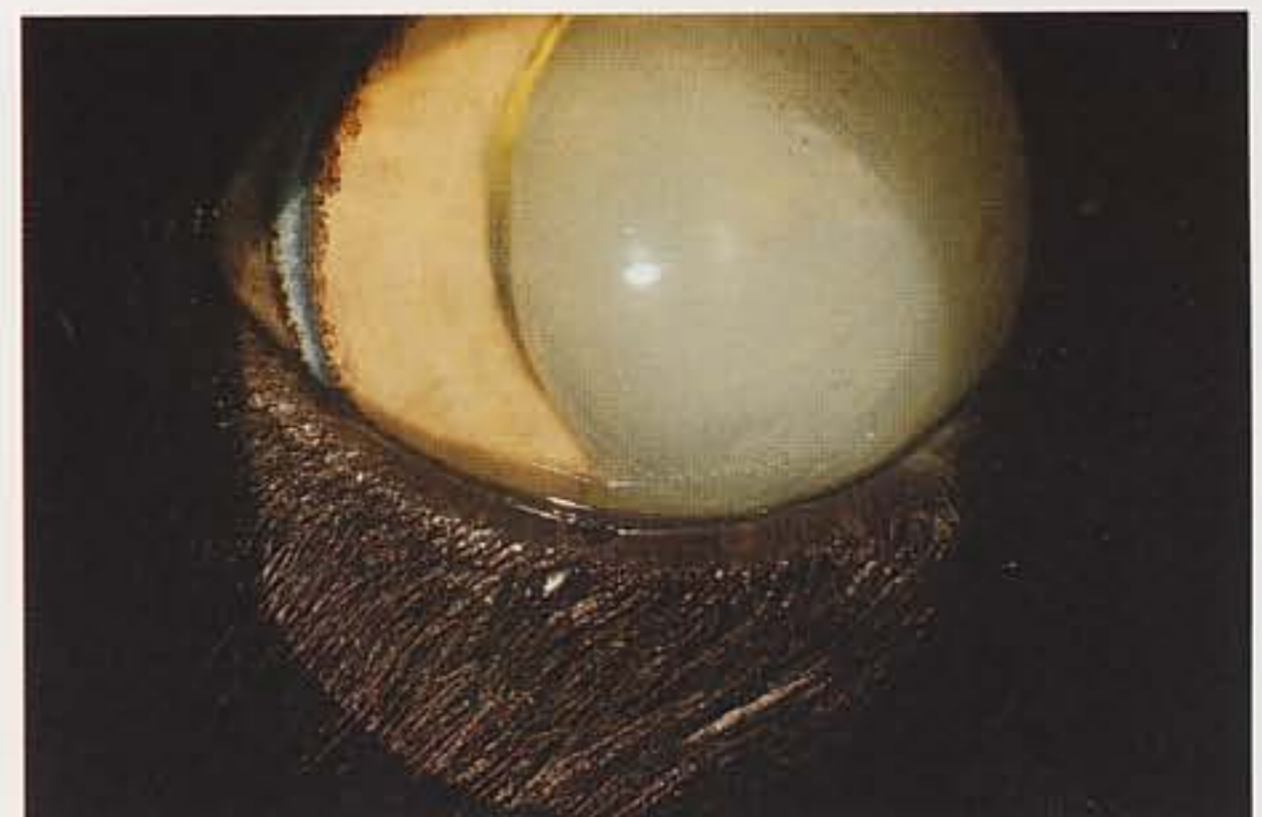

Fig. 9.112 Dislocated cataract (DSH cat, 10 years old) Mature cataract dislocated anteriorly.

# Chapter 10

## Vitreous

### Introduction

Vitreous anomalies and conditions do not figure highly in veterinary ophthalmology; few have an effect on vision, unless particularly severe, and none are painful. Vitreous haemorrhage, particularly in the cat, usually indicates hypertension and is probably the most important clinical sign. Conditions of the vitreous can be conveniently classified into congenital and acquired.

### Congenital (Figs 10.1–10.8)

Persistent hyaloid artery (PHA) (Figs 10.1–10.2) protrudes into the anterior vitreous from a localized non-progressive posterior capsular opacity. No effect on vision.

Persistent hyperplastic primary vitreous and persistent hyperplastic tunica vasculosa lentis (PHPV/PHTVL) (Figs 10.3–10.8) are hereditary and congenital conditions in the Staffordshire Bull Terrier and Doberman with odd cases in other breeds, bilateral in the two breeds named but with variable severity and usually not bilaterally symmetrical. The clinical signs vary from pigment spots to a fibrovascular plaque on the posterior capsule, together

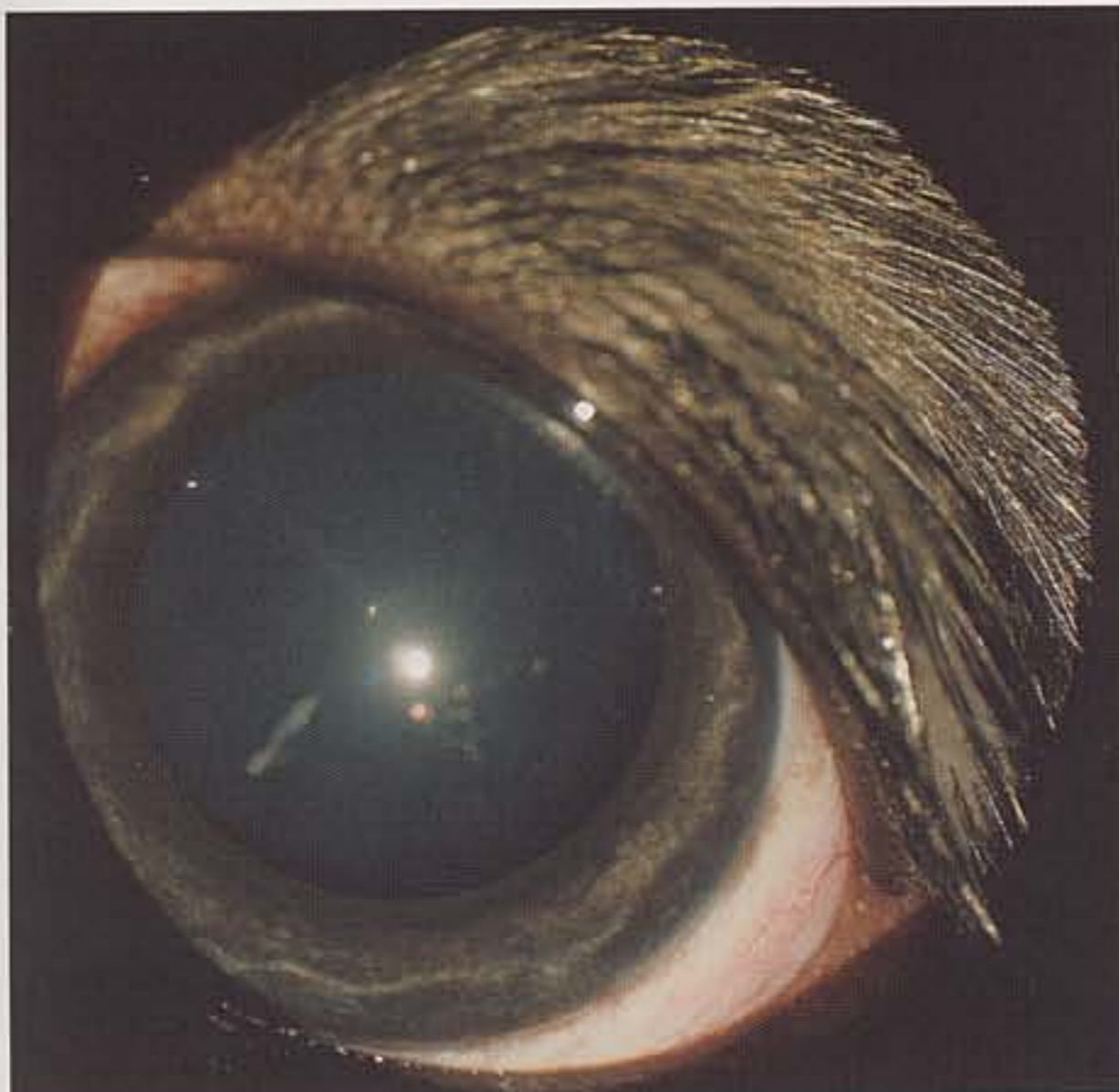


Fig. 10.1 PHA (Cavalier King Charles Spaniel, 7 weeks old) Note the suture lines in relation to the position of the hyaloid artery, i.e. not at the confluence of the suture lines.

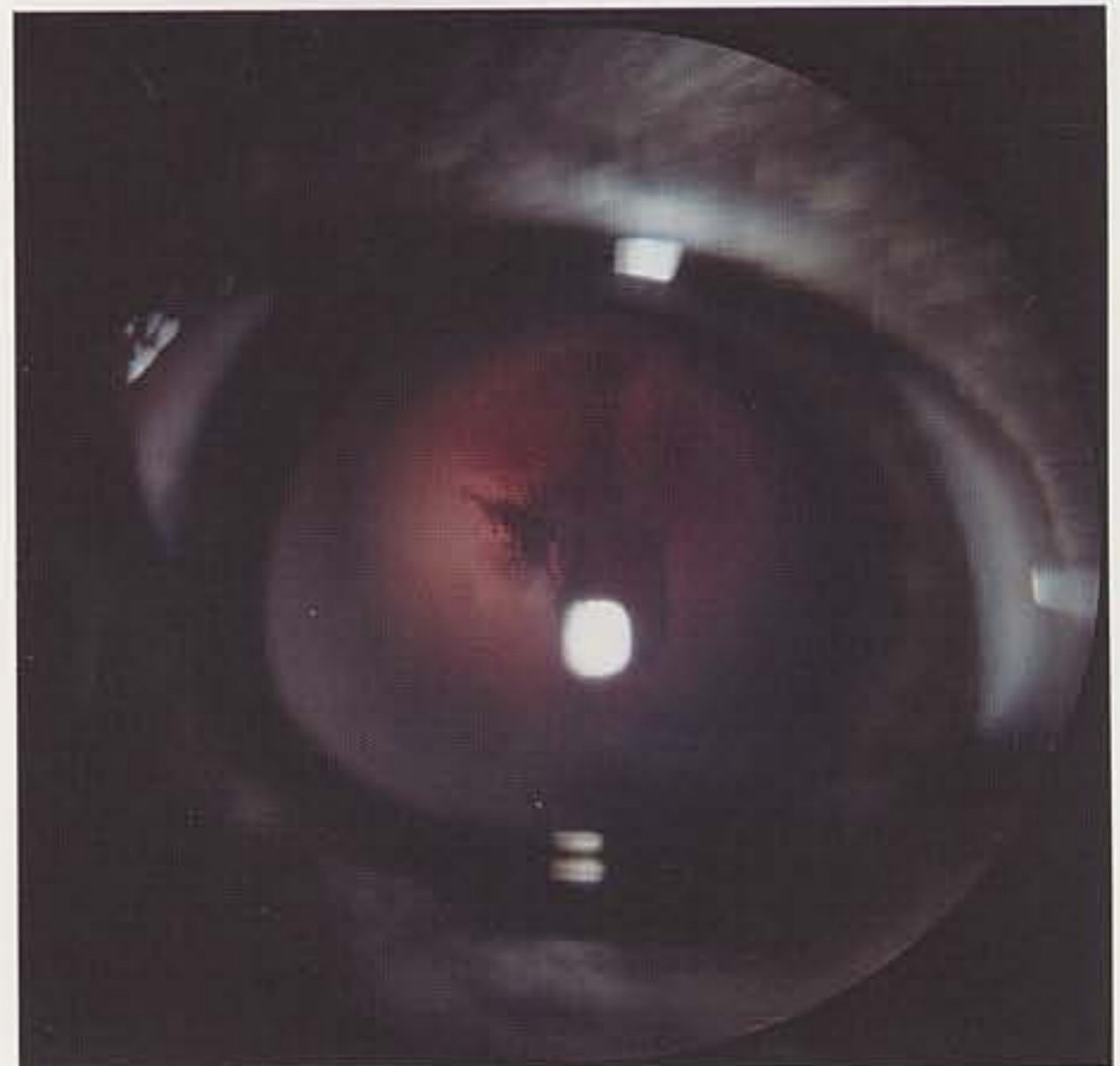

Fig. 10.2 PHA (Shetland Sheepdog, 8 weeks old) Extensive hyaloid artery and haemorrhage. This puppy also had an optic disc coloboma (CEA).

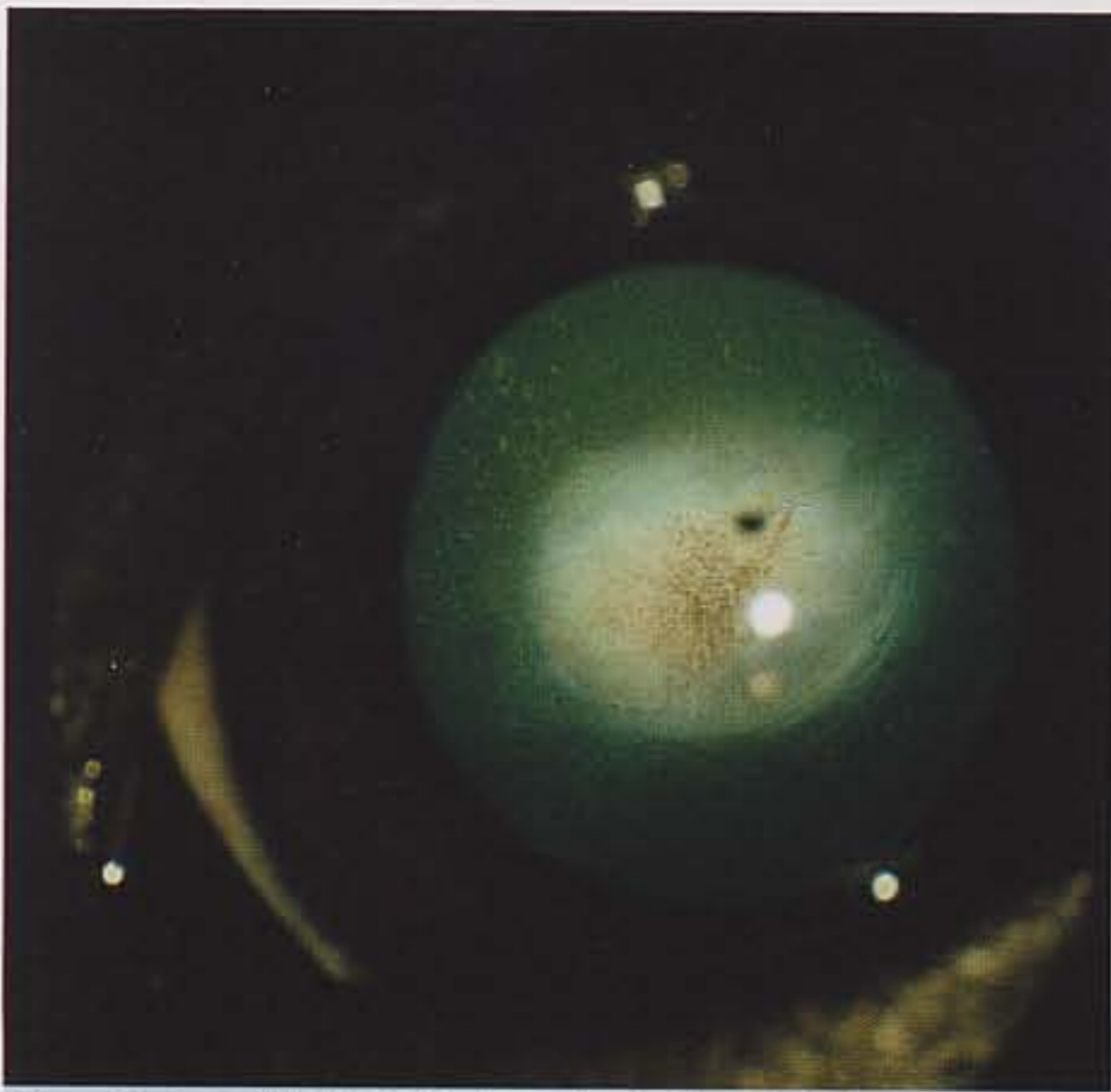

Fig. 10.3 PHPV/PHTVL (Staffordshire Bull Terrier, 5 months old) Posterior plaque and PHA. Bilateral and hereditary in this breed.

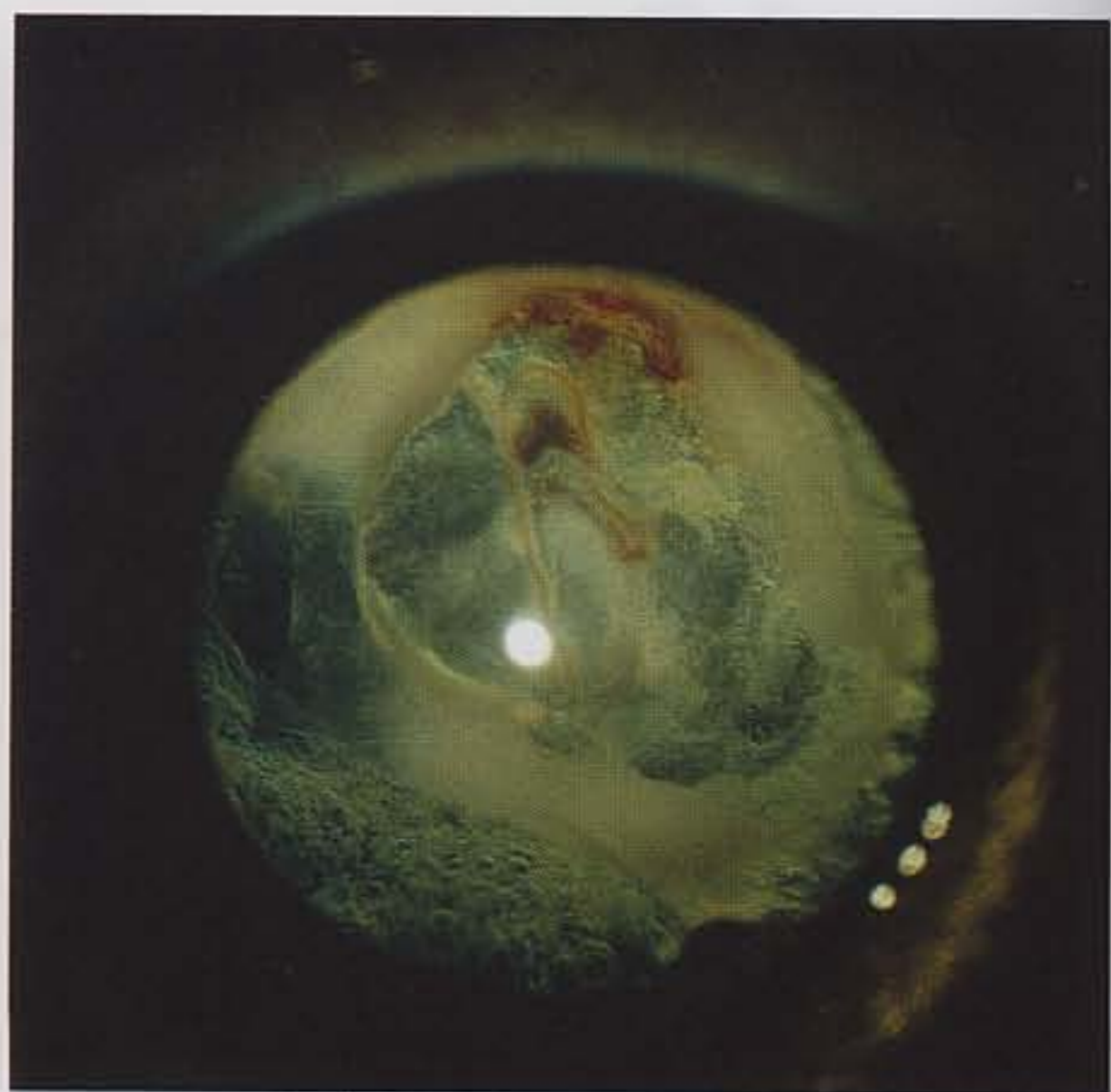

Fig. 10.5 PHPV/PHTVL (Staffordshire Bull Terrier, 6 months old) Posterior lenticonus and intralenticular haemorrhage.

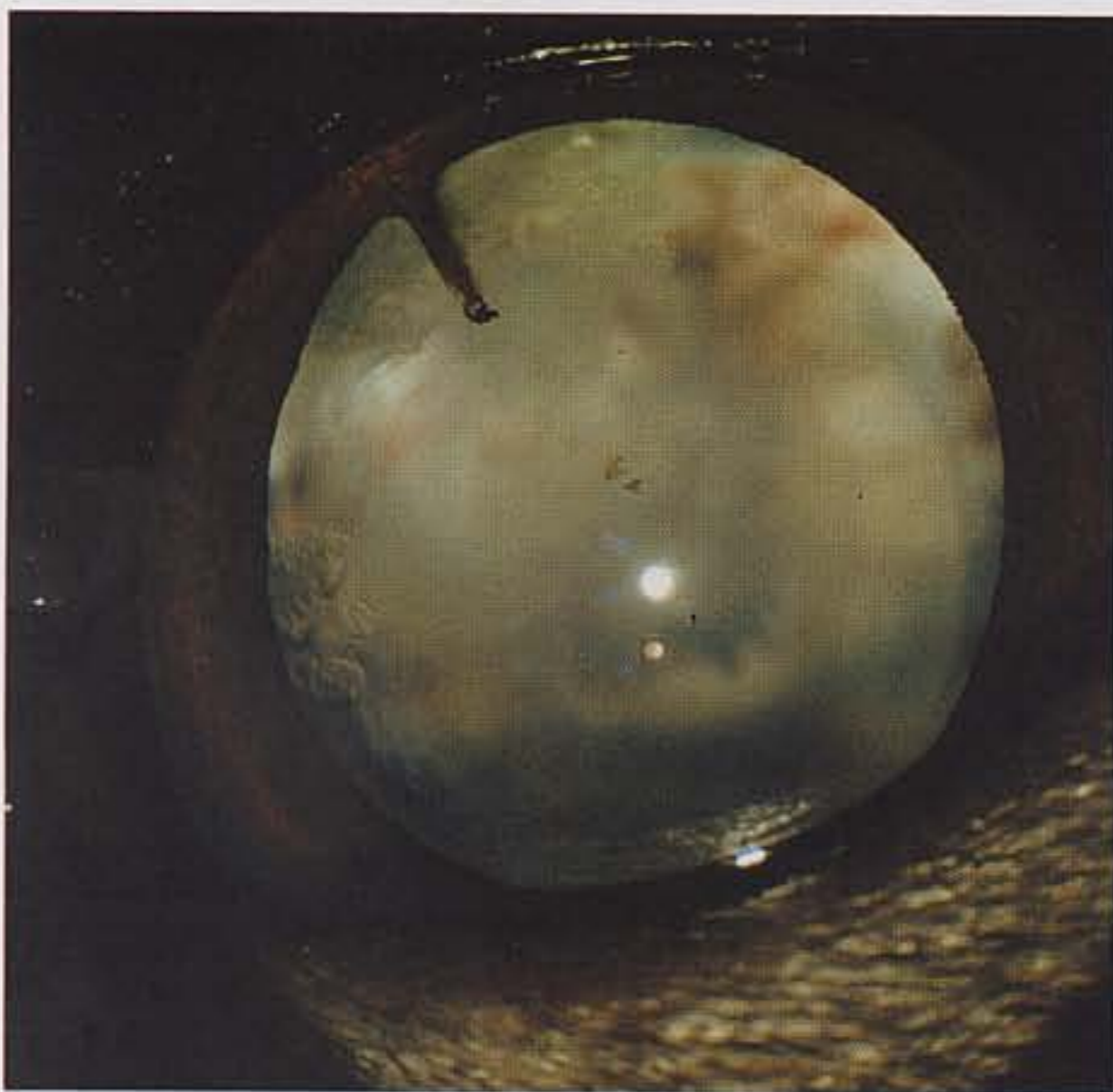

Fig. 10.4 PHPV/PHTVL (Staffordshire Bull Terrier, 5 months old) Posterior plaque, secondary cataract and capsulopupillary vessel.

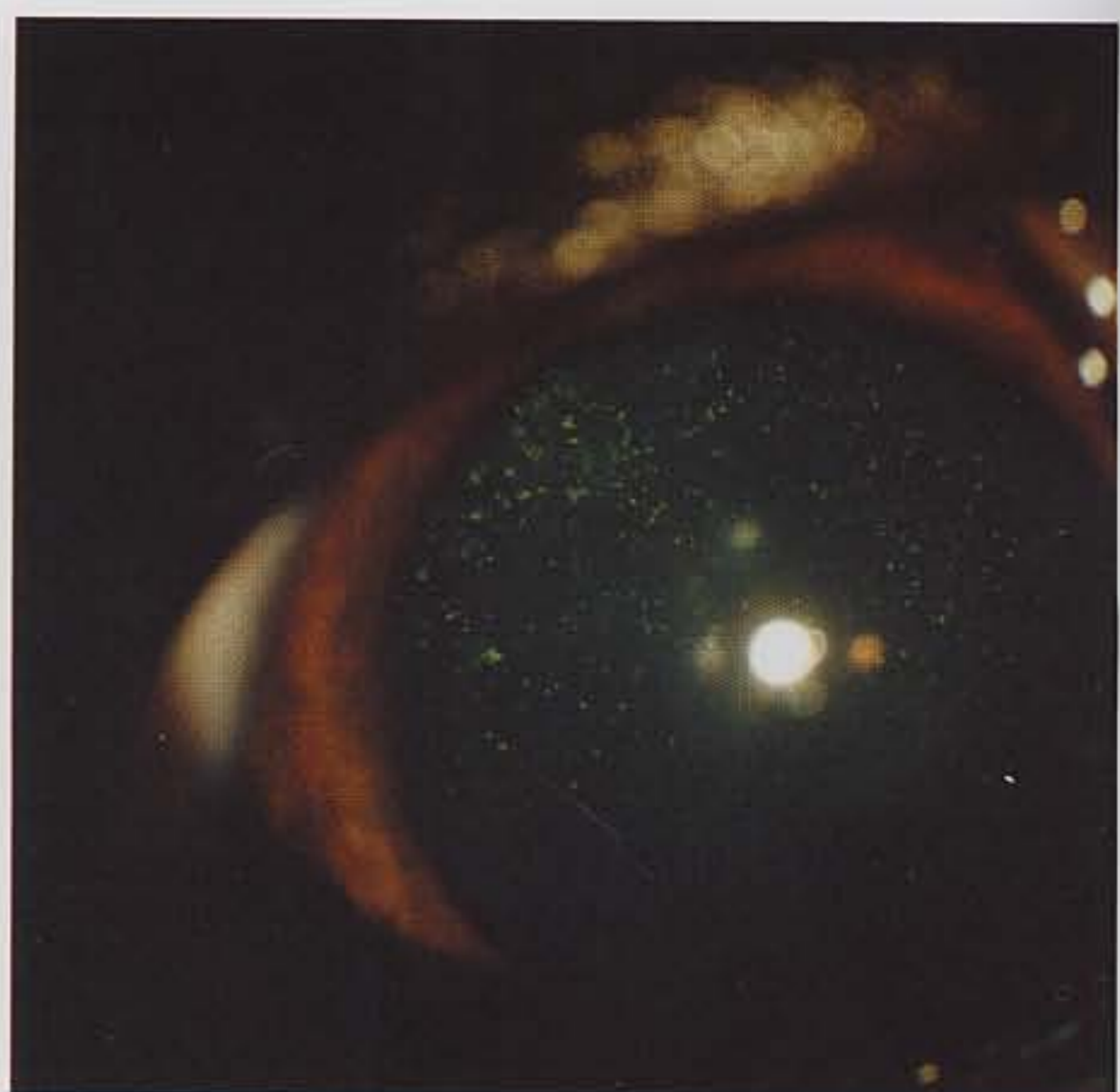


Fig. 10.6 PHPV/PHTVL (Doberman, 4 years old) Pigment foci on the posterior lens capsule. The condition is also hereditary in this breed.

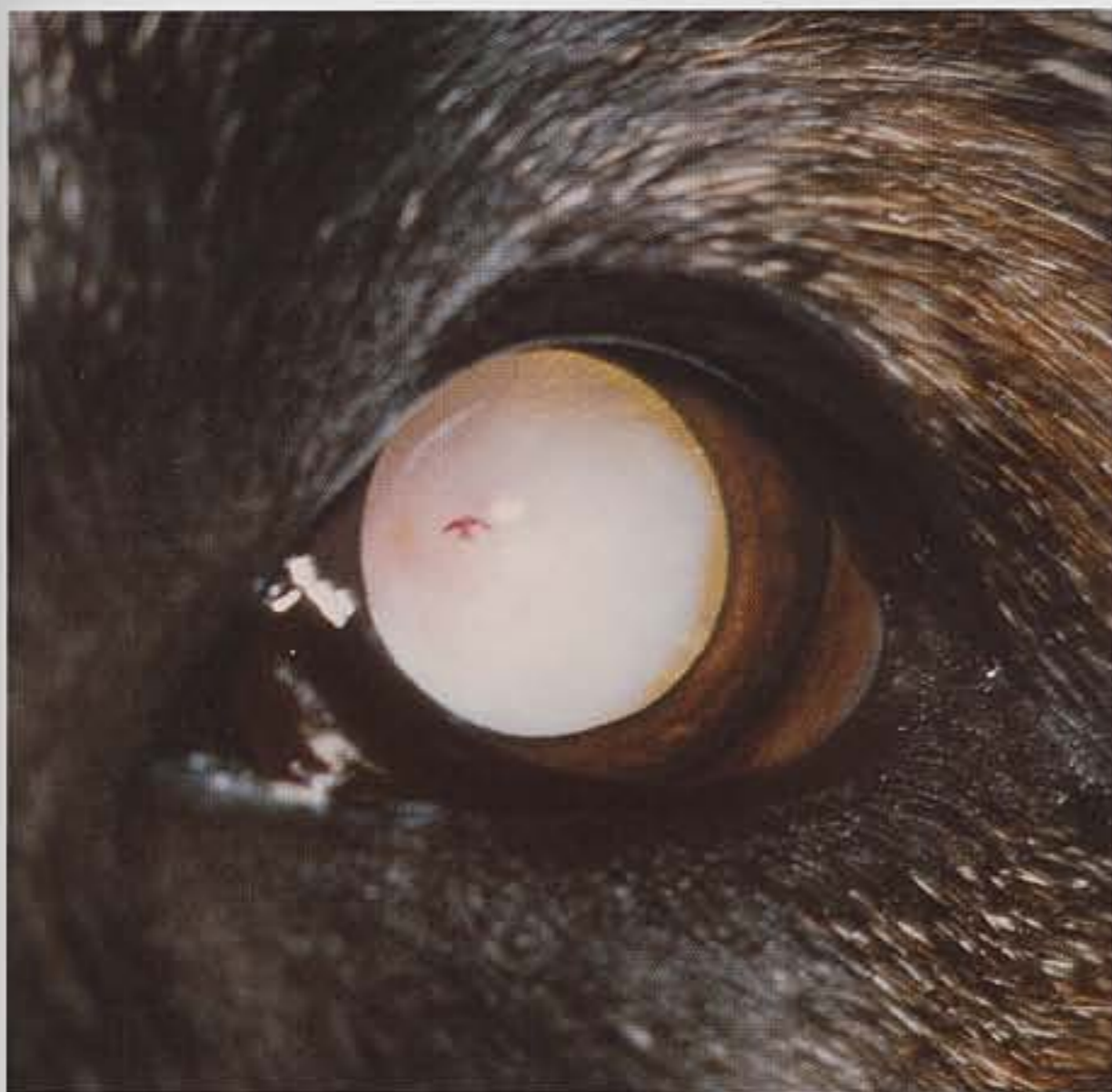

Fig. 10.7 PHPV/PHTVL (German Shepherd Dog, 6 months old) Leucocoria – a differential diagnosis to cataract.

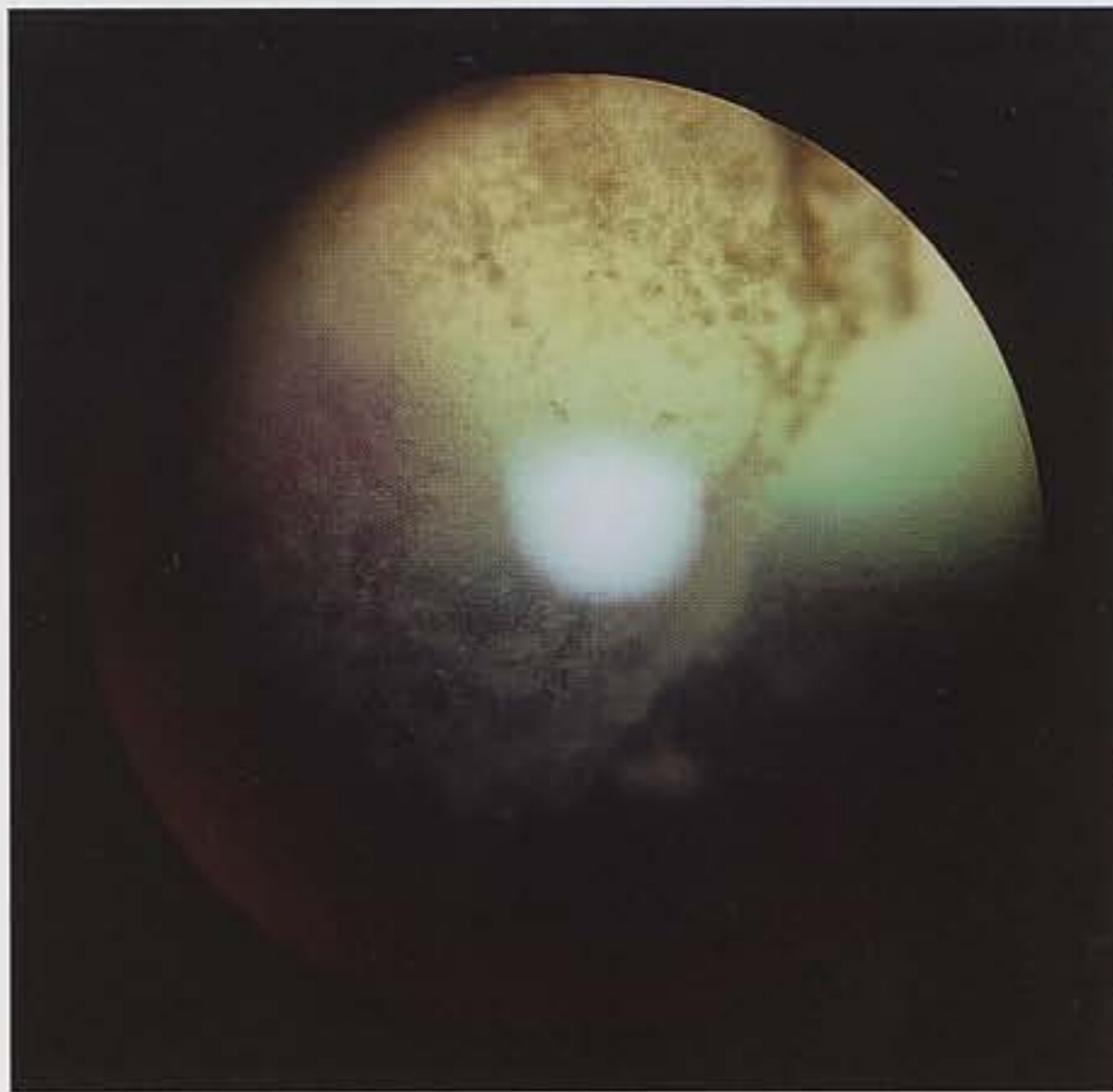

Fig. 10.9 Syneresis (Labrador Retriever, 2 years old) Inflammation of the anterior vitreous of unknown aetiology.

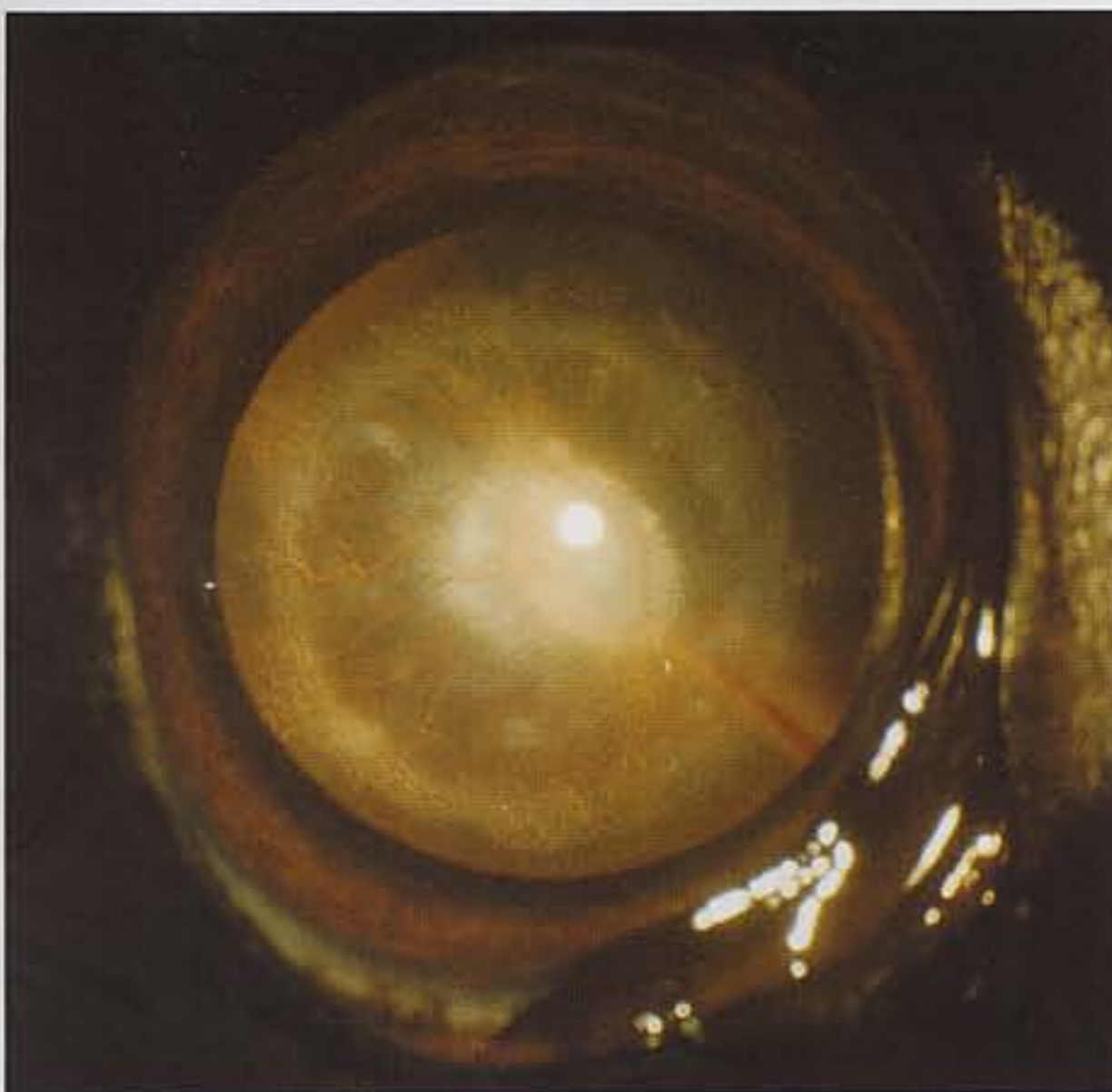


Fig. 10.8 PHPV (Cocker Spaniel, 6 months old) Unilateral case showing large persistent hyaloid artery, posterior plaque and vascular rete.

with congenital anomalies of the lens e.g. coloboma and lenticonus, cataract and intralenticular haemorrhage and PHA. In the Dobermann progressive cataract and blindness have been reported.

### Acquired (Figs 10.9–10.11)

Syneresis or liquefaction is shown in Fig 10.9.

Asteroid hyalosis (Fig 10.10) – small refractile particles suspended throughout the vitreous. No effect on vision.

Synchysis scintillans (Fig 10.11) – fine particles in a liquefied vitreous which settle ventrally in the eye at rest but become temporarily dispersed with eye movement. Often found in conjunction with retinal diseases.

### Haemorrhage (Figs 10.12–10.15)

Causes: trauma; clotting abnormalities; hypertension – particularly important in the cat. Variable effect on vision depending on the severity; usually unocular.

### Foreign bodies (Figs 10.16–10.17)

Occasionally; uveal cysts and parasites have both been recorded.



Fig. 10.10 Asteroid hyalosis (Crossbred, 6 years old) Particles in the vitreous which are stationary, unlike the case in synchysis scintillans (Fig 10.11).

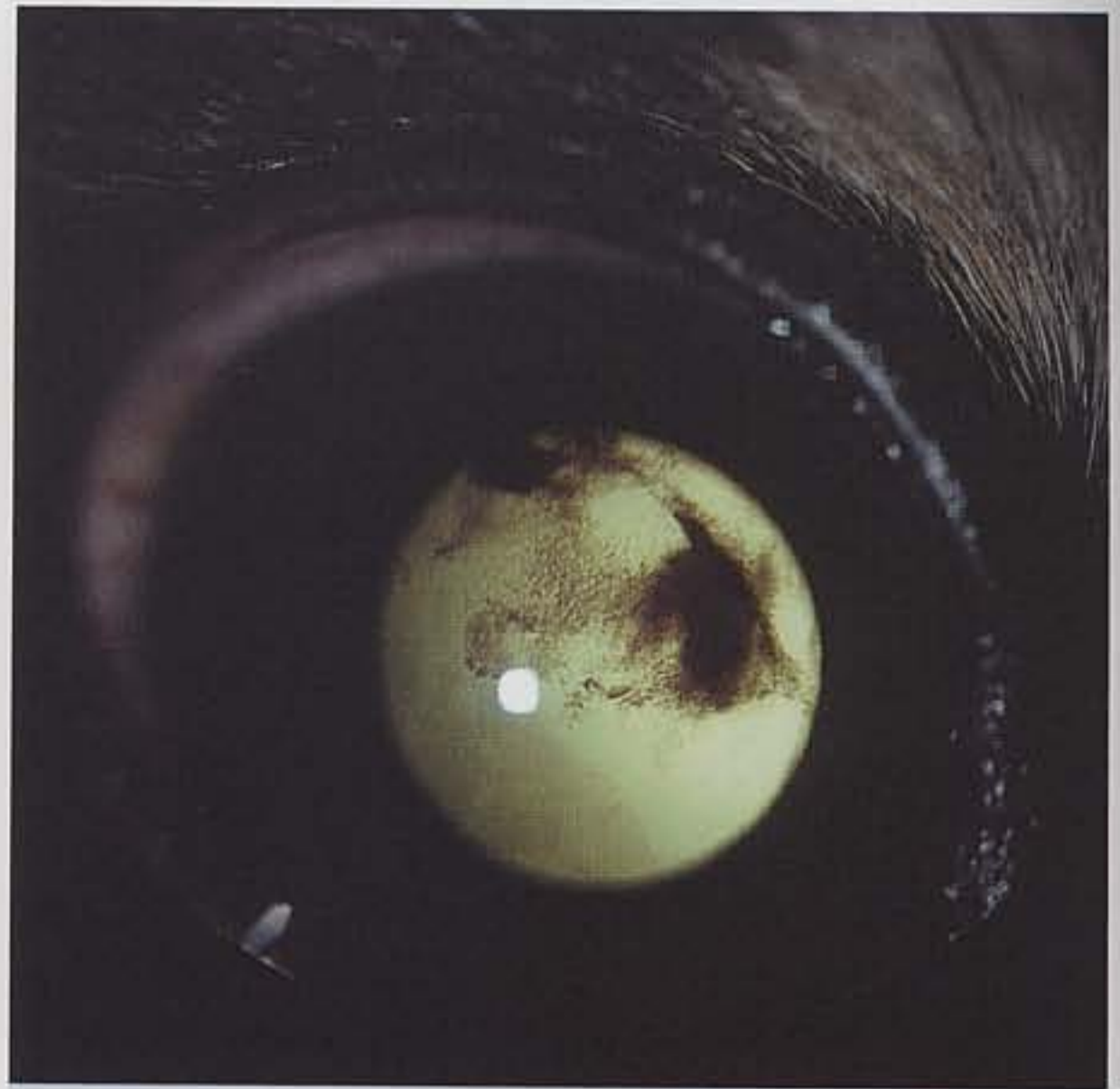

Fig. 10.12 Vitreal haemorrhage (Chihuahua, 4 years old) Haemorrhage in the anterior vitreous due to polycythaemia.

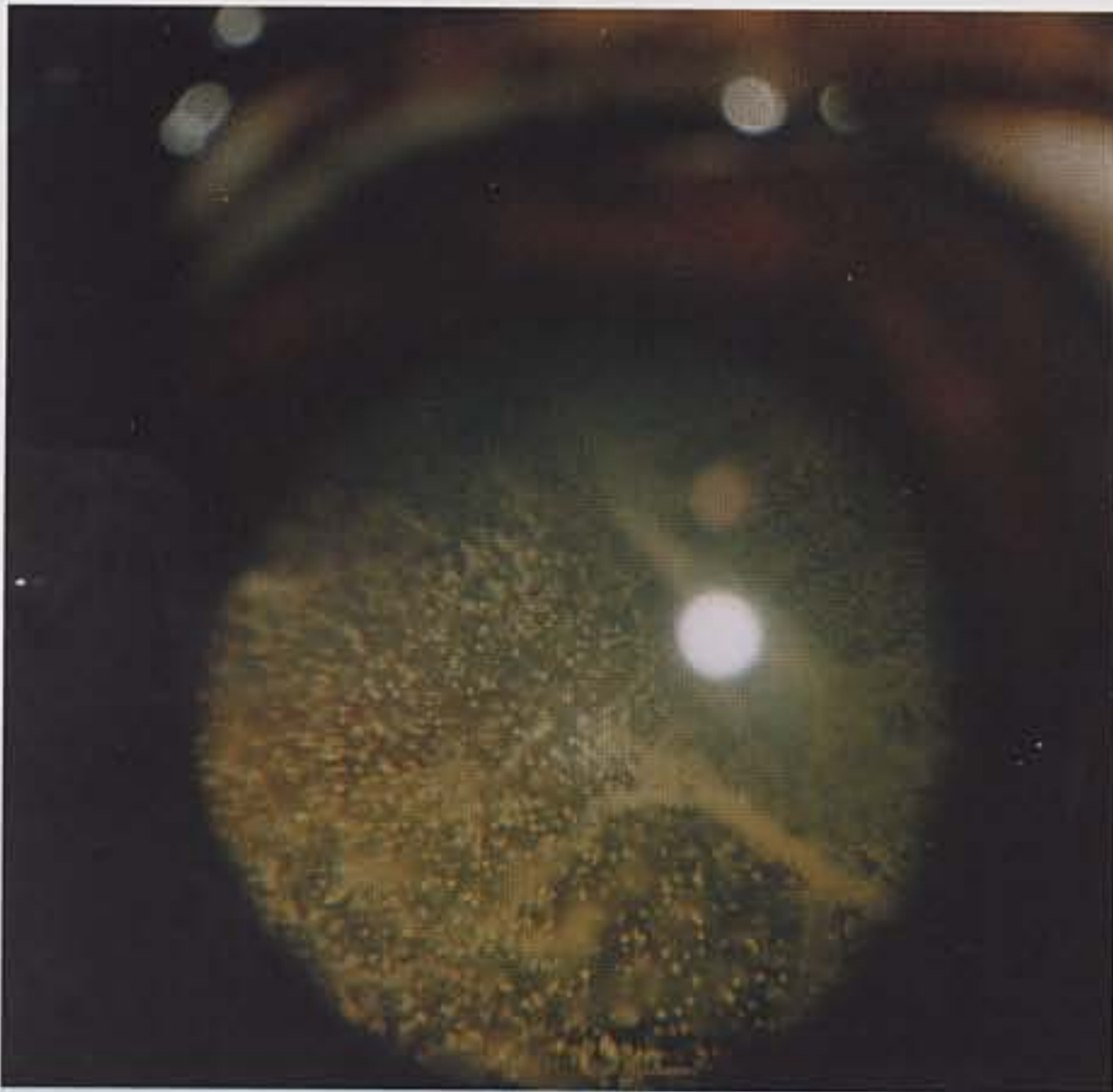

Fig. 10.11 Synchysis scintillans (Golden Retriever, 11 years old) Extensive retinopathy also present with liquefied vitreous.

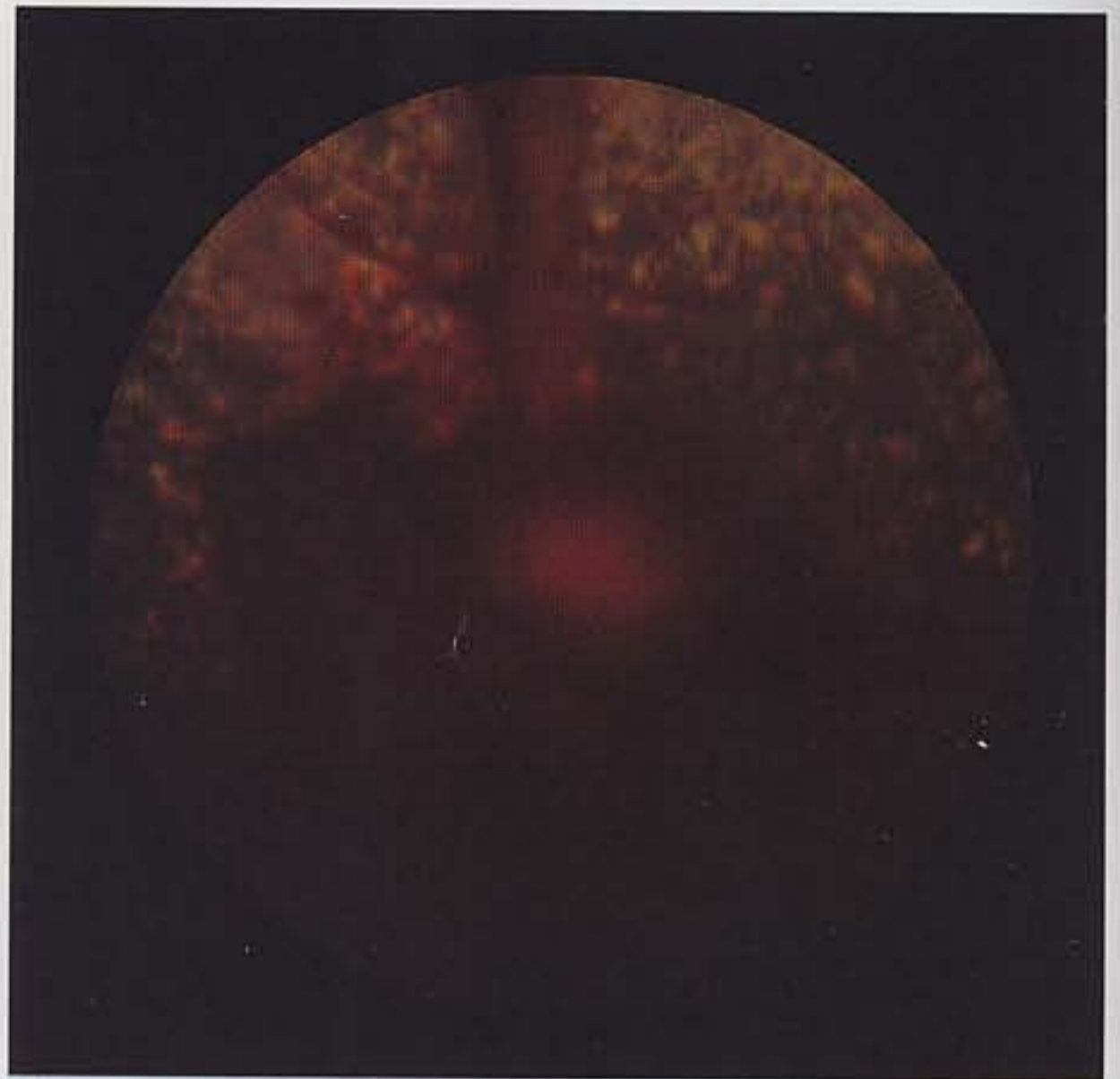


Fig. 10.13 Vitreal haemorrhage (English Springer Spaniel, 3 years old) Haemorrhage in the posterior vitreous following trauma (shot in the eye).

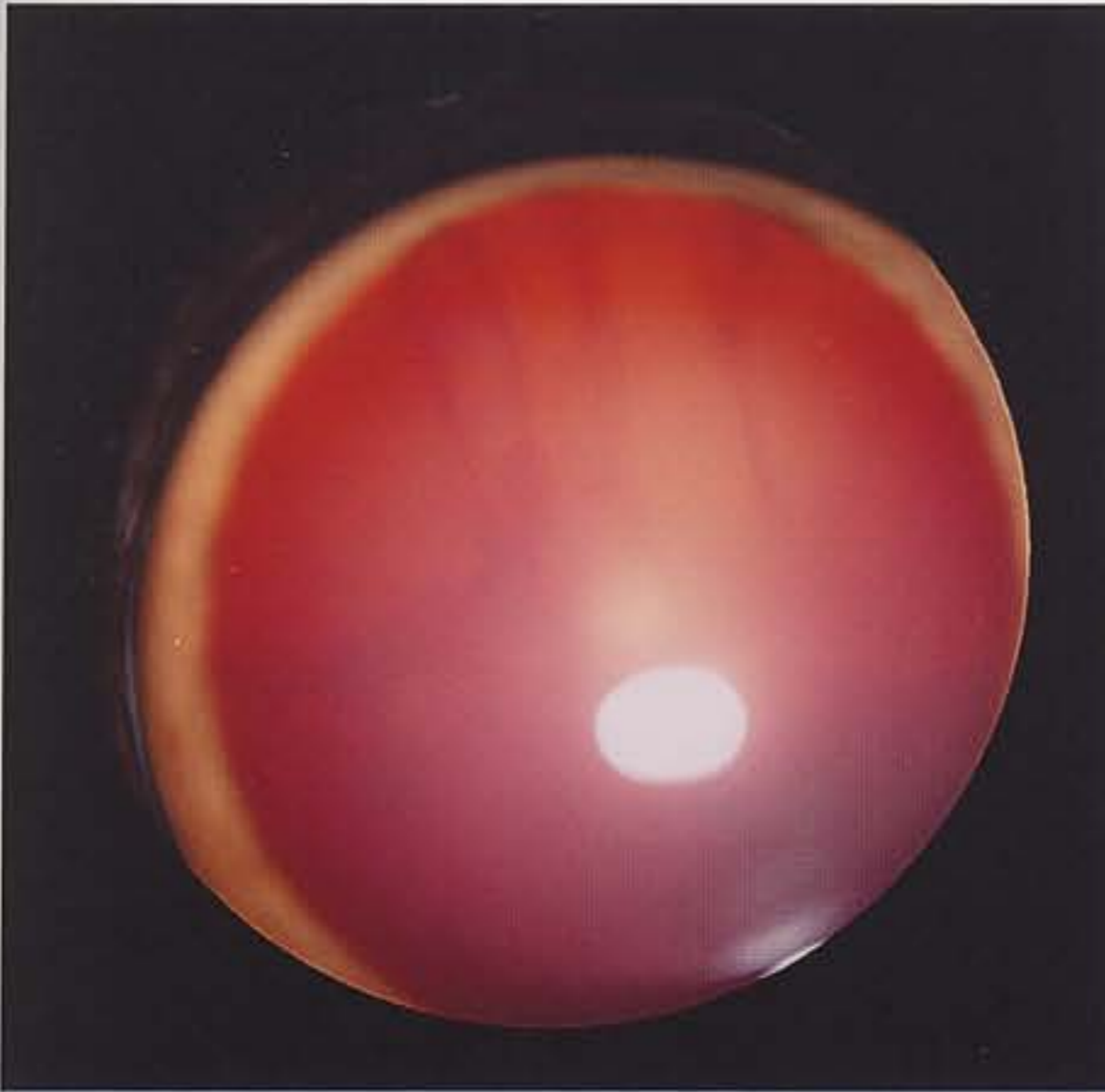

Fig. 10.14 Vitreal haemorrhage (cat) Diffuse haemorrhage in a cat with hypertension.



Fig. 10.16 Cyst in vitreous (Golden Retriever, 9 years old) Uveal cyst in front of the retina.

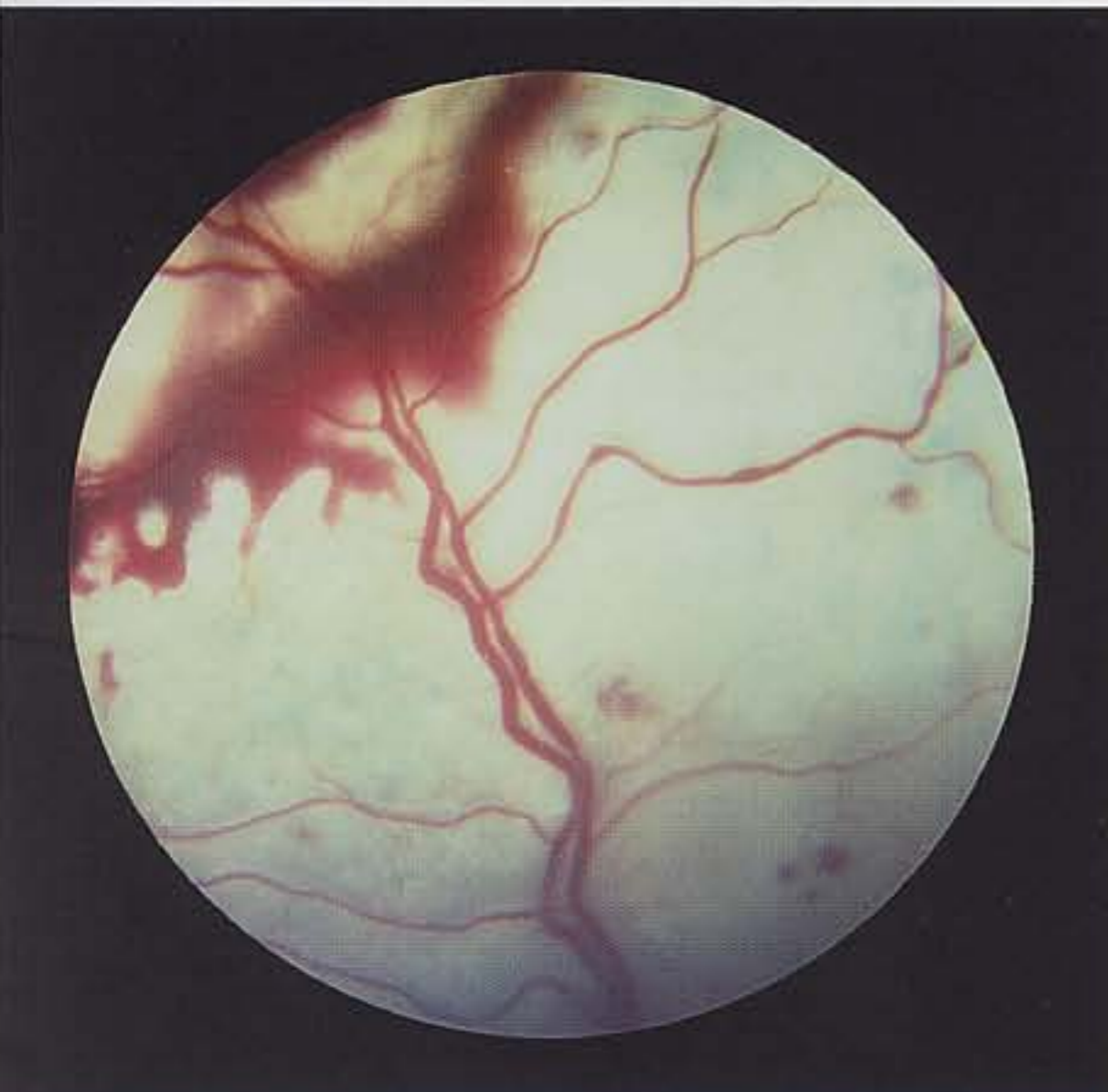


Fig. 10.15 Vitreal haemorrhage (cat) Haemorrhage in the posterior vitreous in front of the retinal vessels, together with some small retinal haemorrhages. Another cat with hypertension.

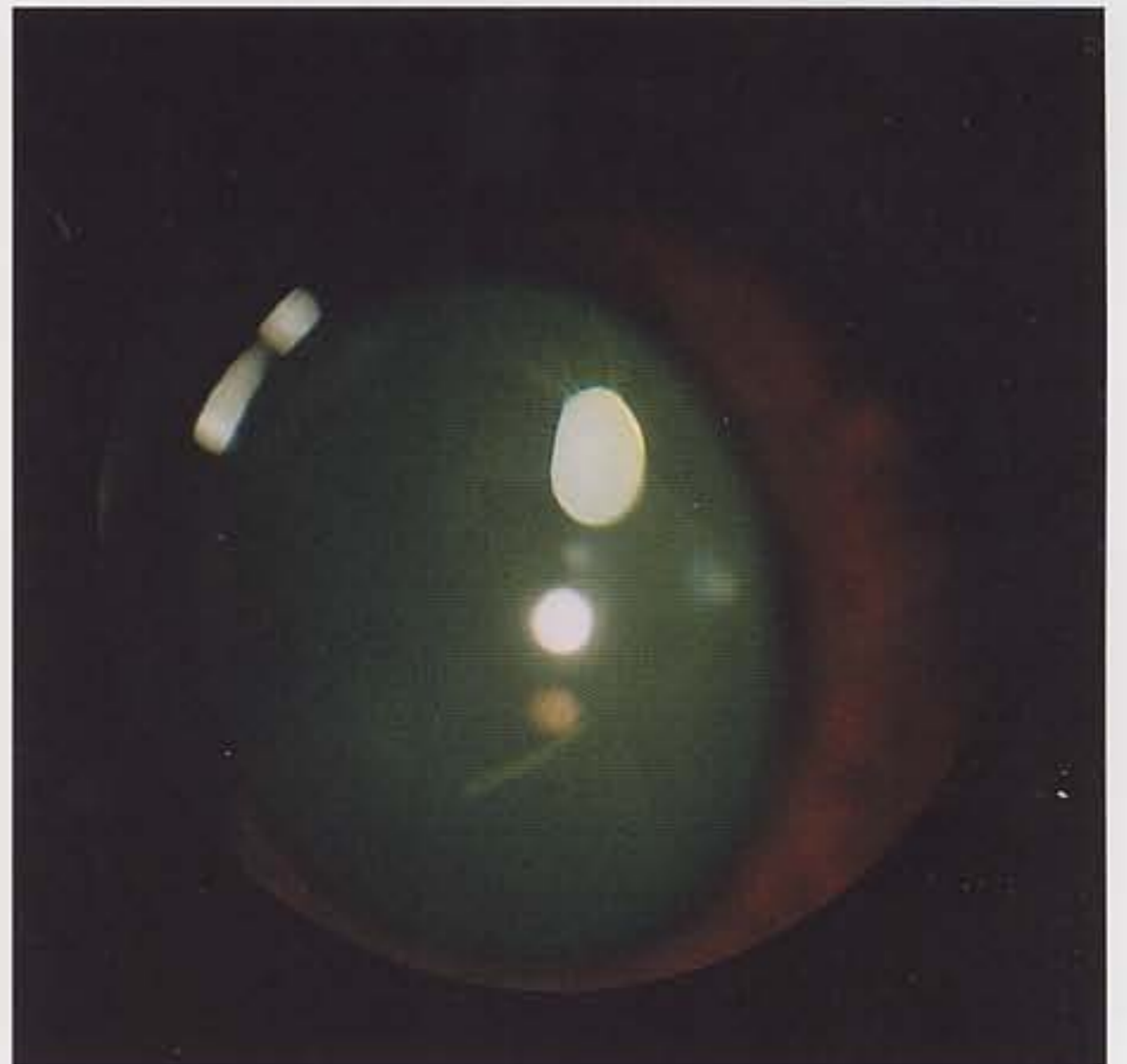

Fig. 10.17 Cyst in vitreous (Flat-Coated Retriever, 2 years old) Oval non-pigmented cyst of unknown origin. An incidental finding.



# Chapter 11

## Fundus

### Introduction

The ocular fundus is the ophthalmoscopic view of the posterior segment of the globe. The fundus comprises the tapetum, tapetum lucidum or tapetal fundus; the tapetum nigrum or non-tapetal fundus; the optic disc, papilla or optic nerve head (Chapter 12); and the retinal blood vessels. Depending upon the presence or absence of pigment in the retinal pigment epithelium and the choroid, parts of the choroid and its circulation, and the sclera, can be seen.

The ocular fundus differs considerably between species and there is also considerable variation in the appearance within each species, particularly in the dog. This normal variation must be known and understood before a diagnosis of abnormality can be made. In certain cases this variation can lead to difficulty in diagnosis and in distinguishing between the normal and abnormal fundus, and even to misdiagnosis.

Certain features and colours of the fundus are related to both coat and iris colours, and even to coat length. In the dog and cat the development of the adult appearance of the fundus takes up to 12–14 weeks, but in the case of the horse, cow and sheep the adult appearance is present from birth, the foal, calf and lamb being born with the eyes open.

### The normal canine fundus

#### *The tapetal fundus (Figs 11.1–11.11)*

The extent of the tapetal fundus in the dog is shown in Fig 11.1. It is best developed in dogs that hunt by sight – the so-called ‘sight hounds’ or ‘gaze hounds’. In the toy breeds, the tapetum may be only partially developed, extending to about half of that shown in Fig 11.1 and it is always the lateral half that is present and the medial half absent. The tapetum may also be completely absent, particularly, but not always, in dogs with degrees of subalbinism and a merle coat colour.

The commonest colour of the tapetum lucidum is yellow with a green and outer blue border (Fig 11.2), but mainly yellow, green and blue colours do occur (Figs 11.3–11.5). Sparsely scattered tapetal colours over a pale fawn background occur in dogs of a number of breeds, and in particular lines or families within a breed (Figs 11.6–11.7).

It should be known that the tapetum is part of the choroid and underlies the retina when viewed ophthalmoscopically. The tapetum can only be seen as, in this area, the retinal pigment epithelium lacks pigment and the appearance of the tapetum is through the retina. It follows, therefore, that if the retina is missing (detachment) or thinned (atrophy or degeneration), the reflection from the tapetal area is enhanced and the situation is described as ‘hyper-reflectivity’. Hyper-reflectivity is a cardinal sign of retinal degeneration, of whatever cause.

Islands of pigment (non-tapetal fundus) may sometimes occur within the tapetal fundus region (Figs 11.5 and 11.10–11.11) and islets, or spots, of tapetal colours may be found in the non-tapetal region (Fig 11.10).

Changes in pigmentation and the presence of abnormal pigment, in both tapetal and non-tapetal areas, are further common signs of retinal degenerations, of both inherited and post-inflammatory causes.

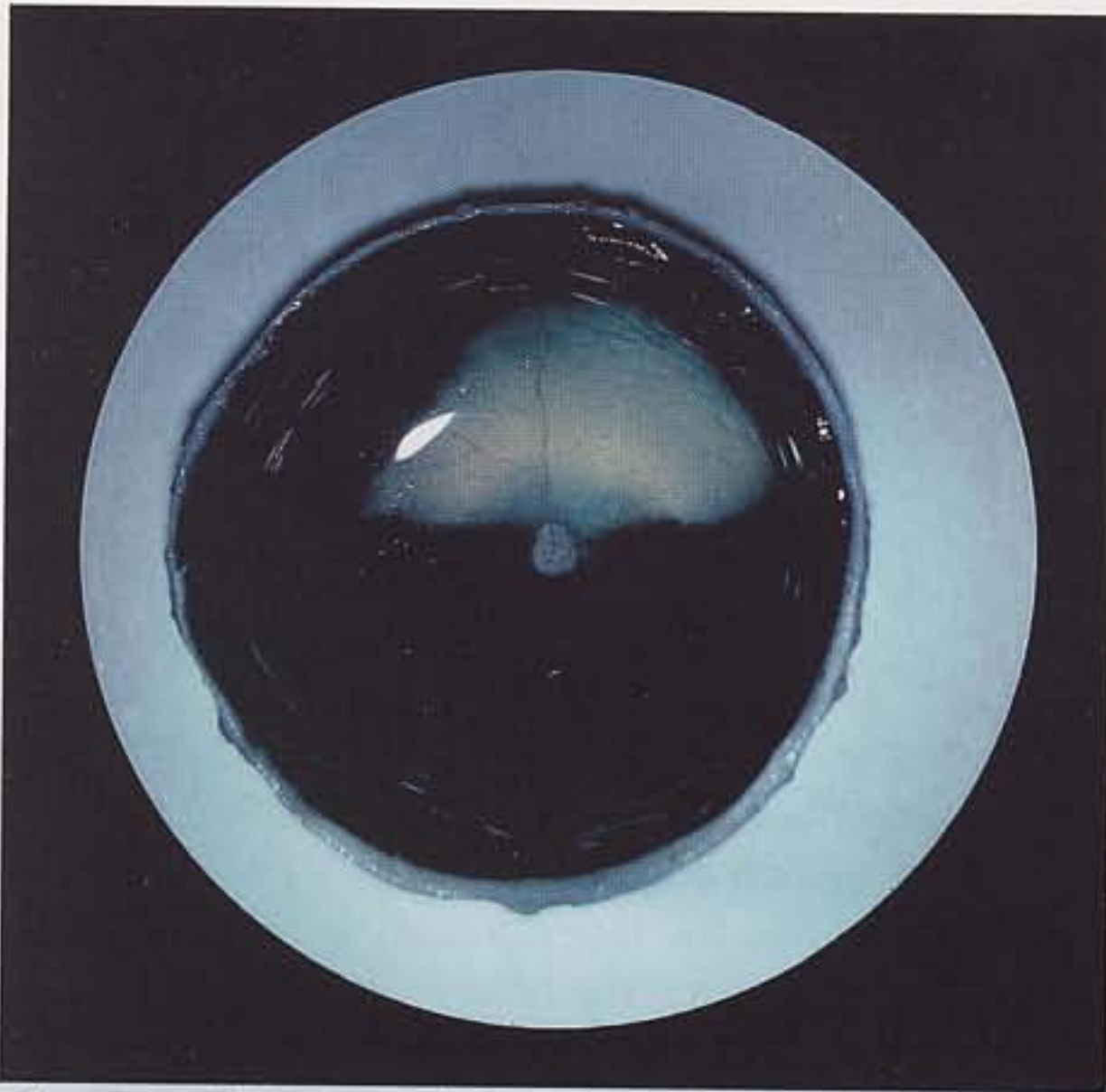


Fig. 11.1 The fundus (Greyhound, young adult) Posterior segment of the canine eye showing the extent of the tapetal fundus.

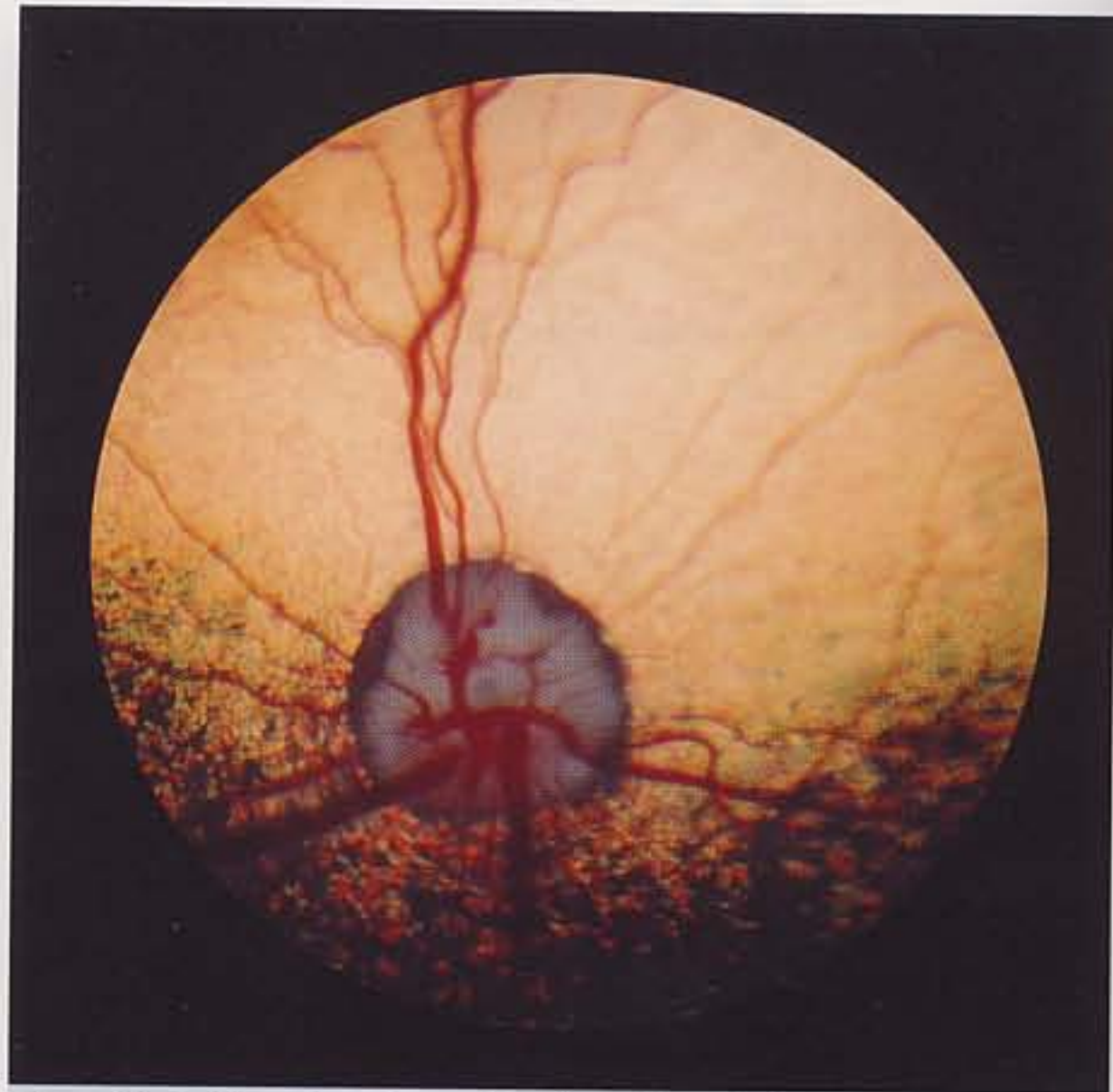


Fig. 11.3 The tapetum (Cocker Spaniel, 2 years old, gold) Yellow tapetal fundus.

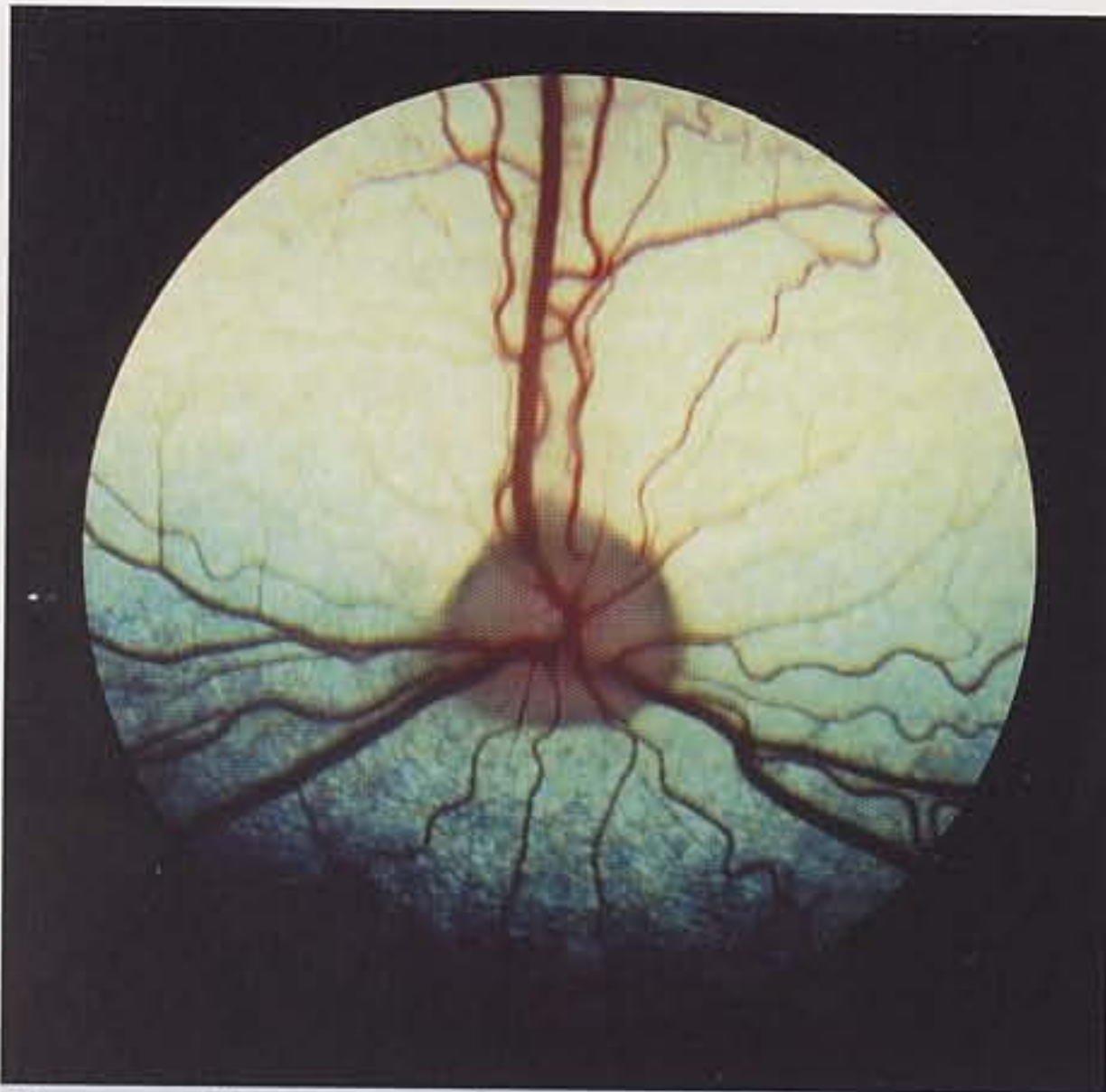


Fig. 11.2 The tapetum (Greyhound, young adult, brindle) Mainly yellow tapetal fundus with a green and blue border.

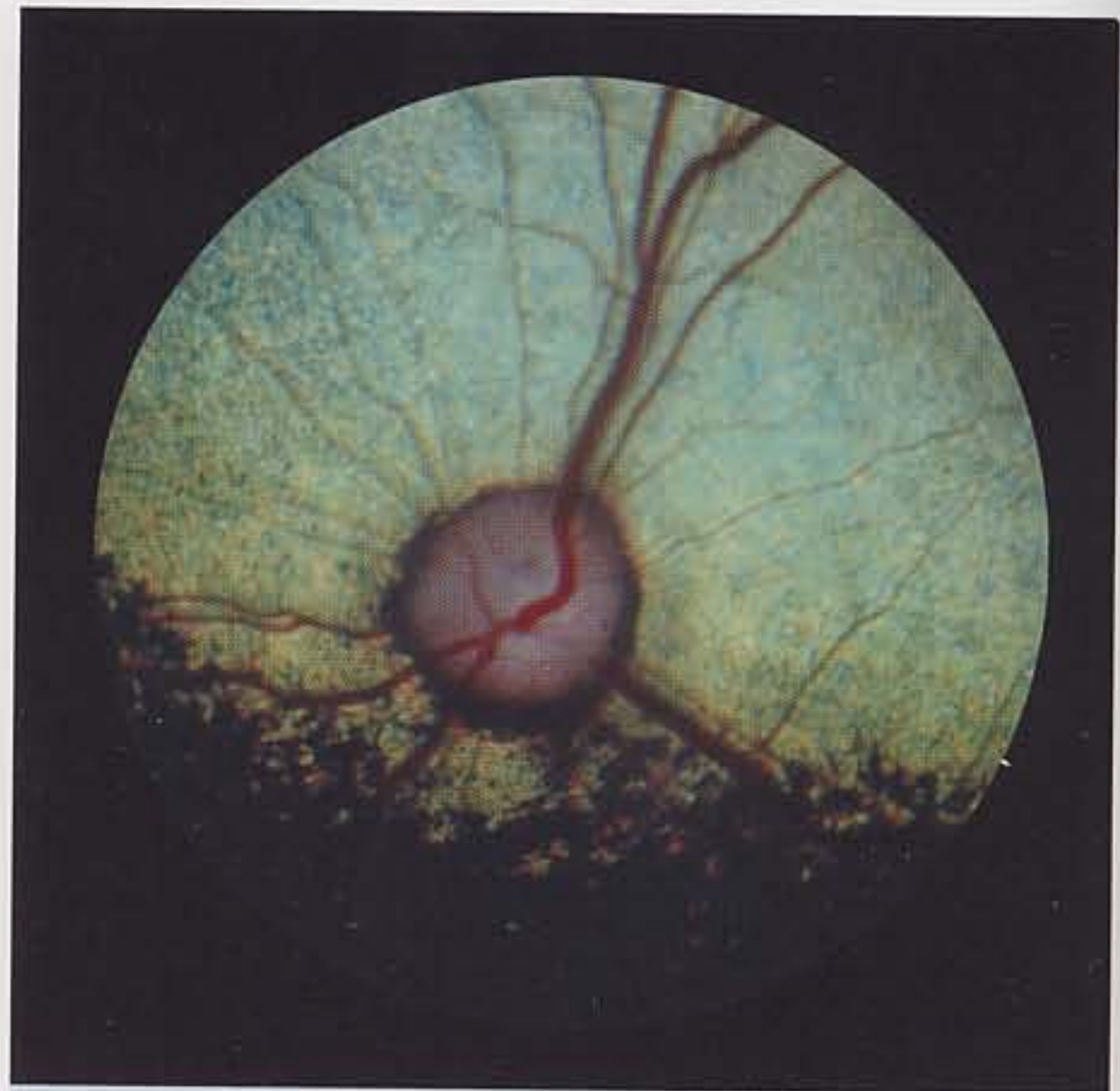

Fig. 11.4 The tapetum (Miniature Poodle, 1 year old, black) Green tapetal fundus. Note the complete pigmented border to the disc.

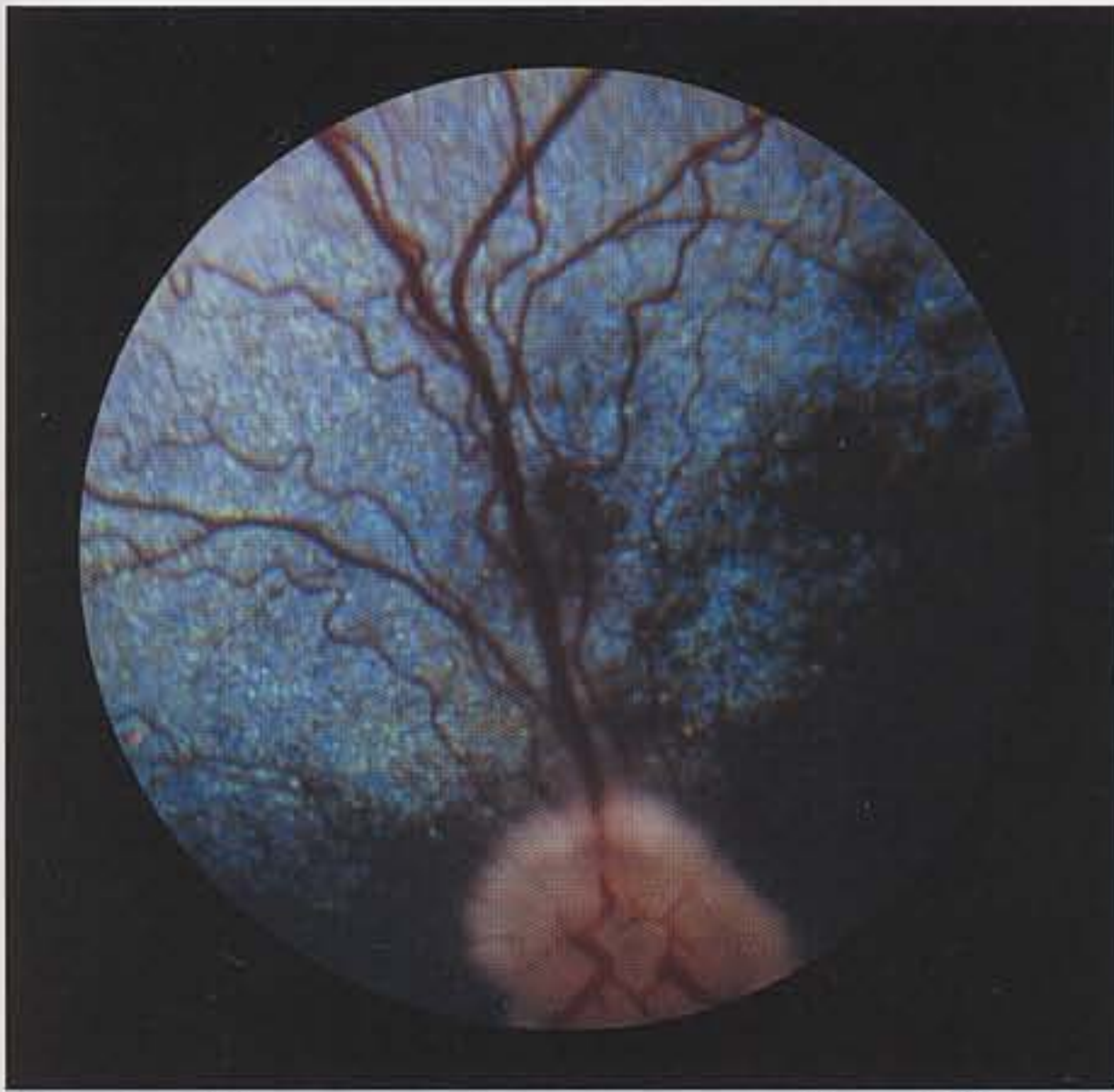

Fig. 11.5 The tapetum (Boxer, 3 years old, red) Blue tapetal fundus.

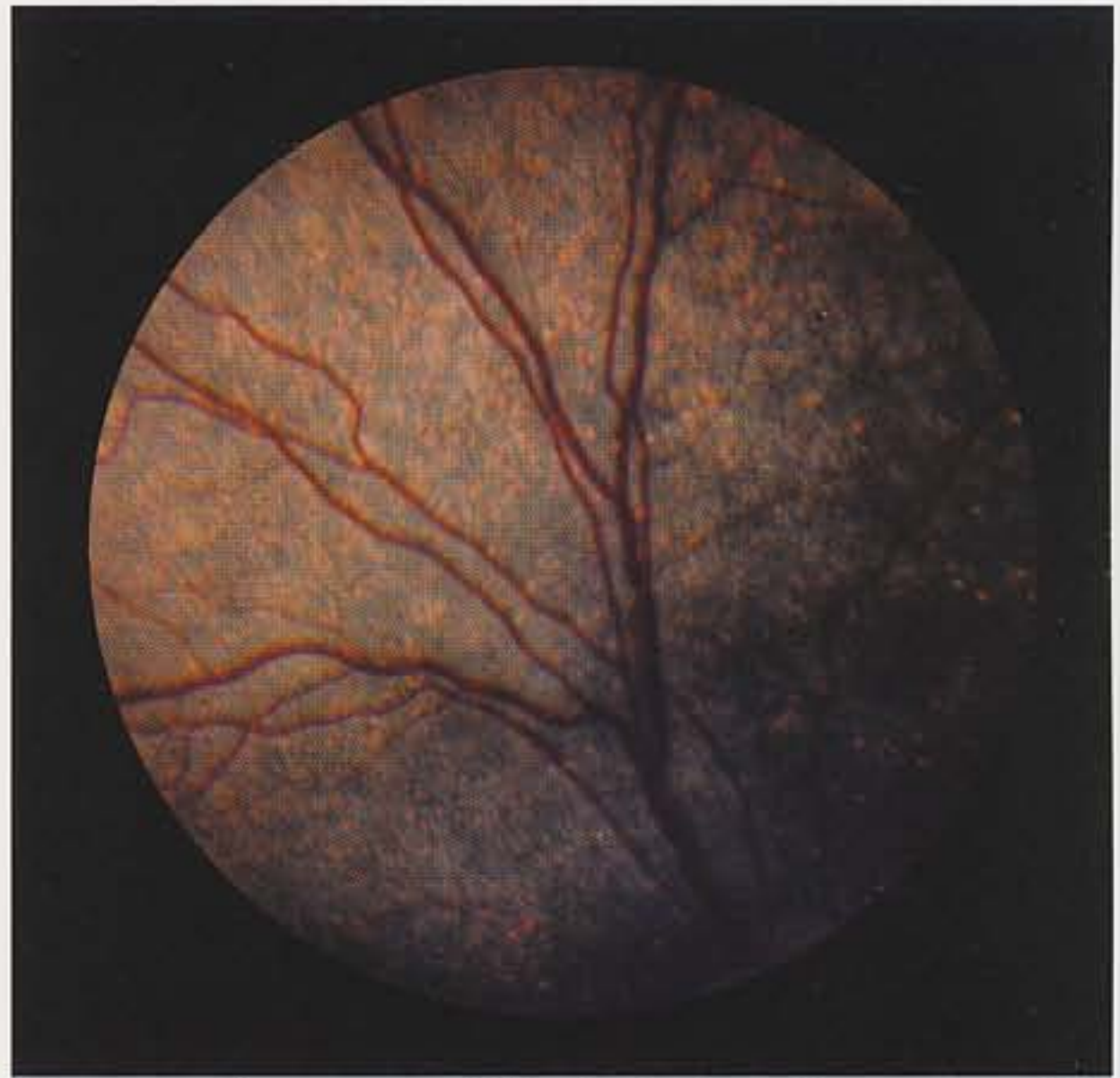


Fig. 11.7 The tapetum (Shetland Sheepdog, 1 year old, merle) Sparsely scattered tapetal colours.

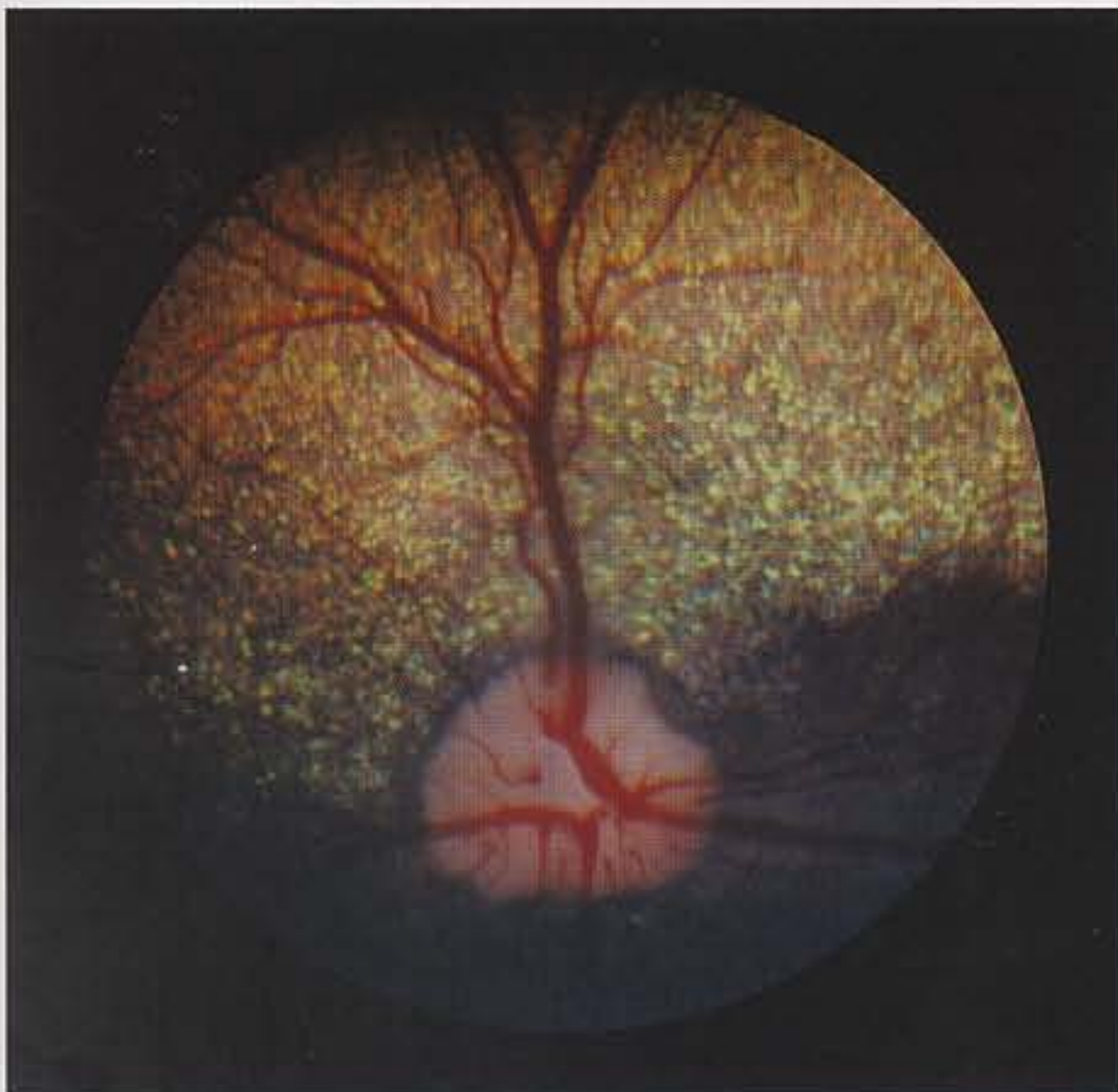


Fig. 11.6 The tapetum (Labrador Retriever, 1 year old, yellow) Sparsely scattered colours over a pale fawn background.

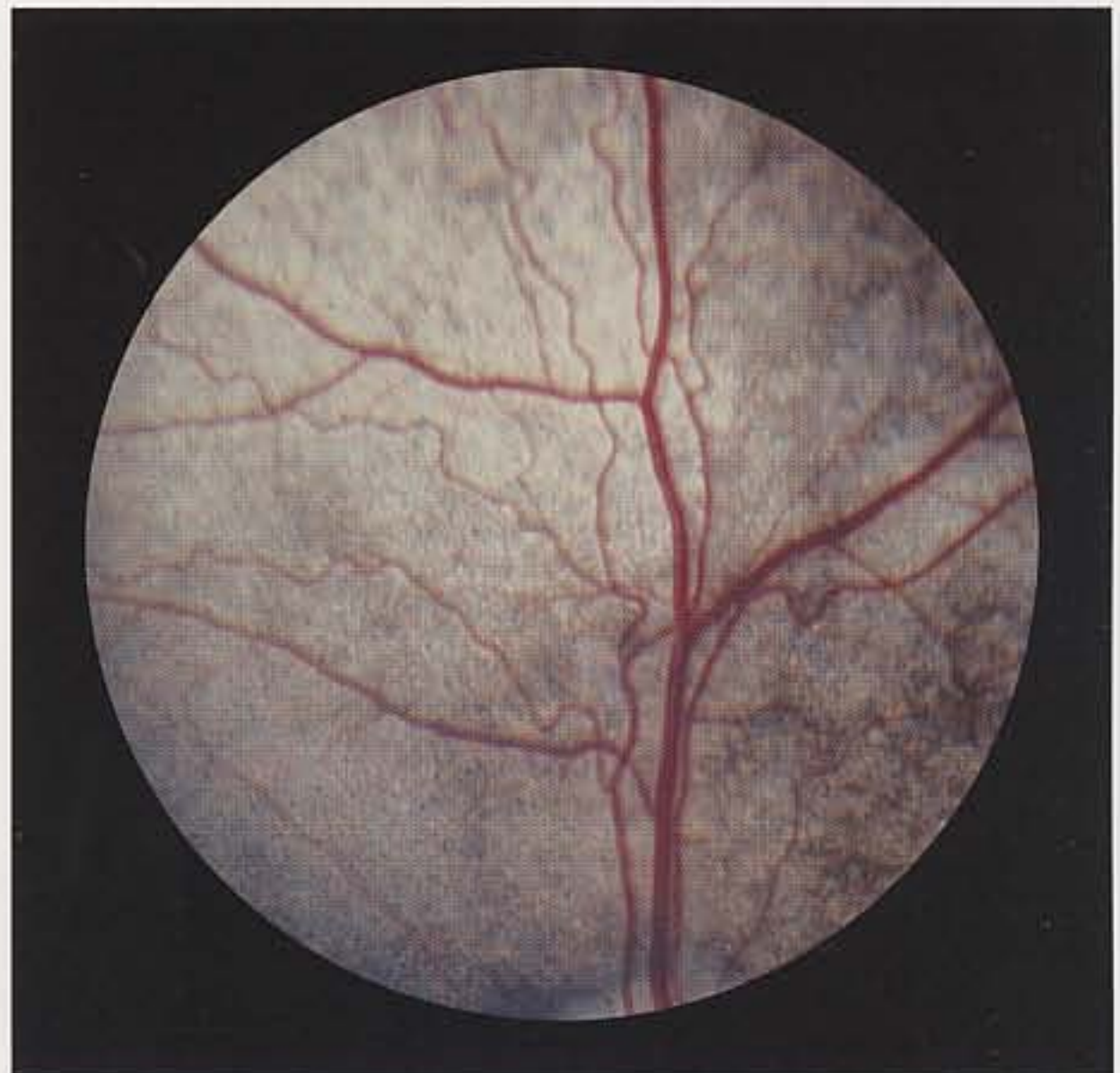


Fig. 11.8 The tapetum (Shetland Sheepdog, 5 years old, merle with brown iris) Pale fawn fundus.

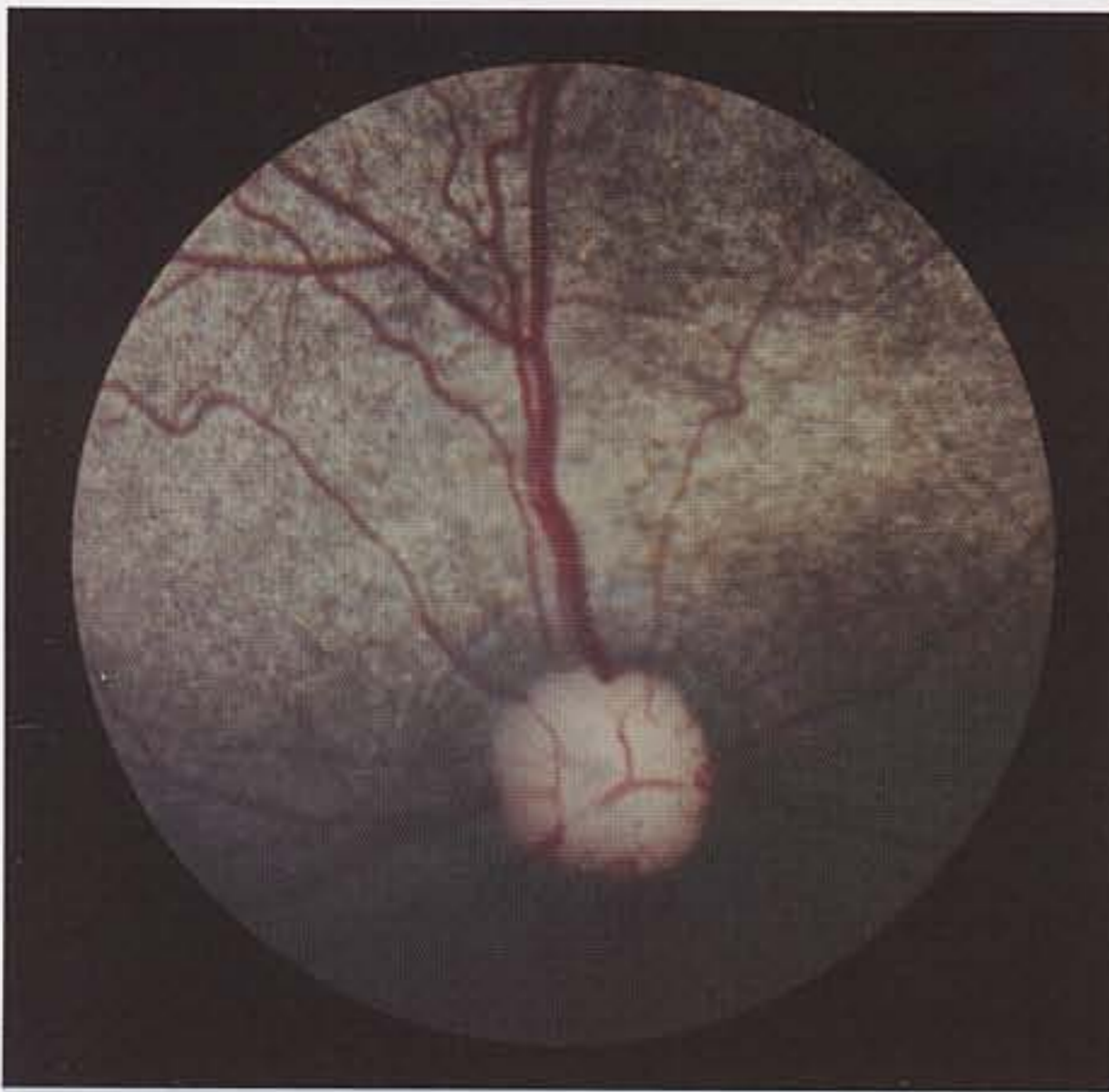


Fig. 11.9 The tapetum (Shetland Sheepdog, 2 years old, merle) Similar to the previous figure, but with a poorly developed tapetum.

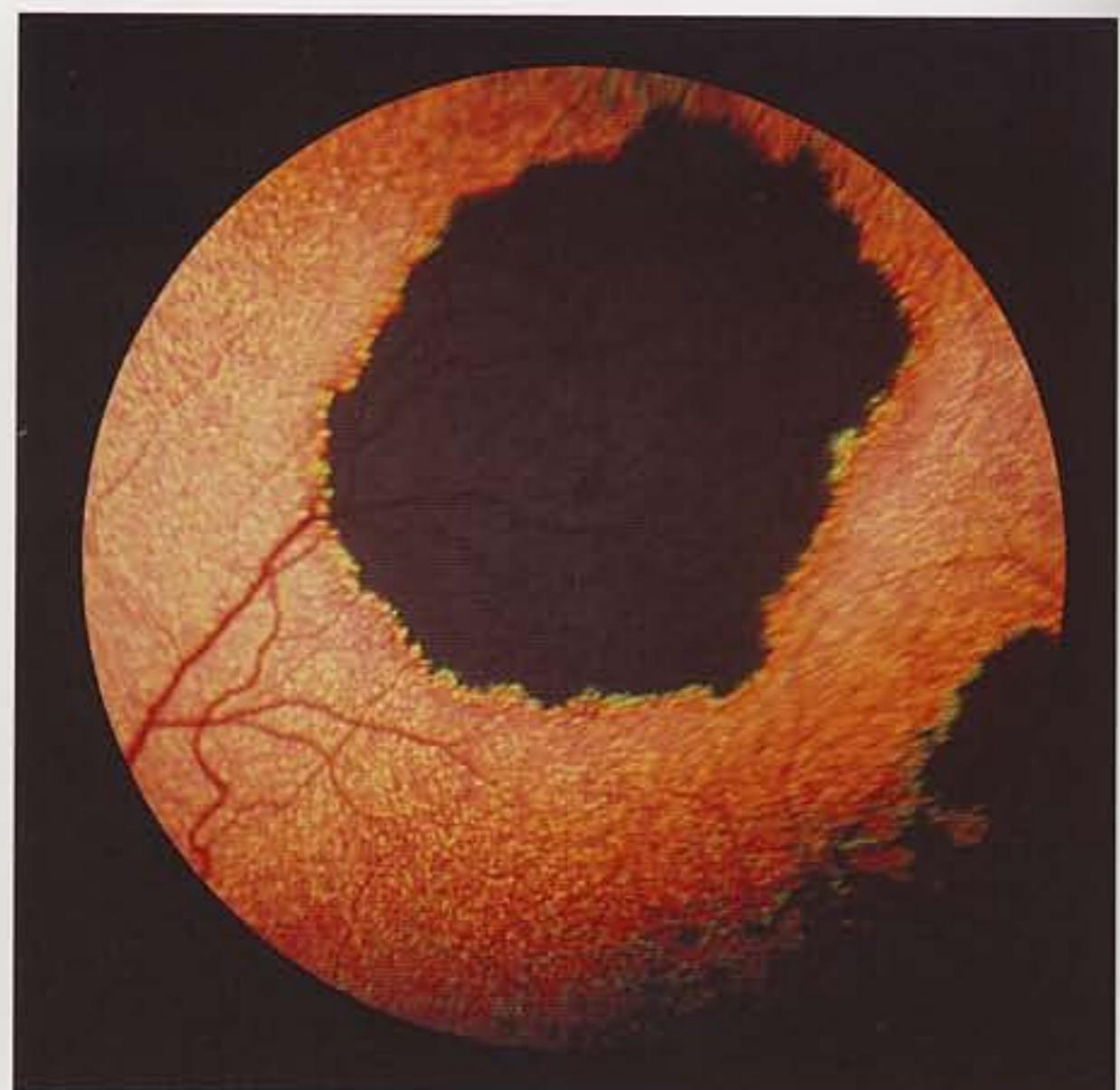

Fig. 11.11 The tapetum (Golden Retriever, 6 years old) Demarcated island of non-tapetal within the tapetal fundus area. Note the normal course of the retinal blood vessel. An unusual finding.

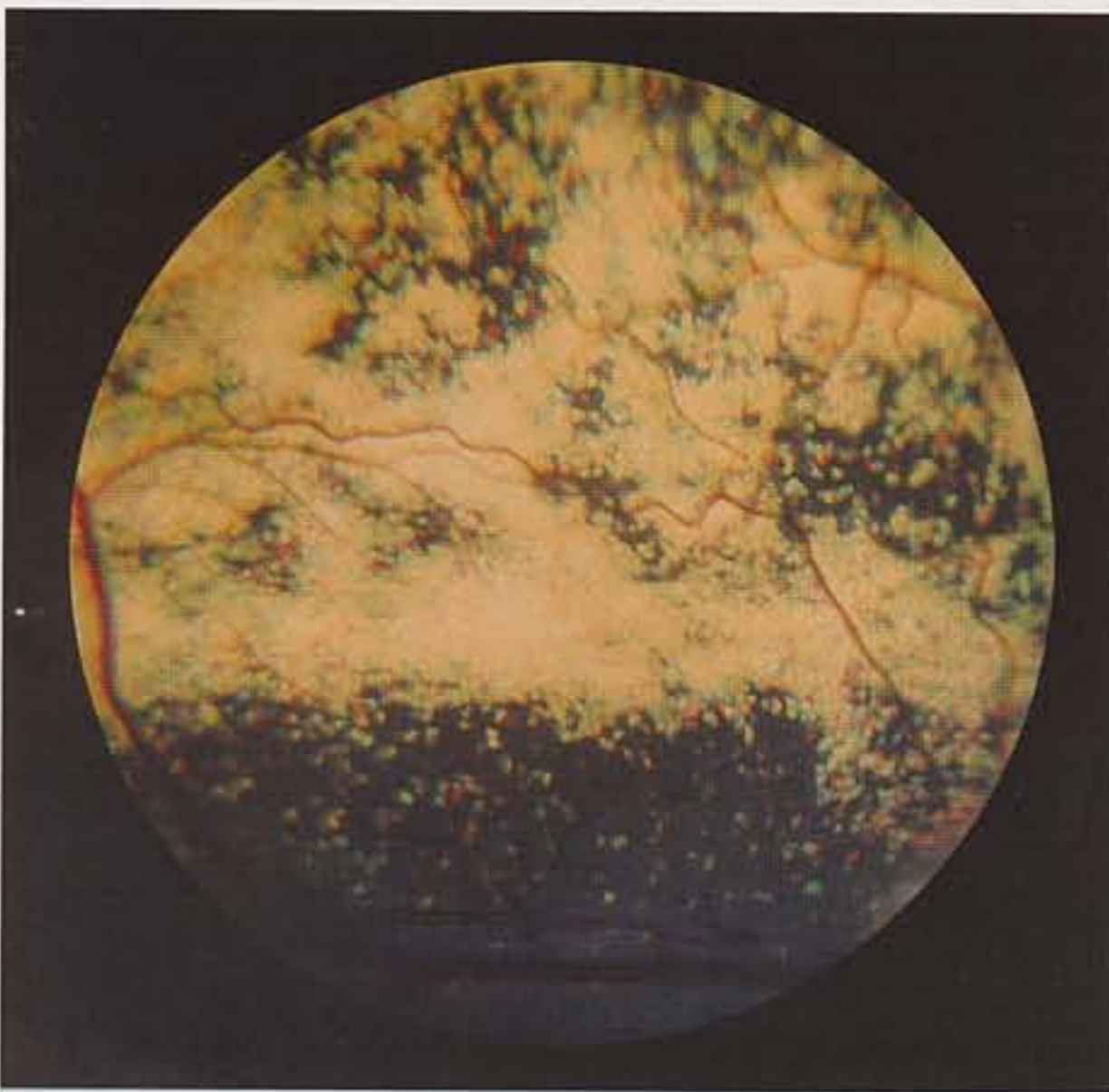


Fig. 11.10 The tapetum (Border Collie, 1 year old, tricolour) Break-up of tapetal fundus by patches of non-tapetal fundus.

### *The tapetal junction (Figs 11.12–11.13)*

The tapetal junction may appear as a gradual merging of tapetal into non-tapetal fundus (Fig 11.12) or as a

sudden change between the two areas (Fig 11.13). Remarkably, the former usually occurs in long-coated dogs and the latter in short-coated dogs, even in varieties of the same breed, e.g. the Border Collie or Dachshund, and in comparison between the Golden Retriever (long-coated) and Labrador Retriever (short-coated).

### *The non-tapetal fundus (Figs 11.14–11.19)*

The usual appearance is of a dark grey/brown homogeneous area (Fig 11.14), but the upper part of the non-tapetal fundus may be paler and more brown than the rest (Fig 11.15).

The non-tapetal fundus in dogs of a brown coat colour (or chocolate or liver) is less heavily pigmented and appears paler (Fig 11.16), sometimes with the tigroid choroidal vascular pattern visible (Fig 11.17).

An unusual red fundus, known as 'ruby eye' (Fig 11.18), and no tapetal development also occurs, as does the complete absence of any tapetal development (Fig 11.19), in dogs and not associated with any degree of subalbinism.

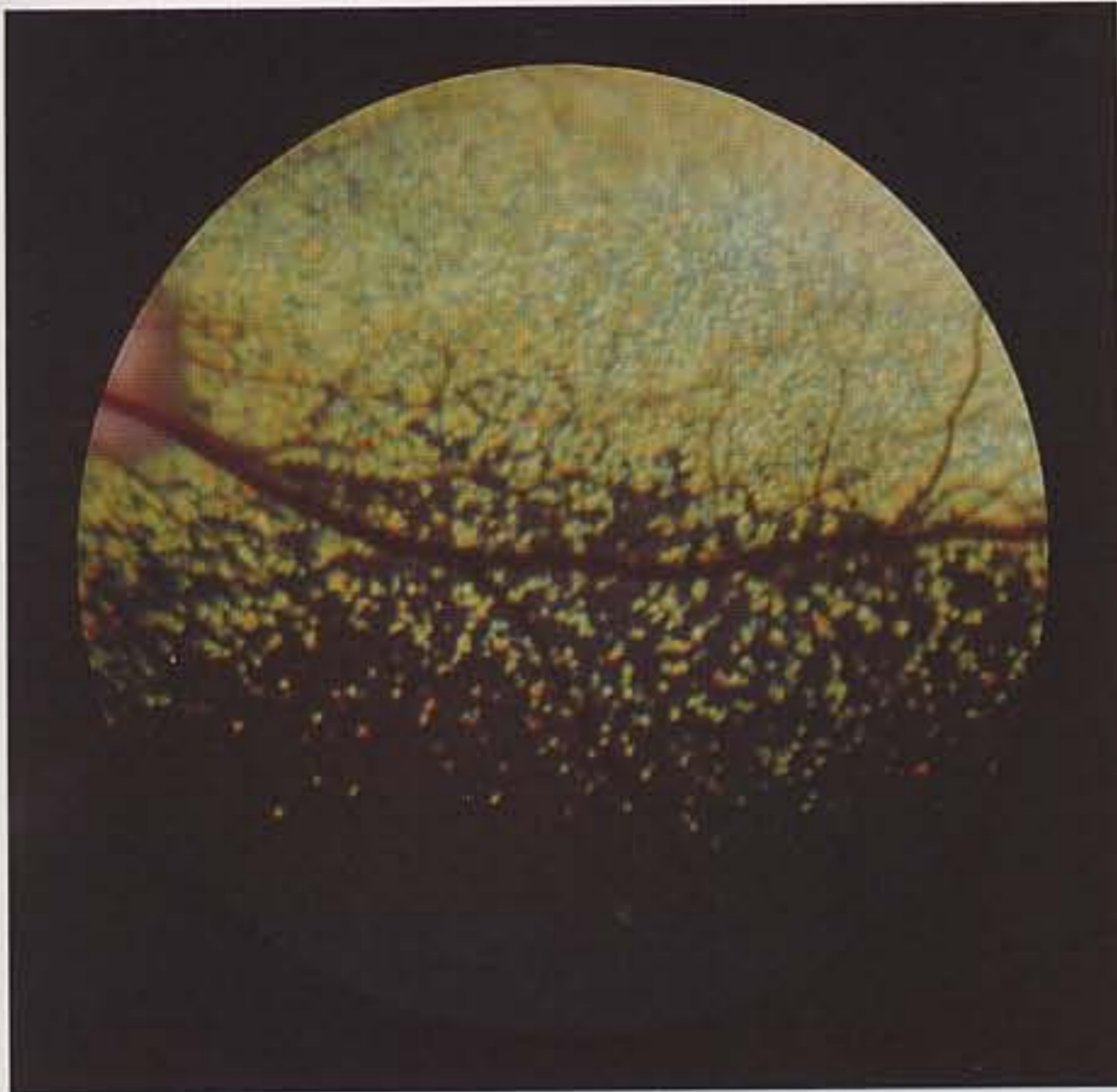


Fig. 11.12 The tapetal junction (Golden Retriever, 4 years old) Gradual merging of tapetal into non-tapetal fundus.

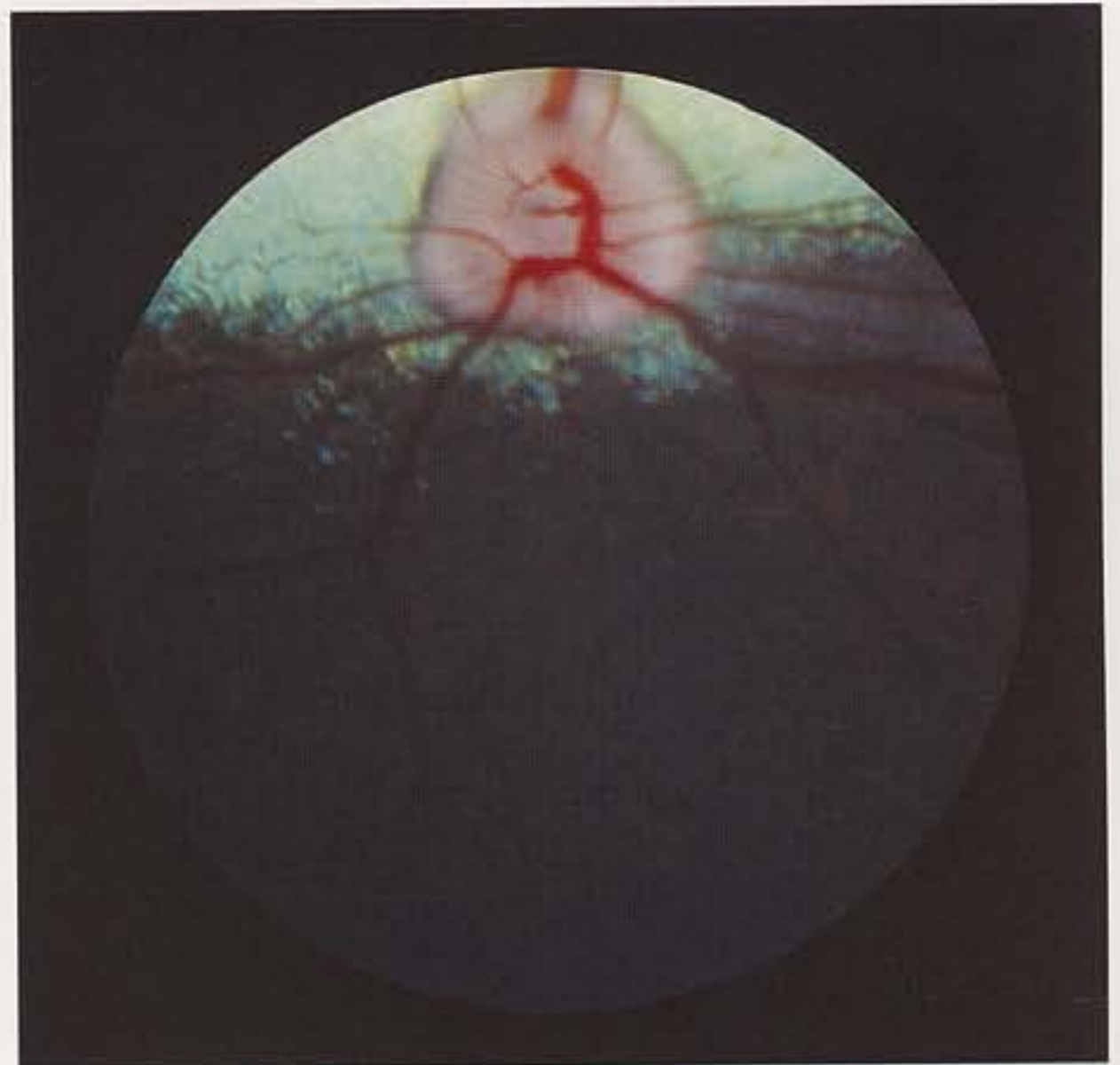


Fig. 11.14 The tapetum nigrum (Greyhound, 4 years old, fawn) The usual appearance with a dark grey-brown homogeneous region.

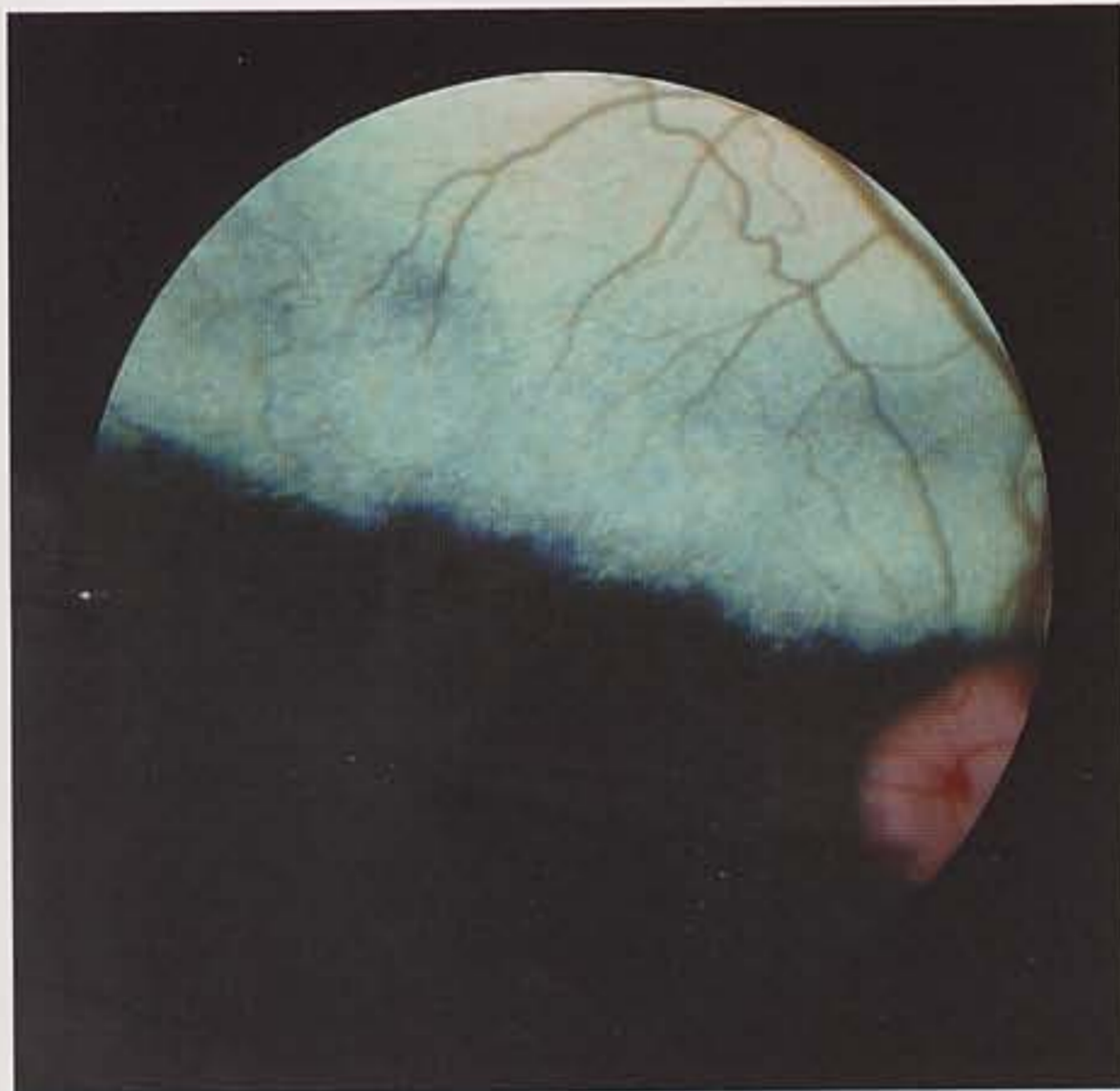

Fig. 11.13 The tapetal junction (Pembroke Corgi, 10 months old, red) Sudden demarcation between the tapetal and non-tapetal fundus. This picture is usually seen in short-coated dogs, whereas the previous figure occurs in the long-coated varieties.

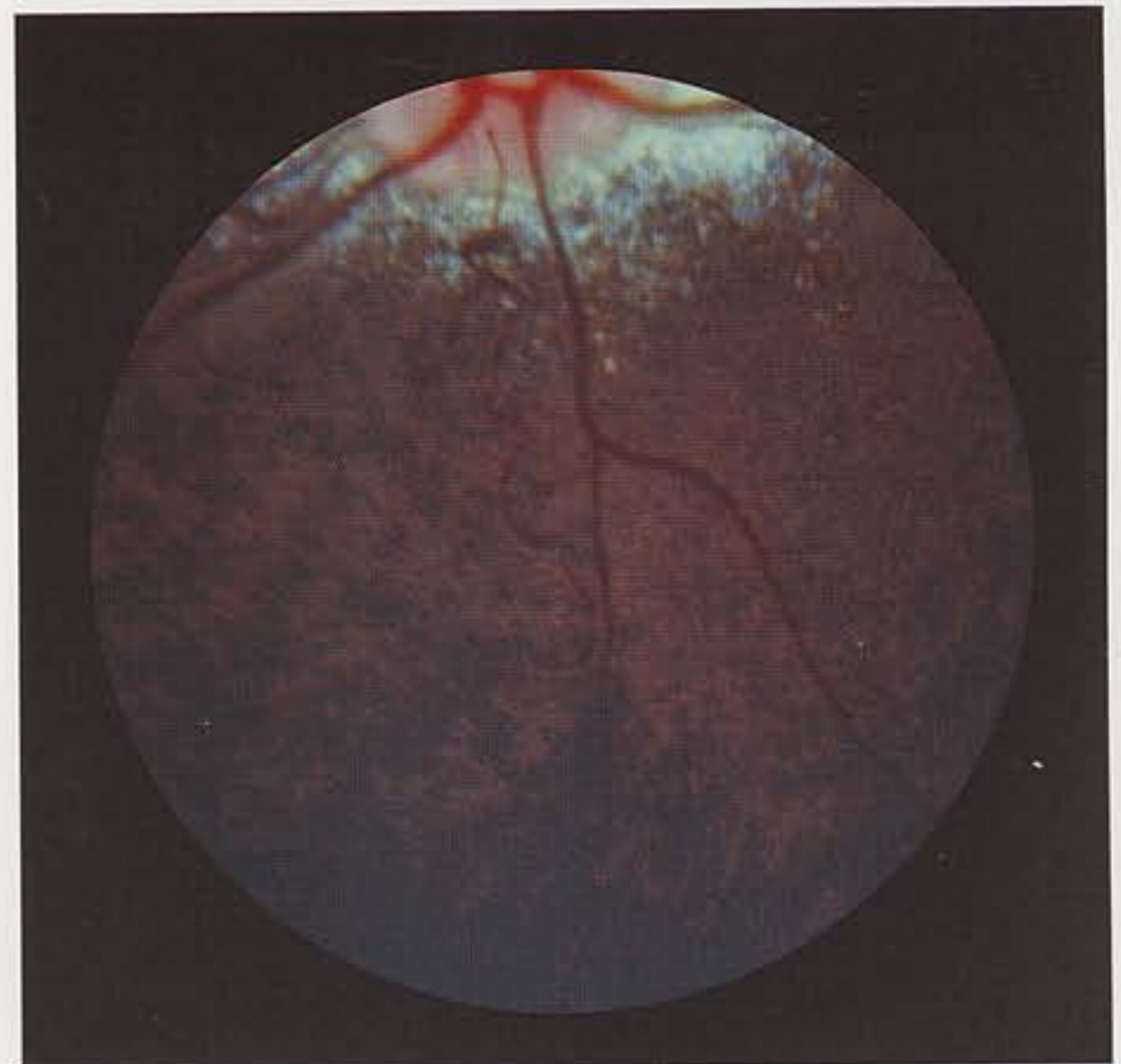

Fig. 11.15 The tapetum nigrum (Labrador Retriever, 4 years old, yellow) The upper non-tapetal fundus may be more brown and paler than below.

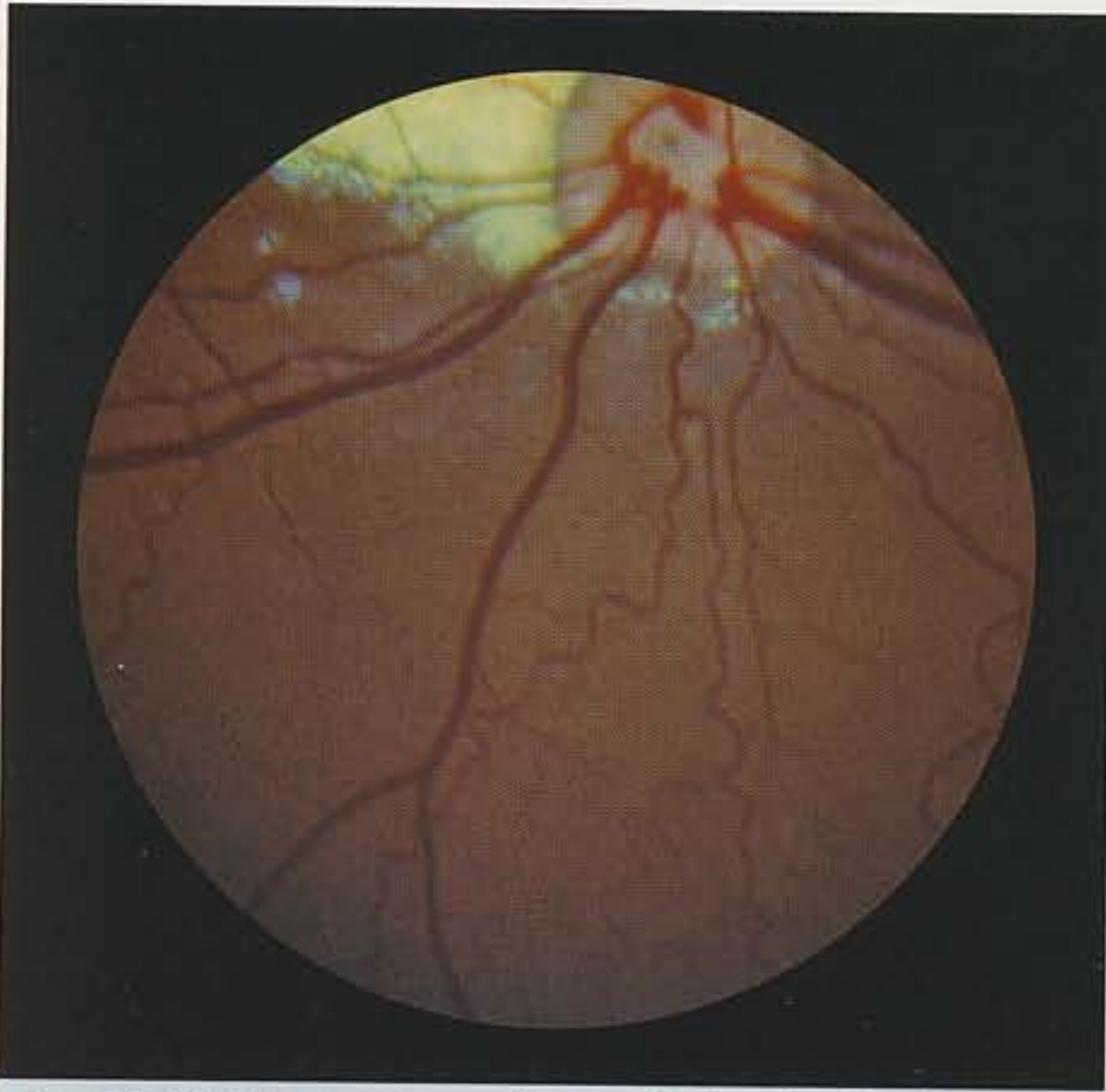

Fig. 11.16 The tapetum nigrum (Labrador Retriever, 1 year old, chocolate) The non-tapetal fundus in dogs of a brown, chocolate or liver coat colour is less heavily pigmented than dogs of other coat colours and appears paler, as does the iris.

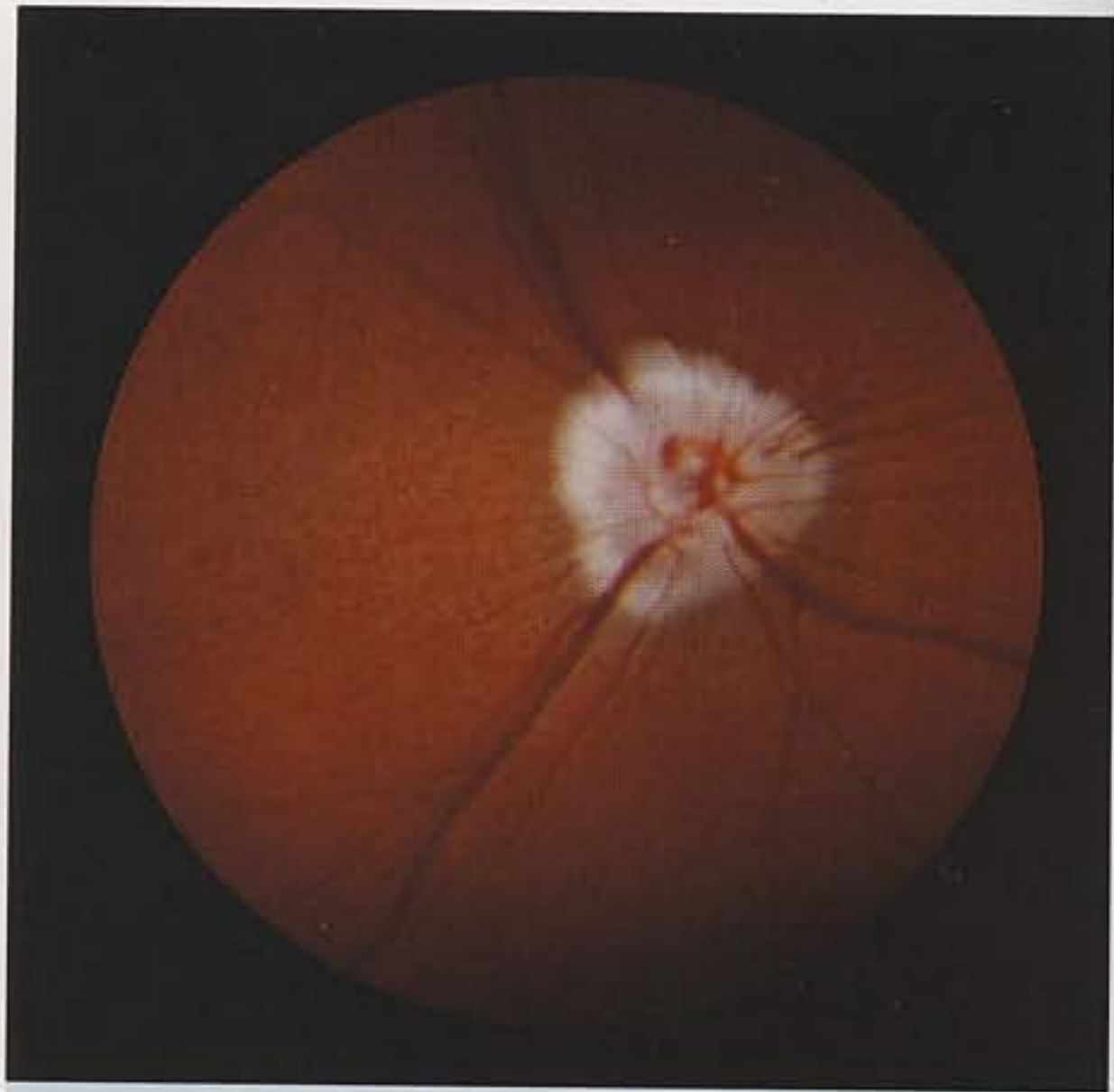

Fig. 11.18 Red fundus (Beagle, 9 months old, tricolour with pale lemon iris) Known as 'ruby eye' due to the red ocular reflex. Rare.

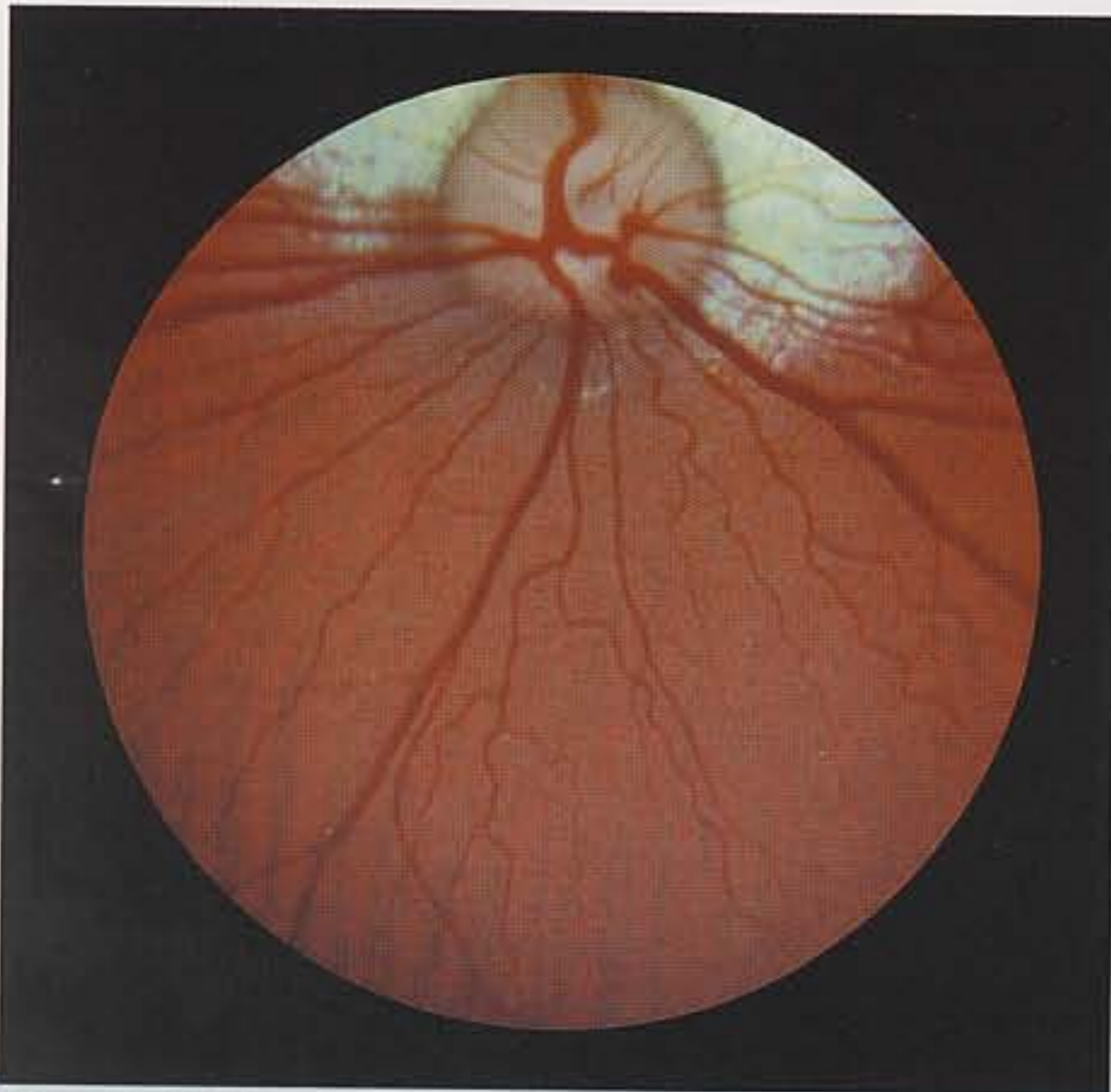


Fig. 11.17 The tapetum nigrum (Pointer, 3 years old, liver) More marked variation than the previous figure (Fig 11.6), with the choroidal vascular pattern producing a tigroid non-tapetal region.

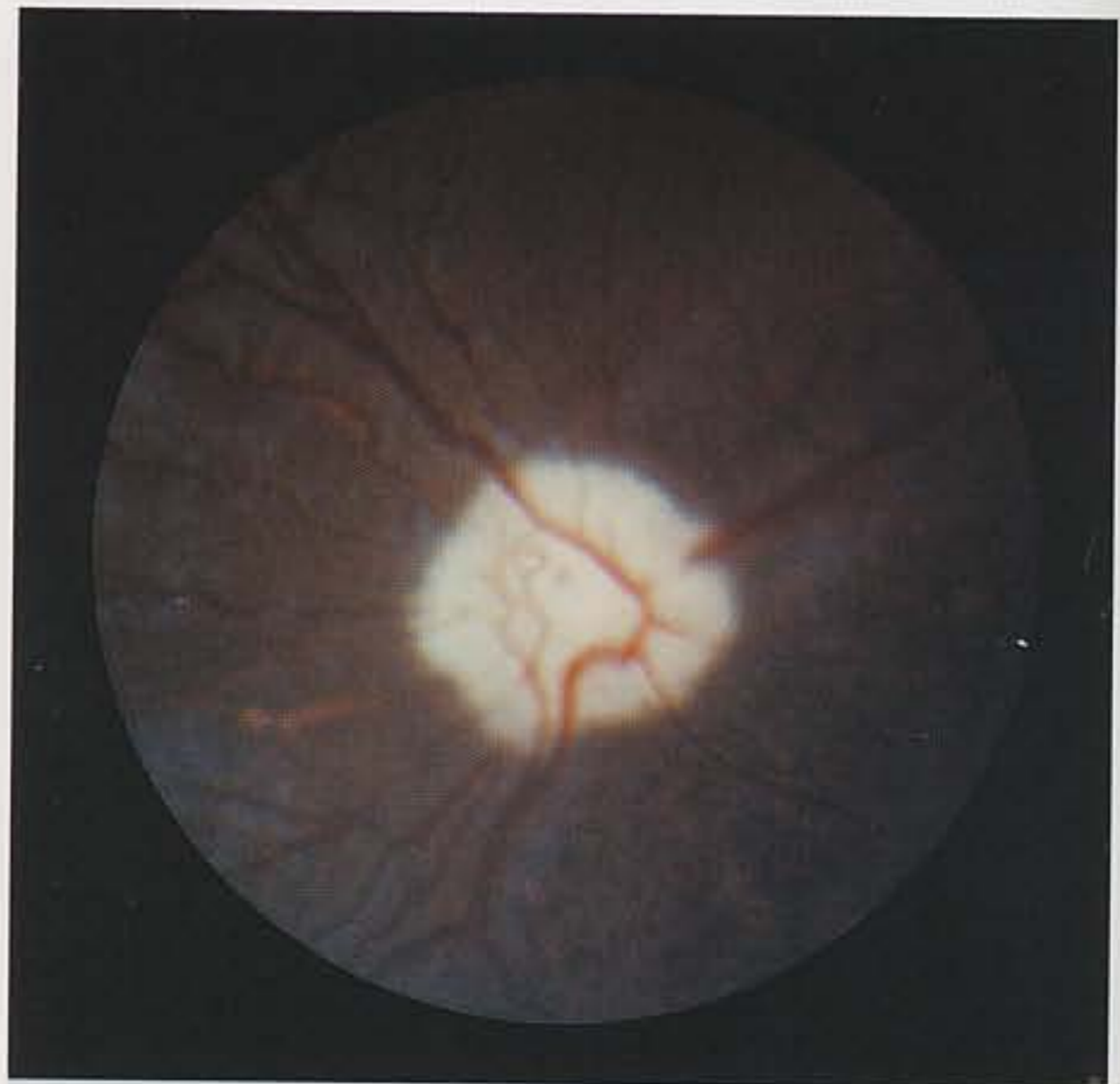


Fig. 11.19 Absence of tapetum (Boston Terrier, 8 years old, brindle) Absence of any tapetal development in a non-merle dog. Unusual.

*The subalbinotic fundus (Figs 11.20–11.25)*

Complete, or segments of, subalbinism of the fundus commonly occur in merle-coated dogs with pale blue or heterochromic irides. The degree of subalbinism

does not correspond to the amount of heterochromia of the iris and often the two eyes are dissimilar.

These subalbinotic areas may be confusing in the diagnosis of the chorioretinal dysplasia in cases of

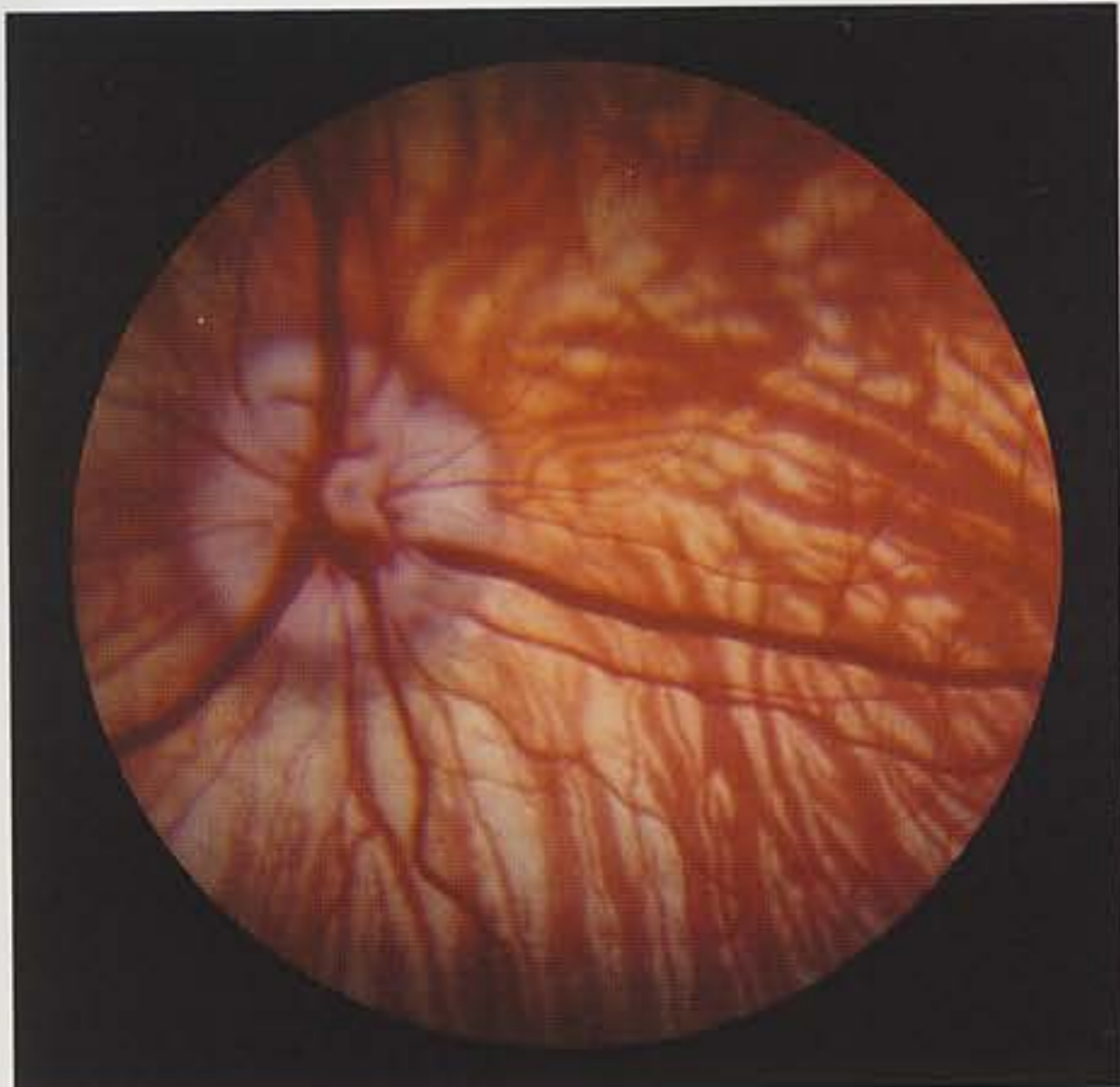


Fig. 11.20 Subalbinotic fundus (Shetland Sheepdog, 3 years old, merle with pale blue iris) Absence of tapetum and much of the choroidal pigment showing choroidal vessels superimposed on the scleral background. Common in dogs with this coat and iris colour.

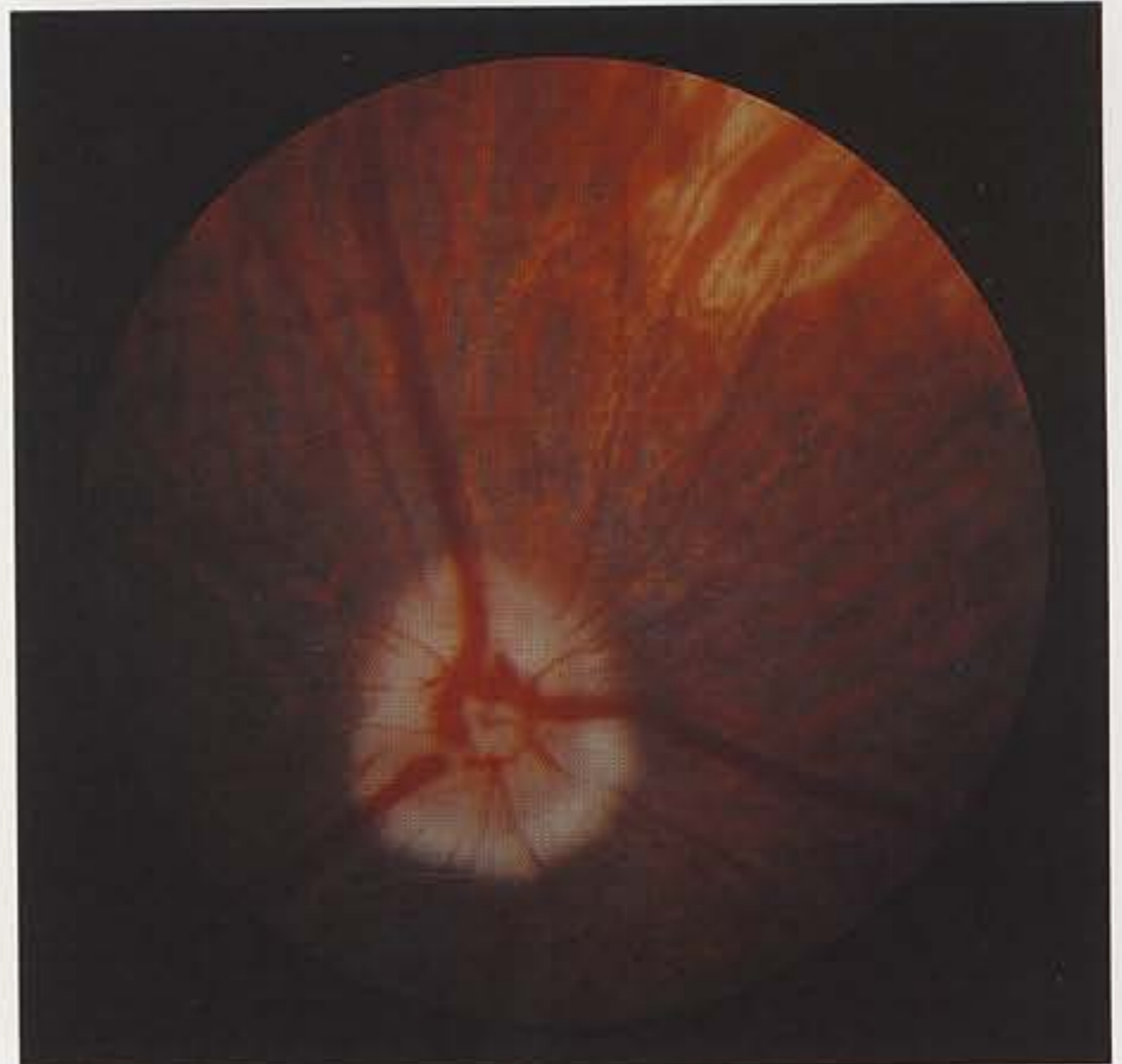


Fig. 11.22 Subalbinotic fundus (Shetland Sheepdog, 1 year old, merle) Note the absence of a tapetum and the segment of subalbinism at 2 o'clock.

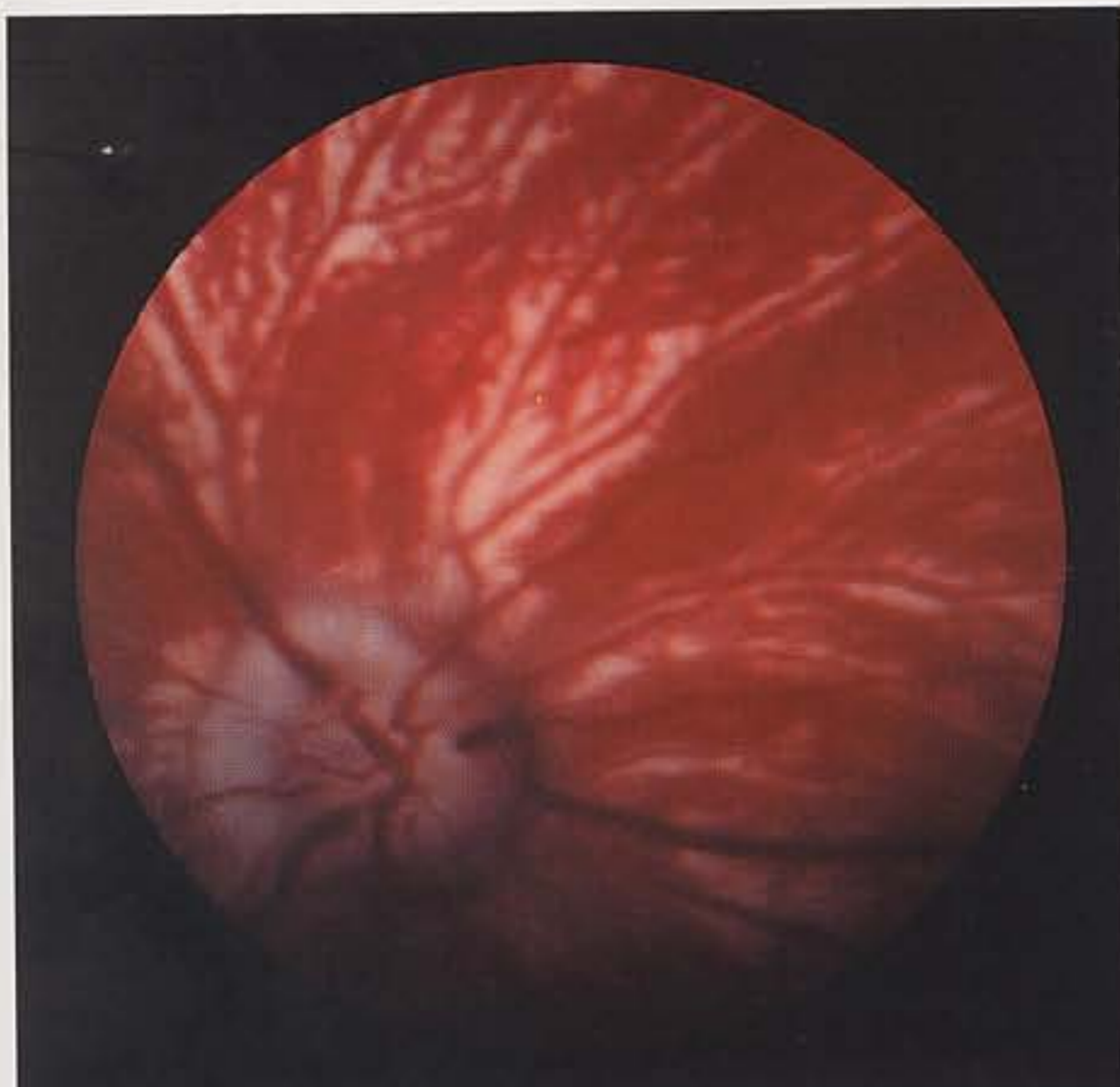

Fig. 11.21 Subalbinotic fundus (Shetland Sheepdog, 2 years old, merle) Similar to previous figure (Fig 11.20).

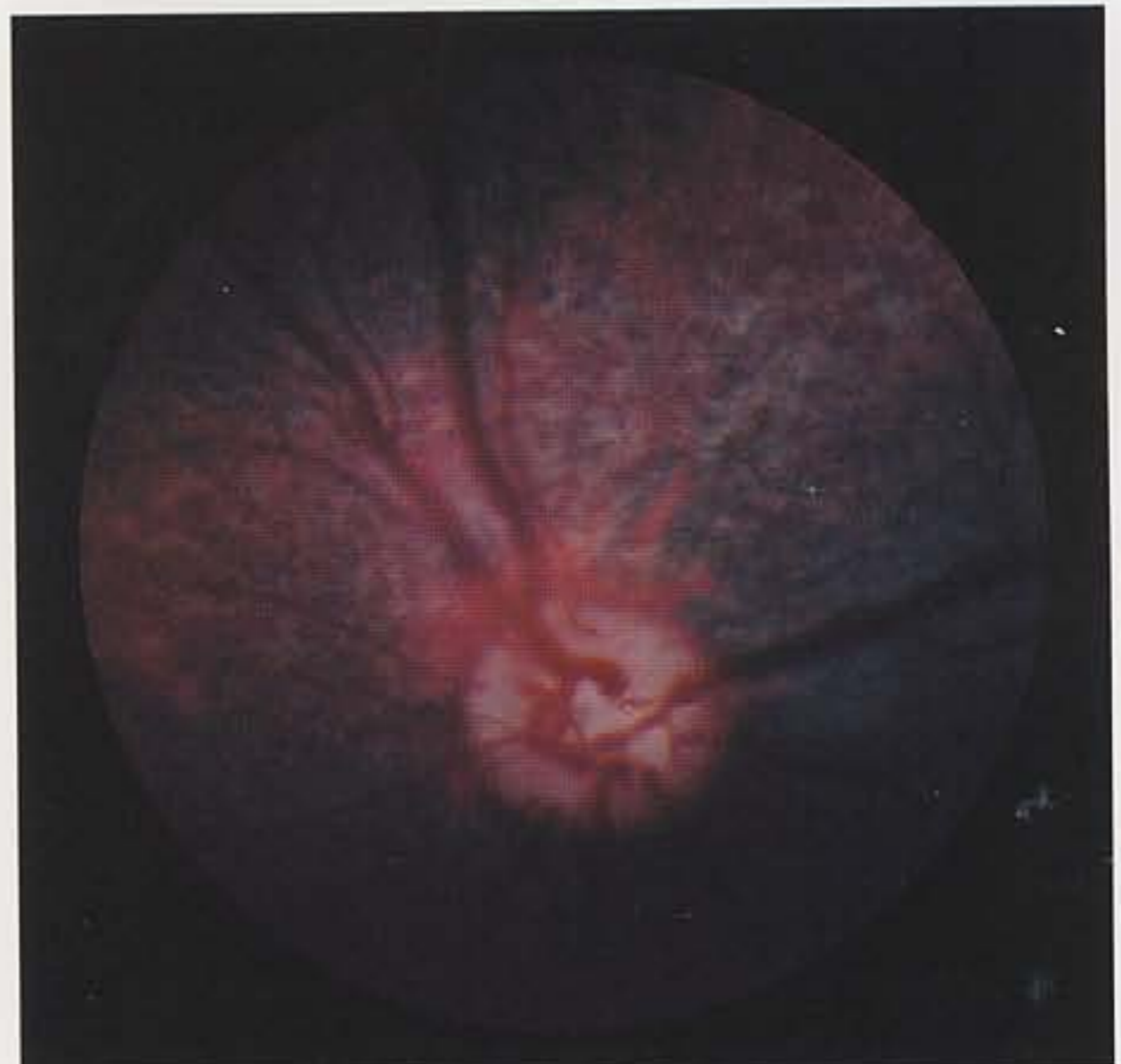

Fig. 11.23 Subalbinotic fundus (Shetland Sheepdog, 5 months old, merle) Subalbinism, mainly peripapillary and above the disc.

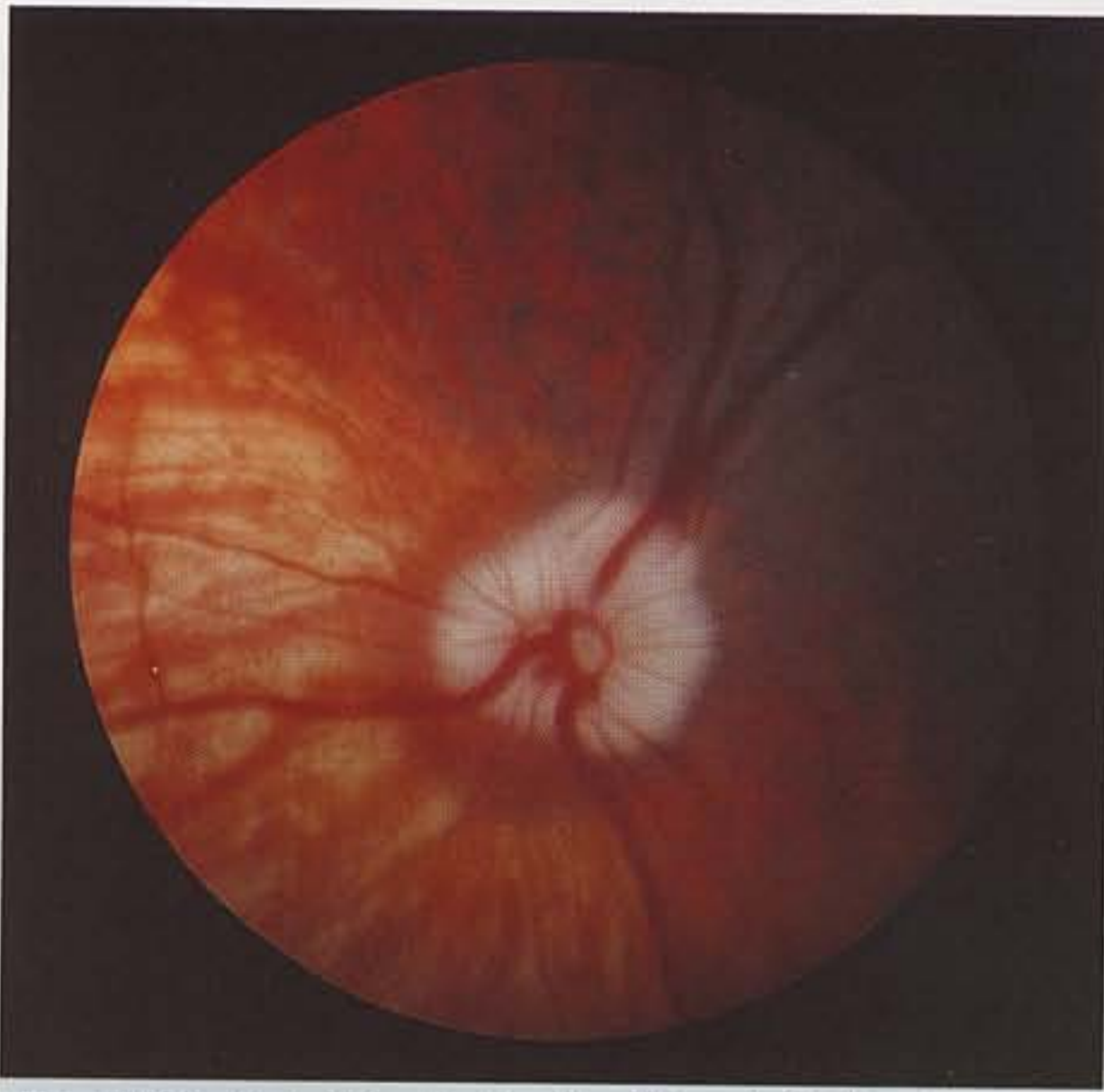


Fig. 11.24 Subalbinotic fundus (Rough Collie, 1 year old, merle) Subalbinism below the disc.

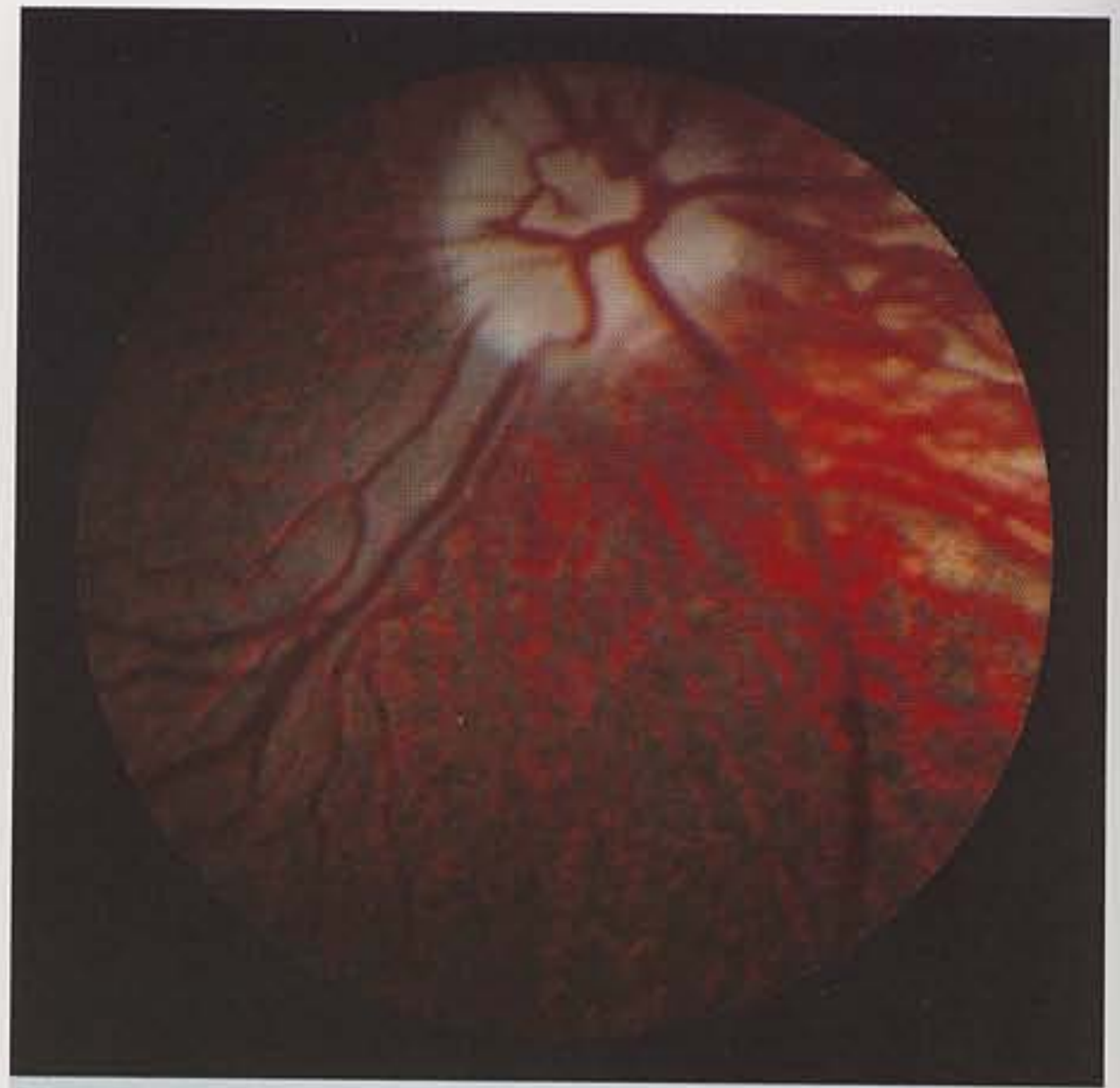


Fig. 11.25 Subalbinotic fundus (Shetland Sheepdog, 10 months old, merle) Similar to previous figures. Note the haphazard distribution of the areas of subalbinism in these examples and compare with pathological chorioretinal dysplasia in Collie eye anomaly in a subsequent section.

Collie eye anomaly (see later section). However, in the normal fundus they are haphazard in their position, whereas in Collie eye anomaly the dysplastic region is always lateral to the optic disc (again, see later section).

### *The optic disc (Figs 11.26–11.40)*

The optic disc in the dog exhibits great variation in its appearance. The position is usually just inside the tapetal fundus when viewed ophthalmoscopically but, depending upon the extent of the tapetal fundus, the disc may appear completely inside it or completely inside the non-tapetal fundus (Figs 11.26–11.28). The size and shape and colour of the disc are other variables and, to some extent, are dependent upon the degree of myelination of the optic nerve fibres which can extend considerable distances into the rest of the fundus. It should be remembered that myelination occurs postnatally and the sizes and shapes of the optic discs in Figures 11.26–11.40 should be compared with those in Figures 11.45–11.51, which show the development of the canine fundus. The normal physiological pit in the dog is a small grey spot which is sometimes

visible in the centre of the disc (Fig 11.37). Some discs have a pigmented ring around part or the whole of their border (Figs 11.38–11.39); others have a hyper-reflective ring (conus), an example of normal hyper-reflectivity (Fig 11.40). Changes in colour, usually pallor, occur with degeneration.

### *The retinal blood vessels (Figs 11.41–11.44)*

The canine retina is described as holangiomatic, with a direct and visible blood supply. There are usually 3–5 major veins which may form a venous circle, partially or completely visible on the surface of the disc. The retinal arterioles emerge towards the edge of the disc. Tortuosity is variable and may be quite marked in certain individuals. The tortuosity of the arterioles is usually greater than the veins. The area centralis (greatest cone density) is an area devoid of retinal vessels, but encircled by fine branches, situated lateral (temporal) and slightly dorsal to the optic disc (Fig 11.44).

Attenuation, or narrowing, of the retinal blood vessels, particularly the arterioles and later the veins, occurs secondary to retinal degeneration. It may be the most obvious ophthalmoscopic change but it is



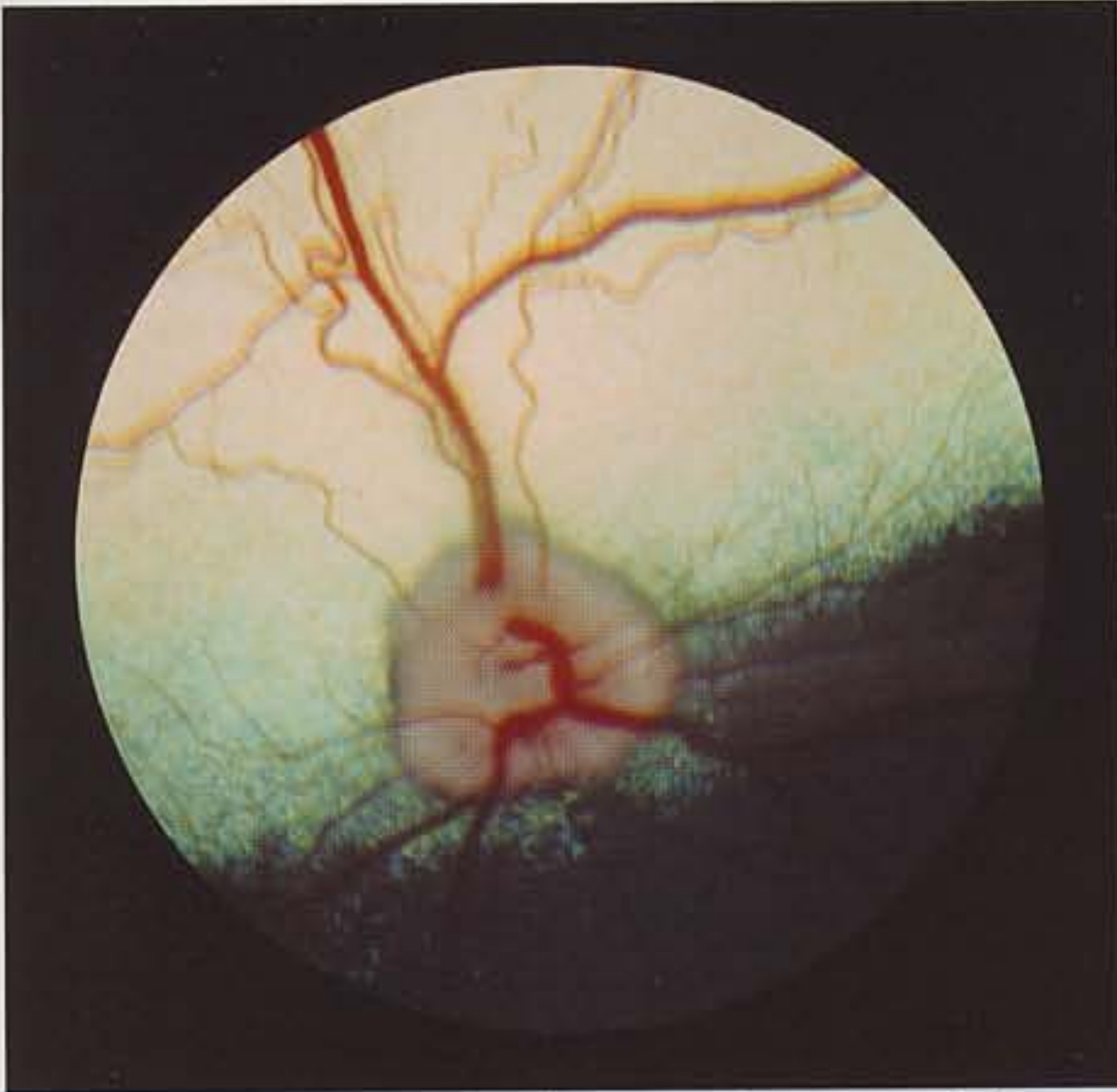

Fig. 11.26 The optic disc (Greyhound, young adult, fawn) The usual position of the disc is just inside the tapetal fundus.

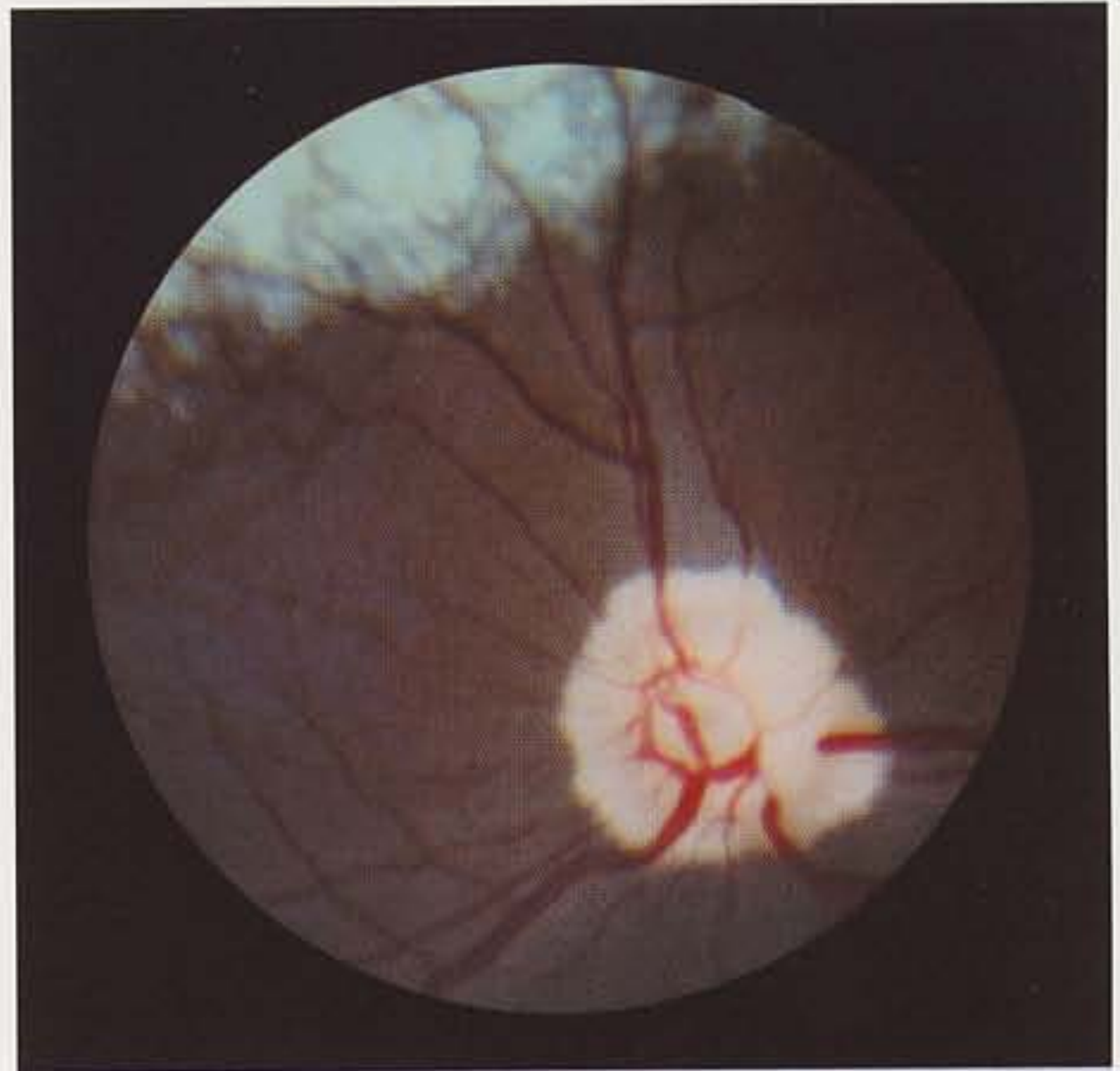


Fig. 11.28 The optic disc (Crossbred, 6 years old, black and tan) Occasionally the disc appears inside the non-tapetal fundus. These disc positions simply reflect the extent of the tapetal fundus and not the position of the optic nerve as it enters the eye.

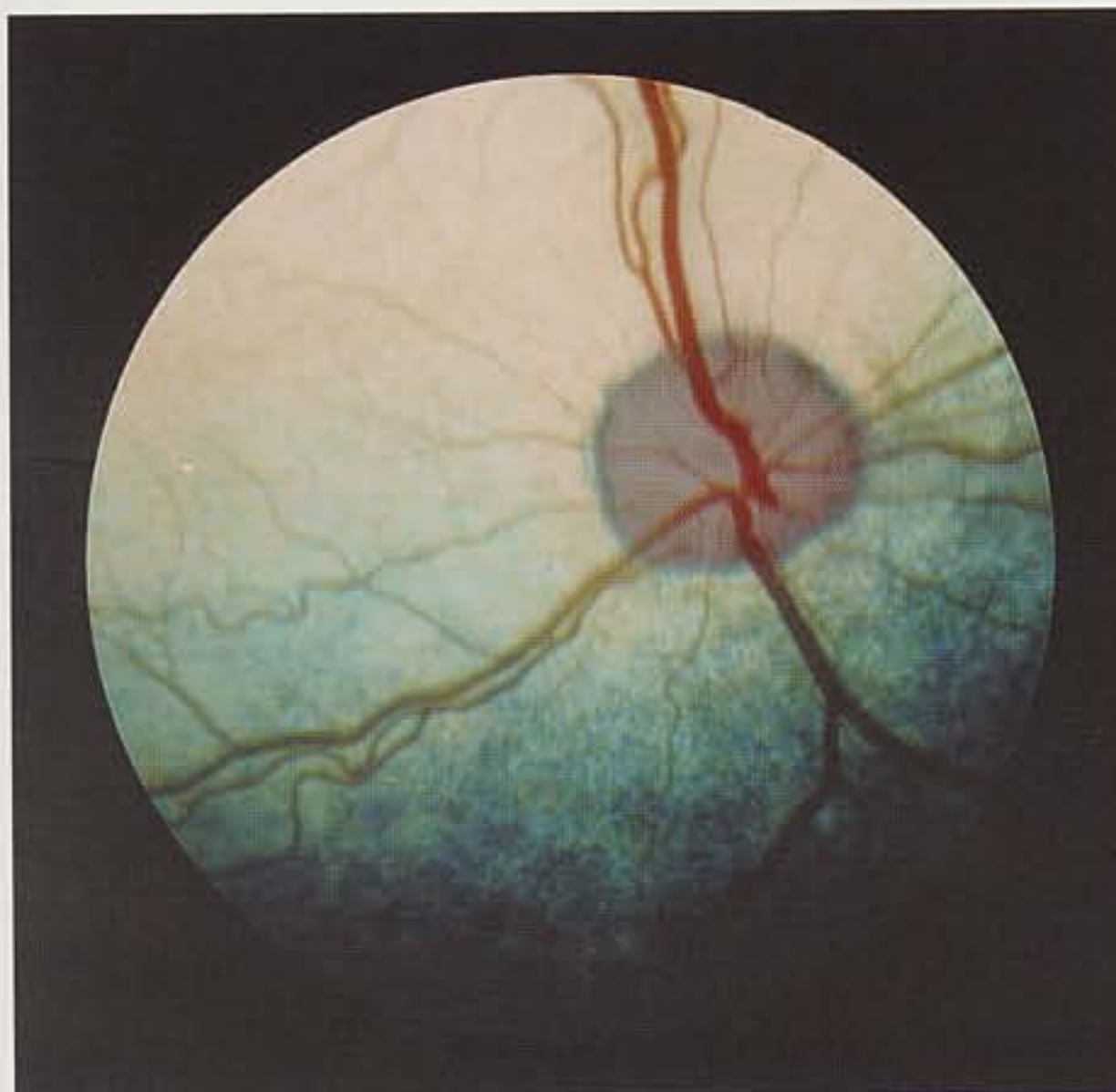


Fig. 11.27 The optic disc (Labrador Retriever, 7 months old, yellow) Occasionally the disc appears completely inside the tapetal fundus.

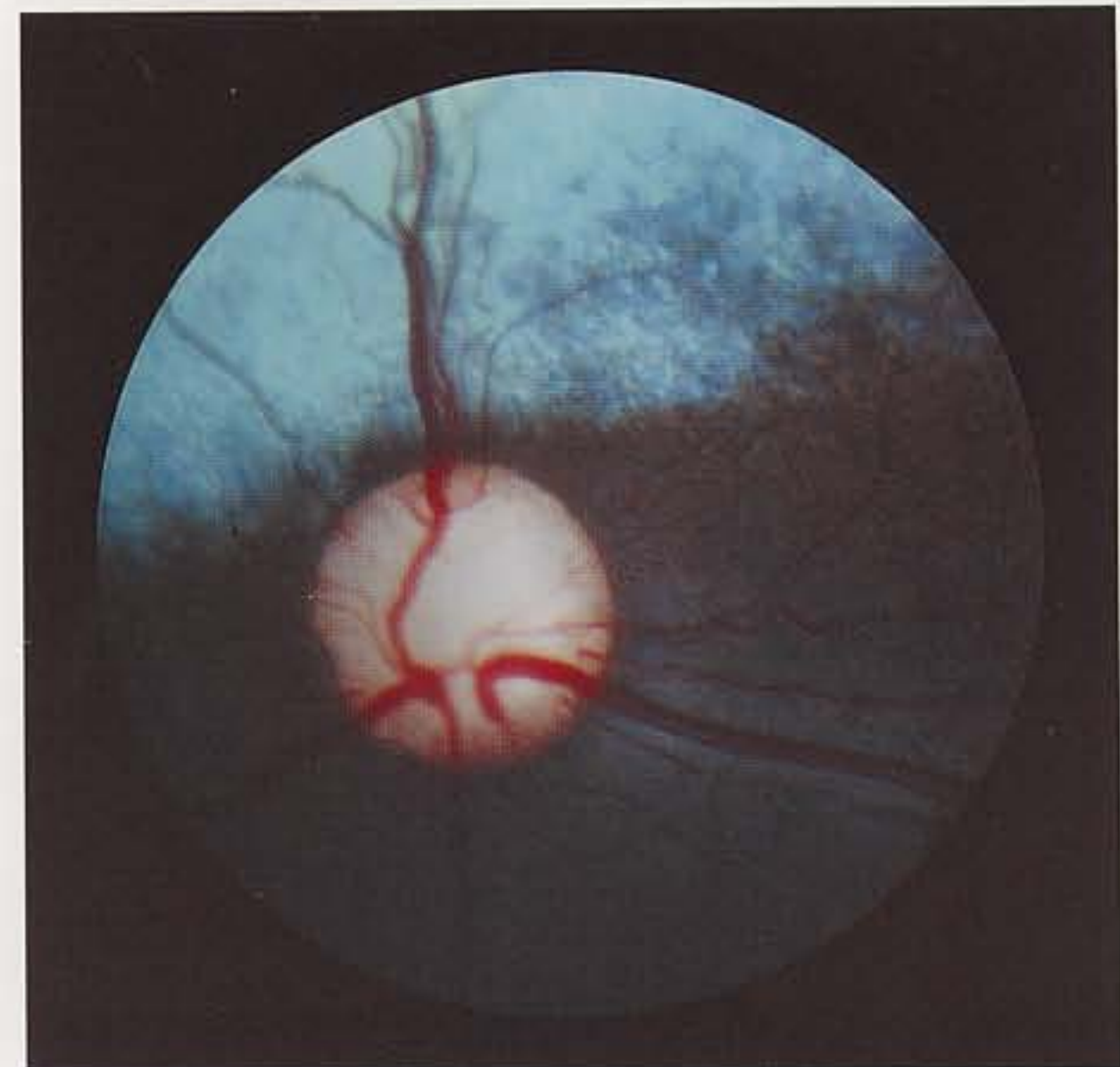

Fig. 11.29 The optic disc (Miniature Longhaired Dachshund, 10 months old, black and tan) The disc varies considerably in size from large (above) to small (see Fig 11.30).

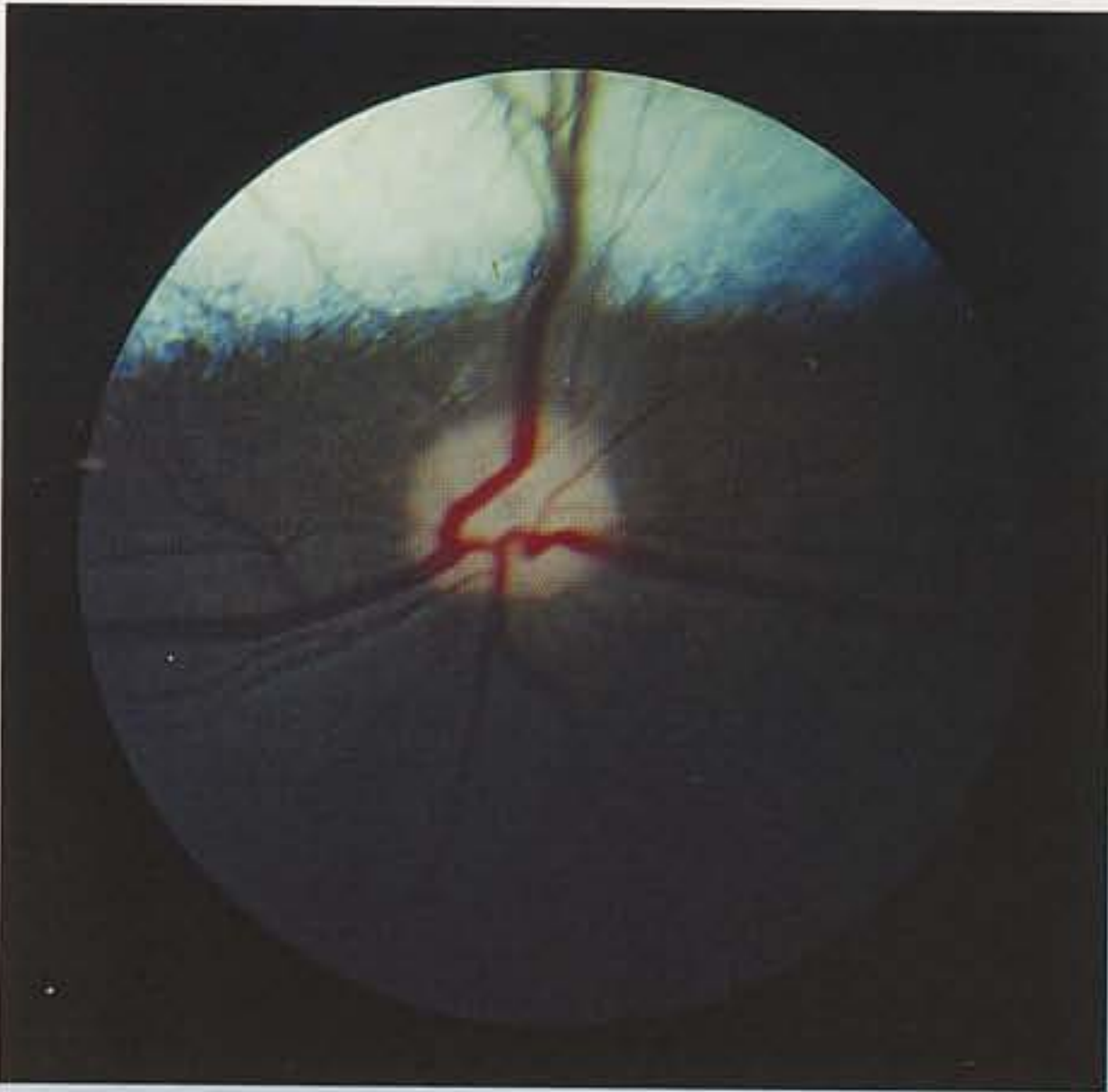


Fig. 11.30 The optic disc (Beagle, 10 months old, tricolour) Micropapilla – normal variant with normal vision and pupillary light reflex. Compare the above disc with pathological optic nerve hypoplasia (Figs 12.11–12.12).

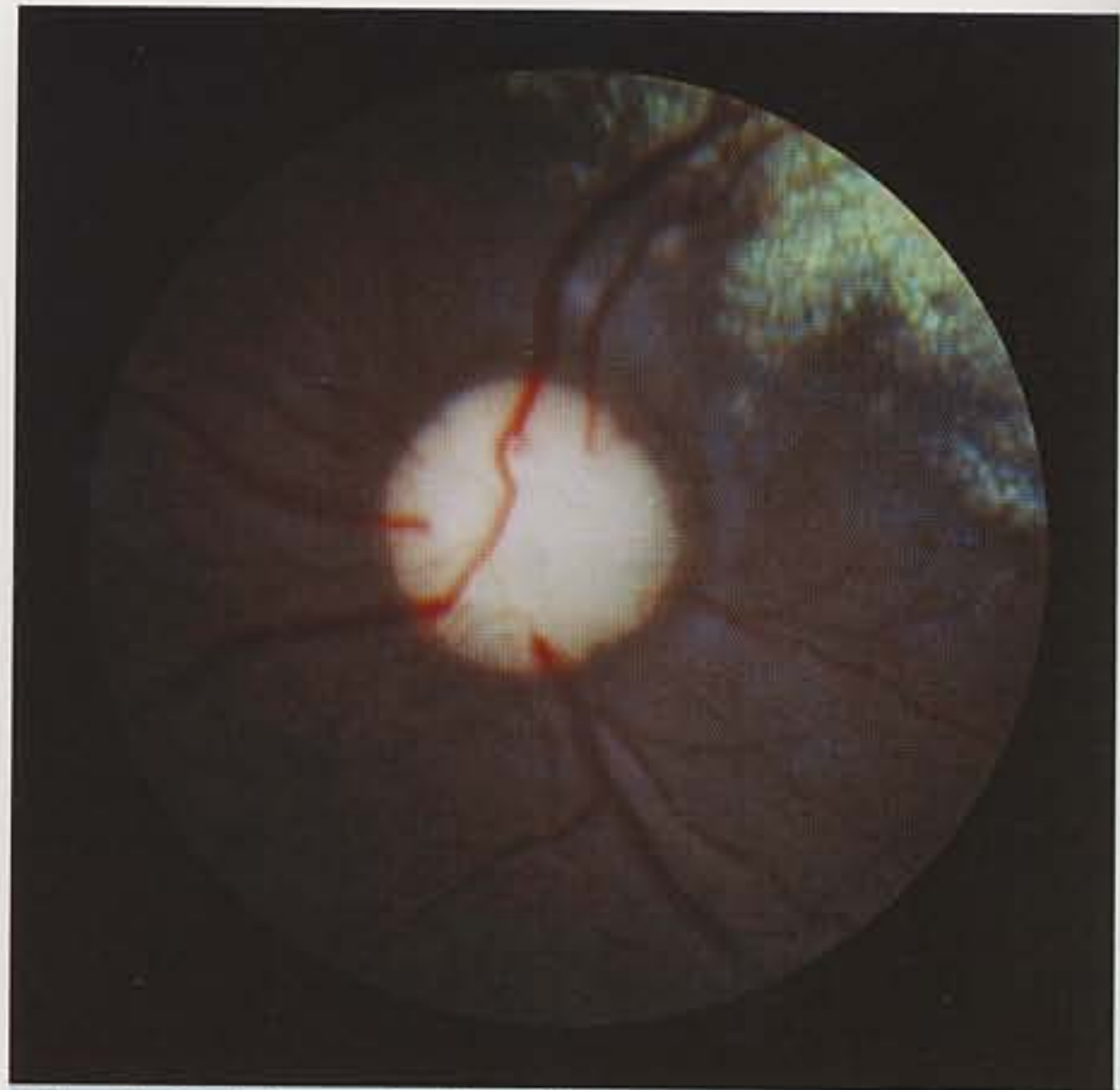


Fig. 11.32 The optic disc (Chihuahua, 4 years old, black and tan) Pale disc but normal retinal blood vessels. Compare with optic atrophy (Figs 12.6–12.7).

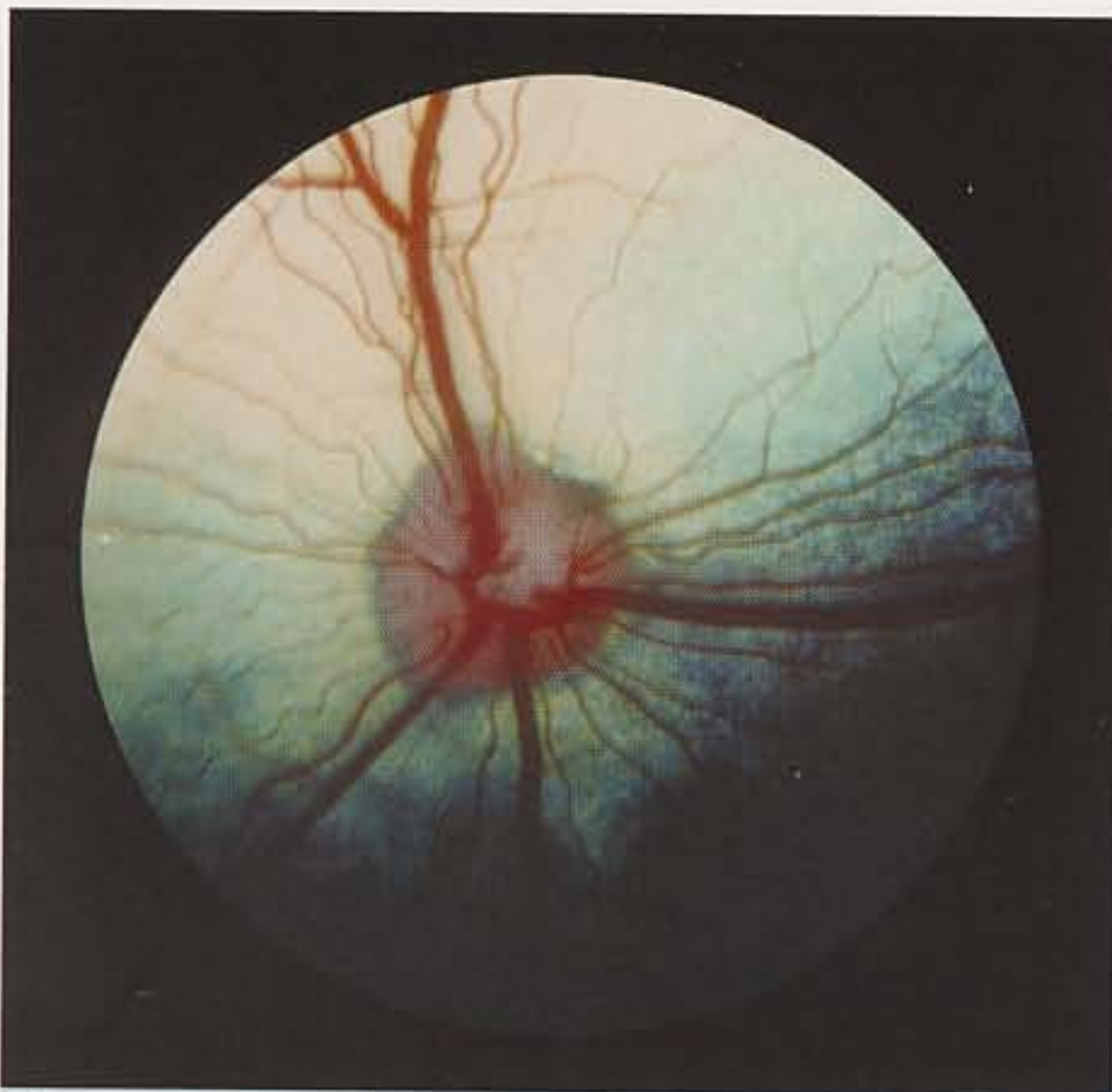

Fig. 11.31 The optic disc (German Shepherd Dog, 1 year old) Variations in colour range from deep pink (above) to white (see Fig 11.32).

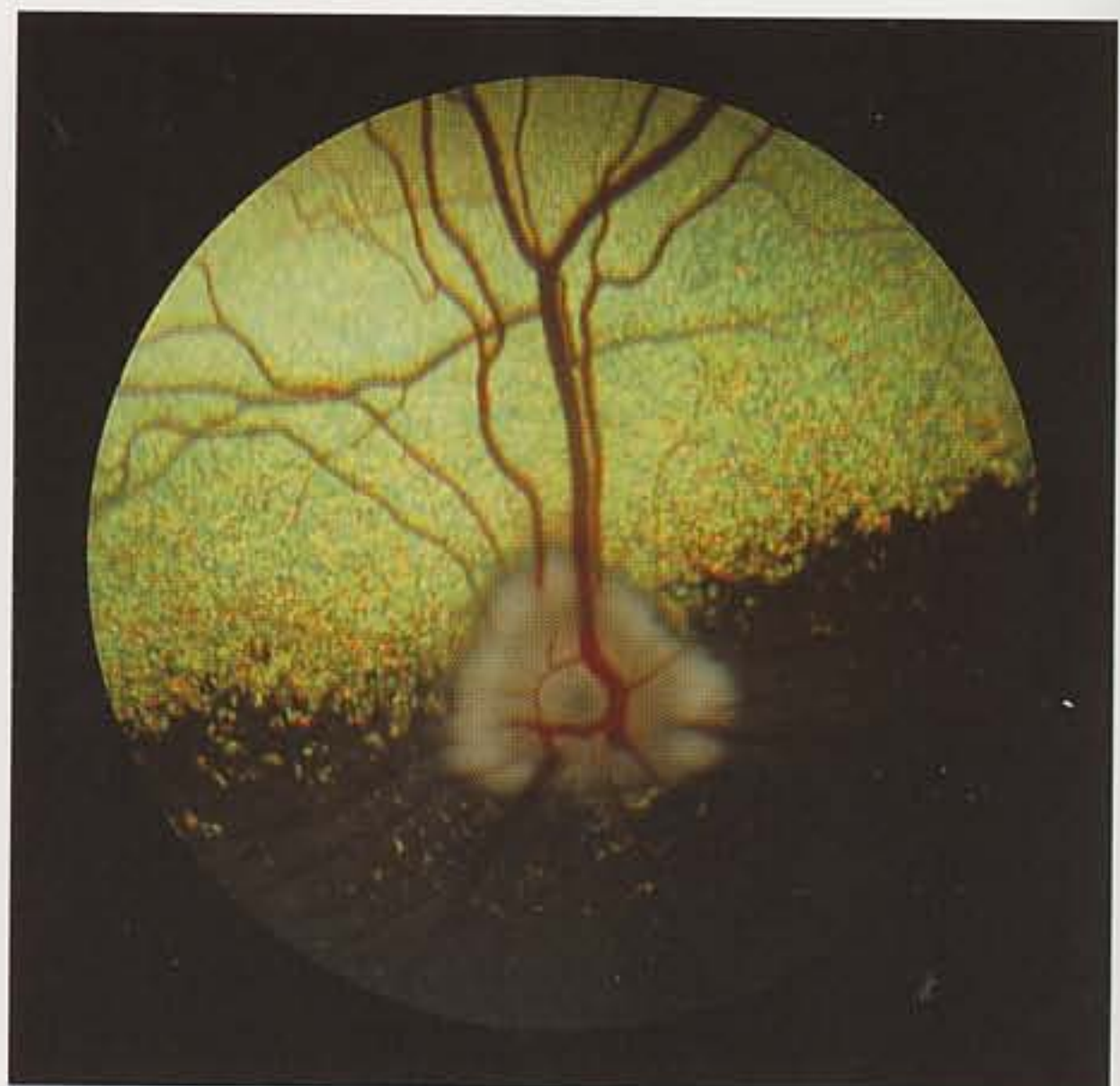

Fig. 11.33 The optic disc (Briard, 5 years old, black) Physiological pit – small grey spot in the centre of the disc.

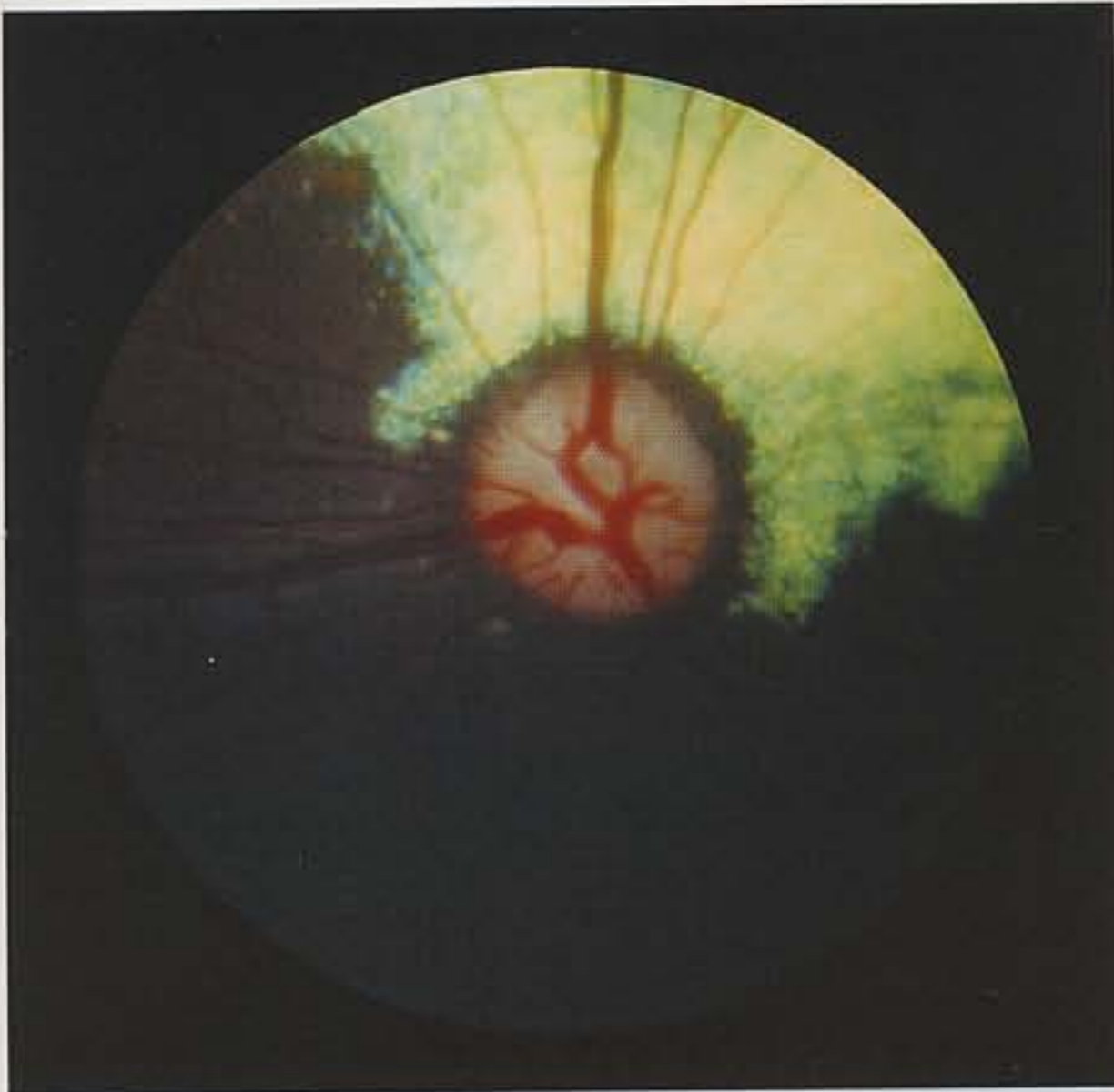


Fig. 11.34 The optic disc (Yorkshire Terrier, 1 year old, black and tan) Partial pigmented ring to the disc.

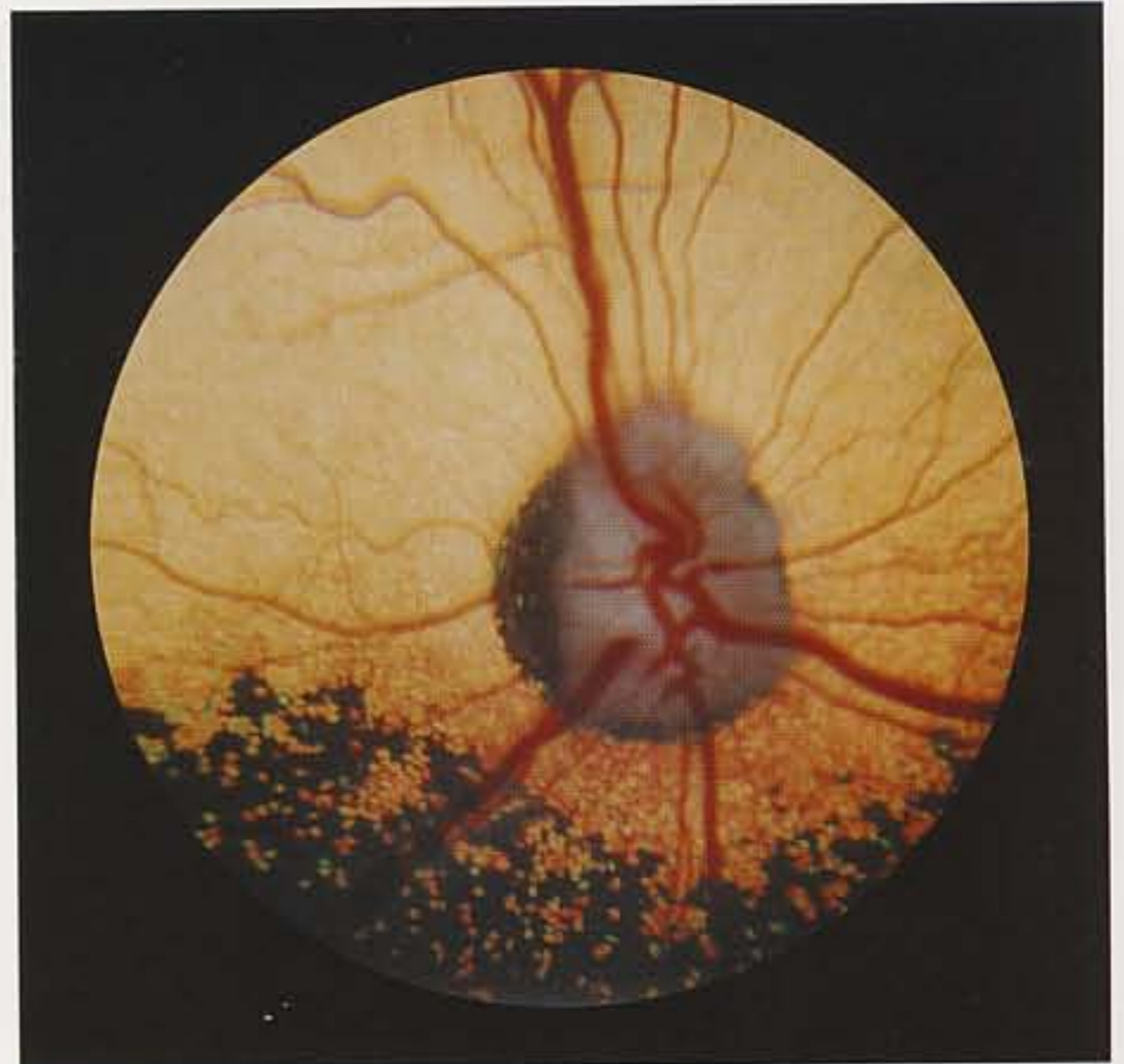


Fig. 11.36 The optic disc (Golden Retriever, 2 years old) Shape of the disc varies considerably in the dog. In this figure the disc is oval with a pigmented area on one side.

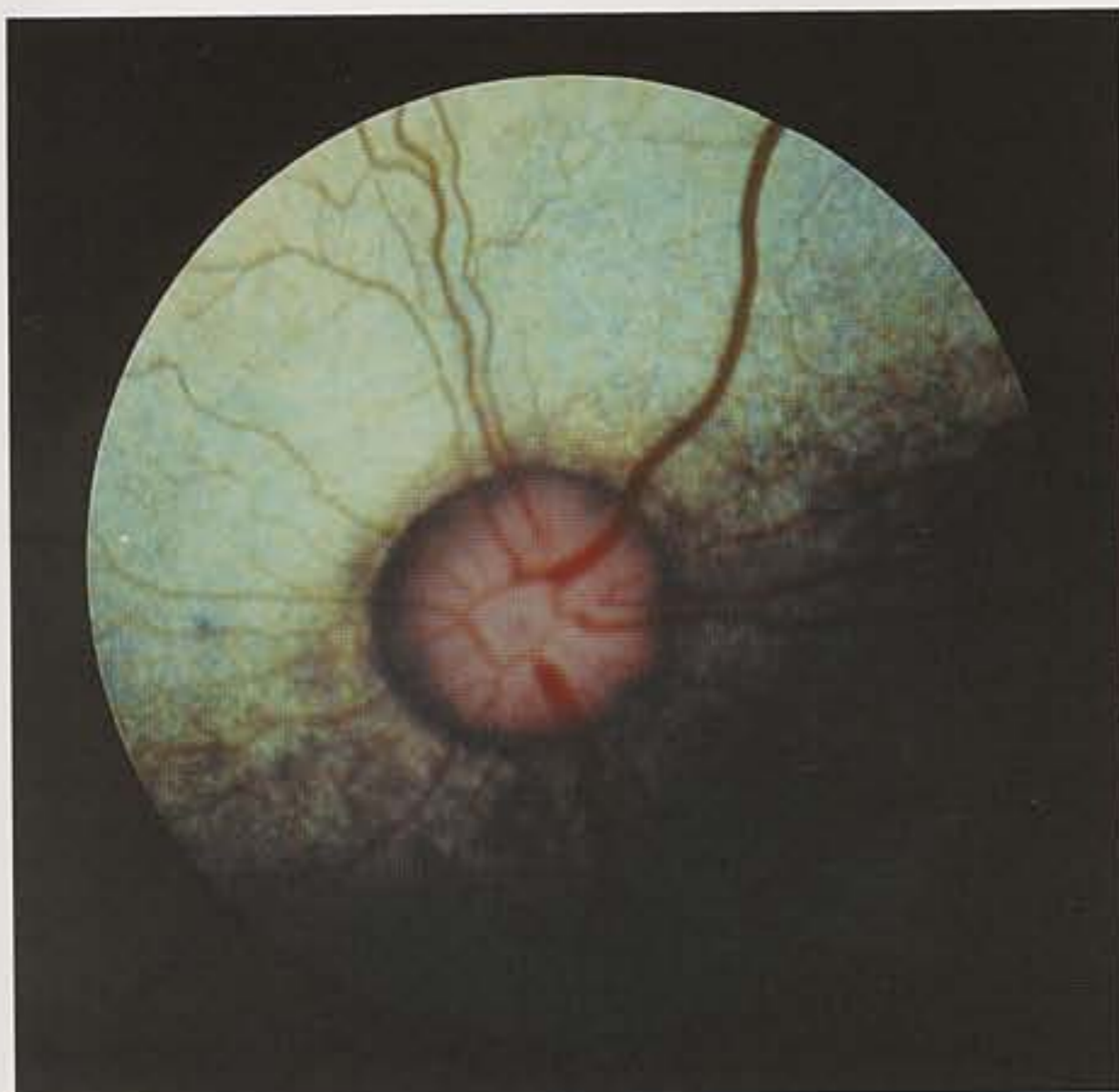

Fig. 11.35 The optic disc (Beagle, 6 months old, tricolour) Complete pigmented ring to the disc.

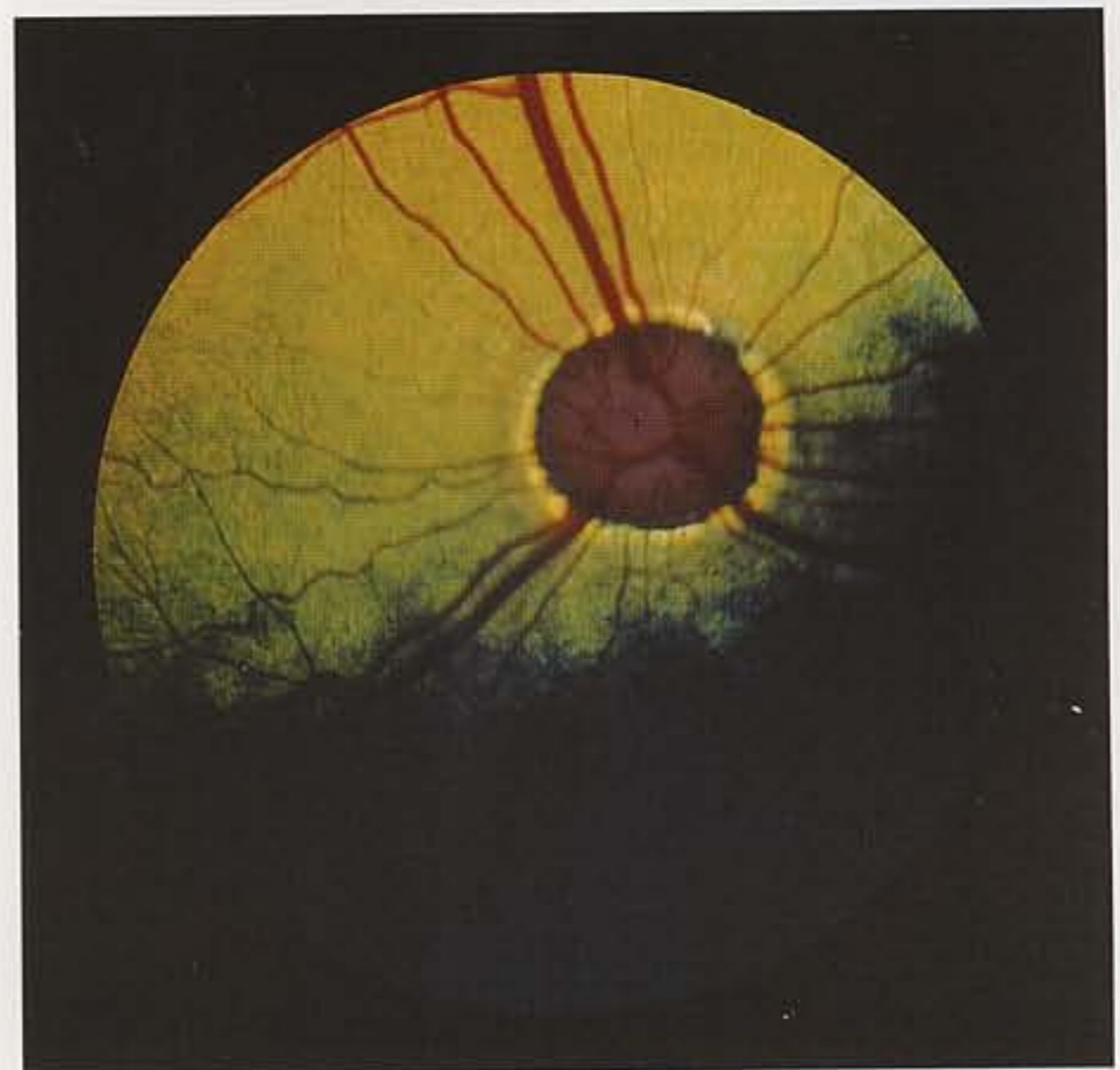


Fig. 11.37 The optic disc (Labrador Retriever, 1 year old, black) Hyper-reflectivity around the edge of the disc, known as conus.

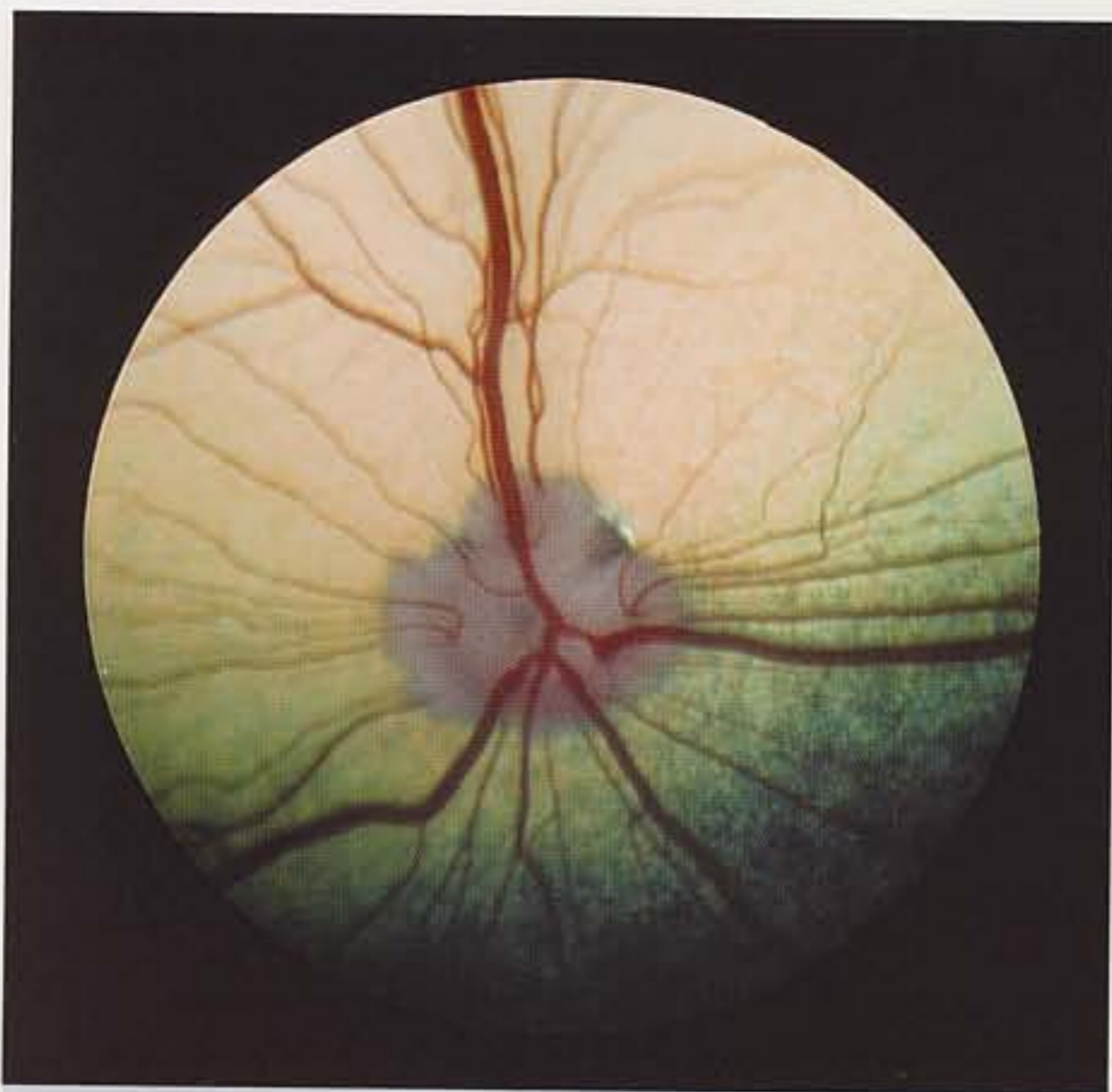


Fig. 11.38 The optic disc (German Shepherd Dog, 2 years old, black and tan) Shamrock-shaped disc.

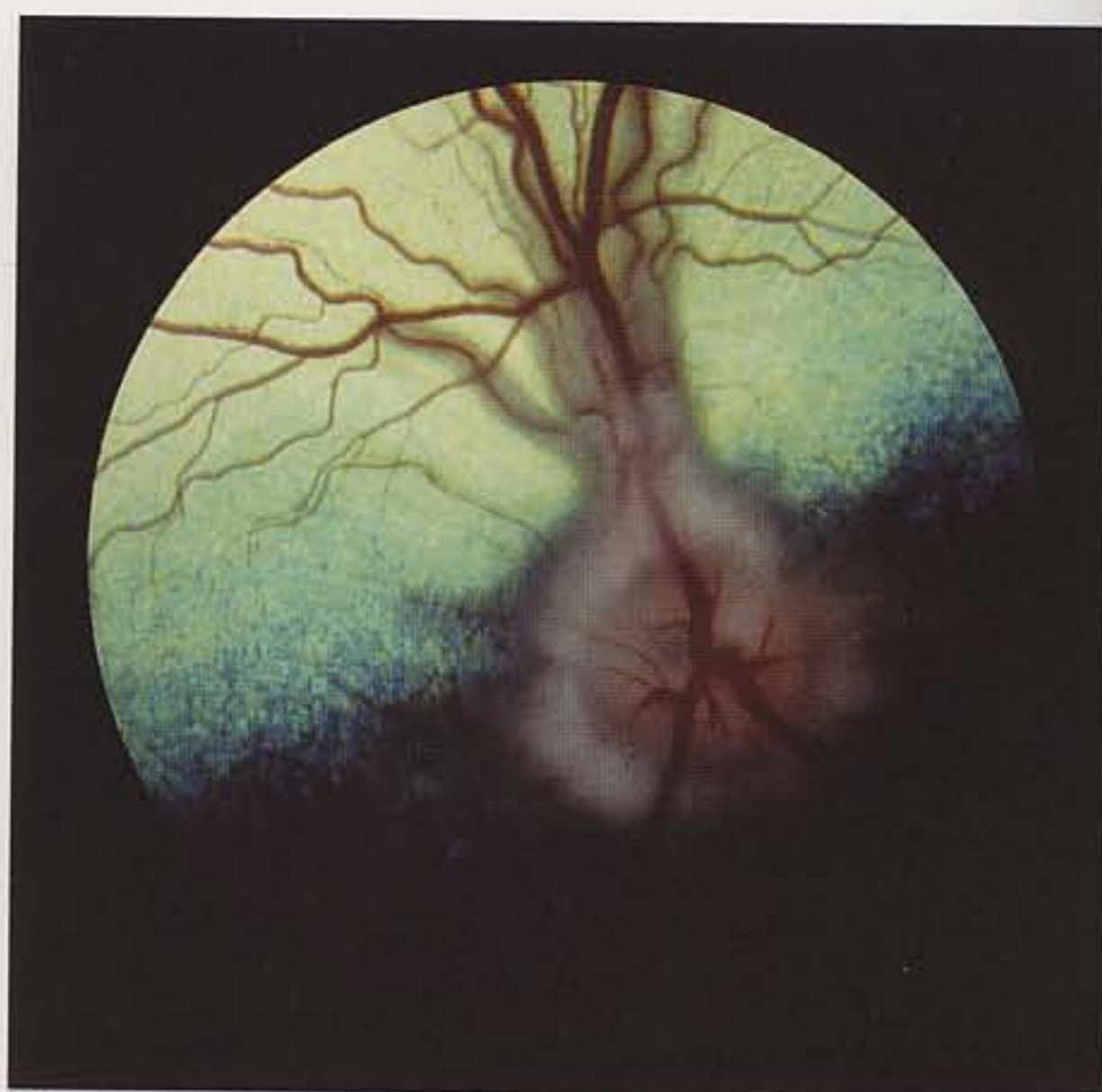

Fig. 11.40 The optic disc (German Shepherd Dog, 1 year old) Medullated fibres extending some distance away from the disc.

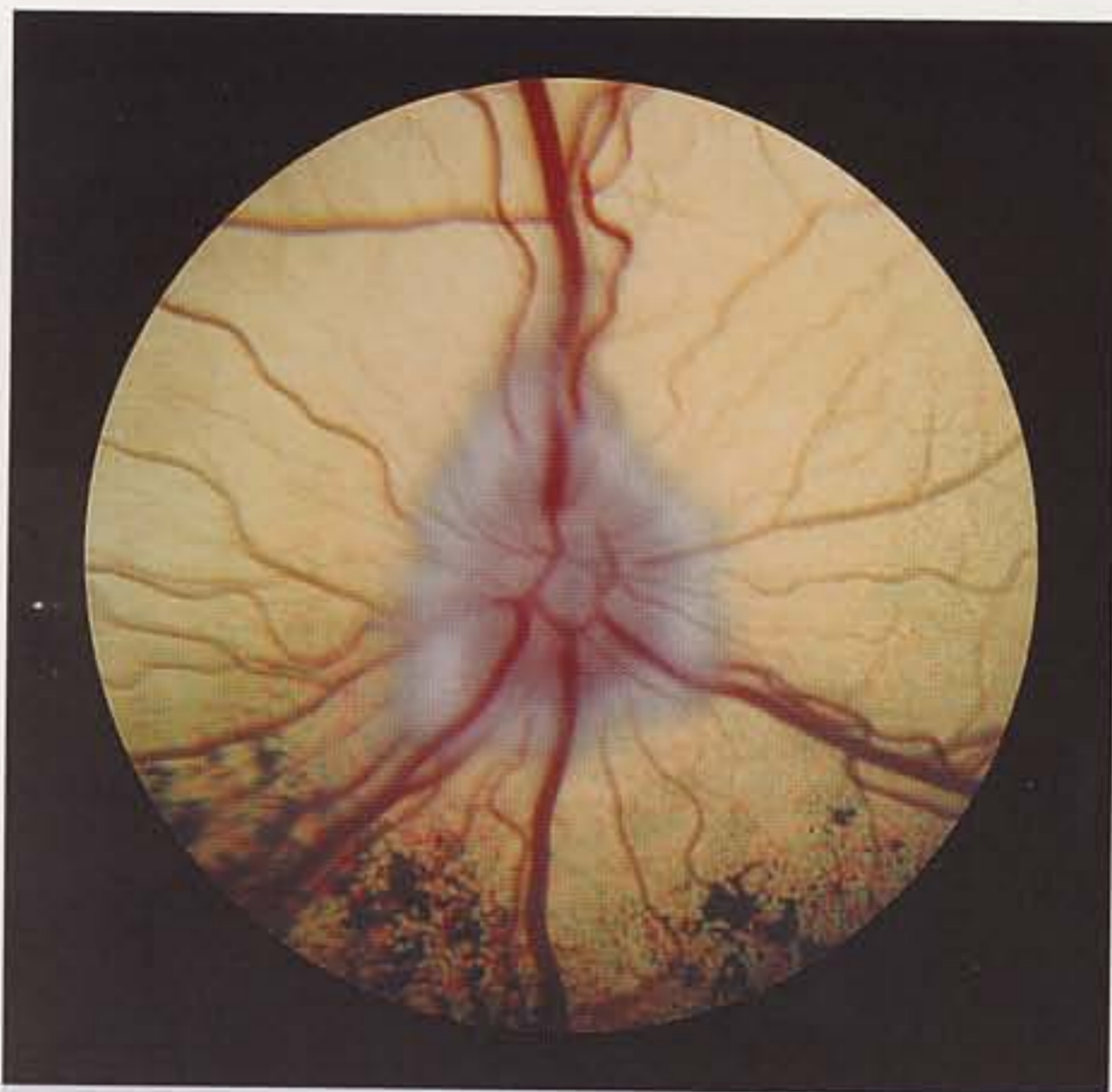

Fig. 11.39 The optic disc (German Shepherd Dog, 10 months old) Large disc due to medullated nerve fibres, sometimes called pseudopapilloedema. This appearance is commonly seen in the German Shepherd Dog and the Golden Retriever.

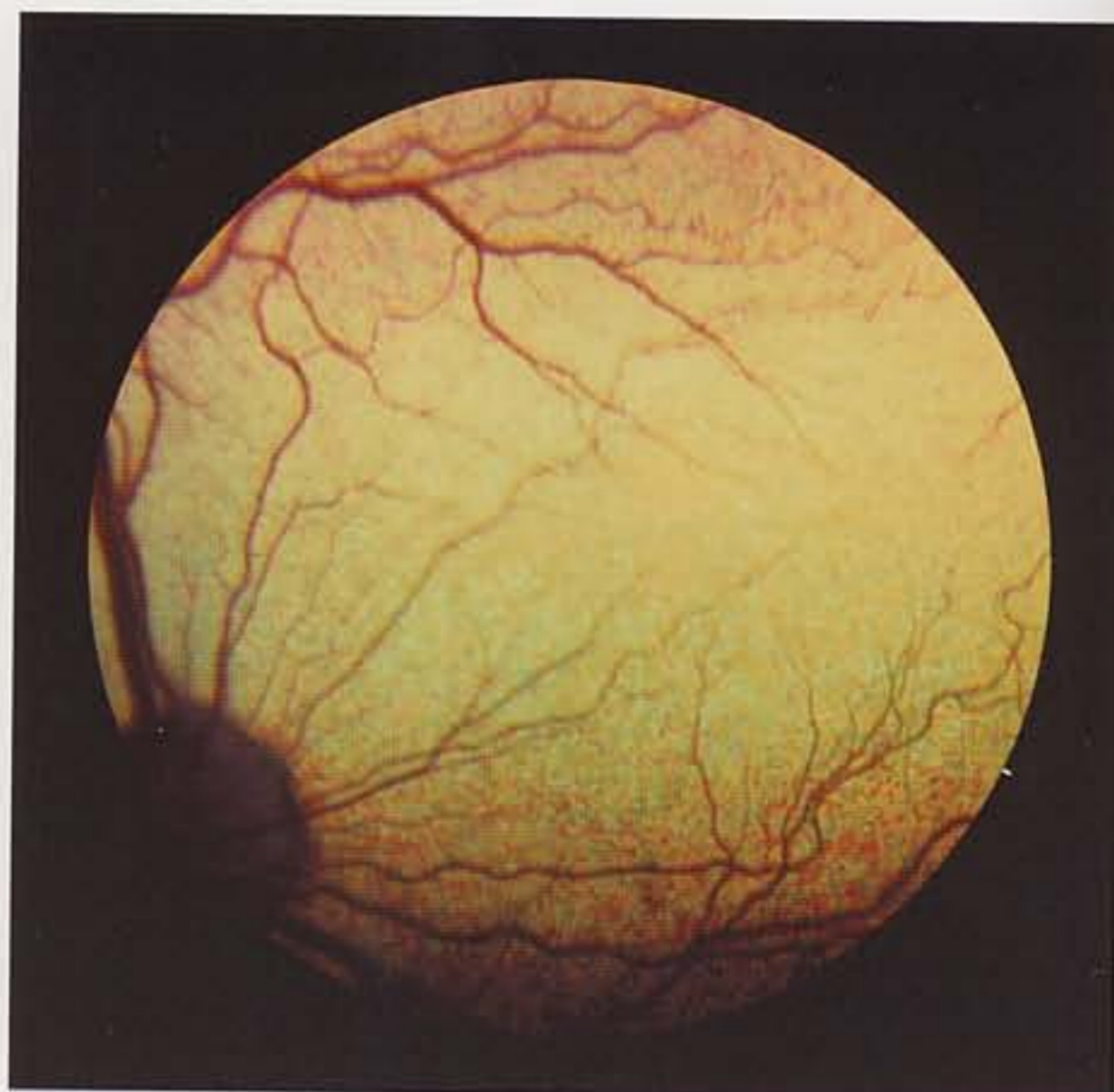


Fig. 11.41 Retinal blood vessels (English Springer Spaniel, 2 years old) Well-developed vascular pattern above and below the area centralis.

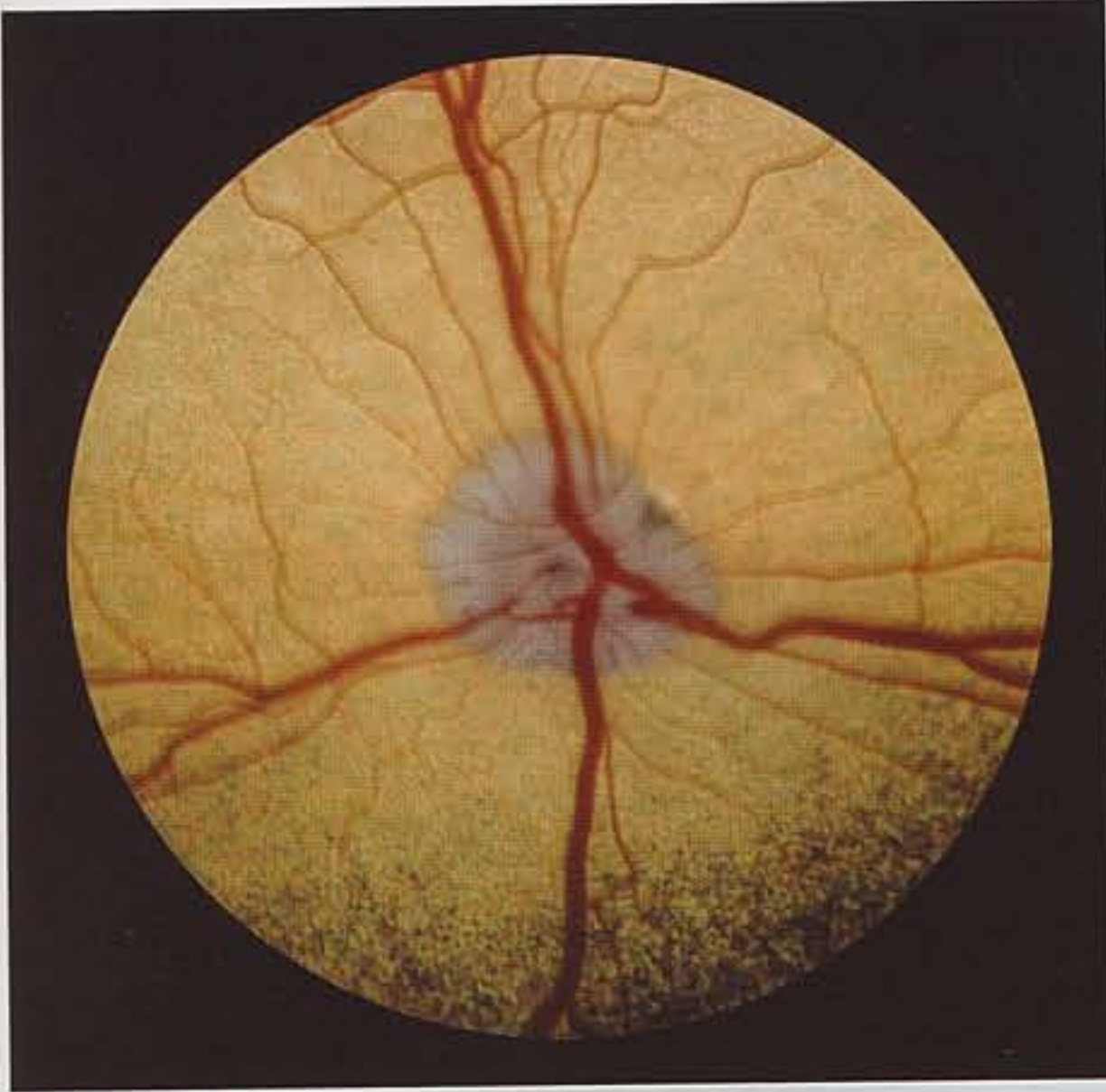

Fig. 11.42 Retinal blood vessels (Border Collie, 1 year old, black and white) Four primary veins.

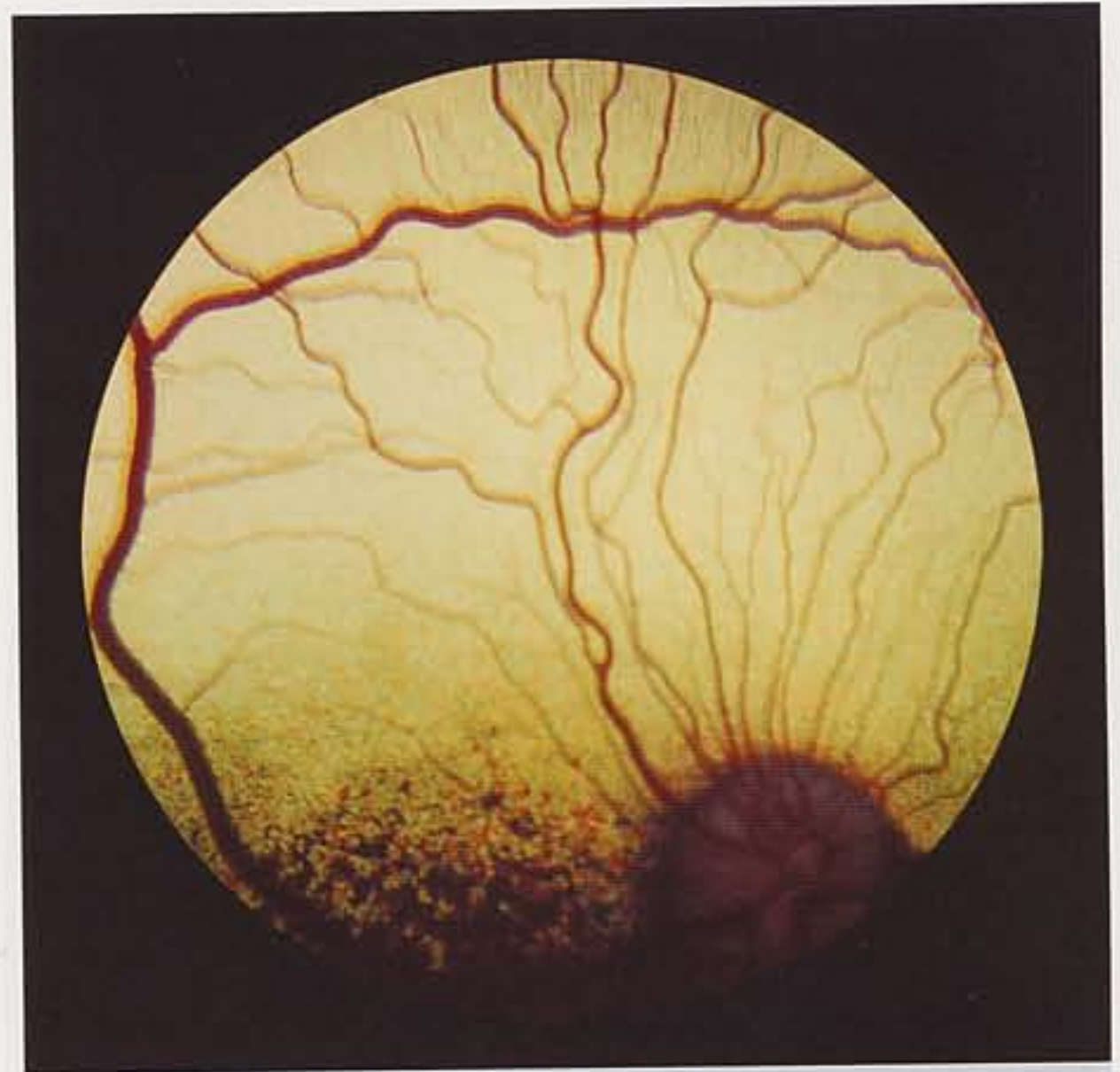


Fig. 11.44 Retinal blood vessels (English Springer Spaniel, 2 years old, liver and white) An unusual vascular pattern.

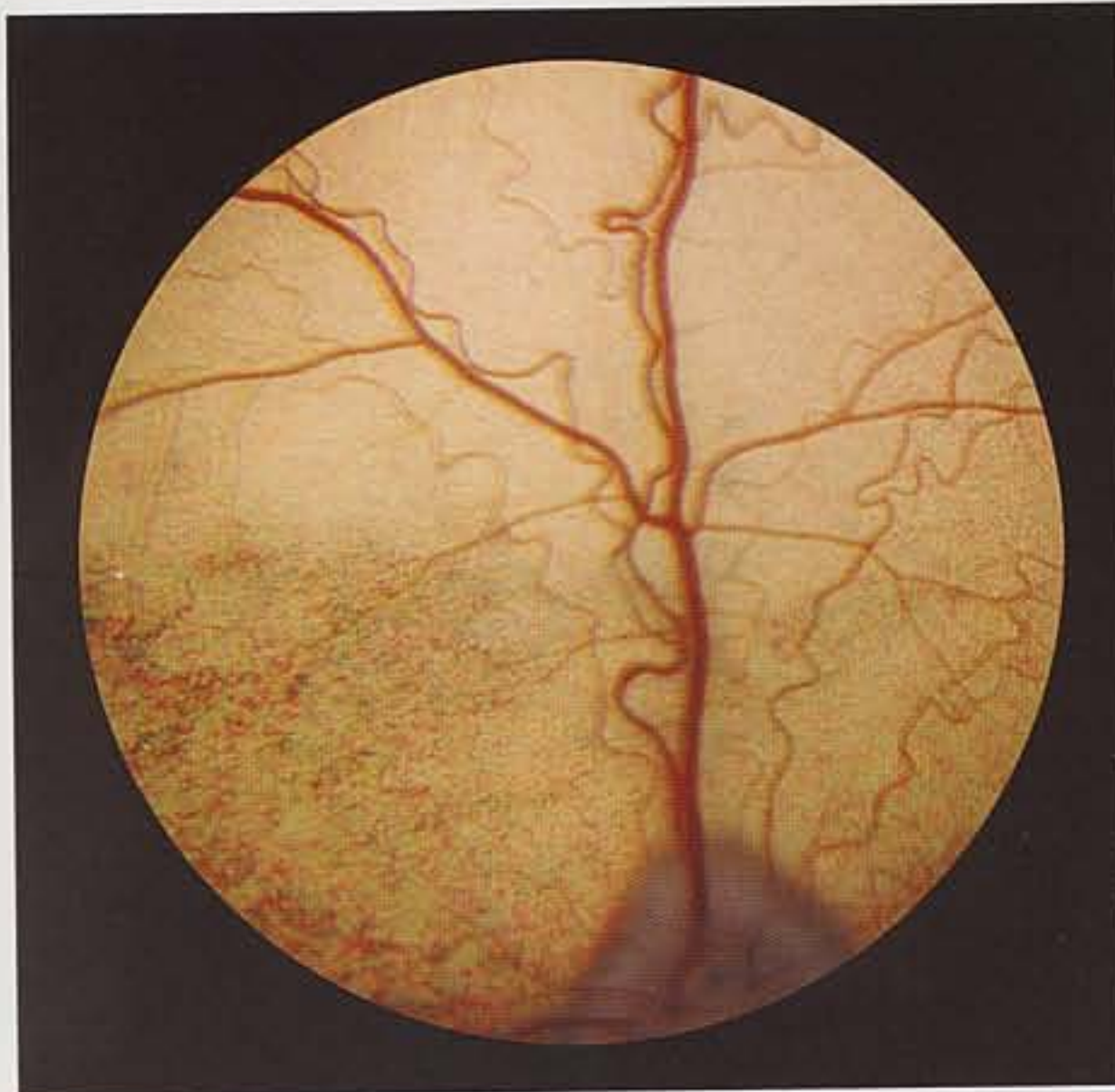

Fig. 11.43 Retinal blood vessels (Rough Collie, 1 year old, tricolour) Note the tortuosity of the retinal arterioles in comparison to the veins. Normal variant.

not the primary change. Changes in the appearance of the vessels may indicate a systemic disease, e.g. anaemia, polycythaemia, lipaemia, etc. The presence and appearance of retinal haemorrhages may also indicate systemic disease, e.g. hypertension, diabetes, etc.

### *Development of the canine fundus (Figs 11.45–11.52)*

The eye of the newborn puppy is normally closed at birth; the kitten is similar but this is not the case in the foal, calf and lamb where the eye is fully open at birth and the fundus appearance is similar to that of the adult. In the puppy it is difficult to examine the fundus before 21 days of age due to the presence of temporary corneal oedema and the pupillary membrane. At first there is no differentiation between tapetal and non-tapetal areas, but at 4–5 weeks the future tapetum lucidum appears as a homogeneous lilac colour with a darkening of the non-tapetal fundus. The adult form is present by 12–16 weeks of age. Figs 11.45–11.52 depict the changing appearance over the first 6 months of life of a Greyhound puppy ('gaze hound'), Figs 11.46–11.52 being the same animal.

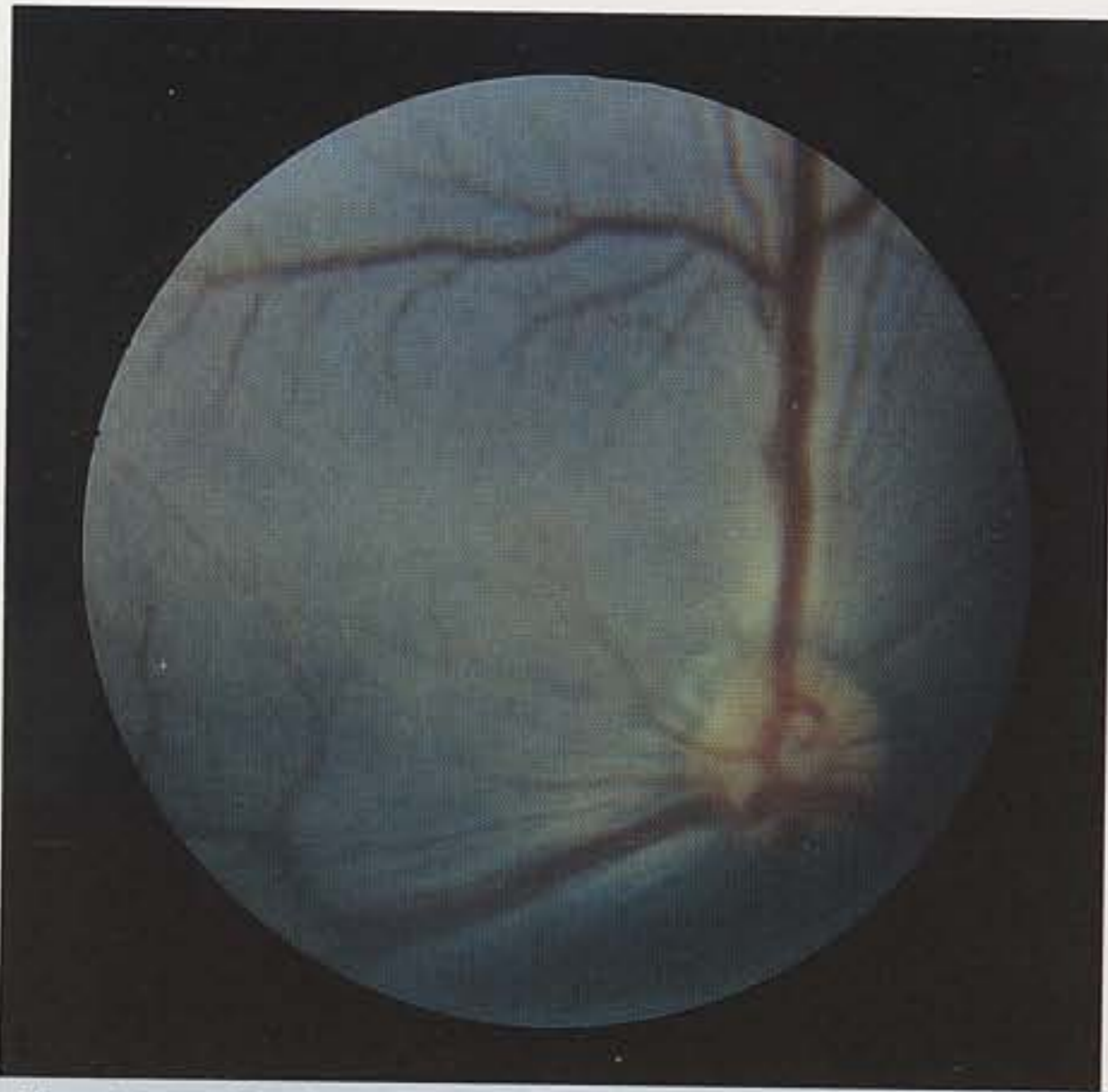

Fig. 11.45 Canine fundus (Greyhound puppy) Very early appearance with no differentiation between tapetal and non-tapetal fundus.

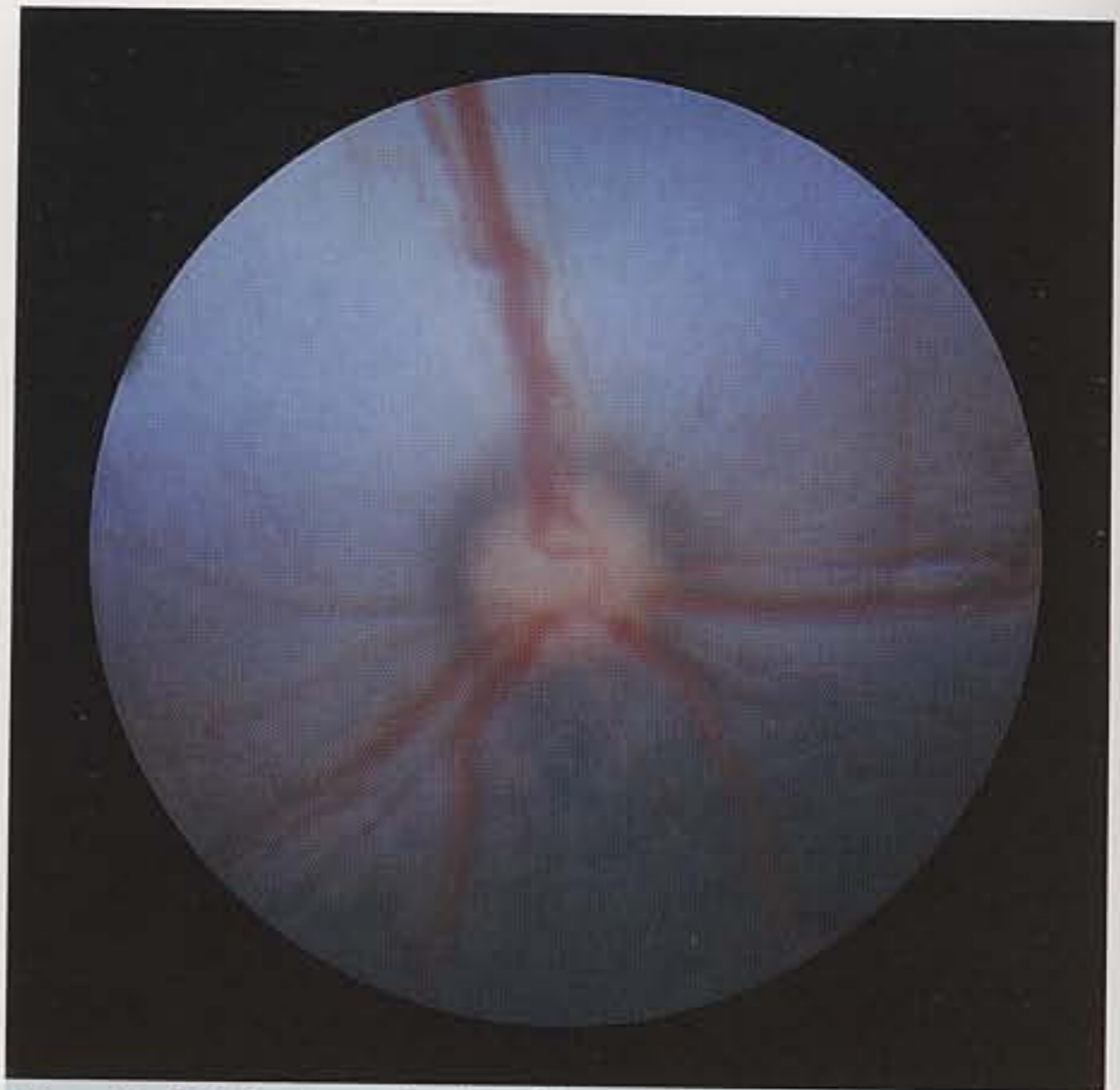


Fig. 11.47 Canine fundus (Greyhound puppy) 27 days old.

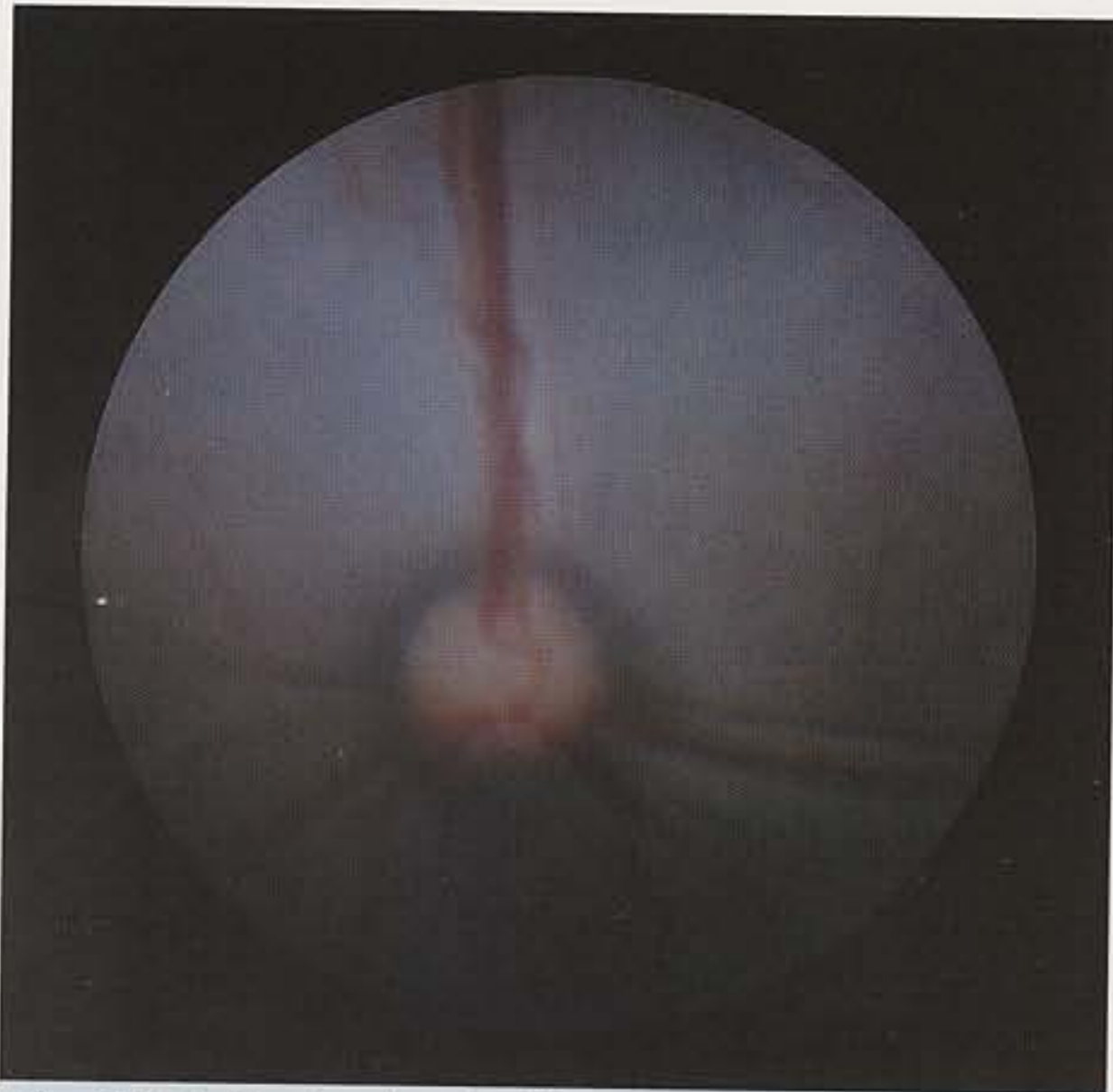

Fig. 11.46 Canine fundus (Greyhound puppy) 23 days old.

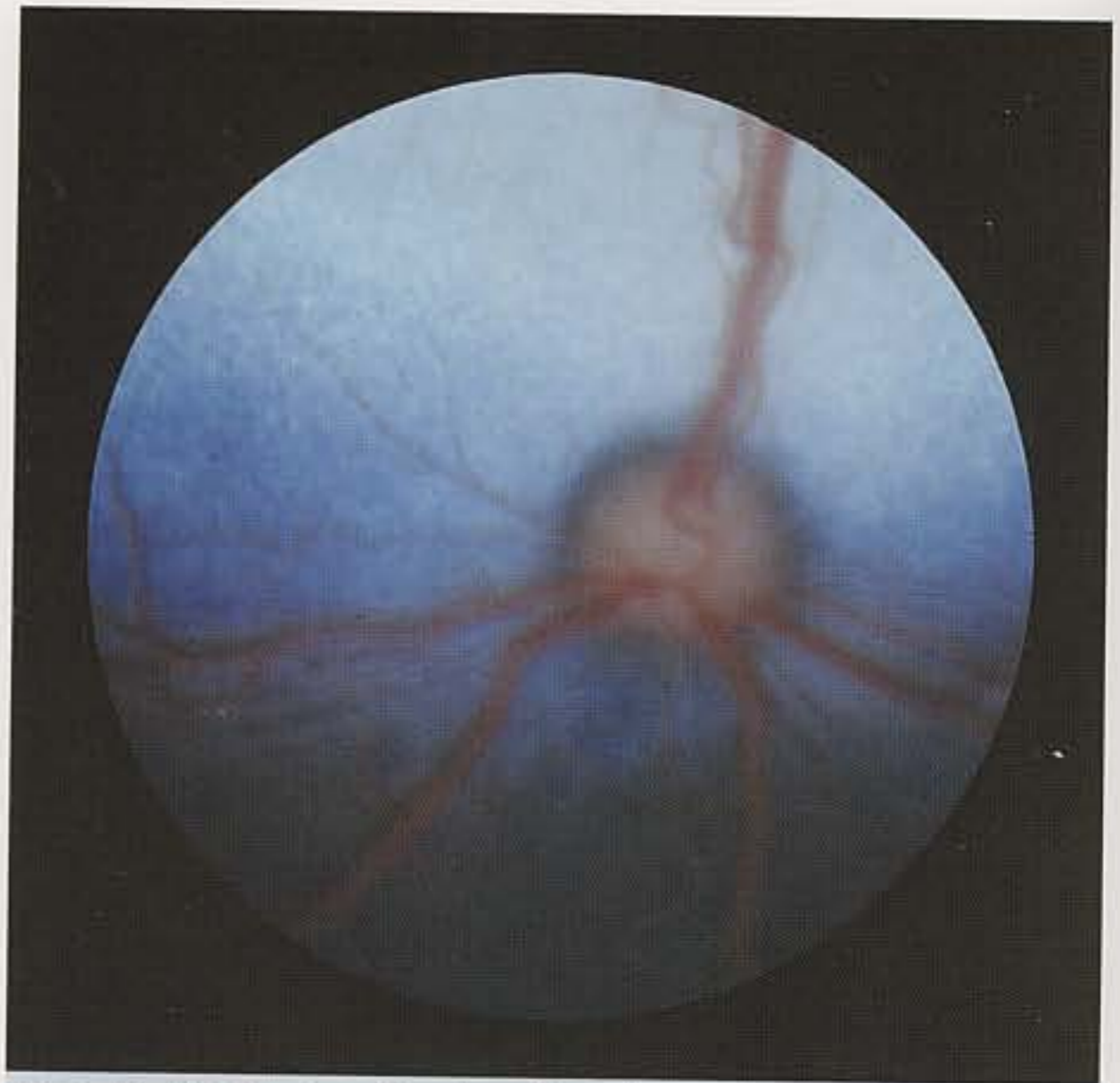


Fig. 11.48 Canine fundus (Greyhound puppy) 51 days old.

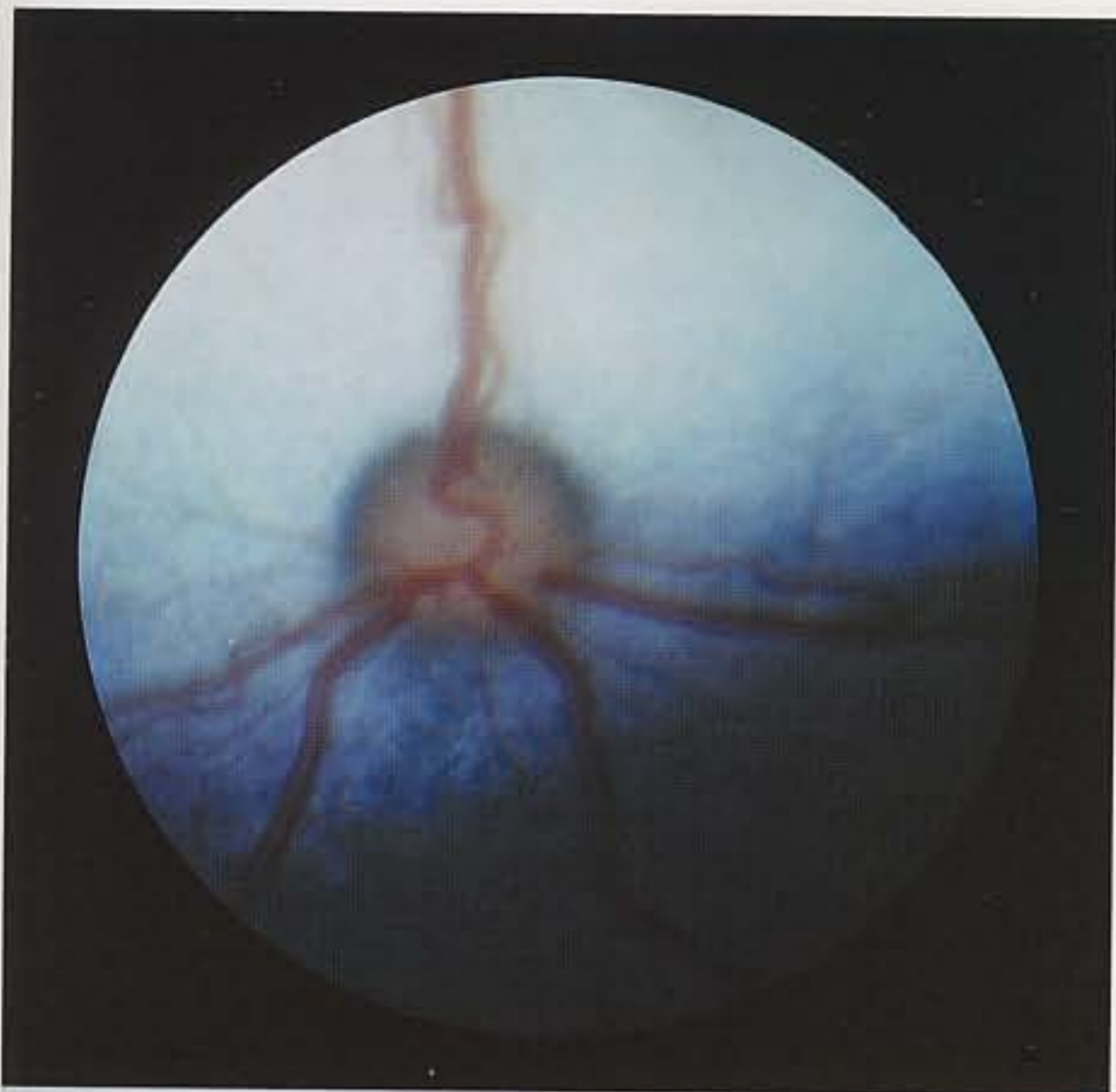

Fig. 11.49 Canine fundus (Greyhound puppy) 58 days old.

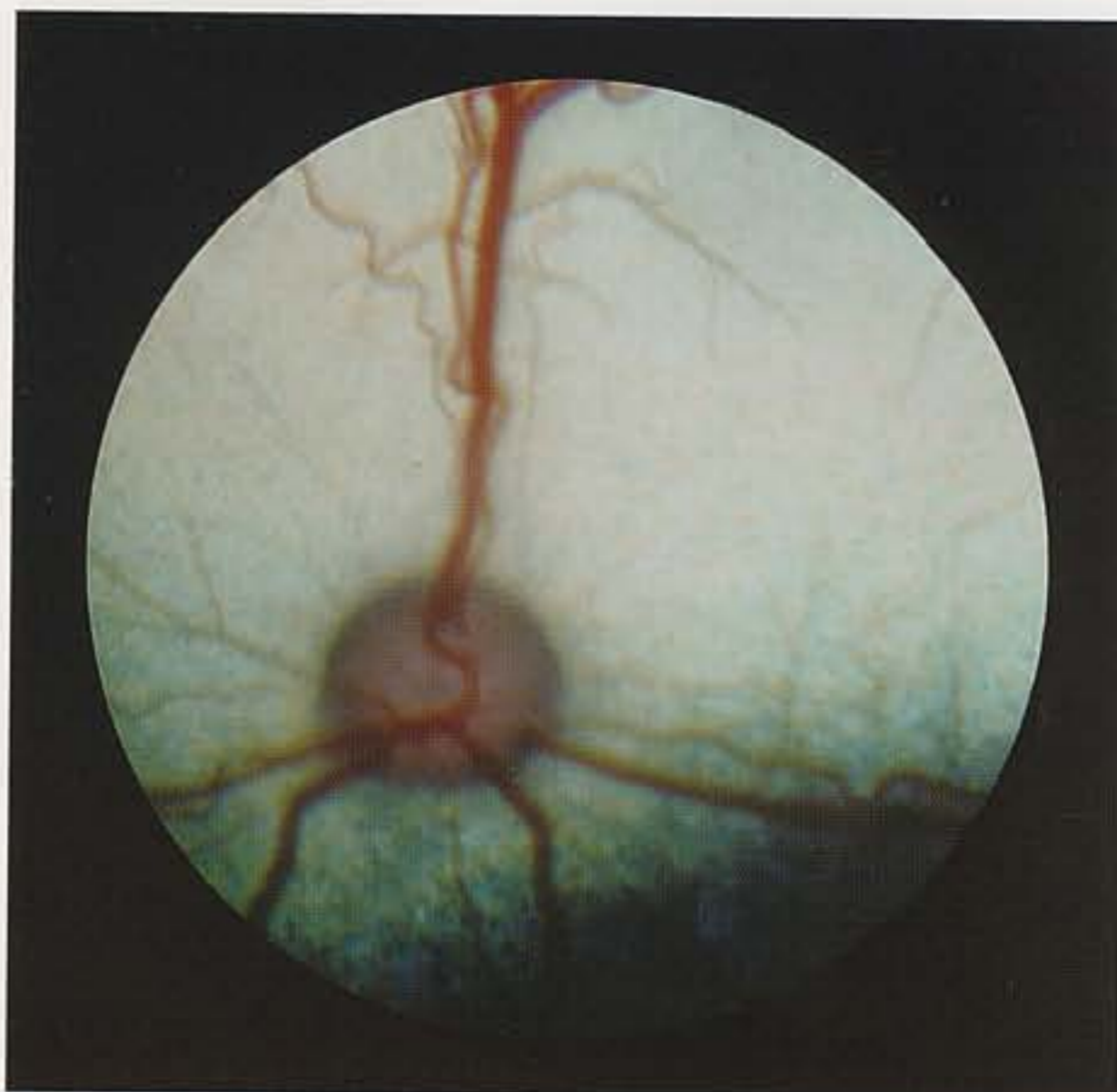


Fig. 11.51 Canine fundus (Greyhound puppy) 3 months old.

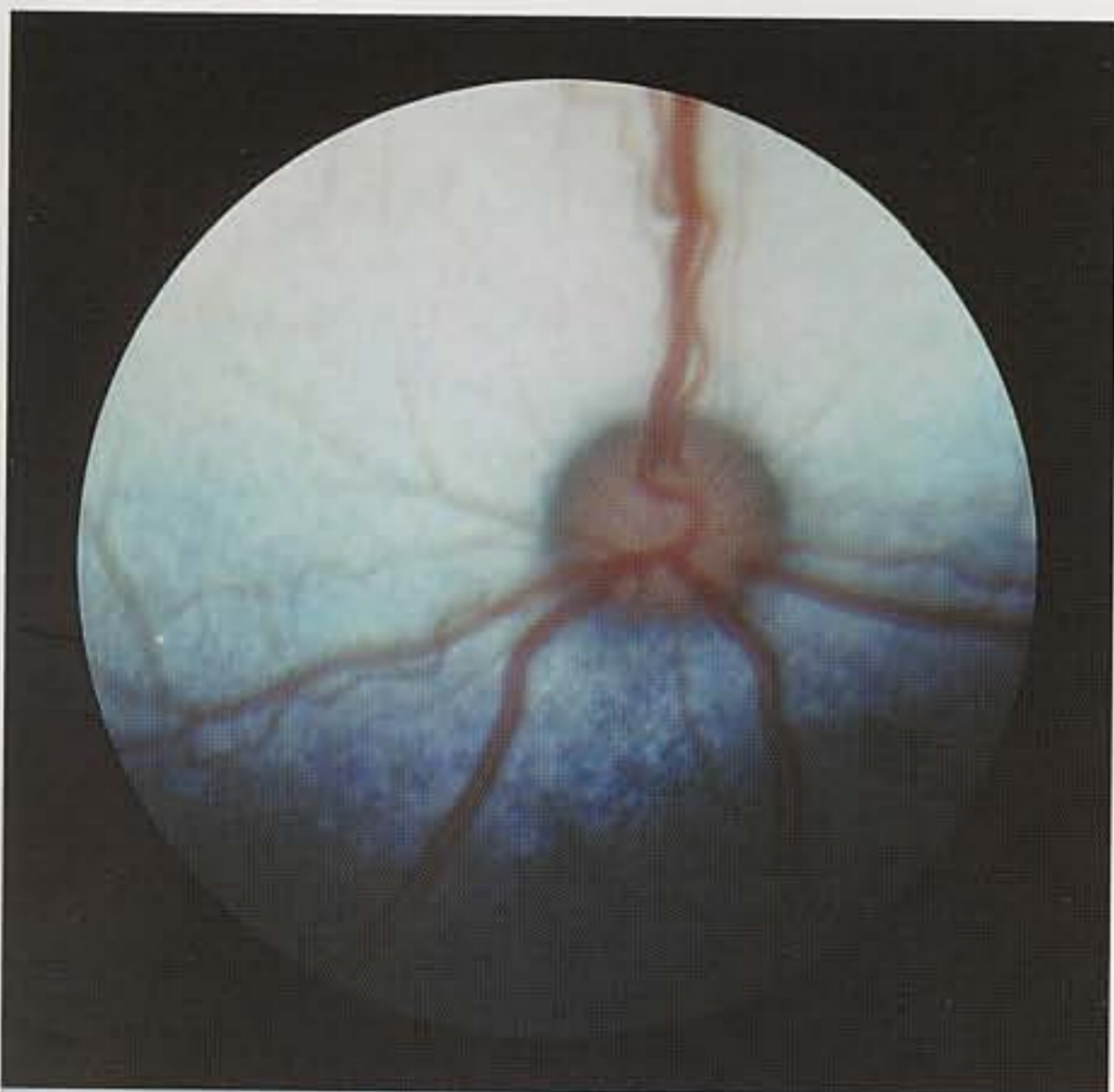


Fig. 11.50 Canine fundus (Greyhound puppy) 65 days old.

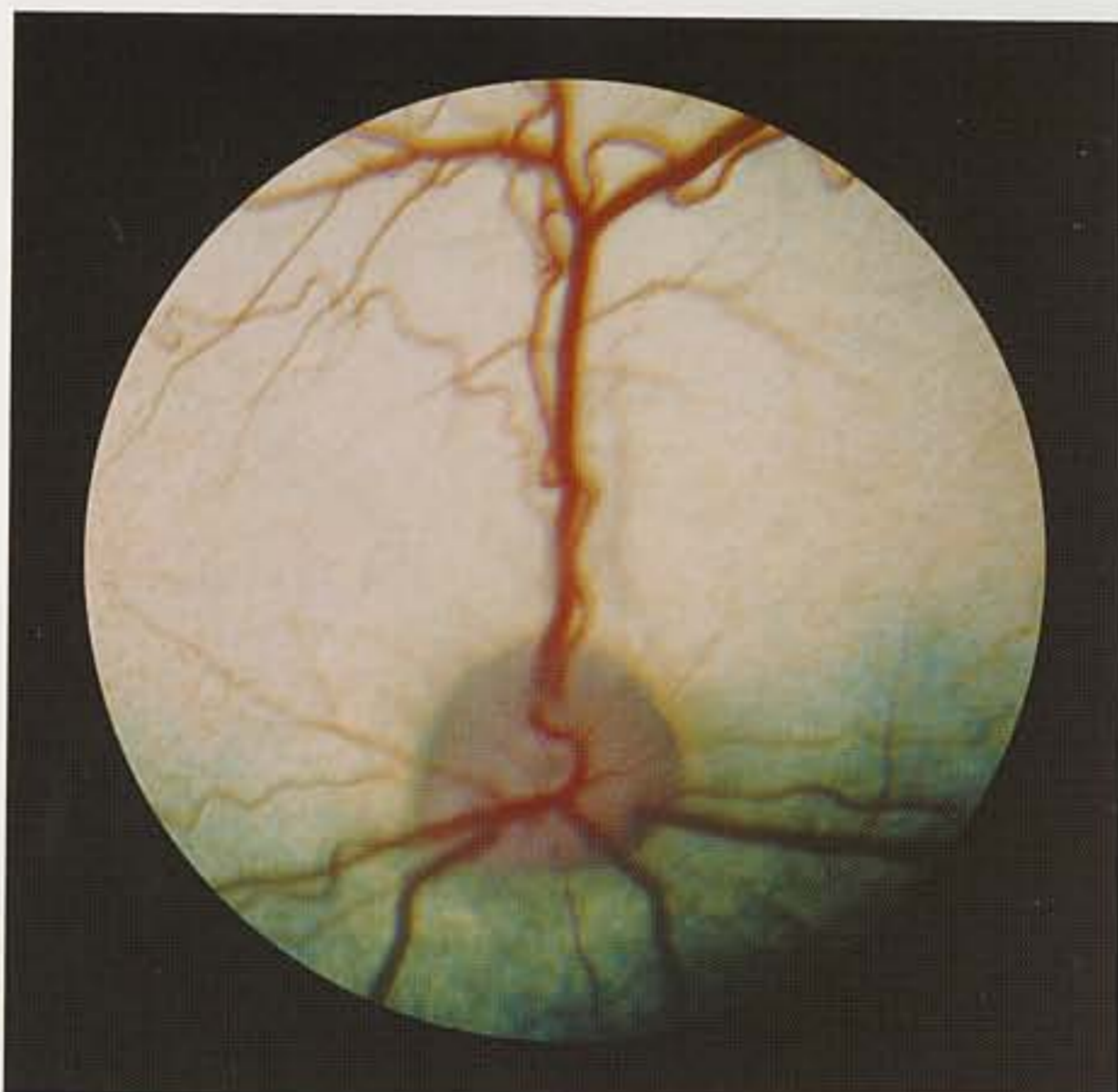


Fig. 11.52 Canine fundus (Greyhound puppy) 6 months old. Normal adult appearance.

## The normal feline fundus

(Figs 11.53–11.64)

The fundus of the cat exhibits considerably less variation than that of the dog. The cat has a triangular and well-developed, highly reflective tapetum. The colour is usually yellow to green and occasionally blue; subalbinism with absence of the

tapetum or with visible choroidal vessels in places occurs in the blue-eyed white, and there is a tigroid, due to the choroidal vessels, in the non-tapetal fundus of the seal-point Siamese. The area centralis is lateral to the optic disc and is devoid of superficial blood vessels. The vascular pattern is classified as holangiomatic, as in the dog. The feline optic disc is small, usually circular, and cupped with a well-

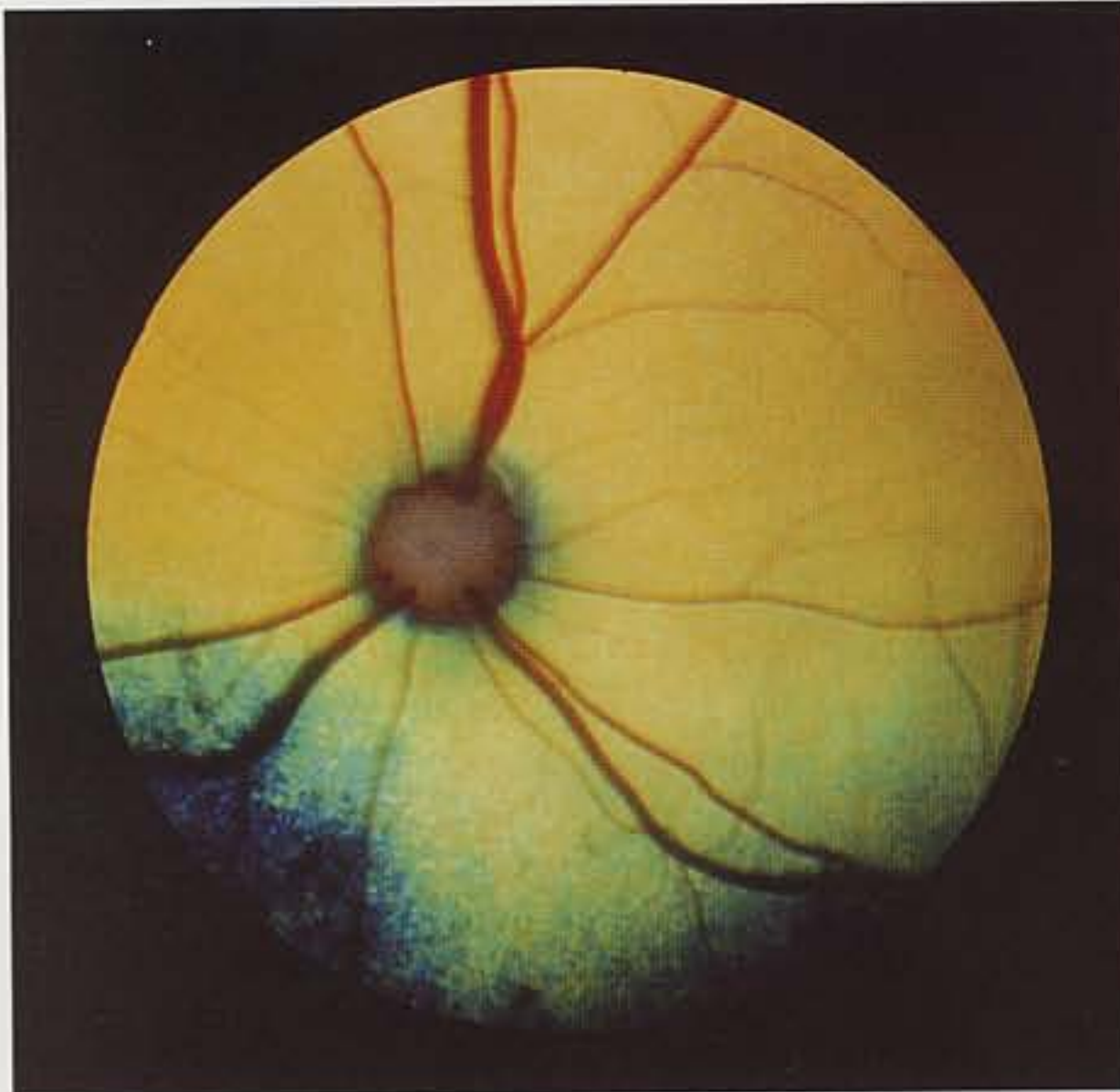


Fig. 11.53 Yellow tapetum (DSH cat, adult)

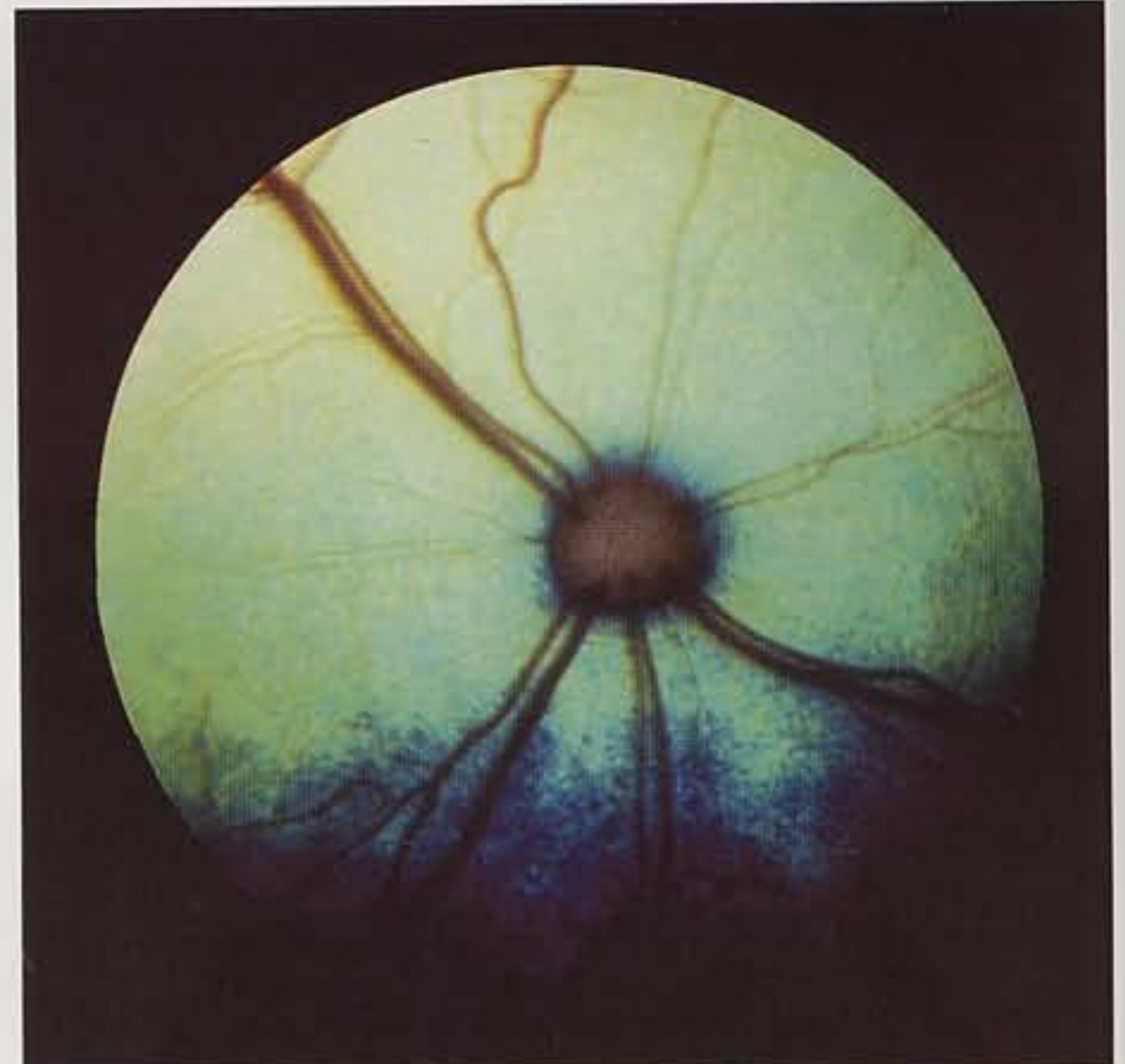

Fig. 11.55 Yellow-green tapetum (DSH cat, adult)

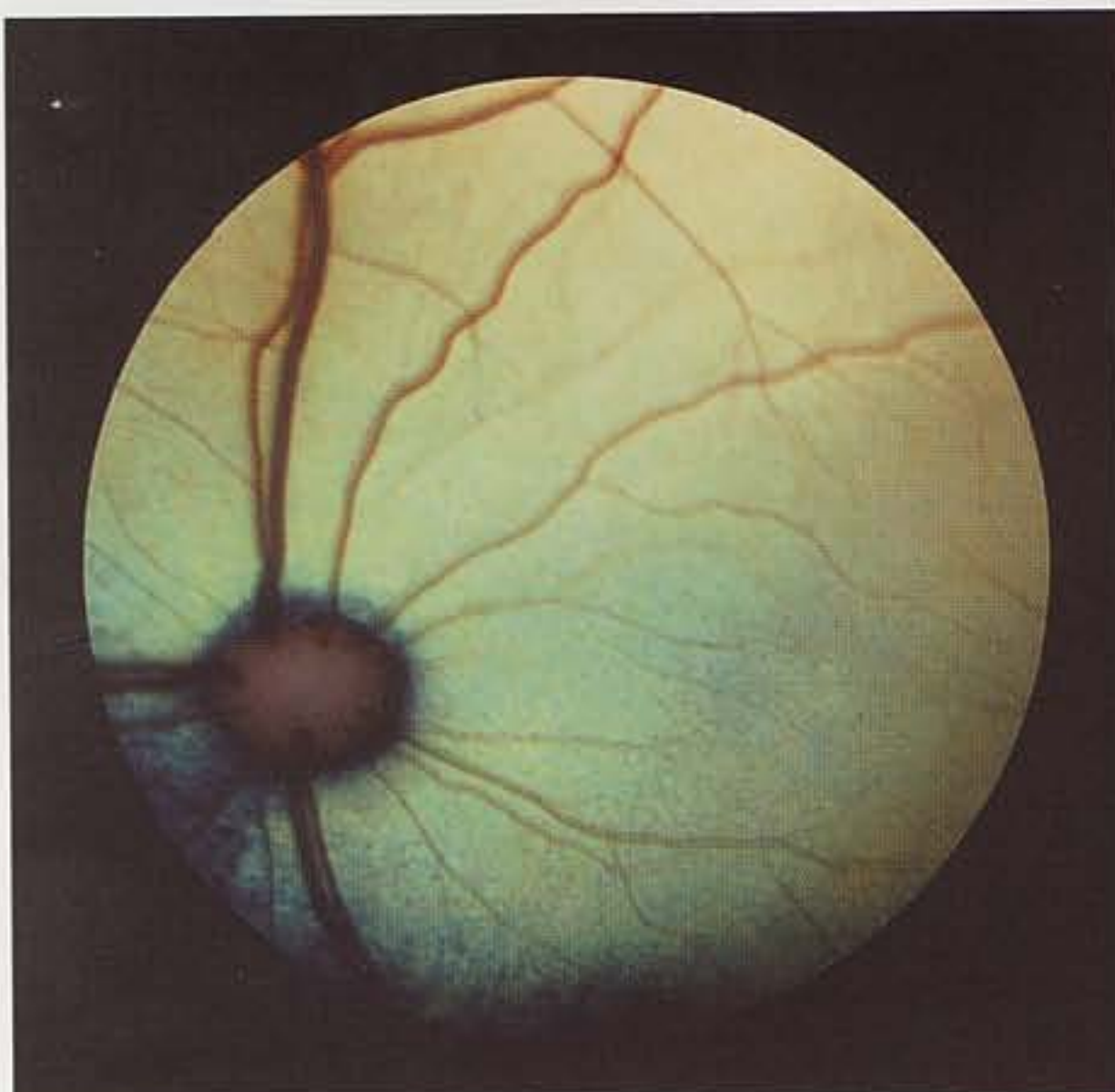


Fig. 11.54 Yellow-green tapetum (DSH cat, adult)

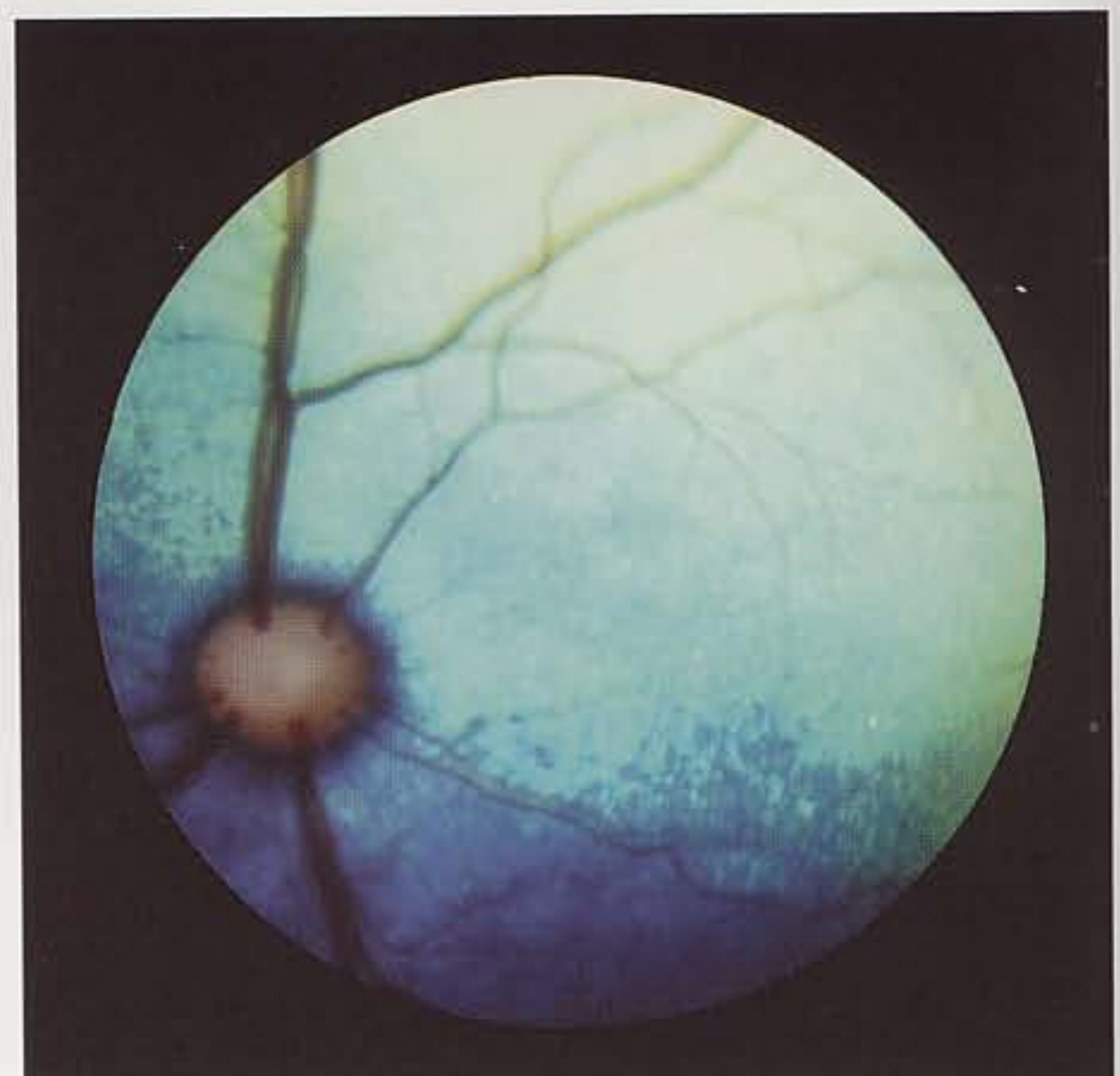


Fig. 11.56 Blue-green tapetum (DSH cat, adult)



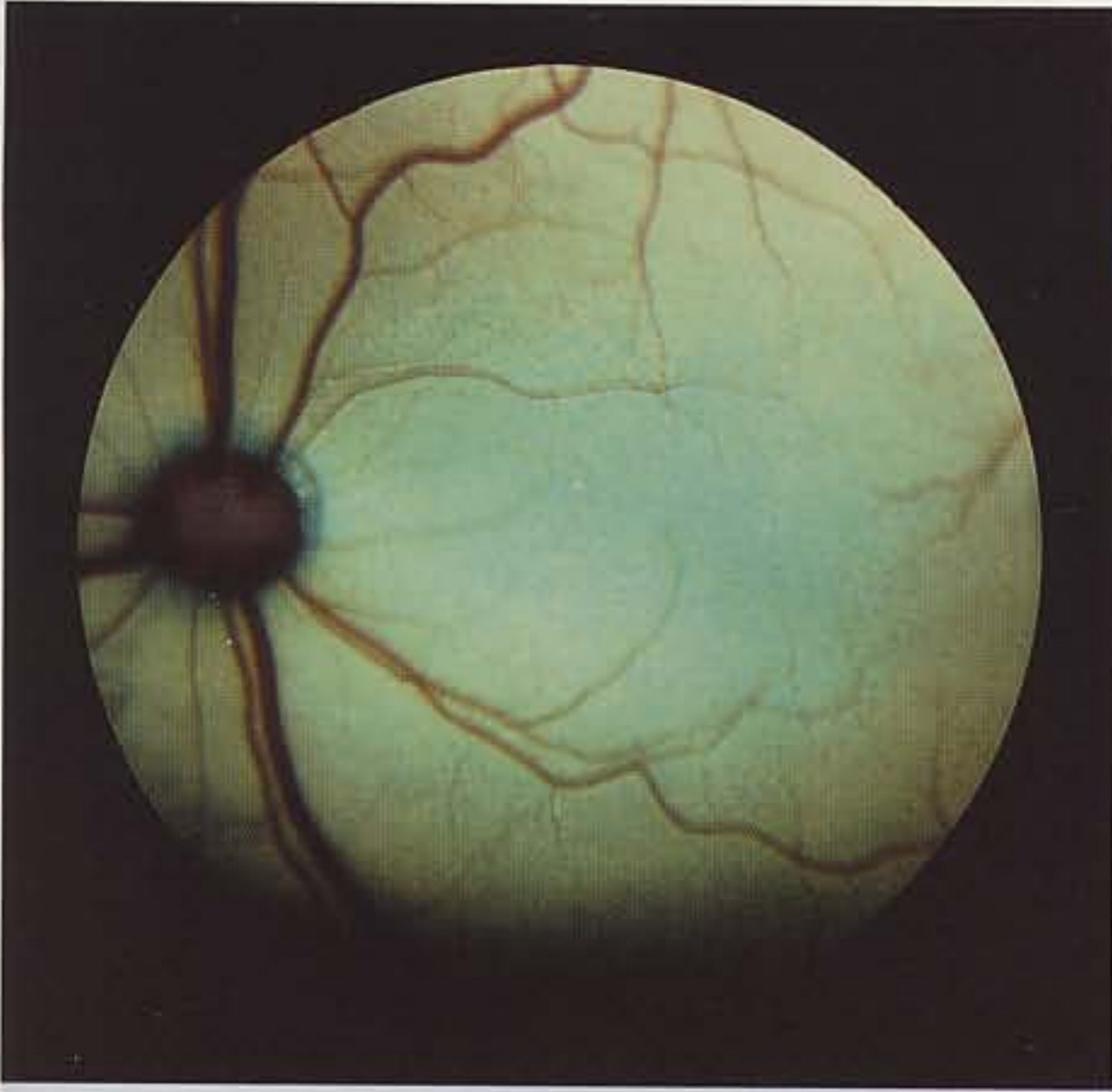

Fig. 11.57 Retinal blood vessels (DSH cat, adult) Note the blood vessels surrounding, but not crossing, the area centralis. Right eye (OD).

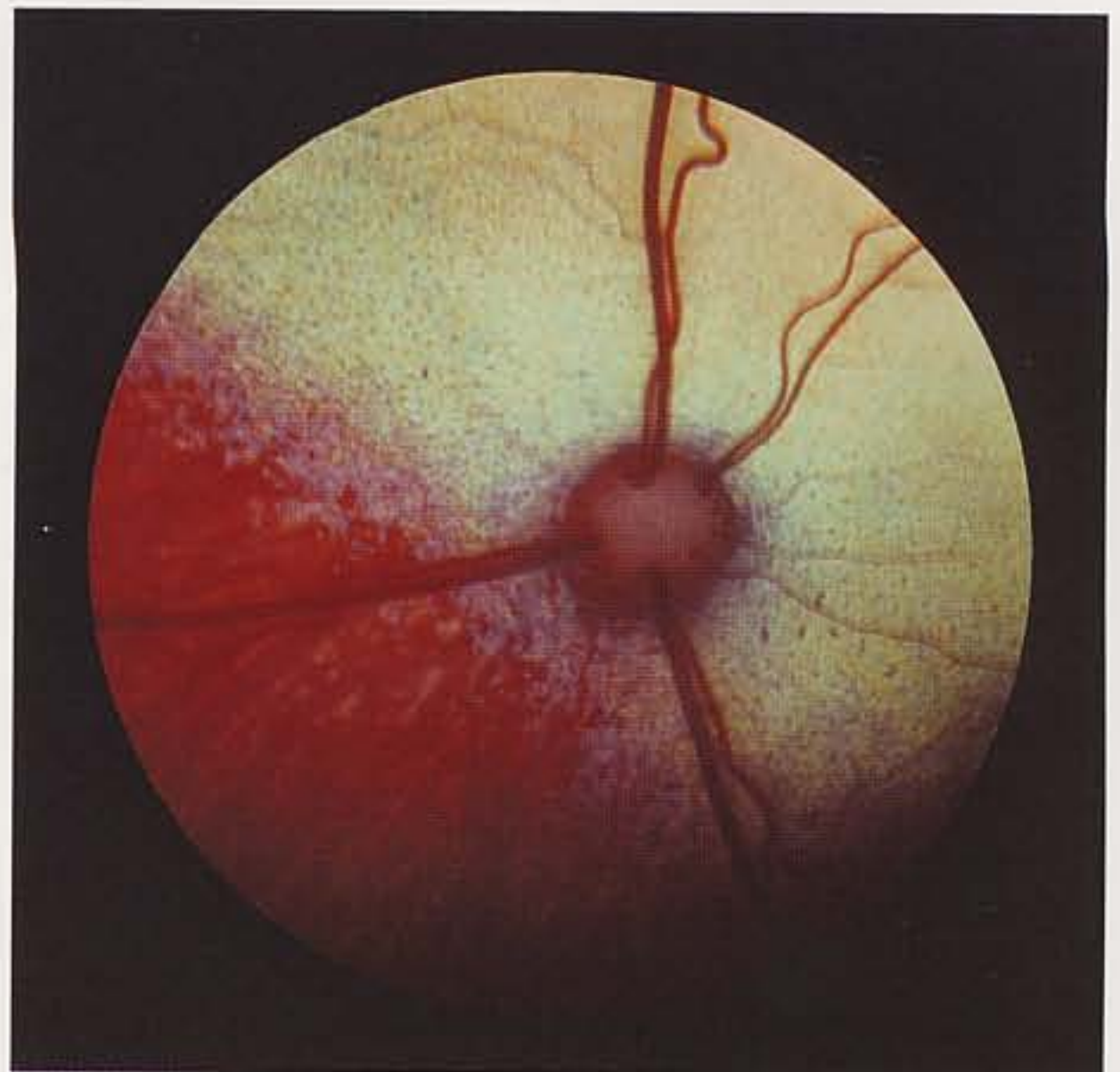

Fig. 11.59 Tigroid non-tapetal fundus (Siamese cat, 2 years old, seal-point)

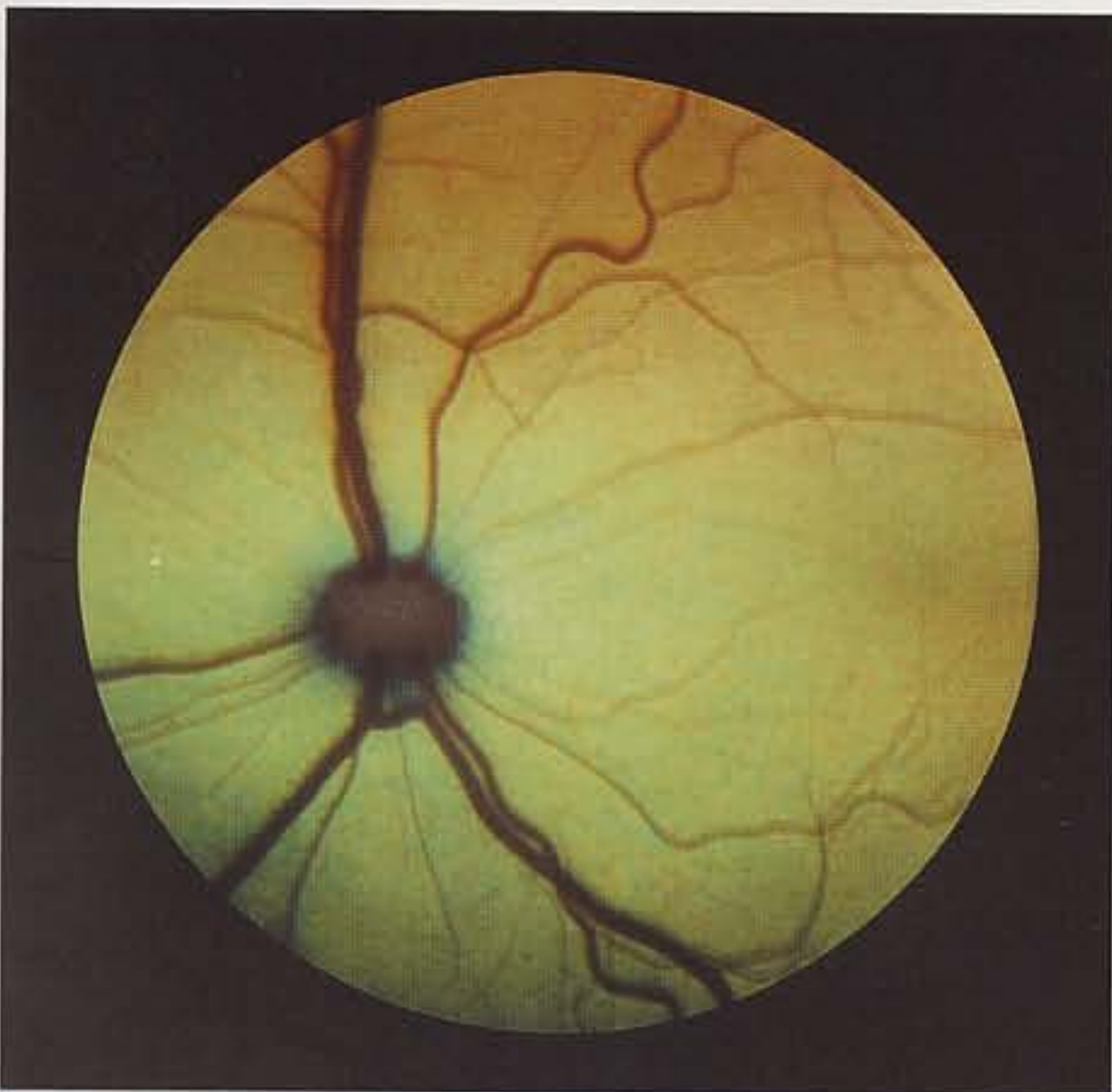


Fig. 11.58 Retinal blood vessels (DSH cat, adult) Note the region lateral and immediately opposite the optic disc, the area centralis, with retinal vessels above and below. Left eye (OS).

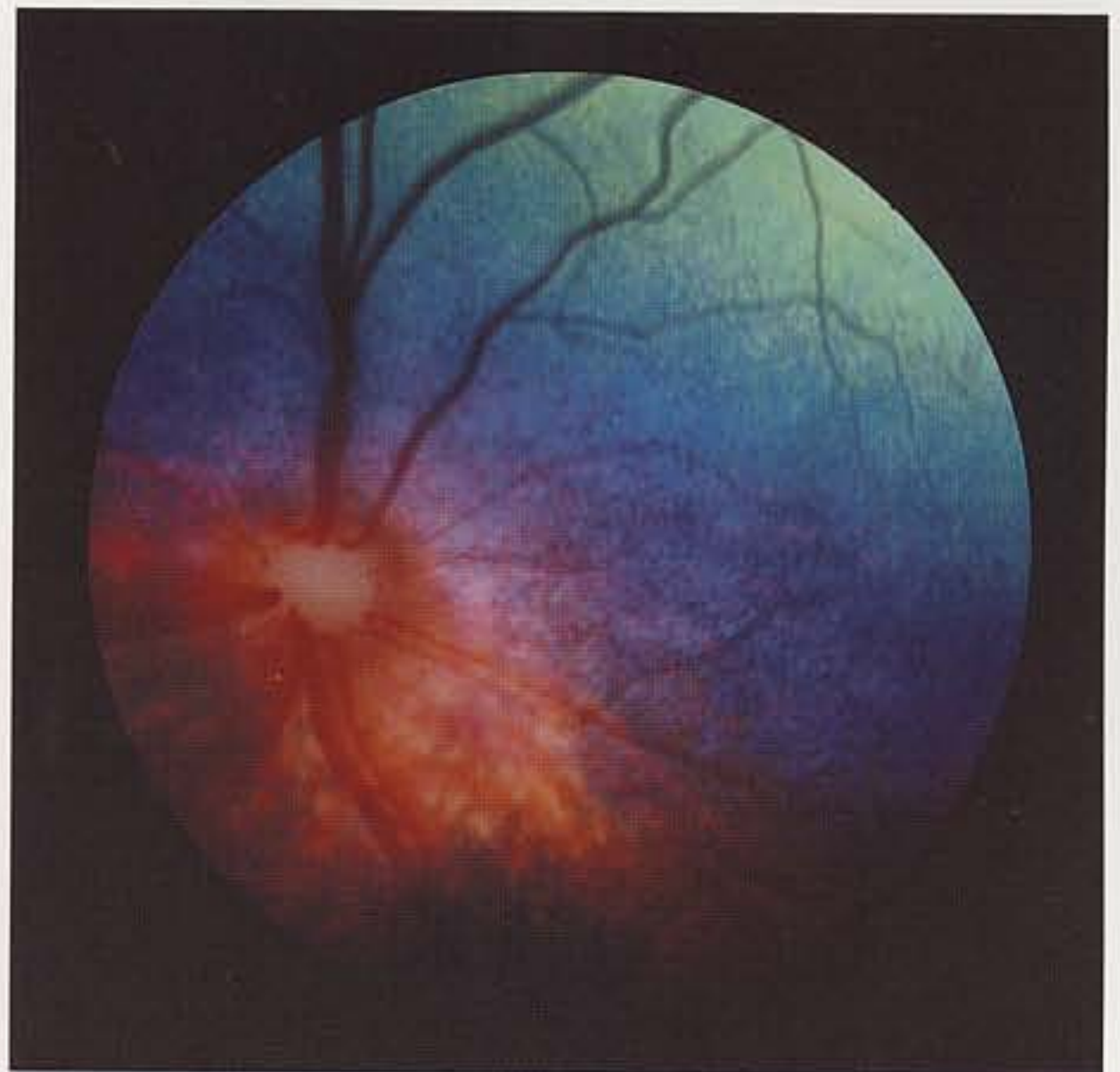


Fig. 11.60 Subalbinism (DSH cat, tabby) Patch of subalbinism around disc

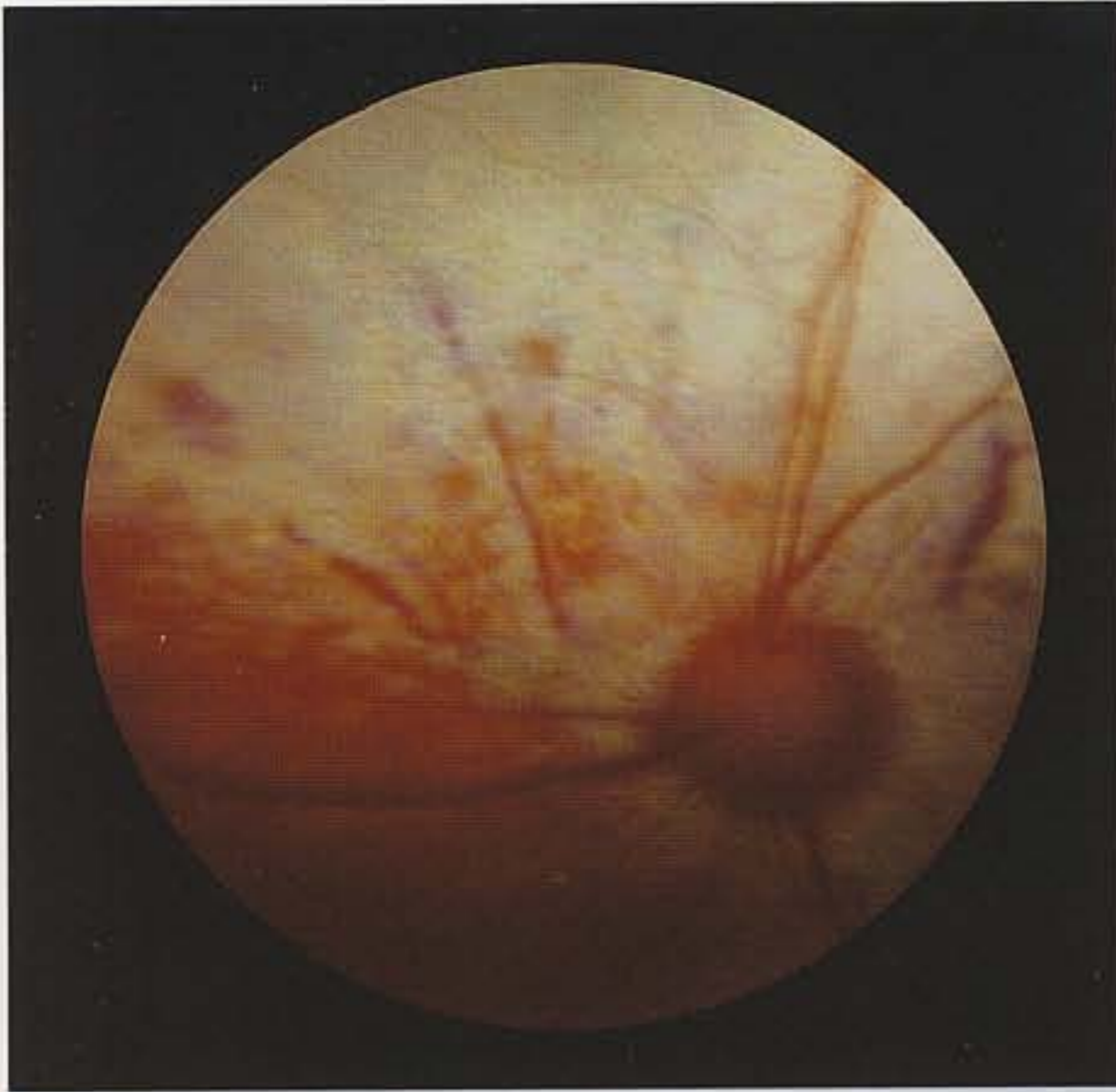


Fig. 11.61 Subalbinism (DSH cat, young adult, blue-eyed white) Note appearance and colours of tapetal and non-tapetal fundus.

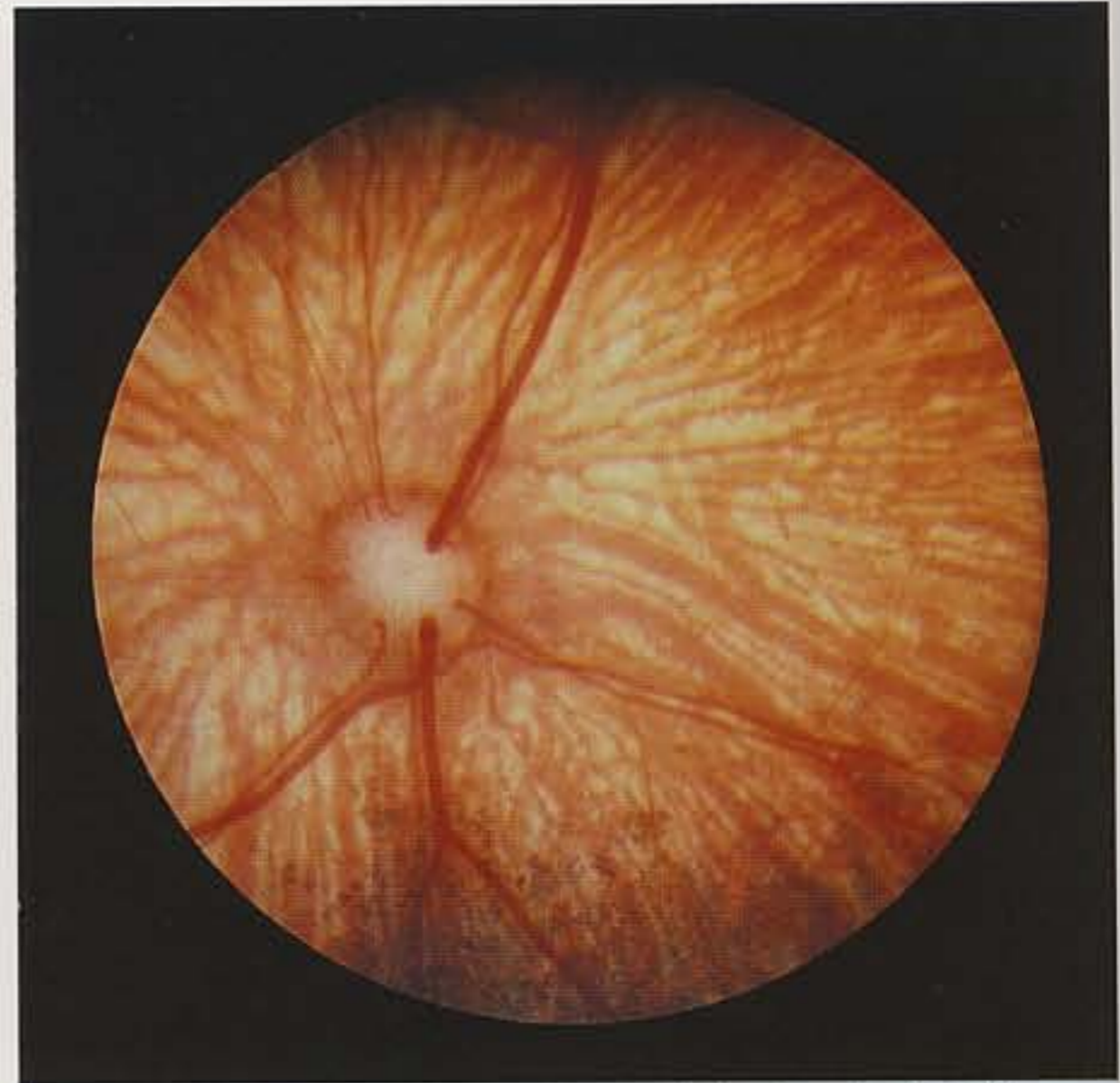


Fig. 11.63 Subalbinism of the whole fundus (DSH cat, young adult, blue-eyed white)

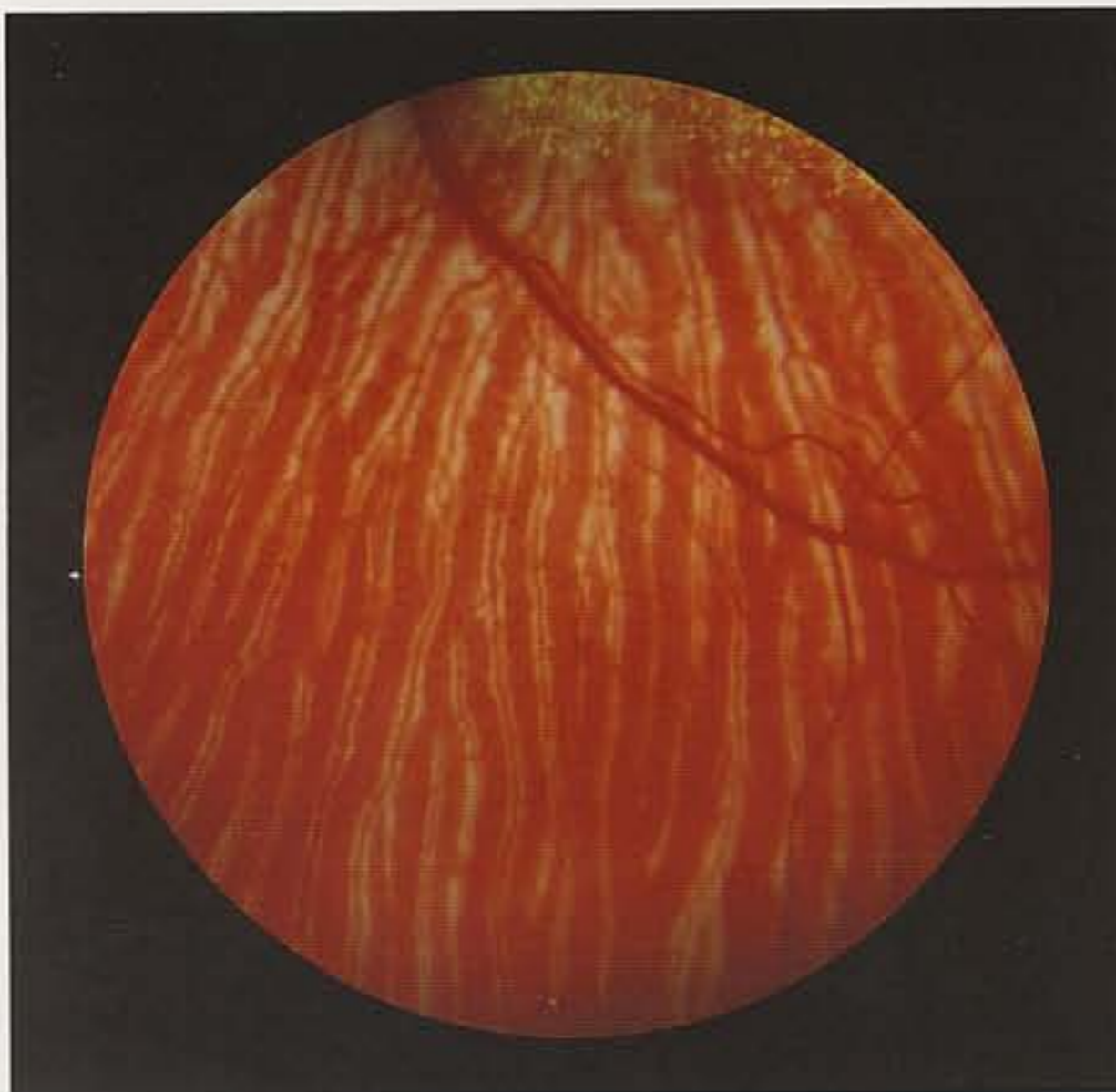


Fig. 11.62 Subalbinism (DSH cat, young adult, blue-eyed white) Choroidal vessels in non-tapetal fundus region.

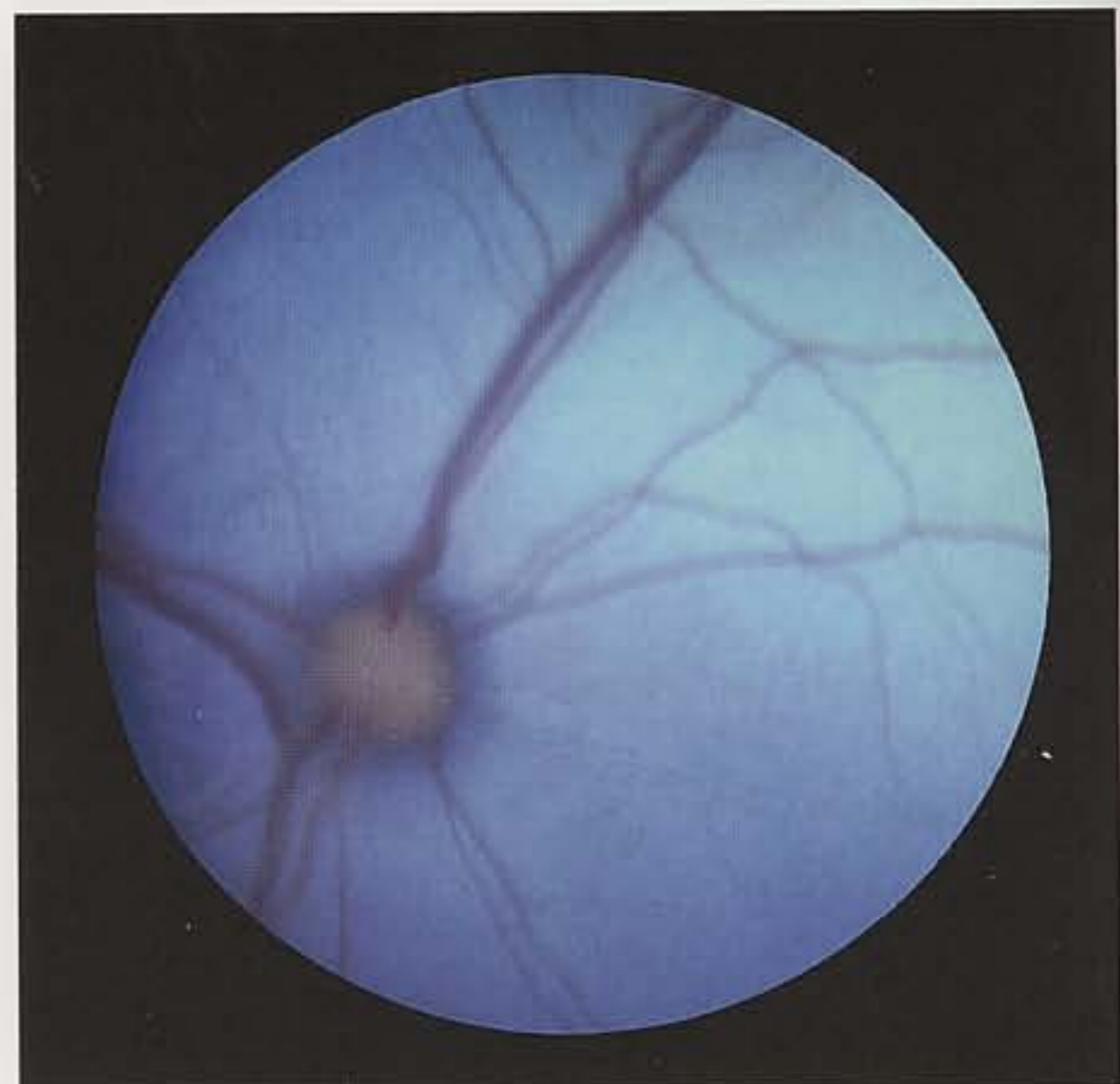


Fig. 11.64 Fundus development (kitten, 8 weeks old) Note comparison to Fig 11.49.

defined edge. The disc is grey in colour and not myelinated, although occasionally myelinated or opaque nerve fibres are visible ophthalmoscopically. Pigmented and hyper-reflective peripapillary rings are sometimes present. Development of the feline fundus, in particular that of the tapetum, is similar to the picture described in the dog.

### The normal equine fundus

(Figs 11.65–11.81)

The ocular fundus of the horse varies somewhat, as might be expected, but again not as widely as in the dog. The tapetum is more extensive than in the carnivores, is dorsal to the optic disc and varies from yellow to green to blue, and sometimes two colours appear in the same eye. The 'stars of Winslow' are frequently prominent in the horse, appearing as small dark dots scattered throughout the tapetum.

Sometimes the course of the choroidal veins converging to a point dorsal to the optic disc appear as blue to purple streaks through a thinned tapetum, particularly in the subalbinotic fundus. The non-tapetal fundus is well pigmented, except for a small area above the upper disc border and the junction with the tapetum. Irregular areas of subalbinism show as reddish coloration in a less densely pigmented non-tapetal fundus. The optic disc is usually roughly oval, sometimes more round. It is granular and pink in colour with a variable edge, sometimes with a notch on the ventral border and an odd blood vessel or two on the surface. Myelination of the optic nerve fibres is an occasional finding and usually occurs at the lateral and medial ventral corners of the disc. The equine fundus is described as paurangiotic with many fine straight arterioles radiating outwards from the disc margin.

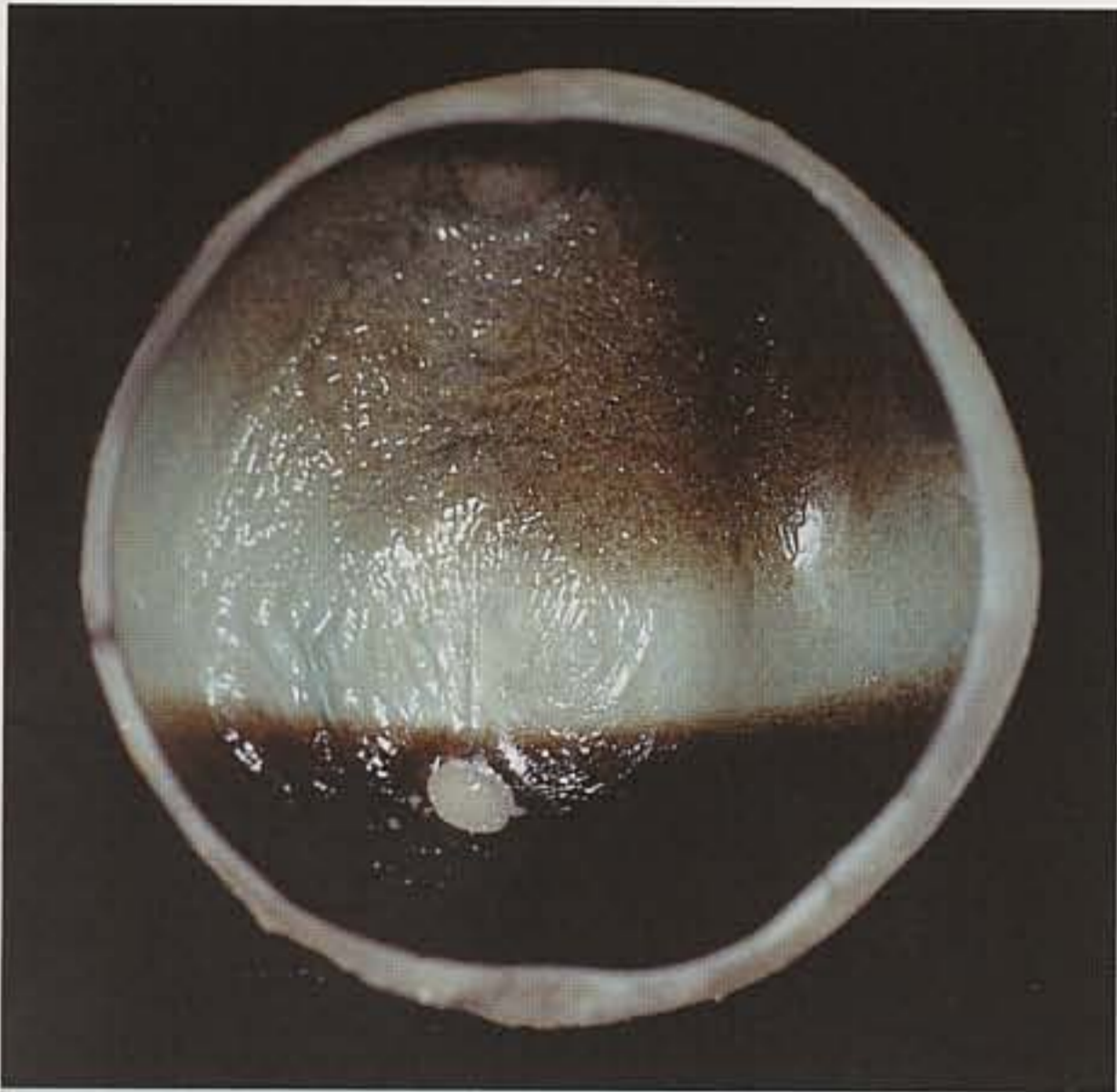

Fig. 11.65 The fundus (Thoroughbred, adult) Posterior segment of the equine eye showing the extent of the tapetal fundus. Compare with Fig 11.1.

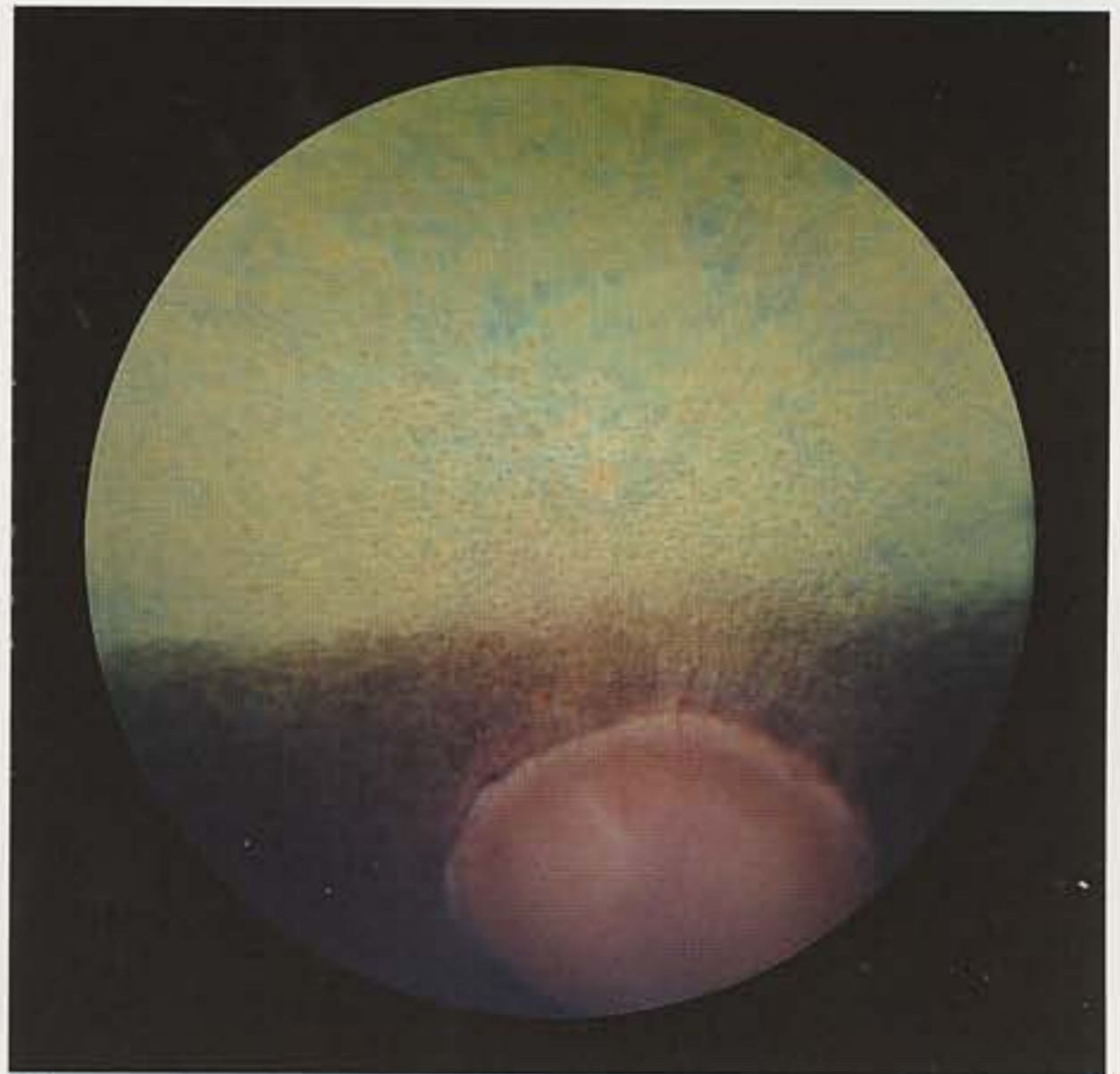


Fig. 11.66 The tapetum (Hunter-type, 6 years old, black) Yellow-green tapetal fundus.

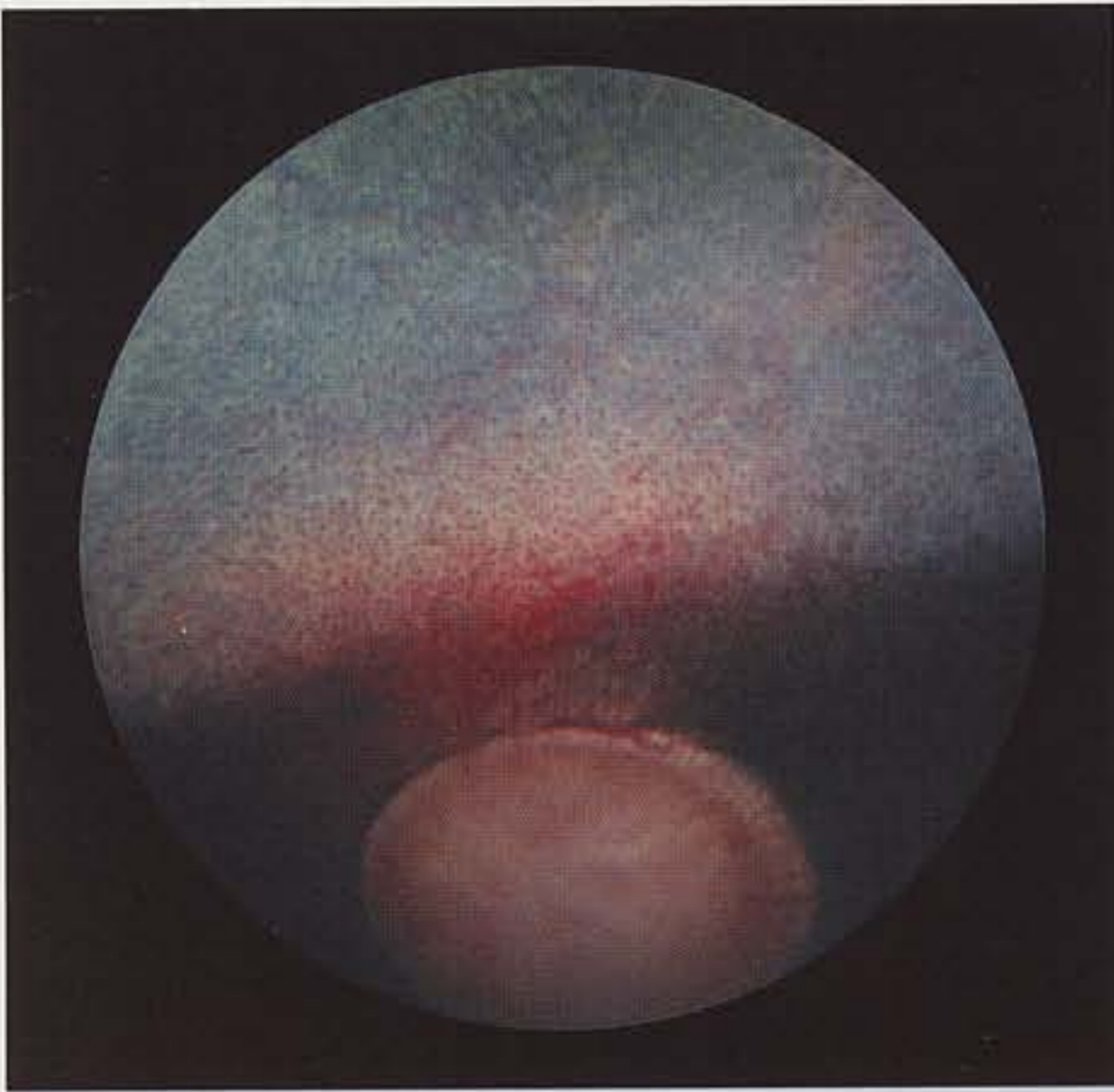

Fig. 11.67 The tapetum (Hunter-type, 6 years old, grey) Blue-lilac tapetal fundus.

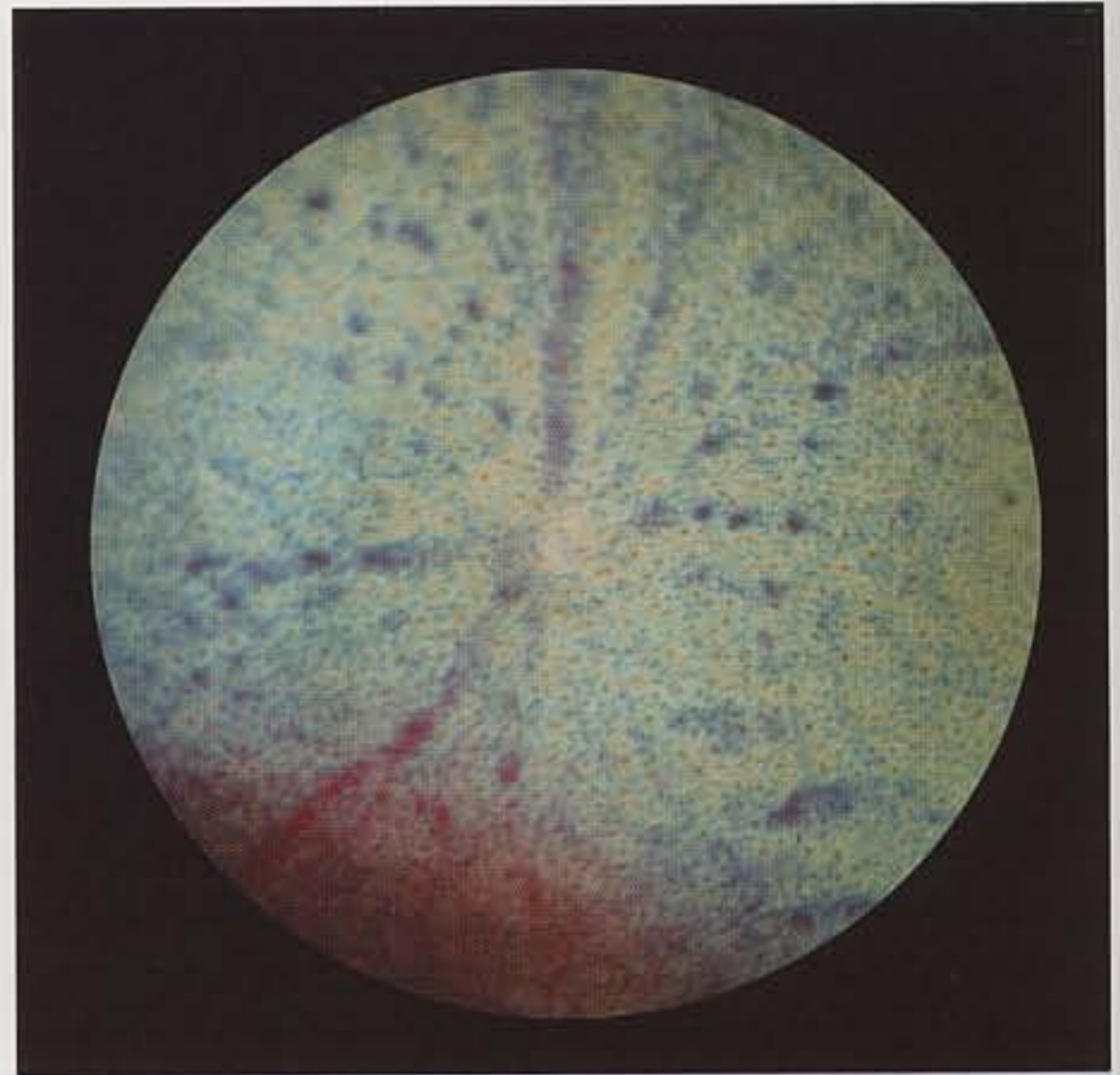


Fig. 11.69 The tapetum (Thoroughbred, 4 years old, chestnut) Pattern due to underlying choroidal vessels.



Fig. 11.68 The tapetum (Welsh pony, 7 years old, blue roan) Two-coloured tapetum (green and yellow).

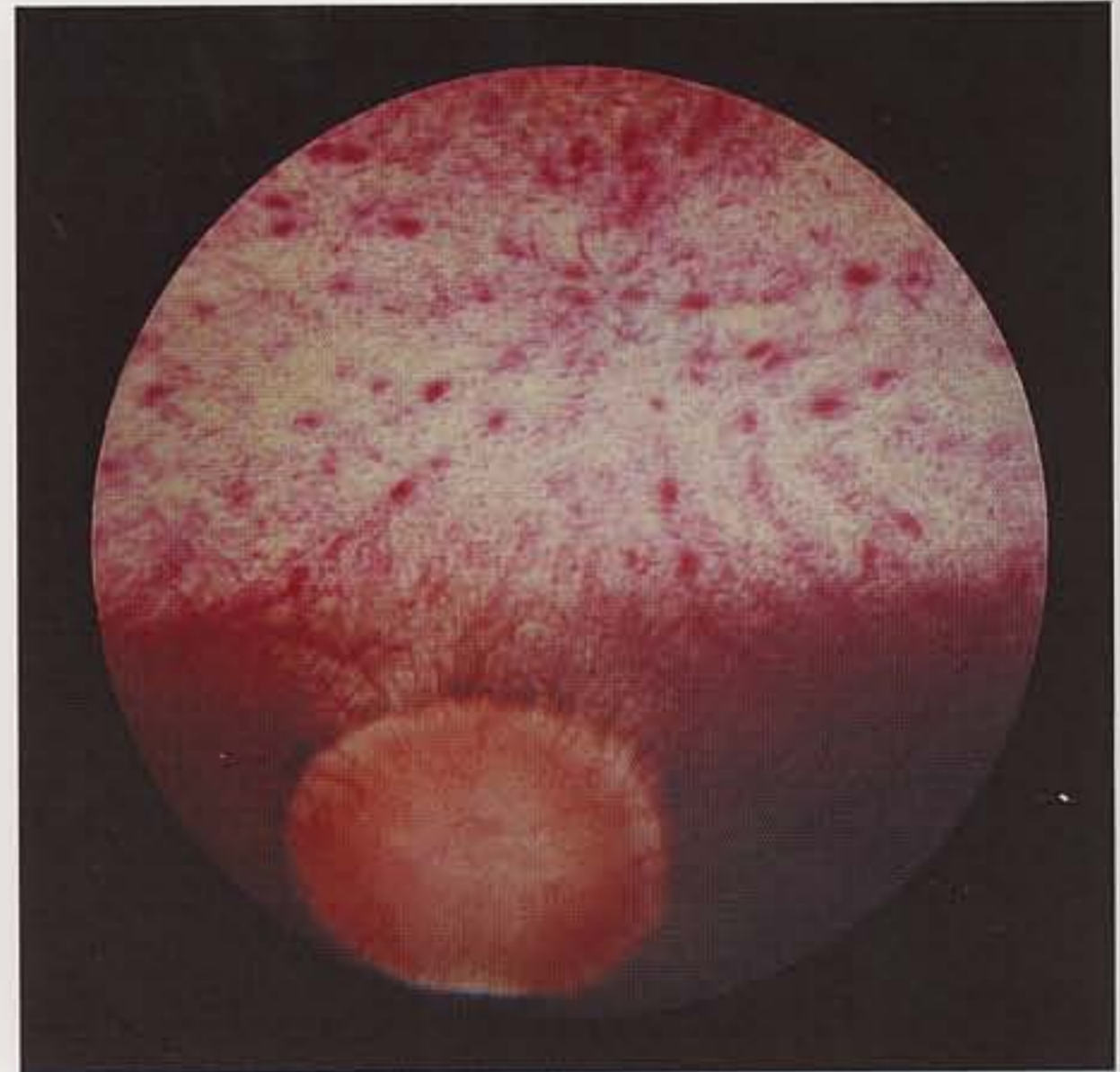


Fig. 11.70 The tapetum (Welsh pony, 1 year old, skewbald) Heterochromic iris; similar pattern to previous figure.

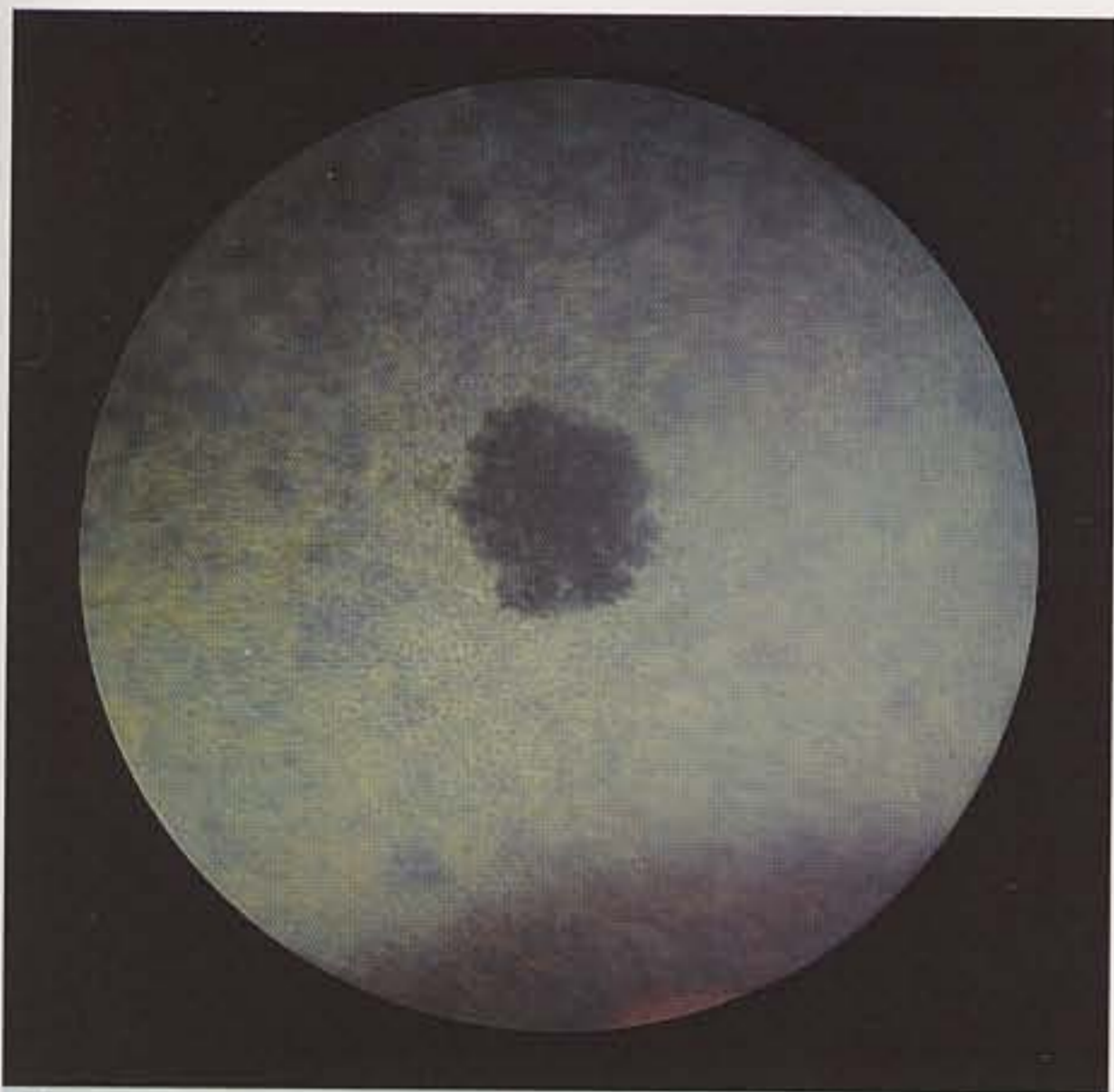


Fig. 11.71 The tapetum (Hunter-type, 6 years old, grey) Island of non-tapetal fundus within the tapetum.

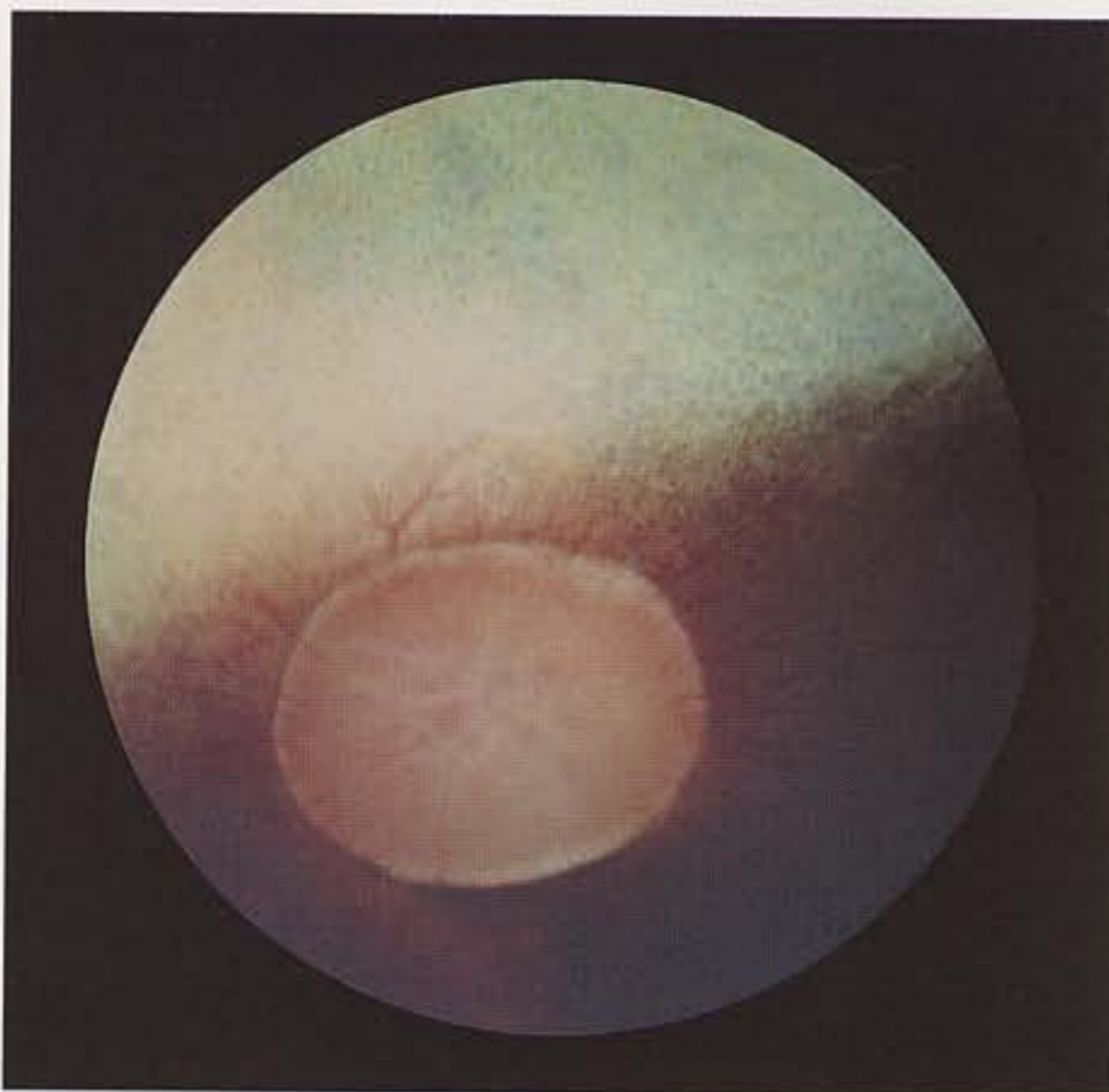

Fig. 11.73 The optic disc (Thoroughbred, 9 years old, bay) Large and in the usual position just inside the non-tapetal fundus.

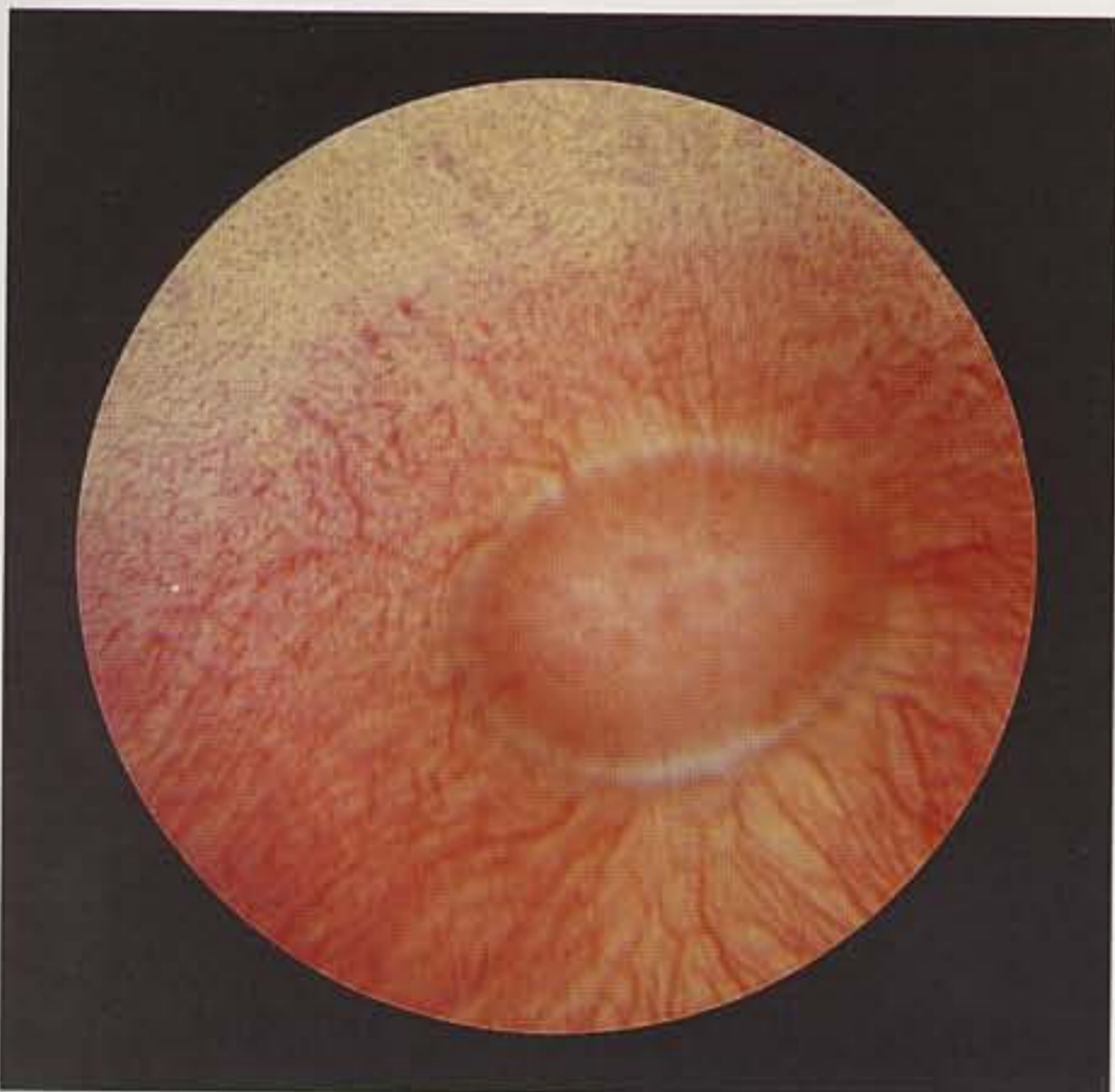

Fig. 11.72 Subalbinism (Palomino  $\times$  albino pony, 8 months old, white) Note the poorly developed tapetum and the visible choroidal vessels in the non-tapetal fundus.

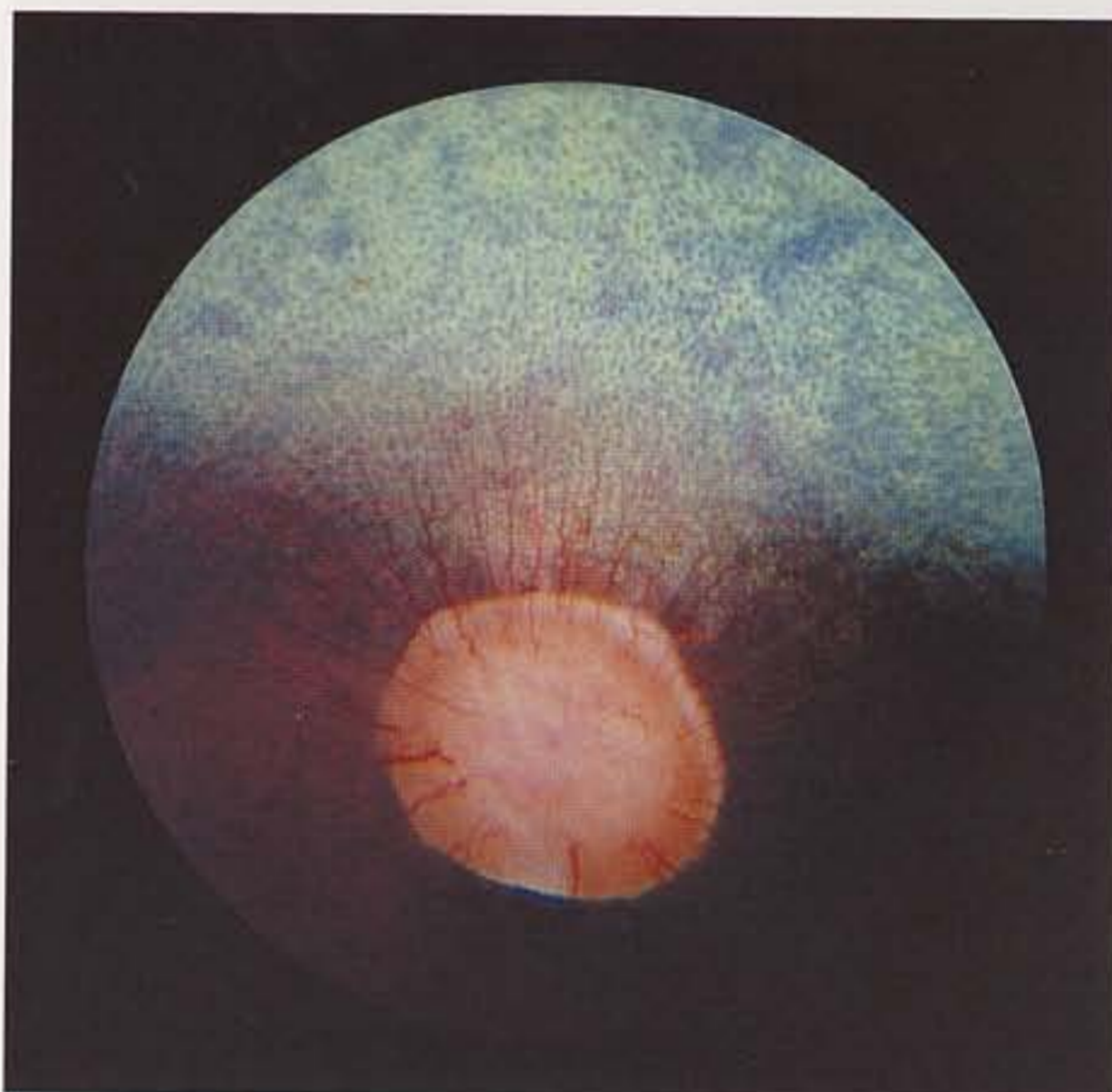

Fig. 11.74 The optic disc (Shetland pony, 4 years old, brown) Small irregular-shaped disc.

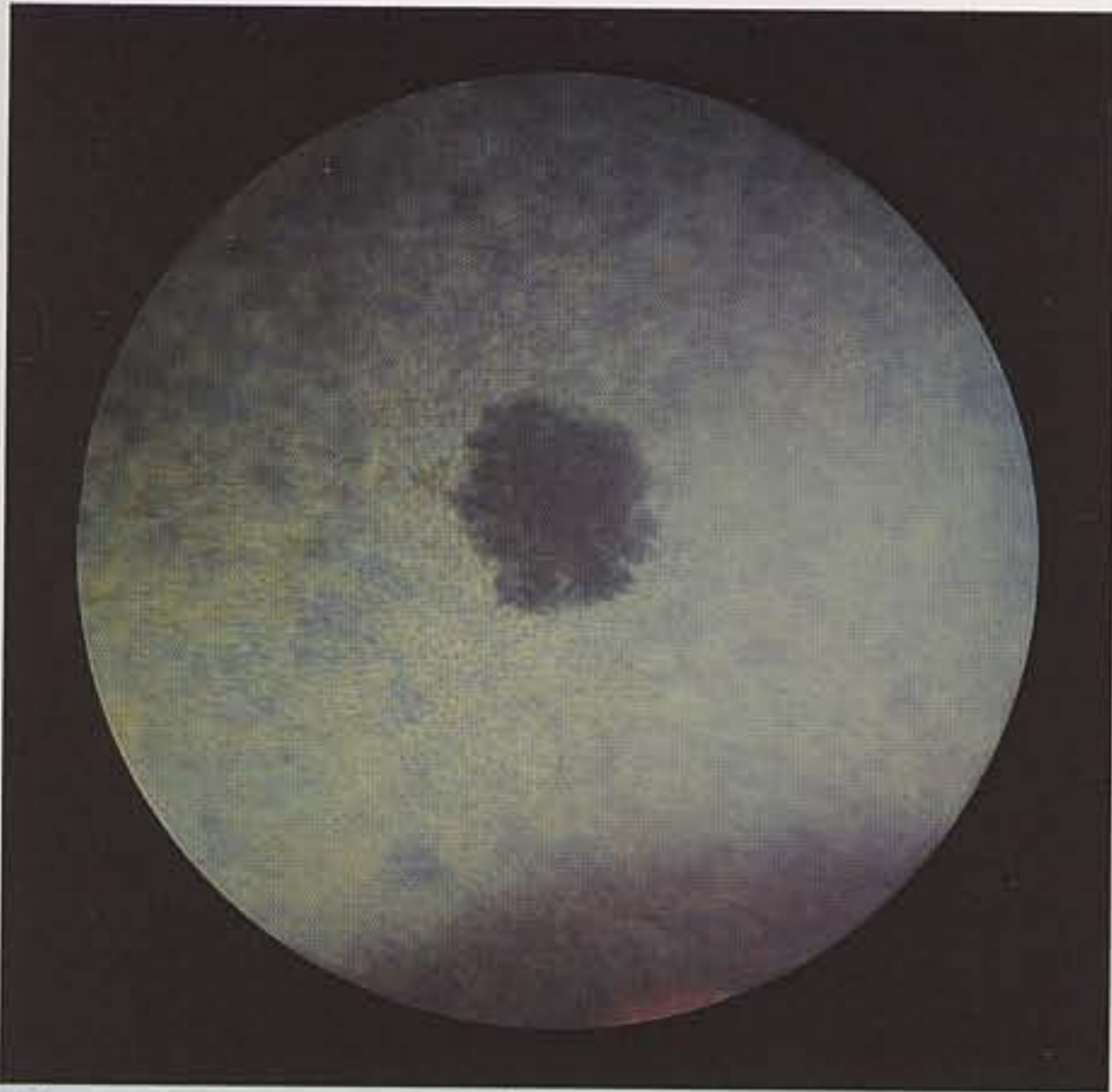


Fig. 11.71 The tapetum (Hunter-type, 6 years old, grey) Island of non-tapetal fundus within the tapetum.

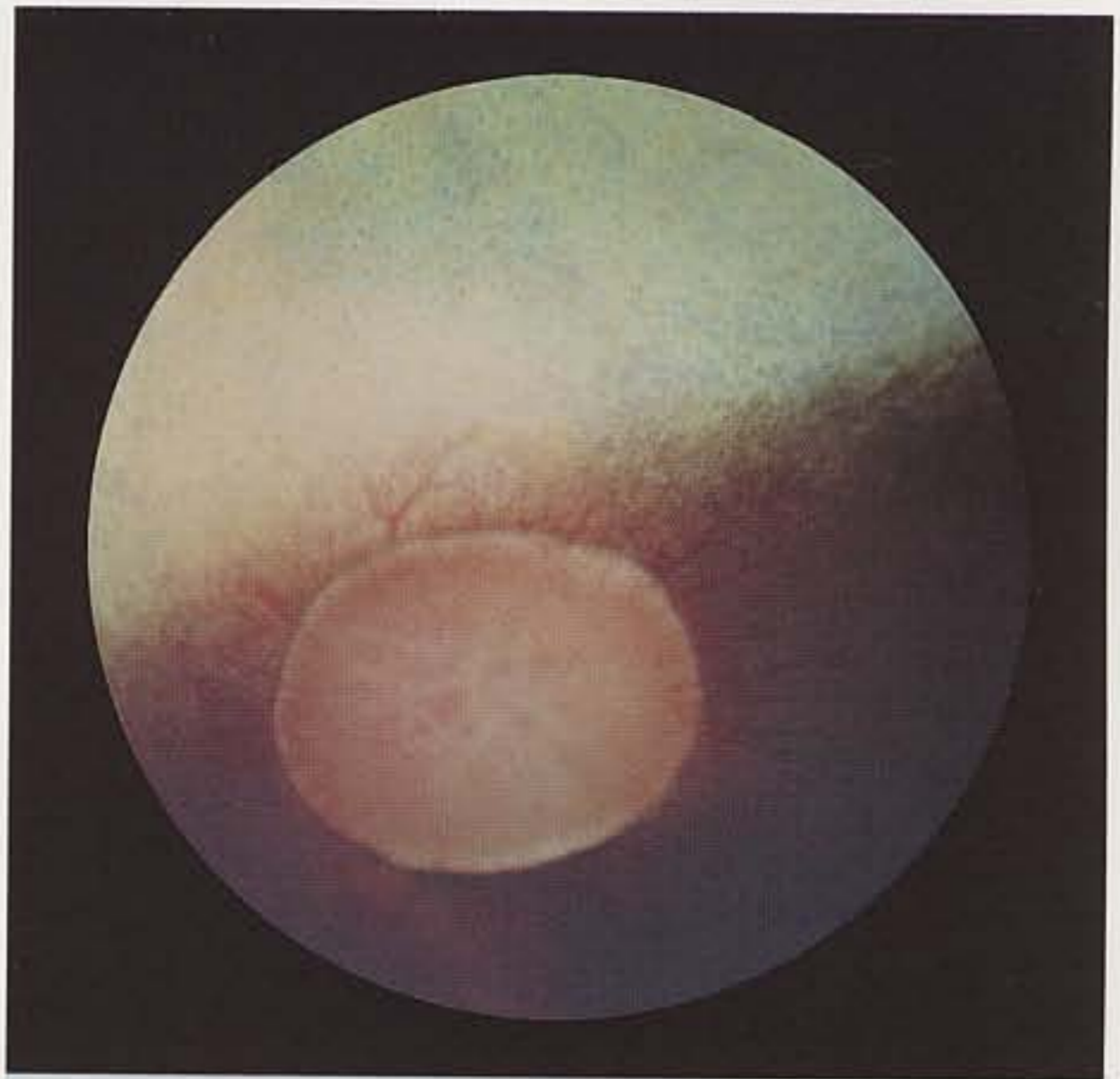


Fig. 11.73 The optic disc (Thoroughbred, 9 years old, bay) Large and in the usual position just inside the non-tapetal fundus.

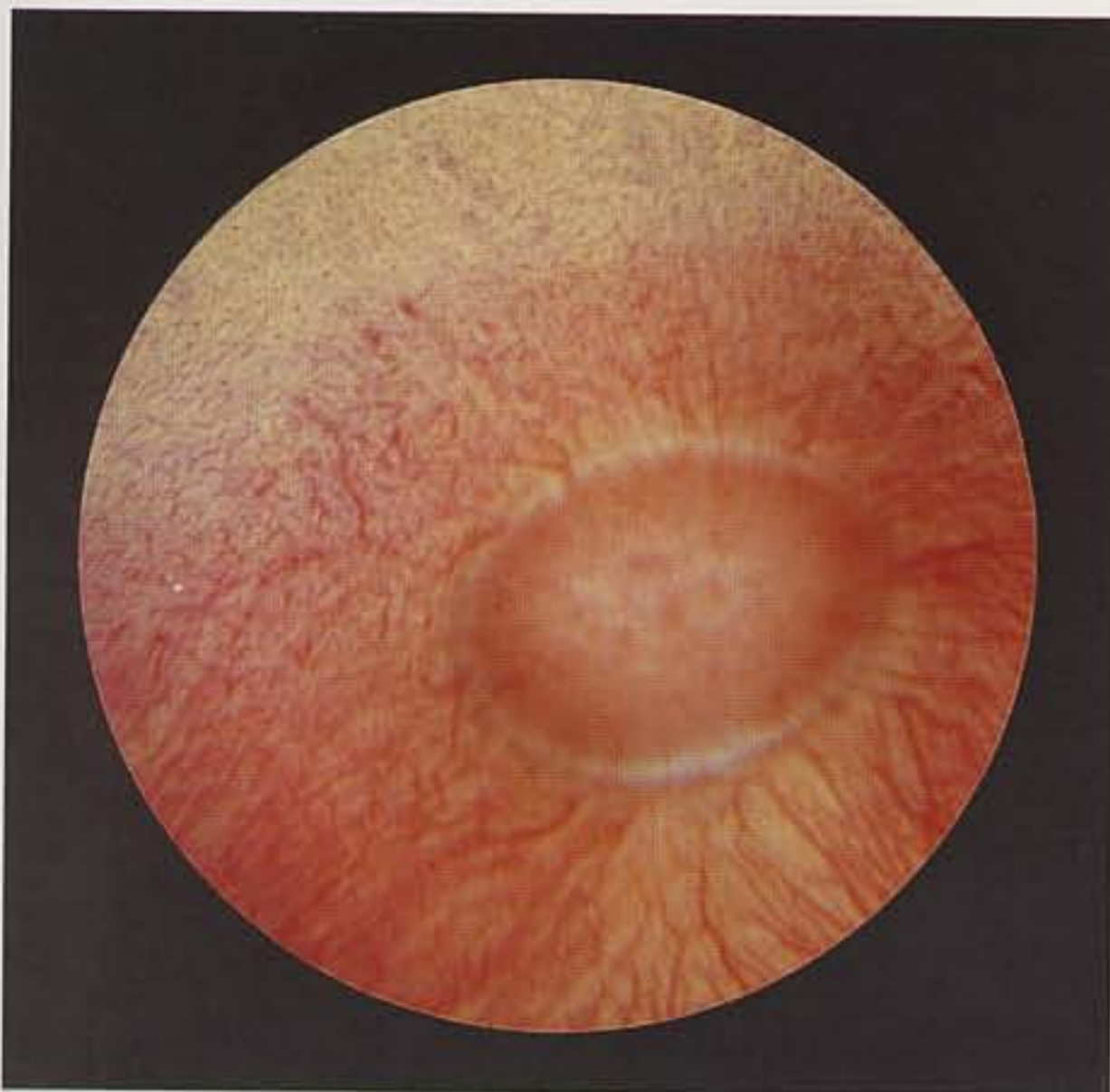

Fig. 11.72 Subalbinism (Palomino x albino pony, 8 months old, white) Note the poorly developed tapetum and the visible choroidal vessels in the non-tapetal fundus.

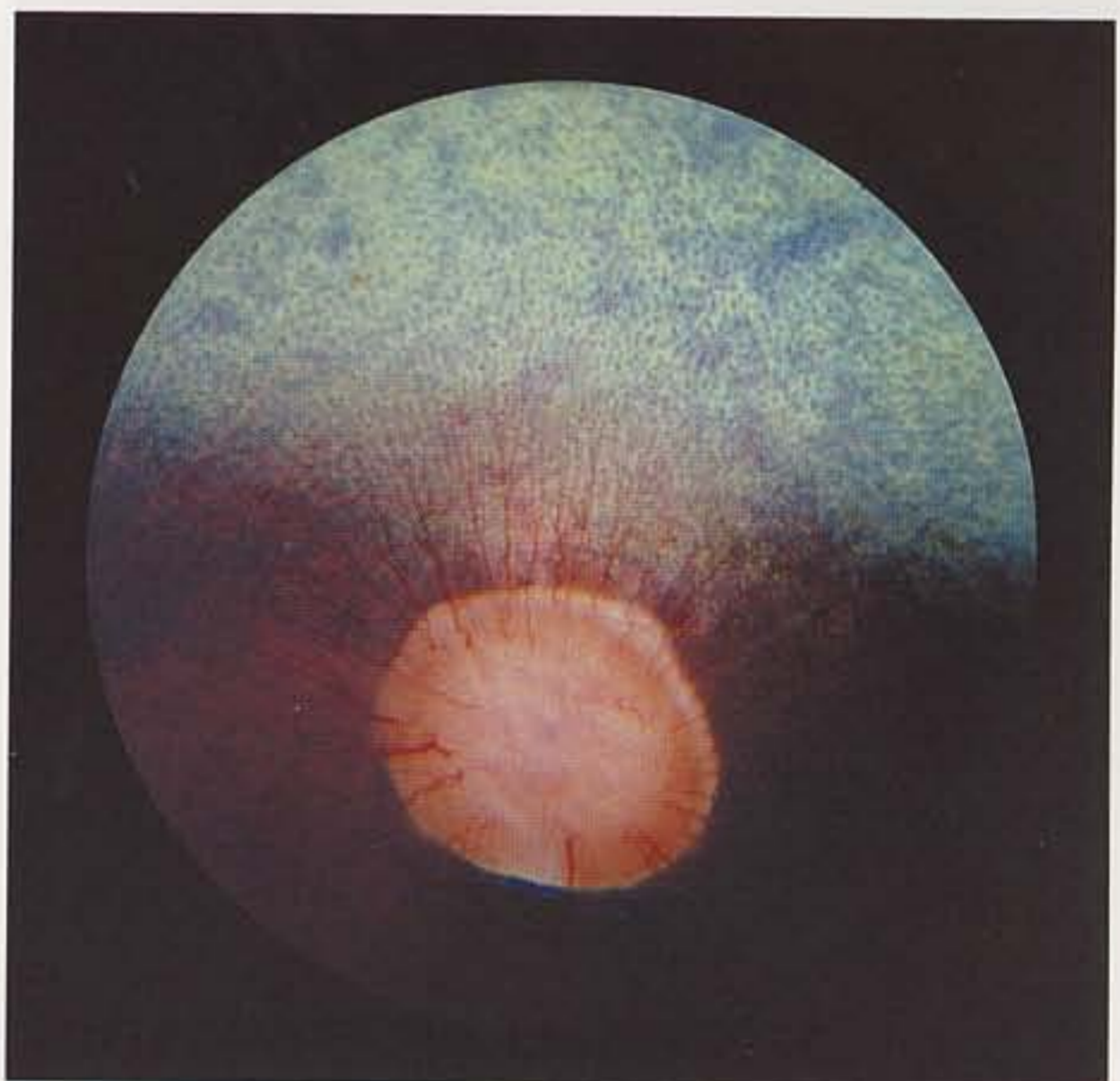

Fig. 11.74 The optic disc (Shetland pony, 4 years old, brown) Small irregular-shaped disc.

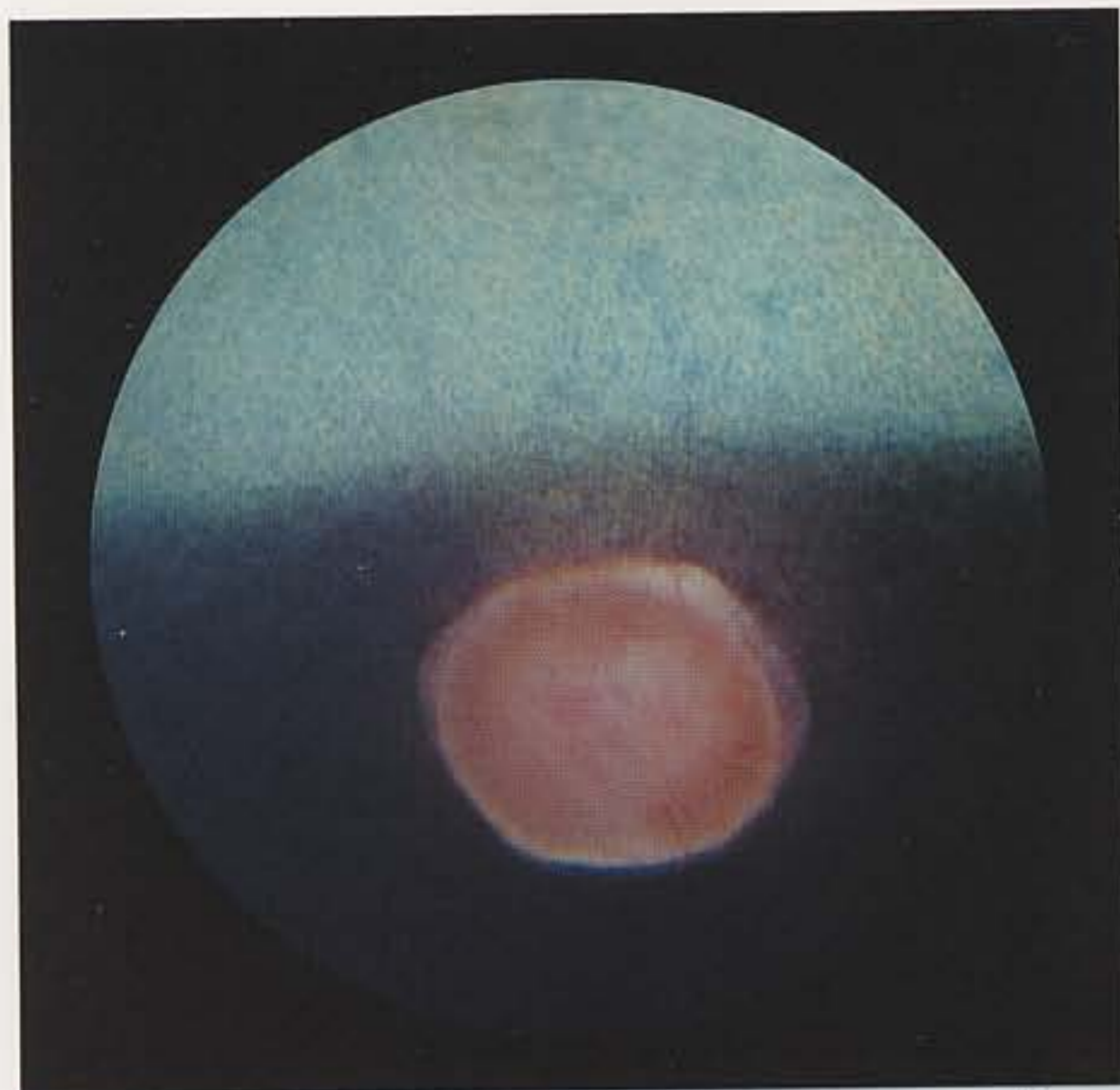


Fig. 11.75 The optic disc (Thoroughbred, 1 year old, chestnut) Disc with a double edge in places.

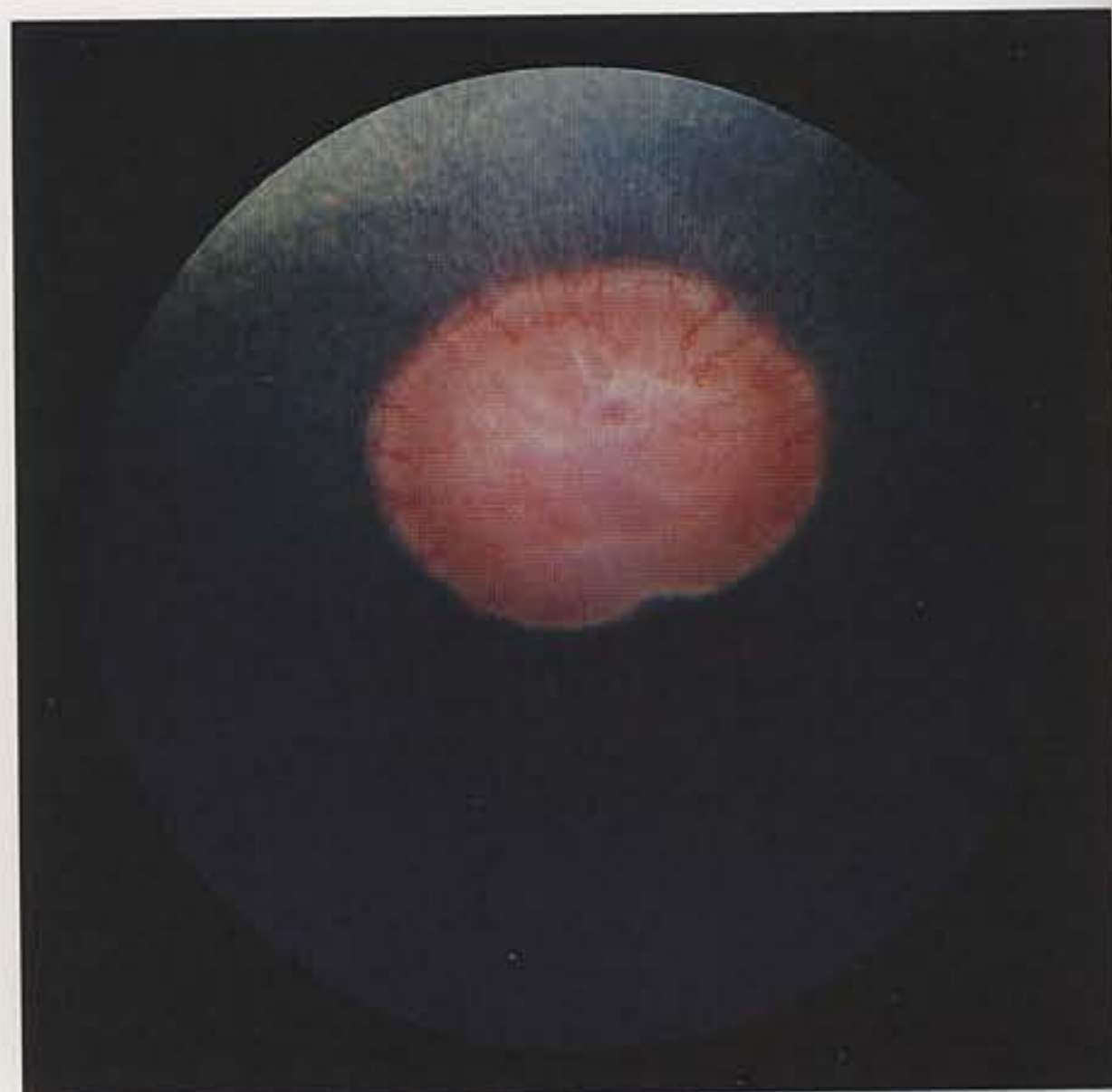

Fig. 11.77 The optic disc (Thoroughbred, 3 years old, chestnut) Indentation along the lower border of the disc.

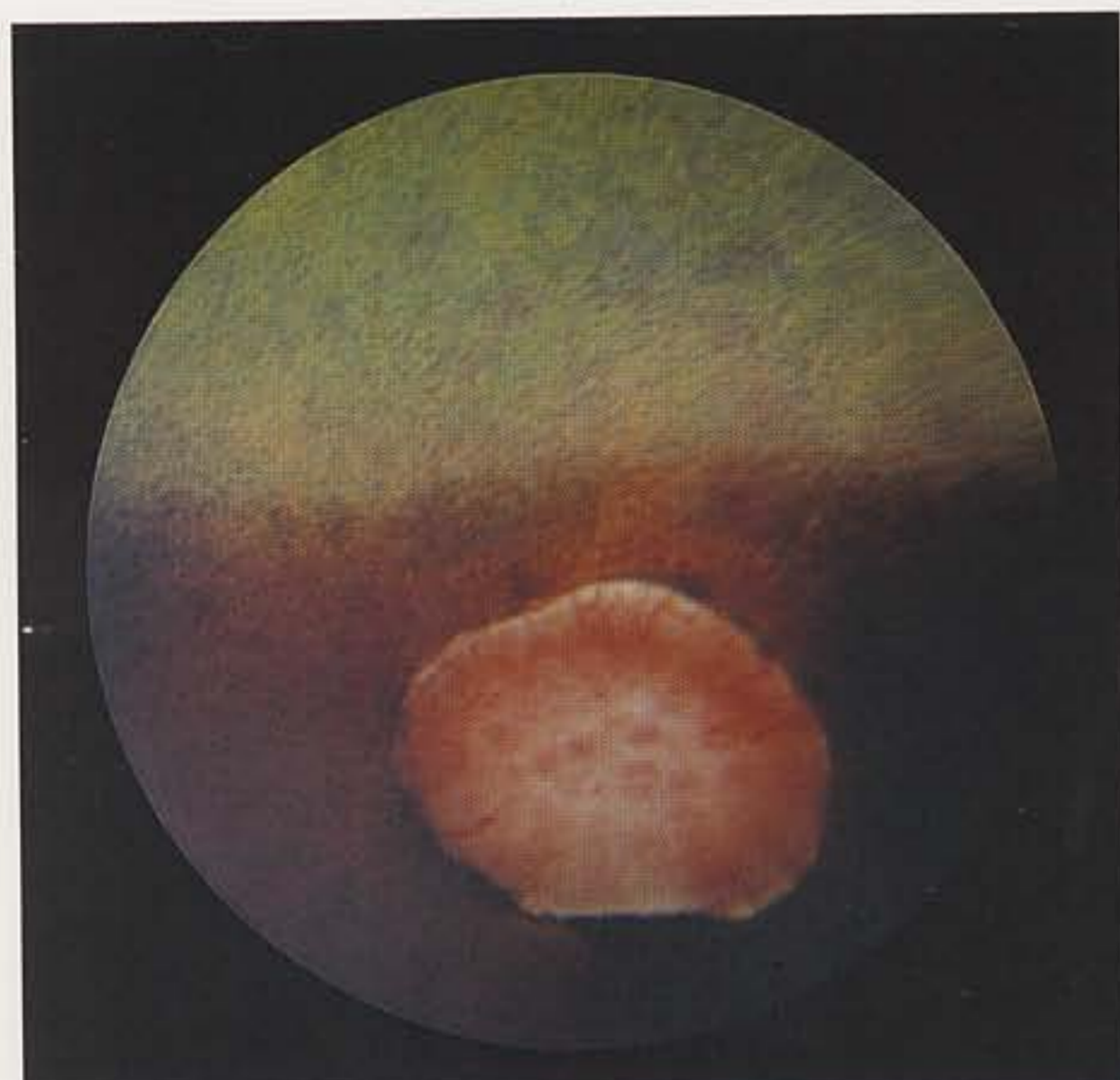

Fig. 11.76 The optic disc (Pony, 15 years old, skewbald) Dark red disc with heavy pigment along the base.

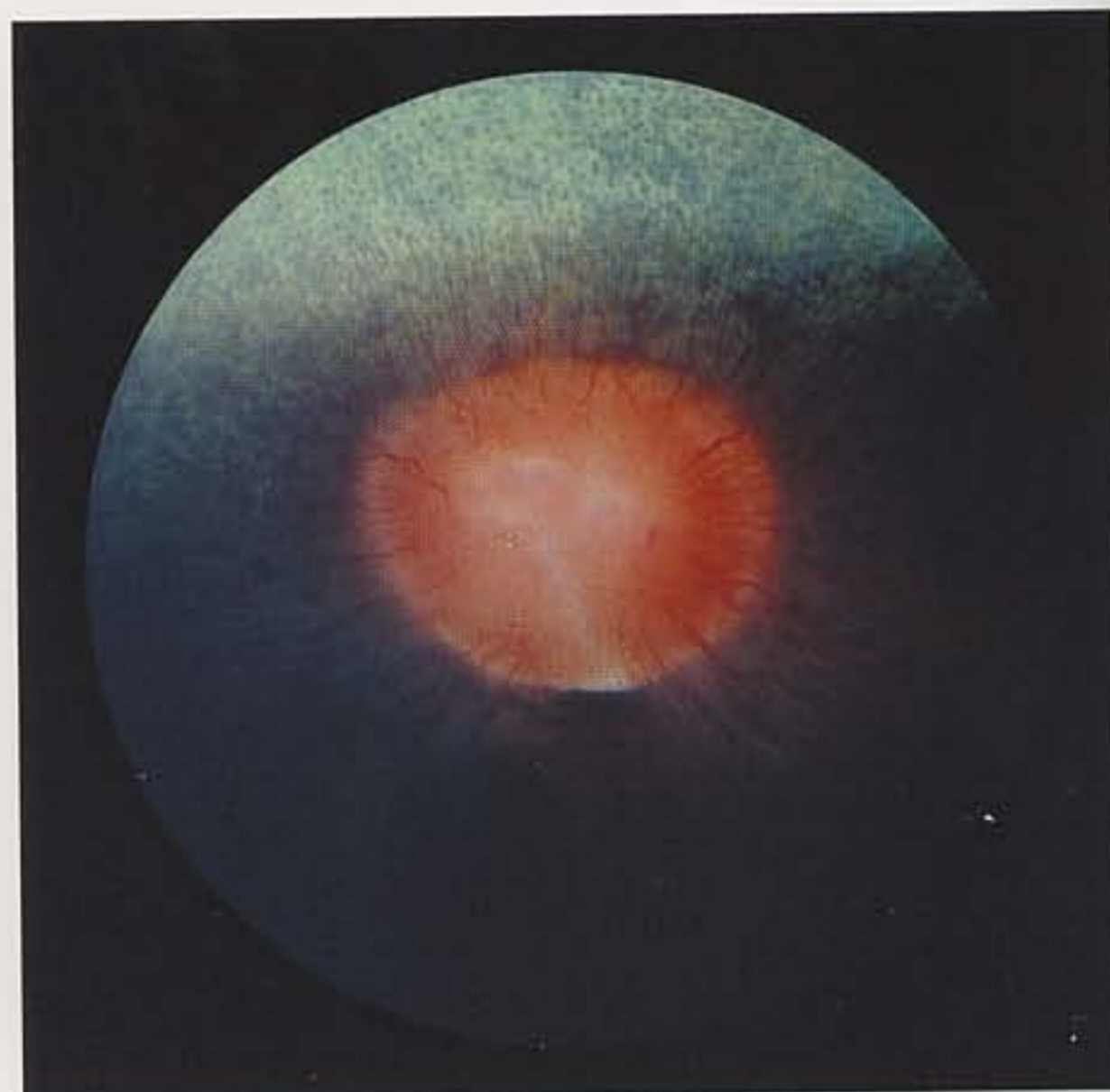


Fig. 11.78 The optic disc (Thoroughbred, 1 year old, bay) Faint medullated nerve fibres around the disc, giving a halo-like effect.

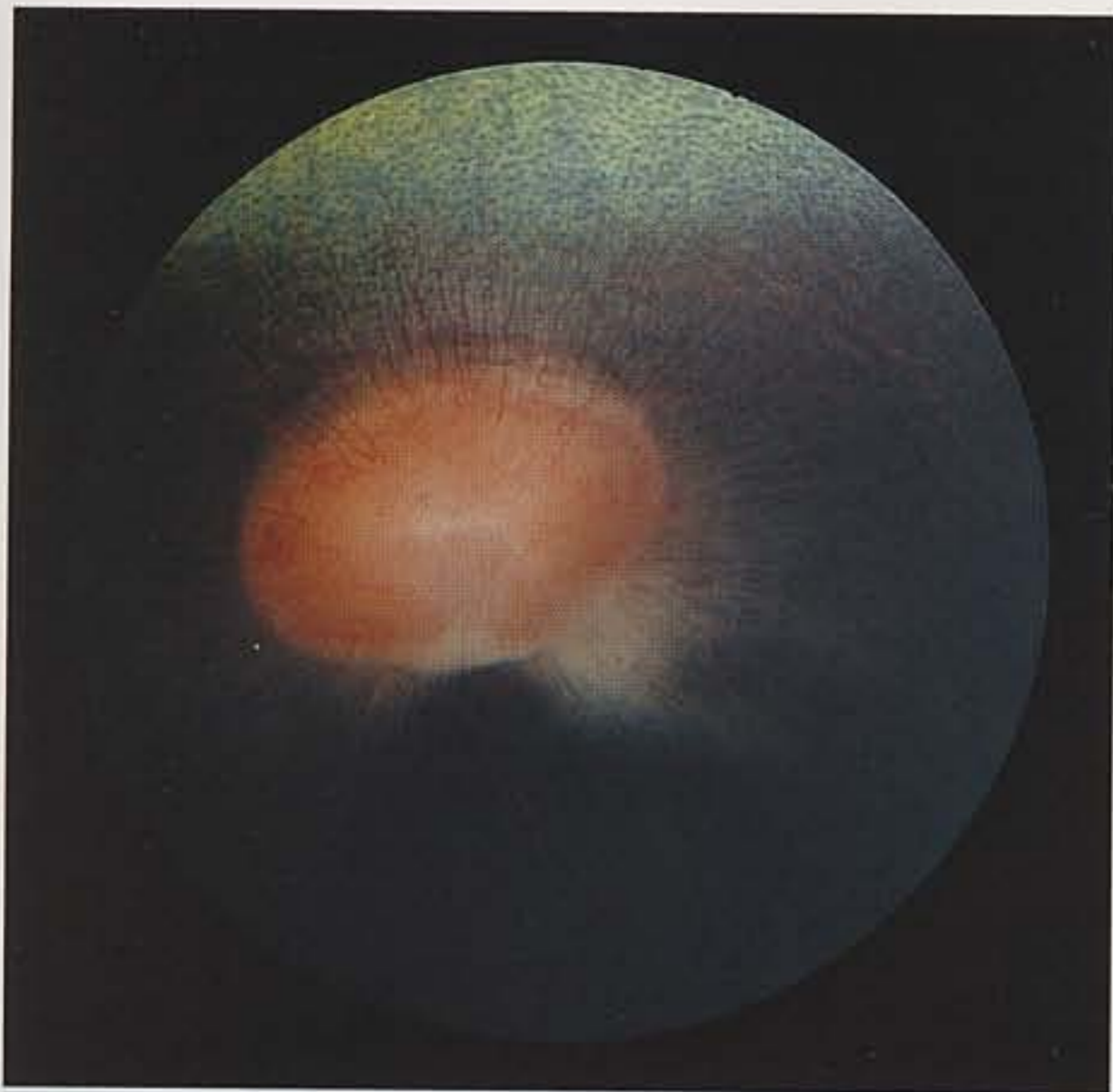

Fig. 11.79 The optic disc (Welsh pony, 8 years old, roan) Medullated nerve fibres particularly at the inferior lateral angle.

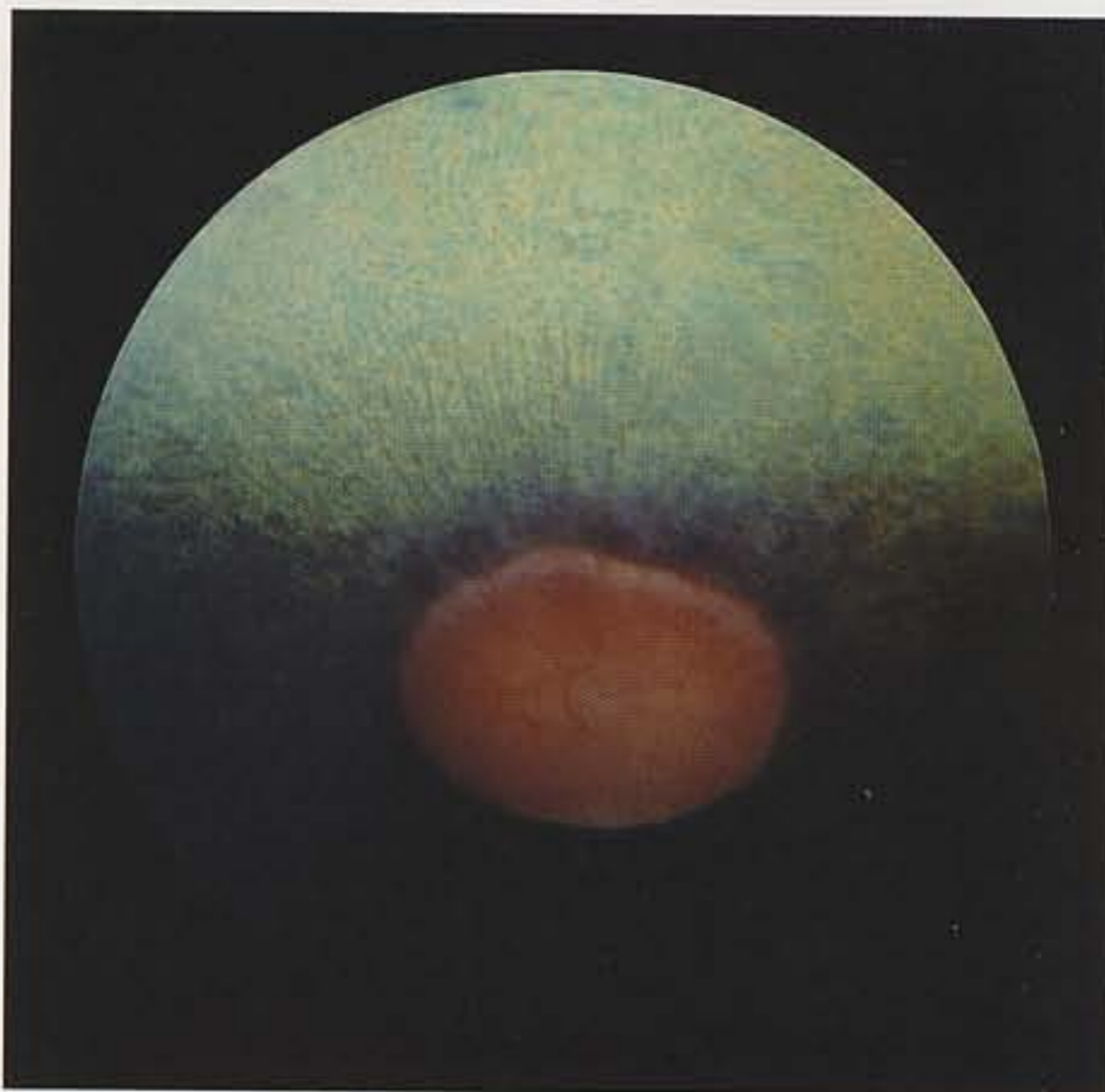

Fig. 11.81 The fundus (donkey, young adult)

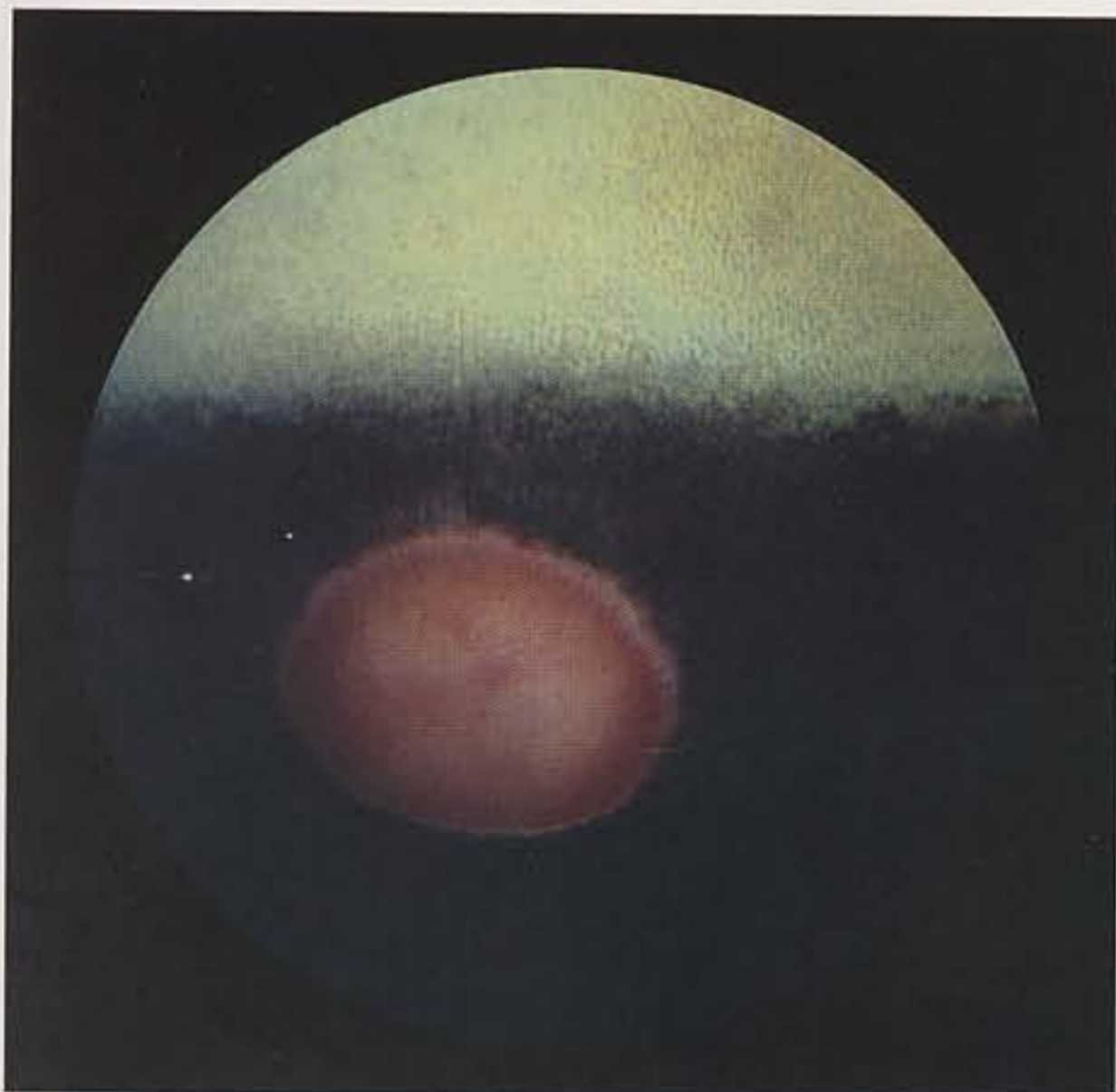

Fig. 11.80 The fundus (Thoroughbred foal, 1 day old) Note the similarity to the adult fundus in this species and compare with the dog in the 'Development of the canine fundus' section (Figs 11.45-11.52).

### The normal bovine and ovine fundus (Figs 11.82-11.91)

The ocular fundus of the cow and sheep are similar but quite unlike the previous species described. Usually a tapetum is present and the non-tapetal fundus is pigmented and dark. The optic disc occurs at about the junction; in the bovine it is more or less circular and the ovine disc tends to be kidney-shaped. The colour of the disc varies from pale pink to dense white, depending upon myelination of the optic nerve fibres. In a number of cases the disc appears dark grey and pronounced myelination is rare. The retinal blood vessels show the greatest difference to the dog, cat and horse. The veins are large, relatively straight and dark bluish-red; the arteries narrower and with a distinct white reflective line along their course and bright red in colour. The difference between vein and artery is obvious in these species. The fundus of the calf and lamb is as in the adult.



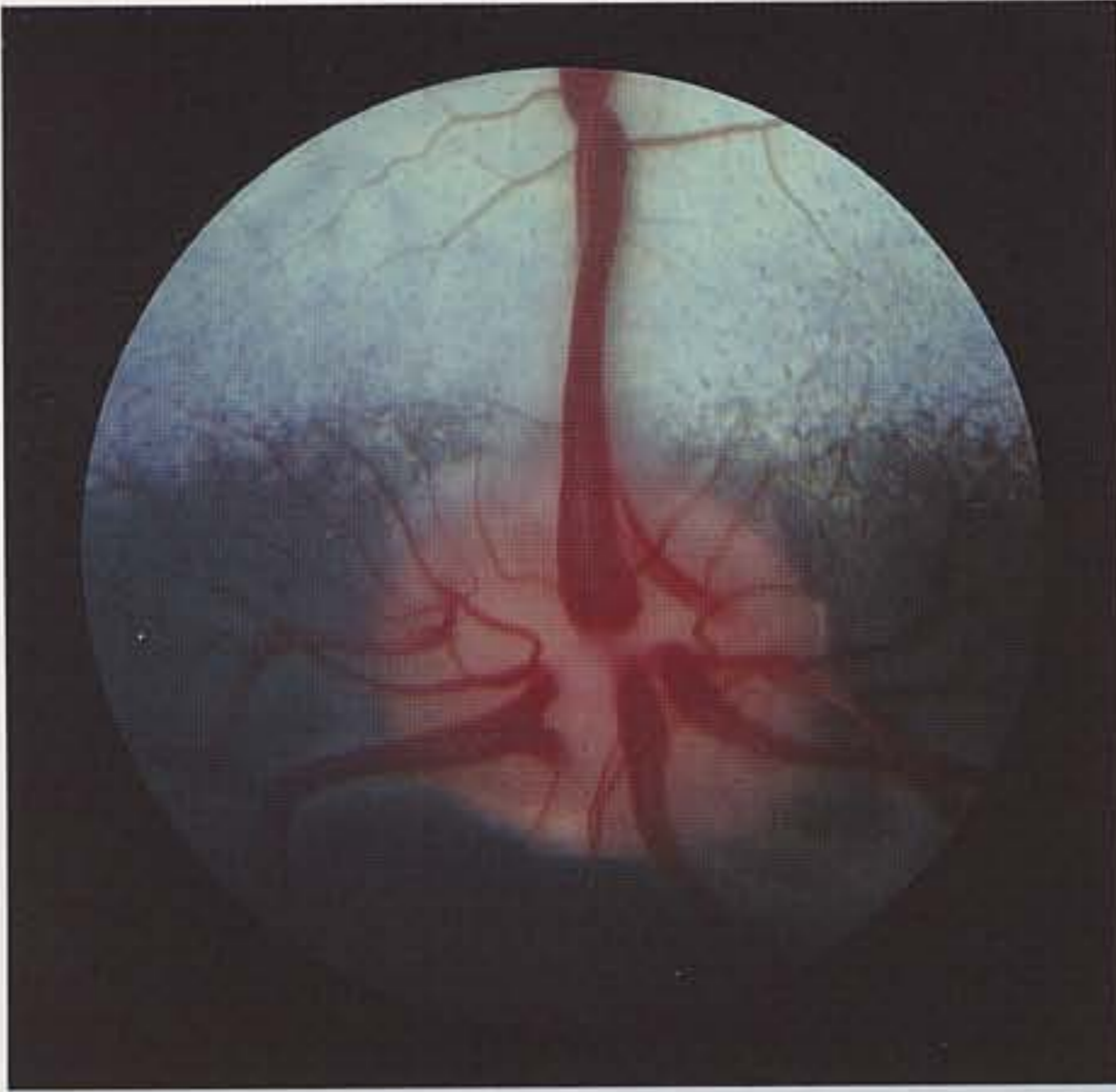


Fig. 11.82 The fundus (Shorthorn calf) Note the obvious difference between artery and vein.

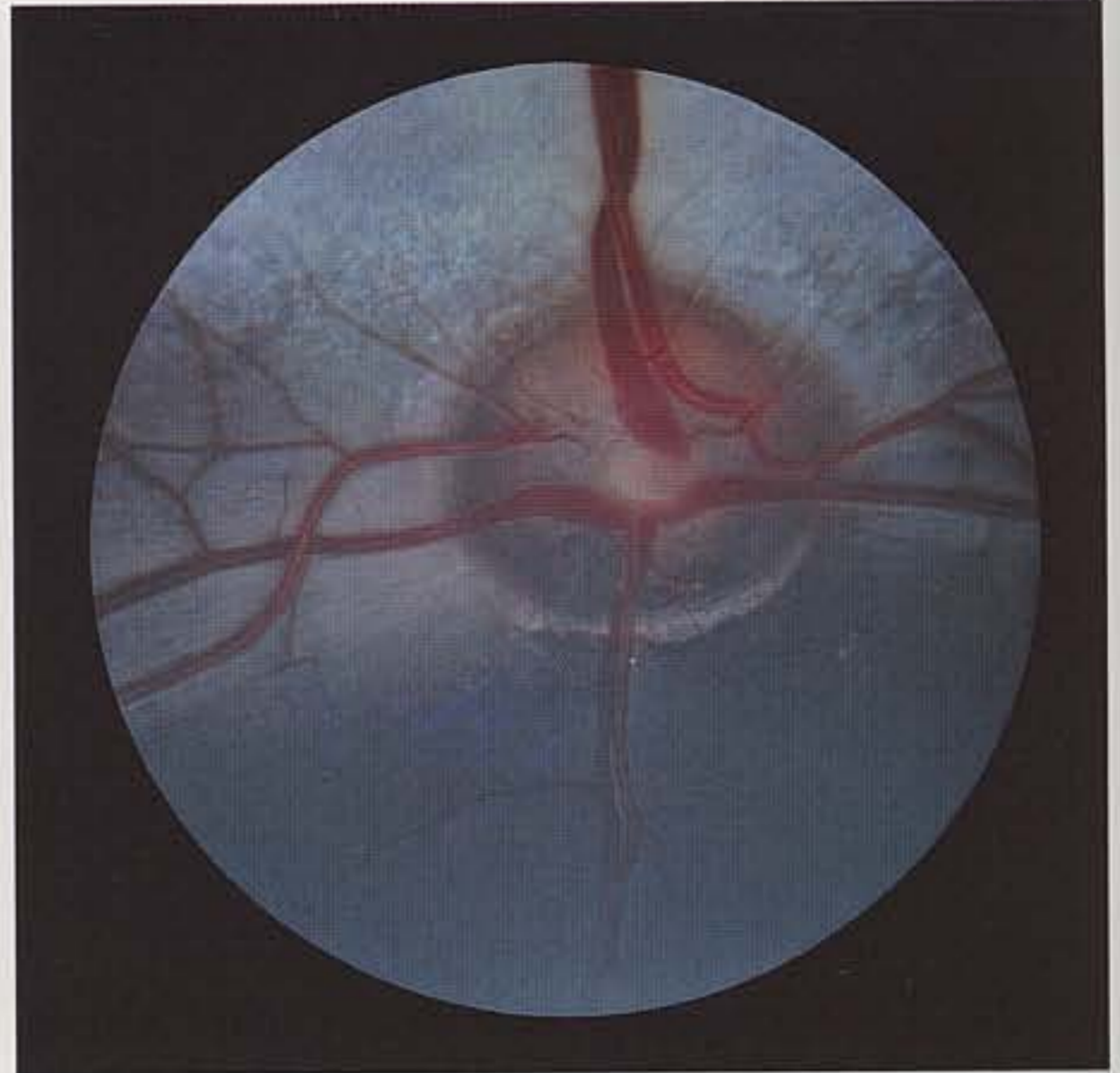


Fig. 11.84 The fundus (Jersey cow) Note the dark colour of the disc.

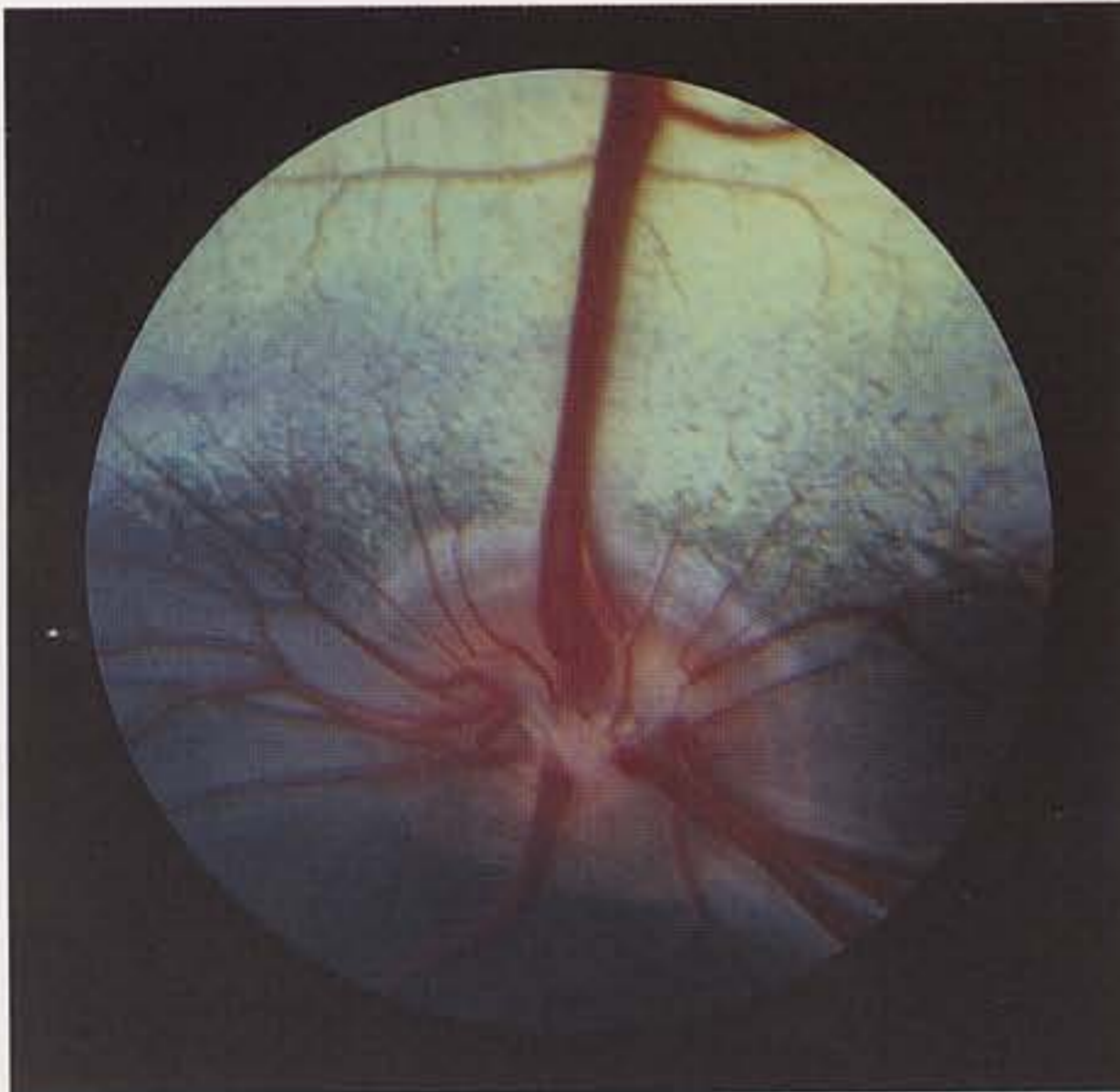


Fig. 11.83 The fundus (Shorthorn calf) Note the conus vestigialis in the centre of the disc.

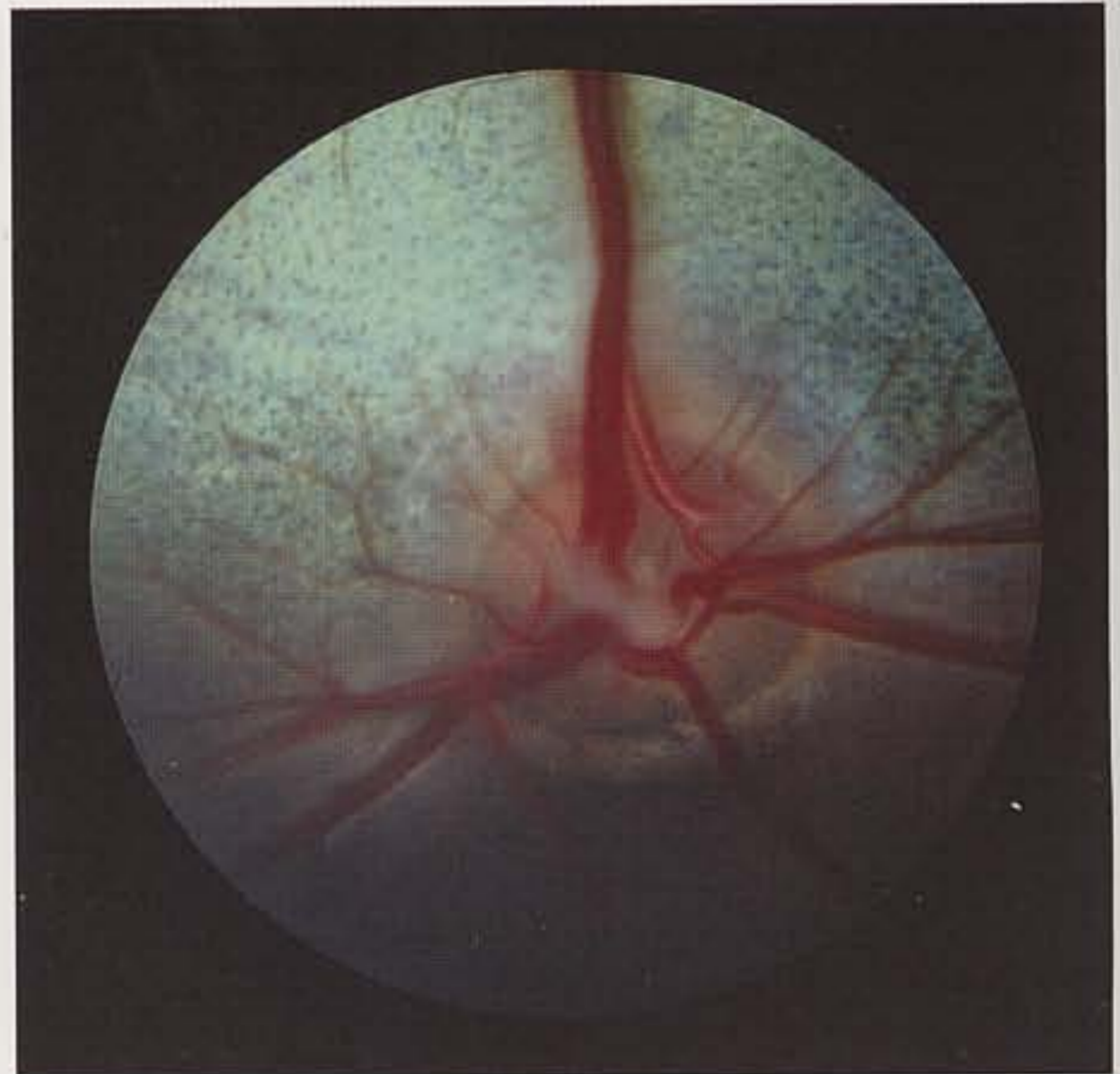

Fig. 11.85 The fundus (Charolais calf) Note the absence of medullated fibres in this young animal.

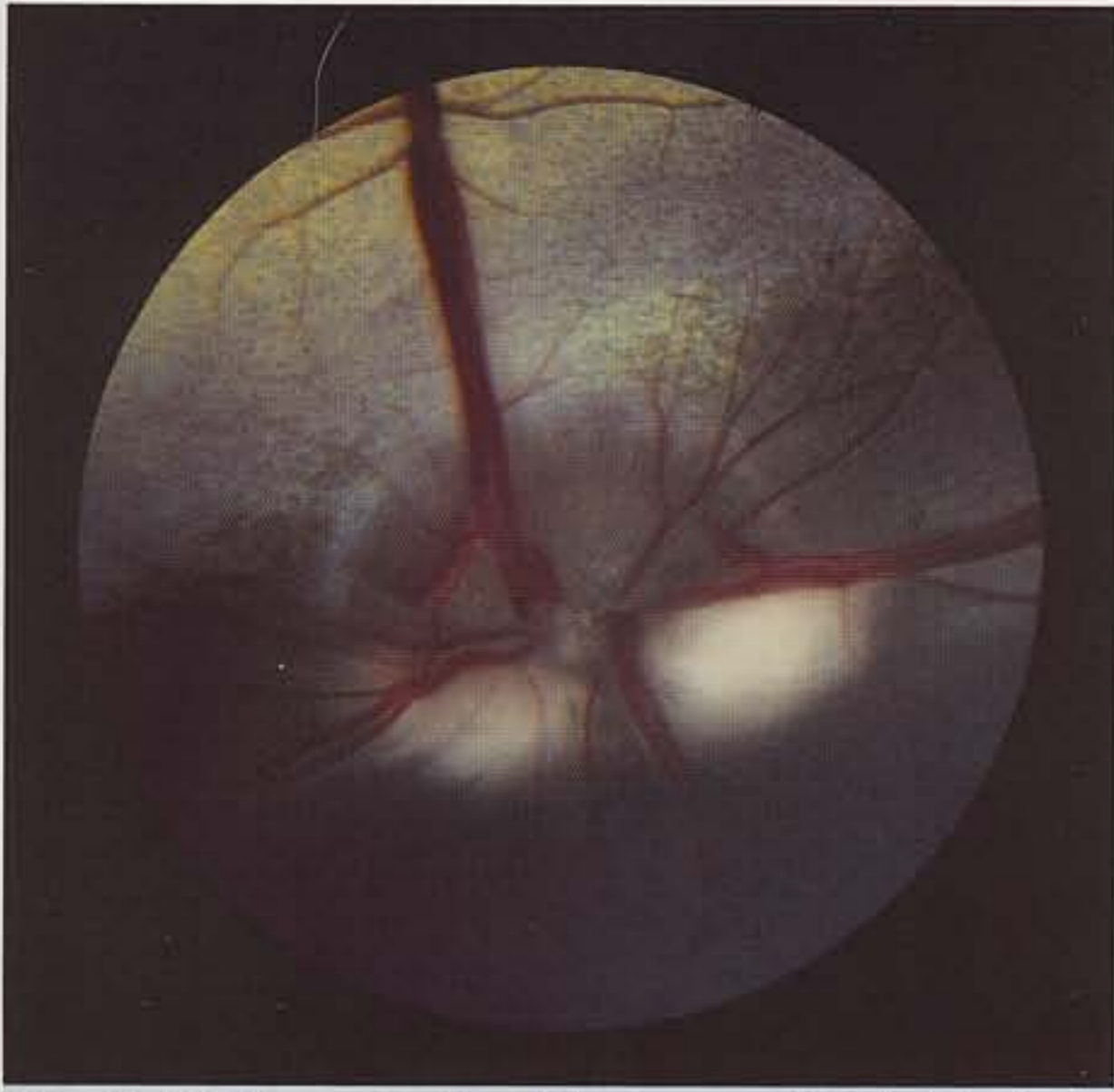


Fig. 11.86 The optic disc (Friesian cow) Medullated fibres in the lower part of the optic disc. Unusual.

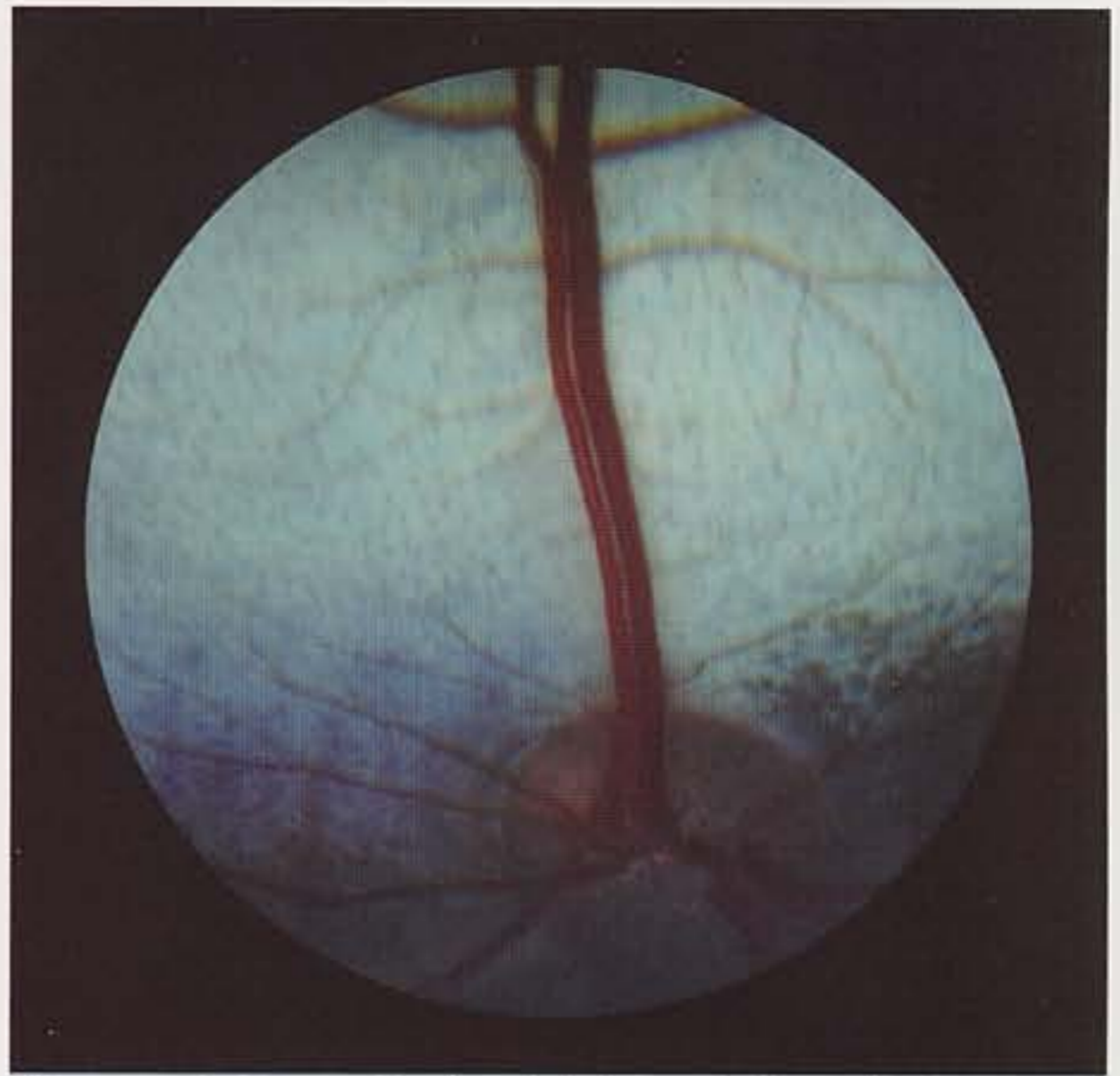


Fig. 11.88 Sheep fundus (adult ewe) Note similarity to the bovine fundus with obvious difference between artery and vein.

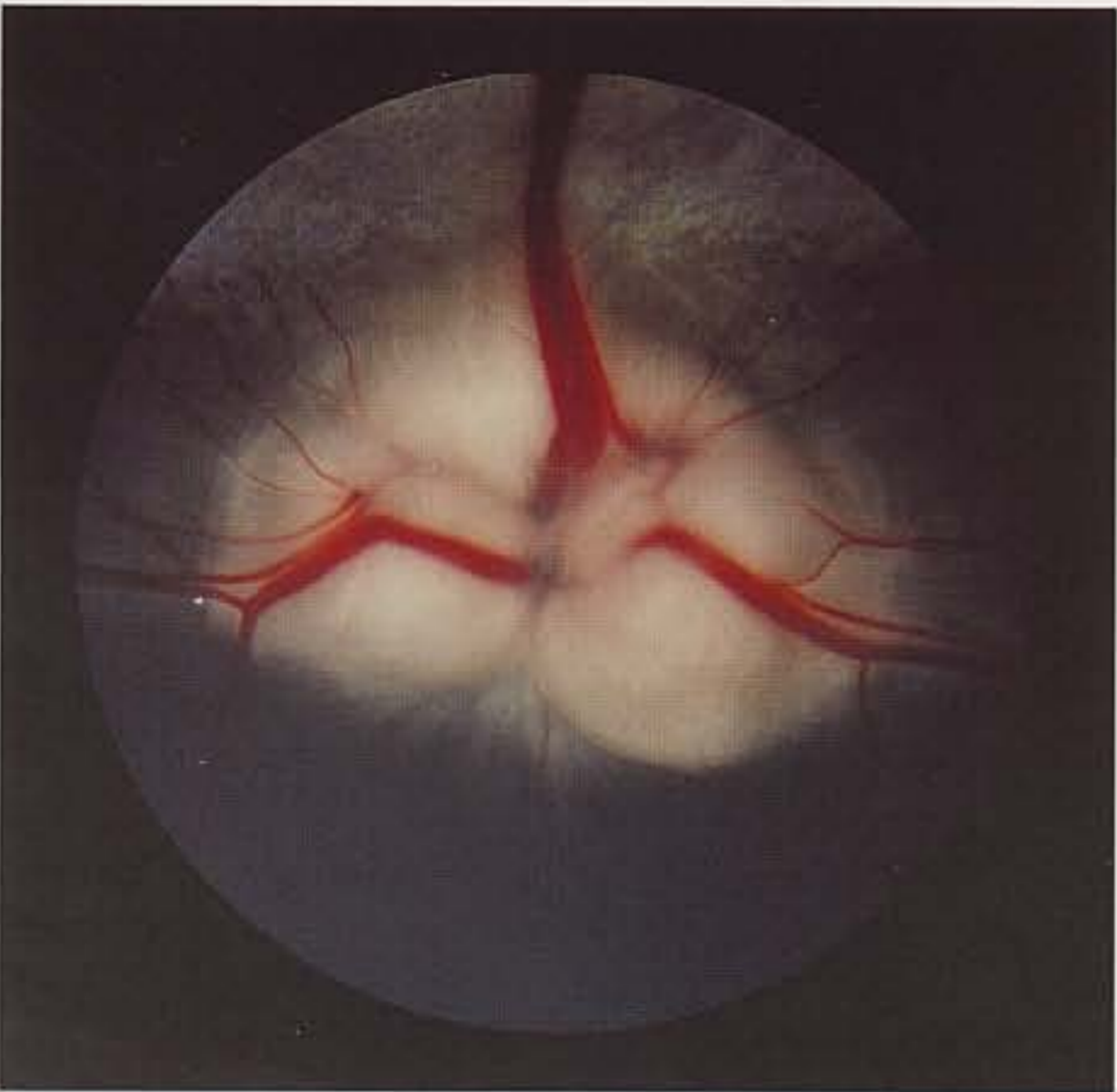


Fig. 11.87 The optic disc (Friesian cow) Medullated fibres of the whole optic disc. Unusual.

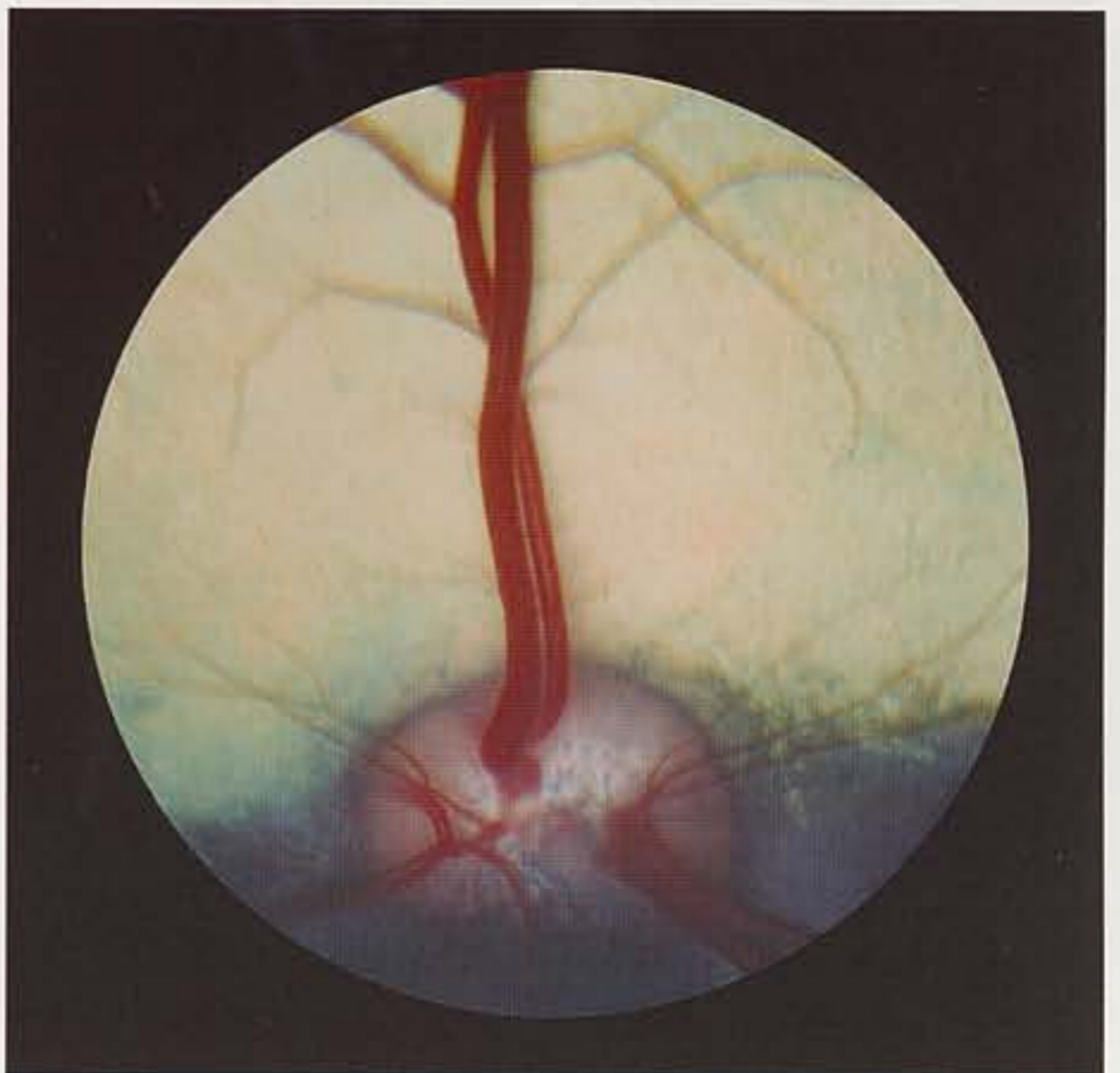


Fig. 11.89 Sheep fundus (adult ewe) Note the difference in colour of the optic disc with the previous figure (Fig 11.88).

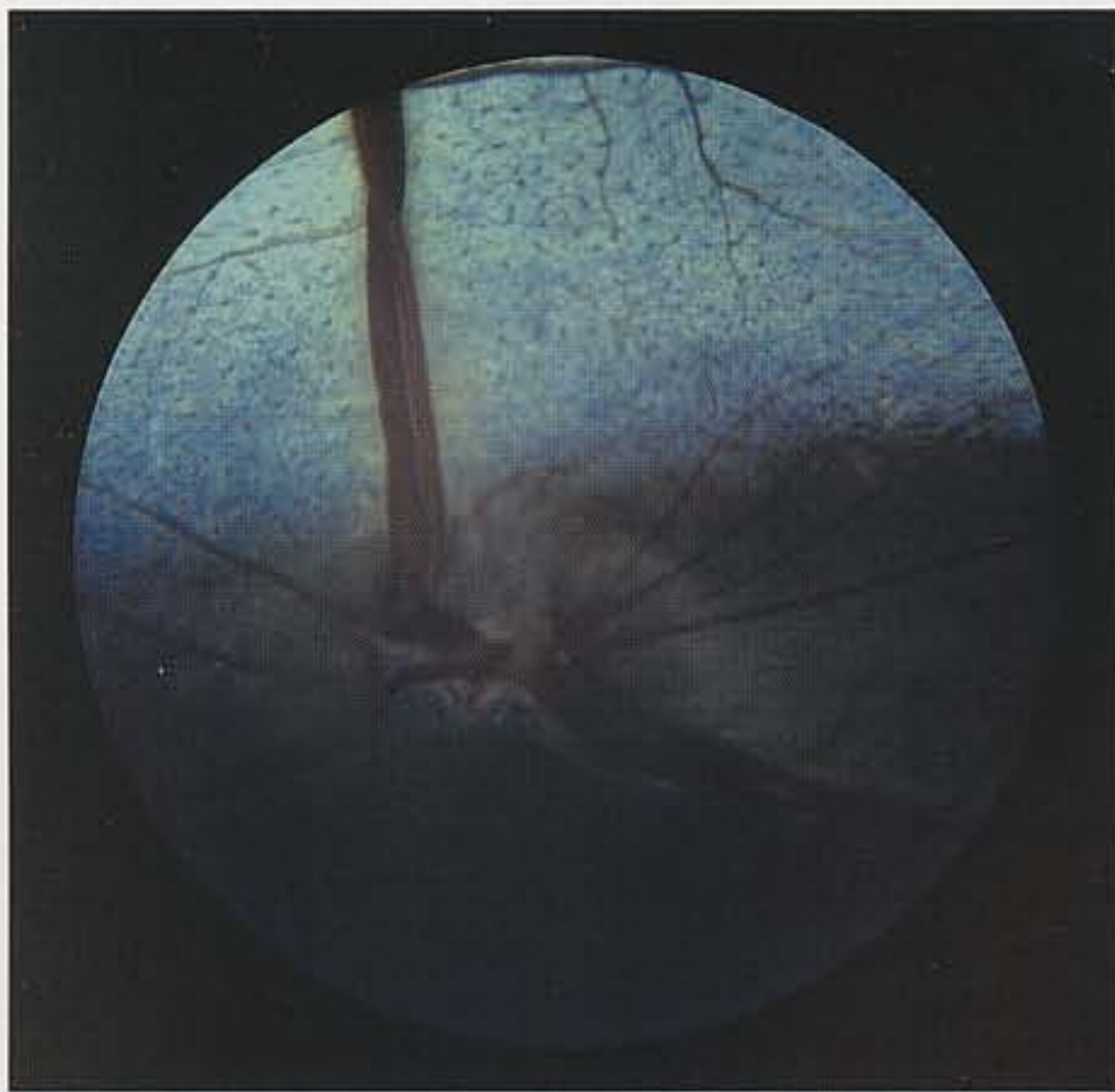


Fig. 11.90 Sheep fundus (Clun cross, adult ewe) Non-medullated optic disc.

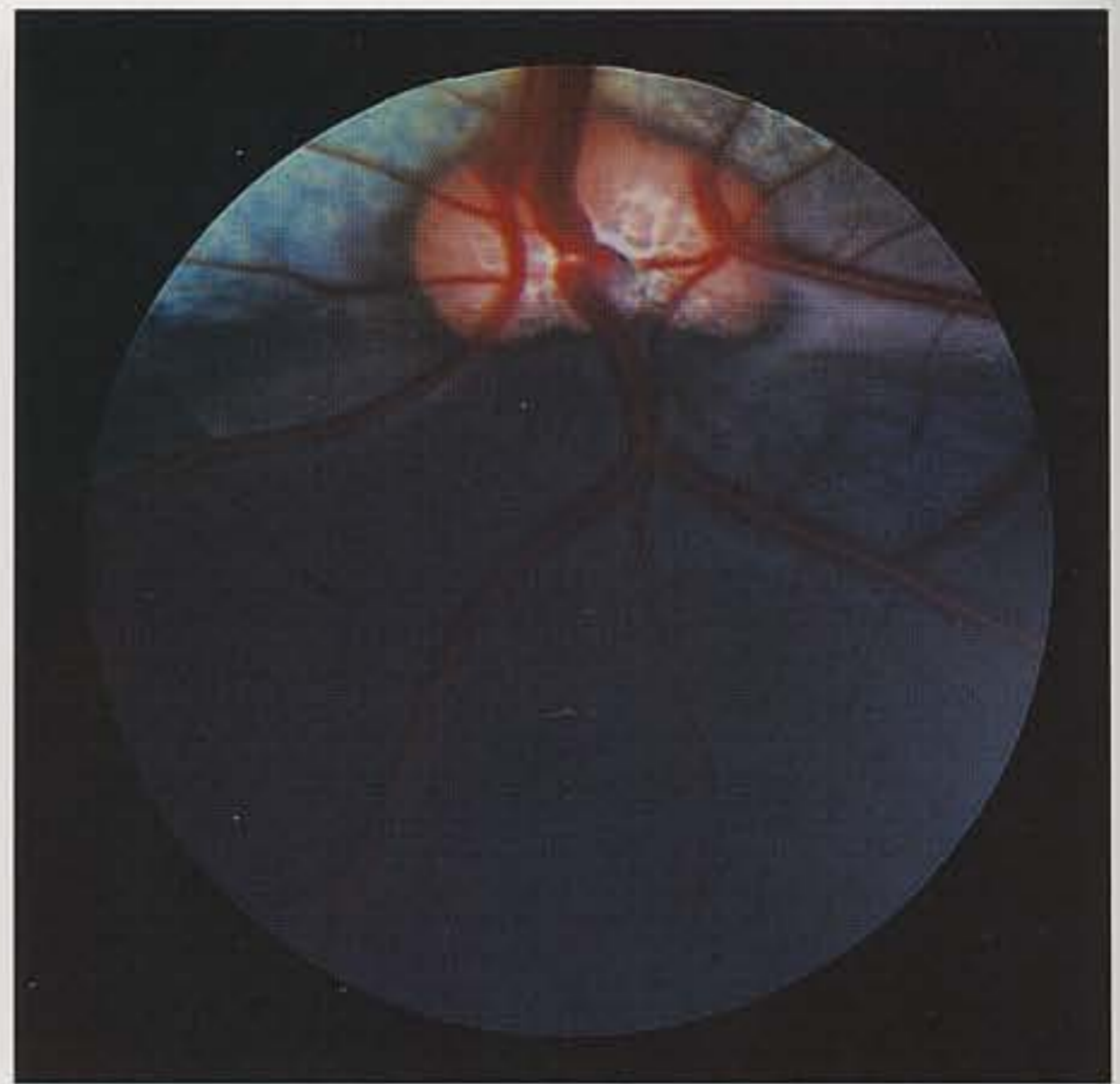


Fig. 11.91 Sheep fundus (adult ewe) Note medullated fibres from the disc on the right side and appearance of the tapetum nigrum.

## The fundus of other species (Figs 11.92–11.97)

Note the absence of a tapetum in all these animals, including the pig, and the presence of an ophthalmoscopically visible macula in the primates.

## Diseases of the retina – the retinopathies

The classification of retinal disease is complex and variable, and will be illustrated here according to species and the condition with notes on diagnosis.

In the dog there are four well-defined hereditary diseases of the fundus, two abiotrophies (generalized progressive retinal atrophy and retinal pigment epithelial dystrophy) and two congenital conditions (Collie eye anomaly and retinal dysplasia). The non-hereditary retinopathies are mainly post-inflammatory and with neither breed nor age incidence. Unless very severe, they are rarely presented to the veterinary surgeon with a history of defective vision, particularly in the UK, and carry a poorly understood aetiology. A few other retinopathies, e.g. sudden acquired retinal degeneration (SARD), haemorrhages and detachments and coloboma, are illustrated.

The cat has two forms of a hereditary retinopathy, both in the Abyssinian breed. One or two other retinal degenerations are shown as well as an unusual and highly specific retinopathy due to a deficiency of the sulphur-containing amino acid taurine.

In the horse post-inflammatory retinal degenerations are illustrated, together with a few other odd conditions.

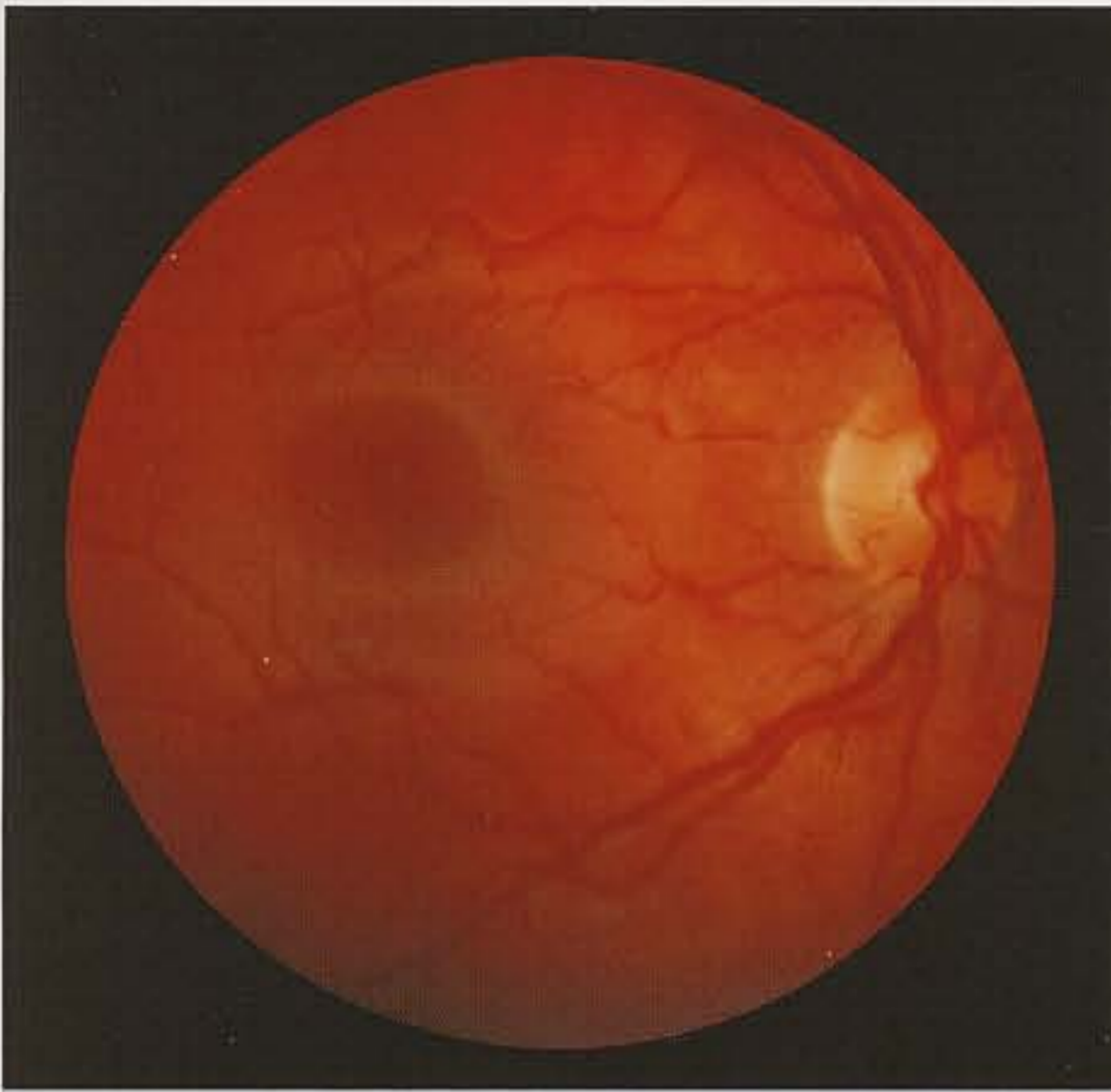


Fig. 11.92 Human (young adult) Note the presence of the macula.

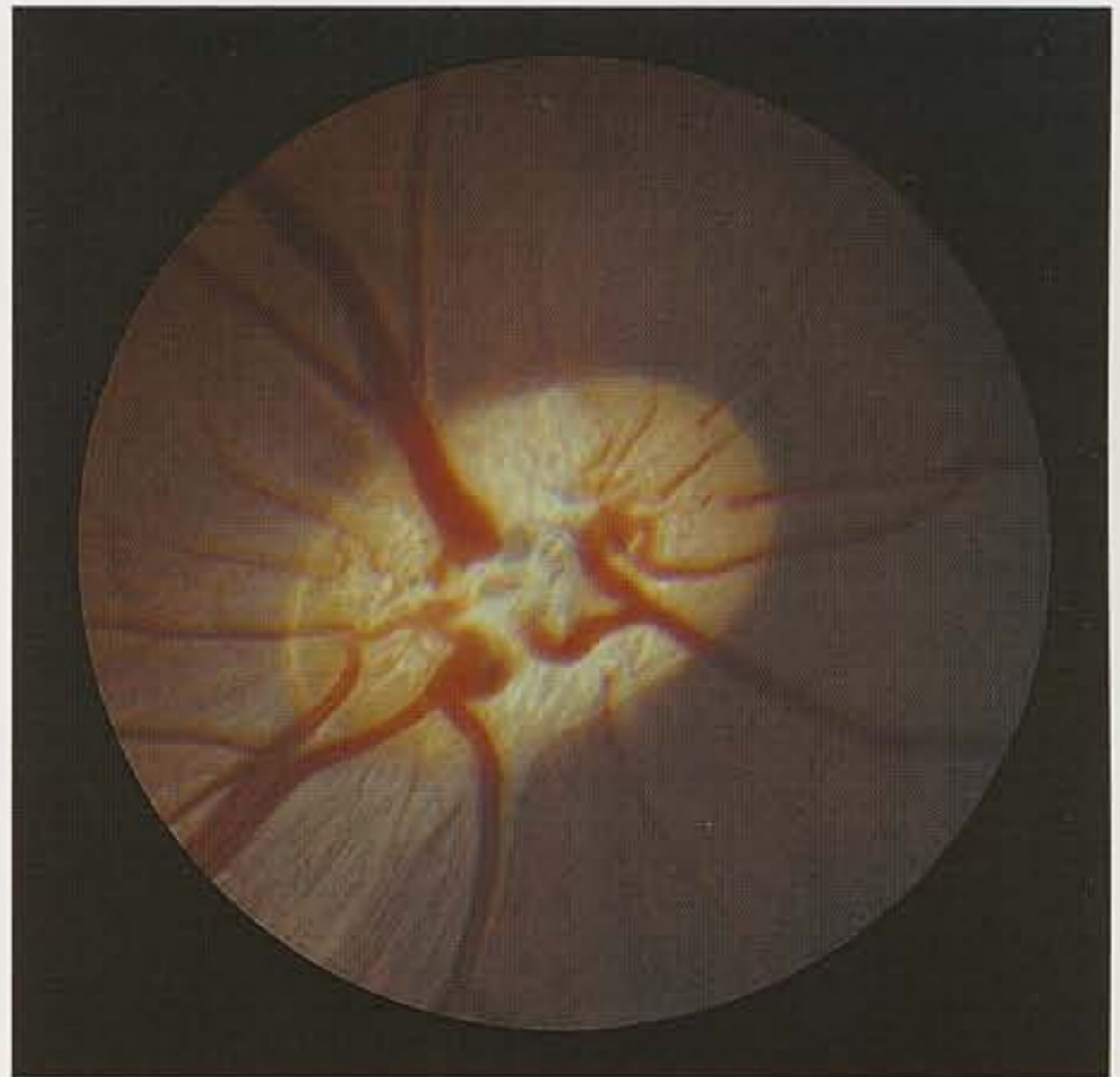


Fig. 11.94 Pig (Large White, adult) Note the absence of a tapetum in this species.

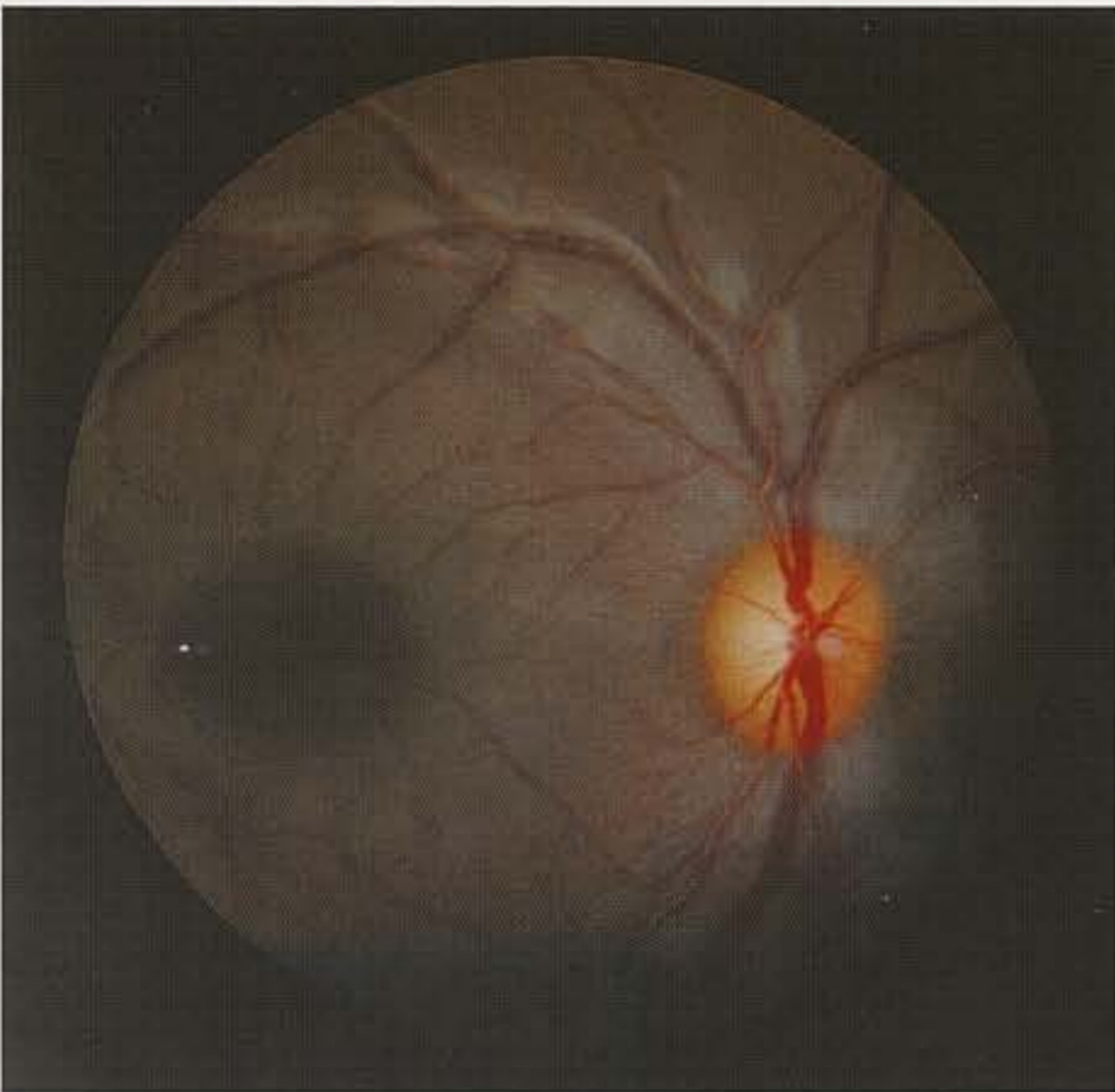


Fig. 11.93 Monkey (baboon, young adult) Note the macula.

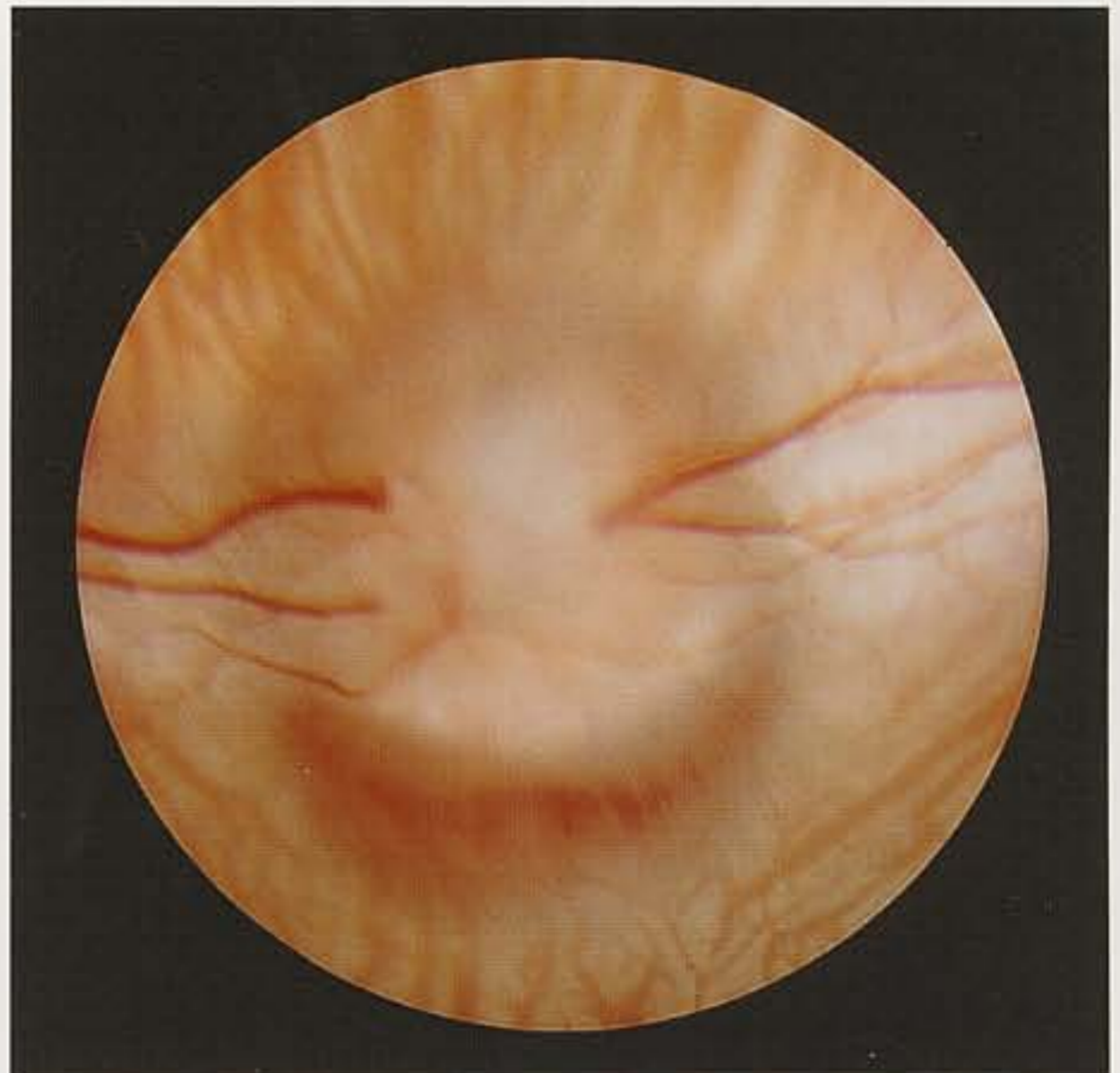

Fig. 11.95 Rabbit (young adult, albino)

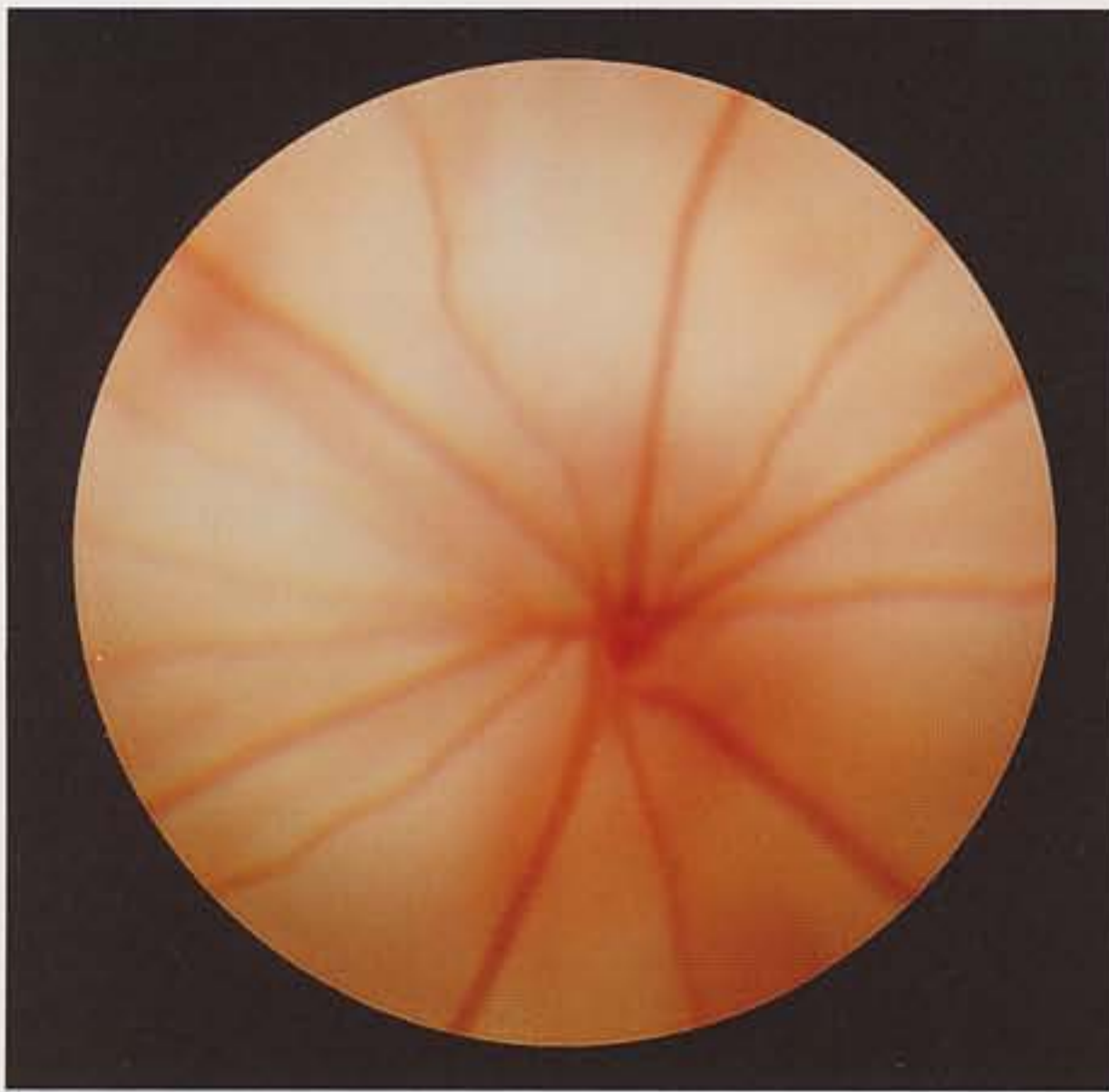


Fig. 11.96 Rat (young adult, albino)

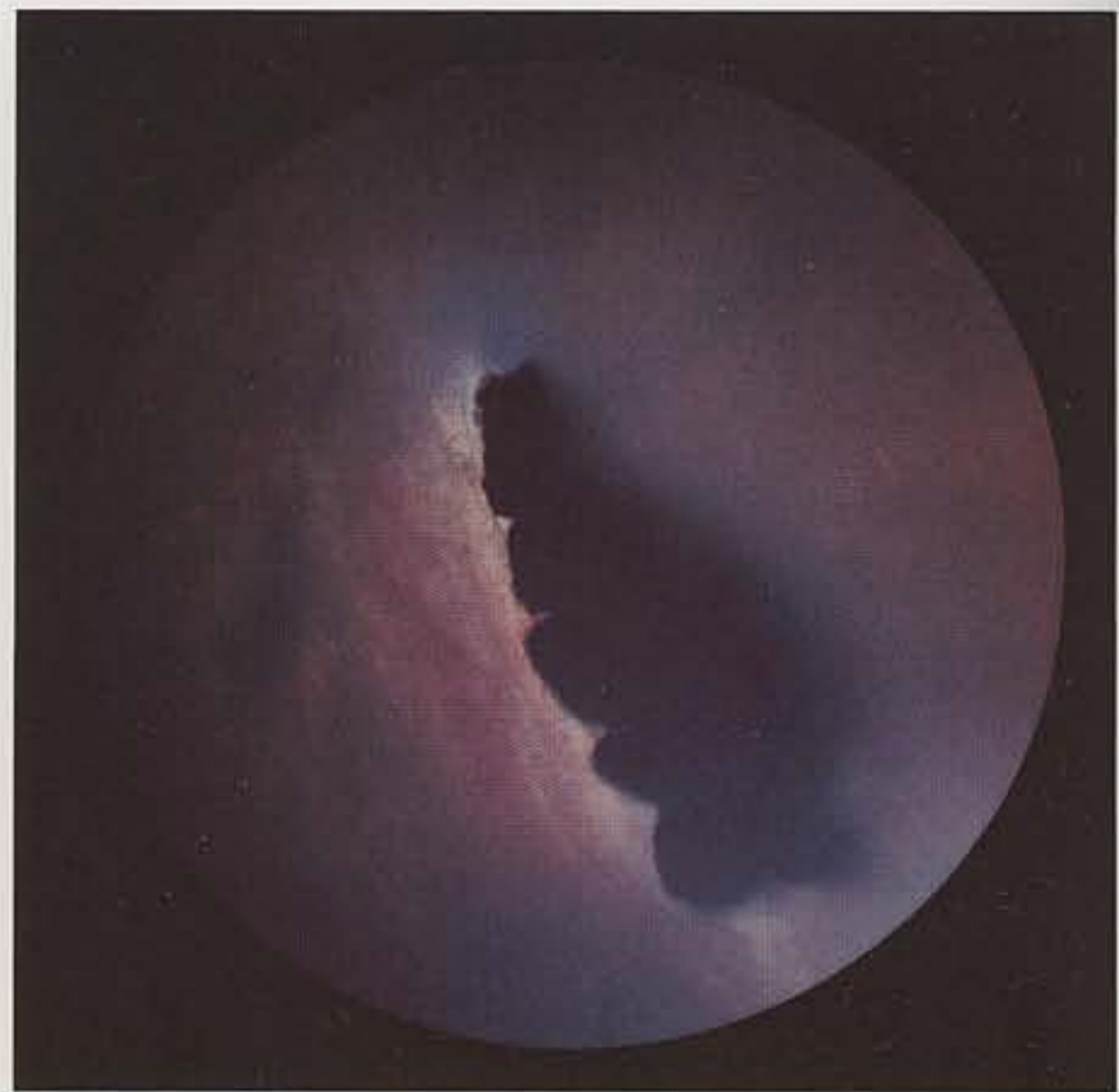

Fig. 11.97 Bird (Tawny Owl) Note the pecten.

The sheep exhibits an interesting toxic retinopathy due to the ingestion of bracken, apparently specific to this species.

### *The dog*

#### **Generalized progressive retinal atrophy (GPRA) (Figs 11.98–11.119)**

In the dog GPRA is hereditary, bilateral and usually symmetrical but, where the two eyes are not identical, the difference in the degree of severity is minimal, and always progressive. GPRA has been subdivided into dysplasias and degenerations according to the time at which the rods and cones atrophy, and with a consequent difference in the age incidence in the different breeds. However, clinically (ophthalmoscopically) all the forms look alike. There is a marked and important breed incidence (see Table 11.1) and certain breeds may exhibit two types. GPRA is not congenital but occurs later in life (abiotrophy) and the age incidence varies from a few months to several years. To date inheritance has always been via a simple, autosomal, recessive gene (cf. the Abyssinian cat), except the Siberian Husky which has been reported as X-linked in the USA. The history is usually of defective vision noticed either at night or in dim light, hence the term 'night blindness', always deteriorating to day blindness and

ultimately total blindness. Occasionally, owners notice a glow in the eyes in certain lights due to the dilated pupils and increased tapetal reflectivity. Cataract is a frequent, if not invariable, sequel in this species (Figs 9.57–9.60).

#### **Retinal pigment epithelial dystrophy (RPED) or central progressive retinal atrophy (CPRA) (Figs 11.120–11.131)**

RPED or CPRA, is another, but dissimilar, bilaterally symmetrical or nearly so, progressive retinal degeneration causing defective vision and ultimately ending in total blindness, although not in all cases as some dogs retain useful peripheral vision into old age. The condition is not congenital, but affects young adult dogs. There is a distinct breed predisposition and RPED was considered to be inherited in those breeds named in Table 11.2, but recently an association of extremely low plasma levels of vitamin E in affected dogs has been shown and it is this that may be inherited. Ophthalmoscopically the presence of brown spots of pigment scattered throughout the tapetal fundus, and with hyperreflectivity present between the spots, is the main diagnostic sign. Attenuation of the retinal blood vessels is a later change and the condition progresses to involve the non-tapetal fundus. Occasionally cataracts are present (Fig 9.61).

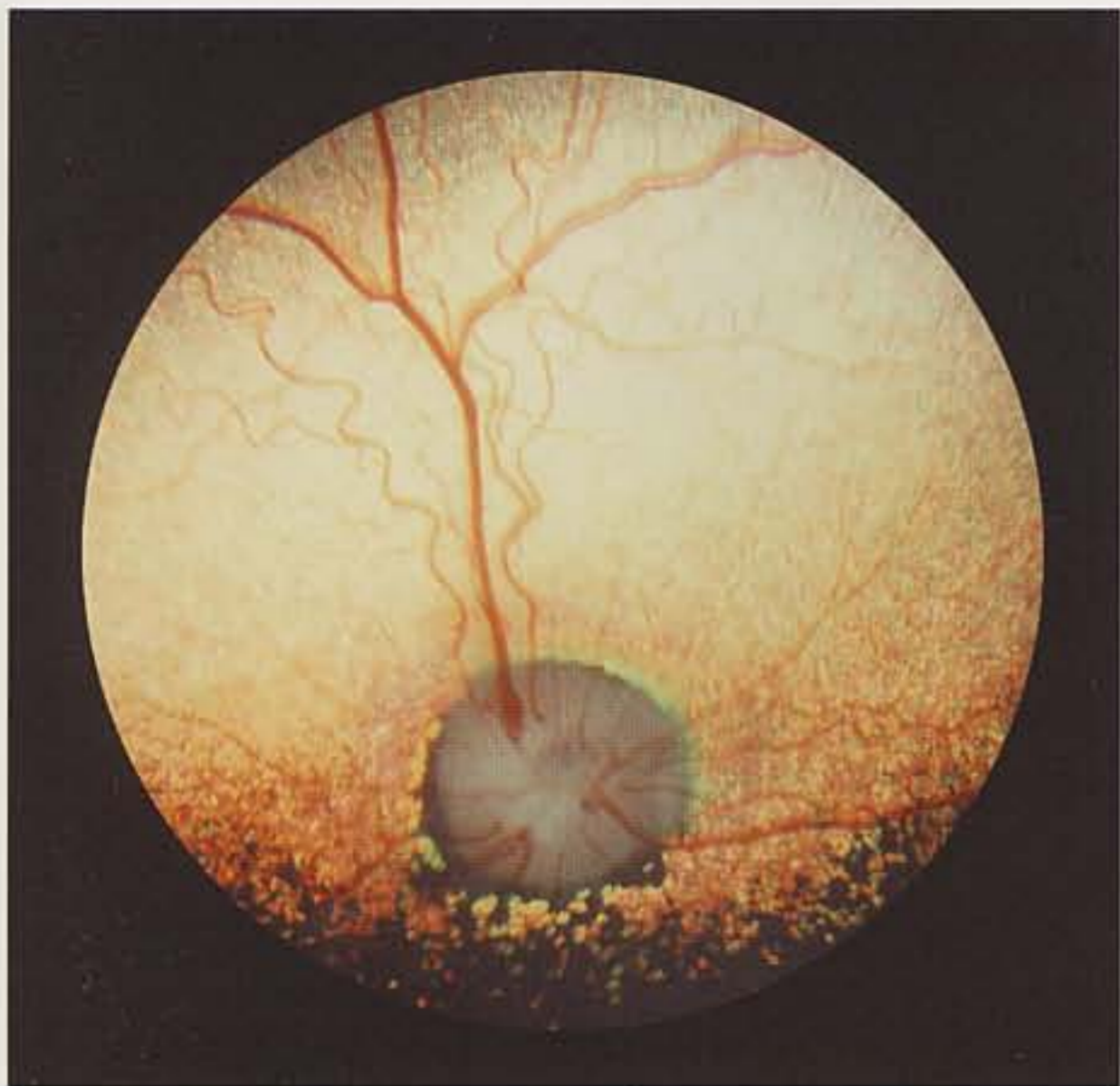

Fig. 11.98 Rod/cone dysplasia (Irish Setter, 3 months old)

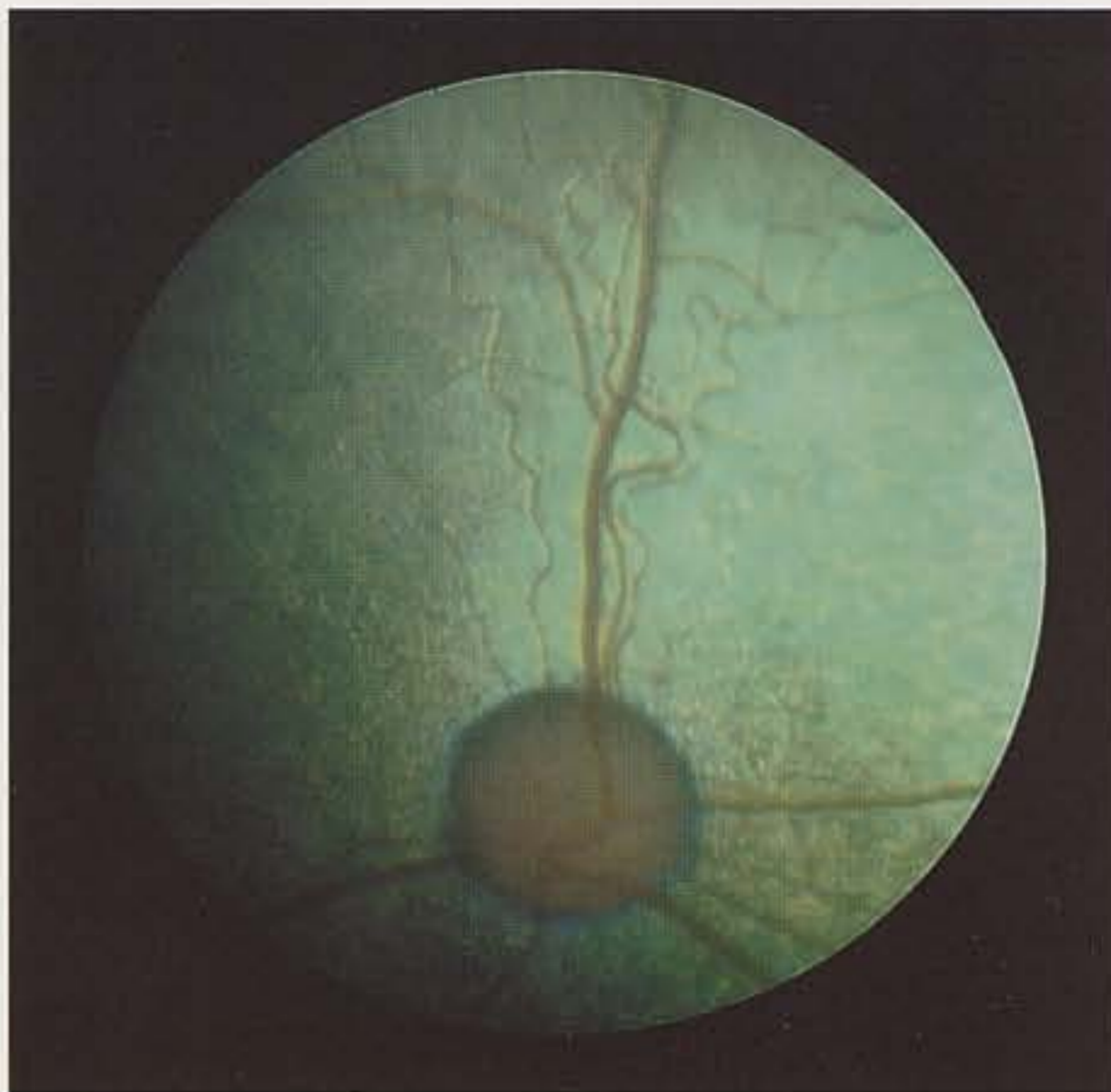


Fig. 11.100 Rod/cone dysplasia (Cardigan Corgi, 3 months old) Obvious and typical changes at an early age as in Fig 11.98.

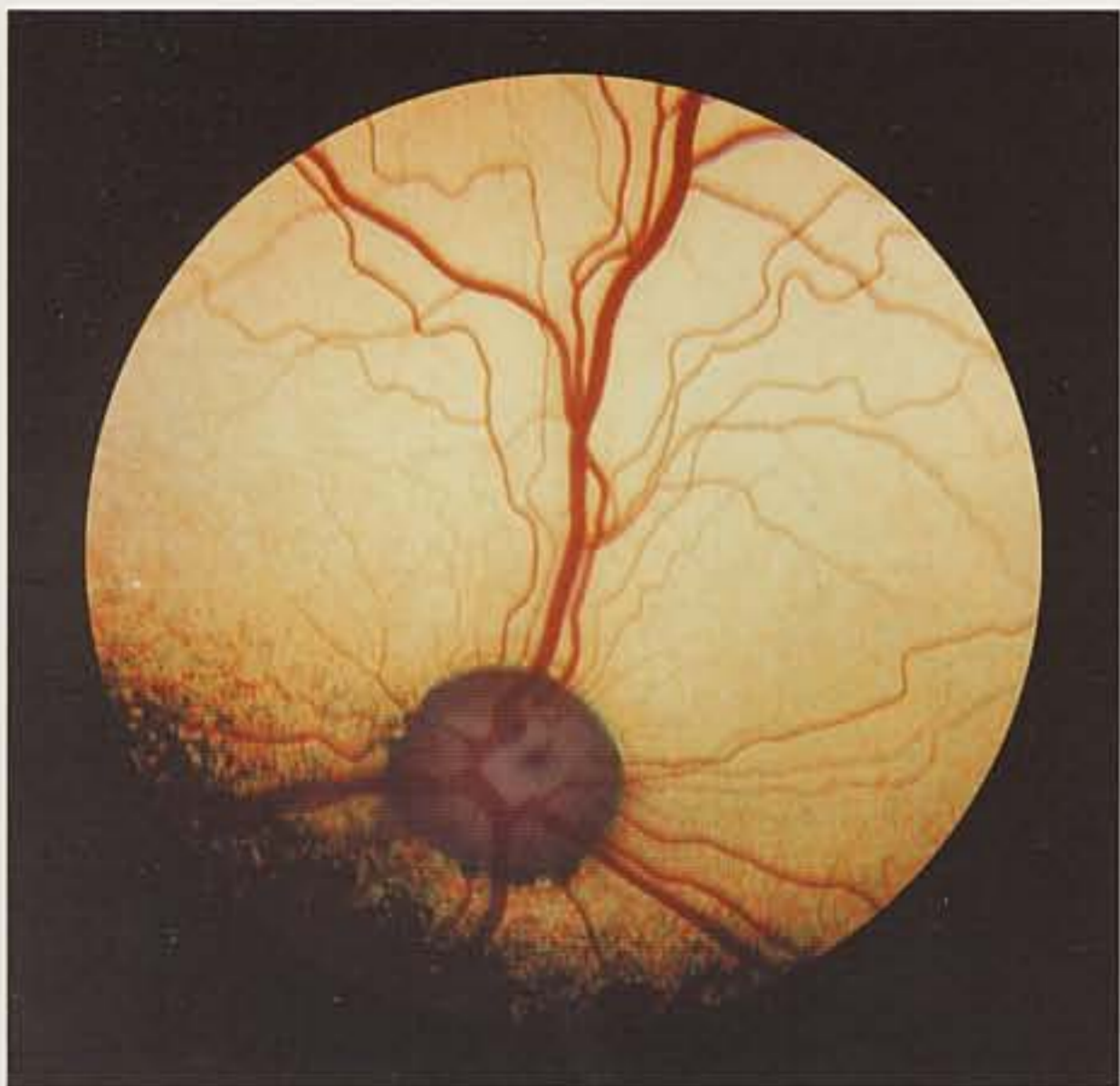


Fig. 11.99 Rod/cone dysplasia (Irish Setter, 3 months old) Littermate to the puppy in Figure 11.98. Note the obvious difference on comparison between normal and abnormal in both tapetal hyper-reflectivity and blood vessel attenuation.

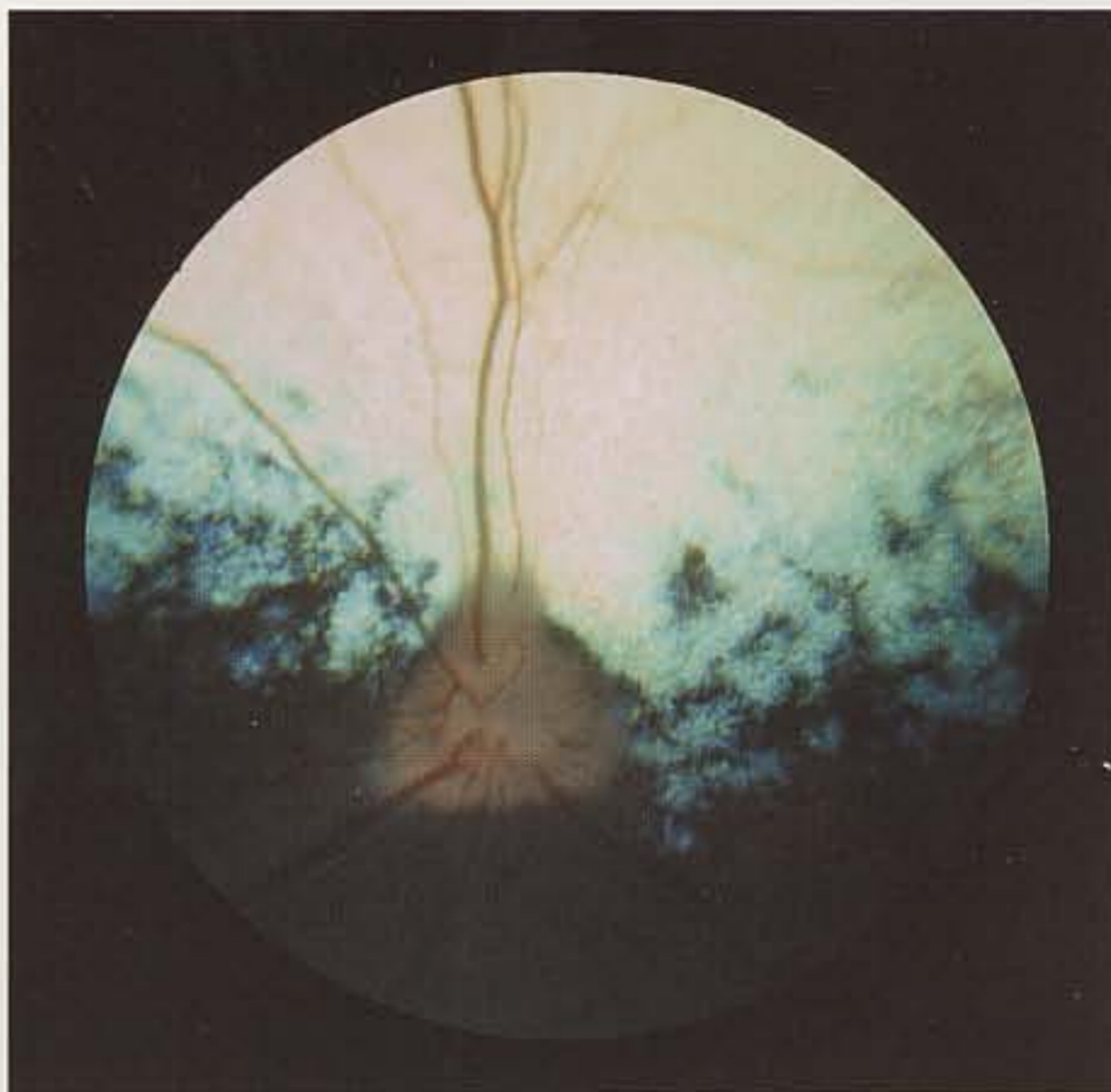


Fig. 11.101 Rod dysplasia, cone degeneration (Elkhound, 20 months old) Typical changes of GPRA.

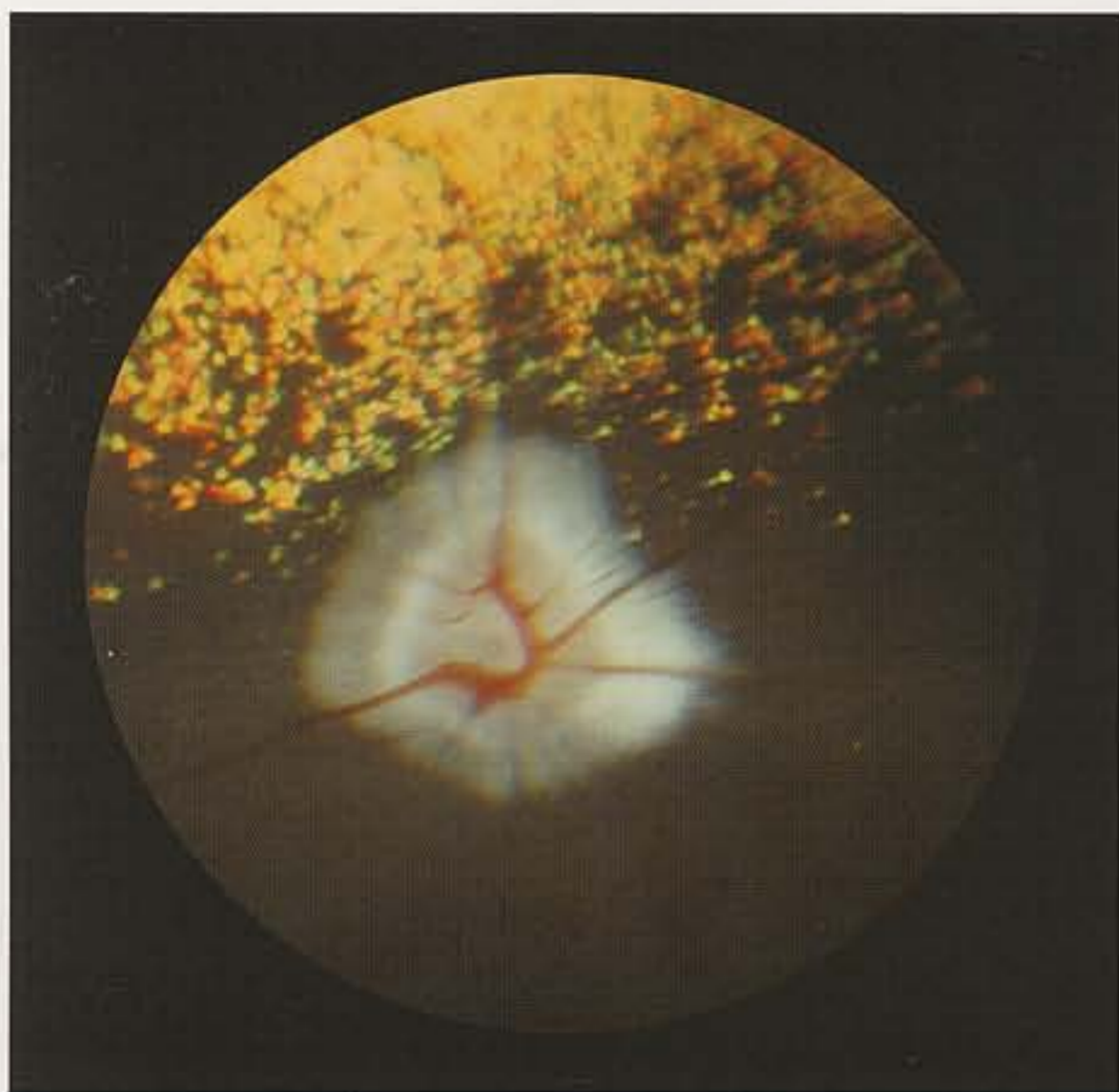


Fig. 11.102 Rod/cone degeneration (Miniature Poodle, 5 years old) Note the narrowed retinal blood vessels away from the disc.

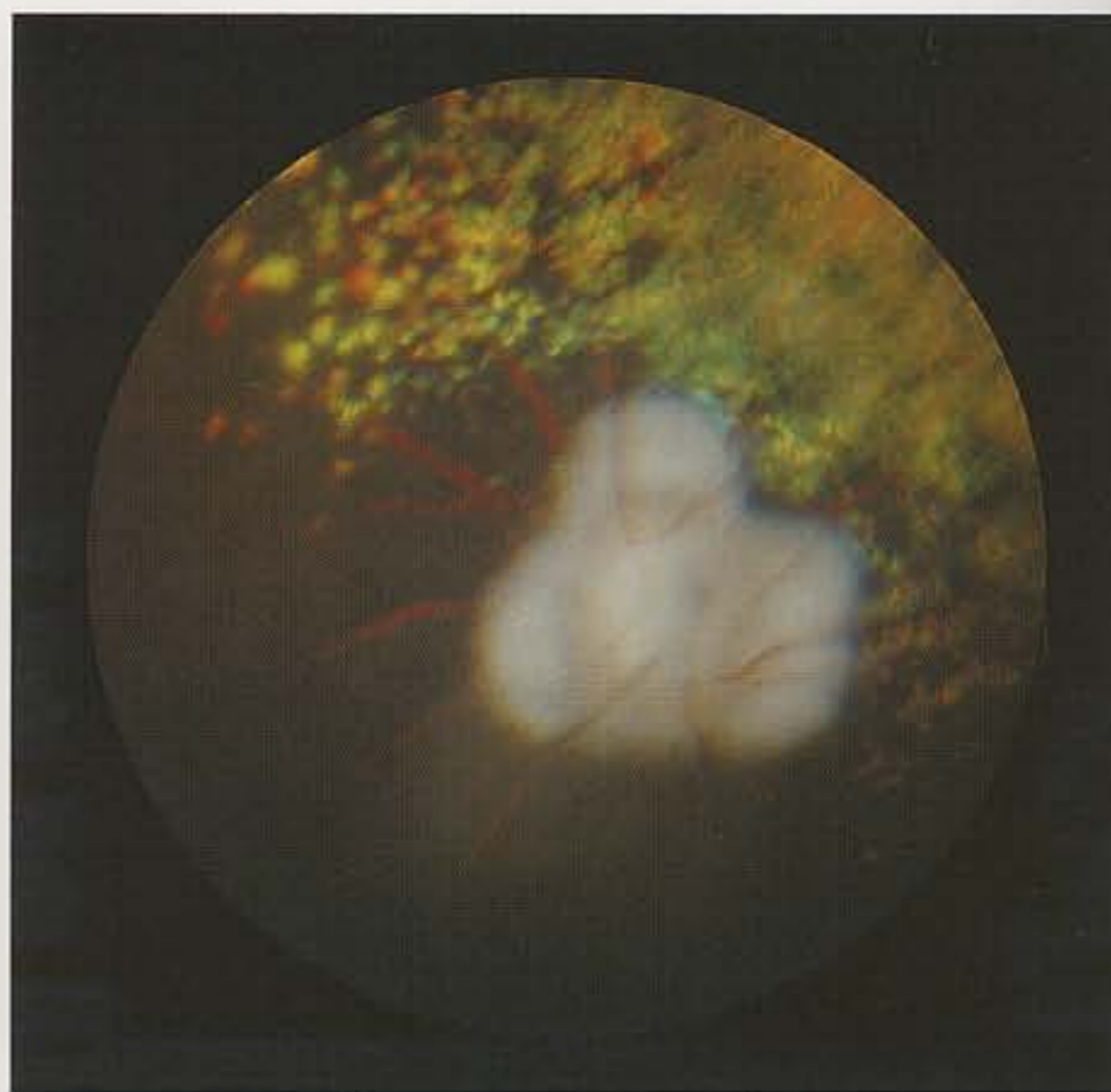

Fig. 11.104 Rod/cone degeneration (Miniature Poodle, 8 years old) Advanced degeneration with pallor of the disc and visible choroidal vessels.

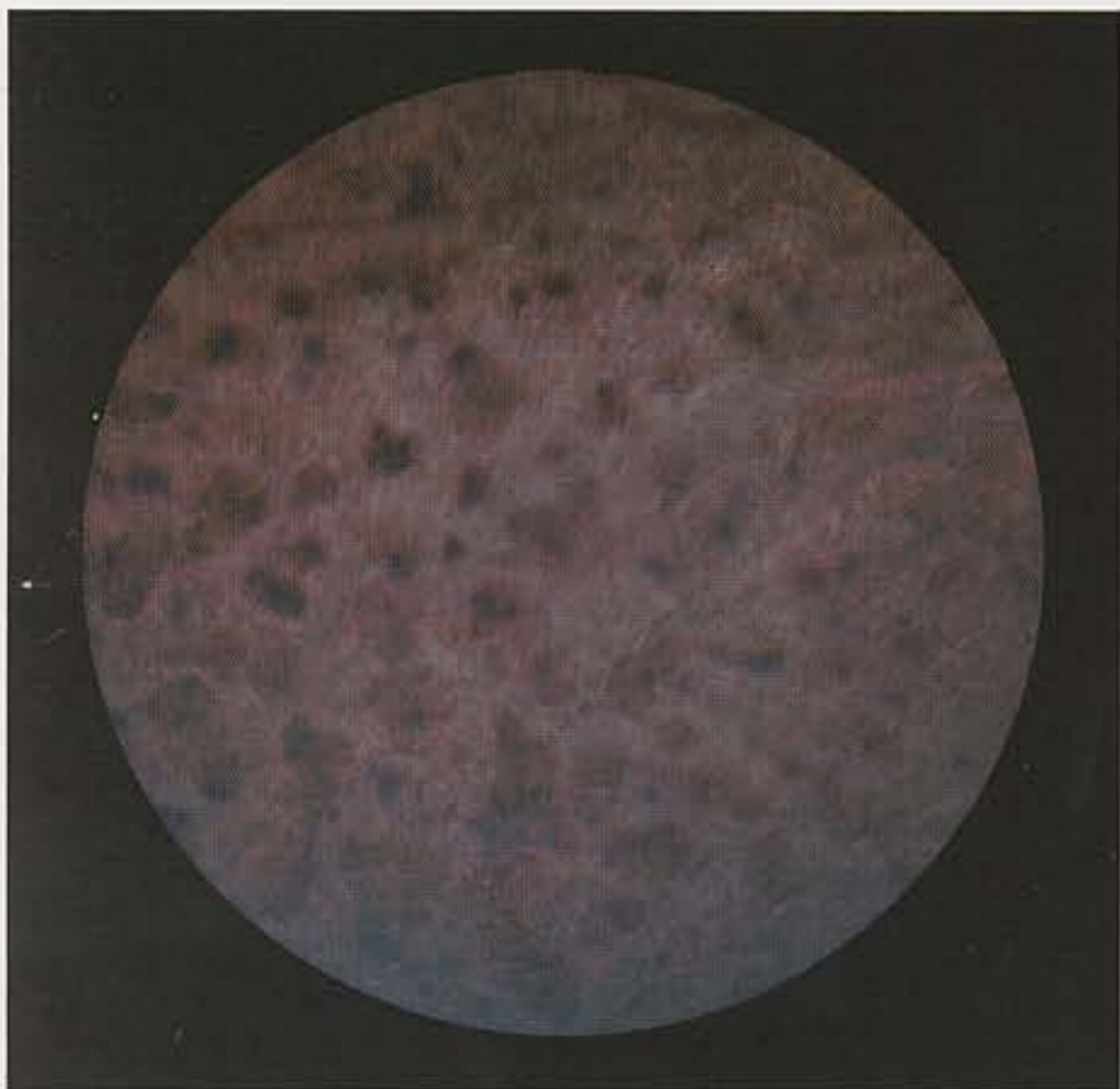


Fig. 11.103 Rod/cone degeneration (Miniature Poodle, 5 years old) Typical appearance of the non-tapetal fundus.

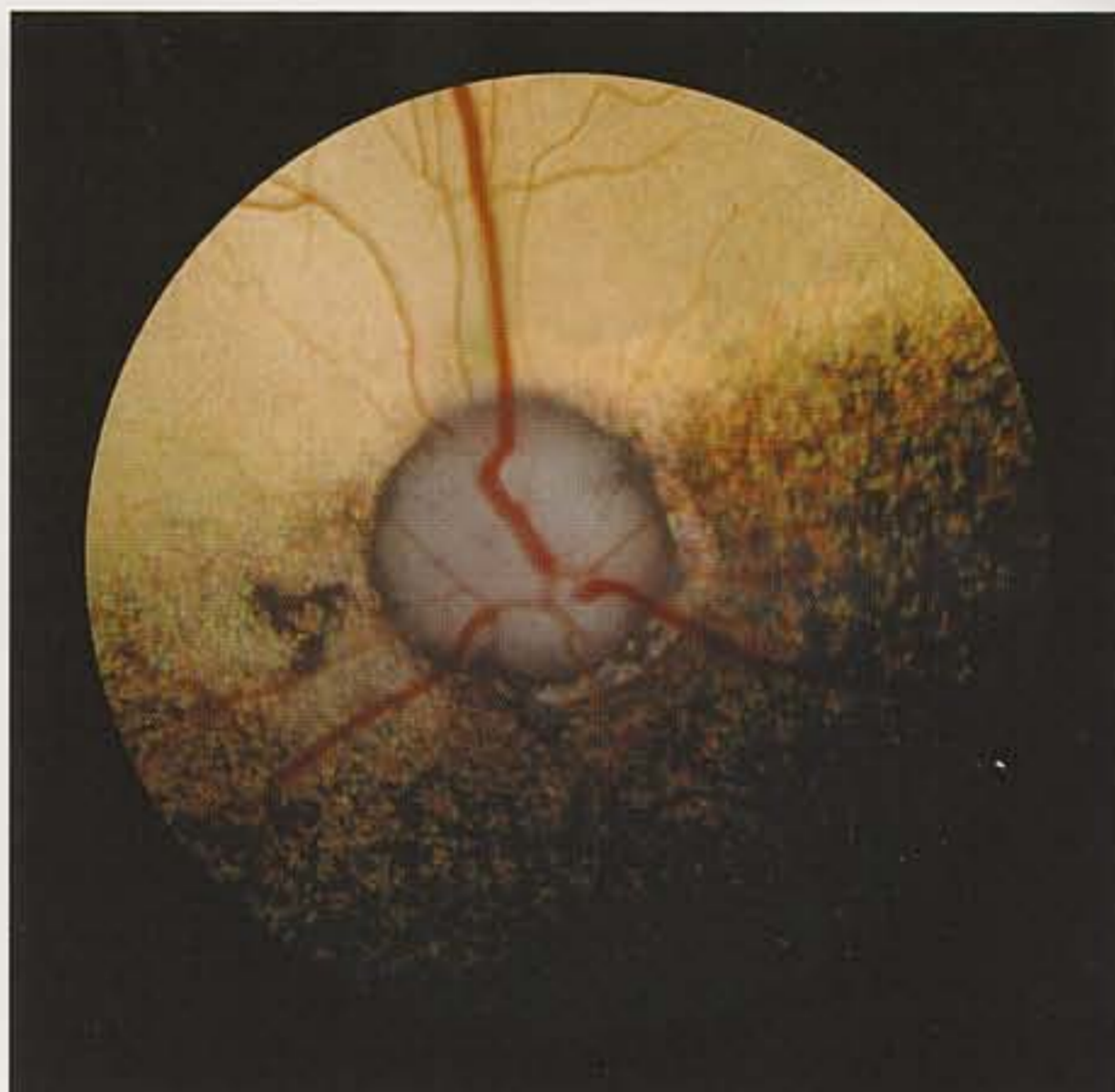


Fig. 11.105 Rod/cone degeneration (Cocker Spaniel, 2 years old) Early ophthalmoscopic changes of tapetal hyper-reflectivity.

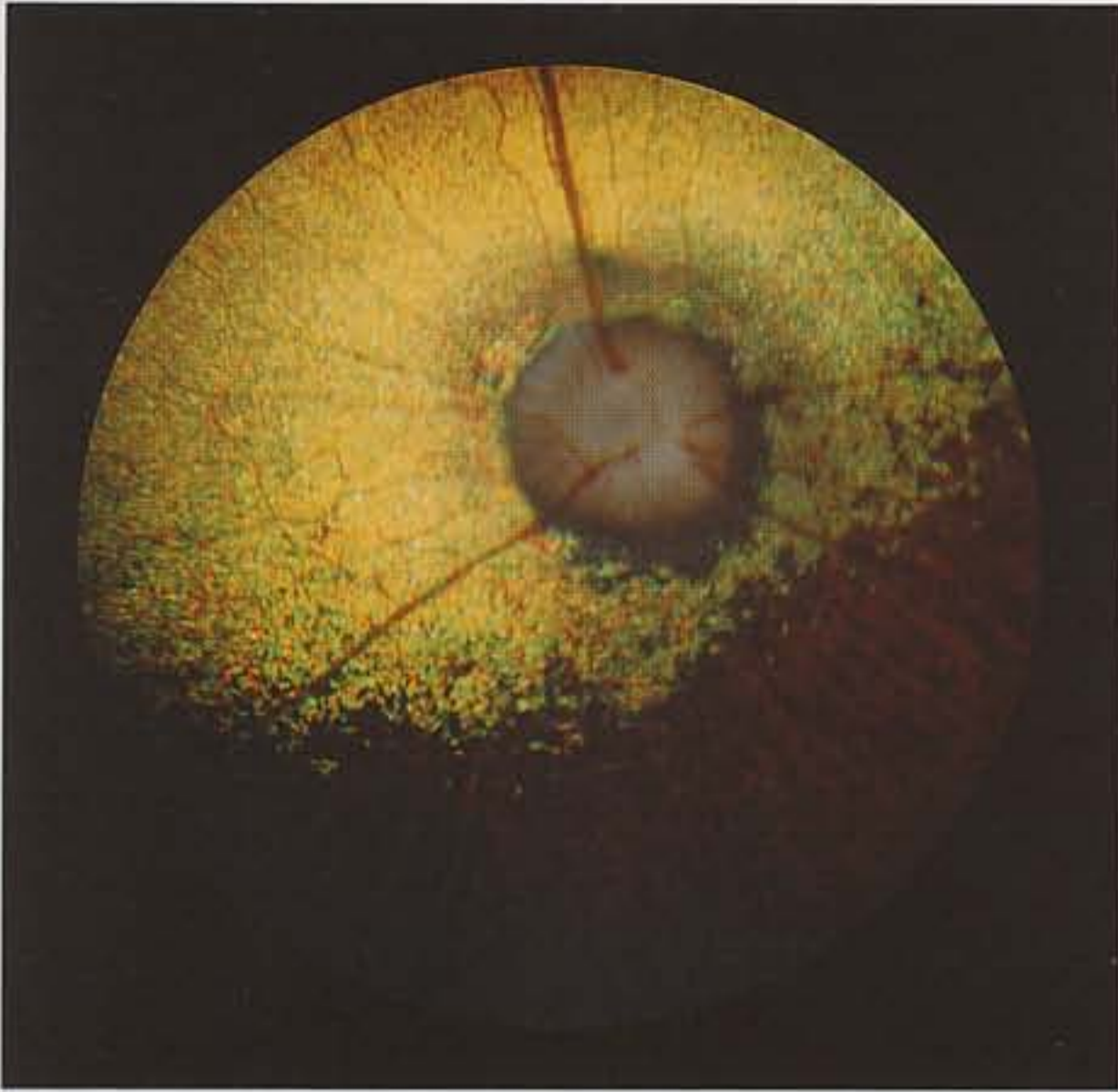

Fig. 11.106 Rod/cone degeneration (Cocker Spaniel, 4 years old, blue roan) Right eye showing obvious ophthalmoscopic signs of blood vessel attenuation and increased tapetal reflectivity.

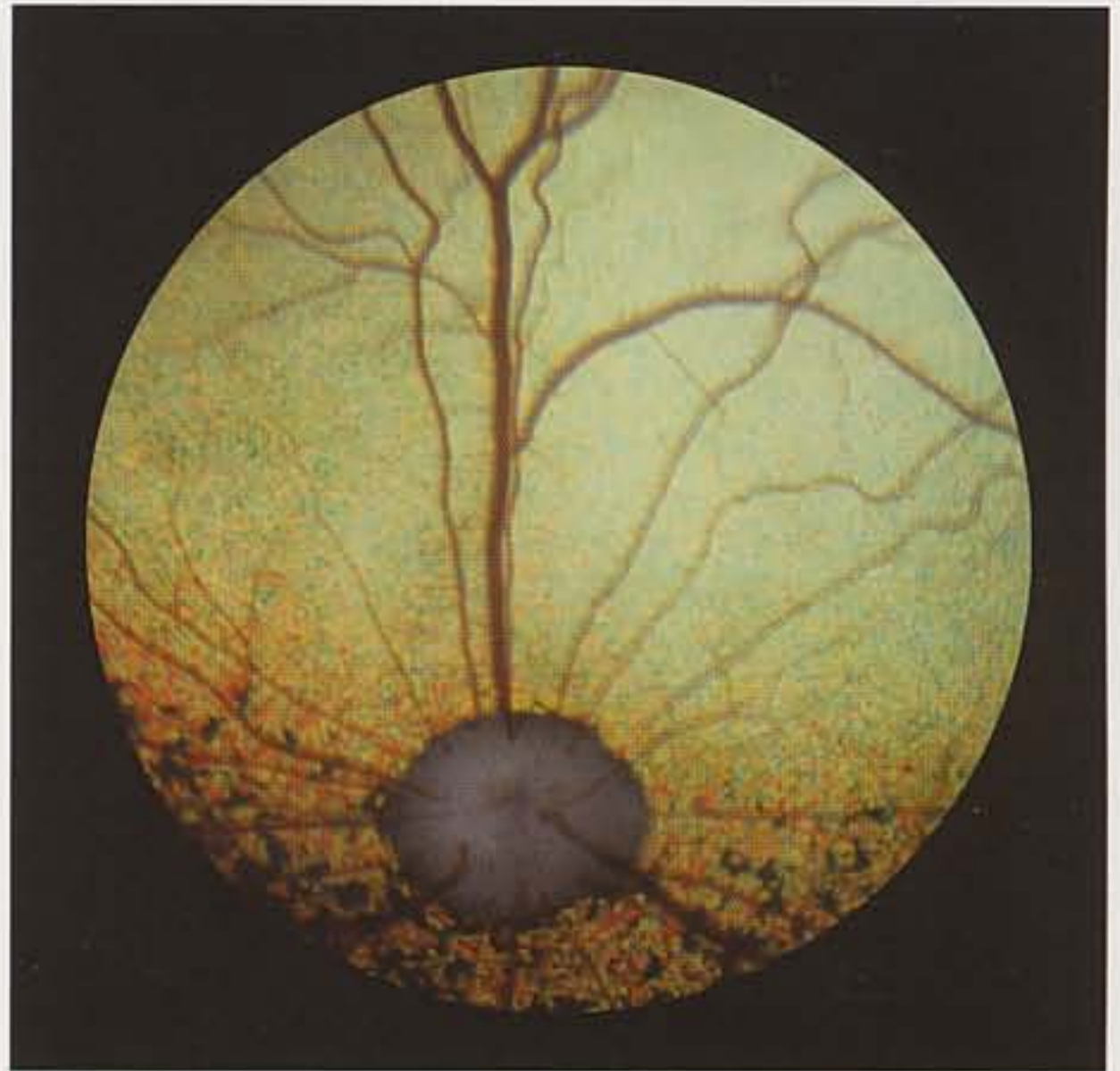

Fig. 11.108 Progressive retinal atrophy (Tibetan Terrier, 15 months old) Early ophthalmoscopic signs.

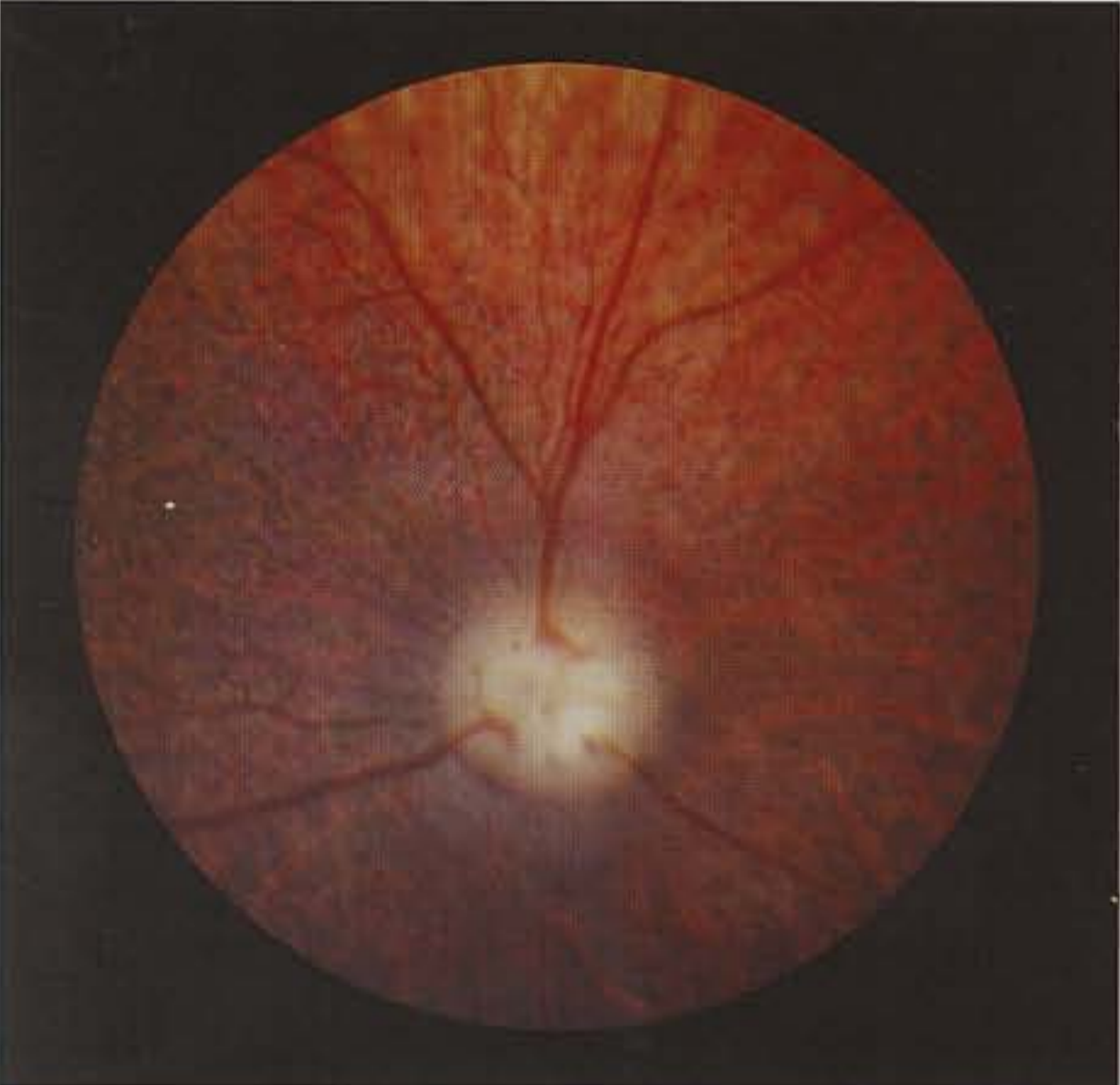

Fig. 11.107 Rod/cone degeneration (Cocker Spaniel, 4 years old, blue roan) Left eye of the same dog as in Figure 11.106, showing less obvious ophthalmoscopic signs due to subalbinism of the fundus and absence of a tapetum.

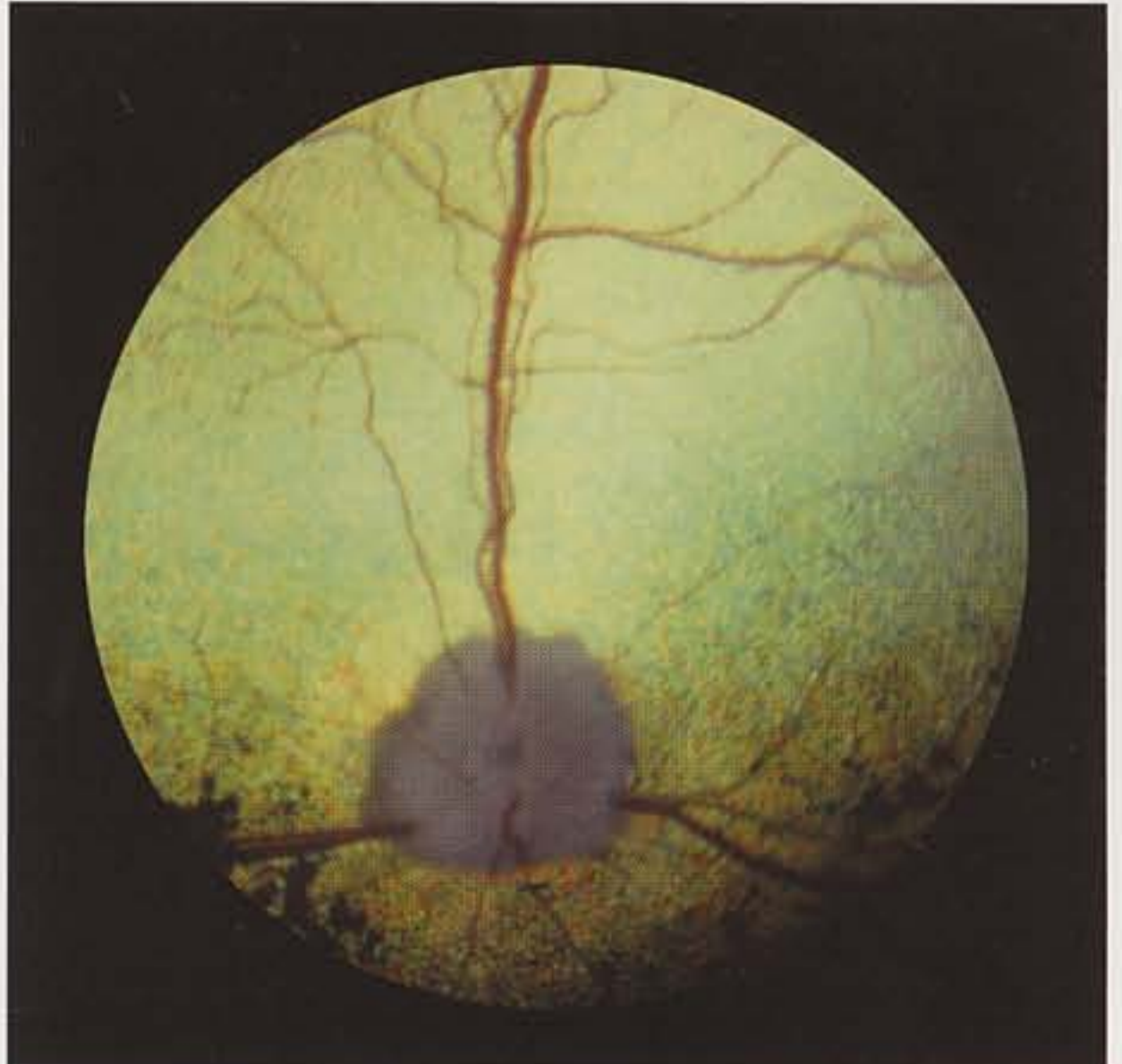

Fig. 11.109 Progressive retinal atrophy (Tibetan Terrier, 18 months old) Ophthalmoscopic signs more obvious.



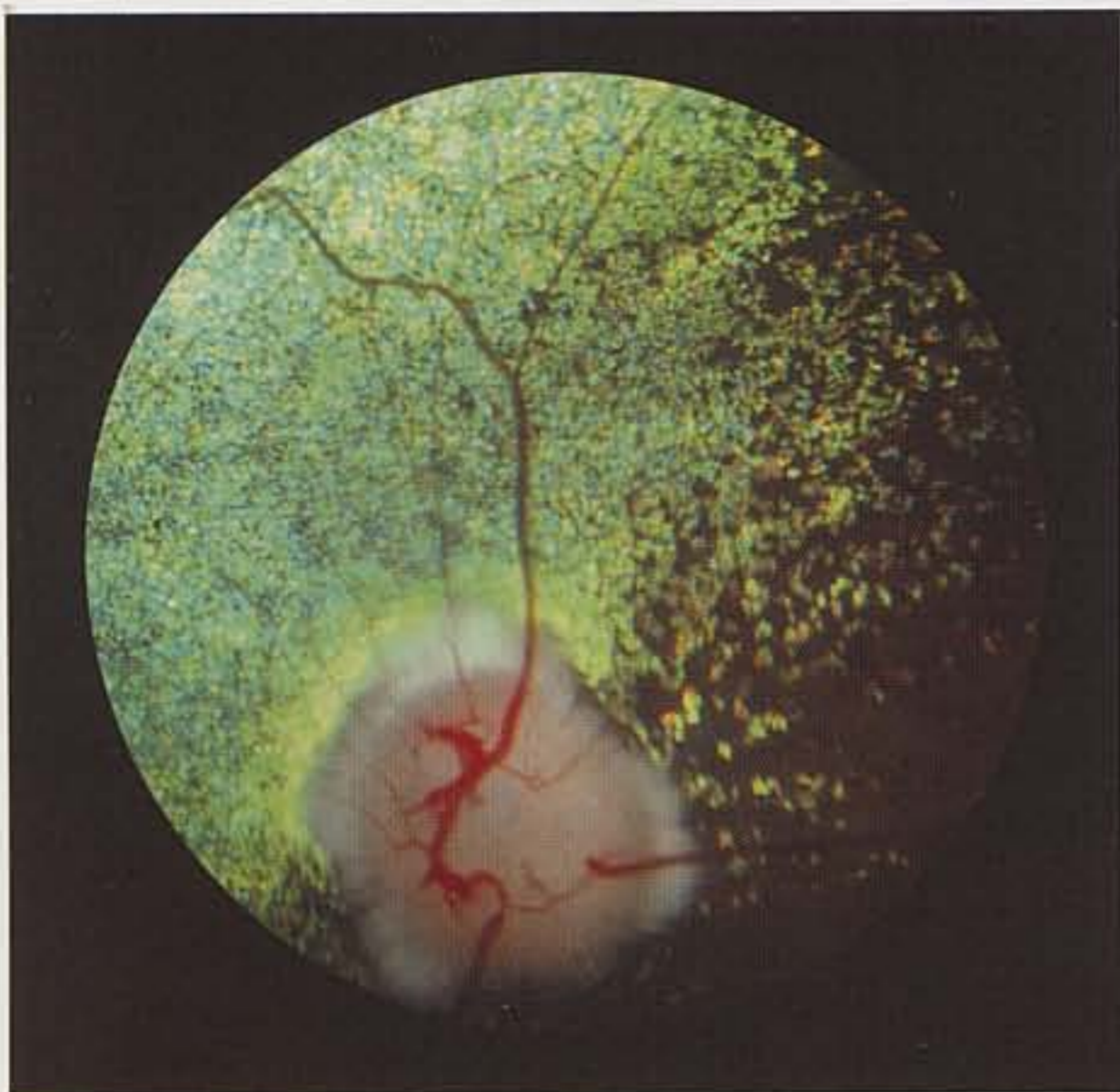

Fig. 11.110 Progressive retinal atrophy (Tibetan Spaniel, 4 years old) Typical signs.

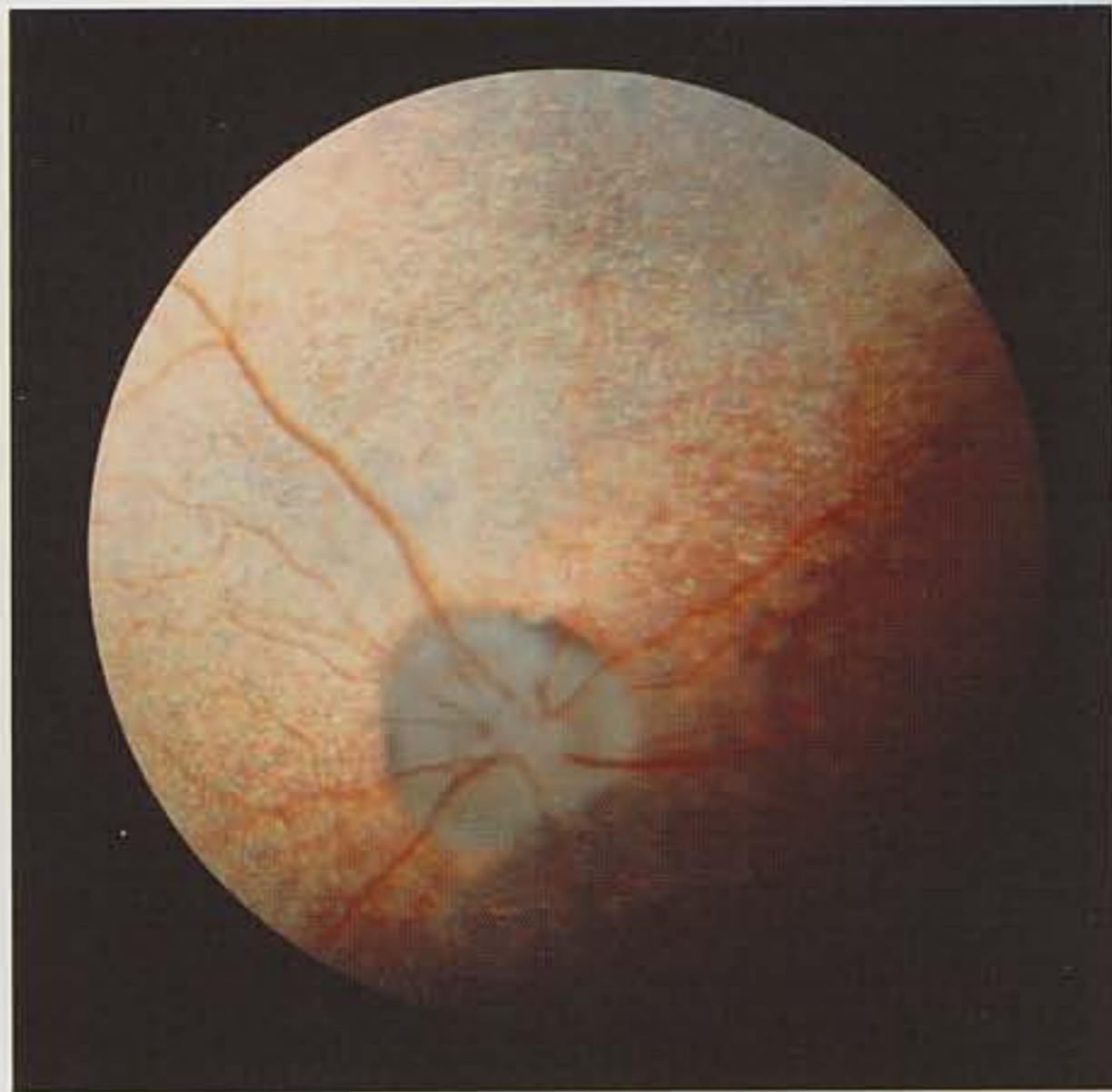


Fig. 11.112 Progressive retinal atrophy (English Springer Spaniel, 21 months old, liver and white) Typical hyper-reflectivity in the tapetal area.

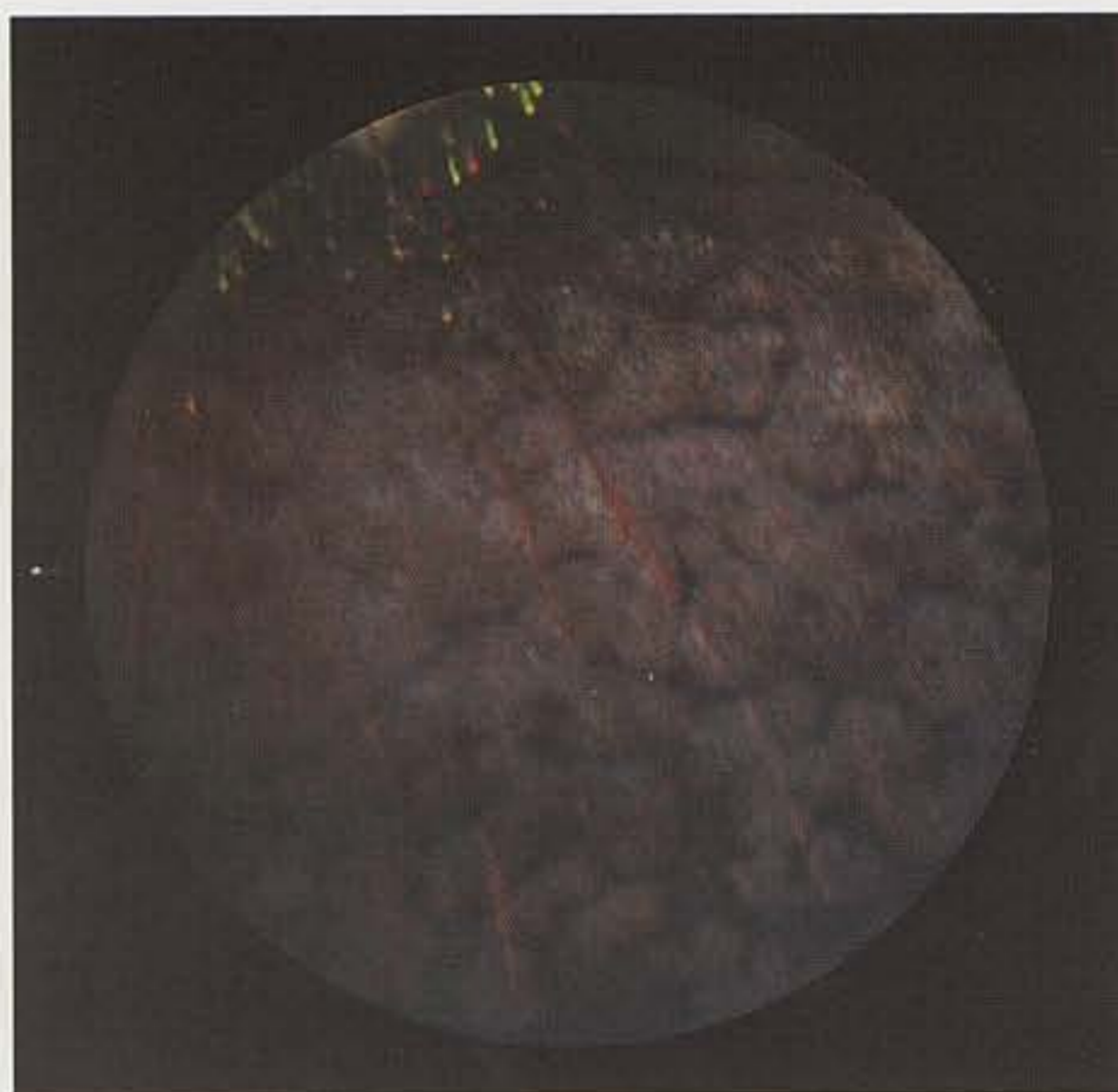

Fig. 11.111 Progressive retinal atrophy (Tibetan Spaniel, 4 years old) Changes in the non-tapetal fundus.

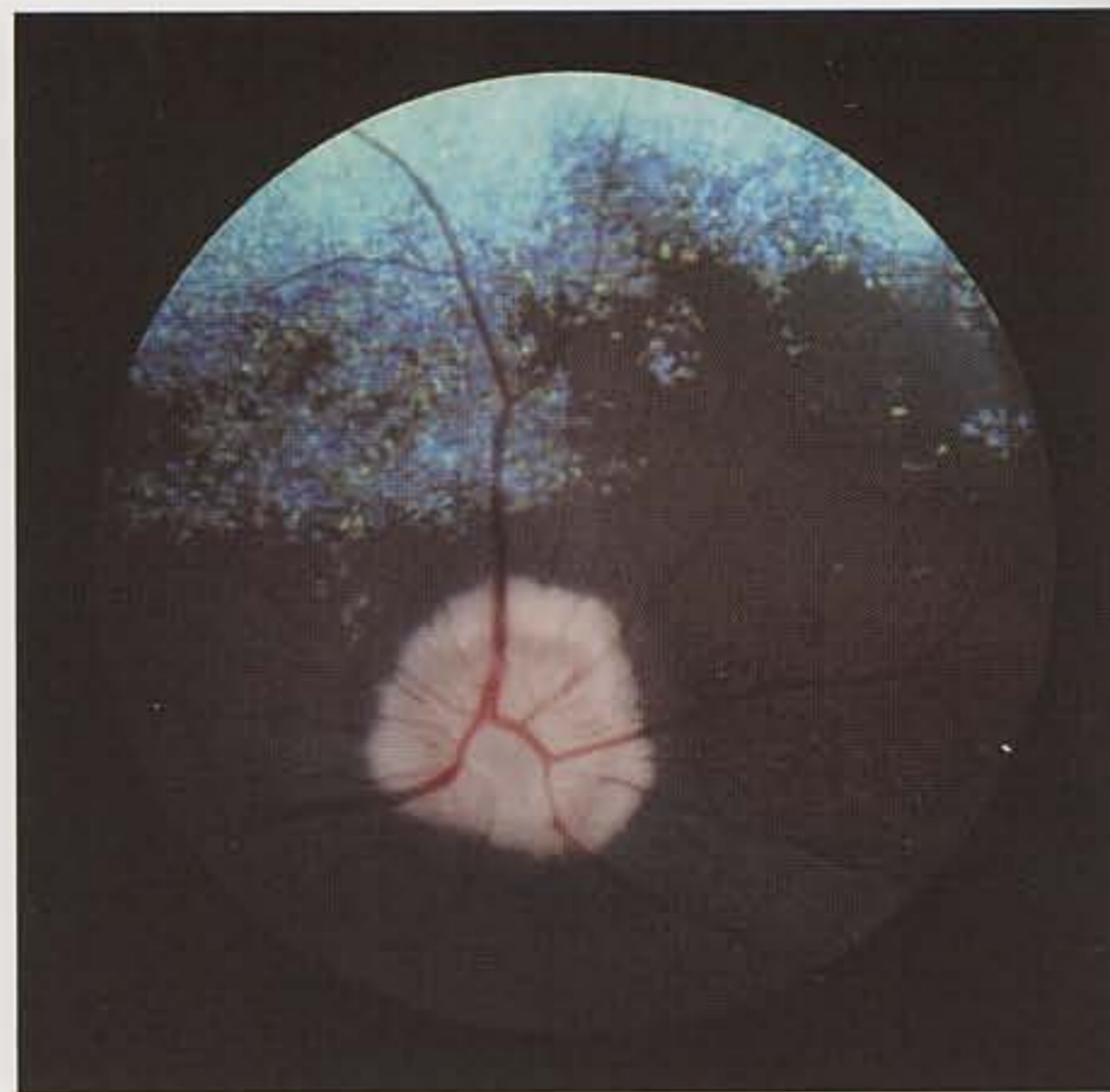

Fig. 11.113 Progressive retinal atrophy (Miniature Schnauzer, 4 years old)

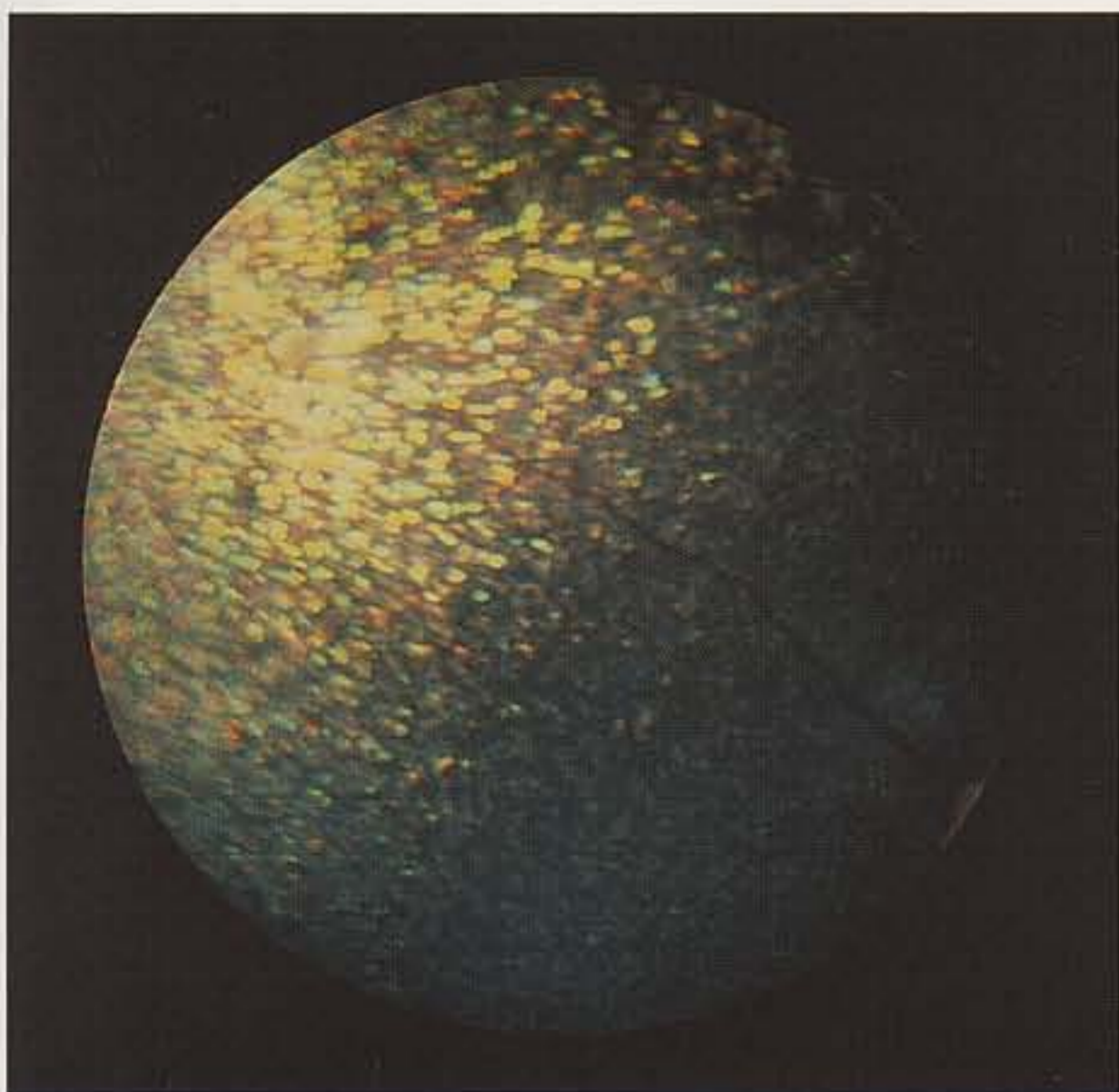


Fig. 11.114 Rod/cone degeneration (Labrador Retriever, 6 years old) Tapetal hyper-reflectivity and early changes in the non-tapetal fundus.

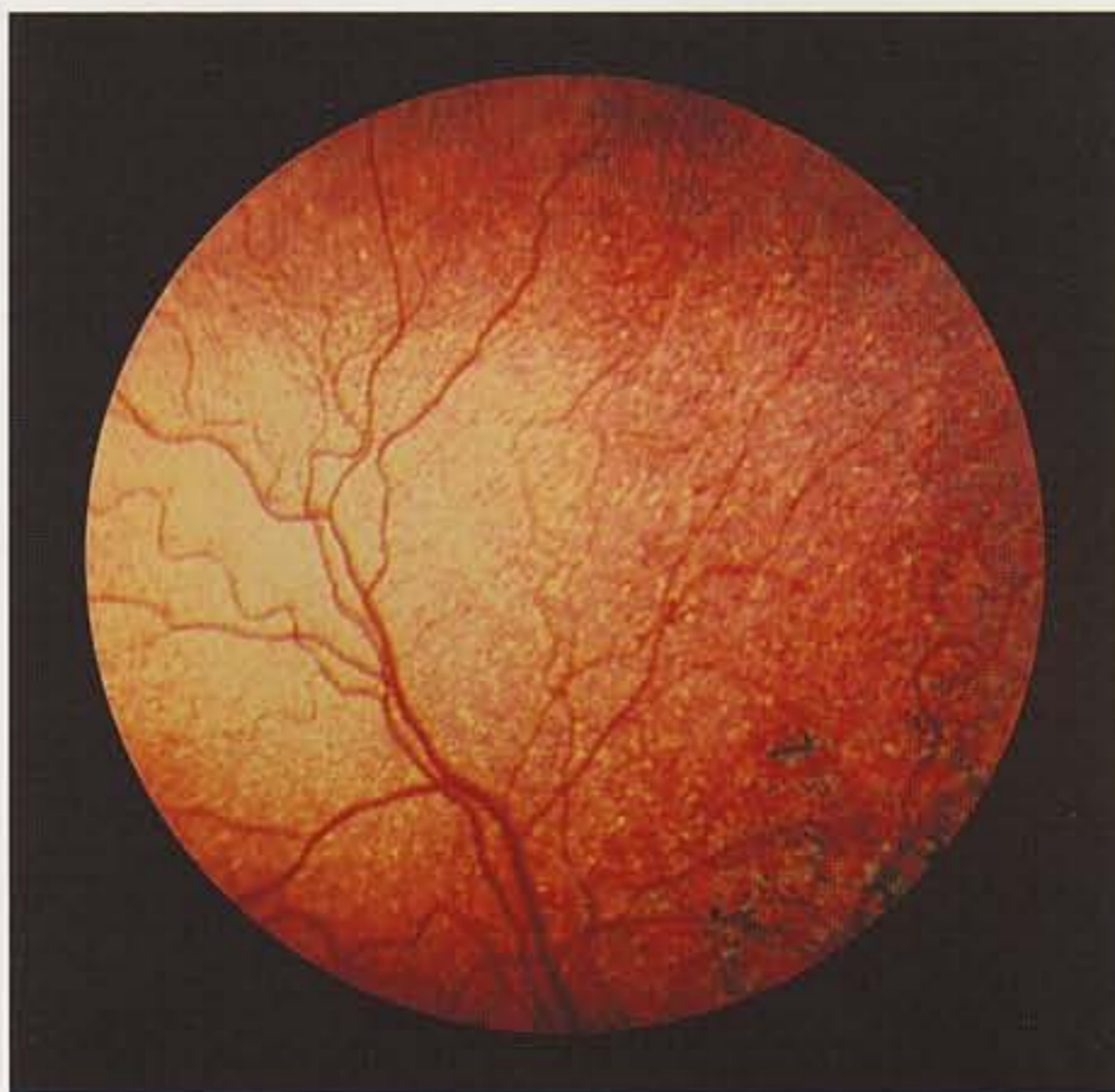


Fig. 11.116 Cone/rod dystrophy (Miniature Longhaired Dachshund, 8 months old) Early ophthalmoscopic changes.

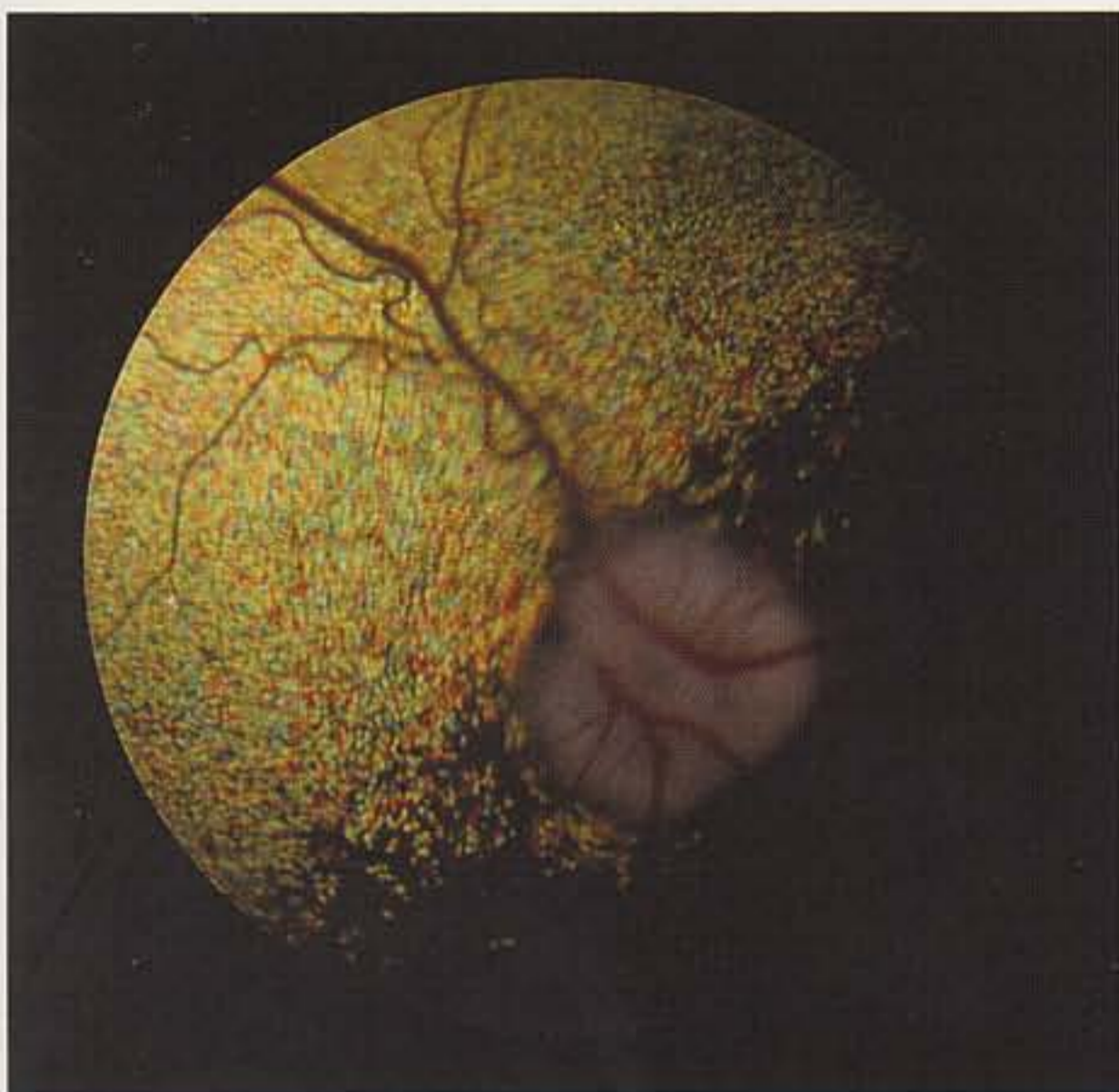


Fig. 11.115 Rod/cone degeneration (Golden Retriever, 4 years old) Early changes in tapetum.

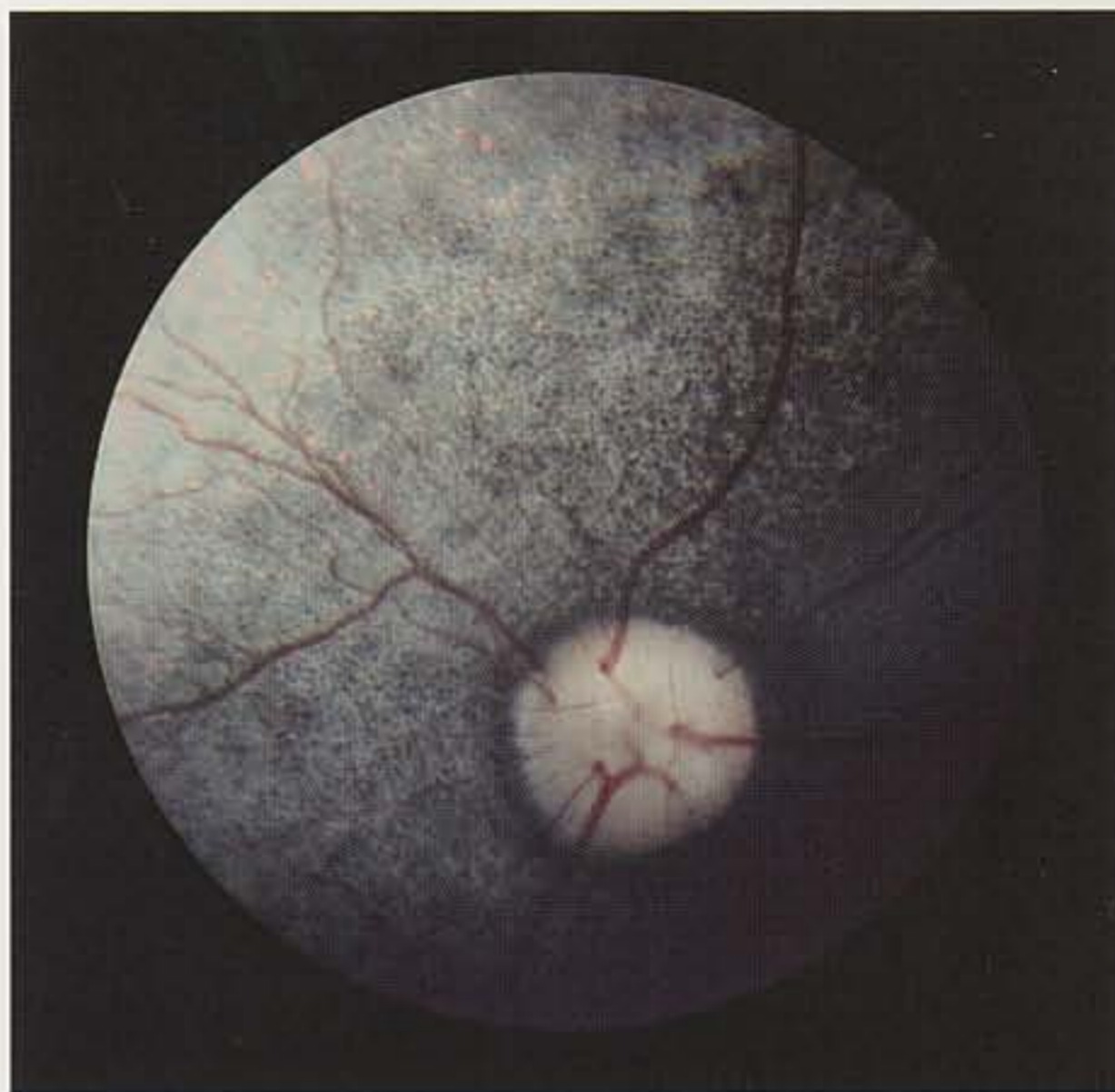


Fig. 11.117 Cone/rod dystrophy (Miniature Longhaired Dachshund, 14 months old) Poor differentiation of the tapetum, but obvious blood vessel attenuation.

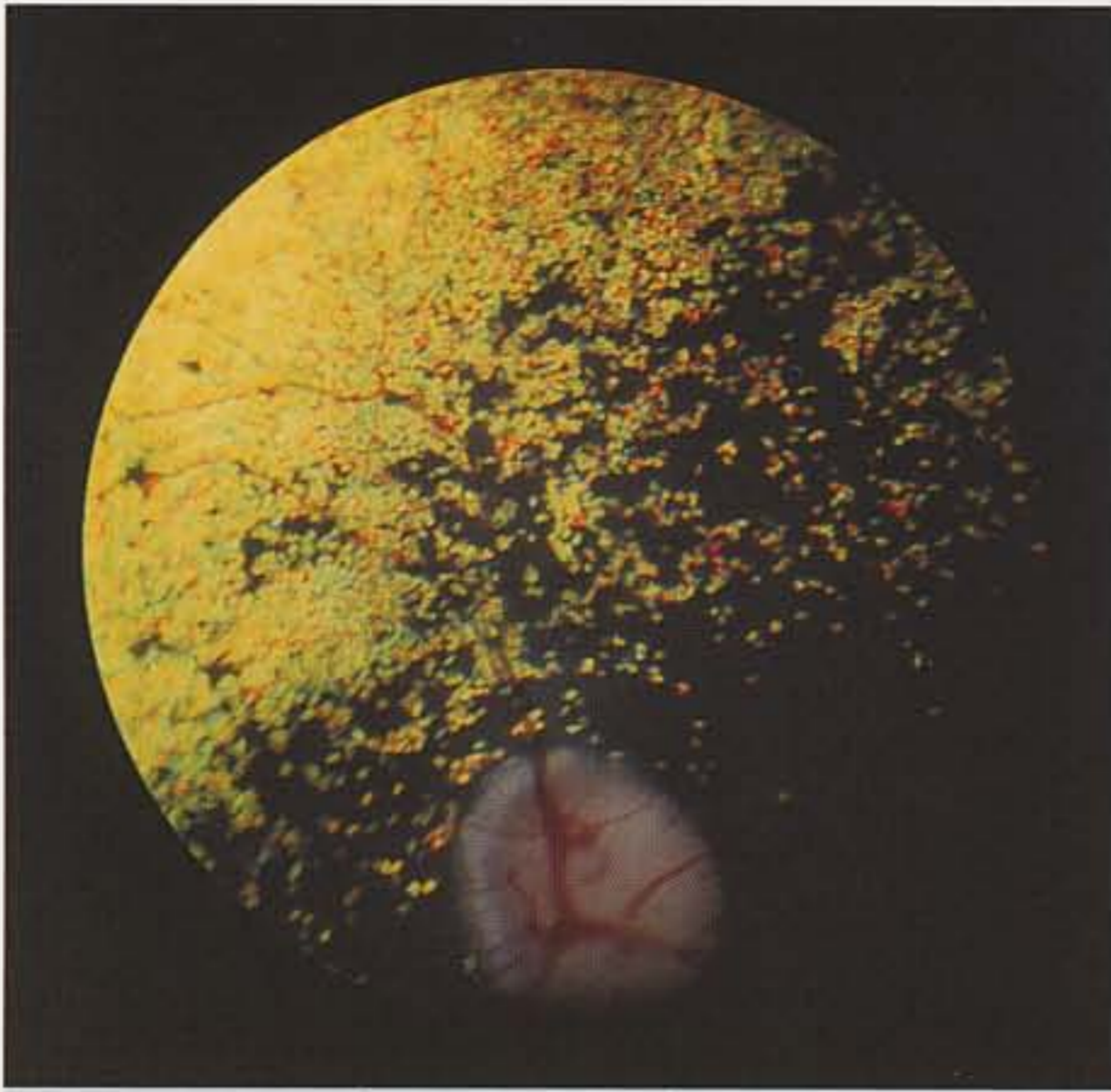


Fig. 11.118 Cone/rod dystrophy (Miniature Longhaired Dachshund, 17 months old) Advanced case.

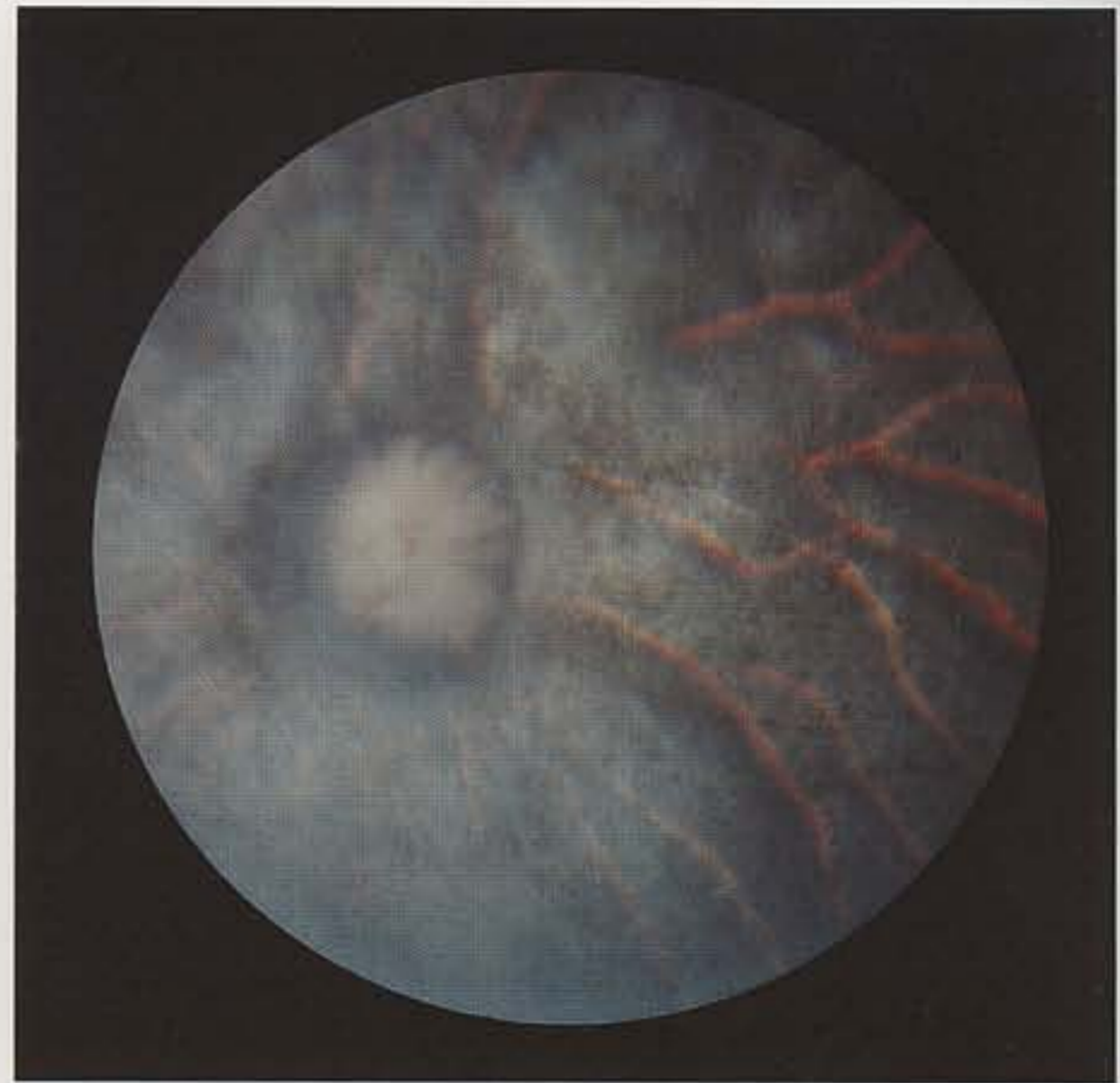


Fig. 11.119 Cone/rod dystrophy (Miniature Longhaired Dachshund, 3 years old) Very advanced case.

Table 11.1 – Generalized progressive retinal atrophy (GPRA): breeds affected

■ Australian Cattle Dog
■ Collie (Rough)
■ Dachshund (Miniature Long-Haired)
■ Finnish Laphund
■ Irish Setter
■ Lhasa Apso
■ Norwegian Elkhound
■ Papillon
■ Poodle (Miniature)
■ Poodle (Toy)
■ Retriever (Chesapeake Bay)
■ Retriever (Golden)
■ Retriever (Labrador)
■ Schnauzer, Miniature
■ Spaniel (American Cocker)
■ Spaniel (Cocker)
■ Spaniel (English Springer)
■ Tibetan Spaniel
■ Tibetan Terrier
■ Welsh Corgi (Cardigan)

#### Collie eye anomaly (CEA) (Figs 11.132–11.164)

CEA is both inherited and congenital and it is non-progressive. CEA is bilateral but not infrequently the two eyes are dissimilar in the degree of severity. CEA affects basically the collie breeds (see Table 11.3). Ophthalmoscopically there are two main lesions. Chorioretinal dysplasia (CRD), or choroidal hypoplasia, is the characteristic lesion always found lateral to the optic disc, either adjacent to the disc or two to three disc diameters away from it. In the more severe cases of CRD, the lesion may extend to surround the disc but in such cases the severest part is always lateral to the disc. The second lesion is a coloboma which may affect a part of the disc or the whole of the disc and sometimes the peripapillary region. The visual deficit varies from no apparent effect (mild CRD cases) to total blindness, the former being much more common than the latter. Intraocular haemorrhage, including hyphaema, sometimes occurs and may be the presenting sign, and total retinal detachment is also an occasional finding. Although the condition is considered to be congenital, these latter two signs of haemorrhage and detachment, both causing blindness, may occur

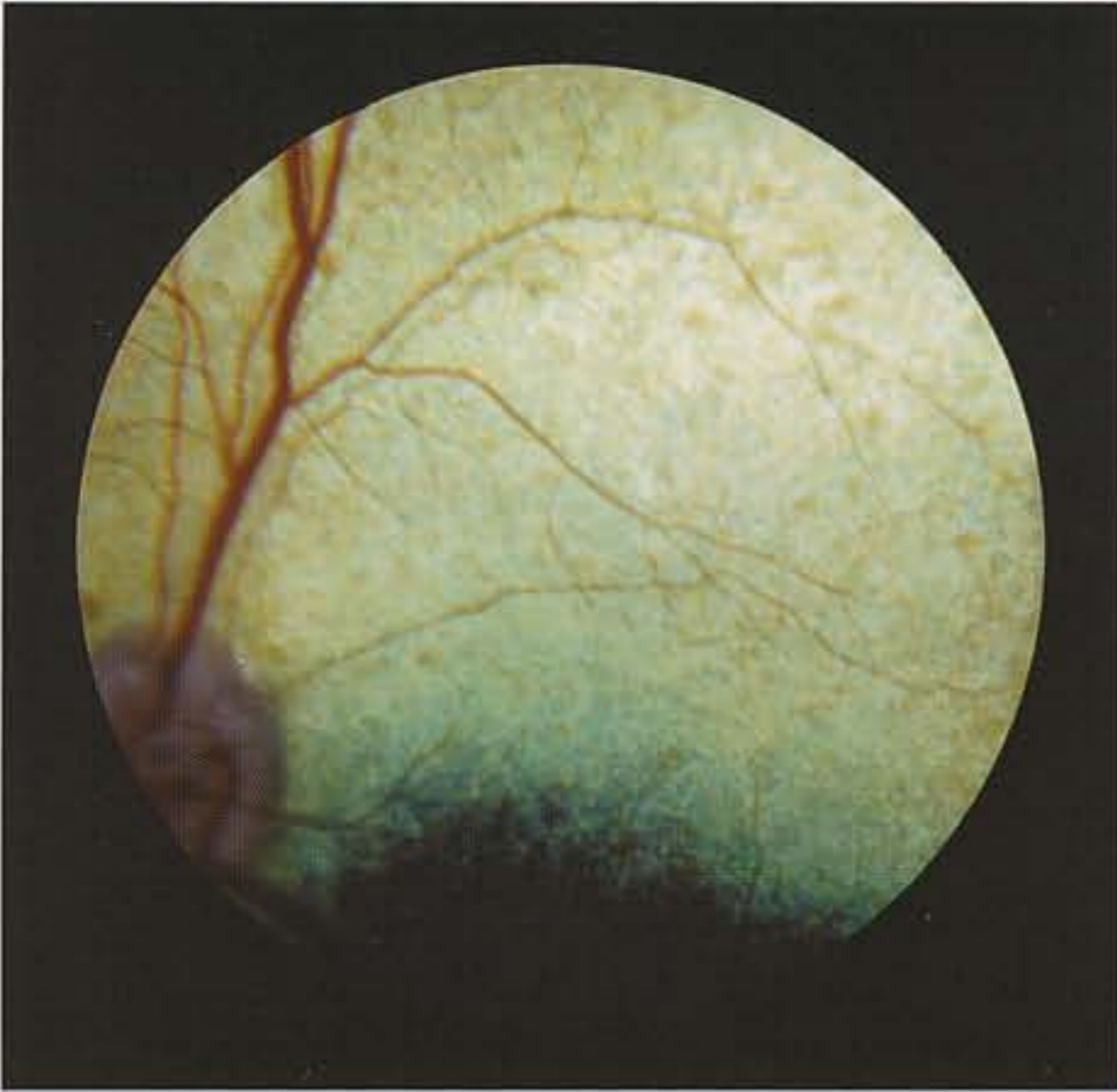

Fig. 11.120 Pigment epithelial dystrophy (Labrador Retriever, 2 years old) Note the early change in the area centralis.

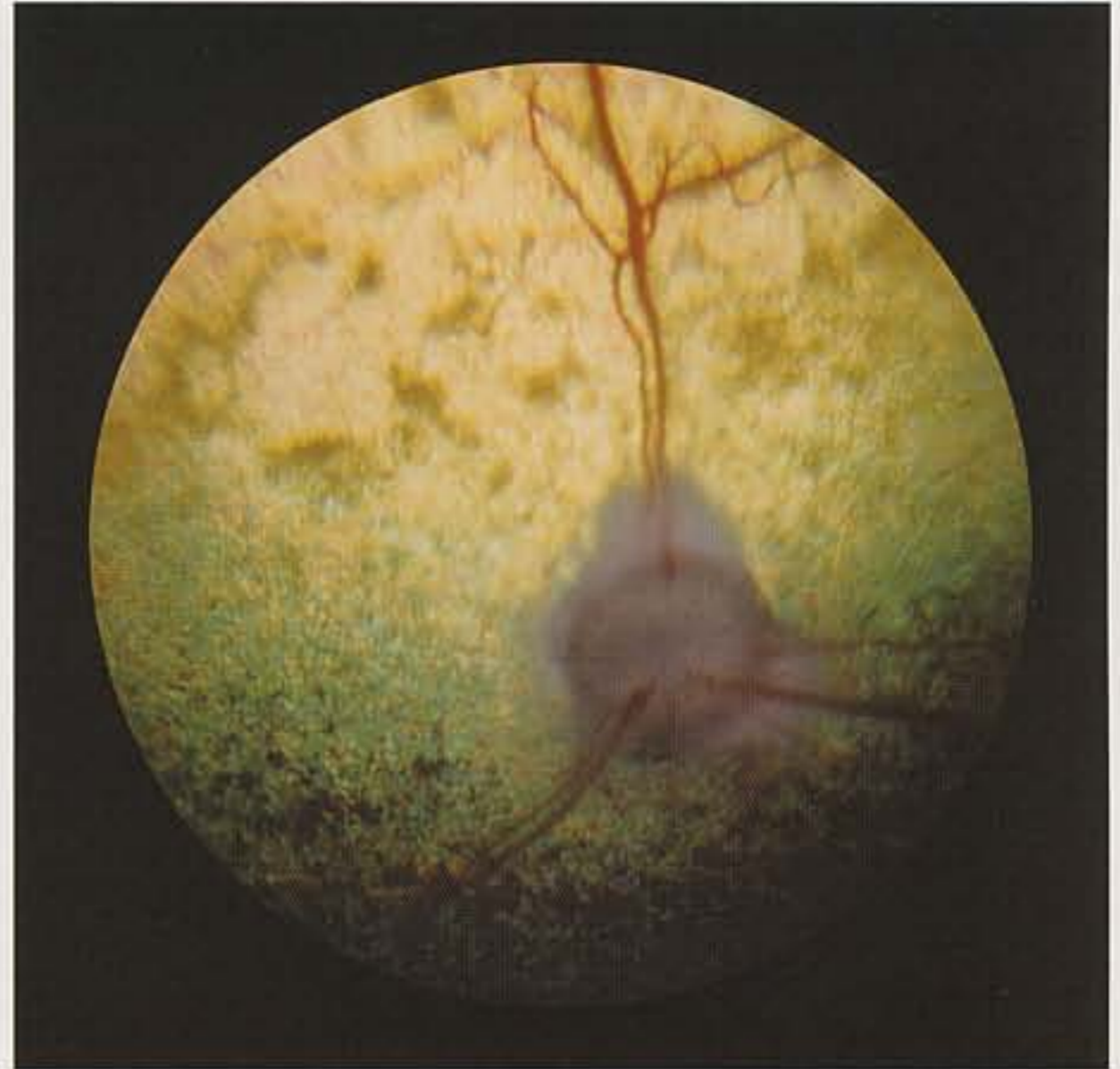

Fig. 11.122 Pigment epithelial dystrophy (Labrador Retriever, 5 years old) Same dog as in Figure 11.121, but one year later.

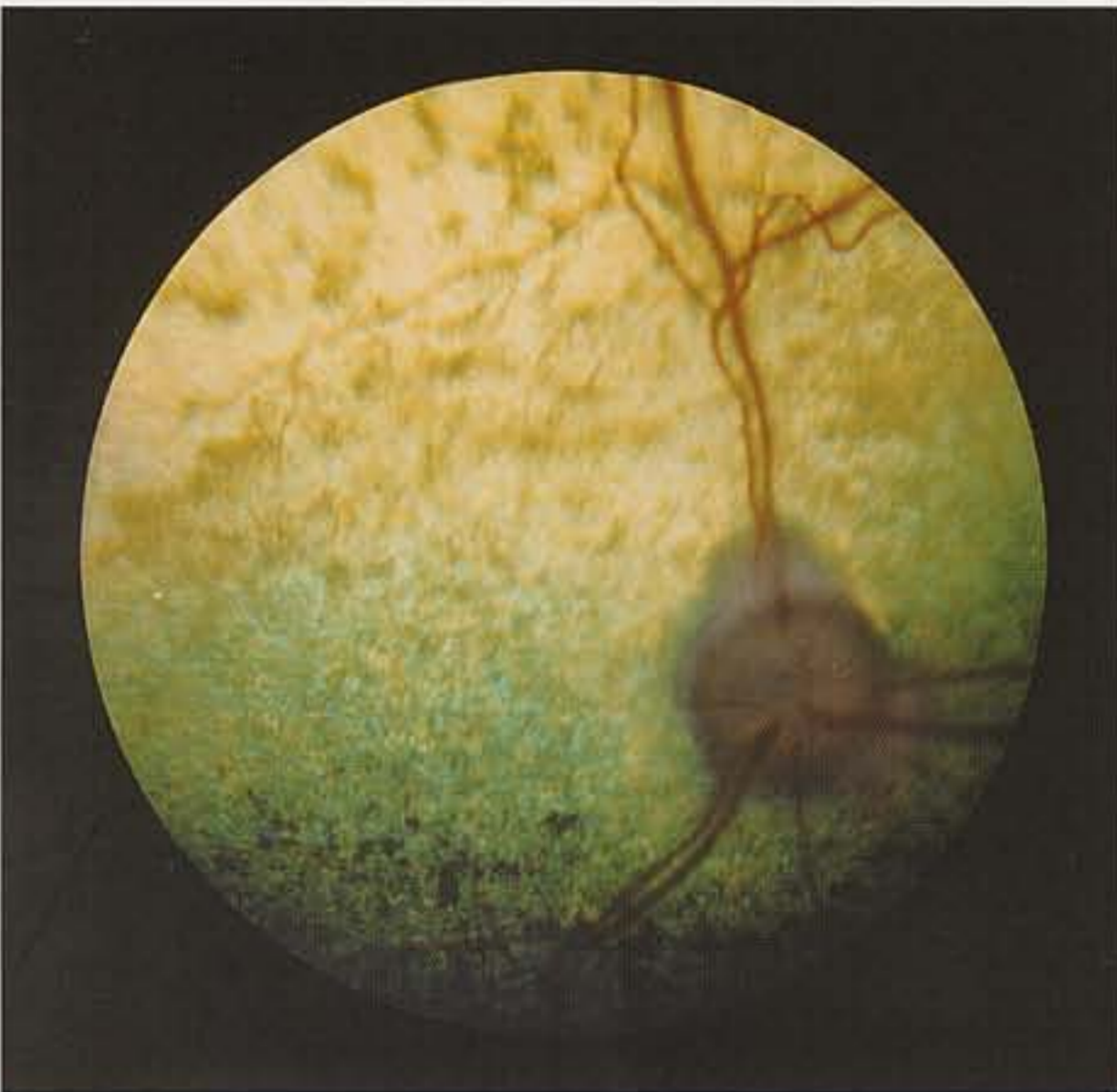


Fig. 11.121 Pigment epithelial dystrophy (Labrador Retriever, 4 years old) Note the pigmentary change in the tapetal fundus.

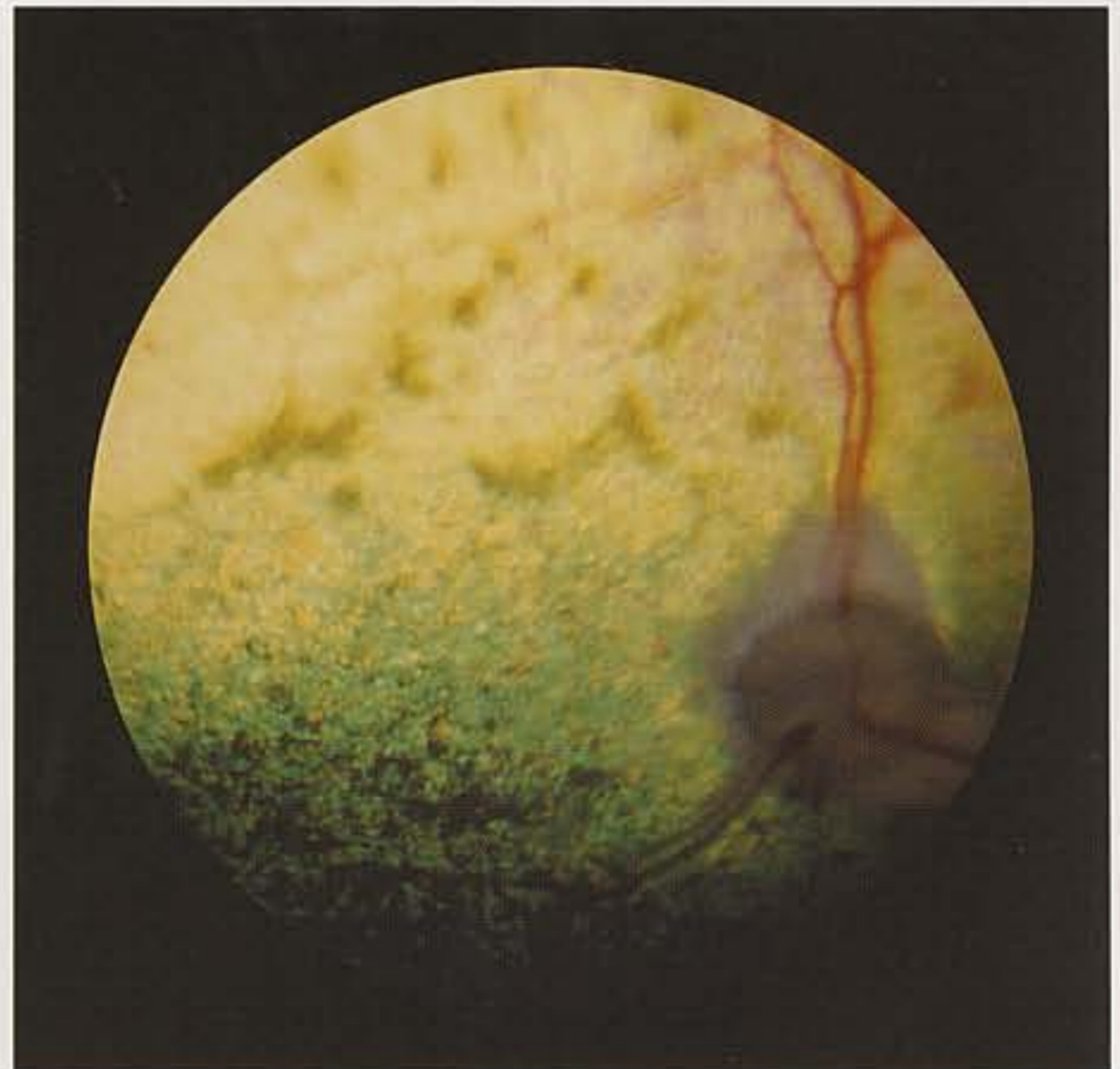


Fig. 11.123 Pigment epithelial dystrophy (Labrador Retriever, 6 years old) Same dog as in Figs 11.121, 11.122. Note the progression of the pigmentary change with fewer but more dense pigment spots.

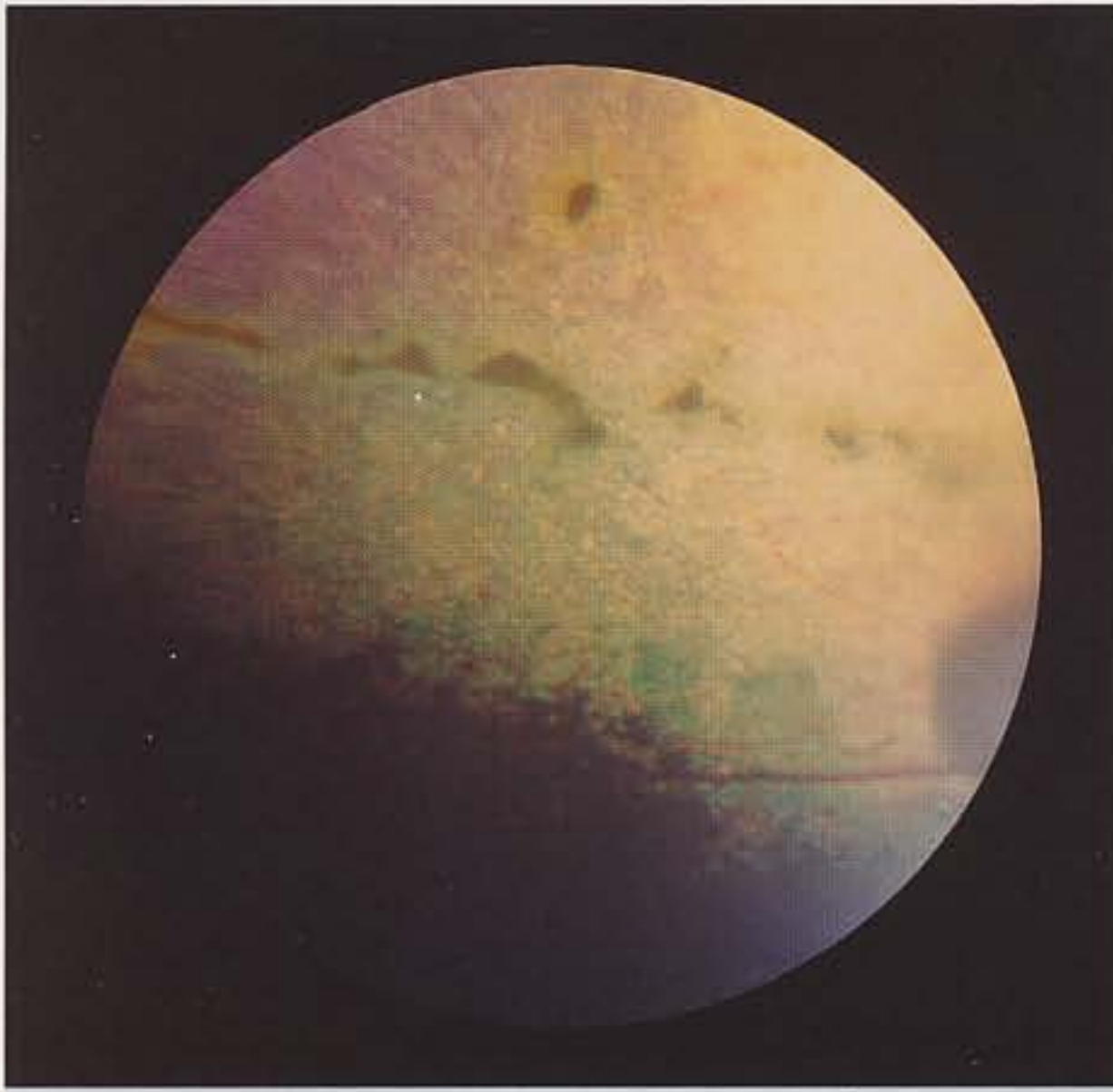


Fig. 11.124 Pigment epithelial dystrophy (Labrador Retriever, 10 years old) Advanced stage with a few dense pigment spots on a hyper-reflective background.

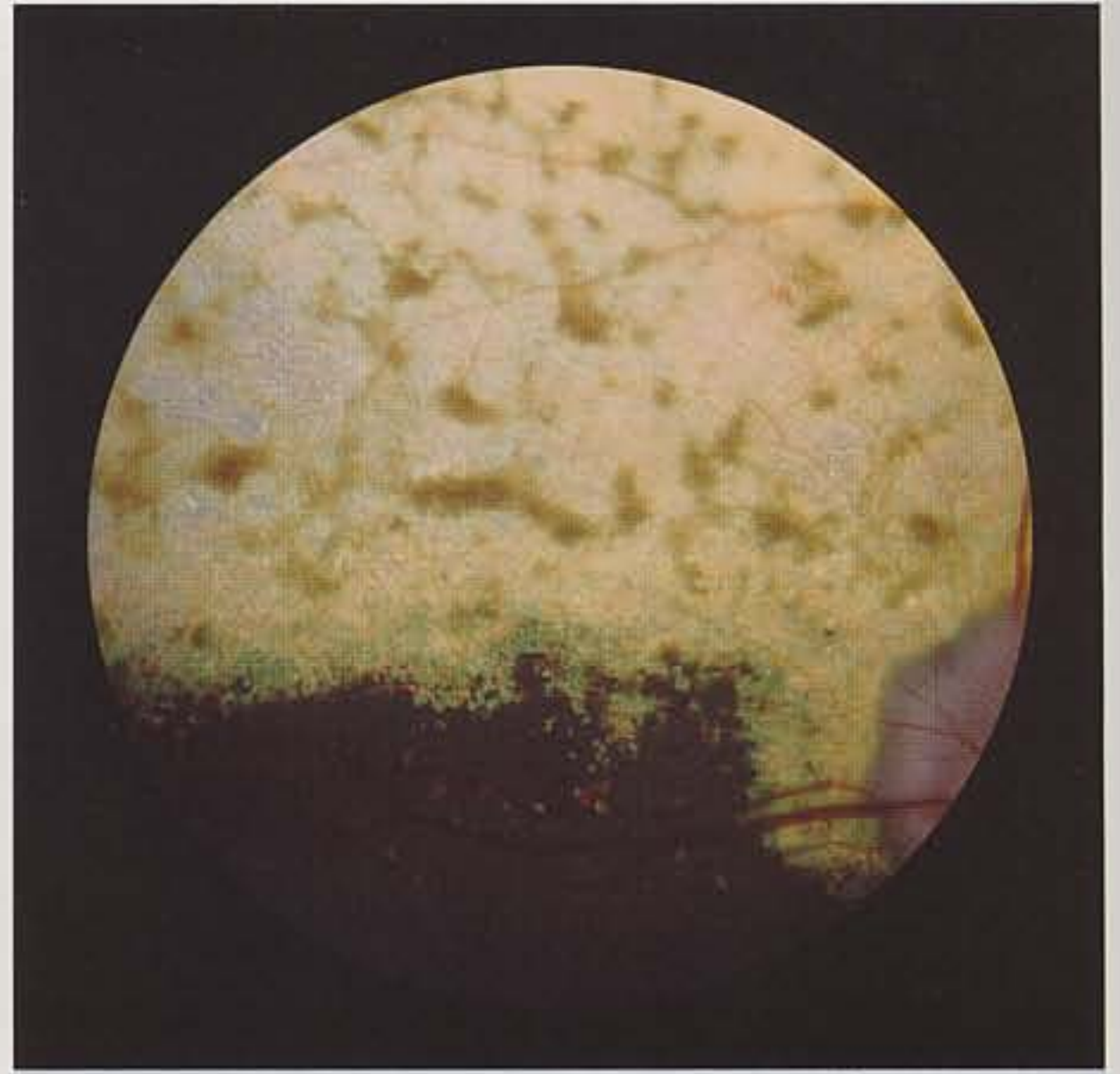


Fig. 11.126 Pigment epithelial dystrophy (Labrador Retriever, 6 years old) Note the increased tapetal reflectivity between the pigment spots.

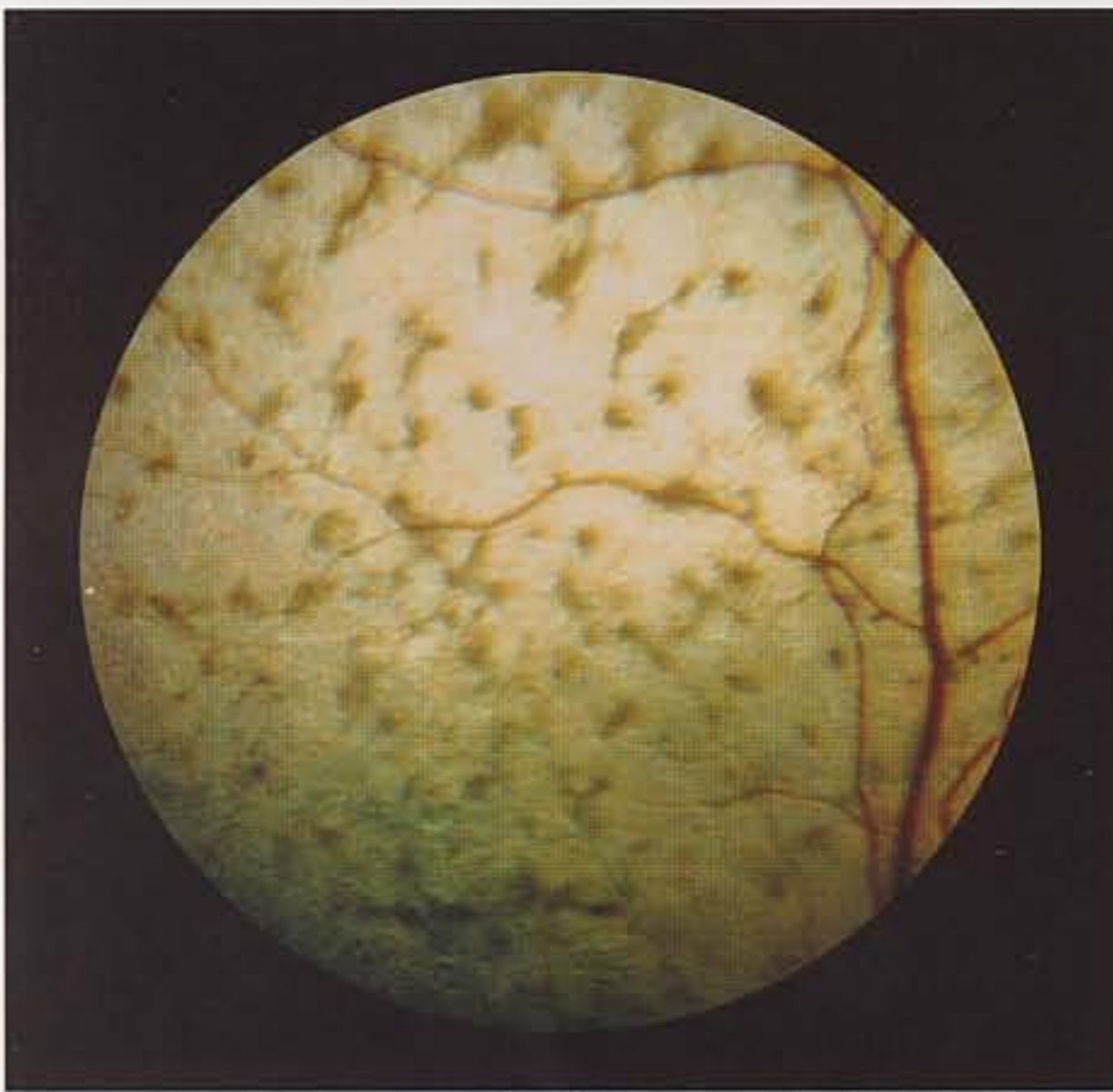

Fig. 11.125 Pigment epithelial dystrophy (Labrador Retriever, 5 years old) Note the pigmentation along the course of the retinal blood vessels.

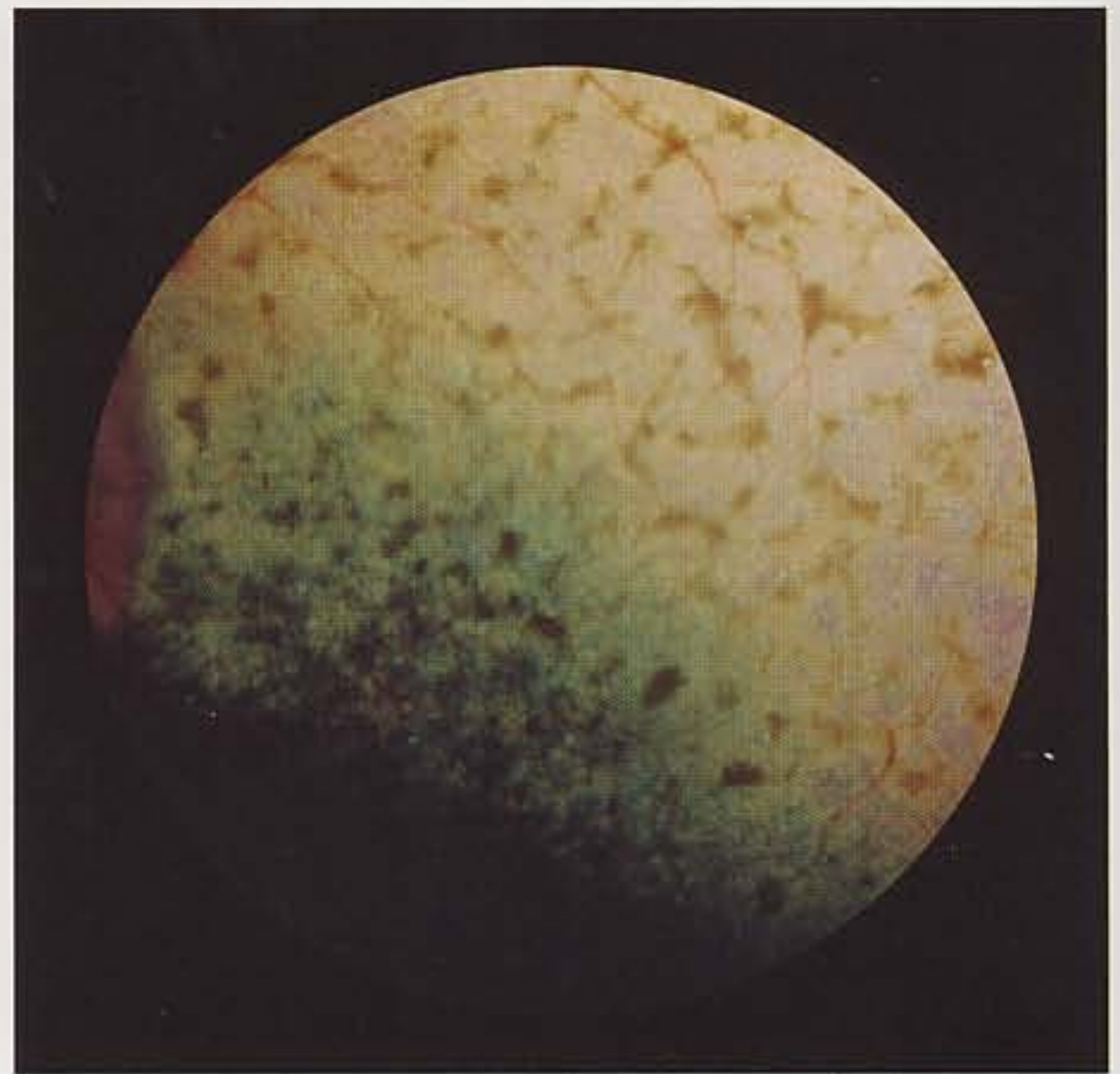


Fig. 11.127 Pigment epithelial dystrophy (Labrador Retriever, 4 years old) Note the difference in the form or shape of the pigment spots from the previous two figures (Figs 11.125, 11.126).

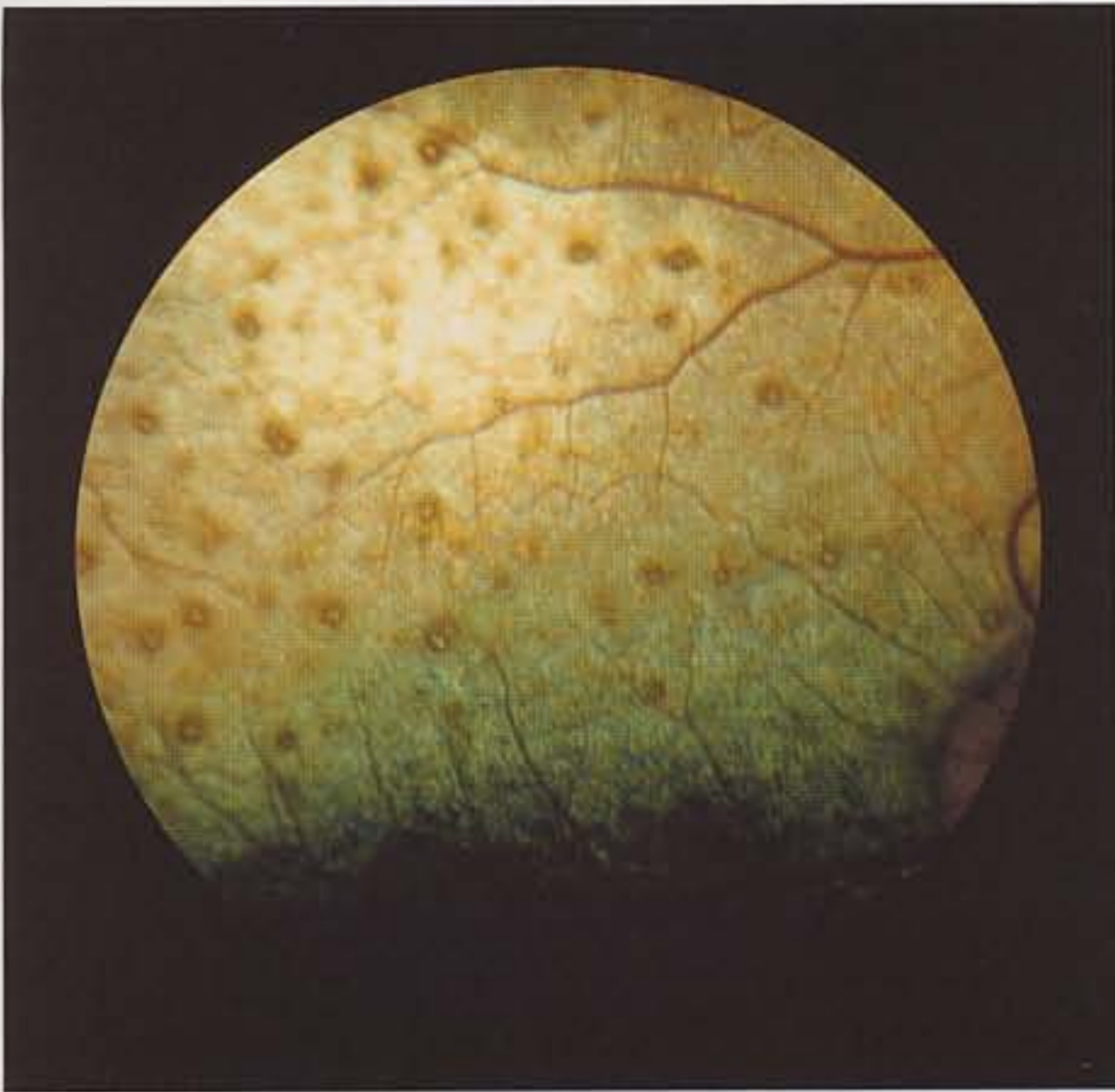

Fig. 11.128 Pigment epithelial dystrophy (Labrador Retriever, 3 years old) Note the cystic appearance of the pigment spots.

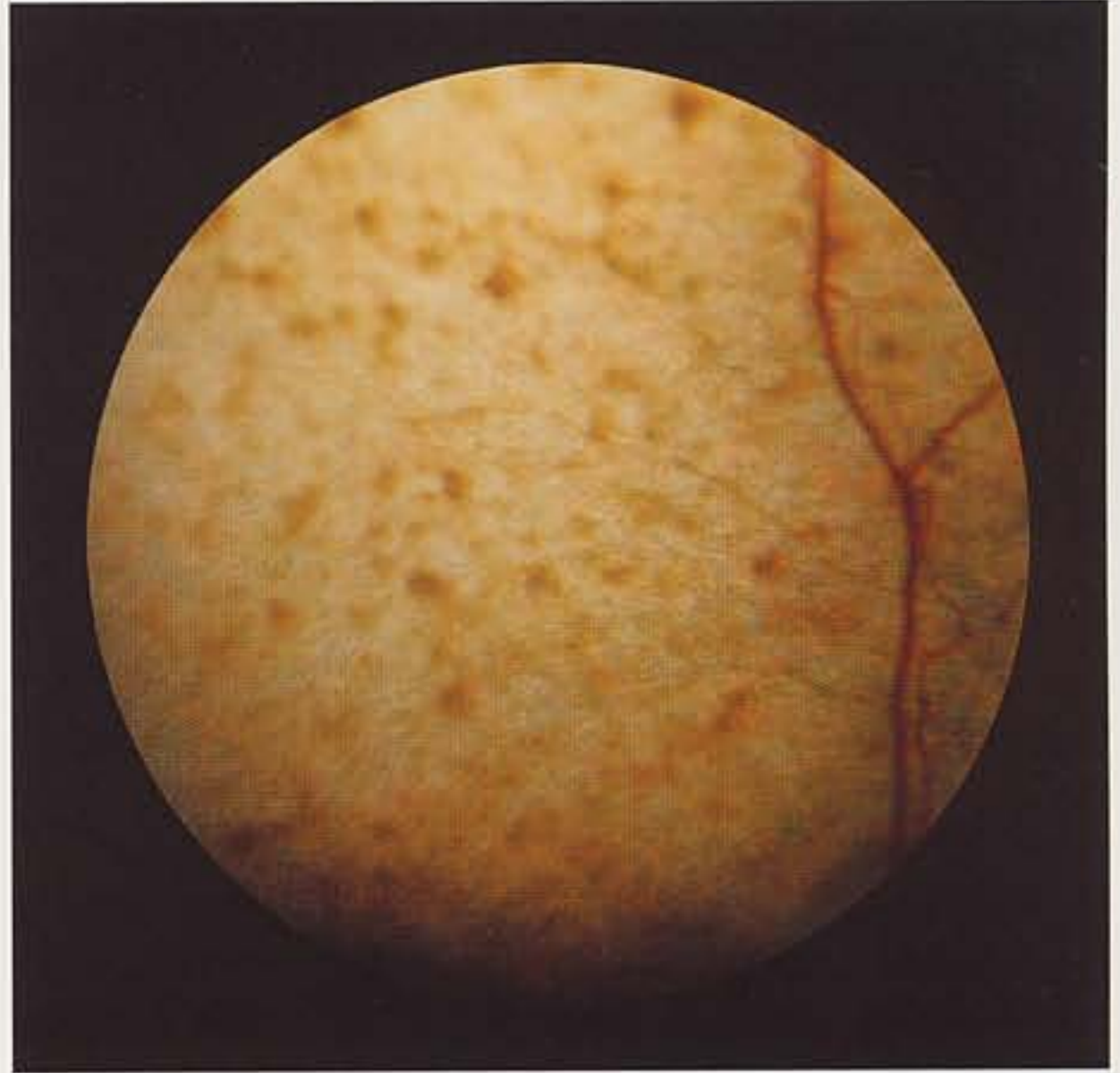

Fig. 11.130 RPED (Rough Collie, 5 years old)

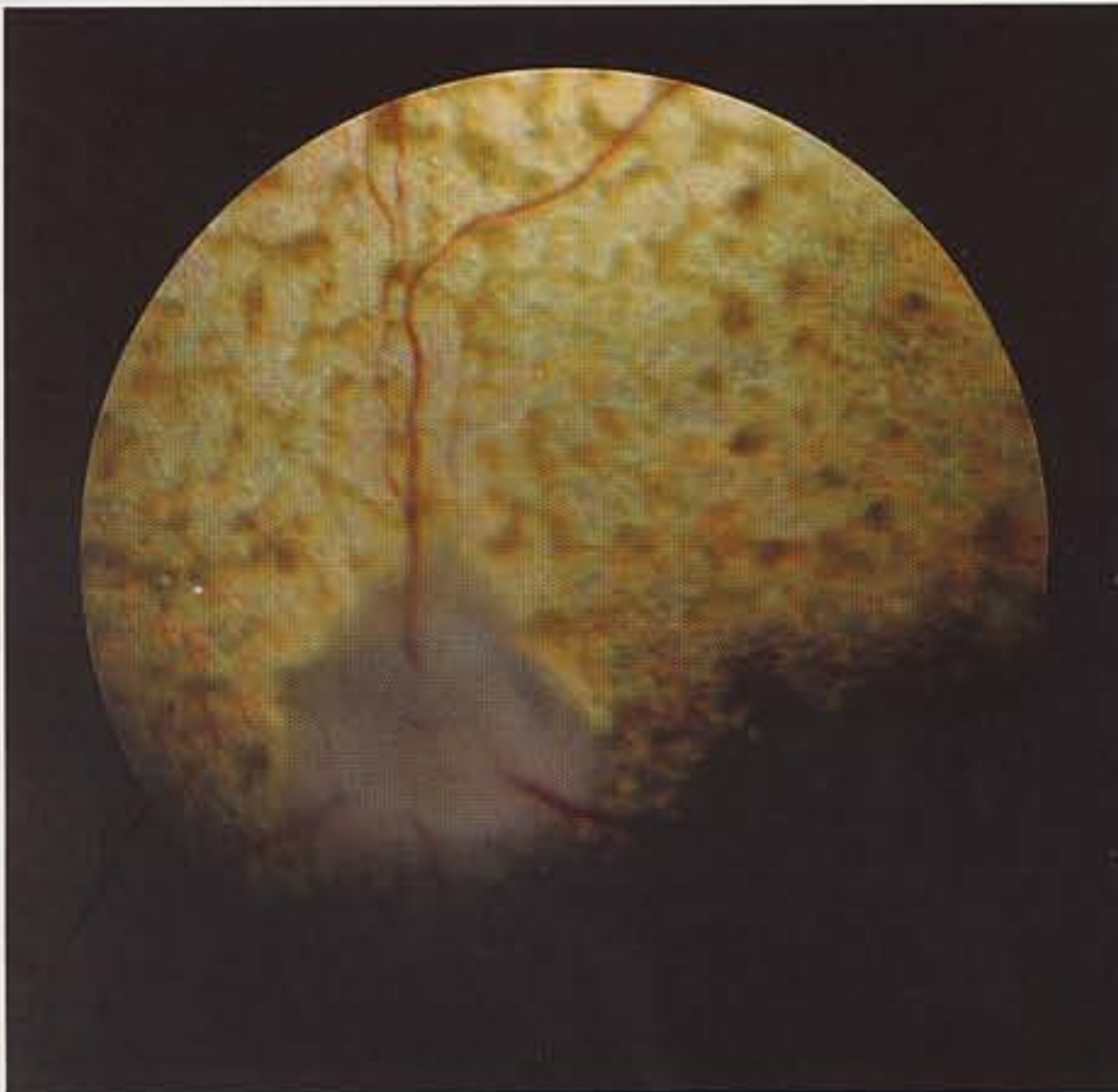

Fig. 11.129 RPED (Border Collie, 6 years old)

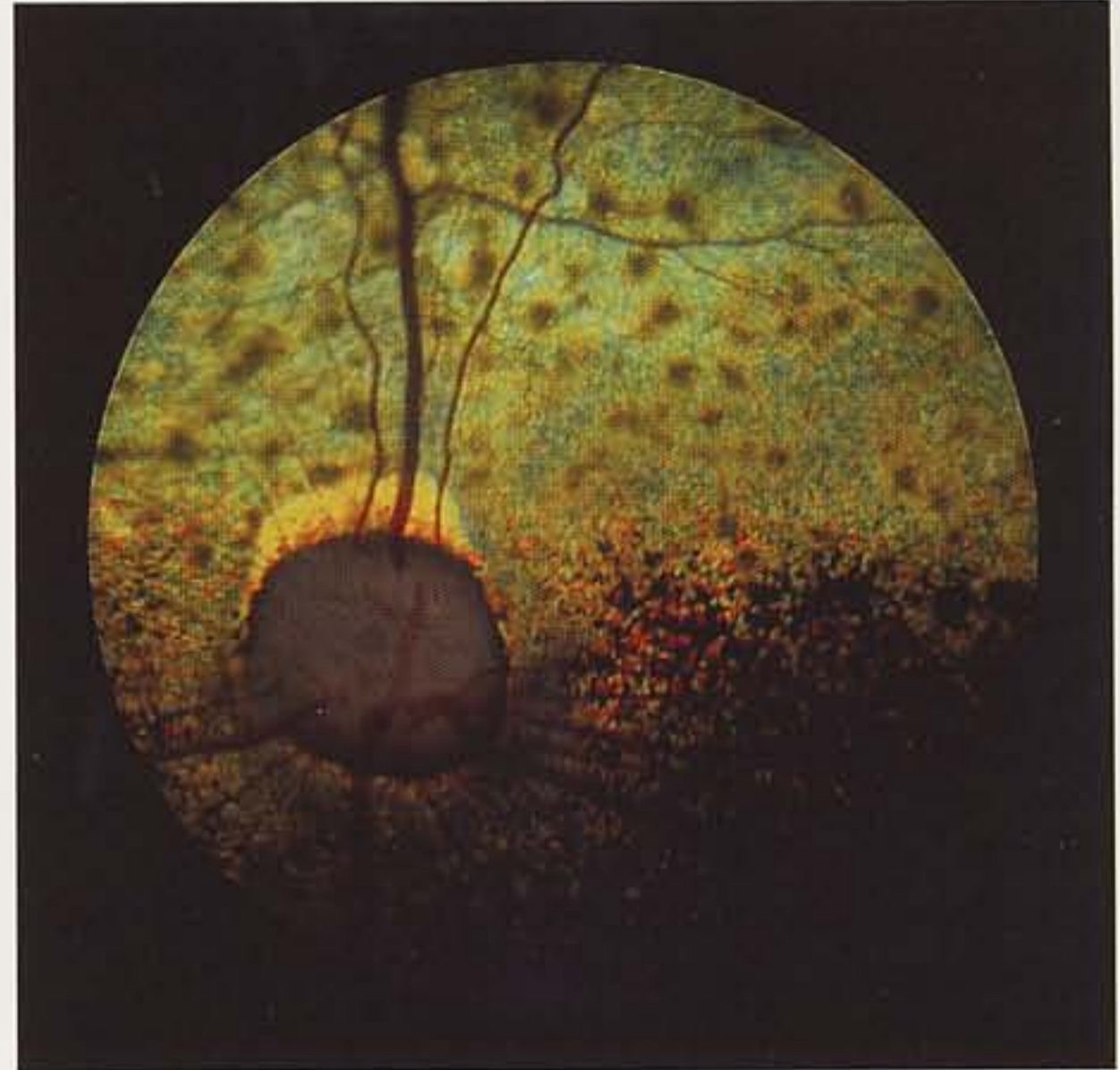

Fig. 11.131 RPED (Briard, 3 1/2 years old)

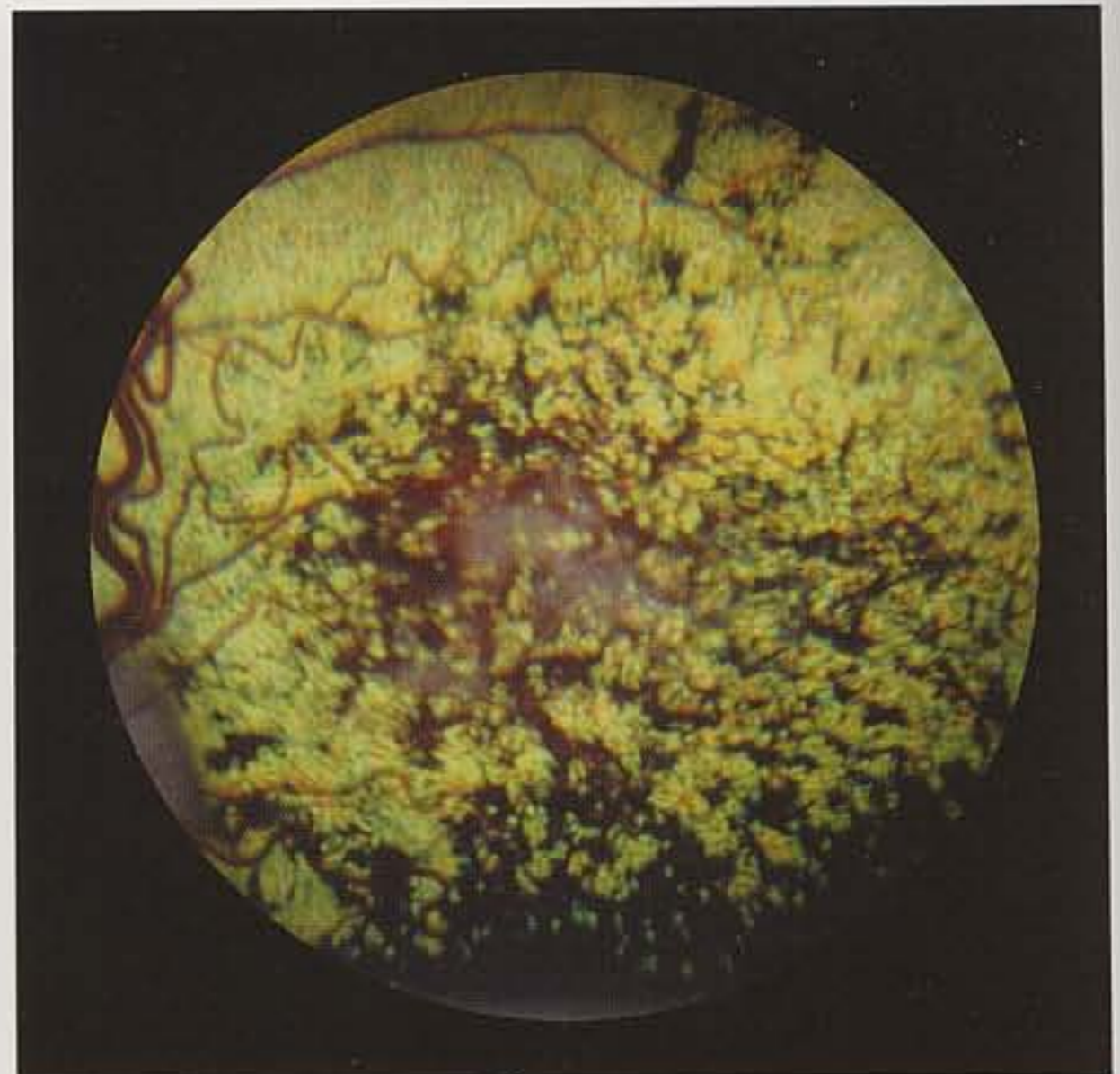
**Table 11.2 – Retinal pigment epithelial dystrophy (RPED): breeds affected**

■ Border Collie
■ Briard
■ Collie (Rough)
■ Collie (Smooth)
■ Polish Lowland Sheepdog
■ Retriever (Golden)
■ Retriever (Labrador)
■ Shetland Sheepdog
■ Spaniel (Cocker)
■ Spaniel (English Springer)
■ Welsh Corgi (Cardigan)

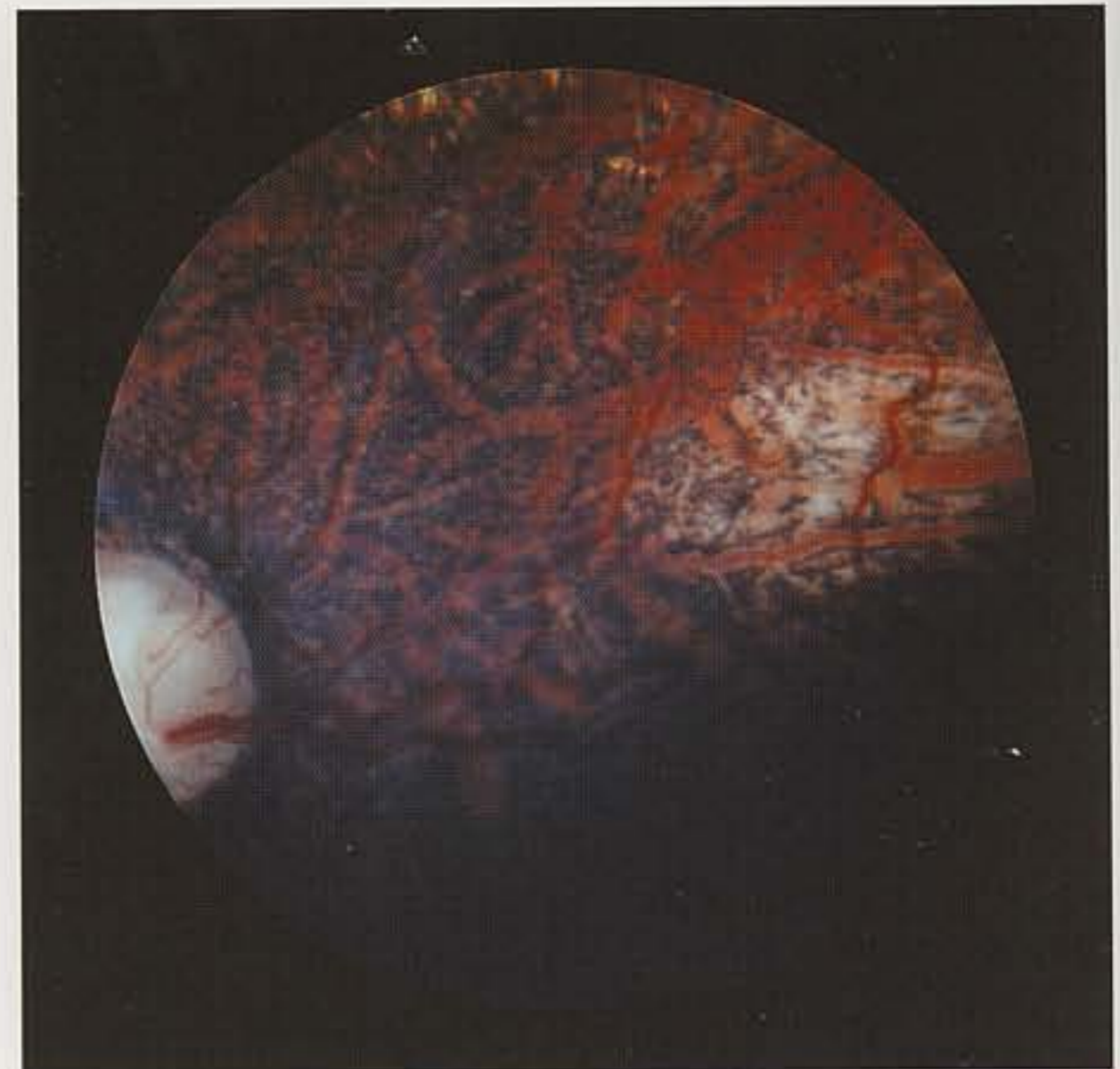in young adult dogs. Inheritance is thought to be due to a simple autosomal recessive gene but recently some doubt has been expressed as to this opinion and, although the lesions appear ophthalmoscopically the same in all the breeds affected, this fact has yet to be proved genetically.

#### **Retinal dysplasia, total (TRD) and multifocal (MRD) (Figs 11.165–11.184)**

Retinal dysplasia (RD) is the second congenital and inherited abnormality of the retina in the dog and with similarities to CEA. It is usually bilateral but by no means always on ophthalmoscopic examination. It is not progressive and the degree of severity of MRD varies considerably. The types of RD and the breeds affected are shown in Table 11.4. In total RD both eyes are affected and an infundibular type of retinal detachment is present in young puppies which are blind and may show forms of ocular nystagmus. In multifocal RD, including the so-called 'geographic' form, retinal folds, varying in number from one to many, occur in the tapetal fundus usually immediately above the optic disc in the central region. In the geographic form a large circumscribed horseshoe-shaped to circular area, sometimes associated with several fine and tortuous blood vessels, is also found in the tapetal fundus, but usually much further away from the disc and towards the edge of the tapetum in the central region. Sometimes retinal folds have been known to disappear with time, even in breeds with primary



**Fig. 11.132 Chorioretinal dysplasia (Border Collie, 4 years old) Minor change in the typical position lateral to the optic disc.**



**Fig. 11.133 Chorioretinal dysplasia (Shetland Sheepdog, 7 months old) More severe change away from the disc.**

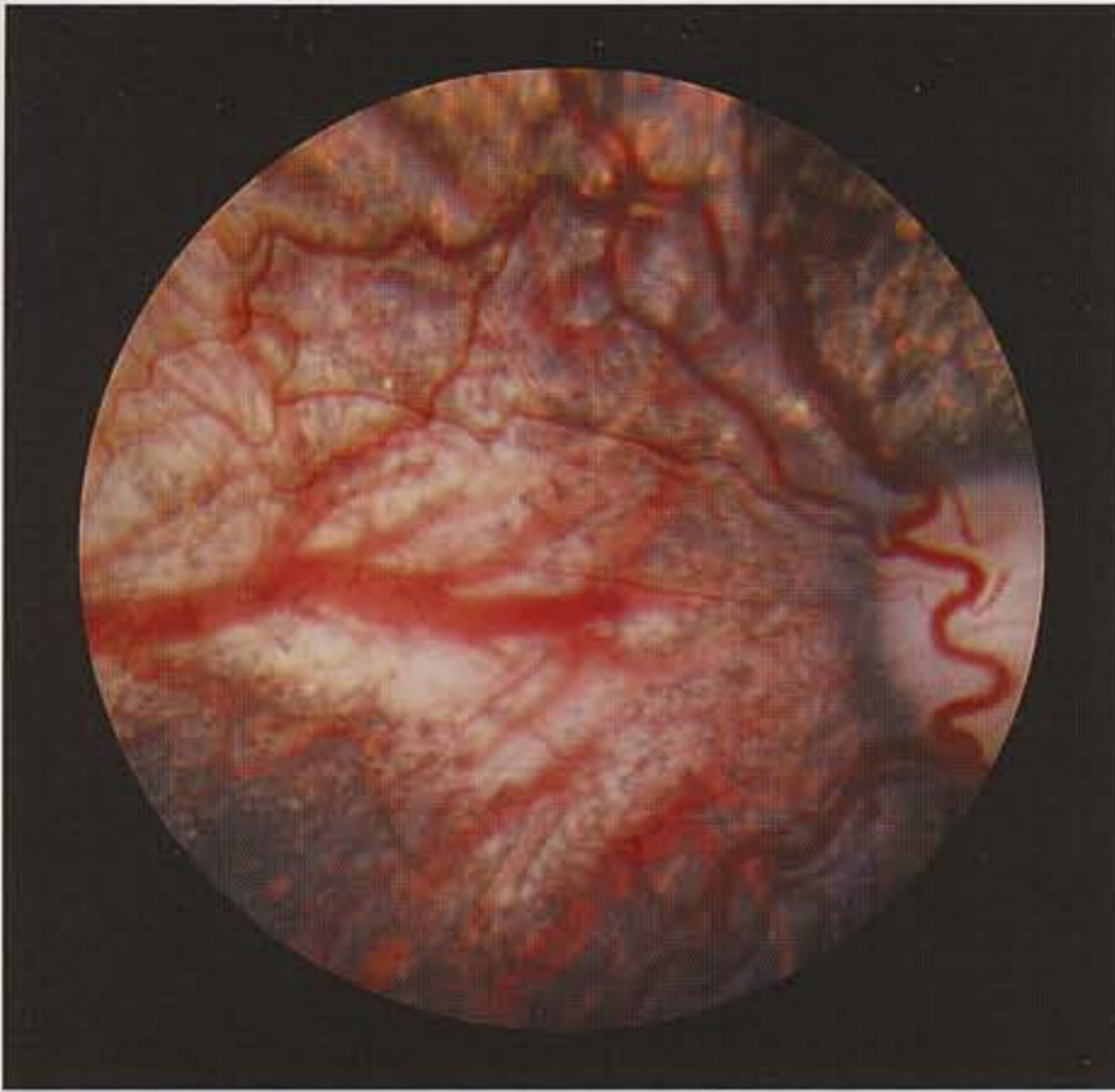


Fig. 11.134 Chorioretinal dysplasia (Shetland Sheepdog, 7 months old) More severe change than in Fig 11.133, in a similar position but adjacent to the disc.

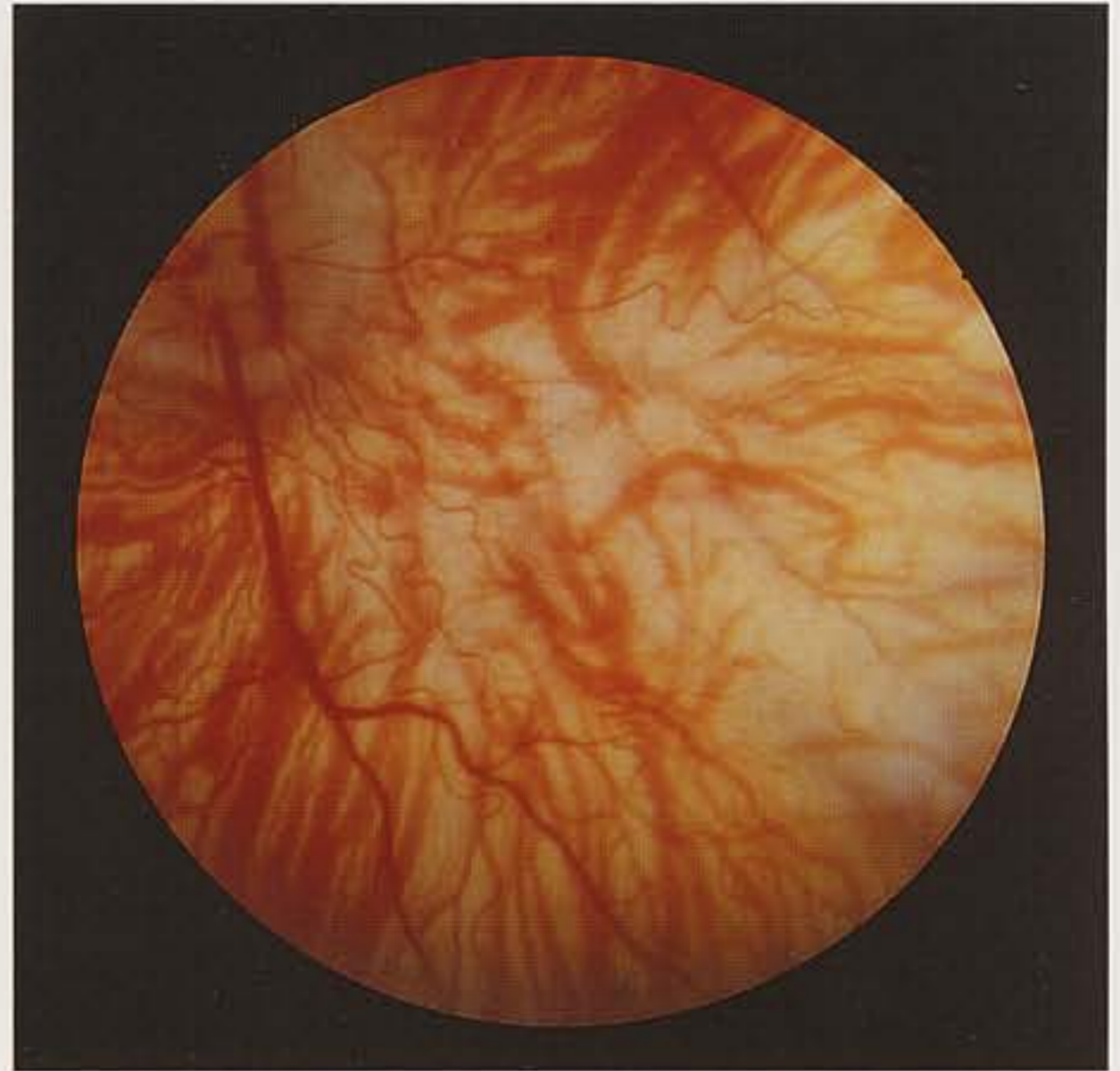


Fig. 11.136 Chorioretinal dysplasia (Rough Collie, 2 years old, blue merle) Typical appearance of the lesion in a subalbino fundus.

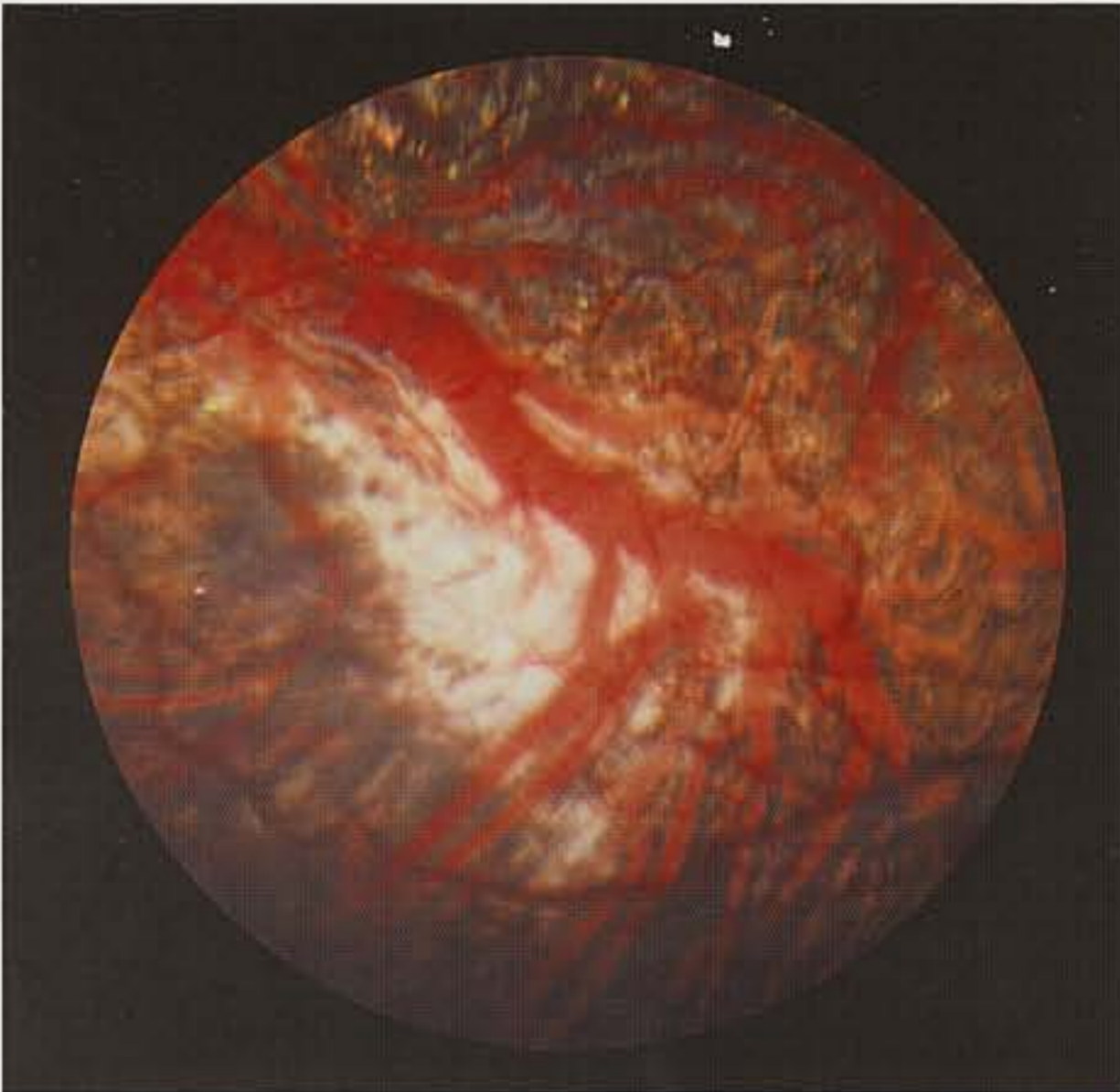


Fig. 11.135 Chorioretinal dysplasia (Shetland Sheepdog, 2 years old) Severe change lateral but not adjacent to the disc.

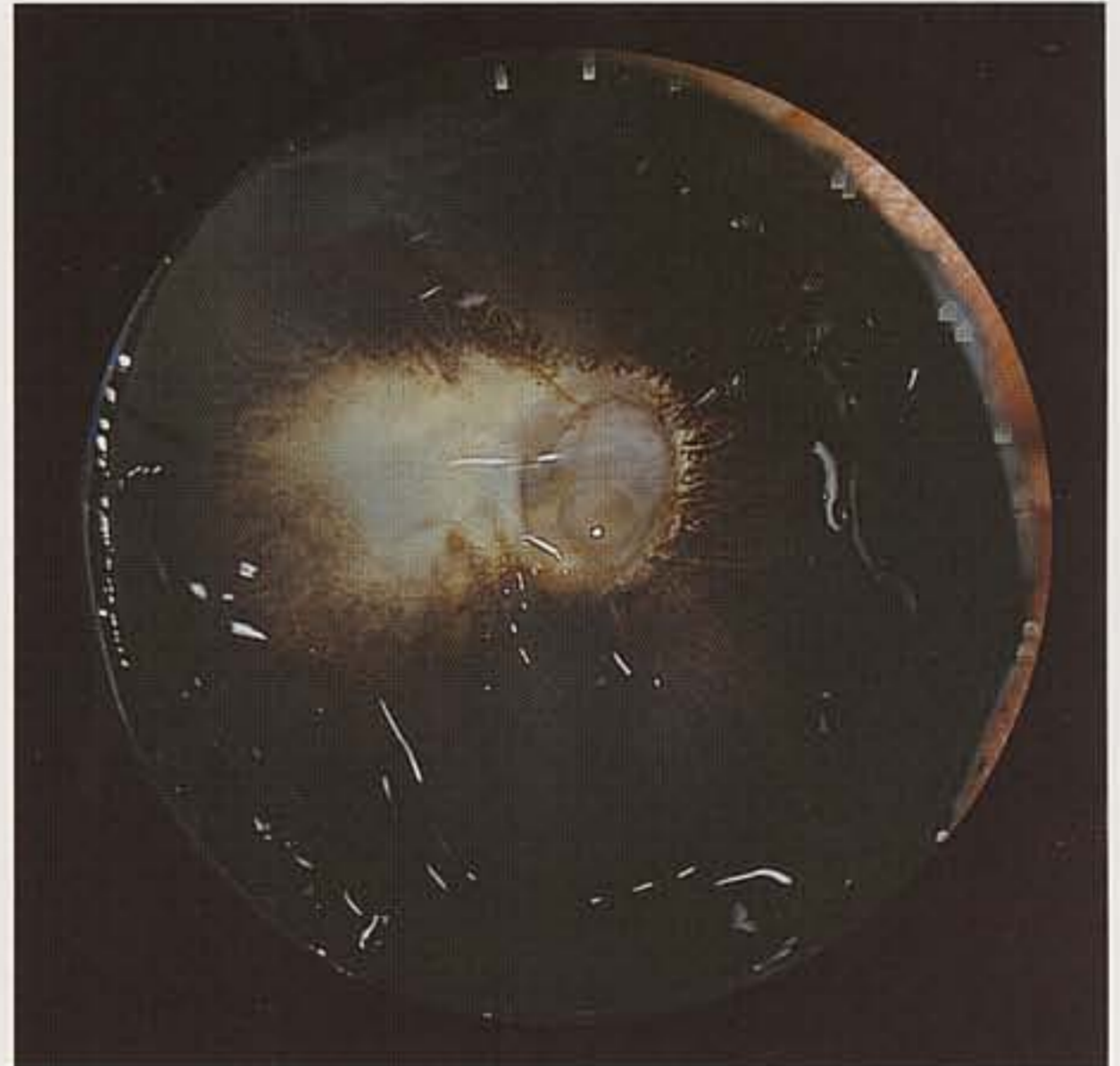


Fig. 11.137 Chorioretinal dysplasia (Border Collie, 2 years old) Posterior segment of the eye showing the 'pale patch' (dysplastic area) opposite the optic disc. Note also the coloboma of the optic disc.



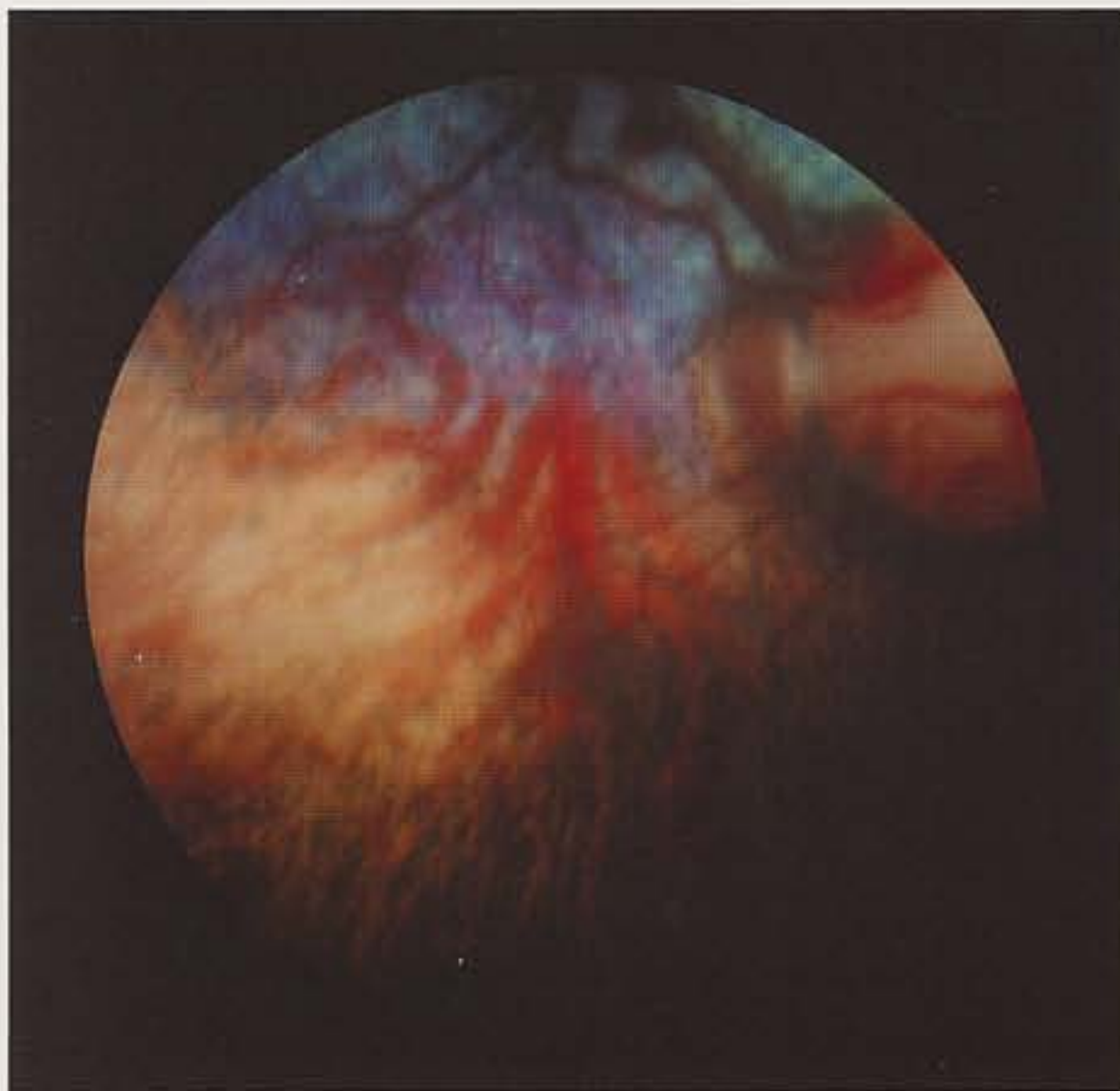


Fig. 11.138 Chorioretinal dysplasia (Rough Collie, 8 weeks old) The appearance of the lesion in a young puppy – note the early tapetal development.

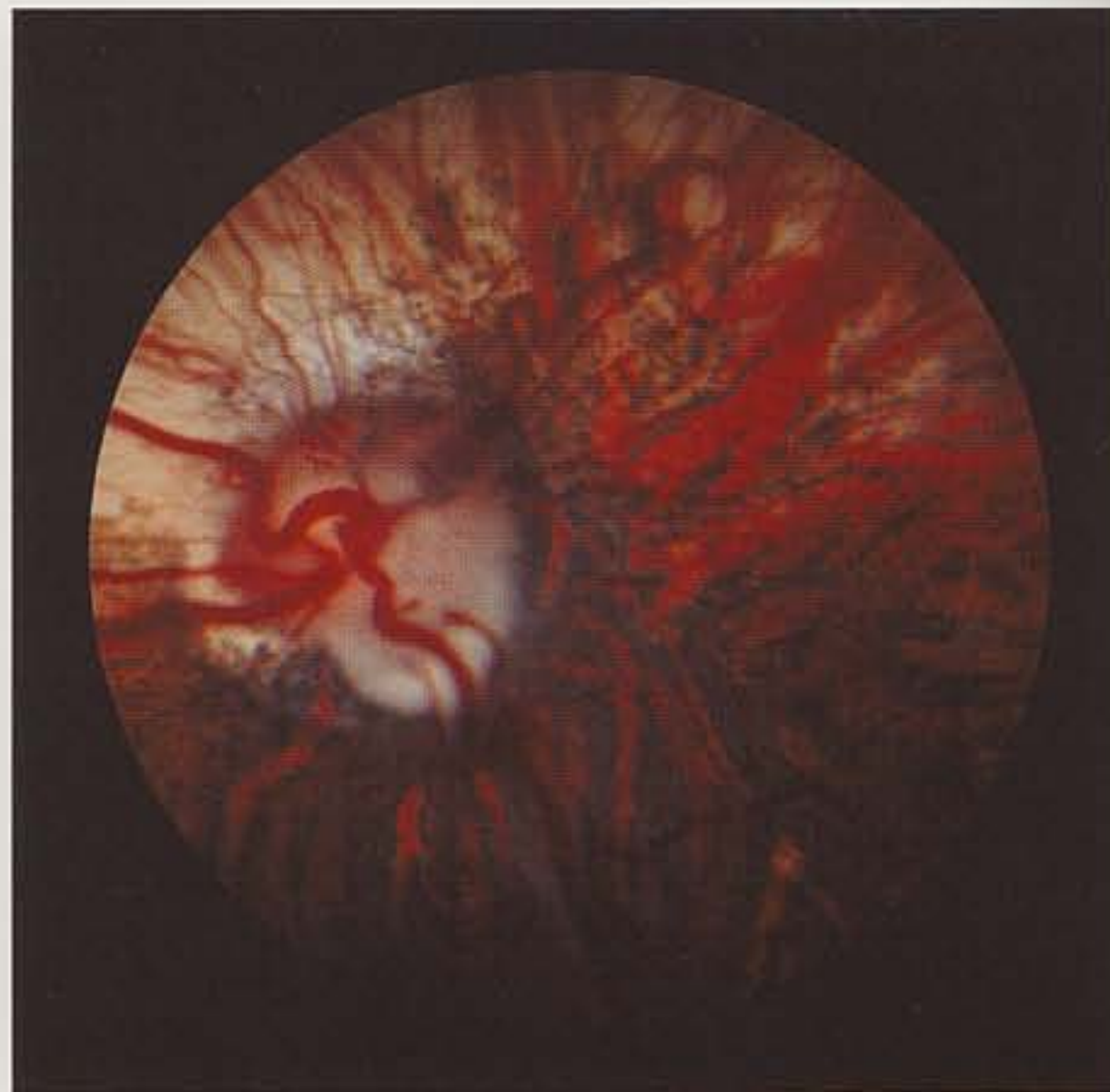

Fig. 11.140 Coloboma (Rough Collie, 1 year old, blue merle) Small coloboma at 12 o'clock (note dipping of disc vessels), together with chorioretinal dysplasia.

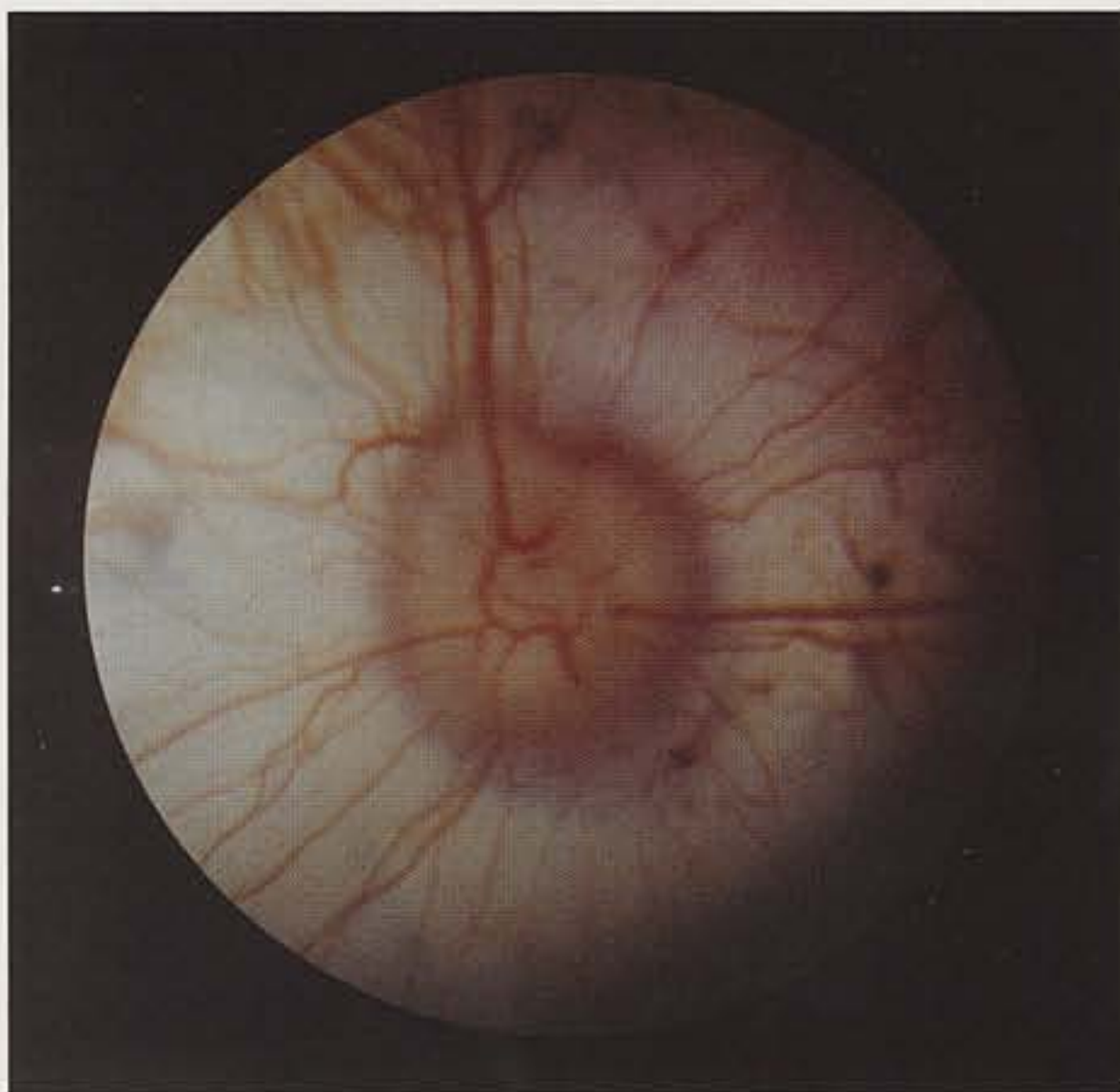


Fig. 11.139 Chorioretinal dysplasia (Shetland Sheepdog, 3 years old, blue merle) Extensive chorioretinal dysplasia in a subalbinotic fundus.

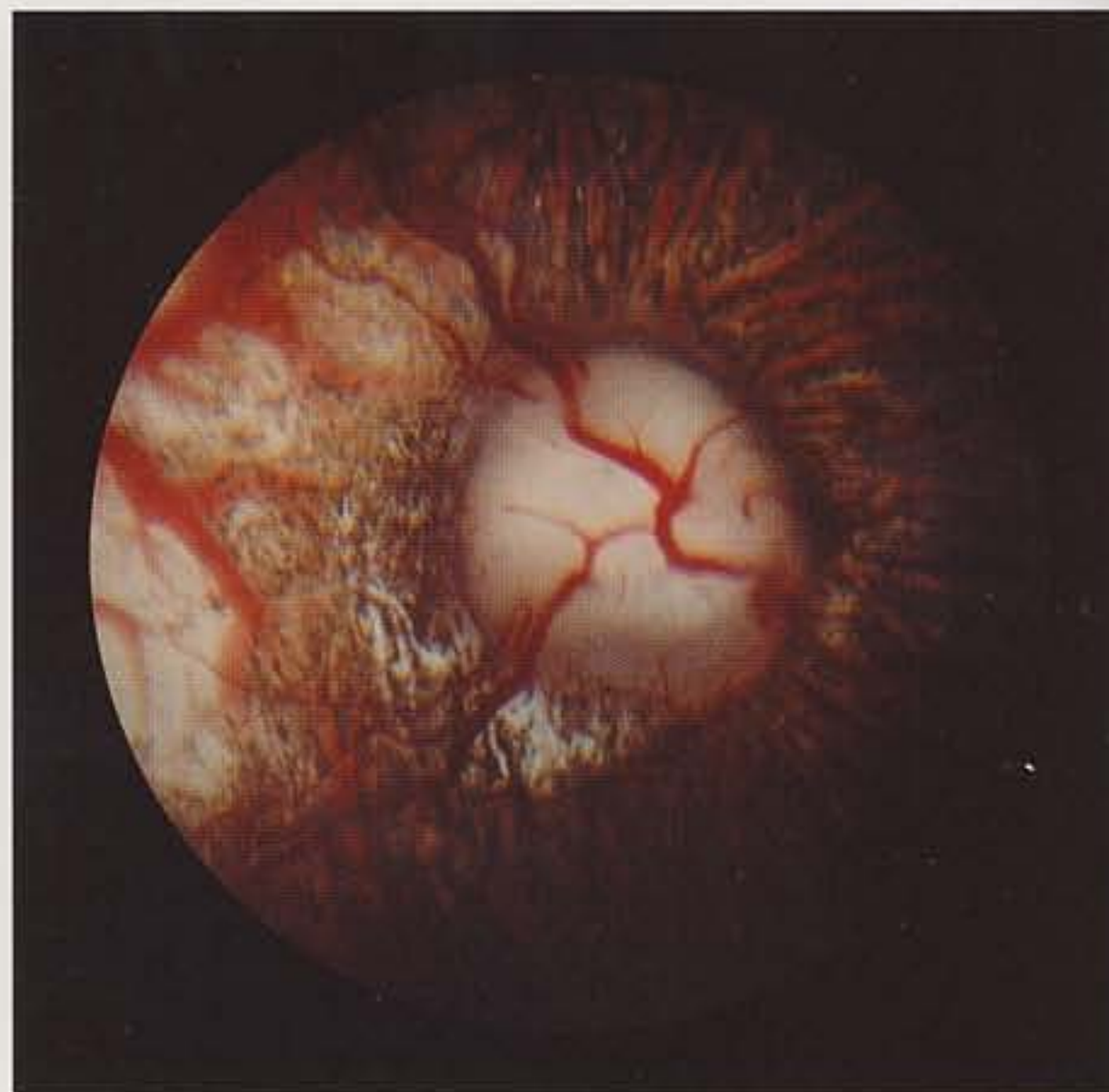


Fig. 11.141 Coloboma (Shetland Sheepdog, 3 years old, sable) Shallow coloboma of the lower part of the optic disc, together with chorioretinal dysplasia.

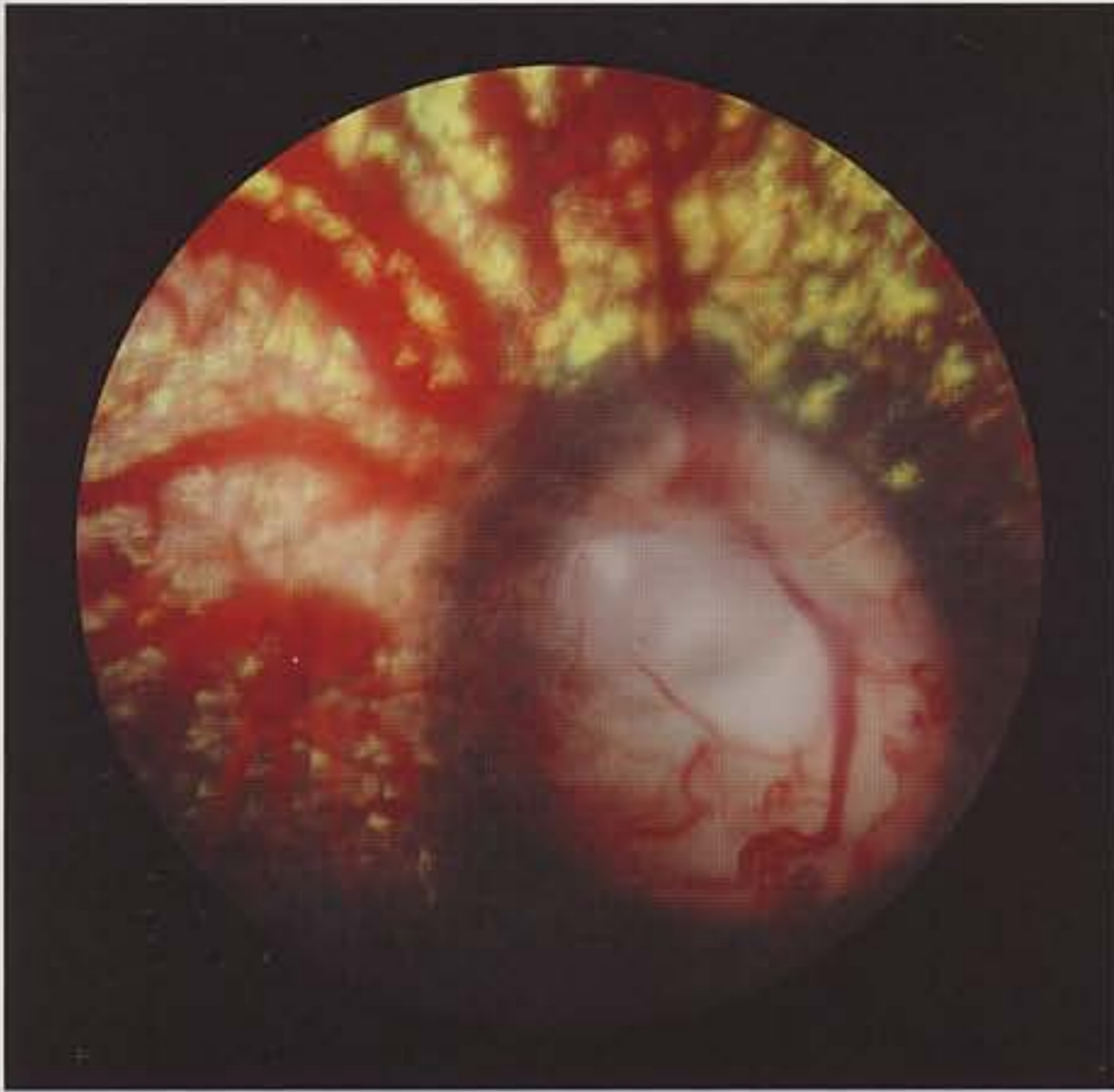


Fig. 11.142 Coloboma (Border Collie, 3 years old) Medium-sized coloboma in the centre of the disc, together with chorioretinal dysplasia.

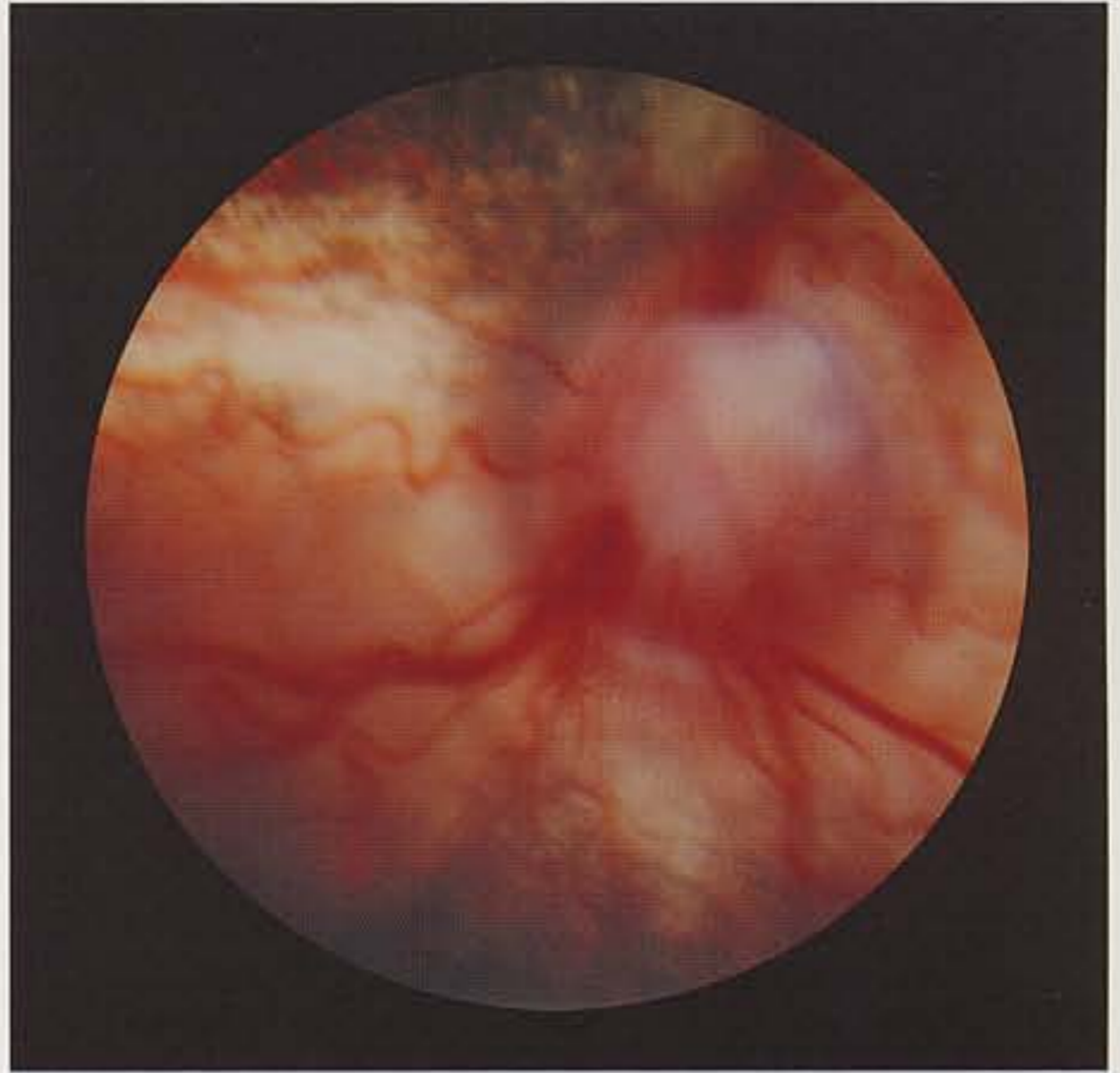

Fig. 11.144 Coloboma (Rough Collie, 7 years old) Large disc coloboma, together with chorioretinal dysplasia and retinal detachment on the left side of the figure.

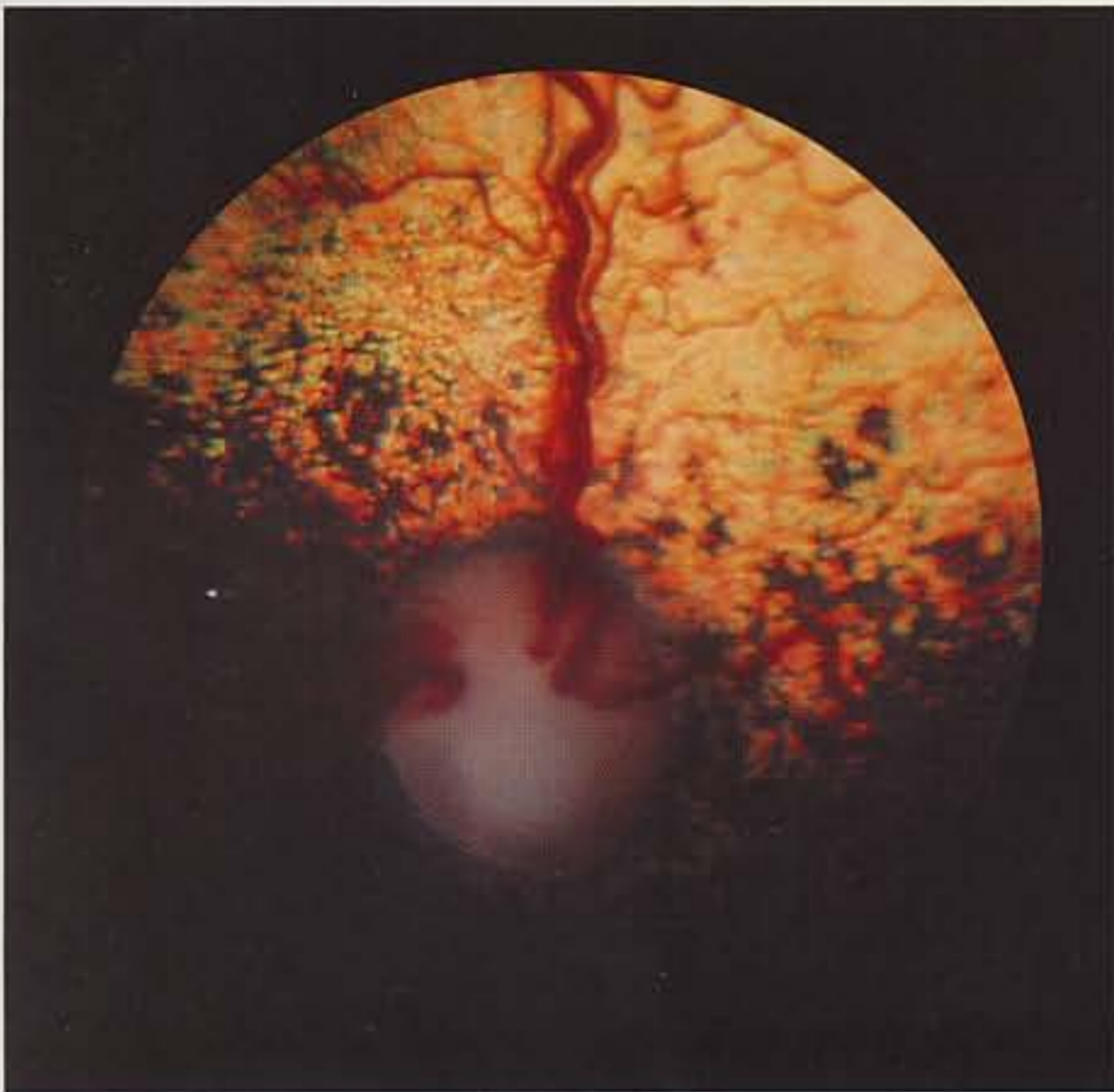


Fig. 11.143 Coloboma (Rough Collie, 1 year old, tricolour) Medium-sized coloboma of the ventral disc.

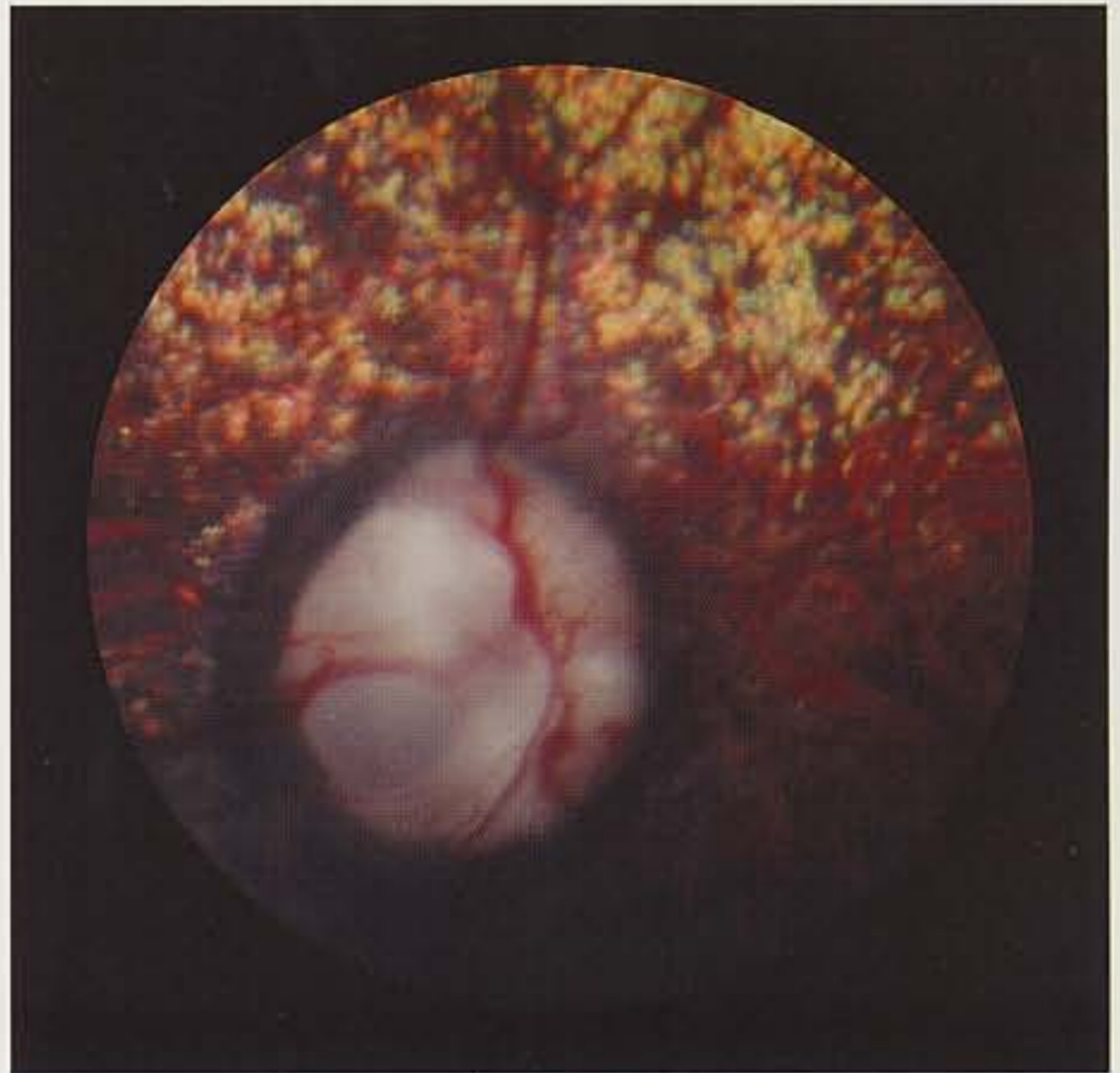


Fig. 11.145 Coloboma (Shetland Sheepdog, 3 years old) Shallow disc coloboma at 7 o'clock.

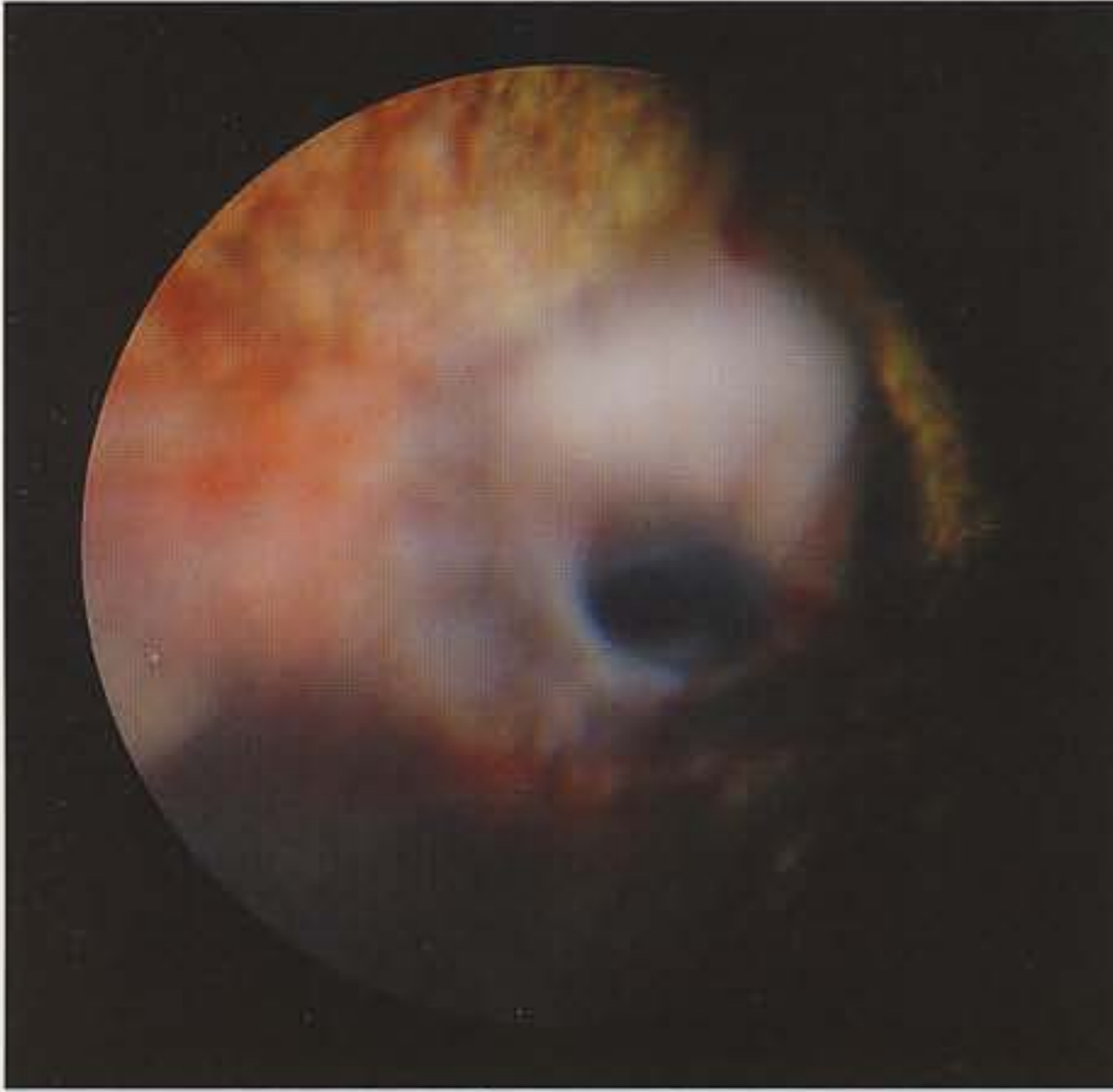

Fig. 11.146 Coloboma (Shetland Sheepdog, 9 months old) Deep disc coloboma at 5 o'clock.

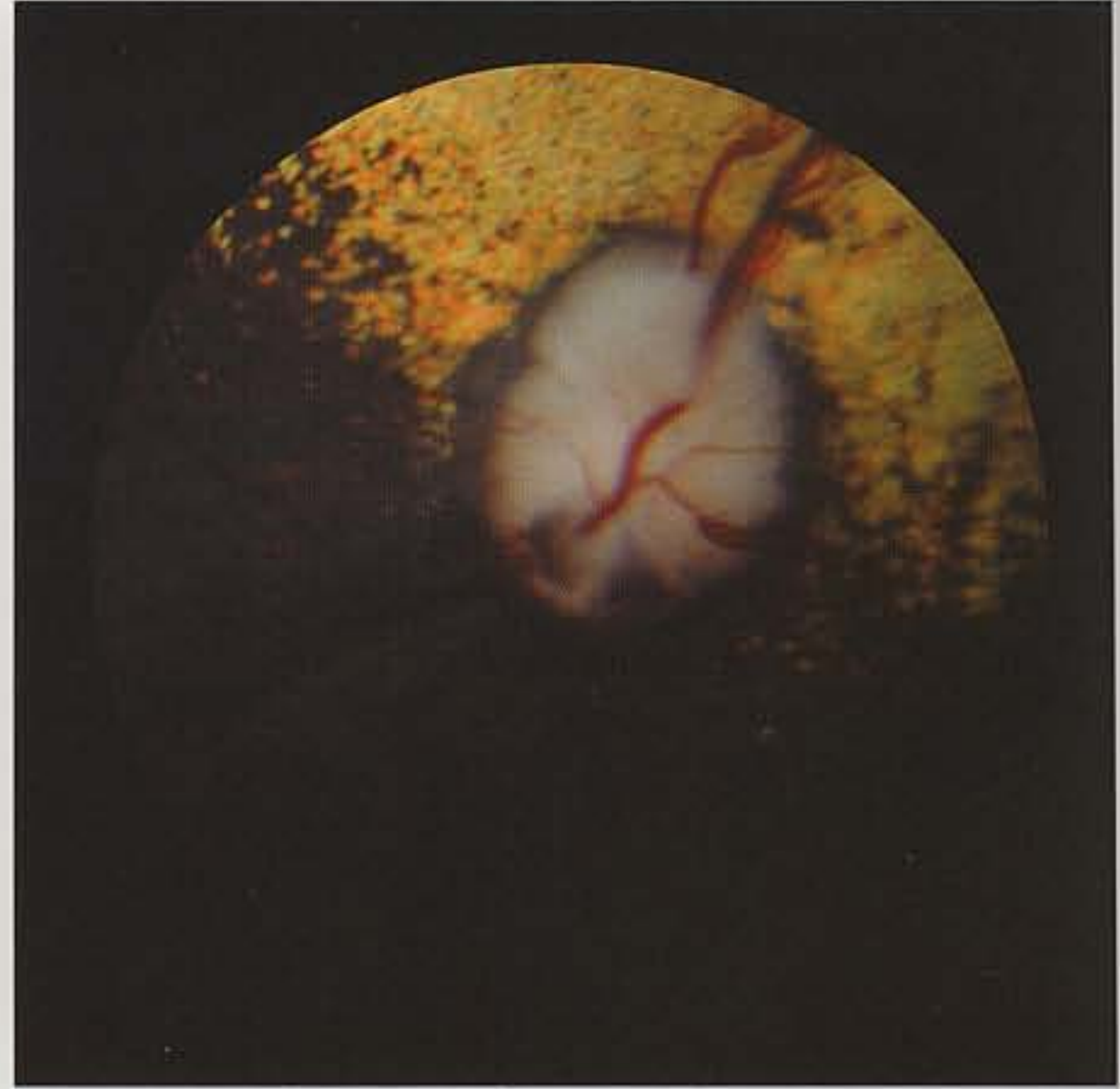

Fig. 11.148 Coloboma (Shetland Sheepdog, 4 years old) Two small colobomas at 6 o'clock.

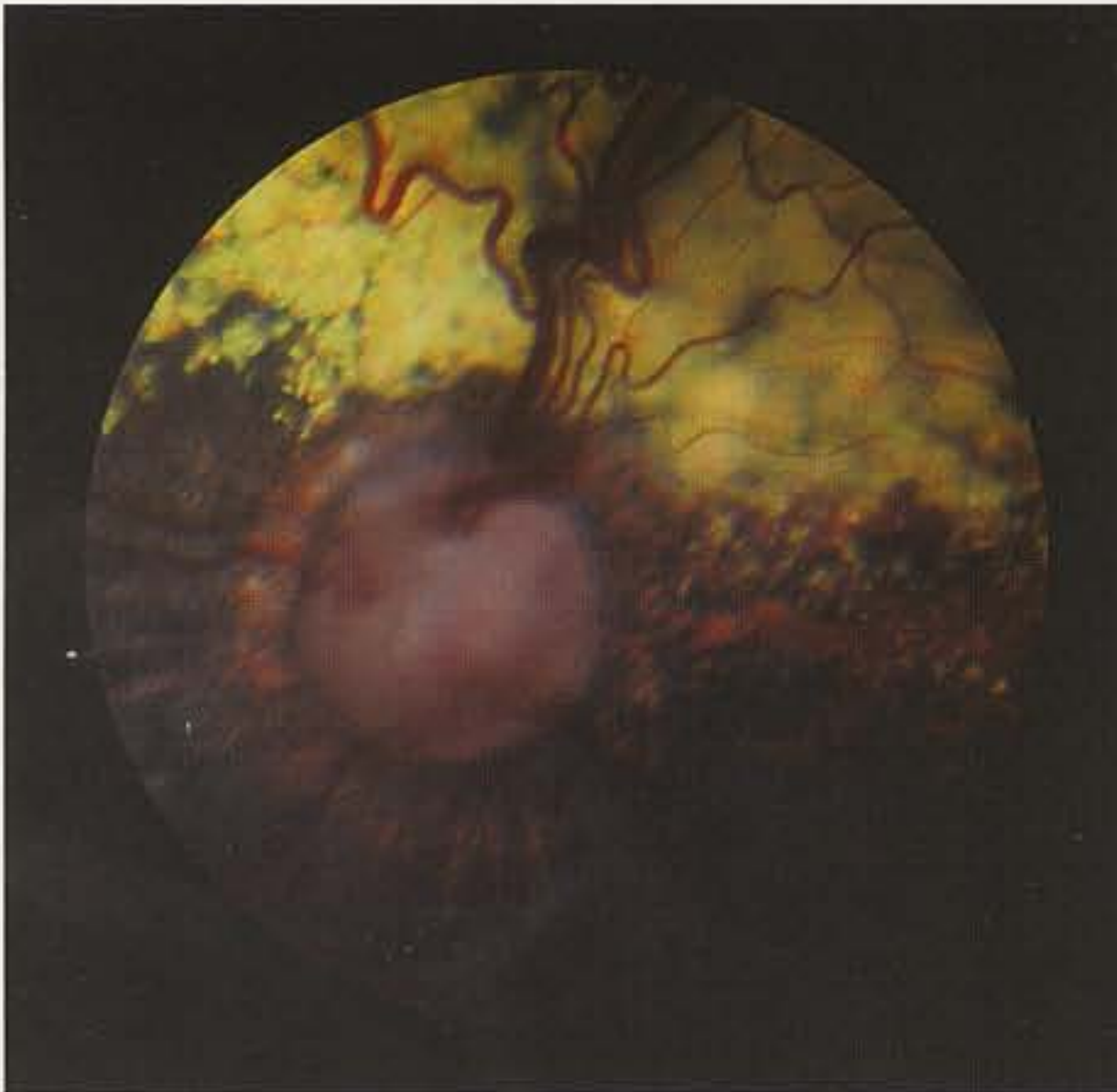


Fig. 11.147 Coloboma (Shetland Sheepdog, 16 months old) Whole disc coloboma with mild chorioretinal dysplasia and retinal detachment in the upper right quadrant.

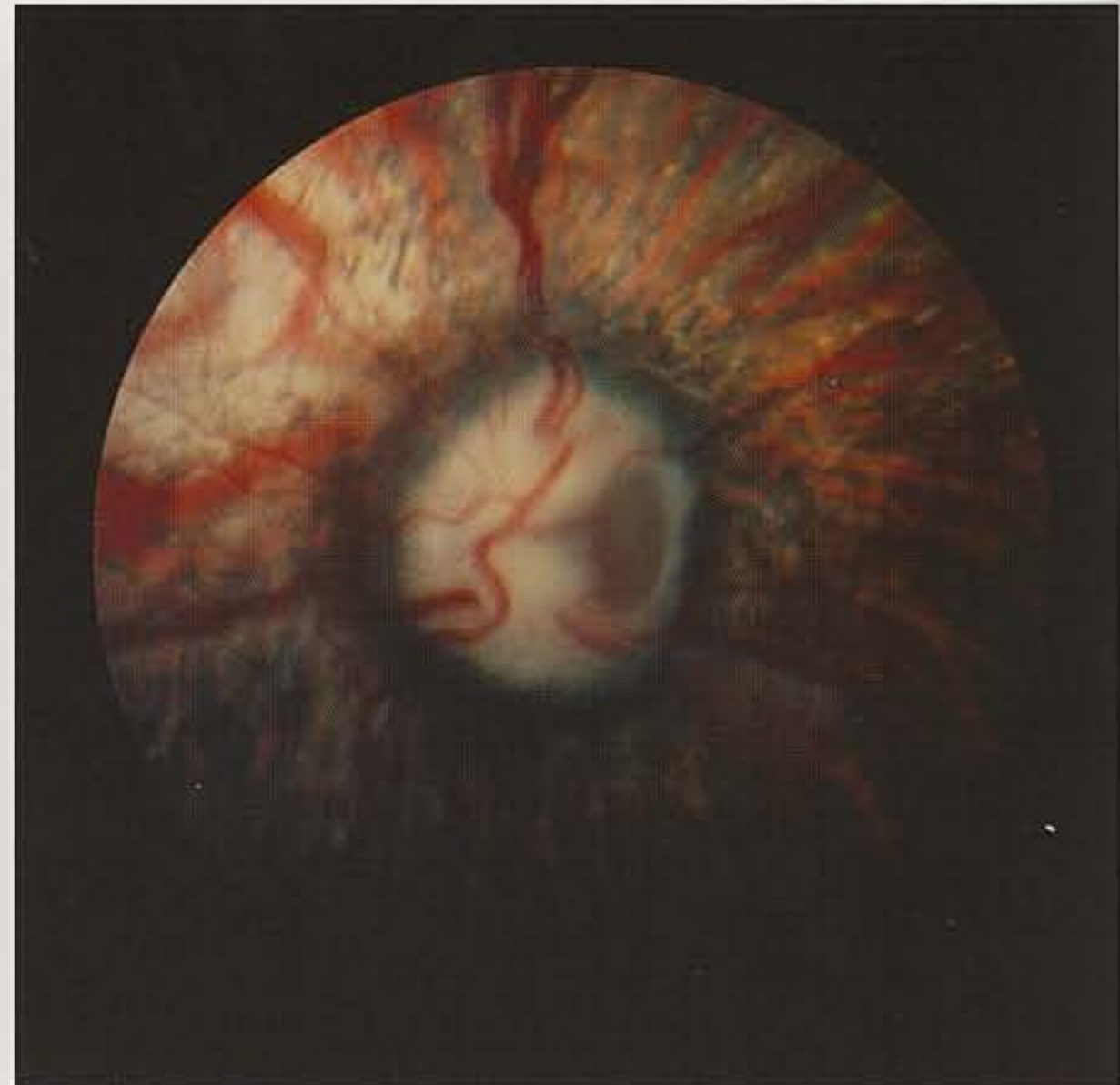


Fig. 11.149 Coloboma (Shetland Sheepdog, 2 years old) Coloboma in atypical position at 3 o'clock, together with chorioretinal dysplasia.

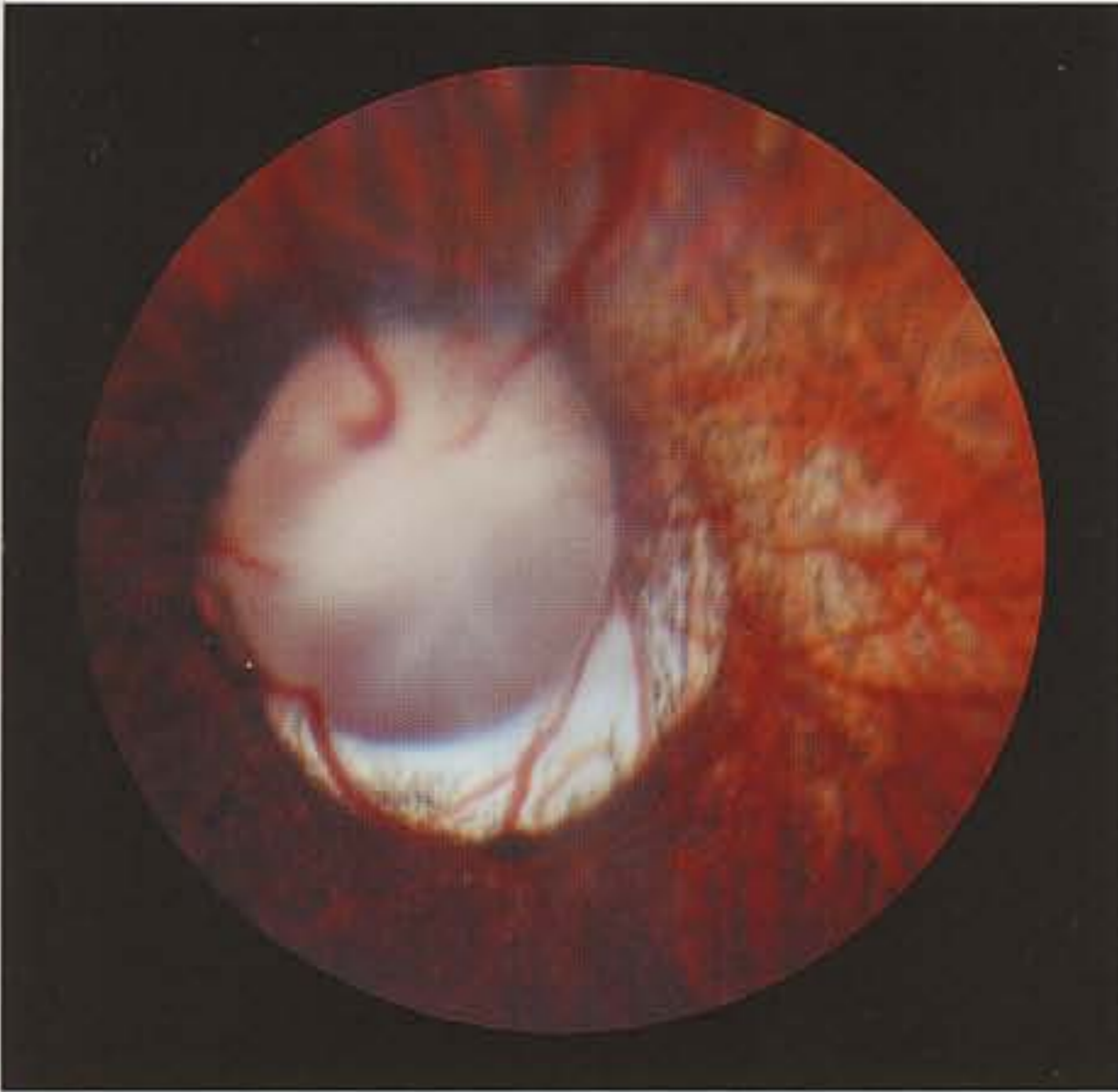


Fig. 11.150 Coloboma (Shetland Sheepdog, 3 years old) Large disc coloboma and adjacent peripapillary region affecting both retina and choroid.

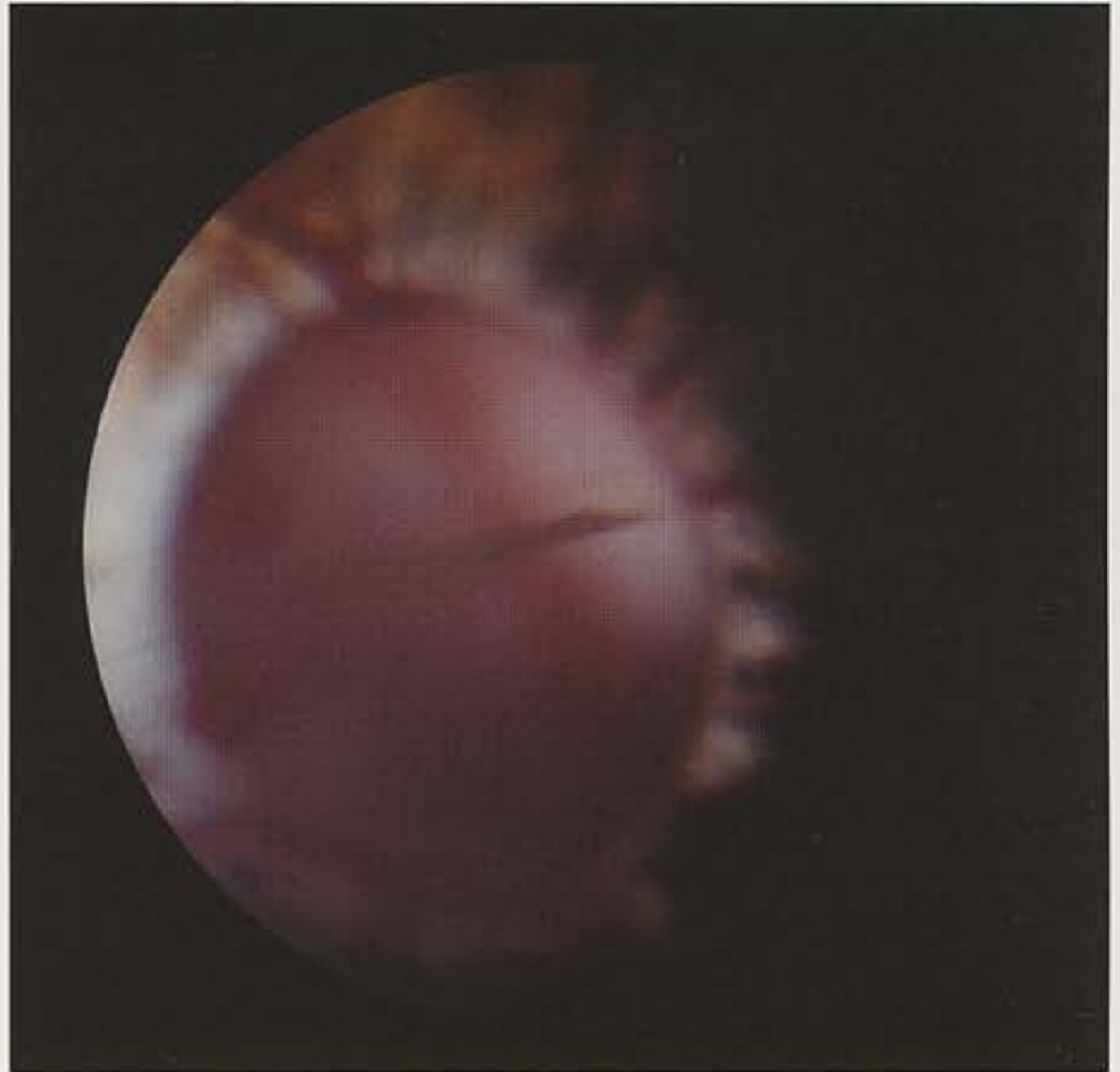


Fig. 11.152 Coloboma (Shetland Sheepdog, 13 weeks old) Same eye as the previous figure but focused to show the persistent hyaloid remnant – a frequent finding in conjunction with colobomas in all species (see also Fig 12.28).

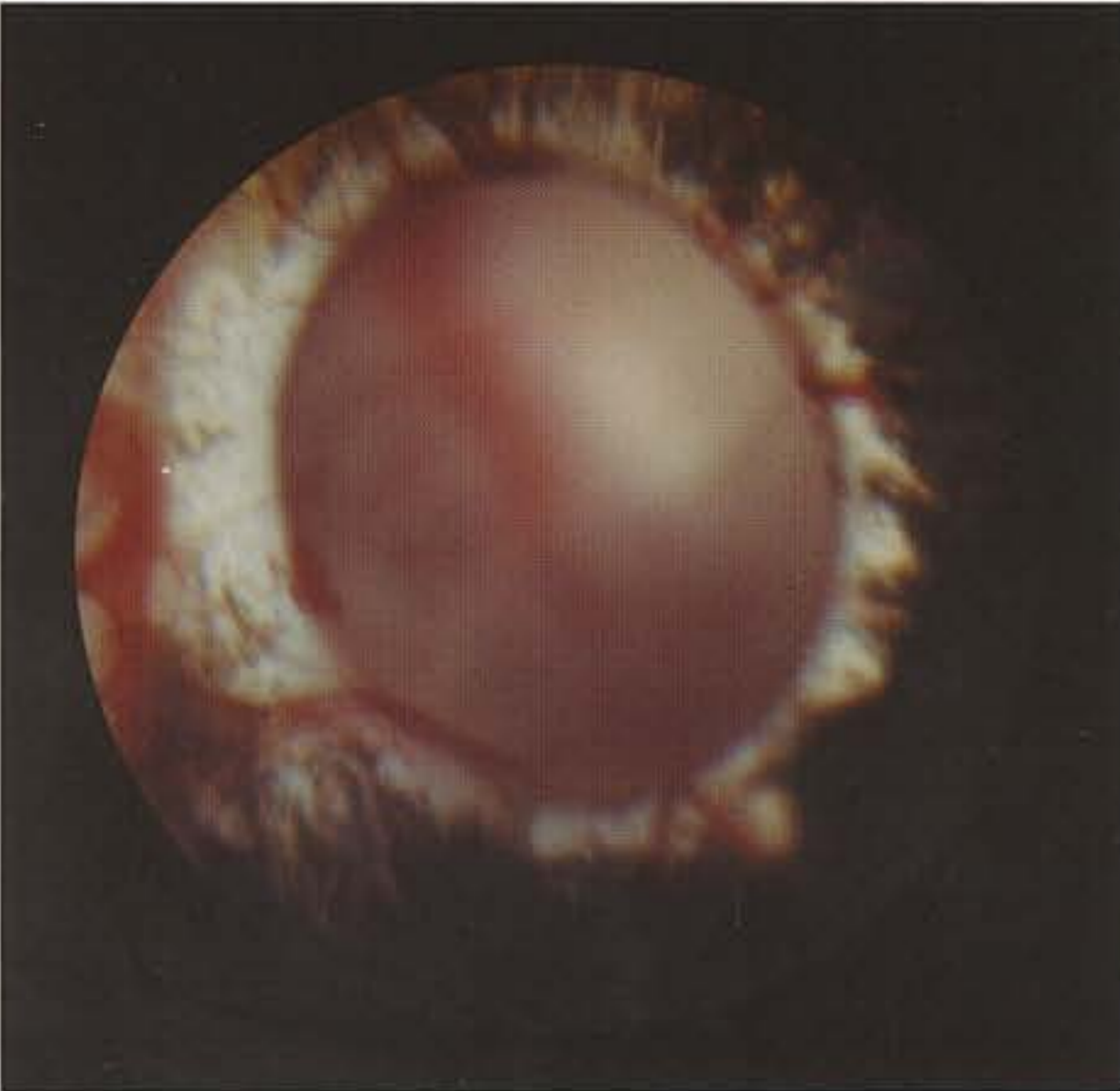

Fig. 11.151 Coloboma (Shetland Sheepdog, 13 weeks old) Extensive disc coloboma.

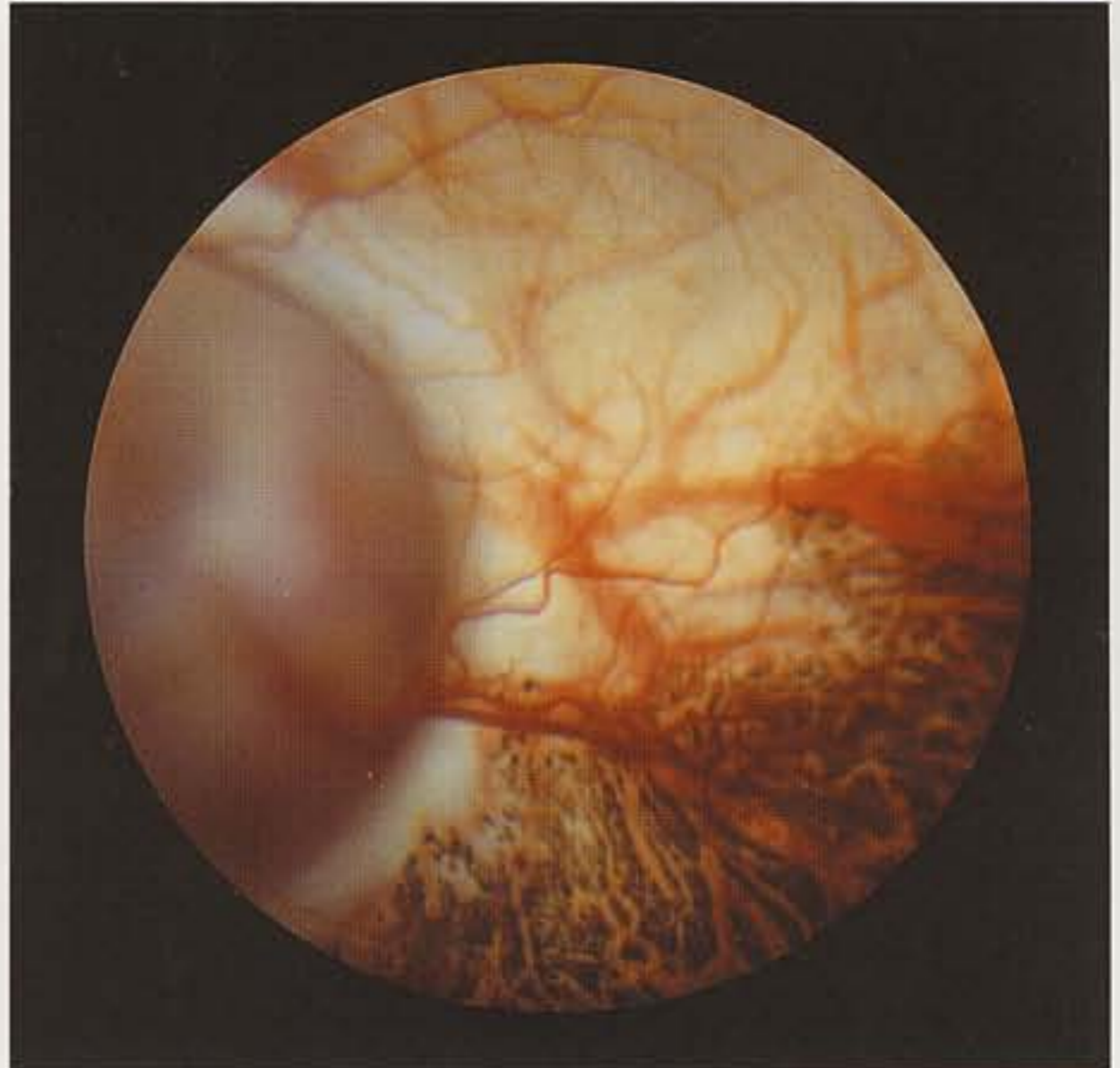

Fig. 11.153 Coloboma (Shetland Sheepdog, adult, blue merle) Extensive coloboma, and note the retinal blood vessels dipping over the edge of the crater.

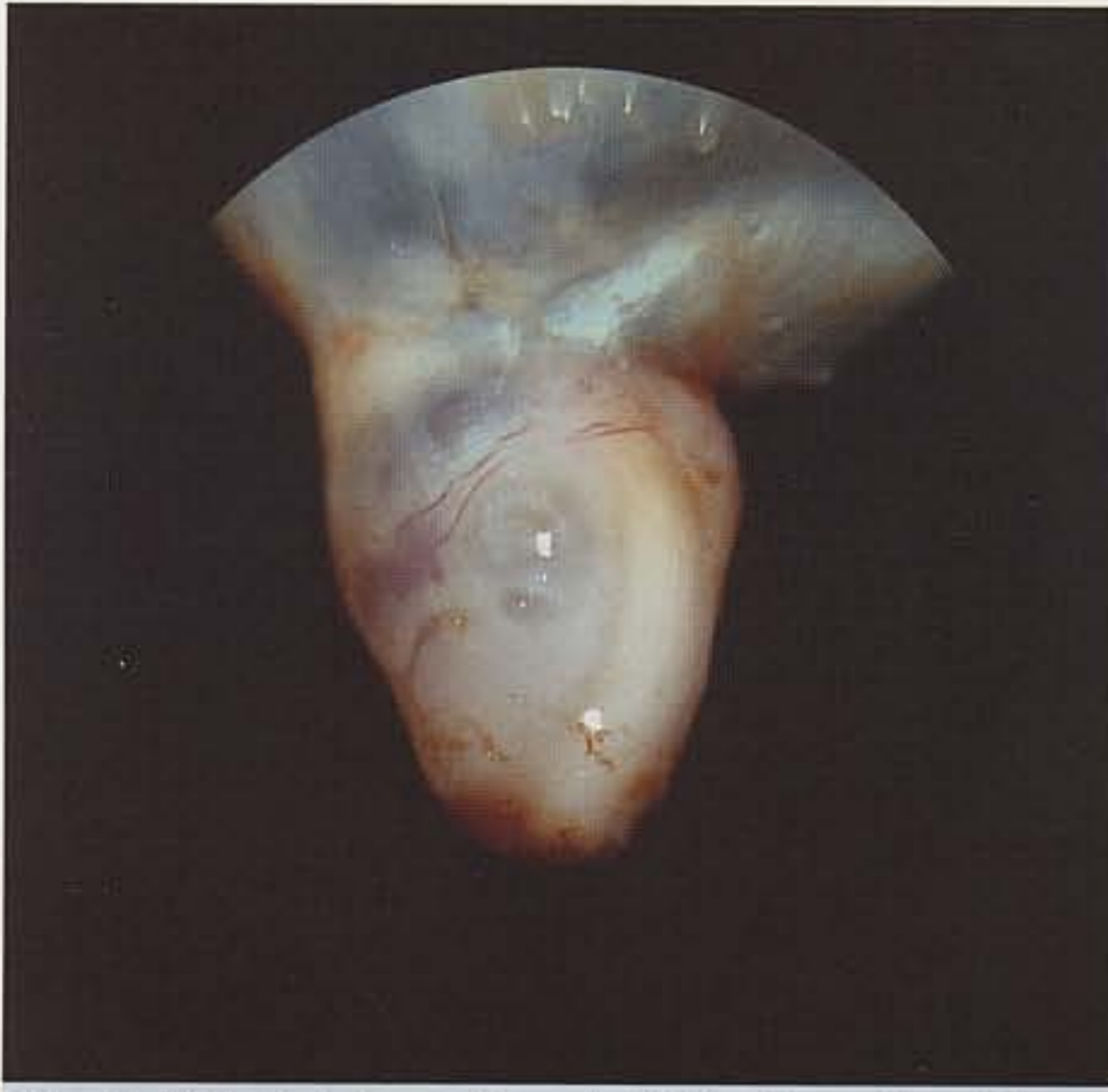

Fig. 11.154 Coloboma (Rough Collie, 6 months old)  
External appearance of coloboma of the optic disc – note the cystic appearance and the optic nerve deflected to the right-hand side.

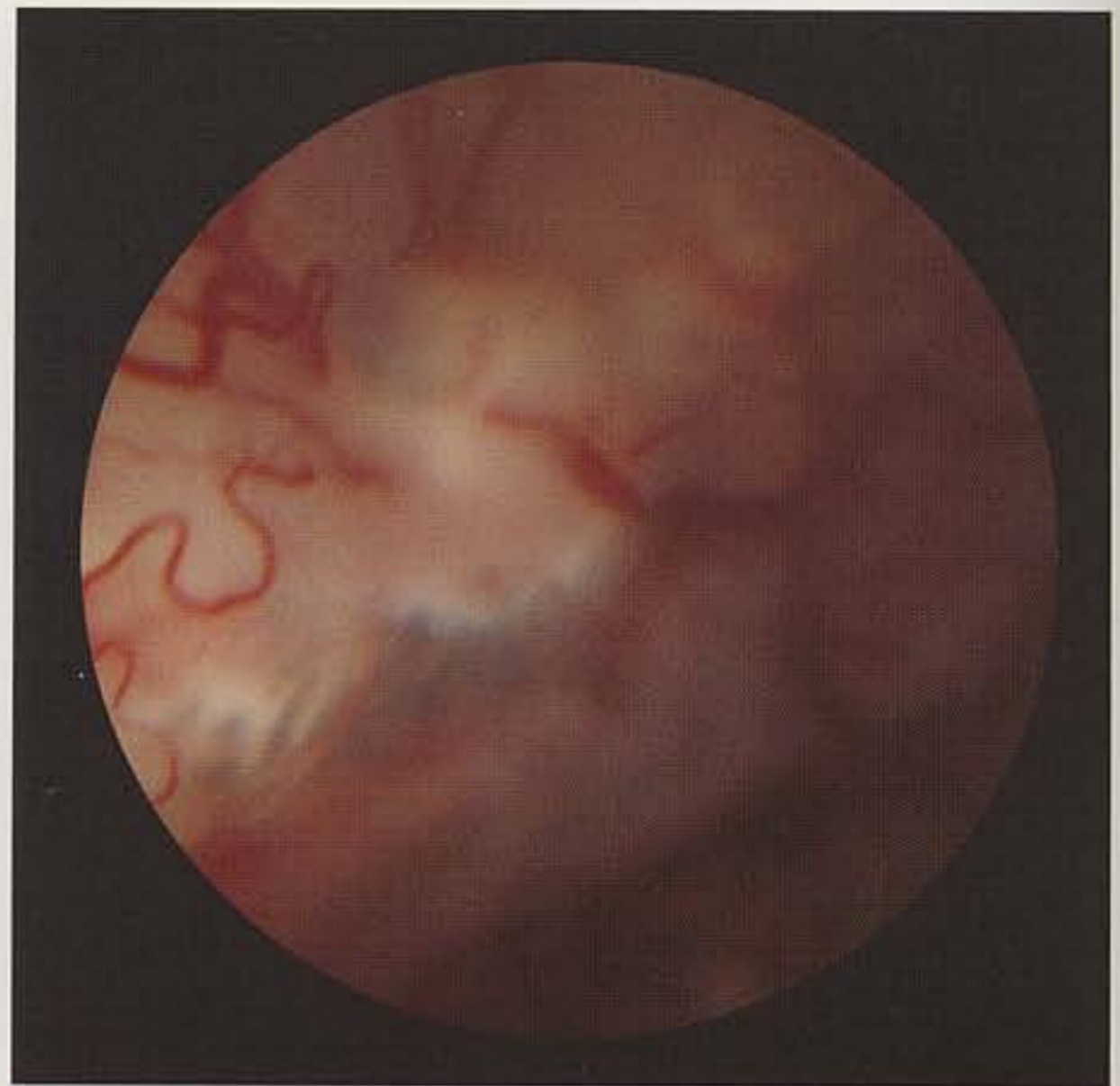

Fig. 11.156 Retinal detachment (Shetland Sheepdog, 9 months old) Extensive retinal detachment.

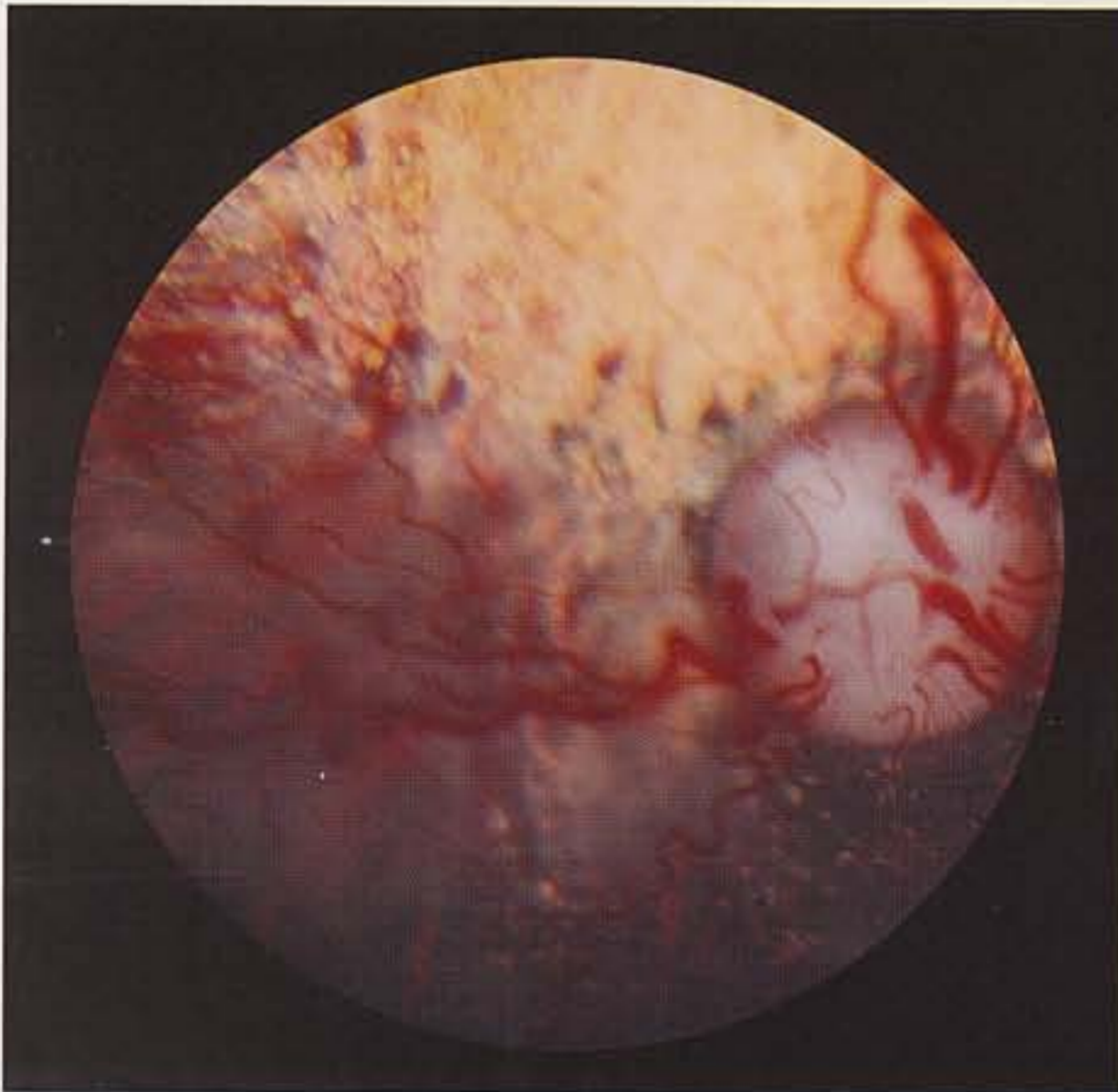

Fig. 11.155 Retinal detachment (Rough Collie, 1 year old) Flat retinal detachment to the left of the optic disc.

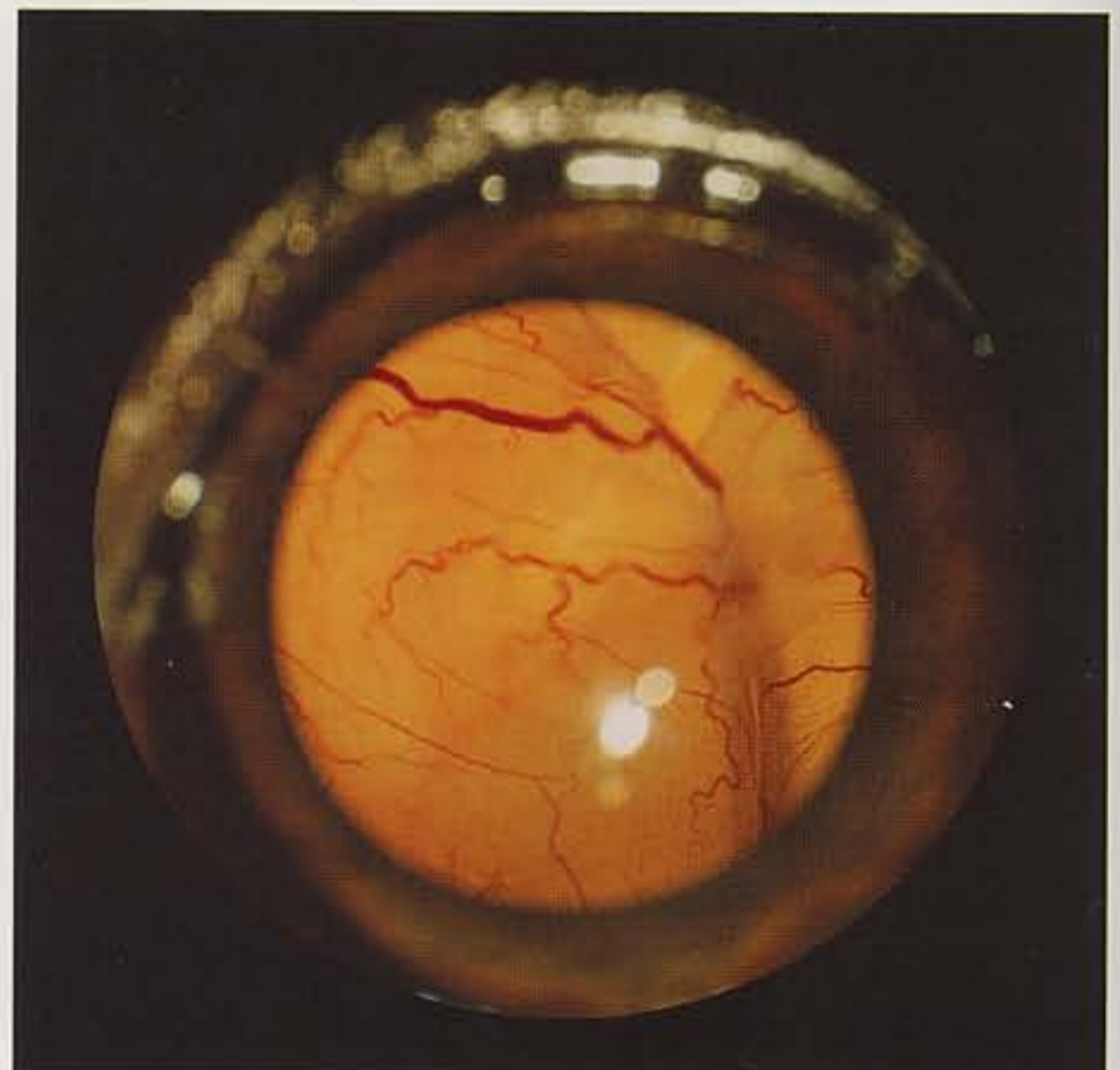

Fig. 11.157 Retinal detachment (Shetland Sheepdog, 17 months old) The appearance of total retinal detachment through a dilated pupil.

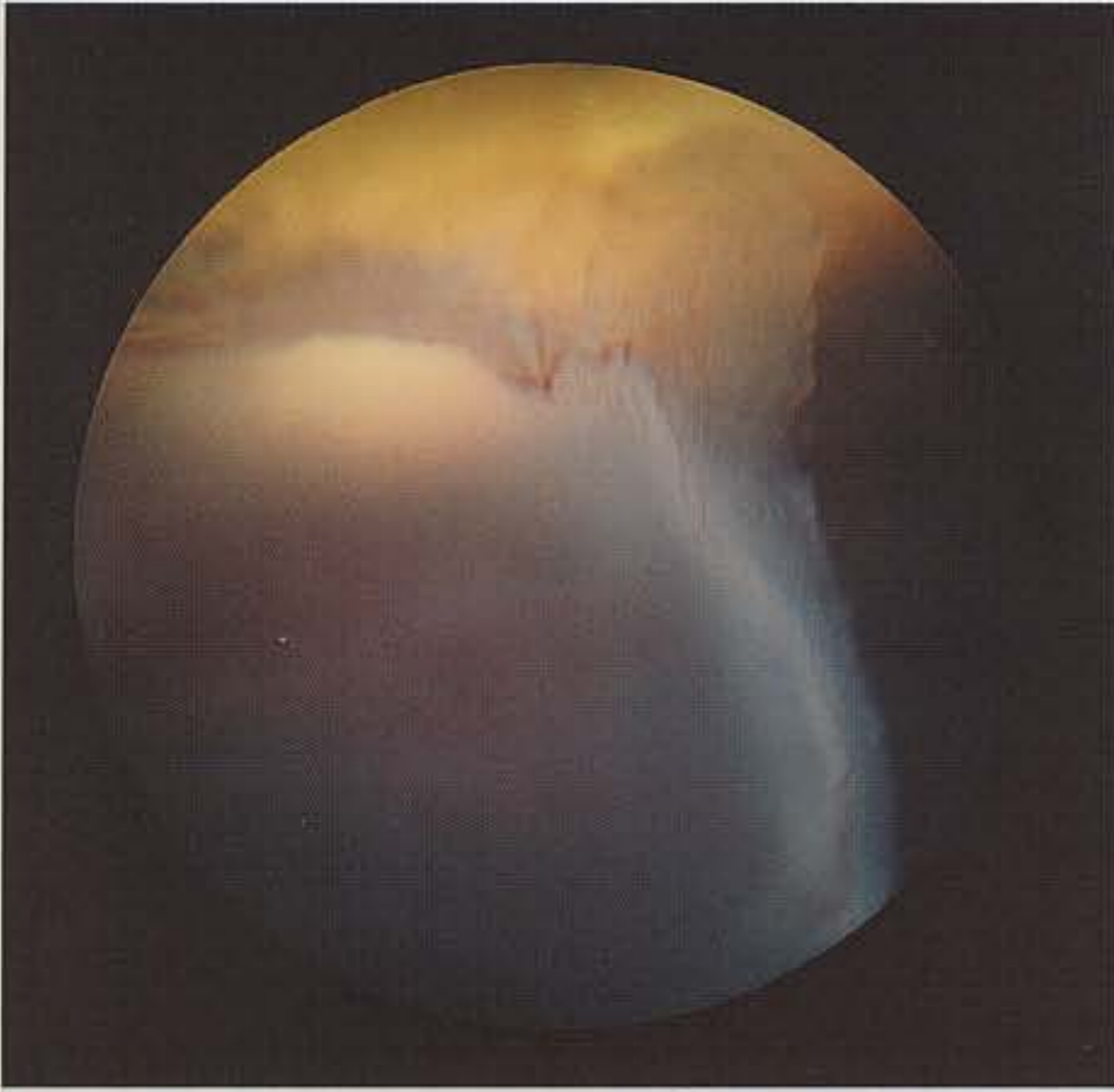

Fig. 11.158 Retinal detachment (Shetland Sheepdog, 9 months old) Retinal detachment and disinsertion.

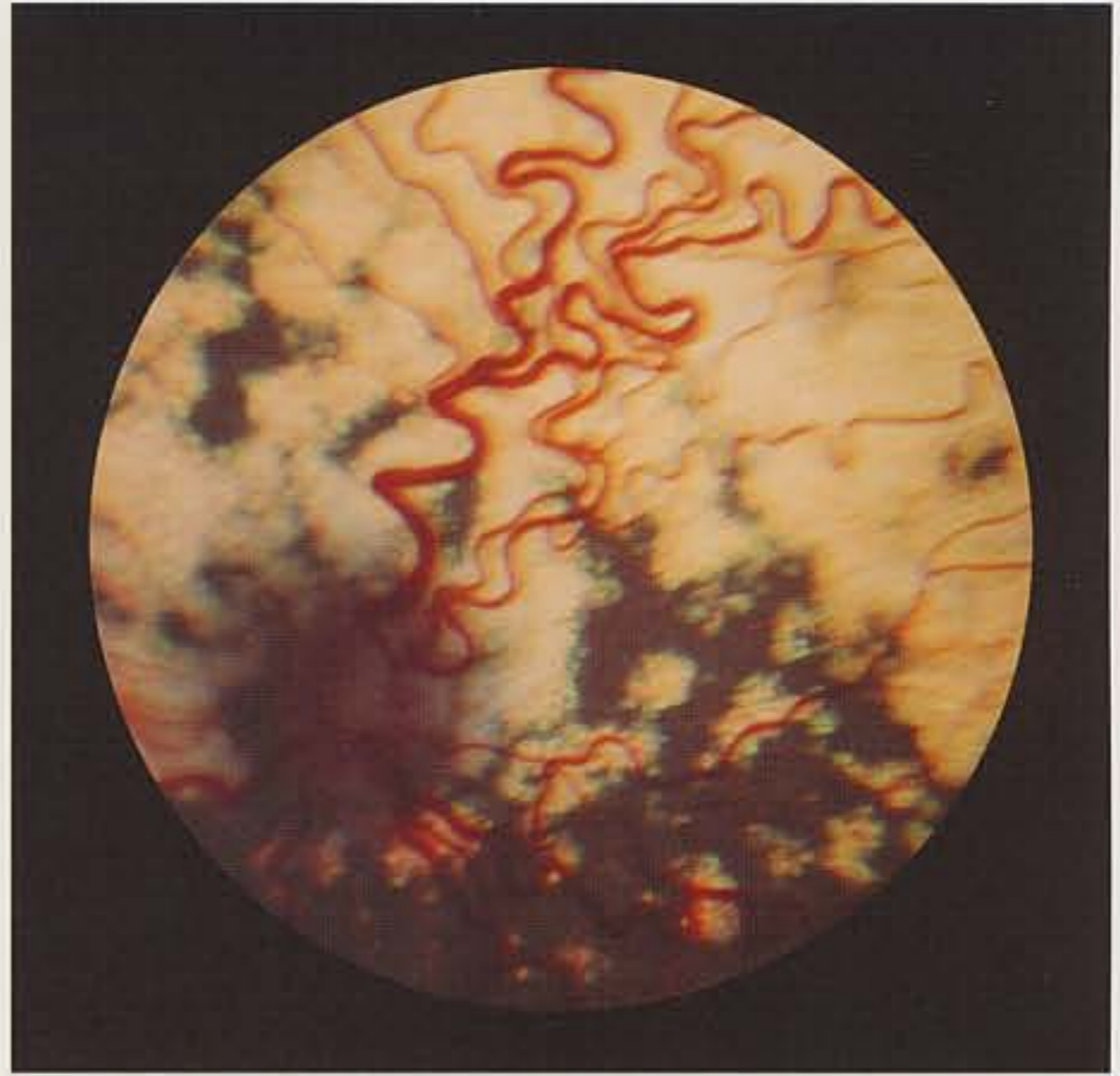

Fig. 11.160 Excessive vascular tortuosity (Rough Collie, 6 months old) Note also the coloboma of the disc.

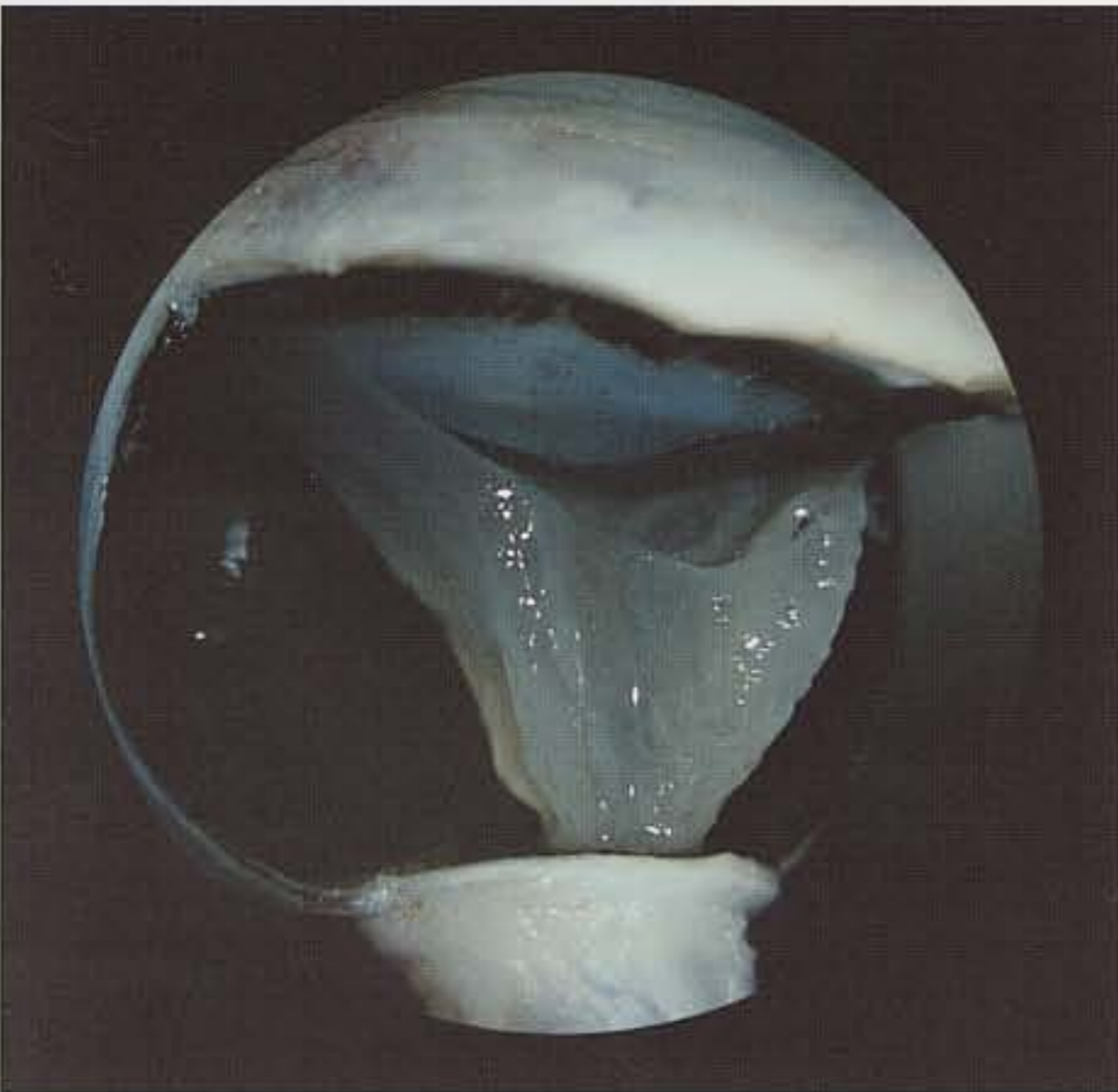

Fig. 11.159 Retinal detachment (Rough Collie, 6 months old) Detachment and disinsertion (post mortem specimen).

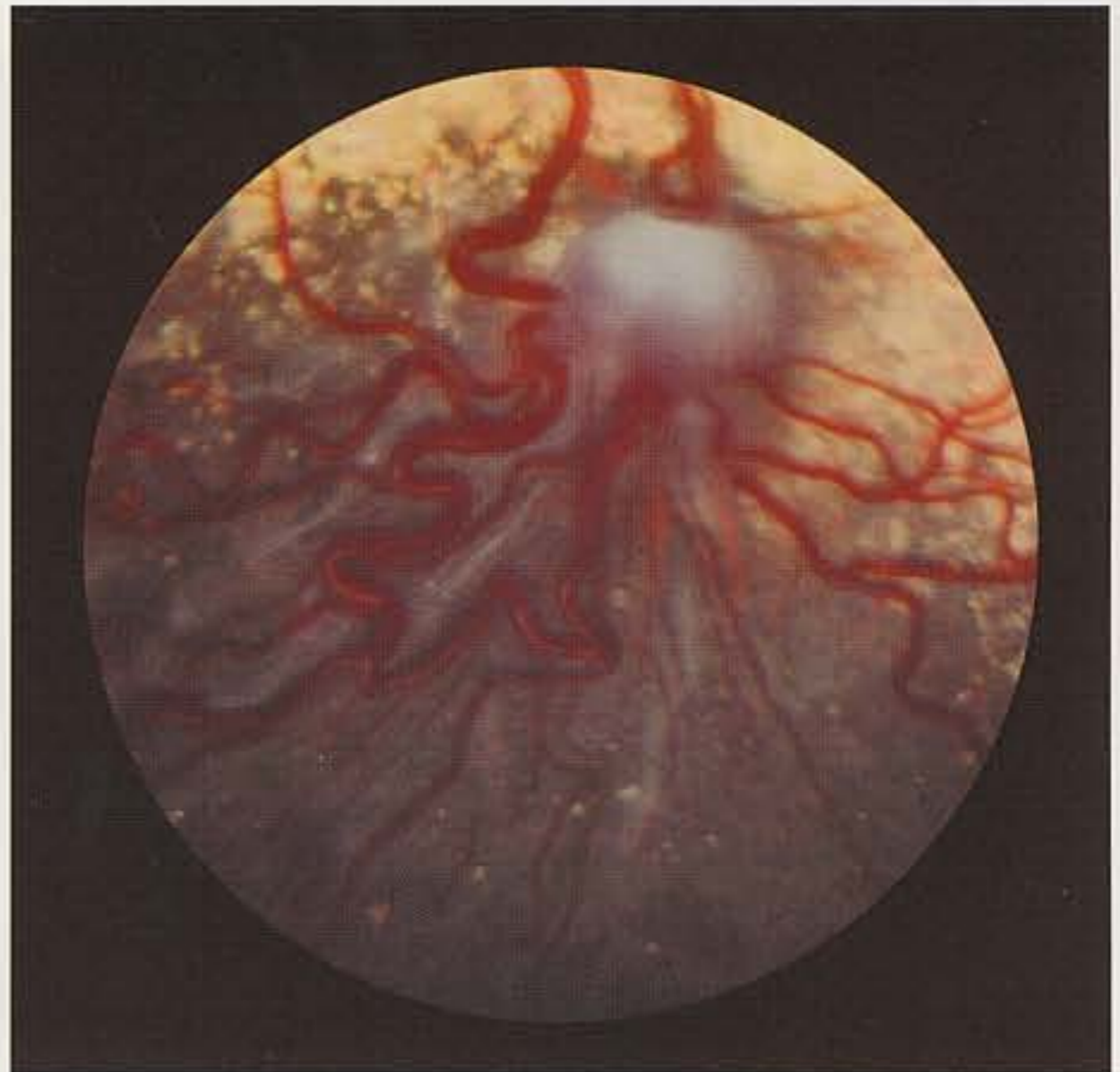

Fig. 11.161 Excessive vascular tortuosity (Rough Collie, 6 months old) Again, excessive tortuosity and disc coloboma.

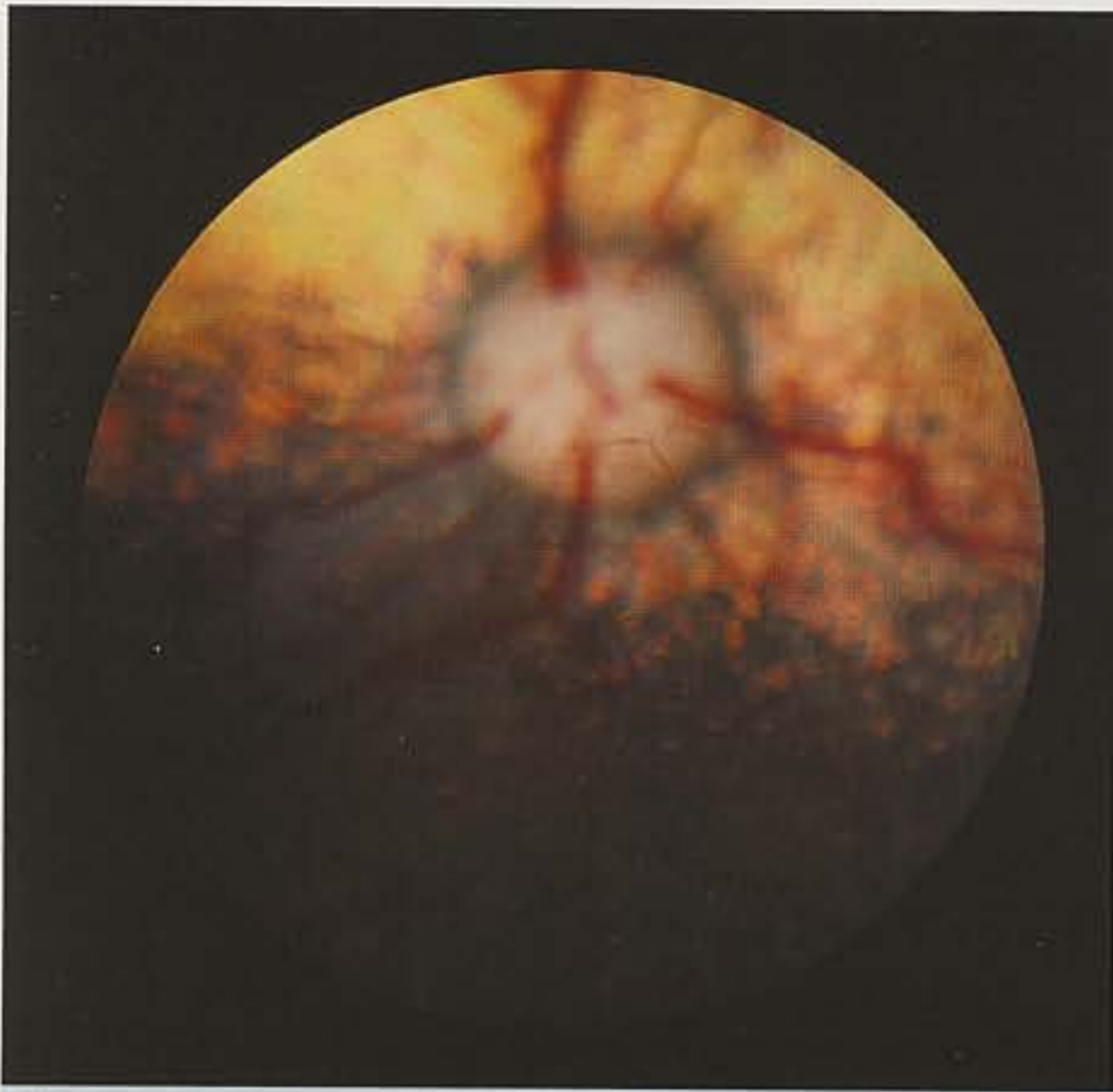


Fig. 11.162 Vascular anomaly (Shetland Sheepdog, 3 years old) Aberrant arteriolar loop at the edge of the disc at 7 o'clock protruding forwards into the vitreous.

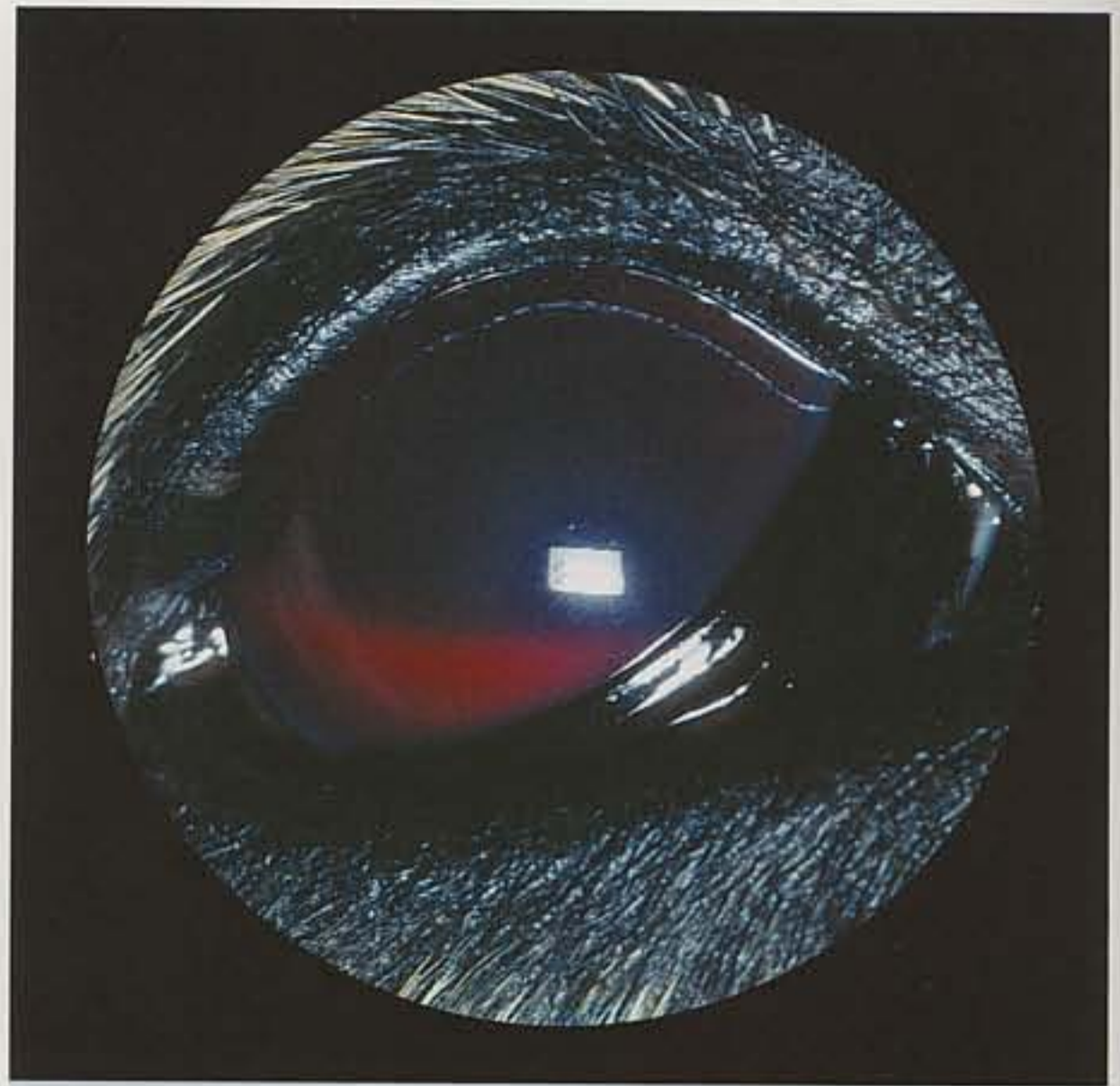

Fig. 11.164 Hyphaema (Rough Collie, 18 months old) Intraocular haemorrhage, may be the presenting sign of collie eye anomaly.

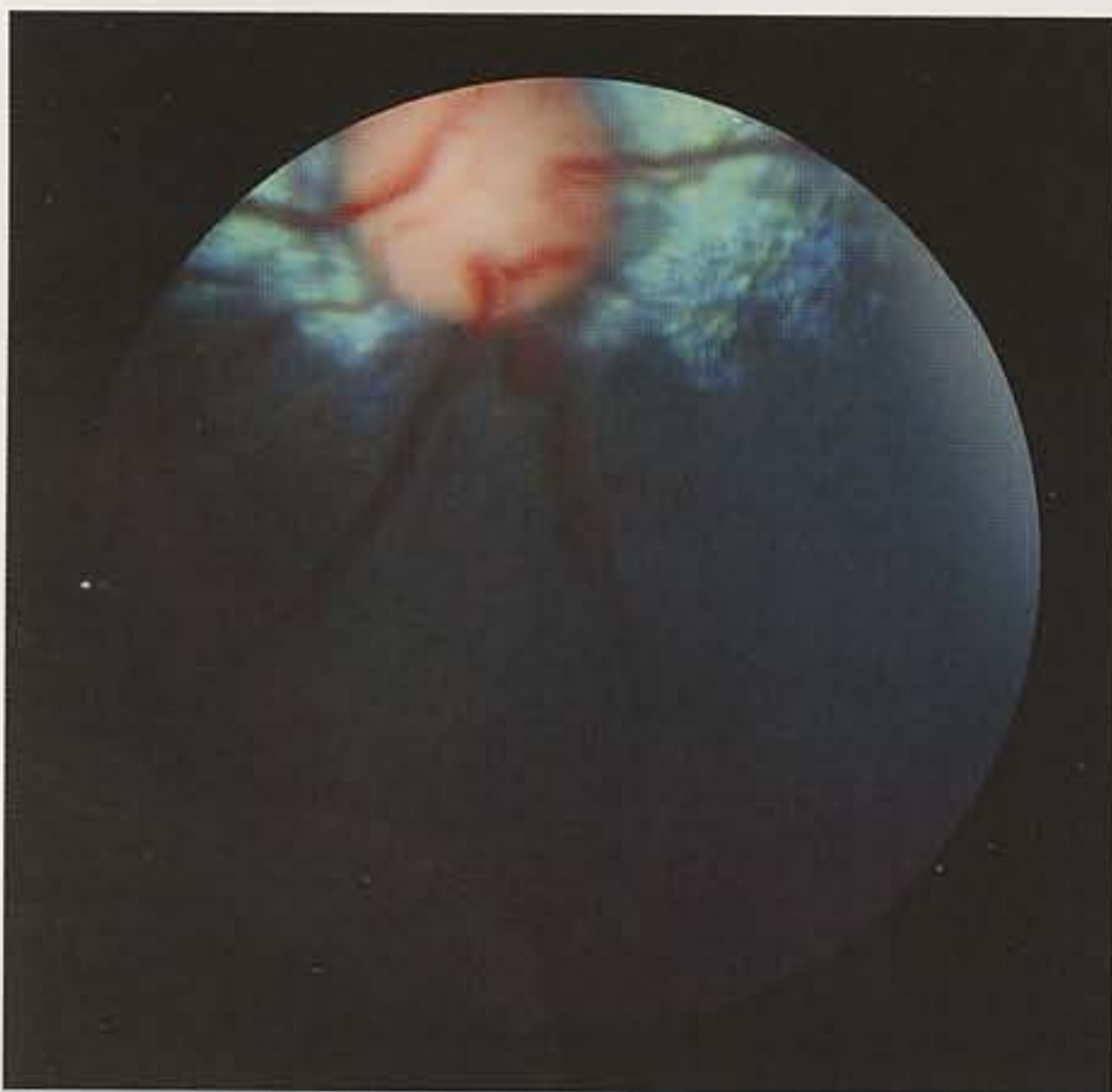

Fig. 11.163 Vascular anomaly (Rough Collie, 7 weeks old) Aneurysm on the retinal blood vessels at 6 o'clock.

Table 11.3 – Collie eye anomaly: breeds affected

- Border Collie
- Collie (Rough)
- Collie (Smooth)
- Lancashire Heeler
- Shetland Sheepdog

hereditary MRD and in the young adult the retinal folds may become hyper-reflective and even pigmented with a distinct similarity to post-inflammatory chorioretinitis. Furthermore, it has been reported that the geographic lesion is not always congenital, appearing after puppyhood. Retinal folds not infrequently occur in association with microphthalmos and other ocular anomalies and in some breeds with skeletal abnormalities. Hereditary RD, in those breeds in which it has been studied, is due to a simple autosomal recessive gene.

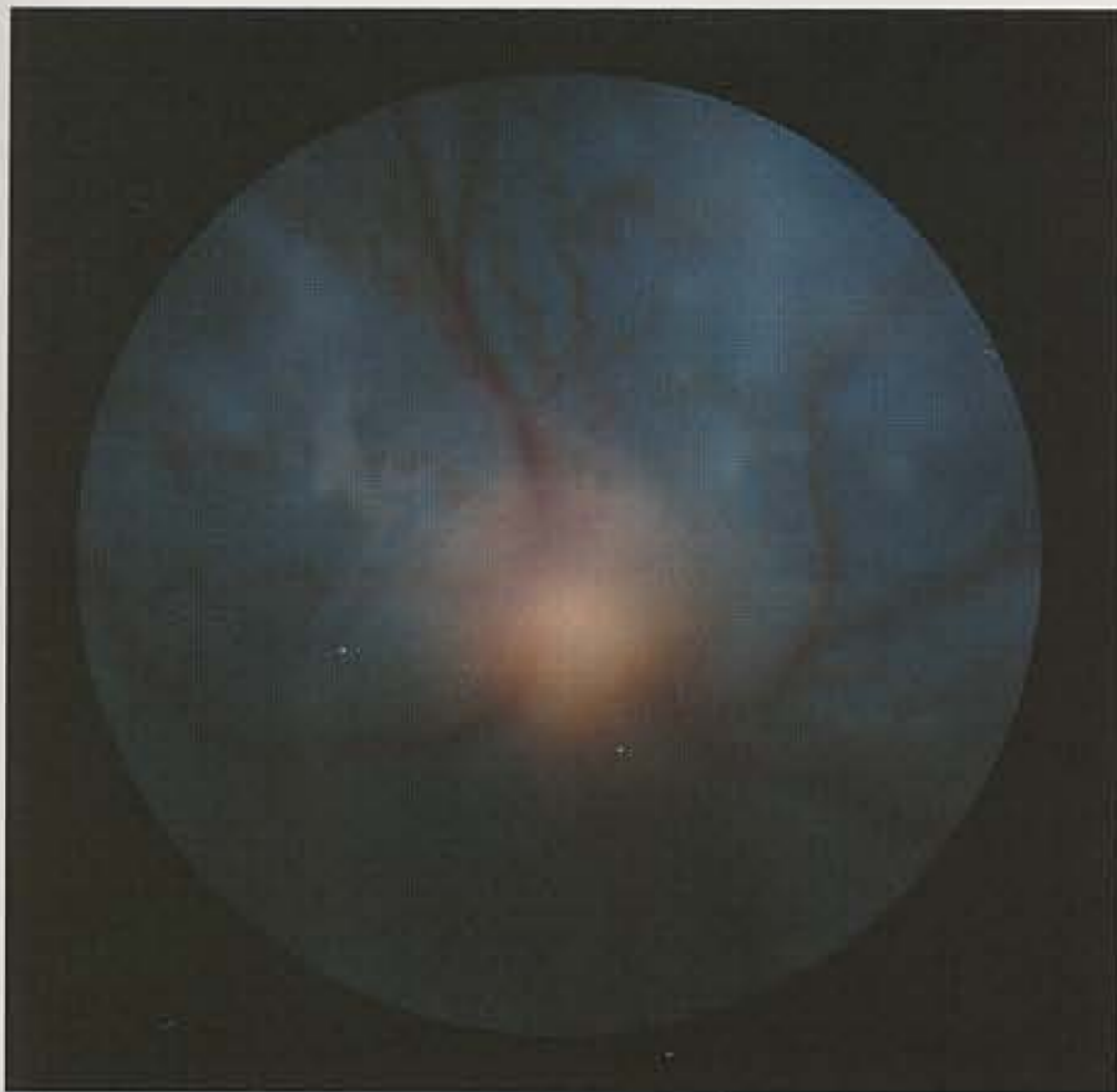


Fig. 11.165 Total retinal dysplasia (Sealyham Terrier, 8 weeks old) The ophthalmoscopic appearance of total retinal detachment (TRD).

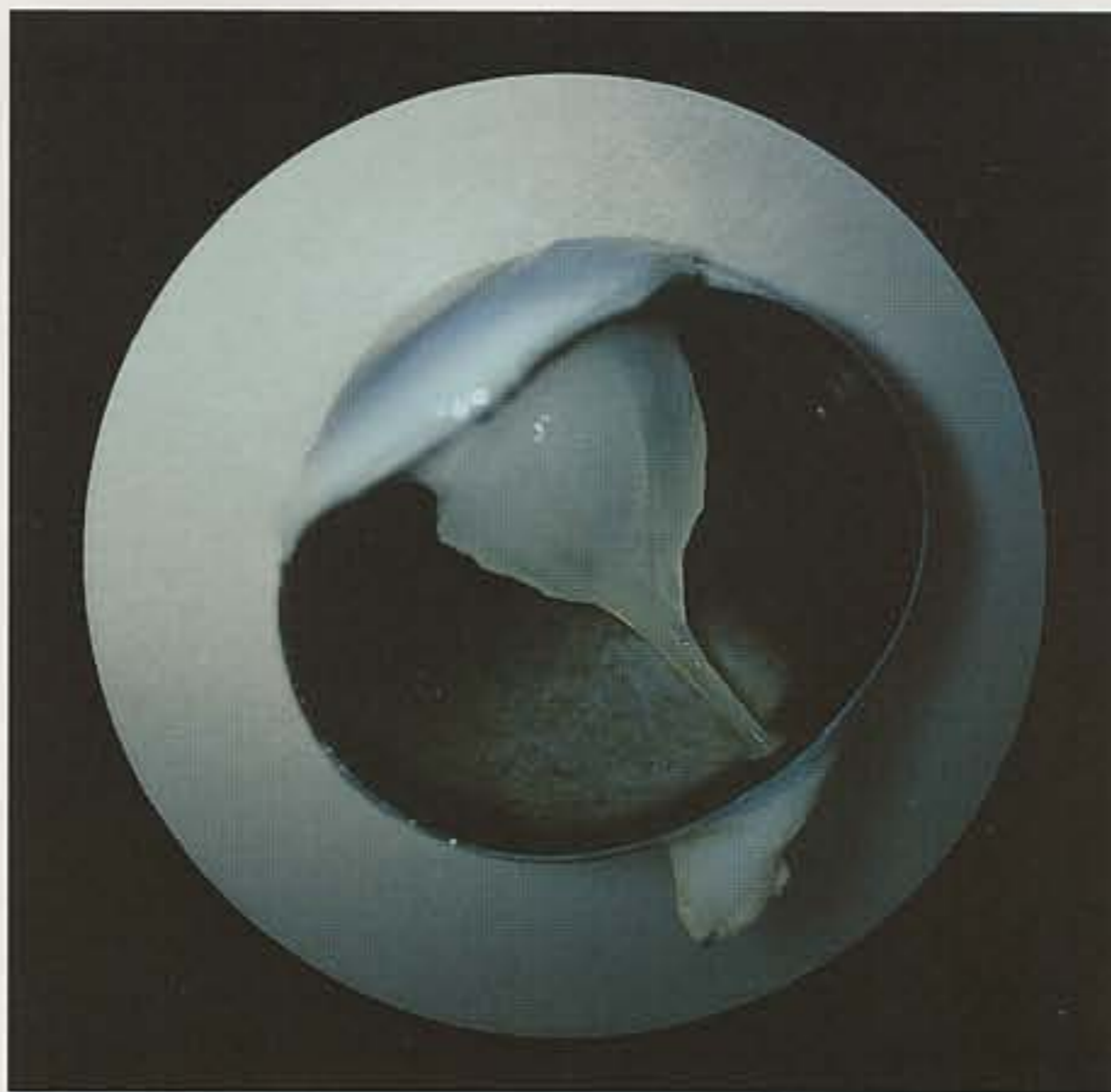

Fig. 11.167 Infundibular detachment (Sealyham Terrier, 3 months old) Similar to Fig 11.166, showing funnel-shaped total detachment around the edge of the lens.

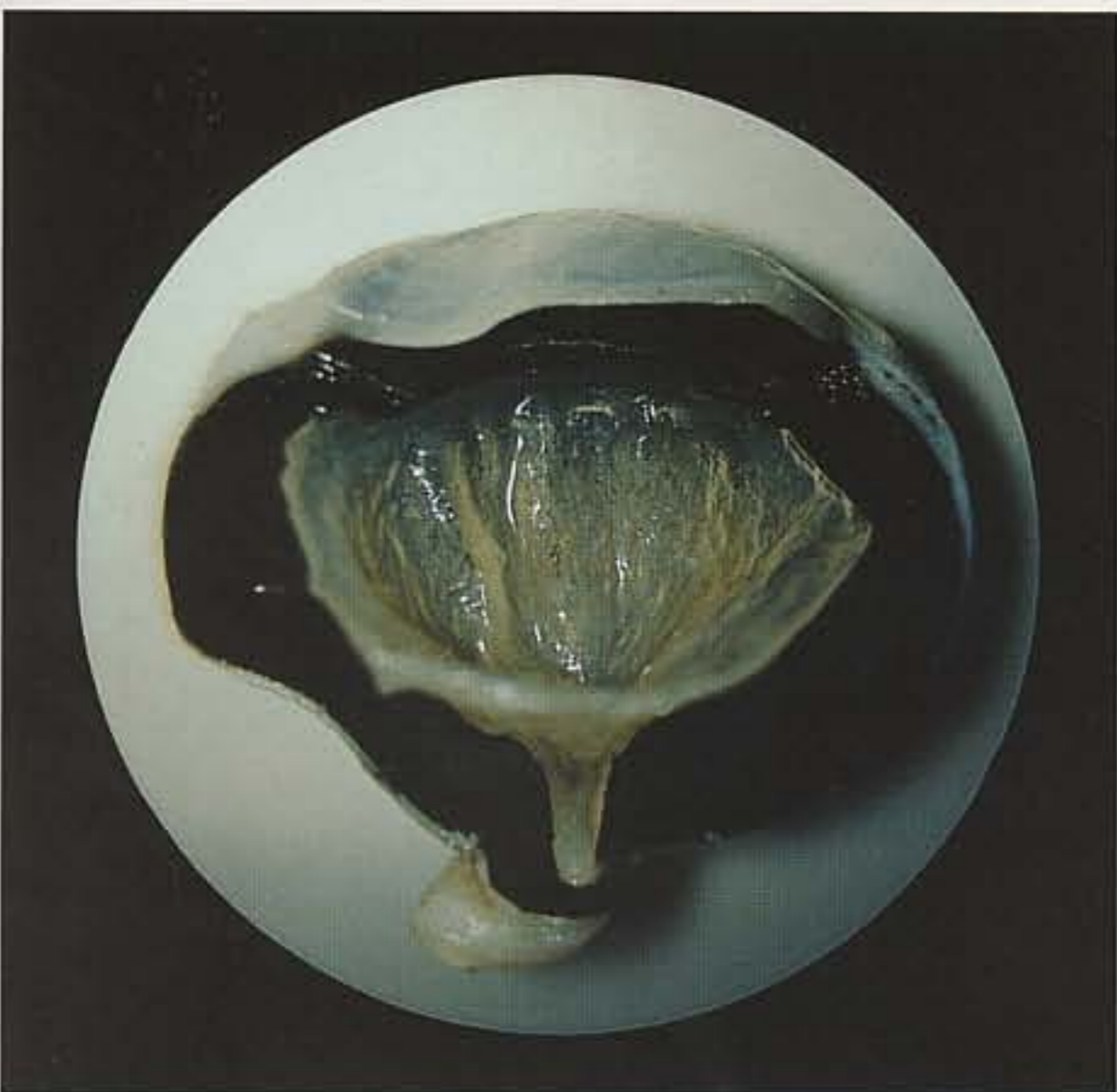

Fig. 11.166 Infundibular detachment (Sealyham Terrier, 4 months old) Post mortem specimen showing total infundibular detachment (lens removed).

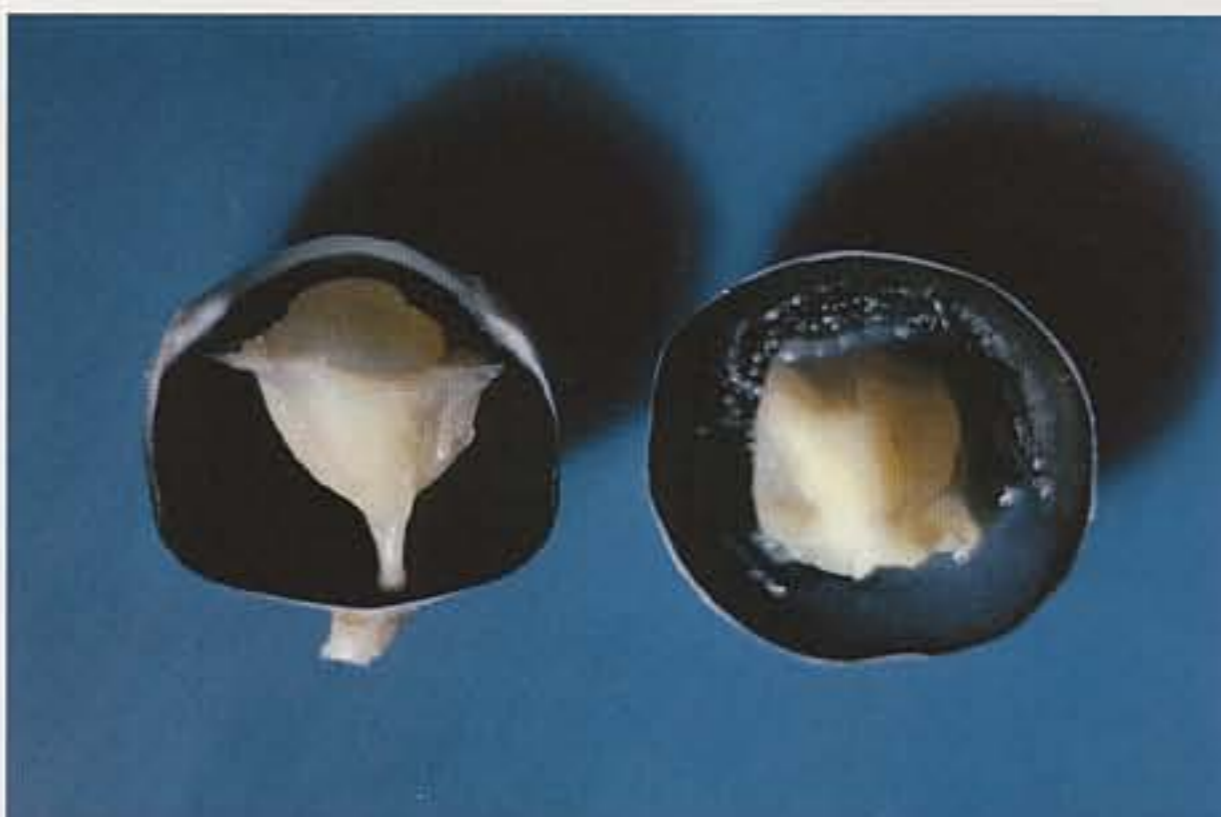

Fig. 11.168 TRD (Labrador Retriever, puppy) Bilateral retinal detachment. Total retinal dysplasia and similar to previous three figures (Figs 11.165–11.167) of Sealyham puppies.



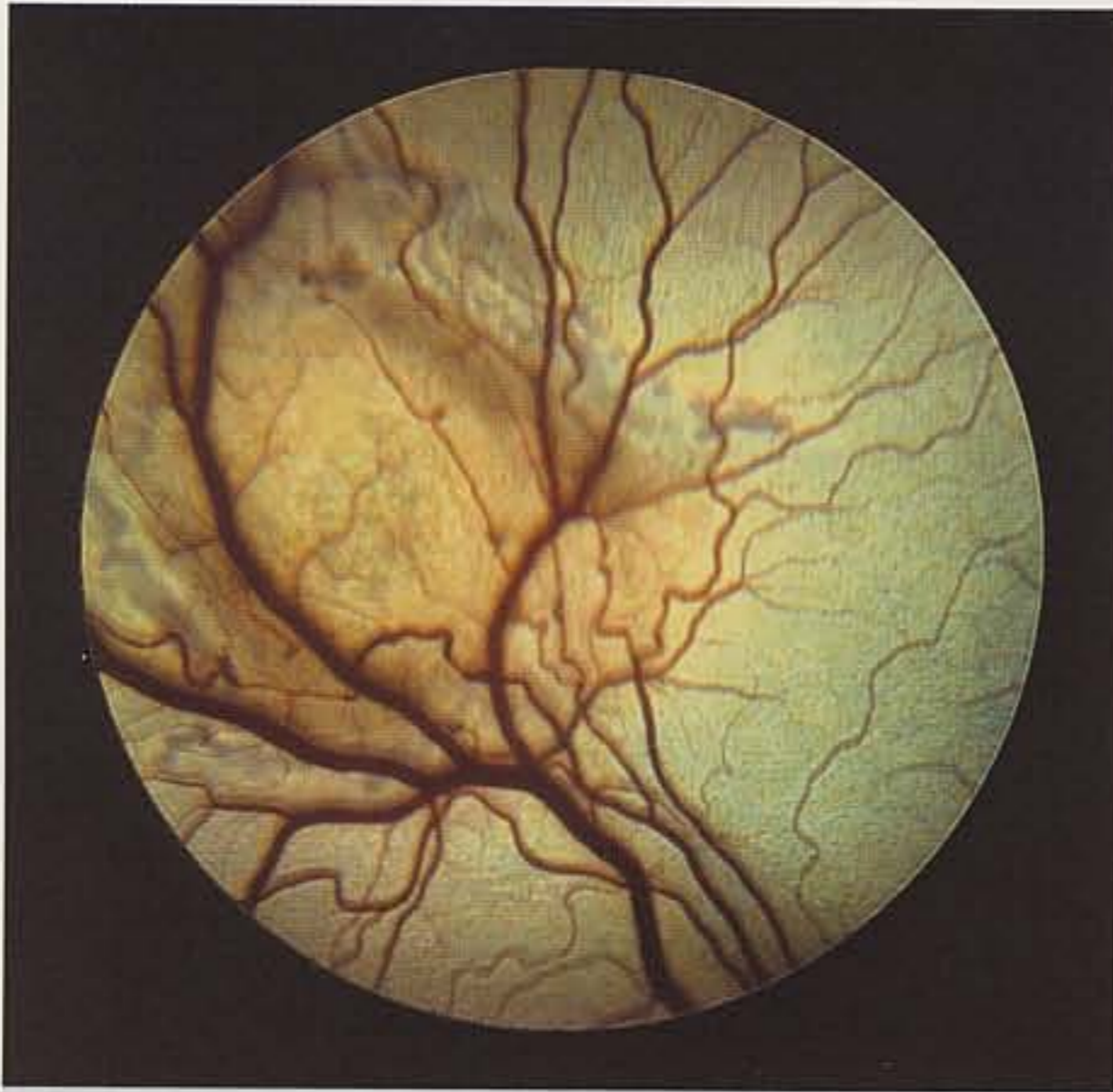


Fig. 11.169 Multifocal retinal dysplasia (MRD) (Labrador Retriever, 13 months old) Area of detachment in the typical area of superior tapetal region, well above the optic disc. Note the abnormal blood vessels.

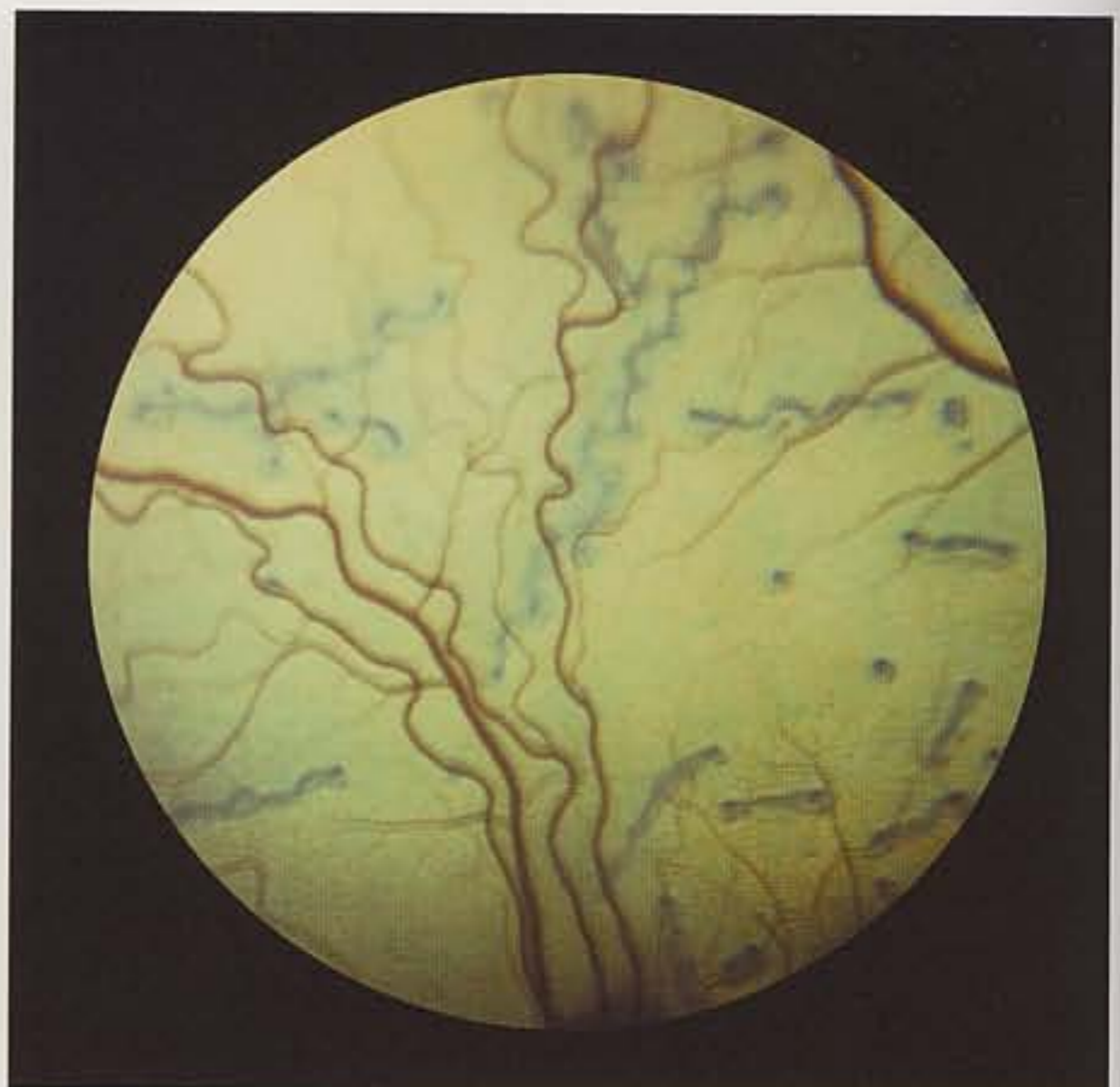

Fig. 11.171 MRD (English Springer Spaniel, 5 months old) Typical retinal folds in tapetal fundus superior to disc.

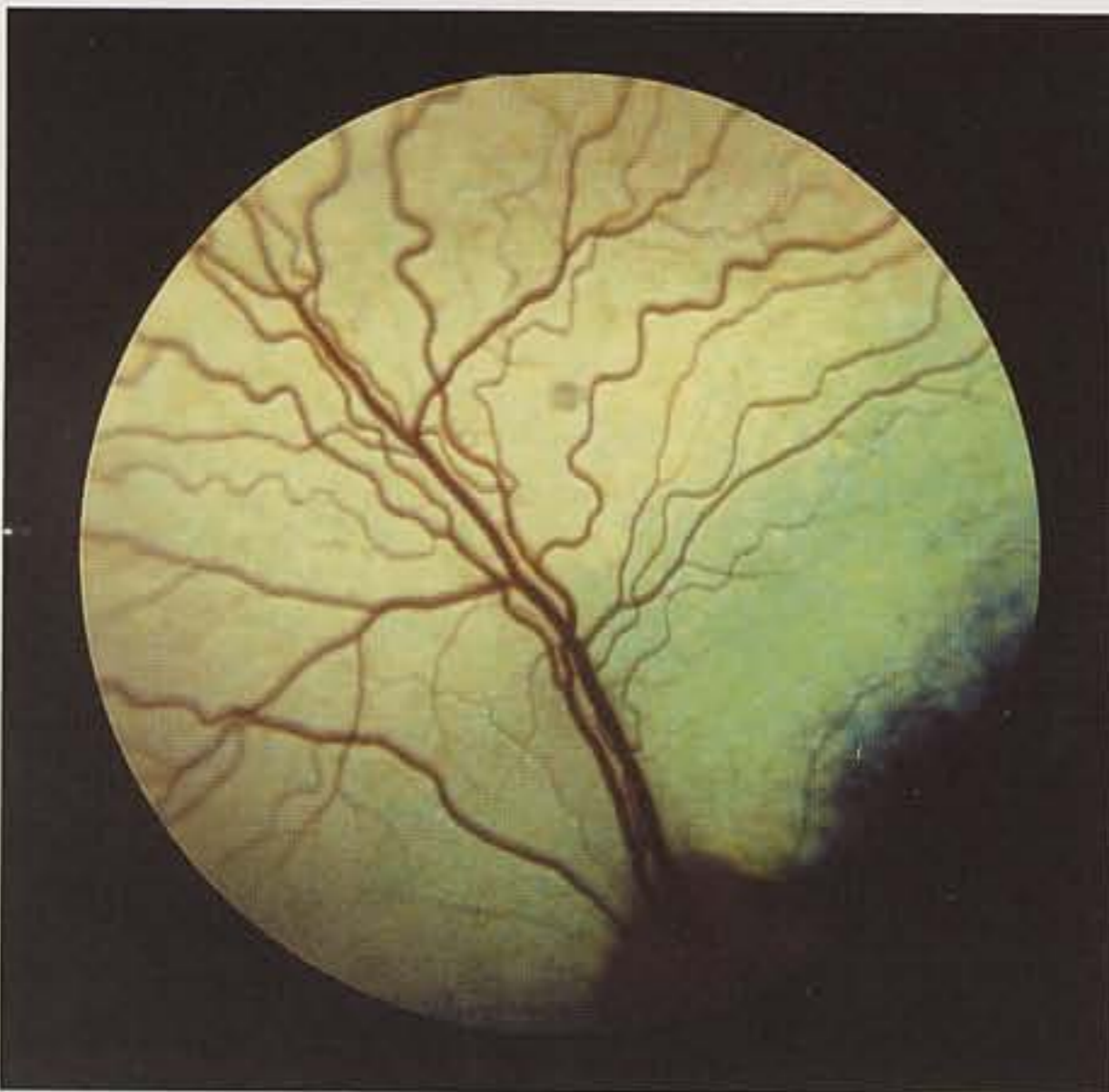

Fig. 11.170 MRD (Labrador Retriever, adult) MRD with minor changes of two small retinal folds.

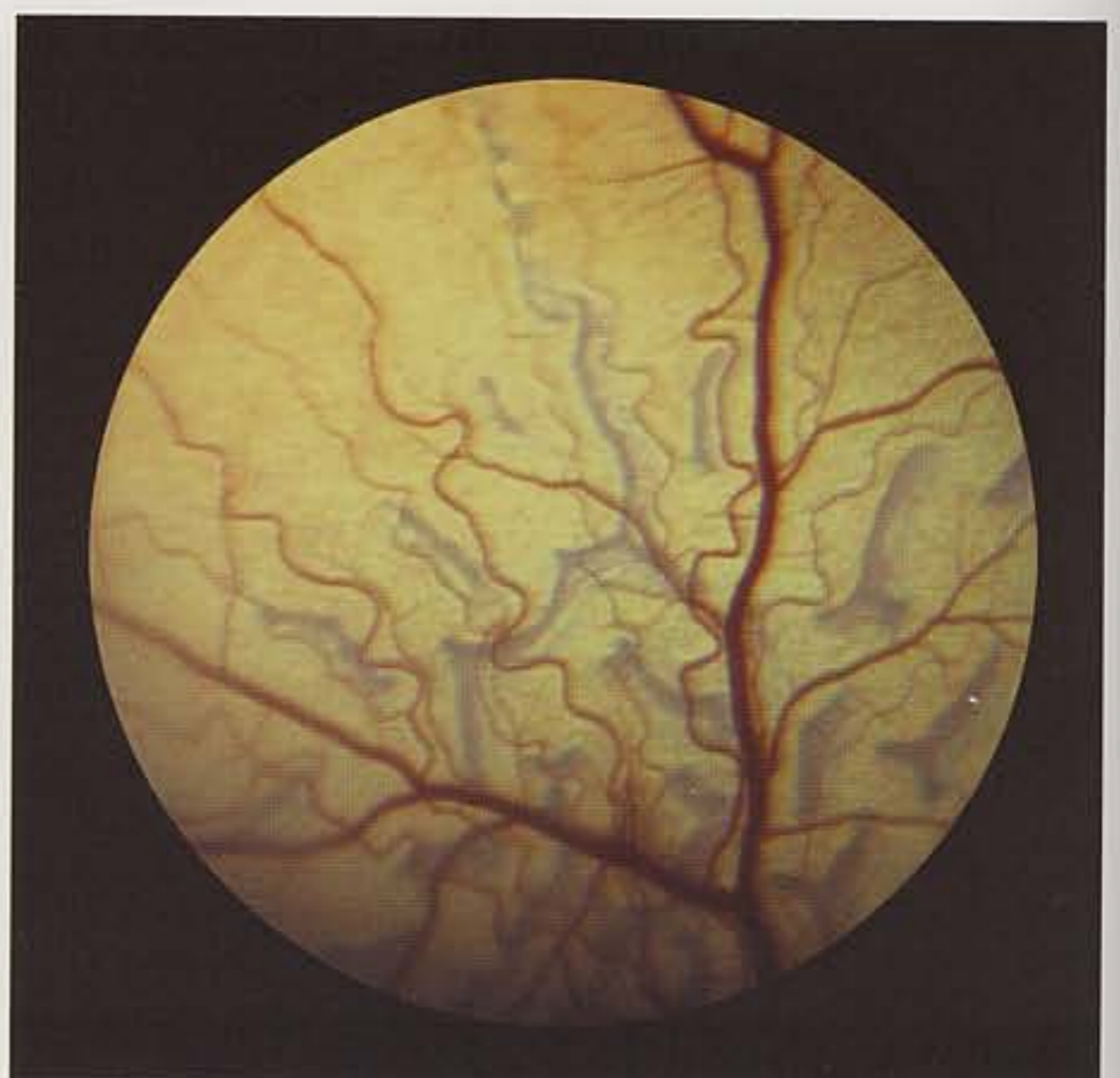

Fig. 11.172 MRD (English Springer Spaniel, 6 months old) Similar to Fig 11.171 but more severe.

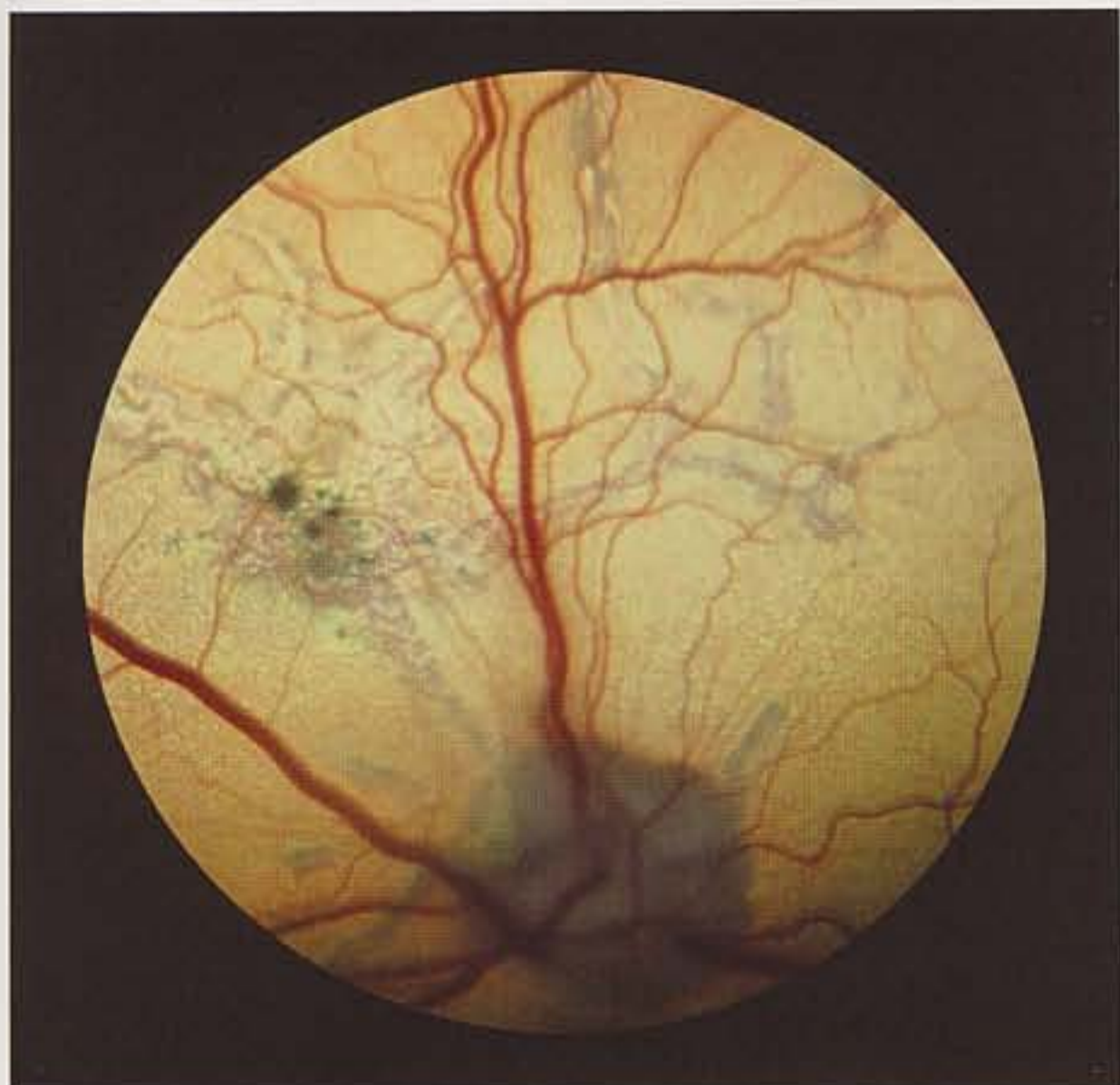

Fig. 11.173 MRD (English Springer Spaniel, 15 months old) Retinal folds; note the area of retinal degeneration with hyper-reflectivity and pigmentation to the left of the main retinal vein.

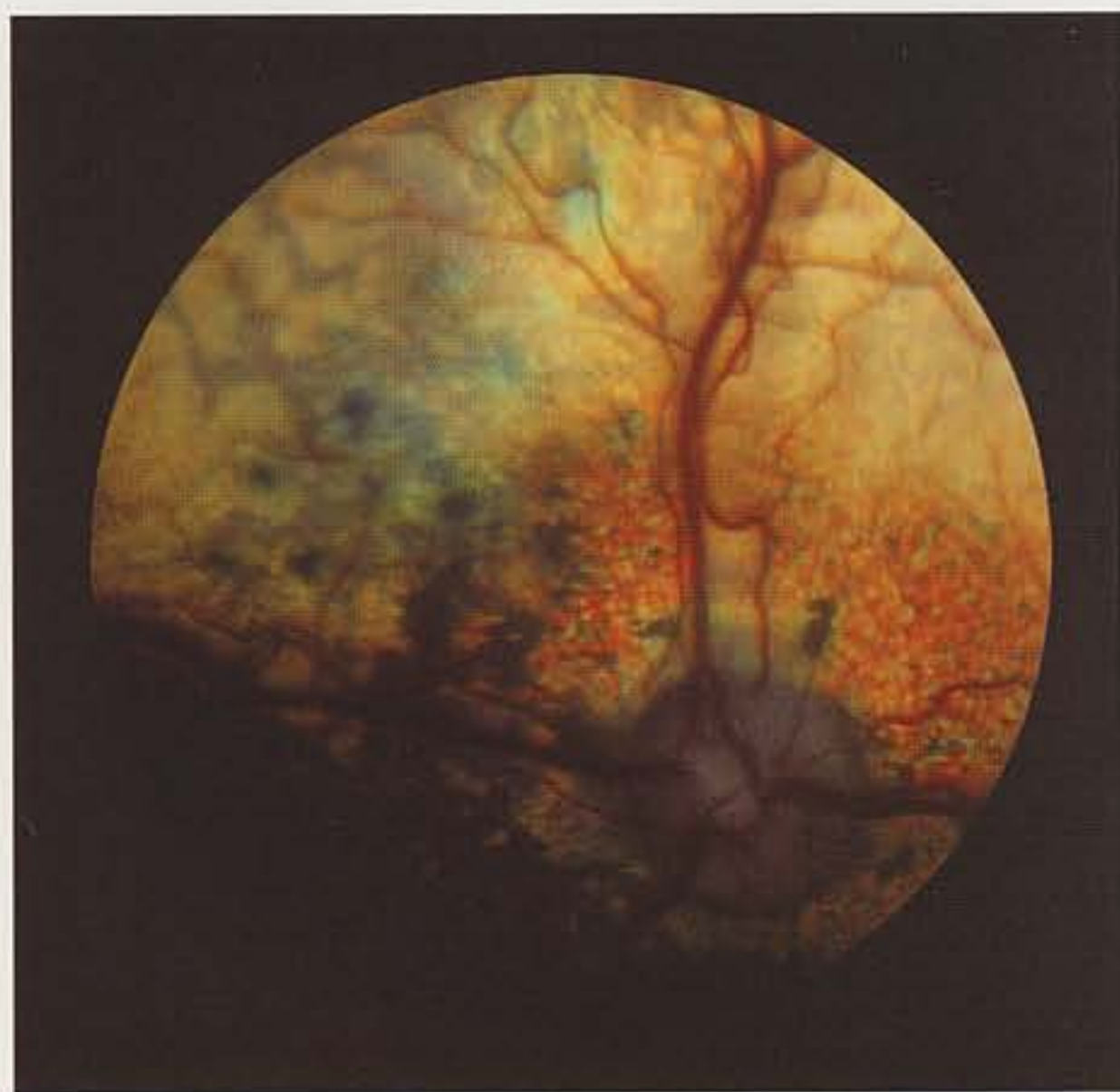


Fig. 11.175 MRD (English Springer Spaniel, 2 years old) More severe case with some retinal detachment.

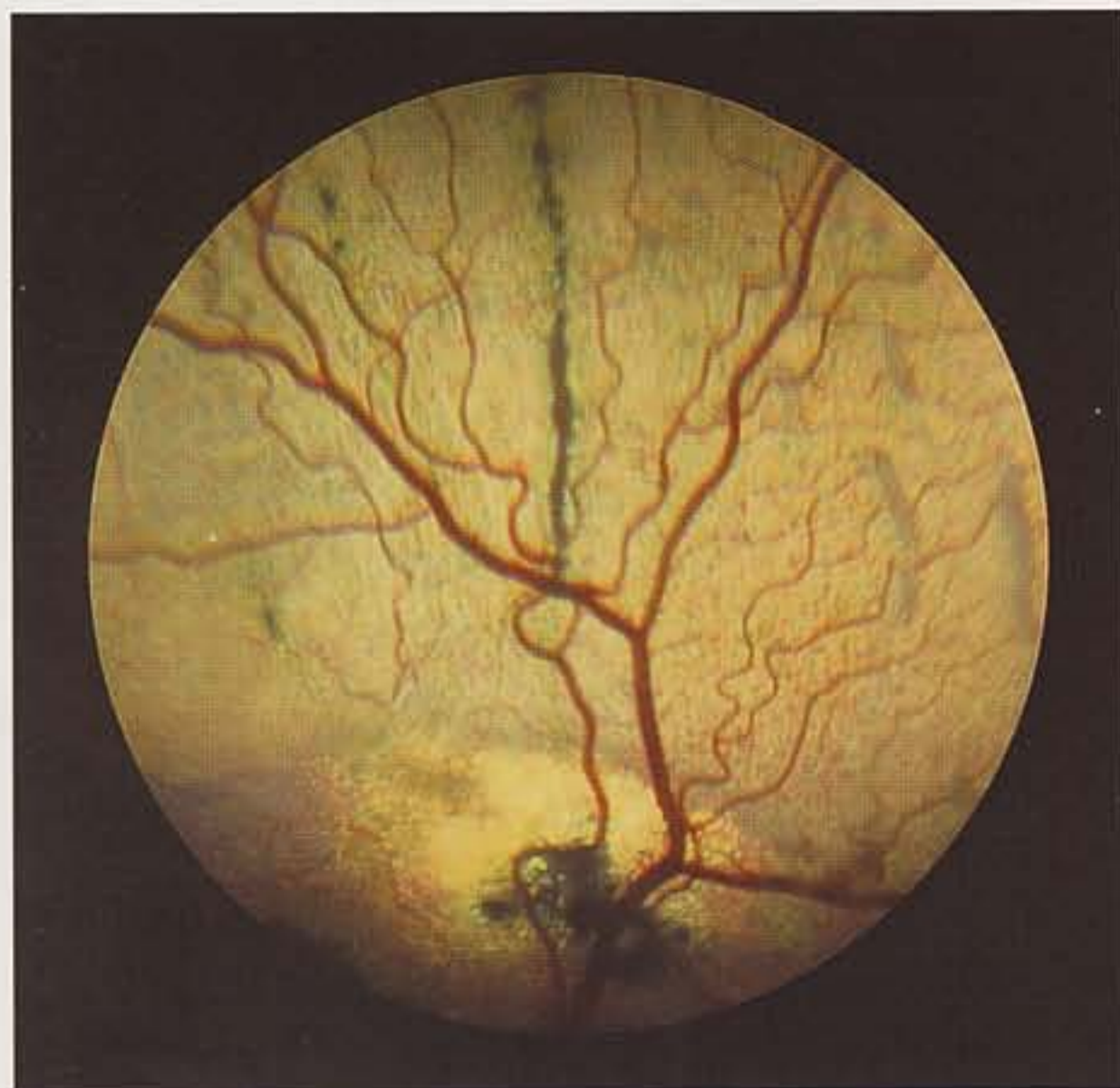

Fig. 11.174 MRD (English Springer Spaniel, 2 years old) Similar changes to Fig 11.173 with folds and area of increased reflectivity and pigmentation above the disc.

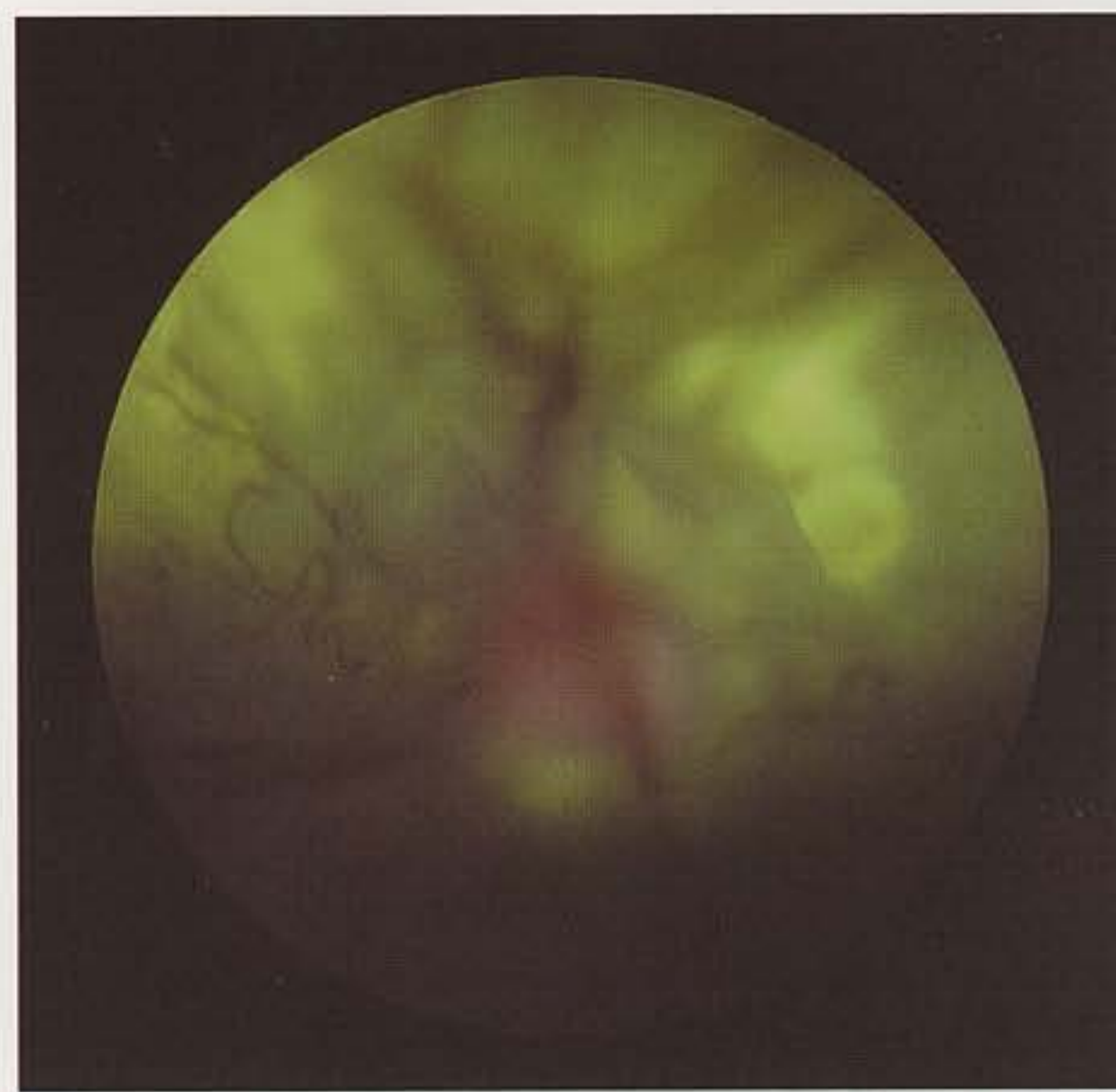

Fig. 11.176 Extensive retinal detachment (English Springer Spaniel, 5 months old)

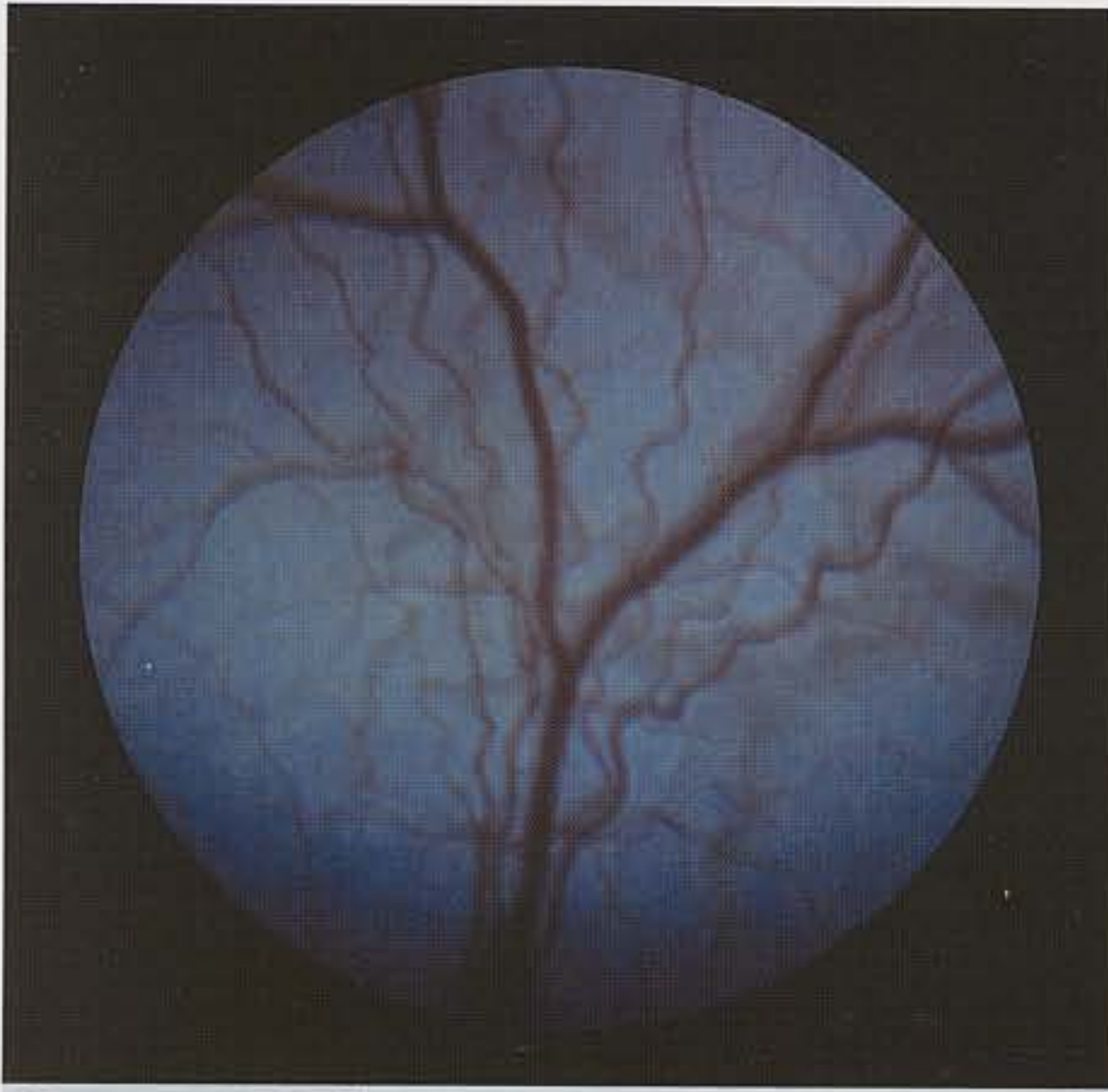


Fig. 11.177 TRD (English Springer Spaniel, 8 months old) Ophthalmoscopic appearance of infundibular detachment. Note similarity to Fig 11.165 in a Sealyham puppy.

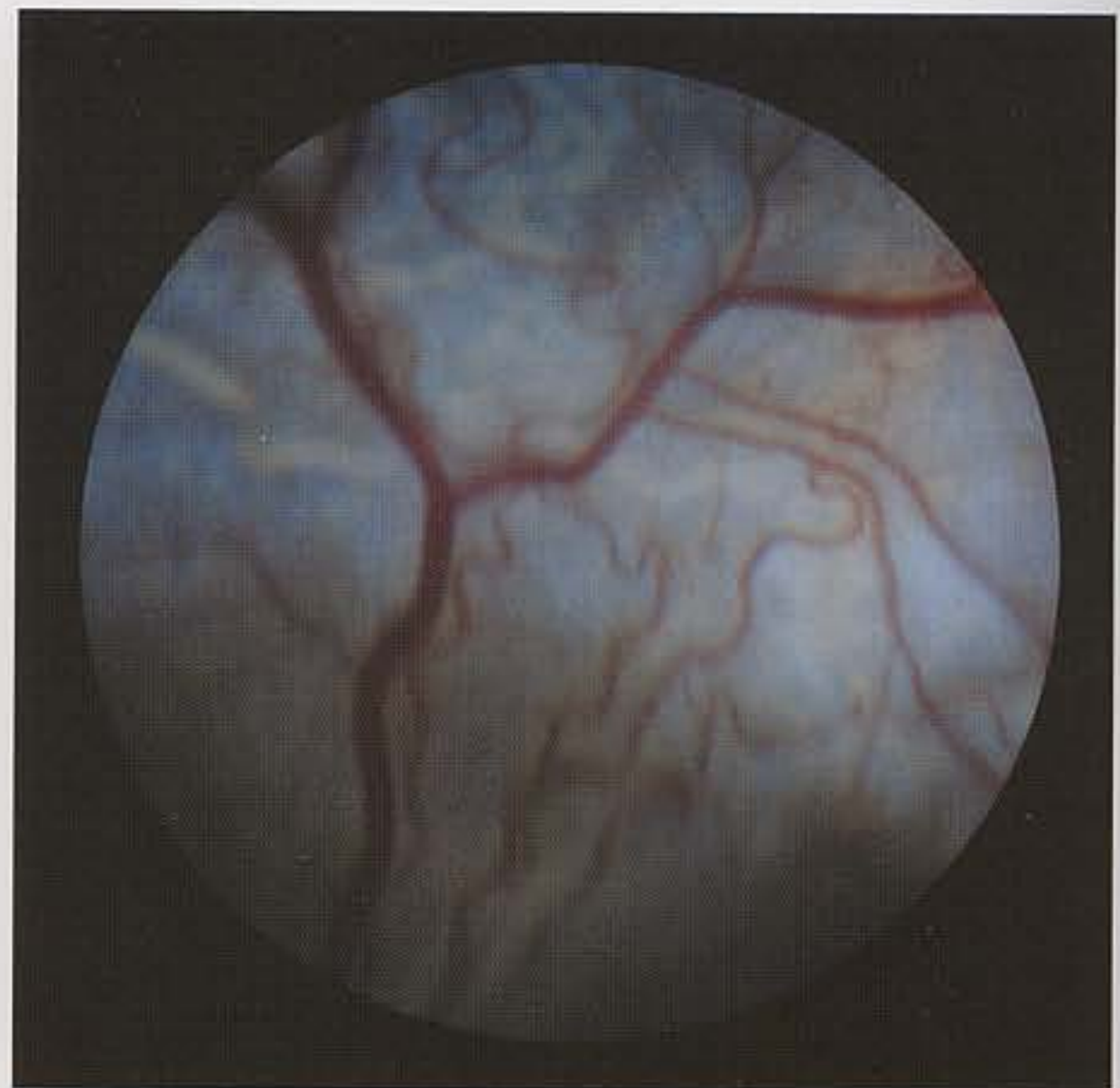

Fig. 11.179 MRD (Cavalier King Charles Spaniel, 7 weeks old) Geographic lesion and folds superior to the disc in an immature tapetal fundus. Note the vascular tortuosity.

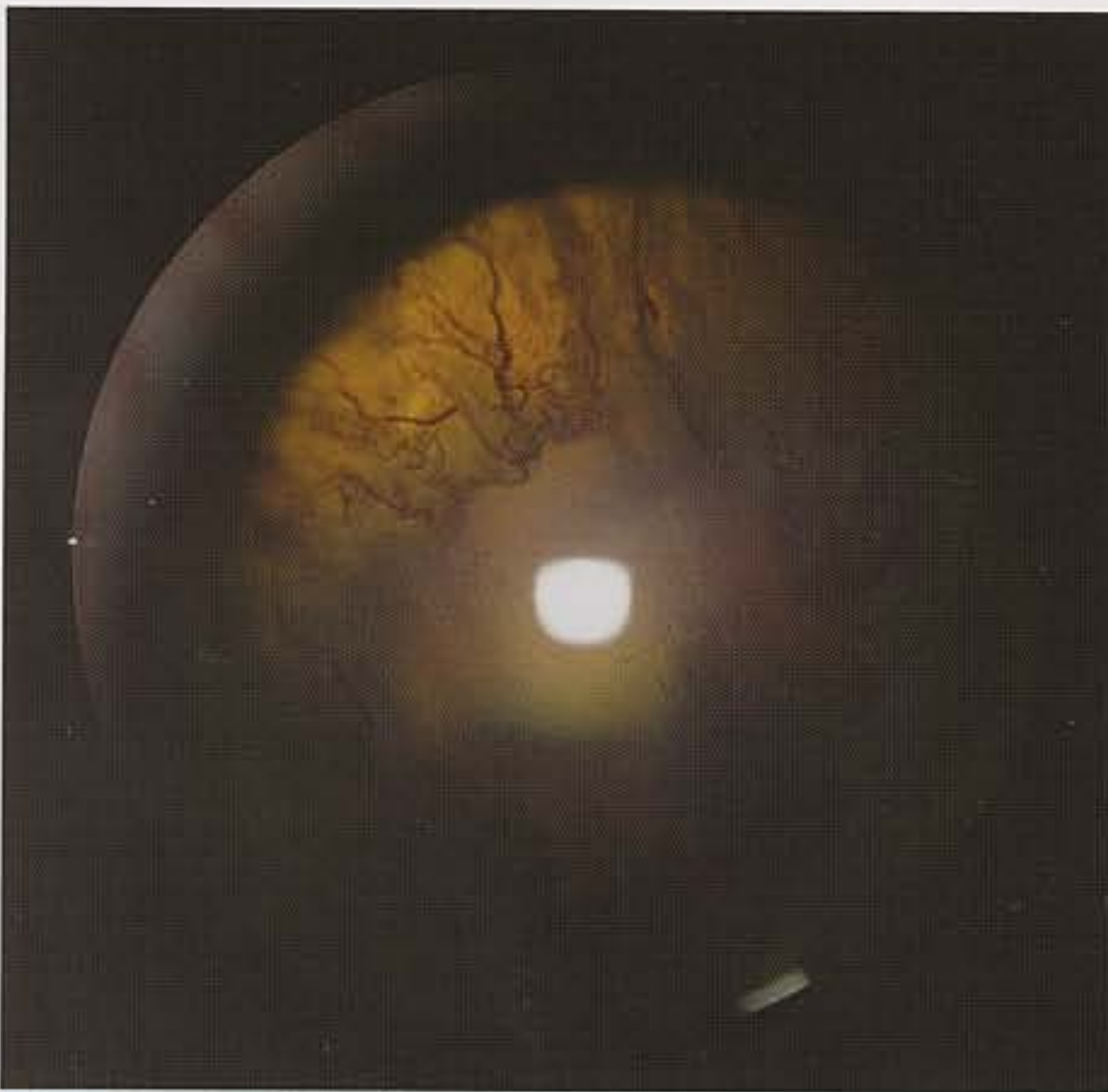

Fig. 11.178 MRD (English Springer Spaniel, 7 weeks old) Retinal folds visible in an immature tapetal fundus.

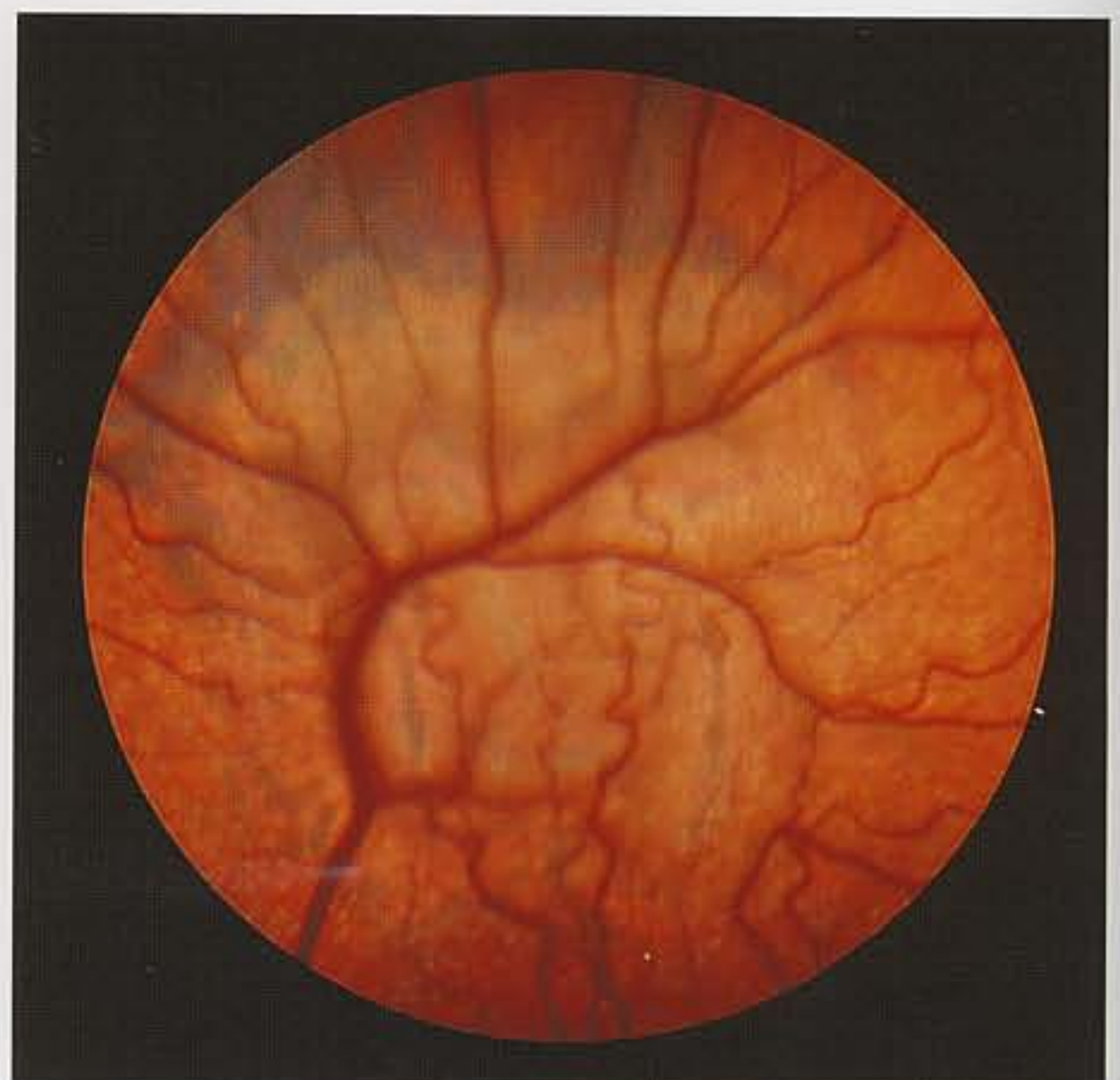


Fig. 11.180 MRD (Cavalier King Charles Spaniel, young adult) Geographic lesion of detachment in superior tapetal fundus.

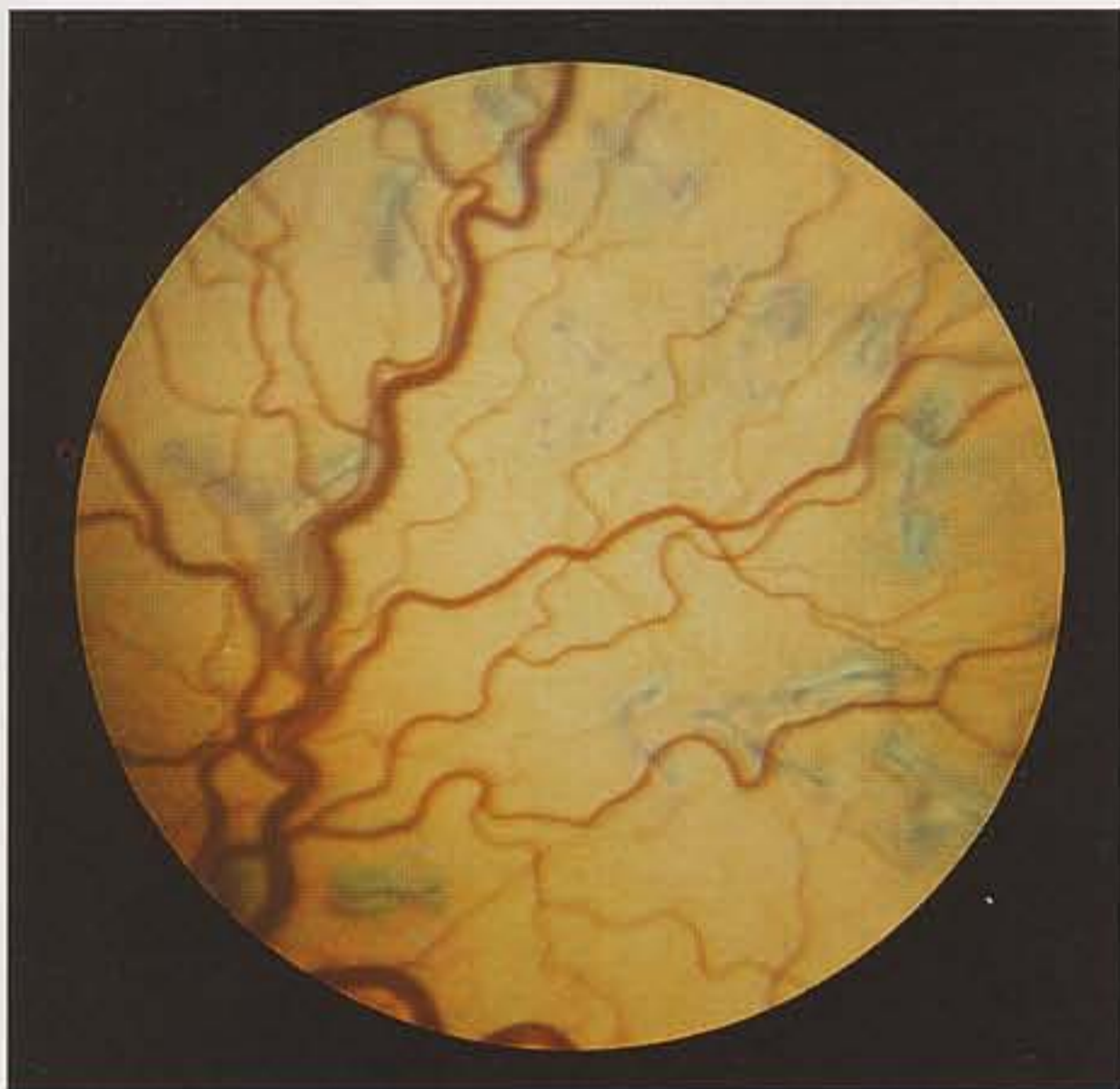


Fig. 11.181 MRD (Cavalier King Charles Spaniel, 5 months old) Retinal folds in tapetal fundus.

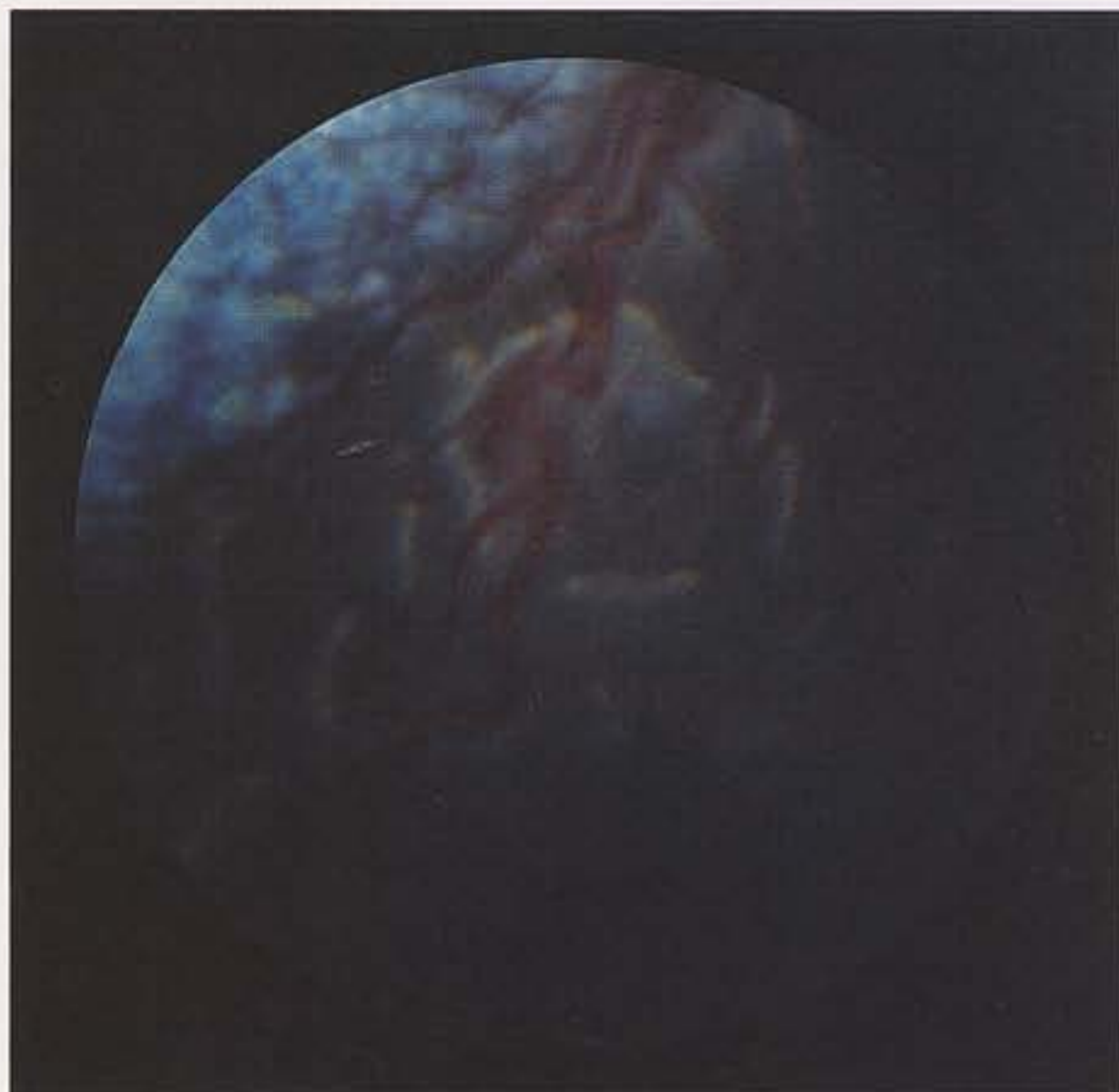

Fig. 11.183 Retinal folds (Rough Collie, 10 weeks old) Retinal folds in the non-tapetal fundus. Originally, and incorrectly, thought to be part of CEA. Possibly associated with degree of microphthalmos.

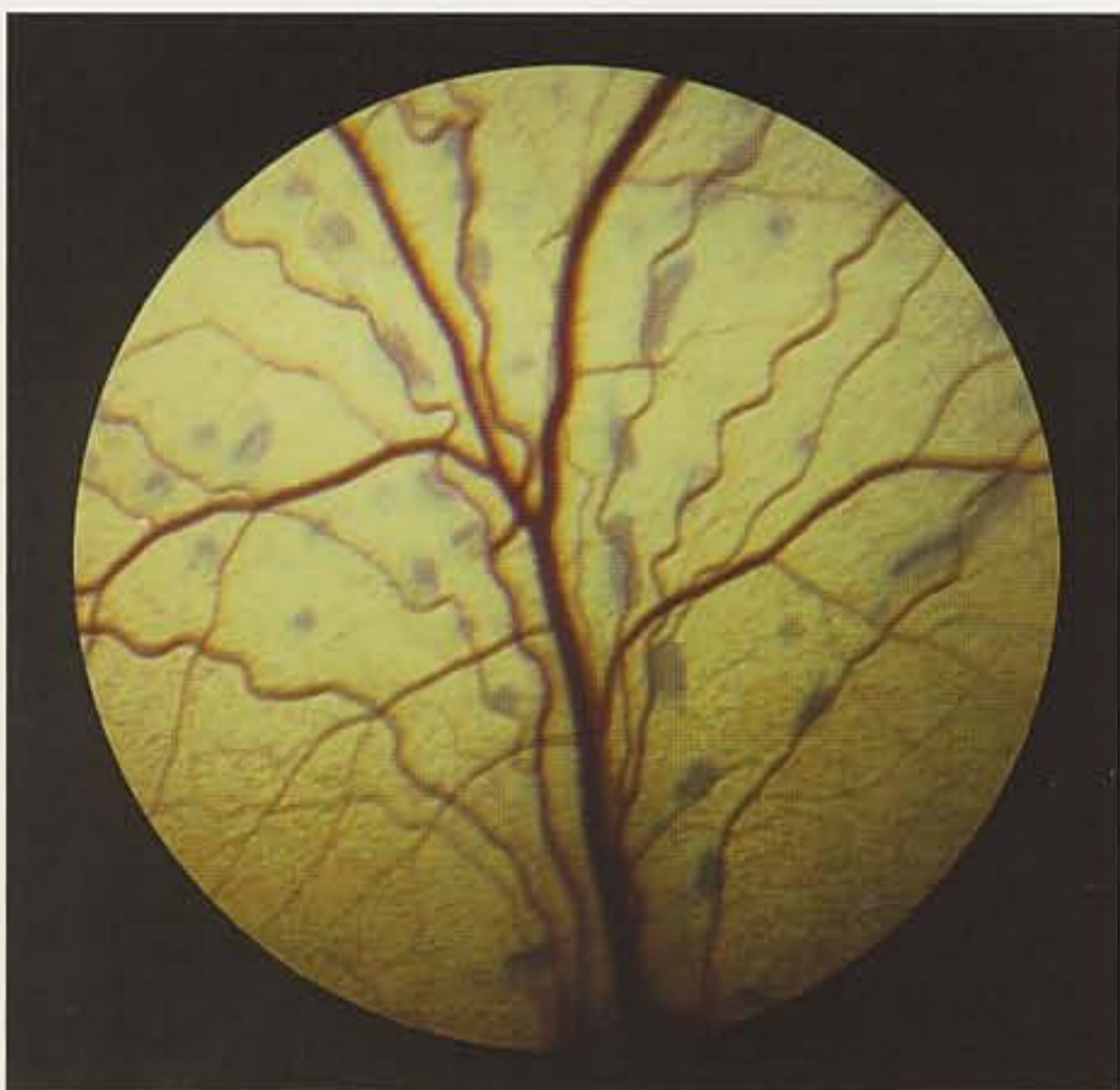


Fig. 11.182 Retinal folds (Golden Retriever (3/4) x Labrador Retriever (1/4)) Congenital retinal folds resembling hereditary MRD but in a cross-bred. Unknown aetiology.

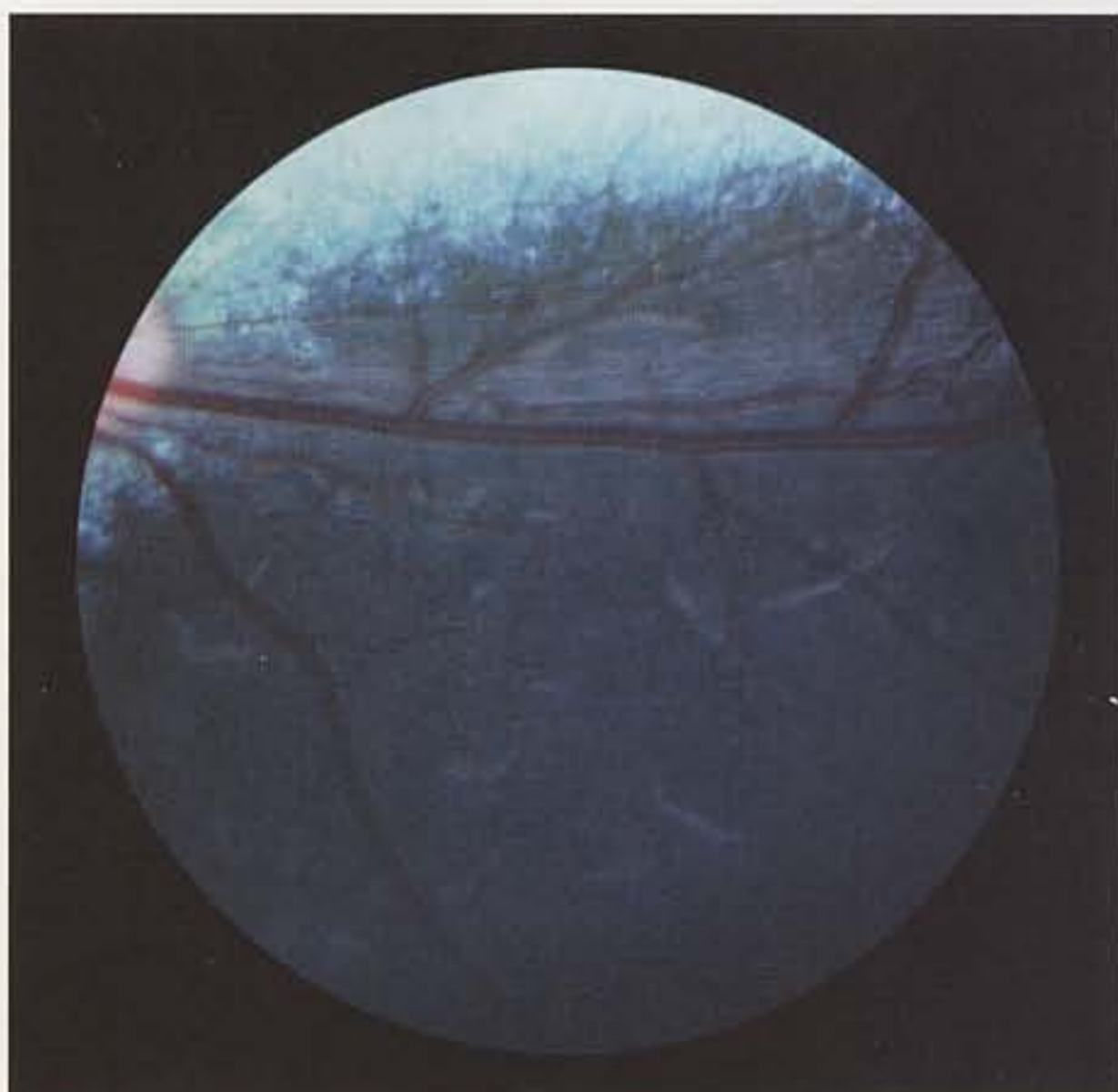

Fig. 11.184 Retinal folds (Beagle, 3 months old) Transient retinal folds in the non-tapetal fundus.

**Table 11.4 – Retinal dysplasia, total (TRD) and multifocal (MRD): breeds affected**

■	Bedlington Terrier – TRD
■	Cavalier King Charles Spaniel – MRD
■	Retriever (Golden) – MRD
■	Retriever (Labrador) – TRD and MRD
■	Rottweiler – MRD
■	Schnauzer, Giant – MRD
■	Sealyham Terrier – TRD
■	Spaniel (English Springer) – TRD and MRD
■	Spaniel (American Cocker) – MRD

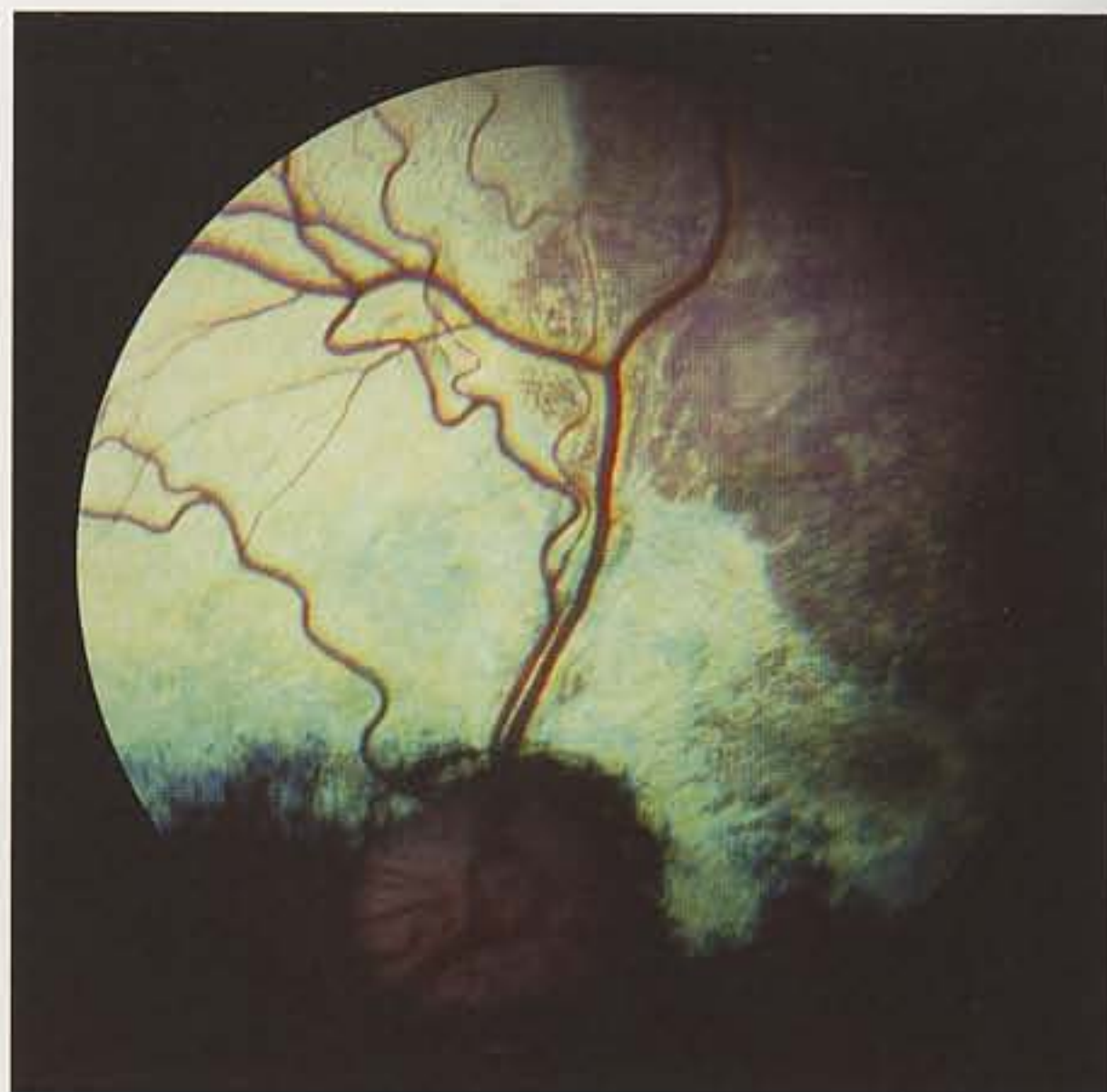
However, there are acquired forms of RD due to other causes, e.g. canine herpesvirus, irradiation, etc. Total RD causes complete blindness but it is rare for MRD to have any effect on vision and most cases showing retinal folds, and even geographic lesions, are only diagnosed on ophthalmoscopic examination and the owner is unaware of any effect on vision.

#### Other retinopathies (Figs 11.185–11.212)

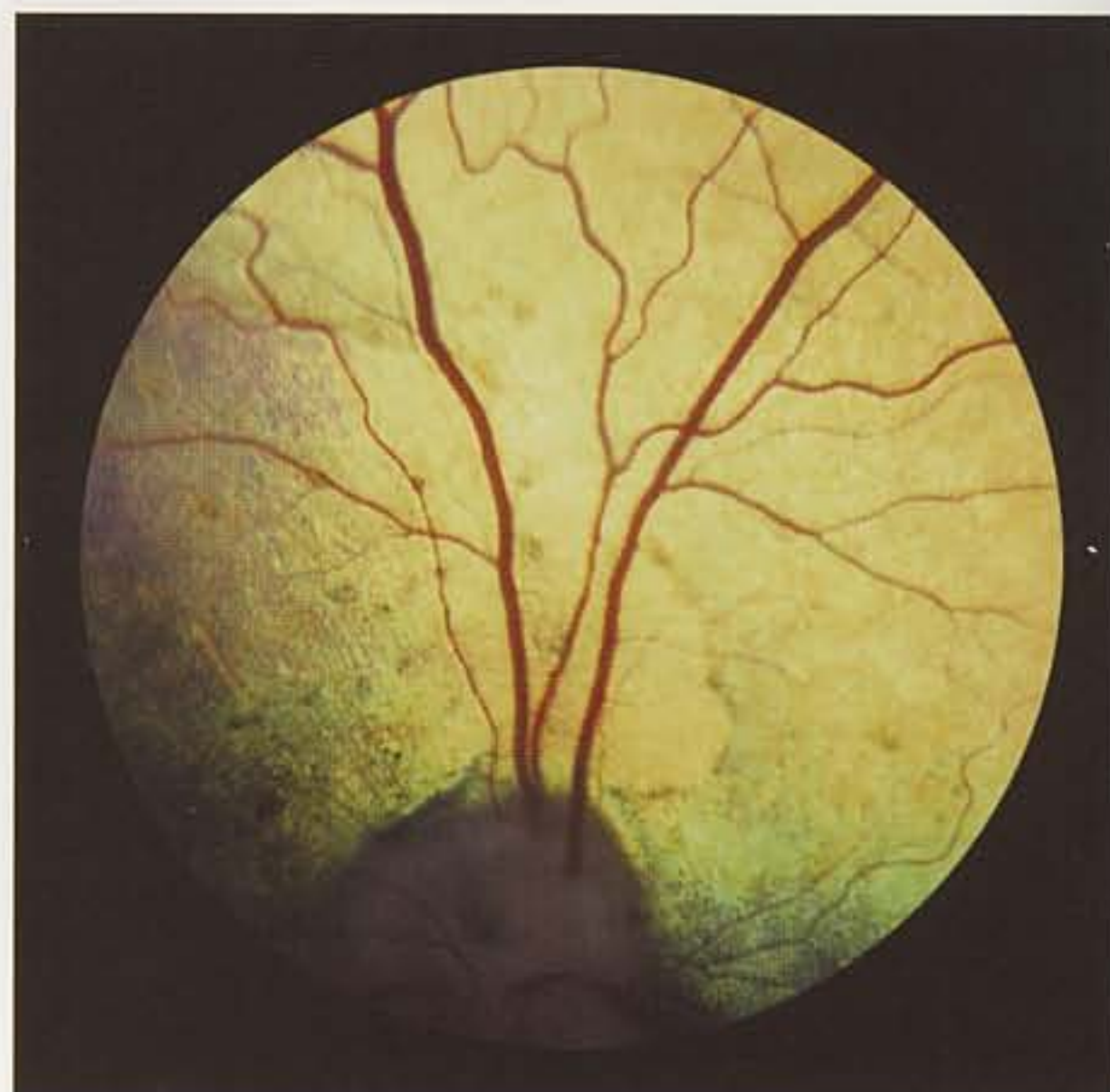As stated above the non-hereditary retinopathies in the dog are mainly post-inflammatory, often of unknown aetiology and rarely are active at the time of examination. They must be distinguished from the hereditary retinopathies as obviously they have no significance as far as parents, progeny and relatives are concerned. Non-hereditary retinopathies may affect one or both eyes and to considerably differing degrees. In addition, the part(s) affected are often clearly defined and haphazard in their distribution in the fundus. There is, of course, no breed or age incidence. Cases of bilateral severe retinal degeneration may sometimes be difficult to distinguish from a hereditary retinopathy in a breed in which GPRA is recognized, but a history of sudden defective vision, as opposed to progressive loss of vision, coupled with the age of the animal, may help to distinguish one from the other.

Sudden acquired retinal degeneration (SARD) is now a well-recognized retinopathy, but of unknown aetiology. Cases present with sudden blindness and with no changes in the ophthalmoscopic appearance, but typical changes of a retinal degeneration appear later at subsequent examinations.

Retinal haemorrhages have a variety of causes and occasional cases of an idiopathic retinal detachment may be seen.



**Fig. 11.185** Post-inflammatory retinopathy (Sheepdog, 1 year old) Note the area of increased reflectivity, denoting retinal degeneration, in the upper right quadrant. Aetiology unknown.



**Fig. 11.186** Post-inflammatory retinopathy (Labrador Retriever, 8 years old) Increased reflectivity in the tapetal region, together with some pigmentary disturbance in the lower left quadrant adjacent to the optic disc. Aetiology unknown.

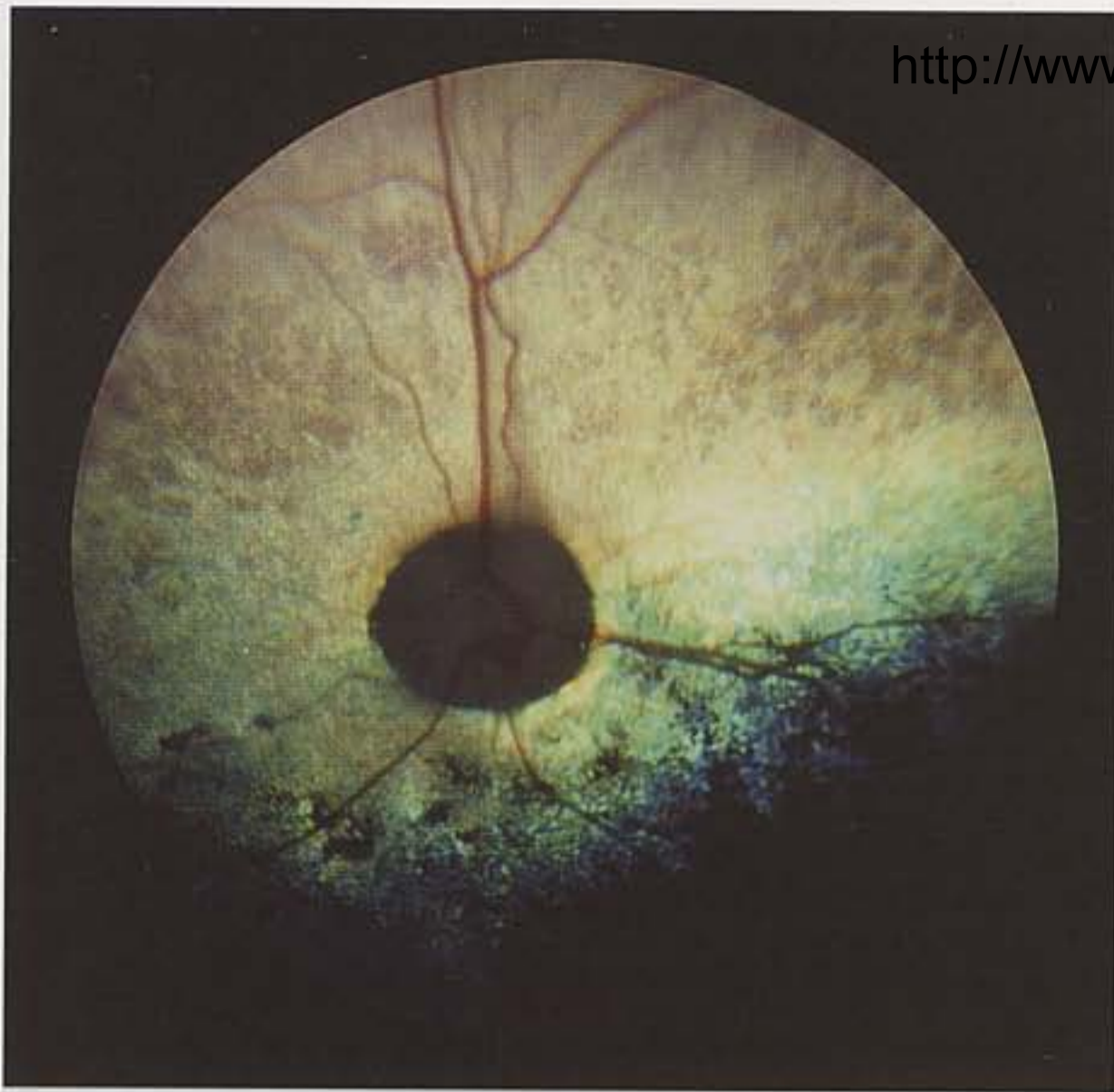

Fig. 11.187 Post-inflammatory retinopathy (Greyhound, 2 years old) Generalized but patchy increased reflectivity, together with early changes of optic atrophy. This was an unvaccinated dog and other littermates were affected with retinal degeneration.

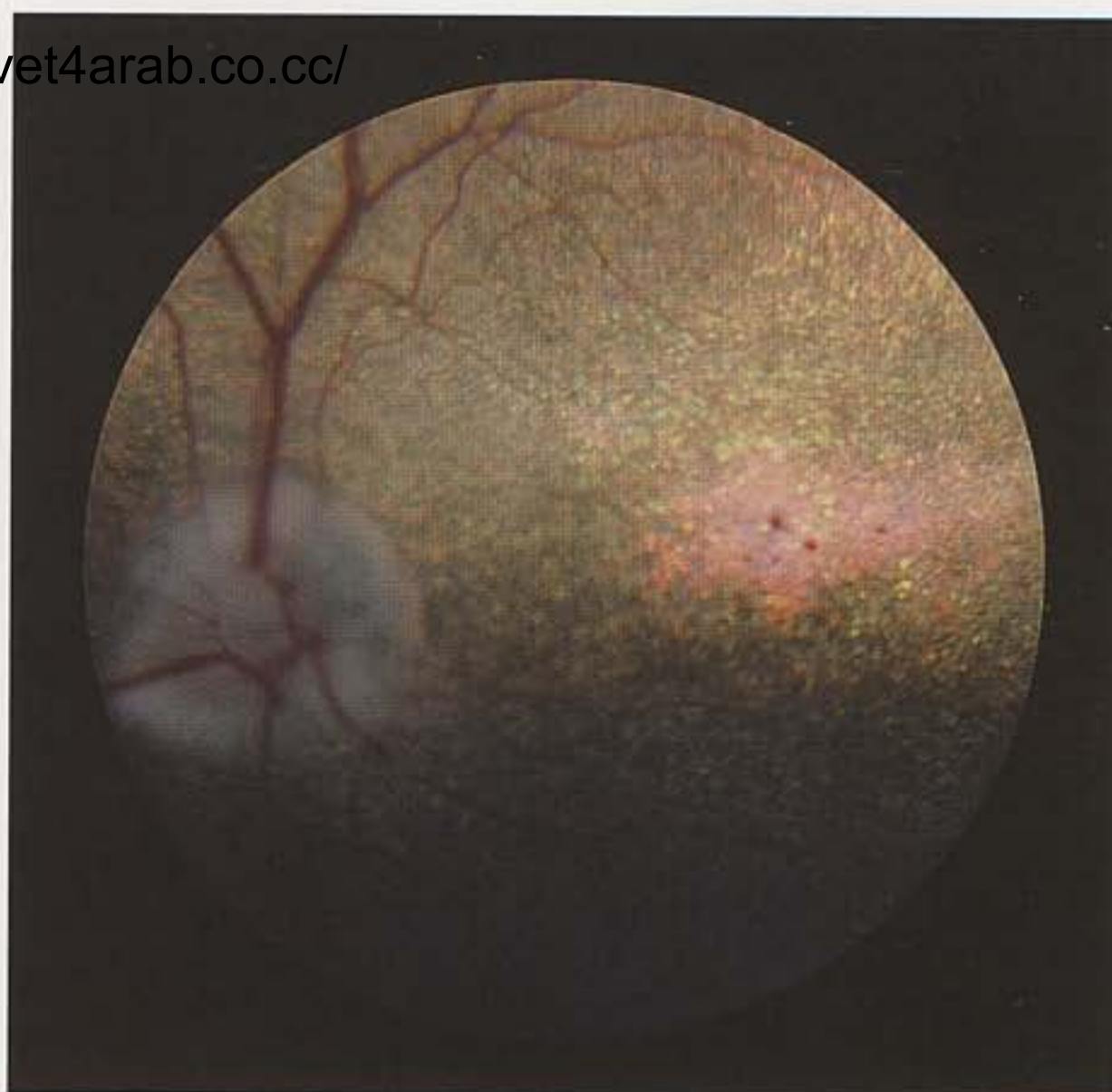

Fig. 11.189 Post-inflammatory retinopathy (Border Collie, 13 years old) Focal area of post-inflammatory retinal degeneration lateral to the disc. The other eye of this dog had a generalized retinopathy.



Fig. 11.188 Post-inflammatory retinopathy (Labrador Retriever, 5 years old) Generalized retinal degeneration. Note the change in colour from green to gold in the more severely affected parts.

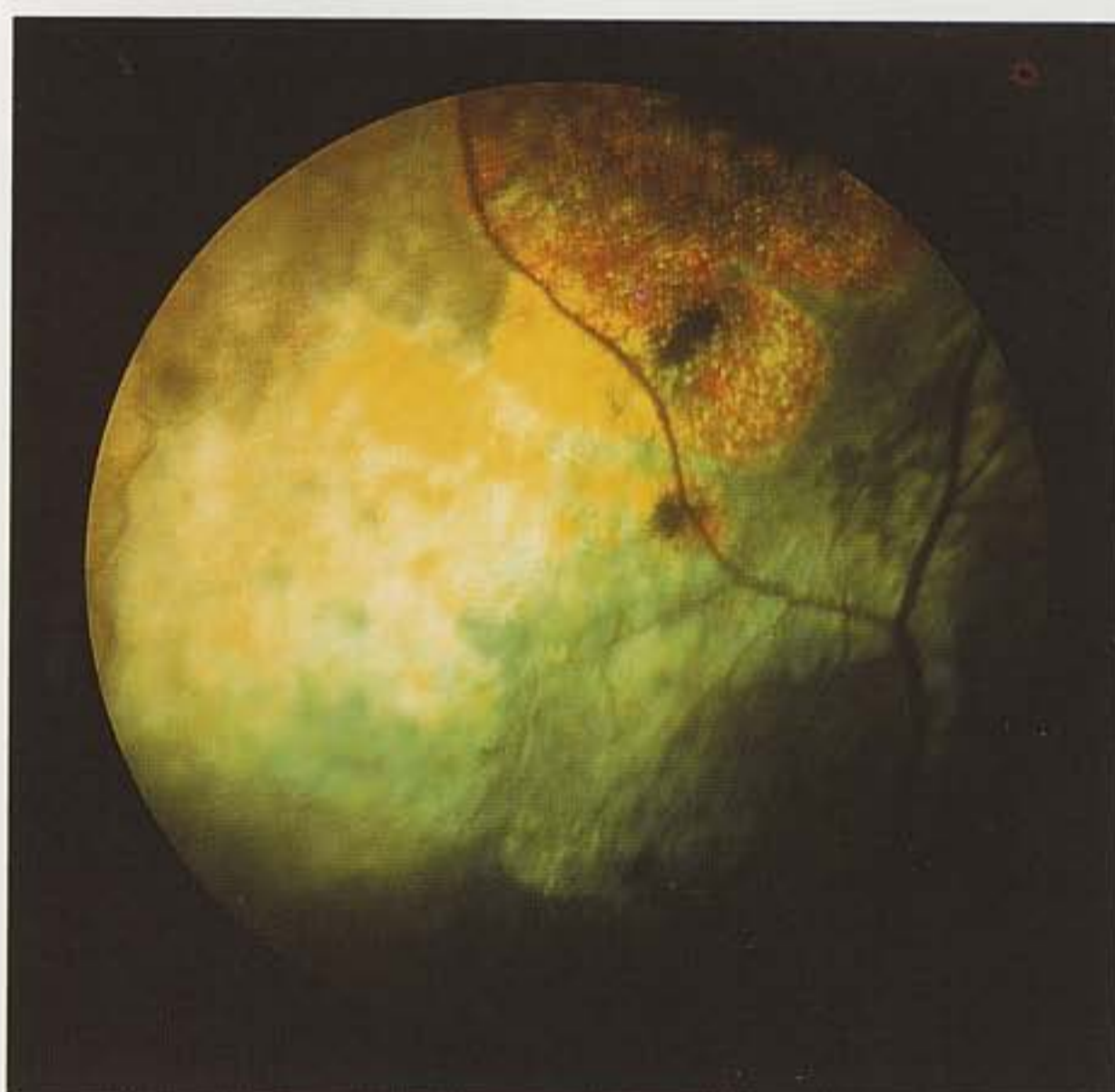

Fig. 11.190 Post-inflammatory retinopathy (German Shepherd Dog, 7 years old) Typical changes with increased reflectivity and abnormal pigmentation and of post-inflammatory origin. The other eye of this dog was normal.

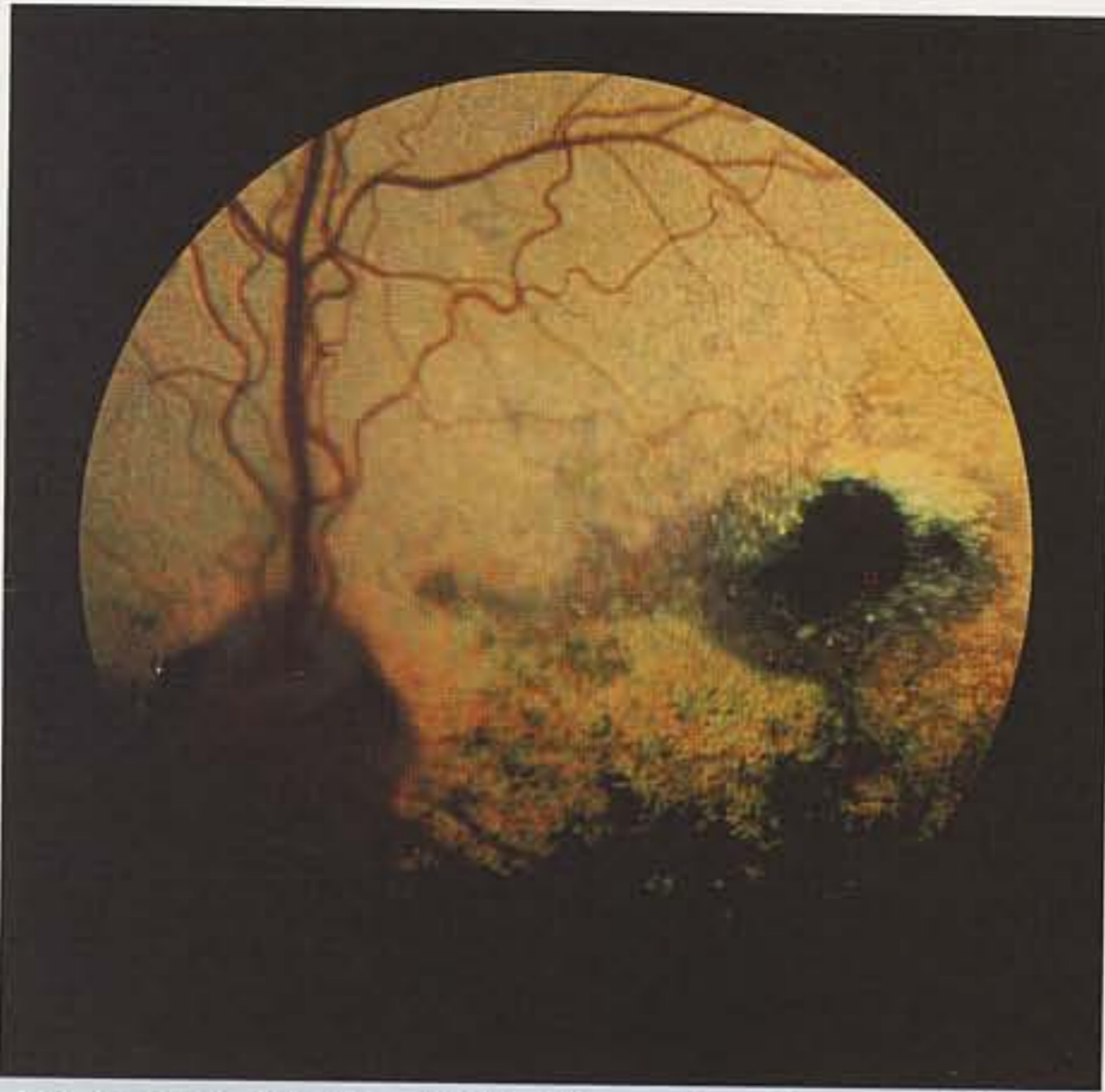

Fig. 11.191 Chorioretinitis (Sheepdog, 6 years old)  
Post-inflammatory chorioretinitis with heavy pigmentation in the centre of the lesion lateral to the disc.

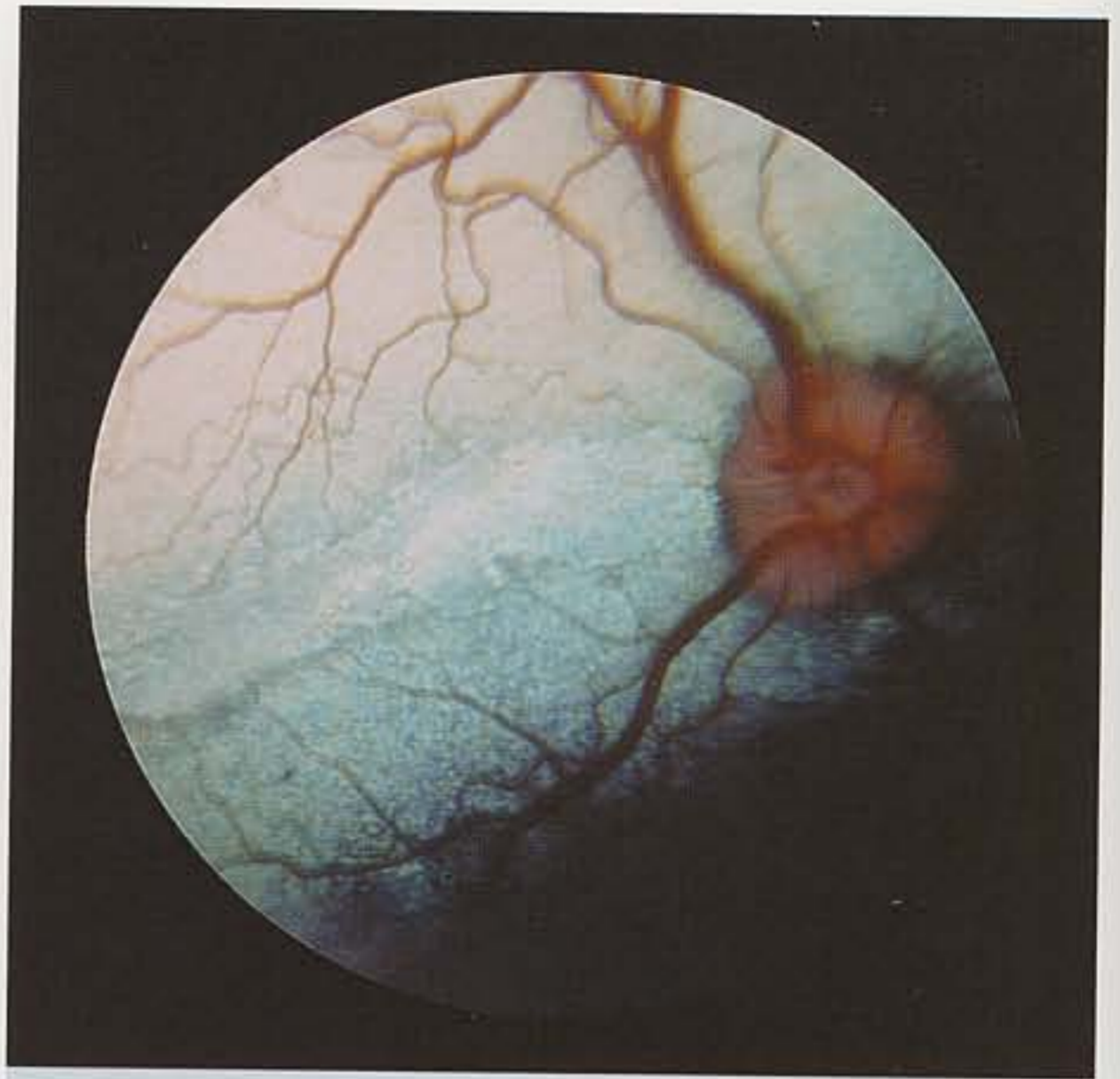

Fig. 11.193 Post-inflammatory retinopathy (Greyhound, 2 years old)  
Elongated focal area of retinal degeneration, peripapillary and extending laterally. This dog had shown clinical signs of canine distemper.

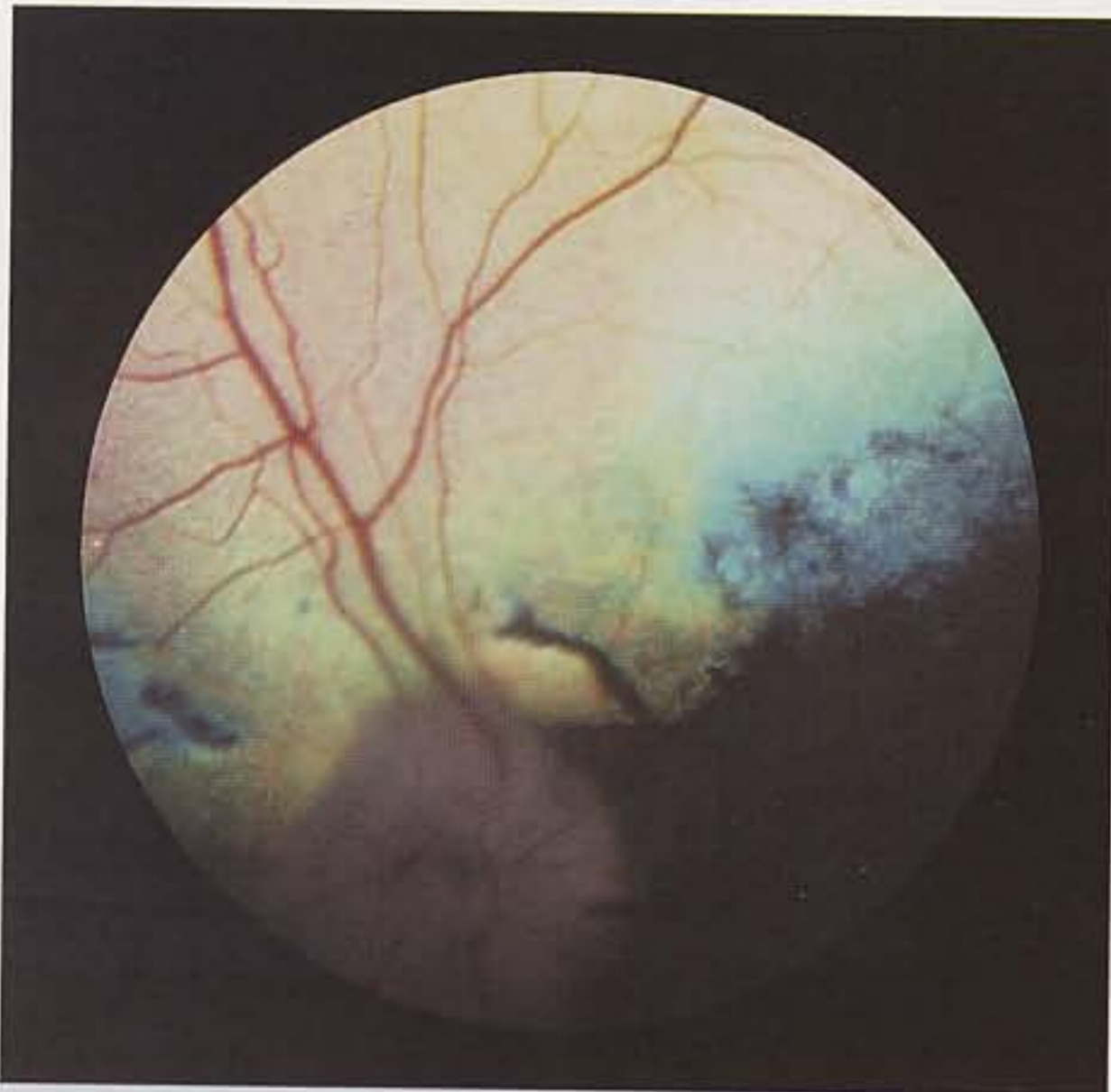


Fig. 11.192 Post-inflammatory retinopathy (Crossbred, 1 year old)  
Abnormal reflectivity and pigmentation. This dog was known to have had canine distemper.

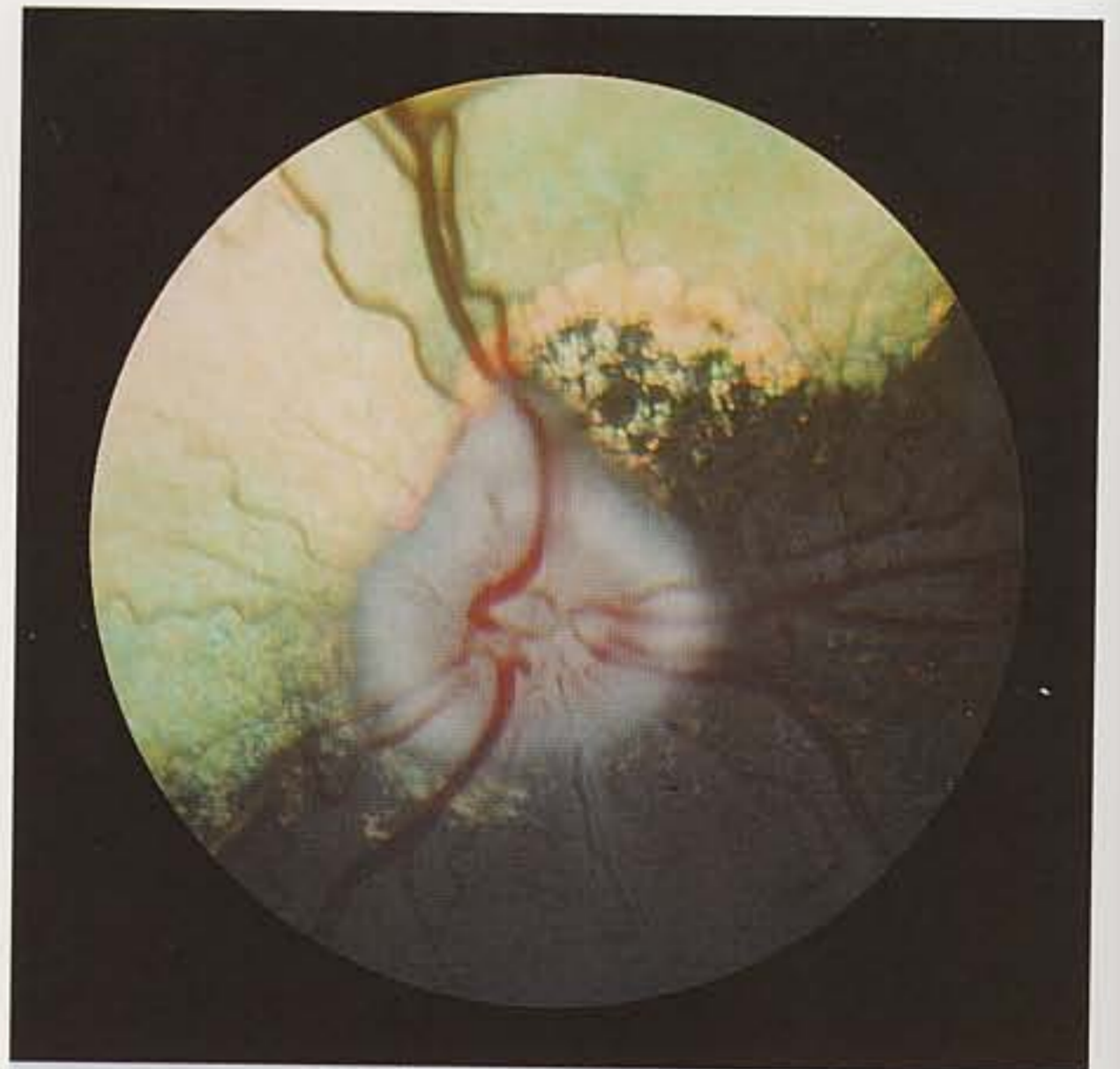

Fig. 11.194 Post-inflammatory retinopathy (Crossbred, 6 years old)  
Peripapillary lesion on the medial side of the disc.

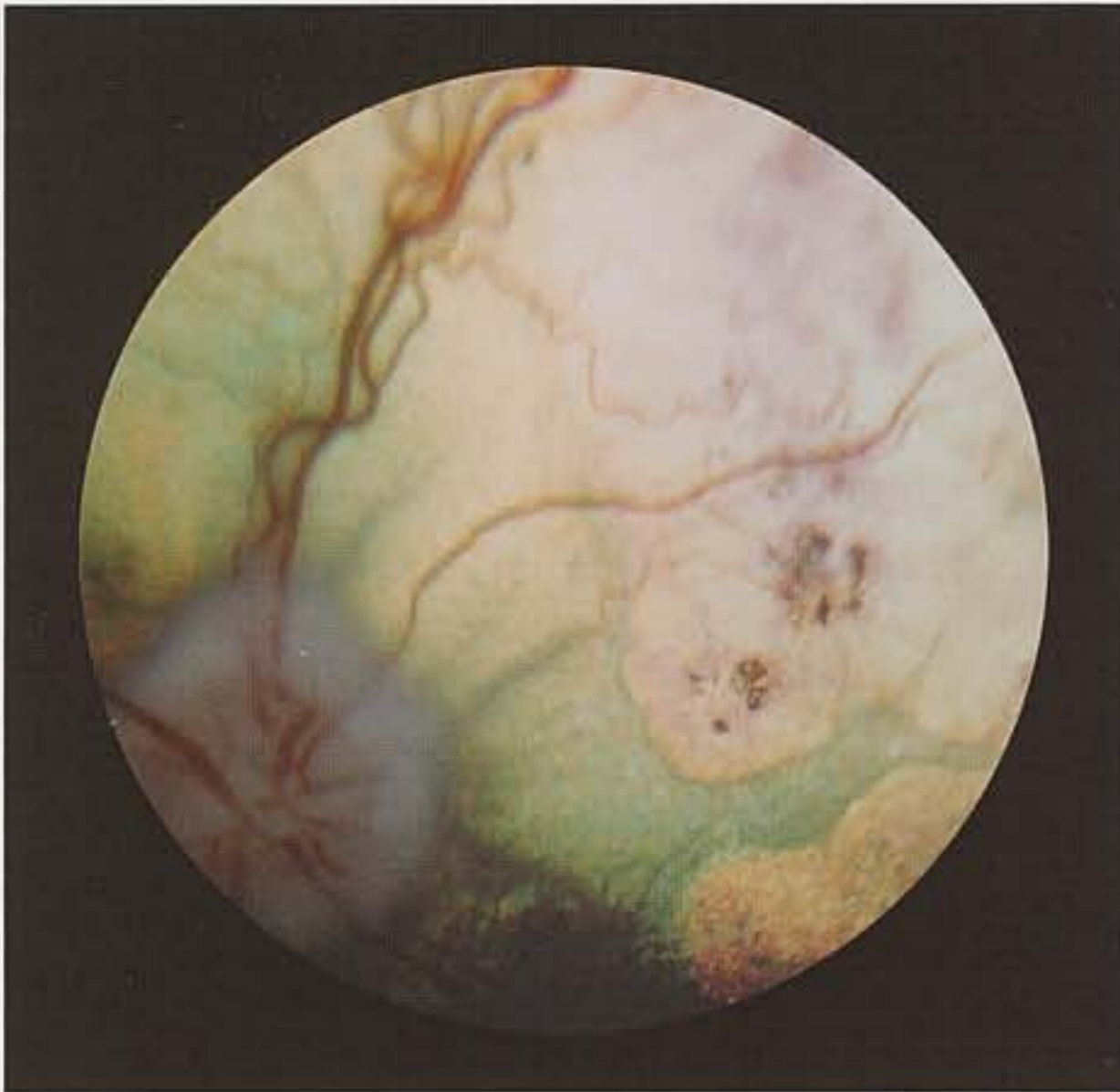

Fig. 11.195 Post-inflammatory retinopathy (Crossbred, 6 years old) The other eye of the dog in Fig 11.194, showing more extensive areas of retinal degeneration and demonstrating the asymmetry of the two eyes. This dog was known to have had pyrexia and fits at a younger age. Lesions in both eyes were non-progressive over several years.

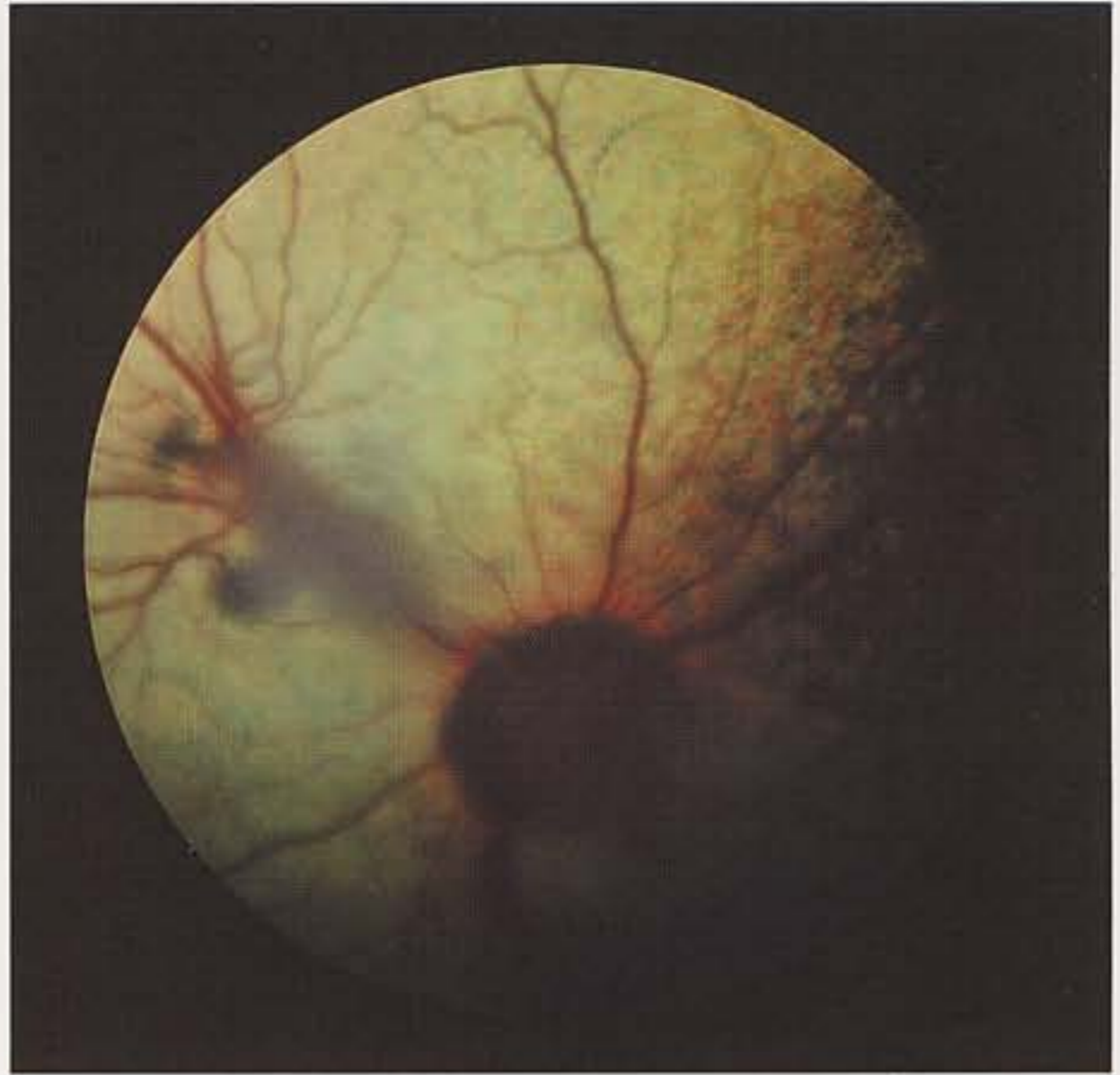


Fig. 11.197 Post-inflammatory retinopathy (English Springer Spaniel, 3 years old) Note the exudate and neovascularization in the region above the disc.

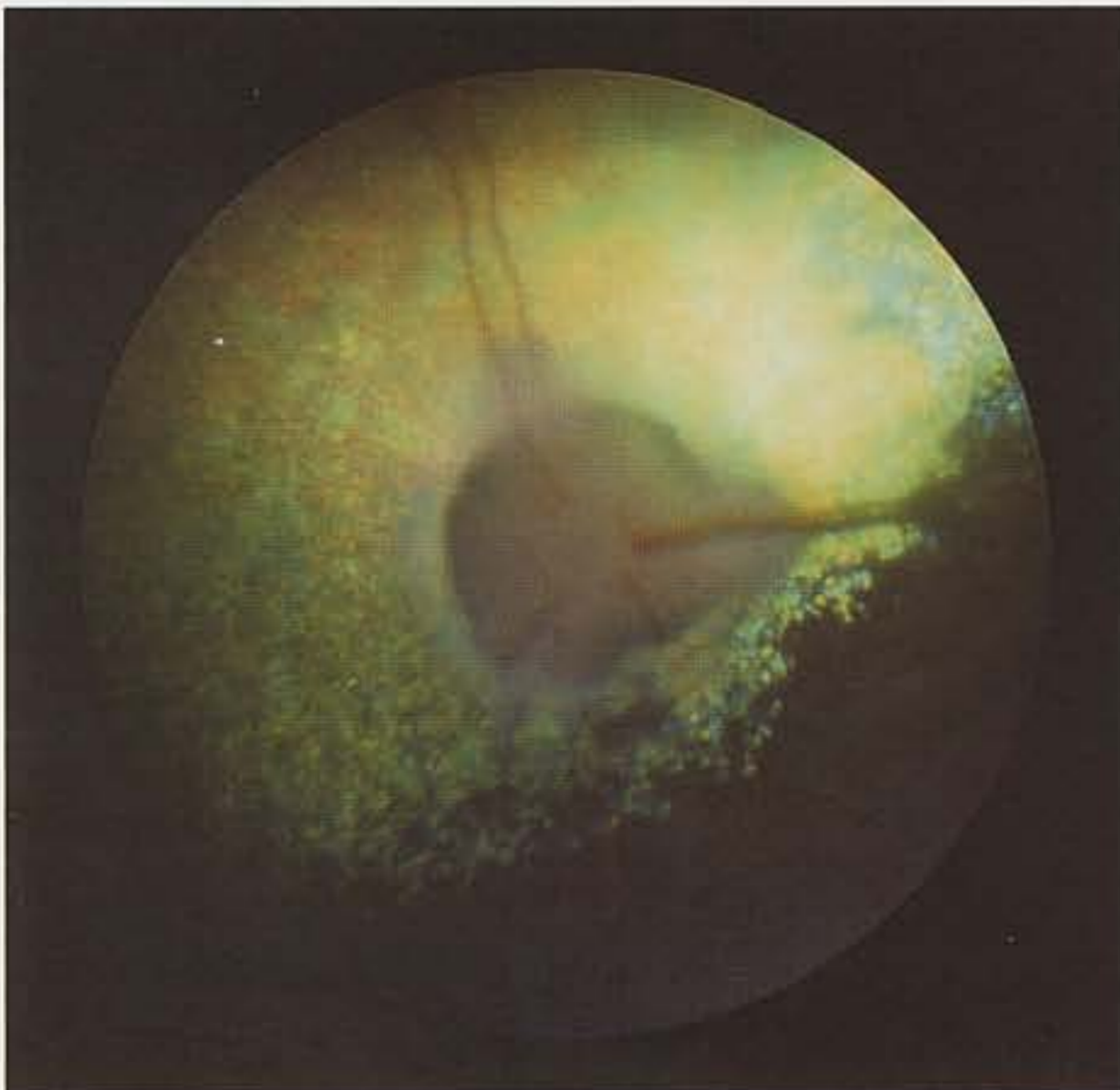

Fig. 11.196 Post-inflammatory retinopathy (Doberman, 8 years old) Advanced and severe retinal degeneration and optic atrophy.

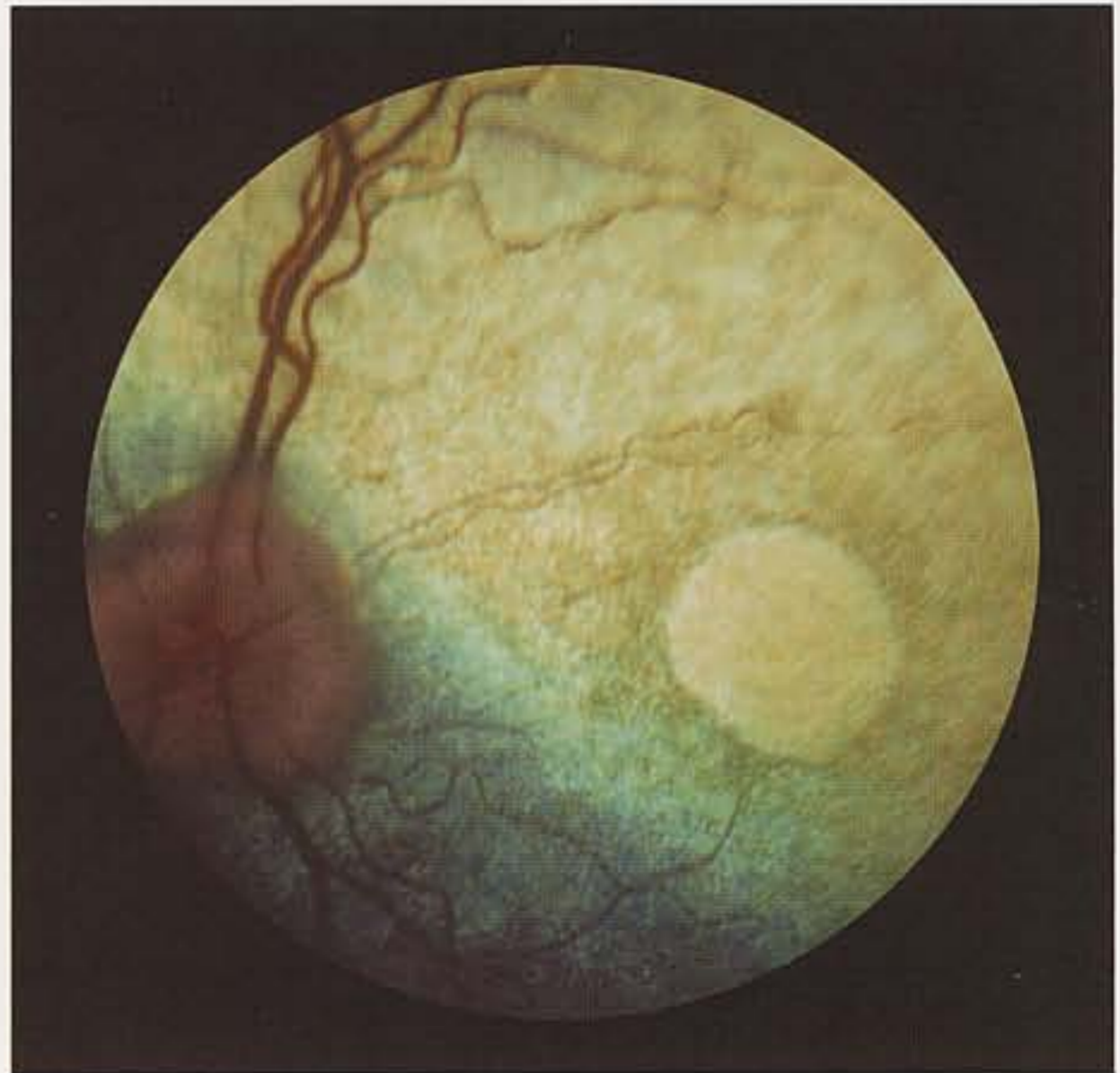

Fig. 11.198 Post-inflammatory retinopathy (Labrador Retriever, 10 years old) Pigmentary retinopathy. Note the difference to central PRA.



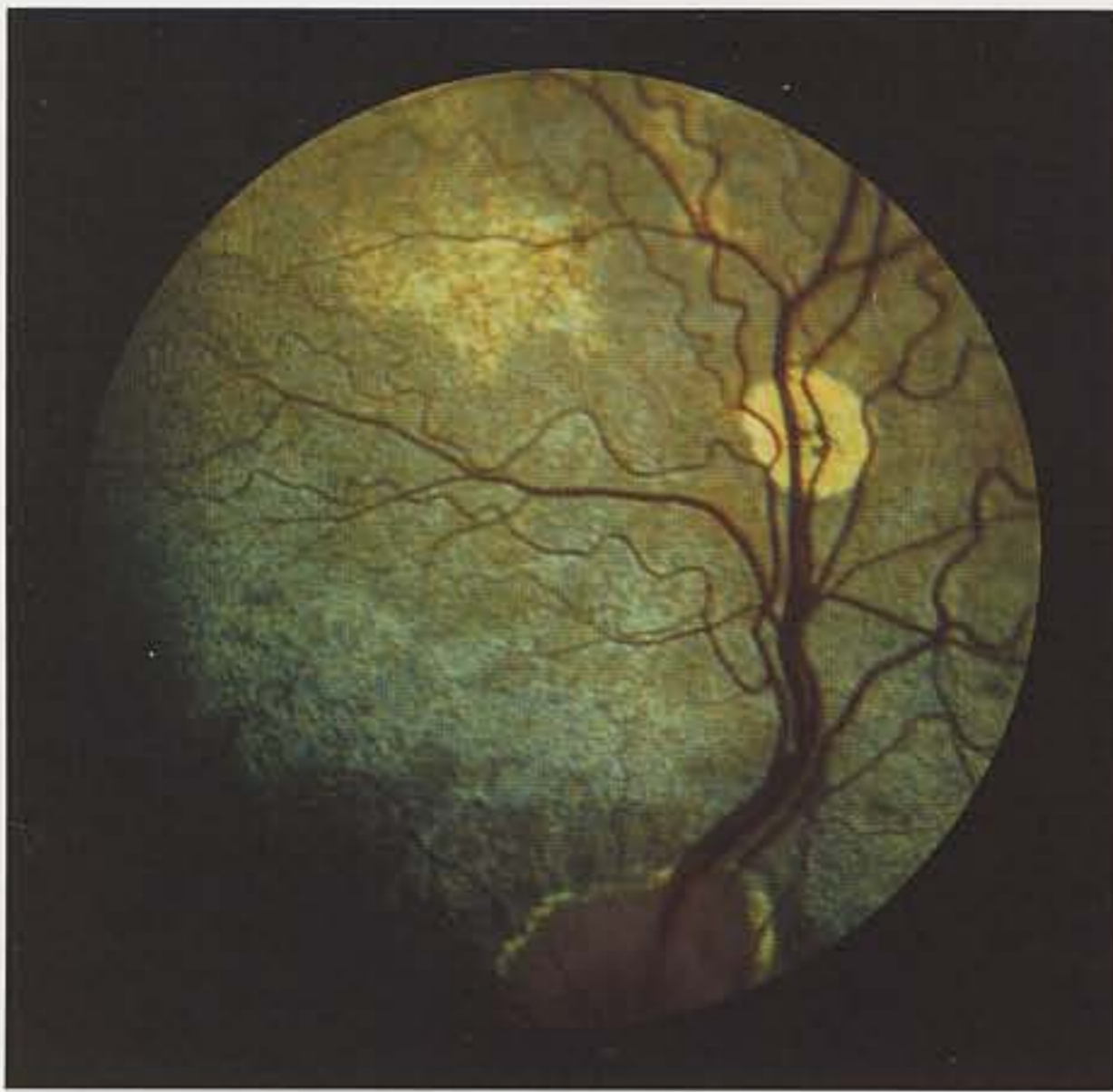

Fig. 11.199 Post-inflammatory retinopathy (Labrador Retriever, 8 years old) Another pigmentary retinopathy with focal areas of tapetal hyper-reflectivity. Again, quite unlike central PRA.

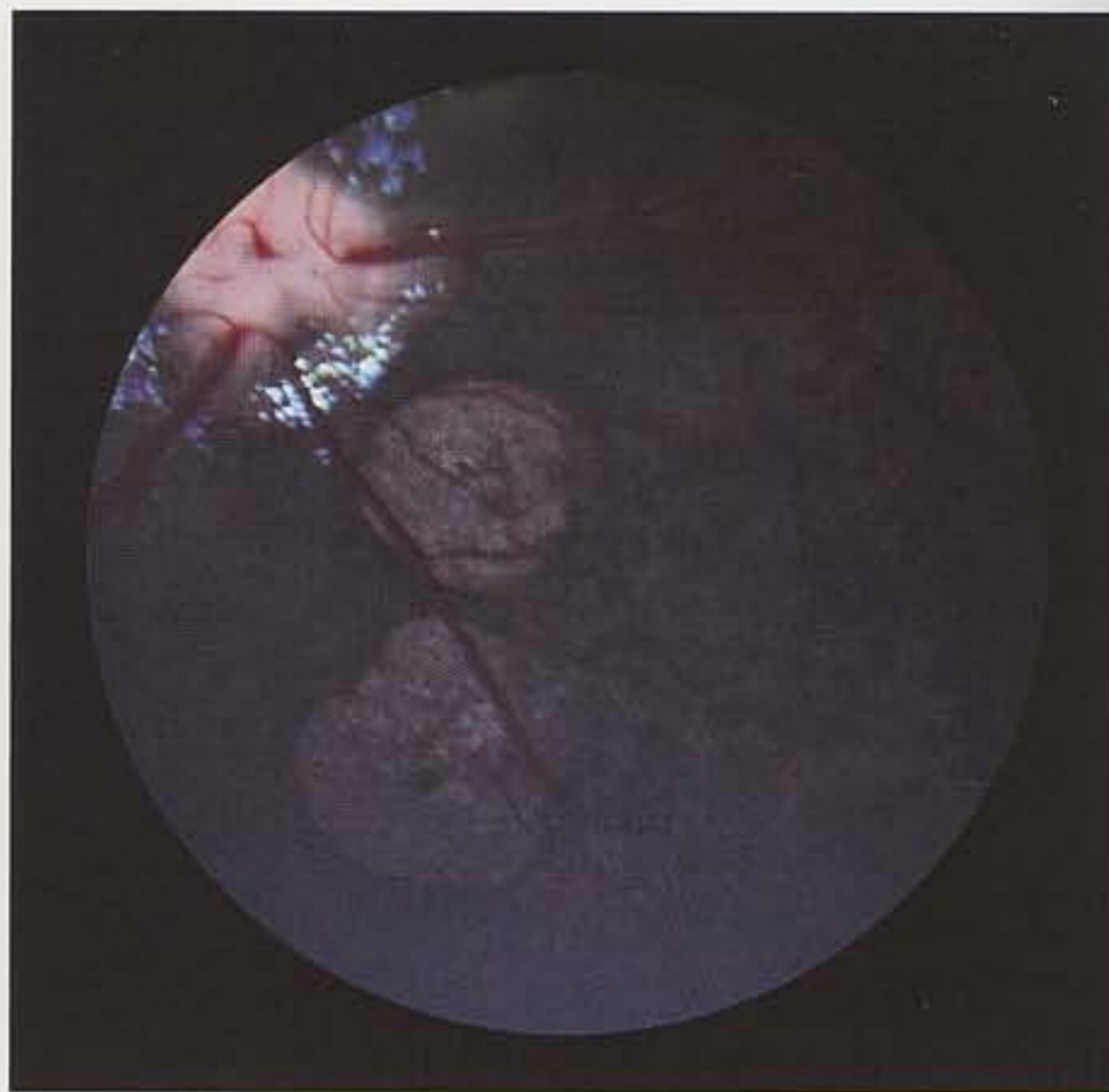


Fig. 11.201 Post-inflammatory retinopathy (Greyhound, 18 months old) Post-inflammatory retinopathy with focal areas of depigmentation in the non-tapetal fundus.

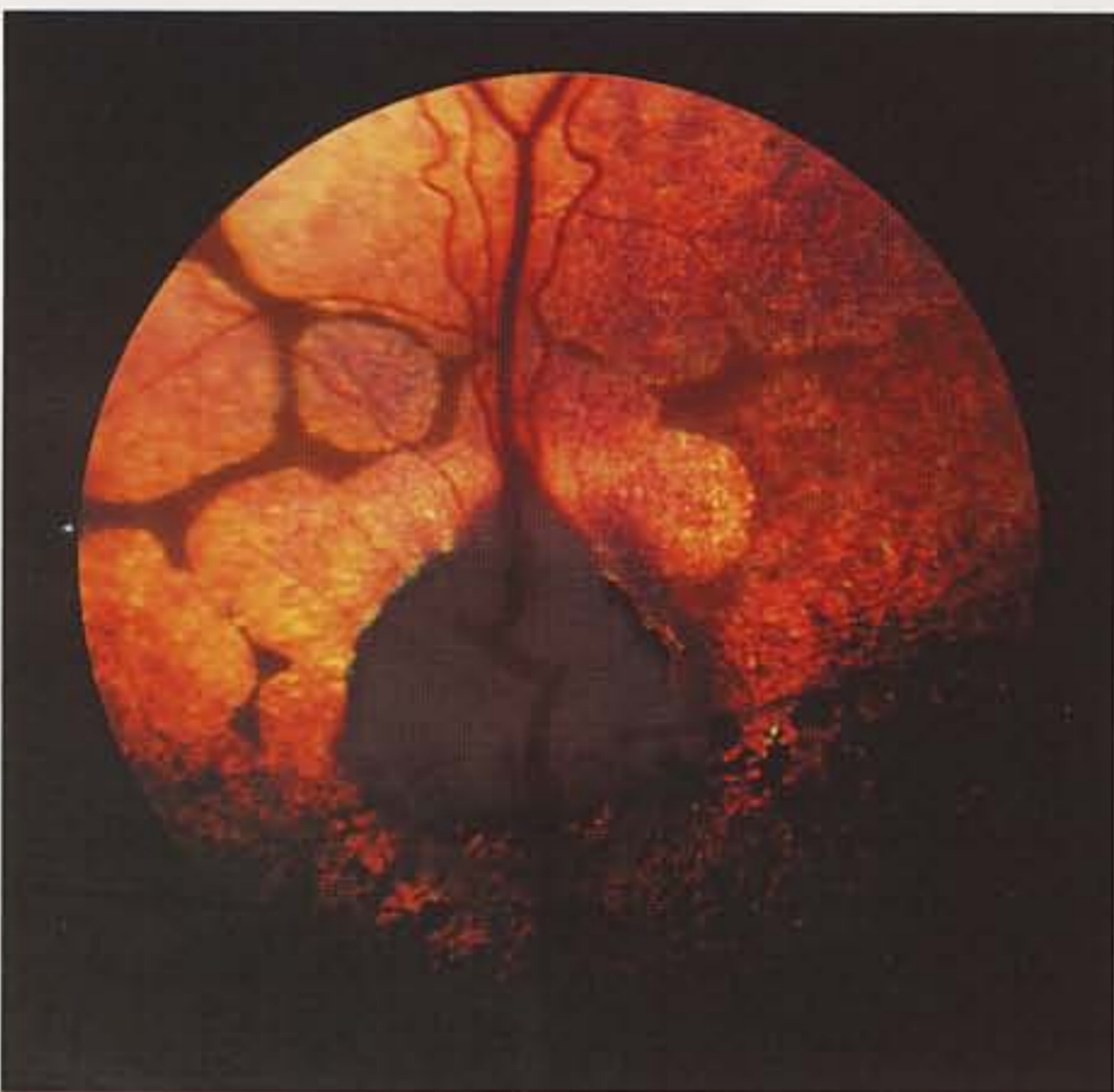

Fig. 11.200 Post-inflammatory retinopathy (Afghan Hound, 5 years old)

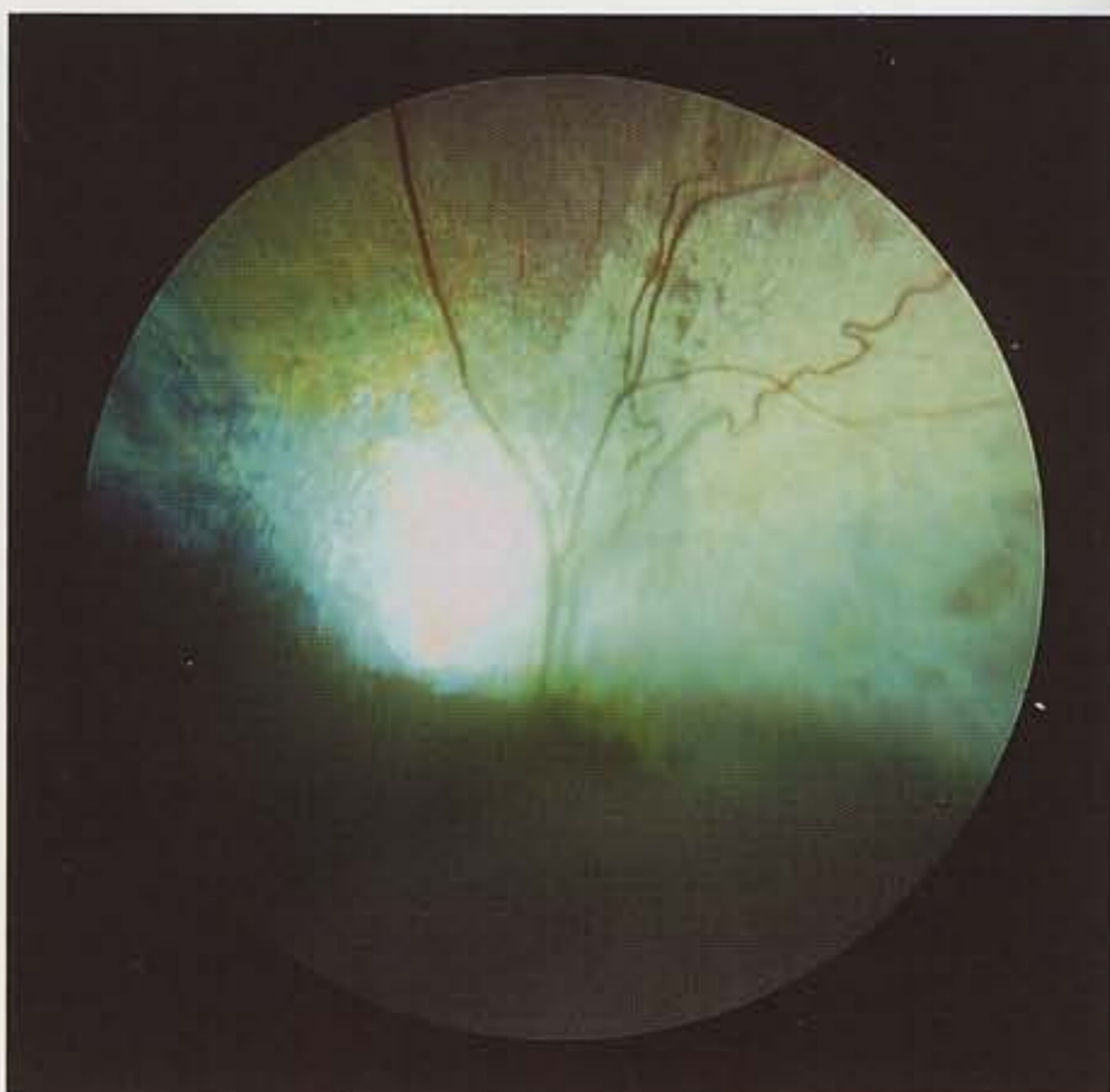

Fig. 11.202 Retinal degeneration (Smooth-haired Fox Terrier, 7 years old) Retinal degeneration due to glaucoma. Note the dislocated lens in the lower part of the photograph.

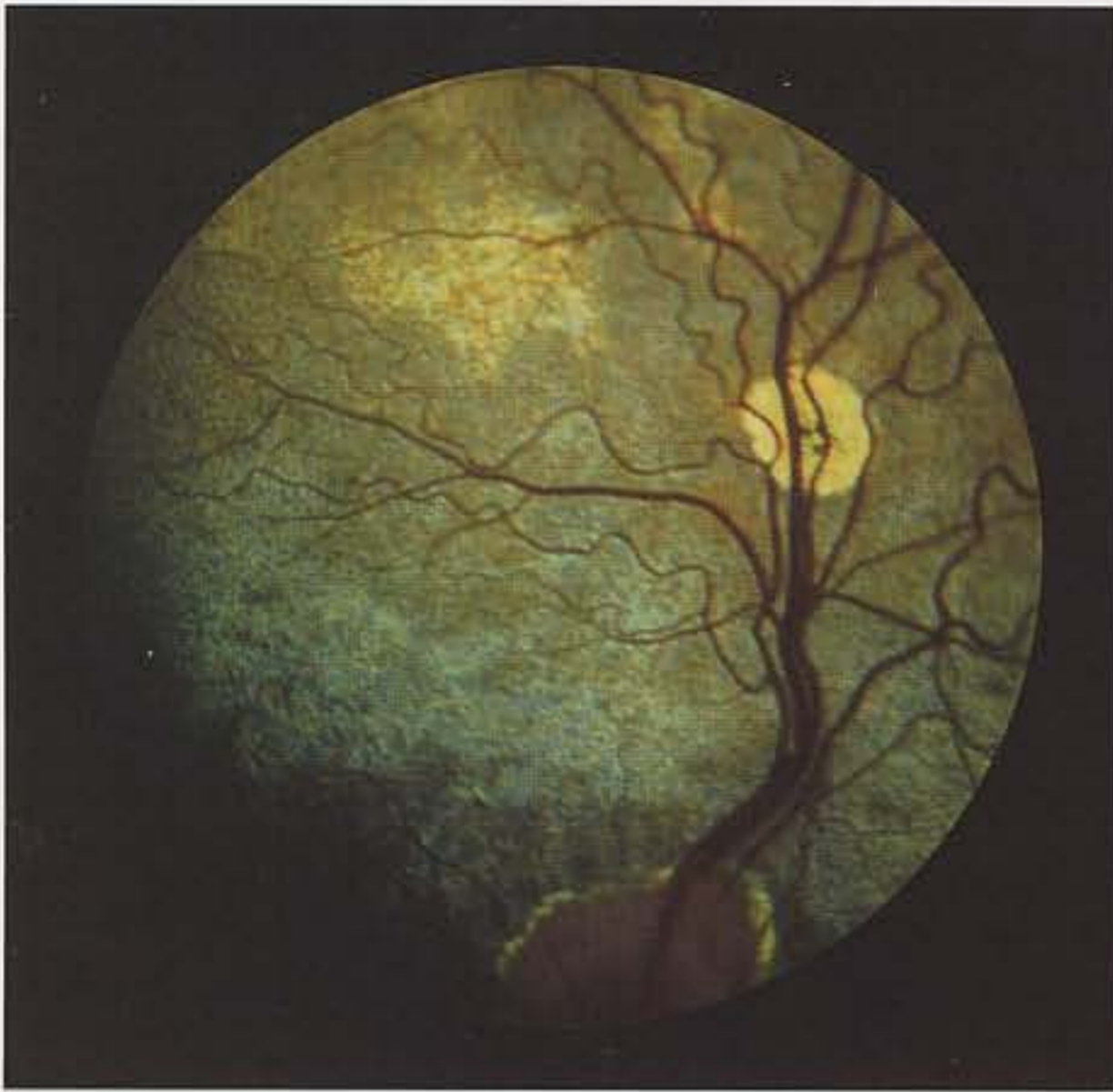


Fig. 11.199 Post-inflammatory retinopathy (Labrador Retriever, 8 years old) Another pigmentary retinopathy with focal areas of tapetal hyper-reflectivity. Again, quite unlike central PRA.

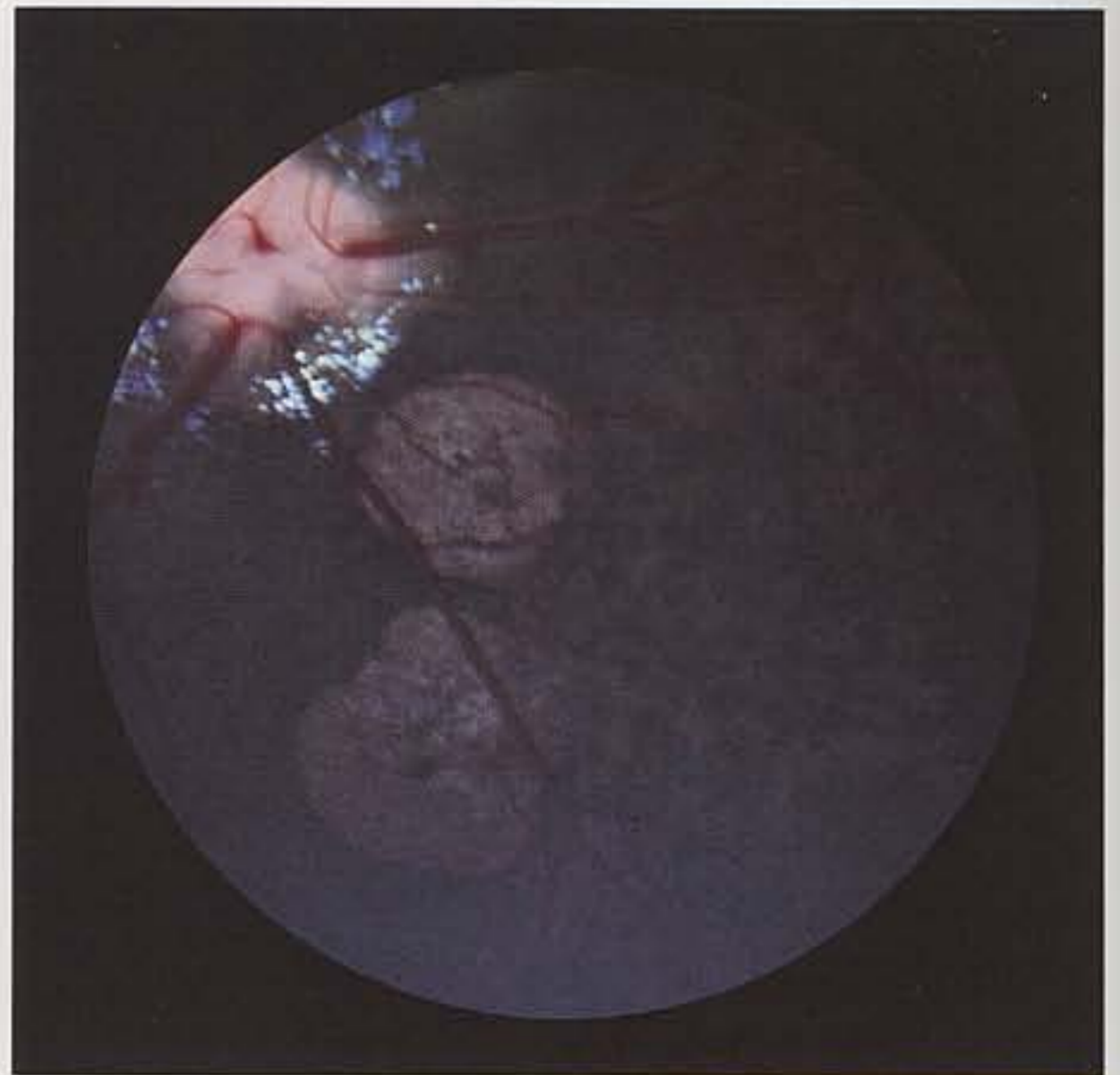

Fig. 11.201 Post-inflammatory retinopathy (Greyhound, 18 months old) Post-inflammatory retinopathy with focal areas of depigmentation in the non-tapetal fundus.

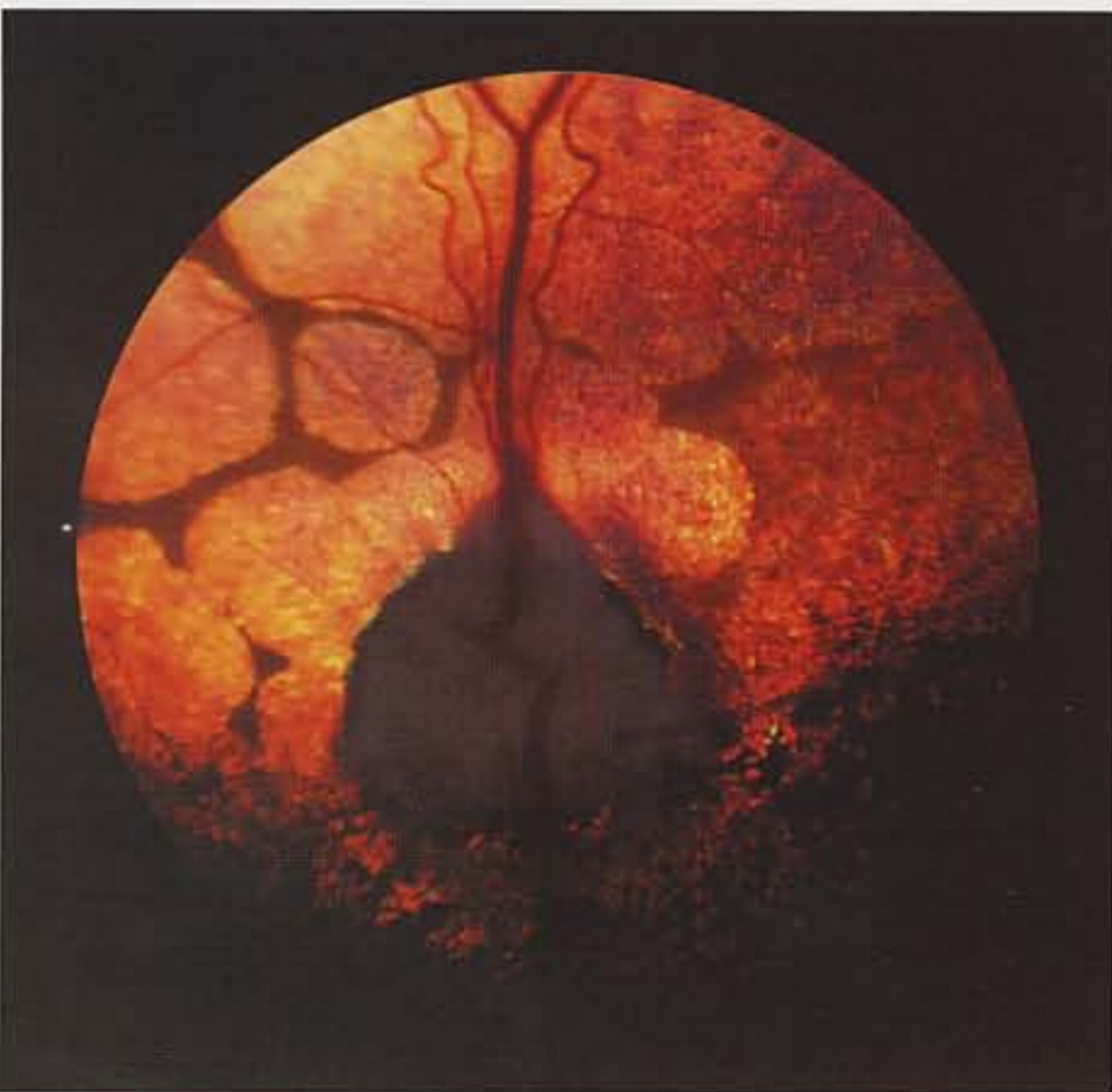

Fig. 11.200 Post-inflammatory retinopathy (Afghan Hound, 5 years old)

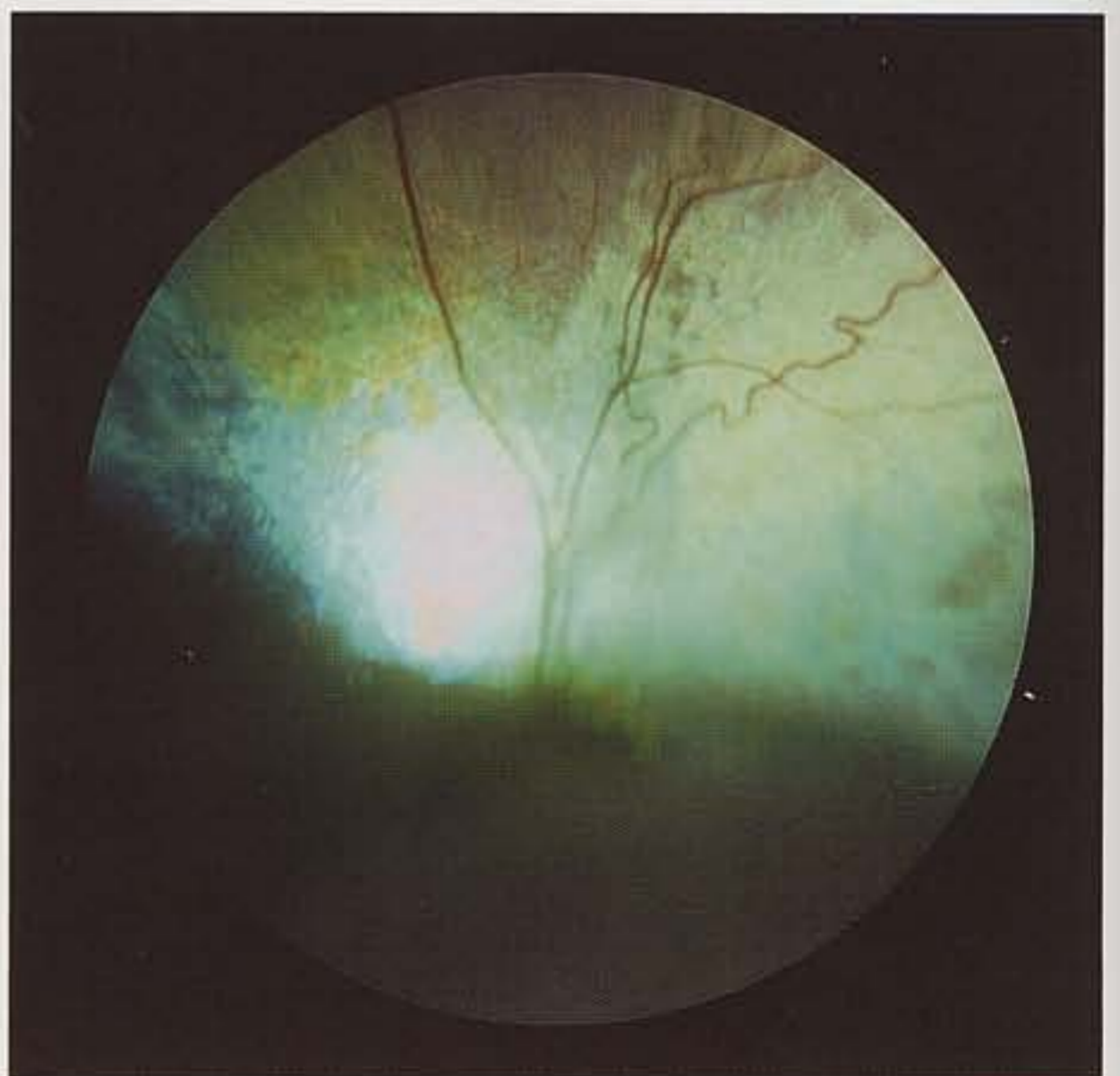


Fig. 11.202 Retinal degeneration (Smooth-haired Fox Terrier, 7 years old) Retinal degeneration due to glaucoma. Note the dislocated lens in the lower part of the photograph.

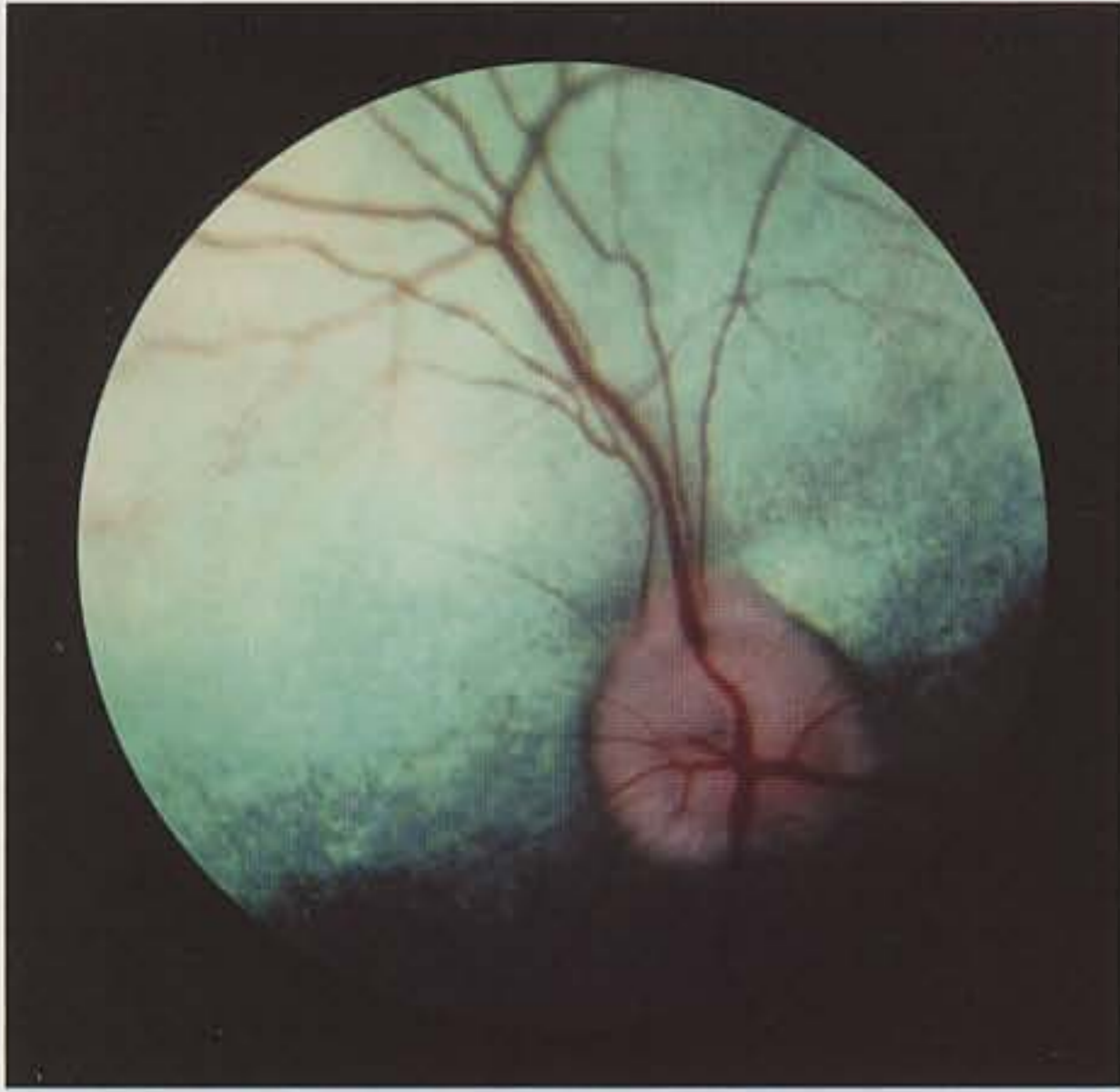

Fig. 11.203 Sudden acquired retinal degeneration (SARD) (Whippet, 8 years old) Note the early overall reflectivity visible in the tapetal region. This dog was presented with sudden blindness but with no ophthalmoscopic changes in the fundus until the subsequent examination.

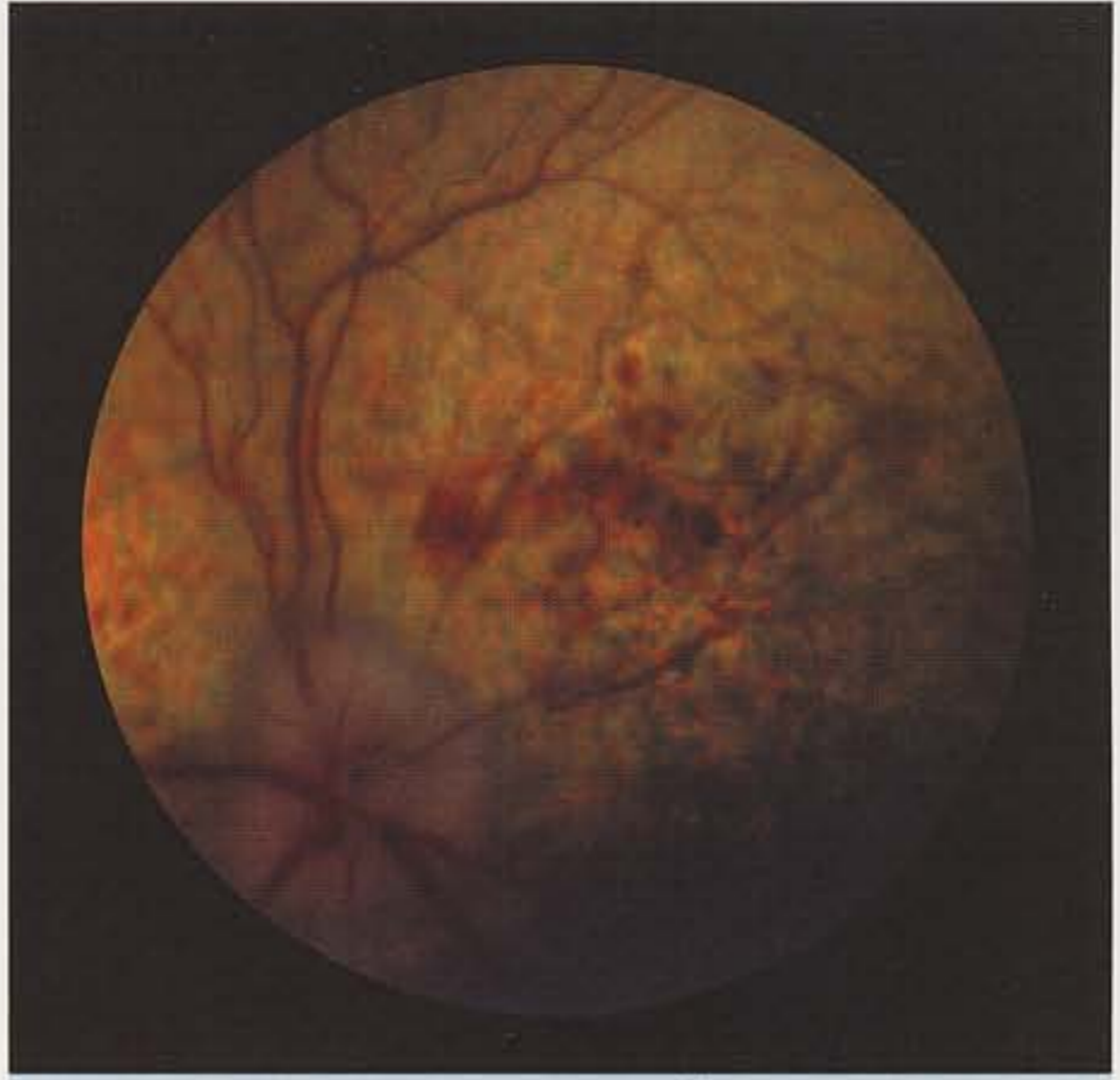

Fig. 11.205 Retinal haemorrhage (Standard Poodle, 8 years old) Diabetic retinopathy, the diabetes of several years duration.

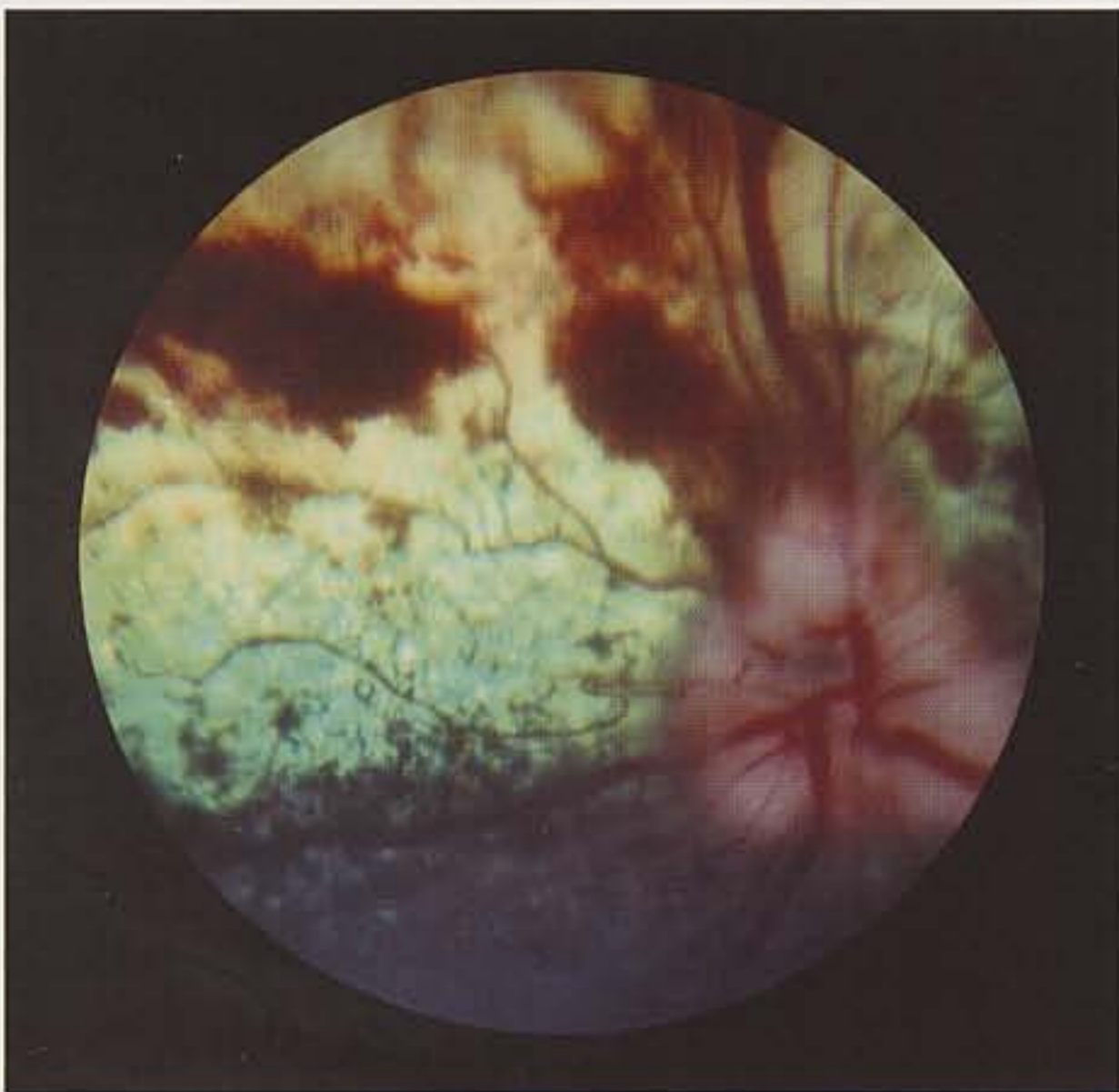

Fig. 11.204 Retinal haemorrhage (Crossbred, 6 years old) Hypertensive retinopathy with renal disease.

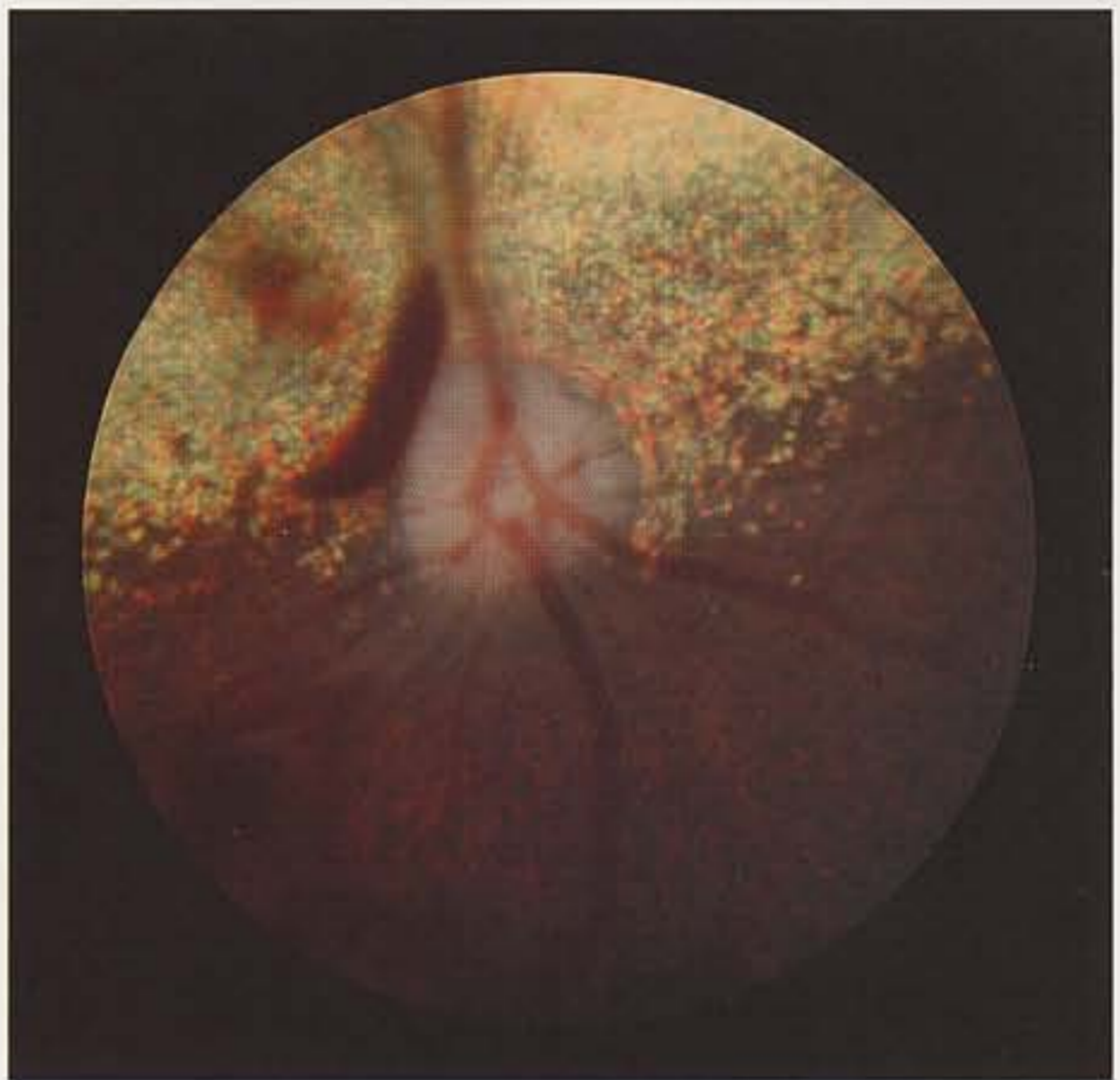


Fig. 11.206 Retinal haemorrhage (Cocker Spaniel, 6 years old) Warfarin poisoning – note the retinal haemorrhage and anaemia of the retinal vessels.

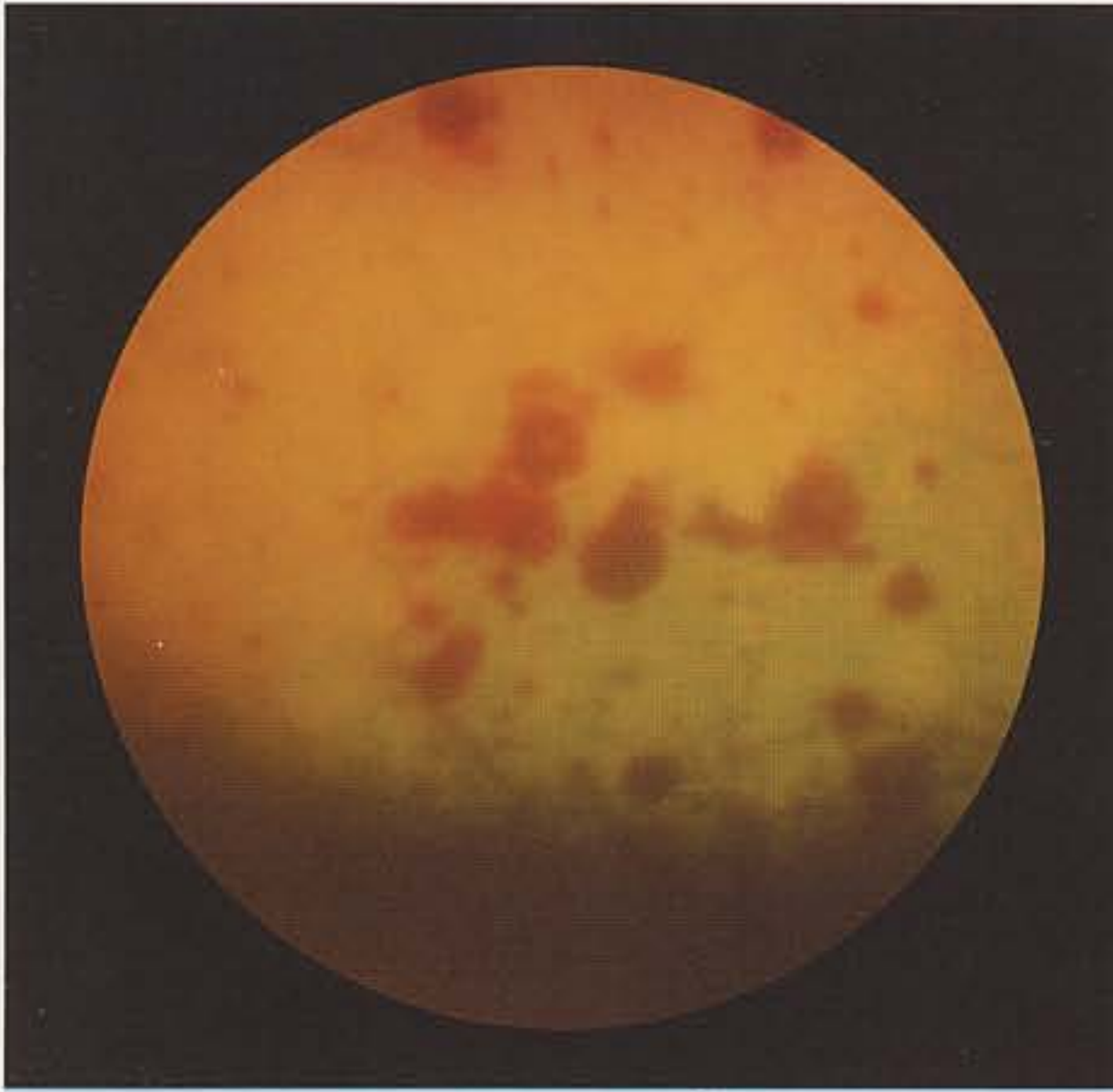


Fig. 11.207 Retinal haemorrhage (Crossbred, 13 years old) Retinal haemorrhage in a case of generalized lymphosarcoma.

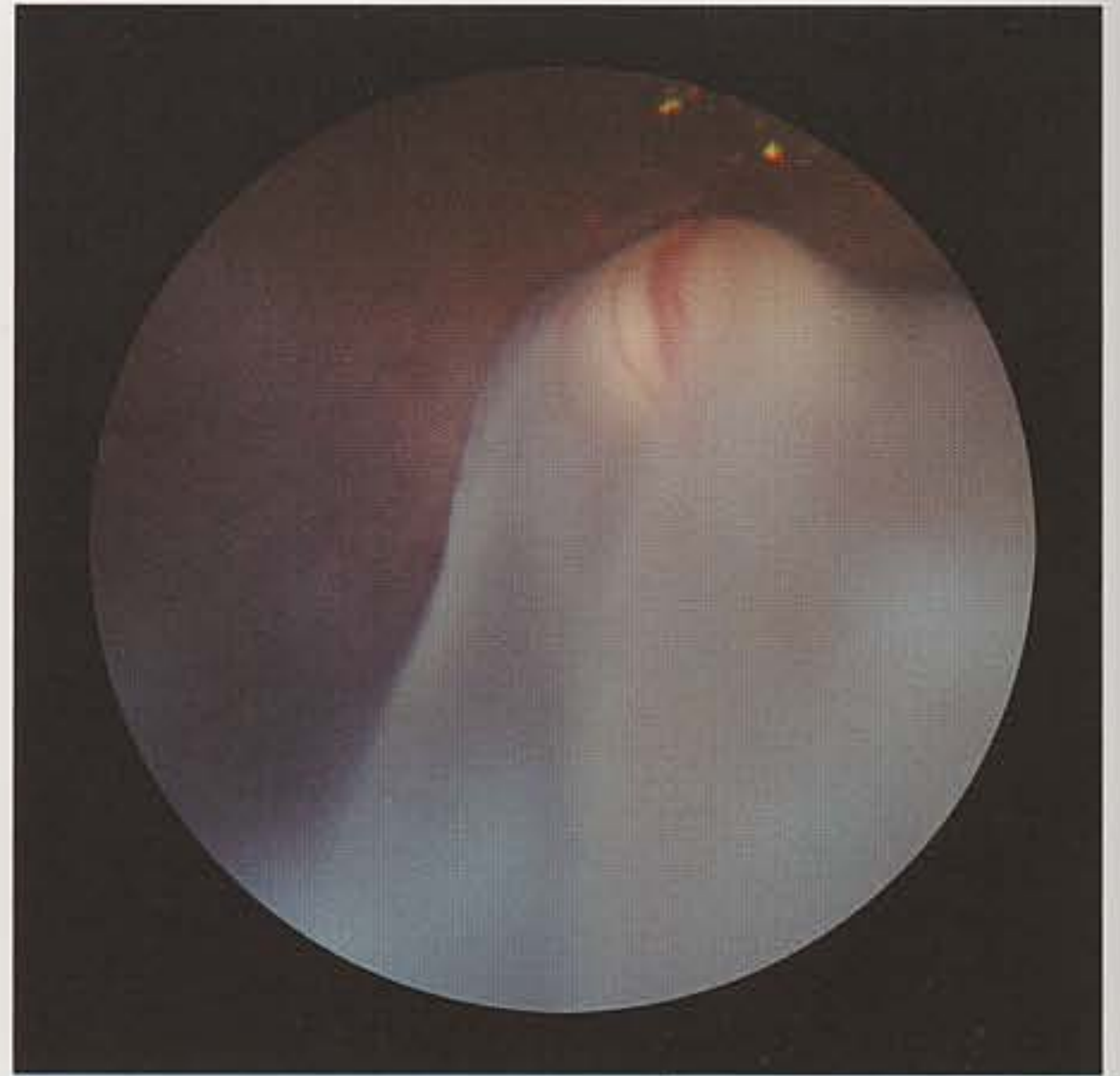


Fig. 11.209 Retinal detachment (Miniature Poodle, 4 years old) Total retinal detachment in both eyes. Aetiology unknown.

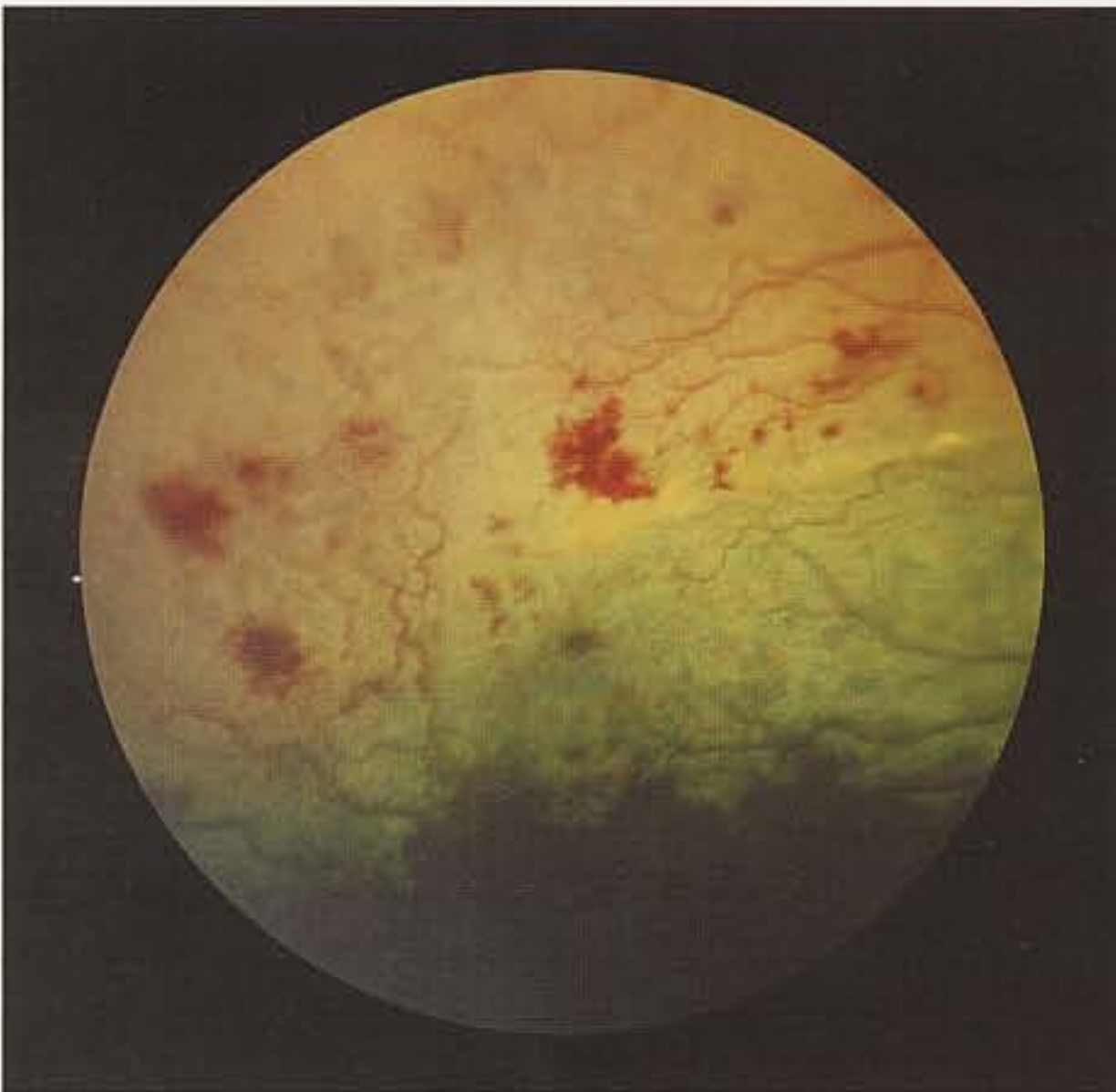


Fig. 11.208 Retinal haemorrhage (Labrador Retriever, 12 years old) Multiple retinal haemorrhages in an aged dog and of unknown aetiology.

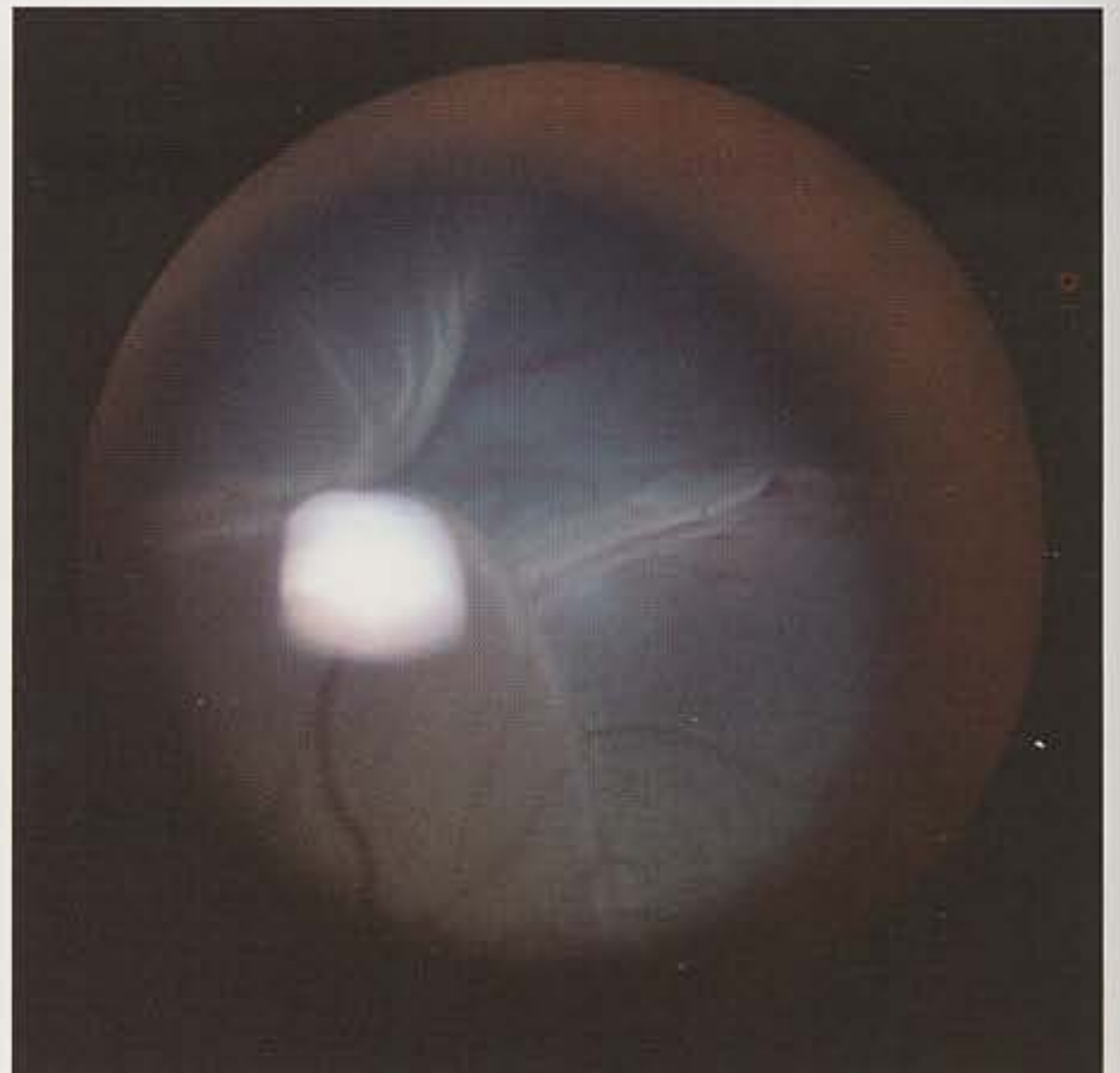

Fig. 11.210 Retinal detachment (Crossbred, 7 years old) Serous or exudative retinal detachment with blisters of detached retina visible through the dilated pupil.

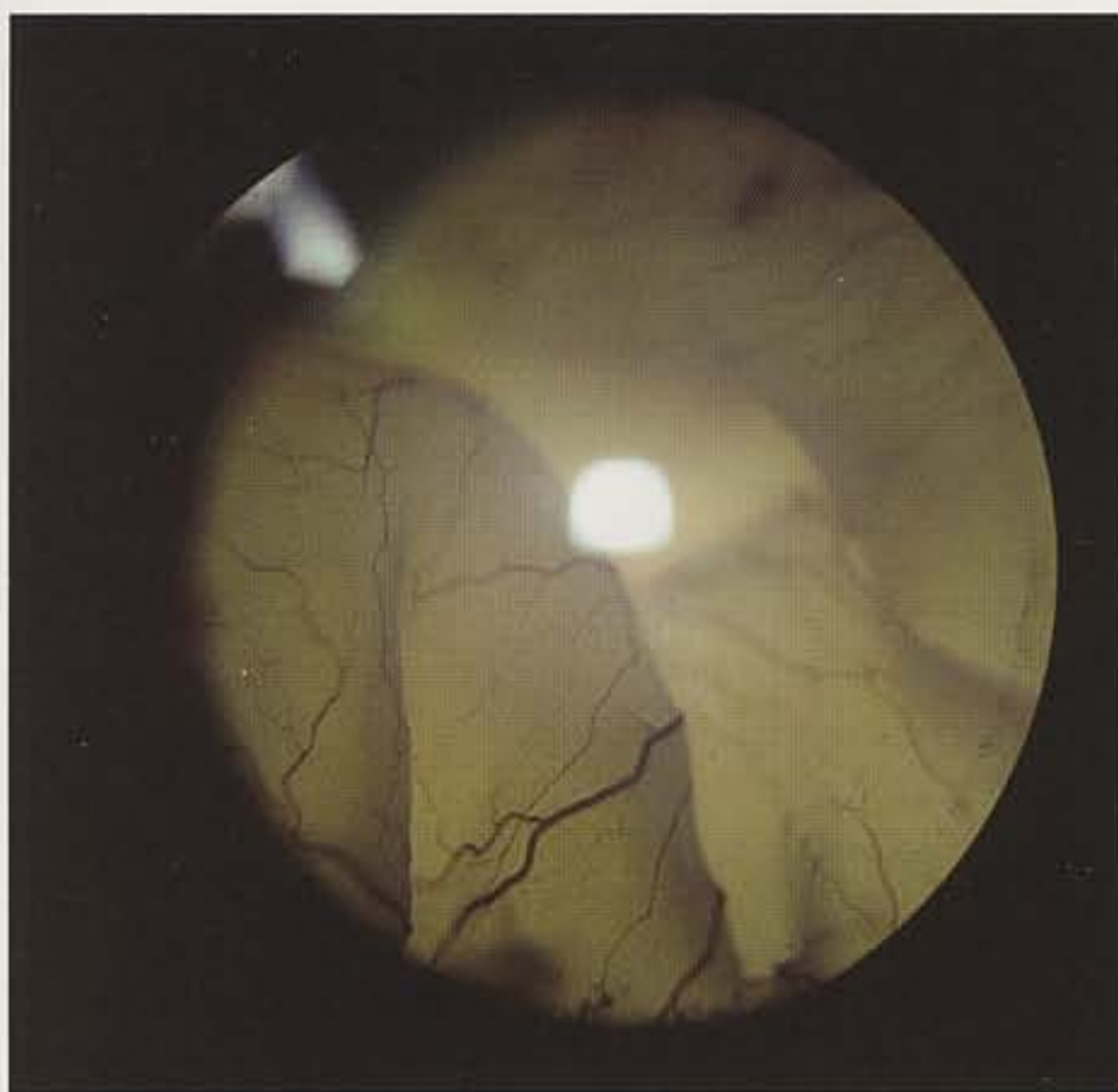

Fig. 11.211 Retinal detachment (Crossbred, 9 years old) Another case of serous retinal detachment.

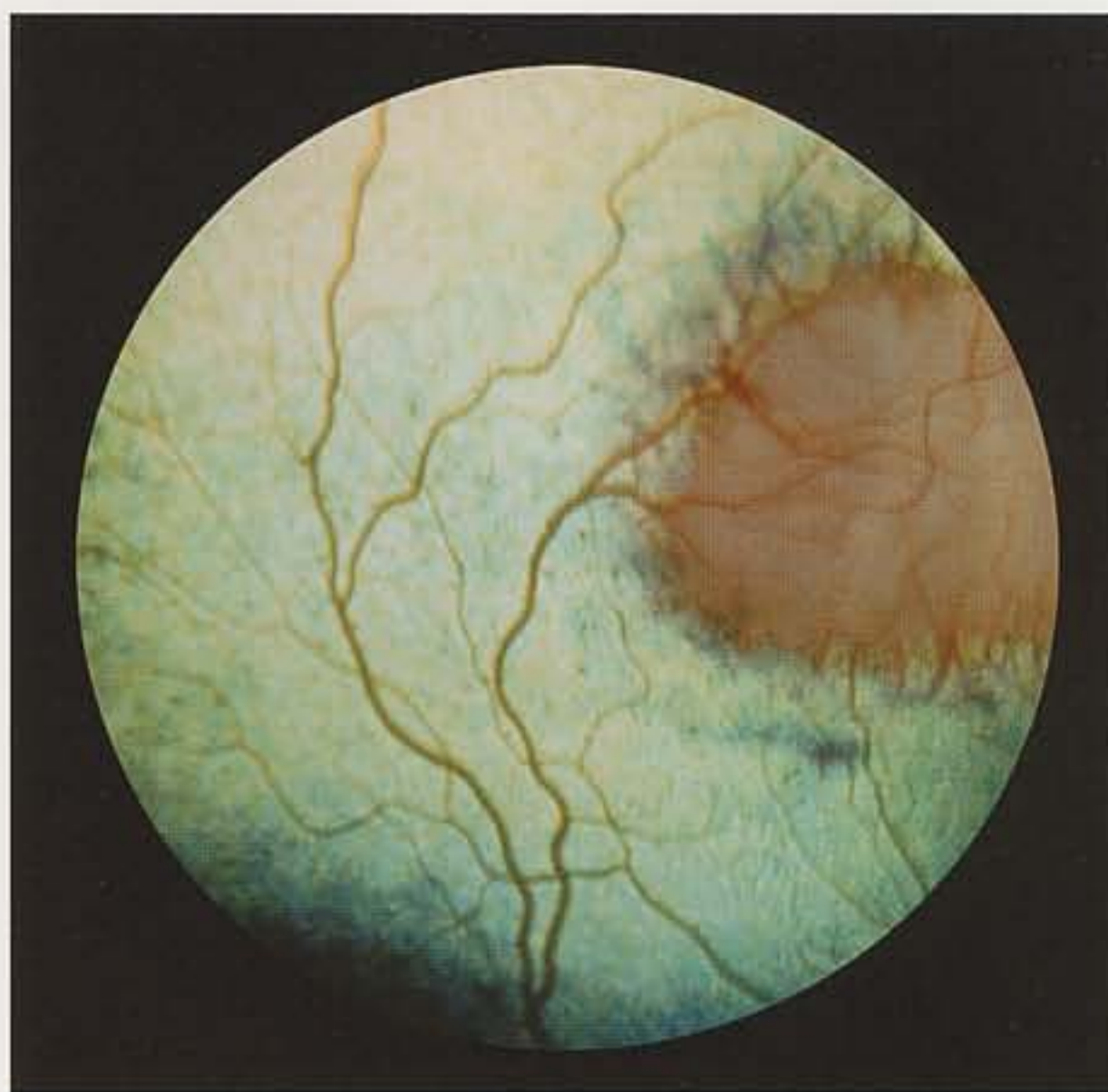

Fig. 11.212 Coloboma (Beagle, 14 months old) Atypical coloboma of retina and choroid. Both eyes were affected, but asymmetrically.

### *Retinopathies in other species*

#### *The cat (Figs 11.213–11.232)*

The cat exhibits two forms of a hereditary generalized progressive retinal atrophy, bilateral and symmetrical, with the classical signs of a retinal degeneration of increased tapetal reflectivity and attenuation of the retinal blood vessels. Both forms are in the Abyssinian breed: the first, a rod/cone dysplasia in kittens, is due to a simple autosomal dominant gene (Figs 11.213–11.218); the second is a degeneration occurring at a later age in young adults and due to a simple autosomal recessive gene.

Odd cases of advanced retinal degeneration (Fig 11.219) and focal post-inflammatory degeneration (Fig 11.220) occur occasionally, and hypertensive retinopathy, usually presenting with sudden blindness due to haemorrhage and/or detachment, is now well recognized in this species.

Taurine deficiency retinopathy (Figs 11.221–11.226), starting at the area centralis and progressing in a band above the optic disc to become generalized in advanced cases, is an interesting and unusual condition only affecting the cat. Occasional cases occur in pet cats.

#### *The horse (Figs 11.233–11.243)*

Retinopathies (chorioretinopathies) in the horse rarely present with evidence of defective vision, but are noted at a routine ophthalmoscopic examination. They are almost invariably inactive and non-progressive. Ophthalmoscopic signs are typically tapetal hyper-reflectivity and pigmentary changes. The aetiology is usually unknown. Occasional cases of retinal detachment, unioocular and binocular, occur but again the aetiology is usually obscure apart from the odd case of known trauma.

#### *The sheep (Figs 11.244–11.246)*

Bright blindness in sheep is a primary toxic retinopathy due to the ingestion of bracken. It is bilateral, symmetrical and progressive unless the cause is removed. There is an associated leucopaenia and ophthalmoscopically the classical signs are evident. Pupils are dilated and the eyes have a bright reflective glow.

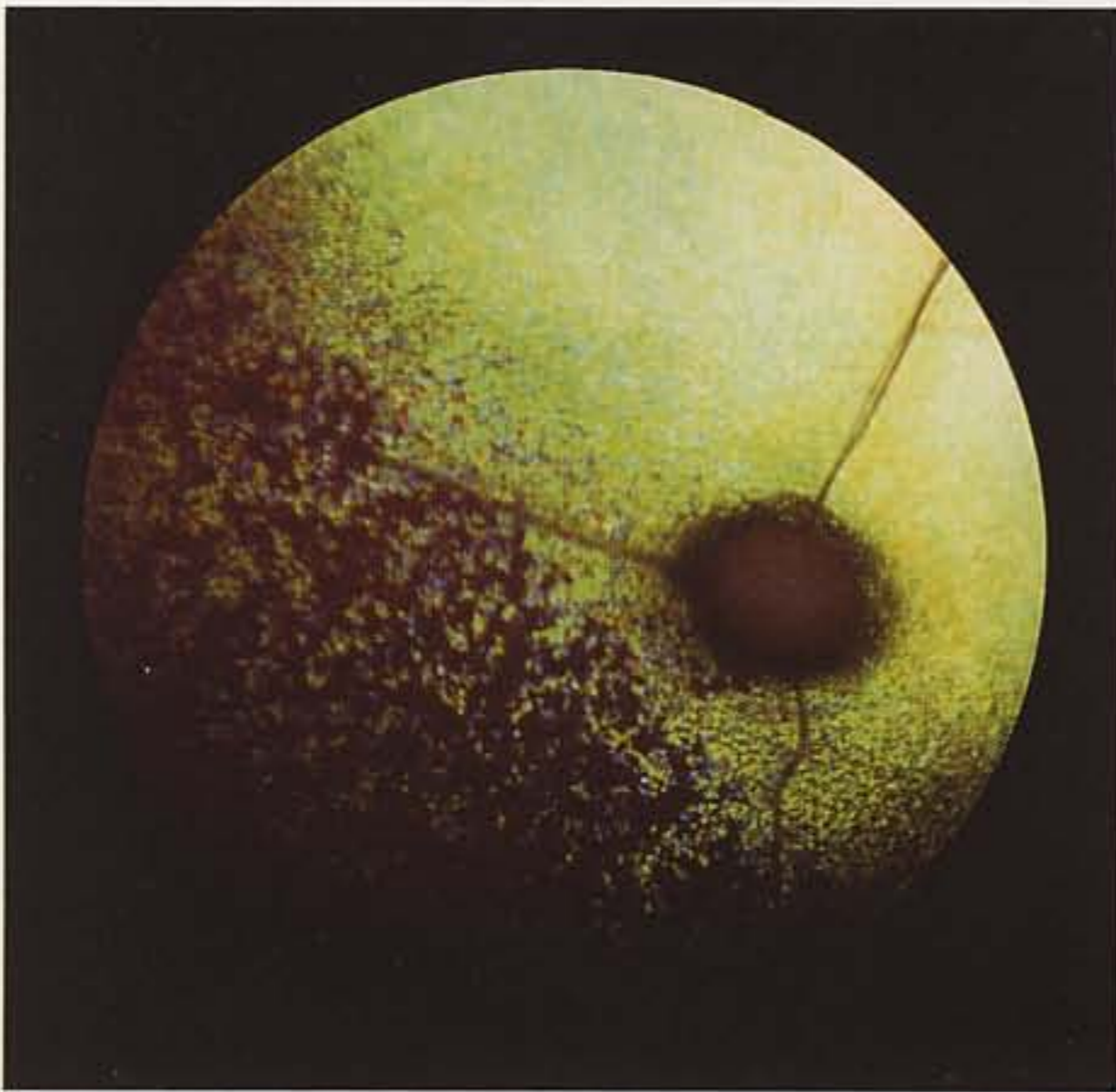

Fig. 11.213 Progressive retinal atrophy (Abyssinian, 6 months old) Rod/cone dysplasia showing classical ophthalmoscopic signs of tapetal hyper-reflectivity and blood vessel attenuation. Hereditary and due to a dominant gene.

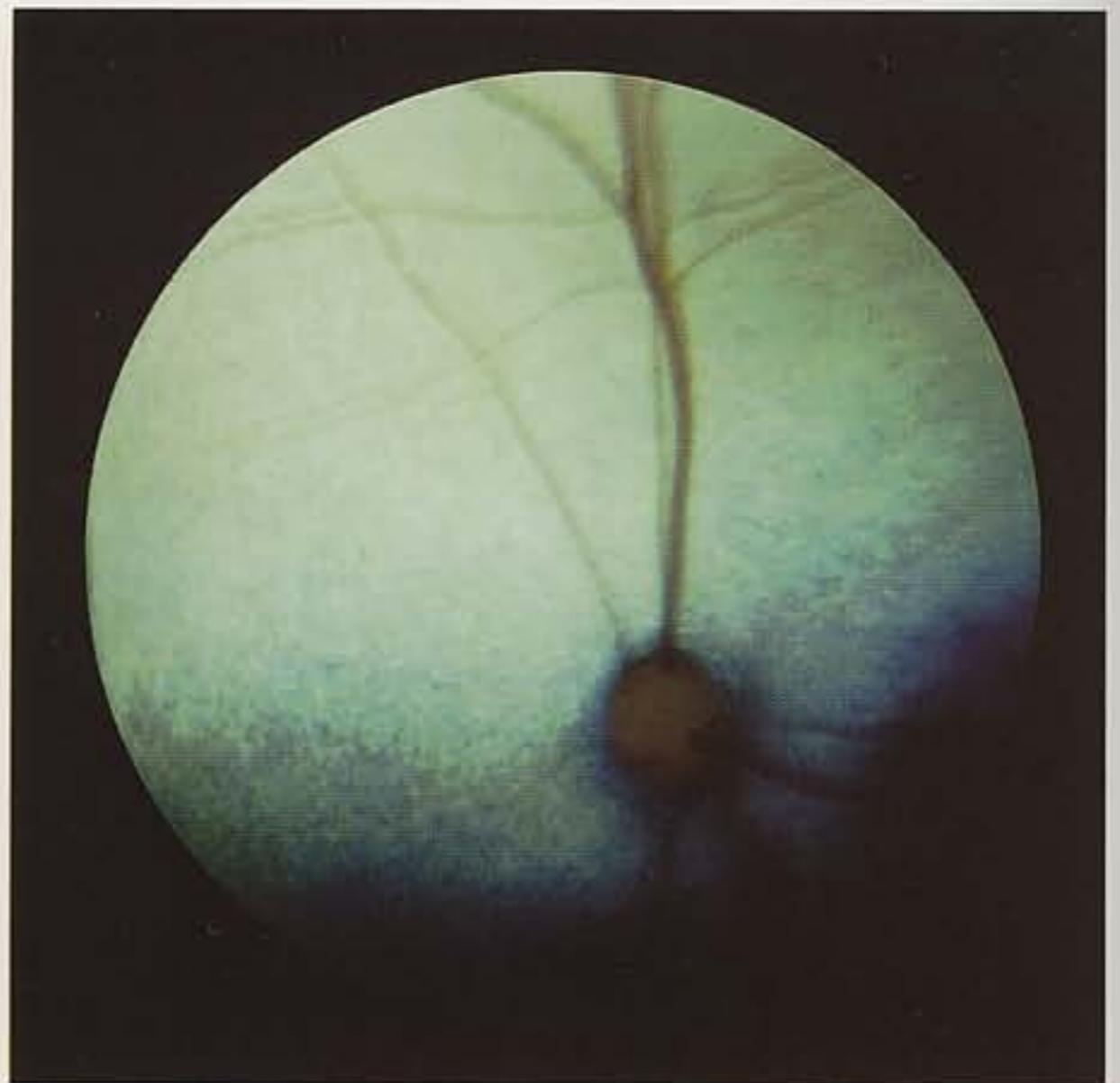

Fig. 11.215 Progressive retinal atrophy (Abyssinian-cross, 10 weeks old) Early changes.

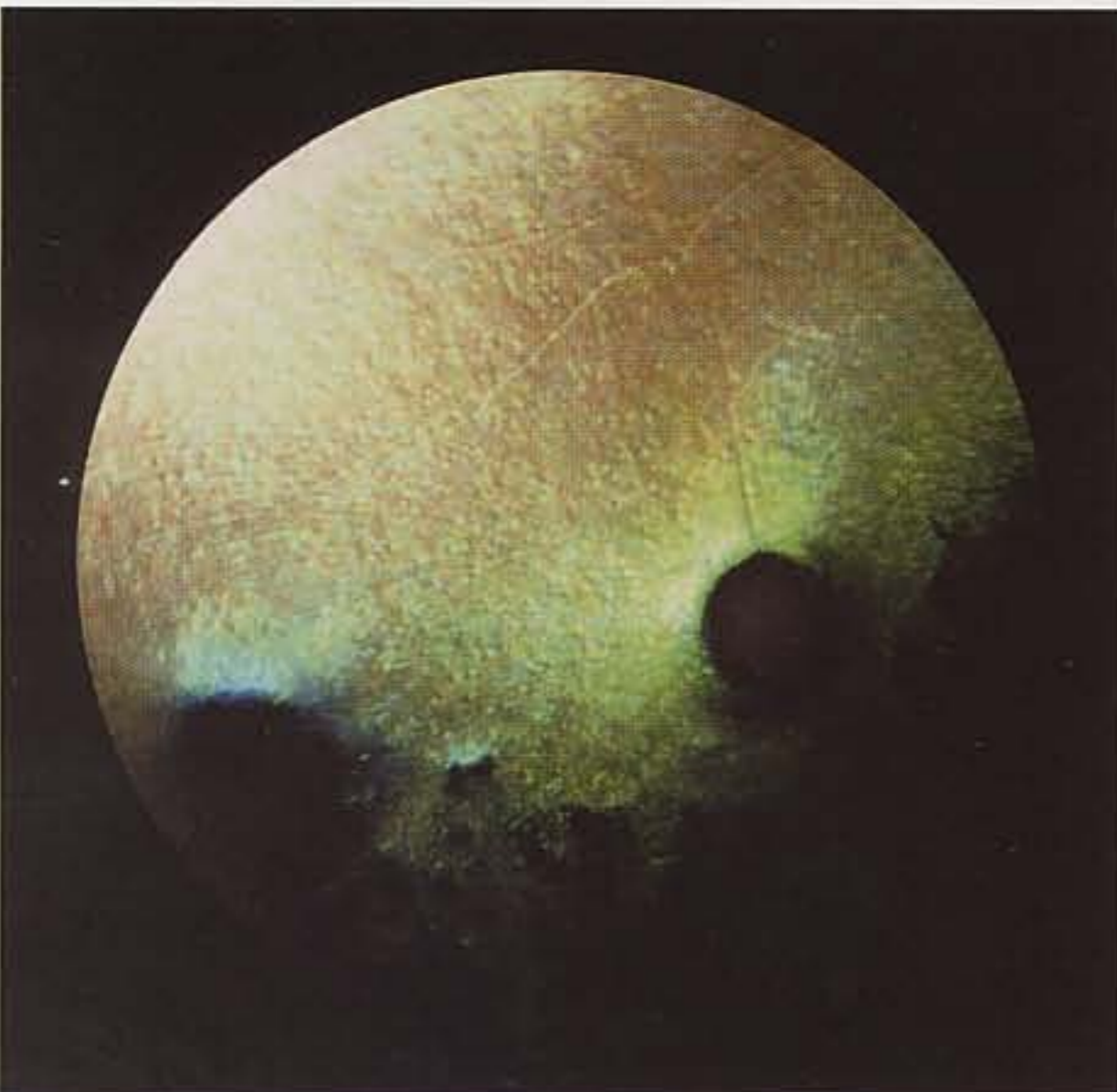

Fig. 11.214 Progressive retinal atrophy (Abyssinian, 12 months old) Advanced rod/cone dysplasia. Note the tapetal degeneration in the area centralis region.

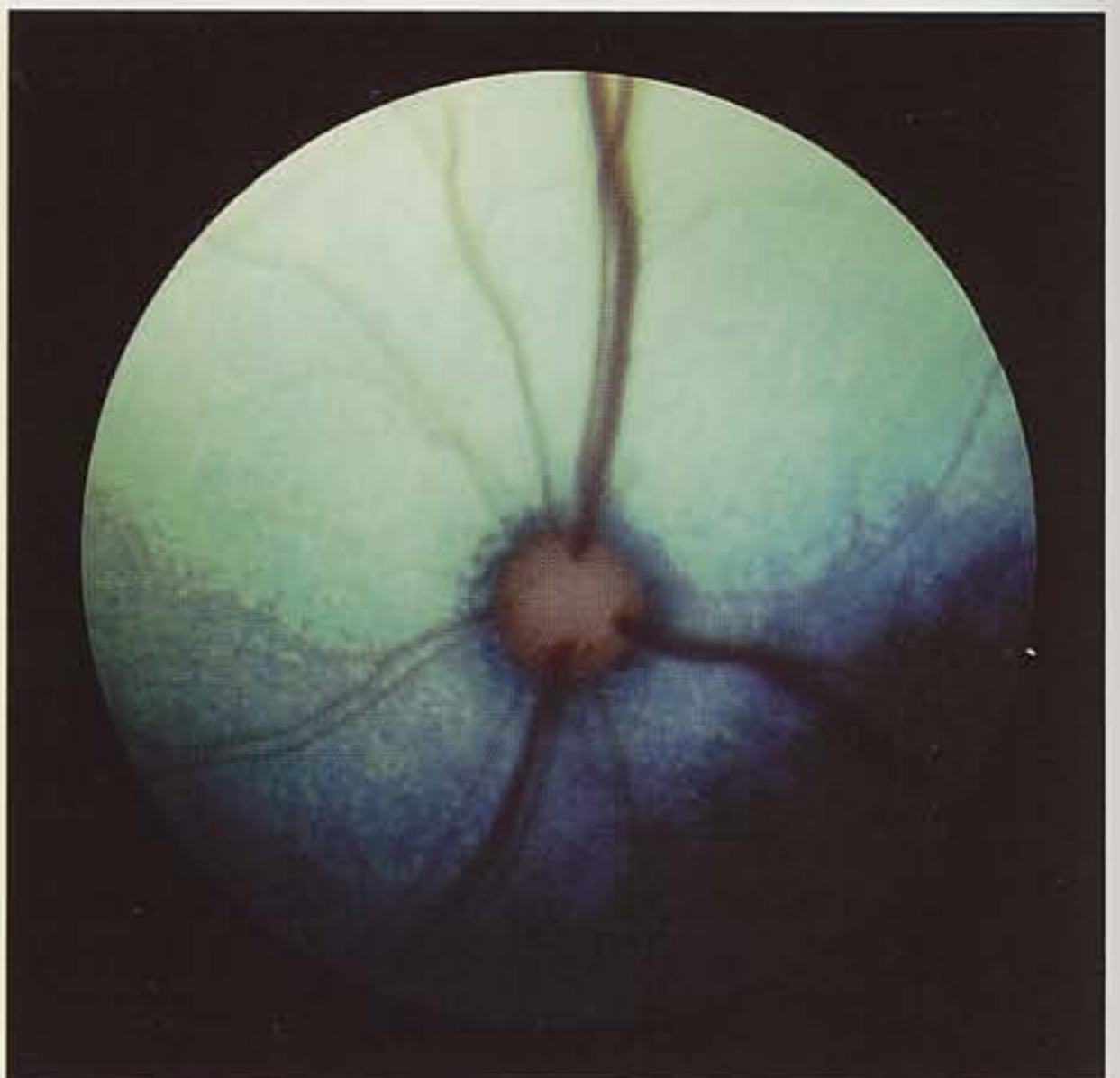


Fig. 11.216 Normal fundus (Abyssinian-cross, 10 weeks old) Littermate control to kitten in Fig 11.215.

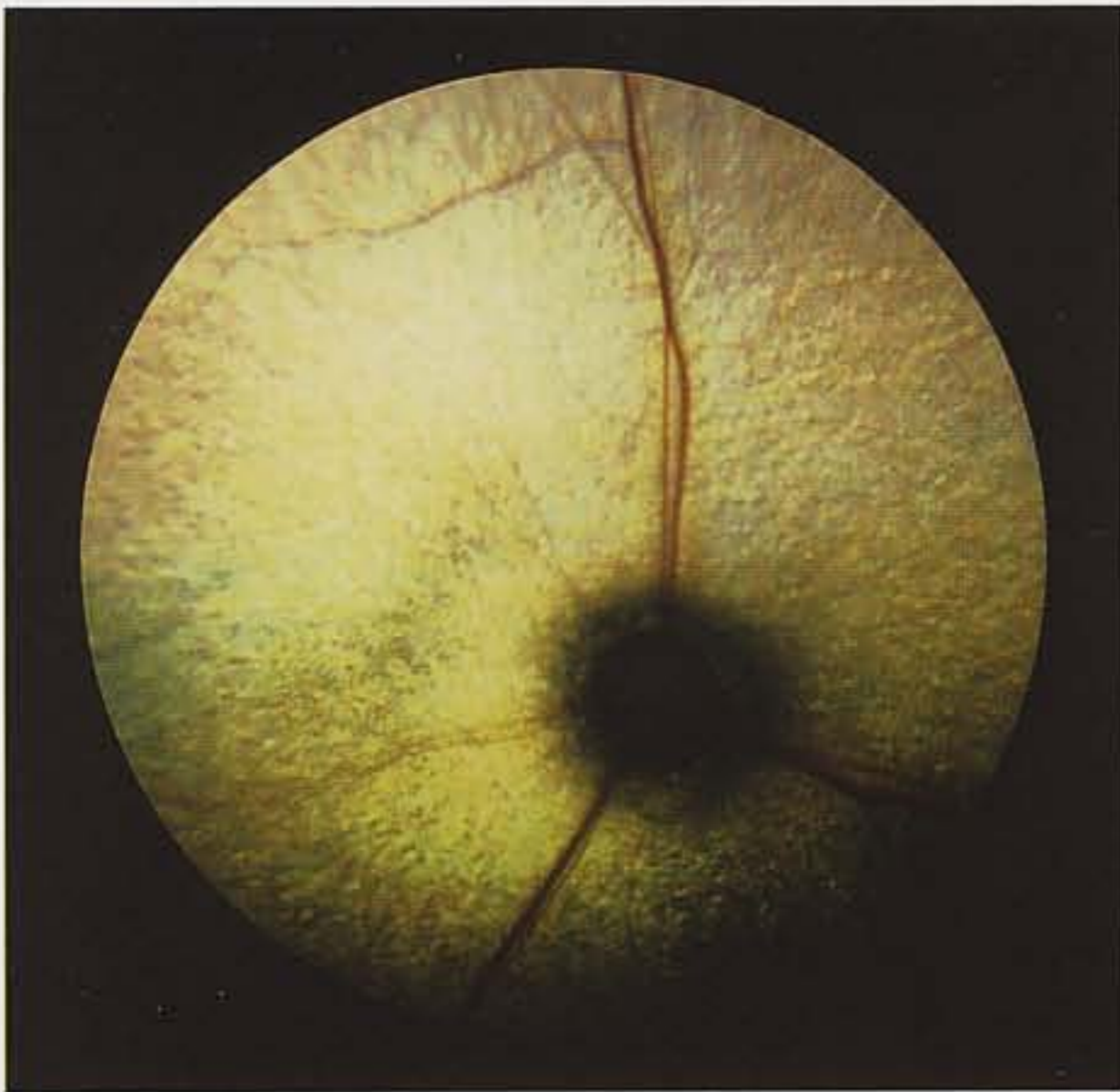


Fig. 11.217 Progressive retinal atrophy (Abyssinian, 6 months old) Note increased tapetal reflectivity and attenuated blood vessels.

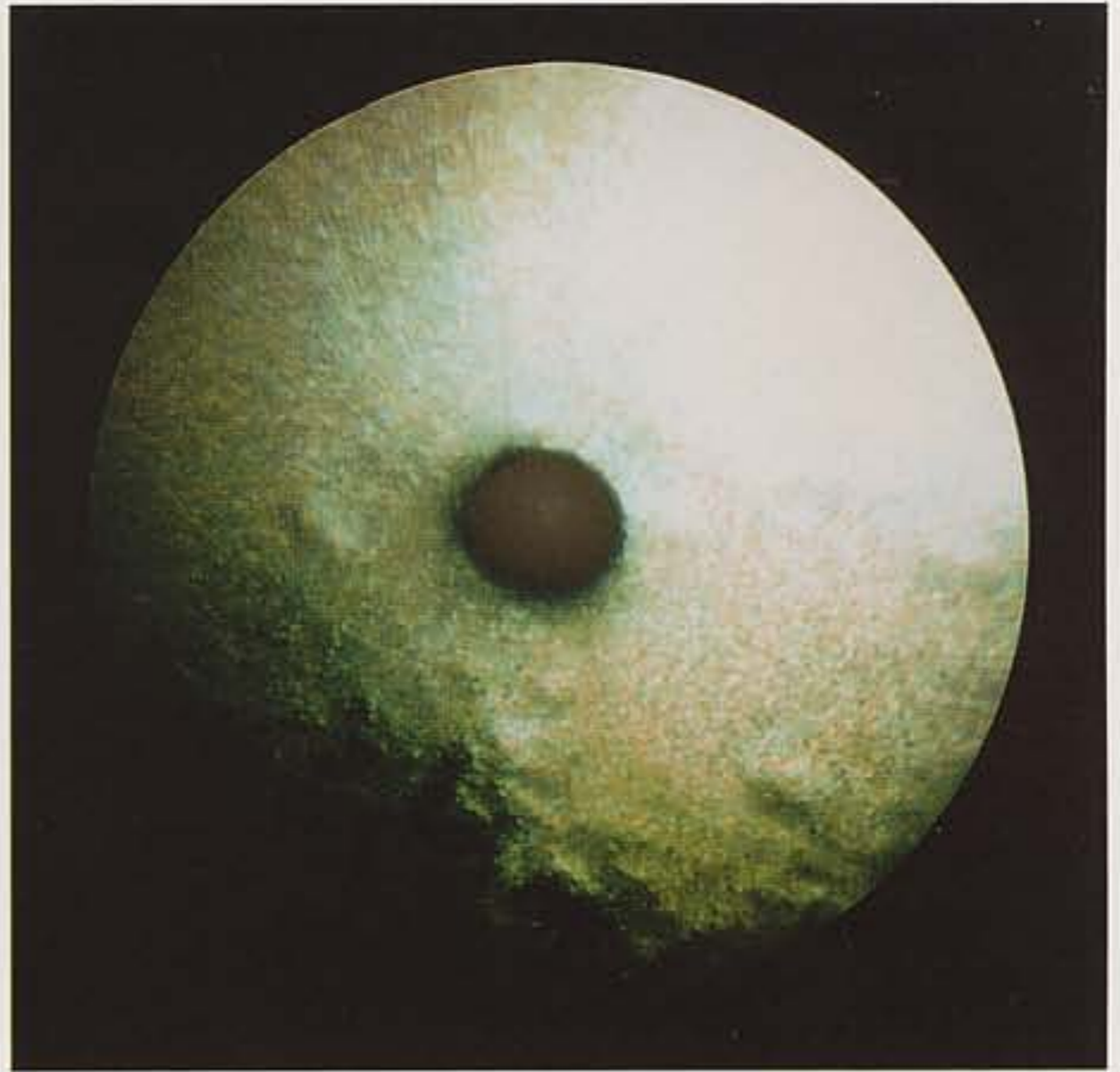

Fig. 11.219 Retinal degeneration (DSH tabby and white, 3 years old) Advanced bilateral retinal degeneration with only ghost vessels remaining. Aetiology unknown.

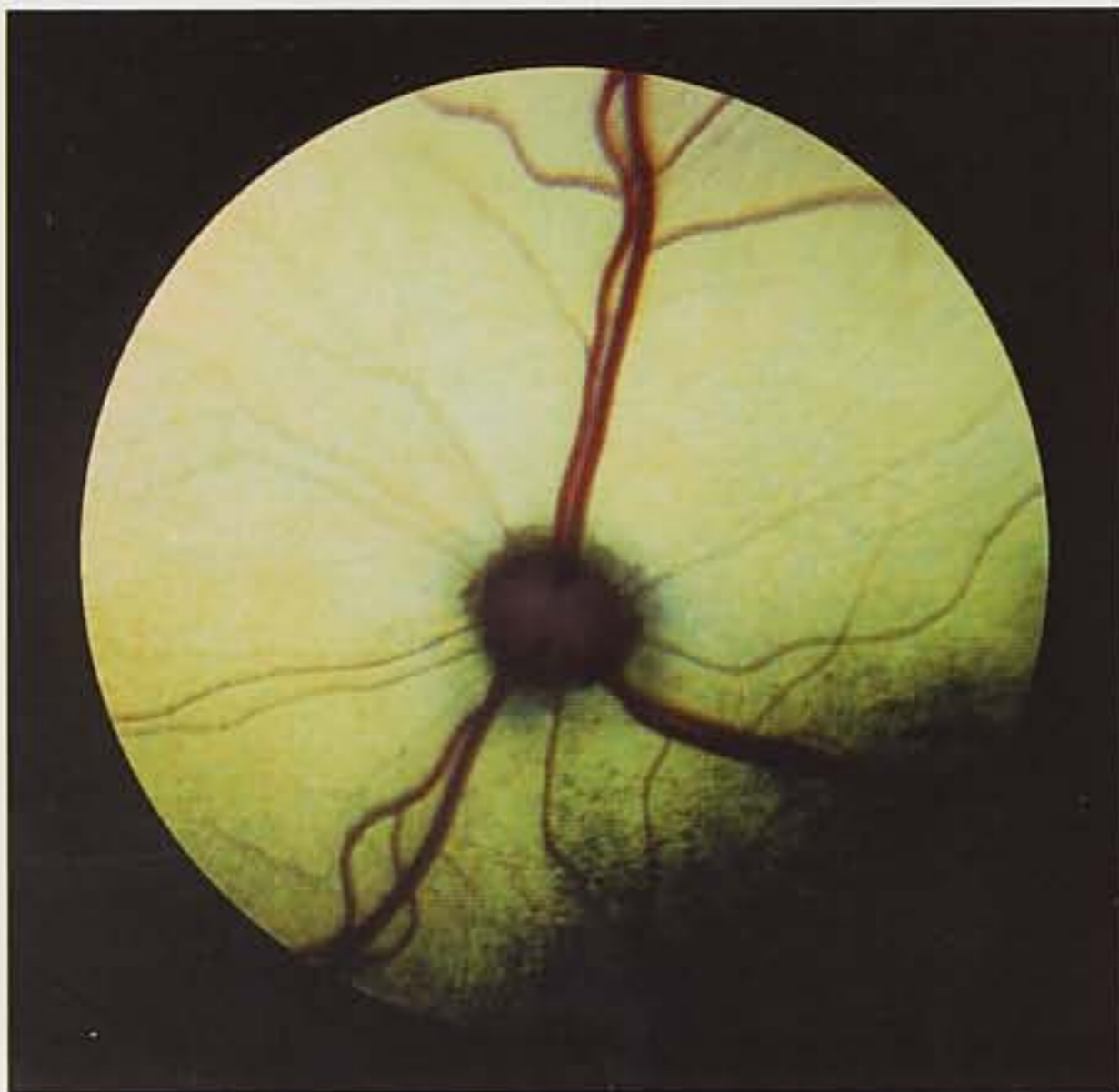

Fig. 11.218 Normal fundus (Abyssinian, 6 months old) Littermate to the cat in Fig 11.217, showing normal tapetal reflectivity and normal retinal blood vessels.

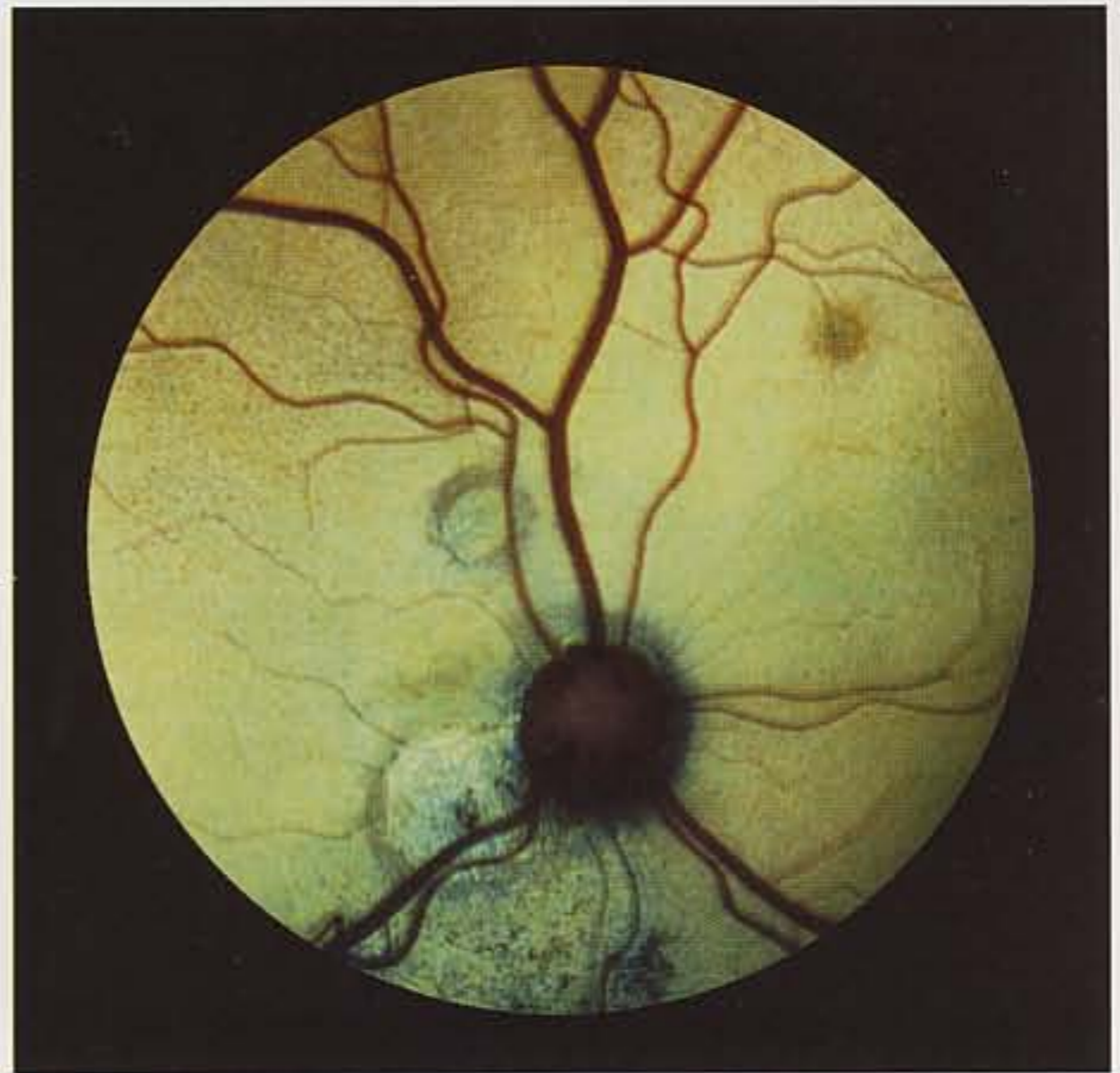


Fig. 11.220 Focal retinal degeneration (DSH, 5 years old) Several areas of focal retinal degeneration. Aetiology probably toxoplasmosis.

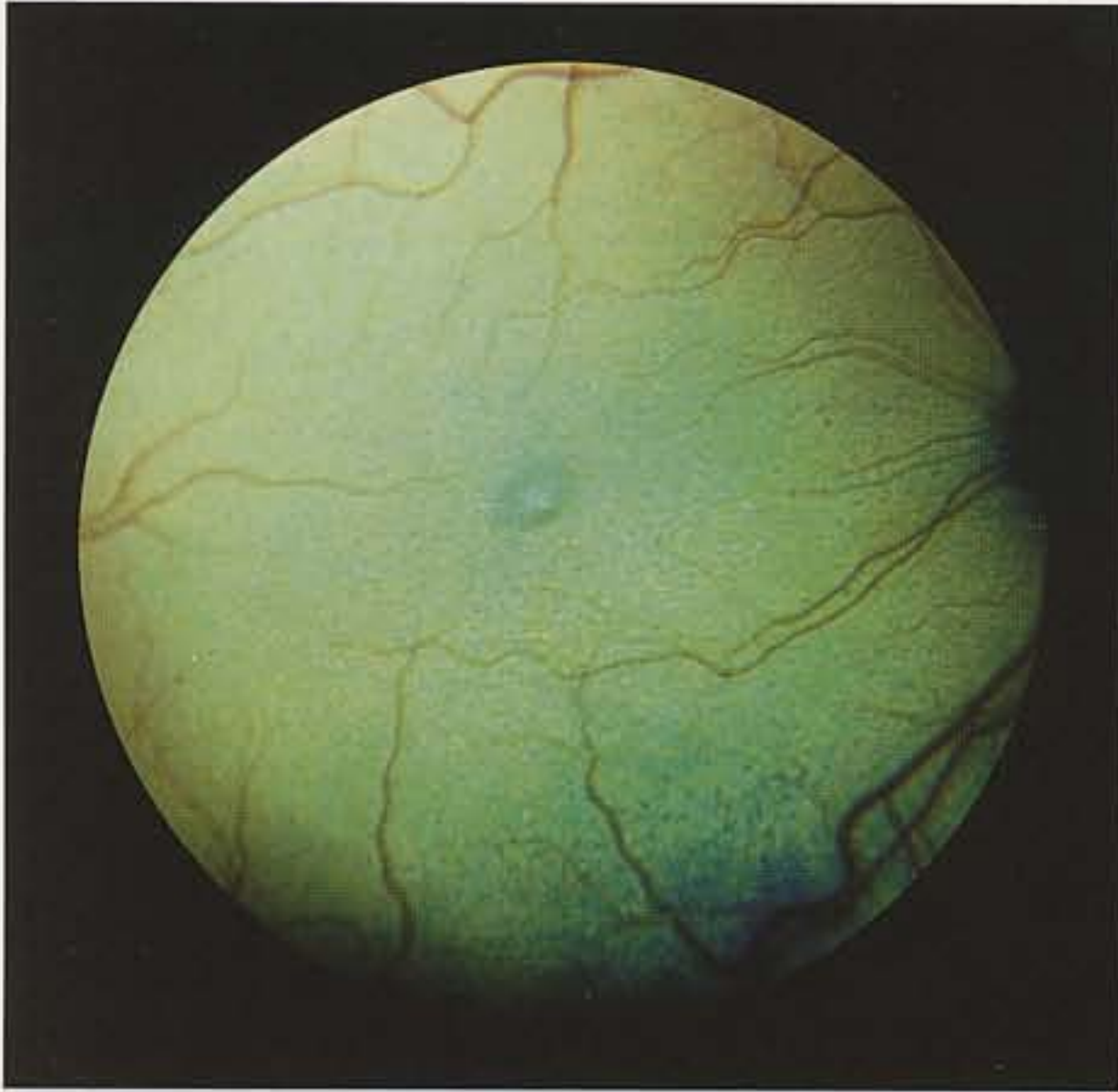

Fig. 11.221 Taurine deficiency retinopathy (experimental DSH) Note the early small focal spot at the area centralis, lateral to the optic disc.

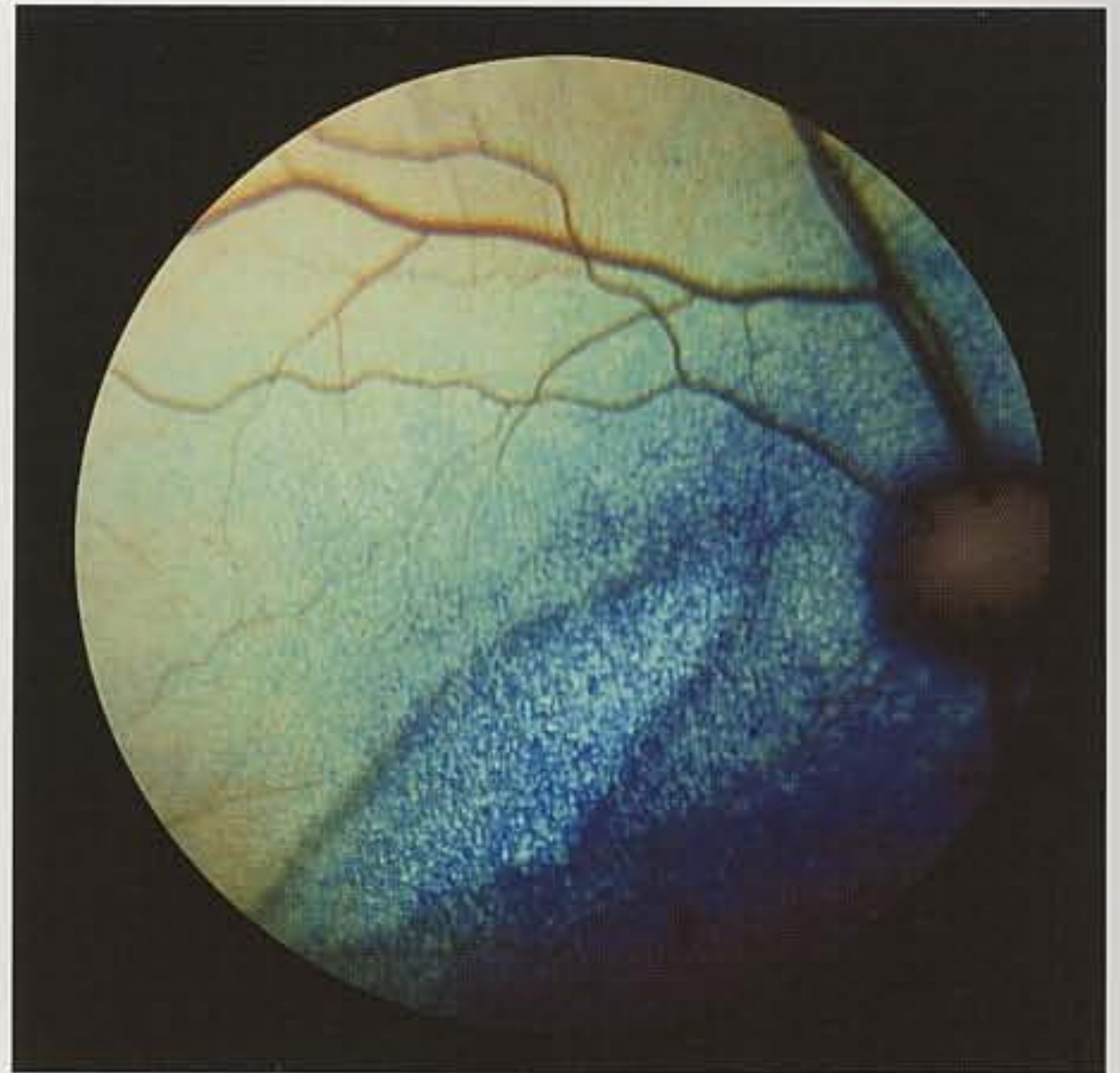


Fig. 11.223 Taurine deficiency retinopathy (experimental DSH) Area of retinal degeneration now approaching the optic disc.

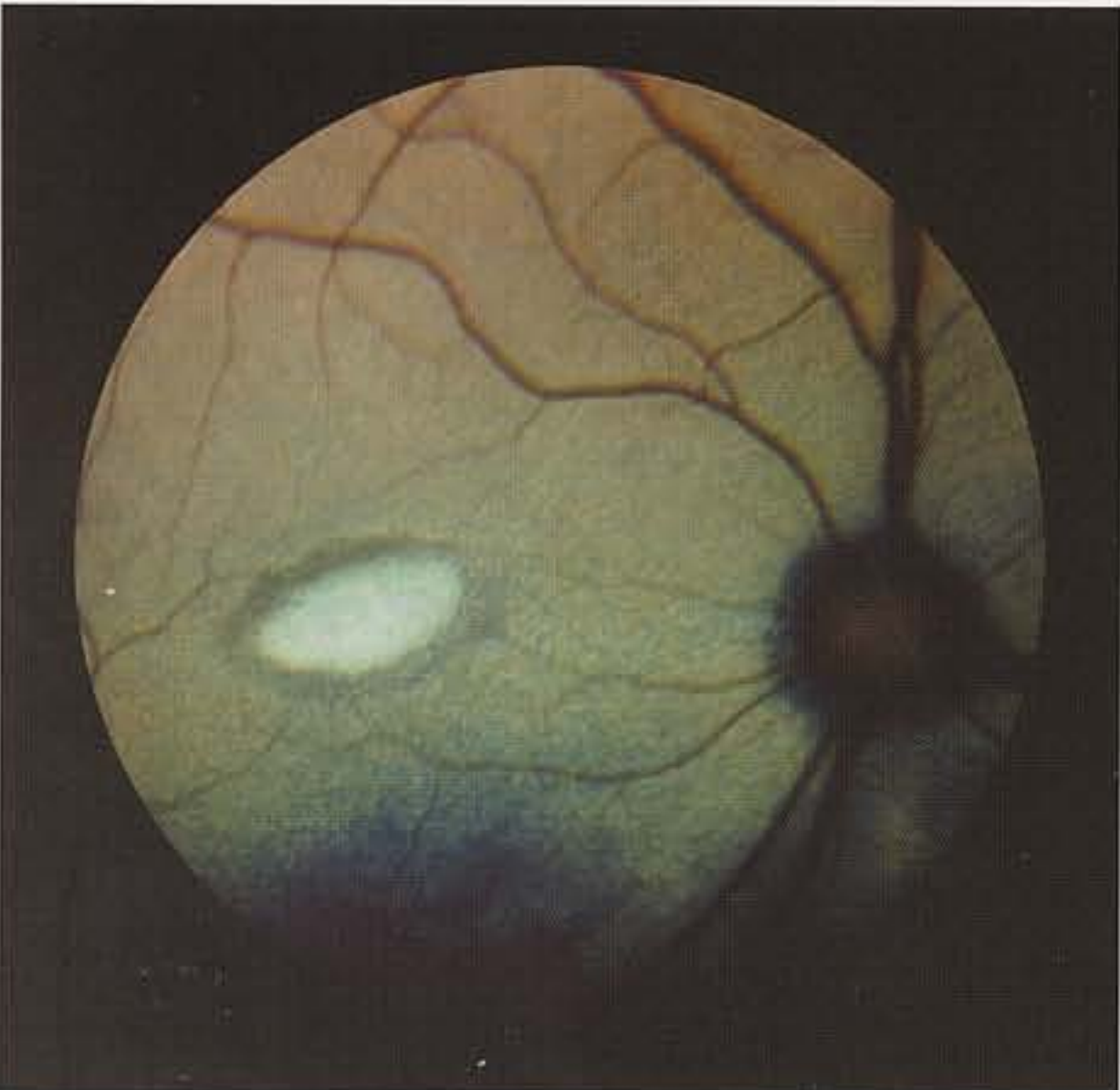

Fig. 11.222 Taurine deficiency retinopathy (experimental DSH) Larger oval reflective area in the same position.

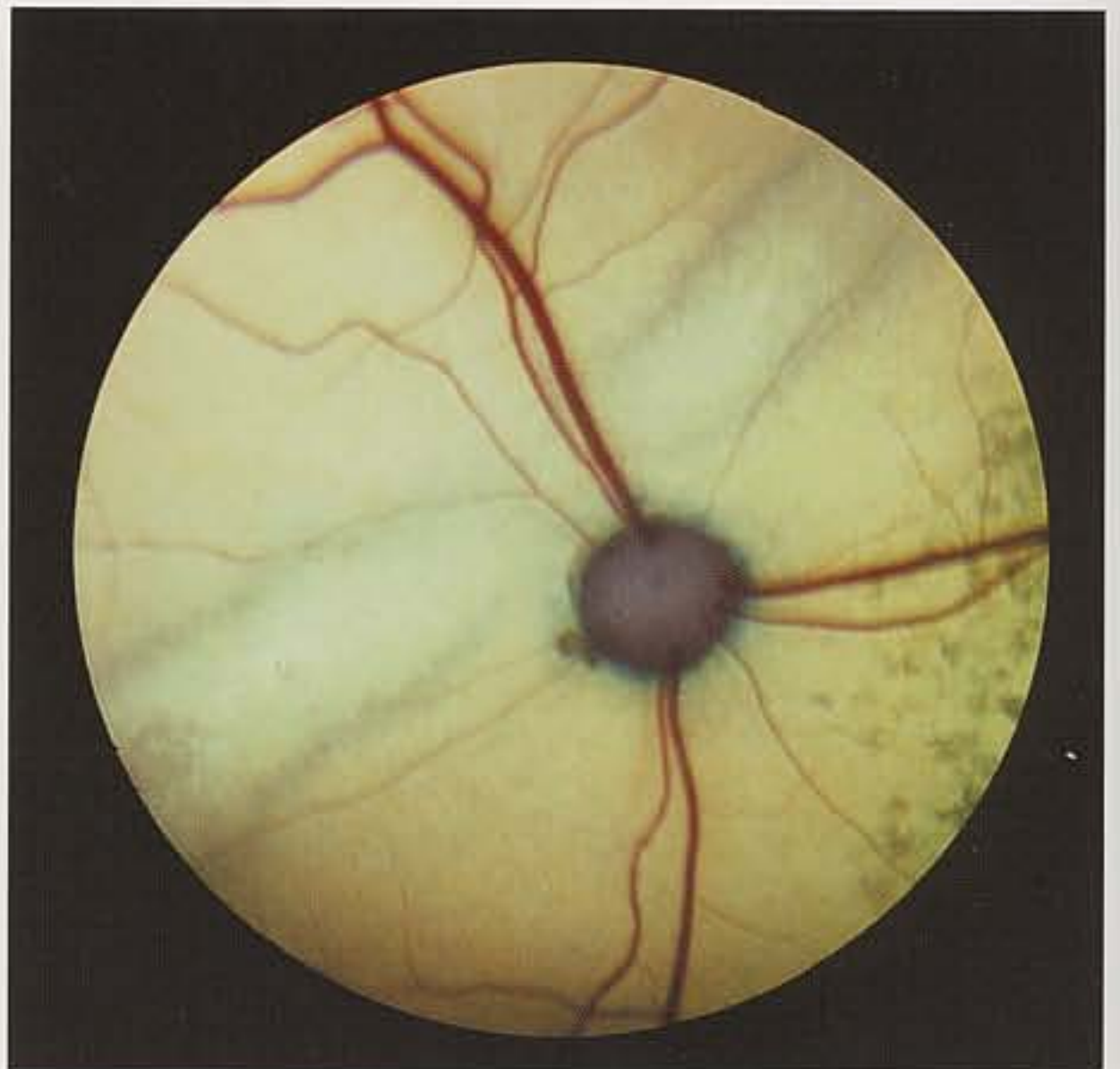


Fig. 11.224 Taurine deficiency retinopathy (experimental DSH) The two areas of retinal degeneration have now met in a bridge immediately superior to the optic disc.



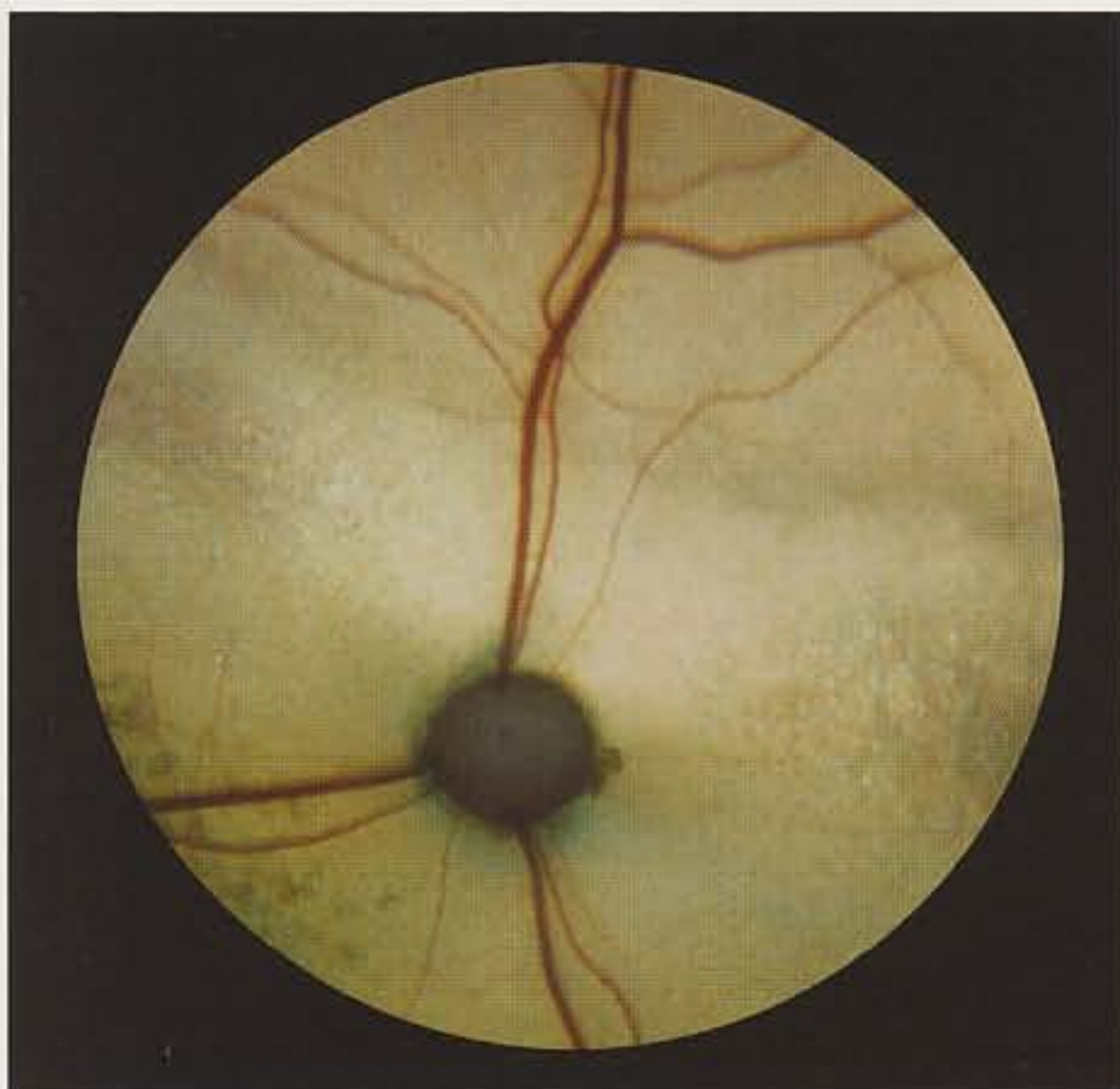


Fig. 11.225 Taurine deficiency retinopathy (experimental DSH) Extension of the bridging degeneration above the disc.

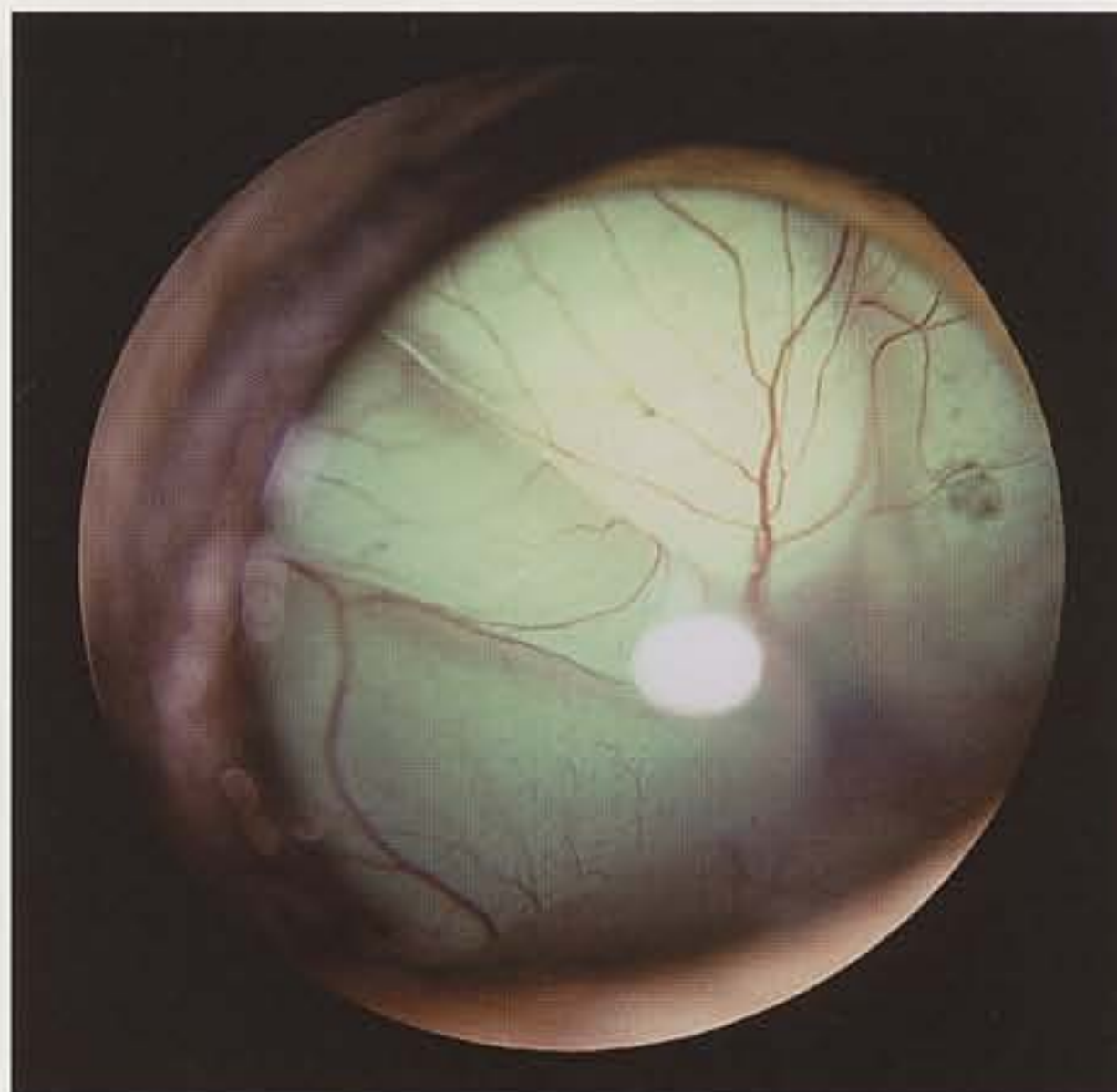

Fig. 11.227 Hypertensive retinopathy (DSH, 13 years old) Serous retinal detachment and sudden blindness.

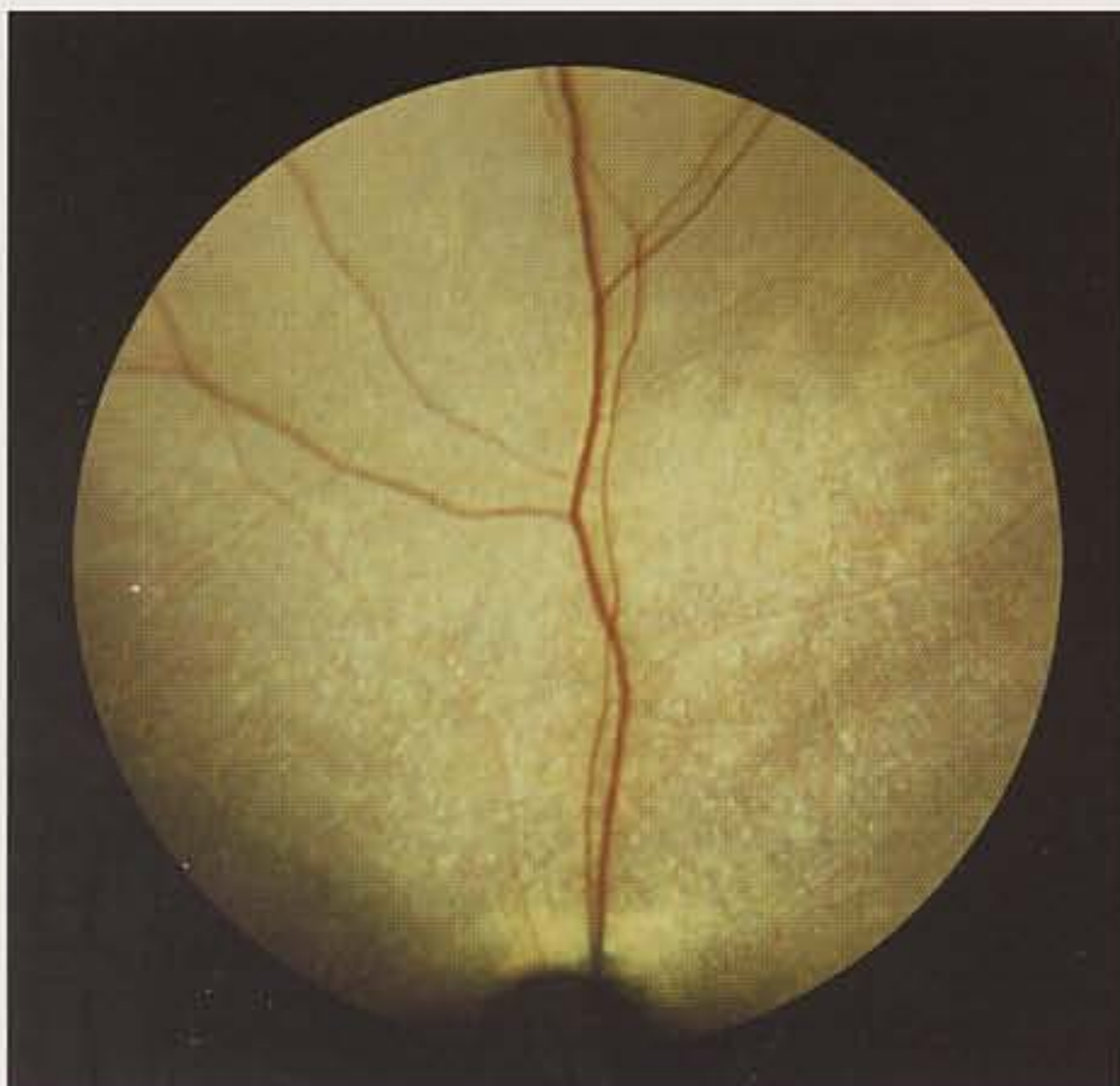

Fig. 11.226 Taurine deficiency retinopathy (experimental DSH) Generalized retinal degeneration in an advanced case. Vision now defective but, prior to this stage, no effect on vision was apparent.

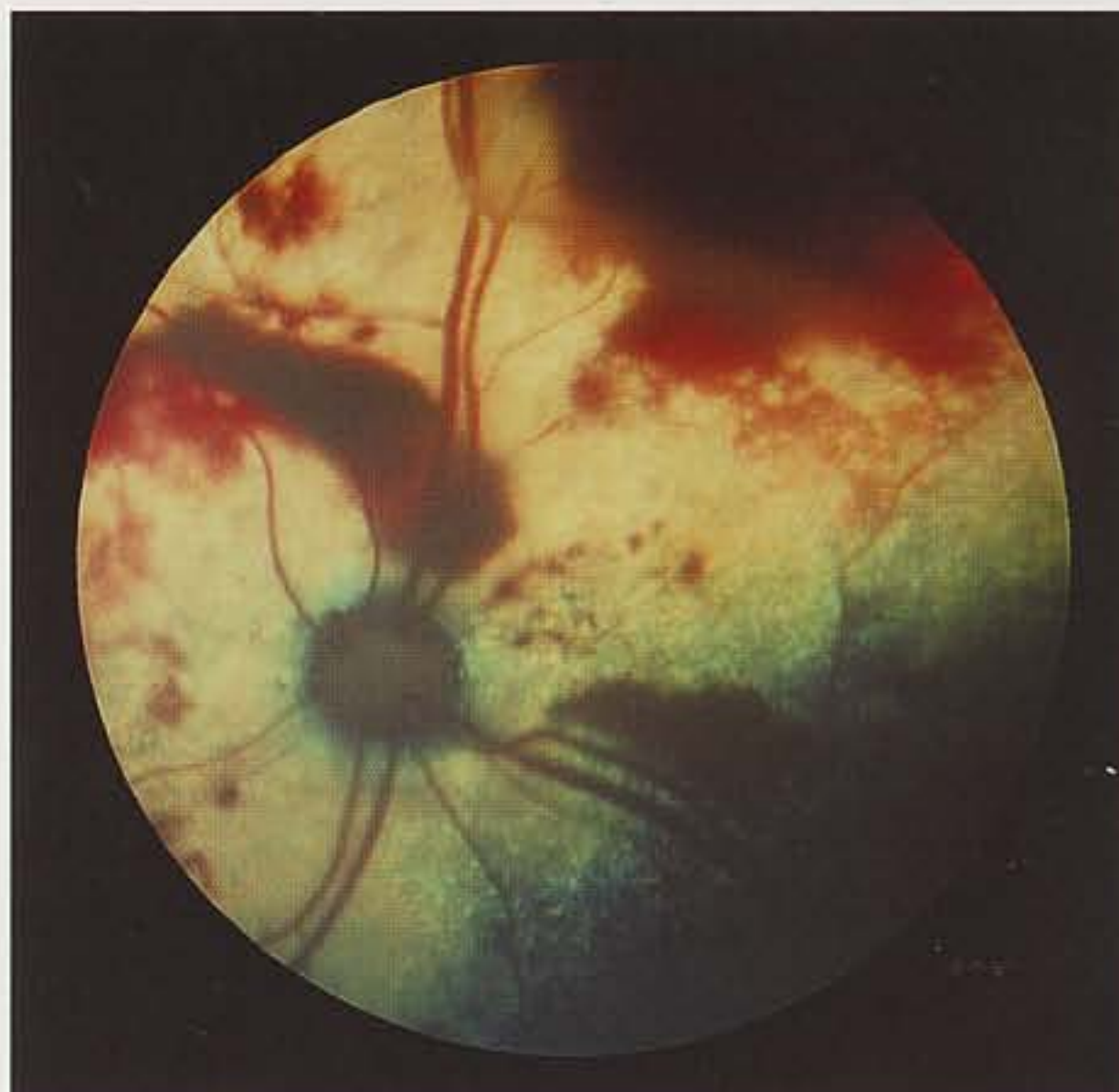

Fig. 11.228 Hypertensive retinopathy (DSH, 12 years old) Retinal haemorrhages.

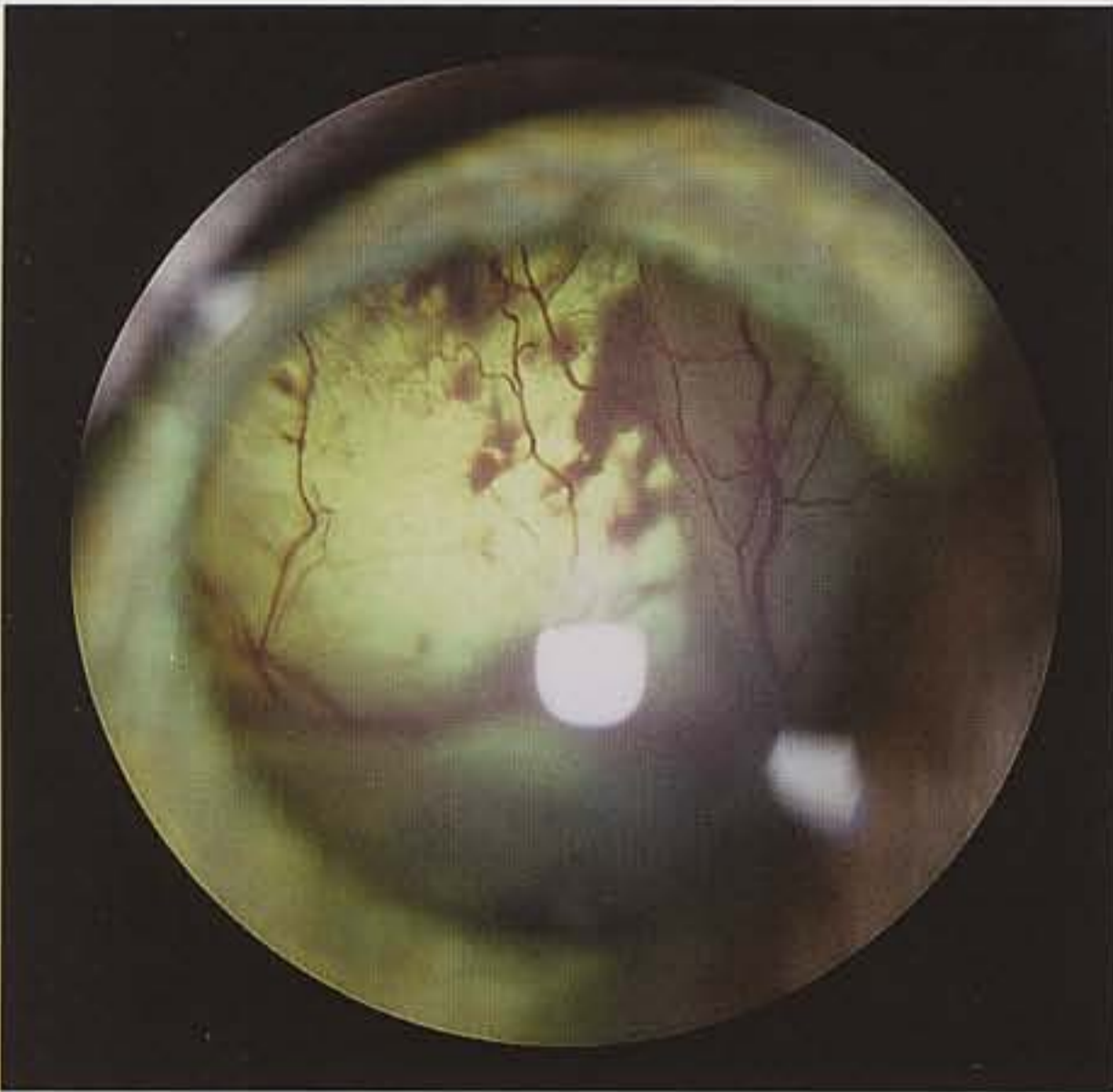

Fig. 11.229 Diabetic retinopathy (DSH, 10 years old)  
Retinal haemorrhages and detachment visible through the pupil following prolonged administration (8 years) of megestrol acetate.

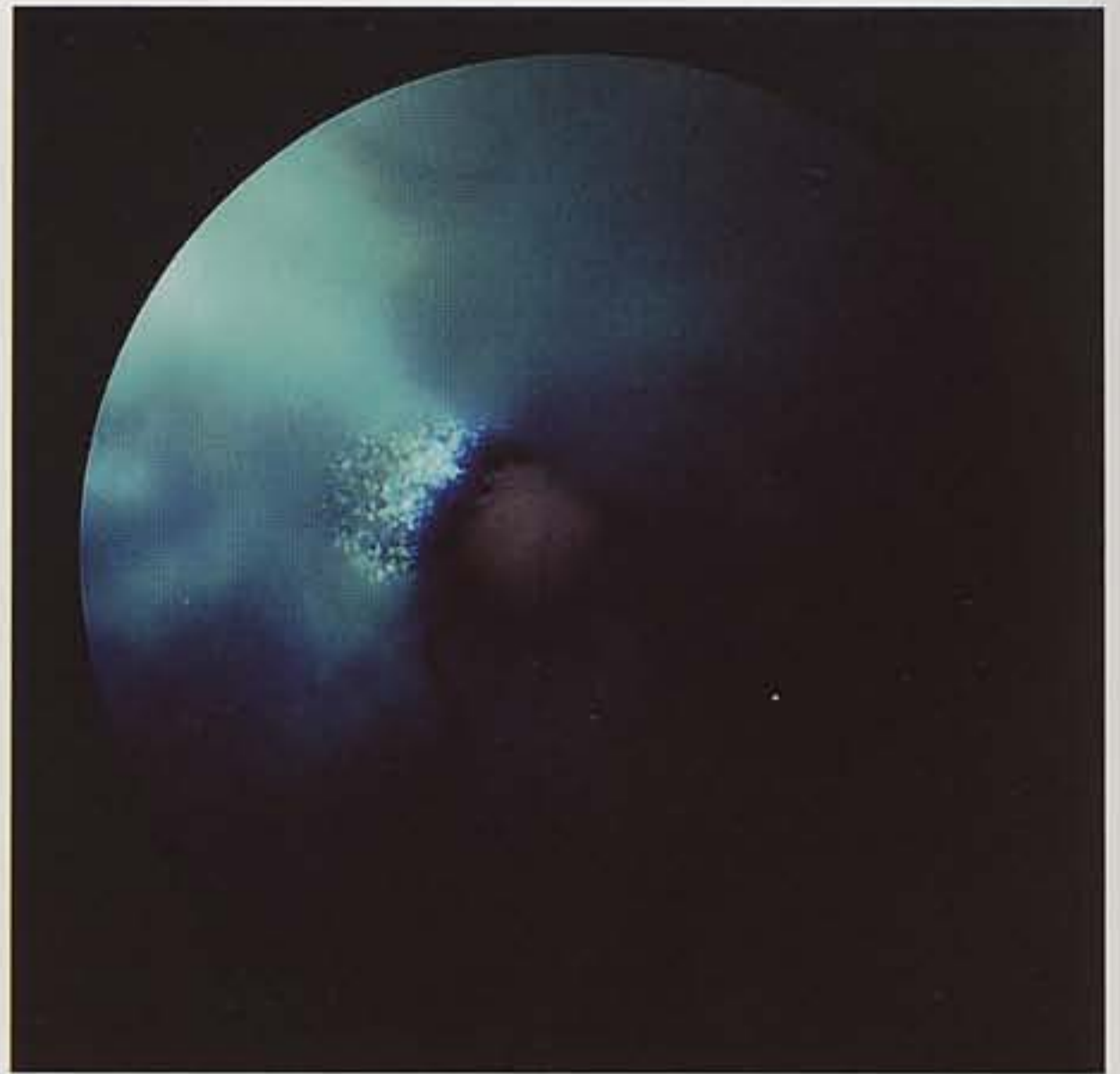


Fig. 11.231 Retinal detachment (DSH, 4 months old)  
Total detachment in both eyes. Note the central hole in the retina. Probably a congenital anomaly and rare.

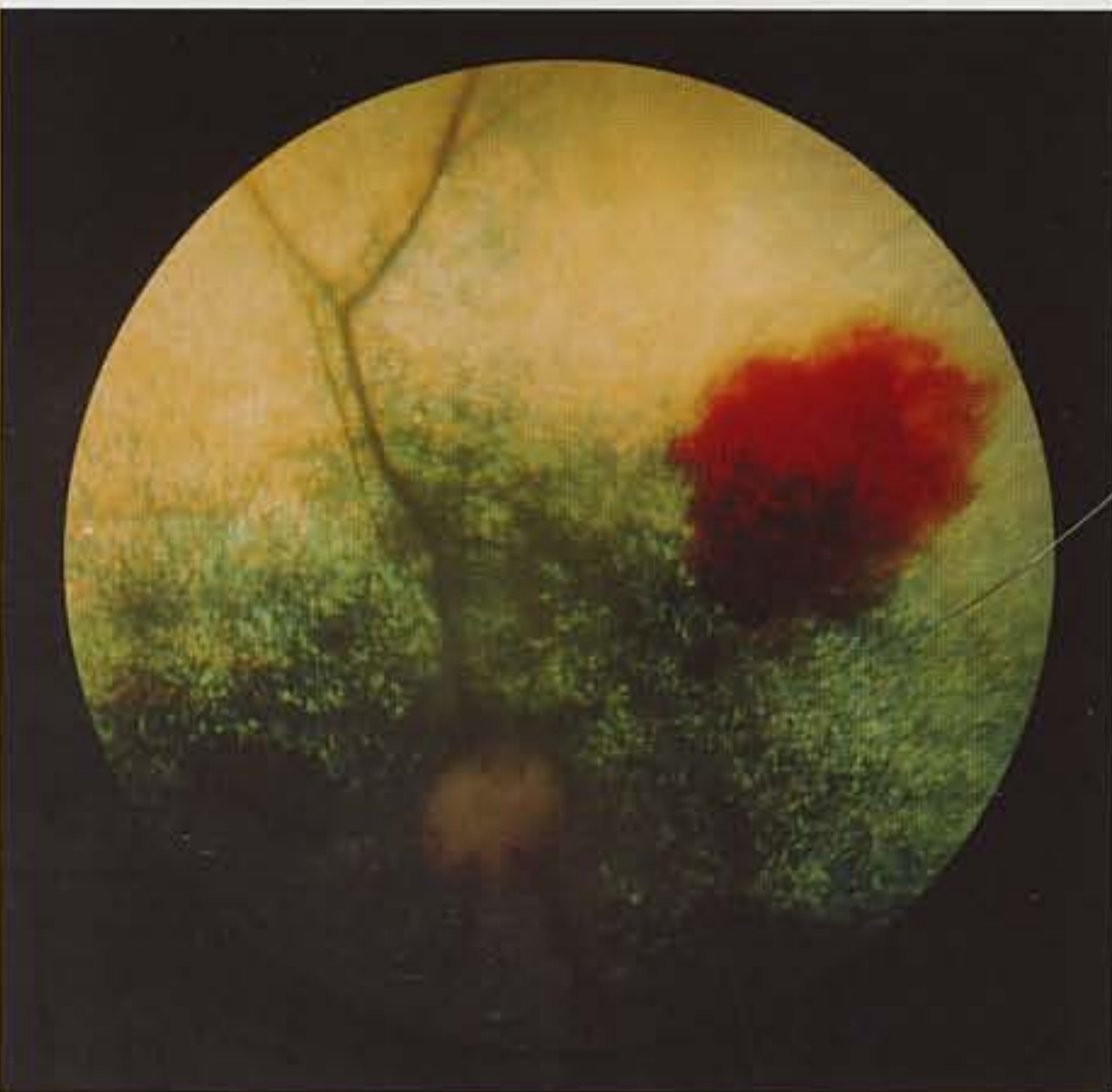

Fig. 11.230 Retinal haemorrhage (DSH, 10 years old)  
Retinal haemorrhage following trauma.

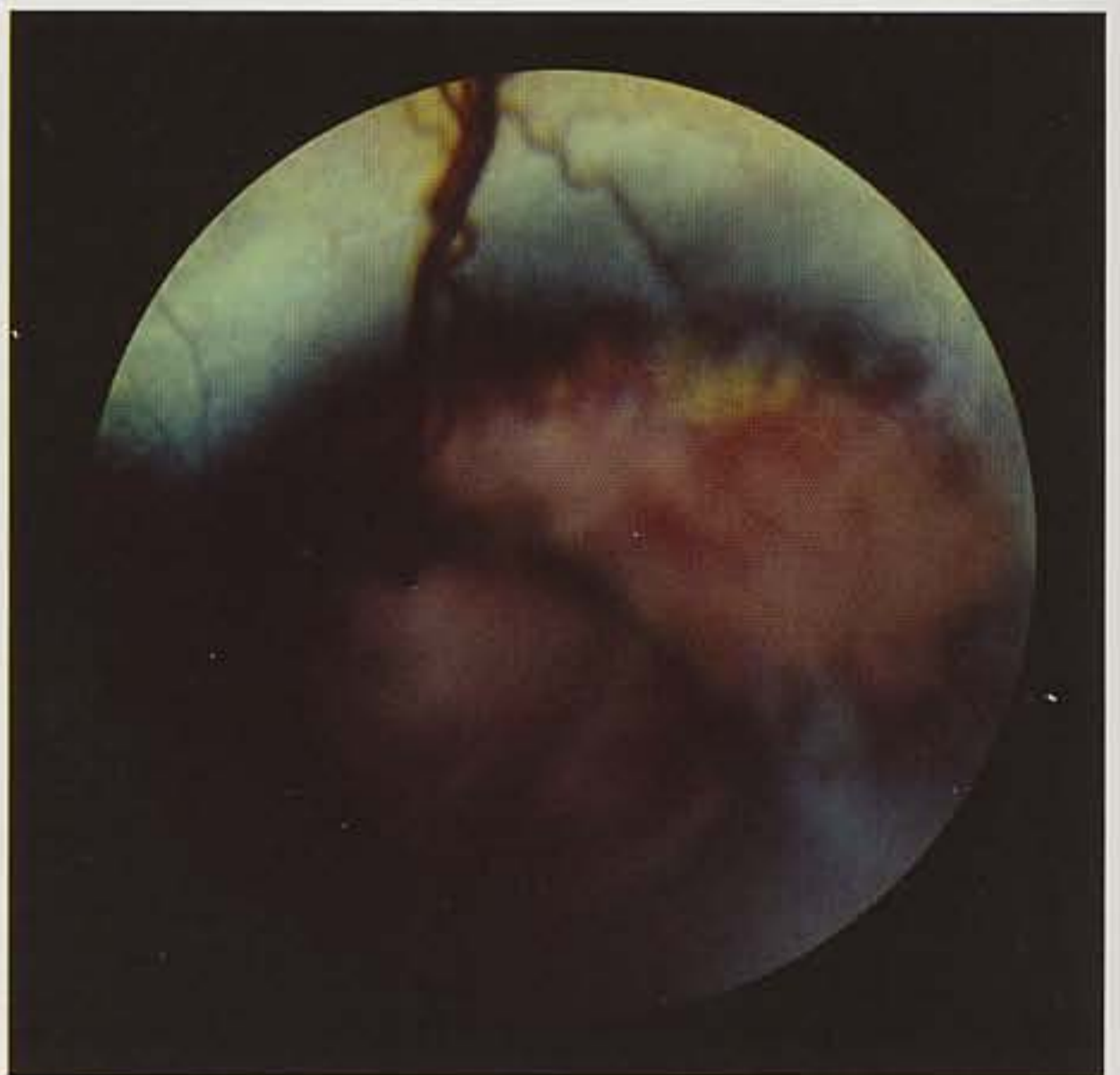

Fig. 11.232 Coloboma (DSH, 12 months old)  
Colobomas affecting the retina, choroid and optic disc.



Fig. 11.233 Chorioretinopathy (Hunter-type, 7 years old) Focal linear lesions in the non-tapetal fundus.

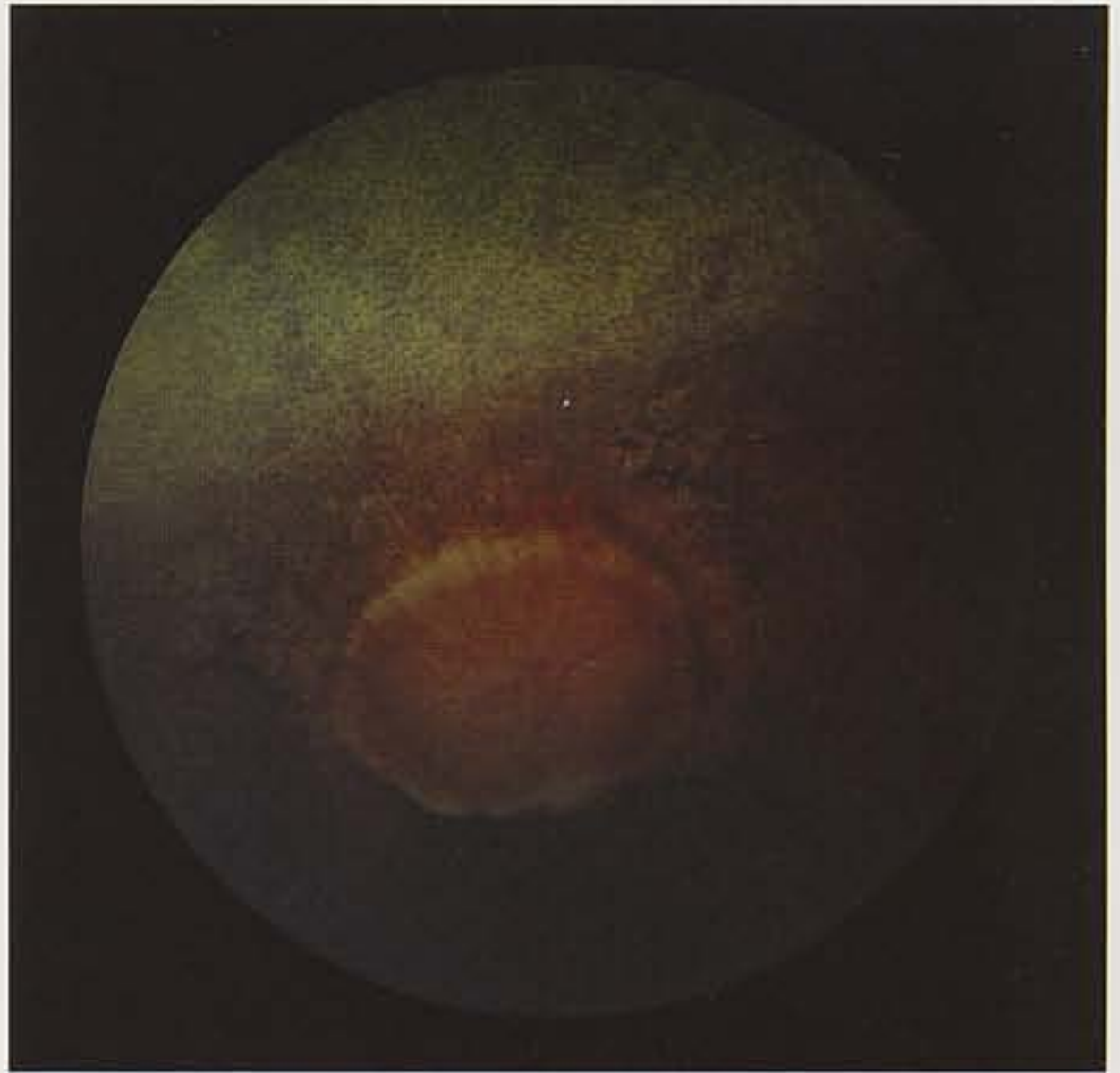


Fig. 11.235 Chorioretinopathy (pony, 25 years old) Peripapillary and pigmentary degeneration.

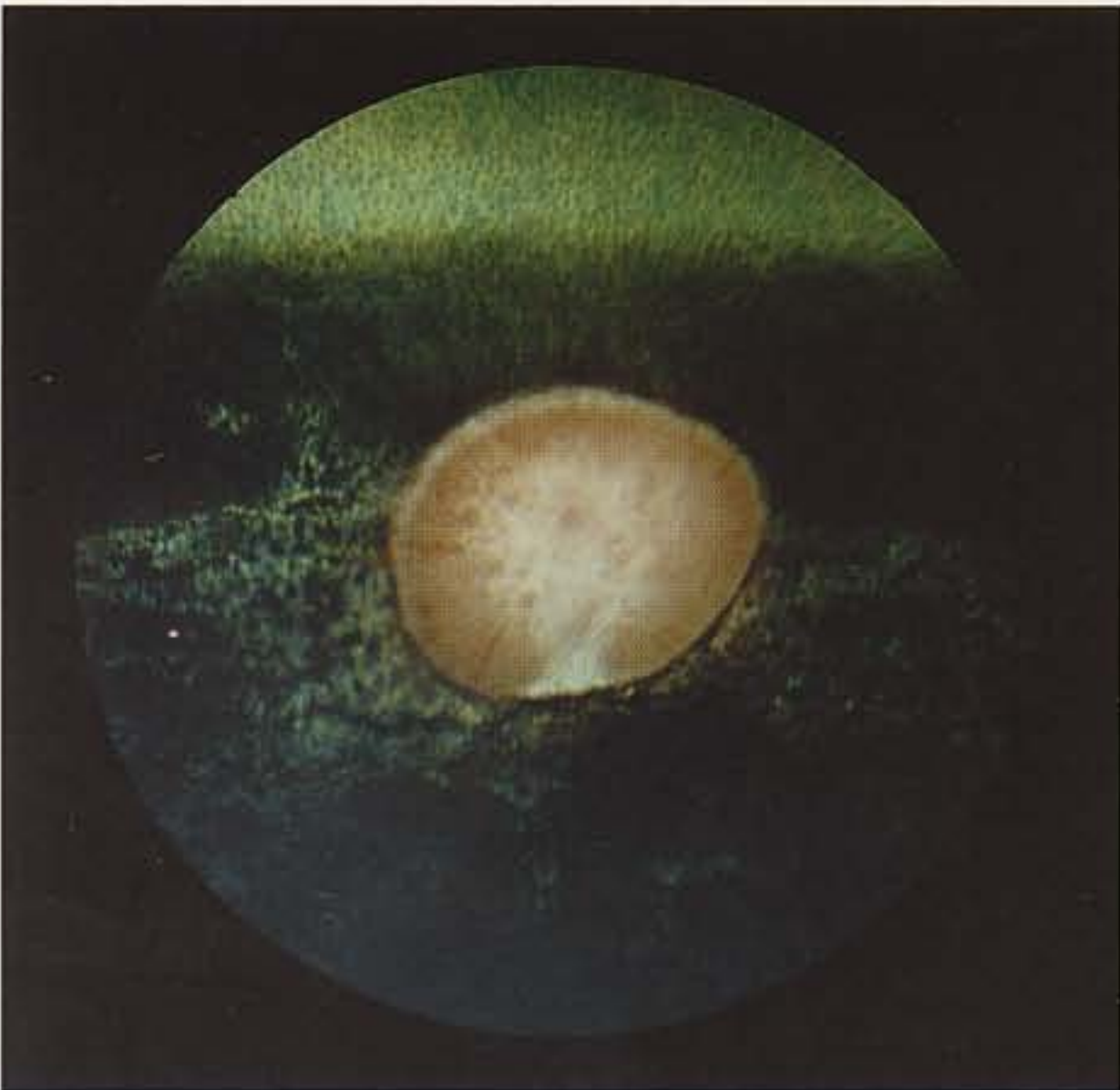

Fig. 11.234 Chorioretinopathy (Hunter-type, 7 years old) Similar lesions to Fig 11.233, peripapillary and on both sides of the disc. The so-called 'butterfly' lesion.

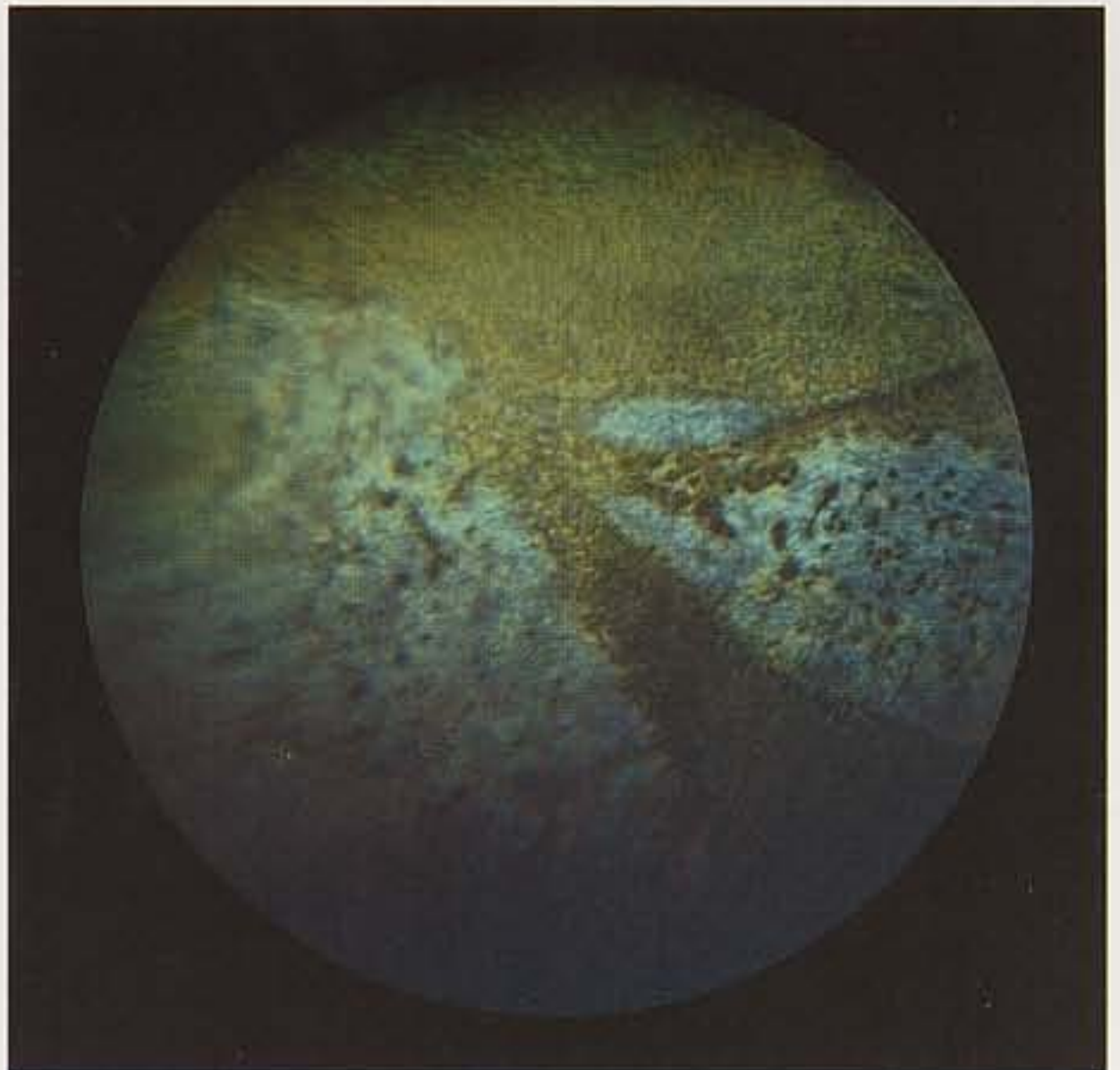

Fig. 11.236 Retinopathy (Hunter-type, 12 years old) Focal lesions of retinal degeneration. Note the change in colour and hyper-reflectivity, together with pigmentary disturbance in the tapetal fundus.

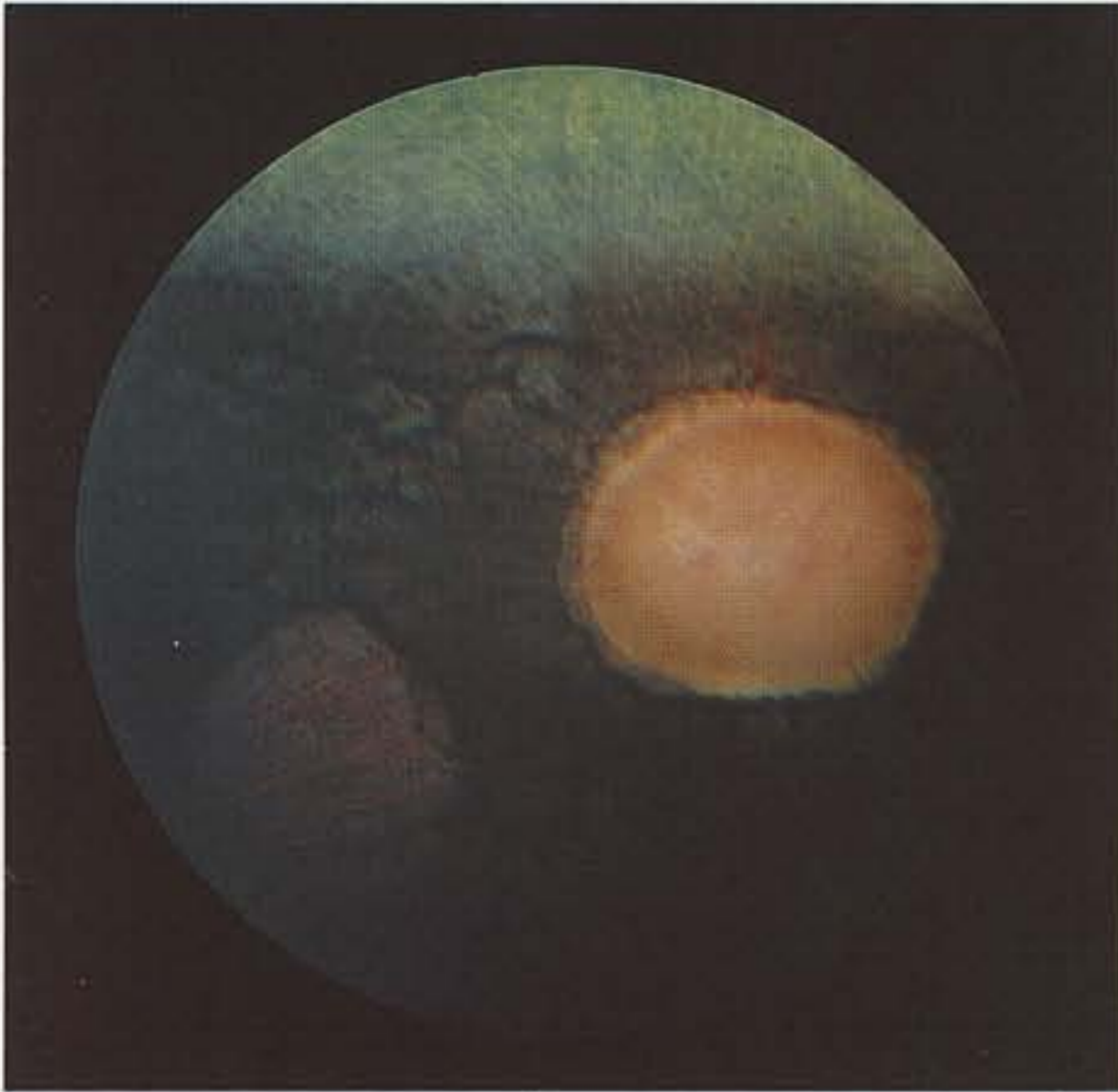


Fig. 11.237 Retinopathy (Thoroughbred, 8 years old) Focal areas of retinal degeneration in the non-tapetal fundus, peripapillary and away from the disc. Some optic atrophy.




Fig. 11.239 Retinopathy (Thoroughbred, 1 year old) Generalized progressive retinal atrophy, bilateral and resulting in defective vision. Note the typical signs and similarity to GPRA in the dog and cat. A rare case.

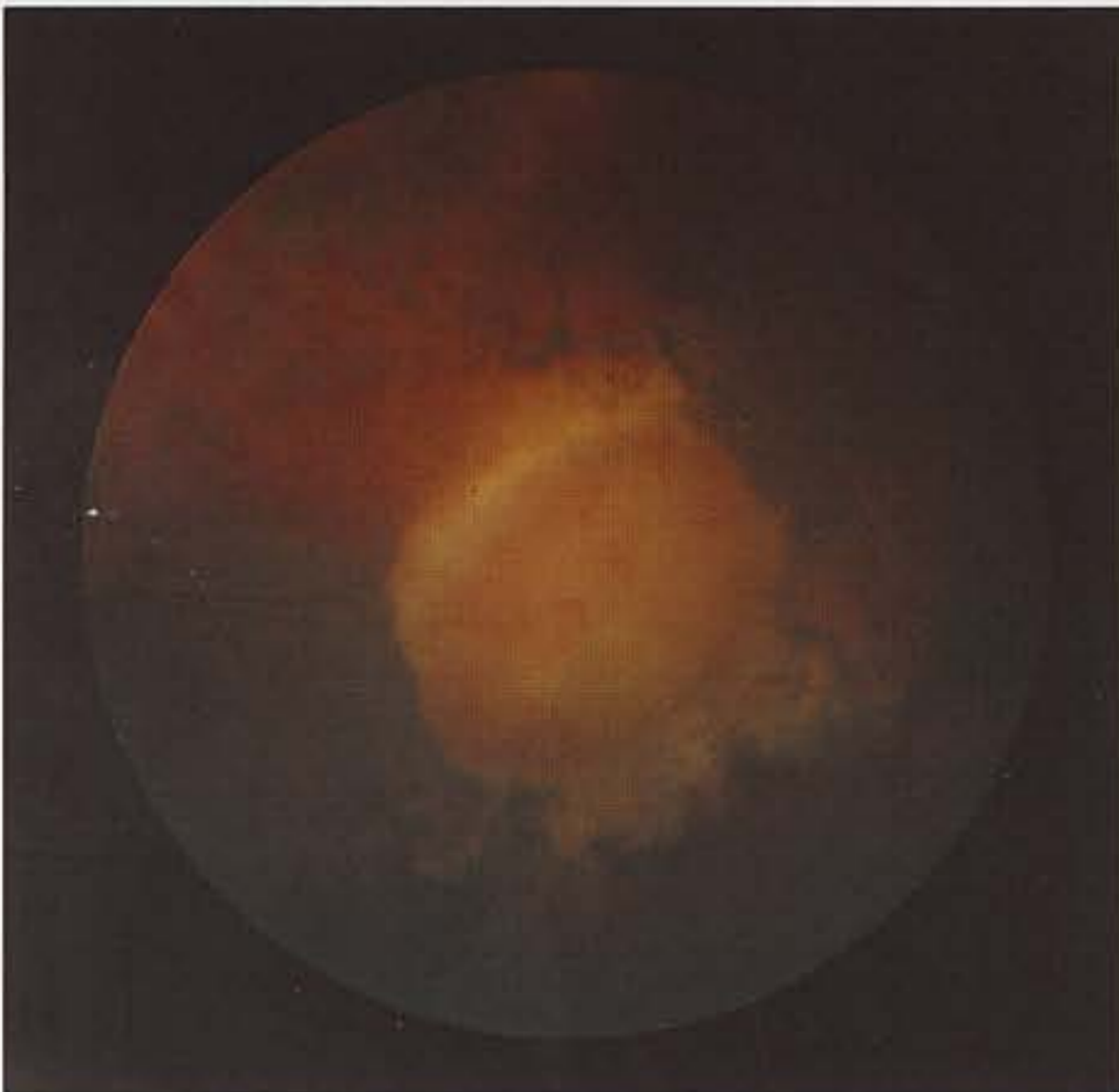

Fig. 11.238 Senile retinopathy (Shetland pony, aged) Peripapillary pigmentary changes and loss of choroidal circulation.

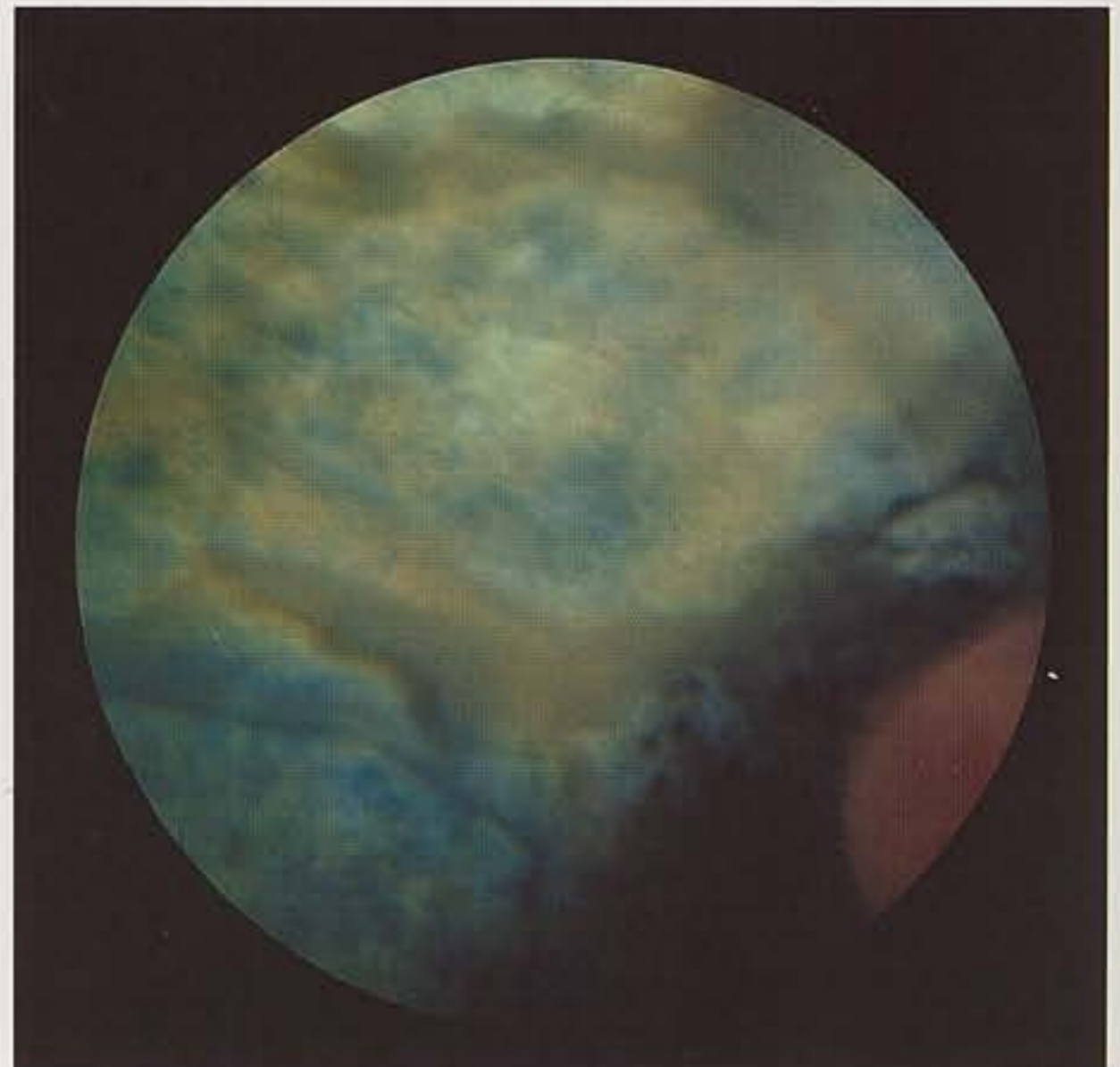


Fig. 11.240 Retinal detachment (Hunter-type, 6 months old) Total detachment in both eyes with total blindness, probably congenital.

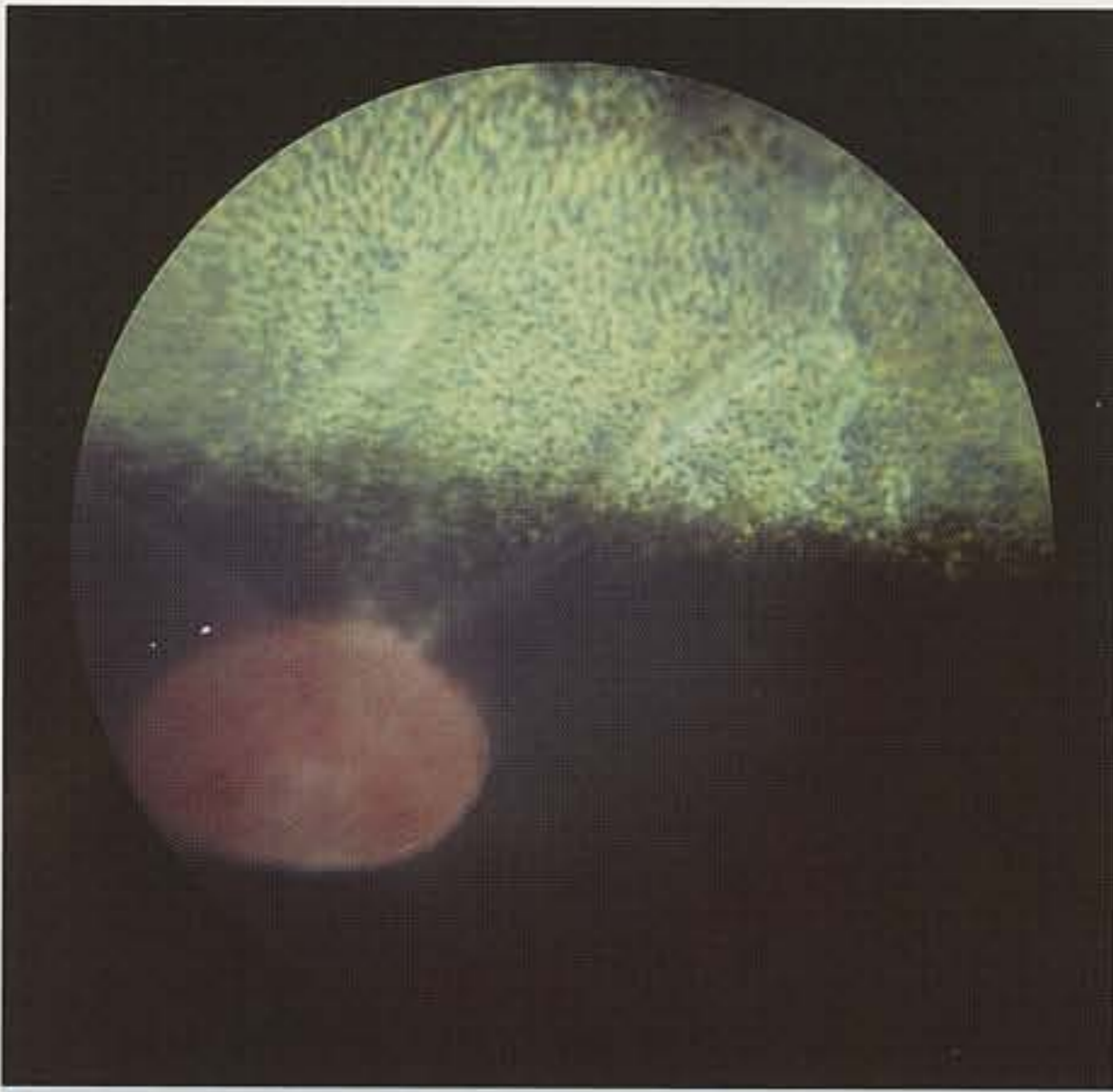


Fig. 11.241 Retinal detachment (Hackney pony, 3 weeks old) Bilateral and congenital.

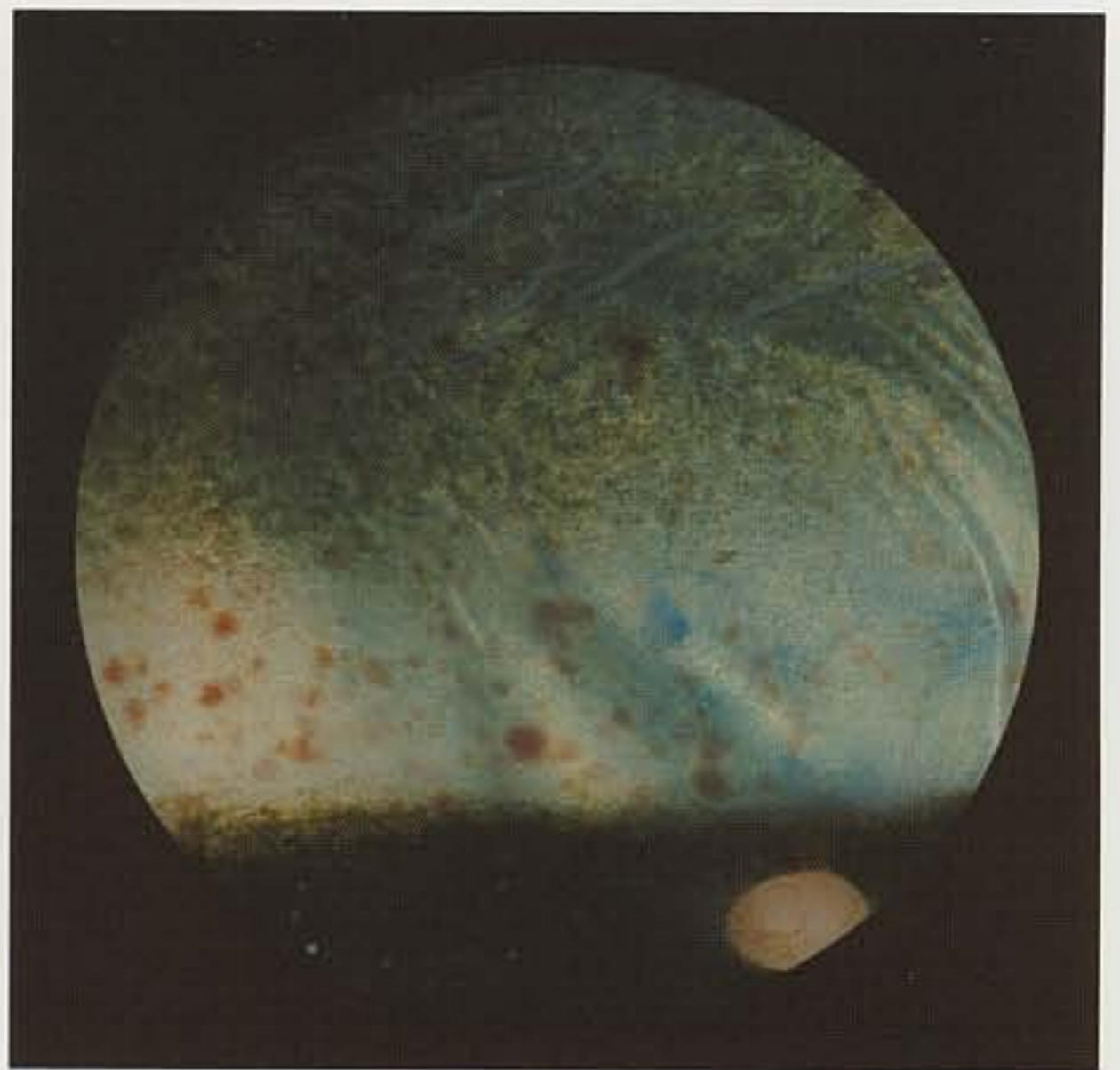


Fig. 11.242 Retinal haemorrhages (Thoroughbred foal, few days old) Multiple small retinal haemorrhages in Convulsive Foal Syndrome (post mortem specimen).

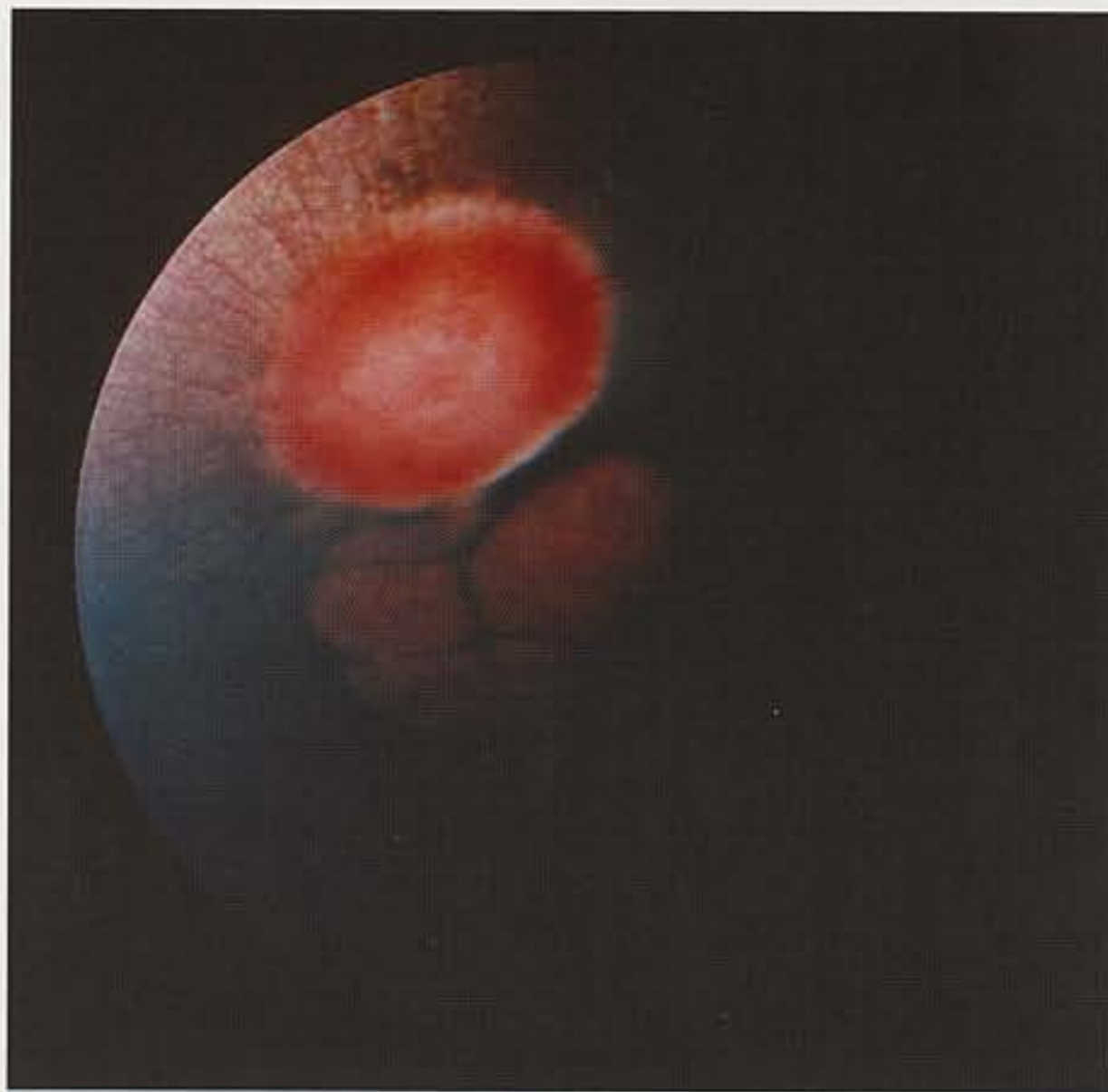


Fig. 11.243 Coloboma (Thoroughbred, 2 months old) Retinal colobomas in the typical position below the disc.

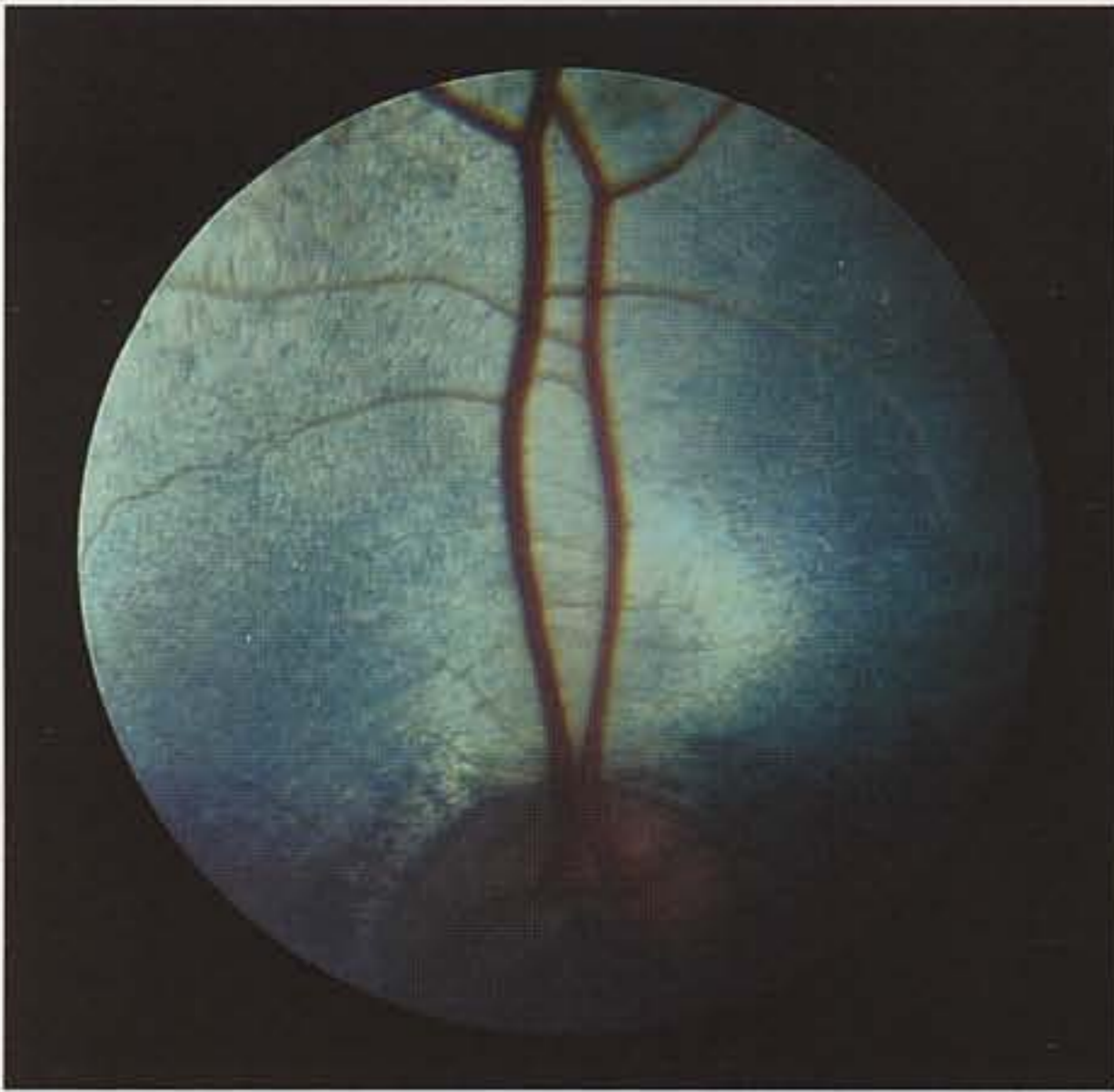


Fig. 11.244 Retinal degeneration (Hill Breed ewe)  
Bright blindness or primary toxic retinopathy due to the ingestion of bracken.

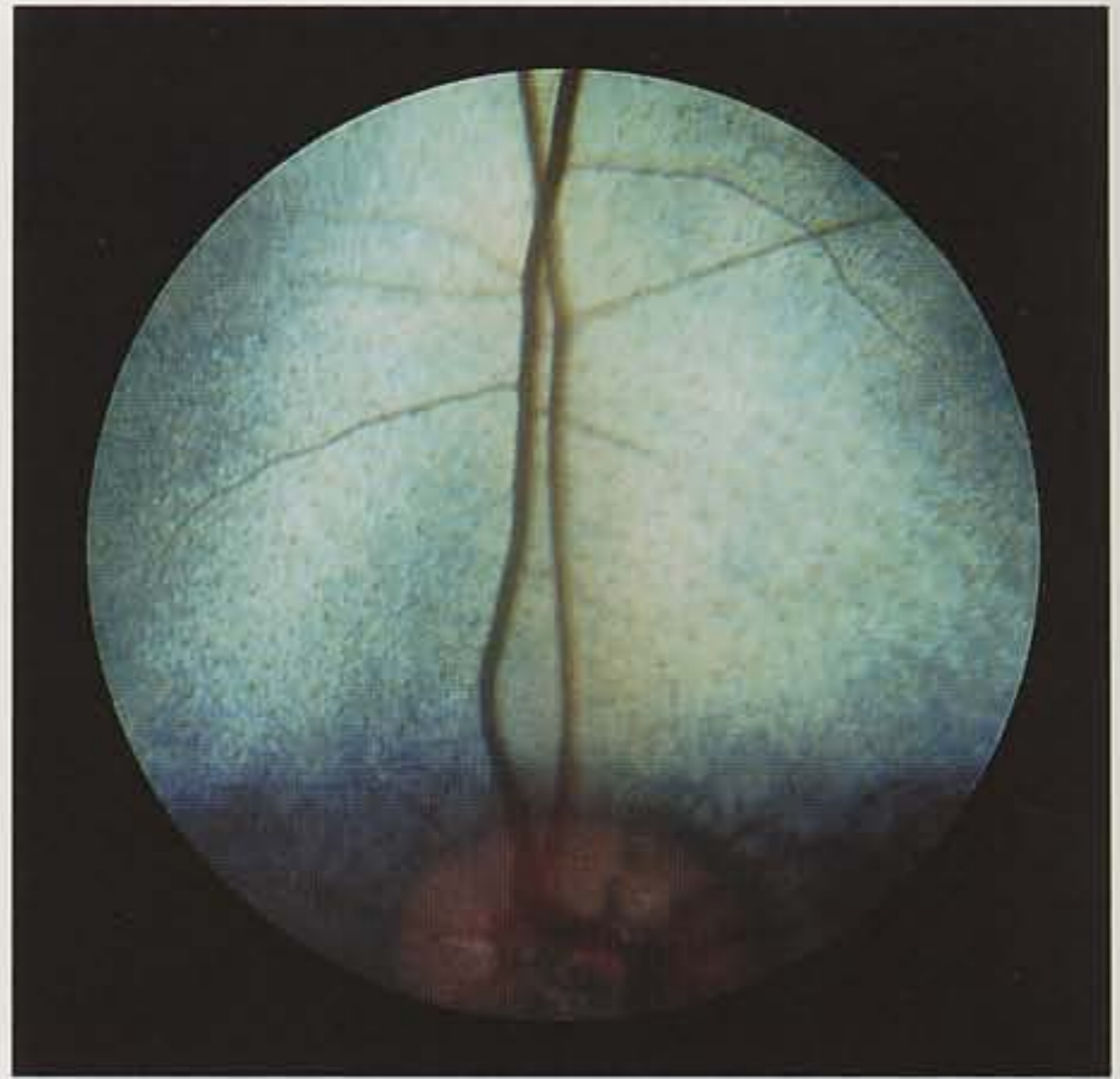


Fig. 11.245 Retinal degeneration (Hill Breed ewe)  
Note the attenuation of the retinal blood vessels.  
Aetiology as previous figure.

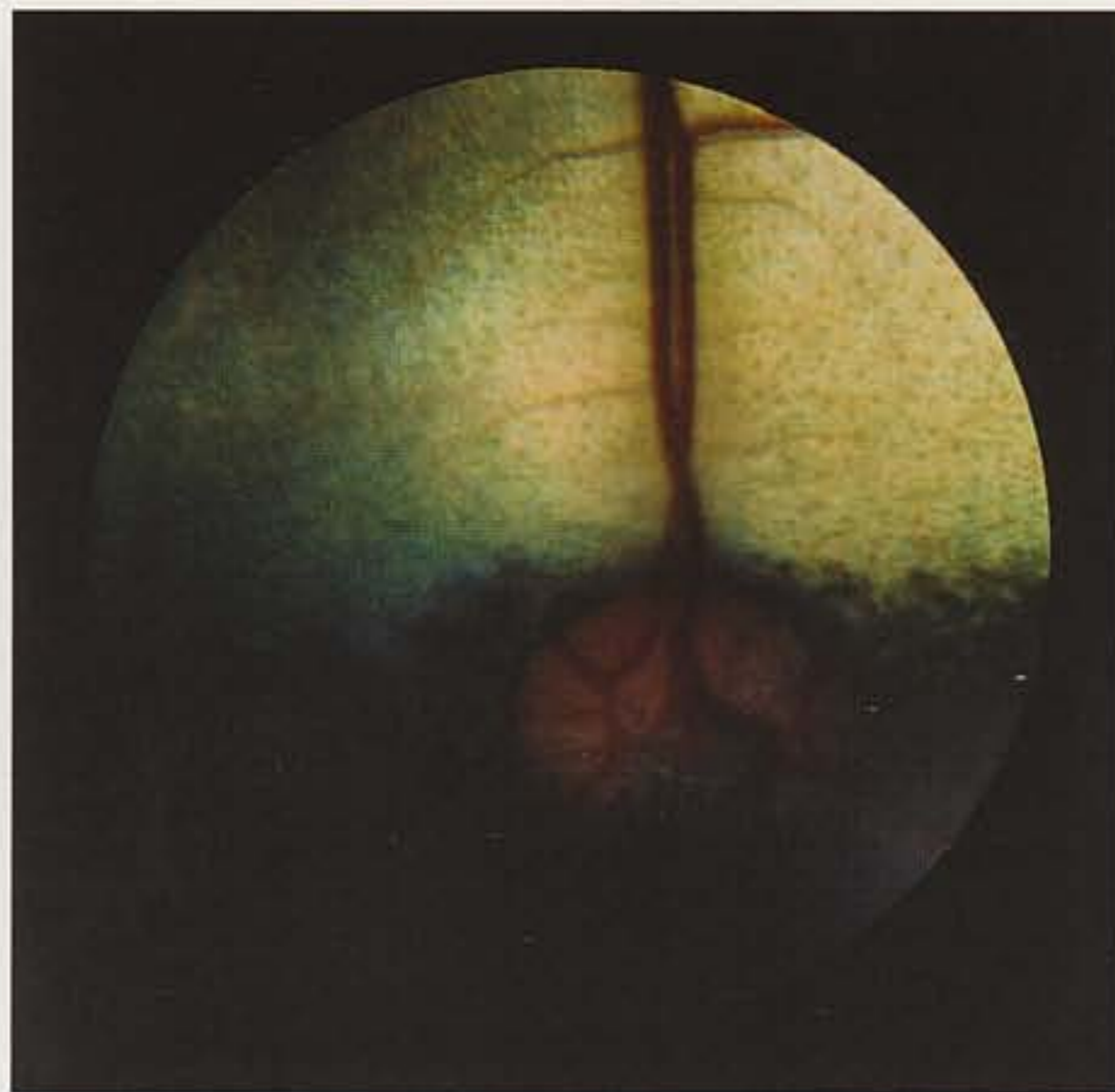


Fig. 11.246 Retinal degeneration (Hill Breed ewe)  
Note the increased tapetal reflectivity. Aetiology as previous figures.

# Chapter 12

## The Optic Nerve

### Introduction

The optic nerve (cranial nerve II), or more particularly the optic nerve head or optic disc as it appears as part of the fundus (Chapter 11), exhibits a few important conditions which will be illustrated. The normal appearance of the optic disc in all the species is shown in the previous section and there will be a degree of overlap between the two chapters, as conditions of the fundus, in particular choroid and retina, not infrequently involve the optic nerve and are visible ophthalmoscopically.

The degree of medullation in all the species varies considerably and this fact does not help in diagnosis. Similarly, the size and colour of the disc also exhibit normal variations, as well as being important factors in pathology.

### Conditions of the optic nerve

(Figs 12.1–12.29)

#### *Acquired conditions*

An increased size of disc occurs in papilloedema (as well as pseudopapilloedema due to excessive medullation); in optic neuritis; in some disc colobomas (see Chapter 11, section on CEA); and in tumours (see Fig 12.10). Papilloedema and optic neuritis appear similar ophthalmoscopically. However, the former is not accompanied by loss of vision unless and until optic atrophy develops, although there may be other signs of a disturbance of the central nervous system. On the other hand, optic

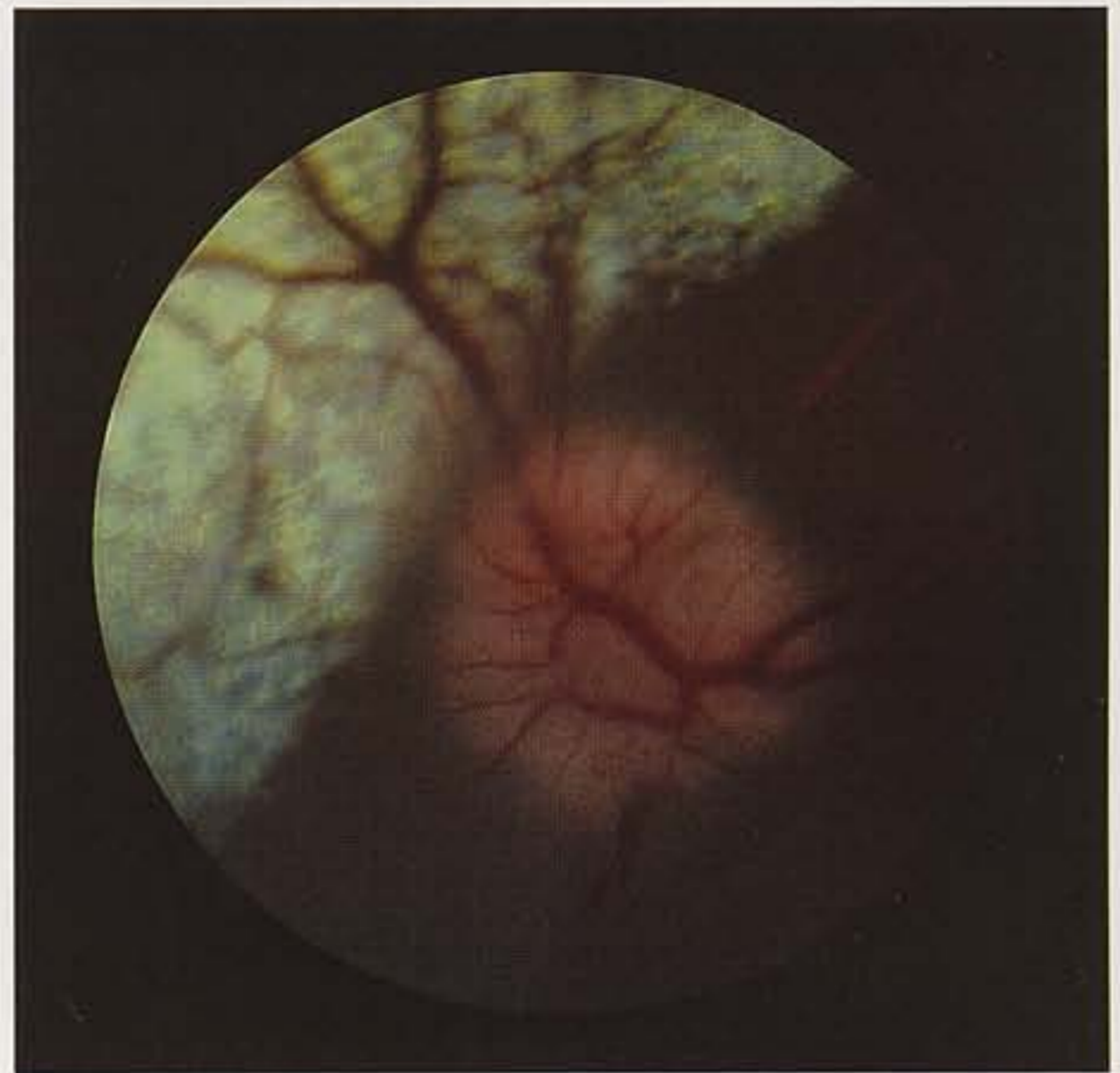

Fig. 12.1 Papilloedema (West Highland White Terrier, 7 years old) Note the enlarged size of the disc and congestion of the retinal veins, in particular the fine ones on the disc itself. The papilloedema was bilateral and a pupillary light reflex was present.

neuritis usually presents as sudden loss of vision with dilated pupils and absence of the pupillary light reflex. Papilloedema is very rare in both the cat and the horse, but is important in cattle as it is the first objective clinical sign in cases of vitamin A deficiency, with ultimate optic atrophy and blindness developing if untreated. Blindness in one or two animals in a group is usually the presenting sign of hypovitaminosis A.

Decrease in size of the optic disc occurs in cases of optic atrophy in all the species; in optic disc cupping due to glaucoma, but mainly in the dog; and in optic nerve hypoplasia.

### *Congenital conditions*

Congenital conditions affecting the optic disc include optic nerve hypoplasia (dog) and coloboma (dog, cat and cattle); hereditary abnormalities include optic nerve hypoplasia (dog) and coloboma of the optic nerve (dog, cat and cattle).

For a summary of causes of blindness, see Table 12.1.

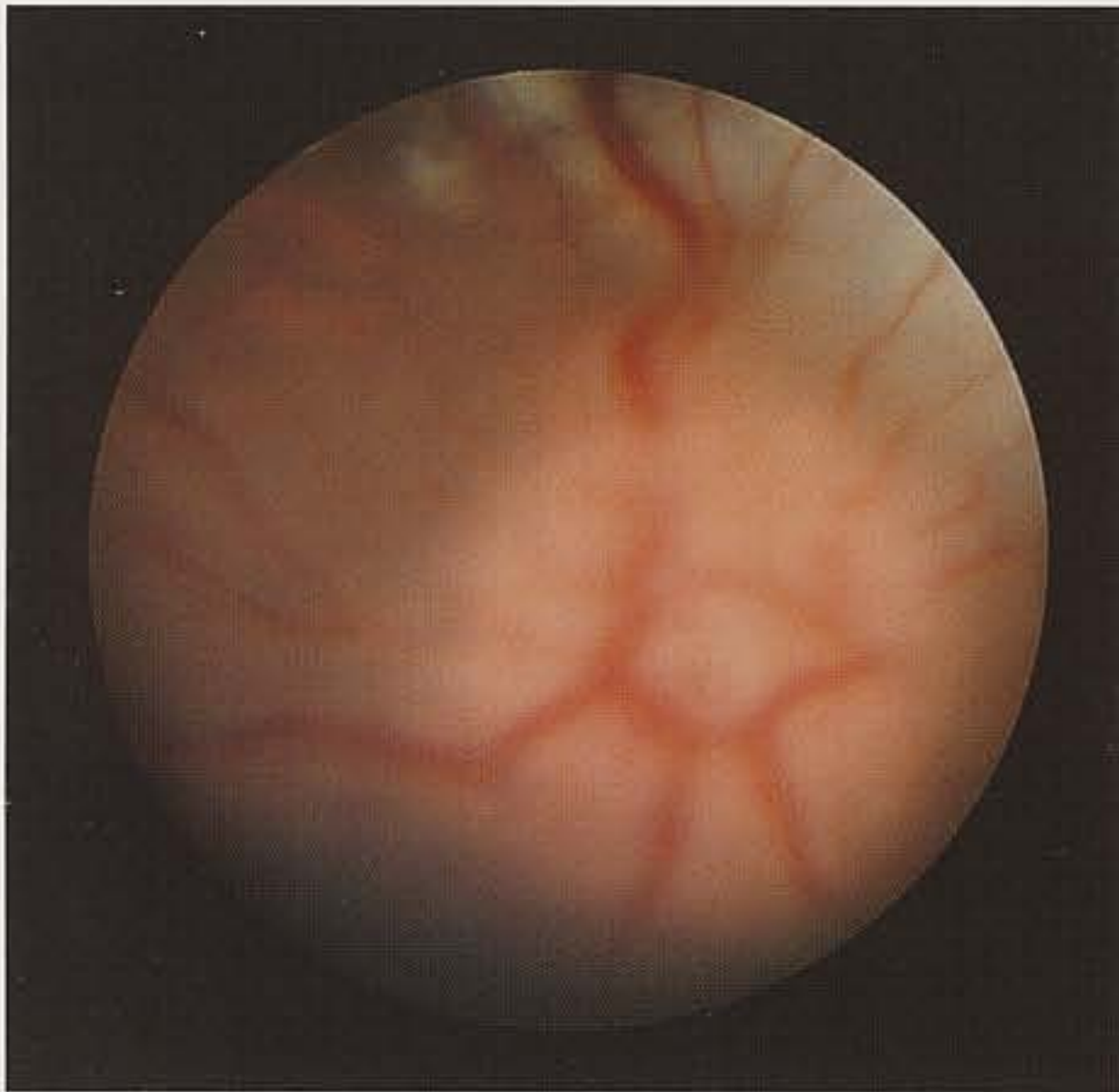

Fig. 12.2 Papilloedema (Griffon, 4 years old) Again note size of disc, fuzzy outline to disc and dipping of the blood vessels as they pass over the edge of the raised disc.

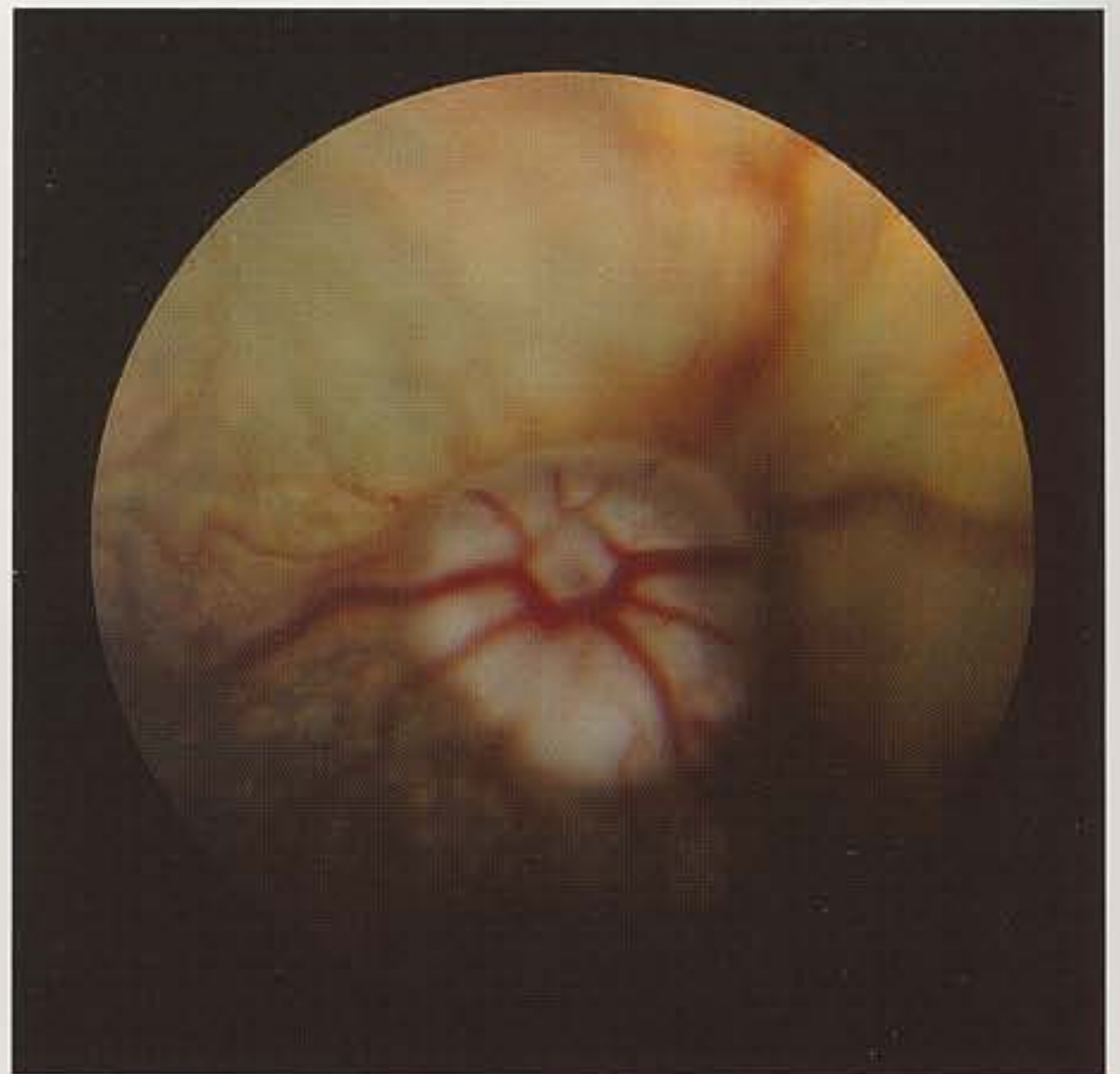


Fig. 12.3 Papilloedema (Miniature Poodle, 8 years old) Note the swollen disc protruding forward into the vitreous.

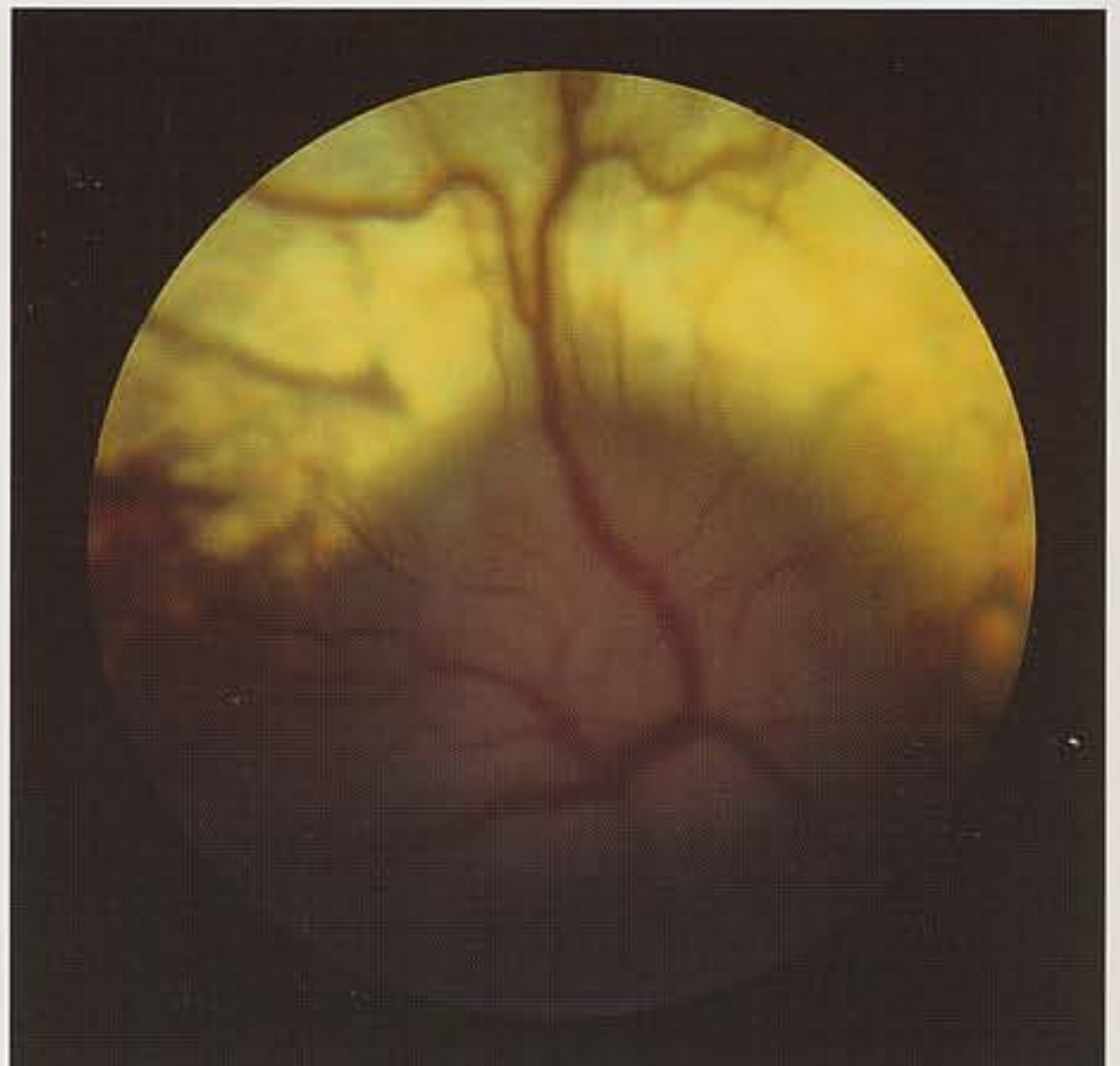

Fig. 12.4 Optic neuritis (Maltese Terrier, 7 years old) Presenting signs were sudden loss of vision and absence of the pupillary light reflex. Note the similar ophthalmoscopic appearance to papilloedema.



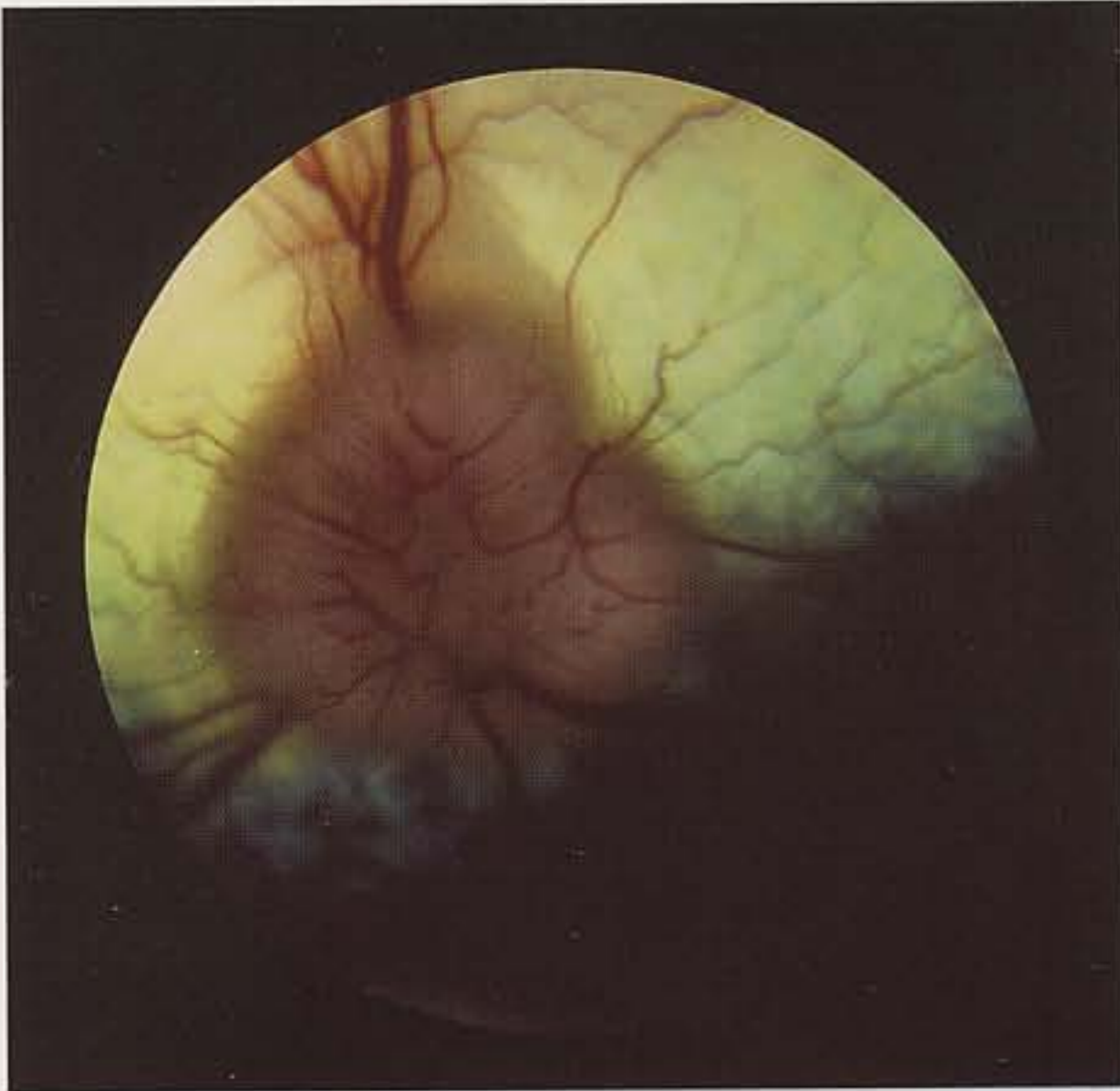

Fig. 12.5 Optic neuritis (Labrador Retriever, 18 months old) The other eye was affected but not as severely. This eye showed optic atrophy months later.

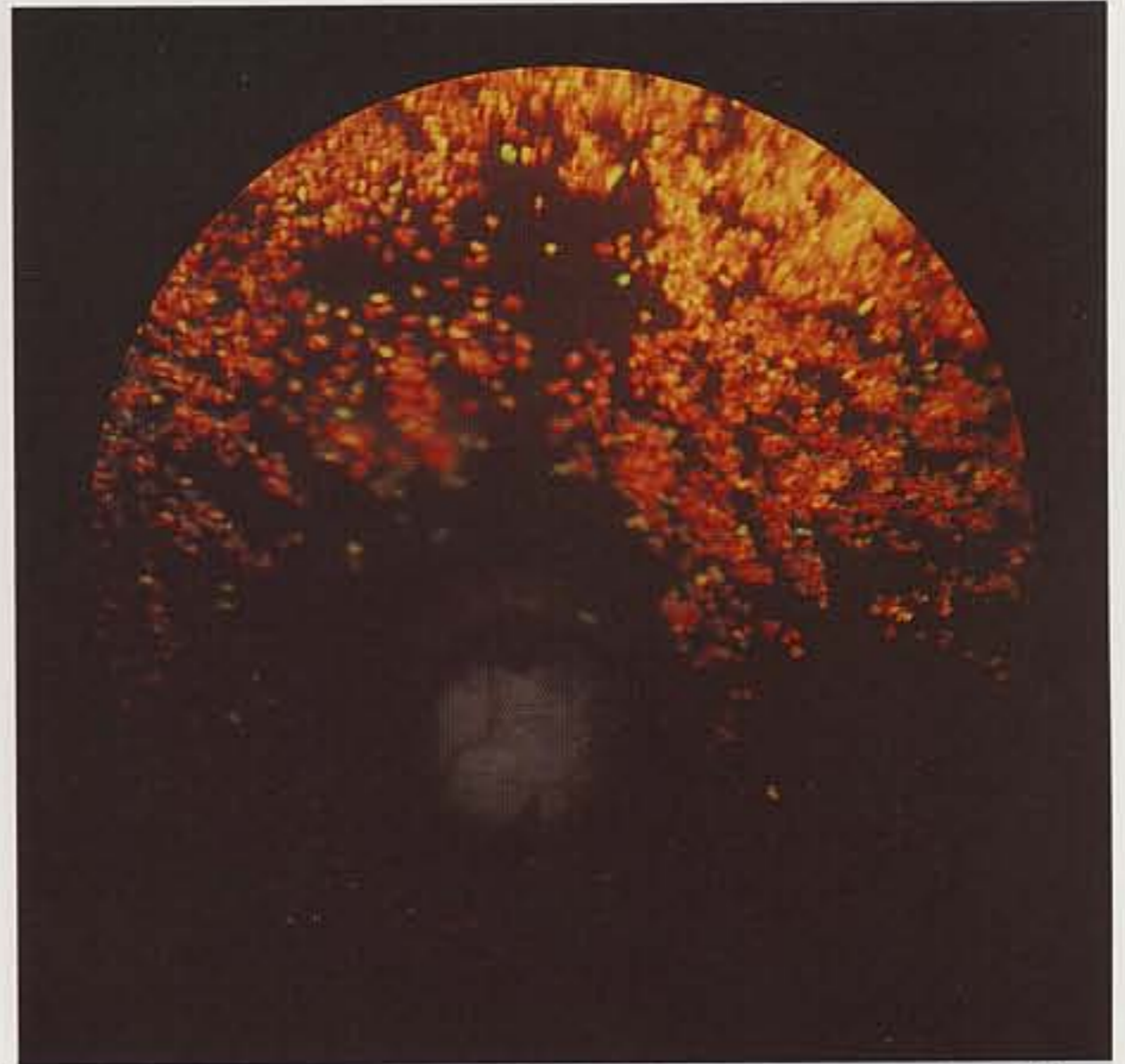

Fig. 12.7 Optic atrophy (Lhasa Apso, 18 months old) Optic atrophy following prolapse of the globe several weeks prior to ophthalmoscopic diagnosis. The eye had been blind since the accident.



Fig. 12.6 Optic atrophy (Border Collie, 5 years old) Post-inflammatory optic nerve atrophy and retinal degeneration of unknown aetiology. The eye was blind.

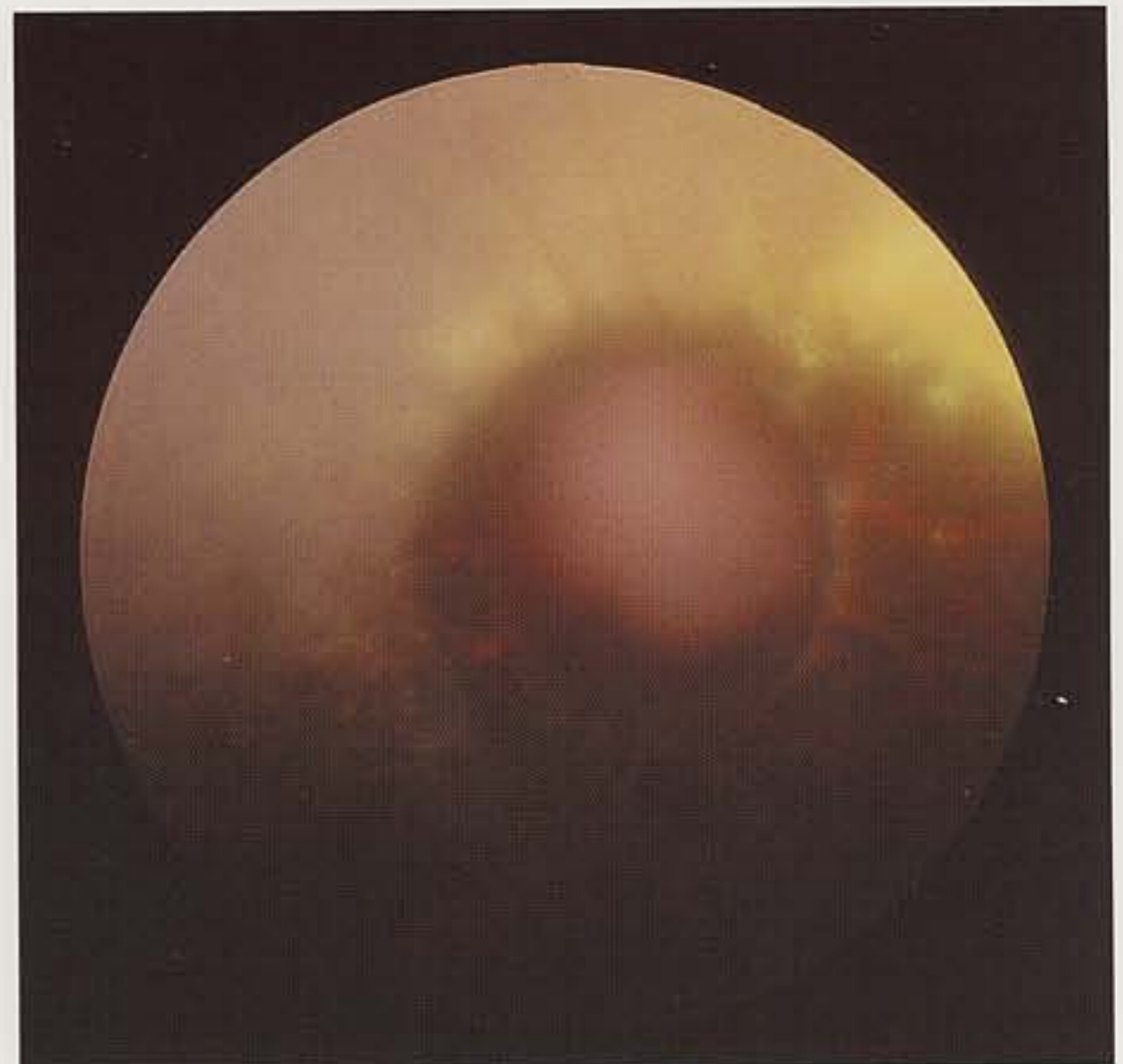


Fig. 12.8 Optic disc cupping (Welsh Springer Spaniel, 2 years old) Severe cupping of the disc due to primary glaucoma.

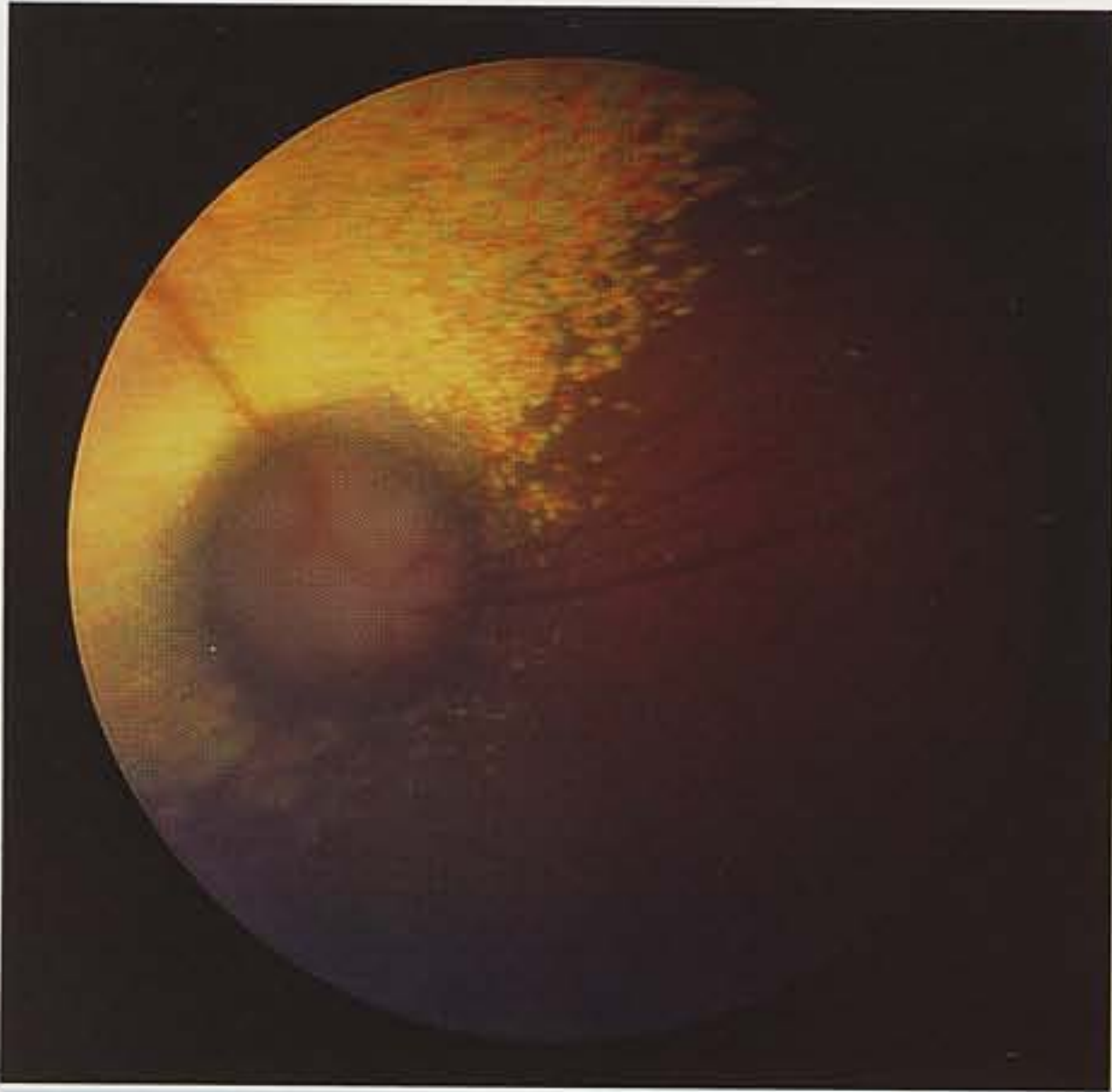


Fig. 12.9 Optic disc cupping (English Springer Spaniel, 5 years old) Cupped disc, together with retinal degeneration, due to primary glaucoma.

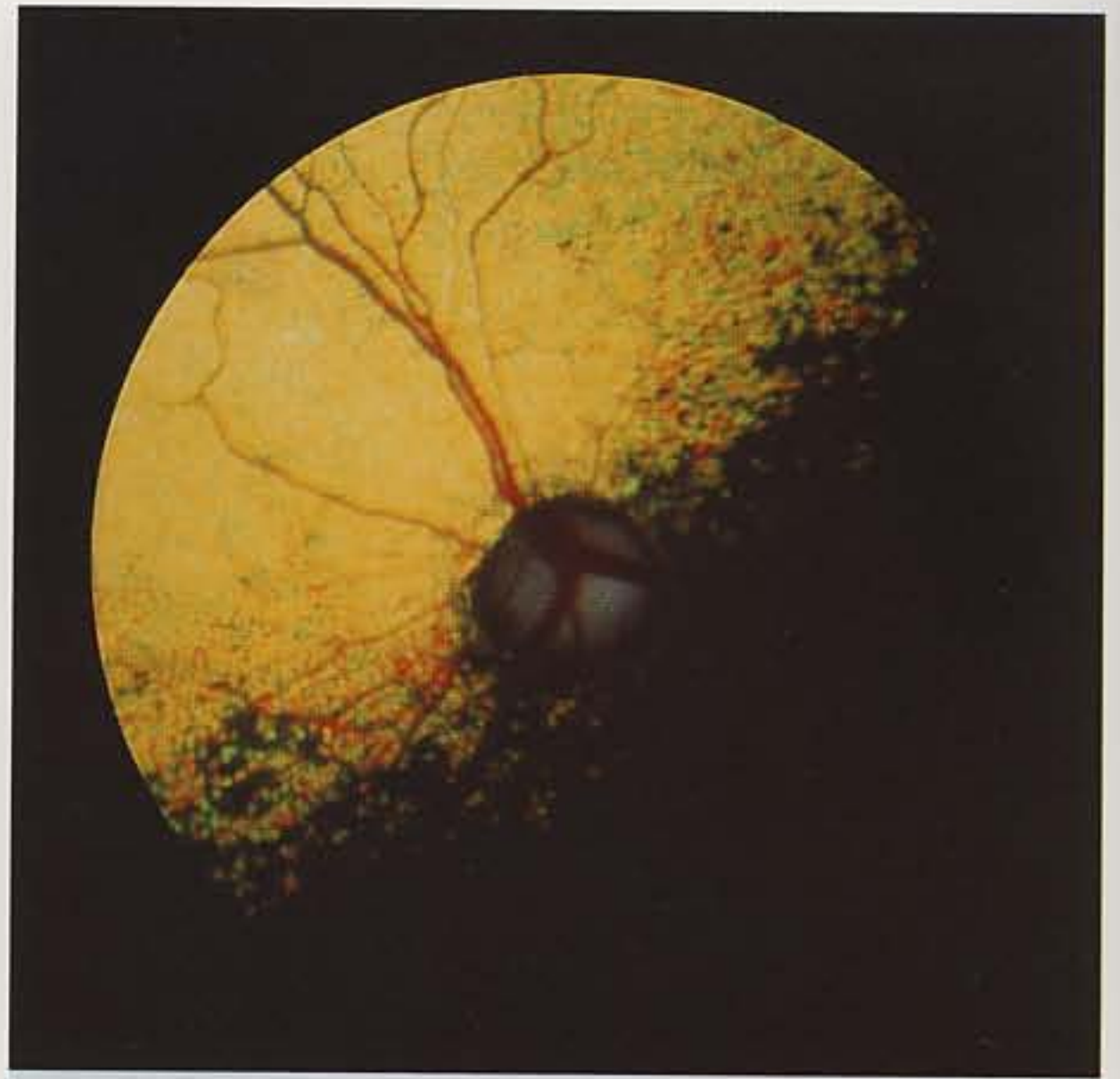

Fig. 12.11 Optic nerve hypoplasia (Toy Poodle, 2 years old) Hereditary in this breed. There was absence of the pupillary light reflex and the dog was blind. Note the large size of the retinal veins on the disc and compare this figure with micropapilla (Fig 11.30).

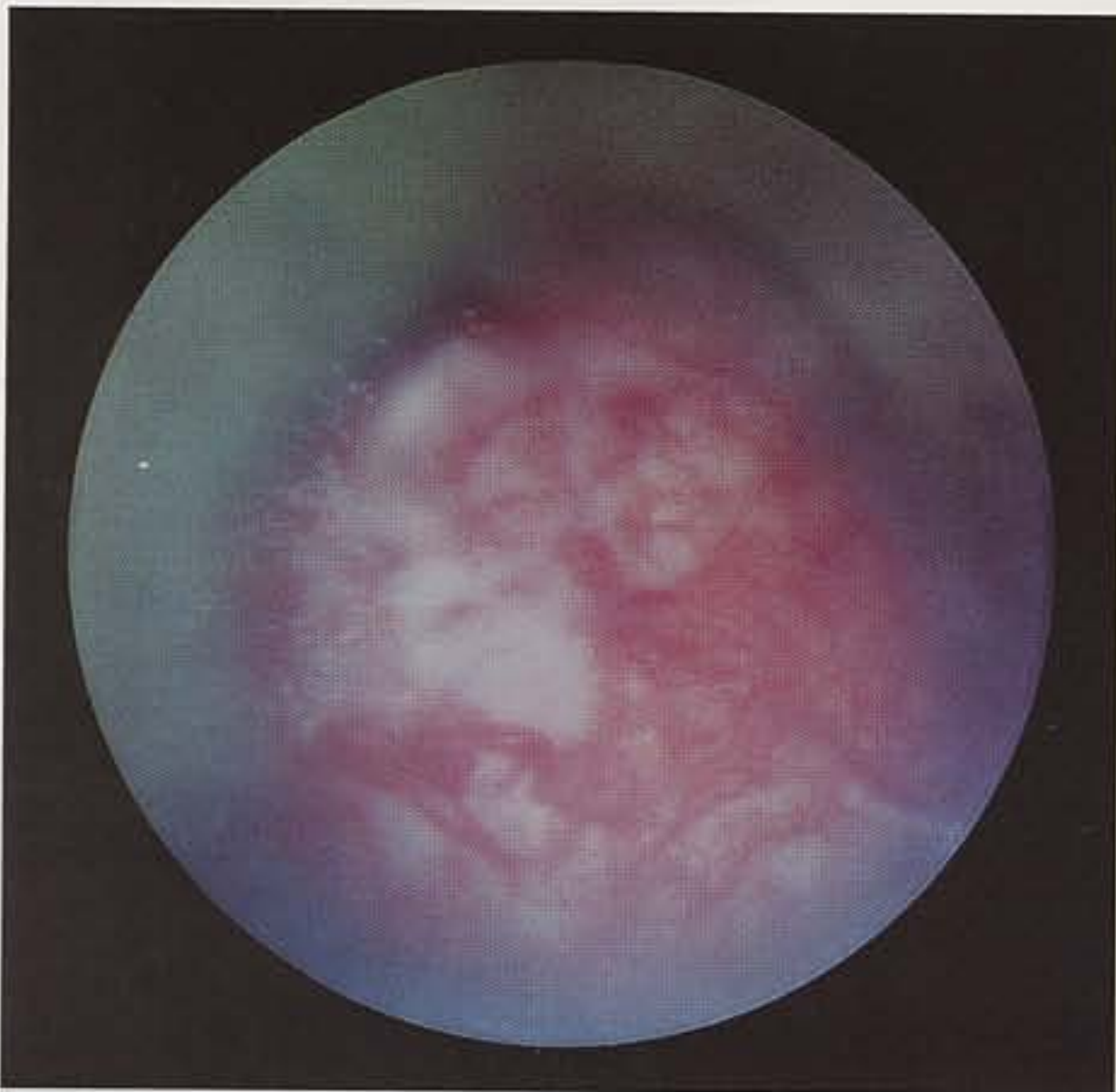


Fig. 12.10 Optic nerve tumour (Miniature Poodle, 7 years old) Retrobulbar meningioma. Note the vascular congestion on the surface of the disc and the vitreal degeneration, particularly evident to the right-hand side of the disc.

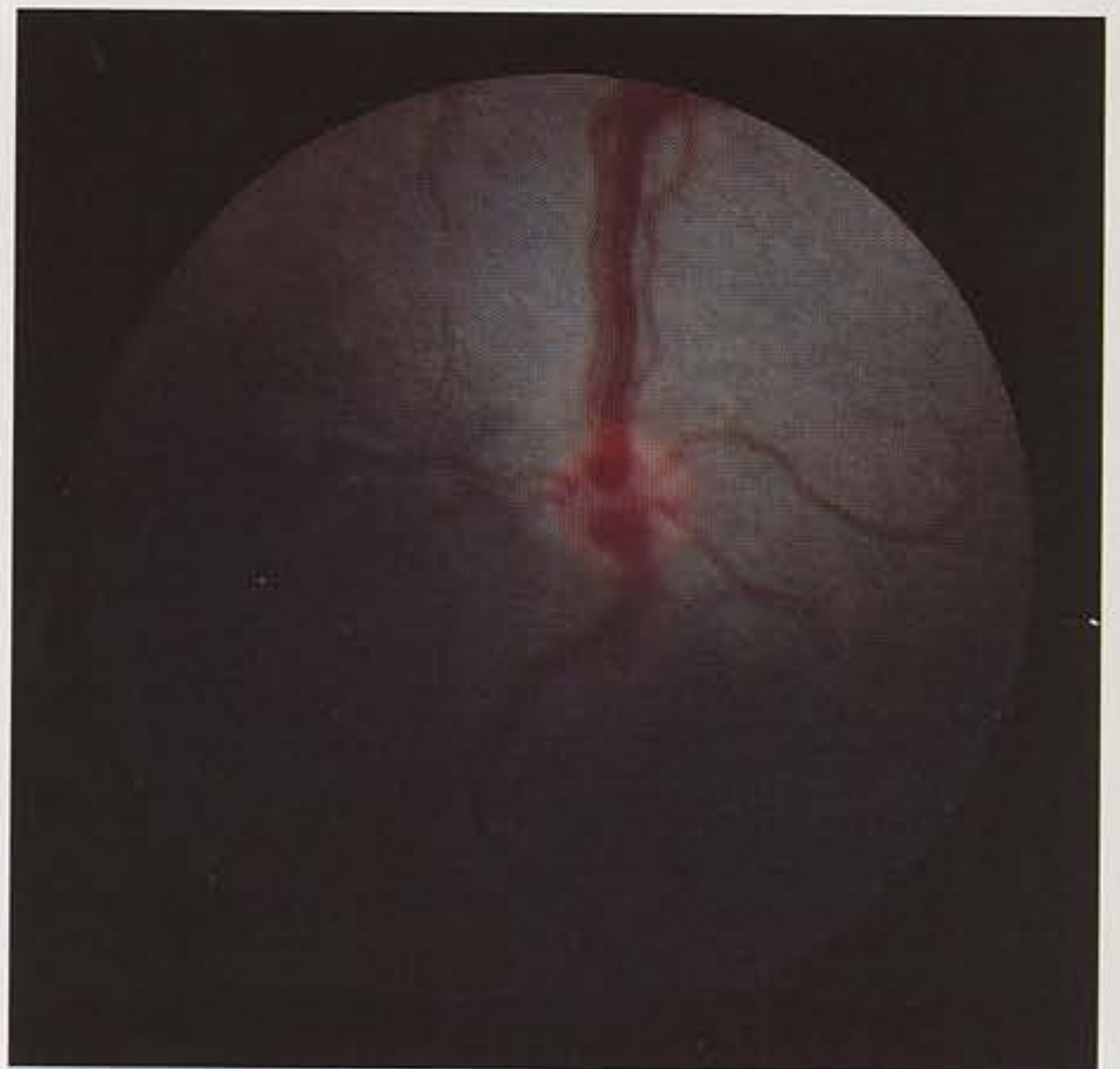

Fig. 12.12 Optic nerve hypoplasia (Shetland Sheepdog, 7 weeks old) Unilateral in this case, the other eye being normal and with a good pupillary light reflex. The affected eye had no direct pupillary reflex.

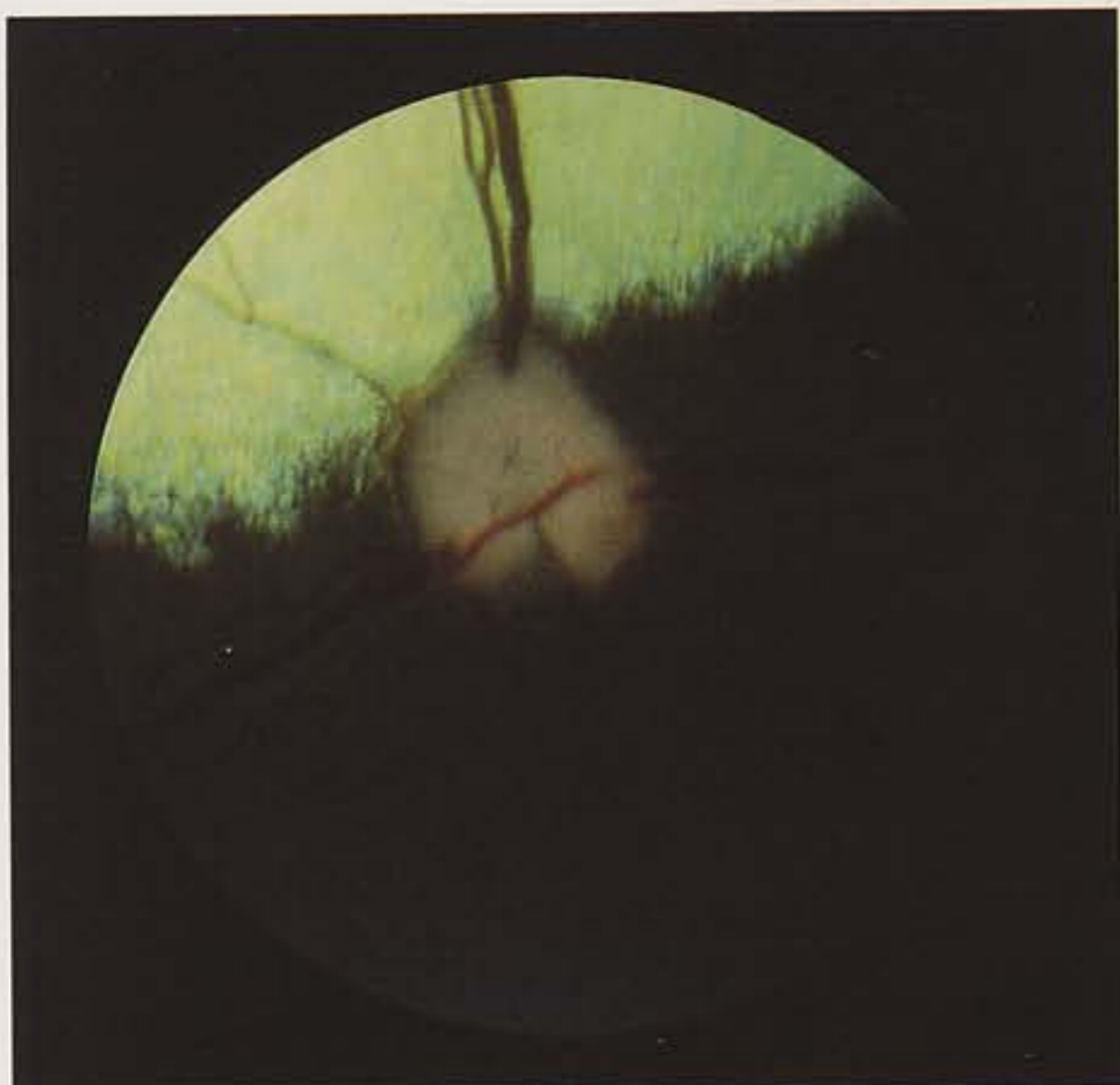

Fig. 12.13 Coloboma (Basenji, 10 years old) Typical coloboma of the optic disc at 6 o'clock. Note dipping of vessels, particularly the one at 6 o'clock. Inherited in this breed in association with persistent pupillary membrane.

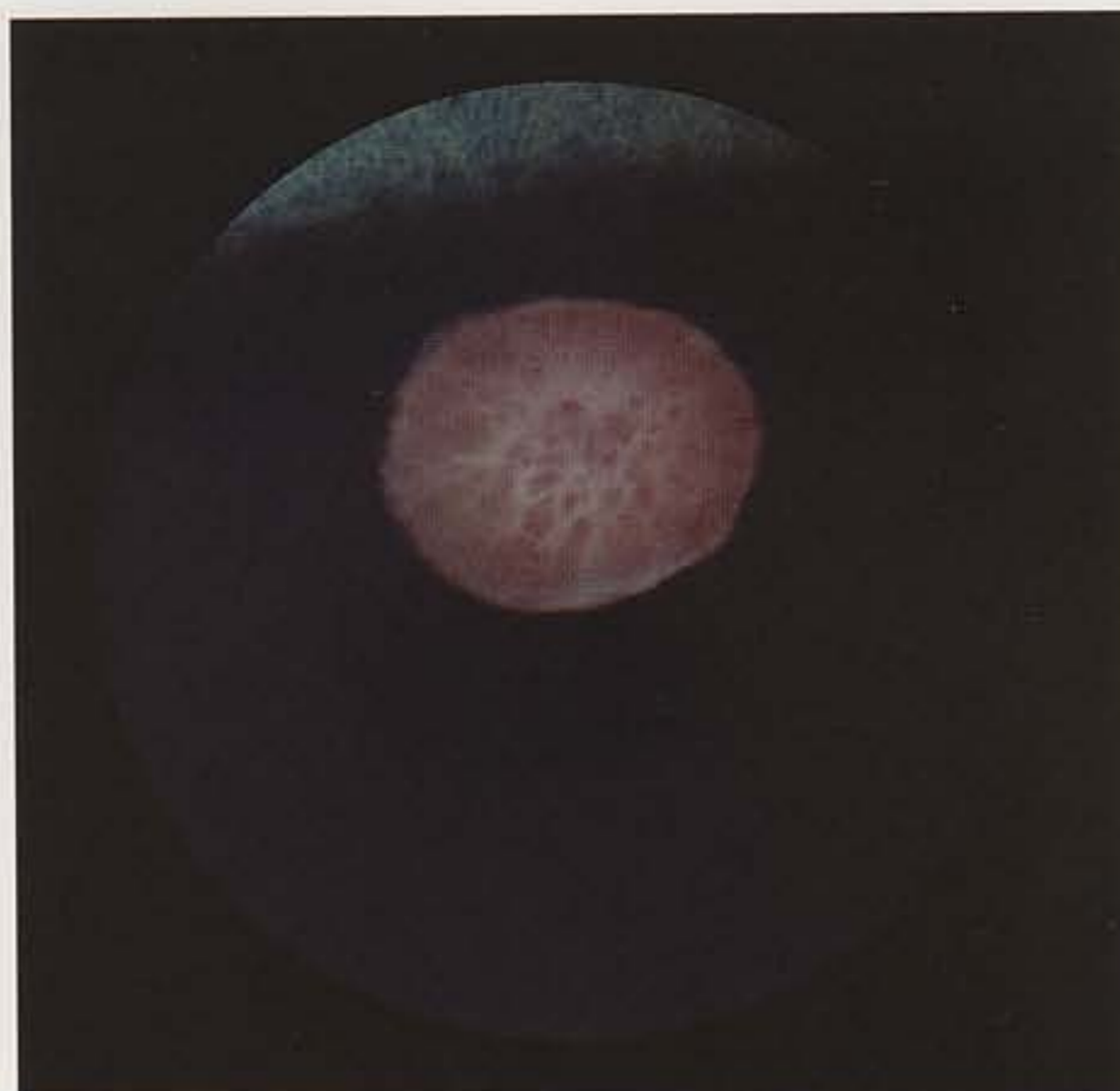

Fig. 12.15 Optic atrophy (Thoroughbred, 6 years old) Unilateral optic atrophy, the other eye being normal, and a consensual light reflex present. Optic atrophy, usually due to trauma, is not uncommon in this species.

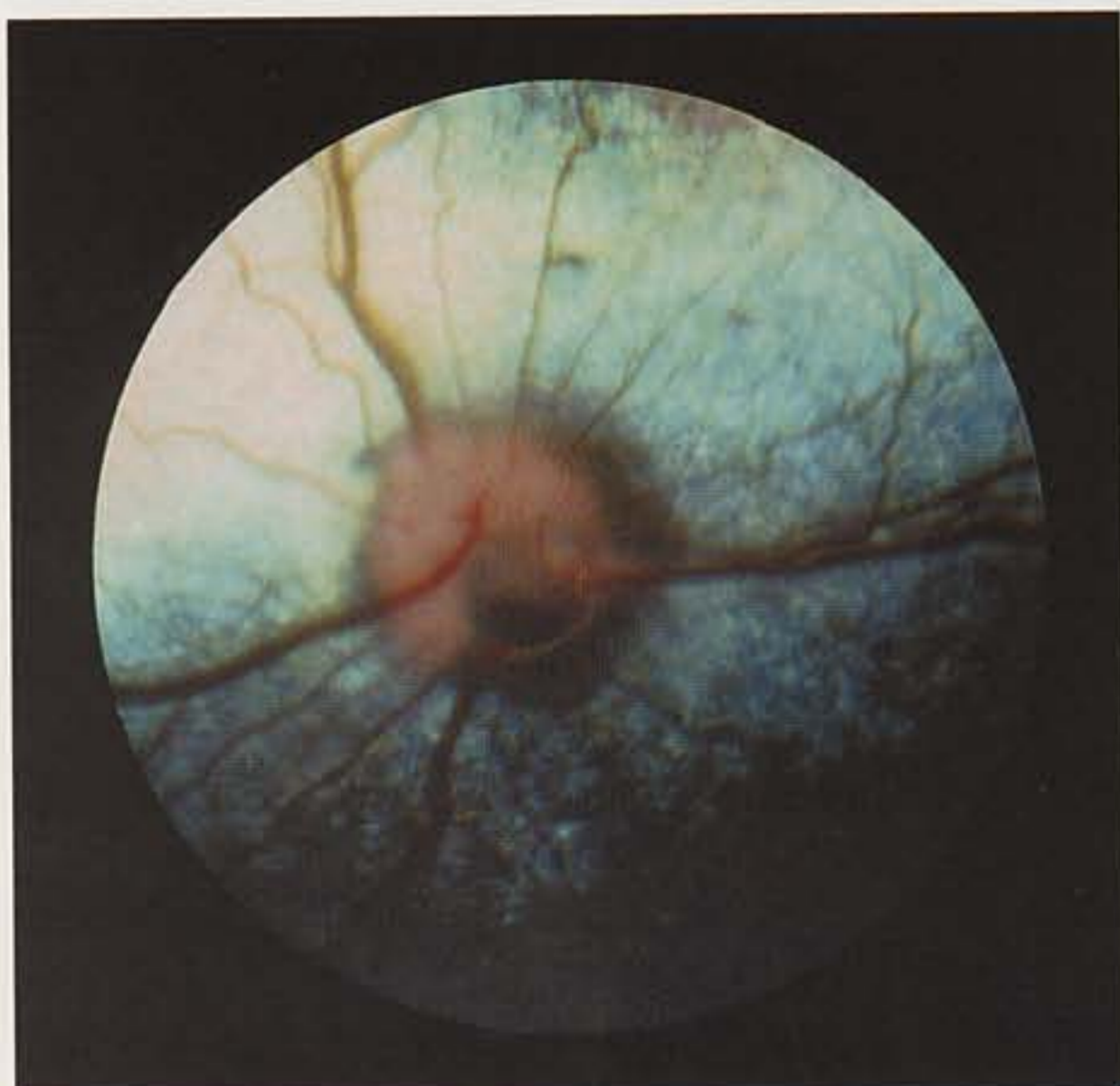


Fig. 12.14 Coloboma (Beagle, 1 year old) Typical disc coloboma at 6 o'clock. Unilateral in this case and with no evidence of heredity in this breed.

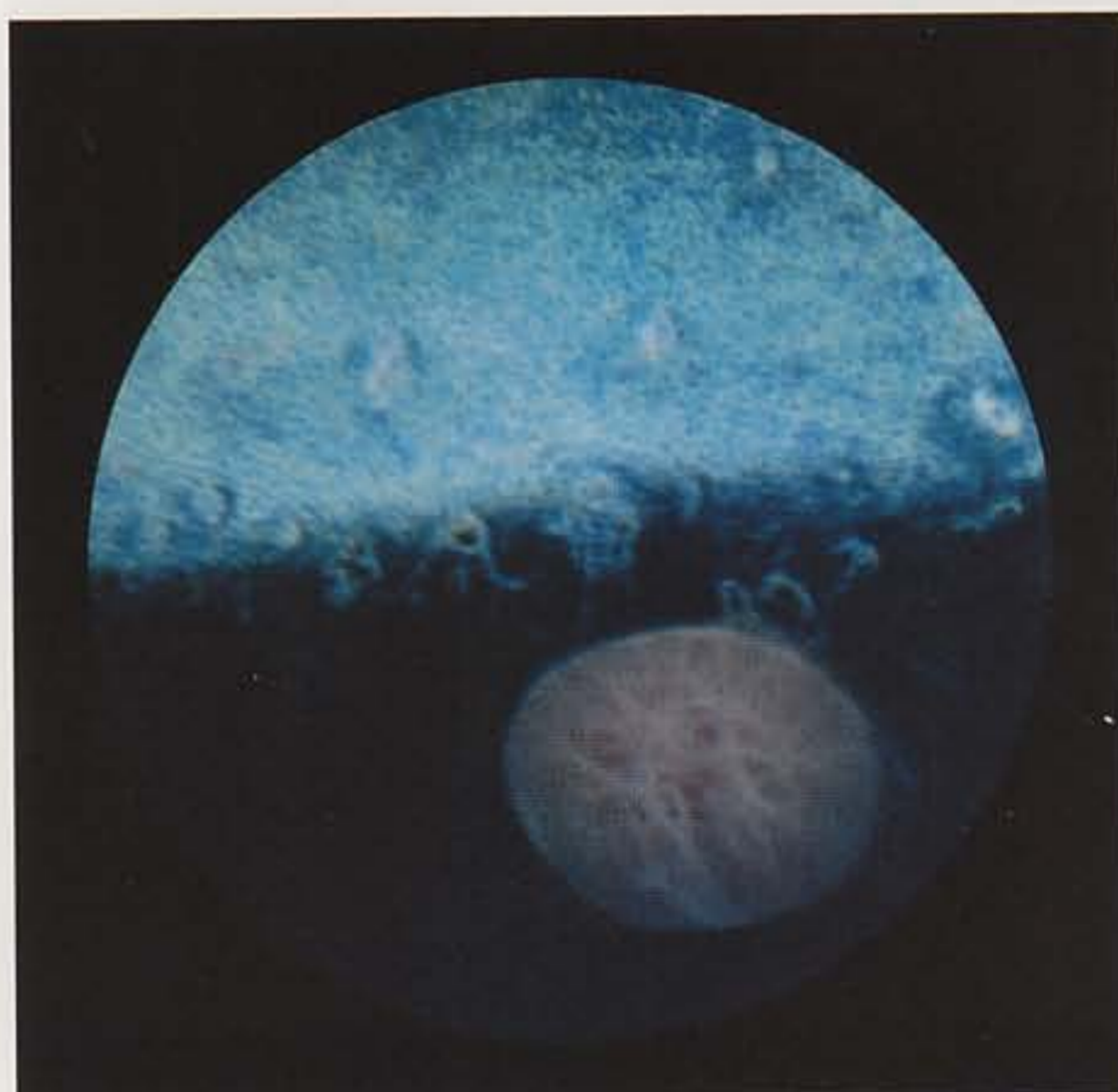


Fig. 12.16 Optic atrophy (Thoroughbred, 1 year old) Bilateral optic atrophy with secondary retinal degeneration. Note the grey disc with absence of retinal vessels.

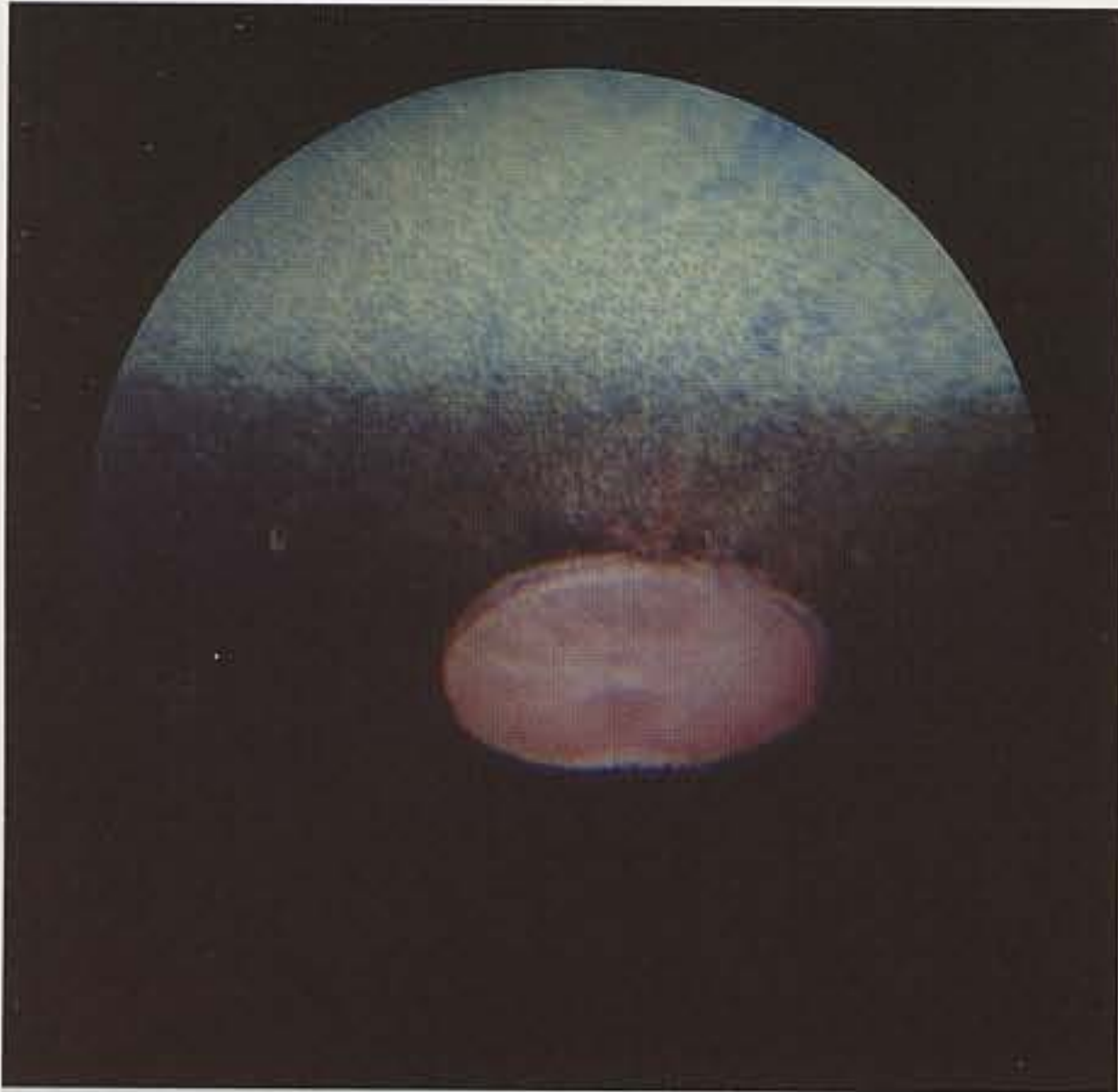


Fig. 12.17 Optic atrophy (Welsh Cob, 5 years old) Note the very pale disc (the shape of the disc is not significant).

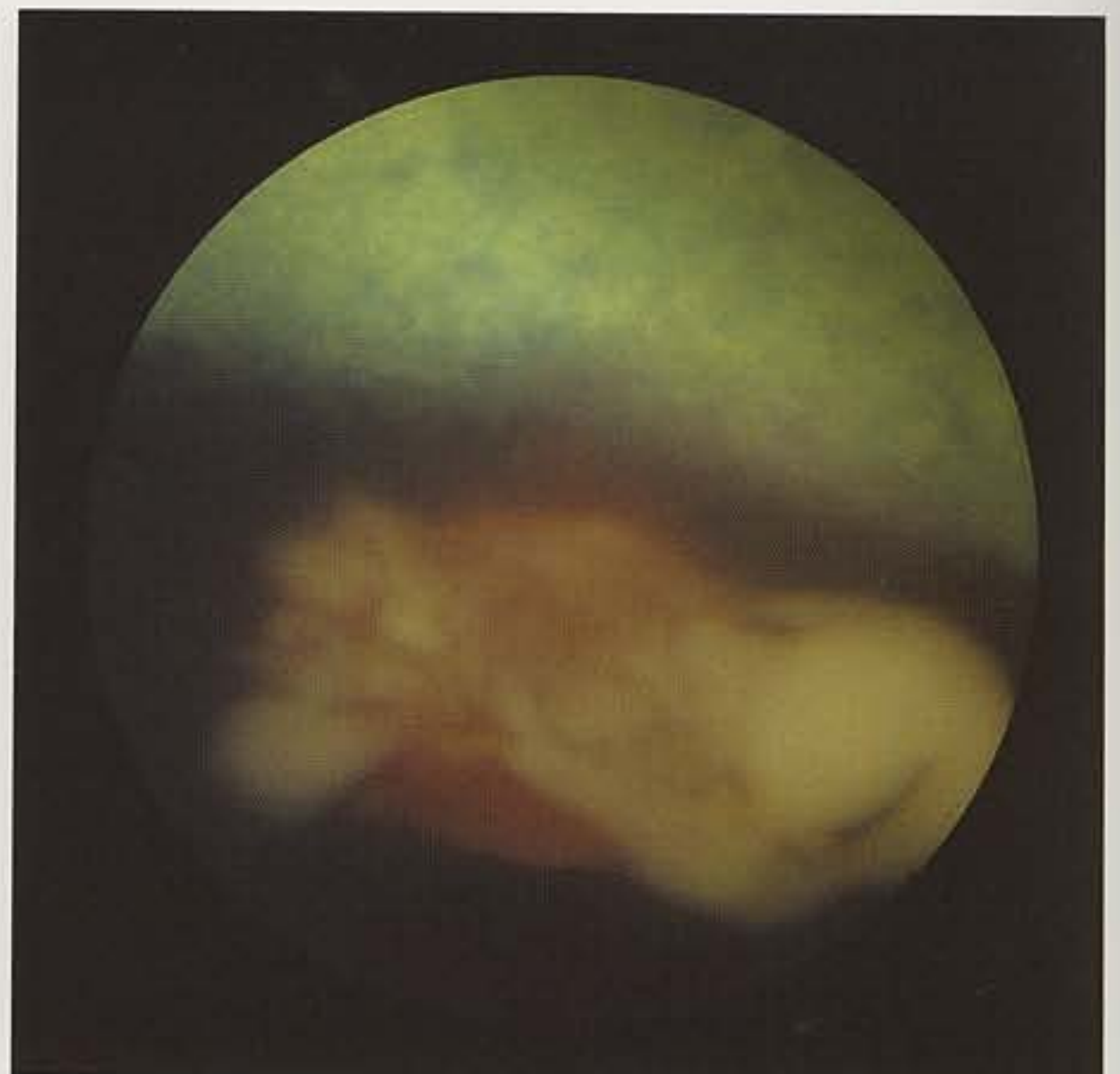


Fig. 12.19 Proliferative optic neuropathy (Thoroughbred, 4 years old) Extrusion of glial material into the vitreous following a massive haemorrhage not involving the eye.

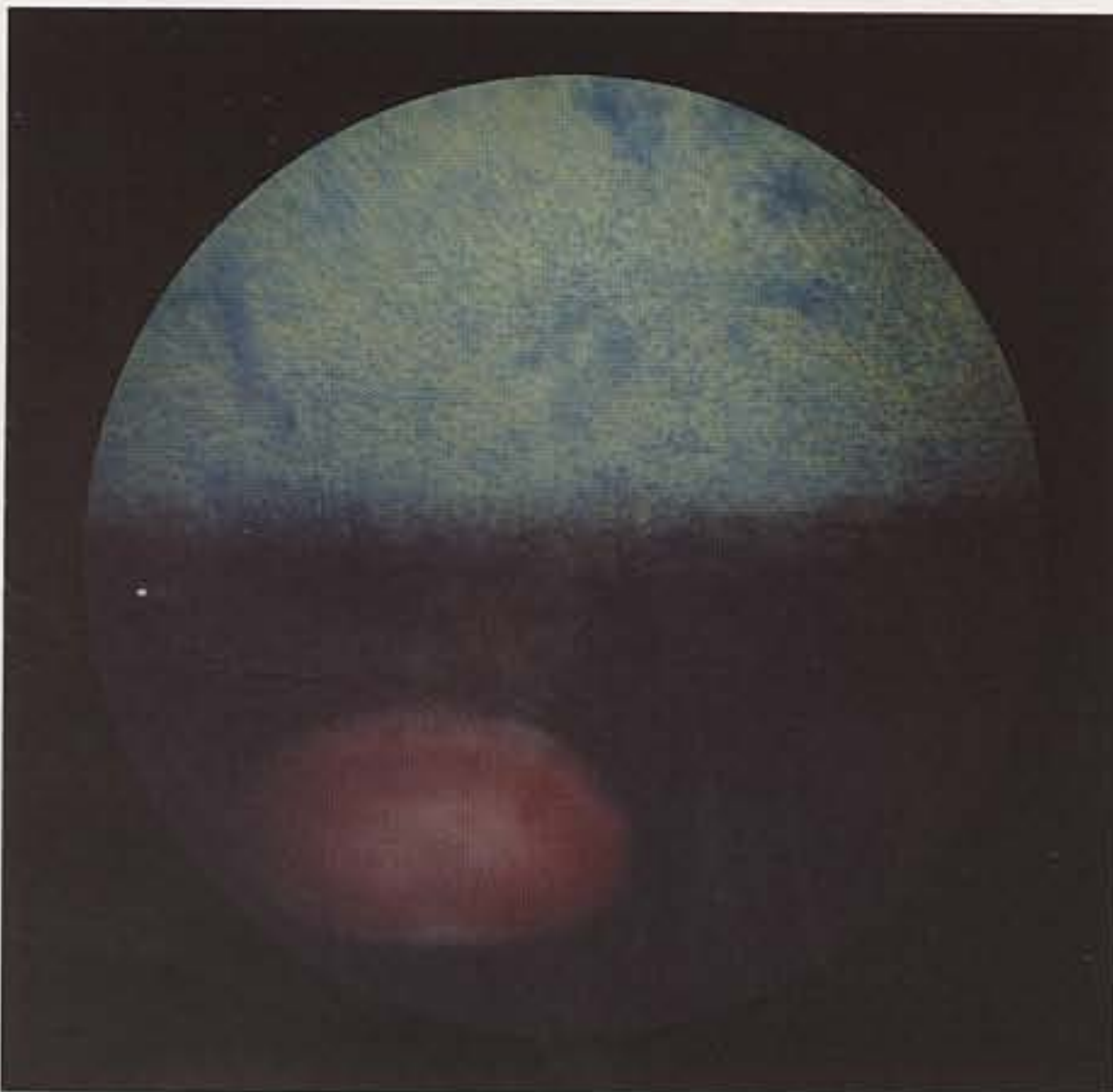


Fig. 12.18 Normal disc (Welsh Cob, 5 years old) The other eye of the same horse shown in Fig 12.17, to compare the disc colour and shape.

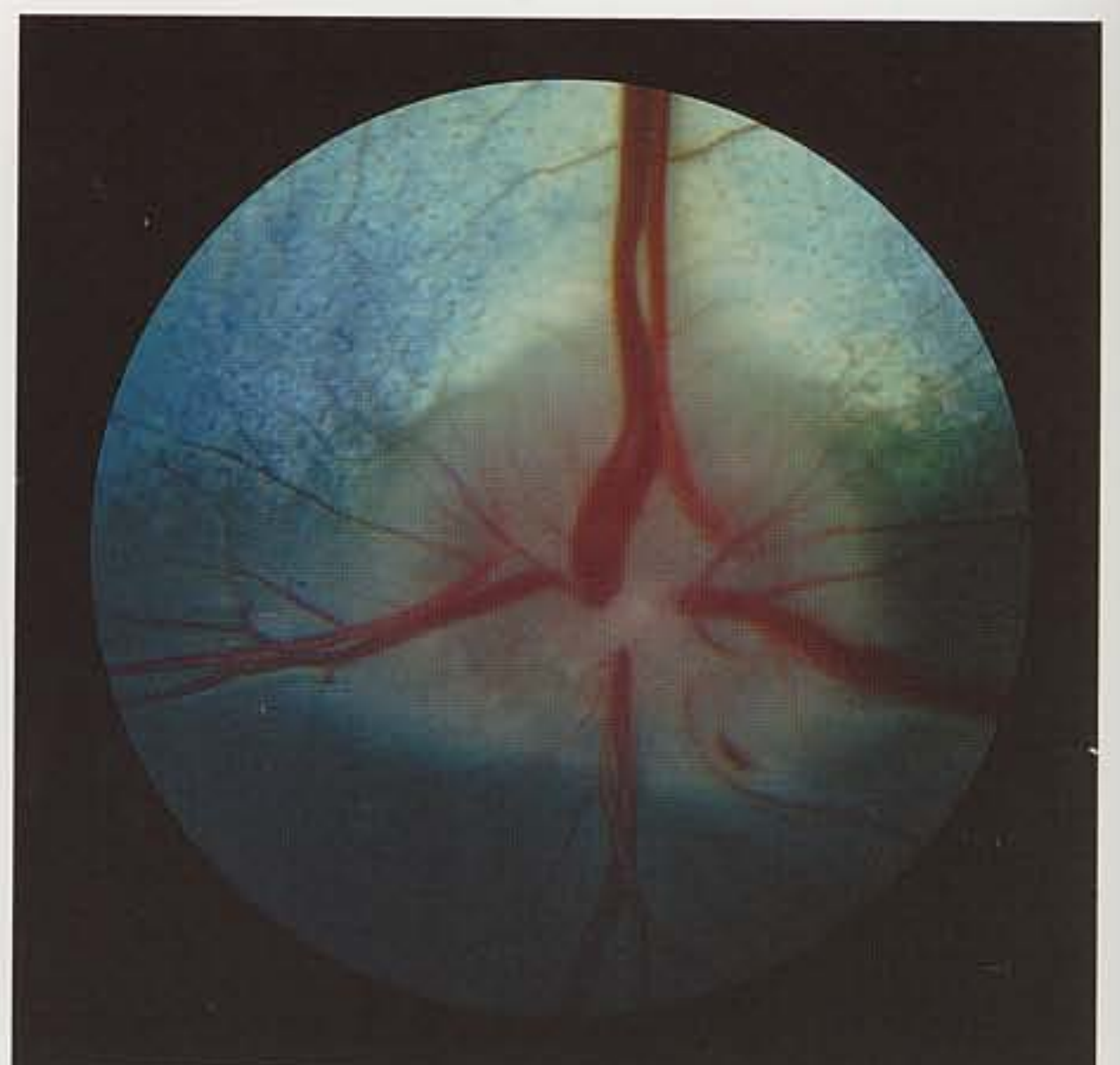

Fig. 12.20 Papilloedema (Ayrshire calf) Papilloedema in vitamin A deficiency. Note the small flame-shaped haemorrhage at 5 o'clock.

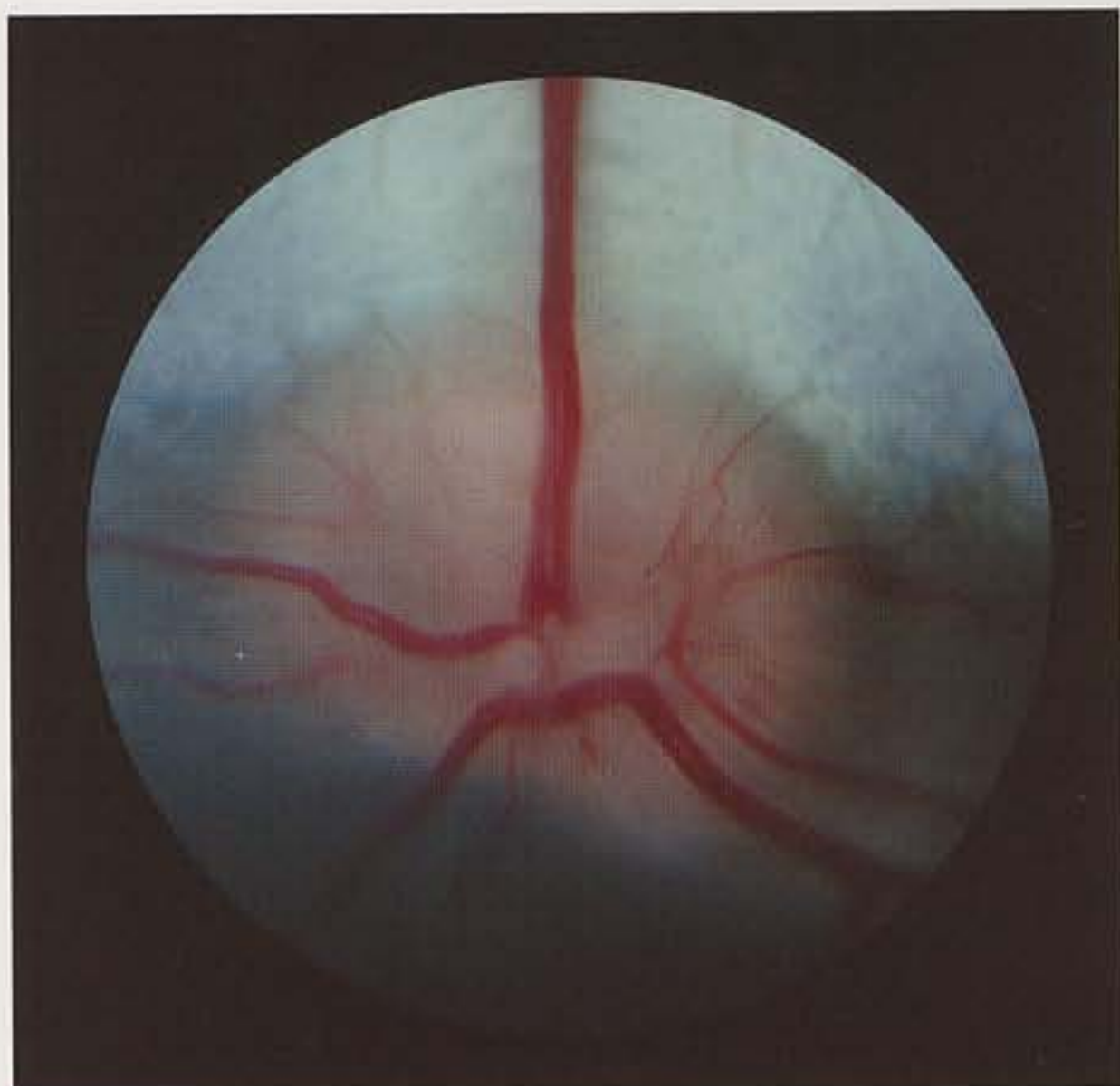


Fig. 12.21 Papilloedema (Shorthorn calf) Advanced papilloedema due to vitamin A deficiency. Note the enlarged disc with fuzzy outline, congested vessels on the disc and vessels dipping over the edge of the disc.

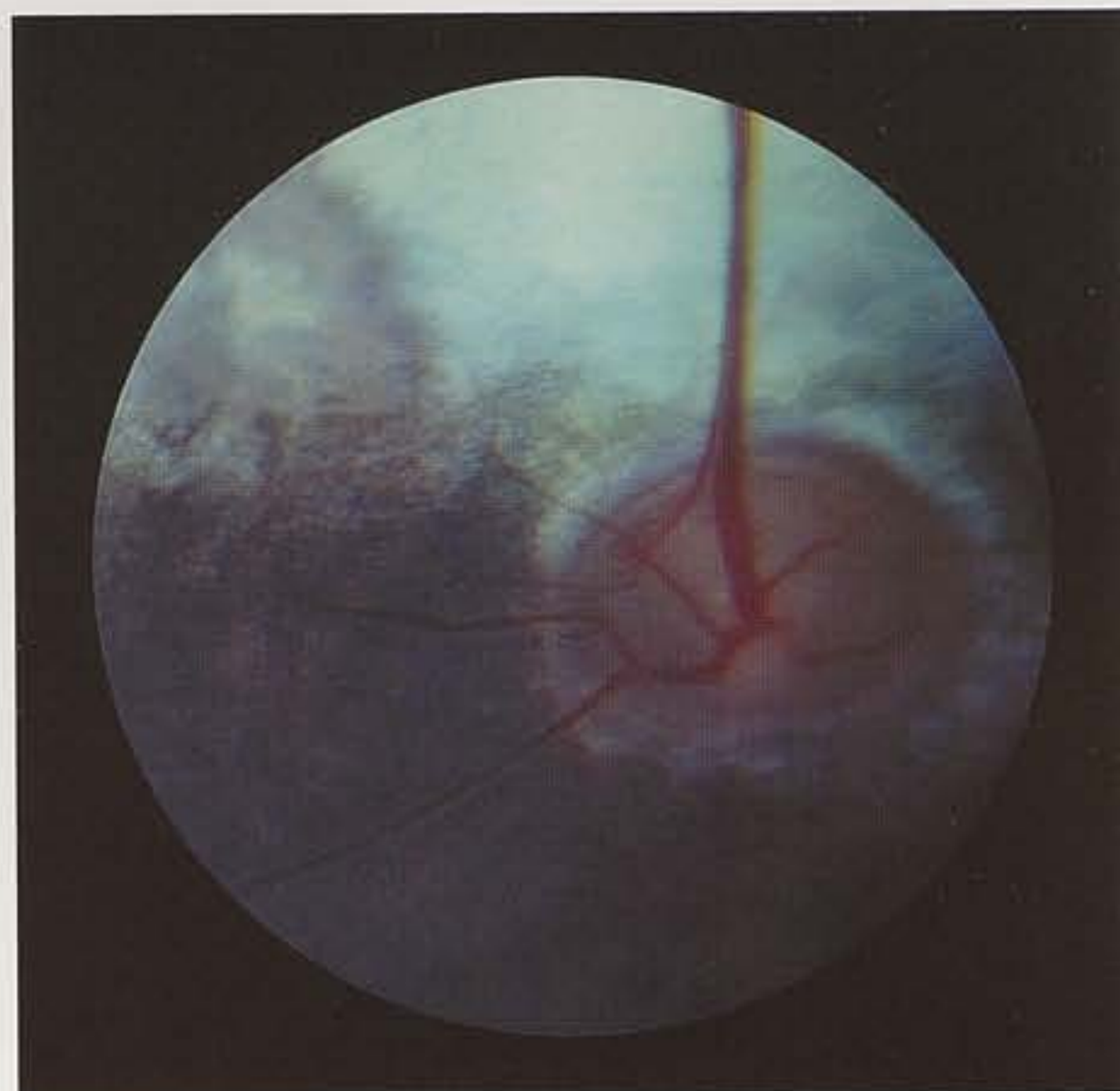

Fig. 12.23 Optic atrophy (Shorthorn heifer, 18 months old) Optic nerve degeneration following papilloedema due to vitamin A deficiency.

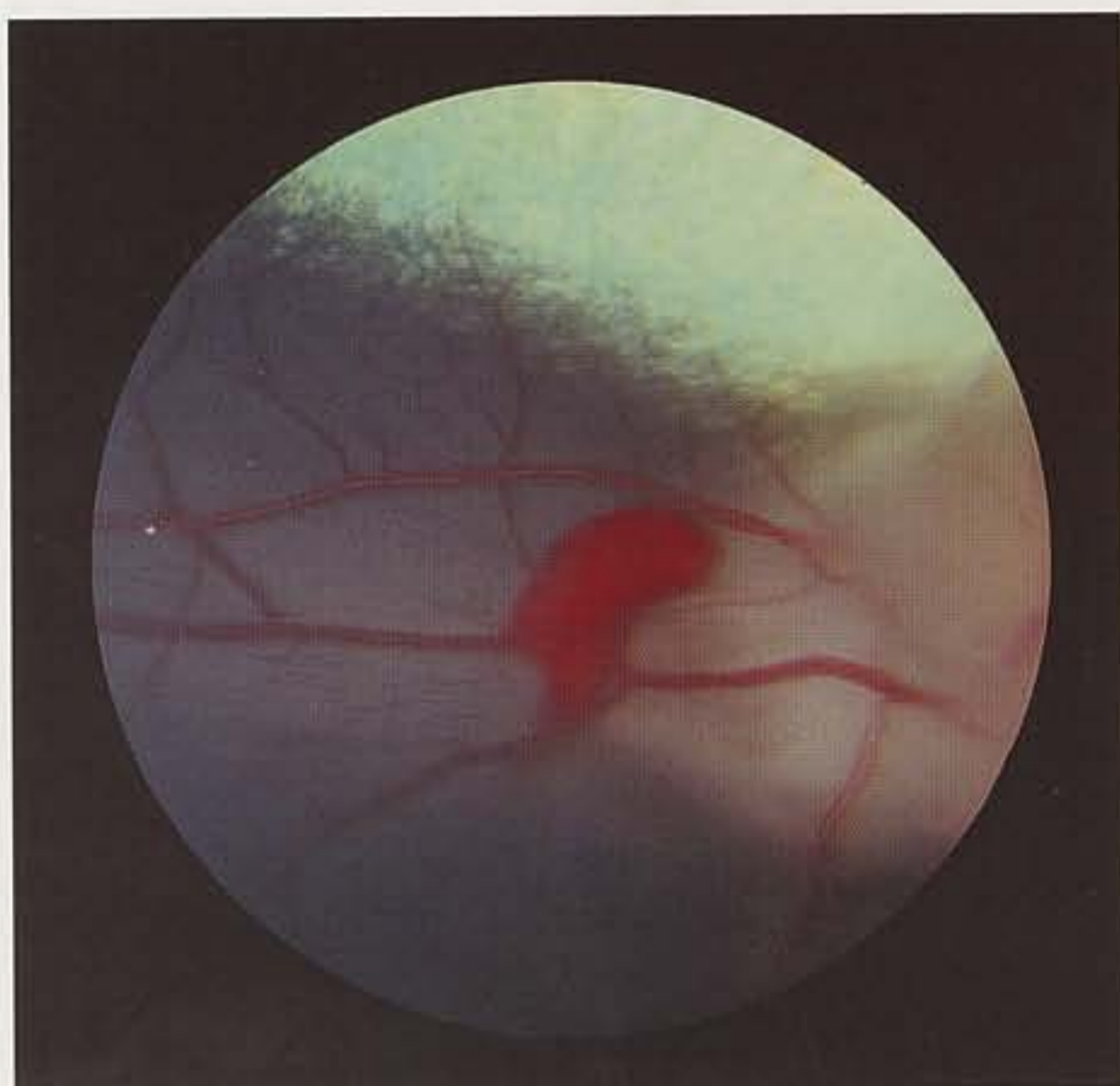


Fig. 12.22 Papilloedema (Friesian bullock) Note the large haemorrhage at the edge of the disc. Another vitamin A deficiency case.



Fig. 12.24 Optic atrophy and retinal degeneration (Guernsey calf) Linear pale areas in the non-tapetal fundus in an advanced case of vitamin A deficiency with early optic disc atrophy. Note the similar appearance to the secondary retinal degeneration with optic atrophy in the horse (Fig 12.16).

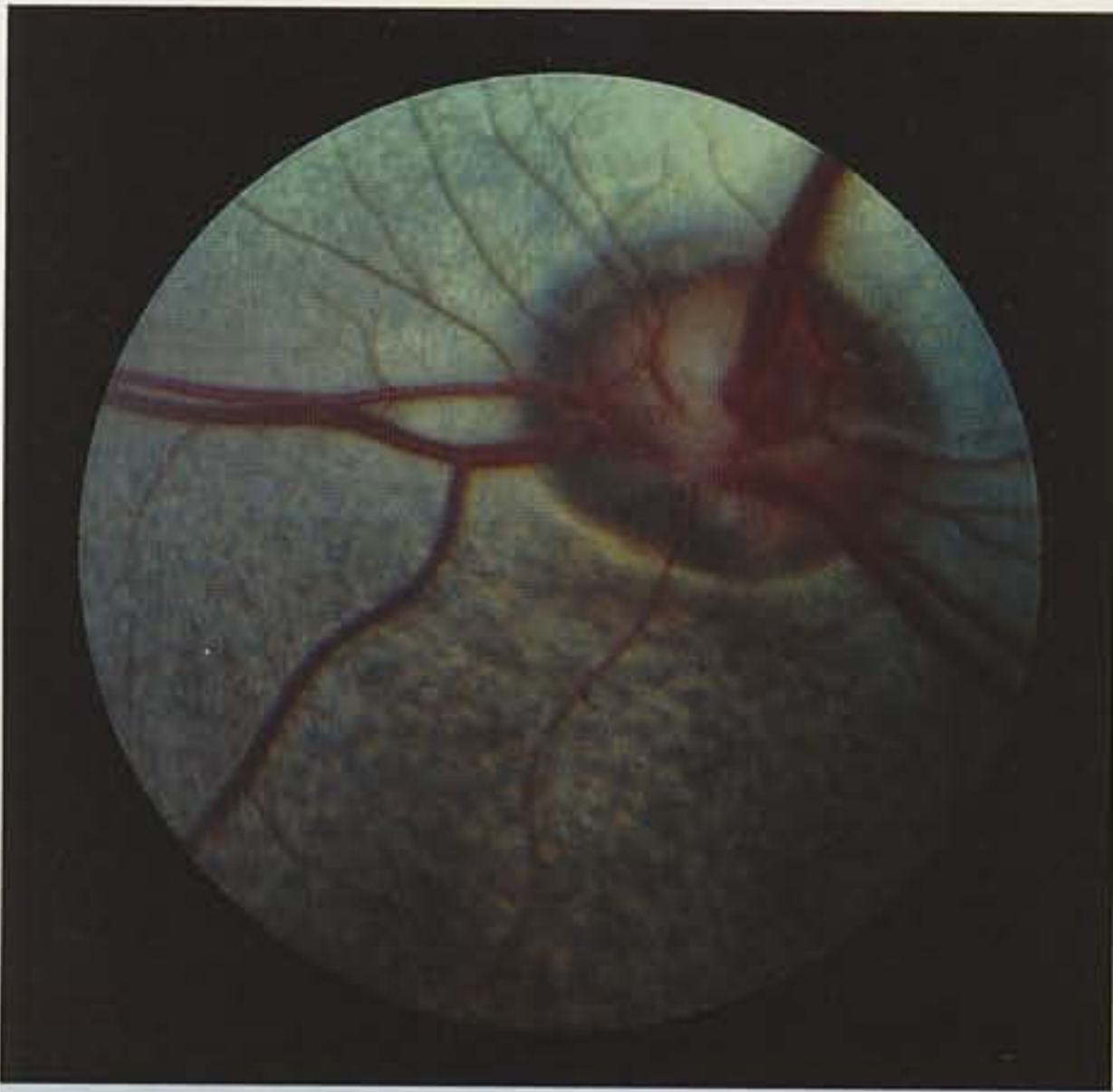


Fig. 12.25 Coloboma (Charolais, 2 years old) Mild colobomatous change with pigmentary disturbance in the non-tapetal fundus below the disc.

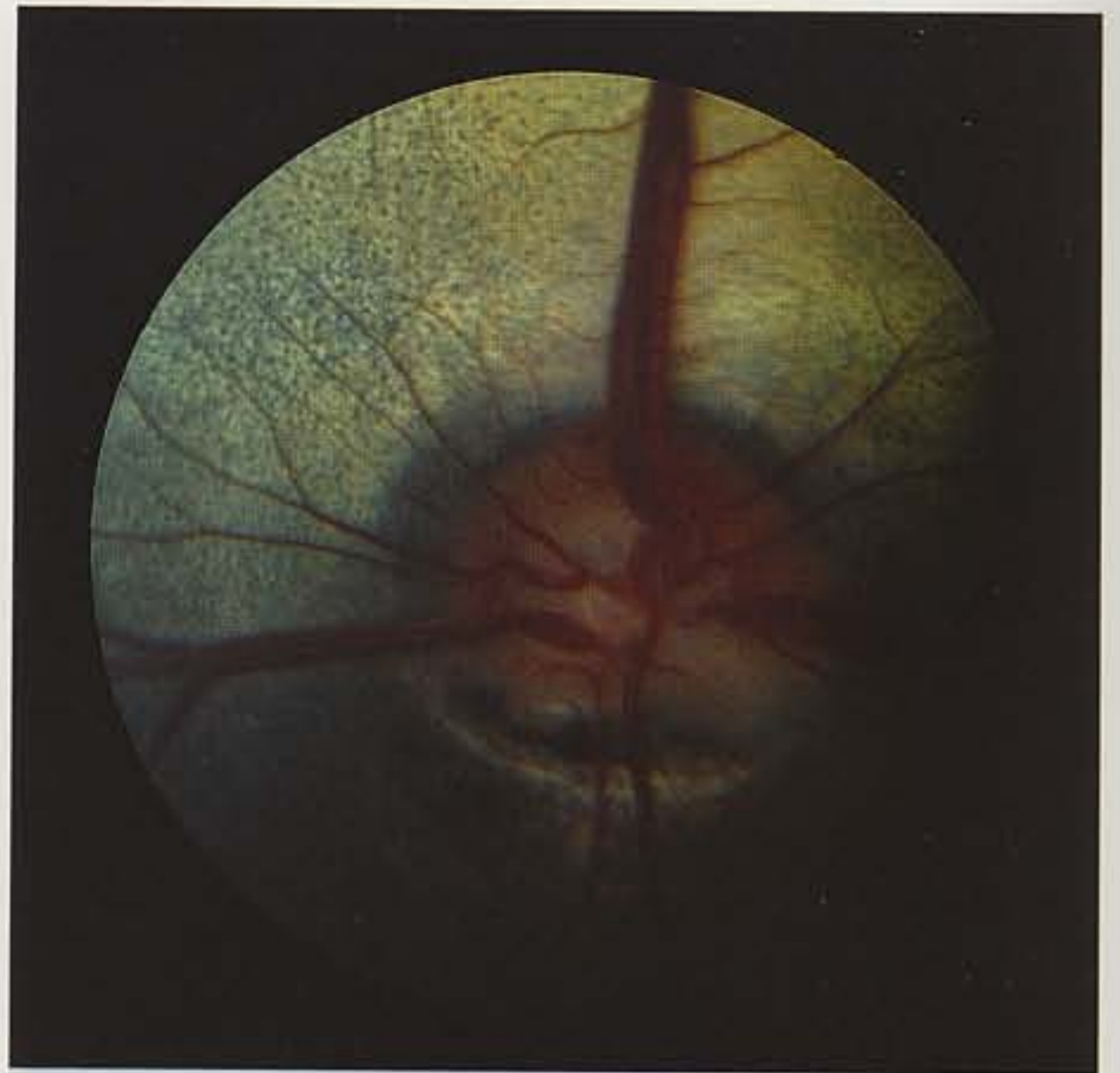


Fig. 12.26 Coloboma (Charolais, male) Mild coloboma at the lower edge of the disc and again note the pigmentary change below the disc similar to Fig 12.25.

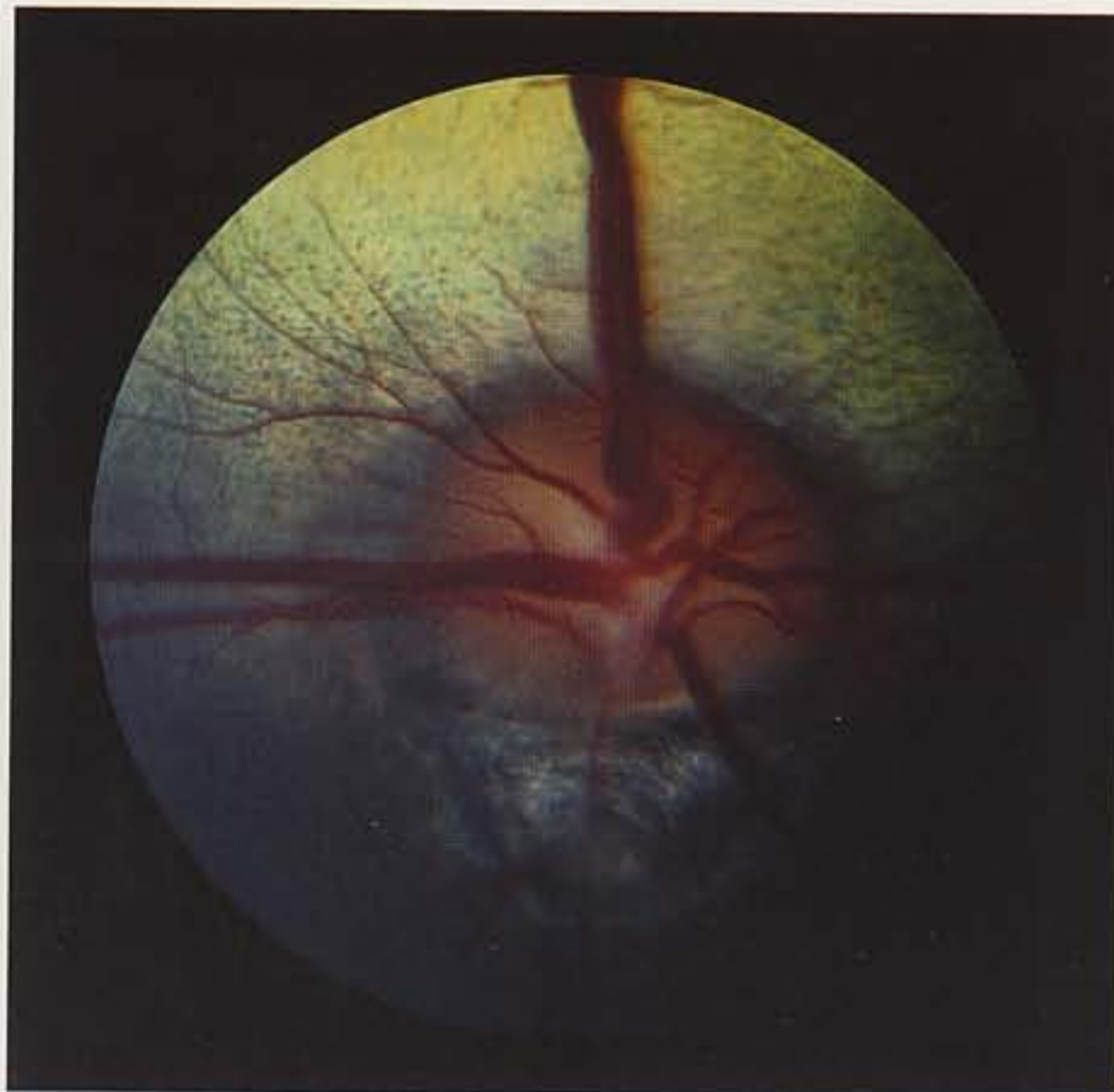


Fig. 12.27 Coloboma (Charolais, male) Triangular coloboma immediately below the disc.

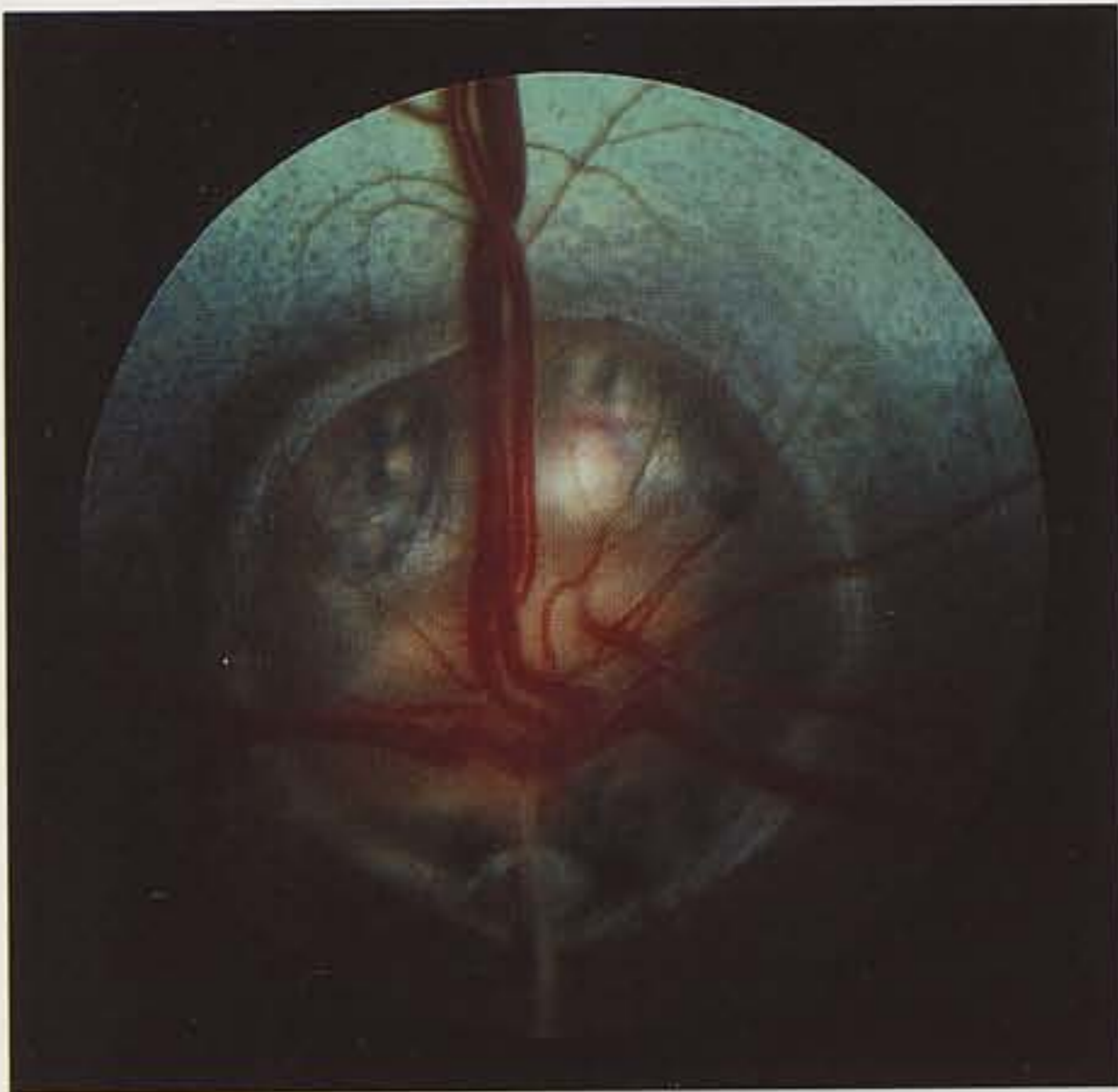


Fig. 12.28 Coloboma (Charolais, female, 4 months old) Coloboma of the whole disc and peripapillary region. Note the abnormal and persistent hyaloid artery.

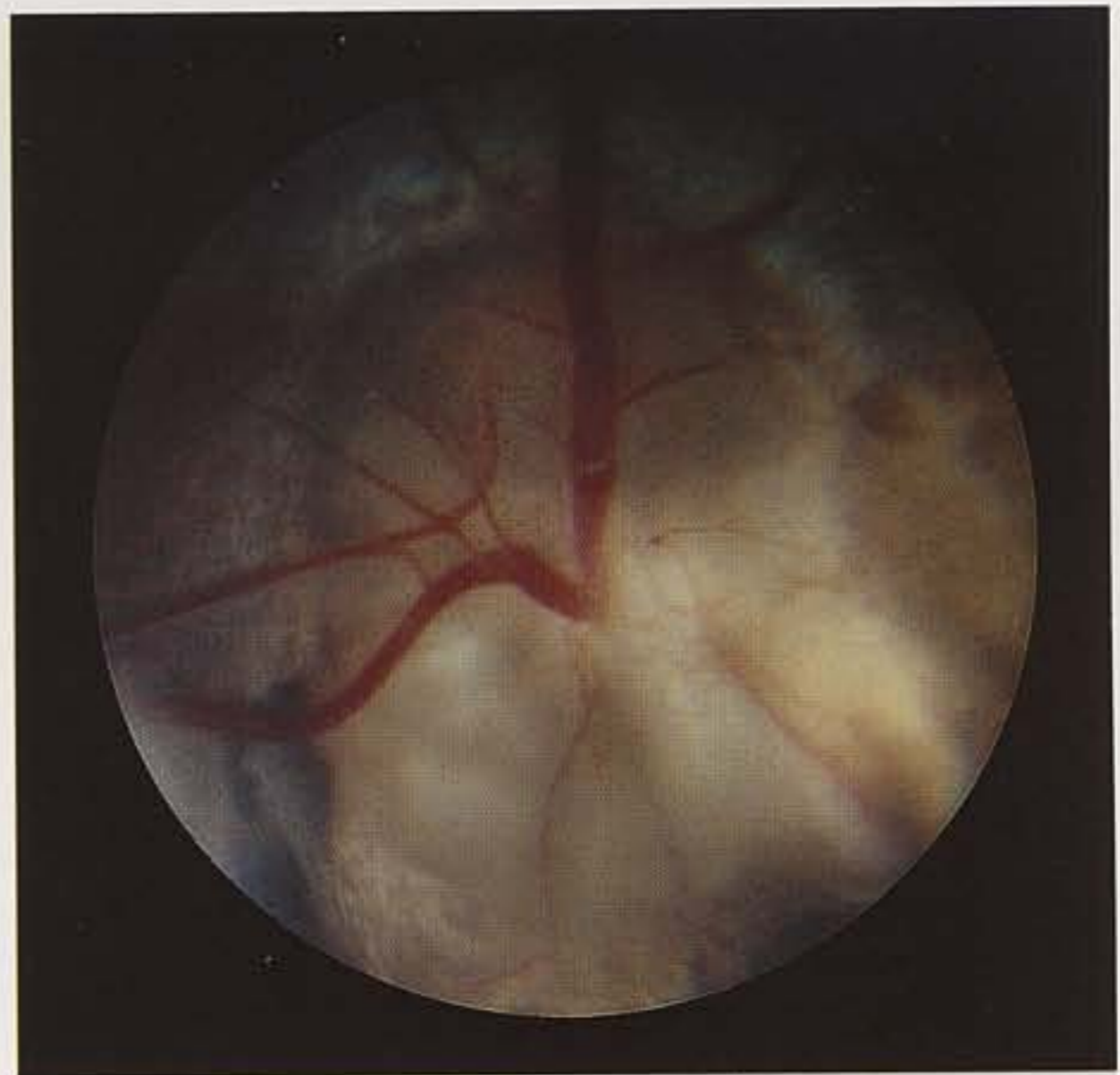


Fig. 12.29 Coloboma (Charolais bull) Severe coloboma of the disc and the surrounding area. This was the only animal in this series with evidence of defective vision.

**Table 12.1 - The blind eye**

Vision loss as a presenting sign is usually due to a bilateral condition, as unioocular blindness is rarely noted by owners unless there is an accompanying sign, e.g. pain or altered appearance of the eye.

**Causes**

- Trauma, e.g. prolapse
- Uveitis – red, painful eye
- Glaucoma – dilated pupil and pain
- Cataract (diabetic cataract can be sudden in onset and is bilateral)
- Haemorrhage – trauma, coagulopathy, neoplasia, Collie eye anomaly (CEA)
- Retinal detachment
- Chorioretinitis – inflammatory lesion, sudden or progressive
- Sudden acquired retinal degeneration (SARD) – fundus normal

- at presentation but flat ERG
- Intracranial lesion – neoplasia: ERG may be normal
- Toxicity, e.g. bright blindness in sheep
- Taurine deficiency (cat)
- Generalized progressive retinal atrophy (GPRA) – slowly progressive: breed incidence
- Retinal pigment epithelial dystrophy (RPED) – progressive but total blindness uncommon: breed incidence
- Collie eye anomaly (CEA) – blindness rare: breed incidence
- Retinal dysplasia: breed incidence
  - Total retinal dysplasia (TRD) – total blindness
  - Multifocal retinal dysplasia (MRD) – defective vision rare
- Papilloedema – eventual vision loss
- Optic neuritis – blindness
- Optic atrophy – blindness

# Index

## A

Abscess, corneal 67  
Acute purulent conjunctivitis 36  
Adenocarcinoma, ciliary body 81  
Adenoma, ciliary body 81  
Amelanotic melanoma 84  
Anterior polar cataract 116  
Aphakic crescent 124  
Aqueous 94, 96  
Asteroid hyalosis 131–2  
Atopic conjunctivitis 36–7

## B

Blepharitis 16–17  
Blind eye 211  
Blood vessels, retinal 142, 146–7, 151  
Buphthalmos 6

## C

Cartilage deformity 26–7  
Cataracts 70, 78  
    and microphthalmos 108–9  
    bilateral 104–5  
    central 102  
    cortical 103  
    dislocated 127  
    early 101  
    late-onset 101  
    nuclear 106–7, 110  
    partial 104  
    posterior polar 98–100, 102–3  
    posterior synechiae and 76  
    progressive 104–5  
    secondary to glaucoma 112  
    secondary to retinal disease 111–12  
    symmetrical 105  
    total 99–105  
    two foci of 103  
Central progressive retinal atrophy (CPRA) 162  
Chemosis 25, 37  
Chorioretinal dysplasia (CRD) 168, 172–4  
Chorioretinitis 188  
Chorioretinopathy 199  
Chronic conjunctivitis 36  
Collie eye anomaly (CEA) 162, 168–72, 180  
Colobomas

    and cataracts 113  
    eyelids 21  
    fundic 176–8, 193, 198  
    optic disc 206–7, 209–10  
    retinal 201  
    uveal tract 78, 84–5  
    with chorioretinal dysplasia 174–5

Cone dysplasia 163

Cone/rod dystrophy 167–8

Conjunctiva

    calcinosis 39  
    cysts 25, 41–2  
    dermoids 41  
    haemorrhages 37–8

Conjunctivitis 35–7

    acute purulent 36  
    atopic 36–7  
    chronic 36  
    follicular 24, 36  
    infectious bovine keratoconjunctivitis (IBK) 52–3  
    keratoconjunctivitis sicca (KCS) 29–30, 53, 57–60

Cornea

    congenital anomalies 68  
    dermoids 68  
    granulation tissue 50–1  
    introduction 47  
    keratitis 48–52  
    keratoconjunctivitis sicca (KCS) 53, 57–60  
    lipid keratopathies 63–5  
    lipidosis 63–5  
    neoplasia 68  
    oedema 60–2  
    opacity 123–4  
    sequestrum 65–6  
    trauma and foreign bodies 66–7  
    ulcers 52–7

Corpora nigra 80

Cysts

    conjunctival 25, 41–2  
    uveal tract 78–80  
    vitreal 133

## D

Deformity of cartilage 26–7  
Dermoids  
    conjunctival 41

    corneal 68

    eyelids 22

Development

    of canine fundus 147–9  
    of feline fundus 152

Diabetic cataract 114

Diabetic retinopathy 198

Dislocation of lens 113, 120–7

Distichiasis 14–16

Dry eye 29–30

## E

Ectopic cilia 14–16

Enophthalmos 2

Epiphora 29–30

Episcleritis 42, 45

Excessive vascular tortuosity 179

Exophthalmos 2–4

Extensive retinal detachment 183

Eyelids

    blepharitis 16–17  
    distichiasis 14–16  
    ectopic cilia 14–16  
    ectropion 13–14  
    entropion 10–13  
    hordeolum - external 18  
    introduction 9  
    meibomian cyst 18  
    meibomianitis 18  
    neoplasia 18–21  
    trichiasis 16–17

## F

Fluorescein patency test 29

Focal retinal degeneration 195

Follicular conjunctivitis 24, 36

Foreign bodies

    conjunctival fornices 41  
    corneal 66–7  
    nictitating membrane 23–4  
    vitreal 131–3

Freckles, iris 82

Fundus

    diseases of the retina 160–202 (*see also*  
        specific disease)  
    introduction 135  
    normal bovine and ovine 157–9



- Fundus, *cont'd*  
 normal canine 135–49  
 normal equine 153–7  
 normal feline 150–3  
 other species 160
- G**  
 Generalized progressive retinal atrophy (GPRA) 111–12, 161–2, 168, 200  
 Glaucoma  
   cataract secondary to 112  
   clinical signs 90–2  
   gonioscopy 94–6  
   introduction 89  
   primary hereditary – breeds affected 93  
   secondary 93, 125  
 Globe and orbit  
   buphthalmos 6  
   enophthalmos 2  
   exophthalmos 2–4  
   hydrophthalmos 6–7  
   introduction 1  
   microphthalmos 4–6  
   nystagmus 8  
   phthisis bulbi 7  
   prolapse 4  
   strabismus 7–8  
 Gonioscopy 94–5  
 Granuloma, nictitating membrane 25
- H**  
 Haemangioma 44  
 Haemorrhages  
   conjunctival 37–8  
   retinal 186, 191–2, 198, 201  
   vitreal 131–3  
 Harada's disease 76  
 Hordeolum, external 18  
 Hydrophthalmos 6–7  
 Hypertensive retinopathy 197  
 Hyphaema 73, 94, 96, 180  
 Hypopyon 94, 96
- I**  
 Imperforate punctum 30, 31, 32  
 Infectious bovine keratoconjunctivitis (IBK) 52–3  
 Inflammation of nictitating membrane 23–6  
 Infundibular detachment 181  
 Iridocyclitis 70–8  
 Iris  
   freckles 82  
   hypoplasia 80  
   iritis 70–8
- K**  
 Keratitis  
   chronic superficial (pannus) 48–51  
   eosinophilic 51–2  
   exposure 49  
   fungal 52  
   infectious bovine keratoconjunctivitis (IBK) 52–3  
   interstitial 48  
   pigmentary 49  
   punctate 49  
 Keratitis precipitata (KP) 72  
 Keratoconjunctivitis sicca (KCS) 29–30, 53, 57–60
- L**  
 Lacrimal system  
   introduction 29–30  
   punctal abnormalities 30–3  
 Lamellar cataract 116  
 Lens  
   cataracts secondary to another condition 110–13  
   congenital cataracts 106–10  
   false cataracts 113  
   introduction 97  
   lens luxation 113, 120–7  
   metabolic, toxic and nutritional cataracts 113  
   primary hereditary non-congenital cataracts 98–106  
 Limbal melanoma 44  
 Lipid keratopathies 63–5  
 Liquefaction 131  
 Lymphosarcoma 44, 82, 83
- M**  
 Meibomian cyst 18  
 Meibomianitis 18  
 Melanoma  
   amelanotic 84  
   ciliary body 80, 81  
   iris 80–3  
   limbal 44  
 Microcornea 68  
 Microphthalmos 4–6, 108–9  
 Micropunctum 31  
 Multicentric lymphosarcoma 82, 83  
 Multifocal retinal dysplasia (MRD) 112, 172, 180, 182–6
- N**  
 Nasolacrimal duct  
   foreign body 32  
   infection 33  
 Neoplasia  
   conjunctival 42–4  
   corneal 68  
   eyelid 18–21  
   globe 8  
   nictitating membrane 27–8  
   optic nerve 206  
   uveal tract 78, 80–5  
 New Forest disease 52–3  
 Nictitans gland 24  
 Nictitating membrane  
   inflammation 23–6  
   introduction 23  
   prominence of 23  
   trauma and foreign bodies 23–4  
 Non-tapetal fundus 138–40, 151  
 Normal eye 2  
 Nutritional cataract 114–15  
 Nystagmus 8
- O**  
 Occluded nasolacrimal puncta 33  
 Occluded punctum 32  
 Ocular discharge 31  
 Oedema, corneal 60–2  
 Opacity  
   corneal 123–4  
   temporary 119–20  
 Optic atrophy 205, 207, 209  
 Optic disc  
   bovine 159  
   canine 142–6  
   cupping 205  
   equine 155–7  
 Optic nerve  
   acquired conditions 203  
   congenital conditions 204–11  
   hypoplasia 206  
   introduction 203  
   tumour 206  
 Optic neuritis 204  
 Orbit see Globe and orbit  
 Orbital adenocarcinoma 2
- P**  
 Pannus 48–51  
 Papilloedema 203–4, 208–9  
 Persistent hyaloid artery (PHA) 113, 129  
 Persistent hyperplastic primary vitreous (PHPV) 102, 129–31  
 Persistent hyperplastic tunica vasculosa lentis (PHTVL) 129–31  
 Persistent pupillary membranes (PPM) 78, 85–7  
 Phthisis bulbi 7  
 Pigment epithelial dystrophy 112, 169–71  
 Pigment on anterior lens capsule 119  
 Plasma cell infiltration 25–6  
 Post-inflammatory degeneration 193  
 Post-inflammatory retinopathy 186–90  
 Posterior lenticonus 107, 112  
 Posterior lentiglobus 107  
 Posterior synechiae 74–6  
 Progressive retinal atrophy 111–12, 165–6, 194–5

- Prolapse  
globe 4  
nictitans gland 26  
subconjunctival fat 39  
Proliferative optic neuropathy 208  
Pseudopapilloedema 203  
Punctal abnormalities 30-3  
Pupil, vitreous in the 121
- R**
- Red eye 89  
Resorption, cataract 117-18  
Retina  
blood vessels 142, 146-7, 151  
degeneration of 190, 193, 195, 200, 202, 209  
detachment of 178-9, 183, 192-3, 198, 201  
diseases of the (see also specific disease)  
canine 160-93  
equine 193, 199-201  
feline 193-8  
ovine 193, 202  
haemorrhage 186, 191-2, 198, 201  
multifocal retinal dysplasia (MRD) 172, 180, 182-6  
retinal atrophy 111-12  
retinal folds 185  
retinal pigment epithelial dystrophy (RPED) 162, 171-2  
total retinal dysplasia (TRD) 172, 180-1, 184, 186  
Retrolbulbar meningioma 206  
Rod/cone degeneration 164-5, 167  
Rod/cone dysplasia 163, 193  
Rubeosis iridis 73
- S**
- Schirmer tear test 29  
Scleritis 42, 45  
Senile nuclear sclerosis 119  
Senile retinopathy 200  
Sequelae 70, 76, 78  
Squamous cell carcinoma  
conjunctival 43  
globe 8  
nictitating membrane 27-8  
Strabismus 7-8  
Stromal cyst 80  
Stye 18  
Subalbinism 151-2, 155  
Subalbinotic fundus 141-2  
Subcapsular cataract 116  
Subconjunctival fat prolapse 39  
Subconjunctival haemorrhage 38  
Subconjunctival masses 38  
Sudden acquired retinal degeneration (SARD) 186, 191  
Symblepharon 38-41, 42
- Synchysis scintillans 131-2  
Syneresis 131
- T**
- Tapetum  
canine 135-9  
equine 153-5  
feline 150  
tapetal fundus 135-8  
tapetal junction 138-9  
tapetum nigrum 139-40  
Taurine deficiency retinopathy 193, 196-7  
Tear streak 30  
Temporary opacity 119-20  
Tigroid non-tapetal fundus 151  
Total retinal dysplasia (TRD) 172, 180-1, 184, 186  
Toxic cataract 115  
Toxoplasmosis 72  
Trauma  
corneal 66-7  
nictitating membrane 23-4  
traumatic cataract 118  
uveal tract 77-8  
Trichiasis 16-17  
Tumour see Neoplasia
- U**
- Ulcers, corneal 52-7  
Uveal tract  
clinical signs of anterior uveitis 70  
congenital anomalies 78-87  
cysts 78-80  
introduction 69  
neoplasia 78, 80-5  
sequelae 70, 76, 78  
trauma 77-8  
Uveitis 70-8, 104
- V**
- Vascular anomaly 180  
Vitreous  
acquired 131-3  
congenital 129-31  
in the pupil 121  
introduction 129  
Voght-Kayanaga-Harada (VLH) 76
- W**
- Warfarin poisoning 38  
Wet eye 29-30
- Index of Dog Breeds*
- A**
- Afghan Hound 81, 102, 190  
Airedale Terrier 45, 60, 72  
Akita 76  
American Cocker Spaniel 62, 103, 104, 117
- B**
- Basenji 206  
Basset Hound 32, 92  
Beagle 13, 18-19, 85, 91, 115, 119-20, 140, 144-5, 185, 193, 207  
Bichon Frise 58  
Border Collie 5, 74, 112-13, 116, 122, 138, 147, 171-3, 175, 187, 205  
Border Terrier 67  
Boston Terrier 101, 140  
Boxer 7, 19, 51, 54, 137  
Briard 144, 171  
Bull Mastiff 86  
Bulldog 26
- C**
- Cairn Terrier 39, 86, 94  
Cardigan Corgi 120, 163  
Cavalier King Charles Spaniel 6, 13, 18, 40, 59, 63-4, 67, 70, 74, 105, 107, 126, 129, 184-5  
Chihuahua 62, 132, 144  
Chow 10, 11, 51  
Clumber Spaniel 13  
Cocker Spaniel 11, 13, 17, 31, 38, 108, 119, 131, 136, 164-5, 191  
Crossbred 41, 50, 72-3, 78, 94, 109, 114, 132, 143, 188-9, 191-3  
Crossbred terrier 32, 122
- D**
- Dobermann 130, 189  
Dogue de Bordeaux 41
- E**
- Elkhound 163  
English Setter 25  
English Springer Spaniel 3, 7, 61, 67, 77, 80, 82, 91, 108, 112, 116-17, 132, 146-7, 166, 182-4, 189, 205
- F**
- Flat-Coated Retriever 15, 16, 133  
Foxhound 114  
French Bulldog 4
- G**
- German Shepherd Dog 3, 5, 25-7, 49-50, 64, 67-8, 104, 131, 144, 146, 187  
German Shorthaired Pointer 10  
Golden Retriever 12, 18, 30, 32, 42, 44-5, 64, 98-9, 132-3, 138-9, 145, 167, 185  
Gordon Setter 44  
Great Dane 6, 10, 28, 84, 118

Greyhound 2, 81, 136, 139, 143, 148, 187-8, 190

Griffon 204

## I

Irish Setter 19, 94, 163

## J

Jack Russell Terrier 57, 62, 74, 118, 121, 123-4, 126

## L

Labrador Retriever 3, 18-19, 22, 28, 36, 44, 78-9, 81, 85, 99-100, 112, 114, 119, 131, 137, 139-40, 143, 145, 167, 169-71, 181-2, 186-7, 189-90, 192, 204

Lakeland Terrier 117

Leonberger 102

Lhasa Apso 205

Longhaired Dachshund 61

Lurcher 116

## M

Maltese Terrier 204

Miniature Longhaired Dachshund 14, 119-20, 143, 167-8

Miniature Poodle 4, 70-1, 74, 84, 92, 111, 136, 164, 192, 204, 206

Miniature Schnauzer 106, 166

Munsterlander 39

## N

Norwegian Buhund 102, 103

## O

Old English Sheepdog 32, 86, 109, 113, 186, 188

## P

Pekingese 15-17, 49

Pembroke Corgi 12, 19, 54, 114, 139

Pointer 140

Pug 55, 65

## R

Rottweiler 10, 85

Rough Collie 2, 33, 45, 63, 142, 147, 171, 173-5, 178-80, 185

## S

Samoyed 58

Sealyham Terrier 6, 122, 125-6, 181

Shar Pei 11

Shetland Sheepdog 5, 8, 15-16, 49, 124, 129, 137-8, 141-2, 172-80, 206

Siberian Husky 64

Smooth-haired Fox Terrier 124, 190

St Bernard 14

Staffordshire Bull Terrier 21, 81, 102, 130

Standard Poodle 105, 191

Standard Schnauzer 92

## T

Tibetan terrier 111, 122-3, 165-6

Toy Poodle 206

## W

Weimaraner 27, 71

Welsh Springer Spaniel 90-1, 93-5, 105, 205

Welsh Terrier 125

West Highland White Terrier 57-9, 109, 203

Whippet 191

Wirehaired Fox Terrier 123

## Y

Yorkshire Terrier 41, 59, 145

## B

Bird 162

## Species Index

### C

Cat 6, 12, 20-2, 24-5, 28, 33, 36-7, 39-42, 44, 51-2, 54, 65-6, 72-3, 75, 78-9, 82-3, 86-7, 95, 118, 127, 133, 150-2, 194-8

Cattle 8, 30, 53, 62, 110, 158-9, 208-10

### D

Donkey 157

### H

Horse 5, 7, 20-1, 28, 31, 37, 43, 53, 55, 57, 63, 68, 71, 75, 76, 79-80, 83-5, 87, 93, 110, 116-17, 153-7, 199-201, 207-8

Human 161

### M

Monkey 161

### P

Pig 161

### R

Rabbit 161

Rat 162

### S

Sheep 12, 159-60, 202

### T

Tiger 115

## Index of Conditions

### C

Congenital Abnormalities 5, 6, 8, 12, 21-2, 30, 40, 47, 59, 68, 78, 84-7, 89, 97, 106-10, 113, 114, 129-31, 160, 162, 168, 172-86, 198, 201, 204, 206-7, 209-10

### H

Hereditary Conditions 12, 14-17, 22, 30, 41, 47, 62, 93, 97, 98-106, 135, 160, 161-2, 163-86, 193-5, 200, 204, 206-7, 209-10

### N

Neoplasia Cases 2, 3, 4, 7, 8, 18-21, 27-8, 42-4, 47, 68, 78, 80-4, 206

# Diagnostic Atlas of Veterinary Ophthalmology

This second edition of the outstanding reference, *Veterinary Ophthalmology*, has been renamed *Diagnostic Atlas of Veterinary Ophthalmology*, reflecting the completely rewritten and expanded text with the addition of nearly 100 photographs. Now with over 700 exclusive photographs, the book is not just a simple collection of images but an aid to diagnosis and differential diagnosis, providing most non-specialists and veterinarians with all they need to know. The text is also used to draw the reader to features associated with diagnosis.

*Diagnostic Atlas of Veterinary Ophthalmology* includes extensive series on the wide variation of the normal fundus particularly in the dog but also the cat, horse and cow as well as examples of other animals. Many of the pathological conditions featured in the new edition illustrate the variations and differing degrees in severity of the abnormalities considered vital in leading the reader to an accurate diagnosis.

## Features:

- Completely rewritten and expanded
- Over 700 colour photographs from the author's unique collection
- Addition of tables of differential diagnoses defining the most significant facts
- A number of new conditions illustrated
- Remains only veterinary ophthalmic atlas covering all domestic species and entirely aimed at diagnosis

