

CASE REPORT

COUNTY OF LOS ANGELES

DEPARTMENT OF CORONER

| | | |
|---|--|-----------------------|
| 1 | APPARENT MODE ACCIDENT | CASE NO 2012-01022 |
| | SPECIAL CIRCUMSTANCES Celebrity, Media Interest | CRYPT SEC1 |

| | | |
|---|--------------------------------|---|
| LAST, FIRST MIDDLE HOUSTON, WHITNEY ELISEBETH | AKA HOUSTON, WHITNEY | # |
|---|--------------------------------|---|

| | | | |
|--|-----------------------------|--------------------|---------------------|
| ADDRESS 360 HAMILTON AVENUE #100 | CITY WHITE PLAINS | STATE NY | ZIP 10601 |
|--|-----------------------------|--------------------|---------------------|

| | | | | | | | | | | | |
|---------------|-----------------------|-----------------|-----------|---------------|-----------------|---------------|---------------|-------------------------------|---------------------|----------------|-------------------|
| SEX FEMALE | RACE APPEARS BLACK | DOB 8/9/1963 | AGE 48 | HGT 66 in. | WGT 151 lbs. | EYES BROWN | HAIR BLACK | TEETH ALL NATURAL TEETH | FACIAL HAIR NONE | ID VIEW Yes | CONDITION FAIR |
|---------------|-----------------------|-----------------|-----------|---------------|-----------------|---------------|---------------|-------------------------------|---------------------|----------------|-------------------|

| | | |
|-------------------|-------------------------------|---|
| MARK TYPE SCAR | MARK LOCATION LEFT FOREARM | MARK DESCRIPTION INNER, LOWER-OLD HEALED |
|-------------------|-------------------------------|---|

| | | | |
|---------|------|-------|-----|
| ADDRESS | CITY | STATE | ZIP |
|---------|------|-------|-----|

| | | | | |
|--------------|-------|-------------|-------------------|------|
| RELATIONSHIP | PHONE | NOTIFIED BY | DATE 2/11/2012 | TIME |
|--------------|-------|-------------|-------------------|------|

| | | | |
|-----|-------------------|-------------|------------|
| SSN | DL ID D9834026 | STATE CA | PENDING BY |
|-----|-------------------|-------------|------------|

| | | | | | | |
|--|------|--------|------|-------|------------|-------------------|
| ID METHOD CALIFORNIA DRIVER'S LICENSE | LA # | MAIN # | CI # | FBI # | MILITARY # | POB NEW JERSEY |
|--|------|--------|------|-------|------------|-------------------|

| | | | | |
|--|----------------------|-------------------------|-------------------|---------------|
| IDENTIFIED BY NAME (PRINT) KRISTY MCCracken | RELATIONSHIP NONE | PHONE (323) 343-0714 | DATE 2/12/2012 | TIME 00:30 |
|--|----------------------|-------------------------|-------------------|---------------|

| | | | |
|---|---|-----------------------|--------------|
| PLACE OF DEATH / PLACE FOUND HOTEL/MOTEL | ADDRESS OR LOCATION 9876 WILSHIRE BOULEVARD #434 | CITY BEVERLY HILLS | ZIP 90210 |
|---|---|-----------------------|--------------|

| | | | | | |
|--------------------------------|---------------|-------------------|------|--|--------------|
| PLACE OF INJURY HOTEL/MOTEL | AT WORK No | DATE 2/11/2012 | TIME | LOCATION OR ADDRESS 9876 WILSHIRE BOULEVARD #434, BEVERLY HILLS, CA | ZIP 90210 |
|--------------------------------|---------------|-------------------|------|--|--------------|

| | | |
|------------------|---------------|--------------------------------------|
| DOB 2/11/2012 | TIME 15:55 | FOUND OR PRONOUNCED BY PARAMEDICS |
|------------------|---------------|--------------------------------------|

| | | | | |
|--|-------------------------|-----------------------|-------------|----|
| OTHER AGENCY INV. OFFICER BEVERLY HILLS P.D. - DETECTIVE HYON | PHONE (310) 285-2156 | REPORT NO. 12-0806 | NOTIFIED BY | NO |
|--|-------------------------|-----------------------|-------------|----|

| | | | |
|------------------------------|-----------------------|-------------------|---------------|
| TRANSPORTED BY JOHN GREEN | TO LOS ANGELES FSC | DATE 2/11/2012 | TIME 01:10 |
|------------------------------|-----------------------|-------------------|---------------|

| | | | |
|-------------------|-------------------|----------------------|---------------|
| FINGERPRINTS? Yes | CLOTHING No | PA RPT No | MORTUARY |
| MED EV Yes | INVEST PHOTO # 75 | SEAL TYPE NOT SEALED | HOSP RPT No |
| PHYS EV Yes | EVIDENCE LOG Yes | PROPERTY? Yes | HOSP CHART No |
| SUICIDE NOTE No | GSR NO | RCPT NO. 257946 | PF NO. |

SYNOPSIS
ACCORDING TO THE REPORTED INFORMATION, THE DECEDENT IS A 48 YEAR-OLD BLACK FEMALE WITH A MEDICAL HISTORY OF USING NARCOTIC SUBSTANCES. THE DECEDENT WAS LAST SEEN ALIVE ON SATURDAY 02/11/2012 BETWEEN 1445-1500 HOURS BY HER PERSONAL ASSISTANT. THE DECEDENT COMPLAINED OF HAVING A SORE THROAT, BUT SHE HAD BEEN COMPLAINING OF THAT FOR THE PAST FEW DAYS. THE ASSISTANT TOLD THE DECEDENT TO TAKE A BATH, TO START GETTING READY FOR TONIGHT. THE ASSISTANT THEN LEFT THE ROOM TO RUN SOME ERRANDS. AT APPROXIMATELY 1535 HOURS, THE ASSISTANT RETURNED AND USED HER KEY TO ENTER THE LOCKED AND SECURED ROOM. ONCE INSIDE, SHE FOUND THE DECEDENT LYING FACE DOWN IN THE BATHTUB FILLED WITH WATER, UNRESPONSIVE. THE ASSISTANT CALLED FOR HER BODYGUARD, AND TOGETHER THEY PULLED THE DECEDENT OUT OF THE BATHTUB. THE ASSISTANT CALLED DOWNSTAIRS TO CALL 911. 911 WAS CALLED AT 1543 HOURS AND OFFICERS FROM THE BEVERLY HILLS POLICE DEPARTMENT AND PARAMEDICS FROM THE BEVERLY HILLS FIRE DEPARTMENT ARRIVED ON-SCENE. ON SATURDAY 02/11/2012 AT 1555 HOURS, PARAMEDICS FROM RESCUE 1 DETERMINED DEATH. THE DECEDENT POSSIBLY OVERDOSED ON A NARCOTIC SUBSTANCE, PRESCRIPTION MEDICATIONS, OVER THE COUNTER MEDICATIONS, AND ALCOHOL. MINOR EXTERNAL TRAUMA WAS NOTED AND THERE ARE NO SIGNS OF FOUL PLAY. DETECTIVE HYON REQUIRES A 2-HOUR NOTIFICATION PRIOR TO THE EXAMINATION. PLEASE SEE CASE NOTES FOR HIS CONTACT INFORMATION.

| | | | | |
|----------------------------|--------------|-------------------|--|-----------------|
| KRISTY MCCracken 491917 | INVESTIGATOR | DATE 2/12/2012 | REVIEWED BY  | DATE 2/12/12 |
| | | TIME 04:45 | | TIME |

FORM #3 NARRATIVE TO FOLLOW?



County of Los Angeles, Department of Coroner Investigator's Narrative



Case Number: 2012-01022

Decedent: HOUSTON, WHITNEY ELISEBETH

Information Sources:

- (1) Beverly Hills Police Department-Report #12-0806 (310)285-2156
Detective Hyon

Investigation:

On Saturday 02/11/2012 at 2104 hours, Sergeant Publicker from the Beverly Hills Police Department called the Los Angeles County Coroner's Office to report a natural versus accidental death of a 48 year-old black female that possibly drowned in a bathtub. On Saturday 02/11/2012 at 2120 hours, Lieutenant Brian Elias assigned this case to me. I arrived on-scene at 2220 hours and I cleared the scene on Sunday 02/12/2012 at 0135 hours. Prior to my arrival, the decedent was removed from the bathtub by her personal assistant and bodyguard, and then Paramedics placed the decedent onto the living room floor in order to render First-Aid. Also prior to my arrival, Paramedics moved the couch from out of the living room, and placed it on the patio in order to render First-Aid on the decedent. The decedent's purse was on that couch, and the decedent's California driver's license had been removed from the wallet, which was inside the purse, prior to my arrival. Also prior to my arrival, the majority of the decedent's prescription medication bottles had been removed from a brown bag that was on top of the table in the southeast corner of the living room, and then placed on top of that same table. After completing my investigation, I changed this from a natural versus accident to an accident. The decedent possibly overdosed on a narcotic substance, prescription medications, over the counter medications, and alcohol. Minor trauma was noted and there are no signs of foul play.

Location:

The incident occurred and the decedent died in the bathroom inside her room #434 at the Beverly Hilton Hotel located at 9876 Wilshire Boulevard, Beverly Hills CA, 90210.

Informant/Witness Statements:

I spoke with Detective Hyon at the scene, and he told me the following:

The decedent checked into the Beverly Hilton Hotel on Monday 02/06/2012. She was here for the Grammy award ceremony on Sunday 02/12/2012, and there was a pre-Grammy Party at the hotel on Saturday 02/11/2012. The decedent was last seen alive by her personal assistant on Saturday 02/11/2012 between 1445-1500 hours. The decedent complained of having a sore throat that had been lingering for the past few days. Before she left, she told the decedent to go take a bath, to start getting ready for tonight. The personal assistant then left to go pick up items at Neiman Marcus. The personal assistant left Neiman Marcus at 1525 hours, and per the door key, she entered the decedent's locked hotel room at 1536 hours. She went into the bathroom, and she found the decedent lying face down in the bathtub, unresponsive, with the top of her head facing west. The bathtub was filled with water, and there was water on the bathroom floor, however, the water was not running. She called out to the bodyguard, and they pulled the decedent out of the bathtub. The assistant then called downstairs telling them to call 911. They received the 911 call at 1543 hours, and Paramedics from the Beverly Hills Fire Department arrived on-scene. On Saturday 02/11/2012 at 1546 hours, Paramedics from Rescue 1 determined death. On Saturday 02/11/2012 at 2135 hours, the water temperature in the bathtub was 93.5 degrees. There are no signs of foul play.

Scene Description:

The Beverly Hilton Hotel is located at 9876 Wilshire Boulevard in Beverly Hills. Room #434 was located on the 4th floor in the southwest portion of the hotel. The living room was located in the west side of the room. Located in the northwest corner was a chair and then a computer tower with a Fedora on top of it. Located along the north wall, central portion was a dresser with a

JLM



County of Los Angeles, Department of Coroner Investigator's Narrative



Case Number: 2012-01022

Decedent: HOUSTON, WHITNEY ELISEBETH

mini-bar in it. On top of it was an open bottle of champagne, along with other miscellaneous items. Located in the north wall, northeast portion was the front door to the room. Located in the east wall were doors leading into the bedroom. Located in the southeast corner was a table with multiple bottles of prescription medications, prescribed to the decedent, multiple blister packs, a loose tablet, and other miscellaneous items on top of it. Located in the south wall was a sliding glass door leading onto a balcony. Just south of these sliding glass doors was a couch with a purse on it. Located in the southwest corner was a lamp. Located on the floor in the southwest portion of the room was an empty blister pack. Located along the west wall, central portion were three tables with plates of food, an open can of beer, a single capsule, along with other miscellaneous items on top of it. The decedent was located lying supine on the floor in the central portion of the living room floor.

The bedroom was located in the east side of the room. Located in the north wall, northwest corner was a closet. Just south of the closet were opened suitcases and a lamp. Located in the north wall, central portion was a door leading into the bathroom. Located along the north wall, central portion was a luggage stand. Located in the northeast corner was a table with a bottle of prescription medication, loose tablets, and other miscellaneous items on top of it. Located along the east wall, central portion was a bed. Located along the east wall, southeast portion was a nightstand with a bottle of beer on it. Located in the south wall were sliding glass doors leading onto the same balcony. Located along the south doors, southeast portion was a chaise lounge. Located along the south wall, southwest portion was another luggage stand with an open suitcase on it. Located in the southwest corner was a 3-drawer dresser with a bottle of prescription medication, loose tablets, a bottle of a supplement, and other miscellaneous items on top of it. Located in the west wall were doors leading into the living room. The carpet in the bedroom was soaked with water.

The bathroom was located in the northeast portion of the room. Located along the north wall, central portion was a bathtub. There was approximately 12" of water in the short end and approximately 13" of water in the deep end. In the bathtub was a towel, a bottle of rubbing alcohol, and a pitcher. Located in the north wall, northeast portion was the toilet stall. Located along the east wall was a counter with a sink and drawers below. Located on the counter in front of the sink was an ashtray filled with multiple cigarette butts. Located on the south portion of the counter was a small spoon with a white crystal like substance in it and a rolled up piece of white paper, along with other miscellaneous items. Located on the north portion of the counter was a bottle of prescription medications, and a ripped open small plastic bag, along with other miscellaneous items. Located in the top drawer, in the north side of the counter were remnants of a white powdery substance, and a portable mirror on a base. On the bottom of that base were more remnants of a white powdery substance. Located in the south wall, central portion was the entrance into the bedroom. Located in the southwest portion of the bedroom was a chair with some clothes on it and a blanket on the floor next to it. Located in the west wall, central portion was a door leading into the shower. The bathroom floor was covered with water.

Evidence:

On Saturday 02/11/2012 hours, I collected a plethora of prescription medication bottles, prescribed to the decedent, multiple blister packs, and a loose tablet from off the top of a table in the southeast corner of the living room. I also collected a capsule from off one of the tables in the west central portion of the living room. I also collected an empty blister pack from off the floor in the southwest portion of the living room. I also collected a bottle of prescription medication, prescribed to the decedent from off a table in the northeast corner of the bedroom. I also collected loose tablets from off the same table in the northeast corner of the bedroom. I also collected a bottle of prescription medication, prescribed to the decedent, a bottle of a supplement, and a loose tablet from off a 3-drawer dresser in the southwest corner of the bedroom. I also collected a bottle of prescription medication, prescribed to the decedent, a



County of Los Angeles, Department of Coroner Investigator's Narrative



Case Number: 2012-01022

Decedent: HOUSTON, WHITNEY ELISEBETH

spoon with a white crystal like substance in it, a rolled up piece of white paper from off the top of a counter along the east wall in the bathroom. I also collected remnants of a white powdery substance from out of a drawer and from the bottom of a mirror in the same drawer in the bathroom counter along the east wall of the bathroom. I later booked all of the bottles of prescription medications, the bottle of the supplement, all of the blister packs, all of the loose tablets and capsules, the spoon, and the white powdery substance at the Forensic Services Center as evidence.

On Saturday 02/11/2012 at 2342 hours, Criminalist Mark Schuchardt used a pubic hair kit on the decedent at the scene. On Saturday 02/11/2012 at 2355 hours, Criminalist Mark Schuchardt collected fingernail clippings from the decedent's hands at the scene. On Sunday 02/12/2012 at 0004 hours, Criminalist Mark Schuchardt collected hair standards from the decedent at the scene. On Sunday 02/12/2012 at 0015 hours, Criminalist Mark Schuchardt used a sexual assault kit on the decedent at the scene. Criminalist Mark Schuchardt later booked the pubic hair kit, the fingernail clippings, the hair standards, and the sexual assault kit at the Forensic Services Center as evidence.

Body Examination:

The decedent is a 48 year-old black female with short black hair, brown eyes, and she has all of her natural teeth. There is an old healed vertical scar approximately 2" in length on her inner lower left forearm. No other scars and no tattoos were noted. The decedent was nude, lying supine on the living room floor. The top of her head was facing south. Her right arm was bent at the elbow with her right hand resting on the floor, against the right central portion of her torso. Her left arm was slightly bent at the elbow with her left hand resting on the floor against her outer upper left thigh. Both of her legs were straight with her right foot pointing north and her left foot was pointing northwest. There was a defibrillator patch on the upper right side of her chest and there was another defibrillator patch on the left central portion of her torso. Both of her eyes were congested and there was a bloody purge coming from her nose. There were 2 superficial abrasions to the left side of her forehead and there was a superficial abrasion to the left side of the bridge of her nose. There was a superficial abrasion to the top of her right shoulder. There was minor skin slippage to the upper central portion of her chest, to the inner left central portion of her chest, and to the lower central portion of her chest. There was minor skin slippage to the upper left side of her abdomen. There was a superficial abrasion to her outer lower left arm. There was a possible old puncture wound to her inner left elbow. There was a superficial abrasion to her inner central left forearm and there were minor abrasions to the top of her left hand, between the middle and ring fingers. There was minor skin slippage to the front of both of her knees and to both of the front central portion of her legs. There was minor skin slippage to her inner upper right calf and to her outer lower left leg. There was skin slippage to the lower central portion of her back. On Sunday 02/12/2012 at 0005 hours, the water temperature in the bathtub was 89.0 degrees. On Sunday 02/12/2012 at 0025 hours, the air temperature inside the living room was 67.0 degrees. On Sunday 02/12/2012 at 0031 hours, the decedent's liver temperature was 96.0 degrees.

Identification:

On Sunday 02/12/2012 at 0030 hours, I positively identified the decedent as Whitney Elisebeth Houston with a DOB of 08/09/1963 by the photograph on her California driver's license at the scene.

Next of Kin Notification:

On Saturday 02/11/2012 at an unknown time, friends notified _____, the decedent's daughter, of her mother's death. I have not spoken with _____ at the time of completion of this report. Please see case notes for further information.



County of Los Angeles, Department of Coroner Investigator's Narrative



Case Number: 2012-01022

Decedent: HOUSTON, WHITNEY ELISEBETH

Tissue Donation:

I did not discuss tissue donation with the decedent's family.

Exam Notification:

Detective Hyon requires a 2-hour notification prior to the examination. Please see case notes for his contact information.

Handwritten signature of Kristy McCracken in black ink.

KRISTY MCCRACKEN #491917

Handwritten signature of the Supervisor in black ink.

SUPERVISOR

Handwritten date "02/12/12" in black ink.

Date of Report

AUTOPSYFILES.ORG

COUNTY OF LOS ANGELES

MEDICAL EVIDENCE

DEPARTMENT OF CORONER

| | |
|-----------|--|
| 3A | CASE # 2012-01022 DECEDENT'S NAME: HOUSTON, WHITNEY ELISEBETH DOD: 2/11/2012 INCOMING MODE: |
|-----------|--|

Page 1 of 2

| Drug Name | Rx Number | Date of Issue | Number Issued | Number Remaining | Form | Dosage | Rx Directions | Physician | Pharmacy Phone/Comments |
|---------------|-------------|---------------|---------------|------------------|--------|------------|----------------------|----------------|---|
| ACIPHEX | 0947381-057 | 1/18/2012 | 30 | 1 | TABLET | 20 MG | TAKE 1 TABLET BY... | DR. K. DOCKERY | WALGREENS (678)566-3284 |
| ALPRAZOLAM | 0457286-047 | 11/1/2011 | 90 | 0 | TABLET | 1 MG | TAKE 1 TABLET BY... | DR. G. CHASE | WALGREENS (313)567-4239 |
| ALPRAZOLAM | 0938452-057 | 12/6/2011 | 15 | 0 | TABLET | 1 MG | TAKE 1 TABLET BY... | DR. R. COLLINS | WALGREENS (678)566-3284 FOR: XANAX |
| AMOX TR-K CLV | 205887 | 10/22/2011 | 14 | 1 | TABLET | 875-125 MG | TAKE 1 TABLET BY... | DR. S. NASSERI | CVS PHARMACY (313)963-1007 GENERIC FOR: AUGMENTIN |
| AMOX/K CLAV | 196205 | 1/31/2012 | 20 | 0 | TABLET | 875 MG | TAKE 1 TABLET BY... | DR. S. NASSERI | MICKEY FINE PHARMACY (310)271-6123 GENERIC FOR: AUGMENTIN |
| AMOX/K CLAV | 197174 | 2/7/2012 | 20 | 15 | TABLET | 875 MG | TAKE 1 TABLET BY... | DR. S. NASSERI | MICKEY FINE PHARMACY (310)271-6123 GENERIC FOR: AUGMENTIN |
| DEXAMETHASON | 196204 | 1/31/2012 | 3 | 0 | TABLET | 2 MG | TAKE 1 TABLET BY... | DR. S. NASSERI | MICKEY FINE PHARMACY (310)271-6123 |
| DEXAMETHASONE | 2130999 | 9/30/2011 | 6 | 0 | TABLET | 1 MG | TAKE 2 TABLETS BY... | DR. S. NASSERI | RITE AID (310)273-3561 |

Paraphernalia Description

1-SMALL SPOON WITH A WHITE CRYSTAL LIKE SUBSTANCE IN ONE END. 1-WHITE ROLLED UP PIECE OF PAPER. 2-PIECES FROM SMALL PLASTIC BAGS. REMNANTS OF A WHITE POWDERY SUBSTANCE. 1-OPEN BOTTLE OF CVS PHARMACY IBUPROFEN 200 MG TABLETS ORIGINALLY WITH 50 TABLETS NOW WITH 9 TABLETS. 4-EMPTY BLISTER PACKS ORIGINALLY WITH 8 TABLETS OF MIDOL COMPLETE. 2-EMPTY BLISTER PACKS OF MIDOL EXTENDED TABLETS. 2-BLISTER PACKS CONTAINING 2 MAXIMUM STRENGTH MUCINEX DM TABLET. 3-EMPTY BLISTER PACKS FOR DIPHENHYDRAMINE HCl 25 MG TABLET. 24-BLISTER PACKS CONTAINING 1 DIPHENHYDRAMINE HCl 25 MG

Investigator:

KRISTY MCCrackEN (491917)

Date:

2/12/2012

ALAM

COUNTY OF LOS ANGELES

MEDICAL EVIDENCE

DEPARTMENT OF CORONER

| | |
|-----------|---|
| 3A | CASE # 2012-01022 DECEDENT'S NAME: HOUSTON, WHITNEY ELISEBETH DOD: 2/11/2012 INCOMING MODE: |
| | Page 2 of 2 |

| Drug Name | Rx Number | Date of Issue | Number Issued | Number Remaining | Form | Dosage | Rx Directions | Physician | Pharmacy Phone/Comments |
|---|--------------------|---------------|---------------|------------------|--------|--------|------------------------|----------------|---|
| MINOCYCLINE HCL | 2017695 | 12/10/2010 | 30 | 6 | TABLET | 100 MG | TAKE 1 TABLET BY... | DR. H. LANCER | RITE AID (310)273-3561 GENERIC FOR: DYNACIN |
| NYSTATIN 100000 SUS MORT | 196206 | 1/31/2012 | 150 | 40 | LIQUID | | TAKE 2 TEASPOONFULS | DR. S. NASSERI | MICKEY FINE PHARMACY (310)271-6123 |
| PREDNISONE | 0947372-057 c/n | 1/18/2012 | 21 | 0 | TABLET | 5 MG | TAKE 6 TABLETS BY... | DR. K. DOCKERY | WALGREENS (678)566-3284 |
| XANAX | 0947847-057 c/n | 1/20/2012 | 15/90 | 0 | TABLET | 1 MG | TAKE 1 TABLET BY... | DR. R. COLLINS | WALGREENS (678)566-3284 |
| Paraphernalia Description 1-SMALL SPOON WITH A WHITE CRYSTAL LIKE SUBSTANCE IN ONE END. 1-WHITE ROLLED UP PIECE OF PAPER. 2-PIECES FROM SMALL PLASTIC BAGS. REMNANTS OF A WHITE POWDERY SUBSTANCE. 1-OPEN BOTTLE OF CVS PHARMACY IBUPROFEN 200 MG TABLETS ORIGINALLY WITH 50 TABLETS NOW WITH 9 TABLETS. 4-EMPTY BLISTER PACKS ORIGINALLY WITH 8 TABLETS OF MIDOL COMPLETE. 2-EMPTY BLISTER PACKS OF MIDOL EXTENDED TABLETS. 2-BLISTER PACKS CONTAINING 2 MAXIMUM STRENGTH MUCINEX DM TABLET. 3-EMPTY BLISTER PACKS FOR DIPHENHYDRAMINE HCl 25 MG TABLET. 24-BLISTER PACKS CONTAINING 1 DIPHENHYDRAMINE HCl 25 MG | | | | | | | | | |
| | | | | | | | | | Investigator: KRISTY MCCrackEN (491917) |
| | | | | | | | | | Date: 2/12/2012 |

ALM

6

WAS ORIGINAL SCENE DISTURBED BY OTHERS? YES NO I

IF YES, NOTE CHANGES IN NARRATIVE FORM #3.

DATE 02/11/12 - 02/12/12

AMBIENT #1 67.0 °F TIME 0025

AMBIENT #2 _____ °F TIME _____

WATER 89.0 °F TIME 0005

2012-01072
HOUSTON
WHITNEY
ACC-012
THERMOMETER # _____

LIVER TEMPERATURE #1 96.0 °F TIME 0031

LIVER TEMPERATURE #2 _____ °F TIME _____

DATE & TIME FOUND 02/11/12 1536 LAST KNOWN ALIVE 02/11/12 1445-1500

APPROX. AGE 48 SEX F EST. HEIGHT 66 EST. WEIGHT 151 CLOTHED? YES NO IF YES, DESCRIBE:

N/A

DESCRIPTION AS TO WHERE REMAINS FOUND AND CONTACT MATERIAL TO BODY:

Lying supine on the living room floor

SCENE TEMPERATURE REGULATED? YES NO IF YES, THERMOSTAT SET AT _____ DEGREES F

LIVOR MORTIS: TIME OBSERVED Unk

RIGOR MORTIS: TIME OBSERVED Unk

NECK FLEXION:

ANTERIOR 2+

POSTERIOR 2+

RT. LATERAL 2+

LT. LATERAL 2+

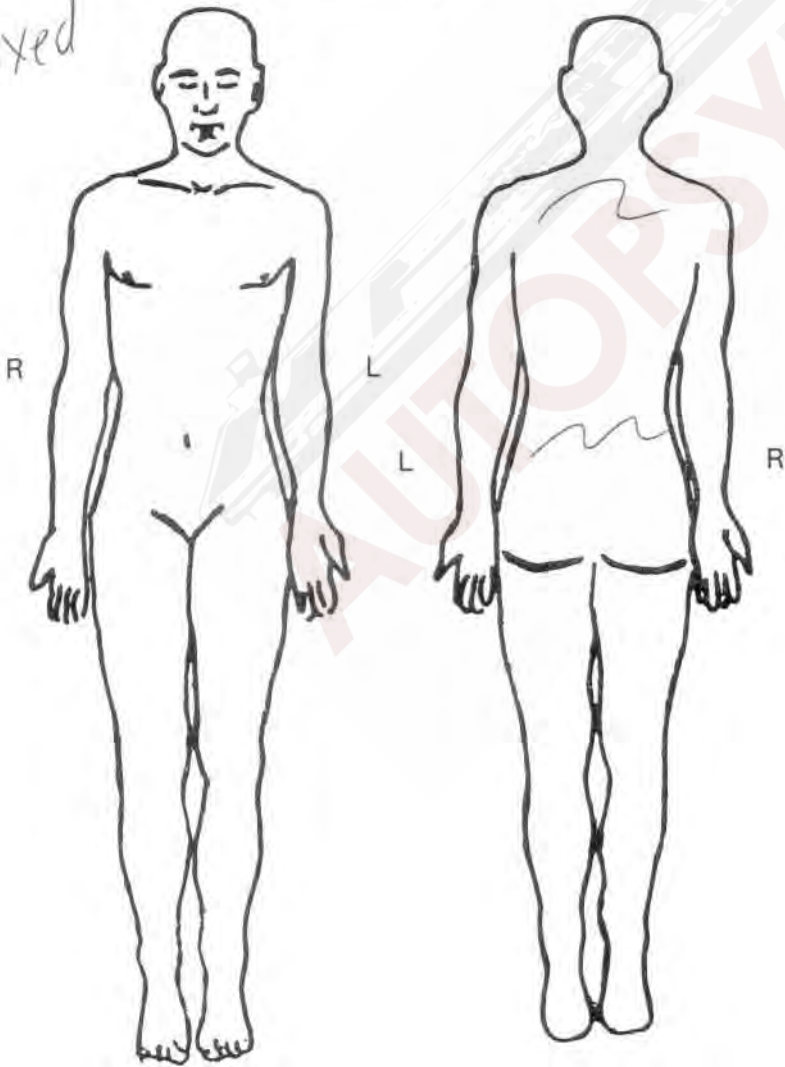
JAW 2+ HIP 2+

SHOULDER 2+ KNEE 2+

ELBOW 2+ ANKLE 2+

WRIST 2+

Fixed



SCALE

- 0 = ABSENT/NEGATIVE
- 1 +
- 2 +
- 3 +
- 4 = EXTREME DEGREE

USE SCALE TO DESCRIBE INTENSITY OF RIGOR MORTIS.

SHADE DIAGRAMS TO ILLUSTRATE THE LOCATION OF LIVOR MORTIS.

DESCRIBE INTENSITY OF COLORATION AND WHETHER LIVOR MORTIS IS PERMANENT OR BLANCHES UNDER PRESSURE.

K. McCracken #491917
CORONER'S INVESTIGATOR

REVIEWED BY:


COUNTY OF LOS ANGELES

12**AUTOPSY REPORT**

No.

2012-01022

HOUSTON, WHITNEY E.

I performed an autopsy on the body of 

at _____

the DEPARTMENT OF CORONER

Los Angeles, California on February 12, 2012 @ 1125 Hours

(Date) (Time)

From the anatomic findings and pertinent history I ascribe the death to:

- (A) DROWNING
DUE TO, OR AS A CONSEQUENCE OF
- (B) EFFECTS OF ATHEROSCLEROTIC HEART DISEASE AND COCAINE USE
DUE TO, OR AS A CONSEQUENCE OF
- (C) _____
DUE TO, OR AS A CONSEQUENCE OF
- (D) _____
OTHER CONDITIONS CONTRIBUTING BUT NOT RELATED TO THE IMMEDIATE CAUSE OF DEATH:

Anatomical Summary:

- I. History of substance abuse.
- A) Perforation of posterior nasal septum.
- II. Atherosclerotic heart disease.
- A) 60% narrowing of right coronary artery.
- III. Pulmonary edema.
- IV. Mild emphysema.
- V. Leiomyomas of uterus.
- VI. Adenomyosis (stroma only).
- VII. Congestion, right colon.
- VIII. Perimortem and postmortem scald burns.
- IX. Antemortem injuries:
- A) Contusion and abrasion of left forehead.
- B) Scald burn of sacrum.
- C) Abrasion of left hand.
- D) Abrasion of right lower leg.
- E) Superficial incision of upper lip.

12**AUTOPSY REPORT**

No.

2012-01022

HOUSTON, WHITNEY E.

Page 2

- X. Resuscitative abrasions of anterior chest.
- XI. Oncocytic microadenoma of adrenal.
- XII. Mild fatty change of liver.
- XIII. Fibrous mastopathy.
- XIV. See separate radiology, dental, microbiology, criminalistics, and toxicology reports.

CIRCUMSTANCES:

The decedent is a 48 year old woman found submerged in a bathtub that contained extremely hot water (93.5°F at 9:35 PM per detective). She was pronounced dead at the scene by paramedics at 3:55 PM on February 11, 2012.

EXTERNAL EXAMINATION:

The body is identified by toe tags and Coroner's identification band on the left ankle and is that of an unembalmed refrigerated adult Black female who appears the stated age of 48 years. The body weighs 151 pounds, measures 66 inches and is well built, muscular and fairly well nourished.

EVIDENCE OF INJURY:

Note: The word "marking" is used below to describe a circumscribed area of abrasion or scald injury.

Head and neck:

The face shows perimortem skin markings as follows:

- 1) A 1/4 x 1/16 inch yellow-brown marking in the central forehead.

12**AUTOPSY REPORT**

No.

2012-01022

HOUSTON, WHITNEY E.

Page 3

- 2) A 1-1/4 x 5/8 inch yellow-brown marking at the lateral edge of the left eyebrow.
- 3) A 5/8 x 1/2 inch yellow-brown marking on the left side of the nose.
- 4) A 1/4 x 3/16 inch yellow-brown marking at the lateral left nostril.

The following injuries inflicted during life (premortem) are seen:

- 1) A 3/4 x 1/4 inch yellow-brown marking of the lateral left forehead with an underlying 5/8 x 1/4 inch contusion.
- 2) A 3/16 inch very superficial incision of the upper lip.

There is a perforation of the posterior nasal septum.

CHEST AND ABDOMEN:

There are resuscitative markings of the chest as follows:

- 1) Two roughly round markings measuring 1 to 1-1/2 inch of the right superior chest and left lateral chest (resuscitation marks from defibrillator pads).
- 2) A 2-1/2 x 1-3/4 inch yellow-brown marking of the central chest (status post cardiopulmonary resuscitation).

12**AUTOPSY REPORT**

No.

2012-01022

HOUSTON, WHITNEY E.

Page 4

The following perimortem skin markings are present:

- 1) 5/8 inch yellow-brown marks of both clavicular regions and the left upper chest.
- 2) A 5/8 inch marking of the left breast.

An antemortem 5 x 3-1/4 inch area of yellow-brown skin slippage with erythema of the superior margin located over the sacrum.

A postmortem liver temperature incision is present at the right costal margin.

EXTEMITIES:

In the area of the right elbow are three 3/8 inch yellow-brown abrasions. On the back of the right hand is a 3/8 inch contusion and a 1/16 inch yellow-brown abrasion. There is an additional yellow-brown abrasion of the tip of the right ring finger measuring 1/8 inch.

On the inner surface of the left upper arm there are four contusions measuring 1/4 to 3/8 inch. On the posterior surface of the left arm around the elbow area are two yellow-brown abrasions measuring 3/8 x 1/4 inch and another measuring 3/8 x 1/3 inch. On the back of the left hand at the knuckle of the ring finger is a small yellow-brown abrasion.

On the anterior surface of the right leg is a 1/4 x 3/8 inch yellow-brown abrasion in the area of the knee. There is a 2-1/2 x 1/8 inch hook-shaped red abrasion of the medial surface of the

12**AUTOPSY REPORT**

No.

2012-01022

HOUSTON, WHITNEY E.

Page 5

right lower leg. There is a 2-1/2 inch zone of skin slippage at the right shin. A smaller zone of skin slippage is present at the lateral right ankle.

On the front of the left leg are 3/4 x 1/2 inch yellow-brown abrasions of the knee and shin. Over the dorsum of the left foot is a 3 x 3 inch area of skin slippage.

Tattoos are not present. Rigor mortis is present in the limbs and jaw. Livor mortis is fixed and distributed posteriorly. The head is normocephalic and is covered by black hair. A brown wig is tightly attached to the hair. This is removed and placed in a paper bag to accompany the body. There is no balding and the hair can be described as wavy. The eyebrows are sparse and show irregular hair distribution. Mustache and beard are absent. Examination of the eyes reveals irides that are brown and sclerae that show injection but no jaundice. There are no petechial hemorrhages of the conjunctivae of the lids or the sclerae. The oronasal passages are unobstructed and show bloody purge. The upper teeth have been replaced with a full arch maxillary dental prosthesis supported by dental implants. There are natural lower teeth present (see dental consultant report). There is no removable denture. The neck is unremarkable. There is no chest deformity. There is no increase in the anterior-posterior diameter of the chest. The abdomen is flat. The genitalia are those of an adult female. There is no genital or anal trauma. The extremities show no edema, joint deformity, abnormal mobility or needle tracks. There is evidence of old surgery. The following scars are present:

- 1) A 3/8 x 1/2 inch scar of the anterior neck near the center.

12**AUTOPSY REPORT**

No.

2012-01022

HOUSTON, WHITNEY E.

Page 6

- 2) Small scars of the inferior margins of the areolae, associated with breast implants.
- 3) A linear scar of the anterior left forearm.
- 4) A faint scar at the anterior pelvic brim.
- 5) A scar at the area of the left hip.
- 6) Two piercings are present in each ear.

There has not been postmortem intervention for organ procurement.

CLOTHING:

The body was not clothed and we did not see the clothing. The decedent was reportedly found nude in the bathtub.

INITIAL INCISION:

The body cavities are entered through the standard coronal incision and the standard Y-shaped incision. No foreign material is present in the mouth, upper airway or trachea except for bloody purge.

NECK:

The neck organs are removed en bloc with the tongue. No lesions are present nor is trauma of the gingiva or oral mucosa demonstrated. There is no edema of the larynx. Both hyoid bone and larynx are intact and without fractures. No hemorrhage is

12**AUTOPSY REPORT**

No.

2012-01022

HOUSTON, WHITNEY E.

Page 7

present in the adjacent throat organs, investing fascia, strap muscles, thyroid or visceral fascia. There are no prevertebral fascial hemorrhages. The tongue shows no trauma.

CHEST AND ABDOMINAL CAVITIES:

Both pleural cavities contain a small quantity of straw colored fluid. No pneumothorax is demonstrated. The parietal pleurae are intact. The lungs are well expanded. Soft tissues of the thoracic and abdominal walls are well-preserved. Breast tissue is sectioned and shows no abnormality. The organs of the abdominal cavity have a normal arrangement and none are absent.

There is no fluid collection. The peritoneal cavity is without evidence of peritonitis. There are no adhesions.

SYSTEMIC AND ORGAN REVIEW

The following observations are limited to findings other than injuries described above.

MUSCULOSKELETAL SYSTEM:

No abnormalities of the bony framework or muscles are present.

CARDIOVASCULAR SYSTEM:

The aorta is elastic and of even caliber throughout with vessels distributed normally from it. It shows lipid streaking. There is no tortuosity or widening of the thoracic segment. The abdominal aorta has minimal atherosclerosis without calcification. There is

12**AUTOPSY REPORT**

No.

2012-01022

HOUSTON, WHITNEY E.

Page 8

no dilatation of the lower abdominal segment. No aneurysm is present. The major branches of the aorta show no abnormality. Within the pericardial sac there is a minimal amount of serous fluid. The heart weighs 340 grams. It has a normal configuration. The chambers are normally developed and are without mural thrombosis. The valves are thin, leafy and competent. There is no endocardial discoloration. There are no focal lesions of the myocardium. There is no abnormality of the apices of the papillary muscles. There are no defects of the septum. The great vessels enter and leave in a normal fashion. The ductus arteriosus is obliterated. The coronary ostia are widely patent. There is segmental coronary atherosclerosis resulting in up to 60% occlusion of the right coronary artery at 4 cm from the ostium, and minimal atherosclerosis of the left anterior descending artery. No focal endocardial, valvular or myocardial lesions are seen. The blood within the heart and large blood vessels is liquid.

RESPIRATORY SYSTEM:

A moderate amount of froth is found in the upper respiratory passages. The mucosa is intact. The lungs are subcrepitant and there is dependent congestion. The left lung weighs 610 grams and the right lung weighs 680 grams. The visceral pleurae are smooth and intact. The parenchyma is moderately edematous. The pulmonary vasculature is without thromboembolism.

GASTROINTESTINAL SYSTEM:

The esophagus is intact. The stomach is not distended. It contains 400 grams of watery fluid with portions of food

12**AUTOPSY REPORT**

No.

2012-01022

HOUSTON, WHITNEY E.

Page 9

material. The mucosa shows reddened congested areas near the fundus, but is otherwise intact. Portions of tablets and capsules cannot be discerned in the stomach. The external appearance of the small intestine and colon is unremarkable. The small intestine and colon are opened along the antimesenteric border and the right colon shows hemorrhagic congested mucosa. The appendix is present. The pancreas occupies a normal position. There is no trauma. The parenchyma is lobular and firm. The pancreatic ducts are not ectatic and there is no parenchymal calcification.

HEPATOBIILIARY SYSTEM:

The liver weighs 1510 grams. It is red-brown and the capsule is thin. The consistency is soft and the cut surface is smooth. There is a normal lobular arrangement. The gallbladder is present. Its wall is thin and pliable. It contains a few cc of bile and no stones. There is no obstruction or dilatation of the extrahepatic ducts. The periportal lymph nodes are not enlarged.

URINARY SYSTEM:

The left kidney weighs 120 grams and the right kidney weighs 120 grams. The kidneys are normally situated and the capsules strip easily revealing a surface that is smooth and dark purple. The corticomedullary demarcation is preserved. The pyramids are not remarkable. The peripelvic fat is not increased. The ureters are without dilatation or obstruction and pursue their normal course. The urinary bladder is unremarkable. It contains 10 grams of amber cloudy urine. The urine is tested by the dipstick method and is negative for glucose and ketones.

12**AUTOPSY REPORT**

No.

2012-01022

HOUSTON, WHITNEY E.

Page 10

GENITAL SYSTEM:

The uterus is asymmetrical and the uterine cavity is not enlarged. There are several intramural and subserosal masses measuring 2.3 to 4 cm in diameter. The masses are well-demarcated and the cut surface is gray-white with a whorled pattern. The fallopian tubes are unremarkable. The endometrium is thin and red-brown. The cervix and vagina have a normal appearance for the age. The ovaries show hemorrhagic luteal cysts.

HEMOLYMPHATIC SYSTEM:

The spleen weighs 120 grams. The capsule is intact. The parenchyma is dark red and firm. There is no increase in the follicular pattern. Lymph nodes throughout the body are small and inconspicuous. The bone is not remarkable. The bone marrow of the vertebra is red and moist.

ENDOCRINE SYSTEM:

The thyroid gland weighs 40 grams. The consistency is unremarkable. Tissue from the parathyroid region is submitted for microscopic evaluation. The adrenals are unremarkable. The thymus is not identified. The pituitary gland is of normal size.

HEAD AND CENTRAL NERVOUS SYSTEM:

There is a small amount of subcutaneous hemorrhage in the region of the left forehead. The hemorrhage does not extend into the orbits or the temporal muscles. The external periosteum and dura mater are stripped showing no fractures of the calvarium or base

12**AUTOPSY REPORT**

No.

2012-01022

HOUSTON, WHITNEY E.

Page 11

of the skull. There are no tears of the dura mater. There is no epidural, subdural or subarachnoid hemorrhage. The brain weighs 1410 grams. The leptomeninges are thin and transparent. A normal convolutionary pattern is observed. Coronal sectioning demonstrates a uniformity of cortical gray thickness. The cerebral hemispheres are symmetrical. There is no softening, discoloration or hemorrhage of the white matter. The basal ganglia are intact. Anatomic landmarks are preserved. Cerebral contusions are not present. The ventricular system is symmetrical without distortion or dilatation. Pons, medulla and cerebellum are unremarkable. There is no evidence of uncal or cerebellar herniation. Vessels at the base of the brain have a normal pattern of distribution. There are no aneurysms. The cranial nerves are intact, symmetrical and normal in size, location and course. The cerebral arteries are without arteriosclerosis.

SPINAL CORD:

The spinal cord is not dissected.

HISTOLOGIC SECTIONS:

Representative specimens from various organs are preserved in two storage jars in 10% formalin. The sections are submitted for slides.

The slide key is: a) skin of the sacral region, b) right coronary atherosclerotic plaque, c) adrenal gland and aorta, d) cardiac intraventricular septum with left anterior descending artery, e) left ventricle, left atrium and circumflex artery, f) right

12**AUTOPSY REPORT**

No.

2012-01022

HOUSTON, WHITNEY E.

Page 12

atrium, right ventricle and right coronary artery, g) and h) sinoatrial node area, i) atrioventricular node area, j) right lung, k) left lung, l) epiglottis and trachea, m) tissue from parathyroid region and thyroid gland, n) esophagogastric junction and gastric mucosa, o) pancreas and liver, p) spleen and right kidney, q) bladder and left kidney, r) uterus and fibroid, s) ovary and right colon mucosa, t) tonsil, u) left frontal scalp, v) breast and appendix.

The following neuropathology slides are submitted: 1) occipital cortex, 2) cerebellum, 3) thalamus, 4) hippocampus, 5) frontal cortex, 6) hypothalamus with mammillary body, 7) brainstem.

TOXICOLOGY:

Blood from the heart, left femoral vein, right femoral vein, bile, liver, urine, stomach contents, vitreous, tracheal air, serum from heart blood, and centrifuged red cells from heart blood have been submitted to the laboratory. A comprehensive screen, vitreous glucose, electrolytes and urea nitrogen, hemoglobin S screen, and alprazolam are requested.

SPECIAL PROCEDURES:

Viral culture of the nasopharynx and bacterial culture of throat have been submitted to the laboratory.

PHOTOGRAPHY:

The investigator took seventy-five scene photographs on February 11, 2012. Thirty-two photographs have been taken prior to and during the autopsy (one intake, 28 pre-autopsy and 3 during

12**AUTOPSY REPORT**

No.

2012-01022

HOUSTON, WHITNEY E.

Page 13

autopsy). The Chief Medical Examiner-Coroner viewed the body with Captain Kades in the photography laboratory prior to the autopsy.

RADIOLOGY:

The body is fluoroscoped and 28 x-rays are obtained by radiologic technologist Diaz. X-rays are submitted for radiologic consultation. Skull radiographs are also submitted for dental consultation.

WITNESSES:

Detectives Hyon and Publicker of Beverly Hills Police Department witnessed the autopsy.

DIAGRAMS USED:

Diagrams Form 20 and 22 were used during the performance of the autopsy. The diagrams are not intended to be a facsimiles.

OTHER PROCEDURES:

Criminalist Schuchardt collected hair, nail clippings, and sexual assault evidence at the scene per Department Protocol.

OPINION:

The decedent is a 48-year-old Black woman who was found submerged face down in a bathtub filled with water in a hotel room.

12**AUTOPSY REPORT**

No.

2012-01022

HOUSTON, WHITNEY E.

Page 14


Autopsy showed atherosclerotic heart disease. Toxicology testing showed cocaine, benzoylecgonine, cocaethylene, marijuana, alprazolam (Xanax), cyclobenzaprine, (Flexeril), and diphenhydramine (Benadryl).

Microbiology and virology studies were not contributory.


Death was due to drowning due to effects of atherosclerotic heart disease and cocaine use. No foul play is suspected. The mode of death is accident.




Christopher Rogers, M.D., MBA
Chief Forensic Medicine Division



DATE



Lakshmanan Sathyavagiswaran, M.D., FRCP(C), FCAP, FACP
Chief Medical Examiner-Coroner



DATE

CR:LS:mtm:c

D-02/12/12

T-02/13/12

13**2012-01022**
Houston, Whitney
(Decedent)**Los Angeles County Department of Coroner
Criminalist Report**

Investigating Agency: **Beverly Hills Police Department**
Investigating Officer: Publicker; Hyon
Agency File No.: **12-0806**

Page 1 of 2

Also see Coroner Investigator Report for additional information, including scene description, case circumstances, condition of body.

On 10 February 2012 at 1906 hours I was notified by Coroner Investigator B. Elias that the Coroner/Chief Medical Examiner, Dr. L. Sathyavagiswaran, was requesting that a criminalist respond to a death scene. At 2122 hours, Beverly Hills Police Department advised that it was ready for our department to respond to the scene. At that time Coroner Investigator K. McCracken and I responded together, arriving at scene, the Beverly Hilton Hotel, 9876 Wilshire Boulevard, room 434, in Beverly Hills, California, 90210.

At 2236 hours, I entered the hotel room and observed an apparent body lying on the floor of the living room and covered entirely with a white linen sheet, approximately ten feet inside the entrance and several feet west of it. East of this room were the bedroom and bathroom. The bathroom floor was flooded, and water, apparently originating from the bathroom, where reportedly the bath tub had overflowed, had soaked the bedroom carpet, at least along the path to the living room; much of the carpeted area of the living room was moist also, even up to where the body lay. After the sheet was lifted I observed the decedent, an adult black female, lying nude and supine on a tan, patterned, carpeted floor. No clothing was near the body; all that was near the body was an apparent white sheet or table cloth bunched on the floor several feet to the left of the decedent's head.

The body was oriented south to north, with the head to the south. The woman's legs were fully extended and slightly apart. The feet, pointing toward the north wall and entrance, were also extended, the soles somewhat facing each other. The left arm was at the side, slightly flexed, in contact with the floor; the hand was palm down, fingers in a relaxed position, with the lateral aspect of the hand in contact with the lateral hip area. The right arm was more flexed than the left, with the hand raised off the floor, palm down, fingers relaxed, but with the wrist more flexed than the left; the lateral aspect was in contact with the lateral abdomen area. The eyes were closed and the face was oriented straight up toward the ceiling. Two large EKG pads, each with a long white cord, were adhered to the body, one at the upper right breast, the other at the left lateral upper abdomen, below the left breast. A circular area of the skin, approximately several inches in diameter, at the midline of the chest and between the breasts, was entirely devoid of its outer layer. This appeared to have been due to skin slippage from decomposition, and then also perhaps by life-saving efforts by others. Additional apparent skin slippage was noted at the lower

13

2012-01022

Page 2 of 2

back and other, smaller areas, were observed in various areas on the body. It should be noted that, per Beverly Hills Police (BHPD) detectives, the body had reportedly been entirely submerged in bath water for what may have been nearly an hour's time, and that the water temperature had reportedly been measured by their personnel to be over 90 degrees Fahrenheit, however long after the body had been removed from the tub.

At the right wrist the woman wore a bracelet made up of a band of numerous small white stones, and attached to the band was a cross made up of similar small white stones. A ring worn on the fourth digit of the right hand had a large white stone, possibly tinged yellow, with small white stones along the band. Each earlobe appeared to be pierced twice. The fingernails and toenails were short, well-kempt, with no colored polish observed. The woman wore a weave of short-length dark brown hair or fibers and some highlighting. The front margin of the weave was in a position slightly back from the front hairline, revealing the woman's natural head hair beneath it; her natural hair was short, dark brown and kinky.

At the time of my examination, the body surfaces were dry, but the head hair and weave appeared to be moist. I collected a Sexual Assault Evidence Kit on the decedent, nothing remarkable being noted. I also collected Fingernail, Hair, and Pubic Hair Kits; I included a clipping from two separate areas of the weave, one representing the highlighted coloring. Investigator McCracken then performed her examination and collected the jewelry items as personal property.

My evidence collection was completed at 0015 hours on 12 February, 2012.
Departure from the scene was at 0041 hours.

EVIDENCE

The following items were collected by me and placed into evidence.

EVIDENCE COLLECTED AT SCENE

Physical Evidence

1. Sexual Assault Evidence Kit.
2. Fingernail Kit.

Reference Item

3. Hair Kit, including weave exemplars.
4. Pubic Hair Kit.

FEB 17 '12

Date report written

MAR 14 '12

Date report signed



Mark S. Schuchardt

Senior Criminalist

cc: Medical File
Case File

13

DENTAL CONSULTATION


2012-01022

Houston, Whitney

March 15, 2012

Reviewed one frontal and one lateral skull radiograph dated 2-12-12.

Decedent has an extensive maxillary dental prosthesis supported by 11 endosseous dental implants. Decedent has one dental implant with a restoration in the lower right molar area. There does not appear to be any active dental disease at the time these radiographs were taken.



Cathy Law, DDS, DABFO
Forensic Dental Consultant



Date

CL/mtm:f
T-3/19/12

AUTOPSYFILES.COM

13

RADIOLOGY CONSULT**2012-01022**
Houston, Whitney E.**REQUEST:**

48 year old black female who died unexpectedly. Evaluate x-ray for abnormal findings.

RADIOGRAPHIC IMAGES:


Whole Body Radiographic Survey-adult.

FINDINGS:

Radiopaque linear densities are present, adjacent to the apical calvarium and the posterior occipital. These are identified as "hair clips" by the attending pathologists. There has been extensive dental prosthetic replacement. There are no visible calvarial or facial bone defects. Mild osteoarthritic changes are present in both a/c joints. The outlines of bilateral breast prostheses are visible. The remainder of the radiographic examination is normal.

IMPRESSIONS:

1. No acute or post traumatic changes are visible.
2. Extensive prosthetic dental replacement.
3. Mild osteoarthritic changes are present in the acromioclavicular joints.
4. Bilateral breast prosthesis.
5. Otherwise negative radiographic examination.


Donald C. Boger, M.D.
Radiology Consultant

2/13/12
Date

DCB/ic
hw 2/13/12

14

I performed a microscopic examination on →

2012-01022

Houston, Whitney

at THE DEPARTMENT OF CORONER

Los Angeles, California

MICROSCOPICS

A section of skin of the back from a burned area (slide A) shows absent epidermis. A portion of the dermis shows heat effect with eosinophilic change. There is perivascular lymphocyte reaction in the upper dermis. No hemorrhage is present but there is vascular congestion.

A section of right coronary artery (slide B) shows atherosclerotic plaque containing cholesterol clefts and calcification. The degree of arterial obstruction is estimated at 60%. No vasculitis or thrombosis is present.

The adrenal gland (slide C) shows a nodule at the junction of the zona fasciculata and zona reticularis. The nodule, which is well encapsulated, consists of oncocytic cells. No malignancy is identified. The remainder of the adrenal gland is unremarkable.

The aorta (slide C) is without atherosclerosis, inflammation, or degeneration.

Sections of heart (slides D, E, F, G, H and I) show significant fibrosis of the myocardium, with hypertrophy of myofibrils. Fibrous atherosclerotic plaques are present in the right coronary artery (slide F). A branch of the left anterior descending artery entering the myocardium shows atherosclerotic calcification and cholesterol clefts (slide D). A small focus of myocardial hemorrhage without vital reaction is present in slide H. The atrioventricular node (slide I) is unremarkable. The mitral valve (slide E) shows mild myxoid degeneration.

Sections of lungs (slides J and K) show mild increase in alveolar size and clubbing of alveolar septae. Within alveoli there are abundant macrophages and rare neutrophils. No significant fibrosis is present. Rare polarizable crystals are present. The left pulmonary hilus (slide K) shows hemorrhage.

Sections of epiglottis and trachea (slide L) are unremarkable. No significant inflammation is present.

The thyroid gland (slide M) shows follicles of roughly equal size with low cuboidal epithelium. No significant inflammation is present. Several portions of skeletal muscle are present on the slide. Parathyroid tissue is not identified on the slide.

Sections of stomach and gastroesophageal junction (slide N) are unremarkable. Gastroesophageal reflux disease is not identified.

The pancreas (slide O) is autolyzed and shows minimal interstitial fibrosis. The liver (slide O) shows centrilobular congestion and mild microvesicular fatty change. No significant liver inflammation or necrosis is present.

A section of spleen (slide P) is unremarkable.

14

2012-01022

Houston, Whitney

Page 2

Sections of right kidney (slide P) and left kidney (slide Q) show mild arteriolar sclerosis. Glomeruli, tubules and interstitium are unremarkable. There is no significant inflammation or infarction.

The bladder (slide Q) is denuded of mucosa. The muscularis is unremarkable.

The uterus (slide R) shows a mass of interlacing bundles of spindle cells. No mitotic figures, calcification, or hyalinization are identified. The myometrium contains scattered portions of endometrial stroma without endometrial glands. A short segment of proliferative endometrium is present.

A section of ovary (slide S) shows a hemorrhagic corpus luteum as well as several corpora albicantia.

The right colon (slide S) shows mucosal autolysis. Blood vessels in the muscularis are congested, but there is no hemorrhage.

A section of tonsil (slide T) shows no acute inflammation.

A section of subcutaneous tissue from the left forehead (slide U) shows no hemorrhage or inflammation.

Sections of breasts (slide V) show scattered normal glands in extensive fibrous stroma. No malignancy or significant inflammation is present.

The appendix (slide W) shows fibrous obliteration of the tip.

NEUROPATHOLOGY MICROSCOPICS

Sections of cerebral cortex (slide 1), cerebellum (slide 2), thalamus (slide 3), frontal cortex (slide 5), and brain stem (slide 7) are unremarkable. Slide 4, taken as hippocampus, shows basal ganglia region. Slide 6, taken as hypothalamus with mammillary body, shows globus pallidus, internal capsule, thalamus and hypothalamus. All are unremarkable.

Note: Slides A through W were reviewed by Drs. Chandrasoma, Lakshmanan and Rogers on 3-5-12. Slides B, D, E, F, G, H and I were reviewed by Drs. Fishbein and Rogers on 2-23-12. Slides 1 through 7 are reviewed by Drs. Itabashi and Rogers on 2-23-12.

DIAGNOSIS

1. Atherosclerotic heart disease
 - a. Atherosclerosis of right and left coronary arteries
 - b. Myocardial fibrosis and fiber hypertrophy


14

2012-01022


Houston, Whitney

Page 3

2. Antemortem scald burn of back
3. Oncocytic microadenoma of adrenal
4. Mild emphysema
5. Mild fatty change of liver
6. Uterine leiomyoma
7. Adenomyosis (stroma only)
8. Fibrous mastopathy
9. Evidence of therapy
 - a. Hemorrhages of myocardium and left pulmonary hilus


CHRISTOPHER ROGERS, M.D., MBA
CHIEF FORENSIC MEDICINE DIVISION

3-29-12
DATE


LAKSHMANAN SATHYAVAGISWARAN, M.D.,FRCP(C),FCAP,FACP
CHIEF MEDICAL EXAMINER-CORONER

3-29-2012
DATE

CR:LS:mtm/f
T-3/7/12

MEDICAL REPORT

15

AUTOPSY CLASS: A B C Examination Only D

FAMILY OBJECTION TO AUTOPSY

Date: 2-21-12 Time: 1125 Dr. Rogers/Lakshmanan
(Print)

FINAL ON: 3-21-2012 By: Lakshmanan
(Print)

APPROXIMATE INTERVAL BETWEEN ONSET AND DEATH

02-01-2012
MAY, W. LINNEY E.
EASTLY HILLS PD SEC

DEATH WAS CAUSED BY: (Enter only one cause per line for A, B, C, and D)

IMMEDIATE CAUSE:

(A) DROWNING

Unknown

DUE TO, OR AS A CONSEQUENCE OF:

(B) EFFECTS OF ATHEROSCLEROTIC HEART DISEASE

Unknown

DUE TO, OR AS A CONSEQUENCE OF: AND COCAINE USE

(C)

DUE TO, OR AS A CONSEQUENCE OF:

(D)

OTHER CONDITIONS CONTRIBUTING BUT NOT RELATED TO THE IMMEDIATE CAUSE OF DEATH:

Age: 48 Gender: Male / Female

PRIOR EXAMINATION REVIEW BY DME

BODY TAG CLOTHING
 X-RAY (No. EE 28) FLUORO
 SPECIAL PROCESSING TAG MED. RECORDS
 AT SCENE PHOTOS (No. 75) (2-14-12)

CASE CIRCUMSTANCES

EMBALMED
 DECOMPOSED
 >24 HRS IN HOSPITAL
 OTHER: _____ (Reason)

TYPING SPECIMEN

TYPING SPECIMEN TAKEN BY: OK
SOURCE: Heart

TOXICOLOGY SPECIMEN

COLLECTED BY: OK
 HEART BLOOD STOMACH CONTENTS
 FEMORAL BLOOD (L) VITREOUS (2)
TECHNIQUE: External Tracheal
 Femoral BLOOD SPLEEN
 BLOOD KIDNEY
 BILE Serum (heart)
 LIVER Red cells from heart (2)
 URINE
URINE GLUCOSE DIPSTICK RESULT: 4+ 3+ 2+ 1+ 0
TOX SPECIMEN RECONCILIATION BY: OK

HISTOLOGY

Regular (No. 2) Oversize (No. _____)
Histopath Cut: Autopsy Lab

TOXICOLOGY REQUESTS

FORM 3A: YES NO
 NO TOXICOLOGY REQUESTED
SCREEN C H T S D
 ALCOHOL ONLY
 CARBON MONOXIDE
 OTHER (Specify drug and tissue)
Vitreous glucose, electrolytes, uric acid
Hemoglobin S screen
Alprazolam

REQUESTED MATERIAL ON PENDING CASES

POLICE REPORT MED HISTORY
 TOX FOR COD HISTOLOGY
 TOX FOR R/O INVESTIGATIONS
 MICROBIOLOGY EYE PATH. CONS.
 RADIOLOGY CONS.
 CONSULT ON:
 BRAIN SUBMITTED
 NEURO CONSULT DME TO CUT
 CRIMINALISTICS
 GSR SEXUAL ASSAULT OTHER

NATURAL SUICIDE HOMICIDE
 ACCIDENT COULD NOT BE DETERMINED

If other than natural causes, HOW DID INJURY OCCUR? 1) FOUND SUBMERGED IN BATHTUB
FILLED WITH WATER 2) COCAINE INTAKE

WAS OPERATION PERFORMED FOR ANY CONDITION STATED ABOVE: YES NO

TYPE OF SURGERY: _____ DATE: _____

ORGAN PROCUREMENT TECHNICIAN: Mc Dowell
PREGNANCY IN LAST YEAR YES NO UNK NOT APPLICABLE

WITNESS TO AUTOPSY EVIDENCE RECOVERED AT AUTOPSY
Item Description:

Hyon Publicker, BHPD

viral culture nasopharynx
v throat culture

3) Autopsy photos - 3 in autopsy room
1 intake photos - 28 in photo lab] Reviewed 2-14-12
OK

Christopher Rogers

RESIDENT

DME

16

2012-01-22
STON, WHITNEY E.
ACC
BEVERLY HILLS PD SEC 1

EXTERNAL EXAM

Sex Female
Race Black
Age 42
Height 66
Weight 151
Hair Brown + brown wig
Eyes Brown
Sclera Congested - no petechiae
Teeth No removable denture
Mouth
Tongue Normal - Waldeyer's rings examined, tonsils taken, micro
Nose Posterior perforation of nasal septum
Chest Postmortem markings
Breasts - Implants "McGhan 230cc"
Abdomen - Postmortem markings
Scar - See Form 20

Genital Edema Skin Decub See diagram

HEART Wt. 340

Pericard Hypert Dilat Muscle Valves Coronar
RV
LV
Septum
LAD - minimal
RCA - 60% at 4cm from ostium

AORTA VEESLS Minimal atherosclerosis

LUNGS Wt

R 680
L 610
Adhes Fluid Atelectasis Oedema Congest Consol Bronchi Nodes
Moderate edema + congestion

PHARYNX - Normal
TRACHEA - Froth
THYROID - 40gm
THYMUS
LARYNX
HYOID
ABDOMINAL WALL FAT

PERITONEUM

Fluid Adhes Normal

LIVER Wt 1510

Caps Lobul Fibros G B Calc Bile ducts
Normal-congested

SPLEEN Wt 120

Color Consist Caps Malpig
Normal-congested

PANCREAS

ADRENALS

KIDNEYS Wt

R 120
L 120
Caps Cortex Pelvis Ureter
Normal

BLADDER - 10 cc urine

GENITALIA - externally normal

Prest Testes Uterus - 150gm, fibroids 2, 3, 4.0cm
Tubes Ovar Normal

OESOPHAGUS

STOMACH 400 gm fluid
Contents Reddened mucosa

DUOB & SM INT - Normal

APPENDIX Present

LARGE INT - focally red mucosa
Anus normal

ABDOM NODS

SKELETON

Spine Marrow Rib Cage Long bones Pelvis
Normal

Subcutaneous
Bruising, L face head
SCALP - CALVARIUM - Normal
BRAIN Wt 1410

Dura Fluid Ventric Vessels Middle-ears Other
Normal

PITUITARY - Normal

Proximal cord normal
Remainder not dissected

SPINAL CORD
Blood, serum, bile, liver, urine, stomach, vitreous, tracheal air
TOXICOLOGY SPECIMENS

SECTIONS FOR HISTOPATHOLOGY

2 stock jars
2 cassette jars

MICROBIOLOGY

Viral culture - nasopharynx
Throat culture

DIAGRAMS 20, 22

X-RAYS 28 x-rays

OTHER PROCEDURES

GROSS IMPRESSIONS

- 1. History of substance abuse
A) Perforation of posterior nasal septum
2. Atherosclerotic heart disease
3. Pulmonary edema
4. Leiomyomas of uterus
5. Acute gastritis and colitis
6. Postmortem scald burns

Date 2-12-12 Time 1445 Deputy Medical Examiner [Signature]



Department of Coroner, County of Los Angeles
FORENSIC SCIENCE LABORATORIES
 Laboratory Analysis Summary Report



To: Dr. Rogers
 Deputy Medical Examiner

PendingTox

The following results have been technically and administratively reviewed and are the opinions and interpretations of the Analyst:

Coroner Case Number: 2012-01022 **Decedent:** HOUSTON, WHITNEY ELIZABETH

| <u>SPECIMEN</u> | <u>SERVICE</u> | <u>DRUG</u> | <u>RESULT</u> | <u>ANALYST</u> |
|-----------------|-----------------|--------------------------------------|---------------|----------------------|
| Blood* | Benzodiazepines | Alprazolam | QNS | S. DeQuintana |
| | Cocaine | Benzoylcegonine | 6.6 ug/mL | D. Anderson |
| | Cocaine | Cocaine | 0.58 ug/mL | D. Anderson |
| Blood, Femoral | Benzodiazepines | Alprazolam | 80 ng/mL | S. DeQuintana |
| | Cocaine | Benzoylcegonine | 7.6 ug/mL | D. Anderson |
| | Cocaine | Cocaine | 0.57 ug/mL | D. Anderson |
| Blood, Heart | Alcohol | Ethanol | Negative | M. Schuchardt |
| | Bases | Cocaine | Present | E. Fu |
| | Bases | Cyclobenzaprine | 0.09 ug/mL | E. Fu |
| | Bases | Diphenhydramine | 0.33 ug/mL | E. Fu |
| | Benzodiazepines | Alprazolam | 85 ng/mL | S. DeQuintana |
| | Cocaine | Benzoylcegonine | 7.3 ug/mL | D. Anderson |
| | Cocaine | Cocaethylene | < 0.03 ug/mL | D. Anderson |
| | Cocaine | Cocaine | 0.61 ug/mL | D. Anderson |
| | ELISA | Acetaminophen | ND | C. Miller |
| | ELISA | Barbiturates | ND | C. Miller |
| | ELISA | Fentanyl | ND | C. Miller |
| | ELISA | Methamphetamine & MDMA | ND | C. Miller |
| | ELISA | Opiates: Codeine & Morphine | ND | C. Miller |
| | ELISA | Opiates: Hydrocodone & Hydromorphone | ND | C. Miller |
| | ELISA | Phencyclidine | ND | C. Miller |
| | ELISA | Salicylate | ND | C. Miller |
| | Marijuana | Carboxy-THC | 49 ng/mL | S. Brooks |
| | Marijuana | Tetrahydrocannabinol (THC) | < 2.5 ng/mL | S. Brooks |
| | Neutrals | Ibuprofen | 5.1 ug/mL | O. Pleitez |
| | Outside Test | Hemoglobin Variant | Negative | PerkinElmer Genetics |

Coroner Case Number: 2012-01022 **Decedent:** HOUSTON, WHITNEY ELIZABETH

| <u>SPECIMEN</u> | <u>SERVICE</u> | <u>DRUG</u> | <u>RESULT</u> | <u>ANALYST</u> |
|-----------------|----------------|--------------|---------------|----------------|
| | Phenytoin | Phenytoin | ND | E. Fu |
| Urine | Alcohol | Ethanol | Negative | M. Schuchardt |
| Vitreous | Outside Test | Electrolytes | * Done | NMS Labs, Inc. |
| | Outside Test | Glucose | * Done | NMS Labs, Inc. |

NOTE: Blood*=Blood drawn from right Femoral Vein. Blood, Femoral=Blood drawn from left Femoral Vein. *Vitreous sample was submitted to NMS Labs, Inc. at a dilution due to the viscosity of the specimen.

Legend:

| | | | | | |
|------|--------------|-------|--------------------------|-------|--------------------------|
| | | mg/dL | Milligram per Deciliter | QNS | Quantity Not Sufficient |
| g | Grams | mg/L | Milligram per Liter | TNP | Test Not Performed |
| g% | Gram Percent | ND | Not Detected | ug | Micrograms |
| Inc. | Inconclusive | ng/g | Nanograms per Gram | ug/g | Micrograms per Gram |
| mg | Milligrams | ng/mL | Nanograms per Milliliter | ug/mL | Microgram per Milliliter |

In accordance with the Department's Evidence Retention Policy, the blood specimen(s) will be retained for one-year and all other specimens for six-months from Autopsy.

Administratively reviewed by:



Daniel T. Anderson, M.S., FTS-ABFT, D-ABC
Supervising Criminalist II
TOXICOLOGY

18/02/29.12

Joseph M. Quashnock, PhD
Laboratory Director

PerkinElmer Genetics, Inc.
PO Box 219
Bridgeville, PA 15017

Date of Report
02/18/2012

(412) 220-2300 Phone

(412) 220-0784 Fax

Page 1 of 1

Initial Release: 02/18/2012 14:58

Date Collected: 02/12/2012 Date Recvd: 02/17/2012 Birth Date: 08/09/1963
 Submitter: Los Angeles Coroner Cond. of Spec: S
 Filter Paper: 3996042 Patient's Name: DOE, JANE Sex: F
 PS ID: 4951371 AKA Name:
 Accession No: 2012045767 Med. Rec. No: 2012-01022
 Mother's Name: Physician: ROGERS

Autopsy Specimen Report

| Screening Test | Outcome |
|-------------------------------|----------|
| Acylcarnitine Profile | Negative |
| CAH 17-OHP | Negative |
| Congenital Hypothyroidism-TSH | Negative |
| Galactose- (Gal and Gal-1-P) | Negative |
| Hemoglobinopathies | Negative |

OUTCOME DEFINITIONS

NEGATIVE - The analyte detected does not exceed the concentration usually found in such analyses. Interpretation should be in conjunction with other findings.

SELECTED REFERENCE RANGE

17 OH P

Cutoff values for 17 hydroxyprogesterone are age dependent. For Infants less than 91 days of age, abnormal is defined as a value > 19.0 ng/mL; for infants 91 days to 1 year of age, abnormal is > 5.0 ng/mL; for age > 1 year, abnormal is > 4.0 ng/mL. Note new reference range for 17-hydroxyprogesterone effective November 1, 2010.

TSH

Cutoff values for TSH are age dependent. For infants < 7 days of age, abnormal is defined as a TSH value >50 uIU/mL; for infants 7 days or older, abnormal is > 30 uIU/mL.

GAL

Abnormal is defined for all infant ages as a total galactose > 20 mg/dL.

Comments:

The results of PerkinElmer Genetics post-mortem testing are analytically accurate within the limits of the test technology used. Factors including specimen source, quality of specimen and patient variables will affect results. Limited information on reference ranges is available. Interpretation of results should be in conjunction with additional clinical or laboratory evidence to help support or disprove the presence of a specific disorder.



UJ/0239-12



NMS Labs

CONFIDENTIAL

3701 Welsh Road, PO Box 433A, Willow Grove, PA 19090-0437
 Phone: (215) 657-4900 Fax: (215) 657-2972
 e-mail: nms@nmslabs.com
 Robert A. Middleberg, PhD, DABFT, DABCC-TC, Laboratory Director

Toxicology Report

Report Issued 03/07/2012 09:02

To: 10139
 Los Angeles County Coroner Medical Examiner
 Attn: Joseph Muto
 1104 N. Mission Road
 Los Angeles, CA 90033

Patient Name DOE, JANE
 Patient ID 2012-01022
 Chain 11392960
 Age Not Given
 Gender Not Given
 Workorder 12058575

Page 1 of 2

Positive Findings:

| <u>Compound</u> | <u>Result</u> | <u>Units</u> | <u>Matrix Source</u> |
|--------------------------------|---------------|--------------|----------------------|
| Potassium (Vitreous Fluid) | 8.5 | mEq/L | Vitreous Fluid |
| Chloride (Vitreous Fluid) | 53 | mEq/L | Vitreous Fluid |
| Creatinine (Vitreous Fluid) | 0.6 | mg/dL | Vitreous Fluid |
| Urea Nitrogen (Vitreous Fluid) | 13 | mg/dL | Vitreous Fluid |
| Glucose (Vitreous Fluid) | < 20 | mg/dL | Vitreous Fluid |

See Detailed Findings section for additional information

* vitreous sample submitted at a
 1/2 dilution due to viscosity

Testing Requested:

| <u>Analysis Code</u> | <u>Description</u> |
|----------------------|---------------------------|
| 01919FL | Electrolytes Panel, Fluid |

Tests Not Performed:

Part or all of the requested testing was unable to be performed. Refer to the **Analysis Summary and Reporting Limits** section for details.

Specimens Received:

| <u>ID</u> | <u>Tube/Container</u> | <u>Volume/ Mass</u> | <u>Collection Date/Time</u> | <u>Matrix Source</u> | <u>Miscellaneous Information</u> |
|-----------|-----------------------|-------------------------|---------------------------------|----------------------|--------------------------------------|
| 001 | Red Top Tube | 1.2 mL | 02/21/2012 13:00 | Vitreous Fluid | |

All sample volumes/weights are approximations.
 Specimens received on 02/22/2012.



SP 3/7/12



CONFIDENTIAL

Workorder 12058575
Chain 11392960
Patient ID 2012-01022

Page 2 of 2

Detailed Findings: ** all samples at a 1/2 dilution (see pg 1)*

| Analysis and Comments | Result | Units | Rpt. Limit | Specimen Source | Analysis By |
|--------------------------------|--------|-------|------------|----------------------|----------------|
| Potassium (Vitreous Fluid) | 8.5 | mEq/L | | 001 - Vitreous Fluid | [Not provided] |
| Chloride (Vitreous Fluid) | 53 | mEq/L | | 001 - Vitreous Fluid | [Not provided] |
| Creatinine (Vitreous Fluid) | 0.6 | mg/dL | | 001 - Vitreous Fluid | [Not provided] |
| Urea Nitrogen (Vitreous Fluid) | 13 | mg/dL | | 001 - Vitreous Fluid | [Not provided] |
| Glucose (Vitreous Fluid) | < 20 | mg/dL | | 001 - Vitreous Fluid | [Not provided] |

Other than the above findings, examination of the specimen(s) submitted did not reveal any positive findings of toxicological significance by procedures outlined in the accompanying Analysis Summary.

Reference Comments:

1. Glucose (Vitreous Fluid) - Vitreous Fluid:

Analysis for Electrolytes Panel, including Sodium, Potassium, Chloride, Creatinine, Urea Nitrogen and Glucose was performed by:
Health Network Laboratories
2024 Lehigh Street
Allentown, PA 18103

Chain of custody documentation has been maintained for the analyses performed by NMS Labs.

Unless alternate arrangements are made by you, the remainder of the submitted specimens will be discarded six (6) weeks from the date of this report; and generated data will be discarded five (5) years from the date the analyses were performed.

Analysis Summary and Reporting Limits:

Acode 01919FL - Electrolytes Panel, Fluid - Vitreous Fluid

-Analysis by [Not provided] for:

| Compound | Rpt. Limit | Compound | Rpt. Limit |
|-----------------------------|------------|--------------------------------|------------|
| Chloride (Vitreous Fluid) | N/A | Potassium (Vitreous Fluid) | N/A |
| Creatinine (Vitreous Fluid) | N/A | Sodium (Vitreous Fluid) | N/A |
| Glucose (Vitreous Fluid) | N/A | Urea Nitrogen (Vitreous Fluid) | N/A |



SP 3/7/12

[Handwritten signature]

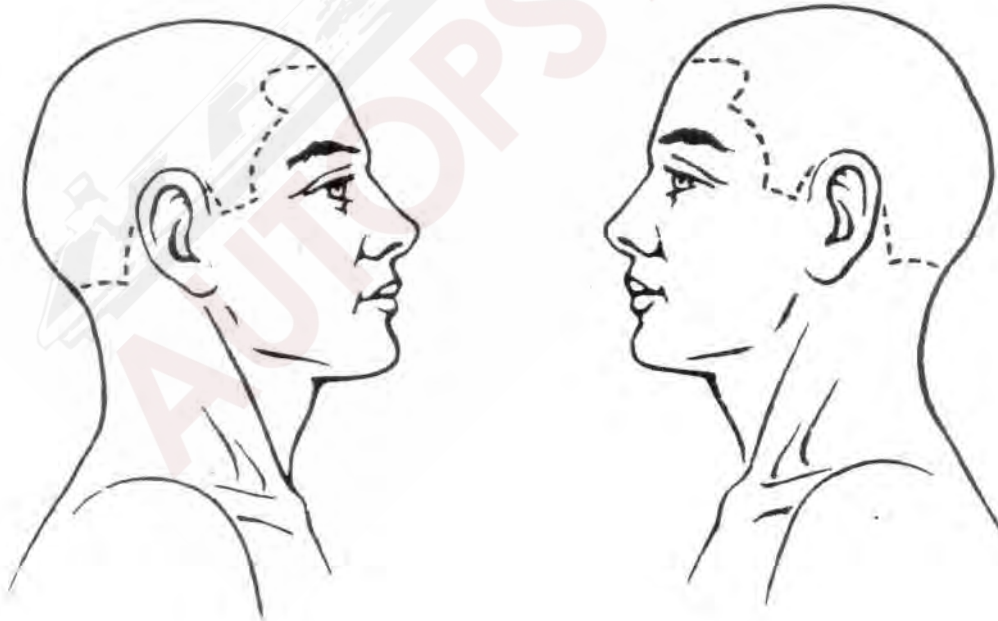
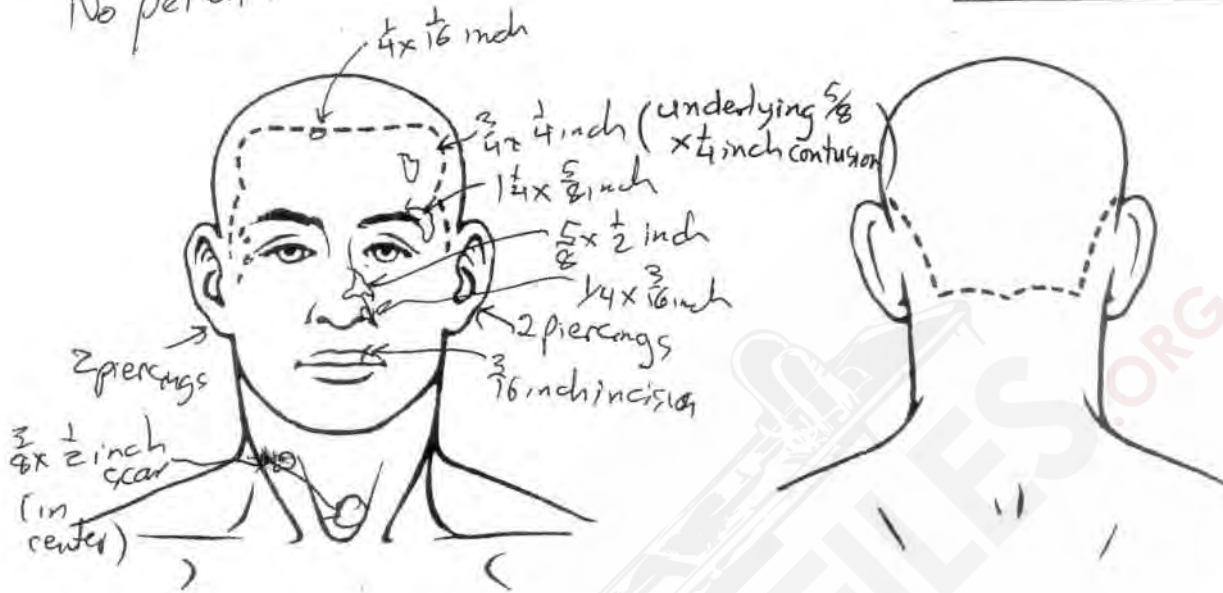
[Handwritten signature]
0239-12

v.8

22

2012-01022
HOUSTON, WHITNEY E.
ACC
BEVERLY HILLS PD SEC

No petechiae



Date

John S. ... 1445
... 2012 M.D.
 Deputy Medical Examiner

COUNTY OF LOS ANGELES

SEXUAL ASSAULT EVIDENCE DATA SHEET

DEPT. OF CORONER

81

Case Reported to Coroner (Date/Time): 02/11/12 3:104h

CC#: 2012-01022

Criminalist: SCHUCHART

Decedent: HOUSTON, WHITNEY

Forensic Science Laboratories

Phone #: 323-343-0530

Fax #: 323-222-5171

Male

Female

SEXUAL ASSAULT EVIDENCE COLLECTION STARTED: Location: scene Date: 02/11/12 Time: 2330

SEXUAL ASSAULT EVIDENCE COLLECTION COMPLETED: Location: scene Date: 02/12/12 Time: 0015

| | Collected: | | | Not Collected |
|---|-------------------------------------|--------------------------|------------|-------------------------------------|
| | Scene | FSC | INITIALS | |
| 1. ORAL CAVITY: Swab set & slide set..... | <input checked="" type="checkbox"/> | <input type="checkbox"/> | <u>huf</u> | <input type="checkbox"/> |
| 2. NECK: Wet swab set..... | <input type="checkbox"/> | <input type="checkbox"/> | | <input checked="" type="checkbox"/> |
| 3. LEFT BREAST: Wet swab set..... | <input checked="" type="checkbox"/> | <input type="checkbox"/> | | <input type="checkbox"/> |
| 4. RIGHT BREAST: Wet swab set..... | <input checked="" type="checkbox"/> | <input type="checkbox"/> | <u>huf</u> | <input type="checkbox"/> |
| 5. EXTERNAL GENITAL: Wet swab set & slide set..... | <input checked="" type="checkbox"/> | <input type="checkbox"/> | | <input type="checkbox"/> |
| 6. VAGINAL CAVITY: Swab set & slide set..... | <input checked="" type="checkbox"/> | <input type="checkbox"/> | | <input type="checkbox"/> |
| 7. CERVICAL: Swab set & slide set..... | <input type="checkbox"/> | <input type="checkbox"/> | <u>huf</u> | <input checked="" type="checkbox"/> |
| 8. PENILE SHAFT: Wet swab set & slide set..... | <input type="checkbox"/> | <input type="checkbox"/> | | <input type="checkbox"/> |
| 9. ANAL OPENING: Wet swab set & slide set..... | <input checked="" type="checkbox"/> | <input type="checkbox"/> | <u>huf</u> | <input type="checkbox"/> |
| 10. RECTAL: Swab set & slide set..... | <input checked="" type="checkbox"/> | <input type="checkbox"/> | <u>huf</u> | <input type="checkbox"/> |
| 11. VAGINAL ASPIRATE..... | <input type="checkbox"/> | <input type="checkbox"/> | <u>huf</u> | <input checked="" type="checkbox"/> |
| 12. PUBIC HAIR COMBING..... | <input checked="" type="checkbox"/> | <input type="checkbox"/> | <u>huf</u> | <input type="checkbox"/> |
| 13. OTHER EVIDENCE packaged with the sexual assault evidence: | | | | |

- _____
- _____
- _____
- _____

14. ALTERNATE LIGHT SOURCE utilized..... YES NO

| Wavelength | Color of Goggles | Findings |
|------------|------------------|----------|
| | | |
| | | |
| | | |
| | | |

COMMENTS: BODY NUDE; REPORTEDLY SUBMERGED ENTIRELY IN 90° BATH WATER FOR APPROX ONE HOUR; NO CLOTHING COLLECTED,
MS Schuchart

Reviewed by DME: C. Roark / [Signature], M.D. Date: 2-14-12 Time: 1145

COUNTY OF LOS ANGELES - DEPARTMENT OF PUBLIC HEALTH
PUBLIC HEALTH LABORATORY - 12750 ERICKSON AVENUE, DOWNEY, CA 90242
J. MICHAEL JANDA, PhD, DIRECTOR (562) 658-1330

NAME: HOUSTON, WHITNEY LOC: L.A. COUNTY CORONERS OFFICE
PATIENT ID# LACCO-201201022 DOB: 08/09/1963 AGE: 48Y SEX: F
REQ'D BY: REFERRED

COLLECTED: 02/12/2012 12:10 RECEIVED: 02/13/2012 14:00
ACC. NO.: M56202 SUBM. ACC. NO.:

TEST NAME TEST RESULT REFERENCE RANGE
INFLUENZA A AND B
VIRUS BY RT-PCR.

SPECIMEN DESCRIPTION NASAL PHARYNGEAL SWAB

Result date, time: 02/13/2012, 14:29

REPORT

INFLUENZA A VIRUS NOT DETECTED BY RT-PCR.
INFLUENZA B VIRUS NOT DETECTED BY RT-PCR.
Result date, time: 02/16/2012, 16:51

REFERENCE RANGE

TEST NAME TEST RESULT
LUMINEX xTAG
RESPIRATORY VIRAL
PANEL MULTIFLEX PCR

INFLUENZA A NOT DETECTED
Result date, time: 02/22/2012, 14:27

INFLUENZA A
SUBTYPE H1 NOT DETECTED
Result date, time: 02/22/2012, 14:27

INFLUENZA A
SUBTYPE H3 NOT DETECTED
Result date, time: 02/22/2012, 14:27

INFLUENZA B NOT DETECTED
Result date, time: 02/22/2012, 14:27

RSV SUBTYPE A NOT DETECTED
Result date, time: 02/22/2012, 14:27

RSV SUBTYPE B NOT DETECTED
Result date, time: 02/22/2012, 14:27

PARAINFLUENZA 1 NOT DETECTED
Result date, time: 02/22/2012, 14:27

PARAINFLUENZA 2 NOT DETECTED
Result date, time: 02/22/2012, 14:27

PARAINFLUENZA 3 NOT DETECTED
Result date, time: 02/22/2012, 14:27

DEPARTMENT OF
CORONER DOCUMENT

HOUSTON, WHITNEY
CLIENT REPORT

CONTINUED
ACCOUNT NO.: LACCO PRINT DATE & TIME: 02/28/2012

PAGE 1
14:39

Dr. Rogers

COUNTY OF LOS ANGELES - DEPARTMENT OF PUBLIC HEALTH
PUBLIC HEALTH LABORATORY - 12750 ERICKSON AVENUE, DOWNEY, CA 90242
J. MICHAEL JANDA, PhD, DIRECTOR (562)658-1330

NAME: HOUSTON, WHITNEY LOC: L.A. COUNTY CORONERS OFFICE
PATIENT ID# LACCO-201201022 DOB: 08/09/1963 AGE: 48Y SEX: F
REQ'D BY: REFERRED

COLLECTED: 02/12/2012 12:10 RECEIVED: 02/13/2012 14:00
ACC. NO.: M56202 SUBM. ACC. NO.:

| TEST NAME | TEST RESULT | REFERENCE RANGE |
|--|--------------------------------------|-----------------|
| LUMINEX xTAG RESPIRATORY VIRAL PANEL MULTIPLEX PCR | (CONTINUED) | |
| | Result date, time: 02/22/2012, 14:27 | |
| HUMAN METAPNEUMOVIRUS | NOT DETECTED | |
| | Result date, time: 02/22/2012, 14:27 | |
| RHINOVIRUS | NOT DETECTED | |
| | Result date, time: 02/22/2012, 14:27 | |
| ADENOVIRUS | NOT DETECTED | |
| | Result date, time: 02/22/2012, 14:27 | |

VIROLOGY

COLLECTED: 02/12/2012 /12:10 RECEIVED: 02/13/2012 /14:00

ACC. NO.: M56203 BATTERY ORDERED: VIRAL CULTURE, COMPREHENSIVE

SPECIMEN DESCRIPTION: NASAL PHARYNGEAL SWAB

REPORT STATUS: FINAL 02/27/2012

DIRECT EXAM: 1. NOT DONE

CULTURE: 1. NO VIRUS ISOLATED IN TISSUE CULTURE

DEPARTMENT OF
CORONER DOCUMENT

HOUSTON, WHITNEY
CLIENT REPORT

END OF REPORT PAGE 2
ACCOUNT NO.: LACCO PRINT DATE & TIME: 02/28/2012 14:39

Rogers
① 2/2/12
R32-12

LAC + USC Medical Center
1200 N. State St., Los Angeles, CA 90033
Ira A. Shulman, M.D., Director, Laboratories & Pathology
02/14/2012 07:00

Page: 1

X186334 COLL: 02/12/2012 1215 REC: 02/12/2012 1402 PHYS: ILLEGIBLE, PHYSICIAN
THROAT/NASOPHARYNGEA FINAL 02/13/2012

MICRO LAB SETUP: UNKNOWN UNKNOWN
SPECIMEN DESCRIPTION: **AUTOPSY THROAT**
SPECIAL REQUESTS: NONE

CULTURE: NORMAL ORAL FLORA ISOLATED IN NORMAL NUMBERS.



END OF REPORT

ACCOUNT #: 906B

HOUSTON, WHITNEY
CC-201201022
CC CORONERS CASE
F 08/09/1963

C O N F I D E N T I A L
SUMMARY REPORT

OR 2/14/12
(Handwritten initials)