

Endocrine Development

Editor: M.O. Savage

Vol. 7

Pediatric and Adolescent Gynecology

Evidence-Based Clinical Practice

Editor

C. Sultan



KARGER

.....

Pediatric and Adolescent Gynecology
Evidence-Based Clinical Practice

.....

Endocrine Development

Vol. 7

Series Editor

Martin O. Savage London

KARGER

.....

Pediatric and Adolescent Gynecology

Evidence-Based Clinical Practice

Volume Editor

Charles Sultan Montpellier

48 figures, 11 in color and 34 tables, 2004

KARGER

Basel · Freiburg · Paris · London · New York ·
Bangalore · Bangkok · Singapore · Tokyo · Sydney

3HAP

.....
Prof. Dr. Charles Sultan

Unité d'Endocrinologie et de Gynécologie Pédiatriques
Service de Pédiatrie I
Hôpital Arnaud de Villeneuve
Centre Hospitalier Universitaire
Montpellier, France

Library of Congress Cataloging-in-Publication Data

Pediatric and adolescent gynecology : evidence-based clinical practice / volume editor,
Charles Sultan.

p. ; cm. – (Endocrine development, ISSN 1421–7082 ; v. 7)

Includes bibliographical references and index.

ISBN 3–8055–7623–4 (hard cover : alk. paper)

1. Pediatric gynecology. 2. Adolescent medicine. 3. Evidence-based medicine. I. Sultan,
Charles. II. Series.

[DNLM: 1. Genital Diseases, Female–Adolescent. 2. Genital Diseases, Female–Child.

3. Evidence-Based Medicine. 4. Genitalia, Female–abnormalities–Adolescent. 5.

Genitalia, Female–abnormalities–Child. WS 360 P37077 2004]

RJ478.P433 2004

618.92'098–dc22

2003061930

Bibliographic Indices. This publication is listed in bibliographic services, including Current Contents® and Index Medicus.

Drug Dosage. The authors and the publisher have exerted every effort to ensure that drug selection and dosage set forth in this text are in accord with current recommendations and practice at the time of publication. However, in view of ongoing research, changes in government regulations, and the constant flow of information relating to drug therapy and drug reactions, the reader is urged to check the package insert for each drug for any change in indications and dosage and for added warnings and precautions. This is particularly important when the recommended agent is a new and/or infrequently employed drug.

All rights reserved. No part of this publication may be translated into other languages, reproduced or utilized in any form or by any means electronic or mechanical, including photocopying, recording, microcopying, or by any information storage and retrieval system, without permission in writing from the publisher.

© Copyright 2004 by S. Karger AG, P.O. Box, CH–4009 Basel (Switzerland)

www.karger.com

Printed in Switzerland on acid-free paper by Reinhardt Druck, Basel

ISSN 1421–7082

ISBN 3–8055–7623–4

.....

Contents

VII Foreword

Savage, M.O. (London)

IX Preface

Sultan, C. (Montpellier)

Background and Tools

1 Gynecologic Clinical Examination of the Child and Adolescent

Thibaud, E. (Paris)

9 Imaging in Pediatric and Adolescent Gynecology

Porcu, E. (Bologna)

The Prepubertal Girl

23 Ambiguous Genitalia in the Newborn: Diagnosis, Etiology and Sex Assignment

Sultan, C.; Paris, F.; Jeandel, C.; Lumbroso, S.; Galifer, R.B.;
Picaud, J.-C. (Montpellier)

39 Vulvo-Vaginal Disorders

Hamel-Teillac, D. (Paris)

57 Precocious Puberty (Complete, Partial)

Stanhope, R.; Traggiai, C. (London)

66 Ovarian Cysts in Prepubertal Girls

Pienkowski, C.; Baunin, C.; Gayrard, M.; Lemasson, F.; Vaysse, P.; Tauber, M. (Toulouse)

77 Sexual Abuse in Prepubertal Children and Adolescents

Herrmann, B. (Kassel); Navratil, F. (Zürich)

- 106 Delayed Puberty**
Fenichel, P. (Nice)
- 129 Menstrual Irregularities.** Evidence-Based Clinical Practice
Tscherne, G. (Graz)
- 140 Adolescent Dysmenorrhea**
Sultan, C.; Jeandel, C.; Paris, F.; Trimeche, S. (Montpellier)
- 148 Hyperandrogenism in Adolescent Girls**
Cortet-Rudelli, C.; Dewailly, D. (Lille)
- 163 Ovarian Masses in Adolescent Girls**
Pienkowski, C.; Baunin, C.; Gayrard, M.; Moulin, P.; Escourrou, G.; Galinier, P.; Vaysse, P. (Toulouse)
- 183 Breast Diseases in Adolescents**
Duflos, C.; Plu-Bureau, G.; Thibaud, E.; Kuttenn, F. (Paris)
- 197 Sexually Transmitted Diseases**
Heinz, M. (Berlin)
- 213 Chronic Pelvic Pain and Recurrent Abdominal Pain in Female Adolescents**
Brown, R.T.; Hewitt, G.D. (Columbus, Ohio)
- 225 Contraception for Adolescents 2003**
Creatsas, G. (Athens)
- 233 Teenage Pregnancy**
Uzan, M.; Seince, N.; Pharisien, I. (Bondy)
- 252 Adolescent Health Care**
Apter, D.; Makkonen, K. (Helsinki)
- 262 Author Index**
- 263 Subject Index**

.....

Foreword

Professor Charles Sultan has edited an outstanding issue of *Endocrine Development*. Professor Sultan is a pediatric endocrinologist with hands-on experience in clinical and basic science, particularly in the field of steroid action. He is one of the few reputed specialists worldwide to have recognised the importance of the subject of pediatric and adolescent gynecology, which spans pediatrics, adolescent medicine, reproductive endocrinology and gynecology. He is to be congratulated for assembling a most impressive group of international contributors.

The goal of this volume, to discuss key issues in gynecology of the child and adolescent, is ambitious but succeeds emphatically. There are few, if any, books which cover the subject as comprehensively as this volume. Basic techniques of clinical and radiological examination are covered. The chapter on ambiguous genitalia will be valuable to the pediatrician, and those on disturbances of puberty are relevant to doctors caring for the child, adolescent and young woman. Hyperandrogenism, a common cause of clinical referral, is covered extensively, as are menstrual irregularities and prevention and care of teenage pregnancy, as well as many other relevant topics.

The overall objective is to improve the care of the female child and adolescent. In addition to emphasis on clinical management, sound and up-to-date science is included to give theoretical background where appropriate. All relevant issues of this important, and arguably neglected field, are covered. I am delighted to welcome this volume as a very worthy addition to the *Endocrine Development* series.

Martin O. Savage, London

.....

Preface

Pediatric and adolescent gynecology is an emerging specialty, at the intersection of pediatrics, pediatric endocrinology, gynecology, pediatric surgery, dermatology, psychiatry, public health medicine and genetics. It thus addresses a wide spectrum of diseases from the newborn period to adolescence.

Progress in molecular biology and genetic research, as well as in imaging techniques, has greatly contributed to our understanding of the pathologies of gynecological development and, indeed, has helped to more clearly define the limits of physiological variation.

The gynecological problems encountered in children and adolescents are often both medically and psychologically complex and thus require a highly skilled and coherent approach. The adolescent, who is no longer a child but not quite an adult, poses a particular management problem to the traditional specialties. In the field of adolescent gynecology more than anywhere else, the medical attitude is often striking by its extremes: from a seemingly indifferent ‘wait-and-see’ policy (true indifference or ignorance?) to an overzealous interventionism – and this at a developmental moment requiring great sensitivity and tact.

This volume does not exhaustively cover the entire field of pediatric and adolescent gynecology. Instead, its goal is to explore some of the most commonly encountered problems seen in clinical practice today. I am deeply grateful to the many experts who graciously agreed to contribute their insights and knowledge on different aspects of this broad field: together they represent a wealth of clinical experience firmly based on some of today’s most exciting research. I have no doubt that their collective offering will enrich the work of practitioners the world over.

On a more personal note, let me conclude by expressing my great appreciation to Dr. Yvette Salomon-Bernard, one of the pioneers in Pediatric and Adolescent Gynecology; Prof. Raphael Rappaport, a longstanding leader in this field; Prof. Claude Migeon who first welcomed me to the Johns Hopkins University Hospital, and Prof. Roger Jean who was my mentor from the very beginning. All of them encouraged the young pediatric endocrinologist that I was (some years ago!) to broaden my clinical work to include pediatric and adolescent gynecology – and I thank them.

Charles Sultan, Montpellier

Sultan C (ed): Pediatric and Adolescent Gynecology. Evidence-Based Clinical Practice. Endocr Dev. Basel, Karger, 2004, vol 7, pp 1–8

.....

Gynecologic Clinical Examination of the Child and Adolescent

Elisabeth Thibaud

Unité d'Endocrinologie et de Gynécologie Pédiatriques,
Hôpital Necker-Enfants Malades, Paris, France

Clinical examination is always necessary and most of the time is sufficient to diagnose and treat the child's gynecological problems. A pelvic ultrasound can often be useful.

Evidence Leading to Gynecological Examination

Reasons for undertaking a gynecological examination include: (1) Gynecological complaints: vaginal discharge, pruritus, vulval or abdominal pains, and bleeding indicating there may be an infection, tumor or malformation. (2) Endocrine reasons: signs of estrogen exposure or androgenization; ambiguous genitalia observed during examination. (3) Suspected or confirmed sexual abuse. The physician is increasingly asked to look for and describe objective evidence of abuse.

Preparation for the Examination

Gynecological examination of the child is very simple and painless. The gynecologist must be very familiar with the anatomy and physiology of the genitalia before and during puberty. The child must be calm and cooperative, which is possible with careful preparation of the examination and attention focused on the child and her mother [1–3]. The child should therefore be asked to explain in her own words the reason for the visit. If, as in most cases, the mother or accompanying adult begins to speak in the child's place, the physician must make sure the child listens, understands and nods to what is being

said regarding her problem. The prerequisite for a well-accepted, non-traumatic and even therapeutic gynecological examination is the respect shown to the child by choosing her as the privileged and active interlocutor. During the examination, the mother must stay if the child is very young. Between the ages of 10 and 13, the child's wish must be respected. Beyond 13 years of age, the teenager must be seen alone.

The Examination

Complete pediatric assessment as well as palpation of the breasts must precede the gynecological examination itself.

Gynecological Examination of a Prepubertal Child

A full gynecological examination of the child mainly includes inspection of external genitalia and in some cases rectal examination. Vaginoscopic examination and samples are limited to certain cases [2].

The child must be comfortable. The best position is the frog-leg position: the child should be in a supine position, her legs flexed, with her knees apart and feet touching (fig. 1). The physician should be sitting in front of her, with a lamp providing ample light from behind. A child under 2 years of age may sometimes be afraid of the table and can instead be examined in the same position on her mother's lap. The abdomen, inguinal areas and labia majora are first inspected. The physician should note the presence of pubic hair. The labia are then gently separated either by pulling the inferior part downward and laterally (fig. 2) or by pulling them anteriorly (fig. 3). The clinician should avoid a solely lateral maneuver, which puts a painful strain on the posterior fourchette and may split it, thus provoking a defensive reaction from the child and hindering further examination. The physician will note the size of the clitoris by pulling up the clitoral hood and inspecting it. This will enable the clinician to differentiate a clitoromegaly from a hood thicker than usual. A normal clitoral glans in a prepubertal child is on average 5 mm in length and 3 mm in transverse diameter and shows little variation after puberty [4] (fig. 4).

A prepubertal child shows thin and sometimes short labia minora. They edge the vulva vestibulum, at the bottom of which the urethra and vagina open. On each side of the urethra, Skene's duct can be seen. Without estrogenization, the vulval mucosa appears thin and red and the perihymeneal tissue may look erythematous [2]. The thick white substance noted in the anterior labia folds is called smegma, not to be mistaken for leukorrhea. The vaginal orifice is edged by the hymen, which varies in size and shape. The hymen will often gape open



Fig. 1. Child's position for gynecological examination.




Fig. 2. Vulval examination: separation of labia majora by pulling the inferior part downward and laterally.

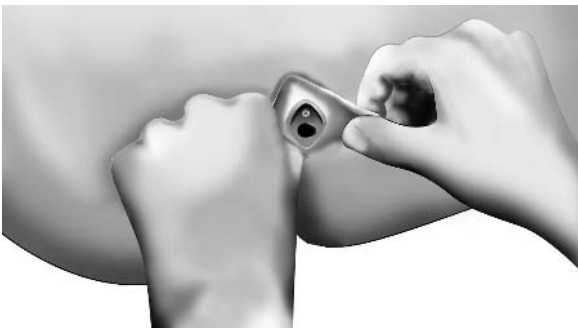


Fig. 3. Vulva examination: separation of labia majora by pulling them anteriorly.

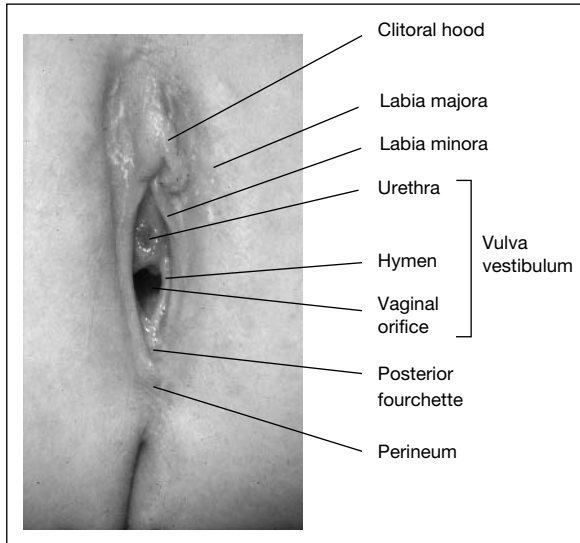


Fig. 4. Prepubertal vulva.

if the child is asked to take a deep breath or cough. If not, the best maneuver consists of gently pulling the labia anteriorly and laterally. The most often observed types of hymen are as follows [5] (fig. 5a–c): (a) the annular hymen with a hymeneal edge varying in size and an annular and regular orifice; (b) the crescentic hymen, the posterior rim of which looks like a crescent and whose ends are attached on the lateral vagina wall; there is no hymeneal suburethral tissue, and (c) the redundant hymen is the most common in girls under 3 years. The hymeneal edge is large and fimbriated.

The first two types of hymen are most common from the age of 3 to the beginning of puberty. On average, the vaginal orifice measures 4–5 mm in girls until the age of 5 and remains under 10 mm until the beginning of puberty. These figures are given as an indication, the diameter of the vaginal orifice varying much with the position of the child, the degree of perineal relaxation, the hymen shape and the level of estrogenization [6, 7].

A narrow and thin hymen does not completely cover the vaginal orifice, enabling examination of the anterior half or two thirds of it without resorting to endoscopy. The most appropriate maneuver is the one described above, which consists in gently pulling the labia majora anteriorly and laterally. The hymen opens and the vaginal axis is corrected. This maneuver is painless and easily accepted by the child. It may sometimes be difficult to visualize the free edge

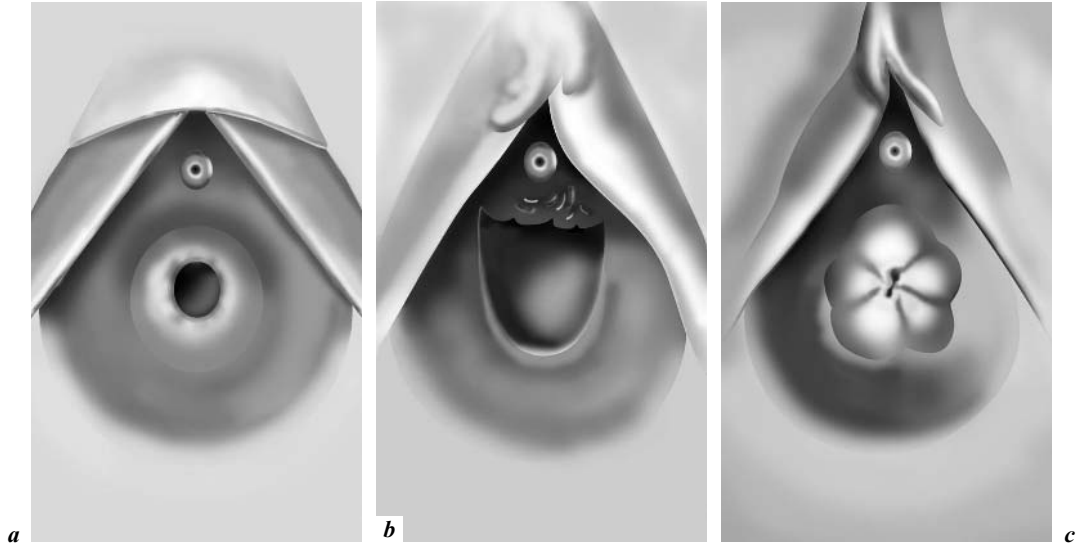


Fig. 5. Configuration of hymen in prepubertal girls: (a) annular hymen, (b) crescentic hymen, and (c) redundant hymen [according to 5].

of the hymen and the vagina with certain types of hymens. Such is the case with redundant hymens, microperforate hymens with a suburethral orifice, and septate hymens. The physician will then use a small urethral catheter to unfold the hymeneal edge and look for hymeneal integrity and an opening (fig. 6a, b).

Rectal examination is the following and last step, using the little finger until the age of 6. It is used to determine the existence and volume of the cervix. The clinician will be able to palpate it on a small midline structure. It should measure about 5 mm in transverse diameter. Ovaries are too small to be felt. Any pelvic mass must evoke a cyst or tumor. The physician can then palpate the vagina and note any foreign body (tumor) or vaginal discharge.

Vaginoscopic examination must be limited to the identification of a tumor or foreign body when the clinical examination and ultrasound do not provide the origin of vaginal bleeding. A child's vagina measures 5 cm in length. The vaginal mucosa appears red, thin and folded. It is very sensitive and petechial lesions may be caused by the vaginoscope. The cervix is small with a centered opening and flush with the vaginal vault, making it difficult to visualize.

Samples for culture purposes are sometimes necessary for bacteriological examination. These samples are required in case of vaginal leukorrhea when not caused by a foreign body. They are rarely necessary in the case of vulvitis unless specific and rare causes such as yeast infections, streptococcus, and so

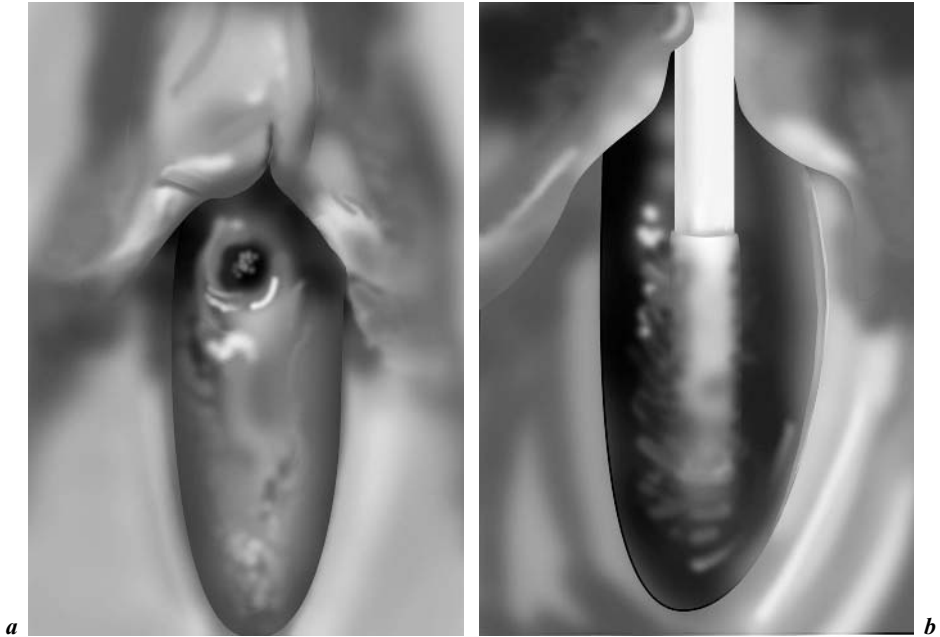


Fig. 6. a Microperforate hymen. *b* Opening unfolded with small catheter.

on, are suspected. Results must be interpreted according to the clinical context since the vaginal mucosa and vulva are the home of normal flora.

Once the perineum and rectum are inspected, the clinical examination is complete.

Gynecological Examination of a Newborn

The examination is conducted as described above. The genitalia are submitted to maternal estrogen effects. Estrogenization signs decrease as of the second week of life and disappear within 6–8 weeks. The labia minora are thick, protruding and sometimes longer than the labia majora. The mucosa is pink and covered with physiologic leukorrhea. The clitoral hood may also be relatively thick, and the size of the clitoris must be assessed by palpation after the clitoral hood has been pulled up. The hymen may be thick, pouting and fimbriated. The orifice is sometimes difficult to visualize and the physician must then use a small urethral catheter to confirm the presence of an opening. The vagina measures 4 cm in length. The vaginal mucosa is thick and covered with pH-acid

white physiologic secretions including lactobacilli. Over the first 10 days of life, there may be neonatal vaginal bleeding.

Gynecological Clinical Examination of the Adolescent

The gynecological examination of an adolescent has a triple objective: (a) clinical assessment; (b) diagnosis and therapy, and (c) establishment of an interpersonal relationship as the basis for support to teenaged girls who may be facing deeply emotional problems related to puberty, sexuality and fertility.

A gynecological examination is never routine. The clinician must be prepared to spend time, listening to the adolescent's concerns and gathering information on the personal and family background. A consultation will be simple and interactive with a healthy, well-informed teenager who is coming for birth control advice or simple menstrual dysfunction. However, with a teen showing, for instance, serious chronic pathology or intersexuality, or who has been sexually abused, the consultation will be difficult, critical and fraught with consequences – all the more so since these situations are not often spoken of.

In any case, the examination principles remain identical: (a) it must be preceded by a full medical assessment; (b) it must be conducted once the patient has been given a thorough explanation of the examination and its objectives and has consented; (c) the least invasive examination that will be sufficient should be performed; (d) examinations should not be omitted solely because of the age of the patient, and (e) the physician will need to recognize cultural issues and respect them.

For an adolescent who is not sexually active, the examination is identical to that of a child. Endoscopy and pelvic examination are not systematically performed. The vulva is estrogenized, the vagina measures 8–10 cm in length and there are physiologic secretions. Upon rectal examination the uterus is often laterally oriented to the left. Vaginal examination is possible if the teen is relaxed and her hymen is yielding. A small speculum may be used if necessary.

For a sexually active patient, vaginal examination, speculum examination and, if necessary, samples are required to look for potential genital infections.

Breast examination is part of the gynecological examination. At the beginning of development the breast is tender. The breast bud can be palpated before being seen; it appears as a small, hard mound beneath an enlarged areola. Physiologic breast development is sometimes unequal in its early stage. There may be a 3- to 12-month difference between the beginning of development in each breast. The breast reaches its fully developed size in 2–4 years, but this period may vary. During the development phase, the breast is often firm upon palpation but rarely sensitive. Skin marks are frequent. They are red when they

first appear and turn progressively white after a few months. They have no pathological meaning.

Once the examination is over, the physician should sit down with the adolescent to discuss potential therapy with the help, if necessary, of an anatomical chart. Parents or caregivers should stay in the waiting room during the examination. Information will be related to them by the adolescent herself or by the physician with her agreement and in her presence. She may ask that some elements of the examination remain confidential and her wish must be respected. A relationship of trust between physician and adolescent is absolutely necessary in the case of a long-term treatment, especially concerning chronic diseases.

References

- 1 Cowell CA: The gynecologic examination of infants, children and young adolescents. *Pediatr Clin North Am* 1981;28:247–266.
- 2 Emans J: Office evaluation of the child and adolescent; in Emans J, Laufer MM, Goldstein DP (eds): *Pediatric and Adolescent Gynecology*. Philadelphia, Lippincott, 1998.
- 3 Rey-Stocker I: Principes généraux d'examen gynécologique; in Salomon-Bernard Y, Thibaud E, Rappaport R (eds): *Gynécologie médico-chirurgicale de l'enfant et de l'adolescente*. Paris, Doin, 1992, pp 63–75.
- 4 Sane K, Pescovitz OH: The clitoral index: A determination of clitoral size in normal girls and in girls with abnormal sexual development. *J Pediatr* 1992;120:264–266.
- 5 Pokorny SF, Kozinetz CA: Configuration and other anatomic details of the prepubertal hymen. *Adolesc Pediatr Gynecol* 1988;1:97–103.
- 6 Gardner JJ: Descriptive study of genitalia variation in healthy, non-abused premenarchal girls. *J Pediatr* 1992;120:251–257.
- 7 McCann J, Voris J, Simon M, Wells R: Comparison of genital examination techniques in prepubertal girls. *Pediatrics* 1990;85:182–187.

Elisabeth Thibaud
Hôpital Necker-Enfants Malades
149, rue de Sèvres, FR-75743 Paris Cédex (France)
Tel. +33 01 44494801, Fax +33 01 44494800
E-Mail elisabeth.thibaud@nck.ap-hop-paris.fr

Sultan C (ed): Pediatric and Adolescent Gynecology. Evidence-Based Clinical Practice. Endocr Dev. Basel, Karger, 2004, vol 7, pp 9–22

.....

Imaging in Pediatric and Adolescent Gynecology

Eleonora Porcu

Infertility and IVF Center, University of Bologna, Italy

Sonography is a versatile diagnostic imaging modality which uses acoustical energy. In the pediatric patient, it can be used in several areas of the body, particularly within the abdomen and pelvis.

Over the last several years, the use of sonography for the evaluation of pediatric disorders has become more widespread for several reasons. These include the non-ionizing character of sonography relative to the radiographic techniques and the enhanced soft tissue detail now afforded by most real-time ultrasound scanners. The increased use and availability of real-time scanners has also contributed to more extensive use of sonography. Since children have very little perivisceral fat, they are almost ideal subjects for ultrasound scanning because high-frequency transducers which afford the best possible resolution can be used. The lack of irradiation allows repeat examinations to be performed without fear of untoward bioeffects due to radiation.

The role of sonography in the evaluation of pediatric gynecologic disorders will no doubt continue to expand, particularly as more pediatricians, gynecologists and radiologists become more familiar with its applications in pediatric gynecology.

The Infant and Adolescent Uterus

The uterus grows progressively during fetal life. After birth, uterine volume is relatively higher, longer and thicker than the prepubertal uterus and shows endometrial and myometrial characteristics very similar to those of adults.

After the first weeks, uterus size regresses, probably because of the withdrawal of maternal hormone stimulation. During childhood the uterus shows no

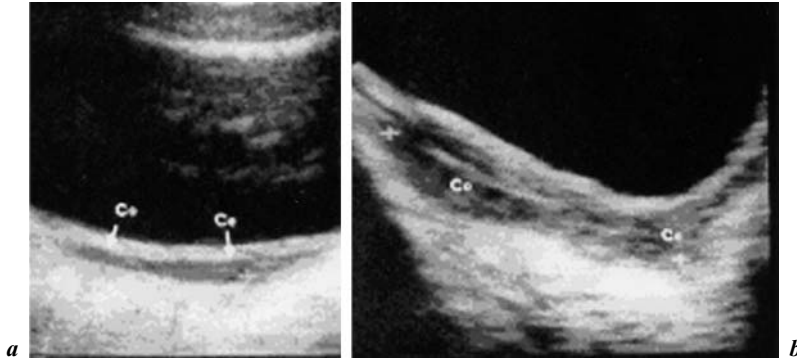


Fig. 1. Ultrasound aspect of uterus before puberty (a) and after puberty onset (b) [from 1].

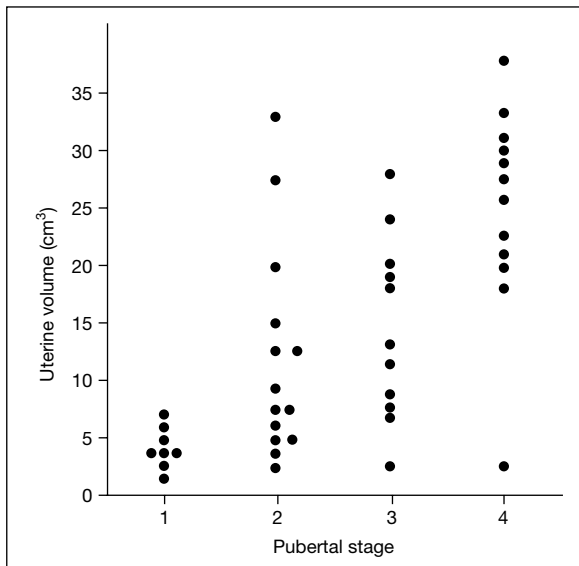


Fig. 2. Uterine volume according to pubertal stage.

changes in size and shape until the age of 7 years (fig. 1) [1]. From this age onward, uterine volume increases progressively at a slow rate before the appearance of secondary sexual characteristics. A sharp acceleration is seen during puberty, which has a good correlation with Tanner stages (fig. 2), age, weight, height and estradiol levels, and the most dramatic changes are seen between stages 3 and 4 of breast development.

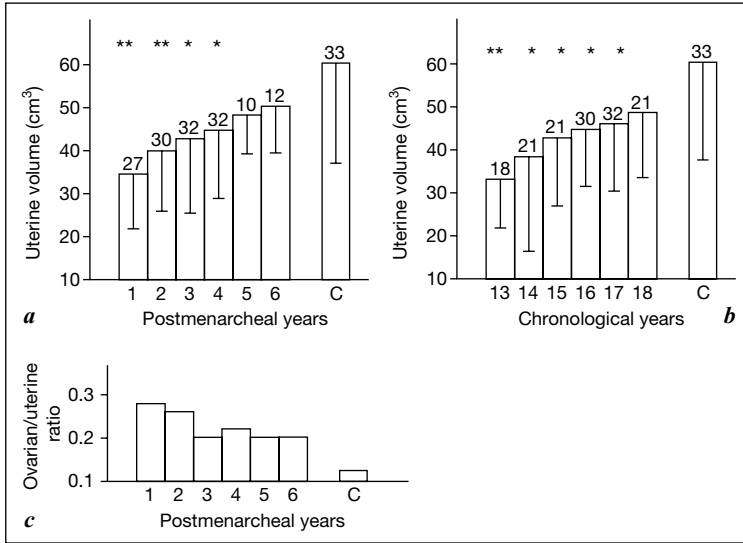


Fig. 3. Mean values (\pm SD) of uterine volume grouped according to gynecologic (a) and chronological years (b) in adolescents. Sexually mature controls (C) are reported. Number of subjects is reported in each column. * $p < 0.01$; ** $p < 0.001$, with respect to control uterine volume. (c) Mean ovarian/uterine ratio in adolescent girls during gynecologic years and sexual mature controls (C) [from 2].

After menarche, the uterus continues to grow, even after the almost complete development of the secondary sexual characteristics [2]. Menarche is a critical step toward the development of the whole reproductive system, especially of the uterus, which assumes a new function. After menarche, uterine growth rate slows and gradually tends to take on the adult size and structure. However, normal adult values are not attained even by the sixth gynecologic year (fig. 3), which shows that full development of this reproductive organ takes even more time, although adult morphology and corpus/cervix ratio are already achieved by menarche.

Among the reproductive hormones, estradiol seems to be the main agent for uterine growth. Other reproductive parameters, such as the frequency of menstrual bleeding and that of ovulation and progesterone levels, do not appear to be related to uterine size and growth rate.

Height and weight correlate with uterine volume before menarche but not afterward, since at this age they have nearly exhausted the developmental changes and vary independently of growth factors. The adrenal steroids dehydroepiandrosterone and dehydroepiandrosterone sulfate, which are reliable

indexes of biologic maturation, continue to increase during adolescence and, interestingly, they correlate with uterine development.

The finding of a still small uterus during adolescence may have reproductive implications. The lack of complete genital tract maturity might partly account for problems such as preterm labor, preeclampsia, and small-for-gestational age infants; these problems are not uncommon in adolescence.

The ovarian/uterine ratio decreases with increasing gynecologic age (fig. 3). The mean value at the first gynecologic year is very similar to that found in the polycystic ovary syndrome, probably because, unlike the uterus, the ovaries seem to have already reached complete growth at menarche. Furthermore, their volume often exceeds the adult value and needs a reduction in size to reach the final maturational step.

Ovarian Development during Puberty and Adolescence

Before the increasingly common use of ultrasound evaluation of the ovaries, anatomical and histological descriptions gave us a dynamic image of the developing ovary documenting that during childhood the ovary is never at rest and follicles grow and degenerate continuously. Peters et al. [3] identified three steps of ovarian growth: the quiescent ovary, with small resting follicles and occasional preantral follicles; the ovary in early growth, with small follicles, preantral follicles and occasional antral follicles not larger than 0.5 mm; and the actively growing ovary that is more and more frequent after the age of 6 when antral follicles, which are usually well distended, become increasingly numerous and large. These follicles have been called 'cystic' but they are normal follicles, some of them healthy, others in degeneration.

The ovarian size increases throughout childhood in relation to a gradual increase in the number as well as in the size of the antral follicles and a progressive increase of the stroma derived from follicle atresia. Besides multiple follicle growth and atresia, partial luteinization of the theca interna and fibrosis of the cortex are common features in the normal process of follicular development throughout infancy and childhood, so that early pubertal ovaries have been described that are indistinguishable from those of the polycystic ovary syndrome.

The advent of ultrasound has enabled clinicians to easily examine ovaries of a large number of girls and, moreover, to follow their development (fig. 4). Antral follicles or microcysts not exceeding 9 mm, as defined by ultrasound, start to increase around the age of 9 with the appearance of fluid areas >9 mm after the age of 11 [1].

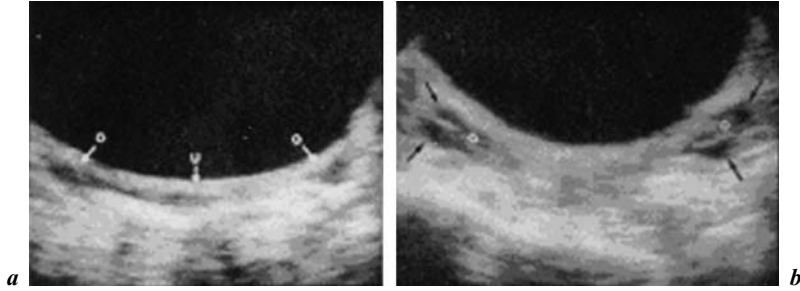


Fig. 4. Ultrasound ovarian appearance before puberty (*a*) and after puberty onset (*b*) [from 1].

In the years immediately before menarche, the cystic structure becomes prevalent. The increase in cystic structure coincides with the beginning of the gonadotropin rise which seems to play a central role in the last stages of follicular development. At this age gonadotropin secretion changes its quality, enhancing its pulsatile characteristics, both episodic and circadian, and sending a faster and more fluctuating signal to the ovaries which accelerate the turnover of follicular development. The follicles increase in size and steroid production.

Figure 5 shows an early pubertal nocturnal rise of LH, with levels remaining very low during the day. However, only a few nocturnal pulses are sufficient to promote the progression of some follicles in the still small ovaries. A higher number of LH pulses can occasionally be present also during the day in premenarcheal girls at mid and late puberty when ovaries show a higher volume and number of follicles compared to the previous stage (fig. 5). In fact there is a positive correlation between Tanner stages and ovarian volume (fig. 6).

The functional result of these integrated movements is the increase in steroidogenesis. Indeed, there is a positive correlation between ovarian volume, estradiol (E_2) and testosterone (T). In the same subject we can find greater or lesser follicular activity at different times in this period of life. Therefore, before menarche, multifollicular ovaries mean more and more activated ovaries but sometimes overactivated ovaries.

Just before menarche, puberty is characterized by the interaction of two evolving systems: the increasing gonadotropins and the actively growing ovary. For correct reproductive development, the two systems should interact in the most appropriate way and time and after puberty the dominant follicle growth should take over, with a decrease in the number of developing follicles.

Any derangement, i.e., an abnormal gonadotropin signal or an excessively prolonged process, may potentially lead to pathology. According to the number of developing follicles the sonographic appearance of the ovaries may be

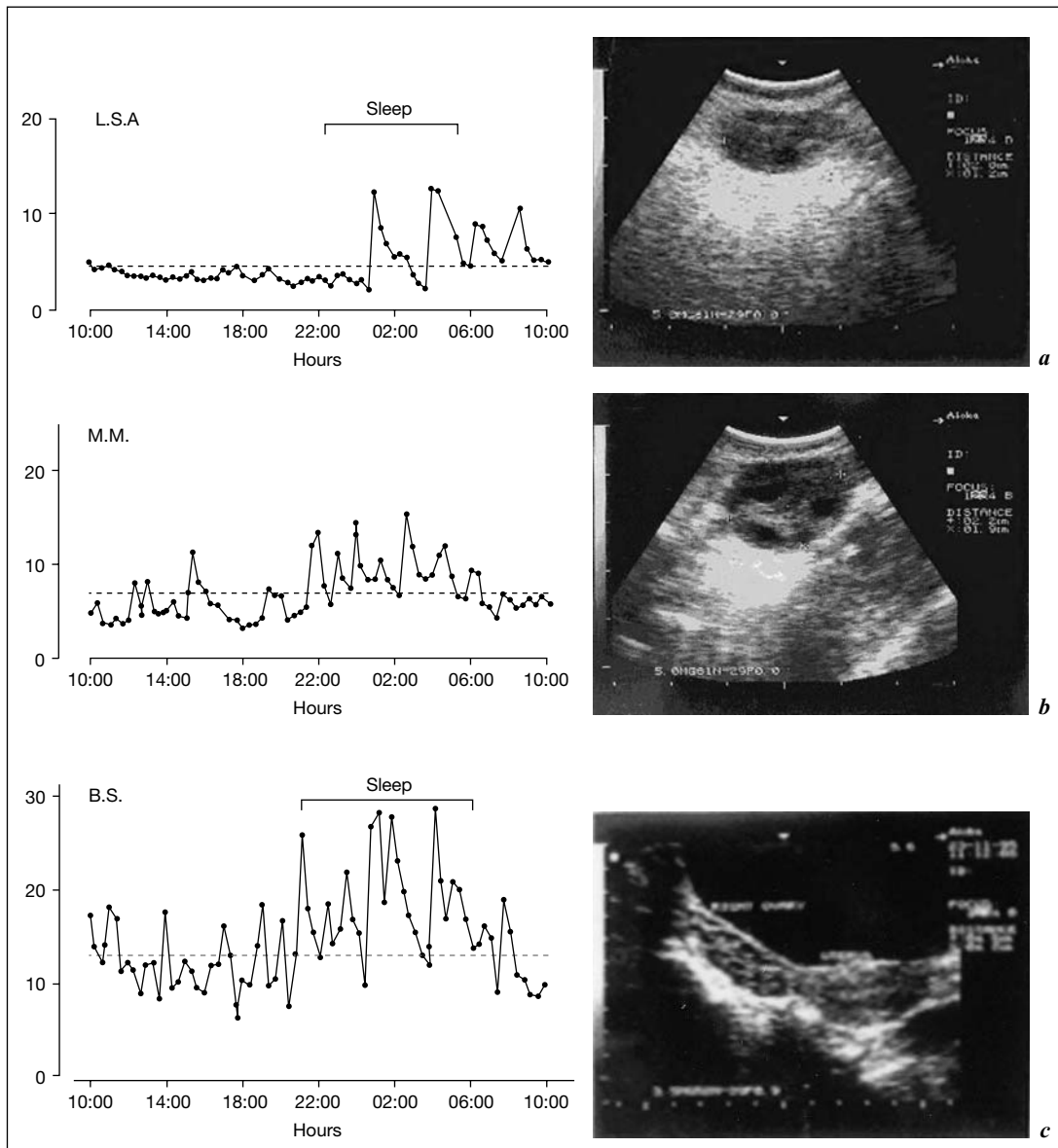


Fig. 5. Gonadotropin profiles and related sonographic ovarian appearance at (a) early, (b) mid and (c) late puberty.

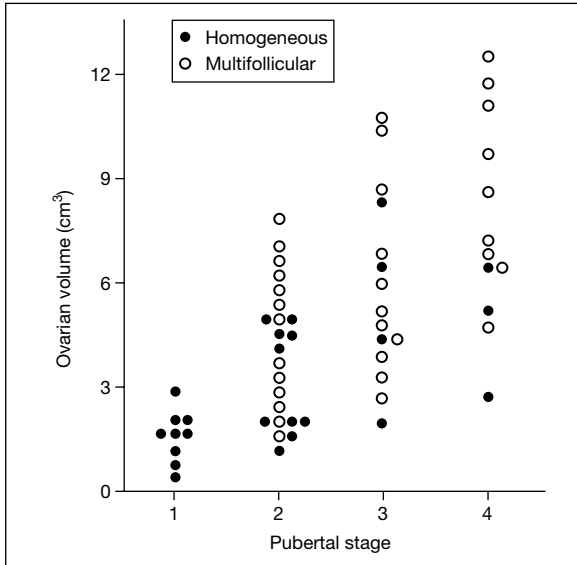


Fig. 6. Ovarian volume according to pubertal stage.

homogeneous, when fewer than four cystic areas are present, and multifollicular, when four or more fluid areas are imaged by ultrasound. It must be stressed, however, that this is an oversimplification since a wide spectrum of images, with a variable number of developing follicles, may be found.

Figure 7 shows that girls with regular cycles have normal ovarian volume and a homogeneous appearance. Girls with irregular cycles, however, have a mean volume significantly higher than those of regular ovulatory adolescents and those of adults. The postpubertal developing ovary is then mostly enlarged and multifollicular [4]. What is the differentiating element with polycystic ovaries (PCO)? Many authors have tried to classify the ‘jungle’ of ovaries with ‘multiple echo-free areas’ or ‘fluid images’, according to the number, size and distribution of cystic areas, the amount of stroma, the ovarian volume, the uterine-ovarian ratio, and the morphofunctional responses to induction of ovulation [5–7].

An appropriate classification might be the one outlined in table 1 where multifollicular ovaries have more than 5 cystic areas spread throughout the stroma (fig. 8) and polycystic ovaries have more than 10 cysts arrayed peripherally (fig. 9).

Adolescent ovarian development passes through different sonographic stages to lead to the normal adult ovary. This evolution is driven by the increasing

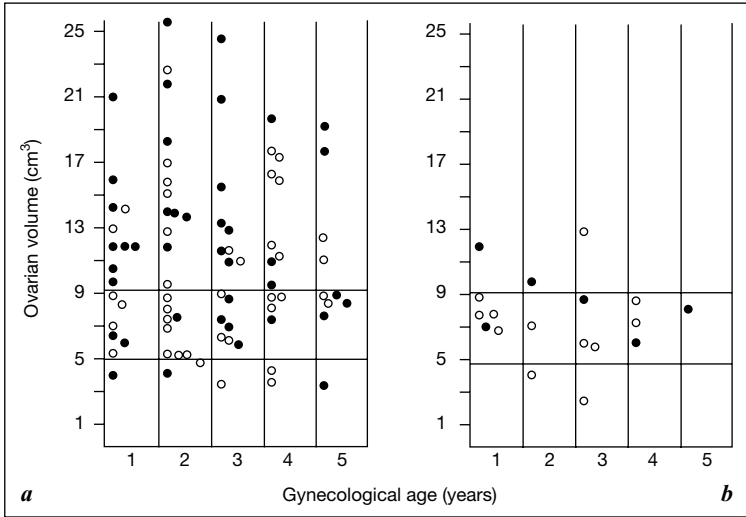


Fig. 7. Distribution of ovarian volume in girls with (a) regular and (b) irregular cycles [from 4].

Table 1. Classification of ovaries

Homogeneous ovaries	Normal or low volume Few cystic areas (<4) not >3–5 mm
Multifollicular ovaries	Normal or increased volume Several cystic areas (>5) 5–10 mm large spread throughout the ovarian stroma
Polycystic ovaries	Normal or increased volume Many cystic areas (>10) 3–8 mm in diameter arranged peripherally or located in the inner part of the ovary
Multifollicular or polycystic ovaries plus leading follicles	The same as above – one or two cystic areas >13 mm

number and regularity of ovulations (fig. 10) [8]. The more ovulations, the lower the ovarian volume and the number of follicles.

The time necessary to ‘learn’ how to ovulate seems crucial for the development of a normal ovarian structure. There seems to exist a sort of temporal window in which the ovaries are still plastic and can undergo morphological changes. Outside of this framework, the ovary has great difficulty moving

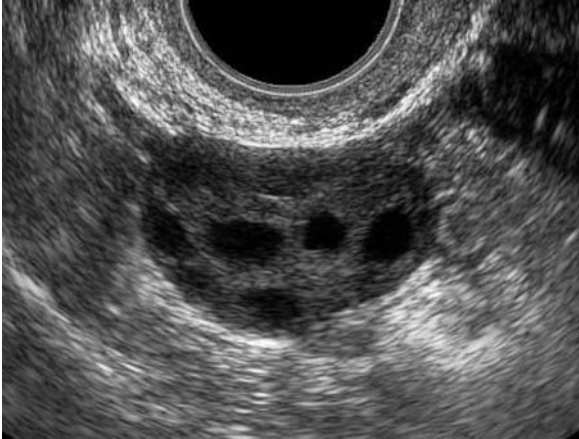

Fig. 8. Sonographic aspect of a multifollicular ovary.

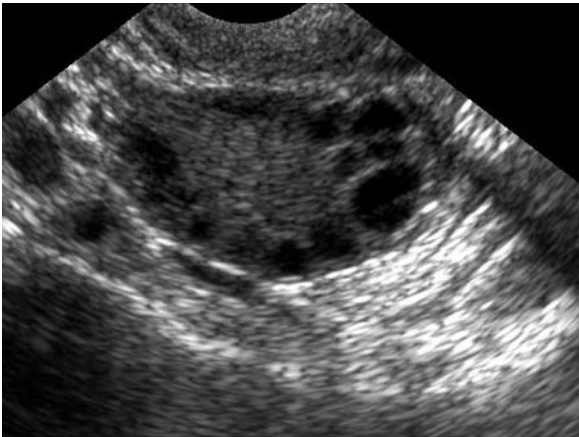


Fig. 9. Sonographic aspect of a polycystic ovary.

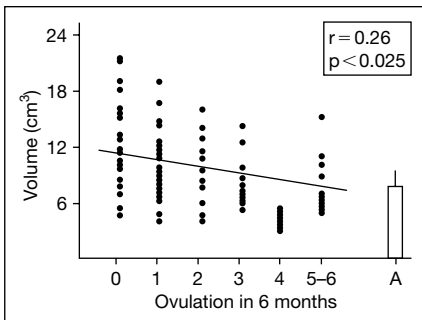


Fig. 10. Ovarian volumes at various frequencies of ovulation. A = Anovulation [from 8].

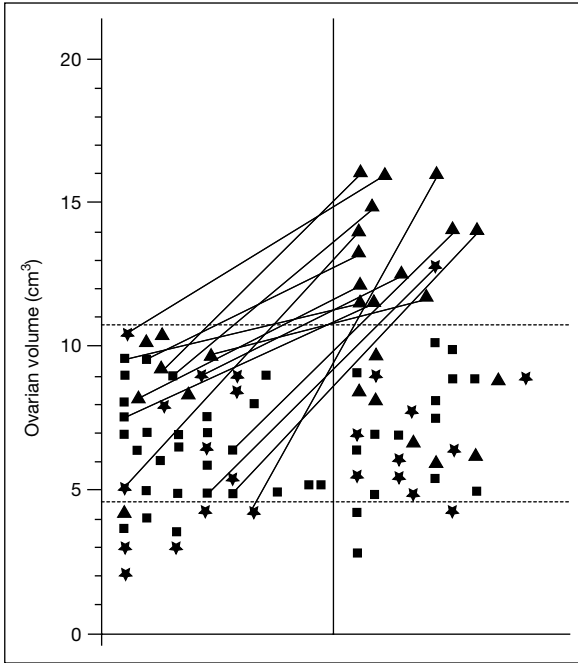


Fig. 11. Longitudinal examination of the ovaries. Distribution of the subjects ($n = 46$) with normal ovarian volume during the first control (left) and outcome of the ovarian volume and morphology as found during last control (right). During the last control, 14 subjects (30%) showed ovarian volume exceeding the normal range; polycystic structure was the dominant feature. Continuous lines connect the subjects with normal ovarian volume during the first control and enlarged ovaries in the last control. Dashed lines indicate normal adult range of ovarian volume. ■ = Homogeneous ovary, first control, $n = 26$; last control, $n = 15$; ★ = Multifollicular ovary, first control, $n = 13$; last control, $n = 11$; ▲ = polycystic ovary, first control, $n = 7$; last control, $n = 20$ [from 9].

beyond the adolescent structure. Years of anovulation and particularly of increased LH secretion mark the ovary irreversibly, increasing the stroma and turning the multifollicular aspects into the polycystic structure.

The duration of anovulation is probably the key factor responsible for the onset of the persistence and worsening of the polycystic structure.

A prospective longitudinal study documented that in the years after the menarche, the ovarian volume changes from normal to enlarged in 30% of the adolescent population (fig. 11) [9]. The postmenarcheal period is frequently the starting point for the polycystic transformation of the ovaries [10–12]. By contrast, in some subjects with enlarged multifollicular and polycystic ovaries

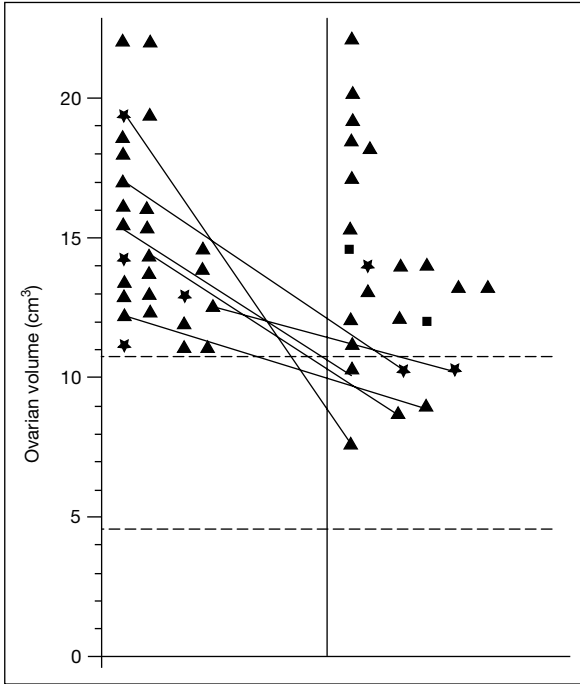


Fig. 12. Longitudinal examination of the ovaries. Distribution of the subjects ($n = 27$) who showed the ovarian volume exceeding normal adult range during the first control (left) and outcome of the ovarian volume and morphology during the last control (right). Six (22%) subjects showed the ovarian volume within the normal range during the last control, but the inhomogeneous structure persisted. Continuous lines connect the subjects with ovaries exceeding normal adult volume during the first control and ovaries within normal range in the last control. Dashed lines indicate normal adult range of ovarian volume. ■ = Homogeneous ovary, first control, $n = 0$; last control, $n = 2$; ★ = multifollicular ovary, first control, $n = 4$; last control, $n = 3$; ▲ = polycystic ovary, first control, $n = 23$; last control, $n = 22$ [from 9].

(22%), ovarian volume can become normal (fig. 12). It is well known that multifollicular morphology of the ovaries may revert to normal when ovulation is achieved. On the other hand, the possibility of achieving a normal adult echographic image with a homogeneous structure of the ovaries during the post-menarcheal period was not observed for the polycystic ovaries. A shift from polycystic to multifollicular appearance was detected in 2 cases only; this is sufficient to confirm that the transition from one structure to the other may occur. A cross-sectional study [13] documented in 139 adolescents a relatively high frequency of ovarian cysts (12%). Most of them were simple

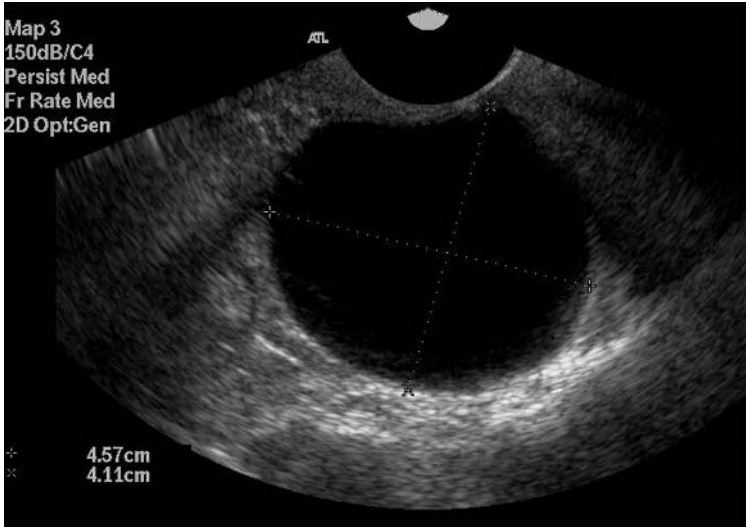

Fig. 13. Functional cyst of the ovary.

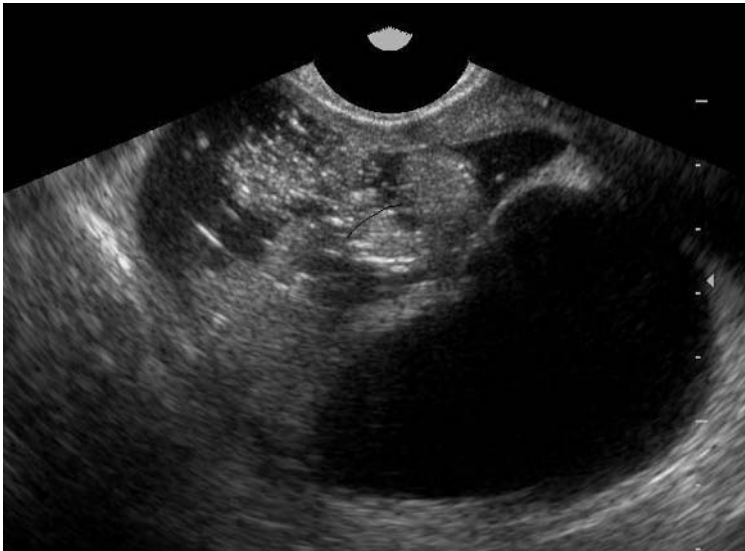

Fig. 14. Benign teratoma.

follicular cysts (fig. 13) and disappeared spontaneously. One cyst was a benign teratoma (fig. 14) and one was an endometrioma (fig. 15) and required surgical intervention. Another possible ovarian pathology is cystadenoma (fig. 16).

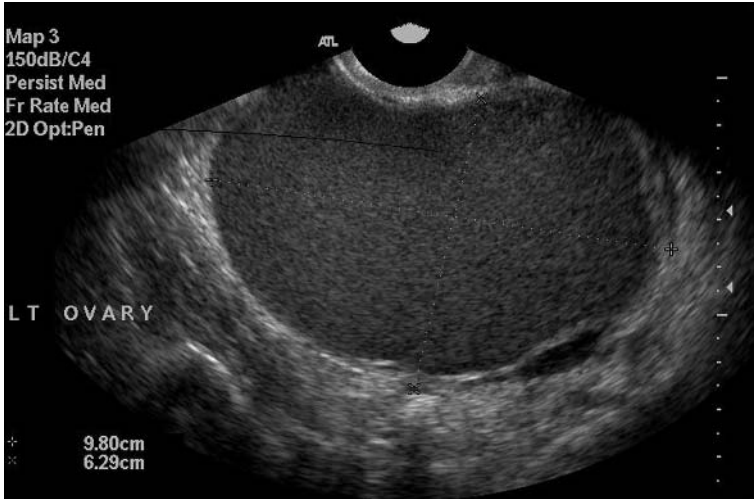

Fig. 15. Endometrioma.

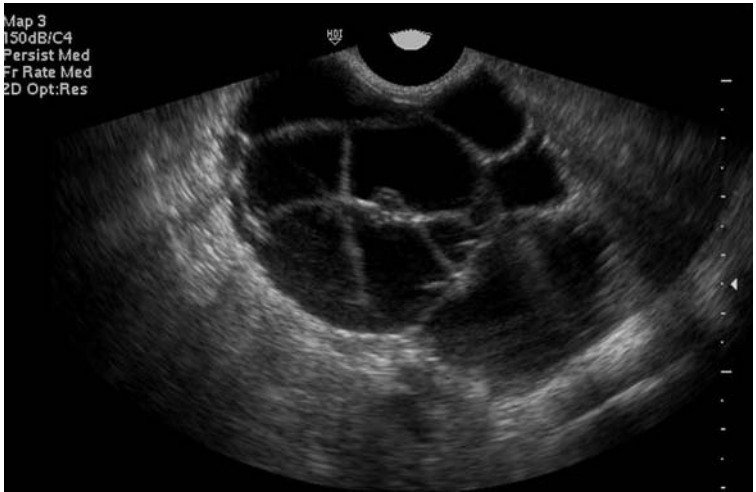

Fig. 16. Cystadenoma.

These data suggest that serial ultrasound evaluations are indicated in adolescence to monitor the correct ovarian development and to prevent or early diagnose pathology.

References

- 1 Orsini LR, Salardi S, Pilu G, Bovicelli L, Cacciari E: Pelvic organs in premenarcheal girls: Real-time ultrasonography. *Radiology* 1984;153:113.
- 2 Porcu E, Venturoli S, Fabbri R, Orsini LF, Sganga E, Brondelli L, Paradisi R, Flamigni C: Uterine development and endocrine relationships after menarche. *Am J Obstet Gynecol* 1989;161:174–177.
- 3 Peters H, Byskov AG, Himelstein-Braw R, Faber M: Follicular growth: The basic event in the mouse and human ovary. *J Reprod Fertil* 1975;45:559.
- 4 Venturoli S, Porcu E, Fabbri R, Paradisi R, Orsini LF, Flamigni C: Ovaries and menstrual cycles in adolescence. *Gynecol Obstet Invest* 1984;17:219–222.
- 5 Tucker M, Adams J, Mason WP, Jacobs HS: Infertility, megalocystic and polycystic ovaries: Differential response to LHRH therapy. *Ups J Med Sci* 1984;89:43.
- 6 Adams J, Polson DW, Abdulwahid N, Morris DV, Franks S, Mason HD, Tucker M, Price J, Jacobs HS: Multifollicular ovaries: Clinical and endocrine features and response to pulsatile gonadotropin releasing hormone. *Lancet* 1985;ii:1375.
- 7 Treasure JL, King EA, Gordon PAL, Wheeler M, Russell GEM: Cystic ovaries: A phase of anorexia nervosa. *Lancet* 1985;ii:1379.
- 8 Venturoli S, Fabbri R, Porcu E, Paradisi R, Orsini LF, Brondelli L, Ruggeri S, Flamigni C: Endocrine and ovarian parameters at various frequencies of ovulation in adolescents. *Arch Gynecol Obstet* 1989;246:107.
- 9 Venturoli S, Porcu E, Fabbri R, Pluchinotta V, Ruggeri S, Macelli S, Paradisi R, Flamigni C: Longitudinal change of sonographic ovarian aspects and endocrine parameters in irregular cycles of adolescence. *Pediatr Res* 1995;38:974–980.
- 10 Porcu E, Venturoli S, Magrini O, Bolzani R, Gabbi D, Paradisi R, Fabbri R, Flamigni C: Circadian variations of luteinizing hormone can have two different profiles in adolescent anovulation. *J Clin Endocrinol Metab* 1987;65:488.
- 11 Porcu E, Venturoli S, Flamigni C: Relations between puberty and the onset of the polycystic ovary syndrome; in *Major Advances in Human Female Reproduction*. New York, Raven Press, 1991, vol 73, p 45.
- 12 Porcu E, Venturoli S, Longhi M, Fabbri R, Paradisi R, Flamigni C: Chronobiologic evolution of luteinizing hormone secretion in adolescence: Development patterns and speculation on the onset of the polycystic ovary syndrome. *Fertil Steril* 1997;67:5.
- 13 Porcu E, Venturoli S, Dal Prato L, Fabbri R, Paradisi R, Flamigni C: Frequency and treatment of ovarian cysts in adolescence. *Arch Gynecol Obstet* 1994;255:69–72.

Dr. Eleonora Porcu
Director, Infertility and IVC Center
University of Bologna, Via Massarenti 13
IT-40138 Bologna (Italy)
Tel. +39 051 6364423, Fax +39 051 305806
E-Mail eleonora.porcu@unibo.it

.....

Ambiguous Genitalia in the Newborn: Diagnosis, Etiology and Sex Assignment

Charles Sultan^{a,b}, Françoise Paris^{a,b}, Claire Jeandel^a, Serge Lumbroso^b, René Benoit Galifer^c, Jean-Charles Picaud^d

^aUnité d'Endocrinologie et de Gynécologie Pédiatriques, Service de Pédiatrie I, Hôpital Arnaud de Villeneuve; ^bService d'Hormonologie et Inserm U.439, Pathologie Moléculaire des Récepteurs, Hôpital Lapeyronie; ^cService de Chirurgie Pédiatrique, Hôpital Lapeyronie, et ^dService de Néonatalogie, Hôpital Arnaud de Villeneuve, CHU Montpellier, France

The observation of ambiguous genitalia signals a medical, surgical and psychological emergency. When a baby is born with ambiguous genitalia, the normally routine announcement of the baby's gender cannot be made to the parents, and its future identity, which is in great part based on gender, will in a very real sense be held in suspension until the most appropriate sex for rearing is chosen. Careful examination of the external genitalia of every newborn should be systematic. Although a newborn's sex is usually evident, sometimes even slight genital malformations signal an underlying disorder that requires medical attention, and, even though rare, some malformations are so striking that the sex cannot be determined. In these cases, the medical team needs a rational and comprehensive management strategy. The most crucial decision will be the choice of sex assignment, which will depend on many complex factors. The first step is thorough examination of the genitals. Defects, including bilateral cryptorchidism, incomplete scrotal fusion, clitoromegaly, and labial fusion, are cause for more extensive investigations and great tact in the initial wording of information given to the parents. Rapid and precise diagnosis is essential, and a rigorous procedure for determining etiology and adequate management will have to be implemented. Ambiguous genitalia in a newborn are always profoundly distressing for parents and the pressure on the medical team to announce gender is strong. Nevertheless, this decision will have far-ranging effects and must only be made when sufficient information is available. Birth registration should be postponed until the diagnostic evaluation has enabled the most appropriate choice of sex for rearing.

A multidisciplinary team of pediatric endocrinologists, obstetricians, radiologists, surgeons, geneticists, biologists and pediatric psychiatrists working in concert is essential for the optimal management of ambiguous genitalia in the newborn [1]. After completion of the work-up, input from all team members is important and final consensus must be sought. At this point, recommendations can be made to the family, bearing in mind the need for careful wording and the great importance of communicating that their baby will here on in have a clear and unambiguous gender. Sex assignment should be based on the potential for an unambiguous appearance, the potential for normal sexual functioning and future fertility.

Diagnosis of Ambiguous Genitalia in the Newborn

When a genital defect is discovered in the neonatal period, complementary clinical, hormonal, genetic, molecular and radiographic investigations are needed to first diagnose the intersex state and then to determine the etiology and orient the therapeutic approach [2].

Clinical Investigations

Thorough physical examination is the key to diagnosis. Methodical general inspection will establish whether the genital defect is a sign of a malformation syndrome. Careful genital inspection will define the extent of the ambiguity by determining the presence, number, size, symmetry and position of gonads. In some cases, the sexual ambiguity is evident. For example, the genital tubercle may show development that is midway between that of a penis and a clitoris (the length and diameter, however, should be evaluated); the genital folds may be completely fused, with a bifid scrotum; the penis may appear abnormally bent and buried or sunken inward; or the urethral orifice may open toward the inner side of the penis, indicating hypospadias. Other signs include posterior fusion of the labia majora and a single perineal orifice at the base of the genital tubercle, between the genital folds, signaling the existence of a urogenital sinus.

Quite often, however, the genital malformation is less obvious. When the malformation is not easy to determine, the clinician's attention should be drawn to the following: an association of cryptorchidism and hypospadias, bilateral cryptorchidism, true clitoridal hypertrophy of the gland and not of the hood, and an oblong mass in the inguinal position in a newborn with female phenotype. Precise measurement of the penis should be made. The mean stretched penile length in the normal full term newborn male is 3.5 cm (± 0.5 cm).

Once the examination has been completed, the clinician should be ready to classify the degree of ambiguity of the external genitalia (genital tubercle and

folds and the urogenital sinus). Prader's five stages may be used or, as is now more often the case, Quigley's 6–7 stages, which offer the advantage of greater descriptive detail.

Grade 1: Individuals with normal male external genitalia such as infertile males with azoospermia and hormonal features of androgen resistance, those with reduced virilization at puberty (so-called 'minimal' androgen resistance).

Grade 2: Individuals who have a univocally male phenotype, but who have mildly defective fetal masculinization, manifested by defects such as isolated hypospadias and/or micropenis.

Grade 3: Individuals with predominantly male phenotype but with more severely defective masculinization in utero, as evidenced by perineal hypospadias, small penis, and cryptorchidism and/or bifid scrotum.

Grade 4: Individuals with ambiguous phenotype and severely limited masculinization evidenced by a phallic structure that is intermediate between a clitoris and a penis, generally accompanied by a urogenital sinus with perineal orifice and labioscrotal folds.

Grade 5: Individuals with essentially female phenotype (i.e., minimal fetal androgen action), including separate urethral and vaginal orifices, with minimal androgenization evidenced by mild clitoromegaly or a small degree of posterior labial fusion.

Grade 6: Individuals with a normal female genital phenotype (i.e., no fetal androgen action) who develop androgen-dependent pubic and/or axillary hair at puberty.

Careful palpation to locate gonads below the genital folds or in the inguinal region provides the first element for diagnostic orientation. If the gonads are absent, a diagnosis of female pseudohermaphroditism seems advisable. If a gonad or gonads are palpated, a diagnosis of male pseudohermaphroditism is indicated. It should be borne in mind, however, that cases presenting with very similar clinical expression may be quite different diagnostically as, for example, a masculinized female newborn with congenital adrenal hyperplasia (CAH) and an undervirilized male newborn.

A careful family history should be obtained from the parents. Detailed information on ambiguous genitalia in other siblings or family members, history of neonatal death, and consanguinity should all be sought. Cases of amenorrhea or infertility in the family will be important elements, and careful attention should be paid to clues of maternal ingestion of drugs or exposure to chemical environmental disruptors during pregnancy. Questions about 'salt losing' in the family should also be raised.

A differential diagnosis should be formulated by the end of the clinical examination (fig. 1). A certain number of complementary investigations will




Fig. 1. Differential diagnosis formulated at completion of the clinical examination.

then need to be carried out, although perhaps not all need to be done in a systematic fashion. Testing for salt losing, however, is mandatory.

Cytogenetic and Molecular Investigations

Buccal smears reveal the presence of Barr bodies (chromatin-positive) equal to the number of X-1. In practice, this screening test is easy and rapid but insufficiently reliable – and thus it is being increasingly replaced by molecular studies of the X or Y chromosome. Karyotyping is systematic, but results are often only available several days later. Because of the urgent need for sex assignment – it is intolerable for parents to wait several weeks to know if their baby is a boy or girl – many hospitals are now also performing PCR analysis of the SRY gene on the Y chromosome, because the results are available within 1 day.

Hormonal Investigations

Hormonal investigations should be based on the clinical and cytogenetic orientation; although most are generally easy to perform, they can at times be quite complex. Certain hormones should be measured on an urgent basis – immediately. Other measurements should be made as quickly as possible, and still others can be made within a few days.

Substantial elevation in 17-hydroxyprogesterone (17-OHP) (and plasma testosterone, which is of lower amplitude) will confirm the diagnosis of CAH, which is due in most cases to a deficiency in 21-hydroxylase.

Basal plasma testosterone levels evaluate the presence of functional Leydig cells. Testicular stimulation with hCG (1,000 U/day for 3 days or

1,500 U every 2 days for 2 weeks) is required to determine the functional value of testicular tissue. An insufficient response (<3 ng/ml) suggests a final diagnosis of gonadal dysgenesis. This same test is also needed to show evidence of an inborn error of testosterone biosynthesis by an augmentation in the precursors (17-OHP, dehydroepiandrosterone, Δ^4 -androstenedione), which contrasts with the absence of variation in the plasma testosterone.

In all cases of undermasculinization of the external genitalia that is associated with an often elevated secretion of testosterone, peripheral androgen receptivity must be investigated. Depending on the group, this is accomplished either by evaluation of the clinical response of the genital tubercle to exogenous testosterone or by measurement of the concentration of receptor sites in the external genitalia.

There is no consensus regarding the dosage, method of administration, timing or duration of therapeutic trials in the newborn with micropenis and ambiguous genitalia. To test for a clinical response to testosterone, an intramuscular injection of 25 mg every 4 weeks for 3 months or 100 mg every 4 weeks for 3 months should bring about an augmentation in length, diameter, and the cavernous bodies of the genital tubercle. An augmentation in phallic length <35 mm is insufficient. Failure to respond implies end-organ resistance to the action of androgens and introduces uncertainty concerning the appropriate sex of rearing.

For the evaluation of androgen receptor concentration, the number of receptors and their affinity for testosterone are measured on cultured genital skin fibroblasts. Concentrations <300 fmol/mg of DNA suggest partial androgen insensitivity.

Imaging Investigations

Exploration of the genitourinary axis is principally carried out by ultrasound and genitography. In certain cases, ultrasound confirms the presence of a uterus and ovaries. Genitography can accurately detect the level of implantation of the vaginal cavity on the urethra, an essential consideration in the choice of therapeutic strategy. Three cases can be found: the vagina opens the length of the vertical urethra, forming a long urogenital sinus; the vaginal opening is in the subvesicle position; or the vagina is located at the junction of the horizontal and vertical portion of the urethra.

Etiology of Ambiguous Genitalia in the Newborn

Generally, the medical team has a final diagnosis and has determined the etiology of the intersex state by the end of 3 weeks.

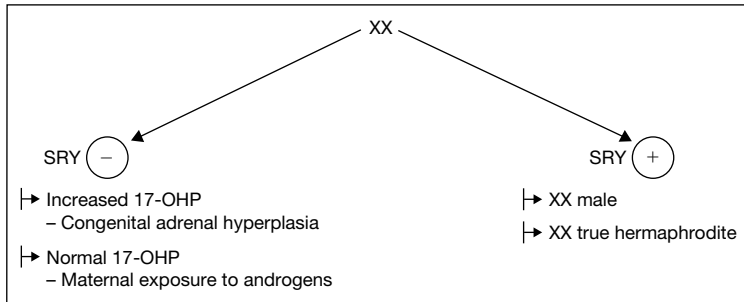


Fig. 2. Gonads are not palpable in the XX newborn, which classically leads to the diagnosis of female pseudohermaphroditism. Excessive androgen production can be traced back to the mother, placenta or the fetal adrenal gland.

XX Newborn

In the XX newborn, gonads are not palpable, which classically leads to the diagnosis of female pseudohermaphroditism. Excessive androgen production can be traced back to the mother (excessive maternal androgen production or maternal exposure to androgens or progestins), the placenta (placental aromatase deficiency) or the fetal adrenal gland (CAH) (fig. 2).

Excessive Maternal Androgens

Any maternal source of elevated androgens can induce virilization in the female fetus. Maternal ingestion of androgens, progestagens, or other drugs is a notable cause. For example, several oral progestational compounds, given to prevent spontaneous abortion in the past, such as 19-nortestosterone, have been implicated. Exogenous steroids administered during pregnancy may cause posterior fusion of the labia, clitoral enlargement and even increased degrees of androgenization. Other drugs, like danazol, which are also used in pregnancy, have been associated with abnormalities of sexual differentiation. Ovarian tumors include luteoma of pregnancy, arrhenoblastoma, hilar-cell tumor, masculinizing ovarian stromal cell tumor, and Krukenberg tumor. Untreated maternal virilizing CAH is another potential cause, though androgen-secreting adrenal tumor in the mother is rare. In both cases, investigation of abnormal androgen production by the mother must be performed immediately after delivery. A discrepancy between marked virilization in the mother and a minimal androgen effect in female offspring indicates placental aromatase activity, which converts androgens to estrogens, or androgen metabolism, which thus becomes less active.

Excessive Placental Androgens

Female pseudohermaphroditism due to placental aromatase deficiency, which has recently been reported by several investigators, illustrates the critical role of placental aromatization in protecting the fetus from excess androgen exposure. A defect in the placental conversion of androgens to estrogens causes virilization in female offspring [7]. In the absence of aromatase, androgens cannot be converted to estrone, estradiol or estriol, and large quantities of androstenedione and testosterone are transferred to the maternal and fetal circulation, resulting in masculinization of the urogenital sinus and external genitalia of the female fetus. The mother may undergo virilization during gestation as well. Cloning and sequencing of the CYP19 aromatase gene has provided new opportunities for identifying mutations. Detection of mutations in this gene has confirmed the fundamental role of aromatase for the fetal-placental unit and for sexual differentiation of the female fetus.

Management of excessive androgens in the female fetus is somewhat difficult and will differ, for example, if there is a family history of female pseudohermaphroditism or if androgen excess is suspected from ultrasonography.

Excessive Fetal Androgens

CAH is the most frequent cause of androgen excess and ambiguous genitalia in the female newborn [3] and the various forms of CAH are due to defects in the biosynthesis of cortisol, with the subsequent excessive ACTH production leading to an accumulation of adrenal androgens and steroid precursors. Adrenal androgens undergo peripheral conversion to testosterone and dihydrotestosterone, and steroid precursors produce specific findings depending upon the exact enzyme deficiency. The enzymatic defects causing female virilization involve 3β -hydroxysteroid dehydrogenase Δ^5 - Δ^4 isomerase (3β -HSD) [4, 17], P₄₅₀C21 hydroxylase (21-OH) [5], and P₄₅₀C11 hydroxylase (11-OH) [6, 16]. The association of ambiguous genitalia and salt loss at birth signals an enzymatic block of the adrenal glands. The differential diagnosis is made by the marked accumulation of the steroid above the enzymatic block: 17-OHP for 21-OH deficiency, 11-deoxycortisol for 11-OH deficiency and pregnenolone and other Δ^5 precursors for 3β -HSD deficiency. The molecular genetics of these defects have been extensively studied [15]. More than 90% of CAH is due to 21-hydroxylase deficiency and, in the newborn period, salt losing is present in 75% of patients. Glucocorticoid treatment should be started as soon as possible and adjusted on the basis of length, weight and steroid levels. Mineralocorticoid should be added if salt losing is documented. 11 β -OH deficiency is associated with hypertension. 3β -Hydroxylase dehydrogenase is exceptional.

Prenatal diagnosis of these defects is possible in high-risk families and prenatal treatment can be offered to the mother of a 21-OH-deficient girl for

future pregnancies. In preterm infants, differential diagnosis with the exceptional clitoridal hypertrophy associated with a high concentration of adrenal androgen should be considered.

True Hermaphroditism

The true hermaphrodite has both testicular and ovarian tissue present in either the same or opposite gonads. Both the external genitalia and the internal duct structures display gradations between male and female. The initial manifestation is ambiguous genitalia in 90% of the cases and, more rarely, isolated clitoromegaly or penile hypospadias is seen. Two thirds of true hermaphrodites are raised as males. Among those raised as females, two thirds will have clitoromegaly. Virtually all patients have a urogenital sinus and in most cases a uterus is present. The most common peripheral karyotype is 46,XX but mosaicisms are observed (XX/XY). SRY gene is present in 10–30% of patients, suggesting that true hermaphroditism is a heterogeneous condition in terms of its genetic background.

The most critical factor in managing true hermaphroditism is gender assignment. A decision of male sex of rearing should be based on both the findings at laparotomy and the potential for adequate penile length. Another important consideration is that true hermaphrodites have the potential for fertility.

XY Newborn

In the XY newborn, gonads are usually palpable and the diagnosis will be male pseudohermaphroditism (fig. 3).

If testosterone rises normally after hCG stimulation, a defect in androgen sensitivity or 5 α -RD is indicated. Androgen resistance is the most common cause of ambiguous genitalia in male pseudohermaphroditism [2].

Complete androgen insensitivity is characterized by an unambiguous female phenotype with a blind vagina pouch and no uterus. Underdevelopment of the clitoris and labia minora may also be observed. The development of an inguinal hernia signals the possibility of complete androgen insensitivity in infancy, whereas this diagnosis is evoked by primary amenorrhea in puberty. Pubertal breast development is normal or augmented in the majority of cases, however, in contrast to absent or scanty axillary and pubic hair. Patients with complete androgen insensitivity develop female habitus. The major treatment decision for complete androgen insensitivity syndrome primarily concerns the optional timing of gonadectomy. Our group performs gonadectomy before puberty and prescribes estrogens during puberty [14].

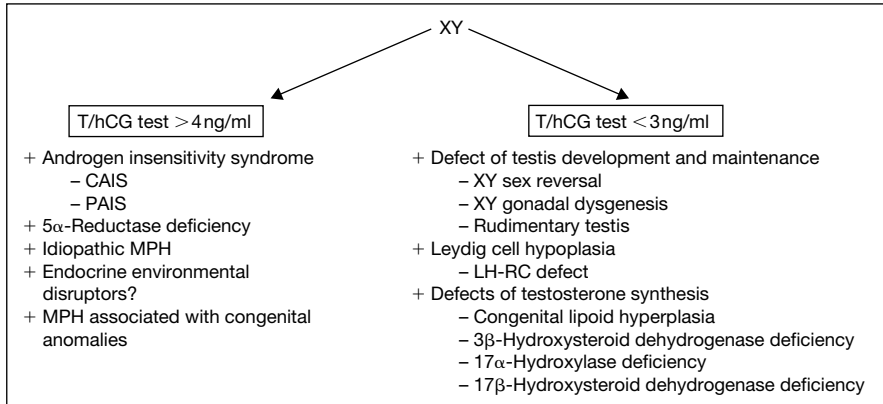


Fig. 3. Gonads are usually palpable in the XY newborn and the diagnosis will be male pseudohermaphroditism.

Partial Androgen Insensitivity Syndrome (PAIS)

PAIS covers a wide spectrum of clinical phenotypes, from patients with predominantly female phenotype (i.e., mild clitoromegaly) to an undervirilized male phenotype. In addition, the wolffian duct may develop to a variable extent. Simple hypospadias or micropenis in children, or undervirilization and gynecomastia in adolescent boys, should also come to medical attention.

Newborns with PAIS have increased LH and testosterone secretion, while estrogen production is also higher: serum SHBG concentrations are intermediate between those of normal male and normal female. The SHBG response to the increase in serum testosterone induced by an hCG stimulation test has been used as an aid in the differential diagnosis between PAIS and other forms of male pseudohermaphroditism.

Androgen binding in genital skin fibroblasts has revealed that defects are heterogeneous since they range between reduced capacity, reduced affinity, thermolability, increased ligand dissociation rate and altered ligand specificity. No research group, however, has been able to report any consistent correlation between the concentration of AR and the degree of undervirilization.

Since the AR gene was cloned, the tools of molecular biology have made it possible to identify mutations within the gene from patients with different phenotypes of PAIS. Screening procedures with sequencing of the AR gene allow identification of subtle changes responsible for missense or nonsense mutations. Measurements of androgen receptor mRNA have been useful in identifying mutations that cause PAIS by altering the state levels or the size of the mRNA. Transfection of constructs expressing the mutant AR in mammalian

cells is the main approach for demonstrating the causative role of the mutation in the development of the androgen insensitivity.

The management of patients with PAIS must be individualized depending on the degree of genital ambiguity, the growth response of the penis to supra-physiologic doses of testosterone and the type of androgen receptor mutation. Although certain androgen receptor defects may be amenable to androgen therapy, multiple reconstruction of external genitalia and azoospermia are good arguments to prefer a female sex of rearing.

5 α -Reductase Deficiency (5 α -RD)

Patients with 5 α -RD are characterized at birth by an undervirilized phenotype: affected newborns exhibit ambiguous genitalia with a hypospadiac phallus resembling a clitoris, a bifid scrotum which is labia-like and a urogenital sinus opening on the perineum. It is worth noting that the testes have been found in the inguinal canal, labia majora or scrotum [9]. The clinical presentation can actually range from almost normal female phenotype to a clear-cut male phenotype with isolated hypospadias, but in all cases wolffian ducts have been differentiated normally into vas deferens, epididymis and seminal vesicles.

The main characteristic of patients with 5 α -RD is the virilization of the external genitalia that occurs at puberty along with the acquisition of male genetic identity in these patients usually raised as females. Diagnosis should be based on physical examination, pedigree analysis, analysis of basal and post-hCG stimulation plasma T and DHT levels, 5 β /5 α urinary steroid metabolite ratio, measurement of 5 α -RD activity in cultured genital skin fibroblasts and finally by analysis of the 5 α -R2 gene.

The characteristic endocrine features of 5 α -RD are as follows: normal male to high levels of plasma T and low levels of plasma DHT, an elevated ratio of the concentration of plasma T to DHT in adulthood and after stimulation with hCG in childhood, and elevated ratios of urinary 5 β - to 5 α -metabolites of androgen and C21 steroids. The biological diagnosis of 5 α -RD is mainly supported by an increased T/DHT ratio.

From a biochemical point of view, the decrease in 5 α -reductase activity in the intact genital skin fibroblasts supports the diagnosis of 5 α -RD but enzymatic activity is sometimes in the normal range. The decreased activity in sonicated cell extracts at acidic pH provides strong evidence that the mutation resulted in a loss of type 2 enzyme activity.

Isolation and sequencing of the cDNA encoding 5 α -reductase type 2 provides the molecular tools required for definition of the gene abnormalities responsible for 5 α -RD. The management of 5 α -RD is primarily dependent upon the phenotypic findings and gender at the time of diagnosis. Given the severe defect of the external genitalia, most newborns are raised as female!

Gonadectomy should be performed early to prevent masculinization, along with vaginoplasty and clitoridal reduction. If the diagnosis is made in puberty, one can consider raising such a child as a male.

If testosterone does not rise after the therapeutic trial, either testicular dysgenesis, which is an anomaly in testicular determination [11], or a disturbance in testicular biosynthesis may be responsible. Genitography is useful for differential diagnosis. When a vagina and uterine cavity are found, the diagnosis of testicular dysgenesis is likely. When a blind vagina without a uterine cavity is found, the diagnosis is instead disturbance in testicular biosynthesis.

Abnormal Testicular Determination

Dysgenetic Testis. Newborns with dysgenetic testis present with bilateral dysgenetic testes, persistent müllerian structures, cryptorchidism, and inadequate virilization [1]. This disorder shows wide clinical heterogeneity. Because the uterus is present, the sex of rearing should be female and gonadectomy is recommended as for mixed gonadal dysgenesis. These patients should be screened routinely for tumor.

Defect of Testis Maintenance. Bilateral vanishing testis (or embryonic testicular regression) is characterized by an XY karyotype and absent or rudimentary testes. The syndrome entails the presence of testes that vanish during embryogenesis, although the etiology is unclear: the regression of the testes in utero may be due to genetic mutation, a teratogen factor or bilateral torsion. Clinically, the syndrome encompasses a spectrum of phenotypes, ranging in severity from genital ambiguity to a male phenotype with an empty scrotum.

Patients with a defect in testis maintenance will be managed according to their position in the clinical spectrum of the disorder. In *true agonadism*, external genitalia are ambiguous and müllerian derivatives are absent or rudimentary due to complete or partial anti-müllerian hormone secretion, without secretion of testosterone. Patients with *rudimentary testis* have a male phenotype with micropenis and small atrophic testis with pre-Sertoli and Leydig cells. Some patients present with perineal hypospadias and persistent müllerian duct structures. *Congenital anorchia* is characterized by the complete absence of testicular tissue at birth, but normal male sexual differentiation without müllerian structures.

Patients with ambiguous genitalia require meticulous assessment to determine the optimal sex of rearing. In the absence of palpable gonads, measurement of basal- or hCG-stimulated testosterone secretion above the female range is informative, but laparotomy or celioscopy followed by histologic analysis of the gonads is absolutely essential. In general, the sex of rearing should be male with testosterone replacement therapy, which will lead to normal puberty and

sexual function. Phenotypic males require long-term androgen replacement, beginning at the time of expected puberty.

Leydig Cell Hypoplasia

Male pseudohermaphrodites with Leydig cell hypoplasia have impaired Leydig cell differentiation and testosterone production. The phenotype is usually female, although it may be ambiguous; in all cases, müllerian structures are absent. Inhibiting mutations in the LH receptor gene [12] have recently been reported in these patients [10].

Defect in Testosterone Synthesis

Decreased androgen production caused by an alteration in the enzymes involved in the testosterone biosynthesis pathway is another cause of male pseudohermaphroditism [11, 13]. Increased fetal production of androgens, on the other hand, results in female pseudohermaphroditism.

Congenital Lipoid Adrenal Hyperplasia (CLAH). CLAH is a rare disease characterized by a defect in the synthesis of the three classes of steroid hormones, resulting in severe salt wasting and female phenotype. Few mutations in humans have been found thus far in the gene encoding for P_{450scC}, which is the principal candidate gene. Recently, the gene responsible for CLAH was cloned and validated by nonsense mutation. This gene encodes for the StAR protein (steroidogenic acute regulatory protein), which is thought to be responsible for the transport of cholesterol to the inner membrane of mitochondria, and thus to the P_{450scC} enzyme complex.

17 α -Hydroxylase Deficiency. Defects in P₄₅₀C17 lead to male pseudohermaphroditism with various degrees of ambiguous genitalia. This is frequently a severe form and is most often diagnosed at puberty, with female phenotype associated with hypertension. Cytochrome P₄₅₀C17 catalyzes the transformation of progesterone and pregnenolone into 17-OH-progesterone and 17-OH-pregnenolone (17 α -hydroxylase activity), respectively, and then into dehydroepiandrosterone and Δ^4 -androstenedione (17,20-lyase activity). The gene encoding for this enzymatic complex, CYP17, is located on chromosome 10q24–25. Several different mutations have been reported in the CYP17 gene leading to either a complete or partial form of the disease.

3 β -HSD Deficiency. Defects in the function of 3 β -HSD result in 46,XY individuals with male pseudohermaphroditism who sometimes show salt wasting in the classic form. Almost 15 mutations of the type II 3 β -HSD enzyme have been reported to date. No mutation of type I has been found, however, which explains how virilization can occur in 46,XX subjects by peripheral, nonsteroidogenic conversion of elevated testosterone precursors.

17 β -Hydroxysteroid Dehydrogenase (17 β -HSD) Deficiency. Type 3 17 β -HSD deficiency is a rare autosomal recessive cause of male pseudohermaphroditism. The typical subject is a 46,XY male born with female external genitalia and testes located in the inguinal canals or labia majora. This disorder is particularly puzzling: the deficiency in testosterone synthesis and the defect in virilization, both of which are usually more complete during embryogenesis than in later life, contrast with the well-differentiated wolffian duct structures, which suggests that androgen acts in utero by an alternate mechanism in these tissues. Substantial virilization is seen at puberty, in association with elevated levels of androstenedione but low to normal plasma levels of testosterone. As in the case of 5 α -RD, pubertal virilization may result from extraglandular testosterone formation due to peripheral conversion of increased testicular androstenedione by unaffected 17 β -HSD isoenzymes. Missense and nonsense mutations, splice junction abnormalities and a small deletion resulting in a frame shift have been described, among other gene alterations. Expression of mutant enzymes after site-directed mutagenesis showed that the missense mutations caused almost complete loss of enzymatic activity.

Although affected newborns are generally considered to be female, the choice of sex of rearing will be greatly influenced by family values and cultural background. When female sex of rearing is maintained, we strongly urge that orchidectomy be carried out during infancy or childhood. When diagnosis is not made before puberty, a gender change to male at that time is acceptable.

Male pseudohermaphroditism may in some cases be part of a multiple malformation syndrome. In other cases, etiology cannot be determined, in which case the so-called idiopathic pseudohermaphroditism should raise the suspicion of environmental contamination by pesticides during gestation [18].

46,XY/XO Newborn

For the 46,XY/XO newborn, the diagnosis is mixed gonadal dysgenesis. The most common karyotype in mixed gonadal dysgenesis is 45,XO/46,XY, but other mosaics have been reported with structurally abnormal or normal Y chromosome. The characteristics include a unilateral testis that is often intra-abdominal, a contralateral streak gonad and persistent müllerian duct structures. Because affected patients are at great risk of gonadal tumor, the gonads should be removed and the patients can then be reared as females. When the abnormality of the external genitalia is minor, however, parents may perceive their child as a boy. Male sex of rearing will then impose life-long surveillance of the gonads. In any case, mixed gonadal dysgenesis is associated with varying degrees of inadequate masculinization [1], and such males would be infertile. It should be

remembered that the distinction between mixed gonadal dysgenesis and Turner syndrome with Y material is unclear.

Sex Assignment of the Intersex Child at Birth

When a child is born with ambiguous genitalia, the medical team must mobilize for a neonatal emergency: in addition to the urgent need to rule out such life-threatening conditions as salt wasting, determination of the most appropriate sex for rearing must be made as rapidly as possible. It cannot be emphasized enough that the parents desperately need to know whether their baby is a girl or a boy! The unambiguous designation of a baby's sex is a key step in the birth process and for the parents of an intersex neonate, the period of waiting to learn their baby's sex is often agonizing. Birth is the meeting of parents' dreams and a real infant, alive and present in the world. When a child is born, one of the first announcements is whether the mother has delivered a boy or a girl – we can easily imagine the profound distress, the helplessness, of parents who are confronted with the intersex status of their newborn.

The clinical examination provides an assessment of the degree of under-virilization and the presence of gonads. Biological assessments are mandatory for plasma 17-OHP and the SRY gene.

Once the investigations have been concluded, the medical team should be ready to undertake their greatest responsibility: the assignment of sex for rearing. This decision must be guided by three parameters: the anatomic condition and functional abilities of the genitalia; the etiology of the genital malformation, and family considerations, which must include recognition of cultural factors, religious convictions, and so on. The choice of declared sex must be – and this bears repeating – the result of full discussion between all protagonists: (a) In *cases of female pseudohermaphroditism*, the newborn with ambiguous genitalia should always be declared to be of female sex. With normal ovaries and uterus, the female pseudohermaphrodite is potentially capable of bearing children. (b) In *cases of male pseudohermaphroditism*, great care should be taken in the declaration of male sex. Major considerations will be the potential for reconstructive surgery, the probability of pubertal virilization, and the 'programmed' response of the external genitalia to exogenous and endogenous testosterone. The presence of testicular tissue, on the other hand, is not an essential factor in this decision.

In cases of gonadal dysgenesis, sex assignment will be based on several criteria. A defect in 5 α -reductase is an indication for male sex for rearing because pubertal virilization will lead to penile development, though it will be subnormal; normal pubic hair development, and the acquisition of male sexual

identity. In contrast, for inborn errors of testosterone biosynthesis, female orientation is advisable if effective male reconstructive surgery appears highly unlikely. When a vagina and uterus are present, female orientation is also preferable if it appears that vaginoplasty can be easily accomplished.

In cases of androgen resistance, a female orientation is unquestionably correct for complete resistance, and it is preferable in cases of partial resistance confirmed by therapeutic testing. In true hermaphroditisms, which are very rare, female sex assignment is to be preferred since ovarian function may be preserved.

Castration is indicated for male pseudohermaphrodites reared as girls. When they are reared as boys, careful gonadal follow-up throughout life is crucial. Since the cumulative risk of gonadal tumor in the intersex child is present even before puberty, we advocate castration in the XY intersex infant with testicular dysgenesis.

A methodical clinical examination and hormonal, radiographic, molecular and genetic investigations are the bases for determining the diagnosis, etiology and optimal management of ambiguous genitalia in the newborn. In conversations with family members, terms such as 'ambiguous genitalia' and 'pseudohermaphrodite' should be avoided and more neutral terms such as 'genital malformation' can be substituted. The family should be informed of the various difficulties and therapeutic options, but excessive detail is unnecessary. Once a decision for the assignment of sex is made, it should be definitive for the parents. The baby will hereafter be referred to by name and as either 'he' or 'she' by all staff in order to help the parents to fix their child's gender firmly in their minds.

Because of the far-ranging consequences, the assignment of sex for rearing should never be the decision of a single physician. The entire multidisciplinary team should remain involved in every step of the diagnostic procedure, the choice of sex for rearing and the treatment strategy. The team also has an important role in guiding the family and ensuring family agreement with and support for the decision, which is the sole means of guaranteeing that the child will be raised with an unambiguous sexual identity.

References

- 1 Migeon CJ, Berkovitz GD, Brown TR: Sexual differentiation and ambiguity; in Kappy MS, Blizzard RM, Migeon CJ (eds): *The Diagnosis and Treatment of Endocrine Disorders in Childhood and Adolescence*. Springfield, Thomas, 1994, pp 573–681.
- 2 Sultan C, Savage MO: Intersex states; in Grossman AB (eds): *Clinical Endocrinology*. London, Blackwell Science, 1998, pp 795–809.
- 3 New M, Mercado A, Cheng K, Jackowski M, Wilson R: Steroid 21-hydroxylase deficiency: Genotype may not predict phenotype; in De Bellis A, Schipani E (eds): *Frontiers in Endocrinology*. Rome, Ares Sero Symp Publications, 1995, vol 14, pp 17–27.

- 4 Simard J, Rheume E, Sanchez R, Merbaki F, Morel Y, Zerah M, New M, Labrie F: Relation between molecular defect and phenotypic manifestation of human 3 β -hydroxysteroid dehydrogenase deficiency; in De Bellis A, Schipani E (eds): *Frontiers in Endocrinology*. Rome, Ares Serono Symp Publications, 1995, vol 14, pp 39–68.
- 5 New MI: Steroid 21-hydroxylase deficiency (congenital adrenal hyperplasia). *Am J Med* 1995;98: 2S–8S.
- 6 White PC, Curnow KM, Pascoe L: Disorders of steroid 11 β -hydroxylase isozymes. *Endocr Rev* 1994;15:421–438.
- 7 Sultan C, Lumbroso S, Poujol N, Lobaccaro J: Intrauterine virilization of female fetuses; in Azziz R, Nestler JE, Dewailly D (eds): *Androgen Excess Disorders in Women*. Philadelphia, Lippincott-Raven, 1997, pp 593–599.
- 8 Quigley CA, Debellis A, Marschke KB, Elawady MK, Wilson EM, French FS: Androgen receptor defects: Historical, clinical and molecular perspectives. *Endocr Rev* 1995;16:271–321.
- 9 Wilson JD, Griffin JE, Russell DW: Steroid 5 α -reductase-2 deficiency. *Endocr Rev* 1993;14: 577–593.
- 10 Sultan C, Lumbroso S: LH receptor defects; in Kempers RD, Cohen J, Haney AF, Younger JB (eds): *Fertility and Reproductive Medicine*. Proc XVI World Congress on Fertility and Sterility, San Francisco, Oct 4–9 1998. New York, Elsevier, 1998.
- 11 Dewing P, Bernard P, Vilain E: Disorders of gonadal development. *Semin Reprod Med* 2002;20: 189–197.
- 12 Themmen A, Verhoef-Post M: LH receptor defects. *Semin Reprod Med* 2002;20:199–204.
- 13 Miller W: Disorders of androgen biosynthesis. *Semin Reprod Med* 2002;20:205–215.
- 14 Sultan C, Lumbroso S, Paris F, Jeandel C, Terouanne B, Belon C, Andran F, Poujol N, Georget V, Gobinet J, Jalaguier S, Auzou G, Nicolas JC: Disorders of androgen action. *Semin Reprod Med* 2002;20:217–227.
- 15 Hughes IA: Congenital adrenal hyperplasia: 21-Hydroxylase deficiency in the newborn and during infancy. *Semin Reprod Med* 2002;20:229–241.
- 16 Peter M: Congenital adrenal hyperplasia: 11 β -Hydroxylase deficiency. *Semin Reprod Med* 2002;20:249–254.
- 17 Simar J, Moisan AM, Morel Y: Congenital adrenal hyperplasia due to 3 β -hydroxysteroid dehydrogenase/ Δ^5 - Δ^4 isomerase deficiency. *Semin Reprod Med* 2002;20:255–276.
- 18 Toppari J: Environmental endocrine disrupters and disorders of sexual differentiation. *Semin Reprod Med* 2002;20:305–311.

Prof. Dr. Charles Sultan
 Unité d'Endocrinologie et de Gynécologie Pédiatriques
 Centre Hospitalier Universitaire, Service de Pédiatrie I
 Hôpital Arnaud de Villeneuve
 FR-34259 Montpellier Cedex 5 (France)
 Tel. +33 4 6733 6643, Fax +33 4 6733 8327
 E-Mail c-sultan@chu.montpellier.fr

.....

Vulvo-Vaginal Disorders

Dominique Hamel-Teillac

Service de Dermatologie, Hôpital Necker-Enfants Malades, Paris, France

A thorough review of vulvo-vaginal disorders in pediatric and adolescent patients would be quite lengthy. This review will address the most common dermatologic vulvo-vaginal diseases but will exclude sexually transmitted disorders. For etiological purposes, one should consider the child's age and the circumstances in which the disease occurred, as well as the isolated or associated character of the lesions. It is important to get a good history, including the time of appearance of the lesions, whether they are congenital or not, and their evolution [1]. Any cutaneous perineal lesion in a child should trigger a careful mucosal, cutaneous and systemic examination, in the presence of the parents if the child is young or in private according to a teenager's preferences.

Labial Adhesions

Adherent or fused labia minora are a common problem in the pediatric population (rate: 1–38%). They occur most often in children from 13 months to 6 years of age, and may be fused totally or only part. Girls may have associated urinary symptoms or vulvar pruritus [2] or may be asymptomatic. Therapy is not always required, as spontaneous separation can occur in which case abstinence is best treatment. When symptomatic, topical estrogen therapy may be offered and, if it fails, manual separation [3].

Diaper Dermatitis in Infancy

Rashes in the diaper area are common in babies [4] between the ages of 7 and 12 months. Most cases will clear with frequent diaper changes and the use of superabsorbent disposable diapers. The differential diagnosis includes mainly

seborrheic dermatitis, candidiasis, irritant contact dermatitis, atopic dermatitis and psoriasis. In cases with an atypical presentation, recurrence, or resistance to usual treatments, one should consider less common diagnoses such as histiocytosis; referral to a dermatologist and a biopsy may be necessary at the time. It is very important to consider the diagnosis of contact dermatitis. The use of colored topical agents is strongly inadvisable because they may mask lesions and prevent semiological analysis.

Based on the Localization of the Dermatitis

One Can Distinguish [5]

'Y' diaper dermatitis: The 'Y' refers to involvement of the folds (inguinal and gluteal folds) which are erythematous, inflammatory and macerated. These lesions may be isolated or associated with satellite vesicular, pustular or papular lesions extending beyond the folds. Sometimes the 'Y' intertrigo is associated with involvement of other folds (groin, retroauricular, or axillae folds) which are manifestations of seborrheic dermatitis. More often, there is neither diarrhea nor oral candidiasis. Treatment includes gentle washing, careful drying, frequent diaper changes, and topical applications (twice a day for 15 days) of an antifungal cream as these lesions are frequently complicated by secondary infection with *Candida albicans*. If the eruption is recalcitrant, or if it lasts for more than 10 days, Langherans' histiocytosis has to be considered (see later).

'W' diaper dermatitis (fig. 1): The 'W' refers the involvement of convex surfaces (convexities of the buttocks, upper thighs, etc.), with sparing of the folds. Most often, the skin is red and dry. This is an 'irritant contact dermatitis', due to maceration and wetness. Treatment consists of careful washing and drying, with frequent diaper changes. This type of diaper dermatitis may have to be differentiated from acrodermatitis enteropathica (see later).

'Mixed diaper dermatitis': Most often, diaper dermatitis is mixed: folds are more or less involved, and there are some maculo-papular rashes on the convexities. In these cases, etiology is often multifactorial (primary irritant dermatitis secondarily infected with bacteria and *Candida*). Allergic contact dermatitis is infrequent [6] in the diaper area.

Jacquet erosive diaper dermatitis is defined primarily as an irritant diaper dermatitis (home washing of cloth diapers and insufficiently frequent diaper changing). It looks like a well-demarcated diaper dermatitis with punched-out ulcers or erosions with elevated borders (pseudoverrucous papules) on the labia majora. Because of improvements in disposable diaper material, this disease today has become extremely rare. It only may be observed in cases of prolonged maceration seen with urinary incontinence and/or prolonged severe diarrhea [7, 8]. Symptomatic treatment is required.

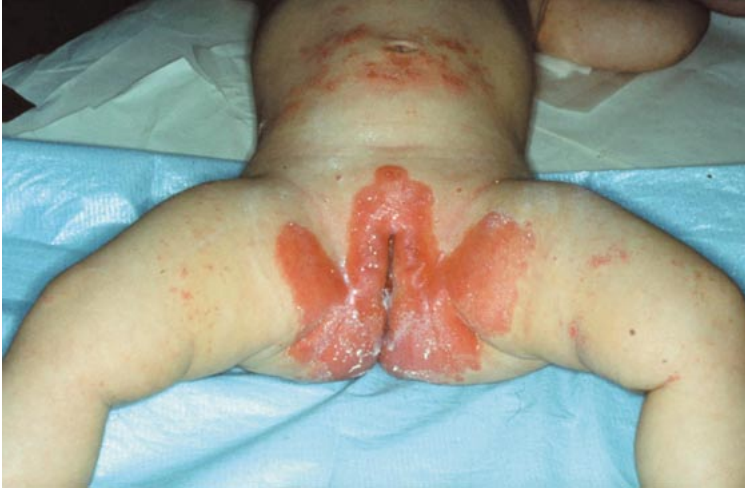

Fig. 1. 'W' diaper dermatitis.

Lucky-Luke diaper dermatitis [9] is a diaper dermatitis with a particular topography recalling the cowboy's pistol belt handles: erythema occurs in the area of the elastic band due to the rubber component.

Other Etiologies Are Less Systematic in Their Location

Children with atopic dermatitis may have a rash in the diaper area. Papular or microvesicular erythematous lesions may be present, most often localized on the upper thighs and convex surfaces. Treatment of atopic dermatitis in the napkin area should not include topical steroids, because of the well-known risk of granuloma gluteale infantum with atrophic scars [10].

Psoriasis can present as well-demarcated, red, non-scaly symmetrical plaques which extend from the vulva to the perianal area, natal cleft, inguinal folds, and mons pubis (fig. 2). The vagina is not involved. The rest of the skin may appear spared, until one searches for nail pitting or scalp or post-auricular erythema. There is often a positive family history [11]. The relationship to psoriasis in later life is uncertain.

Tumoral and Hamartomatous Diseases of the Vulva

Vulvo-vaginal malignant tumors are uncommon in children but early diagnosis and prompt, effective treatment improves prognosis. Here, we will cover malignant tumors of the vagina.

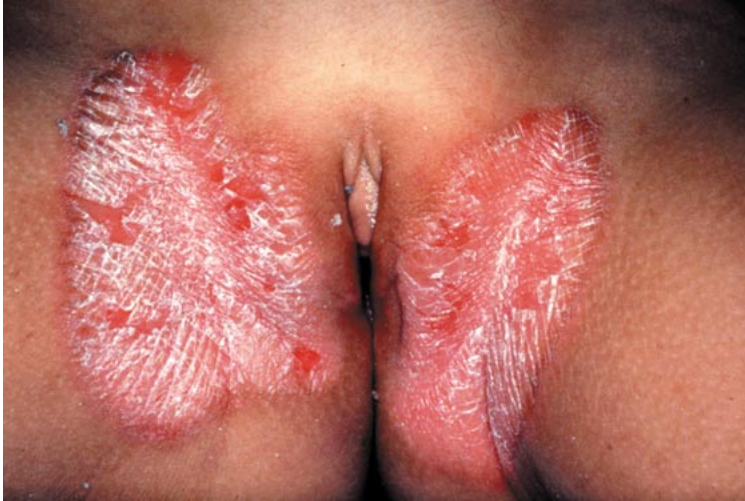

Fig. 2. Psoriasis: red well-demarcated symmetrical plaques.

Tumoral Diseases

Any tumor may involve the genital area [12, 13]; some are present at birth (teratoma) and others can be seen in prepubertal and pubertal girls (intraepithelial neoplasia). The diagnosis of teratoma may at times be made by ultrasound in utero. It should be emphasized that the first symptoms of sarcoma of the vagina are often vaginal discharge and bleeding and sometimes a small polypoid mass that fills, from time to time, the vaginal orifice. These symptoms require endoscopic exploration of the vagina for diagnosis as early as possible. Carcinoma in situ, epidermoid carcinoma, and adenocarcinoma of the vulva are exceedingly rare in children before the age of 16 years. Benign tumors of the vulva include epithelial inclusion cysts, paraurethral cysts, Bartholin's duct cysts (epidermal cysts), hidradenitis, hymeneal tags, hydroceles of the vulva, lipomas, syringomas, myoblastomas, and others. Clinical examination and biopsy, and if necessary surgical resection, allow the diagnosis. In neurofibromatosis type 1, freckling in the inguinal region is a diagnostic criterion, plexiform neurofibromas may be present in the perineal area, and clitoral involvement can be confused with ambiguous genitalia. Nevus may be observed in the perineal area. Congenital nevus can be small or part of giant congenital nevus; surgical treatment is required to reduce the risk of malignant melanoma [14].

Hemangiomas and Vascular Dysplasia May Involve the Perineal Region

Hemangiomas are the most common benign tumors of infancy. Cutaneous ulceration is the most frequent complication with hemangiomas and the

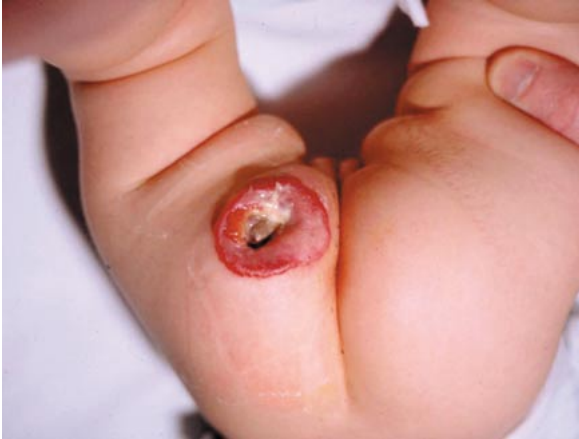

Fig. 3. Ulcerated hemangioma.

perineum is the most frequent site of this complication, in particular with perianal lesions due to maceration. Ulcerations occur most commonly during the rapid proliferation phase of the hemangiomas (before 6 months of life). Ulcerated lesions are very painful, and analgesic therapy is always quite necessary. The use of occlusive dressings and the judicious use of topical and systemic analgesics should be considered on an individual basis for patients with ulcerated hemangiomas (fig. 3). Topical therapy with barrier creams, antimicrobials, and vaseline gauze is often useful. Laser therapy (flash-pumped pulsed dye laser) can be tried as it has been effective in some cases. The use of systemic steroids should be considered when large areas are ulcerated in association with an important subcutaneous component of the hemangioma. Surgical resection is indicated for lesions that fail to respond to these therapies [15]. An angiodysplasia can involve the perineal region, and careful clinical examination of the ano-vulvo-vaginal region and limbs with auscultation will help to classify the lesion. In this localization, isolated port wine stains, Klippel-Trenaunay syndrome, cystic lymphangiomas, and lymphangiodyplasia have to be recognized and treated. In cases of pelvic angiomatous lesions, a careful clinical examination must look for signs of associated external genital and/or anal abnormalities; it is important also to check for the presence of associated midline congenital lumbosacral skin lesions, as these could be markers of spinal dysraphism [16, 17].

Infantile Perianal Pyramidal Protrusion [18]

This term is used to describe a midline protrusion anterior to the anus (fig. 4). It has probably been reported mainly as an acrochordon or a skinfold

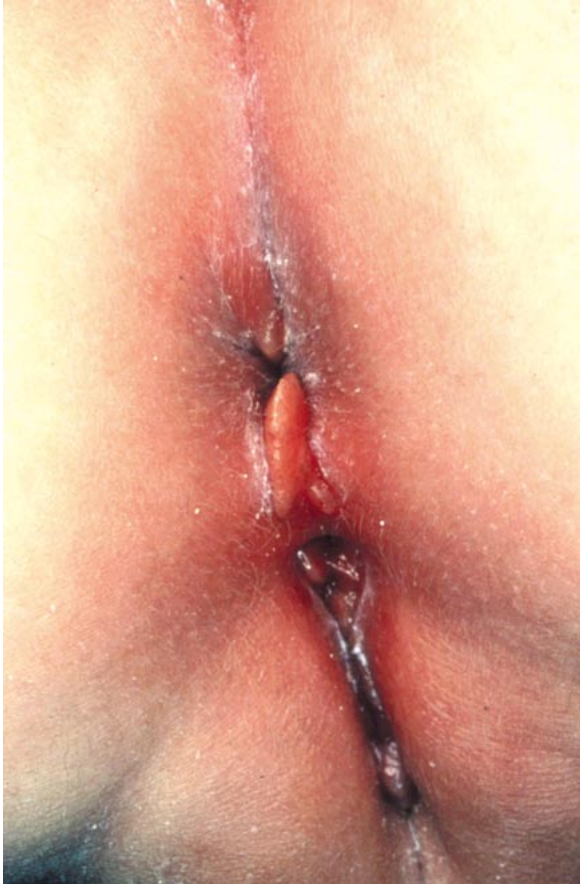

Fig. 4. Infantile perianal pyramidal protrusion.

(skin tag, skin ruga and skin tab). Clinically, it presents characteristically as a pyramidal, smooth and red or rose-colored midline protrusion just anterior to the anus. The average age of the patient is 14 months and 94% of the patients are female. No etiological factors have been determined: there is no history of child abuse. At times infantile pyramidal protrusion has been reported in association with constipation. The time of onset of the protrusion is uncertain; it may enlarge over a few months, but more often, spontaneously regresses in size. It is important to recognize this entity in order to differentiate it from diagnoses of sexual abuse, genital warts, granulomatous lesions of inflammatory bowel disease, or rectal prolapse.

Infectious Diseases (Except Sexually Transmitted Diseases)

Vulvo-Vaginitis [19, 20]

The prepubertal vulva is thin [2], delicate, and susceptible to trauma, infection and irritation as it lacks labial fat pads and pubic hair. The anus is anatomically closer to the introitus, allowing contamination with feces and fecal pathogens. The unestrogenized vaginal mucosa is thin and atrophic, has a neutral pH, and is an excellent medium for bacterial growth. In addition, hygiene in prepubertal children is frequently substandard as maternal supervision diminishes with age. The distinction (by history and clinical examination) between vulvitis and vaginitis has to be made. In vulvitis, dermatologic lesions involve exclusively the vulva and there is no vaginal discharge; often symptomatic treatment and advice will be enough. In cases of vaginitis, there are both clinical vulvo-vaginal manifestations and a vaginal discharge and a sexually transmitted disease has to be excluded.

Vulvitis without vaginal involvement is very common in young girls. Symptoms include pruritus and urinary and/or anal signs. Clinical examination often shows an isolated erythema, without other dermatologic lesions. In these cases, there is no need for bacteriologic swabs as they are related to poor hygiene, irritants, and sometimes pinworms. Recommendations for improved hygiene and avoidance of irritation, in association with treatment of pinworms, are sufficient measures.

Vulvo-vaginitis with a discharge is most likely due to an infection or a retained foreign body. In this case, it is very important to clarify whether there is sexual contamination (sexually active teenagers or children who are being abused): a pertinent history and a clinical examination have to be very carefully conducted. Any discharge must be fully investigated and samples taken for wet smears to screen for *Trichomonas* and *Candida* as well as for Gram staining and bacterial cultures. In prepubertal girls, pathogenic organisms include *Streptococcus pyogenes* (group A β -hemolytic streptococci), *Haemophilus influenzae*, *Streptococcus pneumoniae*, *Staphylococcus aureus*, *Neisseria meningitidis*, *Shigella*, *Yersinia*. *Candida* vulvo-vaginitis may occur in post-pubertal girls but is very rare in early infancy. Sexually transmitted disorders of bacterial origin include *Trichomonas*, gonorrhea and *Chlamydia* infections. In case of persistent vulvo-vaginitis with negative bacterial cultures, a vaginoscopic examination should be performed under anesthesia to rule out a retained foreign body.

Perineal Dermatitis

Bullous impetigo is characterized by the formation of large flaccid bullae arising from normal skin. The bullae rupture leaving red denuded round areas

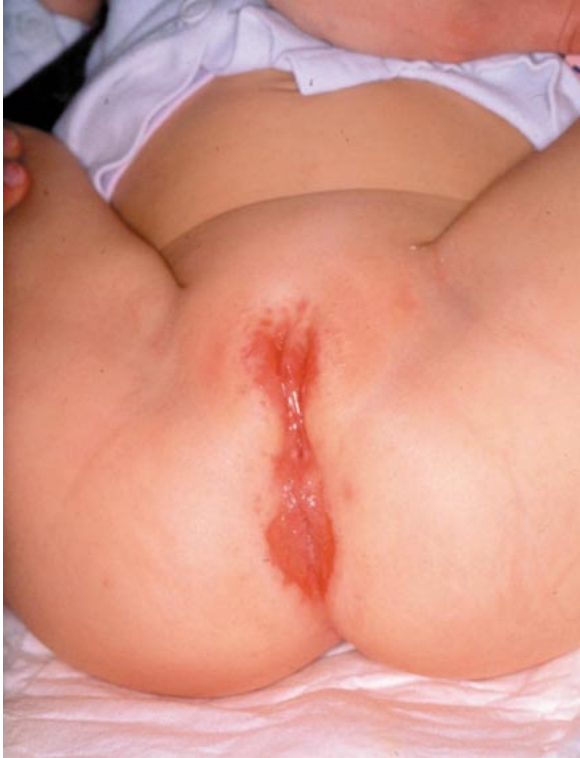

Fig. 5. Perineal streptococcal dermatitis.

with honey-colored crusts. Those lesions spread rapidly and can quickly involve the thighs, buttocks, and abdomen. The causative agent is often *S. aureus* phage type II, which produces an epidermolytic toxin. Treatment is topical and general antibiotherapy.

Perianal dermatitis [21–23] (fig. 5) induces a superficial, perianal, well-demarcated rim of erythema sometimes in association with a vulvo-vaginal erythema. Symptoms range from perianal pruritus and tenderness to abdominal pain and rectal bleeding. In girls, clinical symptoms include dysuria, pruritus, tenderness, and vaginal discharge. Clinical pharyngitis may be present. Microbacterial cultures will grow *group A β-hemolytic streptococci* from perineal samples; streptococci may also be present in pharyngeal samples. Treatment is oral penicillin V for at least 3 weeks. *S. aureus* has also been proven to be the cause in this disease.

Recurrent toxin-mediated perineal erythema [24]. The hallmark of this disease is a strikingly diffuse macular erythema in the perineum occurring

abruptly after a bacterial pharyngitis. Oral mucosal changes, such as strawberry tongue, as well as erythema, edema, desquamation of the hands and feet during convalescence, are usually present as well. Systemic signs are absent. Recurrences are frequent; culture of the pharynx during acute episodes reveals toxin-producing *S. aureus* or *S. pyogenes*.

Viral Infections [4, 11]

Condylomata acuminata [25–27] are anogenital warts caused by a human papillomavirus (HPV) infection. Most commonly, they are caused by HPV types 6, 11, 16 or 18. Sometimes, manual transmission causes condylomata with type 2 HPV. Epidemiologic and experimental inoculation studies suggest that the incubation period for HPV is 1–20 months, but latency periods of at least 2 years are suspected. The majority of condylomata acuminata in children younger than 3 years is due to vertical transmission at birth. Non-sexual transmission includes: hand-genital contact via an infected caregiver, non-sexual intimate behavior, and inadequate hygiene (contaminated towels, etc.). The possibility of sexual transmission must be considered and assessed for all children presenting with a condyloma. This includes directed medical and social history and physical examination of the child. This also includes history of anogenital warts in the family and caregivers. Clinical examination of family members is necessary to look for warts. Condylomata acuminata present as white or flesh-colored, papilloma-like, hyperkeratotic, sharply demarcated, and non-confluent lesions. In children, they are usually perianal and localized preferentially or exclusively on the skin, not on the mucosa. As spontaneous resolution occurs quite often, non-intervention is a reasonable approach in the management of condylomata in children. If necessary, topical non-aggressive treatment should be instituted (podophillotoxin, salicylic acid, imiquimod, etc.); laser treatment or surgical excision and cauterization under general anesthesia may also be offered.

Molluscum contagiosum is caused by a poxvirus and may be localized in the genital area. Each lesion, from 1 to 10 mm, is a dome-shaped papule, flesh-colored or pearly, with an umbilicated center. As it is a self-limited disease, and as treatment is often painful, non-intervention may be an alternative. Among numerous interventions, curettage or cryotherapy may be offered.

Herpes and zoster virus infection may occur in perineal regions. Genital HSV infections are rare in children and sexual contamination should be considered in this localization.

Infestations with Pinworms, Scabies and Lice [2, 20]

Pruritus is quite a frequent symptom in childhood and it is important to keep in mind that vulvar symptoms may be caused by anal pathologies because

the anus is anatomically closer to the introitus. The diagnosis of pinworms is suggested when there is nocturnal anal pruritus; the diagnosis can be made by visualizing the worms or by applying transparent adhesive tape to the perianal skin to look for microscopic eggs. Systematic treatment is a good choice, including a single dose of oral pyrantel pamoate, 11 mg/kg, or mebendazole, 100 mg, for all household members. Both treatments may be repeated 2 weeks later. In the perineal area, scabies nodules are localized in the labia majora; eczematous lesions are concentrated on the hands, abdominal wall, and axillary folds. Pubic lice are rare in childhood.

Lichen Sclerosus

The true frequency of pediatric lichen sclerosus (LSV) is difficult to assess [28]. The average age of onset is about 6 years and the age at diagnosis is around 10 years. The most common symptom is vulvar pruritus; bleeding also occurs very frequently although this sign is not common in adults. LSV is asymptomatic in 10% of cases. Other main complaints are hemorrhagic blisters, fissuring, burning, and constipation. The classical clinical presentation of LSV is an erythema with confluent flat-topped white or ivory-colored papules, usually symmetric and described as ‘keyhole’, ‘hourglass’ or ‘figure eight’ configurations (fig. 6). The main clinical aspects are fissures, hemorrhages and excoriations, especially on the labia minora and clitoris. Unusual features can be local depigmentation or a vitiligo-like aspect. LSV can be asymptomatic, presenting only because of an abnormal appearance. The hymen is not involved, but the lesions extend sometimes to the perianal region. LSV may be misdiagnosed as sexual abuse so the diagnosis must be made cautiously because of the great deal of anxiety it may induce [29–31].

The evolution of LSV seems to be resolution over time but not under the influence of hormonal factors such as menarche. The pathogenesis is unclear [32]: hormonal factors; interaction with cytokines and growth factors, with fibroblasts leading to local changes in collagen; enzyme deficiency; autoimmune disorders; genetic factors; associations with the antigens of the HLA system, infectious agents (virus, mycobacteria, spirochete, especially *Borrelia*), and mechanical factors (friction, Köbner phenomenon) have all been suggested. The etiology is probably multifactorial and appears to include a genetic predisposition, environmental factors and local factors.

Little is said in the literature about complications; moreover, some authors have reported spontaneous remissions (especially at puberty). Constriction of the vaginal introitus with atrophy and stenosis at onset and anal stenosis have been described. Leukoplakia and squamous cell carcinoma of the vulva, which

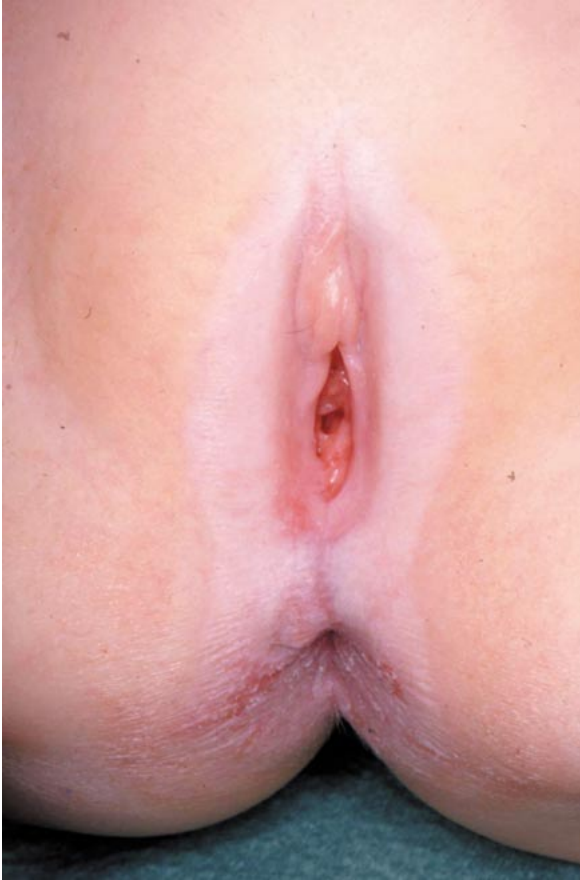

Fig. 6. Lichen sclerosus: vitiligoid aspect.

is a complication in adults, have been reported in a review of the literature as occurring in 7 children.

The treatment of LSV in pediatric patients is now well defined [33, 34]. Topical corticosteroid ointments and emollients, as well as proper perineal hygiene, cotton underwear, and avoidance of trauma and tight clothes are very effective for LSV lesions and reduce the pruritus. The treatment of reference is ultrapotent topical steroids. No severe adverse effects (atrophy, infection, depigmentation, systemic passage) have been observed, except for telangiectasia and striae. Ultrapotent topical steroid is a safe and effective treatment in children, as in adults, and results in fast improvement. This treatment can be prescribed once a day for 2 months and then switched to intermittent use of lower potency topical

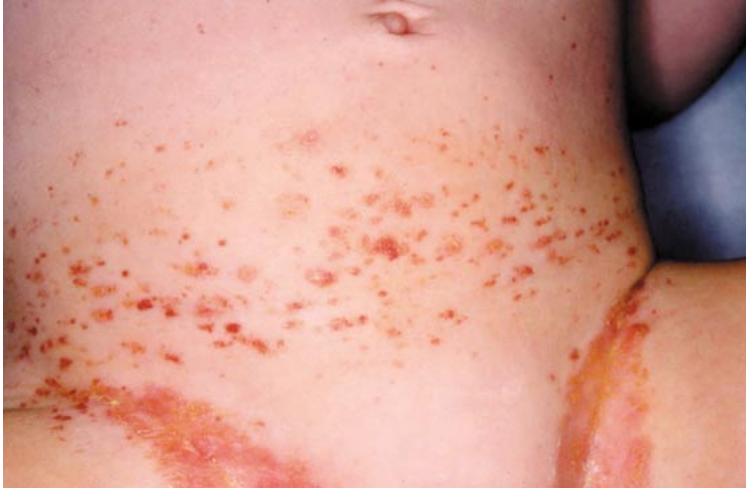

Fig. 7. Histiocytosis.

steroids or occasional use of ultrapotent steroids for maintenance treatment. With early aggressive treatment, long-term sequelae may be prevented. A significant proportion of children have long-term symptoms and atrophic sequelae. Lifelong follow-up is thus recommended, once or twice every year, even after the menarche, according to the type of LSV and the patient's compliance.

Vulvo-Perineal Localization of Dermatologic Disorders

Systemic disorders may be localized in the vulvo-perineal region. Here, we will only emphasize those in which this localization suggests the diagnosis or is of particular importance.

In Langherans' cell histiocytosis [35, 36] (fig. 7), lesions initially are erythematous, purpuric papules and they then become scaly, crusted and sometimes confluent. The preferential localizations are the scalp, the retroauricular folds, and the trunk. The napkin area may be involved, such as the inguinal folds and the perianal region. Involvement of the female genital tract may occur, including the vulva and vagina. In case of persistent inguinal fold involvement in a child, clinical examination should extend to other potential localizations of this disease. If purpuric or crusted papules are present, a histologic examination has to be performed.

Acrodermatitis enteropathica (fig. 8) is a biochemical disorder of zinc metabolism. Cutaneous manifestations are localized in perioral and perianal

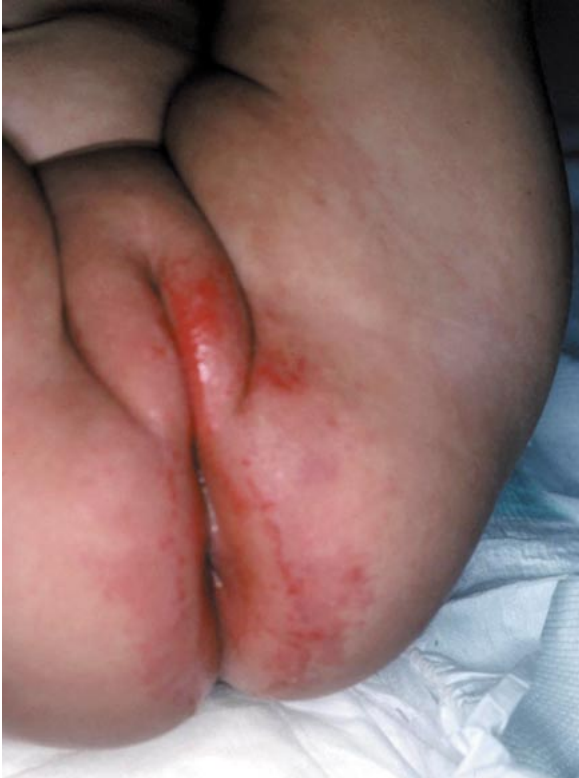

Fig. 8. Acrodermatitis enteropathica.

regions. The clinical picture is a vesiculobullous, pustular hyperkeratotic dermatitis with failure to thrive, diarrhea, apathy, alopecia and fine brittle hair [37]. Differential diagnosis should include biotinidase deficiency and some types of organoacidemia [38].

Lesions of inflammatory bowel disease (fig. 9): Perianal involvement is quite common in Crohn's disease [39], and perianal skin tags, anal and vaginal fissures, abscesses and fistulas are frequent. Isolated swelling of the labia majora may be present for months, before the appearance of other dermatological or gastrointestinal symptoms. Cutaneous biopsies may help the diagnosis by revealing the characteristic granulomatous features. Genital and anal aphthae may occur in Behçet's and Crohn's disease. Given the lack of a pathognomonic laboratory test or histologic findings, clinical criteria must be used to make the diagnosis of Behçet's disease [40]. Genital aphthae usually occur on the vulva and are painful; in the initial presentation, herpes virus

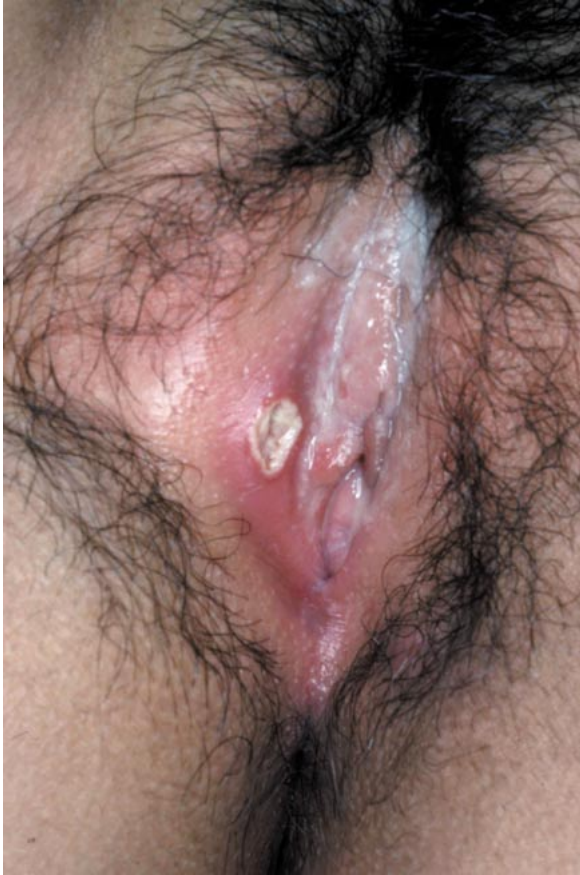

Fig. 9. Aphthous lesion in Behçet's disease.

must be considered in the differential diagnosis. Several patients with neonatal Behçet's disease have been reported, all of whose mothers were affected with the same disease. Treatment depends on severity, and topical and intralesional corticosteroids can be used for genital aphthae, as can applications of viscous lidocaine. Other treatments include colchicine, dapsone, thalidomide and topical tacrolimus.

In Kawasaki's disease [41] (fig. 10), an erythematous, desquamating perineal rash may occur in the second week of symptom onset, almost at the same time as palmoplantar desquamation. This is of importance for the diagnosis of this syndrome, as early diagnosis and treatment is the best way to prevent coronary aneurysms.

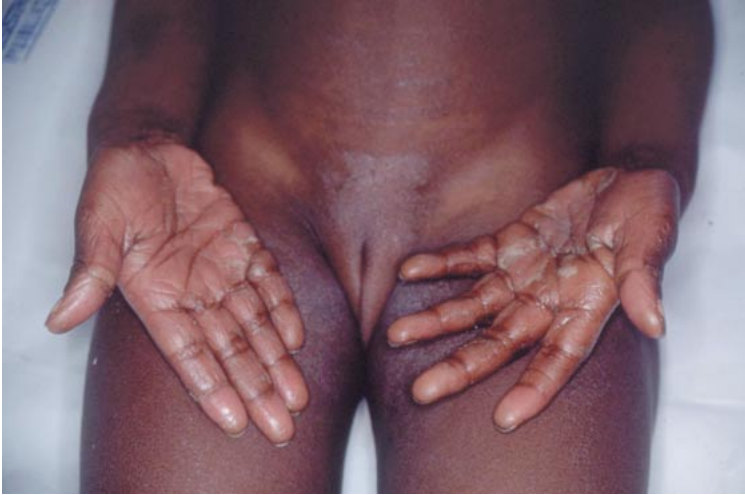

Fig. 10. Perineal desquamation in Kawasaki disease.

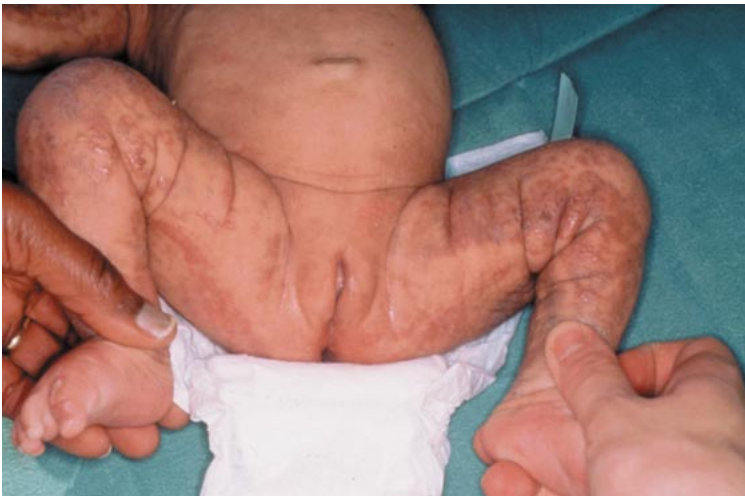

Fig. 11. Incontinentia pigmenti: hyperpigmentation in Blaschko linear distribution.

Any bullous disease may be localized in the perineal area. In the newborn, a sample for bacterial and viral studies must be taken. Staphylococcal and viral diseases require rapid treatment. Genetic bullous disorders are mainly epidermolysis bullosa, congenital and incontinentia pigmenti (fig. 11) (with distribution of

the vesiculobullar lesions along Blaschko's lines). In childhood, autoimmune bullous disorders are uncommon. IgA dermatitis includes blisters in the perineal region and erythema multiforme, Stevens-Johnson syndrome and toxic epidermal necrolysis may involve the perineal area. Coexisting erosions of the other mucous membranes (eyes, mouth) and cutaneous rash help the diagnosis. In case of involvement of the vaginal introitus, post-inflammatory stenosis can occur; local care several times a day is needed to prevent this.

Many dermatoses may involve the perineal area in girls. The age at which lesions occur is very important clue for the diagnosis. In the case of congenital lesions, we should first consider infectious, malformative and genetic diseases. The most common problem of diaper-wearing infants is primary irritant dermatitis due to occlusion and friction; in cases of persistence, rare diagnoses such as acrodermatitis enteropathica or histiocytosis should be considered. It is important to distinguish between an isolated vulvitis (which is very common) and vulvo-vaginitis. Lichen sclerosus seems to be quite a frequent pathology in girls and diagnosis is often delayed. Tumors are rare in childhood but, when suspected, diagnosis is urgent to treat them quickly. Cutaneous and mucosal cultures are needed to adequately manage genital diseases. In atypical cases where sexual abuse is suspected, we recommend a multidisciplinary approach.

References

- 1 Teillac-Hamel D, Delanoe P, Fekete CN, de Prost Y: Dermatoses vulvaires de l'enfant. *Ann Dermatol Venereol* 1992;119:991-998.
- 2 Paek SC, Merritt DF, Mallory SB: Pruritus vulvae in prepubertal children. *J Am Acad Dermatol* 2001;44:795-802.
- 3 Omar HA: Management of labial adhesions in prepubertal girls. *J Pediatr Adolesc Gynecol* 2000;13:183-186.
- 4 Ridley CM: Vulvar disease in the pediatric population. *Semin Dermatol* 1996;15:29-35.
- 5 Jacobs AH: Eruptions in the diaper area. *Pediatr Clin North Am* 1978;25:209-224.
- 6 Karlberg AT, Magnusson K: Rosin components identified in diapers. *Contact Dermatitis* 1996;34:176-180.
- 7 Hara M, Watanabe M, Tagami H: Jacquet erosive diaper dermatitis in a young girl with urinary incontinence. *Pediatr Dermatol* 1991;8:160-161.
- 8 Rodriguez-Poblador J, Gonzalez-Castro U, Herranz-Martinez S, Luelme-Aguilar J: Jacquet erosive dermatitis after surgery for Hirschsprung disease. *Pediatr Dermatol* 1998;15:46-47.
- 9 Roul S, Ducombs G, Leauté-Labreze C, Taieb A: 'Lucky-Luke' contact dermatitis due to baby's diaper: 8 cases. *Ann Dermatol Venereol* 1998;125(suppl 1):130.
- 10 Bonifazi E, Garofalo L, Lospalluti, M, Scardigno A, Coviello C, Meneghini CL: Granuloma gluteale infantum with atrophic scars: Clinical and histological observations in eleven cases. *Clin Exp Dermatol* 1981;6:23-29.
- 11 Fisher G, Rogers M: Vulvar disease in children: A clinical audit of 130 cases. *Pediatr Dermatol* 2000;17:1-16.
- 12 Huffman JW, Dewhurst CJ, Capraro VJ: Tumors of the vulva and vagina during childhood; in *The Gynecology of Childhood and Adolescence*. Philadelphia, Saunders, 1981, pp 225-259.

- 13 Quint EH, Smith YR: Vulvar disorders in adolescent patients. *Pediatr Clin North Am* 1999;46:593–606.
- 14 Bittencourt FV, Marghoob AA, Kopf AW, Koenig KL, Bart RS: Large congenital melanocytic nevi and the risk for development of malignant melanoma and neurocutaneous melanocytosis. *Pediatrics* 2000;106:736–741.
- 15 Kim HJ, Colombo M, Frieden IJ: Ulcerated hemangiomas: Clinical characteristics and response to therapy. *J Am Acad Dermatol* 2001;44:962–972.
- 16 Bouchard S, Yazbeck S, Lallier M: Perineal hemangioma, anorectal malformation, and genital anomaly: A new association? *J Pediatr Surg* 1999;34:1133–1135.
- 17 Albright AL, Gartner JC, Wiener ES: Lumbar cutaneous hemangiomas as indicators of tethered spinal cords. *Pediatrics* 1989;83:977–980.
- 18 Kayashima KI, Tomomichi O: Infantile perianal pyramidal protrusion. *Arch Dermatol* 1996;132:1481–1484.
- 19 Jaquier A, Stylianopoulos A, Hogg G, Grover S: Vulvovaginitis: Clinical features, aetiology, and microbiology of the genital tract. *Arch Dis Child* 1999;81:64–67.
- 20 Piipo S, Lenko H, Vuento R: Vulvar symptoms in paediatric and adolescent patients. *Acta Paediatr* 2000;89:431–435.
- 21 Mogielnicki NP, Schwartzman JD, Elliott JA: Perineal group A streptococcal disease in a pediatric practice. *Pediatrics* 2001;108:276–281.
- 22 Manders SM: Toxin-mediated streptococcal and staphylococcal disease. *J Am Acad Dermatol* 1998;39:383–398.
- 23 Montemarano AD, James WD: *Staphylococcus aureus* as a cause of perianal dermatitis. *Pediatr Dermatol* 1993;10:259–262.
- 24 Manders SM, Heymann WR, Atillasoy E, Kleeman J, Schlievert PM: Recurrent toxin-mediated perineal erythema. *Arch Dermatol* 1996;132:57–60.
- 25 Allen AL, Siegfried EC: The natural history of condylomata in children. *J Am Acad Dermatol* 1998;39:951–955.
- 26 Bromberg K, Hammerschlag M, Rawstron SA, Bilo RAC, Oranje AP: Sexually transmitted diseases in children and adolescents; in Harper J, Oranje A, Prose N (eds): *Textbook of Pediatric Dermatology*. London, Blackwell Science, 2000, vol 2, pp 1510–1529.
- 27 Obalek S, Jablonska S, Favre M, Walczak L, Orth G: Condylomata acuminata in children: Frequent association with papillomaviruses responsible for cutaneous warts. *J Am Acad Dermatol* 1990;23:205–213.
- 28 Powell J, Wojnarowska F: Childhood vulvar lichen sclerosus: An increasingly common problem. *J Am Acad Dermatol* 2001;44:803–806.
- 29 Kellogg ND, Parra JM, Menard S: Children with anogenital symptoms and signs referred for sexual abuse evaluations. *Arch Pediatr Adolesc Med* 1998;153:634–641.
- 30 Warrington SA, San Lazaro C: Lichen sclerosus et atrophicus and sexual abuse. *Arch Dis Child* 1996;75:512–516.
- 31 Powell J, Wojnarowska F: Childhood vulvar lichen sclerosus and sexual abuse are not mutually exclusive diagnoses. *BMJ* 2000;320:311.
- 32 Powell J, Wojnarowska F, Winsey S, Marren O, Welsh K: Lichen sclerosus premenarche: Autoimmunity and immunogenetics. *Br J Dermatol* 2000;142:481–484.
- 33 Garzon MC, Paller AS: Ultrapotent topical corticosteroid treatment of childhood genital lichen sclerosus. *Arch Dermatol* 1999;135:525–528.
- 34 Fischer G, Rogers M: Treatment of childhood vulvar lichen sclerosus with potent topical corticosteroid. *Pediatr Dermatol* 1997;14:235–238.
- 35 Gianotti F, Caputo R: Histiocytic syndromes: A review. *J Am Acad Dermatol* 1985;13:383–404.
- 36 Axiotis CA, Merino MJ, Duray PH: Langherans' cell histiocytosis of the female genital tract. *Cancer* 1991;67:1650–1660.
- 37 Neldner KH, Hambridge KM, Walravens PA: Acrodermatitis enteropathica. *Int J Dermatol* 1978;17:380–387.
- 38 Bodemer C, de Prost Y, Bachelet B, et al: Cutaneous manifestations of methylmalonic acidemia and propionic acidemia: A description of 38 cases. *Br J Dermatol* 1994;131:93–98.

- 39 Palder SB, Shandling B, Bilik R, Griffiths AM, Sherman P: Perianal complications of pediatric Crohn's disease. *J Pediatr Surg* 1991;26:513–515.
- 40 Ghate JV, Jorizzo JL: Behçet's disease and complex aphthosis. *J Am Acad Dermatol* 1999;40: 1–18.
- 41 Fritter BS, Lucky AW: The perineal eruption of Kawasaki syndrome. *Arch Dermatol* 1988;124: 1805–1810.

Dominique Hamel-Teillac

Service de Dermatologie, Hôpital Necker-Enfants Malades

149 rue de Sèvres, FR-75015 Paris (France)

Tel. +331 44494662, Fax +331 44494660

E-Mail dominique.hamel-teillac@nck.ap-hop-paris.fr

.....

Precocious Puberty (Complete, Partial)

R. Stanhope, C. Traggiai

Department of Endocrinology, Great Ormond Street Hospital for Children and The Middlesex Hospital (UCLH), London, UK

Two decades ago, the diagnosis of premature sexual development was considered to be simple; the conditions that were recognised were either central precocious puberty, isolated premature thelarche or an adrenal aetiology. The use of pelvic ultrasound and gonadotrophin-releasing hormone (GnRH) analogue treatment was to completely alter our understanding of these disorders. Pelvic ultrasound led to differentiating ovarian appearances in conditions such as McCune-Albright syndrome and the variation in ovarian maturation in premature thelarche and central precocious puberty. Failure to respond to GnRH analogue therapy in children with precocious puberty led to the concept of gonadotrophin-independent precocious puberty (GIPP). During the 1980s, several variants of premature sexual maturation were described and this was important, both for the natural history of these conditions and the requirement for therapy. Adrenal lesions causing sexual maturation are included in this chapter for completeness. Their diagnosis and management is considerably simpler than premature sexual maturation of a gonadal aetiology.

Investigations

In the diagnosis of disorders of premature sexual maturation, there are two investigative procedures of significance, which are simple and relatively easy to interpret: the GnRH test and pelvic ultrasound assessment.

Pelvic ultrasound is a non-invasive technique which gives two important pieces of information. The uterine volume (and the endometrial thickness) is a measure of oestrogen secretion. The ovarian morphology can be used as an index of gonadotrophin secretion. The initial hormonal events of normal puberty are predominantly LH, rather than FSH, dependent.

There is a nocturnal rise in LH pulsatility and the amplitude gradually increases. When the corresponding increase in oestrogen becomes sufficient to induce breast development, then phenotypic puberty has commenced. However, the endocrine events that culminated in the onset of phenotypic puberty have been occurring for several years. Ovarian morphology changes from about 8 years of age and, in response to pulsatile nocturnal gonadotrophin pulsatility, the ovary develops into a multicystic morphology [1]. The multicystic morphology contains more than six follicles of 4 mm in diameter, or greater. This morphology is different from a polycystic ovarian appearance [2]. The multicystic ovarian appearance is a marker for the presence of pulsatile nocturnal gonadotrophin secretion. Thus, this ovarian morphological appearance is always present in girls with central precocious puberty, as it is in girls with normal puberty. Other disorders of premature sexual maturation have other characteristic morphological appearances, but not multicystic, and these are described in the sections below. With a progressive increase in amplitude of gonadotrophin pulsatility, the next stage of ovarian development, after multicystic, is the appearance of a dominant follicle, >10 mm in diameter.

The GnRH stimulation test has relatively little use in delayed puberty [3] but is of enormous significance in investigating children with premature sexual maturation. Girls with central precocious puberty have a dominant LH response to a bolus of intravenous GnRH, whereas girls with premature thelarche have a predominant FSH response. There is a broad spectrum between these two extremes and this will be discussed under the various specific diseases below. Certainly, without a dominant LH response, it is almost certain that there will be no response to GnRH analogue therapy [4]. Of course, children without a gonadotrophin response to a bolus injection of GnRH are likely to have GIPP, which will require an alternative treatment regimen.

In the investigation of adrenal disorders, an ACTH stimulation test is often helpful and, by measuring intermediate steroid metabolites, such as serum 17-hydroxyprogesterone, as well as urinary steroid metabolites of both cortisol and androgen metabolism, it is possible to distinguish the specific lesion in adrenal steroid biosynthesis.

Precocious Puberty

There are many causes of precocious sexual development and these are probably best categorised into those that are gonadotrophin dependent and independent (table 1). Such a classification helps both in understanding the aetiology the condition, and also in deciding the treatment options. In central precocious puberty, the most characteristic feature is maintenance of the

Table 1. Classification of disorders of premature sexual maturation of a gonadal aetiology

Gonadotrophin dependent

Central precocious puberty

Idiopathic

Hypothalamic tumours/cysts

Low dose cranial irradiation

Primary hypothyroidism with elevated FSH secretion

Tumours producing β -hCG secretion (e.g. hepatic tumours) in boys

Gonadotrophin independent

Testotoxicosis in boys

McCune-Albright syndrome in girls

Hypomelanosis of Ito in girls

Premature thelarche

Premature thelarche variant (also called slowly progressive precocious puberty or exaggerated thelarche)

Isolated menarche

harmony (consonance) of normal puberty. Thus, there is breast and pubic hair development, and a growth acceleration, which all occur in exactly the same sequence of events as in normal puberty, with the exception that this occurs at an earlier age. In all the other variants of premature sexual maturation, this harmony of normal puberty is lost, namely early vaginal bleeding with minimal breast development in McCune-Albright syndrome or breast development in the absence of a growth spurt in premature thelarche.

In the older nomenclature, children with central precocious puberty were described as having ‘complete’ precocious puberty, whereas those with other variants of sexual maturation were called ‘partial’ or ‘incomplete’ precocious puberty. Central precocious puberty is also known as ‘idiopathic’ precocious puberty or gonadotrophin-dependent precocious puberty. The cut-off age for the definition of precocious puberty is 8 years; precocious sexual maturation in a girl under 8 years of age is called precocious.

Adrenal Dysfunction

Various adrenal disorders may cause premature sexual maturation. However, this does not involve ‘gonadarche’ and so there is no breast development. There is usually pubic and axillary hair development with associated cutaneous manifestations of acne, behavioural difficulties and an increase in growth rate with advance in skeletal maturation. Adrenal tumours may present

with such symptoms, but they are usually of a rapid nature and more severe. The clitoris is always enlarged. The serum testosterone is usually >5 nmol/l and it is not difficult to make the diagnosis of the presence of an adrenal tumour clinically. Imaging of the adrenal glands, initially using ultrasound but also CT, will usually reveal the lesion.

Congenital adrenal hyperplasia, of which the commonest form is 21-hydroxylase deficiency, usually presents in the neonatal period with ambiguous genitalia and a salt-losing crisis. However, milder forms of congenital adrenal hyperplasia may present in later childhood with virilisation. The clitoris is almost always enlarged. The diagnosis is made using a standard ACTH test and measuring adrenal metabolites in the blood, as well as the urine.

Simple adrenarche is a diagnosis of exclusion. This is a benign condition where there is pubic hair development, which usually commences between the ages of 5 and 7 years. It is self-limiting and the hair development is usually along the line of the labia majora and not on the mons pubis (as in normal puberty). The clitoris is normal. The growth rate may be mildly accelerated, but this condition is not usually difficult to differentiate from an adrenal tumour or a biosynthetic adrenal steroid disorder. Simple adrenarche is a condition and not a disease, and requires reassurance and not treatment. The serum adrenal androgens are only mildly elevated, either towards the top, or just above, the normal range. However, recent data has suggested that there may be more sinister long-term sequelae for girls with simple adrenarche and this may be associated with the development of hyperinsulinism, obesity and polycystic ovarian disease in later life.

Central Precocious Puberty

This is known as central, idiopathic or gonadotrophin-dependent precocious puberty. The pattern of sexual development is indistinguishable from normal puberty and investigations reveal LH predominance to a GnRH stimulation test and a multicystic ovarian morphology on pelvic ultrasonography. This may be associated with low-dose cranial irradiation [5], especially in girls and when irradiation is given at a young age. Once the initial investigations have indicated that the sexual maturation is gonadotrophin dependent, then imaging of the hypothalamic pituitary region is essential. It used to be considered that most girls with central precocious puberty had 'idiopathic' precocious puberty, whereas with the availability of high-resolution CT scanning, it was appreciated that many such girls had hypothalamic lesions which were most commonly hamartoma [6]. Recent studies in much larger numbers from both Italy [7] and France [8] have shown that there is a significant risk of any girl with central

precocious puberty having a hypothalamic/pituitary tumour with sexual precocity being the only abnormal sign. Although reinforcing the original findings of Cacciari et al. [6] that young girls with central precocious puberty usually have a hypothalamic hamartoma, tumours such as astrocytoma may present with central precocious puberty in girls between the ages of 5 and 7 years, and it is extremely important not to miss such an underlying aetiology at an early stage of the tumour's growth. These findings reinforce the clinical guideline that all girls with central precocious puberty should have neuroradiological imaging of the hypothalamic pituitary region. It is interesting that some tumours of the hypothalamic region, such as hamartoma, optic nerve glioma and astrocytoma, commonly produce precocious puberty, whereas others, such as craniopharyngioma, Langerhans' cell histiocytosis and germinoma, only rarely cause precocious puberty [9] despite involving the same anatomical site. Hamartomata are the commonest hypothalamic tumours found in girls with central precocious puberty. Any surgical excision which may be indicated for intractable fits, would not cause a resolution of the precocious puberty. Interestingly, relatively high LH concentrations, not related to an LH surge, are often an indication of the presence of a tumour in the hypothalamic pituitary region [6].

Since 1980, older treatments with cyproterone acetate or medroxyprogesterone have been superseded by the use of GnRH analogues. These suppress gonadotrophin pulsatility and gonadotrophin secretion, and initially suppress and, hopefully, regress sexual maturation. They are relatively free of side effects and are effective. They can be given either as daily subcutaneous injections, intranasal sprays 2–3 times a day, or by depot injections lasting between 1 and 3 months. If puberty is well advanced and there is an endometrial echo of more than 4 mm in thickness, then it is usually appropriate to use cyproterone acetate in conjunction with a GnRH analogue for the first 3 weeks in order to prevent a uterine withdrawal bleed associated with the initial stimulatory phase of the GnRH analogue's action.

The indications for treating girls with central precocious puberty are to suppress sexual maturation and to help with psychological difficulties. Certainly, GnRH analogue treatment is effective for both of these sequelae, but it is also important to have an expert psychologist available to give appropriate support. When GnRH analogues were initially introduced, there was a promise of increasing final height prognosis. However, there is no convincing evidence that there is an improvement in final height with the exception of 1 or 2 cm. It is probable that the reasons why it was initially considered that height prognosis was improved was the inclusion of patients with thelarche variant (see below) into the cohort of patients considered to have central precocious puberty. There has been some evidence that adding biosynthetic human growth hormone to gonadotrophin-releasing analogue therapy may improve final stature [10].

Isolated Premature Thelarche

Premature thelarche is a benign, self-limiting condition which is characterised by breast development with no other signs of sexual maturation. There is no pubic or axillary hair development, behaviour is normal, growth is normal and the skeletal age is appropriate. The breast development has atypical appearance with relatively immature nipple development and is never more than Tanner Breast Stage III. Breast development is usually asymmetrical and the breasts increase and decrease in size at about 6-weekly intervals. The condition tends to resolve after about 1–2 years and then the onset of normal puberty occurs at the appropriate age and in the normal way. Very occasionally, vaginal bleeding can occur. There have been some reports of women who have had premature thelarche as a child developing large follicular cysts during their menstrual cycles and, thereby, having reduced fertility [11]. However, this has not been substantiated and what limited follow-up has been achieved in further series suggests that there are no long-term sequelae [12]. Isolated premature thelarche is a relatively common condition. It is characterised by FSH dominance and overnight gonadotrophin secretion, which is characterised by single FSH pulses [13]. On ultrasound the ovaries are small, but often contain large follicular cysts, which increase and decrease in synchrony with the breast development [14].

There may well be two types of premature thelarche. The classical type commences during the first year of life and tends to resolve by the age of 2. There is a second form of premature thelarche, of which the age of onset is over 2 years of age and this tends to be more persistent and with a higher incidence of uterine bleeding. In this ‘non-classical’ form of premature thelarche, it may well be associated with progression to gonadotrophin-dependent precocious puberty [15]. Isolated premature thelarche is a condition which is easy to diagnose clinically and requires no treatment.

Thelarche Variant

This encompasses a spectrum of conditions, which lie between premature thelarche and central precocious puberty. It may be difficult to distinguish from central precocious puberty. Indeed, there is a complete spectrum of gonadotrophin secretion in these conditions [16] between LH and FSH dominance. This condition has been described under different names, which has led to confusion. It has been known as unsustained precocious puberty [17], slowly progressive precocious puberty [18], thelarche variant [4] and exaggerated thelarche [19]. In all these conditions, there is a similar clinical description

of breast development, which is similar to that seen in premature thelarche, although the breast cycling is less common. There is usually pubic hair development, so that the condition cannot be classified as ‘isolated’ premature thelarche. However, the rate of growth is usually faster than normal, but without an advanced epiphyseal maturation. Growth prognosis appears to be normal, or near normal. The breast development frequently arrests and, certainly, does not advance to full sexual maturation. Behavioural problems are unusual. The condition only requires reassurance, but if treatment with a GnRH analogue is attempted, it may well result in a change of sexual maturation to central precocious puberty [4].

Patients with this condition of thelarche variant have often been included in patients with central precocious puberty and analysed contemporaneously in their response to GnRH analogue. As the growth prognosis is normal in the thelarche variant, it may well have compromised the analysis of patients with central precocious puberty and produced results which have suggested that GnRH analogue therapy produces an artificially improved benefit in terms of final height attainment. As this condition was only described a decade ago, there are no studies about the effect into adult life and longer-term studies will need to be undertaken.

Isolated Menarche

This is a condition where young girls have cyclical uterine bleeding without any other signs of sexual maturation, and they have normal growth. The natural history during childhood has been described [20] and the pattern of gonadotrophin secretion has also been documented [21], which is predominantly FSH. A clue to the diagnosis is often obtained because of the frequency of uterine bleeding, which is more often 6-weekly than monthly. It is important to exclude a local labial or vaginal cause for the bleeding, and there is often confusion about whether this is related to sexual abuse. No treatment is available and there tends to be a resolution of the condition after 1 or 2 years. No long-term sequelae have been described.

Gonadotrophin-Independent Precocious Puberty

GIPP occurs more commonly in boys (described as testotoxicosis) than in girls. However, when it does occur in girls, it is due to either McCune-Albright syndrome or hypomelanosis of Ito [22]. McCune-Albright syndrome consists of pigmented skin lesions (often referred to as a ‘Coast of Maine’ appearance)

and fibrous dysplasia of the bones. However, the most common presentation is with GIPP and the characteristic skin lesions. The bony lesions often present at a later date and the usual distribution is sphenoid and femur, but any bone can be involved. There may be hypersecretion of numerous endocrine glands, including the ovaries, adrenal glands, thyroid gland, parathyroids and pituitary. Severe McCune-Albright syndrome presenting in the neonatal period almost always presents with Cushing's syndrome from adrenal disease [23] even before the appearance of the classical skin lesions at approximately 6 weeks of age. The ovarian ultrasound appearances have been characterised [24] and the ovaries are large, cystic and usually asymmetric. Because of the gonadotrophin independence, GnRH analogues are unhelpful and treatment should be with a combination of drugs, including cyproterone acetate, medroxyprogesterone, spironolactone, ketoconazole and testolactone. In severe cases, it is usually the bone disease that predominates with both early fracturing and arteriovenous fistulae, causing heart failure.

To summarise: Girls with adrenal causes of premature sexual maturation are usually easy to distinguish. Premature adrenarche is common and is a diagnosis of exclusion. Of disorders of premature sexual maturation of a gonadal aetiology, the commonest is isolated premature thelarche, which is usually a clinical diagnosis. Retention of the normal harmony of puberty suggests central precocious puberty, and this can be confirmed by an intravenous GnRH test and pelvic ultrasound assessment. Once it has been demonstrated that a girl has central precocious puberty, then neuroradiological imaging will be mandatory. Treatment with a GnRH analogue both suppresses sexual maturation and improves psychological problems. Other variants of premature sexual maturation of a gonadal cause only require reassurance.

Acknowledgement

We are grateful to the Child Growth Foundation for their support of CT, as well as to Novo Nordisk Pharmaceuticals Ltd, UK.

References

- 1 Stanhope R, Adams J, Jacobs HS, Brook CG: Ovarian ultrasound assessment in normal children, idiopathic precocious puberty, and during low-dose pulsatile gonadotrophin-releasing hormone treatment of hypogonadotrophic hypogonadism. *Arch Dis Child* 1985;60:116–119.
- 2 Adams J, Franks S, Polson DW, Mason HD, Abdulwahid NA, Tucker M, Morris DV, Price J, Jacobs HS: Multifollicular ovaries: Clinical and endocrine features and response to pulsatile gonadotropin-releasing hormone. *Lancet* 1985;ii:1375–1379.
- 3 Abdulwahid NA, Armar NA, Morris DV, Adams J, Jacobs HS: Diagnostic tests with luteinising hormone-releasing hormone should be abandoned. *Br Med J* 1985;291:1471–1472.

- 4 Stanhope R, Brook CGD: Thelarche variant: A new syndrome of precocious sexual maturation? *Acta Endocrinol (Copenh)* 1990;123:481–486.
- 5 Leiper AD, Stanhope R, Kitching P, Chessells JM: Precocious and premature puberty associated with treatment of acute lymphoblastic leukaemia. *Arch Dis Child* 1987;62:1107–1112.
- 6 Cacciari E, Frejaville E, Cicognani A, et al: How many cases of true precocious puberty in girls are idiopathic? *J Pediatr* 1983;102:357–360.
- 7 Cisternino M, Arrigo T, Pasquino AM, et al: Etiology and age incidence of precocious puberty in girls: A multicentric study. *J Pediatr Endocrinol Metab* 2000;13:695–701.
- 8 Chemaitilly W, Trivin C, Adan L, et al: Central precocious puberty: Clinical and laboratory features. *Clin Endocrinol (Oxf)* 2001;54:289–294.
- 9 Stanhope R: Central precocious puberty and occult intracranial tumours. *Clin Endocrinol (Oxf)* 2001;54:287–288.
- 10 Pucarelli I, Segni M, Ortore M, Moretti A, Iannaccone R, Pasquino AM: Combined therapy with GnRH analog plus growth hormone in central precocious puberty. *J Pediatr Endocrinol Metab* 2000;13(suppl):811–820.
- 11 Cohen A, Zecca S, Gaggero M, Dassori A, Parodi L, Martella M, Romano C: Premature thelarche: The long-term follow-up. *Horm Res* 1996;46(suppl):104.
- 12 Van Winter JT, Noller KL, Zimmerman D, Melton LJ 3rd: Natural history of premature thelarche in Olmsted County, Minnesota, 1940–1984. *J Pediatr* 1990;116:278–280.
- 13 Stanhope R, Abdulwahid NA, Adams J, Brook CG: Studies of gonadotrophin pulsatility and pelvic ultrasound examinations distinguish between isolated premature thelarche and central precocious puberty. *Eur J Pediatr* 1986;145:190–194.
- 14 Stanhope R, Adams J, Brook CG: Fluctuation of breast size in isolated premature thelarche. *Acta Paediatr Scand* 1985;74:454–455.
- 15 Pasquino AM, Pucarelli I, Passeri F, Segni M, Mancini MA, Municchi G: Progression of premature thelarche to central precocious puberty. *J Pediatr* 1995;126:11–14.
- 16 Pescovitz OH, Hench KD, Barnes KM, Loriaux DL, Cutler GB Jr: Premature thelarche and central precocious puberty: The relationship between clinical presentation and the gonadotropin response to luteinizing hormone-releasing hormone. *J Clin Endocrinol Metab* 1988;67:474–479.
- 17 Schwarz HP, Zuppinger K: Unsustained central sexual precocity in girls. *Pediatr Res* 1986;20:1198.
- 18 Fontoura M, Brauner R, Prevot C, Rappaport R: Precocious puberty in girls: Early diagnosis of a slowly progressing variant. *Arch Dis Child* 1989;64:1170–1176.
- 19 Garibaldi LR, Aceto T Jr, Weber C: The pattern of gonadotropin and estradiol secretion in exaggerated thelarche. *Acta Endocrinol (Copenh)* 1993;128:345–350.
- 20 Heller ME, Dewhurst J, Grant DB: Premature menarche without the evidence of precocious puberty. *Arch Dis Child* 1979;54:472–475.
- 21 Saggese G, Ghirri P, Del Vecchio A, Papini A, Pardi D: Gonadotropin pulsatile secretion in girls with premature menarche. *Horm Res* 1990;33:5–10.
- 22 Daubeney PEF, Pal K, Stanhope R: Hypomelanosis of Ito and precocious puberty. *Eur J Pediatr* 1993;152:715–716.
- 23 Bareille P, Azcona C, Stanhope R: Multiple neonatal endocrinopathies in McCune-Albright syndrome. *J Paediatr Child Health* 1999;35:315–318.
- 24 Foster CM, Feuillan P, Padmanabhan V, Pescovitz OH, Beitins IZ, Comite F, Shawker TH, Loriaux DL, Cutler GB Jr: Ovarian function in girls with McCune-Albright syndrome. *Pediatr Res* 1986;20:859–863.

Dr. R. Stanhope
 Department of Endocrinology, Great Ormond Street Hospital for Children
 Great Ormond Street, London WC1N 3JH (UK)
 Tel. +44 207 905 2139, Fax +44 207 404 6191
 E-Mail r.stanhope@ich.ucl.ac.uk

Ovarian Cysts in Prepubertal Girls

C. Pienkowski^a, C. Baunin^b, M. Gayrard^a, F. Lemasson^c,
P. Vaysse^c, M. Tauber^a

^aUnité d'Endocrinologie, Génétique et Gynécologie Médicale; ^bService d'Imagerie Pédiatrique et ^cUnité de Chirurgie Viscérale, Hôpital des Enfants, Toulouse, France

Ovarian cysts can occur in early childhood (between 3 and 8 years of age) but are more common in the neonatal and adolescent periods: The frequency of functional cysts decreases in early childhood and then increases as puberty is approached [1, 2]. During childhood, most large banal cysts are derived from degenerated follicular cysts. These cysts are first formed by ovarian gonadotropin stimulation and result from failure of follicular apoptosis or interaction with other hormonal secretion [3]. Besides functional cysts, cystic neoplasms may be encountered [1, 2]. Moreover, hormone-secreting cysts cause rapid pubertal development or precocious pseudopuberty [3, 4]. In these cases, the possibility of an autonomous ovarian cyst due to G-protein mutation in McCune-Albright syndrome [5–7] should be considered. Ultrasonography has been an excellent tool for detecting the presence of banal cysts in young children and no malignancy has appeared as banal on ultrasonography or computed tomographic scan. Management of ovarian cysts depends on the clinical signs, the sonographic appearance and volume of the mass, and finally its persistence.

Clinical Presentations

Two types of presenting signs may suggest an ovarian cyst, or a cyst may be asymptomatic and discovered incidentally on ultrasonography performed for other reasons. In the case of a painful syndrome, pelvic ultrasonography confirms the diagnosis. In the case of an endocrine syndrome, hormonal investigations are necessary and complete the ultrasound findings.

Painful Abdomino-Pelvic Syndrome

This may be an acute or subacute syndrome of abdomino-pelvic pain associated with non-specific signs (nausea, vomiting, urinary disorders).

Sometimes when the patient is questioned, identical episodes are found to have occurred in the preceding weeks. In some cases, this syndrome is extremely painful and associated with vomiting. When an ovarian complication such as torsion or hemorrhage is feared, emergency surgical treatment is required because adult ovarian function is endangered. The family and physician should be attentive to repeated manifestations as they may signal recurrence; emergency ultrasonography should always be performed. The patient may also present vague pelvic pain associated with perceptible and visible development of an abdomino-pelvic mass.

'Endocrine' Signs

The 'endocrine' syndrome is marked by precocious development of sexual characteristics, which may be associated with increased growth velocity and advanced bone maturation. Rapid breast development followed by metrorrhagia suggests precocious pseudopuberty due to ovarian cysts. Metrorrhagia often consists of recurrent red blood loss lasting 2–3 days. When looking for an etiology, skin pigmentation should be sought, as the association of precocious puberty, 'café-au-lait' skin spots and polyostotic fibrous dysplasia characterizes the McCune-Albright syndrome [5, 6].

Diagnostic Arguments

Pelvic Ultrasonography

Pelvic ultrasonography is central to the management of ovarian cysts. Classically, it is carried out by a suprapubic approach with a full bladder, which allows study not only of the cyst but of all the internal genital organs. An analysis of the cyst itself indicates the size, shape and even volume by measurement of the three diameters, the thickness and regularity of the wall and the nature of the cyst content. An anechogenic, purely liquid image with a thin, regular wall is in favor of a functional cyst (fig. 1, 2). Volume measurement is a basis for surveillance and for the decision of possible needle aspiration [8]. Ultrasonography is then indispensable for topographic localization to guide aspiration. An image which is not purely liquid raises problems of differential diagnosis. If the child is symptomatic, there may be a cystic complication such as hemorrhage or ovarian torsion. The mass may be a tumor with a cystic component, raising the problem of its benign or malignant nature. Certain morphological signs are informative: volume of the tissue component, wall thickness, growths, and rigid septations with angulated junctions. Morphological color Doppler and pulsed Doppler spectral imaging study may also be useful [9], since these techniques provide information on the vascularization of the mass,

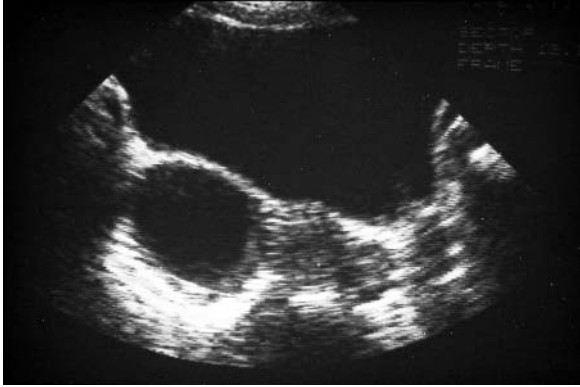

Fig. 1. Functional cyst of the right ovary: purely fluid appearance, anechogenic and homogeneous with a thin, regular wall.

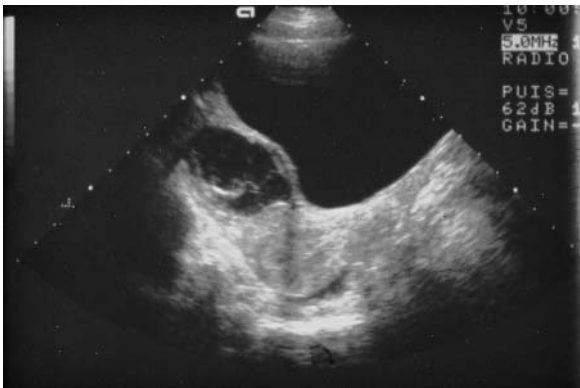

Fig. 2. Complex cyst: heterogeneous, septate appearance. The predominantly fluid component and the curved, pliable septations are in favor of a complicated benign cyst (intracystic hemorrhage in the process of resorption).

for example, by differentiating the avascular but echogenic content of a hemorrhagic cyst from hypervascularized tumoral tissue. At a later stage, ultrasonography is used to investigate the condition of the contralateral ovary and the appearance of the uterus, its dimensions and endometrium. This information is indispensable for therapeutic management.

In the child and adolescent, ultrasonography is limited by the impossibility of using a vaginal approach. However, suprapubic sonography is generally sufficient for appropriate diagnosis and therapeutic management of ovarian cysts. Recourse to other imaging techniques (CT, MRI) is justified essentially

in two circumstances: confirmation of the multitissular nature (fat, calcification) of a dermoid cyst and assessment of the extent of a mass that is tissular rather than liquid and suspected of being malignant [10, 11].

Hormonal Investigation

Plasma measurement of sex steroids (estradiol, testosterone and androgens) and basal or stimulated levels of the gonadotropins LH and FSH must be done in any endocrine syndrome.

Estradiol hypersecretion, associated with undetectable levels of LH and FSH that do not respond to stimulation after an LHRH test, confirms the peripheral origin of the autonomous independent gonadotropin secretion and suggests a secretory ovarian tumor [12, 13]. It is also useful to assess the secretory capacity of a cyst by measurement of estrogens and androgens in the aspiration fluid during the procedure or during percutaneous aspiration.

Tumor Markers

Tumor marker measurement is a useful diagnostic aid in lesions that are difficult to analyze by ultrasonography and in surveillance after tumor removal [14]. Certain markers are specific for tumors with an embryonic component, such as α -fetoprotein in embryonic carcinomas and immature teratomas. β -Human chorionic gonadotropins (β -HCG) are more specific markers of choriocarcinomas and dysgerminomas [14, 15]. Elevated levels in pseudocystic tumors indicate a neoplastic component secreting various protein markers according to tumoral origin [14]. However, we must stress the difficulty of interpreting CA-125 levels measured either in peripheral blood or in the cyst fluid after aspiration, as these levels may be high in functional cysts. Such measurements are more generally used in adult women [16, 17].

The Various Etiologies

Hormonal Activation or Interaction

Central Pituitary Involvement: Transient or Persistent Activation?

Small asymptomatic cysts are a common finding in young girls. Large cysts, although less common, may not always be associated with abnormal sexual development. Occasionally, these cysts may enlarge and continue to produce estrogen, resulting in pubertal development. The incidence of ovarian cysts is very low, <5% in females between birth and age 8, and small cysts are more frequent than large cysts [18]. In a retrospective analysis [18], 1,818 ultrasound studies in prepubertal girls were examined: only 99 patients (4.5%) presented

ovarian cysts. Small cysts of <10 mm (average 2–3 mm) were found in 82 of these patients (83%), large cysts of >20 mm were found in 17, and only 5 of these 17 patients presented pubertal development. The onset of pubertal signs can be transient, with breast development increasing during ovarian cyst formation and decreasing with spontaneous resolution [18, 19]. Unilocular cysts <50 mm may be followed conservatively with ultrasonography until regression. The risk of torsion increases with a diameter >50 mm and with rapid progression.

On the other hand, in premature thelarche, FSH-predominant pulses induced an increased prevalence (two- to three-fold) of detectable ovarian microcysts of small diameter, <10 mm [20]. Therefore, when larger cysts are due to persistent precocious puberty, ultrasonographic measurement of uterine and ovarian volume offers a reliable means of distinguishing between isolated premature thelarche and central precocious puberty [21]. In a review of 26 girls with ovarian cysts, Towne et al. [22] reported that only 4 of the 26 presented persistent isosexual puberty. In precocious puberty, clinical signs such as breast development and pubic pilosity, accelerated growth velocity and advanced bone maturation are evident [3]. This situation is rare and the ovarian cyst must be removed, with hormonal investigations programmed a few weeks later to evaluate hormonal status and differentiate between transient pseudopuberty, which is generally gonadotropin-independent, and true onset of central precocious puberty [3, 19]. These investigations associate an LHRH test and sampling for estradiol measurement [23, 24]. At the present time, if the hormonal results confirm the onset of central pubertal activity with an LH peak after LHRH stimulation, we propose cerebral pituitary MRI and treatment with GnRH analogue [25].

Pseudopuberty due to an Autonomous Cyst

McCune-Albright Syndrome. The best known type of precocious pseudopuberty with recurrent ovarian cysts is McCune-Albright syndrome, which occurs in early childhood [5, 6]. It is manifested by metrorrhagia and rapid breast development in small girls between 2 and 5 years. On questioning, it is not rare to learn of an identical but briefer episode in the preceding months [26]. Pelvic ultrasonography establishes the diagnosis by identifying an ovarian cyst and signs of estrogen impregnation of the uterus. This is peripheral or pseudopuberty, which is confirmed by hormone measurements (elevated estradiol, undetectable LH and FSH levels which do not react to an LHRH test). These cystic lesions may persist, exposing the child to recurrent metrorrhagia; they may also resorb within a few weeks or become complicated by adnexal torsion or hemorrhage [26, 27]. The decision to intervene using ultrasound-guided percutaneous aspiration or surgically by laparoscopy is made according to the individual case [8, 26].

McCune-Albright syndrome is a sporadic disorder, characterized by diffuse anomalies all due to constitutional activation of the Gs-adenylate cyclase-cAMP

transduction system [7]. When the ovary is affected, an estradiol-secreting cyst is produced, in contrast with very low LH and FSH levels that do not respond to stimulation [12, 13]. Recurrent episodes of metrorrhagia due to the development of an ovarian cyst are strongly indicative of this etiology [26, 27]. The difficulty lies in confirming the diagnosis when the cysts remain isolated, with no bone involvement, café-au-lait spots or other endocrine disorder [26, 28, 29].

The other manifestations, whether bone or cutaneous, may appear several years later, as in our clinical experience, where the initial picture has shown few symptoms with bone and cutaneous signs detected several years later [26, 27]. It is thus important to confirm the diagnosis by molecular studies to search for activating mutations of Gs α proteins, which are rarely positive in blood samples. This search can be done in all affected tissues and on ovarian cell samples obtained after cyst fluid aspiration or directly from the cell wall [26, 30, 31]. Discovery of this mutation in patients with isolated recurrent ovarian cysts raises the dual problem of treatment in the child and long-term surveillance [32]. This is a gonado-independent form of puberty and the usual puberty inhibiting treatments are ineffective [33]. Only aromatase inhibitors seem to have a certain efficacy [34].

Other Endocrine Affection

Acquired Infantile Hypothyroidism. During childhood, the onset of signs of hypothyroidism may be very insidious and they may follow their course for several months before diagnosis. Some pictures are atypical. Gordon et al. [35] described the case of a girl with metrorrhagia associated with rapid pubertal development. Pelvic ultrasonography showed large polycystic ovaries. Percutaneous aspiration of the ovarian cysts together with the institution of thyroid replacement therapy led to regression of the cysts and pubertal signs. The same anomalies have been described in the adult with bilateral ovarian cysts. In this case, they are due to interaction between elevated TSH levels and the ovarian FSH receptor.

Adrenal Disorder. Excessive steroid production by the adrenal glands may stimulate small ovarian cysts to develop into large cysts capable of causing gonadotropin-independent precocious puberty, as has been reported in young girls with rapid sexual development. The signs decrease with cyst removal. However, serum 17-hydroxyprogesterone responses to ACTH seem to be in favor of non-classical forms of 21-hydroxylase deficiency [36, 37]. The pathogenic hypothesis is that the adrenal gland might be the source of the increase in steroid sulfates (SDHA). In turn, these steroids could be converted into estrogens by the small follicular cysts that occur as a normal developmental process. Estrogen could stimulate cyst growth and increased gonadotropin-independent estrogen production [36].

Ovarian Neoplasms

Benign Teratomas

Dermoid cysts are the most frequent neoplasms in childhood, with the mean age of diagnosis being 10 years. These are benign germinal tumors that develop slowly but they may become very large. Ultrasonography shows their heterogeneous appearance with a solid cystic component containing ectodermal tissue (skin, hair, dentin) and calcifications which are also clearly visible on plain radiographs. Treatment consists of cystectomy and careful examination of the contralateral ovary. Monitoring by ultrasonography is continued for several years.

Juvenile Granulosa Cell Tumors

These tumors, which develop during childhood, derive from granulosa cells and tend to be of low malignity. These neoplasms manifest by precocious pseudopuberty and most of them have mixed components, both solid and liquid [38]. Purely cystic tumors are principally virilizing granulosa cell tumors [38, 39]. They secrete estrogens or androgens, which accounts for the rapid appearance of pubertal signs and metrorrhagia [40]. They are generally benign and treatment is surgical excision [41]. Postoperative follow-up consists of ultrasonography and measurement of anti-Müllerian hormone (AMH) and inhibin, which are specific markers of this type of tumor. Greatly decreased postoperative levels are a criterion of cure, whereas an increased level raises the fear of recurrence [40].

Other tumors such as sex cord-stromal and mixed germ cell tumors are very rare in childhood. They have been reported in girls with isosexual precocity, but the ultrasonographic appearance is very different with heterogeneous and solid components.

Management (fig. 3, 4)

If a cyst is totally anechogenic, all teams agree that the patient should be monitored for a period ranging from 4 weeks to 6 months [42, 43]. Control ultrasound studies done 2 weeks after diagnosis and then at monthly intervals enable assessment of any change in volume. If there is any clinical or ultrasonographic change or if the cyst persists for more than a reasonable period of observation, excision must be planned as it may be an organic, fluid cyst such as a serous cystadenoma or a dermoid cyst [1, 2, 42, 43].

If adnexal torsion is suspected or if the cyst is heterogeneous, emergency surgery should be performed (see chapter: Ovarian masses in adolescent girls) [1, 2].

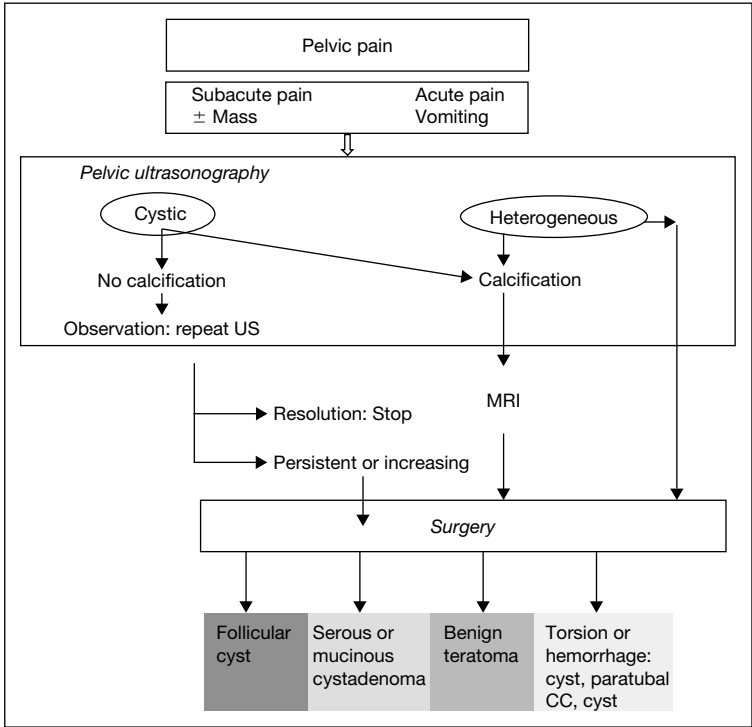


Fig. 3. Cyst management between pelvic pain.

The presence or recurrence of a secretory cyst suggests McCune-Albright syndrome and every effort must be made (aspiration or surgery) to obtain diagnostic evidence by molecular biological analysis; long-term surveillance is also necessary in this case (bone and other endocrine expression). Granulosa cell tumors are very rare and the initial presentation associates precocious pseudopuberty with a heterogeneous mass. Treatment is surgical.

Conclusion

Cysts in the prepubertal period are rarer than in the neonatal and pubertal periods. When found, small cysts (<10 mm) without pathological significance are most common. Cancerous cysts are very rare. Radiologic data confirm the presence of calcifications in benign teratoma. Precocious pseudopuberty with recurrent ovarian cysts evokes the diagnosis of McCune-Albright syndrome and

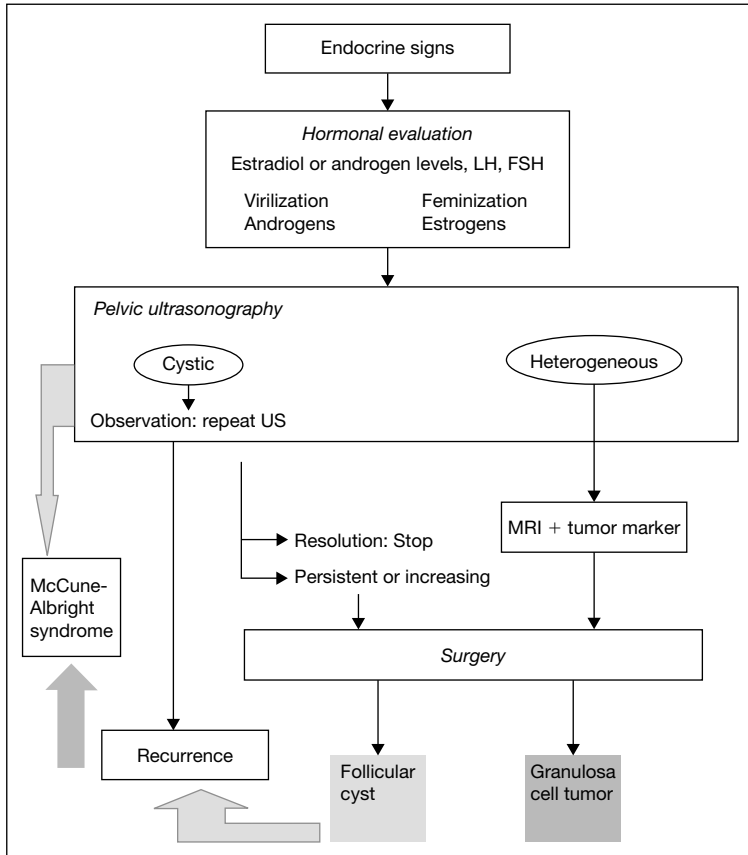


Fig. 4. Cyst management between pubertal signs.

it is necessary to analyze the Gs α gene in cystic ovarian tissue. The finding of this mutation is of importance for long-term follow-up.

References

- 1 Van Winter JT, Simmons PS, Podratz KC: Surgically treated adnexal masses in infancy, childhood and adolescence. *Am J Obstet Gynecol* 1994;170:1780–1786.
- 2 Pfeifer SM, Gosman GG: Evaluation of adnexal masses in adolescents. *Pediatr Clin North Am* 1999;46:573–592.
- 3 Arisaka O, Shimura N, Nakayama Y, Yabuta K, Yoshizawa Y, Hirai Y, Yoshimine T, Kuwabara N: Ovarian cysts in precocious puberty. *Clin Pediatr* 1989;28:44–47.
- 4 Kosloske AM, Goldthorn JF, Kaufman E, Hayek A: Treatment of precocious pseudopuberty associated with follicular cysts of the ovary. *Am J Dis Child* 1984;138:147–149.

- 5 Albright F, Butler AM, Hampton AO, Smith P: Syndrome characterized by osteitis fibrosa disseminata, areas of pigmentation and endocrine dysfunction, with precocious puberty in females: Report of five cases. *N Engl J Med* 1937;216:727–746.
- 6 McCune DJ: Osteitis fibrosa cystica; the case of a nine-year-old girl who also exhibits precocious puberty, multiple pigmentation of skin and hyperthyroidism. *Am J Dis Child* 1936;52:743–744.
- 7 Weinstein LS, Shenker A, Gejman PV, Merino MJ, Friedman E, Spiegel AM: Activating mutations of stimulatory G protein in the McCune-Albright syndrome. *N Engl J Med* 1991;325:1688–1695.
- 8 Caspi B, Goldchmit R, Zalel Y, Appelman Z, Insler V: Sonographically guided aspiration of ovarian cyst with simple appearance. *J Ultrasound Med* 1996;15:297–300.
- 9 Brown DL, Doubilet PM, Miller FH, Frates MC, Laing FC, DiSalvo DN, Benson CB, Lerner MH: Benign and malignant ovarian masses: Selection of the most discriminating gray-scale and Doppler sonographic features. *Radiology* 1998;208:103–110.
- 10 Guinet C, Ghossain MA, Buy JN, Malbec L, Hugol D, Truc JB, Vadrot D: Mature cystic teratomas of the ovary: CT and MR findings. *Eur J Radiol* 1995;20:137–143.
- 11 Mugel T, Ghossain M, Buy JN, Malbec L, Vadrot D: Value of CT scan and MRI in primary tumors of the ovary. *J Chir* 1993;130:486–491.
- 12 Low LC, Wang Q: Gonadotropin independent precocious puberty. *J Pediatr Endocrinol Metab* 1998;11:497–507.
- 13 Foster CM, Ross JL, Shawker T, Pescovitz OH, Loriaux DL, Cutler GB, Comite F: Absence of pubertal gonadotropin secretion in girls with McCune-Albright syndrome. *J Clin Endocrinol Metab* 1984;58:1161–1165.
- 14 Schwartz PE: Ovarian masses: Serologic markers. *Clin Obstet Gynecol* 1991;34:423–432.
- 15 Perrone T, Steeper TA, Dehner L: α -Fetoprotein localization in pure ovarian teratoma. An immunohistochemical study of 12 cases. *Am J Clin Pathol* 1987;88:713–717.
- 16 Elhage A, Nanejian V, Ghossain M, Germanos A: Kystes de l’ovaire: valeurs des explorations paracliniques. *Ref Gynecol Obstet* 2000;7:133–137.
- 17 Pinto MM, Greenebaum E, Simsir A, Kleinman GM, Portnoy LM, Garfinkel R: CA-125 and carcinoembryonic antigen assay vs. cytodiagnostic experience in the classification of benign ovarian cysts. *Acta Cytol* 1997;41:1456–1462.
- 18 Millar DM, Blake JM, Stringer DA, Hara H, Babiak C: Prepubertal ovarian cyst formation: 5 years’ experience. *Obstet Gynecol* 1993;81:434–438.
- 19 Lyon AJ, De Bruyn R, Grant DB: Transient sexual precocity and ovarian cysts. *Arch Dis Child* 1985;60:819–822.
- 20 Freedman SM, Kreitzer PM, Elkowitz SS, Soberman N, Leonidas JC: Ovarian microcysts in girls with premature thelarche. *J Pediatr* 1993;122:246–249.
- 21 Haber HP, Wollmann HA, Ranke MB: Pelvic ultrasonography: Early differentiation between isolated premature thelarche and central precocious puberty. *Eur J Pediatr* 1995;154:182–186.
- 22 Towne BH, Mahour GH, Woolley MM, Isaacs H: Ovarian cysts and tumors in infancy and childhood. *J Pediatr Surg* 1975;10:311–320.
- 23 Marshall WA, Tanner JM: Variation in pattern of pubertal changes in girls. *Arch Dis Child* 1969;44:291–303.
- 24 Boyar R, Finkelstein J, Roffwarg H, Kapen S, Weitzman E, Hellman L: Synchronization of augmented luteinizing hormone secretion with sleep during puberty. *N Engl J Med* 1972;287:582–586.
- 25 Roger M, Chaussain JL, Berlier P, Bost M, Canlorbe P, Colle M, Francois R, Garandeau P, Lahlou N, Morel Y, et al: Long-term treatment of male and female precocious puberty by periodic administration of a long-acting preparation of *D*-Trp6-luteinizing hormone-releasing hormone microcapsules. *J Clin Endocrinol Metab* 1986;62:670–677.
- 26 Pienkowski C, Lumbroso S, Bieth E, Sultan C, Rochiccioli P, Tauber M: Recurrent ovarian cyst and mutation of the *Gs* α gene in ovarian cyst fluid cells: What is the link with McCune-Albright syndrome? *Acta Paediatr* 1997;86:1019–1021.
- 27 Rodriguez-Macias KA, Thibaud E, Houang M, Duflos C, Beldjord C, Rappaport R: Follow up of precocious pseudopuberty associated with isolated ovarian follicular cysts. *Arch Dis Child* 1999; 81:53–56.
- 28 Shenker A, Weinstein LS, Moran A, Pescovitz OH, Charest NJ, Boney CM, Van Wyk JJ, Merino MJ, Feuillan PP, Spiegel AM: Severe endocrine and non-endocrine manifestations of the

- McCune-Albright syndrome associated with activating mutations of stimulatory G protein GS. *J Pediatr* 1993;123:509–518.
- 29 Grant DB, Martinez L: The McCune-Albright syndrome without typical skin pigmentation. *Acta Paediatr Scand* 1983;72:477–478.
- 30 Lumbroso S, Paris F, Sultan C: Activating Gsa mutations: Analysis of 72 patients (104 DNA) presenting with signs of McCune-Albright syndrome. An international collaborative study. 82nd US Endocrine Society Meeting, Toronto, June 21–24, 2000.
- 31 Shenker A, Chanson P, Weinstein LS, Chi P, Spiegel AM, Lomri A, Marie PJ: Osteoblastic cells derived from isolated lesions of fibrous dysplasia contain activating somatic mutations of the Gs α gene. *Hum Mol Genet* 1995;4:1675–1676.
- 32 Laven JS, Lumbroso S, Sultan C, Fauser BC: Dynamics of ovarian function in an adult woman with McCune-Albright syndrome. *J Clin Endocrinol Metab* 2001;86:2625–2630.
- 33 Feuillan PP, Jones J, Oerter KE, Manasco PK, Cutler GB: Luteinizing hormone-releasing hormone (LHRH)-independent precocious puberty unresponsive to LHRH agonist therapy in two girls lacking features of McCune-Albright syndrome. *J Clin Endocrinol Metab* 1991;73:1370–1373.
- 34 Feuillan PP, Jones J, Cutler GB: Long-term testolactone therapy for precocious puberty in girls with the McCune-Albright syndrome. *J Clin Endocrinol Metab* 1993;77:647–651.
- 35 Gordon CM, Austin DJ, Radovick S, Laufer MR: Primary hypothyroidism presenting as severe vaginal bleeding in a prepubertal girl. *J Pediatr Adolesc Gynecol* 1997;10:35–38.
- 36 Chasalow FI, Granoff AB, Tse TF, Blethen SL: Adrenal steroid secretion in girls with pseudo-precocious puberty due to autonomous ovarian cysts. *J Clin Endocrinol Metab* 1986;63:828–834.
- 37 Uli N, Chin D, David R, Geneiser N, Roche K, Marino F, Shapiro E, Prasad K, Oberfield S: Menstrual bleeding in a female infant with congenital adrenal hyperplasia: Altered maturation of the hypothalamic-pituitary-ovarian axis. *J Clin Endocrinol Metab* 1997;82:3298–3302.
- 38 Young RH, Dickersin GR, Scully RE: Juvenile granulosa cell tumor of the ovary. A clinicopathological analysis of 125 cases. *Am J Surg Pathol* 1984;8:575–596.
- 39 Norris HJ, Taylor HB: Virilization associated with cystic granulosa tumors. *Obstet Gynecol* 1969;34:629–635.
- 40 Scully RE, Mark EJ, McNeely WF, McNeely BU: Case records of the Massachusetts General Hospital. Weekly clinicopathological exercises. Case 47-1989. A six-year-old girl with sexual precocity. *N Engl J Med* 1989;321:1463–1471.
- 41 Powell JL, Otis CN: Management of advanced juvenile granulosa cell tumor of the ovary. *Gynecol Oncol* 1997;64:282–284.
- 42 Murray S, London S: Management of ovarian cysts in neonates, children and adolescents. *Adolesc Pediatr Gynecol* 1995;8:64–70.
- 43 Kanizsai B, Orley J, Szigetvari I, Doszpod J: Ovarian cysts in children and adolescents: Their occurrence, behavior and management. *J Pediatr Adolesc Gynecol* 1998;11:85–88.

Catherine Pienkowski

Unité d'Endocrinologie, Génétique et Gynécologie Médicale
Hôpital des Enfants, 330, avenue de Grande Bretagne TSA 70034
FR-31059 Toulouse Cedex 9 (France)
Tel. +33 5 3455 8556, Fax +33 5 3455 8558
E-Mail pienkowski.c@chu-toulouse.fr

.....

Sexual Abuse in Prepubertal Children and Adolescents

Bernhard Herrmann^a, Francesca Navratil^b

^aChild Protection Center, Kinderklinik des Klinikums (Pediatric Department, Klinikum Kassel), Kassel, Germany, and ^bPediatric and Adolescent Gynecology Outpatient Department, Child Protection Center, University of Zürich Children's Hospital, Zürich, Switzerland

Child sexual abuse (CSA) has been and continues to be a diagnostic challenge. Only for little more than two decades has medicine been involved in the diagnosis, treatment and management of sexually abused children and adolescents. CSA is no longer 'another hidden pediatric problem' as Kempe [1978] stated more than 20 years ago. In the USA and – to a lesser extent – in Great Britain, many physicians have integrated knowledge about the recognition of CSA into their medical education and practice. A great number of specialized referral centers evolved and developed a significant expertise in evaluating abused children in a qualified and non-traumatizing manner.

A number of recent reports have summarized the results of numerous studies and research and of the accumulating clinical experience. They have also described the shortcomings and limitations of our current knowledge and outlined the emphasis of further research [Bays and Chadwick, 1993; Navratil, 1995, 1997; Herrmann et al., 1997, 2002; Kerns, 1998; Atabaki and Paradise, 1999]. The American Academy of Pediatrics has published guidelines to facilitate the management of CSA for healthcare providers [AAP, 1999, 2001a]. A couple of recently revised handbooks and a very instructive CD-ROM atlas give an excellent overview of all aspects of medical involvement in CSA evaluation [Finkel and De Jong, 2001; Finkel and Giardino, 2002; Heger et al., 2000; McCann and Kerns, 1999; Hobbs et al., 1999a; Monteleone and Brodeur, 1998; Reece and Ludwig, 2001].

The situation in most countries in Europe seems to be far less satisfying, concerning *pediatrics* as well as *gynecology*, not speaking of *general practice* (for Germany: Herrmann [1999]). We feel an urgent need for *all* physicians

caring for children to develop a basic understanding of behavioral and physical indicators of CSA. Furthermore, the need for specialized referral centers is evident. Child abuse examinations should preferentially be performed by specialists in pediatric and adolescent gynecology. Nevertheless, even those specialists will need supplementary qualification and training in the evaluation of sexually abused children and adolescents. The same goes even more for general pediatricians and gynecologists who engage in this specialty. Given the inherent risk of both under- and overdiagnosis of CSA, both with devastating consequences for children and their families, a thorough understanding of the medical approach is crucial. Performing medical examinations requires sound knowledge about the specifics of anogenital findings in abused and non-abused children as well as knowing the potentials and limitations of medical diagnosis in CSA [Adams, 1999]. This knowledge needs to be contributed and blended into a multiprofessional approach. Especially in Europe, physicians frequently still need to find and define their role within the child protection system. In contrast to the emotional and often unqualified public debate on CSA, medical professionals have a significant responsibility to contribute a rational and objective approach to the multidisciplinary assessment, diagnosis, management and treatment of sexually abused children and adolescents [‘Cool science for a hot topic’ – Kerns, 1989]. Nevertheless, CSA is an emotionally disturbing and troubling event even for medical professionals and requires emotional balance and commitment. The first step to the diagnosis of CSA and of utmost importance is being aware and acknowledging that the problem exists. Recognition of sexual abuse requires a high index of suspicion and familiarity with the historical, physical and behavioral indicators of abuse.

General Considerations on CSA

Although there is no universal definition, *sexual abuse is generally defined* as the involvement of developmentally immature children or adolescents in sexual activities that they do not fully comprehend, to which they are unable to give informed consent and that violate social taboos of family or other adult-child relationships. Adults take advantage of the power and age differential which removes meaningful consent. The adult’s intention to use children for his (or her) sexual arousal and gratification is an important element of the definition. Other definitions describe the unwanted, manipulative and exploitative character of the interaction and recognize the importance of age difference (mostly 4–5 years). Developmental asymmetry and the use of coercion differentiate abuse from normal sexual play [Kempe, 1978; AAP, 1999; Hobbs et al., 1999a; Friedrich et al., 2001; Finkel and De Jong, 2001].

Sexual abuse includes a *spectrum of sexual activities* ranging from non-touching to invasive penetrative abuse. In contrast to the general public opinion CSA is mostly a *chronic sexualized relationship* over months and years between fathers, step-fathers, other relatives or known individuals and the child. Abuse may start in early childhood and continue into adolescence.

Strangers as *offenders* make up approximately 10% of all cases. These occurrences tend to be rather single events and often are more accurately characterized as 'sexual assault'. Most of sexual abuse is committed by men (approx. 90%), with higher numbers of female perpetrators when boys are victimized (up to 25%). At least 20–25% of perpetrators are juveniles. This underscores the importance of early intervention including perpetrator treatment. Probably this is the most effective measure of prevention of further abuse of other children. Offenders appear to be 'normal', socially well-adapted people essentially of all social backgrounds. Many, but not all, have been sexually abused as children, and many abuse more than one child.

Victims are girls in 70–80% of the subjects including all age groups, peaking in the prepubertal school age. Adolescents make up at least 25% of sexual abuse victims and tend to be victimized by peers ('date rape'). Lower socioeconomic status is not consistently demonstrated in the research and may be caused by assessment bias. However, unstable social conditions may predispose a child to sexual abuse. Single-parent homes and step-parents seem to be significant risk factors [Finkelhor, 1994; Leventhal, 1998; Finkel and De Jong, 2001]. Although not reported in all studies, developmentally disabled or handicapped children appear to be at higher risk for sexual abuse particularly when the disability affects communication [Elvik et al., 1990; AAP, 2001b].

Current research indicates a *prevalence* of CSA way in the percent range. That makes CSA for example far more prevalent than all malignancies in childhood together (for Germany: 0.2% – Gutjahr [1993]). Finkelhor [1994] summarized 19 prevalence studies and concluded that a prevalence of 15–20% of women and 5–10% of men having experienced sexual abuse as children would be a reasonable conservative estimate. *Incidence* studies do not report the true occurrence, but only those cases that are recognized. Substantiated reports of CSA to US American Child Protection Agencies increased dramatically from 6,000 to 132,000 from 1976 to 1986, being relatively stable until 1994 and declining since then for unknown reasons [Leventhal, 1998; Atabaki and Paradise, 1999; Jones and Finkelhor, 2001; Finkel and Giardino, 2002].

Because of possible devastating short- and long-term effects, CSA has marked but varying effects on children's health and well-being. A large variety of *short-term behavioral abnormalities and symptoms* have been reported as indicators and presenting symptoms of CSA. They include nearly all emotional,

psychosomatic, self-destructive and anti-social behaviors in children and adolescents, focusing on age-inappropriate sexualized behavior, especially when coercive. However, there is no single diagnostic criterion or specific syndrome within the variety of symptoms which proves CSA by itself. A basic understanding of normative sexual behavior is important to distinguish normal and abnormal sexual play and activity. Inadequate sexual behavior should be interpreted as indicator but not as proof of CSA and its absence does not rule out abuse.

Masked presentations of CSA are common and include the whole range of psychosomatic disorders, with gastrointestinal complaints being most prevalent in younger and chronic pelvic pain in older victims. Feelings of guilt, shame, isolation, lowered self-esteem, criminal behavior and self-injuring behaviors are prevalent among victims of abuse [Hunter et al., 1985; Beitchman et al., 1991, 1992; Berkowitz, 1998; Koverola and Friedrich, 2000; Friedrich, 1998; Friedrich et al., 1998, 2001; Drach et al., 2001]. The abnormal behavior frequently is an important coping mechanism of the victim, well described by Summit as 'Child Sexual Abuse Accommodation Syndrome' [Summit, 1983]. The difficulty in evaluating a history and the non-specific complaints of an individual has been widely discussed in the psychosocial literature [Jones and McGraw, 1987; Everson, 1997].

CSA is associated with substantial increased risk of subsequent psychopathology. Several factors contribute to the great variety of *long-term outcomes* of victims of former CSA from severe to asymptomatic. Sexual abuse varies significantly in severity and extent, the amount of physical force used, the relationship with the offender, frequency and duration of the abuse, the age of the child, preexisting psychosocial problems and positive or negative effects of professional intervention. Other important factors that influence the outcome are preexisting adverse psychological circumstances, coexisting physical abuse or neglect in terms of additional vulnerability potentially compensated by resilience factors (intra- or extrafamilial support) [Paradise et al., 1994].

A variety of reports have highlighted mental health problems (e.g. depression, suicide, multiple personality disorders, post-traumatic stress disorder, eating disorders, anxiety disorders, substance abuse), physical health problems (e.g. functional gastrointestinal disorders, chronic pelvic pain, dysmenorrhea), and psychosexual dysfunction (e.g. sexual dysfunction, promiscuity, adolescent pregnancy, re-victimization, prostitution). Interpersonal, close relationships are often difficult for abuse victims. They tend to have problems with issues of control, anger, shame, trust, dependency and vulnerability [Beitchman et al., 1992; Berkowitz, 1998; Dickinson et al., 1999; Koverola and Friedrich, 2000; Molnar et al., 2001].

General Considerations on Medical Aspects of CSA

The majority of abused children show no physical evidence. The frequency of normal findings varies from 23 to 94%, based on differences in definition of abuse and findings [Adams et al., 1994; Bays and Chadwick, 1993; De Jong and Rose, 1989; Kellog et al., 1998; Bowen and Aldous, 1999]. A meta-analysis by Bays and Chadwick [1993] reported normal findings in more than 50% of abuse victims. In a study by Adams et al. [1994] with the subtitle 'It's normal to be normal', the authors examined 236 children with perpetrator conviction for sexual abuse who had normal genital examination findings in 28%, non-specific in 49%, suspicious in 9%, and abnormal findings in 14%. In case of perpetrator confession of penile-vaginal penetration, still 39% of the victims presented with normal findings in another report [Muram, 1989a]. In a recent study by Berenson et al. [2000], only 2% of 192 girls between 3 and 8 years who reported digital-vaginal or penile-vaginal penetration had hymenal transections, perforations or deep posterior notches. The majority of girls were not examined acutely however. Heger et al. [2002] examined 2,384 children and found normal exams in 95% of children who had disclosed and in 92% in girls who reported penetration.

The most important reason for the *paucity of abnormal findings* is the nature of the abuse itself. Frequently it does not involve physical contact sufficient enough to produce physical sequelae (fondling, oral abuse, masturbation, pornographic photography and others). Therefore the 'absence of evidence is no evidence of absence' (of abuse). Furthermore, smaller children often do not have sufficient knowledge about their anatomy in order to appropriately describe what exactly has occurred. They may interpret any diffuse pain in the anogenital area as invasive or penetrative. There are no data at which age children are developmentally capable of differentiating 'on' from 'in'. Medically, 'penetration' is defined as the introduction of an object beyond the hymenal membrane into the vagina. In a jurisdictional view however, even slight penetration between the labia majora constitutes the legal term 'penetration'. Finally, the outcome and traumatizing nature of CSA is not primarily affected by the fact if penetration has occurred or if medical signs of trauma are evident [Finkel and De Jong, 2001; Finkel and Giardino, 2002].

A significant difference exists between CSA and rape and contributes to the diagnostic difficulties. Children are seldom forcibly raped and in the majority of cases force and restraint are not used. Therefore only some children have obvious sequelae caused by more serious injuries. And those who do, seldom present acutely so that the retrospective interpretation of healed trauma constitutes the major difficulty in evaluating these findings. Those children and adolescents who are victims of stranger assaults or rape will rather present acutely with

evident findings, due to familial support and immediate action taken. Acute findings are easier to document but children seldom disclose in this phase.

Besides the absence of findings due to a physically non-traumatizing abuse, the enormous potential of rapid and often complete healing of most anogenital injuries contributes to the paucity of specific findings. In selected cases, even transections of the prepubertal hymen have been demonstrated to heal to integrity. A single incomplete hymenal rupture may heal as early as 9 days after trauma. More typically though, complete transections to the base of the hymen lead to permanent disfigurements of the hymenal membrane in form of a cleft or concavity [Teixeira, 1981; Bays and Chadwick, 1993; McCann et al., 1992; McCann, 1998; Finkel and De Jong, 2001; Finkel and Giardino, 2002].

The frequency of findings related to abuse will also depend on variables inherent to the healthcare system: qualification and willingness of the examiner to acknowledge CSA as a possible differential diagnosis, the timing of the examination, qualified and empathetic preparation of the child (in order to obtain consent and cooperation), a good lighting source, good documentation for peer review or second opinion and to a smaller amount the availability of technical support (generally a colposcope for magnification, lighting and documentation).

Potentials and Limitations of the Medical Approach

As a normal physical examination is frequent in victims of CSA, the forensic aspect of the evaluation cannot be the primary or exclusive goal. A medical approach to CSA has to reflect the potentials but also the limitations and possible risks of the medical evaluation. It is crucial that the needs of the child have absolute priority over the desire to collect forensic evidence. The physical examination of sexually abused children has the potential to be an emotionally invasive and distressing procedure ('re-victimization') if not performed in a qualified and empathetic manner. Although scientific data to support this view is lacking, the possibility is evident and appears to be a concern for referring non-medical professionals, possibly influencing referral patterns and selection of patients for medical evaluation [Bowen and Aldous, 1999]. This again underscores the paramount importance of interprofessional communication and cooperation. An essential prerequisite of examining possibly abused children in a non-traumatizing manner is to avoid any force or coercion. The experience of specialized child protection centers indicates that well-documented examinations help to avoid repetitive examinations and thereby may even prevent further potential trauma.

The *emotional response to the medical examination* is probably not only influenced by factors inherent to the examination situation itself, but also by multiple other variables, such as preexisting factors (e.g. general anxiety, previous

experiences with the medical system, the age and developmental status of the child) and on the other hand the characteristics and severity of the abuse [Finkel, 1998; Britton, 1998]. Several studies with small samples and the impression of experienced experts in the field indicate that most children seem to cope well with the examination [Lazebnik et al., 1994; De San Lazaro, 1995; Steward et al., 1995; Gully et al., 1999; Waibel-Duncan and Sandler, 2001; Palusci and Cyrus, 2001].

Children who have disclosed sexual abuse should be evaluated for injuries, anogenital infections, sexually transmitted diseases or pregnancy and treated accordingly. Because a majority of abused children have an altered and distorted body image [Joraschky, 1997] it is of paramount importance to reassure the child that its body is normal, physically undamaged, and intact or that it will heal. Doctors, especially pediatricians, who define disease or well-being in other medical settings are powerful authorities in this respect. They can help to relieve feelings of physical abnormality and initiate the process of recovery (*'primary therapeutic aspect of the medical examination'*). Thus the medical examination has an enormous potential to incorporate a therapeutic message into the diagnostic procedure.

In cases of suspected CSA, the *cooperation with other professions* is crucial. The medical examination may contribute valuable aspects to a multidisciplinary approach. Due to evident reasons mentioned above however, a *medical examination can never exclude the possibility of CSA*. Therefore, child protection professionals need to know each other and cooperate in mutual respect. They also need to know their respective potentials and limitations. Medical involvement in CSA cases does not only depend on the clinicians' engagement and skills but also in the confidence the child-protection and law-enforcement system develops in the clinician [Finkel and De Jong, 2001].

History

History-taking should avoid further trauma to the child and still gain a maximum of information. Depending on a possible previous historical evaluation it is not always necessary to repeat questioning on all details of the abuse, which is often difficult and embarrassing for the child. In some cases however, information on the specifics of what has happened will contribute to interpreting physical signs in the light of history. It is advisable to take a separate history from the child and the caretaker if possible. A gentle and open attitude of the examiner and a quiet and accepting atmosphere are essential. The use of anatomically correct dolls is controversial and should be reserved only to very experienced examiners in this field [Leventhal et al., 1989].

History-taking should also be interjected with certain therapeutic messages like ‘it was good to tell’, that many children experience abuse, and that children are never responsible for the abuse. Questions directed to the child should be simple, non-leading and not suggestive of the answer. Scrupulous and verbatim documentation is crucial for further court proceedings and the credibility of the child [Levitt, 2000; Finkel and De Jong, 2001; Horowitz, 1987]. In selected cases, children may disclose sexual abuse during the medical examination, for instance if they are asked if someone has ever touched them ‘in this area’ while the anogenital examination is performed [Palusci et al., 1999].

Physical Examination

The preparation and conduct of the physical examination of sexually abused children requires ‘time, patience and a gentle manner...’ [Horowitz, 1987].

Appropriate timing of the examination is the first step. Most examiners agree to perform immediate examinations due to forensic reasons if the alleged contact took place less than 72 h ago. The same goes for acute bleeding anogenital injuries. Due to typically delayed disclosure, most examinations are non-emergency. The issue of *sedation or anesthesia for the examination* remains controversial. Although some argue in favor because of a reduction of immediate stress, it is not routinely warranted. General anesthesia is usually required in cases of acute bleeding anogenital injuries [Harari and Netzer, 1994; Rogers and Murdoch, 1994; Sury, 1994; Hogan, 1996; Leventhal, 1998].

Anticipating and addressing children’s fears concerning the medical examination are crucial for a successful exam. Younger children rarely have problems with issues of shame. They rather are fearful of painful and unknown procedures. *Any form of force or coercion is strictly contraindicated.* The child should be given as much choice as possible in the procedure to ensure a sense of control. It is important to explain all steps of the examination in an age appropriate terminology. The child should be reassured that the purpose of the examination is to check if everything is ‘alright’, that it is healthy and ‘okay’. Clinical experience indicates that at least for prepubertal children the style and gentleness of the exam are far more important factors for the emotional impact than the gender of the examiner [Horowitz, 1987; Lazebnik et al., 1994; Leventhal, 1998].

The sense of control may be enhanced by examining a ‘fearful’ doll which expresses all the potential fears which children might have in this situation. Asking the child to help the doctor examine the doll lets them anticipate their own examination, gain a sense of control and power and actively cope with their own fears by comforting the doll [B. Herrmann, personal observations].

Even for non-pediatricians, a *complete head-to-toe examination* is mandatory. It should always precede the anogenital examination in order not to focus on the anogenital area (like the abuser has done). The implicit message is that the whole child is important. It also allows estimating the developmental stage and avoids missing extragenital signs of sexual or physical abuse.

The *anogenital examination* in cases of suspected sexual abuse of the prepubertal child is principally an external visualization by varying techniques of separation, traction and positioning. It does not require anal or vaginal palpation or the use of specula. In adolescents the use of specula is appropriate but not mandatory. Stirrups may be used in older consenting children, while often increasing unfamiliarity and fear in younger children [Emans, 2000; Horowitz, 1987; Finkel and De Jong, 2001].

The genital examination begins in the most comfortable and least frightening position, the *supine position* with abducted legs ('frogleg position'). Especially younger children may prefer to be examined on the caretaker's lap. The *separation technique* of the labia majora allows an overview over the external genital structures. The *traction technique* is the mandatory next step and markedly improves visualization and opening of the hymenal orifice, especially when redundant hymenal tissue is present. In this technique the labia majora are grasped between thumb and index finger exerting slight traction down and outwards. Meanwhile, most examiners agree to routinely include the *prone knee-chest position* into the examination except in those cases when visualization in the supine position is complete and satisfactory. In cases with unclear or suspicious findings in the supine position, the knee-chest position is invaluable as it markedly improves unfolding of the hymen due to gravity. The examiner's hands rest on the buttocks with thumbs pointing inwards and slightly pulling upwards and laterally. The persistence of suspicious findings in the knee-chest position improves their validity. Also the visualization of the inner vagina up to the cervix can be achieved without specula in a significant number of cases. Children who have experienced anal penetration may feel uncomfortable and frightened in this position. The response and affect of the child have to be carefully monitored when requesting this position [Finkel and De Jong, 2001].

The *inspection of the anus* is mandatory and can be performed in the prone knee-chest position or in the left lateral decubitus position. The latter is preferable in boys who tend to be abused anally [Horowitz, 1987; McCann et al., 1990a; Emans, 2000].

Pubertal children are preferably examined in the lithotomy position. Visualization of the redundant pubertal hymen can be difficult. Running behind the inner aspect of the membrane circumferentially with a moistened cotton swab can help to identify traumatic changes of the hymenal rim.

Explaining each step of the examination and talking with the child throughout the examination on non-abuse-related issues, or motivating the child to tell a story, allows the child to relax. This enhances cooperation and improves visualization by less muscular tension to the genital tissues [McCann et al., 1990a]. Generally, all visualization and photo documentation should be done before taking swabs. The unestrogenized prepubertal hymen is very sensitive. In cases when screening for sexually transmitted diseases is indicated, the use of small urethral swabs which are moistened with sterile saline helps to avoid a potentially painful contact with the hymen. Large cotton swabs should be avoided in prepubertal children. Alternatively a small urethral catheter can be used to irrigate the posterior portion of the vagina with a small amount of saline which then is aspirated again for further processing.

The *colposcope* is nowadays frequently used for the external visualization of the anogenital area of possibly abused children and adolescents. Mostly equipped with a 35-mm camera or a video system it enhances visualization by incorporating a powerful lighting source, fixed or variable magnification and the possibility of accurate documentation. Photo or video documentation of all abnormal findings allow preservation of visual evidence, later detailed reviewing and discussion of findings and a second opinion or peer review. It also lays the foundation of any research and is an excellent tool for education of students, residents and colleagues. Documented visual evidence may be presented in court and may help to avoid potential further emotional trauma by repeated examinations. Although colposcopy improves the incidence of positive findings only slightly and the unaided examination is sufficient in most cases, it has become a valuable tool in the evaluation of possibly abused children [Teixeira, 1981; Muram and Elias, 1989; Muram et al., 1999; Adams et al., 1990; McCann, 1993; Finkel, 1998].

Forensic Evidence Collection and Interpretation

Forensic evidence is infrequently found in CSA cases due to reasons discussed earlier (delayed disclosure, etc.). However, in selected cases the medical expert in child abuse may be asked for a competent forensic work-up in an acute assault which is usually done at the same time as the physical examination. This requires coordinating specific details of collection, labeling and packaging with the forensic laboratory. Handling of the specimens must be documented with scrutiny to maintain the chain of evidence. Pregnancy and sexually transmitted diseases have forensic significance but are usually not classified in this category.

The decision to perform a forensic exam mainly depends on the time of presentation after the assault. The recommendation of a 72-hour time frame is based on experience in adult victims that semen, seminal fluid and other products

are rarely recoverable after this time. In spite of certain limitations, exceptions and little research in abused children this serves as a reasonable compromise. A recent study by Christian et al. [2000] however did not find any positive swabs for sperm or semen later than 9 h post-contact in 273 children. No forensic evidence was collected after 24 h except for the clothing or linens of the children. Christian et al. concluded that guidelines for forensic evaluation of adult victims may not be appropriate for children.

Sperm may be present on a wet mound for only 0.5 h, in the adult vagina for 12–20 h, rarely up to 48–72 h, in the cervix up to 5 days. Survival time of sperm in the prepubertal vagina is significantly shorter. Dead or immotile sperm is detectable longer. Dry specimens however are quite stable and sperm in stains has been detected up to 12 months [Finkel and De Jong, 2001].

The Wood's lamp or ultraviolet light has traditionally been recommended to identify semen on a victim's skin. Recent research has shown significant limitations and shortcomings: semen and urine were not distinguishable, urine fluoresces considerably longer, and a number of child care products will equally fluoresce undistinguishable from semen [Gabby et al., 1992; Santucci et al., 1999]. Keeping these limitations in mind the Wood's lamp may serve as a screening aid where to take swabs from a victim's body.

The marked elevation of acid phosphatase in the vagina indicates sexual contact within 24–48 h, but it may also turn to normal within 3 h in some cases. p30, a semen glycoprotein of prostatic origin, and MHS-5, an antibody against a vesicle protein, are male-specific and improve sensitivity markedly. Negative results of all tests do not exclude sexual abuse however.

Semen, blood, saliva, body hair and other materials found on the victim may help to prove the identity of the offender by several methods. They include ABO blood group antigens, subtypes of the enzyme phosphoglucomutase, the enzyme peptidase A and most sensitive DNA profiling. Bite mark identification by a forensic odontologist may also determine the offending person by analysis of good-quality photographs taken with a ruler. Swabs from acute bite marks may be analyzed for genetic markers [Finkel and Giardino, 2002; Jenny et al., 1989].

Anogenital Findings

Normal Findings – Anatomy and Terminology

For professionals involved in the evaluation of children for possible sexual abuse, it is crucial to develop a thorough understanding of the appearance of the anogenital anatomy both in abused and non-abused children. It is difficult to describe a finding as abnormal without fully understanding the range of normal

at each developmental level. The increasing knowledge on medical diagnosis in sexual abuse has gone from early imprecise and misleading work [Cantwell, 1983, 1987] to detailed macrophotographic analysis of subtle anogenital findings [Kerns et al., 1992]. As a result of this evolution, the range of findings now interpreted as normal or unspecific (abnormal but not related to abuse) has continuously increased while the number of findings which clearly indicate abusive trauma has decreased [Kerns, 1998; McCann, 1998; Ricci, 1998; Berenson, 1998; Adams, 2001]. In the first decade of medical CSA research, many previously undescribed findings were interpreted as related to trauma in the light of a child's history suggesting abuse. Many of these findings later were demonstrated in studies of non-abused children, mainly by McCann and Berenson [McCann et al., 1989, 1990b; Berenson et al., 1991, 1992, 1993; Berenson, 1993, 1995]. Although there are methodological considerations and limitations to non-abuse studies, this work has greatly enhanced our knowledge. A main concern is the question if the screening tools are specific enough to exclude undisclosed sexual abuse (for discussion of limitations and methods of research, see Berenson [1998] and Ricci [1998]).

The evaluation and description of anogenital findings should be done on the basis of a descriptive and standardized terminology of normal structures. Clinicians involved in describing findings of abused children should speak the same language and describe normal variations and pathologic changes in the same terminology. Although specialists in pediatric and adolescent gynecology are expected to be familiar with the specific terminology, it is worthwhile to have a look at the concepts developed in the recent child abuse literature [APSAC, 1995; Pokorny, 2000]. The documentation in the medical record should be as specific as possible and avoid general terms as 'normal genitalia', not reflecting the great variety of normal. 'Vulva' and 'pudenda' also lack specificity. 'Virgo intacta', 'virginal introitus', 'marital hymen', 'gaping vulva' or 'enlarged vaginal opening' are insufficient, imprecise and not descriptive terms and should be avoided.

The term 'posterior fourchette' may not be familiar in Europe. It describes the posterior joining of the labia minora (frenulum labiorum pudendi minorum), an area which is especially vulnerable to trauma by attempted penile penetration. Sometimes the area from the frenulum to the commissura posterior (posterior joining of the labia majora) is also subsumed under the expression 'posterior fourchette'. The description of genital findings should begin with the external, superficial structures and move on to the inner structures according to the conduct of the examination.

Much of medical research on genital changes in CSA has focused on the hymen. This was especially true in the first decade of research in the 1980s, when considerable efforts were made to attribute the probability of sexual abuse

according to measurements of the hymenal orifice's transverse diameter [Cantwell, 1983, 1987]. Paradise [1989] summarized the debate at the end of the decade in a report titled 'Predictive accuracy and the diagnosis of sexual abuse: A big issue about a little tissue.' She pointed out that 'the diagnosis of sexual abuse inevitably rests not on a genital measurement but on descriptive statements made by a child'. The size of the hymenal opening increases with age and depends on a wide variety of factors like examination position, examination technique, amount of traction used and the degree of relaxation of the child, thus potentially varying within the same examination. Genital measurements have considerably lost significance in the evaluation of children being allegedly sexually abused [Berenson et al., 1992, 2002; Berenson, 1993; McCann et al., 1990a; McCann, 1998; Ingram et al., 2001a]. There even have been reports on post-traumatic scarring leading to entirely closing off the hymenal opening, resembling an imperforate hymen [Berkowitz et al., 1987a; Botash and Jean-Louis, 2001]. With the exception of complex genital abnormalities, all girls are born with hymens – several studies have failed to document a single case of an absent hymen at birth in more than 26,000 newborn girls. Thus, an entity known as 'congenital absence of hymen' does not exist as a sole congenital abnormality [Bays and Chadwick, 1993].

The *appearance of the hymenal membrane* is quite variable and is strongly influenced by the factors mentioned above but also by age and hormonal factors. The whitish-pink hymen of newborn girls is mostly annular, rather thick and redundant due to maternal estrogen influence. The appearance changes markedly due to withdrawal of estrogen thus creating the typical and most prevalent crescentic, semilunar configuration mostly found in children over 3 years of age. The hymen becomes a thin, more translucent and reddish membrane due to vascularization until pubertal raise of estrogen again creates a paler, redundant and fimbriated appearance. Hymenal configurations observed in children are: (1) *Annular* (circumferential, concentric) – mostly in newborns and infants. (2) *Crescentic* (semilunar, posterior rim type) – most frequent in prepubertal girls. (3) *Fimbriated* (denticular) – mainly in newborns, small infants and puberty. (4) *Normal variants* include: sleeve-like (hymen altus), septate, microperforate (= cribriform) or imperforate hymen. An asymmetric appearance is frequent, not abnormal and often results from asymmetric traction [Berenson et al., 1991, 1992; Berenson, 1993, 1995, 1998; McCann et al., 1990b; Emans, 2000].

The hymen is an elastic tissue, unlike the common lay misconception of a piece of paper irrevocably 'broken' by penetration or the idea of an impermeable membrane. The degree of elasticity is difficult to quantify, although penetration of a digit may occur without sequelae. The use of tampons may cause enlargement of the hymenal opening but no disruption of its integrity.

Masturbation in prepubertal girls is clitoral and does not cause injury of the hymen, especially because the prepubertal hymen is well innervated and quite pain-susceptible. Also, physical activities like gymnastics, running, jumping or splits do not lead to hymenal damage [Bays and Chadwick, 1993; Bays, 2001; Emans et al., 1994; Finkelstein et al., 1996].

Among the *hymenal variations* a 'notch' is an angular or V-shaped indentation on the edge of the hymenal membrane. It is referred to as '*concavity*' when its appearance is curved or U-shaped. Superior (also referred to as 'anterior') notches in the supine position are common in non-abused children. The withdrawal of estrogen in infants and resulting involution of tissue in the periurethral area may lead to formation of new superior notches. Notches that extend to the vestibular or vaginal wall have only been reported in abused children and have then been referred to as '*transections*'. No notches between 4 and 8 o'clock have been found in non-abused children, making it a finding consistent with penetrating trauma [Bays and Chadwick, 1993; Berenson, 1998; Finkel and Giardino, 2002].

Other hymenal variations include '*external ridges*' on the external surface of the hymen. They are frequently found in newborns and tend to resolve in most children until 3 years of age. They have previously been misinterpreted as new scar formation. '*Longitudinal intravaginal ridges*' or columns were reported in 25–89%, a variance maybe reflecting age or racial differences in the studies. '*Bumps*' or '*mounds*' (also referred to as '*projections*') mostly occur when an intravaginal ridge attaches to the hymenal rim, but may also exist as isolated finding. They have been found in 7–34% of the non-abused population and also are no indicators of abuse as misconceived in earlier studies. '*Tags*' or elongated projections of the hymenal rim are often incorrectly referred to as polyps. The latter are benign mucosal tumors growing into a lumen, while tags may result from previous vaginal septa or intravaginal ridges protruding from the hymenal rim. Their prevalence ranges from 2 to 25%. '*Vestibular and periurethral supporting bands*' also have been misinterpreted as scar formation while being found in 50–90% of non-abused girls [Emans et al., 1987; Berenson et al., 1991, 1992; Berenson, 1995, 1998; McCann et al., 1990b]. Other variations of normal described in McCann's study were *erythema* of the vestibule (56%), *labial adhesions* (39%), *lymphoid follicles* in the fossa navicularis (34%), and *urethral dilatation* with labial traction (15%). A posterior fourchette midline avascular area also called '*linea vestibularis*' is found in up to 25% and has the potential to be confused with scar tissue [McCann et al., 1990b; Kellog and Parra, 1991, 1993].

Normal perianal findings in both sexes include *erythema* (41%), *increased pigmentation* (30%), *venous congestion* (73%), *midline skin tags* (11%), and smooth midline wedge-shaped areas referred to as '*diastasis ani*' (26%).

The latter results from a congenital anomaly of external sphincter muscle fibers. This finding also has a considerable potential for misinterpretation as scar tissue [McCann et al., 1989]. A recent study found significant differences in perianal anatomy between boys and girls as well as between different examination positions. The authors interpret the differences as a result of anatomical and muscular differences between boys and girls [Myhre et al., 2001].

Findings in Abused Children

The reasons for the paucity of specific findings in sexual abuse victims have been discussed earlier in this text, the abusive physical contact producing no injury being the most prominent reason. The timing of the examination crucially determines the frequency of abnormal findings in those cases where injury has been produced, mainly because of the rapid and often complete healing of anogenital injuries and typically delayed disclosure. The range of findings varies considerably, involving superficial mucosal abrasions and scratches to clear transecting lacerations of anogenital tissues. As the offender frequently uses little physical force, many resulting injuries tend to be superficial and heal rapidly. Most of these findings resolve within 2–3 days after trauma, which is consistent with the characteristics of wound healing. Tissue damage heals by a predictable pathologic process. Superficial damage will heal completely within 5–7 days by regeneration without producing any scar tissue. Serious lacerating wounds heal by repair, leaving a scar of much lesser extent than the primary injury [Finkel and De Jong, 2001]. Thus the kind of findings vary considerably with the nature of the abuse, hereby involved objects, the degree of force used, the age of the child and the frequency of the abuse. The time since the last incidence and a history of pain and/or bleeding were the only two factors which significantly increased the likelihood of detecting abnormal physical findings in two studies [Kerns et al., 1993; Adams et al., 1994].

Female Genitalia

The majority of studies describe findings of female genitalia. *Minor trauma* is frequently caused by genital fondling, rubbing or vulvar coitus (rubbing of the penis between the labia). It mostly leads to unspecific changes like erythema or superficial abrasions of the inner aspects of labia minora, periurethral area, vestibule or the clitoris which heal to integrity within a few days. In cases of digital manipulation, these findings are frequently found in the superior-anterior region in supine position (between 9 and 3 o'clock). A history of dysuria is a valuable corroborating history of this type of sexual abuse. Dysuria may also follow coitus however. Penetration of the hymenal orifice with a small object like a finger may possibly leave no physical sequelae due to the elastic nature of the hymenal tissue [Finkel and De Jong, 2001].

When an *object forcefully penetrates* into the vagina, residual signs are obvious when examined acutely. The extent of injury increases with lower age. The majority of abuse-related findings are found in the posterior area involving the posterior part of the hymen, fossa navicularis, posterior fourchette, the posterior commissure and the lateral walls of the vagina. In rare cases, a perforation of the posterior fornix into the peritoneum may occur. A penile penetration causes disruption of the hymenal rim especially between 5 and 7 o'clock but can be found anywhere between the 3 and 9 o'clock position. This results in incomplete or complete transections and V-shaped notches or clefts of the hymenal membrane. Within a few weeks the notches lose their clear-cut and sharp appearance and develop into a smoother, U-shaped aspect, referred to as concavities. In some cases a narrowing of the posterior rim develops. The edges of the hymenal rim may become thickened or rolled and intravaginal structures may be more readily exposed. Even if repeated penetration may lead to an enlargement of the hymenal transverse diameter, it is no longer considered to be a reliable diagnostic sign as an isolated finding [Paradise, 1989; Paradise et al., 1994; Kerns et al., 1992; McCann et al., 1992; McCann, 1998; McCann and Kerns, 1999; Bays and Chadwick, 1993; AAP, 1999; Adams, 2001; Finkel and Giardino, 2002].

Repeated irritation of genital mucosa may result in chronic inflammation (recurring vulvovaginitis) or in labial agglutination (labial synechia) as an acquired post-inflammatory condition. Both findings may gain significance with a corroborating history [Berkowitz et al., 1987b; McCann et al., 1988; Vandeven and Emans, 1993]. Due to their unspecific nature and prevalence in the prepubertal child, caution should be used when they present as supposed isolated and sole indicators of possible sexual abuse.

Anal Findings

The interpretation of anal signs of abuse (sodomy) in boys and girls is far more controversial than genital signs of trauma. The frequency and significance of findings are subject to substantial disagreement in the literature [Hobbs and Wynne, 1989b; Hobbs et al., 1999b; McCann et al., 1989; Finkel and De Jong, 2001; Finkel and Giardino, 2002]. The ability of the external sphincter to dilate considerably when passing large bolus of fecal matter without any injury to the anal tissues is a major contributing factor. Variables influencing the presence of physical signs include the size of the object introduced, the amount of force used, the age of the victim, the use of lubricants, frequency of episodes and time elapsed since the last episode.

Again, *acute and extensive findings* are not very problematic to interpret. Deep lacerations and significant trauma to the anus are obvious results of anal penetration. In these cases, anoscopy may be helpful for identification of internal injuries like bruising, petechiae, or lacerations and for collection of seminal

products [Ernst et al., 2000]. In the absence of acute findings, anoscopy is not indicated. The significance of *chronic anal signs* remains more problematic. Hobbs and Wynne [1986, 1989a] reported a high incidence of 40–50% of abnormal anal findings in abused children. A significant number of findings seen in allegedly abused children in their study have been demonstrated also to occur in a non-abused population evaluated by McCann et al. [1989].

Anal fissures may result from constipation, but are not frequently reported in constipated children. Flattened anal folds should arouse some concern beyond the diaper age. Anal skin tags are frequently seen in the midline in non-abused children but may result from healed trauma if present outside the midline [Finkel and De Jong, 2001; Finkel and Giardino, 2002; Hobbs et al., 1999b]. Special controversy has evolved about the sign of ‘*reflex anal dilatation*’ (RAD). Although having confidence about the significance of this finding (‘dilatation >0.5 cm’) in earlier studies [Hobbs and Wynne, 1989a], in the recent revised edition of ‘*Child Abuse and Neglect – A Clinician’s Handbook*’, Hobbs and Wynne [1999b] state that ‘further research is needed to improve the understanding and ... significance of the association of RAD with respect to age, constipation, general anesthesia, post-mortem change and neurologic disorders...’. Especially the absence or presence of stool in the rectal ampulla when interpreting this finding is subject to controversy. The paucity of studies to date does not allow final conclusions on the significance of chronic anal findings. In the opinion of the authors, they may be overestimated in British studies [Hobbs and Wynne, 1986, 1989a, 1999a,b; RCP, 1997] and underestimated in American overviews [Finkel and De Jong, 2001]. There is only one article in the American literature specifically examining findings after anal abuse [Muram, 1989b]. As an isolated sign, we do not interpret RAD as diagnostic of CSA. A dilatation >15–20 mm without visible stool however is concerning and warrants further evaluation.

Extragenital Signs of Sexual Abuse

Those signs are infrequent and rather seen in the context of rape: hematomas and bite marks in the so-called erogenous zones, especially the inner thighs, breasts, neck and buttocks; bruising, hematomas and strangulation marks of the neck, the extremities or the flank in the kidney region (due to forceful sodomy); petechiae of the sclerae caused by strangulation; petechiae of the soft palate or tear of the labial frenulum due to forceful oral penetration [Hobbs et al., 1999b; Finkel and De Jong, 2001].

Classification of Findings

In order to categorize anogenital findings, different authors developed classification scales which intend to relate the findings to the probability of

Table 1. Adam's classification system 2001 [modified after Adams, 2001]

Part 1: Anogenital Findings on Examination

<i>Category 1a: Normal</i> ¹	<i>Category 3: Concerning for abuse or trauma</i> ³
Periurethral (or vestibular) bands	Marked (>1.5–2 cm) immediate dilatation of the anus (no stool in rectum)
Longitudinal intravaginal ridge or column	Hymenal notch/cleft extending through >50% of the hymenal rim, persisting in different positions and techniques
Hymenal tag	Acute abrasions, lacerations, or bruising of labia, perihymenal tissues, penis, scrotum, or perineum (DD accident, physical abuse)
Hymenal bump or mound	Bite marks or suction marks on the genitalia or inner thighs
Linea vestibularis	Scar or fresh laceration of the posterior fourchette
Anterior (superior) hymenal cleft/notch (above 3 to 9 o'clock line)	Perianal scar
External hymenal ridge	
<i>Category 1b: Normal variants</i>	<i>Category 4: Clear evidence of blunt force or penetrating trauma</i>
Septate hymen	Acute laceration of the hymen
Failure of midline fusion (perineal groove)	Ecchymosis (bruising) on the hymen
Groove in the fossa in a pubertal girl	Absence of hymenal tissue (confirmed in knee-chest position)
Diastasis ani	Hymenal transection ('complete cleft')
Perianal skin tag	Perianal lacerations extending deep to the external anal sphincter
Increased perianal pigmentation	
<i>Category 1c: Other conditions</i>	<i>Category 2: Non-specific findings</i> ²
Genital hemangiomas (labia, hymen, perihymenal area)	Erythema of internal or external anogenital tissues
Lichen sclerosus et. atrophicus	Increased vascularity of the vestibule
Beçhet's disease (genital ulcers, DD HSV)	Labial adhesion (synechia)
Anogenital streptococcal cellulitis	Vaginal discharge
Molluscum contagiosum, verruca vulgaris	Vesicular lesions in the anogenital area (DD HSV, syphilis)
Vaginitis (enteric organism, streptococci)	Anogenital warts
Urethral prolapse	Thickened hymen (DD post-traumatic swelling, infection, estrogen)
Vaginal foreign body	Anal fissures
	Flattened anal folds
	Anal dilatation of any size (if stool is present in the rectum or after 30 s in knee-chest position)
	Vaginal bleeding (broad DD)
	Notch or cleft in the posterior (inferior) portion of the hymen, <50% of the hymenal rim

Table 1 (continued)

Part 2: Overall Assessment of the Likelihood of Abuse

Class 1: No indication of abuse

Normal exam, no history, no behavioral changes, no witnessed abuse

Non-specific findings with known or likely explanation, no history, no behavioral changes

Child considered at risk for sexual abuse but gives no history, only non-specific behavior changes

Physical findings of anogenital injury with clear and believable history of accidental trauma

Class 2: Possible abuse

Category 1 or category 2 finding in combination with significant behavior changes.

Especially sexualized behaviors, but child unable to give a history of abuse

Herpes type I anogenital lesions, in the absence of a history of abuse and with an otherwise normal examination

Condyloma accuminata. With otherwise normal examination; no other STD present, and child gives no history of abuse

(Condyloma in a child >3–5 years is more likely to be from sexual transmission)

Child has made a statement, but not sufficiently detailed, not consistent or was obtained by leading questions

Class 3: Probable abuse

Child has given a spontaneous, clear, consistent and detailed description of being molested, with or without abnormal or positive physical findings on examination

Positive culture for *Chlamydia trachomatis* from genital area (prepubertal child) or cervix (adolescent); no perinatal transmission

Positive culture for herpes simplex type 2 (genital or anal lesions)

Trichomonas infection (wet mount or culture); no perinatal transmission

Class 4: Definite evidence of abuse or sexual contact

Category 4 physical findings with no history of accident

Finding of sperm or seminal fluid in or on a child's body

Pregnancy

Positive, confirmed cultures for *Neisseria gonorrhoea* (vaginal, urethral, anal, or pharyngeal)

Syphilis, no perinatal transmission

Cases where photographs or videotapes show a child being abused

HIV infection with no possibility of perinatal transmission or via blood products or contaminated needles

DD = Differential diagnosis.

¹Found in newborns and non-abused children.

²Findings that may be the result of CSA but frequently have other causes.

³Findings that have been noted in children with documented abuse and may be suspicious for abuse but for which insufficient data exist to indicate that abuse is the only cause; history is crucial in determining overall significance.

their abusive origin. Especially the newest revision of a scale developed by Adams [1992, 2001] is a comprehensive categorization schema for analyzing and interpreting findings. It consists of two parts, the classification of physical findings alone and the overall assessment of the likelihood of abuse. It is of particular value as it interrelates both the physical findings and the historical findings into a diagnostic decision. After measurements of the posterior rim had been removed in a prior version, this version removed enlarged hymenal opening as a criterion for abuse. In a recent review of Adam's paper, Ricci [2001] cautioned the use of the schema as '...it is important to recognize however, that this schema is a suggestion, a way of organizing one's thoughts about a constellation of findings. Although ... in line with much of the current research ... it is important to recognize that any schema must be interpreted within the context of each individual case.' A revised version of the classification is distributed by the author but not yet published [Adams, pers. commun., 2003]. Guidelines for decision-making, especially in respect to mandated reporting of sexual abuse, have been published by the Committee on Child Abuse and Neglect of the American Academy of Pediatrics [AAP, 1999]. Classification scales help to assess probabilities but must never be misinterpreted as rigid instructions how to interpret anogenital findings. The current state of knowledge and its limitations have to be kept in mind and updated continuously as in all other medical disciplines [Kerns, 1998; McCann, 1998] (table 1).

Sexually Transmitted Diseases

Sexually transmitted diseases (STD) are discussed in a different chapter of this book. We only refer to a few important characteristics with regard to CSA.

STD may be the only medical indicator of sexual abuse in selected cases. The American Center for Disease Control (CDC) states that the diagnosis of a STD in a child beyond the neonatal period suggests sexual abuse [CDC, 1998]. The interpretation differs according to the respective disease. STDs are diagnosed in 1–5% of abused children. The differences result from factors like type and frequency of the abuse, the age of the victim, the methods for testing and varying regional prevalence. Cultures and smears for STD should only be obtained in selected cases as the yield of positive cultures is very low in asymptomatic children [Ingram et al., 1992; Siegel et al., 1995; AAP, 1999; Muram and Stewart, 2000]. Proposed selection criteria for STD screening include genital discharge at examination or in the recent history, a perpetrator with a known or suspected STD or with high-risk behavior, anogenital findings indicating penetrative abuse, a history of genital-to-genital (or -anal) contact or penetration, concern of the patient or its caretakers or specific genital lesions. The screening

includes vaginal and anal cultures for gonorrhea and *Chlamydia* and a vaginal smear for *Trichomonas vaginalis*. Prepubertal gonorrhea and chlamydial infections are localized vaginal infections. Swabs should be taken from the vaginal wall beyond the hymen. Cervical swabs are not indicated before adolescence. Extending the screening to syphilis, hepatitis B and HIV should be done on a case-to-case decision. Adequate and optimal technique of obtaining specimens, choice of testing methods and cultures are of paramount importance due to the forensic implications of positive results. Recently the use of nucleic acid amplification methods has become increasingly popular in testing for STDs. Specific considerations and limitations have to be kept in mind when used for possible prepubertal sexual abuse [Hammerschlag, 2001].

Except in documented congenital infections, confirmed positive cultures for *Neisseria gonorrhoea* in a prepubertal child or serologic proof of an acquired *syphilis* are definite evidence of sexual abuse. Perinatally acquired infections with *Chlamydia trachomatis* have been demonstrated to persist as long as 2 years in the genital area and up to 3 years in the pharynx. Infections appearing after the first 2 years of life are strong indicators of CSA. Infections with *T. vaginalis*, *Herpes genitalis* and *Condylomata acuminata* should raise the suspicion of sexual abuse and warrant further screening [AAP, 1999; Beck-Sagué and Solomon, 1999; Shapiro et al., 1999; Muram and Stewart, 2000; Ingram et al., 2001b].

Differential Diagnosis

Beside the normal findings, normal variants and unspecific findings, there are a number of important differential diagnoses to consider when evaluating children with abnormal anogenital findings for possible sexual abuse.

One of the areas of concern is *accidental genital injuries*. The pattern of injury and accompanying history however frequently provide sufficient information for differentiating them from abusive trauma. Most accidents result from straddling, referring to children falling on hard objects like a bicycle bar or a furniture arm with their genital area. Usually this causes an injury of the external genital structures which are crushed between the object and the underlying bones. The injuries involve the labia majora and minora and the clitoral hood and rarely involve the deep and protected structures like the hymen and the posterior fourchette. Published reports regarding accidental genital injuries describe them to be mostly minor and superficial, located anterior, external and unilateral. In most cases of accidental injuries the hymen is not involved [Dowd et al., 1994; Bond et al., 1995; Pokorny et al., 1992; Pokorny, 1997; West et al., 1989]. Exceptions are rare cases of accidental penetrating injuries [Boos, 1999]. Other types of injury reported in the literature include a case of posterior vaginal

laceration near the hymen by a water slide accident [Kunkel, 1998], seatbelt injuries in motor vehicle accidents [Baker, 1986] and midline splitting injuries with and without hymenal involvement due to inline skating accidents [Herrmann and Crawford, 2002]. All reports stress the overwhelming importance of the history which tends to be spontaneous, acute and dramatic. It is consistent with the injuries and does not change over time or between different caretakers or between caretakers and child. Also, the immediate consultation of medical help favors the diagnosis of accidental trauma.

Dermatologic conditions which need to be differentiated from sexual abuse include erythema and excoriations in *unspecific skin irritation* or *infection*, *diaper dermatitis*, *lack of hygiene*, *irritant substances* (bubble bath, cosmetic care products), *moniliasis*, *genital varicella* and *oxyuriasis*. *Recurring vaginitis* is often an area of concern, especially when expressed in the context of custody debates. The child returning from the separated father after a weekend visit with red genitals may as well have experienced a paternal lack of hygiene, or his aversion to properly clean the genital area because he fears allegations of sexual abuse. Although abuse is possible and parental separation may result from non-disclosed abusive family constellations, research indicates much lower numbers of abused children in this context as commonly thought [Corwin et al., 1987]. *Vaginitis* is the most prevalent pediatric gynecology health problem and requires a systematic approach and broad differential diagnosis. Unclear and recurring vaginitis should warrant concern and further evaluation but is never diagnostic per se [Vandeven and Emans, 1993; Bays, 2001].

An infection caused by *group A β -hemolytic streptococci* may cause a fiery red, edematous and tender vaginal or perianal inflammation, sometimes accompanied by various forms of discharge: thin, thick, serous, blood tinged, creamy, white, yellow or green. Cultures have to be specifically requested as streptococci do not grow on routine media. Treatment is according to pharyngeal infections with a 10-day course of oral penicillin [Mogielnicki et al., 2000].

A frequently mistaken diagnosis of CSA occurs in children who present with anogenital *lichen sclerosus et atrophicus*. After initial white papules that form to white plaques, the skin becomes delicate and atrophic. It is extremely susceptible to minor trauma like wiping with toilet paper, causing fissuring or alarming subepidermal hemorrhages and spontaneous bleeding. The typical presentation is a 'hourglass' or 'figure-of-eight' configuration of decreased pigmentation around the labia majora and the anus [Jenny et al., 1989; Warrington and de San Lazaro, 1996; Young et al., 1993; Herrmann et al., 1998].

Cutaneous bleeding may also be caused by *leukemia*, *disseminated intravascular coagulation*, *purpura fulminans* and other *coagulation disorders*. *Urethral bleeding* is rather caused by urethral prolapse (especially prevalent in African-American girls), polyps, hemangioma, or papilloma than by sexual

abuse [Johnson, 1991]. *Vaginal bleeding* requires careful evaluation of the underlying causes. Most frequently it is caused by *vaginitis* (approx. 70%). Other less frequent causes include *precocious puberty*, *sarcoma botryoides* (embryonal rhabdomyosarcoma), internal or external application of *hormones*, or unspecific, *idiopathic* bleeding [Bays, 2001].

Congenital conditions mistaken for sexual abuse include *hemangioma* of the hymen, vagina and labia. They may bleed or ulcerate. *Failure of midline fusion* is a congenital defect resembling scar tissue. Sometimes it is combined with an anteriorly located anus and also frequently creates confusion and misinterpretation as an abuse-related finding. *Anal findings* to be differentiated from abuse are *fissures* in chronic obstipation, Morbus Crohn, *rectal prolapse* or a *streptococcal A cellulitis* [Bays, 2001].

Overall Assessment

In spite of an abundance of data on medical findings in CSA victims and their differentiation from normal, normal variants and other differential diagnoses, the medical proof of abuse remains the exception when evaluating suspected sexual abuse cases. This would be the case in massive acute anogenital trauma in the absence of a convincing history of accidental trauma, proof of gonorrhea or syphilis (after excluding a congenital infection), pregnancy, proof of semen, sperm cells, acid phosphatase or sperm-specific glycoprotein p30 in or on the body of a child.

The overall assessment of the likelihood of sexual abuse and the final conclusions have to be done conscientiously and need to include all physical findings, possible laboratory results and especially the history obtained from the child. The medical expert contributes a thoughtful and qualified piece of evidence to the multidisciplinary puzzle of evaluating children for possible CSA. Strictly medical interventions in CSA include treatment of injuries, infections, or STDs, and emergency contraception. Reassurance of physical intactness should be an integral part of the medical examination. The ongoing management and interventions in therapeutic, social and legal fields is no longer the duty of the medical expert. She/he participates in referral to therapy, emotional guidance of the family, and assisting the legal system in cases with confirmatory findings. It is crucial to develop extensive interdisciplinary and multiprofessional cooperation and consultation in all cases.

Although we are constantly learning more about the role and significance of medical aspects in suspected sexual abuse cases, the diagnosis 'child sexual abuse' primarily rests on the professionally and qualified obtained descriptive statements made by an abused child.

References

- AAP – American Academy of Pediatrics: Committee on Child Abuse and Neglect. Guidelines for the evaluation of sexual abuse of children. *Pediatrics* 1999;103:186–191 (www.aap.org/policy/re9819.html).
- AAP – American Academy of Pediatrics: Committee on Adolescence. Care of the adolescent sexual assault victim. *Pediatrics* 2001a;107:1476–1479 (www.aap.org/policy/re0067.html).
- AAP – American Academy of Pediatrics: Committee on Child Abuse and Neglect and Committee on Children with Disabilities. Assessment of maltreatment of children with disabilities. *Pediatrics* 2001b;108:508–512 (www.aap.org/policy/0064.html).
- Adams JA, Phillips P, Ahmad M: The usefulness of colposcopic photographs in the evaluation of suspected child sexual abuse. *Adolesc Pediatr Gynecol* 1990;3:75–82.
- Adams JA, Harper K, Knudson S: A proposed system for the classification of anogenital findings in children with suspected sexual abuse. *Adolesc Pediatr Gynecol* 1992;5:73–75.
- Adams JA, Harper K, Knudson S, Revilla J: Examination findings in legally confirmed child sexual abuse: It's normal to be normal. *Pediatrics* 1994;94:310–317.
- Adams JA: Medical evaluation of suspected child sexual abuse: It's time for standardized training, referral centers and routine peer review. *Arch Pediatr Adolesc Med* 1999;153:1121–1122.
- Adams JA: Evolution of a classification scale: Medical evaluation of suspected child sexual abuse. *Child Maltreat* 2001;6:31–36.
- APSAC: Terminology Subcommittee of the American Professional Society on Abuse of Children Taskforce on Medical Evaluation of Suspected Sexual Abuse (APSAC). Practice guidelines: Descriptive terminology in child sexual abuse evaluation. APSAC, 1995, pp 1–8.
- Atabaki S, Paradise JE: The medical evaluation of the sexually abused child: Lessons from a decade of research. *Pediatrics* 1999;104(suppl):178–186.
- Baker R: Seatbelt injury masquerading as child sexual abuse. *Pediatrics* 1986;77:435.
- Bays J, Chadwick D: Medical diagnosis of the sexually abused child. *Child Abuse Negl* 1993;17:91–110.
- Bays J: Conditions mistaken for child sexual abuse; in Reece RM, Ludwig S (eds): *Child Abuse: Medical Diagnosis and Management*, ed 2. Philadelphia, Lippincott Williams & Wilkins, 2001, pp 287–306.
- Beck-Sagué CM, Solomon E: Sexually transmitted diseases in abused children and adolescent and adult victims of rape: Review of selected literature. *Clin Infect Dis* 1999;28:S74–S83.
- Beitchman JH, Zucker KJ, Hood JE, DaCosta GA, Akman D: A review of the short-term effects of child sexual abuse. *Child Abuse Negl* 1991;15:537–556.
- Beitchman JH, Zucker KJ, Hood JE, DaCosta GA, Akman D, Cassavia E: A review of the long-term effects of child sexual abuse. *Child Abuse Negl* 1992;16:101–118.
- Berenson AB, Heger A, Andrews S: Appearance of hymen in newborns. *Pediatrics* 1991;87:458–465.
- Berenson AB, Heger A, Hayes JM, Bailey RK, Emans SJ: Appearance of hymen in prepubertal girls. *Pediatrics* 1992;92:387–394.
- Berenson AB: Appearance of hymen at birth and one year of age: A longitudinal study. *Pediatrics* 1993;91:821–825.
- Berenson AB, Somma-Garcia A, Barnett S: Perianal findings in infants 18 months of age or younger. *Pediatrics* 1993;91:838–840.
- Berenson AB: A longitudinal study of hymenal morphology in the first 3 years of life. *Pediatrics* 1995;95:490–496.
- Berenson AB: Normal anogenital anatomy. *Child Abuse Negl* 1998;22:589–596.
- Berenson AB, Chacko MR, Wiemann CM, et al: A case-control study of anatomic changes resulting from sexual abuse. *Am J Obstet Gynecol* 2000;182:820–824.
- Berenson AB, Chacko MR, Wiemann CM, Mishaw CO, Friedrich WN, Grady JJ: Use of hymenal measurements in the diagnosis of previous penetration. *Pediatrics* 2002;109:228–235.
- Berkowitz CD, Elvik SL, Logan MK: A simulated 'acquired' imperforate hymen following the genital trauma of sexual abuse. *Clin Pediatr* 1987a;6:307–309.
- Berkowitz CD, Elvik SL, Logan MK: Labial fusion in prepubescent girls: A marker for sexual abuse? *Am J Obstet Gynecol* 1987b;156:16–20.

- Berkowitz CD: Medical consequences of child sexual abuse. *Child Abuse Negl* 1998;22:541–550.
- Bond GR, Dowd MD, Landsman I, Rimsza M: Unintentional perianal injury in prepubescent girls: A multicenter, prospective report of 56 girls. *Pediatrics* 1995;95:628–631.
- Boos SC: Accidental hymenal injury mimicking sexual trauma. *Pediatrics* 1999;103:1287–1289.
- Botash AS, Jean-Louis F: Imperforate hymen: Congenital or acquired from sexual abuse? *Pediatrics* 2001;108:e53 (www.pediatrics.org/cgi/content/abstract/108/3/e53).
- Bowen K, Aldous MB: Medical evaluation of sexual abuse in children without disclosed or witnessed abuse. *Arch Pediatr Adolesc Med* 1999;153:1160–1164.
- Britton H: Emotional impact of the medical examination for child sexual abuse. *Child Abuse Negl* 1998;22:573–580.
- Cantwell HB: Vaginal inspection as it relates to child sexual abuse in girls under thirteen. *Child Abuse Negl* 1983;7:171–176.
- Cantwell HB: Update on vaginal inspection as it relates to child sexual abuse in girls under thirteen. *Child Abuse Negl* 1987;11:545–546.
- CDC (Centers for Disease Control): 1998 sexually transmitted disease treatment guidelines. *Morbidity and Mortality Weekly Report* 1998;47(No RR-1):1–116.
- Christian C, Lavelle J, De Jong A, Loisel J, Brenner L, Joffe M: Forensic evidence findings in prepubertal victims of sexual assault. *Pediatrics* 2000;106:100–104.
- Corwin DL, Berliner L, Goodman G, Goodwin J, White S: Child sexual abuse and custody disputes. No easy answers. *J Interpers Violence* 1987;2:91–105.
- De Jong AR, Rose M: Frequency and significance of physical evidence in legally proven cases of child sexual abuse. *Pediatrics* 1989;84:1022–1026.
- De San Lazaro C: Making paediatric assessment in suspected sexual abuse a therapeutic experience. *Arch Dis Child* 1995;73:174–176.
- Dickinson LM, deGruy III FV, Dickinson WP, Candib LM: Health-related quality of life and symptom profiles of female survivors of sexual abuse. *Arch Fam Med* 1999;8:35–43.
- Dowd MD, Fitzmaurice L, Knapp JF, Mooney D: The interpretation of urogenital findings in children with straddle injuries. *J Pediatr Surg* 1994;29:7–10.
- Drach KM, Wientzen J, Ricci LR: The diagnostic utility of sexual behavior problems in diagnosing sexual abuse in a forensic child abuse evaluation clinic. *Child Abuse Negl* 2001;25:489–503.
- Elvik SL, Berkowitz CD, Nicholas E: Sexual abuse in the developmentally disabled: Dilemmas of diagnosis. *Child Abuse Negl* 1990;14:497–502.
- Emans SJ, Woods ER, Flagg NT, Freeman A: Genital findings in sexually abused, symptomatic and asymptomatic girls. *Pediatrics* 1987;79:778–785.
- Emans SJ, Woods ER, Allred EN, Grace E: Hymenal findings in adolescent women: Impact of tampon use and consensual sexual activity. *J Pediatr* 1994;125:153–160.
- Emans SJ: Physical examination of the child and adolescent; in Heger A, Emans SJ, Muram D (eds): *Evaluation of the Sexually Abused Child. A Medical Textbook and Photographic Atlas*, ed 2. New York, Oxford University Press, 2000, pp 57–78.
- Ernst AA, Green E, Ferguson MT, Weiss SJ, Green WM: The utility of anoscopy and colposcopy in the evaluation of male sexual assault victims. *Ann Emerg Med* 2000;36:432–437.
- Everson MD: Understanding bizarre, improbable and fantastic elements in children's accounts of abuse. *Child Maltreat* 1997;2:134–149.
- Finkel MA: Technical conduct of the child sexual abuse medical examination. *Child Abuse Negl* 1998;22:555–566.
- Finkel MA, De Jong AR: Medical findings in child sexual abuse; in Reece RM, Ludwig S (eds): *Child Abuse: Medical Diagnosis and Management*, ed 2. Philadelphia, Lippincott Williams & Wilkins, 2001, pp 207–286.
- Finkel MA, Giardino AP (eds): *Medical Evaluation of Child Sexual Abuse*, ed 2. Thousand Oaks, Sage Publications, 2002.
- Finkelhor D: Current information on the scope and nature of child sexual abuse. *Future Child* 1994;4:31–53.
- Finkelstein E, Amichai B, Jaworowski S, Mukamel M: Masturbation in prepubescent children: A case report and review of the literature. *Child Care Health Dev* 1996;22:323–326.
- Friedrich WN: Behavioral manifestations of child sexual abuse. *Child Abuse Negl* 1998;22:523–531.

- Friedrich WN, Fisher J, Broughton D, Houston M, Shafran CR: Normative sexual behavior in children: A contemporary sample. *Pediatrics* 1998;101:e9 (www.pediatrics.org/cgi/content/full/101/4/e9).
- Friedrich WN, Fisher JL, Dittner CA, et al: Child sexual behavior inventory: Normative, psychiatric and sexual abuse comparisons. *Child Maltreat* 2001;6:37–49.
- Gabby T, Winkleby MA, Boyce T, Fisher DL, Lancaster A, Sensabaugh GF: Sexual abuse of children: The detection of semen on skin. *Am J Dis Child* 1992;146:700–703.
- Gully KJ, Britton H, Hansen K, Goodwill K, Nope JL: A new measure for distress during child sexual abuse examinations: The genital examination distress scale. *Child Abuse Negl* 1999;23:61–70.
- Gutjahr P: Krebs bei Kindern und Jugendlichen (Cancer in Children and Adolescents), ed 3. Köln, Deutscher Ärzte Verlag, 1993.
- Hammerschlag MR: Use of nucleic acid amplification tests in investigating child sexual abuse. *Sex Trans Infect* 2001;77:153–157.
- Harari MD, Netzer D: Genital examination under ketamine sedation in cases of suspected sexual abuse. *Arch Dis Child* 1994;70:197–199 (see comments: Rogers and Murdoch, 1994; Sury 1994).
- Heger A, Emans SJ, Muram D: Evaluation of the Sexually Abused Child. A Medical Textbook and Photographic Atlas, ed 2. New York, Oxford University Press, 2000, pp 57–78.
- Heger A, Ticson L, Velasquez O, Bernier R: Children referred for possible sexual abuse: Medical findings in 2,384 children. *Child Abuse Negl* 2002;26:645–659.
- Herrmann B, Neises M, Veit S: Medizinische Diagnostik bei sexuellem Kindesmissbrauch (Medical diagnosis in child sexual abuse). *Monatsschr Kinderheilkd* 1997;145:1219–1225.
- Herrmann B, Veit S, Neises M: Lichen sclerosus et atrophicus. Wichtige Differentialdiagnose zu sexuellem Missbrauch von Kindern (Lichen sclerosus et atrophicus. Important differential diagnosis to child sexual abuse). *Pädiatr Prax* 1998;55:319–324.
- Herrmann B: Sexueller Kindesmissbrauch: Bedeutung und Stellenwert der medizinischen Diagnostik (Child sexual abuse: Significance and role of medical diagnosis). *Korasion* 1999;14:25–30.
- Herrmann B, Crawford J: Genital injuries in prepubertal girls from inline skating accidents. *Pediatrics* 2002;110:e16 (www.pediatrics.org/cgi/content/full/110/2/e16).
- Herrmann B, Navratil F, Neises M: Sexueller Missbrauch an Kindern. Bedeutung und Stellenwert der medizinischen Diagnostik. *Monatsschr Kinderheilkd* 2002;150:1344–1356.
- Hobbs CJ, Wynne JM: Buggery in childhood – A common syndrome of child abuse. *Lancet* 1986;ii:792–796.
- Hobbs CJ, Wynne JM: Sexual abuse of English boys and girls: The importance of an anal examination. *Child Abuse Negl* 1989a;13:195–200.
- Hobbs CJ, Wynne JM: Letter to the editor. *Child Abuse Negl* 1989b;13:290–293.
- Hobbs CJ, Wynne JM: The examination of the infant and young child – Normal and abnormal. *Curr Paediatr* 1995;5:236–242.
- Hobbs CJ, Hanks HGI, Wynne JM: *Child Abuse and Neglect. A Clinician's Handbook*, ed 2. Edinburgh, Churchill Livingstone, 1999a.
- Hobbs CJ, Wynne JM: Clinical aspects of sexual abuse; in Hobbs CJ, Hanks HGI, Wynne JM (eds): *Child Abuse and Neglect. A Clinician's Handbook*, ed 2. Edinburgh, Churchill Livingstone, 1999b, pp 191–271.
- Hogan M: Oral midazolam for pediatric nonacute sexual abuse examinations. *Child Maltreat* 1996;1:361–363.
- Horowitz DA: Physical examination of sexually abused children and adolescents. *Pediatr Rev* 1987;9:25–29.
- Hunter RS, Kilstrom N, Loda F: Sexually abused children: Identifying masked presentations in a medical setting. *Child Abuse Negl* 1985;9:17–25.
- Ingram DL, Everett D, Lyna PR, White ST, Rockwell LA: Epidemiology of adult sexually transmitted disease agents in children being evaluated for sexual abuse. *Pediatr Infect Dis J* 1992;11:945–950.
- Ingram DM, Everett VD, Ingram DL: The relationship between the transverse hymenal orifice diameter by the separation technique and other possible markers of sexual abuse. *Child Abuse Negl* 2001a;25:1109–1120.
- Ingram DM, Miller WC, Schoenbach VL, Everett VD, Ingram DL: Risk assessment for gonococcal and chlamydial infections in young children undergoing evaluation for sexual abuse. *Pediatrics* 2001b;107:e73 (www.pediatrics.org/cgi/content/full/107/5/e73).

- Jenny C, Kirby P, Fuquay D: Genital lichen sclerosis mistaken for child sexual abuse. *Pediatrics* 1989; 83:597–599.
- Johnson CF: Prolapse of the urethra: Confusion of clinical and anatomic characteristics with sexual abuse. *Pediatrics* 1991;87:722–725.
- Jones DPH, McGraw JM: Reliable and fictitious accounts of sexual abuse to children. *J Interpers Violence* 1987;2:27–45.
- Jones L, Finkelhor D: The decline in child sexual abuse cases. *OJJDP NCJ 184741 Juvenile Justice Bulletin*, January 1–12, 2001.
- Joraschky P: Die Auswirkungen von Vernachlässigung, Misshandlung, Missbrauch auf Selbstwert und Körperbild (The consequences of neglect, physical and sexual abuse on self-esteem and body image); in Egle UT, Hoffmann S, Joraschky P (eds): *Sexueller Missbrauch, Misshandlung, Vernachlässigung*. Stuttgart, Schattauer, 1997, pp 117–130.
- Kellogg ND, Parra JM: Linea vestibularis: A previously undescribed normal genital structure in female neonates. *Pediatrics* 1991;87:926–929.
- Kellogg ND, Parra JM: Linea vestibularis: Follow-up of a normal genital structure. *Pediatrics* 1993;92: 453–456.
- Kellogg ND, Parra JM, Menard S: Children with anogenital symptoms and signs referred for sexual abuse evaluations. *Arch Pediatr Adolesc Med* 1998;152:614–641.
- Kempe CH: Sexual abuse, another hidden pediatric problem: The 1977 C. Anderson Aldrich Lecture. *Pediatrics* 1978;62:382–389.
- Kerns DL: Cool science for a hot topic. Commentary. *Child Abuse Negl* 1989;13:177–178.
- Kerns DL, Ritter ML, Thomas RG: Concave hymenal variations in suspected child sexual abuse victims. *Pediatrics* 1992;90:265–272.
- Kerns DL, Ritter ML, Leong T, Brown WB: Clinical correlates to physical evidence of anogenital trauma in female suspected sexual abuse victims. *Am J Dis Child* 1993;147:122.
- Kerns D: Establishing a medical research agenda for child sexual abuse. *Child Abuse Negl* 1998;22 (spec issue):453–660.
- Koverola C, Friedrich WN: Psychological effects of child sexual abuse; in Heger A, Emans SJ, Muram D (eds): *Evaluation of the Sexually Abused Child. A Medical Textbook and Photographic Atlas*, ed 2. New York, Oxford University Press, 2000, pp 21–40.
- Kunkel NC: Vaginal injury from a water slide in a premenarcheal patient. *Pediatr Emerg Care* 1998;14: 210–211.
- Lazebnik R, Zimet GD, Ebert J, Anglin TM, Williams P, Bunch DL, Krowchuk DP: How children perceive the medical evaluation for suspected sexual abuse. *Child Abuse Negl* 1994;18:739–745.
- Leventhal JM, Hamilton J, Rekedal S, et al: Anatomically correct dolls used in interviews of young children suspected of having been sexually abused. *Pediatrics* 1989;84:900–906.
- Leventhal JM: Epidemiology of sexual abuse of children: Old problems, new directions. *Child Abuse Negl* 1998;22:481–492.
- Levitt CJ: The medical interview; in Heger A, Emans SJ, Muram D (eds): *Evaluation of the Sexually Abused Child. A Medical Textbook and Photographic Atlas*, ed 2. New York, Oxford University Press, 2000, pp 41–56.
- McCann J, Voris J, Simon M: Labial adhesions and posterior fourchette injuries in childhood sexual abuse. *Am J Dis Child* 1988;42:659–663.
- McCann J, Wells R, Simon M, Voris J: Perianal findings in prepubertal children selected for nonabuse: A descriptive study. *Child Abuse Negl* 1989;13:179–193.
- McCann J, Voris J, Simon M, Wells R: Comparison of genital examination techniques in prepubertal girls. *Pediatrics* 1990a;85:182–187.
- McCann J, Wells R, Simon M, Voris J: Genital findings in prepubertal girls selected for nonabuse: A descriptive study. *Pediatrics* 1990b;86:428–439.
- McCann J, Voris J, Simon M: Genital injuries resulting from sexual abuse: A longitudinal study. *Pediatrics* 1992;89:307–317.
- McCann J: The colposcopic genital examination of the sexually abused prepubertal female. *Adolesc Pediatr Gynecol* 1993;6:123–128.
- McCann J: The appearance of acute, healing and healed anogenital trauma. *Child Abuse Negl* 1998;22: 605–616.

- McCann J, Kerns D: The anatomy of child and adolescent sexual abuse. A CD-ROM Atlas/Reference. St Louis, InterCorp, 1999 (www.intercorpinc.com/sabuse.html).
- Mogielnicki NP, Schwartzman JD, Elliott JA: Perineal group A streptococcal disease in a pediatric population. *Pediatrics* 2000;106:274–281.
- Molnar BE, Buka SL, Kessler RC: Child sexual abuse and subsequent psychopathology: Results from the National Comorbidity Survey. *Am J Public Health* 2001;91:753–760.
- Monteleone JA, Brodeur AE: Child Maltreatment; vol 1: A Clinical Guide and Reference; vol 2: A Comprehensive Photographic Reference Identifying Potential Child Abuse, ed 2. St Louis, CW Medical, 1998.
- Muram D: Child sexual abuse: Relationship between sexual acts and genital findings. *Child Abuse Negl* 1989a;13:211–216.
- Muram D: Anal and perianal abnormalities in prepubertal victims of sexual abuse. *Am J Obstet Gynecol* 1989b;161:278–281.
- Muram D, Elias S: Child sexual abuse – Genital tract findings in prepubertal girls. II. Comparison of colposcopic and unaided examinations. *J Obstet Gynecol* 1989;160:333–335.
- Muram D, Arheart KL, Jennings SG: Diagnostic accuracy of colposcopic photographs in child sexual abuse evaluations. *J Pediatr Adolesc Gynecol* 1999;12:58–61.
- Muram D, Stewart D: Sexually transmitted diseases; in Heger A, Emans SJ, Muram D (eds): *Evaluation of the Sexually Abused Child. A Medical Textbook and Photographic Atlas*, ed 2. New York, Oxford University Press, 2000, pp 187–224.
- Myhre AK, Berntzen K, Bratlid D: Perinanal anatomy in non-abused preschool children. *Acta Pædiatr* 2001;90:1321–1328.
- Navratil F: Sexuelle Ausbeutung von Mädchen: Problematik, Schwierigkeiten und Grenzen der klinischen Diagnose (Sexual exploitation of girls: Problems, difficulties and limitations of clinical diagnosis). *Korasion* 1995;10:17–20.
- Navratil F: The genital examination in suspected child sexual abuse. A diagnostic dilemma. *Ann NY Acad Sci* 1997;816:414–421.
- Palusci VJ, Cox EO, Cyrus TA, et al: Medical assessment and legal outcome in child sexual abuse. *Arch Pediatr Adolesc Med* 1999;153:388–392.
- Palusci VJ, Cyrus TA: Reaction to videocolposcopy in the assessment of child sexual abuse. *Child Abuse Neglect* 2001;25:1535–1546.
- Paradise JE: Predictive accuracy and the diagnosis of sexual abuse: A big issue about a little tissue. *Child Abuse Negl* 1989;13:169–176.
- Paradise JE, Rose L, Sleeper LA, et al: Behavior, family function, school performance, and predictors of persistent disturbance in sexually abused children. *Pediatrics* 1994;93:452–459.
- Pokorny SF, Pokorny WJ, Kramer W: Acute genital injury in the prepubertal girl. *Am J Obstet Gynecol* 1992;166:1461–1466.
- Pokorny SF: Genital trauma. *Clin Obstet Gynecol* 1997;40:219–225.
- Pokorny S: Anatomical terms of female external genitalia; in Heger A, Emans SJ, Muram D (eds): *Evaluation of the Sexually Abused Child. A Medical Textbook and Photographic Atlas*, ed 2. New York, Oxford University Press, 2000, pp 109–114.
- RCP – Royal College of Physicians: *Physical Signs of Sexual Abuse in Children: Report of Working Party*, ed 2. London, Royal College of Physicians, 1997.
- Reece RM, Ludwig S (eds): *Child Abuse: Medical Diagnosis and Management*, ed 2. Philadelphia, Lippincott Williams & Wilkins, 2001.
- Ricci LR: Normal anogenital anatomy in children: Commentary. *Child Abuse Negl* 1998;22:597–600.
- Ricci LR: Reviewers note on Adams JA (2001): Evolution of a classification scale: Medical evaluation of suspected child sexual abuse. *Child Maltreat* 2001;6:31–36. Reviewed in *Child Abuse Q Med Update* 8:7.
- Rogers R, Murdoch LJ: Genital examination under ketamine sedation in cases of suspected sexual abuse (letter). *Arch Dis Child* 1994;71:481.
- Santucci KA, Nelson DG, McQuillen KK, Duffy SJ, Linakis JG: Wood's lamp utility in the identification of semen. *Pediatrics* 1999;104:1342–1344.
- Siegel RM, Schubert CJ, Myers PA, Shapiro RA: The prevalence of sexually transmitted diseases in children and adolescents evaluated for sexual abuse in Cincinnati: Rationale for limited STD testing in prepubertal girls. *Pediatrics* 1995;96:1090–1094.

- Shapiro RA, Schubert CJ, Siegel RM: *Neisseria gonorrhoea* infections in girls younger than 12 years of age evaluated for vaginitis. *Pediatrics* 1999;104:e72 (www.pediatrics.org/cgi/content/full/104/6/e72).
- Steward MS, Schmitz M, Steward DS, Joye NR, Reinhart M: Children's anticipation of and response to colposcopic examination. *Child Abuse Negl* 1995;19:997-1005.
- Summit RC: The child sexual abuse accommodation syndrome. *Child Abuse Negl* 1983;7:177-193.
- Sury MRJ: Genital examination under ketamine sedation in cases of suspected sexual abuse (letter). *Arch Dis Child* 1994;71:481.
- Teixeira WR: Hymenal colposcopic examination in sexual offenses. *Am J Forens Pathol* 1981;2:209-215.
- Vandeven AM, Emans SJ: Vulvovaginitis in the child and adolescent. *Pediatr Rev* 1993;14:141-147.
- Waibel-Duncan MK, Sandler HM: Pediatric anogenital examination: A theory-driven exploration of anticipatory appraisal and affects. *Child Maltreat* 2001;6:50-58.
- Warrington S, de San Lázaro C: Lichen sclerosus et atrophicus and sexual abuse. *Arch Dis Child* 1996;75:512-516.
- West R, Davies A, Fenton T: Accidental vulval injuries in childhood. *BMJ* 1989;298:1002-1003.
- Young SJ, Wells DLN, Ogden EJD: Lichen sclerosus, genital trauma and child sexual abuse. *Aust Fam Physician* 1993;22:729-733.

Bernhard Herrmann, MD
Child Protection Center
Kinderklinik des Klinikums (Pediatric Department, Klinikum Kassel)
Mönchebergstrasse 43, DE-34125 Kassel (Germany)
Tel. +49 561 9803389, Fax +49 561 9806951
E-Mail b.herrmann@t-online.de or herrmann@klinikum-kassel.de

.....

Delayed Puberty

Patrick Fenichel

Service d'Endocrinologie et Médecine de la Reproduction,
Centre Hospitalo-Universitaire de Nice, Hôpital de L'Archet, Nice, France

Developmental changes during puberty in girls occur over a period of 3–5 years, usually between 9 and 14 years of age. They include the occurrence of secondary sex characteristics beginning with breast development, the adolescent growth spurt, the onset of menarche – which does not correspond to the end of puberty – and the acquisition of fertility, as well as profound psychological modifications. These events are consecutive to the stimulation of the hypothalamic-pituitary-ovarian axis, which leads to sex-steroid secretions acting on specific receptors. Even though the reactivation of the LHRH pulse generator, already functional since the perinatal period, has been thought for 20 years [1] to be the *primum movens* of puberty, the inhibitory and stimulatory neuro-mediators controlling this reactivation remain to be fully elucidated [2]. Since puberty is a long, ongoing developmental process with significant individual and population differences in timing, the definition of delayed puberty for a given individual needs to be based on simple though arbitrary criteria from epidemiological data.

Although several genes involved in the hypothalamic-pituitary-gonadal maturation cascade have been characterized recently from familial or sporadic cases of primitive isolated hypogonadotropic hypogonadism (IHH) [3], many genes influencing puberty onset remain undetermined [4]. Identification of the Ob gene product and the role of leptin in reproduction [5] have highlighted the influence of nutritional factors, as illustrated by the frequent association of delayed puberty with systemic diseases and/or with a negative energetic balance.

In cases of delayed puberty and/or primary amenorrhea, a complete clinical exam including a detailed history evaluates the development of secondary sex characteristics and looks for an association with growth delay and other specific features to determine etiology. This clinical check-up, which may be completed by biological, radiological and genetic investigations, will try to

distinguish which girls will have permanent sexual infantilism of gonadal, pituitary or hypothalamic origin, which will undergo spontaneous but delayed puberty, and which have primary amenorrhea with developed secondary sex characteristics. Management will have to integrate etiological factors, statural prognosis, bone mass preservation and psychological factors.

Physiological Aspects

Increase in the pulsatile release of LHRH is a necessary condition for puberty onset, as demonstrated 22 years ago by Knobil et al. [1] in rhesus monkeys. Appropriate intermittent pulsatile secretion of LHRH stimulates the pituitary-ovarian axis and controls and maintains the menstrual cycle, allowing ovarian sex-steroid secretion and follicular maturation. The LHRH neurosecretory system already works in the neonatal period, leading to gonadotropin stimulation and estrogenic secretion during the first 6 months of life [6]. It then enters a dormant state during childhood with reduced LHRH pulses, low secretion of gonadotropins, and very low estrogenic secretion. The nocturnal increase in pulse frequency, pulse amplitude and baseline level of LHRH will initiate pubertal maturation, followed by prominent nocturnal increasing amplitude in mid-puberty until the time of the first ovulation. Then, in late puberty, the circadian fluctuation and pulse amplitude will decrease to the adult level [6].

During the early pubertal period, maturation of the LHRH neurosecretory system allows an increase in mean FSH levels, followed by an increase in mean LH levels. Basal levels of LH and amplitude and frequency of LH pulses increase with circadian fluctuations with an increasing ratio of basal LH/FSH. The increase in gonadotropins stimulates ovarian estrogen secretion, which induces peripheral sexual changes and FSH suppression by a negative feedback effect. Periodic changes in the increasing secretion of estrogen will lead to the first vaginal bleeding (menarche) before any LH surge or ovulation [6]. Regular adult ovulatory cycles will occur more than 1 year after menarche. The adult type of pulsatile LHRH release is mandatory for the positive feedback effect of estrogen after a priming effect of the gonadotropic cells by both pulsatile LHRH and increasing levels of estrogen, as illustrated in the model of anorexia nervosa [7].

Increase in pulsatile LHRH release clearly triggers puberty. However, the precise neuronal mechanisms of the reactivation of the LHRH pulse generator and the establishment of the adult type of pulsatile LHRH release remain incompletely elucidated [2]. A classical hypothesis known as the 'gonadostat theory' has proposed that a differential sensitivity of the hypothalamus to the ovarian steroid negative feedback could explain the onset. However, even though

the estrogen-dependent suppression of gonadotropin secretion is stronger in prepubertal girls than in adults, it cannot explain why children with ovarian dysgenesis or total ovarian destruction have very low levels of FSH and LH during infancy until the prepubertal period [8]. In fact, one has to consider the hypothesis that sexual quiescence before the onset of puberty is the consequence of a central inhibition of LHRH release, independent of estrogen negative feedback, and that an autonomous increase in pulsatile LHRH release triggers puberty. Several studies in female monkeys support the evidence that γ -aminobutyric acid (GABA) is the predominant inhibiting neurotransmitter during prepuberty that acts directly or indirectly on LHRH neurons through GABA_A receptors [2]. These receptors are present on LHRH neurons and also on glutamate neurons. Maturation of the hypothalamus and the neurosecretory LHRH system during development and puberty may involve decrease of GABA synthesis and secretion, allowing decrease in the direct inhibition on LHRH neurons and the liberation of the glutamate pathway able to stimulate indirectly LHRH release [2].

Though opioids do not have any inhibiting action on LHRH release before puberty – as they do in the adult during stress – the importance of other inhibitory neurotransmitters before and at the onset of puberty are still under discussion [2]. For example, neuropeptide Y (NPY) plays several important roles in regulating brain function, including food intake behaviors. It seems to have an inhibitory action on LHRH release before puberty and this inhibiting effect decreases during and after puberty [2]. Quantitative or qualitative undernutrition can delay puberty and induce functional amenorrhea [9]. Metabolic factors such as glucose and/or amino acids may act directly by modulating neurons involved in the control of LHRH release. Frisch and McArthur [10] have postulated that a minimal weight, body mass index – or even better, body fat mass – is necessary for the onset of puberty in girls. Actually, leptin, which is the product of the Ob gene and is secreted by adipose tissue, increases in girls during the pubertal stages [11]. Leptin receptors are present in the hypothalamic centers especially on NPY neurons. Leptin could serve as a link between the reproductive function and the energetic balance [12, 13] and participate in puberty onset and the maintenance of the adult hypothalamo-pituitary-ovarian axis. Leptin deficiency is associated with primitive IHH [5], while puberty can be induced by recombinant leptin [14]. However, this induction cannot be obtained before a critical age, which suggests that leptin has to be considered more as a permissive factor not critical for the timing of puberty, rather than as a trigger of onset [15]. Nevertheless, it seems useful to evaluate leptin blood level in girls in all situations of functional delay of puberty associated with negative energetic balance consecutive to general diseases or undernutrition, whether intentional or not.

The hypothalamic-somatotropic-insulin-like growth factor I axis and the hypothalamic-gonadotropic-ovarian axis present striking similarities and interactions during puberty. Both are controlled by a neurosecretory system, which includes pulsatile intermittent secretion (LHRH/GHRH), that will present developmental changes during puberty resulting in an amplification of pulsatile neurohormone secretion. Both are controlled by multiple neural, hormonal and metabolic influences. Interactions between both endocrine systems are not yet well understood but puberty needs a functional growth hormone (GH) axis for full gonadal activation and onset of puberty is associated with a dramatic increase in linear height velocity. In girls, but probably also in boys, estrogens are responsible for the amplifying secretory activity of the GH axis during puberty [16, 17]. Estrogens will induce the height velocity spurt and then influence epiphyseal maturation. Estrogens have in fact a biphasic action on longitudinal growth [18]. At first, very low levels of estrogens may stimulate bone growth indirectly through stimulation of the GH-IGF-1 axis, without affecting sexual maturation, and then higher levels of estrogens stimulate secondary sexual characteristics and epiphyseal fusion [18]. Furthermore, GH secretion will contribute through IGF-1 action to complete ovarian development.

Epidemiological Aspects

Age at onset of puberty varies greatly among individuals and populations and seems to be influenced by both genetic and environmental factors [3]. It follows an approximately normal or gaussian distribution [3]. In girls, the onset of menarche has generally been used as the easiest and most objective indicator for comparative studies. It has been well documented that the average age of menarche has decreased in industrialized northern countries by approximately 2–3 months per decade over the last century [18–20]. This secular trend toward earlier onset has been related to increased socio-economical level, improved nutrition and better health. Nevertheless, this decrease seems to have been attenuated more recently and to have reached a plateau in Europe [20] and the USA [19] with the average age of menarche between 12.5 and 13 years and Tanner stage 5 [21] reached between 14 and 14.5 years. However, the same authors reported that the onset of breast development or Tanner breast stage 2 (B_2) seems to occur earlier than previously thought in the USA [19], although adequate earlier studies of breast development are not available for objective comparison. Whether environmental factors such as endocrine disrupters with estrogenic effects have any influence on this phenomenon remains to be verified [20]. Mean age of B_2 is 9.5 years [19] to 10.9 years [22] and it will take 4 years to reach complete breast development (B_5). One precocious event of

female puberty is the increase in linear growth and the peak in growth velocity (9 cm/year) reached between stages B₃ and B₄ at an age of 12–14 years. Menarche will occur at 12.7 years and ovulatory cycles at age 14. Based on epidemiological data, delayed puberty in girls has been defined as the failure to manifest the initial signs of sexual maturation, which begins in girls with breast development, by the age of 13 years (2 SD above the mean for the population) or as lack of menstruation 5 years after the onset of pubertal development with uncompleted development of secondary sex characteristics [6]. Infantilism is defined by delayed puberty for a bone age of 13 years [6]. Primary amenorrhea is defined by the absence of menstruation in a 15-year-old girl whether secondary sexual characteristics are absent, partially or completely developed [3].

Clinical Aspects

Initial evaluation, based on a detailed history and complete clinical exam, will establish undeveloped, partially or completely developed secondary sex characteristics and precise growth development, look for indications of etiology and assess the degree of anxiety of the patient and her parents. Family history will be studied for consanguinity, delayed puberty onset in parents or siblings, and cases of anosmia or infertility. The patient history will include any disorders during pregnancy, difficulties during labor and delivery with birth trauma, prematurity or hypotrophy, problems of linear growth, anosmia or inadequate nutritional status during childhood associated or not to a chronic disease of the lungs, heart, kidney, blood or gastrointestinal tract. This exam will also focus on food-related behaviors, in particular selective or inadequate diets or signs of anorexia nervosa, excessive intensive sports practice or psychological, affective, relational troubles.

The physical exam includes examination of the breasts (glandular tissue and areolar size), pubic and axillary pilosity and external genitalia rated according to the standard stages [21]; this exam helps to discriminate between true infantilism, arrested pubertal development and primary amenorrhea. Determination of height and weight, as well as the standard deviations from the mean value for chronological age, will be included in a comprehensive chart since birth, completed by the height velocity curve. Physical examination may find associated signs such as galactorrhea, congenital malformations or neurological signs.

Complementary studies include first FSH and LH determination to discriminate between gonadal peripheral origin with high FSH level, hypogonadotropic deficiency with low FSH and LH levels and primary amenorrhea with mature

adult gonadotropin secretions. Radiographic bone age determination will then help to interpret linear growth in relation to pubertal development, and pelvic ultrasound will confirm the presence of ovaries and uterus and rate their developmental stage.

Etiological Aspects

Actually, after this clinical exam and these simple complementary investigations, the physician often has a presumptive diagnosis. The easiest case is when FSH is elevated (hypergonadotropic hypogonadism). In this case the work-up will be completed with a karyotype. If gonadotropins are low it will be less easy: the physician will have to eliminate organic disease such as a tumor by brain MRI, screen for negative energetic balance, and identify genetic causes of isolated IHH before being able to diagnose an idiopathic constitutive delay of puberty.

Hypergonadotropic Hypogonadism

Elevated FSH and/or LH levels reflect peripheral ovarian disease and raise the need to verify female phenotype, check for the presence of ovarian and uterine tissues by ultrasound, and determine the karyotype on peripheral blood lymphocytes before examining the ovaries by celioscopy and biopsy.

Gonadal Dysgenesis with Chromosomal Abnormalities

Turner's Syndrome and Its Variants

Turner's syndrome, the most frequent cause of primitive ovarian failure, associates in its classical monosomic 45,XO form a female phenotype, short stature, several somatic abnormalities and sexual infantilism. In this form, diagnosis has frequently, but not always, been made during infancy [23–25]. Any suggestive malformations (webbed neck, nail dysplasia, high palate, short fourth metacarpal and strabismus), growth retardation and/or elevated FSH must lead to the verification of the karyotype. However, in its variant forms with mosaicism or structural abnormalities of an X chromosome (iso, deletion, translocation X/autosome), there are several phenotypes for pubertal development from infantilism to partial development of secondary sex characteristics, primary amenorrhea or even spontaneous puberty. Indeed, spontaneous puberty

occurs in 10–20% [26, 27], followed by premature ovarian failure especially in cases of mosaicism with few 45,X cells or deletion of the X short arm. Treatment with recombinant GH may be able to accelerate partial pubertal development [28]. In fact, both X chromosomes are necessary for the preservation of ovarian function and oocytes. Specifically, some areas such as the Xq13-q26 region contain genes which are thought to prevent premature follicular atresia. In Turner's syndrome, germinal cells are present and normal until the fourth month of intrauterine life. Regression of gonocytes will then depend on the importance of the X defect. At birth, ovarian morphology can vary from ovarian streaks to macroscopically normal ovaries.

Mosaicism can be associated with the partial presence of a Y chromosome found on cytogenetic analysis. A systematic molecular analysis found it in 1 out of 40 cases [29]. If present, castration will prevent the development of gonadoblastoma [30].

Gonadal Dysgenesis with a 46,XY Karyotype

In the Swyer syndrome which associates a female phenotype, normal or elevated height, non-ambiguous external genital organs, and normal müllerian structures, the gonads are often reduced to undifferentiated streaks. They may have some testicular characteristics. Because they carry the risk of neoplastic transformation, they must be removed. Mutations of the SRY gene will be found only in 20% of cases [31].

Gonadal dysgenesis with a 46,XY karyotype with complete sexual reversion and without genital ambiguity has also been related to other mutated genes involved in sex differentiation: (a) WT1 with Wilms' tumor and renal insufficiency in the Drash syndrome [32] and without Wilms' tumor but another renal pathology in the Frasier syndrome [32]; (b) SOX-9 associated to campomelic dysplasia [33], and (c) DAX-1 with duplication of the Xp21 region [34].

Complete Resistance to Androgens

Mutations of the gene coding for the androgen receptor, located on chromosome X, will lead to various degrees of androgen resistance in boys, with a male pseudohermaphroditism with a 46,XY karyotype and a female phenotype in the complete form [35]. Diagnosis will be made only in the peripubertal period, suggested by primary amenorrhea with no pubic or axillary pilosity but normal breast development. LH level is very high with adult male testosterone level, FSH level is normal, and estradiol is almost at a follicular phase level allowing breast development. The vaginal cavity is short and closed. Ultrasound will confirm the absence of müllerian and wolffian structures and identify abdominal or inguinal testes, which will have to be removed. Estrogens will

complete feminization, though without menstruations due to lack of a uterus; sterility will be without therapeutic solution.

Karyotypically Normal 46,XX Ovarian Dysgenesis

Ovarian dysgenesis with a normal 46,XX karyotype is defined by reduced or altered ovaries, a female phenotype, and normal stature with no turnerian malformations. Diagnosis is suggested by primitive hypergonadotropic hypogonadism with a normal 46,XX karyotype. In some cases a genetic origin has been identified. For the other cases, unidentified autosomal and gonosomal genes may be involved in the development and maintenance of ovarian function:

Syndromic Hypergonadotropic Hypogonadism

Perrault syndrome is an autosomal recessive ovarian dysgenesis with possible deafness [36]. The defective gene has not yet been identified.

Type I BPEIS (blepharophimosis psosis epicanthus inversus syndrome) can be associated with delayed puberty or, more frequently, with premature ovarian failure. The mode of inheritance is autosomal dominant and transmitted by males because women are always infertile with ovarian streaks. The gene has been identified on chromosome 3 [37, 38].

Congenital galactosemia is associated with primary ovarian failure diagnosed mostly at an early age [39]. Metabolic toxicity already impairs follicular cells during fetal life [39].

Inactivating Mutation of the FSH or LH Receptor

An inactivating mutation of the FSH receptor was first described in Finland [40] and is associated with either primary amenorrhea or premature ovarian failure. The ovaries have normal size and biopsies show the presence of multiple pre-antral follicles. This corresponds to the ovarian resistance to gonadotropins, or Savage syndrome. The gene encoding for the FSH receptor is located on chromosome 2 and the mode of inheritance is autosomal recessive. Although two observations were recently described in France [41], a study from the USA failed to find any mutated FSH-R gene among 35 cases of premature ovarian failure [42].

A few observations have been reported [43] with an inactivating mutation of the gene encoding for the LH receptor in homozygotic XX women with primary amenorrhea, developed sex characteristics, and high LH level but normal FSH level [43] with normal ovarian follicles but without any luteal corpus.

Iatrogenic Ovarian Failure

Prepubertal girls treated with radiation therapy or chemotherapy may present gonadal failure with delayed puberty or primary or secondary amenorrhea. In cases of abdominal or pelvic radiotherapy, the ovaries must be surgically removed from the radiation field [44]. Chemotherapy induces follicular atresia, especially when alkylant agents are used [45] or in association with radiotherapy. Cryopreservation of ovarian fragments will be possible in the near future.

Hypogonadotropic Hypogonadism

Delayed puberty may be related to gonadotropin deficiency: FSH and LH plasma levels are low, as are urinary gonadotropins. This insufficiency may be caused by a pituitary defect of the gonadotropic cells, isolated or associated with other pituitary cell deficiencies, by a lesion of the pituitary stalk or by a defect of the hypothalamic center with altered pulsatile secretion of LHRH. Theoretically, the origin of the defect can be differentiated by an LHRH stimulation test (100 μ g IVD). However, even with normal gonadotropic function, preliminary priming with pulsatile LHRH may be necessary to obtain a positive response to LHRH stimulation. LHRH pulsatile secretion cannot be explored directly but it can be assessed indirectly by measuring LH pulsatility every 10 min for 6 or 8 h during the night.

Gonadotropin deficiency may be secondary due to a direct organic lesion of the hypothalamo-pituitary axis (tumoral, inflammatory, vascular or traumatic origin), or to an indirect functional inhibition of the pulsatile LHRH secretion (chronic disease, negative energetic imbalance). Gonadotropin deficiency may also be primitive, caused by a genetic or developmental defect present at birth but unremarkable before puberty. Finally, in absence of any deficiency, delayed puberty may be simply due to a constitutional idiopathic delay in puberty usually associated with growth delay.

Gonadotropin deficiency may be associated with other pituitary defects, especially GH secretion. Impaired growth is suggested by decreased growth velocity and short stature and confirmed by a negative response to dynamic exploration of the somatotropic axis. In cases of isolated gonadotropin deficiency, height is usually normal for age but bone age is retarded in accordance with the delayed puberty and very low or absent response to LHRH. In contrast, girls with functional delayed puberty or constitutional delay are short for chronological age, with normal growth rate for bone age and plasmatic and urinary gonadotropins not so low [46]. If bone age has reached 11 years, gonadotropic deficiency is likely; if not, functional or constitutive delayed of growth and puberty is more likely.

Acquired IHH

Organic Direct Gonadotropin Deficiency

To establish etiological diagnosis, complete medical history and clinical exam are associated with systematic computed tomography (CT) or magnetic resonance imaging (MRI) scans of the hypothalamic and pituitary areas, as well as assessment of the other pituitary endocrine secretions.

Tumoral Origin

Central nervous tumors leading to delayed puberty can affect either the intra- or extrasellar control of gonadotropins and are usually associated to other anterior or posterior pituitary deficiencies.

– Craniopharyngioma is the most frequent tumor associated with delayed puberty in girls. It originates from Rathke's pouch, with generally a suprasellar development around the pituitary stalk. Clinical symptoms of compression (headache or visual disturbances) and/or endocrine deficiencies (asthenia, short stature, diabetes insipidus, infantilism) generally lead to diagnosis between 6 and 15 years of age. Ophthalmological examination finds visual defects such as bilateral temporal field deficit, optic atrophy and papilledema. Full endocrine screening may confirm strong or moderate somatotroph, thyrotroph, corticotroph and vasopressin deficiencies associated to gonadotropin deficiency [47]. Radiographic determination of bone age will verify the presence of bone maturation delay. Supra- and intrasellar calcifications are very much characteristic of such a tumor and are clearly seen on CT scans. Imaging will look for an abnormal sella, a cystic or solid tumor and the presence or absence of hydrocephalus. Treatment associates transphenoidal microsurgery when possible and radiation therapy. Other endocrine deficiencies are supplemented. It is important for future fertility prognosis to discriminate between a pituitary or suprapituitary origin of the gonadotropin deficiency because of the possibility of administering pulsatile intermittent LHRH in suprahypophyseal defects to induce ovulation and pregnancy [48].

– Germinomas or germ cell tumors of the central nervous system (CNS) may cause sexual infantilism with vasopressin and GH deficiency discovered in about the second decade of life. CT and MRI are able to show tumors >0.5 cm in diameter. The tumor may be located in the suprasellar hypothalamic region, the pineal region or another area of the CNS. Radiation therapy is the best treatment.

– Hypothalamic and optic gliomas associated or not to von Recklinghausen disease or astrocytomas seldom cause delayed puberty.

– Hyperprolactinomas can develop during the peripubertal period and lead to arrested pubertal development with primary amenorrhea. In fact,

hyperprolactinemia inhibits pulsatile LHRH secretion, inducing gonadotropin deficiency. Thus, evaluation of the PRL axis is necessary in case of IHH.

– Irradiation of the head in case of CNS tumors, leukemia or tumors of the head and the face may induce progressive hypothalamo-pituitary deficiency including gonadotropin deficiency.

Non-Tumoral Acquired Organic Lesions of CNS

– Histiocytosis X (Hans-Schüller-Christian disease) is characterized by multiple organ infiltration (skin, bone, viscera) by histiocytic cells. Infiltration of the pituitary stalk and hypothalamus is possible with diabetes insipidus and GH or gonadotropin deficiency. Enlargement of the pituitary stalk and diabetes insipidus are very suggestive; however, positive diagnosis requires histological analysis of the lesions that are easy to biopsy [49].

– Sarcoid or tuberculous granuloma or secondary hemochromatosis may also but more rarely infiltrate the hypothalamo-pituitary axis and be associated with delayed puberty in girls.

– Hydrocephalus may be caused by such a condition [50].

– Traumatic, inflammatory, post-infectious or vascular lesions of the hypothalamo-pituitary axis are seldom responsible for such a condition.

Functional IHH

Any situation with a negative energetic balance may interfere with the pattern of LHRH pulsatile secretion [9] through the leptin/NPY pathway or other neurotransmitters. Thus, quantitative and qualitative nutritional status, body mass index, body fat mass and plasma leptin levels are important features to assess in cases of severe systemic and chronic disease. A specific condition is characterized by a negative energetic balance related to a particular nutritional status.

Chronic Disorders

Many chronic diseases are associated with delayed or arrested pubertal development depending on the age of onset. Malnutrition, asthenia, negative energetic balance with reduced body mass index, body fat mass and/or qualitative nutritional deficiency may induce functional IHH by impairing pulsatile LHRH secretion. This must be distinguished from the primary effects of the disease.

– Digestive disease: celiac disease must be considered in cases of unexplained growth retardation and delayed puberty. Digestive manifestations may be absent. Positive diagnosis is made by detection of specific antitransglutaminase antibodies and the typical aspect with atrophic villosities seen on jejunal biopsies [51].

– Inflammatory bowel diseases may also be associated with delayed puberty in cases of weight loss and steroid treatment.

– Chronic pulmonary disease such as cystic fibrosis can induce the same deficiency in large part due to malnutrition [52].

– Chronic renal disease before transplantation or steroid-sensitive nephrotic syndrome.

– Major thalassemia [53] or sickle cell disease [54] can impair sexual maturation in the same way or by iron deposition in the pituitary gland.

Negative Energetic Balance

Undernutrition of any origin, intentional or not, delays puberty in girls. The secular trend toward earlier onset of puberty in girls is consecutive to the generally improved nutrition in developed countries [22]. Food restriction, vegetarian diets, and disturbed food behavior as in anorexia nervosa can be associated with delayed puberty and/or primary or secondary amenorrhea. Anorexia nervosa is a severe disease with distorted body image, food avoidance, severe weight loss with hyperactivity, decreased basal metabolic rate, hypothermia, constipation, bradycardia and hypotension and severe metabolic abnormalities leading sometimes to death. Leptin is very low [55] in relation to weight loss and lack of body fat mass while the gonadal axis remains at or returns to an infantile state.

Intensive exercise in young girls (ballet dancers, athletes, gymnasts) may be associated with delayed puberty due to a negative energetic balance, special diet, and stimulation of the corticotropic axis (endorphins, ACTH, cortisol) under exaggerated stress, leading to impaired pulsatile LHRH secretion [56, 57].

Congenital Gonadotropin Deficiency

Primary gonadotropin deficiency is associated with very low levels of FSH and LH, concordant bone age, normal stature – unless multiple pituitary deficiencies including GH are associated – and normal karyotype. Response to LHRH testing and study of LH pulsatility are useful for diagnosis. Radiographic imaging of the hypothalamic-pituitary regions shows normal findings while baseline and reserve testing of the other hypothalamic-pituitary axes are needed to detect possible multiple pituitary deficiencies. Associated features may sometimes suggest an etiology, for example in cases of familial history of consanguinity or similar cases. Different genes have already been identified and a molecular diagnosis is sometimes possible.

Syndromic Primary Gonadotropin Deficiency

Multiple Endocrine Deficiencies

Idiopathic dwarfism is associated with delayed puberty. After confirmation of the GH deficiency, treatment with recombinant GH will try to induce

pubertal development, which needs IGF-1. IGF-1 enhances ovarian stimulation by LH and FSH. Moreover, multiple pituitary deficiencies, including thyrotroph, corticotroph and gonadotroph, are possible in cases of a mutation of recently identified developmental genes, such as PROP-1 [58].

Obesity

– Prader-Willi syndrome [59] is characterized by massive obesity, infantile hypotonia, mental retardation, short stature, small hands and feet, and characteristic facies. Delayed puberty is of hypothalamic origin and sometimes improves following weight reduction. A deletion of the long arm of chromosome 15 may be found in some patients.

– Laurence-Moon-Bield syndrome associates obesity, polydactyly, mental retardation and retinitis pigmentosa with delayed puberty [60]. The mode of inheritance is autosomal recessive.

– Mutation of the leptin Ob or Ob-R gene is exceptional. Clinical features include morbid obesity with impaired food behavior, decreased basal metabolic rate and IHH. Puberty may be induced by recombinant leptin in cases of mutated Ob gene [5].

– Mutations of the human prohormone convertase 1 (PC1) gene have been reported with obesity, IHH, hypocortisolism, and abnormal glucose homeostasis due to very low insulin level and high proinsulin level [61].

Anosmia: The Kallmann Syndrome (KS)

Association of anosmia with IHH (idiopathic IHH) is called the KS. In boys, it may be due to the mutated X-linked Kal gene [62, 63]. This gene encodes a protein, anosmin, which plays a role in the migration of LHRH neurons and olfactory nerves to the hypothalamus. In fact, in KS only 14% of familial and 11% of sporadic male cases are associated with mutation of the Kal gene [3]. The majority, including female cases of KS, are caused by defects on at least two autosomal genes that are currently unknown [64] with either a dominant or recessive mode of inheritance.

Isolated Idiopathic IHH

Impaired Pulsatile Secretion of LHRH

In absence of anosmia, the Kal gene is not involved, as demonstrated by Quinton et al. [65]. However, familial histories have suggested the role of two different autosomal genes, as just described for non-X-linked Kal gene-related cases of KS [64]. In these patients, partial LHRH neuronal migration is possible, leading to partial LHRH pulsatile secretion [64] and partial pubertal development with primary amenorrhea (table 1).

Table 1. Genetics of primitive hypogonadotropic hypogonadism

Syndrome		Gene	Chromosome	LH pulsatility	LH response to LHRH after pulsatile administration
Pituitary hormone deficiency	Several endocrine deficiencies	PROP-1	19	↘	↘
Obesity					
Prader-Willi	Malformations	Autosomal recessive	15	↘	↗
Laurence-Moon-Bield	Malformations + mental retardation	Ob		↘	↗
Leptin deficiency	Polyphagia, reduced basal metabolic rate	Ob	7	↘	↗
Proconvertase 1 deficiency	Hypocortisolism abnormal gland homeostasis	Ob-R PC1	1	↘	↗
Adrenal hypoplasia	Adrenal insufficiency	Dax 1	X	↘	↗
Anosmia (Kallman syndrome)		Autosomal recessive Autosomal dominant		↘ ↘	↗ ↗
Isolated					
GnRH receptor		GnRH-R	4	↘/-	↘/-
FSH		FSH-β subunit	X	N	↗
Non-X-linked PHH		Autosomal recessive Autosomal dominant		↘ ↘	↗ ↗

Mutation of the LHRH Receptor Gene

In absence of response to the LHRH stimulation test and to pulsatile LHRH administration, a mutation of the LHRH receptor gene, which is located on chromosome 4, can be considered. Several autosomal recessive forms of congenital isolated IHH have been reported with such mutations. However, the phenotype seems to vary from partial to complete forms [66, 67] and the same molecular defect can exhibit different degrees of hypogonadism [68]. Such mutations must be looked for in isolated IHH in cases of absent or impaired response to LHRH stimulation and/or to pulsatile LHRH administration.

Inactivating Mutation of FSH β Subunit

Only a handful of inactivating mutations of the FSH β gene located on Xp21 in women have been reported: one with partially developed secondary sex characteristics [69] and two with primary amenorrhea [70].

Mutation of DAX1 Gene (Double Dose Adrenal Hypoplasia Congenital X-Linked Gene 1)

DAX1 is a transcriptional factor of the orphan nuclear receptor family which is involved in sexual differentiation and development of adrenal gland, hypothalamus, hypophysis and gonads. Mutations of this X-linked gene in males lead to adrenal congenital hypoplasia with neonatal adrenal insufficiency and deferred IHH revealed at adolescence. However, some cases of isolated IHH have been reported in women, which could represent a mild form of male HH associated with congenital adrenal hypoplasia. One observation with a homozygotic mutation in a woman with IHH [71] and two other cases have been found by studying families of male cases and represent heterozygotic female forms with delayed puberty [72].

In fact, all these mutations on these different identified genes account for less than 20% of all IHH cases [3]. Additional gene mutations will certainly be identified to help us to elucidate IHH syndromes and control of gonadotropin secretion.

Constitutional Delay in Growth and Puberty (CDGP)

Delayed puberty as described earlier has a statistical definition based on epidemiological studies. Onset of development, which includes tightly related growth and pubertal development, has a variable timing that depends on genetic and environmental factors [2]. This means that some of the girls who present delayed puberty, generally associated with growth delay and short stature (-2 SD below mean values for height for age) do not have any illness but present a simple variation in the timing of development. In this case, follow-up shows the spontaneous onset of the development of secondary sex characteristics and the acceleration of growth velocity.

However, it is sometimes difficult in the beginning to differentiate between CDGP and true IHH, although some signs can orient the treatment. Evaluation and follow-up are in any case necessary and the principal goal of the clinical, biological and radiological exams is to eliminate organic disease. There might be similar cases of CDGP in parents or siblings. First of all, true somatotropic deficiency must be eliminated. In CDGP, short stature and slow growth velocity correlate well with bone age, which reflects delayed puberty and not chronological age. GH secretion may be low on basal levels while stimulation tests are positive, although at a suboptimal level [73], corresponding in fact to the true

prepubertal status. There are no real hormonal deficiencies as evidenced by combined pituitary function tests and systematic radiological examination such as MRI does not show any tumoral image or abnormal infiltration.

Medical history does not reveal known chronic disease. Celiac disease has been eliminated by negative specific antibodies. Functional delayed puberty with a negative energetic balance must also be eliminated by studying nutritional, psychological and athletic background. It is particularly important to screen selective food behavior or disorders suggesting anorexia nervosa or a severely conflicted affective relationship. In fact, the most difficult differential diagnosis is with IHH in the beginning before regular follow-up. However, adrenarche is also delayed in CDGP but not in IHH. Growth is not delayed in IHH and there is no short stature for age. There are no associated signs such as anosmia, obesity, or malformations in CDGP and when bone age exceeds 11 years, usually pubertal development begins. Biological hormonal data (basal plasma LH, FSH levels, urinary gonadotropins), response to a stimulation test with LHRH, and pulsatile LHRH are statistically lower for IHH than for CDGP and become discriminative for a bone age of 11 years. Lack of LH pulses is highly suggestive for IHH but more difficult to study (measured for 24 h at 10-min intervals). FSH level [74] has been strongly related to lack of LH pulses and LH response to LHRH agonist [75] seems to be more discriminative than the LHRH stimulation test.

Primary Amenorrhea with Developed Secondary Sex Characteristics

In cases of partially or completely developed secondary sexual characteristics, patients will refer to the physician for primary amenorrhea at an age of 14 or 15 years. Gonadotropin levels are normal and can be stimulated by a LHRH test. The clinical exam will check that genitalia are normal using complementary ultrasonography and also look for associated clinical and biological hyperandrogenia.

Abnormalities of the Genitalia

– Cyclic pain and hymeneal convexity suggest the hematocolpos of the unperforated hymen. It will be assessed by ultrasound and treated by radial incisions.

– Complete vaginal partition or vaginal aplasia is visualized using a speculum for virgins. Ultrasound will confirm the presence of a uterus and a hematometria. The goal of surgical treatment will be to obtain a vaginal cavity connecting with the uterus and allowing sexual intercourse.

– In Rokitansky–Kuster-Hauser syndrome [76], vaginal aplasia is associated with uterine hypoplasia or aplasia. Ovaries and fallopian tubes are usually

preserved. Ultrasonographic evaluation is again crucial and will also allow verification of the renal apparatus because renal abnormalities are frequently associated. Laparoscopy will confirm the diagnosis and suggest the most appropriate surgical treatment. Surgery consists in creating a neovaginal cavity by several means to allow sexual intercourse. Pregnancy will nevertheless not be possible because of the lack of a uterus.

– Prepubertal genital tuberculosis with uterine synechia and primary amenorrhea is nowadays exceptional in developed countries.

Hyperandrogenia

Sexual ambiguities have been diagnosed during the neonatal period. However, pubertal development may be associated with progressive hyperandrogenia or virilization including hirsutism, seborrhea, severe acne, alopecia and hyperclitoridism. Clinical hyperandrogenia must be specified by biological evaluation with measurement of plasma androgens, LH and FSH, and assessment of the corticotroph axis including basal and ACTH-stimulated 17-hydroxyprogesterone measurement and ultrasonographic ovarian evaluation.

Mild Adrenal Hyperplasia with Partial Enzymatic Blockage

There are other familial cases of hyperandrogenia or known enzymatic deficiency, short stature and mild hyperandrogenia. Elevated basal or stimulated 17-hydroxyprogesterone suggests the diagnosis of 21-hydroxylase deficiency. 11 β -Hydroxylase and 3 β -hydroxysteroid deshydrogenase are less frequently involved.

Polycystic Ovarian Syndrome (PCO) with Primary Amenorrhea

PCO is suggested by obesity, the presence of acanthosis nigricans reflecting a hyperinsulinic state, hyperandrogenia, and clinical signs of hyperestrogenia. Hormonal evaluation shows high levels of androgens, especially Δ^4 -androstenedione and total testosterone. Basal level of LH is elevated with a strong response to LHRH while FSH remains low. Insulin is high, as well as sex-binding globulin. Ultrasonographic exam shows a typical aspect of the ovaries including enlarged gonads, stromal hypertrophy and multiple peripheral polymicrocysts [77].

Tumoral Syndrome

Rapid virilization and very high levels of plasmatic androgens require ultrasonographic and radiologic examination to look for an ovarian or adrenal androgen-secreting tumor during peripuberty.

Therapeutic Aspects

Treatment of delayed puberty and/or primary amenorrhea requires precise etiological diagnosis, determination of bone age and evaluation of the psychological consequences to the patient and her family in order to evaluate the most appropriate way to give explanations, reassurance and information on the prognosis [78].

Specific treatment must be undertaken when possible to improve pubertal development. This includes surgical treatment of tumors or abnormalities of the genitalia, medical treatment of general diseases, and correction of negative energetic balance by improving quantitative and qualitative food intake, body weight and body fat mass and by reducing intensive sports activity. It also includes treatment of endocrine diseases; pituitary-associated deficiencies must be corrected, in particular GH deficiency, because this will accelerate pubertal maturation. Correction of associated hypothyroidism or inhibition of the corticotrophic axis by dexamethasone in case of adrenal hyperplasia may also be needed.

In cases of PCO, menstruation can easily be obtained by sequential treatment with progesterone: natural micronized progesterone (Utrogestan[®] 200 mg/day orally, 10 or 15 days/month), an isomer of progesterone, dydrogesterone (Duphaston[®] 10 mg/day) or a pregnane compound such as chlormadinone acetate (Luteran[®] 5 mg/day). Weight reduction will also be necessary. If hyperandrogenia is significant and not well accepted, cyproterone acetate, another pregnane compound with high antiandrogenic and antigonadotropic effects, can be used (Androcur[®] 50 mg daily for 15 days associated with estradiol 1 mg daily for 25 days) in pubertal girls with PCO.

Constitutional delay of growth and puberty is classically a situation of waiting and observing until pubertal development occurs spontaneously; meanwhile, parents and patients must be reassured. Some girls will have serious psychological difficulties because of comparisons with their peers and very low self-esteem regarding their short stature and their physical infantile appearance. This can affect success at school, work or socially [79]. In such cases, estrogen administration may have psychobehavioral benefits for such patients. A short, low-dose estrogen treatment (estradiol 0.5 mg/day orally for 3 months) can be proposed at a chronological age of 14/15 years and repeated to induce the beginning of pubertal development, in particular breast development, without advancing bone age too much. This can be continued up to 13 years of bone age [80]. This treatment may help to distinguish between isolated gonadotropin deficiency and constitutional delay of puberty and may induce the beginning of spontaneous pubertal development.

Definitive lack of pubertal development due to an organic congenital or acquired disease requires a protocol of estrogenization [81, 82] with

several goals: (1) to allow the development and maintenance of secondary sex characteristics; (2) to induce the maturation of internal genital organs for future menstruation and adequate uterine development to allow successful pregnancy (nidation); (3) to induce a correct peripubertal growth spurt without reducing the final height; (4) to improve the constitution of bone mass and prevent accelerated loss, and (5) to prevent cardiovascular disease.

Age of treatment has been widely discussed in the past. It depends in fact on the achieved height, bone age and, in case of Turner syndrome, the associated GH treatment. Estrogen therapy is usually started at a bone age between 12 and 13 years. In Turner syndrome, GH treatment is systematically proposed. If GH therapy is started early (between 2 and 10 years), estrogen treatment can be initiated at an age-appropriate time (12/13 years) without compromising adult height [83]. If GH is started later, estrogen therapy will be delayed; however, the statural gain will be lower [84].

Estrogen therapy will begin with low, continuous and progressively increasing doses, without progesterone during the first year of treatment. Ethinyl estradiol, a synthetic estrogen [82], has been widely used (2 µg/day in the beginning to 20 µg at the final adult sequential treatment). Natural estrogens (17β-estradiol) with fewer metabolic side effects are now frequently used (0.2 mg to 2 mg/day) either orally (micronized estradiol) [82] or by transdermic [85] administration (17β-estradiol). Estrogens are first given alone for 1 year with progressive doses up to 0.5 mg estradiol daily and then associated with progesterone. Natural progesterone, 17-hydroxyprogesterone or pregnanes is given in a sequential mode from day 15 to day 24 of the cycle. After 2 or 3 years, adult doses will be adapted. Follow-up will include clinical signs, bone age, ultrasonographic size of the uterus, bone mineral content evaluated by dual-energy X-ray absorpsiometry [86] and psychological evolution and tolerance.

Explanations and information about this chronic hormonal replacement therapy will be given to the patient and her family [87]; the future chances of fertility by ovarian stimulation by menotropins or LHRH pulsatile administration in case of IHH [88] will be discussed. Information concerning oocyte donation [89] should also be suggested in cases of hypergonadotropic hypogonadism.

References

- 1 Knobil E, Plant TM, Wildt L, Belchetz PE, Marshall G: Control of the rhesus monkey menstrual cycle: Permissive role of hypothalamic gonadotropin-releasing hormone. *Science* 1980;207:1371–1373.
- 2 Terasawa E, Fernandez DL: Neurobiological mechanisms of the onset of puberty in primates. *Endocr Rev* 2001;22:111–151.
- 3 Seminara SB, Oliveira LM, Beranova M, Hayes FJ, Crowley WF Jr: Genetics of hypogonadotropic hypogonadism. *J Endocrinol Invest* 2000;9:560–565.

- 4 Palmert MR, Boepple PA: Variation in the timing of puberty: Clinical spectrum and genetic investigation. *J Endocrinol Invest* 2001;86:2364–2368.
- 5 Strobel A, Issad T, Camoin L, et al: A leptin missense mutation associated with hypogonadism and morbid obesity. *Nat Genet* 1998;18:213–215.
- 6 Grumbach MM, Styne DM: Puberty: ontogeny, neuroendocrinology, physiology and disorders; in Wilson JD, Foster DW, Kronenberg HM, Larsen PR (eds): *Williams' Textbook of Endocrinology*, ed 9. Philadelphia, Saunders, 1998, pp 1509–1625.
- 7 Fenichel P, Verdino P, Brucker F, et al: Exploration des hypogonadismes d'origine haute par l'association pompe à LH-RH + test à la LH-RH. *Rev Fr Endocr Clin* 1986;1:27–34.
- 8 Conte FA, Grumbach MM, Kaplan SL: A diphasic pattern of gonadotropin secretion in patients with the syndrome of gonadal dysgenesis. *J Clin Endocrinol Metab* 1975;40:670–674.
- 9 Bringer J, Lefebvre P, Boulet F, et al: Deficiency of energy balance and ovulatory disorders. *Hum Reprod* 1997;12(suppl 1):97–109.
- 10 Frisch R, McArthur JW: Menstrual cycles: Fatness as a determinant of minimum weight for height necessary for their maintenance or onset. *Science* 1974;185:949–951.
- 11 Ahmed ML, Ong KL, Morrell J, Cox L, Drayre N, Perry L, Preece MA, Dunger DB: Longitudinal study of leptin concentrations during puberty: Sex differences and relationship to changes in body composition. *J Clin Endocrinol Metab* 1999;84:899–905.
- 12 Barash A, Cheung C, Weigle S, et al: Leptin is a metabolic signal to the reproductive system. *Endocrinology* 1996;137:3144–3147.
- 13 Foster DL, Nagatani S: Physiological perspectives on leptin as a regulator of reproduction: Role in timing of puberty. *Biol Reprod* 1999;60:205–215.
- 14 Ahima RS, Dushay J, Flier SN, Prabakaran D, Flier JS: Leptin accelerates the onset of puberty in normal female mice. *J Clin Invest* 1997;99:391–395.
- 15 Farooqi IS, Jebb SA, Landmak G, Lawrence E, Cheetham CH, Prentice AM, Hughes IA, McCamish MA, O'Rahilly S: Effects of recombinant leptin therapy in a child with congenital leptin deficiency. *N Engl J Med* 1999;341:879–884.
- 16 Veldhuis JD, Metzger DL, Martha PM, Mauras N, Kerrigan JR, Keenan B, Rogol AD, Pincus SM: Estrogen and testosterone, but not a non-aromatizable androgen, direct network integration of the hypothalamo-somatotrope (growth hormone)-insulin like growth factor I axis in the human: Evidence from pubertal pathophysiology and sex-steroid hormone replacement. *J Clin Endocrinol Metab* 1997;82:3414–3420.
- 17 Kerrigan JR, Rogol AD: The impact of gonadal steroid hormone action on growth hormone secretion during childhood and adolescence. *Endocr Rev* 1992;13:281–298.
- 18 Juul A: The effects of estrogens on linear bone growth. *Hum Reprod Update* 2001;7:303–313.
- 19 Liu XY, Albertson K, Karlberg J: New reference for the age at childhood onset of growth and secular trend in the timing of puberty in Sweden. *Acta Paediatr* 2000;89:637–643.
- 20 Fredriks AM, Van Buuren S, Burgmeijer RJF: Continuing positive secular growth change in the Netherlands 1955–1997. *Pediatr Res* 2000;47:316–323.
- 21 Tanner JM, Whitehouse RH: Clinical longitudinal standards to height, weight, height velocity, and stages of puberty. *Arch Dis Child* 1976;51:170–179.
- 22 Lee PA, Guo SS, Kulin HE: Age of puberty: Data from the USA. *APMIS* 2001;109:81–88.
- 23 De Muinck Keizer-Schrama SMPF, Mul D: Trends in pubertal development in Europe. *Hum Reprod Update* 2001;7:287–291.
- 24 Forest MG: La puberté normale et le retard pubertaire. *Reprod Hum Horm* 2000;2:109–118.
- 25 Säwendahl L, Davenoport ML: Delayed diagnoses of Turner's syndrome: Proposed guidelines for change. *J Pediatr* 2000;137:1–8.
- 26 Rosenfield RL: *Spontaneous Puberty and Fertility in Turner Syndrome*. New York, Dekker, 1990, pp 131–148.
- 27 Toublanc JE, Roger M, Chaussain JL: Etiologies of late puberty. *Horm Res* 1991;36:136–140.
- 28 Price DA, Albertsson-Wikland K: Demography, auxology and response to rhGH treatment in girls with Turner's syndrome in the KIGS. *Acta Paediatr Suppl* 1993;391:69–74.
- 29 Medlej R, Lobaccaro JM, Berta P, Belon C, Leheup B, Toublanc JE, Weill J, Chevalier C, Dumas R, Sultan C: Screening for Y-derived sex determining gene SRY in 40 patients with Turner syndrome. *J Clin Endocrinol Metab* 1992;72:1289–1292.

- 30 Krasna TH, Lee ML, Smilow P, Sciorra L, Eierman L: Risk of malignancy in bilateral streak gonads: The role of the Y chromosome. *J Pediatr Surg* 1992;27:1376–1380.
- 31 Vilain E, McElreavey K, Vidaud M, Richaud F, Fellous M: L'analyse de SRY n'explique pas toute la pathologie du déterminisme du sexe. *Ann Endocrinol* 1991;52:435–436.
- 32 Little M, Wells C: A clinical overview of WTI gene mutations. *Hum Mutat* 1997;9:209–225.
- 33 Wagner T, Wirth J, Meyer J, et al: Autosomal sex reversal and campomelic dysplasia are caused by mutations in and around the SRY-related gene SOX-9. *Cell* 1994;79:1111–1120.
- 34 Bardoni B, Zanaria E, Guioli G, et al: A dosage-sensitive locus at chromosome Xp21 is involved in male-to-male sex reversal. *Nat Genet* 1994;7:497–501.
- 35 Quigley CA, Debellis A, Marschke KB, Elawady MK, Wilson EM, French ES: Androgen receptor defects: Historical, clinical and molecular perspectives. *Endocr Rev* 1995;16:271–321.
- 36 Pallister PD, Opitz JM: The Perreault syndrome: Autosomal recessive ovarian dysgenesis with facultative, non-sex limited sensorineural deafness. *Am J Med Genet* 1979;4:239–246.
- 37 Amati P, Gasarini P, Zlotogora J: A gene for premature ovarian failure associated with eyelid malformation maps to chromosome 3q22-q23. *Am J Hum Genet* 1996;58:1089–1092.
- 38 Nicolino M, Bost M, David M, Chaussain JL: Familial blepharophimosis: An uncommon marker of ovarian dysgenesis. *J Pediatr Endocrinol* 1995;8:127–133.
- 39 Dessart Y, Odievre M, Evian D, Chaussain JL: Insuffisance ovarienne et galactosémie congénitale. *Arch Fr Pédiatr* 1982;39:321–322.
- 40 Huhtaniemi I, Aittomäki K: Mutations of follicle-stimulation hormone and its receptor: Effects on gonadal function. *Eur J Endocrinol* 1998;138:473–481.
- 41 Touraine P, Beau I, Gougeon A, Meduri G, Desroches A, Pichard C, Detoef M, Paniel B, Prieur M, Zorn JR, Milgrom E, Kuttan F, Misrahi M: New natural inactivating mutations of the follicle-stimulating hormone receptor: Correlations between receptor function and phenotype. *Mol Endocrinol* 1999;13:1844–1854.
- 42 Layman LC, Made S, Cohen DP, Jin M, Xie J: The Finnish follicle-stimulating hormone receptor gene mutation is rare in North American women with 46,XX ovarian failure. *Fertil Steril* 1998;69:300–302.
- 43 Latronico AC, Anasti JA, Arnhold JP, Rappaport R, Mendoca BB, Bloise W: Testicular and ovarian resistance to luteinizing hormone caused by inactivating mutations of the luteinizing hormone-receptor gene. *N Engl J Med* 1996;334:507–512.
- 44 Thibaud E, Ramirez M, Brauner R, Flamant F, Zucker JM: Preservation of ovarian function by ovarian transposition performed before pelvic irradiation during childhood. *J Pediatr* 1992;121:880–884.
- 45 Teinturier C, Hartmann O, Valteu-Couanet D, Benhamou E, Bougneres PF: Ovarian function after autologous bone marrow transplantation in childhood: High dose busulfan is a major cause of ovarian failure. *Bone Marrow Transplant* 1998;22:989–994.
- 46 Jungmann E, Trautermann C: The status of the gonadotropin-releasing hormone test in differential diagnosis of delayed puberty in adolescents over 14 years of age. *Med Klin* 1994;89:529–533.
- 47 Bertherat J, Carel JC, Adamsbaum C, Bougnères PF, Chaussain JL: Endocrine evaluation and evolution of intrasellar craniopharyngioma (CPIS): Study of 8 cases. *Arch Pediatr* 1994;10:886–893.
- 48 Fénichel P, Guedj AM, Verdino P, Brucker F, et al: Aménorrhée hypothalamique: intérêts diagnostique et thérapeutique de l'apport pulsatile de gonadoréline. *Presse Méd* 1988;17:61–64.
- 49 Hieronimus S, Hadjali Y, Fredenrich A, Paquis P, Chanallet S, Grimaud A, Michiels JF, Fénichel P: Hypothalamic-pituitary Langerhans' cell histiocytosis: A diagnosis challenge. *Ann Endocrinol* 2000;61:512–516.
- 50 Cholley F, Trinvin C, Sainte-Rose C, Souberbielle JC, Cinalli G, Brauner R: Disorders of growth and puberty in children with non-tumoral hydrocephalus. *J Pediatr Endocrinol Metab* 2001;14:319–327.
- 51 Littlewood JM: Celiac disease in childhood. *Baillères Clin Gastroenterol* 1995;9:295–329.
- 52 Johannesson M, Gottlieb C, Hjelte L: Delayed puberty in girls with cystic fibrosis despite good clinical status. *Pediatrics* 1997;1:29–34.
- 53 Perignon F, Brauner R, Souberbielle JC, de Montalembert M, Girot R: Growth and endocrine function in major thalassaemia. *Arch Fr Pediatr* 1993;50:657–663.
- 54 Soliman AT, el Zalabany M, Amer M, Ansari BM: Growth and pubertal development in transfusion-dependent children and adolescents with major thalassaemia and sickle cell disease: A comparative study. *J Trop Pediatr* 1999;45:23–30.

- 55 Grinspoon S, Gulick T, Askari H, et al: Serum leptin in women with anorexia nervosa. *J Clin Endocr Metab* 1997;81:3861–3863.
- 56 Warren MP, Stiehl AL: Exercise and female adolescents: Effects on the reproductive and skeletal systems. *J Am Med Womens Assoc* 1999;54:115–120.
- 57 Weimann E, Blum WF, Witzel C, Schidegall S, Bohles HJ: Hypoleptinemia in female and male elite gymnasts. *Eur J Clin Invest* 1999;29:853–860.
- 58 Flück C, Deladoey J, Rutishauser K, Eblé A, Marti U, Wu W, Mullis PE: Phenotypic variability in familial combined pituitary hormone deficiency caused by a PROP-1 gene mutation resulting in the substitution of Arg-Cys at codon 120 (R120C). *J Clin Endocrinol Metab* 1998;83:3727–3734.
- 59 Gabilan JC, Royer P: Le syndrome de Prader, Labhardt et Willi. *Arch Fr Pediatr* 1968;25:121–123.
- 60 Seringue P, Allaneau C, Fores C, Guimbaud P: Le syndrome de Bardet-Biedl et ses troubles endocriniens. *Ann Endocrinol* 1969;80:641–643.
- 61 Jackson RS, Creemers JW, Ohagi S, Raffin-Sanson ML, Sanders L, Montague CT, Hutton JC, O’Rahilly S: Obesity and impaired prohormone processing associated with mutations in the human prohormone convertase 1. *Nat Genet* 1997;16:218–220.
- 62 Hardelin JP, Leveilliers J, Blanchard S, Carel JC, Leurtenegger M, Bouloux PMG, Petit C: Heterogeneity in the mutations responsible for X chromosome-linked Kallmann syndrome. *Hum Mol Genet* 1993;2:373–377.
- 63 Layman LC: Genetics of human hypogonadotropic hypogonadism. *Am J Med Genet* 1999;89:240–248.
- 64 Oliveira LM, Seminara SB, Beranova M, Hayes FJ, Valkenburgh SB, Schipani E, Costa EMF, Latronico AC, Crowley WF Jr, Vallejo M: The importance of autosomal genes in Kallmann syndrome: Genotype-phenotype correlations and neuroendocrine characteristics. *J Clin Endocrinol Metab* 2001;86:1532–1538.
- 65 Quinton R, Duke VM, Robertson A, Kirk JM, Matfin G, de Zoysa PA, et al: Idiopathic gonadotrophin deficiency: Genetic questions addressed through phenotypic characterization. *Clin Endocrinol* 2001;55:163–174.
- 66 De Roux N, Young J, Misrahi M, et al: Family with hypogonadotropic hypogonadism and mutations in the gonadotropin-releasing hormone receptor. *N Engl J Med* 1997;337:1597–1602.
- 67 Kottler ML, Chauvin S, Lahlou N, et al: A new compound heterozygous mutation of the gonadotropin-releasing hormone receptor (L314X, G106R) in a woman with complete hypogonadotropic hypogonadism: Chronic estrogen administration amplifies the gonadotropin defect. *J Clin Endocrinol Metab* 2000;85:3002–3008.
- 68 De Roux N, Young J, Brailly-Tabars S, et al: The same molecular defects of the gonadotropin-releasing hormone receptor determine a variable degree of hypogonadism in affected kindred. *J Clin Endocrinol Metab* 1999;84:567–572.
- 69 Matthews CH, Borgato S, Beck-Peccoz P, Adams M, Gambino G: Primary amenorrhea and infertility due to a mutation in the β -subunit of follicle-stimulating hormone. *Nature* 1993;5:83–86.
- 70 Layman LC, Lee EJ, Peak DB, Namnoum AB, Vu KV, Van Lingen B, et al: Delayed puberty and hypogonadism caused by mutations in the follicle-stimulating hormone β -subunit gene. *N Engl J Med* 1997;337:607–611.
- 71 Merke DP, Tajima T, Baron J, Cutler GB Jr: Hypogonadotropic hypogonadism in a female caused by an X-linked recessive mutation in the DAX gene. *N Engl J Med* 1999;340:1248–1252.
- 72 Seminara SB, Acherman JC, Genel M, Jameson JL, Crowley WF Jr: X-linked congenital adrenal hypoplasia: A mutation in DAX1 expands the phenotypic spectrum in males and females. *J Clin Endocrinol Metab* 1999;84:4501–4509.
- 73 Sagesse G, Cesaretti G, Gianessi N, Bracaloni C, Cinquanta L, Cioni C: Stimulated growth hormone secretion in children with delays in pubertal development before and after the onset of puberty. *J Clin Endocrinol Metab* 1992;78:30–35.
- 74 Odink RJ, Shoemaker J, Shoute E, Herdes E, Delemarre-Van de Waal HA: Predictive value of serum follicle-stimulating hormone levels in the differentiation between hypogonadotropic hypogonadism and constitutional delay of puberty. *Horm Res* 1998;49:279–287.
- 75 Ibanez L, Potau N, Zampolli M, Virdis R, Gussinye M, Carrascosa A, Saenger P, Vicens-Calvet E: Use of leuprolide acetate response patterns in the early diagnosis of pubertal disorders: Comparison with the gonadotropin-releasing hormone test. *J Clin Endocrinol Metab* 1994;78:30–35.

- 76 Vassal J, Chartier M, Job JC, Canlorbe P: Une cause rare d'aménorrhée primaire: le syndrome de Rokitansky-Kuster-Hauser. *Ann Pédiatr* 1967;43:1081–1083.
- 77 Sultan C, Farret A, Paris F, Jeandel C, Attal G: Premenarchal expression of polycystic ovarian syndrome. *Pediatr Res* 2001;49:134A.
- 78 Heinrichs C, Bourguignon JP: Treatment of delayed puberty and hypogonadism in girls. *Horm Res* 1991;36:147–152.
- 79 Mazur T, Clopper RR: Pubertal disorders: Psychology and clinical management. *Endocrinol Metab Clin North Am* 1991;20:211–230.
- 80 Crowne EC, Shalet SM, Wallace WH, Eminson DM, Price DA: Final height in girls with untreated constitutional delay in growth and puberty. *Eur J Pediatr* 1991;150:708–712.
- 81 Brook CG: Treatment of late puberty. *Horm Res* 1999;51:101–103.
- 82 Bost M: Les enjeux de la féminisation dans le syndrome de Turner. *Arch Pediatr* 1995;2:1035–1037.
- 83 Reiter EO, Blethen SL, Baptista J, Price L: Early initiation of growth hormone treatment allows age-appropriate estrogen use in Turner's syndrome. *J Clin Endocrinol Metab* 2001;86:1936–1941.
- 84 Chernauek SD, Attie KM, Cara JF, Rosenfeld RG, Frane J: Growth hormone therapy of Turner syndrome: The impact of age of estrogen replacement on final height. *J Clin Endocrinol Metab* 2000;85:2439–2445.
- 85 Illig R, DeCampo C, Lang-Muritano MR, Prader A, Torresani T, Werder EA, Willi U, Schenkel L: A physiological mode of puberty induction in hypogonadal girls by low dose transdermal 17β -oestradiol. *Eur J Pediatr* 1990;150:86–91.
- 86 Bertelloni S, Cinquanta L, Baroncelli GI, Simi P, Rossi S, Sagesse G: Volumetric bone mineral density in young women with Turner's syndrome treated with estrogens plus growth hormone. *Horm Res* 2000;53:72–76.
- 87 Lagrou K, Xhrouet-Heinrichs D, Heinrich C, et al: Age-related perception of stature, acceptance of therapy and psychosocial functioning in human growth hormone-treated girls with Turner's syndrome. *J Clin Endocrinol Metab* 1998;83:1462–1466.
- 88 Fénichel P, Guedj AM, Verdino P, Brucker F, et al: Aménorrhée hypothalamique: intérêts diagnostique et thérapeutique de l'apport pulsatile de gonadolibérine. *Presse Méd* 1988;17:61–64.
- 89 Letur-Könirsch H, DeBouard V, Borghi E, Selva J, Frydman R: Fécondation in vitro et syndrome de Turner. *Gynécologie* 1993;1:191–194.

Prof. Patrick Fénichel
Service d'Endocrinologie et Médecine de la Reproduction
Centre Hospitalo-Universitaire de Nice
Hôpital de L'Archet, BP3079, FR-06202 Nice Cedex 3 (France)
Tel. +33 4 92 03 55 19, Fax +33 4 92 03 54 25, E-Mail fenichel.p@chu-nice.fr

.....

Menstrual Irregularities

Evidence-Based Clinical Practice

Gerhard Tscherne

Graz, Austria

Menstrual Irregularities

Evidence-Based Clinical Practice

The establishment of a regular menstrual cycle is an important process for an adolescent girl. Psychologically it is a sign of becoming an adult and a factor for female identity. Physiologically it means normal function of the hypothalamic-pituitary-ovarian axis and the system of sexual hormones as the basis for future fertility and reproduction. Disturbances of this regulatory system during its development cause dysfunctional uterine bleeding and are a frequent gynecological problem. Adolescent medicine and gynecology focus on recognizing and influencing abnormalities early to prevent clinical consequences. The challenge is to distinguish normal individual variation from real endocrine or organic problems. Avoiding too early and unnecessary interventions without missing relevant abnormalities requires a firm grasp of the process of physiological sexual development with the induction of a regular menstrual cycle as well as of the symptoms and etiology of relevant abnormalities. This permits planning of efficient diagnostic testing and appropriate treatment regimes in the sense of evidence-based clinical practice.

Development of the Menstrual Cycle

Sexual development in puberty begins with activation of the gonadotropin-releasing hormone (GnRH) pulse generator and the *hypothalamic-pituitary system*. GnRH secretion in the hypothalamic centers promotes the secretion of gonadotropins (FSH and LH) in the anterior pituitary gland. LH secretion increases steeply with an increase of LH pulses [1, 2]. This stimulates ovarian

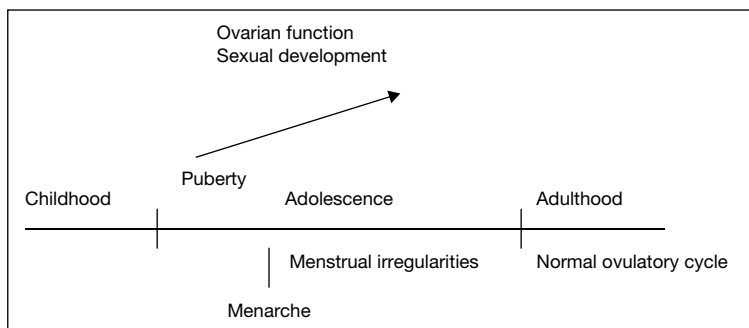


Fig. 1. Sexual development and development of normal ovulatory cycle.

function and estradiol production in the follicles (fig. 1). Estradiol promotes effects on the target organs, particularly proliferation of the *endometrium*. When the endometrium becomes too high for the prevailing estradiol level, its growth is interrupted and estrogen breakthrough bleeding occurs. This is the first menstruation, the *menarche* (fig. 1).

The *age of menarche* varies considerably with the epidemiological situation, and environmental, social and personal factors. In our Central European region, menarche usually occurs between 11 and 13 years of age. At this time the *sexual development* of the breasts and pubic hair is at about Tanner stage B₃, P₃ to B₃, P₄. The beginning of sexual development can usually be recognized about 2 years before menarche. These correlations are important for distinguishing between normal and disturbed development. After menarche, estradiol secretion increases and sexual development continues to the adult form, Tanner stage B₅, P₅, with further development of the reproductive organs.

The *menstrual cycle* after menarche is usually anovulatory with more or less irregular intervals. The quantity of bleeding varies. With increasing estradiol and with beginning and normalizing of the pulsatile secretion of GnRH the cycles gradually become ovulatory. During puberty, pulsatile gonadotropin secretion extends from the night hours into the daytime until the pulse frequency and amplitude reach those of ovulatory menstrual cycles. The establishment of a regular ovulatory cycle takes a rather long time, about 1–3 years after menarche. After the period of estrogen breakthrough bleeding without secretory conversion of the endometrium, ovulation occurs, initially irregular with a deficient luteal phase. The secretion of *progesterone* stabilizes incrementally, again with individual differences. The end result of this continuous development from anovulation, corpus luteum insufficiency and oligomenorrhea is a biphasic ovulatory cycle with normal corpus luteum function. At this

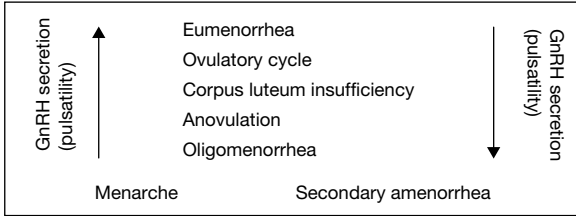


Fig. 2. Development of normal ovulatory cycle and of secondary disturbances in adolescence.

Table 1. Hormone levels during the development to a normal ovulatory cycle

	Puberty	Regular ovulatory cycle (depending on the phase)
LH, mU/ml	1 →	3–8 (peak: –24)
FSH, mU/ml	1 →	5–10 (peak: –26)
Prl, ng/ml		–20
E ₂ , pg/ml	→	30–80 (peak: –400)
P, ng/ml		12–20
DHEA-S, μg/dl	→	195–507
GnRH pulsatility	→	Normal pattern

time the hormone levels are those of normal ovulatory cycles (table 1); GnRH is secreted in pulses, the pulse generator is stabilized, and the regulation systems induce appropriate negative and positive feedback mechanisms. This adult form of the cycle is the basis for normal reproduction. The steps of this developmental process can be reversed in girls with secondary menstrual disturbances after a period of normal cycles (fig. 2).

This physiological process is the basis for recognizing and managing abnormalities in adolescence. Typical problems are the common forms of dysfunctional uterine bleeding, i.e. menorrhagia, hypermenorrhea, metrorrhagia, polymenorrhea and oligomenorrhea (table 2) [3–5].

Possible Causes of Disturbances

During the transition from menarche to a normal ovulatory cycle, a number of influences and noxae may cause abnormalities. The hypothalamic-pituitary-ovarian axis is complex, unstable and vulnerable. This lability,

Table 2. Menstrual irregularities in puberty and adolescence between menarche and normal ovulatory eumenorrhea

Type	Rhythm
Menorrhagia	Polymenorrhea
Hypermenorrhea	
Metrorrhagia	Oligomenorrhea

particularly in puberty and adolescence, is responsible for the frequent occurrence of menstrual cycle disturbances. Physical, psychological and social stresses can influence pulsatile GnRH secretion and consequently the secretion of gonadotropins. In adolescence this can cause primary menstrual irregularities as well as secondary abnormalities. Other reasons for disturbances are chronic illness and systemic diseases, liver disease, renal failure and medications. Endocrine conditions include adrenal disorders, hyperandrogenemia, hyperprolactinemia and abnormal thyroid function.

Prostaglandins play an important role in menstrual bleeding, and an imbalance may be a factor in the pathophysiology of irregular uterine bleeding [3, 5]. Progesterone from the corpus luteum, a key factor for normal menstruation, activates prostaglandin production in endometrial cells. Normally, bleeding is stopped by constriction of endometrial arterioles and vascular stasis by platelet and thrombin plugs and fibrin deposition. Hematologic conditions such as coagulation disorders and defects are relatively common.

Organic causes such as genital tract diseases and uterine pathology or neoplasms are rare in adolescence, but have to be kept in mind and ruled out. Pregnancy-related problems must be excluded.

Clinical Importance of Menstrual Irregularities

Abnormalities of the type of bleeding may be a serious problem for adolescent girls. Menorrhagia or metrorrhagia are disturbing in daily life and may contribute to psychological insecurity. Hypermenorrhea and menorrhagia are uncomfortable and can lead to anemia and iron deficiency. The same applies to polymenorrhea, even if it is combined with menorrhagia. The other abnormality of rhythm, oligomenorrhea, can be an early sign of endocrine abnormalities with possible consequences for clinical care and future reproduction. This is an important aspect. In addition, oncologic and metabolic problems should be considered. A diagnosis should be reached especially in girls with oligomenorrhea in order to detect a relevant endocrine, organic, metabolic or coagulation problem.

Diagnosis – General Aspects

A diagnostic work-up should be initiated if there are symptoms of pathology, i.e., if the menstrual disturbance is beyond the normal spectrum of physiological variability. Most mild and moderate disturbances during adolescence are transient and self-limited. Diagnostic steps should be taken if the problems are severe or persisting. The patient's history is informative concerning her personal situation. Physical and gynecologic examination is performed to evaluate the somatic status. Sexual development and the age of menarche are salient points. If menstrual bleeding has begun, the type and rhythm should be recorded and documented in a menstrual calendar. The normal menstrual cycle has a mean interval of 28 days (± 7 days) with a duration of 4 days ($\pm 2-3$ days). There is a physiological range of menstrual flow up to 80 ml.

Abnormalities of the type of bleeding (menorrhagia, hypermenorrhea, metrorrhagia) can be caused by anovulation, imbalance of hormonal factors, and occasionally coagulation disorders. Endocrine exploration is usually not necessary because the results in these patients are usually quite normal. Assessment of the hematological status and a complete blood count may detect a coagulation disorder. A pregnancy test may be indicated.

Abnormalities of rhythm, particularly oligomenorrhea, can be a sign of a real endocrine disturbance. Endocrine exploration is indicated if a prolonged interval persists for longer than 2 years, and earlier if there are symptoms of endocrine disease. Basic hormone radioimmunoassays suffice. This means measuring follicle-stimulating hormone (FSH), luteinizing hormone (LH), prolactin (Prl), estradiol (E_2), testosterone (T) and dehydroepiandrosterone-sulfate (DHEA-S). The blood sample should be obtained in the early follicular phase. Measuring progesterone (P) in the second phase of the cycle can provide information on luteal function. The measurement of basal body temperature will not be performed by teenage girls. Thyroid function should be assessed by measuring TSH and, possibly, fT_4 .

Further steps depend on the results of these initial tests. A single abnormal hormone level should be confirmed by a repeat test because intra-individual variation is considerable. If the levels are normal or within an individual physiological range, expectant management and reassurance are all that is needed. If testing yields significant abnormalities, further exploration, prophylaxis or treatment may be necessary.

Organic lesions are rare in this age group but have to be ruled out. Signs or symptoms of a tumor, particularly a cerebral lesion, should be investigated with pelvic ultrasound, computed tomography (CT) or magnetic resonance imaging (MRI).

Table 3. Progestins for treatment of menstrual irregularities by substitution in the second part of the cycle (dosages, 10–14 days, usually days 16–25)

19-Nortestosterone derivatives		17 α -Hydroxyprogesterone derivatives	
Norethisterone acetate	5–10 mg	Medroxyprogesterone acetate (MPA)	10 mg
Lynestrenol	5–10 mg	Medrogestone	10 mg
		Dydrogesterone	20 mg

Progestins with antiandrogenic efficacy (combined with Ee as oral contraceptive pill): cyproterone acetate; chlormadinone acetate; Dienogest.

Menstrual Irregularities in Adolescence – Definitions, Treatment and Special Considerations

Menorrhagia

Menorrhagia is defined as prolonged bleeding (longer than 7 days) within a more or less normal interval. The flow may be severe. It is caused by anovulation with low estrogen levels or hormonal imbalance as corpus luteum insufficiency, or insufficient contraction of the myometrium and vessels. The diagnosis is a clinical one. Treatment may be necessary if the duration of bleeding is too long or blood loss excessive. The simplest approach is to administer ergot alkaloids such as methergin or prostaglandin synthetase inhibitors. An endocrine approach is a gestagen in the second part of the cycle. Derivatives of 19-nortestosterone are more efficient than derivatives of 17 α -hydroxyprogesterone or the retroprogesterone dydrogesterone (table 3). A common approach is the administration of medroxyprogesterone acetate (MPA, 10 mg/day for 10–14 days). It is useful to continue progestin treatment for the following two cycles in order to prevent recurrence. Coagulation disorders associated with thrombocytopenia or clotting factor deficiencies require hematological consultation. Administration of a contraceptive pill can be a possibility, as in hypermenorrhea and metrorrhagia.

Hypermenorrhea

Definition: Severe until excessive bleeding within a quite regular cycle, blood loss >80 ml. Severe bleeding is clinically important, particularly if it is combined with menorrhagia. Blood loss and resulting symptoms can be considerable. The reason may be poor contractility of the myometrium and vessels, but a coagulation disorder should also be kept in mind. A coagulation profile should be obtained in this setting and a hematologist consulted if an abnormality is detected.

Otherwise, initial therapy consists of an attempt to promote the contractility of the myometrium and vessels with ergot alkaloids and prostaglandin synthetase inhibitors during the menstruation. A second-line approach consists of an attempt to promote coagulation within the endometrium with tranexamic acid (Cyklokapron) during the time of bleeding. Progestins in the second part of the cycle may be successful as well as an oral contraceptive pill with low dose of estrogen (20 μg Ee or even 15 μg Ee). Surgical intervention (e.g., curettage) is obsolete, but may be necessary in very rare cases. In case of excessive bleeding, hospitalization may be required to prevent shock, restore blood volume and stop bleeding with high doses of conjugated estrogens intravenously.

Metrorrhagia

Metrorrhagia, characterized by bleeding episodes without a recognizable cycle, is a frequent form of irregular bleeding in adolescence. Bleeding occurs at different intervals with different durations and differs in amount from spotting to severe. The reason is usually anovulation. The endometrium proliferates under the influence of estrogen until the concentration is relatively insufficient and breakthrough bleeding occurs. The histologic correlate is glandular hyperplasia and the corresponding formation in the ovary is a persistent follicle.

Treatment consists of the administration of an estrogen-gestagen combination (10 μg ethinyl estradiol + 5 mg norethisterone acetate, 3 \times 1 tablet/day) for 10 days. The estrogen corrects the relative estrogen deficit, thus stopping the bleeding, and the progestagen compound transforms the endometrium. Two to three days after completion of the 10-day course, the secretory endometrium is shed. The withdrawal bleeding may be severe, in such a case the treatment is as for hypermenorrhea. It is possible that after this bleeding the cycle continues quite regularly, as a kind of rebound effect. Alternatively, to prevent recurrence, treatment can be repeated followed by progestins as for menorrhagia (table 3).

If there are problems with the above regimens, an oral contraceptive pill will be successful, even in young patients, as a therapeutic approach. Suitable formulations are monophasic micropills with 20–35 μg ethinyl estradiol and a third-generation progestagen (desogestrel, gestodene, norgestimate). Treatment can be discontinued at any time to observe the further development of the cycle. A possibility is the administration of the pill continuously without bleeding in an interval to correct anemia and an iron deficit.

Polymenorrhea

Definition: Bleeding intervals shorter than 21 days. This anomaly is quite frequent in puberty and adolescence and is caused by hormonal imbalance within an unstable cycle. There may be an estrogen deficit in an anovulatory cycle or a short corpus luteum phase. Polymenorrhea is usually transient and

Table 4. Oligomenorrhea-endocrine parameters for diagnosis of the possible disturbances

	FSH	LH	Prl	E ₂	T	DHEA-S
Hypothalamic origin	↓	↓		↓		
Pituitary origin	↓	↓		↓		
Hyperprolactinemia			↑			
Hyperandrogenemia					↑	↑
Ovarian origin	↑	↑		↓		

self-limited. Treatment is indicated if it persists or is disturbing or if blood loss is considerable. Treatment mainstays are progestagens in the second phase of the cycle (table 3) or an oral contraceptive.

Oligomenorrhea

Definition: Bleeding intervals longer than 35 days. Oligomenorrhea may be transient during the transition to a normal cycle. Evaluation of the physical status, sexual development, and the bleeding pattern is sufficient in this setting. But oligomenorrhea may indicate a relevant endocrine disturbance with possible consequences for future life and health. Exploration is indicated if there are signs or symptoms of an endocrinopathy or organic manifestations. If not, a work-up should be initiated if oligomenorrhea persists for longer than 2 years. In addition, factors such as late menarche and a prolonged interval between beginning of sexual development and menarche are indications for diagnostic evaluation.

Endocrine exploration consists of a basic hormone panel. Levels of FSH, LH, Prl, E₂, T and DHEA-S are sufficient to assess the endocrine situation. If they are all within a physiological range during development, expectant follow-up and reassurance are sufficient. Abnormal levels should be identified and their relevance assessed. Disturbances within the hypothalamus-pituitary-ovarian axis as well as hyperprolactinemia and hyperandrogenemia may be detected. These abnormalities are true endocrinopathies (table 4) and require treatment.

Hypothalamic origin: A variety of physical and psychological stresses can cause oligomenorrhea, particularly during development of the cycle. Stresses can affect the pulsatile secretion pattern of GnRH and, consequently, gonadotropin secretion. Low levels of FSH and LH and relatively low levels of estradiol are characteristic. Low body weight, eating disorders, and heavy exercise and sports are relatively common reasons [6, 7].

Treatment should be initiated if oligomenorrhea persists over a prolonged period or if the long bleeding interval is disturbing. If estradiol secretion is sufficient, progestins in the second part of the cycle are an option to induce secretory conversion of the endometrium and a regular bleeding pattern. Also this prevents permanent proliferation under the influence of estradiol and thus protects against endometrial hyperplasia and carcinoma.

If estradiol secretion is low, an estrogen-progestogen combination is necessary, either as a biphasic combination of natural hormones as in early postmenopause or as a contraceptive pill. The result is a regular bleeding pattern and the correction of an estrogen deficit. Also, bone mass is preserved and osteoporosis prevented [6, 8, 9].

Pituitary origin: From a functional situation, oligomenorrhea of pituitary origin is similar to the hypothalamic form. The management is the same. Low levels of gonadotropins and estradiol are characteristic. Secondary oligomenorrhea may be a sign of an organic lesion such as a brain tumor. The work-up should include evaluation for pituitary tumors and beginning hydrocephalus.

Hyperprolactinemic origin: Hyperprolactinemia is rare in adolescence. An elevated Prl level is diagnostic. Treatment consists of Prl inhibitors to normalize the Prl concentration and GnRH secretion and to induce a normal cycle. Another possible reason is a cerebral tumor or pituitary adenoma.

Hyperandrogenemic origin: Hyperandrogenemia is a frequent cause of oligomenorrhea in adolescence. The increasing production of androstenedione, testosterone, dehydroepiandrosterone and DHEA-S during the development of the adrenal axis in puberty causes a transient hyperandrogenic state. Persistent hyperandrogenemia is characterized by elevated androgens; in routine assays, T and DHEA-S levels are increased. The most common form is the syndrome of polycystic ovary (PCO-S) [10–12]. A possible reason is late-onset AGS, which can be detected by secondary oligomenorrhea. The characteristic parameter for diagnosis is the elevated 17α -hydroxyprogesterone level.

Oligomenorrhea with PCO-S should be treated to induce regular bleeding with transformation of the endometrium to protect against hyperplasia. The best option is a monophasic combined micropill (Ee 20–35 μ g) because the characteristic hormonal pattern is normalized by suppression of the gonadotropins and lowering of the androgens (fig. 3). If there are symptoms of androgenization such as hirsutism, seborrhea and acne, the combination of Ee 35 μ g + cyproterone acetate 2 mg (Diane mite) is useful because of the antiandrogenic effect of this progestin (table 3).

Signs of androgenization can be very distressing for adolescent girls and may be an indication for the pill even if contraception is not required. Late-onset AGS is treated with corticosteroids.

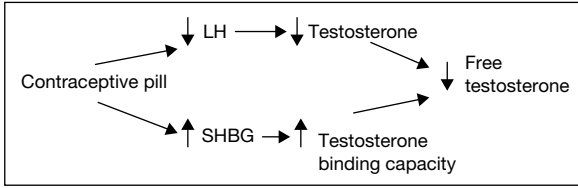


Fig. 3. Influence of a contraceptive pill on the endocrine parameters in patients with polycystic ovary syndrome (PCO-S).

Fertility later in life is reduced, particularly in patients with persistent forms of PCO-S [13, 14]. Weight reduction and contraceptive pill therapy may improve the prognosis for future fertility. Patients with treated AGS can become pregnant.

Ovarian origin: Oligomenorrhea caused by primary ovarian insufficiency may announce the beginning or partial damage of ovarian function. The end result may be ovarian failure with estrogen deprivation as in post-menopause and loss of fertility. Elevated levels of FSH and LH and low amounts of estradiol are characteristic. Chromosomal analysis should be performed to exclude an abnormal karyotype. Other reasons are ovarian hypoplasia and oncologic chemotherapy with the consequence of damage of the ovarian function.

Patients with low estrogen levels are treated with an estrogen/progestogen combination in a cyclic form to induce regular bleeding and correct the estrogen deficit. Future fertility is an important aspect. Possibly ovarian function in patients at risk of ovarian failure in the future can be protected or preserved by suppressing ovarian function with an oral contraceptive or GnRH analogue. Ovarian tissue banking may become an option in the future.

Conclusion

Menstrual irregularities are common in puberty and adolescence during the development of ovarian function and until a regular ovulatory cycle. Most irregularities are transient and self-limited but some are severe and prolonged and require exploration and treatment. Some symptoms (particularly oligomenorrhea) may herald an incipient or preexisting endocrinopathy that requires diagnosis and treatment. Abnormalities of the type of bleeding (menorrhagia, metrorrhagia, hypermenorrhea) are treated symptomatically, mainly with hormonal approaches. Of the abnormalities of bleeding rhythm, oligomenorrhea (much more than polymenorrhea) can signify a relevant underlying endocrinopathy. Adolescents with persisting oligomenorrhea should be evaluated. A basic

hormone panel is appropriate. Hypothalamic, pituitary, hyperprolactinemic, hyperandrogenemic and ovarian forms of oligomenorrhea should be distinguished to plan further diagnostic steps and prompt treatment.

References

- 1 Apter D: Development of the hypothalamic-pituitary-ovarian axis; in *Adolescent Gynecology and Endocrinology*. Ann NY Acad Sci 1997;816:9–21.
- 2 Genazzani A, Petraglia F, Gamba O, Sgarbi L, Greco M, Genazzani AD: Neuroendocrinology of the menstrual cycle; in *Adolescent Gynecology and Endocrinology*. Ann NY Acad Sci 1997;816: 143–150.
- 3 Deligeoroglou E: Dysfunctional uterine bleeding; in *Adolescent Gynecology and Endocrinology*. Ann NY Acad Sci 1997;816:158–164.
- 4 Igleasias EA: Menstrual cycle abnormalities: Diagnosis and management. *Adolesc Med* 1999;10: 255–273.
- 5 Spence J: Functional Menstrual Disorders and Dysmenorrhea: Clinical Approach to Paediatric and Adolescent Gynaecology. Singapore, Oxford University Press, 1998, pp 140–147.
- 6 Hohtari H: Sports and gynaecology; in *Clinical Approach to Paediatric and Adolescent Gynaecology*. Singapore, Oxford University Press, 1998, pp 312–321.
- 7 Warren MP, Perlroth NE: The effects of intense exercise on the female reproductive system. *J Endocrinol* 2001;170:3–11.
- 8 Drinkwater BL, Nilson K, Ott S, Chesnut CA III: Bone mineral density after resumption of menstruation in amenorrheic athletes. *JAMA* 1986;256:380–382.
- 9 Lloyd T, Myers C, Buchanan JR, Demers LM: Collegiate women athletes with irregular menstruation during adolescence have decreased bone density. *Obstet Gynecol* 1988;72:639–642.
- 10 Dramusic V: Hyperandrogenism (polycystic ovarian syndrome, hirsutism, acne, obesity); in *Clinical Approach to Paediatric and Adolescent Gynaecology*. Singapore, Oxford University Press, 1998, pp 157–187.
- 11 Franks S: Polycystic ovary syndrome. *N Engl J Med* 1995;333:853–861.
- 12 Wild RA: Hyperandrogenism in the adolescent. *Obstet Gynecol Clin North Am* 1992;19:71–89.
- 13 Apter D, Vihko R: Endocrine determinants of fertility: Serum androgen concentrations during follow-up of adolescents into the third decade of life. *J Clin Endocrinol Metab* 1990;71:970–974.
- 14 Bates GW, Whitworth NS: Effect of body weight reduction on plasma androgens in obese, infertile women. *Fertil Steril* 1982;38:406–409.

Prof. Dr. Gerhard Tscherne
President of the Austrian Society of Pediatric and Adolescent Gynecology
Brandhofgasse 13, AT-8010 Graz (Austria)
Tel. +43 316 322030, Fax +43 316 3220306
E-Mail irmgard.prassl@klinikum-graz.at

.....

Adolescent Dysmenorrhea

Charles Sultan^{a,b}, Claire Jeandel^a, Françoise Paris^{a,b}, Sihem Trimeche^{a,b}

^aUnité d'Endocrinologie et de Gynécologie Pédiatriques, Service de Pédiatrie I, Hôpital Arnaud de Villeneuve et ^bService d'Hormonologie du Développement et de la Reproduction, Hôpital Lapeyronie et Inserm U.540, CHU Montpellier, France

Primary or functional dysmenorrhea in the adolescent is a painful paroxysmal syndrome that precedes and may accompany menses [1], but it is without pelvic pathology. Secondary or acquired dysmenorrhea, on the other hand, is caused by pelvic alteration such as endometriosis [2], adenomyosis genital infection [3] or ovarian cysts. Although dysmenorrhea is the most frequent gynecological complaint of adolescents [4–7], it is often revealed only when the medical history of the young patient is taken [6]. In fact, fewer than 15% of affected adolescents consult a physician specifically for this pain syndrome [8].

Long considered as an epiphenomenon, primary dysmenorrhea has received greater attention in recent years because of the discovery of the central role of the prostaglandins [9] in myometrium hypercontractility [10, 11] and arteriolar vasoconstriction (fig. 1). In addition, certain non-steroidal anti-inflammatory drugs (NSAIDs) (propionates) have been found to be remarkably efficacious in treating this adolescent syndrome [12]. Adolescent care providers have the important role of educating adolescent girls about menstruation-associated symptoms, as well as of evaluating and effectively treating patients with dysmenorrhea [13].

Clinical Signs

The intensity of the crampy pain is variable. Usually, the pain starts within 1–4 h of menses onset and lasts for 24–48 h. In some cases, the pain starts 1–2 days before menses and continues for 2–3 days. It ranges from a dull ache to a sensation of tightening, contractions, or intolerable colicky pain. In terms of functional manifestations, dysmenorrhea is at times handicapping. The pain is

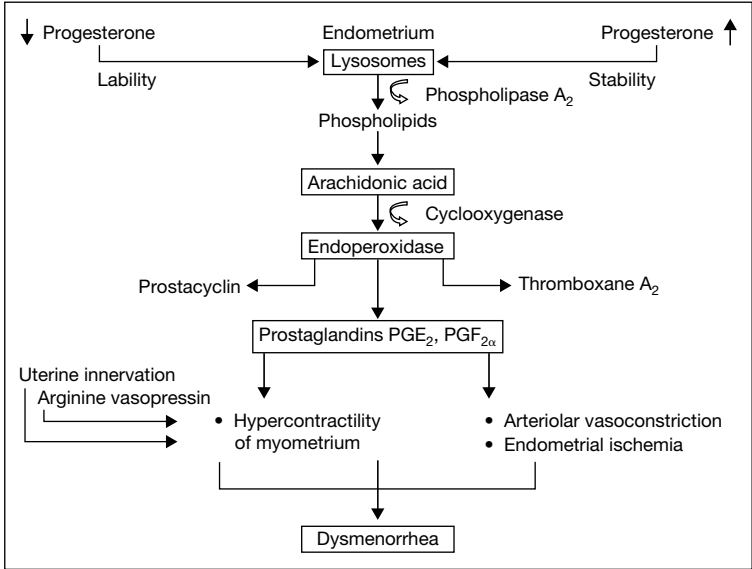


Fig. 1. Pathophysiology of adolescent dysmenorrhea.

usually pelvic, though it may radiate to the inguinal region, the lower back or the legs. It is accompanied by systematic symptoms including headache, nausea and vomiting, diarrhea, asthenia, irritability, dizziness, myalgia, and absenteeism from school. As with any phenomenon of an essentially subjective nature, it is difficult to analyze. To better quantify the dysmenorrhea syndrome, we developed a clinical scale [1] that scores all symptoms from 0 to 3 in terms of intensity (table 1). Such a scale was necessary not only to standardize assessment of dysmenorrhea, but also to evaluate objectively the efficacy of the therapies proposed to patients [14]. Pelvic examination is normal in the adolescent with primary dysmenorrhea.

Prevalence

We conducted an epidemiological study of the prevalence of dysmenorrhea in the middle and high schools in Montpellier, France. As part of a systematic medical examination, participating school physicians established a medical record for every female student. Each record provided detailed information on the clinical sign score and age at menarche, age at onset of dysmenorrhea, clinical severity, frequency, family antecedents, premenstrual syndrome, psychological

Table 1. Clinical scores of adolescent dysmenorrhea

Symptoms	Very severe	Severe	Moderate	No symptom
Pelvic pain	3	2	1	0
Low-back pain	3	2	1	0
Headache	3	2	1	0
Nausea, vomiting	3	2	1	0
Diarrhea, irritable bowel	3	2	1	0
Asthenia	3	2	1	0
Irritability	3	2	1	0
Dizziness	3	2	1	0
Myalgia	3	2	1	0
Faintness	3	2	1	0
Absenteeism	5	3	2	0

problems, parents' professions, and type of medication used for symptom relief (if applicable). Dysmenorrhea was considered to be mild to moderate if the score was >5 , severe was >9 , and very severe >14 .

We examined a total of 4,203 adolescents aged between 14 and 18 years. The prevalence of dysmenorrhea was 21%, with 902 dysmenorrheic adolescents. When we divided the population into two age groups, the frequency was as follows: (1) 14–16 years: 2,207 students, 453 with dysmenorrhea, or 20.5% and (2) 16–18 years: 1,996 students; 449 with dysmenorrhea, or 22%.

The intensity of each clinical sign of dysmenorrhea is shown in table 2. Pelvic pain, low-back pain, severe asthenia and a degree of emotional instability were the four cardinal signs of adolescent dysmenorrhea. When the different symptoms were ranked in descending order, the following could be seen (table 2): 96% of the adolescents reported pelvic pain, 70% asthenia, 59% low-back pain, 57% irritability, and 30% reported nausea and vomiting. Moreover, 29% reported headache, 28% dizziness, 27% myalgia, 20% diarrhea or irritable bowel, and 17% reported faintness.

In terms of the frequency of dysmenorrhea, the following was noted: (a) regularly (every cycle): 57% of cases; (b) frequently (1 out of 2): 28% (c) and occasionally: 15%. The association of dysmenorrhea with breast tenderness and emotional instability, which are typical of premenstrual syndrome, was noted in 26% of the cases.

School absenteeism was high: 35% of the dysmenorrheic students reported missing classes on the first days of menses. Family antecedents were noted in 39% of the adolescents (grandmother, mother, sister).

Table 2. Relative intensity of each clinical item of the adolescent dysmenorrhea, from our epidemiological analysis (% values)

Symptoms	Score 3	Score 2	Score 1
Pelvic pain	54.8	33	7.8
Low-back pain	19.7	21.9	17
Headache	4.2	11	13.9
Vomiting	6.2	11.4	12.3
Diarrhea	3.6	8.3	8.2
Asthenia	153	37.2	17.3
Irritability	18	23.5	15.4
Dizziness	4.1	10	14.4
Myalgia	4.1	10.3	12.6
Faintness	1.7	5.2	9.8

Age of onset: Dysmenorrhea appeared at a chronological age of 10 years in 31 adolescents, 11 years in 136 adolescents, 12 years in 303, 13 years in 249, 14 years in 114, 15 years in 39 and 16 years in 11. When we considered the onset of dysmenorrhea in terms of menarche, we observed that dysmenorrhea accompanied menarche in 31%, and that it appeared at a gynecological age of 1 year in 34%, 2 years for 19%, 3 years for 8%, 4 years for 4%, and 5 years 0.6%.

Evaluation of the therapeutic care of dysmenorrhea in each adolescent revealed that analgesics were used in 29% of the cases, anti-inflammatories in 11%, contraceptives in 4%, and homeopathic treatment in 4%. This seems to indicate that more than half of these adolescents considered dysmenorrhea as either a normal phenomenon or a fatality!

Psychological problems were noted in 24% and these ranged from mother-daughter tensions and school problems up to an extreme refusal of femininity. The socioeconomic status of the family was evaluated by the father's or both parents' professions. The following was noted: unskilled workers (221), office employees (146), middle management (137), self-employed (129), skilled craftsmen, small-business owners (82), farmers (64), retired (26), company executives (7) and unemployed (90).

Etiology

Evidence supports the concept that dysmenorrhea arises through the excess in prostaglandin synthesis from the endometrium itself: elevated levels of $\text{PGF}_{2\alpha}$ have been found in the menstrual fluid, as well as in the blood, of adolescents

with dysmenorrhea. In the uterus, phospholipids from the dead cell membranes are converted to arachidonic acid which can be metabolized by cyclooxygenase, leading to the synthesis of endoperoxides. These endoperoxides are then converted to prostaglandins (PGD₂, PGE₂, PGF_{2α}). PGF_{2α} mediates the pain sensation and stimulates endometrium contraction (fig. 1), while abnormal uterine smooth muscle contractility and modifications of the local blood flow are responsible for abdominal pain [15].

The role of PGs has been strengthened by the observation that the NSAIDs that inhibit PG synthesis can relieve dysmenorrhea and associated symptoms. Rofecoxib, a specific cyclooxygenase-2 inhibitor, effectively treated primary dysmenorrhea, and cyclooxygenase-2-derived prostanoids play a role in the pathophysiology of primary dysmenorrhea [16]. Increased urinary excretion of leukotrienes E(4), inflammatory mediators known to cause potent vasoconstriction and uterine contractions, suggests that these mediators may also be involved in generating dysmenorrhea symptoms in adolescents [13].

Treatment

NSAIDs are the most common pharmacologic treatment for dysmenorrhea: NSAIDs, which are able to inhibit prostaglandin synthetase, have significantly alleviated symptoms of dysmenorrhea in 75% of adolescents. Propionates such as ibuprofen (400 mg/4 h), naproxen (500 mg: half a pill every 6 h) are usually prescribed the day before menstruation and during the acute pain. Funamates, also potent inhibitors of PG synthetase, are better tolerated. Progestagen (dydrogesterone) has also been proved helpful in relieving the symptoms of dysmenorrhea [14].

One small randomized controlled trial including adolescents demonstrated an improvement in dysmenorrhea with high-dose combined oral contraceptive treatment (COC) compared to placebo. The efficacy of low-dose COC in the treatment of adolescent dysmenorrhea has yet to be determined. If effective, well-established safety and non-contraceptive health benefits may make COC an ideal treatment for dysmenorrhea in adolescent girls, according to these authors [17, 18]. In our opinion, COC should be reserved for older adolescents who need a contraceptive method, also, it lessens dysmenorrhea by reducing endometrial development.

Recently, Ziaei et al. [19] reported the effectiveness of vitamin E (500 IU/day) in adolescent dysmenorrhea, and Brouard et al. [20] showed for the first time a therapeutic effect of an orally active vasopressin V1a receptor antagonist in the prevention of dysmenorrhea in young women. A low-fat vegetarian diet was associated with reduction in body weight, dysmenorrhea duration and

intensity [21]. However, as pointed out by some groups, 29% of the prescription drug users may not be using medications effectively [22].

Conclusion

Adolescent dysmenorrhea has long been considered a minor problem of menarche. Its relative frequency, the various degrees of severity, the minimizing attitudes of other family members, multigenerational patterns of self-medication – all these are factors that have contributed to the lack of interest shown by physicians themselves! In 1981, Dawood [23, 24] began to sensitize American physicians to the extent of the problem by attracting their attention to the social and economic repercussions of both school and work absenteeism because of dysmenorrhea. Since then, the demonstration of a hyperproduction of uterine prostaglandins ($\text{PGF}_{2\alpha}$) has led to the development of a specific treatment [25] whose prototype, flurbiprofene (of the propionate group), has been found to have a remarkable efficacy in treating this adolescent syndrome [14].

Dysmenorrhea, because it is a pain syndrome, is essentially evaluated by subjective report. We have thus defined it as the ensemble of symptoms whose total score is ≥ 5 ; that is, greater than simple pelvic discomfort. Using this criterion, the prevalence of dysmenorrhea in a population of 4,203 adolescents from 14 to 18 years was found to be 21%. It is difficult to compare this result with those of other groups, in part because the definition of dysmenorrhea varies considerably in the literature, rendering quantitative comparison highly questionable. Given the wide differences in definition, it is not surprising to note that the prevalence varies (table 4) from 43 to 80% [26] – and up to 91% in one group of American adolescents [27]!

The relationship between dysmenorrhea and ovulation is unknown, with much contradictory data. The establishment of ovulatory cycles is a prerequisite for dysmenorrhea for some groups [3, 6]. Conversely, Balbi et al. [28] reported that early menarche was related to an increase in its prevalence and its severity. In our experience, 31% of the adolescents reported dysmenorrhea at menarche; 34% reported dysmenorrhea appearing 1 year later, and 20%, 2 years later. It therefore seems that neither age of menarche nor the establishment of ovulatory cycles determines the presence of adolescent dysmenorrhea.

Conversely, in line with our own observations, several authors [27, 29–33] have noted that dysmenorrhea included in an adolescent premenstrual syndrome (associating breast tenderness and mood swings) signals the existence of a psychological phenotype [34, 35] specific to the dysmenorrheic adolescent (indolence, lack of athletic activity, mother-daughter symbiosis, familial oversensitivity, and so on) [36–39].

In conclusion, dysmenorrhea leads to important undertreated morbidity in adolescent girls. It is regrettable that, at a time when there are simple, specific and efficacious medications available for the symptoms of dysmenorrhea, they are used by only a third of the adolescents who suffer regularly from this syndrome [40–44]. This speaks clearly of the need for pediatricians, gynecologists and generalists to better inform their patients of the help that is available!

References

- 1 Sultan C, Chotard AM, Sultan N, Rey R, Jean R: Disménorrhées de l'adolescente. *Rev Int Pediatr* 1984;138:25–28.
- 2 Davis GD, Thillet E, Lindemann J: Clinical characteristics of adolescent endometriosis. *J Adolesc Health* 1993;14:362–368.
- 3 Cohen J: Les dysménorrhées; in Chaperon C (ed.): *La douleur en gynécologie*. Paris, Arnette, 1997, pp 131–150.
- 4 Salomon-Bernard Y: Données récentes sur la dysménorrhée primaire, sa physiopathologie, son traitement. *Ann Pediatr* 1984;31:201–208.
- 5 Wildhom O: Dysmenorrhea during adolescence. *Acta Obstet Gynecol Scand* 1979;(suppl 87):61–66.
- 6 Duflos-Cohade C: Les dysménorrhées de l'adolescente. Des douleurs fonctionnelles et un rôle prépondérant des prostaglandines. *Rev Prat* 1988;25:47–49.
- 7 Schroeder B, Sanfilippo JS: Dysmenorrhea and pelvic pain in adolescents. *Pediatr Clin North Am* 1999;46:555–571.
- 8 Banikarim C, Chacko MR, Kelder SH: Prevalence and impact of dysmenorrhea on Hispanic female adolescents. *Arch Pediatr Adolesc Med* 2000;154:1226–1229.
- 9 Sultan N, Sultan C, Rey R, Jean R: Variations of plasma 13,14-dihydro-15-ceto-prostaglandins $F_{2\alpha}$ – In adolescent dysmenorrhea. *Pediatr Res* 1984;18:104.
- 10 Lundstrom V: Uterine activity during the normal cycle and dysmenorrhea; in Dawood MY (ed): *Dysmenorrhea*. Baltimore, Williams & Wilkins, 1981, pp 53–74.
- 11 Mijanovic D: Correlation between certain factors in maturation and primary dysmenorrhea in adolescence. *Jugosl Ginekol Perinatol* 1990;30:79–82.
- 12 Quereux C, Gabriel R: Les dysménorrhées. *Antadys, Theramex*, 1996, pp 3–23.
- 13 Harel Z: A contemporary approach to dysmenorrhea in adolescents. *Paediatr Drugs* 2002;4:797–805.
- 14 Sultan C, Sultan N, Jean R: Evaluation clinique quantitative de l'action de la dydrogesterone dans la dysménorrhée de la jeune fille. *Gynécologie* 1985;36:309–315.
- 15 Tonini G: Dysmenorrhea, endometriosis and premenstrual syndrome. *Minerva Pediatr* 2002;54:525–538.
- 16 Morrison BW, Daniels SE, Kotey P, Cantu N, Seidenberg B: Rofecoxib, a specific cyclooxygenase-2 inhibitor, in primary dysmenorrhea: A randomized controlled trial. *Obstet Gynecol* 1999;94:504–508.
- 17 Davis AR, Westhoff CL: Primary dysmenorrhea in adolescent girls and treatment with oral contraceptives. *J Pediatr Adolesc Gynecol* 2001;14:3–8.
- 18 Sanfilippo JS: Oh, the dilemma of dysmenorrhea – What's new? *J Pediatr Adolesc Gynecol* 2001;14:1–2.
- 19 Ziaei S, Faghihzadeh S, Sohrabvand F, Lamyian M, Emamgholy T: A randomised placebo-controlled trial to determine the effect of vitamin E in treatment of primary dysmenorrhoea. *BJOG* 2001;108:1181–1183.
- 20 Brouard R, Bossmar T, Fournie-Lloret D, Chassard D, Akerlund M: Effect of SR49059, an orally active V1a vasopressin receptor antagonist, in the prevention of dysmenorrhoea. *BJOG* 2000;107:614–619.
- 21 Barnard ND, Scialli AR, Hurlock D, Bertron P: Diet and sex hormone binding globulin, dysmenorrhea and premenstrual symptoms. *Obstet Gynecol* 2000;95:245–250.

- 22 Campbell MA, McGrath PJ: Use of medication by adolescents for the management of menstrual discomfort. *Arch Pediatr Adolesc Med* 1997;151:905–913.
- 23 Dawood MY: Dysmenorrhea and prostaglandins: Pharmacological and therapeutic considerations. *Drugs* 1981;22:42–56.
- 24 Dawood MY: Dysmenorrhea. *Clin Obstet Gynecol* 1990;33:168–178.
- 25 Raux-Demay MC: Les dysménorrhées de l'adolescente. Une explication, un traitement logique. *Rev Prat MG* 1988;38:58–62.
- 26 Kennedy S: Primary dysmenorrhoea. *Lancet* 1997;349:1116.
- 27 Wilson CA, Keye WR Jr: A survey of adolescent dysmenorrhea and premenstrual symptom frequency. A model program for prevention, detection and treatment. *J Adolesc Health Care* 1989;10:317–322.
- 28 Balbi C, Musone R, Menditto A, Di Prisco L, Cassese E, D'Ajello M, Ambrosio D, Cardone A: Influence of menstrual factors and dietary habits on menstrual pain in adolescence age. *Eur J Obstet Gynecol Reprod Biol* 2000;91:143–148.
- 29 Bancroft J, Williamson L, Warner P, Rennie D, Smith SK: Perimenstrual complaints in women complaining of PMS, menorrhagia and dysmenorrhea: Toward a dismantling of the premenstrual syndrome. *Psychosom Med* 1993;55:133–145.
- 30 Busch CM, Costa PT Jr, Whitehead WE, Heller BR: Severe perimenstrual symptoms: Prevalence and effects on absenteeism and health care seeking in a non-clinical sample. *Women Health* 1988;14:59–74.
- 31 Fisher M, Trieller K, Napolitano B: Premenstrual symptoms in adolescents. *J Adolesc Health Care* 1989;10:369–375.
- 32 Freeman EW, Rickels K, Sondheimer SJ: Premenstrual symptoms and dysmenorrhea in relation to emotional distress factors in adolescents. *J Psychosom Obstet Gynaecol* 1993;14:41–50.
- 33 Jamieson DJ, Steege JF: The prevalence of dysmenorrhea, dyspareunia, pelvic pain and irritable bowel syndrome in primary care practices. *Obstet Gynecol* 1996;1:55–59.
- 34 Sundell G, Milson I: Factors influencing the prevalence and severity of dysmenorrhea in young women. *Br J Obstet Gynaecol* 1990;97:588–594.
- 35 Teperi J, Rimpela M: Menstrual pain, health and behaviour in girls. *Soc Sci Med* 1989;29:163–169.
- 36 Gant PA, McDonough PG: Adolescent dysmenorrhea. *Pediatr Clin North Am* 1981;28:389–395.
- 37 Gidwani GP: Longitudinal study of risk factors for occurrence, duration and severity of menstrual cramps in a cohort of college. *Clin Pediatr (Phila)* 1998;37:51.
- 38 Hesla JS: Dysmenorrhea. *Pediatr Adolesc Gynecol* 1992;19:205–221.
- 39 Melone C, Erny R: Le point sur le traitement des dysménorrhées primaires essentielles. *Contracept Fertil Steril* 1993;6:463–465.
- 40 Nabrink M, Birgersson L, Colling-Saltin AS, Solum T: Modern oral contraceptives and dysmenorrhoea. *Contraception* 1990;42:275–283.
- 41 O'Connell BJ: The pediatrician and the sexually active adolescent. Treatment of common menstrual disorders. *Pediatr Clin North Am* 1997;44:1391–1404.
- 42 Rosenfield RL, Barnes RB: Menstrual disorders in adolescence. *Endocrinol Metab Clin North Am* 1993;22:491–505.
- 43 Smith RP: Primary dysmenorrhea and the adolescent patient. *Adolesc Pediatr Gynecol* 1988;1:23–30.
- 44 Smith RP: Cyclic pelvic pain and dysmenorrhea. *Obstet Gynecol Clin North Am* 1993;20:753–764.

Prof. Dr. Charles Sultan
 Unité d'Endocrinologie et de Gynécologie Pédiatriques
 Centre Hospitalier Universitaire, Service de Pédiatrie I
 Hôpital Arnaud de Villeneuve
 FR-34259 Montpellier Cédex 5 (France)
 Tel. +33 4 67336643, Fax +33 4 67338327
 E-Mail c-sultan@chu-montpellier.fr

.....

Hyperandrogenism in Adolescent Girls

Christine Cortet-Rudelli, Didier Dewailly

Department of Endocrinology and Diabetology,
Lille University Hospital, Lille, France

Mild symptoms of hyperandrogenism, such as acne or hyperseborrhea, are frequent in adolescent girls [1], and are often associated with irregular menstrual cycles. In most instances, these symptoms are transient and only reflect the immaturity of the hypothalamic-pituitary-ovary axis during the first years following menarche. In some subjects, however, these manifestations can persist and even worsen, and hirsutism may appear, thus revealing an adrenal or ovarian disorder whose most common cause is the polycystic ovary syndrome (PCOS).

The management of an adolescent hyperandrogenic girl must achieve three main goals: (1) eliminate a severe cause of hyperandrogenism, such as an adrenal or ovarian tumor, or the non-classic adrenal hyperplasia (NCAH); (2) recognize PCOS early on, in order to set up antiandrogen therapy without delay and to initiate the prevention of obesity and insulin resistance, and (3) distinguish the so-called physiological hyperandrogenism of puberty, which will resume within 1–2 years, from a nascent PCOS.

The Physiological Hyperandrogenism of Puberty

At the beginning of puberty, LH pulsatility is only present during sleep. It then extends to the daytime, with amplification of pulse amplitude and acceleration of frequency [2]. This is accompanied by an increase in androgen plasma levels and ovarian enlargement, with acquisition of a multifollicular pattern [3]. These changes parallel those in the GH/IGF1 axis, whose hyperactivity induces a selective insulin resistance. This phenomenon results in a physiological hyperinsulinism which is responsible for the increase in insulin plasma level and decrease in SHBG and IGFBP-1 liver production [reviewed in 4].

The first menstrual cycles in adolescent girls are frequently anovulatory [5]. When compared to ovulatory cycles, they are characterized by higher serum levels of testosterone (T), androstenedione (A) and LH, with the possibility of mild hyperandrogenic symptoms [6]. In most of adolescent girls, these abnormalities will spontaneously resume within 1–2 years, along with the regularization of their menstrual cycles. Conversely, in some others, they will worsen, with progressive constitution of PCOS features, such as hirsutism, anovulation, increased plasma T, A and LH levels and ovarian enlargement (see below) [7]. At this time, however, it is difficult to distinguish biologically and ultrasonically those adolescents with such an evolution from the ones with ‘physiological mini-PCOS’ due to the normal maturational process of puberty [8]. Some features, however, are predictive (see below), in particular the association with oligomenorrhea which should not be viewed too quickly as a normal feature of the first gynecological years [9].

Diagnosis of Hyperandrogenism in Female Adolescents

Clinical Assessment

When an adolescent girl is referred for hyperandrogenism, the first visit must include a thorough record of history and a careful physical examination.

Although infrequent, some clinical symptoms must be carefully searched for, since they draw the clinician’s attention toward a severe disease: (a) rapidly growing hirsutism, with other signs of virilization such as clitoromegaly, temporal balding, voice deepening, and increasing muscle mass, which are indicative of an adrenal or ovarian tumor; (b) symptoms of hypercorticism (Cushing syndrome), and (c) galactorrhea, indicative of a prolactinoma.

In the other situations, symptoms of hyperandrogenism are mild and consist in: (a) hirsutism, whose degree should be quantified according to the Ferriman-Gallwey score; (b) acne, indicative of hyperandrogenism when it occurs early, is inflammatory, and mainly localized in chin, neck and thorax, and (c) alopecia, indicative of hyperandrogenism when it affects the vertex.

Some clinical features are predictive of PCOS: (a) family history of hyperandrogenism and menstrual disorders; (b) history of precocious adrenarche; (c) history of menstrual disorders, mainly oligomenorrhea, persisting more than 2 years after menarche; (d) obesity (body mass index (BMI) $>25 \text{ kg/m}^2$) or abdominal adiposity, with increased waist/hip ratio (WHR), and (e) presence of an acanthosis nigricans.

First Laboratory Assessment

After the first visit, a minimal laboratory screening is mandatory, unless the clinical findings lead to search at once for adrenal or ovarian tumor, or a

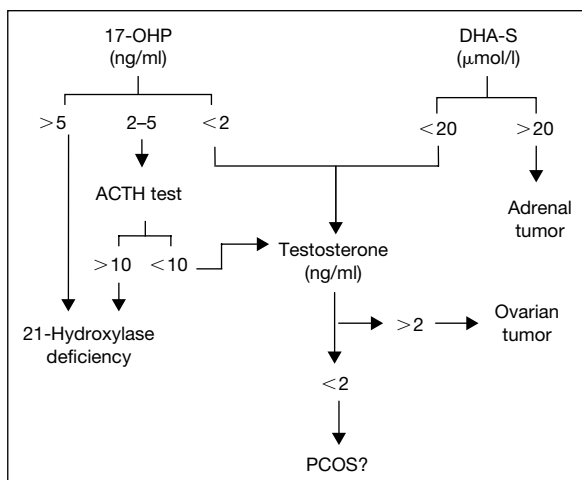


Fig. 1. Flow-chart for the use of hormonal assays in the work-up of hyperandrogenism in adolescent girls.

prolactinoma. Blood sampling must be performed early in the morning, certainly before 10:00 h. This will avoid false negative results due to the circadian decrease in adrenal steroids, mainly 17-hydroxyprogesterone (17-HP), that parallels the one in cortisol and ACTH and occurs later in the day. Second, patients must be investigated in the early follicular phase. This will avoid false positive results due to the steroid production from the corpus luteum. In amenorrheic or oligomenorrheic patients, blood sampling should be performed after a short sequence of progestin treatment.

This laboratory screening must include the assay of total T, DHEAS and 17-HP. Other assays are less useful (e.g., the A assay) or not robust enough (e.g., the free T assay) to fulfill the reliability needed for this first step.

Further Investigations

According to these preliminary results, the diagnostic strategy can follow the flow chart indicated in figure 1:

(a) If an adrenal or ovarian tumor is suspected, adrenal computed tomography or pelvic MRI is indicated, respectively.

(b) If NCAH is suspected (basal 17-HP >2 ng/ml), an ACTH test should be performed. For some authors, the ACTH test is mandatory as soon as the first visit to ascertain the diagnosis of NCAH. However, there is no evidence that its sensitivity in detecting 21-OHD is higher than the one of basal

17-HP determination, providing that the above-mentioned rules are respected [10]. Therefore, the ACTH test is only useful when the morning follicular unsuppressed 17-HP level falls between 2 and 5 ng/ml (6–15 nmol/l), which is the case in approximately 6% of all patients referred for hyperandrogenism (see below).

(c) If the patient is suspected of having PCOS, pelvic ultrasound imaging and metabolic work-up are indicated, in complement to other hormonal assays (see below).

Causes of Hyperandrogenism in Female Adolescents

The Polycystic Ovary Syndrome

Pediatric and adult endocrinologists may encounter PCOS as a mildly virilizing state since it is the most frequent cause of hyperandrogenism in female teenagers and in adult women [11].

Pathophysiology: Puberty and PCOS

The observation that menstrual disturbances and hirsutism commonly originate in puberty [12] and that many of the endocrine alterations of PCOS look like an exaggeration of those that accompany puberty (see above) suggests a pathogenetic link. Among these features, hyperinsulinism may be the clue factor. This metabolic defect may even pre-date the PCOS since it is most likely genetic in nature, although it remains to be proven that this is the case in all patients. An increased body of evidence suggests that it has a role in causing and/or propagating the disease [4]. Hyperinsulinism may interfere early with the pubertal maturation process at the hypothalamic, pituitary, ovarian and adrenal levels, leading to a ‘hyperpubertal state’ [13]. This may trigger a self-perpetuating process causing the outcome of puberty to be PCOS in genetically susceptible young women.

Nevertheless, in lean and normoinsulinemic women, other still unknown factors, either genetic or environmental, may be basic for the development of PCOS [14]. Many studies have been conducted to characterize the dysregulation of LH secretion and to elucidate whether a primary hypothalamic abnormality could explain the onset of PCOS in normoinsulinemic adolescents [reviewed in 15]. So far, however, no data have clearly indicated that this dysregulation does not simply result from the long-term effects of ovarian steroid abnormalities or other peripheral influence.

Clinical Aspects

Although very variable, the phenotypic features of PCOS can be schematically divided into three components, i.e., hyperandrogenic, anovulatory and dys-metabolic. These three components are not necessarily or fully associated [11].

Hyperandrogenism

Usually, symptoms are moderate and consist of increased male-pattern hair growth, acne, seborrhea or alopecia, which reflect mild androgenic stimulation of the pilosebaceous unit. Hyperandrogenism symptoms frequently commence at the time of puberty [16]. In some cases, hyperandrogenism is expressed before puberty as ‘precocious adrenarche’ in patients who subsequently develop PCOS, indicating an early adrenal involvement [17].

Anovulation

This component of PCOS accounts for oligomenorrhea (i.e. menstrual cycle length ≥ 3 months) and secondary amenorrhea, which are the most typical features of the anovulatory PCOS. They very often date back to menarche. Primary amenorrhea is uncommon, but PCOS is still found in about 20% of girls referred for this symptom [18]. These patients have no pubertal delay and are frequently overweight. The amenorrhea is quite reversible under short sequences of progestin treatment, without having to add estrogens. This qualifies this amenorrhea as ‘normoestrogenic’ or ‘type 2 anovulation’ in the World Health Organization (WHO) classification. About 20% of adolescent and adult patients with PCOS report normal menses. However, this does not mean necessarily that they ovulate each cycle. In a recent study [19], 20% of them were in fact anovulatory.

Metabolic Syndrome

Obesity (i.e., BMI >25 kg/m²) is observed in 30–50% of adolescent and adult women with PCOS. Most women with PCOS become overweight just before or during puberty and several lines of evidence suggest that the onset of obesity in this period of life could represent a specific risk factor for the subsequent development of PCOS [4]. Obesity of women with PCOS is frequently characterized by a distribution of fat that favors the upper body segment (increased WHR). This type of fat distribution is detected even in adolescent girls with normal BMI [20] and is associated with greater insulin resistance than if fat is located predominantly in the lower body segment [21]. Papular hypertrophic pigmented skin on the nape of the neck, the axillae, chest and vulva is detected in 5–50% of women with PCOS [22]. This dermal manifestation, acanthosis nigricans, is now recognized as a non-specific marker of moderate to severe insulin resistance.

Diagnosis

Making the diagnosis of PCOS remains a difficult challenge and a controversial issue, especially in adolescent girls. In particular, whether ultrasonography should be used as a universal standard is still disputed.

Hormonal Markers for PCOS

Before the development of ultrasonography (see below), the diagnosis of PCOS was for many years mainly based on an elevated serum LH level and/or an exaggerated LH response to the GnRH test and/or an elevated LH/FSH ratio [23]. However, in other conditions clearly different from PCOS such as mild hypothalamic anovulation or hyperprolactinemia, the LH level may be elevated after GnRH stimulation [24]. Therefore, many authors have questioned the sensitivity as well as the specificity of a high LH level. Recent data emphasized that obesity is a modifier of the biological expression of PCOS in that it attenuates the excessive LH plasma level, by reducing the LH pulse amplitude but not its frequency [23].

In the basal state, the biological hyperandrogenism of PCOS cannot define the syndrome. In most cases, A and T serum levels are modestly and inconstantly elevated, in a non-specific manner. For some authors [25], non-suppression of serum-free T after DXM defines functional ovarian hyperandrogenism in cases where other well-characterized causes of hyperandrogenism have been excluded.

More recently, the GnRH agonist test was proposed as a new functional approach to define PCOS [25]. The dissociation between the 17-HP and A responses suggested a dysregulation of the cytochrome P₄₅₀ C17 α . Therefore, the GnRH agonist test appears to provide an integrated probe to detect the thecal dysregulation of PCOS, in the face of either normal or abnormal LH serum levels. The results of this test correlated well with some other features of PCOS, in particular the serum-free T response to the dexamethasone (DXM) suppression test and the ovarian stromal area [25]. The ovarian stimulation HCG test yielded similar results [26]. However, they are not convenient for the diagnosis of PCOS in practice.

Morphological and Ultrasound Criteria

Numerous parameters have been proposed to define PCO by ultrasound but there is still no consensus about their use for the diagnosis of PCOS. They can be classified as either external or internal morphologic features. Features that describe directly or indirectly the ovarian hypertrophy are relatively objective since they are obtained by measuring physical entities (e.g., ovarian axis, area or volume) in real-time conditions. The ovarian area was previously considered as

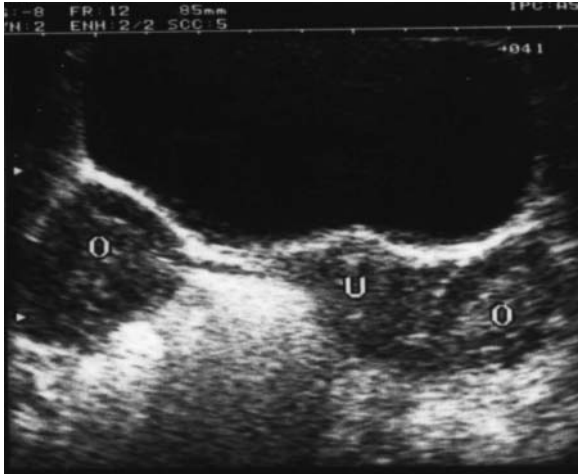

Fig. 2. Sonogram by abdominal route depicting the polycystic appearance of the ovaries in an adolescent girl with PCOS. Note that both ovarian sections are greater than the uterine section. In this representative case, the increased number of subcapsular follicles and the stromal hyperplasia are easily seen.

normal up to 10 cm^2 [27] while the threshold is now almost two times lower (5.5 cm^2) in a more recent series compared to a large control group [28].

The internal morphologic features describe the two main histologic features of PCO, namely the increased number of subcapsular follicles and the stromal hyperplasia. Their analysis is more subjective, especially by the abdominal route, which is the rule in adolescents (fig. 2). Furthermore, the follicular pattern (number and size of follicles) is a non-specific sign which can also be observed in hyperprolactinemia, functional hypothalamic anovulation or even in late puberty or in the early normal follicular phase. Conversely, the hyperechogenicity of ovarian stroma is considered as suggestive of PCO [29], but it is highly dependent on the settings of the ultrasound machine. In order to avoid the subjectivity of this sign in clinical practice, it is recommended that the total ovarian area be used since it is highly correlated to the stromal area [29]. The presence of an ovarian hypertrophy at ultrasonography certifies PCO, but its absence does not exclude the diagnosis.

Screening for Metabolic Syndrome

This should include clinical parameters (family history, BMI, WHR, blood pressure, search for acanthosis nigricans) and biological parameters (glycemia, insulinemia, HDL-C, triglycerides). The optimal means for the assessment of hyperinsulinism is still under debate. Insulin levels are often routinely used as an

index of insulin resistance but they also reflect both pancreatic secretory capacity and insulin extraction by the liver. Glucose clamp techniques and mathematical modeling to measure insulin sensitivity are not easily applied to clinical practice. Indirect markers of insulin action may be more valuable tools. The SHBG level is highly and negatively correlated to the insulin level [30]. Likewise, the IGFBP-1 level is strongly suppressed by hyperinsulinism [31].

Classification of PCOS

Actually, the difficulty of diagnosing PCOS varies according to the clinical presentation. In some cases, only one or two of the three above-mentioned components are present (e.g., ‘ovulatory PCOS’ or ‘non-hirsute anovulatory PCOS’ or ‘lean PCOS’ without hyperinsulinism). In practice, hyperandrogenic PCOS can be schematically split into classic and non-classic forms.

The Classic PCOS

In this situation, the clinical symptoms provide the most powerful presumption and their association in the three components has a very strong diagnostic potency, as well as their occurrence in the late stage of puberty. In this situation, the diagnostic use of ultrasonography is optional. The main difficulty is to avoid the pitfall of the ‘too much evident’ PCOS in adolescents referred either for hyperandrogenism or menstrual disorders. Therefore, it is still wise to check the basal serum T, DHEAS, 17-HP and prolactin (PRL) levels, as well as the urinary-free cortisol level, when obesity is recent and some Cushing syndrome stigmata are present.

The Non-Classic PCOS

PCOS remains the most likely explanation for a so-called idiopathic hirsutism (i.e., with ovulatory menstrual cycles). However, the clinical picture is not reliable enough in the absence of the other PCOS clinical components. Therefore, one should rely on a cost-effective and safe work-up, which includes hormonal assays (see above) and ultrasonography. However, the finding of PCO at ultrasonography must not preclude other diagnosis since it may be incidentally associated with other conditions (in particular NCAH, see other diagnosis).

Non-Classic Adrenal Hyperplasia

NCAH is encountered with relatively high frequency (1–6%) among adolescent and adult patients with hyperandrogenism. This incidence may vary

from one geographic area to another, as reported for classical 21-OHD, because of ethnic and racial clusters [32].

Pathophysiology

The 21-hydroxylase deficiency is responsible for an oversecretion of 17-HP and other steroids that are upstream this enzymatic step. Mutations resulting in NCAH reduce the activity of 21-hydroxylase to 20–50%. This is not sufficient to impair the physiologically needed cortisol production, providing that the amount of precursor required is much greater than normal, thus compensating for the lower enzyme efficiency. The alteration in the enzyme kinetic is therefore sufficient to explain the excessive accumulation of 21-OH precursors, mainly progesterone and 17-HP, in the presence of a normal stimulation by ACTH. This excess is partly converted to androgens, resulting in adrenal hyperandrogenism. Therefore, NCAH is essentially a hyperandrogenic disorder, without overt abnormality in the gluco- and mineralocorticosteroid pathways.

To understand why NCAH expresses itself only during or after puberty, it must be recalled that the steroidogenic changes accompanying adrenarche result in an increased 17,20-lyase and a decreased 3 β -hydroxysteroid dehydrogenase-isomerase activity, thus increasing the adrenal output of Δ 5 androgens [33, 34]. Such a phenomenon acting while 21-hydroxylase is partly deficient could be the physiological trigger of hyperandrogenism in NCAH.

Clinical Aspects

Before the age of 7–8 years, NCAH may mimic an idiopathic premature pubarche or, more rarely, a virilizing ovarian or adrenal tumor, especially when there are symptoms of precocious pseudo-puberty, such as accelerated height velocity and clitoromegaly. In the first series, the prevalence of NCAH compared to the other causes of premature pubarche was debated, varying from 0% to more than 20%, mainly because of differences in diagnostic criteria. More recently, it has been estimated at 6–8% [35], justifying the measurement of the 17-HP morning level in this situation.

Numerous studies have shown that adolescent or adult women with NCAH are seldom more virilized than other women with ovarian causes of hyperandrogenism and that no symptom of hyperandrogenism is specific for NCAH. Furthermore, NCAH may also be detected in individuals having mild symptoms such as acne [36]. Therefore, the clinical presentation cannot be used for the diagnosis of NCAH. Clitoromegaly, male habitus and temporal baldness are

infrequent findings, unless the patient suffers from undiagnosed simple virilizing CAH. Recently, it has been suggested from a multicenter study including 220 patients that NCAH is a progressive disorder since the prevalence of hirsutism increases with the patient's age [37].

Diagnosis

The diagnosis of NCAH should be considered in those patients selected from a basal 17-HP >2 ng/ml (see above) and in whom the post-stimulation 17-HP level exceeds 10 ng/ml (30.3 nmol/l). Between this threshold and the upper normal limit which is about 3 ng/ml in most studies, there is the range of heterozygotes who are unaffected carriers [38] and that of patients with functional ovarian and/or adrenal hyperandrogenism. The former may have a post-stimulation 17-HP level as high as 15 ng/ml, but in any case their basal 17-HP level exceeds 2 ng/ml.

Once the biochemical diagnosis has been obtained, genotypes from adolescent patients with NCAH should be obtained as early as possible, in order to be ready for genetic counseling when they desire a pregnancy.

Other Causes

Adrenal and Ovarian Tumors

These causes of hyperandrogenism are rare. The clinical presentation is often suggestive (see above, Diagnosis of Hyperandrogenism in Female Adolescents). The laboratory investigations will rapidly confirm the clinical suspicion and imaging techniques will localize the tumor (see same section above). Some extreme forms of PCOS, such as hyperthecosis, may also present with similar clinical and hormonal features. However, they are very infrequent in adolescents, unless the patient has an extreme insulin resistance (HAIR-AN syndrome), either genetic or secondary to a congenital or acquired porto-systemic shunt [39].

Cushing Syndrome

Some adrenal tumors may secrete high amounts of androgens and cortisol. Therefore, the clinical presentation might be dominated by symptoms of glucocorticoid excess. Conversely, these symptoms may be mild in a hyperandrogenic

adolescent patient with a pituitary Cushing disease. Therefore, it is wise to check the 24-hour urinary-free cortisol level in any doubtful situation, especially in obese patients with the full-blown PCOS.

Hyperprolactinemia

PRL excess stimulates the secretion of adrenal androgens, mainly DHEAS. Therefore, a mild hyperandrogenism frequently accompanies the clinical expression of a prolactinoma, but it is seldom the main complaint. Conversely, mild hyperprolactinemia frequently occurs in PCOS, but it has no specific expression and often disappears spontaneously.

Idiopathic Hirsutism

This diagnosis is one of exclusion. In particular, it requires that a non-classic form of PCOS has been ruled out (see above, Classification of PCOS). It is often observed in patients with a Mediterranean or Hispanic ethnic background. It is thought to result from increased skin 5 α -reductase activity.

Drugs

Drugs that are most commonly responsible for the development of virilizing effects include anabolic steroids, progestins, antiepileptic drugs, cortrosyn and metyrapone. In one study [40], a large majority of the patients receiving valproate had polycystic ovaries at ultrasounds or an elevated serum T concentration. These abnormalities were more common when treatment had been started before the age of 20 years.

Hirsutism and androgenic alopecia must be differentiated from drug-induced hypertrichosis or hair loss, which are independent from hormone stimulation [41].

Treatment of Hyperandrogenism in Female Adolescents

PCOS

The treatment of hyperandrogenism in women with PCOS aims at interrupting androgen production and/or action. Suppression of ovarian function with oral contraceptives is usually the first line of therapy. It will arrest progression

of hirsutism but does not lead to substantial improvement. This treatment lowers free T levels by reducing serum gonadotropin levels, increasing SHBG levels, and modestly lowering DHEAS levels. One of the new generations of pills containing a non-androgenic progestin such as desogestrel, gestodene or norgestimate is advisable. Cyproterone acetate is the major antiandrogen available outside the USA. It is a potent progestin taken up by fat and released slowly. When given for 21 days every 4 weeks at a 50-mg daily dose, it inhibits pituitary gonadotropin secretion and acts as a potent antiandrogen upon the pilosebaceous unit. An excellent response of hirsutism is seen in up to 90% of cases [42]. It must be administered with an estrogen to avoid irregular bleeding or amenorrhea due to endometrial atrophy. Natural estradiol (either percutaneously or orally, 2 mg/day for 1–21 days) is preferable to ethinyl estradiol, which has more metabolic effects [42]. Spironolactone, 50–100 mg bid, has been shown to be effective and is the most potent and safest antiandrogen available in the USA. It is potentially teratogenic to fetal male genital development and may cause menstrual disturbance. Therefore, it should be prescribed with an oral contraceptive. Corticosteroid therapy is seldom useful.

In obese subjects, weight loss is very important, having beneficial effects on most aspects of the syndrome, such as subjective symptoms, infertility, hyperinsulinemia and related metabolic aberrations, and long-term health risks [43]. Whether a long-term treatment with insulin-sensitizing drugs should be undertaken as soon as adolescence starts is an unsolved issue, until long-term studies demonstrate that the benefit/risk or cost ratio is favorable.

NCAH

As in classic forms, the conventional treatment of NCAH is glucocorticoid therapy. This aims mainly to reduce adrenal hyperandrogenism, while the necessity for cortisol replacement is less evident. Our opinion is that DXM should be used rather than less potent ACTH-inhibiting compounds such as hydrocortisone or prednisone. Very low doses of DXM are needed (0.25–0.5 mg at night). Physicians should not aim to normalize the morning 17-HP plasma level, since it has been shown that adrenal androgens are more sensitive to the glucocorticoid-suppressive effect than are the C-21 steroids [44]. Therefore, the T or A plasma levels, rather than 17-HP, should be monitored. The fact that much of the intra-adrenal abnormalities in NCAH may be ACTH-independent may explain why 17-HP serum levels are frequently not completely normalized by glucocorticoid treatment despite adequate ACTH suppression [45].

Cyproterone acetate instead of DXM or hydrocortisone has been suggested for the treatment of hirsutism due to NCAH. Although we did not perform such a prospective and randomized study, our personal data agree fully with this

proposal, providing the patient has no or only mild adrenal hyperplasia on CT scan. Despite the increased levels of androgens, cyproterone acetate has a powerful antiandrogen effect on peripheral receptors that allows a more rapid and sustained improvement of hirsutism than does hydrocortisone or DXM alone [46]. Furthermore, adverse effects with cyproterone acetate are less than with glucocorticoids. The same remarks apply to spironolactone.

Cosmetic Treatments

These treatments should be encouraged since they complete the effect of antiandrogen therapy. Temporary methods of hair removal include bleaching, depilation (hair shaft destruction), and epilation (removal of the hair by the root). The only permanent method of hair removal currently in use is electrolysis, which can either be galvanic electrolysis, thermolysis, or a blend of the two. Laser epilation is a relatively new technique which may be promising for the future [reviewed in 47].

Conclusions

In most cases, hyperandrogenism in adolescence is related to a nascent PCOS. Since the laboratory and ultrasonic findings are often not conclusive at this age, the diagnosis may remain presumptive providing other diagnoses have been ruled out and the follow-up does not disclose any atypical evolution. Although considered as a benign disease, PCOS may sometimes severely affect the psychological and social behavior of patients. First, hirsutism and other clinical manifestations of hyperandrogenism may induce poor self-image, and this is particularly crucial at the time of adolescence. Second, anxiety may develop about the fertility prognosis. Lastly, the metabolic long-term risks may threaten some patients excessively. Therefore, when PCOS is diagnosed in an individual adolescent or young woman, the clinician should have a long conversation with her, explaining gently and simply what PCOS means in terms of prognosis for her physical and mental health. The right way is a narrow track, between a guilty silence and anxiogenic medical overactivism.

References

- 1 Rosenfield RL: Puberty and its disorders in girls. *Endocrinol Metab Clin North Am* 1991;20:15–42.
- 2 Apter D, Bützow TL, Laughlin GA, Yen SSC: Gonadotropin-releasing hormone pulse generator activity during pubertal transition in girls: Pulsatile and diurnal patterns of circulating gonadotropins. *J Clin Endocrinol Metab* 1993;76:940–949.
- 3 Bridges NA, Cooke A, Healy MJ, Hindmarsh PC, Brook CG: Standards for ovarian volume in childhood and puberty. *Fertil Steril* 1993;60:456–460.

- 4 Ibanez L, Potau N, Carrascosa A: Possible genesis of polycystic ovary syndrome in the periadolescent girl. *Curr Opin Endocrinol Diab* 1998;5:19–25.
- 5 Apter D, Viinikka L, Viikko R: Hormonal pattern of adolescent menstrual cycles. *J Clin Endocrinol Metab* 1978;47:944–954.
- 6 Sieberg R, Nilsson CG, Stenman UH, Widholm O: Endocrinologic features of oligomenorrheic adolescent girls. *Fertil Steril* 1986;46:852–857.
- 7 Venturoli S, Porcu E, Fabbri R, Paradisi R, Gammi L, Passarini M, Orsini LF, Flamigni C: Ovarian multifollicularity, high LH and androgen plasma levels, and anovulation are frequent and strongly linked in adolescent irregular cycles. *Acta Endocrinol* 1986;111:368–372.
- 8 Venturoli S, Porcu E, Fabbri R, Magrini O, Paradisi R, Pallotti G, Gammi L, Flamigni C: Postmenarchal evolution of endocrine pattern and ovarian aspects in adolescents with menstrual irregularities. *Fertil Steril* 1987;48:78–85.
- 9 Van Hooff MH, Voorhorst FJ, Kaptein MB, Hirasig RA, Koppenaar C, Schoemaker J: Endocrine features of polycystic ovary syndrome in a random population sample of 14- to 16-year-old adolescents. *Hum Reprod* 1999;14:2223–2229.
- 10 Azziz R, Hincapie LA, Knochenhauer ES, Dewailly D, Fox L, Boots LR: Screening for 21-hydroxylase-deficient non-classic adrenal hyperplasia among hyperandrogenic women: A prospective study. *Fertil Steril* 1999;72:915–925.
- 11 Dewailly D, Cortet-Rudelli C, Deroubaix-Allart D: Definition, clinical manifestations and prevalence of polycystic ovary syndrome; in Azziz R, Nestler JE, Dewailly D (eds): *Androgen Excess Disorders in Women*. Philadelphia, Raven Press-Lippincott, 1997, pp 259–268.
- 12 Yen SSC: The polycystic ovary syndrome. *Clin Endocrinol* 1980;12:177–189.
- 13 Nobels F, Dewailly D: Puberty and polycystic ovarian syndrome: The insulin/insulin-like growth factor I hypothesis. *Fertil Steril* 1992;58:655–666.
- 14 Van Hooff MH, Voorhorst FJ, Kaptein MB, Hirasig RA, Koppenaar C, Schoemaker J: Polycystic ovaries in adolescents and the relationship with menstrual cycle patterns, luteinizing hormone, androgens and insulin. *Fertil Steril* 2000;74:49–58.
- 15 Marshall JC, Eagleson CA: Neuroendocrine aspects of polycystic ovary syndrome. *Endocrinol Metab Clin North Am* 1999;28:295–324.
- 16 Lucky AW, Rosenfield RL, McGuire J, Rudy S, Helke J: Adrenal androgen hyperresponsiveness to ACTH in women with acne and/or hirsutism: Adrenal enzyme defects and exaggerated adrenarche. *J Clin Endocrinol Metab* 1986;62:840–845.
- 17 Ibanez I, Potau N, Virdis R, Zanpolli M, Terzi C, Gussinye M, Carrascosa A: Postpubertal outcome in girls diagnosed with premature pubarche during childhood: Increased frequency of functional ovarian hyperandrogenism. *J Clin Endocrinol Metab* 1993;76:1599–1603.
- 18 Conway GS, Honour JW, Jacobs HS: Heterogeneity of the polycystic ovary syndrome: Clinical, endocrine and ultrasound features in 556 patients. *Clin Endocrinol* 1989;30:459–470.
- 19 Carmina E, Lobo RA: Do hyperandrogenic women with normal menses have polycystic ovary syndrome? *Fertil Steril* 1999;71:319–322.
- 20 Dewailly D, Cortet-Rudelli C, Deroubaix-Allard D: Markers of abdominal adipose tissue in women: Relationship to ovarian function. *Trends Endocrinol Metab* 1998;9:68–71.
- 21 Pasquali R, Casimirri F, Venturoli D, Antonio M, Morselli L, Reho S, Pezzoli A, Paradisi R: Body fat distribution has weight-independent effects on clinical, hormonal and metabolic features of women with polycystic ovary syndrome. *Metabolism* 1994;6:706–713.
- 22 Dunaif A: Insulin resistance and ovarian hyperandrogenism. *Endocrinologist* 1992;2:248–260.
- 23 Hall JE, Taylor AE, Hayes FJ, Crowley WF Jr: Insights into hypothalamic-pituitary dysfunction in polycystic ovary syndrome. *J Endocrinol Invest* 1998;21:602–611.
- 24 Dewailly D, Duhamel A, Robert Y: Interrelationship between ultrasonography and biology in the diagnosis of polycystic ovarian disease. *Ann NY Acad Sci* 1993;687:206–216.
- 25 Ehrmann DA, Barnes RB, Rosenfield RL: Polycystic ovary syndrome: A form of functional ovarian hyperandrogenism due to dysregulation of androgen secretion. *Endocr Rev* 1995;16:322–353.
- 26 Barnes RB: The pathogenesis of polycystic ovary syndrome: Lessons from ovarian stimulation studies. *J Endocrinol Invest* 1998;21:567–579.
- 27 Ardaens Y, Robert Y, Lemaitre L, Fossati P, Dewailly D: Polycystic ovarian disease: Contribution of vaginal endosonography and reassessment of ultrasonic diagnosis. *Fertil Steril* 1991;55:1062–1068.

- 28 Robert Y, Dubrulle F, Gaillandre G, Ardaens Y, Thomas-Desrousseaux P, Lemaitre L, Dewailly D: Ultrasound assessment of ovarian stroma hypertrophy in hyperandrogenism and ovulation disorders: Visual analysis versus computerized quantification. *Fertil Steril* 1995;64:307–312.
- 29 Dewailly D, Robert Y, Helin I, Ardaens Y, Thomas-Desrousseaux P, Lemaitre L, Fossati P: Ovarian stromal hypertrophy in hyperandrogenic women. *Clin Endocrinol* 1994;41:557–562.
- 30 Nestler JE: Sex hormone binding globulin: A marker for hyperinsulinemia and/or insulin resistance? *J Clin Endocrinol Metab* 1993;76:1221–1224.
- 31 Conway GS, Jacobs HS, Holly JMP, Wass JAH: Effects of luteinizing hormone, insulin, insulin-like growth factor-I, and insulin-like growth factor small binding protein 1 in the polycystic ovary syndrome. *Clin Endocrinol* 1990;33:593–603.
- 32 New MI, Speiser PW: Genetics of adrenal steroid 21-hydroxylase deficiency. *Endocr Rev* 1986;7:331–349.
- 33 Schiebinger RJ, Albertson BD, Cassorla FG, Bowyer DW, Geelhoed GW, Loriaux DL: The developmental changes in plasma adrenal androgens during infancy and adrenarche are associated with changing activities of adrenal microsomal 17-hydroxylase and 17,20-desmolase. *J Clin Invest* 1981;67:1177–1182.
- 34 Dickerman Z, Grant DR, Faiman C, Winter SD: Intra-adrenal steroid concentrations in man: Zonal differences and developmental changes. *J Clin Endocrinol Metab* 1984;59:1031–1036.
- 35 Forrest MG: Adrenal diseases and steroids. *Curr Opin Pediatr* 1990;2:775–785.
- 36 Lucky AW, Rosenfield RL, McGuire J, Rudy S, Helke J: Adrenal androgen hyperresponsiveness to adrenocorticotropin in women with acne and/or hirsutism: Adrenal enzyme defects and exaggerated adrenarche. *J Clin Endocrinol Metab* 1986;62:840–848.
- 37 Moran C, Azziz R, Carmina E, Dewailly D, Fruzzetti F, Ibanez L, Knochenhauer ES, Marcondes JA, Mendonca BB, Pignatelli D, Pugeat M, Rohmer V, Speiser PW, Witchel SF: 21-Hydroxylase deficient non-classic adrenal hyperplasia is a progressive disorder: A multicenter study. *Am J Obstet Gynecol* 2000;183:1468–1474.
- 38 Speiser PW, New MI: Genotype and hormonal phenotype in nonclassical 21-hydroxylase deficiency. *J Clin Endocrinol Metab* 1987;64:86–91.
- 39 Satoh M, Yokoya S, Hachiya Y, Hachiya M, Fujisawa T, Hoshino K, Saji T: Two hyperandrogenic adolescent girls with congenital portosystemic shunt. *Eur J Pediatr* 2001;160:307–311.
- 40 Isojärvi JI, Laatikainen TJ, Pakarinen AJ, Juntunen KS, Myllylä VV: Polycystic ovaries and hyperandrogenism in women taking valproate for epilepsy. *N Engl J Med* 1993;329:1383–1388.
- 41 Cortet-Rudelli C, Desailly R, Dewailly D: Drug-induced androgen excess; in Azziz R, Nestler JE, Dewailly D (eds): *Androgen Excess Disorders in Women*. Philadelphia, Raven Press-Lippincott, 1997, pp 613–622.
- 42 Kuttann F, Rigaud C, Wright F, et al: Treatment of hirsutism by oral cyproterone acetate and percutaneous estradiol. *J Clin Endocrinol Metab* 1980;51:1107–1111.
- 43 Apter D: How possible is the prevention of polycystic ovary syndrome development in adolescent patients with early onset of hyperandrogenism? *J Endocrinol Invest* 1998;21:613–617.
- 44 Parker LN: Control of adrenal androgen secretion. *Endocrinol Metab Clin North Am* 1991;20:401–421.
- 45 Azziz R, Dewailly D, Owerbach D: Clinical Review 56. Non-classic adrenal hyperplasia: Current concepts. *J Clin Endocrinol Metab* 1994;78:810–815.
- 46 Spritzer P, Billaud L, Thalabard JC, Birman P, Mowszowicz I, Raux-Demay MC, Clair F, Kuttann F, Mauvais-Jarvis P: Cyproterone acetate versus hydrocortisone treatment in late-onset adrenal hyperplasia. *J Clin Endocrinol Metab* 1990;70:642–646.
- 47 Lucky AW: Physical treatments of unwanted hair; in Azziz R, Nestler JE, Dewailly D (eds): *Androgen Excess Disorders in Women*. Philadelphia, Raven Press-Lippincott, 1997, pp 779–786.

Christine Cortet-Rudelli
Unité de Soins Normalisée A, 6, rue du Professeur Laguesse
FR-59037 Lille Cedex (France)
Tel. +33 3 2044 4789, Fax +33 3 2044 4184
E-Mail c-cortet@chru-lille.fr

Ovarian Masses in Adolescent Girls

*C. Pienkowski^a, C. Baunin^c, M. Gayrard^a, P. Moulin^a, G. Escourrou^d,
P. Galinier^b, P. Vaysse^b*

^aUnité d'Endocrinologie, Génétique et Gynécologie Médicale; ^bUnité de Chirurgie Viscérale, et ^cService d'Imagerie Pédiatrique, Hôpital des Enfants, Toulouse, et ^dService d'Anatomo-Pathologie CHU Rangueil-Toulouse, Toulouse, France

Whether benign or malignant, functional or organic, fluid or solid [1], ovarian masses are the most common gynecological tumors, with benign tumors and functional cysts greatly predominating. The annual incidence of ovarian neoplasms is estimated at 2.6 cases per 100,000 girls and they are very rarely malignant, representing only 1% of all cancers in children and adolescents [2, 3]. The variety and complexity of the symptoms of these masses pose many diagnostic difficulties and pelvic imaging is of unquestionable value – in particular pelvic ultrasonography, which is the key diagnostic investigation [4]. New surgical techniques have been developed, including laparoscopy, which are generally reserved for the treatment of small persistent benign tumors to remove the cyst and preserve the underlying ovary [5].

Only surgery and histopathological analysis allow precise identification of the exact nature of a complex tumor. Ovarian masses in fact cover a wide range of pathologies, from more or less secretory tumors and benign but complex anomalies to highly aggressive and invasive tumors. Generally, recognition of the precise histological type of the neoplasm goes beyond mere histopathological classification; prognosis and treatment depend on it. The work of Scully [6, 7], who identified numerous categories of tumor, has led to an international classification recognized by the World Health Organization (WHO).

Review of Ovarian Embryology

The gonad appears in the first month of embryonic life as a localized thickening of the antero-internal aspect of the mesonephros, called the genital

ridge, which is covered by the coelomic epithelium. At 6 weeks, the primordial germ cells penetrate the genital ridge and the cells of the coelomic epithelium proliferate to form the primitive sex cords which will surround the primordial germ cells and form the undifferentiated gonad. At 7 weeks, the gonad is undifferentiated and has dual potential. There are three essential stages in ovarian differentiation because Y and above all SRY are absent: the chromosomal stage where two Xs are present [8], the gonadal stage with ovarian orientation under the influence of gonadal differentiation factors, and a later hormonal stage with estrogen secretion. Ovarian differentiation begins at 10 weeks with the development of the primordial follicles in the cortex, while maturation ends at puberty.

Diagnostic Symptoms

The symptoms leading to diagnosis are varied and not necessarily specific to the pelvic region. They may follow a chronic course mainly marked by poorly defined pain, heaviness or a palpable mass. In other cases there may be acute pain or an endocrine syndrome.

The most common complaint is abdominal pain: pain may be subacute, abdominal and pelvic, sometimes recurrent, and may or may not be accompanied by gastrointestinal signs such as nausea or vomiting or urinary signs such as pollakiuria or dysuria. These last may sometimes be the principal signs. Acute pain with a localized, exquisitely painful spot suggests an ovarian complication such as torsion, rupture or hemorrhage, once other acute surgical pathologies of the lesser pelvis have been ruled out.

In other cases, a palpable mass may be detected after a complaint of pelvic heaviness with varying degrees of tenderness. The size of the tumor is not an indication of its potential malignancy. In some voluminous tumors, the upper pole of the mass extends beyond the pubic symphysis and develops within the abdomen. A mass may also be totally asymptomatic and revealed by ultrasonography.

Endocrine manifestations can occur and feminization and estrogen-producing ovarian tumors are more common than virilization. Abnormal estrogen secretion leads to isosexual precocity in young pubertal girls: rapid breast development with vaginal bleeding and enlargement of the uterus are the most common initial manifestations. In adolescent girls, we observe excessive swelling of the breasts accompanied by pain and tenderness and pronounced areolar pigmentation. Excessive irregular vaginal bleeding and metrorrhagia seem to be more frequent than amenorrhea. On the other hand, virilizing tumors are associated with rapid hirsutism, male-type muscular development, clitoral enlargement

and ‘defeminization signs’ with amenorrhea or irregular menses and breast regression.

Clinical examination should be completed by pubertal and menstrual histories in *all* cases, including dates of the first and last menses and detailed information on regularity, abundance and duration. Special attention is paid to disruption of the menstrual cycle, dysmenorrhea and leukorrhea. Questions on sexual activity, contraceptive practices and exposure to sexually transmitted diseases must also be asked. It is important to look for general signs such as fever, fatigue and weight loss.

An adequate pelvic examination is not often possible in virginal patients or those in pain. Rectal examination may allow physicians to palpate pelvic organs and search for a localized painful point and a palpable lateral uterine mass.

Means of Diagnosis

Imaging

Numerous techniques are available and play a fundamental role not only in establishing a positive diagnosis and orienting the etiology, but also in surveillance and the assessment of spread.

The *plain abdominal radiograph* may reveal a mass syndrome. It shows tonal differences (fat), intratumoral calcification or ossification, the skeleton and surrounding soft tissues.

Ultrasonography [9] by an abdominal approach with a full bladder indicates the nature of the mass (fluid, solid, homogeneous or otherwise), its size and borders, its location and relations with adjacent organs and any possible repercussions on the upper urinary tract [10]. Doppler ultrasonography may help to identify the structure of a mass [11]. Certain signs may be useful in evaluating the probable benign or malignant nature of the ovarian mass. These signs have a varying predictive value, which is increased when several elements are found together (poorly defined borders, a thick irregular wall, thick rigid septations with angulated junctions, growths, mainly solid component, size, local spread). The contribution of ultrasonography, and especially Doppler ultrasonography, in pediatric practice is nevertheless limited by the impossibility of endovaginal investigation.

Sectional Imaging: Computed tomography (CT) or magnetic resonance imaging (MRI) help to locate the mass and above all to identify its nature. MRI is particularly valuable for characterizing the various fluid and tissue structures. Various modalities [12–14] identify tissue structure, blood (hemorrhagic complication of a cyst, adnexal torsion), mucus, fat, and the more or less complex association of various components (dermoid cyst, teratoma, endometriosis).

If the tumor is solid, MRI provides arguments as to its malignant or benign nature and its potential in affirming malignancy is considered to be about 86% in the adult [15]. MRI is indispensable at the present time in assessing the spread of malignant tumors.

Laboratory Studies

Laboratory studies are necessary in the first instance and are useful to differentiate other pelvic conditions such as pregnancy and pelvic inflammatory disease (PID). First, a pregnancy test should be routinely performed to exclude an ectopic pregnancy. Leukocytosis, elevated erythrocyte sedimentation rate and C-reactive protein are highly predictive of inflammatory processes such as appendicitis or PID, and screening for sexually transmitted diseases must be done [16, 17]. In this case, medical treatment with broad-spectrum intravenous antibiotics is usually sufficient.

Hormonal Investigations

Endocrine manifestations are due to abnormal secretion of steroid hormones by the tumor: estrogens, androgens or both. Clinical features depend on the abnormal hormonal secretion. Excessive production of sex steroids (estrogens or androgens or both) with suppressed pituitary gonadotropin level (LH and FSH) are in favor of gonad production [18]. High steroid levels are not suppressed by the dexamethasone test and this response can differentiate ovarian origin and adrenal hypersecretion.

Serum Tumor Markers

Some ovarian neoplasms secrete protein or hormone markers that can be assayed in either peripheral blood samples or the ovarian cyst fluid [19]. These substances are not specific markers for ovarian origin but are specific of tissue function. They are less useful in the diagnosis of ovarian mass than for the detection of possible recurrences in the follow-up after initial treatment. The main helpful markers are carcinoembryonic antigen (CEA) in epithelial and germ cell tumors; α -fetoprotein (α FP), which is produced by mixed germ cell tumors and immature teratomas, and human chorionic gonadotropin (hCG), which is elevated in choriocarcinoma and embryonic ovarian carcinomas [19, 20]. Cancer antigen 125 (CA 125) is a protein expressed on the cell membrane of normal ovarian tissue. It is a sensitive but not specific marker for non-mucinous epithelial ovarian cancer. Elevated serum CA 125 is typically associated with ovarian malignancies but it can also be found in association with other intraperitoneal processes such as endometriosis, hydronephrosis, PID and other epithelial gastrointestinal cancers [21–23]. The value of the serum tumor marker CA 125 to date has been in monitoring response to chemotherapy in patients with ovarian

Table 1. Serum tumor markers

Marker	Associated tumor
CA 125	Epithelial tumors (especially serous) Immature teratoma (rare)
α -Fetoprotein	Endodermal sinus tumors Embryonal carcinomas Mixed germ cell tumors Immature teratoma (rare) Polyembryoma (rare)
Human chorionic gonadotropin	Choriocarcinoma Embryonal carcinomas Mixed germ cell tumors Polyembryoma Dysgerminoma (rare)
Carcinoembryonic antigen	Serous tumors Mucous tumors
Lactate dehydrogenase	Dysgerminoma Mixed germ cell tumors
Estradiol	Thecomas Adult granulosa cell tumors
Testosterone	Sertoli cell tumors Leydig (hilus) cell tumors
F9 embryoglycan	Embryonal carcinoma Yolk sac tumor Choriocarcinoma Immature teratoma
Inhibin	Granulosa-theca cell tumor
Müllerian inhibiting substance	Granulosa-theca cell tumor

cancer and in detecting recurrent disease [24]. Inhibin B is a glycoprotein secreted by ovarian granulosa cells. Elevated serum inhibin concentration was reported in granulosa cell tumors [25] and in some mucinous carcinomas. In the postnatal period, granulosa cells also secrete another glycoprotein, müllerian inhibiting substance (MIS). Very elevated serum levels of MIS were found in a woman with an ovarian sex cord tumor [26] (table 1).

Surgery

The recent literature [27–29] shows that in pediatric practice conventional surgery still holds a considerable place, although the present trend is toward

increasing use of laparoscopy. As in other fields, the most appropriate approach may well be video-assisted surgery, as the two techniques are complementary.

Open surgery allows precise intervention on the adnexae while respecting the imperatives of oncological surgery. However, when extensive abdominal investigation (up to the diaphragm) is required, the necessarily wide approach leaves, at the very least, non-negligible esthetic sequelae.

Laparoscopy allows complete exploration of the peritoneal cavity and acquisition of biopsy samples if required – especially of the supramesocolic region – and peritoneal washings for cytological study. Inversely, intervention on the adnexae is less precise than with conventional surgery, even in experienced hands: immobilization of the ovary and fallopian tube and their isolation from neighboring structures to prevent fluid or cell leakage are of lesser quality. Even if this argument may be moderated by the rarity of malignant tumors, it must always be borne in mind when dealing with an ovarian mass; at least one case of peritoneal dissemination after laparoscopic treatment of a teratoma has been published [30]. The most reasonable attitude is probably to associate these two techniques in the wider context of video-assisted surgery.

The first stage consists of laparoscopy using the ‘open’ technique, which avoids the risks of blind performance of pneumoperitoneum. The peritoneal cavity can be completely explored and the ovarian mass assessed (size, surface, connections between the ovarian parenchyma and the tumor), and a functional mass can be treated and an adnexa untwisted if necessary.

When all the clinical, radiological, biological and endoscopic criteria of benignity are met and the organic mass is small in size, tumoral excision (tumorectomy but not adnexectomy) can be envisaged, either within the abdomen by laparoscopy or outside the abdominal cavity after externalization of the adnexa by a short incision at the level of an iliac fossa.

In all other cases, ovarian surgery is carried out by a wide pelvic approach such as the Pfannenstiel technique. Extensive laparotomy is now very infrequent.

Management

In practice, the clinician is confronted by two very different situations: (1) a pelvic mass or an endocrine syndrome is discovered and complementary investigations are required for better definition of the nature of the tumor, and (2) acute abdominal pain and vomiting signal an emergency situation, with the danger of adnexal torsion, and surgery is indicated without further delay.

Ovarian Mass Discovered on Subacute Pain or an Endocrine Syndrome

Once pregnancy and PID have been eliminated, the initial diagnosis is based on the association of plain abdominal radiographs and ultrasonography [10, 31], which (1) confirms the presence of the mass (differential diagnosis with pseudo-masses such as fecalomas, obstructed bladder, pregnancy, urinary disorder or ascites); (2) identifies its location in the upper intervesico-rectal space, thus excluding pelvic tumors of the other spaces and directing attention to the genital apparatus; (3) analyzes its structure: fluid, solid or mixed, and (4) assesses tumor spread.

In most cases, these simple investigations will suggest the diagnosis of an ovarian cyst or teratoma. Viewed in an overall context of suspected leukemia or a lymphoma, they will be sufficient to identify a tissue mass localized in an ovary. Diagnosis may sometimes be more difficult: a complex cyst with a pseudo-solid appearance or teratomas with a marked calcified component. Here tumor marker measurement, sectional imaging and above all MRI come into their own. MRI is more specific in the analysis of the various components and provides indispensable information on the relationships and spread of the mass.

Adnexal Torsion

Torsion is the most common complication of ovarian masses, with a frequency ranging from 3 to 33% [27, 28]. When the ovarian mass manifests with acute pain, torsion is highly probable, ranging from 42% [28] to 80% [32], depending on the series.

Several publications have suggested that ovarian tumors with torsion are usually benign [27, 33, 34]. A possible explanation is that the rapid growth of a malignant tumor leads to peritumoral inflammation and the formation of adhesions. The size of the mass does not appear to be significantly correlated with the presence or absence of torsion [33]. Although torsion has not been shown to correlate with cyst size, larger cysts, and thus heavier ovaries, appear to be less prone to torsion [27]. Moreover, in several publications of acute ovarian torsion, the frequency of associated tumors varies from 32% [35] to 84% [27].

The clinical symptoms of tumoral adnexal torsion are in no way specific. Usually, acute subumbilical abdominal pain is associated with vomiting. The diagnosis can be difficult and the differential diagnosis may include appendicitis, kidney stone, PID, ectopic pregnancy and ruptured ovarian cyst.

Ultrasonography reveals an echogenic pelvic mass [27, 36] that is usually complex (solid and cystic) and the homolateral ovary is not visualized. Effusion in Douglas' pouch is generally a late manifestation. If there are abnormal

calcifications on ultrasound study or on the plain radiograph, a teratoma may be suspected. Lack of blood flow on Doppler ultrasonography suggests arterial obstruction. CT scan may be useful but treatment must not be delayed too long just to obtain complementary imaging or biological tests (tumor markers). Surgical intervention [28] by laparoscopy or laparotomy is in fact the most reliable method of diagnosis and first-stage treatment.

Numerous series of torsions of tumoral or healthy adnexae [27, 35–38] show that in many cases wide excision with oophorectomy or salpingo-oophorectomy was performed. Many reasons were given for excision, such as fear of pulmonary embolism after detorsion or of missing a malignant ovarian tumor on an enlarged adnexa (any ovarian torsion, whether on tumoral or healthy adnexae, presents as a mass), as well as the generally necrotic, bluish-black appearance of the adnexa which is then considered unsalvageable.

In the light of numerous publications, all these reasons are debatable and should lead to a much more conservative attitude with the aim of preserving later fertility: (1) Ovarian detorsion was considered inadvisable because of the theoretical risk of pulmonary embolism from the gonadal veins. There has been no published case confirming this possibility in the child. To the contrary, detorsion as reported by several authors [39–42] did not lead to any thromboembolic incident. (2) Adnexal torsion is often associated with an ovarian tumor but as a rule the latter is benign [27, 28]. As far as we are aware, in children there have been no cases of torsion associated with a malignant tumor [42]. (3) Ovarian viability after detorsion is very difficult to evaluate. Numerous studies in both adults and children have demonstrated the amazing capacity of the ovary not only to revascularize but also to recover satisfactory function after simple detorsion (on condition that only detorsion is performed, together with aspiration of a cystic lesion if necessary, but avoiding cyst excision during the acute phase).

Because of the lack of proof of thromboembolic risk after detorsion, the low incidence of malignancy and the difficulty of evaluating ovarian viability, in cases of adnexal torsion detorsion is perfectly justified whether by laparoscopy [39, 43] or conventional surgery [41, 42]; if necessary it may be associated with aspiration of a cystic lesion if the latter appears benign. Excision of a cyst is probably inadvisable during the acute phase [28].

The child can then be followed by ultrasonography and tumor marker measurement. If an ovarian lesion persists with normal tumor markers, the tumor should be excised at a distance from the acute episode.

Ovarian fixation is usually advisable but this has recently been debated [28] as it may produce adhesions and modify the relation between the ovary and the fallopian tube and thus in itself adversely affect later fertility; also, it does not totally exclude the risk of later torsion [41].

The Various Ovarian Masses

Non-Neoplastic Functional Disorders: Functional Cysts

The development of simple cysts is quite common in adolescents, and the risk of malignancy is close to zero. In the pubertal period, ovaries may contain multiple follicles in different stages of development, and most simple cysts result from the failure of maturing follicles to ovulate and involute. This cystic transformation may be due to either inadequate or excessive ovarian stimulation, as indicated by increased frequency in the pubertal or perimenopausal periods, after treatment to induce ovulation or during treatment with certain microdose progestative contraceptive pills.

The frequency of functional cysts is most certainly underestimated as asymptomatic and spontaneously regressive forms go unrecognized. In a series of 139 observations of adolescent girls who had undergone routine ultrasonography, 12% of the girls had cysts that resolved spontaneously within 3 months [44]. Management depends on clinical symptoms and the diameter and appearance of the cyst. Mere surveillance is only decided if the cyst is a simple one and, inversely, surgery is called for if lesions are suspect and their histological nature must be determined.

When the cyst is unilateral and purely fluid on ultrasonography, surveillance for 3 months with a monthly ultrasound check-up is indicated. Treatment with progestogens or a combined oral contraceptive reduces the time the cyst takes to resolve and decreases the risk of recurrence [45]. In a series of 144 patients, cysts resolved in 3 weeks with estroprogestative treatment compared with 4.5 weeks without treatment [46]. The adolescent should be informed that ultrasonography must be done if acute pain develops, because of the risk of adnexal torsion. If the cyst persists after 3 months or if it rapidly increases in volume, surgery by laparoscopy or laparotomy may be necessary to remove the cyst for histopathological study [47, 48]. This makes it possible to differentiate a simple cyst from a paraovarian or paratubal cyst, a hydrosalpinx or certain epithelial tumors such as serous cystadenomas. These simple cystic processes are not neoplasms and are considered as physiological variations; they are benign and derived from a follicle (first part of the cycle), a corpus luteus (after ovulation) or the cells of the internal theca.

Epidemiology: Predisposing Factors

In the adolescent girl, risk factors such as early menarche, long menstrual cycles or oligomenorrhea may increase the possibility of ovarian cyst. Inversely, the risk decreases if the first menses appeared after the age of 14 years (odds ratio (OR) 0.4), cycles are short and regular (<26 days), and the patient is obese (OR 0.5). The risk is, however, doubled with irregular menses (OR 1.9) [49].

Risk may be affected by tobacco consumption, with a twofold relative increase of risk in patients who are smokers [50].

Special Etiology

Rare cases of aromatase gene mutation have been described in 46,XX girls with primary amenorrhea, bilateral ovarian cysts and impuberism, contrasting with increasing virilization [51, 52]. Aromatase is the enzyme that catalyzes the hydroxylation involved in the conversion of androgens into estrogens [52]. The aromatase deficiency of these girls accounts for their hypergonadotrophic hypogonadism, high androgen levels and macropolycystic ovaries. Estrogen treatment results in feminization, menstruation and ovarian cyst regression [53].

Endometriosis

Endometriosis is characterized by the presence of endometrial tissue outside the uterine cavity. It is rare during puberty and is marked by dysmenorrhea with a large endometrial cyst located in the adnexal fallopian tube or in the ovary, the so-called endometrioma or chocolate cyst. Ultrasonography and MRI may be helpful in identifying an ovarian endometrioma, which is more easily recognizable during the menses. At the onset of disease, surgery is necessary and includes resection of the cyst wall of the endometrioma. Medical treatment can be considered at a later stage.

Several complementary theories have been advanced to explain this disorder: the first is the theory of tubal reflux described by Sampson [54] in 1925. In vaginal aplasia in the syndrome of Rokitansky-Kuster-Mayer-Hauser, ovarian endometrioid nodules are observed earlier and more frequently [55]. A second more recent theory to account for the hypofertility of these patients is that it is caused by a significant decrease in the physiological apoptosis of the endometrial cells. Numerous factors of immunological disturbance, such as fibronectin, interleukins and insulin-like growth factor, seem to play an important role [56]. A Canadian study has stressed the predisposing role of factors such as short cycles, menses lasting more than 5 days, excess weight and above-normal alcohol and caffeine consumption [57].

Benign and Malignant Neoplastic Disorders

The WHO has published a classification of ovarian tumors based on histologic cell type and benign versus malignant nature [6, 7]. This classification is shown in table 2. Staging of malignant ovarian tumors has been defined by the International Federation of Gynecology and Obstetrics (FIGO) [58] (table 3).

Ovarian neoplasms occur in 2–25% of adnexal masses in adolescent series [46, 59, 60]. Germ cell tumors are the most common tumors and represent

Table 2. Modified WHO international histologic classification of ovarian tumors

Common 'epithelial' tumors
Serous
Mucinous
Endometrioid
Clear cell
Other epithelial tumors: Brenner, transitional, small cell
Malignant mixed mesodermal
Unclassified
Sex cord-stromal tumors
Granulosa stromal cell
Granulosa cell
Thecoma-fibroma
Sertoli stromal cell
Sertoli cell tumors
Sertoli-Leydig cell tumors
Well differentiated
Intermediately differentiated
Poorly differentiated
With heterologous elements
Sex cord tumor with annular tubules
Leydig (hilus) cell tumors
Lipid (lipoid) cell tumors
Gynandroblastoma
Germ cell tumors
Dysgerminoma
Endodermal sinus tumor
Embryonal carcinoma
Polyembryoma
Choriocarcinoma
Teratomas
Immature
Mature (dermoid cyst)
Monodermal (struma ovarii, carcinoid)
Mixed forms
Gonadoblastoma
Metastatic
Other

50–60% of ovarian tumors in women aged under 20 [61]. About 95% of these tumors are benign cystic teratomas and 5% are mixed malignant germ cell tumors with several histological components secreting various tumor markers, β -hCG or α FP [62].

Table 3. International federation of gynecology and obstetrics (FIGO) staging of carcinoma of the ovary¹

Stage I	Growth limited to the ovaries
Stage IA	Growth limited to one ovary; no ascites present containing malignant cells No tumor on the external surface; capsule intact
Stage IB	Growth limited to both ovaries; no ascites present containing malignant cells No tumor on the external surfaces; capsules intact
Stage ICa	Tumor classified as either stage IA or IB but with tumor on the surface of one or both ovaries; or ruptured capsule(s); or with ascites containing malignant cells present; or with positive peritoneal washings
Stage II	Growth involving one or both ovaries, with pelvic extension
Stage IIA	Extension and/or metastases to the uterus and/or tubes
Stage IIB	Extension to other pelvic tissues
Stage IICa	Tumor either stage IIA or IIB but with tumor on the surface of one or both ovaries; or with capsule(s) ruptured; or with ascites containing malignant cells present; or with positive peritoneal washings
Stage III	Tumor involving one or both ovaries with peritoneal implants outside the pelvis and/or positive retroperitoneal or inguinal nodes Superficial liver metastasis equals stage III Tumor is limited to the true pelvis but with histologically proven malignant extension to small bowel or omentum
Stage IIIA	Tumor grossly limited to the true pelvis with negative nodes but with histologically confirmed microscopic seeding of abdominal peritoneal surfaces
Stage IIIB	Tumor of one or both ovaries with histologically confirmed implants of abdominal peritoneal surfaces, none >2 cm in diameter; nodes are negative
Stage IIIC	Abdominal implants >2 cm in diameter and/or positive retroperitoneal or inguinal nodes
Stage IV	Growth involving one or both ovaries, with distant metastases If pleural effusion is present, there must be positive cytologic findings to allot a case to stage IV Parenchymal liver metastasis equals stage IV

¹Staging of ovarian carcinoma is based on findings at clinical examination and surgical exploration. The histologic findings are to be considered in the staging, as are the cytologic findings as far as effusions are concerned. It is desirable that a biopsy be taken from suspicious areas outside of the pelvis.

Common epithelial tumors increase in frequency in the second decade, from 16% before 14 years to 28% at 17 years [60]. Serous cystadenomas seem the most common (50% of cases) and the incidence of borderline tumors increases with age. Sex cord-stromal tumors consist of epithelial (granulosa-Sertoli cells) and mesenchymal elements in a variety of combinations. Granulosa cell tumors are the most frequent feminizing tumors and the juvenile form is of low malignant potential [63].

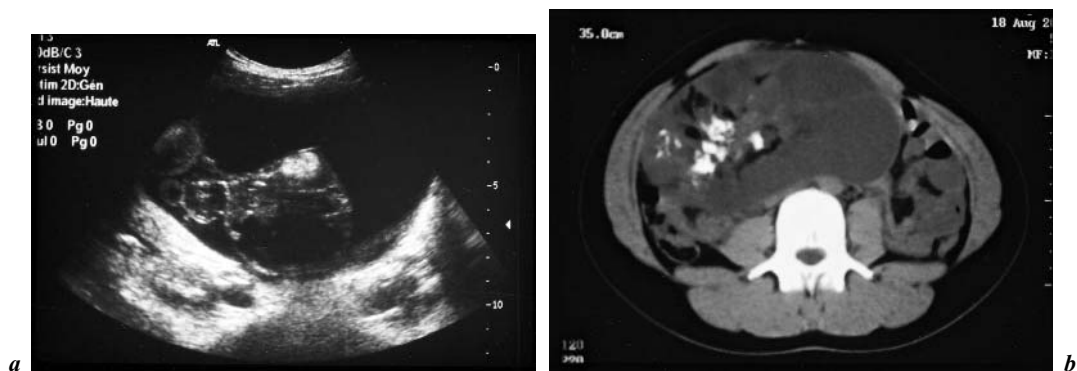


Fig. 1. Dermoid cyst. **a** Ultrasonography. Heterogeneous mass, predominantly fluid, with a tissue component and echogenic calcifications. **b** CT scan. Heterogeneous, multilocular, calcified mass, with a highly suggestive fat content.

Germ Cell Tumors

Mature Cystic Teratoma (fig. 1a, b). Benign cystic teratomas or dermoid cysts are the most common germ cell tumors and in this case all tissue is mature and there is no mitotic activity. Patients may be asymptomatic or present abdomino-pelvic pain or increasing abdominal girth. Due to the weight of the lesion, there is a potential risk of ovarian torsion. Physical examination may reveal a palpable adnexal mass which may be voluminous. Pelvic X-rays may show pelvic calcifications. Ultrasonography can identify an ovarian heterogeneous solid mass. The type of surgery depends on the volume of the tumor and its sonographic appearance [64]. The aim is optimal preservation of the normal ovary with the minimum of risk of adherence or spillage of cyst fluid. It is important to search for malignant cells and bilateral lesions in the cystectomy specimen [65]. In all cases, the cyst is excised and the remaining normal ovary salvaged. Approximately 10% of teratomas are bilateral and careful sonographic and macroscopic examination of the contralateral ovary is necessary. However, several studies have found that histologic examination of an apparently normal ovary leads to identification of a teratoma in fewer than 1% of the cases. Under these conditions, several reports agree that routine biopsy of the contralateral ovary is not in fact necessary [27].

Teratomas are usually benign tumors but their malignant potential is related to the histological differentiation and nuclear atypia of their cells. They can be classified in three types: immature malignant teratomas, mature benign teratomas or monodermal teratomas [66]. Malignancy is determined according to the FIGO classification and the grade adapted for germ cell tumors, with neuroepithelial tissue present in grade 3.

Dysgerminomas. Dysgerminomas are the most frequent malignant germ cell tumors in young women (80% of cases). They are rarely pure dysgerminomas but are often mixed with other cell types and syncytiotrophoblastic types secreting hCG. They are usually large and often secrete hormones and tumor markers such as β -hCG, LDH or α FP, which can be useful in monitoring the course of the disease. Paraneoplastic manifestations are possible [67]. Diagnosis is often made at stage 1A and conservative surgery with salpingo-oophorectomy is the treatment of choice. These tumors are bilateral in 20% of cases and surveillance of the contralateral ovary with systematic biopsy is recommended.

Localized, unilateral forms have an excellent prognosis at 5 years but there is a high recurrence rate. The prognosis is more reserved in mixed bilateral forms with multiple recurrences and an endodermal sinus component [68]. Among the tumors with an unfavorable prognosis are those >10 cm in diameter and with more than one-third mixed component. These tumors are sensitive to chemotherapy and radiotherapy. Chemotherapy protocols are indicated in the more extensive forms (FIGO stages II, III and beyond).

Endodermal Sinus Tumors or Yolk Sac Tumors. These are an association of extra-embryonic mesodermal cells and endodermal cells. The mean age at diagnosis is 19 years and the incidence appears to increase with age [69]. These tumors evolve very rapidly and are only exceptionally bilateral. There are four architectural variants: labyrinthine, pseudo-papillary, polyvesicular and solid. α FP is an excellent marker for diagnosing recurrences, which occur very frequently during the first year. Polychemotherapy protocols have markedly improved survival [70].

Other Tumors. Other tumors include embryonic carcinomas consisting of extra-embryonic and embryonic teratoma-type pluripotential cells. Choriocarcinomas are biphasic tumors composed of cytotrophoblasts and syncytiotrophoblasts secreting β -hCG and α FP.

Common Epithelial Tumors

Epithelial ovarian neoplasms are rare in patients under the age of 20 years. Few series have found any premenarchal adolescents with these lesions [71]. Serous cystadenomas are the most common. They are often unilocular, with a thin wall and a clear content, and they rapidly increase in volume. They are rarely bilateral and their rate of malignancy ranges from 7.5 to 30% [3]. Mucinous cystadenomas are multilocular with a thick content and a wall of variable, irregular thickness. They tend to recur and regular surveillance is necessary over a period of several years. In a series [72] of 19 patients with epithelial ovarian neoplasms and aged under 21 years (range 14–21), 9 serous tumors, 7 mucinous tumors, 2 small cell carcinomas and 1 endometrioid carcinoma were found. Most (84%) were low malignant potential or well-differentiated tumors.

Surgical treatment consisted of unilateral salpingo-oophorectomy in 12 patients, total hysterectomy and salpingo-oophorectomy in 6 patients and cystectomy in 1 patient. Fifteen patients had FIGO stage 1 disease and survival was good with preservation of fertility. Four patients had stage III disease at the time of diagnosis. Two deaths occurred in this series, both in patients with small cell anaplasia.

Mesenchymal and Sex Cord Tumors

Sex cord-stromal tumors are neoplasms which contain granulosa cells, Sertoli cells, Leydig cells and fibroblasts of stromal origin. These tumors are notable for their endocrine activity, with feminizing or predominantly estrogen-producing tumors or virilizing or predominantly androgen-producing tumors, and they account for 3–10% of gonadal tumors. Steroid dosage and specific tumor markers are useful in the follow-up after surgery. Activating mutations of the G-protein genes have been associated with the development of several endocrine neoplasms. Lyons et al. [73] identified a special mutation at codon 179 of $G\alpha_{12}$ (gip2) in two granulosa cell tumors and one thecoma. Other mutations were identified as gsp in Leydig cell tumors. These particular activating mutations of protein genes seem to be involved in the pathogenesis of sex cord-stromal tumors and these putative oncogenes may play a significant role in the molecular mechanism of such tumors [73, 74].

Granulosa Cell Tumors. Ovarian juvenile granulosa cell tumors are usually encountered in children and adolescents and have a more favorable prognosis than the typical adult form [75]. These tumors secrete estrogen and young girls present pseudo-precocious puberty with breast enlargement and vaginal bleeding, while adolescent patients have hypermenorrhea. Virilization occurs in 2–3% of patients with granulosa tumors, especially with cystic tumors [76]. Specific granulosa cell markers are inhibin B and MIS [25, 26]. Microscopically, pure granulosa cell tumors are highly differentiated and a typical microfollicular pattern consisting of Call-Exner bodies is often seen in adult tumors but is rare in juvenile cases. About 90% are diagnosed at an early stage (FIGO stage 1) and prognosis is favorable. More advanced stages have poor clinical outcome and surgery should be completed with chemotherapy (carboplatin and etoposide) [77].

We followed an 11-year-old patient with renal failure who presented rapid breast development with metrorrhagia. Ultrasonography showed a heterogeneous right ovarian tumor (175 ml) with an enlarged uterus (55 mm). Estradiol level was high (150 pg/ml) with suppressed gonadotropin. Various tumor markers such as CEA, α FP and hCG were negative but two results were elevated: inhibin >1,000 pg/ml and MIS, 442 pmol/l. This was an estrogen-producing tumor and at first we suspected a granulosa cell tumor with specific positive tumor markers. WT1 mutations have been reported in granulosa cell tumors [78]

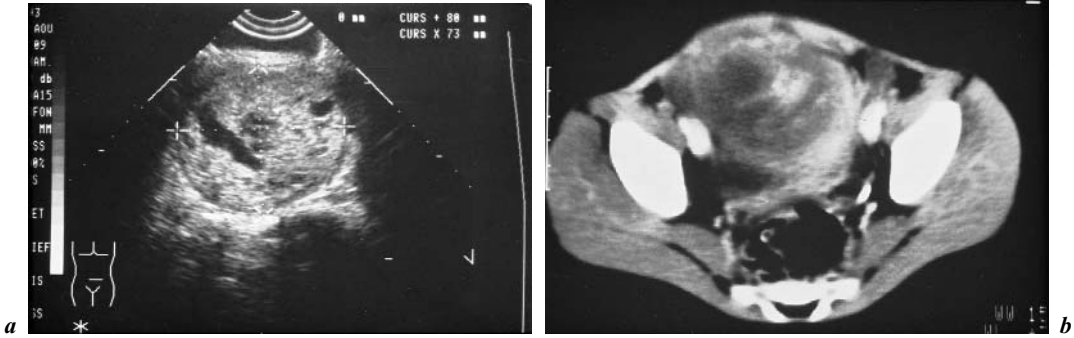


Fig. 2. Fibrosarcoma. **a** Ultrasonography. Heterogeneous ovarian mass with a predominant tissue component. **b** CT scan. Solid tumor with no fat or calcifications, and heterogeneous uptake of contrast agent.

but search for this mutation was negative. Unilateral salpingo-oophorectomy was done and confirmed FIGO stage 1. Two years later the patient is well and surveillance with inhibin B and MIS measurement and ultrasonography is negative.

Thecomas, Fibromas, Fibrosarcomas (fig. 2a, b). Thecomas or fibromas are uncommon before the age of 20. Pure thecomas or fibrothecomas are almost always benign but rare fibrosarcomas with nuclear atypia have a bad prognosis [79]. Tumors may be virilizing or associated with estrogen production or Demon-Meigs syndrome (ascites and pleural effusion). In patients with nevoid basal cell carcinoma syndrome (NBCC or Gorlin syndrome), the first tumor occurs at a median age of 20 years. Gorlin syndrome is an autosomal dominant disorder linked to 9q22.3-q31 comprising ovarian fibroma, basal nevi, jaw cysts and skeletal anomalies [80]. Pure thecomas are composed of theca cells and fibroblasts of ovarian stromal origin and luteinized thecoma.

Sertoli-Leydig Tumors. Leydig cell tumors are rare, unilateral tumors (<0.2% of all ovarian neoplasms) of the sex cord-stromal group and were previously termed androblastomas or arrhenoblastomas. They cause virilization in girls and patients complain of hirsutism, hoarseness, muscular hypertrophy and menstrual disturbances. Hormonal analysis shows a high testosterone level, only partly suppressed by the dexamethasone screening test, and suppressed LH and FSH. Ovarian vein catheterization can yield a diagnosis. These are solid yellowish nodular tumors with polygonal Leydig cells containing eosinophilic cytoplasm with lipid vacuoles. The prognosis is related to the stage and degree of tumoral differentiation. They are low-grade malignant tumors whose prognosis is usually good; unilateral salpingo-oophorectomy is necessary and sufficient [75]. Decrease in testosterone levels and increased gonadotropins are the best markers of a favorable course.

Gynandroblastoma. This is a rare tumor which associates granulosa cells and Sertoli-Leydig cells in varying proportions [81].

Another Rare Tumor, the Gonadoblastoma

The gonadoblastoma is composed of germ cells mixed with sex cord derivatives and dysgerminoma. Although this tumor is benign, it may be associated with a malignant germ cell tumor. Gonadoblastoma is almost only encountered in patients with gonadal dysgenesis (Turner syndrome) associated with the Y fragment [82]. The presence of Y chromosome material (probably not SRY) may cause the development of gonadoblastoma. The risk has recently been estimated at 7–10% [83]. Gonadectomy remains the procedure of choice to exclude malignancy. If the patient or family refuse this possibility, detailed ovarian sonography supplemented with color Doppler at regular intervals may be sufficient to monitor these patients [84].

Conclusion

The detection of adnexal masses is common and the vast majority is benign. These benign masses are predominantly functional ovarian cysts, most of which resolve spontaneously. Ultrasonography is the preferred first-line diagnostic tool. When surgery is necessary, it is necessary to keep in mind the importance of preserving subsequent fertility whenever possible.

References

- 1 Breen JL, Bonamo JF, Maxson WS: Genital tract tumors in children. *Pediatr Clin North Am* 1981; 28:355–374.
- 2 Norris HG, Jensen RD: Relative frequency of ovarian neoplasms in children and adolescents. *Cancer* 1972;30:713–719.
- 3 Pfeifer SM, Gosman GG: Evaluation of adnexal masses in adolescents. *Pediatr Clin North Am* 1999;46:573–592.
- 4 Elhage A, Nanejian V, Ghossain M, Germanos A: Kystes de l’ovaire: valeurs des explorations paracliniques. *Ref Gynecol Obstet* 2000;7:133–137.
- 5 Audebert A: Kystes annexiels: les limites techniques du traitement coelioscopique. A propos d’une série de 1,154 kystes. *Ref Gynecol Obstet* 1999;6:347–351.
- 6 Scully RE: Ovarian tumors. A review. *Am J Pathol* 1977;87:686–720.
- 7 Serov SF, Scully RE, Sobin LH: Histological Typing of Ovarian Tumours. International Histological Classification of Tumours, No 9. Geneva, WHO, 1973, pp 37–55.
- 8 Berta P, Hawkins JR, Sinclair AH, Taylor A, Griffiths BL, Goodfellow PN, Fellous M: Genetic evidence equating SRY and the testis-determining factor. *Nature* 1990;348:448–450.
- 9 Ardaens Y, Guerin B, Coquel P: *Echographie en pratique gynécologique*. Paris, Masson, 1994.
- 10 Adamsbaum C, Carel JC, Panisset S, Kalifa G: Pathologie de la puberté chez la fille. *Stratégies diagnostiques*. *Feuilles Radiol* 1999;39:284–292.
- 11 Brown DL, Frates MC, Laing FC, DiSalvo DN, Doubilet PM, Benson CB, Waitzkin ED, Muto MG: Ovarian masses: Can benign and malignant lesions be differentiated with color and pulsed Doppler US? *Radiology* 1994;190:333–336.

- 12 Ardaens Y, Robert Y, Rouanet JP, Maubon A, Coquel P: IRM en pratique gynécologique. Paris, Masson, 1996.
- 13 Buy JN, Ghossain MA, Mark AS, Deligne L, Hugol D, Truc JB, Poitout P, Vadrot D: Focal hyperdense areas in endometriomas: A characteristic finding on CT. *AJR* 1992;159:769–771.
- 14 Guinet C, Ghossain MA, Buy JN, Malbec L, Hugol D, Truc JB, Vadrot D: Mature cystic teratomas of the ovary: CT and MR findings. *Eur J Radiol* 1995;20:137–143.
- 15 Mugel T, Ghossain M, Buy JN, Malbec L, Vadrot D: Value of CT scan and MRI in primary tumors of the ovary. *J Chir* 1993;130:486–491.
- 16 Golden N, Neuhoff S, Cohen H: Pelvic inflammatory diseases in adolescents. *J Pediatr* 1989;114:138–143.
- 17 McCormack W: Pelvic inflammatory disease. *N Engl J Med* 1994;330:115–119.
- 18 Low LC, Wang Q: Gonadotropin independent precocious puberty. *J Pediatr Endocrinol Metab* 1998;11:497–507.
- 19 Schwartz PE: Ovarian masses: Serologic markers. *Clin Obstet Gynecol* 1991;34:423–432.
- 20 Perrone T, Steeper TA, Dehner LP: α -Fetoprotein localization in pure ovarian teratoma: An immunohistochemical study of 12 cases. *Am J Clin Pathol* 1987;88:713–717.
- 21 Bast RC, Feeney M, Lazarus H, Nadler LM, Colvin RB, Knapp RC: Reactivity of a monoclonal antibody with human ovarian carcinoma. *J Clin Invest* 1981;68:1331–1337.
- 22 Pinto MM, Greenebaum E, Simsir A, Kleinman GM, Portnoy LM, Garfinkel R: CA-125 and carcinoembryonic antigen assay vs. cytodagnostic experience in the classification of benign ovarian cysts. *Acta Cytol* 1997;41:1456–1462.
- 23 Giordano S, Miglionico L, Pellegrino M, De Meco C, Sciannone N, Castriota Scanderbeg A: Hydronephrosis associated with elevated serum levels of CA-125 antigen. Report of a case. *Minerva Pediatr* 1996;48:333–335.
- 24 Tuxen MK, Soletormos G, Dombernowsky P: Serum tumor marker CA-125 in monitoring of ovarian cancer during first-line chemotherapy. *Br J Cancer* 2001;18:1301–1307.
- 25 Lappohn RE, Burger HG, Bournia J: Inhibin is a marker of granulosa cell tumor. *Acta Obstet Gynecol Scand Suppl* 1992;155:61–65.
- 26 Gustafson ML, Lee MM, Scully RE, Moncure AC, Hirakawa T, Goodman A, Muntz HG, Donahoe PK, McLaughlin DT, Fuller AF: Müllerian inhibiting substance as a marker for ovarian sex-cord tumor. *N Engl J Med* 1992;326:466–471.
- 27 Kokoska ER, Keller MS, Weber TR: Acute ovarian torsion in children. *Am J Surg* 2000;180:462–465.
- 28 Cass DL, Hawkins E, Brandt ML, Chintagumpala M, Bloss RS, Milewicz AL, Minifee PK, Wesson DE, Nuchtern JG: Surgery for ovarian masses in infants, children and adolescents: 102 consecutive patients treated in a 15-year period. *J Pediatr Surg* 2001;36:693–699.
- 29 Piippo S, Mustaniemi L, Lenko H, Aine R, Maenpaa J: Surgery for ovarian masses during childhood and adolescence: A report of 79 cases. *J Pediatr Adolesc Gynecol* 1999;12:223–227.
- 30 Varlet F, Reinberg O, Becmeur F, GECl: Laparoscopie et cancer chez l'enfant. *J Coeliochir* 2001;37:27–31.
- 31 Surratt JT, Siegel MJ: Imaging of pediatric ovarian masses. *Radiographics* 1991;11:533–548.
- 32 Towne BH, Mahour GH, Woolley MM, Isaacs H: Ovarian cysts and tumors in infancy and childhood. *J Pediatr Surg* 1975;10:311–320.
- 33 Templeman C, Fallat ME, Blinchevsky A, Hertweck P: Noninflammatory ovarian masses in girls and young women. *Obstet Gynecol* 2000;96:229–233.
- 34 Sommerville M, Grimes DA, Koonings PP, Campbell K: Ovarian neoplasms and the risk of adnexal torsion. *Am J Obstet Gynecol* 1991;164:577–578.
- 35 Spigland N, Ducharme JC, Yazbeck S: Adnexal torsion in children. *J Pediatr Surg* 1989;24:974–976.
- 36 Meyer JS, Harmon CM, Harty MP, Markowitz RI, Hubbard AM, Bellah RD: Ovarian torsion: Clinical and imaging presentation in children. *J Pediatr Surg* 1995;30:1433–1436.
- 37 Mordehai J, Mares AJ, Barki Y, Finaly R, Meizner I: Torsion of uterine adnexa in neonates and children: A report of 20 cases. *J Pediatr Surg* 1991;26:1195–1199.
- 38 Evans JP: Torsion of the normal uterine adnexa in premenarchal girls. *J Pediatr Surg* 1978;13:195–196.
- 39 Shalev E, Mann S, Romano S, Rahav D: Laparoscopic detorsion of adnexa in childhood: A case report. *J Pediatr Surg* 1991;26:1193–1194.

- 40 Dolgin SE, Lublin M, Shlasko E: Maximizing ovarian salvage when treating idiopathic adnexal torsion. *J Pediatr Surg* 2000;35:624–626.
- 41 Eckler K, Laufer MR, Perlman SE: Conservative management of bilateral asynchronous adnexal torsion with necrosis in a prepubescent girl. *J Pediatr Surg* 2000;35:1248–1251.
- 42 Templeman C, Hertweck SP, Fallat ME: The clinical course of unresected ovarian torsion. *J Pediatr Surg* 2000;35:1385–1387.
- 43 Cohen Z, Shinar D, Kopernik G, Mares AJ: The laparoscopic approach to uterine adnexal torsion in childhood. *J Pediatr Surg* 1996;31:1557–1559.
- 44 Porcu E, Venturoli S, Dal-Prato L, Fabbri R, Paradisi R, Flamigni C: Frequency and treatment of ovarian cyst in adolescence. *Arch Gynecol Obstet* 1994;255:69–72.
- 45 Murray S, London S: Management of ovarian cysts in neonates, children and adolescents. *J Adolesc Pediatr Gynecol* 1995;8:64–70.
- 46 Kanizsai B, Orley J, Szigetvari I, Doszpod J: Ovarian cysts in children and adolescents: Their occurrence, behavior and management. *J Pediatr Adolesc Gynecol* 1998;11:85–88.
- 47 Chapron C, Querleu D, Bruhat MA, Madelenat P, Fernandez H, Pierre F, Dubuisson JB: Surgical complications of diagnostic and operative laparoscopy: A series of 29,966 cases. *Hum Reprod* 1998;13:867–872.
- 48 Lipitz S, Seiman DS, Menczer J: Recurrence rates after fluid aspiration from sonographically benign-appearing ovarian cysts. *J Reprod Med* 1992;37:845–848.
- 49 Parazzini F, Moroni S, Negri E, La Vecchia C, Dal Pino D, Ricci E: Risk factors for functional ovarian cysts. *Epidemiology* 1996;7:547–549.
- 50 Holt VL, Daling JR, McKnight B, Stergachis A, Weiss NS: Cigarette smoking and functional ovarian cysts. *Am J Epidemiol* 1994;139:781–786.
- 51 Conte FA, Grumbach MM, Ito Y, Fisher CR, Simpson ER: A syndrome of female pseudohermaphroditism, hypergonadotropic hypogonadism, and multicystic ovaries associated with missense mutations in the gene encoding aromatase ($P_{450arom}$). *J Clin Endocrinol Metab* 1994;78:1287–1292.
- 52 Morishima A, Grumbach MM, Simpson ER, Fisher CR, Qin K: Aromatase deficiency in male and female siblings caused by a novel mutation and the physiological role of estrogens. *J Clin Endocrinol Metab* 1995;80:3689–3698.
- 53 Britt KL, Drummond AE, Cox VA, Dyson M, Wreford NG, Jones ME, Simpson ER: An age-related ovarian phenotype in mice with targeted disruption of aromatase gene. *Endocrinology* 2000;141:2614–2623.
- 54 Sampson JA: Heterotopic or misplaced endometrial tissue. *Am J Obstet Gynecol* 1925;10:649–668.
- 55 Thille A, Legros S: Presentation d'un syndrome de Rokitansky-Kuster-Mayer-Hauser en IRM. *Ref Gynecol Obstet* 2000;7:298–301.
- 56 Sefroui O, Fernandez H: L'endometriose stade 1 et II. *Ref Gynecol Obstet* 1999;6:133–138.
- 57 Berubé S, Marcou S, Maheux R: Characteristics related to the prevalence of minimal or mild endometriosis in infertile women. Canadian Collaborative Group on Endometriosis. *Epidemiology* 1998;9:504–510.
- 58 International Federation of Gynecology and Obstetrics (FIGO) Cancer Committee: Staging announcement. *Gynecol Oncol* 1986;25:303–306.
- 59 Diamond MP, Baxter JW, Peerman CG, Burnett LS: Occurrence of ovarian malignancy in childhood and adolescence. *Obstet Gynecol* 1988;71:858–860.
- 60 Van Winter JT, Simmons PS, Podratz KC: Surgically treated adnexal masses in infancy, childhood and adolescence. *Am J Obstet Gynecol* 1994;170:1780–1786.
- 61 Kurman RJ, Norris HJ: Malignant germ cell tumors of the ovary. *Hum Pathol* 1977;8:551–564.
- 62 Terenziani M, Massimino M, Casanova M, Cefalo G, Ferrari A, Luksch R, Spreafico D, Fontanelli R, Piva L, Fossati-Bellani F: Childhood malignant ovarian germ cell tumors: A monoinstitutional experience. *Gynecol Oncol* 2001;81:436–440.
- 63 Fotiou SK: Ovarian malignancies in adolescence. *Ann NY Acad Sci* 1997;816:338–346.
- 64 Tapper D, Lack EE: Teratomas in infancy and childhood. A 54-year experience at the Children's Hospital Medical Center. *Ann Surg* 1983;198:398–410.
- 65 Mecke H, Savvas V: Laparoscopic surgery of dermoid cysts – Intraoperative spillage and complications. *Eur J Obstet Gynecol Reprod Biol* 2001;96:80–84.

- 66 Aguirre P, Scully RE: Malignant neuroectodermal tumor of the ovary, a distinctive form of monodermal teratoma: Report of five cases. *Am J Surg Pathol* 1982;6:283–292.
- 67 Okoye BO, Harmston C, Buick RG: Dysgerminoma associated with hypercalcemia: A case report. *J Pediatr Surg* 2001;36:E10.
- 68 Kennedy AW: Ovarian neoplasms in childhood and adolescence. *Semin Reprod Endocrinol* 1988;6:79–86.
- 69 Kurman RJ, Norris HJ: Embryonal carcinoma of the ovary. A clinicopathologic entity distinct from endodermal sinus tumor resembling embryonal carcinoma of the adult testis. *Cancer* 1976;38:2420–2433.
- 70 Morris HHB, La Vecchia C, Draper GJ: Endodermal sinus tumor and embryonal carcinoma of the ovary in children. *Gynecol Oncol* 1985;25:7–17.
- 71 Flotho C, Ruckauer K, Duffner U, Bergstasser E, Bohm N, Niemyer CM: Mucinous cystadenoma of the ovary in a 15-year-old girl. *J Pediatr Surg* 2001;36:E6.
- 72 Tsai JY, Saigo PE, Brown C, La Quaglia MP: Diagnosis, pathology, staging, treatment and outcome of epithelial ovarian neoplasm in patients age <21 years. *Cancer* 2001;91:2065–2070.
- 73 Lyons J, Landis CA, Harsh G: Two G-protein oncogenes in human endocrine tumors. *Science* 1990;249:655–659.
- 74 Villares Frago MCB, Latronico AC, Carvalho FM, Zerbini MCN, Marcondes JAM, Araujo LMB, Lando VS, Frazzatto ET, Mendonca BB, Villares SM: Activating mutation of the stimulatory G protein (gsp) as a putative cause of ovarian and testicular human stromal Leydig cell tumors. *J Clin Endocrinol Metab* 1998;83:2074–2078.
- 75 Young RH, Dickersin GR, Scully RE: Juvenile granulosa cell tumors of the ovary: A clinicopathologic analysis of 125 cases. *Am J Surg Pathol* 1984;8:575–596.
- 76 Norris HJ, Taylor HB: Virilization associated with cystic granulosa tumors. *Obstet Gynecol* 1969;34:629–635.
- 77 Powell JL, Otis CN: Management of advanced juvenile granulosa cell tumor of the ovary. *Gynecol Oncol* 1997;64:282–284.
- 78 Little M, Wells C: A clinical overview of WT1 gene mutation. *Hum Mutat* 1997;9:209–225.
- 79 Cronje HS, Niemand I, Bam RH, Woodruff JD: Granulosa and theca cell tumors in children: A report of 17 cases and literature review. *Obstet Gynecol Surv* 1998;53:240–247.
- 80 Kimonis VE, Goldstein AM, Pastakia B, Yang ML, Kase R, DiGiovanna JJ, Bale AE, Bale SJ: Clinical manifestations in 105 persons with nevoid basal cell carcinoma syndrome. *Am J Med Genet* 1997;69:299–308.
- 81 Chalvardjian A, Derzko C: Gynandroblastoma: Its ultrastructure. *Cancer* 1982;50:710–721.
- 82 De Arce MA, Costigan C, Gosden JR, Lawler M, Humphries P: Further evidence consistent with Yqh as an indicator of risk of gonadal blastoma in Y-bearing mosaic Turner syndrome. *Clin Genet* 1992;41:28–32.
- 83 Gravholt CH, Fedder J, Naeraa RW, Muller J: Occurrence of gonadoblastoma in females with Turner syndrome and Y chromosome material: A population study. *J Clin Endocrinol Metab* 2000;85:3199–3202.
- 84 Saenger P, Albertsson-Wikland K, Conway GS, Davenport M, Gravholt CH, Hintz R, Hovatta O, Hulterantz M, Landin-Wilhelmsen K, Lin A, Lippe B, Pasquino AM, Ranke MB, Rosenfeld R, Silberbach M: Recommendations for the diagnosis and management of Turner syndrome. *J Clin Endocrinol Metab* 2001;86:3061–3069.

Catherine Pienkowski
 Unité d'Endocrinologie, Génétique et Gynécologie Médicale
 Hôpital des Enfants
 330, avenue de Grande-Bretagne TSA 70034
 FR-31059 Toulouse Cedex 9 (France)
 Tel. +33 5 3455 8556, Fax +33 5 3455 8558
 E-Mail pienkowski.c@chu-toulouse.fr

.....

Breast Diseases in Adolescents

C. Duflos^{a,b}, G. Phu-Bureau^a, E. Thibaud^b, F. Kuttenn^a

^a Service Endocrinologie-Médecine de la Reproduction et

^b Unité de Gynécologie Pédiatrique, Hôpital Necker, Paris, France

A thorough understanding of the different mammary gland structures and their respective physiological roles helps to detect anatomic variations and diagnose breast disease at various ages. Mammary abnormalities may be classed as either minor aberrations in normal developmental processes, as part of the breast's cyclical activity associated with hormonal changes during the menstrual cycle, or as physiological involution of the mammary gland.

The ANDI (aberrations of normal development and involution) classification proposed by Hughes and co-workers [1, 2] takes into account physiological, histological and pathological findings (table 1). The concept is based on the progression from normal to aberrant (anatomical or physiological deviation) to disease state and the distinctions between them. This classification optimizes therapeutic strategies; when slight abnormality or aberration is diagnosed, the treatment may often be limited, whereas when complex breast disease is diagnosed, the treatment is aggressive, with surgical options.

After a brief review of the physiology of mammary development, the pathologies associated with various histological structures of breast tissue will be detailed.

Embryology

Breast tissue originates from ectodermal layers. During the sixth week of embryogenesis, epidermal cells migrate into the underlying mesenchymal tissue and form primitive mammary ridges. These ridges initially extend from the axilla to the base of the lower limb bud. The validity of this 'theory' was derived from animal study and its validity in humans is now being challenged [3].

Table 1. ANDI classification [adapted from 2, 3]

Age	Physiology	Aberration	Disease
15–25 years	Lobular development	Fibroadenoma	Giant fibroadenoma
	Stromal development	Juvenile hypertrophy	Gigantomastia
	Ductal development	Duct ectasia	Abscess
25–35 years	Cyclical modifications	Cyclical mastalgia Cyclical nodularity	Severe mastalgia
35–45 years	Lobular involution	Cysts	
	Ductal involution	Sclerosing lesions	
	Dilatation	Duct ectasia	Abscess
	Sclerosis	Nipple retraction	

However, congenital lesions in the human are overwhelmingly confined to the axillo-pectoral region [4].

By the tenth week, these structures atrophy at their upper and lower borders, leaving ridges in the pectoral region only. The nipple and areola overlie a bud of breast tissue composed of both the primary mammary ducts and fibrous stroma. Between 10 and 20 weeks, approximately 15–20 major ducts form and then bifurcate into tubules which form the basis of the duct system. The major ducts at this stage have only small vesicles at the distal ends and no lobular development is present. Each duct system opens separately into the nipple. The areola develops at approximately 5 months of gestation.

Interactions between stroma, connective tissue, the vascular network and specialized fat cells result in the development of the breast mammary gland. Rudimentary sebaceous glands and Montgomery's tubercles are present. The breast bud is usually not palpable until 34 weeks of gestation and measures approximately 3 mm at 36 weeks and 4–10 mm at 40 weeks. The final change is completed by the time of birth.

Breast Physiology

The breast remains quiescent in the prepubertal stage and undergoes major changes at puberty under the influence of ovarian hormones. Estrogen increases adipose tissue and initiates stromal and ductal growth. Progesterone is probably important for lobular-alveolar development. These hormones produce the changes seen in the pubertal breast as documented by Marshall and Tanner [5].

Table 2. Tanner stage

S1	Pre-menarchal stage
S2	Breast bud elevation Pinker areolar skin (sometimes dysymmetry)
S3	Growth and protrusion of the nipple Montgomery's tubercle appearance
S4	Elevation of the secondary areolar mound (stage not constant)
S5	Adult breast, regression of the areolar mound Erectile areolar

The adult breast has a major duct system leading to the terminal ductal lobular unit, which has been described in detail by Wellings et al. [6]. Comprising extra- and intralobular terminal ducts and the lobules arising from the intralobular terminal ductule, it is an important localization in the origin of many breast diseases.

The appearance of the breast bud or mound is the first prepubertal sign of the beginning of the estrogen ovarian activity. This development is often asymmetrical. The mean age of appearance is 10.9 (8.5–13.3) years [7], and other secondary sexual characteristics follow, including hair growth and morphological modifications of the vulva. The duration of mammary gland growth is approximately 2–3 years, although sometimes longer. The first menstruation occurs usually 2 years after the S2 period.

Table 2 shows the different Tanner stages leading to adult stage with a surrounding breast and a protruding nipple.

In the newborn, presence of a breast bud is frequent and characterizes neonatal mastitis, a sign of passive in utero hormonal impregnation. In late pregnancy, high levels of luteal and placental hormones in the mother's blood cross the placenta into the fetal circulation and stimulate the fetal breast. This breast bud disappears spontaneously after some weeks. Hormonal manipulation delays this regression and involves a risk of infection (breast abscess); similarly, surgical treatment can definitively damage the future mammary gland [8].

During childhood before 8 years, the development of a breast bud is a warning sign. Indeed, premature thelarche occurs unexpectedly in 70–80% of cases before 2 years. The breast bud can be uni- or bilateral, but the areola is not modified. Breast development is isolated and not accompanied by other pubertal signs (absence of hair growth, prepubertal smear test, absence of growth acceleration and normal bone age). Spontaneous regression is common but clinical follow-up is necessary during the first months in order to detect premature puberty.

During puberty, breast elevation increases at stage S2 and growth and protrusion of the nipple appear. The breast is often painful either spontaneously or on palpation. This palpation is sometimes not easy, especially in stout children. Unilateral breast development should not necessarily suggest pathological tumefaction and does not justify aggressive investigation (biopsy for example), which carries the risk of damaging the future mammary gland.

Throughout the growth period, breast palpation often remains difficult. The mammary gland is firm and tender, with a multinodular aspect making it difficult to distinguish from pathological tumefactions [4]. It is often useful to repeat the examination, preferably in the post-menstrual period. Clinical examination is essential because generally it will lead to diagnosis without complementary investigation. Ultrasonography is the usual complementary investigation in adolescence. Mammography remains exceptional because the high mammary density at this age results in a uniform opaque zone that cannot be interpreted.

Classification of Breast Diseases: The ANDI Concept

Three major phases associated with the physiological processes of the mammary gland characterize this new classification [1].

Lobular Development between Puberty and 25 Years of Age

Lobular development is important during the early reproductive stage (from puberty to 25 years of age). At this time, the high cellular activity of the lobules explains the higher frequency of fibroadenomas at this period. Later, the first lobules are gradually replaced by more mature and less active lobules during the cyclical period, and especially after pregnancy. At the end of reproductive life, involution particularly affects the lobules.

Cyclical Hormonal Modifications between Puberty and 50 Years of Age

The normality of different histological structures of the mammary gland seems to very much depend on a normal, balanced relationship between epithelial and stromal elements. Both these elements are under hormonal control, and the hormonal modifications occurring at each cycle have been much analyzed. However, the interpretation of these *in vitro* studies remains difficult because the correlation with *in vivo* studies is not straightforward; a repeated histological breast biopsy in the same women is not justified. The cyclical modifications of different mammary constituents vary considerably between women, as well as within the same woman after breastfeeding when profound and powerful

hormonal modifications occur. Because of the inevitable variations, the likelihood of minor abnormalities is rather high after 35 years.

Breast Involution between 35 and 55 Years

Involution starts by 35 years of age, sometimes earlier. The process of lobular involution associated with cyclical changes occurs over a long period (20 years). If the balance between these two processes is not respected, minor aberrations are highly probable. This period of fluctuating involution extending over 20 years thus explains the high frequency of minor breast aberrations. It appears that normal epithelial involution of the lobule is dependent on the continuing presence of the specialized stroma around it. Should the stroma disappear too early, the epithelial acini remain and may form microcysts. Since microcyst formation is associated with involution of stroma, breast cysts are rare in adolescent girls [2, 4, 9].

In conclusion, these three periods have distinct clinical presentations, but overlapping and interacting processes also lead to complex clinical situations.

Aberrations or Diseases Linked with the Developmental Process

Congenital Anomalies

Congenital anomalies may be uni- or bilateral and may involve the nipple, the breast or both. Breast abnormalities are classically observed along the line extending from the axilla to the base of the lower limb bud. Congenital defects in the human, however, are overwhelmingly confined to the axillo-pectoral region. Abnormality of volume or form can appear during the development of the mammary gland.

Polythelia. One to 2% of the global population has this abnormality, and an association with renal malformations has been reported in some studies [10]. Often mistaken for a nevus, the supernumerary nipple is easily distinguished by its color, shape and location in the embryonic 'milk line'. The aesthetic damage is minor and no surgical correction is generally needed.

Polymastia or Supernumerary Breast. The most frequent localizations are in the axillary or pectoral position [4, 9]. The volume or pain can be sufficient to warrant surgical treatment. A simple axillary prolongation of the mammary gland without nipple is most often reported and discomfort is usual during pregnancy or breastfeeding.

Athelia and Amastia. Isolated athelia is extremely uncommon and absence of the mammary gland is frequently associated. Bilateral amastia is very rare.

An amastia, whether or not associated with athelia, is characteristic of the Poland syndrome. In the complete form, this syndrome associates unilateral mammary aplasia, absence of the sternal and costal portions of the pectoralis major, absence of the pectoralis minor, and absence of portions of the serratus magnus and external oblique muscle: a brachysyndactyly of the hand from the same side is often associated [11].

The treatment of this syndrome is surgical and the aesthetic result depends on how severely the pectorals and the thorax are affected.

Acquired Abnormalities

Hypotrophy. In hypotrophy, the mammary gland volume is insufficient. The nipple is normal but the definitive breast at stage S5 is small. Mammary hypoplasia is often constitutional and familial. Breast and nipple appearance are normal, as the results of physical examination, but breast volume is quite small. If the physical examination is identical 6 months later in an adolescent more than 17 years, definitive breast size can be concluded.

Breast atrophy is sometimes associated with other pathological situations, such as ovary insufficiency (gonadal dysgenesis or acquired insufficiency) or during hyperandrogenism.

Hypotrophy bordering on amastia can be the consequence of either breast or thoracic surgery in infancy (newborn breast abscess, breast angioma, transmammary thoracic drainage of pleura-pulmonary suppurations, radiotherapy for thoracic tumor) or severe burns. The treatment is principally aesthetic surgery. Oral contraceptives with dominant estrogenic potential may sometimes promote greater mammary development.

Breast Asymmetry. Slight asymmetry is frequent, but when it is very marked, the aesthetic consequences are substantial [12]. The differential diagnosis is unilateral hypertrophy. Palpation of this too voluminous breast reveals normal supple tissue without any nodules. If the morphological aspect of the breast is stage S5, normalization of the two breasts with the same volume is not possible. The only treatment is surgical.

A Becker nevus is frequently associated with unilateral mammary hypoplasia, resulting in asymmetry [13]. This hamartoma appears most often at puberty. Clinically, it is characterized by a clear brown stain, sometimes with layers. Physiopathologically, an increased number of androgenic receptors are present and may be responsible for this underlying condition.

Abnormal Shape. The abnormally shaped breast differs from the harmonious standard breast. The tuberous breast is small with a tight implantation base and a very large nipple. The mammary gland makes a hernia through the nipple [14]. Treatment is surgical.

Aberrations or Diseases Linked with Stromal Tissue Development

The new ANDI classification is well suited to describe mammary hypertrophy. From normal breast volume to simple hypertrophy, or to major hypertrophy like gigantomastia, all the stages from normal development to the pathological disease can be described.

Mammary Hypertrophy: Developmental Aberration

Mammary hypertrophy, which is a simple exaggeration of normal breast volume, can be embarrassing and the source of psychological problems. It can be physically uncomfortable and the source of vertebral disturbances. Clinically, the mammary gland is voluminous but supple. Medical treatment with 19-nortestosterone derivatives has been proposed 15 to 10 days per cycle with good results [15]. The decision of surgical treatment can be made without regard to age.

Gigantomastia: Disease

Gigantomastia is a pathological situation whose sudden appearance and rapid progression make it an emergency. It is a sudden increase in mammary volume that occurs early in reproductive life. Sometimes, the gigantomastia is asymmetric. The breasts are firm and painfully strained with inflammatory signs on the breast skin.

Reported for the first time by Durston in 1669, no etiology can fully explain this phenomenon. Classically, hypersensitivity to estrogens has been evoked, but estrogen receptor concentration is normal and plasma estradiol levels are normal [16]. A process of immune dysfunction has been suggested (especially in the presence of inflammatory signs) because hypertrophy may occur in women with autoimmune diseases like rheumatoid polyarthritis, Hashimoto thyroiditis or myasthenia.

Reduction surgery is often necessary to relieve these young women. The ideal time for treatment is once the disease has been stabilized. After surgery, follow-up is desirable because recurrences have been described, leading to mastectomy with mammary prosthesis if the recurrence is major.

Aberrations or Diseases of Ductal Development

Ductal Ectasia: Anatomic-Physiologic Variation

Ductal ectasia is most frequent in middle-aged women. In adolescence, ectasia has been described as an exaggeration of sinus duct development, with

an epithelium disposed in ‘accordion’ pleats that allows dilatation and stagnation of secretions [11]. At the initial stage of ductal ectasia, which is a variant of normality, a pathologic step such as an abscess can occur, where the stagnation in secretion leads to epithelial ulceration with secretions toward the support tissues, which causes secondary ductal inflammation and infection.

Clinically, ductal ectasia appears like a retro-areolar tumor of 1–3 cm; it is sensitive, discreetly blue and sometimes associated with brownish or even bloody nipple discharge, which occurs either spontaneously or on discreet nipple palpation. Its development is rapid and occurs early in reproductive life, before or just after menarche. Ultrasound confirms the hydroid lesion. Spontaneous progression is mostly favorable with regression of tumefaction and disappearance of nipple discharge. During follow-up, the major risk is infection in the vulnerable nipple. Several relapses can occur in the same or the contralateral breast, or both.

If the disease course is long or if nipple discharge persists, surgical treatment is an option. The histological lesion is ductal ectasia, a distension of one duct associated with an inflammatory reaction, conjunctive fibrosis and sometimes benign epithelial hyperplasia.

The nipple discharge during the course of ductal ectasia must be distinguished from a juxta-areolar discharge from the sebaceous gland set on the areola (Montgomery tubercle). Cure is spontaneous without treatment [17].

Breast Abscess: Disease

Classically described in the post-partum period, breast abscess has also been reported in adolescence. Retro-areolar abscess is the most frequent occurrence, and it is the consequence of a ductal ectasia infection with rupture of the sinusal duct into surrounding tissue and abscess formation. Depending on the stage, nodule size varies, there may or may not be inflammatory signs, and it is often accompanied by fever. Early medical treatment consisting of local anti-inflammatory dressings, and systemic antibiotherapy stops symptoms. Because of the frequency of recurrence, long-term antibiotherapy is needed and should continue even after the disappearance of clinical symptoms. For some authors, umbilical nipple is a risk factor for these recurrent abscesses. If the medical treatment is ineffective, surgery can be proposed. Recurrence is frequent after a simple incision and drain. A global resection of the concerned duct is therefore advised.

Aberrations or Diseases of Lobular Development

Before the peri-menarchal period, the mammary gland consists of only a few ducts. During peri-menarchal development, the principal changes are duct

sprouting and the addition of lobular structures. Estrogen induces connective tissue and vascular growth, which is required for new duct development. The lobules develop particularly during early reproductive life, between 15 and 25 years of age, and the different types have been described by Russo and co-workers [18, 19]. Each period of reproductive life (such as pregnancy, breast-feeding or menopause) is associated with increasingly more differentiated lobules. This explains the frequency of fibroadenoma during early reproductive life, which is an exaggerated development of various lobule structures. Fibroadenomas are classified as benign, since they can almost be considered as aberrations of normal development [20].

Fibroadenoma Simplex: Aberration of Normal Development

The lobular origin explains many features of fibroadenoma, for instance its frequency during the menarchal period, which is a time of maximal lobular development. Fibroadenoma is the most common breast tumor of adolescence. Indeed, its discovery is certainly less frequent by clinical examination than by ultrasound, which usually detects deeper fibroadenomas. The characteristics of adolescent fibroadenoma are accurate enough to be diagnosed certainly after only clinical examination. Often, the tumor is noticed accidentally by the adolescent herself. It is a firm, smooth, round or bosselated, painless and very mobile tumor. Its encapsulation explains this mobility.

The size of a fibroadenoma is generally from 1 to 3 cm. During the growth phase, the tumor doubles in size in 6–12 months and is then likely to remain static for the rest of the patient's life; it may even gradually decrease in size or disappear [11]. In one study, Dent et al. [21, 22] followed 99 young women with clinical and cytological diagnoses of single or multiple fibroadenoma. They found that 107 lumps disappeared out of the 279 tumors followed over 7 to 9 years. In this work, the probability of fibroadenoma disappearance depended only on the young age of the patient. Fibroadenoma development is hormone-dependent. This dependence rapidly diminishes with the lesion's age and the appearance of fibrosis without hormonal receptors, a further possible explanation for the plateauing in the fibroadenoma's growth curve [23]. Ultrasound confirms the evident clinical diagnosis. The ultrasonic features are round or oval sharp contour, weak internal echoes in a uniform distribution and intermediate attenuation, which is more evident if the tumor is young.

The histological features of fibroadenoma are an exaggeration of normal lobular development. The proliferation of stromal and epithelial elements is regular, maintaining a normal relationship as in a normal lobule. There is then a progressive sclerosis of the stromal element and the epithelial element disappears.

For some authors [24, 25], fibroadenoma occurs in women with an estrogen-progesterone imbalance that leads to an 'unopposed estrogen effect'.

Progesterone appears to oppose the estrogen effects on breast epithelial cells. Based on this rationale, some clinicians, at least in our country, propose progestin treatment for various benign breast disorders; for example, for fibroadenoma. 19-Nortestosterone derivatives, used 15–20 days per cycle, have been proposed with good clinical and ultrasound results [15].

Removal of all fibroadenomas is a classical response, but for an adolescent, a few points argue for a more flexible approach: (a) Recurrence after surgery at the site of previous removal or near it – in the same breast or in the contralateral one – is possible [26]. (b) Fibroadenomas are often multiple. Repeated surgery is not recommended for an adolescent in an aesthetic approach [27, 28]. (c) The lumps may spontaneously become smaller or disappear. (d) Medical treatment with progestins provides good results. (e) The risk of malignancy is negligible for women younger than 20, so progestins can be used as a conservative approach without fear.

A conservative approach can be chosen if clinical and ultrasound examinations show unequivocally benign characteristics. Fine needle aspiration can be used for confirmation if clinical or ultrasound features are not entirely typical. After the triple assessment (clinical, ultrasound and cytology), the diagnosis is confirmed, but sometimes the cytological features can be florid if the fibroadenoma is young. Patients can be discharged after 6 months if the lesion remains stable or regressed. Only standard clinical surveillance is necessary. The conservative policy should be reconsidered if the tumor increases in size.

If there is doubt regarding the nature of the presumed fibroadenoma or if the patient wishes to be rid of it, surgery is chosen [29]. The surgical approach must be as aesthetic as possible. The peri-areolar excision is better from this point of view.

Giant Fibroadenoma: Disease

Although fibroadenoma simplex is considered as an aberration of normal lobular development, giant fibroadenoma is a disease. The tumor is >5 cm at onset of menarche or soon after. This encapsulated breast mass with rapid enlargement compresses the adjacent breast tissue with the development of skin ulcers and prominent veins. This sudden growth argues against the hypothesis that giant fibroadenoma arises from the continued progression of small fibroadenoma. It is possible that giant fibroadenoma is a separate de novo condition. The clinical feature is a large well-demarcated breast mass, firmer than the rest of the breast, as opposed to breast asymmetry or unilateral hypertrophy.

A giant fibroadenoma in this age group may be associated with multiple smaller fibroadenomas in the same breast or in the opposite one.

Giant fibroadenoma has been described as being more common in the black population [30]. On the basis of clinical diagnosis, surgery should be recommended as its size imposes this. A cosmetic approach is recommended. Tumor fragmentation is possible.

The histological features are the same as for fibroadenoma simplex, with a normal relationship between epithelial and stromal elements. The florid feature of this proliferation can lead to considerable confusion with cystosarcoma phyllodes, which are very rare under the age of 20. The phyllode tumor is distinct from the giant fibroadenoma by both macroscopic and histological criteria; the diagnosis is essentially histological.

To diagnose the phyllode tumor, both epithelial and fibrous stromal elements must be present, with the stroma showing cellularity, irregularity, hyperchromatism and significant mitosis [31]. The stroma are notably more cellular than in fibroadenoma and are dominant in relation to the epithelial component. Under the age of 20, they almost invariably behave in a benign manner. All should be treated by enucleation. This tumor shows no local recurrence if completely excised. Many diagnoses of phyllode tumor are certainly made in excess.

Multiple Fibroadenomas

Fibroadenomas are often multiple, occurring concurrently or successively in both breasts. Haagensen [11] showed an incidence of 16% in his experience. The development of multiple fibroadenomas, some of them >5 cm in size, has been reported to be at times brutal, with the breast invaded by the fibroadenomatous disease. It is, like giant fibroadenoma, a true disease. The treatment of these multiple fibroadenomas is not surgical due to the risk of aesthetic damage. Medical treatment can be discussed. The use of progestin 19-nortestosterone derivatives, if given early, has shown a diminution of fibroadenoma size and sometimes the disappearance of some tumors.

Aberrations or Disease Associated with Cyclical Variations of Breast Tissue

In the adolescent, the aberrations associated with cyclical variations of mammary gland have little clinical expression. Indeed, in the early pubertal period, cyclical mastalgia is exceptional. But the probability of observing cyclical hormonal mastalgia increases over time from the first menstruation. Cyclical mastalgia must be defined by strict clinical criteria: appearance before menstruation for more than 4 days, disappearance some days after menstruation, and bilaterality.

Cancer

Breast cancer constitutes only about 1% of childhood cancers and <0.1% of all breast cancers occurring in this age group [32–34]. Three clinical presentations have been identified: (1) primary malignancy of the breast: carcinoma (juvenile secretory carcinoma), sarcoma or lymphomas; (2) metastatic disease: rhabdomyosarcoma or leukemia [35], non-Hodgkin's lymphoma, and (3) secondary malignancy: post-radiation therapy (mantle irradiation).

Mammography is not helpful in the diagnosis of breast cancer. It is less sensitive in detecting malignancies in younger patients than in older ones. An accurate strategy is essential to discover the rare malignancy. Physical examination is essential before performing surgical biopsy (a) if the eccentric sub-areolar mass is not centralized beneath the areola in a child before puberty, and (b) since in adolescents with malignancy (current or former), metastatic lesions are more common than primary lesions.

Conclusion

Breast diseases in adolescence show specific characteristics linked to the developmental process and physiology of the mammary gland. The distinction between an aberration (divergence of normal development) and disease, as proposed by the ANDI classification, applies to adolescence particularly well. Moreover, the absence of malignant pathology at this age makes it possible to reassure women early at the first consultation. Diagnoses are most often only clinical. Complementary investigations are sometimes necessary and ultrasound is best. Mammography is not informative at this age.

References

- 1 Hughes LE, Mansel RE, Webster DJTW: Aberrations of normal development and involution (ANDI): A new perspective on pathogenesis and nomenclature of benign breast disorders. *Lancet* 1987;ii:1316–1319.
- 2 Hughes LE, Mansel RE: Aberrations of normal development and involution (ANDI): A concept of benign breast disorders based on pathogenesis; in Hughes LE, Mansel RE, Webster DJT (eds): *Benign Disorders and Diseases of the Breast*, ed 2. Philadelphia, Saunders, 2000, pp 21–34.
- 3 Hughes LE, Mansel RE: Breast anatomy and physiology; in Hughes LE, Mansel RE, Webster DJT (eds): *Benign Disorders and Diseases of the Breast*, ed 2. Philadelphia, Saunders, 2000, pp 7–20.
- 4 Templeman C, Hertweck SP: Breast disorders in the pediatric and adolescent patient. *Obstet Gynecol Clin North Am* 2000;27:19–34.
- 5 Marshall WA, Tanner JM: Variations in pattern of pubertal changes in girls. *Arch Dis Child* 1969; 44:291–303.
- 6 Wellings SR, Jense HM, Mascum MG: An atlas of subgross pathology of the human breast with reference to possible precancerous lesions. *J Nat Cancer Inst* 1975;55:231–273.

- 7 Herman-Giddens ME, Slora EJ, Wasserman RC: Secondary sexual characteristics and menses in young girls seen in office practice: A study from the pediatric research in office settings networks. *Pediatrics* 1997;99:505–512.
- 8 Greydanus DE, Parks DS, Farrell EG: Breast disorders in children and adolescents. *Pediatr Clin North Am* 1989;36:601–638.
- 9 Dehner LP, Hill DA, Deschryver K: Pathology of the breast in children, adolescents and young adults. *Semin Diagn Pathol* 1999;16:235–247.
- 10 Lewis EJ, Crutchfield CE 3rd, Praver SE: Accessory nipples and associated conditions. *Pediatr Dermatol* 1997;14:333–334.
- 11 Haagensen CD: *Diseases of the Breast*. Philadelphia, Saunders, 1986.
- 12 Netscher D, Mosharafa A, Laucirica R: Massive asymmetric virginal breast hypertrophy. *South Med J* 1996;89:434–437.
- 13 Friedel J, Heid E, Dallara JM, Grosshans E: Naevus pharmacologiques ou fonctionnels. *Ann Dermatol Venerol* 1991;118:645–654.
- 14 Ribeiro L, Canzi W, Buss A: Tuberos breast: A new approach. *Plast Reconstr Surg* 1998;101:42–52.
- 15 Mauvais-Jarvis P, Kuttent F: Benign breast disease; in Bardin CW (ed): *Current Therapy in Endocrinology and Metabolism*. 3. Philadelphia, Decker Press, 1994, pp 364–370.
- 16 Jabs AD, Frantz AG, Smith-Vanitz A: Mammary hypertrophy is not associated with increase in estrogen receptors. *Plast Reconstr Surg* 1990;86:64–66.
- 17 Markins F, Giacomontions M, Salisbury S: Nipple discharge and breast lump related to Montgomery's tubercle in adolescent females. *J Pediatr Surg* 1988;23:718–720.
- 18 Russo J, Calaf G, Roi L, Russo IH: Influence of gland age and topography on cell kinetics of normal breast tissue. *J Nat Cancer Inst* 1987;78:413–418.
- 19 Russo J, Russo IH: Toward a physiological approach to breast cancer prevention. *Cancer Epidemiol Biomarkers Prevent* 1994;3:353–364.
- 20 Dixon JM, Mansel RE: Congenital problems and aberrations of normal breast development and involution. *Br Med J* 1994;309:797.
- 21 Cant PJ, Maden MV, Close PM, et al: Case for conservative management of selected fibroadenomas of the breast. *Br J Surg* 1987;74:857–859.
- 22 Dent DM, Cant PJ: Fibroadenoma. *World J Surg* 1989;13:706–710.
- 23 Martin PM, Kuttent F, Serment H: Progesterone receptors in breast fibroadenomas. *J Steroid Biochem* 1979;11:1295–1298.
- 24 Mauvais-Jarvis P, Kuttent F, Gompel A: Antiestrogen action of progesterone in breast tissue. *Breast Cancer Res Treat* 1986;8:179–187.
- 25 Korenman SG: The endocrinology of breast cancer. *Cancer* 1980;46:874–878.
- 26 Dobie V, Walsh J, Lamb J, Dixon JM: Natural history of fibroadenoma of the breast; in Mansel RE (ed): *Recent Developments in the Study of Benign Breast Disease*. London, Parthenon, 1994, pp 75–81.
- 27 Neinstein LS: Breast disease in adolescents and young women. *Pediatr Clin North Am* 1999;46:607–629.
- 28 Hindle W, Alonzo L: Conservative management of breast fibroadenomas. *Am J Obstet Gynecol* 1991;164:1647–1649.
- 29 West K, Rescorta F, Scherrer LR, Grosfeld J: Diagnosis and treatment of symptomatic breast masses in the pediatric population. *J Pediatr Surg* 1995;30:182–187.
- 30 Naidu AG, Thomson SR, Nirmul D: Giant fibroadenoma in Black and Indian adolescents. *South African J Surg* 1989;27:171–172.
- 31 Rajan PB, Cranor MI, Rosen PP: Cystosarcoma phyllodes in adolescent girls and young women: A study of 45 patients. *Am J Surg Pathol* 1998;22:64–69.
- 32 Altman AJ, Schwartz SD: *Malignant Diseases of Infancy, Childhood and Adolescence*, ed 2. Philadelphia, Saunders, 1983, pp 1–505.
- 33 Corpon CA, Black CT, Singletary SE, Andrassy EJ: Breast cancer in adolescent females. *J Pediatr Surg* 1995;30:322–324.
- 34 Rogers DA, Lobe TE, Rao N: Breast malignancy in children. *J Pediatr Surg* 1994;29:48–51.

- 35 Hays DM, Donaldson SS, Shimada H, et al: Primary and metastatic rhabdomyosarcoma in the breast: Neoplasms of adolescent females, a report from the Intergroup Rhabdomyosarcoma Study. *Med Pediatr Oncol* 1997;29:181–189.

Dr. C. Duflos
10, rue Marguerite, FR-75017 Paris (France)
Tel. +33 1 4766 2421, Fax +33 1 4227 9444
E-Mail catherine.duflos@nck.ap-hop-paris.fr

.....

Sexually Transmitted Diseases

Marlene Heinz

Special Surgery of Pediatric and Adolescent Gynecology,
Hospital Lichtenberg, Berlin, Germany

Diseases that are transmitted by sexual behavior are caused by infection with bacteria, viruses, parasites, fungi and protozoa that are transmitted from infected genitalia. The most dangerous sexually transmitted diseases (STDs), the HIV and 50% of hepatitis B are well known to be transmitted invasively only by secretions or blood containing the virus. This means that such transmissions do not depend exclusively on sexual contact, although in all likelihood microlesions can be caused by sexual behavior.

Though there is a lack of worldwide, evidence-based epidemiologic data, published trends show that STDs are a significant health problem both in developed and developing countries. As early as 1996, WHO estimated that more than 1 million people were being infected daily (table 1). About 60% of these infections occur in young people <25 years of age, and 30% of this age group is <20 years. Between the ages of 14 and 19, STDs occur more frequently in girls than boys by a ratio of nearly 2:1; this equalizes by age 20 [1].

The yearly rate of new cases of viral hepatitis B is estimated at 20 million, and it is presumed that 350 million people are chronically infected, particularly in Africa and Asia, meaning 3–5% of the world's population. In 2000, 53 million people were registered as being infected with HIV, with 95% of them in developing countries [2]. Besides HIV and hepatitis B, more than 20 other types of STDs are known, the most common of which are infections of *Chlamydia*, *Neisseria gonorrhoeae*, human papilloma virus (HPV), herpes simplex virus (HSV-1, HSV-2) and syphilis (table 2). It should not be necessary to emphasize that infection by one STD tends to increase the risk of infection by other STDs.

Epidemiologic trends for STDs obviously differ throughout the world and mostly depend on escalating contradictions in social developments. A good

Table 1. STD – a major, worldwide public health problem [1]

Daily infection rate	>1,000,000
Age 20–25	>400,000
Age 0–19	>200,000
Age 14–19 girls	120,000
Ratio girls:boys	2:1

Table 2. Most common STDs (not included: HIV, hepatitis B)

STD	Yearly rates of new diseases worldwide [1]	Co-factor for
<i>Chlamydia</i>	90 M	Gonorrhea
Gonorrhea	60 M	HIV, syphilis
HPV	30 M	All STDs
HSV-1 and -2	20 M	HPV, HIV
Syphilis	12 M	HIV

example is the huge social changes in socialist countries as they open and adapt to the market economy: The 3-fold increase in gonorrhea and 20-fold increase in syphilis from 1989 to 1998 in the People’s Republic of China is similar to findings in Mongolia [3, 4]. The changed situation in Lithuania of the former Soviet Union is also symptomatic, where a 10-fold increase in gonorrhea and a 50-fold increase in syphilis were registered from 1990 to 1996. The increase in syphilis in 18- to 19-year-old women, however, is reported to have grown 200-fold [5].

The very different frequencies of STDs that have been reported are mostly caused by different diagnostic methods with more or less sensitivity and selectivity (see table 11). Another significant problem is the often too small size of the samples selected for the spot checks. Specific determinants of STD epidemiology include sexual education, sexual behavior, and demographic and sociological factors, as well as such crucial, quality of health care factors as accessible pharmaceuticals, available diagnostic and screening methods and treatment. The synergy of these factors ultimately determines the incidence of sexually transmitted infections and their complications.

Adolescents, and particularly those who are already sexually active, are at higher risk of acquiring STDs because of a lack of knowledge and sexual education [6–10].

Table 3. Risk factors for STD in adolescence

<i>Sexual behavior</i>
Age of first sexual intercourse
Number of lifetime partners
Condom use
Kind of sexual intercourse: anal, oral
Homosexuals
<i>Gender</i>
Female
<i>Social reasons</i>
Minority ethnic groups
Poverty
Unemployment
Drugs

Table 4. First sexual intercourse (USA)

<i>Up to 15 years old</i>	
1970 [11]	5%
1988 [11]	26%
1995 [12]	37%
<i>Depending on age in 1995</i>	
Before 13 years	9%
Between 15 and 16 years	28%
Between 17 and 18 years	29%
<i>Up to 18 years old, depending on ethnic group in 1995 [11]</i>	
White	49%
Hispanic	58%
Black	74%

Risk Factors

The most crucial factors of STD risk are sexual behavior and activity, but female gender and specific social factors are important, as well (table 3).

Sexual Behavior

Over the past 30 years, the *mean age of first sexual intercourse* (table 4) has decreased. Although in 1970 fewer than 5% of 15-year-olds had experienced sexual intercourse, in 1988 the average was already 26% [11] and in 1995

Table 5. Sexual behavior in adolescents

<i>Frequency of more than 4 lifetime sexual partners in 15- to 18-year-olds (USA)</i>	
1995 [12]	18%
1997 [13]	16%
2000 [14]	44%
<i>Condom use in sexually active 15- to 18-year-olds (USA, Cuba)</i>	
1991 [12]	46%
1995 [12]	54%
1997 [15]	<50%
2000 [14]	<40%
<i>Experiences in anal/oral intercourse in adolescents (Cuba, USA)</i>	
1991 [15]	21/39%
2000 [16]	19/74%
2000 [17]	11/39%

37% of 15-year-olds were sexually active [12]. This early sexual debut is associated with an increasing *number of lifetime sexual partners* (table 5), which consequently also increases the risk of acquiring STDs. In the group of 15- to 18-year-olds the frequency of having more than 4 lifetime sexual partners increased from 18% in 1995 [12] up to 44% in 2000 [13, 14].

Investigations of the risk of inconsistent use of contraceptives show that more than 50% of all adolescents do not use any contraception at their first sexual intercourse. Adolescents report the *use of a condom* (table 5) during the most recent intercourse but this seems to be decreasing from the 54% reported in 1995 [12, 14, 15]. In any case, it should be noted that condoms do not deliver adequate protection from three of the most widespread STDs, namely HPV, HSV-2 and *Chlamydia*.

Adolescence is a period of intense sexual experimentation that includes both *anal intercourse and homosexuality*, which especially places these young people at high risk [15–18]. In 1995 in Havana, 39% of 11- to 19-year-old girls and boys were found to have had experience in oral-genital sex and 21% in genital-anal sex [15]. More striking, in 2000 in the USA, 74% of 14- to 17-year-olds were reported to have had oral-genital and 19% anal sex (table 5). Epidemiologic studies have revealed significantly higher rates of syphilis, gonorrhea and venereal warts in particular in homosexual males than in heterosexuals [19]. However, the incidence of both gonorrhea and syphilis among homosexuals has decreased since 1980 by up to 80% because of a re-evaluation of sexual practices as a response to the fear of AIDS.

Risk of Gender in Adolescence

Adolescent girls are reported to have the highest rates of STDs and the highest frequency of serious sequelae [20]. On the one hand, this gender risk in adolescence is specifically caused by the characteristic instability of the hypothalamus-hypophysis-ovary axis, which results in a deficiency in progesterone that is in turn linked to an increased vulnerability of the female genital tract to infection. Thus, in adolescents still lacking efficient mucus and the typical absorbent activity of the cervix-ectropium, STD pathogens may settle, develop and ascend more readily into the upper tracts, thereby placing girls at a higher risk for pelvic inflammatory disease (PID) [21].

On the other hand, other factors that contribute to more frequent STDs among females is their earlier start of sexual activity than boys' and their tendency to have sex with older and more experienced partners, who are more likely to carry infections.

Social Reasons

Poor social circumstances and the resulting low quality of life essentially caused by the existing social structure are the most fundamental STD risk factors. Adolescents in socially discriminated against ethnic and minority groups, as well as poor and unemployed adolescents, are reported to have earlier first sexual intercourse, more lifetime partners, and more intercourse without protection [12]. These adolescents frequently use more alcohol and drugs like marijuana, crack or freebase cocaine prior to or during sex and, because of this, they may escalate into high-risk sexual behavior without, unfortunately, using any appropriate protection [22].

It is obvious, too, that these young people have little knowledge of STDs and their sequelae and little contact with the health care system.

The Most Common Infections

Because the goal of this chapter is to deal with the closely defined STDs, as opposed to HIV and hepatitis B, stress is put on the former only. Although new cases of syphilis are estimated annually to be 12 million cases worldwide, with particularly high rates observed in teenagers, this feared and famous-infamous classic STD has not been taken into consideration in this chapter. Concerning *Spirochaeta pallidum*-caused symptoms, stages of disease and sequelae, as well as diagnostic and treatment, see the published reviews [23, 24].

Chlamydia

Chlamydia trachomatis; obligate intracellular parasite. Incubation period: 7–21 days.

Table 6. Incidence of *Chlamydia* in females [23–25]

Patient characterization	Age	Country/year	Incidence
Asymptomatic	14–18	USA/2000	8
	15–19	USA/1997, UK/2000	2
	18–25	UK/2000	9
	18–23	Australia/1997	2
Economically disadvantaged	16–24	USA/1997	4–18
Discomfort, discharge	15–19	Yugoslavia/2000	12
	14–17	Hungary/2000	16
	>18		6

Epidemiology. Chlamydial infections are by far the most frequent bacterial STDs worldwide. However, because of inadequate diagnostic facilities, the incidence of chlamydiae is heavily underestimated. From the few countries that were able to do intensive testing, an initial increase in incidence was reported, which recently has been followed by a reduction as a result of treatment. But it must be emphasized that in adolescents the highest infection rates with *C. trachomatis* are to be found concurrently [25–27].

From the given and estimated rates of chlamydial infections in females up to 25 years of age, probably an average of 6% are infected asymptotically compared to more than 10% of sexually active adolescents. Obviously, chlamydiae are found more often in girls or women suffering from discomfort and discharge (table 6).

Current data also show females who suffer from chlamydial cervicitis, with up to 30% of their male partners carrying positive urethral cultures. Nevertheless, more than 80% of these cases occur asymptotically [28]. Most likely these youngsters are the main source for the spread of chlamydial infection to young females, with other males then becoming infected.

Symptoms, Diseases and Sequelae. Chlamydial infections in girls often occur asymptotically, but some non-specific discharge may be observed. Chlamydial infections of the cervix may progress to the upper genital tract causing PID, endometritis and perihepatitis (Fitz-Hugh-Curtis syndrome). Though symptoms of PID can be mild, the infection itself tends to result in severe tubal scarring causing infertility, ectopic pregnancy and chronic pelvic pain. A sexually active 15-year-old girl, for example, has a 1:8 chance of developing PID as compared with 1:80 for a 24-year-old woman [29].

Associated with *Chlamydia* in more than 80% of the cases are urethritis, conjunctivitis, and arthritis (Reiter's syndrome) as evidence of past or concurrent infection [20].

Table 7. New diagnostic techniques for STDs (DNA amplification methods and cultures; sensitivity >90%)

Germ	Method	Specimen
<i>Chlamydia</i>	PCR/LCR	Cervical smear First voided urine (FVU)
Gonorrhoea	PCR/LCR Culture	FVU Cervical, urethral and anal smear
HPV	PCR	Cervical and urethral smear; warts; urine
HSV asymptomatic	PCR	Vulva, cervical and urethral smear (IgG1/2 antibodies serum; sens. 80–90%)
HSV symptomatic	Culture	Blister smear

Diagnosis. Significant advances in the diagnosis of STDs have been made by the development of independent culture tests for identification of *C. trachomatis*, which may also include *N. gonorrhoeae*, HPV and HSV (table 7). Recently, urine-specimen-based DNA amplification techniques, including polymerase chain reaction (PCR) and ligase chain reaction (LCR), show sensitivities of about 90% and more. These advanced techniques are suitable for both symptomatic men and women and for screening in asymptomatic individuals. Furthermore, many of these techniques permit testing for chlamydiae as well as *N. gonorrhoeae* with sensitivities of more than 95% [30].

Based on smears obtained from the cervix or urethra, the diagnosis of chlamydiae from cell cultures, e.g., McCoy cells, requires more time and is 80% less sensitive than the PCR/LCR methods. Identification tests of *Chlamydia* antibodies by immunofluorescence, immunoperoxidase testing or enzyme immunoassay are not specific for *C. trachomatis* only [31].

Because of the difficulty of distinguishing symptoms of chlamydial infection, screening should be performed every 6 months for sexually active teenagers and particularly for those with urethritis symptoms, bleeding disturbances or frequent partner changes.

Treatment. Various options for antibiotic therapy are available for uncomplicated *Chlamydia* infection (table 8). Single-dose orally administered azithromycin 1 g is well accepted by adolescents compared with doxycycline 100 mg twice a day for 1 week [32].

Adolescents suffering from PID should be admitted to the hospital to start intravenous antibiotic therapy because of the risk of noncompliance and

Table 8. Treatment guidelines for uncomplicated *C. trachomatis* [adapted by 30]

Drug	Daily dose oral	Period
<i>Recommended treatment</i>		
Azithromycin	1,000 mg	Single dose
Doxycycline	2 × 100 mg	7 days
<i>Alternative treatment</i>		
Erythromycin	2 × 500 mg	14 days
	4 × 500 mg	7 days
Ofloxacin	2 × 300 mg	7 days
Amoxicillin	3 × 500 mg	7 days

Table 9. Treatment guidelines for pelvic inflammatory diseases [adapted by 31]

	Drug	Daily dose	Period
<i>Recommendation I</i>			
Inpatient	Clindamycin + gentamycin	4 × 600 mg i.v.	4 days
		2 mg/kg i.v.	1 day
		4 × 1.5 mg/kg i.v.	4 days
After discharge	Clindamycin	4 × 300 mg oral	10–14 days
<i>Recommendation II</i>			
Inpatient	Ciprofloxacin + metronidazole or doxycycline + metronidazole	2 × 500 mg i.v.	4 days
		2 × 500 mg i.v.	4 days
		2 × 100 mg i.v.	4 days
		2 × 500 mg i.v.	4 days
After discharge	Ciprofloxacin + metronidazole or doxycycline + metronidazole	2 × 500 mg oral	10–14 days
		2 × 500 mg oral	10–14 days
		100 mg oral	10–14 days
		2 × 500 mg oral	10–14 days

concerns for serious sequelae [33] (table 9). Because of the high risk of simultaneous asymptomatic infection, sexual partners of infected girls should be treated as well in all cases. No resistance of *C. trachomatis* to tetracycline or erythromycin has yet been found [31].

After treatment, tests should be done 21–28 days following azithromycin treatment and 7–14 days following treatment with other antibiotics.

Neisseria gonorrhoeae

N. gonorrhoeae; fastidious gram-negative diplococcus; infecting mucous membranes. Incubation period: 2–7 days.

Epidemiology. Gonorrhoea is the second most frequently occurring STD and its incidence, although not comparable with that of chlamydiae, is also higher in adolescents than in other age groups. But remarkable here again is the strikingly high number of socially disadvantaged young people [34]. Often, a coexisting infection with chlamydiae is observed.

In contrast to the impression within the public health community, a significantly greater increase in gonorrhoea has been observed in all parts of the world where such diseases are registered systematically. Thus, according to the Neisseria Reference Laboratory in Australia, an increase of more than 3-fold of gonorrhoea has occurred [34–36]. This recent increase in gonorrhoea is presumed to be the result of poor sexual health among young people, a relapse to unsafe sexual behavior and increasing antibiotic resistance associated with treatment failure.

Symptoms, Diseases and Sequelae. Infections of gonorrhoea are asymptomatic in more than 40% of all female cases. The clinical spectrum of gonorrhoea includes all the symptoms, diseases and sequelae that are caused by chlamydial infections, including disseminated infections. In gonorrhoea, however, the discharge is characterized as purulent, and in cases of PID the girls suffer from heavier pain frequently combined with fever.

Diagnosis. As described for chlamydial infections, in gonorrhoea infections the new urine-specimen-based DNA amplification techniques PCR and LCR show the highest sensitivities and acceptance. Therefore, these methods should be used if possible.

Based on smears obtained from the cervix, the urethra and, if need be, the anus, the gold standard method uses cultures of *N. gonorrhoeae*, which shows sensitivities of 90%. This method, used in tandem with tests for antibiotic resistance, is still the most approved for identifying *N. gonorrhoeae*. The considerable sensitivity of *N. gonorrhoeae* against exsiccation or decline in temperature, however, may result in false-negative findings.

Microscopic examination of colored smears used as a screening method only is not suitable to unambiguously classify *N. gonorrhoeae*. Antibody tests as ELISA are less sensitive and are not recommended.

The reported worldwide increase in the local resistance of *N. gonorrhoeae* to antibiotics but is developing differentially. Hence, thorough testing is indicated to characterize this worrisome situation.

Treatment. Uncomplicated gonorrhoea should be treated on an out-patient basis, preferably by a single dose because of the noncompliance of many adolescents. Girls suffering from complicated and disseminated gonorrhoea have to be treated in the hospital [24] (table 10). A simultaneous infection with *Chlamydia* should be considered in all cases of gonorrhoea.

Table 10. Treatment guidelines for *Neisseria gonorrhoeae* [adapted by 24]

Drug		Daily dose	Period
<i>Uncomplicated infection of cervix, urethra, rectum</i>			
Recommended	Spectinomycin or	2,000 mg oral	Single dose
	Ceftriaxone	250 mg oral	Single dose
Alternative	Cefixime or	400 mg oral	Single dose
	Ciprofloxacin or	500 mg oral	Single dose
	Ofloxacin	400 mg oral	Single dose
<i>Disseminated gonococcal infection</i>			
Inpatient	Ceftriaxone or	1 × 1,000–2,000 mg i.v.	7 days
	Cefotaxime	3 × 1,000–2,000 mg i.v.	7 days
After discharge	Cefixime or	3 × 400 mg oral	7 days
	Ciprofloxacin or	2 × 500 mg oral	7 days
	Ofloxacin	2 × 400 mg oral	7 days

Human Papilloma Virus

HPV; about 100 types of DNA virus; infecting epithelial cells only; gynecologically important types HPV-6, -11, -16 and -18. Incubation period: 1–20 months, 2–3 months on average.

Epidemiology. Infections by HPV have been identified most commonly in women between 20 and 24 years of age [37]. Large studies have found that on average more than 40% of all sexually active adolescents are infected with HPV compared with less than half of this percentage for all sexually active women [38].

If one relies on the presence of visible warts, only about 1% of sexually active teenagers are infected. Using the PAP smear, evidence of cervical infection has been found in 2–12%, with the highest rates having been observed in groups of adolescents attending STD clinics. Studies employing a more sensitive diagnostic tool such as DNA hybridization have shown that 9–18% of unselected sexually active women have HPV. Finally, using a DNA amplification technique such as PCR, 46% of unselected sexually active women had evidence of infection [39] (table 11).

Symptoms, Diseases and Sequelae. Most HPV infections are asymptomatic and without clinical manifestations. But a latent infection in one sexual partner may lead to active infection in the other by sexual transmission.

The benign types, HPV-6 and -11, usually infect the ano-urogenital region, causing visible warts that are very painful and connected with high rates of recidivism.

Table 11. Incidence of HPV dependent on sensitivity of diagnostic techniques [35]

Patient characterization	Diagnostic method	Incidence, %
Asymptomatic: Adolescents	PAP smear	2–12
All age groups	DNA hybridization	9–18
All age groups	DNA amplification	46

The potentially malignant types HPV-16 and -18, which are far rarer, infect the cervix and are associated with a higher risk for cervical cancer. However, there are no clinical signs of being infected or discomfort.

Moreover, about 90% of young women overcome these asymptomatic infections within 8–30 months, and this is not dependent on infection by low- or high-risk type HPV [37, 40]. Identified as having the high-risk HPV type, persistently infected adolescents have an increasing risk of high-grade intraepithelial lesions [41].

Diagnosis. Visible ano-urogenital warts are diagnosed by inspection. HPV-DNA tests may be indicated to clarify presumptive diagnosis. Histological investigations should be done in cases of pigmented and ulcerating warts.

Cervical anomalies are best screened routinely both by colposcopy under acetic acid application and PAP smear. However, PAP smears are not perfect because of false-negative rates of 20–60% [42]. HPV tests are recommended for adolescents in cases of suspicious colposcopic findings and/or abnormal PAP smears (PAPIIw, PAPIII). The available methods are DNA hybridization and DNA amplification PCR techniques, and a new method was recently published that identifies HPV antigens by means of monoclonal antibodies. The latter test proves active HPV infections only [43].

Histological investigations should be carried out in cases of more than 1 year in adolescence with persistent high-risk types of infection as detected by colposcopic and/or cytologic data. Most reliable results are obtained using a conization specimen.

Treatment. Ano-urogenital warts which do not cause discomfort and may resolve spontaneously should first be observed. During this time girls should avoid sexual intercourse. For treatment, excision of warts by CO₂ laser is recommended. Self-treatment locally with podophyllotoxin or imiquimod is not suitable for adolescents because of the risk of noncompliance. None of the available therapeutic methods protect from recidivism of HPV.

In cases of high-risk cervical infections with more than 1 year of persistence in adolescence, reliable data from superficially obtained conization

specimens suggest that a decision has to be made about the possibility of an additional surgical procedure. In most cases, the superficial conization itself is sufficient treatment in adolescents.

Herpes Simplex Virus

HSV-1 and -2; DNA viruses; persistently infecting regional ganglion. Incubation period: initial infection 2–7 days.

Epidemiology. Infection with HSV is one of the most common viral infections. Based on reports on antibody titers, three quarters of adults were estimated to be positive for HSV-1, the virus of oral (or labial) herpes, and one quarter was found positive for the genital herpes HSV-2 [44]. But strict division between oral and genital herpes virus does not seem reasonable because HSV-1 antibodies are found in the genital area as well in almost 50% of women suffering from genital herpes, as shown by a Swedish study [45]. Thus, a British report found a lower prevalence of antibodies for HSV-1 in 10% of peri-pubertal girls, which may put them at an increased risk of subsequent genital infection [46].

As expected, a much higher seroprevalence of HSV-2 is found in risk groups, with up to 80% in female sex workers in Germany [2].

Symptoms, Diseases, Sequelae. Fifty percent of all genital herpes infections occur asymptotically. Atypical symptoms are found in 20%, with these cases not being recognized as herpes infection. Only 30% of all genital herpes-infected people unambiguously show clinical symptoms.

The initial genital infection with HSV is characterized by painful groups of small vesicles and ulcers that are localized on both sides of the external genitalia. These spreading viral lesions may last for several weeks. Genital HSV infections in more than 60% of the cases are accompanied by fever, headache, malaise and myalgia. The initial infection is followed in nearly 85% of the cases by at least one recurrence. Recurrent infections usually occur less intensively and do not last as long as the initial one. Subclinical HSV infections may contribute to spreading the disease even by condom-protected sexual intercourse. Hence, for adolescents both proper treatment and adequate knowledge about the high infectivity of HSV are very important. During the initial infection, virus excretion takes place for 12–15 days, during recurrences excretion lasts 3–5 days.

Sequelae of HSV infection may include aseptic meningitis, encephalitis, hepatitis and pneumonitis.

Diagnosis. The best means of identifying genital herpes pathogens are cell cultures, antigen detections and DNA methods. Reliable results for the different diagnostic methods are obtained only by using specimens from florid vesicles. Specimens from already dried-up erosions are far less useful.

Table 12. Treatment guidelines for genital herpes simplex virus [adapted by 24]

Drug	Daily dose	Period
<i>Initial clinical episode</i>		
Acyclovir or	3 × 400 mg oral	7–10 days
Acyclovir or	5 × 200 mg oral	7–10 days
Famcyclovir or	3 × 250 mg oral	7–10 days
Valacyclovir	2 × 1,000 mg oral	7–10 days
<i>Episodic recurrent infection</i>		
Acyclovir or	3 × 400 mg oral	5 days
Acyclovir or	5 × 200 mg oral	5 days
Famcyclovir or	2 × 125 mg oral	5 days
Valacyclovir	2 × 500 mg oral	5 days
<i>Suppressive therapy</i>		
Acyclovir or	2 × 400 mg oral	For several months
Famcyclovir or	2 × 250 mg oral	
Valacyclovir or	1 × 500 mg oral	
Valacyclovir	1 × 1,000 mg oral	
<i>Systemic diseases</i>		
Acyclovir or	3 × 5–10 mg/kg i.v.	5–7 days or more
Foscarnet	3 × 40 mg/kg i.v.	2–3 weeks

Based on the gold standard, both HSV-1 and HSV-2 can be easily cultured. The type of virus determination is obtained by differentially specific fluorescent tests, with sensitivities of about 95%.

Other methods such as direct antigen tests or molecular biologic DNA methods are somewhat less sensitive than cultures. But these methods are suitable for the diagnosis of asymptomatic infections.

Treatment. The aims are to end the excretion of viruses as fast as possible and to alleviate symptoms, which particularly means alleviating the pain.

Virustatic therapy has to be used systemically because virustatic creams are ineffective when topically applied to cases of herpes genitalis. As a therapy for initial and recurring infections, valacyclovir taken orally twice a day is just as efficient as acyclovir 5 times daily [24]. Suppressive treatment in cases of recurrences more than 10 times a year with daily doses of 1,000 mg valacyclovir seems more efficient than the usually prescribed 500 mg/day (table 12).

In cases of severe or systemic disease, virustatic therapy should be instituted intravenously.

Prevention

Prevention as the most effective strategy to avoid spreading STDs among adolescents can be divided into three components [47].

Basic prevention is focused on sexual education as the key to ensure that adolescents get proper knowledge about STDs. Besides uninhibited talks between children and parents about sexual behavior, sexual safety and health issues in general, these matters have to be dealt with at school as early as possible. Because of the policy to ensure the health of our youth, there is an urgent need for basic improvement of the policies regarding the media, for comprehensive and free medical services for children and adolescents and, obviously, for an adequate budget to guarantee the conditions for sexual education at school.

Advanced prevention is focused on already sexually active adolescents to help them to avoid acquiring an STD. This measure includes imparting knowledge about the correct use of condoms and the correlations between alcohol, drugs and STDs. Young people must learn that they are responsible for their own sexual behavior. And last but not least, all adolescents should have easy access to clinical services for STD screening of asymptomatic carriers or in cases of developing symptoms of STD.

Prevention of sequelae and spreading is focused on those adolescents who are already infected and/or are suffering from an STD. In order to avoid particularly serious sequelae such as PID, immediate gynecological treatment has to be implemented, the faster the more likely the chance of avoiding sequelae. Sexual partners should be included in both diagnostic and therapeutical measures to prevent reinfection of the girl and further spreading of STD.

References

- 1 World Health Organization: Office of HIV/AIDS and Sexually Transmitted Diseases. Fact Sheet. Geneva, WHO, 1996.
- 2 Kiehl W: Epidemiologie sexuell übertragbarer Krankheiten; in Petzold D, Gross G (eds): Diagnostik und Therapie sexuell übertragbarer Krankheiten. Leitlinien der Deutschen STD Gesellschaft. Berlin, Springer, 2001, vol 22, pp 133–155.
- 3 Chen XS, Gong XD, Liang GJ, Zhang GC: Epidemiologic trends of sexually transmitted diseases in China. *Sex Transm Dis* 2000;27:138–142.
- 4 Purevdawa E, Moon TD, Baigalmaa C, Davaajav K, Smith ML, Vermund SH: Rise in sexually transmitted diseases during democratization and economic crisis in Mongolia. *Int J STD AIDS* 1997;8:398–401.
- 5 Lapinskaite GS, Bingham JS: Sexually transmitted disease in Lithuania: Some epidemiological and social aspects. *Int J STD AIDS* 1999;10:673–676.
- 6 Cates W Jr: The epidemiology and control of sexually transmitted diseases in adolescents. *Adolesc Med* 1990;1:409–427.
- 7 Schaefer MAB, Moscicki AB: Sexual transmitted diseases; in Hendee WR (ed): *The Health of Adolescents*. San Francisco, Jossey-Bass, 1990, pp 211–249.

- 8 Centers for Disease Control and Prevention: Sexually transmitted diseases treatment guidelines. *MMWR* 1993;42:1–102.
- 9 Holmes KK, Sparling PF, Mardh PA (eds): *Sexually Transmitted Diseases*, ed 3. New York, McGraw-Hill, 1999.
- 10 Institute of Medicine: *The Hidden Epidemic: Controlling Sexually Transmitted Diseases*. Washington, National Academy Press, 1997.
- 11 Centers for Disease Control: *Sexually Transmitted Disease Surveillance 1990*. Atlanta, Centers for Disease Control, 1991.
- 12 Kann L, Warren CW, Harris WA: Youth risk behavior surveillance – United States, 1995. *CDC surveillance summaries*, Sept 27, 1996. *MMWR* 1996;45:1–84.
- 13 Centers for Disease Control 1998. *Youth Risk Behavior Surveillance United States 1997*. *MMWR* 1998;47:1–89.
- 14 Boyer CB, Shafer M, Wibbelsman CJ, Seeberg D, Teitle E, Lovell N: Associations of sociodemographic, psychosocial and behavioral factors with sexual risk and sexually transmitted diseases in teen clinic patients. *J Adolesc Health* 2000;27:102–111.
- 15 Cortes Alfaro A, Garcia Roche RG, Hernandez Sanchez M, Monterrey Gutierrez P, Fuentes Abreu J: Survey on risky sexual behavior and sexually transmitted diseases among adolescent students from Havana City 1996. *Rev Cubana Med Trop* 1999;51:120–124.
- 16 Miller Kim S, Forhand R, Kotchik BA: Adolescent sexual behavior in two ethnic minority groups: A multisystem perspective. *Adolescence* 2000;35:313–333.
- 17 Gates GJ, Sonnenstein FL: Heterosexual genital sexual activity among adolescent males. *Fam Plan Perspect* 2000;32:295–297, 304.
- 18 Zenilman J: Sexually transmitted diseases in homosexual adolescents. *J Adolesc Health Care* 1988;9:129–138.
- 19 Judson FN, Penley KA, Robinson ME: Comparative prevalence of sexually transmitted diseases in heterosexual and homosexual men. *Am J Epidemiol* 1980;112:836–843.
- 20 Braverman PK: Sexually transmitted diseases in adolescents. *Med Clin North Am* 2000;84:869–889.
- 21 Cate W: Teenagers and sexual risk-taking: The best of times and the worst of times. *J Adolesc Health Care* 1991;12:84–94.
- 22 Shrier LA, Emans SJ, Woods ER, DuRant RH: The association of health risk behaviors and problem drug behaviors in high school students. *J Adolesc Health* 1997;20:377–383.
- 23 Brockmeyer NH: Syphilis; in Petzold D, Gross G (eds): *Diagnostik und Therapie sexuell übertragbarer Krankheiten. Leitlinien der Deutschen STD Gesellschaft*. Berlin, Springer, 2001, vol 17, pp 101–111.
- 24 Centers for Disease Control and Prevention (CDC): *Guidelines for Treatment of Sexually Transmitted Diseases*. *MMWR* 47/RR1:1–47.
- 25 US Department of Health and Human Services: *Sexually Transmitted Disease Surveillance 1997*. Atlanta, CDC, 1998.
- 26 Schofield MJ, Minichiello V, Mishra GD, Plummer D, Savage J: Sexually transmitted infections and use of sexual health services among young Australian women: Women’s health Australia study. *Int J STD AIDS* 2000;11:313–323.
- 27 Hughes G, Catchpole M, Rogers PA, Brady AR, Kinghorn G, Mercey D, Thin N: Comparison of risk factors for four sexually transmitted infections: Results from a study of attenders at three genitourinary medicine clinics in England. *Sex Transm Infect* 2000;76:262–267.
- 28 Sciarra JJ: Sexually transmitted diseases: Global importance. *Int J Gynecol Obstet* 1997;58:107–119.
- 29 Lawson MA, Blythe MJ: Pelvic inflammatory disease in adolescents. *Pediatr Clin North Am* 1999;46:767–782.
- 30 Caroll KC, Aldeen WE, Morrison M, Anderson R, Lee D, Mottice S: Evaluation of Abbott LCx ligase chain reaction assay for detection of *Chlamydia trachomatis* and *Neisseria gonorrhoeae* in urine and genital swab specimen from a sexually transmitted disease clinic population. *J Clin Microbiol* 1998;36:1630–1633.
- 31 Naehrer H: Genitale *Chlamydia trachomatis*-Infektionen; in Petzold D, Gross G (eds): *Diagnostik und Therapie sexuell übertragbarer Krankheiten. Leitlinien der Deutschen STD Gesellschaft*. Berlin, Springer, 2001, vol 2, pp 6–12.

- 32 Centers for Disease Control and Prevention (CDC): Guidelines for Treatment of Sexually Transmitted Diseases. *MMWR* 1998;47/RR1:53–59.
- 33 Centers for Disease Control and Prevention (CDC): Guidelines for Treatment of Sexually Transmitted Diseases. *MMWR* 1998;47/RR1:79–86.
- 34 Connor N, Catchpole M: Sexually transmitted diseases among teenagers in England and Wales. *Commun Dis Rep CDR Rev* 1997;7:173–178.
- 35 Gonorrhoea – USA 1998. *MMWR* 2000;49:538–542.
- 36 Donovan B, Bodsworth NJ, Rohrsheim R, McNulty A, Tapsall JW: Increasing gonorrhoea reports – not only in London. *Lancet* 2000;355:1907–1909.
- 37 Moscicki AB: Human papillomavirus infection in adolescents. *Pediatr Clin North Am* 1999;46:783–807.
- 38 Weissenbacher ER, Schneider A, Gissmann L, Gross G, Heinrich J, Hillemanns P, Link M, Petry U, Schneede P, Schneider V, Spitzbart H: Empfehlungen zur Diagnostik und Therapie der HPV Infektion des weiblichen Genitale. München, Medifac Verlag, 2001.
- 39 Krowchuk DP: Sexually transmitted diseases in adolescents: An update. *Comp Ther* 1999;25:265–271.
- 40 Ho GYF, Biermann R, Beardsley L, Chang CJ, Burk RD: Natural history of cervicovaginal human papillomavirus infection in young women. *N Engl J Med* 1998;338:423–428.
- 41 Geissler U: Kanzerisierungsprozess und HPV-Infektion an der Cervix uteri. *Gynäkologie* 2000;5:226–230.
- 42 Emans SJ, Laufer MR, Goldstein DP (eds): *Pediatrics and Adolescent Gynecology*, ed 4. Philadelphia, Lippincott-Raven, 1998.
- 43 Vassilakos P, de Marval F, Munoz M, Broquet G, Campana A: Human papillomavirus DNA assay as an adjunct to liquid-based PAP test in the diagnostic triage of women with an abnormal PAP smear. *Int J Gynaecol Obstet* 1998;61:45–50.
- 44 Petzold D: Herpes genitalis; in Petzold D, Gross G (eds): *Diagnostik und Therapie sexuell übertragbarer Krankheiten. Leitlinien der Deutschen STD Gesellschaft*. Berlin, Springer, 2001, vol 9, pp 52–57.
- 45 Lowhagen GB, Tunback P, Andersson K, Bergstrom T, Johannisson G: First episodes of genital herpes in a Swedish STD population: A study of epidemiology and transmission by the use of herpes simplex virus typing. *Sex Transm Infect* 2000;76:179–182.
- 46 Vyse AJ, Gay NJ, Slomka MJ, Gopal R, Gibbs T, Morgan-Capner P, Brown DW: The burden of infection with HSV-1 and HSV-2 in England and Wales: Implications for changing epidemiology of genital herpes. *Sex Transm Infect* 2000;76:183–187.
- 47 Stray-Pedersen B: Sexually transmitted disease in teenage girls; in Dramusic V, Ratnam SS (eds): *Clinical Approach to Paediatric and Adolescent Gynecology*. Oxford, Oxford University Press, 1998, vol 27, pp 322–383.

Dr. Marlene Heinz
 Special Surgery of Pediatric and Adolescent Gynecology
 Medicine Center Hospital Lichtenberg
 Frankfurter Allee 231A, DE-10365 Berlin (Germany)
 Tel. +49 30 55184344, Fax +49 30 55184343
 E-Mail marheinz@debitel.net

.....

Chronic Pelvic Pain and Recurrent Abdominal Pain in Female Adolescents

Robert T. Brown^{a,b,c}, Geri D. Hewitt^{b,d}

^aDepartments of Pediatrics and ^bObstetrics and Gynecology, The Ohio State University College of Medicine and Public Health; ^cAdolescent Health Section and

^dSection of Pediatric Gynecology, Children's Hospital, Columbus, Ohio, USA

As girls enter gynecologic maturity, pelvic or abdominal pain becomes a frequent complaint. Probably the most common cause of recurrent pelvic pain is menstruation. With dysmenorrhea that is mild to moderate and easily controllable with simple medications, there is little mystery as to cause, and there is little concern as to control. However, when pain is chronic or chronically recurrent, and when it is not treatable with simple medications or other analgesic methods, then investigation is needed to ferret out the cause and to develop an effective treatment plan.

Chronic pelvic pain (CPP) accounts for 10% of all visits to gynecologists [1]. In addition, CPP is the reason for 20–30% of all laparoscopies in adults [2]. Analogously, recurrent abdominal pain (RAP) occurs in 5–15% of female children 6–19 years old [3]. In a community-based study of middle and high school students, 13–17% had weekly abdominal pain. Using criteria for irritable bowel syndrome (IBS), 14% of high school students and 6% of middle school students fit the criteria for adult IBS [4]. As with other difficult to diagnose chronic medical problems, patients with CPP/RAP account for a very large number of office visits and medical resources in proportion to their actual numbers.

Although there are various definitions of chronic pelvic and/or abdominal pain, the accepted pediatric criteria, as stated by Apley and Naish [3] for RAP in children, are three or more bouts of pain severe enough to affect activities over a time period of not less than 3 months. In adults, the diagnosis of CPP requires cyclic or non-cyclic, intermittent or constant discomfort in the pelvic region for at least 6 months [5].

Etiology

There are many etiologies of CPP and of RAP. There are clear organic causes for CPP/RAP and causes that seem to mix organic processes with psychosocial phenomena. Even with endometriosis, a clearly organic cause of pain, it is known that the severity of the symptoms is not correlated with the amount of abnormal tissue seen in the pelvis [6]. The best way to conceptualize chronic pelvic and abdominal pain syndromes is via a biopsychosocial model (BPSM). This model brings together organic factors, psychological factors, and environmental factors into a comprehensive picture that is often needed to explain these symptoms [7, 8].

In the past, many people with chronic pain syndromes were said to have psychosomatic causes of their pain, but in recent years, it has become clear that such syndromes are not solely caused by psychological processes, or are psychosomatic in origin. While that term might not be accurate if it is understood to mean caused solely by psychological factors, the authors feel that the term still has relevance. The real definition of ‘psychosomatic’ does fit the BPSM. According to a current medical dictionary, ‘psychosomatic’ means ‘pertaining to the mind-body relationship’ [9]. A psychosomatic disorder is one in which physical symptoms are *caused by or exacerbated by* psychological factors [9]. To that we would add that recognition needs to be made of the interplay among all these factors, i.e. the BPSM.

We will first discuss gynecologic etiologies of CPP/RAP, then abdominal etiologies, and finally, management issues.

Gynecologic Etiologies

Adolescents with CPP may have a gynecologic etiology of their pain. Inquiries about the patient’s gynecologic health should be part of the initial interview. Items should include age at menarche, menstrual pattern, menstrually related symptoms, and sexual history. Some symptoms may be more suggestive of a gynecologic reason for the pain. These would include pain that is specific to a certain time in the menstrual cycle, pain that is associated with vaginal bleeding, pain which is exacerbated with menses, or pain that is worse with sexual intercourse. If the patient is sexually active or if symptoms suggest a gynecologic etiology, a pelvic examination should be included in the initial assessment. Wet mount examination, Pap smear, and cervical cultures should be obtained if indicated. Bimanual examination should include evaluation of the vagina for patency and tenderness, cervix for cervical motion tenderness, uterosacral ligaments for tenderness or nodularity, uterus for size, shape and

tenderness, and adnexa for tenderness, masses, and mobility. A rectal examination, including stool guaiac, should also be performed to confirm the findings on bimanual examination and evaluate for gastroenterologic causes. Radiologic imaging studies may be indicated to further evaluate an abnormality that is identified on pelvic examination or if the clinician is unable to successfully complete the examination. A pelvic ultrasound, pelvic CT scan, or MRI of the pelvis may be necessary depending on the abnormality suspected.

Dysmenorrhea

Adolescents presenting with CPP may be experiencing dysmenorrhea (see chapter 13 for a more complete discussion of dysmenorrhea). Adolescents are often unable to keep accurate records of their menstrual cycles making it difficult for many of them to recognize a cyclic pattern to their pain. Dysmenorrhea is very common in the adolescent population with surveys reporting up to 92% of teenagers experience dysmenorrhea and up to 50% of them missing school or work because of debilitating symptoms. However, the vast majority of them do not report the symptoms to their parents, and only 14–31% seek help from healthcare providers [10].

Dysmenorrhea is classified as primary dysmenorrhea if it occurs with the absence of pelvic pathology and secondary dysmenorrhea if it occurs in the presence of pelvic pathology. Possible causes of secondary dysmenorrhea include endometriosis, obstructive müllerian malformations, cervical stenosis, uterine polyps or myomas, PID, and ovarian cysts.

Primary dysmenorrhea is much more common than secondary dysmenorrhea and usually presents once ovulatory cycles are established, usually about 6–12 months after menarche. Symptoms usually start with or just prior to the menses. Patients may present with a broad range of symptoms including crampy, spasmodic, labor-like pain over the lower abdomen and back, dull aching or stabbing pain, nausea, vomiting, diarrhea, headache, fatigue, low back pain, thigh pain, dizziness, and syncope. Primary dysmenorrhea occurs due to the metabolism of arachidonic acid through the cyclooxygenase pathway leading to the synthesis of prostaglandins, thromboxanes, and prostacyclin. The human endometrium catalyzes prostaglandins PGF₂ and PGE₂ in increased amounts during the first 36–48 h of menses [11].

The symptoms of primary dysmenorrhea typically begin after ovulatory cycles are established, progress during the teen years, and improve when the patient enters her early twenties. Treatment should include education, reassurance and the maximization of healthy lifestyles with the use of medical interventions as indicated. NSAIDs interfere with the metabolism of arachidonic acid and

therefore represent a mainstay of dysmenorrhea treatment. Therapy should be initiated at the first sign of discomfort or menstrual flow and should be taken in the prescribed doses to gain the most relief. Patients can look forward to a high response rate with NSAAs alone within 6 months of therapy [12]. If the patient fails NSAAs or is sexually active, oral contraceptive pills decrease dysmenorrhea by diminishing the production of prostaglandins from the endometrium. Other therapeutic methods include: TENS (electrical stimulation) units, calcium channel blockers, acupuncture, and depot medroxyprogesterone acetate.

Patients who continue to experience dysmenorrhea despite treatment with NSAIDs and oral contraceptives should be further evaluated for secondary causes of dysmenorrhea such as endometriosis and obstructive müllerian abnormalities. Additional evaluation may include pelvic ultrasound and/or diagnostic laparoscopy.

Endometriosis

Endometriosis is the presence of endometrial glands and stroma outside of the endometrial cavity. The presence of endometriosis in adolescents is well documented [13], however the exact prevalence in adolescents is unknown. The prevalence in menstruating women is reported anywhere from 1 to 17% [14]. The etiology of endometriosis remains unclear. Attempts to explain the pathophysiology of endometriosis have included Sampson's theory of retrograde menstrual flow [15], the coelomic metaplasia theory which suggests that estrogen stimulation transforms coelomic epithelium into endometrial-type glands [16], as well as genetic [17] and immunologic factors [18].

Adolescents with endometriosis typically present with pelvic pain. Patients will typically report worsening symptoms at or near the time of their menses, but they may experience acyclic pain as well. Most adolescents with endometriosis have normal physical findings on examination. Abnormal physical findings may include tenderness on pelvic examination but would rarely include significant masses or nodularity more commonly seen in adults. Patients with dysmenorrhea or CPP unresponsive to NSAIDs and OCPs should be evaluated for endometriosis. The incidence of endometriosis in this population is reported to be as high as 70% [19]. Endometriosis should also be considered in patients with a family history of endometriosis since 6.9% of first-degree relatives of patients with endometriosis have the disease [17].

Diagnostic laparoscopy is required to confirm the diagnosis of endometriosis. Endometriosis in adolescents usually presents at an earlier stage (stage I or II) than in the adult patient and presents with more of the atypical endometriotic implants, which are clear, white, or red in appearance [20].

Early and accurate diagnosis of endometriosis is important in adolescents not only for symptom relief but also to halt the progression of the disease and to preserve fertility.

There is no cure for endometriosis short of a hysterectomy, therefore in the adolescent, treatment is usually conservative in nature with a combination of medical and surgical interventions. Surgical intervention usually begins with diagnostic laparoscopy where all grossly visible lesions are coagulated, resected, or ablated. If indicated other conservative surgical measures include lysis of adhesions with restoration of normal pelvic anatomy. After the primary surgical intervention for diagnosis and conservative treatment, medical therapy is initiated to suppress endometrial glands and stroma to limit the progression of disease. Commonly used medical therapies include OCPs, progestins, danazol, and GnRH analogs [22].

OCPs and depot medroxyprogesterone acetate both offer suppression of endometriosis as well as contraception for the sexually active adolescent. Some clinicians advocate use of continuous OCPs, omitting the placebo week for patients with endometriosis.

Danazol can be very effective for symptom relief, however, it is often poorly tolerated by patients because of the unwanted side effects of acne and weight gain.

GnRH analogs have proven efficacy in the adult population for treatment of endometriosis. Add-back therapy in the form of progestin with or without estrogen has been shown useful in the adult population to minimize the hot flashes and bone mineral density loss noted with the GnRH analogs. GnRH analogs should not be used for longer than 6 months, and there are concerns with using them in younger adolescents with regard to bone mineral density loss [21].

Müllerian Abnormalities

Müllerian abnormalities may present with a wide range of symptoms including cyclic pelvic pain, dyspareunia, amenorrhea, pelvic mass, infertility, and recurrent pregnancy loss. Obstructive abnormalities are more likely to be associated with pelvic pain and endometriosis. Diagnosing an obstructive müllerian abnormality can be difficult and may require a combination of history, examination (potentially examination under anesthesia), radiologic imaging (ultrasound and/or MRI), laparoscopy, and hysteroscopy. Depending on the type of abnormality and the level of obstruction, patients may experience hematosalpinx (fallopian tube), hematometra (uterus), or hematocolpos (vagina).

Patients with imperforate hymen may present with primary amenorrhea, cyclic pelvic pain, and bulging hymenal tissue. Surgical repair includes removing the hymenal tissue and attaching the vaginal mucosa to the hymenal ring. Patients with transverse vaginal may present in a similar manner to patients with imperforate hymen. However, a transverse vaginal septum can be associated with uterine malformations while hymenal abnormalities are not, and repair of the transverse vaginal septum is a more complex procedure involving resection of the septum and reanastomosis of the upper and lower segments of the vaginal mucosa. Vaginal atresia requires surgical correction involving creating a vaginal opening at the apex where hematometra can drain, and creating a new vagina with either the use of vaginal dilators or split-thickness skin grafts.

Two uterine abnormalities associated with outflow tract obstruction can present with pelvic pain; bicornuate uterus with a non-communicating rudimentary horn and uterine didelphys with obstructed Heim vagina and ipsilateral renal agenesis. The former is treated with laparoscopic resection of the non-communicating horn; the latter is treated with resection of the wall of the obstructed vagina so both uteri can drain through the patent vagina.

Pelvic Inflammatory Disease

Pelvic inflammatory disease (PID) is a spectrum of inflammatory disorders involving the upper genital tract of the female reproductive system and may include any combination of endometritis, parametritis, oophoritis, salpingitis, and tubo-ovarian abscess (see chapter 17 for a more complete discussion of PID). PID is a polymicrobial disease involving sexually transmitted infections, predominately *Neisseria gonorrhoea* and *Chlamydia trachomatis* and/or anaerobic and facultative organisms. Risk factors for the development of PID include sexual activity and age. Fifteen to 19-year-old women have the highest hospitalization rates for PID and incidence currently about 1% and rising [22].

The mainstay of PID treatment continues to be broad-spectrum antibiotics that will cover the most likely pathogens. Patients who do not respond to parenteral antibiotics may require diagnostic laparoscopy to rule out the possibility of appendicitis, adnexal torsion, or other surgical emergencies. Tubo-ovarian abscesses that do not respond to antibiotics can be removed laparoscopically or can be drained with CT guidance. CPP can result from PID due to adhesion formation, tubo-ovarian abscesses, and hydrosalpinx. Conservative surgical intervention may be required to alleviate patient symptoms, restore normal pelvic architecture, and preserve, albeit diminished, fertility.

Ovarian Abnormalities

The most common ovarian mass in adolescents is the functional ovarian cyst that will spontaneously regress over 6–8 weeks and that typically does not cause significant symptoms. Typical appearance on ultrasound is that of a unilocular fluid filled mass typically up to 4–5 cm in size. Functional cysts may cause pain if they are persistent in nature, if they rupture, or if they undergo torsion. Other ovarian masses that are less common than functional cysts but that are more likely to be a source of CPP include hemorrhagic corpus luteal cysts, mature cystic teratomas, serous or mucinous cystadenomas, and endometriomas. As previously mentioned, functional ovarian cysts typically regress spontaneously and do not require any further interventions. Persistent functional cysts or other ovarian masses that require surgical intervention should be treated with ovarian cystectomy with preservation of normal ovary for future fertility. Some patients experience lower abdominal pain associated with ovulation. The pain typically lasts for up to 48 h in mid-cycle and can be relieved either with NSAIDs or ovulation suppression with OCPs. Because the symptoms occur monthly, patients may report their symptoms as chronic in nature.

Before leaving gynecologic causes of chronic pain, we should mention two etiologies that are not truly gynecologic but that are frequently encountered in a gynecologic work-up. These include musculoskeletal pain and urinary tract infection (UTI). To screen for musculoskeletal pain, posture should be assessed looking for excessive lordosis, habitual one-legged standing, and leg length discrepancy. The upper and lower back should be palpated as well as the abdominal wall during leg flexion and head and leg raises. Asking the patient to point to the area where the pain hurts the most can be enlightening [23].

UTI as a cause of chronic abdominal pain is not very common, but it is a good idea to obtain a urine analysis when evaluating a young woman for CPP/RAP. If there are findings that suggest a possible UTI, cultures and sensitivities should be obtained.

Abdominal Etiologies

There is no question that chronic abdominal/pelvic pain can be caused by gastrointestinal disorders that have clear organic origins. These include inflammatory bowel disease, gastroesophageal reflux disease, and ulcer disease, among others. While psychosocial factors can affect the symptoms of and the course of these illnesses, there is a clearly demonstrable structural, physiologic, or biochemical abnormality present in each of them. Constipation fits in this category as well, and one must remember that chronic constipation is defined

as chronic retention of stool irrespective of the stooling pattern. The patient can report daily bowel movements and still be constipated if there is incomplete emptying of rectal contents. Suffice it to say for this gynecology text that a detailed history, a meticulous physical examination, and supportive laboratory and imaging studies will reveal these causes of chronic pain fairly readily. Where the diagnostic process may become more difficult is when no clear organic cause is found. However, current thought and standards have been developed which make the diagnostic process much easier.

A group of international pediatric and adult gastroenterology and mental health specialists met and developed symptom-based diagnostic criteria for what have been termed functional disorders that cause RAP [24]. The disorders for which there are patterns to the symptoms, for which no specific diagnostic tests exist, and in which the diagnostic evaluation rules out disorders with similar presentations are called functional disorders of a recognized symptom pattern. The two disorders most commonly found are functional dyspepsia, not usually an issue in girls with CPP, and IBS. The third type of disorder has no detectable organic cause and no recognizable pattern of symptoms; this is called functional abdominal pain [25] (table 1). Analogously, pain can emanate from pelvic organs in no specific pattern as well.

In the functional syndromes, whether IBS, functional dyspepsia, or functional abdominal or pelvic pain, symptoms may result from an alteration in transmission of neural impulses between the enteric nervous system and the central nervous system leading to visceral (intestinal or uterine) hypersensitivity. The emotional state of the patient and the psychosocial situation of the patient then modify the patient's perception of these sensations [25]. What this means is that under the right psychosocial conditions a patient with functional pain is sensitive to bowel distention or to uterine contractions of an intensity that would not be perceived by a person who does not have these syndromes [26–28].

Obviously, stress can play a significant role in contributing to functional pain syndromes in adolescents. While some would think that adolescents have a relatively idyllic life with little stress, that is not the case (table 2).

Management

Management of patients with CPP/RAP begins with the initial evaluation. The approach of the clinician is key in setting the tone for the future relationship with the patient and her family, in convincing the patient that her symptoms are believed to be real, and in assuring her and her family that the clinician will do everything in her/his power to help alleviate the patient's symptoms.

Table 1. Rome criteria for distinguishing the functional gastrointestinal disorders for individuals who have experienced pain of at least 12 weeks' duration in the preceding 12 months

Functional abdominal pain	Functional dyspepsia	Irritable bowel syndrome
Continuous abdominal pain school-age child or adolescent <i>and</i>	Persistent or recurrent pain or discomfort centered in the upper abdomen (above the umbilicus) <i>and</i>	Abdominal pain or discomfort with at least two of the following: relief with defecation, onset associated with a change in frequency of stool, onset associated with a change in form (appearance) of stool
No or only occasional relationship of pain with eating, menses or defecation <i>and</i>	No evidence (including EGD) that organic disease is likely to explain the symptoms <i>and</i>	There are no structural or metabolic abnormalities to explain the symptoms
The pain is not feigned <i>and</i>	No evidence that dyspepsia is exclusively relieved by defecation or associated with the onset of a change in stool frequency or stool form	Associated symptoms: abnormal stool frequency (<3 times/week or >3 times/day), stools alternate between hard and loose, straining, urgency, passing mucus, bloating, and abdominal distention
The patient has insufficient criteria for other functional gastrointestinal disorders that can explain the pain	Ulcer-like pain is the predominant symptoms; dysmotility-like fullness, early satiety and nausea are the predominant symptoms	

A thorough history is essential. The physician must elicit all facets of the symptoms, the situations in which they occur, the intensity, factors which help or exacerbate them, and the impact that the symptoms have on the patient's daily activities and functions, e.g. school absences or limitation of the patient's social activities. Patients and parents must be interviewed separately for at least part of the visit. The parents must be queried as to their fears about what might be causing the patient's symptoms. If they, for example, are worried that the patient might have cancer because an older relative who had cancer presented with chronic pain, the clinician must do all that is possible to convince them of the rarity of cancer as cause of chronic pain in children and adolescents and therefore why cancer in their daughter is not a serious consideration.

A thorough physical examination is necessary. This should include a pelvic examination with attention to the adnexa, uterine tenderness, ligaments, and the rectal tone and contents. The patient's affect should be assessed and compared

Table 2. Stressors for an adolescent

Pubertal changes
Physical growth
Hormonal fluctuations
Developing sexuality
Gender roles
Changing dependence and independence and relations with parents
Developing cognitive abilities
Cultural and societal expectations
Peer pressure
Parental psychopathology
Family dysfunction
School changes
Educational pressures
Family moves
Financial pressures
Sexual, physical or psychologic maltreatment
Physical illness

to their stated expression of tenderness during the examination. A discrepancy between visible signs of discomfort and stated discomfort may be significant.

Once the history and physical examination are completed, pertinent laboratory and imaging studies should be obtained. With almost all causes of CPP, there is little help to be gained from these studies, however.

Finally, at the first visit, a good psychosocial assessment must either be performed or scheduled. This is critical for delineation of stressors that might be precipitating the patient's symptoms. It also can reveal such phenomena as underlying depression and sexual abuse. By asserting, at the beginning of the diagnostic/management process, that psychosocial factors are just as important as organic ones in detecting the cause of CPP/RAP, the clinician demonstrates to the patient and her family the importance of these issues and makes acceptance of them as possible etiologies much more palatable.

Prior to being sent home, the patient needs some management strategies for her symptoms. Patients and parents are very grateful for things that they can do to help alleviate the pain. Simple things are best. These can include use of heat to the abdomen/pelvis to alleviate muscle tenderness. Mild analgesics can be tried. Diet alterations frequently are helpful if a functional bowel syndrome is suspected. The recording of symptoms in a diary that is to be brought in to the physician at the follow-up visit is a valuable tool for clearer elucidation of the symptom pattern.

It is critical at the first visit to explain and to 'sell' the concept of the BPSM to the patient and her family. Frequently, the physician can draw on descriptions of everyday phenomena to explain how the mind, the body, and the social situation are connected. Most teens and adults are aware that when a person has to speak in public, for example, they can get stomach pains or diarrhea. This can be used as an example of such a connection.

Lastly, a follow-up visit needs to be scheduled. At that visit, laboratory and imaging study results are reviewed. If a symptom diary has been kept, it needs to be discussed. If no purely organic cause for the CPP has been found, then the clinician must use this visit and future ones to continue to sell the concept of the BPSM as a cause of functional pain. If depression has been found to be significant, antidepressants can be described. If the patient has been found to have significant amounts of stress in her life, psychotherapy can be very helpful, and it needs to be arranged. Discussions with the girl's school might need to be held in order to help alleviate stressful situations in that environment. Subsequently, frequent visits for reassurance and to minimize the possibility of future crises should be arranged.

CPP/RAP is a problem that commonly confronts the primary care clinician. By using a reasoned approach based on sound evidence, most patients can be relieved of their symptoms and be helped to resume a normal and active life that will lead to a successful adulthood.

References

- 1 Milburn A, Reiter R, Rhomberg A: Multi-disciplinary approach to chronic pain. *Obstet Gynecol Clin* 1993;20:643-661.
- 2 Howard FM: The role of laparoscopy in chronic pelvic pain: Promise and pitfalls. *Obstet Gynecol Survey* 1993;48:357-387.
- 3 Apley J, Naish N: Recurrent abdominal pains: A field survey of 1,000 school children. *Arch Dis Child* 1958;33:165-170.
- 4 Hyams JS, Burke G, Davis PM, Rzepski B, Andrulonis PA: Abdominal pain and irritable bowel syndrome in adolescents: A community-based study. *J Pediatr* 1996;129:220-226.
- 5 Hewitt GD, Brown RT: Chronic pelvic pain in the adolescent: Differential diagnosis and evaluation. *Female Patient* 2000;25:43-48.
- 6 Stovall DW: Endometriosis associated pelvic pain: Evidence for an association between the stage of disease and a history of chronic pelvic pain. *Fertil Steril* 1997;68:13-17.
- 7 Gambone JC, Reiter R: Nonsurgical management of chronic pelvic pain: A multidisciplinary approach. *Clin Chem Obstet Gynecol* 1990;33:205.
- 8 Boyle JT, Hamel-Lambert J: Biopsychosocial issues in functional abdominal pain. *Pediatr Ann* 2001;30:1.
- 9 Dorland's Illustrated Medical Dictionary, ed 28. Philadelphia, Saunders, 1994.
- 10 Klein J, Litt J: Epidemiology of adolescent dysmenorrhea. *Pediatrics* 1981;68:661.
- 11 Dawood MY (ed): *Dysmenorrhea*. Baltimore, Williams & Wilkins, 1981.
- 12 Owens PR: Prostaglandin synthetase inhibitors in the treatment of primary dysmenorrhea: Outcome trials reviewed. *Am J Obstet Gynecol* 1984;148:96.

- 13 Davis GD, Thillet E, Lindemann J: Clinical characteristics of adolescent endometriosis. *J Adolesc Health* 1993;14:362–368.
- 14 Olive DL, Schwartz LB: Endometriosis. *N Engl J Med* 1993;328:1759.
- 15 Sampson JA: Peritoneal endometriosis due to the menstrual dissemination of endometrial tissue into the peritoneal cavity. *Am J Obstet Gynecol* 1927;14:422.
- 16 Suginami H: A reappraisal of the coelomic metaplasia theory by reviewing endometriosis occurring in unusual sites and instances. *Am J Obstet Gynecol* 1991;165:214–218.
- 17 Simpson JL, Elias J, Malinak LR, Buttram VC: Heritable aspects of endometriosis. I. Genetic studies. *Am J Obstet Gynecol* 1980;137:327.
- 18 Dmowski WP, Steele RW, Baker GF: Deficient cellular immunity in endometriosis. *Am J Obstet Gynecol* 1981;141:377.
- 19 Gidwani G: Endometriosis more common than you think. *Contemp Pediatr* 1989;6:99–110.
- 20 David GD, Thillet E, Lindemann J: Clinical characteristics of adolescent endometriosis. *J Adolesc Health* 1993;14:362–368.
- 21 Gidwani GP: Treating endometriosis in the adolescent. *Contemp Ob/Gyn* 1989;33:75.
- 22 MMWR Recommendation and Reports. April 26, 1991;40(RR-5):1–25.
- 23 Schroeder B, Sanfillippo JS: Dysmenorrhea and pelvic pain in adolescents. *Pediatr Clin North Am* 1999;46:566–567.
- 24 Drossman DA (ed): *Rome II: The Functional Gastrointestinal Disorders*. Lawrence/KS, Allen Press, 2000, pp 533–575.
- 25 Zeiter DK, Hyams JS: Clinical aspects of recurrent abdominal pain. *Pediatr Ann* 2001;30:17–21.
- 26 Camilleri M, Choi MG: Irritable bowel syndrome. *Aliment Pharmacol Ther* 1997;11:3–15.
- 27 Drossman DA: The Working Team Committee Chairmen. The functional gastrointestinal disorders and their diagnosis: A coming of age; in Drossman DA (ed): *The Functional Gastrointestinal Disorders. Diagnosis, Pathophysiology, and Treatment. A Multinational Consensus*. Boston, Little Brown, 1994, pp 1–23.
- 28 Lembo T, Munakata J, Mertz H, Niazi N, Kodner A, Nikas V: Evidence for the hypersensitivity of lumbar splanchnic afferents in irritable bowel syndrome. *Gastroenterology* 1994;107:1686–1696.

Robert T. Brown, MD
Adolescent Health Children's Hospital
700 Children's Drive, Columbus, OH 43205 (USA)
Tel. +1 614 722 2458, Fax +1 614 722 2468
E-Mail brownr@pediatrics.ohio-state.edu

.....

Contraception for Adolescents 2003

G. Creatsas

University of Athens Medical School, 2nd Department of Obstetrics and Gynecology, Athens, Greece

Adolescents today represent a significant proportion of the world population. According to the US Census Bureau, the number of women between 15 and 19 years of age will have increased from 8.5 million in 1990 to 9.2 million in 2010. A smaller change is expected till the year 2005, which indicates that, at least until this year, a general aging of the female population will occur since more women will be concentrated in the older cohort [1, 2]. Adolescent sexual behavior has changed as compared to the previous decades. This is mainly due to increasing sexuality during adolescence and to incomplete knowledge of adolescents on the matters related to sexuality and sexual life. It is also known that puberty and the onset of sexual activity start at earlier ages. Various efforts have been made by several organizations to evaluate and improve adolescent sexual behavior. Several parameters of adolescent sexuality such as adolescent pregnancy and abortion, contraception and sexually transmitted diseases have been evaluated in an effort to improve national statistics around the world. However, recent statistics and multinational data banks are limited so that conclusions are usually drawn from data of previous years. It is of major importance that a new multicentric study be undertaken to collect information on adolescent sexuality worldwide.

In this chapter we will consider one of the three parameters mentioned above, i.e. adolescent contraception, which is very much related to sexual behavior during this sensitive period of life.

Contraceptive Methods

As has been reported by the International Federation of Pediatric and Adolescent Gynecology (FIGIJ) the combined oral contraceptives (COCs) are a popular method of contraception during adolescence in Europe. However,

Table 1. Contraceptive choices for adolescents

Condoms
Low-dose oral contraceptives
Double Dutch method (condom + oral contraceptive)
Injectable contraception
Emergency contraception
Barriers (sponge)?

traditional methods such as periodic abstinence and coitus interruptus, still remain, unfortunately, in use at high frequency [3]. On the contrary, young people after consultation prefer the use of condoms. In the USA, Everett et al. [4] recently reported an increase of condom use from 46 to 57% among high school students and a decrease of the COCs use from 21 to 17%. Table 1 presents the recommended contraceptive methods for adolescents.

Condom

Although the condom presents a high failure rate (2–12%) [5], it is considered a safe method of protection from sexually transmitted diseases (STDs). It is a popular method as it is available to adolescents without prescription and at very low cost. It is the responsibility of the Family Planning Units to inform young people on the safety and efficacy of the condom as well as on its correct and consistent use. They should also inform adolescents on the possibility of condom breakage or leakage and the necessity of immediate use of emergency contraception. Weisberg et al. [6] reported that among 253 students from two high schools, girls appeared to have more difficulty in asking how condoms should be used. Thus it is suggested that Family Planning Centers (FPCs) should pay particular attention to the young population to explain to them the pros and cons of condom use, informing them that condom failure is about 10 times higher among teenagers as compared to adults [7]. As opposed to the male condom, the female condom, although available in several countries, is not in practice during adolescence.

Combined Oral Contraceptives

Today the COCs have been considered as the most effective method of contraception for adolescents. Third-generation COCs, particularly the ultra low dose COCs, present no side effects, while at the same time carry several beneficial properties, i.e. regulation of the menstrual period, improvement of acne, hirsutism and suppression of functional ovarian cysts [8]. The ultra low dose COCs with 15 µg ethinylestradiol also provide low discontinuation rates and better compliance since present limited side effects and the 24-day regimen package carries extra placebo pills thus improving compliance [9].

Finally, in a study carried out in our institution, we have shown that the use of the third-generation COCs during adolescence, for a 6-month period, presented no metabolic alterations. In the same study no pregnancies were seen, while intermenstrual bleeding was only 0.7% [10].

Injectable Contraception

The injectable contraceptive methods include Depo-Provera[®] as well as Norplant[®] and Implanon[®] systems. Depo-Provera[®] is given at a standard dose of 150 mg intramuscularly, every 3 months, and yields a rate of 0–5.2 pregnancies per 1,000 women-years [11]; it is in common use in the USA. Other regimens are given for one or half-month periods respectively. There are no studies on a significant number of adolescent girls. The next two injectable systems are becoming more popular. In a study performed at our institution, we have applied the method in 15 adolescents with very good results while we have found neutral effects on the metabolic profile of the young women included in the study [12]. Finally, the injectable contraceptive methods are particularly recommended in retarded young women, who might abuse.

Emergency Contraception

All FPCs and the gynecological units should be capable of providing emergency contraception. The healthcare professionals who deal with adolescents should be also familiar with this method. The regimen with high doses of estrogen yields a failure rate of 1% as compared to the use of COCs where the failure rate is 2%. In case high doses of ethinylestradiol are used within 72 h, the failure rate is no more than 0.1%. Yuzpe [5] has proposed a method utilizing COCs given in doses of ethinylestradiol up to 250 µg twice with a 12-hour interval in between. Finally, there is yet no experience on the use of hormonal intrauterine devices and Mifepristone (RU-486), during adolescence.

Sponge and FemCap[®]

Recently a new sponge impregnated in Nonoxynol-9, benzalkonium and sodium cholate, named Protectaid[®], has been launched and approved in Canada. A multicentric study has shown that this sponge is efficient, with no side effects, and presents no alterations in the vaginal and cervical epithelia. The results from the use of the sponge during adolescence are expected since this device carries spermicidal, antibacterial and antiviral properties, including protection from the human immunodeficiency virus (HIV) [13, 14]. The small size FemCap[®] (24 mm) was developed a few years ago but there is still no data on its extensive use during adolescence. It is recommended to women who are educated and highly motivated or those who cannot tolerate the side effects of the COCs or have contraindications for the use of intrauterine devices [15].

Intrauterine Devices (IUDs)

Although IUDs are very much in use among adult women, their use in nulliparous women is restricted. Also, there is yet no experience on the use of hormonal IUDs or the Gynefix® during adolescence.

Use of Ineffective Methods

Regardless of the above-mentioned effective and safe contraceptive methods, adolescents in their majority, before consultation, still prefer ineffective methods such as periodic abstinence, coitus interruptus and withdrawal prior to ejaculation [3]. The importance of consultation of young individuals, both males and females on safe and efficient contraceptive methods used should be extensively discussed and analyzed with adolescents visiting the Family Planning Units.

Abortion

The use of ineffective methods for protection against adolescent pregnancy leads to an increasing number of undesired pregnancies in many countries so that abortion still remains at high figures and is presented as a method of contraception. In some countries the procedure takes place ‘secretly’ since the method is still illegal. This is the reason why most abortions are unsafe or present a high rate of complications, mainly pelvic infections. Among the 1 million teenagers who became pregnant in the USA, about 40% have chosen termination of pregnancy [16]. The Netherlands present the lowest adolescent pregnancy rate in the world. This is probably due to the general attitude of the population and healthcare professionals towards sexuality and contraception [17].

In most European countries termination of undesired pregnancy is legal in girls older than 16 or 18 years of age and if gestation is less than 12 weeks. Parental consent as well as a psychosocial and medical consultation are necessary for younger individuals [3, 18]. For the termination of pregnancy, most countries use the surgical method. There are no reports on the use of Mifepristone in a significant number of individuals during adolescence. However, the use of the medical methods for termination of undesired pregnancy during adolescence may prove to be a useful method in the future.

Contraception and Sexually Transmitted Diseases

STDs, including HIV infections, implicates contraceptive behavior of adolescents in several issues. This is the main reason that the condoms have

become a popular contraceptive method. The double Dutch method and the use of the contraceptive sponge during adolescence are two of the several attempts which have been undertaken to improve effectiveness and technology of contraception during adolescence, in a way to protect young individuals from STDs.

Adolescents with high-risk sexual behavior should be screened for STDs including *Chlamydia trachomatis*, *Neisseria gonorrhoea* and HIV.

Questions on ectopic pregnancy, infertility and genital cancer present possible implications for young females concerning the future of their reproductive life. STD acquisition by adolescents is increased for a variety of biological and psychosocial reasons. Since sexual activity starts earlier these days, for both boys and girls, young people prefer to start their sexual relations with older partners respectively, who are theoretically more experienced, but on the other hand carry the risk of contamination with STDs. It is reported that half of all new infections of HIV occur among young people [19]. Thus the development of combined methods of contraception, which carry both spermicidal and bactericidal properties, including anti-HIV protection, is absolutely necessary today for the prevention of both adolescent pregnancy and STDs.

Making the Choice

First it is very important to explain to young people that the discussion among them and the healthcare professional is confidential. Both boys and girls must understand that the recommended products are safe and efficient. If they like to discuss the method further with their parents this will also be taken into account, since the parents are not usually well informed which may be the starting point of an argument on the necessity of the use of the method or may need further explanation on the side effects of the proposed method (table 2).

The condom is recommended in all cases, especially if the young couples do not have a permanent relationship. For young girls who have frequent sexual intercourse, low-dose COCs should be recommended. It should be explained that there is only a limited number of side effects, especially if ultra low dose COCs are used. Perhaps they understand that the use of both methods at the same time is an excellent choice. They should also be discouraged to start smoking. The healthcare professionals at FPCs should be available at any time for further explanation through a hotline system and capable of providing emergency contraception at any time, if necessary (table 3).

Another topic for discussion is the increased discontinuation rate. Young women usually stop contraception without any significant reason. The compliance of all methods used during adolescence, with the exception of injectable contraception, is very low. Thus, young people should be advised to

Table 2. Approaching young people

What's the problem? Is there a solution?
Are you ready to start a family?
Consequences of premature sexual life
Doctor, healthcare professional and family
Let them talk – peer, media and school
What does the doctor suggest? Is the method safe?
The cost?
'How often do I have to visit the center?'

Table 3. Factors related to the preference and acceptability of a contraceptive method during adolescence

Previous sexual behavior and sexual history (pregnancy, abortion or STD)
Socioeconomic status
Education level – information and consultation
Privacy
Access to safe sources – family planning centers and adolescent
gynecology unit
Peer, family, school and media
Physician and the healthcare professionals
Duration and kind of relationship
Possible side effects of the method and reversibility

contact their physician or the nearest Health Care Center before they stop or change the method.

Adolescents 2003

Unfortunately, even today the programs offering consultation and information to adolescents do not suffice to enrich the basic knowledge on protection from STDs and other serious complications of premature sexual life. However, we should be optimistic since the abortion and adolescent pregnancy rates in countries with effective sexual education systems have presented a decline.

The decision to abort or to carry out a pregnancy during adolescence is not easy. A number of issues are related to the decision made, such as the negative socioeconomic status, the future fertility options, and the adverse health consequences related to teenage pregnancy [20].

Contraception and good reproductive health represent one of the revolutions of the 21st century [21]. The first should be updated with new research

programs, which by now has presented significant results. The second issue is related to the safe motherhood program, which today is being seriously considered by several bodies, mainly by FIGO. The wish is that sexual education programs start immediately, in those countries which still lack such programs, while healthcare professionals and the family itself should assist young individuals to overcome the difficulties in the beginning of their sexual life and enjoy adolescence.

References

- 1 Trussel J, Vaughan B: Contraceptive use projections: 1990–2010. *Am J Obstet Gynecol* 1992; 167:1160–1164.
- 2 US Bureau of the Census: Fertility of American women. June 1988. *Curr Pop Reprod* 1989;436: 20–24.
- 3 Creatsas G, Vekemans M, Horejsi J, et al: Adolescent sexuality in Europe: A multicentric study. *Adolesc Pediatr Gynecol* 1995;8:59–63.
- 4 Everett SA, Warren CV, Santelli JS, Kann C, Collins JL, Kolbe LJ: Use of birth control pills, condoms and withdrawal among high school students. *J Adolesc Health* 2000;27:112–118.
- 5 Speroff L, Darney P: *A Clinical Guide for Contraception*. Philadelphia, Williams & Wilkins, 1996, p 5.
- 6 Weisberg E, North P, Buxton M: Sexual activity and condom use in high school students. *Med J Aust* 1992;156:612–613.
- 7 Creatsas G, Hassan E: Education and adolescent sexual behavior in contraceptive choices and reality; in van Lunsen RHW, Unzeiting V, Creatsas G (eds): *Proceedings 5th Congress of the European Society of Contraception*. London, Parthenon, 1998, pp 44–50.
- 8 Creatsas E, Koliopoulos C, Mastorakos G: Combined oral contraceptives treatment of adolescent girls with polycystic ovary syndrome. *Ann NY Acad Sci* 2000;900:245–252.
- 9 Oosterbaan HP: An open-label study of the effects of a 24-day regimen of gestodene 60 µg ethinylestradiol 15 µg on endometrial histological finding in healthy women. *Eur J Contracept Reprod Health Care* 1999;4(suppl 2):3–8.
- 10 Creatsas G, Adamopoulos P, Eleftheriou N: Clinical and metabolic effects of the monophasic gestodene ethinylestradiol pill for contraception during adolescence. *Adolesc Pediatr Gynecol* 1991;4:76–79.
- 11 Cromer BA: Depo-Provera®: Wherefore art thou? *Adolesc Pediatr Gynecol* 1992;5:155–162.
- 12 Cardamakis E, Creatsas G, Deligeoroglou E, Tzingounis V: Norplant subdermal implant system as long-term contraception during adolescence (unpubl data).
- 13 Psychoyos A, Creatsas G, Hassan E, Georgoulas V, Gravanis E: Spermicidal and antiviral properties of cholic acid. Contraceptive efficacy of a new vaginal sponge (Protectaid®) containing sodium cholate. *Hum Reprod* 1993;8:866–869.
- 14 Creatsas G, Guerrero E, Guilbert E, Drouin J, Serfaty D, Lemieux L, Suissa S, Colin P: A multi-national evaluation of the efficacy, safety and acceptability of the Protectaid contraceptive sponge. *Eur J Contracept Reprod Health Care* 2001;6:172–182.
- 15 Shihata AA: The FemCap®: A new contraceptive choice; in van Lunsen RHW, Unzeiting V, Creatsas G (eds): *Contraceptive Choices and Realities*. Proceedings 5th Congress of the European Society of Contraception. London, Parthenon, 1998, pp 173–180.
- 16 Alan Guttmacher Institute: *Teenage Pregnancy: The Problem That Hasn't Gone Away*. New York, Alan Guttmacher Institute, 1981.
- 17 Van Lunsen RHW, Arnolds HT, van Maris MGM: Choices and changes in contraceptive behavior: The role of information sources. *Patient Educ Couns* 1994;23:197–202.
- 18 Creatsas G: Improving adolescent sexual behavior: A tool for better fertility outcome and safe motherhood. *Int J Gynecol Obstet* 1997;58:85–92.

- 19 Fergusson D, Lynskey M: Alcohol misuse, adolescent sexual behaviors and risk taking. *Pediatrics* 1996;98:91–96.
- 20 UNDP/UNFPA/WHO/World Bank: Special programme of research development and research. Training in human reproduction (HRP). Biennial report 1994–95. Geneva, WHO, 1996.
- 21 Diczfalusy E: The demographic revolution and our common future. *Maturitas* 2001;38:5–14.

G. Creatsas, MD, FACS
9, Kanari Street
GR-10671 Athens (Greece)
Tel. +30 210 7217835, Fax +30 210 7233330
E-Mail geocre@aretaieio.uoa.gr

.....

Teenage Pregnancy

M. Uzan, N. Seince, I. Pharisien

Hôpital Jean-Verdier, Assistance Publique-Hôpitaux de Paris,
Seine-Saint-Denis, Bondy, France

Neither child nor adult, adolescents constitute an age class by themselves with specific health and behavioral problems, which has prompted some hospitals to create specialized adolescent departments. These units have as their goal the medical, psychological and social management of these individuals in all their complexity. The encounter between the teenager and the medical community nonetheless remains ambivalent, colored by a relational avidity but also a fear of becoming dependent. This age group, which covers the transitional period between childhood and adulthood, is increasingly recognized as having its own pathologies that merit an adapted approach. Does the term youth rhyme with health? An inquiry conducted in 1999 by the Centre de Recherche d'Etude et de Documentation en Economie de la Santé (CREDES) on 2,309 youths, 11–20 years old, showed that 45% suffered from dental problems, 13% had dermatological diseases (especially acne), 7% of the girls had genitourinary infections and 6% had respiratory diseases.

Behavioral disorders, however, characterize particularly well the health problems of today's teenagers: addictive behavior, attempted suicides, road accidents, aggression and/or eating disorders. Although early maternity has always been part of the history of women, pregnancy is often an 'accident' associated with high-risk behavior. Pregnancy can express the anxiety of everyday living, or it may be a poorly adapted response to an already precarious situation or a simple continuation of the family's history.

Teenage Sexuality and Sex Education

In France, the mean age at the time of the first sexual relationship has remained 17 years for both sexes since 1985 [1]. In contrast, the age distribution

for the first sexual experience indicates ever younger participants: 21% of the boys and 10% of the girls first had sexual intercourse at 15 years or younger [2]. Between 15 and 18 years, 47% of the boys and 41% of the girls have already had sexual intercourse with penetration. In the USA, 56% of the girls and 73% of the boys 15–19 years old have had sexual experiences, whereas about 20% of the girls and 33% of the boys have been sexually active before 15 years of age [3]. The mean age for the first sexual experience is the same as in France, i.e., about 17 years for girls and 16 years for boys. All studies have shown that the earlier sexual intercourse is practiced, the more often it is an act of submission rather than of desire.

In 1994, the French national campaign against human immunodeficiency virus infection and its acquired immunodeficiency syndrome (AIDS) made condoms the primary method of contraception for first sexual experiences.

Sexual intercourse during adolescence tends to be sporadic (5–15 times/year) and unplanned (63% occurring during vacations). Furthermore, these relationships are of short duration, rarely exceeding 1 month, which partially explains the first-line use of condoms [4].

Younger teenagers are especially vulnerable to coercive and non-consensual sex. Involuntary sexual activity has been reported by 74% of sexually active girls younger than 14 years and 60% of those under 15 years.

The contraceptive pill is often started several months later because adolescents primarily associate condoms with prevention of AIDS and sexually transmitted diseases rather than with unwanted pregnancy. Nevertheless, use of the pill markedly increases with regular sexual activity to the detriment of condoms. Thus, the dual message ‘pill and condom’ has been poorly integrated into the mores and often remains temporally disassociated.

The national investigation, ‘Adolescents’, conducted in 1993 by M. Choquet (Director of Research at the Institut National de la Santé et de la Recherche Médicale, INSERM) and S. Ledoux found that level of education appears to influence the regularity and number of sexual experiences [5]. Still, 21% of sexually active girls do not use any means of contraception [6]. This should be kept in mind during the preparation of messages to be transmitted to teenagers.

Teenage sexuality passes through two phases [7]: first, infantile sexuality, corresponding to the discovery of one’s body and pleasure of the organ, and then, genital sexuality, reflecting the capacity to reach orgasm and to reproduce. The latter phase, in turn, is composed of two stages: first, the discovery of one’s body and its power, and second, the discovery of the repercussions associated with the complementarity of the sexes (the need for the other).

For the young male, when it ‘works’, he is satisfied. For the young woman, the question of fertility is always lying just under the surface and is what

exposes her most to the risk of pregnancy: the need for ‘verification’ of the good functioning of her body.

Teenage Fertility/Pregnancy by the Numbers

Demographic and epidemiological studies have quantified adolescent pregnancies as follows.

Teenage Pregnancy Rate

This frequency, expressed per 1,000 persons, is the total number of pregnancies (births, abortions and miscarriages) for young women, 10–18 years old, divided by the number of females in this age group.

In France, this rate has been estimated to be 24‰. Only one-third of these pregnancies will be carried to term [8]. According to our inquiry conducted in the Seine-Saint-Denis Department (a northern suburb of Paris with a high-density population of young immigrants or youths of foreign ancestry), this rate was 50‰ [9].

In Great Britain in 1997, approximately 90,000 teenagers 13–19 years old became pregnant; three-fifths of them were carried to term, i.e., 54,000 births [10].

In the USA, the teenage pregnancy rate for 15- to 19-year-olds has been estimated to be 96‰ [8]. During the 1990s, it was evaluated at 177‰ (essentially black and Hispanic adolescents) and represented the highest rate among industrialized countries. Every year, approximately 1 million American teenagers, 11–19 years old, become pregnant (11% of all girls in this age group). Almost 30,000 girls 11–15 years old become pregnant every year [11]. In most states, birth rates were considerably higher for black teens than for whites. However, between 1992 and 1995, greater declines were reported for blacks than whites. Today, Hispanics have the highest teen birth rate. Overall, 50% of these adolescents carry their pregnancies to term; 35% opt for an abortion and 15% miscarry or experience in utero fetal deaths [12].

Adolescent Fertility Rate

In France (1997–2001), this frequency, which represents the birth rate for young women 15–19 years old, was 9.5/1,000; in Seine-Saint-Denis (the French department with the highest birth rate) it was 11.6/1,000 [13], as compared to Great Britain, where it was 34/1,000, and 12/1,000 in Germany and Spain.

In contrast, Sweden and The Netherlands have, by far, the lowest rates, around 2–3/1,000. Even though teenagers in these countries are sexually active at a very young age, the governments are the most motivated. They have developed educational programs to disseminate sex education in schools and the diffusion

of contraception, including authorization of publicity in the media. Among developed nations, the USA has the highest fertility rate for this age group: 55/1,000 (almost half choose to maintain their pregnancy and, among them, 90–95% raise their child).

Percentage of Teenage Pregnancies

This value is defined as the number of births to adolescents, divided by the total number of births in a given country. In our French study, we more specifically decided to consider minors (legally defined as girls under 18 years of age) because they present particular problems. In France, the numbers of births to adolescents declined sharply between 1976 and 1992, from 3.6 to 1%. Over the past 10 years, the percentage has stabilized around 0.85%. In our study in Seine-Saint-Denis, it was 1.9%, but this value reflects a recruitment biased by the population of our area [9]. In 1997, 6,356 births in France were recorded for mothers 18 years old or younger; 954 of the mothers were under 16 years of age.

The American rate was estimated to be 13% compared to the total number of births, i.e., 500,000 births to mothers 11–19 years old. In 1995, more than 1,200 births were recorded for mothers 11–15 years old [11].

Psychological Profiles of Pregnant Adolescents

Teenage pregnancy is neither the result of an accident nor that of destiny. With the exception of rape or incestuous relationships, it is very rare that an adolescent becomes pregnant by ignorance, naivety or inability to use a contraceptive method. Often, another logical explanation can be found, if the young woman is allowed to express herself freely. But to do so, an ‘alliance’ must rapidly be formed with her to create the climate of confidence and complicity necessary to best manage all the problems that can arise during such an early pregnancy. An attempt should be made to unravel the events that led to this situation. In certain cases, it can be useful to view these pregnancies in an ethno-psychological context: indeed, sexuality and procreation are strongly linked in African and Australian societies, while the two are totally independent in Western cultures.

We have been able to identify a certain number of behaviors that correspond to rather particular profiles. For example, some adolescent pregnancies can be defined as ‘cultural’ and are fully approved by the ‘community’. They correspond to a ‘verification’ of the integrity of the body and sexual organs. Furthermore, the pregnancy reassures the young woman of her capacity to procreate and gives her access to the maternal function. Childbearing increases one’s social standing in numerous traditional societies (African, Gypsy and

Maghrebian). Pregnancy constitutes a rite of passage between childhood and the world of adults. It corresponds to the passage of reproductive power from one generation to another. A close association exists among fertility, sexuality and social bonding. Indeed, it is a young woman's reproductive function that is the center of rituals: social recognition of the first menstrual cycles, marriage and deflowering, with subsequent pregnancy and childbirth definitively acknowledging the passage to adulthood. As we will see below, these pregnancies, programmed and anticipated by the couple, the family and clan, evolve normally and the majority of them proceed without any complications. In addition, the risk of abuse of the newborn in this setting is low.

Completely different are the pregnancy and desire for a child that correspond to the search for an object to help overcome a childhood deprivation. This pregnancy produces a child and the young woman becomes a mother; that is to say, she achieves access to adulthood. In France, this status is accorded by law. Attaining recognition as a mother allows her to identify with her mother and often to concretize a latent conflict. All studies have shown that many minor mothers had difficult childhoods and poor relationships with their parents. This pregnancy is thus a corporal 'aggression' with dual intent: to attack her childhood to purposefully annihilate it and to attack her mother by pushing her towards old age. These pregnancies are also qualified as 'miserable', with the infant being used to compensate for the depressive anxieties and sense of abandonment of the adolescent mother. Physical violence, deprivation and negligent parenting during early childhood appear to be strongly associated with early parenthood. As for the origin of many problems of adolescence, poor self-esteem is associated with early pregnancies.

Among risk factors identified by numerous studies are dropping out of school, aggressiveness, and abusive consumption of substances ranging from food to hard drugs. In contrast, a history of sexual abuse during childhood does not appear to be a risk factor for early parenthood.

The last profile of teenagers whose pregnancies seem to be the expression of aggressiveness directed against their own bodies is the 'risk-taking' or 'violent' pregnancy. This behavior can be considered as an ordeal, a test of fire, whose main objective is to expose the body to danger. If boys choose behaviors bearing social risk, such as speeding or delinquency, girls more readily turn towards direct attack on their bodies, for example, attempted suicides or eating disorders.

Pregnancy clearly is a means of attacking the body: attempted suicide is frequently observed shortly before or after the pregnancy, giving the former a different meaning. In general, these impulsive pregnancies occur in the framework of unprotected and high-risk sex and can be considered to be intentionally destructive acts. While pregnancy is an accomplished desire, a savored

satisfaction and a shared pleasure for the adult woman, it is none of these things for the teenager; for her it is all isolation, anxiety and anger.

Outcome of the Pregnancy as a Function of the Adolescent's Age

All the data collected over many years show that the earlier the pregnancy occurs, the more it risks being terminated by abortion.

The 1997 information bulletin of the Institut National d'Etudes Démographiques reported a study comparing 1980 and 1989 [14] for adolescents. With data expressed as abortions per 100 conceptions, in 1980 and 1989, respectively, rates were 59.9 and 61.9% for 14- and 15-year-old girls, and 44.9 and 50.4% for 16- and 17-year-olds. These percentages have remained relatively stable. In Seine-Saint-Denis, the abortion rate for women under 20 years old was 53.1% in 1996, with the national rate estimated at 50.8% [13]. The rates have also remained stable for the general population, with women 14–44 years old undergoing 22.8% abortions in 1980 and 20% in 1989.

Overall, one pregnancy in four ends in abortion in France. These rates have remained relatively stable and are subjected to mandatory reporting in the context of national data collection.

Two comments can be made: The younger the girl the greater the chance the pregnancy will be terminated by abortion. Also, according to official data, abortion rates have remained stable, at around 220,000 per year. These observations highlight the failure of contraception campaigns and the commercialization of emergency 'morning-after' contraception readily accessible because it is sold over the counter in pharmacies.

In 1997, the Institut National d'Etudes Démographiques also reported the results of a second inquiry comparing the outcomes of pregnancies in 1989 and 1991 as a function of the age of the adolescent [14] (table 1). Again, the younger the teenager, the more likely the pregnancy would be terminated. However, a transition period was noted, around 16 years, during which many more pregnancies were allowed to continue.

The percentage of teenage pregnancies that end in abortion has been declining since 1987, as increasing numbers of pregnant adolescents have chosen to give birth [15].

For the inquiry conducted in Seine-Saint-Denis, we tried to identify the parameters characteristic of those adolescents resorting to abortion: (1) three-fourths of them are French citizens (who represent only one-fourth of the teenagers who give birth) as opposed to foreigners or those of foreign ancestry; (2) only 58% are still in school, few are working, 1 out of 3 is totally inactive

Table 1. Evolution of teenage pregnancies, between 1989 and 1991, according to the age of the adolescent

Age years	1989		1991	
	births	abortions	births	abortions
12	7	43	12	34
13	45	187	38	215
14	259	672	203	703
15	827	1,722	783	1,840
16	2,366	3,105	2,119	3,290
17	5,221	4,661	5,064	NA

NA = Not available.

(no work, without qualifications and often with no plans); (3) 10% of them grew up in institutions where they had been placed as children with no family; (4) 5% aborted after having been raped, and, finally, and (5) 12% of them were 'repeaters'. This latter number is particularly disquieting when one realizes that only 800,000 doses of emergency contraception have been sold since its commercialization 2.5 years earlier in May 1999. Furthermore, it speaks eloquently of the inadequacy of preventing unwanted pregnancies. It is possible that the messages for the prevention of AIDS and the campaigns promoting the use of condoms have had a perverse effect on the use of contraception. Indeed, we must mobilize our efforts to train teachers so that they can actively participate and transmit the desired information, and to initiate sex-education classes in junior and senior high schools, like those conducted in The Netherlands.

Intrapersonal factors, such as cognitive level, poor self-esteem, depression, substance abuse, history of sexual abuse, and/or school failure, poor school performance or dropping out, have all been associated with adolescent pregnancy [16].

Problems Associated with Underage Pregnancy

French legislation clearly addresses the pregnancy of teenagers who are minors (under 18 years of age). In France, an unmarried minor alone: (1) can decide to pursue her pregnancy; (2) can legally recognize her descendant and thus accord her lineage, and (3) can exert parental authority over her child, but (4) she remains under the authority of her parents. So while marriage emancipates

a minor, according her recognition as an adult, her pregnancy does not. When she is hospitalized to give birth she must be accompanied by one of her parents who can give signed consent for any type of intervention, for example a cesarean or general anesthesia for forceps insertion. For the adolescent, the pregnancy is assimilated with an act requiring, as for all therapeutic interventions, the signed permission of her parents. Furthermore, the physician is not bound by the ethics of medical confidentiality vis-à-vis the teenager; he/she informs the parents of the status of their daughter.

Very recently, in July 2001, French legislation concerning abortion was modified: a minor is now accorded access to this intervention without the authorization of her parents if she so desires. She must however be accompanied by an adult of her choice.

Early Pregnancies and Aggressions

Aggression during the course of the pregnancy can take different forms: societal and parental, but the medical community also contributes. First of all, there is verbal violence. As the desire to conceive during adolescence is viewed negatively, the pregnancy is often defined as a failure of contraception and it is usually boiled down to a risk that must be avoided at all costs. Sometimes, verbal violence is represented by the use of terms such as an 'epidemic of pregnancies'.

These pregnancies are also the source of internal violence: the teenager will be subjected to the full fury of this so-called accidental or surprise pregnancy. She is confronted with a sexuality that she did not really want to face and the collapse of her childlike feelings of power that rendered her invulnerable. Under these conditions, denial of the pregnancy is considered a defensive refuge of a body inhabited by an alien presence. Moreover, these are the pregnancies that are discovered late and are the source of serious conflict. Finally, this pregnancy forces the young woman to confront her ambivalence, which is not the least of her suffering, enhanced by the culpability of having transgressed a clearly marked boundary.

Some pregnancies result from sexual aggression, either forced incestuous relationships or distress in response to the reconciliation of a falling out, or sometimes from the recovery from depression which gives a reason to live and repair her body. These young women have an immense hunger for love and recognition that they hope to fulfill with their child. Some abortions can be the equivalents of true suicides. The presumed date of delivery of the interrupted pregnancy may serve as the time for commemorative suicide attempts, signaling the pain, the unachieved mourning and the emptiness that are difficult to overcome.

Table 2. Evolution of reported cases¹ of sexual abuse and rape of minors

Aggression	1990	1991	1992	1993	1994	1995	1996	1997	1998	Increase
Abuse	42	124	235	378	327	350	425	514	521	×12
Rape	135	143	180	236	248	273	362	457	372	×3

¹From the Medico-legal Emergency Unit in Seine-Saint-Denis, Prof. M Garnier, Hôpital Jean-Verdier, Bondy, France.

The aggression can also be physical, within the familial entourage: assault and battery, verbal attacks, insults and/or expulsion from home. In some families, the teenager who announces her pregnancy may be putting her life on the line and find herself forced to abort or risk the life of her future newborn.

One of the roles of the doctor is to sometimes serve as a mediator between the adolescent and her parents. It is not unusual that a mother's violence is associated with a painful episode in her own life which is reactivated by the pregnancy of her daughter.

Aggression can also occur in institutional environments, more precisely in school, because it is not unusual to see these young women subjected to degrading measures and relegated to the back of the room, where the sensation of isolation is even more accentuated.

Finally, we must emphasize the risk of aggression by the medical community because this pregnancy forces it to confront its own failure to prevent conception. It can lead to an abortion performed in a climate of verbal aggressiveness when the young patient's consent is not necessarily sought.

Choquet and Ledoux [5] investigated French teenagers 12–19 years old and found 15% had been the object of physical violence, 8% had been physically wounded, 3.8% were the targets of sexual violence and 1% had been raped.

In our medico-legal unit in Seine-Saint-Denis, we recorded between 1990 and 1998 increased abuse of and sexual aggression against minors of both sexes (table 2). These rises may be attributable to the increased ferocity of violence in the suburbs but may also represent the better reporting and recording of events that previously fell by the wayside. Whichever the case, these findings are most disquieting.

Pregnancy and Congenital Malformations

Very few studies have attempted to evaluate the risk of malformations in this population, even though it is clearly a population at risk because it is widely

exposed to factors strongly thought to be implicated, such as nutritional deficiency, smoking, and use of toxic substances, including alcohol, medications and illicit drugs.

The study based on the registry of congenital malformations in California [17] is highly informative. According to this study, which covered 1,028,255 births between 1983 and 1988 and considered only live births, women under 20 years of age had an overall risk of producing children with malformations 11 times higher than that observed for the lowest-risk women aged 25–30 years. The two ends of the curve, which had a J distribution for all abnormalities, corresponded to ≤ 15 and ≥ 45 years.

When chromosomal anomalies were excluded, the curve had a U configuration (end values of the same order of magnitude) with the same phenomenon of the highest prevalence found for the youngest and oldest age groups and the lowest prevalence for women 26–32 years old.

Analysis of the Parisian registry of malformations [18] from 1981 to 1994 covered all the medical abortions performed after prenatal diagnosis of malformations in all Parisian facilities; 1,650 births were recorded for mothers under 18 years old. The frequency of malformations, including chromosomal anomalies, was 3.2%, while it was 2.8% for 20- to 24-year-olds and 3% for women 25–29 years old.

Concerning the pregnant teenage population in the metropolitan Paris area, the most striking are the elevated numbers of cases of anencephalies, cleft palates, polycystic kidney disease, abdominal wall-closing defects and chromosomal anomalies (especially trisomy 21). This enhanced risk of anomalies for children born to adolescent mothers should encourage heightened vigilance during ultrasonography for morphological study of the fetus because more and more of these pregnancies will affect teenagers not benefiting from favorable socioeconomic conditions, i.e., those who smoke, take illicit drugs, and have an unbalanced diet.

Pregnancy and Addictive Behavior

Life-threatening behavior, like smoking, drugs, violence and suicide attempts, are used by the adolescent to cope with a feeling of not being appreciated, boredom, isolation, and a lack of goals and future plans. This is the age of self-directed violence, exteriorized by aggression or risk-taking behavior. In this age group, road accidents constitute the primary cause of death (40%), far in front of suicide (19%) and disease. Another risk is the consumption of toxic substances (alcohol, medications, hard drugs) so as to be 'out of it', but also to lower, more or less consciously, a state of internal tension.

The parents should side with health professionals at the center of this battle of risk prevention.

From the data published in 1994 by Choquet and Ledoux [5] based on an inquiry on French teenagers 11–19 years old, the following characteristics concerning addictive behavior were identified. Concerning tobacco use, 14.5% smoke daily and 8.4% smoke at least 10 cigarettes/day. Advertising of tobacco products can be a factor inciting their use and its prohibition should be continued. Rates of tobacco use were the same for both sexes. The first cigarette was often smoked in junior high school, and girls were more frequently regular smokers. Concerning alcohol consumption, 12.4% drank regularly, several times a week. Drugs were used, defined as more than 10 times, by 5.4% of the adolescents, with hashish leading the list and heroin pulling up the rear; this behavior was predominantly masculine. Drug use was not associated with ethnic origin or French nationality. Still more disquieting was the finding that 3.7% of the teenagers had run away from home and 5–7% had attempted suicide.

The relationships between alcohol and/or drug use and sexual behavior have been extensively analyzed [19]. Both substances can interfere with sexual pleasure and orgasm, in particular when condoms are used. In this study, 64% of the adolescents who had sexual intercourse did so after having consumed alcohol, as compared to 15% who had taken drugs. According to some studies, drug use is responsible for one-third to one-half of homicides committed by teenagers.

Drug use during pregnancy strongly affects fetal and maternal behaviors. All toxic substances can lead to premature delivery and intrauterine growth retardation. All substances other than hallucinogenic drugs can provoke withdrawal syndromes in the mother and the newborn. Alcohol and cocaine are considered to be teratogenic (craniofacial dysmorphism syndrome of newborn alcoholism, and specific cerebral, cardiac or renal malformations) and syndromes associated with weaning justify specifically adapted management of these patients.

Nutritional deficits (caloric, iron and folate intake) associated with dietary habits totally incompatible with pregnancy and episodes of bulimia and/or anorexia probably favor the higher risk of malformations observed in this population. Bulimic episodes correspond to a rather urban syndrome and are more specifically associated with females.

Finally, 17% of teenagers took medications to combat nervousness or anxiety, or to sleep better; these agents are more frequently consumed by girls and their use increases with age.

Suicidal thoughts and acts are more commonly associated with girls: 6.5% had previously attempted suicide, with 1 out of 4 having undertaken more than one attempt; 1.3% had been hospitalized for attempted suicide.

Modifications of the French Abortion Law

The changes in the law concerning abortions were published in the *Journal Officiel* of the French Republic on July 7, 2001. Essentially, the following two points were revised: (1) the legal period during which an abortion can be performed was extended from 10 to 12 weeks (as in the majority of other European countries), and (2) for non-emancipated minors (girls under 18 years old), parental consent or that of the Children's Court was obligatory. Now, consent of a person holding parental authority or, otherwise, of a legal representative (named by the court) is obtained by the physician. If the minor wishes to maintain confidentiality, the doctor must make every effort to obtain her consent to have the holder(s) of parental authority consulted. If the minor does not want to undertake this step or if consent is not obtained, abortions as well as related medical acts and treatments can be performed at the request of the young woman. In this case, the minor must be accompanied in these undertakings by an adult of her choice who is called the 'referent adult'. After the intervention, proposal of a second consultation is mandatory, with the primary objective being to provide new information on contraception.

Worldwide, 10% of the 50 million abortions performed annually concern adolescents 15–19 years old.

Abortion techniques for minors are strictly the same as for older women; that is to say, drug-induced before 5 weeks of gestation and thereafter by aspiration, usually under general anesthesia and only rarely with local anesthesia for this age group.

In our Seine-Saint-Denis study, 46% of the abortions were drug-induced, which indicates that the adolescents had consulted very early, as soon as they had realized they were pregnant and their determination was firmly established. This investigation raised two disturbing points. First, the high rate of repeat abortions in our population, i.e., 12%, especially for 16- and 17-year-olds, most of whom were of French nationality. Concerning the general population, Kaminski et al. [20] published data showing that women undergoing multiple abortions were remarkable by their younger age at the time of the first pregnancy and that the risk of repeating is clearly higher for a first pregnancy before 20 years of age. Second, we observed that 71% of the adolescents had not used any form of contraception during the 3 months preceding the request for an abortion. Only 5% of the conceptions occurred after forgetting to take a contraceptive pill and 24% arose after highly random contraception, condom or withdrawal, practiced very irregularly. A certain number had previously used a contraceptive method but had let it fall to the wayside; this observation is counterbalanced by the irregularity and unprogrammed nature of sexual relationships in this age group.

These two points clearly show that a certain number of sexually active teenagers continue to use abortion as a means of contraception. The transmission of the double message: 'pill and condom', disseminated by national campaigns for contraception, has evidently failed. Nonetheless, it must be emphasized that a number of steps have been taken to facilitate access to contraception for minors in France. First, parental or representative consent is not required for the prescription, delivery or administration of contraceptives to minors. Contraception can be obtained free of charge and anonymously in approved family planning and education centers. Second, a medical prescription is not needed for the delivery of emergency contraception to minors and it can be obtained free of charge in pharmacies. The cost of dispensing morning-after pills is covered by the public health organization, Fonds National de Prévention, d'Education et d'Information Sanitaires (July 2001 decree). Lastly, if a doctor or planning center is not readily available, emergency contraception can be dispensed to minors and adults in second-degree facilities, by the school nurse for example. They assure the psychological support of the student and supervise the programming of medical follow-up. All these recently revised measures attempt by law to prevent as well as lower the number of unwanted pregnancies in France, which is estimated to be 10,000 per year [9].

Course of the Pregnancy and Delivery

A teenage pregnancy, and even more so when the girl is very young, is often discovered late for many reasons: ignorance, fear of talking about it, absence of an interlocutor, anxiety concerning the medical follow-up, fear of being forced to abort and, for some, denial of an initially desired reality that is subsequently dreaded once it is fulfilled. All coincide to delay the official declaration to the national health insurance program and thus the monitoring of the pregnancy. Indeed, certain extreme cases can go to term without being noticed or even suspected by the girl's entourage and therefore end in an unexpected delivery at home or, even worse, in a public site or school. This clandestinity is a major problem because it prevents all medical surveillance, thereby rendering the pregnancy more vulnerable, and puts the future mother in a state of isolation that is detrimental from all points of view.

The diagnosis of this pregnancy is also made difficult by the high number of long and irregular menstrual cycles during this period and the reported dates of the last menstruation are pure fantasy. Indeed, such a date, when vague, should never a fortiori be considered as being etched in stone.

Very often, the adolescent will consult her doctor without causal relationship with her condition and, when unclear symptoms are described, the question of a

possible pregnancy must simply be asked [21]. At the time of the first medical visit, the chief complaint (or presenting problems) may vary from vague and non-specific symptoms, such as a sore throat, abdominal pain or urinary tract symptoms, to more specific signs and symptoms characteristic of pregnancy [22].

Ultrasonography remains the best examination to determine the time of gestation during the first trimester with the aim of leaving enough time to allow the choice of termination. After this legal time limit, all the obligatory examinations will be performed to complete the physical examination and interview, so as to determine the specific risk factors of each adolescent.

In our study [9], only 13% of the pregnancies were seen during the first trimester, respectively 31 and 41% consulted as of the second and third trimesters, and 17% were first seen at the time of delivery. Analysis of the teenager's family situation showed that 42% were married or living with their partner and 58% were single but two-thirds knew who the father of their child was.

Teenage pregnancy is reputed to be at-risk, primarily because of the higher number of low-birth-weight infants. The rate of premature deliveries, around 10% in all studies, is probably more responsible for these low birth weights because true intrauterine growth retardation at the 10th percentile is approximately 13% [9], barely more common than in the general population.

Nutritional disorders are often the most common risk factor, as the protein needs are not always met because of the more frequent vomiting early during pregnancy and later because of the low socioeconomic level. In contrast, for 1 out of 5 cases, too much weight is gained because of the too high intake of glucides and it can result in definitive obesity.

Iron-deficiency anemia is common and must systematically be treated as of the second half of the pregnancy.

The two principal complications are directly associated with the late onset of prenatal care and behavior to 'erase' the pregnancy, combined with the failure to take any physical or dietary precautions and the continuation or even aggravation of addictive behaviors. It should be recalled that, in France, declaring the pregnancy to the national health insurance system during the first trimester opens the door to free prenatal monitoring with one consultation per month (more often for pathological pregnancies), including all the complementary examinations and delivery.

The pregnant teenager is allocated a monthly allowance as a single parent of 600 euros and, as soon as the baby is born and for 3 years thereafter, this amount rises to 750 euros per month.

It is clear that in industrialized countries, unlike underdeveloped nations, pregnancy should not be considered an exclusively medical problem. Other than very young adolescents, under 15 years old, more clearly exposed to preeclampsia and their fetuses to intrauterine growth retardation, the problem is

not so much associated with age as it is with social context: poor social and economic conditions, lack of affective support and, frequently, the absence of prenatal monitoring. This situation explains the importance we accord to the psychosocial support given to these pregnancies to achieve the best possible welcome for the newborn.

A certain number of factors are only slightly or not modifiable: very young age, financial precariousness, a low level of education, and deficient social or familial support. Others are amenable to change: clandestinity and insufficient prenatal care, nutritional deficiencies, habits poorly or not at all adapted to pregnancy (smoking and use of toxic substances), the stress or risk of inappropriate activities, and sexually transmitted genital infections.

In practice, an all-encompassing strategy is applied that can be adapted to respond to the different facets – medical, obstetrical, lifestyle and psychosocial – of the teenager's situation. This approach is best handled by a trained, pluridisciplinary team, in conjunction with the girl's partner and/or parents or parental authority, when possible, with the goal of evaluating the context in which the infant can be welcomed.

For the most disadvantaged adolescents, with no hope of immediately procuring decent resources, particularly those marginalized, estranged or rejected by their families or in a violent environment, etc., entry into a home for unwed mothers is highly desirable. Such a facility reserved for very young mothers would be the best adapted. The few existing institutions are small units with an educational staff and child-care facilities. These structures allow the young woman, before and after the baby's birth, to partake in outside activities (school, professional training), while still benefiting from being 'accompanied' and by personnel trained in child welfare. Unfortunately, these facilities are too rare, well below current needs.

According to all studies, delivery, strictly speaking, has a reputation of being without risk, as long as the pregnancy has been recognized, so that some notions of parenting can be taught before the arrival of the infant. Our study [9] generated results similar to those already published: a large majority (94%) of natural births, 22.5% of which required forceps, and only 5.9% cesareans (while the rate for the general population is around 18%). The old idea, according to which delivery through an immature pelvis can expose the young woman to disproportionate risk and need for a cesarean, has not been confirmed by practice.

In the context of the extreme economic precariousness of these girls, 3% of these 'unexpected' births occurred at home, 10% of the infants were transferred to neonatal units, 1% required neonatal intensive care, 1% of the fetuses died in utero, 1% of the pregnancies followed sexual aggression and 1% of the newborns were abandoned at birth.

Disproportionately high rates of maternal and neonatal mortality are associated with adolescent childbearing, especially for non-white adolescents under 15 years.

Teenage Parenting

The wide interindividual variability of the outcome of the mother-child couple after birth is well known. The stereotype of the 'single unwed mother' with no qualifications and no resources who is inclined to abandon her child needs to be reevaluated. Several studies clearly showed that, when adequately supported during this difficult period, the adolescent mother or young family is perfectly capable of having a good parental attitude [e.g., see 23].

The birth of the child establishes his direct progenitors as parents, who, as such, have rights and responsibilities. Because in some cultures fathering a child is evidence of virility, the young men impregnating adolescent girls may be more likely to be involved in other activities, such as fighting and carrying weapons or gang membership, that also symbolize virility. In this social context, it is thought that 'getting a girl pregnant proves that you are a man'.

In terms of parenting, adolescent mothers have been described as being more strict, punitive and physically aggressive, and less interactive with their children.

Teenage fathers are rarely a strong source of financial support for their adolescent partners and their children: 50% of teenage fathers live with their partner and child for some time after the birth but the divorce rate among adolescent mothers is high.

The child also has rights defined by the International Convention of the Child, ratified in 1989: the right to protection of his identity and his integrity.

The most important consideration at birth for the future of the mother and the child is the way the mother-child bond develops. These mothers, who are still steeped in adolescence, are by all accounts rather skilled with their babies, but their investment in this task can prove rather unstable. They often have a good ability to play with the infant but are stricter than other mothers in their convictions: 'he's hungry', 'he must sleep', etc. In this sense, which readily reminds one of a child playing with a doll, she cuddles and hugs then forgets the 'toy' in a corner only to pick it up again several hours later. The adolescent mother considers her child as her confidant and her comforter but also as her scapegoat, responsible for all her problems. One sees here the rising contradiction between the logic of the teenager, on the one hand, and that of the child, on the other. And, in this climate of contradictions, underlying suffering can come to the surface.

It is thus essential to assure that the adolescent can be adequately assisted to assume her role as mother without the helper usurping it. Too often these

young mothers are watched over and judged rather than helped to pursue their dual itinerary: their uncompleted adolescence and their too early entry into the process of parenting [24].

Good performance in school before the pregnancy and the return to school after the baby's birth are factors of good prognosis and constitute an essential element to the success of future familial and social function.

In France, the Haby Law of 1975 specifies that 'the pregnancy and maternity of students cannot serve as the basis for exclusion from school or the refusal of enrollment'. However, in practice, the return to school is far from being the general rule in as much as many adolescents are already 'disconnected' from the school environment, which is a place associated with failure, not unlike the conception of her child.

It is primordial that: (1) contraception be prescribed for the young mother to prevent the occurrence of a second pregnancy soon after the first, and (2) she be integrated into a social support program. The lack of social and affective support is a factor contributing to a very poor prognosis and assistance under such conditions is far from easy.

For probably the most frequent situation, in which the return to school is impossible, the adolescent must rapidly be guided in a professional choice. The present state of employment of youth in France is not rosy, with jobs requiring ever higher degrees. Thus, a line of work must be found that can, in a relatively short time, open the way to a real job with a decent income. Social, medical and child-care specialists, guidance counselors and the personnel of adapted facilities have the heavy responsibility of helping the young mother be a mother, the young father to be a father, the grandparents not to be overprotective or jailers or excessively removed, and to allow the young mother or couple to also be teenagers.

Upon returning home, the new teenage mother often requires particular assistance and attentions for herself and her child. The French Department for the Protection of Mothers and Children, notified as of the official declaration of the pregnancy, has a capital role to play in protecting the legal rights and defending the social entitlements of both. Specialists in child welfare and/or social workers have to assure the liaison and coordination among the family physician, newborn consultations, adequate housing, an at-home helper...; indeed, an entire network has to be established.

In addition to being accountable for the infant, the young mother may need to entrust her child to the care of someone else for a day or longer periods. Social structures must be able to advise and help the young mother in the search for the best adapted facility. It is probably the isolation of the young mother after leaving the hospital that is to be most feared, because this situation can be a source of profound distress that, in turn, can degenerate into violence directed

against and abuse of the infant. Furthermore, it is known that, for this population, the rates of sudden death of the newborn and mortality attributable to infections are higher during the first year of life.

Prevention of child abuse must be initiated as early as possible during pregnancy. For this reason, our so-called 'parenting' meetings, bringing together all the healthcare actors – medical, psychological and social – have been organized in the maternity departments over the past 3 years to discuss the files of those patients known during the pregnancy to be in a precarious situation and for whom the mother-child relationship may be compromised. Among these patients, pregnant teenagers represent a predominant subpopulation.

As of their fetal life, these babies run the risk of being confronted with their mothers' adolescent conduct, e.g., their projections, actions, absences, regressive or depressive behavior, and their sometimes uncontrollable ambivalence. If these situations persist, the babies risk having severe difficulties in constructing their own feelings of coherence and continuity; living, existing and developing in complete security becomes an act of defiance for them.

An adult woman's pregnancy is a wish that is fulfilled, a satisfaction that is savored and a pleasure that is shared. None of this is true for the pregnant adolescent, who is usually isolated, anxious, angry...

Pregnancy in an adolescent is a risk of an adolescence aborted. We should attempt to manage this suffering so that, if the young woman chooses her adolescence and requests an abortion, she does not immediately repeat the experience, and if she chooses the child at the expense of her adolescence, she can be assisted because, although raising a child is certainly a source of much pleasure, it also forces the parent to confront her capacity to wait and cope with frustration.

All these elements converge to emphasize that a primary public health priority should be the prevention of these pregnancies by distribution of emergency contraception.

References

- 1 Lebreton S, Lachar P: Gynécologie psychosomatique; in Encyclopédie Médicale Chirurgicale Gynécologie. Paris, Masson, 1995, 167-A-10–16.
- 2 Spira A, Bajos N et le Groupe ACSF: Les comportements sexuels en France. Report for the Ministre de la Recherche et de l'Espace. Paris, La Documentation Française, 1993.
- 3 Pierre N, Cox J: Teenage pregnancy prevention programs. *Curr Opin Pediatr* 1997;9:310–316.
- 4 Toulemon L, Leridon H: Les pratiques contraceptives en France; in Avortement et contraception. Paris, Centre de Documentation du Mouvement Français de Planning Familial, 1999, pp 39–44.
- 5 Choquet M, Ledoux S: Adolescents, enquête nationale. Analyse et perspectives. Paris, Inserm, 1994.
- 6 Alvin P, Marcelli D: Médecine de l'adolescent. Paris, Masson, 2000.
- 7 Seince N, Uzan M: Sexualité et contraception de l'adolescente. Mises à jour en gynécologie et obstétrique. Collège National de Gynécologues Obstétriciens Français. Paris, Vigot, 2000.

- 8 Pawlak C: Grossesse à l'adolescence; in Houzel D, Emmanuelli M, Moggio F (eds): Dictionnaire de psychopathologie de l'enfant et de l'adolescent. Paris, PUF, 2000, pp 304–307.
- 9 Uzan M: La prévention et la prise en charge des grossesses des adolescentes. Report to the Directeur Général de la Santé. Paris, Ministère de la Santé, April 1998 (<http://sante.gouv.fr>).
- 10 Frade C: Ninos que tienen ninos. *El Mundo*, year XI, 192, June 20, 1999.
- 11 Ware LM: Les grossesses des adolescentes aux Etats-Unis d'Amérique. *Devenir* 1999;11:23–48.
- 12 Ventura SJ, Clarke SC, Matthews TJ: Recent declines in teenage birth rates in the United States: Variations by state, 1990–94. *Mon Vital Stat Rep* 1996;45:1–6.
- 13 Observatoire Régional de Santé d'Ile-de-France: Santé des Jeunes, Les jeunes en Ile-de-France – Indicateurs départementaux de santé. Paris, Préfecture de la Région Ile-de-France, Sept 2001.
- 14 Bulletin d'information de l'Institut National d'Etudes Démographiques, June 1997, pp 1–155.
- 15 Hotz VJ, McElroy SW, Sanders SG: The impacts of teenage childbearing on the mothers and the consequences of those impacts for government; in Maynard R (ed): *Kids Having Kids*. Washington, The Urban Institute Press, 1997.
- 16 Cates W Jr: Contraception, unintended pregnancies and sexual transmitted diseases: Why isn't a solution possible? *Am J Epidemiol* 1996;143:311–318.
- 17 Croen LA, Shaw GM: Young maternal age and congenital malformations: A population-based study. *Am J Public Health* 1995;85:710–713.
- 18 Goujard J, de Vigan C, Vodovar V: Grossesses précoces et malformations congénitales. Journées Parisiennes d'Obstétrique et Pédiatrie. Paris, Assistance Publique, 1997, pp 65–70.
- 19 Strunin L, Hingson R: Alcohol, drugs and adolescent sexual behaviour. *Int J Addict* 1992;27: 129–146.
- 20 Kaminski M, Crost M, Garel M: Les IVG répétées en France: analyse des bulletins statistiques d'IVG. *Contracept Fertil Stéril* 1997;25.
- 21 Marcelli D, Alvin P: Grossesse et adolescence; in Actes de Colloque, 2ème Journée de Médecine et Santé de l'Adolescent, Dec 9, 2000, Poitiers. Paris, Fondation de France, 2000, pp 39–45.
- 22 Natalie PJ: Pregnancy in adolescence; in Sanfilipo JS, Muram D, Dewhurst J, Lee PA (eds): *Pediatric and Adolescent Gynecology*. Philadelphia, Saunders, 2001, pp 318–332.
- 23 Horwitz SM, Klerman LV, Sung Kuo H, Jekel JF: School-age mothers: Predictor of long-term educational and economic outcomes. *Pediatrics* 1991;87:862–868.
- 24 Pasini W, Beguin F, Bydłowski M, Papiernik E: L'adolescente enceinte. Actes du 6ème Colloque sur la Relation Précoce Parents-Enfants, Geneva, Switzerland.

M. Uzan

Service de Chirurgie Gynécologique et d'Obstétrique
Hôpital Jean-Verdier, Assistance Publique-Hôpitaux de Paris
avenue du 14 Juillet, Seine-Saint-Denis, FR–93143 Bondy Cédex (France)
Tel. +33 1 48026796, Fax +33 1 48026773
E-Mail michele.uzan@jvr.ap-hop-paris.fr

.....

Adolescent Health Care

Dan Apter, Katri Makkonen

The Sexual Health Clinic of the Family Federation of Finland, and
Department of Paediatrics, Helsinki University, Helsinki, Finland

Sexual development brings along dreams and wishes of a new kind of relationship, an opportunity to intimate closeness with another person. A maturing young person is in many aspects lonely and uncertain, and thus sensitive and vulnerable. S/he needs adult support. A growth milieu supporting the self-esteem of the young person together with adequate and sufficient sexual education and health services helps her/him to make choices to maintain and protect her/his sexual health. A good adolescence should be considered as a value in itself, in addition to being the foundation for the welfare of adulthood and forthcoming families.

Adolescent sexual rights are well implemented in the Nordic and some other European countries and the level of sexual health of young people is relatively good. Indicators of this are the low number of unintended pregnancies, abortions and sexually transmitted diseases (STDs) in international comparison [1]. This has not always been the case. Fifty years ago the situation in Finland was quite different: illegal abortions and STDs were common, sex education was non-existent and attitudes towards sexuality and contraception were negative. The overall development in society – strong political commitment, equal education opportunities for boys and girls, development of the health care system, positive attitude change of the state and church have all made it possible to reach the present situation through extended provision of sufficient and reliable sexual education, confidential and high-quality services and wide selection of contraceptive methods. The results have been achieved by persistent and extensive education and promotion of these issues.

Young people in the western countries have for decades lived in a teenage culture which has become a global phenomenon also in the developing world, especially in the big cities. Old traditions no longer offer young people enough protection. Restrictions and prohibitions have not been the solutions to improve

adolescent sexual health. Instead, with parental provision, sufficient and reliable sexual education, confidential and high-quality services and a wide selection of contraceptive methods, young people are able to make informed choices and take responsibility of their own sexuality. There is distinct evidence that sexual education does not provoke young people to start sexual relationships earlier, although this conception still prevails in many societies.

In the Nordic countries the sexual autonomy of young people is generally accepted also within the Church. This is the result of long historical development. A young person matures to make her/his own choices only when s/he values her/himself and her/his partner and has sufficient information on sexuality and sexual health. Sexually active adolescents need appropriate sexual health services.

Many of the problems of adolescence are related to the unwillingness of culture to adapt to the structurally changing position of adolescents in society. In modern society, young people develop physically at a rather young age, but only several years later they are ready for starting a family. It is the growing gap between physical maturity on the one hand and 'social maturity' on the other which causes many of the problems of adolescent sexuality. The mean age at first intercourse for females in Finland is about 17 years, mean age at first marriage 27, and at first delivery 28. Of women delivering babies in 1996, 28% had already graduated from university.

Different cultures have responded to the question of adolescent sexuality in different ways. From an international perspective, it is only recently that some cultures have embarked on a new strategy of accepting adolescent sexuality as a normal phenomenon of life, providing educational and health services, and enabling young people to deal with it in a satisfying and responsible manner. Looking at the results of this strategy in terms of effectiveness and acceptability, there are reasons to believe that this strategy has a wider universal value [2].

Sexual Health for Adolescents Today

Sexual health is based on (1) recognizing sexual rights, (2) sexuality education and counselling, and (3) confidential high quality services.

Adolescence is not only a transition between childhood and adulthood to be passed as smoothly as possible, but in itself an important period. It includes great potency to successful development and health – or it can leave the person physically or psychologically damaged.

Sexual development together with increasing independence and working through one's values are the main issues in adolescence. These processes will happen whether we support it or not. Without guidance we leave the youngster

alone and exposed to risks. S/he uses the materials s/he has got: movies, advertisements, television, magazine stories, pornography, and peer stories. As the information is heterogeneous, the adolescent might engage in unnecessary early experimentation to find out her/himself, with deleterious consequences.

Sexual Rights

We need to recognize that young people are diverse with diverse needs and interests. They are basically optimistic, creative, curious and energetic, and should be involved in planning and producing health services for themselves. Adults too often focus on the crisis of adolescent sexuality citing rates of abortions, STD/HIV infections and sexual risk behaviour, which have been the catastrophes when adolescents have been forced to contact health services. Adoption of a rights-based framework, developed by IPPF (International Planned Parenthood Federation) [3], changes the perspective to look at adolescent sexual health in terms of protection and provision, the rights to information and health care and the undesirable consequences as the violations of these rights. We need to empower young people and involve them in the development of sexual health programs as partners. We need to see the sexuality of an adolescent as a strong and positive resource that s/he will use to build her/his future life.

All young people of the world regardless of sex, religion, colour, sexual orientation or mental and physical ability have the following rights as sexual beings according to the IPPF youth group:

(1) The right to your life, to be yourself – free to make your own decisions, to express yourself, to enjoy sex, to be safe, to choose to marry (or not to marry) and plan a family. The adolescent will step by step take the responsibility of her/his own body and health behaviour. S/he needs adult protection and support, but adults have to respect adolescents' ability to decide themselves.

(2) The right to know – about sex, contraceptives, STDs/HIV, and about your rights. Adolescents should not be exposed to risks due to ignorance. Sexuality education needs to be well planned, of high quality and easily available for appropriate age groups, both in the form of personal counselling and group education.

(3) The right to protect yourself and be protected – from unplanned pregnancies, STDs/HIV and sexual abuse.

(4) The right to have health care – which is confidential, affordable, of good quality and given with due respect. Confidentiality is most important. Adolescents are not likely to visit the same places as their parents.

(5) The right to be involved – in planning programs with and for youth, attending meetings/seminars etc. at all levels and trying to influence authorities through appropriate means.

Sexuality Education

The support provided should be adapted to the developmental stage, which does not follow chronological age. That is why global education programs alone are not very successful. Three kinds of guidance are needed:

(1) Counselling, which occurs in direct interpersonal relationship and is based on recognizing individual needs. Counselling might include very sensitive areas about sexual development, genital functions and sexual relationships, and need to be highly confident and free of oppressing judgments. This type of support is available in school health and adolescent/family planning clinics. A good counsellor can also be anybody nearby the adolescent trust, such as a teacher, a friend's parents or a relative. The own parents cannot easily anymore interfere in these questions, because the awakened sexual drive is one of the strongest powers away from the parents towards independence, although parental support is very important.

(2) Sexuality education is typically given in schools or other social situations, where a group of young persons of similar age listen to lectures, see educational material and can discuss. Sexuality education can be given by a teacher or school nurse, or if so wanted by a trained worker from outside school within the frame of the school curriculum. Education situations can give information and also be interactive, but individual needs are not possible to consider. That is why part of the group does not benefit substantially, because they have not yet reached the stage of wakened interest, or have already proceeded beyond the issues discussed. However, group discussions about sexuality are beneficial in forming attitudes and giving the experience that sexual health questions can be dealt with openly.

(3) A third approach is information campaigns about sexual health through e.g. mass media. Finland has good experience with the *Sixteen magazine* mailed home to all 16-year-olds by the Ministry of Health and Social Affairs. The goals are to promote, facilitate and support the developing sexuality, sexual health and well-being of adolescents. Adults participating in this educational work need to take part in a continuous training process to recognize special needs of different developmental stages, and to respond to changing needs and changing risk factors in the surrounding.

Services

The sexual health services for adolescents can be provided in various settings, as long as certain basic principles are observed. The clinic should have a youth-friendly atmosphere, where young people can feel welcome and comfortable. Unquestionable confidentiality is very important. The providers must not moralize and judge the adolescents, but have a positive attitude in changing risk behaviour and treat adolescents with respect indicating that young people are important. In this way self-esteem is strengthened, and adolescents learn to

respect and take care of themselves and others. A language that is understandable should be used, giving adolescents proper words to use about sexual organs. Information and the services needed should be provided at an affordable price, which preferably means free of charge. The threshold for coming to the clinic should be low, but it is still at the responsibility of the young person her/himself without force or bribery. The adolescents should be able to drop in or get an appointment without having to wait long. A free telephone line for questions is an important part of the services, and nowadays also Internet information services.

Special approaches may be needed to reach disadvantaged and marginalized adolescents who may be suffering from disability, discrimination, poverty, lack of schooling or immigrant status. It is crucial that young people from different communities or with special needs participate in the process to help identify useful changes in training and service delivery [2]. Particularly the participation of young males should be encouraged.

Organization of Health Care

Health care in Finland, as in many other countries, is organized into different levels: primary, secondary and tertiary health care. Primary health care provides the basis of the health care organization and school health care (SHC) is an essential part of it. Primary health care consults secondary and tertiary centres/hospitals as needed. Matters concerning e.g. contraception can mainly be handled by primary health care. In addition to public health care, private sector offers services ranging from primary to tertiary care.

SHC follows the growth and pubertal maturation of schoolchildren and adolescents, preferably with yearly check-ups. In addition to medical history and physical examination of the adolescent, the growth chart is a basic tool in detection of deviations from normal growth or in diagnosis of illness.

General paediatrics and gynaecology are provided by secondary level hospitals. For example, a patient with idiopathic delayed puberty can be followed up by primary health care after a consultation of a specialist in paediatrics. On the other hand, if more sophisticated examinations – such as dynamic testing of the pituitary-ovarian axis – are needed in the confirmation of the diagnosis, a specialist in endocrinology at a tertiary level hospital should be consulted. Karyotype analysis is also usually performed at tertiary level, where the possibly following medical and psychosocial treatment and care will take place.

School Health Care

Finland has not set up a network of youth clinics; specific clinics for adolescents exist only in some of the biggest towns. On the other hand, SHC is an

essential part of primary health care. It is provided in all municipalities and covers health care free of charge for the pupils in primary and secondary education. Thus, clientele of SHC consists of almost the whole population aged from 7 to 16. Its aim is to promote healthy growth and development of the child and adolescent, and health education and counselling are key elements of SHC. In addition, recognition of possible problems and health risks, screening and advice for a healthy way of living belong to preventive health care. SHC collaborates with e.g. parents, teachers, psychologists, physiotherapists and nutritionists.

During the early 1990s, due to economical recession, resources for health and social services were cut in Finland, and many municipalities saved money by reducing the number of people employed in health care. The cutbacks were made in all health and social care services, but in particular in preventive health care. Therefore, the basic prerequisites for good SHC have been discussed and defined [4].

Basic Prerequisites for a Good SHC

(1) SHC should have a sufficient amount of staff. A full-time school nurse should be responsible for the care of not more than 600 pupils. If she works in more than one school, the amount of pupils should be less. A school doctor should have at least one working day per week per 1,000 pupils. In addition to clinical work, the staff should have time to plan SHC activities, to supervise the working conditions at school, to health education of the pupils, to networking and to continuous education of their own. At school a school psychologist and a social worker should also be available.

(2) The workrooms reserved for SHC should be appropriate.

(3) In each health district there should be a named doctor who carries a special responsibility for SHC. She/he is responsible for overall planning of SHC and ensures that SHC has sufficient possibilities to operate and that new workers will be adequately trained to participate in SHC. In larger municipalities also a school nurse is needed to coordinate SHC. Special responsibilities will be taken into account in the salaries of the staff involved.

(4) The staff should use an equivalent of at least 10 working days per year for continuous education regarding SHC.

Aims of a Good SHC

The staff can realistically commit themselves to the following aims of a good SHC when above-mentioned resources are met, and when the staff can take part in continuous professional education.

Health Promotion and SHC

SHC is a part of the school community. Its aim is to ensure that the school provides an environment for its pupils that promote their physical and

emotional health and well-being. SHC actively participates in health education at school.

(1) SCH participates in the preparation of the school's health education plan. In the plan it is agreed what topics are taught, who teaches them and how the process is followed-up. Health knowledge should be taught as a separate subject in all grades.

(2) During every visit to SHC, the pupil should receive personal health education and counselling.

Personal Health Care, Collaboration and Regular Check-Ups

(1) The school nurse should be available daily in schools with more than 400 pupils and the school doctor weekly in schools with more than 600 pupils. The time schedule should be planned in advance and the times should be familiar for the pupils. In all schools a visit to the school doctor should be available within 1–2 weeks.

(2) The school nurse follows each pupil's development and health by yearly check-ups.

(3) A thorough regular check-up by the school doctor and the school nurse should be done when the pupil starts school, and when s/he is aged 11–12, 15 and 17 years. During the check-ups, previous health documents are studied, the teacher is interviewed and the pupil is interviewed and (physically) examined. The parents should be met as well, at least when the pupil is in lower grades. A personal health plan is prepared, its fulfilment is followed-up and the plan is re-evaluated throughout school attendance.

(4) All new pupils will visit the SHC regardless of their grade/age. Those with chronic illness, with high rate of absenteeism, with psychosocial problems, with learning difficulties or with a need of other special attention should be followed-up according to their personal needs. The pupil can also visit the SCH by her/his own request.

(5) The school nurse takes part in all the meetings that consider health problems of an individual pupil or of a group of pupils. The school doctor takes part in such meetings regularly. SHC should be informed in advance of the pupils' problems that will be discussed in a particular meeting.

(6) The school doctor should be consulted in advance when a transferral to special education is planned.

(7) SCH should be provided with sufficient time to regularly collaborate with families, school staff, social work, the nearest children's hospital and other authorities involved in the care of school-aged children and adolescents.

Sexuality Education and Contraceptive Counselling in SHC

Sexuality education is an important part of SHC. Recently it has been emphasized that this applies to both sexes, not only to girls. Taking care of

sexual health includes both physical and socio-emotional factors: the adolescent is offered support in her/his development and in first sexual relationship(s). In SHC it is important to consider adolescents with chronic illnesses and/or handicaps, since often their psychosexual development may not be paid any attention to at all. Those with delayed or precocious puberty may also need enhanced support [5].

Problems in obtaining contraceptive methods are often suggested to cause non-use or inconsistent use of contraception. These include not knowing where and how to get contraceptives, too high costs of contraceptive services as well as feelings of embarrassment or shame in obtaining them [6]. When considering SHC, in addition that the adolescent might know the staff from many years before, proximity of services is an advantage: the threshold for a young person seeking advice regarding e.g. human relationships, including contraception, is lower. School nurses offer advice in sexual issues, help adolescents in making an appointment to a family planning clinic, and sometimes even provide contraceptives, in particular emergency (post-coital) contraception.

Confidentiality is an important issue in contraceptive counselling; young people usually want to keep their personal sex lives private. Interaction with clinical staff is important for adolescents, and it has been found that contraceptive compliance varies directly with clients' attitudes towards the service provider [7]. It is essential that matters concerning adolescent pupil's sexual health be not disseminated from SHC to the teacher, unless the adolescent so wishes.

The Family Federation of Finland emphasized both confidentiality and good interaction with the clinical staff when it started the 'Open House' services for adolescents in the Helsinki capital area in 1988. Open House offers easy accessibility to advice concerning sexuality and contraception, and provides contraceptives such as condoms, oral contraceptives, implants and emergency contraception. Experienced nurses and doctors provide services. The 'Open House' service also function as a model unit, providing continuous education for health care professionals. At present, adolescent boys have a clinic of their own which is run by male staff. Visits to the clinic is free of charge for girls under 18 and boys under 20 years of age.

Situation in Finland

School health services cover practically all children until the age of 16. Regardless of age, adolescents have access to sexuality education, contraceptive services as well as abortion without parental consent according to Finnish law.

During the 1980s, the use of oral contraceptives increased rapidly among adolescents, e.g. among 18-year-old girls from 22% in 1981 to 41% in 1989,

and among 16-year-old girls from 7 to 19%. The situation has been rather stable since [5]. Thus, the proportion of sexually active girls using oral contraceptives is high. In the beginning of a relationship, condoms are often the first choice, with 80% of 17-year-old girls reporting having used condoms at their first intercourse. The use of post-coital contraception has increased particularly among adolescents. A special preparation for this purpose has been on the market since 1987. Of 15- to 16-year-old girls ever having had intercourse, 22% have used post-coital contraception. Of those having used post-coital contraception, 66% had used it once, 17% twice, and only 5% three or more times [5]. Thus the concern that adolescents would start to use emergency contraception regularly, if easily available, instead of other methods, is not supported by the data available. As first-line contraception, condoms backed up with post-coital contraception are strongly recommended, and the condom packages have instructions for post-coital contraception.

The increased use of contraception has profoundly decreased the number of unwanted pregnancies. Since 1975, when the number of legal adolescent abortions was the highest ever, 21.2/1,000 15- to 19-year-old females, the number of abortions decreased until 1995 when the number was 9.3. Thereafter an increase to 14 occurred in 2000. This increase has been related to cutting health care services. Still, the number of adolescent abortions in Finland is low in international comparison. The number of adolescent deliveries also decreased to 10/1,000 in 2000.

Other indicators of sexual health are less reliable. The incidence of *Chlamydia* infection is still common around 20 years of age. The incidences of gonorrhoea, syphilis and HIV are very low in the Nordic countries.

Adolescent sexual behaviour has not changed much anymore during the last 20 years, as indicated by repeated large surveys [5]. By 16 years of age, about 30% of girls have had sexual intercourse and the median age for the first time is about 17 years for girls and slightly higher for boys.

Conclusions

When adolescent sexuality is not condemned but sexuality education and sexual health services are provided instead, it is possible to profoundly improve adolescent sexual health with comparatively small costs. But each year new groups of young people mature, requiring new efforts. Education, counselling and services are all needed. If the resources are not provided or are cut too much, as has recently occurred in Finland, negative effects soon become evident.

References

- 1 King A, Wold B, Tudor-Smith C, Harel Y: The health of youth, a cross-national survey. WHO Reg Publ, Eur Ser No 69. Geneva, WHO, 1996.
- 2 Programming for adolescent health and development. WHO Tech Rep Ser 886. Geneva, WHO, 1999.
- 3 International Planned Parenthood Federation: Charter on sexual and reproductive rights (<http://www.ippf.org/charter/index.htm>).
- 4 Suomen Koulu- ja Nuorisolääketieteen Yhdistyksen hallituksen kannanotto: Hyvän kouluterveydenhuollon edellytykset (Basic prerequisites for good school health care). Suomen Lääkärilehti (Finn Med J) 2000;55:3940–3941.
- 5 Kosunen E: Seksuaalisuus (Sexuality); in Terho P, Ala-Laurila EL, Laakso J, Krogius H, Pietikäinen M (eds): Kouluterveydenhuolto (School Health Care). Jyväskylä, Kustannus Oy Duodecim, 2000, pp 128–132.
- 6 Morrison DM: Adolescent contraceptive behavior: A review. Psychol Bull 1985;98:538–568.
- 7 Jones EF, Forrest JD, Goldman N, Henshaw SK, Lincoln R, Rosoff JI, Westoff CF, Wulf D: Teenage pregnancy in developed countries: Determinants and policy implications. Fam Plann Perspect 1985;17:53–63.

Dan Apter
Chief Physician and Director
The Sexual Health Clinic, Family Federation of Finland
PO Box 849, FIN-00101 Helsinki (Finland)
Tel. +358 9 61622226, Fax +358 9 645017
E-Mail dan.apter@vaestoliitto.fi

.....

Author Index

- Apter, D. 252
Baunin, C. 66, 163
Brown, R.T. 213
Cortet-Rudelli, C. 148
Creatsas, G. 225
Dewailly, D. 148
Duflos, C. 183
Escourrou, G. 163
Fenichel, P. 106
Galifer, R.B. 23
Galinier, P. 163
Gayrard, M. 66, 163
Hamel-Teillac, D. 39
Heinz, M. 197
Herrmann, B. 77
Hewitt, G.D. 213
Jeandel, C. 23, 140
Kuttenn, F. 183
Lemasson, F. 66
Lumbroso, S. 23
Makkonen, K. 252
Moulin, P. 163
Navratil, F. 77
Paris, F. 23, 140
Pharisien, I. 233
Picaud, J.-C. 23
Pienkowski, C. 66, 163
Plu-Bureau, G. 183
Porcu, E. 9
Seince, N. 233
Stanhope, R. 57
Sultan, C. 23, 140
Tauber, M. 66
Thibaud, E. 1, 183
Traggiai, C. 57
Trimeche, S. 140
Tscherne, G. 129
Uzan, M. 233
Vaysse, P. 66, 163

.....

Subject Index

- Abortion
 - French legislation 244, 245
 - frequency, adolescence 228
- Abscess, breast 190
- Acrodermatitis enteropathica,
 - vulvo-perineal localization 50, 51
- Adnexal torsion, management 169, 170
- Adolescent demographics 225
- Adolescent sexual activity 199, 225, 233–235
- Amastia, features and management 188
- Ambiguous genitalia
 - clinical investigations 24–26
 - cytogenic and molecular investigations 26
 - differential diagnosis formulation 25, 26
 - grading 25
 - hormonal investigations 26, 27
 - imaging investigations 27
 - multidisciplinary management 24, 37
 - sex assignment
 - androgen resistance 37
 - family education 37
 - gonadal dysgenesis 36, 37
 - pseudohermaphroditism 36, 37
 - systematic examination 23
- XX newborn etiologies
 - fetal androgen excess 29, 30
 - maternal androgen excess 28
 - placental androgen excess 29
 - true hermaphroditism 30
- XY newborn etiologies
 - bilateral vanishing testis 33, 34
 - complete androgen insensitivity 30
 - dysgenetic testis 33
 - Leydig cell hypoplasia 34
 - partial androgen insensitivity syndrome 31, 32
 - 5 α -reductase deficiency 32, 33
 - testosterone synthesis defects
 - congenital lipoid adrenal hyperplasia 34
 - 17 α -hydroxylase deficiency 34
 - 3 β -hydroxysteroid dehydrogenase deficiency 34
 - 17 β -hydroxysteroid dehydrogenase deficiency 35
 - 46,XY/XO newborn 35, 36
- ANDI classification, *see* Breast diseases
- Androgen resistance
 - delayed puberty 112, 113
 - sex assignment 37
- Athelia, features and management 187
- Behçet's disease, perianal manifestations 51, 52
- Bilateral vanishing testis, features 33, 34
- Breast
 - embryology 183, 184
 - maturation 184–186
- Breast diseases
 - abscess 190
 - acquired abnormalities
 - asymmetry 188
 - hypotrophy 188
 - shape abnormality 188

- Breast diseases (continued)
 - ANDI classification
 - cyclical hormonal modifications
 - between puberty and 50 years of age 186, 187
 - involution between 35 and 55 years of age 187
 - lobular development between puberty and 25 years of age 186
 - overview 184
 - cancer 194
 - congenital anomalies
 - amastia 188
 - athelia 187
 - polymastia 187
 - polythelia 187
 - ductal ectasia 189, 190
 - fibroadenoma
 - fibroadenoma simplex 191, 192
 - giant fibroadenoma 192, 193
 - multiple fibroadenomas 193
 - gigantomastia 189
 - hypertrophy 189
- Bullous impetigo, perineal 45, 46
- Child sexual abuse (CSA)
 - anogenital findings
 - anal findings 92
 - classification 93–96
 - genital trauma 91, 92
 - kind of findings 91
 - normal findings 87–91
 - behavioral abnormalities and symptoms 79, 80
 - definition 78, 79
 - diagnosis
 - emotional response to medical examination 82, 83
 - history taking 83, 84
 - medical examination 82, 83
 - physical findings 81, 82
 - differential diagnosis 97–99
 - extragenital signs 93
 - long-term outcomes 80
 - masked presentations 80
 - offender features 79
 - overall assessment 99
 - physical examination
 - anogenital examination 85, 86
 - fear 84
 - forensic evidence collection and interpretation 86, 87
 - positioning 85
 - timing 84
 - prevalence 79
 - professional response development 77, 78
 - sexually transmitted diseases 96, 97
 - victim features 79
- Chlamydia* infection
 - clinical features 202
 - diagnosis 203
 - epidemiology 202
 - incubation period 201
 - treatment 203, 204
- Chronic pelvic pain (CPP)
 - abdominal etiologies 219, 220
 - definition 213
 - epidemiology 213
 - gynecologic etiologies
 - dysmenorrhea 215, 216
 - endometriosis 216, 217
 - Müllerian abnormalities 217, 218
 - ovarian abnormalities 219
 - overview 214, 215
 - pelvic inflammatory disease 218
 - urinary tract infection 219
 - management 220–223
- Condylomata acuminata, features in children 47
- Congenital adrenal hyperplasia (CAH), features 60
- Congenital lipoid adrenal hyperplasia (CLAH), features 34
- Constitutional delay in growth and puberty (CDGP), features 120, 121
- Contraception, *see also* Oral contraceptives
 - adolescent choices 226, 229, 230
 - adolescent sexual activity 199, 225
 - compliance 229, 230
 - condoms 226
 - education 229, 230
 - emergency contraception 227
 - FemCap® 227

- ineffective methods 228
- injectable contraception 227
- intrauterine device 228
- prospects 230, 231
- school health care impact in Finland 259, 260
- sexually transmitted disease prevention 228, 229
- sponge 227
- Cushing's syndrome, hyperandrogenism 157
- Cysts, *see* Ovarian cysts

- DAX1 mutations 120
- Delayed puberty
 - clinical workup 110, 111
 - complete androgen resistance 112, 113
 - congenital gonadotropin deficiency
 - Kallmann syndrome 118
 - Laurence-Moon-Bield syndrome 118
 - multiple endocrine deficiencies 117, 118
 - Prader-Willi syndrome 118
 - constitutional delay, growth and puberty 120, 121
 - DAX1 mutations 120
 - epidemiology 109, 110
 - follicle-stimulating hormone β -subunit mutations 120
 - genital abnormalities 121, 122
 - gonadal dysgenesis with 46,XY karyotype 112
 - gonadotropin receptor inactivating mutations 114
 - hormonal etiology 107–109
 - hyperandrogenia, causes 122
 - hypergonadotropic hypogonadism
 - iatrogenic ovarian failure 114
 - idiopathic hypergonadotropic hypogonadism
 - chronic diseases 116, 117
 - isolated causes 118–120
 - negative energetic balance 117
 - nontumoral acquired lesions 116
 - tumors 115, 116
 - overview 111
 - syndromic hypergonadotropic hypogonadism 113
- luteinizing hormone-releasing hormone pulsatile secretion impairment 118
- receptor mutations 119
- management 123, 124
- overview 106, 107
- primary amenorrhea, developed secondary sex characteristics 121
- Turner's syndrome 111, 112
- Diaper dermatitis
 - differential diagnosis 39–41
 - types based on localization 40, 41
- Ductal ectasia, features and management 189, 190
- Dysgenetic testis, features 33
- Dysmenorrhea, adolescents
 - age of onset 143
 - chronic pelvic pain 215, 216
 - clinical signs 140, 141
 - etiology 143, 144
 - ovulation relationship 145
 - prevalence 141, 142, 145
 - primary versus secondary 140
 - treatment 144–146, 215, 216
- Endometriosis
 - chronic pelvic pain 216, 217
 - clinical presentation 172
 - etiology 172
- FemCap[®], contraception 227
- Fibroadenoma
 - fibroadenoma simplex 191, 192
 - giant fibroadenoma 192, 193
 - multiple fibroadenomas 193
- Follicle-stimulating hormone (FSH), β -subunit mutations 120
- Genital tumors
 - hemangioma 42, 43
 - types 42
- Gigantomastia, features and management 189
- Gonorrhea, *see* *Neisseria gonorrhoeae* infection
- Gynecologic clinical examination
 - adolescents 7, 8
 - indications 1

- Gynecologic clinical examination
(continued)
newborns 6, 7
preparation 1, 2
prepubertal children 2, 4–6
- Hemangioma, perineal 42, 43
- Herpes simplex virus (HSV)
clinical features 208
diagnosis 208, 209
epidemiology 208
incubation period 208
treatment 209
types 208
- Human papilloma virus (HPV), *see also*
Condylomata acuminata
clinical features 206
diagnosis 207
epidemiology 206
incubation period 206
serotypes 206, 207
treatment 207, 208
- 17 α -Hydroxylase deficiency, features 34
- 3 β -Hydroxysteroid dehydrogenase
deficiency, features 34
- 17 β -Hydroxysteroid dehydrogenase
deficiency, features 35
- Hymen
child sexual abuse, findings 88–90
normal variations 90
- Hyperandrogenism, *see also* Non-classic
adrenal hyperplasia; Polycystic ovary
syndrome
adrenal and ovarian tumors 157
ambiguous genitalia, XX newborn
etiologies
fetal androgen excess 29, 30
maternal androgen excess 28
placental androgen excess 29
- Cushing's syndrome 157
delayed puberty, causes 122
diagnosis in female adolescents
clinical assessment 149
imaging 150, 151
laboratory investigations 149, 150
drug induction 158
hyperprolactinemia 158
- idiopathic hirsutism 158
oligomenorrhea 137, 138
physiological hyperandrogenism of
puberty 148, 149
treatment in adolescents 158–160
- Hypergonadotropic hypogonadism,
delayed puberty
iatrogenic ovarian failure 114
idiopathic hypergonadotropic
hypogonadism
chronic diseases 116, 117
isolated causes 118–120
negative energetic balance 117
non-tumoral acquired lesions 116
tumors 115, 116
overview 111
syndromic hypergonadotropic
hypogonadism 113
- Hypermenorrhea, features and management
134, 135
- Hyperprolactinemia, hyperandrogenism
158
- Idiopathic hirsutism, diagnosis 158
- Incontinentia pigmenti, perianal
manifestations 53, 54
- Infantile perianal pyramidal protrusion,
features 43, 44
- Inflammatory bowel disease, perianal
manifestations 51, 52
- Intercourse, age of first intercourse trends
199
- Intrauterine device (IUD), contraception
228
- Irritable bowel syndrome (IBS), chronic
pelvic pain 220
- Kallmann's syndrome, delayed puberty 118
- Kawasaki's disease, vulvo-perineal
localization 52
- Labial adhesions, features and
management 39
- Langerhans' cell histiocytosis,
vulvo-perineal localization 50
- Laurence-Moon-Bield syndrome, delayed
puberty 118

- Leydig cell hypoplasia, features 34
- Lice, children 47, 48
- Lichen sclerosis
 - complications 48, 49
 - features in children 48, 54
 - management 49, 50
- Luteinizing hormone-releasing hormone (LHRH), delayed puberty
 - pulsatile secretion impairment 118
 - receptor mutations 119
- McCune-Albright syndrome, features 70, 71
- Magnetic resonance imaging (MRI), ovarian masses 165, 166, 169
- Menorrhagia, features and management 134
- Menstrual cycle
 - development and hormonal control 129–131
 - dysmenorrhea, *see* Dysmenorrhea, adolescents
 - irregularities
 - causes 131, 132
 - clinical importance 132, 138, 139
 - diagnosis 133
 - evidence-based clinical practice 129
 - hypermenorrhea 134, 135
 - menorrhagia 134
 - metrorrhagia 135
 - oligomenorrhea
 - definition 136
 - hyperandrogenemic origin 137, 138
 - hyperprolactinemic origin 137
 - hypothalamic origin 136, 137
 - ovarian origin 138
 - pituitary origin 137
 - polymenorrhea 135, 136
- Metrorrhagia, features and management 135
- Molluscum contagiosum, features and management 47
- Müllerian abnormalities, chronic pelvic pain 217, 218
- Neisseria gonorrhoeae* infection
 - clinical features 205
 - diagnosis 205
- epidemiology 205
- incubation period 204
- treatment 205
- Non-classic adrenal hyperplasia (NCAH)
 - clinical features 156, 157
 - diagnosis 157
 - incidence 155, 156
 - pathophysiology 156
 - treatment in adolescents 159, 160
- Nonsteroidal anti-inflammatory drugs (NSAIDs), dysmenorrhea management 144, 215, 216
- Oligomenorrhea
 - definition 136
 - hyperandrogenemic origin 137, 138
 - hyperprolactinemic origin 137
 - hypothalamic origin 136, 137
 - ovarian origin 138
 - pituitary origin 137
- Oral contraceptives
 - combined oral contraceptives 226, 227
 - dysmenorrhea management 144, 215, 216
- Ovarian cysts, *see also* Polycystic ovary syndrome
 - adnexal torsion management 169, 170
 - clinical presentation in children 66, 67
 - functional cysts
 - etiology 172
 - frequency 171
 - predisposing factors 171, 172
 - hormonal etiology
 - adrenal dysfunction 71
 - central pituitary involvement 69, 70
 - hypothyroidism 71
 - McCune-Albright syndrome 70, 71
 - hormonal investigation 69
 - management 72–74
 - polycystic transformation 18–21
 - sonography 18–21, 67–69
 - tumor markers 69
- Ovarian tumors
 - adnexal torsion management 169, 170
 - carcinoma staging 174
 - diagnosis
 - exploratory surgery 167, 168

- Ovarian tumors (continued)
 - diagnosis (continued)
 - hormonal investigations 166
 - laboratory studies 166
 - magnetic resonance imaging 165, 166
 - serum tumor markers 166, 167
 - sonography 165
 - epidemiology 163
 - epithelial tumors 176, 177
 - germ cell tumors
 - cystic teratoma 175
 - dysgerminomas 176
 - yolk sac tumors 176
 - histologic classification 172, 173
 - juvenile granulosa cell tumors 72
 - mesenchymal and sex cord tumors
 - fibromas 178
 - fibrosarcomas 178
 - gonadoblastoma 179
 - granulosa cell tumors 177, 178
 - gynandroblastoma 179
 - Leydig cell tumors 178
 - Sertoli cell tumors 178
 - thecomas 178
 - symptoms 164, 165
 - teratomas 72
- Ovary
 - chronic pelvic pain abnormalities 219
 - embryology 163, 164
 - maturation 12, 13, 15, 16
 - sonography
 - cysts 18–21
 - tumors 165
 - volume 12–14
 - volume
 - classification 15, 16
 - menstrual cycle regularity effects 15
 - ovulation frequency effects 16, 17
- Partial androgen insensitivity syndrome (PAIS), features 31, 32
- Pelvic inflammatory disease (PID), *see also Chlamydia* infection; *Neisseria gonorrhoeae* infection
 - chronic pelvic pain 218
- Perianal dermatitis, features and management 46
- Pinworm, children 47, 48
- Polycystic ovary syndrome (PCOS)
 - classification
 - classic 155
 - non-classic 155
 - clinical features
 - anovulation 152
 - hyperandrogenism 152
 - metabolic syndrome 152
 - delayed puberty 122
 - diagnosis
 - hormonal markers 153
 - metabolic syndrome screening 154, 155
 - sonography 153, 154
 - pathophysiology, puberty 151
 - treatment, adolescents 158, 159
- Polymastia, features and management 187
- Polymenorrhea, features and management 135, 136
- Polythelia, features and management 187
- Prader-Willi syndrome, delayed puberty 118
- Precocious puberty
 - adrenal dysfunction 59, 60
 - central precocious puberty 60, 61
 - classification 58, 59
 - gonadotropin-independent precocious puberty 63, 64
 - hormonal investigation 58
 - isolated menarche 63
 - premature thelarche 62
 - sonographic investigation 57, 58
 - thelarche variant 62, 63
- Pregnancy, teens
 - addictive behavior 242, 243
 - adolescent sexual activity 199, 225, 233–235
 - aggression considerations 240, 241
 - congenital malformations 241, 242
 - course and delivery 245–248
 - fertility rate 235
 - French legislation 239, 240, 244, 245
 - outcome, function of maternal age 238, 239
 - parenting teens 248–250

- psychological profiles, pregnant adolescents 236–238
 - rates
 - frequency 235
 - percentage 236
- Premature thelarche, features 62
- Prostaglandins, dysmenorrhea, role 143, 144
- Psoriasis, infants 41
- Puberty
 - delayed, *see* Delayed puberty
 - hormonal control 106–109
 - precocious, *see* Precocious puberty
- Recurrent abdominal pain (RAP), *see also*
 - Chronic pelvic pain
 - definition 213
 - epidemiology 213
 - management 220–223
- Recurrent toxin-mediated perineal erythema, features 46, 47
- 5 α -Reductase deficiency, features 32, 33
- Scabies, children 47, 48
- School health care (SHC), Finland
 - aims 257
 - contraception use 259, 260
 - health promotion 257, 258
 - overview 256, 257
 - personal health care, collaboration, and regular checkups 258
 - prerequisites 257
 - sex education 258, 259
- Sex assignment, *see* Ambiguous genitalia
- Sex education
 - adolescents 229, 230, 255
 - school health care, Finland 258, 259
- Sexual abuse, *see* Child sexual abuse
- Sexually transmitted diseases (STDs), *see also* *Chlamydia* infection; Herpes simplex virus; Human papilloma virus; *Neisseria gonorrhoeae* infection
 - child sexual abuse 96, 97
 - contraception considerations 228, 229
 - frequencies and types 197, 198
 - prevention 210
 - risk factors
 - gender 201
 - sexual behavior 199, 200
 - social circumstances 201
- Sexual rights, adolescents 252–254
- Sonography
 - ambiguous genitalia investigations 27
 - ovaries
 - cysts 18–21, 67–69
 - tumors 165
 - volume 12–14
 - polycystic ovary syndrome 153, 154
 - precocious puberty 57, 58
 - resolution, children 9
 - uterus 11, 12
- Sponge, contraception 227
- Tanner stages, breast development 185
- Teratoma, benign 72, 175
- Thelarche variant, features 62, 63
- Turner's syndrome, delayed puberty 111, 112
- Ultrasound, *see* Sonography
- Urinary tract infection (UTI), chronic pelvic pain 219
- Uterus
 - maturation 9–12
 - sonography 11, 12
- Vitamin E, dysmenorrhea management 144
- Vulvovaginitis
 - clinical features 45
 - organisms 45

